EIGHTH EDITION

Volume One



Fitzpatrick's DERMATOLOGY IN GENERAL MEDICINE





DVD INCLUDED



Lowell A. Goldsmith • Stephen I. Katz

Barbara A. Gilchrest • Amy S. Paller

David J. Leffell • Klaus Wolff

Mc Graw Hill

EIGHTH EDITION

Volume Two

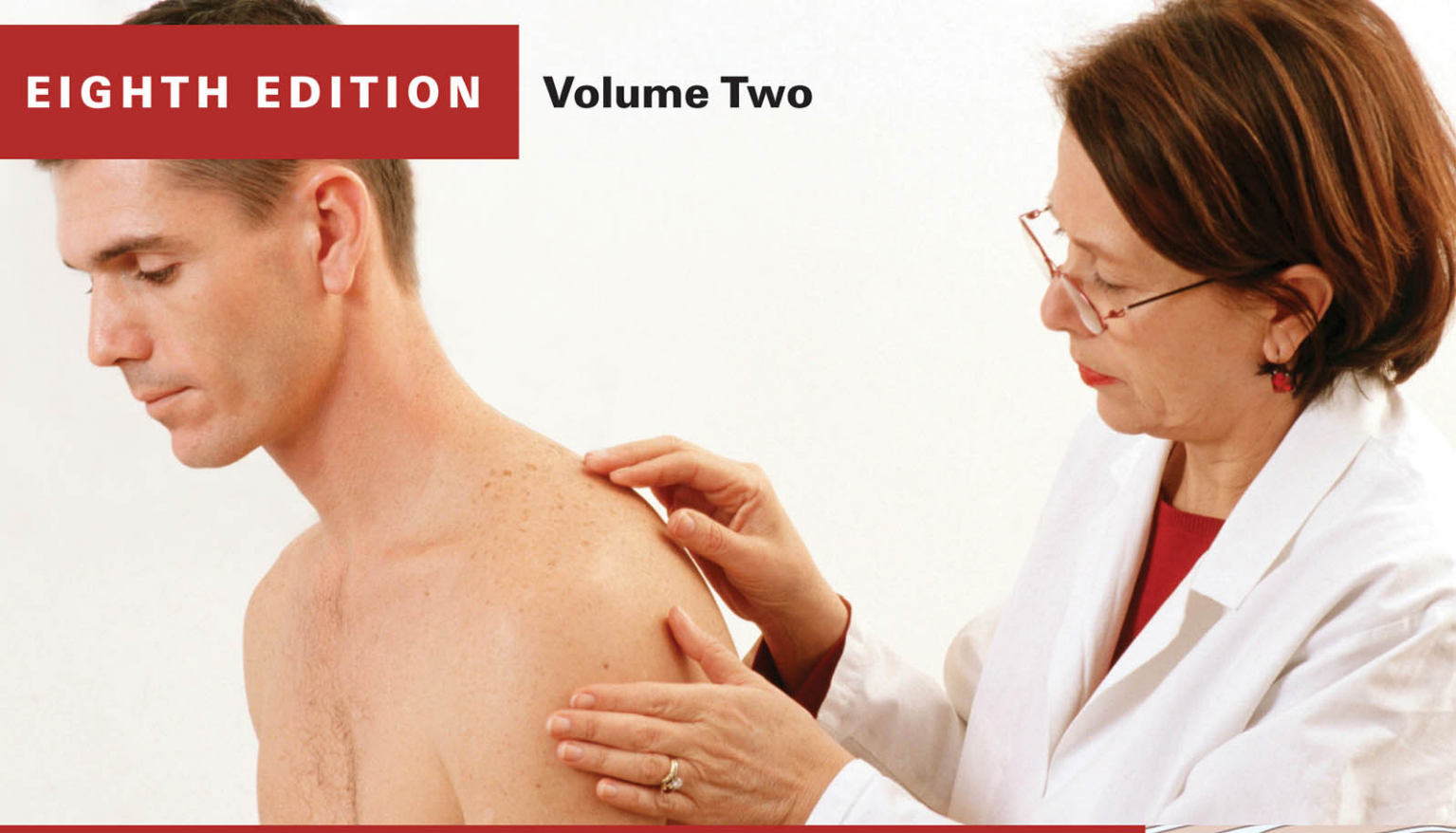

Fitzpatrick's DERMATOLOGY IN GENERAL MEDICINE

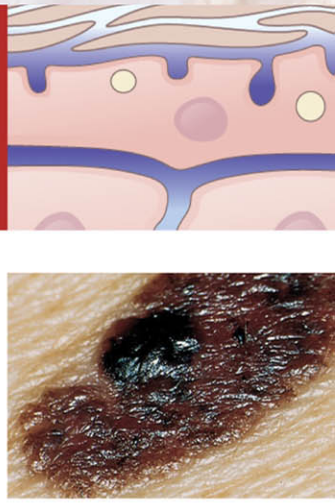



DVD INCLUDED



Lowell A. Goldsmith • Stephen I. Katz
Barbara A. Gilchrest • Amy S. Paller
David J. Leffell • Klaus Wolff

Mc Graw Hill

Fitzpatrick's Dermatology in General Medicine

LOWELL A. GOLDSMITH, MD, MPH
Emeritus Professor of Dermatology
University of North Carolina School of Medicine
Chapel Hill, North Carolina
Dean Emeritus
University of Rochester School of Medicine and Dentistry
Rochester, NY

STEPHEN I. KATZ, MD, PhD
Fellow, American Academy of Dermatology
Schaumburg, IL;
Past President, Society of Investigative Dermatology
Cleveland, OH;
Director, National Institute of Arthritis and Musculoskeletal and Skin Diseases
National Institutes of Health
Bethesda, MD

BARBARA A. GILCHREST, MD
Chair Emerita and Professor of Dermatology
Department of Dermatology
Boston University School of Medicine
Boston, MA

AMY S. PALLER, MD
Walter J. Hamlin Professor and Chair of Dermatology
Professor of Pediatrics
Feinberg School of Medicine
Northwestern University
Chicago, IL

DAVID J. LEFFELL, MD
David Paige Smith Professor of Dermatology and Surgery
Chief, Section of Dermatologic Surgery and Cutaneous Oncology
Department of Dermatology
Yale University School of Medicine
New Haven, CT

KLAUS WOLFF, MD, FRCP
Professor of Dermatology
Chairman Emeritus
Department of Dermatology
Medical University of Vienna
Vienna, Austria

Fitzpatrick's Dermatology in General Medicine

Eighth Edition

EDITORS

LOWELL A. GOLDSMITH, MD, MPH

STEPHEN I. KATZ, MD, PhD

BARBARA A. GILCHREST, MD

AMY S. PALLER, MD

DAVID J. LEFFELL, MD

KLAUS WOLFF, MD, FRCP



New York Chicago San Francisco Lisbon London Madrid Mexico City
Milan New Delhi San Juan Seoul Singapore Sydney Toronto

The McGraw-Hill Companies

Copyright © 2012 by The McGraw-Hill Companies, Inc. All rights reserved. Except as permitted under the United States Copyright Act of 1976, no part of this publication may be reproduced or distributed in any form or by any means, or stored in a database or retrieval system, without the prior written permission of the publisher.

ISBN: 978-0-07-171755-7

MHID: 0-07-171755-2

The material in this eBook also appears in the print version of this title: ISBN: 978-0-07-166904-7,
MHID: 0-07-166904-3.

All trademarks are trademarks of their respective owners. Rather than put a trademark symbol after every occurrence of a trademarked name, we use names in an editorial fashion only, and to the benefit of the trademark owner, with no intention of infringement of the trademark. Where such designations appear in this book, they have been printed with initial caps.

McGraw-Hill eBooks are available at special quantity discounts to use as premiums and sales promotions, or for use in corporate training programs. To contact a representative please e-mail us at bulksales@mcgraw-hill.com.

Previous editions copyright © 2008, 2003, 1999, 1993, 1987, 1979, 1971 by The McGraw-Hill Companies, Inc.

Notice

Medicine is an ever-changing science. As new research and clinical experience broaden our knowledge, changes in treatment and drug therapy are required. The authors and the publisher of this work have checked with sources believed to be reliable in their efforts to provide information that is complete and generally in accord with the standards accepted at the time of publication. However, in view of the possibility of human error or changes in medical sciences, neither the authors nor the publisher nor any other party who has been involved in the preparation or publication of this work warrants that the information contained herein is in every respect accurate or complete, and they disclaim all responsibility for any errors or omissions or for the results obtained from use of the information contained in this work. Readers are encouraged to confirm the information contained herein with other sources. For example and in particular, readers are advised to check the product information sheet included in the package of each drug they plan to administer to be certain that the information contained in this work is accurate and that changes have not been made in the recommended dose or in the contraindications for administration. This recommendation is of particular importance in connection with new or infrequently used drugs.

TERMS OF USE

This is a copyrighted work and The McGraw-Hill Companies, Inc. (“McGraw-Hill”) and its licensors reserve all rights in and to the work. Use of this work is subject to these terms. Except as permitted under the Copyright Act of 1976 and the right to store and retrieve one copy of the work, you may not decompile, disassemble, reverse engineer, reproduce, modify, create derivative works based upon, transmit, distribute, disseminate, sell, publish or sublicense the work or any part of it without McGraw-Hill’s prior consent. You may use the work for your own noncommercial and personal use; any other use of the work is strictly prohibited. Your right to use the work may be terminated if you fail to comply with these terms.

THE WORK IS PROVIDED “AS IS.” McGRAW-HILL AND ITS LICENSORS MAKE NO GUARANTEES OR WARRANTIES AS TO THE ACCURACY, ADEQUACY OR COMPLETENESS OF OR RESULTS TO BE OBTAINED FROM USING THE WORK, INCLUDING ANY INFORMATION THAT CAN BE ACCESSED THROUGH THE WORK VIA HYPERLINK OR OTHERWISE, AND EXPRESSLY DISCLAIM ANY WARRANTY, EXPRESS OR IMPLIED, INCLUDING BUT NOT LIMITED TO IMPLIED WARRANTIES OF MERCHANTABILITY OR FITNESS FOR A PARTICULAR PURPOSE. McGraw-Hill and its licensors do not warrant or guarantee that the functions contained in the work will meet your requirements or that its operation will be uninterrupted or error free. Neither McGraw-Hill nor its licensors shall be liable to you or anyone else for any inaccuracy, error or omission, regardless of cause, in the work or for any damages resulting therefrom. McGraw-Hill has no responsibility for the content of any information accessed through the work. Under no circumstances shall McGraw-Hill and/or its licensors be liable for any indirect, incidental, special, punitive, consequential or similar damages that result from the use of or inability to use the work, even if any of them has been advised of the possibility of such damages. This limitation of liability shall apply to any claim or cause whatsoever whether such claim or cause arises in contract, tort or otherwise.

CONTENTS

Contributors xvii

Preface xxxi

Acknowledgments xxxiii

Volume One

PART 1 INTRODUCTION

SECTION 1. GENERAL CONSIDERATIONS

1 The Epidemiology and Burden of Skin Disease 1
Martin A. Weinstock, MD, PhD & Mary-Margaret Chren, MD

2 Evidence-Based Dermatology 9
Michael Bigby, MD, Rosamaria Corona, DSc, MD, & Moyses Szklo, MD, MPH, DrPH

3 Global Health in Dermatology 15
Roderick J. Hay, DM, FRCP, FRCPath, FMedSci

4 Public Health in Dermatology 21
Hywel C. Williams, MSc, PhD, FRCP, Sinéad M. Langan, MRCP, MSc, PhD, & Carsten Flohr, BM, BCh (Hons), MA, Mphil, MRCPCH, MSc, PhD

SECTION 2. APPROACH TO DERMATOLOGIC DIAGNOSIS

5 Structure of Skin Lesions and Fundamentals of Clinical Diagnosis 26
Amit Garg, MD, Nikki A. Levin, MD, PhD, & Jeffrey D. Bernhard, MD, FRCP (Edin)

6 Basic Pathologic Reactions of the Skin 42
Martin C. Mihm Jr., MD, FACP, Abdul-Ghani Kibbi, MD, FAAD, FACP, George F. Murphy, MD & Klaus Wolff, MD, FRCP

SECTION 3. OVERVIEW OF BIOLOGY, DEVELOPMENT, AND STRUCTURE OF SKIN

7 Development and Structure of Skin 58
David H. Chu, MD, PhD

8 Genetics in Relation to the Skin 75
John A. McGrath, MD, FRCP & W. H. Irwin McLean, FRSE, FMedSci

9 Racial Considerations: Skin of Color 91
Kavitha K. Reddy, MD, Yolanda M. Lenzy, MD, MPH, Katherine L. Brown, MD, MPH, & Barbara A. Gilchrest, MD

PART 2 DISORDERS PRESENTING IN SKIN AND MUCOUS MEMBRANES

SECTION 4. INFLAMMATORY DISORDERS BASED ON T-CELL REACTIVITY AND DYSREGULATION

10 Innate and Adaptive Immunity in the Skin 105
Robert L. Modlin, MD, Lloyd S. Miller, MD, PhD, Christine Bangert, MD, & Georg Stingl, MD

11 Cytokines 126
Ifor R. Williams, MD, PhD & Thomas S. Kupper, MD, FAAD

12 Chemokines 142
Anke S. Lonsdorf, MD & Sam T. Hwang, MD, PhD

13 Allergic Contact Dermatitis 152
Mari Paz Castanedo-Tardan, MD & Kathryn A. Zug, MD

14 Atopic Dermatitis (Atopic Eczema) 165
Donald Y.M. Leung, MD, PhD, Lawrence F. Eichenfield, MD, & Mark Boguniewicz, MD

15 Nummular Eczema, Lichen Simplex Chronicus, and Prurigo Nodularis 182
Susan Burgin, MD

16 Vesicular Palmoplantar Eczema 187
Daven N. Doshi, MD, Carol E. Cheng, MD, & Alexa B. Kimball, MD, MPH

17 Autosensitization Dermatitis 194
Donald V. Belsito, MD

18 Psoriasis 197
Johann E. Gudjonsson, MD, PhD & James T. Elder, MD, PhD

19 Psoriatic Arthritis 232
Dafna D. Gladman, MD, FRCPC & Vinod Chandran, MBBS, MD, DM

20 Reactive Arthritis 243
John D. Carter, MD

21 Pustular Eruptions of Palms and Soles 253
Ulrich Mrowietz, MD

22 Seborrheic Dermatitis 259
Chris D. Collins, MD, FAAD & Chad Hivnor, MD

23 Exfoliative Dermatitis 266
Jane Margaret Grant-Kels, MD, Flavia Fedeles, MD, MS, & Marti J. Rothe, MD

24 Pityriasis Rubra Pilaris 279
Daniela Bruch-Gerharz, MD & Thomas Ruzicka, Prof. Dr. med. Dr. h.c.

25 Parapsoriasis and Pityriasis Lichenoides. 285
Gary S. Wood, MD, Chung-Hong Hu, MD & Rosemarie Liu, MD

26 Lichen Planus 296
Mazen S. Daoud, MD & Mark R. Pittelkow, MD

27 Lichen Nitidus 312
Mazen S. Daoud, MD & Mark R. Pittelkow, MD

28 Graft-Versus-Host Disease 316
Edward W. Cowen, MD, MHSc

29 Skin Disease in Acute and Chronic Immunosuppression 330
Benjamin D. Ehst, MD, PhD & Andrew Blauvelt, MD

SECTION 5. INFLAMMATORY DISEASES BASED ON NEUTROPHILS AND EOSINOPHILS

30 Regulation of the Production and Activation of Neutrophils 345
Steven M. Holland, MD

31 Regulation of the Production and Activation of Eosinophils 351
Kristin M. Leiferman, MD, Lisa A. Beck, MD, & Gerald J. Gleich, MD

32 Acute Febrile Neutrophilic Dermatosis (Sweet Syndrome) 362
Philip R. Cohen, MD, Herbert Hönigsmann, MD, & Razelle Kurzrock, MD, FACP

33 Pyoderma Gangrenosum 371
Frank C. Powell, FRCPI, FAAD, Bridget C. Hackett, MB BCh, BAO, MRCPI, & Daniel Wallach, MD

34 Granuloma Faciale. 380
David A. Mehregan, MD & Darius R. Mehregan, MD

35 Subcorneal Pustular Dermatosis (Sneddon–Wilkinson Disease). 383
Franz Trautinger, MD & Herbert Hönigsmann, MD

36 Eosinophils in Cutaneous Diseases 386
Kristin M. Leiferman, MD & Margot S. Peters, MD

SECTION 6. INFLAMMATORY DISEASES BASED ON ABNORMAL HUMORAL REACTIVITY AND OTHER INFLAMMATORY DISEASES

37 Humoral Immunity and Complement. 401
Lela A. Lee, MD

38 Urticaria and Angioedema 414
Allen P. Kaplan, MD

39 Erythema Multiforme 431
Jean-Claude Roujeau, MD

40 Epidermal Necrolysis (Stevens–Johnson Syndrome and Toxic Epidermal Necrolysis) 439
L. Valeyrie-Allanore, MD & Jean-Claude Roujeau, MD

41 Cutaneous Reactions to Drugs 449
Neil H. Shear, MD, FRCPC & Sandra R. Knowles, BScPhm

42 Pityriasis Rosea. 458
Andrew Blauvelt, MD

43 Erythema Annulare Centrifugum and Other Figurate Erythemas 463
Walter H.C. Burgdorf, MD

44 Granuloma Annulare 467
Julie S. Prendiville, MB, FRCPC

SECTION 7. DISORDERS OF EPIDERMAL DIFFERENTIATION AND KERATINIZATION

45 Epidermal Stem Cells 473
Rebecca J. Morris, PhD

46 Epidermal Growth and Differentiation 478
Pierre A. Coulombe, PhD, Stanley J. Miller, MD, & Tung-Tien Sun, PhD

47 Skin as an Organ of Protection. 486
Ehrhardt Proksch, MD, PhD & Jens-Michael Jensen, MD

48 Irritant Contact Dermatitis 499
Antoine Amado, MD, Apra Sood, MD, & James S. Taylor, MD, FAAD

49 The Ichthyoses 507
Philip Fleckman, MD & John J. DiGiovanna, MD

50 Inherited Palmoplantar Keratodermas 538
Mozheh Zamiri, BSc (Hons), MBChB, MRCP, MD, Maurice A. M. van Steensel, MD, PhD, & Colin S. Munro, MD, FRCP (Glasg)

51 Acantholytic Disorders of the Skin 550
Susan Burge, OBE, DM, FRCP & Alain Hovnanian, MD, PhD

52 Porokeratosis. 563
Grainne M. O'Regan, MRCPI & Alan D. Irvine, MD, FRCP, FRCPI

SECTION 8. DISORDERS OF EPIDERMAL AND DERMAL–EPIDERMAL ADHESION AND VESICULAR AND BULLOUS DISORDERS

53 Epidermal and Epidermal–Dermal Adhesion. . . 569
Leena Bruckner-Tuderman, MD & Aimee S. Payne, MD, PhD

54 Pemphigus. 586
Aimee S. Payne, MD, PhD & John R. Stanley, MD

55 Paraneoplastic Pemphigus 600
Grant J. Anhalt, MD & Daniel Mimouni, MD

56 Bullous Pemphigoid 608
Donna A. Culton, MD, PhD, Zhi Liu, PhD, & Luis A. Diaz, MD

57 Cicatricial Pemphigoid 617
Kim B. Yancey, MD

58 Linear Immunoglobulin A Dermatosis and Chronic Bullous Disease of Childhood 623
Caroline L. Rao, MD & Russell P. Hall III, MD

59 Pemphigoid Gestationis (Herpes Gestationis) . . 630
Jeff K. Shornick, MD, MHA

60 Epidermolysis Bullosa Acquisita. 634
David T. Woodley, MD & Mei Chen, PhD

61 Dermatitis Herpetiformis 642
Arash Ronaghy, MD, PhD, Stephen I. Katz, MD, PhD, & Russell P. Hall III, MD

62 Inherited Epidermolysis Bullosa 649
M. Peter Marinkovich, MD

SECTION 9. DISORDERS OF THE DERMAL CONNECTIVE TISSUE

63 Collagens, Elastic Fibers, and Other Extracellular Matrix Proteins of the Dermis 666
Thomas Krieg, MD, Monique Aumailley, Manuel Koch, PhD, Mon-Li Chu, PhD, & Jouni Uitto, MD, PhD

64 Morphea. 692
Stephanie Saxton-Daniels, MD & Heidi T. Jacobe, MD, MSCS

65 Lichen Sclerosus 702
Ulrich R. Hengge, MD, MBA

66 Dermal Hypertrophies and Benign Fibroblastic/Myofibroblastic Tumors 707
Christine J. Ko, MD

67 Anetoderma and Other Atrophic Disorders of the Skin 718
Catherine Maari, MD & Julie Powell, MD, FRCPC

68 Ainhum and Pseudoainhum 724
Robert T. Brodell, MD & Stephen E. Helms, MD

69 Acquired Perforating Disorders 727
Julia S. Minocha, MD & Bethanee J. Schlosser, MD, PhD

SECTION 10. DISORDERS OF SUBCUTANEOUS TISSUE

70 Panniculitis 732
Iris K. Aronson, MD, Patricia M. Fishman, MD, & Sophie M. Worobec, MD, FAAD

71 Lipodystrophy 755
Abhimanyu Garg, MD

SECTION 11. DISORDERS OF MELANOCYTES

72 Biology of Melanocytes. 765
Hee-Young Park, PhD & Mina Yaar, MD

73 Albinism and Other Genetic Disorders of Pigmentation 781
Thomas J. Hornyak, MD, PhD

74 Vitiligo 792
Stanca A. Birlea, MD, PhD, Richard A. Spritz, MD & David A. Norris, MD

75 Hypomelanoses and Hypermelanoses 804
Hilde Lapeere, MD, PhD, Barbara Boone, MD, PhD, Sofie De Schepper, MD, PhD, Evelien Verhaeghe, MD, Mireille Van Gele, PhD, Katia Ongenae, MD, PhD, Nanja Van Geel, MD, PhD, Jo Lambert, MD, PhD, & Lieve Brochez, MD, PhD

SECTION 12. DISORDERS OF THE ORAL AND GENITAL INTEGUMENT

76 Biology and Pathology of the Oral Cavity 827
Sook-Bin Woo, DMD

77 Diseases and Disorders of the Male Genitalia . . 852
Christopher B. Bunker, MD, FRCP

78 Diseases and Disorders of the Female Genitalia 878
Lynette J. Margesson, MD, FRCPC & F. William Danby, MD, FRCPC, FAAD

PART 3 DISORDERS OF THE SKIN APPENDAGES

SECTION 13. DISORDERS OF THE SEBACEOUS GLANDS

79 Biology of Sebaceous Glands 893
Amanda M. Nelson, PhD & Diane M. Thiboutot, MD

80 Acne Vulgaris and Acneiform Eruptions 897
Andrea L. Zaenglein, MD, Emmy M. Graber, MD, & Diane M. Thiboutot, MD

81 Rosacea 918
Michelle T. Pelle, MD

82 Perioral Dermatitis 925
Leslie P. Lawley, MD & Sareeta R.S. Parker, MD

SECTION 14. DISORDERS OF THE ECCRINE AND APOCRINE GLANDS

83 Biology of Eccrine and Apocrine Glands 929
Theodora M. Mauro, MD

84 Disorders of the Eccrine Sweat Glands and Sweating 936
Robert D. Fealey, MD & Adelaide A. Hebert, MD

85 Disorders of the Apocrine Sweat Glands 947
Christos C. Zouboulis, MD, PhD & Fragkiski Tsatsou, MD, MSc, BSc

SECTION 15. DISORDERS OF THE HAIR AND NAILS

86 Biology of Hair Follicles 960
George Cotsarelis, MD & Vladimir Botchkarev, MD, PhD

87 Keratosis Pilaris and Other Inflammatory Follicular Keratotic Syndromes 973
Paradi Mirmirani, MD & Maureen Rogers, MBBS, FACD

88 Hair Growth Disorders 979
Nina Otberg, MD & Jerry Shapiro, MD, FRCPC, FAAD

89 Biology of Nails and Nail Disorders 1009
Antonella Tosti, MD & Bianca Maria Piraccini, MD, PhD

PART 4 DISORDERS DUE TO THE ENVIRONMENT

SECTION 16. DISORDERS DUE TO ULTRAVIOLET RADIATION

90 Fundamentals of Cutaneous Photobiology and Photoimmunology 1031
Irene E. Kochevar, PhD, Charles R. Taylor, MD, & Jean Krutmann, MD

91 Abnormal Responses to Ultraviolet Radiation: Idiopathic, Probably Immunologic, and Photoexacerbated 1049
Travis W. Vandergriff, MD & Paul R. Bergstresser, MD

92 Abnormal Responses to Ultraviolet Radiation: Photosensitivity Induced by Exogenous Agents 1066
Henry W. Lim, MD

SECTION 17. SKIN CHANGES DUE TO OTHER PHYSICAL AND CHEMICAL FACTORS

93 Thermoregulation 1075
Dean L. Kellogg, Jr., MD, PhD

94 Cold Injuries 1079
Gérald E. Piérard, MD, PhD, Pascale Quatresooz, MD, PhD, & Claudine Piérard-Franchimont, MD, PhD

95 Thermal Injuries 1089
Robert L. Sheridan, MD

96 Skin Problems in Amputees 1095
Calum C. Lyon, MA, FRCP &
Michael H. Beck, FRCP, MBChB

97 Skin Problems in Ostomates 1104
Calum C. Lyon, MA, FRCP &
Michael H. Beck, FRCP, MBChB

98 Corns and Calluses 1111
Thomas M. DeLauro, DPM &
Nicole M. DeLauro, DPM

99 Sports Dermatology 1115
Dirk M. Elston, MD

100 Decubitus (Pressure) Ulcers 1121
Jennifer G. Powers, MD, Lillian Odo, MD, &
Tania J. Phillips, MD, FRCP, FRCPC

101 Body Art 1129
Anne Laumann, MBChB, MRCP(UK), FAAD

PART 5 NEUROCUTANEOUS AND PSYCHOCUTANEOUS ASPECTS OF SKIN DISEASE

SECTION 18. NEUROCUTANEOUS AND PSYCHOCUTANEOUS SKIN DISEASE

102 Neurobiology of the Skin 1137
Martin Steinhoff, MD, PhD &
Thomas A. Luger, MD

103 Pathophysiology and Clinical Aspects of Pruritus 1146
Gil Yosipovitch, MD &
Tejesh S. Patel, MBBS (Lon), BSc (Hons)

104 Psychocutaneous Skin Disease 1158
Evan Rieder, MD & Francisco A. Tausk, MD

105 Cutaneous Manifestations of Drug Abuse 1166
Haley Naik, MD & Richard Allen Johnson, MDCM

106 Skin Signs of Physical Abuse 1177
Howard B. Pride, MD

PART 6 SKIN CHANGES ACROSS THE SPAN OF LIFE

SECTION 19. FROM BIRTH TO OLD AGE

107 Neonatal, Pediatric, and Adolescent Dermatology 1185
Mary Wu Chang, MD

108 Skin Changes and Diseases in Pregnancy 1204
Julie K. Karen, MD &
Miriam Keltz Pomeranz, MD

109 Aging of Skin 1213
Mina Yaar, MD & Barbara A. Gilchrest, MD

PART 7 NEOPLASIA

SECTION 20. CARCINOGENESIS

110 Genome Instability, DNA Repair, and Cancer 1227
Thomas M. Rünger, MD, PhD &
Kenneth H. Kraemer, MD

111 Chemical Carcinogenesis 1239
Adam B. Glick, PhD & Andrzej A. Dlugosz, MD

112 Ultraviolet Radiation Carcinogenesis 1251
Masaoki Kawasumi, MD, PhD &
Paul Nghiem, MD, PhD

SECTION 21. EPIDERMAL AND APPENDAGEAL TUMORS

113 Epithelial Precancerous Lesions 1261
Karynne O. Duncan, MD,
John K. Geisse, MD & David J. Leffell, MD

114 Squamous Cell Carcinoma 1283
Douglas Grossman, MD, PhD & David J. Leffell, MD

115 Basal Cell Carcinoma 1294
John A. Carucci, MD, PhD,
David J. Leffell, MD & Julia S. Pettersen, MD

116 Basal Cell Nevus Syndrome 1304
Anthony E. Oro, MD, PhD &
Jean Y. Tang, MD, PhD

117 Keratoacanthoma 1312
Lorenzo Cerroni, MD & Helmut Kerl, MD

118 Benign Epithelial Tumors, Hamartomas, and Hyperplasias 1319
Valencia D. Thomas, MD, Nicholas R. Snavely, MD,
Ken K. Lee, MD & Neil A. Swanson, MD

119 Appendage Tumors and Hamartomas of the Skin 1337
Divya Srivastava, MD & R. Stan Taylor, MD

120 Merkel Cell Carcinoma 1362
Andrew Tegeder, MS, Olga Afanasiev, BA, &
Paul Nghiem, MD, PhD

121 Mammary and Extramammary Paget's Disease 1371
Sherrif F. Ibrahim, MD, PhD, Roy C. Grekin, MD, &
Isaac M. Neuhaus, MD

SECTION 22. MELANOCYTIC TUMORS

122 Benign Neoplasias and Hyperplasias of Melanocytes 1377
James M. Grichnik, MD, PhD, Arthur R. Rhodes, MD, MPH, & Arthur J. Sober, MD

123 Atypical (Dysplastic) Melanocytic Nevi 1410
James M. Grichnik, MD, PhD & Margaret A. Tucker, MD

124 Cutaneous Melanoma 1416
Evans C. Bailey, MD, PhD, Arthur J. Sober, MD, Hensin Tsao, MD, PhD, Martin C. Mihm Jr, MD, FACP, & Timothy M. Johnson, MD

SECTION 23. TUMORS AND HYPERPLASIAS OF THE DERMIS AND SUBCUTANEOUS FAT

125 Malignant Fibrous, Fibrohistiocytic, and Histiocytic Tumors of the Dermis 1445
Jürgen C. Becker, MD, PhD, Bernadette Liegl-Atzwanger, MD & Selma Ugurel, MD

126 Vascular Tumors 1456
Erin F. Mathes, MD & Ilona J. Frieden, MD

127 Neoplasias and Hyperplasias of Muscular and Neural Origin 1470
Lucile E. White, MD, Ross M. Levy, MD, & Murad Alam, MD, MSci

128 Kaposi's Sarcoma and Angiosarcoma 1481
Erwin Tschachler, MD

129 Neoplasms of Subcutaneous Fat 1489
Thomas Brenn, MD, PhD, FRCPath

Volume Two

PART 8 THE SKIN IN SYSTEMIC DISEASE

SECTION 24. SKIN IN NUTRITIONAL, METABOLIC, AND HERITABLE DISEASE

130 Cutaneous Changes in Nutritional Disease . . . 1499
Melinda Jen, MD & Albert C. Yan, MD

131 Cutaneous Changes in Errors of Amino Acid Metabolism 1525
Peter H. Itin, MD

132 The Porphyrias 1538
David R. Bickers, MD & Jorge Frank, MD, PhD

133 Amyloidosis of the Skin 1574
Helen J. Lachmann, MD, FRCP & Philip N. Hawkins, PhD, FRCP, FRCPath, FMedSci

134 Systemic Autoinflammatory Diseases 1584
Chyi-Chia Richard Lee, MD, PhD & Raphaela Goldbach-Mansky, MD, MHS

135 Xanthomatoses and Lipoprotein Disorders . . . 1600
Ernst J. Schaefer, MD & Raul D. Santos, MD, PhD

136 Fabry Disease 1613
Atul B. Mehta, MD, FRCP, FRCPath & Catherine H. Orteu, MBBS, BSc, MD, FRCP

137 Lipoid Proteinosis and Heritable Disorders of Connective Tissue 1624
Jonathan A. Dyer, MD

138 Cutaneous Mineralization and Ossification . . . 1649
Janet A. Fairley, MD

139 Hereditary Disorders of Genome Instability and DNA Repair 1654
Thomas M. Rünger, MD, PhD, John J. DiGiovanna, MD, & Kenneth H. Kraemer, MD

140 Tuberous Sclerosis Complex 1671
Thomas N. Darling, MD, PhD

141 The Neurofibromatoses 1680
Robert Listernick, MD & Joel Charrow, MD

142 Ectodermal Dysplasias 1691
Alanna F. Bree, MD, Nnenna Agim, MD, & Virginia P. Sybert, MD

143 Genetic Immunodeficiency Diseases 1703
Ramsay L. Fuleihan, MD & Amy S. Paller, MD

SECTION 25. SKIN MANIFESTATIONS OF BONE MARROW OR BLOOD CHEMISTRY DISORDERS

144 Hematologic Diseases 1726
Warren W. Piette, MD

145 Cutaneous Lymphoma 1745
Marc Beyer, MD & Wolfram Sterry, Prof. Dr.

146 Inflammatory Diseases That Simulate Lymphomas: Cutaneous Pseudolymphomas 1767
Gary S. Wood, MD

147 Cutaneous Langerhans Cell Histiocytosis 1782
Carlo Gelmetti, MD

148 Non-Langerhans Cell Histiocytosis 1795
Carlo Gelmetti, MD

149 Mastocytosis 1809
Michael D. Tharp, MD

SECTION 26. SKIN MANIFESTATIONS OF INTERNAL ORGAN DISORDERS

150 The Skin and Disorders of the Alimentary Tract, the Hepatobiliary System, the Kidney, and the Cardiopulmonary System 1819
Graham A. Johnston, MBChB, FRCP & Robin A.C. Graham-Brown, BSc, MB, FRCP, FRCPCH

151 Diabetes Mellitus and Other Endocrine Diseases 1840
Andrea A. Kalus, MD, Andy J. Chien, MD, PhD, & John E. Olerud, MD

152 Sarcoidosis 1869
Richard M. Marchell, MD, Bruce Thiers, MD, & Marc A. Judson, MD

153 Cutaneous Manifestations of Internal Malignant Disease: Cutaneous Paraneoplastic Syndromes 1880
Christine A. DeWitt, MD, Lucinda S. Buescher, MD, & Stephen P. Stone, MD

SECTION 27. THE SKIN IN VASCULAR AND CONNECTIVE TISSUE AND OTHER AUTOIMMUNE DISORDERS

154 Mechanisms of Autoimmune Disease 1901
Insoo Kang, MD & Joseph Craft, MD

155 Lupus Erythematosus 1909
Melissa I. Costner, MD & Richard D. Sontheimer, MD

156 Dermatomyositis 1926
Richard D. Sontheimer, MD, Christopher B. Hansen, MD, & Melissa I. Costner, MD

157 Scleroderma 1942
P. Moinzadeh, MD, Christopher P. Denton, PhD, FRCP, T. Krieg, MD, & Carol M. Black, MD, FRCP, FMedSci

158 Scleredema and Scleromyxedema 1957
Roger H. Weenig, MD, MPH & Mark R. Pittelkow, MD

159 Relapsing Polychondritis 1962
Camille Francès, MD

160 Rheumatoid Arthritis, Rheumatic Fever, and Gout 1965
Warren W. Piette, MD

161 Sjögren's Syndrome 1976
Gabor Illei, MD, PhD, MHS & Stamatina Danielides, MD

SECTION 28. THE SKIN IN INFLAMMATORY AND OTHER VASCULAR DISORDERS

162 Endothelium in Inflammation and Angiogenesis 1986
Peter Petzelbauer, MD, Robert Loewe, MD, & Jordan S. Pober, MD, PhD

163 Cutaneous Necrotizing Venulitis 2003
Nicholas A. Soter, MD

164 Systemic Necrotizing Arteritis 2013
Peter A. Merkel, MD, MPH & Paul A. Monach, MD, PhD

165 Erythema Elevatum Diutinum 2029
Nneka I. Comfere, MD & Lawrence E. Gibson, MD

166 Adamantiades–Behçet Disease 2033
Christos C. Zouboulis, MD, PhD

167 Kawasaki Disease 2042
Anne H. Rowley, MD

168 Pigmented Purpuric Dermatoses 2049
Theresa Schroeder Devere, MD & Anisha B. Patel, MD

169 Cryoglobulinemia and Cryofibrinogenemia 2055
Holger Schmid, MD, MSc PD & Gerald S. Braun, MD

170 Raynaud Phenomenon 2065
John H. Klippel, MD

171 Malignant Atrophic Papulosis (Degos Disease) 2072
Dan Lipsker, MD, PhD

172 Vascular Malformations 2076
Laurence M. Boon, MD, PhD & Miikka Vikkula, MD, PhD

173 Cutaneous Changes in Peripheral Arterial Vascular Disease 2094
Veerendra Chadachan, MD Steven M. Dean, DO, FACP, RPVI, & Robert T. Eberhardt, MD, FACC, FSVM, RPVI

174 Cutaneous Changes in Peripheral Venous and Lymphatic Insufficiency 2110
Craig N. Burkhart, MD, Chris Adigun, MD, & Claude S. Burton, MD

PART 9 DISEASE DUE TO MICROBIAL AGENTS, INFESTATIONS, BITES, AND STINGS

SECTION 29. BACTERIAL DISEASE

175 General Considerations of Bacterial Diseases 2121
Noah Craft, MD, PhD, DTMH

176 Superficial Cutaneous Infections and Pyodermas 2128
Noah Craft, MD, PhD, DTMH

177 Gram-Positive Infections Associated with Toxin Production 2148
Jeffrey B. Travers, MD, PhD & Nico Mousdicas, MBChB, MD

178 Non-Necrotizing Infections of the Dermis and Subcutaneous Fat: Cellulitis and Erysipelas 2160
Adam D. Lipworth, MD, Arturo P. Saavedra, MD, PhD, MBA, Arnold N. Weinberg, MD, & Richard Allen Johnson, MDCM

179 Necrotizing Soft Tissue Infections: Necrotizing Fasciitis, Gangrenous Cellulitis, and Myonecrosis 2169
Adam D. Lipworth, MD, Arturo P. Saavedra, MD, PhD, MBA, Arnold N. Weinberg, MD, & Richard Allen Johnson, MDCM

180 Gram-Negative Coccal and Bacillary Infections 2178
Myron S. Cohen, MD, William A. Rutala, BS, MS, PhD, MPH, & David J. Weber, MD, MPH

181 The Skin in Infective Endocarditis, Sepsis, Septic Shock, and Disseminated Intravascular Coagulation 2194
Laura Korb Ferris, MD, PhD & Joseph C. English, MD

182 Bartonellosis 2201
Timothy G. Berger, MD & Francisco G. Bravo, MD

183 Miscellaneous Bacterial Infections with Cutaneous Manifestations 2210
Scott A. Norton, MD, MPH, MS

184 Tuberculosis and Infections with Atypical *Mycobacteria* 2225
Aisha Sethi, MD

185 Actinomycosis, Nocardiosis, and Actinomycetoma 2241
Francisco G. Bravo, MD, Roberto Arenas, MD, & Daniel Asz Sigall, MD

186 Leprosy 2253
Delphine J. Lee, MD, PhD, FAAD, Thomas H. Rea, & Robert L. Modlin, MD

187 Lyme Borreliosis 2263
Meera Mahalingam, MD, PhD, FRCPath, Jag Bhawan, MD, Daniel B. Eisen, MD, & Linden Hu, MD

SECTION 30. FUNGAL DISEASES

188 Superficial Fungal Infection 2277
Stefan M. Schieke, MD & Amit Garg, MD

189 Yeast Infections: Candidiasis, Tinea (Pityriasis) Versicolor, and *Malassezia* (*Pityrosporum*) Folliculitis 2298
Roopal V. Kundu, MD & Amit Garg, MD

190 Deep Fungal Infections 2312
Roderick J. Hay, DM, FRCP, FRCPath, FMedSci

SECTION 31. VIRAL AND RICKETTSIAL DISEASES

191 General Considerations of Viral Diseases 2329
L. Katie Morrison, MD, Ammar Ahmed, MD, Vandana Madkan, MD, Natalia Mendoza, MD, MS, & Stephen Tyring, MD, PhD

192 Exanthematous Viral Diseases 2337
Leah T. Belazarian, MD, Mayra E. Lorenzo, MD, PhD, Andrea L. Pearson, MD, Susan M. Sweeney, MD, & Karen Wiss, MD

193 Herpes Simplex 2367
Adriana R. Marques, MD & Jeffrey I. Cohen, MD

194 Varicella and Herpes Zoster 2383
Kenneth E. Schmader, MD & Michael N. Oxman, MD

195 Poxvirus Infections 2402
Caroline Piggott, MD, Sheila Fallon Friedlander, MD, & Wynnis Tom, MD

196 Human Papilloma Virus Infections 2421
Elliot J. Androphy, MD & Reinhard Kirnbauer, MD

197 Human T-Lymphotropic Viruses 2434
Erwin Tschachler, MD

198 Cutaneous Manifestations of Human Immunodeficiency Virus Disease 2439
Lily Changchien Uihlein, MD, JD, Arturo P. Saavedra, MD, PhD, MBA, & Richard Allen Johnson, MDCM

199 The Rickettsioses, Ehrlichioses, and Anaplasmoses 2456
Sandra A. Kopp, MD, Analisa V. Halpern, MD, Justin J. Green, MD & Warren R. Heymann, MD

SECTION 32. SEXUALLY TRANSMITTED DISEASES

200 Syphilis. 2471
Kenneth A. Katz, MD, MSc, MSCE

201 Endemic (Nonvenereal) Treponematoses 2493
Nadine Marrouche, MD &
Samer H. Ghosn, MD

202 Chancroid 2501
Stephan Lautenschlager, MD

203 Lymphogranuloma Venereum. 2505
Rim S. Ishak, MD & Samer H. Ghosn, MD

204 Granuloma Inguinale 2510
Abdul-Ghani Kibbi, MD, FAAD, FACP,
Ruba F. Bahhady, MD, & Myrna El-Shareef, MD

205 Gonorrhea, Mycoplasma, and Vaginosis 2514
Ted Rosen, MD

SECTION 33. INFESTATIONS, BITES, AND STINGS

206 Leishmaniasis and Other Protozoan Infections 2527
Joelle M. Malek, MD & Samer H. Ghosn, MD

207 Helminthic Infections 2544
Kathryn N. Suh, MD &
Jay S. Keystone, MD, MSc(CTM), FRCPC

208 Scabies, Other Mites, and Pediculosis 2569
Craig N. Burkhart, MD &
Craig G. Burkhart, MD, MPH

209 Bites and Stings of Terrestrial and Aquatic Life. 2578
Jennifer S. Daly, MD &
Mark Jordan Scharf, MD

210 Arthropod Bites and Stings 2599
Robert A. Schwartz, MD, MPH &
Christopher J. Steen, MD

PART 10 OCCUPATIONAL SKIN DISEASES AND SKIN DISEASES DUE TO BIOLOGIC WARFARE

SECTION 34. OCCUPATIONAL SKIN DISEASES

211 Occupational Skin Diseases Due to Irritants and Allergens 2611
Golara Honari, MD,
James S. Taylor, MD, FAAD, & Apra Sood, MD

212 Occupational Noneczematous Skin Diseases Due to Biologic, Physical, and Chemical Agents: Introduction 2622
Paul X. Benedetto, MD,
James S. Taylor, MD, FAAD, &
Apra Sood, MD

SECTION 35. THE SKIN IN BIOTERRORISM AND BIOLOGIC WARFARE

213 Cutaneous Manifestations of Biologic, Chemical, and Radiologic Attacks 2633
Scott A. Norton, MD, MPH, MSc

PART 11 THERAPEUTICS

SECTION 36. TOPICAL THERAPY

214 Principles of Topical Therapy 2643
Aieska De Souza, MD, MS &
Bruce E. Strober, MD, PhD

215 Pharmacokinetics and Topical Applications of Drugs 2652
Hans Schaefer, PhD, Thomas E. Redelmeier, MD
Gerhard J. Nohynek, PhD, DABT, &
Jürgen Lademann, Prof. Dr. rer. nat. Dr.-Ing. habil.

216 Topical Corticosteroids 2659
Isabel C. Valencia, MD &
Francisco A. Kerdel, MD

217 Topical Retinoids 2665
Anna L. Chien, MD,
John J. Voorhees, MD, FRCP, &
Sewon Kang, MD

218 Topical Antibiotics 2673
Mark W. Bonner, MD & William D. James, MD

219 Topical Antifungal Agents 2677
Whitney A. High, MD, JD, MEng &
James E. Fitzpatrick, MD

220 Topical and Intralesional Cytotoxic Agents 2685
Aieska De Souza, MD, MS,
Megan M. Moore, MD, & Bruce E. Strober, MD, PhD

221 Topical Immunomodulators 2690
Edward M. Esparza, MD, PhD &
Robert Sidbury, MD, MPH

222 Other Topical Medications 2697
Craig N. Burkhart, MD &
Kenneth A. Katz, MD, MSc, MSCE

223 Photoprotection 2707
Henry W. Lim, MD

SECTION 37. SYSTEMIC THERAPY

224 Systemic Glucocorticoids 2714
Victoria P. Werth, MD

225 Dapsone 2721
Joni G. Sago, MD & Russell P. Hall III, MD

226 Aminoquinolines 2726
Susannah E. McClain, MD, Jeffrey R. LaDuca, MD, PhD & Anthony A. Gaspari, MD

227 Cytotoxic and Antimetabolic Agents 2735
Whitney A. High, MD, JD, MEng & James E. Fitzpatrick, MD

228 Retinoids 2759
Anders Vahlquist, MD, PhD & Jean-Hilaire Saurat, MD

229 Antihistamines 2767
Robert A. Wood, MD

230 Antibiotics 2776
Christopher C. Gasbarre, DO, FAAD, Steven K. Schmitt, MD, & Kenneth J. Tomecki, MD

231 Antiviral Drugs 2787
Dirk M. Elston, MD

232 Oral Antifungal Agents 2796
Reza Jacob, MD & Nellie Konnikov, MD

233 Immunosuppressive and Immunomodulatory Drugs 2807
Jeffrey P. Callen, MD

234 Immunobiologicals, Cytokines, and Growth Factors in Dermatology 2814
Stephen K. Richardson, MD & Joel M. Gelfand, MD, MSCE

235 Antiangiogenic Agents 2827
Ricardo L. Berrios, MD, Michael Y. Bonner, BA, Jonathan Hofmekler, BSc, & Jack L. Arbiser, MD, PhD

236 Drug Interactions 2834
Stephen E. Wolverton, MD

SECTION 38. PHYSICAL TREATMENTS

237 Phototherapy 2841
Jennifer A. Cafardi, MD, Brian P. Pollack, MD, PhD, & Craig A. Elmets, MD

238 Photochemotherapy and Photodynamic Therapy 2851
Herbert Hönigsmann, MD, Rolf-Markus Szeimies, MD, PhD, & Robert Knobler, MD

239 Lasers and Flashlamps in Dermatology 2869
Michael Landthaler, MD, Wolfgang Bäumler, PhD, & Ulrich Hohenleutner, MD

240 Radiotherapy 2890
Roy H. Decker, MD, PhD, & Lynn D. Wilson, MD, MPH

SECTION 39. COMPLEMENTARY AND ALTERNATIVE DERMATOLOGY

241 Complementary and Alternative Medicine in Dermatology 2899
Alan Dattner, MD

SECTION 40. SURGERY IN DERMATOLOGY

242 Anatomy and Approach in Dermatologic Surgery 2905
Sumaira Z. Aasi, MD & Brent E. Pennington, MD

243 Excisional Surgery and Repair, Flaps, and Grafts 2921
Jessica M. Sheehan, MD, Melanie Kingsley, MD, & Thomas E. Rohrer, MD

244 Mohs Micrographic Surgery 2950
Joseph Alcalay, MD & Ronen Alkalay, MD, MBA

245 Nail Surgery 2956
Robert Baran, MD

246 Cryosurgery and Electrosurgery 2968
Justin J. Vujevich, MD & Leonard H. Goldberg, MD, FRCP

247 Surgical Complications 2977
Richard G. Bennett, MD

248 Mechanisms of Wound Repair, Wound Healing, and Wound Dressing 2984
Vincent Falanga, MD, FACP & Satori Iwamoto, MD, PhD

249 Treatment for Varicose and Telangiectatic Leg Veins 2997
Robert A. Weiss, MD & Margaret A. Weiss, MD

SECTION 41. COSMETIC DERMATOLOGY

250 Cosmetics and Skin Care in Dermatology 3009
Leslie Baumann, MD

251 Ablative Lasers, Chemical Peels, and Dermabrasion 3021
Elizabeth L. Tanzi, MD &
Tina S. Alster, MD

252 Cosmetic Applications of Nonablative Lasers and Other Light Devices 3032
Elliot T. Weiss, MD,
Anne M. Chapas, MD, &
Roy G. Geronemus, MD

253 Liposuction 3041
William G. Stebbins, MD, Aimee L. Leonard, MD, &
C. William Hanke, MD, MPH, FACP

254 Soft Tissue Augmentation. 3044
Lisa M. Donofrio, MD

255 Botulinum Toxin. 3053
Richard G. Glogau, MD

256 Hair Transplantation and Alopecia Reduction. 3061
Walter P. Unger, MD, Robin H. Unger, MD, &
Mark A. Unger, MD, CCFP

Index I-1

This page intentionally left blank

CONTRIBUTORS

Sumaira Z. Aasi, MD
Associate Professor, Department of Dermatology, Yale University, New Haven, CT [242]

Chris Adigun, MD
Physician (PGY-3), Department of Dermatology, UNC-Chapel Hill, Chapel Hill, NC [174]

Olga K. Afanasiev, BA
Department of Dermatology, University of Washington School of Medicine, Seattle, WA [120]

Nnenna Agim, MD
Assistant Professor, Department of Dermatology, University of Texas Southwestern Medical Center at Dallas, Dallas, TX [142]

Ammar Ahmed, MD
Resident Physician, Department of Dermatology, University of Texas Southwestern Medical Center, Dallas, TX [191]

Murad Alam, MD, MSci
Associate Professor, Departments of Dermatology, Otolaryngology, and Surgery, Feinberg School of Medicine, Northwestern University, Chicago, IL [127]

Joseph Alcalay, MD
Director, Mohs Surgery Unit, Assuta Medical Center, Tel Aviv, Israel [244]

Ronen Alkalay, MD, MBA
Mohs Unit, Assuta Medical Hospital, Tel Aviv, Israel [244]

Tina S. Alster, MD
Director, Laser Surgery, Washington Institute of Dermatologic Laser Surgery, Washington, DC [251]

Antoine Amado, MD
Resident in Dermatology, Dermatology and Plastic Surgery Institute, Cleveland Clinic, Cleveland, OH [48]

Elliot J. Androphy, MD
Department chair Dermatology at Indiana University School of Medicine Indianapolis, IN [196]

Grant J. Anhalt, MD
Professor, Department of Dermatology and Pathology, Johns Hopkins University School of Medicine, Baltimore, MD [55]

Jack L. Arbiser, MD, PhD
Professor, Department of Dermatology, Emory University School of Medicine, Atlanta, GA [235]

Roberto Arenas, MD
Professor, Department of Dermatology, University of Mexico, Mexico, DF [185]

Iris K. Aronson, MD
Associate Professor, Department of Dermatology, University of Illinois College of Medicine, Chicago, IL [70]

Daniel Asz-Sigall, MD
Resident, Dermatology, Cutaneous Oncology and Dermatologic Surgery, Department of Dermatology, ABC Hospital, Mexico City, Mexico [185]

Monique Aumailley
Professor, Center for Biochemistry, Cologne, Germany [63]

Wolfgang Bäumler, PhD
Professor, Department of Dermatology, University of Regensburg, Germany [239]

Ruba F. Bahhady, MD
Resident (PGY-4), Department of Dermatology, American University of Beirut Medical Center, Beirut, Lebanon [204]

Evans C. Bailey, MD, PhD
Lecturer, Department of Dermatology, University of Michigan, Ann Arbor, MI [124]

Christine Bangert, MD
Department of Dermatology, Medical University of Vienna, Vienna, Austria [10]

Robert Baran, MD
Honorary Professor, Department of Dermatology, Nail Disease Center, Cannes, France [245]

Leslie Baumann, MD
Chief Executive Officer, Cosmetic Dermatology, Baumann Cosmetic and Research Institute, Miami Beach, FL [250]

Lisa A. Beck, MD
Associate Professor of Dermatology and Medicine, Department of Dermatology and Medicine, University of Rochester School of Medicine, Rochester, NY [31]

Michael H. Beck, FRCP, MBChB
Honorary Clinical Lecturer, Occupational and Environmental Health Group, University of Manchester, Manchester, UK [96, 97]

Jürgen C. Becker, MD, PhD
Professor, Division of General Dermatology, Medical University of Graz, Graz, Austria [125]

Leah T. Belazarian, MD
Assistant Professor of Medicine and Pediatrics, Department of Medicine, Division of Dermatology, University of Massachusetts Medical School, Worcester, MA [192]

Donald V. Belsito, MD
Clinical Professor, Medicine (Dermatology), University of Missouri, Kansas City, MO [17]

Paul X. Benedetto, MD
Resident Physician, Department of Dermatology, Cleveland Clinic Foundation, Cleveland, OH [212]

Richard G. Bennett, MD
Clinical Professor, Dermatology, University of Southern California, Los Angeles, CA [247]

Timothy G. Berger, MD
Professor, Department of Dermatology, University of California, San Francisco, San Francisco, CA [182]

Paul R. Bergstresser, MD
Professor, Department of Dermatology, University of Texas Southwestern Medical Center, Dallas, TX [91]

Jeffrey D. Bernhard, MD, FRCP (Edin)
Professor Emeritus, University of Massachusetts Medical School, Worcester, MA [5]

Ricardo L. Berrios, MD
Post-Doctoral Fellow, Department of Dermatology, School of Medicine, Emory University, Atlanta, GA [235]

Marc Beyer, MD
Department of Dermatology and Allergy, Charité Universitätsmedizin Berlin, Berlin, Germany [145]

Jag Bhawan, MD
Professor, Department of Dermatology and Pathology, Boston University School of Medicine, Boston, MA [187]

David R. Bickers, MD
Carl Truman Nelson Professor, Department of Dermatology, Columbia University Medical Center, New York, NY [132]

Michael Bigby, MD
Associate Professor, Department of Dermatology, Harvard Medical School, Boston, MA [2]

Stanca A. Birlea, MD, PhD
Instructor, Dermatology and Human Medical Genetics Program, School of Medicine, University of Colorado Denver, Aurora, CO [74]

Carol M. Black, MD, FRCP, FMedSci
Professor, Centre for Rheumatology, University College London, London, UK [157]

Andrew Blauvelt, MD
Professor, Department of Dermatology, Oregon Health & Science University, Portland, OR [29, 42]

Mark Boguniewicz, MD
Professor, Department of Pediatrics, Division of Allergy-Immunology, National Jewish Health, Denver, CO [14]

Mark W. Bonner, MD
Georgia Dermatology
Warner Robins, GA [218]

Michael Y. Bonner, BA
Research Associate, Department of Dermatology, School of Medicine, Emory University, Atlanta, GA [235]

Laurence M. Boon, MD, PhD
Center for Vascular Anomalies
Division of Plastic Surgery St Luc University Hospital, Brussels, Belgium [172]

Barbara Boone, MD, PhD
Dermatologist, Ghent University Hospital, Ghent, Belgium [75]

Vladimir Botchkarev, MD, PhD
Professor, Centre for Skin Sciences, University of Bradford and Bradford, UK [86]

Gerald S. Braun, MD
Department of Nephrology and Clinical Immunology, University Hospital, RWTH University of Aachen, Aachen, Germany [169]

Francisco G. Bravo, MD
Associate Professor, Department of Pathology, Universidad Peruana Cayetano Heredia, Lima, Peru [182, 185]

Alanna F. Bree, MD
Pediatric Dermatologist, Dermatology Specialists of Houston, Bellaire, TX [142]

Thomas Brenn, MD, PhD, FRCPath
Consultant Dermatopathologist, Department of Pathology, Western General Hospital, Edinburgh, UK [129]

Lieve Brochez, MD, PhD
Professor, Department of Dermatology, Ghent University Hospital, Ghent, Belgium [75]

Robert T. Brodell, MD
Professor of Internal Medicine and Clinical Professor of Dermatopathology in Pathology, Department of Internal Medicine and Pathology, Northeastern Ohio Universities College of Medicine and Pharmacy, Rootstown, OH [68]

Katherine L. Brown, MD, MPH
Dermatology Resident, Department of Dermatology, Boston University, Boston, MA [9]

Daniela Bruch-Gerharz, MD
Professor, Department of Dermatology, University Hospital of Düsseldorf, Düsseldorf, Germany [24]

Leena Bruckner-Tuderman, MD
Professor, Department of Dermatology, University Medical Center Freiburg, Freiburg, Germany [53]

Lucinda S. Buescher, MD
Associate Professor, Division of Dermatology, Southern Illinois University, Springfield, IL [153]

Christopher B. Bunker, MD, FRCP
Professor, Department of Dermatology, University College London Hospitals, London, UK [77]

Walter H.C. Burgdorf, MD
Lecturer, Department of Dermatology, Ludwig Maximilian University, Munich, Germany [43]

Susan Burge, OBE DM FRCP
Consultant Dermatologist, Oxford University Hospitals, Oxford, UK [51]

Susan Burgin, MD
Assistant Professor, Department of Dermatology, Harvard Medical School, Boston, MA [15]

Craig G. Burkhart, MD, MPH
Clinical Professor, Department of Medicine, College of Medicine, University of Toledo, Toledo, OH [208]

Craig N. Burkhart, MD
Assistant Professor, Department of Dermatology, The University of North Carolina at Chapel Hill, Chapel Hill, NC [174, 208, 222]

Claude S. Burton, MD
Professor, Department of Dermatology, Duke University School of Medicine, Durham, NC [174]

Jennifer A. Cafardi, MD
Assistant Professor, Department of Dermatology, University of Alabama at Birmingham, Birmingham, AL [237]

Jeffrey P. Callen, MD
Professor of Medicine (Dermatology), Department of Medicine, University of Louisville, Louisville, KY [233]

John D. Carter, MD
Associate Professor, Department of Internal Medicine, Division of Rheumatology, University of South Florida College of Medicine, Tampa, FL [20]

John A. Carucci, MD, PhD
Associate Professor, Department of Dermatology, Weill Cornell Medical College, New York, NY [115]

Mari Paz Castanedo-Tardan, MD
Postdoctoral Research Fellow, Section of Dermatology, Dartmouth-Hitchcock Medical Center, Dartmouth Medical School, Lebanon, NH [13]

Lorenzo Cerroni, MD
Associate Professor, Department of Dermatology, Medical University of Graz, Graz, Austria [117]

Veerendra Chadachan, MD
Vascular Medicine Program, Boston University Medical Center, Boston MA, USA Consultant, Department of General Medicine Vascular Medicine and Hypertension Section, Tan Tock Seng Hospital, Singapore [173]

Vinod Chandran, MBBS, MD, DM
Clinical Research Fellow, Department of Medicine, Division of Rheumatology, University of Toronto, Toronto, ON, Canada [19]

Mary Wu Chang, MD
Associate Clinical Professor, Department of Dermatology, Department of Pediatrics, University of Connecticut School of Medicine, Farmington, CT [107]

Anne M. Chapas, MD
Clinical Assistant Professor, Department of Dermatology, New York University School of Medicine, New York, NY [252]

Joel Charrow, MD
Professor, Department of Pediatrics, Feinberg School of Medicine, Northwestern University, Chicago, IL [141]

Mei Chen, PhD
Professor and Director of Research, Department of Dermatology, University of Southern California, Los Angeles, CA [60]

Carol E. Cheng, MD
Department of Dermatology, Massachusetts General Hospital, Boston, MA [16]

Andy J. Chien, MD, PhD
Assistant Professor, Division of Dermatology, University of Washington School of Medicine, Seattle, WA [151]

Anna L. Chien, MD
Assistant Professor, Department of Dermatology, Johns Hopkins School of Medicine, Baltimore, MD [217]

Mary-Margaret Chren, MD
Professor, Department of Dermatology, University of California, San Francisco, San Francisco, CA [1]

David H. Chu, MD, PhD
Division of Dermatology and Cutaneous Surgery, Scripps Clinic Medical Group, La Jolla, CA [7]

Mon-Li Chu, PhD
Professor, Department of Dermatology & Cutaneous Biology, Thomas Jefferson University, Philadelphia, PA [63]

Jeffrey I. Cohen, MD
Chief, Medical Virology Section, Laboratory of Clinical Infectious Diseases, National Institutes of Health, Bethesda, MD [193]

Myron S. Cohen, MD
Associate Vice Chancellor and Professor of Medicine, Microbiology and Immunology, Departments of Medicine and Epidemiology, University of North Carolina, Chapel Hill, NC [180]

Philip R. Cohen, MD
Clinical Associate Professor, Department of Dermatology, MD Anderson Cancer Center, University of Texas, Houston, TX [32]

Chris D. Collins, MD, FAAD
Professor of Clinical Dermatology US Army & Air Force Dermatology Brooke Army Medical Center, Wilford Hall Medical Center San Antonio, TX [22]

Nneka I. Comfere, MD
Assistant Professor, Department of Dermatology, Mayo Clinic College of Medicine, Rochester, MN [165]

Rosamaria Corona, DSc, MD
Attending Physician, Division of Immunodermatology, Istituto Dermopatico dell'Immacolata, Rome, Italy [2]

Melissa I. Costner, MD
Clinical Associate Professor, Department of Dermatology, University of Texas Southwestern Medical Center, Dallas, TX [155, 156]

George Cotsarelis, MD
Professor, Department of Dermatology, University of Pennsylvania School of Medicine, Philadelphia, PA [86]

Pierre A. Coulombe, PhD
E.V. McCollum Professor and Chair, Department of Biochemistry and Molecular Biology, Johns Hopkins Bloomberg School of Public Health, Baltimore, MD [46]

Edward W. Cowen, MD, MHSc
Head, Dermatology Consultation Service, Dermatology Branch, National Cancer Institute, National Institutes of Health, Bethesda, MD [28]

Joseph Craft, MD
Paul B. Beeson Professor of Medicine and Professor of Immunobiology, Department of Internal Medicine, Yale School of Medicine, Yale University, New Haven, CT [154]

Noah Craft, MD, PhD, DTMH
Assistant Professor, Department of Medicine, Divisions of Dermatology and Adult Infectious Disease, Los Angeles Biomedical Research Institute at Harbor-UCLA Medical Center, Torrance, CA [175, 176]

Donna A. Culton, MD, PhD
Resident Physician, Department of Dermatology, University of North Carolina at Chapel Hill, Chapel Hill, NC [56]

Jennifer S. Daly, MD
Professor, Department of Medicine, University of Massachusetts Medical School, Worcester, MA [209]

F. William Danby, MD, FRCPC, FAAD
Adjunct Assistant Professor, Department of Surgery (Section of Dermatology), Dartmouth Medical School, Hanover, NH [78]

Stamatina Danielides, MD
Sjögren's Syndrome Clinic Gene Therapy and Therapeutics Branch, National Institute of Dental and Craniofacial Research National Institutes of Health Bethesda, MD [161]

Mazen S. Daoud, MD
Private Practice, Dermatology and Dermatopathology, Advanced Dermatology Specialties, Fort Myers, FL [26, 27]

Thomas N. Darling, MD, PhD
Associate Professor, Department of Dermatology, Uniformed Services University of the Health Sciences, Bethesda, MD [140]

Alan Dattner, MD
Chief Scientific Officer, Founder and CEO, www.holisticdermatology.com, New York, NY [241]

Sofie De Schepper, MD, PhD
Professor, Department of Dermatology, Ghent University Hospital, Ghent, Belgium [75]

Aieska De Souza, MD, MS
Dermatopharmacology Fellow, Department of Dermatology, New York University Langone Medical Center, New York, NY [214, 220]

Steven M. Dean, DO, FACP, RPVI
Associate Professor of Internal Medicine, Department of Cardiovascular Medicine, The Ohio State University College of Medicine, Columbus, OH [173]

Roy H. Decker, MD, PhD
Assistant Professor, Department of Therapeutic Radiology, Yale School of Medicine, Yale University, New Haven, CT [240]

Nicole M. DeLauro, DPM
Associate Physician, Podiatric Medicine and Surgery, Foot and Ankle Center of New Jersey, Plainfield, NJ [98]

Thomas M. DeLauro, DPM
Professor, Departments of Medicine and Surgery, New York College of Podiatric Medicine, New York, NY [98]

Christopher P. Denton, PhD, FRCP
Professor of Experimental Rheumatology, Centre for Rheumatology, University College London, London, UK [157]

Theresa Schroeder Devere, MD
Assistant Professor, Department of Dermatology, Oregon Health & Science University, Portland, OR [168]

Christine A. DeWitt, MD
Assistant Professor, Division of Dermatology, Georgetown University Hospital, Washington, DC [153]

Luis A. Diaz, MD
Professor and Chairman, Department of Dermatology, University of North Carolina, Chapel Hill, NC [56]

John J. DiGiovanna, MD
Staff Clinician, DNA Repair Section, Dermatology Branch, Center for Cancer Research, National Cancer Institute, National Institutes of Health, Bethesda, MD [49, 139]

Andrzej A. Dlugosz, MD
Poth Professor of Cutaneous Oncology, Department of Dermatology, University of Michigan Medical School, Ann Arbor, MI [111]

Lisa M. Donofrio, MD
Associate Clinical Professor, Department of Dermatology, Yale School of Medicine, Yale University, New Haven, CT [254]

Daven N. Doshi, MD
Resident, Department of Dermatology, Albert Einstein College of Medicine, Bronx, NY [16]

Karynne O. Duncan, MD
Private Practice, Saint Helena, CA [113]

Jonathan A. Dyer, MD
Assistant Professor, Departments of Dermatology and Child Health, School of Medicine, University of Missouri, Columbia, MO [137]

Robert T. Eberhardt, MD, FACC, FSVM, RPVI
Associate Professor, Department of Medicine, Boston University School of Medicine, Boston, MA [173]

Benjamin D. Ehst, MD, PhD
Assistant Professor, Department of Dermatology, Oregon Health & Science University, Portland, OR [29]

Lawrence F. Eichenfield, MD
Professor, Departments of Pediatrics and Medicine (Dermatology), University of California, San Diego, San Diego, CA [14]

Daniel B. Eisen, MD
Associate Clinical Professor, Dermatology, University of California, Davis, Sacramento, CA [187]

Myrna El Shareef, MD
Department of Dermatology, American University of Beirut Medical Center, Beirut, Lebanon [204]

James T. Elder, MD, PhD
Professor, Department of Dermatology, University of Michigan Medical School, Ann Arbor, MI [18]

Craig A. Elmets, MD
Professor and Chair, Department of Dermatology, University of Alabama at Birmingham, Birmingham, AL [237]

Dirk M. Elston, MD
Director, Department of Dermatology, Geisinger Medical Center, Danville, PA [99, 231]

Joseph C. English, MD
Associate Professor, Department of Dermatology, University of Pittsburgh, Pittsburgh, PA [181]

Edward M. Esparza, MD, PhD
Resident, Division of Dermatology, University of Washington, Seattle, WA [221]

Janet A. Fairley, MD
Professor and Head, Department of Dermatology, University of Iowa, Iowa City, IA [138]

Vincent Falanga, MD, FACP
Professor, Departments of Dermatology and Biochemistry, Boston University School of Medicine, Boston, MA [248]

Robert D. Fealey, MD
Consultant, Department of Neurology, Mayo Clinic College of Medicine, Rochester, MN [84]

Flavia Fedeles, MD, MS
Intern, Internal Medicine, Hospital of St Raphael, New Haven, CT [23]

Laura Korb Ferris, MD, PhD
Assistant Professor, Department of Dermatology, School of Medicine, University of Pittsburgh, Pittsburgh, PA [181]

Patricia M. Fishman, MD
Assistant Professor, Department of Pathology, University of Illinois at Chicago, Chicago, IL [70]

James E. Fitzpatrick, MD
Professor and Vice Chair, Department of Dermatology, University of Colorado, Denver, CO [219, 227]

Philip Fleckman, MD
Professor, Medicine (Dermatology), University of Washington, Seattle, WA [49]

Carsten Flohr, BM, BCh (Hons), MA, Mphil, MRCPCH, MSc, PhD
Senior Lecturer (Associate Professor) and Honorary Consultant Dermatologist, St John's Institute of Dermatology, St Thomas's Hospital and King's College London, London, UK [4]

Camille Francès, MD
Professor, Department of Dermatology-Allergology, Hôpital Tenon, Paris, France [159]

Jorge Frank, MD, PhD
Professor, Department of Dermatology, Maastricht University Medical Center (MUMC), Maastricht, The Netherlands [132]

Ilona J. Frieden, MD
Professor, Department of Dermatology and Pediatrics, School of Medicine, University of California, San Francisco, San Francisco, CA [126]

Sheila Fallon Friedlander, MD
Professor, Departments of Pediatrics and Medicine (Dermatology), School of Medicine, University of California, San Diego, San Diego, CA [195]

Ramsay L. Fuleihan, MD
Associate Professor, Department of Pediatrics, Feinberg School of Medicine, Northwestern University, Chicago, IL [143]

Abhimanyu Garg, MD
Professor, Internal Medicine, University of Texas Southwestern Medical Center, Dallas, TX [71]

Amit Garg, MD
Associate Professor, Department of Dermatology, Boston University School of Medicine, Boston, MA [5, 188, 189]

Christopher C. Gasbarre, DO, FAAD
Associate Staff Physician, Department of Dermatology, Cleveland Clinic, Cleveland, OH [230]

Anthony A. Gaspari, MD
Shapiro Professor, Department of Dermatology, University of Maryland School of Medicine, Baltimore, MD [226]

John K. Geisse, MD
Clinical Professor, Department of Dermatology, University of California, San Francisco, San Francisco, CA [113]

Joel M. Gelfand, MD, MSCE
Assistant Professor of Dermatology and Epidemiology, Departments of Dermatology, Epidemiology and Biostatistics, University of Pennsylvania School of Medicine, Philadelphia, PA [234]

Carlo Gelmetti, MD
Full Professor, Department of Anesthesia, Intensive Care and Dermatologic Sciences, Università degli Studi di Milano, Milano, Italy [147, 148]

Roy G. Geronemus, MD
Director, Dermatology, Laser & Skin Surgery Center of New York, New York, NY [252]

Samer H. Ghosn, MD
Assistant Professor, Department of Dermatology, American University of Beirut Medical Center, Beirut, Lebanon [201, 203, 206]

Lawrence E. Gibson, MD
Professor, Department of Dermatology, Mayo Clinic College of Medicine, Rochester, MN [165]

Barbara A. Gilchrest, MD
Chair Emerita and Professor of Dermatology, Department of Dermatology, Boston University School of Medicine, Boston, MA [9, 109]

Dafna D. Gladman, MD, FRCPC
Professor, Department of Medicine, Division of Rheumatology, University of Toronto, Toronto, ON, Canada [19]

Gerald J. Gleich, MD
Professor of Dermatology and Medicine, Department of Dermatology, School of Medicine, University of Utah, Salt Lake City, UT [31]

Adam B. Glick, PhD
Associate Professor, Center for Molecular Toxicology and Carcinogenesis, Department of Veterinary and Biomedical Sciences, Department of Dermatology, Hershey Medical Center, The Pennsylvania State University, University Park, PA [111]

Richard G. Glogau, MD
Clinical Professor, Department of Dermatology, University of California, San Francisco, San Francisco, CA [255]

Raphaela Goldbach-Mansky, MD, MHS
Acting Chief, National Institute of Arthritis and Musculoskeletal and Skin Diseases Intramural Research Program, Translational Autoinflammatory Disease Section, The National Institutes of Health, Bethesda, MD [134]

Leonard H. Goldberg, MD, FRCP
Medical Director, DermSurgery Associates, PA, Houston, TX [246]

Emmy M. Graber, MD
Assistant Professor of Dermatology, Department of Dermatology, Boston University Medical Center, Boston, MA [80]

Robin A.C. Graham-Brown, BSc, MB, FRCP, FRCPCH
Consultant Dermatologist, Department of Dermatology, University Hospitals of Leicester, Leicester, UK [150]

Jane Margaret Grant-Kels, MD
Professor and Chair, Department of Dermatology, University of Connecticut Health Center, Farmington, CT [23]

Justin J. Green, MD
Department of Dermatology, Robert Wood Johnson Medical School, University of Medicine and Dentistry of New Jersey, Wood Johnson Medical School, Camden, NJ [199]

Roy C. Grekin, MD
Professor, Department of Dermatology, University of California, San Francisco School of Medicine, San Francisco, CA [121]

James M. Grichnik, MD, PhD
Professor, Department of Dermatology, Miller School of Medicine, Miami, FL [122, 123]

Douglas Grossman, MD, PhD
Associate Professor, Department of Dermatology, University of Utah Health Sciences Center, Salt Lake City, UT [114]

Johann E. Gudjonsson, MD, PhD
Assistant Professor, Department of Dermatology, University of Michigan, Ann Arbor, MI [18]

Bridget C. Hackett, MB BCh, BAO, MRCPI
Department of Dermatology, Mater Misericordiae University Hospital, Dublin, Ireland [33]

Russell P. Hall III, MD
J Lamar Callaway Professor and Chair, Department of Dermatology, Duke University Medical Center, Durham, NC [58, 61, 225]

Analisa V. Halpern, MD
Assistant Professor, Department of Medicine, Division of Dermatology, Cooper University Hospital, Rowan University, Camden, NJ [199]

C. William Hanke, MD, MPH, FACP
Visiting Professor of Dermatology, University of Iowa Carver College of Medicine, Iowa City, IA [253]

Christopher B. Hansen, MD
Assistant Professor, Department of Dermatology, University of Utah School of Medicine, Salt Lake City, UT [156]

Philip N. Hawkins, PhD, FRCP, FRCPath, FMedSci
Professor of Medicine, Centre for Amyloidosis and Acute Phase Proteins, University College London Medical School, London, UK [133]

Roderick J. Hay, DM, FRCP, FRCPath, FMedSci
Chairman, International Foundation for Dermatology, London, UK [3, 190]

Adelaide A. Hebert, MD
Professor, Department of Dermatology, University of Texas Medical School at Houston, Houston, TX [84]

Stephen E. Helms, MD
Associate Professor, Department of Medicine, Northeastern Ohio Universities College of Medicine, Rootstown, OH [68]

Ulrich R. Hengge, MD, MBA
Professor, Hautzentrum Prof. Hengge, Düesseldorf, NRW, Germany [65]

Warren R. Heymann, MD
Professor of Medicine and Pediatrics, Head, Division of Dermatology, Robert Wood Johnson Medical School at Camden, University of Medicine & Dentistry of New Jersey, Camden, NJ [199]

Whitney A. High, MD, JD, MEng
Associate Professor, Department of Dermatology, University of Colorado Denver Health Sciences Center, Denver, CO [219, 227]

Chad Hivnor, MD
Associate Program Director, San Antonio Uniformed Services Health Education Consortium, San Antonio, TX [22]

Jonathan Hofmekler, BSc
Associate Researcher, Department of Dermatology, School of Medicine, Emory University, Atlanta, GA [235]

Ulrich Hohenleutner, MD
Professor, Klinik und Poliklinik für Dermatologie, Universitätsklinikum Regensburg, Regensburg, Germany [239]

Steven M. Holland, MD
Chief, Laboratory of Clinical Infectious Diseases, National Institute of Allergy and Infectious Diseases, National Institutes of Health, Bethesda, MD [30]

Golara Honari, MD
Attending Physician, Dermatology and Plastic Surgery Institute, Cleveland Clinic, Cleveland, OH, [211]

Herbert Hönigsmann, MD
Professor of Dermatology, Emeritus Chairman, Department of Dermatology, Medical University of Vienna, Vienna, Austria [32, 35, 238]

Thomas J. Hornyak, MD, PhD
Investigator, Dermatology Branch, National Cancer Institute, National Institutes of Health, Bethesda, MD [73]

Alain Hovnanian, MD, PhD
Departments of Genetics and Dermatology, University René Descartes, Paris, France [51]

Chung-Hong Hu, MD
Department of Dermatology University of Wisconsin Madison, WI [25]

Linden Hu, MD
Associate Professor, Department of Medicine, School of Medicine, Tufts University, Boston, MA [187]

Sam T. Hwang, MD, PhD
Chair and Professor, Department of Dermatology, Medical College of Wisconsin, Milwaukee, WI [12]

Sherrif F. Ibrahim, MD, PhD
Procedural Dermatology Fellow, Department of Dermatology, University of California, San Francisco, San Francisco, CA [121]

Gabor Illei, MD, PhD, MHS
Head, Sjögren's Syndrome Clinic, Molecular Physiology and Therapeutics Branch, National Institute of Dental and Craniofacial Research, National Institutes of Health, Bethesda, MD [161]

Alan D. Irvine, MD, FRCP, FRCPI
Consultant Dermatologist, Paediatric Dermatology, Our Lady's Children's Hospital, Dublin, Ireland [52]

Rim S. Ishak, MD
Department of Dermatology, American University of Beirut Medical Center, Beirut, Lebanon [203]

Peter H. Itin, MD
Professor, Department of Dermatology, School of Medicine, University of Basel, Basel, Switzerland [131]

Satori Iwamoto, MD, PhD
Assistant Professor, Department of Dermatology and Skin Surgery, Boston University School of Medicine, Boston, MA [248]

Reza Jacob, MD
Resident, Department of Dermatology, Boston University School of Medicine, Boston, MA [232]

Heidi T. Jacobe, MD, MSCS
Assistant Professor, Department of Dermatology, University of Texas Southwestern Medical Center, Dallas, TX [64]

William D. James, MD
Paul R. Gross Professor, Department of Dermatology, School of Medicine, University of Pennsylvania, Philadelphia, PA [218]

Melinda Jen, MD
Pediatric Dermatology Fellow, Division of Pediatric and Adolescent Dermatology, Rady Children's Hospital, University of California, San Diego, San Diego, CA [130]

Jens-Michael Jensen, MD
Department of Dermatology, Venereology and Allergy, University of Kiel, Kiel, Germany [47]

Richard Allen Johnson, MDCM
Assistant Professor, Department of Dermatology, Harvard Medical School, Boston, MA [105, 178, 179, 198]

Timothy M. Johnson, MD
Professor, Department of Dermatology, University of Michigan, Ann Arbor, MI [124]

Graham A. Johnston, MBChB, FRCP
Consultant, Department of Dermatology, Leicester Royal Infirmary, Leicester, Leicestershire, UK [150]

Marc A. Judson, MD
Professor of Medicine, Division of Pulmonary and Critical Care Medicine, Department of Medicine, Medical University of South Carolina, Charleston, SC [152]

Andrea A. Kalus, MD
Assistant Professor, Division of Dermatology, University of Washington School of Medicine, Seattle, WA [151]

Insoo Kang, MD
Associate Professor of Medicine, Department of Internal Medicine, Yale School of Medicine, Yale University, New Haven, CT [154]

Sewon Kang, MD
Noxell Professor and Chairman, Department of Dermatology, Johns Hopkins University School of Medicine, Baltimore, MD [217]

Allen P. Kaplan, MD
Clinical Professor, Department of Medicine, Medical University of South Carolina, Charleston, SC [38]

Julie K. Karen, MD
Clinical Assistant Professor, Department of Dermatology, New York University Langone School of Medicine, New York, NY [108]

Kenneth A. Katz, MD, MSc, MSCE
STD Control Officer and Senior Physician, Health and Human Services Agency, County of San Diego, San Diego, CA [200, 222]

Stephen I. Katz, MD, PhD
Fellow, American Academy of Dermatology, Schaumburg, IL; Past President, Society of Investigative Dermatology, Cleveland, OH; Director, National Institute of Arthritis and Musculoskeletal and Skin Diseases, National Institutes of Health, Bethesda, MD [61]

Masaoki Kawasumi, MD, PhD
Department of Medicine, Division of Dermatology, University of Washington, Seattle, WA [112]

Dean L. Kellogg, Jr., MD, PhD
Professor, Department of Medicine, University of Texas Health Science Center, San Antonio, TX [93]

Francisco A. Kerdel, MD
Director, Dermatology Inpatient Unit, Department of Dermatology, University of Miami Hospital, Miami, FL [216]

Helmut Kerl, MD
Professor of Dermatology, Chairman Emeritus, Department of Dermatology, Medical University of Graz, Graz, Austria [117]

Jay S. Keystone, MD, MSc(CTM), FRCPC
Professor, Department of Medicine, University of Toronto, Toronto, ON, Canada [207]

Abdul-Ghani Kibbi, MD, FAAD, FACP
Professor and Chair, Department of Dermatology, Faculty of Medicine, American University of Beirut, Beirut, Lebanon [6, 204]

Alexa B. Kimball, MD, MPH
Associate Professor, Department of Dermatology, Harvard Medical School, Boston, MA [16]

Reinhard Kirnbauer, MD
Associate Professor, Department of Dermatology, Division of Immunology, Allergy and Infectious Diseases (DIAID), Medical University of Vienna, Vienna, Austria [196]

John H. Klippel, MD
President and Chief Executive Officer, Arthritis Foundation, Atlanta, GA [170]

Robert Knobler, MD
Associate Professor, Department of Dermatology, Medical University of Vienna, Vienna, Austria [238]

Sandra R. Knowles, BScPhm
Lecturer, Faculty of Pharmacy, University of Toronto, Toronto, ON, Canada [41]

Christine J. Ko, MD
Associate Professor, Department of Dermatology, Yale School of Medicine, Yale University, New Haven, CT [66]

Manuel Koch, PhD
Associate Professor, Institute for Oral and Musculoskeletal Biology, Medical Faculty, Center for Dental Medicine, University of Cologne, Cologne, Germany [63]

Irene E. Kochevar, PhD
Professor, Department of Dermatology, Harvard Medical School, Boston, MA [90]

Nellie Konnikov, MD
Professor, Department of Dermatology, Boston University School of Medicine, Boston, MA [232]

Sandra A. Kopp, MD
Resident Physician, Department of Dermatology, Robert Wood Johnson Medical School at Camden, University of Medicine & Dentistry of New Jersey, Camden, NJ [199]

Kenneth H. Kraemer, MD
Chief, DNA Repair Section, Dermatology Branch, National Cancer Institute, Bethesda, MD [110, 139]

T. Krieg, MD
Department of Dermatology, University of Cologne, Cologne, Germany [63, 157]

Jean Krutmann, MD
Univ.- Professor Dr. med., Institut für Umweltmedizinische Forschung (IUF), Düsseldorf, NRW, Germany [90]

Roopal V. Kundu, MD
Assistant Professor, Department of Dermatology, Feinberg School of Medicine, Northwestern University, Chicago, IL [189]

Thomas S. Kupper, MD, FAAD
Thomas B. Fitzpatrick Professor, Department of Dermatology, Harvard Medical School, Boston, MA [11]

Razelle Kurzrock, MD, FACP
Chair and Professor, Investigational Cancer Therapeutics, MD Anderson Cancer Center, University of Texas, Houston, TX [32]

Helen J. Lachmann, MD, FRCP
Senior Lecturer/Honorary Consultant, National Amyloidosis Centre, University College London Medical School, London, UK [133]

Jeffrey N. Lackey, MD
Staff Dermatologist, Kimbrough Ambulatory Care Center, Fort George G. Meade, MD [213]

Jürgen Lademann, Prof. Dr. rer. nat. Dr.-Ing. habil.
Department of Dermatology, Center of Experimental and Applied Cutaneous Physiology (CCP), Charité - Universitätsmedizin Berlin, Berlin, Germany [215]

Jeffrey R. LaDuca, MD, PhD
Reflections Dermatology, Skaneateles, NY [226]

Jo Lambert, MD, PhD
Professor, Department of Dermatology, Ghent University Hospital, Ghent, Belgium [75]

Michael Landthaler, MD
Department of Dermatology, University of Regensburg, Regensburg, Germany [239]

Sinéad M. Langan, MRCP, MSc, PhD
Visiting Scholar, Department of Dermatology, University of Pennsylvania, Philadelphia, PA [4]

Hilde Lapeere, MD, PhD
Department of Dermatology, University Hospital Ghent, Ghent, Belgium [75]

Anne Laumann, MBChB, MRCP(UK), FAAD
Associate Professor of Dermatology, Department of Dermatology, Feinberg School of Medicine, Northwestern University, Chicago, IL [101]

Stephan Lautenschlager, MD
Associate Professor, Outpatient Clinic of Dermatology & Venereology, City Hospital Triemli, Zürich, Switzerland [202]

Leslie P. Lawley, MD
Assistant Professor of Dermatology and Pediatrics, Department of Dermatology, School of Medicine, Emory University, Atlanta, GA [82]

Chyi-Chia Richard Lee, MD, PhD
Staff Clinician, Laboratory of Pathology, National Cancer Institute, National Institutes of Health, Bethesda, MD [134]

Delphine J. Lee, MD, PhD, FAAD
Dirks/Dougherty Laboratory for Cancer Research, Director, Department of Translational Immunology, John Wayne Cancer Institute, Santa Monica, CA [186]

Ken K. Lee, MD
Associate Professor, Department of Dermatology, Director of Dermatologic Surgery, Oregon Health and Science University, Portland, OR [118]

Lela A. Lee, MD
Professor, Departments of Dermatology and Medicine, School of Medicine, University of Colorado Denver, Denver, CO [37]

David J. Leffell, MD
David Paige Smith Professor of Dermatology and Surgery, Chief, Section of Dermatologic Surgery and Cutaneous Oncology Department of Dermatology, Yale School of Medicine, Yale University, New Haven, CT [113, 114, 115]

Kristin M. Leiferman, MD
Professor, Department of Dermatology, University of Utah, Salt Lake City, UT [31, 36]

Yolanda M. Lenzy, MD, MPH
Clinical Dermatologist, Family Dermatology of Massachusetts, Brookline, MA [9]

Aimee L. Leonard, MD
Private Practice, New England Dermatology & Laser Center, Springfield, MA [253]

Donald Y.M. Leung, MD, PhD
Professor, Department of Pediatrics, School of Medicine, University of Colorado Denver, Denver, CO [14]

Nikki A. Levin, MD, PhD
Associate Professor, Department of Medicine, Division of Dermatology, University of Massachusetts Medical School, Worcester, MA [5]

Ross M. Levy, MD
Attending Physician, Division of Dermatology, North Shore University Health System, Skokie, IL [127]

Bernadette Liegl-Atzwanger, MD
Institute of Pathology, Medical University Graz, Graz, Austria [125]

Henry W. Lim, MD
Chairman and C.S. Livingood Chair, Department of Dermatology, Henry Ford Hospital, Detroit, MI [92, 223]

Dan Lipsker, MD, PhD
Professor, Department of Dermatology, Université de Strasbourg, Faculté de Médecine, Strasbourg, France [171]

Adam D. Lipworth, MD
Instructor, Department of Dermatology, Harvard Medical School, Harvard University, Boston, MA [178, 179]

Robert Listernick, MD
Professor, Department of Pediatrics, Feinberg School of Medicine, Northwestern University, Chicago, IL [141]

Rosemarie Liu, MD
Private Practice Skin, Cancer Surgery Center Fairfax, VA [25]

Zhi Liu, PhD
Professor, Department of Dermatology, University of North Carolina School of Medicine, Chapel Hill, NC [56]

Robert Loewe, MD
Associate Professor, Department of Dermatology, Medical University of Vienna, Vienna, Austria [162]

Anke S. Lonsdorf, MD
Department of Dermatology, University Hospital of Heidelberg, Heidelberg, Germany [12]

Mayra E. Lorenzo, MD, PhD
Instructor, Department of Dermatology, Harvard Medical School, Boston, MA [192]

Thomas A. Luger, MD
Professor and Chairman, Department of Dermatology, University of Münster, Münster, Germany [102]

Calum C. Lyon, MA, FRCP
Department of Dermatology, York Hospital, York, North Yorkshire, UK [96, 97]

Catherine Maari, MD
Assistant Professor, Department of dermatology, University of Montreal, Montreal, QC, Canada [67]

Vandana Madkan, MD
Dermatologist, Center for Clinical Studies, Dermatological Association of Texas, Houston, TX [191]

Meera Mahalingam, MD, PhD, FRCPath
Professor of Dermatology and Pathology and Laboratory Medicine, Dermatopathology Section, Department of Dermatology, Boston University School of Medicine, Boston, MA [187]

Joelle M. Malek, MD
Chief Resident, Department of Dermatology, American University of Beirut Medical Center, Beirut, Lebanon [206]

Richard M. Marchell, MD
Assistant Professor, Department of Dermatology, Medical University of South Carolina, Charleston, SC [152]

Lynette J. Margesson, MD, FRCPC
Assistant Professor of Obstetrics and Gynecology and Medicine (Dermatology), Section of Dermatology, Department of Obstetrics and Gynecology, Dartmouth Medical School, Hanover, NH [78]

M. Peter Marinkovich, MD
Associate Professor, Department of Dermatology, Stanford University School of Medicine, Stanford, CA [62]

Adriana R. Marques, MD
National Institute of Allergy and Infectious Diseases, National Institutes of Health, Bethesda, MD [193]

Nadine Marrouche, MD
Department of Dermatology, American University of Beirut Medical Center, Beirut, Lebanon [201]

Erin F. Mathes, MD
Department of Dermatology, University of California, San Francisco, San Francisco, CA [126]

Theodora M. Mauro, MD
Service Chief, Dermatology, San Francisco VA Medical Center, San Francisco, CA [83]

Susannah E. McClain, MD
Resident, Department of Dermatology, University of Maryland Medical System, Baltimore, MD [226]

John A. McGrath, MD, FRCP
Professor, St John's Institute of Dermatology, Guy's Campus, King's College London, London, UK [8]

W. H. Irwin McLean, FRSE, FMedSci
Dermatology and Genetic Medicine University of Dundee, Dundee, UK [8]

Darius R. Mehregan, MD
Associate Professor and Hermann Pinkus Chair, Department of Dermatology, Wayne State University, Detroit, MI [34]

David A. Mehregan, MD
Associate Professor, Department of Dermatology, School of Medicine, Wayne State University, Detroit, MI [34]

Atul B. Mehta, MD, FRCP, FRCPath
Professor, Department of Haematology, Royal Free Hospital, University College London School of Medicine, London, UK [136]

Natalia Mendoza, MD, MS
Assistant Professor, Department of Research and Dermatology, Universidad El Bosque, Bogotá, Colombia [191]

Peter A. Merkel, MD, MPH
Professor of Medicine, Section of Rheumatology, Clinical Epidemiology Unit, Boston University School of Medicine, Boston, MA [164]

Martin C. Mihm, MD, FACP
Director, Melanoma Program in Dermatology, Department of Dermatology, Brigham and Women's Hospital, Boston, MA [6, 124]

Lloyd S. Miller, MD, PhD
Assistant Professor, Division of Dermatology, David Geffen School of Medicine, University of California, Los Angeles, Los Angeles, CA [10]

Stanley J. Miller, MD
Associate Professor, Departments of Dermatology and Otolaryngology-Head and Neck Surgery, Johns Hopkins Hospital, Baltimore, MD [46]

Daniel Mimouni, MD
Senior Lecturer, Department of Dermatology, Beilinson Campus, Rabin Medical Center, Petah-Tikva, Israel [55]

Julia S. Minocha, MD
Clinical Research Fellow, Department of Dermatology, Feinberg School of Medicine, Northwestern University, Chicago, IL [69]

Paradi Mirmirani, MD
Department of Dermatology, The Permanente Medical Group, Vallejo, CA [87]

Robert L. Modlin, MD
Klein Professor of Dermatology, and Professor of Microbiology, Immunology and Molecular Genetics, Department of Medicine, David Geffen School of Medicine, University of California, Los Angeles, Los Angeles, CA [10, 186]

P. Moinzadeh, MD
Department of Dermatology, University of Cologne, Cologne, Germany [157]

Paul A. Monach, MD, PhD
Assistant Professor, Department of Medicine, Section of Rheumatology, Vasculitis Center, Boston University School of Medicine, Boston, MA [164]

Megan M. Moore, MD
Department of Dermatology, The Permanente Medical Group, Walnut Creek, CA [220]

Rebecca J. Morris, PhD
Professor, Laboratory of Stem Cells and Cancer, The Hormel Institute, University of Minnesota, Austin, MN [45]

L. Katie Morrison, MD
Department of Dermatology, University of Texas Health Sciences Center, Houston, TX [191]

Nico Mousdicas, MBChB, MD
Associate Professor, Department of Dermatology, Indiana University, Indianapolis, IN [177]

Ulrich Mrowietz, MD
Associate Professor, Psoriasis Center, Department of Dermatology, Campus Kiel, University Medical Center Schleswig-Holstein, Kiel, Germany [21]

Colin S. Munro, MD, FRCP (Glasg)
Professor, Alan Lyell Centre for Dermatology, Southern General Hospital, Glasgow, UK [50]

George F. Murphy, MD
Professor of Pathology, Harvard Medical School Director, Program in Dermatopathology, Brigham and Women's Hospital, Boston MA [6]

Haley Naik, MD
Department of Dermatology, Massachusetts General Hospital, Boston, MA [105]

Amanda M. Nelson, PhD
Department of Dermatology, College of Medicine, The Pennsylvania State University, Hershey, PA [79]

Isaac M. Neuhaus, MD
Assistant Professor, Department of Dermatology, University of California, San Francisco, San Francisco, CA [121]

Paul Nghiem, MD, PhD
Associate Professor, Departments of Medicine and Dermatology, University of Washington, Seattle, WA [112, 120]

Gerhard J. Nohynek, PhD, DABT
Scientific Director, Worldwide Safety Department, L'Oreal R&D, Asnières, France [215]

David A. Norris, MD
Professor and Chairman, Department of Dermatology, School of Medicine, University of Colorado Denver, Denver, CO [74]

Scott A. Norton, MD, MPH, MSc
Professor of Dermatology, Division of Dermatology, Department of Medicine, Georgetown University Hospital, Washington, DC [183, 213]

Lillian Odo, MD
Associate Professor, Department of Dermatology, University of Santo Amaro, São Paulo, SP, Brazil [100]

John E. Olerud, MD
Professor, Medicine, Division of Dermatology, University of Washington, Seattle, WA [151]

Katia Ongenae, MD, PhD
Professor, Department of Dermatology, University Hospital Ghent, Ghent, Belgium [75]

Grainne M. O'Regan, MRCPI
Department of Paediatric Dermatology, Our Lady's Children's Hospital, Dublin, Ireland [52]

Anthony E. Oro, MD, PhD
Associate Professor, Program in Epithelial Biology, School of Medicine, Stanford University, Stanford, CA [116]

Catherine H. Orteu, MBBS, BSc, MD, FRCP
Consultant Dermatologist, Department of Dermatology, Royal Free Hospital, London, UK [136]

Nina Otberg, MD
Hair Clinic, Skin and Laser Center Berlin, Potsdam, Germany [88]

Michael N. Oxman, MD
Professor of Medicine and Pathology, University Of California, San Diego, San Diego, CA [194]

Amy S. Paller, MD
Walter J. Hamlin Professor and Chair of Dermatology, Professor of Pediatrics, Feinberg School of Medicine, Northwestern University, Chicago, IL [143]

Hee-Young Park, PhD
Associate Professor, Department of Dermatology, Boston University School of Medicine, Boston, MA [72]

Sareeta R.S. Parker, MD
Associate Clinical Professor, Department of Dermatology, School of Medicine, Emory University, Atlanta, GA [82]

Anisha B. Patel, MD
Resident, Department of Dermatology, Oregon Health & Science University, Portland, OR [168]

Tejesh S. Patel, MBBS (Lon), BSc (Hons)
Dermatology Resident, Department of Medicine, Division of Dermatology, University of Tennessee Health Science Center, Memphis, TN [103]

Aimee S. Payne, MD, PhD
Assistant Professor, Department of Dermatology, University of Pennsylvania, Philadelphia, PA [53, 54]

Andrea L. Pearson, MD
Resident Physician, Department of Dermatology, University of Massachusetts Medical School, Worcester, MA [192]

Michelle T. Pelle, MD
Attending Physician, Department of Medicine, Scripps Mercy Hospital, San Diego, CA [81]

Brent E. Pennington, MD
Nashville Skin & Cancer, Nashville, TN [242]

Margot S. Peters, MD
Department of Dermatology, Mayo Clinic, Rochester, MN [36]

Julia S. Pettersen, MD
Department of Dermatology, Yale School of Medicine New Haven, CT [115]

Peter Petzelbauer, MD
Professor of Microvascular Research, Department of Dermatology, Medical University of Vienna, Vienna, Austria [162]

Tania J. Phillips, MD, FRCP, FRCPC
Professor of Dermatology, Department of Dermatology, Boston University School of Medicine, Boston, MA [100]

Gérald E. Piérard, MD, PhD
Chief, Dermatopathology Service, Department of Dermatology, University Hospital of Liège, Liège, Belgium [94]

Claudine Piérard-Franchimont, MD, PhD
Professor, Department of Dermatopathology, University Hospital of Liège, Liège, Belgium [94]

Warren W. Piette, MD
Chair, Division of Dermatology, John H. Stroger Jr. Hospital of Cook County, Chicago, IL [144, 160]

Caroline Piggott, MD
Resident, Department of Dermatology, University of California, San Diego, San Diego, CA [195]

Bianca Maria Piraccini, MD, PhD
Researcher, Department of Dermatology, University of Bologna, Bologna, Italy [89]

Mark R. Pittelkow, MD
Professor, Departments of Dermatology and Biochemistry and Molecular Biology, Mayo Clinic College of Medicine, Mayo Medical School, Rochester, MN [26, 27, 158]

Jordan S. Pober, MD, PhD
Professor and Vice Chair, Department of Immunobiology, Yale School of Medicine, Yale University, New Haven, CT [162]

Brian P. Pollack, MD, PhD
Assistant Professor of Dermatology and Pathology/Laboratory Medicine, Emory University, Winship Cancer Institute and the Atlanta VA Medical Center, Atlanta, GA [237]

Miriam Keltz Pomeranz, MD
Clinical Assistant Professor, Department of Dermatology, New York University School of Medicine, New York, NY [108]

Frank C. Powell, FRCPI, FAAD
Associate Professor, Department of Dermatology, University College Dublin, Dublin, Ireland [33]

Julie Powell, MD, FRCPC
Associate Clinical Professor, and Director of Pediatric Dermatology, Department of Pediatrics, Division of Dermatology, CHU Sainte-Justine University of Montreal, Montreal, QC, Canada [67]

Jennifer G. Powers, MD
Resident, Department of Dermatology, Boston University School of Medicine, Boston, MA [100]

Julie S. Prendiville, MB, FRCPC
Clinical Professor, Department of Pediatrics, University of British Columbia, Vancouver, British Columbia, Canada [44]

Howard B. Pride, MD
Associate, Departments of Dermatology and Pediatrics, Geisinger Medical Center, Danville, PA [106]

Ehrhardt Proksch, MD, PhD
Professor, Department of Dermatology, University of Kiel, Kiel, Germany [47]

Pascale Quatresooz, MD, PhD
Lecturer Senior Registrar, Department of Dermatopathology, University Hospital of Liège, Liège, Belgium [94]

Caroline L. Rao, MD
Assistant Professor, Department of Dermatology, Duke University, Durham, NC [58]

Thomas H. Rea, MD
Emeritus Professor, Department of Dermatology, Keck School of Medicine, University of Southern California, Los Angeles, CA [186]

Kavitha K. Reddy, MD
Resident, Department of Dermatology, Boston University School of Medicine, Boston, MA [9]

Thomas E. Redelmeier, MD
Dermatology Department Charite Hospital/Humboldt University, Berlin, Berlin, Germany [215]

Arthur R. Rhodes, MD, MPH
Professor, Department of Dermatology, Rush Medical College, Rush University, Chicago, IL [122]

Stephen K. Richardson, MD
Clinical Assistant Professor, Department of Dermatology, Florida State College of Medicine, Tallahassee, FL [234]

Evan Rieder, MD
Department of Psychiatry, New York University School of Medicine, New York, NY [104]

Maureen Rogers, MBBS, FACD
Emeritus Consultant, Department of Dermatology, Royal Alexandra Hospital for Children, Sydney, Australia [87]

Thomas E. Rohrer, MD
Clinical Associate Professor of Dermatology, Brown University, Alpert School of Medicine, Providence, RI [243]

Arash Ronaghy, MD, PhD
Research Associate, Department of Dermatology, Duke University, Durham, NC [61]

Ted Rosen, MD
Professor, Department of Dermatology, Baylor College of Medicine, Houston, TX [205]

Marti J. Rothe, MD
Associate Professor of Dermatology, Department of Dermatology, University of Connecticut Health Center, Farmington, CT [23]

Jean-Claude Roujeau, MD
Department of Dermatology
Hôpital Henri Mondor
Université Paris XII Créteil
Paris, France [39, 40]

Anne H. Rowley, MD
Professor, Departments of Pediatrics, and Microbiology—Immunology, Feinberg School of Medicine, Northwestern University, Chicago, IL [167]

Thomas M. Rünger, MD, PhD
Professor of Dermatology and Pathology, Department of Dermatology, Boston University School of Medicine, Boston, MA [110, 139]

William A. Rutala, BS, MS, PhD, MPH
Professor, Department of Medicine, University of North Carolina, Chapel Hill, NC [180]

Thomas Ruzicka, Prof. Dr. med. Dr. h.c.
Head and Professor, Department of Dermatolgy and Allergology, Ludwig Maximilian University, Munich, Germany [24]

Arturo P. Saavedra, MD, PhD, MBA
Assistant Professor, Department of Dermatology, Harvard Medical School, Boston, MA [178, 179, 198]

Joni G. Sago, MD
Dermatology Associates of Kingsport, Kingsport, TN [225]

Raul D. Santos, MD, PhD
Director, Lipid Clinic, Heart Institute (InCor), University of São Paulo Medical School Hospital, São Paulo, Brazil [135]

Jean-Hilaire Saurat, MD
Professor, Swiss Center for Human Applied Toxicology, University Medical Center, Geneva, Switzerland [228]

Stephanie Saxton-Daniels, MD
Department of Dermatology, The University of Texas Southwestern Medical Center, Dallas, TX [64]

Ernst J. Schaefer, MD
Senior Scientist and Director Lipid Metabolism Laboratory Jean Mayer USDA HNRCA at Tufts University, Boston, MA [135]

Hans Schaefer, PhD
Professor, Retired [215]

Mark Jordan Scharf, MD
Clinical Professor of Medicine, Division of Dermatology, University of Massachusetts Medical School, Worcester, MA [209]

Stefan M. Schieke, MD
Department of Dermatology, Boston University School of Medicine, Boston, MA [188]

Bethanee J. Schlosser, MD, PhD
Assistant Professor, Department of Dermatology, Feinberg School of Medicine, Northwestern University, Chicago, IL [69]

Kenneth E. Schmader, MD
Professor and Chief, Department of Medicine-Geriatrics, Division of Geriatrics, Duke University Medical School, Durham, NC [194]

Holger Schmid, MD, MSc PD
Department of Internal Medicine, Ludwig Maximilian University, Munich, Germany [169]

Steven K. Schmitt, MD
Head, Section of Bone and Joint Infections, Department of Infectious Disease, Cleveland Clinic, Cleveland, OH [230]

Robert A. Schwartz, MD, MPH
Professor and Head, Department of Dermatology, New Jersey Medical School, Newark, NJ [210]

Aisha Sethi, MD
Assistant Professor, Department of Dermatology, University of Chicago, Chicago, IL [184]

Jerry Shapiro, MD, FRCPC, FAAD
Clinical Professor, Department of Dermatology and Skin Science, University of British Columbia, Vancouver, Canada [88]

Neil H. Shear, MD, FRCPC
Professor, Department of Dermatology & Pharmacology, University of Toronto, Toronto, ON, Canada [41]

Jessica M. Sheehan, MD
Mohs Surgeon and Dermatologist, Northshore Center for Medical Aesthetics, Northbrook, IL [243]

Robert L. Sheridan, MD
Associate Professor, Department of Surgery, Harvard Medical School, Boston, MA [95]

Jeff K. Shornick, MD, MHA
Private Practice [59]

Robert Sidbury, MD, MPH
Associate Professor, Department of Pediatrics, Division of Dermatology, Seattle Children's Hospital, Seattle, WA [221]

Nicholas R. Snavely, MD
Department of Dermatology Oregon Health & Science University Portland, OR [118]

Arthur J. Sober, MD
Professor, Department of Dermatology, Harvard Medical School, Boston, MA [122, 124]

Richard D. Sontheimer, MD
Professor, Department of Dermatology, University of Utah School of Medicine, Salt Lake City, UT [155, 156]

Apra Sood, MD
Associate Staff, Department of Dermatology, Cleveland Clinic, Cleveland, OH [48, 211, 212]

Nicholas A. Soter, MD
Professor of Dermatology, Ronald O. Perelman Department of Dermatology, New York University School of Medicine, New York, NY [163]

Richard A. Spritz, MD
Director, Human Medical Genetics Program, School of Medicine, University of Colorado Denver, Aurora, CO [74]

Divya Srivastava, MD
Assistant Professor, Department of Dermatology, University of Texas Southwestern Medical Center, Dallas, TX [119]

John R. Stanley, MD
Professor, Department of Dermatology, University of Pennsylvania School of Medicine, Philadelphia, PA [54]

William G. Stebbins, MD
Department of Dermatology, Laser and Skin Surgery Center of Indiana, Carmel, IN [253]

Christopher J. Steen, MD
Private Practice, Portland, ME [210]

Martin Steinhoff, MD, PhD
Full Professor, Department of Dermatology, University of California, San Francisco, San Francisco, CA [102]

Wolfram Sterry, Prof. Dr.
Professor and Chairman, Department of Dermatology, Venereology and Allergology, Charité Universitätsmedizin Berlin, Berlin, Germany [145]

Georg Stingl, MD
Professor, Department of Dermatology, Division of Immunology, Allergy and Infectious Diseases, Medical University of Vienna, Vienna, Austria [10]

Stephen P. Stone, MD
Professor, Division of Dermatology, Southern Illinois University School of Medicine, Springfield, IL [153]

Bruce E. Strober, MD, PhD
Assistant Professor, Ronald O. Perelman Department of Dermatology, New York University School of Medicine, New York, NY [214, 220]

Kathryn N. Suh, MD
Assistant Professor, Medicine and Pediatrics, University of Ottawa, Ottawa, ON, Canada [207]

Tung-Tien Sun, PhD
Professor, Departments of Cell Biology, Pharmacology and Urology, School of Medicine, New York University, New York, NY [46]

Neil A. Swanson, MD
Professor and Chair, Department of Dermatology, Oregon Health and Science University Portland, OR [118]

Susan M. Sweeney, MD
Assistant Professor, Division of Dermatology, University of Massachusetts Medical School, Worcester, MA [192]

Virginia P. Sybert, MD
Clinical Professor, Department of Medicine, Division of Medical Genetics, University of Washington School of Medicine, Seattle, WA [142]

Rolf-Markus Szeimies, MD, PhD
Professor and Chairman, Department of Dermatology and Allergology, Klinikum Vest Academic Teaching Hospital, Recklinghausen, Germany [238]

Moyses Szklo, MD, MPH, DrPH
Professor, Departments of Epidemiology and Medicine, Johns Hopkins Schools of Public Health and Medicine, Baltimore, MD [2]

Jean Y. Tang, MD, PhD
Assistant Professor, Dermatology, Stanford University, Redwood City, CA [116]

Elizabeth L. Tanzi, MD
Co-Director, Washington Institute of Dermatologic Laser Surgery, Washington, DC [251]

Francisco A. Tausk, MD
Professor, Department of Dermatology, University of Rochester, Rochester, NY [104]

Charles R. Taylor, MD
Associate Professor, Department of Dermatology, Harvard Medical School, Boston, MA [90]

James S. Taylor, MD, FAAD
Consultant Dermatologist, Department of Dermatology, Dermatology and Plastic Surgery Institute, Cleveland Clinic, Cleveland, OH [48, 211, 212]

R. Stan Taylor, MD
Professor, Department of Dermatology, University of Texas Southwestern, Dallas, TX [119]

Andrew R. Tegeder, MS
Division of Dermatology, University of Washington School of Medicine, Seattle, WA [120]

Michael D. Tharp, MD
The Clark W. Finnerud, MD Professor and Chair, Department of Dermatology, Rush University Medical Center, Chicago, IL [149]

Diane M. Thiboutot, MD
Professor, Department of Dermatology, College of Medicine, The Pennsylvania State University, Hershey, PA [79, 80]

Bruce H. Thiers, MD
Professor and Chairman, Department of Dermatology and Dermatologic Surgery, Medical University of South Carolina, Charleston, SC [152]

Valencia D. Thomas, MD
Assistant Professor, Department of Dermatology, Section of Dermatologic Surgery & Cutaneous Oncology, Yale University School of Medicine, New Haven, CT [118]

Wynnis Tom, MD
Assistant Professor, Departments of Pediatrics and Medicine (Dermatology), University of California, San Diego, San Diego, CA [195]

Kenneth J. Tomecki, MD
Vice Chairman, Department of Dermatology, Cleveland Clinic, Cleveland, OH [230]

Antonella Tosti, MD
Professor, Department of Dermatology & Cutaneous Surgery, Miller School of Medicine, University of Miami, Miami, FL [89]

Franz Trautinger, MD
Professor and Head, Department of Dermatology and Venereology, Landesklinikum St. Poelten St. Poelten, Austria [35]

Jeffrey B. Travers, MD, PhD
Professor of Dermatology, Pharmacology and Toxicology, Departments of Dermatology, Pharmacology and Toxicology, Indiana University School of Medicine, Indianapolis, IN [177]

Hensin Tsao, MD, PhD
Associate Professor, Department of Dermatology, Harvard Medical School, Boston, MA [124]

Fragkiski Tsatsou, MD, MSc, BSc
Dermatology Resident, Departments of Dermatology, Venereology, Allergology and Immunology, Dessau Medical Center, Dessau, Germany [85]

Erwin Tschachler, MD
Professor of Dermatology and Venereology, Department of Dermatology, Medical University of Vienna, Vienna, Austria [128, 197]

Margaret A. Tucker, MD
Director, Human Genetics Program, Division of Cancer Epidemiology and Genetics, National Cancer Institute, Bethesda, MD [123]

Stephen Tyring, MD, PhD
Clinical Professor, Department of Dermatology, University of Texas Health Science Center, Houston, TX [191]

Selma Ugurel, MD
Professor, Department of Dermatology, University of Würzburg, Würzburg, Germany [125]

Lily Changchien Uihlein, MD, JD
Resident, Department of Dermatology, Harvard Medical School, Boston, MA [198]

Jouni Uitto, MD, PhD
Professor and Chair, Department of Dermatology and Cutaneous Biology, Jefferson Medical College, Philadelphia, PA [63]

Mark A. Unger, MD, CCFP
Private Practice, Toronto, ON, Canada [256]

Robin H. Unger, MD
Clinical Professor, Department of Dermatology, Mount Sinai School of Medicine, New York, NY [256]

Walter P. Unger, MD
Clinical Professor, Department of Dermatology, Mt. Sinai School of Medicine, New York, NY [256]

Anders Vahlquist, MD, PhD
Professor, Department of Medical Sciences, Uppsala University, Uppsala, Sweden [228]

Isabel C. Valencia, MD
Dermatopathology, Dermpath Diagnostics Bay Area, Tampa, FL [216]

L. Valeyrie-Allanore, MD
Department of Dermatology, Université Paris XII, Cedex, France [40]

Nanja van Geel, MD, PhD
Professor, Department of Dermatology, Ghent University Hospital, Ghent, Belgium [75]

Mireille Van Gele, PhD
Department of Dermatology, Ghent University Hospital, Ghent, Belgium [75]

Maurice A.M. van Steensel, MD, PhD
Professor, Dermatology, Maastricht University Medical Center, Maastricht, The Netherlands [50]

Travis W. Vandergriff, MD
Chief Resident, Department of Dermatology, University of Texas Southwestern Medical Center, Dallas, TX [91]

Evelien Verhaeghe, MD
Department of Dermatology, Ghent University Hospital, Ghent, Belgium [75]

Miikka Vikkula, MD, PhD
Maitre de Recherces du F.N.R.S.
Human Molecular Genetics (GEHU)
Christian de Duve Institute,
Université catholique de Louvain,
Brussels, Belgium [172]

John J. Voorhees, MD, FRCP
Professor, Department of
Dermatology, University of
Michigan, Ann Arbor, MI [217]

Justin J. Vujevich, MD
Director, Mohs Surgery, Vujevich
Dermatology Associates, PC,
Pittsburgh, PA [246]

Daniel Wallach, MD
Senior Lecturer, Department of
Dermatology, Hôpital Tarnier-
Cochin, Paris, France [33]

David J. Weber, MD, MPH
Professor of Medicine, Pediatrics, and
Epidemiology, University of North
Carolina, Chapel Hill, NC [180]

Roger H. Weenig, MD, MPH
Adjunct Assistant Professor,
Department of Dermatology,
University of Minnesota,
Minneapolis, MN [158]

Arnold N. Weinberg, MD
Professor, Infectious Disease Unit,
Department of Medicine, Harvard
Medical School, Boston, MA
[178, 179]

Martin A. Weinstock, MD, PhD
Professor, Departments of
Dermatology and Community
Health, Brown University,
Providence, RI [1]

Elliot T. Weiss, MD
Laser & Skin Surgery Center of New
York, New York and Southampton,
NY [252]

Margaret A. Weiss, MD
Department of Dermatology
Johns Hopkins University School of
Medicine, Baltimore, MD [249]

Robert A. Weiss, MD
Associate Professor, Department
of Dermatology, Johns Hopkins
University School of Medicine,
Baltimore, MD [249]

Victoria P. Werth, MD
Professor, Department of
Dermatology, University of
Pennsylvania School of Medicine,
Philadelphia, PA [224]

Lucile E. White, MD
Pearland Dermatology and
DermSurgery Associates, The
Methodist Hospital, Houston, TX
[127]

**Hywel C. Williams, MSc,
PhD, FRCP**
Professor of Dermato-Epidemiology,
Centre of Evidence-Based
Dermatology, University of
Nottingham, Nottingham, UK [4]

Ifor R. Williams, MD, PhD
Associate Professor, Department
of Pathology, School of Medicine,
Emory University, Atlanta, GA [11]

Lynn D. Wilson, MD, MPH
Professor, Vice Chairman and
Clinical Director, Therapeutic
Radiology, Yale School of medicine,
Yale University, New Haven, CT [240]

Karen Wiss, MD
Professor, Department of Medicine
(Dermatology) and Pediatrics,
University of Massachusetts
Medical School, Worcester, MA [192]

Klaus Wolff, MD, FRCP
Professor of Dermatology,
Chairman Emeritus, Department of
Dermatology, Medical University of
Vienna, Vienna, Austria [6]

Stephen E. Wolverton, MD
Theodore Arlook Professor of
Clinical Dermatology, Department
of Dermatology, Indiana University
School of Medicine, Indianapolis,
IN [236]

Sook-Bin Woo, DMD
Associate Professor, Department
of Oral Medicine, Infection and
Immunology, Harvard School of
Dental Medicine, Boston, MA [76]

Gary S. Wood, MD
Johnson Professor and Chairman,
Department of Dermatology,
University of Wisconsin School
of Medicine and Public Health,
Madison, WI [25, 146]

Robert A. Wood, MD
Professor, Department of Pediatrics,
Johns Hopkins University School
of Medicine, Baltimore, MD [229]

David T. Woodley, MD
Professor, Department of
Dermatology, The Keck School of
Medicine, University of Southern
California, Los Angeles, CA [60]

Sophie M. Worobec, MD, FAAD
Associate Professor, Department
of Dermatology, Chicago School
of Medicine, University of Illinois,
Chicago, IL [70]

Mina Yaar, MD
Professor, Department of
Dermatology, Boston University
School of Medicine, Boston, MA
[72, 109]

Albert C. Yan, MD
Associate Professor, Departments
of Pediatrics and Dermatology,
School of Medicine, University of
Pennsylvania, Philadelphia, PA
[130]

Kim B. Yancey, MD
Professor and Chair, Department of
Dermatology, University of Texas
Southwestern Medical Center,
Dallas, TX [57]

Gil Yosipovitch, MD
Professor, Department of
Dermatology, Wake Forest
University School of Medicine,
Winston Salem, NC [103]

Andrea L. Zaenglein, MD
Associate Professor, Departments of
Dermatology and Pediatrics, Penn
State Milton S. Hershey Medical
Center, Hershey, PA [80]

**Mozheh Zamiri, BSc (Hons),
MBChB, MRCP, MD**
Specialist Registrar, Alan Lyell
Centre for Dermatology, Southern
General Hospital, Glasgow, Scotland
[50]

Christos C. Zouboulis, MD, PhD
Professor and Director, Departments
of Dermatology, Venereology,
Allergology and Immunology,
Dessau Medical Center, Dessau,
Germany [85, 166]

Kathryn A. Zug, MD
Professor, Section of Dermatology,
Dartmouth Medical School,
Hanover, NH [13]

Melanie Kingsley, MD
Assistant Professor of Dermatology,
Director of Cosmetic Dermatology
and Laser Surgery, Department of
Dermatology, Indiana University
School of Medicine, Indianapolis,
IN [243]

PREFACE

New knowledge drives medical progress and improves patient care. The rapid growth of this knowledge in skin diseases and skin biology makes publication of the eighth edition of *Fitzpatrick's Dermatology in General Medicine* (DIGM) particularly timely. Forty years ago, the first edition of "*Fitz*" was a critical textbook devoted to providing a comprehensive knowledge of dermatology. The relevance of dermatology to general medicine and the basic science foundations of the specialty were defining elements of the new text. This edition, more than ever, reinforces those earlier goals and is designed to be easily accessible to those interested in the clinical and basic science of dermatology. This reference text also highlights the relevance of dermatology to general internal medicine and other disciplines of medicine and surgery. It is written for experienced clinicians and skin biologists worldwide as well as for those in training.

The online edition adds further textual and illustrative detail to almost all chapters and provides extensive and robust literature citations, many with online links, which are especially useful for those who seek an in-depth understanding of a particular topic. The accompanying CD-ROM contains the figures from the print edition in an easily downloaded format for slide production.

Because of the explosion of new knowledge relevant to dermatology and cutaneous biology, chapters have been extensively revised and new chapters have been added on global dermatologic health, ethnic, and racial considerations for normal and diseased skin, and stem cell science. Medical and surgical therapeutics sections have been greatly expanded to reflect the increased importance of procedural dermatology.

Twenty percent of the chapters have new authorship, drawing from expertise around the world. These authors provide new perspectives and guarantee that the content of the book remains fresh and vital.

Schematic diagrams of clinical and basic science mechanisms and clinical care algorithms have been revised to allow rapid intuitive guidance while retaining accuracy and critical detail. This edition is enhanced with additional clinical figures and new tables that permit a "quick look" at key points in each chapter. Finally, the Parts of the book are designated with different colors, thus allowing the reader to easily find sections of interest.

Validated, well-synthesized, and critically interpreted information is essential to improve the care of patients, to prevent skin disease, and to advance cutaneous biology. The current editors of DIGM have striven to fulfill these goals of the original text.

Lowell A. Goldsmith
Stephen I. Katz
Barbara A. Gilchrest
Amy S. Paller
David J. Leffell
Klaus Wolff

This page intentionally left blank

ACKNOWLEDGMENTS

We thank and salute the nearly 500 authors who contributed to the creation of this new and vibrant eighth edition of *Fitzpatrick's Dermatology in General Medicine* (DIGM). The eighth edition of this classic text reflects the amazing growth in new knowledge in basic and clinical sciences related to the skin and to its relationship with other organ systems. The authors have worked assiduously to integrate this new information within the context of established knowledge. The authors, all respected experts in their disciplines, wrote some of the most extensively referenced chapters available either in print or online. We are deeply grateful to them and their staff for their commitment to this text. Their expertise has created chapters that continue to define the comprehensiveness of this textbook.

We are deeply grateful to our families, who appreciated the importance and immensity of our task. They recognized and accepted that editing this textbook demanded many hours of time and evenings spent with a computer screen rather than with them. We thank them for their support during this all-consuming effort.

The editors were supported by talented and dedicated staff, Renate Kosma, Jacy Bernal, Jaime Zagami, Nilda Reyes, and Grace Camire, each of whom handled the correspondence with over 50 authors. The debt that we owe to these individuals cannot be calculated. Many readers of previous editions and dermatology residents from several training programs painstakingly reviewed and critiqued the seventh edition and provided extremely useful advice on improving the content and the presentation for this new edition.

The staff at McGraw-Hill Medical made this text their highest priority. They were led by our ever vigilant and talented editor, Anne M. Sydor, and our project manager for manuscript production and completion, Sarah M. Granlund; and a most professional production team led by Robert Pancotti and Sherri Souffrance in New York and by Sandhya Joshi in India.

A major hallmark and the fresh look for this eighth edition are the hundreds of new figures that required meticulous attention by authors and a creative design and art team at Dragonfly Media Group. For their talented and effective partnership we are forever grateful.

Lowell A. Goldsmith
Stephen I. Katz
Barbara A. Gilchrest
Amy S. Paller
David J. Leffell
Klaus Wolff

This page intentionally left blank

PART 1 Introduction



General Considerations

Chapter 1 :: The Epidemiology and Burden of Skin Disease

:: Martin A. Weinstock & Mary-Margaret Chren

Scientists in health-related fields focus on phenomena at different levels. For laboratory scientists, the focus is at the molecular, cellular, or organ system level; for clinical scientists, the focus is on the patient; and for public health practitioners, the focus is on the population. Epidemiology is the basic science of public health.

Epidemiology has many subdivisions and offshoots. Often the *epidemiology of a disease* in a clinical review refers primarily to its frequency and distribution in the population and estimates of its morbidity and mortality. These data are derived by descriptive epidemiology. Case-control, cohort, and cross-sectional studies may seek to identify risk factors and causes of disease and form the core of analytical epidemiology. Evaluations of public health interventions (experimental epidemiology) constitute the third major branch of classic epidemiology. The basic principles of epidemiology have found broad application in many areas, including understanding the public health implications of naturally occurring and synthetic compounds (molecular epidemiology), the complex interactions of genetic and environmental factors in disease (genetic epidemiology), the formulation of better diagnostic and treatment strategies for patients based on available evidence (clinical epidemiology), and the structuring of health care delivery for better outcomes and greater efficiency (health services research). The reader is referred to other sources for a more detailed discussion of various topics in dermatoepidemiology.[1–3]

TYPES OF EPIDEMIOLOGIC STUDIES

Three of the many types of epidemiologic studies are mentioned here because of their prominence in epidemiologic research. The randomized, controlled trial is a particularly rigorous type of study appropriate to the evaluation of public health interventions. In general, the intervention is performed on a random sample of the study population, and the entire study population is then observed for the occurrence of the outcome in question. The random assignment of intervention allows the more rigorous application of many statistical techniques and reduces the potential for bias. Elimination of biases permits these studies to evaluate the efficacy and impact of an intervention more accurately than trials that do not assign the intervention randomly. Standards for reporting have been published[4] (http://www.consort-statement.org, accessed Jul 7, 2010) and adopted by leading dermatology journals to improve assessment of their validity and their use in subsequent systematic reviews[5] (see Chapter 2).

When evaluating risk factors for disease, it is frequently impossible to assign the risk factor randomly. Hence, inference is based on observational studies. In classical cohort studies, a group with exposure to the risk factor and a group without are chosen and observed over time. Occurrences of the study outcome

are counted and compared between groups. Although more vulnerable to bias than randomized trials, cohort studies, in which exposure to the risk factor is known well before the study outcome is knowable, avoid some potentially serious biases. In a cohort study, the incidence of the study outcome can be measured directly in each group, and the relative risk can be measured directly as the ratio of the incidence between the two groups.

Cohort studies often are quite expensive to conduct because they require following a large population over time and may be impossible if the outcome being studied is uncommon. Hence, observational studies often use the case-control approach, in which cases with the outcome being studied and appropriate controls are investigated to determine their past exposure to the risk factor. Relative risks can be estimated by this approach, although incidence of the disorder cannot. Readers are referred to standard texts for more detail regarding epidemiologic study designs.[6] Case-control and cohort study methods in dermatology also have been reviewed.[7–9]

BIAS AND CONFOUNDING

The problem with inference from observational studies is that one may be led to draw erroneous conclusions. In particular, an association that is found between an exposure and a disease may be an artifact due to one or more of the many forms of bias or confounding. Proper inference regarding cause and effect requires understanding these possible artifacts and their potential impacts.[10]

Selection bias occurs when factors that lead to selection of the study population affect the likelihood of the outcomes or exposures evaluated. For example, a case-control study of cutaneous lymphoma may recruit its cases from sources that typically include a high proportion of referred patients. If controls are recruited from a local clinic population, their socioeconomic status and location of residence may be substantially different from those of the cases simply due to the method of recruitment. Under these circumstances, an association of cutaneous lymphoma with occupation may be noted. It then becomes important to note that the observed association may be due not to a carcinogenic chemical in the workplace but rather to the method by which cases and controls were selected. Similarly, if one were conducting a cohort study of the effect of breast-feeding on the risk of atopic dermatitis, it would be important to select breast-fed and bottle-fed infants from similar environments.

Information bias occurs when the assessment of exposure or outcome may differ between the groups being compared. People who were exposed to a publicized environmental toxin may be more likely to seek care for minor symptoms or signs (and hence be more likely to be diagnosed and treated) than those who were not so exposed, even if the exposure had no biologic effect. Similarly, people who are diagnosed with a disease may be more likely to recall past exposures than healthy controls.

Confounding occurs when an observed association (or lack thereof) between exposure and disease is due to the influence of a third factor on both the exposure and the disease. For example, people who use sunscreens may have more intense sun exposure than those who do not, and intense sun exposure is one cause of melanoma. Hence, observational studies may mistakenly conclude that sunscreen use is a cause of melanoma when the observed association is due to sunscreen use serving as an indicator of a lifestyle involving intense sun exposure.

CAUSAL INFERENCE

Key issues in the public health arena often must rely on observational data for inferring cause and effect; in these situations, the validity and generalizability of the individual studies and of the totality of the evidence must be carefully examined. The following criteria generally are applied for causal inference when an association is found. Although they are described for inferring causality between an exposure and a disease, they are more generally applicable to epidemiologic causal inference.

TIME SEQUENCE

The exposure must precede the disease. This concept is simple and obvious in the abstract but sometimes difficult to establish in practice because the onset of disease may precede the diagnosis of disease by years, and the timing of exposure is often not well defined.

CONSISTENCY ON REPLICATION

Replication of the observed association is key and provides the strongest evidence if the replications are many and diverse and with consistent results. The diversity of the replications refers to varied contexts as well as to study designs with different potential weaknesses and strengths.

STRENGTH OF ASSOCIATION

True causal relationships may be strong (i.e., high relative risk) or weak, but artifactual associations are unlikely to have a high relative risk. If the association between factors x and y is due to the association of both with confounding variable z, the magnitude of the association between x and y always will be less than the magnitude of the association of either with z.

GRADED ASSOCIATION

Also described as *biologic gradient*, this criterion refers to an association of the degree of exposure with occurrence of disease, in addition to an overall association of presence of exposure with disease. This dose-response relation may take many forms, as degree of exposure

may, for example, refer to intensity, duration, frequency, or latency of exposure.

COHERENCE

Coherence refers to plausibility based on evidence other than the existence of an association between this exposure and this disease in epidemiologic studies. Coherence with existing epidemiologic knowledge of the disease in question (e.g., other risk factors for the disease and population trends in its occurrence) and other disorders (including but not limited to related disorders) supports inference. Coherence with existing knowledge from other fields, particularly those relevant to pathogenesis, is critically important when those fields are well developed. It may involve direct links, which are preferred, or analogy. Just as observations in the laboratory assume greater significance when their relevance is supported by epidemiologic data, the reverse is equally true.

EXPERIMENT

Experimental support is critical when feasible. As noted in Section "Types of Epidemiologic Studies," the strongest inferences derive from results of randomized trials, although other experimental designs and quasi-experimental designs may contribute useful evidence.

More detailed discussions of these issues are available.[11,12]

INVESTIGATION OF DISEASE OUTBREAKS

Although outbreaks of disease vary tremendously, use of a standard framework for investigation is important to address the public health issues efficiently (see Chapter 4). The Centers for Disease Control and Prevention has outlined this framework as a series of ten steps, which are described in more detail at http://www.cdc.gov.

1. *Preparation*. Before initiating fieldwork, background information on the disease must be gathered, and appropriate interinstitutional and interpersonal contacts should be made.
2. *Confirm the outbreak*. Publicity, population changes, or other circumstances may lead to an inaccurate perception that more cases than expected have occurred. Hence, local or regional data should be sought to confirm the existence of an increased frequency of disease.
3. *Confirm the diagnosis*. Symptoms and signs of persons affected should be determined and laboratory findings confirmed, perhaps with the assistance of reference laboratories.
4. *Establish a case definition, and find cases*. Careful epidemiologic investigation will involve precise and simple case definitions that can be applied in the field. Efforts to find and count additional cases beyond those reported initially are key to defining the scope of the outbreak.
5. *Establish the descriptive epidemiology*. The cases can now be characterized in terms of *time*, including development of an epidemic curve that describes the changes in magnitude of the outbreak; *place*, including mapping the distribution of cases; and *person*, the demographic and potential exposure characteristics of cases.
6. *Develop hypotheses*. On the basis of the data gathered in steps 1 through 5 and the input of other individuals, plausible hypotheses about causality can be developed for further evaluation.
7. *Conduct analytical epidemiologic investigations*. If the data gathered do not yet clearly prove a hypothesis, cohort and case-control investigations can be conducted to verify or disprove the hypotheses.
8. *Revise hypotheses and obtain additional evidence as needed*. Steps 6 and 7 are repeated, each building on prior iterations, to establish the causal chain of events.
9. *Implement control measures*. As soon as the causal chain of events is understood, prevention and control measures are initiated.
10. *Communicate results*. An outbreak investigation is not complete until the results have been appropriately communicated to the relevant communities.

DESCRIPTIONS OF DISEASE IN POPULATIONS: MEASURES OF DISEASE BURDEN

No single number can completely describe the burden of skin disease because that burden has many dimensions and because the term *skin disease* itself is rather ambiguous. Many disorders with substantial morbidity or mortality, such as melanoma or lupus erythematosus, affect multiple organ systems. The degree of skin involvement may vary widely from patient to patient and within the same patient from time to time. Diseases not typically treated by dermatologists, such as thermal burns, often are excluded from estimates of the burden of skin disease even though they primarily involve the skin. In addition, some diseases treated most often by dermatologists may be classified in a different category by funding agencies or others [e.g., melanoma is classified as an oncologic disorder as opposed to a disease of the skin by the National Institutes of Health and by the *International Classification of Diseases*, (http://www.who.int/classifications/apps/icd/icd10online/, accessed Jul 7, 2010) even though it almost always arises in the skin]. Organ systems are interrelated, and the overlap is sufficiently great that any definition of skin disease is necessarily arbitrary, and any global estimate of the public health burden of these diseases is therefore open to challenge. Typical

measures of disease burden are discussed in the following sections.

MORTALITY

Mortality is a critical measure of disease impact. Death certification is universal in the United States, and the *International Classification of Diseases* code of the underlying cause of each death is recorded. For the year 2006, there were 16,163 deaths reported as due to "skin disease" in the United States, of which most were due to melanoma (Table 1-1). Additional major causes included other skin cancers (primarily keratinocyte carcinomas), infections of the skin, and skin ulcers (primarily decubitus ulcers). Bullous disorders represented less than 2% of these deaths. The total number of skin disease deaths, of course, depends critically on the definition of skin disease, as noted in Section "Descriptions of Disease in Populations: Measures of Disease Burden."

In addition to the total number of deaths, mortality typically is expressed as an age-adjusted rate to facilitate comparisons among populations with different age distributions. Statements of age-adjusted rates of mortality (or other results standardized by age) should be accompanied by an indication of the standard used in the adjustment to avoid potentially misleading inferences. For example, when 1998 melanoma mortality rates are estimated using the 2000 US population standard, the result is 50% higher than when the 1940 US standard population is used (1.8 vs. 1.2 per 100,000 per year for women and 4.1 vs. 2.7 per 100,000 per year for men). Similarly, when years of potential life lost are reported, the reader must be wary of different definitions that may be applied. In one analysis, a decline in years lost from melanoma was noted by one definition that was not observed with another.[13]

TABLE 1-1
Skin Disease Deaths, United States, 2006

Disease	Deaths (*n*)
Cancers	12,301
Melanoma	8,441
Genital	1,126
Lymphoma	91[a]
Other cancers	2,643[a] (primarily basal and squamous cell carcinoma)
Ulcers	1,496
Infections	1,793
Bullous disorders	269
Other causes	304
Total	16,163

[a]We estimate that approximately one-half of keratinocyte carcinoma deaths are misclassified squamous cell carcinomas arising from mucosal surfaces in the head and neck[16] and that cutaneous lymphoma deaths are underestimated by a factor of 2 (see text). [Adapted from http://wonder.cdc.gov/ (verified Apr 27, 2010).]

Careful analyses of mortality include assessment of the validity of the data. Melanoma mortality statistics appear to be reasonably accurate.[14,15] However, deaths from keratinocyte carcinomas are overestimated by a factor of 2 (mostly due to the erroneous inclusion of mucosal squamous cell carcinomas of the head and neck region),[16,17] and conventional estimates of deaths from cutaneous lymphoma miss about half of the actual deaths.[18]

INCIDENCE

Incidence refers to the number of new cases of a disorder. Mortality is low for most skin diseases; hence, incidence may be a more useful measure for the assessment of burden of skin disease. However, many features of skin diseases make their incidence difficult to measure. For example, for many skin disorders, there are no diagnostic laboratory tests, and, in fact, some disorders may evade physician diagnosis (e.g., allergic reactions). Incidence for reportable communicable diseases in the United States is published periodically based on reports to health departments, although underreporting of skin diseases due to failure to present for medical care or to misdiagnosis is a concern (Table 1-2). Incidences of melanoma and cutaneous lymphoma have been published based on data from a system of nationwide cancer registries, yet underreporting remains a potential concern with these data.[19,20] Special surveys have been conducted and administrative datasets analyzed to estimate incidence of other disorders, such as keratinocyte carcinomas, although a system of sentinel registries would improve nationwide assessment.[21,22] For some diseases unlikely to evade medical detection due to their severity, such as toxic epidermal necrolysis, efforts to estimate incidence have met with considerable success.[23,24] Specific contexts that permit more accurate incidence estimates include the workplace; for example, where occupational skin disease is a prevalent problem.[25]

COHORT PATTERNS

Cohort patterns of changes in mortality or incidence typically are observed when exposures determined in childhood predict frequency of disease throughout the life span. A classic example is melanoma mortality, for which sun exposure in childhood is an important determinant. A birth cohort is defined as the group of individuals born within a defined (e.g., 10-year) period. Melanoma mortality generally increases as a power function of age within a birth cohort. Until recent decades, each successive birth cohort had higher risk than its predecessor; hence, the curves of mortality versus age were shifted upward. Thus, the cross-sectional relationship of mortality versus age and the increase in mortality risk during most of the twentieth century followed a cohort pattern. For many countries in the past several decades a decline in melanoma mortality has been observed in younger age groups

TABLE 1-2
New Cases of Selected Reportable Diseases in the United States

	1940	1950	1960	1970	1980	1990	2000	2008
Acquired immunodeficiency syndrome	NA[a]	—	—	—	—	41,595	40,758	39,202
Anthrax	76	49	23	2	1	0	1	0
Congenital rubella	—	—	—	77	50	11	9	0
Congenital syphilis	—	—	—	—	—	3,865	529	227
Diphtheria	15,536	5,796	918	435	3	4	1	0
Gonorrhea	175,841	286,746	258,933	600,072	1,004,029	690,169	358,995	229,315
Hansen disease	0	44	54	129	223	198	91	72
Lyme disease	—	—	—	—	—	—	17,730	26,739
Measles	291,162	319,124	441,703	47,351	13,506	27,786	86	132
Plague	1	3	2	13	18	2	6	1
Rocky Mountain spotted fever	457	464	204	380	1,163	651	495	2,276
Syphilis (primary and secondary)	—	23,939	16,145	21,982	27,204	50,223	5,979	12,195
Toxic shock syndrome	—	—	—	—	—	322	135	66
Tuberculosis[b]	102,984[c]	121,742[c]	55,494	37,137	27,749	25,701	16,377	9,795
US population (millions)	132	151	179	203	227	249	281	304

[a]NA = data not available.
[b]Reporting criteria changed in 1975.
[c]Data include newly reported active and inactive cases.
Adapted from Weinstock MA, Boyle MM: Statistics of interest to the dermatologist. In: *The Year Book of Dermatology and Dermatologic Surgery, 2009*, edited by B Theirs, PG Lang. Philadelphia, Elsevier Mosby, 2009, p. 53-68.

despite an increase in older age groups, suggesting a lower baseline in these mortality-versus-age curves for recent cohorts and hence a likely future decline in overall melanoma mortality.

PREVALENCE

Prevalence refers to the proportion of the population affected by a disorder. Because many skin diseases are nonlethal yet chronic, prevalence is a particularly important measure of frequency in dermatology. Population-based data on prevalence of skin disease for the United States were obtained in the first Health and Nutrition Examination Survey, which was conducted in the early 1970s.[26] Despite its limitations, this study was notable because the sample was representative of the general US population, the number surveyed was large (over 20,000), and the entire surveyed population was examined by physicians (primarily dermatology residents), so the resulting estimates were not dependent on patients' ability or inclination to seek medical care. Indeed, one of the findings of the survey was that nearly one-third of those examined had one or more skin conditions judged to be significant enough to merit a visit to a physician. The most common conditions and their age- and gender-specific prevalence are indicated in Table 1-3 and Fig. 1-1. A similar survey in the United Kingdom of over 2,000 Londoners in 1975 noted that almost one-quarter of adults had a skin condition serious enough to warrant medical care.[27] Other efforts have focused on obtaining prevalence estimates of specific conditions with special surveys.[28,29]

LIFETIME RISK

Lifetime risks for certain disorders are quoted commonly, although their validity can be questioned. Lifetime risk can be measured only in retrospect, and even then it reflects competing causes of mortality in addition to incidence. It is commonly quoted for disorders such as cutaneous malignancies that are changing substantially in incidence, yet those changes are frequently ignored in its calculation, and, in any case, projections of future changes are quite speculative and may be misleading.[30]

TABLE 1-3
Prevalence of Skin Conditions—United States, 1971–1974[a]

	Male	Female	Both Sexes
Dermatophytosis	131	34	81
Acne (vulgaris and cystic)	74	66	70
Seborrheic dermatitis	30	26	28
Atopic dermatitis/eczema	20	18	19
Verruca vulgaris	9	6	8
Malignant tumors	6	5	6
Psoriasis	6	5	6
Vitiligo	6	4	5
Herpes simplex	4	5	4

[a]Cases per 1,000 population.
From Skin conditions and related need for medical care among persons 1–74 years, United States, 1971–1974. *Vital Health Stat* [11], No. 212, US Department of Health, Education, and Welfare, November 1978.

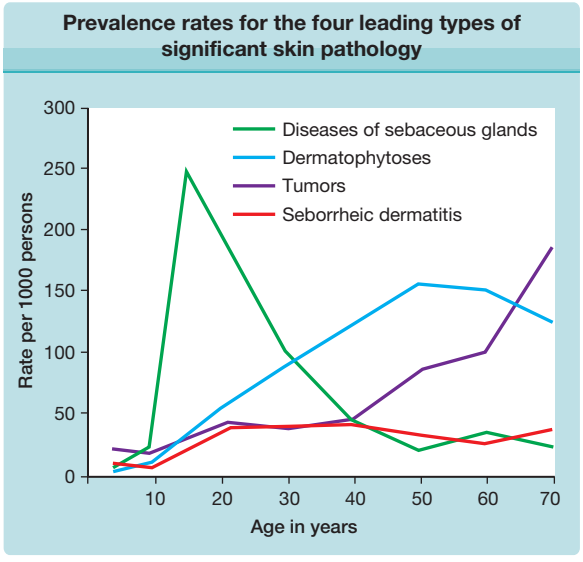

Figure 1-1 Prevalence rates for the four leading types of significant skin pathology among persons 1–74 years, by age, in the United States, 1971–1974.

NUMBER OF PHYSICIAN VISITS

Number of physician visits for a condition is one practical measure of its frequency that may reflect its incidence, prevalence, and severity, as well as access to health care. Table 1-4 lists frequencies of dermatologist and other physician outpatient visits for some of the most common skin conditions. A feature of this measure of disease frequency is its direct relation to expenditures for care of the disease.

OTHER MEASURES OF MORBIDITY: CONCEPTUAL ISSUES

The consequences of skin disease for a population (or the *burden of disease*) are complex; a practical conceptu-

TABLE 1-4
Visits to Non-Federal Office-Based Physicians in the United States, 2006[a]

	Type of Physician		
Diagnosis	Dermatologist[b]	Other	All Physicians
Acne vulgaris	2,217 (8.8%)	[b]	3,274 (0.4%)
Eczematous dermatitis	3,183 (12.6%)	5,377 (0.6%)	8,560 (1.0%)
Warts	1,041 (4.1%)	1,361 (0.2%)	2,401 (0.3%)
Skin cancer	2,672 (10.6%)	928 (0.1%)	3,599 (0.4%)
Psoriasis	692 (2.7%)	[b]	737 (0.1%)
Fungal infections	[b]	1,759 (0.2%)	2,002 (0.2%)
Hair disorders	741 (2.9%)	[b]	1,571 (0.2%)
Actinic keratosis	2,432 (9.6%)	[b]	2,717 (0.3%)
Benign neoplasm of the skin	1,293 (5.1%)	[b]	2,170 (0.2%)
All disorders	25,256 (100%)	876,698 (100%)	901,954 (100%)

[a]Estimates in thousands.
[b]Figure does not meet standard of precision.
Note: Percentage of total visits is in parentheses.
Adapted from Weinstock MA, Boyle MM: Statistics of interest to the dermatologist. In: *The Year Book of Dermatology and Dermatologic Surgery, 2009*, edited by B Theirs, PG Lang. Philadelphia, Elsevier Mosby, 2009, p. 53-68.

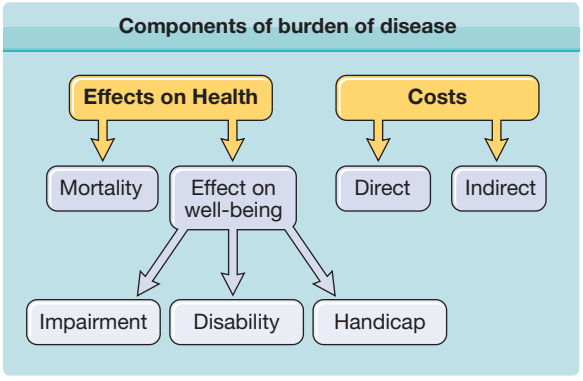

Figure 1-2 Components of burden of disease.

alization is contained in Fig. 1-2. Broadly, components of burden of skin disease are those related to effects on health or costs. Aspects of health include mortality and effects on well-being, including those related to the impairment, disability, or handicap a disease causes. For example, a patient with psoriasis may have thickening and scaling of the palms (a bodily impairment), which may cause disability (e.g., use of the hands), dysfunction (role at work), and effects on quality of life. Costs are either direct (for which funds can be paid) or indirect (for which charges are not routinely assigned, such as lost income because of disease).[31]

The measurement of burden of skin disease is challenging, in part because these conditions typically do not cause mortality and do not result in changes in easily measured laboratory tests. The most important gauges of skin disease status and progression (i.e., the physical examination and patients' reports) can be difficult to measure and compile; in most cases patients' reports of the effects of skin disease on their activities and well-being are crucial for determining the overall consequences of those diseases. The measurement challenges are heightened because people understand and value these aspects of health quite differently due to age, gender, cultural conceptions, or access to health care.

The measurement of nonfatal consequences of disease is the subject of much international scientific and political attention (http://www.who.int/healthinfo/global_burden_disease/en/, accessed Mar 5, 2010, and Chapter 3). An important point for dermatology is that patients' experiences of illness may not be adequately assessed with global measures that focus on single aspects of health, or which were developed without substantial input from patients.[32] For example, skin diseases that are visible and affect appearance may result in social stigma and mood changes, which would not be measured with metrics that are based on dysfunction.

OTHER MEASURES OF MORBIDITY: ISSUES IN QUANTIFICATION

Like all assays, measures of the nonfatal consequences of diseases must be accurate. For example, they must be *reliable* in that the variability in results among subjects who truly differ should be greater than the variability when a stable subject is examined repeatedly. The measures must have evidence of *validity*, which refers to the extent to which an instrument measures what it is supposed to measure and does not measure something else. Health outcome measures also must demonstrate *responsiveness*, the ability to detect clinical change. Furthermore, even when an accurate instrument exists, the clinical significance or *interpretability* of scores or changes in scores often cannot be judged until the tool is used widely and scores are available for many patients with disease of varying severity.[33]

CLINICAL SEVERITY OF DISEASE

A significant challenge for the development of clinimetric measures is developing a consensus among clinicians about the specific features of an individual disease that are important to include in such measures. Substantial progress in the empiric derivation of these features has been made for disease severity measures in certain skin diseases.[34,35] The extent to which a specific skin disease disrupts the skin itself is related both to the percentage of body surface area involved and to physical signs of the eruption, such as the amount of induration and the degree of scale. Given the pleomorphism of skin eruptions, most dermatologic severity-of-disease measures are disease-specific, and for common skin conditions, multiple instruments are often available. Among the most studied instruments to measure clinical severity of disease are the Psoriasis Area and Severity Index (PASI)[36] and the Severity Scoring of Atopic Dermatitis (SCORAD) index.[37] With the PASI, severity of disease is assessed by judgment of the degree of involvement of four body regions with signs of erythema, induration, and desquamation. The SCORAD index combines an assessment of disease area with six clinical signs of disease intensity (scales to measure pruritus and sleep loss also can be included). Standardized reviews of severity measures can be helpful for informing a consensus as well as focusing futures studies; such reviews have recently been published of 20 measures of atopic dermatitis[38] and 53 measures of psoriasis.[39]

PATIENT-REPORTED OUTCOMES

As noted above, patients' reports of their experiences of disease and health care are particularly important for assessing the course of chronic diseases (like most skin diseases). Table 1-5 includes typical aspects of patients' experience that are measured in health care research.

The effects of disease on patients' quality of life can be assessed with generic instruments (which permit comparisons of effects in patients with different diseases), skin-specific instruments (which permit comparisons of patients with different skin diseases), and, more uncommonly, condition-specific instruments (which permit comparisons of patients with the same skin disease). Although more specific instruments may assess aspects of a disease that would be missed with

TABLE 1-5
Typical Instruments Used to Measure Patient Reports

Domain	Typical Instrument(s)	Comment
Overall quality of life	Medical Outcomes Study Short-Form instruments (SF-36)[40] and (SF-12)[41]	36 or 12 items; commonly used in clinical research; interpretable scores
Skin-related quality of life	Dermatology Life-Quality Index[42] Skindex-29[43], Skindex-16[44]	10 items, most commonly used, focuses on functioning 29 or 16 items, focuses on emotional effects, symptoms, and functioning
Disease-specific severity	Patient-Oriented Eczema Measure (POEM)[45], Self-Administered Psoriasis Area and Severity Index (SAPASI)[46]	Correlate well with clinician measures
Symptoms: pruritus	Itch Severity Scale[47], Pruritus-Specific Quality-of-Life Instrument[48]	Demonstrate promising measurement properties
Patient satisfaction	Consumer Assessment of Healthcare Providers and Systems (CAHPS) survey[49]	Correlates with adherence, quality of life, and quality of care
Patient preferences	Utilities[50], Willingness to Pay[51]	Correlations among different measures of preferences can be weak

generic tools, both generic and specific tools contribute unique information to a "snapshot" of a patient's overall health-related quality of life. Substantial progress has been made in the development and testing of patients' reports of the effects of their skin diseases on their activities and quality of life. Although quality of life is the patient-reported outcome most often measured, patients' reports of symptoms, satisfaction with health care, and preferences for health states are other examples. Data continue to be accumulated about the performance of these instruments (including the use of sophisticated psychometric methods and the interpretation of their scores[52]). On a national level, to develop a core set of questions and metrics and to create item banks and repositories of items that perform well using modern analytic techniques, the National Institutes of Health has recently initiated the Patient-Reported Measurement Information System (PROMIS, http://www.nihpromis.org/).

A utility is a numeric measure of the value a patient places on a given health state compared with other health states. In the measurement of utilities, a variety of procedures are used (such as visual analog scales and time tradeoff exercises) to assign a numerical value (or utility) to health states. This value reflects patients' preferences for the health states, in which 1.0 represents perfect health and 0.0 represents death. Utilities are advantageous because they permit the incorporation of patient preferences into medical care decisions. Also, because they describe improvements in morbidity with a single weighted metric, utilities are used for the evaluation of complex tradeoffs such as the calculation of cost-effectiveness, in which the costs of treatments are compared with the values of the health states they make possible. However, utilities are controversial because they can be difficult to measure and can vary among patients in unpredictable ways. An increasing number of studies exist that formally measure utilities of patients with skin diseases.[50]

COSTS

Costs of skin disease depend on the perspective from which they are measured, because the costs to insurers and patients may be quite different from the overall cost to society. Because most skin diseases are chronic and are cared for in the outpatient setting, estimation of both their monetary and intangible costs is difficult. Costs for individual skin conditions have been calculated[53], and therapies have been evaluated in relation to their benefits and effectiveness.[54] In addition, overall direct and indirect cost to payers, patients, and society of 22 skin diseases have been reported.[55]

QUALITY OF CARE IN DERMATOLOGY

Health services research uses many scientific methods from epidemiology, clinical epidemiology, and the quantitative social sciences to study and improve the quality of health care. From the perspective of health services research, access to care, the processes involved in the provision of care, the particular therapeutic interventions, as well as patient and provider characteristics, are all determinants of the quality of care. Studies of both the effectiveness of care (i.e., outcomes of health care as it is usually practiced) and the efficacy of interventions (i.e., the results of interventions implemented in the idealized circumstances of a randomized clinical trial) are important. Many of the examples cited earlier demonstrate a sharpened focus in dermatology on accurate measurement of the clinical encounter. This capacity to measure the progress of chronic diseases and their care will permit rigorous efforts to evaluate and improve the quality of that care.

KEY REFERENCES

Full reference list available at www.DIGM8.com

DVD contains references and additional content

1. Barzilai DA et al: Dermatoepidemiology. *J Am Acad Dermatol* **52**:559, quiz 574, 2005
10. Sackett DL: Bias in analytic research. *J Chron Dis* **32**:51, 1979
12. Hill AB: Environment and disease: Association or causation? *Proc R Soc Med* **58**:295, 1965
38. Schmitt J, Langan S, Williams HC: What are the best outcome measurements for atopic eczema? A systematic review. *J Allergy Clin Immunol* **120**(6):1389-1398, 2007
39. Spuls PI et al: How good are clinical severity and outcome measures for psoriasis?: Quantitative evaluation in a systematic review. *J Invest Dermatol* **130**(4):933-943, 2010
52. Both H et al: Critical review of generic and dermatology-specific health-related quality of life instruments. *J Invest Dermatol* **127**(12):2726-2739, 2007
55. Bickers DR et al: The burden of skin diseases: 2004 a joint project of the American Academy of Dermatology Association and the Society for Investigative Dermatology. *J Am Acad Dermatol* **55**(3):490-500, 2006

Chapter 2 :: Evidence-Based Dermatology

:: Michael Bigby, Rosamaria Corona, & Moyses Szklo

EVIDENCE-BASED MEDICINE AT A GLANCE

- Evidence-based medicine (EBM) is the use of the best current evidence in making decisions about the care of individual patients.
- EBM is predicated on asking clinical questions, finding the best evidence to answer the questions, critically appraising the evidence, applying the evidence to the treatment of specific patients, and saving the critically appraised evidence.
- The EBM approach is most appropriate for frequently encountered conditions.
- Results from well-designed clinical studies involving intact patients are at the pinnacle of the hierarchy of evidence used to practice EBM.
- Recommendations about treatment, diagnosis, and avoidance of harm should take into account the validity, magnitude of effect, precision, and applicability of the evidence on which they are based.

WHAT IS "THE BEST EVIDENCE?"

The acceptance of evidence-based medicine (EBM) in the specialty of dermatology has been slow and reluctant. The term and principles are understood by few and misunderstood by many. EBM is perceived as an attempt to cut costs, impose rigid standards of care, and restrict dermatologists' freedom to exercise individual judgment. Practicing EBM in dermatology is hampered by the continued belief among dermatologists that clinical decisions can be guided by an understanding of the pathophysiology of disease, logic, trial and error, and nonsystematic observation.[7,8] It is hampered also by a lack of sufficient data in many areas. As with EBM in general, therapy is often primarily emphasized; however, evidence-based approaches to diagnosis and avoidance or evaluation of harm are also important considerations.

Practicing EBM is predicated on finding and using the best evidence. Potential sources of evidence include knowledge regarding the etiology and pathophysiology of disease, logic, personal experience, the opinions of colleagues or experts, textbooks, articles published in journals, and systematic reviews. An important principle of EBM is that the quality (strength) of evidence is based on a hierarchy. The precise hierarchy of evidence depends on the type of question being asked (Table 2-1).[9] This hierarchy consists of results of well-designed studies (especially if the studies have findings of similar magnitude and direction, and if there is statistical homogeneity among studies), results of case series, expert opinion, and personal experience, in descending order.[6,8] The hierarchy was created to encourage the use of the evidence that is most likely to be accurate and useful in clinical decision-making. The ordering in this hierarchy has been widely discussed, actively debated, and sometimes hotly contested.[10]

A systematic review is an overview that answers a specific clinical question; contains a thorough, unbiased search of the relevant literature; uses explicit criteria for assessing studies; and provides a structured presentation of the results. A systematic review that uses quantitative methods to summarize results is a meta-analysis.[11,12] A meta-analysis provides an objective and quantitative summary of evidence that is

TABLE 2-1
Grades of Evidence[a,b]

Grade	Level of Evidence	Therapy/Harm	Diagnosis
A	1a	Systematic review (with homogeneity[c]) of RCTs	Systematic review (with homogeneity) of level 1 (see column 2) diagnostic studies, or a CPG validated on a test set.
	1b	Individual RCT (with narrow confidence intervals)	Independent blind comparison of an appropriate spectrum of consecutive patients, all of whom have been evaluated by both the diagnostic test and the reference standard.
	1c	All or none[d]	Very high sensitivity or specificity.
B	2a	Systematic review (with homogeneity) of cohort studies	Systematic review (with homogeneity) of level 2 or better (see column 2) diagnostic studies.
	2b	Individual cohort study [including low-quality RCT (e.g., <80% follow-up)]	Independent blind comparison but either in nonconsecutive patients or confined to a narrow spectrum of study individuals (or both), all of whom have been evaluated by both the diagnostic test and the reference standard or a diagnostic CPG not validated in a test set.
	2c	"Outcomes" research[e]	
	3a	Systematic review (with homogeneity) of case-control studies	Systemic review (with homogeneity) of 3b (see column 2) and better studies.
	3b	Individual case-control study	Independent blind comparison of an appropriate spectrum, but the reference standard was not applied to all study patients.
C	4	Case series (and poor-quality cohort and case-control studies)	Reference standard was not applied independently or not applied blindly.
D	5	Expert opinion without explicit critical appraisal, or based on physiology, bench research, or logical deduction.	

CPG = clinical practice guideline, a systematically developed statement designed to help practitioners and patients make decisions about appropriate health care for specific clinical circumstances; RCT = randomized controlled clinical trial.
[a]These levels were generated in a series of iterations among members of the NHS R&D Centre for Evidence-Based Medicine (Chris Ball, Dave Sackett, Bob Phillips, Brian Haynes, and Sharon Straus). For details see Levels of Evidence and Grades of Recommendation, http://www.cebm.net/levels_of_evidence.asp, accessed May 2001.
[b]Recommendations based on this approach apply to "average" patients and may need to be modified in light of an individual patient's unique biology (e.g., risk, responsiveness) and preferences about the care he or she receives.
[c]*Homogeneity* means lacking variation in the direction and magnitude of results of individual studies.
[d]*All or none* means interventions that produced dramatic increases in survival or outcome, such as the use of streptomycin to treat tubercular meningitis.
[e]Outcomes research includes cost-benefit, cost-effectiveness, and cost-utility analyses.

amenable to statistical analysis.[11] Meta-analysis is credited with allowing the recognition of important treatment effects by combining the results of small trials that individually lacked the power to demonstrate differences among treatments. For example, the benefits of intravenous streptokinase in treating acute myocardial infarction were recognized by means of a cumulative meta-analysis of smaller trials at least a decade before this treatment was recommended by experts and before it was demonstrated to be efficacious in large clinical trials.[13,14] Meta-analysis has been criticized because of the discrepancies between the results of meta-analysis and those of large clinical trials.[14–17] For example, results of a meta-analysis of 14 small studies of the use of calcium to treat preeclampsia showed a benefit to treatment, whereas a large trial failed to show a treatment effect.[14] The frequency of such discrepancies ranges from 10% to 23%.[14] Discrepancies can often be explained by differences in treatment protocols, heterogeneity of study populations, or changes that occur over time.[14]

Publication bias is an important concern regarding systematic reviews. It results when factors other than the quality of the study are allowed to influence its acceptability for publication. Several studies have shown that factors such as sample size, direction and statistical significance of findings, and investigators' perceptions of whether the findings are "interesting" are related to the likelihood of publication.[18,19]

For example, in a study by Dickersin et al, the reasons given by investigators that results of completed studies were not published included "negative results" (28%), "lack of interest" (12%), and "sample size problems" (11%).[18] Results of studies with small samples are

less likely to be published, especially if they have negative results.[18,19] This type of publication bias jeopardizes one of the main goals of meta-analysis (i.e., an increase in power through pooling of the results of small studies). Creation of study registers and advance publication of research designs have been proposed as ways to prevent publication bias.[20,21] Publication bias can be detected by using a simple graphic test (funnel plot) or by several other statistical methods.[22,23] In addition, for many diseases, the studies published are dominated by drug company-sponsored trials of new, expensive treatments. The need for studies to answer the clinical questions of most concern to practitioners is not addressed because sources of funding are inadequate.

Not all systematic reviews and meta-analyses are equal. A systematic review can be only as good as the clinical trials that it encompasses. The criteria for critically appraising systematic reviews and meta-analyses are shown in eTable 2-1.1 in online edition. Detailed explanations of each criterion are available.[11,24]

The type of clinical study that constitutes best evidence is determined by the category of question being asked. Questions about therapy and prevention are best addressed by RCT.[11,24–26] Questions about diagnosis are best addressed by cohort studies.[11,24,27,28] Cohort studies, case-control studies, and postmarketing surveillance studies best address questions about harm.[11,24,29] RCT are a good source of evidence about the harmful effects of interventions for adverse events that occur frequently but not for rare adverse events. Case reports are often the first line of evidence regarding rare adverse events, and sometimes they are the only evidence. Methods for assessing the quality of each type of evidence are available.[11,24]

With regard to questions about therapy and prevention, the RCT has become the gold standard for determining treatment efficacy. Thousands of RCT have been conducted. Studies have demonstrated that failure to use randomization or to provide adequate concealment of allocation resulted in larger estimates of treatment effects, caused predominantly by a poorer prognosis in nonrandomly selected control groups than in randomly selected control groups.[30] However, studies comparing randomized and nonrandomized clinical trials of the same interventions have reached disparate and controversial results.[30–32] Some found that observational studies reported stronger treatment effects than RCT.[30] Others found that the results of well-designed observational studies (with either a cohort or a case-control design) do not systematically overestimate the magnitude of the effects of treatment compared with RCT on the same topic.[31,32] Examining the details of the controversy leads to the following limited conclusions. Trials using historical controls do yield larger estimates of treatment effects than do RCT. Large, inclusive, fully blinded RCT are likely to provide the best possible evidence about effectiveness.[10,33,34]

Although personal experience is an invaluable part of becoming a competent physician, the pitfalls of relying too heavily on personal experience have been widely documented.[3,35,36] Nisbett and Ross extensively reviewed people's ability to draw inferences from personal experience and describe several of these pitfalls.[37] These include the following:

- Overemphasis on vivid anecdotal occurrences and underemphasis on significant statistically strong evidence
- Bias in recognizing, remembering, and recalling evidence that supports preexisting knowledge structures (e.g., ideas about disease etiology and pathogenesis) and parallel failure to recognize, remember, and recall evidence that is more valid
- Failure to accurately characterize population data because of ignorance of statistical principles, including sample size, sample selection bias, and regression to the mean
- Inability to detect and distinguish statistical association and causality
- Persistence of beliefs in spite of overwhelming contrary evidence

FINDING THE BEST EVIDENCE

The ability to find the best evidence to answer clinical questions is crucial for the practice of EBM. Finding evidence requires access to electronic search tools, searching skills, and availability of relevant data. Evidence about therapy is the easiest to find. The most useful sources for locating the best evidence about treatment include the following:

- The Cochrane Library
- The MEDLINE (Medical Literature Analysis and Retrieval System OnLine) and EMBASE (*Exerpta-Medica Database*) databases
- Primary journals
- Secondary journals
- Evidence-based dermatology and EBM books
- The National Guideline Clearing-house (http://www.guideline.gov/)
- The National Institute for Health and Clinical Excellence (http://www.nice.org.uk)

The Cochrane Library contains the Cochrane Database of Systematic Reviews, the Database of Abstracts of Reviews of Effectiveness, the Cochrane Central Register of Controlled Trials, and the Health Technology Assessment Database, among other databases (http://www.thecochranelibrary.com/view/0/index.html). Volunteers write the systematic reviews in the Cochrane Library according to strict guidelines developed by the Cochrane Collaboration. Issue 1, 2010, of the Cochrane Library contained 6,153 completed systematic reviews. The number of reviews of dermatologic topics is steadily increasing.

CRITICALLY APPRAISING THE EVIDENCE

After evidence is found, the next step in practicing EBM is critically appraising the quality of the evidence and determining the magnitude of effects and

the precision of the evidence. The criteria for critically appraising papers about treatment, diagnostic tests, and harmful effects of exposures are shown in eTables 2-1.2, 2-1.3, and 2-1.4 in online edition, respectively.[11,24] Papers that meet these criteria are more likely to provide information that is accurate and useful in the care of patients.[11,24] Critically appraising evidence consists in determining whether the results are:

- valid (i.e., they are as unbiased as possible);
- clinically important; and
- applicable to the specific patient being seen.

Determining the validity of evidence centers on ascertaining whether the evidence was produced in a manner most likely to eliminate and avoid bias. The critical questions to ask to determine the validity of papers about therapy, diagnostic tests, and harmful effects are shown at the tops of eTables 2-1.2, 2-1.3, and 2-1.4 in online edition, respectively.

EVIDENCE ABOUT THERAPY AND PREVENTION

Studies of therapy should randomly assign patients to treatment groups (using a table of random numbers or pseudorandom numbers generated by computer) and ensure concealed allocation (e.g., by using opaque envelopes) so that the treating physician cannot know or anticipate to which treatment group the patient has been assigned. In addition, there should be nearly complete follow-up of all patients entered into the study; intention-to-treat analysis of results; masking of investigators, patients, and statisticians where possible; equal treatment of groups; and similarity between treatment groups with regard to the distributions of prognostic variables. These criteria represent only a small subset of the features of a well-designed and well-reported clinical trial.[35] A more complete set of criteria has been published and recently updated, and adherence to these criteria is required by many of the leading medical journals.[47,48]

Important terms and concepts that must be understood to determine whether the results of a paper about therapy are clinically important include the following:

- The magnitude of the treatment effect
- The precision of this value
- The difference in response rates
- Its reciprocal, the number needed to treat (NNT)
- The confidence interval

In evaluating a clinical trial, the physician should look for clinical outcome measures that are clear-cut and clinically meaningful to the physician and his or her patients.[35] For example, in a study of a systemic treatment for warts, complete disappearance of warts is a meaningful outcome, whereas a decrease in the volume of warts is not. Historically, two principal methods have been used to determine patient outcomes in dermatologic clinical trials. The first involves examining the patient before, during, and at the conclusion of treatment and reporting how the patient appears at the various time points. The second involves determining the degree of improvement during treatment.[49] A third method, determining the impact of therapy on the quality of the patient's life, is being increasingly used in dermatologic trials.[35]

An example of the first method is commonly encountered in therapeutic trials of psoriasis. A common practice is to assign numerical values to (1) the amount of erythema, (2) the amount of scaling, (3) the degree of infiltration, and (4) the body surface area involved, and to formulate an "index" by calculating a derivative of some product of these four numbers.[50,51] The overall condition of the patient can then be represented by this index. A common index is the psoriasis area and severity index, which ranges from 0 to 72.[50] The major problem with indices is that they confound area of involvement with severity of disease.[49] For instance, a patient with thick plaque-type psoriasis of the knees, elbows, and scalp may have the same index as a patient with diffuse but minimal psoriasis of the trunk and arms. Whereas the former condition is notoriously difficult to treat, the latter will generally respond rapidly and easily to many forms of therapy.[49] The second problem with indices is that they lend an air of precision to the analysis and presentation of data that is not warranted.[49] For instance, Tiling-Grosse and Rees demonstrated that physicians and medical students were poor at estimating the area of involvement of skin disease, and therefore some of the components that make up indices may be inaccurate.[52] Finally, calculations of the means, differences in means, and percentages of change in indices in response to treatment often do not convey an accurate clinical picture of the changes that have occurred.[49]

The second method of assessment groups patients according to their degree of improvement. Treatments are then compared in terms of their ability to move patients into categories representing higher degrees of improvement. There are two major problems with this form of assessment. The first is that the categories of improvement are often not well defined. The second problem is that the categories are not additive.[49] That is, 60% to 80% improvement is often assumed to be twice as good as 20% to 40% improvement, but no such numerical relationship exists between these subjectively defined categories.

To be most useful, the outcome variables to be measured must be clearly defined, must be as objective as possible, and must have clinical and biologic significance.[35,49] The best indices and scales are the ones that accurately reflect the state of the disease and the ones whose validity and reliability have been verified by previous work.[35,49,53] The development of scales and indices for assessing cutaneous diseases and the testing of their validity, reproducibility, and responsiveness have been inadequate.[35,49,54] Therefore, a lack of clearly defined and useful outcome variables remains a major problem in interpreting dermatologic clinical trials.

Until better scales are developed, trials with the simplest and most objective outcome variables are

the best. They lead to the least amount of confusion and support the strongest conclusions. Thus, trials in which a comparison is made between death and survival, recurrence of disease and no recurrence, or cure and lack of cure are studies whose outcome variables are easily understood and verified. For trials in which the outcomes are less clear-cut and more subjective, a simple ordinal scale is probably the best choice.[49] The best ordinal scales involve a minimum of human judgment, have a precision that is much smaller than the differences being sought, and are sufficiently standardized so that they can be used by others and produce similar results.[36]

In addition to being clearly defined, outcome variables should have clinical and biologic significance.[25,26] For example, in a therapeutic trial of patients with severe acne, treatment was associated with a decrease in lesion count from a mean of 40 to a mean of 35. This numerical difference may be of statistical significance, but it does not convey the biologic significance of the change in lesion number.[49] This result may mean that some patients with severe acne experienced complete clearance, whereas in others the acne remained the same or got worse. It could also mean that in most patients the acne got slightly better. Furthermore, does an individual patient look better when the lesion number has been reduced from 40 to 35? Is there less scarring and fewer complications?

To strengthen clinical trials and help validate their conclusions, investigators should select only a few outcome variables and should choose them before initiation of the study. Measurement of many outcome variables increases the likelihood that spurious, chance differences will be detected. An ineffective treatment may be found efficacious when tested using poorly designed outcome assessment tools. Conversely, an effective therapy may be found ineffective when an insensitive scale is used.

Special precautions are recommended to recognize and remain skeptical of substitute or surrogate endpoints, especially when no differences are detected in clinically important outcomes.[26,55] Examples of such endpoints include CD4/CD8 ratios instead of survival rates in studies of treatments for acquired immunodeficiency syndrome, antinuclear antibody levels or sedimentation rates instead of clinical measures of disease activity in lupus erythematosus, and volume of warts instead of proportion of patients cleared of warts. The use of carefully chosen and validated surrogate endpoints often allows studies to provide answers to questions that would typically require much larger or longer trials if the targeted clinical endpoint were used. For example, a well-designed short clinical trial may be sufficient to demonstrate that a new drug effectively lowers serum cholesterol level or that a given drug is effective in controlling hypertension. In both cases, much longer and larger studies would be required to demonstrate that the cholesterol-lowering drug and the antihypertensive drug reduced morbidity and mortality from atherosclerotic and hypertensive cardiovascular diseases, respectively. However, surrogate endpoints must correlate with clinical outcomes and their validity must have been demonstrated in prior studies.

Once sound, clinically relevant outcome measures are chosen, the magnitude of the difference between the treatment groups in achieving these meaningful outcomes should be determined. The precision of the estimate of the differences among treatments should be assessed. Useful measures of the magnitude of the treatment effect are the difference in response rate and its reciprocal, the NNT.[11,24,41] The NNT represents the number of patients one would need to treat to achieve one additional cure or clinically relevant improvement.

The confidence interval provides a useful measure of the precision of the treatment effect.[11,24,41,56,57] The calculation and interpretation of confidence intervals have been extensively described.[58] In simple terms, the reported result (known as the *point estimate*) provides the best estimate of the treatment effect. Values become less and less likely as they move away from the reported result within the confidence interval.[11,24,41] The confidence interval provides a range of values in which the "population" or true response to treatment is likely to lie.

Examples of the application of the concepts of NNT and confidence interval are given in a paper identified through a search of the Cochrane Library that reported the results of a RCT the use of a placebo, acyclovir, prednisone, and acyclovir plus prednisone in the treatment of herpes zoster.[59] At day 30 of the trial, 48 of 52 patients treated with acyclovir experienced total healing compared with 22 of 52 patients who received a placebo. The response rates for acyclovir and placebo were 0.92 and 0.42, respectively, and the difference in response rates was 0.5. The NNT was 2 (1/0.5). This result means that for every two patients treated with acyclovir instead of placebo, one additional patient would show total healing by day 30. The 95% confidence interval for the difference in response rates is 0.35 to 0.65, and the 95% confidence interval for the NNT is 2 to 3.

What does it actually mean that the confidence interval for the difference in response rates in the foregoing example is 0.35 to 0.65? If the investigators in this study had the opportunity to repeat the study many times using the same design and procedures, sampling variability would prevent obtaining the same results in each study. Repeated trials were simulated using resampling (resampling is a computer-intensive method that uses the reported results of a trial to simulate the results that would be obtained if the trial were repeated a number of times).[41,60] The results when the trial was repeated 10 and 1,000 times are shown in eFigs. 2-0.1A and 2-0.1B in online edition, respectively. A 95% confidence interval of 0.35 to 0.65 means that if the trial is repeated many times and a confidence interval is calculated for each trial, the true result or response to treatment will be included in 95% of the confidence intervals so produced. Alternatively, if the trial were repeated multiple times, the results would lie within that interval (0.35 to 0.65) 95% of the time.

The population or true response to treatment will most likely lie near the middle of the confidence

interval and will rarely be found at or near the ends of the interval. The population or true response to treatment has only a 1 in 20 chance of being outside of the 95% confidence interval. Unless a given patient is very different from the patients included in the study, his or her response will most likely lie near the middle of the confidence interval. If the 95% confidence interval of the difference in response rates excludes zero difference, one can reject the null hypothesis that the two treatments are the same.[24,41,56,57]

Misinterpreting trials that fail to show statistically significant differences among treatments is a common error in dermatologic clinical trials. It is important to remember that "not statistically significant" means that a difference has a reasonably high probability of having been due to chance; it does not mean that there is no difference or that treatment is necessarily ineffective.[35] Significant differences in treatment effects in comparison trials may be missed if the number of subjects tested is small. For example, in a 1978 survey of 71 published trials with negative results, Freiman et al found that a 25% or 50% improvement in outcome might have been missed in 57 (80%) and 34 (48%) of the studies, respectively.[61] A follow-up study conducted by Moher, Dulberg, Wells in 1994 indicated that a 25% or 50% improvement in outcome might have been missed in 84% and 64%, respectively, of 102 studies with negative results.[62] The sample sizes of many dermatologic trials are often inadequate to detect clinically important differences.

The acceptance of a significance level of .05 as the cutoff for rejecting the null hypothesis is a tradition based on quality control standards and is not an absolute truth. At times (e.g., when treatments have substantial side effects) more stringent standards are required, and paradoxically, results that do not meet the $p = 0.05$ standard sometimes may be clinically significant. For example, consider a hypothetical trial of a new chemotherapeutic agent involving 30 patients with metastatic melanoma randomly assigned to treatment groups that produced a 5-year survival rate of 7 of 15 among patients treated with the new agent and 3 of 15 among control patients treated with conventional surgery, chemotherapy, and radiation. Whereas the result does not achieve statistical significance when analyzed by χ^2 testing (Yates corrected $\chi^2 = 1.35$; $p = 0.25$), the result is nonetheless potentially significant. If the therapy is beneficial and the estimated difference in response rates is the true difference in response rates, it may result in the saving of 2,880 lives annually (based on 8,650 deaths from melanoma annually and the improvement in survival in this hypothetical example). Because of the biologic and clinical importance of the results suggested by the trial, the treatment should be investigated in a study that uses a larger patient group and has more power to detect a significant difference if one exists.[35]

The potential benefit of the treatment may be further revealed by the use of confidence intervals. To determine whether a treatment effect may have been missed in a study reporting negative (not statistically significant) results, one should look at the upper boundary of the 95% confidence interval. If this value would be clinically important if it were the true response, then an important treatment effect may have been missed in the study. Consider our hypothetical new treatment for metastatic melanoma. The cure rates for the new treatment and the conventional treatment were 47% and 20%, respectively, and the difference between them was thus 27%. The 95% confidence interval for the difference in cure rates was –10% to 51%. The upper boundary of the difference in cure rates was 51%. This difference would clearly have a significant impact on the treatment of patients with metastatic melanoma (the NNT is 2!), and therefore a significant treatment advance may have been missed in this study. Also note that the 95% confidence interval of the difference in cure rates includes zero difference; therefore, we cannot conclude with a high degree of confidence that the response rates of the two treatments are different. However, when zero is included as one of the values in the confidence interval, the inference that the therapy is not efficacious fails to consider the fact that the best estimate of effect is the point estimate (e.g., the observed difference in cure rates of 27% in our hypothetical example).[63] In other words, the values contained in the confidence interval are not equally likely and become less and less likely as they move away from the point estimate. Thus, in the example, a difference of 25% (close to the observed 27%) is much more likely than a difference of –5% (far from the observed 27%).[35]

APPLYING EVIDENCE TO SPECIFIC PATIENTS

Applying the evidence to treatment of specific patients involves determining whether the evidence from studies is applicable to a given patient. This decision is based on the patient's condition and values. It involves asking a series of questions that are specific to the type of evidence being considered (see eTables 2-1.2–2-1.4 in online edition). When faced with the task of determining whether the results of a particular study are applicable to specific patients, physicians should determine whether there are any compelling reasons that the result should not be applied.[35] Applying evidence to specific patients always involves physician's judgment.

KEY REFERENCES

Full reference list available at www.DIGM8.com

DVD contains references and additional content

2. Sackett DL et al: Evidence based medicine: What it is and what it isn't. *BMJ* **312**:71, 1996
6. Cochrane A: *Effectiveness and Efficiency*. London, Royal Society of Medicine Press, 1999
7. Sackett DL et al: *Clinical Epidemiology: A Basic Science for Clinical Medicine*. Boston, Little, Brown and Company, 1991, p. 441
13. Greenhalgh T: *How to Read a Paper: The Basics of Evidence Based Medicine*. London, BMJ Publishing Group, 4th edition, BMJ books, 2010
26. Sackett D et al: *Evidence-Based Medicine: How to Practice and Teach EBM*. Edinburgh, Churchill Livingstone, 1996, p. 250

37. Bigby M, Gadenne AS: Understanding and evaluating clinical trials. *J Am Acad Dermatol* **34**:555, 1996
39. Nisbett R, Ross L: *Human Inference: Strategies and Shortcomings of Social Judgment.* Englewood Cliffs, New Jersey, Prentice-Hall, 1980, p. 330
49. PubMed clinical queries using research methodology filters: http://www.ncbi.nlm.nih.gov/entrez/query/static/clinicaltable.html, accessed August 26, 2011.
52. Higgins JPT, Green S, eds.: Cochrane handbook for systematic reviews of interventions 5.1.0 [updated March 2011]. The Cochrane Collaboration. 2011. Available form www.cochrane-handbook.org, accessed August 26, 2011
63. Gardner MJ, Altman DG, eds.: *Statistics with Confidence,* 2nd edition. London, BMJ, 2005

Chapter 3 :: Global Health in Dermatology

:: Roderick J. Hay

The word "global" describing something that is worldwide is not a concept that is difficult to understand, whereas the term "health" is frequently misused on the assumption that it simply means freedom from disease. However, *health* and *disease* are not merely examples of the converse, a point that is captured by the mission statement of the World Health Organization (WHO), whose objective is to promote health. The WHO definition of health, which is widely used as the definitive descriptor of health, says that *health* is a state of complete physical, mental, and social well-being and not merely the absence of *disease* or infirmity. Therefore, global health implies a worldwide mission to promote complete well-being.

HEALTH AND GLOBAL INTERDEPENDENCE

The rational basis for this idea is simple as no nation or region is a complete island in terms of health; what affects one country may well, in time, affect another. The most obvious examples of this concept from past history involve the spread of infections. At present, there is a concerted effort to follow the international spread of HIV or avian influenza. Both present global risks to health, which is the reason why their current distributions are tracked regularly and with accuracy.[1] Spread of these diseases has occurred and will continue to occur through a combination of both social and economic factors and the movement of populations and individuals. Yet historically, infectious diseases that have spread rapidly to cause maximum chaos have often resulted from a relatively minor, and often unrecognized, episode rather than a large movement of individuals. For instance, the impact that a localized outbreak of bubonic plague had on medieval Europe when the besieged Genoese garrison in Caffa, in the Crimea, fled by ship bringing the rat host with them was not foreseen.[2] The subsequent epidemic, caused by *Yersinia pestis*, known as the Black Death, reduced the population of Europe by a third over the following 2 years. In addition to the mortality and distress, it resulted in profound social and economic changes that long outlived the epidemic itself. Predicting and tracking the international course of infections is now a key element of global surveillance.

However, global health problems and disease are not limited to infections, although the propensity to spread is more demonstrable in this group; chronic noninfectious conditions are also global. The relentless increase in the prevalence of diabetes mellitus type 2 in aging populations is such an example. Global health is affected by other factors that include the impact of social, economic, and environmental change on populations. This reflects the fact that human populations are no more isolated socially than they are geographically, but manifest a measure of interdependence where what happens in Kazakhstan may be reflected, in time, in New York City. In the case of diabetes, the causes of changes in health status are different; the international dissemination and adoption of Western dietary behaviors are, at least partly, responsible for this. Health-determining trends such as diet, lifestyles, or global warming are all examples of noninfective risk factors that may affect global health. The international spread of risks to health may follow different routes, often simultaneously.

In many parts of Europe and the United States, the decline of tuberculosis was a marker of economic progress in the twentieth century,[3] the main reduction in disease incidence, and subsequently mortality, preceding by many years the development of new specific treatments such as streptomycin or the introduction of BCG immunization. This health improvement reflected the huge social changes made during this era, such as the provision of sustainable and affordable water supplies and drainage, heating schemes, better housing, and nutrition. While the increasing prosperity and subsequent social reforms that affected the industrialized Western nations in the late nineteenth and early twentieth centuries had a huge impact, mainly for the good, in promoting better health, in international terms the benefits were relatively restricted and not global in their reach; large areas of the world did not benefit from this change. In the recent report by Michael Marmot,[4] the continuing influence of social and economic conditions on both national and global health are

clearly demonstrated and poor social and economic status linked closely to poor health indicators such as high maternal and infant mortality. He cites Sweden as an example of a country that has adopted a policy where the creation of appropriate social conditions would ensure the health of the nation. Much of this health initiative concentrates on social initiatives such as improvement of participation, economic security, and healthy working. This type of policy has been supported in both rich and poor countries. For instance, the Mexican initiative, Programa de Educacion, Salud y Alimentacion (Progresa), which provides financial incentives for families to adopt measures that will ensure social improvements leading to better health, is a good example.[5] While this may seem oversimplistic, poor health is often an indicator of social ills and vice versa; the two are interdependent. Health can make a significant impact on both micro- and macroeconomics; conversely economic performance has a direct impact on health. The WHO report on macroeconomics and health[6] asserted the view that the investment of both time and money on health improvement had multiple benefits through reduction of mortality and increase in the healthy employed, measures that would lead to improvement in both family and national economics. By ensuring good health of their populations nations would improve economic performance and social conditions, which, in turn, would improve health status of their peoples. So good health is an important facet of social and economic development, just as poor health is an indicator of poor performance in both domains. Therefore, global health becomes an important social aspiration in a world where international collaboration and interdependence as well as increasing global industry are slowly replacing, or at any rate adding another dimension to, the nation state.[7]

GLOBAL BURDEN OF DISEASE PROJECT

In order to determine the impact of global health, a consortium of international bodies such as the World Bank in 1990 commissioned a report on the global burden of disease (GBD); a project that has now gone through several iterations involving other organizations, including WHO and an international group of universities.[8] In doing this work, there were two key objectives, namely: (1) to provide up-to-date information on the incidence of disease states in all the regions of the globe and (2) to assess their impact on mortality and disability. In carrying out this work, the interdependence of health and social and economic well-being was clearly recognized. These large surveys of global disease have had to draw on the availability of studies that can provide the necessary information. A subsequent development from GBD, aimed at health in developing countries, was the Disease Control Priorities Project (DCPP), an international report focusing on sustainable measures of disease elimination or control.[9] The latest GBD round of studies is incomplete at the time of writing.[8] However, it differs from other studies in that much of the work of collecting data is the task of specialist groups, including one for dermatology. The target is to provide data covering diseases and risk factors (such as consumption of alcohol or atmospheric pollution) in the WHO designated regions and, where this is missing, to provide robust means of adducing the data using defined mathematical models. The study aims to target disease incidence at two time points—(1) 1990 and (2) 2005. It will also provide measures of mortality as well as disability. The methods used to assess the latter is more refined than previously in that lay panels (i.e., patients) will be asked to assign the weighting that determines the disability that accompanies disease states.

GLOBAL HEALTH AND THE SKIN

Within this international perspective, there is a similar connection between global health, dermatology, and the spread of skin disease. Dermatology is subject to the same factors that regulate the spread of other diseases and determine its control; infection, social, and economic factors are all important in determining the prevalence and impact of skin disease.[10] Skin infections are very common in all societies; tinea pedis (athlete's foot), onychomycosis, scabies and childhood pyoderma, viral warts, and recurrent human herpes virus (HHV1) are all examples of everyday skin infections that affect many people. There are also examples to show that this spread is mediated by human contact and, where there is facility for this to occur, for instance, in a swimming pool in the case of human papilloma virus infections of the feet and tinea pedis, there is a higher incidence of disease.[11] Likewise, movements of numbers of individuals through travel, migration, or war increase the chance of global spread of these infections. For instance, the world diffusion of infection due to *Trichophyton rubrum* is said to have followed the displacements of populations and the movement of soldiers in the 1914–1918 and 1939–1945 wars.[12] More recently, the spread of *Staphylococcus aureus* bearing the *Panton–Valentin leukocidin* (PVL) virulence gene causing furunculosis has been tracked, in some cases, to international travel.[13] Despite this, in some parts of the world there are still unique and geographically localized skin infections, largely because these occur in remote areas. The lower limb infection of children and young adults seen in remote regions of the developing world where there is a high rainfall, tropical ulcer (Fig. 3-1), is an example of a condition that has remained relatively isolated[14]; the fungal infection of the skin, tinea imbricata, is a further example.[15] However, even where there is relative isolation, changes over time such as migration can lead to epidemic spread of previously endemic disease. Tinea capitis has undergone a remarkable transformation in the Western hemisphere in the past 50 years. It has seen the introduction of an effective treatment regimen with griseofulvin initially and subsequent decline in infection rates followed by the relentless spread of one dermatophyte fungus, *Trichophyton tonsurans*, initially from a zone of endemic disease in



Figure 3-1 Tropical ulcer. (From CDC/K. Mae Lennon, Tulane Medical School; Clement Benjamin.)

Mexico, where it still remains as a stable infection of moderate incidence, to reach epidemic proportions in children in inner cities, initially in the United States, but subsequently in Canada, Europe, the West Indies, and Latin America.[16] The spread appears to follow an increased susceptibility to infection of children with African Caribbean hair type; in recent years it has begun to spread in Africa as well.

In a similar way, noninfectious skin disease, as with other illnesses, is also affected by those social and economic changes that are international in dimension. The complex history of the medical reaction to the fashion for sun exposure was formed initially by the recognition of the health promoting, and then health limiting, effects of sun and ultraviolet (UV) light.[17] The current concern over excessive exposure to both natural sun or UV exposure, for instance, in sunbed parlors, or as part of UV therapies, is an important stage in an exercise that started as genuine attempt at health promotion. The ancient Greeks, for instance, promoted sun exposure or heliotherapy as beneficial for a number of medical problems.[3] While largely ignored for the best part of two millennia the revolution in medical ideas in the nineteenth century led to sun exposure being adopted as a health-giving practice with the discovery of Vitamin D and the award of the Nobel Prize to Finsen for light therapy. Health-giving sun exposure was adopted widely and became a fashion that was the rage of the health conscious, delivered in spa environments such as William Kellogg's Battle Creek clinic.[18] However, the habit, perhaps fueled by the recognition that exposure to natural light was in some ways health giving, led inevitably to one of the consequences, the sun tan. It is not certain if the recognition of the suntanned skin as fashionable can all be laid at the door of Coco Chanel, who is said to have been overexposed to the sun during a holiday in Cap Antibes in France. The resulting effect on her skin color was soon to be adopted by the fashionable and white wherever they lived.[19] Soon it became a global trend in fashion. The recognition that sun exposure also led to a rising incidence of skin cancer followed more slowly, but perhaps with greater speed than that concerned with the connection between smoking and lung cancer. Protection against sun exposure has become a major global focus of preventive measures of public health medicine, from public education to the risks involved to early detection of melanoma and nonmelanoma skin cancers. Dermatological organizations have reacted with admirable speed to the recognition of the risk of UV exposure. This has been accomplished through seminars, magazine articles, public health campaigns, and training camps. The introduction of educational programs in schools has been a welcome addition.

The trend to the opposite, skin lightening, in women of color has been an equally global trend where the use of skin bleaching products has been adopted by different cultures throughout the world. The common agents in use include hydroquinone- or steroid-containing creams—with a resulting risk of the development of skin disease such as ochronosis and more general medical problems, including low birth weight infants in pregnant women using topical corticosteroids to achieve lightening.[20] As with infections, there are also examples of skin diseases that are caused by social customs or economic conditions that remain geographically localized. *Erythema ab igne* of the forearms is almost unknown in most parts of the world but is associated with the cooking of tortillas (enfermedad de las tortilleras)—so it is only seen where the tortilla is a staple of diet; oral submucous fibrosis occurs where the Betel nut is chewed is another example. However, some noninfective skin conditions occur in isolated communities for a different reason, genetic susceptibility, such as actinic dermatitis seen in native American communities in North and South America (Fig. 3-2). These are not the only examples of the relation between noninfectious skin disease as an international concern and social and economic factors. One of the earliest public health campaigns that crossed national boundaries stemmed from the recognition that industrial workers exposed to oil during the operation of large-scale spinning were



Figure 3-2 Actinic cheilitis. Mexico, Guerrero State.

susceptible to skin cancer and the ingestion of arsenic at work or as a medication was also potentially harmful through the development of skin cancer.[21] Recently, much international interest has focused on the changing face of atopic dermatitis and although the evidence suggests that this is a condition associated with societies enjoying improved socioeconomic status,[22] the quest for modifiable risks whose resolution may, in turn, provide benefit to children with this condition is now the subject of a global initiative (the ISAAC study).

So skin disease is subject to different, but nonetheless global influences, compared with other illnesses and in the pursuit of skin health there is a great need to promote international cooperation. This objective is identified, not just in order to share learning experiences, but also because the burden of skin disease is spread unequally around the world and many of the poorest nations face the greatest problems.[9] Here, the social and economic factors plus uncontrolled or poorly controlled infection play key roles in determining the pattern of disease.

SKIN DISEASE IN RESOURCE POOR ENVIRONMENTS

In the poorest countries skin disease usually ranks as one of the first three common disorders encountered in frontline medical facilities, i.e., the first point of call for a patient seeking treatment. Whereas in the developed countries many of the problems facing dermatologists and primary care practitioners are noninfectious skin diseases, the opposite is true in developing countries where infections dominate the pattern of presentation.[23] Where infections occur in the industrialized countries, the general public have widespread access to treatment through pharmacies or primary care doctors as well as specialists. Access to treatment is limited by a number of factors that range from poor training of health care workers to the need to journey considerable distances in order to obtain help.[24] Likewise in the poorest communities ready access to cash is more limited, with a large part of household economics depending on self-sufficiency in growing food or creating housing from local materials. Cash is necessary for some things such as clothing and for additional food. Treatment of even the simplest of conditions such as scabies or pyoderma presents a competing call on the available household cash income (Fig. 3-3); poor or ineffective treatment is a drain on resources that would otherwise be spent on food. The exact sums are small but their impact is large.[25]

The burden of skin disease is often unrecognized at national or international level as it is perceived to come low in the global league table of illnesses and, compared with diseases that carry a significant mortality such as HIV, community acquired pneumonias and tuberculosis, skin disease-related mortality is low. However, as skin problems are generally found to be amongst the most common presentations of diseases seen in a primary care setting in tropical[9] and nontropical[10] areas, in some regions, where transmissible diseases such as tinea imbricata or onchocerciasis are endemic, they are the commonest reason for an individual to present themselves for treatment. The GBD estimates for 2001 indicated that skin disease was associated with mortality rates of 20,000 in Sub-Saharan Africa.[8] This was comparable to mortality rates attributed to meningitis and hepatitis B, obstructed labor, and rheumatic heart disease in the same region. The disability rate calculated as disability adjusted life years (DALYs) in the same report showed an estimated total of 896,000 DALYs recorded for the region in the same year; this was comparable to that attributed to gout, endocrine disease, panic disorders, and war-related injury. While, as described before, these figures are currently being reassessed, it suggests that the burden of disease due to skin-related illness is high. Many of the international studies that have focused on the impact of illness on individuals utilize disability scores. Those interested in skin disease frequently use patient-focused measures Quality of Life (QOL) scales.[26] While these may be less objective they do, by concentrating on the impact of disease on personal values and performances, provide, according to many interested in the impact of disease, a more realistic measure of how patients are likely to use health services. Assessing the impact of skin

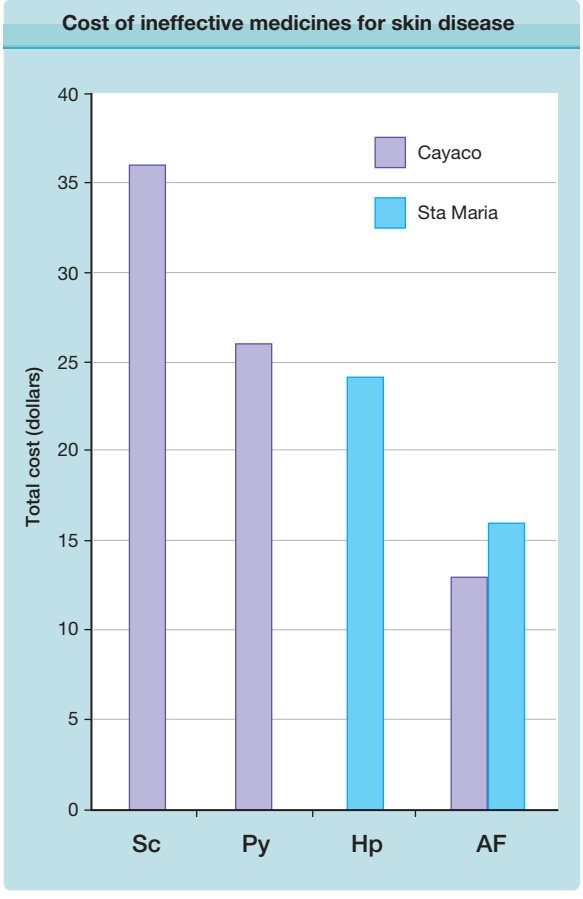

Figure 3-3 Cost of ineffective medicines for skin disease in two rural communities, Mexico. Sc = scabies; Py = pyoderma; Hp = hypopigmentation; AF = expected cost of additional food during the same period.

disease on quality of life in comparison with other chronic nondermatological diseases is difficult. However, the decline in QOL for patients with the common skin disease, acne, is similar to that experienced by patients with chronic disorders such as asthma, diabetes, and arthritis; all showed comparable deficits in objective measurements of life quality.[26] Skin disease related to HIV, which constitutes an important skin disease burden, particularly in Sub-Saharan Africa, leads to a similar diminution of QOL compared with non-HIV related skin problems, although the use of antiretroviral therapy produces a significant improvement.[27]

PRACTICAL PROBLEMS IN SKIN CARE

Despite the unequal comparison of mortality rates with other diseases, there are a number of important and relevant reasons why the needs of the populace for effective remedies or control policies for skin conditions should be in place. Firstly, the diseases are very common and patients present in very large numbers in primary care settings. In some cases more than 60% of the population has at least one skin disease.[23] Even though significant numbers never seek treatment for a variety of reasons, including lack of awareness that treatments are available, the workload generated by patients presenting with skin problems at primary care level can be huge. This is a problem in all countries but particularly in those with the lowest gross domestic product.[28] Children and the elderly, in particular, are affected, adding to the burden of disease in already vulnerable groups. Secondly, the morbidity can cause significant disability through disfigurement or restriction of movement. For instance, the effects of elephantiasis secondary to lymphatic filariasis last for years after the elimination of the filarial parasites. As stated previously, the relative economic cost of treating even trivial skin complaints in families in poor regions reduces the capacity of families to contribute to their local economies as their disposable cash is exchanged for poor medicine rather than other goods.[25] The skin is often the site where changes of a number of other neglected tropical diseases are present. Leprosy, onchocerciasis, guinea worm, HIV/AIDS, tuberculosis, yaws, and Buruli ulcer are all examples.[29] A shortage of elementary skills in the recognition and management of disease that present with skin abnormalities reduces the capacity for surveillance of these important diseases. In truth, skin disease in the tropics is a neglected problem that should be added to the list of neglected tropical diseases.

Globally, one of the current problems highlighted in a number of studies has been the management of skin disease in primary care settings. In the developing world high treatment failure rates of over 70% are common in frontline health posts.[30] The same may be true in settings in industrialized nations where lack of recognition of some skin problems at primary care level is a factor limiting effective treatment. This situation is compounded by changes to the undergraduate medical curriculum where, in many countries, the factual and academic content, such as knowledge of skin or eye disease, has been reduced to allow students to assimilate greater patient-oriented skills such as communication; the gap in learning for those not intending to follow a career in subjects, such as dermatology, yet who have some responsibility for managing skin problems, has not yet been plugged satisfactorily. One way forward in streamlining the capacity to cope with common diseases, such as skin disease, has been to prioritize treatment options. For instance, in the developing world a small number of common skin diseases, mainly infections, account for the vast majority of the disease burden. Therefore, implementation of effective treatment targeted on these conditions confers significant gains to both personal and public health. Two prime examples are scabies[31,32] and pyoderma.[33] In the industrialized nations concerted efforts to prevent or diagnose skin cancer at an early stage have formed key elements of public health strategy.[34]

IDENTIFYING RISK

In Western societies there have been few studies aimed at estimating disease prevalence or risk, a necessary prelude to health intervention. However, a study in Lambeth, South London in 1976 using a questionnaire-based population-centered approach, backed by random examination, revealed an overall 52% prevalence of skin disease of which just over half the cases were judged by the investigators to require treatment.[35] The NHANES study in the United States[36] produced very similar figures. More recent studies of skin disease burden in the United States and the United Kingdom confirm these earlier investigations. Studies from developing countries have generally been conducted through systematic community-based surveys backed by clinical examination. Published figures for skin disease prevalence in developing countries range from 20% to 80%.[9] From these studies it became clear that different populations have different levels of awareness of illness. For instance, in a study in Ethiopia between 47% and 53% of members of two rural communities claimed to have skin disease.[30] However, when they were examined 67% of those who denied having a skin problem were found to have a treatable skin condition; the majority of these were infections. Tinea capitis, which is equally common in the same population may be ignored because it is common knowledge that this follows a benign and asymptomatic course in many patients, although in those communities where the clinical form of tinea capitis, favus, occurs, the local populations recognize that this type of infection is associated with permanent scalp scarring and so present for treatment.

The main risk factors associated with skin disease in developing countries are largely socioeconomic; the most important of these appears to be household overcrowding estimated by person per room in living accommodation. For instance, in Tanzania, Gibbs found that 27% of patients had treatable skin disease in surveying two village communities; once again infections were the most common diseases found.[37] Overcrowding was a major risk factor in this latter survey. What also

seems to influence the overall prevalence and pattern of skin conditions is the existence of a number of common contagious diseases, notably scabies and pyoderma, in certain areas. Hot and humid climatic conditions may also predispose to certain skin infections such as pyoderma, thereby affecting the distribution of disease.

SKIN DISEASE—THE PATTERN AT COMMUNITY LEVEL AND INTERNATIONAL INITIATIVES

Using the World Bank figures (World Development Indicators 2002) for low-income populations in 2000, the estimated numbers of individuals infected with pyoderma and scabies based on the highest prevalence figures from community surveys in the developing world are 400 and 600 million, those based on the lowest prevalence figures are 40 and 50 million. For tinea capitis the estimated number of cases based on the highest estimates of prevalence for Sub-Saharan Africa alone is 78 million.[9]

Overall these data suggest that significant improvements could be made in reducing the burden of skin disease by focusing on the small group of conditions, particularly infections, which comprise the majority of the community caseload. This may be accomplished by community control programs (see Chapter 4). The examples of scabies and skin cancer have already been cited. There are now a number of different bodies that understand the need to prioritize and have started, at first individually but increasingly in collaboration, to try to improve this situation.

The main focus of these efforts has been the identification of the health needs for skin disease in poor countries, the simplest methods of dealing with the majority and the development of programs to cope with these. In most cases, the key elements necessary to deliver an effective program are as follows:

a. Data on skin disease and current resources that could be mobilized to deal with the problem.
b. Education of those charged with improving skin health.
c. Evidence of the efficacy of each project.

DATA ON SKIN DISEASE

Data on the global epidemiology of skin disease are inadequate, not just because current estimates of global health are subject to enormous variations. In skin disease a major and recurrent problem has been the very small number of studies that document the prevalence or incidence of disease at population level. The reasons are not difficult to identify. Firstly, because skin disease is not associated with significant mortality, the first international indicators of disease activity, death rates, have not triggered a demand at governmental or even regional levels for comprehensive epidemiological surveys. Secondly, and allied to the first point, the disability associated with skin disease is often thought to be minor—another reason why there has been few central calls for further investigation. There are also practical reasons why studies of this nature have been few until recently. Because the diagnosis of changes in the skin depends on a visual assessment, whose accuracy is largely based on experience, it becomes very difficult to teach those without the relevant experience to assign diagnostic labels. It is only comparatively recently that attempts have been made to simplify and validate diagnostic criteria for use in large population studies and those originating from the international studies of allergy now provide a global picture of the prevalence of atopic dermatitis.[38] However, this is but one example and there have been a few similar initiatives in other areas of dermatology, for example, classification of skin changes in lymphatic filariasis.[39] The upshot has been that skin disease has remained a subject where epidemiological studies have relied on the diagnosis of a trained observer, usually a dermatologist. The large studies of global disease have had to draw on the availability of a few surveys that can provide the necessary information. Most of these are the fruits of a comparatively small number of dermatologists who have taken on the task of investigating the impact of skin disease and developing measures for assessing disease prevalence and quality of life. Yet there are examples where disease presenting in the skin has attracted more global attention. Yaws, for instance, was one of the first examples of an infectious disease that was targeted by WHO for elimination through mass penicillin therapy.[40] In the first few years, the campaign made extraordinary advances with massive reductions in the numbers of new cases. As with other diseases lack of resources and major disruption, such as human conflict, have ensured that there are still pockets of yaws that have yet to be brought under control. The recognition of the risk of skin cancer has stimulated regional and national initiates in areas such as Australia[34]; but there are still few cancer registries that collect data on nonmelanoma skin cancer.

EDUCATION AND TRAINING

More effort has gone into education to improve knowledge of skin disease and its management and the examples of initiatives established by departments and national and international dermatology societies are important to recognize. These range from the national programs of skin cancer prevention to Web sites that promote public awareness. These often also include training for other health professionals, such as pharmacists, who may encounter skin disease. In the developing world the International Foundation for Dermatology has established a number of such programs.[41,42] The first of these, the Regional Dermatology Training Centre (RDTC) in Moshi, Tanzania was set up as collaboration between the International Foundation for Dermatology; The Ministry of Health and the Good Samaritan Foundation is an example of a training initiative that affects many countries. The Centre trains clinical officers with regional responsibility for skin disease, sexually transmitted infection, and leprosy, and more recently it has established an international dermatology residency-

training program for Sub-Saharan Africa. Other programs of training or assistance established in Mexico,[43] Mali,[44] Ethiopia,[45] Haiti,[46] Fiji,[47] and Cambodia amongst others are all examples of international collaboration to improve skin health in poorer countries.

HOW EFFECTIVE ARE THESE INITIATIVES?

These initiatives have been less successful in the provision of evidence that the campaigns have worked. There are some data from the sun protection programs that the incidence of advanced melanoma is improved by early screening measures.[48] However, measuring the impact of education on disease incidence is difficult, but it is clearly needed in order to justify the outlay of time and expense.

SUMMARY

In summary, the global incidence of disease affecting the skin is very large; the disability related to it is less, but is nonetheless significant. Managing this burden remains the responsibility of those specially trained in the field. Increasingly, dermatologists and dermatological nurses have turned their attention to adopting measures that benefit a wider group of individuals than the patient sitting on the other side of the consulting desk. To do so means setting up partnerships and alliances both nationally and internationally. Whether developing or assisting local or global public health schemes to control, eliminate, or improve skin problems through education or community initiatives is realistic is a matter for debate. What is certain, though, is that intervention to improve the health of those with skin problems within communities improves both the health of the people as well as the image of the profession.

KEY REFERENCES

Full reference list available at www.DIGM8.com

DVD contains references and additional content

5. Levine R and the What Works Working Group: *Millions Saved. Proven Successes in Global Health.* Washington DC, Center for Global Development, 2004
9. World Health Organization: *Global Burden of Disease for the Year 2001 by World Bank Region.* Disease Control Priorities Project, http://www.fic.nih.gov/dcpp, 2005
23. Mahe A: *Epidemiology and Management of Common Skin Diseases in Children in Developing Countries*. WHO 2005, whqlibdoc.who.int/hq/2005/WHO_FCH_CAH_05.12_eng.pdf
32. Lawrence G et al: Control of scabies, skin sores and haematuria in children in the Solomon Islands: Another role for ivermectin. *Bull WHO* **83**:34, 2003
42. Hay R, Marks R: The International Foundation for Dermatology: An exemplar of the increasingly diverse activities of the International League of Dermatological Societies. *Br J Dermatol* **150**:747, 2004

Chapter 4 :: Public Health in Dermatology

:: Hywel C. Williams, Sinéad M. Langan, & Carsten Flohr

PUBLIC HEALTH IN DERMATOLOGY AT A GLANCE

- Public health dermatology promotes skin health.
- Modern public health dermatology is still relatively underdeveloped.
- Doctors help individual patients but have little influence on the health of entire populations.
- Conversely, the impact of large population interventions is rarely appreciated by individuals.
- Prevention is often more logical than only treating sick individuals.
- A "low-risk" approach of reducing risk in the whole population for diseases such as melanoma may achieve more than a "high-risk" approach of targeting just those who have skin cancer or who are at higher risk of developing skin cancer.
- When entire populations are considered, a little bit of harm affecting a lot of people can add up to more than a lot of harm affecting a few people.
- Modern public health dermatology has had some success in the reduction of skin cancer incidence and control of infectious diseases.
- Low-technology educational interventions directed at entire communities can result in more benefit than high-technology drugs targeted at a few ill individuals.

WHAT IS PUBLIC HEALTH MEDICINE ALL ABOUT?

DEFINITION

The World Health Organization defines health as "a state of complete physical, mental and social well-being and not merely the absence of disease or infirmity."[1] The key message of this definition is that health is a holistic measure that is influenced by socioeconomic factors and inequality. Public health is a discipline in which the level of focus is on the health of *populations* as opposed to that of *individuals*, as is the case in clinical medicine. A useful definition of public health is as follows:

> *Public health is the science and the art of preventing disease, prolonging life, and promoting physical health and mental health and efficiency through organized community efforts toward a sanitary environment, the control of community infections, the education of the individual in principles of personal hygiene, the organization of medical and nursing service for the early diagnosis and treatment of disease and the development of the social machinery to ensure to every individual in the community a standard of living adequate for the maintenance of health.*[2]

This definition articulates some of the roles of public health practitioners in relation to society and health. It also highlights the four key areas of public health action: (1) preventing disease and promoting health, (2) improving medical care, (3) promoting health-enhancing behavior, and (4) modifying the environment.[3]

HISTORICAL PERSPECTIVES

As early as in the fifth century BC, Hippocrates suggested a clear link between environmental factors and disease states. In more recent centuries, the physician John Snow helped to establish the field of public health during the 1854 London cholera epidemic.[4] By carefully counting the number of deaths from cholera according to population denominators in specific London districts, he was able to establish that household water supply might be the key common factor leading to cholera deaths. Snow hypothesized that cholera was a water-borne disease, and he was able to trace the origin of the epidemic to a contaminated water pump in Broad Street, Soho. Consequently, he ordered removal of the pump handle, which was followed by a dramatic reduction in cholera deaths. Thus, Snow first made detailed planned observations, then analyzed the data, formulated a hypothesis, tested this hypothesis through experiment, and finally mounted a campaign to prevent further disease. This led to a widespread political campaigning for clean water from which millions have benefited worldwide ever since. What is intriguing about Snow's work on the causal relationship between water and cholera is that it preceded the discovery of the *Vibrio cholerae* organism by Koch a third of a century later.

Public health has played a key role in the prevention and treatment of dermatologic diseases. One of the first historical examples is scurvy. In 1746, James Lind discovered through observation, analysis, and performance of a controlled trial that scurvy in sailors was a dietary disease that could be cured by administration of oranges and lemons[5] (see eFigs. 4-0.1 and 4-0.2 in online edition). Lind's treatise preceded the discovery of vitamin C by more than a century. In 1775, Percivall Pott was the first to describe an occupationally induced cancer by noting that the mortality from scrotal cancer was 200 times higher in chimney sweeps than in other workers.[6] He attributed the excess mortality to tar and soot exposure in combination with poor personal hygiene. The first carcinogenic polycyclic aromatic hydrocarbon was not discovered until 1933. In the early twentieth century, pellagra was a major public health problem (see eFig. 4-0.3 in online edition). There were 100,000 deaths from the disease in a 40-year period and over 3 million sufferers in the United States at that time. In 1914, Dr. Joseph Goldberger noticed that inmates at the Georgia State Sanatorium developed high rates of pellagra whereas the nurses and attendants did not, and concluded that the origin of pellagra was probably a disease caused by a dietary deficiency. He confirmed his hypothesis with controlled clinical trials.[7] The deficient dietary factor, niacin, was discovered in 1937.

Collectively, these examples illustrate the importance and potential power of public health in the prevention of disease. These examples also highlight the fact that knowledge of disease pathophysiology (i.e., mechanisms) is not always a prerequisite to determining the cause or risk factors for a disease and the potential for effective public health interventions.

HIGH-RISK AND LOW-RISK APPROACHES TO PUBLIC HEALTH

Traditionally, dermatology, like other branches of specialist medicine, has concentrated on the treatment of those who have fallen ill, those who believe they are ill, or people at high risk of developing disease. For instance, we prescribe topical corticosteroids for those with atopic dermatitis, and we may give advice on sun protection to patients who previously had a malignant melanoma. We may see such melanoma patients on a regular basis in skin cancer follow-up clinics to monitor treatment success and to be able to detect recurrences or new early second melanomas. Doctors and patients alike tend to be highly motivated when such an approach is used. The potential benefits seem obvious, and although there may be adverse effects associated with the prescribed treatment, such as skin thinning with prolonged use of topical corticosteroids, or a scar from excision of a melanoma, many patients will accept such risks, because appropriate treatment leads to a tangible and significant improvement of symptoms and improved quality of life or survival. Such an

approach to tackling disease has often been referred to in the literature as the *high-risk* approach, because it focuses on the treatment and detection of those at high risk of developing disease and those who have already fallen ill.[8]

In contrast to the high-risk approach, the ultimate aim of public health medicine and public health dermatology is to prevent the development of disease in the first place whenever possible, not only by forestalling it in those identified as being at high risk (e.g., because of a strong family history), but by shifting the entire distribution of a certain exposure in a healthier direction for the whole population (population strategy). Such a low-risk approach can be implemented through large-scale public health education campaigns aimed at fundamentally changing the entire population's behavior and lifestyle. For example, based on the data of the Framingham study one can extrapolate that a reduction of everybody's blood pressure by 10 mm Hg would result in an overall reduction in mortality from heart disease of around 30%.[8] In dermatology, a good example of a such a population strategy is attempts to change the general population's sun exposure behavior to reduce exposure to ultraviolet light and ultimately skin cancer incidence and mortality through public health education campaigns that are national (e.g., Australia) or international (e.g., the World Health Organization's INTERSUN program, http://www.who.int/uv/intersunprogramme/en/) in scope (Fig. 4-1). This makes sense particularly in a country like Australia, because a strong association between ultraviolet radiation and melanocytic and nonmelanocytic skin cancer is well established, and such risk is distributed widely through the predominantly fair-skinned population. Skin cancer is an important cause of death in economically active younger people, and treatments for all forms of skin cancer pose an important burden on many countries' health care resources. Simple measures, such as avoiding sun exposure during peak hours of radiation and wearing suitable clothing, can provide adequate protection. The state of Victoria, Australia, has the most comprehensive population-based primary prevention campaign against skin cancer in the world (SunSmart campaign, http://www.sunsmart.com.au/), and it has been reported that this program's public investment was worthwhile. Not only has it resulted in a significant reduction in skin cancer incidence and mortality, but the returns from savings on skin cancer treatments have also exceeded the overall costs of the SunSmart campaign.[9]

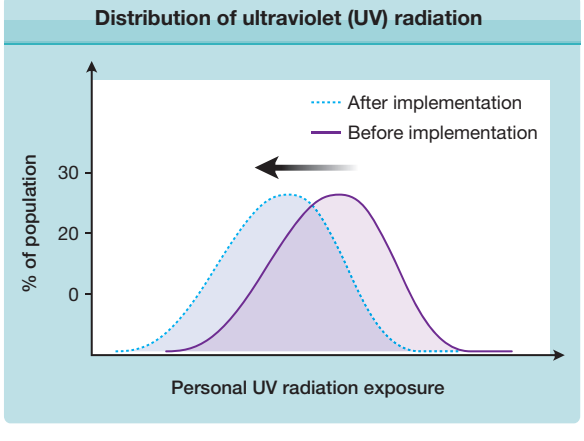

Figure 4-1 Distribution of ultraviolet (UV) radiation exposure before (*solid line*) and after (*dashed line*) implementation of a population strategy to reduce personal UV radiation exposure.

In view of the above, it seems obvious that upstream prevention is more desirable than treating sick individuals who come for treatment downstream after a long chain of pathologic events, some of which may be irreversible. However, it is generally more difficult to persuade healthy individuals to protect themselves against prolonged sun exposure than to persuade those who have already had a malignant melanoma excised. Partly because of this, funding for population prevention strategies is often difficult to obtain, yet the whole population will potentially benefit, as long as such interventions are evidence based and sustainable. It is also worth pointing out that although a public health intervention such as vaccination against measles has dramatically reduced the incidence of disease at a population level, it is impossible to say which individuals have been helped by such a population intervention—a phenomenon known as the *prevention paradox*.

A population strategy is not suitable for trying to control all skin diseases at present, because such a strategy depends on the knowledge of modifiable risk factors. In the many cases for which exposures that predispose to a particular skin condition are unknown, prevention through avoidance is not possible, and the only option available is treatment of disease rather than primary disease prevention.

BALANCING BENEFIT AND HARM

Making the conceptual jump from thinking about individual patients to thinking about entire populations can be challenging for practicing dermatologists, especially because such jumps can come up with some surprising results. For example, a dermatologist with an interest in contact dermatitis might see a case of severe hand dermatitis in a printer caused by allergic contact dermatitis from a chemical and then publicize such a case in a respected journal.[10] Another dermatologist reading such a case report might come to the conclusion that allergic contact dermatitis is an important cause of hand dermatitis in printers. Yet when this dermatologist visits the workplace to conduct a survey of all cases of hand eczema in printers, it becomes apparent that true allergic contact dermatitis is probably quite rare, and by far the most common cause of hand eczema is constant low-grade exposure to soap and water from repeated washing and friction from paper and dirt.[11] Thus, it is possible that a little bit of harm affecting a lot of individuals can add up to much more in absolute terms (the realm of the public health/occupational health physician) than a lot of harm affecting one or two workers (the realm of the dermatologist).

Another well-known example of such a phenomenon is the effects of smoking on reduction in cardiovascular disease. Even though the association between tobacco smoking and lung cancer (relative risk of 14.0) is much stronger than that between smoking and cardiovascular disease (relative risk of 1.6), strategies for smoking cessation save around twice as many lives from cardiovascular disease than from lung cancer simply because heart disease is much more common than lung cancer.[12] Therefore, from a public health perspective the population-attributable risk (the proportion of the disease that may be attributable to a particular risk factor) is more important than other traditional measures of risk, such as the relative risk (whose magnitude may tell us something about the strength of a particular association). In a study of risk factors for psoriasis in Italy, Naldi et al found that smoking accounted for up to 26% of all cases.[13] In individuals with psoriasis who smoked and who also had a family history of psoriasis, an increased body mass index might accounted for up to 48% of disease.[13] The fact that smoking and obesity are modifiable risk factors suggests that psoriasis is preventable, at least to some degree, in this population.

PUBLIC HEALTH APPROACHES IN DERMATOLOGY

So far, we have illustrated the public health approach in dermatology using mainly historical examples. Yet although current dermatologic research is still relatively dominated by the pursuit of studies in which the unit of analysis is at a cellular or subcellular level, there are some good examples of public health dermatology "in action."

One of the classic studies illustrating the public health approach "in action" for infectious skin disease was that conducted by Taplin and colleagues concerning scabies among Kuna Indians on the San Blas Archipelago.[14] These islands off the coast of Panama were plagued by very high rates of scabies in children in the 1980s, which led to misery and secondary bacterial infections. Despite the use of the best treatments available to combat the problem, the population burden of scabies remained largely unchanged. Only after the adoption of a public health approach in which everyone in defined areas was treated did the prevalence of scabies fall dramatically from approximately 33% to approximately 1%. Similar dramatic decreases in scabies prevalence (from 25% to 1%) and in associated pyoderma and possibly poststreptococcal nephritis have been observed through the use of population-based treatment with ivermectin in the Solomon Islands.[15] Another example is the Global Alliance to Eliminate Lymphatic Filariasis (GAELF; http://www.filariasis.org/), an alliance between the World Health Organization, ministries of health, and the private sector aimed at the worldwide eradication of this devastating disease by 2020. GAELF is probably the biggest public health program ever and involves mass treatment of around 750 million people in 48 countries with antifilarial drugs and also includes public health education and advice on skin care of lymphedematous legs to prevent further morbidity. Public health interventions are not restricted to administration of pharmaceutical drugs but can also include educational interventions such as the public education campaigns for reducing skin cancer through reduction in ultraviolet light exposure. One such successful program has been the introduction of basic dermatologic care in Mali through the development of a training program for general health care workers on the management of common skin diseases.[16] The proportion of patients with skin disease with a clear diagnosis increased from 42% before the training to 81% after it. Although such dramatic effects might be overestimated in a simple before-and-after study, the effects were sustained for up to 18 months after training. Paradoxically, these improvements in care were associated with a 25% reduction in prescription costs, which suggests that inappropriate empirical prescribing was a source of unnecessary expenditure before the training. Other researchers have also documented how scarce family income can be wasted on inappropriate treatment for skin diseases such as pyoderma and scabies in Mexico.[17] Ryan has described the role of educational clinics in the prevention of skin cancers as well as the management of early lesions in the albino population of 170,000 in Tanzania.[18] The principles of community dermatology in the face of mobile populations are also discussed elsewhere.[19]

Three further points in relation to public health dermatology are worth noting. The first is that although dermatologists are best placed to provide an accurate diagnosis of skin diseases, such provision may not be realistic for interventions on a public health scale in poorer countries, where there is a strong argument for embedding dermatological skills into primary health care services as has been done successfully in training health care workers in the diagnosis of leprosy in Mali.[20] The second is that public health interventions, like drug treatments, are not without their potential drawbacks. For example, limiting sun exposure in order to reduce the incidence of skin cancer may be associated with drawbacks including depression and less skin synthesis of vitamin D, deficiency of which may be associated with a range of diseases such as cancer, bone disease, and heart disease.[21] Yet recent studies of seasonal variations in vitamin D levels suggest that the commonly held view that 10 to 20 minutes sun exposure during the summer is enough to boost overall 25 hydroxy Vitamin D levels is wrong, and that sufficient sun exposure for a worthwhile benefit would be countered by an unacceptable burden of skin cancer.[22] Therefore, fortifying foods with Vitamin D seems a safer public health option than increasing sun exposure for maintaining adequate vitamin D levels.[23] Balancing benefits and harms requires special consideration in public health simply because they affect so many people. Whilst some public health interventions, such as immunization or advice on reduction of sun exposure, allow some degree of choice for individuals to heed or ignore as they choose, others, such as fluoridation of water or addition of iodine to salt, are less amenable to personal modification. Third is that although many public health interventions may not sound as "high

tech" as drugs targeted at specific biologic receptors, they may be more effective and appropriate for sick populations. The concept that a little bit of harm affecting a lot of people can add up to more than a lot of harm affecting a few people was developed earlier, but a similar maxim also holds true: sometimes a low-technology beneficial intervention that can be applied to a large population can add up to far greater benefit in population terms than a high-technology solution that will benefit only a few.

FUTURE OF PUBLIC HEALTH IN DERMATOLOGY

Some dermatologists, rather than just viewing the world of skin disease from within the narrow confines of a private practice or hospital-based practice, have already conducted population-based needs assessments for dermatologic care, followed by organization of the appropriate services at a population level. A health care needs assessment conducted in the United Kingdom found that skin diseases are one of the commonest reasons why people consult their family doctor where training was paradoxically the least.[24] New data from the World Health Organization project on the Global Burden of Diseases will include important information on the comparative burden of skin diseases compared with other skin diseases (http://www.who.int/healthinfo/global_burden_disease/en/). New methods of communication such as social networking Internet sites have become an increasingly important source of public health information.[25]

There are increasing international collaborations to try to prevent and reduce the burden of skin diseases at a global level through health care planning and focused interventions. These are carried out through organizations such as the International Foundation for Dermatology (http://www.ifd.org/) in conjunction with the International League of Dermatological Societies (http://web.ilds.org/). The International League of Dermatological Societies is working to improve community dermatologic programs in developing countries, focusing on better diagnosis and clear evidence-based guidance for the management of common dermatoses. Training courses have been established, such as those at the Regional Dermatology Training Centre in Moshi, Tanzania (http://www.global-campus.org/rdtc) and short courses in Guerrero, Mexico, and Mali. One of the key aims of these programs is to educate at the primary care level, with the idea that the trainees will then multiply such knowledge by training others in their own countries. As Weinstock points out in Chapter 1, the burden of skin diseases is high. Many skin diseases such as infections, cancer, and atopic eczema can already benefit from a public health approach. What is needed to redress the relative paucity of public health dermatology is to understand the concept that populations are as important as individuals and to build on the sort of collaboration championed by the International Foundation for Dermatology.

KEY REFERENCES

Full reference list available at www.DIGM8.com

DVD contains references and additional content

2. Winslow CEA: The untilled field of public health. *Mod Med* **2**:183, 1920
7. Goldberger J, Wheeler GA, Syndenstricker E: A study of the diet of nonpellagrous and pellagrous households. *JAMA* **71**:944, 1918
8. Rose G: Sick individuals and sick populations. *Int J Epidemiol* **14**:32, 1985
9. Carter R, Marks R, Hill D: Could a national skin cancer primary prevention campaign in Australia be worthwhile? An economic perspective. *Health Promot Int* **14**:73, 1999
14. Taplin D et al: Community control of scabies: A model based on use of permethrin cream. *Lancet* **337**:1016, 1991
16. Mahé A et al: Integration of basic dermatological care into primary health care services in Mali. *Bull World Health Organ* **83**:935, 2005
18. Ryan TJ: Healthy skin for all. *Int J Dermatol* **33**:829, 1994

SECTION 2

Approach to Dermatologic Diagnosis

Chapter 5 :: Structure of Skin Lesions and Fundamentals of Clinical Diagnosis

:: Amit Garg, Nikki A. Levin, & Jeffrey D. Bernhard

"You see, but you do not observe"

—Holmes to Watson in "*Scandal in Bohemia*," by Arthur Conan Doyle, 1892

SKIN LESIONS AND DIAGNOSIS AT A GLANCE

- A patient and thorough approach to the evaluation decreases the risk of making an incorrect diagnosis or overlooking another diagnosis.
- Knowledge and appropriate use of dermatological terminology are fundamental.
- Recognition of disease patterns requires repeated patient encounters.
- The history is indispensable in elucidating complex diagnoses.
- The entire mucocutaneous surface, as well as the hair and nails, should be examined whenever reasonable.
- Morphologic characteristics derived from cell type in skin must be carefully scrutinized.
- Diseases have characteristic morphology and distribution.
- Common pitfalls in dermatologic diagnosis exist and can be avoided.

THE ART AND SCIENCE OF DERMATOLOGIC DIAGNOSIS

The diagnosis and treatment of diseases that affect the skin rest on the physician's ability to use the language of dermatology, to recognize the primary and sequential lesions of the skin, and to recognize the various patterns in which they occur. In this chapter, we discuss a fundamental approach to the patient presenting with a skin problem. We introduce the technical vocabulary of dermatologic description, the "dermatology lexicon." It is important to know and use this standard terminology, as it is the first step in generating a differential diagnosis. Once a lesion has been described as a pearly, flesh-colored, telangiectatic, ulcerated nodule, the experienced physician puts basal cell carcinoma at the top of the differential diagnosis. It is also important to use standard dermatologic terminology for consistency in clinical documentation, in research, and in communication with other physicians.

The process of examining and describing skin lesions may be likened to that of viewing a painting. First, one stands back and takes in the whole "canvas," viewing the patient from a few feet away, at which distance an overall assessment of the patient's general and cutaneous health may be made. One may note such findings as skin color and turgor, presence of pallor or jaundice, degree of sun damage, and the overall number and location of lesions. Next, one looks more closely at the "trees" or "mountains" that make up the landscape, describing and categorizing the specific lesions on the patient. Finally, one may closely examine the details of the canvas, taking in the texture and brush-strokes, using magnification to see the borders of a nevus or compressing a lesion to see if it blanches. Just as a knowledgeable viewer of art may recognize a work of Georges Seurat by its tiny, dot-like brush strokes, an experienced observer of the skin can recognize a melanoma by its asymmetry, irregular borders, and multiple colors.

APPROACH TO THE PATIENT

HISTORY

Dermatology is a visual specialty and some skin lesions may be diagnosed at a glance. Nonetheless, the history is important and in complex cases, such as the

patient with rash and fever or the patient with generalized pruritus, history may be crucial. Dermatologists vary in whether they prefer to take a history prior to, during, or after performing a physical examination. In practice, many take a brief history, perform a physical examination, then undertake more detailed questioning based on the differential diagnosis that the examination suggests.

For the following reasons, it is often useful to at least briefly examine the patient before taking a lengthy history:

- Certain skin conditions, such as classic plaque-type psoriasis or molluscum contagiosum, for example, present with such distinctive morphologies that the diagnosis may be immediately obvious, rendering extensive history taking unnecessary.
- A patient's history may contain "red herrings," which lead the physician away from, rather than toward, the correct diagnosis. Examination of the patient before taking a history may yield a more complete and unbiased differential diagnosis.
- In certain situations, such as the evaluation of alopecia, initial examination of the patient to determine what type of hair loss is present allows the physician to pursue a line of questions pertinent to that type of alopecia.

In taking a history from a patient presenting with a new skin complaint, the physician's primary goal is to establish a diagnosis, with a secondary goal of evaluating the patient as a candidate for therapy. In patients whose diagnosis is already established, the physician's goals are to reevaluate the original diagnosis, monitor disease progress and complications, and modify treatment accordingly.

Box 5-1 presents a suggested approach to obtaining the history in a patient presenting with a skin problem. Clearly, not all of the questions are necessary for every patient. The physician will need to tailor the history depending on whether the chief complaint is a growth or an eruption, a nail or hair disorder, or another condition, and whether it is a new problem or a follow-up visit for an ongoing condition.

EXAMINATION OF THE DERMATOLOGIC PATIENT

SCOPE OF THE COMPLETE CUTANEOUS EXAMINATION.

The complete cutaneous examination includes inspection of the entire skin surface, including often-overlooked areas such as the scalp, eyelids, ears, genitals, buttocks, perineal area, and interdigital spaces; the hair; the nails; and the mucus membranes of the mouth, eyes, anus, and genitals. In routine clinical practice, not all of these areas are examined unless there is a specific reason to do so, such as a history of melanoma or a particular localizing complaint. A guide to performing the physical examination of the patient presenting with a skin problem is presented in Box 5-2.

ADVANTAGES TO PERFORMING A COMPLETE CUTANEOUS EXAMINATION.

Although it is not always essential or practical to perform a complete skin examination, there are many advantages to doing so, especially for new patients and challenging cases:

- Identification of potentially harmful lesions (e.g., skin cancers) of which the patient is unaware; any patient with a history of skin cancer or a chief complaint of a "new growth" deserves a full skin examination.
- Identification of benign lesions (e.g., seborrheic keratoses, angiokeratomas) that the patient was concerned about but reluctant to mention, thereby enabling the physician to provide reassurance.
- Finding hidden clues to diagnosis (e.g., scabies lesions on the penis, psoriatic plaques on the buttocks, Wickham striae of lichen planus on the buccal mucosa, nail pitting in alopecia areata).
- Opportunity for patient education (e.g., lentigines are a sign of sun damage and suggest the need for improved sun protection).
- Opportunity to convey the physician's concern about the patient's skin health as a whole. Patients appreciate this and also regard the physician as thorough.

BARRIERS TO PERFORMING A COMPLETE SKIN EXAMINATION.

Despite the advantages of performing a full cutaneous examination, numerous barriers exist that may prevent the dermatologist from performing such an evaluation for every patient. Understandably, patients may decline a full examination when their chief complaint is relatively minor or localized, such as a wart or acne. In other cases, patients may express resistance to disrobing for a full examination due to embarrassment, especially when the physician is of the opposite gender. Sometimes the physician is uncomfortable performing a complete skin examination with the concern that a patient may misinterpret the examination as improper. In many instances, time constraints and lack of personnel to serve as chaperones limit the ability to perform full skin examination.

IDEAL CONDITIONS FOR THE COMPLETE SKIN EXAMINATION.

A complete skin examination is most effective when performed under ideal conditions. It is most important to have excellent lighting, preferably bright, even light that simulates the solar spectrum. Without good lighting, subtle but important details may be missed. The patient should be fully undressed, wearing only a gown that is easily moved aside, with a sheet over the legs, if desired. Underwear, socks, and shoes should be removed, as should any makeup or eyeglasses. The examining table should be at a comfortable height, with a head that reclines, an extendable footrest, and gynecologic stirrups. The examining room should be at a comfortable temperature for the lightly dressed patient. It should contain a sink for hand washing and disinfecting hand foam, as patients are reassured by seeing their physician wash hands before the examination. If the patient and physician are of opposite genders, having a chaperone in

BOX 5-1 HISTORY TAKING IN DERMATOLOGIC DIAGNOSIS

CHIEF COMPLAINT AND HISTORY OF THE PRESENT ILLNESS

- ***Duration:*** When the condition was first noted and dates of any recurrences or remissions
- ***Periodicity:*** For example, constant, waxing and waning, worst at night, worst in winter
- ***Evolution:*** How the condition has spread or developed over time; often useful to ask patient whether lesion "always looked this way," or if not, how it looked when it first started
- ***Location:*** Where lesions were first noted and how they have spread, if applicable
- ***Symptoms:*** For example, pruritus, pain, bleeding, nonhealing, change of preexisting moles
- ***Severity:*** Especially for painful or pruritic conditions, it can be useful to ask patient to rate severity on a ten-point scale in order to follow severity over time
- ***Ameliorating and Exacerbating Factors:*** Relation to sun exposure, heat, cold, wind, trauma, and exposure to chemicals, topical products, plants, perfumes or metals, relation to menses or pregnancy
- Preceding illness, new medications, new topical products, or exposures
- Therapies tried, including over-the-counter or home remedies, and response to therapy
- Prior similar problems, prior diagnosis, results of biopsies or other studies performed

PAST MEDICAL HISTORY

- A history of all chronic illnesses, particularly those that may manifest in the skin, (diabetes, renal and hepatic disease, infection with HIV or hepatitis viruses, polycystic ovarian syndrome, lupus, thyroid disease) and those that are associated with skin disease (asthma, allergies)
- History of surgical procedures, including organ transplantation and bariatric surgery
- ***Immunosuppression:*** Either iatrogenic, infectious, genetic
- Pregnancies
- Psychiatric disease
- History of blistering sunburns, exposure to arsenic or ionizing radiation
- ***Medication History:*** A detailed history with particular attention to those medications started recently
- Prescription
- Over-the-counter medications
- Vitamins and dietary supplements
- Herbal remedies
- ***Allergies:*** To medications, foods, environmental antigens, and contactants
- ***Social History:*** Occupation, hobbies and leisure activities, alcohol and tobacco use, illicit drug use, sexual history (including high-risk activities for sexually transmitted diseases), dietary history, bathing habits, pets, living conditions (e.g., alone, with family, homeless, in an institution), history of travel or residence in endemic areas for infectious diseases, ethnicity, religious practices
- ***Family History:*** Of skin disease, atopy (atopic dermatitis, asthma, hay fever) or skin cancer
- ***Review of Systems:*** Constitutional symptoms (fatigue, weight loss, fever, chills, night sweats), acute illness symptoms (headache, photophobia, stiff neck, nausea, vomiting, cough, rhinorrhea, sneezing, myalgias, arthralgias), symptoms of conditions such as hypothyroidism (cold intolerance, weight gain, constipation) or psoriatic arthritis (joint pain, swelling and stiffness), which may accompany a dermatologic condition

the room can make the examination more comfortable for both.

RECOMMENDED TOOLS FOR THE COMPLETE SKIN EXAMINATION. Although the physician's eyes and hands are the only essential tools for examination of the skin, the following are often useful and highly recommended:

- A magnifying tool such as a loupe, magnifying glass, and/or dermatoscope.
- A bright focused light such as a flashlight or penlight to sidelight lesions.
- Glass slides or a hand magnifier for diascopy.
- Alcohol pads to remove scale or surface oil.
- Gauze pads or tissues with water for removing makeup.
- Gloves to be used for examination when scabies or another highly infectious condition (secondary syphilis) is suspected, when examining mucus membranes, and vulvar and genital areas, and when performing any procedure.
- A ruler for measuring lesions.
- Number 15 and number 11 scalpel blades for scraping and incising lesions, respectively.
- A camera for photographic documentation.
- A Wood's lamp (365 nm) for highlighting subtle pigmentary changes.

BOX 5-2 PHYSICAL EXAMINATION IN DERMATOLOGIC DIAGNOSIS

GENERAL IMPRESSION OF THE PATIENT

- Well or ill
- Obese, cachectic, or normal weight
- ***Skin Color:*** Degree of pigmentation, pallor (anemia), carotenemia, jaundice
- ***Skin Temperature:*** For example, warm, cool, and clammy
- ***Skin Surface Characteristics:*** Xerosis (dryness), seborrhea (excessive oil), turgor, hyper- or hypohidrosis (excessive or decreased sweating), and texture
- ***Degree of Photoaging:*** Lentigines, actinic purpura, rhytides

Describe the Distribution of Lesions: Localized (isolated), grouped, regional, generalized, universal, symmetrical, sun-exposed, flexural, extensor extremities, acral, intertriginous, dermatomal, follicular

PRIMARY LESIONS

- Define their type (e.g., papule, plaque, bulla)
- Describe their shape (e.g., arcuate, annular, linear)
- Describe any secondary changes (e.g., crusting, excoriations)

PALPATION

- Superficial (e.g., scaly, rough, smooth)
- Deep (e.g., firm, rubbery, mobile)

ASPECTS OF GENERAL PHYSICAL EXAMINATION THAT MAY BE HELPFUL

- Vital signs
- Abdominal examination for hepatosplenomegaly
- Pulses
- Lymph node examination (especially in cases of suspected infection and malignancy)

TECHNIQUE OF THE DERMATOLOGIC PHYSICAL EXAMINATION. Just as there is no one correct way to perform a general physical examination, each physician approaches the complete skin examination with his or her own style. A common thread to effective styles of skin examination is consistency in the order of examining different body areas to ensure that no areas are overlooked. One approach to the complete skin examination is presented here. First, observe the patient at a distance for general impressions (e.g., asymmetry due to a stroke, obesity, pallor, fatigue, jaundice). Next, examine the patient in a systematic way, usually from head to toe, uncovering one area at a time to preserve patient modesty. Move the patient (e.g., from sitting to lying) and the illumination as needed for the best view of each body area. Palpate growths to determine whether they are soft, fleshy, firm, tender, or fluid-filled. Use of the hands to stretch the skin is especially useful in diagnosis of basal cell carcinoma, in which stretching skin reveals a "pearly" quality often not seen on routine inspection. A magnifier worn on the head leaves both hands free for palpation of lesions. Certain lesions, such as porokeratosis, are best examined with side lighting that reveals depth and the details of borders. During the examination, patients often find it reassuring for the physician to name and demystify benign lesions as they are encountered.

Special examination techniques for hair disorders are discussed in Chapter 88; these include having the patient sit in a chair so that the entire scalp is easily examined, parting the patient's hair at the front and occiput, and gently tugging on hairs to determine the fraction of loose (telogen) hairs. Examination of the nails is discussed in Chapter 89.

After completing the examination, it is important to document the skin findings, including the type of lesions and their locations, either descriptively or on a body map. Careful documentation is particularly important for suspicious lesions that are to be biopsied, so that the exact location may be found and definitively treated at a later date. Instant or digital photography is a useful adjunct for documentation.

INTRODUCTION TO MORPHOLOGY

Siemens (1891–1969) wrote, "he who studies skin diseases and fails to study the lesion first will never learn dermatology." His statement reinforces the notion that the primary skin lesion, or the evolution thereof, is the essential element on which clinical diagnosis rests. Joseph Jakob von Plenck's (1738–1807) and Robert Willan's (1757–1812) work in defining basic morphologic terminology have laid the foundation for the description and comparison of fundamental lesions, thereby facilitating characterization and recognition of skin disease as, Wolff and Johnson state, to read words, one must recognize letters; to read the skin, one must

recognize the basic lesions. To understand a paragraph, one must know how words are put together; to arrive at a differential diagnosis, one must know what the basic lesions represent, how they evolve, and how they are arranged and distributed.

Variation and ambiguity in the morphologic terms generally accepted by the international dermatology community have engendered barriers to communication among physicians of all disciplines, including dermatologists. In dermatologic textbooks, the papule, for example, has been described as no greater than 1 cm in size, less than 0.5 cm, or ranging from the size of a pinhead to that of a split pea. Thus, in forming a mental image of a lesion or eruption after hearing its morphologic description, physicians sometimes remain irresolute. The mission of the Dermatology Lexicon Project has been to create a universally accepted and comprehensive glossary of descriptive terms to support research, medical informatics, and patient care. Morphologic definitions in this chapter parallel and amplify those of the Dermatology Lexicon Project. Table 5-1 contains a summary of the lesions discussed.



Figure 5-1 Papule. Multiple, well-defined papules of varying sizes are seen. Flat tops and glistening surface are characteristic of lichen planus.

RAISED LESIONS

PAPULE. A papule is a solid, elevated lesion less than 0.5 cm in size in which a significant portion projects above the plane of the surrounding skin. Papules surmounted with scale are referred to as papulosquamous lesions. Sessile, pedunculated, dome-shaped, flat-topped, rough, smooth, filiform, mammillated, acuminate, and umbilicated constitute some common shapes and surfaces of papules. A clinical example is lichen planus (Fig. 5-1; see Chapter 26).

PLAQUE. A plaque is a solid plateau-like elevation that occupies a relatively large surface area in comparison with its height above the normal skin level and has a diameter larger than 0.5 cm. Plaques are further characterized by their size, shape, color, and surface change. A clinical example is psoriasis (Fig. 5-2; see Chapter 18).

NODULE. A nodule is a solid, round or ellipsoidal, palpable lesion that has a diameter larger than 0.5 cm. However, size is not the major consideration in the definition of nodule. Depth of involvement and/or substantive palpability, rather than diameter, differentiates a nodule from a large papule or plaque. Depending on the anatomic component(s) primarily involved, nodules are of five main types: (1) epidermal, (2) epidermal–dermal, (3) dermal, (4) dermal–subdermal, and (5) subcutaneous. Some additional features of a nodule that may help reveal a diagnosis include whether it is warm, hard, soft, fluctuant, movable, fixed, or painful. Similarly, different surfaces of nodules, such as smooth, keratotic, ulcerated, or fungating, also help direct diagnostic considerations. A clinical example of a nodule is nodular basal cell carcinoma (Fig. 5-3; see Chapter 115).

Tumor, also sometimes included under the heading of nodule, is a general term for any mass, benign or malignant. A *gumma* is, specifically, the granulomatous nodular lesion of tertiary syphilis.

CYST. A cyst is an encapsulated cavity or sac lined with a true epithelium that contains fluid or semi-

TABLE 5-1
The Lesions of the Skin

Raised	Depressed	Flat	Surface Change	Fluid Filled	Vascular
Papule	Erosion	Macule	Scale	Vesicle	Purpura
Plaque	Ulcer	Patch	Crust	Bulla	Telangiectasia
Nodule	Atrophy	Erythema	Excoriation	Pustule	Infarct
Cyst	Poikiloderma	Erythroderma	Fissure	Furuncle	
Wheal	Sinus		Lichenification	Abscess	
Scar	Striae		Keratoderma		
Comedo	Burrow		Eschar		
Horn	Sclerosis				
Calcinosis					



Figure 5-2 Plaque. Well-demarcated pink plaques with a silvery scale representing psoriasis vulgaris.

solid material (cells and cell products such as keratin). Its spherical or oval shape results from the tendency of the contents to spread equally in all directions. Depending on the nature of the contents, cysts may be hard, doughy, or fluctuant. A clinical example is a cystic hidradenoma (Fig. 5-4; see Chapter 119).

WHEAL. A wheal is a swelling of the skin that is characteristically evanescent, disappearing within hours. These lesions, also known as *hives* or *urticaria*, are the result of edema produced by the escape of plasma through vessel walls in the upper portion of the dermis. Wheals may be tiny papules or giant plaques, and they may take the form of various shapes (round, oval, serpiginous, or annular), often in the same patient. Borders of a wheal, although sharp, are not stable and in fact move from involved to adjacent uninvolved areas over a period of hours. The flare, or ring of pink erythema, of a wheal may be intense if superficial vessels are dilated. If the amount of edema is sufficient to compress superficial vessels, wheals may in fact be white in the center or around the periphery, producing a zone of pallor. With associated inflammatory disruption of the vessels walls, wheals may have a deeper red color, may be purpuric, and are more persistent.



Figure 5-3 Nodule. A nodular basal cell carcinoma with well-defined, firm nodule with a glistening surface through which telangiectasia can be seen.



Figure 5-4 Cyst. A bluish colored resilient cyst filled with a mucous-like material on the cheek is cystic hidradenoma.

A clinical example is dermatographism (Fig. 5-5; see Chapter 38).

Angioedema is a deeper, edematous reaction that occurs in areas with very loose dermis and subcutaneous tissue such as the lip, eyelid, or scrotum. It may occur on the hands and feet as well, and result in grotesque deformity.

SCAR. A scar arises from proliferation of fibrous tissue that replaces previously normal collagen after a wound or ulceration breaches the reticular dermis. Scars have a deeper pink to red color early on before becoming hypo- or hyperpigmented. In most scars, the epidermis is thinned and imparts a wrinkled appearance at the surface. Adnexal structures, such as hair



Figure 5-5 Wheal. A sharply demarcated wheal with a surrounding erythematous flare occurring within seconds of the skin being stroked.



Figure 5-6 Comedo. Open and closed comedones on the face of this patient with acne.

follicles, normally present in the dermis are absent. Hypertrophic scars typically take the form of firm papules, plaques, or nodules. Keloid scars are also elevated. Unlike hypertrophic scars (see eFig. 5-5.1 in online edition; see Chapter 66), keloids exceed, with web-like extensions, the area of initial wounding. Atrophic scars are thin depressed plaques.

COMEDO. A comedo is a hair follicle infundibulum that is dilated and plugged by keratin and lipids. When the pilosebaceous unit is open to the surface of the skin with a visible keratinaceous plug, the lesion is referred to as an *open comedo*. The black color of the comedo is due to the oxidized sebaceous content of the infundibulum ("blackhead"). A closed infundibulum in which the follicular opening is unapparent accumulates whitish keratin and is called a *closed comedo*. A clinical example is comedonal acne (Fig. 5-6; see Chapter 80).

HORN. A horn is a hyperkeratotic conical mass of cornified cells arising over an abnormally differentiating epidermis. A clinical example is verruca vulgaris (see eFig. 5-6.1 in online edition; see Chapter 196).

CALCINOSIS. Deposits of calcium in the dermis or subcutaneous tissue may be appreciated as hard, whitish nodules or plaques, with or without visible alteration of the skin's surface. A clinical example is cutaneous calcinosis in dermatomyositis (see eFig. 5-6.2 in online edition; see Chapter 156).

DEPRESSED LESIONS

EROSION. An *erosion* is a moist, circumscribed, depressed lesion that results from loss of a portion or all of the viable epidermal or mucosal epithelium. The defect extending to the most superficial part of the dermis may result in pinpoint bleeding in a sievelike fashion. Erosions may result from trauma, detachment of epidermal layers with maceration, rupture of vesicles or bullae, or epidermal necrosis, for example. Unless they become secondarily infected, erosions do not scar. A clinical example is toxic epidermal necrolysis (Fig. 5-7; see Chapter 40).

ULCERS. An ulcer is a defect in which the epidermis and at least the upper (papillary) dermis have been destroyed. Breach of the dermis and destruction of adnexal structures impede reepithelialization, and the defect heals with scarring. Borders of the ulcer may be rolled, undermined, punched out, jagged, or angular. The base may be clean, ragged, or necrotic. Discharge may be purulent, granular, or malodorous. Surrounding skin may be red, purple, pigmented, reticulated, indurated, sclerotic, or infarcted. A clinical example is pyoderma gangrenosum (Fig. 5-8; see Chapter 33).

ATROPHY. *Atrophy* refers to a diminution in the size of a cell, tissue, organ, or part of the body. An atrophic epidermis is glossy, almost transparent, paper thin and wrinkled, and may not retain normal skin lines. Atrophy of the papillary or reticular dermal connective tissue manifests as a depression of the skin. Atrophy of the panniculus results in a more substantial depression of the skin. eFig. 5-8.1 in online edition shows aged skin of the arm in an elderly woman (see Chapter 109).



Figure 5-7 Erosion. Sloughing of the skin in this patient with toxic epidermal necrolysis leaves behind a large erosion.



Figure 5-8 Ulcer. A large ulcer with a ragged base and heaped-up pink erythematous border on the leg representing progressing pyoderma gangrenosum.

POIKILODERMA. As a morphologic term, *poikiloderma* refers to the combination of atrophy, telangiectasia, and varied pigmentary changes (hyper- and hypo-) over an area of skin. This combination of features may give rise to a dappled appearance to the skin. A clinical example is chronic radiodermatitis (see eFig. 5-8.2 in online edition).

SINUS. A sinus is a tract connecting deep suppurative cavities to each other or to the surface of the skin. A clinical example is hidradenitis suppurativa (see eFig. 5-8.3 in online edition; see Chapter 85).

STRIAE. Striae are linear depressions of the skin that usually measure several centimeters in length and result from changes to the reticular collagen that occur with rapid stretching of the skin. A clinical example is striae distensae (see eFig. 5-8.4 in online edition; see Chapter 108).

BURROW. A burrow is a wavy, threadlike tunnel through the outer portion of the epidermis excavated by a parasite. A clinical example is scabetic burrow (see eFig. 5-8.5 in online edition; see Chapter 208).

SCLEROSIS. *Sclerosis* refers to a circumscribed or diffuse hardening or induration of the skin that results from dermal fibrosis. It is detected more easily by palpation, on which the skin may feel board-like, immobile, and difficult to pick up. A clinical example is morphea (see eFig. 5-8.6 in online edition; see Chapter 64).

FLAT AND MACULAR LESIONS

MACULE. A macule is flat, even with the surface level of surrounding skin, and perceptible only as an area of color different from the surrounding skin or mucous membrane. Maculosquamous is a neologism invented to describe macules with fine nonpalpable scaling, which may become apparent only after light scraping and scratching.

Perhaps the most important additional feature of a lesion other than primary morphology is color. Lesional color, which is often the first visual assessment made, is reliably reproducible with particular types of pathologies, such as destruction of melanocytes, dilatation of dermal blood vessels, or inflammation of vessel walls with extravasation of red blood cells. As such, color provides meaningful insight into pathologic processes of the skin and facilitates clinical diagnosis. Pigmentary changes represent an important and common type of macular color change and may be described as hyperpigmented (as in postinflammatory hyperpigmentation), hypopigmented (as in tinea versicolor), or depigmented (as in vitiligo).

Table 5-2 describes characteristic colors that may be noted with inspection of altered skin. A clinical example is lentigo (Fig. 5-9; see Chapter 122).

PATCH. A patch is similar to a macule; it is a flat area of skin or mucous membranes with a different color from its surrounding. However, a patch is larger than



Figure 5-9 Macule. Uniform-colored brown macule with slightly irregular, sharply defined borders representing a lentigo on the lip.

0.5 cm, and it may have a fine, very thin scale. Clinical examples include vitiligo, where the term "patch" may be used to describe larger macules or a "patchy" configuration (Fig. 5-10; see Chapter 74), and also cutaneous T-cell lymphoma, where early lesions may be thin slightly scaly patches.

ERYTHEMA. Erythema represents the blanchable pink to red color of skin or mucous membrane that is due to dilatation of arteries and veins in the papillary and reticular dermis. It exists in different colors, and to dub a primary lesion as *erythematous* alone is incomplete. Describing erythema with the color it most closely resembles provides a meaningful clue to diagnosis. For example, violaceous erythema brings to mind a differential distinct from salmon pink-colored erythema, even if both types of erythema involve papules. A clinical example is dusky erythema, as may be seen in a fixed drug eruption (see eFig. 5-10.1 in online edition; see Chapter 41).

ERYTHRODERMA. Erythroderma is a generalized deep redness of the skin involving more than 90% of the body surface within days to weeks. Type of scaling

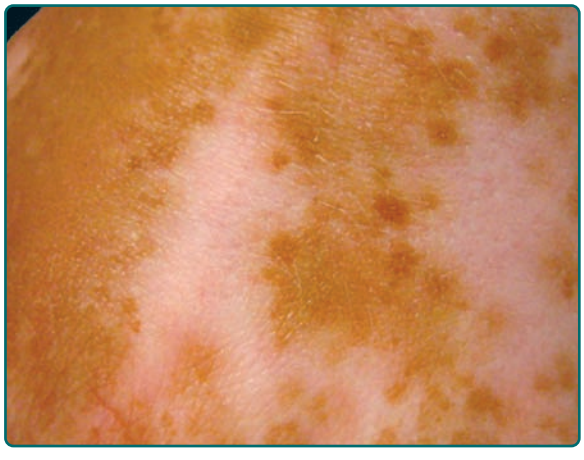

Figure 5-10 Patch. Depigmented patches within areas of normal skin tone representing vitiligo.

TABLE 5-2
Implications of Color Changes in Altered Skin

Color	Pathology	Diagnostic Consideration
Apple jelly	Granulomatous inflammation	Tuberculosis, sarcoidosis, leishmaniasis
Black	Melanin, necrosis	Melanoma, purpura fulminans, calciphylaxis
Blue	Deep dermal pigment, reduced hemoglobin, tattoo, medication	Blue nevus, amiodarone
Brown	Melanin, hemosiderin, chronic inflammation, postinflammatory, dried serum	Nevus, melasma
Copper	Inflammation with plasma cells	Secondary syphilis
Green	Deep hemosiderin, pyocyanin pigment, tissue eosinophilia	*Pseudomonas* infection, tattoo, Wells syndrome
Gray	Deep melanin or other pigment deposition	Chloroquine toxicity, Mongolian spot, erythema dyschromicum perstans
Lilac	Inflammation, dilatation of deep dermal blood vessels	Borders of evolving morphea, dermatomyositis
Orange	Granulomatous inflammation with histiocytes having abundant cytoplasm	Juvenile xanthogranuloma
Pearly	Epidermal proliferation without surface keratin	Basal cell carcinoma
Pink	Acute inflammation, dilatation of superficial dermal blood vessels, hemorrhage	Eczema
Red	Hemorrhage, acute inflammation, dilatation of blood vessels	Psoriasis, drug eruptions
Salmon pink	Inflammation with involvement of epidermis, dilatation of blood vessels' inflammation with edema	Pityriasis rubra pilaris, psoriasis, urticaria
Violet	Hemorrhage, deep hemosiderin, lichenoid inflammation	Lichen planus, Kaposi sarcoma
White	Reduced or absent melanin synthesis, postinflammatory	Tinea versicolor, albinism, vitiligo
Yellow	Superficial *Staphylococcus* or *Streptococcus* infection mixed with keratinized cells, carotenoids, hemosiderin, bile pigment, accumulated lipid	Impetigo, xanthomas, sebaceous hyperplasia, necrobiosis lipoidica diabeticorum, jaundice

or desquamation, which follows establishment of the generalized erythema, noted is suggestive of the primary process (Table 5-3). A clinical example is Sézary syndrome (see eFig. 5-10.2 in online edition; see Chapters 23 and 145).

SURFACE CHANGE

SCALE, DESQUAMATION (SCALING). A scale is flat plate or flake arising from the outermost layer of the stratum corneum. Groups of coherent cornified cells packed with filamentous proteins desquamate in scales imperceptibly from the skin's surface under normal circumstances on a regular basis as the epidermis is replaced completely every 27 days. When epidermal differentiation is disordered, accumulation and casting of stratum corneum become apparent as scale that ranges in size from fine dust-like particles to extensive parchment-like sheets. In some cases, scale is observed only after scratching the lesion, a phenomenon known as *latent desquamation*. Scaly lesions are often described as "hyperkeratotic," a term that is used both clinically and histopathologically.

Not all scales are similar, and the expert dermatologist with a well-trained eye can obtain diagnostically useful information from close examinations of the type of scale present. Table 5-3 describes the types of scale one may encounter. A clinical example is psoriasis vulgaris (Fig. 5-11; see Chapter 18).

HYPERKERATOSIS. Leider and Rosenblum define hyperkeratosis as "excessive cornification." Siemens states that "the stratum corneum may be thinned or thickened." In the latter, thickening may consist of normal keratin (hyperkeratosis) or of an abnormal keratin in which the cellular nuclei are retained and are stainable (parakeratosis). Different types of hyperkeratosis can be discerned histopathologically, but in clinical parlance "hyperkeratosis" refers to an excessive or thickened stratum corneum, often but not always scaly.

TABLE 5-3
Types of Scale

Type of Scale	Description	Prototype Diagnosis
Crack-like/craquelé	Desquamation giving the appearance of dried, cracked skin.	Eczema craquelé
Exfoliative	Scales split of from the epidermis in finer scales or in sheets.	Drug reaction
Follicular	Scales appear as keratotic plugs, spines, or filaments.	Keratosis pilaris
Gritty	Densely adherent scale with a sandpaper texture.	Actinic keratosis
Ichthyosiform	Scales are regular polygonal plates arranged in parallel rows or diamond patterns (fish-like, tesselated).	Ichthyosis vulgaris
Keratotic/hyperkeratotic	Scales appear as heaped-up column of scale.	Cutaneous horn
Lamellar	Scales are thin large plates or shields attached in the middle and looser around the edges.	Lamellar ichthyosis
Pityriasiform	Scale is small and branny.	Pityriasis rosea
Psoriasiform (micaceous and ostraceous)	Scale is silvery and brittle and forms thin platelets in several loose sheets, like mica (micaceous scale). Large scales may accumulate in heaps, giving the appearance of an oyster shell (ostraceous scale).	Psoriasis vulgaris
Seborrheic	Scales are thick, waxy or greasy, yellow-to-brown, flakes.	Seborrheic dermatitis
Wickham striae	Scale appears as a lacy white pattern overlying violaceous flat-topped papules.	Lichen planus

CRUSTS (ENCRUSTED EXUDATES). Crusts are hardened deposits that result when serum, blood, or purulent exudate dries on the surface of the skin. The color of crust is a yellow-brown when formed from dried serous secretion; turbid yellowish-green when formed from purulent secretion; and reddish-black when formed from hemorrhagic secretion. Removal of the crust may reveal an underlying erosion or ulcer. A clinical example is impetigo (Fig. 5-12; see Chapter 176).



Figure 5-11 Scale. Brittle silvery scales forming thin platelets in several loose sheets, like mica, on this plaque of psoriasis.

EXCORIATIONS. Excoriations (see eFig. 5-12.1 in online edition) are surface excavations of epidermis that result from scratching.

FISSURE. A fissure is a linear loss of continuity of the skin's surface or mucosa that results from excessive tension or decreased elasticity of the involved tissue. Fissures frequently occur on the palms and soles where the thick stratum corneum is least expandable. A clinical example is fissure on the palm associated with contact dermatitis (see eFig. 5-12.2 in online edition; see Chapter 13).

LICHENIFICATION. Repeated rubbing of the skin may induce a reactive thickening of the epidermis, with changes in the collagen of the underlying superficial dermis. These changes produce a thickened skin



Figure 5-12 Crust. Glistening, honey-colored, delicate crusts under the nose representing impetigo.



Figure 5-13 Lichenification. An area of thickened skin with accentuated skin markings induced by repeated rubbing, representing lichenification noted in lichen simplex chronicus.

with accentuated markings, which may resemble tree bark. A clinical example is lichen simplex chronicus (Fig. 5-13; see Chapter 15).

KERATODERMA. Keratoderma is an excessive accumulation of scale (hyperkeratosis) that results in a yellowish thickening of the skin, usually on the palms or soles, that may be inherited (abnormal keratin formation) or acquired (mechanical stimulation). A clinical example is plantar keratoderma in psoriasis (see eFig. 5-13.1 in online edition; see Chapter 18).

ESCHAR. The presence of an eschar implies tissue necrosis, infarction, deep burns, gangrene, or other ulcerating process. It is a circumscribed, adherent, hard, black crust on the surface of the skin that is moist initially, protein rich, and avascular. A clinical example is thermal burn (see eFig. 5-13.2 in online edition; see Chapter 95).

FLUID-FILLED LESIONS

VESICLE AND BULLA. A vesicle is a fluid-filled cavity or elevation smaller than or equal to 0.5 cm, whereas a bulla (blister) measures larger than 0.5 cm. The fluid in the cavity exerts equal pressure in all directions to give rise to a spherical shape. Because of their size, bullae are easily identifiable as tense or flaccid weepy blisters. Clear, serous, hemorrhagic, or pus-filled contents may be visualized when the cavity wall is thin and translucent enough. Vesicles and bullae arise from cleavage at various levels of the epidermis (intraepidermal) or of the dermal–epidermal interface (subepidermal). The amount of pressure required to collapse the lesion may help predict whether the bulla is intraepidermal or subepidermal. However, reliable differentiation requires histopathologic examination of the blister cavity edge.

A clinical example of vesicle is the blistering aspect of impetigo caused by toxin-producing staphylococci (Fig. 5-14A; see Chapter 177). A clinical example of bulla is a bullous pemphigoid (Fig. 5-14B; see Chapter 56).

PUSTULE. A pustule is a circumscribed, raised cavity in the epidermis or infundibulum containing pus. The purulent exudate, composed of leukocytes with



Figure 5-14 Vesicle (**A**) and bulla (**B**). Fragile subcorneal translucent vesicles representing impetigo caused by a toxin-producing *Staphylococcus* (**A**) and large tense subepidermal bullae filled with serous or hemorrhagic fluid in this patient with bullous pemphigoid (**B**).



Figure 5-15 Pustule. Two pustules representing superficial pyoderma.

or without cellular debris, may contain bacteria or may be sterile. Depending on its sterility, the exudate may be white, yellow, or greenish-yellow in color. Pustules may vary in size and, in certain situations, may coalesce to form "lakes" of pus. When associated with hair follicles, pustules may appear conical and contain a hair in the center. A clinical example is superficial pyoderma (Fig. 5-15; see Chapter 176).

FURUNCLE. A furuncle (see eFig. 5-15.1 in online edition; see Chapter 176) is a deep necrotizing folliculitis with suppuration. It presents as an inflamed follicle-centered nodule usually greater than 1 cm with a central necrotic plug and an overlying pustule. Several furuncles may coalesce to form a carbuncle.

ABSCESS. An abscess (see eFig. 5-15.2 in online edition; see Chapter 176) is a localized accumulation of purulent material so deep in the dermis or subcutaneous tissue that the pus is usually not visible on the surface of the skin. An abscess is a pink erythematous, warm, tender, fluctuant nodule.

PURPURA/VASCULAR LESIONS

PURPURA. Extravasation of red blood from cutaneous vessels into skin or mucous membranes results in reddish-purple lesions included under the term *purpura*. The application of pressure with two glass slides or an unbreakable clear lens (diascopy) on a reddish-purple lesion is a simple and reliable method for differentiating redness due to vascular dilatation (erythema) from redness due to extravasated erythrocytes or erythrocyte products (purpura). If the redness is nonblanching under the pressure of the slide, the lesion is purpuric. As extravasated red blood cells decompose over time, the color of purpuric lesions change from bluish-red to yellowish-brown or green.



Figure 5-16 Purpura. Nonblanching red erythematous papules and plaques (palpable purpura) on the legs, representing leukocytoclastic vasculitis.

Petechiae are small, pinpoint purpuric macules. Ecchymoses are larger, bruise-like purpuric patches. These lesions correspond to a noninflammatory extravasation of blood. If a lesion is purpuric and palpable ("palpable purpura"), the suggestion of an inflammatory insult to the vessel wall as a cause of extravasation of blood and inflammatory cells exists. A clinical example is leukocytoclastic vasculitis (Fig. 5-16; see Chapter 163).

TELANGIECTASIA. Telangiectasia (see eFig. 5-16.1 in online edition; see Chapter 174) are persistent dilatations of small capillaries in the superficial dermis that are visible as fine, bright, nonpulsatile red lines or net-like patterns on the skin.

INFARCT. An infarct is an area of cutaneous necrosis resulting from a bland or inflammatory occlusion of blood vessels in the skin. A cutaneous infarct presents as a tender, irregularly shaped dusky reddish-gray macule or firm plaque that is sometimes depressed slightly below the plane of the skin. A clinical example is cholesterol emboli (Fig. 5-17; see Chapter 173).

SHAPE, ARRANGEMENT, AND DISTRIBUTION OF LESIONS

Once the type or types of lesions have been identified, one needs to describe their shape, arrangement, and pattern of distribution, all useful characteristics in morphologic diagnosis. For example, a single scaly plaque on a patient's trunk may have a broad differential diagnosis, but the same plaques symmetrically



Figure 5-17 Infarct. Dusky purple discoloration representing an area of infarction that eventuates in tissue necrosis. This patient had cholesterol emboli lodged in the distal end arteries of the toes.



Figure 5-19 Nummular lesion. (Illustration by Glen Hintz, MS. Dermatology Lexicon Project.)

distributed on the elbows, knees, and umbilicus would be highly suggestive of psoriasis. The following descriptions of shapes and arrangements of skin lesions may be applied to single or multiple lesions. For example, a single lesion may be linear or multiple lesions may assume a linear pattern.

SHAPE OR CONFIGURATION OF SKIN LESIONS

- *Annular (Fig. 5-18):* Ring-shaped; implies that the edge of the lesion differs from the center, either by being raised, scaly, or differing in color (e.g., granuloma annulare, tinea corporis, erythema annulare centrifugum).
- *Round/nummular/discoid (Fig. 5-19):* Coin-shaped; usually a round to oval lesion with uniform morphology from the edges to the center (e.g., nummular eczema, plaque-type psoriasis, discoid lupus).
- *Polycyclic (see eFig. 5-19.1 in online edition):* Formed from coalescing circles, rings, or incomplete rings (e.g., urticaria, subacute cutaneous lupus erythematosus).
- *Arcuate (see eFig. 5-19.2 in online edition):* Arc-shaped; often a result of incomplete formation of an annular lesion (e.g., urticaria, subacute cutaneous lupus erythematosus).
- *Linear (see eFig. 5-19.3 in online edition):* Resembling a straight line; often implies an external contactant or Koebner phenomenon has occurred in response to scratching; may apply to a single lesion (e.g., a scabies burrow, poison ivy dermatitis, or bleomycin pigmentation) or to the arrangement of multiple lesions (e.g., lichen nitidus or lichen planus).
- *Reticular (Fig. 5-20):* Net-like or lacy in appearance, with somewhat regularly spaced rings or partial rings and sparing of intervening skin (e.g., livedo reticularis, cutis marmorata).
- *Serpiginous (Fig. 5-21):* Serpentine or snake-like (e.g., cutaneous larva migrans, in which the larva migrates this way and that through the skin in a wandering pattern).

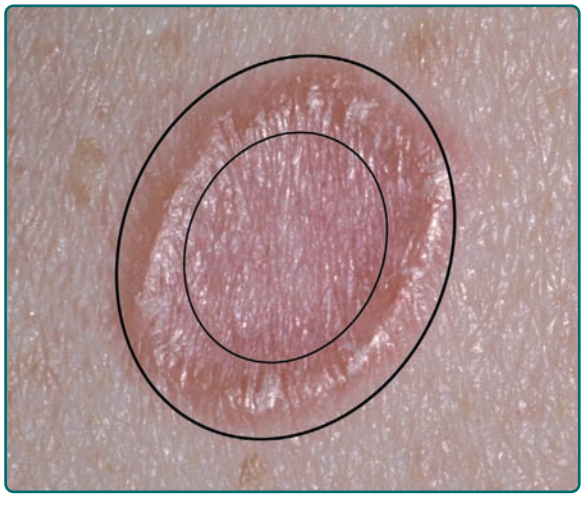

Figure 5-18 Annular lesion. (Illustration by Glen Hintz, MS. Dermatology Lexicon Project.)

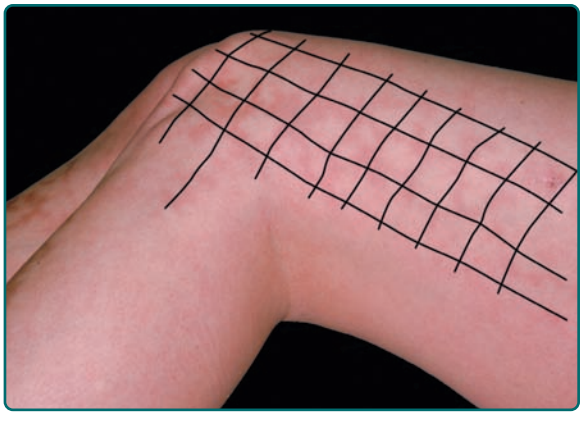

Figure 5-20 Reticular lesion. (Illustration by Glen Hintz, MS. Dermatology Lexicon Project.)



Figure 5-21 Serpiginous lesion. (Illustration by Glen Hintz, MS. Dermatology Lexicon Project.)

- *Targetoid (see eFig. 5-21.1 in online edition):* Target-like, with at least three distinct zones (e.g., erythema multiforme).
- *Whorled (Fig. 5-22):* Like marble cake, with two distinct colors interspersed in a wavy pattern; usually seen in mosaic disorders in which cells of differing genotypes are interspersed (e.g., incontinentia pigmenti, hypomelanosis of Ito, linear and whorled nevoid hypermelanosis).

ARRANGEMENT OF MULTIPLE LESIONS

- *Grouped/herpetiform (Fig. 5-23):* Lesions clustered together (e.g., classic example is herpes simplex virus 1 reactivation noted as grouped vesicles on an erythematous base; also seen with certain arthropod bites).
- *Scattered (see eFig. 5-23.1 in online edition):* Irregularly distributed.

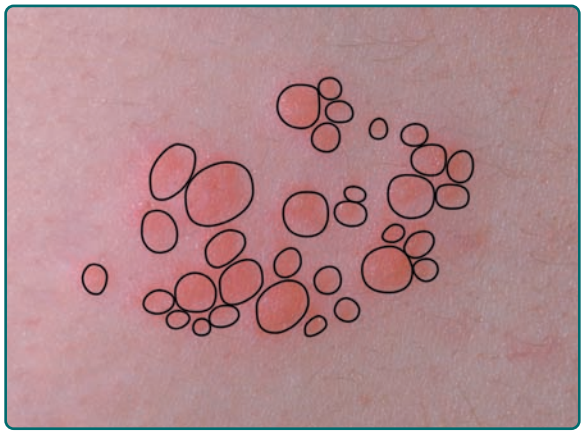

Figure 5-23 Grouped: clustered. (Illustration by Glen Hintz, MS. Dermatology Lexicon Project.)

DISTRIBUTIONS OF MULTIPLE LESIONS

- *Dermatomal/zosteriform:* Unilateral and lying in the distribution of a single spinal afferent nerve root; the classic example is herpes zoster (see Chapter 194).
- *Blaschkoid (Fig. 5-24):* Following lines of skin cell migration during embryogenesis; generally longitudinally oriented on the limbs and circumferential on the trunk, but not perfectly linear (see also



Figure 5-22 Whorled: marbled appearance. (Illustration by Glen Hintz, MS. Dermatology Lexicon Project.)



Figure 5-24 Lesions in the distribution described by Blaschko for developmental lesions.

TABLE 5-4
Selection of Cutaneous Signs[a]

Cutaneous Sign	Description	Significance
Apple-jelly sign	A yellowish hue is produced from pressure on the lesion with a glass slide.	Noted in granulomatous processes.
Asboe–Hansen sign	Lateral extension of a blister with downward pressure.	Noted in blistering disorders in which the pathology is above the basement membrane zone.
Auspitz sign	Pinpoint bleeding at the tops of ruptured capillaries with forcible removal of outer scales from a psoriatic plaque.	Not entirely sensitive or specific for psoriasis.
Butterfly sign	Butterfly-shaped sparing from excoriations of the nonreachable interscapular region.	Noted in disorders associated with pruritus and implies that the physical findings are a consequence of rubbing and scratching.
Buttonhole sign	A flesh-colored, soft papule feels as though it can be pushed through a "buttonhole" into the skin.	Noted in a neurofibroma.
Carpet tack sign	Horny plugs at the undersurface of scale removed from a lesion.	Noted in lesions of chronic cutaneous lupus.
Crowe sign	Axillary freckling.	Noted in neurofibromatosis type I; may be seen as part of lentiginosis profuse.
Darier sign	Urticarial wheal produced in a lesion after it is rubbed with the rounded end of a pen. The wheal, which is strictly confined to the borders of the lesion, may not appear for several minutes.	Noted in urticaria pigmentosa and rarely with cutaneous lymphoma or histiocytosis.
Dermatographism	Firmly stroking unaffected skin produces a wheal along the shape of the stroke within seconds to minutes.	Symptomatic dermatographism represents a physical urticaria.
Pseudo-Darier sign	Transient induration of a lesion or piloerection after rubbing.	Noted in congenital smooth muscle hamartoma.
Fitzpatrick (dimple) sign	Dimpling of the skin with lateral compression of the lesion with the thumb and index finger produces dimpling due to tethering of the epidermis to the dermal lesion.	Characteristic of dermatofibroma.
Gottron sign	Raised or flat pink to violaceous erythema and/or papules of metacarpal or interphalangeal joints, olecranon, patellae, or malleoli.	Classically used in reference to dermatomyositis.
Hair collar	Ring of dark long scalp hair encircling a congenital lesion.	Associated with aplasia cutis, encephalocele, meningocele, or heterotopic brain tissue.
Heliotrope sign	Violaceous erythema over eyelids.	Noted in dermatomyositis.
Hertoghe sign	Thinning or loss of the outer third of the eyebrow.	May be associated with atopic dermatitis, hypothyroidism, systemic sclerosis.
Hutchinson nail sign	Periungual extension of pigment to the proximal and lateral nail folds.	Noted in subungual melanoma.
Hutchinson nose sign	Vesicles on the tip of the nose in a patient with herpes zoster of the face.	Due to the involvement of the nasociliary branch of ophthalmic nerve (V1) and indicates a higher likelihood of ocular disease.
Leser–Trélat sign	Sudden eruption of inflammatory seborrheic keratoses-like lesions.	Associated with systemic malignancy. Also reported with benign neoplasms, eczema, pregnancy, and leprosy.
Nikolsky sign	Lateral pressure on unblistered skin with resulting shearing of the epidermis.	Noted in blistering disorders in which the pathology is above the basement membrane zone. Relevant entities include pemphigus vulgaris and toxic epidermal necrolysis.
Oil drop sign	Area of yellowish discoloration resembling an oil drop involving the nail bed distally (but not involving the free edge).	Indicates onycholysis noted in psoriatic nail disease.
Russell sign	Abrasions, lacerations, callosities of metacarpal and proximal interphalangeal joints.	Due to trauma from incisor teeth during self-induced vomiting in bulimia.
Shawl sign	Erythema over upper back and shoulders.	Classically used in reference to dermatomyositis.
Trousseau sign	Recurrent migratory superficial thrombophlebitis of small and large cutaneous veins.	Associated with internal malignancy (usually pancreatic), Behçet disease, rickettsial infections.
Ugly duckling sign	A pigmented lesion, among numerous atypical but clinically benign nevi, that stands out from the rest and may be a melanoma.	Helpful in screening numerous pigmented lesions in a low-risk individual. Once the lesion is distinguished from the others, it may be evaluated further for abnormal clinical features.

[a]Others are discussed in the chapters on diseases in which the signs occur.

TABLE 5-5
Ten Pointers and Pitfalls in Dermatologic Diagnosis

- Approach each and every evaluation with patience and thoroughness.
- Beware of "snap," "curbside," or "doorway" diagnoses.
- Examine the entire mucocutaneous surface, as well as the hair and nails.
- A new or changing mole should be carefully evaluated.
- Do not remove tissue without sending a portion for histologic examination.
- If the dermatopathologic findings are not consistent with the clinical impression, obtain another biopsy.
- If forced to choose between incongruent clinical and pathologic impression, follow clinical lead (cautiously).
- Generalized pruritus of more than 1 month's duration mandates a complete systemic workup.
- Seemingly nonspecific rashes may just be camouflaged specific disorders.
- Drug-induced eruptions can mimic most skin conditions.
- Be wary of the "atypical" diagnosis. Atypical "this" may be "typical" that to someone who has seen it before.
- Consider all other reasonable possibilities before making a diagnosis of factitial disorder.

Section "Shape or Configuration of Skin Lesions"); described by Alfred Blaschko and implies a mosaic disorder (e.g., incontinentia pigmenti, inflammatory linear verrucous epidermal nevus).

- *Lymphangitic:* Lying along the distribution of a lymph vessel; implies an infectious agent that is spreading centrally from an acral site, usually a red streak along a limb due to a staphylococcal or streptococcal cellulitis.
- *Sun exposed:* Occurring in areas usually not covered by clothing, namely the face, dorsal hands, and a triangular area corresponding to the opening of a V-neck shirt on the upper chest (e.g., photodermatitis, subacute cutaneous lupus erythematosus, polymorphous light eruption, squamous cell carcinoma).
- *Sun protected:* Occurring in areas usually covered by one or more layers of clothing; usually a dermatosis that is improved by sun exposure (e.g., parapsoriasis, mycosis fungoides).
- *Acral:* Occurring in distal locations, such as on the hands, feet, wrists, and ankles (e.g., palmoplantar pustulosis, chilblains).
- *Truncal:* Occurring on the trunk or central body.
- *Extensor:* Occurring over the dorsal extremities, overlying the extensor muscles, knees, or elbows (e.g., psoriasis).
- *Flexor:* Overlying the flexor muscles of the extremities, the antecubital and popliteal fossae (e.g., atopic dermatitis).
- *Intertriginous:* Occurring in the skin folds, where two skin surfaces are in contact, namely the axillae, inguinal folds, inner thighs, inframammary skin, and under an abdominal pannus; often related to moisture and heat generated in these areas (e.g., candidiasis).
- *Localized:* Confined to a single body location (e.g., cellulitis).
- *Generalized:* Widespread. A generalized eruption consisting of inflammatory (red) lesions is called an *exanthema* (rash). A macular exanthema consists of macules, a papular exanthema of papules, a vesicular exanthema of vesicles, etc. (e.g., viral exanthems, drug eruption).
- *Bilateral symmetric:* Occurring with mirror-image symmetry on both sides of the body (e.g., vitiligo, plaque-type psoriasis).
- *Universal:* Involving the entire cutaneous surface (e.g., erythroderma, alopecia universalis).

Table 5-4 describes some clinically relevant maneuvers and morphologic signs that point to particular integumentary or systemic diseases.

As the late Thomas B. Fitzpatrick often said, "dermatologists are physicians who can diagnose a rash!" They may also be internists, surgeons, biochemists, or immunologists; but without competency in dermatologic diagnosis they cannot qualify as dermatologists. However, this skill is not specific to dermatologists. Any physician who makes the effort to study the skin and learn the dermatologic lexicon can develop a functional appreciation of the fundamentals of diagnosis. The advanced diagnostic eye can only be acquired by endlessly repeated encounters in which the physician is forced not only to look at, but also to observe, the rash while an experienced mentor points the way. The most common error in dermatologic diagnosis is to regard the lesions as nonspecific "rashes" rather than as aggregates of specific individual lesions. As in surveying a blood smear, a "general impression" is not enough: The morphologic aspects of each individual cell must be carefully scrutinized and judged to be normal or abnormal. Too often, physicians adopt a speedy, superficial approach to the skin that they would not apply to any other organ that they examine (Table 5-5).

Lewis Thomas has said that "Medicine is no longer the laying on of hands, it is more like the reading of signals from machines." In dermatology, there can be no replacement for the laying on of hands, and the physician is repeatedly gratified by reading signals not from machines, but from people.

SUGGESTED READINGS

Bernhard JD et al: Maculopapularism. *Am J Dermatopathol* **8**:173, 1986

Dermatology Lexicon Project. *For Diagnostic Caretgories,* http://www.aad.org/dermlex/, and *Lesion Morphology and Diagrams,* http://www.logicalimages.com/educationalTools/learnDerm.htm (accessed Aug 29, 2011)

Federman, DG et al: Full-body skin examinations: the patient's perspective. *Arch Dermatol* **140**:530, 2004
Feinstein AR: *Clinical Judgment*. Baltimore, Williams & Wilkins, 1967
Haxthausen H: How are dermatological diagnoses made? *Trans St Johns Hosp Dermatol Soc* **30**:3, 1951
Jackson R: *Morphological Diagnosis of Skin Disease*. Grimsby, Ontario, Manticore, 1998
Jackson R: The importance of being visually literate. *Arch Dermatol* **111**:632, 1975
Leider M, Rosenblum M: *A Dictionary of Dermatological Words, Terms, and Phrases*. New York, McGraw-Hill, 1968
Siemens HW: *General Diagnosis and Therapy of Skin Diseases*. Chicago, University of Chicago Press, 1958, Translated by K Wiener
Thomas L: *The Youngest Science: Notes of a Medicine-Watcher*. New York, Viking Press, 1983, p. 58
Winkelmann RK (chairman): The International League of Dermatologic Societies Committee on Nomenclature. Glossary of basic dermatologic lesions. *Acta Derm Venereol Suppl (Stockh)* **130**:1, 1987
Wolff K, Johnson RA: *Fitzpatrick's Color Atlas and Synopsis of Clinical Dermatology*, 5th edition. New York, McGraw-Hill, 2005 and 2009

Chapter 6 :: Basic Pathologic Reactions of the Skin

:: Martin C. Mihm Jr., Abdul-Ghani Kibbi, George F. Murphy, & Klaus Wolff

BASIC PATHOLOGIC REACTIONS AT A GLANCE

- Different tissue compartments interconnect anatomically and interact functionally. These are the reactive units of skin.
- The superficial reactive unit comprises the epidermis, the junction zone, and the papillary body with its vascular system.
- The reticular dermis with the deeper dermal vascular plexus is the second reactive unit.
- The third reactive unit is the subcutaneous tissue with its septal and lobular compartments.
- Hair follicles and glands are a fourth reactive unit embedded into these three units.
- Pathologic processes may involve these reactive units alone or several of them in a concerted fashion.
- The heterogeneity and interaction of these individual cutaneous compartments explain why a few basic pathologic reactions lead to a multiplicity of clinical and pathologic reaction patterns.

The skin is composed of different tissue compartments that interconnect anatomically and interact functionally. It is difficult to envisage epidermal function without signals from the dermis or passenger leukocytes traveling to and from the skin. On the other hand, epidermis, dermis, and subcutaneous tissue are heterogeneous in nature and an analysis of pathologic processes involving the skin should therefore consider both this heterogeneity and the interactions of the individual cutaneous compartments; only then will it be understood why a few basic reactions lead to a multiplicity of reaction patterns within this tissue.

Pathophysiologically, the skin can be subdivided into three reactive units that extend beyond anatomic boundaries (Fig. 6-1); they overlap and can be divided into different subunits that respond to pathologic stimuli according to their inherent reaction capacities in a coordinated pattern.

The superficial reactive unit comprises the subunits epidermis, the junction zone, the subjacent loose, delicate connective tissue of the papillary body and its capillary network, and the superficial vascular plexus (see Fig. 6-1, SRU). The reticular layer of the dermis represents a second reactive unit and is composed of coarse connective tissue and the deeper dermal vascular plexus (see Fig. 6-1, DRU). The third reactive unit, the subcutaneous tissue, is also anatomically and functionally heterogeneous; septal and lobular compartments may be involved either alone or together (see Fig. 6-1, S). Hair follicles and glands are a separate (fourth) reactive unit embedded in these three basic units.

SUPERFICIAL REACTIVE UNIT

EPIDERMIS

(See Fig. 6-1, E)

Keratinocytes, which have the capacity to synthesize keratin protein, represent the bulk of the epidermis. The epidermis, an ectodermal epithelium, also harbors a number of other cell populations such as melanocytes, Langerhans cells, Merkel cells, and

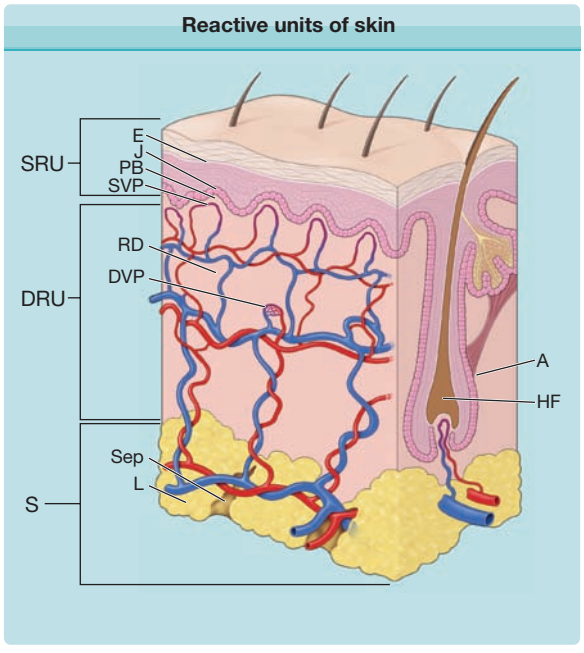

Figure 6-1 Reactive units of skin. The superficial reactive unit (SRU) comprises the epidermis (E), the junction zone (J), and the papillary body (PB) with the superficial microvascular plexus. The dermal reactive unit (DRU) consists of the reticular dermis (RD) and the deep dermal microvascular plexus (DVP). The subcutaneous reactive unit (S) consists of lobules (L) and septae (Sep). A fourth unit is the appendages (A; hair and sebaceous glands are the only appendages shown). HF = hair follicle.

cellular migrants (see Chapter 7). The basal cells of the epidermis undergo proliferation cycles that provide for the renewal of the epidermis and, as they move toward the surface of the skin, undergo a differentiation process that results in surface keratinization. Thus, the epidermis is a dynamic tissue in which cells are constantly in nonsynchronized replication and differentiation; this precisely coordinated physiological balance between progressive keratinization as cells approach the epidermal surface to eventually undergo programed cell death and be sloughed, and their continuous replenishment by dividing basal cells is in contrast to the relatively static minority populations of Langerhans cells, melanocytes, and Merkel cells. However, at the same time, these dynamic keratinocytes are interconnected through cohesive molecular interactions that guarantee the continuity, stability, and integrity of the epithelium. Stability for this directional cellular flow is provided by the basal membrane complex (see Chapter 53), which anchors the epidermis to the dermis, and the stratum corneum, which encases the epidermis on the outside. It is here that individual cell differentiation ceases as the keratinizing cells are firmly interconnected by an intercellular cement-like substance forming a permeability barrier (see Chapter 47). These forces of cohesion are finally lost at the surface of the epidermis where the individual cornified cells are sloughed (desquamated). Therefore, pathologic changes within the epidermis may relate to the replicative kinetics of epidermal cells, their differentiation, alterations in cohesive forces, or a combination of these factors (see Chapter 46). These primary factors may also influence the stability and migratory characteristics of Langerhans cell, melanocytes, and migrant lymphocytes, accounting for the complexity of certain reaction patterns that arise from primary pathological defects in the epidermal layer. For example, unless a Langerhans cell expresses the chemokine receptor CCR6, it cannot migrate from the dermis to the epidermis, and without expression of the CCR7 receptor, migration to the lymph node is not possible. Because cytokines that regulate the expression of such receptors are synthesized and secreted by keratinocytes within the immediate microenvironment of Langerhans cells, impairment of keratinocyte homeostasis may have far-reaching functional implications that are reflected in the complexity of the resultant reaction patterns.

DISTURBANCES OF EPIDERMAL CELL KINETICS. The mitotic rate of germinative basal cells, the desquamation rate of corneocytes, and the generation time of epidermal cells determine the homeostasis of the epidermis (see Chapter 46). Under physiologic conditions, there is a balance among proliferation, differentiation, and desquamation. Enhanced cell proliferation accompanied by an enlargement of the germinative cell pool and increased mitotic rates lead to an increase of the epidermal cell population and thus to a thickening of the epidermis (*acanthosis*) (Fig. 6-2A). A shift in the ratio of resting to proliferating cell as is the case in psoriasis (see Chapter 18) will lead to both an increase in the turnover of the entire epidermis and to a considerable increase of the volume of germinative cells that have to be accommodated at the dermal–epidermal junction. This, in turn, results in a widening and elongation of the rete ridges, which is accompanied by a compensatory elongation of the connective tissue papillae, resulting in an expansion of the dermal–epidermal interface and, consequently, in an increased surface area for dermal–epidermal interactions (see Fig. 6-2).

In contrast to acanthosis is epidermal *atrophy*. Although there are many causes, one primary etiology is a decrease in epidermal proliferative capacity, as may be seen with physiological aging or after the prolonged use of potent topical or systemic steroids. With atrophy, the epidermal rete ridges are initially lost, followed by progressive thinning of the epidermal layer. Depending on the underlying causes and how they affect the keratinocyte differentiation program, there may also be hyperkeratosis or parakeratosis (thickening of the stratum corneum or retention of nuclei into the stratum corneum, respectively). It is likely that many forms of acanthosis and atrophy have primary effects of the homeostasis and function of keratinocyte stem cells, critically important slow-cycling minority populations of epidermal cells that are normally sequestered in the bulge areas of hair follicles and at tips of epidermal rete ridges.

DISTURBANCES OF EPIDERMAL CELL DIFFERENTIATION. A simple example of disturbed epidermal differentiation is parakeratosis, in which

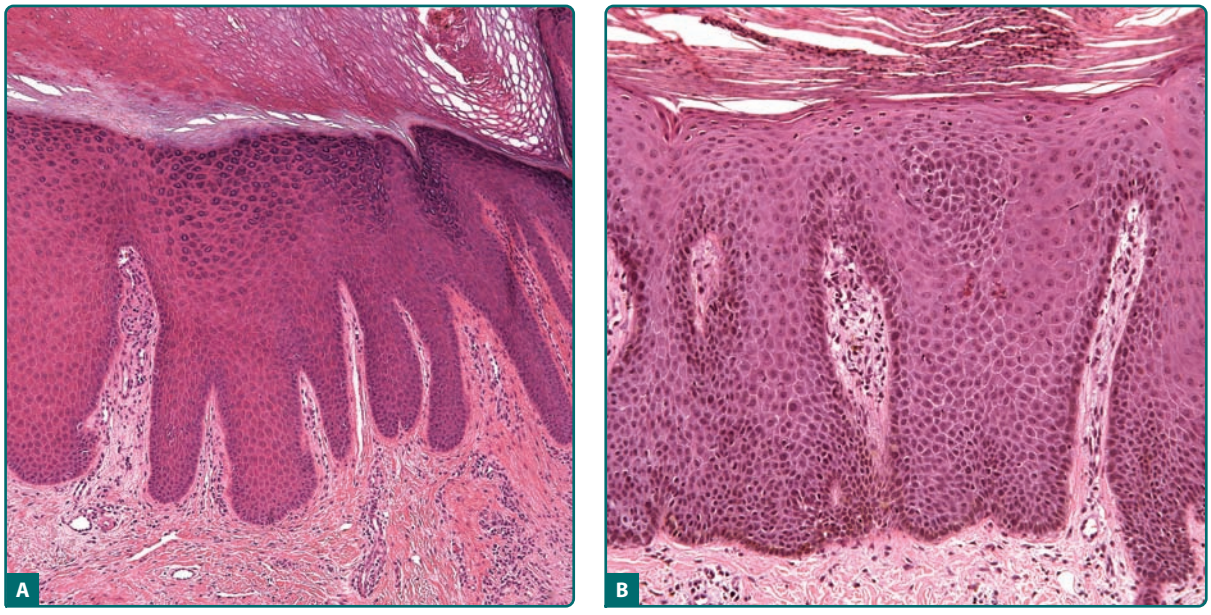

Figure 6-2 **A**. Acanthosis. This sign of increased epidermal kinetics is illustrated in a photomicrograph of psoriasis. **B**. Parakeratosis, the retention of nuclei in the horny layer, is evident.

faulty and accelerated cornification leads to a retention of pyknotic nuclei of epidermal cells at the epidermal surface that is normally formed by anucleate cell remnants that form a "basket-weave" architectural pattern (see Fig. 6-2B). A parakeratotic stratum corneum is not a continuous sheet of cornified cells but a loose structure with gaps between cells; these gaps lead to a loss of the barrier function of the epidermis.

Parakeratosis can be the result of incomplete differentiation in postmitotic germinative cells due to factors that influence the timing and complex integrity of the differentiation program whereby keratin pairs of relatively low molecular weight are progressively assembled as cells approach the epidermal surface. Alternatively, parakeratosis can also be the result of reduced transit time, which does not permit epidermal cells to complete the entire differentiation process, as for example in psoriasis. However, "parakeratosis" of cellophane-stripped epidermis becomes microscopically visible as early as 1 hour after trauma; here, parakeratosis does not represent disturbed differentiation; rather, it results from direct cellular injury to a viable epidermis deprived of its protective horny layer. Therefore, the morphologic term *parakeratosis* may signify a programed disturbance of differentiation and maturation, alterations in cell replication kinetics, or direct cellular injury.

Dyskeratosis represents altered, often premature or abnormal, keratinization, of individual keratinocytes but it also refers to the morphologic presentation of apoptosis of keratinocytes. Dyskeratotic cells have an eosinophilic cytoplasm and a pyknotic nucleus and are packed with keratin filaments arranged in perinuclear aggregates. Such a cell will tend to round up and lose its attachments to the surrounding cells. Therefore, dyskeratosis is often associated with acantholysis (see Section "Disturbances of Epidermal Cohesion") but not vice versa (Fig. 6-3).

In some diseases, dyskeratosis is the expression of a genetically programed disturbance of keratinization as is the case in Darier disease (see Chapter 51). Dyskeratosis may occur in actinic keratosis and squamous cell carcinoma. Dyskeratosis may also be caused by direct physical and chemical injuries. In the sunburn reaction, eosinophilic, apoptotic cells—so-called sunburn cells—are found within the epidermis within the first 24 hours after irradiation with ultraviolet B (UVB) (see Chapter 90), and similar cells may occur after

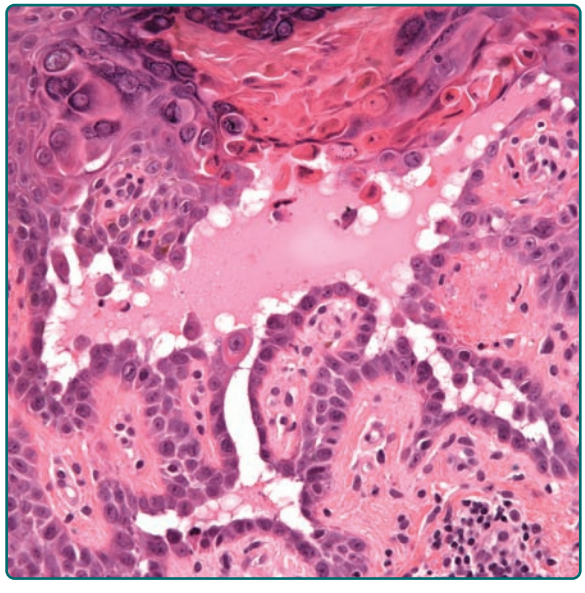

Figure 6-3 The association of dyskeratosis and acantholysis is seen in this high-power view of Darier disease, which also demonstrates the intraepidermal cleft formation resulting from these phenomena.

TABLE 6-1

Classification of Intraepidermal Blisters by Anatomic Level with Clinical Examples

Granular layer
Friction blister
Pemphigus foliaceus
Subcorneal pustular dermatosis
Staphylococcal scalded-skin syndrome/bullous impetigo
Spinous layer
Eczematous dermatitis
Herpes virus infection
Familial benign pemphigus
Suprabasal
Pemphigus vulgaris
Darier disease
Basal layer
Erythema multiforme
Lupus erythematosus
Lichen planus
Epidermolysis bullosa

high-dose systemic cytotoxic treatment. Individual cell death within the epidermis is a regular phenomenon in graft versus host reactions of the skin (see Chapter 28) and in erythema multiforme (see Chapter 39). It is important to remember that although both premature or abnormal keratinization and apoptosis may produce an end product referred to as "dyskeratosis," the early events and mechanisms responsible are different. Whereas cells early in the process of abnormal keratinization often have increased eosinophilic keratin aggregates within their cytoplasm with viable-appearing nuclei, apoptotic cells during early evolutionary stages have shrunken, pyknotic, and sometimes fragmented nuclei in the setting of normal-appearing cytoplasm.

DISTURBANCES OF EPIDERMAL COHESION. Epidermal cohesion is the result of a dynamic equilibrium of forming and dissociating intercellular contacts. Specific intercellular attachment devices (desmosomes) and the related intercellular molecular interactions are responsible for intercellular cohesion. However, epidermal cohesion must permit epidermal cell motion. Desmosomes dissociate and reform at new sites of intercellular contact as cells migrate through the epidermis and keratinocytes mature toward the epidermal surface. Intercellular cohesive forces are strong enough to guarantee the continuity of the epidermis as an uninterrupted epithelium but, on the other hand, are adaptable enough to permit locomotion, permeability of the intercellular space, and intercellular interactions.

The most common result of disturbed epidermal cohesion is the intraepidermal vesicle, a small cavity filled with fluid. A classification of intraepidermal blistering by anatomic level is shown in Table 6-1.

Three basic morphologic patterns of intraepidermal vesicle formation are classically recognized. *Spongiosis* is an example of the *secondary* loss of cohesion between epidermal cells due to the influx of tissue fluid into the epidermis. Serous exudate may extend from the dermis into the intercellular compartment of the epidermis; as it expands, epidermal cells remain in contact with each other only at the sites of desmosomes, acquiring a stellate appearance and giving the epidermis a sponge-like morphology (spongiosis). As the intercellular edema increases, individual cells rupture and lyse, and microcavities (spongiotic vesicles) result (Fig. 6-4). Confluence of such microcavities leads to larger blisters. Epidermal cells may also be separated by leukocytes that disturb intraepidermal coherence; thus, the migration of leukocytes into the epidermis and spongiotic edema are often a combined phenomenon, best illustrated by acute allergic contact

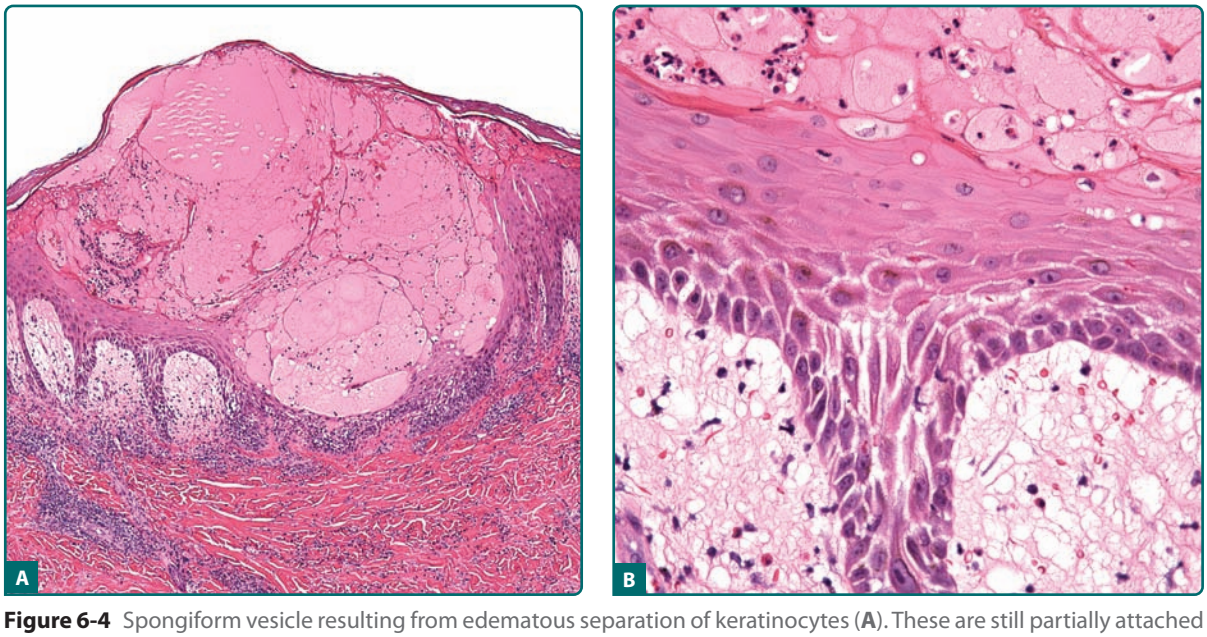

Figure 6-4 Spongiform vesicle resulting from edematous separation of keratinocytes (**A**). These are still partially attached to each other by desmosomes and have thus acquired a stellate appearance as is evident at higher magnification (**B**).

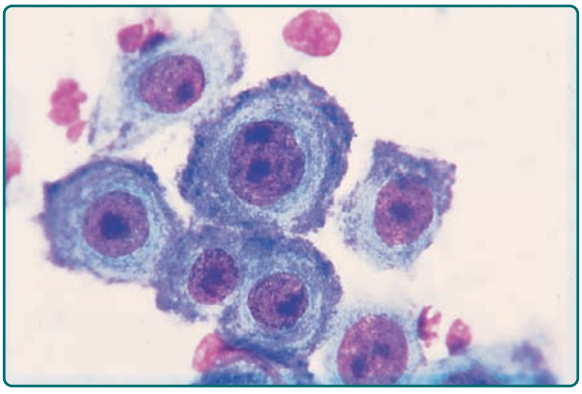

Figure 6-5 Acantholysis. Single as well as clusters of acantholytic cells are seen. The round shapes result from the loss of intercellular connections. Cytologic smear preparation of pemphigus vulgaris.

dermatitis. The accumulation of polymorphonuclear leukocytes within the epidermis, the resulting separation of epidermal cells, and their subsequent destruction by neutrophil-derived enzymes, eventually lead to the formation of a spongiform pustule, one of the histopathologic hallmarks of psoriasis (see Chapter 18).

Acantholysis is a *primary* loss of cohesion of epidermal cells. This is initially characterized by a widening and separation of the interdesmosomal regions of the cell membranes of keratinocytes, followed by splitting and a disappearance of desmosomes (see Chapter 53). The cells are intact but are no longer attached; they revert to their smallest possible surface and round up (Figs. 6-3 and 6-5). Intercellular gaps and slits result, and the influx of fluid from the dermis leads to a cavity, which may form in a suprabasal (Fig. 6-6), midepidermal, or even subcorneal location. Acantholytic cells can easily be demonstrated in cytologic smears (see Fig. 6-5) and in some conditions have diagnostic significance.

Acantholysis occurs in a number of different pathologic processes that do not have a common etiology and pathogenesis. Acantholysis may be a primary event leading to intraepidermal cavitation (primary acantholysis) or a secondary phenomenon in which epidermal cells are shed from the walls of established intraepidermal blisters (secondary acantholysis). Primary acantholysis is a pathogenetically relevant event in diseases of the pemphigus group (see Chapter 54), in which it results from the interaction of autoantibodies and antigenic determinants on the keratinocyte membranes and related desmosomal adhesive proteins, and in the staphylococcal scalded-skin syndrome, where it is caused by a staphylococcal exotoxin (epidermolysin) (see Chapter 177). In familial benign pemphigus, it results from the combination of a genetically determined defect of the keratinocyte cell membrane and exogenous factors (see Chapter 51). A similar phenomenon, albeit more confined to the suprabasal epidermis, occurs in Darier disease, where it is combined with dyskeratosis in the upper epidermal layers (see Fig. 6-3) and a compensatory proliferation of basal cells into the papillary body (see Chapter 51). When acantholysis results from viral infection, it is usually combined with other cellular phenomena such as ballooning, giant cells, and cytolysis (Fig. 6-7; see Chapters 193 and 194).

Indeed, a loss of epidermal cohesion can also result from a primary dissolution of cells (i.e., cytolysis). In the epidermolytic forms of epidermolysis bullosa, genetically defective and thus structurally compromised basal cells rupture as a result of trauma so that the cleft forms through the basal cell layer independently from preexisting anatomic boundaries (see Chapter 62). Cytolytic phenomena in the stratum granulosum are characteristic for epidermolytic hyperkeratosis, bullous congenital ichthyosiform erythroderma, ichthyosis hystrix, and some forms of hereditary palmoplantar keratoderma (see Chapters 49 and 50).



Figure 6-6 Pemphigus vulgaris. An intraepidermal suprabasal cleft is visible that has resulted from suprabasal acantholysis. It contains acantholytic and inflammatory cells.

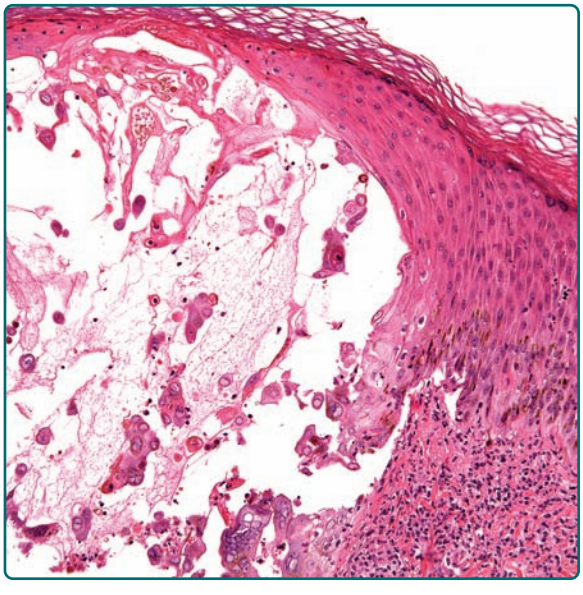

Figure 6-7 Herpes simplex infection. The epidermis shows marked ballooning degeneration, cytolysis, and intraepidermal vesiculation. Acantholytic and multinucleated epidermal giant cells are a clue to herpetic infection.

DERMAL–EPIDERMAL JUNCTION

(See Fig. 6-1, J)

Epidermis and dermis are structurally interlocked by means of the epidermal rete ridges and the corresponding dermal papillae, and foot-like submicroscopic cytoplasmic microprocesses of basal cells that extend into corresponding indentations of the dermis. Dermal–epidermal attachment is enforced by hemidesmosomes that anchor basal cells onto the basal lamina; this, in turn, is attached to the dermis by means of anchoring filaments and microfibrils (see Chapter 53). These structural relationships correlate with complex molecular interactions that serve to bind the epidermis, basement membrane, and superficial dermis in a manner that promotes resistance to potentially life-threatening epidermal detachment. The basal lamina is not a rigid or impermeable structure because leukocytes, Langerhans cells, or other migratory cells pass through it without causing a permanent breach in the junction. After being destroyed by pathologic processes, the basal lamina is reconstituted; this represents an important phenomenon in wound healing and other reparative processes. Functionally, the basal lamina is part of a unit that, by light microscopy, appears as the periodic acid-Schiff–positive "basement membrane" and, in fact, represents the entire junction zone. This consists of the lamina lucida, spanned by microfilaments, and subjacent anchoring fibrils, small collagen fibers, and extracellular matrix (see Chapter 53). The junction zone is a functional complex that is primarily affected in a number of pathologic processes.

DISTURBANCES OF DERMAL–EPIDERMAL COHESION. The destruction of the junction zone or its components usually manifests as disturbance of dermal–epidermal cohesion and leads to blister formation. These blisters appear to be subepidermal by light microscopy (Fig. 6-8), but in reality may be localized at different levels and result from pathogenetically heterogeneous processes. A classification of blisters at the junction by anatomic level is given in Table 6-2. Subepidermal blister formation occurs in forms of epidermolysis bullosa (see Chapter 62) or can be the result of a complex inflammatory process that involves the entire junction zone, as is the case in lupus erythematosus, erythema multiforme, or lichen planus; therefore, it may be a phenomenon occurring in a group of etiologically and pathogenetically heterogeneous conditions. In bullous pemphigoid (see Fig. 6-8), cleft formation runs through the lamina lucida of the basal membrane and is caused by autoantibodies directed against specific antigens on the cytomembrane of basal cells (*junctional blistering*) (see Fig. 6-8A; see Chapter 56). The presence of eosinophil granules that contain major basic protein that is toxic to keratinocytes also causes keratinocyte injury and may present as eosinophilic apongiosis (Fig. 6-8B). Junctional blistering also occurs in the junctional forms of epidermolysis bullosa, but here it is due to the hereditary impairment or absence of molecules important for dermal–epidermal cohesion (see Chapter 62; see Table 6-2).

TABLE 6-2

Classification of Blisters at the Dermal–Epidermal Junction by Anatomic Level with Clinical Examples

Junctional (at the lamina lucida)
Junctional epidermolysis bullosa
Bullous pemphigoid
Dermolytic (below basal lamina)
Epidermolysis bullosa dystrophicans
Epidermolysis bullosa acquisita
Porphyria cutanea tarda
Dermatitis herpetiformis

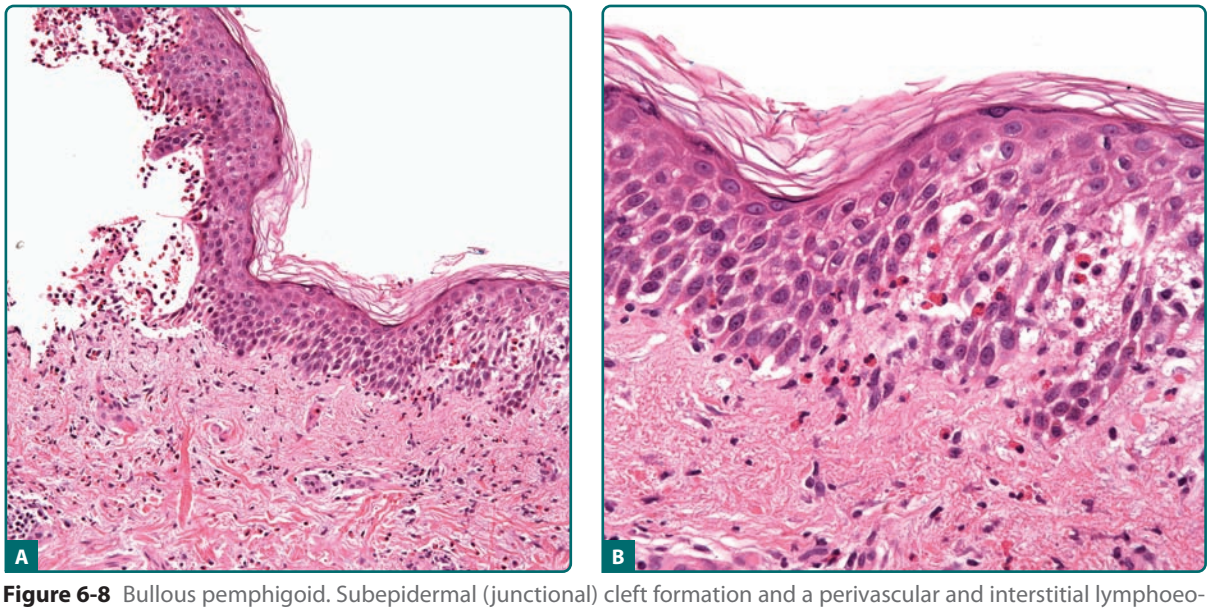

Figure 6-8 Bullous pemphigoid. Subepidermal (junctional) cleft formation and a perivascular and interstitial lymphoeosinophilic infiltrate are characteristic (**A**). Eosinophilic spongiosis can also occur (**B**).

In subepidermal blistering, the target of the pathologic process is below the basal lamina (dermolytic blistering) (see Table 6-2). Reduced anchoring filaments and increased collagenase production result in dermolytic dermal–epidermal separation in recessive epidermolysis bullosa (see Chapter 62); circulating autoantibodies directed against type VII collagen in anchoring fibrils are the cause of dermolytic blistering in acquired epidermolysis bullosa (see Chapter 60). Other immunologically mediated inflammatory mechanisms result in dermolytic blistering in dermatitis herpetiformis (see Chapter 61), and physical and chemical changes in the junction zone and papillary body are the cause for a dermolytic cleft formation after trauma in porphyria cutanea tarda (see Chapter 132).

MOLECULAR AND CELLULAR MECHANISMS FOR REACTION PATTERNS AFFECTING THE SUPERFICIAL REACTIVE UNIT

Although Virchow envisioned what is today known as the superficial reactive unit as a simple layer of cells involved in producing environmentally protective surface keratin, we now realize that this layer is a potent producer of regulatory and stimulatory molecules that, when perturbed, choreograph architectural and cytologic changes that produce the reaction patterns that we equate with specific clinical disorders. Upon immunological stimulation via cytokines with attendant activation of signal transduction pathways, for example, the keratinocyte often acquires an "activated" phenotype whereby the nucleus enlarges, the nucleolus becomes more prominent, and the cell may actually appear atypical. Hyperproliferation frequently accompanies keratinocyte activation, and biosynthetic alterations also may develop, resulting in production of additional factors, such as keratinocyte-derived cytokines, that further fuel the activated phenotype. In such instances, epidermal thickening and increased mitotic activity is evidenced by conventional histology, and Ki-67 staining will disclose evidence of suprabasal cell cycling. It is likely that such activated and hyperproliferative states involve stimulation at the level of the epidermal and follicular stem cell compartments, as is also seen in wound healing responses. In such circumstances, normally quiescent stem cells that are normally sequestered at the tips of epidermal rete ridges and in the bulge regions of hair follicles begin to proliferate and differentiate, further driving the acanthotic epidermal thickening. Alterations in epidermal kinetics are frequently also evidenced by faulty differentiation. Premature differentiation may trigger defective cell adhesion, and hence cells may seem abnormally keratinized (dyskeratotic) as well as separated (acantholytic). Other factors that may perturb adhesion may provide exquisite correlation between the molecular composition of the superficial reactive unit and the morphology of the reaction patterns themselves, as is the case in various forms of pemphigus, where the level of keratinocyte dyshesion and acantholytic blister formation follows precisely the concentration gradients of the targeted adhesive proteins (desmogleins 1 and 3) that assist in binding keratinocytes at the level of the desmosome.

The patterns of cellular inflammation that affect the superficial reactive unit also are dictated at a molecular level. Circulating leukocytes, often T cells, bind the endothelium of postcapillary venules of the superficial vascular plexus upon cytokine-induced endothelial activation (see also dermal reaction patterns in Section "Molecular and Cellular Mechanisms for Reaction Patterns Affecting the Dermis"). This results in expression of endothelial–leukocyte adhesion molecules at the endothelial surface that slows circulating leukocytes to a roll, followed by more secure directed binding and transvascular diapedesis. Cells so extravasated may remain in the perivascular space or migrate upward toward the nearby epidermal layer as a consequence of chemokinetic and chemotactic gradients. Depending on their immunologic mission, the responding leukocytes may either produce cytotoxic injury at the dermal–epidermal interface, or migrate through the basement membrane into the epidermis in the company of transudate that contributes to the intercellular edema that forms the pattern of spongiosis. Thus, depending on the nature of the provocative stimulus as well as the complex downstream molecular events that are set into motion, specific reaction patterns result that, upon recognition, provide key diagnostic information.

PATHOLOGIC REACTIONS OF THE ENTIRE SUPERFICIAL REACTIVE UNIT

(See Fig. 6-1, SRU)

Most pathologic reactions of the superficial skin involve the subunits of the superficial reactive unit jointly and thus include the papillary body of the dermis with the superficial microvascular plexus. This is a highly reactive tissue compartment consisting of capillaries, pre- and postcapillary vessels (see Chapter 162), mast cells, fibroblasts, macrophages, dendritic cells, and peripatetic lymphocytes all embedded in a loose connective tissue and extracellular matrix (Fig. 6-9). The prominence of involvement of one of the components over the others may lead to the development of different clinical pictures. A few examples of such interactions are detailed below.

ALLERGIC CONTACT DERMATITIS. (See Chapter 13.) In allergic contact dermatitis, there is an inflammatory reaction of the papillary body and superficial microvascular plexus and spongiosis of the epidermis (see Fig. 6-4) with signs of cellular injury and parakeratosis. Lymphocytes infiltrate the epidermis early in the process and aggregate around Langerhans cells, and this is followed by spongiotic vesiculation (Fig. 6-10). Parakeratosis develops as a consequence of epidermal injury and proliferative responses, and the inflammation in the papillary body and around the superficial venular plexus stimulates mitotic processes within the epidermis, which, in turn, result in acanthosis and epidermal hyperplasia in chronic lesions.

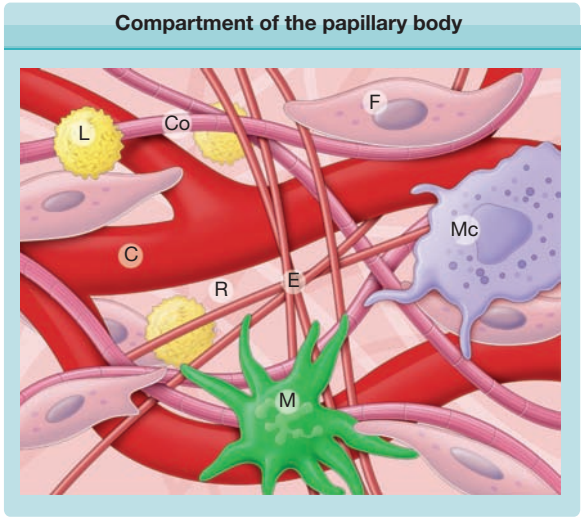

Figure 6-9 The compartment of the papillary body consists of capillaries (C), fibroblasts (F), macrophages and dendritic cells (M), peripatetic lymphocytes (L) and mast cells (Mc), all embedded in a loose connective tissue of extracellular matrix, thin collagen fibers (Co), elastic fibers (E) that are mostly oriented perpendicularly to the skin surface, and branched reticulin fibers (R).

The reaction pattern that involves the superficial vascular plexus of vessels is one of a superficial perivascular lymphocytic infiltrate, often with admixed eosinophils and histiocytes. As noted above, many of these lymphocytes also migrate into the epidermal layer to produce a pattern referred to as *exocytosis*. The superficial perivascular pattern of inflammation is one of a number of inflammatory patterns that may be of assistance at low magnification in generating an initial differential diagnostic algorithm for various types of dermatitis. Pathophysiologically, very early forms of allergic contact dermatitis (e.g., within 24 hours) will exclusively involve perivascular lymphocytes, their influx preceded by mast cell degranulation that releases factors promoting adhesive interactions with superficial dermal endothelium. The epidermal changes follow soon thereafter.

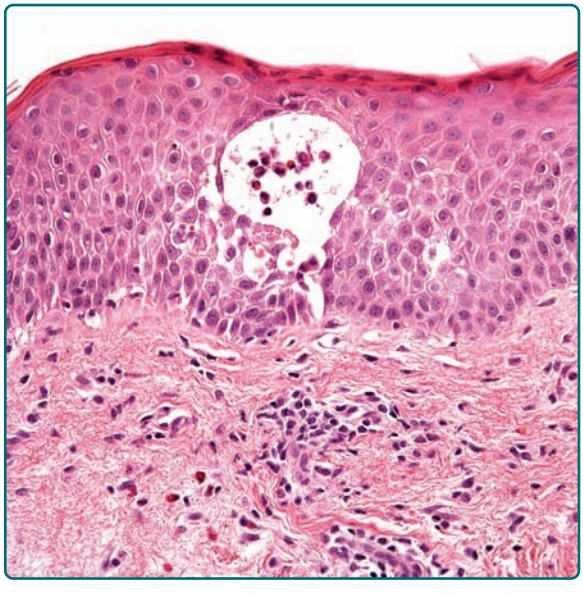

Figure 6-10 Contact dermatitis. Intraepidermal spongiotic vesicles and pronounced intercellular edema are present in the epidermis. The dermis contains perivascular aggregates of lymphocytes and histiocytes admixed with occasional eosinophils.

PSORIASIS. (See Chapter 18.) The initial lesion of psoriatic lesions appears to be the perivascular accumulation of lymphocytes and monocytoid elements within the papillary body and superficial venules and focal migration of leukocytes (often neutrophils, although T cells are integral to pathogenesis as well) into the epidermis. Acanthosis caused by increased epidermal proliferation, elongation of rete ridges sometimes accompanied by an undulant epidermal surface (papillomatosis), and edema of the elongated dermal papillae together with vasodilatation of the capillary loops and a progressive perivascular inflammatory infiltrate develop almost simultaneously (see Fig. 6-2); the disturbed differentiation of the epidermal cells results in parakeratosis, and small aggregates of neutrophils infiltrating the epithelium from tortuous capillaries (squirting capillaries) result in spongiform pustules and, in the parakeratotic stratum corneum, to Munro microabscesses. The stimulus for increased epidermal proliferation follows signals released from T cells that are attracted to the epidermis by the expression of adhesion molecules at the keratinocyte surface and are maintained by cytokines released by keratinocytes (see Chapter 18). Therefore, the composite picture characteristic of psoriasis results from a combined pathology of the papillary body with participation of superficial venules, the epidermis, and circulating cells.

Psoriasis is an instructive example of the limited specificity of histopathologic reaction patterns within the skin because psoriasiform histologic features occur in a number of diseases unrelated to psoriasis.

INTERFACE DERMATITIS. Inflammation along the dermal–epidermal junction associated with vacuolation or destruction of the epidermal basal cell layer characterizes interface dermatitis. This common type of reaction may lead to papules or plaques in some skin diseases and bullae in others.

ERYTHEMA MULTIFORME. (See Chapter 39.) Two types of reactions occur. In both there is interface dermatitis characterized by lymphocytes scattered along a vacuolated dermal–epidermal junction.

LUPUS ERYTHEMATOSUS. (See Chapter 155.) Inflammation, edema, and a lymphocytic infiltrate in the papillary body and superficial venular plexus, as well as in the deeper layers of the dermis, are hallmarks of lupus erythematosus. The main target is the dermal–epidermal junction, where scattered lymphocytes appear and immune complex deposition leads to broadening of the PAS-positive basement membrane zone, accompanied by hydropic degeneration and

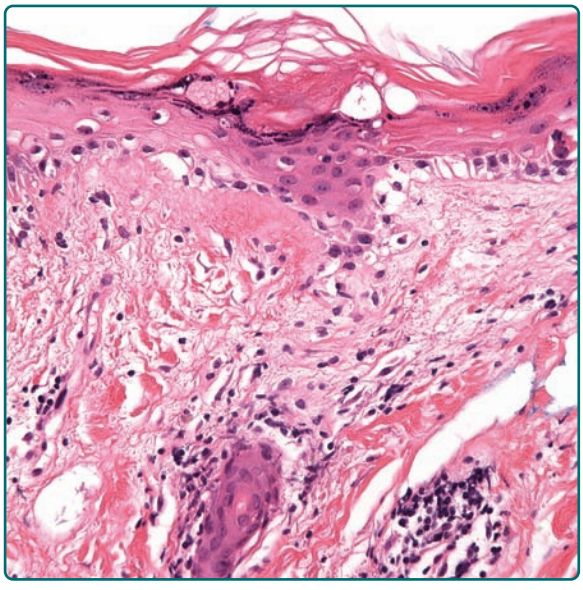

Figure 6-11 Lupus erythematosus. Hyperkeratosis, thinned epidermis devoid of rete ridges, and vacuolization of the basement membrane zone are present.

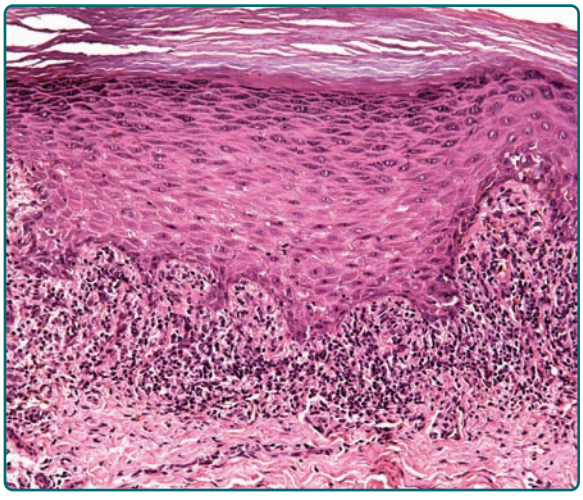

Figure 6-12 Lichen planus. There is hyperkeratosis, wedge-shaped hypergranulosis, basal cell vacuolization, and a lymphocytic infiltrate at the dermal–epidermal junction. This infiltrate "hugs" the basal cell layer and is associated with many cytoid bodies.

destruction of basal cells and progressive atrophy (Fig. 6-11). Cytoid bodies in the form of anucleate keratin aggregates that may undergo amyloid transformation result from apoptosis of individual epidermal cells that are infiltrated and coated by immunoglobulins. The changes in the junctional zone reflect on epidermal differentiation resulting in thickening of stratum corneum (orthokeratosis) and parakeratosis. Lupus erythematosus readily illustrates the heterogeneity, as well as the lack of specificity, of cutaneous reaction patterns: histologically, it is possible to distinguish between acute and chronic lesions but not between cutaneous and systemic lupus erythematosus. In certain chronic, persisting lesions, the changes in the junctional zone initially associated with atrophy secondarily result in hyperplasia, hyperkeratosis, and an increased interdigitation between epidermis and connective tissue, whereas in acute cases, the destruction of the basal cell layer may lead to subepidermal blistering.

LICHEN PLANUS. (See Chapter 26.) This disease also exhibits a primarily junctional reaction pattern with accumulation of a dense lymphocytic infiltrate in the subepidermal tissue and cytoid bodies at the junction (Fig. 6-12). Lymphocytes encroach on the epidermis, destroying the basal cells, but they do not infiltrate the suprabasal layers and blister formation only rarely ensues. These alterations are accompanied by changes of epidermal differentiation—there is a widening of the stratum granulosum (*hypergranulosis*) and hyperkeratosis. Identical changes can be seen in the epidermal type of graft-versus-host disease (see Chapter 28). Current thinking imputes a delayed hypersensitivity reaction to a keratinocyte antigen, the nature of which is unclear. The association of $CD8^+$ lymphocytes in apposition to and even surrounding apoptotic keratinocytes (so-called *satellitosis*) supports this view. The expression of Fas/FasL is also in favor of a role for apoptosis in the pathogenesis of these lesions.

DERMATITIS HERPETIFORMIS. (See Chapter 61.) This condition is usually included among the classic bullous dermatoses; however, it illustrates that the preponderance of one or several pathologic reaction patterns may obscure the true pathogenesis of the condition. The deposition of immunoglobulin A and complement on fibrillar and nonfibrillar sites within the tips of the dermal papillae, and the activation of the alternative pathway of the complement cascade, lead to an influx of leukocytes (primarily neutrophils), which form small abscesses at the tips of the dermal papillae, as well as inflammation and edema (Fig. 6-13). This explains why

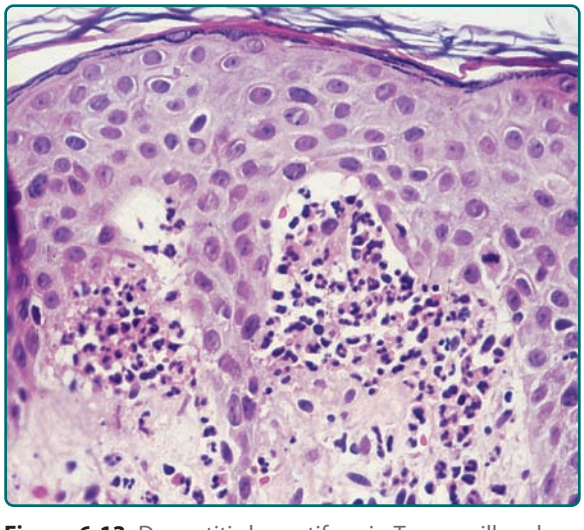

Figure 6-13 Dermatitis herpetiformis. Two papillae show microabscesses composed of neutrophils. Vacuolization and early cleft formation are evident in both papillae.

the primary clinical lesion in dermatitis herpetiformis is urticarial or papular in nature, because only in the case of massive neutrophil infiltration will there be tissue destruction and cleft formation below the lamina densa that results in clinically visible vesiculation.

RETICULAR DERMIS

(See Fig. 6-1, DRU)

The dermis represents a strong fibroelastic tissue with a network of collagen and elastic fibers embedded in an extracellular matrix with a high water-binding capacity (see Chapter 63). In contrast to the tightly interwoven fibrous components of this reticular layer of the dermis (Fig. 6-14), the previously described fibrous texture of the papillary body and the perifollicular and perivascular compartments is loose (see Fig. 6-9), and the orientation of the collagen bundles here follows the structures they surround.

The dermis contains a superficial and deep vascular network. In the upper dermis, the superficial plexus supplies individual vascular districts consisting of several dermal papillae. Superficial and deep networks are connected so intimately that the entire dermal vascular system represents a single three-dimensional unit (see Chapter 162). On the other hand, there are profound functional differences between superficial and deep dermal vascular networks, which explain the differences of homing patterns of inflammatory cells to these sites.

As for the superficial microvascular system, two reaction patterns occur: (1) acute inflammatory processes in which the epidermis and junctional zone are often involved together with the vascular system, and (2) more chronic processes that often remain confined to the perivascular compartment. In this context, it should be noted that the cytologic composition ("acute vs. chronic inflammation") of an inflammatory infiltrate within the skin does not always mirror the temporal characteristics of an inflammatory process. Thus, polymorphonuclear leukocytic infiltrates are not always synonymous with an acute process; conversely, chronic processes are not always represented by a lymphohistiocytic infiltrate.

Inflammation confined to the superficial connective tissue–vascular unit is characterized by endothelial activation, vascular dilatation, increased permeability, edema, a reduction of intravascular blood flow, an accumulation of red blood cells in the capillary loops, and cellular infiltration of the perivascular tissue. Depending on the degree of inflammation, the macroscopic corollary of the histologic changes represents erythematous, urticarial, and infiltrative (papular) lesions. The release of mediators from immunoglobulin E-laden mast cells in type I immune reactions, such as immune forms of urticaria, is histologically manifested primarily as vasodilatation, edema of the papillary body, and a rather sparse infiltrate of leukocytes (neutrophils) and histiocytic elements around the superficial venules (Fig. 6-15). These lesions usually resolve relatively rapidly without any residual pathology. However, more massive reactions lead to a dense perivascular infiltrate (Fig. 6-16A), and this may represent a transition to those processes where edema is less pronounced and where dense lymphocytic infiltrates surround the vessels in a sleeve-like fashion, as is the case in cutaneous drug eruptions (see Figs. 6-16A and 6-16B). More dramatic alterations occur when the vascular system itself is the target of the inflammatory process, resulting in a destruction of at least some of the

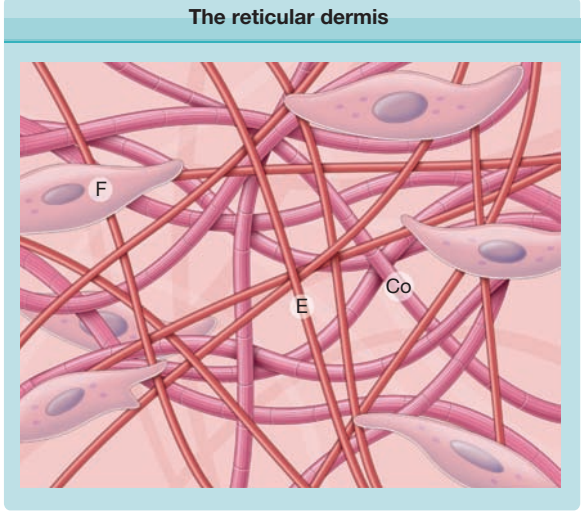

Figure 6-14 The reticular dermis is tightly woven fibroelastic tissue with a network of thick, banded collagen fibers (Co) and elastic (E) fibers embedded in an extracellular matrix. All are produced by fibroblasts (F). This tissue is much denser, relatively acellular, and has fewer capillary vessels than the papillary body (compare with Fig. 6-9).

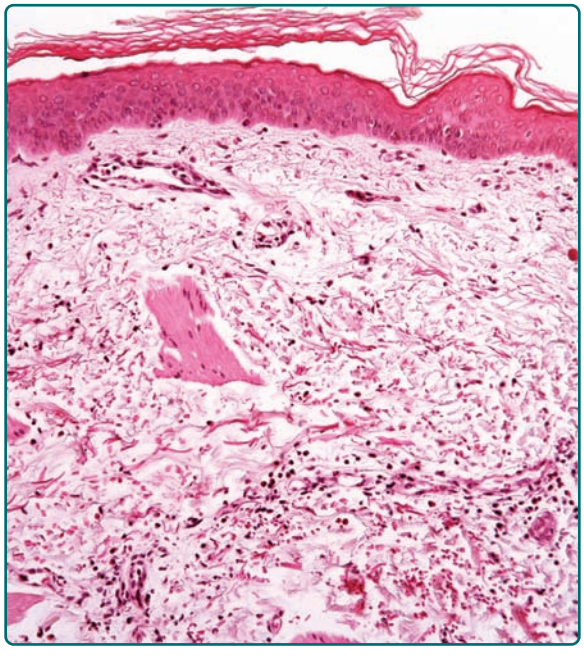

Figure 6-15 Urticaria. Characteristic of this reaction is a sparse, perivascular lymphocytic infiltrate with few eosinophils. Note the slight edema in the dermis and around the postcapillary venules.

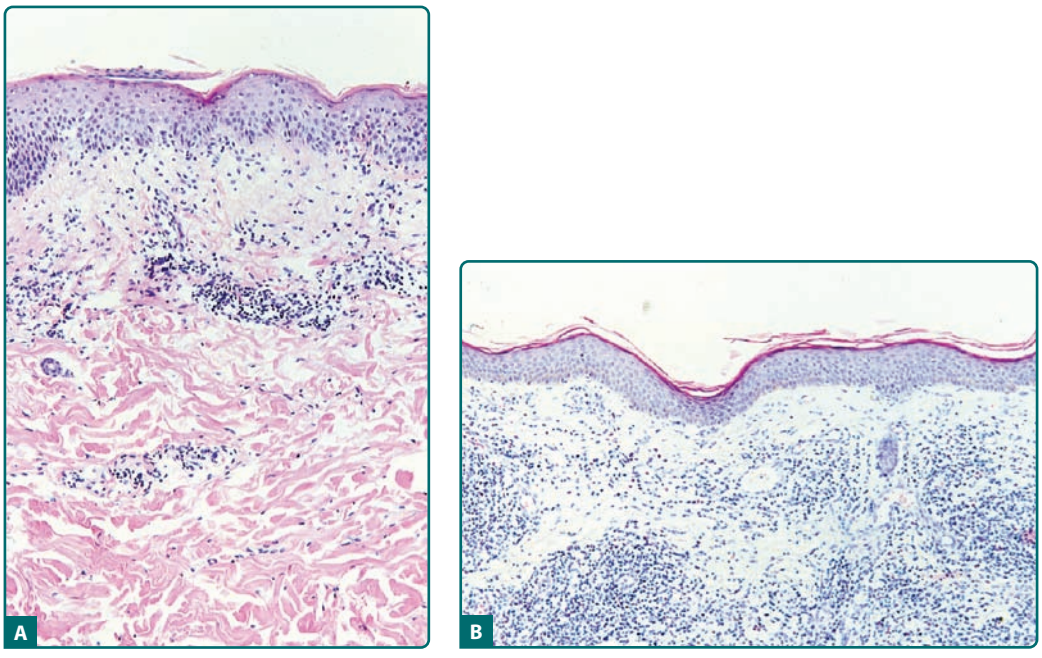

Figure 6-16 Drug eruption. **A.** Throughout the dermis, perivascular sleeves of mononuclear cells, mainly lymphocytes, are present about superficial and deep venules. There is slight edema in the papillary body and minimal interface dermatitis in this reaction to nifedipine. **B.** More pronounced, even nodular, mononuclear cell infiltrates around vessels in a drug reaction to a β blocker.

vessel components, as is the case in necrotizing vasculitis. These exudative changes result in clinical palpable purpura (Fig. 6-17; see Chapter 163).

Chronic inflammatory reactions of the superficial microvascular plexus usually reveal lymphocytic infiltrates in close association with the vascular walls and are clinically manifested as erythema. In purpura simplex (see Chapter 168), damage to the vessel wall is much less evident than in necrotizing vasculitis, but the integrity of the vessels is also impaired, as is evidenced by hemorrhage into the tissue. Lymphocytes and, as a secondary reaction, histiocytic elements partly laden with phagocytosed material including iron, constitute the inflammatory infiltrate.

The reaction patterns described for the vascular system of the papillary body and the superficial venular

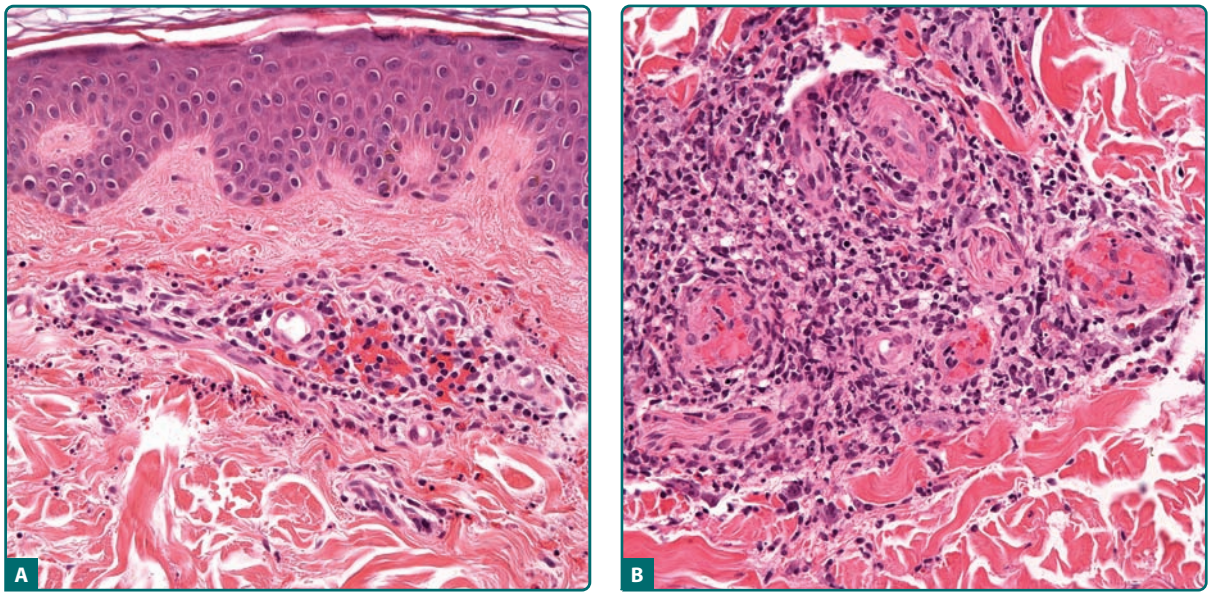

Figure 6-17 Necrotizing vasculitis. An inflammatory infiltrate composed mostly of neutrophils and nuclear dust is present both around and in the wall of a venule where fibrin is also deposited (**A**). More severe reaction with destruction of vessels (**B**).

plexus also occur in the deep dermis, but there are morphologic and functional differences because here larger vessels are involved. Lymphocytic infiltrates surrounding the vessels in a sleeve-like fashion lead to clinical signs only when they are substantial, and then they represent the histopathologic substrate for papular or nodular lesions. This is the case with drug eruptions (see Chapter 41; see Fig. 6-16B) and it is also true for deep-seated infiltrates in lupus erythematosus. In the case of necrotizing vasculitis of the medium-sized and larger vessels, there is usually a much more pronounced inflammatory infiltrate, clinically appearing as papular and nodular lesions, and secondary changes due to the interruption of the vascular flow are more pronounced: necrosis, blistering, and ulceration result as is the case in cutaneous panarteritis nodosa of the macroscopic type (see Chapter 164). In contrast to the macroscopic variant, microscopic polyarteritis nodosa affects vessels of varying sizes including venules and arterioles, involves lungs and kidneys, and is positive for perinuclear neutrophil antibodies. Granulomatous vasculitis also leads to nodular lesions, whereas the hyalinizing vascular changes and vascular occlusion in livedoid vasculitis result in ischemic necrosis (see Chapter 163).

LYMPHOCYTIC INFILTRATES

Although lymphocytic infiltrates occur in the majority of inflammatory dermatoses, there are a number of pathologic processes in which such infiltrates are the most prominent features and thus determine the histologic picture. Lymphocytic infiltrates are formed in inflammatory or proliferative conditions and in the latter may represent a benign or malignant process. They may differ in their cytologic appearance and distribution, may be confined to the periadventitial compartments of the vascular system (superficial and deep perivascular dermatitis), or may occur diffusely throughout the collagenous tissue (diffuse dermatitis). They may be confined almost exclusively to the papillary dermis (interface dermatitis) and spare the subepidermal compartment or may exhibit pronounced epidermotropism. They may be independent of vessels, sparse (interstitial dermatitis) or nodular (nodular dermatitis). Because lymphocytes are a heterogeneous population of cells, the analysis of such infiltrates should take into account not only the cytomorphology and distribution pattern but histochemical properties and immunologic markers as well. The analysis of round cell infiltrates by monoclonal antibodies (immunophenotyping) and determination of their clonality are important aspects of dermatopathology (see Chapter 146).

Among the many possible reaction patterns characterized by lymphocytic infiltrates, several typical patterns can be distinguished.

- Superficial perivascular infiltrates are often accompanied by secondary reactions of the epidermis. Lymphoid cells surround the vascular channels in a sleeve-like fashion but often extend diffusely to the epidermis, which may reveal focal parakeratosis in these areas. Clinically, these changes are often characterized as palpable figurate erythemas such as erythema annulare centrifugum, but polymorphic light eruption, drug eruptions (see Fig. 6-16A), or insect bites can produce a similar histopathologic picture.
- Lymphocytic cuffing of venules without involvement of the papillary body and the epidermis may occur in figurate erythemas and in drug eruptions (see Fig. 6-16B). The infiltrates of chronic lymphocytic leukemia show a similar distribution pattern but are usually more pronounced.
- Perivascular lymphocytic infiltrates with a mucinous infiltration of the nonperivascular connective tissue may be found in lymphocytic infiltration of Jessner–Kanof, reticular erythematous mucinosis or in lupus erythematosus (Fig. 6-18) and dermatomyositis (see Chapters 155 and 156).
- Nodular lymphocytic infiltrates, which extend throughout the dermis exhibiting focal accumulations of histiocytic cells and thus acquiring the appearance of lymphoid follicles, are typical of lymphocytoma cutis (see Chapter 146). Phagocytosed polychrome bodies in histiocytic cells (tingible body macrophages), mitoses in the center of the lymphoid follicles, and an admixture of eosinophils are characteristic features, as is the fact that the papillary body is usually spared so that a conspicuous grenz zone is found between the infiltrate and the epidermis.
- Nonfollicular lymphocytic infiltrates sparing the superficial reactive unit may also occur in benign lymphoid hyperplasias, but in these cases, the differentiation from malignant lymphoma is very difficult. Polymorphic infiltrates showing histiocytes,

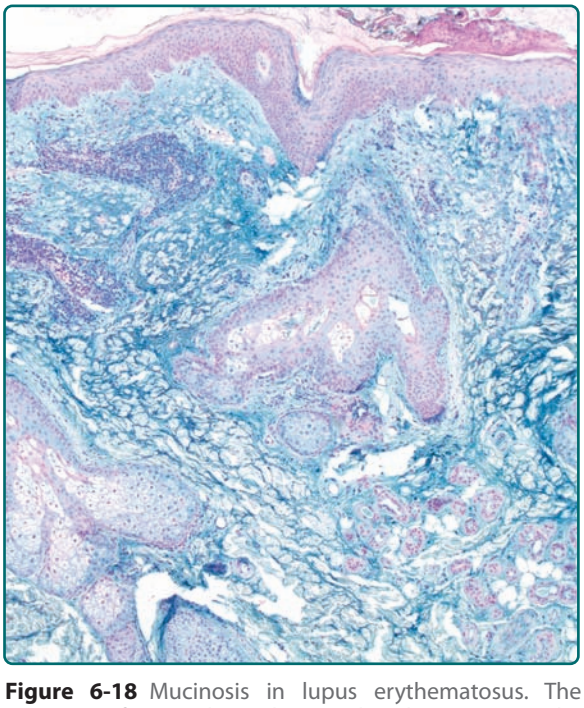

Figure 6-18 Mucinosis in lupus erythematosus. The prominent feature shown here is abundant mucin in the superficial dermis and middermis.

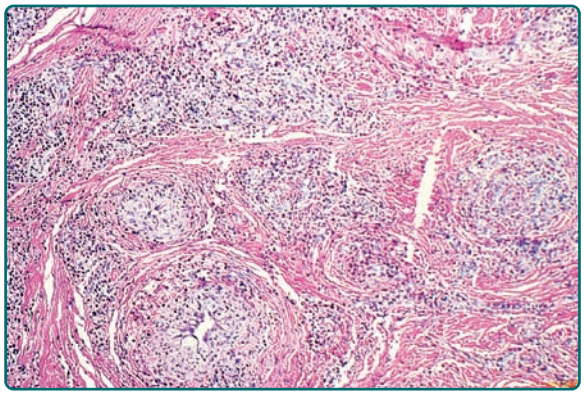

Figure 6-19 Angiolymphoid hyperplasia. Numerous vascular channels are surrounded by aggregates of inflammatory cells made up of lymphocytes and eosinophils. Note the protrusion of endothelial cells into the lamina of these vessels.

plasma cells, and occasional eosinophils are usually benign, whereas most malignant non-Hodgkin lymphomas exhibit a more monomorphous cytologic picture.

- Nodular accumulations of lymphocytes with an admixture of plasma cells and eosinophils accompanied by vascular hyperplasia are characteristic of angiolymphoid hyperplasia (Fig. 6-19), in which blood vessel walls are thickened and the endothelial cells proliferate and become swollen, and enlarged.
- Atypical lymphocytic infiltrates involving both the superficial and deeper dermis, and cytologically characterized by pronounced pleomorphism of the cellular infiltrate, are characteristic of lymphomatoid papulosis, one of the spectrum of $CD30^+$ lymphoproliferative disorders (see Chapter 145). This condition exemplifies the problems that arise when the histopathology of a lesion is used alone to determine whether a process is benign or malignant. Without knowledge of the clinical features and the course of disease, a definite diagnosis is extremely difficult.

POLYMORPHONUCLEAR LEUKOCYTIC INFILTRATES

Although neutrophils are the classic inflammatory cells of acute bacterial infections, there are diseases in which neutrophils dominate the histopathology, even in the absence of a bacterial cause. In pyoderma gangrenosum, massive neutrophilic infiltration of the dermis leads to sterile abscesses, breakdown of the tissue, and ulceration (see Chapter 33). In dermatitis herpetiformis, neutrophils accumulate in the tips of dermal papillae and form papillary abscesses (see Fig. 6-13) that precede the dermolytic blister formation described in Section "Disturbances of Dermal–Epidermal Cohesion" (see also Chapter 61). In erythema elevatum diutinum, neutrophils are the predominant cells centering around superficial and middermal vessels, which exhibit fibrinoid homogenization of their walls (toxic hyalin) and signs of vasculitis (see Chapter 163). The neutrophil is also the predominant cell in the early stages of the more common necrotizing vasculitis (see Fig. 6-17). Neutrophils also represent the majority of the often massive inflammatory infiltrate in acute febrile neutrophilic dermatosis, which is accompanied by pronounced subepidermal edema (see Chapter 32).

GRANULOMATOUS REACTIONS

Skin is an ideal tissue for granuloma formation in which histiocytes play a key role. Although these cells are involved at one time or another in practically all inflammatory processes, it is only the proliferation and focal aggregation of histiocytic cells that may be termed a *granuloma*. When such cells are closely clustered they resemble epithelial tissue, hence the designation *epithelioid cells*. Development of giant cells, storage of phagocytosed material, and the admixture of inflammatory cells, such as lymphocytes, plasma cells, and eosinophils, may render the histologic picture of a granulomatous reaction more complex. To these have to be added vascular changes and alterations in the fibrous structure of the connective tissue. Granulomas almost always lead to destruction of preexisting tissue, particularly elastic fibers, and in such instances result in atrophy, fibrosis, or scarring. Tissue damage or destruction manifests either as necrobiosis or fibrinoid or caseous necrosis, or it may result from liquefaction and abscess formation or from replacement of preexisting tissue by fibrohistiocytic infiltrate and fibrosis.

Sarcoidal granulomas (see Chapter 152) are typically characterized by naked nodules consisting of epithelioid cells, occasional Langerhans giant cells, and only a small number of lymphocytes (Fig. 6-20). Silica, zirconium, and beryllium granulomas and a number of foreign-body granulomas may have such histopathologic features.

Granulomatous reactions of the skin comprise a large spectrum of histopathologic features. Palisading granulomas surround necrobiotic areas of the

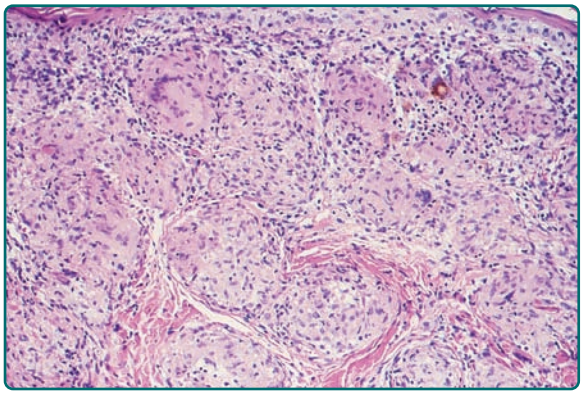

Figure 6-20 Sarcoidal granuloma. In the dermis, numerous "naked" tubercles consisting of epithelioid cells and scant lymphocytes are seen. The overlying epidermis is atrophic.

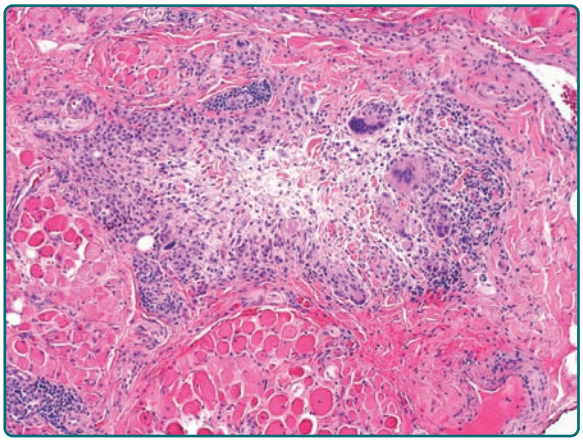

Figure 6-21 Granuloma annulare. A well-circumscribed palisading granuloma is seen in the dermis. Necrobiotic collagen is surrounded by histiocytes, lymphocytes, and a few scattered multinucleated giant cells.

connective tissue with histiocytes in radial alignment (Fig. 6-21). Granuloma annulare, necrobiosis lipoidica, rheumatoid nodules, and the juxtaarticular nodules of syphilis belong to this group. These reactions may have significance as signs of systemic disease. For example, when there are prominent neutrophils in the necrobiotic area of granuloma annulare or necrobiosis, one may suspect an associated inflammatory bowel disease. Endocrinopathies can also be associated with these disorders, diabetes mellitus is a classic example associated with necrobiosis lipoidica. Of course, rheumatoid nodules can be associated with rheumatoid arthritis but can also occur as a result of trauma in some cutaneous locations. Drugs may also cause these reactions.

Infectious granulomas with a sarcoidal appearance may occur in tuberculosis, syphilis, leishmaniasis, leprosy, or fungal infections. Necrosis can also develop within the granuloma proper, as is the case for fibrinoid necrosis in sarcoidosis, caseation in tuberculosis, or the necrosis developing in mycotic granulomas. Many of the infectious granulomas are associated with epidermal hyperplasia, often exhibiting intraepidermal abscesses in which the causative organism can be found, often in a multinucleate giant cell. In the dermis there is a mixture of cells, including histiocytes, epithelioid cells, eosinophils, neutrophils, and lymphocytes.

It is often difficult to classify granulomatous reactions within the skin by histopathology alone, for even completely different etiologic conditions such as immunopathies and some forms of vasculitis are associated with the development of granulomas.

A specific form of granulomatous reaction results when the cellular infiltrate consists almost exclusively of the key granuloma cell, the *histiocyte*. One property of this cell is its capacity to store phagocytosed material. In xanthomatous reaction patterns, histiocytes take up and store fat and are thus transformed into foam cells. They are distributed either diffusely, as is the case in diffuse normolipemic xanthomatosis, or as an aggregate infiltrate mimicking a tumor, as in the xanthomas occurring in the hyperlipoproteinemias and xanthelasma (see Chapter 135).

FIBROUS DERMIS AND EXTRACELLULAR MATRIX

(See Fig. 6-1, DRU)

Sclerosing processes of the skin involve mainly the connective tissue of the dermis (see Figs. 6-1, DRU, and 6-14) but usually reflect dynamic changes of structure and function that involve practically all compartments of this organ. The hallmark of scleroderma (see Chapter 157) is the homogenization, thickening, and dense packing of the collagen bundles, a narrowing of the interfascicular clefts within the reticular dermis, and the disappearance of the boundary between this portion of the dermis and the papillary body. There is also a diminution of the small papillary and subpapillary vessels, which appear narrowed, and, in the early stages, a perivascular lymphocytic infiltrate and edema. The impressive thickening of the dermis not only results from an increase of its fibrous components, but is also caused by the fibrosis of the superficial layers of the subcutaneous fat that follows lymphocytic infiltration and a histiocytic reaction.

Sclerodermoid changes may be found in the toxic oil syndrome and l-tryptophan disease, eosinophilic fasciitis (see Chapter 36), and mixed connective tissue disease; they also occur in pachydermoperiostosis, where an increase of fibroblasts and ground substance accompany the sclerotic changes, and in porphyria cutanea tarda, which shows typical hyalinization of the papillary vessels. In lichen sclerosus, there is a massive edema of the papillary body and a dense lymphocytic infiltrate that initially hugs the epidermis and later separates the edematous papillary body from the reticular dermis (see Chapter 65). As sclerosis sets in, there is also a disappearance of elastic tissue from the papillary body; the concomitant involvement of the epidermis includes hydropic degeneration of basal cells, atrophy, and, at the same time, hyperkeratosis. Changes in the junctional zone in this condition may occasionally lead to a separation of the epidermis from the dermis and thus to blister formation.

Faulty synthesis or cross-linking of collagen results in a number of well-defined diseases or syndromes but leads to relatively few characteristic histopathologic changes. In the different types of the Ehlers–Danlos syndrome (see Chapter 137), the faulty collagen cannot be recognized histopathologically, and only the relative increase of elastic tissue may indicate that something abnormal has occurred in the dermis. In generalized elastolysis, a fragmentation of elastic fibers is the histopathologic substrate of the clinical appearance of cutis laxa, and the fragmentation and curled and clumped appearance of elastic fibers are similarly diagnostic in pseudoxanthoma elasticum (see Chapter 137). On the other hand, in actinic elastosis, the histologic correlate of dermatoheliosis, all components of the superficial connective tissue are involved (see Chapter 109). Except for a narrow grenz zone below the epidermis, the papillary body, and the superficial layers of the

reticular dermis are filled with clumped and curled fibers that progressively become homogenized and basophilic. They are stained by dyes that have an affinity for elastic tissue and thus histochemically behave similar to elastic fibers.

Such profound changes of dermal architecture become clinically apparent: the taut and firm connective tissue in scleroderma reflects the sclerotic texture and homogenization of the collagen bundles seen histologically; the loose folds of cutis laxa are a result of the fragmentation of elastic fibers; the cobblestone-like papules in pseudoxanthoma elasticum correspond to the focal aggregation of the pathologically altered elastic material; and the coarseness of skin lines and surface profile in dermatoheliosis are the clinical manifestations of the focal aggregation of elastotic material.

MOLECULAR AND CELLULAR MECHANISMS FOR REACTION PATTERNS AFFECTING THE DERMIS

The reaction patterns that affect the dermis take the forms of cellular infiltrations as well as acellular patterns that primarily are based in the extracellular matrix. However, these two general categories are difficult to separate, as there is constant interplay between the cellular and acellular components of the dermis. As discussed above, the vascular plexuses in the dermis are the primary conduits for influx of cellular elements, and leukocyte–endothelial adhesion molecule expression play a critical role in regulating leukocyte entry and the reaction patterns that result. The adhesive molecules themselves assist in regulating the relative strength and kinetics of the influx of various cell types, and hence some stimuli may provoke an adhesion cascade that favors entry of neutrophils or eosinophils, whereas others may result in infiltration of primarily mononuclear cells. Moreover, once inflammatory cells have extravasated into the dermal interstitium, their migratory fate and secondary morphological alterations are also in large part determined by molecular cues in their new microenvironment. Hence, an encounter with insect bite venom may provoke interstitial accumulation of histiocytes and eosinophils, and perhaps poorly formed granulomas, whereas an immune response in the setting of Lyme disease may provoke intensely perivascular localization of lymphocytes conjuring up the appearance of a "coat-sleeve." Mediators released by cellular infiltrates may have a profound effect on the extracellular matrix as well, resulting in additional dermal reaction patterns. For example, fibrogenic mediators such as TGFβ, may have a variety of effects on dermal homeostasis, including fibroblast transformation in the direction of myofibroblasts, with attendant collagen synthesis as might be seen as a normal response to wounding, but in this setting resulting in the diffuse dermal thickening that correlates with the reaction pattern typical of morphea scleroderma.

SUBCUTANEOUS FAT

(See Fig. 6-1, S)

Inflammatory processes in the subcutaneous adipose tissue take a slightly different course than in the connective tissue of the dermis because of the specific anatomy of the subcutis (see Chapters 7 and 70). Inflammation of subcutaneous fat reflects either an inflammatory process of the adipose tissue proper or the fat lobules (see Fig. 6-1, L) or a process arising in the septa (see Fig. 6-1, Sep); it can involve small venules and capillaries or arise from the larger muscular vessels. The histopathologic manifestations may vary accordingly. Small-vessel pathology is usually manifested locally, involving the neighboring fat lobules, whereas the destruction or occlusion of a larger vessel influences the entire tissue segment. Destruction of fat, be it of a traumatic or inflammatory nature, leads to the release of fatty acids that by themselves are strong inflammatory stimuli, attracting neutrophils and scavenger histiocytes and macrophages; phagocytosis of destroyed fat usually results in lipogranuloma formation.

Septal processes that follow inflammatory changes of the trabecular vessels are usually accompanied by edema, infiltration of inflammatory cells, and a histiocytic reaction. This is the classic appearance in erythema nodosum (Fig. 6-22; see Chapter 70). Recurring septal inflammation may lead to a broadening of the interlobular septa, fibrosis, the accumulation of histiocytes and giant cells, and may result in vascular proliferation. By contrast, in nodular vasculitis (Fig. 6-23), large-vessel vasculitis in the septal area is accompanied by necrosis of the fat, followed by histiocytic reactions, epithelioid cell granulomas within the fat lobules, and a fibrotic reaction sclerosing the entire subcutaneous fat. On the other hand, lobular panniculitis results from the necrosis of fat lobules as the primary event, as is the case in idiopathic nodular panniculitis (see Chapter 70), followed by an accumulation of neutrophils and leukocytoclasia. The lipid material

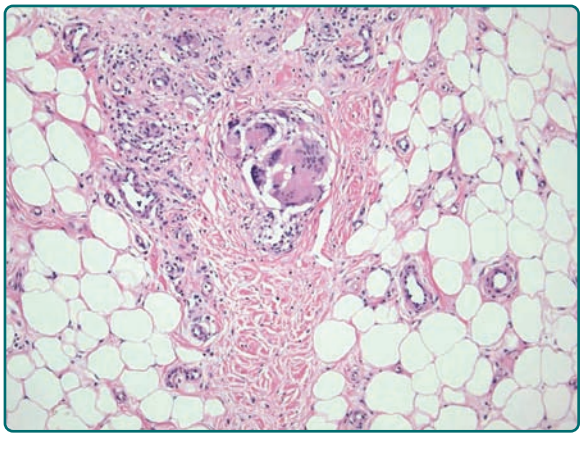

Figure 6-22 Erythema nodosum. A chronic granulomatous inflammatory infiltrate with giant cells extends along the thickened septum into the adjacent fat lobule.

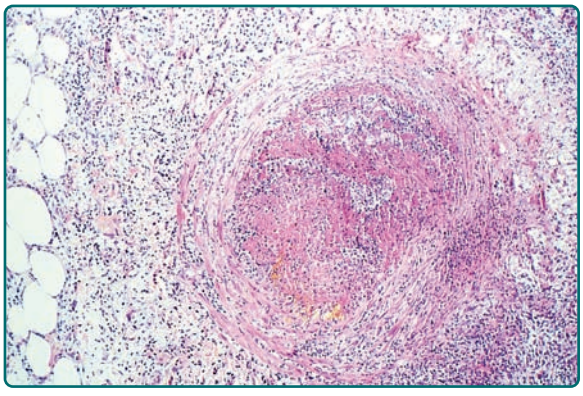

Figure 6-23 Nodular vasculitis. The characteristic features illustrated are severe vasculitis with necrosis of the large vessel wall and occlusion of the lumen. Necrosis of the fat lobules is present, as well as an acute and chronic inflammatory cell infiltrate.

derived from necrotic adipocytes contains free and esterified cholesterol, neutral fats, soaps, and free fatty acids, which, in turn, exert an inflammatory stimulus. Histiocytic cells migrate into the inflamed fat, and phagocytosis leads to foam cell formation. Epithelioid granulomas with giant cells may also result, and all types of fibrosis may develop. Therefore, fat necrosis is the primary, and inflammation the secondary, event in this type of panniculitis.

The inherent capacity of the adipose tissue to respond to pathologic stimuli also holds true for disease conditions that affect the subcutaneous tissue only secondarily or result from exogenous factors. Traumatic panniculitis leads to necrosis of fat lobules and a reactive inflammatory and granulomatous tissue response. After the injection of oils or silicone, large cystic cavities may be formed, whereas after the injection of pentazocine, for instance, fibrosis and sclerosis dominate the histopathologic picture. Oily substances may remain within the adipose tissue for long periods without causing a significant tissue reaction; oil cysts evolve that are surrounded by multiple layers of residual connective tissue, so that the tissue acquires a "Swiss cheese" appearance. Animal or vegetable oils often lead to tuberculoid or lipophagic granulomas with massive histiocytic reactions, foam cells, and secondary fibrosis.

Panniculitis also occurs as a result of infectious agents (cocci, mycobacteria, and other bacterial and fungal organisms) or a specific disease process. In sarcoidosis, fat is gradually replaced by epithelioid cell nodules and, in lymphoma, by specific lymphomatous infiltrates. In lupus panniculitis, a dense lymphocytic infiltrate of the septal and lobular tissue determines the histopathologic picture, as does involvement of vessels manifesting as vasculitis. However, destruction of fat, liquefaction, and lipogranuloma may be so pronounced that the vascular component can hardly be recognized, and the histopathologic picture may resemble idiopathic nodular panniculitis.

MOLECULAR AND CELLULAR MECHANISMS FOR REACTION PATTERNS AFFECTING THE SUBCUTIS

We are in the infancy of understanding the molecular underpinnings of various reaction patterns in the subcutis. This is in part because our understanding of the normal physiology of subcutaneous fat has only recently moved past the historical notion of energy storage. We now know that the subcutis is a potent source of stem cells that have remarkable differentiation plasticity and thus implications for use in regenerative medicine. The fat lobule itself is much more that an energy storage site; it also generates a variety of proinflammatory and thrombogenic cytokines that, as is the case with epidermally derived cytokines, are likely to play a key role in regulating the various reaction patterns to which fat is heir. Moreover, given its location deep to the dermal–epidermal environmental interface, the subcutaneous fat has the spatial attributes to serve as a barometer for systemic molecular cues that may herald generalized disease. Finally, perturbation in the fat producing specific reaction patterns in association with aberrant cytokine production may themselves contribute to systemic health and disease, as is currently speculated with regard to proinflammatory mediators produced in the subcutis that may contribute to the evolution of some forms of cardiovascular disease.

SUGGESTED READINGS

Ackerman AB et al: *Histologic Diagnosis of Inflammatory Skin Diseases: An Algorithmic Method Based on Pattern Analysis*, 2nd edition. Baltimore, Williams & Wilkins, 1997

Bailey EA et al: Marginal zone lymphoma (low-grade B cell lymphoma of mucosa-associated lymphoid tissue type) of skin and subcutaneous tissue. *Am J Surg Pathol* **20**:1011, 1996

Biederman T, Rocken M, Carballido JM: TH1 and TH2 lymphocyte development and regulation of TH cell-mediated immune responses of the skin. *J Invest Dermatol Symp Proc* **9:**5, 2004

Cerroni L et al: *An Illustrated Guide to Skin Lymphoma*. Oxford, Blackwell Sciences, 1998

Crowson AN, Magro CM: The cutaneous pathology of lupus erythematosus: A review. *J Cutan Pathol* **28:**1, 2001

Crowson AN et al: Cutaneous vasculitis: A review. *J Cutan Pathol* **30:**161, 2003

Elder DE et al: *Lever's Histopathology of the Skin*, 8th edition. Philadelphia, Lippincott Williams and Wilkins, 2004

Magro CM et al: Granuloma annulare and necrobiosis lipoidica tissue reactions as a manifestation of systemic disease. *Hum Pathol* **27:**50, 1996

Magro CM et al: *The Lymphoid Proliferations*. New York, Wiley-Liss, 2006

McKee PH et al: *Pathology of the Skin*, 3rd edition. Philadelphia, Elsevier Mosby, 2005

Murphy GF, Mihm MC Jr.: *Inflammatory Diseases of the Skin*. AFIP Fascicle, third series, AFIP September 2006

Schaerli P, Moser B: Chemokine: Control of primary and memory T-cell traffic. *Immunol Res* **31:**57, 2005

Udey MC: Skin dendritic cells in immunity and autoimmunity. *J Investig Dermatol Symp Proc* **9:**1507, 2004

SECTION 3

Overview of Biology, Development, and Structure of Skin

Chapter 7 :: Development and Structure of Skin

:: David H. Chu

STRUCTURE AND FUNCTION OF SKIN AT A GLANCE

- Three major layers—epidermis, dermis, hypodermis:
  - Epidermis: major permeability barrier, innate immune function, adhesion, and ultraviolet protection.
  - Dermis: major structural element, three types of components—cellular, fibrous matrix, and diffuse and filamentous matrix. Also site of vascular, lymphatic, and nerve networks.
  - Hypodermis (subcutis): insulation, mechanical integrity, containing the larger source vessels and nerves.

SKIN: AN OVERVIEW

Skin is a complex organ that protects its host from its environment, at the same time allowing interaction with its environment. It is much more than a static, impenetrable shield against external insults. Rather, skin is a dynamic, complex, integrated arrangement of cells, tissues, and matrix elements that mediates a diverse array of functions: skin provides a physical permeability barrier, protection from infectious agents, thermoregulation, sensation, ultraviolet (UV) protection, wound repair and regeneration, and outward physical appearance (Table 7-1). These various functions of skin are mediated by one or more of its major regions—the epidermis, dermis, and hypodermis (Fig. 7-1; see also Fig. 6-1, Chapter 6). These divisions are interdependent, functional units; each region of skin relies upon, and is connected with, its surrounding tissue for regulation and modulation of normal structure and function at molecular, cellular, and tissue levels of organization (see Chapter 6).

Whereas the epidermis and its outer stratum corneum provide a large part of the physical barrier provided by skin, the structural integrity of skin as a whole is provided primarily by the dermis and hypodermis. Antimicrobial activities are provided by the innate immune system and antigen-presenting dendritic cells of the epidermis, circulating immune cells that migrate from the dermis, and antigen-presenting cells of the dermis (see Chapter 10). Protection from UV irradiation is provided in great measure by the most superficial cells of the epidermis. Inflammation begins with the keratinocytes of the epidermis or immune cells of the dermis, and sensory apparatus emanates from nerves that initially traverse the hypodermis to the dermis and epidermis, ending in specialized receptive organs or free nerve endings. The largest blood vessels of the skin are found in the hypodermis, which serve to transport nutrients and immigrant cells (see Fig. 6-1, Chapter 6). The cutaneous lymphatics course through the dermis and hypodermis, serving to filter debris and regulate tissue hydration. Epidermal appendages provide special protective or sensory functions. Skin also determines a person's physical appearance, influenced by pigmentation provided by melanocytes, with body contours, appearance of age, and actinic damage influenced by the epidermis, dermis, and hypodermis. The skin begins to be organized during embryogenesis, where intercellular and intracellular signals, as well as reciprocal cross talk between different tissue layers, are instrumental in regulating the eventual maturation of the different components of skin.

What follows is an integrated description of the major structural features of the skin and how these structures allow the skin to achieve its major functions, followed by a review of their embryologic origins. Also highlighted are illustrative cutaneous diseases that manifest when these functions are defective. Understanding the genetic and molecular bases of skin disease has confirmed, and in some cases revealed, the many factors and regulatory elements that play critical roles in skin function.

EPIDERMIS

One of the most fundamental and visible features of skin is the stratified, cornified epidermis (Fig. 7-2). The epidermis is a continually renewing structure that gives rise to derivative structures called append-

TABLE 7-1
Functions of Skin

Function	Tissue Layer	Some Associated Diseases
Permeability barrier	Epidermis	Atopic dermatitis Ectodermal dysplasias Ichthyoses Keratodermas Exfoliative dermatitis Bullous diseases
Protection from pathogens	Epidermis Dermis	Verruca vulgaris Ecthyma Cellulitis Leishmaniasis Human immunodeficiency virus Tinea pedis/corporis
Thermoregulation	Epidermis Dermis Hypodermis	Ectodermal dysplasias Raynaud Hyperthermia
Sensation	Epidermis Dermis Hypodermis	Diabetic neuropathy Leprosy Pruritus Postherpetic neuralgia
Ultraviolet protection	Epidermis	Xeroderma pigmentosum Oculocutaneous albinism
Wound repair/regeneration	Epidermis Dermis	Keloid Venous stasis ulcer Pyoderma gangrenosum
Physical appearance	Epidermis Dermis Hypodermis	Melasma Vitiligo Scleroderma Lipodystrophy

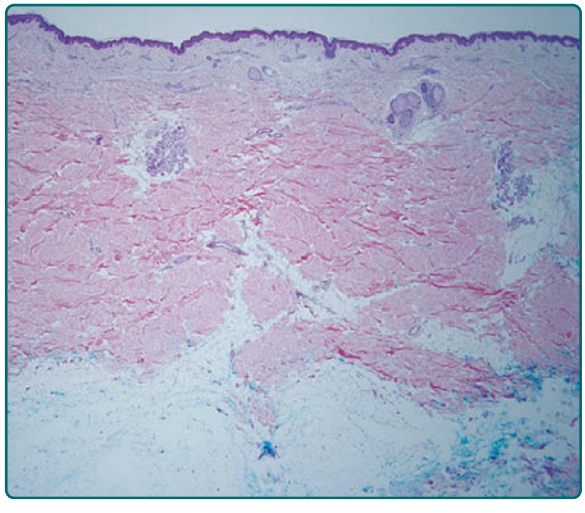

Figure 7-1 The major regions of skin. Skin is composed of three layers: (1) epidermis, (2) dermis, and (3) hypodermis. The outermost epidermis is separated from the dermis by a basement membrane zone, the dermal–epidermal junction. Below the dermis lies the subcutaneous fat (hypodermis). Epidermal appendages, such as hair follicles and eccrine and apocrine sweat glands, begin in the epidermis but course through the dermis and/or the epidermis. Blood vessels, lymphatics, and nerves course through the subcutaneous fat and emerge into the dermis.

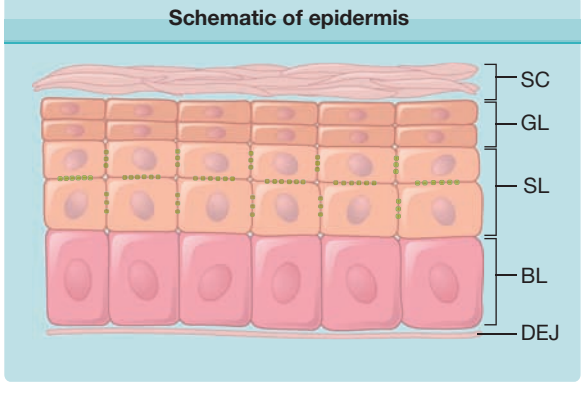

Figure 7-2 Schematic of epidermis. The epidermis is a stratified, cornified epithelium. The deepest layer consists of basal cells (BL) that rest upon the basement membrane of the dermal–epidermal junction (DEJ). These cells differentiate into the cells of the spinous layer (SL), characterized by abundant desmosomal spines. Spinous cells eventually become granular layer cells (GL), producing many of the components of the cornified envelope. Ultimately, the terminally differentiated keratinocytes shed their nuclei and become the stratum corneum (SC), a cross-linked network of protein and glycolipids.

ages (pilosebaceous units, nails, and sweat glands). The epidermis ranges in thickness from 0.4 to 1.5 mm, as compared with the 1.5- to 4.0-mm full-thickness skin. The majority of cells in the epidermis are keratinocytes that are organized into four layers, named for either their position or a structural property of the cells. These cells progressively differentiate from proliferative basal cells, attached to the epidermal basement membrane, to the terminally differentiated, keratinized stratum corneum, the outermost layer and barrier of skin (see Chapter 46). Intercalated among the keratinocytes at various levels are the immigrant resident cells—melanocytes, Langerhans cells, and Merkel cells. Other cells, such as lymphocytes, are transient inhabitants of the epidermis and are extremely sparse in normal skin. There are many regional differences in the epidermis and its appendages. Some of these differences are apparent grossly, such as thickness (e.g., palmoplantar skin vs. truncal skin, Fig. 7-3); other differences are microscopic.

Pathologic changes in the epidermis can occur as a result of a number of different stimuli: repetitive mechanical trauma (as in lichen simplex chronicus), inflammation (as in atopic dermatitis and lichen planus), infection (as in verruca vulgaris), immune system activity and cytokine abnormalities (as in psoriasis, Fig. 7-4), autoantibodies (as in pemphigus vulgaris and bullous pemphigoid), or genetic defects that influence differentiation or structural proteins [as in epidermolysis bullosa (EB) simplex, epidermolytic ichthyosis and other ichthyoses, and Darier disease].

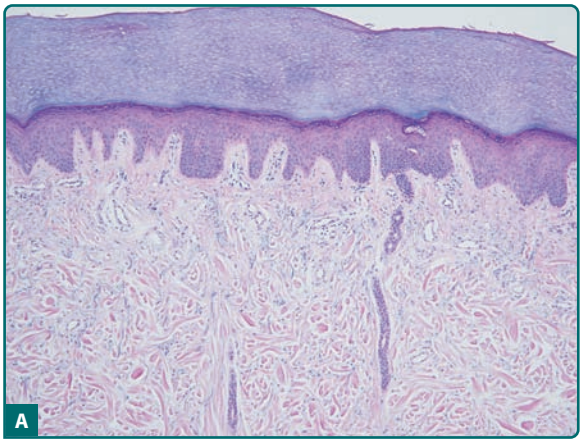

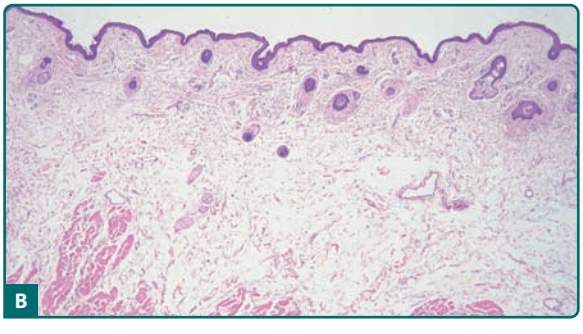

Figure 7-3 Anatomic variation in epidermal thickness. **A.** Acral skin. **B.** Eyelid skin. Note that the epidermis is considerably thicker in (**A**) than (**B**), including the compact layers of the stratum corneum, as well as the deeper epidermal layers.

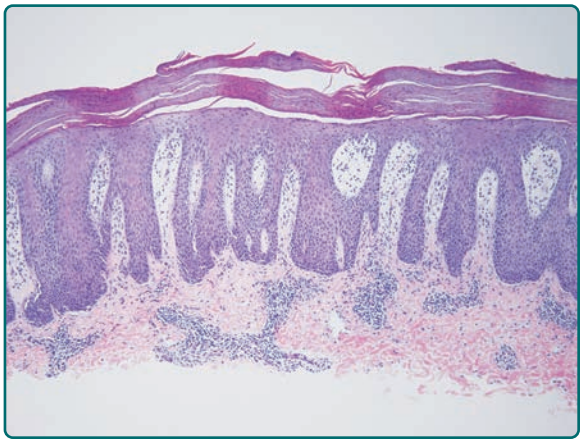

Figure 7-4 Epidermal hyperplasia. Hyperproliferation of the epidermis can occur due to a number of causes, as manifested in diseases such as psoriasis (pictured), as well as lichen simplex chronicus, atopic dermatitis, lichen planus, and verruca vulgaris.

LAYERS OF THE EPIDERMIS

BASAL LAYER. The keratinocyte is an ectodermally derived cell and is the primary cell type in the epidermis, accounting for at least 80% of the total cells. The ultimate fate of these cells is to contribute the components for the epidermal barrier as the stratum corneum. Thus, much of the function of the epidermis can be gleaned from the study of the structure and development of the keratinocyte.

Keratinocyte differentiation (keratinization) is a genetically programed, carefully regulated, complex series of morphologic changes and metabolic events whose endpoint is a terminally differentiated, dead keratinocyte (corneocyte) that contains keratin filaments, matrix protein, and a protein-reinforced plasma membrane with surface-associated lipids (see Chapter 46).

Keratins are a family of intermediate filaments and are the hallmark of all epithelial cells, including keratinocytes.[1,2] They serve a predominantly structural role in the cells. Fifty-four different functional keratin genes have been identified in humans—34 epithelial keratins and 17 hair keratins.[3] The coexpression of specific keratin pairs is dependent on cell type, tissue type, developmental stage, differentiation stage, and disease condition (Table 7-2). Furthermore, the critical role of these molecules is underscored by the numerous manifestations of disease that arise because of mutations in these genes (see Table 7-2). Thus, knowledge of keratin expression, regulation, and structure provides insight into epidermal differentiation and structure.

The basal layer (stratum germinativum) contains mitotically active, columnar-shaped keratinocytes that attach via keratin filaments (K5 and K14) to the basement membrane zone at hemidesmosomes (see Chapter 53), attach to other surrounding cells through

TABLE 7-2
Expression Patterns of Keratin Genes and Keratin-Associated Diseases

Basic	Acidic	Tissue Expression	Disease Association
1	10	Suprabasal keratinocytes	Epidermolytic ichthyosis; diffuse nonepidermolytic PPK (keratin 1)
1	9	Suprabasal keratinocytes (palmoplantar skin)	Epidermolytic PPK (epidermolytic hyperkeratosis)
2	10	Upper spinous and granular layers	Superficial epidermolytic ichthyosis
3	12	Cornea	Meesmann's corneal dystrophy
4	13	Mucosal epithelium	White sponge nevus
5	14	Basal keratinocytes	Epidermolysis bullosa simplex
6a	16	Outer root sheath, hyperproliferative keratinocytes, palmoplantar keratinocytes	Pachyonychia congenita; focal nonepidermolytic PPK
6b	17	Nail bed, epidermal appendages	Pachyonychia congenita; steatocystoma multiplex
8	18	Simple epithelium	Cryptogenic cirrhosis

PPK = palmoplantar keratoderma.

desmosomes, and that give rise to cells of the more superficial, differentiated epidermal layers. Membrane-bound vacuoles that contain pigmented melanosomes are transferred from melanocytes by phagocytosis.[4] The pigment within melanosomes contributes to the overall skin pigmentation perceived macroscopically.[5] The basal layer is the primary location of mitotically active cells of the epidermis. Cell kinetic studies suggest that the basal layer cells exhibit different proliferative potentials (stem cells, transit amplifying cells, and postmitotic cells), and in vivo and in vitro studies suggest that there exist long-lived epidermal stem cells (see Chapter 45).[6,7] Because basal cells can be expanded in tissue culture and used to reconstitute sufficient epidermis to cover the entire skin surface of burn patients,[8,9] such a starting population is presumed to contain long-lived stem cells with extensive proliferative potential, located within the basal epidermal layer (at the base of *epidermal proliferating units*) and the hair follicle bulge.[10–13]

The second type of cell, the transit amplifying cells of the basal layer, arises as a subset of daughter cells produced by the infrequent division of stem cells, either by symmetric or asymmetric cell division.[14] These cells provide the bulk of the cell divisions needed for stable self-renewal and are the most common cells in the basal compartment. These cells subsequently give rise to the third class of epidermal basal cells, the postmitotic cells that undergo terminal differentiation. In humans, the normal transit time for a basal cell, from the time it loses contact with the basal layer to the time it enters the stratum corneum, is at least 14 days. Transit through the stratum corneum and subsequent desquamation require another 14 days. These periods of time can be altered in hyperproliferative or growth-arrested states.

SPINOUS LAYER. The shape, structure, and subcellular properties of spinous cells correlate with their position within the midepidermis. They are named for the spine-like appearance of the cell margins in histologic sections. Suprabasal spinous cells are polyhedral in shape with a rounded nucleus. As these cells differentiate and move upward through the epidermis, they become progressively flatter and develop organelles known as *lamellar granules* (see Section "Granular Layer"). Spinous cells also contain large bundles of keratin filaments, organized around the nucleus and inserted into desmosomes peripherally.

Spinous cells retain the stable K5/K14 keratins that are produced in the basal layer and only synthesize new messenger RNA (mRNA) for these proteins in hyperproliferative disorders. Instead, new synthesis of the K1/K10 keratin pair occurs in this epidermal layer. These keratins are characteristic of an epidermal pattern of differentiation and thus are referred to as the *differentiation-specific* or *keratinization-specific keratins*. However, in hyperproliferative conditions such as psoriasis, actinic keratoses, and wound healing, synthesis of K1 and K10 mRNA and protein is downregulated, and the synthesis and translation of messages for K6 and K16 are favored. Correlated with this change in keratin expression is a disruption of normal differentiation in the subsequent granular and cornified epidermal layers (see Sections "Granular Layer" and "Stratum Corneum"). mRNA for K6 and K16 are present throughout the epidermis normally, but the message is only translated on stimulation of proliferation.

The "spines" of spinous cells are abundant desmosomes, calcium-dependent cell surface modifications that promote adhesion of epidermal cells and resistance to mechanical stress (see Chapters 46 and 53).[15] Although desmosomes are related to adherens junctions, the latter associate with actin microfilaments at cell–cell interfaces, via a distinct set of cadherins (e.g., E-cadherin) and intracellular catenin adapter

TABLE 7-3
Diseases Resulting from Disruption of Desmosomal Proteins

Protein	Diseases
Desmoglein 1	Pemphigus foliaceus Striate palmoplantar keratoderma Staphylococcal scalded-skin syndrome Bullous impetigo
Desmoglein 3	Pemphigus vulgaris
Desmoglein 4	Autosomal recessive hypotrichosis
Plakoglobin	Palmoplantar keratoderma with wooly hair and arrhythmogenic right ventricular cardiomyopathy (Naxos disease)
Plakophilin 1	Ectodermal dysplasia/skin fragility syndrome (skin erosions, dystrophic nails, sparse hair, and painful palmoplantar keratoderma)
Plakophilin 2	Arrhythmogenic right ventricular cardiomyopathy
Desmoplakin	Lethal acantholytic epidermolysis bullosa Striate palmoplantar keratoderma, type I Palmoplantar keratoderma with left ventricular cardiomyopathy and wooly hair Autosomal dominant arrhythmogenic right ventricular cardiomyopathy

molecules. That the desmosomes are integral mediators of intercellular adhesion is clearly demonstrated in diseases in which these structures are disrupted, by genetic disorders, autoantibodies, or bacterial proteases (Table 7-3).[16,17]

The importance of calcium as a mediator of adhesion is well illustrated in the cases of two conditions that exhibit characteristic epidermal dyscohesion: (1) Darier disease (keratosis follicularis) and (2) Hailey–Hailey disease (benign chronic pemphigus) (see Chapter 51).[18] Both of these diseases are caused by mutations in genes that regulate calcium transport, *SERCA2* in Darier disease and *ATP2C1* in Hailey–Hailey disease.

Lamellar granules are also formed in this layer of epidermal cells (Fig. 7-5). These secretory organelles deliver precursors of stratum corneum lipids into the intercellular space (see Chapter 47). Genetic diseases demonstrate the importance of steroid and lipid metabolism for sloughing of cornified cells—in recessive X-linked ichthyosis, for example, mutation of steroid sulfatase results in a retention hyperkeratosis (see Chapter 49).[19]

GRANULAR LAYER. Named for the basophilic keratohyalin granules that are prominent within cells at this level of the epidermis, the granular layer is the site of generation of a number of the structural components that will form the epidermal barrier, as well as a number of proteins that process these components (see Fig. 7-2).[20,21] Keratohyalin granules (see Fig. 7-5) are composed primarily of profilaggrin, keratin filaments, and loricrin. It is in this layer that the cornified cell envelope begins to form, with the conversion of profilaggrin to filaggrin. After aggregation with keratin to form macrofilaments, filaggrin is degraded into molecules such as urocanic acid and pyrrolidone carboxylic acid, which contribute to hydration of the stratum corneum and help filter UV radiation. Loricrin is a cysteine-rich protein that forms the major protein component of the cornified envelope. Upon its release from keratohyalin granules, loricrin binds to desmosomal structures and is subsequently cross-linked to the plasma membrane by tissue transglutaminases (TGMs, primarily TGMs 3 and 1) to form the cornified cell envelope.

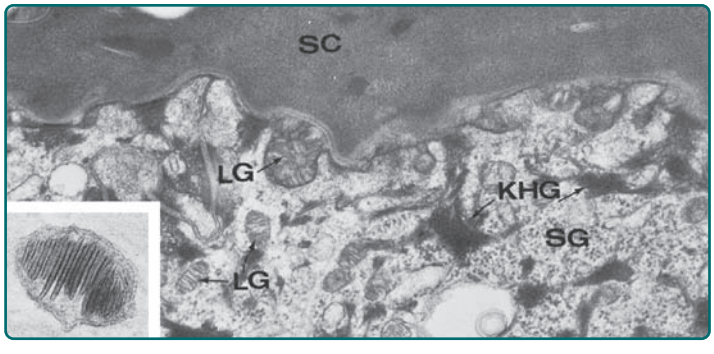

Figure 7-5 Junction of the stratum granulosum (SG) and stratum corneum (SC). Lamellar granules (LG) are in the intercellular space and cytoplasm of the granular cell. Keratohyalin granules (KHG) are also evident. *Inset:* Lamellar granule, ×28,750. (From Holbrook K: Structure and development of the skin. In: *Pathophysiology of Dermatologic Disease*, 2nd edition, edited by Soter NA, Baden HP. New York, McGraw-Hill, 1991, p. 7, with permission. Inset used with permission from EC Wolff-Schreiner, MD.)

Mutations in the *TGM1* gene have been shown to be the basis of some cases of lamellar ichthyosis.[22,23] Another form of ichthyosis, ichthyosis vulgaris, is caused by mutations in the gene encoding filaggrin.[24,25] Loricrin abnormalities result in a form of Vohwinkel syndrome with ichthyosis and pseudoainhum, as well as the disease progressive symmetric keratoderma.[26–28] These findings emphasize the importance of proper formation of the cornified envelope in normal epidermal keratinization.

The final stage of granular cell differentiation into a corneocyte involves the cell's own programed destruction, during which process almost all cellular contents are destroyed, with the exception of the keratin filaments and filaggrin matrix.[20]

STRATUM CORNEUM (SEE CHAPTER 47).

Complete differentiation of granular cells results in stacked layers of anucleate, flattened cornified cells that form the stratum corneum. It is this layer that provides mechanical protection to the skin and a barrier to water loss and permeation of soluble substances from the environment.[21,29] The stratum corneum barrier is formed by a two-compartment system of lipid-depleted, protein-enriched corneocytes surrounded by a continuous extracellular lipid matrix. These two compartments provide somewhat segregated but complementary functions that together account for the "barrier activity" of the epidermis. Regulation of permeability, desquamation, antimicrobial peptide activity, toxin exclusion, and selective chemical absorption are all primarily functions of the extracellular lipid matrix. On the other hand, mechanical reinforcement, hydration, cytokine-mediated initiation of inflammation, and protection from UV damage are all provided by the corneocytes.

NONKERATINOCYTES OF THE EPIDERMIS

Melanocytes are neural crest-derived, pigment-synthesizing dendritic cells that reside primarily in the basal layer (see Chapter 72).[30] The function of melanocytes has been highlighted by disorders in melanocyte number or function. The classic dermatologic disease, vitiligo, is caused by the autoimmune depletion of melanocytes.[31] Causes of other disorders of pigmentation are found in various defects in melanogenesis, including melanin synthesis, melanosome production, and melanosome transport and transfer to keratinocytes (see Chapters 72 and 75). Regulation of melanocyte proliferation and homeostasis is under intensive study as well as a means to understanding melanoma (see Chapter 124).[32] Keratinocyte–melanocyte interactions are critical for melanocyte homeostasis and differentiation, influencing proliferation, dentricity, and melanization.

Merkel cells are slow-adapting type I mechanoreceptors located in sites of high-tactile sensitivity (see Chapter 120).[33] They are present among basal keratinocytes in hairy skin and in the glabrous skin of the digits, lips, regions of the oral cavity, and the outer root sheath of the hair follicle. Keratin 20 is restricted to Merkel cells in the skin and thus may be the most reliable molecular marker. Ultrastructurally, Merkel cells are easily identified by the membrane-bounded, dense-core granules that collect opposite the Golgi and proximal to an unmyelinated neurite (Fig. 7-6). These granules contain neurotransmitter-like substances and markers of neuroendocrine cells, including Met-enkephalin, vasoactive intestinal peptide, neuron-specific enolase, and synaptophysin. Although increasingly more is being learned about the normal function of Merkel cells, they are of particular clinical note because Merkel cell-derived neoplasms are particularly aggressive and difficult to treat (see Chapter 120).

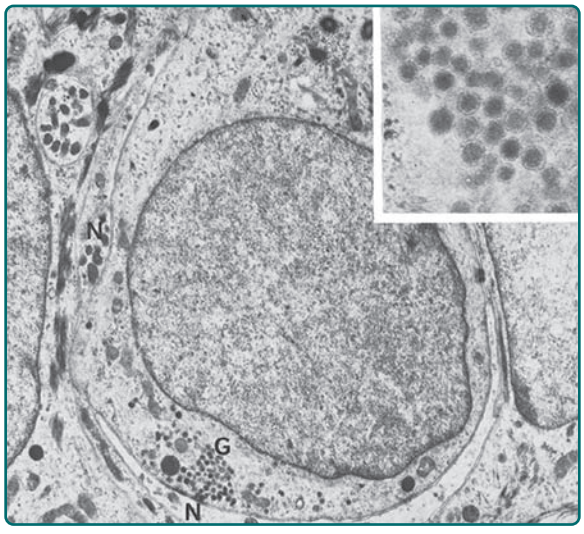

Figure 7-6 Merkel cells from the finger of a 130-mm CR (crown-rump) 21-week human fetus. Note nerve (N) in direct contact with the lateral and basal surfaces of the cell and dense core cytoplasmic granules (G). ×13,925. *Inset:* Merkel cell granules, ×61,450.

Langerhans cells are dendritic antigen-processing and antigen-presenting cells in the epidermis (see Chapter 10).[34] Although they are not unique to the epidermis, they form 2% to 8% of the total epidermal cell population, mostly found in a suprabasal position. The cytoplasm of the Langerhans cells contains characteristic small rod- or racket-shaped structures called *Langerhans cell granules* or *Birbeck granules* (Fig. 7-7). Langerhans cells principally function to sample and present antigens to T cells of the epidermis. Because of these functions, they are implicated in the pathologic mechanisms underlying allergic contact dermatitis, cutaneous leishmaniasis, and human immunodeficiency virus infection. Langerhans cells are reduced in the epidermis of patients with certain conditions, such as psoriasis, sarcoidosis, and contact dermatitis; they are functionally impaired by UV radiation, especially UVB.

Because of their effectiveness in antigen presentation and lymphocyte stimulation, dendritic cells and Langerhans cells have become prospective vehicles for tumor therapy and tumor vaccines. These cells are loaded with tumor-specific antigens, which will

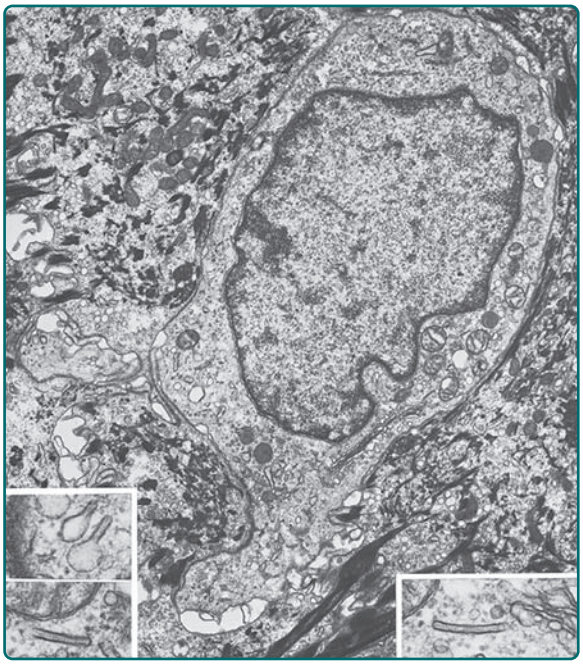

Figure 7-7 Langerhans cell. Note indented nucleus, lysosomes, as well as rod- and racket-shaped cytoplasmic granules (Birbeck granules), and the absence of keratin filaments. ×13,200. *Inset:* Birbeck granules ×88,000. (Used with permission from N. Romani, MD.)

then stimulate the host immune response to mount an antigen-specific, and therefore tumor-specific, response.

DERMAL–EPIDERMAL JUNCTION

The dermal–epidermal junction (DEJ) is a basement membrane zone that forms the interface between the epidermis and dermis (see Chapter 53).[35,36] The major functions of the DEJ are to attach the epidermis and dermis to each other and to provide resistance against external shearing forces. It serves as a support for the epidermis, determines the polarity of growth, directs the organization of the cytoskeleton in basal cells, provides developmental signals, and serves as a semipermeable barrier.

The DEJ can be subdivided into three supramolecular networks: (1) the hemidesmosome-anchoring filament complex, (2) the basement membrane itself, and (3) the anchoring fibrils. The critical role of this region in maintaining skin structural integrity is revealed by the large number of mutations in DEJ components that cause blistering diseases of varying severity, covered in detail in Chapter 62. These bullous diseases are grouped according to the level of the cleavage within the DEJ—the most superficial, EB simplex, involves basal keratinocyte cleavage. Junctional EB occurs within the lamina lucida and lamina densa regions. Dystrophic EB is the deepest level of blistering, within the sublamina densa/anchoring filaments. Chapter 53 provides a detailed discussion of the DEJ networks.

DERMIS

The dermis is an integrated system of fibrous, filamentous, diffuse, and cellular connective tissue elements that accommodates nerve and vascular networks, epidermally derived appendages, and contains many resident cell types, including fibroblasts, macrophages, mast cells, and transient circulating cells of the immune system (see Figs. 6-9 and 6-14). The dermis makes up the majority of skin and provides its pliability, elasticity, and tensile strength. It protects the body from mechanical injury, binds water, aids in thermal regulation, and includes receptors of sensory stimuli. The dermis interacts with the epidermis in maintaining the properties of both tissues, collaborates during development in the morphogenesis of the DEJ and epidermal appendages (see Section "Development of Skin Appendages"), and interacts in repairing and remodeling skin after wounding.

The dermis is arranged into two major regions: (1) the upper papillary dermis and (2) the deeper reticular dermis. These two regions are readily identifiable on histologic section, and they differ in their connective tissue organization, cell density, and nerve and vascular patterns. The papillary dermis abuts the epidermis, molds to its contours, and is usually no more than twice its thickness (see Fig. 6-9). The reticular dermis forms the bulk of the dermal tissue. It is composed primarily of large-diameter collagen fibrils, organized into large, interwoven fiber bundles, with branching elastic fibers surrounding the bundles (see Fig. 6-14). In normal individuals, the elastic fibers and collagen bundles increase in size progressively toward the hypodermis. The subpapillary plexus, a horizontal plane of vessels, marks the boundary between the papillary and reticular dermis. The lowest boundary of the reticular dermis is defined by the transition of fibrous connective tissue to adipose connective tissue of the hypodermis.

FIBROUS MATRIX OF THE DERMIS

The connective tissue matrix of the dermis is comprised primarily of collagenous and elastic fibrous tissue.[37,38] These are combined with other, nonfibrous connective tissue molecules, including finely filamentous glycoproteins, proteoglycans (PGs), and glycosaminoglycans (GAGs) of the "ground substance."[39]

Collagen forms the bulk of the acellular portion of the dermis, accounting for approximately 75% of the dry weight of skin, and providing both tensile strength and elasticity. (For details regarding the polypeptide structure and distribution of collagens, see Chapter 63.) The periodically banded, interstitial collagens account for the greatest proportion of collagen in adult dermis (type I, 80% to 90%; type III, 8% to 12%; and type V, <5%). Type VI collagen is associated with fibril and in the interfibrillar spaces. Type IV collagen is confined to the basal lamina of the DEJ, vessels, and epidermal appendages. Type VII collagen forms anchoring fibrils at the DEJ.

Elastic connective tissue (see Chapter 63) is a complex molecular mesh, extending from the lamina densa of the DEJ throughout the dermis and into the connective tissue of the hypodermis.[38] Elastic fibers return the

skin to its normal configuration after being stretched or deformed. They are also present in the walls of cutaneous blood vessels and lymphatics and in the sheaths of hair follicles. Mutations in elastin, the elastic fiber matrix component, cause the disease cutis laxa. Elastic fibers are normally located between bundles of collagen fibers, although in certain pathologic conditions, such as Buschke–Ollendorff syndrome, both elastic and collagen fibers become assembled within the same bundle. The importance of the elastic fiber network is clearly seen in the number of multisystem diseases that arise because of mutations in components of this network. The defect underlying pseudoxanthoma elasticum (PXE) is a mutation in *ABCC6*, a member of the large adenosine triphosphate-dependent transmembrane transporter family. Thus, this disease that is characterized by loss of skin elasticity and calcified elastic fibers is unlikely a primary defect in elastic tissue, but rather a metabolic disorder with secondary involvement of elastic fibers.[40–42] In addition to genetic mutations, solar radiation and aging also contribute to elastic fiber damage.[43]

FILAMENTOUS AND DIFFUSE MATRIX COMPONENTS OF THE DERMIS (SEE CHAPTER 63)

The fibrous and cellular matrix elements are embedded within more amorphous matrix components, which also are found in basement membranes.[44–46] PGs are large molecules consisting of a core protein that determines which GAGs will be incorporated into the molecule. The PG/GAG complex can bind water up to 1,000 times its own volume and have roles in regulation of water binding and compressibility of the dermis, as well as increasing local concentrations of growth factors through binding (e.g., basic fibroblast growth factor). They also link cells with the fibrillar and filamentous matrix, influencing proliferation, differentiation, tissue repair, and morphogenesis.

The major PGs in the adult dermis are chondroitin sulfates/dermatan sulfate, including biglycan, decorin, and versican; heparan/heparan sulfate PGs, including perlecan and syndecan; and chondroitin-6 sulfate PGs, which are components of the DEJ (see Chapter 63). Glycoproteins interact with other matrix components via integrin receptors. They facilitate cell migration, adhesion, morphogenesis, and differentiation. Fibronectin is synthesized by both epithelial and mesenchymal cells, and it covers collagen bundles and the elastic network. Vitronectin is present on all elastic fibers except for oxytalan. Tenascin is found around the smooth muscle of blood vessels, arrector pili muscles, and appendages such as sweat glands.

CELLULAR COMPONENTS OF THE DERMIS

Fibroblasts, macrophages, and mast cells are the regular residents of the dermis, mostly found around the papillary region and surrounding vessels of the subpapillary plexus (see Fig. 6-20), as well as in the reticular dermis between collagen fiber bundles. The fibroblast is a mesenchymally derived cell that migrates through the tissue and is responsible for the synthesis and degradation of fibrous and nonfibrous connective tissue matrix proteins and a number of soluble factors. Fibroblasts provide a structural extracellular matrix framework as well as promote interaction between epidermis and dermis by synthesis of soluble mediators. Studies of human fibroblasts indicate that even within a single tissue, phenotypically distinct populations exist, some of which relate to regional anatomical differences.[47,48] These cells are also instrumental in wound healing and scarring, increasing their proliferative and synthetic activity during these processes.

The monocytes, macrophages, and dermal dendrocytes constitute the mononuclear phagocytic system of cells in the skin. Macrophages are derived from precursors in the bone marrow, differentiate into circulating monocytes, and then migrate into the dermis to differentiate. These cells are phagocytic; process and present antigen to immunocompetent lymphoid cells; are microbicidal, tumoricidal, secretory, and hematopoietic (see Chapter 10); and are involved in coagulation, atherogenesis, wound healing, and tissue remodeling.

Mast cells (see Chapter 149) are specialized secretory cells that, in skin, are present in greatest density in the papillary dermis, near the DEJ, in sheaths of epidermal appendages, and around blood vessels and nerves of the subpapillary plexus. The surface of dermal mast cells is coated with fibronectin, which probably assists in securing cells within the connective tissue matrix. Mast cells are secretory cells that are responsible for immediate-type hypersensitivity reaction in skin and are involved in the production of subacute and chronic inflammatory disease. They synthesize secretory granules composed of histamine, heparin, tryptase, chymase, carboxypeptidase, neutrophil chemotactic factor, and eosinophilic chemotactic factor of anaphylaxis, which are mediators in these processes. Mast cells can become hyperplastic and hyperproliferative in mastocytosis (see Chapter 149).

The dermal dendrocyte is a dendritic, highly phagocytic fixed connective tissue cell in the dermis of normal skin. Similar to many other bone marrow-derived cells, dermal dendrocytes express factor XIIIa and CD45, and they lack typical markers of fibroblasts. These cells are particularly abundant in the papillary dermis and upper reticular dermis, frequently in the proximity of vessels of the subpapillary plexus. Dermal dendrocytes function in the afferent limb of an immune response as antigen presenting cells (see Chapter 10). They are also likely the cells of origin of a number of benign fibrotic proliferative conditions in the skin, such as dermatofibromas and fibroxanthomas (see Chapter 66).

CUTANEOUS VASCULATURE

BLOOD VESSELS (SEE CHAPTER 162)

The blood vessels of skin provide nutrition for the tissue and are involved in temperature and blood pressure regulation, wound repair, and numerous immunologic

events.[49] The microcirculatory beds in skin progress from arterioles to precapillary sphincters. Extending from the sphincters are arterial and venous capillaries, which become postcapillary venules, and finally, collecting venules. When compared with vasculature of other organs, the vessels of skin are adapted to shearing forces, as they have thick walls supported by connective tissue and smooth muscle cells. Special cells, known as *veil cells*, surround the cutaneous microcirculation, defining a domain for the vessels within the dermis while remaining separate from the vessel walls.

The rich vascular network of the skin is located at boundaries within the dermis and supplies the epidermal appendages (see Fig. 163-2). The vessels that supply the dermis branch from musculocutaneous arteries that penetrate the subcutaneous fat and enter the deep reticular dermis. At this point, they are organized into a horizontal arteriolar plexus. From this plexus, ascending arterioles extend toward the epidermis. These arterioles contain two layers of smooth muscle cells, as well as pericytes, a second type of contractile cell of the vessel wall. At the junction between the papillary and reticular dermis, terminal arterioles form the subpapillary plexus. Capillary loops then extend from the terminal arterioles of the plexus into the papillary dermis. At the apex of each capillary loop is the thinnest portion, allowing for transport of material out of the capillary. The descending limbs of capillary loops are venous capillaries that drain into venous channels of the subpapillary plexus. The postcapillary venules of the subpapillary plexus are responsive to histamine and are therefore often the sites of inflammatory cells during these responses.

Certain regions of skin, such as the palms and soles, contain direct connections between arterial and venous circulation as potential shunts around congested capillary beds. These sites consist of an ascending arteriole (a glomus body), which is modified by three to six layers of smooth muscle cells and has associated sympathetic nerve fibers.

In the adult, the cutaneous vasculature normally remains quiescent, in part due to inhibition of angiogenesis by factors such as thrombospondin. Pathogenic stimuli sometimes result in secondary angiogenesis, from tumors or during wounding. One of the key mediators of such angiogenesis is vascular endothelial growth factor (VEGF), often secreted by tumors or by keratinocytes (see Chapter 162).[50,51]

Numerous disorders can manifest themselves within the cutaneous vasculature. Leukocytoclastic vasculitis (cutaneous necrotizing venulitis) occurs within the venules in response to a number of potential pathogenic mechanisms (see Chapter 163). Stasis dermatitis, urticaria, polyarteritis nodosa, thrombosis, and thrombophlebitis all affect vessels in the skin, of different sizes, some by occlusion of vessels (vasculopathy) and others by inflammation of the vessels (vasculitis).

LYMPHATICS

The lymph channels of the skin regulate pressure of the interstitial fluid by resorption of fluid released from vessels and in clearing the tissues of cells, proteins, lipids, bacteria, and degraded substances.[52,53] The vessels begin in blind-ending initial lymphatics in the papillary dermis. They drain into a horizontal plexus of larger lymph vessels located deep to the subpapillary venous plexus. A vertical system of lymphatics then carries fluid and debris through the reticular dermis to another deeper collecting plexus at the reticular dermis–hypodermis border. Lymph flow within the skin depends on movements of the tissue caused by arterial pulsations and larger scale muscle contractions and movement of the body, with backflow prevented by bicuspid-like valves within the vessels.

Lymphatic vessels are often collapsed in skin and therefore are only seen with difficulty on histologic section. They are composed of a large lumen and a thinner wall than blood vessels. Molecular characterization of these vessels has identified Prox1, VEGFR-3, and LYVE-1 as specific markers of lymphatic character.[53]

Certain pathologic conditions involve or highlight the function of lymphatic vessels, such as lymphedema, lymphangioma circumscriptum, and stasis dermatitis. The importance of lymphatics in the progression and spread of cancer is also becoming more clear, as melanoma cells destroy endothelial cells of the initial lymphatics to gain entry to the lymph circulation, and recent studies have shown that tumors themselves can promote lymphangiogenesis as part of their early program on the way to metastasis.[51,54] The discovery of the molecular defects in hereditary lymphedemas has implicated the VEGFR-3 and FoxC2 in lymphatic development. One of the most heavily studied lymphangiogenic molecules is VEGF-C (Chapter 162).

CUTANEOUS NERVES AND RECEPTORS (SEE CHAPTERS 102 AND 103)

The nerve networks of the skin contain somatic sensory and sympathetic autonomic fibers.[55] The sensory fibers alone (free nerve endings) or in conjunction with specialized structures (corpuscular receptors) function as receptors of touch, pain, temperature, itch, and mechanical stimuli. The density and types of receptors are regionally variable, accounting for the variation in acuity at different sites of the body. Receptors are particularly dense in hairless areas such as the areola, labia, and glans penis. Sympathetic motor fibers are codistributed with the sensory nerves in the dermis until they branch to innervate the sweat glands, vascular smooth muscle, the arrector pili muscle of hair follicles, and sebaceous glands.

The nerves of skin branch from musculocutaneous nerves that arise segmentally from spinal nerves. The pattern of nerve fibers in skin is similar to the vascular patterns—nerve fibers form a deep plexus, then ascend to a superficial, subpapillary plexus.

Free nerve endings include the penicillate and papillary nerve fibers and are the most widespread sensory receptors in skin. In humans, they are ensheathed by Schwann cells and a basal lamina. Free nerve endings are particularly common in the papillary dermis.

The penicillate fibers are the primary nerve fibers found subepidermally in haired skin. These are rapidly adapting receptors that function in the perception of touch, temperature, pain, and itch. Because of overlapping innervation, discrimination tends to be generalized in these regions. On the other hand, free nerve endings present in nonhaired, ridged skin, such as the palms and soles, project individually without overlapping distribution and so are thought to function in fine discrimination.

Papillary nerve endings are found at the orifice of a follicle and are thought to be particularly receptive to cold sensation. Hair follicles also contain other receptors, slow-adapting receptors that respond to the bending or movement of hairs. Cholinergic sympathetic fibers en route to the eccrine sweat gland and adrenergic and cholinergic fibers en route to the arrector pili muscle are carried along with the sensory fibers in the hair basket.

Free nerve endings are also associated with individual Merkel cells. In haired skin, touch domes are associated with hair follicles. In palmoplantar skin, these complexes are found at the site where the eccrine sweat duct penetrates a glandular epidermal papilla.

Corpuscular receptors, both Meissner's and Pacinian, contain a capsule and inner core and are composed of both neural and nonneural components. The capsule is a continuation of the perineurium, and the core includes the nerve fiber surrounded by lamellated wrappings of Schwann cells. Meissner's corpuscles are elongated or ovoid mechanoreceptors located in the dermal papillae of digital skin and oriented vertically toward the epidermal surface (Fig. 7-8).

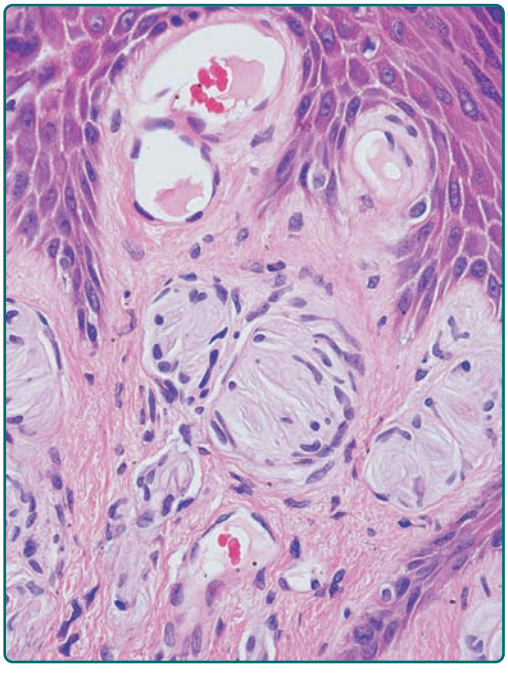

Figure 7-8 Meissner's corpuscle. Note the capsule and inner core located in the dermal papillae. These collections of cells serve as mechanoreceptors.

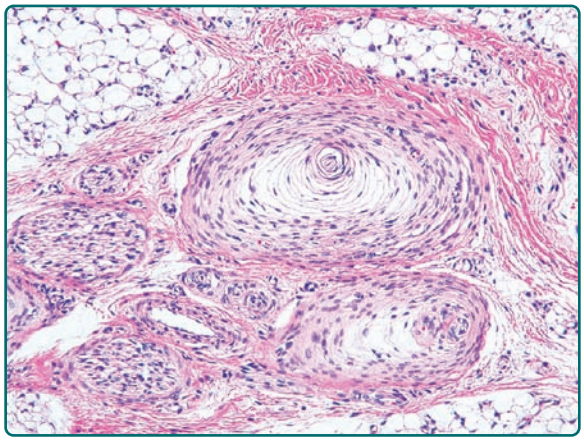

Figure 7-9 Pacinian corpuscle. Note the characteristic perineural capsule, likened to the appearance of an "onion-skin." Pacinian corpuscles serve as rapidly adapting mechanoreceptors that respond to vibrational stimuli.

The Pacinian corpuscle lies in the deep dermis and subcutaneous tissue of skin that covers weight-bearing surfaces of the body. It has a characteristic capsule and lamellar wrappings (Fig. 7-9). Pacinian corpuscles serve as rapidly adapting mechanoreceptors that respond to vibrational stimuli.

HYPODERMIS (SUBCUTIS)

The tissue of the hypodermis insulates the body, serves as a reserve energy supply, cushions and protects the skin, and allows for its mobility over underlying structures. It has a cosmetic effect in molding body contours. The boundary between the deep reticular dermis and the hypodermis is an abrupt transition from a predominantly fibrous dermal connective tissue to a primarily adipose subcutaneous one (see Fig. 6-1, Chapter 6). Despite this clear distinction anatomically, the two regions are still structurally and functionally integrated through networks of nerves and vessels and through the continuity of epidermal appendages. Actively growing hair follicles span the dermis and extend into the subcutaneous fat, and the apocrine and eccrine sweat glands are normally confined to this depth of the skin.

Adipocytes form the bulk of the cells in the hypodermis.[56,57] They are organized into lobules defined by septa of fibrous connective tissue. Nerves, vessels, and lymphatics are located within the septa and supply the region. The synthesis and storage of fat continues throughout life by enhanced accumulation of lipid within fat cells, proliferation of existing adipocytes, or by recruitment of new cells from undifferentiated mesenchyme. The hormone leptin, secreted by adipocytes, provides a long-term feedback signal regulating fat mass. Leptin levels are higher in subcutaneous than omental adipose, suggesting a role for leptin in control of adipose distribution as well.

The importance of the subcutaneous tissue is apparent in patients with Werner syndrome (see Chapter 139),

in which subcutaneous fat is absent in lesion areas over bone, or with scleroderma (see Chapter 157), where the subcutaneous fat is replaced with dense fibrous connective tissue. Such regions in Werner patients ulcerate and heal poorly. The skin of patients with scleroderma is taut and painful. In the hereditary and acquired lipodystrophies, loss of subcutaneous fat disrupts glucose, triglyceride, and cholesterol regulation, and causes significant cosmetic alteration, increasing the interest in possible hormonal therapy for these disorders (see Chapter 71).[58] The subcutaneous tissue is involved in different inflammatory conditions (Chapter 70).

DEVELOPMENT OF SKIN

Significant advances in the understanding of the molecular processes responsible for the development of skin have been made over the last several years. Such advances increase the understanding of clinicopathologic correlation among some inherited disorders of skin and allow for the early diagnosis of such diseases. The developmental progression of various components of the skin is well documented, and a time line indicating the events that occur during embryonic and fetal development is provided (Table 7-4).[59,60] Of note, the estimated gestational age (EGA) is used throughout this chapter; this system refers to the age of the fetus, with fertilization occurring on day 1. To avoid confusion, it should be pointed out that obstetricians and most clinicians define day 1 as the first day of the last menstrual period (menstrual age), in which fertilization occurs on approximately day 14. Thus, the two dating systems differ by approximately 2 weeks, such that a woman who is 14 weeks pregnant (menstrual age) is carrying a 12-week-old fetus (EGA).

Conceptually, fetal skin development can be divided into three distinct but temporally overlapping stages, those of (1) specification, (2) morphogenesis, and (3) differentiation. These stages roughly correspond to the embryonic period (0–60 days), the early fetal period (2–5 months), and the late fetal period (5–9 months) of development, respectively. The earliest stage, specification, refers to the process by which the ectoderm lateral to the neural plate is committed to become epidermis, and subsets of mesenchymal and neural crest cells are committed to form the dermis. It is at this time that patterning of the future layers and specialized structures of the skin occurs, often via a combination of gradients of proteins and cell–cell signals. The second stage, morphogenesis, is the process by which these committed tissues begin to form their specialized structures, including epidermal stratification, epidermal appendage formation, subdivision between the dermis and subcutis, and vascular formation. The last stage, differentiation, denotes the process by which these newly specialized tissues further develop and assume their mature forms. Table 7-5 integrates specification, morphogenesis, and differentiation with skin morphology and genetic diseases.

For simplification and greater clarity, the stages of development of the epidermis—dermis and hypodermis, dermal–epidermal junction, and epidermal appendages—are presented sequentially.

EPIDERMIS

EMBRYONIC DEVELOPMENT. During the third week after fertilization, the human embryo undergoes gastrulation, a complex process of involution and cell redistribution that results in the formation of the three primary embryonic germ layers: (1) ectoderm, (2) mesoderm, and (3) endoderm. Shortly after gastrulation, ectoderm further subdivides into neuroectoderm and presumptive epidermis. The specification of the presumptive epidermis is believed to be mediated by the bone morphogenetic proteins (BMPs). Later during this period, BMPs again appear to play a critical role, along with Engrailed-1 (En1), in specifying the volar versus interfollicular skin.[61–63] By 6 weeks EGA, the ectoderm that covers the body consists of basal cells and superficial periderm cells.

The basal cells of the embryonic epidermis differ from those of later developmental stages. Embryonic basal cells are more columnar than fetal basal cells, and they have not yet formed hemidesmosomes. Although certain integrins (e.g., α6β4) are expressed in these cells, they are not yet localized to the basal pole of the cells. Before the formation of hemidesmosomes and desmosomes, intercellular attachment between individual basal cells appears to be mediated by adhesion molecules such as E- and P-cadherin, which have been detected on basal cells as early as 6 weeks EGA. Keratins K5 and K14, proteins restricted to definitive stratified epithelia, are expressed even at these early stages of epidermal formation.

At this stage, periderm cells form a "pavement epithelium." These cells are embryonic epidermal cells that are larger and flatter than the underlying basal cells. Apical surfaces contact the amniotic fluid and are studded with microvilli. Connections between periderm cells are sealed with tight junctions rather than desmosomes. By the end of the second trimester, these cells are sloughed and eventually form part of the vernix caseosa. Like stratified epithelial cells, periderm cells express K5 and K14, but they also express simple epithelial keratins K8, K18, and K19.

Aplasia cutis (see Chapter 107) may reflect focal defects in either epidermal specification or development caused by somatic mosaicism, or mutations that occur postzygotically. However, the molecular defect for this disorder is not known. The fact that few genetic diseases have been described in which either epidermal specification or morphogenesis is defective likely reflects the fact that such defects would be incompatible with survival.

EARLY FETAL DEVELOPMENT (MORPHOGENESIS). By the end of 8 weeks of gestation, hematopoiesis has switched from the extraembryonic yolk sac to the bone marrow, the classical division between embryonic and fetal development. By this time, the epidermis begins its stratification and formation of an intermediate layer between the two preexisting cell layers. The cells in this new layer are similar to the cells of the spinous layer in mature epidermis. Like spinous cells, they express keratins K1/K10 and the desmosomal

TABLE 7-4
Timing of the Major Events in the Embryogenesis of Human Skin[a]

	First Trimester			Second Trimester			Third Trimester		
	1	2	3	4	5	6	7	8	9
Epidermis									
Appearance of epidermal cell layers									
Stratum basale	X								
Periderm	X								
Stratum intermedium		X							
Stratum granulosum						X			
Stratum corneum						X			
Periderm disappearance						X			
Epidermal cell junctions									
Desmosomes without associated keratin filaments	X								
Desmosomes with associated keratin filaments		X							
Tight junctions	X								
Hemidesmosomes			X						
Antigens									
Pemphigus and pemphigoid antigen			X						
A, B, H blood group antigens			X						
Immigrant cells									
Present, but type uncertain		X							
Melanocyte									
With premelanosomes		X							
With melanosomes that synthesize melanin				X					
Transfer of melanosomes to keratinocytes						X			
Langerhans cells			X						
Merkel cells				X					
Epidermal appendages									
Pilosebaceous apparatus									
Hair follicle development begins			X						
Hair exposed on skin surface and patterns established on the scalp			X						
Sebaceous gland primordium				X					
Sebaceous gland function				X					
Apocrine gland primordium						X			
Apocrine gland function							X		
Eccrine sweat glands (trunk)									
Duct and gland patent and functioning						X			
Nails									
Nail fold and establishment of matrix primordium			X						
Nail plate forms				X					
Keratinization of epidermis and appendages									
Dorsal ridge of presumptive nail			X						
Nail plate				X					
Palmar/plantar surface of digits				X					
Hair cone				X					
Hair tract				X					
Hair shaft					X				
Sebaceous duct					X				
Eccrine sweat gland duct (intraepidermal)						X			
Apocrine duct						X			

(continued)

TABLE 7-4
Timing of the Major Events in the Embryogenesis of Human Skin[a] (Continued)

	First Trimester			Second Trimester			Third Trimester		
	1	2	3	4	5	6	7	8	9
Dermis									
Structural organization									
Papillary and reticular regions established				X					
Dermal papillae established					X				
Dermal–subcutaneous boundary		X							
Panniculus adiposus established				X					
Connective tissue matrix proteins									
Collagen present by ultrastructural observation		X							
Collagen present by biochemical analysis									
Type I	?	X							
Type III	?	X							
Elastic microfibrils	?	X							
Elastic matrix				X					
Elastic fibrous networks						X			

[a]Data are representative of the trunk unless stated otherwise.

protein desmoglein-3. The cells are still highly proliferative and, during this period of development, they evolve into a multilayer structure that will eventually replace the degenerating periderm.

Expression of the *p63* gene plays a critical role in the proliferation and maintenance of the basal layer cells. Epidermal stratification does not occur in mice deficient for *p63*. In humans, although no null mutations have been isolated, partial loss of *p63* function mutations have been identified in ankyloblepharon, ectodermal dysplasia, and cleft lip/palate syndrome (Hay–Wells syndrome) as well as ectrodactyly, ectodermal dysplasia, and cleft lip/palate syndrome (see Chapter 142).[64–66] The preexisting basal cell layer also undergoes morphologic changes at this time, becoming more cuboidal and expressing new keratin genes, *K6*, *K8*, *K19*, and *K6/K16*, that are usually expressed in hyperproliferative tissues. The basal layer also begins to elaborate proteins that will ultimately anchor them to the developing basal lamina (see Section "Dermal–Epidermal Junction"), including hemidesmosomal proteins BPAG1, BPAG2, and collagens V and VII (see Chapters 53, 56, and 62).

Embryonic lines of ectodermal formation are revealed in mosaic disorders that follow the lines of Blaschko, including congenital, nevoid, and acquired conditions.[67–69] Molecular demonstration of genetic mosaicism has been reported for a number of X-linked disorders, as well as epidermal nevi in epidermolytic hyperkeratosis.[70]

LATE FETAL DEVELOPMENT (DIFFERENTIATION).

Late fetal development reveals the further specialization and differentiation of keratinocytes in the epidermis. It is at this time that the granular and stratum corneal layers are formed, and the rudimentary periderm is sloughed. Keratinization of the surface epidermis is a process of keratinocyte terminal differentiation, which begins at 15 weeks EGA. The granular layer becomes prominent, and important structural proteins are elaborated in the basal layer cells. The hemidesmosomal proteins plectin and α6β4 integrin are expressed and correctly localized at this time. Mutations in these genes result in various bullous genodermatoses (reviewed in Chapter 62). The more superficial cells undergo further terminal differentiation, and the keratin-aggregating protein filaggrin is expressed at this time.

The formation of the cornified envelope is a late feature of differentiating keratinocytes, and it relies on a number of different modifications to create an impermeable barrier. Enzymes such as transglutaminase, LEKTI (encoded by the gene *SPINK-5*), phytanoyl coenzyme A reductase, fatty aldehyde dehydrogenase, and steroid sulfatase are all important in the elaboration of the cornified envelope and mature lipid barrier, and defects in these enzymes can lead to abnormal epidermal barrier formation (see Chapter 49).

SPECIALIZED CELLS WITHIN THE EPIDERMIS.

The three major nonepidermal cell types—(1) melanocytes, (2) Langerhans cells, and (3) Merkel cells—can be detected within the epidermis by the end of the embryonic period. Melanocytes are derived from the neural crest, a subset of neuroectoderm cells. Pigment mosaicism (formerly called *hypomelanosis of*

TABLE 7-5
Proteins Involved in Cutaneous Development and Differentiation

	Epidermis	Dermis/SQ	DEJ	Appendages
Specification	■ **BMPs** ■ **Engrailed-1** ■ (Aplasia cutis)	■ **Lmx-1B** (Nail–patella syndrome) ■ **Engrailed-1** ■ **Wnt7a**	■ Not known	■ **Lmx-1B** ■ **Wnt7a** ■ **NGFR**
Morphogenesis	■ **p63** ■ **Dlx-3** (Tricho-dento-osseous syndrome) ■ **PORCN** (Focal dermal hypoplasia/Goltz syndrome)	■ **Lamin A/C, ZMPE STE24** (Progeria, restrictive dermopathy) ■ **PTEN** (Proteus-like syndrome) ■ **AKT1** mosaic activating mutation (Proteus syndrome).	■ **Laminin 1** ■ **Collagen IV** ■ **Heparin sulfate** ■ **Proteoglycans**	■ **Ectodysplasin A (EDA)** (X-linked hypohidrotic ectodermal dysplasia) ■ **Connexin 30** (Autosomal hypohidrotic ectodermal dysplasia, type 2) ■ **EDA receptor** (Autosomal hypohidrotic ectodermal dysplasia, type 3) ■ **MSX1** (Witkop syndrome/ tooth and nail syndrome) ■ **c-kit** (Piebaldism) ■ **PAX-3** (Waardenburg types 1,3) ■ **p63** (Hay-Wells/AEC, EEC) ■ **β-catenin** (pilomatricomas) ■ **Shh** ■ **Wnt** ■ **BMPs** ■ **FGF5** ■ **LEF1** ■ **Dlx-3**
Differentiation	Structural proteins ■ **K5, K14** (EB simplex) ■ **Plectin** (EB with MD) ■ **BPAG2** (GABEB) ■ **α6 β4 integrin** (EB with PA) ■ **K1, K10** (EI) ■ **K1, K9** (Vorner, Unna-Thost, Greither) ■ **Loricrin** (NCIE, Vohwinkel, progressive symmetric erythrokeratodermia) ■ **Filaggrin** (ichthyosis vulgaris) Post-translational modifiers ■ **LEKTI** (Netherton) ■ **Transglutaminase 1** (lamellar ichthyosis; NCIE) ■ **Phytanoyl CoA hydroxylase** (Refsum) ■ **Fatty aldehyde dehydrogenase** (Sjögren-Larsson) ■ **Steroid sulfatase/arylsulfatase C** (X-linked ichthyosis) Transporter/channel proteins ■ **ABCA12** (harlequin fetus) ■ **Connexin 26** (KID syndrome, palmoplantar keratoderma with deafness) ■ **Connexin 30.3** or **31** (erythro-keratoderma variabilis, progres-sive symmetric erythrokerato-dermia) ■ **SERCA2** (keratosis follicularis) ■ **ATP2C1** (Hailey–Hailey disease) Signal transduction proteins ■ **Patched** (basal cell nevus syndrome)	■ **Capillary morphogenesis protein-2** (juvenile hyaline fibromatosis, infantile systemic hyalinosis) ■ **Collagen I,** α**1,** or α**2** (osteogenesis imperfecta) ■ **Collagen V,** α**1,** or α**2** (Ehlers–Danlos syndrome) ■ **Collagen VII** (dystrophic EB) ■ **Fibrillin** (Marfan syndrome) ■ **Elastin** (cutis laxa) ■ **ABCC6** (PXE) ■ **Tie-2** (inherited venous malformations) ■ **Endoglin, activin receptor-like kinase 1** (HHT/Osler-Weber-Rendu) ■ **VEGF receptor-3** (hereditary lymphedema type I) ■ **MFH1** (hereditary lymphedema type II) ■ **Prox-1** ■ **LYVE-1**	■ **BPAG2** ■ **Collagen VII** ■ **α6 β4 integrin** ■ **Laminin 5** (junctional EB)	Hair ■ **BMPs** ■ **Hoxc13** ■ **Foxn1** ■ **Plakoglobin** (Naxos disease) ■ **Plakophilin/desmosomal band 6** (ectodermal dysplasia, skin fragility syndrome) ■ **Hairless** (papular atrichia) Nail ■ **K6a, K16** (pachyonychia congenita) ■ **K6b, K17** (pachyonychia congenita, steatocystoma multiplex) ■ **Plakophilin** Sebaceous gland ■ **Blimp-1** ■ **K6b, K17**

AEC = ankyloblepharon-ectodermal dysplasia-clefting; BMPs = bone morphogenetic proteins; BPAG = bullous pemphigoid antigen; EB = epidermolysis bullosa; EEC = ectrodactyly-ectodermal dysplasia-clefting; EI = epidermolytic ichthyosis; GABEB = generalized atrophic benign epidermolysis bullosa form of non-Herlitz junctional EB; HHT = hereditary hemorrhagic telangiectasia; K = keratin; KID = keratitis-ichthyosis-deafness; MD = multiple dystrophy; NCIE = nonbullous congenital ichthyosiform erythroderma; NGFR = nerve growth factor receptor; PA = pyloric atresia; PXE = pseudoxanthoma elasticum.
Protein names are indicated in **boldface**. Associated diseases/genodermatoses are listed in parentheses. Multiple names for the same protein or syndrome are separated by /. Genes and associated diseases can be found in Online Mendelian Inheritance in Man (OMIM) at http://www.ncbi.nlm.nih.gov/omim.

Ito and *linear and whorled hypermelanosis*) (see Chapter 75) following the lines of Blaschko may reflect the migratory paths of melanoblasts, or alternatively, mosaic defects in pigment transfer from melanocytes to keratinocytes. The founders of each melanoblast clone originate at distinct points along the dorsal midline, traversing ventrally and distally to take up residence in the epidermis.

Melanocytes are first seen within the epidermis at 50 days EGA. Melanocytes express integrin receptors in vivo and in vitro and may use these to migrate to the epidermis during embryonic development. Migration, colonization, proliferation, and survival of melanocytes in developing skin depend on the cell surface tyrosine kinase receptor, *c-kit*, and its ligand, stem cell factor.[71,72] Melanin becomes detectable between 3 and 4 months EGA, and by 5 months, melanosomes begin to transfer pigment to keratinocytes. Many genetic disorders of pigmentation have been characterized and are presented in detail in Chapters 73, 75, and 143. In the adult, a pool of melanocyte precursor cells resides in the upper permanent portion of the hair follicle, capable of producing mature melanocytes.[71,73,74]

Langerhans cells, another immigrant population, are detectable by 40 days EGA. They begin to express CD1 on their surface and to produce their characteristic Birbeck granules by the embryonic–fetal transition. By the third trimester, most of the adult numbers of Langerhans cells will have been produced.[75]

Merkel cells, as described earlier in the chapter (see Section "Nonkeratinocytes of the Epidermis"), reside in the epidermis. They are first detectable in the volar epidermis of the 11- to 12-week EGA human fetus. The embryonic derivation of this population of cells is controversial, as there is experimental evidence supporting both in situ differentiation of Merkel cells from epidermal ectoderm as well as migration from the neural crest.[33,76]

DERMAL AND SUBCUTANEOUS DEVELOPMENT

The origin of the dermis and subcutaneous tissue is more diverse than that of the epidermis, which is exclusively ectodermally derived. The embryonic tissue that forms the dermis depends on the specific body site.[77,78] Dermal mesenchyme of the face and anterior scalp is derived from neural crest ectoderm. The limb and ventral body wall mesenchyme is derived from the lateral plate mesoderm. The dorsal body wall mesenchyme derives from the dermomyotomes of the embryonic somite. LIM homeobox transcription factor 1β (Lmx1B) and Wnt7a are important in the specification of the dorsal limb.[79–81] En1 and BMPs, on the other hand, specify the volar (ventral) limb mesenchyme (see Table 7-5).[66,80]

The embryonic dermis, in contrast to the mature dermis, is cellular and amorphous, with few organized fibers. The mature dermis contains a complex mesh of collagen and elastic fibers embedded in a matrix of PGs, whereas the embryonic mesenchyme contains a large variety of pluripotent cells in a hydrated gel that is rich in hyaluronic acid. These mesenchymal cells are thought to be the progenitors of cartilage-producing cells, adipose tissue, dermal fibroblasts, and intramembranous bone. Dermal fibers exist as fine filaments but not thick fibers. The protein components of the future elastin and collagen fibers are synthesized during this period but not assembled. At this point, there is no obvious separation between cells that will become musculoskeletal elements and those that will give rise to the skin dermis.

Proteus syndrome, exhibits focal defects in multiple tissues, probably and is the result of genetic mosaicism affecting genes important in this process caused by *AKT1* associated activating mutations.[81a] Rarely is the mutation found in peripheral blood cells demonstrating the importance of studying affected tissues. (see Chapter 118). Mutations causing a global defect in this process would likely be incompatible with life.

The superficial mesenchyme becomes distinct from the underlying tissue by the embryonic–fetal transition (about 60 days EGA). By 12–15 weeks, the reticular dermis begins to take on its characteristic fibrillar appearance in contrast to the papillary dermis, which is more finely woven. Large collagen fibers continue to accumulate in the reticular dermis, as well as elastin fibers, beginning around midgestation and continuing until birth. By the end of the second trimester, the dermis has changed from a nonscarring tissue to one that is capable of forming scars. As the dermis matures, it also becomes thicker and well organized, such that at birth, it resembles the dermis of the adult, although it is still more cellular.

Many well-known clinical syndromes and molecules have been discovered that affect this final stage of dermal differentiation. These diseases include dystrophic EB (see Chapter 62), Marfan syndrome, Ehlers–Danlos syndrome, cutis laxa, PXE, hereditary hemorrhagic telangiectasia, and osteogenesis imperfecta (see Chapter 137).

SPECIALIZED COMPONENTS OF THE DERMIS

BLOOD VESSELS AND NERVES. Cutaneous nerves and vessels begin to form early during gestation, but they do not evolve into those of the adult until a few months after birth. The process of vasculogenesis requires the in situ differentiation of the endothelial cells at the endoderm–mesoderm interface. Originally, horizontal plexuses are formed within the subpapillary and deep reticular dermis, which are interconnected by groups of vertical vessels. This lattice of vessels is in place by 45–50 days EGA.

At 9 weeks EGA, blood vessels are seen at the dermal–hypodermal junction. By 3 months, the distinct networks of horizontal and vertical vessels have formed. By the fifth month, further changes in the vasculature derive from budding and migration of endothelium from preexisting vessels, the process of angiogenesis. Depending on the body region, gestational age, and presence of hair follicles and glands, this pattern can vary with blood supply requirements.

Defects in vascular development have been described (see Chapter 172). In the Klippel–Trénaunay syndrome, unilateral cutaneous vascular malformations develop, with associated venous varicosities, edema, and hypertrophy of associated soft tissue and bone. In Sturge–Weber syndrome, many cutaneous capillary malformations are seen in the lips, tongue, nasal, and buccal mucosae. Some familial defects in vascular formation result from mutations in the gene encoding Tie-2 receptor tyrosine kinase. Capillary malformations seen in hereditary hemorrhagic telangiectasia have been linked to mutations in transforming growth factor-β-binding proteins—endoglin, and activin receptor-like kinase 1.

LYMPHATICS. Accumulating evidence suggests that lymphatics originate from endothelial cells that bud off from veins. The pattern of embryonic lymphatic vessel development parallels that of blood vessels. Recent studies have identified new genes that appear to be specific for some of the earliest lymphatic precursors. *LYVE-1* and *Prox-1* are genes considered to be critical for earliest lymphatic specification, whereas *VEGF-R3* and *SLC* may be important in later lymphatic differentiation.[53]

NERVES. The development of cutaneous nerves parallels that of the vascular system in terms of patterning, maturation, and organization. Nerves of the skin consist of somatic sensory and sympathetic autonomic fibers, which are predominantly small and unmyelinated. As these nerves develop, they become myelinated, with associated decrease in the number of axons. This process may continue as long as puberty.

SUBCUTIS

As mentioned in Section "Specialized Components of the Dermis," by 50–60 days EGA, the hypodermis is separated from the overlying dermis by a plane of thin-walled vessels. Toward the end of the first trimester, the matrix of the hypodermis can be distinguished from the more fibrous matrix of the dermis. By the second trimester, adipocyte precursors begin to differentiate and accumulate lipids. By the third trimester, fat lobules and fibrous septae are found to separate the mature adipocytes. The molecular pathways that define this process are currently an area of intense investigation. Although few regulators important in embryonic adipose specification and development have been identified, several factors critical for preadipocyte differentiation have been demonstrated, including leptin, a hormone important in fat regulation, and the peroxisome proliferator-activated receptor family of transcription factors.[57]

DERMAL–EPIDERMAL JUNCTION

The dermal–epidermal junction is an interface where many inductive interactions occur that result in the specification or differentiation of the characteristics of the dermis and epidermis. This zone includes specialized basement membrane, basal cell extracellular matrix, the basal-most portion of the basal cells, and the superficial-most fibrillar structures of the papillary dermis. Both the epidermis and dermis contribute to this region.

As early as 8 weeks EGA, a simple basement membrane separates the dermis from the epidermis and contains many of the major protein elements common to all basement membranes, including laminin 1, collagen IV, heparin sulfate, and PGs. Components specific to the cutaneous basement membrane zone, such as proteins of the hemidesmosome and anchoring filaments, are first detected at the embryonic–fetal transition. By the end of the first trimester, or around the time of late embryonic development, all basement membrane proteins are in place. The α6 and β4 integrin subunits are expressed earlier than most of the other basement membrane components. However, they are not localized to the basal surface until 9.5 weeks EGA, coincident with the time that the hemidesmosomal proteins are expressed and hemidesmosomes are first observed. At the same time, anchoring filaments (laminin-332) and anchoring fibrils (collagen VII) begin to be assembled. The actual synthesis of collagen VII can be detected slightly earlier, at 8 weeks EGA.

Many congenital blistering disorders have been demonstrated to be a result of defects in proteins of the DEJ (for details, see Chapters 53 and 62). The severity of the disease, plane of tissue separation, and involvement of noncutaneous tissues depend on the proteins involved and the specific mutations. These genes are important candidates for prenatal testing.

DEVELOPMENT OF SKIN APPENDAGES

Skin appendages, which include hair, nails, and sweat and mammary glands, are composed of two distinct components: (1) an epidermal portion, which produces the differentiated product, and (2) the dermal component, which regulates differentiation of the appendage. During embryonic development, dermal–epidermal interactions are critical for the induction and differentiation of these structures (Fig. 7-10). Disruption of these signals often has profound influences on development of skin appendages. Hair differentiation serves as a paradigm for appendageal development, because it is the appendage that has been studied most intensely.[82,83]

HAIR (SEE CHAPTER 86)

Dermal signals are initially responsible for instructing the basal cells of the epidermis to begin to crowd at regularly spaced intervals, starting between days 75 and 80 on the scalp. This initial grouping is known as the *follicular placode* or *anlage*. From the scalp, follicular placode formation spreads ventrally and caudally, eventually covering the skin. The placodes then signal back to the underlying dermis to form a "dermal condensate," which occurs at 12–14 weeks EGA. This process is thought to be a balance of placode

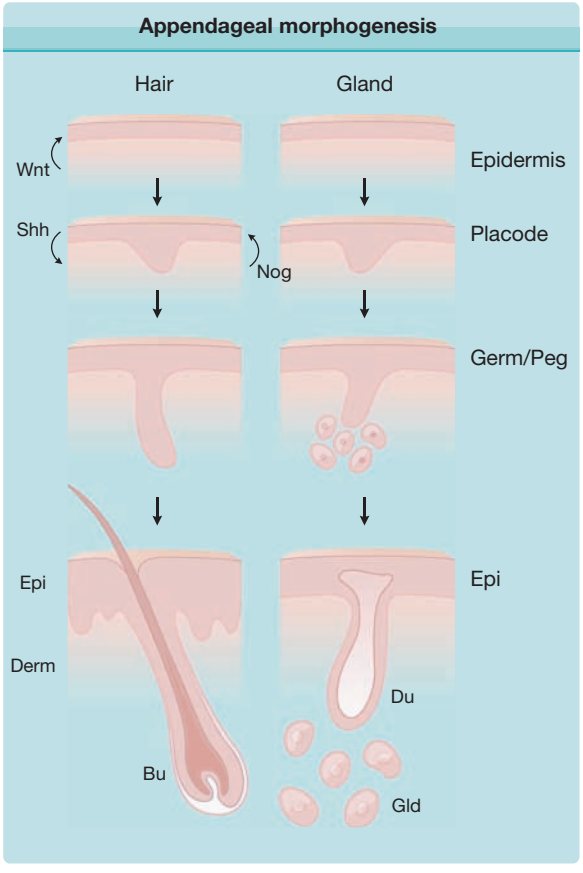

Figure 7-10 Appendageal morphogenesis. Through a series of reciprocal epithelial (epidermal)–mesenchymal (dermal) signals, including Wnt, sonic hedgehog (Shh), and Noggin (Nog), appendages such as the hair follicle and eccrine gland begin as epidermal invaginations (placodes), which signal the organization of specialized dermis (dermal condensate). This dermal condensate subsequently signals the differentiation of the epidermal downgrowth into the germ, peg, and mature appendageal structure. Bu = bulge; Derm = dermis; Du = duct; Epi = epidermis; Gld = gland.

promoters and placode inhibitors.[83] Wnt family signaling molecules are proposed to promote placode formation, whereas BMP family molecules are postulated to inhibit follicle formation. Subsequent reciprocal signaling between the epidermal and dermal components of the appendage result in its ultimate development and maturation.

In addition to the widened bulge at the base, two other bulges form along the length of the developing follicle, termed the *bulbous hair peg*. The uppermost bulge is the presumptive sebaceous gland, whereas the middle bulge serves as the site for insertion of the arrector pili muscle. This middle bulge is also the location of the multipotent hair stem cells, which are capable of differentiating into any of the cells of the hair follicle, and also have the potential to replenish the entire epidermis, as has been seen in cases of extensive surface wounds or burns.

By 19–21 weeks EGA, the hair canal is completely formed and the hairs on the scalp are visible above the surface of the fetal epidermis. They continue to lengthen until 24–28 weeks, at which time they complete the first hair cycle (see Chapter 86). With subsequent hair cycles, hairs increase in diameter and coarseness. During adolescence, vellus hairs of androgen-sensitive areas mature to terminal-type hair follicles.

SEBACEOUS GLANDS (SEE CHAPTER 79)

Sebaceous glands mature during the course of follicular differentiation. This process begins between 13 and 16 weeks EGA, at which point the presumptive sebaceous gland is first visible as the most superficial bulge of the maturing hair follicle. The outer proliferative cells of the gland give rise to the differentiated cells that accumulate lipid and sebum. After they terminally differentiate, these cells disintegrate and release their products into the upper portion of the hair canal. Sebum production is accelerated in the second and third trimesters, during which time maternal steroids cause stimulation of the sebaceous glands. Hormonal activity is once again thought to influence the production of increased sebum during adolescence, resulting in the increased incidence in acne at this age.

NAIL DEVELOPMENT (SEE CHAPTER 89)

Presumptive nail structures begin to appear on the dorsal digit tip at 8–10 weeks EGA, slightly earlier than the initiation of hair follicle development. The first sign is the delineation of the flat surface of the future nail bed. A portion of ectoderm buds inward at the proximal boundary of the early nail field, and gives rise to the proximal nail fold. The presumptive nail matrix cells, which differentiate to become the nail plate, are present on the ventral side of the proximal invagination. At 11 weeks, the dorsal nail bed surface begins to keratinize. By the fourth month of gestation, the nail plate grows out from the proximal nail fold, completely covering the nail bed by the fifth month. Mutations in *p63* affect nail development in syndromes such as ankyloblepharon, ectodermal dysplasia, and cleft lip/palate syndrome, as well as ectrodactyly, ectodermal dysplasia, and cleft lip/palate syndrome. Functional *p63* is required for the formation and maintenance of the apical ectodermal ridge, an embryonic signaling center essential for limb outgrowth and hand plate formation. Wnt7a is thought to be important for dorsal limb patterning, and thus nail formation. In contrast to follicular development, Shh is not required for nail plate formation. Also similar to follicular differentiation, *LMX1b* and *MSX1* are important for nail specification; *LMX1b* and *MSX1* are mutated in nail–patella syndrome and Witkop syndrome, respectively.[84–86] *Hoxc13* appears to be an important homeodomain-containing gene for both follicular and nail appendages, at least in murine models.[87]

ECCRINE AND APOCRINE SWEAT GLAND DEVELOPMENT (SEE CHAPTER 83)

Eccrine glands begin to develop on the volar surfaces of the hands and feet, beginning as mesenchymal pads between 55 and 65 days EGA. By 12–14 weeks EGA, parallel ectodermal ridges are induced, which overlay these pads. The eccrine glands arise from the ectodermal ridge. By 16 weeks EGA, the secretory portion of the gland becomes detectable. The dermal duct begins around week 16, but the epidermal portion of the duct and opening are not complete until 2 weeks EGA.

Interfollicular eccrine and apocrine glands, in contrast, do not begin to bud until the fifth month of gestation. Apocrine sweat glands usually bud from the upper portion of the hair follicle. By 7 months EGA, the cells of the apocrine glands become distinguishable.

Although not much is known with regard to the molecular signals responsible for the differentiation of these structures, the *EDA*, *EDAR*, *En1*, and *Wnt10b* genes have been implicated. Hypohidrotic ectodermal dysplasia results from mutations in *EDA* or the *EDAR* (see Chapter 142).

KEY REFERENCES

Full reference list available at www.DIGM8.com

DVD contains references and additional content

7. Blanpain C, Fuchs E: Epidermal stem cells of the skin. *Annu Rev Cell Dev Biol.* **22**:339-373, 2006
17. Lai-Cheong JE et al: Genetic diseases of junctions. *J Invest Dermatol* **127**(12):2713-2725, 2007
21. Segre JA: Epidermal barrier formation and recovery in skin disorders. *J Clin Invest* **116**(5):1150-1158, 2006
35. Ko MS, Marinkovich MP: Role of dermal-epidermal basement membrane zone in skin, cancer, and developmental disorders. *Dermatol Clin* **28**(1):1-16, 2010
48. Rinn JL et al: Anatomic demarcation by positional variation in fibroblast gene expression programs. *PLoS Genet* **2**(7):e119, 2006
54. Tammela T, Alitalo K: Lymphangiogenesis: Molecular mechanisms and future promise. *Cell* **140**(4):460-476, 2010
60. Loomis CA: Development and morphogenesis of the skin. *Adv Dermatol* **17**:183-210, 2001
66. Koster MI: p63 in skin development and ectodermal dysplasias. *J Invest Dermatol* **130**(10):2352-2358, 2010
72. Robinson KC, Fisher DE: Specification and loss of melanocyte stem cells. *Semin Cell Dev Biol* **20**(1):111-116, 2009
75. Liu K, Nussenzweig MC: Origin and development of dendritic cells. *Immunol Rev* **234**(1):45-54, 2010
81a. Lindhurst MJ et al: A mosaic activating mutation in *AKT1* associated with the Proteus syndrome. *N Eng J Med* **365**:611-619, 2011

Chapter 8 :: Genetics in Relation to the Skin

:: John A. McGrath & W. H. Irwin McLean

THE HUMAN GENOME IN DERMATOLOGY

In the 30 years since the first human gene, placental lactogen, was cloned in 1977, huge investments in time, money, and effort have gone into disclosing the innermost workings of the human genome. The Human Genome Project, which began in 1990, has led to sequence information on more than 3 billion base pairs (bp) of DNA, with identification of most of the estimated 25,000 genes in the entire human genome.[1] Although a few relatively small gaps remain, the near completion of the entire sequence of the human genome is having a huge impact on both the clinical practice of genetics and the strategies used to identify disease-associated genes. Laborious positional cloning approaches and traditional functional studies are gradually being transformed by the emergence of new genomic and proteomic databases.[2] Some of the exciting challenges that clinicians and geneticists now face are determining the function of these genes, defining disease associations and, relevant to patients, correlating genotype with phenotype. Nevertheless, many discoveries are already influencing how clinical genetics is practiced throughout the world, particularly for patients and families with rare, monogenic inherited disorders. The key benefits of dissection of the genome thus far have been the documentation of new information about disease causation, improving the accuracy of diagnosis and genetic counseling, and making DNA-based prenatal testing feasible.[3] Indeed, the genetic basis of more than 2,000 inherited single gene disorders has now been determined, of which about 25% have a skin phenotype. Therefore, these discoveries have direct relevance to dermatologists and their patients. Recently, studies in rare inherited skin disorders have also led to new insight into the pathophysiology of more common complex trait skin disorders.[4] This new information is expected to have significant implications for the development of new therapies and management strategies for patients. Therefore, for the dermatologist understanding the basic language and principles of clinical and molecular genetics has become a vital part of day-to-day practice. The aim of this chapter is to provide an overview of key terminology in genetics that is clinically relevant to the dermatologist.

THE HUMAN GENOME

Normal human beings have a large complex genome packaged in the form of 46 chromosomes. These consist of 22 pairs of autosomes, numbered in descending order of size from the largest (chromosome 1) to the smallest (chromosome 22), in addition to two sex chromosomes, X

and Y. Females possess two copies of the X chromosome, whereas males carry one X and one Y chromosome. The haploid genome consists of about 3.3 billion bp of DNA. Of this, only about 1.5% corresponds to protein-encoding exons of genes. Apart from genes and regulatory sequences, perhaps as much as 97% of the genome is of unknown function, often referred to as "junk" DNA. However, caution should be exercised in labeling the noncoding genome as "junk," because other unknown functions may reside in these regions. Much of the noncoding DNA is in the form of repetitive sequences, pseudogenes ("dead" copies of genes lost in recent evolution), and transposable elements of uncertain relevance. Although initial estimates for the number of human genes was in the order of 100,000, current predictions, based on the essentially complete genome sequence, are in the range of 20,000 to 25,000.[1] Surprisingly, therefore, the human genome is comparable in size and complexity to primitive organisms such as the fruit fly. However, it is thought that the generation of multiple protein isoforms from a single gene via alternate splicing of exons, each with a discrete function, is what contributes to increased complexity in higher organisms, including humans. In addition to protein-encoding genes, there are also many genes encoding untranslated RNA molecules, including transfer RNA, ribosomal RNA, and, as recently described, microRNA genes. MicroRNA is thought to be involved in the control of a large number of other genes through the RNA inhibition pathway. Very recently, it has emerged that tracts of the genome are transcribed at low levels in the form of exotic new RNA species, including natural antisense RNA and long interspersed noncoding RNA. These transcripts are emerging as key regulatory molecules. Thus, a much greater proportion of the genome is actively transcribed than was previously recognized and this trend is likely to continue in the current "postgenome" era of human genetics.

The draft sequence of the human genome was completed in 2003. Subsequently, small gaps have been filled, and the sequence has now been extensively annotated in terms of genes, repetitive elements, regulatory sequences, polymorphisms, and many other features recognizable by in silico data mining methods informed, wherever possible, by functional analysis. This annotation process will continue for some time as more features are uncovered. The human genome data, and that for an increasing number of other species, is freely available on Web sites (Table 8-1). Some regions of the genome, particularly near the centromeres, consist of long stretches of highly repetitive sequences that are difficult or impossible to clone and/or sequence. These heterochromatic regions of the genome are unlikely to be sequenced and are thought to be structural in nature, mediating the chromosomal architecture required for cell division, rather than contributing to heritable characteristics.

GENETIC AND GENOMIC DATABASES

Given the size and complexity of the human genome and other genomes now available, analysis of these enormous datasets in any kind of meaningful way is heavily reliant on computers. Even storage and retrieval of the sequence data associated with mammalian genome require considerable computer power and memory, and even the assembly of the raw sequence of any mammalian genome would have been unfeasible without computers. Many Web browsers for accessing genome data are available and the most useful of these are listed in Table 8-1. Each of these interfaces, which are the ones which the authors find most useful and user-friendly, contains a wide variety of tools for analysis and searching of sequences according to keyword, gene name, protein name, and homology to DNA or protein sequence data.

TABLE 8-1
Websites for Accessing Human Genome Data

Website	URL
University of California, Santa Cruz	http://genome.ucsc.edu/
National Center for Biotechnology Information	http://www.ncbi.nlm.nih.gov
ENSEMBL	http://www.ensembl.org/
Online Mendelian Inheritance in Man	http://www.ncbi.nlm.nih.gov/entrez/query.fcgi?db=omim

The main source of historical, clinical, molecular, and biochemical data relating to human genetic diseases is the Online Mendelian Inheritance in Man (OMIM) (see Table 8-1). All recognized genetic diseases and nonpathogenic heritable traits, including common diseases with a genetic component, as well as all known genes and proteins, are listed and reviewed by OMIM number with links to PubMed.

CHROMOSOME AND GENE STRUCTURE

Human chromosomes share common structural features (Fig. 8-1). All consist of two chromosomal arms, designated as "p" and "q." If the arms are of unequal length, the short arm is always designated as the "p" arm. Chromosomal maps to seek abnormalities are based on the stained, banded appearance of condensed chromosomes during metaphase of mitosis. During interphase, the uncondensed chromosomes are not discernible by normal microscopy techniques. Genes can now be located with absolute precision in terms of the range of bp that they span within the DNA sequence for a given chromosome. The bands are numbered from the centromere outwards using a system that has evolved as increasingly discriminating chromosome stains, as well as higher resolution light microscopes, became available. A typical cytogenetic chromosome band is 17q21.2, within which the type I keratin genes reside (see Fig. 8-1).

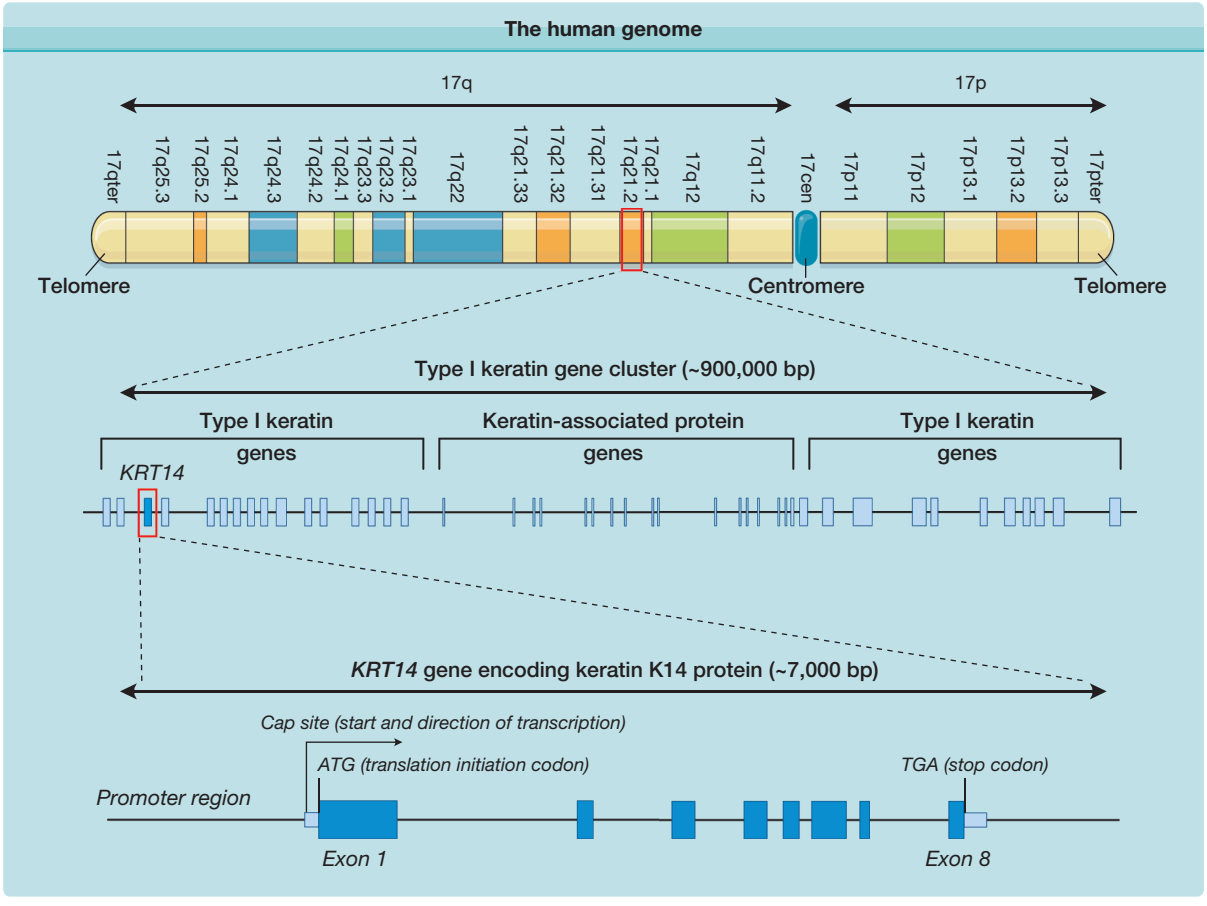

Figure 8-1 Illustration of the complexity of the human genome. At the top, the short (p) and long (q) arms of human chromosome 17 are depicted with their cytogenetic chromosome bands. One of these band regions, 17q21.2, is then highlighted to show that it is made up of approximately 900,000 base pairs (bp) and contains several genes, including 27 functional type I keratin genes. Part of this region is then further amplified to show one keratin gene, *KRT14*, encoding keratin 14, which is composed of eight exons.

The ends of the chromosomal arms are known as *telomeres*, and these consist of multiple tandem repeats of short DNA sequences. In germ cells and certain other cellular contexts, additional repeats are added to telomeres by a protein–RNA enzyme complex known as *telomerase*. During each round of cell division in somatic cells, one of the telomere repeats is trimmed off as a consequence of the DNA replication mechanism. By measuring the length of telomeres, the "age" of somatic cells, in terms of the number of times they have divided during the lifetime of the organism, can be determined. Once the telomere length falls below a certain threshold, the cell undergoes senescence. Thus, telomeres contribute to an important biological clock function that removes somatic cells that have gone through too many rounds of replication and are at a high risk of accumulating mutations that could lead to tumorigenesis or other functional aberration.[5]

The chromosome arms are separated by the centromere, which is a large stretch of highly repetitious DNA sequence. The centromere has important functions in terms of the movement and interactions of chromosomes. The centromeres of sister chromatids are where the double chromosomes align and attach during the prophase and anaphase stages of mitosis (and meiosis). The centromeres of sister chromatids are also the site of kinetochore formation. The latter is a multiprotein complex to which microtubules attach, allowing mitotic spindle formation, which ultimately results in pulling apart of the chromatids during anaphase of the cell division cycle.

The majority of chromosomal DNA contains genes interspersed with noncoding stretches of DNA of varying sizes. The density of genes varies widely across the chromosomes so that there are gene-dense regions or, alternately, large areas almost devoid of functional genes. An example of a comparatively gene-rich region of particular relevance to inherited skin diseases is the type I keratin gene cluster on chromosome band 17q21.2 (see Fig. 8-1). This diagram also gives an idea of the sizes in bp of DNA of a typical chromosome and a typical gene located within it. This gene cluster spans about 900,000 bp of DNA and contains 27 functional type I keratin genes, several genes encoding keratin-associated proteins, and a number of pseudogenes (not shown). Because chromosome 17 is one of the smaller chromosomes, Fig. 8-1 starts to give some idea of the overall complexity and organization of the genome.

Protein-encoding genes normally consist of several exons, which collectively code for the amino acid sequence of the protein (or open reading frame). These are separated by noncoding introns. In human genes, few exons are much greater than 1,000 bp in size, and introns vary from less than 100 bp to more than 1 million bp. A typical exon might be 100 to 300 bp in size. The *KRT14* gene encoding keratin 14 (K14) protein is one of the genes in which mutations lead to epidermolysis bullosa (EB) simplex (see Chapter 62) and is illustrated in Fig. 8-1. *KRT14* is contained within about 7,000 bp of DNA and consists of eight modestly sized exons interspersed by seven small introns. Although all genes are present in all human cells that contain a nucleus, not every gene is expressed in all cells of tissues. For example, the *KRT14* gene is only active in basal keratinocytes of the epidermis and other stratified epithelial tissues and is essentially silent in all other tissues. When a protein-encoding gene is expressed, the RNA polymerase II enzyme transcribes the coding strand of the gene, starting from the cap site and continuing to the end of the final exon, where various signals lead to termination of transcription. The initial RNA transcript, known as *heteronuclear RNA*, contains intronic as well as exonic sequences. This primary transcript undergoes splicing to remove the introns, resulting in the messenger RNA (mRNA) molecule.[6] In addition, the bases at the 5′ end (start) of the mRNA are chemically modified (capping) and a large number of adenosine bases are added at the 3′ end, known as the *poly-A tail*. These posttranscriptional modifications stabilize the mRNA and facilitate its transport within the cell. The mature mRNA undergoes a test round of translation which, if successful, leads to the transport of the mRNA to the cytoplasm, where it undergoes multiple rounds of translation by the ribosomes, leading to accumulation of the encoded protein. If the mRNA contains a nonsense mutation, otherwise known as a *premature termination codon mutation*, the test round of translation fails, and the cell degrades this mRNA via the nonsense-mediated mRNA pathway.[7] This is a mechanism that the cell has evolved to remove aberrant transcripts, and it may also contribute to gene regulation, particularly when very low levels of a particular protein are required within a given cell.

Splicing out of introns is a complex process. The genes of prokaryotes, such as bacteria, do not contain introns, and so mRNA splicing is a process that is specific to higher organisms. In some more primitive eukaryotes, RNA molecules contain catalytic sequences known as *ribozymes*, which mediate the self-splicing out of introns without any requirement for additional factors. In mammals, splicing involves a large number of protein and RNA factors encoded by several genes. This allows another level of control over gene expression and also facilitates alternative splicing of exons, so that a single gene can encode several functionally distinct variants of a protein. These isoforms are often differentially expressed in different tissues. In terms of the gene sequences important for splicing, a few bp at the beginning and at the end of an intron, known as the 5′ splice site (or splice donor site) and the 3′ splice site (or splice acceptor site) are crucial. A few other bp within the intron, such as the branch point site located 18–100 bp away from the 3′ end, are also critical. Mutations affecting any of the invariant residues of these splice sites lead to aberrant splicing and either complete loss of protein expression or generation of a highly abnormal protein.

The mRNA also contains two untranslated regions (UTR): (1) the 5′UTR upstream of the initiating ATG codon and (2) the 3′UTR downstream of the terminator (or stop codon, which can be TGA, TAA, or TAG). The 5′ UTR can and often does possess introns, whereas the 3′UTR of more than 99% of mammalian genes does not contain introns. The nonsense-mediated mRNA decay pathway identifies mutant transcripts by means of assessing where the termination codon occurs in relation to introns. The natural stop codon is always followed immediately by the 3′UTR, which, in turn, does not normally possess any introns. If a stop codon occurs in an mRNA upstream of a site where an intron has been excised, this message is targeted for nonsense-mediated decay. The only genes that contain introns within their 3′UTR sequences are expressed at extremely low levels. This is one of the ways in which the cell can determine how much protein is made from a particular gene.

Gene complexity is widely variable and not necessarily related to the size of the protein encoded. Some genes consist of only a single small exon, such as those encoding the connexin family of gap junction proteins. Such single exon genes are rapid and inexpensive to analyze routinely. In contrast, the type VII collagen gene, *COL7A1*, in which mutations lead to the dystrophic forms of EB (see Chapter 62), has 118 exons, meaning that 118 different parts of the gene need to be isolated and analyzed for molecular diagnosis of each dystrophic EB patient. The filaggrin gene (*FLG*) on chromosome 1, recently shown to be the causative gene for ichthyosis vulgaris (see Chapter 49) and a susceptibility gene for atopic dermatitis (see Chapter 14), has only three exons. However, the third exon of *FLG* is made up of repeats of a 1,000-bp sequence and varies in size from 12,000 to 14,000 bp among different individuals in the population. This unusual gene structure makes routine sequencing of genes such as *COL7A1* or *FLG* difficult, time consuming, and expensive.

GENE EXPRESSION

Each specific gene is generally only actively transcribed in a subset of cells or tissues within the body. Gene expression is largely determined by the promoter elements of the gene. In general, the most important region of the promoter is the stretch of sequence immediately upstream of the cap site. This proximal promoter region contains consensus binding sites for a variety of transcription factors, some of which are general in nature and required for all gene expression, others are specific to particular tissue or cell lineage, and some are absolutely specific for a given cell type and/or stage of development or differentiation. The size of the promoter can vary widely according to gene family or between the individual genes themselves. For

example, the keratin genes are tightly spaced within two gene clusters on chromosomes 12q and 17q, but these are exquisitely tissue specific in two different ways. First, these genes are only expressed in epithelial cells, and therefore their promoters must possess regulatory sequences that determine epithelial expression. Therefore, these regulatory elements are specific for cells of ectodermal origin. Second, these genes are expressed in very specific subsets of epithelial cells, and so there must be a second level of control that specifies which epithelial cell layers express specific keratin genes. This is best illustrated in the hair follicle, where there are many different epithelial cell layers, each with a specific pattern of keratin gene expression (see Chapter 86).[8]

Transcription factors are proteins that either bind to DNA directly or indirectly by associating with other DNA-binding proteins. Binding of these factors to the promoter region of a gene leads to activation of the transcription machinery and transcription of the gene by RNA polymerase II. The transcription factor proteins are encoded by genes that are in turn controlled by promoters that are regulated by other transcription factors encoded by other genes. Thus, there are several tiers of control over gene expression in a given cell type, and the intricacies of this can be difficult to fully unravel experimentally. Nevertheless, by isolation of promoter sequences from genes of interest and placing these in front of reporter genes that can be assayed biochemically, such as firefly luciferase that can be assayed by light emission, the activity of promoters can be reproduced in cultured cells that normally express the gene. Combining such a reporter gene system with site-directed mutagenesis to make deletions or alter small numbers of bp within the promoter can help define the extent of the promoter and the important sequences within it that are required for gene expression. A variety of biochemical techniques, such as DNA footprinting, ribonuclease protection, electrophoretic mobility shift assays, or chromatin immunoprecipitation, can be used to determine which transcription factors bind to a particular promoter and help delineate the specific promoter sequences bound. Expression of reporter genes under the control of a cloned promoter in transgenic mice also helps shed light on the important sequences that are required to recapitulate the endogenous expression of the gene under study. Keratin promoters are unusual in that, generally, a small fragment of only 2,000 to 3,000 bp upstream of the gene can confer most of the tissue specificity. For this reason, keratin promoters are widely used to drive exogenous transgene expression in the various specific cellular compartments of the epidermis and its appendages for experiments to determine gene, cell, or tissue function.[9]

Some promoter or enhancer sequences act over very long distances. In some cases, sequences located millions of bp distant, with several other genes in the intervening region, somehow influence expression of a target gene. In some genetic diseases, mutations affecting such long-range promoter elements are now emerging. These types of mutations appear to be rare, but since they occur so far away from the target gene and are therefore very difficult to find, this class of mutation may, in fact, be more common than is immediately obvious. In general, relatively few disease-causing mutations have been shown to involve promoters, but this class of defect is probably greatly underrepresented because the sequences that are important for promoter activity are poorly characterized. Prediction of transcription factor binding sites by computer analysis is an area for further study. Although these undoubtedly exist, there are relatively few examples so far of pathogenic defects in microRNA or other noncoding regulatory RNA species.

FINDING DISEASE GENES

In establishing the molecular basis of an inherited skin disease, there are two key steps. First, the gene linked to a particular disorder must be identified, and second, pathogenic mutations within that gene should be determined. Diseases can be matched to genes either by genetic linkage analysis or by a candidate gene approach.[10] Genetic linkage involves studying pedigrees of affected and unaffected individuals and isolating which bits of the genome are specifically associated with the disease phenotype. The goal is to identify a region of the genome that all the affected individuals and none of the unaffected individuals have in common; this region is likely to harbor the gene for the disorder, as well as perhaps other nonpathogenic neighboring genes that have been inherited by linkage disequilibrium. Traditionally, genome-wide linkage strategies make use of variably sized microsatellite markers scattered throughout the genome, although for recessive diseases involving consanguineous pedigrees, a more rapid approach may be to carry out homozygosity mapping using single nucleotide polymorphism (SNP) chip arrays. By contrast, the candidate gene approach involves first looking for a clue to the likely gene by finding a specific disease abnormality, perhaps in the expression (or lack thereof) of a particular protein or RNA, or from an ultrastructural or biochemical difference between the diseased and control tissues. Nevertheless, the genetic linkage and candidate gene approaches are not mutually exclusive and are often used in combination. For example, to identify the gene responsible for the autosomal recessive disorder, lipoid proteinosis (see Chapter 137), genetic linkage using microsatellites was first used to establish a region of linkage on 1q21 that contained 68 genes.[11] The putative gene for this disorder, *ECM1* encoding extracellular matrix protein 1, was then identified by a candidate gene approach that searched for reduced gene expression (lack of fibroblast complementary DNA) in all these genes. A reduction in *ECM1* gene expression in lipoid proteinosis compared with control provided the clue to the candidate gene because there were no differences in any of the other patterns of gene expression. Ultrastructural and immunohistochemical analyses can also provide clues to underlying gene pathology. For example, loss of hemidesmosomal inner plaques noted on transmission electron microscopy and a complete absence of skin immunostaining

for the 230-kDA bullous pemphigoid antigen (BP230) at the dermal–epidermal junction, led to the discovery of loss-of-function mutations in the dystonin (*DST*) gene, which codes for BP230, in a new form of autosomal recessive epidermolysis bullosa simplex.[12]

Having identified a putative gene for an inherited disorder, the next stage is to find the pathogenic mutation(s). This can be done by sequencing the entire gene, a feat which is becoming easier as technologic advances make automated nucleotide sequencing faster, cheaper, and more accessible. However, the large size of some genes may make comprehensive sequencing impractical, and therefore initial screening approaches to identify the region of a gene that contains the mutation may be a necessary first step. There are many mutation detection techniques available to scan for sequence changes in cellular RNA or genomic DNA, and these include denaturing gradient gel electrophoresis, chemical cleavage of mismatch, single stranded conformation polymorphism, heteroduplex analysis, conformation sensitive gel electrophoresis, denaturing high-performance liquid chromatography and the protein truncation test.[13]

The most critical factor that determines the success of any gene screening protocol is the sensitivity of the detection technique. In addition, when choosing a mutation screening strategy using genomic DNA, the size of the gene and its number of exons must be taken into account. The sensitivities of these methods vary greatly, depending on the size of template screened. For example, single-stranded conformation polymorphism has a sensitivity of >95% for fragments of 155 bp, but this is reduced to only 3% for 600 bp. Once optimized, denaturing gradient gel electrophoresis has a sensitivity of about 99% for fragments of up to 500 bp, and conformation sensitive gel electrophoresis is expected to have a sensitivity of 80% to 90% for fragments of up to 600 bp. Chemical cleavage of mismatch, on the other hand, has a sensitivity of 95% to 100% for fragments >1.5 kilobases (kb) in size and is ideal for screening compact genes where more than one exon can be amplified together using genomic DNA as the template. All these techniques detect sequence changes such as truncating and missense mutations as well as polymorphisms; however, the protein truncation test screens only for truncating mutations and is predicted to have a sensitivity of >95% and can be used for RNA or DNA fragments in excess of 3 kb.

Whichever approach is taken, having identified a difference in the patient's DNA compared with the control sample, the next stage is to determine how this segregates within a particular family and also whether it is pathogenic or not. Very recently, great advances have been made in DNA sequencing technology, with the emergence of "next generation sequencing" (NGS) technology. Currently, it is quite feasible to carry out whole exome sequencing in an individual using NGS, i.e., sequencing of all the protein-encoding exons in the genome, in a matter of days and for only a few thousand dollars. It is expected that whole genome sequencing, at a cost of $1,000 or less will be a commonplace in 2–3 years. This incredible new technology is set to revolutionize human genetics once more, and in particular, will facilitate identification of mutated genes in small kindreds that are not tractable by genetic linkage methods. These advances will also impact on diagnosis—in the near future it may be faster and cheaper to sequence a patient's whole genome rather than to do targeted sequencing of specific genes or regions.

GENE MUTATIONS AND POLYMORPHISMS

Within the human genome, the genetic code of two healthy individuals may show a number of sequence dissimilarities that have no relevance to disease or phenotypic traits. Such changes within the normal population are referred to as *polymorphisms* (Fig. 8-2). Indeed, even within the coding region of the genome, clinically irrelevant substitutions of one bp, known as *SNPs*, are common and occur approximately once every 250 bp.[14] Oftentimes, these SNPs do not change the amino acid composition; for example, a C-to-T transition in the third position of a proline codon (CCC to CCT) still encodes for proline, and is referred to as a *silent mutation*. However, some SNPs do change the nature of the amino acid; for example, a C-to-G transversion at the second position of the same proline codon (CCC to CGC) changes the residue to arginine. It then becomes necessary to determine whether a missense change such as this represents a nonpathogenic polymorphism or a pathogenic mutation. Factors favoring the latter include the sequence segregating only with the disease phenotype in a particular family, the amino acid change occurring within an evolutionarily conserved residue, the substitution affecting the function of the encoded protein (size, charge, conformation, etc.), and the nucleotide switch not being detectable in at least 100 ethnically matched control chromosomes. Nonpathogenic polymorphisms do not always involve single nucleotide substitutions; occasionally, deletions and insertions may also be nonpathogenic.

A mutation can be defined as a change in the chemical composition of a gene. A missense mutation changes one amino acid to another. Mutations may also be insertions or deletions of bases, the consequences of which will depend on whether this disrupts the normal reading frame of a gene or not, as well as nonsense mutations, which lead to premature termination of translation (see Fig. 8-2). For example, a single nucleotide deletion within an exon causes a shift in the reading frame, which usually leads to a downstream stop codon, thus giving a truncated protein, or often an unstable mRNA that is readily degraded by the cell. However, a deletion of three nucleotides (or multiples thereof) will not significantly perturb the overall reading frame, and the consequences will depend on the nature of what has been deleted. Nonsense mutations typically, but not exclusively, occur at CpG dinucleotides, where methylation of a cytosine nucleotide often occurs. Inherent chemical instability of this modified cytosine leads to a high rate of mutation to thymine. Where this alters the codon (e.g., from CGA to TGA), it will change an arginine residue to a stop codon. Nonsense mutations

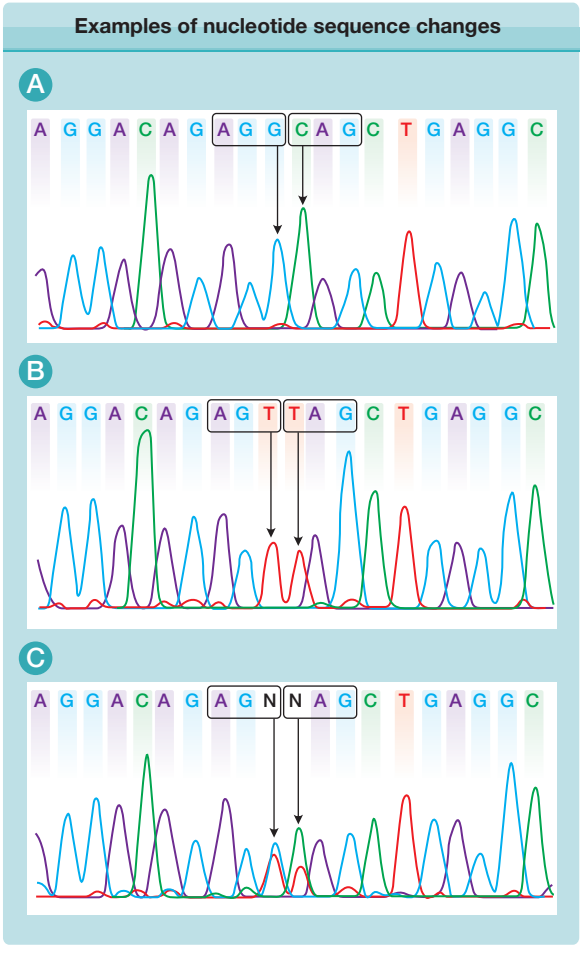

Figure 8-2 Examples of nucleotide sequence changes resulting in a polymorphism and a nonsense mutation. **A.** Two adjacent codons are highlighted. The AGG codon encodes arginine and the CAG codon encodes glutamine. **B.** The sequence shows two homozygous nucleotide substitutions. The AGG codon now reads AGT (i.e., coding for serine rather than arginine). This is a common sequence variant in the normal population and is referred to as a *nonpathogenic missense polymorphism*. In contrast, the glutamine codon CAG now reads TAG, which is a stop codon. This is an example of a homozygous nonsense mutation. **C.** This sequence is from one of the parents of the subject sequenced in **B** and shows heterozygosity for both the missense polymorphism AGG > AGT and the nonsense mutation CAG > TAG, indicating that this individual is a carrier of both sequence changes.

usually lead to a reduced or absent expression of the mutant allele at the mRNA and protein levels. In the heterozygous state, this may have no clinical effect [e.g., parents of individuals with Herlitz junctional EB are typically carriers of nonsense mutations in one of the laminin 332 (laminin 5) genes but have no skin fragility themselves; see Chapter 62], but a heterozygous nonsense mutation in the desmoplakin gene, for example, can result in the autosomal dominant skin disorder, striate palmoplantar keratoderma (see Chapter 50). This phenomenon is referred to as *haploinsufficiency* (i.e., half the normal amount of protein is insufficient for function).

Apart from changes in the coding region that result in frameshift, missense, or nonsense mutations, approximately 15% of all mutations involve alterations in the gene sequence close to the boundaries between the introns and exons, referred to as *splice site mutations*. This type of mutation may abolish the usual acceptor and donor splice sites that normally splice out the introns during gene transcription. The consequences of splice site mutations are complex; sometimes they lead to skipping of the adjacent exon, and other times they result in the generation of new mRNA transcripts through utilization of cryptic splice sites within the neighboring exon or intron.

Mutations within one gene do not always lead to a single inherited disorder. For example, mutations in the *ERCC2* gene may lead to xeroderma pigmentosum (type D), trichothiodystrophy, or cerebrofacioskeletal syndrome, depending on the position and type of mutation. Other transacting factors may further modulate phenotypic expression. This situation is known as *allelic heterogeneity*. Conversely, some inherited diseases can be caused by mutations in more than one gene (e.g., non-Herlitz junctional EB; see Chapter 62) and can result from mutations in either the *COL17A1*, *LAMA3*, *LAMB3*, or *LAMC2* genes. This is known as *genetic heterogeneity*. In addition, the same mutation in one particular gene may lead to a range of clinical severity in different individuals. This variability in phenotype produced by a given genotype is referred to as the *expressivity*. If an individual with such a genotype has no phenotypic manifestations, the disorder is said to be *nonpenetrant*. Variability in expression reflects the complex interplay between the mutation, modifying genes, epigenetic factors, and the environment and demonstrates that interpreting what a specific gene mutation does to an individual involves more than just detecting one bit of mutated DNA in a single gene.

MENDELIAN DISORDERS

There are approximately 5,000 human single-gene disorders and, although the molecular basis of less than one-half of these has been established, understanding the pattern of inheritance is essential for counseling prospective parents about the risk of having affected children. The four main patterns of inheritance are (1) autosomal dominant, (2) autosomal recessive, (3) X-linked dominant, and (4) X-linked recessive.

For individuals with an autosomal dominant disorder, one parent is affected, unless there has been a de novo mutation in a parental gamete. Males and females are affected in approximately equal numbers, and the disorder can be transmitted from generation to generation; on average, half the offspring will have the condition (Fig. 8-3). It is important to counsel affected individuals that the risk of transmitting the disorder is 50% for each of their children, and that this is not influenced by the number of previously affected or unaffected offspring. Any offspring that are affected will have a 50% risk of transmitting the mutated gene to the next generation, whereas for any unaffected offspring, the risk of the next generation being affected

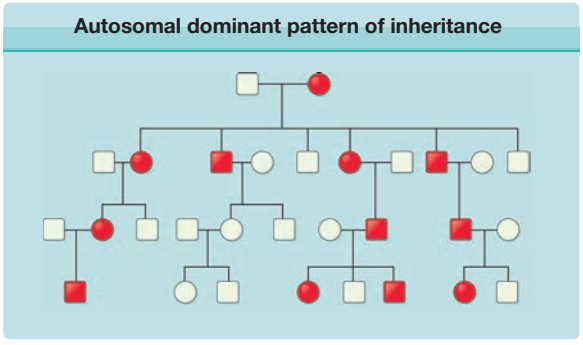

Figure 8-3 Pedigree illustration of an autosomal dominant pattern of inheritance. Key observations include: the disorder affects both males and females; on average, 50% of the offspring of an affected individual will be affected; affected individuals have one normal copy and one mutated copy of the gene; affected individuals usually have one affected parent, unless the disorder has arisen de novo. Importantly, examples of male-to-male transmission, seen here, distinguish this from X-linked dominant and are therefore the best hallmark of autosomal dominant inheritance. Filled circles indicate affected females; filled squares indicate affected males; unfilled circles/squares represent unaffected individuals.

is negligible, providing that the partner does not have the autosomal dominant condition. Some dominant alleles can behave in a partially dominant fashion. The term *semidominant* is applied when the phenotype in heterozygous individuals is less than that observed for homozygous subjects. For example, ichthyosis vulgaris is a *semidominant* disorder in which the presence of one or two mutant profilaggrin gene (*FLG*) alleles can strongly influence the clinical severity of the ichthyosis.

In autosomal recessive disorders, both parents are carriers of one normal and one mutated allele for the same gene and, typically, they are phenotypically unaffected (Fig. 8-4). If both of the mutated alleles are transmitted to the offspring, this will give rise to an autosomal recessive disorder, the risk of which is 25%. If one mutated and one wild-type allele is inherited by the offspring, the child will be an unaffected carrier, similar to the parents. If both wild-type alleles are transmitted, the child will be genotypically and phenotypically normal with respect to an affected individual. If the mutations from both parents are the same, the individual is referred to as a *homozygote*, but if different parental mutations within a gene have been inherited, the individual is termed a *compound heterozygote*. For someone who has an autosomal recessive condition, be it a homozygote or compound heterozygote, all offspring will be carriers of one of the mutated alleles but will be unaffected because of inheritance of a wild-type allele from the other, clinically and genetically unaffected, parent. This assumes that the unaffected parent is not a carrier. Although this is usually the case in nonconsanguineous relationships, it may not hold true in first-cousin marriages or other circumstances where there is a familial interrelationship. For example, if the partner of an individual with an autosomal recessive disorder is also a carrier of the same mutation, albeit clinically unaffected, then there is a 50% chance of the offspring inheriting two mutant alleles and therefore also inheriting the same autosomal recessive disorder. This pattern of inheritance is referred to as *pseudodominant*.

In X-linked dominant inheritance, both males and females are affected, and the pedigree pattern may resemble that of autosomal dominant inheritance (Fig. 8-5). However, there is one important difference. An affected male transmits the disorder to all his daughters and to none of his sons. X-linked dominant inheritance has been postulated as a mechanism in incontinentia pigmenti (see Chapter 75), Conradi–Hünermann syndrome, and focal dermal hypoplasia (Goltz syndrome), conditions that are almost always limited to females. In most X-linked dominant

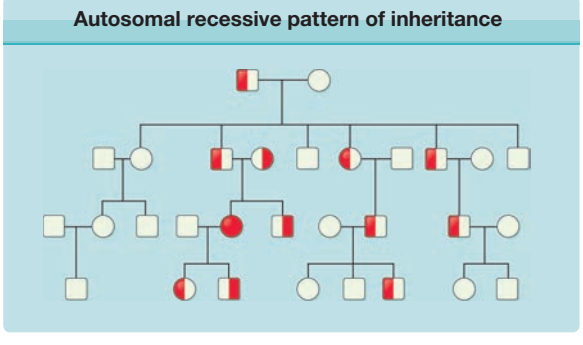

Figure 8-4 Pedigree illustration of an autosomal recessive pattern of inheritance. Key observations include: the disorder affects both males and females; there are mutations on both inherited copies of the gene; the parents of an affected individual are both heterozygous carriers and are usually clinically unaffected; autosomal recessive disorders are more common in consanguineous families. Filled circle indicates affected female; half-filled circles/squares represent clinically unaffected heterozygous carriers of the mutation; unfilled circles/squares represent unaffected individuals.

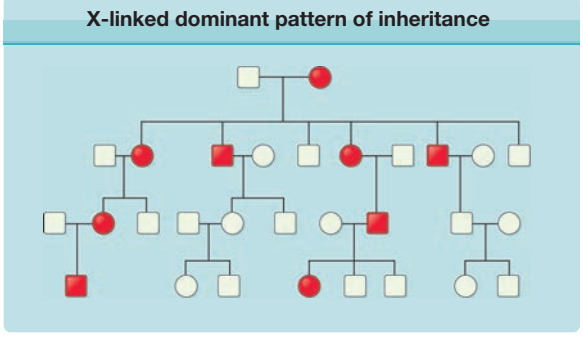

Figure 8-5 Pedigree illustration of an X-linked dominant pattern of inheritance. Key observations include: affected individuals are either hemizygous males or heterozygous females; affected males will transmit the disorder to their daughters but not to their sons (no male-to-male transmission); affected females will transmit the disorder to half their daughters and half their sons; some disorders of this type are lethal in hemizygous males and only heterozygous females survive. Filled circles indicate affected females; filled squares indicate affected males; unfilled circles/squares represent unaffected individuals.

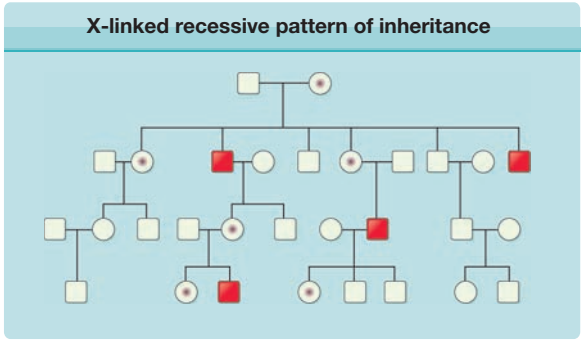

Figure 8-6 Pedigree illustration of an X-linked recessive pattern of inheritance. Key observations include: usually affects only males but females can show some features because of lyonization (X-chromosome inactivation); transmitted through female carriers, with no male-to-male transmission; for affected males, all daughters will be heterozygous carriers; female carrier will transmit the disorder to half her sons, and half her daughters will be heterozygous carriers. Dots within circles indicate heterozygous carrier females who may or may not display some phenotypic abnormalities; filled squares indicate affected males; unfilled circles/squares represent unaffected individuals.

disorders with cutaneous manifestations, affected males may be aborted spontaneously or die before implantation (leading to the appearance of female-to-female transmission). Most viable male patients with incontinentia pigmenti have a postzygotic mutation in NEMO and no affected mother; occasionally, males with an X-linked dominant disorder have Klinefelter syndrome with an XXY genotype.

X-linked recessive conditions occur almost exclusively in males, but the gene is transmitted by carrier females, who have the mutated gene only on one X chromosome (heterozygous state). The sons of an affected male will all be normal (because their single X chromosome comes from their clinically unaffected mother) (Fig. 8-6). However, the daughters of an affected male will all be carriers (because all had to have received the single X chromosome from their father that carries the mutant copy of the gene). Some females show clinical abnormalities as evidence of the carrier state (such as in hypohidrotic ectodermal dysplasia; see Chapter 142); the variable extent of phenotypic expression can be explained by lyonization, the normally random process that inactivates either the wild-type or mutated X chromosome in each cell during the first weeks of gestation and all progeny cells.[15] Other carriers may not show manifestations because the affected region on the X chromosome escapes lyonization (as in recessive X-linked ichthyosis) or the selective survival disadvantage of cells in which the mutated X chromosome is activated (as in the lymphocytes and platelets of carriers of Wiskott–Aldrich syndrome; see Section "Mosaicism").

CHROMOSOMAL DISORDERS

Aberrations in chromosomes are common. They occur in about 6% of all conceptions, although most of these lead to miscarriage, and the frequency of chromosomal abnormalities in live births is about 0.6%. Approximately two-thirds of these involve abnormalities in either the number of sex chromosomes or the number of autosomes; the remainder is chromosomal rearrangements. The number and arrangement of the chromosomes is referred to as the *karyotype*. The most common numerical abnormality is trisomy, the presence of an extra chromosome. This occurs because of nondisjunction, when pairs of homologous chromosomes fail to separate during meiosis, leading to gametes with an additional chromosome. Loss of a complete chromosome, monosomy, can affect the X chromosome but is rarely seen in autosomes because of nonviability. A number of chromosomal disorders are also associated with skin abnormalities, as detailed in Table 8-2.

Structural aberrations (fragility breaks) in chromosomes may be random, although some chromosomal regions appear more vulnerable. Loss of part of a chromosome is referred to as a *deletion*. If the deletion leads to loss of neighboring genes this may result in a contiguous gene disorder, such as a deletion on the X chromosome giving rise to X-linked ichthyosis (see Chapter 49) and Kallman syndrome. If two chromosomes break, the detached fragments may be exchanged, known as *reciprocal translocation*. If this process involves no loss of DNA it is referred to as a *balanced translocation*. Other structural aberrations include duplication of sections of chromosomes, two breaks within one chromosome leading to inversion, and fusion of the ends of two broken chromosomal arms, leading to joining of the ends and formation of a ring chromosome. Chromosomal anomalies may be detected using standard metaphase cytogenetics but newer approaches, such as SNP arrays and comparative genomic hybridization arrays, can also be used for karyotyping. Array-based cytogenetic tools do not rely on cell division and are very sensitive in detecting unbalanced lesions as well as copy number-neutral loss of heterozygosity. These new methods have become commonplace in diagnostic genetics laboratories. A further possible chromosomal abnormality is the inheritance of both copies of a chromosome pair from just one parent (paternal or maternal), known as *uniparental disomy*.[16] *Uniparental heterodisomy* refers to the presence of a pair of chromosome homologs, whereas *uniparental isodisomy* describes two identical copies of a single homolog, and *meroisodisomy* is a mixture of the two. Uniparental disomy with homozygosity of recessive alleles is being increasingly recognized as the molecular basis for several autosomal recessive disorders, and there have been more than 35 reported cases of recessive diseases, including junctional and dystrophic EB (see Chapter 62), resulting from this type of chromosomal abnormality. For certain chromosomes, uniparental disomy can also result in distinct phenotypes depending on the parental origin of the chromosomes, a phenomenon known as *genomic imprinting*.[17,18] This parent-of-origin, specific gene expression is determined by epigenetic modification of a specific gene or, more often, a group of genes, such that gene transcription is altered, and only one inherited copy of the relevant imprinted gene(s) is expressed in the embryo. This means that,

TABLE 8-2
Chromosomal Disorders with a Skin Phenotype

Chromosomal Abnormality	Synonym	General Features	Skin Manifestations
Trisomy 21	Down syndrome	Small head with flat face Nose short and squat Ears small and misshapen Slanting palpebral fissures Thickened eyelids Eyelashes short and sparse Shortened limbs, lax joints Fingers short, sometimes webbed Hypoplastic iris, lighter outer zone (Brushfield's spots)	1–10 year: dry skin, xerosis, lichenification 10+ year: increased frequency of atopic dermatitis, alopecia areata, single crease in palm and fifth finger Other associations: skin infections, angular cheilitis, geographic tongue, blepharitis, red cheeks, folliculitis, seborrheic dermatitis, boils, onychomycosis, fine hypopigmented hair, vitiligo, delayed dentition and hypoplastic teeth, acrocyanosis, livedo reticularis, cutis marmorata, calcinosis cutis, palmoplantar keratoderma, pityriasis rubra pilaris, syringomas, elastosis perforans serpiginosa, anetoderma, hyperkeratotic form of psoriasis, collagenoma, eruptive dermatofibromas, urticaria pigmentosa, leukemia cutis, keratosis follicularis spinulosa decalvans
Trisomy 18	Edwards syndrome	Severe mental deficiency Abnormal skull shape Small chin, prominent occiput Low-set, malformed ears "Rocker bottom" feet Short sternum Malformations of internal organs Only 10% survive beyond first year	Cutis laxa (neck), hypertrichosis of forehead and back, superficial hemangiomas, abnormal dermatoglyphics, single palmar crease, hyperpigmentation, ankyloblepharon filiforme adnatum
Trisomy 13	Patau syndrome	Mental retardation Sloping forehead due to forebrain maldevelopment (holoprosencephaly) Microphthalmia or anophthalmia Cleft palate/cleft lip Low-set ears "Rocker bottom" feet Malformations of internal organs Survival beyond 6 months is rare	Vascular anomalies (especially on forehead) Hyperconvex nails Localized scalp defects Cutis laxa (neck) Abnormal palm print (distal palmar axial triradius)
Chromosome 4, short arm deletion		Microcephaly Mental retardation Hypospadias Cleft lip/palate Low-set ears, preauricular pits	Scalp defects
Chromosome 5, short arm deletion		Mental retardation Microcephaly Cat-like cry Low-set ears, preauricular skin tag	Premature graying of hair
Chromosome 18, long arm deletion		Hypoplasia of midface Sunken eyes Prominent ear antihelix Multiple skeletal and ocular abnormalities	Eczema in 25% of cases
45 XO	Turner syndrome	Early embryonic loss; prenatal ultrasound findings of cystic hygroma, chylothorax, ascites and hydrops Short stature, amenorrhea Broad chest, widely spaced nipples Wide carrying angle of arms Low misshapen ears, high arched palate Short fourth/fifth fingers and toes Skeletal abnormalities, coarctation of aorta	Redundant neck skin and peripheral edema Webbed neck, low posterior hairline Cutis laxa (neck, buttocks) Hypoplastic, soft upturned nails Increased incidence of keloids Increased number of melanocytic nevi and halo nevi Failure to develop full secondary sexual characteristics Lymphatic hypoplasia/lymphedema
47 XXY	Klinefelter syndrome	No manifestations before puberty Small testes, poorly developed secondary sexual characteristics Infertility Tall, obese, osteoporosis	May develop gynecomastia Sparse body and facial hair Increased risk of leg ulcers Increased incidence of systemic lupus erythematosus
48 XXYY		Similar to Klinefelter syndrome	Multiple cutaneous angiomas Acrocyanosis, peripheral vascular disease
47 XYY		Phenotypic males (tall) Mental retardation Aggressive behavior	Severe acne
49 XXXXY		Low birth weight Slow mental and physical development Large, low-set, malformed ears Small genitalia	Hypotrichosis (variable)
Fragile X syndrome		Mental retardation Mild dysmorphism Hyperextensible joints, flat feet	—

during development, the parental genomes function unequally in the offspring. The most common examples of genomic imprinting are Prader–Willi (OMIM #176270) and Angelman (OMIM #105830) syndromes, which can result from maternal or paternal uniparental disomy for chromosome 15, respectively. Three phenotype abnormalities commonly associated with uniparental disomy for chromosomes with imprinting are (1) intrauterine growth retardation, (2) developmental delay, and (3) reduced stature.[19]

MITOCHONDRIAL DISORDERS

In addition to the 3.3 billion bp nuclear genome, each cell contains hundreds or thousands of copies of a further 16.5-kb mitochondrial genome, which is inherited solely from an individual's mother. This closed, circular genome contains 37 genes, 13 of which encode proteins of the respiratory chain complexes, whereas the other 24 genes generate 22 transfer RNAs and two ribosomal RNAs used in mitochondrial protein synthesis.[20] Mutations in mitochondrial DNA were first reported in 1988, and more than 250 pathogenic point mutations and genomic rearrangements have been shown to underlie a number of myopathic disorders and neurodegenerative diseases, some of which show skin manifestations, including lipomas, abnormal pigmentation or erythema, and hypo- or hypertrichosis.[21] Mitochondrial DNA mutations are very common in somatic mammalian cells, more than two orders of magnitude higher than the mutation frequency in nuclear DNA.[22] Mitochondrial DNA has the capacity to form a mixture of both wild-type and mutant DNA within a cell, leading to cellular dysfunction only when the ratio of mutated to wild-type DNA reaches a certain threshold. The phenomenon of having mixed mitochondrial DNA species within a cell is known as *heteroplasmy*. Mitochondrial mutations can induce, or be induced by, reactive oxygen species, and may be found in, or contribute to, both chronologic aging and photoaging.[23] Somatic mutations in mitochondrial DNA have also been reported in several premalignant and malignant tumors, including malignant melanoma, although it is not yet known whether these mutations are causally linked to cancer development or simply a secondary bystander effect as a consequence of nuclear DNA instability. Indeed, currently there is little understanding of the interplay between the nuclear and mitochondrial genomes in both health and disease. Nevertheless, it is evident that the genes encoded by the mitochondrial genome have multiple biologic functions linked to energy production, cell proliferation, and apoptosis.[24]

COMPLEX TRAIT GENETICS

For Mendelian disorders, identifying genes that harbor pathogenic mutations has become relatively straightforward, with hundreds of disease-associated genes being discovered through a combination of linkage, positional cloning, and candidate gene analyses. By contrast, for complex traits, such as psoriasis and atopic dermatitis, these traditional approaches have been largely unsuccessful in mapping genes influencing the disease risk or phenotype because of low statistical power and other factors.[25,26] Complex traits do not display simple Mendelian patterns of inheritance, although genes do have an influence, and close relatives of affected individuals may have an increased risk. To dissect out genes that contribute and influence susceptibility to complex traits, several stages may be necessary, including establishing a genetic basis for the disease in one or more populations; measuring the distribution of gene effects; studying statistical power using models; and carrying out marker-based mapping studies using linkage or association. It is possible to establish quantitative genetic models to estimate the heritability of a complex trait, as well as to predict the distribution of gene effects and to test whether one or more quantitative trait loci exist. These models can predict the power of different mapping approaches, but often only provide approximate predictions. Moreover, low power often limits other strategies such as transmission analyses, association studies, and family-based association tests. Another potential pitfall of association studies is that they can generate spurious associations due to population admixture. To counter this, alternative strategies for association mapping include the use of recent founder populations or unique isolated populations that are genetically homogeneous, and the use of unlinked markers (so-called *genomic controls*) to assign different regions of the genome of an admixed individual to particular source populations. In addition, and relevant to several studies on psoriasis, linkage disequilibrium observed in a sample of unrelated affected and normal individuals can also be used to fine-map a disease susceptibility locus in a candidate region.

In recent years, advances in the identification of many millions of SNPs across the entire genome, as well as major advances in gene chip technology that allows up to 2 million SNPs to be typed in a given individual for a few hundred dollars, coupled with high powered computation, have led to the current era of genome-wide association studies (GWAS).[27] This has become the predominant technology for tacking complex traits, with GWAS having already been performed for psoriasis, atopic eczema, vitiligo, and alopecia areata. GWAS for other dermatological complex traits are underway. A typical GWAS design involves collecting DNA from a well-phenotyped case series of the condition of choice, preferably from an ethnically homogenous population. Normally, 2,000 or more cases are required versus 3,000 ethnically matched random population controls. Correct clinical ascertainment of the cases is paramount and so GWAS represents a great opportunity for close cooperation between physicians and scientists. These 5,000 or more individuals are genotyped for 500,000 to 2 million SNPs, generating billions of data points. For each SNP across the genome, a statistical test is performed and a *P* value derived. If an SNP is closely linked to a disease susceptibility gene, then a particular genotype will be greatly enriched in the case series compared to the general unselected

population. The *P* values are plotted along each chromosome ("Manhattan plot") and where disease susceptibility loci exist, there are clusters of strong association. Typically, *P* values of 10^{-10} or lower are indicative of a true locus, although this generally has to be replicated in a number of other case-control sets for confirmation. Although SNP-based GWAS is currently the weapon of choice in complex trait genetics, it has limitations. If a causative lesion in a susceptibility locus is very heterogeneous, i.e., if there are multiple mutations or other changes that cause the susceptibility, then the locus is poorly identified by GWAS. Furthermore, across the entire field of complex trait genetics, relatively few causative genes have emerged (the role of the filaggrin gene in atopic dermatitis, below, being a notable exception). In the majority of cases, there is currently little clue about what defect the associated SNPs are linked to that actually causes the disease susceptibility.

However, recently, a conventional genetics approach has revealed fascinating new insight into the pathophysiology of one particular complex trait, namely atopic dermatitis (eczema). This finding emanated from the discovery that the disorder ichthyosis vulgaris was due to loss-of-function mutations in the gene encoding the skin barrier protein filaggrin (see Chapters 14 and 49).[28] To dermatologists, the clinical association between this condition and atopic dermatitis is well known, and the same loss-of-function mutations in filaggrin have subsequently been shown to be a major susceptibility risk factor for atopic dermatitis, as well as asthma associated with atopic dermatitis, but not asthma alone.[4] This suggests that asthma in individuals with atopic dermatitis may be secondary to allergic sensitization, which develops because of the defective epidermal barrier that allows allergens to penetrate the skin to make contact with antigen-presenting cells. Indeed, transmission–disequilibrium tests have demonstrated an association between filaggrin gene mutations and extrinsic atopic dermatitis associated with high total serum immunoglobulin E levels and concomitant allergic sensitizations.[29] These recent data on the genetics of atopic dermatitis demonstrate how the study of a "simple" genetic disorder can also provide novel insight into a complex trait. Therefore, Mendelian disorders may be useful in the molecular dissection of more complex traits.[30]

MOSAICISM

The presence of a mixed population of cells bearing different genetic or chromosomal characteristics leading to phenotypic diversity is referred to as *mosaicism*. There are several different types of mosaicism, including single gene, chromosomal, functional, and revertant mosaicism.[31] Multiple expression patterns are recognized.[32]

Mosaicism for a single gene, referred to as *somatic mosaicism*, indicates a mutational event occurring after fertilization. The earlier this occurs, the more likely it is that there will be clinical expression of a disease phenotype as well as involvement of gonadal tissue (gonosomal mosaicism); for example, when individuals with segmental neurofibromatosis subsequently have offspring with full-blown neurofibromatosis (see Chapter 141). However, in general, if the mutation occurs after generation of cells committed to gonad formation, then the mosaicism will not involve the germ line, and the reproductive risk of transmission is negligible. *Gonosomal mosaicism* refers to involvement of both gonads and somatic tissue, but mosaicism can occur exclusively in gonadal tissue, referred to as *gonadal mosaicism*. Clinically, this may explain recurrences among siblings of autosomal dominant disorders such as tuberous sclerosis or neurofibromatosis, when none of the parents has any clinical manifestations and gene screening using genomic DNA from peripheral blood samples yields no mutation. Segmental mosaicism for autosomal dominant disorders is thought to occur in one of two ways: either there is a postzygotic mutation with the skin outside the segment and genomic DNA being normal (type 1), or there is a heterozygous genomic mutation in all cells that is then exacerbated by loss of heterozygosity within a segment or along the lines of Blaschko (type 2). This pattern has been described in several autosomal dominant disorders, including Darier disease, Hailey–Hailey disease (see Chapter 51), superficial actinic porokeratosis (see Chapter 52), and tuberous sclerosis (see Chapter 140).

The lines of Blaschko were delineated over 100 years ago; the pattern is attributed to the lines of migration and proliferation of epidermal cells during embryogenesis (i.e., the bands of abnormal skin represent clones of cells carrying a mutation in a gene expressed in the skin).[33] Apart from somatic mutations [either in dominant disorders, such as epidermolytic ichthyosis (formerly called bullous congenital ichthyosiform erythroderma) leading to linear epidermolytic ichthyosis (epidermal nevus of the epidermolytic hyperkeratosis type) (see Chapter 49), or in conditions involving mutations in lethal dominant genes such as in McCune–Albright syndrome], mosaicism following Blaschko's lines is also seen in chromosomal mosaicism and functional mosaicism (random X-chromosome inactivation through lyonization). Monoallelic expression on autosomes (with random inactivation of either the maternal or paternal allele) is also feasible, and probably underdocumented.[34] Chromosomal mosaicism results from nondisjunction events that occur after fertilization. Clinically, this is found in the linear mosaic pigmentary disorders (hypomelanosis of Ito (see Chapter 75) and linear and whorled hyperpigmentation). It is important to point out that hypomelanosis of Ito is not a specific diagnosis but may occur as a consequence of several different chromosomal abnormalities that perturb various genes relevant to skin pigmentation, which has led to the term "pigmentary mosaicism" to describe this group of disorders.

Functional mosaicism relates to genes on the X chromosome, because during embryonic development in females, one of the X chromosomes, either the maternal or the paternal, is inactivated. For X-linked dominant disorders, such as focal dermal hypoplasia (Goltz syndrome) or incontinentia pigmenti (see Chapter 75), females survive because of the presence of some cells in which the X chromosome without the mutation is

active and able to function. For males, these X-linked dominant disorders are typically lethal, unless associated with an abnormal karyotype (e.g., Klinefelter syndrome; 47, XXY) or if the mutation occurs during embryonic development. For X-linked recessive conditions, such as X-linked recessive hypohidrotic ectodermal dysplasia (see Chapter 142), the clinical features are evident in hemizygous males (who have only one X chromosome), but females may show subtle abnormalities due to mosaicism caused by X-inactivation, such as decreased sweating or reduced hair in areas of the skin in which the normal X is selectively inactivated. There are 1,317 known genes on the X chromosome, and most undergo random inactivation but a small percentage (approximately 27 genes on Xp, including the steroid sulfatase gene, and 26 genes on Xq) escape inactivation.

Revertant mosaicism, also known as *natural gene therapy*, refers to genetic correction of an abnormality by various different phenomena including back mutations, intragenic crossovers, mitotic gene conversion, and second site mutations.[35,36] Indeed, multiple different correcting events can occur in the same patient. Such changes have been described in a few genes expressed in the skin, including the keratin 14, laminin 332, collagen XVII, collagen VII, and kindlin-1 (fermitin family homolog 1) genes in different forms of EB (Fig. 8-7; see Chapter 62). The clinical relevance of the conversion process depends on several factors, including the number of cells involved, how much reversal actually occurs, and at what stage in life the reversion takes place. Attempts have been made to culture reverted keratinocytes and graft them to unreverted sites,[37] a pioneering approach that may have therapeutic potential for some patients.

Apart from mutations in nuclear DNA, mosaicism can also be influenced by environmental factors, such as viral DNA sequences (retrotransposons) that can be incorporated into nuclear DNA, replicate, and activate or silence genes through methylation or demethylation. This phenomenon is known as *epigenetic mosaicism*; such events may be implicated in tumorigenesis but have not been associated with any genetic skin disorder.



Figure 8-7 Revertant mosaicism in an individual with non-Herlitz junctional epidermolysis bullosa. The subject has loss-of-function mutations on both alleles of the type XVII collagen gene, *COL17A1*, but spontaneous genetic correction of the mutation in some areas has led to patches of normal-appearing skin (areas within black marker outline) that do not blister. (From Jonkman MF et al: Revertant mosaicism in epidermolysis bullosa caused by mitotic gene conversion. *Cell* **88**:543, 1997, with permission.)

EPIGENETICS

Disease phenotypes reflect the result of the interaction between a particular genotype and the environment, but it is evident that some variation, for example, in monozygotic twins, is attributable to neither. Additional influences at the biochemical, cellular, tissue, and organism levels occur, and these are referred to as *epigenetic phenomena*.[38] Single genes are not solely responsible for each separate function of a cell. Genes may collaborate in circuits, be mobile, exist in plasmids and cytoplasmic organelles, and can be imported by nonsexual means from other organisms or as synthetic products. Even prion proteins can simulate some gene properties. Epigenetic effects reflect chemical modifications to DNA that do not alter DNA sequence but do alter the probability of gene transcription. Mammalian DNA methylation machinery is made up of two components: (1) DNA methyltransferases, which establish and maintain genome-wide DNA methylation patterns, and (2) the methyl-CpG-binding proteins, which are involved in scanning and interpreting the methylation patterns. Analysis of any changes in these processes is known as *epigenomics*.[39] Examples of modifications include direct covalent modification of DNA by methylation of cytosines and alterations in proteins that bind to DNA. Such changes may affect DNA accessibility to local transcriptional complexes as well as influencing chromatin structure at regional and genome-wide levels, thus providing a link between genome structure and regulation of transcription. Indeed, epigenome analysis is now being carried out in parallel with gene expression to identify genome-wide methylation patterns and profiles of all human genes. For example, there is considerable interindividual variation in cytosine methylation of CpG dinucleotides within the major histocompatibility complex (MHC) region genes, although whether this has any bearing on the expression of skin disorders such as psoriasis remains to be seen. New sensitive and quantitative methylation-specific polymerase chain reaction-based assays can identify epigenetic anomalies in cancers such as melanoma.[40] DNA hypermethylation contributes to gene silencing by preventing the binding of activating transcription factors and by attracting repressor complexes that induce the formation of inactive chromatin structures. With regard to melanoma, such changes may impact on several biologic processes, including cell cycle control, apoptosis, cell signaling, tumor cell invasion, metastasis, angiogenesis, and immune recognition. A further but as yet unresolved issue is whether there is heritability of epigenetic characteristics. Likewise, it is unclear whether environmentally induced changes in epigenetic status, and hence gene transcription and phenotype, can be transmitted through more than one generation. Such a phenomenon might account for the cancer susceptibility of grandchildren

of individuals who have been exposed to diethylstilbestrol, but this has not been proved. However, germ line epimutations have been identified in other human diseases, such as colorectal cancers characterized by microsatellite instability and hypermethylation of the *MLH1* DNA mismatch repair gene, although the risk of transgenerational epigenetic inheritance of cancer from such a mutation is not well established and probably small. Over the course of an individual's lifespan, epigenetic mutations (affecting DNA methylation and histone modifications) may occur more frequently than DNA mutations, and it is expected that, over the next decade, the role of epigenetic phenomena in influencing phenotypic variation will gradually become better understood.[41]

HISTOCOMPATABILITY ANTIGEN DISEASE ASSOCIATION

Human leukocyte antigen (HLA) molecules are glycoproteins that are expressed on almost all nucleated cells. The HLA region is located on the short arm of chromosome 6, at 6p21, referred to as the *MHC*. There are three classic loci at HLA class I: (1) HLA-A, (2) HLA-B, and (3) HLA-Cw, and five loci at class II: (1) HLA-DR, (2) HLA-DQ, (3) HLA-DP, (4) HLA-DM, and (5) HLA-DO. The HLA molecules are highly polymorphic, there being many alleles at each individual locus. Thus, allelic variation contributes to defining a unique "fingerprint" for each person's cells, which allows an individual's immune system to define what is foreign and what is self. The clinical significance of the HLA system is highlighted in human tissue transplantation, especially in kidney and bone marrow transplantation, where efforts are made to match at the HLA-A, -B, and -DR loci. MHC class I molecules, complexed to certain peptides, act as substrates for $CD8^+$ T-cell activation, whereas MHC class II molecules on the surface of antigen-presenting cells display a range of peptides for recognition by the T-cell receptors of $CD4^+$ T helper cells (see Chapter 10). Therefore, MHC molecules are central to effective adaptive immune responses. Conversely, however, genetic and epidemiologic data have implicated these molecules in the pathogenesis of various autoimmune and chronic inflammatory diseases. Several skin diseases, such as psoriasis (see Chapter 18), psoriatic arthropathy (central and peripheral), dermatitis herpetiformis, pemphigus, reactive arthritis syndrome (see Chapter 20), and Behçet disease (see Chapter 166), all show an association with inheritance of certain HLA haplotypes (i.e., there is a higher incidence of these conditions in individuals and families with particular HLA alleles). However, the molecular mechanisms by which polymorphisms in HLA molecules confer susceptibility to certain disorders are still unclear. This situation is further complicated by the fact that, for most diseases, it is unknown which autoantigens (presented by the disease-associated MHC molecules) are primarily involved. For many diseases, the MHC class association is the main genetic association. Nevertheless, for most of the MHC-associated diseases, it has been difficult to unequivocally determine the primary disease-risk gene(s), owing to the extended linkage disequilibrium in the MHC region. However, recent genetic and functional studies support the long-held assumption that common MHC class I and II alleles themselves are responsible for many disease associations, such as the HLA cw6 allele in psoriasis. Of practical clinical importance is the strong genetic association between certain HLA alleles and the risk of adverse drug reactions. For example, in Han Chinese and some other Asian populations, HLA-B*1502 confers a greatly increased risk of carbamazepine-induced Stevens–Johnson syndrome and toxic epidermal necrolysis. Therefore, screening for HLA-B*1502 before starting carbamazepine in patients from high-risk populations is recommended or required by regulatory agencies.[42]

GENETIC COUNSELING

The National Society of Genetic Counselors (http://www.nsgc.org) has defined genetic counseling as "the process of helping people understand and adapt to the medical, psychological and familial implications of genetic contributions to disease." Genetic counseling should include: (1) interpretation of family and medical histories to assess the chance of disease occurrence or recurrence; (2) education about inheritance, testing, management, prevention, resources, and research; and (3) counseling to promote informed choice and adaptation to the risk or condition.[43]

Once the diagnosis of an inherited skin disease is established and the mode of inheritance is known, every dermatologist should be able to advise patients correctly and appropriately, although additional support from specialists in medical genetics is often necessary. Genetic counseling must be based on an understanding of genetic principles and on a familiarity with the usual behavior of hereditary and congenital abnormalities. It is also important to be familiar with the range of clinical severity of a particular disease, the social consequences of the disorder, the availability of therapy (if any), and the options for mutation detection and prenatal testing in subsequent pregnancies at risk for recurrence (one useful site is http://www.genetests.com).

A key component of genetic counseling is to help parents, patients, and families know about the risks of recurrence or transmission for a particular condition. This information is not only practical but often relieves guilt and can allay rather than increase anxiety. For example, it may not be clear to the person that he or she cannot transmit the given disorder. The unaffected brother of a patient with an X-linked recessive disorder such as Fabry disease (see Chapter 136), X-linked ichthyosis (see Chapter 49), Wiskott–Aldrich syndrome (see Chapter 143), or Menkes syndrome (see Chapter 88) need not worry about his children being affected or even carrying the abnormal allele, but he may not know this.

Prognosis and counseling for conditions such as psoriasis in which the genetic basis is complex or still

unclear is more difficult (see Chapter 18). Persons can be advised, for example, that if both parents have psoriasis, the probability is 60% to 75% that a child will have psoriasis; if one parent and a child of that union have psoriasis, then the chance is 30% that another child will have psoriasis; and if two normal parents have produced a child with psoriasis, the probability is 15% to 20% for another child with psoriasis.[44] Ongoing discoveries in other diseases, such as melanoma genetics, can also impact on genetic counseling. The identification of family-specific mutations in the *CDKN2A* and *CDK4* genes, as well as risk alleles in the *MC1R* and *OCA2* genes and other genetic variants, allow for more accurate and informative patient and family consultations.[45]

PRENATAL DIAGNOSIS

In recent years, there has been considerable progress in developing prenatal testing for severe inherited skin disorders (Fig. 8-8). Initially, ultrastructural examination of fetal skin biopsies was established in a limited number of conditions. In the late 1970s, the first diagnostic examination of fetal skin was reported for epidermolytic hyperkeratosis and Herlitz junctional EB (see Chapter 62).[46,47] These initial biopsies were performed with the aid of a fetoscope to visualize the fetus. However, with improvements in sonographic imaging, biopsies of fetal skin are now taken under ultrasound guidance. The fetal skin biopsy samples obtained during the early 1980s could be examined only by light microscopy and transmission electron microscopy. However, the introduction of a number of monoclonal and polyclonal antibodies to various basement membrane components during the mid-1980s led to the development of immunohistochemical tests to help complement ultrastructural analysis in establishing an accurate diagnosis, especially in cases of EB.[48] Fetal skin biopsies are taken during the midtrimester. For disorders such as EB, testing at 16 weeks' gestation is appropriate. However, for some forms of ichthyosis, the disease-defining structural pathology may not be evident at this time, and fetal skin sampling may need to be deferred until 20 to 22 weeks of development.

Nevertheless, since the early 1990s, as the molecular basis of an increasing number of genodermatoses has been elucidated, fetal skin biopsies have gradually been superseded by DNA-based diagnostic screening using fetal DNA from amniotic fluid cells or samples of chorionic villi; the latter are usually taken at 10 to 12 weeks' gestation (i.e., at the end of the first trimester).[49,50] In addition, advances with in vitro fertilization and embryo micromanipulation have led to the feasibility of even earlier DNA-based assessment through preimplantation genetic diagnosis, an approach first

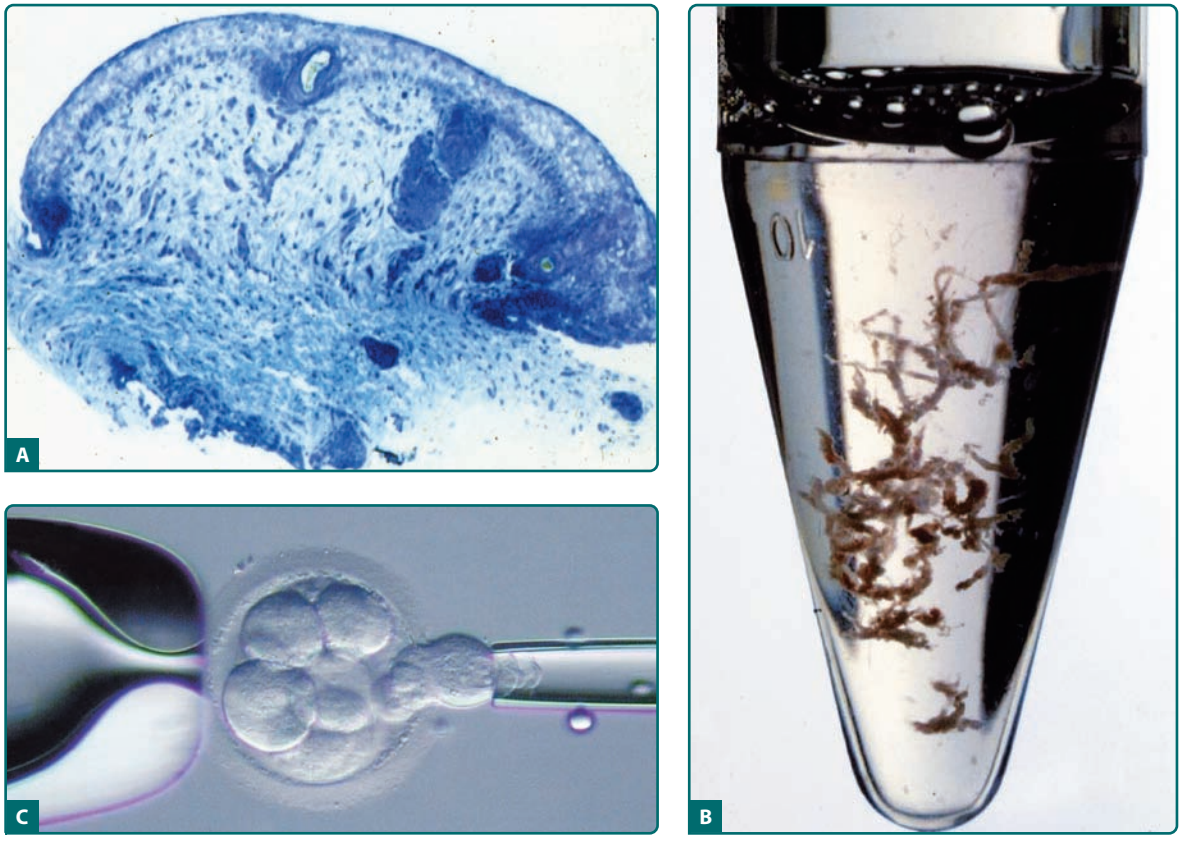

Figure 8-8 Options for prenatal testing of inherited skin diseases. **A.** Fetal skin biopsy, here shown at 18 weeks' gestation. **B.** Chorionic villi sampled at 11 weeks' gestation. **C.** Preimplantation genetic diagnosis. A single cell is being extracted from a 12-cell embryo using a suction pipette.

successfully applied in 1990, for risk of recurrence of cystic fibrosis.[51] Successful preimplantation testing has also been reported for severe inherited skin disorders.[52] This is likely to become a more popular, though still technically challenging, option for some couples, in view of recent advances in amplifying the whole genome in single cells and the application of multiple linkage markers in an approach termed *preimplantation genetic haplotyping*.[53] This approach has been developed and applied successfully for Herlitz junctional epidermolysis bullosa.[54] For some disorders, alternative less invasive methods of testing are now also being developed, including analysis of fetal DNA or RNA from within the maternal circulation and the use of three-dimensional ultrasonography.

In the current absence of effective treatment for many hereditary skin diseases, prenatal diagnosis can provide much appreciated information to couples at risk of having affected children, although detailed and supportive genetic counseling is also a vital element of all prenatal testing procedures.

GENE THERAPY

The field of gene therapy can be subdivided in different ways.[55] First, there are approaches aimed at treatment of recessive genetic diseases where homozygous or compound heterozygous loss-of-function mutations lead to complete absence or complete functional ablation of a vital protein. These types of diseases are amenable to gene replacement therapy, and it is this form of gene therapy that has tended to predominate because it is generally technically more feasible than treatment of dominant genetic conditions.[56] In dermatology, these include diseases such as lamellar ichthyosis (see Chapter 49), where in most cases, there is hereditary absence of transglutaminase-1 activity in the outer epidermis, or the severe Hallopeau–Siemens form of recessive dystrophic EB, where there is complete absence of type VII collagen expression due to recessive mutations.[57]

The second form of gene therapy, in broad terms, is aimed at treatment of dominant-negative genetic disorders and is known as *gene inhibition therapy*. Here, there is a completely different type of problem to be tackled because these patients already carry one normal copy of the gene and one mutated copy. The disease results because an abnormal protein product produced by the mutant allele, dominant-negative mutant protein, binds to and inhibits the function of the normal protein produced by the wild-type allele. In many cases, it can be shown from the study of rare recessive variants of dominant diseases that one allele is sufficient for normal skin function, and so if a means could be found of specifically inhibiting the expression of the mutant allele, this should be therapeutically beneficial. However, finding a gene therapy agent that is capable of discriminating the wild-type and mutant alleles, which can differ by as little as one bp of DNA, is challenging and, until recently has resulted in little success. A typical dominant-negative genetic skin disease is EB simplex (see Chapter 62), caused by mutations in either of the genes encoding keratins 5 or 14. The vast majority of cases are caused by dominant-negative missense mutations, changing only a single amino acid, carried in a heterozygous manner on one allele.[58]

Gene therapy approaches can also be broadly subdivided according to whether they involve in vivo or ex vivo strategies.[55] Using an in vivo approach, the gene therapy agent would be applied directly to the patient's skin or another tissue. A disadvantage of the skin as a target organ for gene therapy is that it is a barrier tissue that is fundamentally designed to prevent entry of foreign nucleic acid in the form of viruses or other pathogenic agents. This is an impediment to in vivo gene therapy development but is not insurmountable due to developments in liposome technology and other methods for cutaneous macromolecule delivery.[59] In an ex vivo approach, a skin biopsy would be taken, keratinocytes or fibroblasts would be grown and expanded in culture, treated with the gene therapy agent, and then grafted onto or injected back into the patient. The skin is a good organ system for both these approaches because it is very accessible for in vivo applications. In addition, the skin can be readily biopsied, and cell culture and regrafting of keratinocytes can be adapted for ex vivo gene therapy.

Gene replacement therapy systems have been developed for lamellar ichthyosis (see Chapter 49) and the recessive forms of EB (see Chapter 62), among other diseases. These mostly consist of expressing the normal complementary DNA encoding the gene of interest from some form of gene therapy vector adapted from viruses that can integrate their genomes stably into the human genome. Therefore, such viral vectors can lead to long-term stable expression of the replacement gene.[60] Early studies tended to use retroviral vectors or adeno-associated viral vectors, but these have a number of limitations. For example, retroviruses only transduce dividing cells and therefore fail to target stem cells; consequently, gene expression is quickly lost due to turnover of the epidermis through keratinocyte differentiation. Furthermore, there have been some safety issues in small-scale human trials for both retroviral and adeno-associated viral vectors. Lentiviral vectors, derived from short integrating sequences found in a number of immunodeficiency viruses, have the advantage of being able to stably transduce dividing and nondividing cells, with close to 100% efficiency and at low copy number. These may be the current vectors of choice, but they also have potential problems because their preferred integration sites in the human genome are currently ill defined and may lead to concerns about safety. However, with a wide variety of vectors under development and testing, it should become clear in future years which vectors are effective and safe for human use. Ultimately, like all novel therapeutics, animal testing can only act as a guide because the human genome is quite different and may react differently to foreign DNA integration, so that phase I, II, and III human trials or adaptations thereof will ultimately have to be performed to determine efficacy and safety. Currently, small-scale clinical trials are ongoing for junctional EB and are planned for a number of other genodermatoses, mainly concentrating on the more severe recessive conditions.

Treatment of dominant-negative disorders has recently started to receive a great deal of attention with the discovery of the RNA inhibition pathway in humans and the finding that small synthetic double-stranded RNA molecules of 19 to 21 bp, known as *short inhibitory RNA* (siRNA), can efficiently inhibit expression of human genes in a sequence-specific, user-defined manner.[58,61] There is currently a great deal of attention being focused on development of siRNA inhibitors to selectively silence mutant alleles in dominant-negative genetic diseases, such as the keratin disorders—EB simplex and pachyonychia congenita (PC). Currently, the big challenge in this rapidly evolving new field is finding an effective, noninvasive method to get siRNA through the stratum corneum and into keratinocytes or other target cells. A number of groups are working on means of delivering siRNA to skin and other organ systems, and there is currently much optimism about these developing into clinically applicable agents in the near future.

In particular, a great deal of rapid progress has been made in PC in recent years. Following development of reporter gene methodology to rapidly screen many different siRNA species, two siRNAs were identified that could specifically and potently silence mutant keratin K6a mRNA differing from the wild-type mRNA by only a single nucleotide, i.e., these siRNAs represent allele-specific gene silencing agents. Following a battery of preclinical studies in cells and animal models to show efficacy, the K6a mutation-specific siRNA was manufactured to Good Manufacturing Practice standards and was shown to have an excellent toxicity profile in rodents, as per a small molecule drug. This facilitated FDA approval for a double blind split body Phase 1b clinical trial in a single volunteer with PC. The trial was successful, with a number of objective measures showing statistically significant clinical improvement. This study, funded by the patient advocacy organization PC Project (www.pachyonychia.org), was the first in human siRNA trial using a mutation-specific gene silencing approach and only the fifth siRNA trial in humans. This personalized medicine strategy gives hope for patients with incurably dominant genodermatoses and future trials in EB simplex are currently in the planning stages.

KEY REFERENCES

Full reference list available at www.DIGM8.com

DVD contains references and additional content

1. Hsu F et al: The UCSC known genes. Bioinformatics **22**:1036, 2006
2. Tsongalis GJ, Silverman LM: Molecular diagnostics: A historical perspective. *Clin Chim Acta* **369**:188, 2006

15. Happle R: X-chromosome inactivation: Role in skin disease expression. *Acta Paediatr Suppl* **95**:16, 2006

39. Callinan PA, Feinberg AP: The emerging science of epigenomics. *Hum Mol Genet* **15**:R95, 2006

56. Ferrari S et al: Gene therapy in combination with tissue engineering to treat epidermolysis bullosa. *Expert Opin Biol Ther* **6**:367, 2006

Chapter 9 :: Racial Considerations: Skin of Color

:: Kavitha K. Reddy, Yolanda M. Lenzy, Katherine L. Brown, & Barbara A. Gilchrest

SKIN OF COLOR AT A GLANCE

- Race and ethnicity are closely related but distinct factors that may influence skin disease prevalence or presentation.
- The Fitzpatrick skin phototype classification was developed to convey risk of photodamage in white skin and is often less useful in describing skin of color.
- The complex polygenic basis for variation in human skin, hair, and eye color has been partially elucidated.
- The structure and function of skin of color is similar or identical to that of white (Caucasian) skin, other than differences related to pigmentation.
- Differences in the character of hair among whites, Asians, and Africans relate to shape of the hair follicle and thickness of the cuticle layer.
- African hair displays low tensile strength and easy breakage. This fragility may be compounded by chemical or heat application, apparently predisposing to several types of alopecia.
- Postinflammatory hyper- or hypopigmentation is often prominent and long lasting in skin of color; preventive and therapeutic measures should be considered in the plan of care.



Figure 9-1 A spectrum of human pigmentary variation observed among Boston medical trainees. (Photograph by Michael Krathen, MD.)

RACIAL AND ETHNIC INFLUENCES ON SKIN DISEASE AND THERAPY

In the United States and worldwide, myriad cutaneous phenotypes characterize mankind. Most striking is the range of skin and hair color (Fig. 9-1). The Census Bureau estimates that half of the US population will be of non-European descent by the year 2050.[1] There are currently more than 95 million persons in the United State[2] and billions of individuals worldwide categorized as having "skin of color." There has been increasing awareness of racial and ethnic influences (see Table 9-1) on skin biology and on diagnosis and treatment of skin disease.

The literature regarding "skin of color" primarily focuses on promoting awareness of normal and abnormal skin conditions in a patient regardless of skin phenotype. It seeks to identify risks and benefits of treatments in diverse skin types, to develop effective treatments for common dermatoses in skin of color, recognizing the importance of individualized therapy, and to avoid stereotyping and generalization.

DEFINING SKIN OF COLOR

In defining skin of color, it is important to consider the reasons for doing so. Many have questioned the common propensity of medical practitioners to state a patient's race among the first few words, as a primary identifier. The skin type, color, or ethnic background of most patients may be better suited to the physical examination or to relevant points in the history. The International Committee of Medical Journal Editors' *Uniform Requirements for Manuscripts Submitted to Biomedical Journals* recommends that authors using variables such as race or ethnicity should "define how they measured the variables and justify their relevance."[6] The *Journal of the American Academy of Dermatology* similarly suggests that authors inclined to submit racial, ethnic, or skin color descriptors in manuscripts ask themselves a series of questions regarding whether such identification is important to the understanding or pedagogical value of the manuscript, whether the patient would self-identify in the same way and how this is known, whether the descriptor used could be open to racist interpretation, and what the evidence is that the descriptor plays a role in the entities described.[7]

Most would argue that "nonwhite" skin is "skin of color." However, there is a diverse array of phenotypes within the nonwhite and white spectra, and two categories are inadequate to describe them. The most commonly used classification system in dermatologic practice is the Fitzpatrick phototype,[8,9] designed to provide an estimate of skin cancer and photoaging risk, in which individuals are assigned a number

TABLE 9-1
Race Versus Ethnicity

Term	Derivation	Current Usage or Implication
Race	<Latin, root	A population distinguished as a more or less distinct group by genetically transmitted physical characteristics; originally geographically segregated Groups increasingly blurred by interracial offspring Determined at conception, immutable May influence disease predilection/susceptibility
Ethnicity	<Greek, race or distinct population with its own customs	A social construct in which a group of individuals shares a language, cultural practices, or customs Self-assigned and somewhat mutable Often but not always associated with race May influence treatment choices and exposure to disease-promoting or disease-preventing factors

Stein J, Urdang L, eds.: *Derivations from the Random House Dictionary of the English Language*. New York, Random House, 1967. Usage or implication is the authors' distillation of a large and contradictory literature.[3–5]

based on their ability to burn and tan after a single, rather modest sun exposure. The original Fitzpatrick system consisted of types I–IV; types V and VI were soon added with the goal of representing individuals of Asian/Indian and African/Aboriginal origin, respectively. Skin of color is now commonly regarded as encompassing types IV through VI,[10] but many patients and physicians would argue that the spectrum is broader. For example, Japanese women not infrequently describe themselves as having type II skin. In any case, for the purpose of studying nonwhite skin, the Fitzpatrick system has several limitations. Although intended to utilize patient-reported characteristics, in practice a patient is commonly "assigned" to a type without benefit of a history. Also, the Fitzpatrick type has been shown in studies not to correspond well to constitutive skin color and to correlate poorly with minimal erythema dose (MED) values.[11] Interestingly, the physician-assigned skin phototype has been shown to correlate moderately with race, and race assignment does not correlate well with objective measures of pigmentation or self-reported skin phototype, suggesting that assignment of Fitzpatrick types is often based on perceived race rather than either objective skin color or response to ultraviolet (UV) light.[12]

Other scales have been developed with a goal of more accurately defining skin pigmentation and corresponding to defined clinical features. It has been suggested that for skin of color a scale based on propensity to postinflammatory hyperpigmentation, for example, might be more useful than one based on burning and tanning responses to UV exposure.[10] A variety of visual scales seek to convey skin color more accurately and precisely and to measure changes over time. These include the physician's global assessment, melasma area and severity index (MASI), visual hyperpigmentation scale,[13] and skin tone color scale.[14] Skin photometers employing UV light, polarized light, reflectance spectroscopy, tristimulus colorimetry, and spectrophotometry are also available and can provide an objective skin color score.[13] However, it is possible that, parallel to the Fitzpatrick phototype classification for white skin, a classification system based on patient perceptions of desirable or adverse responses to environmental challenges would be most useful in managing dermatologic patients with skin of color. For example, asking the patient about the frequency, severity, and duration of postinflammatory hyperpigmentation in the past may provide critical guidance when considering a skin care or treatment regimen.

STRUCTURE AND FUNCTION IN SKIN OF COLOR

The perceived skin color is the result of the spectrum of incident light and its absorption and reflection by chromophores in the skin. It is largely determined by melanin amount, type (ratio of black/brown eumelanin to red/yellow pheomelanin), and intracellular distribution and location within the layers of the skin. The number of melanocytes in a given area of skin is similar among all individuals. Vascular pigments

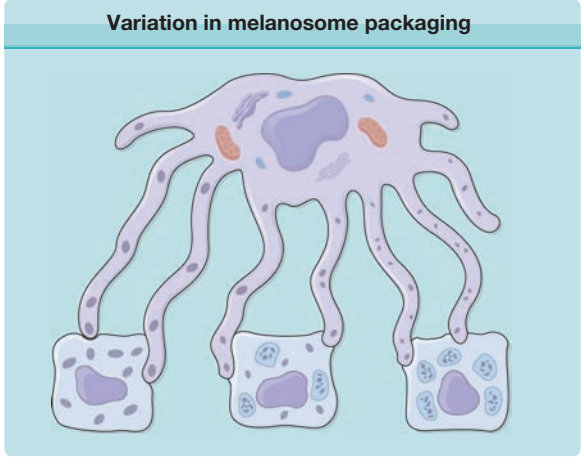

Figure 9-2 Variation in melanosome packaging within the keratinocyte of skin of differing colors. White skin (*right*) typically shows spherical melanosomes clustered within a membrane, black skin has larger elliptical melanosomes dispersed singly, and Asian or golden brown skin typically has a combination of the two (*middle*). (Used with permission from Jag Bhawan, MD.)

oxyhemoglobin and deoxyhemoglobin also play a role in observed color along with capillary blood flow, dietary pigments carotene and lycopene, collagen, the spectrum of ambient light, reflection, refraction, and absorption of light by the skin, and transparency of the stratum corneum and epidermis.[15] Endocrine, inflammatory, neural, and pharmacologic factors also influence skin color.

Melanosome size and distribution vary in skin of differing colors (Fig. 9-2). In individuals of African descent, the melanosomes are typically large and dispersed singly in the keratinocytes. In white individuals, melanosomes are smaller and grouped within a membrane. In Asian skin, a combination of individual and clustered melanosomes is found.[16] Melanin may also be degraded more slowly in skin of color.[17] Increasing melanin provides higher natural photoprotection, due to a greater absorption of UV photons, but also typically increases risk of pigmentary disorders including hypopigmentation or hyperpigmentation as a result of physiologic responses to trauma or inflammation.[18] For further discussion, see Chapter 72.

Structural or functional differences in white versus nonwhite human skin beyond those related to photoprotection[19] and pigmentary alterations are not known. Conflicting data have been presented on variations in lipid content, sebum content, and the number of stratum corneum layers and compaction.[20] Histologic sections of normal skin generally appear identical aside from the difference in melanin. Whether there are genetically determined functional differences of the skin associated with skin color is the subject of study and debate.[15]

GENETICS OF PIGMENTATION

There is a polygenic basis for human pigmentation. Genes already implicated in pigmentary variation

TABLE 9-2
Genes with Polymorphisms that Influence Human Pigmentary Variation

Gene	Gene Product	Recognized Function	Pigmentary Variation Effect
TYR	Tyrosinase	Rate-limiting enzyme in melanin biosynthesis	Europeans and South Asians: lighter/darker skin within group; little variation among races
TYRP1 (*TRP1*)	5,6-Dihydroxyindole-2-carboxylic acid oxidase or tyrosinase related protein 1	Enzyme in melanin biosynthesis	Europeans: lighter/darker skin and eye color
OCA2 (*HERC2*)	P protein	L-Tyrosine transmembrane transporter	Blond/brown hair, blue/nonblue eyes; East Asians, Africans: lighter/darker skin Loss of function causes oculocutaneous albinism type 2
SLC45A2 (*MATP*)	Membrane-associated transporter protein	Transmembrane transport	Black/nonblack hair; dark/light skin; dark/light eyes
SLC 24A4	Sodium/potassium/calcium exchanger 4	Transmembrane potassium-dependent sodium/calcium exchanger	Blond/brown hair; blue/green eyes
SLC24A5	Sodium/potassium/calcium exchanger 5	Transmembrane potassium-dependent sodium/calcium exchanger	Africans and Asians: ancestral form (111Ala), darker skin; Europeans: variant (111Thr), lighter skin
MC1R	Melanocortin 1 receptor	Receptor for melanocyte-stimulating hormone (MSH) and ASIP	Red hair–fair skin: *R151C*, *R160W*, *D294H* mutations; loss of function increases pheomelanin
ASIP	Agouti-signaling protein	Ligand for *MC1R*; antagonist for MSH that increases pheomelanin	Inactivating mutations associated with dark hair/eyes
KITLG	*KIT* ligand (steel factor, stem cell factor, mast cell growth factor)	Ligand of *KIT* tyrosine–kinase receptor (cell-migration effects)	Blond/brown hair; lighter/darker skin
IRF4	Interferon regulatory factor 4	Regulator of RNA polymerase II transcription factor activity	Light/dark hair
TPCN2	Two-pore calcium channel 2	Lysosomal membrane calcium channel	Blond/brown hair

of human skin, hair, and iris include *TYR*, *TYRP1*, *OCA2/HERC2*, *SLC45A2 (OCA4/MATP)*, *SLC24A5*, *SLC24A4*, *MC1R*, *ASIP*, *KITLG*, *IRF4*, and *TPCN2*[21,22] (Table 9-2).

Examination of mitochondrial DNA and Y chromosome analysis suggests that all humans descended from three African females and three African males.[22,23] It is believed that some of these descendants stayed in Africa, while others migrated to Europe and Asia and from Asia across the polar land bridge to the Americas. West Africans with the ancestral variant of the *SLC24A5* gene expressing alanine at amino acid 111 have dark brown skin. East Asians also have this form of *SLC24A5*.[24] A variant of the *SLC24A5* gene with threonine at amino acid 111 is nearly constant in those of European ancestry, determining lighter skin types, and is believed to have resulted from natural selection.[24] *SLC24A5* encodes a potassium-dependent sodium/calcium exchanger that is hypothesized to play a role in melanosome morphogenesis and melanogenesis through changes in intraorganellar calcium concentration and pH. The *SLC24A5* variation is believed to explain 25–38% of the melanin difference between Africans and Europeans.[24] Polymorphisms of *SLC45A2*, *OCA2*, and *KITLG* have also been shown to contribute to pigmentation differences between European and African populations.[25]

Within European-derived populations, *TYR*, *OCA2*, *MC1R*, *ASIP*, and *IRF4* polymorphisms account for much of the observed pigmentary variation.[25] The best studied concerns the highly polymorphic *MC1R*, a melanocyte surface receptor that when activated by its ligand αMSH increases intracellular cAMP levels, induces the microphthalmia transcription factor MiTF and ultimately increases black/brown eumelanin synthesis. A number of loss-of-function variant alleles of *MC1R* have been identified and shown to result in a fair-skinned red-hair phenotype.[26] Other *MC1R* variant alleles result in blond or light brown hair and fair skin.[26] Conversely, dark brown or black hair and dark skin are observed in individuals expressing the wild type *MC1R*. Risk of skin cancer, including melanoma,

is also affected by the inherited *MC1R* alleles and is generally correlated with fair skin color.[26] However, some variant alleles appear to confer an increased risk independent of their effect on pigmentation.[26]

No genetic basis for the different pigmentary phenotypes of Africans compared with Asians has yet been identified. Both have the ancestral form of *SLC24A5* and *MC1R*, suggesting that evolution to lighter skin colors may have occurred independently in Europe and in Asia. The genes regulating pigmentation differences among Asians are not adequately characterized, although *OCA2* variant alleles have been associated recently with some East Asian skin pigmentation variations. South Asian skin pigmentation shows considerable variation; variants of *SLC24A5*, *SLC45A2*, and *TYR* have been associated with these pigmentary differences.[27]

The "Hispanic" skin color group is least well defined. It is genotypically and phenotypically variable, representing mixtures of European (largely Spanish), African, and Central and South American Native origins. The Hispanic phenotype often differs on average in different geographic areas. Perhaps because of these challenges, genetic determinants of Hispanic skin color remain virtually unstudied.

VARIATION IN HAIR CHARACTERISTICS

Human hair is typically categorized into three major distinct groups: (1) Asian, (2) Caucasian, and (3) African.[28] However, the world's population encompasses people of multiple and mixed backgrounds, resulting in the existence of multiple hair types.[29] All hair exhibits common characteristics of morphology, chemical makeup, and molecular structure. There are nevertheless differences in hair morphology and physical properties that contribute to the unique features of the hair fiber, response to hair treatments, and development of disease processes in different groups.[30] Understanding the biology and the differences in physical properties of various hair types can assist clinicians in managing hair and scalp problems. A variety of terms are used in the dermatologic literature to describe different hair types based upon an author's personal preference, country of origin, or current trends. To date, most studies have focused on African hair, which presents the greatest array of clinical disorders.

BIOCHEMICAL COMPOSITION

African or black hair is known to be more affected by breakage, with easily observed fragility in vivo.[31] There are no known chemical differences in black versus Caucasian or Asian hair to explain this observed fragility. The biochemical composition of hair in people from different geographic regions and racial groups has been shown to be virtually identical in terms of keratin and amino acid content,[32,33] despite significant differences in tensile strength, combability, and moisture content. In contrast, numerous studies have described the physical differences in hair from people of different races.[34–37] As well, African-Americans have a significantly lower hair density (number of follicles per unit area) than whites (22.4 vs. 35.5 follicles); and a study examining Asian scalp biopsies found lower hair density than in Caucasians.[38] Such differences must be taken into account in the interpretation of scalp biopsy specimens.[39]

HAIR SHAPE

Initially, the cross-sectional shape of the hair shaft was thought to determine the macroscopic appearance of hair and to distinguish people of different genetic backgrounds.[40] The round cross-section of Asian hair was thought to result in straight hair, the elliptical or flattened cross-section of African hair to result in curly hair and an intermediate to round and elliptical cross-section results in wavy to straight European hair (Table 9-3). However, three-dimensional computer-aided reconstructions of scalp biopsy cross-sections suggest that the shape of the hair follicles (helical or curved in Africans vs. straight and perpendicular to the skin surface in Asians) also play an important role. The finding that Caucasians can have hair follicles that are elliptical in cross-section and yet have straight hair shafts further implies that the three-dimensional

TABLE 9-3
Comparison of Physical Properties of Hair

Racial Group	African	Caucasian	Asian
Cross-sectional shape	Elliptical	Ovoid	Round
Hair follicle shape	Curved	Variable	Straight
Tensile strength	Low	High	High
Work of combing	High	Low	Low
Moisture content	Low	High	High
Average number of cuticle layers	Highly variable (6–8 along the major axis, 1–2 along the minor axis)	Constant (4–5)	Constant (6–7)

structure of the hair follicle is responsible for the shape of the hair shaft. In vitro experiments comparing the growth of curly and straight hair found that follicles producing curled hairs, when dissected out of the scalp and placed in culture, continue to grow curled hair shafts.[41] This suggests that the shape of the hair may be genetically programed by the bulb, with or without the usual dermal environment.[42]

HAIR STRUCTURE

Recent studies have identified Asian-specific alleles of the *EDAR* and *FGFR2* genes that are associated with thick, straight hair.[43,44] Likewise, a recent genome-wide association scan for hair morphology (straight, wavy, curly) in Australians of European descent suggested that polymorphisms of the trichohyalin gene (*TCHH*), which is expressed in the developing inner root sheath of the hair follicle, contributes to the variance in hair morphology.[45] A quantitative study examining hair formation in seven populations demonstrated African hair to have the highest amount of curvature and kinking and a periodic widening and narrowing of the cuticle layer. The cuticle layer of curly hair averages 6–8 layers thick at the end of the major axis but only 1–2 layers at the ends of the minor axis, a weak point susceptible to hair damage from mechanical and chemical forces.[46] A study of cuticle differences between Asian (Koreans specifically) and Caucasian hair revealed a 40% larger mean hair diameter, an increased number of cuticle layers, and a thicker cuticle layer in Asian compared to Caucasian hair (Table 9-3).[47] Cuticle thickness may play a role in determining the different characteristics of hair, such as chemical reactivity to hair coloring or perms, resistance to UV radiation, and mechanical resilience.

Differences have also been observed in the rate of hair growth. Although hair from individuals of European descent has been observed to grow an average of 1 cm a month,[48] African hair grows an average of 0.77 cm a month.[49–51] In a comparative light and scanning electron-microscopic study of African, European, and Asian hair, African subjects who did not have a hair cut for over 1 year had hair lengths significantly shorter than would be expected at a growth rate of 1 cm per month. Possible contributors to the differences in hair length, other than a slower growth rate, could include a significantly shorter anagen phase of the hair cycle or perhaps repeated breakage of African hair. In the same comparative study of African, European, and Asian hair, the African hair appeared as a tightly coiled spring-like structure. Compared with shafts from other ethnic groups, many shafts contained trichonodosis or knots (10–16% vs. 0.15%) and other shafts appeared broken (eFig. 9-2.1 in online edition). The study found a lower incidence (<40%) of hairs with attached roots in the African hair samples compared with more than 75% and approximately 90%, respectively, for the Caucasian and Asian samples; and a greater incidence of tips with frayed or serrated appearance when compared to Asian and Caucasian hair that had cut tips. These data suggest that most of the African hair collected from combing in this study was broken and not shed.[51] This raises the question of whether African hair is breaking off during grooming because of increased fragility.

TENSILE STRENGTH

Hair fragility is measured using tests of tensile strength, and it has been suggested that the force needed to break African hair fibers is less than that for other population groups. In a review of tensile strength tests obtained from four different private laboratories, two showed no difference between African hair and that of Caucasian and Asian hair and the other two found African hair to be weaker. Others found a lower tensile strength of both wet and dry curly African hair compared to wet and dry Caucasian hair.

The strength of hair has been shown to be dependent upon the integrity of its sulfur-rich proteins and disulfide bonds. In a study of trichothiodystrophy (TTD), a condition characterized by reduced sulfur-rich proteins and increased hair fragility, control hairs from African, Asian, and Caucasian subjects had statistically comparable sulfur staining using transmission electron microscopy and specific sulfur stains, while hair of patients with TTD was distinct.[52] Examination of cultured curly hairs in vitro showed a variable thickness of the outer root sheath, which was thicker on the concave side of the follicle, indicating some alteration in the differentiation process of hair compartments. It is unclear whether the lack of symmetry of the African hair bulb increases the tendency to mechanical damage, but it is likely that the shape of African hair makes it susceptible to physical damage as a result of certain grooming practices. In addition, intraracial variation in the degree of curl may influence mechanical properties. In a comparative study of African-American hair with different degrees of curl, from a loose to a tight curl pattern, mechanical fragility of hair increased with a tighter curl pattern.[53] Certain ethnic hair care practices, such as repeatedly subjecting hair to extremely high temperatures or processing with chemical straighteners, may further damage African hair.

COMBING PROPERTIES

In a study examining the amount of work required (measured in joules) to pass a comb through locks of hair, it was found that the work of combing wet African-American hair is almost five times that of combing wet straight hair. For dry hair, the work is 50 times greater. The teeth of a comb and method of combing can influence the extent of resulting damage. Broken hairs from combing are more numerous and of shorter length in curly African-American hair compared to straight Caucasian and Asian hair. Knots or trichonodes that are commonly seen in tightly curled hair are sites especially susceptible to damage by comb teeth.

MOISTURE CONTENT AND STATIC ELECTRICITY

African-American hair demonstrated a slightly lower water content than Caucasian hair.[37] The spiraling of the hair shaft may be another reason for increased hair dryness in African-American hair, as sebum from sebaceous glands cannot effectively navigate the twist and turns of the hair shaft, leading to a drier, more brittle hair. The relative "dryness" of African-American hair is worsened by the cumulative effect of environmental forces. Features of such weathering include a damaged cuticle, longitudinal fissures known as "split ends," and transverse fissures resembling the nodes of trichorrhexis nodosa.

When combing untreated curly hair, a highly negative electrostatic charge develops, in contrast to the low positive electrostatic charge for untreated straight hair. The highly negative charge on African-American hair may be the result of decreased moisture content and increased pulling force from combing. Also, the higher electrostatic charges in African-American hair can produce "flyaway" hair and can lead to difficulty in styling.

HAIR DISORDERS MORE COMMON IN SKIN OF COLOR

The differences in physical properties and hair care practices may explain certain dermatologic disorders in patients with skin of color. These include central centrifugal cicatricial alopecia (CCCA) (Fig. 9-3), traction alopecia (TA), pseudofolliculitis barbae (PFB), and acne keloidalis nuchae (AKN) (Table 9-4). The curved African hair follicle has been proposed to contribute to the pathogenesis of PFB and AKN,[54,55] though this has been debated.[56,57]

DIAGNOSIS AND TREATMENT OF SKIN DISEASE

No clear difference has been found between the structure and function of skin of varying colors aside from the visible pigmentary changes and associated variation in photoprotection.[15] Skin often responds to trauma or inflammation with hyperpigmentation; and this is often more prominent and long lasting in darker skin (Fig. 9-4). Hypopigmentation may similarly be more common and more apparent in skin of darker color. Treatment of skin disorders may also affect pigmentation, either positively or negatively (Fig. 9-5). Finally, epidermal melanin may alter disease presentation by masking erythema. Hypertrophic scarring and keloids are more frequent in black and Asian skin than white skin, a major problem for which the pathogenesis remains unknown. There are also some variations in the prevalence and presentation of certain skin diseases in patients with skin of color (Table 9-5). Not all of these can be attributed to pigmentation differences, but other contributing factors are as yet unidentified.



Figure 9-3 Central centrifugal cicatrizing alopecia (CCCA) early (**A**) and late (**B**) in the disease course. (Photographs used with permission from Lynne Goldberg, MD.)

TABLE 9-4
Hair Disorders that Commonly Affect Persons of African Descent

Disorder	Alternative Names	Presumed Pathophysiology	Clinical Features	Preventive Measures	Treatment[a]
Central centrifugal cicatricial alopecia (CCCA)[58]	■ Hot comb alopecia ■ Follicular[59] Degeneration syndrome[60]	■ Genetic predisposition ■ Heat injury ■ Chemical relaxers ■ Traction with rollers,[61] tight sewn-in and glued-in hair weaves, braids with extension hair[62]	■ Progressive: begins on the scalp vertex and advances centrifugally (Figs. 9-3A and 9-3B); noninflamed late stage; smooth patch of alopecia with loss of follicular orifices	■ Minimize use of heat, braids, weaves ■ Discontinue or decrease chemical relaxer frequency	■ Aimed at symptoms and halting progression ■ Intralesional triamcinolone, topical steroids (in vehicle of patient's choice) ■ Antiseborrheic shampoos ■ Oral tetracyclines or hydroxychloroquine[63,64] ■ Minoxidil for miniaturized or regrowing hairs[65] ■ Hair transplantation (for stable disease)[66,67]
Traction alopecia (TA)	■ Traumatic alopecia ■ Associated with traction folliculitis[68,69]	■ Hairstyles that place chronic traction on the hair follicle: ponytails,[70] tight braids and cornrows,[71,72] nylon hairbrushes,[73] elastic hair bands,[74] rollers,[75,76] and tight knotting (Sikh men[77,78]) ■ Highest risk of TA seen in women who attach extensions to relaxed hair[79]	■ Distribution of hair loss reflects that of maximal traction, but is most commonly seen at the scalp margins (eFig 9-5.1 in online edition)	■ Avoid the chronic use of styles that place traction on the follicles ■ Rotate hairstyles more frequently	■ Remove offending source ■ Trial of intralesional triamcinolone (if caught early) ■ Minoxidil for miniaturized or regrowing hairs[54] ■ Hair transplantation (for individuals no longer placing traction on the hair)[55,66]
Pseudofolliculitis barbae (PFB) and acne keloidalis (nuchae) (AKN)[56,57]	■ Razor bumps	■ Curved nature of the hair shaft resulting in ingrown hairs[80,81] ■ Primary scarring alopecia, AKN.[82,83]	■ Presents as multiple keloidal papules or plaques most commonly in the beard area in PFB and occipital scalp/neck in AKN (eFigs. 9-5.2 and 9-5.3 in online edition)	■ Avoid shaving	■ Depilation ■ Laser hair removal ■ Intralesional triamcinolone for keloids

[a]There have been no clinical trials for the treatment of patients with CCCA or TA or, so little evidence-based data exist regarding treatment regimens.

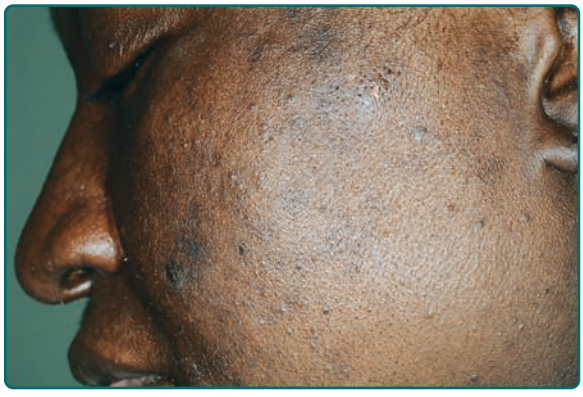

Figure 9-4 Acne with postinflammatory hyperpigmentation on the cheek of an African-American woman.

Treatment choices often affect pigmentation (Table 9-6). For example, topical corticosteroids may produce unwanted hypopigmentation in treated skin but may also speed resolution of postinflammatory hyperpigmentation. Cryotherapy, which preferentially damages melanocytes, may produce striking and/or irreversible pigment loss. Conversely, the irritation associated with many topical therapies and dermatologic procedures may produce unwanted hyperpigmentation. Awareness of these possibilities, careful choice of therapies and detailed patient education can avoid these iatrogenic problems.

SKIN CANCER

Cutaneous melanoma merits particular attention in skin of color because of the trend toward poorer prognosis. Lesions are more often of the acral or subungual subtype than the more common superficial spreading type seen in whites and present at more advanced stages. Some estimate that 20% of the world's melanoma cases occur in skin of color.[119] The incidence rates have remained relatively stable in Asians and blacks, while a large increase in melanoma incidence in the past century, attributed to increased UV exposure, has occurred in white populations.[120] Not surprisingly, lightly pigmented Hispanic skin has a risk similar to that of whites, while darkly pigmented Hispanic skin has a risk similar to Asians and blacks.[121]



Figure 9-5 Perioral hyperpigmentation secondary to retinoid dermatitis in an African-American man treated for acne. (Used with permission from RM Halder, MD and reproduced with permission from Halder RM: *Dermatology and Dermatologic Therapy of Pigmented Skins*. Boca Raton, CRC Press, 2006.)

Acral and subungual melanomas are associated with higher mortality than nonacral melanoma.[122] While the absolute incidence of acral melanomas is nearly identical for black and white Americans (1.7 vs. 2.0 per 100,000, respectively),[123] acral melanomas in darker populations tend to present later with large surface areas (>3 cm) and more advanced disease. According to SEER data (1986–1991), US blacks were 3-fold more likely to have distant metastases compared to US whites (12% vs. 4%, respectively).[120] Similarly, a study of subungual melanomas showed blacks had a 3.5-fold higher mortality rate than whites, even after controlling for Clark's level and stage.[124] However, existing data are inadequate to determine whether race is an independent risk factor for biologic aggressiveness in melanoma or whether the differences are instead a function of delayed diagnosis due to darker background pigmentation, the higher prevalence of benign palmar and plantar lentigines and pigmented bands on nails with which melanomas may be confused, or socioeconomic factors that affect the care received.

Public education and melanoma screening campaigns typically target Caucasians and often do not provide relevant information or convey the risk to those with skin of color, and in fact may even provide false reassurance. Development of education campaigns directed toward skin of color may aid in improving detection and prognosis, but until then individualized patient counseling and education remain important.

Nonmelanoma skin cancers (NMSC) also occur in skin of color, though far less commonly than in whites. Basal and squamous cell carcinomas (BCC and SCC) tend not to occur in sun-exposed areas, but rather at sites of nonhealing ulcers or other chronic proliferative stimulation. The incidence rate of SCC in blacks is reported as 3.4 per 100,000 and 1.8–3.2 in Asians. One series showed a rate of 5.8–6.4 BCC per 100,000 in Asians.[125] Gorlin's syndrome (basal cell nevus syndrome) occurs in all populations and may demonstrate few BCCs in skin of color, so careful observation of other findings including palmar pits, frontal bossing, and odontogenic cysts are important in screening for the disease, which has increased risk of internal malignancy and should prompt referral for genetic counseling. Immunosuppressed patients with skin of color, like whites, are at increased risk for NMSC and should be screened for malignancy. Cutaneous T-cell lymphoma has a 1.2–2-fold increased incidence and a higher mortality rate in blacks than in whites.[126–128]

COSMETIC AND PROCEDURAL DERMATOLOGY

It is important for providers to be cognizant of the options, effectiveness, and potential adverse effects

TABLE 9-5
Dermatologic Diseases with Special Considerations in Skin of Color

Dermatologic Disease	Considerations
Normal Findings and Nevi	
■ Pigmentary demarcation lines	Six types recognized[84] Most prominent on the arms
■ Melanonychia striata	Common, increases with age A single nail affected with >6 mm width lesion and variegation in color should prompt consideration of malignancy in appropriate setting
■ Palmoplantar melanosis	Common, increases with age Consider acral lentiginous melanoma in large, changing, or raised lesions
■ Circumscribed dermal melanocytosis	Blue-gray macules and patches present at birth Occur in all skin colors, more common in darker skin Typically resolve in childhood Term "Mongolian Spot" not preferred
■ Nevus of Ito/Ota	Nevoid form of dermal melanocytosis More frequent in Asian populations
Scars	
■ Hypertrophic scars and keloids	Blacks affected 5–16 times more often than Caucasians[85] Coiffure keloid can result from tightly braided hair styles[86]
Inflammatory Disease	
■ Confluent and reticulate papillomatosis	More prevalent in darker-skinned individuals and young women
■ Lichen planus	Certain subtypes such as lichen planus pigmentosus and lichen planus actinicus have a predilection for darker-skinned individuals.[87,88]
■ Lichen nitidus	May be hypo- or hyperpigmented in darker skin[89]
■ Lichen striatus	Can present as hypopigmented (rather than erythematous) papules lesions followed by hypopigmented macules.[90]
■ Pseudofolliculitis barbae	Curled shaved hairs penetrate inwards inciting inflammatory response Commonly leads to scarring and postinflammatory hyperpigmentation Laser hair removal, chemical delapitories, increased beard length with less frequent shaving, single-blade razors, and gentle lifting of ingrown hair loops out of skin provide improvement
■ Acne keloidalis nuchae	Mostly in males with skin of color Etiology poorly understood Avoid close cutting or shaving and friction Treatment includes medical anti-inflammatory therapies and surgical options
■ Scarring alopecias	More common in skin of color (See Table 9-4)
Acquired Pigmentary Disorders	
■ Idiopathic guttate hypomelanosis	Affects ~50% of African-Americans over 50 years of age No effective treatment available
■ Melasma	Women with darker skin types have a higher incidence[91,92]; Hispanics seem particularly at risk
■ Periorbital hypermelanosis	Can be more striking in darker-skinned individuals
■ Pityriasis alba	While estimated to affect 1–5% of all children, some reports indicate up to 25% of African-American children and 35% of Hispanic children
■ Postinflammatory hyper- and hypopigmentation	Often more apparent and more persistent in darker-skinned individuals Preventive and therapeutic measures warranted
■ Tinea versicolor	More common in tropical climates Higher incidence rates reported in black individuals[93,94]
■ Vitiligo	Often more striking in darker-skinned individuals Trichrome lesions more common in darker skin types[95] Vogt–Koyanagi–Harada syndrome tends to be more severe in Asians Evidence shows linkage to chromosome 4q13-q21 in Chinese families[96]

(continued)

TABLE 9-5
Dermatologic Diseases with Special Considerations in Skin of Color (Continued)

Dermatologic Disease	Considerations
Congenital Pigmentary Disorders	
■ Piebaldism	Often more striking in darker-skinned individuals
■ Oculocutaneous albinism (OCA)	Although OCA affects all racial groups (1:17,000 persons worldwide),[97] regional incidence depends on gene pools, social customs, and other environmental factors. Particularly high rates of OCA have been noted in Cuna Moonchild Indians in Panama (1:160)[98], Native Americans of the Hopi and Zuni tribes (1:227 and 1:240, respectively), Mayans in Guatemala (1:6500), South Africa (OCA2, 1:3900; OCA3, 1:8500), Nigeria (1:1100), Tanzania (OCA2, 1:1429), Zimbabwe (OCA2, 1:2833)[97,99,100] Hermansky–Pudlak syndrome is a rare form of tyrosinase-positive OCA found almost exclusively in Puerto Ricans (1:1800 Puerto Ricans)[101] In Japan, 24% of albino patients have OCA type 4[102]
Neoplastic Disease	
■ Mycosis fungoides	Can present as hypopigmented macules or patches in a central, rather than acral, distribution.[103]
■ Melanoma	Differences in anatomic distribution and type More often at advanced stage at presentation Poorer overall prognosis even for same risk factors
■ Nonmelanoma skin cancer	Occurs uncommonly but not rarely in skin of color, usually in the context of chronic proliferation, as at the site of a nonhealing wound
Other	
■ Sarcoidosis	Ten times more likely in blacks than in whites[104] Hypopigmented lesions more common in persons of color[105,106] Morbidity and mortality higher in African-Americans than in Caucasians[107]
■ Lichen amyloidosis	Increased prevalence in Asians, Middle Easterners, and South Americans[108–111]
■ Dermatosis papulosa nigra	Incidence as high as 70% in African-Americans[112]
■ Ashy dermatosis	Scattering of incident light by an irregular "dry" stratum corneum; management as for xerosis with emollients and gentle skin care

of cosmetic treatments for conditions affecting darker skin types. The cosmetic procedure literature has focused primarily on white skin, and often does not discuss outcomes in dark-skinned patients. However, this is changing as greater numbers of patients with skin of color seek cosmetic and procedural treatments.

PREVENTIVE MEASURES

Photoaging has been a prevalent issue for Caucasians, but nonwhites also demonstrate changes associated with photoaging, particularly facial lentigines and other forms of dyspigmentation that often appear up to two decades earlier in women with skin of color, after controlling for latitude of residence. Hence, sun protection is recommended for optimal prevention of age-associated changes, regardless of skin color. However, dyschromia (irregular pigmentation) unrelated to photoaging is perhaps the most frequent complaint for patients with skin of color. Prevention and minimization of postinflammatory pigmentary changes due to trauma and irritation, whenever possible, are paramount. Avoidance of melanogenic stimulation by direct sun exposure is also critical in this context, although care must be taken to assure adequate vitamin D levels through oral supplementation if vitamin D photosynthesis is minimized (see Chapter 90).

TOPICAL THERAPIES FOR HYPERPIGMENTATION

In treating hyperpigmentation, it is important to consider the location of deposited pigment. Dermal pigmentation retained in melanophages is not affected by topical therapies and is highly resistant to all treatment modalities. However, increased epidermal melanin can often be improved with topical therapy that reduces melanogenetic stimulation, tyrosinase activity, or melanin transfer to keratinocytes (Table 9-6). Topical therapies generally produce slow and subtle improvements, and treatment expectations should be discussed with patients.

COSMETIC CAMOUFLAGE

Camouflage makeups that hide dyschromic areas continue to represent a significant aid for some patients,

TABLE 9-6
Topical Therapies for Hyperpigmentation

Therapeutic Agent(s), by Category	Special Considerations
UV Protection	
■ Sunscreens	Prevent UV-induced tanning and may hasten resolution of postinflammatory hyperpigmentation; recommended for most patients with hyperpigmentation concerns, can be used concomitantly with other therapies
Tyrosinase Inhibitors[a]	
■ Azelaic acid	Dicarboxylic acid derived from *Plasmodium ovale* cultures
■ Hydroquinone	Higher concentrations may lead to irritation; low risk of permanent depigmentation and ochronosis (typically seen at concentrations >6%); shows increased efficacy in combination therapy with 0.01% fluocinonide cream and 0.05% tretinoin
■ Arbutin	Hydroquinone derivative; inhibits tyrosinase and DHICA[113]
■ Licorice extract	Active ingredient glabridin decreases tyrosinase activity and has anti-inflammatory effects[114]
■ Paper Mulberry	Potent tyrosinase inhibition[115]
■ Vitamin C	Product should be stable for efficacy Also provides anti-inflammatory effect
■ Tretinoin	Inhibits tyrosinase transcription and glycosylation; normalizes epidermal melanin distribution
■ Kojic acid	Fungal derivative; inhibits tyrosinase
■ *N*-Acetylglucosamine	Inhibits conversion of protyrosinase to tyrosinase[116]
■ Pycnogenol	Flavanoid compounds with antioxidant activity; oral treatment (25 mg TID) may improve melasma[117]
Melanosome Transfer Inhibition[a]	
■ Niacinamide	Amide of niacin (B3), inhibits melanosome transfer to keratinocytes[118]
■ Soy	Soybean trypsin inhibitor (STI) and Bowman-Birk inhibitor (BBI) inhibit cleavage of PAR-2, reducing melanosome transfer
Increased Cellular Turnover	
■ α-Hydroxy and β-hydroxy acids	Reduce corneocyte adhesion

[a]Reported mechanism of action, based on data of varying strength.

and can be less expensive than other options. Branded products include Veil Cover Cream, Keromask, Dermacolor, and Dermablend. These and the many other marketed formulations must be judged by the user on the basis of esthetics, cost, and other factors of importance to the individual. Referral to a professional makeup artist or camouflage makeup therapist for application demonstration and education regarding proper use can provide significant benefit.

PROCEDURAL DERMATOLOGY IN SKIN OF COLOR. Superficial and medium depth chemical peels, when appropriately selected and performed, are appropriate for Fitzpatrick skin types IV–VI. Specific choices regarding chemical agent depend on the efficacy, safety, desired depth of peel, and the physician's preference and experience. Microdermabrasion is appropriate for all skin types, is often used for acne and other types of facial scarring, and is a good option for those unable to tolerate peels or extensive recovery times.

Laser treatment in patients with skin of color should be selected with the knowledge that epidermal melanin can act as a competitive chromophore. Inadvertent absorption of laser energy by epidermal melanin can lead to scarring and dyspigmentation.

PATIENT INDIVIDUALIZATION

The spectrum of human phenotypes results from a combination of genetic and environmental influences. Complexities of racial and ethnic contributors to disease susceptibility, clinical presentation, and therapeutic response are still poorly understood. Because there is on average greater genetic diversity between any two individuals (85–90%) than between races (10–15%),[129] and because genes determining pigmentation make up an exceedingly small proportion of the genome, it is desirable that race not be overemphasized in determining a dermatologic plan of care. The welcome movement toward considering skin types as a continuous spectrum rather than dichotomously as white and nonwhite may one day render obsolete the term "skin of color."

KEY REFERENCES

Full reference list available at www.DIGM8.com

DVD contains references and additional content

1. US Interim Projections by Age, Sex, Race and Hispanic Origin, 2000–2050. *US Census Bureau*, http://www.census.gov/population/www/projections/usinterimproj/natprojtab01a.pdf, accessed August 30, 2011
10. Taylor SC: Skin of color: Biology, structure, function, and implications for dermatologic disease. *J Am Acad Dermatol* **46**(2 Suppl. Understanding):S41-S62, 2002
21. Sturm RA: Molecular genetics of human pigmentation diversity. *Hum Mol Genet* **18**(R1):R9-R17, 2009
24. Lamason RL et al: SLC24A5, a putative cation exchanger, affects pigmentation in zebrafish and humans. *Science (New York, N.Y.)* **310**(5755):1782-1786, 2005
26. Rees JL. Genetics of hair and skin color. *Ann Rev Genet* **37**:67-90, 2003
30. Wolfram LJ: Human hair: A unique physicochemical composite. *J Am Acad Dermatol* **48**(Suppl. 6):S106-S114, 2003
31. McMichael AJ: Hair breakage in normal and weathered hair: Focus on the Black patient. *J Investig Dermatol Symp Proc/Soc Investig Dermatol, Inc.* **12**(2):6-9, 2007
41. Bernard BA: Hair shape of curly hair. *J Am Acad Dermatol* **48**(Suppl. 6):S120-S126, 2003
42. Thibaut S et al: Human hair shape is programmed from the bulb. *Br J Dermatol* **152**(4):632-638, 2005
57. Kelly AP: Pseudofolliculitis barbae and acne keloidalis nuchae. *Dermatol Clin* **21**(4):645-653, 2003
120. Ries L, Eisner M, Kosary C: *SEER Cancer Statistics Review, 1975–2001.* Bethesda, MD, National Cancer Institute, 2004
123. Stevens NG, Liff JM, Weiss NS: Plantar melanoma: Is the incidence of melanoma of the sole of the foot really higher in blacks than whites? *Int J Cancer* **45**(4):691-693, 1990
126. Criscione VD, Weinstock MA: Incidence of cutaneous T-cell lymphoma in the United States, 1973–2002. *Arch Dermatol* **143**(7):854-859, 2007
129. Myles S et al: Identifying genes underlying skin pigmentation differences among human populations. *Hum Genet* **120**(5):613-621, 2007

This page intentionally left blank

Disorders Presenting in Skin and Mucous Membranes

PART 2



Inflammatory Disorders Based on T-Cell Reactivity and Dysregulation

Chapter 10 :: Innate and Adaptive Immunity in the Skin

:: Robert L. Modlin, Lloyd S. Miller, Christine Bangert, & Georg Stingl

INNATE AND ADAPTIVE IMMUNITY AT A GLANCE

- Innate immune responses
  - are used by the host to immediately defend itself;
  - determine the quality and quantity of many adaptive immune responses;
  - are short lived;
  - have no memory;
  - include physical barriers (skin and mucosal epithelia);
  - include soluble factors such as complement, antimicrobial peptides, chemokines, and cytokines;
  - include cells such as monocytes/macrophages, dendritic cells, natural killer cells, and polymorphonuclear leukocytes.
- Adaptive immune responses
  - have memory;
  - have specificity;
  - are long lasting;
  - in skin, are initiated by dendritic antigen-presenting cells in the epidermis (Langerhans cells) and by dermal dendritic cells;
  - are executed by T lymphocytes and antibodies produced by B lymphocytes/plasma cells.

The human immune system is comprised of two distinct functional parts: (1) innate and (2) adaptive. These two components have different types of recognition receptors and differ in the speed in which they respond to a potential threat to the host (Fig. 10-1). Cells of the innate immune system, including macrophages and dendritic cells (DCs), use pattern recognition receptors encoded directly by the germ line DNA, respond to biochemical structures commonly shared by a variety of different pathogens, and elicit a rapid

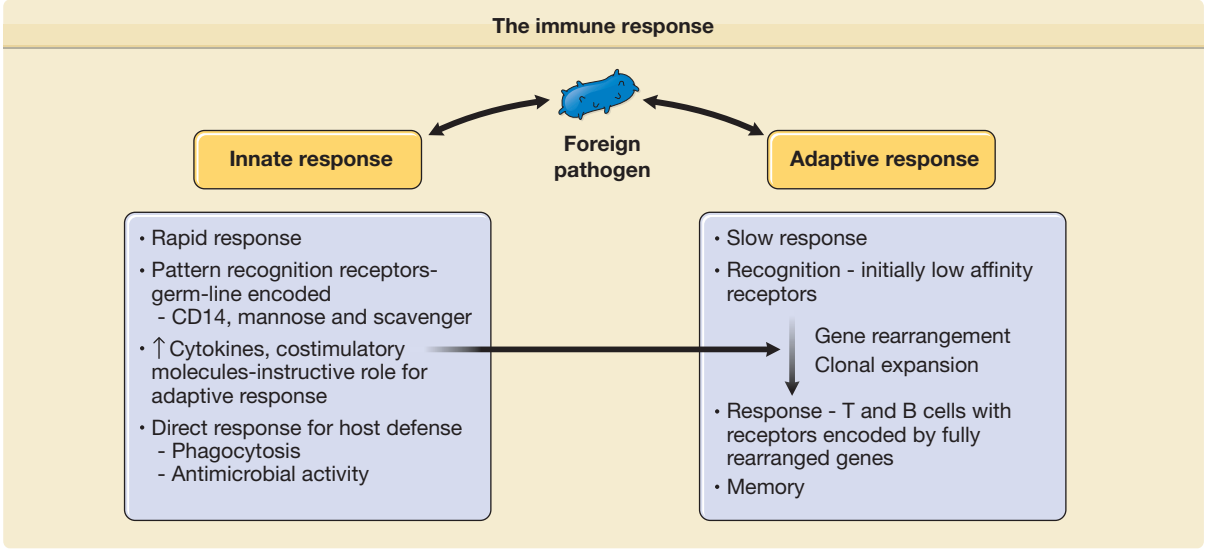

Figure 10-1 The immune system of higher vertebrates uses both innate and adaptive immune responses. These immune responses differ in the way they recognize foreign antigens and the speed with which they respond; yet, they complement each other in eradicating foreign pathogens.

response against these pathogens, although no lasting immunity is generated. In contrast, cells of the adaptive immune system, T and B lymphocytes, bear specific antigen receptors encoded by rearranged genes, and in comparison to the innate response, adaptive immunity develops more slowly. A unique feature of the adaptive immune response is its ability to generate and retain memory; thus, it has the capability of providing a more rapid response in the event of subsequent immunologic challenge. Although the innate and adaptive immune responses are distinct, they interact and can each influence the magnitude and type of their counterpart. Together, the innate and adaptive immune systems act in synergy to defend the host against infection and cancer. This chapter describes the roles of the innate and adaptive immune response in generating host defense mechanisms in skin.

INNATE IMMUNE RESPONSE

Immune mechanisms that are used by the host to immediately defend itself are referred to as *innate immunity*. These include physical barriers such as the skin and mucosal epithelium; soluble factors such as complement, antimicrobial peptides, chemokines, and cytokines; and cells, including monocytes/macrophages, DCs, natural killer cells (NK cells), and polymorphonuclear leukocytes (PMNs) (Fig. 10-2).

Our present understanding of innate immunity is based on the studies of Elie Metchnikoff who, in 1884, published studies on the water flea *Daphnia* and its interaction with a yeast-like fungus.[1] He demonstrated that cells of the water flea, which he termed "phagocytes," were attracted to and engulfed the foreign spores, which were subsequently "killed and destroyed." Thus, Metchnikoff described the key direct functions of cells of the innate immune system: (1) rapid detection of microbes, (2) phagocytosis, and (3) antimicrobial activity. In addition to this direct role in host defense, the innate immune system has an indirect role in instructing and determining the type of adaptive T and B cell responses. Finally, by inducing inflammation, the innate immune response can also induce tissue injury.

PHYSICAL AND CHEMICAL BARRIERS[2]

Physical structures prevent most pathogens and environmental toxins from harming the host. The skin and the epithelial lining of the respiratory, gastrointestinal, and the genitourinary tracts provide physical barriers between the host and the external world. Skin, once thought to be an inert structure, plays a vital role in protecting the individual from the external environment. The epidermis impedes penetration of microbial organisms, chemical irritants, and toxins; absorbs and blocks solar and ionized radiation; and inhibits water loss (see Chapter 47).

MOLECULES OF THE INNATE IMMUNE SYSTEM

COMPLEMENT.[3] (See eFig. 10-2.1 in online edition; see also Chapter 37). One of the first innate defense mechanisms that awaits pathogens that overcome the epithelial barrier is the alternative pathway of complement. Unlike the classical complement pathway that requires antibody triggering, the lectin-dependent pathway as well as the alternative pathway of complement activation can be spontaneously activated by microbial surfaces in the absence of specific antibodies (see eFig. 10-2.1 in online edition). In this way, the host defense mechanism is activated immediately

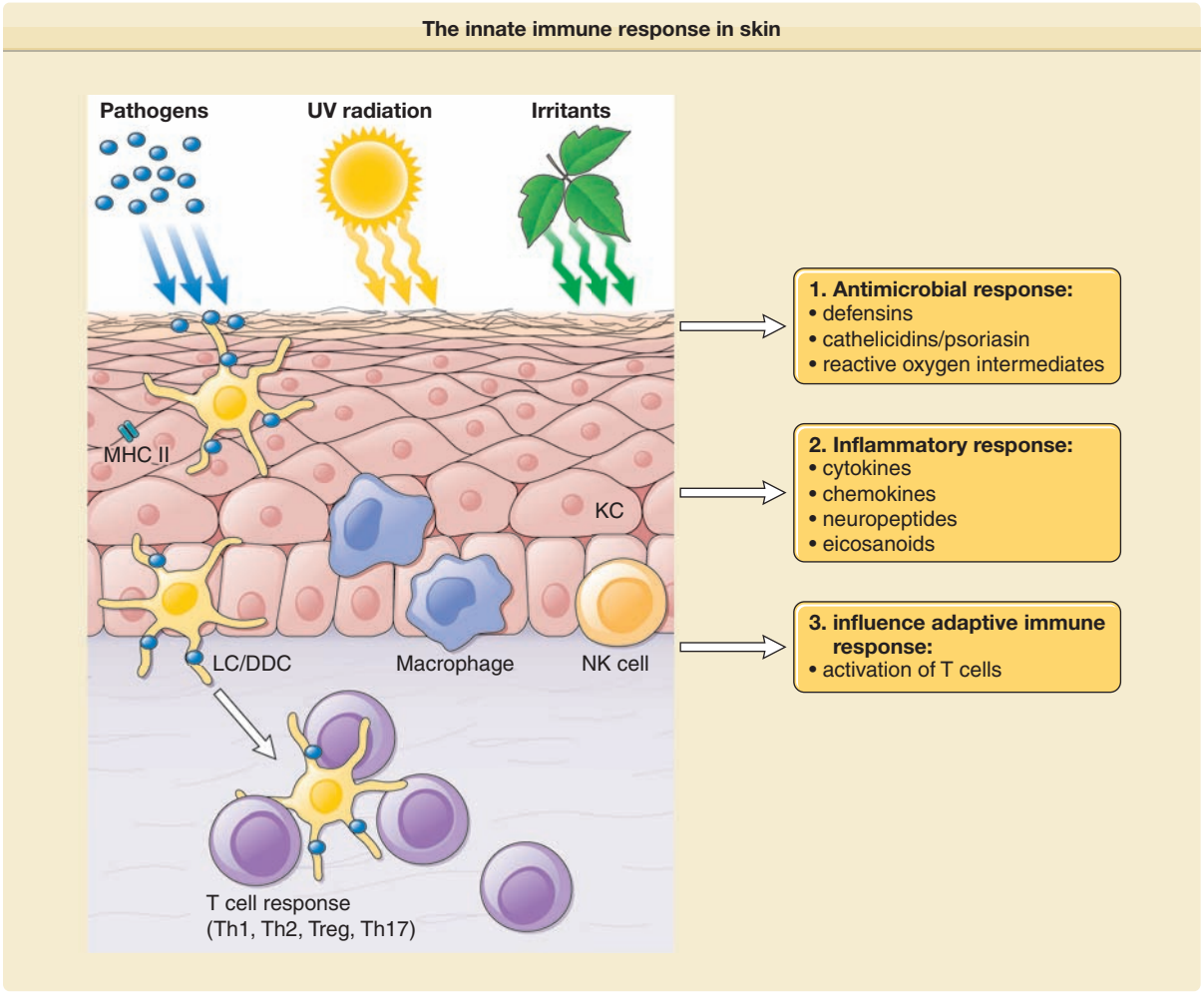

Figure 10-2 The innate immune response in skin. In response to exogenous factors, such as foreign pathogens, ultraviolet (UV) radiation, and chemical irritants, innate immune cells [granulocytes, mononuclear phagocytes, natural killer (NK) cells, keratinocytes] mount different types of responses including (1) release of antimicrobial agents; (2) induction of inflammatory mediators, such as cytokines, chemokines, neuropeptides, and eicosanoids; and (3) initiation and modulation of the adaptive immune response. DDC = dermal dendritic cell; KC = keratinocyte; LC = Langerhans cell; MHC II = major histocompatibility complex class II; Th1 = type I T cells; Th2 = type II T cells; Th17 = type 17 T cells; T reg = regulatory T cells.

after encountering the pathogen without the 5–7 days required for antibody production.

ANTIMICROBIAL PEPTIDES.[4]

Antimicrobial peptides serve as an important evolutionarily conserved innate host defense mechanism in many organisms. They typically are positively charged and are amphipathic, possessing both hydrophobic and hydrophilic surfaces. The antimicrobial activity of these peptides is thought to relate to their ability to bind membranes of microbes (through their hydrophobic surface) and form pores in the membrane, leading to microbial killing. There are numerous antimicrobial peptides identified in various human tissues and secretions. This section will focus on antimicrobial peptides identified in resident skin cells, including human β-defensins (HBD-1, HBD-2, HBD-3), cathelicidin (LL-37), psoriasin, and RNase 7, which have all been demonstrated to be produced by keratinocytes, and dermcidin, which is secreted in human sweat. In addition, there are numerous other antimicrobial peptides that are produced by cells that infiltrate the skin and may participate in cutaneous innate immune responses.[5]

β-Defensins are cysteine-rich cationic low-molecular-weight antimicrobial peptides. The first human β-defensin, HBD-1, is constitutively expressed in the epidermis and is not transcriptionally regulated by inflammatory agents. HBD-1 has antimicrobial activity against Gram-negative bacteria and appears to play a role in keratinocyte differentiation. A second human β-defensin, HBD-2, was discovered in extracts of lesions from psoriasis patients.[6] Unlike HBD-1 expression, HBD-2 expression is inducible by components of microbes, including *Pseudomonas aeruginosa*, *Staphylococcus aureus*, and *Candida albicans*.[6] Not only can components of microbes stimulate expression of HBD-2, but proinflammatory cytokines such as tumor necrosis factor-α (TNF-α) and interleukin 1 (IL-1) can also induce HBD-2 transcription in keratinocytes.[6] When tested for antimicrobial activity, HBD-2 was effective

against Gram-negative bacteria such as *Escherichia coli* and *P. aeruginosa* and has a weak bacteriostatic effect against Gram-positive bacteria such as *S. aureus*.[6] HBD-3 is another β-defensin that was first isolated from extracts of lesions from psoriasis patients.[7] Contact with TNF-α and with bacteria was found to induce HBD-3 messenger RNA expression in keratinocytes. In addition, HBD-3 demonstrated potent bactericidal activity against *S. aureus* and vancomycin-resistant *Enterococcus faecium*. Therefore, HBD-3 is among the first human β-defensins in skin to demonstrate effective antimicrobial activity against Gram-positive bacteria. The localization of human β-defensins to the outer layer of the skin and the fact the β-defensins have antimicrobial activity against a variety of microbes suggest that human β-defensins are an essential part of cutaneous innate immunity. Furthermore, evidence indicating that human β-defensins attract DCs and memory T cells via CC chemokine receptor 6 (CCR6)[8] provides a link between the innate and the adaptive immunity in skin.

Cathelicidins are cationic peptides with a structurally variable antimicrobial domain at the *C*-terminus. Whereas in mammals like pigs or cattle a variety of cathelicidin genes exists, men (and mice) possess only one gene. The human precursor protein hCAP18 (human cathelicidin antimicrobial protein 18) is produced by skin cells, including keratinocytes, mast cells, neutrophils, and ductal cells of eccrine glands. Neutrophil proteases (i.e., proteinase 3) process hCAP18 into the effector molecule LL-37 (named LL-37 for the 37-amino acid active antimicrobial peptide liberated from the *C*-terminus of the protein), which plays an important role in cutaneous host defense because of its pronounced antibacterial,[9,10] antifungal,[11] and antiviral[12,13] activities. LL-37 further contributes to innate immunity by attracting mast cells and neutrophils via formyl peptide receptor-like 1 and by inducing mediator release from the latter cells via a G protein-dependent, immunoglobulin (Ig) E-independent mechanism.[14] It has now been shown that LL-37 is secreted into human sweat, where it is cleaved by a serine protease-dependent mechanism into its peptides RK-31 or KS-30. Interestingly, these components display an even more potent antimicrobial activity than intact LL-37.[15] One of the most important inducers of LL-37 expression is vitamin D, which can be triggered by Toll-like receptor (TLR) activation of the vitamin D receptor and vitamin D-1-hydroxylase genes, leading to enhanced antimicrobial killing.[16,17]

In atopic dermatitis (see Chapter 14), LL-37 is downregulated, probably due to the effect of the T2 cytokines IL-4 and IL-13, which renders atopic skin more susceptible to skin infections with, for example, *S. aureus*, vaccinia virus (eczema vaccinatum), or herpes simplex virus (HSV) (eczema herpeticum).[10,12,13] Furthermore, patients with rosacea have been found to possess high levels of aberrantly processed forms of cathelicidin peptides (due to posttranslational processing by stratum corneum tryptic enzyme), which contributes to the increased inflammation in the skin.[18] Cathelicidin can also form complexes with self-DNA, which promotes activation of TLR9 on plasmacytoid dendritic cells in the dermis, resulting in enhanced cutaneous inflammation that contributes to psoriasis pathogenesis.[19]

Another important human antimicrobial peptide has now been identified, psoriasin (S100A7),[20] which elicits its antimicrobial effect by permeabilization of bacterial membranes.[21] It is secreted predominantly by keratinocytes and plays a major role in killing the common gut bacterium *E. coli*. In fact, in vivo treatment of human skin with antipsoriasin antibodies results in the massive growth of *E. coli*.[20] Furthermore, expression of psoriasin by keratinocytes has been shown to occur via TLR5 stimulation by *E. coli* flagellin.[22] In addition to antimicrobial activity, psoriasin also functions as a chemoattractant for CD4 cells and neutrophils.[23]

RNase 7 was originally isolated from the stratum corneum from healthy human skin.[24] RNase 7 has potent ribonuclease activity but also broad-spectrum antimicrobial activity against *S. aureus*, *P. acnes*, *P. aeruginosa*, *E. coli*, and *C. albicans.* RNase 7 production can be induced in cultured human keratinocytes by IL-1β, IFN-γ, and bacterial challenge. Interestingly, high expression of RNase 7 in human skin confers protection against *S. aureus* cutaneous infection.[25]

Dermcidin is an antimicrobial peptide that is expressed by human sweat glands.[26] Dermcidin goes through postsecretory proteolytic processing in sweat that gives rise to anionic and cationic dermcidin peptides that are secreted onto the skin surface. These dermcidin peptides have broad antimicrobial activity against *S. aureus*, *E. coli*, *E. faecalis*, and *C. albicans.* Although the mechanism of action of dermcidin activity is unknown, it does not involve pore formation like other antimicrobial peptides.[27]

PATTERN RECOGNITION RECEPTORS. How do the cells of the innate immune system recognize foreign pathogens? One way that pathogens can be recognized and destroyed by the innate immune system is via receptors on phagocytic cells. Unlike adaptive immunity, the innate immune response relies on a relatively small set of germ line-encoded receptors that recognize conserved molecular patterns that are shared by a large group of pathogens. These are usually molecular structures required for survival of the microbes and therefore are not subject to selective pressure. In addition, pathogen-associated molecular patterns are specific to microbes and are not expressed in the host system. Therefore, the innate immune system has mastered a clever way to distinguish between self and nonself and relays this message to the adaptive immune system.

Of key importance was the discovery of the Toll-like receptors (TLRs), named after the *Drosophila* Toll gene whose protein product, Toll, participates in innate immunity and in dorsoventral development in the fruit fly.[30,31] The importance of Toll signaling in mammalian cells was confirmed by the demonstration that the transmembrane leucine-rich protein TLR4 is involved in lipopolysaccharide (LPS) recognition.[32]

In addition to TLRs, there exist a variety of other molecules that sense the presence of pathogens. These include the NOD proteins (see below), triggering

receptors expressed on myeloid cell (TREM) proteins,[33] the family of Siglec molecules,[34] and a group of *C*-type lectin receptors.[35] The latter are prominently expressed on antigen-presenting cells (APCs) as, for instance, dectin-1 and DC-SIGN [DC-specific intercellular adhesion molecule 3 (ICAM-3) grabbing nonintegrin], which is actually expressed on tissue macrophages.[36] They are able to mediate efficient binding of microorganisms; facilitate phagocytosis; and induce activation of signaling pathways that result in antimicrobial activity.

Members of the TREM protein family function as amplifiers of innate responses. Extreme examples of the consequences of microbe activation of TREM proteins are life-threatening septicemia and the deadly hemorrhagic fevers caused by Marburg and Ebola virus infection.[37]

TOLL-LIKE RECEPTORS.[38]

There is now substantial evidence to support a role for mammalian TLRs in innate immunity (Fig. 10-3). First, TLRs recognize pathogen-associated molecular patterns present in a variety of bacteria, fungi, and viruses. Second, TLRs are expressed at sites that are exposed to microbial threats. Third, the activation of TLRs induces signaling pathways that, on the one hand, stimulate the production of antimicrobial effector molecules, and, on the other, promote the expression of costimulatory molecules and the release of cytokines and, as a result, the augmentation of the adaptive response. Fourth, TLRs directly activate host defense mechanisms that then combat the foreign invader.

Experiments performed in the Modlin laboratory[39] and others[40] led to the exciting finding that microbial lipoproteins trigger host responses via TLR2, requiring the acyl functions for activity. Subsequently, triacylated lipoproteins were found to activate TLR2/1 heterodimers,[41] whereas diacylated lipoproteins were found to activate TLR2/6 heterodimers.[42] For recognition of bacteria, the TLR system is redundant: TLR9 is activated by unmethylated DNA sequences (CpG dinucleotides) found in bacterial DNA[43] and TLR5 activated by bacterial flagellin.[44] Specific TLRs are involved in viral recognition: TLR3 is activated by viral derived double-stranded RNA[45] and TLR7 and TLR8 by virus-derived single-stranded RNA.[46] The finding that different TLRs have distinct patterns of expression, particularly on monocytes, macrophages, dendritic cells, B cells, endothelia, and epithelia, suggests that each TLR could trigger a specific host response. Furthermore, TLRs are expressed in specific

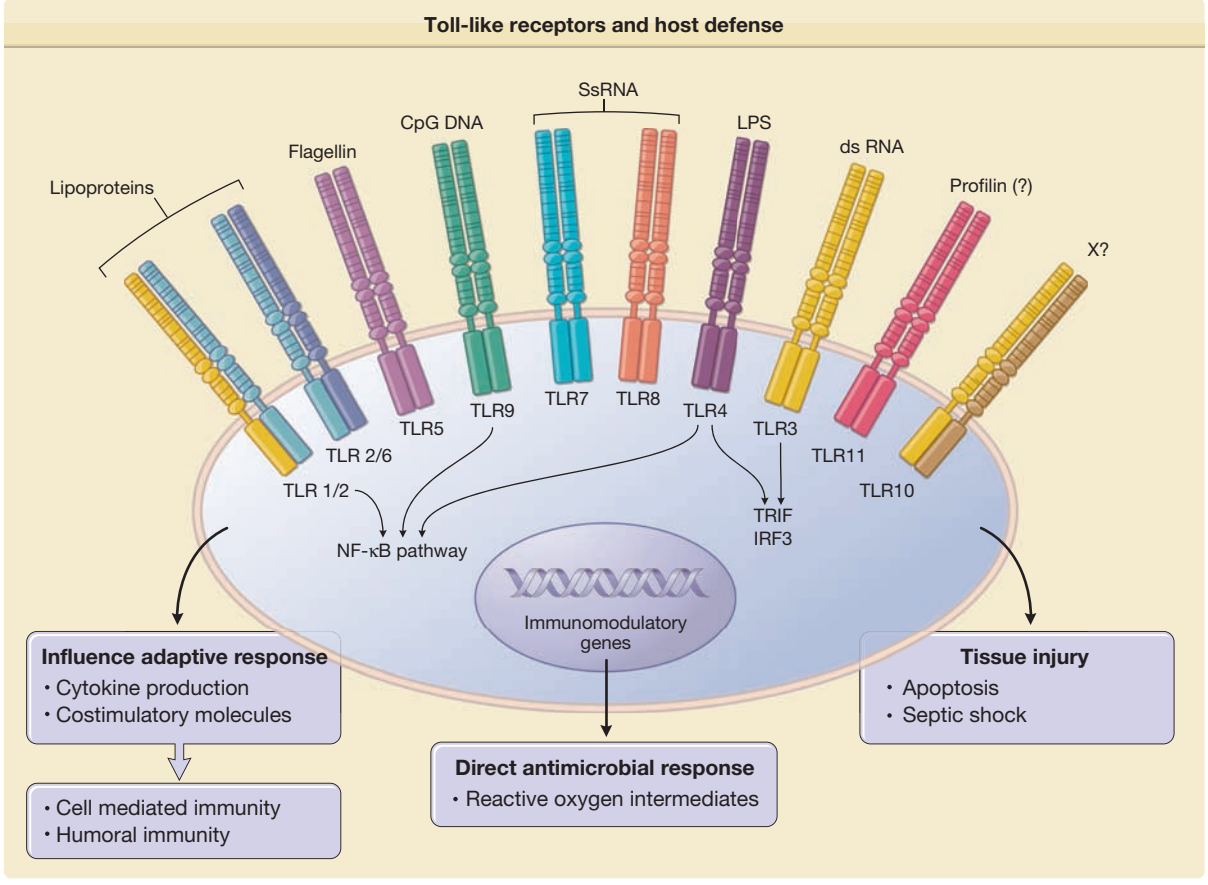

Figure 10-3 Toll-like receptors (TLRs) mediate innate immune response in host defense. Activation of TLRs by specific ligands induces (1) cytokine release and costimulatory molecules that instruct the type of adaptive immune response; (2) direct antimicrobial response; and (3) tissue injury. CpG DNA = immunostimulatory cytosine- and guanine-rich sequences of DNA; dsRNA = double-stranded RNA; LPS = lipopolysaccharide; NF-κB = nuclear factor κB; ssRNA = single-stranded RNA; X = ligand unknown.

subcellular compartments: TLR7, 8, and 9 are located in endosomes, where they encounter microbial pathogens in the endocytic pathway. The other TLRs are expressed on the cell surface and detect microbial ligands in the extracellular environment.

The expression of TLRs on cells of the monocyte/macrophage lineage is consistent with the role of TLRs in modulating inflammatory responses via cytokine release. Because these cells migrate into sites that interface with the environment—lung, skin, and gut—the location of TLR-expressing cells would situate them to defend against invading microbes. TLR expression by adipocytes, intestinal epithelial cells, and dermal endothelial cells supports the notion that TLRs serve a sentinel role with regard to invading microorganisms. The regulation of TLR expression is critical to their role in host defense, yet few factors have been identified that modulate this process. IL-4 acts to downregulate TLR expression,[47] which suggests that T helper 2 (T2) adaptive immune responses might inhibit TLR activation.

DETAILED STUDIES OF TLR

TLR-Induced Cytokine Release. TLR activation of a variety of cell types has been shown to trigger release of both proinflammatory and immunomodulatory cytokines.[48–52] TLR activation of monocytes and DC induces IL-12 and IL-18, required for generation of a Th1 response, and IL-1β, IL-6, IL-23, involved in the generation of a Th17 response, as well as the anti-inflammatory IL-10.[53–56] The relative induction of specific cytokine patterns determines the type of adaptive T-cell response (see Chapter 11).

MΦ and DC Differentiation. TLRs can regulate phagocytosis either through enhancing endosomal fusion with the lysosomal compartment[57] or through induction of a phagocytic gene program including multiple scavenger receptors.[58] Activation of TLRs on monocytes leads to the induction of IL-15 and IL-15R, triggering differentiation into $CD209^+$ MΦ[36] with microbicidal activity.[59] Activation of TLRs on monocytes also induces GM-CSF and GM-CSFR, triggering differentiation into immature DC with the capacity to release cytokines and efficiently present antigen to T cells.[36] In addition, activation of TLRs on immature DC leads to further maturation with enhanced T-cell stimulatory capacity.[60]

TLR-Induced Antimicrobial Activity. In *Drosophila*, Toll is critical for host defense. The susceptibility of mice with spontaneous mutations in TLRs to bacterial infection indicates that mammalian TLRs play a similar role. Activation of TLR2 by microbial lipoproteins induces activation of the inducible nitric oxide (NO) synthase (NOS-II or iNOS) promoter,[39] which leads to the production of NO, a known antimicrobial agent. There is strong evidence that TLR2 activation leads to killing of intracellular *Mycobacterium tuberculosis* in both mouse and human macrophages.[54] In mouse macrophages, bacterial lipoprotein activation of TLR2 leads to a NO-dependent killing of intracellular tubercle bacilli. In human monocytes and alveolar macrophages, bacterial lipoproteins similarly activate TLR2 to kill intracellular *M. tuberculosis*; however, this occurs by an antimicrobial pathway that is NO-independent. Instead, a key antimicrobial mechanism for TLR-activated human monocytes involves induction of the 25-hydroxyvitamin D3-1α-hydroxylase (CYP27b1), which converts the 25D into the active 1,25D form, upregulation and activation of the vitamin D receptor (VDR), and downstream induction of the antimicrobial peptide cathelicidin.[16,59,61–63] The ability of TLR2/1 activation to upregulate expression of CYP27b1 and the VDR is IL-15 dependent.[36] Simultaneous triggering of IL-1β activity and activation of the VDR induces HBD-2, also required for antimicrobial activity.

Activation of TLRs 3, 4, 7, 8, and 9 leads to induction of antiviral activity, dependent on type I IFN secretion and involving specific signaling pathways.[64] Two TLR-mediated pathways have been identified: type I IFN production occurs through a MyD88-independent pathway in response to TLR3 and TLR4 activation,[65] and, following stimulation with agonists of TLRs 7, 8, and 9, through a MyD88-dependent pathway.[66]

The activation of TLRs can also be detrimental, leading to tissue injury. The administration of LPS to mice can result in manifestations of septic shock, which is dependent on TLR4.[32] Evidence suggests that TLR2 activation by *Propionibacterium acnes* induces inflammatory responses in acne vulgaris, which lead to tissue injury.[67] Aliprantis et al demonstrated that microbial lipoproteins induce features of apoptosis via TLR2.[40] Thus, microbial lipoproteins have the ability to elicit both TLR-dependent activation of host defense and tissue pathology. This dual signaling pathway is similar to TNF receptor and CD40 signaling, which leads to both nuclear factor-κB activation and apoptosis.[68,69] In this manner, it is possible for the immune system to use the same molecules to activate host defense mechanisms and then, by apoptosis, to downregulate the response from causing tissue injury. Activation of TLR can lead to the inhibition of the major histocompatibility complex (MHC) class II antigen presentation pathway, which can downregulate immune responses leading to tissue injury but may also contribute to immunosuppression.[70] Finally, Toll activation has been implicated in bone destruction.[52]

The critical biologic role of TLRs in human host defense can be deduced from the finding that TLR4 mutations are associated with LPS hyporesponsiveness in humans.[71] By inference, one can anticipate that humans with genetic alterations in TLR may have increased susceptibility to certain microbial infections. Furthermore, it should be possible to exploit the pathway of TLR activation as a means to endorse immune responses in vaccines and treatments for infectious diseases as well as to abrogate responses detrimental to the host.

CELLS OF THE INNATE IMMUNE SYSTEM

PHAGOCYTES. Two key cells of the innate immune system are characterized by their phagocytic function:

macrophages and PMNs. These cells have the capacity to take up pathogens, recognize them, and destroy them. Some of the functions of these cells are regulated via TLRs and complement receptors as outlined earlier.

PMNs are normally not present in skin; however, during inflammatory processes, these cells migrate to the site of infection and inflammation, where they are the earliest phagocytic cells to be recruited. These cells have receptors that recognize pathogens directly (see Pattern Recognition Receptors), and due to their expression of FcγRIII/CD16 and C3bR/CD35, can phagocytose microbes coated with antibody and with the complement component C3b. As a consequence, granules (containing myeloperoxidase, elastase, lactoferrin, collagenase, and other enzymes) are released, and microbicidal superoxide radicals (O_2^-) are generated (see Chapter 30).

Effector Functions of Phagocytes. Activation of phagocytes by pathogens induces several important effector mechanisms, for example, triggering of cytokine production. A number of important cytokines are secreted by macrophages in response to microbes, including IL-1, IL-6, TNF-α, IL-8, IL-12, and IL-10 (see also Chapter 11).

Another important defense mechanism triggered in phagocytes in response to pathogens is the induction of direct antimicrobial responses. Phagocytic cells such as PMNs and macrophages recognize pathogens, engulf them, and induce antimicrobial effector mechanisms to kill the pathogens. The induction and/or release of toxic oxygen radicals, lysosomal enzymes, and antimicrobial peptides leads to direct killing of microbial organisms.[4] Similarly, activation of TLRs on macrophages induces these various antimicrobial pathways as already discussed above.

Macrophage Subsets and Functional Programs. Cytokines of the adaptive T-cell response influence macrophage differentiation: IFN-γ treatment results in "classically activated" macrophages, with antimicrobial activity, whereas in contrast IL-4 or IL-13 triggers differentiation into "alternatively activated" macrophages, which contribute to humoral and antiparasite immunity.[82,83] Cytokines produced by the innate immune response also induce distinct macrophage differentiation programs.[84] IL-10 induces the phagocytic program in macrophages, leading to the uptake of lipids and bacteria. In contrast, IL-15 induces a macrophage antimicrobial program. These data establish that the innate immune response, by selectively inducing IL-10 versus IL-15, differentially programs macrophages for phagocytosis versus antimicrobial responses that largely determines the outcome of infection.

Phagocytic cells of the innate immune system can also be activated by cells of the adaptive immune system. CD40 is a 50-κDa glycoprotein present on the surface of B cells, monocytes, DCs, and endothelial cells. The ligand for CD40 is CD40L, a type II membrane protein of 33 kDa, preferentially expressed on activated $CD4^+$ T cells and mast cells. CD40–CD40 ligand interaction plays a crucial role in the development of effector functions. $CD4^+$ T cells activate macrophages and monocytes to produce TNF-α, IL-1, IL-12, interferon-γ (IFN-γ), and NO via CD40–CD40L interaction. CD40L has also been shown to rescue circulating monocytes from apoptotic death, thus prolonging their survival at the site of inflammation. In addition, CD40–CD40L interaction during T-cell activation by APCs results in IL-12 production. Therefore, it can be concluded that CD40–CD40L interactions between T cells and macrophages play a role in maintenance of T1-type cellular responses and mediation of inflammatory responses. Other studies have established a role for CD40–CD40L interactions in B-cell activation, differentiation, and Ig class switching.[85] In addition, CD40–CD40L interaction leads to upregulation of B7.1 (CD80) and B7.2 (CD86) on B cells. This costimulatory activity induced on B cells then acts to amplify the response of T cells. These mechanisms underscore the importance of the interplay between the innate and the adaptive immune system in generating an effective host response.

NATURAL KILLER CELLS.[86] NK cells appear as large granular lymphocytes. In humans, the vast majority of these cells exhibit the $CD3^-$, $CD56^+$, $CD16^+$, $CD94^+$, and $CD161^+$ phenotype. Their function is to survey the body looking for altered cells, be they transformed or infected with viruses (e.g., cytomegalovirus), bacteria (e.g., *Listeria monocytogenes*), or parasites (e.g., *Toxoplasma gondii*). These pathogens are then killed directly via perforin/granzyme- or Fas/Fas ligand (FasL)-dependent mechanisms or indirectly via the secretion of cytokines (e.g., IFN-γ).

How Do NK Cells Discriminate Between Normal and Transformed or Pathogen-Infected Tissue? All nucleated cells express the MHC class I molecules. NK cells have receptors, termed *killer inhibitory receptors*, which recognize the self-MHC class I molecules. This recognition results in the delivery of a negative signal to the NK cell that paralyzes it. If a nucleated cell loses expression of its MHC class I molecules, however, as often happens after malignant transformation or virus infection, the NK cell, on encountering it, will become activated and kill it.

In addition, NK cells have activating receptors that bind MHC-like ligands on target cells. One such receptor is NKGD2, which binds to the human nonclassic MHC class I chain-related A and B molecules, MICA and MICB.[87] MICA and MICB are not expressed in substantial amounts on normal tissues, but are overexpressed on carcinomas.[88] NK cells are able to kill MICA/MICB-bearing tumors, which suggests a role for NKGD2 in immune surveillance.

Another cell type that, at least in mice, could serve a similar function is the IFN-producing killer DC, which shares several features with DCs and NK cells.[89,90] Their human equivalent has yet to be identified.

KERATINOCYTES. Once thought to only play a role in maintaining the physical barrier of the skin, keratinocytes, the predominant cells in the epidermis, can participate in innate immunity by mounting

an immune and/or inflammatory response through secretion of cytokines and chemokines, arachidonic acid metabolites, complement components, and antimicrobial peptides.

Keratinocytes of unperturbed skin produce only a few of these mediators, such as the cytokines IL-1, IL-7, and transforming growth factor-β (TGF-β), constitutively. Resident keratinocytes contain large quantities of preformed and biologically active IL-1α as well as immature IL-1β in their cytoplasm.[91] The likely in vivo role of this stored intracellular IL-1 is that of an immediate initiator of inflammatory and repair processes after epidermal injury. IL-7 is an important lymphocyte growth factor that may have a role in the survival and proliferation of the T lymphocytes of human skin. Some evidence exists for the IL-7-driven propagation of lymphoma cells in Sézary syndrome.

TGF-β, in addition to its growth-regulating effects on keratinocytes and fibroblasts, modulates the inflammatory as well as the immune response[92] and is important for LC development (see in Langerhans Cells).[93] On delivery of certain noxious, or at least potentially hazardous, stimuli (e.g., hypoxia, trauma, nonionizing radiation, haptens, or other rapidly reactive chemicals like poison ivy catechols, silica, LPS, and microbial toxins), the production and/or release of many cytokines is often dramatically enhanced. The biologic consequences of this event are manifold and include the initiation of inflammation (IL-1, TNF-α, IL-6, members of the chemokine family), the modulation of LC phenotype and function (IL-1, GM-CSF, TNF-α, IL-10, IL-15), T-cell activation (IL-15, IL-18),[94,95] T-cell inhibition (IL-10, TGF-β),[96] and skewing of the lymphocytic response in either the type 1 (IL-12, IL-18),[97] type 2 (thymic stromal lymphopoietin),[98] or Th17 (IL-23) direction.[99] In some cases, keratinocytes may also play a role in amplifying inflammatory signals in the epidermis originating from numerically minor epidermal cell subsets. One prominent example is the induction of proinflammatory cytokines such as TNF-α in keratinocytes by LC-derived IL-1β in the initiation phase of allergic contact dermatitis.[100] In the presence of a robust stimulus, keratinocyte-derived cytokines may be released into the circulation in quantities that cause systemic effects. During a severe sunburn reaction, for example, serum levels of IL-1, IL-6, and TNF-α are clearly elevated and probably responsible for the systemic manifestations of this reaction, such as fever, leukocytosis, and the production of acute-phase proteins.[101] There is also evidence that the ultraviolet (UV) radiation-inducible cytokines IL-6 and IL-10 can induce the production of autoantibodies and thus be involved in the exacerbation of autoimmune diseases such as lupus erythematosus. The fact that secreted products of keratinocytes can reach the circulation could conceivably also be used for therapeutic purposes. The demonstration by Fenjves et al[102] that grafting of apolipoprotein E gene-transfected human keratinocytes onto mice results in the detection of apolipoprotein E in the circulation of the mouse supports the feasibility of such an approach.

Some of the innate functions of keratinocytes can be elicited by TLR activation, since keratinocytes express TLRs 1–6 and 9. Thus, by sensing microbial pathogens via TLRs, keratinocytes may act as first-responders in cutaneous innate immunity. Activation of TLRs leads to keratinocyte production of proinflammatory cytokines (including TNF-α and IL-8), antimicrobial peptides (HBD-2 and HBD-3), and reactive oxygen mediators (iNOS).[103–105] Activation of TLR3 and TLR9 on keratinocytes induces production of type I interferon (IFN-α/β), which may be important in promoting antiviral immune responses.[105] Lastly, these TLR-mediated responses can be enhanced via danger signals such as toxins, irritants, UV light, purines generated during an infection (P2×7 receptor activation), and activation of other pattern-recognition receptors (NOD1 and NOD2), which all promote inflammasome-mediated activation of caspase-1 that results in cleavage of pro-IL-1β into its active form.[106]

Another important function of keratinocytes is the production/secretion of factors governing the influx and efflux of leukocytes into and out of the skin. Two good examples are the chemokines thymus and activation-regulated chemokine (TARC; CC chemokine ligand 17, or CCL17) and cutaneous T cell-attracting chemokine (CTACK)/CCL27 and their corresponding receptors CCR4 and CCR10, selectively expressed on skin-homing T lymphocytes. Blocking of both chemokines drastically inhibits the migration of T cells to the skin in a murine model of contact hypersensitivity (CHS).[107] KC-derived macrophage inflammatory protein 3α (MIP-3α)/CCL20 also plays an important role in leukocyte recruitment to the epidermis. Its secretion is triggered or enhanced by IL-17 and its counterreceptor CCR6 is present on LC precursors and certain T cells.[108–110] The T17 cytokines, IL-17, IL-21, and IL-22 also modulate other keratinocyte innate immune functions. For example, IL-17 and IL-22 promote keratinocyte production of antimicrobial peptides, including HBD-2, cathelicidin, and psoriasin.[111,112] In addition, IL-21 and IL-22 induce keratinocyte proliferation, leading to epidermal hyperplasia and acanthosis as seen in psoriasis.[113,114]

The demonstration of cytokine receptors on and cytokine responsiveness of keratinocytes established that the functional properties of these cells can be subject to regulation by cells of the immune system. As a consequence, keratinocytes express, or are induced to express, immunologically relevant surface moieties that can be targeted by leukocytes for stimulatory or inhibitory signal transduction.

In addition to cytokines, keratinocytes secrete other factors such as neuropeptides, eicosanoids, and reactive oxygen species. These mediators have potent inflammatory and immunomodulatory properties and play an important role in the pathogenesis of cutaneous inflammatory and infectious diseases as well as in aging.

Keratinocytes synthesize complement and related receptors including the C3b receptor [complement receptor 1 (CR1), CD35], the Epstein-Barr virus receptor CR2 (C3d receptor, CD21), the C5a receptor (CD88), the membrane cofactor protein (CD46), the decay-accelerating factor (CD55), and complement protectin (CD59). CD59 may protect keratinocytes from attack by complement. Its engagement by CD2 stimulates the

secretion of proinflammatory cytokines from keratinocytes. Membrane cofactor (CD46) is reported to be a receptor for M protein of group A *Streptococci* and for measles virus.[115] Its ligation induces proinflammatory cytokines in keratinocytes such as IL-1α, IL-6, and GM-CSF.

ADAPTIVE IMMUNE RESPONSE

The strength and the type of the innate response determines both the quantity and quality of an adaptive response initiated by dendritic APCs in the epidermis (LCs) and dermis (dermal DCs or DDCs) and executed by T lymphocytes and antibodies.

LYMPHOCYTES

Three subsets of lymphocytes exist in the human immune system: B cells, T cells, and NK cells (see Section "Cells of the Innate Immune System"). The adaptive immune response is mediated by T and B lymphocytes. The unique role of these cells is the ability to recognize antigenic specificities in all their diversity. All lymphocytes derive from a common bone marrow stem cell. This finding has been exploited in various clinical settings, with attempts to restore the entire lymphocyte pool by bone marrow or stem cell transplantation.

B CELLS. B cells mature in the fetal liver and adult bone marrow. They produce antibody-protein complexes that bind specifically to particular molecules defined as antigens. As a consequence of recombinatorial events in different Ig gene segments (V or variable; D or diversity; J or joining), each B cell produces a different antibody molecule (eFig. 10-3.1 in online edition). Some of this antibody is present on the surface of the B cell, conferring the unique ability of that B cell to recognize a specific antigen. B cells then differentiate into plasma cells, the actual antibody-producing and -secreting cells. Plasma-cell secreted Ig comprise the dimer IgA, the monomers IgD, IgE, and IgG as well as the pentamer IgM that mediate humoral immune responses. In general, antibodies bind to microbial agents and neutralize them or facilitate uptake of the pathogen by phagocytes that destroy them. Briefly, IgA can be found in mucosal tissues, saliva, tears, or breast milk and prevents colonization by various pathogens. IgD functions mainly as an antigen receptor on B cells and, as recently discovered, activates mast cells and basophils to produce antimicrobial factors.[116] IgE binds to allergens on mast cells and basophils and can thereby trigger histamine release and allergic reactions including anaphylaxis and urticaria. In addition, some evidence exists that it can protect against parasitic and helminthic infections. IgG provides the majority of antibody responses that contribute to the immune defense against extracellular pathogens. It is the only antibody that is capable of crossing the placenta in order to protect the fetus. Finally, IgM is available either surface-bound on B cells or as secreted form and eliminates microbes in the early stages of humoral immunity before there is sufficient IgG production. Antibodies are also responsible for mediating certain pathologic conditions in skin. In particular, antibodies against self-antigens (mostly IgG, but also IgA) lead to autoimmune disease, typified in the pathogenesis of pemphigus and bullous pemphigoid (see Chapter 37 for more details about B cells and antibody production).

T CELLS. T cells mature in the thymus, where they are selected to live or to die. Those T cells that will have the capacity to recognize foreign antigens are positively selected and can enter the circulation. Those T cells that react to self are negatively selected and destroyed. T cells have the unique ability to direct other cells of the immune system. They do this, in part, by releasing cytokines. For example, T cells contribute to cell-mediated immunity (CMI), required to eliminate intracellular pathogens, by releasing cytokines that activate macrophages and other T cells. T cells release cytokines that activate NK cells and permit the growth, differentiation, and activation of B cells.

T cells can be classified and subdivided in different ways: (1) on the basis of the T cell receptor; (2) on the basis of the accessory molecules CD4 and CD8; (3) on the basis of their virginity, i.e., their activation status (naive, memory, effector T cells); and (4) on the basis of their functional role in the immune response, which is often linked to the cytokine secretion property of the respective cell population. We have used the abbreviations Th1 and Th2 to distinguish $CD4^+$ helper T cell subtypes but, as discussed below, many of the functional attributes, including cytokine production, of Th cells are not as clearly defined as previously thought and some cytokine profiles are also attributable to $CD8^+$ cytotoxic T cells (Tc) (see Section "Functionality").

T-Cell Antigen Receptor (TCR). The T-cell antigen receptor (TCR) is a complex of molecules consisting of an antigen-binding heterodimer (α/β or γ/δ chains) that is noncovalently linked with five CD3 subunits [(1) γ, (2) δ, (3) ε, (4) ζ, or (5) η). The TCR chains have amino acid sequence homology with structural similarities to Ig heavy and light chains. The genes encoding TCR molecules are encoded as clusters of gene segments (V, J, D, C, or constant) that rearrange during T-cell maturation (eFig. 10-3.1 in online edition). Together with the addition of nucleotides at the junction of rearranged gene segments, this recombinatorial process, which involves the enzymes recombinase activating gene 1 and 2, results in a heterogeneity and diversity of the antigen recognition unit that is broad enough to allow for a successful host defense. TCR α/β or TCR γ/δ molecules must be paired with CD3 molecules to be inserted into the T-cell surface membrane[117] (see Fig. 10-4). The TCR chains form the actual antigen-binding unit, whereas the CD3 complex mediates signal transduction, which results in either productive activation or nonproductive silencing of the T lymphocyte. Most T cells express α/β TCRs, which typically bind antigenic peptides presented by MHC molecules. Immunity provided by α/β T cells includes Th1, Th2, Th17 and T reg responses (see Section "Functionality").

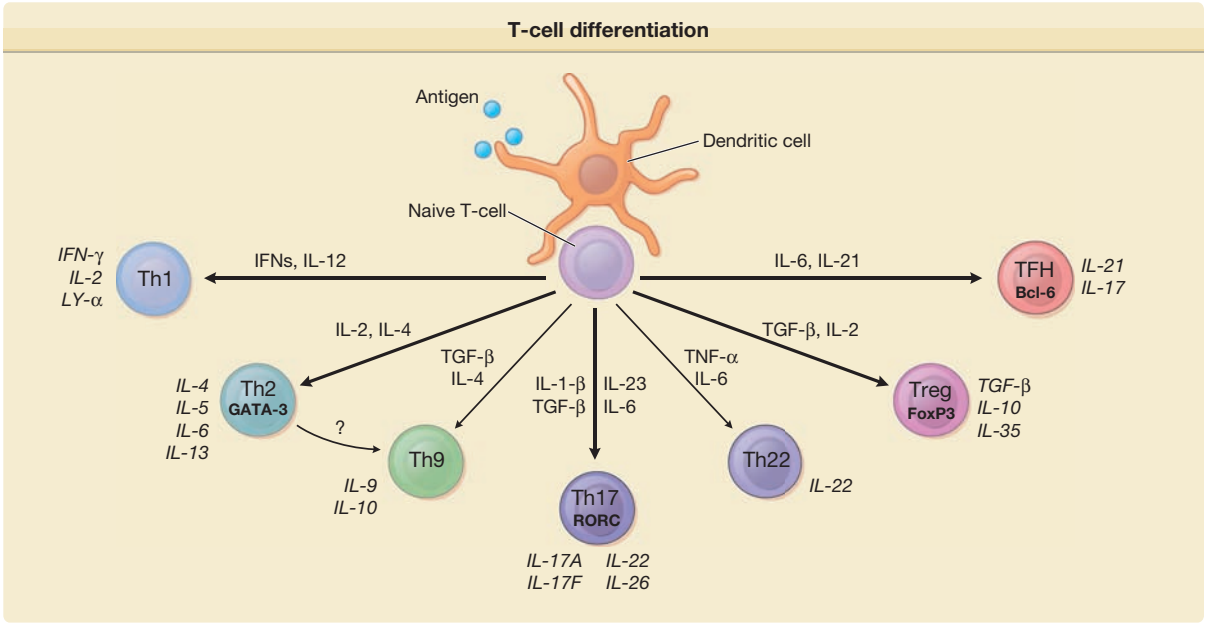

Figure 10-4 Schematic view of events governing and occurring in T-cell differentiation. Depending on the type and activation status of the antigen-presenting dendritic cells (DCs) and on the type and amounts of cytokines secreted by these and/or other cells, naive T cells will expand and differentiate into various directions, i.e., Th1 cells, Th2 cells, Th9 cells, Th17 cells, Th22 cells, T reg cells, and Tfh cells. They exhibit different types of transcription factors (e.g., T-bet, GATA-3, RORC, FoxP3, Bcl-6) and secrete different types of cytokines.

In contrast, only a small subset of T cells express γ/δ TCRs. These T cells have the capacity to directly bind pathogen-derived glycoproteins or nonclassical MHC molecules. It has been shown that γ/δ T cells in men and mice predominantly display a tissue-associated TCR repertoire as well as a memory phenotype, both probably due to chronical stimulation by nonpeptide antigens within the tissue. Importantly, they act early during immune response and are therefore termed "innate-like effectors." Previous studies conducted in mice infected with *Listeria monocytogenes* or *Nippostrongylus brasiliensis* revealed that $\tilde{\gamma}/\delta$ T cells discriminate early between these pathogens and react by IFN-γ versus IL-4 production, skewing $\tilde{\alpha}/\beta$ T-cell responses in a Th1 or Th2 direction, respectively.[118] Meanwhile, growing evidence exists that human and murine $\tilde{\gamma}/\delta$ T cells also have the capacity to produce IL-17 during bacterial or viral infections and thereby significantly contribute to the early innate immune defense.[119–121]

CD4⁺ Helper T Cells. The original observation that CD4⁺ T cells are critical for helping B cells to produce antibodies by triggering their differentiation into plasma cells in the humoral response coined the term "T helper cells" (Th cells). During the past years these lymphocytes have been characterized extensively. To our current knowledge, CD4⁺ T cells represent a heterogeneous cell population with diverse function depending on environmental requirements that play a central role in humoral and cell-mediated immunity. Effector CD4⁺ T cells protect against pathogens mainly by their production of Th1, Th2, or Th17 cytokines (i.e., IFN-γ, IL-4, IL-17) and influence immune responses through both "helper" and "effector" functions. In contrast, regulatory CD4⁺ T cells have the capacity to downregulate disproportionate effector responses to (self-) antigen (see Section "Functionality").

CD8⁺ Cytotoxic T Cells. In responding to an intracellular pathogen (e.g., a virus) the T cell must lyse the infected cell. To do so, it must be able to recognize and respond to antigenic peptides encoded by this pathogen and displayed on the cell surface. For this to occur, antigens arising in the cytosol are cleaved into small peptides by a complex of proteases, called the *proteasome*. The peptide fragments are then transported from the cytosol into the lumen of the endoplasmic reticulum, where they associate with MHC class I molecules. These peptide–class I complexes are exported to the Golgi apparatus and then to the cell surface (see Section "General Principles of Antigen Presentation"). The maturation of a CD8⁺ T cell to a killer T cell requires not only the display of the antigenic signal but also the delivery of helper signals from CD4⁺ T cells, for which the functional interaction between CD40 on the APC and CD40L on the CD8⁺ T cell can substitute.

VIRGINITY

Naive T Cells. After positive selection in the thymus, mature T cells with low affinity for self-peptide/MHC molecules are released into the blood stream and form the long-lived pool of naive T cells. In order to survive, naive T cells require IL-7 signaling and a low level of self-reactivity entertained by constant TCR engagement with self-p/MHC molecules.[145]

Functionality. With regard to the functional capacities of various T-cell subsets, it was originally assumed that $CD4^+$ cells predominantly subserve helper functions and that $CD8^+$ cells act as killer cells. Many exceptions to this rule are now known to exist; for example, both $CD4^+$ and $CD8^+$ regulatory cells are found, but $CD4^+$ cells are still commonly referred to as helper T cells (Th cells) and $CD8^+$ cells as cytotoxic T cells (Tc cells).

During an immune response, naive Th/Tc cells can differentiate into several functional classes of cells: (1) Th1 cells (type 1 T cells); (2) Th2 cells (type 2 T cells); (3) Th17 cells; (4) natural killer T cells (NKT); (5) regulatory T cells (T reg); and (6) T follicular helper (Tfh) cells (Fig. 10-4). Originally, all these T-cell subsets have mainly been defined as $CD4^+$ Th cells. In the meantime we have learned that both $CD4^+$ Th and $CD8^+$ Tc cells can produce cytokines allowing their classification into these distinct T-cell subsets. The functional commitment of effector T-cell populations is controlled by the expression of lineage-specific transcription factors, but individual T cells can also express cytokines that are not lineage-specific. It therefore remains to be determined whether T cells display heterogeneity within a lineage or whether each distinct cytokine-expression pattern already reflects a separate lineage. It seems that T cells, although already polarized, still possess a high degree of functional plasticity that allows further differentiation depending on various factors such as the strength of antigenic signaling, cytokines, or interactions with other cells encountered in their microenvironment.[155]

T HELPER 1/T HELPER 2 PARADIGM. T cells that produce IL-2, IFN-γ, and TNF are termed *Th1 cells*. They are the main carriers of cell-mediated immunity (CMI). Other T cells produce IL-4, IL-5, IL-6, IL-13, and IL-15. These are termed *Th2 cells* and are primarily responsible for extracellular immunity (see below).[160,161] Many factors influence whether an uncommitted T cell develops into a mature Th1 or Th2 cell. The cytokines IL-12 and IL-4, acting through signal transducer and activator of transcription (STAT) 4 and 6, respectively, are key determinants of the outcome, as are antigen dose, level of costimulation, and genetic modifiers. Certain transcription factors have causal roles in the gene-expression programs of Th1 and Th2 cells. For example, the T-box transcription factor T-bet is centrally involved in Th1 development, inducing both transcriptional competence of the IFN-γ locus and selective responsiveness to the growth factor IL-12.[162] By contrast, the zinc-finger transcription factor GATA-3 seems to be crucial for inducing certain key attributes of Th2 cells, such as the transcriptional competence of the Th2 cytokine cluster, which includes the genes encoding IL-4, IL-5, and IL-13.[163,164]

In murine models of intracellular infection, resistant versus susceptible immune responses appear to be regulated by these two T-cell subpopulations.[165–167] Th1 cells, primarily by the release of IFN-γ, activate macrophages to kill or inhibit the growth of the pathogen and trigger cytotoxic T-cell responses, which results in mild or self-curing disease. In contrast, Th2 cells facilitate humoral responses and inhibit some cell-mediated immune responses, which results in progressive infection. These cytokine patterns are cross-regulatory. The Th1 cytokine IFN-γ downregulates Th2 responses. The Th2 cytokines IL-4 and IL-10 downregulate both Th1 responses and macrophage function. The result is that the host responds in an efficient manner to a given pathogen by making either a Th1 or Th2 response. Sometimes, the host chooses an inappropriate cytokine pattern, which results in clinical disease.

Of particular interest to immunologists is the delineation of factors that influence the T-cell cytokine pattern. The innate immune response is one important factor involved in determining the type of T-cell cytokine response.

The ability of the innate immune response to induce the development of a Th1 response is mediated by release of IL-12, a 70-kDa heterodimeric protein.[168] For example, in response to various pathogens, APCs including DCs and macrophages release IL-12, which acts on NK cells to release IFN-γ. The presence of IL-12, IL-2, and IFN-γ, with the relative lack of IL-4, facilitates Th1 responses. In contrast, in response to allergens or extracellular pathogens, mast cells or basophils release IL-4, which in the absence of IFN-γ leads to differentiation of T cells along the Th2 pathway. It is intriguing to speculate that keratinocytes may also influence the nature of the T-cell cytokine response. Keratinocytes can produce IL-10, particularly after exposure to UVB radiation.[96] The released IL-10 can specifically downregulate T1 responses, thus facilitating the development of Th2 responses.

Th17 CELLS.[169] Not every T-cell-mediated immune response and/or disease can be easily explained by the T1/T2 paradigm. Certain T-cell subpopulations are characterized by the secretion of IL-17. These cells are therefore termed *Th17 cells*. It was originally assumed that Th1 and Th17 cells arise from a common T1 precursor, but it now appears that Th17 cells are a completely separate and early lineage of effector $CD4^+$ T cells produced directly from naive $CD4^+$ T cells. This was proven by the identification of the Th17-specific transcription factor ROR (RAR-related orphan nuclear receptor) that regulates the expression of IL-17, IL-23R, and CCR6 in Th17 cells.[170] The expression of CCR6 is unique for Th17 cells amongst T cells and regulates their migration into epithelial sites depending on its ligand CCL20.[171] Recently, it has been demonstrated that Th17 cells may originate from a small subset of $CD4^+$ T cells bearing the NK-cell-associated *C*-type lectin NKP-1A (CD161), which are present in cord blood and newborn thymus.[172] Differentiation of human Th17 cells strongly depends on IL-23, a member of the IL-12 family, as well as on IL-1β, IL-6, and low doses of TGF-β[173,174]; murine Th17-lineage commitment is mainly induced by IL-6 and TGF-β. Importantly, the induction of Th17 cells from naive precursors may be inhibited by IFN-γ and IL-4, using a cross-regulatory mechanism between Th1, Th2, and Th17 cells. One of the main physiological roles of Th17 cells is to promote protection against fungi, protozoa, viruses, and various extracellular bacteria, but Th17 cells have also been

linked to a growing list of autoimmune and inflammatory diseases such as neuroinflammatory disorders, asthma, lupus erythematosus, rheumatoid arthritis, Crohn's disease and, most notably, psoriasis.[99,175] Very recent evidence exists that Th17 cells might also play a role in antitumor immunity.[176] Importantly, IL-17 expression is not restricted to $CD4^+$ cells only, but has also been detected in $CD8^+$ T cells.[177] Th17 cells exert their function by producing effector cytokines including IL-17A, IL-17F, IL-22, and IL-26. Whereas IL-17 is believed to contribute to the pathogenesis of these diseases by acting as potent proinflammatory mediator, IL-22 has been described as a multifunctional cytokine with inflammatory as well as protective properties. In vitro stimulation of normal keratinocytes with IL-22, for example, results in inhibition of keratinocyte differentiation followed by epidermal hyperplasia and upregulated expression of proinflammatory genes in these cells.[178]

REGULATORY T CELLS. An important type of immunomodulatory T cells that controls immune responses are the so-called *regulatory T cells (T reg cells)*, formerly known as *T suppressor cells*.[181] T reg cells are induced by immature APCs/DCs and play key roles in maintaining tolerance to self-antigens in the periphery. Loss of T reg cells is the cause of organ-specific autoimmunity in mice that results in thyroiditis, adrenalitis, oophoritis/orchitis, etc. T reg cells are also critical for controlling the magnitude and duration of immune responses to microbes. Under normal circumstances, the initial antimicrobial immune response results in the elimination of the pathogenic microorganism and is then followed by an activation of T reg cells to suppress the antimicrobial response and prevent host injury. Some microorganisms (e.g., *Leishmania* parasites, mycobacteria) have developed the capacity to induce an immune reaction in which the T reg component dominates the effector response. This situation prevents elimination of the microbe and results in chronic infection.

The best-characterized T reg subset is the $CD4^+$/$CD25^+$/CTLA-4^+/$GITR^+$ (glucocorticoid-induced TNF receptor family-related gene)/$FoxP3^+$ lymphocytes.[182] The transcription factor FoxP3 is specifically linked to the suppressor function, as evidenced by the findings that mutations in the *FoxP3* gene cause the fatal autoimmune and inflammatory disorder of scurfy in mice and IPEX (*i*mmune dysregulation, *p*olyendocrinopathy, *e*nteropathy, *X*-linked) in humans. The cytokines TGF-β and IL-10 are thought to be the main mediators of suppression.

During the past years the situation has become even more complicated, because, at least under certain conditions, subsets with different phenotypes have been associated with regulatory functions such as $CD4^+$, $CD8^+$, and NKT cells. Accordingly, the existence of T reg cells coexpressing IL-17 and FoxP3 has been described.[183] $CD8^+$ cells can also be activated to become suppressor cells by antigenic peptides that are presented in the context of an MHC class Ib molecule [Qa1 in mice; human leukocyte antigen E (HLA-E) in humans]. $CD8^+$ T reg cells suppress T cells that have intermediate affinity for self or foreign antigens and are primarily involved in self–nonself discrimination. In addition, recent data provides evidence for a suppressive function of human FoxP3-, TGf-β-producing γ/δ T cells.[184]

T FOLLICULAR HELPER (Tfh) CELLS. Tfh cells represent a distinct subset of $CD4^+$ T cells found in limited numbers, especially in B-cell areas of lymph nodes and spleen.

Homing and long-term residency in B-cell follicles of these newly described T cells is secured by their surface expression of CXCR5. They have a crucial role in orchestrating T-cell-dependent effector and memory B-cell responses, produce IL-21 and express inducible T-cell costimulator (ICOS) and programed cell death 1 (PD-1) as costimulatory and coinhibitory molecules, respectively. Specific differentiation of Tfh cells was associated to the transcription factor Bcl6 as well as to the cytokines IL-6 and IL-21.[185–187]

LYMPHOCYTES IN NORMAL AND DISEASED SKIN. As opposed to normal mouse skin, in which a resident population of dendritic epidermal T cells uniformly equipped with a nonpolymorphic, canonical $\tilde{\gamma}\delta$ TCR exists, the lymphocytes of normal human skin are mainly located in the dermis and predominantly express the $\tilde{\alpha}\beta$ TCR rather than the γ/δ TCR. While the majority of epidermal T cells exhibit the $CD8^+$/$CD4^-$ phenotype, dermal T cells are mainly $CD4^+$/$CD8^-$, belong to the CD45RO memory population, express the addressins CLA (cutaneous lymphocyte antigen) and CCR4 which they use for skin-homing purposes,[188] and are largely devoid of CCR7 and L-selectin, i.e., addressins promoting the homing of lymphocytes to the lymphoid organs.[152,189] This situation is true also for homeostatic conditions which means that a cutaneous pool of effector memory cells is already in place when danger is imminent. Some of these effector memory T cells have a rather long life span and have been found in different skin conditions, for example, at sites of HSV infection of mice [190,191] and men[192] as well as in clinically resolved, hyperpigmented fixed drug eruptions.[193]

Normal human skin contains approximately 1 million T cells per cm^2, 2%–3% of which reside within the epidermis,[194] primarily in the basal and suprabasal layers. The T cells of the dermis are preferentially clustered around postcapillary venules of the superficial plexus high in the papillary dermis and are often situated just beneath the dermal–epidermal junction and within, or in close proximity to, adnexal appendages such as hair follicles and eccrine sweat ducts.

The process of T-cell trafficking to the skin is guided by a series of receptor–ligand interactions between cells. It is of note that DCs are capable of imprinting homing receptor expression on T cells,[195] which means that T cells programed by skin and/or skin-derived DCs will preferentially return to the skin. One such moiety is the glycoprotein cutaneous lymphocyte antigen (CLA) that defines a subset of memory T cells that home to skin. It is a glycosylated form of P-selectin–glycoprotein ligand 1 that is expressed constitutively

on all human peripheral blood T cells. The level of CLA on cells is regulated by an enzyme, α (1,3)-fucosyltransferase VII, which modifies P-selectin glycoprotein ligand 1. In this manner, CLA+ cells bind to both E-selectin and P-selectin, whereas CLA^- cells bind P-selectin, but not E-selectin.[196,197] The chemokine–chemokine receptor system is the other major regulator and coordinator of leukocyte migration to the skin (see Chapter 12).

SKIN HOMING OF MEMORY T CELLS. Of particular importance for skin homing of memory T cells, independent of their polarization, is the interaction of CCL17 and CCL22 with CCR4 and of CCL27 with its counterreceptor CCR10 on CLA+ T cells. CCL17 is synthesized by activated keratinocytes, DCs and endothelial cells of the skin, while CCL22 is mainly of macrophage and DC origin. The CCR10 ligand, CCR27, appears to be exclusively produced by epidermal keratinocytes.[198] Although it was originally assumed that functionally different T-cell subsets can be distinguished from each other by their chemokine receptor expression pattern and their responsiveness to the respective chemokines, the situation is less clear now. Reportedly, T1 cells selectively bear CXCR3 and CCR5, T2 cells preferentially exhibit CCR8 and CCR3, and T17 as well as T reg express CCR6, allowing them to respond to the keratinocyte- and endothelial cell-derived chemokine CCL20.[199,200]

From all that has been said so far, one can surmise that the accumulation of T cells in skin is not stochastic. This is indeed the case as exemplified by the dominance of $CD8^+$ T cells in skin lesions, but not in the peripheral blood of patients with lepromatous leprosy[201] as well as by the clonality of the T-cell population in cutaneous T-cell lymphoma, in which a single V gene usage is found to predominate in different skin lesions from the same individual.[202,203] A limited TCR V gene usage has also been reported to be present in skin lesions of leprosy,[204] psoriasis,[205] basal cell carcinoma, and countless other reactions in which T cells are present.

The most direct indication of relevant T-cell populations in skin is determination of the number of antigen-specific T cells. It has been documented that 1 in 1,000 to 1 in 10,000 T cells in the peripheral blood, but only 1 in 50 to 1 in 100 T cells recognize the antigen causing the disease at sites of inflammation.[206,207] Thus, there is as much as a 100-fold enrichment of antigen-reactive T cells at the site of cutaneous inflammation.

With regard to survival and/or expansion of T cells of human skin/epidermis, it appears that IL-2, IL-7, and IL-15 play important roles.[208] Notably, the latter two T-cell growth factors can be produced by human epidermal cells, and all of them are frequently overexpressed in T cell-rich skin lesions, for example, in patients with tuberculoid leprosy. For a long period of time, the Th1/Th2 paradigm was used to explain the pathogenesis and, more often, the course of infectious, inflammatory and, even, neoplastic skin diseases. Leprosy and leishmaniasis are outstanding examples of diseases in which the clinical manifestations are decisively determined by the dominance of either Th1 or Th2 cells. With the identification of new function-based T-cell subpopulations (e.g., T0 cells, Th17 cells, Th22 cells), this classification is too rigid and no longer tenable. In fact, we come to realize that the T-cell pathogenesis of certain diseases that we had originally considered to belong into either the Th1 (e.g., psoriasis, allergic contact dermatitis) or the Th2 world (atopic dermatitis) is very complex and sometimes even stage-specific. Th17 and/or Th22 cells are apparently major players in psoriasis[158] and allergic contact dermatitis.[177] In atopic dermatitis, the acute lesions harbor not only Th2, but also Th17 and Th22 cells; in the chronic stage, however, Th1 cells seem to predominate. In syphilis, perhaps not only Th1 cells, but also $CD8^+$IFN-γ-producing Th17 cells do confer immunologic resistance to T. pallidum.[209,210] Th17 cells may also be important in the pathogenesis of *Borrelia burgdorferi*-induced Lyme arthritis, which was long attributed to be a solely Th1 cell-mediated response.[211,212] In patients with cutaneous T cell lymphoma (CTCL), Th2 responses dominate the inflammatory infiltrate of the skin, especially at late stages.[213] In early lesions, however, infiltrating $CD3^+CD45RO^+CLA^+CCR4^+$ T cells also express IFN-γ and IL-17 (see Chapter 145). In basal cell carcinomas the presence of a Th2-dominated environment with an increased expression of IL-4 and IL-10 as well as tumor-surrounding T reg cells may be responsible for tumor growth[214] (see Chapter 115). In alopecia areata, recent data suggest a role for Th1 cells.[215]

ANTIGEN PRESENTING CELLS

While lymphocytes are the only cells capable of recognizing antigenic moieties, the recognition process per se, at least as far as T cells are concerned, is dependent on the presence of antigen-presenting cells (APC). Unlike B cells, T cells cannot recognize soluble protein antigen per se; their antigen receptor (TCR) is designed to recognize antigen-derived peptides bound to MHC locus-encoded molecules expressed by APCs. Most $CD8^+$ T cells, destined to become cytotoxic T cells, recognize the endogenous antigen in association with MHC class I molecules.[216] Because most nucleated cells transcribe and express MHC class I genes and gene products, it is evident that many cell types can serve as APCs for MHC class I-restricted antigen presentation and/or as targets for MHC class I-dependent attack by T cells. For the antigen-specific activation of $CD4^+$ T cells, exogenous antigen-derived peptides are usually presented in the context of MHC class II molecules.[216] In this situation, peptides are generated in the endocytic, endosomal/lysosomal pathway and are bound to MHC class II molecules. The resulting MHC-peptide complex is expressed at the APC surface for encounter by the TCR of $CD4^+$ T cells. In the MHC class II-dependent antigen presentation pathway, dendritic cells (DCs), including Langerhans cells (LCs) and dermal dendritic cells (DDCs), B cells, and activated monocytes/macrophages are the major APC populations. Among these, DCs act as professional APC, i.e., are capable of migration and stimulating antigen-specific responses in naive, resting T cells.

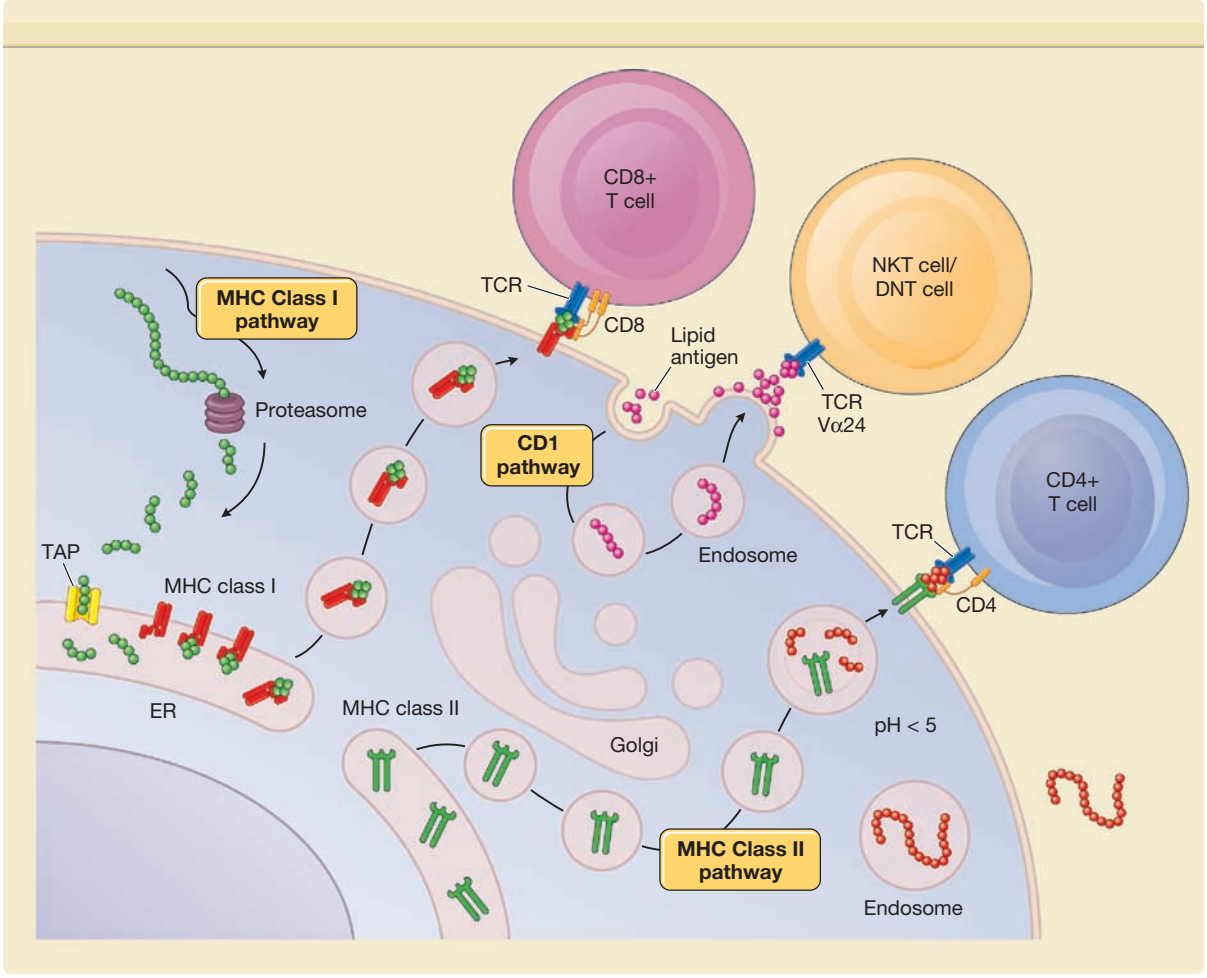

Figure 10-5 Antigen-processing pathways. The intracellular antigen-processing pathways for major histocompatibility complex (MHC) class I, MHC class II, and CD1 presentation are shown. The MHC class I pathway involves the processing of cytoplasmic proteins, whereas the MHC class II pathway involves the processing of exogenous proteins. The CD1 pathway regulates the processing and presentation of self-glycosphingolipids and bacterial lipoglycans. DN T cell = double-negative ($CD4^-/CD8^-$) T cell; ER = endoplasmic reticulum; MIIC = MHC class II lysosomal peptide-loading compartment; NKT cell = natural killer T cell; TAP = transporter associated with antigen processing; TCR = T-cell receptor.

GENERAL PRINCIPLES OF ANTIGEN PRESENTATION. (Fig. 10-5)

Major Histocompatibility Complex Class I-Restricted Antigen Presentation: Classic Pathway.[217,218] Immediately after their biosynthesis, MHC class I heavy and light (β_2-microglobulin) chains are inserted into the membranes of the endoplasmic reticulum. The third subunit of the functional MHC class I complex is the peptide itself. The major sources of peptides for MHC class I loading are cytosolic proteins, which can be targeted for their rapid destruction through the catalytic attachment of ubiquitin. These cytosolic proteins can be self-proteins, viral particles, or neoantigens (altered self-proteins). Cytosolic proteinaceous material undergoes enzymatic digestion by the proteasome to yield short peptide chains of 8–12 amino acids, an appropriate length for MHC class I binding. In its basic conformation, the proteasome is a constitutively active "factory" for self-peptides. IFN-γ, by replacing or adding certain proteasomal subunits, induces "immunoproteasomes," presumably to fine-tune the degradation activity and specificity to the demands of the immune response. The processed peptides are translocated to the endoplasmic reticulum by the transporter associated with antigen processing (TAP), an MHC-encoded dimeric peptide transporter. With the aid of chaperons (calnexin, calreticulin, tapasin), MHC class I molecules are loaded with peptides, released from the endoplasmic reticulum, and transported to the cell surface. Several infectious agents with relevance to skin biology have adopted strategies to subvert MHC class I presentation, and thus the surveillance of cell integrity, by interfering with defined molecular targets. Important examples of such interference are the inhibition of proteasomal function by the Epstein–Barr virus-encoded EBNA-1 protein, the competition for peptide–TAP interactions by a herpes

simplex virus protein, and the retention or destruction of MHC class I molecules by adenovirus- and human cytomegalovirus-encoded products.

Alternative Pathway (Cross-Presentation). Under certain conditions, exogenous antigen can reach the MHC class I presentation pathway. Significant evidence for this cross-presentation first came from in vivo experiments in mice demonstrating that viral, tumor, and MHC antigens can be transferred from MHC-mismatched donor cells to host bone marrow-derived APCs to elicit antigen-specific cytotoxic T-cell responses that are restricted to self-MHC molecules.[219] In vitro studies have defined that exosomes (i.e., small secretory vesicles of approximately 100 nm in diameter secreted by various cell types, including tumor cells), heat shock proteins, immune complexes, and apoptotic cells (taken up via CD36 and αvβ3 or αvβ5 integrins) can all serve as vehicles for the delivery of antigen to DCs in a manner that permits the cross-presentation of antigen. In all in vitro systems in which a direct comparison has been made, DCs, including LCs, but not monocytes/macrophages, were capable of cross-presentation.[220,221] Three distinct pathways are currently exploited by which antigen can access MHC class I molecules of DCs: (1) a recycling pathway for MHC class I in which antigen is loaded in the endosome; (2) a pathway by which retrograde transport of the antigen from the endosome to the endoplasmic reticulum facilitates entry into the classic MHC class I antigen presentation pathway; and (3) an endosome to the cytosol transport pathway, which again allows antigen processing via the classic MHC class I antigen presentation pathway.

Major Histocompatibility Complex Class II-Restricted Antigen Presentation.[216] MHC class II molecules predominantly bind peptides within endosomal/lysosomal compartments. Sampling peptides in these subcellular organelles allow class II molecules to associate with a broad array of peptides derived from proteins targeted for degradation after internalization by fluid phase or receptor-mediated endocytosis, macropinocytosis, or phagocytosis. One of the striking structural differences between MHC class I and class II molecules is the conformation of their peptide-binding grooves. Whereas MHC class I molecules have binding pockets to accommodate the charged termini of peptides and thus selectively associate with short peptides, the binding sites of MHC class II molecules are open at both ends. Thus, MHC class II molecules bind peptides with preferred lengths of 15–22 amino acids but can also associate with longer moieties. An important chaperone for MHC II molecules and responsible for the correct folding and the functional stability of MHC II molecules is the type II transmembrane glycoprotein invariant chain (Ii; CD74). Ii also prevents class II molecules from premature loading by peptides intended for binding to MHC class I molecules in the endoplasmic reticulum and participates in the sorting of MHC II toward the endocytic pathway.[222] Depending on the cell type and the activation status of a cell, the half-life of class II–peptide complexes varies from a few hours to days. It is particularly long (more than 100 hours) on DCs that have matured into potent immunostimulatory cells of lymphoid organs on encounter with an inflammatory stimulus in nonlymphoid tissues. The very long retention of class II–peptide complexes on mature DCs ensures that only the peptides generated at sites of inflammation will be displayed in lymphoid organs for T cell priming. Cytokines have long been known to regulate antigen presentation by DCs. In fact, proinflammatory (TNF-α, IL-1, IFN-γ) and anti-inflammatory (IL-10, TGF-β1) cytokines regulate presentation in MHC class II molecules in an antagonistic fashion. Mechanistically, regulatory effects include the synthesis of MHC components and proteases, and the regulation of endolysosomal acidification.[223,224]

CD1-Dependent Antigen Presentation.[225,226] Besides peptides, self-glycosphingolipids and bacterial lipoglycans may also act as T-cell-stimulatory ligands. Molecules that bind and present these moieties belong to the family of nonpolymorphic, MHC class I- and II-related CD1 proteins. CD1 molecules are structurally close to MHC class I molecules, but functionally related to MHC class II molecules. In the skin, members of the CD1 family are expressed mainly by LCs and DDCs. The CD1 isoforms CD1a, CD1b, CD1c, and CD1d sample both recycling endosomes of the early endocytic system and late endosomes and lysosomes to which lipid antigens are delivered. Unlike in the MHC class II pathway, antigen loading in the CD1 pathway occurs in a vacuolar acidification-independent fashion. T cells expressing a Vα24-containing canonic TCR, NKT cells, and $CD4^-$/$CD8^-$ T cells include the most prominent subsets of CD1-restricted T cells. CD1-restricted T cells play important roles in host defense against microbial infections. Accordingly, human subjects infected with *M. tuberculosis* showed stronger responses to CD1c-mediated presentation of a microbial lipid antigen than control subjects, and activation of CD1d-restricted NKT cells with a synthetic glycolipid antigen resulted in improved immune responses to several infectious pathogens. Thus, the CD1 pathway of antigen presentation and glycolipid-specific T cells may provide protection during bacterial and parasite infection, probably by the secretion of proinflammatory cytokines, the direct killing of infected target cells, and B cell help for Ig production.

DENDRITIC CELLS. DCs are the only APC capable of interacting with naive T cells. Depending on the DC activation status (i.e., mature versus immature), this cellular contact will result in either productive or nonproductive T-cell responses. Originally, DCs were identified in peripheral lymphoid organs in mice (lymphoid DC).[227] A few years later the presence of DC in nonlymphoid tissue (nlDC) was first demonstrated as evidenced by the expression of Fc and C3 receptors as well as MHCII antigens on epidermal LC.[228–230] This finding anchored LC as cells of the immune system.

DCs populate nearly every mammalian tissue under homeostatic (indigenous DC) and inflammatory (inflammatory DC) conditions (Fig. 10-6). Both indigenous and inflammatory DCs ultimately derive from

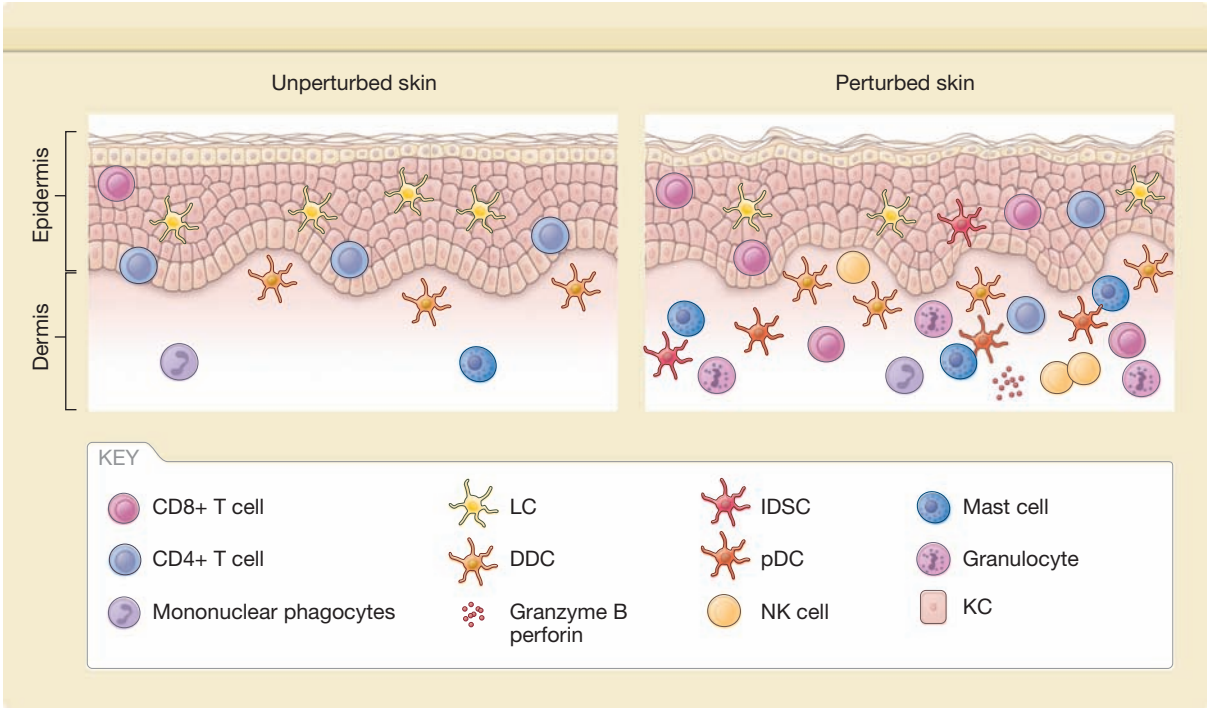

Figure 10-6 Resident and passenger leukocytes of the skin. Unperturbed skin: under homeostatic, steady-state conditions, the skin harbors only limited numbers of leukocytes. They consist mainly of dendritic cells (Langerhans cells in the epidermis and dermal dendritic cells in the dermis) and, to a lesser extent, of T cells in the epidermis (largely $CD8^+$) and dermis (largely $CD4^+$) and a few mononuclear phagocytes and mast cells. Granulocytes, NK cells, B cells, and inflammatory dendritic cells are essentially absent. Perturbed skin: upon delivery of exogenous (e.g., microorganisms, chemical irritants, ultraviolet radiation) and perhaps endogenous danger signals, resident skin cells such as keratinocytes become activated and, as a consequence, initiate an inflammatory tissue response arising mainly from circulating, but probably also resident leukocytes. KC = keratinocyte; LC = Langerhans cells; DDC = dermal dendritic cells; pDC = plasmacytoid dendritic cells; IDSC = inflammatory dendritic skin cells; NK cell = natural killer cells.

hematopoietic stem and progenitor cells (HSPC) in the bone marrow. HSPCs give rise to progenitor cells that can further differentiate into one or more DC subsets.[231,232] DC precursors can be found in multiple locations throughout the body such as the bone marrow, the thymus as well as the peripheral lymphoid organs including the blood.[233–235] These blood-derived DC precursors populate nonlymphoid tissues and organs using specific chemokine receptor–ligand pathways (e.g., CCR2-CCL2, CCR5-CCL5, CCR6-CCL20).[236–239] Upon arrival in the periphery, they either undergo a process of differentiation or maintain their density by self-renewal.[234] Inflammatory DCs are mainly mobilized into the tissues from peripheral blood precursors upon receipt of danger signals. They probably do not constitute a DC subpopulation per se, but rather represent an activated state of a given DC.

Within the periphery, differentiated DCs accumulate in extravascular areas and survey their surroundings for microbial invasion, always prepared for antigen capture. Under homeostatic conditions, the overwhelming majority of DCs are in an immature state that allows them to efficiently take up antigen (e.g., serum proteins, extracellular matrix components, dead cells) with the help of specific receptor sites (e.g., Langerin, macrophage mannose receptor, C-type lectin receptor DEC-205, low-affinity IgG receptor CD32/FcγRII, high-affinity IgE receptor FcεRI, the thrombospondin receptor CD36, DC-SIGN), but does not endow them with immunostimulatory properties for naive resting T cells. DCs apparently increase their efficacy in antigen-uptake by repetitively extending and retracting their dendrites through intercellular spaces (dSEARCH: dendrite surveillance extension and retracting cycling habitude).[240] Antigen-engulfment triggers DC maturation, which is followed by DC detachment from neighboring cells and trafficking to draining lymph nodes dependent on CCR7 signaling.[241–243]

DC trafficking from nonlymphoid to lymphoid tissues occurs, in a limited fashion, also under homeostatic conditions,[244,245] but is much more enhanced upon the delivery of danger signals. During this journey, DCs have to overcome several obstacles such as vessel walls, connective tissue, basement membranes, or other anatomical barriers. To be capable of traveling, DCs are equipped with distinct proteolytic enzymes such as matrix metalloproteinase 2 (MMP-2) and MMP-9 that lead to the degradation of extracellular matrix proteins.[246–248] Interstitial DC migration is partly controlled by tissue inhibitors of metalloproteinases (TIMPs), which inhibit MMP activity under nondanger conditions. However, upon maturation of DCs, TIMP expression is downregulated and MMPs exert their function.[249] In the LN, DCs rapidly extend their dendrites in a "probing" way thereby

establishing physical contacts with adjacent T cells, as in vivo two-photon intravital microscopy of inguinal lymph nodes of mice has revealed.[250,251] The display of MHC-peptide complexes on the DC surface delivers the "first signal" to T cells thereby starting communication, i.e., the triggering of the TCR by the APC-bound peptide-MHC complex. Upon activation, DCs display an upregulated and prolonged surface expression of MHCII as compared with nonactivated APC. Although this event may be sufficient to induce the proliferation of primed T cells, it is insufficient for the productive activation of naive T cells. The occurrence of the latter requires the receipt of "second signals," which are also delivered by professional APCs. In fact, antigen-specific T cells that encounter MHC-expressing cells that cannot deliver second signals (e.g., MHC class II-induced keratinocytes, endothelial cells, fibroblasts) enter a state of anergy.[252] Second signals, which include secreted cytokines and membrane-bound costimulatory molecules, determine the magnitude and quality of primary and secondary T-cell responses. Upon contact with the DC-derived cytokine IL-12, for example, T cells turn into type 1 IFN-γ-producing cells, whereas DC-derived IL-23 may skew T-cell responses in the type 17 direction (see Section "Functionality"). Upon danger stimuli, DCs produce a variety of additional cytokines such as IL-1β, TNF-α, TGF-β, or IL-6 that all have the potential to polarize distinct T-cell responses. Costimulatory molecules on DCs are upregulated during the process of maturation induced by surface receptors triggered by ligands secreted or presented by other somatic cells or, alternatively, by microbial products (danger signals).[253] The best-defined costimulatory molecules are the two members of the B7 family, B7.1/CD80 and B7.2/CD86. LCs/DCs in situ do not express or express only minute amounts of these costimulatory molecules, but greatly upregulate these moieties during maturation. Other costimulatory molecules include the ICAM-1 that binds to LFA-1 and LFA-3, the ligand of T cell-expressed CD2. Other important ligand–receptor pairs that positively affect T-cell activation by DCs include heat-stable antigen CD24/CD24L, CD40/CD40L, CD70/CD27L, OX40 (CD134)/OX40L, and receptor activator of nuclear factor κB (RANK)/RANKL. Another costimulatory molecule of great importance is the membrane-bound glycoprotein CD83. It is significantly upregulated during DC maturation and enhances $CD8^+$ T cell proliferation upon binding to an as yet unknown CD83 ligand on T cells whose expression is strictly dependent on CD28-mediated costimulation.[254,255]

Recent evidence suggests that DCs/LCs themselves can actively induce immune tolerance. The main mechanism to maintain immune tolerance is deletion of T cells with high affinity to self-peptide/MHC complexes in the thymus by inducing apoptosis (negative selection). Another variation of tolerance is T cell-anergy induced by contact with APC that do not provide second signals. Finally, DCs, at least in their immature state, preferentially activate T reg cells.[256] When antigen is targeted to these nonactivated DCs in vivo, antigen-specific hyporesponsiveness occurs.[257–261] This finding has therapeutic implications for the treatment of autoimmune diseases.[262]

Mechanisms responsible for the tolerance-inducing property of nonactivated DCs, although not entirely understood, include (1) a reduced expression of MHC-antigen complexes[263] and costimulatory molecules[264] on the cell surface; (2) expression of the coinhibitory receptor ligands programed cell death-ligand 1 (PD-L1/B7-H1) and, to a lesser extent, PD-L2 (B7-DC)[265–267]; (3) the secretion of immunosuppressive cytokines such as IL-10,[268] which fits well to the finding of T reg induction by UV-irradiated, IL-10-producing T reg cells[269]; (4) the expression of immunoinhibitory enzymes such as indoleamine 2,3-dioxygenase[270]; and (5) the receipt of signals interfering with the maturation and migration of DCs, for example, neuropeptides such as CGRP[271] and vasoactive intestinal peptide,[272] or the engagement of the CD47/SHPS-1 signal transduction cascade.[273,274] It appears that these different factors are not equally operative in all situations. LCs, for example, can activate self-antigen-specific CD8 T cells in the steady state, which leads to chronic skin disease,[275] and, at the same time, LCs are dispensable for[276] or can even downregulate[277] the induction of CHS.

Dendritic Cells of Normal and Diseased Skin. In essentially unperturbed normal human skin we find several APC including epidermal *Langerhans cells* (LC) and *dermal dendritic cells*[278] (DDC). LCs and DDCs are lineage-negative (Lin^-), bone marrow-derived leukocytes, which phenotypically and functionally resemble other DCs present in most, if not all, lymphoid and nonlymphoid tissues.[279] As gatekeepers of the immune system, they control the response to events perturbing tissue/skin homeostasis. In other species such as mice an additional DC subset has been described recently, namely $CD103^+CD207^+$ cells, which in humans have yet to be identified.[280–282] Healthy skin also harbors other cells which at least theoretically could subserve APC function, such as basophils and mast cells. While these cells have been shown to play a role in the modulation of cutaneous immune responses, their functions as APC remain to be defined.

Under inflammatory conditions, DC types that are not residents of the normal cutaneous environment appear in the skin. These include DCs from the plasmacytoid lineage, so-called *plasmacytoid DC* (pDCs) and *inflammatory dendritic skin cells* (IDSC), which originate from myeloid precursors and phenotypically resemble myeloid DCs (mDC) of the peripheral blood.

LANGERHANS CELLS.[283] In 1868, the medical student Paul Langerhans, driven by his interest in the anatomy of skin nerves, identified a population of dendritically shaped cells in the suprabasal regions of the epidermis after impregnating human skin with gold salts.[284] These cells, which later were found in virtually all stratified squamous epithelia of mammals, are now eponymously referred to as *Langerhans cells* (Fig. 10-7).

The expression of the Ca^{2+}-dependent lectin Langerin (CD207) is currently the single best feature discriminating LCs from other cells. Langerin is a transmembrane molecule associated with and sufficient to form Birbeck granules, the prototypic, and cell type-defining organelles of LCs (see Fig. 10-7). Birbeck granules are

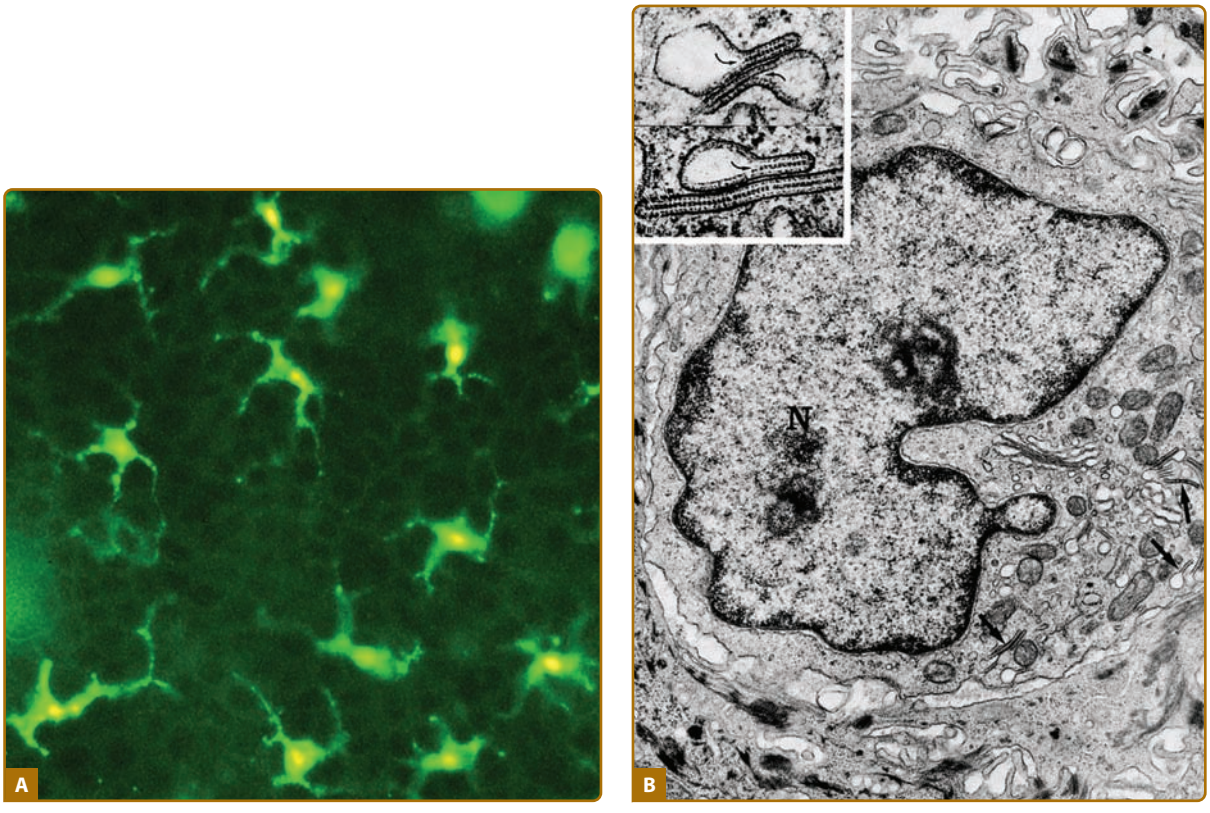

Figure 10-7 A. Langerhans cells in a sheet preparation of murine epidermis as revealed by antimajor histocompatibility complex class II (fluorescein isothiocyanate) immunostaining. **B.** Electron micrograph of a Langerhans cell in human epidermis. *Arrows* denote Birbeck granules. N = nucleus. (From Stingl G: New aspects of Langerhans cell functions. *Int J Dermatol* **19**:189, 1980, with permission.) *Inset:* High-power electron micrograph of Birbeck granules. The *curved arrows* indicate the zipper-like fusion of the fuzzy coats of the vesicular portion of the granule. The delimiting membrane envelops two sheets of particles attached to it and a central lamella composed of two linear arrays of particles. (From Wolff K: The fine structure of the Langerhans cell granule. *J Cell Biol* **35**:466, 1967, with permission.)

pentilaminar cytoplasmic structures frequently displaying a tennis racket shape at the ultrastructural level. The additional presence of Langerin on the cell surface coupled with its binding specificity for mannose suggests that Langerin is involved in the uptake of mannose-containing pathogens by LCs. However, the disruption of the Langerin gene in experimental animals does not result in a marked loss in LC functionality.[285] Additional molecules besides Langerin allow the identification of LCs within normal unperturbed epidermis. These include CD1a; the MHC class II antigens HLA-DR, HLA-DQ, and HLA-DP; and CD39, a membrane-bound, formalin-resistant, sulfhydryl-dependent adenosine triphosphatase (ATPase).

The tissue distribution of LC varies regionally in human skin. On head, face, neck, trunk, and limb skin, the LC density ranges between 600 and 1,000/mm^2. Comparatively low densities (approximately 200/mm^2) are encountered in palms, soles, anogenital and sacrococcygeal skin, and the buccal mucosa. The density of human LCs decreases with age, and LC counts in skin with chronic actinic damage are significantly lower than those in skin not exposed to UV light (Fig. 23-7). HLADR$^+$/ATPase$^+$ DCs can be identified in the human epidermis by 6–7 weeks of estimated gestational age. These cells must originate from hemopoietic progenitor cells in the yolk sac or fetal liver, the primary sites of hemopoiesis during the embryonic period. Until week 14 of estimated gestational age (EGA), these cells acquire the full phenotypic profile of LC in a stepwise fashion.[286] The relative numeric stability of LC counts during later life must be achieved by a delicate balance of LC generation and immigration into the epidermis and LC death and emigration from the epidermis. Within the epidermis, LCs are anchored to surrounding keratinocytes by E-cadherin-mediated homotypic adhesion.[287] This anchoring and the display of TGF-β1 also prevent terminal differentiation and migration, thus securing intraepidermal residence for the cells under homeostatic conditions. Two nonmutually exclusive pathways of LC repopulation of the epidermis may exist: (1) LC division within the epidermis, and (2) the differentiation of LCs from skin-resident or blood-borne precursors. Evidence for the first possibility is the demonstration of cycling/mitotic LCs in the epidermis,[288] although it remains to be established whether this cell division alone suffices for maintaining the epidermal LC population.

The observation that the half-life of LCs within unperturbed murine epidermis is around 2–3 months[289] suggests a significant turnover of the epidermal LC population even under noninflammatory conditions. In seeming contradiction stands the observation that the LC

population of human skin grafted onto a nude mouse remains rather constant for the life of the graft, despite epidermal proliferation and the absence of circulating precursors for human LCs. Moreover, epidermal LCs in mice whose bone marrow was lethally irradiated and subsequently transplanted are only partially replaced by LCs of donor origin,[290] whereas DCs in other organs are efficiently exchanged for donor DCs.[238] Together, these observations suggest that a precursor cell population resides in the dermis that is engaged constantly in the self-renewal of the epidermal LC population under noninflammatory conditions. The prime candidate LC precursors are dermal $CD14^+/CD11c^+$ cells that have the potential to differentiate in vitro into LCs in a TGF-β1-dependent fashion.[291]

Under inflammatory conditions (e.g., UV radiation exposure, graft-versus-host disease), an additional pathway of epidermal LC recruitment becomes operative. In this situation, LC precursors enter the tissue, and their progeny populate the epidermis in a fashion dependent on chemoattraction mediated by LC-expressed chemokine receptors CCR2 and CCR6,[239] the ligands of which are secreted by endothelial cells and keratinocytes. Thus, CCR6 and its ligand MIP-3α/CCL20 may be essential for epidermal LC localization in vivo, as postulated previously in studies of LCs differentiated from human progenitor cells in vitro.[108] The action of MIP-3α/CCL20 may be assisted or replaced under noninflammatory situations by the chemokine BRAK/CXCL14, which is constitutively produced by keratinocytes.[292] The differentiation stage of the biologically relevant circulating LC precursors entering inflamed skin in vivo remains to be resolved. However, evidence exists that common myeloid progenitors, granulocyte–macrophage progenitors, monocytes, and even common lymphoid progenitors can give rise to the emergence of an epidermal LC population in experimental animals.[293,294]

Compelling evidence exists from in vitro and in vivo studies that LCs play a pivotal role in the induction of adaptive immune responses against antigens introduced into and/or generated in the skin (immunosurveillance). This is best illustrated by the early observation that LC-containing, but not LC-depleted, epidermal cell suspensions pulse-exposed to either soluble protein antigens or haptens elicit a genetically restricted, antigen-specific, proliferative T cell response.[295] Inaba et al[296] found that freshly isolated LCs ("immature" LCs) can present soluble antigen to primed MHC class II-restricted T cells but are only weak stimulators of naive, allogeneic T cells. In contrast, LCs purified from epidermal cell suspensions after a culture period of 72 hours or LCs purified from freshly isolated murine epidermal cells and cultured for 72 hours in the presence of GM-CSF and IL-1 ("mature" LC) are extremely potent stimulators of primary T cell-proliferative responses to alloantigens,[296] soluble protein antigens,[297] and haptens.[297] Immature LCs, however, far excel cytokine-activated LCs in their capacity to take up and process native protein antigens.[298] Accordingly, immature rather than mature LCs express antigen uptake receptors. Mature LCs, although fully capable of presenting preprocessed peptides, have lost their capacity to process and present native protein antigens.[298]

Upon perturbance of skin homeostasis (e.g., TLR ligation, contact with chemical haptens, hypoxia), LCs gain access to antigen/allergen encountering the epidermis by distending their dendrites through epidermal tight junctions, thereby demonstrating strikingly remarkable cooperation between keratinocytes and LC.[299] After a few hours, LCs begin to enlarge, to display increased amounts of surface-bound MHC class II molecules, and to migrate downward in the dermis, where they enter afferent lymphatics and, finally, reach the T-cell zones of draining lymph nodes.[300] During this process, LCs undergo phenotypic changes similar to those that occur in single epidermal cell cultures,[301] i.e., downregulation of molecules or structures responsible for antigen uptake and processing as well as for LC attachment to keratinocytes (e.g., Fc receptors, E-cadherin) and upregulation of moieties required for active migration and stimulation of robust responses of naive T cells (e.g., CD40, CD80, CD83, CD86). The mechanisms governing LC migration are becoming increasingly clear. TNF-α and IL-1β (in a caspase 1-dependent fashion) are critical promoters of this process, whereas IL-10 inhibits its occurrence. Increased cutaneous production and/or release of the proinflammatory cytokines are probably one of the mechanisms by which certain immunostimulatory compounds applied to or injected into the skin [e.g., imiquimod, unmethylated cytosine–phosphate–guanosine (CpG) oligonucleotides] accelerate LC migration. Another example is the topical application of contact sensitizers (e.g., dinitrofluorobenzene), which leads to the activation of certain protein tyrosine kinases, the modification of cellular content and structure of intracytoplasmic organelles (increase in coated pits and vesicles, endosomes and lysosomes, Birbeck granules), and increased in situ motility of these cells.[302] Interestingly, Cumberbatch et al[303] reported that, in psoriasis, LCs are impaired in their migratory capacity. This was somewhat unexpected in view of the remarkable overexpression of TNF-α in psoriatic skin. These investigators also found that the failure of TNF-α and/or IL-1β to induce LC migration from uninvolved skin was not attributable to an altered expression of receptors for these cytokines. An important hurdle for emigrating LCs is the basement membrane. During their downward journey, LCs probably attach to it via α_6-containing integrin receptors and produce proteolytic enzymes such as type IV collagenase (MMP-9) to penetrate it and to pave their way through the dense dermal network into the lymphatic system. IL-16 also induces LC mobilization. This process could perhaps be operative in atopic dermatitis. In this disease, DCs of lesional skin exhibit surface IgE bound to high-affinity Fc receptors (FcεRI), and allergen-mediated receptor cross-linking results in enhanced IL-16 production. Evidence is accumulating that DC migration occurs in an active, directed fashion. Osteopontin is a chemotactic protein that is essential in this regard. It initiates LC emigration from the epidermis and attracts LCs to draining nodes by interacting with an *N*-terminal epitope of the CD44 molecule.[304] The entry into and active transport of cutaneous DCs

within lymphatic vessels appears to be mediated by MCPs binding to CCR2 and by secondary lymphoid-organ chemokine/CCL21 produced by lymphatic endothelial cells of the dermis and binding to CCR7 on maturing LCs and DDCs.[242,305] Interestingly, CCL21 expression is upregulated in irritant and allergic contact dermatitis, which implicates its regulated impact on DC emigration from the skin.[306]

DERMAL DENDRITIC CELLS. Like resident LCs in the epidermis, dermal dendritic cells (DDCs) constitute another resident DC subpopulation in normal and inflamed skin that is capable of activating the immune system upon receipt of danger signals. Located primarily in the vicinity of the superficial vascular plexus, DDCs have been identified by their surface expression of CD1b, CD1c (BDCA-1), CD11c, CD36, CD205, MHCII, as well as the subunit A of the clotting proenzyme factor XIII (FXIIIa).[307] They can be distinguished from LCs by the absence of Langerin expression and lack of Birbeck granules. Based on the positive reactivity for FXIIIa, DDCs from dermal single-cell suspensions were originally classified into at least three different subsets: (1) $CD1a^-/CD14^-$ cells, (2) $CD1a^-/CD14^-$ cells, and (3) $CD1a^-/CD14^+$ cells. Many assays conducted with DDCs during the past years revealed that they possess functional features of both macrophages and DCs, i.e., the capacity of efficient phagocytosis on the one hand as well as antigen-presenting, migratory and T-cell-stimulating capacities on the other hand.[308,309]

LC Versus DDC in Skin Immunity. (Fig. 10-8). What is the function of LCs/DDCs in normal skin? Is there a natural flux of LCs/DDCs to the regional lymph nodes? If so, what are the consequences of such an occurrence? Evidence exists that melanin granules captured in the skin accumulate in the regional lymph nodes but not in other tissues. The further observation of only very few melanin granule-containing cells in TGF-$\beta1^{-/-}$ mice suggests that, under steady-state conditions, epidermal and/or dermal antigens are carried to the regional lymph nodes by TGF-β1-dependent cells (most likely LCs/DDCs) only. It appears that T lymphocytes encountering such APCs in vivo are rendered unresponsive in an antigen-specific manner.[259] It is therefore conceivable that immature resident skin DC, i.e., LCs and DDCs, are endowed with tolerogenic skills inhibiting inflammatory T-cell responses in the steady state and, consequently, that absence of pathogenic T-cell autoimmunity and/or lack of reactivity against seemingly innocuous environmental compounds (e.g., aeroallergens) in the periphery is primarily the consequence of an active immune response rather than the result of its nonoccurrence.

In the past few years, there has been a heavy debate about the relative sensitizing capacity of LCs versus DDCs in skin-derived immune responses. This discussion was initiated by seemingly controversial results obtained with different types of LC-depleted mice undergoing contact sensitization.

INFLAMMATORY DENDRITIC CELLS.[309] DCs appearing in inflamed skin can be subdivided into two major subpopulations, i.e., (1) inflammatory dendritic epidermal/dermal cells (IDECs/IDDCs) and (2) plasmacytoid dendritic cells (pDCs). The former ones will be referred to as inflammatory dendritic skin cells (IDSCs).

Inflammatory Dendritic Skin Cells (IDSC). It is still unclear whether IDSCs represent a subpopulation of myeloid DCs which, upon danger stimuli, are recruited to the sites of inflammation from the blood, or whether indigenous DDCs are converted into specialized IDSCs that have the capacity to adapt their function according to the kind of danger signal delivered. Supporting the idea of circulating DC precursors infiltrating the skin upon danger signals, potential precursor cells including pre-DCs[320,321] or hematopoietic precursor cells[234] have been identified.

Much work on the identification and characterization of epidermal and/or dermal inflammatory DC populations in various skin diseases has lately been provided by different groups.[322–325] In the dermis of psoriatic lesions, the number of $CD11c^+$ DCs is 30-fold increased as compared to normal skin.[325,326] In contrast to steady-state DDC, these dermal $CD11c^+$ DCs are $CD1c^-$, but produce a number of proinflammatory cytokines (e.g., TNF-α) and inducible oxide synthetase (iNOS) and were therefore termed TIP-DCs (TNF-α and iNOS-producing DCs). Initially identified in 2003 in a murine model of *Listeria monocytogenes* infection,[327] they have been located in the lamina propria of human gut[328] as well as in imiquimod-treated human basal cell carcinoma.[324] Imiquimod and the other imidazoquinolines as ligands of TLR7/8 induce strong inflammation and, ultimately, regression of viral acanthomas and other superficial skin neoplasms.[329] Upon treatment, TIP-DCs are abundantly present around regressing tumor cell islands[330] and, interestingly, can express molecules of the lytic machinery such as perforin, granzyme B, and TRAIL, suggesting their cytotoxic potential. In psoriasis, TIP-DC have the capacity to prime T cells to become Th1, Th17, and a mixture of Th1/Th17 cells, which simultaneously produce IFN-γ and IL-17[325] and may contribute to the pathogenesis of the disease. In addition, their pathogenic role is indicated by downregulation of TNF-α, iNOS, and other cytokines they produce, namely, IL-20 and IL-23, upon effective psoriasis treatment.[331] Recent work also identified TRAIL on $CD11c^+$ $CD1c^-$ TIP-DCs in psoriasis, proposing a proinflammatory, cell-damaging interaction with keratinocytes that express activating TRAIL receptors (death receptor 4 and decoy receptor 2).[332]

In the epidermis of atopic dermatitis (AD) skin, the emergence of inflammatory dendritic epidermal cells (IDECs) has been well documented.[333] They are characterized by the expression of CD1a, CD1b, CD1c, CD11c, FcεRI, CD23, HLA-DR, CD11b, CD206 (MMR/macrophage mannose receptor), and CD36.[333,334] In situ staining of costimulatory molecules on epidermal $CD1a^+$ DC in AD skin showed that mainly cells with the phenotype of IDEC display CD80 and CD86, whereas $Langerin^+$ $CD1a^+$ epidermal LC are almost devoid of these molecules.[335] CD86 signaling is critical for the stimulatory capacity of IDEC. Evidence exists that, upon engagement of FcεRI on IDEC, an immune

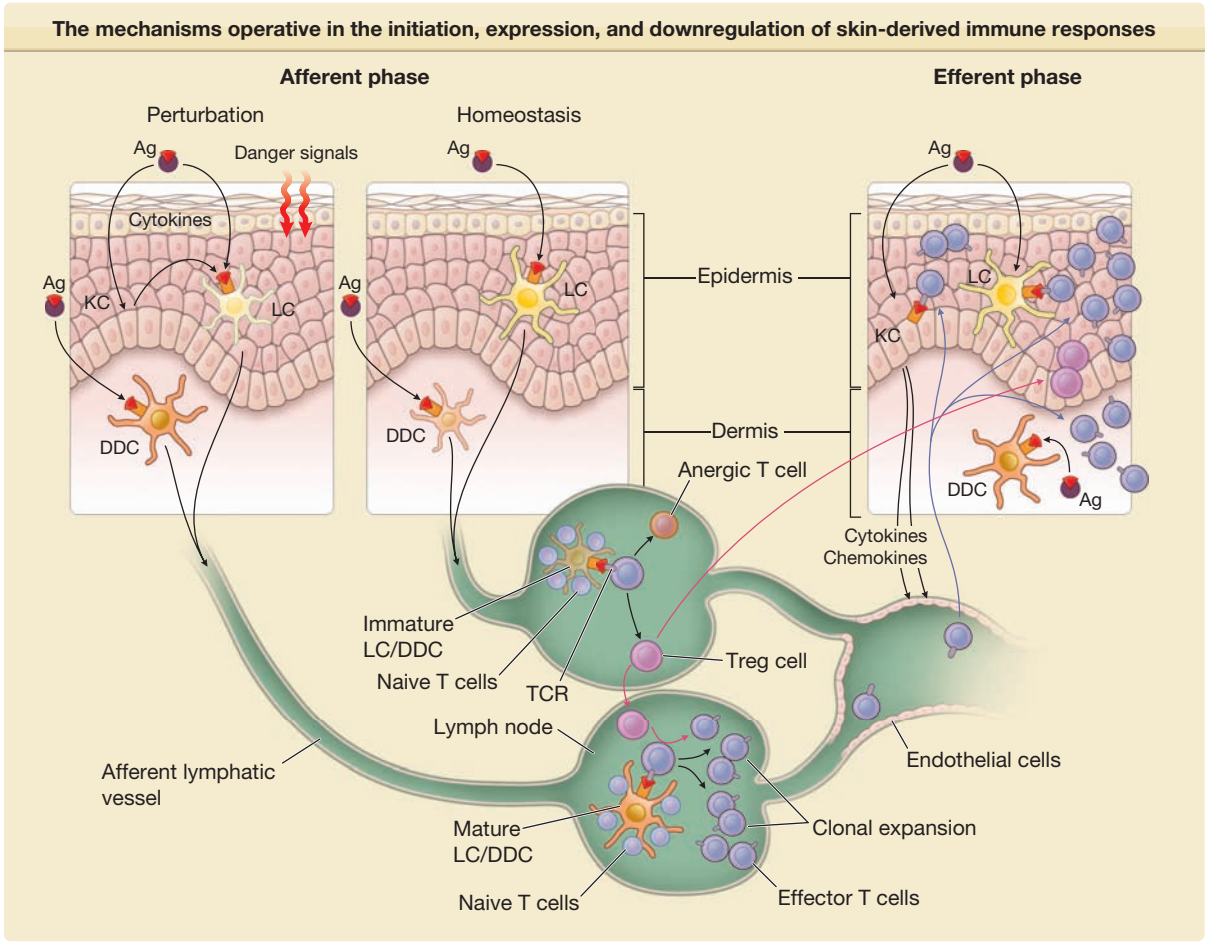

Figure 10-8 The mechanisms operative in the initiation, expression, and downregulation of skin-derived immune responses. Induction of T cell immunity via the skin: Antigens administered to or occurring in the skin (microbial products, haptens, etc.) will be picked up, engulfed, processed and presented by dendritic antigen-presenting cells in the epidermis (LC = Langerhans cells) and/or the dermis (DDC = dermal dendritic cells). When danger signals, particularly those reaching beyond the dermal–epidermal junction, are present at the time of antigenic exposure, these DC will undergo a process of maturation as evidenced by an enhanced expression of MHC antigens, costimulatory molecules (CD80, CD86, CD40, CD83, etc.), and immunostimulatory cytokines (IL-1β, IL-6, IL-12, IL-23) as well as their enhanced emigration from the skin to the paracortical areas of the draining lymph nodes. At this site, the skin-derived DCs provide activation stimuli to the naive resting T cells surrounding them. This occurs in an antigen-specific fashion and thus results in the expansion of the respective clone(s). T cells thus primed begin to express skin-homing receptors (e.g., CLA) as well as receptors for various chemoattractants that promote their attachment to dermal microvascular endothelial cells of inflamed skin and, ultimately, their entry into this tissue. Elicitation of T-cell-mediated tissue inflammation and pathogen clearance: on receipt of a renewed antigenic stimulus by activated skin DCs or other APCs, the skin-homed T cells expand locally and display the effector functions needed for the elimination of the pathogen. Downregulation and prevention of cutaneous T cell immunity: In the absence of danger signals (tissue homeostasis), antigen-loaded skin DCs leave their habitat and migrate toward the draining lymph node. These cells or, alternatively, resident lymph node DCs that had picked up antigenic moieties from afferent lymphatics present this antigen in a nonproductive fashion, i.e., they induce antigen-specific T-cell unresponsiveness or allow the responding T cell(s) to differentiate into immunosuppressive T regulatory cells. The latter may limit antigen-driven clonal T-cell expansion during primary immune reactions in lymph nodes and during secondary immune reactions at the level of the peripheral tissue. Such events can result in the downregulation of both desired (antitumor, antimicrobial) and undesired (hapten-specific, autoreactive) immune responses. Ag = antigen; T = T naive cell; T* = anergic T cell; TCR = T-cell receptor; T reg = regulatory T cells; EM T cells = effector memory T cells.

response triggered by these cells is skewed into the Th1 direction.[336] Recent work also located a substantial number of $CD1a^+$ $CD11c^+$ Langerin-DC within the dermis of AD lesions. Interestingly, these cells showed an upregulation of the chemokines CCL17 and CCL18 and can thereby provide a Th2 polarizing environment.[323] Importantly, this subset of IDSC does not produce iNOS or TNF-α, thus confirming the presence of different inflammatory DC subsets in different cutaneous pathologies.

Plasmacytoid Dendritic Cells.[337] pDCs are DCs that are characterized by a highly developed endoplasmic reticulum, which results in their plasma

cell-like appearance.[338] Functionally, pDCs display a unique ability to produce up to 1,000 times more natural IFNs than any other blood mononuclear cell in response to TLR ligands and thus were also named *principal type 1 IFN-producing cells*.[339]

KEY REFERENCES

Full reference list available at www.DIGM8.com

DVD contains references and additional content

3. Gasque P: Complement: A unique innate immune sensor for danger signals. *Mol Immunol* **41**:1089, 2004
5. Schauber J, Gallo RL: Antimicrobial peptides and the skin immune defense system. *J Allergy Clin Immunol* **122**:261, 2008
38. Akira S et al: Pathogen recognition and innate immunity. *Cell* **124**:783, 2006
75. Martinon F et al: The inflammasomes: Guardians of the body. *Annu Rev Immunol* **27**:229, 2009
117. von Boehmer H: Selection of the T-cell repertoire: Receptor-controlled checkpoints in T-cell development. *Adv Immunol* **84**:201, 2004
151. Surh CD, Sprent J: Homeostasis of naive and memory T cells. *Immunity* **29**:848, 2008
169. Korn T et al: IL-17 and Th17 cells. *Annu Rev Immunol* **27**:485, 2009
179. Bendelac A et al: The biology of NKT cells. *Annu Rev Immunol* **25**:297, 2007
182. Shevach EM: Mechanisms of foxp3+ T regulatory cell-mediated suppression. *Immunity* **30**:636, 2009
186 Schaerli P et al: CXC chemokine receptor 5 expression defines follicular homing T cells with B cell helper function. *J Exp Med* **192**:1553, 2000
189. Sallusto F, Mackay CR: Chemoattractants and their receptors in homeostasis and inflammation. *Curr Opin Immunol* **16**:724, 2004
207. Modlin RL et al: Learning from lesions: Patterns of tissue inflammation in leprosy. *Proc Natl Acad Sci U S A* **85**:1213, 1988
218. Hammer GE et al: The final touches make perfect the peptide-MHC class I repertoire. *Immunity* **26**:397, 2007
253. Matzinger P: An innate sense of danger. *Ann N Y Acad Sci* **961**:341, 2002
258. Steinman RM et al: Dendritic cell function in vivo during the steady state: A role in peripheral tolerance. *Ann N Y Acad Sci* **987**:15, 2003
274 Seiffert K, Granstein RD: Neuroendocrine regulation of skin dendritic cells. *Ann N Y Acad Sci* **1088**:195, 2006
283. Romani N et al: Langerhans cells and more: Langerin-expressing dendritic cell subsets in the skin. *Immunol Rev* **234**:120, 2010
309. Zaba LC et al: Resident and "inflammatory" dendritic cells in human skin. *J Invest Dermatol* **129**:302, 2009
337. Lande R, Gilliet M: Plasmacytoid dendritic cells: Key players in the initiation and regulation of immune responses. *Ann N Y Acad Sci* **1183**:89, 2010

Chapter 11 :: Cytokines

:: Ifor R. Williams & Thomas S. Kupper

CYTOKINES AT A GLANCE

- Cytokines are polypeptide mediators that function in communication between hematopoietic cells and other cell types.
- Cytokines often have multiple biologic activities (pleiotropism) and overlapping biologic effects (redundancy).
- Primary cytokines, such as interleukin 1 and tumor necrosis factor-α, are sufficient on their own to trigger leukocyte influx into tissue.
- Most cytokines signal through either the nuclear factor-κB or the Jak/STAT signaling pathways.
- Cytokine-based therapeutics now in use include recombinant cytokines, inhibitory monoclonal antibodies, fusion proteins composed of cytokine receptors and immunoglobulin chains, topical immunomodulators such as imiquimod, and cytokine fusion toxins.

THE CONCEPT OF CYTOKINES

When cells and tissues in complex organisms need to communicate over distances greater than one cell diameter, soluble factors must be employed. A subset of these factors is most important when produced or released transiently under emergent conditions. When faced with an infection- or injury-related challenge, the host must orchestrate a complex and carefully choreographed series of steps. It must mobilize certain circulating white blood cells precisely to the relevant injured area (but not elsewhere) and guide other leukocytes involved in host defense, particularly T and B cells, to specialized lymphatic tissue remote from the infectious lesion but sufficiently close to contain antigens from the relevant pathogen. After a limited period of time in this setting (i.e., lymph node), antibodies produced by B cells and effector-memory T cells, can be released into the circulation and will localize at the site of infection. Soluble factors produced by resident tissue cells at the site of injury, by leukocytes and platelets that are recruited to the site of injury, and by memory T cells ultimately recruited to the area, all conspire to generate an evolving and effective response to a challenge to host defense. Most important, the level of this response must be appropriate to the challenge and the duration

of the response must be transient; that is, long enough to decisively eliminate the pathogen, but short enough to minimize damage to healthy host tissues. Much of the cell-to-cell communication involved in the coordination of this response is accomplished by cytokines.

Cytokines (which include the large family of chemokines, discussed in Chapter 12) are soluble polypeptide mediators that play pivotal roles in communication between cells of the hematopoietic system and other cells in the body.[1] Cytokines influence many aspects of leukocyte function including differentiation, growth, activation, and migration. While many cytokines are substantially upregulated in response to injury to allow a rapid and potent host response, cytokines also play important roles in the development of the immune system and in homeostatic control of the immune system under basal conditions. The growth and differentiation effects of cytokines are not limited to leukocytes, although we will not discuss soluble factors that principally mediate cell growth and differentiation of cells other than leukocytes in this chapter. The participation of cytokines in many parts of immune and inflammatory responses has prompted the examination of a variety of cytokines or cytokine antagonists (primarily antibodies and fusion proteins) as agents for pharmacologic manipulation of immune-mediated diseases. Only a few classes of effective cytokine drugs have emerged from the lengthy pathway of clinical trials to achieve FDA approval and widespread therapeutic use, but some of these drugs are now valuable therapeutics in dermatology. This chapter discusses these approved drugs and other promising biological agents still in clinical trials.

General features of cytokines are their pleiotropism and redundancy. Before the advent of a systematic nomenclature for cytokines, most newly identified cytokines were named according to the biologic assay that was being used to isolate and characterize the active molecule (e.g., T-cell growth factor for the molecule that was later renamed *interleukin 2*, or IL-2). Very often, independent groups studying quite disparate bioactivities isolated the same molecule that revealed the pleiotropic effects of these cytokines. For example, before being termed *interleukin 1* (IL-1), this cytokine had been variously known as *endogenous pyrogen*, *lymphocyte-activating factor*, and *leukocytic endogenous mediator*. Many cytokines have a wide range of activities, causing multiple effects in responsive cells and a different set of effects in each type of cell capable of responding. The redundancy of cytokines typically means that in any single bioassay (such as induction of T-cell proliferation), multiple cytokines will display activity. In addition, the absence of a single cytokine (such as in mice with targeted mutations in cytokine genes) can often be largely or even completely compensated for by other cytokines with overlapping biologic effects.

CLASSIFICATIONS OF CYTOKINES

The first cytokines described had distinct and easily recognizable biological activities, exemplified by IL-1, IL-2, and the interferons (IFNs). The term cytokine was first coined by Cohen in 1975, to describe several such activities released into the supernatant of an epithelial cell line.[2] Prior to this, such activities had been thought to be the exclusive domain of lymphocytes (lymphokines) and monocytes (monokines) and were considered a function of the immune system. Keratinocyte cytokines were first discovered in 1981,[3] and the list of cytokines produced by this epithelial cell rivals nearly any other cell type in the body.[4,5] The number of molecules that can be legitimately termed cytokines continues to expand and has brought under the cytokine rubric molecules with a broad range of distinct biological activities. The progress in genomic approaches has led to identification of novel cytokine genes based on homologies to known cytokine genes. Making sense of this plethora of mediators is more of a challenge than ever, and strategies to simplify the analysis of the cytokine universe are sorely needed.

PRIMARY AND SECONDARY CYTOKINES

A simple concept that continues to be extremely useful for discussion of cytokine function is the concept of "primary" and "secondary" cytokines.[6] Primary cytokines are those cytokines that can, by themselves, initiate all the events required to bring about leukocyte infiltration in tissues. IL-1 (both α and β forms) and tumor necrosis factor (TNF; includes both TNF-α and TNF-β) function as primary cytokines, as do certain other cytokines that signal through receptors that trigger the nuclear factor κB (NF-κB) pathway. IL-1 and TNF are able to induce cell adhesion molecule expression on endothelial cells [selectins as well as immunoglobulin superfamily members such as intercellular adhesion molecule 1 (ICAM-1) and vascular cellular adhesion molecule 1 (VCAM-1)], to stimulate a variety of cells to produce a host of additional cytokines, and to induce expression of chemokines that provide a chemotactic gradient allowing the directed migration of specific leukocyte subsets into a site of inflammation (see Chapter 12). Primary cytokines can be viewed as part of the innate immune system (see Chapter 10), and in fact share signaling pathways with the so-called *Toll-like receptors (TLRs)*, a family of receptors that recognize molecular patterns characteristically associated with microbial products.[7] Although other cytokines sometimes have potent inflammatory activity, they do not duplicate this full repertoire of activities. Many qualify as secondary cytokines whose production is induced after stimulation by IL-1 and/or TNF family molecules. The term *secondary* does not imply that they are less important or less active than primary cytokines; rather, it indicates that their spectrum of activity is more restricted.

T-CELL SUBSETS DISTINGUISHED BY PATTERN OF CYTOKINE PRODUCTION

Another valuable concept that has withstood the test of time is the assignment of many T-cell-derived cytokines into groups based on the specific helper T-cell

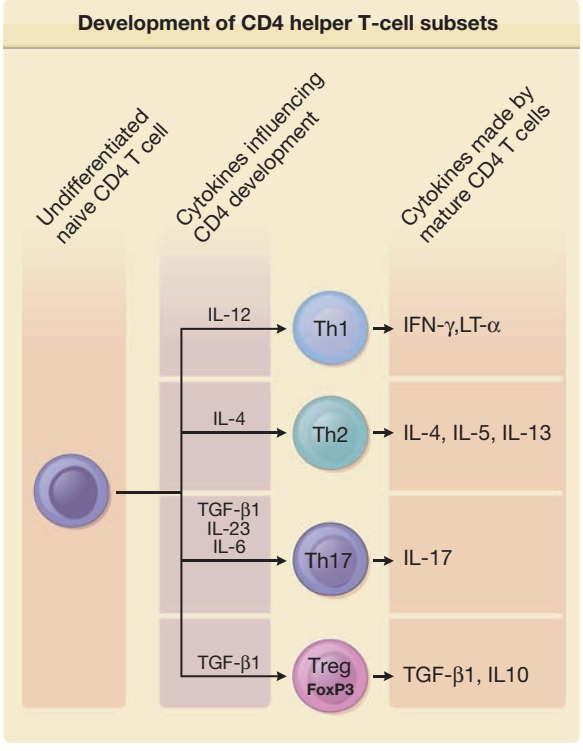

Figure 11-1 Cytokines control the development of specific CD4 helper T-cell subsets. The cytokine milieu at the time of activation of naive undifferentiated CD4 T cells has a profound influence on the ultimate pattern of cytokine secretion adopted by fully differentiated T cells. Subsets of effector CD4 T cells with defined patterns of cytokine secretion include T helper 1 (Th1), Th2, and Th17 cells. Regulatory CD4 T cells (Treg cells) express the FoxP3 transcription factor, and their effects are mediated in part by their production of transforming growth factor-β1 (TGF-β1) and/or interleukin 10 (IL-10). IFN = interferon; LT = lymphotoxin. (Adapted from Tato CM, O'Shea JJ: What does it mean to be just 17? *Nature* **441**:166, 2006.)

subsets that produce them (Fig. 11-1). The original two helper T-cell subsets were termed *Th1* and *Th2*.[8] Commitment to one of these two patterns of cytokine secretion also occurs with CD8 cytotoxic T cells and γ/δ T cells. Dominance of type 1 or type 2 cytokines in a T-cell immune response has profound consequences for the outcome of immune responses to certain pathogens and extrinsic proteins capable of serving as allergens. Over two decades after the original description of the Th1 and Th2 subsets, strong evidence has emerged that there are other functionally significant patterns of cytokine secretion by T cells. Most prominent among these newer T-cell lineages are *Th17* cells and *regulatory T cells* (or *Treg cells* for short). The Th17 subset is distinguished by production of a high level of IL-17, but many Th17 cells also secrete IL-21 and IL-22. Th17 cells promote inflammation, and there is consistent evidence from human autoimmune diseases and mouse models of these diseases that IL-17-producing cells are critical effectors in autoimmune disease.[9] A subset of T cells known as Treg cells has emerged as a crucial subset involved in the maintenance of peripheral self-tolerance.[10] Two of the most distinctive features of Treg cells are their expression of the FoxP3 transcription factor and production of transforming growth factor-β (TGF-β), a cytokine that appears to be required for Treg cells to limit the excess activity of the proinflammatory T-cell subsets.[11] IL-10 is also a significant contributor to the suppressive activity of Treg cells, particularly at some mucosal interfaces.[12] Additional proposed helper T-cell subsets are follicular helper T cells (Tfh) that specialize in providing B cell help in germinal centers, Th9 cells distinguished by high levels of IL-9 production that function in antiparasite immunity along with Th2 cells, and Th22 cells associated with skin inflammation that produce Th22, but not other Th17-associated cytokines. Not only does each of these T-cell subsets exhibit distinctive patterns of cytokine production, cytokines are key factors in influencing the differentiation of naive T cells into these subsets. IL-12 is the key Th1-promoting factor, IL-4 is required for Th2 differentiation, and IL-6, IL-23, and TGF-β are involved in promoting Th17 development.

STRUCTURAL CLASSIFICATION OF CYTOKINES

Not all useful classifications of cytokines are based solely on analysis of cytokine function. Structural biologists, aided by improved methods of generating homogenous preparations of proteins and establishment of new analytical methods (e.g., solution magnetic resonance spectroscopy) that complement the classical X-ray crystallography technique, have determined the three-dimensional structure of many cytokines. These efforts have led to the identification of groups of cytokines that fold to generate similar three-dimensional structures and bind to groups of cytokine receptors that also share similar structural features. For example, most of the cytokine ligands that bind to receptors of the hematopoietin cytokine receptor family are members of the four-helix bundle group of proteins. Four-helix bundle proteins have a shared tertiary architecture consisting of four antiparallel α-helical stretches separated by short connecting loops. The normal existence of some cytokines as oligomers rather than monomers was discovered in part as the result of structural investigations. For example, interferon-γ (IFN-γ) is a four-helix bundle cytokine that exists naturally as a noncovalent dimer. The bivalency of the dimer enables this ligand to bind and oligomerize two IFN-γ receptor complexes, thereby facilitating signal transduction. TNF-α and TNF-β are both trimers that are composed almost exclusively of β-sheets folded into a "jelly roll" structural motif. Ligand-induced trimerization of receptors in the TNF receptor family is involved in the initiation of signaling.

SIGNAL TRANSDUCTION PATHWAYS SHARED BY CYTOKINES

To accomplish their effects, cytokines must first bind with specificity and high affinity to receptors on the cell surfaces of responding cells. Many aspects of the

TABLE 11-1
Major Families of Cytokine Receptors

Receptor Family	Example	Major Signal Transduction Pathway(s) Leading to Biologic Effects
IL-1 receptor family	IL-1R, type I	NF-κB activation via TRAF6
TNF receptor family	TNFR1	NF-κB activation involving TRAF2 and TRAF5 Apoptosis induction via "death domain" proteins
Hematopoietin receptor family (class I receptors)	IL-2R	Activation of Jak/STAT pathway
IFN/IL-10 receptor family (class II receptors)	IFN-γR	Activation of Jak/STAT pathway
Immunoglobulin superfamily	M-CSF R	Activation of intrinsic tyrosine kinase
TGF-β receptor family	TGF-βR, types I and II	Activation of intrinsic serine/threonine kinase coupled to Smad proteins
Chemokine receptor family	CCR5	Seven transmembrane receptors coupled to G proteins

CCR = CC chemokine receptor; IFN = interferon; IL = interleukin; Jak = Janus kinase; M-CSF = macrophage colony-stimulating factor; NF-κB = nuclear factor κB; STAT = signal transducer and activator of transcription; TGF = transforming growth factor; TNF = tumor necrosis factor; TRAF = tumor necrosis factor receptor-associated factor.

pleiotropism and redundancy manifested by cytokines can be understood through an appreciation of shared mechanisms of signal transduction mediated by cell surface receptors for cytokines. In the early years of the cytokine biology era, the emphasis of most investigative work was the purification and eventual cloning of new cytokines and a description of their functional capabilities, both in vitro and in vivo. Most of the cytokine receptors have now been cloned, and many of the signaling cascades initiated by cytokines have been described in great detail. The vast majority of cytokine receptors can be classified into a relatively small number of families and superfamilies (Table 11-1), the members of which function in an approximately similar fashion. Table 11-2 lists the cytokines of particular relevance for cutaneous biology, including the major sources, responsive cells, features of interest, and clinical relevance of each cytokine. Most cytokines send signals to cells through pathways that are very similar to those used by other cytokines binding to the same class of receptors. Individual cytokines often employ several downstream pathways of signal transduction, which accounts in part for the pleiotropic effects of these molecules. Nevertheless, we propose here that a few major signaling pathways account for most effects attributable to cytokines. Of particularly central importance are the NF-κB pathway and the Jak/STAT pathway, described in the following sections.

NUCLEAR FACTOR κB, INHIBITOR OF κB, AND PRIMARY CYTOKINES

A major mechanism contributing to the extensive overlap between the biologic activities of the primary cytokines IL-1 and TNF is the shared use of the NF-κB signal transduction pathway. IL-1 and TNF use completely distinct cell surface receptor and proximal signaling pathways, but these pathways converge at the activation of the NF-κB transcription factor. NF-κB is of central importance in immune and inflammatory processes because a large number of genes that elicit or propagate inflammation have NF-κB recognition sites in their promoters.[13] NF-κB-regulated genes include cytokines, chemokines, adhesion molecules, nitric oxide synthase, cyclooxygenase, and phospholipase A2.

In unstimulated cells, NF-κB heterodimers formed from p65 and p50 subunits are inactive because they are sequestered in the cytoplasm as a result of tight binding to inhibitor proteins in the IκB family (Fig. 11-2). Signal transduction pathways that activate the NF-κB system do so through the activation of an IκB kinase (IKK) complex consisting of two kinase subunits (IKKα and IKKβ) and a regulatory subunit (IKKγ). The IKK complex phosphorylates IκBα and IκBβ on specific serine residues, yielding a target for recognition by an E3 ubiquitin ligase complex. The resulting polyubiquitination marks this IκB for rapid degradation by the 26S proteasome complex in the cytoplasm. Once IκB has been degraded, the free NF-κB (which contains a nuclear localization signal) is able to pass into the nucleus and induce expression of NF-κB-sensitive genes. The presence of κB recognition sites in cytokine promoters is very common. Among the genes regulated by NF-κB are *IL-1β* and *TNF-α*. This endows *IL-1β* and *TNF-α* with the capacity to establish a positive regulatory loop that favors persistent inflammation. Cytokines besides IL-1 and TNF that activate the NF-κB pathway as part of their signal transduction mechanisms include IL-17 and IL-18.

Proinflammatory cytokines are not the only stimuli that can activate the NF-κB pathway. Bacterial products

TABLE 11-2
Cytokines of Particular Relevance for Cutaneous Biology

Cytokine	Major Sources	Responsive Cells	Features of Interest	Clinical Relevance
IL-1α	Epithelial cells	Infiltrating leukocytes	Active form stored in keratinocytes	IL-1Ra used to treat rheumatoid arthritis
IL-1β	Myeloid cells	Infiltrating leukocytes	Caspase 1 cleavage required for activation	IL-1Ra used to treat rheumatoid arthritis
IL-2	Activated T cells	Activated T cells, Treg cells	Autocrine factor for activated T cells	IL-2 fusion toxin targets CTCL
IL-4	Activated Th2 cells, NKT cells	Lymphocytes, endothelial cells, keratinocytes	Causes B-cell class switching and Th2 differentiation	—
IL-5	Activated Th2 cells, mast cells	B cells, eosinophils	Regulates eosinophil response to parasites	Anti-IL-5 depletes eosinophils
IL-6	Activated myeloid cells, fibroblasts, endothelial cells	B cells, myeloid cells, hepatocytes	Triggers acute-phase response, promotes immunoglobulin synthesis	Anti-IL-6R used to treat rheumatoid arthritis
IL-10	T cells, NK cells	Myeloid and lymphoid cells	Inhibits innate and acquired immune responses	—
IL-12	Activated APCs	Th1 cells	Promotes Th1 differentiation, shares p40 subunit with IL-23	Anti-p40 inhibits Crohn's disease and psoriasis
IL-13	Activated Th2 cells, nuocytes	Monocytes, keratinocytes, endothelial cells	Mediates tissue responses to parasites	—
IL-17	Activated Th17 cells	Multiple cell types	Mediates autoimmune diseases	Potential drug target in autoimmune disease
IL-22	Activated Th17 cells and Th22 cells	Keratinocytes	Induces cytokines and antimicrobial peptides	Contributes to psoriasis
IL-23	Activated dendritic cells	Memory T cells, Th17 cells	Directs Th17 differentiation, mediates autoimmune disease	Anti-p40 inhibits Crohn's disease and psoriasis
IL-25	Activated Th2 cells, mast cells	Th17 cells	Promotes Th2 differentiation, inhibits Th17 cells	—
IL-27	Activated APCs	Th1 cells	Promotes Th1 differentiation	—
IL-35	Treg cells	Th17 cells and Treg cells	Inhibits Th17 cells and expands Treg cells	—
TNF-α	Activated myeloid, lymphoid, and epithelial cells	Infiltrating leukocytes	Mediates inflammation	Anti-TNF-α effective in psoriasis
IFN-α and IFN-β	Plasmacytoid dendritic cells	Most cell types	Major part of innate antiviral response	Elicited by topical imiquimod application
IFN-γ	Activated Th1 cells, CD8 T cells, NK cells, dendritic cells	Macrophages, dendritic cells, naive T cells	Macrophage activation, specific isotype switching	IFN-γ used to treat chronic granulomatous disease
TSLP	Epithelial cells including keratinocytes	Dendritic cells, B cells, Th2 cells	Promotes Th2 differentiation	Involved in atopic diseases

APC = antigen-presenting cell; CTCL = cutaneous T-cell lymphoma; IFN = interferon; IL = interleukin; NK = natural killer; NKT = natural killer T cell; Th = T helper; TNF = tumor necrosis factor; Treg = T regulatory; TSLP = thymic stromal lymphopoietin.

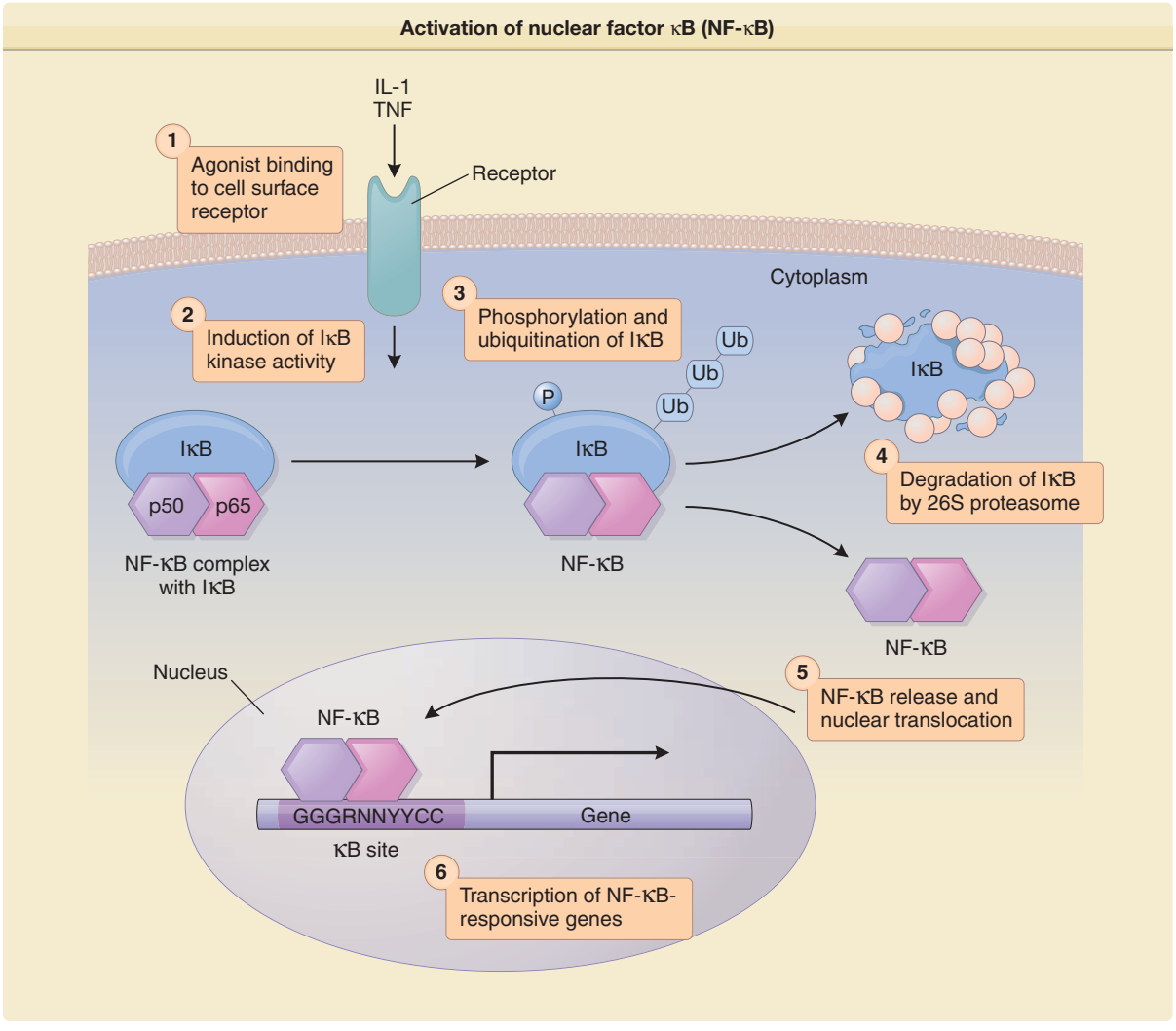

Figure 11-2 Activation of nuclear factor κB (NF-κB)-regulated genes after signaling by receptors for primary cytokines or by Toll-like receptors (TLRs) engaged by microbial products. Under resting conditions, NF-κB (a heterodimer of p50 and p65 subunits) is tightly bound to an inhibitor called Iκ*B* that sequesters NF-κB in the cytoplasm. Engagement of one of the TLRs or the signal transducing receptors for interleukin 1 (IL-1) or tumor necrosis factor (TNF) family members leads to induction of IκB kinase activity that phosphorylates IκB on critical serine residues. Phosphorylated IκB becomes a substrate for ubiquitination, which triggers degradation of IκB by the 26S proteasome. Loss of IκB results in release of NF-κB, which permits it to move to the nucleus and activate transcription of genes whose promoters contain κB recognition sites. Ub = ubiquitin.

(e.g., lipopolysaccharide, or LPS), oxidants, activators of protein kinase C (e.g., phorbol esters), viruses, and ultraviolet (UV) radiation are other stimuli that can stimulate NF-κB activity. TLR4 is a cell surface receptor for the complex of LPS, LPS-binding protein, and CD14. The cytoplasmic domain of TLR4 is similar to that of the IL-1 receptor type 1 (IL-1R1) and other IL-1R family members and is known as the *TIR* domain (for Toll/IL-1 receptor).[14] When ligand is bound to a TIR domain-containing receptor, one or more adapter proteins that also contain TIR domains are recruited to the complex. MyD88 was the first of these adapters to be identified; the other known adapters are TIRAP (TIR domain-containing adapter protein), TRIF (TIR domain-containing adapter inducing IFN-β), and TRAM (TRIF-related adapter molecule). Engagement of the adapter, in turn, activates one or more of the IL-1R-associated kinases (IRAK1 to IRAK4) that then signal through TRAF6, a member of the TRAF (TNF receptor-associated factor) family, and TAK1 (TGF-β-activated kinase) to activate the IKK complex.[15]

JAK/STAT PATHWAY

A major breakthrough in the analysis of cytokine-mediated signal transduction was the identification of a common cell surface to nucleus pathway used by the majority of cytokines. This Jak/STAT pathway was first elucidated through careful analysis of signaling initiated by IFN receptors (Fig. 11-3), but was subsequently shown to play a role in signaling by all

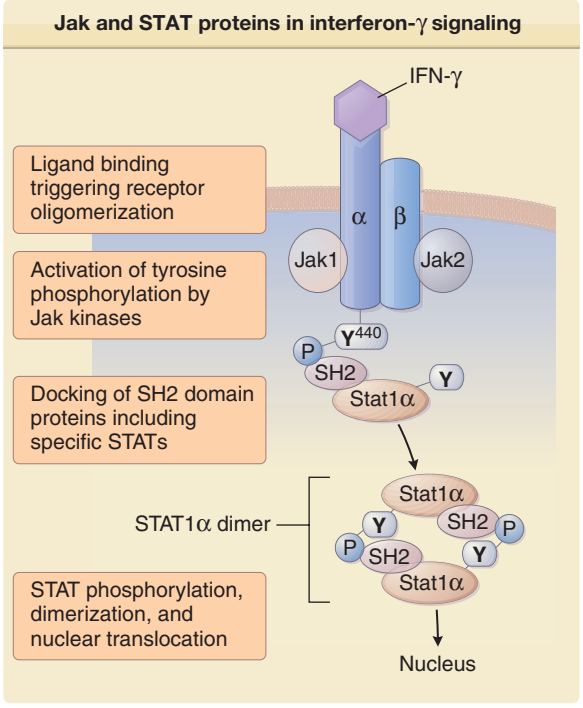

Figure 11-3 Participation of Jak (Janus kinase) and STAT (signal transducer and activator of transcription) proteins in interferon-γ (IFN-γ) signaling. Binding of human IFN-γ (a dimer) to its receptor brings about oligomerization of receptor complexes composed of α and β chains. The nonreceptor protein tyrosine kinases Jak1 and Jak2 are activated and phosphorylate critical tyrosine residues in the receptor such as the tyrosine at position 440 of the α chain (Y^{440}). STAT1α molecules are recruited to the IFN-γ receptor based on the affinity of their Src homology 2 (SH2) domains for the phosphopeptide sequence around Y^{440}. Receptor-associated STAT1α molecules then dimerize through reciprocal SH2-phosphotyrosine interactions. The resulting STAT1α dimers translocate to the nucleus and stimulate transcription of IFN-γ-regulated genes.

cytokines that bind to members of the hematopoietin receptor family.[16] The Jak/STAT pathway operates through the sequential action of a family of four nonreceptor tyrosine kinases (the Jaks or *Ja*nus family *k*inases) and a series of latent cytosolic transcription factors known as *STATs* (*s*ignal *t*ransducers and *a*ctivators of *t*ranscription). The cytoplasmic portions of many cytokine receptor chains are noncovalently associated with one of the four Jaks [Jak1, Jak2, Jak3, and tyrosine kinase 2 (Tyk2)].

The activity of the Jak kinases is upregulated after stimulation of the cytokine receptor. Ligand binding to the cytokine receptors leads to the association of two or more distinct cytokine receptor subunits and brings the associated Jak kinases into close proximity with each other. This promotes cross-phosphorylation or autophosphorylation reactions that in turn fully activate the kinases. Tyrosines in the cytoplasmic tail of the cytokine receptor as well as tyrosines on other associated and newly recruited proteins are also phosphorylated. A subset of the newly phosphorylated tyrosines can then serve as docking points for attachment of additional signaling proteins bearing Src homology 2 (SH2) domains. Cytoplasmic STATs possess SH2 domains and are recruited to the phosphorylated cytokine receptors via this interaction. Homodimeric or heterodimeric STAT proteins are phosphorylated by the Jak kinases and subsequently translocate to the nucleus. In the nucleus they bind recognition sequences in DNA and stimulate transcription of specific genes, often in cooperation with other transcription factors. The same STAT molecules can be involved in signaling by multiple different cytokines. The specificity of the response in these instances may depend on the formation of complexes involving STATs and other transcription factors that then selectively act on a specific set of genes.

INTERLEUKIN 1 FAMILY OF CYTOKINES (INTERLEUKINS 1α, 1β, 18, 33)

IL-1 is the prototype of a cytokine that has been discovered many times in many different biologic assays. Distinct genes encode the α and β forms of human IL-1, with only 26% homology at the amino acid level. Both IL-1s are translated as 31-kDa molecules that lack a signal peptide, and both reside in the cytoplasm. This form of IL-1α is biologically active, but 31-kDa *IL-1β* must be cleaved by caspase 1 (initially termed *interleukin-1β-converting enzyme*) in a multiprotein cytoplasmic complex called the *inflammasome* to generate an active molecule.[17]

In general, IL-1β appears to be the dominant form of IL-1 produced by monocytes, macrophages, Langerhans cells, and dendritic cells, whereas IL-1α predominates in epithelial cells, including keratinocytes. This is likely to relate to the fact that epithelial IL-1α is stored in the cytoplasm of cells that comprise an interface with the external environment. Such cells, when injured, release biologically active 31-kDa IL-1α and, by doing so, can initiate inflammation.[6] However, if uninjured, these cells will differentiate and ultimately release their IL-1 contents into the environment. Leukocytes, including dendritic and Langerhans cells, carry their cargo of IL-1 inside the body, where its unregulated release could cause significant tissue damage. Thus, biologically active IL-1β release from cells is controlled at several levels: *IL-1β* gene transcription, *caspase 1* gene transcription, and availability of the adapter proteins that interact with caspase 1 in the inflammasome to allow the generation of mature IL-1β. IL-1β stimulates the egress of Langerhans cells from the epidermis during the initiation of contact hypersensitivity, a pivotal event that leads to accumulation of Langerhans cells in skin-draining lymph nodes. Studies of mice deficient in *IL-1α* and *IL-1β* genes suggest that both molecules are important in contact hypersensitivity, but that IL-1α is more critical.

Active forms of IL-1 bind to the IL-1R1 or type 1 IL-1 receptor.[14] This is the sole signal-transducing receptor for IL-1, and its cytoplasmic domain has

little homology with other cytokine receptors, showing greatest homology with the *Toll* gene product identified in *Drosophila*. A second cell surface protein, the IL-1R accessory protein, or IL-1RAcP, must associate with IL-1R1 for signaling to occur. When IL-1 engages the IL-1R1/IL-1RAcP complex, recruitment of the MyD88 adapter occurs, followed by interactions with one or more of the IRAKs. These kinases in turn associate with TRAF6. Stepwise activation and recruitment of additional signaling molecules culminate in the induction of IKK activity. The net result is the activation of a series of NF-κB-regulated genes.

A molecule known as the *IL-1 receptor antagonist*, or IL-1ra, can bind to IL-1R1 but does not induce signaling through the receptor. This IL-1ra exists in three alternatively spliced forms, and an isoform produced in monocytes is the only ligand for the IL-1R1 that both contains a signal peptide and is secreted from cells. Two other isoforms of IL-1ra, both lacking signal peptides, are contained within epithelial cells. The function of IL-1ra seems to be as a pure antagonist of IL-1 ligand binding to IL-1R1, and binding of IL-1ra to IL-1R1 does not induce the mobilization of IL-1RAcP. Consequently, although both IL-1α/β and IL-1ra bind with equivalent affinities to IL-1R1, the association of IL-1R1 with IL-1RAcP increases the affinity for IL-1α/β manyfold while not affecting the affinity for IL-1ra. This is consistent with the observation that a vast molar excess of IL-1ra is required to fully antagonize the effects of IL-1. The biologic role of IL-1ra is likely to be in the quenching of IL-1-mediated inflammatory responses, and mice deficient in IL-1ra show exaggerated and persistent inflammatory responses.

A second means of antagonizing IL-1 activity occurs via expression of a second receptor for IL-1, IL-1R2. This receptor has a short cytoplasmic domain and serves to bind IL-1α/β efficiently, but not IL-1ra. This 68-kDa receptor can be cleaved from the cell surface by an unknown protease and released as a stable, soluble 45-kDa molecule that retains avid IL-1-binding function. By binding the functional ligands for IL-1R1, IL-1R2 serves to inhibit IL-1-mediated responses. It is likely that IL-1R2 also inhibits IL-1 activity by associating with IL-1RAcP at the cell surface and removing and sequestering it from the pool available to associate with IL-1R1. Thus, soluble IL-1R2 binds to free IL-1, whereas cell surface IL-1R2 sequesters IL-1RAcP. Expression of IL-1R2 can be upregulated by a number of stimuli, including corticosteroids and IL-4. However, IL-1R2 can also be induced by inflammatory cytokines, including IFN-γ and IL-1, probably as a compensatory signal designed to limit the scale and duration of the inflammatory response. Production of IL-1R2 serves to make the producing cell and surrounding cells resistant to IL-1-mediated activation. Interestingly, some of the most efficient IL-1-producing cells are also the best producers of the IL-1R2.

IL-18 was first identified based on its capacity to induce IFN-γ. One name initially proposed for this cytokine was IL-1γ, because of its homology with IL-1α and IL-1β. Like IL-1β, it is translated as an inactive precursor molecule of 23 kDa and is cleaved to an active 18-kDa species by caspase 1. It is produced by multiple cell types in skin, including keratinocytes, Langerhans cells, and monocytes. IL-18 induces proliferation, cytotoxicity, and cytokine production by Th1 and natural killer (NK) cells, mostly synergistically with IL-12. The IL-18 receptor bears striking similarity to the IL-1 receptor.[14] The binding chain (IL-18R) is an IL-1R1 homolog, originally cloned as IL-1Rrp1. IL-18R alone is a low-affinity receptor that must recruit IL-18RAcP (a homolog of IL-1RAcP). As for IL-1, both chains of the IL-18 receptor are required for signal transduction. Although there is no IL-18 homolog of IL-1ra, a molecule known as *IL-18-binding protein* binds to soluble mature IL-18 and prevents it from binding to the IL-18R complex.

More recently, it has become clear that there is a family of receptors homologous to the IL-1R1 and IL-18R molecules,[14] having in common a TIR motif (Fig. 11-4). All of these share analogous signaling pathways initiated by the MyD88 adapter molecule. One of these receptors, originally known as *ST2*, was initially characterized as a gene expressed by Th2 cells, but not by Th1 cells. The description of a natural ligand for ST2 designated IL-33 has added a new member to the IL-1 family that shares characteristic features of other cytokines in the family, such as a requirement for

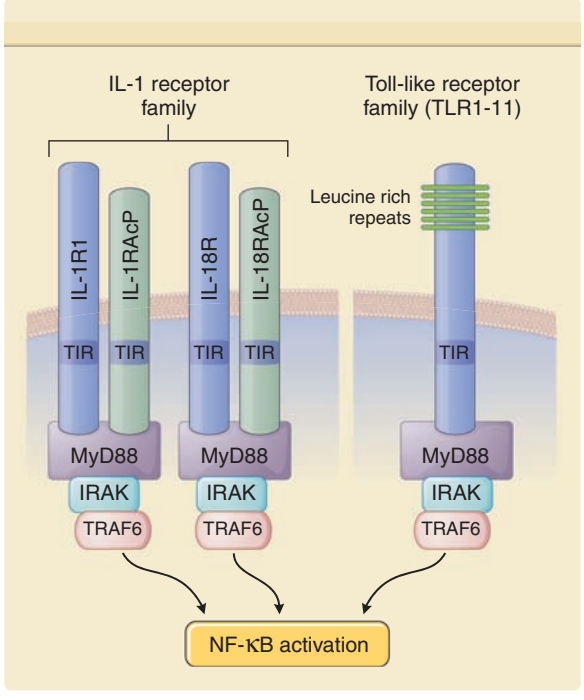

Figure 11-4 The interleukin 1 receptor (IL-1R) family and Toll-like receptors (TLRs) use a common intracellular signaling pathway. Receptors for cytokines in the IL-1 family (typified by the IL-1 and IL-18 receptors) share a common signaling domain with the TLRs (TLR1 to TLR11) called the *Toll/IL-1 receptor (TIR)* domain. The TIR domain receptors interact with TIR domain-containing adapter proteins such as MyD88 that couple ligand binding to activation of IL-1R-associated kinase (IRAK) and ultimately activation of nuclear factor κB (NF-κB). IL-1RAcP = IL-1R accessory protein; TRAF = tumor necrosis factor receptor-associated factor.

processing by caspase 1 to release a mature form of the ligand.[18] IL-33 stimulation of Th2 cells promotes their production of the characteristic Th2 cytokines IL-4, IL-5, and IL-10.[19] IL-1R1, IL-18R, IL-33R (ST2), the TLRs, and their ligands are all best viewed as elements of the innate immune system that signal the presence of danger or injury to the host.

When IL-1 produced by epidermis was originally identified, it was noted that both intact epidermis and stratum corneum contained significant IL-1 activity, which led to the concept that epidermis was a shield of sequestered IL-1 surrounding the host, waiting to be released on injury. More recently, it was observed that high levels of the IL-1ra coexist within keratinocytes; however, repeated experiments show that in virtually all cases, the amount of IL-1 present is sufficient to overcome any potential for inhibition mediated by IL-1ra. Studies have now shown that mechanical stress to keratinocytes permits the release of large amounts of IL-1 in the absence of cell death. Release of IL-1 induces expression of endothelial adhesion molecules, including E-selectin, ICAM-1, and VCAM-1, as well as chemotactic and activating chemokines. This attracts not only monocytes and granulocytes but a specific subpopulation of memory T cells that bear cutaneous lymphocyte antigen on their cell surface. Memory T cells positive for cutaneous lymphocyte antigen are abundant in inflamed skin, comprising the majority of T cells present. Therefore, any injury to the skin, no matter how trivial, releases IL-1 and attracts this population of memory T cells. If they encounter their antigen in this microenvironment, their activation and subsequent cytokine production will amplify the inflammatory response. This has been proposed as the basis of the clinical observation of inflammation in response to trauma, known as the *Koebner reaction*.

Several biologics that act by inhibiting IL-1 function have been developed for clinical use including recombinant IL-1Ra (anakinra), antibody to IL-1β (canakinumab), and an IgG Fc fusion protein that includes the ligand binding domains of the type I IL-1R and IL-1RAcP (rilonacept, also known as IL-1 Trap). All of these agents are efficacious in countering the IL-1-induced inflammation associated with a group of rare autoinflammatory diseases called the cryopyrin-associated periodic syndromes (CAPS). Anakinra was initially US Food and Drug Administration (FDA) approved as a therapy for adult rheumatoid arthritis. IL-1 inhibition is also being tested as a therapy for gout, an inflammatory arthritis triggered by uric acid-mediated activation of inflammasomes that generate IL-1β.

TUMOR NECROSIS FACTOR: THE OTHER PRIMARY CYTOKINE

TNF-α is the prototype for a family of related signaling molecules that mediate their biologic effects through a family of related receptor molecules. TNF-α was initially cloned on the basis of its ability to mediate two interesting biologic effects: (1) hemorrhagic necrosis of malignant tumors, and (2) inflammation-associated cachexia. Although TNF-α exerts many of its biologically important effects as a soluble mediator, newly synthesized TNF-α exists as a transmembrane protein on the cell surface. A specific metalloproteinase known as *TNF-α-converting enzyme (TACE)* is responsible for most TNF-α release by T cells and myeloid cells. The closest cousin of TNF-α is TNF-β, also known as *lymphotoxin α (LT-α)*. Other related molecules in the TNF family include lymphotoxin β (LT-β) that combines with LT-α to form the LT-α1β2 heterotrimer; Fas ligand (FasL); TNF-related apoptosis-inducing ligand (TRAIL); receptor activator of NF-κB ligand (RANKL); and CD40 ligand (CD154). Although some of these other TNF family members have not been traditionally regarded as cytokines, their structure (all are type II membrane proteins with an intracellular *N*-terminus and an extracellular *C*-terminus) and signaling mechanisms are closely related to those of TNF. The soluble forms of TNF-α, LT-α, and FasL are homotrimers, and the predominant form of LT-β is the membrane-bound LT-α1β2 heterotrimer. Trimerization of TNF receptor family members by their trimeric ligands appears to be required for initiation of signaling and expression of biologic activity.

The initial characterization of TNF receptors led to the discovery of two receptor proteins capable of binding TNF-α with high affinity. The p55 receptor for TNF (TNFR1) is responsible for most biologic activities of TNF, but the p75 TNF receptor (TNFR2) is also capable of transducing signals (unlike IL-1R2, which acts solely as a biologic sink for IL-1). TNFR1 and TNFR2 have substantial stretches of close homology and are both present on most types of cells. Nevertheless, there are some notable differences between the two TNFRs.

Unlike cytokine receptors from several of the other large families, TNF signaling does not involve the Jak/STAT pathway. TNF-α evokes two types of responses in cells: (1) proinflammatory effects, and (2) induction of apoptotic cell death (Fig. 11-5). The proinflammatory effects of TNF-α that include upregulation of adhesion molecule expression and induction of secondary cytokines and chemokines, stem in large part from activation of NF-κB and can be transduced through both TNFR1 and TNFR2. Induction of apoptosis by signaling through TNFR1 depends on a region known as a *death domain* that is absent in TNFR2, as well as interactions with additional proteins with death domains within the TNFR1 signaling complex. Signaling initiated by ligand binding to TNFR1, Fas, or other death domain-containing receptors in the TNF family eventually leads to activation of caspase 8 or 10 and the nuclear changes and DNA fragmentation characteristic of apoptosis.

At least two TNFR family members (TNFR1 and the LT-β receptor) also contribute to the normal anatomic development of the lymphoid system. Mice deficient in TNF-α lack germinal centers and follicular dendritic cells. TNFR1 mutant mice show the same abnormalities plus an absence of Peyer's patches. Mice with null mutations in LT-α or LT-β have further abnormalities in lymphoid organogenesis and fail to develop peripheral lymph nodes.

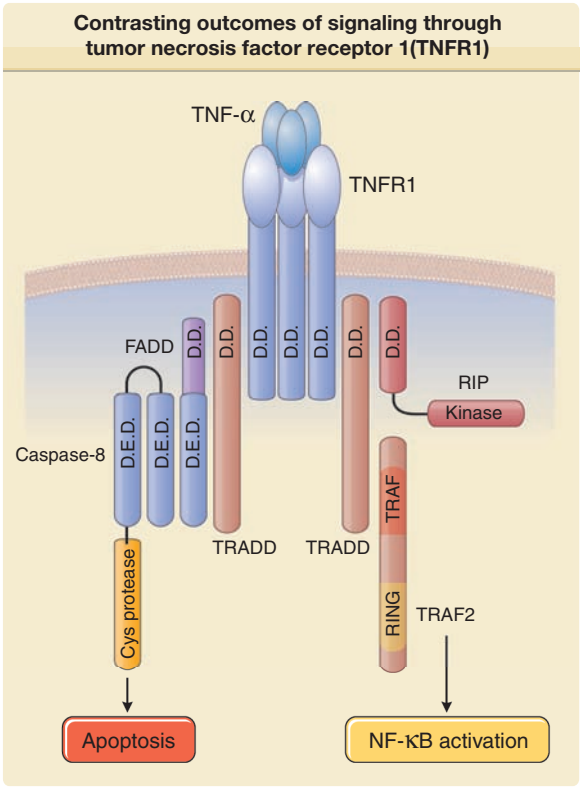

Figure 11-5 Two contrasting outcomes of signaling through tumor necrosis factor receptor 1 (TNFR1). Engagement of TNFR1 by trimeric tumor necrosis factor-α (TNF-α) can trigger apoptosis and/or nuclear factor κB (NF-κB) activation. Both processes involve the adapter protein TNFR-associated death domain (TRADD), which associates with TNFR1 via interactions between "death domains" (D.D.) on both proteins. For NF-κB activation, TNFR-associated factor 2 (TRAF2) and receptor-interacting protein (RIP) are required. Induction of apoptosis occurs when the death domain-containing protein Fas-associated death domain protein (FADD) associates with TRADD. FADD also contains a "death effector domain" (D.E.D.) that interacts with caspase 8 to initiate the apoptotic process. Cys = cysteine. (Adapted from Yuan J: Transducing signals of life and death. *Curr Opin Cell Biol* **9**:247, 1997; and Nagata S: Apoptosis by death factor. *Cell* **88**:355, 1997.)

TNF-α is an important mediator of cutaneous inflammation, and its expression is induced in the course of almost all inflammatory responses in skin. Normal human keratinocytes and keratinocyte cell lines produce substantial amounts of TNF-α after stimulation with LPS or UV light. Cutaneous inflammation stimulated by irritants and contact sensitizers is associated with strong induction of TNF-α production by keratinocytes. Exposure to TNF-α promotes Langerhans cell migration to draining lymph nodes, allowing for sensitization of naive T cells. One molecular mechanism that may contribute to TNF-α-induced migration of Langerhans cells toward lymph nodes is reduced expression of the E-cadherin adhesion molecule after exposure to TNF-α. Induction of CC chemokine receptor 7 on both epidermal and dermal antigen-presenting cells correlates with movement into the draining lymphatics. The predominant TNFR expressed by keratinocytes is TNFR1. Autocrine signaling loops involving keratinocyte-derived TNF-α and TNFR1 lead to keratinocyte production of a variety of TNF-inducible secondary cytokines.

The central role of TNF-α in inflammatory diseases, including rheumatoid arthritis and psoriasis, has become evident from clinical studies. Clinical drugs that target the TNF pathway include the humanized anti-TNF-α antibody infliximab, the fully human anti-TNF-α antibody adalumimab, and the soluble TNF receptor etanercept. Drugs in this class are FDA approved for the treatment of several autoimmune and inflammatory diseases, including Crohn's disease and rheumatoid arthritis. These three anti-TNF drugs are also FDA approved for the treatment of psoriasis and psoriatic arthritis (see Chapter 234). This class of drugs also has the potential to be valuable in the treatment of other inflammatory dermatoses. Paradoxically, they are not effective against all autoimmune diseases—multiple sclerosis appears to worsen slightly after treatment with these agents. The TNF antagonists are powerful immunomodulating drugs, and appropriate caution is required in their use. Cases of cutaneous T-cell lymphoma initially thought to represent psoriasis have rapidly progressed to fulminant disease after treatment with TNF antagonists. TNF antagonists can also allow the escape of latent mycobacterial infections from immune control, with a potentially lethal outcome for the patient.

IL-17 FAMILY OF CYTOKINES

IL-17 (also known as IL-17A) was the first described member of a family of related cytokines that now includes IL-17B through F. IL-17A and IL-17F have similar proinflammatory activities, bind to the same heterodimeric receptor composed of the IL-17RA and IL-17RC receptor chains, and act to promote recruitment of neutrophils and induce production of antimicrobial peptides. These IL-17 species normally function in immune defense against pathogenic species of extracellular bacteria and fungi. Signaling by IL-17A and IL-17F depends on STAT3; mutations in STAT3 associated with the hyper-IgE syndrome block IL-17 signaling and lead to recurrent skin infections with *Staphylococcus aureus* and *Candida albicans*. Less is currently known about the actions of IL-17B, C, and D. IL-17E, also known as IL-25, is a product of Th2 cells and mast cells that signals through IL-17RB. A total of five receptor chains for IL-17 family cytokines have been identified, but how each of these individual receptor chains associates to form receptors for all the members of the IL-17 family remains to be worked out. These IL-17 receptor chains are homologous to each other, but display very limited regions of homology to the other major families of cytokine receptors. Recent expansion of interest in Th17 cells and the entire IL-17 family is closely linked to observations that the immunopathology of autoimmune disease in human patients and mouse models is often associated with an inappropriate expansion of Th17 cells. Thus, the cytokines produced by Th17 cells and the receptors that

transduce these signals may turn out to be useful targets for therapies designed to dampen autoimmunity.

LIGANDS OF THE CLASS I (HEMATOPOIETIN RECEPTOR) FAMILY OF CYTOKINE RECEPTORS

The hematopoietin receptor family (also known as the *class I cytokine receptor family*) is the largest of the cytokine receptor families and comprises a number of structurally related type I membrane-bound glycoproteins. The cytoplasmic domains of these receptors associate with nonreceptor tyrosine kinase molecules, including the Jak kinases and src family kinases. After ligand binding and receptor oligomerization, these associated nonreceptor tyrosine kinases phosphorylate intracellular substrates, which leads to signal transduction. Most of the multiple-chain receptors in the hematopoietin receptor family consist of a cytokine-specific α chain subunit paired with one or more shared receptor subunits. Five shared receptor subunits have been described to date: (1) the common γ chain (γ_c), (2) the common β chain shared between the IL-2 and IL-15 receptors; (3) a distinct common β chain shared between the granulocyte-macrophage colony stimulating factor (GM-CSF), IL-3, and IL-5 receptors; (4) the IL-12Rβ2 chain shared by the IL-12 and IL-23 receptors; and (5) finally the glycoprotein 130 (gp130) molecule, which participates in signaling by IL-6 and related cytokines.

CYTOKINES WITH RECEPTORS THAT INCLUDE THE γ_c CHAIN

The receptor complexes using the γ_c chain are the IL-2, IL-4, IL-7, IL-9, IL-13, IL-15, and IL-21 receptors. Two of these receptors, IL-2R and IL-15R, also use the IL-2Rβ_c chain. The γ_c chain is physically associated with Jak3, and activation of Jak3 is critical to most signaling initiated through this subset of cytokine receptors.[20]

INTERLEUKIN 2 AND INTERLEUKIN 15. IL-2 and IL-15 can each activate NK cells and stimulate proliferation of activated T cells. IL-2 is a product of activated T cells, and IL-2R is largely restricted to lymphoid cells. The *IL-15* gene is expressed by nonlymphoid tissues, and its transcription is induced by UVB radiation in keratinocytes and fibroblasts and by LPS in monocytes and dendritic cells. Multiple isoforms of IL-15Rα are found in various hematopoietic and nonhematopoietic cells. The IL-2R and IL-15R complexes of lymphocytes incorporate up to three receptor chains, whereas most other cytokine receptor complexes have two. The affinities of IL-2R and IL-15R for their respective ligands can be regulated, and to some extent, IL-2 and IL-15 compete with each other. The highest affinity receptor complexes for each ligand (approximately 10^{-11} M) consist of the IL-2Rβ_c and γ_c chains, as well as their respective α chains (IL-2Rα, also known as CD25, and IL-15Rα). γ_c and IL-2Rβ_c without the α chains form a functional lower affinity receptor for either ligand (10^{-8} to 10^{-10} M). Although both ligands transmit signals through the γ_c chain, those signals elicit overlapping but distinct responses in various cells. Activation of naive CD4 T cells by T-cell receptor and costimulatory molecules induces expression of IL-2, IL-2Rα, and IL-2Rβ_c, which leads to vigorous proliferation. Prolonged stimulation of T-cell receptor and IL-2R leads to expression of FasL and activation-induced cell death. Although IL-2 signaling facilitates the death of CD4 T cells in response to sustained exposure to antigen, IL-15 inhibits IL-2-mediated activation-induced cell death as it stimulates growth. Similarly, IL-15 promotes proliferation of memory CD8 T cells, whereas IL-2 inhibits it. IL-15 is also involved in the homeostatic survival of memory CD8 T cells, NK cells, and NK T cells. These contrasting biologic roles are illustrated by mice deficient in IL-2 or IL-2Rα that develop autoimmune disorders, and mice deficient in IL-15 or IL-15Rα, which have lymphopenia and immune deficiencies. Thus, IL-15 appears to have an important role in promoting effector functions of antigen-specific T cells, whereas IL-2 is involved in reining in autoreactive T cells.[21]

INTERLEUKIN 4 AND INTERLEUKIN 13. IL-4 and IL-13 are products of activated Th2 cells that share limited structural homology (approximately 30%) and overlapping but distinct biologic activities. A specific receptor for IL-4, which does not bind IL-13, is found on T cells and NK cells. It consists of IL-4Rα (CD124) and γ_c and transmits signals via Jak1 and Jak3. A second receptor complex that can bind either IL-4 or IL-13 is found on keratinocytes, endothelial cells, and other nonhematopoietic cells. It consists of IL-13Rα1 and IL-4Rα and transmits signals via Jak1 and Jak2. These receptors are expressed at low levels in resting cells, and their expression is increased by various activating signals. Curiously, exposure of monocytes to IL-4 or IL-13 suppresses expression of IL-4Rα and IL-13Rα1, whereas the opposite effect is observed in keratinocytes. Both signal transduction pathways appear to converge with the activation of STAT6, which is both necessary and sufficient to drive Th2 differentiation. IL-13Rα2 is a cell surface receptor homologous to IL-13Rα1 that specifically binds to IL-13 but is not known to transmit any signals.[20]

The biologic effects of engagement of the IL-4 receptor vary depending on the specific cell type, but most pertain to its principal role as a growth and differentiation factor for Th2 cells. Exposure of naive T cells to IL-4 stimulates them to proliferate and differentiate into Th2 cells, which produce more IL-4, which in turn leads to autocrine stimulation that prolongs Th2 responses. Thus the expression of IL-4 early in the immune response can initiate a cascade of Th2 cell development that results in a predominately Th2 response. The genes encoding IL-4 and IL-13 are located in a cluster with IL-5 that undergoes structural changes during Th2 differentiation that are associated with increased expression. Although naive T cells can make low levels of IL-4 when activated, IL-4

is also produced by activated NK T cells. Mast cells and basophils also release preformed IL-4 from secretory granules in response to FcεRI-mediated signals. A prominent activity of IL-4 is the stimulation of class switching of the immunoglobulin genes of B cells. Nuocytes and natural helper cells are recently identified populations of innate immune effector cells that provide an early source of IL-13 during helminth infection. As critical factors in Th2 differentiation and effector function, IL-4 and IL-13 are mediators of atopic immunity. In addition to controlling the behavior of effector cells they also act directly on resident tissue cells, such as in inflammatory airway reactions.[22]

INTERLEUKIN 9 AND INTERLEUKIN 21. IL-9 is a product of activated Th2 cells exposed to TGF-β that acts as an autocrine growth factor as well as a mediator of inflammation.[23] It is also produced by mast cells in response to IL-10 or stem cell factor. It stimulates proliferation of T and B cells and promotes expression of immunoglobulin E by B cells. It also exerts proinflammatory effects on mast cells and eosinophils. IL-9-deficient mice exhibit deficits in mast cell and goblet cell differentiation. IL-9 can be grouped with IL-4 and IL-13 as cytokines that function as effectors of allergic inflammatory processes and may play an important role in asthma and allergic disorders. IL-21 is also a product made by the Th2, Th17, and Tfh lineages that signals through a receptor composed of a specific α chain (IL-21R) homologous to the IL-4R α chain and γ_c.[24] Absence of an intact IL-21 receptor is associated with impaired Th2 responses.[25]

INTERLEUKIN 7 AND THYMIC STROMAL LYMPHOPOIETIN. Mutations abrogating the function of IL-7, IL-7Rα (CD127), γ_c, or Jak3 in mice or humans cause profound immunodeficiency as a result of T- and NK-cell depletion.[20] This is principally due to the indispensable role of IL-7 in promoting the expansion of lymphocytes and regulating the rearrangement of their antigen receptor genes. IL-7 is a potent mitogen and survival factor for immature lymphocytes in the bone marrow and thymus. The second function of IL-7 is as a modifier of effector cell functions in the reactive phase of certain immune responses. IL-7 transmits activating signals to mature T cells and certain activated B cells. Like IL-2, IL-7 has been shown to stimulate proliferation of cytolytic T cells and lymphokine-activated killer cells in vitro and to enhance their activities in vivo. IL-7 is a particularly significant cytokine for lymphocytes in the skin and other epithelial tissues. It is expressed by keratinocytes in a regulated fashion, and this expression is thought to be part of a reciprocal signaling dialog between dendritic epidermal T cells and keratinocytes in murine skin. Keratinocytes release IL-7 in response to IFN-γ, and dendritic epidermal T cells secrete IFN-γ in response to IL-7.

An IL-7-related cytokine using one chain of the IL-7 receptor as part of its receptor is thymic stromal lymphopoietin (TSLP). TSLP was originally identified as a novel cytokine produced by a thymic stromal cell line that could act as a growth factor for B- and T-lineage cells. The TSLP receptor consists of the IL-7Rα and a second receptor chain (TSLPR) homologous to but distinct from the γ_c chain. TSLP has attracted interest because of its ability to prime dendritic cells to become stronger stimulators of Th2 cells. This activity may permit TSLP to foster the development of some types of allergic diseases.[26,27]

CYTOKINES WITH RECEPTORS USING THE INTERLEUKIN 3 RECEPTOR β CHAIN

The receptors for IL-3, IL-5, and GM-CSF consist of unique cytokine-specific α chains paired with a common β chain known as *IL-3R*β or β_c (CD131). Each of these factors acts on subsets of early hematopoietic cells.[28] IL-3, which was previously known as *multilineage colony-stimulating factor*, is principally a product of CD4+ T cells and causes proliferation, differentiation, and colony formation of various myeloid cells from bone marrow. IL-5 is a product of Th2 CD4+ cells and activated mast cells that conveys signals to B cells and eosinophils. IL-5 has a costimulatory effect on B cells in that it enhances their proliferation and immunoglobulin expression when they encounter their cognate antigen. In conjunction with an eosinophil-attracting chemokine known as *CC chemokine ligand 11* or *eotaxin*, IL-5 plays a central role in the accumulation of eosinophils that accompanies parasitic infections and some cutaneous inflammatory processes. IL-5 appears to be required to generate a pool of eosinophil precursors in bone marrow that can be rapidly mobilized to the blood, whereas eotaxin's role is focused on recruitment of these eosinophils from blood into specific tissue sites. GM-CSF is a growth factor for myeloid progenitors produced by activated T cells, phagocytes, keratinocytes, fibroblasts, and vascular endothelial cells. In addition to its role in early hematopoiesis, GM-CSF has potent effects on macrophages and dendritic cells. In vitro culture of fresh Langerhans cells in the presence of GM-CSF promotes their transformation into mature dendritic cells with maximal immunostimulatory potential for naive T cells. The effects of GM-CSF on dendritic cells probably account for the dramatic ability of GM-CSF to evoke therapeutic antitumor immunity when tumor cells are engineered to express it.[29,30]

INTERLEUKIN 6 AND OTHER CYTOKINES WITH RECEPTORS USING GLYCOPROTEIN 130

Receptors for a group of cytokines including IL-6, IL-11, IL-27, leukemia inhibitory factor, oncostatin M, ciliary neurotrophic factor, and cardiotrophin-1 interact with a hematopoietin receptor family member, gp130, which does not appear to interact with any ligand by itself. The gp130 molecule is recruited into signaling complexes with other receptor chains when they engage their cognate ligands.

IL-6 is the most thoroughly characterized of the cytokines that use gp130 for signaling and serves as a paradigm for discussion of the biologic effects of this family of cytokines. IL-6 is yet another example of a highly pleiotropic cytokine with multiple effects. A series of different names (including *IFN-β_2*, *B-cell stimulatory factor 2*, *plasmacytoma growth factor*, *cytotoxic T cell differentiation factor*, and *hepatocyte-stimulating factor*) were used for IL-6 before it was recognized that a single molecular species accounts for all of these activities. IL-6 acts on a wide variety of cells of hematopoietic origin. IL-6 stimulates immunoglobulin secretion by B cells and has mitogenic effects on B lineage cells and plasmacytomas. IL-6 also promotes maturation of megakaryocytes and differentiation of myeloid cells. Not only does it participate in hematopoietic development and reactive immune responses, but IL-6 is also a central mediator of the systemic acute-phase response. Increases in circulating IL-6 levels stimulate hepatocytes to synthesize and release acute-phase proteins.

There are two distinct signal transduction pathways triggered by IL-6. The first of these is mediated by the gp130 molecule when it dimerizes on engagement by the complex of IL-6 and IL-6Rα. Homodimerization of gp130 and its associated Jak kinases (Jak1, Jak2, Tyk2) leads to activation of STAT3. A second pathway of gp130 signal transduction involves Ras and the mitogen-activated protein kinase cascade and results in phosphorylation and activation of a transcription factor originally designated *nuclear factor of IL-6*.

IL-6 is an important cytokine for skin and is subject to dysregulation in several human diseases, including some with skin manifestations. IL-6 is produced in a regulated fashion by keratinocytes, fibroblasts, and vascular endothelial cells as well as by leukocytes infiltrating the skin. IL-6 can stimulate the proliferation of human keratinocytes under some conditions. Psoriasis is one of several inflammatory skin diseases in which elevated expression of IL-6 has been described. Human herpesvirus 8 produces a viral homolog of IL-6 that may be involved in the pathogenesis of human herpes virus-8-associated diseases, including Kaposi sarcoma and body cavity-based lymphomas.

The other cytokines using gp130 as a signal transducer have diverse bioactivities. IL-11 inhibits production of inflammatory cytokines and has shown some therapeutic activity in patients with psoriasis. Exogenous IL-11 also stimulates platelet production and has been used to treat thrombocytopenia occurring after chemotherapy. IL-27 is discussed in the next section with the IL-12 family of cytokines.

INTERLEUKIN 12, INTERLEUKIN 23, INTERLEUKIN 27, AND INTERLEUKIN 35: PIVOTAL CYTOKINES REGULATING T HELPER 1 AND T HELPER 17 RESPONSES

IL-12 is different from most other cytokines in that its active form is a heterodimer of two proteins, p35 and p40. IL-12 is principally a product of antigen-presenting cells such as dendritic cells, monocytes, macrophages, and certain B cells in response to bacterial components, GM-CSF, and IFN-γ. Activated keratinocytes are an additional source of IL-12 in skin. Human keratinocytes constitutively make the p35 subunit, whereas expression of the p40 subunit can be induced by stimuli including contact allergens, phorbol esters, and UV radiation.

IL-12 is a critical immunoregulatory cytokine that is central to the initiation and maintenance of Th1 responses. Th1 responses that are dependent on IL-12 provide protective immunity to intracellular bacterial pathogens. IL-12 also has stimulatory effects on NK cells, promoting their proliferation, cytotoxic function, and the production of cytokines, including IFN-γ. IL-12 has been shown to be active in stimulating protective antitumor immunity in a number of animal models.[31]

Two chains that are part of the cell surface receptor for IL-12 have been cloned. Both are homologous to other β chains in the hematopoietin receptor family and are designated β1 and β2. The β1 chain is associated with Tyk2 and the β2 chain interacts directly with Jak2. The signaling component of the IL-12R is the β2 chain. The β2 chain is expressed in Th1 but not Th2 cells and appears to be critical for commitment of T cells to production of type 1 cytokines. IL-12 signaling induces the phosphorylation of STAT1, STAT3, and STAT4, but it is STAT4 that is essential for induction of a Th1 response.

IL-23 is a heterodimeric cytokine in the IL-12 family that consists of the p40 chain of IL-12 in association with a distinct p19 chain. IL-23 has overlapping activities with IL-12, but also induces proliferation of memory T cells. Interest in IL-23 has been sparked by the observation that IL-23 promotes the differentiation of T cells producing IL-17 (Th17 subset). The IL-23 receptor consists of two chains: (1) the IL-12Rβ1 chain that forms part of the IL-12 receptor and (2) a specific IL-23 receptor.[32]

The third member of the IL-12 family to be discovered was IL-27. IL-27 is also a heterodimer and consists of a subunit called *p28* that is homologous to IL-12 p35 and a second subunit known as *EBI3* that is homologous to IL-12 p40. IL-27 plays a role in the early induction of the Th1 response. The IL-27 receptor consists of a receptor called *WSX-1* that associates with the shared signal-transducing molecule gp130.[32,33]

The newest member of the IL-12 family is IL-35. The IL-35 heterodimer is composed of the p35 chain of IL-12 associated with the IL-27β chain EBI3. In contrast to the other IL-12 family cytokines, IL-35 is selectively made by Treg cells, promotes the growth of Treg cells, and suppresses the activity of Th17 cells.[34]

The IL-12 family of cytokines has emerged as a promising new target for anticytokine pharmacotherapy. The approach that has been developed the furthest to date is targeting both IL-12 and IL-23 with monoclonal antibodies directed against the p40 subunit that is part of both cytokines. Ustekinumab is an antihuman p40 monoclonal antibody that has shown therapeutic activity against psoriasis comparable to that of TNF inhibitors and has received FDA approval for the treatment of psoriasis.[35] The development of

anti-p40 therapies is several years behind anti-TNF-α drugs, but development of additional anti-p40 biologics for clinical use is anticipated.

LIGANDS OF THE CLASS II FAMILY OF CYTOKINE RECEPTORS

A second major class of cytokine receptors with common features includes two types of receptors for IFNs, IL-10R, and the receptors for additional IL-10- related cytokines including IL-19, IL-20, IL-22, IL-24, and IL-26.

INTERFERONS: PROTOTYPES OF CYTOKINES SIGNALING THROUGH A JAK/STAT PATHWAY

IFNs were one of the first families of cytokines to be characterized in detail. The IFNs were initially subdivided into three classes: (1) IFN-α (the leukocyte IFNs), (2) IFN-β (fibroblast IFN), and (3) IFN-γ (immune IFN). The α and β IFNs are collectively called *type I IFNs*, and all of these molecules signal through the same two-chain receptor (the IFN-αβ receptor).[36] The second IFN receptor is a distinct two-chain receptor specific for IFN-γ. Both of these IFN receptors are present on many cell types within skin as well as in other tissues. Each of the chains comprising the two IFN receptors is associated with one of the Jak kinases (Tyk2 and Jak1 for the IFN-αβR, and Jak1 and Jak2 for the IFN-γR). Only in the presence of both chains and two functional Jak kinases will effective signal transduction occur after IFN binding. A new class of IFNs known as *IFN-γ* or *type III IFNs* has now been identified that has a low degree of homology with both type I IFNs and IL-10.[37] The current members of this class are IL-28A, IL-28B, and IL-29. Although the effects of these cytokines are similar to those of the type I IFNs, they are less potent. These type III IFNs use a shared receptor that consists of the β chain of the IL-10 receptor associated with an IL-28 receptor α chain.

Viruses, double-stranded RNA, and bacterial products are among the stimuli that elicit release of the type I IFNs from cells. Plasmacytoid dendritic cells have emerged as a particularly potent cellular source of type I IFNs. Many of the effects of the type I IFNs directly or indirectly increase host resistance to the spread of viral infection. Additional effects mediated through IFN-αβR are increased expression of major histocompatibility complex (MHC) class I molecules and stimulation of NK cell activity. Not only does it have well-known antiviral effects, but IFN-α also can modulate T-cell responses by favoring the development of a Th1 type of T-cell response. Finally, the type I IFNs also inhibit the proliferation of a variety of cell types, which provides a rationale for their use in the treatment of some types of cancer. Forms of IFN-α enjoy considerable use clinically for indications ranging from hairy cell leukemia, various cutaneous malignancies, and papillomavirus infections (see Chapter 196). Some of the same conditions that respond to therapy with type I IFNs also respond to topical immunomodulatory agents like imiquimod. This synthetic imidazoquinoline drug is an agonist for the TLR7 receptor, whose natural ligand is single-stranded RNA. Imiquimod stimulation of cells expressing TLR7 elicits local release of large amounts of type I IFNs from plasmacytoid dendritic cells, which can trigger clinically useful antiviral and tumor inhibitory effects against genital warts, superficial basal cell carcinoma, and actinic keratoses. Resiquimod is a related synthetic compound that activates both TLR7 and TLR8, eliciting a slightly different spectrum of cytokines.[38]

Production of IFN-γ is restricted to NK cells, CD8 T cells, and Th1 CD4 T cells. Th1 cells produce IFN-γ after engagement of the T-cell receptor, and IL-12 can provide a strong costimulatory signal for T-cell IFN-γ production. NK cells produce IFN-γ in response to cytokines released by macrophages, including TNF-γ, IL-12, and IL-18. IFN-γ has antiviral activity, but it is a less potent mediator than the type I IFNs for induction of these effects. The major physiologic role of IFN-γ is its capacity to modulate immune responses. IFN-γ induces synthesis of multiple proteins that play essential roles in antigen presentation to T cells, including MHC class I and class II glycoproteins, invariant chain, the Lmp2 and Lmp7 components of the proteasome, and the TAP1 and TAP2 intracellular peptide transporters. These changes increase the efficiency of antigen presentation to CD4 and CD8 T cells. IFN-γ is also required for activation of macrophages to their full antimicrobial potential, enabling them to eliminate microorganisms capable of intracellular growth. Like type I IFNs, IFN-γ also has strong antiproliferative effects on some cell types. Finally, IFN-γ is also an inducer of selected chemokines (CXC chemokine ligands 9 to 11) and an inducer of endothelial cell adhesion molecules (e.g., ICAM-1 and VCAM-1). Because of the breadth of IFN-γ's activities, it comes the closest of the T-cell cytokines to behaving as a primary cytokine.

INTERLEUKIN 10: AN "ANTI-INFLAMMATORY" CYTOKINE

IL-10 is one of several cytokines that primarily exert regulatory rather than stimulatory effects on immune responses. IL-10 was first identified as a cytokine produced by Th2 T cells that inhibited cytokine production after activation of T cells by antigen and antigen-presenting cells. IL-10 exerts its action through a cell surface receptor found on macrophages, dendritic cells, neutrophils, B cells, T cells, and NK cells. The ligand-binding chain of the receptor is homologous to the receptors for IFN-α/β and IFN-γ, and signaling events mediated through the IL-10 receptor use a Jak/STAT pathway. IL-10 binding to its receptor activates the Jak1 and Tyk2 kinases and leads to the activation of STAT1 and STAT3. The effects of IL-10 on antigen-presenting cells such as monocytes, macrophages, and dendritic cells include inhibition of expression of class II MHC and costimulatory molecules (e.g., B7–1, B7–2) and decreased production of T cell-stimulating cytokines (e.g., IL-1, IL-6, and IL-12). At least four viral

genomes harbor viral homologs of IL-10 that transmit similar signals by binding to the IL-10R.[39]

A major source of IL-10 within skin is epidermal keratinocytes. Keratinocyte IL-10 production is upregulated after activation; one of the best-characterized activating stimuli for keratinocytes is UV irradiation. UV radiation-induced keratinocyte IL-10 production leads to local and systemic effects on immunity. Some of the well-documented immunosuppressive effects that occur after UV light exposure are the result of the liberation of keratinocyte-derived IL-10 into the systemic circulation. IL-10 also plays a dampening role in other types of cutaneous immune and inflammatory responses, because the absence of IL-10 predisposes mice to exaggerated irritant and contact sensitivity responses.

NOVEL INTERLEUKIN 10-RELATED CYTOKINES: INTERLEUKINS 19, 20, 22, 24, AND 26

A series of cytokines related to IL-10 have been identified and shown to engage a number of receptor complexes with shared chains.[40] IL-19, IL-20, and IL-24 transmit signals via a complex consisting of IL-20Rα and IL-20Rβ. IL-22 signals through a receptor consisting of IL-22R and IL-10Rβ. The receptors for these IL-20 family cytokines are preferentially expressed on epithelial cells including keratinocytes. Increased expression of these cytokines and their receptors is associated with psoriasis. The IL-20 family cytokines have profound effects on the proliferation and differentiation of human keratinocytes in culture.[41] Transgenic mice overexpressing IL-20, IL-22, or IL-24 develop epidermal hyperplasia and abnormal keratinocyte differentiation.[42] All of these findings point to a significant role for these cytokines in the epidermal changes associated with cutaneous inflammation. T cells producing IL-22 that elaborate a distinct set of cytokines from Th1, Th2 and Th17 cells have been isolated from the epidermis of patients with psoriasis and other inflammatory skin disorders. The IL-22 produced by these T cells promotes keratinocyte proliferation and epidermal acanthosis.[43,44]

TRANSFORMING GROWTH FACTOR-β FAMILY AND ITS RECEPTORS

TGF-β1 was first isolated as a secreted product of virally transformed tumor cells capable of inducing normal cells in vitro to show phenotypic characteristics associated with transformation. Over 30 additional members of the TGF-β family have now been identified. They can be grouped into several families: the prototypic TGF-βs (TGF-β1 to TGF-β3), the bone morphogenetic proteins, the growth/differentiation factors, and the activins. The TGF name for this family of molecules is somewhat of a misnomer, because TGF-β has antiproliferative rather than proliferative effects on most cell types. Many of the TGF-β family members play an important role in development, influencing the differentiation of uncommitted cells into specific lineages. TGF-β family members are made as precursor proteins that are biologically inactive until a large prodomain is cleaved. Monomers of the mature domain of TGF-β family members are disulfide linked to form dimers that strongly resist denaturation.

Participation of at least two cell surface receptors (type I and type II) with serine/threonine kinase activity is required for biologic effects of TGF-β.[45] Ligand binding by the type II receptor (the true ligand-binding receptor) is associated with the formation of complexes of type I and type II receptors. This allows the type II receptor to phosphorylate and activate the type I receptor, a "transducer" molecule that is responsible for downstream signal transduction. Downstream signal transmission from the membrane-bound receptors in the TGF-β receptor family to the nucleus is primarily mediated by a family of cytoplasmic Smad proteins that translocate to the nucleus and regulate transcription of target genes.

TGF-β has a profound influence on several types of immune and inflammatory processes. An immunoregulatory role for TGF-β1 was identified in part through analysis of TGF-β1 knockout mice that develop a wasting disease at 20 days of age associated with a mixed inflammatory cell infiltrate involving many internal organs. This phenotype is now appreciated to be a result in part of the compromised development of regulatory T cells when TGF-β1 is not available. Development of cells in the dendritic cell lineage is also perturbed in the TGF-β1-deficient mice, as evidenced by an absence of epidermal Langerhans cells and specific subpopulations of lymph node dendritic cells. TGF-β-treated fibroblasts display enhanced production of collagen and other extracellular matrix molecules. In addition, TGF-β inhibits the production of metalloproteinases by fibroblasts and stimulates the production of inhibitors of the same metalloproteinases (tissue inhibitors of metalloproteinase, or TIMPs). TGF-β may contribute to the immunopathology of scleroderma through its profibrogenic effects.[46]

CHEMOKINES: SECONDARY CYTOKINES CENTRAL TO LEUKOCYTE MOBILIZATION

Chemokines are a large superfamily of small cytokines that have two major functions. First, they guide leukocytes via chemotactic gradients in tissue. Typically, this is to bring an effector cell to where its activities are required. Second, a subset of chemokines has the capacity to increase the binding of leukocytes via their integrins to ligands at the endothelial cell surface, which facilitates firm adhesion and extravasation of leukocytes in tissue. The activities of this important class of cytokines are sufficiently complex that they are the subject of a separate chapter (Chapter 12).

CYTOKINE NETWORK—THERAPEUTIC IMPLICATIONS AND APPLICATIONS

This chapter has attempted to bring some degree of order and logic to the analysis of a field of human biology that continues to grow at a rapid rate. Although many things may change in the world of cytokines, certain key concepts have stood the test of time. Principal among them is the idea that cytokines are emergency molecules, designed to be released locally and transiently in tissue microenvironments. When cytokines are released persistently, the result is typically chronic disease. One potential way to treat such diseases is with cytokine antagonists or other drugs that target cytokines or cytokine-mediated pathways.

Cytokines and cytokine antagonists are being used therapeutically by clinicians, and development of additional agents continues. With certain notable exceptions, systemic cytokine therapy has been disappointing and is often accompanied by substantial morbidity. In contrast, local and transient administration of cytokines may yield more promising results. An example of this approach is the transduction of tumor cells to express GM-CSF to create the therapeutic cancer vaccines that are capable of boosting antitumor immune responses.[30] Conversely, multiple biologics that specifically block cytokine activity have been developed and approved for clinical use. Antibodies and TNF receptor–Fc fusion proteins are FDA-approved antagonists of TNF-α activity that are highly effective at inducing durable remissions in psoriasis (see Chapters 18 and 234). Antibodies against the p40 subunit shared by IL-12 and IL-23 are also active in treating psoriasis. An IL-1 receptor-Fc fusion protein, an antibody to IL-1β, and recombinant IL-1Ra are all effective therapy for patients with the cryopyrin-associated periodic syndromes. IL-1Ra is FDA-approved for treatment of adult rheumatoid arthritis. A class of pharmacologic agents that inhibits the production of multiple T cell-derived cytokines is the calcineurin inhibitors. Tacrolimus and pimecrolimus both bind to the immunophilin FK-506 binding protein-12 (FKBP-12), producing complexes that bind to calcineurin, a calcium-dependent phosphatase that acts on proteins in the nuclear factor of activated T-cells (NFAT) family to promote their nuclear translocation and activation of cytokine genes (including IL-2, IL-4, and IFN-γ)[47] (see Chapters 221 and 233). Finally, fusion toxins linked to cytokines, such as the IL-2 fusion protein denileukin diftitox, exploit the cellular specificity of certain cytokine–receptor interactions to kill target cells (see Chapter 234). Denileukin diftitox is FDA approved for the treatment of cutaneous T-cell lymphoma and has also shown therapeutic activity in other types of lymphoid malignancies.[48] Each of the aforementioned approaches is still relatively new and open to considerable future development. An understanding of cytokines by clinicians of the future is likely to be central to effective patient care.

KEY REFERENCES

Full reference list available at www.DIGM8.com

DVD contains references and additional content

1. Oppenheim JJ: Cytokines: Past, present, and future. *Int J Hematol* **74**:3, 2001
3. Luger TA et al: Epidermal cell (keratinocyte)-derived thymocyte-activating factor (ETAF). *J Immunol* **127**:1493, 1981
4. Kupper TS: The activated keratinocyte: A model for inducible cytokine production by non-bone marrow-derived cells in cutaneous inflammatory and immune responses. *J Invest Dermatol* **94**:146S, 1990
5. Albanesi C, Pastore S: Pathobiology of chronic inflammatory skin diseases: Interplay between keratinocytes and immune cells as a target for anti-inflammatory drugs. *Curr Drug Metab* **11**:210, 2010
6. Kupper TS: Immune and inflammatory processes in cutaneous tissues. Mechanisms and speculations. *J Clin Invest* **86**:1783, 1990
7. Beutler B: Microbe sensing, positive feedback loops, and the pathogenesis of inflammatory diseases. *Immunol Rev* **227**:248, 2009
9. O'Quinn DB et al: Emergence of the Th17 pathway and its role in host defense. *Adv Immunol* **99**:115, 2008
10. Josefowicz SZ, Rudensky A: Control of regulatory T cell lineage commitment and maintenance. *Immunity* **30**:616, 2009
15. Kawai T, Akira S: The role of pattern-recognition receptors in innate immunity: Update on Toll-like receptors. *Nat Immunol* **11**:373, 2010
16. O'Shea JJ, Murray PJ: Cytokine signaling modules in inflammatory responses. *Immunity* **28**:477, 2008
17. Martinon F, Mayor A, Tschopp J: The inflammasomes: Guardians of the body. *Annu Rev Immunol* **27**:229, 2009
27. Ziegler SF, Artis D: Sensing the outside world: TSLP regulates barrier immunity. *Nat Immunol* **11**:289, 2010
35. Griffiths CE et al: Comparison of ustekinumab and etanercept for moderate-to-severe psoriasis. *N Engl J Med* **362**:118, 2010
43. Eyerich S et al: Th22 cells represent a distinct human T cell subset involved in epidermal immunity and remodeling. *J Clin Invest* **119**:3573, 2009
44. Fujita H et al: Human Langerhans cells induce distinct IL-22-producing $CD4^+$ T cells lacking IL-17 production. *Proc Natl Acad Sci U S A* **106**:21795, 2009

Chapter 12 :: Chemokines

:: Anke S. Lonsdorf & Sam T. Hwang

CHEMOKINES AT A GLANCE

- Chemokines and their receptors are vital mediators of cellular trafficking.
- Most chemokines are small proteins with molecular weights in the 8- to 10-kDa range.
- Chemokines are synthesized constitutively in some cells and can be induced in many cell types.
- Chemokines play roles in inflammation, angiogenesis, neural development, cancer metastasis, hematopoiesis, and infectious disease.
- In skin, chemokines play important roles in atopic dermatitis, psoriasis, melanoma, melanoma metastasis, and some viral (including retroviral) infections.
- Promising therapeutic applications of chemokines include the prevention of T-cell arrest on activated endothelium or blocking infection of T cells by human immunodeficiency virus 1 using CC chemokine receptor 5 analogs.

INTRODUCTION

The skin is an organ in which the migration, influx, and egress of leukocytes occur in both homeostatic and inflammatory processes. Chemokines and their receptors are accepted as vital mediators of cellular trafficking. Since the discovery of the first *chemo*attractant cyto*kine* or chemokine in 1977, 50 additional new chemokines and 17 chemokine receptors have been discovered. Most chemokines are small proteins with molecular weights in the 8–10 kDa range and are synthesized constitutively in some cells and can be induced in many cell types by cytokines. Initially associated only with recruitment of leukocyte subsets to inflammatory sites,[1] it has become clear that chemokines play roles in angiogenesis, neural development, cancer metastasis, hematopoiesis, and infectious diseases. This chapter will focus primarily on the function of chemokines in inflammatory conditions, but will also touch upon the role of these molecules in other settings as well.

An overview of the structure of chemokines and chemokine receptors will be provided that will detail the molecular signaling pathways initiated by the binding of a chemokine to its cognate receptor. Expression patterns of chemokine receptors will be detailed because of the many types of immune cells that potentially can be recruited to skin under inflammatory conditions. Individual chemokine receptors will be highlighted in regard to biologic function, including facilitation of migration of effector T cells into the skin and the egress of antigen-presenting cells out of the skin. Finally, the roles of chemokines and their receptors in several cutaneous diseases—atopic dermatitis, psoriasis, cancer, and infectious disease—provide a better idea of the diversity of chemokine function in skin.

STRUCTURE OF CHEMOKINES

Chemokines are grouped into four subfamilies based on the spacing of amino acids between the first two cysteines. The CXC chemokines (also called α-chemokines) show a C–X–C motif with one nonconserved amino acid between the two cysteines. The other major subfamily of chemokines lacks the additional amino acid and is termed the CC subfamily (or β-chemokines). The two remaining subfamilies contain only one member each: the C subfamily is represented by lymphotactin, and fractalkine is the only member of the CXXXC (or CX3C) subfamily. Chemokines can also be assigned to one of two broad and, perhaps, overlapping functional groups. One group (e.g., RANTES, MIP-1α/β LARC, etc.) mediates the attraction and recruitment of immune cells to sites of active inflammation while other (e.g., SLC and SDF-1) appear to play a role in constitutive or homeostatic migration pathways.[2]

The complexity and redundancy in the nomenclature of chemokines has led to the proposal for a systematic nomenclature for chemokines based on the type of chemokine (C, CXC, CX3C, or CC) and a number based on the order of discovery as proposed by Zlotnik and Yoshie.[2] For example, stromal-derived factor-1 (SDF-1), a CXC chemokine, has the systematic name CXCL12. Because both nomenclatures are still in wide use, the original names (abbreviated in most cases) as well as systematic names will be used interchangeably throughout the chapter. Table 12-1 provides a list of chemokine receptors of interest in skin that are discussed in this chapter as well as the major chemokine ligands that bind to them.

Chemokines are highly conserved and have similar secondary and tertiary structure. Based on crystallography studies, a disordered amino terminus followed by three conserved antiparallel β-pleated sheets is a common structural feature of chemokines. Fractalkine is unique in that the chemokine domain sits atop a mucin-like stalk tethered to the plasma membrane via a transmembrane domain and short cytoplasmic tail.[30] Although CXC and CC chemokines form multimeric structures under conditions required for structural studies, these associations may be relevant only when

TABLE 12-1
Chemokine Receptors in Skin Biology

Chemokine Receptor	Chemokine Ligand	Expression Pattern	Comments	References
CCR1	MIP-1α (CCL3), RANTES (CCL5), MCP-3 (CCL7)	T, Mo, DC, NK, B	Migration of DC and monocytes; strongly upregulated in T cells by IL-2	12
CCR2	MCP-1 (CCL2),-3,-4 (CCL13)	T, Mo	Migration of T cells to inflamed sites; replenish LC precursors in epidermis; involved in skin fibrosis via MCP-1	3–5
CCR3	Eotaxin (CCL11) >RANTES, MCP-2 (CCL8),3,4	Eo, Ba, Th2, K	Migration of Th2 T cells and "allergic" immune cells	6,7
CCR4	TARC (CCL17), MDC (CCL22)	T (benign and malignant)	Expression in Th2 > Th1 cells; highly expressed on CLA^+ memory T cells; TARC expression by keratinocytes may be important in atopic dermatitis; may guide trafficking of malignant as well as benign inflammatory T cells	8–12
CCR5	RANTES, MIP-1α,β (CCL3,4)	T, Mo, DC	Marker for Th1 cells; migration to acutely inflamed sites; may be involved in transmigration of T cells through endothelium; major HIV-1 fusion coreceptor	3,13
CCR6	LARC (CCL20)	T, DC, B	Expressed by memory, not naive, T cells; possibly involved in arrest of memory T cells to activated endothelium and recruitment of T cells to epidermis in psoriasis	76,77,82
CCR7	SLC (CCL21), ELC (CCL19)	T, DC, B, melanoma cells	Critical for migration of naive T cells and "central memory" T cells to secondary lymphoid organs; required for mature DC to enter lymphatics and localize to lymph nodes; facilitates nodal metastasis	14–18
CCR9	Thymus-expressed chemokine (CCL25)	T, melanoma cells	Associated with melanoma small bowel metastases	19
CCR10	CTACK (CCL27)	T (benign and malignant), melanoma cells	Preferential response of CLA+ T cells to CTACK in vitro; may be involved in T cell (benign as well as malignant) homing to epidermis, where CTACK is expressed; survival of melanoma is skin	20–23
CXCR1,2	IL-8 (CXCL8), MGSA/ GRO α (CXCL1), ENA-78 (CXCL5)	N, NK, En, melanoma cells	Recruitment of neutrophils (e.g., epidermis in psoriasis); may be involved in angiogenesis; melanoma growth factor	24–26
CXCR3	IP-10 (CXCL10), Mig (CXCL9), I-TAC (CXCL11)	T	Marker for Th1 Cells and may be involved in T cell recruitment to epidermis in CTCL; induces arrest of activated T cells on stimulated endothelium	27,28
CXCR4	SDF-1α,β (CXCL12)	T, DC, En, melanoma cells	Major HIV-1 fusion coreceptor; involved in vascular formation; involved in melanoma metastasis to lungs	3,29
CX3CR1	Fractalkine (CX3CL1)	T, Mo, MC, NK	May be involved in adhesion on activated T cells, Mo, NK cells to activated endothelium	30,31

GRO = growth regulated oncogene; MGSA = melanoma growth stimulatory activity; Mig = monokine-induced by IFN-γ; I-TaC = interferon-inducible T-cell alpha chemoattractant; SDF = stromal-derived factor; MCP = monocyte chemattractant protein; MIP = macrophage inflammatory protein; RANTES = regulated upon activation, normal T cell expressed and secreted; IL-8 = interleukin-8; TARC = thymus and activation-regulated chemokine; LARC = liver and activation-regulated chemokine (also known as MIP-3α); SLC = secondary lymphoid-tissue chemokine; MDC = macrophage-derived chemokine; CTACK = cutaneous T cell attracting chemokine; T = T cells; Mo = monocytes; DC = dendritic cells; Eo = eosinophils; Ba = basophils; B = B cells; En = endothelial cells; Th1,2 = T helper 1,2 cell; N = neutrophils; MC = mast cells; NK = natural killer cells; CLA = cutaneous lymphocyte-associated antigen; HIV = human immunodeficiency virus.

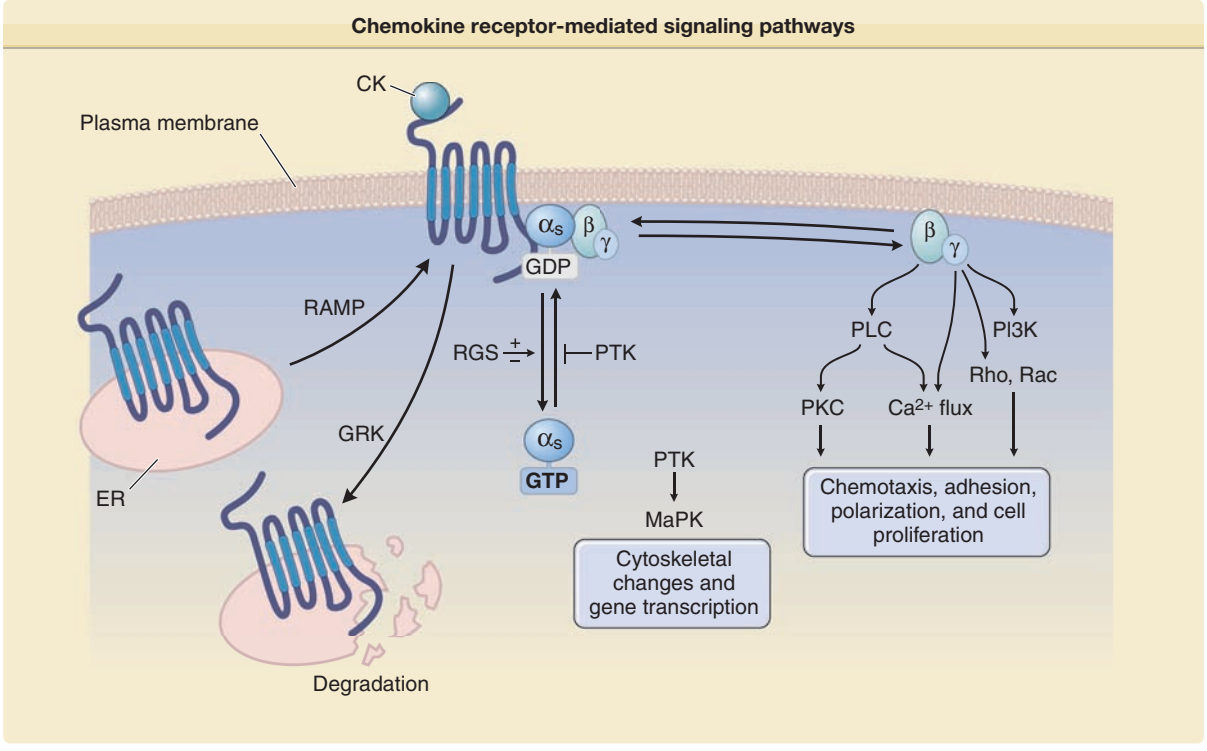

Figure 12-1 Chemokine receptor-mediated signaling pathways. RAMP = receptor-activity-modifying protein; RGS = regulator of G-protein signaling; GRK = G-protein coupled receptor kinase; DG = 1,2-diacylglycerol; PLC = phospholipase C; PIP2 = phosphatidylinositol-4,5-bisphosphate; IP3 = inositol-1,4,5-triphosphate; PKC = protein kinase C; CK = chemokine; PTX = pertussis toxin; ER = endoplasmic reticulum; PTK = protein tyrosine kinase(s); MAPK = Mitogen activated protein kinase.

chemokines associate with cell-surface components such as glycosaminoglycans (GAGs) or proteoglycans. Since most chemokines have a net positive charge, these proteins tend to bind to negatively charged carbohydrates present on GAGs. Indeed the ability of positively charged chemokines to bind to GAGs is thought to enable chemokines to preferentially associate with the lumenal surface of blood vessels despite the presence of shear forces from the blood that would otherwise wash the chemokines away.

CHEMOKINE RECEPTORS AND SIGNAL TRANSDUCTION

Chemokine receptors are seven transmembrane spanning membrane proteins that couple to intracellular heterotrimeric G-proteins containing α, β, and γ subunits.[2] They represent a part of a large family of G-protein coupled receptors (GPCR), including rhodopsin, that have critical biologic functions. Leukocytes express several Gα protein subtypes: s, i, and q, while the β and γ subunits each have 5 and 11 known subtypes, respectively. This complexity in the formation of the heterotrimeric G-protein may account for specificity in the action of certain chemokine receptors. Normally G-proteins are inactive when GDP is bound, but they are activated when the GDP is exchanged for GTP (Fig. 12-1). After binding to a ligand, chemokine receptors rapidly associate with G-proteins, which in turn increases the exchange of GTP for GDP. Pertussis toxin is a commonly used inhibitor of GPCR that irreversibly ADP-ribosylates Gα subunits of the α_i class and subsequently prevents most chemokine receptor-mediated signaling.

Activation of G-proteins leads to the dissociation of the G_α and $G_{\beta\gamma}$ subunits (Fig. 12-1). The G_α subunit has been observed to activate protein tyrosine kinases and mitogen-activated protein kinase, leading to cytoskeletal changes and gene transcription. The G_α subunit retains GTP, which is slowly hydrolyzed by the GTPase activity of this subunit. This GTPase activity is both positively and negatively regulated by GTPase-activating proteins [also known as regulator of G-protein signaling (RGS) proteins]. The $G_{\beta\gamma}$ dimer initiates critical signaling events in regard to chemotaxis and cell adhesion. It activates phospholipase C (PLC)[32] leading to formation of diacylglycerol (DAG) and inositol triphosphate [Ins(1,4,5)P_3]. Ins(1,4,5)P_3 stimulates Ca^{2+} entry into the cytosol, which along with DAG, activates protein kinase C isoforms. While the $G_{\beta\gamma}$ subunits have been shown to be critical for chemotaxis, the $G_{\alpha\alpha}$ subunit has no known role in chemotactic migration. There is also evidence that binding of chemokine receptors results in the activation of other intracellular effectors including Ras and Rho, phosphatidylinositol-3-kinase [PI(3)K].[33]

RhoA and protein kinase C appear to play a role in integrin affinity changes, while PI(3)K may be critical for changes in the avidity state of LFA-1. Other proteins have been found that regulate the synthesis, expression, or degradation of G-protein coupled receptors. For example, receptor-activity-modifying proteins (RAMPS) act as chaperones of seven transmembrane spanning receptors and regulate surface expression as well as the ligand specificity of chemokine receptors (Fig. 12-1). Importantly, after chemokine receptors are exposed to appropriate ligands, they are frequently internalized, leading to an inability of the chemokine receptor to mediate further signaling. This downregulation of chemokine function, which has been termed "desensitization," occurs because of phosphorylation of Ser/Thr residues in the *C*-terminal tail by proteins termed GPCR kinases (GRK) and subsequent internalization of the receptor (Fig. 12-1). Desensitization may be an important mechanism for regulating the function of chemokine receptors by inhibiting cell migration as leukocytes arrive at the primary site of inflammation.

CHEMOKINES AND CUTANEOUS LEUKOCYTE TRAFFICKING

Generally speaking, chemokines are thought to play at least three different roles in the recruitment of host defense cells, predominantly leukocytes, to sites of inflammation.[34] First, they provide the signal or signals required to cause leukocytes to come to a complete stop (i.e., arrest) in blood vessels at inflamed sites such as skin. Second, chemokines have been shown to have a role in the transmigration of leukocytes from the lumenal side of the blood vessel to the ablumenal side. Third, chemokines attract leukocytes to sites of inflammation in the dermis or epidermis following transmigration. Keratinocytes and endothelial cells are a rich source of chemokines when stimulated by appropriate cytokines. In addition, chemokines and their receptors are known to play critical roles in the emigration of resident skin dendritic cells (i.e., Langerhans cells and dermal dendritic cells) from the skin to draining lymph nodes (LN) via afferent lymphatic vessels, a process that is essential for the development of acquired immune responses.

This section will be divided into three subsections. The first will introduce basic concepts of how all leukocytes arrest in inflamed blood vessels prior to transmigration by introducing the multistep model of leukocyte recruitment. The second will detail mechanisms of T cell migration, while the final subsection will focus on the mechanisms by which chemokines mediate the physiological migration of DC from the skin to regional LN.

THE MULTISTEP MODEL OF LEUKOCYTE RECRUITMENT

In order for leukocytes to adhere and migrate to peripheral tissues, they must overcome the pushing force of the vascular blood stream as they bind to activated endothelial cells at local sites of inflammation. According to the multistep or cascade model of leukocyte recruitment (Fig. 12-2), one set of homologous adhesion molecules termed *selectins* mediates the transient attachment of leukocytes to endothelial cells while another set of adhesion molecules termed *integrins* and their receptors (*immunoglobulin superfamily members*) mediates stronger binding (i.e., arrest) and transmigration.[35] The selectins (E-, L-, and P-selectins) are members of a larger family of carbohydrate-binding proteins termed lectins. The selectins bind their respective carbohydrate ligands located on protein scaffolds and thus mediate the transient binding or "rolling" of leukocytes on endothelial cells.

The skin-associated vascular selectin known as E-selectin is upregulated on endothelial cells by inflammatory cytokines such as tumor necrosis factor (TNF)-α and binds to sialyl Lewis x-based carbohydrates. E-selectin ligands form distinct epitopes known as the cutaneous lymphocyte-associated antigen (CLA). CLA is expressed by 10%–40% of memory T cells and has been suggested as a marker for skin-homing T cells.[36] At least two chemokine receptors (CCR10 and CCR4) show preferential expression in CLA^+ memory T cells.[8,20] While E-selectin is likely to be an important component of skin-selective homing, there is also evidence to suggest that L-selectin is involved in T cell migration to skin.[37,38]

In the second phase of this model, leukocyte integrins such as those of the β_2 family must be "turned on" or activated from their resting state in order to bind to their counter receptors such as intercellular adhesion molecule-1 (ICAM-1) that are expressed by endothelial cells. A vast array of data suggest that the binding of chemokines to leukocyte chemokine receptors plays a critical role in activating both β1 and β2 integrins.[33,39] Activation of chemokine receptors leads to a complex signaling cascade (Fig. 12-1) that causes a conformational change in individual integrins that leads to increases in the affinity and avidity of individual leukocyte integrins for their ligands. Furthermore, later steps of migration (i.e., transmigration or diapedesis) have been shown to be dependent on chemokines as well in selective cases.[13] In the case of neutrophils, their ability to roll on inflamed blood vessels likely depends on their expression of L-selectin and E-selectin ligands while their arrest on activated endothelia likely depends on their expression of CXCR1 and CXCR2 as described below for wound healing. Integrin activation via chemokine-mediated signals appears to be more complex in T cells, which appear to use multiple chemokine receptors, and is described in more detail below.

CHEMOKINE-MEDIATED MIGRATION OF T CELLS

Antigen-inexperienced T cells are termed naive and can be identified by expressing three cell surface proteins: CD45RA (an isoform of the pan-leukocyte marker), L-selectin, and the chemokine receptor CCR7. These T cells migrate efficiently to secondary LN,

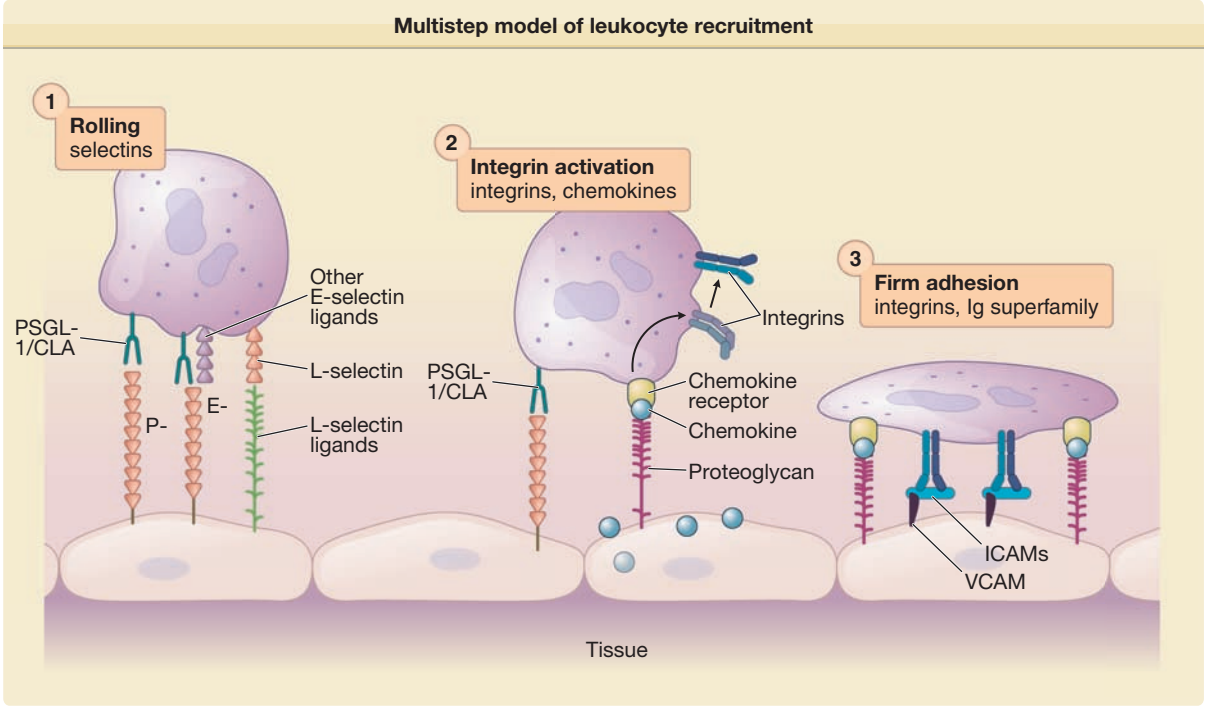

Figure 12-2 Multistep model of leukocyte recruitment. Leukocytes, pushed by the blood stream, first transiently bind or "roll" on the surface of activated endothelial cells via rapid interactions with P-, E-, or L-selectin. Chemokines are secreted by endothelial cells and bind to proteoglycans that present the chemokine molecules to chemokine receptors on the surface of the leukocyte. After chemokine receptor ligation, intracellular signaling events lead to a change in the conformation of integrins and changes in their distribution on the plasma membrane resulting in "Integrin Activation." These changes result in high affinity/avidity binding of integrins to endothelial cell intercellular adhesion molecules (ICAMs) and vascular cell adhesion molecule-(VCAM)-1 in a step termed "Firm Adhesion," which is then followed by transmigration of the leukocyte between endothelial cells and into tissue.

where they may make contact with antigen-bearing dendritic cells from the periphery. Once activated by dendritic cells presenting antigen, T cells then express CD45RO, are termed "memory" T cells, and appear to express a variety of adhesion molecules and chemokine receptors, which facilitate their extravasation from blood vessels to inflamed peripheral tissue. A specific subset of $CCR7^{-}$, L-selectin memory T cells has been proposed to represent an effector memory T cell subset that is ready for rapid deployment at peripheral sites in terms of their cytotoxic activity and ability to mobilize cytokines.[14]

Although chemokines are both secreted and soluble, the net positive charge on most chemokines allows them to bind to negatively charged proteoglycans such as heparin sulfate that are present on the lumenal surface of endothelial cells, thus allowing them to be presented to T cells as they roll along the lumenal surface (Fig. 12-2). After ligand binding, chemokine receptors send intracellular signals that lead to increases in the affinity and avidity of T-cell integrins such as LFA-1 and VLA-4 for their endothelial receptors ICAM-1 and VCAM-1, respectively.[40] Only a few chemokine receptors (CXCR4, CCR7, CCR4, and CCR6) are expressed at sufficient levels on resting peripheral blood T cells to mediate this transition. With activation and IL-2 stimulation, increased numbers of chemokine receptors (e.g., CXCR3) are expressed on activated T cells, making them more likely to respond to other chemokines. In several different systems, inhibition of specific chemokines produced by endothelial cells or chemokine receptors found on T cells dramatically influences T cell arrest in vivo and in vitro.[41]

CXCR3 serves as a receptor for chemokine ligands Mig, IP-10, and I-Tac. All three of these chemokines are distinguished from other chemokines by being highly upregulated by interferon-γ. Resting T cells do not express functional levels of CXCR3, but upregulate this receptor with activation and cytokines such as IL-2. Once expressed on T cells, CXCR3 is capable of mediating arrest of memory T cells on activated endothelial cells.[27] The expression of its chemokine ligands is strongly influenced by the cytokine interferon-γ, which synergistically works with pro-inflammatory cytokines such as TNF-α to increase expression of these ligands by activated endothelial cells[27] and epithelial cells.

In general, activation of T cells by cytokines such as IL-2 is associated with the enhanced expression of CCR1, CCR2, CCR5, and CXCR3. Just as Th1 and Th2 (T cell) subsets have different functional roles, it might have been predicted that these two subsets of T cells would express different chemokine receptors. Indeed, CCR4[9,42,43] and CCR3[6] are associated with Th2 cells in vitro while Th1 cells are associated with CCR5 and CXCR3.[44]

In some instances, chemokine receptors may be regarded as functional markers that characterize distinct T helper cell subsets while also promoting their recruitment to inflammatory sites characterized by "allergic" or "cell-mediated" immune responses, respectively. When T cells are activated in vitro in the presence of Th1-promoting cytokines, CXCR3 and CCR5 appear to be highly expressed, while in the presence of Th2-promoting cytokines, CCR4, CCR8, and CCR3 expression predominates. In rheumatoid arthritis, a Th1-predominant disease, many infiltrating T cells express CCR5 and CXCR3[45] whereas, in atopic disease, CCR4 expressing T cells may be more frequent.[9] CCR6 has recently been described as a marker for a newly characterized T-helper subset, expressing the hallmark effector cytokines IL-17 and IL-22.[46] These so-called Th17 cells play a central role in the pathogenesis of psoriasis and other chronic inflammatory autoimmune diseases.[47] However, in normal skin, the majority of skin resident T cells also coexpress CCR6, suggesting that CCR6 and CCL20 interactions regulate T cell infiltration in the skin under inflammatory as well as homeostatic conditions.[48]

While certain chemokine receptors characterize distinct T-cell subsets, flexible regulation of their expression may increase the migratory potential of circulating T cells to diverse tissues. For example, under some conditions, both Th1 and Th2 type T cells can express CCR4.[43] Similarly, T regulatory cells (Treg) and Th17 cells share chemokines receptors with other T cell lineages but may alter their chemokine receptor expression profiles, depending on the microenvironment in which they are activated.[49]

The epidermis is a particularly rich source of chemokines, including RANTES, MIP-3α (CCL20), MCP-1, IP-10, IL-8, LARC, and TARC, which likely contribute to epidermal T cell migration. Keratinocytes from patients with distinctive skin diseases appear to express unique chemokine expression profiles. For instance, keratinocytes derived from patients with atopic dermatitis synthesized mRNA for RANTES at considerably earlier time points in response to IL-4 and TNF-α in comparison to healthy individuals and psoriatic patients.[50] Keratinocytes derived from psoriatic patients synthesized higher levels of IP-10 with cytokine stimulation as well as higher constitutive levels of IL-8,[50] a chemokine known to recruit neutrophils. IL-8 may contribute to the large numbers of neutrophils that localize to the suprabasal and cornified layers of the epidermis in psoriasis. IP-10 may serve to recruit activated T cells of the Th1 helper phenotype to the epidermis and has been postulated to have a role in the recruitment of malignant T cells to the skin in cutaneous T cell lymphomas.[28]

CTACK/CCL27 is selectively and constitutively expressed in the epidermis, and its expression is only marginally increased under inflammatory conditions.[21] Interestingly, CTACK has been reported to preferentially attract CLA^+ memory T cells in vitro[21] and has been demonstrated to play a role in the recruitment and function of skin-homing T cells in inflammatory disease models.[51,52]

CHEMOKINES IN THE TRAFFICKING OF DENDRITIC CELLS FROM SKIN TO REGIONAL LYMPH NODES

Antigen-presenting cells, including dendritic cells (DC) of the skin, are critical initiators of immune responses and their trafficking patterns are thought to influence immunological outcomes. Their mission includes taking up antigen at sites of infection or injury and bringing these antigens to regional LN where they both present antigen and regulate the responses of T and B cells. Skin-resident DCs are initially derived from hematopoietic bone marrow progenitors[53] and migrate to skin during the late prenatal and newborn periods of life. Under resting (steady state) conditions, homeostatic production by keratinocytes of CXCL14 (receptor unknown) may be involved in attracting $CD14^+$ DC precursors to the basal layer of the epidermis.[54] Similarly, Langerhans cells (LC) as well as CD1c+ LC precursors are strongly chemoattracted to keratinocyte-derived CCL20.[55] Under inflammatory conditions, when skin-resident DC and LC leave the skin in large numbers, keratinocytes release a variety of chemokines, including CCL2 and CCL7 (via CCR2)[4] and CCL20 (via CCR6),[56] which may attract monocyte-like DC precursors to the epidermis in order to replenish the LC population.

When activated by inflammatory cytokines (e.g., TNF-α and IL-1β), lipopolysaccharide, or injury, skin DC, including LC, leave the epidermis, enter afferent lymphatic vessels, and migrate to draining regional LN where they encounter both naive and memory T cells. Chemokines guide the DC on this journey. Activated DC specifically upregulate expression of CCR7, which binds to secondary lymphoid tissue chemokine (SLC/CCL21), a chemokine expressed constitutively by lymphatic endothelial cells[15,57] (eFig. 12-2.1 in online edition). SLC guides DC into dermal lymphatic vessels and helps retain them in SLC-rich regional draining LN (Fig. 12-3).[58]

Interestingly, naive T cells also strongly express CCR7 and use this receptor to arrest on high endothelial venules.[59] The importance of the CCR7 pathway is demonstrated by LC from CCR7 knockout mouse that demonstrate poor migration from the skin to regional LN[16] and by the observation that antibodies to SLC block migration of DC from the periphery to LN.[15] Thus, CCR7 and its ligands facilitate the recruitment of at least two different kinds of cells—naive T cells and DC—to the LN through two different routes under both inflammatory[16] and resting conditions.[58]

After DC reach the LN, they must interact with T cells to form a so-called "immunological synapse" that is critical for T cell activation. Activated DC secrete a number of chemokines, including macrophage-derived chemokine (MDC),[60] which attracts T cells to the vicinity of DC and promotes adhesion between the two cell types.[61,62] CCR5 (via CCL3/4) has also been identified as mediating recruitment of naive CD8+ T

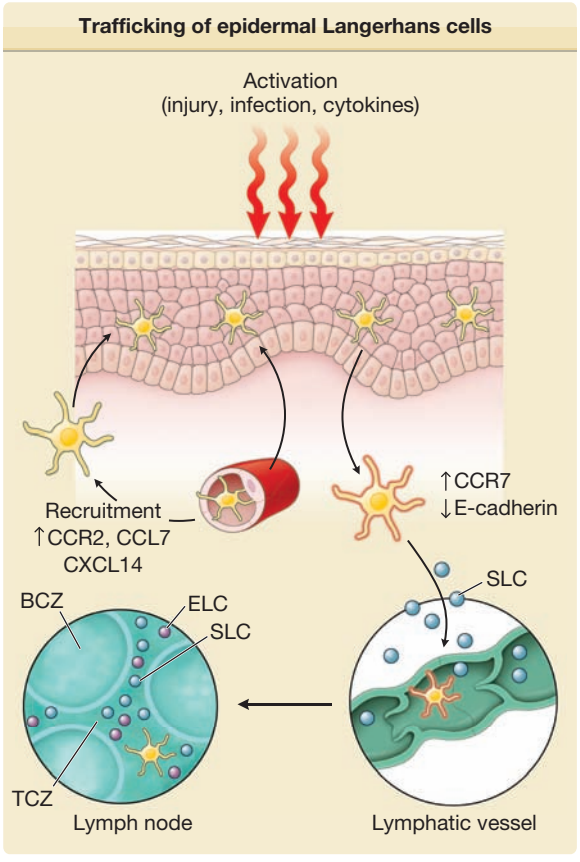

Figure 12-3 Trafficking of epidermal Langerhans cells to regional lymph nodes. Langerhans cells are activated by a variety of stimuli including injury, infectious agents, and cytokines such as IL-1α and TNF-α. Having sampled antigens, the activated LC downregulate E-cadherin and strongly upregulate CCR7. Sensing the CCR7-ligand, SLC (●), produced by lymphatic endothelial cells, the LC migrate into lymphatic vessels, passively flow to the lymph nodes, and stop in the T-cell zones (TCZ) that are rich in two CCR7 ligands, SLC and ELC. Note that chemokines also contribute to the recruitment of LC under both resting and inflammatory conditions. BCZ, B-cell zones.

cells to aggregates of antigen-specific $CD4^+$ T cells and DC.[63] Therefore, chemokines orchestrate a complex series of migration patterns bringing both DC and T cells to the confines of the LN, where expression of chemokines by DC themselves appears to be a direct signal for binding of the T cell (Fig. 12-3).

CHEMOKINES IN DISEASE

ATOPIC DERMATITIS

Atopic dermatitis is a prototypical Th2-mediated, allergic skin disease with multifactorial genetic and environmental factors involved in its pathogenesis. Although multiple chemokines have been associated with the atopic phenotype, the roles of CCR4 and CCR10 in AD have been particularly well documented.[64] Clinical data from humans as well as experimental data in the NC/Nga mouse model of atopic dermatitis suggest that the Th2-associated chemokine receptor, CCR4, in conjunction with its ligand, TARC/CCL17, may play a role in recruiting T cells to atopic skin. In patients with atopic dermatitis, $CLA^+CCR4^+CCR10^+$ lymphocytes were found to be increased in the peripheral blood and in lesional skin compared to controls.[9] Moreover, serum levels of TARC/CCL17 and CTACK/CCL27 in atopic dermatitis patients were significantly higher than concentrations found in healthy or psoriatic controls and correlated with disease severity.[10]

CCL18, whose receptor is currently unknown, has been reported to be expressed at higher levels in the skin of patients with atopic disease compared to psoriasis.[65] CCL18 is produced by antigen-presenting cells and attracts CLA^+ memory T cells to the skin.[66] Elevated levels of CCL18 can be found in the skin and sera of patients with AD but show a significant decrease after therapy.[67] Of note, CCL18 and another chemokine, CCL1 (produced by mast cells and endothelial cells), are elicited in volunteer skin after topical challenge with dust mite allergen and *Staphylococcal superantigen*.[65,68]

The recruitment of eosinophils to skin is a frequently observed finding in allergic skin diseases, including atopic dermatitis and cutaneous drug reactions, and likely is mediated by chemokines. Eotaxin/CCL11 was initially isolated from the bronchoalveolar fluid of guinea pigs after experimental allergic inflammation and binds primarily to CCR3, a receptor expressed by eosinophils,[69] basophils, and Th2 cells.[6] Injection of eotaxin into the skin promotes the recruitment of eosinophils while anti-eotaxin antibodies delay the dermal recruitment of eosinophils in the late-phase allergic reaction in mouse skin.[70] Immunoreactivity and mRNA expression of eotaxin and CCR3 are both increased in lesional skin and serum of patients with atopic dermatitis, but not in nonatopic controls.[71,72] Eotaxin has also been shown to increase proliferation of CCR3-expressing keratinocytes in vitro.[73] Finally, expression of eotaxin (and RANTES) by dermal endothelial cells has been correlated with the appearance of eosinophils in the dermis in patients with onchocerciasis that experience allergic reactions following treatment with ivermectin.[74] The observations above suggest that production of eotaxin and CCR3 may contribute to the recruitment of eosinophils and Th2 lymphocytes in addition to stimulating keratinocyte proliferation.

PSORIASIS

Psoriasis is characterized by hyperplasia of the epidermis (acanthosis) and a prominent dermal and epidermal inflammatory infiltrate, typically resulting in thickened, hyperkeratotic plaques. The inflammatory infiltrate of psoriatic skin is predominantly composed of Th1- and Th17-polarized memory T cells, as well as neutrophils, macrophages, and increased numbers of dendritic cells.[75] As shown in eFig. 12-3.1 in online edition and reviewed by others,[64] there is a growing body of evidence supporting a central role for chemokines in regulating the complex events leading to psoriatic

skin inflammation. Chemokines, including CCL20[76] and CCL17[8] mediate the arrest of effector memory T cells on endothelial cells that synthesize these chemokines.[77] In addition, both CCL17 and CCL20 can be synthesized by keratinocytes, possibly contributing to T cell migration to the epidermis.

While psoriasis has traditionally been considered a classical Th1-associated disease, accumulating evidence points to an important pathogenetic contribution of Th17 cells, which strongly express CCR6.[79] Th17 cells, their signature effector cytokines IL-17 and IL-22, as well as high levels of IL-23, a major growth and differentiation factor for Th17 cells, are abundant in psoriatic skin lesions.[80] Recent research suggests that CCR6 and its ligand, CCL20, are important mediators of psoriasis since both CCL20 as well as CLA^+CCR6^+ skin-homing Th17 cells are found in abundance in lesional psoriatic skin.[80,81] Moreover, CCR6-deficient mice failed to develop psoriasis-like inflammation[82] in response to intradermal IL-23 injections, a murine model for human psoriasis[83] (eFig. 12-3.2 in online edition). Interestingly, CCR6 was required for both T cell dependent as well as T cell independent skin inflammation in this model.[82]

Neutrophils found in the epidermis of psoriatic skin are probably attracted there by high levels of IL-8, which would act via CXCR1 and CXCR2. In addition to attracting neutrophils, IL-8 is an ELR^+ CXC chemokine that is known to be angiogenic, and it may also attract endothelial cells. This may lead to the formation of the long tortuous capillary blood vessels in the papillary dermis that are characteristic of psoriasis. Moreover, keratinocytes also express CXCR2 and thus may be autoregulated by the expression of CXCR2 ligands in the skin. Of note, an IL-8/CXCL8-producing population of memory T cells that express CCR6 has been isolated from patients with acute generalized exanthematous pustulosis (AGEP), a condition induced most commonly by drugs (e.g., aminopenicillins) and characterized by small intraepidermal or subcorneal sterile pustules.[84] Similar T cells have been isolated from patients with Behçet's disease and pustular psoriasis.[78] It is possible that this subpopulation of T cells contributes to neutrophil accumulation in the stratum corneum (Munro's abscesses) in psoriasis and other inflammatory skin disorders characterized by neutrophil-rich infiltrates in the absence of frank infection.

CANCER

Chemokines may play a role in tumor formation and immunity in several distinct ways, including the control of angiogenesis and the induction of tumor immune responses.[85] CXC chemokines that express a three-amino-acid motif consisting of glu-leu-arg (ELR) immediately preceding the CXC signature are angiogenic while most non-ELR CXC chemokines, except SDF-1, are angiostatic. Interestingly, it is not clear that ELR^- chemokines actually bind to chemokine receptors in order to reduce angiogenesis. It has been proposed that they act by displacing growth factors from proteoglycans. In any event, the balance between ELR^+ versus ELR^- chemokines is thought to contribute to the complex regulation of angiogenesis at tumor sites. IL-8, a prototypical ELR^+ chemokine, can be secreted by melanoma cells and has been detected in conjunction with metastatic dissemination of this cancer,[86] which may be related to its ability to attract circulating tumor cells to primary tumors and to influence leukocyte and endothelial cell recruitment.[87,88] IL-8 may also act as an autocrine growth factor for melanoma[24] as well as several other types of cancer. Although CXCR1 and CXCR2 bind IL-8 in common, several other ELR^+ CXC chemokines also bind to and activate CXCR2.

Tumors, including melanoma, have long been known to secrete chemokines that can attract a variety of leukocytes. The question arises as to why this is not deleterious to the tumor itself. Breast cancers, for instance, are known to secrete macrophage chemotactic protein-1 (MCP-1), a chemokine that attracts macrophages through CCR2. Higher tissue levels of MCP-1 correlate with increasing number of macrophages within the tissue. While chemokines secreted by tumor cells do lead to recruitment of immune cells, this does not necessarily lead to increased clearance of the tumor.[89]

Inflammatory cells such as macrophages may actually play a critical role in cancer invasion and metastasis. Firstly, MCP-1 may increase expression of macrophage IL-4 through an autocrine feedback loop and possibly skew the immune response from Th1 to Th2. Interestingly, MCP-1-deficient mice show markedly reduced dermal fibrosis following dermal challenge with bleomycin, a finding of possible relevance to the pathogenesis of conditions such as scleroderma.[5] Secondly, macrophages may promote tumor invasion and metastasis.[90] The antitumor effects of specific chemokines may occur by a variety of mechanisms. ELR^- CXCR3 ligands such as IP-10 are potently antiangiogenic and may act as downstream effectors of IL-12-induced, NK cell-dependent angiostasis.[91] Of note, some cancer cells can synthesize LARC, attracting immature DC that express CCR6.[92] Experimentally, LARC has been transduced into murine tumors, where it attracts DC in mice and suppresses tumor growth in experimental systems.[93] Lastly, chemokines produced by tumor cells may attract $CD4^+CD25^+$ T regulatory cells (Tregs) that suppress host antitumor cytolytic T cells.[94]

Tumor metastasis is the most common cause of mortality and morbidity in cancer. With skin cancers such as melanoma, there is a propensity for specific sites such as brain, lung, and liver, as well as distant skin sites. Cancers may also metastasize via afferent lymphatics and eventually reach regional draining LN. The discovery of nodal metastasis often portends a poor prognosis for the patient. In fact, the presence of nodal metastases is one of the most powerful negative predictors of survival in melanoma.[95]

Chemokines may play an important role in the site-specific metastases of cancers of the breast and of melanoma[96] (Fig. 12-4). Human breast cancer as well as melanoma lines express the chemokine receptors CXCR4

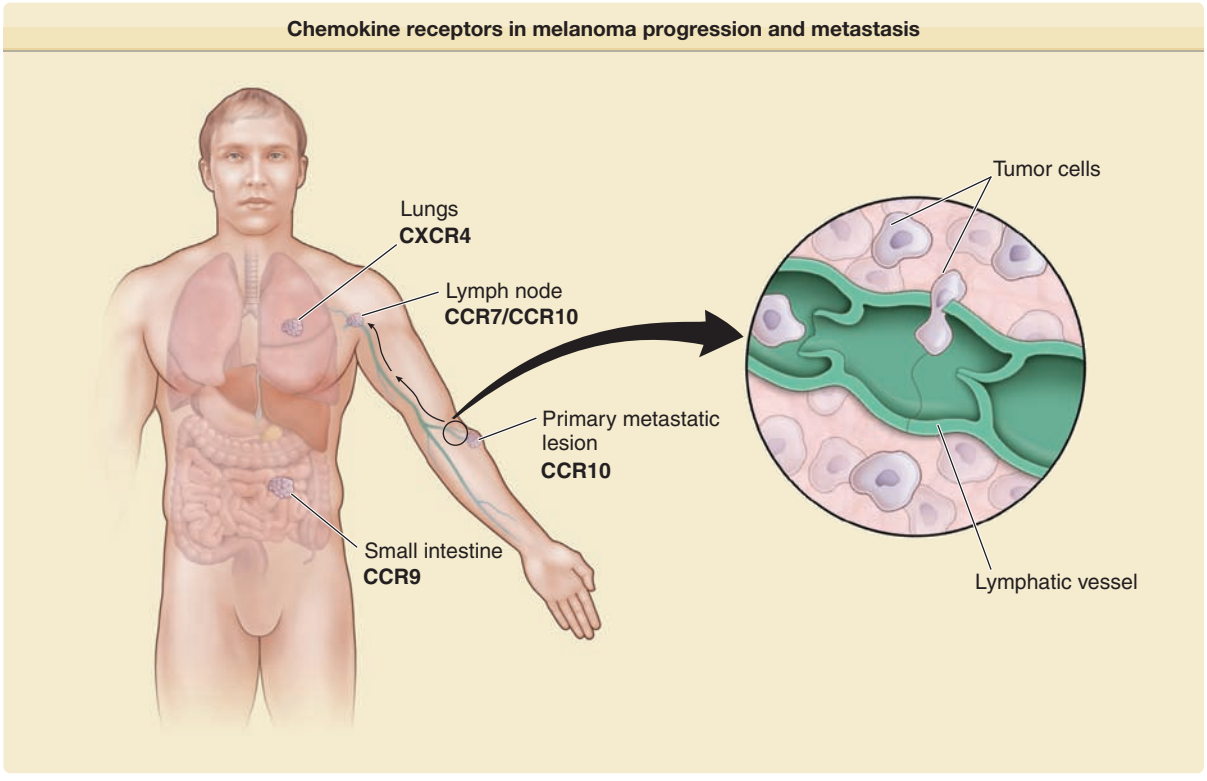

Figure 12-4 Chemokine receptors in melanoma progression and metastasis. Chemokine receptors play distinct roles in melanoma metastasis.[96] CCR10 may enhance survival of primary melanoma tumors and skin metastases. CCR7, CCR10, and, possibly, CXCR4 may contribute to lymph node metastasis. CXCR4 appears to be involved in primary tumor development and metastasis at distant organ sites such as the lungs. CCR9 has been implicated in melanoma small bowel metastasis in patients.

and CCR7, whereas normal breast epithelial cells and melanocytes do not appear to express these receptors.[97] CXCR4 is expressed in over 23 different solid and hematopoietic cancers. Broad expression of this receptor may be due to its regulation by hypoxia, a condition common to growing tumors, via the hypoxia inducible factor-1α transcription factor.[98] Notably stromal fibroblasts within human cancers express the CXCR4 ligand, CXCL12, which stimulates tumor growth as well as angiogenesis.[99] In several different animals of breast cancer[97] and melanoma metastasis,[29] inhibition of CXCR4 with antibodies or peptides resulted in dramatically reduced metastases to distant organs. Expression of CCR7 by cancer cells, including gastric carcinoma and melanoma, appears to be critical for invasion of afferent lymphatics and LN metastasis. CCR7-transfected B16 murine melanoma cells were found to metastasize with much higher efficiency to regional LN compared to control B16 cells after inoculation into the footpad of mice,[17] but CCR7 also directly stimulates primary B16 tumor development as well.[100] CCR9 may also play a role in melanoma metastasis to the small bowel, which shows high expression of the CCR9 ligand, CCL25.[19]

CCR10 is highly expressed by melanoma primary tumors[22] and is correlated with nodal metastasis in melanoma patients[101] and in experimental animal models (eFig. 12-4.1 in online edition).[22] Engagement of CCR10 by CTACK results in activation (via phosphorylation) of the phosphatidylinositol 3-kinase (PI3K) and Akt signaling pathways, leading to antiapoptotic effects in melanoma cells.[22] Because CTACK is constitutively produced by keratinocytes, it may act as a survival factor for both primary as well as secondary (metastatic) melanoma tumors that express CCR10. In fact, CCR10-activated melanoma cells become resistant to killing by melanoma antigen-specific T cells (eFig. 12-4.1 in online edition).[22] Interestingly, CCR4,[11] CXCR4,[102] and CCR10[23,103] have been implicated in the trafficking and/or survival of malignant T (lymphoma) cells to skin. Thus, a limited number of specific chemokine receptors appear to play distinct, nonredundant roles in facilitating cancer progression and metastasis (summarized in Fig. 12-4).

INFECTIOUS DISEASES

Although chemokines and chemokine receptors may have evolved as a host response to infectious agents, recent data suggest infectious organisms may have coopted chemokine- or chemokine receptor-like molecules to their own advantage in selected instances. A variety of microorganisms express chemokine receptors, including US28 by cytomegalovirus and Kaposi's sarcoma herpes virus (or human herpes virus-8) G-protein coupled receptor (GPCR). In the case of KSHV GPCR, this receptor is able to promiscuously

bind several chemokines. More importantly, it is constitutively active and may work as a growth promoter in Kaposi's sarcoma.[104]

The human immunodeficiency virus (HIV)-1, the causative agent of the acquired immunodeficiency syndrome (AIDS), is an enveloped retrovirus that enters cells via receptor-dependent membrane fusion (see Chapter 198). CD4 is the primary fusion receptor for all strains of HIV-1 and binds to HIV-1 proteins, gp120 and gp41. However, different strains of HIV-1 have emerged that preferentially use CXCR4 (T-tropic) or CCR5 (M-tropic) or either chemokine receptor as a coreceptor for entry. While other chemokine coreceptors can potentially serve as coreceptors, most clinical HIV-1 strains are primarily dual-tropic for either CCR5 or CXCR4.[3]

The discovery of a 32-base pair deletion (Δ32) in CCR5 in some individuals that leads to low levels of CCR5 expression in T cells and dendritic cells and correlates with a dramatic resistance to HIV-1 infection demonstrated a clear role for CCR5 in the pathogenesis of HIV-1 infection.[105] Interestingly, the frequency of Δ32 mutations in humans is surprisingly high, and the complete absence of CCR5 in homozygotes has only been associated with a more clinically severe form of sarcoidosis. Otherwise, these individuals are healthy. In fact, there is an association of less severe autoimmune diseases in patients with these mutations.[106]

LC reside in large numbers in the genital mucosa and may be one of the first initial targets of HIV-1 infection.[107] Since infected (activated) LC likely enter dermal lymphatic vessels and then localize to regional LN as described earlier, the physiologic migratory pathway of LC may also coincidentally lead to the transmission of HIV-1 to T cells within secondary lymphoid organs. CCR5 is expressed by immature or resting LC in the epidermis and is the target of CCR5 analogs of RANTES that block HIV infection.[108] Already, an FDA-approved small molecule inhibitor of CCR5, maraviroc, is available for use in treatment of HIV disease and may show fewer adverse effects than certain reverse transcriptase inhibitors.[109] CXCR4 antagonists may also be of clinical utility with T- or dual-tropic viruses.[110] A newly described autosomal dominant genetic syndrome comprised of *w*arts (human papilloma virus (HPV)-associated), *h*ypogammaglobulinemia, *i*nfections, and *m*yelokathexis (WHIM) is the result of an activating mutation (deletion) in the cytoplasmic tail of the CXCR4 receptor or in yet unidentified downstream regulators of CXCR4 function.[111,112] Bacterial infections are common because myelokathexis is associated with neutropenia and abnormal neutrophil morphology. The nearly universal presence of HPV infections associated with this syndrome can involve multiple common, as well as genital, wart subtypes (eFig. 12-4.2 in online edition) and suggest a critical role for normal CXCR4 function in immunological defense against this common human pathogen.

SUMMARY

The skin is rich in cells (keratinocytes, fibroblasts, endothelial cells, and immune cells) that are able to produce chemokines. Chemokines not only orchestrate the migration of inflammatory cells but also play roles in angiogenesis, cancer metastasis, and cellular proliferation. Other unanticipated biologic roles may ultimately be discovered. Just two of the promising therapeutic applications of chemokines (or molecules that mimic chemokines) may be in (1) preventing undesirable migration into the skin by preventing arrest of T cells or other inflammatory cells on activated endothelium, and (2) blocking the infection of dendritic cells and T cells by HIV-1 virus using CCR5 analogs. Signaling pathways are just beginning to be understood, and further work needs to be done to understand the regulation of these receptors, the specificity of intracellular activities, and the mechanism by which chemokine receptors work in the face of multiple chemokines present in many inflammatory sites.

KEY REFERENCES

Full reference list available at www.DIGM8.com

DVD contains references and additional content

1. Charo IF, Ransohoff RM: The many roles of chemokines and chemokine receptors in inflammation. *N Engl J Med* **354**(6):610-621, 2006
2. Zlotnik A, Yoshie O: Chemokines: A new classification system and their role in immunity. *Immunity* **12**(2):121-127, 2000
29. Murakami T et al: Expression of CXC chemokine receptor (CXCR)-4 enhances the pulmonary metastatic potential of murine B16 melanoma cells. *Cancer Res* **62**:7328-7334, 2002
34. Homey B: Chemokines and inflammatory skin diseases. *Adv Dermatol* **21**:251-277, 2005
58. Ohl L et al: CCR7 governs skin dendritic cell migration under inflammatory and steady-state conditions. *Immunity* **21**(2):279-288, 2004
82. Hedrick MN et al: CCR6 is required for IL-23-induced psoriasis-like inflammation in mice. *J Clin Invest* **119**(8): 2317-2329, 2009

Chapter 13 :: Allergic Contact Dermatitis

:: Mari Paz Castanedo-Tardan & Kathryn A. Zug

ALLERGIC CONTACT DERMATITIS AT A GLANCE

- Allergic contact dermatitis (ACD) is a cell-mediated (type IV), delayed type, hypersensitivity reaction caused by skin contact with an environmental allergen.
- Prior sensitization to a chemical is required for allergy to develop.
- The clinical manifestation of ACD is an eczematous dermatitis. The acute phase is characterized by pruritus, erythema, edema, and vesicles usually confined to the area of direct exposure. Recurrent contact to the allergen in a sensitized individual will result in chronic disease, characterized by lichenified erythematous plaques with variable hyperkeratosis and fissuring that may spread beyond the areas of direct exposure.
- Itch and swelling are key components of the history and can be a clue to allergy.
- The hands, feet, and face (including the eyelids) are some of the common sites for ACD.
- Patch testing is fundamental for the identification of causal allergens and is indicated for patients with persistent or recurrent dermatitis in whom ACD is suspected.
- Avoidance is the mainstay of treatment for ACD. Educating patients about avoidance of the allergen and its potentially related substances, and providing suitable alternatives are crucial to a good outcome.

As the largest organ in the human body, the skin is a complex and dynamic organ that serves among many other purposes, the function of maintaining a physical and immunologic barrier to the environment. Therefore, the skin is the first line of defense after exposure to a variety of chemicals. Allergic contact dermatitis (ACD) accounts for at least 20% or more of the new incident cases in the subgroup of *contact dermatitides* (irritant contact dermatitis accounts for the remaining 80%).[1] ACD, as the name implies, is an adverse cutaneous inflammatory reaction caused by contact with a specific exogenous allergen to which a person has developed allergic sensitization. More than 3,700 chemicals have been implicated as causal agents of ACD in humans.[2] Following contact with an allergen, the skin reacts immunologically, giving the clinical expression of eczematous inflammation. In ACD the severity of the eczematous dermatitis can range from a mild, short-lived condition to a severe, persistent, chronic disease. Appropriate allergen identification through proper epicutaneous patch testing has been demonstrated to improve quality of life as measured by standard tools,[3] as it allows for appropriate avoidance of the inciting allergen and possibly sustained remission of this potentially debilitating condition. Recognition of the presenting signs and symptoms, and appropriate patch testing are crucial in the evaluation of a patient with suspected ACD.

EPIDEMIOLOGY

A small but substantial number of studies have investigated the prevalence of contact allergy in the general population and in unselected subgroups of the general population. In 2007, Thyssen and colleagues[4] performed a retrospective study that reviewed the main findings from previously published epidemiological studies on contact allergy in unselected populations including all age groups and most publishing countries (mainly North America and Western Europe). Based on these heterogeneous published data collected between 1966 and 2007, the median prevalence of contact allergy to at least one allergen in the general population was 21.2%. Additionally, the study found that the most prevalent contact allergens in the general population were nickel, thimerosal, and fragrance mix. Importantly, the prevalence of contact allergy to specific allergens differs between various countries[5,6] and the prevalence to a specific allergen is not necessarily static, as it is influenced by changes and developments in the regional environment, exposure patterns, regulatory standards, and societal customs and values.

On a final note about epidemiology, contact allergy caused by ingredients found in personal care products (cosmetics, toiletries) is a well-known problem, with approximately 6% of the general population estimated to have a cosmetic-related contact allergy.[19,20] Contact allergy to ingredients in personal care products will be further discussed in this chapter.

AGE

Over the past decade, multiple studies have recognized contact dermatitis as an important cause of childhood dermatitis, and a common diagnosis among

children; being equally as likely in childhood as in adulthood,[21,22] although the most common allergens identified differ between the age groups. On the other hand, although fragrance mix allergy is an important sensitizer in all ages, certain studies, such as the 2001 Augsburg study, which was based on adults aged 28–75 years, have shown a significant increase in fragrance mix allergy with increasing age.[23] Similarly, Magnusson et al[24] demonstrated a high prevalence rate (4.7%) of *Myroxylon pereirae* (balsam of Peru—a marker for fragrance allergy) sensitization among 65-year-old Swedish patients. Similarly, a recent Danish study demonstrated the prevalence allergy to preservatives being higher among those aged 41–60 years.[25]

GENDER AND RACE

Because very few studies have looked at the induction of allergic contact sensitization in men and women under controlled circumstances, gender differences in the development of ACD are largely unknown. When the human repeat-insult patch testing method was used to assess induction rates for ten common allergens, women were more often sensitized to seven of the ten allergens studied.[26] With regard to frequency, Thyssen and colleagues found that the median prevalence of contact allergy among the general population was 21.8% in women versus 12% in men. When looking specifically at nickel sensitivity, the same study showed that the prevalence was much higher among women than men (17.1% in woman vs. 3% in men). This might be due to the fact that numerous studies have demonstrated that pierced ears are a significant risk factor for development of nickel allergy.[27–31] Thus, the higher prevalence of nickel allergy in women may be explained by the higher median prevalence of pierced ears in women in comparison with men (81.5% in women vs. 12% in men) of the population studied.

The role of race, if any, in the development of ACD to some potent allergens such as *para*-phenylenediamine (PPD), remains controversial.[32,33] Limited studies have suggested lower sensitizations rates to nickel and neomycin in African Americans compared to Caucasians. With regard to the patch-test protocol, the evaluation of positive reactions may be slightly more difficult in darker skin types (Fitzpatrick types V and VI), as erythema may not be as obvious, posing the risk of overlooking a mild positive allergic reaction. However, the edema and papules/vesicles are usually obvious and palpable; therefore palpation of the patch-test site can help to detect allergic reactions in patients with darker skin types. Finally, the darker the skin, the more difficult it is to mark the patch-test site after removal. For very dark skin, a florescent marking ink is probably best, the markings being located by a Wood's light in a darkened room.[34]

ETIOLOGY AND PATHOGENESIS

Allergic contact dermatitis represents a classic cell-mediated, delayed (type IV) hypersensitivity reaction. Such immunological reaction, results from exposure and subsequent sensitization of a genetically susceptible host, to an environmental allergen, which on reexposure triggers a complex inflammatory reaction. The resulting clinical picture is that of erythema, edema, and papulo-vesiculation, usually in the distribution of contact with the instigating allergen, and with pruritus as a major symptom Fig. 13-1.[35] To mount such reaction, the individual must have sufficient contact with a sensitizing chemical, and then have repeated contact with that substance later. This is an important distinction to irritant contact dermatitis (ICD) in which no sensitization reaction takes place, and the intensity of the irritant inflammatory reaction is proportional to the dose—concentration and amount of the irritant. In ACD, only minute quantities of an allergen are necessary to elicit overt allergic reactions. There are two distinct phases in the development of ACD: the sensitization phase and the elicitation phase.[36]



Figure 13-1 Erythematous papules and vesicles are characteristics of contact allergy in the acute stage.

SENSITIZATION PHASE

Most environmental allergens are small, lipophilic molecules with a low molecular weight (<500 Daltons). The unprocessed allergen is more correctly referred to as a hapten. Once the hapten penetrates the skin, it binds with epidermal carrier proteins to form a hapten–protein complex, which produces a complete antigen. Next, the antigen presenting cells (APC) of the skin (Langerhans cells and/or dermal dendritic cells), take up the hapten–protein complex and express it on its surface as an HLA-DR molecule. The antigen-presenting cell then migrates via the lymphatics to regional lymph nodes where it presents the HLA-DR–antigen complex to naive antigen-specific T cells that express both a CD4 molecule that recognizes the HLA-DR and more specifically a T-cell receptor CD3 complex that recognizes the processed antigen. The antigen can also be presented in the context of the MHC class I molecules, in which case it would be recognized by CD8 cells. Subsequently, the naive T cells are primed and differentiate into memory (also referred to as effector T cells) which undergo clonal expansion, acquire skin-specific homing antigens, and emigrate out of the

BOX 13-1 NEW DEVELOPMENTS IN CONTACT DERMATITIS

Emerging evidence suggests that innate immune cells such as Natural Killer (NK) cells play a significant role in ACD.

NK T cells (a hybrid between an NK cell and a conventional T cell) have been found to be necessary for the initiation of ACD and are also present in the elicitation phase of ACD.

Recent studies suggest that **Langerhans cells** (LC) that have been credited with an indispensable role in ACD may not be essential for the development of contact hypersensitivity. New studies of mice that lack LHCs suggest that they may even play a regulatory role in ACD.

Dermal dendritic cells may be the antigen presenting cells (APC) that complement epidermal LCs.

T-regulatory (T-reg) cells may be critical in the control of ACD (resolution of T-cell inflammation). Loss of T-reg cell activity may play a role in chronic inflammation.

Mast cells appear to be pivotal in determining the magnitude of the inflammatory reaction.

Keratinocytes play a role in all phases of ACD; from the initiation phase when their production of TNF-α after antigen exposure modulates APC migration and T-cell trafficking; through the peak of the inflammatory phase when they interact directly with epidermotrophic T cells; to the resolution of ACD through tolerogenic antigen presentation and the production of anti-inflammatory cytokines such as IL-10 and IL-16, which recruit T-regs.

From Gober MD, Gaspari AA: Allergic contact dermatitis. *Curr Dir Autoimmun* **10**:1, 2008.

lymph node into the circulation.[37,38] These clones of CD4+ Th1 and CD8+ type 1 cytotoxic T cells are then able to act as effectors on target cells presenting the antigen in the future.[39] The sensitization phase generally lasts 10–15 days and is often asymptomatic.[40] Subsequent exposure to the antigen, or rechallenge, leads to an elicitation phase. Such rechallenge can occur via multiple routes, including transepidermal, subcutaneous, intravenous, intramuscular, inhalation, and oral ingestion.[41]

ELICITATION PHASE

During this phase, both the APCs and the keratinocytes can present antigen and lead to subsequent recruitment of hapten-specific T cells. In response, the T cells release cytokines, including IFN-γ and TNF-α, which, in turn, recruit other inflammatory cells while stimulating macrophages and keratinocytes to release more cytokines.[42,43] An inflammatory response occurs as monocytes migrate into the affected area, mature into macrophages, and thereby attract more T cells. This localized proinflammatory state results in the classical clinical picture of spongiotic inflammation (redness, edema, papules and vesicles, and warmth). Recent advances in the knowledge of the pathophysiology of ACD have demonstrated the important role of the skin innate immunity in the sensitization process; have revisited the dogma that Langerhans cells are mandatory for ACD; and have addressed the nature, mode, and site of action of the regulatory T cells that control the skin inflammation (Box 13-1) (see also Chapter 10).[44,45] This new understanding may facilitate the development of strategies for tolerance induction, as well as the identification of novel targets for pharmacological agents for the treatment of ACD.

CLINICAL APPROACH

An algorithmic approach to the patient is described in the following sections.

CONSIDERATION OF THE DIAGNOSIS

The character and distribution of the dermatitis should raise the index of suspicion for ACD. Therefore, any patient who presents with an eczematous dermatitis should be regarded as possibly having ACD (Fig. 13-2). Additionally, one must also consider contact allergy in patients with other types of dermatitis (e.g., atopic) that is persistent and recalcitrant despite appropriate standard therapies, as well as in patients with erythroderma, or scattered generalized dermatitis.[46] Furthermore, it is important to note that patients with stasis dermatitis are at increased risk of developing ACD from topical medications and lotions which are often applied under occlusion over chronically inflamed and broken skin (Fig. 13-3). For that reason, ACD should always be in the differential of eczematous lesions surrounding leg ulcers. Finally, it is important to avoid some commonly held misconceptions about ACD that can alter a physician's ability to recognize contact dermatitis. These were described by Marks and DeLeo and include the following:

- ACD is not always bilateral even when the antigen exposure is bilateral (i.e., shoe or glove allergy).
- Even when exposure to an allergen is uniform (e.g., contact allergy to an ingredient of a cream that is applied on all of the face), eczematous manifestations are very often patchy.
- ACD can and does affect the palms and the soles.



Figure 13-2 Typical appearance of eczematous dermatitis compatible with ACD. **A.** Note the erythematous scaly plaques with some fissuring on the hands. **B.** Erythematous papules, scattered on the extensor forearms. This is a typical picture of contact allergy to a skin care product ingredient.

HISTORY TAKING

The first step in the diagnosis of ACD is a careful medical and environmental exposure history. History taking should begin with a discussion of the present illness focusing on the site of onset of the problem and the topical agents used to treat the problem (including over the counter and prescription medications). A past history of skin disease, atopy, and general health should be routinely investigated. This is followed by a detailed history of the usage of personal care products (soap, shampoo, conditioner, deodorant, lotions, creams, medications, hair styling products, etc.), and investigation of the patient's avocations or hobbies. The occupation should be ascertained as well, and if it appears contributory, or there are potential allergenic exposures, then a thorough occupational history should be taken. Occupations requiring frequent hand washing, glove use, or frequent chemical exposure should be prime suspects, among others.



Figure 13-3 Stasis dermatitis is a risk factor for the development of contact allergy. This is likely because of more frequent application of products that contain contact allergens to this area. Products without high frequency positive allergens are preferred in this area.

CLINICAL MANIFESTATIONS

CUTANEOUS FINDINGS

The classic presentation of ACD is a pruritic, eczematous dermatitis initially localized to the primary site of allergen exposure. Geometric or linear patterns or involvement of focal skin areas, may also be suggestive of an exogenous etiology (Fig. 12-4B). A linear or streaky array on the extremities, for example, often represents ACD from poison ivy, poison oak, or poison sumac. Occasionally, the actual sensitizing substance in these plants, an oleoresin named *urushiol* may be aerolized when the plants are burned, leading to a more generalized and severe eruption on exposed areas such as the face and arms. Transfer of the resin from sources other than directly from the plant (such as clothes, pets, or hands) may result in rashes on unexpected sites (i.e., genital involvement in a patient with poison ivy). Thus, relevant historic data gathered from thoughtful questioning may prove as useful as the distribution of the lesions.

It is important to note that lesions of ACD will vary morphologically depending on the stage of the disease. For example, during the acute phase, lesions are marked by edema, erythema, and vesicle formation. As the vesicles rupture, oozing ensues and papules and plaques appear. Stronger allergens often result in vesicle formation, whereas weaker allergens often lead to papular lesion morphology, with surrounding erythema and edema. Subacute ACD on the other hand, will present with erythema, scaly juicy papules and weeping; whereas chronic ACD can present with scaling, fissuring, and lichenification. A key symptom for allergy is pruritus, which seems to occur more typically with allergy, than a complaint of burning.[47]



Figure 13-4 ACD to *para*-phenylenediamine. **A.** Notice the eczema on the distribution of the hairline and behind the ears. **B.** Dermatitis on the forehead where the bangs came in contact with the skin of the same patient. **C.** *para*-Phenylenediamine, the most frequent relevant allergen in hair dye, is a strong sensitizer. It will darken the patch-test site. There is a strong edematous and vesicular reaction that is spreading, a 3+ reaction to this patch test.

Moreover, there are some noneczematous clinical variants of ACD that are infrequently observed.[48] These include among others:

- *Purpuric ACD* is mainly observed on the lower legs and/or feet and has been reported with a wide variety of allergens including textile dyes.
- *Lichenoid ACD* is considered a rare variant. Clinical features mimic lichen planus and has been associated with metallic dyes in tattoos. Oral lichenoid ACD from dental amalgams can resemble typical oral lichen planus.
- *Pigmented ACD* has been mainly described in populations from Asian ethnicity.
- *Lymphomatoid ACD* is based only on histopathological criteria (presence of significant dermal infiltrate displaying features of pseudolymphoma). Clinical signs which are nonspecific include erythematous plaques, sometimes very infiltrated, at the site of application of the contact allergen. Some examples include allergy to metal, allergy to hair dye, and to dimethylfumarate, a mold inhibitor found in sachets within some furniture implicated in causing a severe epidemic of ACD.

TOPOGRAPHIC APPROACH

Dermatitis distribution is usually the single most important clue to the diagnosis of ACD. Typically, the area of greatest eczematous dermatitis is the area of greatest contact with the offending allergen(s). Location, in fact, can be one of the most valuable clues as to which chemical might be the culprit of a patient's ACD. For instance, an eczematous dermatitis in the peri/infraumbilical area suggests contact allergy to metal snaps in jeans and belt buckles, whereas eczema distributed around the hairline and behind the ears suggests contact allergy to an ingredient(s) in hair products (hair dyes, shampoo, conditioners, styling products) (Fig. 13-4). Using the same rationale, eczema on the dorsum of the feet suggests contact allergy to products used to make shoe uppers like leather, rubber, or dyes, while eczematous dermatitis on the weight-bearing surfaces of the feet suggests contact allergy to products used to make insoles/soles like rubber and adhesive materials. Notably, facial, eyelid, lip, and neck patterns of dermatitis should always raise suspicion of a cosmetic-related contact allergy. However, for all of these presentations, correct identification of the

culprit chemical(s) will still require patch testing, since even the most astute and experienced clinician is, for the most part, unable to properly surmise the positive allergen(s) prior to testing. The pattern of dermatitis should be mainly used in determining whether or not to patch test, and which allergens and screening series to test.

Occasionally, the topographic approach does not hold, and the distribution can actually be misleading. This mainly refers to cases of ectopic ACD or airborne ACD. Ectopic ACD can follow two circumstances: *Auto transfer,* in which the allergen is inconspicuously transferred to other body sites by the fingers—the classical example being nail lacquer dermatitis located on the eyelids or lateral aspects of the neck; and *hetero-transfer,* in which the offending allergen is transferred to the patient by someone else (spouse, parent, etc.); this is described in the literature as connubial or consort ACD.

A discussion of allergens in the context of common patterns of presentation is briefly detailed below.

FACE. The face is a common site for ACD. Among patients with facial dermatitis, women are more commonly affected than men, particularly by cosmetic-associated allergens such as fragrances, PPD, preservatives, and lanolin alcohols (eFig. 13-4.1 in online edition).[49] Allergens can be applied to the face directly but can also be indirectly transferred from airborne or hand-to-face exposure. In addition to allergens found as ingredients in cosmetics, products used to apply them—such as cosmetic sponges, have also been reported to produce facial dermatitis in rubber-sensitive patients.[50] A similar situation is seen with nickel-plated objects used on the hair, such as bobby pins and curlers that may produce scalp and facial dermatitis in nickel-sensitive patients.

SCALP. Allergens applied to the scalp most often produce patterns of dermatitis on the forehead and lateral aspect of the face, eyelids, ears, neck, and hands; whereas the scalp remains uninvolved, suggesting that the scalp is particularly "resistant" to contact dermatitis. Nevertheless, patients exquisitely sensitive to certain ingredients in hair products such as PPD or glyceryl monothioglycolate may show a marked scalp reaction with edema and crusting. PPD is one of the most potent sensitizers known and is widely used as an ingredient in hair dyes. In general, PPD sensitization manifests on the face and scalp of female adult patients who had contact with a hair dye.[51–54] Glyceryl thioglycolate (GMT), on the other hand, is a chemical substance used in permanent wave solutions. Allergic sensitivity to GMT can manifest as intense scalp reactions with scaling, edema, and crusting.[55]

EYELIDS. The eyelids are one of the most sensitive skin areas, and are highly susceptible to irritants and allergens perhaps due to the thinness of the eyelid skin, as compared with the rest of the skin, and perhaps because they can accumulate the offending chemical in the skin folds. Transfer of small amounts of allergens used on the scalp, face, or hands can be enough to cause an eczematous reaction of the eyelids, while the primary sites of contact remain unaltered (eFig. 13-4.2 in online edition). Similarly, volatile agents may affect the eyelids first and exclusively, causing airborne eyelid contact dermatitis. Sources of contact dermatitis of the eyelids include cosmetics such as mascara, eyeliners and eye shadows, adhesive in fake eyelashes, and nickel and rubber in eyelash curlers. Furthermore, marked edema of the eyelids is often a feature of hair-dye dermatitis.[56] As mentioned earlier in this chapter, eyelids are also known for being a typical site for "ectopic contact dermatitis" caused by ingredients found in nail lacquer, such as tosylamide formaldehyde resin (TSFR), the chemical added to nail varnish to facilitate adhesion of the varnish to the nail and epoxy resin, also added to some nail polishes. Topical antibiotics (like bacitracin and neomycin) and certain metals such as gold[57] can also cause eyelid contact dermatitis. In fact, in the 2007 NACDG analysis of contact allergens associated with eyelid dermatitis,[58] gold was the most common allergen accounting for pure eyelid dermatitis. Notably, it has been observed that upon contact with hard particles such as titanium dioxide (used to opacify facial cosmetics, and in sunscreens as a physical blocker of ultraviolet light), gold found in jewelry may abrade, resulting in the release of gold particles that can then make contact with facial and eyelid skin, causing dermatitis.[59] Aside from gold, fragrances and preservatives have been found to be the main cosmetic allergens to cause dermatitis limited to the eyelids.[60]

LIPS. According to an NACDG study, approximately one-third of patients with cheilitis—without other areas of dermatitis—are typically found to have an allergen as a contributing factor.[61,62] Allergic contact cheilitis (ACC) has been reported to result from the use of a wide array of products including cosmetics such as lip balms, lipsticks, lip glosses, moisturizers, sunscreens, nail products, and oral hygiene products (mouthwashes, toothpastes, dental floss) (Fig. 13-5).[63–65]



Figure 13-5 Allergic Contact Cheilitis. Fragrances and flavorings are top among the most common causes of contact allergy in patch-tested patients with cheilitis.

ACC has a marked female predominance, with most studies reporting a range of 70.7%–90% female patients.[66] This is likely explained by the assumption that women wear more cosmetics and lip products than men. Most studies have reported fragrance allergens [such as fragrance mix and *Myroxylon pereirae* (Balsam of Peru)] as the most common cause of contact allergy in patch-tested patients with cheilitis.[67] Of note, some uncommonly reported allergens, namely, benzophenone-3 and gallates, may be relevant to a dermatitis localized to the lips. Benzophenone-3, a major constituent of many sunscreens, is also a common ingredient in many lip products and is increasingly reported as a culprit for ACC.[68,69] Gallates are antioxidants used in waxy or oily products such as lip balms, lipsticks, and lip glosses.[70]

NECK. The neck is also a highly reactive site for ACD. Cosmetics applied to the face, scalp, or hair often initially affect the neck. Nail-polish ingredients (tosylamide formaldehyde resin and epoxy resin) are common culprits in this region.[71] Furthermore, as a cultural practice, perfumes are sprayed on the neck. In a fragrance-sensitized individual, the practice of repeated application of fragrances to the anterior neck may result in the appearance of a dermatitic plaque on the neck, which has been coined the *"atomizer sign."*[72] Also, in this topographic area, metal allergy can manifest as chronic eczematous dermatitis from exposure to necklaces and jewelry clasps that contain nickel and/or cobalt.

TORSO. The torso can encounter fragrances, preservatives, surfactants, and other chemicals from the use of personal care products; yet it is also susceptible to allergens found in textiles. Textile-associated allergens include disperse dyes (azoanilines) and formaldehyde-releasers used as durable press chemical finishes (DPCF). In the past, finishes used to contain large amounts of free formaldehyde, which led to many cases of allergic contact dermatitis to clothing in the 1950s and 1960s. However, currently most finishes are based on modified dimethylol dihydroxyethyleneurea, which releases less formaldehyde. Importantly, recent studies have shown that the amount of free formaldehyde in most garments will likely be below the threshold for the elicitation of dermatitis for all but the most sensitive patients, and that the amount of free cyclized urea in clothes is unlikely to be high enough to cause sensitization.[73]

AXILLAE. Heat, humidity, and friction of the axillary fold may contribute to the leaching of textile resins and dyes and dermatitis accentuation in these areas.[74] The axillary region is also uniquely exposed to deodorants and antiperspirants. These products contain most notably the contact allergens fragrances and preservatives (formaldehyde releasers, parabens, etc.). A commonly observed effect with the use of these products is the sparing of the axillary vault, mainly secondary to perspiration diluting the allergens. Aerosolized exposure of the allergens through antiperspirant/deodorants in spray, may lead to scattering of the allergen and the resulting picture may be that of scattered satellite papules.

HANDS AND FEET. Hand dermatitis has a particularly high incidence secondary to the fact that the hands are the main means of interaction with the environment, with increased possibility for numerous allergen exposures. Hand dermatitis accounts for as much as 80% of the occupationally related skin diseases, especially in certain "wet work" occupations such as health care workers, food handlers, etc.[75] Thus, careful consideration should be given to occupation-specific exposures in the evaluation of patients with hand dermatitis. As an example, a hairdresser may be sensitized to ingredients in hair-care products such as PPD, glyceryl monothioglycolate, or cocamidopropyl betaine (a surfactant-detergent, commonly found in shampoos), whereas a construction worker may become allergic to chromium through exposure to wet cement. Clinical clues that should raise a higher index of suspicion of ACD include the involvement of the finger web spaces and the dorsal hands, as well as the predominance of pruritus as a symptom. Still the multifactorial etiology of hand dermatitis (irritant exposure, atopy, pompholyx or chronic vesicular hand eczema, psoriasis, dermatophyte infection, among others) adds to the complexity of both diagnosing and treating these patients. Chronic hand dermatitis is an indication for patch testing, as causal or contributing allergy can result in improvement or resolution of the problem. Similarly, the evaluation of foot dermatitis should include patch testing with the allergens most commonly associated with this condition. These include, rubber-related chemicals (such as mercaptobenzothiazole, carba mix, thiuram mix, mercapto mix, black rubber mix, and mixed dialkyl thioureas) potentially present as components of shoes and insoles; glues and adhesives used in shoe manufacturing like 4-*tert*-butylphenol formaldehyde resin; and potassium dichromate found in tanned leather-made shoes. Testing materials should also include topical antibiotics, corticosteroids, or antifungal medications (both over-the-counter and prescription) that may have been used by the patient to treat the affected area.

Other topographic areas affected by ACD include the oral mucosa, which may present with contact stomatitis from dental metals and the perianal area, which may react to sensitizing chemicals in proctologic preparations such as benzocaine.

SCATTERED GENERALIZED DERMATITIS

Patients with scattered generalized dermatitis (SGD) usually present a difficult diagnostic and therapeutic challenge. Patch testing can be a strategy for evaluating ACD as a potential relevant factor. In 2008, Zug and NACDG colleagues [76] examined the yield of patch testing as well as the relevant allergens in patients with SGD referred for patch testing. Of 10,061 patients studied during a period of 4 years, 14.9% had SGD.

Men and patients with a history of atopic eczema were more likely to have dermatitis in this distribution. Of the total of patients presenting with SGD, 49% had at least one relevant positive patch-test reaction. Preservatives, fragrances, propylene glycol, cocamidopropyl betaine, ethyleneurea melamine formaldehyde, and corticosteroids were among the more frequently relevant positive allergens.

SYSTEMIC CONTACT DERMATITIS

In 2001, members of the International Contact Dermatitis Research Group (ICDRG) developed the concept of the *allergic contact dermatitis syndrome* (ACDS).[77] This concept considers the various facets of contact allergy, including morphological aspects and staging by symptomatology. ACDS has three stages that can be defined (Table 13-1) and with many causes (Table 13-2).

Systemic contact dermatitis describes a systemic reactivation of allergic contact dermatitis; in other words, a cutaneous eruption in response to systemic (nontopical) exposure to an allergen.[78] In considering the chains of events resulting in the development of systemic reactivation of ACD, the ICDRG has suggested that the occurrence of some successive steps is necessary. Initially, direct skin contact with an allergen results in sensitization. Second, in some relatively uncommon cases, weeks or even years after that first episode of ACD, the patient is systemically exposed to exactly the same allergen, or to a related substance that is chemically closely related to it (cross-sensitization), elicitating a systemic reactivation of ACD. There are multiple routes of exposure for the elicitation of systemic contact dermatitis—subcutaneous, intravenous, intramuscular, inhalation, and oral ingestion. It is important then to note, that by definition, in systemic contact dermatitis, there is no occurrence of topical skin contact to the allergen. Clinically, systemic contact dermatitis has a wide spectrum of presentation, from a recall reaction (dermatitis at the site of prior topical sensitization), to widespread dermatitis and erythroderma. Other patterns that have been associated with systemic contact dermatitis include axillary vaults, upper inner thighs, and buttocks—sometimes described as "baboon syndrome,"[79] which has been associated with some internally ingested allergens, i.e., cashew nut shell oil causing a cross-reaction to the allergen urushiol. Dyshidrotic hand eczema/pompholyx are conditions in which oral challenges with nickel, and *Myroxylon pereirae* have demonstrated flaring of this type of hand eczema in some studies (eFig. 13-5.1 in online edition).[80] Of particular notoriety is the allergen *Myroxylon pereirae* also known as balsam of Peru, a substance derived from *Myroxolon balsamum*, a tree that is native to the country of El Salvador. Because the main components of *Myroxylon pereirae* (cinnamic acid, cinnamyl cinnamate, benzyl benzoate, benzoic acid, benzyl alcohol, and esterified polymers of coniferyl alcohol) are naturally derived, they have a significant number of natural cross-reactors. Certain foods, such as tomatoes and tomato-containing products, citrus fruit peel/zest, chocolate, ice cream, wine, beer, vermouth, dark colored sodas, and spices such as cinnamon, cloves, curry, and vanilla, have chemical ingredients related to balsam of Peru.[81] Consumption of these foods may result in a systemic reactivation of ACD in some patients allergic to balsam of Peru. Salam and Fowler drew attention to this ability of orally ingested balsam-related substances to induce systemic contact dermatitis, and reported that, in their study, remarkably almost half of the subjects with a positive patch test to *Myroxylon pereirae* who followed a balsam of Peru-reduction diet, had a significant to complete improvement of their dermatitis. Finally, some oral or IV medications may cause systemic reactivation of ACD in patients

TABLE 13-1
Stages of the Allergic Contact Dermatitis Syndrome

Stage 1	The skin symptoms are limited to the site (s) of application of contact allergen(s).
Stage 2	There is a regional dissemination of symptoms (via lymphatic vessels), extending from the site of application of allergen(s).
Stage 3	Can be further subdivided in **Stage 3A**: Corresponds to hematogenous dissemination of ACD at a distance. **Stage 3B**: Corresponds to systemic reactivation of ACD (nontopical trigger)

Data from Lachapelle JM: Dermato-allergolie de contact. *Nouv Dermatol (Strasbourg)* **20**:450, 2001 and Lachapelle JM, Maibach HI: *Patch Testing and Prick Testing: A Practical Guide*. Berlin, Germany, Springer-Verlag, 2003.

TABLE 13-2
Systemic Drugs that Can Cause Systemic Reactivation of ACD

Contact Allergen[a]	Related Drug with Potential to Cause Systemic Reactivation of ACD
Ethylenediamine dihydrochloride (stabilizer infrequently found in skin care products)	Aminophylline Piperazine antihistamines: hydroxyzine, cetirizine, levocetirizine and meclizine
Thiuram (rubber antioxidant)	Tetraethyl thiuram disulfide (generic name: disulfiram)
Thimerosal (mercury-derived preservative)	Piroxicam

[a]To which a patient had previously become sensitized by direct, topical application of the contact allergen to the skin.

previously sensitized to related allergens by direct skin contact[82–85] (Table 13-2).

FREQUENCY APPROACH

Because "frequent is frequent," the approach to a patient with suspected ACD can also be done taking into account the most likely culprits based on frequency data of a given region, and the patient's occupation or other individual exposures. This approach should not replace by any means actual patch testing; nevertheless, a working knowledge of the most common allergens can prove to be useful when evaluating a patient with suspected ACD. Next is a brief description of the most frequently patch-test positive allergens in North America.

NICKEL. Nickel is a ubiquitous metal used in a wide range of products including those that have a prolonged contact with the skin (costume jewelry, suspenders, zippers, button snaps, belt buckles, eyeglasses frames, cell phones, nickel-containing coins, keys, among many others). There is a well-documented rising incidence of nickel allergy in the United States and elsewhere, with high nickel sensitization rates documented in children.[86] Ear piercing at an early age, in addition to the trend of a greater number of other body piercings, are consistently linked to the rise in nickel sensitization in the recent decade.[87,88] Currently, nickel allergy is the most common cause of contact dermatitis in the industrial world, particularly affecting females.[89] Several studies have examined the striking discrepancy of sensitization incidence to nickel in females versus males and have associated this with ear piercing.[90,91] Classically, nickel contact dermatitis presents as an eruption on the earlobes, the neckline, the wristband, or the periumbilical area since those are common areas for exposure to nickel-containing jewelry or button snaps, zippers, and belt buckles. Facial dermatitis caused by nickel has also been reported to musical instruments and more recently to cell phones.[92] Furthermore, the presence of nickel in implantable medical devices and potential complications derived from nickel allergy is a rising subject of discussion. The relevance of nickel allergy in the failure of metal orthopedic implants and cardiac devices is not clear. Documented cases of joint replacement failure associated with nickel or other metal sensitivity are clearly rare, and arthroplasty prostheses rarely cause a problem in the nickel sensitive individual. Existing publications are largely retrospective and thus can only suggest a possible association of nickel allergy with implant failure rather than determine causation.[93] Similarly, eczematous reactions temporally related to joint replacement or implantation of other orthopedic devices (i.e., metallic plates and screws) although reported, are infrequent (eFig. 13-5.2 in online edition). More studies are needed in this area.

In an attempt to prevent the development of nickel sensitivity, Denmark in 1990, and the rest of the European Union in 1994, have regulated the amount on nickel that may be released from objects with direct and prolonged skin contact (≤0.5 μg nickel/cm^2/week; revision for 2004: ≤0.2 μg nickel/cm^2/week for items inserted into pierced parts of the body). Recent evidence indicates that the prevalence of nickel allergy is decreasing among young Danish females from 27.6% in 1985 to 16.8% in 2007.[94] The American Academy of Dermatology and the American Contact Dermatitis Society favor enacting similar legislation in the United States.

FRAGRANCES. Fragrances are aromatic compounds that impart a smell or odor. They can be natural (from botanical or animal products) or synthetic in origin. It has been estimated that between 1% and 4% of the general population is allergic to fragrances.[95,96] Fragrance allergy is one of the two top causes of contact allergy to personal care products; the typical sites of involvement include the face and hands, as well as behind the ears, neck, and axillae, in addition to a scattered generalized distribution of eczematous dermatitis.[97,98] Two of the main substances used by most patch-test groups for screening are among the top ten allergens in North America. The first is *fragrance mix I*, which is a mixture of eight fragrance allergens, and the second is *Myroxylon pereirae* (MP) also known as balsam of Peru (BOP), whose main components are fragrance ingredients.[99] MP is considered to be a good marker for fragrance allergy, able to identify approximately 50% of fragrance allergic individuals.[100] MP-related substances can be found in products such as cosmetics, perfumes, pharmaceutical preparations, toothpastes and mouthwashes, as well as in scents and flavorings for foods and drinks. Similarly, certain foods, such as the ones mentioned earlier in the chapter, contain chemical ingredients related to MP. Surgical adhesives used postprocedure to secure dressings also may cross-react and produce dermatitis in individuals sensitive to MP.

NEOMYCIN. Neomycin belongs to the aminoglycoside family of antibiotics commonly used in topical formulations for the prevention and treatment of superficial skin, ear, and eye infections. The frequency of neomycin sensitization in the general population is 1.1%,[101] while reported sensitization rates in selected patient populations referred for patch testing vary from as low as 1.1[102] to as high as 10%, the latter reported by the NACDG.[103] This high rate of sensitization in North America may be due to the availability of this antibiotic in numerous over-the-counter preparations, especially "triple antibiotic" creams and ointments.[104] Subgroups at higher risk include patients with stasis dermatitis and leg ulcers, anogenital dermatitis, and otitis externa. Because antibiotic preparations are applied to already damaged skin, ACD from neomycin is not always easily recognized. It often presents as persistence or worsening of a preexisting dermatitis.[105] Additionally, it may mimic cellulitis; the clue for contact allergy is itching rather than pain. An intensification of itch and the progression of lesions beyond the initial site of involvement may offer clues to the



Figure 13-6 This eczematous dermatitis was caused by the most frequent preservative allergen, quaternium-15, which was present in the patient's moisturizer.

correct diagnosis. Occupational dermatitis involving the hands can occur in nurses, physicians, pharmacists, dentists, and veterinarians.[106]

FORMALDEHYDE AND FORMALDEHYDE-RELEASING PRESERVATIVES. Formaldehyde is a colorless gas with preservative and disinfectant properties. Although there is a wide range of uses for formaldehyde-like cleansing products, glues, biocides, and photographic developers, currently it is rarely used *as-is* in personal care because it has demonstrated to be a frequent sensitizer.[107] Therefore, many manufacturers have replaced the use of formaldehyde with formaldehyde-releasing preservatives (FRPs) to preserve personal care products.[108] FRPs include quaternium-15, imidazolidinyl urea (Germall), diazolidinyl urea (Germall II), DMDM hydantoin (Glydant), 2-bromo-2-nitropropane-1, 3-diol (Bronopol), and tris nitromethane (Tris Nitro).[109] Of these, Quaternium-15 is the most common cosmetic preservative allergen (Figs. 13-6 and 13-7).[110–112]

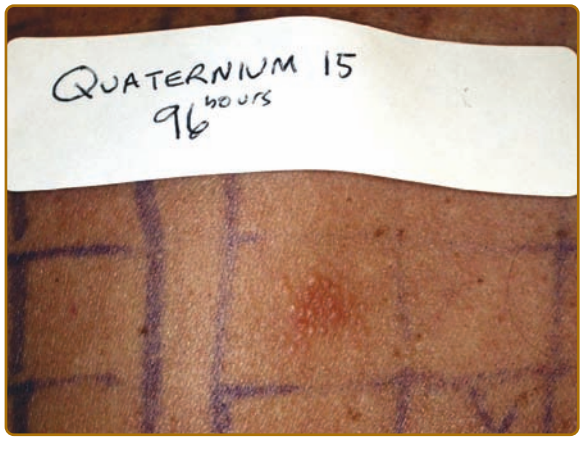

Figure 13-7 An example of a weak, 1+ reaction to quaternium-15.

COBALT. Cobalt is a metal which is often added to other metals to increase overall strength. Cobalt is commonly a contaminant present in nickel ores and is frequently a minor element in nickel compounds.[113] As with nickel, a majority of sensitization exposures result from contact with jewelry, clothing snaps, buckles, coins, keys, and other metal objects. Furthermore, it can also be found in prosthetic joint replacements, dental alloys, ceramics, paints, tattoo dyes, cement (mostly in Europe), and multivitamins containing vitamin B12 (cobalt is a main component of vitamin B12, Cyanocobalamine).[114] Concomitant allergy to nickel and cobalt is often observed among patients with dermatitis, probably as a result of cosensitization. In general, the best way of avoiding contact with metallic cobalt is by avoiding contact with nickel-plated objects that come in direct contact with the skin.

BACITRACIN. Bacitracin is a topical antibiotic frequently used for postoperative and general wound care by both the medical profession and the general public since it is readily available in over-the-counter preparations. Bacitracin is known to be a common sensitizer and can cause not only allergic contact dermatitis but also urticarial reactions and even, rarely, anaphylaxis.[115] It is important to note that despite its high prevalence, bacitracin is not included as a screening allergen in the currently available T.R.U.E. Test series, which will be further discussed briefly in this chapter. Interestingly, patients often show simultaneous sensitivity to bacitracin and neomycin, although the two substances are not chemically related, meaning there is coreactivity but not cross-reactivity between both substances. Independent sensitization probably occurs to both antibiotics, which are often used simultaneously in over-the-counter combinations.[116]

METHYLDIBROMOGLUTARONITRILE/PHENOXYETHANOL. Methyldibromoglutaronitrile/Phenoxyethanol (MDGN/PE) is a preservative combination also known as *Euxyl K400*. It has become an increasingly important sensitizing agent,[117] resulting in a ban on use in Europe, first from stay-on cosmetics in 2005, and later from rinse-off cosmetics in 2007, in an attempt to decrease the rates of contact allergy.[118] The use of MDGN/PE is not banned in cosmetics produced outside the European Union, and therefore toiletries sold elsewhere may contain MDGN/PE, albeit at a lesser concentration than had been allowed European formulations. Most allergic reactions to MDGN/PE are due to the use of personal care products containing the allergen, especially creams, lotions, wet wipes, and liquid soaps.

***para*-PHENYLENEDIAMINE.** PPD is an oxidizing agent used as a permanent hair dye. Both consumers and hairdressers alike are at risk for sensitization. As mentioned earlier in this chapter, contact allergy to PPD often presents as facial dermatitis near the

hairline, but it may also involve the eyelids and the neck, while the scalp may or may not be spared.[119] Once oxidized, PPD is no longer allergenic, thus, dyed hair itself does not pose further risk of allergic stimulation. This is in contrast to permed hair, in which the allergen, glyceryl monothioglycolate, retains ability to further stimulate dermatitis in the allergic individual (i.e., an allergic hairdresser cutting the hair of a client who has had GMT permanent waving applied to the hair weeks ago). PPD has the potential to cross-react with other *para*-amino group chemicals such as *para*-aminobenzoic acid (PABA), sulfonylureas, hydrochlorothiazide, benzocaine, procainamide, and certain azo and aniline dyes.[120,121] Additionally, PPD has gained notoriety for its use in adulterating natural henna to make "black henna," a substance increasingly used to make temporary tattoos.[122,123]

PATCH TESTING

ALLERGEN SELECTION

T.R.U.E. TEST. The commercially available patch-test screening tool with US Food and Drug Administration (FDA) approval is the Thin-layer Rapid Use Epicutaneous (T.R.U.E.) Test (Mekos Laboratories AS, Hillerod, Denmark). As of March 2010, there were 28 (plus 1 negative control) T.R.U.E. Test allergens organized into three panels (panels 1.1, 2.1, and 3.1). Of the top 30 most frequently positive NACDG screening allergens for the 2005–2006 period, Zug and NACDG colleagues found that 10 important allergens were not currently available for testing and identification with the T.R.U.E. Test panels: bacitracin, methyldibromoglutaronitrile, bronopol, cinnamic aldehyde, propylene glycol, DMDM hydantoin, iodopropynyl butylcarbamate, ethyleneurea/melamine formaldehyde, disperse blue 106, and amidoamine. Of these, bacitracin is likely the most important. Named Allergen of the Year in 2003 by the American Contact Dermatitis Society, bacitracin is now the seventh most frequently positive allergen according to prevalence data from this study group (Fig. 13-8).

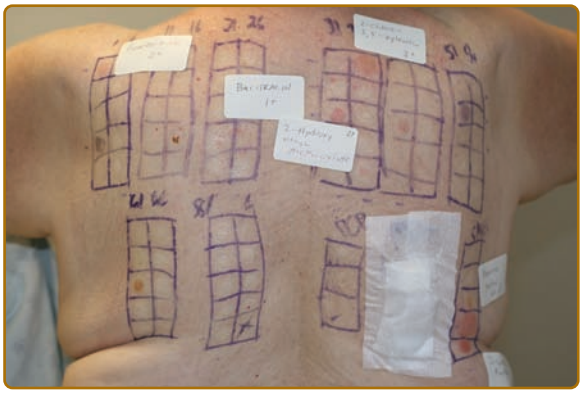

Figure 13-8 This patient had multiple relevant positive patch tests. Bacitracin, chloroxylenol, and 2-hydroxyethyl methacrylate are relevant to this patient's severe dermatitis but are not allergens on the currently available commercial screening series.

RESULT INTERPRETATION

Reading reactions elicited by the patch test is a crucial step in the patch-test procedure. Patches should be applied to healthy skin on the patient's back and left under occlusion for 48 hours (eFig. 13-8.2 in online edition). Traditionally, patch-test reading is carried out in most patch-test clinics twice: the day of patch-test removal 48 hours after application (day 2 = D2), and 96 hours after epicutaneous exposure (day 4 = D4), or day 7. It is important to note that certain allergens are acknowledged for being "late-reactors." For example, if neomycin or PPD allergies are suspected, additional readings at 5–7 days may be needed.[125] Likewise, some researchers have also found that readings for metals and corticosteroids should sometimes be delayed to 7 days.[126] The reason for this is that all these allergens are characterized as being "late-bloomers." On the other hand, a study by Geier and colleagues showed that by delaying readings to 7 days, some reactions to certain fragrances and preservative allergens may dissipate.[127] Therefore, the optimal protocol is probably to read the test at day 2 and day 4, the conventional way, and then on day 7 if allergies to metals, topical antibiotics (neomycin), and PPD are strongly suspected, or if the patient notes a newly developed reaction after day 4. Patients are instructed to report back to their physician should any additional positive reactions appear at day 5 or beyond to detect any late reactors or active sensitization that may have occurred. At each test reading, it is traditional to note the results as negative or positive, and grade the positive results on a quantitative scale. The ICDRG has recommended to score patch-test reactions according to the scoring system recommended by Wilkinson and colleagues[128] which is on a + to +++ scoring system; where + represents a weak nonvesicular reaction but with palpable erythema; ++ represents a strong (edematous or vesicular) reaction; and +++ represents an extreme (bullous or ulcerative) reaction (Figs. 12-6C and 13-7). Very weak or questionable reactions where there is only faint or macular (nonpalpable) erythema are recorded by a question mark (?+), and irritant reactions are recorded as "IR." Irritant patch-test reactions have varied clinical signs which are related to the nature and the concentration of the irritant[129] and are classically described as (1) erythematous reactions limited to the site of application of the chemical, with sharp, well-delineated margins; discretely scaly (may look "chapped") and usually not edematous. Among the patch-test allergens, fragrance mix, cocamidopropyl betaine, iodopropynyl butylcarbamate, glutaraldehyde, and thiuram mix are identified as the most common allergens to produce such marginal irritant reactions. (2) Purpuric reactions with petechial hemorrhage, which are seen in about 5% of patients tested to cobalt chloride. This is sometimes referred as *punctate purpura of cobalt* and should always be interpreted as an irritant reaction. Another top allergen that has been

observed to cause purpuric reactions during patch testing is PPD. (3) Pustular reactions: there can be a unique large pustule at the site of application (more characteristic of caustic, strong irritant reactions), or more commonly, small follicular pustules over an erythematous background. This type of reaction mainly occurs with metallic salts such as potassium dichromate, cobalt, nickel, gold, and copper, and mainly in atopic patients. Other patch-test reactions that should be interpreted with caution given their mild irritant potential include the preservatives formaldehyde, benzalkonium chloride, and iodopropynyl butylcarbamate (IPBC); the rubber allergen carba mix, fragrance chemicals such as fragrance mix I and propolis (bee glue); the foaming agent cocamidopropyl betaine; and the emulsifiers: oleamidopropyl dimethylamine and triethanolamine. It is important to mention that even paying close attention to the aforementioned morphological features, irritant reactions are still difficult to interpret, and the morphology of the patch-test response can still be a confusing guide to whether the response is allergic or irritant. When morphology is not enough, it is advisable to keep in mind that in general when the patch-test reaction is sufficiently strong, an irritant reaction will be early appearing (during the first reading), and promptly healing (often times the reaction is not as strong or sometimes not even present during the second reading). In contrast, a strong allergic reaction usually spreads, is more slowly disappearing, and is more clearly eczematous.

ASSIGNING CLINICAL RELEVANCE

The diagnosis of contact allergy is mainly determined by the outcome of patch testing. However, a positive test reaction is not necessarily an indicator of clinical disease, i.e., ACD, as the patch test only measures whether the individual is sensitized or not. Sensitization does not necessarily equate with clinical allergic disease. A good example of this point is the case of thimerosal. This mercuric preservative is unique in the sense that it commonly causes positive patch-test reactions but very seldom nowadays does thimerosal allergy account for the patient's dermatitis. Most allergic patients have presumably been sensitized to this preservative through vaccination but have no clinical disease associated with this sensitization.[130] Establishing the relevance of a positive patch-test result is critical. However, it should be noted that lack of relevance does not mean a patient is not allergic to the chemical in question, but more specifically that this chemical is not the causal agent for the dermatitis currently being evaluated. Therefore determination of current clinical relevance is essential in declaring ACD.

DIFFERENTIAL DIAGNOSIS

The differential diagnosis of ACD includes a wide range of inflammatory skin disorders (Box 13-2).[135,136]

BOX 13-2 DIFFERENTIAL DIAGNOSIS OF ACD

DIAGNOSIS	DIAGNOSTIC CLUES
Irritant contact dermatitis (ICD)	Physical findings can be indistinguishable clinically; in general there is an absence of vesiculation (only very strong irritants produce vesicles) and burning exceeds itching. Does not spread beyond the area of contact with continued exposure.
Atopic dermatitis	Distribution of skin findings can be helpful; atopic patients can and do develop contact allergies. Worsening disease can indicate new contact allergy development.
Nummular dermatitis (ND)	Widespread ACD can assume this pattern in certain patients; nonetheless, the classical morphology of coin-shaped, well-demarcated plaques on the legs, dorsal hands, and extensor surfaces favors ND.
Seborrheic dermatitis	Greasy and scaly papulosquamous plaques usually located in the hair-bearing regions, glabella, and nasolabial folds.
Asteatotic eczema	Parchment-like patches with no edema or vesiculation on the lower legs.
Stasis dermatitis	Papulosquamous plaques with dyschromia located on the shins and medial surfaces of the lower legs, with presence of concomitant varicosities.
Pompholyx and/or dyshidrotic eczema	Deep-seated vesicles on palms, soles, sides of the fingers, and volar edges.
Psoriasis	When it presents in its classic form, diagnosis can be straightforward, however, when the lesions are few and limited to the hands and/or feet differentiation can be more difficult. Classical location and predominance in areas of trauma (Koebnerization) can be helpful as well as the presence (if any) of concomitant arthritis.
Mycosis fungoides (patch/plaque stage cutaneous T-cell lymphoma)	The well demarcated, atrophic, poikilodermatous, scaly patches and plaques of MF are usually found in nonsun-exposed areas of the skin, such as the trunk, breasts, hips, and buttocks (bathing suit distribution).

Histologically, the presence of eosinophilic spongiosis and multinucleate dermal dendritic fibrohystiocytic cells is especially suggestive of ACD, when encountered in the presence of a lymphocytic infiltrate, dermal eosinophils, and hyperkeratosis.[137]

COMPLICATIONS

COMPLICATIONS OF PATCH TESTING

Patch testing is considered a safe diagnostic procedure and unwanted effects are seldom encountered. The most common side effect is itching at the site of a positive test reaction, and irritation and pruritus from tape application. Less commonly, postinflammatory hypo- or hyperpigmentation can occur. Hyperpigmentation is more likely in darkly pigmented persons; it fades progressively with time and the use of topical corticosteroids. It is important to note that exposure to sunlight or artificial UV immediately following removal of patch tests especially to fragrance materials, can lead to hyperpigmentation of the patch-test site in relation with photosensitivity. Persistence of a positive reaction is another adverse reaction that may occur. A patch-test reaction that may persist for more than 1 month is that due to gold in a gold sensitive patient. Induction of a dermatitis flare-up at the original site of an existing or preexisting dermatitis (that was caused by the positive patch-test allergen) can also occur. This can be minimized by testing patients free of any current active dermatitis. Also, a positive patch-test reaction in a patient who has active psoriasis or lichen planus may reproduce these dermatoses at the patch-test sites (as a *Koebner phenomenon*), during the weeks following patch testing.[138] These lesions can be cleared with the use of topical corticosteroids. Finally, the possibility of becoming sensitized (active sensitization) to one of the tested allergens exists; however, it has proven to be low.[139] Serious adverse effects during patch testing such as anaphylactoid reactions from allergens known to cause a type I (immediate) hypersensitivity reaction such as bacitracin and neomycin are exceptionally rare.

COMPLICATIONS DERIVED FROM FAILURE TO PATCH TEST

The greatest hazard is omission to patch-test appropriate patients with dermatitis. Such omission potentially dooms the patient to repeated episodes of avoidable contact dermatitis. In 2004, the American Academy of Dermatology and the Society of Investigative Dermatology studied the burden of skin disease and estimated that 72 million people in the United States suffer from ACD.[140] It is the third most common reason for patients to seek consultation with a dermatologist, accounting for 9.2 million visits in 2004 alone. Likewise, in that same year, primary care physicians received 5 million visits for unexplained dermatitis or eczema.[141] Whereas many of these patients will respond readily to standard treatments, there will be others that demonstrate recalcitrant eczema. It has been estimated that approximately 16% of all chronic eczema patients would benefit from patch testing.[142] Clinical experience suggests this number is much larger. Based on those figures, it could be estimated that approximately 2.2 million patients each year in the United States would benefit from patch testing.

PROGNOSIS/CLINICAL COURSE

It is difficult to assess the actual prognosis of ACD because there is no standardized instrument for such evaluation. The disruption of work, ability to return to work, and improvement of dermatitis with time are among outcome measures that have been studied in patients with ACD. Recent study designs have aimed to capture the increasingly important outcome measure of health-related quality of life (QoL).[143] When different QoL assessment tools have been applied to populations of patients with ACD it has been demonstrated that ACD negatively impacts QoL significantly. Holness and colleagues[144] found that pain, itching, embarrassment, work interference, and sleep difficulties were the most significant effects in QoL of their patch-test population. Kadyk et al[145] found the greatest impact on emotions, followed by symptoms, functioning, and occupational impact. Similarly, Woo and colleagues[146] reported that patients with the final diagnosis of ACD had a mean baseline QoL equal to that of patients experiencing hair loss and psoriasis. Zug et al[147] found that patients referred for patch testing were severely affected by frustration, reported feeling annoyed, and had a great concern about the persistence of their skin problem. Notably a factor that is strongly predictive of a negative impact on QoL is hand involvement of ACD. Similarly, the extent of the disease[148] and the duration of symptoms before diagnosis are both correlated with a poor prognosis and recalcitrant disease.[149] On the other hand, increased patient knowledge has been associated with improved prognosis in some studies.[150,151] Much of this information is extrapolated from data regarding occupational contact dermatitis.

TREATMENT

Because allergen identification can be achieved through proper patch testing, there is a good potential for a sustained remission. Therefore, identification and removal of the inciting agent(s), and they are often multiple, should always be the goal in the diagnosis and treatment of ACD.[152]

KEY REFERENCES

Full reference list available at www.DIGM8.com

DVD contains references and additional content

22. Zug KA et al: Contact allergy in children referred for patch testing: North American contact dermatitis group data, 2001–2004. *Arch Dermatol* **144**:1329, 2008
44. Gober MD, Gaspari AA: Allergic contact dermatitis. *Curr Dir Autoimmun* **10**:1, 2008

48. Lachapelle JM, Maibach HI: *Patch Testing and Prick Testing: A Practical Guide*. Berlin, Germany, Springer-Verlag, 2003
86. Kornik R, Zug KA: Nickel. *Dermatitis* **19**:3, 2008
93. Schram SE, Warshaw EM, Laumann A: Nickel hypersensitivity: A clinical review and call to action. *Int J Dermatol* **49**:115, 2010
103. Zug KA et al: Patch-test results of the North American contact dermatitis group, 2005–2006. *Dermatitis* **20**:149, 2009
108. Scheman A et al: Contact allergy: Alternatives for the 2007 North American contact dermatitis group (NACDG) standard screening tray. *Dis Mon* **54**:7, 2008
140. Bickers DR et al: The burden of skin diseases: 2004 a joint project of the American Academy of Dermatology association and the society for Investigative dermatology. *J Am Acad Dermatol* **55**:490, 2006
143. Skoet R, Zacharie R, Agner T: Contact dermatitis and quality of life: A structured review of the literature. *Br J Dermatol* **149**:79, 2003
160. Jacob SE, Steele T: Corticosteroid classes: A quick reference guide including patch test substances and cross reactivity. *J Am Acad Dermatol* **54**:723, 2006

Chapter 14 :: Atopic Dermatitis (Atopic Eczema)

:: Donald Y.M. Leung, Lawrence F. Eichenfield, & Mark Boguniewicz

ATOPIC DERMATITIS AT A GLANCE

- Prevalence peak of 15–20% in early childhood in industrialized countries.
- A chronic or chronically relapsing disorder with major features of:
  - Pruritus;
  - Eczematous dermatitis (acute, subacute, or chronic) with typical morphology and age-specific patterns;
  - Facial and extensor involvement in infancy; and
  - Flexural eczema/lichenification in children and adults.
- Commonly associated with the following:
  - Personal or family history of atopy (allergic rhinitis, asthma, atopic dermatitis).
  - Xerosis/skin barrier dysfunction.
  - Immunoglobulin E reactivity.
  - Genetic basis influenced by environmental factors with alterations in immunologic responses in T cells, antigen processing, inflammatory cytokines, host defense proteins, allergen sensitivity, and infection.

INTRODUCTION

Atopic dermatitis (AD) is a chronically relapsing skin disease that occurs most commonly during early infancy and childhood. It is frequently associated with abnormalities in skin barrier function, allergen sensitization, and recurrent skin infections. There is no single distinguishing feature of AD or a diagnostic laboratory test. Thus, the diagnosis is based on the constellation of clinical findings listed in Table 14-1.[1]

EPIDEMIOLOGY

Since the 1960s, there has been a more than threefold increase in the prevalence of AD.[2] AD is a major public health problem worldwide, with a prevalence in children of 10–20% in the United States, Northern and Western Europe, urban Africa, Japan, Australia, and other industrialized countries.[3] The prevalence of AD in adults is approximately 1–3%. Interestingly, the prevalence of AD is much lower in agricultural regions of countries such as China and in Eastern Europe, rural Africa, and Central Asia. However, the most recent data from the International Study of Asthma and Allergies in Childhood (ISAAC) Phase Three study confirms that AD is a disease with high prevalence, affecting patients in both developed and developing countries.[4] There is also a female preponderance for AD, with an overall female/male ratio of 1.3:1.0.

The basis for this increased prevalence of AD is not well understood. However, wide variations in preva-

TABLE 14-1
Features of Atopic Dermatitis

Major Features
Pruritus
Rash on face and/or extensors in infants and young children
Lichenification in flexural areas in older children
Tendency toward chronic or chronically relapsing dermatitis
Personal or family history of atopic disease: asthma, allergic rhinitis, atopic dermatitis
Other Common Findings
Dryness
Dennie–Morgan folds (accentuated lines or grooves below the margin of the lower eyelid)
Allergic shiners (darkening beneath the eyes)
Facial pallor
Pityriasis alba
Keratosis pilaris
Ichthyosis vulgaris
Hyperlinearity of palms and soles
White dermatographism (white line appears on skin within 1 minute of being stroked with blunt instrument)
Conjunctivitis
Keratoconus
Anterior subcapsular cataracts
Elevated serum immunoglobulin E
Immediate skin test reactivity

lence have been observed within countries inhabited by similar ethnic groups, suggesting that environmental factors are critical in determining disease expression. Some of the potential risk factors that may be associated with the rise in atopic disease include small family size, increased income and education both in whites and blacks, migration from rural to urban environments, and increased use of antibiotics, that is, the so-called Western lifestyle.[5,6] This has resulted in the "hygiene hypothesis" that allergic diseases might be prevented by "infection in early childhood transmitted by unhygienic contact with older siblings."[7] Given the increase in autoimmune diseases such as diabetes, abnormalities in T regulatory cells have also been implicated.

ETIOLOGY AND PATHOGENESIS

AD is a highly pruritic inflammatory skin disease that results from complex interactions between genetic susceptibility genes resulting in a defective skin barrier, defects in the innate immune system, and heightened immunologic responses to allergens and microbial antigens.[8]

DECREASED SKIN BARRIER FUNCTION

AD is associated with a marked decrease in skin barrier function due to the downregulation of cornified envelope genes (filaggrin and loricrin), reduced ceramide levels, increased levels of endogenous proteolytic enzymes, and enhanced transepidermal water loss.[9,10] Addition of soap and detergents to the skin raises its pH, thereby increasing activity of endogenous proteases, leading to further breakdown of epidermal barrier function. The epidermal barrier may also be damaged by exposure to exogenous proteases from house dust mites and *Staphylococcus aureus* (*S. aureus*). This is worsened by the lack of certain endogenous protease inhibitors in atopic skin. These epidermal changes likely contribute to increased allergen absorption into the skin and microbial colonization. Because epicutaneous, as compared to systemic or airway, sensitization to allergen results in higher level allergic immune responses, decreased skin barrier function could act as a site for allergen sensitization and predispose such children to the development of food allergy and respiratory allergy.[11]

IMMUNOPATHOLOGY OF ATOPIC DERMATITIS

Clinically unaffected skin of AD patients manifests mild epidermal hyperplasia and a sparse perivascular T cell infiltrate.[12] Acute eczematous skin lesions are characterized by marked intercellular edema (spongiosis) of the epidermis. Dendritic antigen-presenting cells [e.g., Langerhans cells (LCs), macrophages] in lesional and, to a lesser extent, in nonlesional skin of AD exhibit surface-bound immunoglobulin E (IgE) molecules. A sparse epidermal infiltrate consisting primarily of T lymphocytes is also frequently observed.

In the dermis of the acute lesion, there is an influx of T cells with occasional monocyte-macrophages. The lymphocytic infiltrate consists predominantly of activated memory T cells bearing CD3, CD4, and CD45 RO (suggesting previous encounter with antigen). Eosinophils are rarely present in acute AD. Mast cells are found in normal numbers in different stages of degranulation.

Chronic lichenified lesions are characterized by a hyperplastic epidermis with elongation of the rete ridges, prominent hyperkeratosis, and minimal spongiosis. There is an increased number of IgE-bearing LCs in the epidermis, and macrophages dominate the dermal mononuclear cell infiltrate. Mast cells are increased in number but are generally fully granulated. Neutrophils are absent in AD skin lesions even in the setting of increased *S. aureus* colonization and infection. Increased numbers of eosinophils are observed in chronic AD skin lesions. These eosinophils undergo cytolysis with release of granule protein contents into the upper dermis of lesional skin. Eosinophil-derived extracellular major basic protein can be detected in a fibrillar pattern associated with the distribution of elastic fibers throughout the upper dermis. Eosinophils are thought to contribute to allergic inflammation by the secretion of cytokines and mediators that augment allergic inflammation and induce tissue injury in AD through the production of reactive oxygen intermediates and release of toxic granule proteins.

CYTOKINES AND CHEMOKINES

Atopic skin inflammation is orchestrated by the local expression of proinflammatory cytokines and chemokines.[12] Cytokines such as tumor necrosis factor-α (TNF-α) and interleukin 1 (IL-1) from resident cells [keratinocytes, mast cells, dendritic cells (DCs)] bind to receptors on the vascular endothelium, activating cellular signaling pathways, which leads to the induction of vascular endothelial cell adhesion molecules. These events initiate the process of tethering, activation, and adhesion to vascular endothelium followed by extravasation of inflammatory cells into the skin. Once inflammatory cells have infiltrated into the skin, they respond to chemotactic gradients established by chemokines that emanate from sites of injury or infection.

Acute AD is associated with the production of T helper 2 type (Th2) cytokines, notably IL-4 and IL-13,[13] which mediate immunoglobulin isotype switching to IgE synthesis and upregulate expression of adhesion molecules on endothelial cells. The important role that Th2 cytokines play in the skin's inflammatory response is supported by the observation that transgenic mice genetically engineered to overexpress IL-4 in their skin develop inflammatory pruritic skin lesions similar to AD, suggesting that local skin expression of Th2 cytokines plays a critical role in AD. There has also been considerable interest in IL-31, which is a novel Th2 cytokine that induces severe pruritus and dermatitis in experimental animals. IL-31 has also been found to be increased in AD skin and serum levels of IL-31 correlate with severity of skin disease.[14]

In chronic AD, there is an increase in the production of IL-5, which is involved in eosinophil development and survival. Increased production of granulocyte macrophage colony-stimulating factor in AD inhibits apoptosis of monocytes, thereby contributing to the persistence of AD.[15] The maintenance of chronic AD also involves production of the Th1-like cytokines IL-12 and IL-18, as well as several remodeling-associated cytokines, including IL-11 and transforming growth factor-1.[16]

The skin-specific chemokine, cutaneous T cell-attracting chemokine [CTACK; CC chemokine ligand 27 (CCL27)], is highly upregulated in AD and preferentially attracts skin homing cutaneous lymphoid antigen $(CLA)^+$ CC chemokine receptor 10^+ ($CCR10^+$) T cells into the skin.[17] CCR4 expressed on skin homing CLA^+ T cells can also bind to CCL17 on the vascular endothelium of cutaneous venules. Selective recruitment of CCR4-expressing Th2 cells is mediated by macrophage-derived chemokine and thymus and activation-regulated cytokine, both of which are increased in AD. Severity of AD has been linked to the magnitude of thymus and activation-regulated cytokine levels. In addition, chemokines such as fractalkine, interferon (IFN)-γ-inducible protein 10, and monokine induced by IFN-γ are strongly upregulated in keratinocytes and result in Th1-cell migration toward epidermis, particularly in chronic AD. Increased expression of the CC chemokines, macrophage chemoattractant protein-4, eotaxin, and RANTES (regulated on activation, normal T cell expressed and secreted) contribute to infiltration of macrophages, eosinophils, and T cells into both acute and chronic AD skin lesions.

KEY CELL TYPES IN ATOPIC DERMATITIS SKIN

ANTIGEN-PRESENTING CELLS. DCs play an important role in detecting environmental allergens or pathogens via pattern recognition receptors such as Toll-like receptors (TLR). AD skin contains two types of high-affinity, IgE receptor-bearing (FcεR) myeloid DCs: (1) LCs and (2) inflammatory dendritic epidermal cells (IDECs). IgE-bearing LCs appear to play an important role in cutaneous allergen presentation to IL-4-producing Th2 cells.[18] In this regard, IgE-bearing LCs from AD skin lesions, but not LCs that lack surface IgE, are capable of presenting allergens to T cells. These results suggest that cell-bound IgE on LCs facilitates capture and internalization of allergens into LCs before their processing and antigen presentation to T cells. IgE-bearing LCs that have captured allergen likely activate memory Th2 cells in atopic skin, but they may also migrate to the lymph nodes to stimulate naïve T cells there to further expand the pool of systemic Th2 cells. Stimulation of FcεRI on the surface of LCs by allergens induces the release of chemotactic signals and recruitment of precursor cells of IDECs and T cells in vitro. Stimulation of FcεRI on IDECs leads to the release of proinflammatory signals, which contribute to amplification of the allergic immune response.

In contrast to other inflammatory skin diseases, such as allergic contact dermatitis or psoriasis vulgaris, very low numbers of plasmacytoid DCs (pDCs), which play an important role in host defense against viral infections, can be detected within the AD skin lesion.[19] pDCs in the peripheral blood of patients with AD have been shown to bear the trimeric variant of FcεRI on their cell surface, which is occupied by IgE molecules. The modified immune function of pDCs of patients with AD after FcεRI-mediated allergen stimulation might contribute to a local deficiency of type I IFNs, thereby contributing to increased susceptibility of AD patients toward viral skin infections such as eczema herpeticum.[20]

T CELLS. Skin homing memory T cells play an important role in the pathogenesis of AD, particularly during the acute phase of illness. This concept is supported by the observation that primary T-cell immunodeficiency disorders are frequently associated with eczematous skin lesions that clear after successful bone marrow transplantation.[21] Furthermore, in animal models of AD, the eczematous rash does not occur in the absence of T cells. In addition, treatment with topical calcineurin inhibitors (TCIs), which target activated T cells, significantly reduces the clinical skin rash of AD.[22]

Several studies have demonstrated the presence of Th2-like T cells in acute AD that produce cytokines that enhance allergic skin inflammation. During the chronic phase of AD, there is a switch to Th1-like cells that primarily produce IFN-γ. These Th1-like cells induce the activation and apoptosis of keratinocytes.[23] Recently, T regulatory (Treg) cells have been described as a further subtype of T cells that have immunosuppressive function and cytokine profiles distinct from both Th1 and Th2 cells.[24] Treg cells are able to inhibit the development of both Th1 and Th2 responses. Mutations in a nuclear factor expressed in Treg cells, FoxP3, result in IPEX (immune dysregulation, polyendocrinopathy, enteropathy, X-linked) syndrome characterized by elevated serum IgE, food allergy, and dermatitis that may be eczematous or psoriasiform. A deficiency of resident Treg cells has also been reported in AD skin.[25] Interestingly, staphylococcal superantigens subvert Treg cell function and may thereby augment skin inflammation.[26]

There has also been considerable interest in the role of Th17 cells in the immunopathogenesis of AD.[27] These cells produce inflammatory cytokines such as IL-17 and are thought to play a role in host defense by inducing keratinocytes to produce antimicrobial peptides as well as promote neutrophil chemotaxis. Th17 cells are increased in the skin lesions of autoimmune diseases, such as psoriasis, where they may promote inflammatory responses, including neutrophil infiltration but also reduce skin infection.[28] Compared to psoriasis, AD skin lesions have significantly fewer T cells expressing IL-17, but increased numbers of IL-4$^+$ cells.[29] Furthermore, it has been found that the Th2 cytokines, IL-4 and IL-13, inhibit IL-17 induced generation of antimicrobial peptides.[30] Interestingly, an independent increase of IL-22 expressing cells, originally thought to be produced by Th17 cells, can be found in AD skin and it has been suggested that these may contribute to epidermal hyperplasia.[31]

KERATINOCYTES. Keratinocytes play a critical role in the augmentation of atopic skin inflammation. AD keratinocytes secrete a unique profile of chemokines and cytokines after exposure to proinflammatory cytokines. This includes high levels of RANTES after stimulation with TNF-α and IFN-γ.[32] They are also an important source of thymic stromal lymphopoietin (TSLP), which activates DCs to prime naïve T cells to produce IL-4 and IL-13 (i.e., promotes Th2 cell differentiation).[33] The importance of TSLP in AD pathogenesis is supported by the observation that mice genetically manipulated to overexpress TSLP in the skin develop AD-like skin inflammation. Skin-derived TSLP is also thought to trigger the development of asthma.[34,35]

Keratinocytes are critical to the skin's innate immune responses, expressing Toll-like receptors, producing proinflammatory cytokines and antimicrobial peptides (such as human β defensins and cathelicidins) in response to tissue injury or invading microbes.[36] Several studies have now demonstrated that AD keratinocytes produce reduced amounts of antimicrobial peptides and this may predispose such individuals to skin colonization and infection with *S. aureus*, viruses, and fungi. However, this defect appears to be acquired as the result of Th2-cytokine (IL-4, IL-10, and IL-13) mediated inhibition of TNF-α and IFN-γ-induced antimicrobial peptide generation.

GENETICS

AD is a complex disease that is familially transmitted with a strong maternal influence.[37] Genome-wide linkage studies of families with AD have implicated chromosomal regions that overlap with other inflammatory skin diseases such as psoriasis. Together with candidate gene studies, these have provided interesting insights into the pathogenesis of AD. Although many genes are likely to be involved in the development of AD, there has been particular interest in the potential role of skin barrier/epidermal differentiation genes and immune response/host defense genes.

Loss-of-function mutations in *FLG*, which encodes the epidermal barrier protein, filaggrin, have been demonstrated to be a major predisposing factor for AD,[38] as well as ichthyosis vulgaris, a common keratinizing disorder associated with AD (Figs. 14-1 and 14-2). Patients with filaggrin null mutations often have early onset, severe eczema, high level allergen sensitization, and develop asthma later in childhood. Of note, the filaggrin gene is found on chromosome 1q21 that contains genes (including loricrin and S100 calcium-binding proteins) in the epidermal differentiation complex, known to be expressed during terminal differentiation of the epidermis. DNA microarray analyses have demonstrated upregulation of S100 calcium-binding proteins and downregulation of loricrin and filaggrin in AD. Candidate gene approaches have also implicated variants in the *SPINK5* gene, which is expressed in the uppermost epidermis where its product, LEKT1, inhibits two serine proteases involved in desquamation and inflammation (stratum corneum tryptic enzyme and stratum corneum chymotryptic



Figure 14-1 Ichthyosis vulgaris commonly accompanies atopic dermatitis and is thought to be responsible for the barrier defect in a subset of patients. Note the larger scales on the lower extremities.



Figure 14-2 Hyperlinear palms.

enzyme). Stratum corneum tryptic enzyme and stratum corneum tryptic enzyme expression is increased in AD, suggesting that an imbalance of protease versus protease inhibitor activity may contribute to atopic skin inflammation.[9]

These observations establish a key role for impaired skin barrier function in the pathogenesis of AD, as impaired skin barrier formation allows increased transepidermal water loss and, importantly, increased entry of allergens, antigens, and chemicals from the environment resulting in skin inflammatory responses. It is important to note that these filaggrin mutations, and likely other mutations affecting the skin barrier, can occur in clinically normal individuals, and in patients with ichthyosis vulgaris without clinical evidence of skin inflammation. The majority of patients with AD outgrow their inflammatory skin disease by adolescence. Thus, AD is a complex trait that involves interactions between multiple gene products requiring environmental factors and the immune response to result in the final clinical phenotype. Chromosome 5q31-33 contains a clustered family of functionally related cytokine genes—*IL-3*, *IL-4*, *IL-5*, *IL-13*, and granulocyte macrophage colony-stimulating factor—which are expressed by Th2 cells. A case control comparison has suggested a genotypic association between the T allele of the 590C/T polymorphism of the IL-4 gene promoter region with AD. Because the T allele is associated with increased IL-4 gene promoter activity when compared to the C allele, this suggests that genetic differences in transcriptional activity of the *IL-4* gene influence AD predisposition. In addition, an association of AD with a gain-of-function mutation in the α subunit of the IL-4 receptor has been reported, providing further support of the concept that *IL-4* gene expression plays a role in AD. Functional mutations in the promoter region of the CC chemokines, RANTES, and eotaxin, as well as variants in IL-13, the α subunit of the high affinity cell surface receptor for IgE (FcεR1) found on basophils and mast cells suggest an overlapping of genetic basis with other atopic diseases.

Recent studies demonstrating a significant association between *TSLP* gene polymorphisms and AD provide further support for the importance of Th2 polarization in this disease.[37] The involvement of T cell γ interferon and *IL-18* genes support the role of $CD4^+$ T cells and dysregulation of *Th1* genes in the pathophysiology of AD. As well, reports of AD association with polymorphisms of the *NOD1* gene, which encodes cytosolic pathogen recognition receptor and Toll-like receptors, suggest an important role for host defense genes in the pathogenesis of AD. The reader is referred to Chapter 10 and reference 35 for a detailed discussion of the genetics of AD.

BASIS OF PRURITUS IN ATOPIC DERMATITIS

Pruritus is a prominent feature of AD, manifested as cutaneous hyperreactivity and scratching following exposure to allergens, changes in humidity, excessive sweating, and low concentrations of irritants. Control of pruritus is important because mechanical injury from scratching can induce proinflammatory cytokine and chemokine release, leading to a vicious scratch–itch cycle perpetuating the AD skin rash. The mechanisms of pruritus in AD are poorly understood. Allergen-induced release of histamine from skin mast cells is not an exclusive cause of pruritus in AD, because H_1 antihistamines are not effective in controlling the itch of AD.[39] However, recent studies demonstrating a potential role for H_4 receptors in skin pathobiology suggests that histamine may play a contributory role.[40] However, the observation that treatment with topical corticosteroids and calcineurin inhibitors is effective at reducing pruritus suggests that the inflammatory cells play an important role in pruritus.[41,42] Molecules that have been implicated in pruritus include T-cell-derived cytokines such as IL-31, stress-induced neuropeptides, and proteases which can act on protease-activated receptors, eicosanoids, and eosinophil-derived proteins.[43,44] The reader is referred to Chapter 103 for a detailed discussion of the pathophysiology of pruritus.

CLINICAL FINDINGS

The diagnosis of AD is based on the constellation of clinical features summarized in Table 14-1. AD typically begins during infancy. Approximately 50% of patients develop this illness by the first year of life and an additional 30% between the ages of 1–5 years. Between 50–80% of patients with AD develop allergic rhinitis or asthma later in childhood. Many of these patients outgrow their AD as they are developing respiratory allergy.

CUTANEOUS LESIONS

Intense pruritus and cutaneous reactivity are cardinal features of AD. Pruritus may be intermittent throughout the day but is usually worse in the early evening and night. Its consequences are scratching, prurigo papules (Fig. 14-3), lichenification (Fig. 14-4), and eczematous skin lesions. Acute skin lesions are



Figure 14-3 Prurigo papules in a patient with atopic dermatitis.



Figure 14-4 Lichenification and excoriations on the dorsal aspect of the hand in a child with atopic dermatitis.

characterized by intensely pruritic, erythematous papules associated with excoriation, vesicles over erythematous skin, and serous exudate (Fig. 14-5). Subacute dermatitis is characterized by erythematous, excoriated, scaling papules (Fig. 14-6). Chronic AD is characterized by (1) thickened plaques of skin, (2) accentuated skin markings (lichenification), and (3) fibrotic papules (prurigo nodularis; Fig. 14-7). In chronic AD, all three stages of skin reactions frequently coexist in the same individual. At all stages of AD, patients usually have dry, lackluster skin.

The distribution and skin reaction pattern vary according to the patient's age and disease activity. During infancy, the AD is generally more acute and primarily involves the face (Fig. 14-8), scalp, and the extensor surfaces of the extremities (Fig. 14-9). The diaper area is usually spared. In older children, and in those who have long-standing skin disease, the patient develops the chronic form of AD with lichenification and localization of the rash to the flexural folds of the extremities (Fig. 14-10). AD often subsides as the patient grows older, leaving an adult with skin that is prone to itching and inflammation when exposed to exogenous irritants. Chronic hand eczema may be the primary manifestation of many adults with AD (Fig. 14-11). Other associated features of AD are listed in Table 14-1.

LABORATORY TESTS

Laboratory testing is not needed in the routine evaluation and treatment of uncomplicated AD. Serum



Figure 14-5 **A.** Pronounced weeping and crusting of eczematous lesions in childhood atopic dermatitis. **B.** Excoriated papules and crusting (with secondary infection) in an acute flare of atopic dermatitis.



Figure 14-6 Confluent erythematous papules on the cheeks of an infant with subacute atopic dermatitis. Chronic exposure to saliva and moist food at this location has been thought to contribute to the distribution.



Figure 14-7 Severe lichenification and hyperpigmented prurigo papules seen in a patient with chronic atopic dermatitis.

IgE levels are elevated in approximately 70–80% of AD patients. This is associated with sensitization against inhalant and food allergens and/or concomitant allergic rhinitis and asthma.[8] In contrast, 20–30% of AD patients have normal serum IgE levels. This subtype of AD has a lack of IgE sensitization against inhalant or food allergens. However, some of these patients may possess IgE sensitization against microbial antigens such as *S. aureus* toxins, and *Candida albicans* or *Malassezia sympodialis* can be detected. As well, some of these patients show positive reactions using the atopy patch test despite negative immediate skin tests.

The majority of patients with AD also have peripheral blood eosinophilia. Patients with AD have increased spontaneous histamine release from basophils. These findings likely reflect a systemic Th2 immune response in AD especially those patients who have elevated serum IgE levels. Importantly, the peripheral blood skin homing CLA^+ T cells in AD expressing either CD4 or CD8 spontaneously secrete IL-5 and IL-13, which functionally prolong eosinophil survival and induce IgE synthesis.

DIAGNOSIS AND DIFFERENTIAL DIAGNOSIS

Table 14-1 lists the clinical features of AD. Of the major features, pruritus and chronic or remitting eczematous dermatitis with typical morphology and distribution are essential for diagnosis. Other features, including allergy or elevated IgE, are variable, and some of the "associated features" in the table may not be useful discriminators of individuals with AD from the unaffected general population. Various diagnostic criteria have been proposed to assist with clinical diagnosis,



Figure 14-8 Edematous, erythematous eyelids with lichenification and hyperpigmentation in an adolescent with atopic dermatitis. Note the infraocular (Dennie–Morgan) folds.



Figure 14-9 Itching infant with atopic dermatitis. (Used with permission from Oholm Larsen, MD.)

definition of patients for clinical studies, and epidemiologic population studies.[45] A refined list of diagnostic criteria suitable for epidemiologic studies has been derived and validated by workers in the United Kingdom.[46]



Figure 14-10 Childhood atopic dermatitis with lichenification of antecubital fossae and generalized severely pruritic eczematous plaques.



Figure 14-11 Typical papules, vesicles, and erosions seen in atopic hand dermatitis.

Box 14-1 lists a number of inflammatory skin diseases, immunodeficiencies, skin malignancies, genetic disorders, infectious diseases, and infestations that share symptoms and signs with AD. These should be considered and ruled out before a diagnosis of AD is made. Infants presenting in the first year of life with failure to thrive, diarrhea, a generalized scaling erythematous rash, and recurrent cutaneous and/or systemic infections should be evaluated for severe combined immunodeficiency syndrome. Wiskott–Aldrich syndrome is an X-linked recessive disorder characterized by cutaneous findings almost indistinguishable from AD (see Chapter 143). It is associated with thrombocytopenia, variable abnormalities in humoral and cellular immunity, and recurrent severe bacterial infections. The hyper-IgE syndrome is characterized by elevated serum IgE levels, defective T-cell function, recurrent deep-seated bacterial infections, including cutaneous abscesses due to *S. aureus* and/or pruritic skin disease due to *S. aureus* pustulosis, or by recalcitrant dermatophytosis. A papulopustular eruption of the face and scalp may be seen in early life. Although *S. aureus* is an important pathogen in this disorder, infection with other bacteria, viruses, and fungi may occur, particularly when patients are on chronic antistaphylococcal antibiotic prophylaxis. Hyper-IgE is most commonly an autosomal dominant disorder due to mutations in *STAT3*, which also features pneumonia with pneumatocele formation, dental anomalies with retained primary teeth, bone fractures, and osteopenia. Autosomal recessive forms of hyper-IgE syndrome show severe eosinophilia, recurrent viral and bacterial infections, an increased risk of autoimmune disease, and serious neurologic manifestations, but not the pneumatoceles and dental or skeletal defects. To date, deficiencies of Tyk2 and dedicator of cytokinesis 8 protein (DOCK8) deficiency have been found, leading to a global defect in T-cell activation.[47]

It is important to recognize that an adult who presents with an eczematous dermatitis with no history of childhood eczema, respiratory allergy, or atopic family history may have allergic contact dermatitis. A contact

BOX 14-1 DIFFERENTIAL DIAGNOSIS OF ATOPIC DERMATITIS

MOST LIKELY

- Contact dermatitis (allergic and irritant)
- Seborrheic dermatitis
- Scabies
- Psoriasis
- Ichthyosis vulgaris
- Keratosis pilaris
- Dermatophytosis

CONSIDER

- Asteatotic eczema
- Lichen simplex chronicus
- Nummular dermatitis
- Juvenile palmar–plantar dermatosis
- Impetigo
- Drug eruptions
- Perioral dermatitis
- Pityriasis alba
- Photosensitivity disorders (hydroa vacciniforme; polymorphous light eruption, porphyrias)
- Molluscum dermatitis

LESS COMMON/RARE DISORDERS PREDOMINANT IN ADOLESCENTS AND ADULTS

- Cutaneous T-cell lymphoma (mycosis fungoides or Sézary syndrome)
- Human immunodeficiency virus-associated dermatoses
- Lupus erythematosus
- Dermatomyositis
- Graft-versus-host disease
- Pemphigus foliaceus
- Dermatitis herpetiformis
- Photosensitivity disorders (hydroa vacciniforme, polymorphous light eruption, porphyrias)

LESS COMMON/RARE DISORDERS PREDOMINANT IN INFANTS/CHILDREN

Metabolic/Nutritional

- Phenylketonuria
- Prolidase deficiency
- Multiple carboxylase deficiency
- Zinc deficiency (acrodermatitis enteropathica; prematurity; deficient breast milk zinc; cystic fibrosis)
- Others: biotin, essential fatty acids, organic acidurias

Primary Immunodeficiency Disorders

- Severe combined immunodeficiency disorder
- DiGeorge syndrome
- Hypogammaglobulinemia
- Agammaglobulinemia
- Wiskott–Aldrich syndrome
- Ataxia-telangiectasia
- Immune dysregulation, polyendocrinopathy, enteropathy, X-linked (IPEX) syndrome
- Hyperimmunoglobulin E syndrome (autosomal dominant and recessive forms)
- Chronic mucocutaneous candidiasis
- Omenn syndrome

Other Genetic Syndromes

- Netherton syndrome

Inflammatory, Autoimmune Disorders

- Eosinophilic gastroenteritis
- Gluten-sensitive enteropathy
- Neonatal lupus erythematosus

Proliferative Disorders

- Langerhans cell histiocytosis

allergen should be considered in any patient whose AD does not respond to appropriate therapy. Of note, contact allergy to topical glucocorticoids and TCIs has been reported in patients with chronic dermatitis. In addition, cutaneous T-cell lymphoma must be ruled out in any adult presenting with chronic dermatitis poorly responsive to topical glucocorticoid therapy. Ideally, biopsies should be obtained from three separate sites, because the histology may show spongiosis and cellular infiltrate similar to AD. Eczematous dermatitis has been also reported with human immunodeficiency virus as well as with a variety of infestations such as scabies. Other conditions that can be confused with AD include psoriasis, ichthyoses, and seborrheic dermatitis.

COMPLICATIONS

OCULAR PROBLEMS

Eye complications associated with severe AD can lead to significant morbidity. Eyelid dermatitis and chronic blepharitis are commonly associated with AD and may result in visual impairment from corneal scarring. Atopic keratoconjunctivitis is usually bilateral and can have disabling symptoms that include itching, burning, tearing, and copious mucoid discharge. Vernal conjunctivitis is a severe bilateral recurrent chronic inflammatory process associated with papillary hypertrophy, or cobblestoning of the upper eyelid

conjunctiva. It usually occurs in younger patients and has a marked seasonal incidence, often in the spring. The associated intense pruritus is exacerbated by exposure to irritants, light, or sweating. Keratoconus is a conical deformity of the cornea believed to result from chronic rubbing of the eyes in patients with AD and allergic rhinoconjunctivitis. Cataracts were reported in the early literature to occur in up to 21% of patients with severe AD. However, it is unclear whether this was a primary manifestation of AD or the result of the extensive use of systemic and topical glucocorticoids, particularly around the eyes. Indeed, more recent studies suggest that routine screening for cataracts in patients with AD may not be productive unless there is concern about potential side effects from steroid therapy.

INFECTIONS

AD can be complicated by recurrent viral skin infections that may reflect local defects in T-cell function.[48] The most serious viral infection is herpes simplex (see Chapter 193), which can affect patients of all ages, resulting in Kaposi varicelliform eruption or eczema herpeticum. After an incubation period of 5–12 days, multiple, itchy, vesiculopustular lesions erupt in a disseminated pattern; vesicular lesions are umbilicated, tend to crop, and often become hemorrhagic and crusted (Fig. 14-12). Punched out and extremely painful erosions result. These lesions may coalesce to large, denuded, and bleeding areas that can extend over the entire body.

Although smallpox infections have been eradicated worldwide since the late 1970s, threats of bioterrorism (with smallpox and other infectious agents) have made nations reconsider their policies toward initiating vaccination programs. In AD patients, smallpox vaccination (or even exposure to vaccinated individuals) (see Chapter 195) may cause a severe widespread eruption (called *eczema vaccinatum*) that appears very similar to eczema herpeticum. Thus, in patients with AD, vaccination is contraindicated unless there is a clear risk of smallpox. In addition, decisions regarding vaccination of family members should take into consideration the potential of eczema vaccinatum in household contacts.



Figure 14-12 Eczema herpeticum. Typical vesicles and crusting in a patient with disseminated disease.

Superficial fungal infections are also more common in atopic individuals and may contribute to the exacerbation of AD. Patients with AD have an increased prevalence of *Trichophyton rubrum* infections compared to nonatopic controls. There has been particular interest in the role of *M. sympodialis* (*Pityrosporum ovale* or *P. orbiculare*) in AD. *M. sympodialis* is a lipophilic yeast (see Chapters 188 and 189) commonly present in the seborrheic areas of the skin. IgE antibodies against *M. furfur* are commonly found in AD patients and most frequently in patients with head and neck dermatitis. In contrast, IgE sensitization to *M. sympodialis* is rarely observed in normal controls or asthmatics. Positive allergen patch-test reactions to this yeast have also been demonstrated. The potential importance of *M. sympodialis* as well as other dermatophyte infections is further supported by the reduction of AD skin severity in such patients after treatment with antifungal agents.

S. aureus is found in more than 90% of AD skin lesions. Honey-colored crusting, folliculitis, and pyoderma are indicators of secondary bacterial skin infection, usually due to *S. aureus*, that requires antibiotic therapy. Regional lymphadenopathy is common in such patients. The importance of *S. aureus* in AD is supported by the observation that patients with severe AD, even those without overt infection, can show clinical response to combined treatment with antistaphylococcal antibiotics and topical glucocorticoids. Although recurrent staphylococcal pustulosis can be a significant problem in AD, deep-seated *S. aureus* infections occur rarely and should raise the possibility of an immunodeficiency syndrome such as hyper-IgE syndrome. Methicillin-resistant *S. aureus* has become an increasingly important pathogen in patients with AD.[49]

HAND DERMATITIS

Patients with AD often develop nonspecific, irritant hand dermatitis. It is frequently aggravated by repeated wetting and by washing of the hands with harsh soaps, detergents, and disinfectants. Atopic individuals with occupations involving wet work are prone to develop an intractable hand dermatitis in the occupational setting. This is a common cause of occupational disability.

EXFOLIATIVE DERMATITIS

Patients with extensive skin involvement may develop exfoliative dermatitis (see Chapter 23). This is associated with generalized redness, scaling, weeping, crusting, systemic toxicity, lymphadenopathy, and fever. Although this complication is rare, it is potentially life threatening. It is usually due to superinfection, for example, with toxin-producing *S. aureus* or herpes simplex infection, continued irritation of the skin, or inappropriate therapy. In some cases, the withdrawal of systemic glucocorticoids used to control severe AD may be a precipitating factor for exfoliative erythroderma.

PROGNOSIS AND CLINICAL COURSE

The natural history of AD is not completely known because studies have been flawed in terms of inadequate sample size, an unclear definition of remission, inadequate length of follow-up, selection bias in the initial cohort, and excessive loss of patients to follow-up. Nevertheless, although the outcome of AD may be difficult to predict in any given individual, the disease generally tends to be more severe and persistent in young children. Periods of remission appear more frequently as the patient grows older. Spontaneous resolution of AD has been reported to occur after age 5 years in 40–60% of patients affected during infancy, particularly if their disease is mild. Although earlier studies suggested that approximately 84% of children outgrow their AD by adolescence, more recent studies have reported that AD disappears in approximately 20% of children followed from infancy until adolescence, but becomes less severe in 65%. In addition, more than one-half of adolescents treated for mild dermatitis may experience a relapse of disease as adults. Filaggrin mutations have been associated with higher rates of persistent atopic dermatitis into later childhood and adulthood.[50] Importantly, for occupational counseling, adults whose childhood AD has been in remission for a number of years may present with hand dermatitis, especially if daily activities require repeated hand wetting. The following predictive factors correlate with a poor prognosis for AD: widespread AD in childhood, associated allergic rhinitis and asthma, family history of AD in parents or siblings, early age at onset of AD, being an only child, and very high serum IgE levels.

TREATMENT

Successful treatment of AD requires a systematic, multipronged approach that incorporates education about the disease state, skin hydration, pharmacologic therapy, and the identification and elimination of flare factors such as irritants, allergens, infectious agents, and emotional stressors (Fig. 14-13).[51,52] Many factors lead to the symptom complex characterizing AD. Thus, treatment plans should be individualized to address each patient's skin disease reaction pattern, including the acuity of the rash, and the trigger factors that are unique to the particular patient. In patients refractory to conventional forms of therapy, alternative anti-inflammatory and immunomodulatory agents may be necessary.[53]

TOPICAL THERAPY

CUTANEOUS HYDRATION. Patients with AD have abnormal skin barrier function with increased transepidermal water loss and decreased water content and dry skin (xerosis) contributing to disease morbidity by the development of microfissures and cracks in the skin, which serve as portals of entry for skin pathogens, irritants, and allergens. *FLG* gene mutations have also been shown to result in decreased epidermal levels of natural moisturizing factor.[54] This problem can become aggravated during the dry winter months and in certain work environments. Warm soaking baths for approximately 10 minutes followed by the application of an occlusive emollient or topical medication to retain moisture can give such patients excellent symptomatic relief. Bathing without emollient use may result in drier skin.[55] Use of an effective emollient combined with hydration therapy helps to restore and preserve the stratum corneum barrier, and may decrease the need for topical glucocorticoids. Moisturizers are available in the form of lotions, creams, or ointments. Some lotions and creams may be irritating due to added preservatives, solubilizers, and fragrances. Lotions containing water may be drying due to an evaporative effect.

Hydrophilic ointments can be obtained in varying degrees of viscosity according to the patient's preference. Occlusive ointments are sometimes not well tolerated because of interference with the function of the eccrine sweat ducts and the induction of folliculitis. In these patients, less occlusive agents should be used.

Topical therapy to replace abnormal epidermal lipids, improve skin hydration, and decrease skin barrier dysfunction may be useful therapeutically. Studies have shown benefits of topical preparations with distinct compositions of lipids and ceramides, as well as a nonsteroidal cream containing palmitamide MEA, an essential fatty acid, and a hydrolipidic cream with glycyrrhetinic acid (MAS063ADP).[56,57] Further clinical studies to define the benefits relative to traditional moisturizers and topical anti-inflammatory agents will be helpful.

Hydration, by baths or wet dressings, promotes transepidermal penetration of topical glucocorticoids. Dressings may also serve as an effective barrier against persistent scratching, allowing more rapid healing of excoriated lesions.[58] Wet dressings, or "wet wraps" are recommended for use on severely affected or chronically involved areas of dermatitis refractory to therapy.[59] However, overuse of wet dressings may result in maceration of the skin complicated by secondary infection. Wet dressings or baths also have the potential to promote drying and fissuring of the skin if not followed by topical emollient use. Thus, wet dressing therapy is reserved for poorly controlled AD and should be closely monitored by a physician.

TOPICAL ANTI-INFLAMMATORY THERAPY

A recent study looked at TEWL, as well as several other parameters of epidermal barrier including stratum corneum hydration and dye penetration.[60] The authors found improvement in all parameters when AD patients were treated with both a topical steroid (betamethasone valerate 0.1% cream) and a topical calcineurin inhibitor (pimecrolimus 1% cream) applied to paired lesions of the upper extremities. Electron

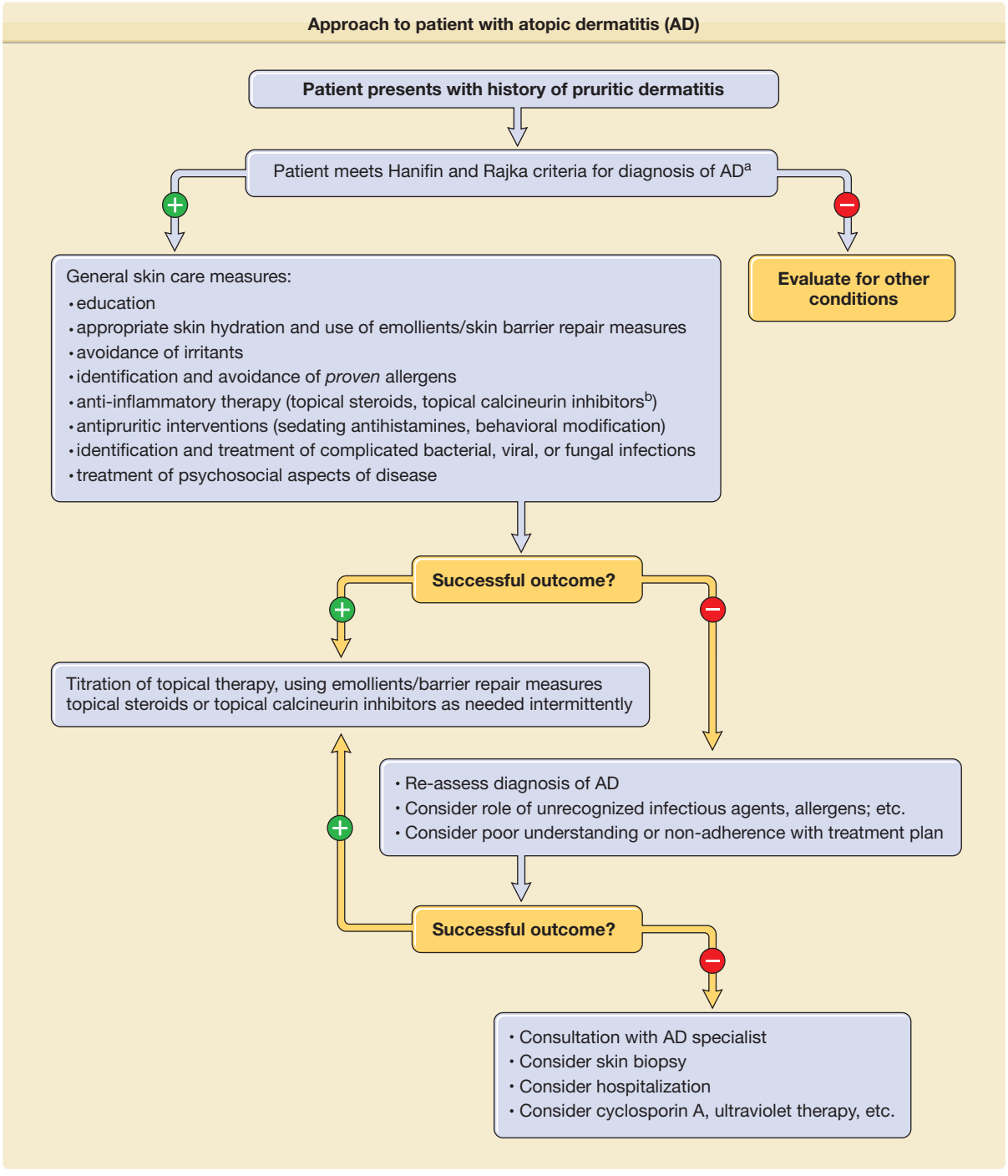

Figure 14-13 Approach to patient with atopic dermatitis (AD). [a]See Table 14-1. [b]Second-line therapy per black box warning.

microscopic evaluation of barrier structure showed prevalently ordered stratum corneum lipid layers and regular lamellar body extrusion in the calcineurin inhibitor-treated skin but inconsistent extracellular lipid bilayers and only partially filled lamellar bodies in the steroid-treated skin. Both treatments normalized epidermal differentiation and reduced epidermal hyperproliferation. Both anti-inflammatory therapies increased expression of filaggrin and involucrin in the skin. Betamethasone valerate was superior in reducing clinical symptoms and epidermal proliferation, but twice daily use over the 3-week period of the study led to epidermal thinning. The authors concluded that since pimecrolimus improved the epidermal barrier and did not cause cutaneous atrophy, it might be more suitable for long-term treatment of AD. However, the finding that the topical steroid was more effective in reducing clinical symptoms and inflammation

supports the use of topical steroids for acute intervention of AD flares.

TOPICAL GLUCOCORTICOID THERAPY. Topical glucocorticoids are the cornerstone of treatment for anti-inflammatory eczematous skin lesions. Because of potential side effects, most physicians use topical glucocorticoids only to control acute exacerbations of AD. However, recent studies suggest that once control of AD is achieved with a daily regimen of topical glucocorticoid, long-term control can be maintained in a subset of patients with twice weekly applications of topical fluticasone to areas that have healed but are prone to developing eczema.[61]

Patients should be carefully instructed in the use of topical glucocorticoids to avoid potential side effects. The potent fluorinated glucocorticoids should be avoided on the face, the genitalia, and the intertriginous areas. A low-potency glucocorticoid preparation is generally recommended for these areas. Patients should be instructed to apply topical glucocorticoids to their skin lesions and to use emollients over uninvolved skin. Failure of a patient to respond to topical glucocorticoids is sometimes due in part to an inadequate supply. It is important to remember that it takes approximately 30 g of cream or ointment to cover the entire skin surface of an adult once. To treat the entire body twice daily for 2 weeks requires approximately 840 g (2 lb) of topical glucocorticoids.

There are seven classes of topical glucocorticoids, ranked according to their potency based on vasoconstrictor assays. Because of their potential side effects, the ultrahigh-potency glucocorticoids should be used only for very short periods of time and in areas that are lichenified but not on the face or intertriginous areas. The goal is to use emollients to enhance skin hydration and low-potency glucocorticoids for maintenance therapy. Midpotency glucocorticoids can be used for longer periods of time to treat chronic AD involving the trunk and extremities. Newer formulations of topical steroids include gel formulations without alcohol bases that moisturize skin, and solutions, oils, foams, and shampoos that may be useful on hair-bearing surfaces.

Factors which influence topical glucocorticoid potency and side effects include the molecular structure of the compound, the vehicle, the amount of medication applied, the duration of application, occlusion, as well as host factors, including age, body surface area and weight, skin inflammation, anatomic location of treated skin, and individual differences in cutaneous or systemic metabolism. Side effects from topical glucocorticoids are directly related to the potency ranking of the compound and the length of use, so it is incumbent on the clinician to balance the need for a more potent steroid with the potential for side effects. In addition, ointments have a greater potential to occlude the epidermis, resulting in enhanced systemic absorption when compared to creams. Side effects from topical glucocorticoids can be divided into local side effects and systemic side effects resulting from suppression of the hypothalamic–pituitary–adrenal axis. Local side effects include the development of striae, skin atrophy, perioral dermatitis, and acne rosacea. The potential for potent topical glucocorticoid to cause adrenal suppression is greatest in infants and young children. Several topical steroid formulations have been specifically tested for safety and received specific US Federal Drug Administration (FDA) approval for use in younger children such as desonide hydrogel and nonethanolic foam, fluocinolone acetonide oil, and fluticasone 0.05% cream.[62–65] Mometasone cream and ointment are approved for children aged 2 years and older.

Because normal-appearing skin in AD shows evidence of immunologic dysregulation, the use of topical corticosteroids as maintenance therapy has been reported in several controlled studies.[66] Once control of AD with a once daily regimen was achieved, long-term control could be maintained with twice weekly application of fluticasone to previously involved areas. Given recent insights into skin barrier and immunologic abnormalities and colonization of normal-appearing skin in AD by *S. aureus*, it is important to appreciate that proactive therapy is an attempt to control residual disease, not just application of an active drug to nonaffected skin.[67]

TOPICAL CALCINEURIN INHIBITORS. Topical tacrolimus and pimecrolimus have been developed as nonsteroidal immunomodulators.[68] Tacrolimus ointment 0.03% has been approved for intermittent treatment of moderate to severe AD in children aged 2 years and older, with tacrolimus ointment 0.1% approved for use in adults; pimecrolimus cream 1% is approved for treatment of patients aged 2 years and older with mild–moderate AD. Both drugs have proven to be effective with a good safety profile for treatment up to 4 years with tacrolimus ointment[69] and up to 2 years with pimecrolimus cream.[70] A frequently observed side effect with TCIs is a transient burning sensation of the skin. Importantly, treatment with TCIs is not associated with skin atrophy,[71] thus they are particularly useful for the treatment of areas such as the face and intertriginous regions. Ongoing surveillance and recent reports have not shown a trend for increased frequency of viral superinfections, especially eczema herpeticum.[72] The long-term safety of TCIs has not been established. Rare cases of skin malignancy and lymphoma have been reported with topical tacrolimus, though the level of data quality and applicability of these reports was judged low in the report of a scientific consensus conference.[73] Importantly, a case-control study of a large database that identified a cohort of 293,253 patients with AD found no increased risk of lymphoma with the use of TCIs.[74] Twice to three times weekly maintenance therapy using tacrolimus ointment has also been reported in both adults and children with AD.[75,76]

IDENTIFICATION AND ELIMINATION OF TRIGGERING FACTORS

GENERAL CONSIDERATIONS. Patients with AD are more susceptible to irritants than are unaffected individuals. Thus, it is important to identify and

eliminate aggravating factors that trigger the itch–scratch cycle. These include soaps or detergents, contact with chemicals, smoke, abrasive clothing, and exposure to extremes of temperature and humidity. Alcohol and astringents found in toiletries are drying. When soaps are used, they should have minimal defatting activity and a neutral pH. New clothing may be laundered before wearing to decrease levels of formaldehyde and other added chemicals. Residual laundry detergent in clothing may be irritating. Using a liquid rather than powder detergent and adding a second rinse cycle facilitates removal of the detergent.

Recommendations regarding environmental living conditions should include temperature and humidity control to avoid problems related to heat, humidity, and perspiration. Every attempt should be made to allow children to be as normally active as possible. Certain sports, such as swimming, may be better tolerated than other sports involving intense perspiration, physical contact, or heavy clothing and equipment, but chlorine should be rinsed off immediately after swimming and the skin lubricated. Although ultraviolet (UV) light may be beneficial to some patients with AD, sunscreens should be used to avoid sunburn. However, because sunscreens can be irritants, care should be used to identify a nonirritating product.

SPECIFIC ALLERGENS. Foods and aeroallergens such as dust mites, animal danders, molds, and pollens have been demonstrated to exacerbate AD. Potential allergens can be identified by taking a careful history and carrying out selective skin-prick tests or specific serum IgE levels. Negative skin tests or serum tests for allergen-specific IgE have a high predictive value for ruling out suspected allergens. However, a normal total serum IgE level does not rule out the possibility of allergen-specific IgE being present. Positive skin or in vitro tests, particularly to foods, often do not correlate with clinical symptoms and should be confirmed with controlled food challenges and elimination diets. Avoidance of foods implicated in controlled challenges results in clinical improvement. Extensive elimination diets, which in some cases can be nutritionally deficient, are rarely, if ever, required, because even with multiple positive skin tests, the majority of patients react to three or fewer foods on controlled challenge. In dust mite-allergic patients with AD, prolonged avoidance of dust mites has been found to result in improvement of their skin disease. Avoidance measures include use of dust mite-proof encasings on pillows, mattresses, and box springs; washing bedding in hot water weekly; removal of bedroom carpeting; and decreasing indoor humidity levels with air conditioning. Because there are many triggers contributing to the flares of AD, attention should be focused on identifying and controlling the flare factors that are important to the individual patient. Infants and young children are more likely to have food allergies, whereas older children and adults are more likely to be sensitive to environmental aeroallergens. Contact allergens have been increasingly recognized in AD. A recent study found that of children with relevant positive reactions, 34% had a diagnosis of AD.[77]

EMOTIONAL STRESSORS. Although emotional stress does not cause AD, it often exacerbates the illness. AD patients often respond to frustration, embarrassment, or other stressful events with increased pruritus and scratching. In some instances, scratching is simply habitual and less commonly associated with significant secondary gain. Psychological evaluation or counseling should be considered in patients who have difficulty with emotional triggers or psychological problems, contributing to difficulty in managing their disease. It may be especially useful in adolescents and young adults who consider their skin disease disfiguring. Relaxation, behavioral modification, or biofeedback may be helpful in patients with habitual scratching.[58]

INFECTIOUS AGENTS. Antistaphylococcal antibiotics are very helpful in the treatment of patients who are heavily colonized or infected with *S. aureus*.[78] Cephalosporins or penicillinase-resistant penicillins (dicloxacillin, oxacillin, or cloxacillin) are usually beneficial for patients who are not colonized with resistant *S. aureus* strains. Because erythromycin-resistant *Staphylococci* are common, erythromycin and newer macrolide antibiotics are usually of limited utility. Topical antimicrobials such as mupirocin, fusidic acid, or more recently retapamulin offers some utility in the treatment of impetiginized lesions. A Cochrane Database analysis of interventions for impetigo found that topical mupirocin and topical fusidic acid are equal to or more effective than oral treatment for patients with limited disease and that fusidic acid and mupirocin are of similar efficacy.[79] Patients should be cautioned against using topical antibiotics in an "as-needed" manner that can lead to resistant organisms.[80]

Use of neomycin topically can result in development of allergic contact dermatitis as neomycin is among the more common allergens causing contact dermatitis. However, in patients with extensive superinfection, a course of systemic antibiotics is most practical. Methicillin-resistant *Staphylococci* may require culture and sensitivity testing to assist in appropriate antibiotic selection. Baths with dilute sodium hypochlorite (bleach) may also benefit AD patients with superinfected eczema, especially those with recurrent MRSA, although they can occasionally be irritating. Of note, a controlled study of twice weekly bleach baths for 3 months showed clinical benefit, although skin colonization by *S. aureus* did not disappear, even when combined with intranasal mupirocin 5 days each month.[81]

Herpes simplex can provoke recurrent dermatitis and may be misdiagnosed as *S. aureus* infection. The presence of punched-out erosions, vesicles, and/or infected skin lesions that do not respond to oral antibiotics should initiate a search for herpes simplex. This

can be diagnosed by a Giemsa-stained Tzanck smear of cells scraped from the vesicle base, direct immunofluorescence assay, polymerase chain reaction identification of herpes genetic material, or by viral culture. For infection suspected to be caused by herpes simplex, topical anti-inflammatory agents might be discontinued, at least temporarily. Antiviral treatment for cutaneous herpes simplex infections is of critical importance in the patient with widespread AD because life-threatening dissemination has been reported. Acyclovir, 400 mg three times daily for 10 days or 200 mg four times daily for 10 days by oral administration (or an equivalent dosage of one of the newer antiherpetic medications), is useful in adults with herpes simplex confined to the skin. Intravenous treatment may be necessary for severe disseminated eczema herpeticum. The dosage should be adjusted according to weight in children.

Dermatophyte infections can complicate AD and may contribute to exacerbation of disease activity. Patients with dermatophyte infection or IgE antibodies to *Malassezia* may benefit from a trial of topical or systemic antifungal therapy.

PRURITUS. The treatment of pruritus in AD should be directed primarily at the underlying causes. Reduction of skin inflammation and dryness with topical glucocorticoids and skin hydration, respectively, often symptomatically reduce pruritus. Inhaled and ingested allergens should be eliminated if documented to cause skin rash in controlled challenges. Systemic antihistamines act primarily by blocking the H_1 receptors in the dermis, thereby ameliorating histamine-induced pruritus. However, histamine is only one of many mediators that can induce pruritus of the skin. Therefore, certain patients may derive minimal benefit from antihistaminic therapy. Some antihistamines are also mild anxiolytics and may offer symptomatic relief through tranquilizing and sedative effects. Studies of newer, nonsedating antihistamines show variable results in the effectiveness of controlling pruritus in AD, although they may be useful in the subset of AD patients with concomitant urticaria or concurrent allergic rhinitis.

Because pruritus is usually worse at night, the sedating antihistamines, for example, hydroxyzine or diphenhydramine, may offer an advantage with their soporific side effects when used at bedtime. Doxepin hydrochloride has both tricyclic antidepressant and H_1- and H_2-histamine receptor-blocking effects. It can be used in doses of 10–75 mg orally at night or up to 75 mg bid in adult patients. If nocturnal pruritus remains severe, short-term use of a sedative to allow adequate rest may be appropriate. Treatment of AD with topical antihistamines is generally not recommended because of potential cutaneous sensitization. However, short-term (1 week) application of topical 5% doxepin cream has been reported to reduce pruritus without sensitization. Of note, sedation is a side effect of widespread application of doxepin cream, and allergic contact dermatitis has been reported.

TAR PREPARATIONS

Coal tar preparations may have antipruritic and anti-inflammatory effects on the skin, although usually not as pronounced as those of topical glucocorticoids.[82] Tar preparations may be useful in reducing the potency of topical glucocorticoids required in chronic maintenance therapy of AD. Newer coal tar products have been developed that are more acceptable with respect to odor and staining of clothes than some older products. Tar shampoos can be beneficial for scalp dermatitis and are often helpful in reducing the concentration and frequency of topical glucocorticoid applications. Tar preparations should not be used on acutely inflamed skin, because this often results in skin irritation. Side effects associated with tars include folliculitis and photosensitivity. There is a theoretic risk of tar being a carcinogen based on observational studies of workers using tar components in their occupations; however, epidemiologic studies do not confirm similar outcomes when used topically.[83]

PHOTOTHERAPY

Natural sunlight is frequently beneficial to patients with AD. However, if the sunlight occurs in the setting of high heat or humidity, thereby triggering sweating and pruritus, it may be deleterious to patients. Broadband UVB, broadband UVA, narrowband UVB (311 nm), UVA-1 (340 to 400 nm), and combined UVAB phototherapy can be useful adjuncts in the treatment of AD. Investigation of the photoimmunologic mechanisms responsible for therapeutic effectiveness indicates that epidermal LCs and eosinophils may be targets of UVA phototherapy, with and without psoralen, whereas UVB exerts immunosuppressive effects via blocking of function of antigen-presenting LCs and altered keratinocyte cytokine production. Photochemotherapy with psoralen and UVA light may be indicated in patients with severe, widespread AD, although studies comparing it with other modes of phototherapy are limited. Short-term adverse effects with phototherapy may include erythema, skin pain, pruritus, and pigmentation. Long-term adverse effects include premature skin aging and cutaneous malignancies (see Chapters 237 and 238 for detailed discussion of phototherapy and photochemotherapy, respectively).

HOSPITALIZATION

AD patients who appear erythrodermic or who have widespread severe skin disease resistant to outpatient therapy should be hospitalized before considering systemic alternative therapies (see section "Systemic Therapy"). In many cases, removing the patient from environmental allergens or emotional stresses, intense patient education, and assurance of compliance with therapy results in a sustained improvement in their AD. Clearing of the patient's skin during

hospitalization also allows the patient to undergo allergen skin testing and appropriately controlled provocative challenges to correctly identify or rule out potential allergens.

SYSTEMIC THERAPY

Systemic therapies discussed below were reviewed in a consensus conference.[53]

SYSTEMIC GLUCOCORTICOIDS. The use of systemic glucocorticoids, such as oral prednisone, is rarely indicated in the treatment of chronic AD. Some patients and physicians prefer the use of systemic glucocorticoids to avoid the time-consuming skin care involving hydration and topical therapy. However, the dramatic clinical improvement that may occur with systemic glucocorticoids is frequently associated with a severe rebound flare of AD after the discontinuation of systemic glucocorticoids. Short courses of oral glucocorticoids may be appropriate for an acute exacerbation of AD whereas other treatment measures are being instituted. If a short course of oral glucocorticoids is given, it is important to taper the dosage and to begin intensified skin care, particularly with topical glucocorticoids and frequent bathing followed by application of emollients to prevent rebound flaring of AD.

CYCLOSPORINE. Cyclosporine is a potent immunosuppressive drug that acts primarily on T cells by suppressing cytokine transcription. The drug binds to cyclophilin, an intracellular protein, and this complex, in turn, inhibits calcineurin, a molecule required for initiation of cytokine gene transcription. Multiple studies demonstrate that both children and adults with severe AD, refractory to conventional treatment, can benefit from short-term cyclosporine treatment. Various oral-dosing regimens have been recommended: 5 mg/kg has generally been used with success in short-term and long-term (1 year) use, whereas some authorities advocate body-weight-independent daily dosing of adults with 150 mg (low dose) or 300 mg (high dose) daily of cyclosporine microemulsion. Treatment with cyclosporine is associated with reduced skin disease and an improved quality of life (see Chapter 233 for further discussion). Discontinuation of treatment may result in rapid relapse of skin disease, although some patients may have sustained remission. Elevated serum creatinine or more significant renal impairment and hypertension are specific side effects of concern with cyclosporine use.

ANTIMETABOLITES. Mycophenolate mofetil is a purine biosynthesis inhibitor used as an immunosuppressant in organ transplantation, which has been used for treatment of refractory inflammatory skin disorders (see Chapter 233). Open-label studies report that short-term oral mycophenolate mofetil, 2 g daily, as monotherapy results in clearing of skin lesions in adults with AD resistant to other treatment, including topical and oral steroids and psoralen and UVA light. The drug has generally been well tolerated with the exception of one patient developing herpes retinitis that may have been secondary to this immunosuppressive agent. Dose-related bone marrow suppression has also been observed. Similar results were previously reported in another open study of ten patients with a mean reduction in the SCORAD (SCORing Atopic Dermatitis) index of 68% in all ten patients. Of note, not all patients benefit from treatment. Therefore, the medication should be discontinued if patients do not respond within 4 to 8 weeks. Dose finding and well-controlled studies are needed for this drug.

Methotrexate is an antimetabolite with potent inhibitory effects on inflammatory cytokine synthesis and cell chemotaxis. Methotrexate has been used for adult AD patients with recalcitrant disease, although controlled trials are lacking. Dosing more frequently than the typical weekly dosing for psoriasis has been advocated.[84] In open-label studies, initial improvement was observed after a period ranging from 2 weeks to 3 months (mean 9.95 weeks +/– 3.17).

Azathioprine is a purine analog with anti-inflammatory and antiproliferative effects. It has been used for severe AD, and several controlled trials have been reported in adults and children.[85,86] Myelosuppression is a significant adverse effect. Thiopurine methyl transferase levels may predict individuals at risk.[87]

OTHER THERAPIES

INTERFERON-γ. IFN-γ is known to suppress IgE responses and downregulate Th2 cell proliferation and function. Several studies of patients with AD, including a multicenter, double-blind, placebo-controlled trial[88] and two long-term open trials,[89,90] have demonstrated that treatment with recombinant human IFN-γ results in clinical improvement. Reduction in clinical severity of AD correlated with the ability of IFN-γ to decrease total circulating eosinophil counts. Influenza-like symptoms are commonly observed side effects early in the treatment course.

OMALIZUMAB. Treatment of patients with severe AD and elevated serum IgE levels with monoclonal anti-IgE has shown lack of efficacy in three adult patients[91] and significant improvement in three adolescent patients.[92] In an open study of 11 adult patients with high IgE levels treated with anti-IgE, some patients had very good clinical improvement, others had none and several had worsening of their AD based on change in SCORAD.[93] To date, specific markers have not been found to identify potential responders.

ALLERGEN IMMUNOTHERAPY. Unlike allergic rhinitis and extrinsic asthma, immunotherapy with aeroallergens has not proven to be efficacious in the treatment of AD. There are anecdotal reports of both disease exacerbation and improvement. A recent study of specific immunotherapy over 12 months in adults with AD sensitized to dust mite allergen showed improvement in SCORAD as well as reduction in

topical steroid use.[94] However, well-controlled studies are still required to determine the role for immunotherapy with this disease. More recently, a controlled study with sublingual immunotherapy showed benefit in a subset of children with AD sensitized to dust mite allergen.[95] This data need to be reproduced in a larger pediatric population, given the natural history of AD.

EXTRACORPOREAL PHOTOPHERESIS. Extracorporeal photopheresis consists of the passage of psoralen-treated leukocytes through an extracorporeal UVA light system. Clinical improvement in skin lesions associated with reduced IgE levels has been reported in a few patients with severe, resistant AD who were treated with extracorporeal photopheresis and topical glucocorticoids.[96]

PROBIOTICS. Perinatal administration of the probiotic *Lactobacillus rhamnosus* strain GG was shown to reduce the incidence of AD in at-risk children during the first 2 years of life.[97] Mothers were given either placebo or *Lactobacillus* GG daily for 4 weeks before delivery and then either the mother (if breast-feeding) or the infant continued with daily therapy for 6 months. In a follow-up study, the same group assessed the persistence of potential to prevent AD at 4 years.[98] The results suggest that the preventive effect of *Lactobacillus* GG on AD could extend beyond infancy.

In a second study, children with AD treated with two *Lactobacillus* strains for 6 weeks experienced improvement of their eczema compared to placebo-treated patients, although their SCORAD index did not change significantly.[99] The treatment response was found to be more pronounced in patients with positive skin-prick tests and elevated IgE levels. Another study of children with moderate to severe AD treated for 8 weeks with *L. fermentum* in a placebo-controlled study showed persistent improvement in SCORAD at 16 weeks.[100] These studies suggest that probiotics, or at least some *Lactobacillus* strains, may have preventative, lasting effects on the incidence of AD in a subset of patients. More research into subgroups of responders, optimal therapy [route (i.e., directly to infant or via mother's milk); length of treatment; strain of *Lactobacillus*], as well as mechanisms involved is clearly needed.[101]

A recent meta-analysis found a modest role for probiotics in children with moderately severe disease in reducing SCORAD (mean change from baseline, –3.01; 95% confidence interval, –5.36 to –0.66; P = .01).[102] Duration of probiotic administration, age, and type of probiotic used did not affect outcomes. Another meta-analysis found that current evidence is more convincing for probiotics' efficacy in prevention, rather than treatment of AD in children.[103] In contrast to earlier studies, supplementation with *Lactobacillus* GG during pregnancy and early infancy neither reduced the incidence of AD nor altered the severity of AD in affected children, but was associated with increased rate of recurrent episodes of wheezy bronchitis.[104] A Cochrane review concluded that probiotics are not an effective treatment for eczema in children and that probiotic treatment carries a small risk of adverse events.[105]

CHINESE HERBAL MEDICATIONS. Several placebo-controlled clinical trials have suggested that patients with severe AD may benefit from treatment with traditional Chinese herbal therapy (see Chapter 241). They had significantly reduced skin disease and decreased pruritus. However, the beneficial response of Chinese herbal therapy is often temporary, and effectiveness may wear off despite continued treatment. The possibility of hepatic toxicity, cardiac side effects, or idiosyncratic reactions remains a concern. The specific ingredients of the herbs also remain to be elucidated and some preparations have been found to be contaminated with corticosteroids. At present, Chinese herbal therapy for AD is considered investigational.

ORAL VITAMIN D. A pilot randomized, double-blind placebo-controlled study looked at the benefit of oral vitamin D supplementation in children with AD from February to March in Boston.[106] Eleven pediatric patients primarily with mild AD were treated with either vitamin D (1,000 IU ergocalciferol) or placebo once daily for a month. IGA score improved in four of six subjects in the vitamin D group (80%), as compared to one of five subjects in the placebo group (p = 0.04). In addition, there was a greater reduction in EASI score in the vitamin D, as compared to the placebo group, although the difference was not statistically significant. In addition, in a controlled study, 14 healthy subjects and 14 subjects with AD were supplemented with 4,000 IU per day of oral vitamin D_3 (cholecalciferol) for 3 weeks.[107] Expression of the AMP cathelicidin was significantly increased in the skin biopsies of AD lesions, as compared to those in healthy skin or uninvolved AD skin, suggesting a role for oral vitamin D in improving innate immune responses in AD patients.[108]

TABLE 14-2
Online Resources for Patients With AD and Their Families

Coping Strategies and Support Groups	
	National Eczema Association (www.nationaleczema.org)
	Under My Skin: A Kid's Guide to Atopic Dermatitis (www.undermyskin.com)
Specialized AD Care	
	American Academy of Dermatology EczemaNet (www.skincarephysicians.com/eczemanet/index.html)
	The Eczema Center at Rady Children's Hospital (www.eczemacenter.org)
	National Jewish Health (www.njc.org)
	Northwestern University Eczema Care and Education Center (www.eczemacarecenter.com)
Information on Allergic Triggers	
	American Academy of Allergy, Asthma & Immunology (www.aaaai.org)
	Food Allergy & Anaphylaxis Network (www.foodallergy.org)

EDUCATION AS INTERVENTION

Education may be considered as a therapeutic intervention for the management of atopic dermatitis.[51,52] Intensive disease education has been shown in randomized, controlled trials to improve subjective quality-of-life and objective eczema severity scores.[109] Intensive education may include comprehensive "center-based" patient/family teaching, written "handouts," and care plans, patient/family support groups, and Internet-accessed media. Several resources available online are listed in Table 14-2.

KEY REFERENCES

Full reference list available at www.DIGM8.com

DVD contains references and additional content

1. Cork MJ et al: Epidermal barrier dysfunction in atopic dermatitis. *J Invest Dermatol* **129**:1892, 2009
8. Bieber T: Atopic dermatitis. *N Engl J Med* **358**:1483, 2008
9. Cork MJ et al: Epidermal barrier dysfunction in atopic dermatitis. *J Invest Dermatol* **129**:1892, 2009
10. O'Regan GM et al: Filaggrin in atopic dermatitis. *J Allergy Clin Immunol* **122**:689, 2008
36. De Benedetto A et al: Atopic dermatitis: A disease caused by innate immune defects? *J Invest Dermatol* **129**:14, 2009
37. Barnes KC: An update on the genetics of atopic dermatitis: Scratching the surface in 2009. *J Allergy Clin Immunol* **125**:16, 2010
48. Boguniewicz M, Leung DY: Recent insights into atopic dermatitis and implications for management of infectious complications. *J Allergy Clin Immunol* **125**:4, 2010
53. Akdis CA et al: Diagnosis and treatment of atopic dermatitis in children and adults: European Academy of Allergology and Clinical Immunology/American Academy of Allergy, Asthma and Immunology/PRACTALL Consensus Report. *J Allergy Clin Immunol* **118**:152, 2006
58. Boguniewicz M et al: A multidisciplinary approach to evaluation and treatment of atopic dermatitis. *Semin Cutan Med Surg* **27**:115, 2008
67. Wollenberg A, Bieber T: Proactive therapy of atopic dermatitis–An emerging concept. *Allergy* **64**:276, 2009

Chapter 15 :: Nummular Eczema, Lichen Simplex Chronicus, and Prurigo Nodularis

:: Susan Burgin

NUMMULAR ECZEMA

NUMMULAR ECZEMA AT A GLANCE

- Also known as *discoid eczema*.
- A chronic disorder of unknown etiology.
- Papules and papulovesicles coalesce to form nummular plaques with oozing, crust, and scale.
- Most common sites of involvement are upper extremities, including the dorsal hands in women, and the lower extremities in men.
- Pathology may show acute, subacute, or chronic eczema.

EPIDEMIOLOGY

Nummular eczema is predominantly a disease of adulthood. Men are more frequently affected than women. The peak incidence in both males and females is around 50–65 years of age. There is a second peak in women around 15–25 years of age. Nummular eczema is rare in infancy and childhood. The peak age of onset in childhood is 5 years.[1]

ETIOLOGY AND PATHOGENESIS

The pathogenesis of nummular eczema is still unknown. The vast majority of patients with nummular eczema do not have a personal or family history of atopy,[2,3] although nummular plaques may be seen in atopic eczema. Numerous factors have been implicated as causal. The state of hydration of the skin in elderly patients has been shown to be decreased.[4] The role of infection previously received much attention in the literature. An internal focus of infection, including teeth, upper respiratory tract, and lower respiratory tract, was found in 68% of patients in one study.[5] Eleven of thirteen patients without a history of atopic eczema improved after odontogenic infections were treated.[6] A role for environmental allergens, such as the house dust mite and *Candida albicans* has also been touted.[4] Nummular eczema has been reported during therapy with isotretinoin and gold.[7,8] Generalized nummular eczema is seen in patients with hepatitis C undergoing combination therapy with interferon α-2b and ribavirin.[9,10] Mercury amalgam was implicated as a cause in two patients.[11]

CLINICAL FINDINGS

Well-demarcated coin-shaped plaques form from coalescing papules and papulovesicles. Pinpoint oozing and crusting eventuate, and are distinctive (Figs. 15-1 and 15-2). Crust may however cover the entire surface (Fig. 15-3). Plaques range from 1 to 3 cm



Figure 15-1 Nummular eczema. Coin-shaped plaques with pinpoint erosions and excoriations. (Image from Division of Dermatology, University of the Witwatersrand, Johannesburg, South Africa, with permission, from Professor D. Modi.)



Figure 15-3 Nummular eczema in a child. Crusted plaques. (Used, with permission, from P. Lio, M.D., Northwestern University's Feinberg School of Medicine, Chicago.)

in size. The surrounding skin is generally normal but may be xerotic. Pruritus varies from minimal to severe. Central resolution may occur, leading to annular forms. Chronic plaques are dry, scaly, and lichenified. The classic distribution of lesions is the extensor aspects of the extremities. In women, the upper extremities, including the dorsal aspects of the hands, are more frequently affected than the lower extremities.[2] Exudative discoid and lichenoid dermatitis of Sulzberger-Garbe may represent a variant of nummular dermatitis.[12]



Figure 15-2 Nummular eczema. Single plaque showing pinpoint erosions and crusting.

LABORATORY TESTS

Patch testing may be useful in chronic recalcitrant cases to rule out a superimposed contact dermatitis. In a series from India, just under half of 50 patients were patch-test positive to colophony, nitrofurazone, neomycin sulfate, and nickel sulfate.[13] Serum IgE levels are normal.

SPECIAL TESTS

Histopathologic changes are reflective of the stage at which the biopsy is performed. Acutely, there is spongiosis, with or without spongiotic microvesicles. In subacute plaques, there is parakeratosis, scale-crust, epidermal hyperplasia, and spongiosis of the epidermis (Fig. 15-4). There is a mixed cell infiltrate in the dermis. Chronic lesions may resemble lichen simplex chronicus microscopically.

DIFFERENTIAL DIAGNOSIS

See Box 15-1.

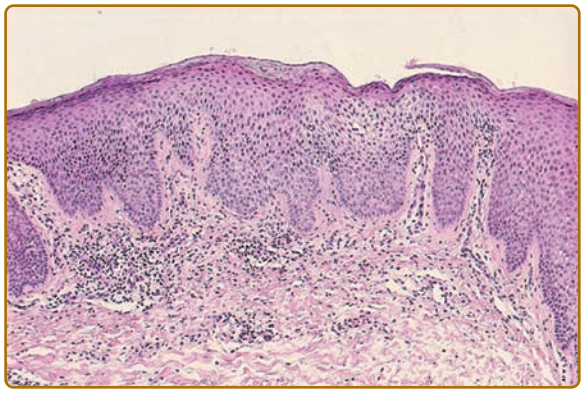

Figure 15-4 Histopathology of nummular eczema. Parakeratosis containing plasma and neutrophils (scale-crust) and psoriasiform epidermal hyperplasia with spongiosis are present, with a superficial dermal perivascular infiltrate of lymphocytes, macrophages, and eosinophils.

COMPLICATIONS

Nummular eczema may be complicated by secondary bacterial infection.

PROGNOSIS/CLINICAL COURSE

The course is usually chronic. Recurrence at prior sites of involvement is a feature of the disease.[5]

TREATMENT

Topical steroids in the mid- to high-potency range are the mainstay of treatment. The calcineurin inhibitors, tacrolimus and pimecrolimus, and tar preparations are also effective. Emollients can be added adjunctively if there is accompanying xerosis. Oral antihistamines are useful if pruritus is severe. Oral antibiotics are indicated when secondary infection is present. For widespread involvement, phototherapy with broad- or narrow-band ultraviolet B may be beneficial.

BOX 15-1 DIFFERENTIAL DIAGNOSIS OF NUMMULAR ECZEMA

Most Likely

- Allergic contact dermatitis
- Stasis dermatitis
- Atopic dermatitis
- Tinea corporis

Consider

- Impetigo
- Psoriasis (longstanding plaques)
- Mycosis fungoides (longstanding plaques)
- Paget's disease, when there is unilateral involvement of nipple/areola
- Other nummular dermatoses:
  - Fixed drug eruption
  - Pityriasis rotunda

Always Rule Out

- Tinea corporis

LICHEN SIMPLEX CHRONICUS/ PRURIGO NODULARIS

LICHEN SIMPLEX CHRONICUS AT A GLANCE

- A chronic, severely pruritic disorder characterized by one or more lichenified plaques.
- Most common sites of involvement are scalp, nape of neck, extensor aspects of extremities, ankles, and anogenital area.
- Pathology consists of hyperkeratosis, hypergranulosis, psoriasiform epidermal hyperplasia, and thickened papillary dermal collagen.

PRURIGO NODULARIS AT A GLANCE

- A pruritic disorder that runs a chronic course.
- Hyperkeratotic firm nodules vary in size from 0.5 to 3 cm and may be excoriated.
- Associations include atopic dermatitis, or systemic causes of pruritus.
- Pathology consists of hyperkeratosis, hypergranulosis, psoriasiform epidermal hyperplasia, thickened papillary dermal collagen, and characteristic neural hypertrophy.

EPIDEMIOLOGY

Lichen simplex chronicus affects adults, predominantly from ages 30 to 50. Females are affected more commonly than males. Prurigo nodularis may occur at any age, but most patients are between 20 and 60 years.[14] Men and women are equally affected. Patients with coexistent atopic dermatitis have been found to have any earlier age of onset (mean: 19 years) as compared to the nonatopic group (mean: 48 years).[15]

ETIOLOGY AND PATHOGENESIS

Lichen simplex chronicus is induced by rubbing and scratching secondary to itch. The prurigo nodule is induced by picking and scratching most commonly, but not always, in response to itch. Various factors incite itch in both disorders and not all are well understood. A variable association between lichen simplex chronicus and atopic disorders has been reported, ranging from around 26% to 75%.[16,17] Similarly, a subset of patients with prurigo nodularis has coexistent atopic eczema. Here, prurigo nodules occur in concert with subacute prurigo, lichenification, and xerosis. "Besnier prurigo" refers to the pruriginous nodules seen in atopic dermatitis. In the nonatopic nodular prurigo group, systemic causes of pruritus, including renal insufficiency, hyper- or hypothyroidism, liver failure, HIV disease, parasitic infection, or an underlying malignancy must be excluded. Hepatitis B and C have been reported as associations without liver failure.[18] Prurigo nodularis has also been reported to occur in the setting of celiac disease in the presence or absence of dermatitis herpetiformis.[19,20] The relationship between lichen simplex chronicus and radiculopathy has been preliminarily investigated.[21] Further studies are needed to clarify whether an association exists.

Environmental factors have been implicated in inducing itch, such as heat, sweat, and irritation associated with anogenital lichen simplex chronicus.[17] The presence of emotional or psychological factors in patients with prurigo nodularis and lichen simplex chronicus has been alluded to in the literature. One study of prurigo nodularis patients found that around half of 46 patients had a history of depression, anxiety, or other treatable psychological disorders.[22] Lichen simplex chronicus patients also had higher depression scores in one study.[23] Whether these emotional factors are secondary to the primary dermatologic disease or whether they are primary and causative, altering perception of itch, is unclear. It has been postulated that neurotransmitters that affect mood, such as dopamine, serotonin, or opioid peptides modulate perception of itch via descending spinal pathways.[14] Obsessive-compulsive disorder (OCD) has also been associated with picking in these disorders.[24]

At a microscopic level, increased numbers of Merkel cells are also seen adjacent to the dermal nerve fibers and mast cells in prurigo nodularis. It is thought that this complex may mediate the abnormally heightened perception of touch and itch in these patients. Nerve growth factor (NGF) is overexpressed in prurigo nodularis lesions and it has been implicated in the pathogenesis of the characteristic cutaneous neural hyperplasia seen.[25] NGF is produced and released by mast cells, which are increased in number and size on histologic sections. It upregulates the expression of neuropeptides, such as calcitonin gene-related peptide and substance P. These are thought to mediate inflammation and itch.[17]

CLINICAL FINDINGS

HISTORY. Severe itching is the hallmark of lichen simplex chronicus. Itching may be paroxysmal, continuous, or sporadic. Rubbing and scratching may be conscious and to the point of replacing the sensation of itch with pain, or may be unconscious, occurring during sleep. Itch severity is worse with sweating, heat, or irritation from clothing. Itching is also worse in times of psychological distress.[18]

CUTANEOUS LESIONS. In lichen simplex chronicus, repeated rubbing and scratching gives rise to a lichenified, scaly plaque with excoriations. Hyper- and hypopigmentation are seen with chronicity. Usually, only one plaque is present; however, more than one site may be involved. The most common sites of involvement are the scalp, the nape of the neck (especially in women), the ankles, the extensor aspects of the extremities, and the anogenital region.[26] The labia majora in women and the scrotum in men (Fig. 15-5) are the most common sites of genital involvement.[16] The upper inner thighs may also be affected.

Prurigo nodules vary in size from 0.5 to 3 cm and are firm to hard on palpation. The surface may be hyperkeratotic or crateriform. There is often overlying excoriation. Pruritus is usually severe. Limbs are affected in most cases, especially the extensor aspects (Fig. 15-6). The abdomen and sacrum were the next most common sites of involvement in one study.[22] Face and palms are rarely involved; however, nodules may occur on any site that can be reached by the patient. Lesions may vary in number from few to more than one hundred. Nodules resolve with postinflammatory hyper- or hypopigmentation with or without scarring.

RELATED PHYSICAL FINDINGS. In patients with atopic eczema, the intervening skin is often lichenified and xerotic. In nonatopic patients, cutaneous signs of underlying systemic disease or lymphadenopathy, signifying lymphoma, may be present.

LABORATORY TESTS

In patients with prurigo nodularis in whom an underlying systemic cause of pruritus is suspected, a complete blood count with differential count, renal, liver, and thyroid function tests may be ordered. A chest X-ray may be obtained to screen for lymphoma. HIV testing may also be indicated. The need for a more extensive evaluation may be individualized based on patient history and results of the aforementioned tests.

SPECIAL TESTS

On histopathologic sections, lichen simplex chronicus shows varying degrees of hyperkeratosis with para- and orthokeratosis, hypergranulosis, and psoriasiform epidermal hyperplasia. The papillary dermis shows thickening of collagen with coarse collagen bundles and vertical streaks. There is a variable inflammatory infiltrate around the superficial vascular plexus with lymphocytes, histiocytes, and eosinophils. A biopsy may also reveal a primary pruritic disorder that has led to secondary lichenification, such as psoriasis.

The epidermal findings in prurigo nodularis are similar to lichen simplex chronicus. The lesion is more



Figure 15-5 Lichen simplex chronicus of the scrotum: lichenification, hyper- and hypopigmentation with excoriation. (Image from Division of Dermatology, University of the Witwatersrand, Johannesburg, South Africa, with permission, from Professor D. Modi.)



Figure 15-6 Prurigo nodularis. (Used, with permission, from Professor D. Modi, Division of Dermatology, University of the Witwatersrand, Johannesburg, South Africa.)

papular with bulbous epidermal hyperplasia. Papillary dermal changes also resemble lichen simplex chronicus. There may be cutaneous neural hypertrophy with thickened nerve bundles and an increase in nerve fibers by S-100 staining. This finding was seen in the minority of cases in a recent study.[27]

DIFFERENTIAL DIAGNOSIS

See Boxes 15-2 and 15-3.

COMPLICATIONS

Sleep studies have shown that disturbances in the sleep cycle in lichen simplex chronicus are present. Non-REM sleep is disturbed and patients have an increased arousal index (brief awakenings from sleep) caused by scratching.[28]

PROGNOSIS/CLINICAL COURSE

Both diseases run a chronic course with persistence or recurrence of lesions. Exacerbations occur in response to emotional stress.

TREATMENT

Treatment is aimed at interrupting the itch–scratch cycle. Both components should be addressed. Systemic causes of itch should be identified and addressed. In

BOX 15-2 DIFFERENTIAL DIAGNOSIS OF LICHEN SIMPLEX CHRONICUS

Most Likely
- Lichenified atopic eczema
- Lichenified psoriasis
- Hypertrophic lichen planus

Consider
- Genital: extramammary Paget's disease

Always Rule Out
- Vulva, perianally: underlying lichen sclerosus, HPV, or tinea cruris
- Scrotum: underlying HPV or tinea cruris

BOX 15-3 DIFFERENTIAL DIAGNOSIS OF PRURIGO NODULARIS

Most Likely

- Perforating disease
- Hypertrophic lichen planus
- Pemphigoid nodularis
- Actinic prurigo
- Multiple keratoacanthomas

Consider

- Nodular scabies
- Dermatitis herpetiformis

both conditions, first-line measures to control itch include potent topical steroids as well as nonsteroidal antipruritic preparations such as menthol, phenol, or pramoxine. Emollients are an important adjunct. Intralesional steroids, such as triamcinolone acetonide, given in varying concentrations according to the thickness of the plaque or nodule are beneficial. Topical tacrolimus has been successfully employed as a steroid-sparing agent. Sedating antihistamines, such as hydroxyzine, or tricyclic antidepressants, such as doxepin, may be used to abolish nighttime itch in both conditions. Selective serotonin reuptake inhibitors (SSRIs) have been recommended for relief of daytime pruritus or in patients with OCD.[17]

Capsaicin, calcipotriene, and cryotherapy, with or without intralesional steroid injections, have all been successfully used in prurigo nodularis. Both broad- and narrow-band ultraviolet B, as well as topical or oral PUVA show efficacy and are indicated in widespread cases. The 308 nm excimer monochromatic light, UVA1 phototherapy, and naltrexone were all effective in small series.[29–31] Thalidomide and cyclosporine have also been shown to be beneficial.

The importance of avoiding scratching should be addressed with the patient. Nails should be kept short and occlusive measures, such as plastic films, topical steroid tape, or Unna boots in widespread cases may be needed.

KEY REFERENCES

Full reference list available at www.DIGM8.com

DVD contains references and additional content

5. Krogh HK: Nummular eczema: Its relationship to internal foci of infection. A survey of 84 case records. *Acta Derm Venereol* **40**:114-126, 1960
9. Moore MM, Elpern DJ, Carter DJ: Severe, generalized nummular eczema secondary to interferon alfa-2b plus ribavirin combination therapy in a patient with chronic hepatitis C virus infection. *Arch Dermatol* **140**:215-217, 2004
13. Krupa Shankar DS, Shrestha S: Relevance of patch testing in patients with nummular dermatitis. *Indian J Dermatol Venereol Leprol* **71**:406-408, 2005
15. Tanaka M et al: Prurigo nodularis consists of two distinct forms: Early-onset atopic and late-onset non-atopic. *Dermatology* **190**:269-276, 1995
17. Lynch PJ: Lichen simplex chronicus (atopic/neurodermatitis) of the anogenital region. *Dermatol Ther* **17**:8-19, 2004
28. Koca R et al: Sleep disturbance in patients with lichen simplex chronicus and its relationship to nocturnal scratching: A case control study. *South Med J* **99**:482-485, 2006

Chapter 16 :: Vesicular Palmoplantar Eczema

:: Daven N. Doshi, Carol E. Cheng, & Alexa B. Kimball

VESICULAR PALMOPLANTAR ECZEMA AT A GLANCE

- An acute and/or chronic dermatitis clinically characterized by small to large blisters on the palms and soles.
- Histopathology characterized by spongiotic vesicles.
- Considered an endogenous dermatitis, distinct from dermatitis caused by exogenous factors such as contact, allergy, or irritation.
- Can be divided into four categories: (1) pompholyx, (2) chronic vesiculobullous hand dermatitis, (3) hyperkeratotic hand dermatitis, and (4) id reactions.
- Does not respond well to treatment.

Vesicular palmoplantar eczema is a dermatitis of the hands and feet characterized by small to large blisters clinically and spongiotic vesicles histologically. It can manifest as either an acute or a chronic dermatitis, or both. Because clinical and histologic presentations of the variants of hand dermatitis, including vesicular palmoplantar eczema, often overlap, making a precise diagnosis can be difficult. For example, patients with pompholyx, the most acute form of vesicular palmoplantar eczema, have been noted to have higher incidence rates of both atopy and contact dermatitis than controls.

With the preceding caveat in mind, vesicular palmoplantar eczema can be divided into four categories: (1) *pompholyx*, (2) *chronic vesiculobullous hand dermatitis*, (3) *hyperkeratotic hand dermatitis*, and (4) *id reactions* (see Chapter 17). These conditions can be grouped under the category of endogenous hand dermatitis, in contrast to dermatitis clearly caused by exogenous factors such as contact allergy or irritation.

Pompholyx is a term best reserved for acute explosive outbreaks of small to large vesicles and bullae on the palms and soles. It tends to occur more often in the spring and fall, and may be associated with stress. Other etiologic factors are less well established. *Cheiropompholyx* and *podopompholyx* are terms occasionally used to describe cases affecting the palms or soles, respectively. *Chronic vesiculobullous hand dermatitis*, also known as *dyshidrotic hand eczema* or *dyshidrotic hand dermatitis*, is usually characterized by small vesicles on the lateral aspects of the fingers. "Dyshidrosis," a dysfunction of the sweat gland, was long postulated to be a cause, but its role has been subsequently disproved. However, the terminology persists and is commonly used. A third category is chronic *hyperkeratotic hand dermatitis*, an entity that generally occurs on the central palms. Unlike the other classifications of vesicular palmoplantar eczema, vesicles do not dominate the clinical presentation. However, the spongiosis observed histologically is indistinguishable from the other categories. An *id reaction* is a vesiculobullous dermatitis, generally appearing on the lateral aspects of the fingers, elicited by an infection elsewhere in the body. The most common cause is a fungal infection. Treatment of the underlying causative factor usually leads to resolution. Endogenous hand dermatitis can be exacerbated by exogenous factors, most notably irritant dermatitis and allergic contact dermatitis. In addition, atopy may in some cases predispose to the development of vesicular palmoplantar eczema.

EPIDEMIOLOGY

Differences in classification and definition have made it difficult to assess the true incidence of the endogenous hand disorders. Most studies have focused on the prevalence of exogenous hand disorders as seen in occupational settings. Pompholyx is the least common presentation of hand dermatitis; in one population study, the 1-year prevalence of pompholyx was estimated to be 0.5%.[1] In the same study, hyperkeratotic hand dermatitis represented 2% of all hand dermatoses.[1] Other studies have noted prevalence rates ranging from 1% to 5%, with the variation in the frequency of vesicular hand eczema attributable in part to the lack of a common condition.[2,3,4]

ETIOLOGY AND PATHOGENESIS

With the exception of the id reaction, a direct cause of vesicular palmoplantar eczema is rarely identified. A number of etiologic factors have been associated with pompholyx, including atopy (see Chapter 14), contact allergy (see Chapter 13), psychological stress, and hot weather.[1] Pompholyx has also been reported after ingestion of piroxicam,[5] after ingestion of certain metals in predisposed or sensitized patients most commonly nickel, cobalt, and chromate[5] and after intravenous immunoglobulin therapy, with 39 cases reported to date.[6,7] There has also been a report of five cases of photo-induced pompholyx in patients with a reported history of photo-induced disease that was reproduced when the patients were phototested with an ultraviolet A (UVA) source.[5] Histologic evaluation confirmed the diagnosis of pompholyx and a true photosensitivity rather than photoaggravation. Additionally, there has been evidence of association of vesicular hand eczema following dermatophytid from tinea pedis.[8] In a study of 398 patients with hand eczema, those with culture positive tinea pedis were found to have an increased relative risk of 3.58 ($p < 0.05$) for vesicular hand eczema.[9]

EXACERBATING FACTORS

Contact allergy is common in patients affected with vesicular palmoplantar eczema, especially the chronic type, but the causal relationship is not always clear. There are cases in which contact allergy has exacerbated preexisting hand dermatitis and also reports that ingestion of certain metals, including nickel, cobalt, and chromium, have caused flares. However, in other cases, the causal relationship may be the reverse. The skin's impaired barrier function in vesiculobullous hand dermatitis (see Chapter 47) may in some cases lead to sensitization and a higher prevalence of contact dermatitis in the affected population. Investigations into the role of atopy (see Chapter 14) have yielded mixed results. Some studies have shown levels of personal or familial atopy as high as 50% in affected subjects, compared to 11.5% of controls, but other studies have demonstrated no difference in the prevalence in people with vesiculobullous hand dermatitis versus controls.[10]

CLINICAL FINDINGS

POMPHOLYX

Figure 16-1 is an algorithm showing the approach to the patient with vesicular palmoplantar eczema. Pompholyx can even be severe enough to neces-

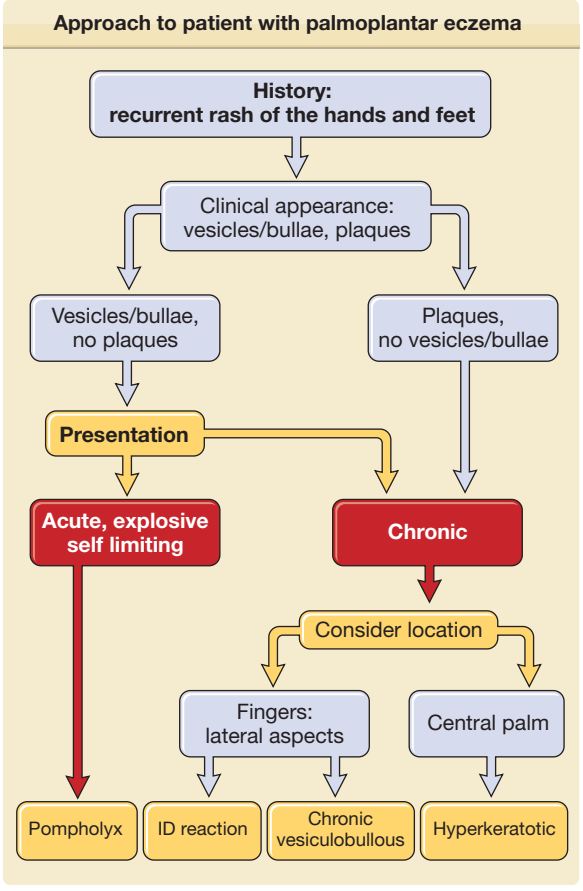

Figure 16-1 Approach to the patient with vesicular palmoplantar eczema.

sitate hospitalization. In true acute pompholyx, there is an explosive outbreak of deep-seated vesicles on the palms, the lateral aspects of the fingers (Fig. 16-2), and sometimes the soles, usually in a symmetric pattern. Discomfort and itching usually precede the development of the blisters, which have been described as having a "tapioca" appearance (see Fig. 16-3). Blisters may coalesce then desiccate and resolve without rupture (Fig. 16-4). Intact, large blisters can be drained, but should not be unroofed. However, large blisters may rupture spontaneously, leaving oozing or dried up erosions (Fig. 16-5).

This acute phase is generally followed by desquamation of the affected areas. Individual outbreaks are usually self-limited over 2–3 weeks, although they may recur. Secondary bacterial infection is common, often resulting in a local cellulitis, and can sometimes potentiate the development of lymphatic damage, resulting in lymphedema. Attacks are most common among adolescents and young adults and seem to be more common in the spring and summer months. Outbreaks have been shown to be associated with dermatophyte infection, contact dermatitis, in particular cosmetic and hygiene products, metals and internal reactivation from drugs, foods, or metals.



Figure 16-3 Chronic vesiculobullous hand dermatitis. There is a vesicular dermatitis on the lateral sides of the fingers. Note the tapioca-like, deep-seated vesicles.



Figure 16-2 Chronic dyshidrotic hand dermatitis of bilateral hands. There is hyperkeratosis of the palms and fingers sparing the dorsal hand. Deep-seated vesicles at different stages can be seen.



Figure 16-4 Cheiropompholyx. Apart from small vesicles, there are large bullae, some purulent; others have collapsed and are drying up.



Figure 16-5 Podopompholyx. Large blisters have ruptured leaving erosions that are drying up. Note large bulla on the arch of the right foot: The roof of the blister still contains tapioca-like vesicles. This is characteristic.

CHRONIC VESICULOBULLOUS DERMATITIS

Chronic vesiculobullous hand dermatitis is more common than pompholyx and more difficult to manage because of its relapsing course. The clinical presentation includes small 1- to 2-mm vesicles filled with clear fluid localizing to the lateral aspects of the fingers, palms, and soles as in pompholyx (see Fig. 16-3). As the condition becomes more chronic, the clinical appearance may evolve and subsequently appear more fissured and hyperkeratotic (as in Figs. 16-2 and 16-6). A clear history of vesicles or exacerbations characterized by blistering may help to narrow the classification of a given presentation of hand dermatitis.

HYPERKERATOTIC HAND DERMATITIS

Patients with hyperkeratotic hand dermatitis are usually male and generally present with chronic keratotic pruritic plaques, sometimes with fissures on the central palm (see Fig. 16-6). This condition may be the end result of contact allergy, excoriation, and irritation, but generally the cause is not identifiable, and contact allergy does not seem to play an important role. This hand dermatitis commonly occurs in middle-aged to elderly men and is often very refractory to treatment. Friction in lichen simplex chronicus may be an important factor in some cases. Plantar involvement is present in a minority of cases.



Figure 16-6 Hyperkeratotic hand dermatitis. There are pruritic keratotic plaques on the central palm: Occasional vesiculation and fissuring may occur.



Figure 16-7 Id reaction to tinea pedis. Erythematous, partially dried up vesicles on the foot. Lesions are very pruritic.

ID REACTION

(See Chapter 17)

In an id reaction, erythematous vesicles usually are seen on the lateral aspects of the fingers and the palms and are typically pruritic (Fig. 16-7). This eruption of vesicles is usually sudden and classically occurs in response to an intense inflammatory process, especially fungal infections, taking place somewhere else on the body. The id reaction is thought to be an allergic reaction to fungi or to some antigen created during inflammation. Treatment of the underlying infection results in resolution.

LABORATORY FINDINGS

In the diagnostic workup of vesicular palmoplantar eczema, it is important to first examine the feet to exclude a dermatophytid. Secondly, a potassium hydroxide examination of the hand should be performed to rule out tinea manuum. Finally, patch testing should be performed to rule out a contact dermatitis or a systemic reaction to a contact allergen. There are no *specific* laboratory findings characteristic of vesicular palmoplantar eczema, although IgE levels may be elevated in atopic patients.

PATHOLOGY

The histology of these entities depends on the chronicity of the disease. The primary vesicle appears

as an intraepidermal spongiotic vesicle that does not involve the acrosyringia on either conventional and electron microscopy. Lymphocytic infiltration is common in the epidermis, with a mixed infiltrate observed in the dermis. In more chronic cases, the epidermis may show hyperproliferation, hyperkeratosis, or even psoriasiform epidermal hyperplasia. Periodic acid-Schiff staining can be helpful in excluding fungal elements.

DIAGNOSIS

The diagnosis of vesiculobullous hand dermatitis is usually made on the basis of clinical presentation, history, and sometimes histology. Patch testing may be useful in helping to distinguish this entity from other palmoplantar disorders or in eliminating other exacerbating factors such as irritant exposure and contact allergy.

There are many other skin conditions of the hands and feet that can be difficult to distinguish from vesiculobullous hand dermatitis. Several of the diagnoses may also coexist.

DIFFERENTIAL DIAGNOSIS

(Box 16-1)

Allergic contact dermatitis (see Chapter 13) may be clinically indistinguishable from other forms of hand eczema, and patch testing should be considered for those with recurrent, atypical, or persistent forms of the disease. In a recent study of 422 patients with hand eczema, the ten most common allergens with positive patch testing were nickel, cobalt, thiuram mix, balsam of Peru (*Myroxylon pereirae* resin), formaldehyde, colophony, potassium dichromate, benzoyl peroxide, fragrances methylchloroisothiazolinone/methylisothiazolinone, and sesquiterpene lactone mix.[11,12] Although frequently considered, laundry detergents rarely cause allergic contact dermatitis. Irritants (see Chapter 48) are by far the most common causes of hand dermatitis that are often exacerbated by occupational exposures. The irritant dermatitis is usually symmetric and chronic, and affects the dorsal fingertips and web spaces.

Atopic hand dermatitis (see Chapter 14) is associated with a number of factors: hand dermatitis before age 15 years, persistent eczema on the body, dry or itchy skin in adult life, and widespread atopic dermatitis in childhood. The backs of the hands, particularly the fingers, are affected with erythema, vesiculation, crusting, excoriation, and scale.

Infections, most commonly from tinea, can mimic endogenous hand dermatitis. In cases of asymmetric or atypical cases, or in cases of small vesicles confined to the feet, a potassium hydroxide examination may be useful in ruling out primary tinea infection. In chronic cases of hand dermatitis, fungal and bacterial infections may be superimposed, and treatment may result in improvement of clinical symptoms. Herpes simplex may, in unusual cases, present as blisters on the hands.

Psoriasis and psoriasiform hand dermatitis (see Chapter 18) are most prominent over pressure points. Psoriasis can normally be distinguished by its sharply marginated, nummular, or circinate scaly plaques; relative lack of itching; silvery scales; and the presence of psoriasis elsewhere. Psoriasiform hand dermatitis can occur without a family or personal history of psoriasis. It is a diagnosis made primarily on clinical and histologic presentation. At times, however, it appears as though eczematous, hyperkeratotic, and psoriatic diatheses coexist. Repeated pressure or friction may cause hyperkeratosis in some individuals.

Pustular eruptions of the palms and soles (see Chapter 21) are generally easy to distinguish because, unlike the presentation of clear fluid-filled blisters and bullae of hand dermatitis, pustules are the primary lesions. For example, in pustular psoriasis, the vesicles are cloudy and painful.

Keratolysis exfoliativa (recurrent focal palmar peeling) is a chronic, asymptomatic, and noninflammatory peeling of the palms and soles, most commonly seen during the summer months. It is thought to occur more frequently in people with hyperhidrosis in these areas. Scaling usually starts from one to two fine points and expands outward to larger circular areas. The condition is usually self-limited and asymptomatic, requiring only emollients.

Bazex acrokeratosis paraneoplastica is a rare, acute, erythematous, scaling, vesiculobullous hand dermatitis with nail dystrophy associated with neoplasia, usually squamous carcinomas of the upper digestive or respiratory tracts, although there have been some reports of similar findings in patients with colon cancer and genitourinary tumors.

Other blistering diseases, such as pemphigoid, pemphigus, or epidermolysis bullosa, may affect the hands and feet, but usually do so in the setting of blisters elsewhere on the body.

BOX 16-1 DIFFERENTIAL DIAGNOSIS OF VESICULAR PALMOPLANTAR ECZEMA

Most Likely

- Allergic contact dermatitis
- Irritant contact dermatitis
- Atopic hand dermatitis
- Infections, commonly from tinea

Consider

- Bazex acrokeratosis paraneoplastica
- Psoriasis
- Psoriasiform hand dermatitis
- Pustular eruption of palms and soles
- Keratolysis exfoliativa
- Bullous disorders
- Herpes simplex (never bilateral)

BOX 16-2 TREATMENTS FOR VESICULAR PALMOPLANTAR ECZEMA

	TOPICAL	PHYSICAL	SYSTEMIC
First line	▪ Corticosteroids	▪ Ultraviolet A-1 ▪ Psoralen and ultraviolet A ▪ Narrowband ultraviolet B	▪ Prednisone ▪ Cyclosporine ▪ Mycophenolate mofetil ▪ Methotrexate ▪ Alitretinoin
Second line	▪ Drying agents ▪ Tacrolimus ▪ Pimecrolimus ▪ Retinoids ▪ Calcipotriene	▪ Grenz ray ▪ Iontophoresis ▪ Sympathectomy ▪ Intradermal botulinum toxin	▪ Entanercept
Third line			▪ Azathioprine

COMPLICATIONS

Secondary bacterial infection of the vesicles can result in cellulitis, lymphedema, and, in rare instances, septicemia.[13]

PROGNOSIS AND CLINICAL COURSE

Pompholyx tends to occur as intermittent explosive outbreaks and becomes less frequent in middle-aged individuals. The more chronic forms of vesicular palmoplantar eczema, however, are much more persistent and frustrating to manage and often require multiple therapeutic approaches over time.

TREATMENT

(Box 16-2)

Treatment of vesiculobullous hand dermatitis should be based on the acuity of the condition, the severity of the disease, the prominence of blisters versus chronic changes, and any relevant history that reveals possible cofactors.

TOPICAL THERAPY

Topical steroids, typically high potency (class 1 or 2), are usually first-line agents. They are often more effective if used under occlusion, although this approach may increase the chance of infection. Topical drying agents, such as Domeboro soaks, Burow's solutions (aluminum subacetate), or dilute potassium permanganate solution (1–8,000) may be useful in acute forms with a predominance of vesicles.

Nonsteroidal topical immunomodulating agents, such as tacrolimus and pimecrolimus, have been studied for treatment of individuals with mild to moderate chronic hand dermatitis with improvements from baseline.[5] Topical tacrolimus was shown to be as effective as momethasone furoate 0.1% ointment in a randomized, blinded trial in patients with vesicular pompholyx of the palms. After 2 weeks of treatment, the Dyshidrotic Eczema Area and Severity Index (DASI) was reduced by more than 50%.[14]

Hyperkeratotic palmar eczema is notoriously difficult to manage. Topical retinoids and calcipotriene, both of which act to regulate epidermal cell maturation, have anecdotally been shown to improve this category of hand dermatitis.[1]

SYSTEMIC THERAPY

For recurrent pompholyx and chronic vesicular dermatitis, oral prednisone may be required and is often effective if treatment is initiated early, at the onset of the itching prodrome. However, because of significant side effects, systemic glucocorticoids are typically inappropriate for long-term management. Intralesional and intramuscular steroid injections can also be considered for short-term use in acute episodes when intensive topical therapy fails.

Cyclosporine has been studied at dosing levels of 3 mg/kg/day and 5 mg/kg/day in the treatment of chronic vesicular dermatitis. Although patients showed improvement with treatment, relapses occurred shortly after discontinuation of cyclosporine.[15]

Mycophenolate mofetil has been used in the treatment of chronic vesicular dermatitis at dosing levels of 2–3 g/day (in divided doses). It has been anecdotally shown to improve chronic vesicular dermatitis that has been otherwise recalcitrant to corticosteroids, iontophoresis, and phototherapy. However, it has also been anecdotally shown to induce biopsy-proven dyshidrotic eczema.

Methotrexate has proven a useful therapy of a wide range of skin diseases. In chronic vesicular eczema,

it has been reported to partially or completely clear lesions at low doses ranging from 12.5 to 22.5 mg/week.[15] However, its wide spectrum of potential side effects remains a limiting factor to its use in this particular skin disease.

Alitretinoin, (9-*cis*-retinoic acid) is a novel retinoid with anti-inflammatory properties and one of the newer therapies under study for palmoplantar vesicular eczema. It is the only medication specifically approved for the treatment of adults with hand eczema unresponsive to topical steroids in some countries outside of the United States.[19] In a large controlled study with over 1,000 patients it was successful in the treatment of chronic hyperkeratotic hand eczema and offers another treatment option for patients refractory to treatments with corticosteroids, radiation therapy, tretinoin, isotretinoin, and acitretin.[20]

UVB, systemic, topical, and bathwater psoralen and UVA light with or without PUVA have been used in severe cases of chronic vesicular hand eczema. Studies evaluating the use of UVA-1 compared localized high-dose UVA-1 irradiation against topical cream psoralen UVA for the treatment of dyshidrotic eczema demonstrated that UVA-1 irradiation and topical PUVA showed similar beneficial responses.[23,24] In addition, the potential side effects noted with PUVA, such as phototoxic reactions and long-term carcinogenic risk, are theoretically reduced with UVA-1 therapy. UV therapy is thought to work by induction of apoptosis of T and B lymphocytes.

OTHER THERAPIES

Iontophoresis, sympathectomy, and intradermal botulinum toxin are effective therapies for hyperhidrosis and have been studied as treatments for chronic vesicular dermatitis.[15] Tap water iontophoresis with pulsed direct current showed no benefit for subjects with hand dermatitis over controls in time to improvement, but those who were treated had much longer remissions, by a factor of months.[6] Intradermal botulinum toxin A was shown to have a beneficial effect in patients with treatment-refractory vesicular dermatitis, especially in those patients whose condition was aggravated by hyperhidrosis.[25] This therapy may also be used in conjunction with topical corticosteroids.[26]

FUTURE THERAPIES

RADIATION THERAPY AND IMMUNOTHERAPY. The use of etanercept has also been shown in a case report to be successful in treatment of recalcitrant dyshidrotic eczema for a 4-month period before relapse occurred.[16]

Azathioprine has been shown to be efficacious in a study that included six patients with pompholyx; however, a separate case study of its use reported development of myelotoxicity.[17,18]

Superficial radiotherapy (Grenz ray) is still sometimes used at a few centers. This condition may be one of the last indications for this treatment modality, and has been shown to be successful in some patients with resistant chronic eczema of the hand in a double-blind study.[14] Megavoltage radiation therapy (1,200 cGy) has also been tried in patients with severe chronic vesicular hand dermatitis with moderate success in long-term remission.[21,22]

LEUOKOTRIENE INHIBITORS. Leukotriene receptor antagonists and inhibitors are oral medications that act by inhibiting proinflammatory mediators in the 5-lipoxygenase pathway and have been shown to block the effects of leukotrienes successfully in asthma, allergic rhinitis, and recently in atopic dermatitis. No specific trial has been reported yet with these medications on pompholyx.

Phosphodiesterases-4 (PDE4) modulate the release of inflammatory mediators and have recently been investigated as a novel therapeutic approach in the treatment of inflammation-associated diseases. Animal models of PDE4 inhibitors have displayed strong anti-inflammatory action in models of allergic contact dermatitis. The safety and efficacy in pompholyx has yet to be evaluated.

Tumor necrosis factor inhibitors (e.g., infliximab) have been successful for treatment of psoriatic arthritis and psoriasis, among other chronic inflammatory diseases. No data is available on pompholyx.

Two severity indices, (1) the dyshidrosis area and severity index and (2) the total sign and symptoms score, have been validated and may prove useful in clinical trials to better assess the effectiveness of these and future therapies.

PREVENTION

Prevention is a critical part of therapy in most cases, especially when known exacerbating factors are present. Avoidance of commonly encountered allergens, such as foods and plants, and irritants, such as soaps, solvents, acids, and alkalis, can be helpful. Vinyl gloves, rather than latex, are recommended because of the risk of either having an underlying allergy or of developing one in the setting of impaired barrier function. Patch testing may be considered for patients to identify relevant allergens. Modification of environmental exposure to exacerbating factors, such as friction and cold air, may also help with persistent or refractory disease. Frequent use of emollients, specifically novel barrier creams or ointments, help to preserve the normal skin-barrier function. Maintaining a low-cobalt diet has been suggested to decrease the number of dyshidrotic flares.[28]

KEY REFERENCES

Full reference list available at www.DIGM8.com

DVD contains references and additional content

1. Agrup G: Hand eczema and other hand dermatoses in South Sweden [thesis]. *Acta Derm Venereol* **49**(Suppl. 61): 1-91, 1969

6. Lehucher-Michel MP et al: Dyshidrotic eczema and occupation: A descriptive study. *Contact Derm* **43**:200, 2000
9. Meding B, Swanbeck G: Epidemiology of different types of hand eczema in an industrial city. *Acta Derm Venereol* **69**:227, 1989
11. Ogden S: Recalcitrant hand pompholyx: Variable response to entanercept. *Clin Exp Dermatol* **31**:145-146, 2006
14. Polderman MCA et al. A double-blind placebo-controlled trial of UVA-1 in the treatment of dyshidrotic eczema. *Clin Exp Dermatol* **28**:584-587, 2003
16. Scerri L: Azathioprine in dermatological practice. An overview with special emphasis on its use in non-bullous inflammatory dermatoses. *Adv Exp Med Biol* **455**:343-348, 1999
20. Swartling C et al: Treatment of dyshidrotic hand dermatitis with intradermal botulinum toxin. *J Am Acad Dermatol* **47**:667, 2002
23. Vecchietti G et al: Severe eczematous skin reaction after high-dose intravenous immunoglobulin infusion: Report of 4 cases and review of the literature. *Arch Dermatol* **142**(2):213-217, 2006
25. Veien NK: Acute and recurrent vesicular hand dermatitis. *Dermatol Clin* **27**:337-353, 2009

Chapter 17 :: Autosensitization Dermatitis

:: Donald V. Belsito

AUTOSENSITIZATION DERMATITIS AT A GLANCE

- An acute disorder triggered by infection, stasis and contact dermatitides, ionizing radiation, blunt trauma, and retained suture material.
- Widespread, pruritic, usually papulovesicular eruption, most frequently affecting the extremities.
- Related features are those of the precipitating disorder.
- Pathology is nondiagnostic and most often consistent with an acute spongiotic process of the epidermis with a superficial, perivascular, lymphohistiocytic infiltrate of the dermis containing occasional eosinophils.

EPIDEMIOLOGY

Autosensitization dermatitis refers to a phenomenon in which an acute dermatitis develops at cutaneous sites distant from an inflammatory focus, and where the secondary acute dermatitis is not explained by the inciting cause of the primary inflammation. The classic presentation of autosensitization is that seen in patients with venous stasis disease,[1] where as many as 37% of patients have been reported to develop at least one episode of autosensitization,[2] and those with dermatophyte infections, where 4–5% reported having had dermatophytid reactions.[3]

ETIOLOGY AND PATHOGENESIS

The term *autosensitization dermatitis* was coined in 1921 by Whitfield to describe reaction patterns ranging from a generalized, erythematous, morbilliform, and urticarial eruption after blunt trauma to a generalized, petechial, papulovesicular dermatitis after the acute irritation of chronic stasis dermatitis.[4] Subsequently, the vesicular id reactions associated with infections caused by tuberculosis,[5] histoplasmosis,[6] dermatophytes,[7] and bacteria[8] were included under this rubric.[9–11] Noneczematous reaction patterns, including erythema multiforme[12] and neutrophilic lobular panniculitis,[13] have also been ascribed to autosensitization associated with various infections. Other precipitating factors for autosensitization have included the application of irritant or sensitizing chemicals,[14] ionizing radiation,[15,16] and retained suture material.[17]

Although the disease was originally thought to be due to autosensitization to epidermal antigens,[11] this concept has not been experimentally verified. In murine studies designed to determine whether keratinocyte-derived proteins can serve as antigenic carriers for hapten, Fehr et al[18] derived major histocompatibility complex-restricted, T-cell receptor α/β, $CD4^+$ T-cell clones that proliferated in response to keratinocyte extracts unconjugated to hapten. In these studies, such autoreactive T-cell clones could not be derived after treatment with irritants. Nonetheless, the authors speculated that T cells autoreactive to keratinocyte antigens may be generated during the course of contact hypersensitivity and lead to the development of an id reaction.

In the most extensive study to date,[1] only 4 of 81 patients with autosensitization dermatitis had serum antibodies cytotoxic to autologous or homologous skin. However, the role of such autoantibodies in mediating the disorder, even in these four patients, must be interpreted cautiously, given the high frequency of epidermal autoantibodies in the normal adult population.[19]

In an experiment in which guinea pigs were injected with autologous skin, Wilhelmj et al[20] reported dermatitis in 2 of 11 guinea pigs, but it was not clear whether these reactions were immunologic and, if so, what the

causal allergen(s) was. Other investigators using similar techniques have been unable to induce cutaneous disease in animals by means of epidermal extracts.[21] In contrast, 19 of 24 patients with active autosensitization who were intradermally challenged with water-soluble extracts of autologous epidermal scale developed a reaction.[22]

The term *autosensitization* is probably a misnomer. The disease is more likely due to a hyperirritability of the skin induced by either immunologic or nonimmunologic stimuli. Factors such as irritation, sensitization, infection, and wounding, which are known to precipitate autosensitization, have been reported to release a variety of epidermal cytokines.[23,24] Once hematogenously disseminated in sufficient amounts, these cytokines could heighten the sensitivity of skin to a variety of nonspecific, but otherwise innocuous, stimuli, producing a pattern of "spillover" reactions[25] that have been classically termed *autosensitization*. Such a hypothesis would account for (a) the results in humans of delayed-type hypersensitivity testing with autologous epidermal scale,[22] (b) the histopathologic findings noted in the disease (see section "Clinical Findings"), and (c) the activated T lymphocytes occasionally observed in the blood of patients with autosensitization.[26] The characteristic distribution of the disease might perhaps be explained if the skin overlying the arms and legs was found to contain increased numbers of, or more avid receptors for, various cytokines than the skin of the face or hands. Such a geographic variation in the distribution of bullous pemphigoid antigen has been observed and hypothesized to account for the clinical patterns of this autoimmune disease.[27] Application of modern biotechnological tools should provide insight into the mysteries of autosensitization.

CLINICAL FINDINGS

Typically, 1 to 2 weeks after an acute inflammation, an extremely pruritic, symmetric, scattered, erythematous eruption with macules, papules, and vesicles develops (Fig. 17-1). The eruption involves the forearms, thighs, legs, trunk, face, hands, neck, and feet in descending order of frequency.[2,11] During the evolution of the dermatitis, its morphology may change in a manner consistent with the chronicity (i.e., vesicles to scale). Histopathologically, the findings are not pathognomonic: spongiotic epidermal vesicles



Figure 17-1 Stasis dermatitis with autosensitization. An elderly woman with a long-standing history of stasis dermatitis presented with gradual worsening of the edema; pruritus; and multiple, punctate, superficial, excoriated ulcers overlying the medial malleoli (**A**). Nine days after the ulcers appeared, she developed an acute, extremely pruritic, erythematous, papulovesicular eruption over the forearms (**B**), which progressively involved the upper arms, upper torso, and hands. The acute papulovesicular dermatitis also involved the lower extremities and can be noted overlying the chronic stasis dermatitis (**A**).

BOX 17-1 DIFFERENTIAL DIAGNOSIS

Most Likely

- Allergic contact dermatitis
- Irritant contact dermatitis
- Atopic dermatitis
- Nummular dermatitis

Consider

- Polymorphous light eruption
- Pityriasis rosea
- Eruptive (guttate) psoriasis

Always Rule Out

- Infectious processes
  - Dermatophyte infections
  - Scabies and other mite infestations
  - Viral exanthems
- Drug eruptions

associated with a superficial, perivascular lymphohistiocytic infiltrate of the dermis, which may contain scattered eosinophils.[28] Immunophenotypic studies of skin have revealed that most of the lymphocytes in the epidermis are $CD3^+$ and $CD8^+$ T cells, whereas those in the dermis are primarily $CD4^+$.[25] In the majority of individuals with autosensitization,[1] deposition of antibody or complement in affected skin is not detected.

As previously mentioned, noneczematous autosensitization patterns have also been reported. Both erythema multiforme[12] and neutrophilic lobular panniculitis[13] have been reported to be induced by a variety of infectious processes. The histology in these cases is consistent with the reaction pattern for erythema multiforme and lobular panniculitis, respectively.

DIFFERENTIAL DIAGNOSIS

See Box 17-1.

PROGNOSIS AND CLINICAL COURSE

The eruption often persists and spreads until the underlying causative primary site of inflammation is treated.

TREATMENT

Treatment is best directed toward the inciting disease. The frequently weeping, vesicular eruption of autosensitization benefits from drying agents such as aluminum sulfate and calcium acetate. Given the likely involvement of cytokines and inflammatory mediators sensitive to glucocorticoids[29] or macrolactams,[30] systemic and/or topical treatment with these drugs may be helpful. To prevent the secondary effects of excoriation, pruritus must be controlled with topical antipruritic agents or oral antihistamines. However, one must remain alert to the possibility of inducing an allergy in existing dermatitic skin with topical medicaments.

KEY REFERENCES

Full reference list available at www.DIGM8.com

DVD contains references and additional content

1. Parish WE et al: A study of auto-allergy in generalized eczema. *Br J Dermatol* **77**:479, 1965
2. Haxthausen H: Generalized "ids" ("autosensitization") in varicose eczema. *Acta Derm Venereol (Stockh)* **35**:271, 1955

12. Atzori L, Pau M, Aste M: Erythema multiforme ID reaction in atypical dermatophytosis: A case report. *J Eur Acad Dermatol Venereol* **17**:699, 2003
13. Magro CM, Dyrsen ME, Crowson AN: Acute infectious id panniculitis/panniculitic bacterid: A distinctive form of neutrophilic lobular panniculitis. *J Cutan Pahtol* **35**:941, 2008

16. Linn J et al: Radiotherapy-induced id reaction. *Am J Clin Oncol* **28**:105, 2005
18. Fehr BS et al: T cells reactive to keratinocyte antigens are generated during induction of contact hypersensitivity in mice. A model for autoeczematization in humans? *Am J Contact Dermat* **11**:145, 2000

23. Williams IR, Kupper TS: Immunity at the surface: Homeostatic mechanisms of the skin immune system. *Life Sci* **58**:1485, 1996

Chapter 18 :: Psoriasis

:: Johann E. Gudjonsson & James T. Elder

PSORIASIS AT A GLANCE

- Worldwide occurrence: Affects 2%–3% of Americans; prevalence ranges from 0.1% to 3% in various populations.
- A chronic disorder with polygenic predisposition combined with triggering environmental factors such as trauma, infection, or medication.
- Erythematous scaly papules and plaques; pustular and erythrodermic eruptions occur.
- Most common sites of involvement are scalp, elbows, knees, hands, feet, trunk, and nails.
- Psoriatic arthritis occurs in 10%–25% of patients; pustular and erythrodermic forms may be associated with fever.
- Pathology is characterized by uniform elongation of the rete ridges, with dilated blood vessels, thinning of the suprapapillary plate, and intermittent parakeratosis. Epidermal and perivascular dermal infiltrates of lymphocytes, with neutrophils occasionally in aggregates in the epidermis.

EPIDEMIOLOGY

PREVALENCE

Psoriasis is universal in occurrence. However, its prevalence in different populations varies from 0.1% to 11.8%, according to published reports.[1] The highest reported incidences in Europe have been in Denmark (2.9%) and the Faeroe Islands (2.8%). A recent study of 1.3 million Germans found a prevalence of 2.5%.[2] Similar prevalence (ranging from 2.2% to 2.6%) has been measured in the United States. A higher prevalence in East Africans as opposed to West Africans may explain the relatively low prevalence of psoriasis in African-Americans (1.3% vs. 2.5% in white Americans).[3] The incidence of psoriasis is also low in Asians (0.4%), and in an examination of 26,000 South American Indians, not a single case was seen. Psoriasis is equally common in males and females.[4,5]

AGE OF ONSET

Psoriasis may begin at any age, but it is uncommon under the age of 10 years. It is most likely to appear between the ages of 15 and 30 years. Possession of certain HLA Class I antigens, particularly *HLA-Cw6*, is associated with an earlier age of onset and with a positive family history. This finding led Henseler and Christophers[6] to propose that two different forms of psoriasis exist: type I psoriasis, with age of onset before 40 years and HLA-associated, and type II, with age of onset after 40 years and lacking HLA associations, although many patients do not fit into this classification. There is no evidence that type I and type II psoriasis respond differently to treatment.

ETIOLOGY AND PATHOGENESIS

Psoriasis is a chronic inflammatory skin disease, with a strong genetic basis, characterized by complex alterations in epidermal growth and differentiation and multiple biochemical, immunologic, and vascular abnormalities, and a poorly understood relationship to nervous system function. Its root cause remains unknown. Historically, psoriasis was widely considered to be a primary disorder of keratinocytes. With the discovery that the T-cell specific immunosuppressant cyclosporine A (CsA) was highly active against psoriasis, research became more focused on T cells and the immune system. Nevertheless, accumulating evidence shows that keratinocytes are an integral part of the cutaneous immune reponse in psoriasis.[7]

PATHOGENESIS OF PSORIASIS

DEVELOPMENT OF LESIONS. Detailed light, electron microscopic, immunohistochemical, and molecular studies of involved and uninvolved skin of both newly appearing and established psoriatic lesions provide a useful framework for inferring cause-and-effect relationships between the many cellular events that take place in a psoriatic lesion. They are illustrated schematically in Fig. 18-1 and with actual photomicrographs in Fig. 18-2.

Uninvolved Psoriatic Skin. The normal-appearing skin of psoriatic patients has long been known to manifest subclinical morphologic and biochemical changes, particularly involving lipid biosynthesis.[67,68] These changes were predominantly found in the stratum corneum and included changes in the levels and composition of phospholipids, free α-amino acids, hydrolytic enzymes, and several dehydrogenases. These changes led to the use of the term "histochemical parakeratosis" to describe these findings.[67] Much more recent studies using microarray technology to search for differences in gene expression between normal and uninvolved psoriatic skin have identified groups of coordinately regulated genes involved in lipid biosynthesis and innate immune defense.[69]

Development of psoriatic lesions

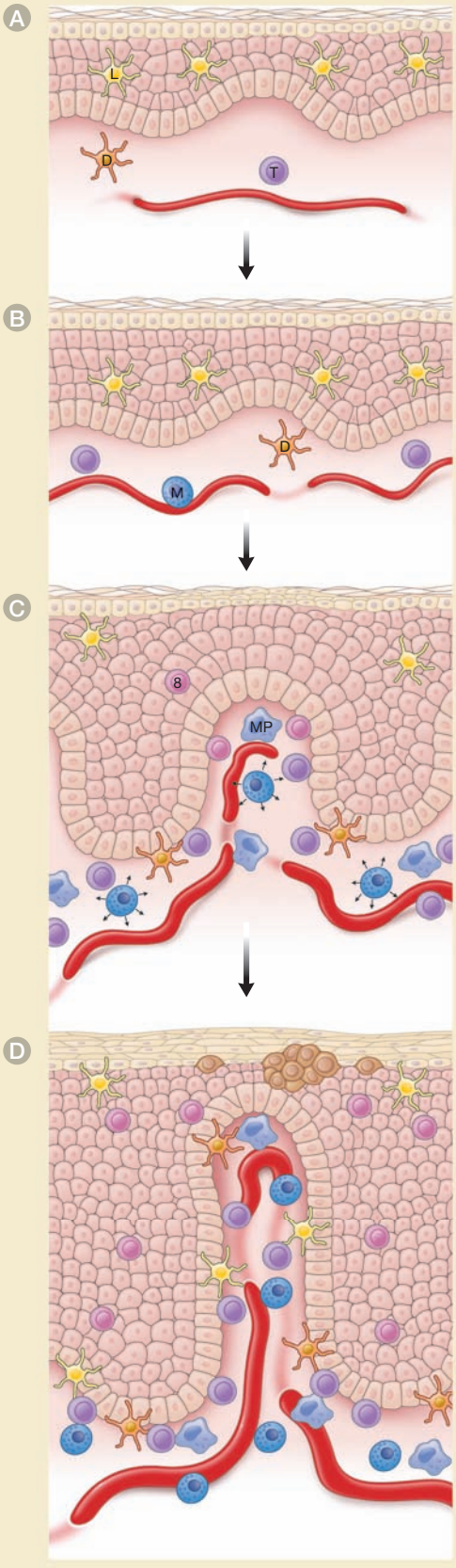

Figure 18-1 Development of psoriatic lesions. This figure depicts the transition from normal skin to fully developed lesion described in the text. Normal skin from a healthy individual (*panel* **A**) contains epidermal Langerhans cells, scattered immature dendritic cells (D), and skin-homing memory T cells (T) in the dermis. Normal-appearing skin from a psoriatic individual (*panel* **B**) manifests slight capillary dilatation and curvature, and a slight increase in the numbers of dermal mononuclear cells and mast cells (M). A slight increase in epidermal thickness is usually present. In chronic plaque psoriasis, the intensity of these changes may depend on distance from an established lesion. The transition zone of a developing lesion (*panel* **C**) is characterized by progressive increases in capillary dilatation and tortuosity, numbers of mast cells, macrophages (MP), and T cells, and mast cell degranulation (small arrows). In the epidermis, there is increasing thickness with increasingly prominent rete pegs, widening of the extracellular spaces, transient dyskeratosis, spotty loss of the granular layer, and parakeratosis. Langerhans cells (L) begin to exit the epidermis, and inflammatory dendritic epidermal cells (I) and $CD8^+$ T cells (8) begin to enter the epidermis. The fully developed lesion (*panel* **D**) is characterized by fully developed capillary dilatation and tortuosity with a tenfold increase in blood flow, numerous macrophages underlying the basement membrane, and increased numbers of dermal T cells (mainly $CD4^+$) making contact with maturing dermal dendritic cells (D). The epidermis of the mature lesion manifests markedly increased (approximately tenfold) keratinocyte hyperproliferation extending to the lower suprabasal layers, marked but not necessarily uniform loss of the granular layer with overlying compaction of the stratum corneum and parakeratosis, increased numbers of $CD8^+$ T cells, and accumulation of neutrophils in the stratum corneum (Munro's microabscesses).

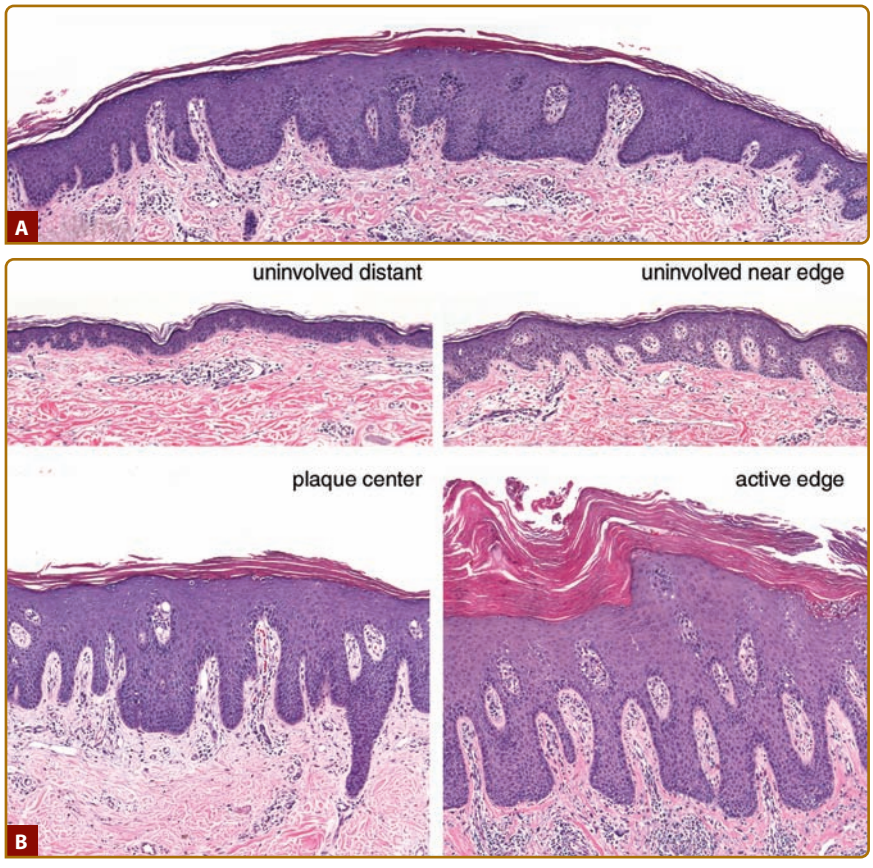

Figure 18-2 Histopathology of psoriasis. **A.** Pinpoint papule of psoriasis. In the transition from the edges to the center of the lesion, note progressive thickening of epidermis with elongation of rete pegs, increasing dilatation and tortuosity of vessels, and increasing mononuclear cell infiltrate. Also note the transition from basket-weave to compact stratum corneum with loss of granular layer in the center of the lesion. (4-mm punch biopsy, hematoxylin and eosin, scale bar = 100 µM.) **B.** Comparison of uninvolved versus involved skin. Four 4-mm biopsies were taken from the same individual sampled in **A** on the same day. "Uninvolved distant" skin was taken from the upper back 30 cm from the nearest visible lesion of psoriasis. "Uninvolved near edge" skin was taken 0.5 cm from the edge of a 20-cm plaque, which had been present for several years, according to the patient. "Center plaque" skin was taken from a relatively inactive (less red and scaly) area in the center of this plaque. "Involved edge" skin was taken from an active (more red and scaly) area about 1 cm inside the edge of the same plaque. In comparing "uninvolved distant" to "uninvolved near edge" skin, note that the latter manifests increased thickness and early elongation of the rete pegs, dilatation and early tortuosity of blood vessels, and increased numbers of mononuclear cells in the upper dermis, many of which are in a perivascular location. In this patient, "uninvolved near edge" skin also manifests an increased frequency of dyskeratotic keratinocytes, a finding that has been noted previously at the periphery of psoriatic lesions.[53] In comparing less active to more active areas of the plaque, note that the more active area manifests increased dermal mononuclear infiltrate, increased hyperkeratosis and parakeratosis, and Munro's microabscesses. (4-mm punch biopsies, hematoxylin, and eosin, scale bar = 100 µM.)

Initial Lesion. In the initial pinhead-sized macular lesions there is marked edema, and mononuclear cell infiltrates are found in the upper dermis.[70] These findings are usually confined to the area of one or two papillae. The overlying epidermis soon becomes spongiotic, with focal loss of the granular layer. The venules in the upper dermis dilate and become surrounded by a mononuclear cell infiltrate.[67] Similar findings have been described in early macules and papules of psoriasis[71] and in clinically normal-appearing skin 2–4 cm away from any active lesion in patients undergoing an acute flare of guttate psoriasis.[72]

Developing Lesion. Studies of the clinical margins of somewhat larger lesions (0.5–1.0 cm) reveal an approximately 50% increase in epidermal thickening in the "normal-appearing" skin immediately adjacent to lesions.[67] There is a large increase in the metabolic activity of epidermal cells, including the stratum corneum, increased DNA synthesis, an increased number of mast cells and dermal macrophages, and increased mast cell degranulation.[67,73,74] Subsequent studies revealed increased numbers of dermal T cells[75] and dendritic cells (DCs)[76] in both uninvolved and involved psoriatic skin relative to normal skin. Toward the center of the lesion, a "marginal zone" can be identified, with increasing band-like epidermal thickness, increasing parakeratosis and capillary elongation, and perivascular infiltration of lymphocytes and macrophages, without exudation into the epidermis. More centrally,

rete ridges begin to develop in the marginal zone, before finally transitioning into the fully developed psoriatic plaque. Squamous cells manifest enlarged extracellular spaces with only a few desmosomal connections. Parakeratosis is typically mounded or spotty.

Mature Lesion. Mature lesions of psoriasis are characterized by uniform elongation of rete ridges, with thinning of the epidermis overlying the dermal papillae.[67,71] Epidermal mass is increased three to five times, and many more mitoses are observed, frequently above the basal layer. About 10% of basal keratinocytes are cycling in normal skin, whereas this value rises to 100% in lesional psoriatic skin.[77] Widening of the extracellular spaces between keratinocytes persists but is less prominent than in developing lesions and is more uniform than the typical spongiosis of eczematous skin lesions. The tips of the rete ridges are often clubbed or fused with adjacent ones, with thin, elongated, edematous papillae containing dilated, tortuous capillaries. Parakeratosis, with accompanying loss of the granular layer, is often horizontally confluent but may alternate with orthokeratosis,[78] and hyperkeratosis is more extensive than in the transitional zone. The inflammatory infiltrate around the blood vessels in the papillary dermis becomes more intense but still consists of lymphocytes, macrophages, DCs, and mast cells. Unlike the initial lesion and the transitional zone, lymphocytes are observed in the epidermis of the mature lesion. Neutrophils exit from the tips of a subset of dermal capillaries (the "squirting papillae"), leading to their accumulation in the overlying parakeratotic stratum corneum (Munro's microabscesses) and, less frequently, in the spinous layer (spongiform pustules of Kogoj). Collections of serum can also be seen in the epidermis and the stratum corneum.[67,71]

CELLULAR PARTICIPANTS IN PSORIASIS

T Cells.[79,80] In 1984, it was demonstrated that the eruption of psoriatic skin lesions coincided with epidermal influx and activation of T cells,[75] and shortly thereafter it was further shown that resolution of psoriasis during phototherapy was preceded by depletion of T cells, predominantly from the epidermis.[81] Several studies found CsA to be highly effective in psoriasis,[82,83] and this effect was demonstrated to be primarily through blockade of T cells rather than keratinocytes.[84] Furthermore, psoriasis has been triggered or cured by bone marrow transplantation, depending on whether the donor or the host was psoriatic.[85,86] The role of T cells in psoriasis was functionally demonstrated in 1996 when it was shown that the psoriasis process could be induced by injecting activated autologous T cells into uninvolved psoriatic skin transplanted onto severe combined immunodeficient mice.[87] Available data indicate that the T-cell responses are antigen-specific rather than mediated by superantigens, as clonal populations of both $CD4^+$ and $CD8^+$ T cells have consistently been identified in psoriatic lesions.[88–91] However, most of the T cells in a psoriatic lesion are not clonally expanded and may accumulate in response to the cytokine environment of the lesion. There is virtually no evidence for B-cell involvement or antibody-mediated processes in psoriasis.

The best-characterized T cells are the $CD4^+$ and $CD8^+$ subsets. Predominantly of the memory phenotype ($CD45RO^+$), these cells express the cutaneous lymphocyte antigen (CLA), a ligand for E-selectin, which is selectively expressed on skin capillaries and therefore provides them with access to the skin.[92] $CD8^+$ T cells are predominantly located in the epidermis, whereas $CD4^+$ T cells are predominantly located in the upper dermis.[93,94] The cytokine profile of psoriatic lesions is rich in interferon (IFN)-γ,[95] indicative of T helper 1 (Th1) polarization of $CD4^+$ cells, and T cytotoxic 1 (Tc1) polarization of $CD8^+$ cells[96] (Fig. 18-3). Two other subsets of $CD4^+$ T cells, stimulated by IL-23 and characterized by production of IL-17 (Th17 cells) and/or IL-22 (Th22 cells), are also found in psoriatic lesions and have been shown to play a major role in maintaining chronic inflammation in psoriasis[97,98] as well as other autoinflammatory conditions.[99–101] While the majority of CD4 T cells are Th1, about 20% of them produce IL-17 (Th17) and ~15% produce IL-22 (Th22).[98] Similarly, $CD8^+$ epidermal T cells producing IFN-γ (Tc1), IL-17 (Tc17), and IL-22 (Tc22) are found in psoriasis.[98] These T-cell subsets have considerable functional plasticity and conversions of Tc17 to Tc1[102] and Th17 to Th1[103–105] have been described. In mice most Th17 cells also elaborate IL-22, which mediates dermal inflammation and epidermal hyperplasia after intracutaneous injection of IL-23.[106] However, in humans, this overlap is much less pronounced, with largely distinct populations of Th17 and Th22 cells.[98,107–109]

Regulatory T cells suppress immune responses in an antigen-specific fashion, and are responsible not only for downregulating successful responses to pathogens but also for the maintenance of immunologic tolerance.[110] Several different populations of regulatory T cells (T-regs) exist but the best characterized one is the $CD4^+$ $CD25^+$ subset.[111] A recent study of this subset in psoriasis demonstrated impaired inhibitory function and failure to suppress effector T-cell proliferation,[112] possibly due to a tissue environment rich in IL-6 produced by endothelial, dendritic, and Th17 cells.[113]

Natural killer T cells (NKT cells) are a heterogeneous subpopulation of T lymphocytes defined by coexpression of the T-cell receptor (TCR) and natural killer (NK) lineage markers such as CD16, CD56, CD57, CD94, and CD161. Unlike conventional T cells, NKT cells recognize glycolipid antigens in the context of the MHC Class I-like antigen-presenting molecule CD1d. NKT cells constitute only a small fraction of lymphocytes. Nevertheless, their ability to rapidly secrete large amounts of cytokines, including IFN-γ, IL-4, IL-2, IL-5, IL-10, IL-13, IL-17, and TNF-α, positions them as potentially important regulators of T-cell differentiation at sites of inflammation. While NKT cells are increased in psoriatic lesions relative to uninvolved or normal skin, their precise role in psoriasis remains unclear.[114]

Natural Killer Cells. Like NKT cells, NK cells are major producers of IFN-γ and serve as a bridge

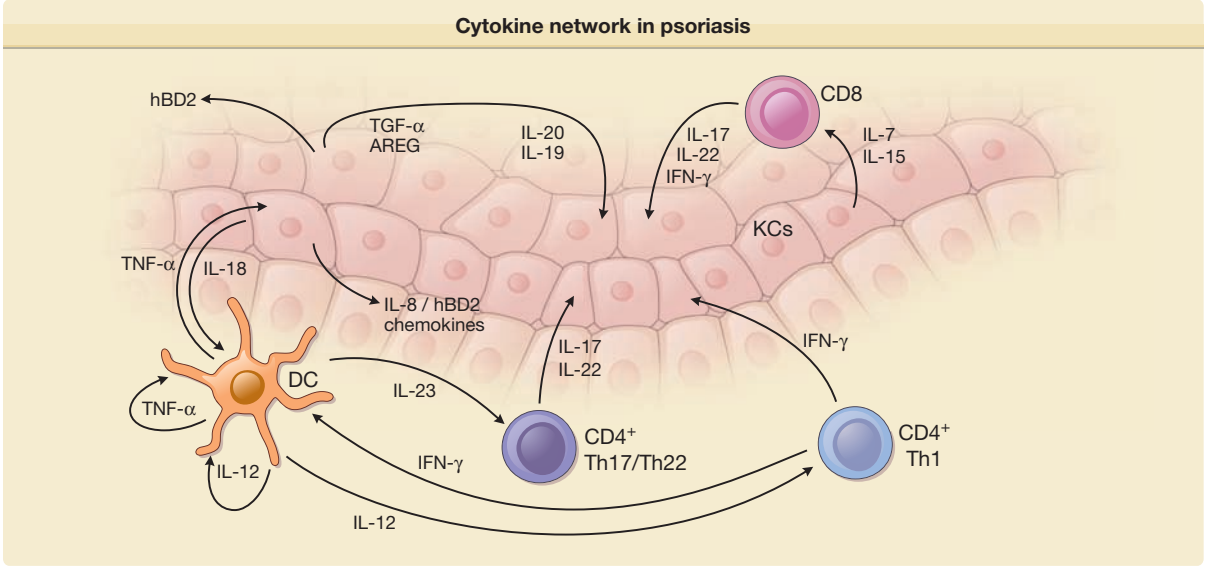

Figure 18-3 The cytokine network in psoriasis. IFN-γ is produced by Th1 cells, and TNF-α is produced by activated T-cells and DCs. IFN-γ amplifies the production of IL-23 by DC. In turn, IL-23 maintains and expands subsets of $CD4^+$ T cells, called Th17 and Th22 cells, which are characterized by production of IL-17 and IL-22, respectively. CD8+ T cells are predominantly found in the epidermis, and their entry into the epidermis is necessary for lesion development. IL-17, TNF-α, IFN-γ, and IL-22 synergistically promote activation of the innate keratinocyte defense response involving secretion of antimicrobial peptides such as human-β-defensin 2 (hBD-2), IL-8 and other chemokines, and growth factors such as TGF-α, AREG, IL-19, and IL-20. Keratinocytes also produce IL-7 and IL-15, which influence the survival and turnover of CD8+ T cells, and IL-18, which via IL-12 causes DC to further increase the production of IFN-γ by T-cells.

between innate and acquired immunity. Unlike NKT cells, NK cells do not express the T-cell receptor. NK cells are present in psoriasis,[115,116] and can trigger the formation of psoriasis lesions in a xenograft model system.[117] NK cells are regulated in part by killer immunoglobulin-like receptors (KIRs), which recognize HLA-C and other MHC Class I molecules. KIRs are a family of ~15 closely linked genes located on chromosome 19q13.4,[118] some of which stimulate and others of which inhibit NK cell activation. KIR genes have been associated with psoriasis[119–121] and psoriatic arthritis.[122,123] It has been proposed that susceptibility to psoriatic arthritis is determined by the overall balance of activating and inhibitory genotypes.[121,124] Although it is attractive to speculate that the association of psoriasis with *HLA-Cw6* might reflect a KIR-mediated dysregulation of NK cells, it is known that a number of other HLA-C protein alleles recognize the same inhibitory receptor (*KIR2DL1*), including HLA-Cw2, HLA-Cw4, HLA-Cw5, HLA-Cw15, and HLA-Cw17. Thus, it is not straightforward to explain the action of HLA-Cw6 in psoriasis on the basis of KIR recognition alone.

Dendritic Cells. Treatments directed primarily against key costimulatory molecules expressed by "professional" antigen-presenting DCs markedly improve psoriasis.[79] This suggests that T cells in psoriatic lesions are in constant communication with DCs, which have a role in both the priming of adaptive immune responses and the induction of self-tolerance[125] (see Chapter 10). Several subsets of DCs have been defined, and many of these are found in markedly increased numbers within psoriatic lesions.[125–128] Although DCs are believed to be central to the pathogenesis of psoriasis, the specific role of each subset is still somewhat unclear.

Langerhans Cells. Usually defined by a $Langerin^+$, $CD1a^+$ surface phenotype, Langerhans cells (LCs) are considered to be immature DCs (iDCs). LCs have a well-defined role as antigen-presenting cells (APCs) in contact dermatitis,[129] but their role in psoriasis is currently somewhat unclear. While the density of LC is decreased in lesional psoriasis in terms of cells per unit area,[126,130] the number of LC per unit length of epidermis is similar in normal, uninvolved, and lesional skin.[128] DCs lacking the characteristic Birbeck granule but positive for the maturation molecule DC-LAMP found in the dermis of psoriatic lesions could be derived from epidermal or dermal iDC.[131] Recently, LC have been shown to preferentially drive Th22 differentiation, relative to dermal DC.[132] Interestingly, migration of LCs in response to inflammatory cytokines is markedly impaired in uninvolved psoriatic epidermis relative to normal skin,[133] especially in type I (early onset) psoriasis.[134]

Dermal Dendritic Cells. Dermal DCs do not express activation markers in resting normal skin and in that context can be considered as another type of iDC that is similar to myeloid iDCs found in other tissues.[128,135] Immunophenotyping studies have revealed that the population of dermal DCs is quite complex, and that psoriasis lesions demonstrate a marked increase in the number and maturation state of dermal DC.[126,136,137]

Identified initially by strong expression of MHC Class II and/or factor XIIIa,[138] it is now appreciated that factor XIIIa+ cells are macrophages rather than DCs, and that the most reliable marker for myeloid-derived dermal DC is CD11c.[139] There appears to be three types of myeloid-derived ($CD11c^+$) DCs in psoriasis lesions.[128,139,140] The first is the population of "resident" dermal DCs that are also seen in normal skin. These $CD11c^+/CD1c^+$ DC account for about 10%–15% of DCs in psoriasis lesions. These cells are relatively more mature than inflammatory DCs (see Section "Inflammatory Dendritic Epidermal Cells"), but less so than fully mature DCs. The second population comprises mature DCs that are marked by DC-LAMP or CD83. The $DC\text{-}LAMP^+$ DCs form large aggregates with T cells in the dermis, whereas the $CD83^+$ DCs are more diffuse. It has been suggested that fully mature DCs may be the sustaining force for chronic T-cell activation in skin and the characteristics of these cells are very similar to those in lymph nodes.[128,139–141] The third population of myeloid DCs are the inflammatory DCs, which are $CD11c^+/CD1c^-$, and are less mature than the resident $CD1c^+$ subset. These cells make IL-23 and probably help drive Th17 differentiation.[142] About 80%–90% of DCs in psoriasis lesions are these relatively immature, inflammatory DCs and, interestingly, the total number of these cells can exceed the number of T cells in lesions. A subset of these inflammatory DC express high levels of TNF-α and iNOS, and by analogy to similar if not identical cells in mice, have been called "TIP-DC" (for TNF-α and iNOS-producing DC). Consistent with our recent genetic findings,[64] TIP-DCs are increased up to 30-fold in psoriatic lesions.[128] There appears to be substantial plasticity in this population of cells, as the cytokine milieu in atopic dermatitis promotes the emergence of dermal DC that chemotactically attract a different subset of T cells than those found in psoriasis.[143]

Inflammatory Dendritic Epidermal Cells. Thought to be either monocyte-derived iDCs,[144] or a variant of inflammatory myeloid DC that migrate into the epidermis,[145] inflammatory dendritic epidermal cells (IDECs) are distinguished from LCs by the lack of Birbeck granules and lower expression of CD1a. Unlike LCs, IDECs are nearly absent in normal skin, and their numbers are markedly increased in the epidermis of active psoriasis lesions, as well as a large number of other inflammatory dermatoses.[126,130]

Plasmacytoid Dendritic Cells. Plasmacytoid DCs (pDCs) are inefficient presenters of antigens to T cells. However, they regulate inflammation and link innate with adaptive immunity, producing large amounts of IFN-α when activated[146] (see Chapter 10). Absent from normal skin, pDCs are significantly increased in both uninvolved and involved psoriatic skin, but activated only in involved skin.[126,147] Interestingly, inhibition of pDCs was shown to prevent development of psoriasis in a mouse xenograft model.[147] Conversely, imiquimod, which has been reported to exacerbate psoriasis,[148] likely acts through this type I IFN system by binding to Toll-like receptor 7 on pDCs.[149] Although IFN-α appears to have a role in psoriatic lesional development and exacerbations,[147] its role in stable chronic plaque psoriasis has been questioned.[150]

Mast Cells. Mast cells have long been observed in initial and developing psoriasis lesions,[67] with prominent mast cell degranulation in both eruptive psoriasis[72] and in lesions reappearing after discontinuation of topical corticosteroid suppression.[74] Interestingly, skin-derived mast cell release of preformed and newly synthesized mediators is potently suppressed byCsA and tacrolimus,[151] suggesting that the antipsoriatic effects of these compounds could be mediated by mast cells as well as T cells. Recently, mast cells have been shown to be a major source of IL-17 production in both rheumatoid arthritis synovium[152] and in psoriatic lesions.[153]

Macrophages. Macrophages are prominent in initial and developing psoriasis lesions.[67] CD163 has recently been shown to be a reliable marker for skin-derived macrophages,[139] and as mentioned earlier, these cells also express Factor XIIIa.[154] A population of $CD11c^-$, $CD1a^+$, $CD68^+$ macrophages is found scattered just under the basement membrane, subadjacent to proliferating keratinocytes expressing the macrophage chemokine MCP-1 (CCL2).[155–157] These phagocytically active cells could be involved in generating fenestrations (holes) in the epidermal basement membrane.[158] Recent studies in two different mouse models of psoriasis, one dependent on and the other independent of T cells, showed that selective elimination of macrophages led to prompt improvement of lesions. These findings suggest that macrophages may play a key role in the pathogenesis of psoriasis, at least in part via production of tumor necrosis factor (TNF)-α, iNOS, and IL-23.[154,159–161]

Neutrophils. Although neutrophils are commonly seen in the upper epidermis of psoriatic lesions, they appear late during the development of lesions, their number is quite variable, and their role in the pathogenesis of psoriasis is unclear. Studies in one of the same mouse models used to implicate macrophages indicate that neutrophils are probably unnecessary for lesional development.[161]

Keratinocytes. As detailed below, keratinocytes are a major producer of proinflammatory cytokines, chemokines, and growth factors,[162] as well as other inflammatory mediators such as eicosanoids[163] and mediators of innate immunity such as cathelicidins, defensins, and S100 proteins.[164] Psoriatic keratinocytes are engaged in an alternative pathway of keratinocyte differentiation called *regenerative maturation*.[165] Regenerative maturation is activated in response to immunologic stimulation in psoriasis,[166] but the mechanism by which this occurs is presently unknown.

Other Cell Types. Other cell types, such as endothelial cells and fibroblasts, are also likely to be participants in the pathogenic process. Endothelial cells are

strongly activated in developing and mature lesions of psoriasis[67,71] and in addition to delivering a tenfold increase in blood flow to the lesion, they play a major role in controlling the flux of leukocytes and serum proteins into psoriatic tissue.[167–169] Fibroblasts support keratinocyte proliferation in a paracrine manner,[170] and this process is exaggerated in psoriasis.[171] Fibroblasts produce many chemotactic factors and support the migration of T cells out of psoriatic lesions.[172] Thus, fibroblasts may also be intimately involved in psoriasis by directing the localization of T cells.

SIGNALING MOLECULES IN PSORIASIS

Cytokines and Chemokines. The cytokine network in psoriasis is extremely complex, involving the actions and interactions of multiple cytokines, chemokines, and growth factors, and their receptors in addition to other mediators produced by multiple cell types. Combinations of cytokines and growth factors can result in effects that are not seen when these factors are studied individually. For example, T-cell clones isolated from psoriatic skin lesions are able to promote keratinocyte proliferation in an IFN-γ-dependent manner,[173,174] but by itself, IFN-γ has an antiproliferative effect on cultured keratinocytes.[175]

The most prominent cytokines currently thought to be involved in the pathogenesis of psoriasis are summarized in Fig. 18-3. Besides IFN-γ,[96,176] a plethora of cytokines and chemokines are upregulated in psoriasis, including the cytokines TNF-α,[177] IL-2,[95] IL-6,[178] IL-8,[179] IL-15,[180] IL-17,[181] IL-18,[182] IL-19, IL-20, IL-22,[183] IL-21,[184] IL-23,[97,100,101] and the chemokines MIG/CXCL9, IP-10/CXCL10, I-TAC/CXCL11, and MIP-3α/CCL20.[7,185] More complex abnormalities have been observed for other immunomodulatory cytokines and their receptors, including IL-1 and TGF-β.[186–188] IL-23 is currently believed to play a central role in the pathogenesis of psoriasis through its role in maintaining and expanding specific subsets of $CD4^+$ T cells characterized by production of IL-17 (Th17)[189] and IL-22 (Th22).[106] IFN-γ plays a role in amplifying this process by stimulating antigen-presenting cells to produce more IL-23.[190] The entry of activated, cytokine secreting, $CD8^+$ T cells into the epidermis promotes epidermal hyperplasia[191] and activation of keratinocyte innate defense response with resulting production of antimicrobial peptides, cytokines, chemokines, and growth factors (see Fig. 18-3). The other major cytokine producers in psoriatic lesions are DC and macrophages,[154] with additional contributions from mast cells, neutrophils, and endothelial cells. Overall, this creates a highly complex network of inflammatory signals between the main cellular participants.

Innate Immune Mediators. In addition to cytokines and chemokines, several mediators of innate immunity are abnormally expressed in psoriasis.[164] Prominent among the innate immune mediators are the antimicrobial peptides human β-defensin-2 (hBD-2) and cathelicidin (LL-37), both of which are much more highly overexpressed in psoriasis than in atopic dermatitis.[192,193] Notably, expression of HBD-2 and LL-37 is increased in response to proinflammatory and type I cytokines (TNF-γ, IL-1, and IFN-γ) and suppressed by type II cytokines (IL-4, IL-10, and IL-13).[194] These differences in antimicrobial peptide expression help to explain why approximately 30% of patients with atopic dermatitis have bacterial or viral infections, as opposed to only 7% of psoriasis patients, even though both conditions have a defective skin barrier.[195] They may also explain why psoriasis patients, though frequently colonized with *Staphylococcus aureus*, are not markedly improved by antibiotic treatment, whereas atopic dermatitis patients often obtain dramatic benefit from antibiotic therapy. The S100 proteins are a large family of dimeric low-molecular-weight proteins that bind calcium and other divalent cations. S100A2, S100A7 (psoriasin), and the S100A8/A9 heterodimer (calprotectin) are markedly overexpressed in psoriasis lesions.[196] These proteins exert chemotactic and antimicrobial activity, the latter through sequestration of zinc ions,[197,198] and have been shown to function as TLR4 ligands on $CD8^+$ T cells, upregulating IL-17 expression and inducing autoimmunity.[199] Nitric oxide is produced in large amounts by DCs in psoriasis, triggering multiple signal transduction events.[137] Finally, the complement component C5a is a potent chemoattractant for neutrophils and may contribute to the accumulation of neutrophils in the stratum corneum of psoriasis.[200] Interestingly, it is also the most potent chemoattractant for DCs in psoriatic scale extracts.[201] Many of these mediators are regulated in response to Toll-like receptors, providing a mechanism whereby the innate immune system can rapidly recognize a wide variety of pathogens according to their pathogen-associated molecular patterns[202] (see Chapter 10).

Eicosanoids. The role of eicosanoids in psoriasis remains unclear.[203] Levels of free arachidonic acid, leukotriene B4, 12-hydroxyeicosatetraenoic acid, and 15-hydroxyeicosatetraenoic acid are markedly increased in lesional skin, whereas levels of prostaglandins E and F2α are increased less than twofold.

Growth Factors. Multiple growth factors are overexpressed in psoriasis.[204] Members of the epidermal growth factor (EGF) family induce their own production in keratinocytes, including transforming growth factor-α, amphiregulin (AREG), and heparin-binding EGF-like growth factor.[205] Studies in xenografted mice found a reduction in epidermal hyperplasia after antibody-mediated neutralization of AREG.[206] Activation of the EGF receptor stimulates keratinocyte production of vascular endothelial growth factor (VEGF),[167] perhaps accounting for the long-standing observation that the angiogenic properties of normal and psoriatic skin associate with the epidermis.[207] Nerve growth factor (NGF) is also overexpressed by keratinocytes in psoriatic skin, and NGF receptors are increased in the peripheral nerves of lesional skin. Psoriasis has been shown to clear in denervated skin,[208] and psoriasis improved after NGF blockade in xenografted mice.[209] Moreover, direct connections have been documented between terminal nerve fibers and DCs in the skin, and

neuropeptides have been shown to modulate DC function.[210] Paracrine growth factors produced outside the epidermal compartment may also play an important role in stimulating epidermal hyperplasia in psoriasis, including insulin-like growth factor-1[211] and keratinocyte growth factor.[212]

Proteases and Their Inhibitors. The psoriatic lesion is characterized by marked overexpression of multiple classes of proteinases by both keratinocytes and leukocytes. Metalloproteinases release TNF-α, several EGF-like growth factors, and many other cytokines and growth factors from their membrane-anchored precursors.[213] Leukocyte-derived elastase has also been implicated in the release of EGF-like growth factors.[214] Serine proteases directly activate protease-activated receptors.[215] Each of these mechanisms may contribute to stimulation of keratinocyte proliferation. The protease inhibitors elafin, serpinB3, and serpinB13 (hurpin) are among the most markedly overexpressed genes in psoriatic lesions,[216,217] suggesting that homeostatic mechanisms are strongly engaged in an effort to regulate the proteolytic environment of psoriatic lesions.

Integrins. Several observations suggest an early role for α5 integrins and their ligand fibronectin in psoriasis. Fibronectin is increased in psoriatic epidermis,[218] and it has been suggested that fibronectin gains access to the epidermis via fenestrations in the epidermal basement membrane.[219] Fibronectin receptors (α5 integrins) are only weakly expressed in normal skin, but are strongly expressed in uninvolved as well as involved psoriatic skin,[219] and fibronectin selectively increases the proliferation of keratinocytes cultured from uninvolved psoriatic skin.[219] Receptors for collagen and laminin-5 (α2β1 and α3β1 integrins, respectively) are confined to the basal layer of normal skin but are strongly expressed in suprabasal keratinocytes as part of the regenerative maturation program.[220] Interestingly, forced expression of β1 integrins in the suprabasal compartment results in epidermal hyperplasia.[221] Finally, the entry and retention of $CD8^+$ T cells into the epidermis requires binding of type IV collagen by α1β1 integrin and binding of E-cadherin by αEβ7 integrin, respectively.[191,222]

Signal Transduction. As would be expected given this plethora of intercellular signaling alterations, multiple signal transduction mechanisms are dysregulated in psoriatic epidermis, including receptor tyrosine kinase, mitogen-activated protein kinase, Akt, STAT, Src family kinase, Wnt,[223] and NF-κB pathways. These abnormalities affect immunocyte activation and trafficking as well as keratinocyte responses of proliferation, differentiation, and survival. As described below, many of the susceptibility variants associated with psoriasis have a role in regulating these signaling pathways, particularly the NF-κB pathway.[34,64] This is a challenging area of research, as signal transduction experiments are typically conducted on cell lines in culture, whereas the phenotype of psoriasis requires intercellular interactions and differentiation conditions that can only be obtained *in vivo*. Animal models are helping to define signal transduction abnormalities at a functional level. Space does not allow detailed consideration of these pathways in psoriasis, nor of the animal models being used to study them. Interested readers are referred to several reviews for deta ils.[50,188,224–226]

PSORIASIS: INTEGRATING GENETICS AND IMMUNOLOGY

HLA-Cw6. (Fig. 18-4). As has been made clear by detailed fine mapping, genetic linkage, and association studies, HLA-C is by far the major genetic risk factor for psoriasis.[30,34,35,38,57] Because it presents antigens to $CD8^+$ T cells, HLA-Cw6 is an excellent candidate for functional involvement in psoriasis. Psoriasis has long been known to be triggered by streptococcal pharyngitis, and is the only infection that has been shown to trigger psoriasis in a prospective cohort study.[227] Because tonsillar T cells are cutaneous lymphoid antigen (CLA)-positive and recognize activated skin endothelium[228] they can traffic into the skin, explaining why the same CLA-positive T-cell clones are found in the tonsils and in the lesional skin of psoriatic patients.[229] $CD8^+$ T cells comprise at least 80% of the T cells in the epidermis of psoriatic lesions,[230] and epidermal invasion correlates with lesional development.[94,231,232] $CD8^+$ T cells selectively traffic to the epidermis because they express integrin α1β1 (also known as VLA-1), which binds to type IV basement membrane collagen,[191] as well as integrin αEβ7, which binds to keratinocyte E-cadherin.[222] Once in the epidermis, $CD8^+$ T cells "interrogate" peptides bound to HLA-Cw6 on the surface of dendritic APCs and/or keratinocytes. In normal immune responses, $CD4^+$ T cells provide critical help in processing and presentation of intracellular viral components and tumor antigens, in a process called *cross-priming*. While $CD4^+$ and $CD8^+$ memory T cells can traffic between the skin and lymph nodes and blood, increasing evidence suggest that they spend most of their time in the skin itself.[233] This may help to account for the characteristic distribution of psoriatic plaques, which tend to recur in the same places after therapeutic or spontaneous improvement.

As mentioned earlier, there is a very strong association between *HLA-Cw6* and guttate psoriasis. This form of psoriasis is often self-limiting[5,234] but can progress to chronic plaque psoriasis, which has a fluctuating inflammatory course in the absence of ongoing streptococcal infection. The transition from guttate to chronic plaque psoriasis likely reflects a transition from a self-limited cutaneous immune reaction triggered by streptococci encountered in the tonsils during a guttate flare, to a persistent and inappropriate immune reaction directed against host proteins in chronic plaque disease.[235] The mechanisms by which normal immunologic tolerance of self-proteins is broken during this transition remain to be elucidated.

Non-MHC Genes. (Fig. 18-5). As reviewed earlier, in the online edition, the advent of GWAS has identified an increasing number of convincing genetic association signals for psoriasis outside the MHC

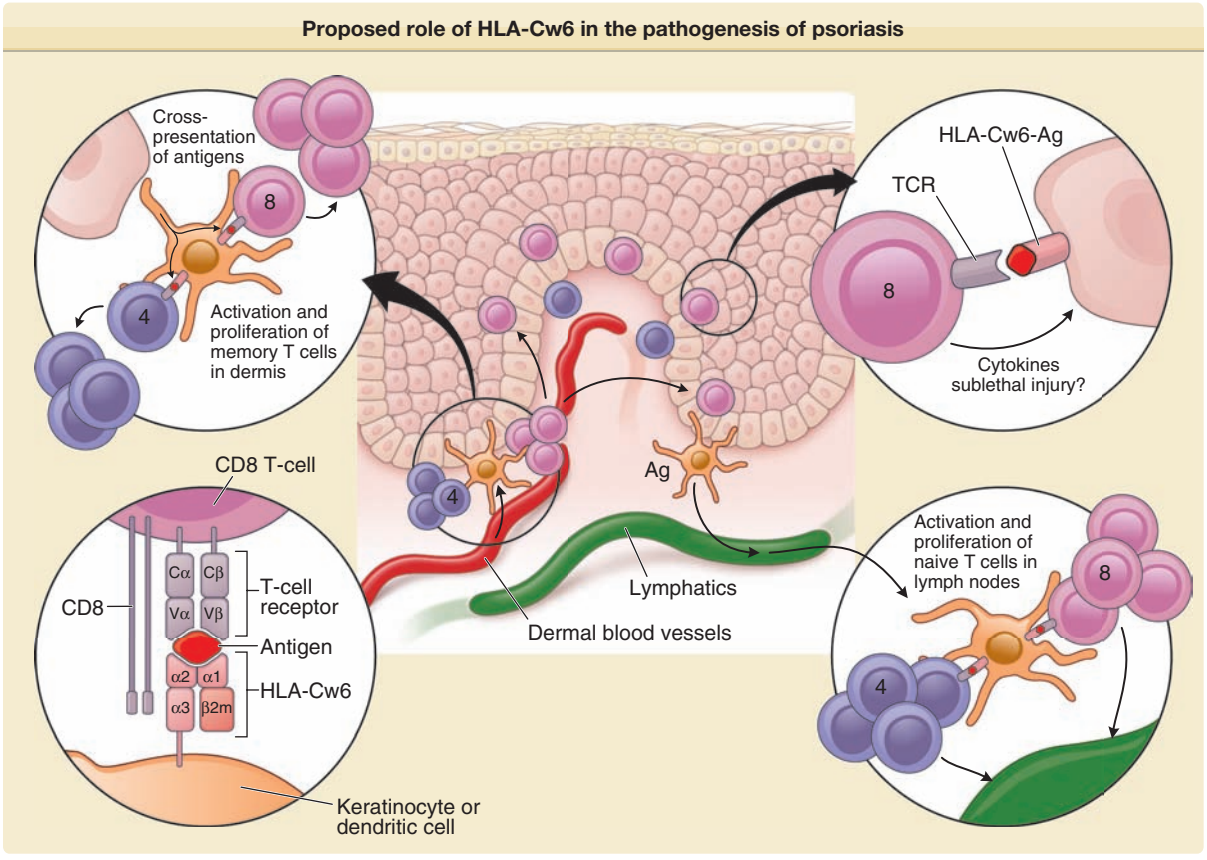

Figure 18-4 Proposed role of HLA-Cw6 in the pathogenesis of psoriasis. Antigen (Ag) in the binding pocket of HLA-Cw6 interacts with a T-cell receptor. The role of HLA-Cw6 in psoriasis is likely to be twofold. HLA-Cw6 is active in cross-presenting peptides on the surface of dendritic cells, allowing activation and clonal expansion of antigen-specific $CD8^+$ T cells. This process is dependent on $CD4^+$ T-cell help for cross-presentation of intracellular antigens and is likely to happen both in the dermis (activation of memory resident T cells) and local lymph nodes (activation of naive T cells). Subsequently, the $CD8^+$ T cells are able to migrate into the epidermis where they encounter HLA-Cw6 on the surface of the keratinocytes presenting those same pathogenic peptides. Activated CD8+ T-cells may recognize peptides presented by HLA-Cw6 on keratinocyte cell surface. Because these T-cells express perforin, they could directly damage keratinocytes in the traditional cytotoxic manner.[435] Activated $CD8^+$ T cells could also trigger the local release soluble factors, including cytokines, chemokines, eicosanoids, and/or innate immune mediators, which could further increase local inflammation and stimulate keratinocyte proliferation.[173] In response to either insult, keratinocytes could respond by elaborating autocrine growth factors such as TGF-α and AREG, thereby encouraging their own proliferation and survival.[436]

(Table 18-1). The genes contained within these associated regions fit very well with our current concepts of psoriasis pathogenesis. This integration is further reinforced by the pronounced clinical responsiveness of psoriasis to biological agents that specifically target the genetically implicated pathways. Most of the non-MHC associations identified thus far fall into four interconnected functional axes: (1) IFN-γ/IL-23/IL-17 signaling, (2) NF-κB signaling, (3) inflammatory DC function, and (4) keratinocyte differentiation. While the actual functional genetic variations that are ultimately responsible for these associations remain to be determined, these discoveries provide a rationale for biological and therapeutic dissection of the implicated pathways.

IFN-γ/IL-23/IL-17 Signaling. Three strong regions of association map near genes involved in IL-23 signaling: (1) *IL12B* (encoding the p40 subunit of IL-23 and IL-12), (2) *IL23A* (encoding the p19 subunit of IL-23), and (3) *IL23R* (encoding a subunit of the IL-23 receptor).[34,60,61] These associations are further supported by the impressive efficacy of biologics targeting the p40 subunit common to IL-12 and IL-23,[268] along with the fact that *IL12B* and *IL23A* are markedly overexpressed in psoriatic lesions, whereas *IL12A* is not.[269] IL-23 signaling promotes cellular immune responses by promoting the survival and expansion of a subset of IL-17-expressing T cells that protects epithelia against microbial pathogens.[270] Given the similarities between skin and gut as epithelial tissues, it is notable that inflammatory bowel disease (IBD) is clinically associated with psoriasis[271] and the same genetic variation in *IL23R* that increases risk for both diseases.[272] Ankylosing spondylitis (AS) is another HLA-Class I-associated autoimmune disorder that is clinically associated with IBD[273] and genetically associated with *IL23R*.[274] Psoriatic arthritis (PsA) shares a number of clinical

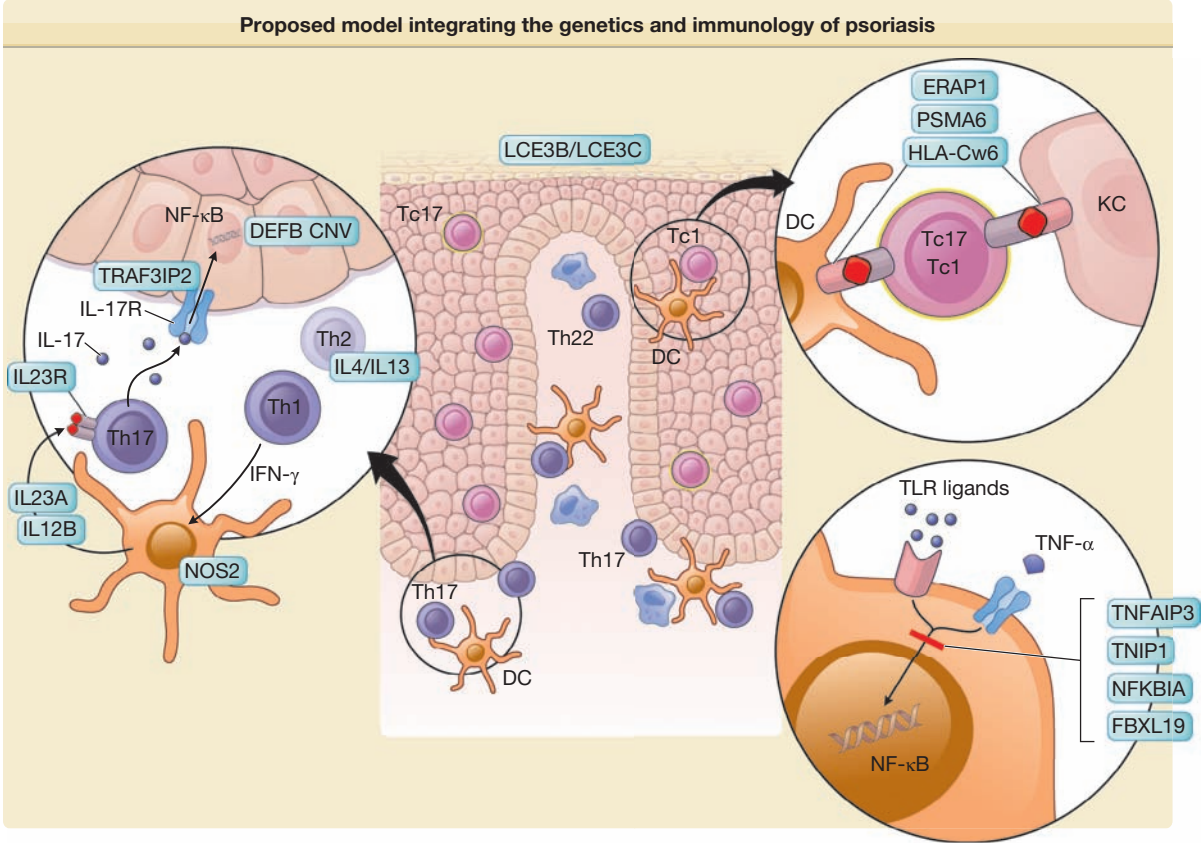

Figure 18-5 Proposed model integrating the genetics and immunology of psoriasis. The majority of the CD8+ T-cells (lilac) are located in the epidermis, whereas CD4+ T-cells (blue) predominate in the dermis along with antigen presenting cells/dendritic cells (DCs) (blue) and macrophages (Mφs)(light blue). Confirmed association signals are indicated by the likely candidate genes they contain. Please see text for additional details. (Adapted from Nair RP et al: Psoriasis bench to bedside: Genetics meets immunology. *Arch Dermatol* **145**(4):462-464, 2009, with permission.)

similarities with AS, and is genetically associated with *IL12B*, *IL23A*, and *IL23R*[34,275,276] (see Chapter 19).

IFN-γ is a major product of activated Th1 cells that stimulates DC to produce IL-23.[190] Several psoriasis susceptibility loci contain genes involved in interferon signaling (IFIH1, IL28R, and TYK2)[61] Together with IL-1, IL-23 promotes the survival and proliferation of IL-17-expressing T cells (Th17), thereby explaining why Th1 and Th17 are colocalized in psoriasis lesions and in many other sites of inflammation.[190] Given the well-known reciprocal relationship between Th1 and Th2 differentiation, it is notable that another psoriasis susceptibility region contains the *IL4* and *IL13* genes.[34,63] In addition to biasing T-cell differentiation away from Th1 and toward Th2, IL-4 inhibits Th17 cell development.[277] Both IL-4 and IL-13 are expressed at high levels in atopic dermatitis, but only at very low levels in psoriasis.[278] Moreover, treatment of psoriasis with IL-4 resulted in significant clinical improvement,[279] accompanied by reduced expression of IL-23 (but not of IL-12) and reduced numbers of Th17 cells.[280] The fact that significant genetic signals at both ends of this polarizing spectrum (IL-23, on the one hand, and IL-4/IL-13, on the other), with IFN-γ positioned between them, suggests that Th1-Th2-Th17 balance is a key functional and genetic determinant of psoriasis.

NF-κB Signaling. At least five psoriasis-associated genomic regions contain genes involved with controlling signaling through the transcription factor NF-κB: (1) *TNFAIP3*, (2) *TNIP1*, (3) *NFKBIA*, (4) *FBXL19*, and (5) *TRAF3IP2*.[34,58,59,61,64] TNF-α is a major activator of NF-κB signaling, and these associations are clinically reinforced by the dramatic therapeutic response of psoriasis to anti-TNF biologicals (see Section "Treatment"). *TNFAIP3* and *TNIP1*, respectively encode A20 and ABIN-1, which interact with each other to regulate the ubiquitin-mediated destruction of IKKγ/NEMO, a central nexus of NF-κB signaling.[281] *TNFAIP3* is genetically associated with rheumatoid arthritis (RA),[282,283] and both *TNFAIP3* and *TNIP1* are associated with systemic lupus erythematosus (SLE).[284–287] The polymorphisms implicated in RA and SLE show no association with psoriasis, suggesting that each of these common autoimmune diseases is driven by a different variant of the *TNFAIP3* gene. Interestingly, in mice, *Tnfaip3* is associated with atherosclerosis,[288] which is now known to be a major comorbidity of psoriasis.[289] *NFKBIA* encodes IκBα, which inhibits NF-κB signaling by sequestering it in the cytoplasm. *FBXL19* and *TRAF3IP2* are significantly more strongly associated with PsA than with purely cutaneous psoriasis.[58,64] *FBXL19* is structurally related to *FBXL11*, an F-box family mem-

TABLE 18-1
Genome-Wide Significant Psoriasis Susceptibility Loci

SNP ID (rs number)[a]	Chromosomal Band	Risk Allele (frequency in controls)[b]	Odds Ratio[b]	*p*-Value[c]	Notable Gene(s) in Associated Region	Independently Confirmed	Reference
rs12191877	6p21.33	T (0.147)	2.64	<1 E-100	*HLA-C, CDSN*	Y	Nair et al[34]
rs17728338	5q33.1	A (0.054)	1.59	1 E-20	*TNIP1*	Y	Nair et al[34]
rs2082412	5q33.3	G (0.798)	1.44	2 E-28	*IL12B*	Y	Cargill et al,[60] Nair et al[34]
rs33980500	6q21	T (0.071)	1.38	1 E-16	*TRAF3IP2*	Y	Ellinghaus et al[58]
rs4649203	1p36	A (0.770)	1.36	7 E-8	*IL28RA*	N	Strange et al[61]
rs2066808	12q13.3	A (0.932)	1.34	1 E-09	*IL23A, STAT2*	Y	Nair et al[34]
rs17716942	2p24	A (0.900)	1.29	1 E-13	*IFIH1*	N	Strange et al[61]
rs20541	5q31.1	G (0.790)	1.27	5 E-15	*IL13, IL4*	N	Nair et al[34]
rs4085613	1q21.3	C (0.421)	1.27	7 E-30	*LCE3C, LCE3D*	Y	Zhang et al[57]
rs495337	20q13.13	C (0.551)	1.25	1 E-08	*RNF114*	Y	Capon et al[62]
rs2431697	5q33.3	C (0.177)	1.19	1 E-08	*PTTG1*	N	Stuart et al[59]
rs4795067	17q11.2	G (0.349)	1.19	4 E-11	*NOS2*	Y	Stuart et al[59]
rs610604	6q23.3	G (0.320)	1.19	9 E-12	*TNFAIP3*	Y	Nair et al[34]
rs10782001	16p11.2	G (0.368)	1.16	9 E-10	*FBXL19*	N	Stuart et al[64]
rs12586317	14q13.2	T (0.751)	1.16	2 E-08	*NFKBIA, PSMA6*	Y	Stuart et al[64]
rs3751385	13q12.11	T (0.478)	1.14	2 E-10	*GJB2*	N	Stuart et al[59]
rs10088247	8p23.2	C (0.183)	1.13	5 E-09	*CSMD1*	N	Stuart et al[59]
rs2201841	1p31.3	G (0.295)	1.13	3 E-08	*IL23R*	Y	Nair et al[34]
rs151823	5q15	A (0.495)	1.12	9 E-09	*ERAP1*	Y	Stuart et al[59]
rs514315	18q22.1	T (0.742)	1.12	6 E-09	*SERPINB8*	N	Stuart et al[59]
rs702873	2p16	G (0.620)	1.12	4 E-09	REL	Y	Strange et al[61]
rs9304742	19q13.41	T (0.649)	1.11	2 E-09	*ZNF816A*	N	Stuart et al[59]
NA[d]	8p23.1	NA[d]	NA[d]	3 E-08	β-defensin genes	N	Hollox et al[66]

[a]The most significant SNP in the associated region is shown.
[b]Risk allele frequencies and odds ratios are computed for the replication sample (discovery sample excluded due to the winner's curse phenomenon).
[c]*P*-value is calculated for the combined discovery and replication samples. Only genes that reached a genome-wide significance criterion of $p = 7 \times 10^{-8}$ are shown.
[d]Not applicable because the disease association is with copy number variation rather than SNP.

ber recently shown to inhibit NF-κB activity by lysine demethylation.[290] FBXL11 contains domains known to be required for demethylase activity, but FBLX19 does not.[291] Thus, FBXL19 might act as a dominant negative inhibitor of demethylase activity, thereby serving to activate NF-κB. *TRAF3IP2* encodes Act1, a ubiquitin ligase that interacts with TRAF (tumor necrosis factor receptor-associated factors) proteins and the IKK complex to activate NF-κB. Interestingly, Act1 is a key component of IL-17-mediated signaling through the IL-17 receptor, allowing the incorporation of TRAF6 into the IL-17 receptor signaling complex, with consequent activation of NF-κB.[292] Thus, Act1 may serve as a key link between the IFN-γ/IL-23/IL-17 axis on the one hand, and the NF-κB axis on the other.

Inflammatory DC Function. Beyond the major role of *HLA-Cw6* described earlier, it is noteworthy that two other regions of association contain genes whose products function in antigen presentation: (1) *PSMA6*, which encodes a proteosomal subunit involved in MHC Class I antigen processing,[64] and (2) *ERAP1*, an IFN-γ-inducible aminopeptidase that trims peptides for optimal binding to the MHC Class I peptide groove. As noted above, inflammatory DC produce large amounts of TNF-α and nitric oxide in addition to their well-recognized functions in antigen presentation. Thus, it seems more than coincidental that another novel region of association contains *NOS2*, which encodes iNOS, the enzyme responsible for nitric oxide production by DC. Reflective of the massive increase

in inflammatory dermal dendritic cells characteristic of psoriasis lesions, *NOS2* is markedly overexpressed in lesional skin.[64] In addition to iNOS, these inflammatory DC produce large amounts of TNF-α, which synergizes strongly with IL-17 to induce a marked increase expression of innate inflammatory mediators such as hBD2 by keratinocytes.[58]

Keratinocyte Differentiation. Given that hyperproliferation and altered differentiation of keratinocytes figure prominently in psoriasis pathophysiology, it is perhaps surprising that relatively few of the psoriasis-associated regions highlight genes that function primarily in keratinocytes. The most well-established association is an insertion–deletion polymorphism of the late cornified envelope genes *LCE3B* and *LCE3C*, which was independently discovered in European[65] and Chinese[57] populations. Located in the EDC, these genes are expressed very late during keratinocyte terminal differentiation[293] and are markedly overexpressed in psoriasis,[294] wound healing, and epidermal stress.[65,293] Another reported genetic association involving keratinocytes involves increased *DEFB4* copy number.[66] Whether or not this association is ultimately confirmed, it is notable that *DEFB4* is one of the most highly overexpressed genes in psoriatic lesions.[295] Finally, *TRAF3IP2* is known to function in epidermal cells, as shRNA-mediated knockdown of *TRAF3IP2* abrogates the TNF-α + IL-17-mediated upregulation of *DEFB4* in human keratinocytes.[58]

CLINICAL FINDINGS

Figure 18-6 is an algorithm showing clinical findings and treatment for psoriasis.

HISTORY

It is useful to determine the age at onset and the presence or absence of a family history of psoriasis, as younger age of onset and positive family history have been associated with more widespread and recurrent disease.[6,21] In addition, the physician should inquire about the prior course of the disease, as major differences exist between "acute" and "chronic" disease. In the latter form, lesions may persist unchanged for months or even years, whereas acute disease shows sudden outbreak of lesions within a short time (days). Likewise, patients have great variability in regard to relapses. Some patients have frequent relapses occurring weekly or monthly, whereas others have more stable disease with only occasional recurrence. The frequently relapsing patients tend to develop more severe disease with rapidly enlarging lesions covering significant portions of the body surface[296] and may require more rigorous treatment compared to those with more stable disease. Certain medications may worsen psoriasis (see Section "Treatment"). The physician should also inquire about joint complaints. Although osteoarthritis is extremely common and can coexist with psoriasis, a history of onset of joint symptoms before the fourth decade and/or a history of warm, swollen joints should raise the suspicion of psoriatic arthritis (see Chapter 19).

CUTANEOUS LESIONS[297]

The classic lesion of psoriasis is a well-demarcated, raised, red plaque with a white scaly surface (Fig. 18-7). Lesions can vary in size from pinpoint papules to plaques that cover large areas of the body. Under the scale, the skin has a glossy homogeneous erythema, and bleeding points appear when the scale is removed, traumatizing the dilated capillaries below (the Auspitz sign) (Fig. 18-8).[297] Psoriasis tends to be a symmetric eruption, and symmetry is a helpful feature in establishing a diagnosis. Unilateral involvement can occur, however. The psoriatic phenotype may present a changing spectrum of disease expression even within the same patient.

Koebner phenomenon (also known as the *isomorphic response*) is the traumatic induction of psoriasis on nonlesional skin; it occurs more frequently during flares of disease and is an all-or-none phenomenon (i.e., if psoriasis occurs at one site of injury it will occur at all sites of injury) (Fig. 18-9). The Koebner reaction usually occurs 7–14 days after injury, and approximately 25% of patients may have a history of trauma-related Koebner phenomenon at some point in their lives.[298] Estimates of lifetime prevalence rise as high as 76% when factors such as infection, emotional stress, and drug reactions are included.[4] The Koebner phenomenon is not specific for psoriasis but can be helpful in making the diagnosis when present.

CLINICAL PATTERNS OF SKIN PRESENTATION[297]

PSORIASIS VULGARIS, CHRONIC STATIONARY PSORIASIS, PLAQUE-TYPE PSORIASIS.

Psoriasis vulgaris is the most common form of psoriasis, seen in approximately 90% of patients. Red, scaly, symmetrically distributed plaques are characteristically localized to the extensor aspects of the extremities, particularly the elbows and knees, along with scalp, lower lumbosacral, buttocks, and genital involvement (see Fig. 18-7). Other sites of predilection include the umbilicus and the intergluteal cleft. The extent of involvement varies widely from patient to patient. There is constant production of large amounts of scale with little alteration in shape or distribution of individual plaques. Single small lesions may become confluent, forming plaques in which the borders resemble a land map (psoriasis geographica). Lesions may extend laterally and become circinate because of the confluence of several plaques (psoriasis gyrata). Occasionally, there is partial central clearing, resulting in ring-like lesions (annular psoriasis) (Fig. 18-10). This is usually associated with lesional clearing and portends a good prognosis. Other clinical variants of plaque psoriasis have been described depending on the morphology of

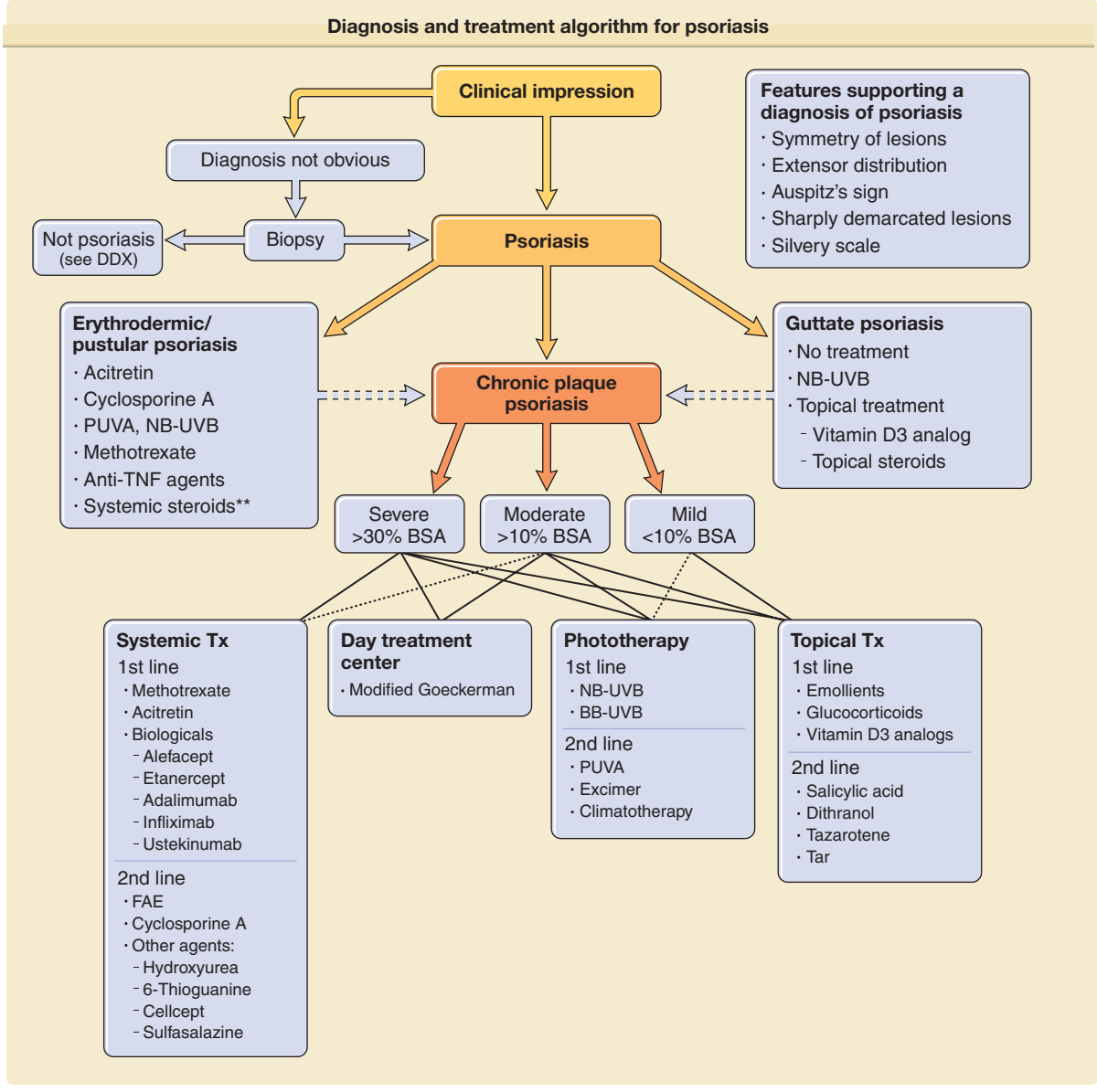

Figure 18-6 Diagnosis and treatment algorithm for psoriasis. The diagnosis of psoriasis is usually based on clinical features. In those few cases in which clinical history and examination is not diagnostic, biopsy is indicated to establish the correct diagnosis. The majority of psoriasis cases fall into three major categories: guttate, erythrodermic/pustular, and chronic plaque, of which the latter is by far the most common. Guttate psoriasis is often a self-limited disease with spontaneous resolution within 6–12 weeks. In mild cases of guttate psoriasis, treatment may not be needed, but, with widespread disease, ultraviolet B (UVB) phototherapy or narrowband UVB in association with topical therapy is very effective. Erythrodermic/pustular psoriasis is often associated with systemic symptoms and necessitates treatment with fast-acting systemic medications. The most commonly used drug for erythrodermic and pustular psoriasis is acitretin. In occasional cases of pustular psoriasis, systemic steroids may be indicated (**). *Dotted arrows* indicate that guttate, erythrodermic, and pustular forms often evolve into chronic plaque psoriasis. Therapeutic choices for chronic plaque psoriasis are typically based on the extent of the disease. Among the main treatment regimens (topical treatment, phototherapy, day treatment centers, and systemic treatments), first-line and second-line modalities are indicated by the *solid* and *dashed lines*, respectively. Individuals with conditions that limit their activities, including painful palmoplantar involvement and psoriatic arthritis, may require more potent treatments irrespective of the extent of affected body surface area. Likewise, psychological issues and the impact on quality of life should be taken into consideration. Within each treatment regimen, first-line and second-line choices are grouped. Cyclosporin A is not considered a first-line long-term systemic treatment due to its side effects, but short-term treatment can be helpful for induction of remission. If patients have incomplete response to or are unable to tolerate individual first-line systemic medications, combination regimens (Table 18-6), rotational treatments, or use of biologic therapies should be considered. BB-UVB = broadband UVB; BSA = body surface area; DDx = differential diagnosis; FAE = fumaric acid ester; NB-UVB = narrowband UVB; PUVA = psoralen, and UVA light; tx = therapy.



Figure 18-7 A–F. Chronic plaque psoriasis located at typical sites. Note marked symmetry of lesions. (Photos used with permission from Dr. Johann Gudjonsson and Mr. Harrold Carter.)

the lesions; particularly those associated with gross hyperkeratosis (see Fig. 18-10). *Rupioid psoriasis* refers to lesions in the shape of a cone or limpet. *Ostraceous psoriasis*, an infrequently used term, refers to a ring-like, hyperkeratotic concave lesion, resembling an oyster shell. Finally, elephantine psoriasis is an uncommon form characterized by thickly scaling, large plaques, usually on the lower extremities. A hypopigmented ring (Woronoff ring) surrounding individual psoriatic lesions may occasionally be seen and is usually associated with treatment, most commonly UV radiation or topical corticosteroids (see Fig. 18-10C). The pathogenesis is not well understood but may result from inhibition of prostaglandin synthesis.[299]

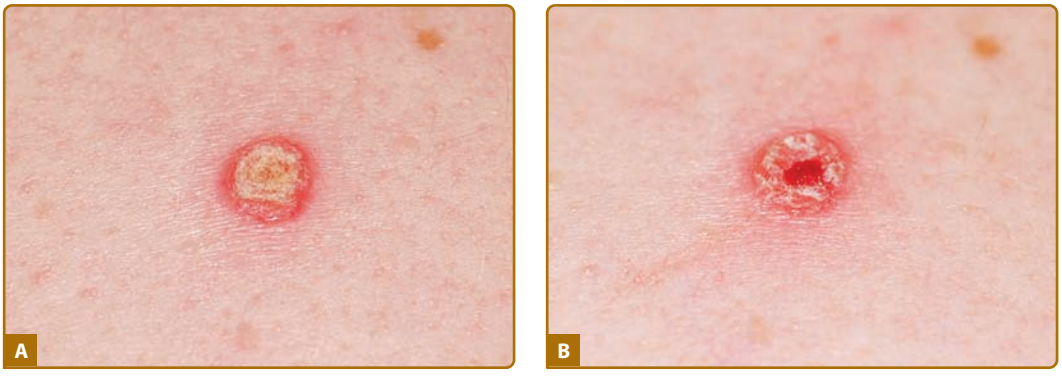

Figure 18-8 Auspitz sign. Note point of bleeding after scale is removed. (Photos used with permission from Dr. Johann Gudjonsson and Ms. Laura Vangoor.)



Figure 18-9 Koebner phenomenon. **A.** Psoriasis appearing in keratome biopsy sites 4 weeks after biopsy. (Photo used with permission from Mr. Harrold Carter.) **B.** Flare of psoriasis on the back after a sunburn. Note sparing of sun-protected areas. (Photo used with permission from Dr. James Rasmussen.)

GUTTATE (ERUPTIVE) PSORIASIS. Guttate psoriasis (from the Latin *gutta*, meaning "a drop") is characterized by eruption of small (0.5–1.5 cm in diameter) papules over the upper trunk and proximal extremities (Fig. 18-11). It typically manifests at an early age and as such is found frequently in young adults. This form of psoriasis has the strongest association to HLA-Cw6,[26] and streptococcal throat infection frequently precedes or is concomitant with the onset or flare of guttate psoriasis.[300] However, antibiotic treatment has not been shown to be beneficial or to shorten the disease course.[301] Patients with a history of chronic plaque psoriasis may develop guttate lesions, with or without worsening of their chronic plaques.

SMALL PLAQUE PSORIASIS. Small plaque psoriasis resembles guttate psoriasis clinically, but can be distinguished by its onset in older patients, by its chronicity, and by having somewhat larger lesions (typically 1–2 cm) that are thicker and scalier than in guttate disease. It is said to be a common adult-onset presentation of psoriasis in Korea and other Asian countries.[141]

INVERSE (FLEXURAL) PSORIASIS. Psoriasis lesions may be localized in the major skin folds, such as the axillae, the genito-crural region, and the neck. Scaling is usually minimal or absent, and the lesions show a glossy sharply demarcated erythema, which is often localized to areas of skin-to-skin contact (Fig. 18-12). Sweating is impaired in affected areas.[302]

ERYTHRODERMIC PSORIASIS. (See also Chapter 23). Psoriatic erythroderma represents the generalized form of the disease that affects all body sites, including the face, hands, feet, nails, trunk, and extremities (Fig. 18-13). Although all the symptoms of psoriasis are present, erythema is the most prominent feature, and scaling is different compared with chronic stationary psoriasis. Instead of thick, adherent, white scale there is superficial scaling. Patients with erythrodermic psoriasis lose excessive heat because of generalized vasodilatation, and this may cause hypothermia. Patients may shiver in an attempt to raise their body temperature. Psoriatic skin is often hypohidrotic due to occlusion of the sweat ducts,[303] and there is an attendant risk of hyperthermia in warm climates. Lower extremity edema is common secondary to vasodilatation and loss of protein from the blood vessels into the tissues. High-output cardiac failure and impaired hepatic and renal function may also occur. Psoriatic erythroderma has a variable presentation, but two forms are thought to exist.[304] In the first form, chronic plaque psoriasis may worsen to involve most or all of the skin surface, and patients remain relatively responsive to therapy. In the second form, generalized erythroderma may present suddenly and unexpectedly or result from nontolerated external treatment (e.g., UVB, anthralin), thus representing a generalized Koebner reaction. Generalized pustular psoriasis [see Section "Generalized Pustular Psoriasis (von Zumbusch)"] may revert to erythroderma with diminished or absent pustule formation. Occasional diagnostic problems may arise in differentiating psoriatic erythroderma from other causes (see Chapter 23).

PUSTULAR PSORIASIS. Several clinical variants of pustular psoriasis exist: generalized pustular psoriasis (von Zumbusch type), annular pustular psoriasis, impetigo herpetiformis, and two variants of localized pustular psoriasis—(1) pustulosis palmaris et plantaris and (2) acrodermatitis continua of Hallopeau. In children, pustular psoriasis can be complicated by sterile, lytic lesions of bones[305,306] and can be a manifestation of the SAPHO syndrome (synovitis, acne, pustulosis, hyperostosis, osteitis).[307]

Generalized Pustular Psoriasis (von Zumbusch). Generalized pustular psoriasis (von Zumbusch)



Figure 18-10 Unusual forms of plaque-type psoriasis **A.** Annular psoriasis on the flank. **B.** Rupioid psoriasis in an infant. Note cone-shaped lesions. **C.** Psoriatic patient undergoing modified Goeckerman therapy (ultraviolet B light, coal tar, and topical steroid), demonstrating Woronoff rings. **D.** Elephantine psoriasis of the lower extremities. Note psoriatic involvement of toenails. (Photographs used with permission from Dr. Johann Gudjonsson, Mr. Harrold Carter, and Ms. Laura Vangoor.)



Figure 18-11 Guttate psoriasis, involving thigh (**A**), hands (**B**), and back (**C** and **D**). The patient in **D** went on to develop chronic plaque psoriasis. (Photos used with permission from Drs. Johann Gudjonsson and Trilokraj Tejasvi, Mr. Harrold Carter, and Ms. Laura Vangoor.)



Figure 18-12 Flexural psoriasis. Note the well-demarcated, beefy-red, shiny plaques in **A**. The infant in **B** is suffering from "napkin psoriasis." (Photos used with permission from Dr. Johann Gudjonsson and Mr. Harrold Carter.)

is a distinctive acute variant of psoriasis. It is usually preceded by other forms of the disease. Attacks are characterized by fever that lasts several days and a sudden generalized eruption of sterile pustules 2–3 mm in diameter (Fig. 18-14). The pustules are disseminated over the trunk and extremities, including the nail beds, palms, and soles. The pustules usually arise on highly erythematous skin, first as patches (Fig. 18-14C) and then becoming confluent as the disease becomes more severe. With prolonged disease, the fingertips may become atrophic. The erythema that surrounds the pustules often spreads and becomes confluent, leading to erythroderma. Characteristically, the disease occurs in waves of fevers and pustules. The



Figure 18-13 Erythrodermic psoriasis. The patient shown in panel **A** rapidly developed near-complete involvement and complained of fatigue and malaise. Note islands of sparing. The patient shown in panels **B** and **C** had total body involvement with marked hyperkeratosis and desquamation. (Photos used with permission from Mr. Harrold Carter and Dr. Johann Gudjonsson.)



Figure 18-14 Pustular psoriasis. **A** and **B**, von Zumbusch-type generalized pustular psoriasis. Note tiny pustules, 1–2 mm in diameter, on erythematous skin. **C** and **D**, localized pustular psoriasis of the leg and foot, respectively. **E**, resolving pustular psoriasis, note extensive areas of desquamation. (Photos **C**–**E** used with permission from Drs. Johann Gudjonsson, Trilokraj Tejasvi, and Neena Khanna.)

etiology of generalized psoriasis von Zumbusch type is unknown. Various provoking agents include infections, irritating topical treatment (Koebner phenomenon), and withdrawal of oral corticosteroids.[308] This form of psoriasis is usually associated with prominent systemic signs and can potentially have life-threatening complications such as hypocalcemia,[309] bacterial superinfection, sepsis, and dehydration.[310] Severe pustular psoriasis can be difficult to control and requires a potent treatment regimen with rapid onset of action to avoid life-threatening complications. Drugs commonly used include etretinate, methotrexate (MTX), cyclosporine, infliximab,[311,312] or oral corticosteroids (see Section "Treatment").[313] Cases of acute respiratory distress syndrome associated with generalized pustular psoriasis have been reported.[314] Two recent reports have identified recessive loss-of function mutations in the *IL36RN* gene encoding IL-36 receptor antagonist (IL-36ra) in patients with generalized pustular psoriasis. Consistent with the prominent inflammation associated with generalized pustular psoriasis, IL-36ra is an anti-inflammatory cytokine that inhibits signaling by three related IL-1 like proteins (IL-36alpha, beta, and gamma).[315,316]

Exanthematic Pustular Psoriasis. Exanthematic pustular psoriasis tends to occur after a viral infection and consists of widespread pustules with generalized plaque psoriasis. However, unlike the von Zumbusch pattern, there are no constitutional symptoms, and the disorder tends not to recur.[297] There is an overlap between

this form of pustular psoriasis and acute generalized exanthematous pustulosis, a type of drug eruption.

Annular Pustular Psoriasis. Annular pustular psoriasis is a rare variant of pustular psoriasis. It usually presents in an annular or circinate form. Lesions may appear at the onset of pustular psoriasis, with a tendency to spread and form enlarged rings, or they may develop during the course of generalized pustular psoriasis. The characteristic features are pustules on a ring-like erythema that sometimes resembles erythema annulare centrifugum. Identical lesions are found in patients with impetigo herpetiformis, an entity defined by some as a variant of pustular psoriasis occurring in pregnancy.[317] Onset in pregnancy is usually early in the third trimester and persists until delivery.[318] It tends to develop earlier in subsequent pregnancies. Impetigo herpetiformis is often associated with hypocalcemia.[309,319] There is usually no personal or family history of psoriasis.[320]

Localized Pustular Psoriasis Variants. Localized pustular psoriasis variants, including pustulosis palmaris et plantaris and acrodermatitis continua (of Hallopeau), are discussed in Chapter 21.

SEBOPSORIASIS. A common clinical entity, sebopsoriasis presents with erythematous plaques with greasy scales localized to seborrheic areas (scalp, glabella, nasolabial folds, perioral and presternal areas, and intertriginous areas). In the absence of typical findings of psoriasis elsewhere, distinction from seborrheic dermatitis is difficult. Sebopsoriasis may represent a modification of seborrheic dermatitis by the genetic background of psoriasis and is relatively resistant to treatment. Although an etiologic role of *Pityrosporum* remains unproven, antifungal agents may be useful.[321]

NAPKIN PSORIASIS. Napkin psoriasis usually begins between the ages of 3 and 6 months and first appears in the diaper (napkin) areas as a confluent red area (see Fig. 18-12B) with appearance a few days later of small red papules on the trunk that may also involve the limbs. These papules have the typical white scales of psoriasis. The face may also be involved with red scaly eruption. Unlike other forms of psoriasis, the rash responds readily to treatment and tends to disappear after the age of 1 year.

LINEAR PSORIASIS. Linear psoriasis is a very rare form. The psoriatic lesion presents as linear lesion most commonly on the limbs but may also be limited to a dermatome on the trunk. This may be an underlying nevus, possibly an inflammatory linear verrucous epidermal nevus (ILVEN), as these lesions resemble linear psoriasis both clinically and histologically. The existence of a linear form of psoriasis distinct from ILVEN is controversial.[322]

RELATED PHYSICAL FINDINGS

NAIL CHANGES IN PSORIASIS. (See also Chapter 89). Nail changes are frequent in psoriasis, being found in up to 40% of patients,[21] and are rare in the absence of skin disease elsewhere. Nail involvement increases with age, with duration and extent of disease, and with the presence of psoriatic arthritis. Several distinct changes have been described and can be grouped according to the portion of the nail that is affected (Table 18-2).[323]

TABLE 18-2
Nail Changes in Psoriasis

Nail Segment Involved	Clinical Sign
Proximal matrix	Pitting, onychorrhexis, Beau lines
Intermediate matrix	Leukonychia
Distal matrix	Focal onycholysis, thinned nail plate, erythema of the lunula
Nail bed	"Oil drop" sign or "salmon patch," subungual hyperkeratosis, onycholysis, splinter hemorrhages
Hyponychium	Subungual hyperkeratosis, onycholysis
Nail plate	Crumbling and destruction plus other changes secondary to the specific site
Proximal and lateral nail folds	Cutaneous psoriasis

Modified from Del Rosso JQ et al: Dermatologic diseases of the nail unit. In: *Nails: Therapy, Diagnosis, Surgery*, edited by RK Scher, CR Daniel. Philadelphia, W.B., Saunders, 1997, p. 172, with permission.

Nail pitting is one of the commonest features of psoriasis, involving the fingers more often than the toes (Fig. 18-15). Pits range from 0.5 to 2.0 mm in size and can be single or multiple. The proximal nail matrix forms the dorsal (superficial) portion of the nail plate, and psoriatic involvement of this region results in pitting due to defective keratinization. Other alterations in the nail matrix resulting in deformity of the nail plate (onychodystrophy) include leukonychia, crumbling nail, and red spots in the lunula. Onychodystrophy has a stronger association with psoriatic arthritis than other nail changes.[21] Oil spots and salmon patches are translucent, yellow–red discolorations observed beneath the nail plate often extending distally toward the hyponychium, due to psoriasiform hyperplasia, parakeratosis, microvascular changes, and trapping of neutrophils in the nail bed.[324,325] Unlike pitting, which is also seen in alopecia areata and other disorders, oil spotting is considered to be nearly specific for psoriasis. Splinter hemorrhages result from capillary bleeding underneath the thin suprapapillary plate of the psoriatic nail bed. Subungual hyperkeratosis is due to hyperkeratosis of the nail bed and is often accompanied by onycholysis (separation of the nail plate from the nail bed), which usually involves the distal aspect of the nail. Anonychia is total loss of the nail plate. Although nail changes are rarely seen in the localized pustular variant of pustulosis palmaris et plantaris,



Figure 18-15 Nail psoriasis. Panel **A** demonstrates distal onycholysis and oil drop spotting. Panel **B** demonstrates nail pitting. Panel **C** demonstrates subungual hyperkeratosis. Panel **D** demonstrates onychodystrophy and loss of nails in a patient with psoriatic arthritis. (Photos used with permission from Drs. Johann Gudjonsson and Allen Bruce, and Mr. Harrold Carter.)

anonychia can be seen in other forms of pustular psoriasis.

GEOGRAPHIC TONGUE. (See also Chapter 76). Geographic tongue, also known as *benign migratory glossitis* or *glossitis areata migrans*, is an idiopathic inflammatory disorder resulting in the local loss of filiform papillae. The condition usually presents as asymptomatic erythematous patches with serpiginous borders, resembling a map. These lesions characteristically have a migratory nature. Geographic tongue has been postulated to be an oral variant of psoriasis, as these lesions show several histologic features of psoriasis, including acanthosis, clubbing of the rete ridges, focal parakeratosis, and neutrophilic infiltrate. In addition, the prevalence of geographic tongue is increased in psoriatic patients.[326] However, geographic tongue is a relatively common condition and is seen in many nonpsoriatic individuals, so its relationship to psoriasis needs further clarification.

PSORIATIC ARTHRITIS. Arthritis is a common extracutaneous manifestation of psoriasis seen in up to 40% of patients. It has a strong genetic component, and several overlapping subtypes exist. This condition is discussed in Chapter 19.

LABORATORY TESTS

Although histopathologic examination is rarely necessary to make the diagnosis, it can be helpful in difficult cases. The histopathologic findings of guttate and chronic plaque psoriasis have already been described (see Section "Development of Lesions"). In early lesions of pustular psoriasis, the epidermis is usually only slightly acanthotic, whereas psoriasiform hyperplasia is seen in older and persistent lesions. Neutrophils migrate from dilated vessels in the upper dermis into the epidermis where they aggregate beneath the stratum corneum and in the upper Malpighian layer to form the spongiform pustules of Kogoj.

Other laboratory abnormalities in psoriasis are usually not specific and may not be found in all patients. In severe psoriasis vulgaris, generalized pustular psoriasis, and erythroderma, a negative nitrogen balance can be detected, manifested by a decrease of serum albumin.[327]

Psoriasis patients manifest altered lipid profiles, even at the onset of their skin disease.[328] Patients had 15% higher levels of high-density lipoproteins, and their cholesterol–triglyceride ratio for very low-density lipoprotein particles was 19% higher. Furthermore, plasma apolipoprotein-A1 concentrations were

11% higher in psoriasis patients. Whether these differences in lipid profile can explain or are contributing to an increased incidence of cardiovascular events in psoriasis remains to be seen.

Serum uric acid is elevated in up to 50% of patients and is mainly correlated with the extent of lesions and the activity of disease. There is an increased risk of developing gouty arthritis. Serum uric acid levels usually normalize after therapy.

Markers of systemic inflammation can be increased, including C-reactive protein, α_2-macroglobulin, and erythrocyte sedimentation rate. However, such elevations are rare in chronic plaque psoriasis uncomplicated by arthritis. Increased serum immunoglobulin (Ig) A levels and IgA immune complexes, as well as secondary amyloidosis, have also been observed in psoriasis, and the latter carries a poor prognosis.[329]

SPECIAL TESTS

Immunostaining techniques, fluorescence-activated cell sorting of dissociated cell suspensions, and assessment of T-cell receptor gene rearrangements have been of major importance in elucidating the pathogenesis of psoriasis and in characterizing the response to antipsoriatic therapies but are generally not required for diagnosis or management.

DIFFERENTIAL DIAGNOSIS

(Box 18-1)

COMPLICATIONS

Patients with psoriasis have an increased morbidity and mortality from cardiovascular events, particularly those with severe and long duration of psoriasis skin disease.[330,331] Risk of myocardial infarction is particularly elevated in younger patients with severe psoriasis.[289] In a recent study of 1.3 million German health care recipients, metabolic syndrome was 2.9-fold more frequent among psoriatic patients, and the most common diagnoses were hypertension (35.6% in psoriasis vs. 20.6% in controls) and hyperlipidemia (29.9% vs. 17.1%). The frequencies of rheumatoid arthritis

BOX 18-1 DIFFERENTIAL DIAGNOSIS OF PSORIASIS

PSORIASIS VULGARIS

Most Likely
- Discoid/nummular eczema
- Cutaneous T-cell lymphoma (CTCL)
- Tinea corporis

Consider
- Pityriasis rubra pilaris
- Seborrheic dermatitis
- Subacute cutaneous lupus erythematosus
- Erythrokeratoderma (the fixed plaques of keratoderma variabilis and/or progressive symmetric erythrokeratoderma)
- Inflammatory linear verrucous epidermal nevus
- Hypertrophic lichen planus
- Lichen simplex chronicus
- Contact dermatitis
- Chronic cutaneous lupus erythematosus/discoid lupus erythematosus
- Hailey–Hailey disease (flexural)
- Intertrigo (flexural)
- *Candida* infection (flexural)

Always Rule Out
- Bowen's disease/squamous cell carcinoma *in situ*
- Extramammary Paget's disease

GUTTATE

Most Likely
- Pityriasis rosea
- Pityriasis lichenoides chronica
- Lichen planus

Consider
- Small plaque parapsoriasis
- PLEVA
- Lichen planus
- Drug eruption

Always Rule Out
- Secondary syphilis

ERYTHRODERMIC

Most Likely
- Drug-induced erythroderma
- Eczema
- CTCL/Sézary syndrome
- Pityriasis rubra pilaris

PUSTULAR

Most Likely
- Impetigo
- Superficial candidiasis
- Reactive arthritis syndrome
- Superficial folliculitis

Consider
- Pemphigus foliaceus
- Immunoglobulin A pemphigus
- Sneddon–Wilkinson disease (subcorneal pustular dermatosis)
- Migratory necrolytic erythema
- Transient neonatal pustular melanosis
- Acropustulosis of infancy
- Acute generalized exanthematous pustulosis

[prevalence ratio (PR) 3.8], Crohn's disease (PR 2.1), and ulcerative colitis (PR 2.0) were also increased.[2] Psoriasis remained associated with after controlling for age, sex, smoking status, obesity, diabetes, and NSAID use.[332] Psoriasis patients have also been shown to have increased relative risk of both Hodgkin lymphoma and cutaneous T-cell lymphoma, especially in patients with more severe disease.[333]

Psoriasis is emotionally disabling, carrying with it significant psychosocial difficulties. Emotional difficulties arise from concerns about appearance, resulting in lowered self-esteem, social rejection, guilt, embarrassment, emptiness, sexual problems, and impairment of professional ability.[334] The presence of pruritus and pain can aggravate these symptoms. Psychological aspects can modify the course of illness; in particular, feeling stigmatized can lead to treatment noncompliance and worsening of psoriasis.[335] Likewise, psychological stress can also lead to depression and anxiety.[336] The prevalence of suicidal ideation and depression in patients with psoriasis is higher than that reported in other medical conditions and the general population.[337] Thus, although the disease is not threatening to life itself, psoriasis can very significantly impair quality of life.[338] A comparative study reported reduction in physical and mental functioning comparable with that seen in cancer, arthritis, hypertension, heart disease, diabetes, and depression.[339] According to a recent survey, 79% of patients with severe psoriasis reported a negative impact on their lives.[340]

PROGNOSIS AND CLINICAL COURSE

NATURAL HISTORY[297]

Guttate psoriasis is often a self-limited disease, lasting from 12 to 16 weeks without treatment.[297] It has been estimated that one-third to two-thirds of these patients later develop the chronic plaque type of psoriasis.[5,234] In contrast, chronic plaque psoriasis is in most cases a lifelong disease, manifesting at unpredictable intervals. Spontaneous remissions, lasting for variable periods of time, may occur in the course of psoriasis in up to 50% of patients. The duration of remission ranges from 1 year to several decades. In two separate studies, remission ranged from 17% to 55%. In another study of patients followed for 21 years, 71% had persistent lesions, 13% were free of the disease, and 16% had intermittent lesions.[297] The cause of spontaneous remission is unknown, but could reflect successful generation of self-tolerance under the model of immunologic self-reactivity discussed earlier (see Section "Psoriasis as an Autoimmune Disease").

Erythrodermic and generalized pustular psoriasis have a poorer prognosis, with the disease tending to be severe and persistent.[297]

MODIFYING FACTORS

OBESITY. It has been demonstrated that obese individuals are more likely to present with severe psoriasis (defined as >20% body surface area involvement).[341] However, obesity does not appear to have a role in defining the onset of psoriasis.[341]

SMOKING. Smoking (more than 20 cigarettes daily) has also been associated with more than a twofold increased risk of severe psoriasis.[342] Unlike obesity, smoking appears to have a role in the onset of psoriasis.[341] Recently, a gene–environment interaction has been identified between low activity of the cytochrome P_{450} gene *CYP1A1* and smoking in psoriasis.[343]

INFECTION. An association between streptococcal throat infection and guttate psoriasis has been repeatedly confirmed.[300,343] Streptococcal throat infections have also been demonstrated to exacerbate preexisting chronic plaque psoriasis.[227]

Severe exacerbation of psoriasis can be a manifestation of human immunodeficiency virus (HIV) infection.[345] Like psoriasis in general, HIV-associated psoriasis has a strong association with HLA-Cw6.[345] Interestingly, the prevalence of psoriasis in HIV infection is no higher than in the general population (1%–2% of patients),[346,347] indicating that this infection is not a trigger for psoriasis but rather a modifying agent. Psoriasis is increasingly more severe with progression of immunodeficiency but can remit in the terminal phase.[348,349] This paradoxical exacerbation of psoriasis may be due to loss of regulatory T cells and increased activity of the CD8 T-cell subset.[300] Psoriasis exacerbation in HIV disease may be effectively treated with antiretroviral therapy.[350] Psoriasis has also been associated with hepatitis C infection.[351]

DRUGS. Medications that exacerbate psoriasis include antimalarials, β blockers, lithium, nonsteroidal anti-inflammatory drugs, IFNs-α and -γ, imiquimod, angiotensin-converting enzyme inhibitors, and gemfibrozil.[352] Imiquimod acts on pDCs and stimulates IFN-α production,[147] which then strengthens both innate and Th1 immune responses. Exacerbations and onset of psoriasis have been described in patients receiving TNF inhibitor therapy. The majority of these cases are palmoplantar pustulosis, but about one-third develop chronic plaque psoriasis.[353] Lithium has been proposed to cause exacerbation by interfering with calcium release within keratinocytes, whereas β blockers are thought to interfere with intracellular cyclic adenosine monophosphate levels.[352] The mechanisms by which the remaining medications exacerbate psoriasis are largely unknown. Patients with active or unstable psoriasis should receive advice when traveling to countries where antimalarial prophylaxis is needed.

TREATMENT

GENERAL CONSIDERATIONS

A broad spectrum of antipsoriatic treatments, both topical and systemic, is available for the management of psoriasis. As detailed in Tables 18-3–18-6, it

TABLE 18-3
Topical Treatments for Psoriasis[359]

	Topical Steroids	Vitamin D Analogs	Tazarotene	Calcineurin Inhibitors
Mechanism of action	Bind to glucocorticoid receptors, inhibiting the transcription of many different AP-1- and NF-κB-dependent genes, including IL-1 and TNF-α.	Bind to vitamin D receptors, influencing the expression of many genes. Promote keratinocyte differentiation.	Metabolized to tazarotenic acid, its active metabolite,[361] which binds to retinoic acid receptors. Normalizes epidermal differentiation, exhibits a potent antiproliferative effect, and decreases epidermal proliferation.	Bind to FK506-binding protein (FKBP) and inhibit calcineurin, decreasing the activation of the transcription factor, NF-AT, with resultant decrease in cytokine transcription, including IL-2.
Dosing	10,000-fold range of potency. High-potency steroids are applied to affected areas twice daily for 2–4 weeks and then intermittently (weekends).	Calcipotriene, 0.005%, to affected areas twice daily. Often used alternating with topical steroids (i.e., vitamin D analogs on weekdays, topical steroids on weekends).	Available in 0.05% and 0.1% formulations, both as cream and gels. Apply every night to affected area.	Application to affected areas twice daily.
Efficacy	Very effective as short-term treatment.	Efficacy is increased by combination with topical steroids. Can be combined with various other therapies.	Efficacy is increased by combination with topical steroids.[361]	Effective for treatment of facial and flexural psoriasis[269] but minimally for chronic plaque psoriasis.[268]
Safety	Suppression of the hypothalamic–pituitary–adrenal axis (higher risk in children). Atrophy of the epidermis and dermis. Formation of striae. Tachyphylaxis.[258]	Development of irritation at the site of application is common.[258] Isolated reports of hypercalcemia in patients who applied excessive quantities.[363]	When used as monotherapy, significant proportion of patients develop irritation at the site of application.[364]	Burning sensation at the site of application. Case reports of development of lymphoma.
Contraindications	Hypersensitivity to the steroid, active skin infection.	Hypercalcemia, vitamin D toxicity.	Pregnancy, hypersensitivity to tazarotene.	Use only with caution for treatment of children younger than the age of 2 years.
Remarks/long-term use	Long-term use increases risk of side effects.	Calcipotriol is well tolerated and continues to be clinically effective with minimum of adverse effects in long-term use.[365,366]	Combination of steroid with tazarotene may reduce atrophy seen with superpotent topical steroids.[362] If added during phototherapy, the ultraviolet doses should be reduced by one-third.[258]	Due to anecdotal reports of association with malignancy, this class of medications recently received a black-box warning by the US Food and Drug Administration.
Pregnancy category	C	C	X	C

AP = activator protein; IL = interleukin; NF = nuclear factor; NF-AT = nuclear factor of activated T cells.

is notable that most if not all of these treatments are immunomodulatory. When choosing a treatment regimen (see Fig. 18-6) it is important to reconcile the extent and the measurable severity of the disease with the patient's own perception of his or her disease. In this context, it is notable that a recent study found that 40% of patients felt frustrated with the ineffectiveness of their current therapies, and 32% reported that treatment was not aggressive enough.[350] As psoriasis is a chronic condition, it is important to know the safety

TABLE 18-4
Phototherapy of Psoriasis[385]

	Narrowband UVB (NB-UVB; 310–331 nm)	Broadband UVB (BB-UVB)	Psoralen and UVA Light (PUVA)	Excimer Laser (308 nm)
Dosing	Dosage based on either the Fitzpatrick skin type or MED. Determine MED. Initial treatment at 50% of MED followed by three to five treatments weekly. Lubricate before treatment. Treatments 1–20; increase by 10% of initial MED. Treatments ≥21; increase as ordered by physician.[385] Maintenance therapy after >95% clearance: 1×/week for 4 weeks, keep dose the same 1×/2 weeks for 2 weeks, decrease dose by 25% 1×/4 weeks, 50% of highest dose.[385]	The dosage may be administered according to the Fitzpatrick skin type.[437] Initial treatment at 50% of MED followed by three to five treatments weekly. Treatment 1–10 increase dose by 25% of initial MED. Treatments 11–20; increase by 10% of initial MED. Treatments ≥21; increase as ordered by physician.[385]	Dose based on MPD is recommended. If MPD testing is impractical, a regimen based on skin type may be used. Initial dose 0.5–2.0 J/cm^2, depending on skin type (or MPD). Treat twice weekly, increments of 40% per week until erythema, then maximum 20% per week. No further increments once 15 J/cm^2 is reached.[369]	The dose of energy delivered is guided by the patient's skin type and thickness of plaque. Further doses are adjusted based on response to treatment or development of side effects.[385] Treatment usually given twice weekly.
Efficacy	>70% improvement in a split body study after 4 weeks of treatment. Nine out of eleven patients showed clearance.[368] More effective than BB-UVB.[274,275,368]	47% improvement in a split body study after 4 weeks, only 1 out of 11 patients showed clearance.[367]	Induces remission in 70%–90% of patients.[370–373] Less convenient than NB-UVB but may be more effective.[278]	High response rates. In one study, 85% of patients showed a ≥90% improvement in PASI after average 7.2 weeks of treatment[438] While in another study showed greater than 75% improvement in 72% of patients in an average of 6.2 treatments.[439]
Safety	Photodamage, polymorphic light eruption, increased risk of skin aging and skin cancers although lower than that for PUVA.[374]	Photodamage, polymorphic light eruption, increased risk of skin aging and skin cancers.	Photodamage, premature skin aging, increased risk of melanoma and nonmelanoma skin cancers, ocular damage. Eye protection required with oral psoralens.	Erythema, blisters, hyperpigmentation and erosions. Long-term side effects not yet clear but likely similar to NB-UVB.
Contraindications	Absolute: ■ Photosensitivity disorders. Relative: ■ Photosensitizing medications, melanoma, and nonmelanoma skin cancers.	Absolute: ■ Photosensitivity disorders. Relative: ■ Photosensitizing medications, melanoma, and nonmelanoma skin cancers.	Absolute: ■ Light-sensitizing disorder, lactation, melanoma. Relative: ■ Age <10 years, pregnancy, photosensitizing medications, nonmelanoma skin cancers, severe organ dysfunction.	Absolute: ■ Photosensitivity disorders. Relative: ■ Photosensitizing medications, melanoma, and nonmelanoma skin cancers.
Remarks	Effective as a monotherapy, but coal tar (Goeckerman regimen), anthralin (Ingram regimen), or systemic therapies may increase effectiveness in resistant cases.[367]	Coal tar (Goeckerman regimen), anthralin (Ingram regimen), or systemic therapies may increase effectiveness in resistant cases.	<200 total treatments (or <2000 J/cm^2 UVA) are recommended.[375] Combination with oral retinoids can reduce cumulative UVA exposure.	Normal skin is spared from unnecessary radiation exposure, as therapy is selectively directed toward lesional skin.[283]

MED = minimal erythema dose; MPD = minimal phototoxic dose; UVB = ultraviolet B; PASI = Psoriasis Area and Severity Index; UVA = ultraviolet A.

TABLE 18-5
Systemic Treatments for Psoriasis[390,398]

	Cyclosporine A	Methotrexate	Acitretin	Fumaric Acid Esters
Mechanism of action	Binds cyclophilin, and the resulting complex blocks calcineurin, reducing the effect of the NF-AT in T cells, resulting in inhibition of IL-2 and other cytokines.	Blocks dihydrofolate reductase, leading to inhibition of purine and pyrimidine synthesis. Also blocks AICAR transformylase, leading to accumulation of anti-inflammatory adenosine.[376]	Binds to retinoic acid receptors. May contribute to improvement by normalizing keratinization and proliferation of the epidermis.	Interferes with intracellular redox regulation, inhibiting NF-κB translocation. Skews the T-cell response toward a Th2-like pattern.[377]
Dosing	High-dose approach: ■ 5 mg/kg daily, then tapered. Low-dose approach: ■ 2.5 mg/kg daily, increased every 2–4 weeks up to 5 mg/kg daily.[378] Tapering is recommended on discontinuation.	Start with a test dose of 2.5 mg and then gradually increase dose until a therapeutic level is achieved (average range, 10–15 mg weekly; maximum, 25–30 mg weekly).[378]	Initiate at 25–50 mg daily and escalate and titrate to response.[378]	Initiate at low dose, and escalate dose weekly. After treatment response is achieved, the dose should be individually adjusted. The maximum dose is 1.2 g/day.[300]
Efficacy	Very effective, up to 90% of patients achieve clearance or marked improvement.[379,380]	May reduce the severity of psoriasis by at least 50% in more than 75% of patients.[261]	Modestly effective as monotherapy.[261]	80% Mean reduction in Psoriasis Area and Severity Index.[381]
Safety	Nephrotoxicity, HTN, immunosuppression. Increased risk of malignancy if before PUVA.	Hepatotoxicity, chronic use may lead to hepatic fibrosis. Fetal abnormalities or death, myelosuppression, pulmonary fibrosis, severe skin reactions. Rarely, severe opportunistic infections.	Hepatotoxicity, lipid abnormalities, fetal abnormalities or death, alopecia, mucocutaneous toxicity, hyperostosis.	GI symptoms, including diarrhea. Flushing ± headaches. Lymphopenia, acute renal failure.[300,381]
Monitoring	BP. Obtain baseline CBC, CMP, magnesium, uric acid, lipids, UA. Repeat tests every 2–4 weeks, then every month along with BP.[286]	Baseline CBC and LFTs. Monitor CBC and LFTs weekly until target dose is achieved, then every 4–8 weeks.[286] Liver biopsy every 1.5 g (high risk) to every 3.5–4.0 g (low risk) of cumulative dose or use procollagen III assay.	Baseline LFTs, CBC, lipids, pregnancy test. Repeat LFTs, CBC, lipids every week for 1 month then every 4 weeks. Pregnancy test every month for females. Spinal X-rays if symptoms.	Baseline CBC, CMP, UA. Repeat tests every month for the first 6 months and bimonthly thereafter.[300]
Contraindications	Absolute: ■ Uncontrolled HTN, abnormal renal function, history/current malignancy.	Absolute: ■ Pregnancy, lactation, bone marrow dysfunction, alcohol abuse.[390] Relative: ■ Hepatic dysfunction, hepatitis, renal insufficiency, severe infections, reduced lung function	Absolute: ■ Pregnancy during or within 3 years after termination of acitretin, breastfeeding.	Absolute: ■ Patients with chronic disease of the GI tract or renal disease. Pregnant or lactating women. Malignancy (or history of).[300]
Remarks/long-term use	Intermittent short-course treatments appear to be safer than chronic long-term use.[380,382]	With appropriate monitoring, long-term use appears to be safe.	Retinoids have been combined with PUVA and occasionally with UVB in an attempt to minimize the side effects and to improve therapeutic response.[261]	Not US Food and Drug Administration-approved for psoriasis but widely used in Europe. New formulations may reduce risk of GI symptoms.
Pregnancy category	C	X	X	C

(*continued*)

TABLE 18-5
Systemic Treatments for Psoriasis (Continued)

	Hydroxyurea	6-Thioguanine	Mycophenolate Mofetil	Sulfasalazine
Mechanism of action	Inhibits ribonucleotide diphosphate reductase, which converts ribonucleotides to deoxyribonucleotides, thus selectively inhibiting DNA synthesis in proliferating cells.	Purine analog that interferes with purine biosynthesis, thereby inducing cell cycle arrest and apoptosis.	A noncompetitive inhibitor of inosine monophosphate dehydrogenase, blocking *de novo* purine biosynthesis. Selectively cytotoxic for cells that rely on *de novo* purine synthesis (i.e., lymphocytes).	Anti-inflammatory agent, inhibits 5-lipoxygenase, molecular mechanism unclear.
Dosing	500 mg daily, increased to 1.0–1.5 g daily based on response and tolerance.[286]	Starting dose is 80 mg twice weekly, with 20-mg increments every 2–4 weeks. Maximum dose, 160 mg three times weekly.[286]	Doses often initiated at 500– 750 mg bid and then increased to 1.0–1.5 g bid.	Starting dose: 500 mg tid. If tolerated after 3 days, increase dose to 1 g tid. If tolerated after 6 weeks, increase dose to 1 g qid.[286]
Efficacy	In a study of 85 patients with extensive chronic plaque psoriasis, 61% had satisfactory remission.[383]	A small retrospective cohort study demonstrated >90% improvement in up to 80% of patients.[306]	Appears to be only moderately effective for treatment of psoriasis.[381,382]	Appears to be moderately effective treatment for severe psoriasis.[386]
Safety	Bone marrow suppression, macrocytosis. Teratogenicity and mutagenicity. Dermatologic side effects: lichen planus-like eruptions, exacerbation of postirradiation erythema, leg ulcers, and dermatomyositis changes.	Bone marrow suppression; GI complaints, including nausea and diarrhea; hepatic dysfunction. Instances of hepatovenous-occlusive disease have been reported.[306]	GI, including constipation, diarrhea, nausea and vomiting, bleeding. Myelosuppression, leukopenia. Headaches, HTN, peripheral edema. Infectious disease, lymphoma.	Headache, nausea, and vomiting, which occur in approximately one-third of patients. Rashes, pruritus, and hemolytic anemia (associated with G6PD deficiency).
Monitoring	Baseline CBC, CMP, LFTs. Repeat baseline tests weekly for 4 weeks then every 2–4 weeks for at least 12 weeks. Then repeat tests every 3 months.[286] Hold dosage if WBC $<2.5 \times 10^9$/L, platelet count is $<100 \times 10^9$/L or severe anemia.	Baseline CBC, CMP, LFTs. Repeat baseline tests weekly during dose escalation, then every 2 weeks. Hold if WBC $\leq 4.0 \times 10^9$/L, platelet count is $<125 \times 10^9$/L, or hemoglobin <110 g/L.[286]	Baseline CBC and CMP. Repeat laboratory tests weekly × 6 weeks, then every 2 weeks × 2 months, and then monthly. Monitor BP.	Baseline CBC, CMP, and G6PD. Repeat CBC and CMP weekly for 1 month, then every 2 weeks for 1 month, then monthly for 3 months, and then every 3 months.
Contraindi-cations	Absolute: ■ Prior bone marrow depression (leukopenia, thrombocytopenia, anemia), pregnancy, lactation. Relative: ■ Renal abnormalities.	Absolute: ■ Patients with inherited deficiency of thiopurine methyltransferase enzyme have increased risk of myelosuppression. Liver toxicity. Pregnancy.	Absolute: ■ Patients with severe infections, malignancy.[286]	Absolute: ■ Hypersensitivity to sulfasalazine, sulfa drugs, salicylates, intestinal or urinary obstruction, porphyria. Precaution in patients with G6PD deficiency.
Remarks/long-term use	Limited experience with long-term treatment.	Patients have been effectively maintained on treatment for up to 33 months.[387]	Limited experience with long-term treatment.	Limited experience with long-term treatment.
Pregnancy category	D	D	C	B

AICAR = 5-Aminoimidazole-4-carboxamide ribonucleotide; BP = blood pressure; CBC = complete blood cell count; CMP = comprehensive metabolic panel; G6PD = glucose-6-phosphate dehydrogenase; GI = gastrointestinal; HTN = hypertension; LFTs = liver function tests; NF = nuclear factor; NF-AT = nuclear factor of activated T cells; PUVA = psoralen and UVA light; Th = T helper; UA = urinalysis; UV = ultraviolet; WBC = white blood cell count.

TABLE 18-6
Combination Treatments for Psoriasis

	Topical Vitamin D3	Topical Cortico-steroids	Dithranol	Coal Tar	Tazarotene	Ultraviolet B (UVB)	Psoralen and UVA Light (PUVA)	Metho-trexate (MTX)	Cyclo-sporine A (CSA)
Etaner-cept[440,441]	+	+	±	±	+	++	±	+	±
Acitretin	++	+	+	+	+	++	++	–	±
CsA	++	+	+	+	+	±	–	±	
MTX	+	+	+	+	+	±	±		
PUVA	++	+	+	–	++	±			
UVB	+/++	+	+/++	+/++	++				
Tazarotene	+	++	+	+					
Coal tar	+	+	+/++						
Dithranol	+	+							
Topical cortico-steroids	+/++								

– = contraindicated combination; ± = insufficient evidence; + = recommended combination; ++ = strongly recommended combination. Blank boxes are represented elsewhere in the table.
Reasons for contraindicated combinations: CsA with PUVA; increased risk of squamous cell carcinoma. Coal tar with PUVA, severe phototoxic responses. Acitretin with MTX, hepatotoxicity.
Adapted from van de Kerkhof PC: Therapeutic strategies: Rotational therapy and combinations. *Clin Exp Dermatol* **26**:356, 2001, with permission.

of a treatment during long-term use. In most treatments, the duration of a treatment is restricted because of the cumulative toxicity potential of an individual treatment, and, in some instances, treatment efficacy may diminish with time (tachyphylaxis). Some treatments, such as calcipotriol, MTX, and acitretin, can be regarded as appropriate for continuous use.[354] These treatments maintain efficacy and have low cumulative toxicity potential. In contrast, topical corticosteroids, dithranol, tar, photo(chemo) therapy, and cyclosporine are not indicated for continuous chronic use, and combinatorial or rotational treatments[354] are suggested. However, patients with stable chronic plaque psoriasis who respond well to local treatments may not require a change of treatment.[354] In cases of itchy/pruritic psoriasis, treatments with an irritative potential, such as dithranol, vitamin D_3 analogs, and photo(chemo) therapy, should be used cautiously, whereas treatments with potent anti-inflammatory effects, such as topical corticosteroids, are more appropriate.[354]

In patients with erythrodermic and pustular psoriasis, treatments with an irritant potential should be avoided, and acitretin, MTX, or short-course cyclosporine are the treatments of first choice.[354] See Boxes 18-2 and 18-3 for special considerations in the treatment of women of child-bearing potential and pregnancy and children.

TOPICAL TREATMENTS

(See Table 18-3.)[355,356]

Most cases of psoriasis are treated topically. As topical treatments are often cosmetically unacceptable and time-consuming to use, noncompliance is on the order of 40%.[357] In most cases, ointment formulations are more effective than creams but are less cosmetically acceptable. For many patients, it is worth prescribing both cream and ointment formulations; cream for use in the morning and ointment for nighttime.[358] Topical agents are also used adjunctively for resistant lesions in patients with more extensive psoriasis and who are concurrently being treated with either UV light or systemic agents.[359] It is worth noting that around 400 g of a topical agent is required to cover the entire body surface of an average-sized adult when used twice daily for 1 week.[360]

CORTICOSTEROIDS. Glucocorticoids exert many if not all of their myriad effects by stabilizing and causing nuclear translocation of glucocorticoid receptors, which are members of the nuclear hormone receptor superfamily. Topical glucocorticoids are commonly first-line therapy in mild to moderate psoriasis and in sites such as the flexures and genitalia, where other topical treatments can induce irritation. Improvement is usually achieved within 2–4 weeks, with maintenance treatment consisting of intermittent applications (often restricted to the weekends). Tachyphylaxis to treatment with topical corticosteroids is a well-established phenomenon in psoriasis.[361] Long-term topical corticosteroids may cause skin atrophy, telangiectasia, striae (Fig. 18-16D) and adrenal suppression.

BOX 18-2 TREATMENT OF WOMEN OF CHILD-BEARING POTENTIAL AND DURING PREGNANCY

- Special caution needs to be exercised when treating women of child-bearing potential and during pregnancy.
- Medications such as methotrexate and oral retinoids should be avoided or used with extreme caution and then only along with appropriate contraception.
- In selected cases, isotretinoin rather than acitretin may be the preferred agent due to its much shorter half-life.
- As methotrexate is fetotoxic and an abortifactant and retinoids are potent teratotoxins, the use of these agents is absolutely contraindicated in pregnancy.
- Many women experience improvement or remission during periods of pregnancy, thus decreasing the need for the more potent agents.
- If treatment is needed, emollients and other topical agents are first-line agents, often in association with ultraviolet B phototherapy.
- Many of the topical agents, such as topical steroids and calcipotriene, are pregnancy category C agents, and caution should be exercised with their use.
- Several of the biologic agents are category B and can be used in pregnancy. Likewise, cyclosporine A may be considered, as it is pregnancy category C and is nonteratogenic.
- Systemic psoralen and ultraviolet A light (PUVA) has been used on occasion in selected cases and appears to be safe.

BOX 18-3 TREATMENT OF CHILDREN

- Children represent a large fraction of psoriasis patients, as the disease commonly presents during childhood or adolescence.
- As for adults, first-line treatment is with topical agents, often in association with ultraviolet B phototherapy.
- Due to its carcinogenic risk and opportunity for long-term exposure, psoralen and ultraviolet A light is generally contraindicated in childhood.
- Likewise, the decision to treat with systemic agents should be carefully assessed, as the long-term potential side effect profile of many of the systemic agents is still unknown. However, many of the systemic agents have been used successfully in severe recalcitrant cases.

Another concern is that when topical steroids are discontinued, patients may rebound, sometimes worse than it was prior to treatment.[359] This class of agents is discussed in detail in Chapter 216.

VITAMIN D_3 AND ANALOGS.[362] Vitamin D exerts its actions by binding to the vitamin D receptor, another member of the nuclear hormone receptor superfamily. Vitamin D_3 acts to regulate cell growth, differentiation, and immune function, as well as calcium and phosphorous metabolism. Vitamin D has been shown to inhibit the proliferation of keratinocytes in culture and to modulate epidermal differentiation. Furthermore, vitamin D inhibits production of several proinflammatory cytokines by psoriatic T-cell clones, including IL-2 and IFN-γ.[363]

Analogs of vitamin D that have been used for the treatment of skin diseases are calcipotriene (also known as calcipotriol), tacalcitol, and maxacalcitol. In short-term studies, potent topical corticosteroids were found to be superior to calcipotriene. When compared with short-contact anthralin or 15% coal tar, calcipotriene was the more effective agent. The efficacy of calcipotriene is not reduced with long-term treatment.[364] Calcipotriene applied twice daily is more effective than once-daily use. Hypercalcemia is the only major concern with the use of topical vitamin D preparations. When the amount used does not exceed the recommended 100 g/week, calcipotriene can be used with a great margin of safety.[365] Vitamin D analogs are often used in combination with or in rotation with topical corticosteroids in an effort to maximize therapeutic effectiveness while minimizing steroid-related skin atrophy.

ANTHRALIN (DITHRANOL). Dithranol (1,8-dihydroxy-9-anthrone) is a naturally occurring substance found in the bark of the araroba tree in South America. It can also be synthesized from anthrone. Dithranol is made up in a cream, ointment, or paste. Dithranol is approved for the treatment of chronic plaque psoriasis. Its most common use has been in the treatment of psoriasis, particularly on plaques resistant to other therapies. It can be combined with UVB phototherapy with good results (the Ingram regimen). Most common side effects are irritant contact dermatitis and staining of clothing, skin, hair, and nails. Anthralin possesses antiproliferative activity on human keratinocytes along with potent anti-inflammatory effects. Classic anthralin therapy starts with low concentrations (0.05%–0.1%) incorporated in petrolatum or zinc paste and given once daily. To prevent autooxidation, salicylic acid (1%–2%) should be added. The concentration is increased weekly in individually adjusted increments up to 4% until the lesions resolve. Scalp psoriasis should be treated with great caution as anthralin can stain hair purple to green.

COAL TAR. The use of tar to treat skin diseases dates back nearly 2000 years. In 1925, Goeckerman introduced the use of crude coal tar and UV light for the treatment of psoriasis. Tar is the dry distillation product of organic matter heated in the absence of oxygen. Its mode of action is not understood, and, because of

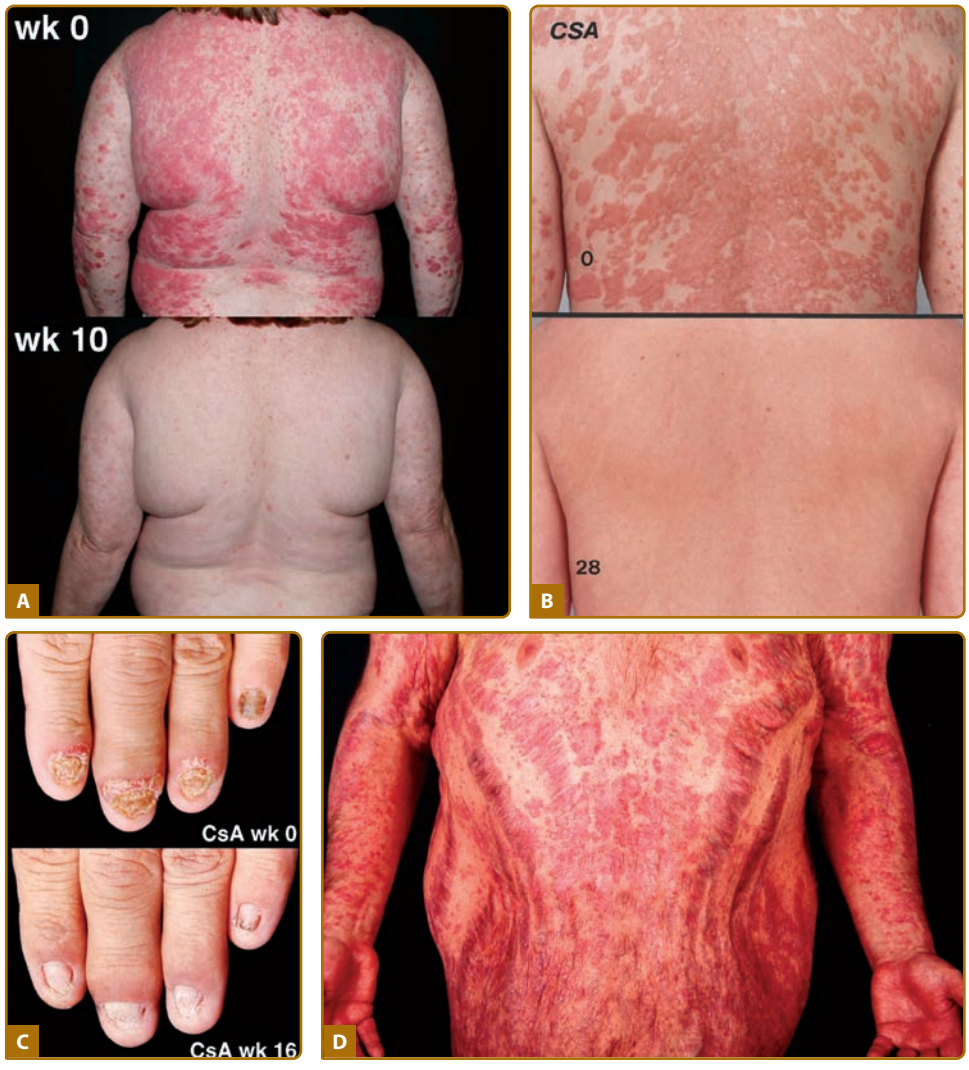

Figure 18-16 Positive and negative outcomes of psoriasis treatment. Panel **A** illustrates near-complete improvement of psoriasis after 10 weeks of infliximab therapy. Panel **B** illustrates marked improvement after 28 days of oral cyclosporine A treatment. Panel **C** illustrates marked reduction in nail dystrophy after 16 weeks of cyclosporine A treatment. Panel **D** illustrates severe atrophy with striae distensae after several years of treatment with potent topical steroid creams. (Photos used with permission from Mr. Harrold Carter.)

its inherent chemical complexity, tar is not pharmacologically standardized. It was recently suggested that carbazole, a coal-derived chemical, is the main active ingredient in tar.[366] Tar appears to exert its action through suppression of DNA synthesis and consequent reduction of mitotic activity in the basal layer of the epidermis, and some components in tar appear to have anti-inflammatory activity. Coal tar, in concentrations up to 20% (5%–20%) can be compounded in creams, ointments, and pastes. It is often combined with salicylic acid (2%–5%), which by its keratolytic action leads to better absorption of the coal tar.[297] Occasionally, patients become sensitive to the coal tar and develop allergic reactions. A folliculitis may occur after the use of coal tar. Furthermore, it has an unwelcome smell and appearance and can stain clothing and other items. Coal tar is carcinogenic.

TAZAROTENE. Tazarotene is a third-generation retinoid for topical use that reduces mainly scaling and plaque thickness, with limited effectiveness on erythema. It is thought to act by binding to retinoic acid receptors, but its molecular targets are unknown. It is available in 0.05% and 0.1% gels, and a cream formulation has been developed. When this drug is used as a monotherapy, a significant proportion of patients develop local irritation. This retinoid dermatitis is worse with the 0.1% formulation. Efficacy of this drug can be enhanced by combination with mid- to high-potency glucocorticoids or UVB phototherapy. When used in combination with phototherapy, it lowers the minimal erythema dose (MED) for both UVB and UVA. It has been recommended that UV doses be reduced by at least one-third if tazarotene is added in the middle of a course of phototherapy.[367]

TOPICAL CALCINEURIN INHIBITORS. (See Chapter 221.) Tacrolimus (FK-506) is a macrolide antibiotic, derived from the bacteria *Streptomyces tsukubaensis* that, by binding to immunophilin (FK506-binding protein), creates a complex that interacts and inhibits calcineurin, thus blocking both T-lymphocyte signal transduction and IL-2 transcription. Pimecrolimus is also a calcineurin inhibitor and works in a manner similar to tacrolimus and CsA.

In a study of 70 patients with chronic plaque psoriasis treated with topical tacrolimus, there was no improvement beyond that seen for placebo.[368] However, for treatment of inverse and facial psoriasis, these agents appear to provide effective treatment.[369,370] The main side effect of these medications is a burning sensation at application site. Anecdotal reports of lymph node or skin malignancy require further evaluation in controlled studies, and these drugs have a US Food and Drug Administration (FDA) "black-box warning."

SALICYLIC ACID. (See also Chapter 222.) Salicylic acid is a topical keratolytic agent. Its mechanism of action includes reduction of keratinocyte adhesion and lowering the pH of the stratum corneum. This results in reduced scaling and softening of the plaques,[371] thereby enhancing absorption of other agents. Therefore, salicylic acid is often combined with other topical therapies such as corticosteroids and coal tar. Topical salicylic acid decreases the efficacy of UVB phototherapy[359] and systemic absorption can occur, particularly in patients with abnormal hepatic or renal function and when applied to more than 20% of the body surface area. No placebo-controlled studies have been performed to verify the efficacy and safety of salicylic acid as a monotherapy.[359]

BLAND EMOLLIENTS. Between treatment periods, skin care with emollients should be performed to avoid dryness. Emollients reduce scaling, may limit painful fissuring, and can help control pruritus. They are best applied immediately after bathing or showering. The addition of urea (up to 10%) is helpful to improve hydration of the skin and remove scaling of early lesions. The use of liberal bland emollients over a thin layer of topical prescription treatments improves hydration while minimizing treatment costs.

PHOTOTHERAPY[372]

(See Table 18-4) (See Chapters 237 and 238.)

Phototherapy of psoriasis with artificial light sources dates back to 1925 when Goeckerman introduced a combination of topical crude coal tar and subsequent UV irradiation. In the 1970s, it was shown that broadband UVB radiation alone, if given in doses that produce a faint erythematous reaction, could clear the milder clinical forms of psoriasis. Major steps forward were the introduction of photochemotherapy with psoralen and UVA light (PUVA) in the 1970s and narrow band UVB (311–313 nm) in the 1980s.

The mechanism of action of phototherapy appears to involve selective depletion of T cells, predominantly those that reside in the epidermis.[166,230] The mechanism of depletion appears to involve apoptosis[373] and is accompanied by a shift from a Th1 immune response toward a Th2 response in the lesional skin.[374]

ULTRAVIOLET B LIGHT (290–320 nm). The initial therapeutic UVB dose lies at 50%–75% of the MED. Treatments are given two to five times per week. As peak UVB erythema appears within 24 hours of exposure, increments can be performed at each successive treatment. The objective is to maintain a minimally perceptible erythema as a clinical indicator of optimal dosing. Treatments are given until total remission is reached or until no further improvement can be obtained with continued treatment. The main side effects of UVB phototherapy are summarized in Chapter 237.

Narrowband (312 nm) UVB (NBUVB) phototherapy is superior to conventional broadband UVB (290–320 nm) with respect to both clearing and remission times.[375,376] Although early studies found NB-UVB to be as effective as psoralen and UVA light (PUVA),[377,378] a recent controlled trial found that PUVA was more effective, albeit less convenient.[379] On clearing, treatment is either discontinued or patients are subjected to maintenance therapy for 1 or 2 months. During this period, the frequency of UVB treatments is reduced while maintaining the last dose given at the time of clearing.[372]

Systemic drugs, such as retinoids, increase the efficacy of UVB light, particularly in patients with chronic and hyperkeratosis plaque-type psoriasis.[380,381] Because they are known to inhibit carcinogenesis in experimental animals, retinoids may possibly reduce the carcinogenic potential of UVB phototherapy.

PSORALEN AND ULTRAVIOLET A LIGHT. (See Chapter 238.) PUVA is the combined use of psoralens (P) and long-wave ultraviolet A radiation (UVA). The combination of drug and radiation results in a therapeutic effect, which is not achieved by the single component alone. Remission is induced by repeated controlled phototoxic reactions. A detailed account of PUVA therapy and its short-term and long-term side effects is to be found in Chapter 238.

EXCIMER LASER.[362] (See Chapter 239.) Supraerythemogenic fluences of UVB and PUVA are known to result in faster clearing of psoriasis,[383] however, the limiting factor for the use of such high fluences lies with the intolerance of the uninvolved surrounding skin as psoriatic lesions can often withstand much higher UV exposures.[384] The monochromatic 308-nm excimer laser can deliver such supraerythemogenic doses of light (up to 6 MED, usually in the range of 2–6 MEDs) to lesional skin, however, only focally. The dosing is guided by the patients' skin type and thickness of the plaque with subsequent doses based on the response to therapy or development of side effects.[385] In a study on 124 patients, 72% of study subjects achieved at least 75% clearing in an average of 6.2 treatments delivered twice weekly.[384] The role of this treatment seems to be indicated for patients with stable recalcitrant plaques particularly in the elbows and knee region.

PHOTODYNAMIC TREATMENT.[386] (See Chapter 238.) Photodynamic therapy has been tried for several inflammatory dermatoses, including psoriasis. In a randomized study on the effect of topical aminolevulinic acid-based photodynamic therapy, 29 patients demonstrated unsatisfactory clinical response and frequent occurrence of pain during and after treatment, prompting the authors to declare this as an inadequate treatment option for psoriasis.

CLIMATIC THERAPY.[387] It is well known that going to a sunny climate can improve psoriasis, although a small proportion of patients actually deteriorate. Patients should be warned not to overexpose themselves in the first few days, as sunburn may actually progress to psoriasis (Koebner phenomenon). The best-studied effects are from the Dead Sea area, and those therapeutic effects may be attributed, at least partially, to the unique climatic characteristic of that location. As it is situated 400 m below sea level, the evaporation of the sea forms an aerosol that stays in the atmosphere above the sea and surrounding beaches. This aerosol screens out the majority of the UVB rays but not the UVA. This mixture of UV light appears to be sufficient to clear psoriasis but without sunburn. Thus, patients can stay on the shores of the Dead Sea for long periods of time with greatly reduced risk of sunburn. This treatment is carried out over a period of 3–4 weeks, and improvements comparable to NB-UVB or PUVA treatments are observed. The main disadvantages of this treatment are time and expense.

SYSTEMIC ORAL AGENTS[388–390]

(See Table 18-5.)

METHOTREXATE. MTX is highly effective for chronic plaque psoriasis[389] and is also indicated for the long-term management of severe forms of psoriasis, including psoriatic erythroderma and pustular psoriasis.[388] For mechanisms of action, see Chapters 227 and 233. When first used for the treatment of psoriasis, MTX was thought to act directly to inhibit epidermal hyperproliferation via inhibition of dihydrofolate reductase (DHFR). However, it was found to be effective at much lower doses (0.1–0.3 mg/kg weekly) in the management of psoriasis, psoriatic arthritis, and other inflammatory conditions such as rheumatoid arthritis. At these concentrations, MTX inhibits the *in vitro* proliferation of lymphocytes, but not proliferation of keratinocytes.[391] It is now thought that the inhibition of DHFR is not the main mechanism of anti-inflammatory action of MTX, but rather the inhibition of an enzyme involved in purine metabolism [AICAR (5-aminoimidazole-4-carboxamide ribonucleotide) transformylase]. This leads to accumulation of extracellular adenosine, which has potent anti-inflammatory activities, particularly for neutrophils.[392] Consistent with a DHFR-independent mechanism of action, concomitant administration of folic acid (1–5 mg/day) reduces certain side effects, such as nausea and megaloblastic anemia, without diminishing the efficacy of antipsoriatic treatment.[393] The cellular targets of MTX action in psoriasis are still under investigation, but its mechanism of action may involve modulation of adhesion molecules, such as intercellular adhesion molecule 1, rather than induction of lymphocyte apoptosis.[394]

The very long half-life of MTX may account for its efficacy after weekly administration and may also help to explain why its onset of action is rather slow (therapeutic effects usually require 4–8 weeks to become evident). MTX is renally excreted and should therefore not be administered to patients with impairment in renal function, as MTX side effects are generally dose-related. Short-term toxicity and long-term concerns are discussed in Chapter 227.

In the most recent guidelines[395,396] it is suggested that patients be divided into two separate groups based on their risk factors for liver injury: the low-risk patients follow the American College of Rheumatology (ACR) guidelines and are not asked to undergo liver biopsy until they have reached a cumulative MTX dose of 3.5–4.0 g. In contrast, those patients with one or more risk factors continue to follow the previously published[397] more stringent guidelines requiring baseline liver biopsy either before treatment or after 2–6 months of treatment, and then at each cumulative MTX dose of 1.0–1.5 g.[395,398] The risk factors include current or past alcohol consumption, persistent abnormalities of liver function enzymes, personal, or family history of liver disease, exposure to hepatotoxic drugs or chemicals, diabetes mellitus, hyperlipidemia, and obesity.[395]

Some groups have recommended the use of amino terminal type III procollagen peptide (PIIINP) assay for screening of liver fibrosis.[292] Specific guidelines have been developed for monitoring PIIINP levels in psoriatic patients,[292] but the FDA has not yet approved the use of this assay for diagnostic use within the United States.

Another well-known side effect of MTX is myelosuppression, especially pancytopenia, which usually occurs in the setting of folate deficiency. Leucovorin calcium (folinic acid) is the only antidote for the hematologic toxicity of MTX. When an overdose is suspected, an immediate leucovorin dose of 20 mg should be given parenterally or orally, and subsequent doses should be given every 6 hours.[399] Pneumonitis can develop, and mucosal and skin ulcerations have also been reported in patients treated with MTX.[399,400]

Discontinuation of MTX treatment is required in the event of hepatotoxicity, hematopoietic suppression, active infections, nausea, and pneumonitis. MTX is also teratogenic and should therefore not be prescribed for women who are pregnant or breastfeeding. Several classes of drugs, including nonsteroidal anti-inflammatory drugs and sulfonamides, may interact with MTX to increase toxicity.

ACITRETIN.[401] Acitretin is a second-generation, systemic retinoid that has been approved for the treatment of psoriasis since 1997 and is discussed in Chapter 228.

The clinical forms most responsive to etretinate or acitretin as monotherapy include generalized pustular and erythrodermic psoriasis. Acitretin induces clearance of psoriasis in a dose-dependent fashion.

Overall, higher starting doses appeared to clear psoriasis faster.[402] The mechanism of action of retinoids for psoriasis is not fully understood.

The optimal initial dose of acitretin for psoriasis is reported at 25 mg/day, with a maintenance dose of 20–50 mg/day. Adverse effects, such as hair loss and paronychia, occur more frequently with higher initial dose (i.e., ≥50 mg/day). Most patients relapse within 2 months after discontinuing etretinate or acitretin. Acitretin should be discontinued if liver dysfunction, hyperlipidemia, or diffuse idiopathic hyperostosis develops.

CYCLOSPORINE A. Cyclosporine A (CsA) is a neutral cyclic undecapeptide derived from the fungus *Tolypocladium inflatum Gams*. Its mechanism of action and side effects are discussed in Chapter 233. The only formulation approved for treatment of psoriasis is available as an oral solution or in capsules. It is highly effective for cutaneous psoriasis and can also be effective for nail psoriasis (see Fig. 18-16B). CsA is particularly useful in patients who present with widespread, intensely inflammatory, or frankly erythrodermic psoriasis. Dosage ranges from 2 to 5 mg/kg/day.[403] Because the nephrotoxic effects of CsA are largely irreversible, CsA treatment should be discontinued if kidney dysfunction and/or hypertension occur. CsA-induced hypertension may be treated with calcium antagonists such as nifedipine.[404] The most common adverse effects noted in patients using CsA for short periods of time are neurologic, including tremors, headache, paresthesia, and/or hyperesthesia. Long-term treatment of psoriasis with low-dose CsA was found to increase risk of nonmelanoma skin cancers.[405] However, unlike organ transplant patients treated with higher doses of CsA, there is little or no increased risk of lymphoma.

FUMARIC ACID ESTERS. Fumaric acid was first reported in 1959 to be beneficial in the systemic treatment of psoriasis[406] and is licensed in Germany for treatment of psoriasis. Because fumaric acid itself is poorly absorbed after oral intake, esters are used for treatment. The esters are almost completely absorbed in the small intestine, and dimethyl fumarate is rapidly hydrolyzed by esterases to monomethyl fumarate, which is regarded as the active metabolite. The mode of action of fumaric acid esters (FAEs) in the treatment of psoriasis is not fully understood, but experimental data point toward a skewing of the Th1-dominated T-cell response in psoriasis to a Th2-like pattern and inhibition of keratinocyte proliferation.[406] Patients with severe concomitant disease, chronic disease of the gastrointestinal tract, chronic kidney disease, or with bone marrow disease leading to leukocytopenias or leukocyte dysfunction should not be treated. Likewise, pregnant or lactating women and patients with malignant disease (including positive history of malignancy) should be excluded from treatment. Prolonged therapy (up to 2 years) to prevent relapse in psoriasis patients with high disease activity is possible. Another therapeutic option is short-course intermittent therapy. FAEs are given until a major improvement is achieved and are then withdrawn. If a patient remains lesion-free during prolonged treatment, the FAE dose should be gradually decreased to reach the individual's threshold.[406] Therapy with FAEs can be stopped abruptly. Rebound phenomena have not been observed.[406]

SULFASALAZINE. Sulfasalazine is an uncommonly used systemic agent in the management of psoriasis. In the only prospective double-blind study on the efficacy of sulfasalazine in psoriasis, moderate effects were seen, with 41% of the patients showing marked improvement, 41% with moderate, and 18% with minimal improvement after 8 weeks of treatment.[407]

SYSTEMIC STEROIDS. (See Chapter 224.) In general, systemic steroids should not be used in the routine care of psoriasis. When systemic steroids are used, clearance of psoriasis is rapid, but the disease usually breaks through, requiring progressively higher doses to control symptoms. If withdrawal is attempted, the disease tends to relapse promptly and may rebound in the form of erythrodermic and pustular psoriasis.[408] However, systemic steroids may have a role in the management of persistent, otherwise uncontrollable, erythroderma and in fulminant generalized pustular psoriasis (von Zumbusch type) if other drugs are ineffective.

MYCOPHENOLATE MOFETIL. (See Chapter 233.) Mycophenolate mofetil is a prodrug of mycophenolic acid, an inhibitor of inosine-5′-monophosphate dehydrogenase. Mycophenolic acid depletes guanosine nucleotides preferentially in T and B lymphocytes and inhibits their proliferation, thereby suppressing cell-mediated immune responses and antibody formation. The drug is usually well tolerated with few side effects. Few studies have been done on this medication for psoriasis, but, in a prospective open-label trial on 23 patients with dosage between 2 and 3 g daily, a 24% reduction of the Psoriasis Area and Severity Index (PASI) was seen after 6 weeks, with 47% improvement at 12 weeks.[409]

6-THIOGUANINE. 6-Thioguanine is a purine analog that has been highly effective for psoriasis.[410] Apart from bone marrow suppression, gastrointestinal complaints including nausea and diarrhea can occur, and elevation of liver function tests is common.[388] Isolated instances of hepatic veno-occlusive disease have been reported.[411]

HYDROXYUREA. Hydroxyurea is an antimetabolite that has been shown to be effective as monotherapy, but nearly 50% of patients who achieve marked improvement develop bone marrow toxicity with leukopenia or thrombocytopenia. Megaloblastic anemia is also common but rarely requires treatment.[388] Cutaneous reactions affect most patients treated with hydroxyurea, including leg ulcers, which are the most troublesome.[412]

COMBINATION TREATMENTS

(See Table 18-6.)

Combination treatment may increase efficacy and reduce side effects, and so may result in a more substantial improvement, or alternatively, may permit

reduced doses to reach the same improvement as compared with monotherapy.[354] Data on combination of biologics with other systemic or topical agents are not yet widely available, but some combinations commonly used in the treatment of inflammatory arthritides, such as a combination of MTX and anti-TNF agents,[413] may be appropriate for treatment of recalcitrant psoriatic disease.

BIOLOGIC TREATMENTS[414–417]

(See Table 18-7.) (See also Chapter 234.)

Based on the continuous progress in psoriasis research and advances in molecular biology, a new class of agents—targeted biologic therapies—has emerged.[414,415] These agents are designed to block specific molecular steps important in the pathogenesis of psoriasis or have been transferred to the psoriasis arena after being developed for other inflammatory diseases. Currently, three types of biologics are approved or are in development for psoriasis: (1) recombinant human cytokines, (2) fusion proteins, and (3) monoclonal antibodies, which may be chimeric or humanized. Due to the risk of the development of antibodies to mouse sequences, humanized or fully human antibodies are preferred for clinical use.

Using internationally acknowledged safety and efficacy endpoints, the overall utility and benefit of biologics have been demonstrated based on the percentage of patients achieving at least a 50% improvement in PASI (PASI-50), a 75% improvement in PASI (PASI-75), the impact of treatment on quality of life, and safety and tolerability.[417] In general, these agents have antipsoriatic activity roughly comparable to that of MTX and lack its risk of hepatotoxicity. However, they are far more expensive, carry risks of immunosuppression, infusion reactions, and antibody formation, and their long-term safety remains to be evaluated. In the opinion of the authors, use of biologic agents should be reserved for treatment of severe psoriasis that is either unresponsive to MTX or in patients for whom the use of MTX is contraindicated.

ALEFACEPT. Alefacept is a human lymphocyte function-associated antigen (LFA)-3-IgG1 fusion protein designed to prevent the interaction between LFA-3 and CD2. The LFA-3-CD2 signal plays an important role in activation of T cells. The LFA-3 portion of alefacept binds to the CD2 receptor on T cells, blocking the interaction between LFA-3 and CD2, thus interfering with the activation of T cells, inducing apoptosis and modifying the inflammatory process. CD2 is upregulated on memory effector T cells, explaining the preferential depletion of these cells by alefacept.[418] One-third to one-half of psoriatic patients do not respond to alefacept; the reasons for this remain unclear. However, evidence indicates that repeated administration of alefacept leads to improved response, and that responses to alefacept are durable.[415]

EFALIZUMAB. Efalizumab (anti-CD11a) is a humanized monoclonal antibody developed for treatment of plaque psoriasis. It is directed against CD11a, the α subunit of LFA-1, and thus blocks the interaction of LFA-1 with its ligand intercellular adhesion molecule 1. This blockade inhibits T-cell activation, cutaneous T-cell trafficking, and T-cell adhesion to keratinocytes.[419,420] Some patients have shown evidence of exacerbation of the disease at the end of the dosing period.[421] This medication is not longer in clinical use as it was withdrawn from the market in 2009 after reports of an increased incidence of progressive multifocal leukoencephalopathy of approximately one in 500 treated patients.[422]

TUMOR NECROSIS FACTOR-α ANTAGONISTS. The clinical application of TNF antagonists in inflammatory diseases has exploded on the clinical realm in a manner reminiscent of the discovery of the activity of corticosteroids.[423] TNF-α is a homotrimeric protein that exists in both transmembrane and soluble forms, the latter resulting from proteolytic cleavage and release. It is still unclear which form is more important in mediating its proinflammatory activities or the relative importance of the two p55- and p75-kd TNF-α-binding receptors.[424]

Currently, four anti-TNF biologics are available in the United States. Infliximab is a chimeric monoclonal antibody that has high specificity, affinity, and avidity for TNF-α. An example of an excellent treatment outcome with infliximab is shown in Fig. 18-16A. Etanercept is a human recombinant, soluble, TNF-α receptor-Fc IgG fusion protein that binds TNF-α and neutralizes its activity. Adalimumab and golimumab are fully human recombinant IgG1 monoclonal antibodies and specifically targets TNF-α. Currently golimumab is only FDA-approved for psoriatic arthritis. Clinical trials have shown that each of these agents is well tolerated and appears suitable for long-term use in chronic plaque psoriasis. However, like all the targeted biologic therapies, they carry risks of immunosuppression, and their long-term safety requires further study.

Clinical studies have found infliximab and adalimumab to be slightly more effective than etanercept in the treatment of psoriasis. It is likely that the differential effects of these agents are associated with selectivity in their ability to perturb these receptor ligand interactions. It is known that infliximab, adalimumab, golimumab, and etanercept bind TNF differently; infliximab and adalimumab bind to both soluble and membrane-bound TNF, whereas etanercept binds primarily to soluble TNF.[425] Binding to membrane-bound TNF can induce a dose-dependent increase in apoptosis of T cells, but the relevance of this mechanism in psoriasis has not been evaluated.

ANTI-p40 (IL-12/IL-23 ANTAGONIST)

Ustekinumab is a human monoclonal antibody that binds the shared p40 subunit of IL-12 and IL-23 and prevents interaction with their receptors.[426] This treatment blocks IL-12, which is critical for Th1 differentiation, but its inhibitory effect on IL-23 may be more important. As described earlier, IL-23 supports chronic

TABLE 18-7
Biologic Treatments for Psoriasis[390,442]

	Alefacept	Ustekinumab	Etanercept	Infliximab	Adalimumab
Mechanism	Binds CD2 on T cells, blocking the CD2-LFA3 interaction, thus interfering with T-cell activation and causing T-cell apoptosis.	Binds p40 (the common subunit of IL-12 and IL-23). Blocks Th1 and Th17 differentiation and proliferation.	Human recombinant, soluble TNF-α receptor. Binds TNF-α and neutralizes its activity.	Chimeric monoclonal antibody that has high specificity, affinity, and avidity for TNF-α.	Fully human recombinant monoclonal antibody that specifically targets TNF-α.
Dosing	15 mg IM once weekly for 12 weeks. Multiple subsequent 12-week courses are possible in responders, with a minimum interval of 12 weeks between courses.	Subcutaneous injections. Weight based dosing. Individuals weighing <100 kg (220 lbs); 45 mg, >100 kg 90 mg. Injections at week 0, 4, and then every 12 weeks.	25- to 50-mg injections subcutaneously twice weekly. Commonly given as 50 mg BIW for 12 weeks followed by 50 mg weekly.	Intravenous infusions over 2 hours. 5–10 mg/kg at weeks 0, 2, and 6.	Initial dose of 80 mg, followed by 40 mg given every other week starting one week after the initial dose.
Efficacy	PASI-75 at 14 weeks (2 weeks after last dose) 24%. Patients who respond maintain improvement for extended periods of time. Repeat courses are safe and well tolerated.[388]	PASI-75 at 12 weeks, 67% and 71%–78% at week 28[443]	PASI-75 at 12 weeks, 34% and at 24 weeks, 44%.[393] For the 25 mg BIW vs. 49% and 59% for the 50 mg BIW dosing.[444]	PASI-75 at 10 weeks, 82% (5 mg/kg) and 91% (10 mg/kg).[394] At week 26 (following a single course), 57% of patients maintained PASI-50, and 50% maintained PASI-75.[394]	PASI-75 at 16 weeks, 71%[445]
Safety	Lymphopenia, malignancy, serious infections. Not recommended for human immunodeficiency virus-positive patients. Effects of live vaccines not studied.	Serious infections, increased risk of malignancy, reversible posterior leuko-encephalopathy syndrome. Live vaccinations not recommended.	Serious infections, exacerbation of MS, pancytopenia, malignancy, worsening congestive heart failure. Lupus-like symptoms (anti-dsDNA positive). Live vaccinations should not be given.	Infusion-related reactions, infections, worsening of MS, malignancy or lymphoproliferative disease, worsening heart failure. Lupus-like symptoms (anti-dsDNA positive). Live vaccinations should not be given.	Injection site reactions, infections, lupus-like syndrome, worsening heart failure, cytopenias, neurologic events.[396] Live vaccinations should not be given.
Monitoring	$CD4^+$ T-cell counts every 2 weeks during treatment.	Baseline PPD/ QuantiFERON-TB Gold	Baseline PPD/ QuantiFERON-TB Gold	Baseline PPD/ QuantiFERON-TB Gold.	Baseline PPD/ QuantiFERON-TB Gold.
Long-term administration	Up to nine courses have been administered over 4–5 years in small number of patients with incremental benefits.	Clinical trials have established safety up to 76 weeks.[443] Appears to be similar to TNF-α inhibitors	PASI response continues to increase to week 24. Large databases in patients with other immunologic diseases indicate safety.	As intermittent therapy. Large databases in patients with other immunologic diseases indicate relative safety.	Similar to other TNF-α inhibitors.
Pregnancy category	B	B	B	B	B

BIW = twice weekly; dsDNA = double-stranded DNA; LFA = lymphocyte function-associated antigen; MS = multiple sclerosis; PASI-50 = 50% improvement in Psoriasis Area and Severity Index; PASI-75 = 75% improvement in Psoriasis Area and Severity Index; PPD = purified protein derivative (of tuberculin); TNF = tumor necrosis factor.

inflammation mediated by Th17[99–101] and Th22 cells.[427] Clinical studies have found ustekinumab to be slightly more effective than etanercept in the treatment of psoriasis,[428] but direct comparison to infliximab or adalimumab has not been reported.

Numerous new drugs are currently in clinical trials for treatment of psoriasis as outlined in a comprehensive review.[429] As would be predicted from the immunological and genetic studies depicted in Figs. 18-3 and 18-5, a humanized monoclonal antibody directed against the IL-17 receptor appears to be highly effective in early clinical trials.[430]

Extensive guidelines are available for specific clinical scenarios, including severe scalp psoriasis,[431] intertriginous psoriasis,[432] concomitant hepatitis C or HIV infection,[396,433] and in erythrodermic psoriasis.[434]

PREVENTION

There is no known prevention for psoriasis.

KEY REFERENCES

Full reference list available at www.DIGM8.com

DVD contains references and additional content

7. Nestle FO et al: Skin immune sentinels in health and disease. *Nat Rev Immunol* **9**(10):679-691, 2009
10. Elder JT et al: The genetics of psoriasis. *Arch Dermatol* **130**(2):216-224, 1994
30. Nair RP et al: Sequence and haplotype analysis supports HLA-C as the psoriasis susceptibility 1 gene. *Am J Hum Genet* **78**(5):827-851, 2006
34. Nair RP et al: Genome-wide scan reveals association of psoriasis with IL-23 and NF-κB pathways. *Nat Genet* **41**(2):199-204, 2009
57. Zhang XJ et al: Psoriasis genome-wide association study identifies susceptibility variants within LCE gene cluster at 1q21. *Nat Genet* **41**(2):205-210, 2009
69. Gudjonsson JE et al: Global gene expression analysis reveals evidence for decreased lipid biosynthesis and increased innate immunity in uninvolved psoriatic skin. *J Invest Dermatol* **129**(12):2795-2804, 2009
71. Ragaz A, Ackerman AB: Evolution, maturation, and regression of lesions of psoriasis. New observations and correlation of clinical and histologic findings. *Am J Dermatopathol* **1**(3):199-214, 1979
79. Nestle FO, Kaplan DH, Barker J: Psoriasis. *N Engl J Med* **361**(5):496-509, 2009
106. Zheng Y et al: Interleukin-22, a T(H)17 cytokine, mediates IL-23-induced dermal inflammation and acanthosis. *Nature* **445**(7128):648-651, 2007
108. Trifari S et al: Identification of a human helper T cell population that has abundant production of interleukin 22 and is distinct from T(H)-17, T(H)1 and T(H)2 cells. *Nat Immunol* **10**(8):864-871, 2009
110. Wing K, Sakaguchi S: Regulatory T cells exert checks and balances on self tolerance and autoimmunity. *Nat Immunol* **11**(1):7-13, 2010
128. Zaba LC, Krueger JG, Lowes MA: Resident and "inflammatory" dendritic cells in human skin. *J Invest Dermatol* **129**(2):302-308, 2009
159. Clark RA, Kupper TS: Misbehaving macrophages in the pathogenesis of psoriasis. *J Clin Invest* **116**(8):2084-2087, 2006
164. Braff MH et al: Cutaneous defense mechanisms by antimicrobial peptides. *J Invest Dermatol* **125**(1):9-13, 2005
183. Sa SM et al: The effects of IL-20 subfamily cytokines on reconstituted human epidermis suggest potential roles in cutaneous innate defense and pathogenic adaptive immunity in psoriasis. *J Immunol* **178**(4):2229-2240, 2007
190. Kryczek I et al: Induction of memory IL-17+ T cell trafficking and expansion by IFN-gamma: Mechanism and pathological relevance. *J Immunol* **181**:4733-4741, 2008
191. Conrad C et al: Alpha1beta1 integrin is crucial for accumulation of epidermal T cells and the development of psoriasis. *Nat Med* **13**(7):836-842, 2007
193. de Jongh GJ et al: High expression levels of keratinocyte antimicrobial proteins in psoriasis compared with atopic dermatitis. *J Invest Dermatol* **125**(6):1163-1173, 2005
226. Gudjonsson JE et al: Mouse models of psoriasis. *J Invest Dermatol*. **127**(6):1292-1308, 2007
232. Boyman O et al: Spontaneous development of psoriasis in a new animal model shows an essential role for resident T cells and tumor necrosis factor-alpha. *J Exp Med* **199**(5):731-736, 2004
233. Clark RA: Skin-resident T cells: The ups and downs of on site immunity. *J Invest Dermatol* **130**(2):362-370, 2010
247. Suarez-Farinas M et al: Evaluation of the psoriasis transcriptome across different studies by gene set enrichment analysis (GSEA). *PLoS One* **5**(4):e10247, 2010
257. Besgen P et al: Ezrin, maspin, peroxiredoxin 2, and heat shock protein 27: Potential targets of a streptococcal-induced autoimmune response in psoriasis. *J Immunol* **184**(9):5392-5402, 2010
289. Gelfand JM et al: Risk of myocardial infarction in patients with psoriasis. *JAMA* **296**(14):1735-1741, 2006
359. Menter A et al: Guidelines of care for the management of psoriasis and psoriatic arthritis. Section 3. Guidelines of care for the management and treatment of psoriasis with topical therapies. *J Am Acad Dermatol* **60**(4):643-659, 2009
385. Menter A et al: Guidelines of care for the management of psoriasis and psoriatic arthritis: Section 5. Guidelines of care for the treatment of psoriasis with phototherapy and photochemotherapy. *J Am Acad Dermatol* **62**(1):114-135, 2010
395. Kalb RE et al: Methotrexate and psoriasis: 2009 National Psoriasis Foundation Consensus Conference. *J Am Acad Dermatol* **60**(5):824-837, 2009
398. Menter A et al: Guidelines of care for the management of psoriasis and psoriatic arthritis: Section 4. Guidelines of care for the management and treatment of psoriasis with traditional systemic agents. *J Am Acad Dermatol* **61**(3):451-485, 2009
442. Menter A et al: Guidelines of care for the management of psoriasis and psoriatic arthritis: Section 1. Overview of psoriasis and guidelines of care for the treatment of psoriasis with biologics. *J Am Acad Dermatol* **58**(5):826-850, 2008
443. Leonardi CL et al: Efficacy and safety of ustekinumab, a human interleukin-12/23 monoclonal antibody, in patients with psoriasis: 76-week results from a randomised, double-blind, placebo-controlled trial (PHOENIX 1). *Lancet* **371**(9625):1665-1674, 2008

Chapter 19 :: Psoriatic Arthritis

:: Dafna D. Gladman & Vinod Chandran

PSORIATIC ARTHRITIS AT A GLANCE

- Psoriatic arthritis (PsA) is an inflammatory arthritis associated with psoriasis and seronegative for rheumatoid factor.
- Genetic and environmental factors underlie susceptibility to PsA and immune-mediated inflammation leads to inflammation in musculoskeletal structures.
- Clinical features of PsA include peripheral and axial arthritis, enthesitis, dactylitis, and tenosynovitis.
- Extra-articular involvement in addition to skin and nail involvement may include conjunctivitis, uveitis, and inflammatory bowel disease.
- Investigations may reveal elevated acute phase reactants, although conventional tests such as erythrocyte sedimentation rate and C-reactive protein are normal in up to 50% of patients.
- Radiographs may reveal soft-tissue swelling, periostitis, erosions, pencil-in-cup change, ankylosis, sacroiliitis, or syndesmophytes.
- Pharmacotherapy is the mainstay of treatment, and antitumor necrosis factor agents are safe, efficacious, and effective.

DEFINITION AND CLASSIFICATION

Psoriatic arthritis (PsA) is an inflammatory musculoskeletal disease that affects people with psoriasis or their near relatives. It affects musculoskeletal structures such as the peripheral and axial joints, entheses, and tendon sheaths. The eye and mucous membranes are also often involved. Thus, the disease has varied manifestations that make diagnosis and assessment sometimes difficult.

The original case definition for PsA was provided by Moll and Wright in 1973.[1] They defined PsA as an inflammatory arthritis associated with cutaneous psoriasis, seronegative for rheumatoid factor. Rheumatoid factor is a marker for rheumatoid arthritis (RA); thus, the definition was meant to help distinguish PsA from RA, which at that time was a more recognized form of inflammatory arthritis. The CASPAR study group recently developed a new set of criteria for classification of PsA using data collected prospectively in patients with long-standing disease (Box 19-1).[2] The CASPAR criteria had specificity of 98.7% and sensitivity of 91.4% in the original study, with excellent sensitivity in both early and late disease. The criteria allow classifying patients even when they do not have current, past, or family history of psoriasis and are now used in epidemiologic and genetic studies in PsA.

ETIOLOGY AND PATHOGENESIS

GENETICS

PsA has a strong genetic component. The estimated recurrence risk ratio (λ) in first-degree relatives (FDRs) of probands with PsA ranges from 30.4 to 55, indicating a high genetic contribution to disease susceptibility.[8] Strong heritability was also demonstrated in a recent study from Iceland where patients known to have PsA in Reykjavik were linked to the Icelandic genealogy database.[9] FDRs to fourth-degree relatives of patients with PsA had relative risks of 39, 12, 3.6, and 2.3, respectively, reflecting a strong genetic component. The decrease of λ-1 more rapidly than by a factor of 2 with the degree of relationship indicates that multiple genes contribute to susceptibility with some interaction of effects. Genes associated with PsA include HLA alleles, MHC Class I related chain (MIC) genes, *TNFA*, *IL23R*, *IL1*, and killer-cell immunoglobulin-like receptor (KIR) genes. HLA-B13, -B16 and its splits -B38 and -B39, -B17, and -Cw6 are associated with psoriasis, with or without arthritis, -B27 and -B7 are specifically associated with PsA.[8] However, since most patients with PsA have cutaneous psoriasis it is difficult to determine whether genetic associations found in patients with PsA when compared to healthy controls is associated with psoriasis or with PsA. A recent genome-wide association study was able to investigate association with PsA and differences between PsA and psoriasis alone.[10] HLA-C, *IL12B*, and *TNIP1* were associated with PsA when compared to normal controls. There was a statistically significant difference between PsA and psoriasis alone at three loci [(1) HLA-C, (2) *IL12B*, and (3) *IL23R*]. HLA-C and *IL23R* were more strongly associated with psoriasis alone, and *IL12B* with PsA. A smaller GWAS also identified a novel PsA (and potentially psoriasis) locus on chromosome 4q27 that harbors the interleukin 2 (*IL2*) and interleukin 21 (*IL21*) genes.[11]

Genetic polymorphisms can also influence PsA phenotype. HLA-B39 alone, HLA-B27 in the presence of HLA-DR7, and HLA-DQ3 only in the absence of HLA-DR7, confers increased risk for disease progression.[12] TNF polymorphisms are associated with erosive disease and joint damage progression in early PsA.[13] The

BOX 19-1 THE CASPAR CRITERIA

To meet the CASPAR (ClASsification criteria for Psoriatic ARthritis) criteria*, a patient must have inflammatory articular disease (joint, spine, or entheseal) with three points from the following categories:

- Evidence of current psoriasis, a personal history of psoriasis, or a family history of psoriasis. Current psoriasis is defined as psoriatic skin or scalp disease present today as judged by a rheumatologist or dermatologist. A personal history of psoriasis is defined as a history of psoriasis that may be obtained from a patient, family physician, dermatologist, rheumatologist, or other qualified health care provider. A family history of psoriasis is defined as a history of psoriasis in a first- or second-degree relative according to patient report.
- Typical psoriatic nail dystrophy including onycholysis, pitting, and hyperkeratosis observed on current physical examination. A negative test result for the presence of rheumatoid factor by any method except latex but preferably by enzyme-linked immunosorbent assay or nephelometry, according to the local laboratory reference range.
- Either current dactylitis, defined as swelling of an entire digit, or a history of dactylitis recorded by a rheumatologist. Radiographic evidence of juxtaarticular new bone formation, appearing as ill-defined ossification near joint margins (but excluding osteophyte formation) on plain radiographs of the hand or foot.

*Current psoriasis is assigned a score of 2; all other features are assigned a score of 1. From Taylor W et al: Classification criteria for psoriatic arthritis. *Arthritis Rheum* **54**(8):2665-2673, 2006.

interleukin-4 receptor gene (*IL4R*) I50V SNP is associated with erosive PsA, although the association was not consistently shown.[14,15]

PATHOGENESIS

The immune system, especially the lymphocytes, play an important role in the pathogenesis of PsA. The traditional model of the pathogenesis is that autoimmunity directed against a common skin and joint autoantigen(s) leads to chronic autoreactive T-cell driven inflammation. Genetic susceptibility predisposes the T-cell receptor repertoire to recognition of target self-peptides expressed in target tissues. Prior response to exogenous ligands encoded by pathogens as well as prior episodes of inflammation result in expansion of memory effector CD8+ T cells that recognize stress-related self-antigens and initiates and maintains pathways of inflammation mediated by the expression of transcription factors such as nuclear factor-κB and activator protein-1, resulting in skin and synovial inflammation.[18] The primary defects in this model involve expression of an autoantigen, binding of autoantigen peptides by MHC Class 1 molecules leading to initial clonal activation and expansion of an adaptive immune response. However, recent imaging, histological, and genetic studies have made us reconsider this view, especially with respect to joint and nail diseases. Clinically unrecognized enthesitis is commonly seen in PsA and in psoriasis without arthritis.[19] Enthesitis is associated with adjacent osteitis or bone and synovial inflammation. Nail disease is a marker for PsA in patients with psoriasis, since it occurs in almost 90% of patients with PsA, but less than 50% of those with psoriasis alone. The nail is closely related to the distal interphalangeal (DIP) joints and the related extensor tendon insertion sites, and the association between DIP joint disease, adjacent nail lesions, and entheseal inflammation was recently demonstrated.[20] It is proposed that the synovial membrane and entheses form a "synovioentheseal complex," and that enthesitis is the unifying pathologic lesion that may explain the varied clinical manifestations of PsA.[21] In this model, tissue specific factors, including microtrauma, lead to regional innate immune activation and persistent inflammation. The genetic association of PsA with Class 1 HLA alleles and *KIR* genes as well as the association between juvenile PsA and Mediterranean Fever (*MEFV*) and NLR family, pyrin domain containing 3 (*NLRP3*) genes indicate that PsA is closer to the "autoinflammatory" end rather than the "autoimmune" end of the spectrum of immune-mediated diseases.[22] Disease localization in autoinflammatory diseases is determined predominantly by the innate immune response to local tissue specific factors.

There is also evidence that the monocyte–macrophage system plays a major role in the initiation and perpetuation of joint inflammation. Monocytes differentiate into macrophages, osteoclasts, Langerhans cells, or dendritic cells in response to microenvironmental signals.[23] In entheseal tissues, monocytes are the principal cells that infiltrate fibrocartilage. Monocytes are also present in the synovial lining of psoriatic joints, and they infiltrate the subsynovial lining. An increased frequency of circulating osteoclast precursors was identified in the circulation and synovial tissues of PsA patients. These precursors, derived from circulating CD14+ monocytes, differentiate into osteoclasts after exposure to monocyte colony stimulating factor (M-CSF) and receptor activator of nuclear factor κB ligand (RANKL) expressed by synovial lining cells in inflamed psoriatic synovium, and is responsible for bone erosions. The frequency of circulating osteoclast precursors in PsA patients decline rapidly following treatment with anti-TNF agents and may explain its antierosive effects.

CLINICAL FINDINGS

The CASPAR classification criteria define PsA as an inflammatory musculoskeletal disease that can involve the joints, spine or entheses. Clinical features of PsA include peripheral arthritis, axial arthritis (spondylitis),



Figure 19-1 Swelling and erythema of the left third metacarpophalangeal joint (*arrow*) indicating inflammatory arthritis in a patient with psoriatic arthritis.

enthesitis, dactylitis, and tenosynovitis. The typical features of inflammatory arthritis are joint pain, swelling, stiffness, redness, and reduction in mobility. The arthritis of PsA is often of gradual onset and involves one or more joints. Typically early PsA is oligoarticular (affecting less than five joints) (Fig. 19-1). Early PsA often involves the joints of the lower limbs, but any joint of the body may be affected. Oligoarticular PsA subsequently evolves into polyarthritis. Joints that are typically affected in patients with PsA include the DIP joints (Fig. 19-2). Commonly the nails near these affected joints demonstrate the nail changes that are typical for psoriasis. The distribution of the joint involvement in PsA is often asymmetric. However, as the number of joints affected increases, there is a tendency toward symmetry.[26] Patients with PsA have less pain than those with RA.[27] Therefore, they may be oblivious to the degree of inflammation in their joint. In addition to peripheral arthritis, PsA affects the axial joints in 30%–50% of patients with PsA. Axial inflammatory arthritis presents with inflammatory back and/or neck pain, typically associated with stiffness and worse after periods of prolonged inactivity such as nighttime sleep. Inflammatory axial pain and stiffness usually improve with activity. However, evidence of radiographic involvement of the axial joints may be present in a substantial proportion of patients presenting with peripheral PsA in the absence of axial symptoms.[28] Axial arthritis leads to restriction in the mobility of the spine. The process can lead to a completely fused and immobile spine, sometimes called "bamboo spine."

Dactylitis, defined as inflammatory swelling of an entire finger or toe, is a characteristic manifestation of PsA (Fig. 19-3). This is due to inflammation of the joints, tendons, bones, and soft tissues in the digit(s). Persistent dactylitis leads to destruction of the joints in that digit. Dactylitis is a marker of severity of psoriatic arthritis. Enthesitis, defined as inflammation at the entheses (site where ligaments or tendons attach to bone), is another important manifestation of PsA. The most common sites to be affected by enthesitis are the plantar fascia on the sole of the feet (plantar fasciitis) and Achilles tendon insertion at the back of the heel (Achilles enthesitis). Enthesitis can also affect other sites including tendon insertion sites on the patella, shoulder, elbows, pelvis, spinous processes, and chest wall. Tenosynovitis, or inflammation of the tendon sheath, may affect tendons in the hands, wrists, and around the ankles. (Box 19-2).

The category of asymmetric oligoarthritis includes those patients with four or less joints affected by arthritis. The joints involved are usually of the lower limbs and there is lack of symmetry. In the category of sym-



Figure 19-2 Psoriatic nail dystrophy and arthritis of the fifth distal interphalangeal joint (*arrow*) in a patient with psoriatic arthritis.



Figure 19-3 Dactylitis of the third toe (*arrow*) in a patient with psoriatic arthritis.

BOX 19-2 PATTERNS OF PsA ACCORDING TO MOLL AND WRIGHT*

Five patterns of PsA were originally described by Moll and Wright.* These include the following:

1. Asymmetric oligoarthritis
2. Symmetric polyarthritis similar to rheumatoid arthritis
3. Spondyloarthritis
4. Distal interphalangeal joint arthritis
5. Arthritis mutilans

*From Moll JM, Wright V: Psoriatic arthritis. *Semin Arthritis Rheum* **3**:55, 1973.

metric polyarthritis, five or more joints are involved in a symmetric fashion. Therefore, it is sometimes difficult to distinguish it from RA. The spondyloarthritis category includes patients with predominant involvement of the spine (axial arthritis), similar to the involvement in patients with AS. As the name suggests, the category of distal interphalangeal joint arthritis includes those patients with predominant involvement of the DIP joints. Arthritis mutilans describes a category with severe arthritis leading to shortening and destruction of fingers and toes (see eFig. 19-3.1 in online edition). Although, these categories were described initially, it was soon realized that as the longer the duration of the disease the higher the number of joints involved and the involvement becomes more symmetric. Distal joint involvement also is common and is seen in all categories. Arthritis mutilans is also a manifestation of severity of the arthritis process and not an exclusive category. Therefore, experts nowadays tend to classify the disease as peripheral arthritis alone, peripheral arthritis with axial arthritis, and axial arthritis alone.[29]

SKIN INVOLVEMENT. Most patients with PsA have psoriasis vulgaris. In about 70% of people with PsA, psoriasis develops first and the arthritis manifests itself after a variable duration, on average within 10 years. However, in about 15%, both arthritis and psoriasis develops simultaneously, and in the remaining, the arthritis develops first, and cutaneous psoriasis manifests itself a few years later. Patients seen in dermatology clinics and those hospitalized with psoriasis have high prevalence of PsA compared to patients with psoriasis seen in the community. Patients reporting greater extent of psoriasis also reported a higher prevalence of PsA when surveyed in a telephone interview.[30] Thus, patients with more severe psoriasis may have a higher prevalence of PsA. However, most patients attending rheumatology clinics for their arthritis have only mild to moderate psoriasis.

NAIL INVOLVEMENT. Psoriatic nail dystrophy usually manifests as pitting and onycholysis (see Chapter 18). Although 40% of patients with psoriasis without PsA have nail lesions, nail involvement is much more frequent in patients with PsA affecting close to 90% of patients.[31] Thus, nail lesions are the only clinical feature that distinguishes patients with psoriatic arthritis from those with uncomplicated psoriasis. The nail bed is closely linked to the DIP joints; nail involvement is associated with arthritis of these joints.

EXTRA-ARTICULAR MANIFESTATIONS. Apart from the involvement of the skin, nails, and joints, people with PsA also have involvement of other important organs. Eye involvement is not infrequent. Conjunctivitis is occasionally seen and uveitis may occur in 2.3% of patients.[32] Mucous membrane inflammation presents with painful mouth ulcers and urethritis. Inflammatory bowel disease in PsA may resemble Crohn disease and/or ulcerative colitis and can cause abdominal pain, loose stools, and bleeding.

LABORATORY INVESTIGATIONS. Laboratory tests are usually done at diagnosis and periodically thereafter. However, there is to date no diagnostic test for PsA. The acute phase reactants [erythrocyte sedimentation rate (ESR) and C-reactive protein (CRP)] are often normal. ESR and/or CRP are raised in less that 50% of people with PsA. Rheumatoid factor is usually negative and helps exclude RA. HLA-B*27 is positive in 20% of patients with PsA. Radiological investigations (X-ray, ultrasonography, and magnetic resonance imaging) can provide important clues to diagnosis and to the extent of inflammation and damage. However, only the presence of periostitis and new bone formation near joint margins may be considered reasonably specific to PsA.[2] Although, these tests are not by themselves diagnostic, they help in ruling out other conditions that may mimic PsA. Synovial fluid if obtained demonstrates inflammation and helps exclude crystal arthritis and infections. Investigations such as blood count, and liver and kidney functions are often obtained to monitor side effects of drug therapy.

RADIOLOGIC FEATURES OF PsA. Imaging is an important modality in the assessment of patients with PsA. Imaging complements clinical assessment and helps in confirming the diagnosis as well as in determining disease severity. The various modalities used in assessment of PsA include X-rays, ultrasound, computerized-tomography scan (CT scan), magnetic resonance imaging (MRI), and bone scan.

Plain Radiographs (X-rays). X-rays are the mainstay in the radiologic assessment of PsA. X-rays are relatively cheap, easily available, and can be read by most physicians. Once PsA is suspected clinically, radiographs of the hands, feet, pelvis, spine, and other affected joints are done to look for changes suggestive of PsA. X-rays are also used to assess disease severity, as well as to follow disease progression. Radiographic changes generally reflect damage to the joints rather than acute inflammation. In early disease, X-rays of the hands and feet show soft tissue swelling around the joints involved. If dactylitis is present, soft tissue swelling will involve the whole finger or toe. In more severe disease, erosions develop near the joint margin and are markers of disease severity (Fig. 19-4). Erosions may be paramarginal, in contrast to RA were



Figure 19-4 Radiograph of the feet of a patient with psoriatic arthritis showing solitary large erosion at the head of the fourth metatarsal bone (*arrow*).

the erosions are usually marginal. In PsA erosions are often accompanied by new bone formation. The combination of erosions and new bone formation at joint margins is characteristic of PsA (Fig. 19-5). Following the development of erosions there may be joint space narrowing, and finally total joint destruction may occur, either total joint lysis and the so called "pencil-in-cup" change or complete bony bridging through the joint termed ankylosis (Fig. 19-6).

X-rays of the pelvis often show changes reflecting the presence of sacroiliitis. Earliest notable changes include widening of the joint space, which is often difficult to appreciate (eFig. 19-6.1 in online edition). Subsequently,



Figure 19-5 Radiograph of the hands of a patient with psoriatic arthritis showing erosions, joint space narrowing and new bone formation at the wrists, carpometacarpal, metacarpophalangeal, proximal interphalangeal, and distal interphalangeal joints.

erosions develop, followed by sclerosis and subsequent bony bridging across the joints, ultimately leading to complete fusion of the joint (eFig. 19-6.2 in online edition). X-rays of the neck and the back often show changes that reflect consequences of inflammation at the spinal joints. The earliest changes on lateral view of the spine include shiny vertebral corners, erosions, and squaring of vertebrae. This is followed by bone bridging, or marginal syndesmophytes, beginning from the ends of the vertebrae across the disc space. Complete bony bridging can occur. If most of the vertebrae are bridged, it is called "bamboo" spine. These changes closely resemble the changes in AS (Fig. 19-7). Often in PsA, the syndesmophytes can develop from sites away from the vertebral body. The presence of these "nonmarginal" syndesmophytes is characteristic of PsA (eFig. 19-7.1 in online edition). The changes described can at occur at any site—cervical and lumbar vertebrae are frequently involved. In the cervical spine, occasionally atlanto-axial subluxation may be present and can lead to serious consequences.

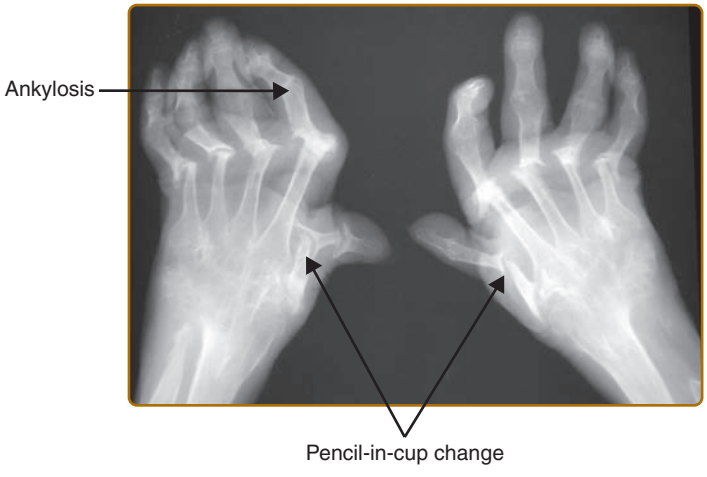

Figure 19-6 Advanced destructive changes in the hand joints including pencil-in-cup change and ankylosis in a patient with psoriatic arthritis.

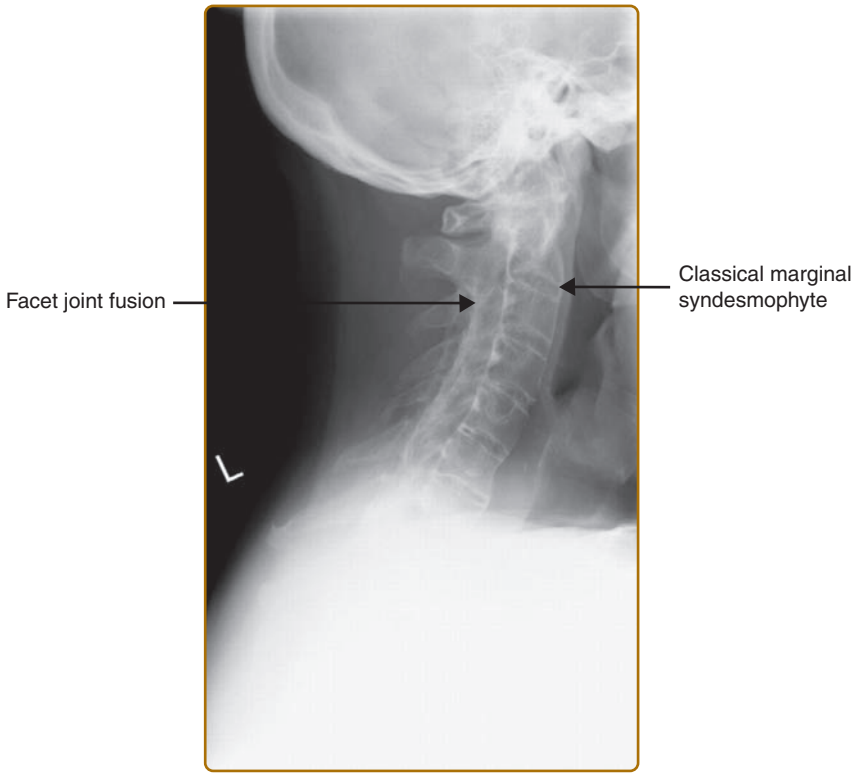

Figure 19-7 Lateral radiograph of the cervical spine showing anterior marginal syndesmophytes and fusion of the facet joints in a patient with psoriatic arthritis.

ULTRASOUND IMAGING. Ultrasound combined with Doppler evaluation, can detect active inflammation in joints and entheses. Ultrasound can also detect erosions before they appear on X-rays especially in the hand joints. It can also be used to guide injections into joints.[33]

MAGNETIC RESONANCE IMAGING (MRI). MRI scans along with contrast can detect active inflammation. MRI can also show erosions in the bone even before they are seen on plain X-rays.[34] Bone edema which often precedes the development of overt erosions is also detected easily. MRI scans are also very useful in detecting active inflammation in the spine and MRI changes are usually evident much before any abnormality is visualized on X-rays.[34] Thus, MRI evaluation is crucial in the diagnosis of early disease, especially affecting the spine.

COMPUTERIZED TOMOGRAPHY. CT scans are most useful when joints or the spine need to be evaluated in detail, especially when an MRI is unavailable or contraindicated. CT scans also give a detailed view of the joints. Bones are viewed better than in MRIs. However, CT scans involve considerable exposure to radiation.

COURSE AND PROGNOSIS

PsA has a variable course and prognosis. While some patients do well with small number of joints involved, and no significant damage, others progress very quickly, developed marked joint damage and disability.[35] Over 10 years of follow-up, 55% of the patients had at least five clinically damaged joints.[36] By the time patients present to a PsA clinic, 67% have at least one erosion.[31] Even in early disease, of 129 patients seen within 5 months of onset of symptoms 47% developed erosions within the first 2 years.[37] Factors associated with progression of joint damage include the number of actively inflamed and damaged joints at presentation, the ESR at presentation, and the number of actively inflamed joints at each visit.[38–41] There are patients with PsA who achieve remission, defined as no actively inflamed joints for 12 months.[42] In a longitudinal observation cohort 17.6% of the patients achieved remission, but only six patients had a complete remission with no actively inflamed joints, no damage, and off therapy. The period of remission lasted for 2.6 years, after which 52% of the patients flared. Thus, active disease must be treated aggressively, particularly in the presence of erosive changes. Quality of life and function of patients with PsA are reduced compared to the general population.[43,44] PsA patients have worse quality of life and function than patients with psoriasis alone.[45]

COMORBIDITIES. Patients with psoriasis and PsA have an increased prevalence of cardiovascular disease (CVD). In patients with PsA, the standardized prevalence ratio of hypertension, myocardial infarction, and angina is higher than the general population.[46–48] For other comorbidities, see Chapter 18.

MORTALITY IN PsA. Although population-based studies have shown that PsA is not associated with increased mortality, clinic-based studies have shown that patients with PsA have an elevated mortality risk, although the risk seems to have declined over the last decade.[49] The four leading causes of death are diseases of the circulatory or respiratory system, malignancies, and injuries/poisoning. Evidence of previously active and severe disease, as manifested by the prior use of medications and by radiologic changes as well as an elevated ESR at presentation, are prognostic indicators for death.[50]

EARLY DIAGNOSIS

PsA has an unpredictable clinical course. Radiographic damage can occur within 2 years of disease onset in almost half of patients with PsA, and the disease usually follows a chronic, progressive course.[37,51] With the availability of effective therapy it is hoped that early diagnosis will help prevent damage. Since cutaneous psoriasis precedes or occurs simultaneously with joint disease in 85% of patients with PsA, screening patients with psoriasis for PsA has the potential to help detect PsA early.[52]

Several screening tools have been recently developed.[53] The Psoriasis and Arthritis Questionnaire (PAQ) and its modification, Psoriatic Arthritis Screening and Evaluation (PASE) questionnaire, Psoriasis Epidemiology Screening Tool (PEST) questionnaire, and Psoriasis and Arthritis Screening Questionnaire (PASQ) were developed specifically to screen for PsA in patients with psoriasis, whereas the Toronto Psoriatic Arthritis Screen (ToPAS) was developed for use in the general population as well as in patients with psoriasis. The PASE, PEST, and ToPAS questionnaires have high sensitivity and specificity. Imaging studies using scintigraphy, MRI, and ultrasound have also shown abnormalities in subjects with psoriasis, who do not have overt PsA.[19,54,55] Soluble biomarkers have also been evaluated as a marker for screening for PsA in patients with psoriasis; C-reactive protein and Matrix Metalloproteinase-3 have shown promise.[56,57] Circulating osteoclast precursors are elevated in patients with PsA and psoriasis, and decrease with anti-TNF therapy.[58] In prospective studies, clinical predictors for PsA in patients with psoriasis include presence of scalp or intergluteal/perianal psoriasis, ≥3 affected sites, and presence of nail dystrophy.[59]

DIFFERENTIAL DIAGNOSIS. A number of arthritic conditions may occur in patients with psoriasis and these must be differentiated from PsA (Table 19-1). Since psoriasis is a common condition, occurring in 2%–3% of the population, and rheumatoid arthritis, the most common form of inflammatory arthritis, may occur in 1% of the population, the co-occurrence of rheumatoid arthritis and psoriasis would be expected by chance alone in 2 in 10,000 people. Since RA, like PsA is inflammatory in nature, the differentiation may be difficult. Osteoarthritis, which is the commonest form of arthritis, occurs in about 5% of the population and it may coexist with psoriasis. While osteoarthritis is not usually an inflammatory form of arthritis, it affects the DIP joints, a site commonly affected in patients with PsA. Patients with PsA also have increased prevalence of hyperuricemia and gout, and occasionally gouty arthritis may mimic PsA. PsA also has to be distinguished from other SpA.[60]

TABLE 19-1
Differential Diagnosis of Arthritis in Patients With Psoriasis

Manifestation	PsA	RA	Gout	Osteoarthritis
Age at onset	36s	40s	Any age	Over 50
M:F	1.1:1	1:3	3:1	1:1
Joint affected	Proximal and distal interphalangeal joints, small and large	Proximal interphalangeal and metacarpophalangeal joints, small and large	Toes, knees ankles	Weight bearing, distal hands
Symmetry	Usually asymmetric	Symmetric	Usually asymmetric	May be symmetric
Redness over joint	Yes	No	Yes	No
Spinal disease	Yes, inflammatory	No	No	Yes, degenerative
Dactylitis	Yes	No	Podagra	No
Enthesitis	Yes	No	No	No
Nodules	No	Yes, extensor surfaces	Tophi	Heberden's and Bouchard's
Psoriasis	100%	1–3%	1–3%	1–3%
Nail lesions	87%	No	No	No

The diagnosis of PsA is considered when a patient presents with inflammatory musculoskeletal disease. This may be in the form of arthritis, dactylitis, enthesitis, or spondylitis. The presence of cutaneous psoriasis is an important clue and this should be looked for carefully, especially in hidden regions such as the scalp, umbilicus, below breasts, or in the natal cleft. Nails should be carefully inspected for changes of nail psoriasis as the evidence of psoriasis may be present in the nail only. The pattern of involvement in PsA is often asymmetric. This is not usually the case in RA, which tends to be symmetric. A characteristic pattern of PsA is the "ray" pattern—involvement of all joints in a particular finger or toe, as opposed to joints beside one another. The "ray" distribution is typical for PsA, and is not usually seen in either RA or OA. The presence of dactylitis is an important feature. It is a typical feature for PsA and is not seen in RA. The only other arthritic condition that may manifest with dactylitis is reactive arthritis, which is not associated with psoriasis but where psoriasis-like lesions can occur (see Chapter 20). Spinal involvement presenting as inflammatory neck or back pain with or without restriction of mobility is present in about half of the patients with PsA, especially in well-established disease. It is not a feature of RA. The presence of spinal and peripheral arthritis makes the diagnosis of PsA very likely, and virtually rules out RA.

The diagnosis of PsA may sometimes be made even in the absence of psoriasis. If the above characteristic features are present even without cutaneous psoriasis, the diagnosis may be considered. The diagnosis is especially likely if there is a family history of psoriasis or PsA. The diagnosis may also be made if characteristic radiographic features such as "pencil-in-cup" changes, bony ankylosis, new bone formation close to sites of erosions, and nonmarginal syndesmophytes are present.

Laboratory tests have only a minor role to play in making the diagnosis of PsA. Characteristically, rheumatoid factor test is negative, although a positive test does not rule out the diagnosis. Elevated erythrocyte sedimentation rate (ESR) or C-reactive protein (CRP) is present only in about half of the patients. However, these are markers of severity. ESR is a predictor of progression of joint damage and mortality, and CRP is a predictor of progression of radiological damage.[38,41,50] Other tests usually done are routine tests such as blood counts, and liver and kidney function tests. Although these tests are not important in making a diagnosis, they give important information on the presence of comorbid conditions and are important in monitoring treatment. If synovial fluid can be aspirated from the joint, it can be tested to confirm inflammation and to rule out other causes of inflammation like infection and crystals. Synovial biopsies, usually done using an arthroscope, show evidence of chronic inflammation, and are sometimes required to rule out chronic infection. As outlined above, imaging is most important in making a diagnosis of PsA.

TREATMENT

Pharmacotherapy is the cornerstone of management of PsA. Drug therapy depends on the severity and stage of the arthritis and severity of skin disease. Patients should ideally be under the care of a team of health professional comprising rheumatologists, dermatologists, physiotherapists, and occupational therapists. However, if the primary problem is skin disease and the arthritis is mild, the subject may be managed by a dermatologist after a complete assessment by a rheumatologist. Periodic assessment by a rheumatologist in such cases would be ideal. On the other hand, if the primary problem is joint disease, the rheumatologist should primarily manage the patient, with the dermatologist confirming the diagnosis of psoriasis and providing input if skin disease remains poorly controlled.

Drug therapy for psoriatic arthritis may be classified as in Box 19-3.

BOX 19-3 DRUG THERAPY FOR PsA

- Symptom modifying therapy
- Therapy with "Disease modifying" Antirheumatic Drugs (DMARDs)
- Therapy with biologic agents

NONSTEROIDAL ANTI-INFLAMMATORY DRUGS (NSAIDs)

NSAIDs are useful in the treatment of PsA and give relief to symptoms such as pain and stiffness. However, NSAIDs do not prevent disease progression, and may worsen skin lesions. They may be used as sole therapy in treating mild PsA and for symptomatic management of pain, inflammatory swelling and morning stiffness. With the recent reports of increased risk of myocardial infarction and stroke with long term use of COX-2 inhibitors, the use of nonselective NSAIDs like naproxen, ibuprofen, diclofenac, indomethacin, or aspirin (with or without misoprostol/H2-blockers/proton pump inhibitors) is preferable. If symptoms persist, or if more joints accrue after adequate trials with two different NSAIDs, Disease Modifying Antirheumatic Drug (DMARD) use should be considered.

CORTICOSTEROIDS

Corticosteroid therapy in the form of intra-articular injections of corticosteroids (triamcinolone, methylprednisolone) into the joints either at the bedside in the clinic or under ultrasound guidance is often used for rapid relief of symptoms when only one or a few joints are affected. This form of therapy has been proven effective in PsA.[66] Oral corticosteroids are used occasionally for symptom relief when there is polyarthritis or when there is inadequate response to NSAIDs and there is significant disability. However, glucocorticosteroids need to be used with extreme caution with slow taper, since psoriasis worsens in many instances and could occasionally evolve into more severe forms like pustular psoriasis. Treatment with oral steroids is usually resorted to as short-term therapy, until other

longer acting drugs take effect. Long-term steroid therapy is associated with significant toxicity such as high blood pressure, cataracts, weight gain, diabetes, osteoporosis, and avascular necrosis of bone.

DISEASE MODIFYING DRUG THERAPY

There is a paucity of clinical trials with traditional disease modifying agents (DMARDs) in PsA.[67] A recently published systematic review and meta-analysis of efficacy and toxicity of DMARDs and biological agents for PsA showed that treatment was more effective than placebo (RR = 0.35; 95% CI 0.25, 0.49) but caused more toxicity (RR = 2.33; 95% CI 1.61, 3.37).[67]

METHOTREXATE. Although methotrexate is used most commonly to treat PsA, oral methotrexate (MTX) has been evaluated in only one RCT.[68] This 12-week placebo-controlled trial of low-dose oral MTX given at a dose of 2.5–5.0 mg every 12 hours in three consecutive doses per week was terminated early after recruiting only 37 patients. MTX significantly improved physician global assessment, but there were no significant effects on tender and swollen joint scores, patient global assessment, and ESR. However, a retrospective analysis of PsA patients treated with MTX for 24 months therapy compared to a matched cohort not thus treated did not show any difference in radiographic progression scores in the two groups.[69] A reappraisal from the same cohort showed that in the last decade treatment with MTX has changed to include patients with shorter disease duration and less damage, at increased dose, and that there may be better response with less progression of damage.[70] In spite of lack of evidence from RCTs, based on efficacy in RA and psoriasis, rheumatologists have been using MTX as a first-line DMARD. Patients on MTX require regular monitoring of blood counts, liver function tests, and creatinine. Significant test abnormalities require adjustment of dose or treatment cessation. Although liver toxicity can occur in the absence of abnormal serum liver function tests, regular liver biopsies are not typically ordered by rheumatologists as they may be by dermatologists. The occurrence of liver fibrosis and cirrhosis seem to be higher in patients with psoriasis when compared to patients with RA, reflected in the differing guidelines in rheumatology and dermatology. There is increased prevalence of obesity, metabolic syndrome and type-2 diabetes in patients with psoriasis. Patients with psoriasis treated with MTX and having risk factors for liver disease, especially diabetes type 2 or obesity, are at higher risk of developing severe liver fibrosis compared to those without such risk factors, even when lower cumulative methotrexate doses are given.[71] These risk factors are important for nonalcoholic steatohepatitis even when there is no exposure to MTX. Thus it is unclear whether weekly low-dose MTX independently increases risk for cirrhosis. In clinical practice, it will thus be prudent to get serial liver biopsies after a cumulative MTX dose of 1.5 g especially in those patients who have risk factors for fibrosis and cirrhosis such as obesity, metabolic syndrome, type 2 diabetes, viral hepatitis, and significant alcohol use.

SULFASALAZINE. Five RCTs have evaluated sulfasalazine (SSZ) in the treatment of PsA; its benefits were moderate.[67] In the largest of these, 221 PsA patients were treated with SSZ, 2 g/day, for 36 weeks.[72] The psoriatic arthritis response criteria (PsARC) developed specifically for this study showed statistically significant improvement in the treatment group (57.8% for SSZ compared with 44.6% for placebo, $P = 0.05$). But, the only individual measure within the responder index to do so was the patient global assessment, and longitudinal analysis revealed only a trend favoring SSZ treatment. A systematic review revealed that the effect size for SSZ was less than 0.2, the level required to confirm response.[73] SSZ has not been shown to prevent progression of joint damage.[74]

CYCLOSPORINE A. Cyclosporine A (CsA) is effective in controlling psoriasis. A three-arm RCT comparing CsA 3 mg/kg/day added to standard therapy, SSZ 2 g/day added to standard therapy, and standard therapy alone, showed that CsA was well tolerated and was more efficacious that standard therapy and SSZ.[76] In the most recently published RCT, CsA was compared to placebo as an add-on treatment, in patients with PsA demonstrating an incomplete response to MTX monotherapy. There was significant improvement at 12 months in the swollen joint count, C-reactive protein, PASI, and synovitis detected by high-resolution ultrasound. There was no improvement in the Health Assessment Questionnaire or pain scores.[77] Thus, CsA has a role in the management of PsA either on its own or as an add-on treatment to MTX. However, it is not well tolerated. Its effect on joint damage has not been assessed.

GOLD. Although not shown to protect from progression of joint damage, Gold has been used in the treatment of PsA, with intramuscular gold being more efficacious.[78] With significant concern about toxicity, slow mode of action, problems with availability, and availability of more effective drugs, it is seldom used nowadays.

ANTI-TNF AGENTS. (See also Chapter 234.) Anti-TNF agents have revolutionized the management of PsA. There are currently four agents marketed for the treatment of PsA. In the placebo-controlled portion of the phase 3 Etanercept trial in PsA ($n = 205$), ACR 20 response was achieved by 59% of Etanercept treated patients versus 15% in the placebo group ($P < 0.0001$).[81] Skin response, as measured by the PASI score in patients with body surface area (BSA) involvement at least 3% showed a 75% improvement in 23% and 3%, respectively at 24 weeks ($P = 0.001$). Measures of function and quality of life significantly improved. Significant inhibition of progression of joint space narrowing and erosions was shown. In the open label extension of this study, at 2 years, effectiveness was maintained.

The drug was well tolerated. A more recent trial compared Etanercept 50 mg twice weekly for 12 weeks, followed by 50 mg weekly, compared with 50 mg weekly throughout in 752 patients with psoriasis affecting >10% of body surface area and at least two swollen and tender joints.[82] There was no difference in the response to arthritis at week 12 or 24, although the skin response was better at week 12. No difference in skin response was evident at week 24. Dactylitis and enthesitis also showed improvement from baseline.

In the IMPACT II phase 3 study, Infliximab in 200 PsA patients showed significant benefit. At week 14, 58% of Infliximab-treated patients and 11% of placebo patients achieved an ACR 20 response ($P < 0.001$). Presence of dactylitis and enthesitis decreased significantly in the Infliximab group. At 24 weeks, PASI 75 was achieved by 64% of the evaluable treatment group and 2% of the placebo group ($P < 0.001$).[83] Infliximab also significantly inhibits radiographic progression, and improves function and quality of life.[83,84]

In the phase 3 Adalimumab Effectiveness in Psoriatic Arthritis Trial (ADEPT), 313 subjects were studied.[85] At 12 weeks, 58% of patients receiving Adalimumab 40 mg every other week achieved ACR 20 response compared with 14% of patients receiving placebo ($P < 0.001$). PASI 75 was achieved by 59% in the Adalimumab-treated group and 1% in the placebo group ($P < 0.001$) in those 69 patients in each group who were evaluable for PASI scoring. Radiographic progression of disease was significantly inhibited, and there was improvement in disability and quality of life scores.[85]

The latest anti-TNF agent to be approved for PsA is Golimumab. In the GO-REVEAL trial, 405 patients active PsA were randomly assigned to receive subcutaneous injections of placebo (Golimumab 50 mg or Golimumab 100 mg every 4 weeks.[86] At week 14, 51% of patients receiving Golimumab 50 mg and 45% of patients receiving Golimumab 100 mg achieved an ACR 20 response, compared with 9% of patients receiving placebo ($P < 0.001$ for all comparisons). Among the 74% of patients in whom at least 3% of the body surface area was affected by psoriasis at baseline, 40% of those in the Golimumab 50 mg group and 58% of those in the Golimumab 100 mg group had at least 75% improvement in the PASI at week 14, compared with 3% of placebo-treated patients ($P < 0.001$ for both doses). Improvement was also demonstrated in the HAQ score, SF-36, NAPSI, and enthesitis. There was no difference in the arthritis outcomes between the two doses of Golimumab and it is marked only for PsA at a monthly dose of 50 mg. Significant improvement in dactylitis was seen only in the 100 mg dose, although a trend was evident with the 50 mg dose.[86] Golimumab was also shown to inhibit progression of radiographic damage.[87]

Thus, the anti-TNF agents have shown the greatest efficacy of any treatment to date in the various clinical aspects of PsA. Their efficacy in joint disease activity, inhibition of structural damage, function, and quality of life are similar, and they are well tolerated, with injection site reactions being the most significant. On comparing with traditional DMARDs, anti-TNF agents had the best efficacy/toxicity ratio (number needed to harm/number needed to treat = 0.25); tolerability was least with gold and leflunomide, and poor with SSZ.[67] There are no direct head-to-head trials comparing the efficacy of various anti-TNF agents in PsA. However, a meta-analysis of anti-TNF RCTs showed that the three anti-TNF agents [(1) Infliximab, (2) Etanercept, and (3) Adalimumab] were significantly more effective than placebo.[88] There were no significant differences between anti-TNF agents and placebo in the proportions of patients experiencing withdrawal for any reason, due to adverse events, serious adverse or upper respiratory tract infections. Pooled rates for injection site reactions were significantly higher for Adalimumab and Etanercept than for placebo, but there was no significant difference in the proportion of patients experiencing infusion reactions with Infliximab compared against placebo. Indirect analysis did not demonstrate any significant differences between the anti-TNF agents.[88]

Data from biologics registries that have been maintained in Europe suggest that drug survival (the length of time a patient continues to take a particular drug) of anti-TNF agents is significantly higher in SpA compared to RA.[89,90] Concomitant MTX was associated with better drug survival in RA and PsA, but not for AS.[90,91] There is a tendency toward shorter persistence with treatment for Infliximab when compared with Etanercept and Adalimumab.[91,92] Risk factors for drug discontinuation include female sex, comorbidity, using Infliximab rather than Etanercept, and absence of concomitant therapy with MTX.[91,92]

USTEKINUMAB. (See also Chapter 234.) Ustekinumab is a human monoclonal antibody that inhibits receptor binding of IL-12 and IL-23 has been shown to be very efficacious in treating psoriasis and is marketed for this indication.[93] A phase 2 trial in 146 subjects with PsA showed that at week 12, 42% of patients in active arm and 14% in the placebo arm achieved an ACR 20 response ($p = 0.0002$).[94] Of 124 participants with psoriasis affecting 3% or more body surface area, 52% in the active arm and three of 5% in the placebo arm had a PASI 75 response ($p < 0.0001$). The drug was well tolerated.[94] A larger phase 3 trial is underway.

ANTI T CELL AGENTS. (See also Chapter 234.) Alefacept is a fully human lymphocyte function associated antigen-3/immunoglobulin G1 fusion protein that targets memory-effector T cells is an effective therapy for psoriasis.[95] In combination with MTX, Alefacept is efficacious in PsA. In a phase 3 trial with 185 patients, 54% of patients in the Alefacept plus MTX group achieved an ACR 20 response, compared with 23% of patients in the placebo plus MTX group ($P \leq 0.001$) at week 24.[96] In patients with psoriasis involving ≥3% BSA ($n = 87$), a PASI 50 response at week 14 was achieved by 53% of patients receiving Alefacept plus MTX compared with 17% of those receiving placebo plus MTX ($P < 0.001$).[96] Alefacept in combination with MTX is thus a treatment option in patients failing standard therapy.

Abatacept (CTLA4-Ig) is a recombinant human fusion protein that binds to the CD80/86 receptor on an antigen-presenting cell, thus blocking the second

signal activation of the CD28 receptor on the T-cell. It is approved for use in RA.[97] Results from a phase 2 study using Abatacept in PsA show that Abatacept at 10 mg/kg significantly improved ACR 20 and physical function in PsA patients. Abatacept treatment also resulted in less joint damage by MRI evaluation.[98]

SURGICAL PROCEDURES

There are few studies addressing surgery in patients with PsA. It has been reported that about 7% of the patients with PsA require surgery and that the likelihood of surgery increased with disease duration.[99] The average disease duration at the time of surgery was 13 years. The most common surgical procedure was total hip replacement followed by total knee replacement. Joint replacement in the metacarpophalangeal joints was also performed, followed by fusion surgery for the fingers, wrists, and ankles. Few patients had synovectomies, including knee, wrist, and elbow. The majority of the patients had only one procedure, but in 28% several procedure were performed. The upper and lower extremities were involved in a similar number of patients with few patients having both upper and lower extremity surgery. Surgery was predicted by the number of actively inflamed joints and the extent of X-ray damage at presentation to the clinic. Patients with the highest number of severely affected joints both clinically and on radiographs were more likely to have surgery. Although patients who had surgery had more severe disease, their health outcomes were not worse than those who did not have surgery.[99] In another study of the type and outcome of reconstructive surgery for different patterns of psoriatic arthritis over a 10-year period was studied.[100] The patients were divided into three groups: (1) distal joint involvement, (2) oligoarticular, and (3) polyarticular. It was shown that the majority of patients had polyarticular disease. The majority of the operations done in this group of patients included complex hand and foot reconstruction, followed by hip replacements, and surgical fusion of different joints. In the oligoarticular group most of the procedures involved joint replacement, usually the hip or knee. Patients with distal arthritis had fusions in the distal joints. Patients with polyarticular disease had lower level of physical functioning according to the scores on the physical function domain of a quality of life questionnaire. Patients with severe axial arthritis may develop marked deformity of the spine and on occasion require surgery to correct this deformity. While there are no reported studies specifically describing spinal surgery in patients with PsA, the procedures are similar to those performed in patients with AS.

RECOMMENDATIONS FROM GRAPPA

Based on formal literature reviews of therapies for peripheral joints, spine, skin and nails, enthesitis, and dactylitis, the GRAPPA group has developed a treatment grid categorizing each domain as mild, moderate, or severe based on measures of disease severity and impact on function and quality of life in order to help clinicians with treatment decisions.[101] GRAPPA recommends that all domains of the disease be considered to define severity of "psoriatic disease." The worst individual domain should guide the management of all domains of PsA. Thus, if the skin domain is severe, but the peripheral arthritis is mild, the patient is classified as heaving severe disease and treated for severe psoriasis as appropriate. GRAPPA has also suggested treatment strategies applicable to patients worldwide.

KEY REFERENCES

Full reference list available at www.DIGM8.com

DVD contains references and additional content

2. Taylor W et al: Classification criteria for psoriatic arthritis: Development of new criteria from a large international study. *Arthritis Rheum* **54**:2665, 2006
3. O'Neill T, Silman AJ: Psoriatic arthritis. Historical background and epidemiology. *Baillieres Clin Rheumatol* **8**:245, 1994
7. Chandran V, Raychaudhuri SP: Geoepidemiology and environmental factors of psoriasis and psoriatic arthritis. *J Autoimmun* **34**:J314, 2010
8. Duffin KC et al: Genetics of psoriasis and psoriatic arthritis: Update and future direction. *J Rheumatol* **35**:1449, 2008
10. Nair RP et al: Genome-wide scan reveals association of psoriasis with IL-23 and NF-kappaB pathways. *Nat Genet* **41**:199, 2009
21. McGonagle D et al: The concept of a "synovio-entheseal complex" and its implications for understanding joint inflammation and damage in psoriatic arthritis and beyond. *Arthritis Rheum* **56**:2482, 2007
41. Bond SJ et al: Predictors for radiological damage in psoriatic arthritis: Results from a single centre. *Ann Rheum Dis* **66**:370, 2007
46. Gladman DD et al: Cardiovascular morbidity in psoriatic arthritis. *Ann Rheum Dis* **68**:1131, 2009
68. Ravindran V, Scott DL, Choy EH: A systematic review and meta-analysis of efficacy and toxicity of disease modifying anti-rheumatic drugs and biological agents for psoriatic arthritis. *Ann Rheum Dis* **67**:855, 2008
89. Saad AA et al: Risks and benefits of tumor necrosis factor-alpha inhibitors in the management of psoriatic arthritis: Systematic review and metaanalysis of randomized controlled trials. *J Rheumatol* **35**:883, 2008
102. Ritchlin CT et al: Treatment recommendations for psoriatic arthritis. *Ann Rheum Dis* **68**:1387, 2009

Chapter 20 :: Reactive Arthritis

:: John D. Carter

REACTIVE ARTHRITIS AT A GLANCE

- Reactive arthritis is one of the spondyloarthritides. It is an inflammatory syndrome that typically begins 1–4 weeks after certain genitourinary or gastrointestinal infections.
- Most patients do not have the "classic triad" of symptoms (synovitis, urethritis, and conjunctivitis) and other organs are often involved (namely the skin).
- Key clinical features are asymmetric arthritis of a few joints, most often large joints of the lower extremities, often accompanied by axial arthritis and enthesitis typically at the Achilles tendon or plantar fascia and sacroiliac joints.
- Psoriasiform lesions on the soles—keratoderma blenorrhagicum—or penis—circinate balanitis—occur in one-third of patients and inflammatory eye disease is present in a similar proportion. Urethritis may occur with or without urogenital infection.
- HLA-B27 appears to increase disease susceptibility and chronicity of reactive arthritis, but recent data suggest it might portend more fulminate symptoms thereby serving as a diagnostic bias.
- *Chlamydia, Salmonella, Campylobacter, Shigella,* and *Yersinia* are definitive triggers of reactive arthritis, but other infections may also act as initiators.
- Although reactive arthritis often is self-limited in weeks to months, as many as 30%–50% of patients will develop chronic disease that often waxes and wanes.

ETIOLOGY AND PATHOGENESIS

TRIGGERING ORGANISMS

Bacteria that commonly cause ReA are *Salmonella*, *Shigella*, *Campylobacter*, *Yersinia*, and *Chlamydia trachomatis*. Indeed, these organisms represent the definitive triggers of ReA; however many other infectious agents have been implicated as potential causes (Box 20-1). *Chlamydia trachomatis* (Ct) is the most common etiologic agent causing ReA in the United States.[14,22] Despite the obvious difference of initial route of infection (i.e., gastrointestinal vs. genitourinary), another distinction exists. The postdysentery form of ReA is always preceded by a symptomatic infection, and recent data suggest the more severe the initial gastrointestinal infection, the more likely ReA develops.[23–25] However, an initial Ct infection is often asymptomatic.[26–28] Recent data suggest that an initial asymptomatic Ct infection is a common cause of ReA.[29] In this study, the majority of patients diagnosed with uSpA, because of no known preceding infection prior to the onset of their arthritis, were found to be polymerase chain reaction (PCR) positive for Chlamydiae on synovial tissue analysis. This is in keeping with previous data suggesting that 78% of subjects who develop ReA after a venereal infection had an asymptomatic infection.[30] A number of published studies also indicate that *Chlamydophila (Chlamydia) pneumonaie* (Cpn), a related respiratory pathogen, is another causative agent in ReA, albeit at a lower frequency.[31–33]

Chlamydiae are Gram-negative, obligate intracellular organisms. The attack rate of ReA after a Ct infection is approximately 5%.[30] Synovial tissue analyses from patients affected with postchlamydial ReA have shown that these organisms traffic from the initial site of infection to the synovium. These synovium-based Chlamydiae exist in a morphologically aberrant but metabolically active viable state termed chlamydial persistence.[34,35] The pattern of gene expression is attenuated and significantly different than that seen during normal active infection. For example, during persistence of Ct expression of the major outer membrane protein (*omp1*) gene and several genes required for the cell division process are severely downregulated. This is coupled with differential regulations of the three paralog genes specifying *Chlamydia trachomatis* heat shock proteins (HSP)-60 [(1) Ct110, (2) Ct604, and (3) Ct755].[36] The exact role that these synovium-based persistent Chlamydiae play in terms of disease pathogenesis or disease propagation is not completely understood. Of note, it has been demonstrated that these same persistent Chlamydiae traffic to other end organs, specifically the skin in patients with suspect keratoderma blenorrhagicum.[37]

Other recent data relating to *Chlamydia*-induced ReA force us to reconsider our traditional paradigms. Because these pathogens are responsible for genital infections, it was logical to assume that the genital strains of *C. trachomatis* were responsible for triggering ReA. However, there are several serovars of *C. trachomatis*, specifically serovars A through K. Serovars A, B, and C are ocular (trachoma) serovars and the remainders (serovars D through K) are genital. Remarkably, a recent study analyzing the chlamydial serovars of 36 subjects with known *C. trachomatis*-induced ReA demonstrated that all 36 synovial tissue samples were positive for the ocular serovars, not the genital serovars.[38] It

BOX 20-1 TRIGGERING MICROBES OF REACTIVE ARTHRITIS

DEFINITE CAUSES

Postvenereal

Chlamydia trachomatis

Postenteric

Salmonella (*S. enteritidis*, *S. typhimurium*, *S. bovismorbificans*, *S. blockley*)
Shigella (*S. flexneri*, *S. dysenteriae*, *S. sonnei*, *S. boydii*)
Campylobacter (*C. jejuni*, *C. coli*)
Yersinia (*Y. enterocolitica*, *Y. pseudotuberculosis*)

PROBABLE CAUSES

Chlamydophila (Chlamydia) pneumoniae
Ureaplasma urealyticum
Bacille Calmette-Guérin (intravesicular)

POSSIBLE CAUSES

Bacillus cereus
Brucella abortus
Clostridium difficile
Escherichia coli
Helicobacter pylori
Hafnia alvei
Lactobacillus
Neisseria meningitidis serogroup B
Pseudomona
Intestinal parasites (*Strongyloides stercolis*, *Taenia saginata*, *Giardia lamblia*, *Ascaris lumbricoides*, *Filariasis*, and *Cryptosporidium*)

OTHER TYPES OF INFLAMMATORY ARTHRITIS IN WHICH BACTERIA MAY PLAY A CAUSATIVE ROLE

Borrelia burgdorferi (Lyme disease)
Propionbacterium acnes (SAPHO)
Streptococcus sp. (poststreptococcal reactive arthritis)
Trophyrema whippelii (Whipple's disease)

Reprinted with permission from Carter JD: Reactive arthritis: Defined etiologies, emerging pathophysiology, and unresolved treatment. *Infect Dis Clin North Am* **20**:827, 2006.

is known that genital infection with the ocular strains do occur, but are rare.[39,40] The infrequent rate of genital infections with the ocular strain might explain the low attack rate of ReA in patients with acute chlamydial infections.

HOST FACTORS

Reactive arthritis represents the classic interplay of host and environment. The environmental triggers outlined above play and undeniable role in disease genesis; the concept of bacterial persistence lends speculative support that these pathogens might also play a role in disease propagation. Certain bacterial serovars or species might be particularly arthritogenic or more prone to dissemination. However, genetic susceptibility also clearly plays a role. Because ReA is one of the spondyloarthritides, much of the focus on host genetics has centered on HLA-B27. There are also data indicating that patients with HIV are at increased risk for ReA and the symptoms can improve with antiretroviral HIV therapy.[57]

The prevalence of HLA-B27 and reactive arthritis varies around the world.[58] In Caucasian populations, HLAB27 is present in 7%–9% of individuals. Older literature suggested that as many as 70%–80% of patients with ReA were HLA-B27 positive.[59,60] However, several large epidemiological studies of ReA now dictate that, in reality, about 30%–50% of ReA patients are positive for this antigen.[45,61–67] More recent data even suggest there might be no association with HLA-B27 and ReA.[25,47,64] The vast majority of data regarding the prevalence of HLA-B27 in ReA comes from epidemiological studies of postenteric ReA after outbreaks with certain enteric pathogens. Therefore, the true prevalence of HLA-B27 in postchlamydial ReA is less well defined.

The possibility exists that HLA-B27 plays more of a role with phenotypic disease expression rather than a true genetic susceptibility locus. Several large ReA studies demonstrate that HLA-B27 positive patients have more severe symptoms, thereby making the condition more clinically apparent.[23] This haplotype might also increase one's risk for developing the complete triad of symptoms.[68] It should also be noted that the variation in the prevalence of HLA-B27 in various studies described above could, at least in part, be explained by the potential role that HLA-B27 plays on phenotypic expression. The studies cited above suggesting that HLA-B27 has little to no role in disease susceptibility include patients with milder symptoms, whereas the previous studies demonstrating a higher HLA-B27 prevalence only include patients with more fulminate symptoms sometimes requiring the complete triad of symptoms.

Whether HLA-B27 is more important in disease susceptibility or clinical expression, it clearly plays a role in ReA. Many theories exist regarding its pathophysiologic role, but none are proven. Since HLA-B27 is a Class I histocompatability antigen, it has been postulated that HLA-B27 presents arthritogenic microbial peptides to T cells stimulating an autoimmune response, so called molecular mimicry.[69] Conversely, B27 itself may serve as the autoantigen that is targeted by the immune system.[70] It is also possible that exposure to the triggering bacteria may subvert self-tolerance to the B27 antigen.[71] Another theory suggests that the role of HLA-B27 may be to enhance invasion of the causative organisms into human intestinal epithelial cells in patients with postenteric ReA.[72] Vast data demonstrate that misfolding of HLA-B27 can lead to the unfolded protein response enhancing the production of interleukin-23;[73] however this unfolded pro-

tein response has not been definitively linked to ReA. HLA-B27 has multiple alleles that could influence host response and disease susceptibility. One study suggests that although HLA-B*2705 is the most common allele observed in B27-positive ReA patients, this allele is seen less frequently than in the other SpA's and in B27 healthy controls.[74]

While HLA-B27 is important to pathogenesis in ReA, it is not the sole determinant. Clearly patients who are HLA-B27 negative can develop ReA. It has been suggested that HLA-B*5703 increases the risk for the classic triad of symptoms in patients who develop ReA.[75] Gene expression analyses suggest that proangiogenic factors account for genetic susceptibility of ReA.[76] Much remains to be learned about other HLA loci or even non-HLA genes that might be important in the pathophysiology of ReA.

PATHOPHYSIOLOGY

It is apparent that the causative bacteria of ReA are incorporated intracellularly, either in-part or in-whole, then taken from the site of initial infection and trafficked to the synovium. However, what governs this process is not yet evident. It is also not clear if their presence in the affected organs represents a trigger for an autoimmune response, or if these organisms are the source for the inflammatory process. It appears that this phenomenon of cellular uptake, trafficking, and host tolerance is multifactorial in nature.

Although the causative organisms are intracellular pathogens, the process of cellular uptake is not entirely apparent. Indeed the specific mechanisms for cellular uptake of these microbes are probably different for each organism. In the case of Chlamydiae, the quest to find a specific extracellular ligand has been unsuccessful. Intriguing recent data suggest that there might not be a specific chlamydial ligand, rather these pathogens might utilize a different ligand entirely. Apolipoprotein E (ApoE4) that is adherent to the surface of chlamydial elementary bodies (EB) attaches to the host cell low-density lipoprotein (LDL) receptor family carrying the EB with it.[77] However, this only appears to be true of *C. pneumoniae*, not *C. trachomatis*. In the case of *Salmonella*, type 1 fimbriae mediate the attachment of this organism to the cell leading to internalization.[78]

Toll-like receptors (TLR) are a key component of the innate immune system. Because they are among the first line of defense against microbes and they recognize extracellular pathogens, they could play a role in ReA. All of the definitive triggering organisms are Gram-negative with a lipopolysaccharide (LPS) component to their cell wall, and TLR-4 recognizes LPS. TLR-4 deficient mice exposed to *Salmonella* demonstrate dramatically increased bacterial growth and demise.[79] Other animal data have shown that effective host clearance of Ct depends on appropriate TLR-4 expression by neutrophils.[80] However, recent human data suggest that TLR-2, not TLR-4, is important in determining ReA disease susceptibility after a *Salmonella* infection.[81]

In terms of cytokine response in ReA, it appears that both Th1 and Th2 are important, but the Th2 pathway predominates. Although ReA patients have higher serum TNF-α (Th1) than normal controls,[82] lower levels of TNF-α have been demonstrated in ReA compared to other types of inflammatory arthritis.[83–85] Synovial fluid analyses from patients with ReA demonstrate higher levels of IL-10 and lower levels of TNF-α and IFN-γ (favoring a Th2 profile).[84,85] Interestingly, in terms of postchlamydial ReA, lower levels of these same two cytokines (TNF-α and IFN-γ) have been associated with increased chlamydial replication and overall bacterial burden in vitro.[86–88] The suppression of Th1 cytokines is likely mediated through suppression of IL-12 synthesis.

Data also exist suggesting that these cytokine levels can change over time. ReA patients with a disease duration of greater than 6 months secreted significantly less TNF-α.[83] Temporal relationships of these different Th1 and Th2 cytokines might also be important in disease manifestations. Slight changes in the Th1/Th2 balance may explain the relapsing course that is frequently seen chronic ReA. Animal data also suggest that blunting of the initial cytokine response of TNF-α, IFN-γ, and Interleukin-4 (IL-4) to an acute chlamydial infection leads to decreased bacterial clearance.[89] Therefore, lower initial responses of these Th1 cytokines may increase the likelihood of developing ReA. These animal data provide an interesting potential correlate to the fact that asymptomatic chlamydial infections in humans can often lead to ReA.

CLINICAL MANIFESTATIONS

In spite of the fact that ReA has several distinct etiologic agents and the apparent differences in the pathophysiology depending on the triggering microbe, the clinical features of ReA are congruent regardless of the initiating infection. The clinical syndrome that encompasses ReA can involve many different organ systems, although it has a predilection for the synovium, urethra, eye, and the skin (Box 20-2). The symptoms start within 1–4 weeks of the initial infection. However, as stated with Chlamydiae, the inciting infection could be asymptomatic obfuscating the diagnosis. It has traditionally been felt that the vast majority of cases of ReA resolve spontaneously within weeks to months, but more recent data suggest that 30%–50% of cases can become chronic.[45,61–67] One series suggested that 63% of patients develop chronic symptoms.[18] In general, if a patient experiences symptoms of longer than 6 months duration, then they are felt to have chronic disease (Box 20-3). Typically, patients have more significant symptoms during the acute phase; these can include constitutional symptoms (malaise, fatigue) and fever. If the symptoms persist, then the long-term manifestations tend to be milder. In these chronic cases, it is not unusual for the symptoms to wax and wane.

ReA is often misdiagnosed or underdiagnosed. The reasons are varied, but an overreliance on the "classic" clinical triad of symptoms lends to this underdiagnosis. Some of the earliest descriptions of ReA included

BOX 20-2 CLINICAL MANIFESTATIONS OF ReA

ACUTE SYMPTOMS

Articular

Most commonly present with oligoarthritis, but can also present with polyarthritis or monoarthritis

Axial	*Frequently involved* Sacroiliac joints Lumbar spine *Occasionally involved* Thoracic spine (usually seen in chronic ReA) Cervical spine (usually seen in chronic ReA) Cartilaginous joints (symphysis pubis; sternoclavicular and costosternal joints)
Peripheral	*Frequently involved* Large joints of the lower extremities (especially knees)
Dactylitis (sausage digit)	Very specific for a spondyloarthropathy

Enthesitis

Hallmark feature: inflammation at the transitional zone where collagenous structures such as tendons and ligaments insert into bone.

Common sites: plantar fasciitis, Achilles tendonitis; but any enthesis can be involved.

Mucosal

Oral ulcers (generally painless)

Sterile dysuria (occurs with both postvenereal and postdysentery forms)

Cutaneous

Keratoderma blenorrhagicum	Pustular or plaque-like rash on the soles and/or palms Grossly and histologically indistinguishable from pustular psoriasis Can also involve nails (onycholysis, subungal keratosis, nail pits), scalp, extremities
Circinate balanitis	Erythema or plaque-like lesions on the shaft and/or glans of penis

Ocular

Conjunctivitis	Typically during acute stages only
Anterior uveitis (iritis)	Often recurrent
Rarely described	Scleritis, pars planitis, iridocyclitis, and others

Cardiac

Pericarditis (uncommon)

patients with this triad of symptoms. For many years, clinicians felt this triad was necessary for the diagnosis. In 1976, the concept of "Incomplete Reiter syndrome" was introduced describing a case series of 13 patients, who were predominately HLA-B27 positive, and presented with oligoarthritis, heel pain, periostitis, dactylitis, and mucocutaneous lesions, but no urethritis or conjunctivitis.[90] It is now apparent that the majority of cases do not involve the three classic organ systems.

ARTICULAR

ReA nearly always involves an inflammatory arthritis. It is unclear if some patients with other symptoms of ReA, such as recurrent uveitis or enthesitis without arthritis, might represent cases of ReA as well. Patients with ReA can develop an inflammatory arthritis that involves the axial skeleton and/or the peripheral joints.

The axial arthritis of ReA (Box 20-2) presents as pain and stiffness in the low back and/or buttocks. A classic feature is prolonged pain and stiffness in the morning or after periods of rest or inactivity. These symptoms tend to improve with activity or exercise. The cause of the pain includes inflammation in the synovial portion of the sacroiliac joints and enthesitis of these same joints, pelvis, and lumbar spine. The combination of synovitis and enthesitis of the sacroiliac joints results in one of the classic features of ReA, i.e., sacroiliitis. These symptoms

BOX 20-3 CLINICAL MANIFESTATIONS OF ReA

CHRONIC SYMPTOMS (≥6 MONTHS)

Articular

Axial	Sacroiliac joints Lumbar spine Thoracic spine Cervical spine Cartilaginous joints (symphysis pubis; sternoclavicular joints)
Peripheral	Large joints of the lower extremities (especially knees)
Dactylitis (sausage digit)	Very specific for a spondyloarthropathy

Enthesitis

Chronic inflammation can cause collagen fibers to undergo metaplasia forming fibrous bone

Chronic enthesitis leads to radiographic findings:

- Plantar/Achilles spurs
- Periostitis
- Nonmarginal syndesmophytes
- Syndesmoses of the sacroiliac joints

Mucosal

Sterile dysuria

Cutaneous

Keratoderma blennorrhagicum

Circinate balanitis

Ocular

Anterior uveitis (iritis)	Often recurrent
Rarely described	Scleritis, pars planitis, iridocyclitis, and others

Cardiac

Aortic regurgitation

Valvular pathologies

Reprinted with permission from Carter JD, Hudson AP: Reactive arthritis: Clinical aspects and medical management. *Rheum Dis Clin North Am* **35**:21, 2009.

might be more pronounced during the acute phase of the illness. It is important to note that sacroiliitis can often be documented on plain radiographs, but these imaging studies might be of lesser utility in patients with acute symptoms since radiographic evidence of sacroiliitis can take weeks to months to develop. In patients with a high index of suspicion of acute disease and normal plain radiographs, advanced imaging with magnetic resonance imaging (MRI) might prove useful (Fig. 20-1). Such advanced imaging can show evidence of early inflammatory sacroiliitis that might be otherwise missed by conventional radiographs.[91] Plain radiographs remain the imaging investigation of choice for patients with chronic disease. ReA patients with radiographic sacroiliitis typically have unilateral or bilateral asymmetric findings.

The axial inflammatory arthritis of ReA involves the thoracic and cervical spine less often than the lumbar spine. If present, symptoms are similar including prolonged pain and stiffness in the morning and improvement with activity. In addition to sacroiliitis, patients can also develop spinal changes on plain radiographs. The most typical finding is nonmarginal syndesmophytes (eFig. 20-1.1 in online edition). These are thick, bridging, comma-shaped bony growths between vertebral bodies. These are most often seen in patients with chronic disease. Finally, the axial symptoms can include inflammation in cartilaginous joints, such as the symphysis pubis or sternoclavicular joints, with resultant radiographic changes.

The peripheral arthritis of ReA most often is an inflammatory oligoarthritis; there is a predilection for the large joints of the lower extremities. However, patients can also present with a polyarthritis or even monoarthritis. This clinical picture involving one or a few joints, particularly of the lower extremities contrasts with other types of inflammatory arthritis, such as rheumatoid arthritis, that typically present with a symmetrical polyarthritis. As with the axial symptoms, these tend to be more pronounced during the acute stage and can relapse and remit. In patients with more chronic or severe cases the small joints of the hands and feet can be involved. Radiographic features of peripheral joints in patients with chronic disease can include erosive changes, periostitis, and possibly even "pencil-in-cup" deformities most often associated with psoriatic arthritis.

Dactylitis (sausage digit) is a valuable diagnostic clue for potential ReA (Fig. 20-2). Dactylitis represents diffuse inflammation of an entire finger or toe. While not specific to ReA, if present, it is strongly suggestive of a spondyloarthropathy. Besides the spondyloarthropathies, only a few conditions, namely sarcoidosis and gout, cause dactylitis. One series suggested that ReA was the most common diagnosis in patients presenting with dactylitis; 28% of ReA patients had this finding as part of their constellation of symptoms.[92]

ENTHESITIS

Enthesitis, or fibrocatilagenous enthesitis, is inflammation at the transitional zone where collagenous structures such as tendons, ligaments, and joint capsules insert into bone. This is a hallmark feature of ReA (as well as for other types of spondyloarthritis). There are two main phases of enthesitis: (1) subchondral osteitis and (2) reparative ossification. The inflammation starts in the intraosseous portion of the enthesis, eventually destroying the bone and cartilage plate. The defect is rapidly filled with newly formed bone that extends to the terminal part of the tendon producing an enthesophyte (eFig. 20-2.1 in online edition). Common types of enthesitis in ReA are Achilles tendonitis and plantar fasciitis, but inflammation can occur at any enthesis.

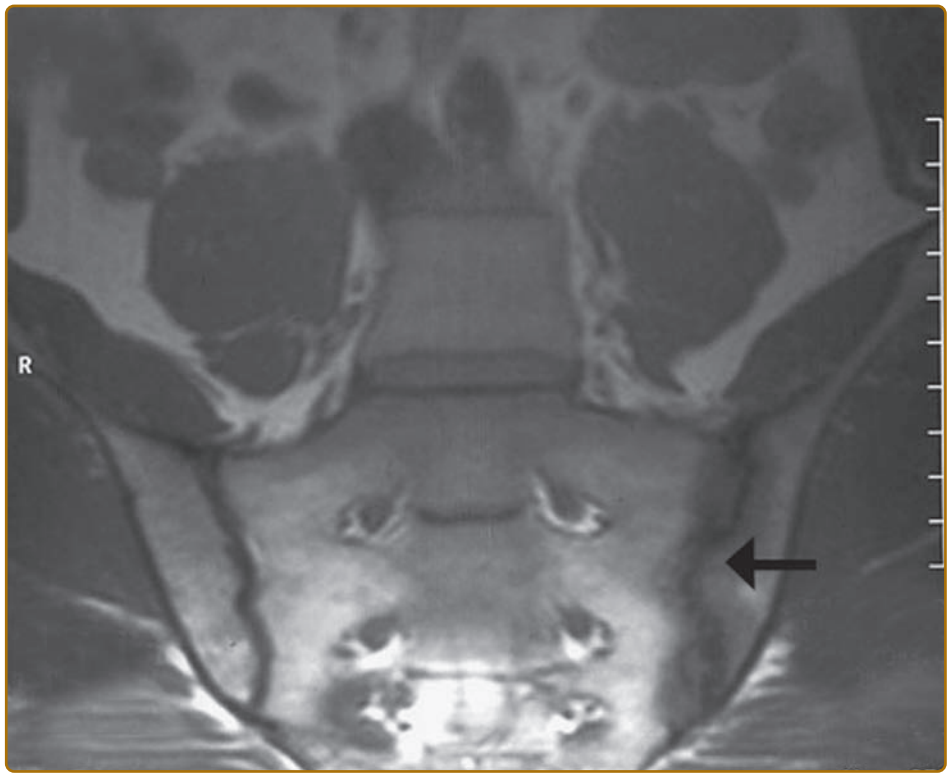

Figure 20-1 Magnetic resonance image showing unilateral sacroiliitis.



Figure 20-2 Dactylitis of second toe (sausage toe).

Sacroiliitis represents a combination of synovitis and enthesitis.[93] A recent report of >6,000 cases of culture-confirmed infections with bacterial enteric pathogens revealed that enthesitis was the most common finding in those individuals who developed ReA.[25]

CUTANEOUS

Dermatologic manifestations of ReA are several. The two most common are keratoderma blenorrhagicum and circinate balanitis. Keratoderma blenorrhagicum is a pustular or plaque-like rash that most often occurs in a palmoplantar distribution (Fig. 20-3). These



Figure 20-3 Keratoderma blennorrhagicum.

typically begin as erythematous macules or vesicles. These vesicles are often pustular in nature, but they can also be hemorrhagic; over time they can become thickened or papular forming a horny excrescence. These chronic lesions can become hyperpigmented and may coalesce. Rarely these lesions can occur in a more general distribution involving the entire body[94]; this is felt to be more likely in the setting of HIV. Interestingly, keratoderma blenorrhagicum is clinically and histologically indistinct from pustular psoriasis.[95] Histologic findings include hyperkeratosis and parakeratosis, elongation and hypertrophy of the rete ridges, general epidermal hyperplasia, and extensive neutrophilic infiltration with formation of microabscesses and spongiform pustules. Recently it has been demonstrated that these lesions are PCR positive for *Chlamydia trachomatis* in patients with suspected *Chlamydia*-induced ReA.[37]

Circinate balanitis is a cutaneous manifestation of ReA involving the penis. These are erythematous, pustular, or plaque-like lesions that most often involve the glans of the penis, but they can include the shaft and rarely the scrotum (Fig. 20-4). It has been suggested that these lesions on the glans can exhibit different characteristics depending on whether the patient is circumcised or not. In circumcised males, hyperkeratotic plaques are most typical and in uncircumcised patients they often begin as vesicles or pustules that may coalesce into a circinate pattern (Fig. 20-4).[96] Females with ReA can rarely get ulcerative vulvitis that has similar appearance to circinate balanitis.

Patients with ReA may also have nail involvement, which is similar to psoriasis and presents as onycholysis, subungal keratotic debris, transverse ridges, periungual scaly lesions, and nail pitting. These changes occur in about 20%–30% of ReA patients.[96] The relationship between distal interphalangeal arthritis and nail involvement is well recognized in psoriatic arthritis,[97] the same is also likely to be true for ReA, but there are no definitive data in this regard.

The true prevalence of keratoderma blenorrhagicum and circinate balanitis in patients ReA remains somewhat uncertain. Previous data have suggested that they occur in about 10%[98] and 50%[99] of patients, respectively and it was felt that they are more common in patients who are HLA-B27 positive.[100] However, as is the case with ReA in general, it is not clear if this genetic marker truly increases the occurrence of these cutaneous manifestations or if it has served as a diagnostic bias. More recent data demonstrate that circinate balanitis more strongly correlates with a previous chlamydial infection than previously thought.[101] In this same study, there was no apparent association with HLA-B27 and the majority of patients had no other signs or symptoms of ReA. The fact that these lesions are also clinically and histological indistinct from pustular psoriasis can also obfuscate the diagnosis.



Figure 20-4 Circinate balanitis.

OCULAR

(Boxes 20-2 and 20-3)

Although the original "classic triad" of symptoms of ReA included eye involvement, conjunctivitis was specifically mentioned. Not only do patients with ReA develop conjunctivitis, they often develop iritis/anterior uveitis. Although both conditions can occur at any time during the condition, it has traditionally been felt that conjunctivitis most often occurs during the early stage and less frequently becomes chronic whereas iritis/anterior uveitis occurs both as an acute and chronic (intermittent) problem. However, a long-term study of 25 ReA subjects with eye involvement at the time of diagnosis demonstrated that long-term ocular complications included conjunctivitis and anterior uveitis in 96% and 92% of patients, respectively.[102] Other long-term complications were seen in this study including posterior uveitis (64%), keratitis (64%), cataract (56%), intermediate uveitis (40%), scleritis (28%), cystoid macular edema (28%), papillitis (16%), and glaucoma (16%). These data suggest that patients with ocular involvement at the time of diagnosis are at increased risk for many long-term ocular complications; perhaps this risk is higher than previously appreciated.

MUCOSAL

(Boxes 20-2 and 20-3)

Mucosal involvement of the mouth, oral pharynx, and tongue can occur in patients with ReA, but these are infrequent. If they occur, typical lesions on the oropharnyx include diffuse erythema, macules, and plaques. They are often painless and might go unnoticed by the patient. Such lesions will sometimes present with bleeding. Lesions involving the tongue are most often circinate or annular in appearance. More

common mucosal manifestations include intestinal inflammatory lesions that resemble those of inflammatory bowel disease. One study found that 67% of subjects with ReA had histologic evidence of ileocolitis, even in the absence of gastrointestinal symptoms.[103] This finding might be higher in patients with postenteric ReA. Finally, it is well described that patients with ReA develop sterile dysuria. Interestingly this occurs with equal frequency in both postvenereal and postenteric ReA. This sterile dysuria can become a chronic intermittent problem for some patients. Prostatitis, cystitis, and pelvic inflammatory disease have also been described.[104,105]

CARDIAC

(Boxes 20-2 and 20-3)

Cardiac involvement from ReA is rare. There are sparse reports of ReA patients developing pericarditis, aortic regurgitation, or valvular pathologies. When they occur, they are more likely in chronic disease. These manifestations are rare enough in the acute setting that routine echocardiography is not recommended.[106] Electrocardiographic abnormalities can occur in the acute setting with significant arrhythmias occurring in approximately 5% of patients.[107]

DIAGNOSIS

Diagnostic criteria are broad and rely on clinical symptoms.[100,108] Difficulties with these diagnostic criteria have been raised.[109] The traditional disease definition also suggests that ReA represents a sterile inflammatory arthritis, but data presented above, specifically pertaining to Chlamydiae, challenge this paradigm. Although not pathognomonic for the condition, the documentation of the DNA presence of one of the causative organisms by PCR in synovial tissue or fluid of patients who fulfill the clinical criteria for ReA represents the most accurate means of diagnosing the condition.[110] Unfortunately, such synovial tissue analysis is not readily available for the majority of clinicians. Stool and urogenital sampling for the causative organisms in patients with chronic disease have been analyzed, but many patients test negative limiting the utility of this approach.[111,112] Serologic testing for antibodies to the causative organisms is unreliable. Because more than half of affected patients are HLA-B27 negative, this genetic antigen should not be utilized as a diagnostic tool. Therefore, at the current time we are left without a practical diagnostic test. Recognition of an underlying spondyloarthritis and identifying one of the triggering infections remains the most practical means of diagnosis ReA until better diagnostic tests are widely available. A diagnostic algorithm is shown in Figure 20-5.

TREATMENT

In the setting of acute or mild ReA, treatment is most often symptomatic and conservative. It is important to remember that many of the symptoms of acute ReA are self-limiting. The initial treatment of choice for the arthritis is nonsteroidal anti-inflammatory (NSAIDs). Not only is there a breadth of clinical experience with NSAIDs demonstrating their efficacy, there are also two randomized trials that have formally evaluated their use in ReA. The first was a double-blind crossover study comparing azapropazone to indomethacin in patients with both psoriatic arthritis and ReA.[113] Both medications were efficacious with a trend favoring indomethacin. Neither medication helped with the skin manifestations of either condition. The second was another double-blind crossover study comparing ketoprofen to indomethacin in 50 patients with ReA.[114] Both drugs were efficacious in treating the articular symptoms with no significant difference between the two. There were slightly more adverse events with indomethacin in both studies. Corticosteroids are quite helpful in patients with more severe articular symptoms. It has been suggested that systemic corticosteroids might be more efficacious in the treatment of peripheral articular symptoms rather than the axial symptoms.[115] Because ReA often involves one or few joints, intra-articular corticosteroids are often a useful treatment strategy.

Initial treatment of many of the extra-articular features of ReA includes topical corticosteroids. These have been utilized to treat iritis/uveitis, keratoderma blenorrhagicum, and circinate balanitis.[115] Given the similarities between the cutaneous manifestations of ReA and psoriasis, it is not surprising that other medications used to treat psoriasis have been advocated as potential treatments for keratoderma blenorrhagicum and/or circinate balanitis. Data suggest that topical calcipotriene is a useful treatment modality for keratoderma.[116] Emollients, keratolytics, coal tar, and phototherapy have also been advocated for keratoderma blenorrhagicum. In severe cases of keratoderma blenorrhagicum and circinate balanitis methotrexate (low-dose regimen as for psoriasis) and etretinate (0.5 mg/kg body weight) have been found to be beneficial but no formal clinical trials have been performed!

In spite of the fact that ReA often remits, as many as 30%–50% of patients will develop chronic disease. Both the articular and extra-articular features can persist. Because ReA can lead to pathologic sequelae (e.g., joint damage, visual impairment, skin disfigurement) resulting in decreased health-related quality of life, more definitive treatments have been sought. Paralleling the opposing schools of thought regarding the true role bacterial persistence plays in the pathophysiology of the disease, both traditional disease modifying antirheumatic drugs (DMARDs) and antibiotics have been assessed as potential therapeutic options. The latter have been studied in both acute and chronic disease, whereas the former are most often reserved for patients with chronic symptoms.

Several DMARDs have been advocated as treatments for ReA. These include sulfasalazine, methotrexate, azathioprine, and cyclosporine. Surprisingly, only one of these, sulfasalazine, has been formally evaluated in prospective clinical trials. Sulfasalazine

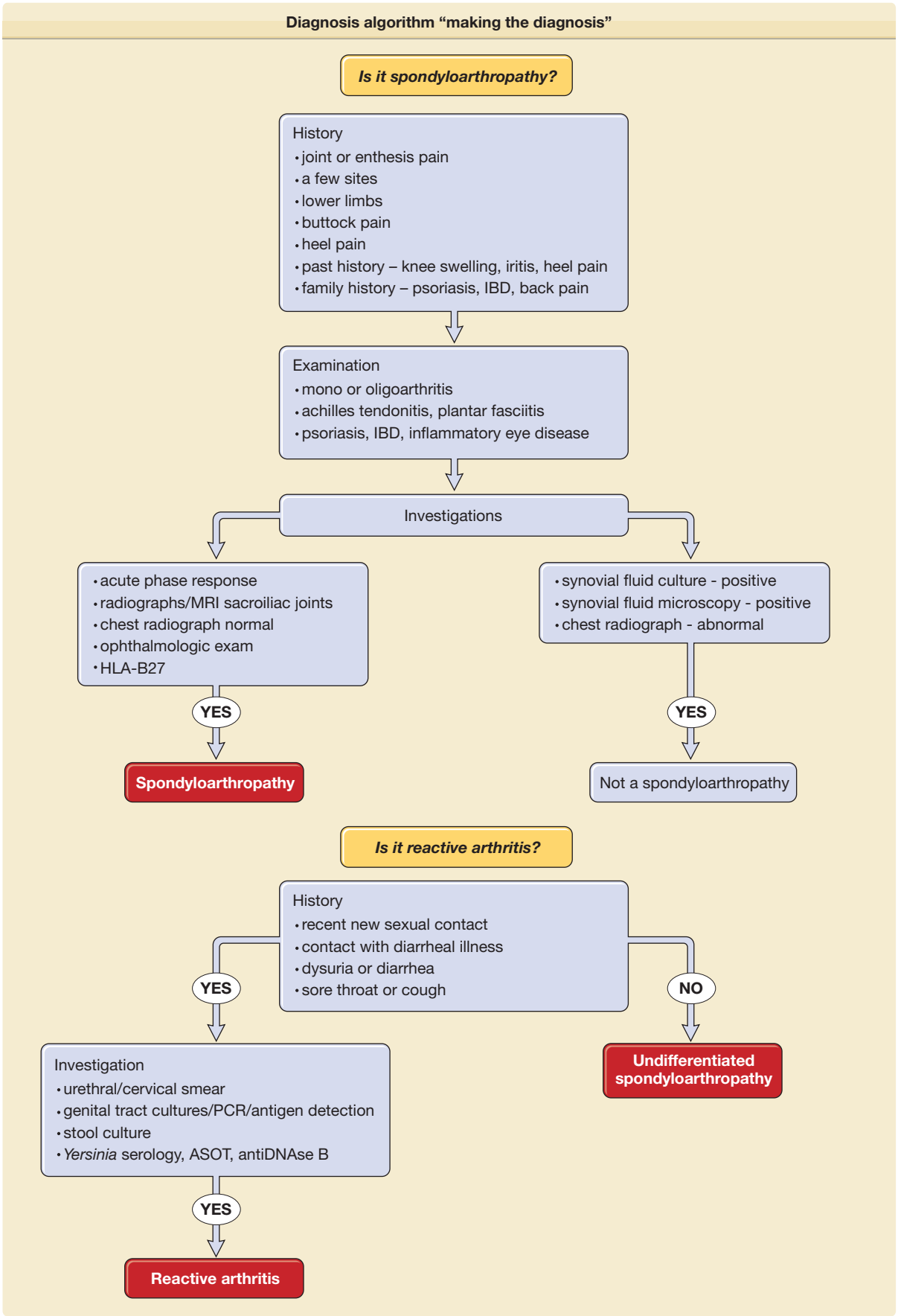

Figure 20-5 Diagnostic algorithm "making the diagnosis." Anti-DNAse B = antideoxyribonuclease B; ASOT = antistreptolysin O titer; IBD = inflammatory bowel disease; MRI = magnetic resonance imaging; PCR = polymerase chain reaction.

has been studied as a potential treatment for both acute and chronic ReA. In the acute ReA study, there was no significant difference between sulfasalazine and placebo in terms of pain, number of swollen joints, and erythrocyte sedimentation rate (ESR) after 6 months of therapy.[117] In addition, there was no apparent efficacy difference in patients regarding the initial triggering infection, HLA-B27 status, or presence/absence of axial arthritis. However, it is important to remember that acute ReA often remits spontaneously, so this potentially confounds these data. Sulfasalazine has also been studied in the setting of chronic ReA.[118] In this study, all patients had failed NSAIDs and were followed for 36 weeks' duration. There was a trend favoring sulfasalazine over placebo in terms of overall response. Sulfasalazine fared significantly better than placebo in some of the secondary endpoints including a longitudinal analysis and ESR.

The tumor necrosis factor (TNF)-α antagonists have demonstrated remarkable success treating several types of inflammatory arthritis including other types of spondyloarthritides, namely ankylosing spondylitis and psoriatic arthritis. Therefore it might seem logical that they would be useful therapeutic agents for ReA. However, several studies suggest that ReA is more of a Th2 driven disease.[83–85] Conversely, ReA patients have higher serum TNF-α levels than normal controls.[82] Adding to this complexity, it has been suggested that the Th1 versus Th2 predominance depends on the cell analyzed (synovial fluid derived T-cell clones vs. synovial fluid mononuclear cells).[82] It should also be noted that, in the case of chlamydial persistence, chlamydial replication is inversely proportional to TNF-α levels.[86–88] There are no randomized trials in ReA to accurately assess the efficacy of anti-TNF therapy, but several case reports and a small open label study suggest clinical benefit with these drugs in the treatment of ReA.[119–122] It might also be noteworthy that a rare, but defined, adverse event of anti-TNF therapy, in general, includes the onset of de novo psoriasis.[123] The similarities of keratoderma blenorrhagicum and pustular psoriasis are well described. The majority of these cases of anti-TNF therapy induced psoriasis occurs on the palms and/or soles and is pustular in nature. Three reported cases have been shown to be PCR positive for *Chlamydia trachomatis* on lesional skin biopsies.[37] The exact pathophysiology of these de novo cases of psoriasiform lesions remains unknown.

The fact that certain bacterial organisms are responsible for the genesis of ReA makes the notion of using antibiotics plausible. Data have demonstrated that the causative bacterial organisms traffic to the synovium and in the case of persistent synovium-based Chlamydiae, specifically, these organisms exist in a viable, albeit aberrant, state. This important difference in postchlamydial and postenteric ReA suggests a potential difference in antimicrobial response.

The first prospective, double-blind trial assessed antibiotics in the setting of acute ReA.[124] In this trial, 3 months of therapy with lymecycline significantly decreased the duration of illness in those subjects with postchlamydial ReA, but not those with the postenteric variety. This led to several studies assessing the utility of long-term treatment with various antibiotics, including ciprofloxacin, azithromycin, and doxycycline, in the ensuing years that produced negative results.[67,125–128] However, the initial concept that postchlamydial and postenteric ReA might behave differently in terms of therapeutic response was somewhat lost in these follow-up studies. More recently, data have suggested that a prolonged course of combination antibiotics is an efficacious treatment specifically for chronic postchlamydial ReA. Initially, an open-label comparison of doxycycline with rifampin versus doxycycline monotherapy suggested superiority with the former.[65] A double-blind, placebo-controlled follow-up study demonstrated that 6-month courses of doxycycline with rifampin and azithromycin with rifampin were significantly better than placebo.[129] In this study, all patients had to be PCR positive for Chlamydiae in order to be randomized to treatment. Significantly more patients on combination antimicrobial therapy converted to PCR negative compared to those treated with placebo after 6 months of therapy.

CONCLUSION

In terms of chronic diseases, ReA is unique in that the etiologic agents are known. This insight into disease initiation has led to significant advances in the understanding of this condition but much remains to be learned regarding its pathophysiology. In an almost ironic fashion, the definitive nature of disease genesis is juxtaposed with convoluted evolution regarding disease terminology and the original overreliance on the "classic triad" of symptoms; these issues have now been clarified. However, there remains ambiguity regarding a definitive therapeutic approach. Ongoing studies will hopefully answer the latter.

KEY REFERENCES

Full reference list available at www.DIGM8.com

DVD contains references and additional content

25. Townes JM et al: Reactive arthritis following culture-confirmed infections with bacterial enteric pathogens in Minnesota and Oregon: A population-based study. *Ann Rheum Dis* **67**:1689, 2008
29. Carter JD et al: Chlamydiae as etiologic agents in chronic undifferentiated spondylarthritis. *Arthritis Rheum* **60**:1311, 2009
30. Rich E et al: Reactive arthritis in patients attending and urban sexually transmitted disease clinic. *Arthritis Rheum* **39**:1172, 1996
34. Gerard HC et al: Synovial chlamydia trachomatis in patients with reactive arthritis/Reiter's syndrome are viable but show aberrant gene expression. *J Rheumatol* **25**:734, 1998
38. Gerard HC et al: Patients with Chlamydia-associated arthritis have ocular (trachoma), not genital, serovars of C. trachomatis in synovial tissue. *Microb Pathog* **48**:62, 2010
96. Wu BI, Schwartz RA: Reiter's syndrome: The classic triad and more. *J Am Acad Dermatol* **59**:113, 2008
129. Carter JD et al: Combination antibiotics as a treatment for chronic Chlamydia-induced reactive arthritis. *Arthritis Rheum* Feb 12, 2010. [Epub ahead of print]

Chapter 21 :: Pustular Eruptions of Palms and Soles

:: Ulrich Mrowietz

PALMOPLANTAR PUSTULOSIS AT A GLANCE

- Chronic inflammatory disorder with sterile pustule formation.
- Affects only palms and soles.
- Disabling in severe cases.
- High rate of recurrence.
- Often resistant to treatment.
- Can be part of SAPHO (synovitis, acne, pustulosis, hyperostosis, osteitis) syndrome.

Pustular eruptions of the palms and soles include palmoplantar pustulosis (PPP), acrodermatitis continua (Hallopeau disease), and infantile acropustulosis. The entities present with chronic and persistent eruptions of sterile, purulent vesicles.

A drug-induced rash clinically resembling PPP has been described in patients treated with tumor necrosis factor-α (TNF-α)-antagonists.

PALMOPLANTAR PUSTULOSIS

PPP is a chronic pustular dermatosis localized on the palms and soles only. High resistance to treatment and a high recurrence rate are characteristic. Histologically, it is characterized by intraepidermal vesicles filled with neutrophils.

Although many textbooks describe PPP along with psoriasis, it has an entity of its own.

The involvement of palms and soles has a great impact on life quality and the ability to work.

EPIDEMIOLOGY AND GENETICS

PPP has a worldwide distribution. It is a rare condition, but the exact incidence is not known. Females show a higher prevalence than males, with a ratio of approximately 3:1. Onset of the disease occurs mostly between the ages of 20 and 60 years; rarely, the condition occurs after the sixth decade of life, and in 10% of the patients the onset is before the age of 20 years.

HLA typing of patients with PPP reveals no increased frequency of any of the known psoriasis-linked alloantigens.[1] In a direct comparison among chronic-plaque psoriasis, guttate psoriasis, and PPP, the three major candidate genes within the PSORS1 region [(1) *HLA-Cw*6*, (2) *HCR*WWCC*, and (3) *CDSN*5*] showed a high association to guttate and chronic plaque psoriasis, not, however, to PPP.[2] Investigation of the apolipoprotein E alleles e2, e3, and e4 in chronic plaque and guttate psoriasis as well as in PPP in acitretin responders and nonresponders showed that the frequency of the e4 allele was significantly higher in the psoriasis groups but not in PPP patients as compared to healthy controls.[3] In chronic plaque psoriasis and psoriatic arthritis an association with TNF-α-238 and -308 promoter polymorphisms have been found; however, the association has not been found in PPP.[4] Studies from Japan provide evidence for phenotypic and genetic heterogeneity of PPP according to its association/provocation with tonsillitis. In patients in whom PPP was not associated with tonsillitis, the phenotype frequency of the TNF-β2 allele of the TNF-β gene and of the allele B of the TNF-α gene was significantly higher as compared to controls.[5]

Genetic association studies in a Caucasian cohort revealed that genes encoding for cytokines of the IL-10 family, namely, IL-19, IL-20, and IL-24 show haplotypes conferring increased risk for PPP.[6]

These findings further substantiate the notion that PPP and psoriasis represent different entities.

ETIOLOGY AND PATHOGENESIS

The cause of PPP is not known. An imbalance of the protease/antiprotease system in the skin consisting of decreased antileukoprotease (elafin/SKALP) activity in pustular psoriasis has been discussed as a possible mechanism of pustule formation.[7] Exacerbation of PPP has been observed after patch testing with metals and was accompanied by elevated leukotriene B4 levels in plasma and pustules.[8]

In a long-term survey from Japan, the incidence of PPP was found to be positively correlated to heavy smoking (more than 20 cigarettes per day), tonsillitis, and seasonal factors such as high humidity and high temperature.[9,10]

The most striking association in PPP is smoking. In two Swedish surveys, 95% of PPP patients were smokers at onset of disease and cessation of smoking was the most important measure to treat the disease.[11,12] There is evidence from immunohistochemical studies that nicotinic acetylcholine receptors are modulated in lesional skin from smoking PPP patients when compared to disease-free smokers and healthy controls suggesting an abnormal response to nicotine in PPP.[13] The possible involvement of neutrophils infiltrating sweat glands and ducts expressing choline acetyltransferase and the α-3 and α-7 nicotinic acetylcholine receptors as a target for nicotine/smoking was discussed as an important mechanism for manifestation and/or maintenance of PPP.[14]

Investigating the tissue of tonsils of PPP-patients a unique formation of lymphoid follicles surrounded

by reticular crypt epithelial cells was found which was absent in tonsils of controls.[15] Culturing crypt epithelial cells it was shown that p53-related expression factors contributed to an upregulation of *IL-6* gene expression. The possible importance of IL-6 for PPP has been emphasized previously and it has been shown that tonsillectomy leads to improvement of lesions.[16] In another study, the expression of inducible costimulator (ICOS), a costimulatory receptor on activated T cells was higher in the tissue of tonsils of PPP-patients as compared to controls.[17] Tonsillectomy or treatment of dental foci resulted in a marked and sustained improvement of lesions suggesting a major role of focal infections as a trigger for PPP. The role of T cells in the tonsils for PPP is further substantiated by the demonstration of an increased expression of cutaneous lymphocyte-associated antigen (CLA) on CD3+ T cells in tonsils and in diseased skin together with an enhanced expression of the CLA-ligand E-selectin.[18]

Grafting involved PPP-skin onto SCID/CB-17 mice injected with lymphocytes from tonsils of PPP patients together with heat shock protein 60 induced high antiheat shock protein 65-IgG levels together with an increase of IL-6 and interferon α.[19] Recruitment of lymphocytes seems to be mediated by the chemokine CCL20/MIP3 α the receptor of which, CCR6, is significantly expressed on tonsilar T cells of PPP patients as compared to controls. Indeed, Tonsillectomy resulted in a decreased CCR6 expression on peripheral PPP T cells.[20]

The observation of either PPP or new onset psoriasis in patients treated with anti-TNF-α agents is not yet understood[21] but a shift from a TNF-α-driven immune response toward an interferon-dominated inflammatory response is discussed.[22] In an animal model, the neutralization of TNF-α-induced skin inflammation resulted in an increased expression of IL-1β, IL-6, IL-17, IL-21, and IL-22 and a suppression of FoxP3-positive regulatory T cells.[23] In the light of the importance of T cells and IL-6 for the development of PPP this shift may at least in part explain this appears relevant.

CLINICAL FINDINGS

The primary lesions are pustules of nearly equal size measuring two to four mm in diameter. Crops of pustules usually arise within a few hours on otherwise normal-appearing palmar and plantar skin (Fig. 21-1). Involvement is usually symmetric but unilateral location on palms and/or soles can be seen. Single lesions then become surrounded by an erythematous ring. Sometimes, the pustules extend to the dorsa of the fingers, the feet, or over the volar wrists (see Fig. 21-1C). Episodes of new pustular eruptions occur at varying intervals and remain strictly confined to the sites of predilection.

As pustules become older, their yellow color changes to dark brown, so that in untreated PPP, the lesions show various shades of color (see Fig. 21-1). Dried pustules are shed within approximately 8 to 10 days.

Symptoms include itching or a burning sensation, which may precede new crops of lesions. However, in severe eruptions, pain and the inability to stand, walk, or do manual work may greatly reduce the quality of life.

DISEASE ASSOCIATIONS. (Box 21-1.) An association of PPP and osteoarthritis of the anterior chest wall was first described in Japan.[24] As reported by Swedish authors, involvement of the manubriosternal joint is present in 6% and of the sternoclavicular joints in 10% of patients.[25] Scintigraphic investigations showed sternocostoclavicular joint involvement to be present in 16 of 73 (22%) patients.[26] For this condition, the term *SAPHO* (synovitis, acne, pustulosis, hyperostosis, osteitis) has been established.[27] Clinical manifestations of SAPHO syndrome are similar when they occur either with severe acne (mostly acne conglobata) or PPP (see Chapter 80). The primary lesion consists of a sterile abscess containing neutrophils. The site of predilection is the anterior chest wall. Involvement of the sacroiliacal joints may occur.[28]

PPP is also seen in patients with chronic recurrent multifocal osteomyelitis as well as with noninfectious inflammatory bone lesions.

An association of PPP with gluten-sensitivity has been suggested as far back as 1991.[29] In a more recent study of 123 patients with PPP IgA-antibodies against gliadin were found in 18% of patients and against tissue transglutaminase in 10%, respectively.[30] In these patients CD3+ and CD8+ T cells were increased in numbers in duodenal biospsies. In 6% of patients diagnosis of celiac disease was made. Patients who tested positive for any of the antibodies showed total or nearly total clearance of skin lesions when they adhered to a gluten-free diet.

HISTOPATHOLOGY. Histologically, there is an intraepidermal cavity filled with polymorphonuclear leukocytes associated with spongiform changes within the surrounding epidermis (Fig. 21-2). Eosinophils and mast cells are present in increased numbers in PPP biopsies from lesional skin. Another hallmark is the inability to visualize the epidermal part of the eccrine duct in PPP specimens indicating an involvement of the acrosyringium.[31]

LABORATORY FINDINGS. The lesions of PPP are sterile; a moderately increased white blood cell count may occasionally be observed, but all other laboratory tests are usually normal. In patients with an infectious trigger, infection-associated laboratory parameters, such as C-reactive protein, may be increased. Increased levels of antigliadin and/or tissue transglutaminase antibodies may be found.

BOX 21-1 DISEASE ASSOCIATIONS OF PPP

- SAPHO syndrome
- Chronic recurrent multifocal osteomyelitis and noninfectious inflammatory bone lesions
- Gluten sensitivity



Figure 21-1 Palmoplantar pustulosis. **A** and **B.** Groups of pustules measuring 2 to 4 mm in diameter occur on erythematous skin on palms and soles. Both feet and both hands are normally affected symmetrically but can also be found on one side only. **C** and **D.** Lesions may occasionally spread beyond the predilection sites, and pustules may appear on the wrists. Within several days after pustule formation, lesions dry, flatten, and acquire a brownish color. This may be followed by eczematous changes with scaling and fissuring.

DIAGNOSIS AND DIFFERENTIAL DIAGNOSIS

(Box 21-2)

PPP is a distinct entity. The course of the disease, together with the characteristic morphology, permits the proper diagnosis. The disease must be differentiated from dyshidrotic eczematous dermatitis (pompholyx), especially when pustules due to secondary infection are present (see Chapter 16). In that condition, the onset is also acute, but clear vesicles of various sizes are scattered on the palms, soles, and volar and interdigital aspects of the fingers. These may coalesce and secondarily become pustular because of secondary bacterial infection.

Pustular variants of tinea of the palms and soles or pustules developing in infected scabies may resemble

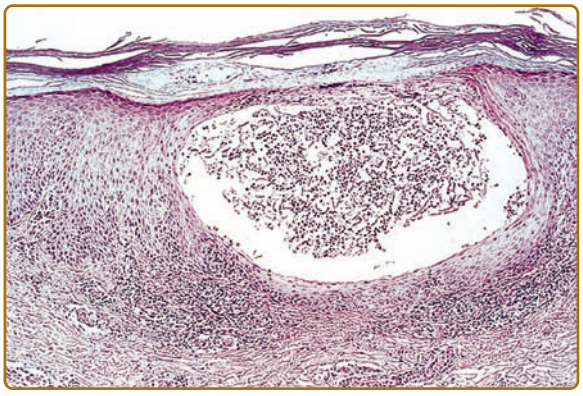

Figure 21-2 Histologically, there is a spongiform pustule and a moderate lymphohistiocytic infiltrate.

PPP. Bacterial cultures or demonstration of hyphae or mites clearly separate these entities from PPP.

Rare clinical variants such as vesicopustular mycosis fungoides palmaris et plantaris,[32] localized pustular vasculitis,[33] or palmoplantar involvement of generalized pustular psoriasis may also resemble PPP.

PROGNOSIS/CLINICAL COURSE

The clinical course of PPP is highly unpredictable. In patients with active disease with ongoing development of fresh pustules at the beginning of treatment relapse within a few days after cessation of any therapy or dose-reduction is highly likely. In phases of remission fewer pustules are produced, but the skin may remain erythematous and hyperkeratotic, sometimes resembling eczema. Cessation of smoking may help to extend disease-free intervals and to decrease activity of PPP.

TREATMENT

PPP is difficult to treat and all reported treatments have a high recurrence rate. Treatment modalities of PPP are summarized in Box 21-3.

In patients with limited disease or only focal lesions topical therapy with corticosteroids (potent and super-potent) is the treatment of choice. Increased efficacy can be obtained by occlusive therapy. When PPP involves larger parts of palms and/or soles systemic treatment with or without additional topical therapy should be initiated.

In a meta-analysis of several trials a modest efficacy of retinoids (etretinate/acitretin) or PUVA (oral, topical, bath) was established when compared to placebo. The addition of a retinoid to PUVA (re-PUVA) resulted in increased efficacy. Cyclosporine showed good evidence of improvement up to clearance but no data support was given for long-term cyclosporine therapy.[34]

In a recent open trial in 52 patients with PPP 35% could be controlled by topical therapy. In those patients requiring systemic therapy acitretin was found most efficacious followed by colchicine and methotrexate.[35] Efficacy of fumaric acid ester therapy in PPP has been described.[36]

In six female PPP-patients oral itraconazole (100 mg/day for 4 weeks followed by 100 mg every other day for 4 weeks) lead to a complete clearance in three out of six and in mild improvement in the other three patients. All patients relapsed within 1 month after cessation of therapy but therapeutic response could be regained in two of the three former responders.[37]

In an open trial in 15 patients 15 mg alefacept i.m. weekly for 16 weeks was found to be successful in the majority of cases.[38] However, in another series of 15 PPP patients alefacept 15–30 mg weekly was found efficacious only in some cases with a maximum response at week 10.[39] There is debate as to whether TNF-α antagonists may be beneficial in PPP. Whereas in chronic plaque type psoriasis and generalized pustular psoriasis the anti-TNF-α monoclonal antibody infliximab was found to be highly effective, this agent was found to be both beneficial and to worsen PPP.[40,41] In the SAPHO syndrome, infliximab led to a complete remission of osteoarticular disease but PPP deteriorated during treatment.[42] In a small placebo-controlled trial in 15 PPP-patients etanercept given 2 × 50 mg weekly s.c. for 6 months only few patients showed a significant clinical response.[43]

BOX 21-2 DIFFERENTIAL DIAGNOSIS

Most Likely

- Dyshidrotic eczema with secondary bacterial infection
- Pustular tinea of palms and soles

Consider

- Keratoderma blenorrhagicum in Reiter disease
- Involvement of palms and soles in generalized pustular psoriasis
- Infected scabies with pustulation
- Vesicopustular mycosis fungoides of palms and soles
- Localized pustular vasculitis

MANAGEMENT AND PREVENTION

(See Box 21-4)

Cessation of smoking and, according to data mainly generated in Asian countries, tonsillectomy may help to prevent new eruptions of PPP. In patients tested positive for antigliadin and/or tissue transglutaminase antibodies and/or with proven celiac disease a gluten-free diet seems to be a preventive measure.

ACRODERMATITIS CONTINUA (HALLOPEAU)

Acrodermatitis continua is a rare, sterile, pustular eruption of the tips of the fingers or toes that slowly extends proximally. Continuous pustulation leads to nail destruction and atrophy of the distal phalanx.

BOX 21-3 TREATMENTS FOR PALMOPLANTAR PUSTULOSIS AND ACRODERMATITIS CONTINUA[a]

	TOPICAL		PHYSICAL	SYSTEMIC	
First line	Potent and superpotent steroids Calcipotriol	bid, plastic film occlusion bid	PUVA (Bath—4/week psoralen and ultraviolet light	Acitretin	0.5 mg/kg/bw/day
Second line	Anthralin Tazarotene	Once daily bid		Methotrexate Cyclosporine	10–25 mg/wk 3–5 mg/kg/bw, when effective individual titration of dose
Third line				Fumaric acid esters[b] Colchicine Itraconazole Alefacept[c] TNF-α-antagonists	According to dose-escalation scheme, corresponding to a maximum of 720 mg of dimethylfumarate/day 1–2 mg/day 100 mg/day for 4 weeks followed by 100 mg every other day for 4 weeks 15–30 mg/weekly Dosing as recommended for psoriasis

[a]For treatment of acrodermatitis continua no data are available besides case-reports for some of the recommended treatments.
[b]Registered in Germany only.
[c]Registered in United States, Canada, and Switzerland only.

In 1888, Crocker described a relapsing bullous and pustular eruption on hands and feet; this was further delineated by Hallopeau.[44,45] Acrodermatitis continua is now classified as a form of acropustular psoriasis.

EPIDEMIOLOGY

There are no data on the prevalence or incidence of acrodermatitis continua.

BOX 21-4 MANAGEMENT OF PALMOPLANTAR PUSTULOSIS AND PREVENTION

- ***In the presence of anti-gliadin IgA- and/or tissue transglutaminase-antibodies and/or celiac disease***
  - Gluten-free diet
- ***In smokers***
  - Refer patients to antismoking programs
- ***Also consider***
  - Tonsillectomy

ETIOLOGY AND PATHOGENESIS

The etiology of acrodermatitis continua remains enigmatic. Even triggering factors have not been described yet. Pustule formation may involve similar pathways as discussed for PPP, but due to the rarity of the disease this has not been studied.

CLINICAL FINDINGS

Acrodermatitis continua most often begins at the tips of one or two fingers (Fig. 21-3), less often on the toes. The nail folds are affected very early, and trauma is thought to play an initiating role. The first signs consist of small pustules, which, on bursting, leave an erythematous, shiny area in which new pustules develop. These then tend to coalesce, forming polycyclic lakes of pus. As the disease extends proximally, the affected area shows either glossy erythema or a crusted, keratotic, and fissured surface with newly formed pustules underneath (see Fig. 21-3). Pustulation of the nail bed and the nail matrix almost always occurs and quite often leads to loss of the nail plate or severe onychodystrophy (see Fig. 21-3). Acrodermatitis continua of long duration may show complete destruction of the nail matrix and thus lead to anonychia. The skin becomes shiny and



Figure 21-3 **A.** Acrodermatitis continua demonstrating acral pustule formation and subungual lakes of pus with destruction of the nail plate. **B.** Repeated eruptions lead to nail loss and severe atrophy. Note micropustulation within the atrophic epidermis of the distal phalanges.

severely atrophic, and there is atrophic thinning of the distal part of the phalanx.

The disease may remain confined to the original site, sometimes up to several years, but more often it spreads proximally to cover the hand, dorsum of forearm, or foot. In such instances more than one extremity is involved. Acrodermatitis continua may be associated with generalized pustular psoriasis of the Zumbusch type (see Chapter 18).

HISTOPATHOLOGY. The main histopathologic feature of acrodermatitis continua is a subcorneal cavity filled with neutrophils. Epidermal cell necrosis and spongiosis does not occur, but the roof and shoulder zones adjacent to the pustule show aggregated leukocytes between the epidermal cells, forming spongiform pustules. There is a moderate lymphohistiocytic infiltrate in the upper dermis, together with focal edema.

Lesions of long duration show severe atrophy of the papillary dermis and thinning of the epidermis.

LABORATORY FINDINGS. Systemic abnormalities are absent, and laboratory tests are usually within normal ranges. The pustules are sterile. In advanced cases, X-ray may reveal atrophy of the distal phalanx and arthropathy of the interphalangeal joints.

DIFFERENTIAL DIAGNOSIS

Acrodermatitis continua at an early stage must be differentiated from acute paronychia caused by bacteria or fungi and from herpetic lesions (see Chapter 193). Cultures and smears help rule out infectious causes. The distal localization and the tendency of the pustules to become confluent, forming denuded, erythematous, or crusted lesions, distinguishes acrodermatitis continua from PPP or pustular dyshidrotic eczema. Atrophy and loss of nails do not occur in these conditions. Contact dermatitis with secondary infection and pustulation has less clearly defined margins, runs a different clinical course, and lacks the persistence typical for acrodermatitis continua.

PROGNOSIS/CLINICAL COURSE

Acrodermatitis continua shows a chronic course with a tendency of the lesions to spread proximally. Spontaneous improvement is rare, and episodes of acute pustulation occur without apparent cause. The development of pustules at other sites, or even the eruption of generalized pustular psoriasis, supports the idea that acrodermatitis continua is a variant of psoriasis. When uncontrolled, irreversible destruction of the complete nail apparatus occurs.

TREATMENT

As in pustular psoriasis, no specific drug is able to induce lasting remissions. Potent or superpotent topical steroids, preferentially under occlusion, are useful in blocking pustulation. Caution is advised in cases already showing atrophy. PUVA suppresses the eruption of new pustules and can be employed for long periods as maintenance treatment (see Chapter 238).

Treatment with a combination of systemic acitretin and local calcipotriol/calcipotriene was successful in one patient in a left–right comparison.[46] In recalcitrant patients, dapsone may be tried.[47] Recently, topical treatment with tacrolimus 0.1% ointment alone or in sequential combination with calcipotriol was found successful.[48] Numerous case reports describe the successful use of anti-TNF-α agents in acrodermatitis continua.[49] With respect to the recalcitrant nature of the diseases combination therapy of adalimumab, etanercept, or infliximab with either acitretin or methotrexate may be advisable in order to maintain treatment response when stopping anti-TNF-α-therapy while continuing acitretin or methotrexate.

In principle, regimens used for treatment of PPP may also be used for therapy of acrodermatitis continua (see Box 21-3). The therapeutic result lasts as long as the drugs are given, and relapses occur after withdrawal.

PREVENTION

There are no data on preventive measures for acrodermatitis continua.

INFANTILE ACROPUSTULOSIS

Infantile acropustulosis is discussed in Chapter 107.

KEY REFERENCES

Full reference list available at www.DIGM8.com

DVD contains references and additional content

2. Asumalahti K et al: Genetic analysis of PSORS1 distinguishes guttate psoriasis and palmoplantar pustulosis. *J Invest Dermatol* **120**:627, 2003
12. Michaelsson G et al: The psoriasis variant palmoplantar pustulosis can be improved after cessation of smoking. *J Am Acad Dermatol* **54**:737, 2006
15. Koshiba S et al: Tonsillar crypt epithelium of palmoplantar pustulosis secretes interleukin-6 to support B-cell development via p63/p73 transcription factors. *J Pathol* **214**:75-84, 2008
21. Rallis E et al: Onset of palmoplantar pustular psoriasis while on adalimumab for psoriatic arthritis: A 'class effect' of TNF-alpha antagonists or simply an anti-psoriatic treatment adverse reaction? *J Dermatolog Treat* **1**:1-3, 2009
34. Chalmers R et al: Interventions for chronic palmoplantar pustulosis. *The Cochrane Library* **4**:1-49, 2009
49. Puig L et al: Treatment of acrodermatitis continua of Hallopeau with TNF-blocking agents: Case report and review. *Dermatology* **220**:154-158, 2010

Chapter 22 :: Seborrheic Dermatitis

:: Chris D. Collins & Chad Hivnor

SEBORRHEIC DERMATITIS AT A GLANCE

- Both infantile and adult forms exist.
- It is characterized by sharply demarcated, yellow to red to brown, greasy or bran-like scaling patches and plaques.
- Lesions favor scalp, ears, face, presternal chest, and intertriginous areas.
- Flares occur when sebaceous glands are most active (first few months of life, and post puberty).
- Generalized and erythrodermic forms rarely occur.
- The etiology is unclear but there are associations with *Malassezia* yeasts, sebum secretion and composition, and certain drugs.
- May be a cutaneous marker of HIV and AIDS, especially when severe, atypical, and therapy-resistant.

INTRODUCTION

Seborrheic dermatitis is a common, chronic papulosquamous disorder affecting infants and adults alike. It is characteristically found in regions of the body with high concentrations of sebaceous follicles and active sebaceous glands including the face, scalp, ears, upper trunk, and flexures (inguinal, inframammary, and axillary).[1] Less commonly involved sites include interscapular, umbilical, perineum, and the anogenital crease.[2] The dermatitis presents with pink to erythematous, superficial patches and plaques with a yellow, branny and sometimes greasy scale. Excessive flaking on the face and scalp can lead to social embarrassment which can have a negative impact on one's quality of life, especially in women, younger patients, and those with a higher educational level.[3] Mild forms are most commonly encountered, but severe psoriatic and erythrodermic forms can be seen as well.[1] Seborrheic dermatitis is one of the most common dermatoses seen in human immunodeficiency virus (HIV) and acquired immunodeficiency syndrome (AIDS) patients along with certain neurological disorders such as Parkinson disease.[4,5] These patients tend to have widespread, erythrodermic, and treatment resistant forms. Severe forms are also seen with immunosupression in premature infants and congestive heart failure patients.[6,7] African-Americans and other darkly pigmented races are susceptible to the annular or petaloid variant of seborrheic dermatitis, which may be confused for discoid lupus, secondary syphilis, or sarcoidosis.[8] A rare pityriasiform variety of seborrheic dermatitis with ovoid scaling patches can be seen on the trunk and the neck, mimicking pityriasis rosea and secondary syphilis. A higher incidence of seborrheic dermatitis is also seen in patients with alcoholism and endocrinologic diseases that lead to obesity.[9]

EPIDEMIOLOGY

Seborrheic dermatitis is separated into two age groups, an infantile self-limited form primarily during the first 3 months of life and an adult form that is chronic. A male predominance is seen in all ages, without any racial predilection, or horizontal transmission. The prevalence of seborrheic dermatitis is 3%–5% of young adults, and 1%–5% of the general population, although its lifetime incidence is significantly higher.[10]

ETIOLOGY AND PATHOGENESIS

The exact pathogenesis of seborrheic dermatitis is yet to be fully elucidated, but this dermatosis is commonly linked with the yeast *Malessezia*, immunologic abnormalities, sebaceous activity, and patient susceptibility.[14,15] The amount of sebum produced is not an essential factor, as not all patients with seborrheic dermatitis will have increased levels of sebum production. On the other hand, some patients with elevated sebum levels may not have seborrheic dermatitis either.[16] Patients with seborrheic dermatitis show higher skin surface lipid levels of triglycerides and cholesterol, but lower levels of free fatty acids and squalenes. Both *Malassezia* species and the resident flora *Propionobacterium acnes* have lipase activity resulting in transformation of triglycerides into free fatty acids.[17] All seven species of *Malassezia* are lipophilic except the zoophilic species, *Malassezia pachydermatis*. The free fatty acids and reactive oxygen radicals produced in turn have antibacterial activity that alters the normal skin flora. Some authors believe this disturbance in flora, lipase activity, and free oxygen radicals may be more closely linked to seborrheic dermatitis than an altered immune response.[18]

IMMUNOLOGY

Many patients have normal levels of *Malassezia* species on the skin, but have an abnormal immune response to it resulting in a depressed helper T cell response and less production of phytohemagglutinin and concanavalin when compared to control subjects.[19,20] Levels of antibodies are the same in both patients with and without seborrheic dermatitis. *Malassezia* species also play a role in the inflammatory response with stimulation of the alternative complement pathway.[21] A disturbed lymphocytic cellular immune response to *Malassezia*, results in elevated levels of interleukin (IL)-10, with a drop in IL-2 and interferon-γ.[22] Both normal and elevated levels of antibodies to *Malassezia furfur* can be seen in patients with seborrheic dermatitis. *Malassezia* can lead to inflammation on the skin from metabolic products produced and complement activation via the direct and alternative pathways.

PHYSICAL FACTORS

Seasonal fluctuations in humidity and temperature are noted to flare this disease, particularly with low humidity and cold temperatures in the winter and early spring, with some relief in the summer.[23] Facial PUVA (psoralen plus ultraviolet radiation) treatments and facial trauma (i.e., scratching) are also reported to trigger seborrheic dermatitis as well.[24]

MICROBIAL EFFECTS

The pathogenesis of seborrheic dermatitis has been disputed since it was originally described over a hundred years ago. The presence or imbalance of microbial flora likely plays a role in the disease. Although some patients may have cultures showing *Candida albicans, Staphylococcus aureus, Propionobacterium acnes*, and other aerobic bacteria, none have been linked to the pathogenesis of seborrheic dermatitis.[25] Infants commonly have secondary contamination and infection with *Candida* species. The pathogenic role of *Malassezia furfur* (previously known as *Pityrosporum ovale*) is also controversial. The number of yeasts on the skin does not directly correlate with the severity of seborrheic dermatitis also. Patients with both dandruff and seborrheic dermatitis generally have abundant yeast counts when compared to controls supporting the role of yeast in the disease. A higher rate of seborrheic dermatitis is also seen in patients with *Pityrosporum folliculitis* and tinea versicolor.[26] Clearance of seborrheic dermatitis with antifungals and recurrence following cessation of therapy also supports the premise that *Malassezia* species is pathogenic.[27]

DRUGS

Several drugs are known to trigger seborrheic dermatitis like eruptions including griseofulvin, cimetidine, lithium, methyldopa, arsenic, gold, auranofin, aurothioglucose, buspirone, chlorpromazine, ethionamide, haloperidol, interferon-α, phenothiazines, stanozolol, thiothixene, psoralen, methoxsalen, and trioxsalen.

NEUROTRANSMITTER ABNORMALITIES

Many neurologic disorders have been associated with seborrheic dermatitis, with most of them resulting in some facial immobility and sebum accumulation. These include Parkinson's, Alzheimer's, syringomyelia, epilepsy, cerebrovascular infarcts, postencephalitis, mental retardation, poliomyelitis, quadriplegia, trigeminal nerve injury and other facial nerve palsies.[28] The fact that administration of L-dopa improves seborrheic dermatitis in some Parkinson patients, and some neuroleptic drugs that induce Parkinsonian symptoms can induce seborrheic dermatitis suggests that neurotransmitters may play a role in this dermatitis.[29] Depression and emotional stress have also been reported to trigger seborrheic dermatitis.[30] A high rate of this dermatitis is also seen among combat troops.[31] In summary, these groups of patients do not have increased rates of sebum, but rather excessive accumulation of sebum on the skin.

ABERRANT EPIDERMAL PROLIFERATION

Patients with seborrheic dermatitis may have epidermal hyperproliferation or dyskeratinization related to increased activity of calmodulin, which is also seen in psoriasis.[32] This explains why patients with seborrheic dermatitis improve while being treated with a

number of different cytostatic medications such as azeleic acid.[12]

NUTRITIONAL DISORDERS

Seborrheic dermatitis has not been proven to be associated with any vitamin deficiency. Patients with zinc deficiency (acrodermatitis enteropathica, and acrodermatitis enteropathica like conditions) may have an eruption that appears similar to seborrheic dermatitis and improves with zinc supplementation, while seborrheic dermatitis patients do not improve with zinc supplementation.[33] Infants with deficiency in biotin, holocarboxylase, biotinidase, and free fatty acids may also have seborrheic-like dermatitis. But again, biotin supplementation has not been substantiated to improve seborrheic dermatitis.[34]

GENETIC FACTORS

A family history of seborrheic dermatitis is often reported, but only recently has a mutation (*ZNF750*) encoding a zinc finger protein (C2H2) been described resulting in a seborrhea-like dermatitis. This Israeli Jewish Moroccan family presented with an autosomal dominant seborrhea-like dermatosis.[35]

PSORIASIS AND SEBORRHEIC DERMATITIS

The controversial term *sebopsoriasis* is often used in patients when there appears to be an overlap of psoriasis and seborrheic dermatitis. It tends to localize to the scalp, face, and presternal chest as seen with seborrheic dermatitis. However, the margins tend to be better defined, more erythematous and with thicker scales than those seen with seborrheic dermatitis. The biopsy can be indistinguishable from psoriasis, similar to the chronic form of seborrheic dermatitis.[36]

CLINICAL FINDINGS

In all patients with seborrheic dermatitis, there is a so-called seborrheic stage, which is often combined with a gray–white or yellow–red skin discoloration, prominent follicular openings, and mild to severe pityriasiform scales. Several forms can be distinguished (Table 22-1).

TABLE 22-1
Clinical Patterns in Seborrheic Dermatitis

INFANTILE: Scalp (cradle cap), trunk (flexures and napkin area), Leiner's disease (nonfamilial and familial C3/C5 dysfunction).
ADULT: Scalp, face, eyelids (blepharitis), trunk (petaloid, pityriasiform, flexural, eczematous, follicular, generalized, erythrodermic).

PROGNOSIS AND CLINICAL COURSE

Self-limited with a good prognosis in infants compared to chronic and relapsing in adults. There is no evidence to suggest infants with seborrheic dermatitis will have disease as adults. Generalized flares and erythroderma can sometimes occur.[37]

SEBORRHEIC DERMATITIS IN INFANTS COMPARED TO ADULTS

The infantile form occurs during the first few weeks to 3 months of life, is self-limited, and corresponds to the time when the neonate produces sebum, which then regresses until puberty.[38] It is commonly concentrated on the vertex of the scalp (i.e., cradle cap) with adherent, yellow–brown, greasy scale, which can sometimes spread to the entire scalp with inflammatory, erythematous, and oozing crusts. Lesions can be seen on the face, neck and can be disseminated to the trunk and extremities with inflammatory glistening plaques in intertriginous sites such as the axillae and groin (Fig. 22-1). A differential diagnosis should be undertaken in any infant with a widespread form of seborrheic dermatitis (Box 22-1). Atopic dermatitis patients tend to have lesions on the forearms and shins, while sparing the axillae. Lesions isolated to the diaper region suggest seborrheic dermatitis. Radioallergosorbent assay test screening to egg whites, milk antibodies,



Figure 22-1 Seborrheic dermatitis in an infant. Widespread pattern of seborrheic dermatitis with psoriasiform lesions on the trunk and groin.

BOX 22-1 DIFFERENTIAL DIAGNOSIS OF INFANTILE SEBORRHEIC DERMATITIS

Most Likely

- Atopic dermatitis

Consider

- Scabies, psoriasis

Rule Out

- Langerhans cell histiocytosis

soybean, and total immunoglobulin E levels, may be helpful in discerning infantile seborrheic dermatitis from atopic dermatitis. Some authors believe that infantile seborrheic dermatitis is actually a variant of atopic dermatitis rather than a separate entity. Extensive involvement plus lesions on the palms and soles with severe pruritis suggests scabies. Infantile psoriasis can also be extensive, with erythematous plaques and scale, with less scale in intertriginous sites. Extensive involvement with moist erythematous plaques and petechial lesions of intertriginous sites and the scalp suggests Langerhans cell histiocytosis (Letterer–Siwe) and should be biopsied for confirmation and treated appropriately.

The adult form on the other hand, tends to be chronic and can persist from the fourth through the seventh decades of life, with a peak at age 40. Lesions may also be seen on the face with prominent symmetry (Fig. 22-2), particularly medial eyebrows, forehead, upper eyelids, nasolabial folds (Fig. 22-3), and lateral nares. Other sites commonly involved include retroauricular regions, external auditory canal, auricle, and conchae bowl (Fig. 22-4), scalp (Fig. 22-5), occiput, and neck. The presternal region of the chest, upper back (Fig. 22-6), and umbilicus can be involved as well, and can be petaloid or arcuate with fine pink scale. Intertriginous sites such as axillary and inguinal regions show less scale and mimic intertrigo. See Box 22-2 for site-specific differential diagnosis of seborrheic dermatitis. Erythema and pruritis are common, as well as burning or tingling sensitivity reported as well, particularly on the scalp. *Pityrosporum folliculitis* can be seen as well with diffuse monomorphic tiny pustules and papules with peripheral erythema on the trunk. Diagnosis can be confirmed with a KOH (potassium hydroxide) preparation. Immunocompromised patients more commonly get this form of folliculitis. The adult form typically begins during puberty corresponding with androgen activity, which

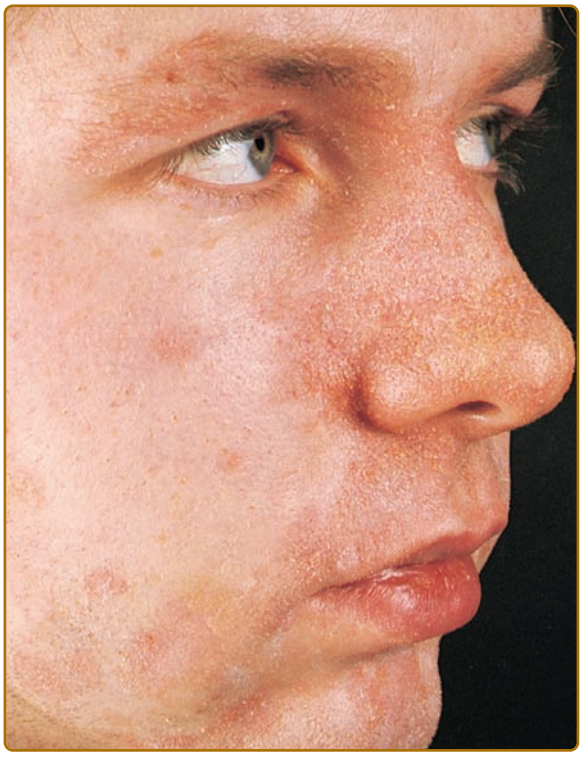

Figure 22-2 Seborrheic dermatitis with involvement of nasolabial folds, cheeks, eyebrows, and nose.



Figure 22-3 Seborrheic dermatitis of the nasolabial fold.



Figure 22-4 Seborrheic dermatitis of the ear: external canal, concha bowl, and auricle.



Figure 22-5 Seborrheic dermatitis of the scalp, ear, sideburn area, beard, and face with diffuse scale and inflammation.

results in an increase in size and activity of sebaceous glands. Prepubertal patients tend to not get seborrheic dermatitis because of this lack of androgen stimulation of sebaceous glands, and have also not been shown to have excessive colonization of *Malessezia* species.

ERYTHRODERMA DESQUAMATIVUM (LEINER'S DISEASE)

Leiner first described this controversial condition in 1908, dermatitis seborrhoides infantum, and is considered a severe, widespread, erythrodermic form of infantile seborrheic dermatitis.[39] These patients have symptoms of fever, anemia, diarrhea, vomiting, weight loss, and sometimes death if not treated properly with intense IV hydration, temperature regulation, and antibiotics if they have secondary bacterial infection. There is both a familial and nonfamilial form of Leiner's. The hereditary form has been associated with deficiencies of complement C3, C5, and phagocyte malfunction therefore resulting in defective opsonization of bacteria. Patients with the hereditary form may necessitate treatment with fresh frozen plasma and whole blood to supplement these complement deficiencies.[40]



Figure 22-6 Seborrheic dermatitis of the upper back.

BOX 22-2 SITE-SPECIFIC DIFFERENTIAL DIAGNOSIS OF SEBORRHEIC DERMATITIS

Scalp*	Psoriasis, atopic dermatitis, impetigo, tinea capitis* (mimics dandruff in children)
Face	Psoriasis, rosacea, contact dermatitis, impetigo, discoid lupus, sarcoid (petaloid type in African-Americans), drug-induced photosensitivity
Ear canal	Psoriasis, contact dermatitis
Eyelids	Atopic dermatitis, psoriasis, *Demodex folliculorum* infestation
Chest, back	Pityriasis rosea, tinea versicolor, subacute cutaneous lupus, psoriasis vulgaris
Groin, buttock	Intertrigo (fungal, candidal, erythrasma), glucagonoma, extramammary Paget's disease, zinc deficiency
Intertriginous	Inverse psoriasis, candidiasis, erythrasma, contact dermatitis, tinea intertrigo, Langerhans cell histiocytosis (Letterer Siwe in infants)
Generalized*	Scabies, secondary syphilis, pemphigus foliaceous, pemphigus erythematosus, Leiner's (infants), drug eruption
Erythrodermic*	Psoriasis, contact dermatitis, pityriasis rubra pilaris, drug eruption, mycosis fungoides (Sezary syndrome), lichen planus, chronic actinic dermatitis, HIV, Hodgkin's disease, paraneoplastic syndrome, leukemia cutis

*Diffuse scalp dermatitis or inflammatory alopecia in children warrants fungal culture, KOH prep. Widespread truncal types warrant scabies prep and RPR to rule out syphilis. Erythrodermic type should be biopsied.

PITYRIASIS AMIANTACEA

Pityriasis amiantacea was first described by Alibert in 1832, and is also known as asbestos scalp, tinea asbestina, keratosis follicularis amiantacea, and porrigo



Figure 22-7 Pityriasis amiantacea. Masses of sticky silvery scales adhere to the scalp and cause matting of hairs they surround.

amiantacea.[41] The use of the term tinea amiantacea is discouraged since tinea capitis is rarely associated with pityriasis amiantacea. This is a localized or diffuse condition, in which inflammation and massive silvery scaling of the scalp results in thick, matted, sticky hair (Fig. 22-7). This condition can occur at any age, especially adolescents and young females. It is most commonly seen with psoriasis (35%), and eczematous conditions like seborrheic dermatitis and atopic dermatitis (34%).[42] Case reports of patients with lichen planus and Darier's have had associated pityriasis amiantacea.[43] Middle-aged females with lichen simplex chronicus can have patches of pityriasis amiantacea as well. Alopecia may result and is nonscarring unless secondary scalp infection occurs with *Streptococcus* or *Staphylococcus* and should be treated appropriately. Staphylococcal isolates in the matted hairs can be found in up to 96% of patients.[42] Young females commonly have concomitant postauricular scale and fissures.

SEBORRHEIC DERMATITIS IN HIV AND AIDS PATIENTS

Patients with HIV and AIDS have severe and extensive seborrheic dermatitis (Fig. 22-8) that tends to be refractory to standard therapy.[44] Treatment with 400 mg of oral ketoconazole daily for 2 weeks may be necessary. The initial facial eruption may appear as a butterfly rash, similar to the acute facial eruption associated with systemic lupus erythematosus. The histopathology also differs from seborrheic dermatitis in HIV seronegative patients in that they have much more parakeratosis, necrosis, lymphocytes, and focal leukocytosis.[45] Seborrheic dermatitis usually occurs when CD4+ counts are between 200–500 cells/mm^3 and as one of the earliest skin manifestations of HIV patients.[46]

HISTOPATHOLOGY

Depending on the stage of the lesion biopsied, the changes seen include acute, subacute, and chronic spongiotic dermatitis. In acute lesions there is folliculocentric scale crust composed of orthokeratosis and focal parakeratosis with scattered neutrophils, mild focal



Figure 22-8 **A** and **B.** Widespread unusual distribution pattern of seborrheic dermatitis in a patient with AIDS. **A.** Moist patches on the centrofacial region, beard and scalp. **B.** Moist lesions on the chest. In patients with AIDS, the disease responds poorly to conventional therapy.

TABLE 22-2
Histopathologic Differences Between Classic Seborrheic Dermatitis and AIDS-Associated Seborrheic Dermatitis

Classic Seborrheic Dermatitis	AIDS-Associated Seborrheic Dermatitis
Epidermis	
Limited parakeratosis	Widespread parakeratosis
Rare necrotic keratinocytes	Many necrotic keratinocytes
No interface obliteration	Focal interface obliteration with clusters of lymphocytes
Prominent spongiosis	Sparse spongiosis
Dermis	
Thin-walled vessels	Many thick-walled vessels
Rare plasma cells	Increased plasma cells
No leukocytoclasis	Focal leukocytoclasis

From Soeprono FF et al: Seborrheic-like dermatitis of acquired immunodeficiency syndrome: A clinicopathologic study. *J Am Acad Dermatol* **14**:242, 1986, with permission.

spongiosis, and a sparse superficial perivascular infiltrate of lymphocytes and histiocytes. Subacute lesions show mild psoriasiform hyperplasia and numerous yeast species in the stratum corneum in addition to the above findings. Chronic lesions show even more psoriasiform hyperplasia and crusting scales in a folliculocentric distribution, superficial dilation of capillaries and venules, and minimal spongiosis. The chronic form may be difficult to distinguish from psoriasis clinically and pathologically, but the folliculocentric distribution supports seborrheic dermatitis.

HIV and AIDS patients with seborrheic dermatitis show histopathologic findings consistent with severe, chronic seborrheic dermatitis (Table 22-2). Patients with pityriasis amiantacea show, spongiosis, mild exocytosis of lymphocytes and acanthosis. The asbestos-like scale seen is due to a thick layering of hyperkeratosis and parakeratosis surrounding the outer hair shafts. Patients with dandruff (pityriasis simplex capillitii, aka pityriasis capitis) show minimal parakeratotic foci of scale, without any spongiosis or inflammatory infiltrates.[47]

TREATMENT

INFANTILE SEBORRHEIC DERMATITIS

This benign, self-limited form responds readily to shampoos, emollients, and mild topical steroids. Infants with prolonged inflammation on the scalp or intertriginous areas can be treated with low potency topical corticosteroids (hydrocortisone 1% cream or lotion for a few days), followed by topical imidazoles (2% ketoconazole cream, lotion, or 1% shampoo). Aggressive removal of scale with keratolytics or mechanical removal is discouraged to prevent further inflammation. However, mild baby shampoos, with or without 3% salicylic acid applications, can help remove thick, stubborn scale on the scalp. Secondary infections with candidiasis or *Staphylococcus* should be treated appropriately. Infants with seborrheic dermatitis do not respond to dietary alterations or restrictions (milk-free, etc.) and vitamin supplementation that may help patients with atopic dermatitis.[38,48–51]

ADULT SEBORRHEIC DERMATITIS

Adults tend to have chronic and recurrent disease, and as such, the patients should be informed that the aim of treatment will be to control rather than cure the disease. Scalp seborrheic dermatitis can be treated with shampoos containing zinc pyrithione, selenium sulfide (1%–2.5%), imidazoles (1%–2% ketoconazole shampoo, creams, lotions, or foams), ciclopirox (cream, gel, and shampoo), salicylic acid (shampoos, creams), coal tar (creams, shampoos), or mild detergents. Dandruff (pityriasis simplex capillitii) involves the face and scalp as well with extensive scale, but shows minimal to no inflammation and erythema. Dandruff responds to more frequent shampooing or a longer period of lathering. Shampoos may be used on the scalp, beard and chest, but may flare the disease if used on the face or other intertriginous areas if left on for extended periods. Xanthotrichia or yellow hair has been reported in patients using selenium sulfide shampoo. Severe and thick scale on the scalp can respond to overnight application of topical corticosteroids (low-, mid-, or high-potency creams, lotions, or foams depending on the severity) with shower cap occlusion as needed, Baker's P&S solution, tar shampoo, or salicylic acid (ointment or shampoo, especially for patients with pityriasis amiantacea). Alternative effective treatments include coconut oil compound (ointment combination of coal tar, salicylic acid and sulfur). Patients should avoid aggressive manipulation. Hair sprays and hair pomades should be stopped. Treatment of any underlying secondary microbial infection should be treated as well. Patients with severe inflammatory disease that fail the above regimens may respond to a 1-week course of systemic glucocorticoids (prednisolone 0.5 mg/kg body weight/day), while cautioning the patient of side effects and informing them of potential rebound flares following discontinuation of the medication.[52–57]

Treatment of the face, trunk, and ears includes short courses of low potency topical glucocorticoids (Class IV or lower) to suppress the initial inflammation. Excessive and long-term topical corticosteroid application should be discouraged as well to prevent steroid acne, steroid rosacea, perioral dermatitis, and rebound phenomenon. Topical calcineurin inhibitors (pimecrolimus and tacrolimus) have anti-inflammatory and antifungal (tacrolimus) properties without the long-term side effects of topical corticosteroid use. Topical antifungals such as ketoconazole, miconazole, fluconazole, itraconazole, econazole, bifonazole, climbazole, ciclopirox, and ciclopiroxolamine have all been used with varying success. Sulfur or sulfonamide combinations, or propylene glycol topical have also been used. Benzoyl peroxide wash 5%–10% can be used as

well. Recommend patients to avoid alcohol-containing solutions that flare the disease. Aluminum acetate solution can be used to maintain seborrheic otitis externa. Patients with seborrheic blepharitis can be treated with warm to hot compresses and washing with baby shampoo followed by gentle cotton tip debridement of thick scale. Avoid ocular glucocorticoids. Ophthalmic sodium sulfacetamide ointment can be used for resistant seborrheic blepharitis.[58–68]

There are many other alternative treatments. Oral antifungals should be reserved for severe and refractory cases due to potential drug interactions and side effects. Allylamines may also be effective including topical butenafine and naftifine cream for mild cases versus oral terbinafine for extensive involvement. Lithium succinate and lithium gluconate, both available in some countries, have antifungal properties that can be used for treatment as well. Vitamin D3 analogs (calcipotriol cream or lotion) have both anti-inflammatory and antifungal properties and can be used in selected patients as well. Other alternatives include topical metronidazole cream or gel, once to twice daily. Oral isotretinoin in low doses (2.5–5 mg daily; or 0.1–0.3 mg/kg/day) over 3–5 months can be used in refractory disease, of course while observing requirements in child-bearing females. Phototherapy with narrowband ultraviolet B or psoralen plus ultraviolet A can also be used in severe and refractory disease, but may be ineffective if patients have thick hair.[17,69,74]

ACKNOWLEDGMENTS

We would like to thank Gerd Plewig and Thomas Jansen for their previous editions of this chapter on seborrheic dermatitis and the use of their format, tables, boxes, and photos while revising this chapter.

KEY REFERENCES

Full reference list available at www.DIGM8.com

DVD contains references and additional content

2. Johnson BA et al: Treatment of seborrheic dermatitis. *Am Fam Physician* **61**:2703-2714, 2000
15. DeAngelis YM et al: Three etiologic facets of dandruff and seborrheic dermatitis: Malassezia fungi, sebaceous lipids, and individual sensitivity. *J Investig Dermatol* **10**:295-297, 2007
48. Arora V et al: Management of infantile seborrheic dermatitis. *Am Fam Physician* **75(6)**:807, 2007
53. Shin H et al: Clinical efficacies of topical agents for the treatment of seborrheic dermatitis of the scalp: A comparative study. *J Dermatol* **36(3)**:131-137, 2009
56. Nowicki R: Modern management of dandruff. *Pol Merkur Lekarski* **20**(115):121-124, 2006
58. Bikowski J: Facial seborrheic dermatitis: A report on current status and therapeutic horizons. *J Drugs Dermatol* **8**(2):125-133, 2009
67. Gupta AK et al: Etiology and management of seborrheic dermatitis. *Dermatology* **208**(2):89-93, 2004

Chapter 23 :: Exfoliative Dermatitis

:: Jane Margaret Grant-Kels, Flavia Fedeles, & Marti J. Rothe

EXFOLIATIVE DERMATITIS AT A GLANCE

- Exfoliative dermatitis (ED) is defined as diffuse erythema and scaling of the skin involving more than 90% of the total body skin surface area.
- Systemic and potentially life-threatening complications include fluid and electrolyte imbalance, thermoregulatory disturbance, fever, tachycardia, high-output failure, hypoalbuminemia, and septicemia.
- Common underlying etiologies are psoriasis, atopic dermatitis, and other spongiotic dermatoses, drug hypersensitivity reactions, and cutaneous T-cell lymphoma (CTCL). The cause of ED is unknown (idiopathic) in approximately 20% of cases.
- Diagnostic workup includes a complete history and physical examination, with careful analysis of pertinent clinical clues and dermatohistopathology. Other laboratory workup is often required and determined by clinical clues.
- Management of ED involves combining symptomatic relief with addressing the underlying etiology and potential systemic complications. Inpatient hospitalization is required in acute cases.
- Prognosis is variable and depends primarily on the underlying etiology. Drug-induced ED has the best prognosis while malignancy-associated ED has the highest mortality.

EPIDEMIOLOGY

Several large studies have reported a widely varied incidence of exfoliative dermatitis (ED) ranging from 0.9 to 71.0 per 100,000 outpatients.[1–4] A male predominance has been described, with a male-to-female ratio of approximately 2:1 to 4:1. Any age group can be affected, and with most studies excluding children, the average age of disease onset varies from 41 to 61. ED is a rare disease in children, and only little epidemiologic data is available for pediatric populations. One study found 17 patients, recorded over a 6-year period, with a mean age of onset of 3.3 years and a male-to-female ratio of 0.89:1.[5] ED occurs in all races.[6]

A preexisting dermatosis plays a role in more than one-half of the cases of ED. Psoriasis is the most common underlying skin disease (almost one-fourth of the cases). In a recent study of severe psoriasis, ED was reported in 87 of 160 cases.[7]

ETIOLOGY AND PATHOGENESIS

Establishing the etiology of ED can be challenging since it can be caused by a variety of cutaneous and systemic diseases (Table 23-1). A compilation of 18 published studies[1,2,4,6,8–21] from various countries on ED shows that a preexisting dermatosis is the most frequent cause in adults (52% of ED cases; range, 27%–68%) followed by drug hypersensitivity reactions (15%), and cutaneous T-cell lymphoma (CTCL) or Sézary syndrome (5%). No underlying etiology is identified in approximately 20% of ED cases (range, 7%–33%) and these cases are classified as idiopathic.

Psoriasis is the most common underlying skin disease to cause ED (23% of cases), followed by spongiotic dermatitis (20%). Possible triggers for psoriatic ED include the following:

- Medications, such as lithium, terbinafine, and antimalarials
- Topical irritants including tars
- Systemic illness
- Discontinuation of potent topical or oral corticosteroids, methotrexate, or biologics (efalizumab)[22,23]
- Infection including human immunodeficiency virus (HIV)
- Pregnancy
- Emotional stress
- Phototherapy burns

Less common causes of ED in adults include immunobullous disease; connective tissue disease; infections, including scabies and dermatophytes; pityriasis rubra pilaris (PRP) (4% of dermatoses); and underlying malignancy. Even in patients with underlying dermatoses, it is critical to consider other possible etiologies. In one case series, malignancy-related ED was identified in seven patients, five of whom had a preexisting dermatosis.[11] In about 5%–10% of idiopathic ED cases, erythrodermic CTCL was ultimately diagnosed.[24] Solid organ malignancies as well as hematologic and reticuloendothelial malignancies may manifest as ED.

In neonates and infants, the differential diagnosis includes dermatoses (such as psoriasis, atopic dermatitis, and seborrheic dermatitis), drugs, and infection (particularly staphylococcal scalded-skin syndrome). In addition, several congenital disorders including the ichthyoses, both bullous and nonbullous congenital ichthyosiform erythroderma, Netherton syndrome, and immunodeficiencies should be considered (Box 23-1).

Topical and systemic medications are implicated in a significant percentage of ED cases (15%; range, 4%–39%) and the introduction of new drugs is likely to increase the incidence of ED. Both allopathic and naturopathic medications have been suggested to cause ED and the list is constantly expanding (Table 23-2). The most commonly implicated drugs include calcium channel blockers, antiepileptics, antibiotics (penicillin family, sulfonamides, vancomycin), allopurinol, gold, lithium, quinidine, cimetidine, and dapsone. However, most of the drugs are reported in single case reports. In addition to drugs, the contrast medium iodixanol (Visipaque) used during percutaneous coronary interventions has recently been reported to cause ED.[25]

Currently, the pathogenic mechanisms of ED have not been elucidated. It is not well understood how a preexisting dermatosis progresses to ED, an underlying disease manifests as ED, or the de novo ED develops. While the clinical presentation is similar in patients with diverse etiologies of ED, it is likely that different pathways lead to the common end result of skin-selective recruitment of inflammatory cells.

Cytokines, chemokines, and their receptors are believed to play an important role in the pathogenesis of ED. A study of cytokine profile in dermal infiltrates showed that there may be differences in pathophysiologic mechanisms between benign ED and Sézary syndrome—a T helper 1 cytokine profile was found in benign ED while a T helper 2 cytokine profile was found in Sézary syndrome.[26] In a recent report, an overexpression of both T helper 1- and T helper 2-related chemokine receptors (CCR4, CCR5, and CXCR3) was found in ED of inflammatory origin, while a selective overexpression of CCR4 was found in Sézary syndrome,[27] suggesting that Sézary syndrome is a T helper 2 disorder and that different pathways may contribute to skin homing of reactive lymphocytes in different etiologies of ED. Another study showed that Sézary syndrome and inflammatory ED are characterized by different memory T-cell subset expression, further suggesting different pathophysiologic mechanisms.[28]

The interaction between adhesion molecules and their ligands is important during inflammatory and immunological responses. Increased circulating levels of adhesion molecules (intercellular adhesion molecule 1, vascular cell adhesion molecule 1, and E-selectin) have been reported in benign reactive ED secondary to psoriasis and atopic dermatitis compared to controls.[29] In contrast, no differences in expression levels of these molecules on endothelial cells were found in different types of ED, leading to the hypothesis that there are similarities in end-stage immunologic pathways in different types of ED.[30]

TABLE 23-1
Diseases Associated With Exfoliative Dermatitis

Dermatoses	Systemic	Infections	Malignancy	Congenital
▪ Spongiotic dermatitis ▪ Atopic dermatitis[a] ▪ Seborrheic dermatitis[2] ▪ Contact dermatitis ▪ Stasis dermatitis ▪ Bullous ▪ Pemphigus foliaceus[69] ▪ Paraneoplastic pemphigus[74] ▪ Bullous pemphigoid ▪ Hailey–Hailey[77] ▪ Papulosquamous ▪ Psoriasis[a] ▪ Generalized pustular psoriasis[87] ▪ Pityriasis rubra pilaris[a] ▪ Impetigo herpetiformis[93] ▪ Photosensitive ▪ Chronic actinic dermatitis ▪ Actinic reticuloid[97] ▪ Adverse drug[a] ▪ Acute generalized exanthematous pustulosis ▪ Toxic epidermal necrolysis ▪ Other ▪ Pseudolymphoma[103] ▪ Erythema gyratum repens[107] ▪ Perforating folliculitis[109] ▪ Radiation recall dermatitis[111] ▪ Senile erythroderma with hyper-IgE[115]	▪ Dermatomyositis[43–48] ▪ Subacute cutaneous lupus[49–51] ▪ Acute graft-versus-host disease[56,a] ▪ Postoperative transfusion induced[59] ▪ Thyrotoxicosis[60] ▪ Sarcoidosis[64–67] ▪ Hypercalcitonemia[70] ▪ Idiopathic hypereosinophilic syndrome[75] ▪ Monoclonal gammopathy of undetermined significance[76] ▪ Hemophagocytic histiocytosis, viral associated[78,79]	▪ Bacterial ▪ Tuberculosis[52] ▪ Congenital syphilis[57] ▪ Viral ▪ Hepatitis C[61] ▪ Human immunodeficiency virus ▪ Human herpesvirus 6[71] ▪ Fungal ▪ Dermatophyte[14,18] ▪ Histoplasmosis[80–82] ▪ Congenital cutaneous candidiasis[84] ▪ Parasite ▪ Norwegian scabies[88] ▪ Toxoplasmosis[90] ▪ Leishmaniasis[94] ▪ Toxin-mediated infections ▪ Staphylococcal scalded-skin syndrome[a] ▪ Toxic shock syndrome	▪ Solid tumors ▪ Lung[14,17,18,53,54] ▪ Prostate[14,18,58] ▪ Thyroid[14] ▪ Liver[14,62] ▪ Gallbladder[68] ▪ Melanoma[18,72] ▪ Breast[18] ▪ Ovary[18] ▪ Fallopian tube[83] ▪ Esophagus[85] ▪ Stomach[17,86] ▪ Rectum[18] ▪ Colon[91] ▪ Thymus[95] ▪ Buschke–Loewenstein tumor[96] ▪ Lymphoproliferative ▪ Cutaneous T-cell lymphoma[a] ▪ Sézary syndrome ▪ Papuloerythroderma of Ofuji ▪ Hodgkin lymphoma[12,14,15,100] ▪ B-cell lymphoma[102] ▪ (Cutaneous) anaplastic large cell lymphoma[104,105] ▪ Angioimmunoblastic T-cell lymphoma[108] ▪ Castleman disease[110] ▪ Acute myeloid leukemia M6[112] ▪ Acute myelomonocytic leukemia[116] ▪ Adult T-cell leukemia[117] ▪ T-cell prolymphocytic l eukemia[118] ▪ Chronic lymphocytic leukemia[12] ▪ Chronic myelogenous leukemia[119] ▪ Chronic eosinophilic leukemia[120] ▪ Myelodysplasia[121] ▪ Premalignant myeloproliferative disorder[122] ▪ Multiple myeloma[34] ▪ Reticulum cell sarcoma[8] ▪ Angioimmunoblastic lymphadenopathy[123] ▪ Cutaneous lymphoid hyperplasia ▪ Hypereosinophilic syndrome[124–126] ▪ Mastocytosis (type II–IV)[127,128] ▪ Histiocytosis[129] ▪ Rosai–Dorfman disease	▪ Immunodeficiency ▪ Common variable hypogammaglobulinemia[55] ▪ Wiskott–Aldrich syndrome ▪ Severe combined immunodeficiency ▪ Omenn syndrome[63] ▪ Leiner disease ▪ Hyperimmunoglobulin E (hyper-IgE) syndrome[73] ▪ Secretory IgA deficiency ▪ Metabolic ▪ Maple syrup urine disease ▪ Neutral lipid storage disease ▪ Essential fatty acid deficiency ▪ Propionic acidemia[89] ▪ Holocarboxylase synthetase deficiency[92] ▪ Ichthyosis ▪ Bullous congential ichthyosiform erythroderma ▪ Nonbullous congenital ichthyosiform erythroderma ▪ Netherton syndrome[98] ▪ Conradi–Hünermann syndrome[99] ▪ Epidermolytic hyperkeratosis ▪ Keratitis, ichthyosis, and deafness[101] ▪ Lamellar ichthyosis ▪ Lethal congenital erythroderma[106] ▪ Sjögren–Larsson syndrome ▪ Other ▪ Ankyloblepharon–ectodermal dysplasia–clefting syndrome (AEC)[113,114]

[a]Most common diseases.

BOX 23-1 DIFFERENTIAL DIAGNOSIS

Most Likely

- Spongiotic dermatitis (20%–24%) (atopic, 9%; contact dermatitis, 6%; seborrheic dermatitis, 4%; chronic actinic dermatitis, 3%)
- Psoriasis (23%)
- Drug hypersensitivity reaction (15%)
- Cutaneous T-cell lymphoma (5%)
- Idiopathic (approximately 20%)

Consider

- Contact dermatitis
- Immunobullous disease (superficial pemphigus, bullous pemphigoid, paraneoplastic pemphigus)
- Infection (scabies, dermatophytosis)
- Toxin-mediated (toxic shock syndrome, staphylococcal scalded-skin syndrome)
- Chronic actinic dermatitis
- Pityriasis rubra pilaris
- Collagen vascular disease
- Paraneoplastic (solid tumors and hematologic)
- Primary immunodeficiency
- Congenital ichthyoses

Always Rule Out

- Cutaneous T-cell lymphoma
- Drug-induced hypersensitivity syndrome
- Paraneoplastic

The complex interaction between adhesion molecules and cytokines likely contributes to the significantly increased mitotic and epidermal turnover rate in ED. The scaling of ED skin is a reflection of decreased transit time through the epidermis and leads to significant loss of protein, amino acids, and nucleic acids. Protein loss may increase by 25%–30% via scaling in psoriatic ED, and 10%–15% in nonpsoriatic ED.[31] Additionally, protein-losing enteropathy may contribute to hypoalbuminemia.

Some patients with chronic idiopathic ED have been reported to develop CTCL that has led to concern that patients with chronic idiopathic ED may be at increased risk for progression to mycosis fungoides or Sézary syndrome.[18,32] The chronic T-cell stimulation in these patients has been suggested to promote the development of CTCL.[33–37] Recently, a premalignant or pre-Sézary-like condition has been described in elderly patients with chronic or relapsing ED without progression to hematologic malignancy characterized by a monoclonal expansion of $CD4^+CD7^-CD26^-$ lymphocytes.[34] The term monoclonal T-cell dyscrasia of undetermined significance (MTUS), a T-cell equivalent to monoclonal gammopathy of undetermined significance, has been proposed for this condition, which is believed to be probably benign.[34] However, chronic idiopathic ED may also represent primary chronic, undiagnosed CTCL. Indeed, in up to 10% of idiopathic ED cases, erythrodermic CTCL is ultimately diagnosed.[24]

A role for immunoglobulin (Ig) E in ED has been proposed based on the observation of increased IgE levels in many types of ED. For example, it has been theorized that elevations in IgE in psoriatic ED may point to a change from a T helper 1 cytokine profile in psoriasis to a T helper 2 cytokine in psoriatic ED.[38] This secondary mechanism is different than the primary overproduction of IgE in atopic dermatitis. Hyper-IgE syndrome is an immune deficiency that has been associated with ED, and has high IgE production due to selective insufficient interferon-γ secretion.[39] The mechanisms related to this elevation of IgE may be related to the underlying disease process or to the manifestation of the disease as ED. Again, the mechanisms of IgE elevation appear to be different in different types of ED.

Recently, it has been theorized that *Staphylococcus aureus* colonization or another antigen, such as toxic shock syndrome toxin-1, may play a role in the pathogenesis of ED.[40,41] Research on the immunopathogenesis of toxin-mediated infection demonstrates staphylococcal pathogenicity islands encoding superantigens (see Chapter 177). These islands carry the genes for the toxins of toxic shock syndrome and staphylococcal scalded-skin syndrome.[42] 83% of patients with ED were noted to have *S. aureus* colonization in the nares, while 17% had colonization in the skin; however, only one in six patients was *S. aureus* enterotoxin positive.[41] (See Tables 23-1 and 23-2.)

CLINICAL FINDINGS

Figure 23-1 is an algorithm showing the approach to a patient with ED.

HISTORY

A detailed history of a patient who presents with ED is an important tool for diagnosing the underlying etiology. The patients may have a history of dermatoses (psoriasis, atopic dermatitis) or a systemic medical condition. A thorough medication history should be elicited, including naturopathic and over the counter therapies. Patients with history of psoriasis and atopic dermatitis should be queried specifically regarding use of topical and systemic corticosteroids, methotrexate, and other systemic medications; topical irritants; systemic illness; infection; phototherapy burns; pregnancy; and emotional stress. ED patients commonly report thermoregulatory disturbances, malaise, fatigue, and pruritus; these symptoms are not specific to any etiology.

The onset of symptoms is important to assess different etiologies of ED. Primary skin diseases have a slower course while drug reactions usually have a rapid onset and resolution. One exception is ED associated with drug hypersensitivity reactions due to anticonvulsants, antibiotics, and allopurinol. This reaction develops in 2–5 weeks after medication is started

TABLE 23-2
Drugs Implicated in Exfoliative Dermatitis[a]

Antibiotics
- Aztreonam
- Cefoxitin[130,131]
- Doxycycline[123]
- Gentamicin[136]
- *Isoniazid*[2,12,15]
- Minocycline
- Neomycin
- *Penicillin*[8,12,14,15]
- Ribostamycin[145]
- Rifampin
- *Streptomycin*[2,14]
- Sulfasalazine[153,154]
- *Sulfonamides*[12,14]
- Teicoplanin[158]
- Thiacetazone[2]
- Tobramycin[163]
- Trimethoprim[1,164]
- Vancomycin[166,167]

Antivirals
- Dideoxyinosine[171]
- Indinavir[173]
- Interferon α [176]
- Zidovudine[178]

Antilepromatous
- Clofazimine[183]
- *Dapsone*[185–190]

Antifungals
- Nystatin[197]
- Terbinafine[201]
- Ketoconazole[205]
- Griseofulvin[207]

Antiepileptics
- *Carbamazepine*[10,17,209,210]
- Lamotrigine[214]
- *Phenytoin*[12,17,215,216]
- *Phenobarbital*[219]
- Aztreonam

Anti-inflammatory
- Aspirin
- Celecoxib[132]
- Diflunisal[135]
- Metamizole[137]
- Phenylbutazone[2]
- Piroxicam[140]

Cardiac drugs
- Amiodarone[143]
- Captopril[146]
- Diltiazem[148,149]
- Enalapril[151]
- Isosorbide dinitrate[12]
- Mexiletine
- Nifedipine[159]
- Nitroglycerin[161]
- Practolol[1]
- *Quinidine*[8,17]
- Verapamil[168]

Chemotherapy
- Bevacizumab[172]
- Carboplatin[174]
- Cisplatin[177]
- Denileukin diftitox[179]
- Doxorubicin[182]
- Fluorouracil
- Imatinib[191–193]
- Mitomycin C[195]
- Pentostatin[198]
- Vinca alkaloids[202]

Diabetic
- *Sulfonylureas*
- Chlorpropamide[208]

Psychiatric
- *Barbiturates*
- Bupropion[217]
- Chlorpromazine[1]
- Desipramine[221]
- Escitalopram[222]
- Etumine[10]
- Fluoxetine[224]
- Imipramine[221]
- Lithium[225]
- *Phenothiazines*
- Methylphenidate[226]
- Aspirin

Other
- *Allopurinol*[1,10,12,17]
- *Antimalarials*[8,12,14,133,134]
- Arsenicals
- Bacille Calmette-Guérin immunization[138]
- Bromodeoxyuridine[139]
- Cimetidine[141]
- Clodronate[142]
- Codeine[14,144]
- Efalizumab[147]
- Ephedrine[150]
- Epoprostenol[152]
- Erythropoietin[155,156]
- Ethylenediamine[157]
- Fluindione[160]
- Furosemide[162]
- *Gold*[1,8,14,17]
- Homeopathic medicine (NatMur200)[165]
- Hypericum (St. John's wort)[169]
- Interleukin 2[170]
- Iodine[14]
- Leflunomide[175]
- Mercurials[14,15]
- Omeprazole[180,181]
- Phenolphthalein[14]
- Propolis[184]
- Pseudoephedrine[194]
- Ranitidine[196]
- Retinoids[199,200]
- Rhus (lacquer)[203,204]
- Roxatidine acetate hydrochloride[206]
- Terbutaline[12]
- Tetrachloroethylene[14]
- Thalidomide[211–213]
- Thiazide[12]
- Timolol eye drops[218]
- Tocilizumab[220]
- Tramadol
- Tumor necrosis factor-α[170]
- Valiya narayana[223]
- Allopurinol[1,10,12,17]

[a]Most commonly implicated drugs are in italics.

and may remain ongoing after discontinuation of the medication. Associated signs of a possible drug etiology include fever, lymphadenopathy, organomegaly, edema, leukocytosis with eosinophilia, and liver and renal dysfunction.[153,215]

History and clinical presentation alone may not be sufficient to diagnose ED due to internal malignancy. Important clues for this diagnosis are an absence of prior skin disease, gradual onset, and a lack of response to standard therapies. A history of transplant should raise suspicion of CTCL, as it has been found that there is a higher frequency of ED secondary to CTCL in post-transplant patients.[227]

CUTANEOUS LESIONS

The classic presentation of ED is erythematous patches that increase in size and coalesce into generalized red erythema with a shiny appearance. By definition, ED involves more than 90% of the patient's skin surface (Fig. 23-2). A few days after the onset of erythema, fine

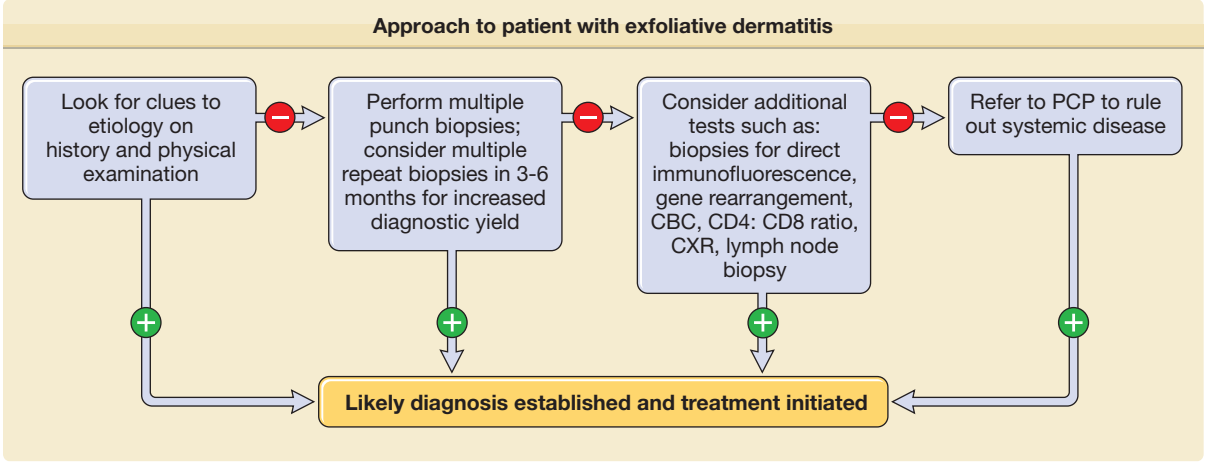

Figure 23-1 Approach to patient with exfoliative dermatitis. CBC = complete blood cell count; CXR = chest X-ray; PCP = primary care physician.

white or yellow scaling begins, classically arising in the flexures. Plate-like scaling may occur acutely and on the palms and soles. The scaling progresses further, giving the skin a dull red appearance. With chronicity, edema and lichenification lead to skin induration. Ectropion and epiphora may develop secondary to chronic periorbital involvement (Fig. 23-3). Palmoplantar keratoderma (Fig. 23-4) has been noted in up to 80% of patients with chronic ED.[18]

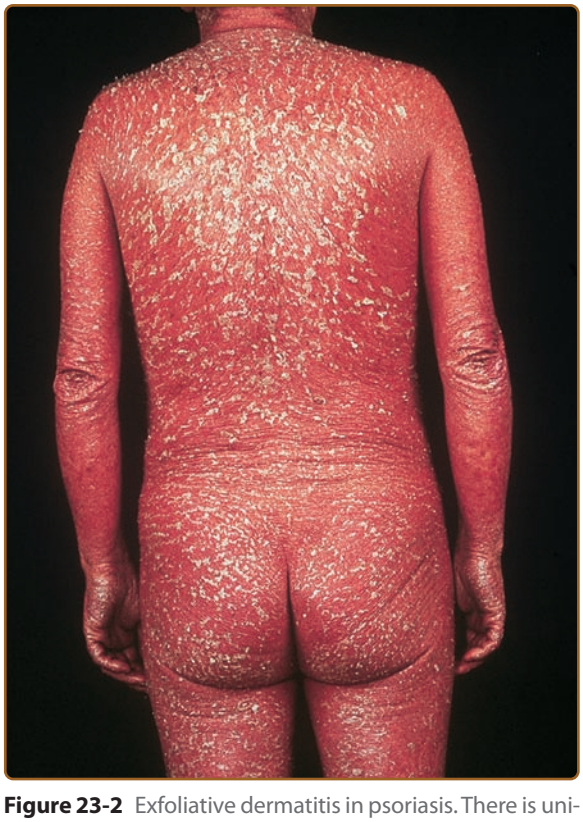

Figure 23-2 Exfoliative dermatitis in psoriasis. There is universal erythema, thickening of the skin, and heavy scaling. The patient had fatigue, malaise, and was shivering.

Some patients develop involvement of their hair and nails. Scaling of the scalp, alopecia, and in some cases, diffuse effluvium can be seen. Nail changes may include onycholysis, subungual hyperkeratosis, splinter hemorrhages, paronychia, Beau's lines, and, occasionally, onychomadesis.[2] Shore-line nails with alternating bands of nail plate discontinuity represent drug-induced ED reflecting the periods of time the drug was used.[228]

Sparing of the nose and paranasal areas (the "nose sign") has been described in some studies. Areolar sparing has been noted in some cases of CTCL, drug reactions, "eczema," psoriasis, photosensitivity, and PRP.[229] Typically, there is not mucosal involvement. Eruptive seborrheic keratoses may arise in patients with ED.[230–232] The keratoses often resolve spontaneously as the ED subsides.

The cutaneous lesions may suggest the underlying etiology of ED. For example, in early psoriatic ED, classic psoriatic plaques may be seen. Gottron's papules, heliotrope rash, and muscle weakness may be present in ED caused by dermatomyositis. Papuloerythroderma of Ofuji typically spares the abdominal skin folds (the "deck chair" sign).



Figure 23-3 Blepharitis, epiphora, and ectropion in atopic exfoliative dermatitis.



Figure 23-4 Pityriasis rubra pilaris exfoliative dermatitis with keratoderma. Note keratoderma with an orange hue and thickening of the thumbnails.

SPECIFIC FEATURES OF UNDERLYING DISEASES

Features of underlying diseases may aid in diagnosis (see Table 23-3 and eFigures 23-4.1–23-4.4 in online edition).

RELATED PHYSICAL FINDINGS

Related physical findings due to ED of any etiology may include the following:

- Tachycardia due to increased blood flow to the skin and fluid loss due to disrupted epidermal barrier.
- High-output cardiac failure has been infrequently reported secondary to the high-flow state in ED.[233]
- Thermoregulatory disturbances can result in hyperthermia or less commonly hypothermia; however, most patients complain of feeling chilly.
- Generalized lymphadenopathy occurs in more than one-third of patients.[2,12,15] The clinician must distinguish between dermatopathic lymphadenopathy and lymphoma. If lymphadenopathy is prominent, a lymph node biopsy may be required.
- Hepatomegaly may occur in about one-third of patients [2,12,15] and is more commonly seen in drug-induced ED.
- Splenomegaly has also been rarely reported[12] and is most commonly associated with lymphoma.
- Peripheral pedal or pretibial edema may occur in up to 54% of patients.[15,32] Rarely, facial edema has been reported in drug-induced ED.

LABORATORY TESTS

Laboratory tests are most often not diagnostic and not specific. Common laboratory abnormalities found in ED patients include anemia, leukocytosis, lymphocytosis, eosinophilia, increased IgE, decreased serum albumin, and an elevated erythrocyte sedimentation rate. Fluid loss may lead to electrolyte abnormalities and abnormal renal function (elevated creatinine level). Elevated IgE levels have been noted in patients with ED unrelated to atopic dermatitis,[10,12,18] including in 81.3% of psoriatic ED patients.[38] Eosinophilia is nondiagnostic and has been found in 20% of ED patients.[17] However, when highly elevated eosinophil counts are noted, the possibility of associated Hodgkin disease must be investigated.

It is very important to differentiate benign erythrodermic inflammatory diseases from Sézary syndrome. In cases where erythrodermic CTCL is suspected, a thorough evaluation of skin, blood, and lymph node samples is required for definitive diagnosis. Studies have shown that a level of 20% or more circulating Sézary cells is a useful diagnostic criterion for Sézary syndrome, whereas less than 10% is nonspecific.[17,32] Exceptions do occur, such as in certain severe drug-induced reactions that can mimic Sézary syndrome (as hydantoin hypersensitivity).[234] Several benign dermatoses, including psoriasis, atopic dermatitis, discoid lupus, lichen planus, and "parapsoriasis" show the presence of Sézary cells in numbers less than 10%.[235] Demonstration of a clonal T cell receptor gene rearrangement is recommended for a sensitive and specific differentiation of Sézary syndrome from other etiologies of ED.

In a recent study, quantitative real-time polymerase chain reaction analysis of the expression values of five genes [(1) *STAT4*, (2) *GATA-3*, (3) *PLS3*, (4) *CD1D*, and (5) *TRAIL*] has proven useful for molecular diagnosis of Sézary syndrome[236] (see Chapter 145). Several molecular markers of Sézary cells have been recently studied (Twist, EphA4, T-plastin). In one report, CD158K/KIR3DL2, a killer immunoglobulin-like receptor normally expressed by subsets of circulating T CD8+ lymphocytes and natural killer cells, has been

TABLE 23-3
Specific Features of Underlying Disease Process[a]

Underlying Disease Process	Clinical Clues	
Idiopathic erythroderma ("red man syndrome")	Elderly men Chronic and relapsing course Dermatopathic lymphadenopathy	Pruritus Palmoplantar keratoderma
Psoriasis (see Chapter 18)	History of localized disease Personal or family history of psoriasis Classic psoriasiform plaques on elbows, knees, sacrum, etc. Well-circumscribed plaques at margins of erythroderma (eFig. 23-4.3 in online edition)	Large lamellar scales Psoriatic nail changes: pits, oil drop sign, onycholysis, subungual hyperkeratosis Collarettes of scale suggestive of ruptured pustules of pustular psoriasis Psoriatic arthritis
Atopic dermatitis (see Chapter 14)	History of localized disease, most often moderate to severe Personal or family history of atopy (atopic dermatitis, asthma, rhinoconjunctivitis) Marked pruritus	Classic atopic lesions in antecubital and popliteal fossae Lichenification and prurigo nodularis Excoriations Focal skin atrophy from years of use of potent topical steroids
Spongiotic dermatitis of other etiologies, such as contact dermatitis (see Chapter 13) (eFig. 23-4.1 in online edition) or stasis dermatitis (see Chapter 174)	Distribution of original skin lesions History of contactant History of preexisting venous disease	
Drug reaction (see Chapter 41)	Recent start of new drug, or use of frequently implicated drug Rapid onset of rash and progression to exfoliative Dermatitis	Lymphadenopathy Organomegaly Fever
Cutaneous T-cell lymphoma (see Chapter 145)	Severe debilitating pruritus Fissured, painful keratoderma Hepatosplenomegaly	Lymphadenopathy Alopecia Leonine facies
Immunobullous disease Pemphigus foliaceus and fogo selvagem (see Chapter 54) Bullous pemphigoid (see Chapter 56) Paraneoplastic pemphigus (see Chapter 55)	 Flaccid blisters Collarettes of scale at sites of previous blisters Superficial erosions and crusts Tense blisters (early lesions) Deep erosions and superficial ulcers Urticarial plaques Mucosal erosions and crusting prominent Rash resembles erythema multiforme Failure to thrive (i.e., cachexia)	 Pruritus Elderly patient
Paraneoplastic ED	Failure to thrive (i.e., cachexia)	
Pityriasis rubra pilaris (see Chapter 24)	Initial lesion: seborrheic dermatitis-like eruption of the scalp Worsening postsun exposure Generalized salmon-colored slightly infiltrated erythema (eFig. 23-4.4 in online edition)	Islands of sparing (eFig. 23-4.4 in online edition) Palmoplantar keratoderma, often orange (Fig. 23-4) Follicular pink papules of elbows, wrists, dorsal fingers or in skin spared from ED
Chronic actinic dermatitis (see Chapter 91)	Photo-accentuation	
Acute graft-versus-host disease (see Chapter 28)	History of bone marrow transplantation or blood transfusion	Initial lesion: palmar erythema Progression to toxic epidermal necrolysis
Dermatomyositis (see Chapter 156)	Gottron papules Heliotrope sign Poikiloderma	Periungual telangiectasia Muscle weakness
Sarcoidosis (see Chapter 152)	Apple jelly papules, plaques, and/or nodules	
Norwegian scabies (see Chapter 208)	Down syndrome or nursing home patient Burrows	Massively thickened nails Keratoderma

ED = exfoliative dermatitis.
[a]Features of underlying diseases may aid in diagnosis.

found to be useful as a molecular marker of Sézary syndrome in skin samples of patients with ED.[237] Another study suggests that Sézary syndrome may be differentiated from inflammatory ED based on different memory T-cell subset expression and that CD27 expression may be helpful as an additional diagnostic tool.[28]

Immunophenotyping of skin lymphocytes may be a helpful adjunct study in differentiation of Sézary syndrome from actinic reticuloid. Sézary patients show a clonal $CD4^+$ predominance while in patients with underlying actinic reticuloid,[238] there is a $CD8^+$ lymphocyte predominance. More specifically, $CD28^+/CD5^+/NKa^-/CD4^+$ T cells with reduction of CD3, CD4, CD7, CD2, and/or T-cell receptor α/β supports the diagnosis of Sézary syndrome in ED patients.[239] The nuclear contour index may also be a helpful investigation for the same differentiation.

HISTOPATHOLOGY

The histopathology findings differ depending on the underlying etiology (Table 23-4). Multiple skin punch biopsies over time are required in addition to clinical evaluation to make a diagnosis. The biopsy specimens often reveal a nonspecific picture that includes hyperkeratosis, parakeratosis, acanthosis, and a chronic inflammatory infiltrate, which may mask features of the underlying etiology. The histologic features may vary depending upon the stage of the disease and the severity of inflammation. One-third of biopsy specimens of erythroderma fail to reveal the underlying diagnosis.[240] The histologic features of the underlying disease may be more subtle than usually seen in that disease entity when unassociated with ED.[240] When dermatopathologists blinded to clinical information reviewed biopsies of erythroderma,[241] an accurate diagnosis was made only 50% of the time. Therefore, multiple punch biopsies obtained simultaneously and repeated over time are recommended to maximize the possibility of histopathologic diagnosis. Direct immunofluorescence, various special stains, immunoperoxidase studies, immunophenotyping, and gene rearrangement studies may be required to determine the underlying cause.

SPECIAL TESTS

Laboratory testing is driven by the patient's medical history and clinical presentation. In addition to multiple skin biopsies, lymph node biopsies may be required to differentiate dermatopathic lymphadenopathy from lymphomatous involvement. Radiologic workup should be undertaken if the condition is thought to be paraneoplastic. If a lymphoproliferative disease is considered as a possible cause of the ED, a thorough evaluation should be done that includes CD4:CD8 ratios, Sézary cell counts, immunophenotyping of skin and blood, and analysis of T-cell clonality by cytogenetics or T-cell receptor gene analysis.

COMPLICATIONS

A variety of metabolic and physiological changes occur in ED, including fluid and electrolyte imbalances, thermoregulatory disturbance, high-output cardiac failure,[233] cardiogenic shock,[242] acute respiratory distress syndrome,[243] decompensation of chronic liver disease,[244] and gynecomastia.[245] Hypoalbuminemia is common since there is an increase of protein loss via scaling (by 10%–15% in nonpsoriatic ED and up to 25%–30% in psoriatic ED[31]) as well as increase in metabolism and decrease in protein synthesis.[246] These processes lead to a negative nitrogen balance, muscle wasting, and edema.

Another common complication in ED is body temperature dysregulation. Increased skin perfusion combined with increased transepithelial water loss and loss of heat due to increased metabolic rate[247] leads to hypothermia. Furthermore, the capillaries cannot respond appropriately to temperature changes via vasoconstriction and vasodilation. Fluid and electrolytes loss from leaky capillaries leads to fluid and electrolyte imbalances. The shunting of blood to the skin may lead to high-output cardiac failure, which is of particular concern in patients with cardiac conditions and the elderly.[233]

There is an increased susceptibility to bacterial colonization in ED due to inflammation, fissuring, and excoriation of the skin. Sepsis may occur occasionally. Staphylococcal sepsis in particular is especially a risk for patients with CTCL and HIV-positive ED.[40,243,248]

PROGNOSIS AND CLINICAL COURSE

There are many factors affecting the clinical course and prognosis of ED, such as the underlying etiology, patient's comorbidities, age, speed of onset, and early therapy. In drug-induced ED, the course is usually rapid and upon discontinuation of the offending drug the ED clears readily and patients recover completely.[1] An important exception to this is the severe systemic hypersensitivity reactions that develop usually within 2–5 weeks after the medication is started and may persist for weeks after discontinuation of the drug. When the underlying etiology is a primary skin disease as in psoriatic and atopic ED, typically improvement takes weeks to months; however, chronic and persistent cases occur. Recurrence of psoriatic ED occurs in 15% of patients after initial resolution.[133]

ED can prove fatal especially in the very young and the elderly. Variable mortality rates (from 3.73% to 64%) have been reported in studies over the past 51 years.[4,10,12,14,16,20] In early series of ED, high mortality rates were reported in patients with severe drug reactions, lymphoproliferative malignancy, pemphigus foliaceus, and idiopathic ED.[8] The causes of death were complications such as sepsis, pneumonia, and cardiac failure.[8,14,20] Lower mortality rates have been reported in more recent studies with most deaths occurring in

TABLE 23-4
Histologic Clues of Underlying Disease

Disease	Diagnostic Features	Special Tests
Actinic reticuloid	Atypical mononuclear cells admixed amongst inflammatory cells Superficial and deep perivascular, interstitial, and lichenoid lymphocytic infiltrate Overlying lichen simplex chronicus With or without spongiosis	Immunophenotyping to differentiate actinic reticuloid from Sézary syndrome Predominance of CD8+ lymphocytes in skin and peripheral blood
Atopic dermatitis	Superficial perivascular lymphocytic infiltrate with eosinophils Spongiosis Occasional eosinophilic spongiosis Parakeratosis With or without lichen simplex chronicus	
Contact dermatitis	Same as atopic dermatitis	Patch testing, as appropriate Patch testing may be attempted when patient has partial clearing either spontaneously or with treatment
CTCL/Sézary	Atypical mononuclear cells singly and linearly along the basal cell layer Intraepidermal nests of atypical cells (Pautrier's microabscesses) Spongiosis absent or minimal Often lichenoid infiltrate	Immunophenotyping to detect clonal T-cell population in skin (and blood)
Dermatomyositis/ Subacute cutaneous lupus erythematosus	Interface dermatitis with vacuolar alteration Epidermal atrophy Colloid bodies Increased dermal mucin	Direct immunofluorescence ANA Muscle enzymes
Dermatophytosis	Hyphae within stratum corneum Mounds of parakeratosis Neutrophils in stratum corneum Papillary dermal edema	KOH scraping PAS stain Culture
Drug eruption, morbilliform type	Interface dermatitis Vacuolar alteration Necrotic keratinocytes at all levels of epidermis Perivascular and interface inflammation with eosinophils	
Acute graft-versus-host disease	Vacuolar alteration Dyskeratosis in close proximity to epidermal lymphocyties ("satellite cell necrosis") Subepidermal clefting possible	Direct immunofluorescence
Idiopathic	Nonspecific Usually subacute or chronic spongiotic dermatitis-like changes	
Lymphoprolifereative disease	Nodular or diffuse infiltrate of monomorphous mononuclear cells Lower dermal cellular infiltrate usually denser than that of the upper part Neoplastic mononuclear cells often within adnexal structures and walls of blood vessles	Immunophenotyping
Paraneoplastic	Nonspecific and variable changes	
Pemphigoid	Subepidermal bulla Dermal eosinophils Eosinophilic spongiosis	Direct immunofluorescence
Pemphigus	Intraepidermal bulla Acantholysis Eosinophilic or neutrophilic spongiosis	Direct immunofluorescence

(continued)

TABLE 23-4
Histologic Clues of Underlying Disease (Continued)

Disease	Diagnostic Features	Special Tests
Paraneoplastic pemphigus	Suprabasal acantholysis Necrotic keratinocytes Vacuolar alteration with lichenoid lymphotcytic infiltrate	Direct immunofluorescence
Pityriasis rubra pilaris	Epidermal hyperplasia Horizontal and vertical alternating orthokeratosis and parakeratosis Dilated plugged follicular infundibulum	
Psoriasis	Psoriasiform epidermal hyperplasia Confluent parakeratosis layered with neutrophils Spongiform pustules Hypogranulosis Dilated tortuous papillary blood vessels	
Sarcoidosis	Naked tubercles (dermal granulomas with little or no mantle of surrounding lymphocytes)	Chest X-ray
Scabies	Superficial and deep perivascular and interstitial inflammation Many eosinophils Frequent spongiosis Stratum corneum with mite or excreta and crusting possible	Scraping of burrows to identify a mite or excreta
Seborrheic dermatitis	Spongiotic psoriasiform dermatitis Parakeratosis and neutrophils at lips of the follicular ostia	
Stasis with autoeczematization	Spongiotic dermatisis Often eosinophils Lower leg biopsies demonstrate thick-walled superficial blood vessels, extravasated red blood cells, and siderophages	
Infantile exfoliative dermatitis ichthyoses Nonbullous congenital ichthyosiform erythroderma (Lamellar ichthysosis) Bullous congenital ichthyosiform erythroderma	Changes of the specific type of inherited ichthyosis (epidermolytic hyperkeratosis) Can be nondiagnostic changes Nondiagnostic Orthohyperkeratosis and acanthosis Epidermolytic hyperkeratosis Massive orthohyperkeratosis Acanthosis Hypergranulosis	Electron microscopy Genetic testing Translgutaminase-1 deficiency in cultured keratinocytes Genetic testing to detect mutations in *TGM1* Electron microscopy: cholesterol clefts and lipid droplets in the stratum corneum Mutations in keratin genes *KRT1* and *KRT10*
Netherton syndrome	Nondiagnostic Parakeratotic hyperkeratosis Diminished or absent granular layer Acanthosis PAS may stain stratum corneum strongly eosinophilic	Electron microscopy: premature lamellar body secretion Foci of electron-dense material in intracellular spaces of stratum corneum

patients with malignancy-associated ED,[1,12,17] usually due to underlying disease progression, treatment complications, or sepsis.[12] In a recent study, an average of 30-month follow-up of 80 ED patients demonstrated a death rate of 3.75% (3 of 80 patients) with deaths due to pneumonia in patients with pemphigus foliaceus and Sézary syndrome.[16]

ED secondary to malignancy including CTCL is most often chronic and refractory. For mycosis fungoides and Sézary syndrome-related ED, positive prognostic factors include age younger than 65 years, symptom duration greater than 10 years before diagnosis, absence of evidence of lymphoma involving a lymph node, and the absence of circulating Sézary cells in mycosis fungoides.[249] Mean survival ranges from 1.5 to 10.2 years based on these prognostic indicators.[249]

Idiopathic ED patients often have chronic symptoms and recurrences, which require long-term steroid therapy. Complete remission occurs in one-third of idiopathic ED patients and partial remission in one-half of patients.[18,32] Patients with chronic idiopathic ED are at increased risk of evolution to the diagnosis

of CTCL.[10,12,18,32] A proportion of patients with chronic ED have been shown to have a monoclonal T-cell dyscrasia, which may indicate a possible premalignant or pre-Sézary-like condition (monoclonal T-cell dyscrasia of undetermined significance).[35]

In pediatric patients presenting with fever and ED, certain parameters (older age, vomiting, presence of focal infection, specific laboratory values) can be used to predict which patients are likely to develop hemodynamic deterioration.[250] Predictors of developing toxic shock syndrome in this population included age ≥3 years, ill appearance, elevated creatinine, and hypotension on arrival.[250]

TREATMENT

The treatment of ED is summarized in Box 23-2. Patients presenting acutely with ED may require inpatient management due to significant fluid and electrolyte imbalance and hemodynamic or respiratory compromise. However, most patients can be managed on an outpatient basis. Regardless of etiology, the initial management involves fluid, electrolyte, and nutritional replacement. Children presenting with erythroderma and fever should be hospitalized and managed aggressively since they are likely to develop hemodynamic deterioration.[250]

The patient should be nursed in a warm (preferably 30°C–32°C) and humid environment for comfort and skin moisture, as well as to prevent hypothermia. Gentle local skin care, including oatmeal baths and wet dressings to weeping or crusted lesions, bland emollients, and low-potency topical steroids should be started. High-potency topical steroids[251] and topical immunomodulators, such as tacrolimus,[252] should be avoided as systemic absorption may occur due to the increased skin permeability and large surface area

BOX 23-2 THERAPY

	TOPICAL	SYSTEMIC	DOSAGE
First line	Oatmeal baths	Sedating antihistamines	
	Wet dressings	Systemic antibiotics if secondary infection	
	Bland emollients	Diuretics for peripheral edema	
	Low-potency corticosteroids	Fluid and electrolyte replacement	
Second line (once etiology established)	Single agent	Corticosteroids for drug hypersensitivity reactions, immunobullous disease, atopic dermatitis.	1–2 mg/kg/day with taper
		Cyclosporine for psoriasis, atopic dermatitis	4–5 mg/kg/day
		Methotrexate for psoriasis, atopic dermatitis, pityriasis rubra pilaris	5–25 mg qwk depending on renal function and response to treatment
		Acitretin for psoriasis, pityriasis rubra pilaris	25–50 mg qd
		Mycophenolate mofetil for psoriasis, atopic dermatitis, immunobullous disease	1–3 g qd
		Infliximab for psoriasis and pityriasis rubra pilaris	5–10 mg/kg
		Etanercept for psoriasis and pytirasis rubra pilaris	25 mg SC two times/week
	Combination therapy	Methotrexate and infliximab for psoriasis	2.7–4.4 mg/kg infliximab and 5–7.5 mg/week methotrexate
		Infliximab and acitretin for psoriasis and pityriasis rubra pilaris	5 mg/kg infliximab and 0.3–0.6 mg/kg acitretin (psoriasis) 5 mg/kg infliximab and 0.2 mg/kg/day acitretin (pityriasis rubra pilaris)
		Cyclosporine and etretinate for psoriasis	3.5–4 mg/kg/day cyclosporine and 0.5–0.6 mg/kg/day etretinate

involved. Other topical irritants such as anthralin, tar, hydroxyl acid moisturizers, and vitamin D analogs should also be avoided.

Antihistamines can be administered for sedation and antipruritic effects. Systemic antibiotics are required for patients with evidence of localized and systemic secondary infection. Septicemia secondary to *Staphylococcus* infection is often a complication of ED and requires aggressive antibiotic and supportive treatment. Even patients without evidence of secondary infection may benefit from systemic antibiotic therapy as bacterial colonization may exacerbate ED. Pedal and periorbital edema should be treated with diuretics and adequate fluid intake should be maintained. All nonessential and possible offending medications should be discontinued, including drugs such as lithium and antimalarials that may trigger a flare in patients with underlying psoriasis. Folate supplementation and a diet of 130% of normal dietary requirements for protein are recommended to replace nutrient losses.[31,253]

Determining the underlying etiology early is essential for definitive treatment of ED as ED may be refractory to therapy until the cause is treated. Consensus treatment recommendations for erythrodermic psoriasis have been recently put forth by the National Psoriasis Foundation.[254] Therapy should be based on the severity of disease and underlying comorbidities. Systemic agents such as methotrexate, cyclosporine, acitretin, mycophenolate mofetil, and azathioprine can be helpful as single agents or in combination.[254] Experience with biologics, although limited so far, is very promising. A number of small case series and reviews suggest that infliximab alone or in combination with methotrexate can lead to rapid and dramatic control of psoriatic ED and high rates or remission.[255–259] There are emerging data suggesting that etanercept may also be effective[260,261] as well as single case reports of adalimumab[262] and alefacept[263] being successfully used in psoriatic ED. Currently, there is no data to support a role of ustekimumab in the treatment of erythrodermic psoriasis, although given its good efficacy for plaque-type psoriasis it may eventually prove to be useful. Systemic steroids should be avoided given the danger of rebound erythrodermic flare and exacerbation of the disease. A recent case series supports the use of infliximab in patients with erythrodermic and recalcitrant chronic plaque psoriasis who have failed multiple therapies including biologics.[264]

Etanercept has also been used as a steroid-sparing agent with relief of pruritus in Sézary syndrome in two patients.[265] However, etanercept should be used with caution in these patients because of risk of further immunosuppression. Options for treatment of CTCL include topical corticosteroids, psoralen plus ultraviolet A (UVA), total skin electron beam irradiation, systemic chemotherapy including CHOP-like regimens (*c*yclophosphamide, *h*ydroxydaun*o*mycin, vincristine, and *p*rednisone), interferon-α, extracorporeal photochemotherapy, and biologics such as monoclonal antibodies (alemtuzumab),[266,267] bexarotene (selective retinoic X receptor retinoid),[268,269] and denileukin diftitox.

Systemic corticosteroids are useful for drug hypersensitivity reactions. In severe and persistent cases, intravenous Ig may be used. Cyclosporine, methotrexate, azathioprine, mycophenolate mofetil, and systemic corticosteroids may be helpful for spongiotic (eczematous) dermatitis. PRP usually responds to systemic retinoids or methotrexate. Recently, case reports and case series have showed that tumor necrosis factor (TNF)-α antagonists (infliximab, etanercept, adalimumab) alone or in combination therapy can be very useful in the treatment of adult-onset PRP[270–277] and juvenile PRP.[278,279] Papuloerythroderma of Ofuji has been treated with topical and systemic corticosteroids, cyclosporine, interferon, etretinate, and most recently with a combination of retinoid plus psoralen and UVA light.[280] Rituximab has proven useful in the treatment of erythrodermic pemphigus foliaceus in a recent case report.[281]

When the underlying cause of ED is unknown, empiric therapy with systemic agents, including methotrexate, cyclosporine, acitretin, mycophenolate mofetil, and systemic corticosteroids, has been used. It should be emphasized that a strong suspicion for psoriatic ED precludes systemic corticosteroid use due to risk for a rebound flare. Immunosuppressive drugs should not be used until CTCL has been ruled out with the most current laboratory testing.

PREVENTION

Prevention of ED depends on controlling the underlying cause. Medications and irritants that have previously caused ED should be avoided. It is important that the patients maintain careful records of allergies including potentially cross-reactive medications, such as topical agents (e.g., ED occurring secondary to systemic gentamicin use in a patient with known contact allergy to neomycin[136] and ED secondary to pseudoephedrine use in a patient with a contact allergy to phenylephrine).[194] Systemic steroids should be avoided in patients with psoriasis to prevent rebound flares. Educating patients with underlying diseases (e.g., psoriasis, atopic dermatitis) about possible triggers of ED (irritants, abrupt discontinuation of certain therapies) may also be helpful to prevent ED.

KEY REFERENCES

Full reference list available at www.DIGM8.com

DVD contains references and additional content

1. Hasan T, Jansen CT: Erythroderma: A follow-up of fifty cases. *J Am Acad Dermatol* **8**(6):836-840, 1983
2. Sehgal VN, Srivastava G: Exfoliative dermatitis. A prospective study of 80 patients. *Dermatologica* **173**(6): 278-284, 1986
3. Sigurdsson V, Steegmans PH, van Vloten WA: The incidence of erythroderma: A survey among all dermatologists in The Netherlands. *J Am Acad Dermatol* **45**(5):675-678, 2001

4. Wong KS et al: Generalised exfoliative dermatitis–A clinical study of 108 patients. *Ann Acad Med Singapore* **17**(4):520-523, 1988
16. Rym BM et al: Erythroderma in adults: A report of 80 cases. *Int J Dermatol* **44**(9):731-735, 2005
31. Kanthraj GR et al: Quantitative estimation and recommendations for supplementation of protein lost through scaling in exfoliative dermatitis. *Int J Dermatol* **38**(2):91-95, 1999
35. Gniadecki R, Lukowsky A: Monoclonal T-cell dyscrasia of undetermined significance associated with recalcitrant erythroderma. *Arch Dermatol* **141**(3):361-367, 2005
241. Walsh NM et al: Histopathology in erythroderma: Review of a series of cases by multiple observers. *J Cutan Pathol* **21**(5):419-423, 1994
254. Rosenbach M et al: Treatment of erythrodermic psoriasis: From the medical board of the National Psoriasis Foundation. *J Am Acad Dermatol* **62**(4):655-662, 2010 [Epub Aug 8, 2009]

Chapter 24 :: Pityriasis Rubra Pilaris

:: Daniela Bruch-Gerharz & Thomas Ruzicka

PITYRIASIS RUBRA PILARIS AT A GLANCE

- A papulosquamous disorder of unknown etiology that often progresses to erythroderma and causes a disabling keratoderma of the palms and soles.
- The disease is subclassified into six types including both hereditary and acquired forms.
- The typical features of pityriasis rubra pilaris include follicular hyperkeratosis and a reddish orange, scaling dermatitis with islands of normal skin.
- Confusion with psoriasis presents the major problem in diagnosis, particularly in early phases of the disease.
- Histopathological examination reveals hyperkeratosis, alternating vertical and horizontal parakeratosis, and a mild superficial perivascular lymphocytic infiltrate.
- No single therapy is universally effective, and some cases do not respond to multiple therapies. The most successful treatment options are retinoids, photochemotherapy (PUVA), and antimetabolites (methotrexate).

EPIDEMIOLOGY

Pityriasis rubra pilaris is a rare, chronic disorder with an estimated incidence ranging from 1 in 5,000 to 1 in 50,000 dermatology patients. The age distribution is bimodal with peak incidences in the first and fifth decades of life. The disease occurs in all races and affects the sexes equally.[1]

ETIOLOGY AND PATHOGENESIS

Although an underlying dysfunction in vitamin A metabolism has been suggested, the etiology and pathogenesis of pityriasis rubra pilaris are still poorly understood. Thus, the role of vitamin A deficiency remains uncertain as attempts to produce keratotic lesions by vitamin A deprivation have been unsuccessful. Moreover, the deficiency of retinol-binding protein as an underlying pathogenic mechanism resulting in inadequate transport of vitamin A to the skin has yet to be ascertained. There are some cases in which pityriasis rubra pilaris may result from immune system dysregulation and abnormal response to various antigenic triggers.[2] A report of an exanthematous form of juvenile pityriasis rubra pilaris that followed an upper respiratory infection and initially resembled Kawasaki disease supports the hypothesis of a superantigen-mediated process. Finally, genetic factors with an autosomal dominant pattern of inheritance have been supposed to play a critical role for the induction of pityriasis rubra pilaris. Nevertheless, affected relatives are not observed in the classical acute-onset disease and are infrequent in other variants.

CLINICAL FINDINGS

CUTANEOUS LESIONS

Pityriasis rubra pilaris is generally believed to comprise more than a single entity and a classification scheme based on clinical characteristics and course has been proposed by Griffiths[1] (Table 24-1).

Type I (classic adult) is the most common subtype with over 50% of all cases. Characteristically, patients present with an eruption of follicular hyperkeratotic papules that spread in cephalocaudal direction (Fig. 24-1). As the disease further evolves, a reddish

TABLE 24-1
Classification Scheme of Pityriasis Rubra Pilaris (Types I–V According to Griffiths[1])

Type	Description	%	Clinical Characteristics	Distribution	Course
I	Classic adult	>50	**Erythroderma** with islands of normal skin ("nappes claires"), follicular hyperkeratosis, waxy diffuse **palmoplantar keratoderma**	Generalized, beginning on the head and neck, then spreading caudally	Often resolves within an average period of 3 years
II	Atypical adult	5	Combination of **follicular hyperkeratosis** and **ichthyosiform lesions** on the legs, sparse scalp hair	Generalized	Long duration (>20 years)
III	Classic juvenile	10	**Similar to type I** but appears in years 1 or 2 of life	Generalized	Often resolves within an average period of 1–2 years
IV	Circumscribed juvenile	25	Prepubertal children; well-demarcated scaly, **erythematous plaques on the elbows and knees**, resembling localized psoriasis	Localized	Uncertain, some cases clear in the late teens
V	Atypical juvenile	5	Begins in first few years, accounts for most familial cases; **follicular hyperkeratosis**, **scleroderma-like appearance of the hands and feet**	Generalized	Chronic course, improvement with retinoids but relapses when stopped
VI	HIV-associated	NA[a]	**Similar to type I** with variable beginning; associated with acne conglobata, hidradenitis suppurativa and lichen spinulosus	Generalized	May respond to antiretroviral triple therapy

[a]Data not available.



Figure 24-1 Acuminate follicular papules of pityriasis rubra pilaris. Close-ups of discrete (**A**) and confluent (**B**) lesions.



Figure 24-2 Generalized pityriasis rubra pilaris (**A**) with a reddish orange, scaling dermatitis, and islands of normal skin ("nappes claires"), shown in more detail in (**B**).

orange, scaling dermatitis appears that often progresses to a generalized erythroderma over a period of 2–3 months (Fig. 24-2). A diagnostic hallmark of pityriasis rubra pilaris are sharply demarcated islands of unaffected skin ("nappes claires") in a random distribution (Fig. 24-2B). Many patients develop a waxy, diffuse, yellowish keratoderma of the palms and soles (Fig. 24-3).[3] Nail changes are not uncommon and include distal yellow–brown discoloration, nail plate thickening, splinter hemorrhages, and subungual hyperkeratosis. Eventually, the mucous membranes may be affected with a diffuse whitish appearance of the buccal mucosa as well as lacy white plaques and erosions. Hair and teeth are normal.

Type II is an atypical variant with onset in adult age. Areas of follicular hyperkeratosis as well as ichthyosiform scaling, especially on the legs, dominate the clinical picture. This variant lacks the typical cephalocaudal progression observed in type I, and there is less tendency for the patients to become erythrodermic. Sparseness of the scalp hair is occasionally seen.

Type III (classic juvenile) typically begins in years 1 or 2 of life and shows all the morphological features of type I (Fig. 24-4).

Type IV (circumscribed juvenile) affects approximately 25% of the patients. This type usually presents several years after birth and is characterized by well-demarcated hyperkeratotic erythematous plaques on the elbows and knees, resembling localized psoriasis. According to Griffith,[1] these lesions do not progress to the widespread types I and III. Yet, some cases show marked palmoplantar keratoderma.

Type V is an atypical variant of juvenile pityriasis rubra pilaris that usually presents in the first few years of life and has a more chronic course. This type is distinguished by follicular hyperkeratosis with only minimal erythema and a scleroderma-like appearance of the hands and feet. Most cases of familial pityriasis rubra pilaris belong to this type, which may even represent a different clinical entity sharing features with several poorly defined ichthyotic disorders such as follicular ichthyosis and the erythrokeratodermas.

Other reports have described a **type VI** variant associated with HIV infection. The clinical features of this variant are similar to type I but with increased severity and additional manifestations of acne conglobata, hidradenitis suppurativa, and lichen spinulosus.

RELATED FINDINGS

There have been rare cases of a pityriasis rubra pilaris-like eruption, clinically and histologically, in patients with dermatomyositis, often associated with internal neoplasia. Concomitant rheumatologic disorders, mainly inflammatory polyarthritis, have also been reported. In addition, numerous other noncutaneous diseases were considered to be related to pityriasis rubra pilaris, which are probably all fortuitous.



Figure 24-3 Keratoderma in pityriasis rubra pilaris. Palmar (**A**) and plantar (**B**) erythema and waxy hyperkeratosis are frequent manifestations. Sometimes, there is an orange–yellow tint.

PATHOLOGY

Pathological findings in pityriasis rubra pilaris vary according to the duration of the disease. The findings are most likely to be diagnostic in the acute phase, when hyperkeratosis, acanthosis with broad short rete ridges and alternating orthokeratosis and parakeratosis oriented in both horizontal and vertical directions can be observed. Usually, there is a sparse superficial, perivascular lymphocytic infiltrate in the underlying dermis. Keratinous plugs of the follicular infundibula as well as perifollicular areas of parakeratosis may also be present. A prominent granular layer and dilated, but not tortuous capillaries are features that help to distinguish pityriasis rubra pilaris from psoriasis, its most important differential diagnosis.

DIFFERENTIAL DIAGNOSIS

See Box 24-1.



Figure 24-4 Juvenile pityriasis rubra pilaris. **A.** Confluence of lesions leads to extensive erythroderma. **B.** Characteristic scattered islands of unaffected skin are evident. So is the plantar hyperkeratosis.

BOX 24-1 DIFFERENTIAL DIAGNOSIS OF PITYRIASIS RUBRA PILARIS

Most Likely
- Localized
  - Psoriasis
  - Ichthyosis
- Generalized
  - Psoriasis
  - Erythrokeratoderma

Consider
- Localized
  - Follicular eczema
  - Lichen planus acuminatus
  - Keratosis pilaris
- Generalized
  - Pityriasis lichenoides chronica
  - Ichthyosiform erythroderma

Always Rule Out
- Generalized (therapy-resistant cases)
- HIV infection
- Cutaneous T-cell lymphoma

COMPLICATIONS

Systemic symptoms are uncommon except when generalized erythroderma occurs, and then they are comparable to those seen in exfoliative dermatitis (see Chapter 23). Occasionally, a mild ectropion may develop when the face becomes uniformly erythematous. Even though rare, moderate to severe pruritus or burning sensations may occur.

PROGNOSIS/CLINICAL COURSE

The classic adult disease (type I) usually remits completely within an average of 3 years. However, recurrences are recognized in up to 20% of patients, sometimes after long periods of subclinical disease. In the classic juvenile variant (type III) spontaneous clearing is commonly observed in 1 to 2 years. However, the atypical variants (type II and IV) have a less favorable prognosis for remission, some cases of type IV improve in late teens. Moreover, there is little or no tendency of type V to resolve spontaneously, improvements with retinoids have been described but relapses occurred when treatment was withdrawn. Clinical manifestations in the HIV-associated type VI are severe and occasionally fatal, with death occurring due to complications of cutaneous sepsis.

TREATMENT

(Box 24-2)

BOX 24-2 TREATMENTS FOR PITYRIASIS RUBRA PILARIS

FIRST LINE

Topical
- Emollients (water-in-oil emulsion)
- Keratolytics (salicylic acid, urea)
- Vitamin D3 (calcipotriol)

Physical
- Photochemotherapy (topical or systemic PUVA)
- Extracorporeal photopheresis

Systemic
- Retinoids (0.5–0.75 mg/kg acitretin/day)
- Methotrexate (10–25 mg weekly)
- Triple antiretroviral therapy[7] (HIV-associated variant)

SECOND LINE

Topical
- Glucocorticoids (medium to high potency)
- Vitamin A analogs (tazarotene)

Physical
- UVA1 phototherapy
- UVB (narrowband) phototherapy
- UVB phototherapy

Systemic
- Azathioprine (100–150 mg/day)
- Cyclosporine A (5 mg/kg/day)
- Fumaric acid esters[4]
- TNF-α antagonists[6]

Patients with pityriasis rubra pilaris are often irresponsive to multiple therapies, both topical and systemic.[3] Because of the relative rarity of the disease and its variable course, the chances for clinical trials assessing treatment options have been limited. Previous treatment strategies, which relied on megadoses of oral vitamin A or the anabolic steroid stanazol, proved to be largely ineffective.

Currently, oral retinoids are the first line of therapy in patients with pityriasis rubra pilaris. Isotretinoin has been reported to be of some value, although a comprehensive review suggests that acitretin may be more effective in clearing patients. Accordingly, most patients are treated first with acitretin. Alitretinoin, a novel panagonist retinoid (see Chapter 228), might be an alternative option for systemic treatment in patients refractory to conventional therapy. Treatment with methotrexate, using the guidelines established for psoriasis, has shown variable rates of success. Some cases respond well to photochemotherapy (PUVA), some may flare, and others require combination treatment with retinoids or methotrexate. In patients with severe symptoms, effective amelioration of the disease may require extracorporeal photopheresis but there are no evidence-based data.

Immunosuppressive agents are of inconsistent benefit. Thus, controversy persists about the role of cyclosporine in the treatment of pityriasis rubra pilaris. While most studies show lack of efficacy, several cases of adult-type pityriasis rubra pilaris showed significant clearance in 2–4 weeks. Some patients are helped by azathioprine, but this effect is also inconsistent. The use of glucocorticosteroids in the management of pityriasis rubra pilaris has been studied, but there is no evidence to suggest a beneficial effect. Whether phototherapy can be effective is controversial. Ultraviolet B (UVB) irradiation, which is efficiently used for psoriasis, has not been helpful or even worsened pityriasis rubra pilaris. UVA1 phototherapy may be a satisfactory alternative.

When conventional treatment strategies fail, new therapeutic approaches may include the use of immunomodulatory drugs. Fumaric acid esters were reported as successful in inducing remission in a patient with juvenile pityriasis rubra pilaris unresponsive to the usual treatment options.[4] Kerr and Ferguson reported a patient with type II adult-onset pityriasis rubra pilaris resistant to multiple therapies whose condition improved markedly with high-dose human intravenous immunoglobulin (IVIg) infusions.[5] Moreover, there is accumulating evidence indicating that blockade of tumor necrosis factor (TNF-α), which is beneficial in psoriasis and psoriasis–arthritis, is effective in the adult- and juvenile-onset types of pityriasis rubra pilaris as well.[6]

Topical treatment with keratolytics (where possible under an occlusive plastic dressing) has proved a valuable mode of adjuvant therapy in pityriasis rubra pilaris. For symptomatic relief, emollients and antihistamines provide significant benefit. Topical therapy with calcipotriol showed encouraging results. Its disadvantage is that total body treatment for the erythrodermic patient could be toxic. Success has been reported with topical aminonicotinamide 1%, although it is not commonly used.[3]

Pityriasis rubra pilaris associated with HIV infection has responded to triple antiretroviral therapy.[7]

Present therapeutic options (including drug doses) for pityriasis rubra pilaris used in adults and children are listed in Box 24-2.

PREVENTION

Pityriasis rubra pilaris is a rare, but socially and psychologically disabling condition, occurring in children and adults of both sexes. Suicide remains a risk in patients with generalized disease. Therefore, knowledge of the clinical pattern and cutaneous findings is crucial for an early therapeutic intervention, and may prevent protracted illness and serious complications in this clinically challenging condition.

KEY REFERENCES

DVD contains additional content

1. Griffiths WAD: Pityriasis rubra pilaris. *Clin Exp Dermatol* **5**:105, 1980
2. Batinac T et al: Pityriasis rubra pilaris in association with laryngeal carcinoma. *Clin Exp Dermatol* **34**:e917, 2009
3. Clayton BD et al: Adult pityriasis rubra pilaris: A 10-year case series. *J Am Acad Dermatol* **36**:959, 1997
4. Coras B et al: Fumaric acid esters therapy: A new treatment modality in pityriasis rubra pilaris? *Br J Dermatol* **152**:388, 2005
5. Kerr AC, Ferguson J: Type II adult-onset pityriasis rubra pilaris successfully treated with intravenous immunoglobulin. *Br J Dermatol* **156**:1055-1056, 2007
6. Müller H et al: Infliximab monotherapy as first-line treatment for adult-onset pityriasis rubra pilaris: Case report and review of the literature on biologic therapy. *J Am Acad Dermatol* **59**:S65, 2009
7. González-López A et al: HIV-associated pityriasis rubra pilaris responsive to triple antiretroviral therapy. *Br J Dermatol* **140**:931, 1999

Chapter 25 :: Parapsoriasis and Pityriasis Lichenoides

:: Gary S. Wood, Chung-Hong Hu, & Rosemarie Liu

PARAPSORIASIS

PARAPSORIASIS AT A GLANCE

- Also known as parapsoriasis en plaques.
- Parapsoriasis occurs worldwide and affects mainly adults.
- Large-plaque parapsoriasis (LPP) and small-plaque parapsoriasis (SPP) are recognized.
- Large and small "plaque" lesions actually present as flat patches rather than infiltrated plaques.
- Lesions are chronic and favor nonsun-exposed skin; LPP may be poikilodermatous.
- Pathology consists of superficial, mostly $CD4^+$ T-cell infiltrate; dominant clonality is more common in LPP than in SPP.
- LPP appears to exist on a continuum with patch-stage mycosis fungoides (MF) and progresses to overt MF at a rate of approximately 10% per decade.
- SPP has minimal risk of progression to overt MF in the experience of most experts.
- Treatment options include topical corticosteroids; ultraviolet B (UVB) irradiation, and psoralen and ultraviolet A (UVA) irradiation; excimer laser; and topical cytotoxic drugs.

HISTORICAL ASPECTS

The term parapsoriasis was coined originally by Brocq in 1902.[1] As shown in Table 25-1, the currently accepted classification of parapsoriasis includes large- and small-plaque forms of parapsoriasis en plaques (often referred to simply as *parapsoriasis*) as well as acute and chronic forms of pityriasis lichenoides [known today as *pityriasis lichenoides et varioliformis acuta* (PLEVA) and *pityriasis lichenoides chronica* (PLC), respectively].[2] Pityriasis lichenoides was first described in 1894 by Neisser[3] and Jadassohn.[4] In 1899, Juliusberg delineated the chronic form and named it PLC.[5] Mucha redescribed the acute form in 1916 and distinguished it from the chronic form.[6] Habermann named the acute variant PLEVA in 1925.[7] Mucha–Habermann disease is synonymous with PLEVA. Some authors regard lymphomatoid papulosis as a variant of pityriasis lichenoides, whereas others consider it to be a separate disease.[2,8–10] Lymphomatoid papulosis is discussed in Chapter 145 as part of the spectrum of $CD30^+$ cutaneous lymphoproliferative disorders.

EPIDEMIOLOGY

Large-plaque parapsoriasis (LPP) and small-plaque parapsoriasis (SPP) are, in general, diseases of middle-aged and older people, with a peak incidence in the fifth decade. Occasionally, lesions arise in childhood and may be associated with pityriasis lichenoides. SPP shows a definite male predominance of approximately 3:1. LPP is probably more common in males, but the difference is not as striking as in SPP. Both occur in all racial groups and geographic regions.

ETIOLOGY AND PATHOGENESIS

It is likely that a complete understanding of the pathogenesis of parapsoriasis will develop with our understanding of the pathogenesis of both chronic dermatitis and mycosis fungoides (MF), because parapsoriasis appears to bridge these disorders. The T cells that mediate most inflammatory skin diseases belong to the skin-associated lymphoid tissue (SALT).[11] These T cells express the cutaneous lymphocyte-associated antigen and traffic between the skin and the T-cell domains of peripheral lymph nodes via the lymphatics and bloodstream. MF (see Chapter 145) has been shown to be a neoplasm of SALT T cells. Sensitive polymerase chain reaction (PCR)-based tumor clonality assays have underscored the SALT nature of MF tumor clones by showing that they can continue to traffic after neoplastic transformation[12] and can even participate in delayed-type hypersensitivity reactions to contact allergens.[13] This implies that rather than being a skin lymphoma per se, MF is actually a SALT lymphoma, i.e., a malignancy of a T-cell circuit rather than of one particular tissue. Trafficking of MF tumor cells has been detected even in patients with very early stage disease whose lesions were consistent clinicopathologically with LPP.[12,14] Therefore, it can be said that at least in some cases LPP is a monoclonal proliferation of SALT T cells that have the capacity to traffic between the skin and extracutaneous sites.

TABLE 25-1
Classification of Parapsoriasis

1. Parapsoriasis en plaques
   A. Large-plaque parapsoriasis variants: poikilodermatous, retiform
   B. Small-plaque parapsoriasis variant: digitate dermatosis
2. Pityriasis lichenoides
   A. Pityriasis lichenoides chronica (Juliusberg)
   B. Pityriasis lichenoides et varioliformis acuta (Mucha–Habermann)

This view is also supported by the presence of structural and numerical chromosomal abnormalities in the peripheral blood mononuclear cells of patients with LPP.[15] In this context, LPP can be regarded as the clinically benign end of the MF disease spectrum, which eventuates in transformed large cell lymphoma at its malignant extreme. To say that these diseases belong to the same disease spectrum is not to say that they are biologically equivalent disorders. To lump them all together simply as "MF" would be to ignore their distinctive clinicopathologic features, which are likely due to genetic and/or epigenetic differences, such as the *p53* gene somatic mutations observed in some cases of large cell transformation of MF.[16–18] It is likely that several such differences separate these clinicopathologically defined disorders in a stepwise fashion analogous to the sequential acquisition of somatic mutations that occurs in the colon cancer disease spectrum as colonic epithelial cells progress through normal, hyperplastic, in situ carcinoma, invasive carcinoma, and metastatic carcinoma stages.[19,20]

A unifying feature of the parapsoriasis group of diseases is that all of them appear to be cutaneous T-cell lymphoproliferative disorders: LPP,[12,21–28] SPP,[23,28,29] pityriasis lichenoides,[28,30–32] and lymphomatoid papulosis[23,33–35] have all been shown to be monoclonal disorders in many cases.[36] These relationships suggest that progression from LPP through the various stages of the MF disease spectrum is accompanied by an increasing gradient of dominant T-cell clonal density resulting from mutations that confer increasing growth autonomy to the neoplastic T-cell clone.[37] Interestingly, analysis of peripheral blood has demonstrated that clonal T cells are often detectable in patients with LPP/early MF[27,28] or SPP,[28,38] which again supports the systemic SALT nature of these "primary" skin disorders.

Dominant clonality as seen in the parapsoriasis disease group, follicular mucinosis, pagetoid reticulosis, and certain other disorders does not equate to clinical malignancy. In fact, most patients with these diseases experience a benign clinical course, and in some cases the disease resolves completely. In addition, other types of chronic cutaneous T-cell infiltrates sometimes exhibit dominant clonality, including primary (idiopathic) erythroderma and nonspecific chronic spongiotic dermatitis. This has given rise to the concept of clonal dermatitis,[14,39] originally described in the context of clonal nonspecific chronic spongiotic dermatitis but later expanded to include other nonlymphomatous cutaneous T-cell infiltrates that harbor occult monoclonal T-cell populations. Several cases of clonal dermatitis, some of which have progressed to MF, have been identified.[14,21,39] We suspect that for each disease with a potential for progression to MF, the principal risk may reside in the subset showing clonal dermatitis, because this is the subset in which dysregulation has begun to occur.

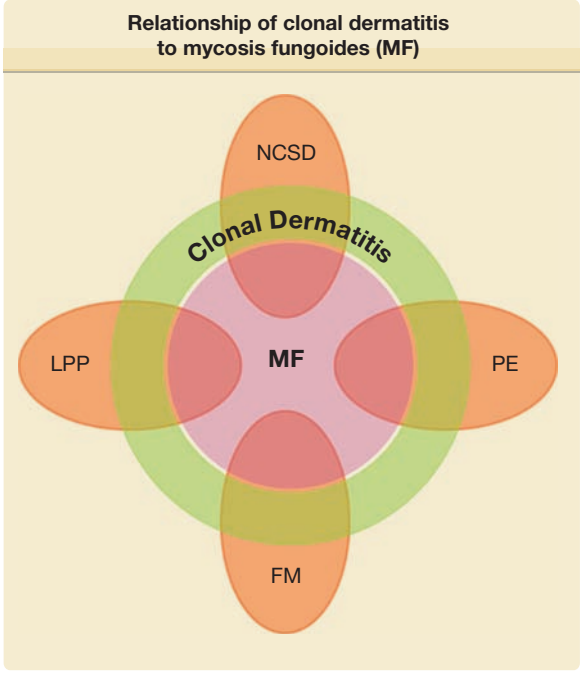

Figure 25-1 The relationship of clonal dermatitis to mycosis fungoides (MF) and various types of chronic dermatitis. The proportions of each entity that represent clonal dermatitis and mycosis fungoides vary with each disease and are not drawn to scale. FM = follicular mucinosis; LPP = large-plaque parapsoriasis; NCSD = nonspecific chronic spongiotic dermatitis; PE = primary erythroderma.

The postulated relationships among MF, clonal dermatitis, and selected types of chronic dermatitis are depicted in Fig. 25-1. Each of the entities shown is postulated to be at risk for MF through a clonal dermatitis intermediate. In this model, MF becomes the final common pathway for the clonal evolution of neoplastic T cells emerging from the polyclonal SALT T-cell populations present in each of the various precursor diseases.

Various viruses have been proposed to play a role in the pathogenesis of MF. None has been substantiated thus far. The most recent virus implicated in both LPP and MF is HHV-8; however, conflicting reports await resolution.[40–42]

CLINICAL FINDINGS

CUTANEOUS LESIONS. LPP lesions are either oval or irregularly shaped patches or very thin plaques that are asymptomatic or mildly pruritic. They are usually well marginated but may also blend imperceptibly into the surrounding skin. The size is variable, but typically most lesions are larger than 5 cm, often measuring



Figure 25-2 Large-plaque parapsoriasis. Irregularly shaped patches of variable size on the arm of a 16-year-old girl.

BOX 25-1 DIFFERENTIAL DIAGNOSIS OF POIKILODERMA

- Large-plaque parapsoriasis
- Dermatomyositis
- Lupus erythematosus
- Chronic radiation dermatitis
- Bloom syndrome
- Rothmund–Thomson syndrome
- Dyskeratosis congenita
- Xeroderma pigmentosum

more than 10 cm in diameter. Lesions are stable in size and may increase in number gradually. They are found mainly on the "bathing trunk" and flexural areas (Fig. 25-2). Extremities and the upper trunk, especially the breasts in women, also may be involved. They are light red–brown or salmon pink, and their surface is covered with small and scanty scales. Lesions may appear finely wrinkled—"cigarette paper" wrinkling. Such lesions exhibit varying degrees of epidermal atrophy. Telangiectasia and mottled pigmentation also are observed when the atrophy becomes prominent (Fig. 25-3). This triad of atrophy, mottled pigmentation, and telangiectasia defines the term *poikiloderma* or *poikiloderma atrophicans vasculare*, which also may be seen in other conditions (Box 25-1).

Retiform parapsoriasis refers to a rare variant of LPP that presents as an extensive eruption of scaly macules and papules in a net-like or zebra-stripe pattern that eventually becomes poikilodermatous (Fig. 25-4).

SPP characteristically occurs as round or oval discrete patches or very thin plaques, mainly on the trunk (Fig. 25-5). The lesions measure less than 5 cm in diameter; they are asymptomatic and covered with fine, moderately adherent scales. The general health of the patient is unaffected. A distinctive variant with lesions of a finger shape, known as *digitate dermatosis*,[43] has yellowish or fawn-colored lesions (Fig. 25-6). It follows lines of cleavage of the skin and gives the appearance of a hug that left fingerprints on the trunk. The long axis of these lesions often measures greater than 5 cm. Chronic superficial dermatitis is a synonym for SPP.[44] Digitate lesions with a yellow hue were referred to in the past as *xanthoerythrodermia perstans*.[2]



Figure 25-3 Large-plaque parapsoriasis. Poikilodermatous variant.



Figure 25-4 Large-plaque parapsoriasis. Retiform variant.



Figure 25-5 Small-plaque parapsoriasis. Small, discrete patches less than 5 cm in diameter.

LABORATORY TESTS

HISTOPATHOLOGY. In early LPP lesions, the epidermis is mildly acanthotic and slightly hyperkeratotic with spotty parakeratosis. The dermal lymphocytic infiltrate tends to be perivascular and scattered (Fig. 25-7). In the more advanced lesions one observes an interface infiltrate with definite epidermotropism. These invading lymphocytes may be scattered singly or in groups, sometimes associated with mild spongiosis. In addition, the poikilodermatous lesions show atrophic epidermis, dilated blood vessels, and melanophages (Fig. 25-8). Immunohistologic studies have revealed similar features in LPP and early MF, including a predominance of $CD4^+$ T-cell subsets, frequent CD7 antigen deficiency, and widespread epidermal expression of Class II HLA (HLA-DR).[22–24,45–48]

SPP exhibits mild spongiotic dermatitis with focal areas of hyperkeratosis, parakeratosis, scale crust, and exocytosis. In the dermis, there is a mild superficial perivascular lymphohistiocytic infiltrate and dermal edema (Fig. 25-9). There is no progression of the histologic features with time. Immunohistologic studies reveal a predominantly $CD4^+$ T-cell infiltrate with nonspecific features resembling those seen in various types of dermatitides.[47]

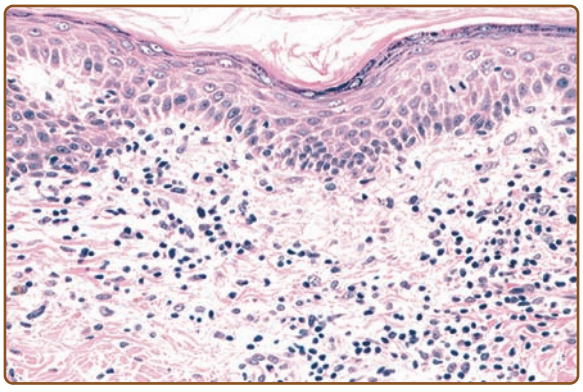

Figure 25-7 Large-plaque parapsoriasis. Mildly hyperkeratotic and focally parakeratotic epidermis with moderately dense superficial perivascular infiltrate. Lymphoid cells are mostly small, cytologically normal lymphocytes, and there is focal single-cell epidermotropism. (Used with permission from Helmut Kerl, MD.)

DIAGNOSIS AND DIFFERENTIAL DIAGNOSIS

LPP is distinguished from SPP by the larger size, asymmetric distribution, and irregular shape of its



Figure 25-6 Small-plaque parapsoriasis. Digitate dermatosis variant. Typical "fingerprint" patches on the flank. Note that their length often exceeds 5 cm.

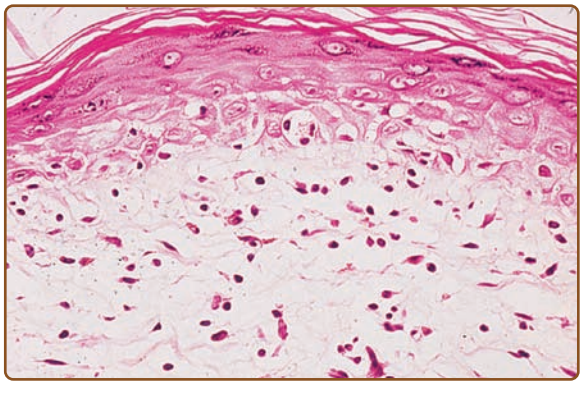

Figure 25-8 Large-plaque parapsoriasis. Atrophic variant. Sparse superficial lymphoid infiltrate with mild epidermotropism and epidermal atrophy.

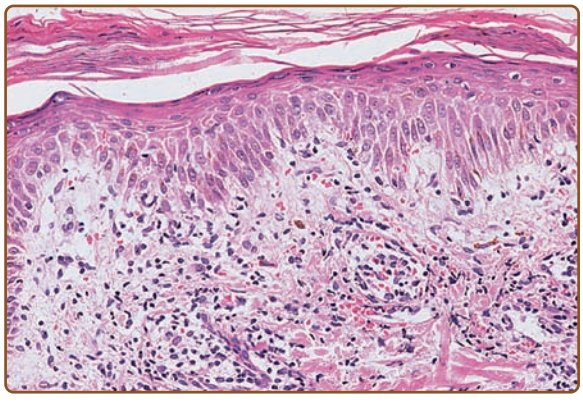

Figure 25-9 Small-plaque parapsoriasis. Superficial perivascular lymphoid infiltrate, mild spongiosis, parakeratosis, and focal scale crust.

lesions, which are less discrete and often poikilodermatous. LPP may be clinically and histopathologically indistinguishable from the patch stage of MF. Both LPP and SPP are readily distinguished from more advanced infiltrated plaques of MF because parapsoriasis lesions are, by definition, not thicker than patches or at most very thin plaques. This is so because the English equivalent of the French term *plaques* is *patches*, i.e., lesions that are essentially flat and devoid of induration or palpable infiltration.[49] Failure to appreciate this important distinction has led to considerable confusion and misuse of the terms *large-plaque parapsoriasis* and *small-plaque parapsoriasis* by some individuals. These designations more appropriately might be thought of as *large-patch parapsoriasis* and *small-patch parapsoriasis*.

The degree to which LPP is differentiated from early MF depends primarily on the histopathologic criteria used to diagnose the latter disorder. Unfortunately, there are no universally accepted minimal criteria for the diagnosis of MF; however, one set proposed by the International Society for Cutaneous Lymphoma is presented in Table 25-2.[50] This algorithm is based on a holistic integration of clinical, histopathologic, immunopathologic, and clonality data. It differs significantly from many prior approaches because it does not rely solely on histopathologic features.[51] Assuming that histopathologic examination does not disclose features diagnostic of some other dermatosis, these criteria allow lesions to be classified as either patch-stage MF or not. For the practical purposes of clinical management, patients presenting clinically with patch lesions whose features result in a score of four points or more are considered to have unequivocal MF. Obviously, the more liberal the criteria, the more cases could be considered to be MF. However, there will always be some cases that fail to meet any specific set of criteria, and the designation *LPP* is a useful term to apply to them because it guides treatment and follow-up and conveys an understanding that the risk of dying from lymphoma is small.

The clinical and/or histopathologic differential diagnosis of LPP also includes those collagen vascular diseases and genodermatoses exhibiting poikilodermatous features, lichenoid drug eruptions, secondary syphilis, chronic radiodermatitis, and occasionally several other diseases tabulated in Box 25-2. These

TABLE 25-2
Algorithm for the Diagnosis of Patch-Stage Mycosis Fungoides (Four Points are Required)

Parameter	2 Points	1 Point
Clinical: Persistent, progressive patches and plaques ± Nonsun-exposed distribution Variation in size and shape Poikiloderma	Any two	Any one
Histopathologic: Superficial dermal T-cell infiltrate ± Epidermotropism Nuclear atypia	Both	Either
Immunopathologic: CD2, CD3, or CD5 <50% CD7 <10% Epidermal–dermal discordance	Not applicable	Any one
Molecular biologic: Dominant T-cell clonality	Not applicable	Present

Note: Epidermotropism implies the lack of significant spongiosis (intraepidermal lymphoid cells associated with spongiosis is termed *exocytosis* rather than *epidermotropism*). Discordance refers to differential antigen expression between the epidermis and dermis, as opposed to the biopsy specimen as a whole.
From Pimpinelli N et al: Defining early mycosis fungoides. *J Am Acad Dermatol* **53**:1053, 2005, with permission.

BOX 25-2 DIFFERENTIAL DIAGNOSIS OF LARGE-PLAQUE PARAPSORIASIS (LPP) AND SMALL-PLAQUE PARAPSORIASIS (SPP)

Most Likely

- LPP
  - Tinea corporis
  - Plaque-type psoriasis
  - Contact dermatitis
  - Subacute cutaneous lupus erythematosus
- SPP
  - Nummular dermatitis
  - Pityriasis rosea
  - Plaque and guttate psoriasis
  - Pigmented purpuric dermatoses
  - Pityriasis lichenoides chronica

Consider

- LPP
  - Xerotic dermatitis
  - Atopic dermatitis
  - Dermatomyositis
  - Drug eruption
  - Erythema dyschromicum perstans
  - Pigmented purpuric dermatoses
  - Early inflammatory morphea
  - Atrophoderma of Pasini–Pierini
  - Erythema annulare centrifugum
  - Pityriasis rubra pilaris
  - Genodermatoses with poikiloderma
  - Chronic radiodermatitis
- SPP
  - Tinea versicolor
  - Seborrheic dermatitis
  - Drug eruption

Always Rule Out

- LPP
  - Mycosis fungoides
- SPP
  - Mycosis fungoides
  - Secondary syphilis

generally can be distinguished by their associated clinical findings. Histopathologic differentiation among these diseases is covered largely in the discussion of pseudo-MF in Chapter 146.

SPP, when it presents with its distinctive digitate dermatosis lesions parallel to skin lines in a truncal distribution, stands out from other types of parapsoriasis. Individual SPP lesions may show some superficial resemblance to PLC. SPP is distinguished from psoriasis by the absence of the Auspitz sign (see Chapter 18), micaceous scale, nail pits, and typical psoriatic lesions involving the scalp, elbows, and knees. Histologically, its mild spongiotic dermatitis and absence of other characteristic features distinguish it from PLC, psoriasis, and several of the other entities listed in Box 25-2. Clinical features are also important, such as the herald patch of pityriasis rosea and the papulovesicular coin-shaped patches favoring the lower extremities in nummular dermatitis.

Sometimes patients with MF may exhibit small patches of disease at presentation; however, these lesions typically have histopathologic features at least consistent with MF and generally are associated with larger, more classic lesions of MF elsewhere on the skin. They also may show poikilodermatous features not seen in SPP. Furthermore, the presence of well-developed, moderate to thick small plaques, as seen in some MF patients, is incompatible with the diagnosis of SPP because the latter disorder includes only lesions that are no more than patches or very thin plaques. It is also important to recognize that partially treated or early relapsing lesions of MF may show only nonspecific features that should not be taken as evidence of a pathogenetic link to SPP or any other dermatosis.

COMPLICATIONS

LPP can be associated with other forms of parapsoriasis and overt cutaneous lymphomas as detailed elsewhere in this chapter. Both LPP and SPP occasionally can develop areas of impetiginization secondary to excoriation.

PROGNOSIS AND CLINICAL COURSE

Both LPP and SPP may persist for years to decades with little change in appearance clinically or histopathologically. Approximately 10%–30% of cases of LPP progress to overt MF.[2,52–54] In this context, LPP represents the clinically benign end of the MF disease spectrum, with transformation to large cell lymphoma at the opposite extreme. The rare retiform variant is said to progress to overt MF in virtually all cases.[2]

In contrast to LPP with its malignant potential, SPP is a clinically benign disorder in the experience of most experts. Patients with this disease as defined in this chapter rarely develop overt MF.[11,44,55,56] Despite this fact and what most observers consider to be its nonspecific histopathologic features, some authors favor lumping SPP within the MF disease spectrum as a very early, nonprogressive variant.[55,57] This issue has been debated at length.[31,57,58] A few studies report progression from SPP to MF in about 10% of cases but may have used different criteria than described in this chapter.[53,54]

TREATMENT

Patients with SPP should be reassured and may forego treatment. The disease may be treated with emollients,

BOX 25-3 TREATMENT OF LARGE-PLAQUE PARAPSORIASIS AND SMALL-PLAQUE PARAPSORIASIS

FIRST LINE

- Emollients
- Topical corticosteroids
- Topical tar products
- Sunbathing
- Broadband UVB phototherapy
- Narrowband UVB phototherapy

SECOND LINE

(Mainly for large-plaque parapsoriasis cases considered to be early mycosis fungoides)

- Topical bexarotene
- Topical imiquimod
- Psoralen and UVA phototherapy
- Topical mechlorethamine
- Topical carmustine (BCNU)
- Excimer laser (308 nm)

topical tar preparations, topical corticosteroids, and/or broadband or narrowband UVB phototherapy (Box 25-3).[59] Response to therapy is variable. Patients should initially be examined every 3–6 months and subsequently every year to ensure that the character of the process is stable.

LPP requires more aggressive therapy: high-potency topical corticosteroids with phototherapy such as broadband UVB, narrowband UVB, or psoralen and UVA (PUVA). The goal of treatment is to suppress the disorder to prevent possible progression to overt MF. Other methods of treatment, such as topical nitrogen mustard, have been used, particularly for the poikilodermatous type. Localized lesions may respond to excimer laser (308 nm).[60,61] The patient should be examined carefully every 3 months initially and every 6 months to 1 year subsequently for evidence of progression. Repeated multiple biopsies of suspicious lesions should be performed. Cases that satisfy the clinicopathologic criteria for early MF can be treated with broadband UVB, narrowband UVB, PUVA, topical nitrogen mustard, topical bexarotene gel, topical imiquimod, or topical carmustine (BCNU).[62] Electron-beam radiation therapy generally is reserved for more advanced, infiltrated lesions of MF.

PREVENTION

Because LPP and SPP are uncommon diseases that appear to affect patients randomly, there are no known preventive measures.

PITYRIASIS LICHENOIDES

PITYRIASIS LICHENOIDES AT A GLANCE

- Pityriasis lichenoides et varioliformis acuta (PLEVA) and pityriasis lichenoides chronica (PLC) represent two ends of a disease spectrum; both entities and intermediate forms can coexist.
- All forms are characterized by spontaneously resolving, temporally overlapping crops of papules.
- PLEVA papules last for weeks and may develop crusts, vesicles, pustules, or ulcers.
- PLC papules persist for months and develop scales.
- All forms contain interface, cytolytic T-cell infiltrates with variable epidermal destruction.
- In PLEVA, $CD8^+$ cells predominate.
- In PLC, $CD8^+$ or $CD4^+$ cells predominate.
- Dominant T-cell clonality can be detected in all forms, more often in PLEVA than in PLC.
- Treatment depends on severity and ranges from topical steroids, systemic antibiotics, UV irradiation, and psoralen and UVA to systemic immunosuppressants.

EPIDEMIOLOGY

Pityriasis lichenoides affects all racial and ethnic groups in all geographic regions.[63–68] It is more common in children and young adults but can affect all ages with seasonal variation in onset favoring fall and winter. There is a male predominance of 1.5:1 to 3:1. PLC is three to six times more common than PLEVA.

ETIOLOGY AND PATHOGENESIS

The etiology of pityriasis lichenoides is unknown. Some cases have been associated with infectious agents such as *Toxoplasma gondii*,[69,70] Epstein-Barr virus,[70,71] cytomegalovirus,[70,71] parvovirus B19,[70,72,73] and human immunodeficiency virus.[74,75] At least one case was linked repeatedly with estrogen–progesterone therapy, another with chemotherapy drugs, and a third with radiocontrast iodide.[76–78] It is uncertain

whether these agents are actively involved in disease pathogenesis or merely coincidental bystanders; however, several cases associated with toxoplasmosis have cleared fairly quickly in response to specific therapy.[69] A tenfold higher level of maternal keratinocytes have been reported in the epidermis of children with PL compared to controls.[79]

Immunohistologic studies have shown a reduction in $CD1a^+$ antigen-presenting dendritic (Langerhans) cells within the central epidermis of pityriasis lichenoides lesions.[80] Keratinocytes and endothelial cells are $HLA\text{-}DR^+$, which suggests activation by T-cell cytokines.[80] $CD8^+$ T cells predominate in PLEVA, whereas either $CD8^+$ or $CD4^+$ T cells predominate in PLC.[80–82] Many of these T cells express memory proteins (CD45RO) and cytolytic proteins (TIA-1 and granzyme B).[72,73] Dominant T-cell clonality has been demonstrated in about half of PLEVA cases and a minority of PLC cases.[32,83,84] In aggregate, these findings raise the possibility that pityriasis lichenoides is a variably clonal cytolytic memory T-cell lymphoproliferative response to one or more foreign antigens. Deposition of immunoglobulin M, C3, and fibrin in and around blood vessels and along the dermal–epidermal junction in early acute lesions suggests a possible concomitant humoral immune response, although this could be a secondary phenomenon.

The relationship of pityriasis lichenoides to lymphomatoid papulosis remains controversial[10,51,80] (see also Chapters 145 and 146). Common features include dominant T-cell clonality and spontaneous resolution of papular, predominantly lymphoid lesions. Furthermore, individual lesions with the clinicopathologic characteristics of either pityriasis lichenoides or lymphomatoid papulosis can coexist in the same patient, either concurrently or serially. It remains to be determined whether this can be explained as an artifact of sampling lymphomatoid papulosis lesions at various stages of their evolution. The presence of large $CD30^+$ atypical lymphoid cells is the hallmark of lymphomatoid papulosis (at least types A and C).[84] Furthermore, these cells are typically $CD4^+$ and often lack one or more mature T-cell antigens such as CD2, CD3, and CD5. These features serve to distinguish lymphomatoid papulosis from pityriasis lichenoides. Although occasional $CD30^+$ cells can be seen in a wide variety of dermatoses, the presence of any appreciable number should favor lymphomatoid papulosis over pityriasis lichenoides as a matter of definition. It may be that the "PLC-PLEVA" and "lymphomatoid papulosis–$CD30^+$ anaplastic large cell lymphoma" disease spectra are intersecting rather than overlapping entities, i.e., although pityriasis lichenoides is a distinct cutaneous T-cell disorder, it is possible that it may sometimes serve as fertile soil for the development of the $CD30^+$ T-cell clone characteristic of lymphomatoid papulosis.

CLINICAL FINDINGS

CUTANEOUS LESIONS. PLC and PLEVA exist on a clinicopathologic continuum.[2,51] Therefore, individual patients may exhibit a mixture of acute and chronic lesions sequentially or concurrently. In addition, lesions representing clinical or histopathologic intergrades between the extremes may also occur at any time.



Figure 25-10 Pityriasis lichenoides chronica. Polymorphous appearance ranging from early erythematous papules to scaling brown–red lesions and tan-brown involuting, flat papules, and macules.

Lesions are often asymptomatic but can be pruritic or burning, especially in the more acute cases. PLC typically presents as recurrent crops of erythematous scaly papules that spontaneously regress over several weeks to months (Fig. 25-10). PLEVA manifests as recurrent crops of erythematous papules that develop crusts, vesicles, pustules, or erosions before spontaneously regressing within a matter of weeks (Fig. 25-11). The more severe ulcerative variant is known as *pityriasis lichenoides with ulceronecrosis and hyperthermia (PLUH)* or *febrile ulceronecrotic Mucha–Habermann disease (FUMHD)*.[85] It presents as purpuric papulonodules with central ulcers up to a few centimeters in diameter (Fig. 25-12). Some have proposed that this severe variant is actually an overt T-cell lymphoma.[31] Pityriasis lichenoides lesions tend to concentrate on the trunk and proximal extremities, but any region of the skin and even mucous membranes can be involved. Rare regional or segmental lesion distributions have been described,[10,86] as has rare conjunctival nodular inflammation.[87] Although there are usually numerous coexistent lesions, occasionally only a small number of lesions will be present at any one time. All forms of pityriasis lichenoides can result in postinflammatory hypopigmentation or hyperpigmentation.[63] Chronic lesions can resolve with



Figure 25-11 Pityriasis lichenoides et varioliformis acuta. **A.** Adolescent with multiple erythematous papules and crusted lesions in various stages of evolution. **B.** Larger papulovesicular and hemorrhagic, crusted lesions in an adult. Note varioliform scars adjacent to active lesions on posterior thigh and leg. **C.** Pustules, crusts, and necrotic-centered papules with erythematous, indurated base.

postinflammatory hypopigmentation, sometimes presenting as idiopathic guttate hypomelanosis. Chronic lesions rarely lead to scars. In contrast, acute lesions result in deeper dermal injury and consequently often resolve leaving varioliform (smallpox-like) scars. The presence of lesions in various stages of evolution imparts a polymorphous appearance that is characteristic of pityriasis lichenoides.



Figure 25-12 Pityriasis lichenoides, ulceronecrotic, hyperacute variant. Large necrotic eschar with halo erythema developing in febrile patient with antecedent pityriasis lichenoides et varioliformis acuta.

LABORATORY TESTS

Miscellaneous nonspecific abnormalities in blood test results occur but are of little practical value. Leukocytosis and a decreased CD4/CD8 ratio can occur.

HISTOPATHOLOGY. As with the morphology of the clinical lesions, pityriasis lichenoides can exhibit a range of histopathologic features encompassing acute, chronic, and intermediate lesional variants (Figs. 25-13 and 25-14). All cases of pityriasis lichenoides contain an interface dermatitis that is denser and more wedge shaped in the acute lesions. The infiltrate is composed mainly of lymphocytes with a variable admixture of neutrophils and histiocytes. There is exocytosis, parakeratosis, and extravasation of erythrocytes. Epidermal damage ranges from intercellular and extracellular edema in less severe cases to extensive keratinocyte necrosis, vesicles, pustules, and ulcers. The acute variants can exhibit lymphocytic vasculitis with fibrinoid degeneration of blood vessel walls.

Occasional $CD30^+$ lymphoid cells and occasional atypical lymphoid cells may be seen as a nonspecific finding in many cutaneous lymphoid infiltrates. The

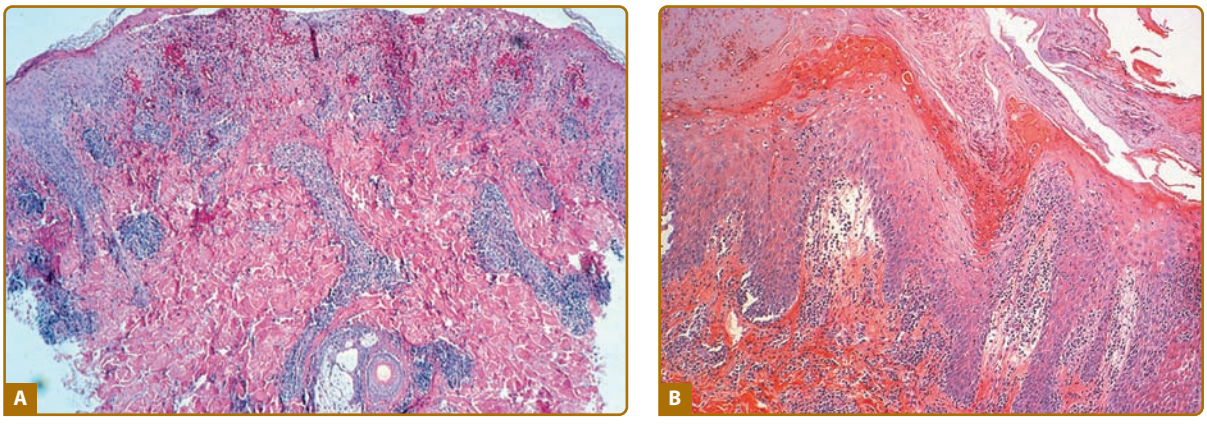

Figure 25-13 Pityriasis lichenoides et varioliformis acuta. **A.** Ulcerated papule with epidermal necrosis, hemorrhage, and superficial and deep perivascular lymphocytic infiltrate. Hematoxylin and eosin (H&E) stain. **B.** Parakeratosis and crust with marked spongiosis and epidermal necrosis. Lymphocyte exocytosis and basal hydropic changes. H&E stain.

presence of an appreciable numbers of these cells is not consistent with classic pityriasis lichenoides of any type and should raise concern for the lymphomatoid papulosis–CD30$^+$ anaplastic large cell lymphoma disease spectrum.[30] Other immunohistologic features and the clonality of pityriasis lichenoides are discussed in Section "Etiology and Pathogenesis" under Section "Pityriasis Lichenoides."

DIFFERENTIAL DIAGNOSIS

The differential diagnosis of pityriasis lichenoides includes many papular eruptions (Box 25-4). Those that develop crusts, vesicles, pustules, or ulcers are grouped with PLEVA, whereas those that form predominantly scaly papules are grouped with PLC. Most of them can be excluded based on history and typical clinicopathologic features. A few, such as secondary syphilis and virus-associated lesions, can also be excluded based on serologic tests. Among the most challenging diseases to distinguish from pityriasis lichenoides are lymphomatoid papulosis and macular or papular variants of MF.[88–91] As detailed earlier, the presence of large atypical lymphoid cells (often CD30$^+$) differentiates lymphomatoid papulosis from pityriasis lichenoides.[84] Macular or papular variants of MF are rare. They exhibit classic histopathological features of MF, including small atypical epidermotropic lymphoid cells with convoluted nuclei and a band-like superficial dermal lymphoid infiltrate.[90]

COMPLICATIONS

Secondary infection is the most common complication of pityriasis lichenoides. PLEVA may be associated with low-grade fever, malaise, headache, and arthralgia. Patients with PLUH/FUMHD can develop high fever, malaise, myalgia, arthralgia, and gastrointestinal and central nervous system symptoms. Occasionally, debilitated patients may die.[85,92] PLC has been associated uncommonly with LPP in children.[44] Despite their sometimes dominant T-cell clonal nature, PLC and PLEVA are considered clinically benign disorders

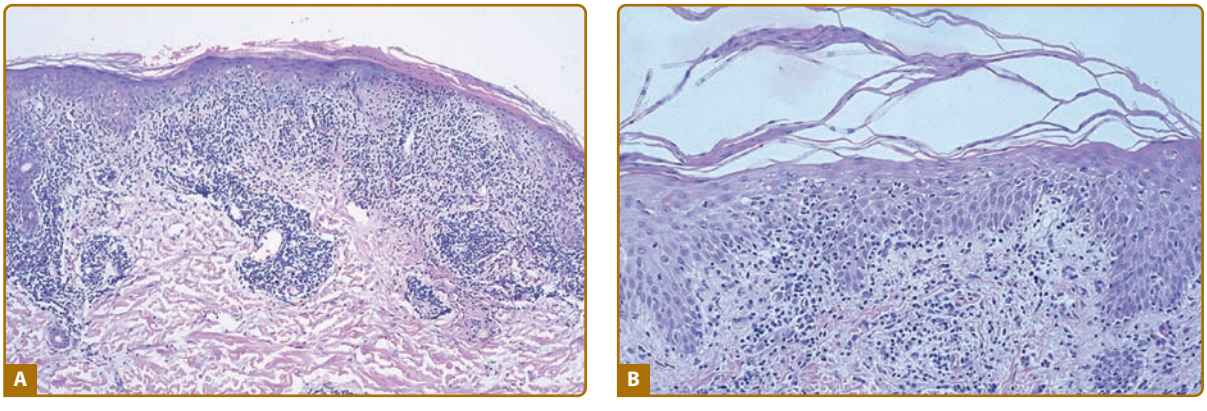

Figure 25-14 Pityriasis lichenoides chronica. **A.** Compact parakeratosis, lymphocytic exocytosis, occasional eosinophilic necrotic keratinocytes, edema, and diffuse lymphocytic infiltrate localizing to epidermal–dermal interface and perivascular sites within the dermis. Hematoxylin and eosin (H&E) stain. **B.** Parakeratosis, spongiosis, and a predominant mononuclear cell infiltrate in the epidermis and dermis with papillary edema. H&E stain.

BOX 25-4 DIFFERENTIAL DIAGNOSIS OF PITYRIASIS LICHENOIDES ET VARIOLIFORMIS ACUTA (PLEVA) AND PITYRIASIS LICHENOIDES CHRONICA (PLC)

Most Likely

- PLEVA
  - Arthropod bites, stings, infestations
  - Leukocytoclastic vasculitis
  - Viral exanthem (e.g., varicella-zoster, herpes simplex)
- PLC
  - Pityriasis rosea
  - Drug eruption
  - Guttate psoriasis

Consider

- PLEVA
  - Folliculitis
  - Rickettsiosis
  - Erythema multiforme
  - Dermatitis herpetiformis
- PLC
  - Spongiotic dermatitis, papular variant
  - Small-plaque parapsoriasis
  - Lichen planus
  - Gianotti–Crosti syndrome

Always Rule Out

- PLEVA
  - Lymphomatoid papulosis
  - Secondary syphilis
- PLC
  - Lymphomatoid papulosis
  - Mycosis fungoides (papular variant)
  - Secondary syphilis

BOX 25-5 TREATMENT OF PITYRIASIS LICHENOIDES ET VARIOLIFORMIS ACUTA AND PITYRIASIS LICHENOIDES CHRONICA

FIRST LINE

- Topical corticosteroids
- Antibiotics (erythromycin 500 mg PO 2–4 × daily[96]; tetracycline 500 mg PO 2–4 × daily,[97] minocycline 100 mg PO twice daily; azithromycin 500 mg PO on day 1 and 250 mg PO on days 2–5 bimonthly[93])
- Phototherapy (sunbathing, UVB,[90] UVA + UVB,[98] narrowband UVB[99])

SECOND LINE

- Topical tacrolimus[100,101]
- Prednisone (60/40/20 mg PO taper, 5 days each)[102]
- Methotrexate (10–25 mg PO weekly)[103,104]
- Phototherapy (UVAI, psoralen + UVA)
- Cyclosporine (2.5–4 mg/kg/day total dose divided into twice-daily PO doses; use the minimum)[75]
- Retinoids (e.g., acitretin 25–50 mg PO daily)[105]
- Photodynamic therapy[94]
- Bromelain (pineapple extract)[95]

without significant linkage to lymphomas or other malignancies.

PROGNOSIS AND CLINICAL COURSE

Pityriasis lichenoides has a variable clinical course characterized by recurrent crops of lesions that spontaneously resolve. The disorder may resolve spontaneously within a few months or, less commonly, persist for years. PLEVA usually has a shorter duration than PLC. Although the conclusion was not confirmed by subsequent investigation, one report suggested that the duration of pityriasis lichenoides in children correlated better with its clinical distribution than with the relative abundance of acute and chronic lesions, which often coexisted.[67] From longest to shortest duration, the distribution of lesions ranged from peripheral (distal extremities) to central (trunk) to diffuse.

TREATMENT

The mainstay of traditional therapy has been a combination of topical corticosteroids and phototherapy (Box 25-5). Systemic antibiotics in the tetracycline and erythromycin families are used primarily for their anti-inflammatory rather than antibiotic effects. One newer option is azithromycin.[93] Cases with minimal disease activity may not require any treatment. Photodynamic therapy has been used successfully for PLC.[94] The more acute the clinical course and the more severe the individual lesions, the more systemic therapy is indicated. Methotrexate is often effective in relatively low doses. Calcineurin inhibitors and retinoids may also be beneficial. Severe cases of PLEVA and PLUH often require systemic corticosteroids or similar drugs to gain control of systemic symptoms. Topical and systemic antibiotics may be needed to treat secondary infections complicating ulcerated skin lesions. These agents are often selected initially to cover Gram-positive pathogens, but subsequent use should be guided by culture results. Bromelain, a pineapple extract, cleared PLC lesions in 8/8 cases.[95]

PREVENTION

There are no known preventive measures.

KEY REFERENCES

Full reference list available at www.DIGM8.com

DVD contains references and additional content

2. Lambert WC, Everett MA: The nosology of parapsoriasis. *J Am Acad Dermatol* **5**(4):373-395, 1981
39. Wood GS et al: Detection of clonal T-cell receptor gamma gene rearrangements in early mycosis fungoides/Sezary syndrome by polymerase chain reaction and denaturing gradient gel electrophoresis (PCR/DGGE). *J Invest Dermatol* **103**(1):34-41, 1994
43. Hu CH, Winkelmann RK: Digitate dermatosis. A new look at symmetrical, small plaque parapsoriasis. *Arch Dermatol* **107**(1):65-69, 1973
44. Samman PD: The natural history of parapsoriasis en plaques (chronic superficial dermatitis) and prereticulotic poikiloderma. *Br J Dermatol* **87**(5):405-411, 1972
50. Pimpinelli N et al: Defining early mycosis fungoides. *J Am Acad Dermatol* **53**(6):1053-1063, 2005
53. Vakeva L et al: A retrospective study of the probability of the evolution of parapsoriasis en plaques into mycosis fungoides. *Acta Derm Venereol* **85**(4):318-323, 2005
64. Bowers S, Warshaw EM: Pityriasis lichenoides and its subtypes. *J Am Acad Dermatol* **55**(4):557-572, 2006; quiz 573-556
65. Ersoy-Evans S et al: Pityriasis lichenoides in childhood: A retrospective review of 124 patients. *J Am Acad Dermatol* **56**(2):205-210, 2007
66. Khachemoune A, Blyumin ML: Pityriasis lichenoides: Pathophysiology, classification, and treatment. *Am J Clin Dermatol* **8**(1):29-36, 2007
85. Sotiriou E et al: Febrile ulceronecrotic Mucha-Habermann disease: A case report and review of the literature. *Acta Derm Venereol* **88**(4):350-355, 2008

Chapter 26 :: Lichen Planus

:: Mazen S. Daoud & Mark R. Pittelkow

LICHEN PLANUS AT A GLANCE

- Worldwide occurrence: Less than 1%.
- Lesions: Symmetric, grouped, erythematous to violaceous, flat-topped, polygonal papules.
- Distribution: Widespread, predilection for flexural aspects of arms and legs.
- Variants: Based on configuration, morphology of lesion, and site of involvement.
- Pathology: Basal epidermal keratinocyte damage and lichenoid interface lymphocytic reaction.

Lichen planus (Greek *leichen*, "tree moss"; Latin *planus*, "flat") is a unique, common inflammatory disorder that affects the skin, mucous membranes, nails, and hair. The appearance of lichen planus-like lichenoid dermatoses has been likened to the scurfy, finely furrowed, dry excrescences of the symbiotic vegetation known as *lichen*. Although this morphologic comparison may be antiquated, lichen planus is a distinctive entity with prototypic "lichenoid" papules that show distinctive color and morphology, develop in typical locations, and manifest characteristic patterns of evolution. Microscopic features are also distinctive, although the microscopic pattern of inflammation and skin response is shared by several dermatoses. The term *lichenoid reaction*[1] is the histologic description used to capsulize the pathologic characteristics of skin diseases resembling lichen planus.

The four Ps—(1) purple, (2) polygonal, (3) pruritic, and (4) papule—is the mnemonic device often used to recall the constellation of symptoms and skin findings that characterize lichen planus.

HISTORICAL ASPECTS

EPIDEMIOLOGY

The exact incidence and prevalence of lichen planus are unknown, but the overall prevalence is believed to be somewhat around 1% of the general population. Estimates between 0.14% and 1.27% have been reported worldwide and approximately 0.44% in the United States. No racial predilection has been observed.[2,3]

At least two-thirds of cases occur between the ages of 30 and 60 years of age. No sexual predilection is evident. Females are usually affected in their 50s and 60s, whereas males develop lichen planus at a somewhat earlier age. The disease is less common in the very young and the elderly. The development of lichen planus may be affected by seasonal or environmental factors.[2]

Fewer than 100 cases of familial lichen planus have been reported. The familial form tends to be more protracted and severe and presents in erosive, linear, or ulcerative patterns or with atypical features affecting young adults and children.[4] Some believe that the familial form represents a separate, unique dermatosis.

Different HLA haplotypes were reported in familial lichen planus, including HLA-B7, -Aw19, -B18, and -Cw8. In nonfamilial lichen planus, HLA-A3, -A5, -A28, -B8, -B16, and -Bw35 are more common.[5] HLA-B8 is more common in patients with oral lichen planus as a sole manifestation, and HLA-Bw35 is more strongly associated with cutaneous lichen planus.

ETIOLOGY AND PATHOGENESIS

It is evident that specific immunologic mechanisms control the development of lichen planus. T-cell mediated pathologic alterations involving proinflammatory and counterregulatory mechanisms function in the pathogenesis of lichen planus.[6] No consistent alterations in immunoglobulins (Igs) have been shown in lichen planus, and humoral immunity most likely is a secondary response in immunopathogenesis.

Cell-mediated immunity, on the other hand, plays the major role in triggering the clinical expression of the disease. Both $CD4^+$ and $CD8^+$ T cells are found in lesional skin of lichen planus. Progression of disease may lead to preferential accumulation of $CD8^+$ cells. The majority of lymphocytes in the infiltrate of lichen planus are $CD8^+$ and CD45RO (memory) positive cells and express the α–β T-cell receptor (TCR), and in a minority, the γ–δ receptor. This later cell subtype is not normally found in healthy skin. These cells are considered responsible for the development of the most characteristic change observed in the lichenoid reaction, namely, apoptosis.[7] The inflammatory process that leads to apoptosis is complex and not fully understood. The epithelium–lymphocyte interaction can be divided into three major stages: (1) antigen recognition, (2) lymphocyte activation, and (3) keratinocyte apoptosis.

LICHEN PLANUS-SPECIFIC ANTIGEN RECOGNITION

It is evident that the majority of T cells in the infiltrate of lichen planus, both within the epithelium and adjacent to damaged basal keratinocytes, are activated $CD8^+$ cytotoxic lymphocytes. Evidence from oral lichen planus suggests that $CD8^+$ lesional T cells recognize a lichen planus-specific antigen associated with major histocompatibility complex (MHC) class I on lesional keratinocytes. The nature of this antigen is unknown. Theoretically, the antigen may be an autoreactive peptide, thus classifying lichen planus as an autoimmune disease. Alternatively, it may represent an exogenous antigen such as an altered protein, drug, contact allergen, viral or infectious agent, or an unidentified immunogenic target. Innate immune responses that become activated by exogenous stimuli in a genetically susceptible individual may trigger the development of lichen planus and, further, involves a small but significant lesional population of $CD56^+CD16^-$ NK lymphocytes that secrete interferon-γ, tumor necrosis factor (TNF)-α, and only minimal amounts of IL-22, IL-17, or IL-4.

The role of T-helper (CD4) cells in the pathogenesis of lichen planus is not fully defined. T cells may become activated via professional antigen-presenting cells such as Langerhans cells, dendritic cells, or accessory cells such as epidermal keratinocytes in association with members of the MHC II and specific cytokines. T-helper lymphocytes may also propagate $CD8^+$ cytotoxic lymphocytes through cellular cooperation and release of cytokines.

The nature of antigenic stimulation is not known. Contact sensitizers such as metals could act as haptens and elicit an immunologic response. Enhanced lymphocyte reactivity to inorganic mercury, a component of dental amalgam, has been found in patients with oral lichenoid reactions. Low-grade chronic exposure to mercury, and possibly to other metals such as gold, may stimulate a lymphocytic reaction that manifests as lichen planus. A list of contact chemicals and drugs that can elicit lichenoid reactions is discussed in Section "Drug-Induced Lichen Planus." With more widespread use of biologics for various chronic inflammatory diseases, cases of lichenoid, interface dermatitis are being recognized and implicate dysregulated cytokine production, including upregulation of type-I interferon expression in the setting of tumor necrosis factor (TNF)-α blockage.[8] The role of infection in the development of lichen planus has been repeatedly raised over the years. Though provocative, no conclusive evidence has molecularly linked lichen planus to any of the following infections or microorganisms: syphilis, herpes simplex virus 2, human immunodeficiency virus (HIV), amebiasis, chronic bladder infections, hepatitis C virus (HCV), *Helicobacter pylori*, or human papillomavirus.

CYTOTOXIC LYMPHOCYTE ACTIVATION

Following antigen recognition, $CD8^+$ T cells are activated. Activated cytotoxic lymphocytes undergo lesional tissue clonal expansion, leading to oligoclonal and occasionally to monoclonal proliferation as detected by analysis of the TCR-γ chain gene products.

Activated lymphocytes, both by helper subsets (Th1 and Th2) and cytotoxic-suppressor cells, release soluble mediators (cytokines and chemokines), such as interleukin (IL)-2, IL-4, IL-10, interferon (IFN)-γ, tumor necrosis factor (TNF)-α, and transforming growth factor-β1, that attract lymphocytes and regulate their biologic activities within and adjacent to the epithelium. Both pro- and anti-inflammatory cytokines, i.e., mixed Th1 and Th2 cytokine products, are generated simultaneously. The balance between lymphocytic activation and down regulation determines the clinical behavior of the disease. IFN-γ, produced by T-helper cells during the antigen recognition stage, induces keratinocytes to produce lymphotoxin-α and TNF-α, and to upregulate MHC class II, thus increasing interactions with T-helper cells. Furthermore, IFN-γ upregulates the expression of intercellular adhesion molecule-1 and vascular cell adhesion molecule-1 by basal keratinocytes, Langerhans cells, and other

macrophage-dendritic cells. IFN-γ and IL-4 are elevated in saliva from oral lichen planus. Intercellular adhesion molecule-1 is a ligand for the β_2-integrin, leukocyte function-associated antigen-1, on the surface of lymphocytes, which further enhances the interaction of these lymphocytes with the antigen-presenting cells. Laminin-5 and collagen types IV and VII are increased in lesional lichen planus and serve as ligands for β1-integrin on the surface of lymphocytes, thus allowing for enhanced association of lymphocytes with the basement membrane. Integrin α3 is present on activated, skin-homing T cells and may localize these effector cells to the epidermal–dermal interface and basement membrane, which contain epiligrin/laminin-5, a ligand for this integrin. This close interaction between lymphocytes and basement membrane targets metalloproteinases produced by lymphocytes to alter extracellular matrix proteins and integrins, and the process eventuates in apoptosis, basement membrane disruption, reduplication, and subepidermal cleft formation (see Section "Pathology"). TNF-α upregulates the expression of matrix metalloproteinase (MMP)-9 mRNA in lesional T lymphocytes, thus further enhancing basement membrane disruption (see Section "Keratinocyte Apoptosis").[9]

Keratinocytes also participate in the response by producing IL-1β, IL-4, IL-6, granulocyte–macrophage colony-stimulating factor, and TNF-α. These cytokines further activate tissue macrophages and peripheral blood mononuclear cells and upregulate expression of cell surface adhesion molecules and migration activity. Keratinocyte-produced cytokines also upregulate expression of specific keratin genes. Keratin (K)17, usually restricted to adnexal structures, is variably expressed in the basal and suprabasal layers of the interfollicular epithelium of affected epidermis. K6 and K16 also become detectable in the basal and suprabasal layers. K4 and K13 are reduced in the suprabasal compartment in areas with orthokeratosis, associated with increased production of K1 and K10.

KERATINOCYTE APOPTOSIS

The exact mechanisms used by activated cytotoxic T cells to trigger apoptosis of keratinocytes are not completely known. Possible mechanisms include: (1) T-cell secreted TNF-α binding to the TNF-α R1 receptor on the keratinocyte surface, (2) T-cell surface CD95L (Fas ligand) binding CD95 (Fas) on the keratinocyte, and (3) T-cell secreted granzyme B entering the keratinocyte via perforin-induced membrane pores. In lichen planus, granzyme B predominates in lesional epidermis versus perforin in graft-versus-host disease.[10] All these mechanisms may activate the keratinocyte caspase cascade, resulting in keratinocyte apoptosis. Caspase 3 is frequently found to be elevated in both cutaneous and oral lichen planus lesional skin.[11]

Recruited lymphocytes may further contribute to apoptosis via a different mechanism, the loss of a basement membrane-derived cell survival signal that normally prevents the onset of apoptosis. Hence, basement membrane disruption may trigger apoptosis. Principle mediators are the MMPs, a family of zinc-containing endoproteinases that primarily function to degrade connective tissue matrix proteins. The action of these enzymes is also regulated by inhibitors such as tissue inhibitors of metalloproteinases (TIMPs) (see Chapter 63). It has been shown that lesional T cells in lichen planus have higher MMP-9 levels than peripheral blood T cells. Lesional T-cell MMP-9 activity increases following stimulation with TNF-α, but not TIMP-1, an inhibitor for MMP-9. These observations suggest that T-cell secreted MMP-9 disrupts epithelial basement membranes, blocking cell survival signals to keratinocytes and inducing apoptosis.

Various other environmental, behavioral, or infectious factors have been observed on occasion to be associated with the development or exacerbation of lichen planus. However, no well-established association has been documented between emotional stress, tobacco use, or oral or gastrointestinal candidiasis and development of lichen planus.

SPECIFIC AND GLOBAL GENE RESPONSES.

Recent studies using microarray technologies to examine and characterize in greater detail various inflammatory and immune-mediated skin diseases have provided considerable new insights into mechanisms mediating-specific inflammatory responses, including lichen planus, oral lichen planus, lichen planopilaris as well as lichenoid eruptions, and interface dermatitis. Lichen planus was distinguished from atopic dermatitis, psoriasis, and healthy skin by elevated expression of type I interferon-induced genes and a specific cytokine expression pattern.[12] CXCL9, the ligand for CXCR3 was the most significant marker for lichen planus. In the scarring alopecias, specifically lichen planopilaris, microarray analysis implicates the loss of peroxisome proliferator-activated receptor (PPAR) γ expression in contributing to proinflammatory lipid accumulation and inflammatory cell infiltration leading to pilosebaceous destruction.[13] Recently, Brn2, a transcription factor expressed by keratinocytes as well as lymphocytes, when overexpressed in epidermis, has been found to not only cause epidermal changes characteristic of lichen planus but also inflammatory, interface cellular reactivity.[14]

CLINICAL FINDINGS

CUTANEOUS LESIONS

The classic cutaneous lesion of lichen planus is a faintly erythematous to violaceous, flat-topped, polygonal papule, sometimes showing a small central umbilication (Fig. 26-1). Papules are grouped and tend to coalesce. A thin, transparent, and adherent scale may be discerned atop the lesion. Fine, whitish puncta or reticulated networks referred to as *Wick-ham striae* are present over the surface of many well-developed papules (see Fig. 26-1). These are considered to be highly characteristic and are more easily observed after applying oil, xylene, or water and visualizing the



Figure 26-1 Flat-topped, polygonal, sharply defined papules of violaceous color, grouped and confluent. Surface is shiny and reveals fine white lines (Wickham striae). Note pigmentation of resolving lesions.



Figure 26-2 Generalized lichen planus. Small, flat-topped violaceous papules, some grouped, some disseminated, becoming confluent on the trunk.

lesions with a magnifying lens or a handheld dermatoscope. The surface alteration may result from localized thickening of the keratohyalin-containing cell layers of the stratum granulosum, although a focal increase in the activity of lichen planus may account for the morphologic alteration of Wickham striae.

Lichen planus usually develops over several weeks. Sometimes multiple lesions develop rapidly with dissemination following the initial appearance. In generalized disease (Fig. 26-2), the eruption often spreads within 1–4 months from onset. The initial lesions almost always appear on the extremities, especially the legs.

The lesions are usually distributed symmetrically and bilaterally over the extremities. Lichen planus tends to involve the flexural areas of the wrists, arms, and legs (see Fig. 26-1). The thighs, lower back, trunk, and neck may also be affected. Oral mucous membranes (Fig. 26-3) and the genitalia (Fig. 26-4) are additional sites of involvement. The face is usually spared in classical cases, and palmoplantar involvement is unusual. Inverse lichen planus usually affects the axillae, groin, and inframammary areas.

Lichen planus tends to be quite pruritic, although some patients are completely asymptomatic. The degree of pruritus is generally related to the extent of involvement, with more intense pruritus in generalized form. An exception is hypertrophic lichen planus, which is more localized but extremely pruritic. Oral involvement is generally asymptomatic unless erosions or ulcers developed, after which it becomes extremely painful. In the acute, evolving stages of the disease, scratching, injury, or trauma may induce an isomorphic (Koebner) response (Fig. 26-5). Lichen planus usually heals with hyperpigmentation (see Fig. 26-1), which is more prominent among patients with darker skin color. Hypopigmentation uncommonly develops after resolution of lesions.

Most reports of lichen planus in children have come from the Indian subcontinent, suggesting that children

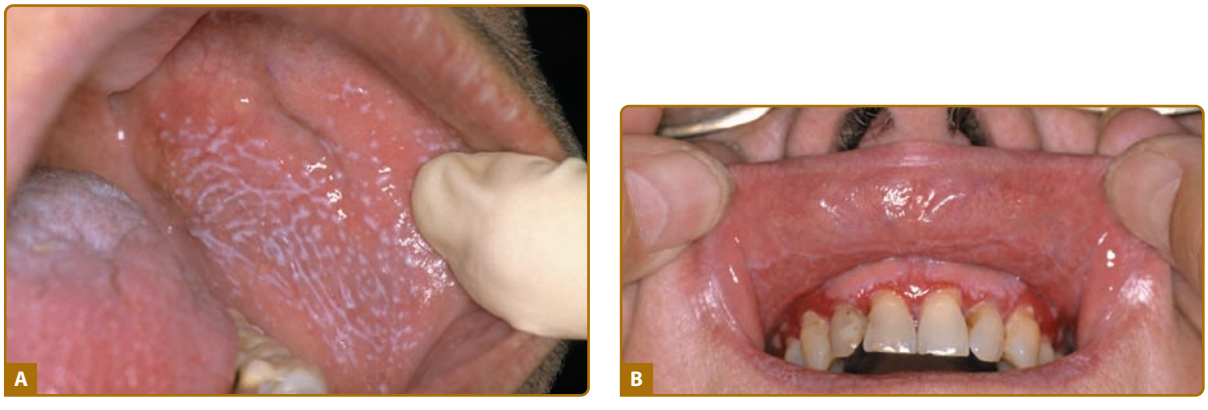

Figure 26-3 Mucosal lichen planus. **A.** A typical lace-like whitish reticulated pattern of oral lesions is seen on the buccal mucosa. **B.** Erosive gingivitis. Here lichen planus manifests as painful erosions on the gingiva.



Figure 26-4 Lichen planus on the penis. Agminate pattern of lesions involving the glans, sulcus, and meatus (not seen) of the penis.

of South Asian origin are more susceptible to developing lichen planus.[15] Although the clinical and pathologic features of childhood lichen planus are similar to those in adults, scalp, nail, and hair involvement are not common. Mucous membrane involvement, thought to be rare, may occur in up to one-third of patients. The hypertrophic variant occurs in one-fourth of children with lichen planus.



Figure 26-5 Lichen planus. Linear pattern with Koebner response adjacent to clustered papules on the flexural wrist.

CLINICAL VARIANTS

Many variations in the clinical presentation have been described and are generally categorized according to (1) the configuration of lesions, (2) the morphologic appearance, or (3) the site of involvement. These variations are patterned by subtle or unknown properties of the disease. The prototypic papule can be altered or modified in configuration, morphology, or anatomic distribution.

CONFIGURATION OF LESIONS

Annular Lichen Planus. Annular lesions occur in approximately 10% of cases and commonly develop as arcuate groupings of individual papules that develop rings or peripheral extension of clustered papules with central clearing. They tend to occur in blacks and are more common on the penis and scrotum (see Chapter 75). It occurs also when larger lesions on trunk and extremities reach 2–3 cm in diameter and become hyperpigmented with a raised outer rim. Actinic lichen planus (see below), seen in subtropical zones on sun-exposed, dark-skinned young adults and children, is frequently annular in shape.

Linear Lichen Planus. Papules of lichen planus may develop a linear pattern secondary to trauma (koebnerization) (see Fig. 26-5) or, rarely, in less than 0.2% of cases as a spontaneous, isolated eruption, usually on the extremities following Blaschko lines. The segmental formation is thought to be due to a postzygotic mutation that affects one of the genes predisposing its development that lead to the formation of a keratinocyte clone that is more susceptible to development of lichen planus.[16] Drug-induced linear lichen planus has also been reported.[17,18]

It is important to differentiate linear lichen planus from nevus unius lateris, lichen striatus, inflammatory linear verrucous epidermal nevus, linear psoriasis, and linear Darier–White disease, which have different presentations clinically and histopathologically.

MORPHOLOGY OF LESIONS

Hypertrophic Lichen Planus. Hypertrophic lichen planus (*lichen planus verrucosus*) usually occurs on the extremities, especially the shins and interphalangeal joints, and tends to be the most pruritic variant (Fig. 26-6).[19] Lesions are thickened and elevated, purplish or reddish-brown in color, and hyperkeratotic. Occasionally, verrucous plaques develop. Lesions may show accentuated and elevated follicular induration and chalk-like scale. This variant usually heals with scar formation and hyper- or hypopigmentation. Chronic venous insufficiency is frequently present.

Atrophic Lichen Planus. The atrophic variant is rare and is characterized by the presence of a few

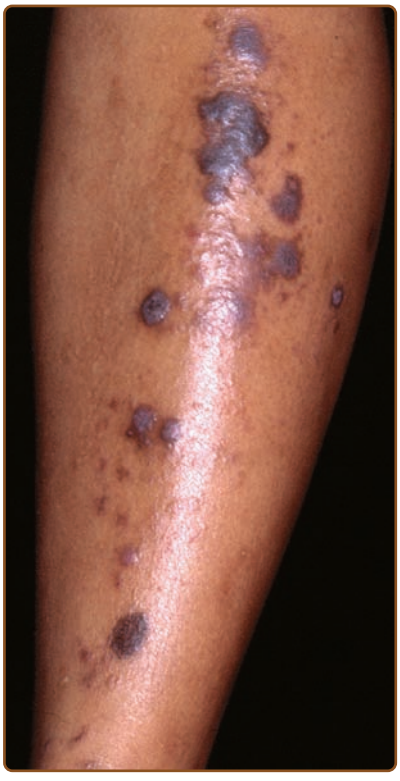

Figure 26-6 Hypertrophic lichen planus in the pretibial region of a dark-skinned individual. Lesions are almost nodular and very dark with the violaceous sheen of lichen planus. Lesions may later become hyperkeratotic.

well-demarcated, white-bluish papules or plaques, sometimes more erythematous, with central superficial atrophy.[2] The lesions are a few millimeters wide but may coalesce to form larger plaques. They are most common on the lower extremities or trunk. The lesions often resemble *lichen sclerosus et atrophicus*. However, the histologic features are diagnostic.

Vesiculobullous Lichen Planus. The development of vesicles and bullae in lichen planus is rare. (Fig. 26-7). The bullae, which appear most commonly on the extremities, arise from existing papules of lichen planus and rarely from normal-appearing skin. They may appear suddenly during an acute flare of disease and are usually associated with mild constitutional symptoms. These lesions usually resolve in a few months.



Figure 26-7 Vesiculo-bullous lichen planus. Vesicles and bullae with violaceous-erythematous papules and plaques on the foot.



Figure 26-8 Erosive–ulcerative lichen planus showing erosions, ulcers, and granulation tissue and scarring of toes, interdigital web spaces, and soles.

Bulla arising in oral lichen planus can lead to painful erosions. Histologically, subepidermal separation is present in addition to typical features. Bullae formation does not necessarily indicate a longer duration of the disease. Bullae arising from normal skin are more characteristic of *lichen planus pemphigoides* and should be differentiated by direct and indirect immunofluorescence (see below).

Erosive and Ulcerative Lichen Planus. A rare variant presents with chronic, painful bullae and ulcerations of the feet with often, cicatricial sequelae (Fig. 26-8). Patients typically have nails, and mucosal involvement in addition to classical skin lesions, which often aids in establishing the diagnosis. Permanent loss of toenails and cicatricial alopecia of the scalp are common. Squamous cell carcinoma (SCC) may develop in lesions of ulcerative lichen planus.[20]

Erosions and ulcerations may also develop in more severe cases of oral lichen planus.

Follicular Lichen Planus. Follicular lichen planus may occur alone or in association with other forms of cutaneous or mucosal lichen planus.[16] The term *lichen planopilaris* has been used to describe this distinctive variant, but other terms include *lichen planus follicularis*, *peripilaris*, and *acuminatus*. Individual keratotic follicular papules and studded plaques are seen. Sites of predilection include the trunk and medial aspects of the proximal extremities.[21] Follicular lichen planus may affect the scalp with the development of cicatricial alopecia (see Section "Lichen Planus of the Scalp"; Fig. 26-9). The triad of follicular lichen planus of skin (lichen planus spinulosus) and/or scalp, multifocal cicatricial alopecia of the scalp, and nonscarring alopecia of the axillary and pubic areas, has been described as Graham–Little–Piccardi–Lassueur (or Graham–Little–Feldman) syndrome. Sometimes more typical lesions of the skin and nails are seen. Other variants of follicular lichen planus include the *lichen planus follicularis tumidus* with oval pseudotumoral plaques of the mastoid area, postmenopausal frontal fibrosing alopecia,[22] and lichen planoporitis, with the lichenoid

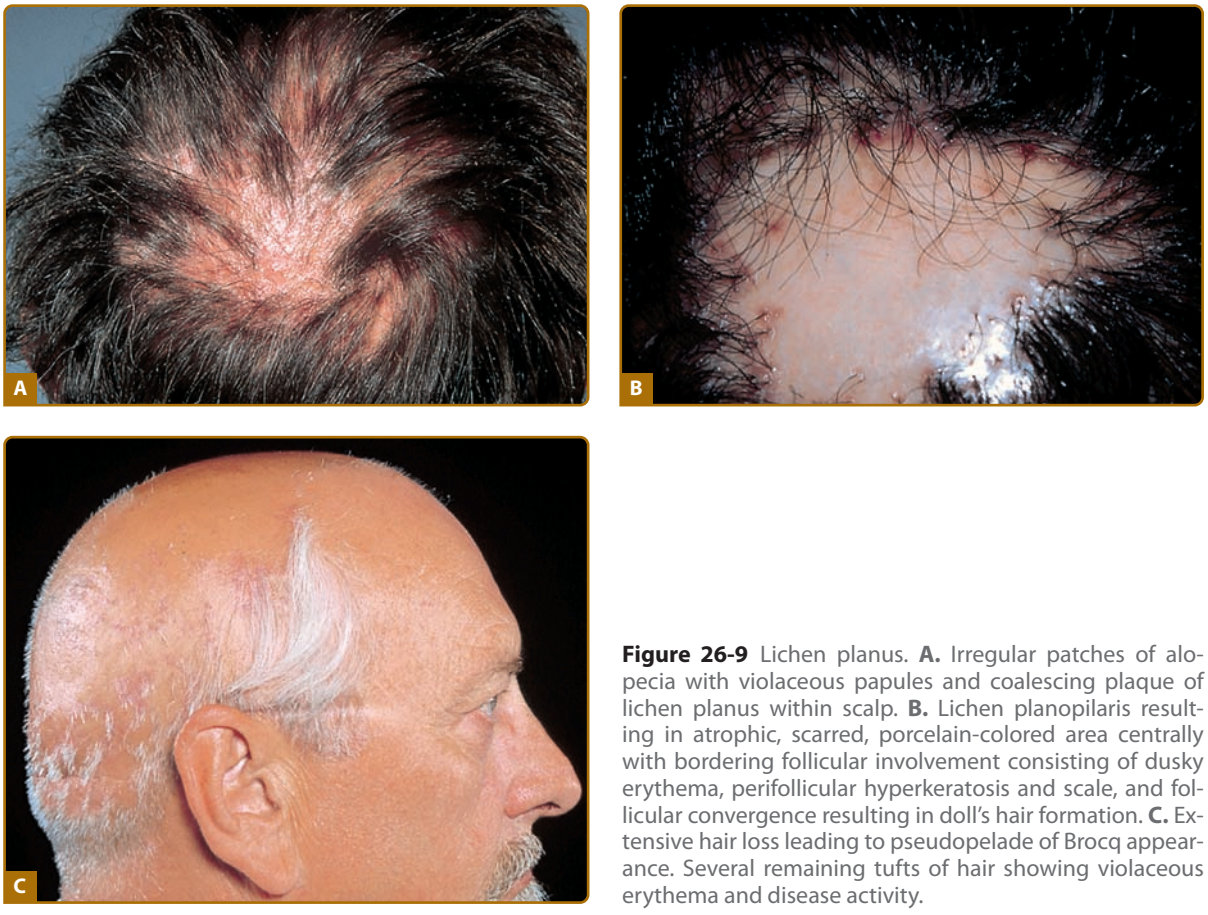

Figure 26-9 Lichen planus. **A.** Irregular patches of alopecia with violaceous papules and coalescing plaque of lichen planus within scalp. **B.** Lichen planopilaris resulting in atrophic, scarred, porcelain-colored area centrally with bordering follicular involvement consisting of dusky erythema, perifollicular hyperkeratosis and scale, and follicular convergence resulting in doll's hair formation. **C.** Extensive hair loss leading to pseudopelade of Brocq appearance. Several remaining tufts of hair showing violaceous erythema and disease activity.

reaction centered over the acrosyringium and eccrine ducts entering the epidermis.

Lichen Planus Pigmentosus. This variant is characterized by hyperpigmented, dark-brown macules in sun-exposed areas and flexural folds. This entity tends to occur in patients with darker pigmented skin. Histologically, an atrophic epidermis, a vacuolar alteration of the basal cell layer with a scarce lymphohistiocytic lichenoid infiltrate, and pigment incontinence are seen. This variant bears significant similarity to ashy dermatosis or *erythema dyschromicum perstans*. It may represent an overlap in the phenotypic spectrum of lichenoid inflammation in darkly pigmented skin, with ethnic and genetic factors influencing the expression of disease (see Chapter 75).[23] In cases where the inflammatory phase was minimal, such as lichen planus "invisible de Gougerot," the pigmentation may be the only sign of the disease.

Actinic Lichen Planus. Also known as *lichen planus subtropicus*, *lichen planus tropicus*, *summertime actinic lichenoid eruption*, *lichen planus actinicus*, *lichen planus atrophicus annularis*, and *lichenoid melanodermatosis*. Actinic lichen planus affects young people of the Middle East in spring and summer, where sunlight appears to have a precipitating effect. Exposed areas of the face, dorsal hands and arms, and the nape of the neck are usually affected. Papules are hyperpigmented with violaceous-brown color and a thready, rolled edge showing well-defined borders. Annular lesions are common, but pigmented and linear forms were seen.[24,25] Typical lichen planus lesions may be present over the extremities. Pruritus and scaling are minimal.

Other Variants. A perforating variant has been described in which transepidermal elimination of lichen planus-like inflammatory tissue is observed. Guttate lichen planus is another variant that resembles guttate psoriasis but with the characteristic lichenoid histology. Exfoliative and exanthematous forms are very rare and may represent manifestations of lichenoid drug reactions (Fig. 26-10). The rare entity of invisible lichen planus describes lesions that are not perceptible with visible light illumination but become apparent with Wood's lamp examination. Pruritus is present and biopsy evaluation shows lichenoid histology. This entity may be a minimal variant of lichen planus "invisible de Gougerot."

SITE OF INVOLVEMENT

Lichen Planus of the Scalp. Lichen planopilaris (LPP) or follicular lichen planus may affect the scalp in a distinctive clinical and histologic pattern that affect women more than men.[26–30] LPP can be subdivided into three variants: (1) classic LPP, (2) frontal fibrosing alopecia, and (3) Lassueur–Graham–Little–Piccardi



Figure 26-10 Lichen planus-like eruption. Generalized violaceous papules with superficial scale coalescing to form erythematous variant. History of associated drug exposure leading to lichenoid reaction.

syndrome. In classic LPP, individual keratotic follicular papules that coalesce and merge over the scalp to form patches are typically seen. Perifollicular erythema and acuminate keratotic plugs are characteristic features. Follicular-centered lesions are usually observed under close inspection of the scalp and orifices, particularly at the margins of the alopecic area or within patches still bearing hair. Cutaneous, nail, or mucous membrane involvement with lichen planus may also be present. Patients present with uni- or multifocal hair loss that may be extensive and sometimes involve the entire scalp (see Fig. 26-9). The condition can have major psychological impact on affected individuals.

End-stage disease is characterized by a nondescript scarring alopecia that has led to the use of several clinical terms describing the entity: *lichen planopilaris*, *folliculitis decalvans et atrophicus*, *lichen spinulosus at folliculitis decalvans*, and Graham–Little syndrome.

Frontal fibrosing alopecia is an uncommon condition characterized by progressive frontotemporal recession due to inflammatory destruction of hair follicles. It is more common in postmenopausal women, but it can occur in younger women. It may be associated with mucocutaneous lichen planus. Recession of the hairline may progress inexorably over many years, but this is not inevitable.[22,31]

Pseudopelade of Brocq is a rare clinical syndrome of scarring alopecia and fibrosis, in which distinct pathologic features are absent. It is generally accepted that pseudopelade of Brocq is the end stage of follicular fibrosis caused by a primary inflammatory dermatosis such as lichen planus, lupus erythematosus, pustular-scarring forms of folliculitis, or fungal infections, including favus, scleroderma, and sarcoidosis.

Mucosal Lichen Planus. Lichen planus can affect the mucosal surfaces of mouth, vagina, esophagus, conjunctiva, urethra, anus, nose, and larynx. Its prevalence is estimated at approximately 1% of the adult population. Oral involvement occurs in approximately 60%–70% of patients with lichen planus. It may be the only manifestation in 20%–30% of patients.

In *oral lichen planus*, different types have been described, including reticular, plaque-like, atrophic, papular, erosive/ulcerative, and bullous forms (see Fig. 26-3).[32,33] The reticular pattern is considered the most common, but patients with erosive form are more likely to seek medical help due to the symptomatology (pain and burning sensation) and chronicity. Most patients have more than one type. The buccal, gingival, and glossal mucosae are the most commonly affected areas. The palate, floor of the mouth, retromolar pads, and lips may also be affected. Gingival involvement may take the form of gingival stomatitis or desquamative gingivitis, and could be the sole presentation in 8% of oral lichen planus. On the other hand, lichen planus is the most common cause for desquamative gingivitis.[34]

Oral lichenoid reaction is similar clinically and histologically to oral lichen planus, however, with identifiable etiology. Differentiating these two entities is often difficult. It is usually seen on the buccal mucosa adjacent to amalgam dental fillings.[35,36] Patch tests frequently show positive reactions to mercury, gold, and other metals.[37,38]

Bilateral reticular keratotic or atrophic changes of the buccal mucosa and lichenoid atrophic patches over the dorsal tongue have been described in patients with HIV infection. The eruptions usually follow zidovudine or ketoconazole intake.

Esophageal Lichen planus is rare and affects the proximal esophagus. It manifests as progressive dysphagia and odynophagia. Endoscopic findings can include lacy white papules, pinpoint erosions, desquamation, pseudomembranes, and stenosis. Histologically, it shows parakeratosis, epithelial atrophy, and lack of hypergranulosis. Squamous cell carcinoma of esophagus may develop after longstanding disease.[39,40]

Male genitalia are involved in 25% of cases, and the glans penis is most commonly affected, with annular lesions frequently present (see Fig. 26-4). *Anal lesions* of mucosal lichen planus present with leukokeratosis, hyperkeratosis, fissuring, and erosions (Fig. 26-11).

Vulvar and vaginal lichen planus is present in over half of patients with oral lichen planus.[41] Clinically, the condition is often asymptomatic unless erosions develop.



Figure 26-11 Lichen planus. Perianal leuko- and hyperkeratosis with hypertrophic, folded violaceous epithelium, fissures, and healing biopsy site.

Burning, itching, pain and abnormal discharge then become common.[42] Examination reveal patches of leukoplakia or erythroplakia, sometimes with erosions, and, occasionally, as a more generalized desquamative vaginitis. Vaginal adhesions and labial agglutination may result.

The *vulvo-vaginal gingival syndrome* is characterized by involvement of vulvar and gingival tissues. Erythema and erosions of the gingivae and tongue and, occasionally, white reticulated plaques, is associated with desquamation and erosions of vulva and vagina.[43]

Conjunctival lichen planus may manifest as cicatricial conjunctivitis. Histologically, irregular thickening with reduplication of the basement membrane is seen. Direct immunofluorescence distinguishes ophthalmic lichen planus from cicatricial pemphigoid.

Lichen Planus of the Nails. (See also Chapter 89.) Nail involvement occurs in 10%–15% of patients.[44] Lichen planus limited to the nails is uncommon, and the initial involvement is followed, in many cases, by the development of typical lesions elsewhere. Lichen planus of nails is infrequent in children. Thinning, longitudinal ridging, and distal splitting of the nail plate (onychoschizia) are the most common findings. Onycholysis, longitudinal striation (onychorrhexis), subungual hyperkeratosis, or even absence (anonychia) of the nail plate can also be seen. Twenty-nail dystrophy (trachyonychia) may represent an isolated nail finding of lichen planus. Psoriasis and alopecia areata can also lead to these distinctive nail changes. Nail loss may result from ulcerative lichen planus involving the nail unit. Pterygium or forward growth of the eponychium with adherence to the proximal nail plate is a classic finding of lichen planus of the nail (Fig. 26-12). An atrophic cicatrizing form of lichen planus with random and progressive nail loss in Asians and blacks has also been reported. The tenting or pup-tent sign is observed as a result of nail bed involvement that elevates the nail plate and may cause longitudinal splitting.[2]

Inverse Lichen Planus. The inverse pattern occurs only rarely and is characterized by red-brownish, discrete papules, and nodules. The eruption occurs mainly in the flexural areas such as axillae, inframammary, groin, and, less likely, the popliteal and antecubital areas. Koebnerized lesions are occasionally present.



Figure 26-12 Lichen planus. Classic pterygium formation and tenting of several fingers with loss of nail plates.

Palmoplantar Lichen Planus. This is a rare variant that is difficult to diagnose if present as an isolated finding. Very pruriginous, erythematous, scaly plaques with or without hyperkeratosis are characteristic. Lesions are often seen on the internal plantar arch. Yellowish, compact keratotic papules or papulonodules are seen on the lateral margins of the fingers and hand surfaces; however, they are less likely to affect the fingertips. They appear like callosities with an inflammatory, erythematous halo. The lesions resemble psoriasis vulgaris, warts, calluses, porokeratosis, hyperkeratotic eczema, tinea, or secondary syphilis.[45] Palmoplantar lichen planus may also present as erosive–ulcerative type (see Section "Erosive and Ulcerative Lichen Planus").

SPECIAL FORMS OF LICHEN PLANUS OR LICHENOID ERUPTIONS

Drug-Induced Lichen Planus. Lichen planus-like or lichenoid eruptions describe a group of cutaneous reactions identical or similar to lichen planus (see Fig. 26-10).[46] *Lichenoid drug eruptions* have been reported after ingestion, contact, or inhalation of certain chemicals (Table 26-1). They may be localized or generalized with eczematous papules and plaques and variable desquamation. They typically manifest postinflammatory hyperpigmentation and alopecia, and do not exhibit classic Wickham striae. The eruptions usually appear symmetrically on the trunk and extremities, unlike the flexural distribution of classic lichen planus. Mucous membrane involvement is less common and is often associated with specific drugs and chemicals. A *photodistributed pattern* is often found in sun exposed areas, and several drugs frequently induce this reaction (see Table 26-1).

The latency period for development of a lichenoid drug eruption by these agents varies from months to a year or more based on the dosage, host response, previous exposure, and concomitant drug administration. Resolution of the eruptions is quite variable, but most disappear in 3–4 months, except in gold-induced lichenoid eruption that may require up to 2 years after discontinuation. For many inciting drugs, the severity and extent of the eruption influences the rate of clearance. Occasionally, the lichenoid drug eruption disappears or may recur intermittently despite continuation of treatment.

Lichenoid contact dermatitis may result from contact with compounds such as color film developers, dental restoration materials, metals (e.g., mercury, silver, and gold), and aminoglycoside antibiotics.[46] *Oral lichenoid drug eruptions* are mostly related to dental restoration metals such as mercury, silver, and gold.

Lichen Planus–Lupus Erythematosus Overlap Syndrome. This is a rare variant characterized by lesions that share features of lichen planus and lupus erythematosus. Atrophic plaques and patches with hypopigmentation and a livid red to blue–violet color with telangiectasia and minimal scaling are characteristic. Transient bullae may develop. Classic lesions of lichen planus, photosensitivity,

TABLE 26-1
Agents Inducing Lichen Planus and Lichenoid Reactions

Common inducers
- Gold salts
- β blockers
- Antimalarials
- Diuretics; Thiazide, Furosemide, Spironolactone
- Penicillamine

Less common
- ACE inhibitors
- Calcium channel blockers
- Sulfonylurea
- Nonsteroidal anti-inflammatory drugs
- Ketoconazole
- Tetracycline
- Phenothiazine
- Sulfasalazine
- Carbamazepine
- Lithium
- Antituberculosis
- Iodides
- Radiocontrast media
- Radiotherapy
- Antipsoriatic therapy: Etanercept, Infliximab, Adalimumab
- Omalizumab

Inducers of lichen planus by contact
- Color film developers
- Dental restorative materials
- Musk ambrette
- Nickel
- Gold

Inducers of photodistributed lichenoid eruption
- 5-Fluorouracil (Efudex)
- Carbamazepine (Tegretol)
- Chlorpromazine (Compazine, Thorazine)
- Diazoxide (Proglycem)
- Ethambutol
- Pyritinol
- Quinine
- Quinidine (Quinaglute)
- Tetracycline
- Thiazide
- Furosemide (Lasix)

Inducers of oral lichen planus and lichenoid eruption
- Allopurinol (Zyloprim)
- ACE inhibitors
- Cyanamide
- Dental restorative materials, Mercury, Silver, Gold
- Gold salts
- Ketoconazole (Ketoconazole)
- Nonsteroidal anti-inflammatory drugs
- Penicillamines (Cuprimine)
- Sulphonylurea
- Interferon-α and Ribavirin

ACE = angiotensin-converting enzyme.



Figure 26-13 Lichen planus–lupus erythematosus overlap syndrome. Lichenoid lesions involving dorsal hand and forearm with direct immunofluorescence evidence of lupus erythematous.

pruritus, and follicular plugging are also not common. Lesions may develop anywhere, but are most common on the extremities (Fig. 26-13). Some patients with this overlap syndrome may progress to systemic lupus erythematosus. In other instances, laboratory evaluation may reveal only a weak-positive antinuclear antibody. This disease variant is characterized by a prolonged course and lack of response to treatment. Histologically, a lichenoid reaction typical for lichen planus and histologic features of lupus erythematosus are usually present in the same biopsy.[47] By direct immunofluorescence, cytoid bodies staining with IgG, IgM, and C3 intraepidermally or at the dermal–epidermal junction, as seen in classic lichen planus, are most common. Linear to granular deposition of IgM and C3 (as seen in lupus erythematosus, but not in lichen planus) and shaggy deposition of fibrinogen at the basement membrane zone, typical of lichen planus have been observed occasionally.[47]

Lichen Planus Pemphigoides. *Lichen Planus Pemphigoides* is characterized by the development of tense blisters atop lesions of lichen planus or the development of vesicles de novo on uninvolved skin or oral mucosa (Fig. 26-14). It is important to differentiate this entity from bullous lichen planus, in which blisters develop in lesions of long-standing lichen planus as a result of intense lichenoid inflammation and extensive liquefaction degeneration of basal keratinocytes. The etiology of this variant is not clear. It was proposed that basal cell keratinocyte damage by lymphocytes in lichen planus may unmask hidden antigenic



Figure 26-14 Lichen planus pemphigoides. Lichenoid maculopapular erythema, erosions, and bullae with direct immunofluorescence showing features of bullous pemphigoid. Indirect immunofluorescence also was positive.

determinants and lead to autoantibody formation and induction of bullous lesions. Captopril was described to induce this entity also.[48] Histologic findings resemble those of lichen planus. Direct immunofluorescence shows linear deposition of IgG and C3 at the dermal–epidermal junction.[49] Sera from these patients react with the epidermal side of NaCl-split human skin. Circulating IgG autoantibodies react to the major noncollagenous extracellular domain (NC16A) of the 180-kDa bullous pemphigoid antigen within the basement membrane zone. Further mapping showed that lichen planus pemphigoides serum reacts with amino acids 46–59 of domain NC16A, a protein segment that was previously shown to be unreactive with bullous pemphigoid sera. This newly described epitope is designated *MCW-4*.[50]

Lichenoid Reaction of Graft-Versus-Host Disease. (See Chapter 28.) Chronic graft-versus-host disease (GVHD) (occurring 100 days after transplant) may present as a lichenoid eruption indistinguishable clinically and histologically from lichen planus. Lichenoid GVHD favors the trunk, buttocks, hips, thighs, palms, and soles. In oral mucosa, xerostomia and oral ulcerations are occasionally seen. Histologically, the findings in lichen planus and oral GVHD are similar, although more infiltrating $CD3^+$ T lymphocytes are present in oral lichen planus than in GVHD.[52] Natural killer cells, Leu-8-positive T cells (homing receptor: CD62L, LECAM), CD25-positive lymphocytes, and the CD4:CD8 ratio were not different. Langerhans cells are often increased in both conditions.

Lichenoid Keratosis. Lichenoid keratoses are brown to red, scaling maculopapules found on sun-exposed skin of extremities. Histologic features of lichen planus are present, with the additional finding of focal parakeratosis. They frequently occur with solar lentigo, seborrheic keratosis, and actinic keratosis and likely represent an "involuting lichenoid plaque."[53]

RELATED FINDINGS

Lichen planus is seen with increased frequency in association with liver diseases such as autoimmune chronic active hepatitis, primary biliary cirrhosis, and postviral chronic active hepatitis.[55] The association with primary biliary cirrhosis is observed regardless of treatment with D-penicillamine, a drug that may cause an exacerbation of lichen planus.

Hepatitis C infection has been implicated in triggering lichen planus. The prevalence of HCV infection varied between 16% and 29% in southern European patients with lichen planus.[56,57] On the other hand, many studies from northern Europe and the United States did not substantiate any link.[58,59] Genetic factors controlling disease susceptibility and prevalence of certain HCV genotypes in certain geographic areas may have significantly influenced these results. No strong link between hepatitis B infection and lichen planus is shown.[60] Lichen sclerosus is seen in 16% of cases of erosive vaginal lichen planus.[41]

There is no evidence to link lichen planus to diabetes mellitus, autoimmune diseases, or internal malignancies. Cases of severe erosive gingivitis and stomatitis with histologic appearance of lichen planus in association with internal malignancies may represent cases of paraneoplastic autoimmune multiorgan syndrome (PAMS) or paraneoplastic pemphigus (see Chapter 55).

LICHEN PLANUS AND MALIGNANT TRANSFORMATION

There has been considerable controversy as to whether oral lichen planus inherently harbors malignant potential.[61,62] It is currently believed that the risk of malignant transformation is fairly low (Fig. 26-15). Risk factors that increase the likelihood of developing oral cancer are long-standing disease, erosive or atrophic types, tobacco use, and possibly esophageal involvement. It is generally accepted that about 2% of patients with oral lichen planus develop SCC.[32] The majority of these cases are in situ carcinoma or with microinvasive pattern. The most common site for cancer is the tongue, followed by buccal mucosa, gingiva, and, rarely, the lip. Clinically, the lesions appear as indurated, nonhealing ulcers, or exophytic lesions with a keratotic surface. Red atrophic plaques could also be seen and often correlate with SCC in situ. Advanced cases could result in nodal metastases and occasionally death.

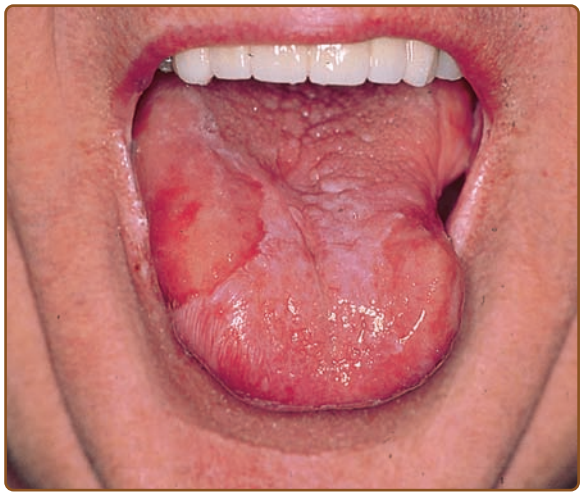

Figure 26-15 Lichen planus and squamous cell carcinoma. Long-standing oral lichen planus with scarring changes of tongue. Circumscribed erythroplakia and erosions of the right lateral tongue was biopsied and confirmed squamous cell carcinoma.

The risk of skin malignancy in cutaneous lichen planus is extremely low. Most patients developing SCC in cutaneous lichen planus had a history of either arsenic or X-ray exposure.

LABORATORY TESTS

No specific abnormalities of laboratory analyses are seen in lichen planus. The total white blood cell count and lymphocytes may be decreased. This could be related to cytokine activation and local trafficking of cells to skin or other tissue compartments.

Patch tests in patients with oral or cutaneous lichen planus usually reveal positive results in a majority of patients.[63] Sensitivity to mercury and gold is often positive in one-half of the cases. Chromate, flavoring agents, acrylate, and thimerosal are common sensitizers. Avoidance of these clinically relevant sensitizers results in amelioration of disease. Dyslipidemia is more common in patients with lichen planus than controls.[64]

PATHOLOGY

The two major pathologic findings in lichen planus are (1) basal epidermal keratinocyte damage and (2) lichenoid-interface lymphocytic reaction. The epidermal changes include hyperkeratosis, wedge-shaped areas of hypergranulosis, and elongation of rete ridges that resemble a sawtooth pattern (Fig. 26-16). Multiple apoptotic cells or colloid-hyaline (Civatte) bodies are seen at the dermal–epidermal junction. Eosinophilic colloid bodies are present in the papillary dermis. A band-like lymphocytic infiltrate is seen in the papillary dermis that abuts the epidermis. Plasma cells are more prominent in mucous membrane specimens. Few eosinophils are seen in drug-induced lichen planus or lichenoid drug eruptions. Melanin pigmentation is invariably present and is more pronounced in

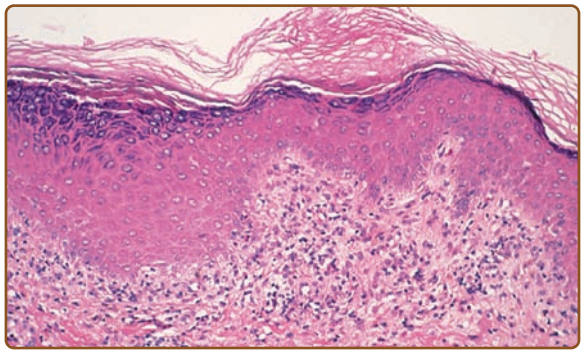

Figure 26-16 Lichen planus. Typical hyperkeratosis, hypergranulosis, early sawtooth changes, and lichenoid interface reaction of classic lichen planus.

older, waning lesions, in dark-skinned individuals and lichen planus pigmentosus. Separation of the epidermis in small clefts (Max Joseph cleft formation) is occasionally seen (Fig. 26-17).

Direct immunofluorescence shows numerous apoptotic cells at the dermal–epidermal junction (60%) staining with IgM and, occasionally, with IgG and IgA. Shaggy deposition of fibrinogen at the dermal–epidermal junction (55%) is characteristic of lichen planus (Fig. 26-18).[65] Immunocytochemical studies show that the majority of the cells in the infiltrate are T lymphocytes, with scattered B lymphocytes. An increased density of Langerhans cells, dermal dendritic cells, and histiocytes have also been seen, especially in early active lesions.

The presence of abundant plasma cells and eosinophils in the infiltrate, focal parakeratosis and hypogranulosis, and the presence of cytoid bodies high in the stratum corneum favor lichenoid tissue eruptions. Furthermore, lymphocytic infiltration is less dense. The differential diagnosis of lichen planus is shown in Boxes 26-1 and 26-2.

PROGNOSIS AND CLINICAL COURSE

Lichen planus is an unpredictable disease that typically persists for 1–2 years, but which may follow a chronic, relapsing course over many years.[66] The duration

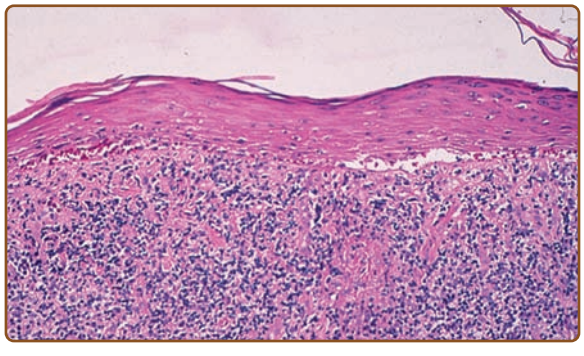

Figure 26-17 Lichen planus. More extensive epidermal alterations with hydropic changes, thinned epidermis, focal wedge-shaped hypergranulosis, compact orthokeratosis, and pronounced lichenoid inflammation with focal hemorrhage.

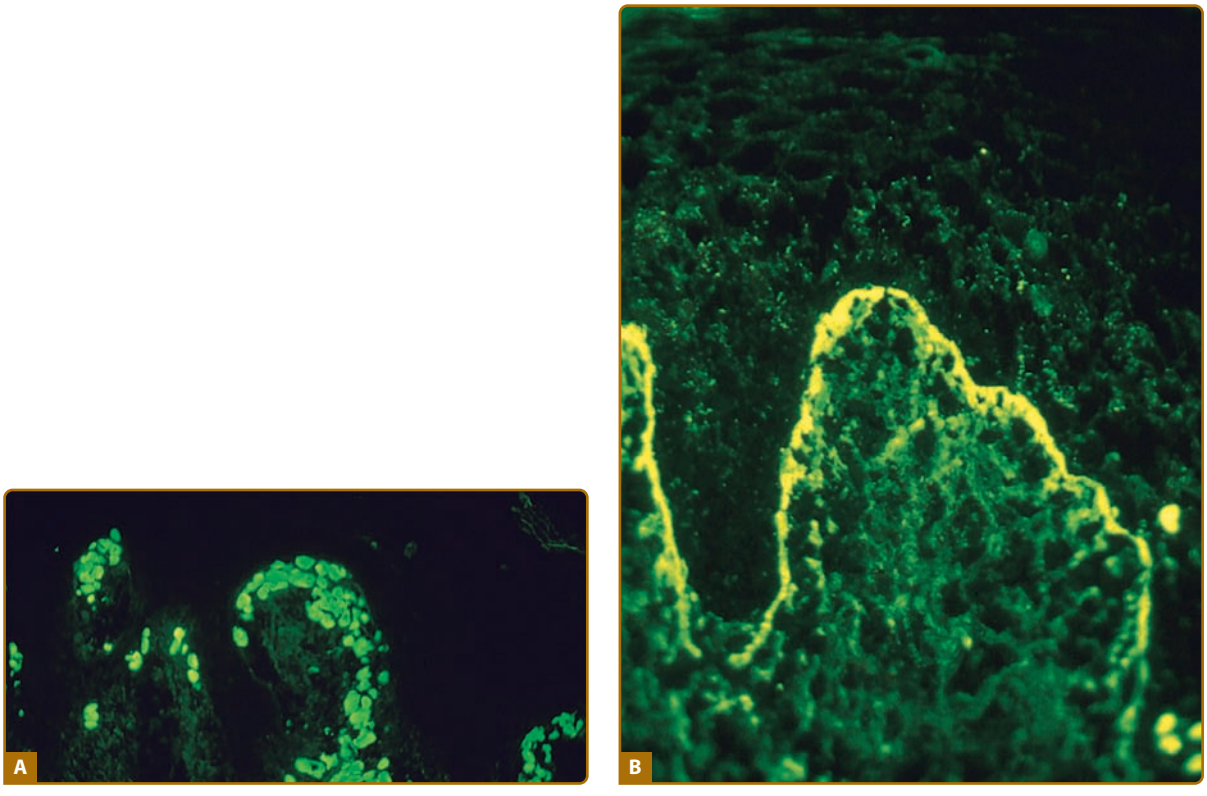

Figure 26-18 Lichen planus. Direct immunofluorescence examination of involved skin. **A.** Numerous immunoglobulin M-positive cytoids at the dermal–epidermal junction. **B.** Fibrinogen/fibrin, shaggy pattern at the dermal–epidermal junction.

varies according to the extent and site of involvement and morphology of lesions. Generalized eruptions tend to have a rapid course and heal spontaneously faster than limited cutaneous disease. Lichen planopilaris is one of the most chronic and often progressive disease variants with little potential for hair regrowth after follicular inflammation and destruction. Hypertrophic lichen planus typically follows a protracted, unremitting course. Spontaneous regression is also an uncommon feature of oral lichen planus. The mean

BOX 26-1 DIFFERENTIAL DIAGNOSIS OF LICHEN PLANUS

Classic	Psoriasis
	Drug eruption
	Lichen simplex chronicus
Annular	Granuloma annulare
	Tinea
Linear	Nevus unius lateris
	Lichen striatus
	Linear epidermal nevus
Hypertrophic	Lichen simplex chronicus
	Prurigo nodularis
	Lichenoid cutaneous amyloidosis
	Kaposi sarcoma
Atrophic	Lichen sclerosus
Follicular	Lichen nitidus
	Lichen spinulosus
Childhood	Lichen nitidus
	Lichen striatus
	Pityriasis lichenoides
	Papular acrodermatitis of childhood

BOX 26-2 DIFFERENTIAL DIAGNOSIS OF SITE-SPECIFIC LICHEN PLANUS

Nail	Psoriasis
	Onychomycosis
	Alopecia areata
Genital	Psoriasis
	Seborrheic dermatitis
Palms and soles	Secondary syphilis
Lichen planopilaris	Cicatricial alopecia
	Lupus erythematosus
	Inflammatory folliculitis
	Alopecia areata
	Cicatricial pemphigoid
	Keratosis follicularis spinulosa decalvans
Mucosal	Paraneoplastic pemphigus
	Candidiasis
	Lupus erythematosus
	Leukokeratosis
	Secondary syphilis
	Traumatic patches

duration for oral lichen planus is 5 years. The reticular variant has a better prognosis than erosive disease that does not heal spontaneously. Generally, the duration of disease conforms to the following order, from shortest duration to longest duration: (1) generalized, (2) cutaneous, (3) cutaneous + mucous membrane, (4) mucous membrane, (5) hypertrophic, and (6) lichen planopilaris.

Relapse of disease occurs in 15%–20% of cases and tends to occur in the same area as the initial episode. Recurrences are more common in generalized lichen planus and are usually of shorter duration.

TREATMENT

Management of lichen planus can be challenging and discouraging for both the patient and physician. Lichen planus may be associated with only minor symptoms or may cause considerable discomfort and disability. Hence, treatment options should be assessed for attendant risks and benefits and tailored to the extent and severity of disease. Avoidance of exacerbating drugs, unless necessary, and minimizing trauma to skin and mucosal tissues are routinely recommended.

Various drugs have been proposed for the treatment of mucosal and cutaneous lichen planus and the majority of these consist of small series of patients or anecdotes.[67] Many of the advocated treatments lack conclusive evidence for efficacy.

MUCOSAL LICHEN PLANUS

(Box 26-3)

GENERAL MEASURES. For oral lichen planus, good oral hygiene and regular personal and professional dental care need to be encouraged. Replacement of amalgam or gold dental restorations with composite material is frequently of considerable benefit in patients with oral lichenoid reactions, even in the apparent absence of relevant patch test results. Chronic lesions on the buccal mucosa in contact with metal or other contact sensitizers frequently heal promptly after replacement. Occasionally, lesions at sites distant to oral lesions may also clear after removal of metal restorations. Gingival lesions may respond less favorably. The decision to undergo removal and restoration is often difficult and usually depends on the chronicity, severity, and clinical and patch-test evidence for involvement by the metal/prosthesis as well as the level of frustration of the patient.

Topical Steroids. Topical steroids are the first-line therapy in mucosal lichen planus.[67–69] Use of occlusive materials suitable for mucous membranes, such as Orabase, may provide protection, sustained tissue contact with the medication, and alleviate the discomfort associated with erosive lesions. Triamcinolone acetonide (0.1%), Fluocinonide gel, 0.1% fluocinolone acetonide, and 0.025% clobetasol propionate in Orabase showed good results.[70] Application four to six times a day is recommended. Treatment is often complicated by oral candidiasis. The use of chlorhexidine gluconate mouthwashes and topical anticandidal medications is recommended during therapy.[71]

Topical corticosteroids are sometimes compounded with anesthetics to provide symptomatic benefit for patients with difficulty eating and chewing, for

BOX 26-3 TREATMENT FOR ORAL LICHEN PLANUS

	TOPICAL		PHYSICAL	SYSTEMIC	
First line	▪ Topical steroids	Four–six times daily		▪ Anticandidal systemic steroids	30–80 mg/day
	▪ Tacrolimus (Protopic)	1–4 per day		▪ Etretinate	75 mg/day
	▪ Pimecrolimus (Elidel)	1–4 per day		▪ Acitretin	25–50 mg/day
	▪ Tretinoin gel	2 per day		▪ Isotretinoin	20–40 mg/day
	▪ Isotretinoin gel	2 per day			
	▪ Lidocaine	PRN			
	▪ Intralesional steroids	5–40 mg/mL			
Second line	▪ Cyclosporine mouthwash	2–4 daily (1 mg/mL)	▪ Extracorporeal photopheresis[a]	▪ Hydroxychloroquine	50–200 mg/day Antipsoriatic dose
	▪ Topical Rapamycin[a]			▪ Alefacept[a] and Efalizumab*	
				▪ Cyclosporine	3–10 mg/kg/day
				▪ Thalidomide	Variable
				▪ Azathioprine, Methotrexate, cyclophosphamide, mycophenolate mofetil	Variable

[a]Experimental.
*No longer on market

example, Intralesional Triamcinolone acetonide 10 mg/mL or at diluted concentrations, if effective and safe.[72]

Glucocorticoids containing vaginal and rectal suppositories are usually helpful for mucosal involvement in these areas. Topical ultrapotent corticosteroid is an effective treatment for erosive lichen planus of the vulva, giving relief of symptoms in 71%.[73]

Systemic Glucocorticoids. Systemic glucocorticoids provide effectiveness in erosive oral and vulvovaginal lichen planus to achieve rapid relief during periods of exacerbations.[74] Systemic dosing can be used alone, or, more commonly, in conjunction with topical glucocorticoids. Prednisone dose range from 30 to 80 mg/day, tapered over 3–6 weeks, and Betamethasone 5 mg on two consecutive days per week show benefit. Relapses are common after dose reduction or discontinuation. Higher doses are often needed for esophageal lichen planus in addition to intralesional steroid injection and mechanical dilatation.[75] Oral candidiasis is a common complication.

Retinoids. Topical retinoic acid (tretinoin gel) has been shown to be effective in erosive as well as plaque-like oral lesions, however, site irritation often makes it less attractive. Isotretinoin gel is also effective, especially in nonerosive oral lesions. However, recurrence is common after discontinuation of therapy.[76] Topical retinoids are often used in conjunction with topical glucocorticoids. Although not proven in clinical trials, this may improve the efficacy and lessen the side effects.

Etretinate orally has been used at 75 mg/day (0.6–1.0 mg/kg/day) in erosive oral lichen planus with significant improvement in the majority of patients. Relapses are common after discontinuation of medication.[77] Two-thirds of patients showed marked improvement or complete remission within 8 weeks of instituting acitretin, 30 mg/day.[78] The topical use of isotretinoin gel is effective also in oral disease.[79]

Tacrolimus and Pimecrolimus. Tacrolimus, effective in erosive mucosal disease, provides rapid relief from pain and burning with minimal side effects.[80,81] It is at least equally effective to clobetasol propionate 0.05% ointment and triamcinolone acetonide 0.1% paste in the treatment of oral lichen planus.[82–84]

Pimecrolimus 1% cream was shown to be as effective as triamcinolone acetonide 0.1% paste in treating oral lichen planus, and proved to be effective in treating vulvar disease.[85–87]

Cyclosporine. Topical application of cyclosporine, 100 mg/mL, 5 mL three times daily has shown benefit for oral lichen planus. Application modalities include mouthwashes and manual administration with local massage. Topical cyclosporine washes seem to be effective in oral lichen planus, especially the severe erosive forms,[88,89] but they do not appear to be better than local glucocorticoid therapy.[90] Lack of effectiveness in a few cases, high cost of this medication, and lack of proper commercial formulation for topical application limit its use. Oral cyclosporine at dose regimens of 3–10 mg/kg/day has been used for severe ulcerative disease and in cases with esophageal involvement.[91]

Miscellaneous. *Antifungal agents* (e.g., fluconazole, itraconazole) are useful in reducing candidal overgrowth associated with glucocorticoids use.

Hydroxychloroquine at 200–400 mg/day for at least 6 months is also used cautiously because antimalarials are implicated as possible inducers of lichen planus.[92]

Thalidomide should be reserved for cases recalcitrant to other remedies. The dose could be started at 50 mg/day and increased gradually to 200 mg/day.[93]

Dapsone can be used orally at 100–200 mg daily and has proved effective in two-thirds of patients with cutaneous and oral disease.

Extracorporeal photochemotherapy twice a week for 3 weeks and then tapered has had favorable results.[94,95] Alefacept at 15 mg every week for 12 weeks and Efalizumab (no longer on market) 0.7 mg/kg subcutaneously at week 0 followed by 1.0 mg/kg weekly from week 1 to week 11 exhibited therapeutic response in erosive lichen planus.[96–98] Frequent topical hyaluronic acid gel preparation (0.2%) appears to be of some benefit.[99] Aloe vera gel is also effective in improving the symptoms.[100] Topical rapamycin (1 mg/mL) twice a day for 3 months may be effective in some refractory erosive cases.[101]

Successful treatment of severe long-standing erosive vulvovaginal lichen planus using 10–15 mg of oral methotrexate once weekly in conjunction with topical clobetasol dipropionate 0.05% ointment and tacrolimus 0.03%–0.10% ointment within 4–8 weeks.[102]

CUTANEOUS LICHEN PLANUS

(Box 26-4)

TOPICAL GLUCOCORTICOIDS. A large variety of topical and systemic therapies are available for the treatment of cutaneous lichen planus, and this range of options may be attributed to the chronicity, symptomatology, and variable responsiveness of the dermatosis. *Topical glucocorticoids* are typically used for limited cutaneous disease. Potent topical glucocorticoids with occlusion, are often needed.

Intralesional triamcinolone acetonide (5–10 mg/mL) is effective in treating oral and cutaneous lichen planus. This may also be used in lichen planus of the nails with injection of the proximal nail fold every 4 weeks. Regression of lesions occurs within 3–4 months. For hypertrophic lichen planus, higher concentrations of intralesional glucocorticoid (10–20 mg/mL) may be required. Regular and close observation should be performed to monitor for any signs of atrophy or localized hypopigmentation that should prompt cessation of therapy. Intralesional injection is of special value in lichen planopilaris.[27]

Systemic glucocorticoids are often useful and effective in doses greater than 20 mg/day (e.g., 30–80 mg prednisone) for 4–6 weeks with subsequent taper over 4–6 weeks. Symptoms are often alleviated, and patients in the early stages of evolution or experiencing a flare have marked benefit and attenuation or aborted progression of disease. In lichen planopilaris, potent topical glucocorticoids in conjunction with oral glucocorticoids,

BOX 26-4 TREATMENT FOR CUTANEOUS LICHEN PLANUS

	TOPICAL		PHYSICAL	SYSTEMIC	
First line	▪ Topical steroids ▪ Intralesional steroids ▪ Tacrolimus ▪ Pimecrolimus	1–2 per day 5–20 mg/mL Variable Variable	▪ Psoralen and ultraviolet A light Broad band UVB Narrow band UVB	▪ Systemic steroids ▪ Etretinate ▪ Acitretin ▪ Isotretinoin	30–80 mg/day 10–75 mg/day 25–50 mg/day 20–40 mg/day
Second line				▪ Cyclosporine ▪ Dapsone ▪ Hydroxychloroquine ▪ Azathioprine ▪ Mycophenolate mofetil	3–10 mg/kg/day 100–200 mg/day 200–400 mg/day 75–150 mg/day 1,000 mg bid
Special forms				▪ Doxycycline, tetracycline, and nicotinamide ▪ Interferon-α 2b ▪ Metronidazole ▪ Cyclophosphamide ▪ Methotrexate	Lichen planus pemphigoides Generalized Generalized Refractory lichen planus Refractory lichen planus

30–40 mg/day, for at least 3 months, seems to be successful. Relapse typically occurs following discontinuation. Long-term, chronic continuation of oral or injected glucocorticoids is contraindicated in most cases because of the high risk of complications.

RETINOIDS. The systemic retinoids demonstrate anti-inflammatory activity and have been used in the treatment of lichen planus. Remission and marked improvement was achieved with 30 mg/day of acitretin for 8 weeks.[78] Oral tretinoin is used at 10–30 mg/day with marked improvement and mild side effects.[103] Low-dose etretinate (10–20 mg/day) use has been associated with complete remission of cutaneous, oral, and nail lichen planus after 4–6 months of treatment. Prompt beneficial response was noted with the use of 75 mg/day of etretinate,[104] but side effects of retinoids are dose related and may limit use of higher dose therapeutic regimens.

PHOTOCHEMOTHERAPY. Psoralen and ultraviolet A (PUVA) light photochemotherapy is usually successful in generalized cutaneous lichen planus.[105] It has been used in conjunction with oral glucocorticoids to hasten the response. Trioxsalen, 50 mg added to 150 L of water, then exposing the patients to UVA after 10 minutes of bathing gave good results.[106] UVA-1 phototherapy may also benefit more protracted lichen planus. UVB, both broad and narrow band, are safe and efficient treatment options for generalized disease.[107–109]

IMMUNOSUPPRESIVE AGENTS. *Systemic cyclosporine* has been used successfully in recalcitrant lichen planus.[110] The administered dose can range from 3 to 10 mg/kg/day. Pruritus usually disappears after 1–2 weeks. Clearance of the rash is seen in 4–6 weeks. Low doses (1.0–2.5 mg/kg/day) are probably sufficient to achieve remission. Adverse effects as well as relapse after discontinuation of the drug, limit its use to severe cases.[111]

Azathioprine is useful in recalcitrant, generalized cutaneous lichen planus and in lichen planus pemphigoides.[112] *Methotrexate* is of value in generalized and erosive vulvar lichen planus.[113] *Mycophenolate mofetil* was effective at reducing the signs and symptoms of active lichen planopilaris in 83% of patients who had failed multiple prior treatments after at least 6 months of treatment.[114] Similar results are seen with mycophenolate mofetil at a dose of 1500 mg twice daily.[115] Cyclophosphamide should be reserved for refractory cases due to its toxicity.

MISCELLANEOUS. *Hydroxychloroquine* is effective in decreasing symptoms and signs in Lichen planopilaris and its variant frontal fibrosing alopecia in 69% and 83% of patients after 6 and 12 months of treatment, respectively.[116] It is also the main treatment in actinic lichen planus at 200–400 mg/day in addition to sun protection.[24]

Thalidomide can be used in lichen planus unresponsive to other therapies.[117,118] Oral *metronidazole* 500 mg twice daily for 1–2 months also reportedly clears the majority of cases of generalized lichen planus.[119]

Based on the benefit in bullous pemphigoid, combination therapy with *tetracycline* or *doxycycline* and *nicotinamide* has been reported as useful in the treatment of

lichen planus pemphigoides.[120] Tetracycline should be considered in lichen planopilaris.[27]

A case of generalized Lichen planus with oral involvement was treated with adalimumab, a tumor necrosis factor (TNF) antagonist with good results[121] and Alefacept.[122]

Low-molecular-weight heparin in low doses has lymphoid antiproliferative and immunomodulatory properties.[123,124] At a dose of 3 mg weekly, heparin injections have been reported to significantly improve the symptoms of pruritus and activity of the disease. Four to six injections of heparin induced complete regression of lesions within 4–10 weeks. Cutaneous involvement and reticulated oral lesions had the best response. Oral erosive lichen planus showed minimal improvement with this regimen.

Skin grafting has been beneficial in the management of ulcerative lichen planus of the feet that is recalcitrant to other treatments.

KEY REFERENCES

Full reference list available at www.DIGM8.com

DVD contains references and additional content

2. Boyd AS, Nelder KH: Lichen planus. *J Am Acad Dermatol* **25**:593, 1991
7. Wenzel J, Tuting T: An IFN-associated cytotoxic cellular immune response against viral, self-, or tumor antigens is a common pathogenetic feature in "interface dermatitis." *J Invest Dermatol* **128**:2392, 2008
12. Wenzel J et al: Gene expression profiling of lichen planus reflects CXCL9+-mediated inflammation and distinguishes this disease from atopic dermatitis and psoriasis. *J Invest Dermatol* **128**:67, 2008
15. Balasubramaniam P, Ogboli M, Moss C: Lichen planus in children: Review of 26 cases. *Clin Exp Dermatol* **33**:457, 2008
19. Lehman JS, Tollefson MM, Gibson LE: Lichen planus. *Int J Dermatol* **48**:682, 2009
26. Kang H et al: Lichen planopilaris. *Dermatol Ther* **21**:249, 2008
29. Mehregan DA et al: Lichen planopilaris: Clinical and pathologic study of forty-five patients. *J Am Acad Dermatol* **27**:935, 1992
35. Cobos-Fuentes MJ et al: Oral lichenoid lesions related to contact with dental materials: A literature review. *Med Oral Patol Oral Cir Bucal* **14**:e514, 2009
42. Kennedy CM, Galask RP: Erosive vulvar lichen planus: Retrospective review of characteristics and outcomes in 113 patients seen in a vulvar specialty clinic. *J Reprod Med* **52**:43, 2007
46. Ellgehausen P et al: Drug-induced lichen planus. *Clin Dermatol* **16**:325, 1998
54. Oliver GF et al: Lichenoid dermatitis: A clinicopathologic and immunopathologic review of sixty-two cases. *J Am Acad Dermatol* **21**:284, 1989
62. Eisen D: The clinical features, malignant potential, and systemic associations of oral lichen planus: A study of 723 patients. *J Am Acad Dermatol* **46**:207, 2002
66. Carbone M et al: Course of oral lichen planus: A retrospective study of 808 northern Italian patients. *Oral Dis* **15**:235, 2009
67. Zakrzewska JM et al: A systematic review of placebo-controlled randomized clinical trials of treatments used in oral lichen planus. *Br J Dermatol* **153**:336, 2005
75. Wedgeworth EK et al: Management of symptomatic esophageal involvement with lichen planus. *J Clin Gastroenterol* **43**:915, 2009

Chapter 27 :: Lichen Nitidus

:: Mazen S. Daoud & Mark R. Pittelkow

LICHEN NITIDUS AT A GLANCE

- Small, glistening, flesh-colored to pink or reddish-brown papules of unknown etiology.
- Distinctive, circumscribed infiltrate of lymphocytes and histiocytes in papillary dermis situated directly beneath thinned epidermis.
- There is no associated systemic disease.
- Prognosis is good.

Lichen nitidus (Latin nitidus, "shiny" or "glistening") is an uncommon, usually asymptomatic cutaneous eruption first described by Felix Pinkus in 1901 and further characterized by him in 1907.[1,2] Lichen nitidus consists of small, glistening, flesh-colored to pink or reddish-brown papules that may be limited to the penis, genitalia, abdomen, and extremities or, less frequently, may occur as a generalized condition. The histopathologic findings are characteristic. Although the condition is often chronic, the prognosis is good, and no clearly associated systemic illnesses have been documented.

EPIDEMIOLOGY

Epidemiologic characteristics of lichen nitidus have not yet been defined completely. Lichen nitidus occurs infrequently and has been reported to affect blacks more than Caucasians; children and young adults more than the elderly; and males more than females. The incidence is estimated to be approximately 3.4 cases/10,000 population, based on a 25-year survey of skin diseases in African-Americans.[3] The crude ratio of lichen nitidus to lichen planus is 1.7:100, based on pathologic diagnosis of cases evaluated over several decades at the Mayo Clinic.

ETIOLOGY AND PATHOGENESIS

Once considered a tuberculoid reaction, lichen nitidus is currently regarded as a disorder of unknown etiology. The relationship between lichen nitidus and lichen planus has been debated for many years.[4] The coexistence of both diseases in some patients, development of lichen planus following generalized lichen nitidus,[5] and the clinical similarities to small lichen planus papules were used to support the view that lichen nitidus is a variant of lichen planus. However, most experienced clinicians, as well as research studies, favor the separation of these two diseases as distinct entities based on both clinical and immunodermatopathologic differences and the characteristic and distinctive histologic changes. Table 27-1 summarizes some of these differences and similarities. Another etiologic theory of lichen nitidus proposes that an allergen may cause epidermal and dermal antigen-presenting cells (e.g., Langerhans cells) to activate a cell-mediated response, initiate lymphocyte accumulation, and form discrete inflammatory papules. The presence of large numbers of Langerhans cells in the infiltrate supports this theory.[6] Specific cytokines produced by the inflammatory cells influence the immune response and may shift the T lymphocyte response toward the T helper 2 subset that has the potential to produce the superficial dermal granulomas seen in lichen nitidus.[7] Functional impairment in cellular immunity has been reported in generalized lichen nitidus,[8] and lichenoid photoeruptions similar to lichen nitidus were seen in a patient with HIV infection.[9] Rare cases of lichen nitidus associated with atopic dermatitis, Crohn's disease, and juvenile chronic arthritis have been reported. Induction of allergic contact dermatitis by topical application of dinitrochlorobenzene in a patient with lichen nitidus cleared the eruption, presumably by altering the cellular immunity, cellular infiltration, and cytokine expression.[7]

A rare familial presentation of lichen nitidus has been reported, although no genetic factors of the disease have been identified.[10]

CLINICAL FINDINGS

Lichen nitidus is composed of multiple, discrete, smooth, and flat, round papules. Individual papules are 1–2 mm in size, flesh-colored to slightly pink or, in blacks, hypopigmented, with a glistening appearance (Fig. 27-1). Sometimes, minimal scale is present or can be elicited by rubbing the surface of the papules. Occasionally, the papules are grouped and the isomorphic or Koebner phenomenon is observed. Lesions may occur anywhere over the skin surface; however, the most frequent sites of predilection are the flexural surfaces of the arms and the wrists, lower abdomen, breasts, the glans and shaft of the penis, and other areas of the genital region. Infrequently lichen nitidus is a generalized eruption.

Rare sites of involvement include mucous membranes, nails, palms, and soles. Rare clinical variants include vesicular, hemorrhagic and purpuric, spinous follicular, linear, generalized, and lichen nitidus actinicus types.[11–16] (See Table 27-2.)

TABLE 27-1
Comparison of Features Between Lichen Nitidus and Lichen Planus

	Lichen Nitidus	Lichen Planus
Incidence	Rare	Common
Lesion		
Size	Usually 1–2 mm	Variable, usually larger
Shape	Round	Polygonal
Color	Flesh, pink, red–brown	Erythematous to violaceous
Wickham striae	Absent	Present
Mucosal changes	Rare	Variably present
Pruritus	Uncommon	Usually present, marked
Histopathology		
Hyperkeratosis	Variable and focal	Usually present
Parakeratosis	Mostly present	Not found
Infiltrate	Focal in one to three papillary bodies	Band-like, extends through many rete ridges
Lymphocytes	Variable	Vast majority of cells
Histiocytes	Variable, almost always present	Almost none
Giant cells	Occasional	None
Dyskeratotic	Occasional	Very common
Immunopathology		
Cytoids	Usually negative	Immunoglobulin M and other conjugates
Basement membrane	Usually negative	Fibrinogen, other conjugates
Immunohistochemistry		
$CD4^+$ lymphocytes	Majority of cells	Majority of cells
$CD68^+$ cells	Common	Uncommon



Figure 27-1 Lichen nitidus. **A.** Pinpoint to pinhead, discrete, dome-shaped papules over upper back, shoulder, and arm. Side-lighting, as performed here, enhances visualization of multiple small lesions. **B.** Individual papules, flesh- to pink-colored over chest and arm, becoming more grouped over anterior axilla.

Actinic lichen nitidus appears in patients with dark skin in areas with significant sun exposure such as face and arms. It can recur with repetitive exposure to the sun and show seasonal pattern.[17] It has been reported in the literature under summertime lichenoid actinic eruptions.[18] Palmoplantar involvement may manifest several morphologic forms that range from pinpoint papules to keratoderma.[19] Bilateral hyperkeratosis of palms and soles with erythema, fissuring, and a texture resembling fine sandpaper has been observed.[14,19] Occasionally, minute keratotic spicules on the palmar surfaces or multiple pinpoint papules that extend to the dorsa of the extremities occur (Fig. 27-2). Nail abnormalities usually manifest as longitudinal, beaded ridging, and terminal splitting with or without irregular pitting.[20] Lichen nitidus is usually asymptomatic; however, pruritus is occasionally present and sometimes intense. There are no constitutional symptoms or systemic abnormalities associated with the disease.

PATHOLOGY

A dense mass of infiltrating lymphohistiocytic cells is situated immediately below the epidermis and results in widening of the papillary dermis with elongation and the appearance of embracement by neighboring rete ridges (Fig. 27-3). The overlying epidermis is thinned and occasionally demonstrates central parakeratosis without hypergranulosis. This is a characteristic diagnostic finding, when observed (see Fig. 27-3B). Minimal hydropic degeneration with few dyskeratotic cells is usually observed. Occasionally, the epidermis may partially detach from the dermis. Colloid bodies are rarely seen. The dermal infiltrate is well circumscribed and composed of closely associated histiocytes, few lymphocytes, and occasional foreign body or Touton-type giant cells. Usually, no plasma cells or eosinophils are seen. Palmar lesions may show a deep parakeratotic plug. Transepithelial elimination of the inflammatory infiltrate has been described (perforating lichen nitidus).[21] Purpuric or hemorrhagic lesions are associated with capillary wall degeneration and red blood cell extravasation.[12]

The majority of the cells in the infiltrate are T lymphocytes ($CD4^+$ cells predominate over $CD8^+$)

TABLE 27-2
Rare Forms of Lichen Nitidus

Site of Involvement	Clinical Variant
Generalized	Actinic
Palmar	Vesicular
Plantar	Hemorrhagic
Linear	Spinous follicular
Nail involvement	Perforating
	Purpuric



Figure 27-2 Lichen nitidus. Wrist and palmar involvement with development of hyperkeratotic lesions.

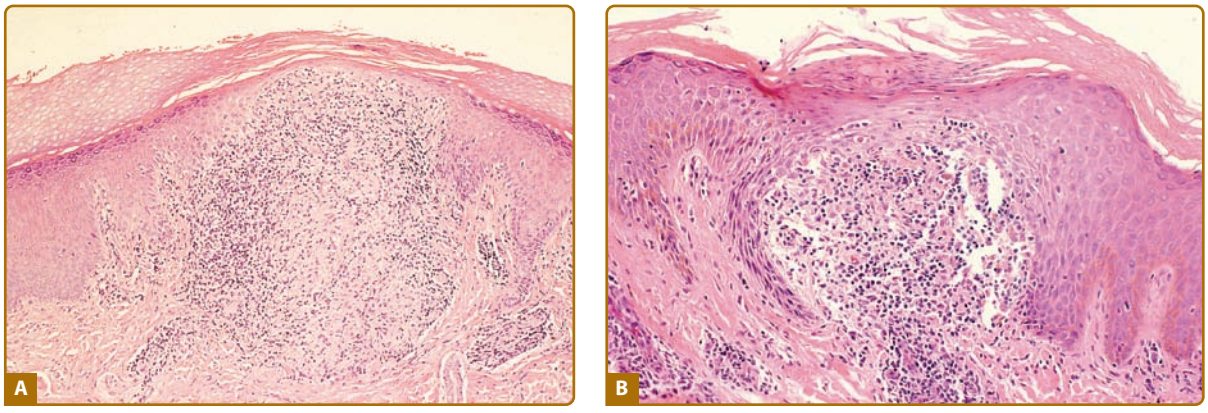

Figure 27-3 Lichen nitidus. **A.** Distinctive, circumscribed infiltrate of papillary dermis situated directly beneath thinned epidermis. Many histiocytes mingle with lymphocytes that are enveloped by bordering rete ridges. (Hematoxylin and eosin × 40.) **B.** Central parakeratosis, epidermal thinning, and loss of granular layer with focus of granuloma-appearing, inflammatory cells and reactive, finger-like extensions of epidermis. (Hematoxylin and eosin × 80.)

intermixed with few to many histiocyte–macrophages (CD68 positive), as well as epidermal Langerhans cells and indeterminate cells (S100 protein positive). Direct immunofluorescence examination of lichen nitidus is usually negative.[22]

DIFFERENTIAL DIAGNOSIS

Differential diagnosis of lichen nitidus is summarized in Box 27-1.

PROGNOSIS AND CLINICAL COURSE

Lichen nitidus is typically a focal, asymptomatic, chronic inflammatory reaction that eventually resolves spontaneously after months to 1 year in two-thirds of patients or, less frequently, over a few years. Rarely, the eruption may persist indefinitely. New lesions may continue to develop as older lesions resolve. Lesions heal without scar formation or pigmentary abnormalities.

TREATMENT

Because the disease is asymptomatic and self-limiting, no intervention is required in most cases. Treatment of lichen nitidus is warranted when it is associated with protracted pruritus, become generalized or for cosmetic reasons.[23] Topical glucocorticoids may yield favorable results. A short course of oral glucocorticoids may also be helpful and hasten resolution of more extensive, generalized, or symptomatic disease.[24] Psoralen and ultraviolet A light (UVA),[25] UVA and UVB phototherapy,[24] astemizole,[26] acitretin or etretinate,[20,27] low-dose cyclosporine,[28] and oral itraconazole[29] have also been used successfully when indicated for more problematic disease. Oral retinoids and local PUVA are effective treatments in palmoplantar type.[19]

Narrowband UVB could be a safe and effective treatment in generalized lichen nitidus.[30,31] Tacrolimus ointment was also reported to be effective after 1 month of therapy.[32] History of exposure to tuberculosis in the setting of lichen nitidus should be investigated and, when appropriate, treated with antituberculous medications.[33] Low-molecular-weight heparin was used safely and successfully at weekly dose of 3 mg subcutaneously.[34] Various treatment modalities are summarized in Table 27-3.

BOX 27-1 DIFFERENTIAL DIAGNOSIS OF LICHEN NITIDUS

Most Likely

- Lichen planus
  - CD8 lymphocytes predominate
  - No granulomatous inflammation
- Psoriasis
  - Plaques have silvery scale
- Verruca plana
  - Variable in size
  - Verrucous surface
  - Fewer lesions than lichen nitidus
  - Less likely to involve multiple anatomic areas
- Keratosis pilaris
  - More keratotic and scaling
  - Hand dermatitis
  - Palmoplantar involvement of lichen nitidus

Consider

- Lichen spinulosus
- Papular eczema
- Lichen scrofulosorum
- Lichenoid syphilitic lesions
- Bowenoid papulosis
- Sarcoidosis
- Lichen amyloidosus

TABLE 27-3
Treatment of Lichen Nitidus

	Topical	Physical	Systemic
First line	Topical steroids Sun protection for actinic type Topical tacrolimus	Narrowband UVB Local PUVA UVA and UVB phototherapy	Antihistamines
Second line		Psoralen plus UVA	Oral steroids Oral retinoids Cyclosporine 4 mg/kg/day Itraconazole Antituberculous agents Astemizole Enoxaparin Sodium 3 mg SC weekly

KEY REFERENCES

Full reference list available at www.DIGM8.com

DVD contains references and additional content

4. Smoller BR, Flynn TC: Immunohistochemical examination of lichen nitidus suggests that it is not a localized papular variant of lichen planus. *J Am Acad Dermatol* **27**:232, 1992
5. Di Lernia V: Lichen planus appearing subsequent to generalized lichen nitidus in a child. *Pediatric Dermatol* **24**(4):453, 2007
19. Thibaudeau A et al: Palmoplantar lichen nitidus: A rare cause of palmoplantar hyperkeratosis. *Ann Dermatol Venereol* **131**(8-9):822, 2004
23. Efstathios Rallis MD et al: Generalized purpuric lichen nitidus. Report of a case and review of the literature. *Dermatol Online J* **13**(2):5, 2007
31. Park JH et al: Treatment of generalized lichen nitidus with narrowband ultraviolet. *Br J Am Acad Dermatol* **54**:545, 2006
34. Cholongitas E et al: Persistent generalized lichen nitidus successfully treated with Enoxaparin Sodium. *Am J Clin Dermatol* **9**:349, 2008

Chapter 28 :: Graft-Versus-Host Disease

:: Edward W. Cowen

GRAFT-VERSUS-HOST DISEASE AT A GLANCE

- Acute graft-versus-host disease (GVHD) is a serious and potentially life-threatening sequelae of allogeneic hematopoietic stem cell transplantation. Skin manifestations range from a mild, asymptomatic exanthem-like eruption to full-thickness skin loss resembling toxic epidermal necrolysis. Hepatic involvement is characterized by elevated total bilirubin. Gastrointestinal disease manifests as abdominal pain, nausea/vomiting, and secretory diarrhea.
- The most important risk factor for chronic GVHD is a history of acute GVHD. Traditionally, acute features present prior to day 100 posttransplantation, and chronic manifestations after 100 days; however, overlap between "classic" acute and chronic features may occur.
- Chronic GVHD of the skin is remarkably variable in clinical presentation. Epidermal involvement may resemble lichen planus, keratosis pilaris, or psoriasis. Sclerotic changes may resemble lichen sclerosus, morphea, systemic sclerosis, or eosinophilic fasciitis.
- The pathogenesis of chronic GVHD is poorly understood and nearly every organ system is at risk. The skin, oral mucosa eyes, gastrointestinal tract, and lungs are most frequently involved. In many cases, organ system disease resembles known autoimmune conditions.
- Optimal dermatologic management of chronic GVHD of the skin requires an understanding of other organ involvement, infection status, and cancer relapse risk. Close communication with the transplant physician and a "team approach" to multispecialty management is needed.

EPIDEMIOLOGY

Approximately 50,000 hematopoietic stem cell transplantation (HCT) procedures are performed worldwide each year for an expanding array of hematologic malignancies and marrow failure syndromes, metabolic disorders, and immunodeficiencies. HCT may utilize autologous, syngeneic, or allogeneic donor hematopoietic stem cell (HC). During autologous transplantation the patient's own HC are returned to the patient following preparative chemotherapy. Syngeneic transplantation is the transfer of HC between identical twins. Allogeneic HCT (allo-HCT) is the transfer of HC from a related (nonidentical) or unrelated donor to a recipient. Graft-versus-host disease (GVHD) is the primary cause of nonrelapse-related morbidity and mortality in allo-HCT and also rarely occurs following transplantation of solid organs or transfusion of blood products.

Transplantation regimens have advanced rapidly since the first successful allo-HCT was performed in 1968.[1] Peripheral blood, rather than bone marrow, is now the primary source of donor HC at many transplant centers, and reduced intensity (nonmyeloablative) conditioning has permitted older patients and others who would not tolerate myeloablative chemotherapy a chance for cure with HCT. More recently, umbilical cord blood has gained prominence as a stem cell source in both pediatric and adult HCT. Donor leukocyte infusions (DLI), the administration of additional donor HC to the recipient weeks or even months after HCT, are also frequently utilized to augment graft-versus-malignancy effect.

These evolving trends in HCT, in conjunction with other known donor/recipient risk variables (Box 28-1), contribute to a wide range of reported GVHD incidence. Nevertheless, the degree of HLA-mismatch between donor and recipient remains the single most important predictor of GVHD.[2] Acute GVHD develops in approximately 40% of fully matched sibling donor HCT, whereas 80% of mismatched unrelated HCT result in acute GVHD.[3,4] Risk estimates of chronic GVHD also vary widely and confounding factors such as improving early posttransplant survival may be influencing the apparent trend in increasing chronic GVHD incidence.[5] The most significant additional risk factor for chronic GVHD is a history of antecedent acute GVHD.[5]

Skin involvement is often the first indicator of acute GVHD (81%), followed by gastrointestinal (54%) and liver disease (50%).[6] Similarly, the majority of patients who develop chronic GVHD manifest skin symptoms at some point in their disease course. The risk of chronic skin involvement is increased by the use of peripheral blood HCT (PB-HCT) compared with bone marrow HCT (BM-HCT). At one center, approximately 90% of patients who developed chronic GVHD following PB-HCT manifested skin symptoms.[7] In most published reports, the incidence of sclerotic versus nonsclerotic chronic skin manifestations has not been differentiated. Although sclerotic involvement is less common than "lichenoid" GVHD and tends to occur later post-HCT, sclerotic features, particularly deep-seated fascial changes, may have an insidious onset, and "lichenoid" involvement is not a prerequisite to the development of sclerotic features. In one series of 196 patients post-HCT, only 7 (3.6%) developed sclerotic manifestations (mean 2.0 years after HCT).[8] In a review of 133 patients who survived at least 4 months after allo-HCT, the 5-year cumulative incidence of sclerotic GVHD was 10.5% (15.5% among patients with chronic GVHD). In this series, only 21% manifested "lichenoid" changes prior to the onset of skin sclerosis.[9] In a referral setting for patients with primarily refractory disease at the NIH, 81/110 (74%) consecutive patients had skin involvement, 58/110 (53%) of whom had sclerotic manifestations.[10]

BOX 28-1 MAJOR RISK FACTORS FOR THE DEVELOPMENT OF GRAFT-VERSUS-HOST DISEASE

HLA-incompatibility
Patient age (elderly > adult > pediatric)
Female donor (especially multiparous)/male recipient
Stem cell source (peripheral blood > bone marrow > cord blood)
T-cell replete graft
Unrelated donor
Donor leukocyte infusion
Interruption or rapid tapering of immunosuppression

ETIOLOGY AND PATHOGENESIS

In 1966, Billingham proposed three basic requirements for GVHD: (1) immunocompetent transplanted cells, (2) host antigens recognizable by the transplanted cells and lacking in the donor, and (3) a host incapable of mounting an immune response to the transplanted cells.[11] The immunocompetent cells are now known to be T-cells, which target human leukocyte antigens (HLAs) expressed on host tissues. GVHD still develops in 40% of recipients of HLA-identical grafts, however. In this setting, GVHD is due to mismatch of key minor histocompatibility antigens (e.g., HY, HA-3).[12] Tissue damage from the recipient's underlying disease, infection, and pretransplant conditioning also plays a key role in induction of the inflammatory response through pro-inflammatory cytokine production and antigen-presenting cell (APC) activation.[13,14]

Following activation of host APCs, T-cell activation and differentiation drives the response in acute GVHD. This appears to be primarily a Th1-driven process with massive release of interferon-γ, interleukin-2 (IL2), and TNF-α.[14] Genetic polymorphisms in tumor necrosis factor (TNF)-α, interleukin-10, interferon-γ, and transforming growth factor (TGF)-β have been linked to increased risk and severity of GVHD.[15–17] Although many therapies for acute GVHD target IL-2 or its receptor (CD25), these approaches (calcineurin inhibitors, daclizumab) may have the unintended

consequence of adversely impacting the $CD4^+CD25^+$ regulatory T-cell population.[14,18] Decreased T-regulatory cells are associated with severity of acute GVHD and poor response to GVHD treatment.[19] The final effector phase of acute GVHD is characterized by cell damage via cytotoxic T-cells, natural killer cells, and soluble inflammatory mediators, including TNF-α, interferon γ, and interleukin-1.[14]

In comparison to acute GHVD, the pathophysiology of chronic GVHD is less well understood. Features of alloimmunity and autoimmunity and the broad spectrum of disease manifestations implicate multiple immunological pathways beyond T-cell alloreactivity. In fact, in contrast to acute GVHD, T-cell depletion of the graft does not necessarily reduce the incidence of chronic disease.[20] Murine models of GVHD have demonstrated both Th1 and Th2 responses, depending on the setting; however, these models typically demonstrate specific aspects of GVHD, but do not recapitulate the full breadth of immunological and clinical abnormalities seen in human disease.[21]

The role of B-cell function in chronic GVHD has garnered renewed interest following the success of the anti-CD20 antibody rituximab in chronic GVHD.[22] Autoantibody formation (e.g., antinuclear antibody, anti-ds DNA antibody) is a frequent finding in chronic GVHD, although the antibodies lack the specificity of typical autoimmune disease. B-cells may play several key roles in facilitating the T-cell response in chronic GVHD. Acting as APCs, B-cells prime T-cells to respond to minor histocompatibility antigens (mHA), and high-titers of antibodies directed against mHA are associated with cGVHD.[23,24] Similarly, soluble levels of B-cell activating factor of the TNF family (BAFF), a cytokine which inhibits apoptosis of B-cells and promotes differentiation into plasma cells, correlate with cGVHD activity. [25,26]

The mechanisms responsible for chronic GVHD-induced fibrosis in the skin and elsewhere (e.g., bronchiolitis obliterans) remains uncertain. A two-phase model has been proposed in which the innate pathway is activated through Toll-like receptors, leading to an alloreactive T-cell response. This is followed by a fibrotic phase driven by platelet-derived growth factor (PDGF) and PDGF receptor (PDGFR), which in turn activates TGF-β.[21] TGF-β is a potent profibrotic cytokine, capable of stimulating collagen production, abrogating metalloproteinase activity, and sensitizing fibroblasts to a constitutive-activated state via autocrine signaling.[27] Furthermore, stimulatory antibodies directed against PDGFR have been identified by one group in patients with chronic GVHD as well as patients with systemic sclerosis.[28,29] This has led to significant interest in imatinib mesylate, a multikinase inhibitor with potent activity against PDGFR signaling (and other receptors), for the treatment of GVHD-related fibrosis.[30,31] However, to date, detection of PDGFR antibodies in sclerotic skin disease has not been replicated by other groups,[32] and administration of imatinib prior to the onset of GVHD does not appear to eliminate the risk of developing skin sclerosis.[33] The mechanism of action of imatinib therefore, remains unclear, and other mechanisms, including T-cell inhibition[34] and inhibition of fibrosis via "nonclassic" pathways downstream of TGF-β, such as cellular Abelson (c-Abl) may be relevant.[27]

CLINICAL FINDINGS

HISTORY

Accurate diagnosis of acute GVHD requires clinicopathologic correlation. Because the skin eruption (and histology) may be nonspecific at the time of first presentation, a careful history is invaluable. Key donor/recipient characteristics include degree of HLA-match, use of related versus unrelated donor, and T-cell depletion of the graft. Reduced-intensity conditioning may delay the onset of acute GVHD symptoms beyond the 100-day period.[35] The timing of neutrophil engraftment, new medication exposures, and evidence of other organ involvement (e.g., elevated total bilirubin, diarrhea) provide additional data for clinicopathologic correlation.

Features of acute GVHD following recent blood transfusion should raise concern for transfusion-associated GVHD (TA-GVHD). TA-GVHD is an often fatal sequelae of administration of cellular blood products to immunocompromised HCT recipients, and therefore all blood products in these patients are now irradiated. TA-GVHD may also occur following transfusion of unirradiated blood products to children with congenital immunodeficiency, including Wiskott—Aldrich and ataxia-telangiectasia, as well as in the immunocompetent setting. In the latter scenario, the diagnosis may be easily missed. TA-GVHD in the immunocompetent setting follows transfusion of an unirradiated blood product that contains donor lymphocytes that are homozygous for the HLA haplotype of the recipient. A history of blood product transfusion from a relative or genetically similar population is an important feature. For example, in Japan, the estimated risk of randomly receiving blood from a homozygous donor is 1 in 874.[36] In this form of TA-GVHD, the donor lymphocytes in the blood product are not recognized as foreign, leading to a GVHD reaction similar to classic acute GVHD. Beginning 10 days after transfusion, fever and skin rash (histologically consistent with GVHD) develops, followed by liver dysfunction and diarrhea. Death from pancytopenia usually occurs within several weeks.[37]

As with acute disease, a new diagnosis of chronic GVHD is best made based on history, cutaneous examination, and histology. A previous history of acute GVHD is the single greatest risk factor for chronic disease. Because acute symptoms may develop after 100 days posttransplant and chronic symptoms may develop before then, the revised classification of acute and chronic GVHD symptoms includes additional subtypes of GVHD with overlapping features or timing of acute and chronic symptoms (Fig. 28-1).[38] Recent tapering of immunosuppressant medication or DLI given to augment the graft-versus-malignancy response are two common triggers of skin activity. DLI, in particular may present with an acute GVHD skin eruption consistent

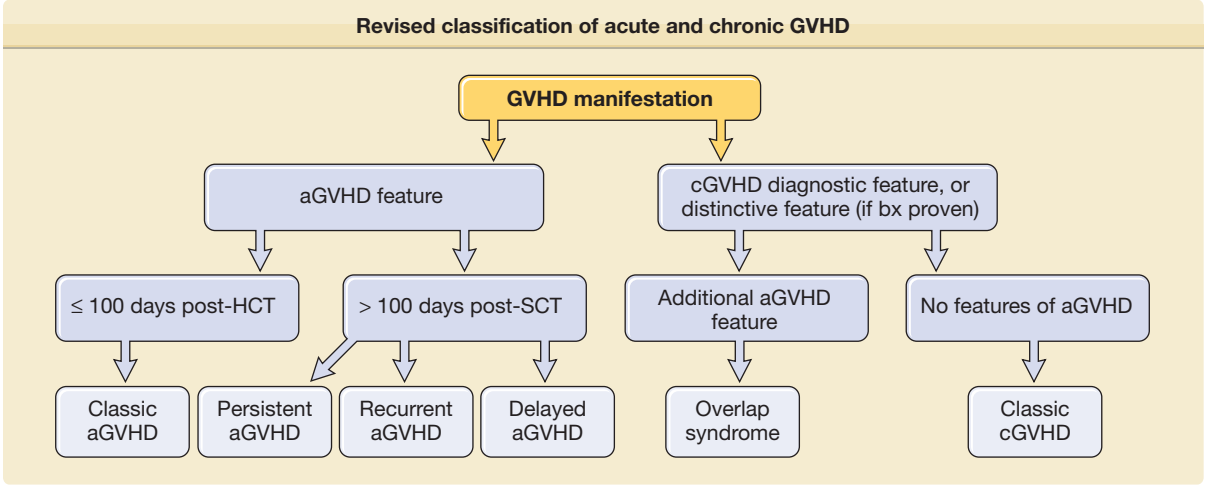

Figure 28-1 Revised classification of acute and chronic GVHD. (Adapted from Filipovich AH et al: National Institutes of Health consensus development project on criteria for clinical trials in chronic graft-versus-host disease: I. Diagnosis and staging working group report. *Biol Blood Marrow Transplant* **11**(12):945-956, 2005.)

with acute GVHD rather than the papulosquamous eruption of chronic disease (Fig. 28-2D). Cutaneous or systemic infection may also induce a flare of skin GVHD, as will drug exanthems, which can result in a diagnostic challenge given the clinical and histologic similarities between viral exanthem, drug eruption, and GVHD.[39] Important clues to sclerotic and fascial disease includes a history of edema of an extremity, muscle cramping, decreased flexibility, and complaints of skin tightness, particularly at the waistband and brassiere-line.[10] Although GVHD in other organ systems may not necessarily flare in synchrony with skin involvement, the presence of other organ system involvement is helpful when the cutaneous features are nondiagnostic. Common GVHD symptoms include oral and ocular sicca and oral pain, particularly with spicy foods. Also common, but less specific, are symptoms of fatigue, poor appetite, and weakness. Dysphagia may indicate the presence of esophageal strictures or webbing. Bronchiolitis obliterans manifests as dry cough, wheezing, and dyspnea, but requires pulmonary function tests and computerized tomography (CT) scans to rule out infection and other etiologies. Finally, it is important to remember that despite the phenotypic variability in chronic GVHD of the skin, not every skin manifestation in a patient after HCT is due to GVHD, so a careful dermatologic history to detect other possible diagnoses is prudent.

CUTANEOUS LESIONS

Acute GVHD initially presents with erythematous-dusky macules and papules of the volar and plantar surfaces and ears that may rapidly become a diffuse morbilliform exanthema (Fig. 28-2A and 28-2B; Box 28-2). Very early involvement may manifest as erythema limited to hair follicles (Fig. 28-2C). Pruritus is variable and is not useful to distinguish acute GVHD from other causes. Erythroderma may develop, and, in severe cases, spontaneous bullae with skin sloughing resembling toxic epidermal necrolysis. Widespread erythrodermic involvement, particularly the presence of skin sloughing portends a very poor prognosis. In contrast to chronic disease, postinflammatory pigmentary changes following acute GVHD are uncommon.

In appreciation of the tremendous variability in clinical presentation of chronic skin GVHD, it is no longer useful to dichotomize chronic GVHD of the skin into either "lichenoid" or "sclerodermoid" categories. In the transplant community, the term "lichenoid" has been utilized to denote any involvement of the skin in which erythema or scaling is present; however,

BOX 28-2 ACUTE GVHD ORGAN SYSTEM MANIFESTATIONS

SKIN
- Erythema of palms, soles, ears
- Perifollicular erythema
- Generalized exanthem
- Bullae/necrolysis

GASTROINTESTINAL
- Abdominal pain
- Anorexia
- Ileus
- Mucositis
- Vomiting
- Secretory diarrhea

LIVER
- Endothelialitis
- Pericholangitis
- Cholestatic hyperbilirubinemia



Figure 28-2 Spectrum of acute graft-versus-host skin manifestations. Acute cutaneous graft-versus-host reaction. Erythematous macules involving the ears (**A**), palms (**B**), and soles are characteristic of early cutaneous involvement. **C.** Follicular graft-versus-host disease. Perifollicular invovlement is an early manifestation of skin involvement. **D.** GVHD-associated necrolysis. Acute GVHD with bullae formation and skin sloughing following donor leukocyte for relapsed acute lymphoblastic leukemia 10 months following allogeneic HCT.

"lichenoid" is a histologic pattern, not a clinical one, and, therefore, usage of it is best reserved to pathologic description. Futhermore, although chronic GVHD may resemble lichen planus (Fig. 28-3), other patterns are frequently observed, such as poikiloderma (Fig. 28-4) and skin lesions resembling lupus erythematosus, keratosis pilaris, or psoriasis.[40] Postinflammatory hyperpigmentation is common following the resolution of epidermal involvement, particularly in darkly pigmented individuals, and may persist for many months after the skin disease becomes quiescent.

The fibrotic changes of chronic GVHD are also remarkably variable, and the term "sclerodermoid" is an inadequate descriptor of the varied sclerotic tissue abnormalities in the dermis, subcutaneous tissue, and fascia (Fig. 28-5). As in systemic sclerosis, an



Figure 28-3 Lichen planus-like chronic GVHD. Reticulate violaceous plaques with dry scale on the posterior neck and upper back.



Figure 28-4 Poikilodermic chronic GVHD. Hypopigmentation, hyperpigmentation, and erythema on the chest and proximal arms.

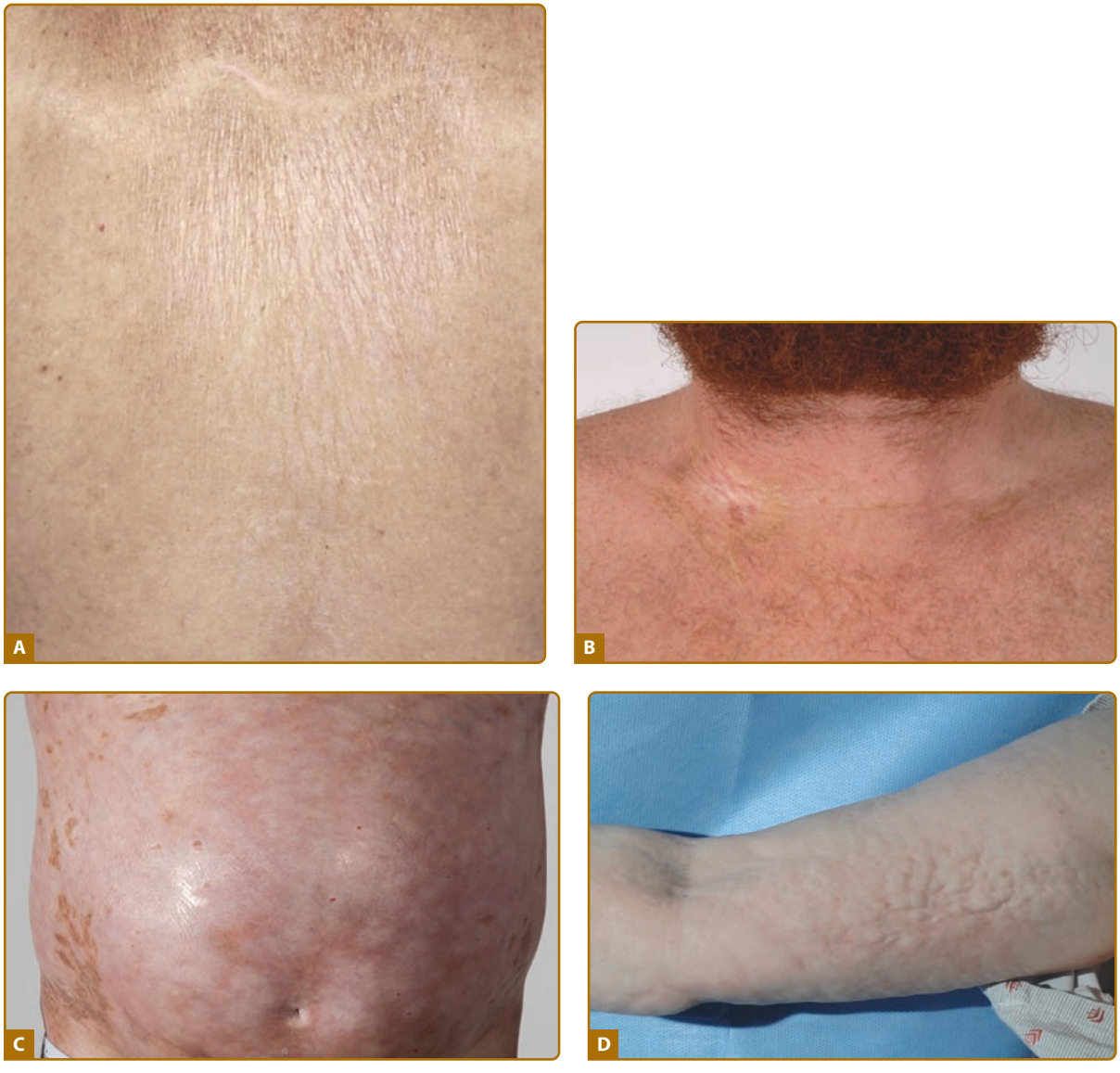

Figure 28-5 Clinical spectrum of sclerotic GVHD skin manifestations. **A.** Guttate white plaques on the upper back resembling lichen sclerosus. **B.** Morphea-like sclerotic plaques at sites of previous indwelling line placement near the clavicle (isotopic response). **C.** Diffuse dermal sclerosis resembling scleroderma on the anterior torso with patchy hyperpigmentation. **D.** Subcutaneous fibrosis of chronic GVHD. There is prominent rippling with a firm nodular texture extending along the medial arm resembling eosinophilic fasciitis. There is associated decreased range of motion at the elbow.

edematous phase may herald the onset of skin fibrosis, but fingers and toes are usually spared and the typical acral to proximal progression characteristic of systemic sclerosis is not seen in chronic GVHD. In constrast to systemic sclerosis, facial involvement is rarely involved in sclerotic-type GVHD. As mentioned above, fibrosis may occur primarily in the upper dermis, through the full-thickness of dermis, or in the subcutaneous fat and fascia. Early superficial fibrotic involvement resembles lichen sclerosus, often manifesting as porcelain-white atrophic plaques on the upper back (Fig. 28-5A). A common pattern of GVHD-associated fibrosis involves patchy sclerotic plaques with hypo- and hyperpigmentation mimicking morphea. Sclerosis of this type may exhibit an isomorphic response, localizing to the sites of minor skin trauma, particularly the waistband area, or may develop at sites of previous scar formation (Fig. 28-5B).[41] Diffuse dermal involvement may result in a "pipe-stem" appearance of the lower extremities with marked reduction in limb volume and overlying shiny hidebound skin with loss of hair resembling scleroderma (Fig. 28-5C). Deeper involvement of the subcutaneous fat results in irregular hyperpigmented sclerotic plaques with intervening areas of edematous skin closely resembling deep morphea/morphea profunda.[42] Bullae may develop at sites of fibrosis, particularly on the lower legs, as a result of dermal edema, as has been described in bullous morphea profunda.[43] Patchy hyperpigmentation ("leopard spots") may be visible prior to the diagnosis of dermal sclerotic involvement.[44]

Primary involvement of the subcutaneous fat and fascia results in a diffuse firm, rippled pattern to the skin resembling eosinophilic fasciitis (Fig. 28-5D).[45] Features of overlying epidermal GVHD involvement and pigmentary changes may be absent. Fascial involvement is often most visible on the medial arms and thighs and be accentuated by abduction and supination of the arm. Prominent "grooving" demarcating fascial bundles and along the path of superficial vessels may be observed. Careful palpation of the skin is helpful in detecting deep-seated irregularities in skin texture and differentiation from cellulite. Dermal fibriosis or fascial involvement without overlying dermal thickening may lead to progressive loss of joint range of motion and contracture formation.

Nail involvement in chronic GVHD typically results in longitudinal ridging and thin, easily broken nails. Partial or complete anonychia and dorsal pterygium formation may occur. Other unusual skin sequelae of chronic GVHD include milia formation, porokeratosis, often on the buttock area,[46] angioma formation at sites of skin sclerosis,[47] nipple hyperkeratosis,[48] vitiligo,[49] and alopecia, either diffuse or focal areas of alopecia areata.[50]

Different manifestations of sclerotic and and non-sclerotic skin disease may be present in the same individual, making accurate quantification of disease activity challenging. The chronic GVHD NIH Consensus Development Project provided more precise terminology for organ system involvement and defined features specific for diagnosis of chronic GVHD in the setting of HCT (Box 28-3). Diagnostic cutaneous features of GVHD include poikiloderma, lichen-planus-like lesions, and sclerotic skin changes.[38]

RELATED PHYSICAL FINDINGS

Acute GVHD is primarily a disorder of the skin, GI tract, and liver (Box 28-2), typically presenting with skin rash, new onset elevation of total bilirubin, and/or voluminous diarrhea. By contrast, chronic GVHD is remarkably diverse in its breadth of organ system manifestations (Box 28-3). The most frequently affected sites are skin and nails, oral mucosa, eyes, liver, lungs, and marrow (usually thrombocytopenia).[5] Esophageal webs/strictures, vagino-vulvar disease, myositis, nephrotic syndrome, and pericarditis are less frequent sequelae of chronic disease.

Mucosal disease is second only to skin involvement in frequency in chronic GVHD. Mucoceles are common, as are erosions, lichen-planus-like changes with Wickham's striae, and sicca symptoms. Dryness and violaceous erythema of the lips are common. Genital involvement significantly impairs sexual function and quality of life and may be overlooked if a specific examination and directed questions regarding genital symptoms are not undertaken. Involvement of the penis may induce phimosis. Vulvo-vaginal involvement presents as erythema, erosions/fissures, vestibulitis, vaginal stenosis, labial resorption, or complete agglutination of the introitus leading to hematocolpos (Fig. 28-6).[51]



Figure 28-6 Severe chronic GVHD of the vulva. The labia minora are partially resorbed with residual vulvitis and atrophic mucosa. Surrounding reticulate hyperpigmentation of the nonmucosal skin is consistent with postinflammatory changes of chronic GVHD.

BOX 28-3 SIGNS AND SYMPTOMS OF CHRONIC GVHD BASED ON NIH CONSENSUS CRITERIA

SKIN AND MUCOSAL INVOLVEMENT

Skin
- Alopecia
- Angiomatous papules
- Bullae
- **Erythema**
- Hypo- or hyperpigmentation
- Ichthyosis-like
- Keratosis-pilaris-like
- **Lichen planus-like[a]**
- Lichen sclerosus-like[a]
- Maculopapular
- **Morphea-like[a]**
- Poikiloderma[a]
- Scleroderma-like[a]
- Sweat impairment
- Ulceration

Nails
- Brittleness
- **Longitudinal ridging or splitting**
- Onycholysis
- Pterygium unguis

Subcutaneous tissue
- Fasciitis[a]
- Panniculitis

Oral mucosa
- Erythema
- Gingivitis
- Hyperkeratotic plaques[a]
- **Lichen planus-like[a]**
- **Mucocele**
- Mucosal atrophy
- Mucositis
- Pseudomembrane
- Restriction of oral opening from sclerosis[a]
- Ulcer
- Xerostomia

Genital mucosa
- Lichen planus-like[a]
- Vulvar erosions/fissures
- Vaginal scarring/stenosis[a]

OTHER ORGAN SYSTEM INVOLVEMENT

Cardiovascular
- Pericardial effusion
- Cardiac conduction abnormality
- Cardiomyopathy

Ophthalmologic
- Blepharitis
- Cicatricial conjunctivitis
- Confluent punctuate keratopathy
- **Keratoconjunctivitis sicca**
- Photophobia

Gastrointestinal
- Esophageal web[a]
- Esophageal stricture/stenosis[a]
- Exocrine pancreatic insufficiency

Hematopoeitic
- Eosinophilia
- Hypo-/hypergammaglobulinemia
- Lymphopenia
- **Thrombocytopenia**

Hepatic
- Elevated total bilirubin
- Elevated alkaline phosphatase
- **Elevated transaminases**

Musculoskeletal
- Arthralgia
- Arthritis
- Edema
- Myalgia
- Myositis/polymyositis

Neurologic
- Peripheral neuropathy

Pulmonary
- **Bronchiolitis obliterans +/– organizing pneumonia[a]**
- Pleural effusion

Renal
- Nephrotic syndrome

Rheumatologic
- Autoantibodies
- Myasthenia gravis

[a]Diagnostic features of cGVHD based on NIH Consensus Criteria. Other signs and symptoms listed are not considered sufficient to establish a diagnosis of chronic GVHD without further testing or evidence of other organ system involvement. The most common GVHD manifestations are shown in **bold.**

Adapted from Filipovich AH et al: National Institutes of Health consensus development project on criteria for clinical trials in chronic graft-versus-host disease: I. Diagnosis and staging working group report. *Biol Blood Marrow Transplant* **11**(12):945-956, 2005.

HISTOPATHOLOGY. The histological grading scale for acute GVHD is shown in Table 28-1. The hallmark feature of acute GVHD is the presence of necrotic keratinocytes accompanied by a dermal lymphocytic infiltrate (usually sparse) and basal vacuolar alteration (Fig. 28-7). Early GVHD involvement with follicular erythema correlates with involvement limited to the hair follicle. Subepidermal cleft formation (Grade III) is indicative of more severe involvement, whereas complete separation of epidermis

TABLE 28-1
Histologic Grading of Acute GVHD

Histologic Grading Scheme for Acute Cutaneous Graft-Versus-Host Reaction	
Grade	**Description**
0	Normal skin or changes not referable to graft-versus-host disease
1	Basal vacuolization of the dermalepidermal junction
2	Basal vacuolization, necrotic epidermal cells, lymphocytes in the dermis and/or epidermis
3	Subepidermal cleft formation plus grade 2 changes
4	Separation of epidermis from dermis plus grade 2 changes

Adapted from Lerner KG et al: Histopathology of graft-versus-host reaction (GVHR) in human recipients of marrow from HLA-matched sibling donors. *Transplantation* **18**:367, 1974.

from dermis (Grade IV) correlates with clinical findings resembling toxic epidermal necrolysis. Grade IV involvement may be impossible to differentiate histologically from drug-induced toxic epidermal necrolysis and requires careful clinical correlation. The presence of eosinophils has been used in the past to argue against a diagnosis of GVHD; however, the presence of scattered eosinophils may lead to a false diagnosis of drug eruption[52] and, unless very large numbers of eosinophils are present, this feature cannot be used as a reliable indicator of a drug hypersensitivity reaction.[53] Engraftment syndrome is a poorly understood phenomenon at the time of neutrophil engraftment following autologous-HCT or allo-HCT characterized by a nonspecific erythematous skin eruption, fever, and pulmonary edema.[54] Histologically, it may not be possible to distinguish engraftment rash from early (Grade I) acute GVHD.

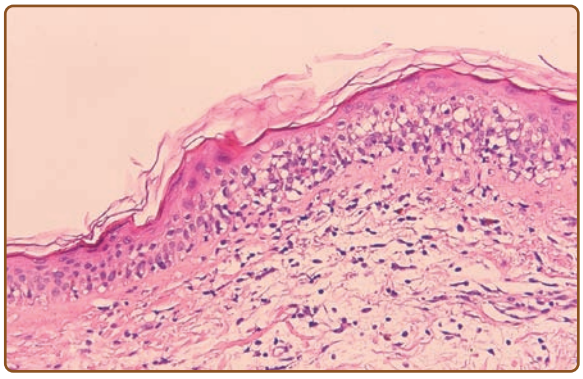

Figure 28-7 Histopathologic features of acute cutaneous graft-versus-host disease, Grade II. Inflammation of the upper dermis is present, with extension of lymphocytes into the dermis and interface change.

Epidermal changes in chronic GVHD may be indistinguishable from those of acute disease (Fig. 28-8A). Acanthosis and wedge-shaped hypergranulosis may be seen. Sclerotic involvement of the upper dermis may resemble lichen sclerosus, with atrophy, hyperkeratosis, follicular plugging, and pale, homogenized appearance of the upper dermis collagen (Fig. 28-8B).[45] If epidermal changes of GVHD are not present, dermal fibrosis with thickened collagen bundles and loss of periadnexal fat involvement may be indistinguishable from morphea/scleroderma. Subcutaneous and fascial involvement accordingly demonstrates changes in the fat septae and fascia, including thickening, edema, and fibrosis. Variable lymphocytes, histiocytes, and eosinophils may be seen.[45]

Histology of involvement of the oral mucosa reflects similar interface changes as those seen in epidermal GVHD, but without associated acanthosis.[55] Lymphocytic infiltration of the salivary glands resembles changes seen in Sjögren's syndrome.

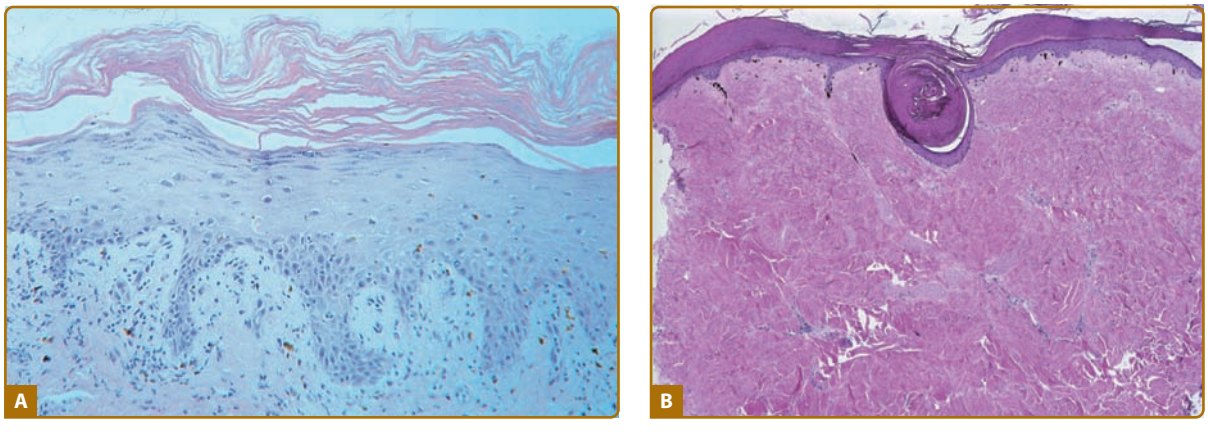

Figure 28-8 Histologic features of epidermal and sclerotic-type chronic cutaneous graft-versus-host disease. **A.** Histopathologic features of a lichen planus-like reaction. Acanthosis, hypergranulosis, hyperkeratosis, and pointed rete ridges are present. The inflammatory infiltrate is less dense than that usually seen in idiopathic lichen planus. **B.** Sclerotic-type GVHD. There is mild, compact hyperkeratosis or the epidermis with keratin plugging. There is hyalinization of the collagen throughout the dermis with loss of appendegeal structures.

LABORATORY TESTS

Diagnosis of acute GVHD skin involvement is based on histopathologic correlation, particularly exclusion of drugs and infectious causes. The presence of a normal leukocyte count is indicative of engraftment but no specific laboratory testing is diagnostic. Liver function testing and total bilirubin levels and quantification of diarrhea volume are used in conjunction with skin disease to stage the disease (Table 28-2).

Although autoimmune markers are seen in the majority of patients after alloHCT, their presence is generally not specific for the development of chronic GVHD manifestations, with the possible exception of sclerotic disease. In one study, elevated ANA titer was detected in 70% of patients with limited chronic disease and 94% of patients with extensive chronic disease compared to 23.5% of patients who did not develop chronic GVHD.[56] The presence of more than one autantibody also correlated with risk of extensive disease ($p = 0.04$); however, ANA titer does not correlate with disease severity. In this study, the presence of a nucleolar ANA pattern also indicated a potential association with sclerotic disease ($p = 0.06$).[56] In another multivariate analysis limited to sclerotic-type chronic GVHD patients, the presence of autoantibodies and serum eosinophilia were both associated with increased risk of sclerotic-type chronic GVHD.[9]

Identifying specific biomarkers of disease activity is an area of research emphasis in acute and chronic GVHD.[57] Plasma levels of elafin, a protease secreted in response to IL-1 and TNF-α, was recently identified as a candidate marker capable or differentiating acute GVHD skin from rashes of other etiologies. In this study, immunohistochemical staining of skin biopsies for elafin also discriminated acute GVHD from drug exanthem, suggesting a potential diagnostic application of this biomarker.[58]

SPECIAL TESTS (INCLUDING IMAGING STUDIES)

Suspicion of subcutaneous sclerotic and fascial disease and myositis may be confirmed by magnetic resonance imaging, particularly in cases in which definitive sclerotic changes are not observed or when a fascial or muscle biopsy is deferred.[45,59,60]

DIFFERENTIAL DIAGNOSIS

See Box 28-4.

COMPLICATIONS

Skin erosions and ulceration due to chronic GVHD may lead to secondary infection. Sclerotic changes resulting in restriction in joint function lead to functional disability and joint contractures. Restrictive lung disease may result from sclerotic involvement of the torso. HCT survivors are at increased risk for melanoma[61] and nonmelanoma[62] skin cancer due to previous exposure to ionizing radiation, GVHD-associated immunodysregulation, and immunosuppressive treatment for GVHD. The risk of cutanous squamous cell carcinoma (SCC) may also be increased by long-term treatment with voriconazole, a potent photosensitizer, which may be employed for antifungal treatment or prophylaxis.[63] Multiple SCC have also been reported after PUVA for GVHD.[64]

PROGNOSIS/CLINICAL COURSE

Although the presence of GVHD is associated with decreased risk of malignancy relapse, GVHD is also a cause of significant morbidity and mortality, particularly

TABLE 28-2
Staging and Grading of Acute GVHD Clinical and Laboratory Manifestations

Stage	Skin	Liver	Gut
1	Rash <25% BSA	Bilirubin 2 mg/dL to <3 mg/dL	Diarrhea 500–1,000 mL/day or persistent nausea
2	Rash 25%–50% BSA	Bilirubin 3–6 mg/dL	Diarrhea 1,000–1,500 mL/day
3	Rash >50% BSA	Bilirubin 6–15 mg/dL	Diarrhea >1,500 mL/day
4	Erythroderma w/bullae formation	Bilirubin >15 mg/dL	Severe abdominal pain with or without ileus
Grade			
I	Stages 1–2	None	None
II	Stage 3	Stage 1	Stage 1
III		Stages 2–3	Stages 2–4
IV	Stage 4	Stage 4	

Adapted from Przepiorka D et al: 1994 Consensus Conference on Acute GVHD Grading. *Bone Marrow Transplant* **15**(6):825-828, 1995.

BOX 28-4 DIFFERENTIAL DIAGNOSIS OF GRAFT-VERSUS-HOST DISEASE

Acute GVHD

Drug eruption
Rash of engraftment syndrome
Transient acantholytic dermatosis
Toxic epidermal necrolysis (for Stage IV disease)
Viral exanthem

Chronic GVHD

Epidermal involvement
- Drug eruption
- Lichen planus
- Pityriasis lichenoides chronica
- Psoriasis

Sclerotic involvement
- Eosinophilic fasciitis
- Lichen sclerosus
- Morphea
- Nephrogenic systemic fibrosis
- Radiation dermatitis
- Systemic sclerosis

in patients who develop refractory disease. A number of systemic risk factors portend a poor prognosis, including a history of progressive involvement from acute to chronic GVHD,[65] thrombocytopenia (fewer than 100,000 cells/mL),[66] elevated bilirubin,[67] older age, gastrointestinal symptoms, and lack of response to therapy at 6 months.[68] The two primary dermatologic features associated with poor prognosis are extensive (>50%) skin involvement[69] and "lichenoid" skin histology.[65]

TREATMENT

MANAGEMENT OF ACUTE GVHD

Treatment of acute GVHD is usually undertaken in the hospital, given the proximity to the date of HCT and the need for close observation. Patients with mild (Grade I) skin involvement without hepatic or gastrointestinal symptoms may respond to high-potency topical steroids. However, more severe skin involvement or the presence of internal organ involvement necessitates treatment with systemic corticosteroids (methylprednisone 2 mg/kDa/day). Patients with skin sloughing require meticulous skin care, infection surveillance, and fluid management similar to toxic epidermal necrolysis. Approximately 50% of patients respond to systemic corticosteroids—however, those who require salvage therapy typically receive one or more immunosuppressive agents, including calcineurin inhibitors (tacrolimus, cyclosporine), mycophenolate mofetil, and sirolimus, which are of variable success (Box 28-5).[70] Phototherapy (PUVA,[71] NB-UVB,[72]

BOX 28-5 SYSTEMIC TREATMENT OF ACUTE CUTANEOUS GVHD

FIRST LINE
- Corticosteroids (IV methylprednisone 2 mg/kg/day)[112,113]
- Tacrolimus (usually on prophylactic treatment)[114]
- Cyclosporine (usually on prophylactic treatment)[115]

SECOND LINE
- Mycophenolate mofetil[116,117]
- Etanercept[74,118]
- Infliximab[119,120]
- Denileukin diftitox[121]
- Pentostatin[122]
- Antithymocyte globulin[123,124]

OTHER SALVAGE THERAPY
- Extracorporeal photopheresis[125,126]
- Alefacept[127]
- Mesenchymal stem cell therapy[76,77]
- Anti-CD25 antibodies
- Daclizumab[128]
- Inolimomab[129]
- Baxiliximab[130,131]
- ABX-CBL (anti-CD147)[132]
- Anti-CD3 (visilizumab)[133]
- Anti-CD52 (alemtuzumab)[134,135]
- Psoralen plus UVA (PUVA)[71,136]
- Narrowband-UVB[72]
- Ultraviolet A1 (340–400 nm)[73]

UVA1[73]) has also been used in small series for acute GVHD, but is logistically challenging in the inpatient setting and should be administered cautiously to avoid inducing erythema.

Extracorporeal photopheresis (ECP), anti-TNF–α therapy, and multipotent mesenchymal stromal cells (MSC) are additional strategies that have shown recent success for the treatment of acute skin GVHD. In a review of salvage therapies for acute GVHD, 60%–76% of patients with skin involvement responded to ECP; however, responses decreased with increasing skin severity.[70] Levine et al[74] demonstrated complete remission (CR) of skin symptoms in 81% of patients treated with steroids and etanercept compared to steroids alone (CR = 47%). Similarly, infliximab has also shown variable success in acute treatment-refractory skin GVHD (33%–60%).[70] Finally, preliminary reports of the success of MSC, bone marrow-fibroblast derived cells capable of differentiation into adipocytes, chondrocytes, and osteoblasts, in patients with refractory acute GVHD has generated significant interest in this novel therapy.[75–77] In a 2008 study, 39/55 (71%) of participants with steroid-resistant acute GVHD sustained a complete or partial response to MSC infusion.[77] Responses were seen regardless of MSC source (HLA-matched, haploidentical, or third party unmatched

donors), and immunogenicity was not observed. The immunomodulatory mechanism of MSC is unclear, but may be through induction of regulatory T-cells.[78,79] Several MSC studies are underway for the treatment or prophylaxis of acute and chronic GVHD as well as for other chronic conditions, including Crohn's disease, multiple sclerosis, systemic sclerosis, and lupus erythematosus.

MANAGEMENT OF CHRONIC GVHD

Among the myriad topical, phototherapy-based, and systemic treatments that have been used in patients with chronic GVHD who cannot be tapered from systemic corticosteroids or who are steroid-refractory, no single treatment has demonstrated proven superiority (Table 28-3). Determination of a preferred second-line agent has been complicated by poor understanding of the disease process and a lack of high-quality clinical trials. The need to spur clinical trial development in the field of chronic GVHD was acknowledged by the chronic GVHD NIH Consensus Project, which included a standardized system of organ system assessments and recommendations for clinical trial design[80] Unfortunately, validated measures of cutaneous disease activity are still lacking, and the most common skin assessments tools, body surface estimates and use of Rodnan scoring (derived from systemic sclerosis trials) are not applicable for all manifestations of chronic GVHD skin activity.[81] Ideally, dermatologic collaboration in future therapeutic trials will permit better quantification of cutaneous disease response.

The dermatologist should play a key role in the multidisciplinary approach to chronic GVHD management, beginning with careful assessment of the subtype and extent of skin involvement. Together with an understanding of other organ system activity, infection risk, relapse risk, and GVHD prognostic risk factors, a decision regarding the appropriateness of topical, physical (e.g., phototherapy), and systemic therapy can then be made. If systemic therapy is prescribed by the transplant physician, periodic dermatologic monitoring is advised to differentiate adverse drug reactions or other new skin disease from GVHD,[82] to assess cutaneous disease response, and to monitor for infection and skin malignancy.

Nonsclerotic lichen-planus like and other papulosquamous chronic GVHD manifestations may respond well to topical steroid treatment and serve to reduce exposure to systemic immunosuppression.[83] Topical emollients and antipruritic agents may provide relief of pruritus and skin irritation; however, oral antihistamines may worsen sicca symptoms in patients with oral and ocular dryness. Choi and Nghiem[84] described a response to topical tacrolimus 0.1% ointment in 13/18 patients with chronic GVHD; however, all patients eventually required other therapy to control their skin disease. Subsequent reports have also described response to topical pimecrolimus 1% cream.[85,86] Topical calcineurin inhibitors are particularly useful for treatment of areas at high risk of skin atrophy, such as the face (including the lips) and intertriginous surfaces. Topical tacrolimus may not be tolerable at sites of significant inflammation or erosions. Hydroquinone in combination with tretinoin and topical dexamethasone has anecdotally been reported to improved periocular lichenoid type chronic GVHD and hyperpigmentation.[87] Topical tretinoin may also benefit milia formation following GVHD skin activity.

Phototherapy may be of benefit for both sclerotic and nonsclerotic chronic GVHD, but data are limited to anecdotal cases and a small number of noncontrolled case series. Vogelsang[88] described improvement in 31/40 patients treated with PUVA.[88] Three patients in this series had skin sclerosis—two demonstrated

TABLE 28-3
Systemic Treatment of Chronic Cutaneous GVHD

Treatment	Type of Chronic Skin Involvement	
	Sclerotic Features	Non-sclerotic
First line		
■ Prednisone PO 1 mg/kg/day	Sc[137]	Ns[137]
■ Tacrolimus	Sc[138]	Ns[138]
■ Cyclosporine	Not specified[139]	
Second line		
■ Extracorporeal photopheresis	Sc[100,140]	Ns[100,140]
■ Hydroxychloroquine	Ns[a141]	
■ Mycophenolate mofetil	Sc[117]	Ns[117]
■ Pentostatin	Sc[142]	Ns[142]
■ Rapamycin (sirolimus)	Sc[143,144]	Ns[143,144]
■ Rituximab	Sc[22,145]	Ns[22,145]
■ PUVA	Sc[b89]	Ns[b89]
■ UVB	Sc[91]	Ns[91]
■ NBUVB	Ns[90]	
■ UVA1	Sc[97,98]	Ns[98]
Other		
■ Daclizumab	Not specified[146]	
■ Methotrexate	Sc[147]	Ns[147,148]
■ Imatinib mesylate	Sc[30,31]	
■ Azathioprine	Sc[44]	
■ Clofazamine	Sc[149]	Ns[149]
■ Etanercept	Not specified[118,150]	
■ Etretinate	Sc[104]	
■ Mesenchymal stem cells	Sc[107]	
■ Thalidomide	Not specified[151,152]	
■ Alefacept	Not specified[153]	
■ Total lymphoid irradiation	Sc[154]	Ns[154]

Sc: sclerotic skin disease; Ns: Nonsclerotic skin disease.
[a]Sclerotic and nonsclerotic disease treated in this study; however, sclerotic disease did not respond.
[b]Bath-PUVA.

transient benefit, but developed severe phototoxicity, and the third did not respond to treatment. Smaller series with PUVA-bath (6 patients),[89] narrow-band UVB (10 patients, pediatric),[90] and UVB (5 patients),[91] have also described chronic GHVD responses, primarily in patients with "lichenoid" disease. Over the last several years, however, there has been growing experience with UVA1 for sclerotic skin conditions, suggesting potential application in chronic GVHD. Longer wavelength UVA1 (340–400 nm) does not require psoralen ingestion/topical application and penetrates deeper into the dermis than full spectrum UVA. Several reports have described skin softening following UVA1 treatment of lichen sclerosus,[92] localized morphea,[93–95] and sclerotic-type GVHD.[73,96–98] Wetzig et al[73] used medium-dose UVA-1 phototherapy in seven patients with lichenoid GVHD and three with sclerotic GVHD. All three patients with sclerotic GVHD demonstrated partial response or improvement. Ständer et al[97] described softening of skin lesions, improved joint mobility, and healing of skin erosions in five adult patients with medium-dose UVA-1 and one child treated with low-dose UVA-1. Calzavara Pinton et al[98] described five patients with sclerotic involvement treated with MD UVA-1 therapy leading to complete resolution in three patients and partial response in two patients. UVA-1 may accentuate pigmentary abnormalities.[99] Although UVA-1 is not yet widely available in the Unites States, it appears to be well tolerated, acceptable for pediatric use,[96] and is not associated with persistent photosensitivity or potential gastrointestinal issues that may occur with oral psoralen use.

Phototherapy may be appropriate for patients with limited epidermal or sclerotic disease in whom systemic therapy is not otherwise warranted (e.g., without internal organ system involvement), or in whom systemic immunosuppressive therapy is contraindicated (e.g., active infection); however further controlled trials are needed to directly compare phototherapy modalites and to determine the optimum dose and treatment schedule. Skin cancer risk assessment and concurrent use of photosensitizing medications should also be considered. Multiple squamous cell carcinomas have been reported following PUVA treatment for chronic GVHD [64] and the risk of melanoma is elevated in patients following HSCT.[61] Photosensitizing medication use is common, including voriconazole therapy, which may further increase the risk of squamous cell carcinoma formation in the setting of chronic GVHD.[63]

Extracorporeal photopheresis (ECP) is another option for patients with cutaneous disease, particularly patients with extensive or sclerotic involvement. During ECP, the white cell compartment of the blood is removed from the patient via pheresis, mixed with 8-methyoxypsoralen, irradiated with UVA light, and then returned to the patient. In a retrospective review of 71 chronic GVHD patients who were treated with ECP, 59% of patients with cutaneous involvement responded, including 67% of those patients categorized as sclerotic involvement.[100] ECP may be particularly useful for patients with deep-seated sclerotic involvement of the subcutaneous tissue and fascia. Although GVHD-related fasciitis resembles eosinophilic fasciitis (EF), in contrast to EF, it does not respond well to steroid therapy and may result in significant long-term functional disability. Several case reports describe successful use of ECP for EF,[101] and GVHD-related fasciitis.[41,102,103] ECP is a time-consuming procedure and requires a dedicated pheresis center which is not available at all medical facilities. As with phototherapy, the optimal frequency and duration of ECP treatment is unclear. Typically, intensive treatment (2× weekly or every other week) is initiated, followed by an attempt to decrease frequency if a response is achieved.

Limited data are available supporting the use of systemic retinoids for chronic GVHD. Marcellus et al[104] reported improvement in 20/27 evaluable patients with sclerotic disease treated with etretinate; however, six patients could not tolerate the treatment due to scaling or skin breakdown. Ghoreschi et al[105] described PUVA-bath treatment in 14 patients with sclerotic-type GVHD, five of whom received concurrent treatment with isotretinoin 10–20 mg/daily. Overall improvement was reported in 7/14 patients; however, skin ulceration was a significant issue in both PUVA-bath only and combination treatment groups, and the small sample size precluded statistical comparison between groups.[105] Further prospective studies are needed to determine the tolerability and efficacy of systemic retinoid therapy.

Imatinib mesylate, a multikinase inhibitor with activity against bc-abl, c-kit, PDGFR, and other kinases, has been reported to benefit patients with sclerotic GVHD in a small number of case reports.[30,31,106] The drug is generally well tolerated in the setting of treatment for chronic myelogenous leukemia; however, the tolerability and efficacy of the drug in chronic GVHD is an area of ongoing clinical trial investigation. Common side effects include peripheral and periorbital edema, myalgia, and fatigue. Second generation agents with similar targeted tyrosine kinase inhibitory activity (nilotinib, dasatinib) also hold potential as therapeutic options for sclerotic disease, as does the use of MSC, based on the experience with acute GVHD. Recently, a single case of sclerotic-type GVHD was reported with a response to MSC therapy.[107]

TREATMENT OF CHRONIC ORAL AND VULVO-VAGINAL DISEASE

Limited oral mucosal disease can be controlled with application of high-potency topical corticosteroid gel (fluocinonide gel 0.05%, clobestasol gel 0.05%). Refractory lesions may respond to intralesional triamcinolone injection (0.3–0.4 mL/L cm^2).[83] Topical application of tacrolimus 0.1% ointment may also be used;[108] however, systemic absorption has been reported[109] and, therefore, serum tacrolimus levels are reasonable following initiation of intra-oral treatment. Generalized oral disease can significantly impair oral intake and quality of life and often result in the need for systemic intervention. Corticosteroid rinses (dexamethasone 0.5 mg/mL; prednisolone 15 mg/mL) are beneficial

for widespread involvement and should be swished in the mouth 4–6 minutes 4–6 times daily.[83] Cyclosporine and azathioprine rinses may also be used for refractory disease, but require pharmacy compounding. As mentioned above, patients with salivary gland disease should avoid oral antihistamines as well as other xerogenic medications (SSRIs, tricyclic antidepressants). Dental hygiene is very important in patients with decreased salivary function and home fluoride treatment is frequently recommended. Salivary stimulants (e.g., sugar-free gum) and sialogogue therapy (cevimeline, pilocarpine) are recommended for patients with severe salivary gland dysfunction.[83] Although sclerotic involvement of perioral skin involvement is uncommon, in this setting aggressive systemic therapy is indicated.

Genital erosions and fissures associated with chronic vulvo-vaginal disease may be treated with clobetastol proprionate ointment nightly, which should be tapered to a maintenance level of 2–3 times weekly. If estrogen is not contraindicated, hormone replacement via topical cream, vaginal ring, or oral replacement may improve genital skin integrity. Limited vaginal scarring/synechiae can be treated with dilators or manual lysing; however, thick vaginal scarring may require surgical intervention.[110]

PREVENTION

GVHD prevention begins prior to transplantation with the selection of the most closely HLA-matched donor, the GVHD prophylaxis regimen and, in some cases, manipulation of the T-cell content of the graft. T-cell depletion is accomplished through ex vivo T-cell negative selection or enrichment of the $CD34^+$ stem cell population, or through in vivo treatment with anti-T-cell therapy. The benefits of T-cell depletion, however, are offset by higher rates of graft failure, cancer relapse, and infection.[14] Prophylactic immunosuppressive therapy is initiated concomitantly with the administration of the hematopoietic graft, but, as with T-cell depletion, such therapy must be balanced with potential for diminished graft-versus-leukemia/lymphoma effect and long-term infection risks. In general, available strategies for the prevention of acute GVHD are rarely effective in the prevention of chronic GVHD, emphasizing the distinct pathophysiology of these two GVHD manifestations. Ideally, personalized immunogenomics will evolve to allow careful titration of T-cell graft content and prophylactic immunosuppression to maximize graft acceptance and graft-versus-leukemia effect and at the same time minimize infection risk and other complications associated with long-term immunosuppression.

Similar to solid-organ transplantation, skin cancer screening and patient education regarding photoprotective measures is a key preventive strategy in patients with chronic GVHD.[83] Patients are also at elevated risk of systemic infection, and therefore, implementation of preventive infectious disease recommendations and careful monitoring for cutaneous infection, particularly in patients with chronic skin erosions/ulcerations, is prudent.[83] Finally, patient education regarding early signs of skin sclerosis and fascial involvement, including skin tightness, edema, muscle cramping, and range of motion restriction, may facilitate early diagnosis and initiation of treatment.

KEY REFERENCES

Full reference list available at www.DIGM8.com

DVD contains references and additional content

14. Ferrara JLM et al: Graft-versus-host disease. *The Lancet* **373**(9674):1550-1561, 2009
38. Filipovich AH et al: National Institutes of Health consensus development project on criteria for clinical trials in chronic graft-versus-host disease: I. Diagnosis and staging working group report. *Biol Blood Marrow Transplant* **11**(12):945-956, 2005
40. Hymes SR et al: Cutaneous manifestations of chronic graft-versus-host disease. *Biol Blood Marrow Transplant* **12**(11):1101-1113, 2006
45. Schaffer JV et al: Lichen sclerosus and eosinophilic fasciitis as manifestations of chronic graft-versus-host disease: Expanding the sclerodermoid spectrum. *J Am Acad Dermato* **53**(4):591-601, 2005
80. Pavletic SZ et al: Measuring therapeutic response in chronic graft-versus-host disease: National Institutes of Health Consensus Development Project on Criteria for Clinical Trials in Chronic Graft-versus-Host Disease: IV. Response Criteria Working Group report. *Biol Blood Marrow Transplan* **12**(3):252-266, 2006
83. Couriel D et al: Ancillary therapy and supportive care of chronic graft-versus-host disease: National institutes of health consensus development project on criteria for clinical trials in chronic Graft-versus-host disease: V. Ancillary Therapy and Supportive Care Working Group Report. *Biol Blood Marrow Transplant* **12**(4):375-396, 2006

Chapter 29 :: Skin Disease in Acute and Chronic Immunosuppression

:: Benjamin D. Ehst & Andrew Blauvelt

SKIN DISEASE IN ACUTE AND CHRONIC IMMUNOSUPPRESSION AT A GLANCE

- Skin manifestations in patients who have hematologic malignancies, have undergone bone marrow transplantation, or are immunosuppressed by drugs are common and varied.
- Many of these skin diseases occur in immunocompetent individuals as well.
- In patients with acute immunosuppression, infections occur that are normally controlled by neutrophils and macrophages.
- In patients who have long-term immunosuppression, T-cell function is impaired and skin diseases are often similar to those seen in patients with human immunodeficiency virus infection.
- Salient dermatologic features particularly associated with immunosuppression are important diagnostic signs and indicators for therapy.

Impairment of the body's immune system results from a variety of causes, including natural aging, ultraviolet radiation, diabetes, malnutrition, cancer, and iatrogenic suppression. While few skin conditions appear solely in immunocompromised individuals, clinical presentations may be morphologically atypical, follow unusual clinical courses, or prove harder to treat than in individuals with intact immunity. This chapter focuses on dermatologic manifestations in immunosuppressed patients without human immunodeficiency virus (HIV) disease, predominantly in those with immunosuppression induced by drugs, conditions surrounding solid organ and bone marrow transplantation, and hematologic malignancy. Skin manifestations of HIV disease are described in Chapter 198. Other chapters cover graft-versus-host disease (see Chapter 28), skin signs associated with primary immunodeficiency disorders (see Chapter 143), and detailed side effects of medications, including corticosteroids, cancer chemotherapeutic agents, immunosuppressants, and cytokines (see Chapters 224, 227, 233, and 234). The salient clinical features particularly associated with immunosuppression are emphasized here.

While a variety of inflammatory skin diseases and paraneoplastic processes occur in the setting of immunosuppression, infections, and malignancy are most commonly seen and are discussed herein. When approaching an immunocompromised patient, it is helpful to determine the time frame of the immune loss as well as the specific immune defect. This chapter is divided into two major subsections based on this concept: acute immunosuppression and chronic immunosuppression. When patients are acutely immunosuppressed, usually from iatrogenic ablation of the immune system or from acute leukemia, infections occur that are normally controlled by innate immunity, which typically involve neutrophils and macrophages. In chronically immunosuppressed individuals, such as organ transplant patients and those taking corticosteroids on a long-term basis, T-cell function is impaired, and diseases will often be similar to those observed in HIV disease. Thus, it is helpful to understand the underlying immune defects associated with the medical conditions of each patient (Table 29-1), because it helps to focus the history taking and physical examination toward skin manifestations of specific pathogens.

In ill-immunosuppressed patients, disease often manifests in the skin. Appropriate evaluation and diagnosis of skin lesions are critical to the overall health of these individuals, because the skin is often a window to more severe systemic illness. In particular, unusual presentations of infection with typical pathogens and infections with rare opportunistic pathogens are common in these patients. Diagnosis is also made more difficult by the variety of organisms that share similar morphologies and the wide variety of morphologic presentations of a single organism (Table 29-2). This makes prompt clinical evaluation and extensive use of skin biopsy and culture necessary to make an accurate diagnosis and initiate prompt treatment to obviate significant morbidity and mortality.

ACUTE IMMUNOSUPPRESSION

The prototype of an acutely immunosuppressed patient needing dermatologic evaluation is the neutropenic patient undergoing chemotherapy around the time of hematopoietic transplantation. Pancytopenia and neutropenia in particular predispose to invasive infections caused by Gram-negative and -positive bacteria and the fungal organisms *Candida* and *Aspergillus*.[1] These complications from many cancer therapies often pose a more immediate threat to survival than the malignancy itself. In the past two decades, overall mortality due to infection among patients undergoing hematopoietic transplantation has decreased significantly with the use of better prophylaxis and nonmyeloablative regimens, but still represents an ongoing risk to survival. The causes of infection-related death

TABLE 29-1
Opportunistic Infections that are Commonly Associated with Specific Underlying Immune Defects

Immune Defect	Usual Conditions	Common Bacterial Pathogens	Common Viral Pathogens	Common Fungal Pathogens
Defective cell-mediated immunity	Organ transplantation, metastatic cancer, Hodgkin disease, glucocorticoid, or cyclosporine therapy	*Listeria, Salmonella, Nocardia, Mycobacterium avium-intracellulare, M. tuberculosis, Legionella*	Cytomegalovirus, herpes simplex virus, varicella zoster virus	*Candida, Cryptococcus, Histoplasma, Coccidioides*
Defective humoral immunity	Multiple myeloma, chronic lymphocytic leukemia	*Streptococcus pneumoniae, Haemophilus influenzae, Neisseria meningitidis*	Enteroviruses	—
Neutropenia	Cancer chemotherapy, acute leukemia, adverse drug reaction	Aerobic Gram-negative bacteria; *Staphylococcus aureus, Streptococcus viridans, Staphylococcus epidermidis*	Herpes simplex virus	*Candida, Aspergillus*
Defective neutrophil function	Chronic granulomatous disease, myeloperoxidase deficiency	Catalase-positive bacteria: *S. aureus, Escherichia coli*	—	*Candida*
Hyposplenism	Splenectomy, hemolytic anemia	*S. aureus, Streptococcus*	—	*Candida*
Defective complement components	Congenital or acquired deficiencies	*S. pneumoniae* (C2, C3, C5 alternate), *H. influenzae* (C2, C3, alternate), *S. aureus* (C5), Enterobacteriaceae (C5), *Salmonella*(alternate), *N. meningitidis* (C6–C8)	—	—
Skin barrier disruption	Intravascular catheters, decubitus ulcers, burns	*Staphylococcus, M. fortuitum,* Gram-negative bacteria, anaerobes	—	*Candida, Aspergillus, Mucor*

TABLE 29-2
Cutaneous Morphologies and Associated Organisms in Immunosuppression[a]

Organism	Ecthymatous Lesions	Morbilliform Eruption	Vesicles	Erythemas (Cellulitic Patches and Plaques)	Ulcers
Bacteria					
Pseudomonas aeruginosa	X		X		
Streptococcus viridians		X		X (facial)	
Staphylococcus sp.	X	X			
Aeromonas hydrophilia	X				
Nocardia spp.				X	
Vibrio vulnificus				X	X
Fungi					
Aspergillus sp.	X		X (hemorrhagic)		X (necrotic)
Zygomycetes organisms	X			X (facial)	X (necrotic)
Fusarium sp.	X				
Cryptococcus neoformans				X	X
Histoplasma capsulatum				X	X (mucosal)
Coccidioides immitis	X				
Viruses					
Herpes simplex virus			X	X	X
Varicella zoster virus			X	X	X
Cytomegalovirus					X (mucosal)

[a]Each organism has a wide variety of presentations, and not all are included in this table.

have remained relatively stable, with death due to bacterial infections being the most common (36%), followed by deaths due to infection by viruses (31%), fungi (28%), and parasites (5%).[2,3] Infections in the acute period following solid organ transplantation are less opportunistic and tend to reflect the usual nosocomial pathogens associated with surgical procedures and hospitalization.[4]

BACTERIAL INFECTIONS

Bacteria are responsible for most infections during acute neutropenic episodes. Empiric antimicrobial therapy for fever and neutropenia was first introduced in the 1970s when 60%–70% of infections were due to Gram-negative bacteria such as *Escherichia coli*, *Pseudomonas aeruginosa*, and *Klebsiella* species. Dramatic shifts have occurred since that time, such that over 50% of bacterial infections in cancer patients are now caused by Gram-positive organisms, and 75%–80% in patients that are bacteremic.[5,6] The use of indwelling intravascular catheters, medications predisposing to mucositis, and prophylactic fluoroquinolones are all thought to play a role in the shift to Gram-positive organisms, such as coagulase-negative staphylococci, *Staphylococcus aureus*, Enterococcus species, and viridians group streptococci.[7] The emergence of drug-resistant organisms, including methicillin-resistant *Staphylococcus aureus* and vancomycin-resistant *Enterococcus*, as well as polymicrobial infections also complicates the situation.[6]

Routine cellulitis from staphylococcal and streptococcal organisms is a common manifestation of skin infection in the acutely immunocompromised host. Muted clinical signs and symptoms can be found in this population, so care must be taken to rule out deeper involvement as occurs in necrotizing fasciitis.[8] Bacteremia may result from skin and soft-tissue infections such as folliculitis, furuncles, and wound infections. Bone marrow transplant patients and other patients with neutropenia are prone to streptococcal bacteremia and may develop facial flushing, a widespread erythematous, petechial or purpuric eruption of macules and papules, and desquamation of the palms and soles.[9] Staphylococcal scalded-skin syndrome, which typically occurs in children (see Chapter 177), can occur in immunosuppressed adults.[10]

Ecthyma gangrenosum is one of the more specific clinical signs of bacteremia and is characterized by a painful erythematous to dusky nodule or plaque that rapidly develops a central pustule or hemorrhagic vesicle, followed by necrosis (Fig. 29-1). The groin, perianal area, and axillae are the most common locations. There may be one or many lesions. Classically described in patients with *Pseudomonas* septicemia, it is now recognized that other bacterial and fungal organisms, including *S. aureus*, *Aeromonas hydrophilia*, *Serratia marcescens*, *K. pneumoniae*, *E. coli*, *Aspergillus*, and *Mucor* species, can also cause similar lesions.[11,12] Necrosis is secondary to underlying focal vasculitis, which can be observed in skin biopsy specimens. Diagnosis is made by culture of the organism from skin or blood.



Figure 29-1 Ecthyma gangrenosum secondary to *Pseudomonas aeruginosa* infection in a bone marrow transplant patient.

Patients with neutropenia, cystic fibrosis, or extensive burns are particularly susceptible to systemic *P. aeruginosa* infection (see Chapter 180).[13] The mortality rate of *P. aeruginosa* bacteremia in transplant patients is high at upwards of 40%.[14] Other cutaneous manifestations of *P.* septicemia may appear initially as grouped vesicles, cellulitis, subcutaneous nodules, petechiae, purpura, or folliculitis.[15] Progression to ulcerative and necrotic lesions that are more characteristic of ecthyma gangrenosum may occur. Primary cutaneous infection, usually at the site of a medical procedure, can also cause ecthyma gangrenosum-like lesions. As is common with other infections in neutropenic patients, primary lesions can lead to bacteremia and should be treated aggressively.

FUNGAL INFECTIONS

In the acute transplant setting, invasive fungal infections are less common than bacterial infection, but cause much greater mortality. Mortality rates range from 40% to close to 100%, especially when treatment is delayed.[16] Prolonged neutropenia is a significant risk factor and recovery from disseminated fungal infections is rare unless neutropenia resolves. Candidiasis and aspergillosis represent the two most common invasive fungal infections that occur in patients who are undergoing cytotoxic chemotherapy or stem cell transplantation or who have acute myeloproliferative disorders.[17] However, they are not unique to the neutropenic patient and are encountered in settings such as surgical and neonatal intensive care units, and in patients with cell-mediated immune dysfunction such as those undergoing long-term immunosuppression after solid organ transplantation. Additional risk factors for opportunistic fungal infection include hyperalimentation, antibiotic use, hyperglycemia, corticosteroid use, and central venous catheter use. Other fungal organisms causing infection in hosts with acute neutropenia include *Trichosporum* species, *Fusarium* species, and organisms in the Zygomycetes class.[18]

CANDIDIASIS. Candidiasis (see Chapter 189) remains the most common opportunistic fungal infection worldwide, although its role in invasive infections is changing in certain immunosuppressed populations.[19] *Candida* species still account for more than half of invasive fungal infections in solid organ transplant recipients, but aspergillosis has become more common in hematopoietic stem cell transplant recipients.[20–22] Historically, most candidal infections were due to *Candida albicans*, but there has been an emergence of other organisms in recent years, including *C. glabrata*, *C. krusei, C. parapsilosis*, and *C. tropicalis*.[17] In certain populations of patients with hematologic malignancy or stem cell transplantation, non-*C. albicans* species now predominate, so awareness of local and regional patterns of infection is important.[20,23]

The classic triad of fever, myalgias, and erythematous skin lesions in a septic patient not responding to antibiotic therapy is highly suggestive of disseminated candidiasis. Fungi may seed numerous organs, causing myositis, meningitis, endocarditis, pneumonitis, cerebritis, esophagitis, bursitis, osteomyelitis, arthritis, and endophthalmitis. Cutaneous lesions are present in only 5%–10% of individuals with disseminated candidiasis.[15,24] Lesions are characteristically painless, nonblanching, discrete, erythematous macules, papules, or nodules (Fig. 29-2) and may develop central purpuric, pustular, or necrotic changes. Involvement is usually generalized, but occasional patients have very few lesions limited to the proximal extremities. The major clinical differential diagnosis includes infections caused by other opportunistic pathogens and drug eruptions. Histologically, periodic acid-Schiff-positive yeast forms are seen in the dermis, usually in association with vascular damage and mild inflammation. *Candida* can be grown from sterile skin lesion samples in approximately 50% of patients. Tissue scrapings from dermal skin can be obtained at the time of biopsy with a scalpel or small-diameter curette for slide examination and can be an invaluable aid in making a rapid diagnosis in an acutely ill patient.



Figure 29-2 Early cutaneous lesion of disseminated candidiasis in a neutropenic patient after chemotherapy for non-Hodgkin lymphoma.

The treatment of choice for presumed disseminated candidiasis is usually intravenous liposomal amphotericin B, although the new class of echinocandins are also being evaluated.[25,26] Culture results are again important since *C. glabrata*, *C. albicans*, *C. tropicalis*, and *C. parapsilosis* are showing resistance to fluconazole, and *C. krusei* is naturally resistant.[22] Newer azoles, including voriconazole and posaconazole, are effective against *Candida* species, although breakthrough infections with resistant *C. glabrata* have already been reported with voriconazole (see Chapter 232).[27]

ASPERGILLOSIS. While aspergillosis remains the second most common cause of opportunistic fungal infection in immunosuppressed patients as a whole, it has now surpassed *Candida* as the most common cause of invasive fungal infection in hematopoietic stem cell transplant patients and certain hematologic malignancies.[15,16,20] Incidence rates vary in different immunosuppressed groups, but may reach 25% in acute leukemia and organ transplant patients.[28] Persistent neutropenia and neutrophil dysfunction are risk factors for disseminated infection. Infection rates are also high for patients undergoing allogeneic stem cell transplantation, and risk factors in this group are expanded to include immunosuppression for graft-versus-host disease prophylaxis, graft-versus-host disease itself, and other infectious diseases, especially cytomegalovirus (CMV) infection. Invasive infection with *Aspergillus* was classically seen during acute periods of neutropenia, but shifts in conditioning regimens and other strategies to promote earlier engraftment have led to infections after 30–40 days posttransplantation.[20] This observation emphasizes that immune defenses other than those mediated by granulocytes are important for protection against invasive fungal infections, and against *Aspergillus* infections in particular.

The incidence of invasive aspergillosis is also increasing in nonclassic immunocompromised hosts such as critically ill patients in the intensive care unit. Environmental factors also clearly contribute to the development of aspergillosis, especially in primary cutaneous disease. These include hospital construction (which increases spore counts in ventilation systems), the use of indwelling catheters (which provide portals of entry for organisms), and contamination of tape and arm boards used to secure catheters. Mortality rates have improved with the introduction of newer antifungal agents, but remain higher than 50% in stem cell and organ transplant recipients.[28,29]

A. fumigatus is the most common cause of disseminated infections, although emerging strains of *A. flavus*, *A. niger,* and *A. terreus* are accounting for more disease.[20] Reports suggest that *A. flavus* is associated most commonly with primary cutaneous disease.[30] *A. terreus* is more likely to be resistant to amphotericin B, and multiple tri-azole resistant *A. fumigatus* has been described.[28]

Primary cutaneous aspergillosis often develops at paronychial locations, sites of intravenous catheters, or under areas of occlusion. Lesions initially appear as



Figure 29-3 Ecthymatous lesion of primary cutaneous aspergillosis in a child after bone marrow transplantation. (Used with permission from Jonathan Alexander, MD, Portland, OR.)

small cellulitic areas and progress quickly to necrotic ulcers with black eschars (Fig. 29-3) due to the angioinvasive nature of the organism. In patients with *Aspergillus* sinusitis, necrotic ulcers with black eschars can occur in the anterior nares and on the nasal septum, palate, and skin overlying the nasal bridge. MRI may be useful in diagnosing the underlying sinusitis, and prior treatment with amphotericin B does *not* exclude the diagnosis as surgical treatment may be needed in this setting.[31–33]

Pulmonary, and less often primary cutaneous or sinus, infection can easily become invasive and lead to disseminated disease in immunocompromised hosts. Patients with disseminated aspergillosis often present with unremitting fever despite antibiotic use. The central nervous system, heart, kidneys, and gastrointestinal tract may also be involved. Cutaneous manifestations of disseminated aspergillosis are uncommon, occurring in only 5%–10% of patients.[30] Lesions begin as single or multiple painful, erythematous papules, nodules, or plaques. They rapidly expand and develop central hemorrhagic vesicles or bullae, then eschar. In tissue sections, diagnosis can be made by demonstration of nonpigmented septated hyphae that branch at acute angles. Blood culture results often are not positive or reliable because *Aspergillus* is found commonly as a laboratory contaminant. Voriconazole has become the first-line agent for treatment of invasive aspergillosis. Alternatives include caspofungin, liposomal amphotericin B, itraconazole, and posaconazole.[29] Surgical removal of isolated lesions of primary cutaneous aspergillosis can be attempted, although this may not necessarily prevent secondary disseminated infection in patients with persistent neutropenia.

ZYGOMYCOSIS. Zygomycosis is the third most common opportunistic fungal infection in immunosuppressed hosts, and may account for closer to 50% of invasive fungal infections in certain populations such as renal transplant patients.[18] The term *zygomycosis* is used to describe a group of fungal infections caused by ubiquitous Zygomycetes found in soil and decaying matter. Infections in humans are mostly caused by the order Mucorales (mucormycosis) and include the genera of *Mucor*, *Rhizopus*, *Absidia*, *Rhizomucor*, and *Cunninghamella*. The term *zygomycosis* is now preferred over *mucormycosis* because it is broader and more relevant when organisms are not identifiable. Like aspergillosis, zygomycosis is rare in individuals without underlying immunodeficiency or predisposing conditions. Host defenses usually prevent the germination of spores unless the inoculation is too great, as in trauma or surgical wounds. Chronic medical conditions that affect macrophage function, such as diabetes or corticosteroid-induced immunosuppression, lead to an inability to inhibit spore germination, and these patients are at increased risk of infection. Additional risk factors besides immunosuppression include iron overload, burns, intravenous illicit drug use, and malnourishment. Recently, the use of voriconazole in immunosuppressed patients with presumed or diagnosed aspergillosis may account for part of the increase in zygomycotic infections.[27]

Primary infection can occur by inhalation, by direct inoculation into damaged skin, or by ingestion. Patients with prolonged neutropenia present most often with pulmonary disease and dissemination. The mortality rate in these individuals is very high, approaching 100%.[34] Diabetic patients with sustained hyperglycemia and metabolic acidosis are predisposed to primary rhinocerebral (66%) and pulmonary (16%) infections.[35] Malnutrition and gastrointestinal disease predispose patients to primary gastrointestinal tract infection. Wounds and burn injuries predispose to primary cutaneous infection. Each type of primary infection can lead to hematogenous spread and disseminated infection of numerous organs (especially the brain).

The clinicopathologic hallmarks of cutaneous zygomycosis are vascular invasion, ischemic infarction, and necrosis, which result in painful erythematous nodules and plaques that ulcerate rapidly and form central black eschars.[34] Clinical manifestations of primary cutaneous disease can range from necrotic papules to cellulitis, to subcutaneous nodules with rapid extension and dissemination especially in neutropenic patients.[36] Rhinocerebral zygomycosis typically begins with facial edema and erythema (Fig. 29-4), bloody nasal discharge, and ulceration of the palate or nasal septum. Within a few days, necrotic skin lesions, headache, focal neurologic defects, exophthalmos, and altered vision develop and can progress to seizures, stupor, coma, and death. Disseminated disease from a noncutaneous primary site infrequently presents with skin findings.[36]

Diagnosis of zygomycosis is usually made by demonstration of nonseptated hyphae (with branching at right angles) within infected tissue. The treatment of choice for disseminated disease is lipid preparations of



Figure 29-4 Rapidly progressing zygomycosis in a man with diabetes.

intravenous amphotericin B and surgical debridement. Some advocate the addition of posaconazole. If possible, reversal or removal of underlying predisposing conditions should be attempted.[18]

FUSARIOSIS. *Fusarium* is a filamentous mold found in soil and plants belonging to the fungal group of hyalohyphomycoses. Disseminated infections are found in severely immunocompromised individuals, whereas immunocompetent patients have localized lesions at areas of skin breakdown. Neutropenic patients are particularly susceptible to infection and rapid dissemination.[31] The source of infection in patients undergoing acute immunosuppressive therapy is often the skin, especially from cellulitis developing at the site of onychomycosis, local trauma, or insect bites. Nasal sinuses are another source of primary infection that can lead to dissemination following acute immunosuppression.[18] In disseminated disease, patients present with multiple painful erythematous papules and nodules, some with central necrosis. Lesions are often at different stages of development, and a specific presentation of papules evolving into target-like lesions with a ring of normal-appearing skin and an outer rim of erythema has been observed.[31] Skin lesions in disseminated disease often precede fungemia and are found in approximately 75% of patients making dermatologic evaluation valuable.[8] The mortality rate in patients who are persistently neutropenic is about 80%, compared with 30% in patients whose immune systems recover. Disease in solid organ transplant recipients may occur later than in patients with hematologic malignancies. Newer triazole antifungals such as voriconazole have some efficacy against infection with *Fusarium* species, for which treatment options have traditionally been limited. Surgical resection of localized skin infection is useful. Granulocyte transfusions may also play a role in treatment.[18]

TRICHOSPORONOSIS. *Trichosporon beigelii*, a yeast-like organism that causes white piedra in the tropics, may produce acute systemic infection in immunosuppressed patients, most commonly in the setting of neutropenia.[31] *Trichosporon* is an emerging pathogen in organ transplant recipients as well.[18] Patients with disseminated trichosporonosis are acutely ill. They may have fever, hypotension, pulmonary infiltrates, renal involvement, and hepatosplenomegaly. Skin lesions occur in 30% of patients and appear similar to cutaneous lesions of disseminated candidiasis (multiple red papules that may ulcerate). Definitive diagnosis is made by culture, and the treatment of choice is fluconazole or itraconazole; amphotericin B resistance is common.[18]

VIRAL INFECTIONS

Viral infections are predominantly associated with defects in cellular immune function and are not typically expected to cause problems in patients whose main immunologic defect is neutropenia.[4] The most common viral infection that occurs in patients who are undergoing induction chemotherapy for lymphoma or an acute leukemia or who are in the first few weeks after a hematopoietic stem cell transplantation is reactivation of latent herpes simplex virus (HSV) infection (see Chapter 193).[37] Clinical presentations in acutely immunosuppressed patients include an increased severity of oral mucositis, intraoral ulcers outside of the gingival margin, and necrotizing gingivitis. Pneumonitis can occur from either contiguous spread from the oropharynx or from viremia.[37] Antiviral prophylaxis with acyclovir is very effective in preventing disease during chemotherapy and following hematologic and solid organ transplantation. When disease does occur in transplant patients, approximately 10% of cases are resistant to acyclovir because of a mutation in the gene coding for thymidine kinase, which is the enzyme required for efficacy of acyclovir, valacyclovir, and famciclovir (see Chapter 231).[38] The treatment of choice in these patients is foscarnet, although reports of resistance to both agents is increasing.[37,39,40]

Reactivation of varicella zoster virus (VZV) (see Chapter 194) usually occurs 3 months or longer after transplantation and is relatively rare in the acutely immunosuppressed patient. VZV infection in adults with leukemia or after solid organ transplantation is rarely primary, but more often represents reactivation of latent virus. In this setting, patients are at increased risk for both skin and systemic dissemination of virus (Fig. 29-5).[41] Before the use of antiviral prophylaxis in bone marrow transplantation, disseminated primary varicella or zoster infection was associated with mortality rates of 30%.[42]

CHRONIC IMMUNOSUPPRESSION

Patients with chronic immunosuppression include those that are iatrogenically immunosuppressed because they are taking medications that impair the



Figure 29-5 Disseminated varicella zoster virus in a patient after induction chemotherapy.

immune system and those with chronic diseases that are associated with immune dysfunction, such as diabetes mellitus. Moreover, individuals with cancer often have immune system defects before aggressive cytotoxic, radiation, or surgical therapy.[43] For example, tumors can secrete immunosuppressive factors (e.g., transforming growth factor-β1 and interleukin-10) or induce T-cell anergy, which help them evade normal immune responses and lead to further systemic immunosuppression.

The population of patients taking long-term immunosuppressive medications is growing as solid organ transplantation becomes a therapeutic option for many human diseases and the survival of patients in the short and long term has improved. These individuals require lifelong therapy with immunosuppressive drugs to maintain function of the transplanted organ. Cyclosporine, tacrolimus, sirolimus, prednisone, mycophenolate mofetil, azathioprine (see Chapters 227 and 233), and the newer agents daclizumab and basiliximab are the drugs used most commonly to prevent graft-versus-host disease, predominately by inhibiting cell-mediated immunity (i.e., T-cell function).[44] Humoral immunity (i.e., B-cell function) remains relatively intact in these patients. Thus, opportunistic diseases in most transplant patients are dominated by viral and fungal infections, intracellular bacterial infections, and virus-associated malignancies—conditions that are controlled predominantly by cell-mediated immune mechanisms in immunocompetent hosts.

BACTERIAL INFECTIONS

MYCOBACTERIAL INFECTIONS. Atypical mycobacteria (see Chapter 184) are ubiquitous organisms found in soil and water. The most common organisms in this group include *Mycobacterium marinum*, *M. chelonae*, *M. fortuitum*, *M. abscessus*, *M. kansasii*, *M. haemophilum*, and *M. avium-intracellulare*. Before the epidemic of acquired immunodeficiency syndrome (AIDS), most cases occurred in persons with underlying pulmonary disease. However, nontuberculous mycobacterial infections after transplantation are increasing in frequency and severity, with the highest incidence (up to 5%) seen in recipients of hematopoietic stem cell transplants. One-third present with catheter-related infections, although skin lesions are rare in this population. Skin involvement is the most commonly reported manifestation of nontuberculous mycobacterial infections in solid organ recipients except lung and heart transplant recipients, who are more likely to have pulmonary involvement. One-third of these patients have localized or disseminated cutaneous disease and the rapid growing species *M. chelonae*, *M. fortuitum*, and *M. abscessus* are most commonly isolated.[45,46] Median time to infection varies depending on the type of transplant, ranging from 4 months posttransplant in stem cell recipients, to 30 months in heart recipients.

Atypical mycobacterial infections in the skin are characterized by diverse morphologies, including reddish brown nodules and plaques (eFig. 29-5.1 in online edition), abscesses (Fig. 29-6), and ulcers.[47] *M. avium-intracellulare* and *M. haemophilum* commonly cause disseminated infection, which can involve the lungs, lymph nodes, liver, spleen, bone marrow, and skin. Organisms can be identified by special stains or by culture of specimens from affected skin. Specific antimycobacterial antibiotic treatment regimens are complex and depend on the mycobacterial species, results of sensitivity testing, extent and severity of disease, and presence or absence of underlying immune defects.[45,46]

M. tuberculosis infection is a common worldwide problem, especially in individuals with impaired immunity. For example, individuals receiving high-dose corticosteroids are prone to active pulmonary tuberculosis. Cutaneous tuberculosis is usually more common in the setting of immunosuppression. Specifically, scrofuloderma (tuberculous lymphadenitis with extension to overlying skin) and numerous cutaneous lesions of miliary tuberculosis may occur more commonly in patients with underlying immune defects.[48]



Figure 29-6 *Mycobacterium chelonae* infection in a patient receiving long-term, high-dose glucocorticoid treatment.

NOCARDIOSIS. *Nocardia* species (see Chapter 185) are ubiquitous filamentous bacteria found in soil. While *N. asteroides* was historically considered the most common species associated with human disease, the recent availability of molecular diagnostics has allowed recategorization such that infections are now reported with a variety of species, including *N. farcinica*, *N. nova*, *N. brasiliensis*, *N. asteroids sensu strictu*, and *N. cyriacigeorgica*, among others.[49] Species identification is important as some show more virulence and antimicrobial resistance than others (e.g., *N. farcinica*), and infection patterns may differ (e.g., *N. brasiliensis* is often the cause of primary cutaneous disease). Infection can be seen in immunocompetent hosts, but the majority of infections (60%) involve patients with immune compromise, particularly those receiving long-term corticosteroid therapy (the most important risk factor), solid organ or bone marrow transplant recipients, cancer patients, AIDS patients, intravenous drug users, and individuals with chronic pulmonary disease.[50,51] Infections in patients treated with rituximab and tumor necrosis factor-α inhibitors have also been reported. In transplant patients, the mean onset of infection is 9 months after transplantation, although it can occur as early as 1 month afterward. Before the use of cyclosporine to prevent rejection, infection rates were much higher in transplant recipients, and this decline is attributed to decreased use of corticosteroids.[49]

Most cases of nocardiosis in transplant patients (approximately 80%) present as primary pulmonary disease and dissemination occurs in up to 40% of cases. The brain is commonly involved with disseminated infection, while approximately a third of cases show cutaneous involvement. Rarely, the skin is the primary location of infection.[49] Several types of skin lesions have been described, including lower extremity subcutaneous nodules with pustules (Fig. 29-7), erythema nodosum-like disease, abscesses with sinus tract formation, mycetoma, sporotrichoid nodules, and cellulitis.[8,52,53] Diagnosis is based on demonstration of Gram-positive, partially acid-fast, branching bacilli in tissue or tissue exudates, or is determined by tissue culture, although it often takes several weeks for organisms to grow. Molecular techniques may now aid in identification as well. The treatment of choice remains trimethoprim-sulfamethoxazole (TMP-SMX); however, the severely ill or those with cerebral or disseminated infection may benefit from the addition of amikacin and/or imipenem. Numerous other antibiotics have been reported to be efficacious as well, such as linezolid, minocycline, other carbapenems, and third-generation cephalosporins. In addition, incision and drainage of cutaneous abscesses should be performed.[50] The duration of treatment and the use of long-term prophylactic therapy to prevent primary or recurrent disease in transplant patients or patients on chronic corticosteroids are currently under debate. For instance, breakthrough infections in solid organ and hematopoietic transplant patients receiving traditional thrice weekly doses of TMP-SMX have occurred, and general resistance to sulfonamides is increasing.[51,54]



Figure 29-7 Nocardiosis in a man with glioblastoma.

BACILLARY ANGIOMATOSIS. Bacillary angiomatosis (see Chapter 182) is caused by infection with the bacterium *Bartonella henselae* or *B. quintana* and usually occurs in AIDS patients and other immunocompromised hosts.[55] Cutaneous lesions appear as painful, dome-shaped vascular papules and nodules (often resembling pyogenic granulomas). Disseminated infection may occur and involve the liver, spleen, bone marrow, and brain. Fever and lymphadenopathy may be present. Patients often have a history of scratches or bites by cats, the natural reservoir for *B. henselae* and *B. quintana*. Diagnosis is made by demonstration of pleomorphic bacilli in tissue specimens with Warthin–Starry silver stain. Preferred treatments include oral erythromycin or azithromycin, or doxycycline.[56]

OTHER BACTERIAL INFECTIONS. (See Chapters 177–180.) Cellulitis caused by *Streptococcus pyogenes*, *Streptococcus pneumoniae*, or *S. aureus* may progress rapidly and cause necrotizing fasciitis in immunosuppressed patients (Fig. 29-8). Solid organ recipients also may develop recurrent cellulitis of the elbow, a condition termed "transplant elbow" that has been attributed to staphylococcal infection.[8,57]

Individuals with underlying complement deficiencies (loss of late-phase components C5–C9) or alcoholism are susceptible to infection with *Neisseria meningitidis*.[58] Patients have acute septicemia, meningitis, disseminated intravascular coagulation, and widespread petechiae and purpura (Fig. 29-9).

Persons with underlying hepatic disease (commonly alcoholic cirrhosis or hepatitis) are prone to infection with *Vibrio vulnificus*, a Gram-negative bacillus commonly found in seawater, shellfish, clams, and oysters.[59] Infection occurs by ingestion of contaminated seafood or by direct cutaneous inoculation after contact with contaminated seawater. Patients classically present with rapidly evolving septicemia and painful cellulitis, bullae, or ulcers on the lower extremities (Fig. 29-10). *Aeromonas* can cause a similar picture in immunosuppressed patients.[15,60]

Capnocytophaga canimorsus is a commensal bacterium found in the saliva of dogs and cats that is transmitted to humans by bites or scratches. Hosts particularly susceptible to septicemia and widespread organ

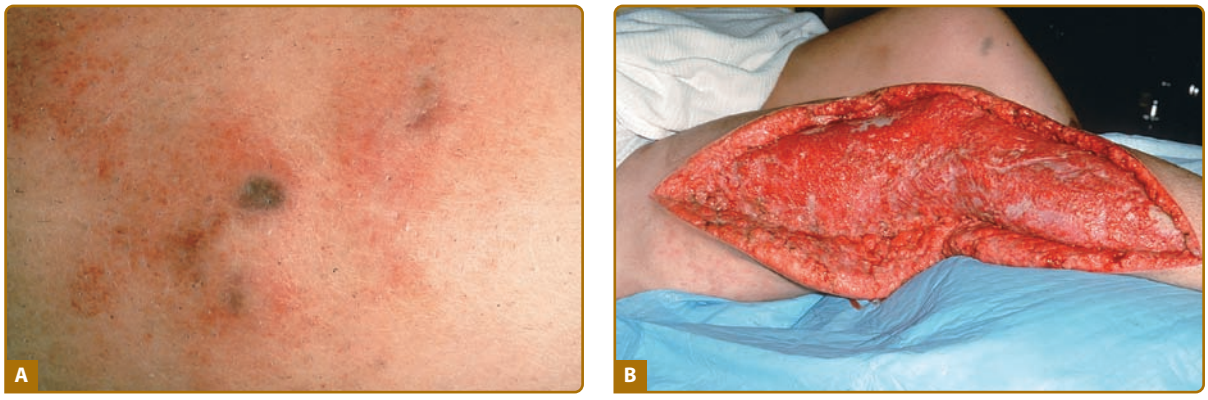

Figure 29-8 Early (**A**) and late [after surgical debridement (**B**)] lesions of necrotizing fasciitis caused by *Streptococcus pyogenes* in an intravenous drug abuser with underlying Job syndrome.

involvement include alcoholics, asplenic patients, and those taking glucocorticosteroids. Skin lesions occur commonly and include widespread macules, papules, purpura, and gangrene. Septicemia carries a mortality rate of 10%–50%.[61,62]

In immunosuppressed patients, *Salmonella* species have been associated with cutaneous abscesses and necrotizing fasciitis of the head and neck.[63]

FUNGAL INFECTIONS

CANDIDIASIS. Although mucocutaneous candidiasis (see Chapter 189) is less serious than disseminated candidiasis in the setting of acute immunosuppression (as described earlier), it is a significant source of morbidity in hosts with chronic cell-mediated immune dysfunction. Studies in organ transplant recipients suggest rates of oral candidiasis anywhere between 7% and 64%, depending on the type of transplant and the location of the study population.[41,64] Patients with chronic mucocutaneous candidiasis have specific underlying immune deficits in fighting candidal infections, including alterations in dendritic cells and the T helper type 17 cells (Th17), and usually have chronic widespread disease without systemic involvement.[65–67]

Patients with oral mucosal candidiasis most commonly have pseudomembranous, white, friable plaques that leave a raw, erythematous undersurface when scraped. Less common oral lesions include erythematous or atrophic plaques as well as angular cheilitis. Esophageal involvement should be suspected in any patient with oral candidiasis complaining of pain or difficulty swallowing. Moist intertriginous areas are common locations of cutaneous lesions and are characterized by tender erythematous papules and plaques, often with satellite pustules. Onychomycosis and paronychia caused by *Candida* species are common in patients with chronic mucocutaneous candidiasis. For mucocutaneous disease, topical therapy with nystatin or clotrimazole and oral fluconazole are the treatments of choice. Prophylactic treatment with fluconazole is



Figure 29-9 Acute meningococcemia in a man with acquired complement deficiency.



Figure 29-10 *Vibrio vulnificus* infection in an alcoholic patient after minor trauma sustained while swimming in the ocean.



Figure 29-11 White superficial onychomycosis in a renal transplant patient receiving cyclosporine.

often recommended for patients at high risk for infection, such as those who have recently undergone organ transplant surgery, although as noted before resistance to this agent is increasing.[68]

DERMATOPHYTOSIS. Dermatophytoses (see Chapter 188) are common uncomplicated infections in normal hosts, but immunosuppressed patients may have widespread, aggressive infection that can be resistant to topical and systemic therapy.[31,69] The overall incidence of dermatophyte infection is likely not higher in immunocompromised patients compared to normal hosts.[70] Specific presentations seen in immunocompromised patients include multiple lesions, a wide distribution, tinea capitis in adults, and Majocchi granuloma. Manifestations more suggestive of immunosuppression include both white superficial onychomycosis and proximal subungual onychomycosis. In the former, the surfaces of affected nails have a white, chalky appearance (Fig. 29-11), and hyphae are observed readily in superficial nail plate scrapings. These conditions should prompt a search for underlying immune deficiency.[31,69]

CRYPTOCOCCOSIS. *Cryptococcus neoformans* (see Chapter 190) is a yeast-like encapsulated fungus that is ubiquitous and is found commonly in soil enriched with bird feces. Primary infection is almost always via the respiratory tract by inhalation of airborne spores and usually is asymptomatic in healthy individuals. Organ transplant recipients are now the population at highest risk of developing disseminated disease, because improved antiretroviral agents have decreased the incidence in those with HIV disease.[71] Patients receiving high-dose systemic corticosteroids are another group susceptible to hematogenous spread and disseminated infection, while incidences in those with diabetes mellitus, chronic lymphocytic leukemia, chronic myeloid leukemia, multiple myeloma, and Hodgkin disease are lower. Cryptococcal disease in hematopoietic stem cell transplant recipients is very rare.[72] The central nervous system is most commonly involved during dissemination, although infection may occur in many organs including the lungs, bone marrow, heart, liver, spleen, kidneys, thyroid, lymph nodes, adrenal glands, and skin.

Cutaneous lesions occur in up to 20% of patients with disseminated infection, however, skin lesions may be present in two-thirds of organ transplant patients receiving tacrolimus.[73] In transplant patients, erythematous, edematous, warm, painful plaques on the extremities (clinically indistinguishable from bacterial cellulitis) have been reported most frequently (Fig. 29-12A).[74] Umbilicated papules (resembling molluscum contagiosum), nodules, pustules, vesicles, and ulcers also may occur (Fig. 29-12B).[75] Oral mucosal cryptococcal nodules and ulcerations also have been described. Lesions may be isolated or multiple and can be quite painful.



Figure 29-12 Cellulitis and subsequent necrosis (**A**) and molluscum-like lesions (**B**) of cutaneous cryptococcosis. (Used with permission from Jonathan Alexander, MD, Portland, OR and Yale Residents' slide collection, respectively.)

Although primary skin disease may occur in the absence of pulmonary infection, diagnosis of cutaneous cryptococcosis always warrants an investigation for systemic infection, especially because disseminated disease may not always be evident clinically.[76] Cerebrospinal fluid can be assessed for cryptococcal polysaccharide antigens. Budding encapsulated yeasts can be identified readily in skin biopsy specimens as well as in material obtained by a scraping of skin lesions. The yeast stain red with periodic acid-Schiff and mucicarmine stains and black with methenamine silver stain. India ink can be used to accentuate the capsule in a skin scraping. *Cryptococcus* can be isolated in culture of cutaneous tissue. The treatment of choice for cryptococcosis is a lipid formulation of amphotericin B with or without flucytosine. Fluconazole is used as alternative primary treatment and is the treatment of choice for prophylaxis in individuals at high risk for recurrent infection.[77]

HISTOPLASMOSIS. *Histoplasma capsulatum* (see Chapter 190) is a dimorphic fungus found in soil endemic to the central and eastern regions of the United States. As with cryptococcosis, inhalation of airborne spores causes primary pulmonary infection that usually leads to self-limited disease in otherwise healthy individuals. Disseminated disease is rare and most often occurs in individuals with deficiencies in cell-mediated immunity. In addition to pneumonia, immunosuppressed hosts may show fever, renal failure, central nervous system involvement, hepatosplenomegaly, lymphadenopathy, and myelosuppression.[78]

Mucocutaneous lesions occur in 5%–25% of patients with disseminated infection and may be an initial sign of disease. The head and neck region are favored and the oropharynx is the most common site. Mucosal lesions present with nodules or plaques that progress to ulcers with indurated borders. Skin findings are diverse and include molluscum-like papules, acneiform papules and pustules, and cellulitis.[15,79] The organism grows very slowly in culture so diagnosis is best achieved by direct examination of tissue. Numerous small, oval, yeast-like fungi can be seen within the cytoplasm of dermal macrophages. Antigen testing is also available, but cross-reaction can occur with blastomycosis and other fungal infections (though not with cryptococcus). The treatment of choice for disseminated histoplasmosis in an immunosuppressed host is intravenous amphotericin B. For patients who are not acutely ill, oral itraconazole may be used; itraconazole is also recommended for immunosuppressed patients to prevent recurrent disease.[78]

COCCIDIOIDOMYCOSIS. *Coccidioides immitis* (see Chapter 190), the causative agent of coccidioidomycosis, is endemic to soil in the southwestern United States, and infection is usually acquired through inhalation of spores, which causes pulmonary disease.[78] Although progressive primary infection may occur in immunosuppressed patients, reactivation of a prior, clinically unapparent infection is more common. The risks of dissemination and fatal infection are greater among men, pregnant women, non-Caucasians, and immunosuppressed patients with defects in cell-mediated immunity. Thus, disseminated coccidioidomycosis can occur in any immunocompromised patient who lives or has lived previously in an endemic area.

Immunosuppressed patients with disseminated disease may have fever, pneumonia, bone involvement, skin lesions, and/or meningitis. Mortality remains high at around 30%, but has improved with targeted prophylaxis in the organ transplant population.[80] Primary cutaneous lesions of coccidioidomycosis are extremely rare and usually resolve in healthy individuals, whereas lesions persist in immunocompromised patients. Morphologies are varied and include multiple verrucous papules, abscesses, and ulcerated papules and plaques. Nonspecific findings seen in systemic disease include erythema multiforme, urticaria, a maculopapular rash, and erythema nodosum.[15]

Definitive diagnosis of coccidioidomycosis is made by culture or demonstration of characteristic endosporulating spherules in smears or biopsy specimens. Serologic studies may prove helpful, but may give false-negative results in the immunocompromised. In disseminated infections in immunosuppressed hosts, treatments for life-threatening disease include amphotericin B until infection is controlled, followed by itraconazole or fluconazole. Immunosuppressed patients with meningeal disease may require lifelong therapy.[81]

BLASTOMYCOSIS. *Blastomyces dermatitidis* (see Chapter 190) is endemic to the soil of the Ohio and Mississippi river valleys. Infection is acquired through inhalation of spores. Immunosuppressed patients are prone to disseminated disease involving the lungs, bone, genital tract, and skin, although infection in this population is still rare. Skin is the most common extrapulmonary site of involvement.[15,78] Lesions appear as verrucous or ulcerated plaques with serpiginous borders located on the head, neck, or distal extremities. Ulcerative lesions begin as subcutaneous nodules and pustules.[82] Diagnosis is made on demonstration of broad-based, budding, thick-walled yeasts in exudates or skin scrapings from the edges of lesions or by tissue culture. In life-threatening disseminated infection, intravenous amphotericin B is the treatment of choice, whereas less severe disease is treated with oral itraconazole.[83]

OTHER FUNGAL INFECTIONS. *Alternaria* is a common saprophytic fungus that can cause opportunistic infection in the setting of organ transplantation, Cushing syndrome, autoimmune bullous disease, and lymphoproliferative disorder. Over half of the patients reported to have cutaneous alternariosis were taking systemic corticosteroids, and secondary increased skin fragility has been implicated as a risk factor. There are two routes of infection: traumatic inoculation and secondary colonization of a preexisting skin lesion. Presentations include indurated plaques, ulcers, and pustules.[84,85]

Penicillium marneffei is a dimorphic fungus that is endemic to Southeast Asia (see Chapter 190). Most infections are associated with HIV disease, but cases

in immunosuppressed patients residing or traveling to endemic areas have occurred.[86] Tinea versicolor and folliculitis caused by *Pityrosporum ovale* (also known as *Malassezia furfur;* see Chapter 189) may be more prevalent, widespread, and persistent in immunosuppressed hosts. In addition, *Pityrosporum* has been reported to cause indwelling catheter-associated fungemia in immunosuppressed hosts, especially in those receiving parenteral lipid preparations.[8]

VIRAL INFECTIONS

HERPES VIRUS INFECTION. Herpes viruses (see Chapters 193 and 194) include HSV-1, HSV-2, VZV, CMV, Epstein–Barr virus (EBV), human herpes virus 6 (HHV-6), HHV-7, and Kaposi sarcoma-associated herpes virus (KSHV or HHV-8). Infections are most prevalent in patients with acquired defects in cell-mediated immunity. Herpes viruses infect hosts for life and remain dormant in the nuclei of latently infected cells. Suppression of immunity often leads to reactivation (i.e., a latent to lytic switch).

Recurrent HSV-1, HSV-2, and VZV infections are common in cancer and posttransplant patients, with the majority experiencing reactivation with at least one of these three viruses. Clinically apparent HSV outbreaks occur in up to 68% of organ transplant patients not on prophylaxis.[87] Herpes zoster (recurrent VZV infection) is most likely to occur during the first year after transplantation with a 20–100-fold increased incidence in immunocompromised patients (approximately 10% incidence).[37,88] Although presentations can be identical to those in immunocompetent hosts, lesions atypical in morphology and distribution often occur. For example, in immunosuppressed hosts recurrent lesions due to HSV or VZV may be isolated, nondermatomal, disseminated, necrotic, ulcerative, or verrucous (Figs. 29-13 and 29-14). In the mouth, chronic recurrent HSV infection can form white plaques and can be confused clinically with candidiasis. Lesions can occur in atypical locations, such as the tongue. Severe pain often is associated with both skin and oral lesions, and postherpetic pain is common. Protracted clinical courses of recurrent HSV or VZV infection are also more common in the setting of immunosuppression. In short, any painful, eroded lesion in an immunocompromised patient, regardless of its distribution or age, should be evaluated for both HSV and VZV by Tzanck preparation, immunofluorescence testing for viral antigen, polymerase chain reaction testing, and/or viral culture. Importantly, systemic infection involving the lungs, central nervous system, liver, heart, and gastrointestinal tract may occur. Treatment with systemic acyclovir or a related antiherpesviral drug is always necessary. Prophylactic treatment to prevent recurrent episodes should be considered for individual patients if warranted. Foscarnet is the drug of choice for acyclovir-resistant viruses.[37]

Reactivation and recurrent disease associated with CMV are major causes of morbidity and mortality in patients with marked immunosuppression, occurring in 20%–60% of transplant recipients depending



Figure 29-13 Severe chronic herpes simplex infection in a patient receiving long-term, high-dose glucocorticoids for autoimmune disease.



Figure 29-14 Severe recurrent varicella zoster virus infection in a child with acute lymphocytic leukemia.

on the type of transplant and other risk factors.[37,89] Disease is most commonly caused by reactivation of preexisting CMV infection, although CMV may be transmitted from donor to host in solid organ transplantation. CMV also exerts indirect effects in transplant patients, contributing to an increase in graft loss and risk of other opportunistic infections. CMV retinitis, gastroenteritis, hepatitis, and pneumonitis are the most common clinical disease manifestations. Cutaneous lesions can occur in 10%–20% of patients and are varied and nonspecific, including ulcers, papules, vesicles, petechiae, and morbilliform eruptions. Oral ulcers caused by CMV, particularly on the lateral aspects of the tongue, are most common. Painful, punched-out perianal ulcers have been reported and coinfection with HSV can occur. Tzanck preparations of specimens from the bases of ulcers may show multinucleated giant cells, and CMV-infected dermal endothelial cells may be seen in tissue sections by routine microscopy, appearing as large cells with intranuclear inclusions surrounded by clear halos (owl-eye nuclei). In addition, CMV can be cultured from infected skin. The treatment of choice for systemic CMV disease is intravenous ganciclovir, although intravenous foscarnet, cidofovir, or CMV immunoglobulin also may be effective.[37,41] Prophylaxis of at-risk transplant patients is routine.[39]

HHV-6 and HHV-7, herpes viruses closely related to CMV, can also cause widespread multiorgan infection in immunosuppressed individuals. Disease itself is usually mild, but indirect effects of viral reactivation may allow other infections to occur and contribute to allograft failure.[90]

Unlike the other herpes virus infections, EBV and KSHV infections are associated with malignancies in the setting of immunosuppression. Specifically, chronic reactivated EBV infection is associated with non-Hodgkin lymphoma and other lymphoproliferative disorders, whereas chronic KSHV infection is associated with Kaposi sarcoma (KS), primary effusion lymphoma, and the plasmablastic variant of Castleman disease. Their neoplastic potential is discussed further later. Oral hairy leukoplakia is a unique presentation of EBV reactivation within oral mucosal epithelial cells, classically seen in patients with AIDS, but also seen in other immunosuppressed individuals (see Chapter 198).[37] Lesions appear as adherent, white, corrugated plaques on the lateral aspects of the tongue. Histologically, there is hyperkeratosis and vacuolated suprabasal epithelial cells. Oral hairy leukoplakia may respond to topical podophyllin or high-dose acyclovir, although it is usually asymptomatic and does not require treatment. It has been regarded as a poor prognostic indicator in HIV-infected individuals, but the clinical significance of oral hairy leukoplakia in transplant patients is not known.

HUMAN PAPILLOMAVIRUS INFECTION. Warts (see Chapter 196) caused by human papillomavirus (HPV) infection are a common problem in post-transplant patients and in others receiving long-term immunosuppressive drug therapy. The prevalence of warts increases with longer duration of immune compromise, with up to 95% of individuals affected 5 years after transplant surgery.[91] In this setting, lesions may be numerous, persistent, and difficult to eradicate. The morphology of the lesions may be typical or atypical. Atypical lesions appear as scaly macules and plaques, occur more commonly in sun-exposed areas, and are associated with HPV types observed in patients with epidermodysplasia verruciformis (e.g., HPV types 5 and 8). Several studies have reported that systemic retinoids (i.e., isotretinoin or acitretin) can prevent or decrease wart formation and prevent a variety of premalignant and malignant cutaneous lesions in post-transplant patients. In these patients, the association between HPV infection and cutaneous genital and non-genital squamous cell carcinoma (SCC) is complex, as discussed later.

HUMAN POLYOMAVIRUS INFECTION. Polyomaviruses are small double-stranded DNA viruses found in a variety of species including humans. The first two described, BK virus (BKV) and JC virus (JCV), were identified in the 1970s and cause nephropathy in kidney transplant patients and progressive multifocal leukoencephalopathy in immunosuppressed individuals, respectively. Neither produce skin lesions.[92] In 2008, another polyomavirus was identified in tumors from patients with the neuroendocrine tumor Merkel cell carcinoma (MCC; see Chapter 120 and later in this chapter), subsequently termed Merkel cell polyomavirus (MCPyV).[93] MCPyV can be found in 24%–89% of MCC with the highest rates in North American and European populations. Integration of the virus into MCC tumor genomes suggests a direct oncogenic role of MCPyV.[94] Risk factors for MCC include advanced age and excessive sun exposure, and the incidence is greatly increased in the setting of immunosuppression, especially in organ transplant recipients.[95]

PARASITIC INFESTATIONS: CRUSTED SCABIES

Crusted (or Norwegian or keratotic) scabies infestation (see Chapter 208) typically occurs in the settings of mental deficiency, malnutrition, or immunosuppression. Clinically, patients present with multiple widespread, thick, gray, or yellowish scaly plaques (eFig. 29-14.1 in online edition), with numerous mites present within lesions. Unlike in common scabies, pruritus may be minimal. Several courses of treatment with topical permethrin, as well as keratolytics, may be necessary to cure patients. Oral ivermectin is useful in these patients.[96]

CANCER

NONMELANOMA SKIN CANCER. Nonmelanoma skin cancer (NMSC; see Chapters 114 and 115) is the most common malignancy in adult solid organ transplant patients and causes significant morbidity and mortality. The overwhelming majority of these neoplasms are SCCs; however, the incidence of basal cell carcinomas and other cutaneous malignancies is

also increased.[97] For SCC, the risk may be 200 times higher in transplant patients than in the general population and increases exponentially with length of immunosuppression.[98,99] The cumulative incidence is a staggering 80% after 20 years of immunosuppressive therapy in renal transplant patients residing in Australia with its large amount of ultraviolet exposure.[100] The incidence of other epithelial proliferative diseases, including actinic keratoses, keratoacanthomas, porokeratosis, appendageal tumors, and sebaceous carcinomas, is greatly increased as well.

The pathogenesis of NMSC in posttransplant patients is multifactorial and has been studied and reviewed extensively.[99,101–103] Prior history of NMSC was the most important predictor of risk in one comprehensive study.[104] The distribution of lesions and the populations at highest risk suggest that sun exposure is one of the most important risk factors.[105] Risk also increases with age and is greater for those with fair skin type, those living near the equator, and those with documented histories of significant sun exposure. In addition, gene mutations in the tumor suppressor gene *p53* characteristic of those caused by ultraviolet radiation are found within NMSC in transplant patients.[106,107] The commonly used immunosuppressive medications, including azathioprine and the calcineurin inhibitors cyclosporine and tacrolimus, are not only directly carcinogenic, but their additional effects on the immune system diminish immune surveillance mechanisms that potentially serve to eradicate precancerous lesions. On the other hand, sirolimus which blocks the mammalian target of rapamycin (m-TOR) pathway, has chemoprotective effects, including blocking tumor growth and angiogenesis.[108] Switching from a calcineurin inhibitor to sirolimus-based therapy reduces the rates of internal malignancies and skin cancer in renal transplant patients.[109]

The role of HPV infection in organ transplant recipients is unclear. HPV is known to cause cervical and anal SCC and can be detected in cutaneous cancers of transplant patients (Fig. 29-15). Furthermore, epidermodysplasia verruciformis-associated HPV types (5, 8, and others) have been detected in cutaneous SCC, and there is suspicion that infections by these viruses may occur at an increased rate in immunosuppressed patients. However, asymptomatic infection has been identified in the general population, and thus it is unclear whether these HPV types are transcriptionally active and pathogenic in forming skin cancers in the setting of immunosuppression.[103,110–112]

Importantly, SCC in posttransplant patients can be clinically aggressive leading to increased morbidity and mortality than in the normal population. Local invasion, recurrence after primary treatment, and distant metastases are not uncommon and are all associated with a higher rate of mortality in organ transplant recipients.[113,114] Oral mucosal leukoplakia and oral SCC also occur more commonly in immunocompromised individuals.[99] Lip lesions are particularly common, which suggests a pathogenic role for sunlight in lesion formation.

Careful and regular examination of skin and oral mucosa by both patients and dermatologists is required for all transplant patients, with an emphasis on monitoring of potentially premalignant lesions (e.g., actinic keratoses, porokeratosis, leukoplakia) for morphologic changes and initiation of treatment as indicated. Ideally, patients would be treated for precancerous lesions before transplant surgery. All transplant patients should be advised to maximize sun precautions.[115] Oral retinoids, especially acitretin, have been used successfully to decrease the occurrence of new SCCs and actinic keratoses in transplant patients, but can be difficult to tolerate.[116] A range of dosages has been used, and good effects with minimal side effects have been reported at daily dosages of 0.2–0.4 mg/kg/day.[117] It is a common clinical observation that when the medication is discontinued, numerous cancerous lesions arise (described as a rebound effect).[118] Thus, when retinoids are considered for prophylaxis of NMSC, they should be considered as a long-term treatment.



Figure 29-15 Caucasian renal transplant patient with warts, actinic keratoses, and squamous cell carcinomas. (Used with permission from Jonathan Alexander, MD, Portland, OR.)

Recent studies have demonstrated that voriconazole, an oral broad-spectrum antifungal frequently used for the long-term management of chronically immunosuppressed patients, is associated with photosensitivity, accelerated photoaging, pseudoporphyria cutanea tarda, aggressive squamous cell carcinoma and melanoma. This accelerated cancer risk occurs in both children and adults. Thus, strict photoprotective measures should be recommended when voriconazole is used for prevention or treatment of fungal diseases.[119,120]

MELANOMA. The incidence of melanoma (see Chapter 124) and widespread atypical melanocytic nevi may be increased in transplant recipients and in other immunosuppressed patients.[97] In particular, children who have had transplants appear to be at higher risk for the development of melanoma (15% of all skin cancers) compared with adults (6% of all skin cancers).[121] Most melanomas arise from precursor nevi

in these patients. Melanomas have also been reported to originate from donor organs causing metastatic disease in graft recipients.[122]

LYMPHOMA. Lymphoproliferative disorders (see Chapter 145) are common devastating complications following transplantation and are often related to EBV-mediated proliferation of B-cells. Extranodal involvement is common, including involvement of the gastrointestinal tract, lungs, central nervous system, the transplanted organ, and skin.[4,123] Cutaneous lesions present as violaceous macules to firm papules and plaques, similar to presentation in immunocompetent individuals. Lymphoma with purely cutaneous involvement is rare after transplantation. Most reported cases represent lymphomas of B-cell origin and are occasionally $CD30^+$. The presence of EBV is often detected. Prognosis is generally better if there is cutaneous involvement alone, perhaps due to the ease of detection.[37,124] Cutaneous T-cell lymphomas account for 30% of cases of cutaneous lymphomas in transplant patients. EBV is not associated with development in these patients. Clinical presentation is similar to that in nontransplant patients, except that there is an increased incidence of erythroderma. Prognosis is also worse than for cutaneous T-cell lymphoma in the general population.[125]

KAPOSI SARCOMA. The occurrence of KS (see Chapter 128) is increased in patients receiving immunosuppressive therapy after organ transplantation, with an incidence of 0.5%–5%. Risk factors in transplant recipients include male sex and Mediterranean, Jewish, Arabic, Caribbean, or African descent, as in the classic form of the disease.[37,126] All cases of KS, regardless of clinical or geographic setting, are associated with KSHV infection. The vast majority of patients with posttransplant KS are KSHV seropositive before transplantation. Rarely, posttransplant KS can occur when KSHV-infected organs are transplanted into KSHV seronegative recipients.[126,127]

Clinically, skin lesions of posttransplant KS are identical to other forms of KS. As in classic KS, transplant-associated disease is found most commonly on the lower legs and feet, although the groin and oral cavity are also common locations. Typically, early KS lesions are deep red to violaceous macules or patches. With time, lesions develop into papules, plaques, nodules, or tumors. Visceral involvement occurs in 25% of renal transplant patients and 50% of those with heart or lung transplants.[128] Reduction in immunosuppressive treatment often causes disease regression, although these patients remain at risk for developing KS at a later time if immunosuppressive therapy is reinstituted. Recently, regression of KS lesions in transplant patients after switching to a sirolimus-based regimen have been reported.[129] Additional treatments include local excision or radiation therapy, intralesional therapy, and systemic chemotherapy.

MERKEL CELL CARCINOMA. MCC (see Chapter 120) is an unusual, aggressive skin cancer of neuroendocrine cells (Fig. 29-16). The incidence of MCC is increased and the cancer presents at a younger age in transplant recipients.[95] Sentinel lymph node biopsy is becoming part of the standard of care in this population due to the high rate of lymph node metastases. Wide surgical resection and adjuvant radiation is recommended. The mortality rate is high at 56% at 2 years after diagnosis, which is nearly twice the rate for immunocompetent individuals. Less than 10% of individuals with distant metastasis survive longer than 3 years. There are early suggestions that MCC tumors positive for MCPyV DNA convey a better disease course than those lacking evidence of viral oncogenesis.[92,130,131]

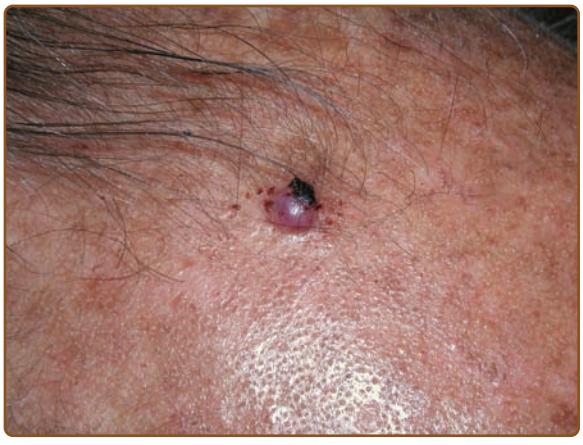

Figure 29-16 Merkel cell carcinoma on the scalp of a heart transplant patient. (Used with permission from Jonathan Alexander, MD, Portland, OR.)

KEY REFERENCES

Full reference list available at www.DIGM8.com

DVD contains references and additional content

4. Fishman JA: Infection in solid-organ transplant recipients. *N Engl J Med* **357**(25):2601-2614, 2007
7. Feld R: Bloodstream infections in cancer patients with febrile neutropenia. *Int J Antimicrob Agents* **32**(Suppl. 1):S30-S33, 2008
15. Lopez FA, Sanders CV: Dermatologic infections in the immunocompromised (non-HIV) host. *Infect Dis Clin North Am* **15**(2):671-702, xi, 2001
18. Kubak BM, Huprikar SS: Emerging & rare fungal infections in solid organ transplant recipients. *Am J Transplant* **9**(Suppl. 4):S208-S226, 2009
31. Mays SR, Bogle MA, Bodey GP: Cutaneous fungal infections in the oncology patient: Recognition and management. *Am J Clin Dermatol* **7**(1):31-43, 2006
37. Tan HH, Goh CL: Viral infections affecting the skin in organ transplant recipients: Epidemiology and current management strategies. *Am J Clin Dermatol* **7**(1):13-29, 2006
57. Wolfson JS, Sober AJ, Rubin RH: Dermatologic manifestations of infections in immunocompromised patients. *Medicine (Baltimore)* **64**(2):115-133, 1985
97. Vajdic CM, van Leeuwen MT: Cancer incidence and risk factors after solid organ transplantation. *Int J Cancer* **125**(8):1747-1754, 2009
114. Ulrich C et al: Skin cancer in organ transplant recipients–where do we stand today? *Am J Transplant* **8**(11):2192-2198, 2008
128. Farge D: Kaposi's sarcoma in organ transplant recipients. The Collaborative Transplantation Research Group of Ile de France. *Eur J Med* **2**(6):339-343, 1993

SECTION 5

Inflammatory Diseases Based on Neutrophils and Eosinophils

Chapter 30 :: Regulation of the Production and Activation of Neutrophils

:: Steven M. Holland

REGULATION OF THE PRODUCTION AND ACTIVATION OF NEUTROPHILS AT A GLANCE

- Human bone marrow commits enormous resources to the creation of neutrophils, producing approximately 10^{11} daily with a circulating half-life of approximately 7.5 hours and tissue survival for 1–2 days.
- Neutrophils are absolutely required for the prevention of infection and are not yet amenable to significant external replacement therapy.
- The neutrophil not only plays a central role in host defense, it can be responsible for significant tissue damage as well.
- The pathophysiology of the neutrophil indicates pathways, which can be exploited to enhance protection from infection. Selective abrogation of those pathways that are injurious in certain settings is also possible.
- Regulation of neutrophil responses in the skin is a major concern.

NEUTROPHILS

This section presents an overview of neutrophil biology and function and uses a few well-characterized defects of myeloid function as illustrations.

ONTOGENY AND DEVELOPMENT

Similar to other components of the hematopoietic system, the neutrophil is ultimately derived from a pluripotent hematopoietic stem cell. The development of the myeloid stem cell is largely determined by ambient cytokines and reflected in its surface markers, morphology, and functional characteristics. The myeloblast is fully committed to the neutrophil lineage and is the first morphologically distinct cell in neutrophil development. Subsequent stages of neutrophil development occur under the influence of granulocyte colony-stimulating factor (G-CSF) and granulocyte–macrophage colony-stimulating factor (GM-CSF). Four to six days are required for maturation through the mitotic phase to the myelocyte, and 5–7 days more for the myelocyte to develop into a mature neutrophil, including the metamyelocyte and band stages, before emerging as a fully developed neutrophil. Development of neutrophils through the myelocyte stage normally occurs exclusively in the bone marrow, which is composed of approximately 60% developing neutrophils. The mature neutrophil measures 10–12 μm and has a highly condensed, segmented, multilobulated nucleus, usually with three to five lobes. Although 10^{11} neutrophils are generated daily, this number can rise tenfold in the setting of infection. The calculated circulating granulocyte pool is 0.3×10^9 cells/kg blood and the marginated pool is 0.4×10^9 cells/kg blood, comprising only 3% and 4% of the total granulocyte pool, respectively. The bone marrow releases 1.5×10^9 cells/kg blood/day to this pool but keeps 8.8×10^9 cells/kg blood in the marrow in reserve. An additional reserve of immature and less competent neutrophils, 2.8×10^9 cells/kg blood, is also available.

G-CSF is critically important for neutrophil production.[1] Mice deficient in G-CSF show reduced neutrophil numbers and cannot upregulate neutrophil numbers in response to infection. Interestingly, G-CSF production is under the influence of IL-17, a cytokine of importance in regulation of epithelial defenses.

BIOLOGIC FUNCTIONS

GRANULE CONTENT AND FUNCTION. (Table 30-1.) Neutrophils are characterized by cytoplasmic granules and partially condensed nuclei. Granules are first found at the promyelocyte stage.[2] Primary (azurophilic) granules are the first to arise, measure

TABLE 30-1
Human Neutrophil Components

Primary Granules	Secondary Granules	Other Cytoplasmic Organelles
Neutrophil ▪ Galectin-10		
Enzymes ▪ Bactericidal/permeability-increasing protein ▪ Defensins ▪ Lysozyme ▪ Myeloperoxidase ▪ Elastase ▪ Cathepsin G ▪ Proteinase 3 ▪ Azurocidin ▪ Phospholipase A2 ▪ 5-Lipoxygenase ▪ Cyclooxygenase	▪ p15s ▪ Lysozyme ▪ Proteinase 3	
Acid hydrolases ▪ Cathepsin B ▪ Cathepsin D ▪ β-Glycerophosphatase ▪ β-Glucuronidase ▪ *N*-acetyl-β-glucosamine ▪ α-Mannosidase	▪ Cathepsin B ▪ Cathepsin D	Cathepsin B Cathepsin D β-Glycerophosphatase β-Glucuronidase *N*-acetyl-β-glucosamine α-Mannosidase

approximately 0.8 µm in diameter, and contain numerous antimicrobial products including lysozyme, myeloperoxidase, and defensins.[3] Primary granules are only synthesized at the promyelocyte stage. The promyelocyte gives rise to the myelocyte, the last cell of the neutrophil lineage with proliferative potential. Therefore, cytokines or agents that increase total neutrophil production must act at or before the myelocyte stage. The smaller eosinophilic secondary (specific) granules appear during the myelocyte stage. These granules measure about 0.5 µm in diameter and contain lactoferrin, collagenase, gelatinase, vitamin B_{12}-binding protein, and complement receptor 3 (CR3; CD11b/CD18). $gp91^{phox}$ and $p22^{phox}$ comprise the specific granule component cytochrome b_{558}, defects in which cause chronic granulomatous disease (CGD), characterized by infections with particular catalase-producing bacteria. Gelatinase also cleaves and potentiates the activity of the chemokine interleukin-8 (IL-8). Because primary granules are synthesized early and distributed to daughter cells during division, they are eventually outnumbered by about 3:1 by the specific granules, which are produced throughout the myelocyte stage.

Granules fuse in a sequential fashion with incoming phagocytic vacuoles, such as those containing ingested bacteria. Secondary granules fuse to the phagosome within the first 30 seconds after ingestion and release their enzymes, many of which function best at neutral or alkaline pH. By 3 minutes after ingestion, the primary granules have fused to the phagolysosome leading to rapid lowering of the intravacuolar pH. For objects too large to be ingested, or certain stimuli, degranulation to the cell surface occurs with release of granule contents into the surrounding environment. This can be inferred by detection of lactoferrin levels in blood.

An example of disordered granule biogenesis is Chédiak–Higashi syndrome (CHS), a rare autosomal recessive disorder with abnormal pigmentation due to a generalized abnormality of primary granule and lysosome formation (see Chapter 143).

NEUTROPHIL-SPECIFIC GRANULE DEFICIENCY. Neutrophil-specific granule deficiency is a rare, autosomal recessive condition clinically characterized by a profound susceptibility to bacterial infections. There is a paucity or absence of neutrophil-specific granules, specific granule proteins (e.g., lactoferrin) and their respective messenger RNAs, and very low levels of the primary granule products defensins and their messenger RNAs. Specific granule deficiency is due to loss of the transcriptional factor CCAAT/enhancer binding protein ε (CEBPε), which is essential in normal myeloid development. Acquired abnormalities of neutrophil granules are seen in some myeloid leukemias, in which primary granule contents may be aberrantly accumulated (e.g., Auer rods in acute myelogenous leukemia).

TISSUE TRAFFICKING

CHEMOATTRACTANTS AND CHEMOTAXIS. Metchnikoff discovered over a century ago that

neutrophils move toward very slight gradients of chemical signals, now termed *chemoattraction*. The "classic" chemoattractants are *N*-formylmethionyl-leucyl-phenylalanine (fMLF), complement factor 5a (C5a), leukotriene B_4, and platelet-activating factor (PAF). More recently, chemokines (*chemo*attractant cyto*kines*), a class of small (<10 kDa) extremely active chemoattractant proteins have been identified (see Chapter 12).

IL-8 is a potent chemoattractant and neutrophil activator (see Chapter 12). Its blockade by neutralizing antibody in rabbit models of pulmonary inflammation prevented neutrophil accumulation and reperfusion injury, confirming its central role in neutrophil recruitment to sites of inflammation. Cellular sources for IL-8 include neutrophils, monocytes, T cells, B cells, natural killer cells, basophils, eosinophils, fibroblasts, endothelial cells, keratinocytes, and smooth muscle. Exudative neutrophils are particularly effective at synthesizing IL-8, probably through a calcium-regulated mechanism.

Exuberant neutrophil function is implicated in Sweet syndrome (acute febrile neutrophilic dermatosis) as shown by the frequent association of the syndrome with hematologic malignancies, dysmyelopoiesis, and sometimes with the use of G-CSF (see Chapter 32).

The classic chemoattractants and chemokines use similar receptors that have in common seven transmembrane regions, an extracellular amino terminal domain, and transduce their signals through pertussis toxin-sensitive heterotrimeric G proteins. These are the same type of receptors through which light, neuropeptides, and neurotransmitters signal. Chemoattractant receptor signaling entails exchange of bound guanine diphosphate for guanine triphosphate by the α subunit of the heterotrimeric G protein, which in turn leads to the dissociation of the β–γ subunit of the complex, stimulation of phospholipase C, and generation of inositol triphosphate and diacylglycerol from phosphatidylinositol bisphosphate. Inositol triphosphate stimulates the release of calcium from intracellular "calciosomes," whereas diacylglycerol activates protein kinase C. Extracellular calcium also enters the cell, preparing it for subsequent movement, generation of oxidants, and secretion of vesicles.

Ras-related guanosine triphosphatases of the ρ superfamily are also involved in actin cytoskeletal regulation and adhesion. Phosphatidylinositol 3-kinase is activated by rho and ras and is necessary for the neutrophilic respiratory burst, adhesion, endothelial transmigration, and chemotaxis. Mitogen-activated protein (MAP) kinases are serine/threonine kinases that include p38, Erk1, Erk2, and Jnk and are involved in neutrophil signaling and adhesion. Inhibition of p38 impairs chemotaxis and tumor necrosis factor (TNF)-α-mediated superoxide production, adhesion, and release of secondary granules. Erk activation is required for neutrophil homotypic aggregation. Salicylates inhibit neutrophil adhesion through Erk inhibition.

Several chemokine receptors also function as requisite human immunodeficiency virus (HIV) coreceptors. Mutations in the chemokine receptor CCR5 that are protective against HIV infection led to development of chemokine receptor blockers for treatment of HIV infection (maraviroc and vicriviroc).

ADHESION. Neutrophils exist as free-flowing (those which are sampled on blood drawing) and marginated cells (those which are attached to the endothelium or are traversing the lung, skin, or other tissues). Neutrophils rolling along the endothelium recognize sites of activation (e.g., chemokine expression), adhere to those sites, and traverse the endothelium to enter the tissue and fight infection. Leukocyte physical interaction with endothelium and other leukocytes is mediated by integrins, selectins, and intercellular adhesion molecules (ICAMs; Fig. 30-1).

Elaboration of chemoattractants or display of activation markers on endothelium triggers leukocyte high affinity binding by β_2 integrins, heterodimeric surface molecules largely stored in the secondary granules of neutrophils that are displayed on the cell surface upon leukocyte activation. There are three β_2 integrin heterodimers comprised of different α chains, CD11a, -b, and -c, and a common β chain, CD18. Each CD11/CD18 complex has separate and overlapping activities. CD11a/CD18 [leukocyte function-associated molecule 1 (LFA-1)] binds to other leukocytes and mediates tight adhesion to the endothelium through ICAM-1 and ICAM-2. CD11b/CD18 (Mac-1, Mo-1, or CR3) binds to the inactivated form of the third component of complement (C3bi) and thereby facilitates complement-mediated phagocytosis. CD11b/CD18 also binds to bacteria directly, to fibrinogen, and to endothelium through ICAM-1. The divalent cations Ca^{2+} and Mg^{2+}/Mn^{2+} mediate adhesion through β_2 integrin "A" domains containing a metal ion-dependent adhesion site. CD11b/CD18 may also induce the expression of the β_1 integrin very late antigen 6 [VLA-6 (CD49f/CD29)], derived from neutrophilic granules, to aid in tissue infiltration. The integrin-associated protein (CD47), expressed on neutrophils and endothelial and epithelial cells, is also involved in the transendothelial and transepithelial migration of neutrophils.[4] Metalloproteinases may be involved in cleavage of L-selectin, allowing neutrophil migration through the basement membrane.

Absence of CD18 causes lack of CD18/CD11 heterodimers and is called *leukocyte adhesion deficiency type 1* (*LAD1*). Neutrophils lacking CD18 roll normally along the endothelium but are unable to stick to the vessel wall or exit the circulation after chemotactic stimulation. Absence of LFA-1 (CD11a/CD18) makes neutrophils unable to bind tightly to and traverse activated endothelium to infected areas. Therefore, LAD1 patients have chronic neutrophil leukocytosis, partly from inability of neutrophils to bind tightly to endothelium and exit the circulation, thus leading to a reduction in the marginated pool and an increase in the circulating pool of neutrophils. Poor neutrophil penetration to sites of bacterial invasion leads to necrotic ulcers that lack neutrophils on biopsy. Absence of Mac-1 (CD18/CD11b or CR3) leads to inability to perform complement-mediated phagocytosis, although antibody-mediated phagocytosis remains intact.

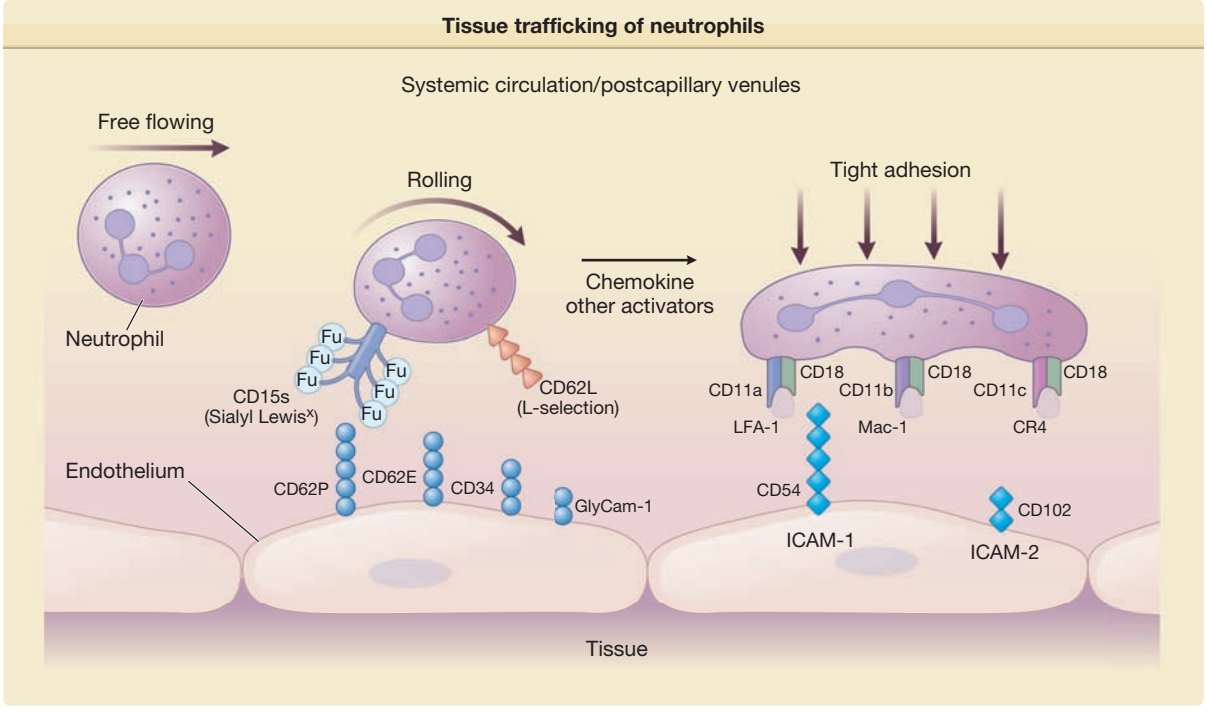

Figure 30-1 Tissue trafficking of neutrophils. The interaction of selectins and integrins on the leukocyte surface with their endothelial addressins is depicted (neutrophils on the top and eosinophils on the bottom). The leukocytes are in a laminar flow pattern. Following tissue signals that activate endothelial selectins and glycoproteins, a subset of leukocytes begin to roll along the vascular wall. For the neutrophil, this typically involves the interaction of CD15s with CD62P (P-selectin) and CD62E (E-selectin) on the endothelial cell or CD62L (L-selectin) with CD34 or glycosylation-dependent cell adhesion molecule 1 (GlyCAM-1) on the endothelial cell. Abnormalities in fucosylation of CD15s cause leukocyte adhesion deficiency 2 (LAD2). Activation of leukocytes by chemoattractants leads to the expression of integrins with higher avidity conformations. In the case of the neutrophil, the relevant integrins are the β_2 family members [lymphocyte function-associated antigen 1 (LFA-1), Mac-1, and CR4]; whereas eosinophils express a more limited number of β_2 family members (LFA-1 and Mac-1), but also express a β_1 integrin VLA-4 and β_7 integrin ($\alpha_4\beta_7$). The β_2 integrins bind to ICAM-1 and ICAM-2, whereas the β_1 and β_7 integrins bind VCAM-1 and mucosal addressin cell adhesion molecule-1 (MadCAM-1), respectively. Defects in CD18, the β chain of the β_2 integrins, lead to the inability of neutrophils to exit the circulation at sites of infection and is called leukocyte adhesion deficiency 1. Interestingly, eosinophils, monocytes, and lymphocytes are observed at sites of infection in these patients, as these cells can use β_1 integrins to mediate the firm adhesion step required for leukocyte transendothelial migration. See figure in Chapter 31 for a similar analysis of eosinophil function.

LAD1 is diagnosed by fluorescent-activated cell sorting (FACS), which shows levels of CD18 and its coexpressed molecules CD11a, CD11b, and CD11c. Severe LAD1 (<0.5% of normal protein expression) is a disorder manifested by delayed umbilical stump separation, umbilical stump infection, persistent leukocytosis in the absence of active infection (>15,000/μL), and severe, destructive periodontitis with the loss of teeth and alveolar bone. Recurrent infections of the skin, upper and lower airway, bowel, perirectal area, and septicemia are common and usually due to *Staphylococcus aureus* or Gram-negative rods. Severe LAD1 patients should receive bone marrow transplantation in early childhood. Moderate LAD1 (2.5%–10.0% of normal protein expression) patients tend to be diagnosed later in life and have fewer life-threatening infections. Leukocytosis, delayed wound healing, and periodontal disease are still common.

Neutrophil "rolling" along the endothelium is mediated through selectins, surface glycoproteins on the endothelium, and sialyl-Lewis X (CD15s), a surface glycoprotein on neutrophils (see Fig. 30-1). Endothelial cells express E-selectin (CD62E) and P-selectin (CD62P), whereas leukocytes express L-selectin (CD62L). Although endothelial E-selectin and P-selectin bind to the sialyl-Lewis X (CD15s) antigen on neutrophils, the neutrophil molecule L-selectin probably binds to distinct antigens on endothelium, including CD34, and is highly sensitive to glycosylation. L-selectin is shed by neutrophils on activation, thereby allowing neutrophil migration into sites of inflammation. Cross-linking of L-selectin on neutrophils results in superoxide generation and may result in upregulation of TNF-α, IL-8, and tyrosine phosphorylation and activation of MAP kinase. LAD2 is the disease that occurs when CD15s is improperly fucosylated. These patients have neutrophilia, recurrent

pulmonary, periodontal, and cutaneous infections, and abnormal chemotaxis. The defect is in the gene *SLC35C1*, a GDP-fucose transporter. Because the disease affects sugar transport it is now classified as a congenital disorder of glycosylation (CDG), and known as CDG IIc. Interestingly, although infections are common early in life, LAD2 (CDG IIc) patients appear to improve with age. Administration of oral fucose to some patients with LAD2 has been inconsistently therapeutic. Most patients also have mental retardation, short stature, distinctive facies, and the Bombay (hh) blood phenotype, indicating the multiple systems in which fucosylation is critical. LAD3 (previously known as LAD1 variant) is associated with a syndrome like Glanzmann's thrombasthenia, and is due to mutations in *KINDLIN3 (FERMT3)*, a molecule responsible for β1, β2, and β3 integrin activation in leukocytes and platelets leading to recurrent infections and bleeding.

The CD18 integrin pathway is critical for inflammation in the skin, but not necessary for accumulation of neutrophils in the lung or peritoneum. Therefore, although CD18-dependent pathways are critical for cutaneous inflammation, CD18-independent pathways exist for pulmonary and peritoneal inflammation. Further, in the setting of congenital absence of CD18, compensatory pathways exist in the mouse to respond to peritoneal inflammation.

PHAGOCYTOSIS. Phagocytosis is the culmination of object recognition, binding, signaling, adherence, cytoskeletal remodeling, engulfment, and membrane fusion. Two mechanisms are well characterized, one mediated by immunoglobulin and the other mediated by complement.

Receptors for the Fc portions of immunoglobulin G [IgG (FcγR)] are present on many components of the cellular immune response, including neutrophils, monocytes, macrophages, eosinophils, and basophils. FcγRI (CD64) is a receptor for IgG1 and IgG3 on monocytes, macrophages, and eosinophils and is upregulated on neutrophils after interferon-γ (IFN-γ) stimulation. FcγRII (CD32) binds IgG with rather low affinity, and prefers IgG1 and IgG3. FcγRIII (CD16) binds IgG1 and IgG3 with intermediate affinity. Neutrophil FcγRIIIB is bound to the membrane through a glycan phosphatidyl inositol linkage, which is largely cleavable by phosphatidyl inositol-specific phospholipase C. As FcγRIIIB has no cytoplasmic domain, its role in signal transduction may be through association with FcγRII. Cross-linking of these receptors by antibody leads to rapid engulfment of targets with the release of granule contents and oxygen metabolites into the phagolysosome. If the target is too large, degranulation occurs against the antibody-coated surface.

The complement receptors CR1 and CR3 are expressed on the surfaces of neutrophils, eosinophils, and basophils. Complement receptor 1 is designated *CD35* and is found on many cell types. It binds C3b and enhances its degradation to C3dg by factor I, thereby removing that molecule from further activation of the alternative pathway. CR3, CD11b/CD18, binds iC3b and fibrinogen as well as certain bacteria, parasites, and fungi. CR1 and CR3 are not per se able to stimulate phagocytosis, but in the presence of a second signal, such as one given through FcγR or by cytokines, phagocytosis proceeds.

MECHANISMS OF KILLING. Neutrophil granules contain enzymes and proteins for killing ingested bacteria and fungi. Some of these bactericidal mechanisms are dependent on the generation of oxygen metabolites for microbicidal activity, but others are not. In addition to mobilizing their own resources, neutrophils produce a multitude of cytokines that stimulate and attract other phagocytes as well as lymphocytes.

OXYGEN-INDEPENDENT PATHWAYS. Bactericidal/permeability-increasing protein (BPI) is a highly potent antibacterial granule protein synthesized and stored in the primary granules. It is a highly basic (isoelectric point >9.6) protein of 452 amino acids and approximately 58 kDa. Sequence homology to lipopolysaccharide (LPS)-binding protein, a critical endotoxin binding acute-phase reactant, suggests that it acts by directly binding to LPS. BPI is cytotoxic to Gram-negative bacteria at concentrations as low as 10^{-9} M, but much less effective against Gram-positive organisms. Binding to LPS leads to insertion of BPI into the outer membrane of the organism and eventual insertion into the inner membrane. Arrest of bacterial growth is solely dependent on the *N*-terminal half of the molecule. The *C*-terminal fragment serves as an anchor to the membrane. BPI appears to act inside the phagolysosome. Not all Gram-negative rods are sensitive to BPI, especially *Burkholderia (Pseudomonas) cepacia* and *Serratia marcescens*, pathogens in patients who lack oxidative killing.

Defensins are small (<4 kDa) cationic proteins in the primary granules of neutrophils involved in killing ingested Gram-positive and Gram-negative bacteria. Defensins are synthesized during the promyelocyte/myelocyte stage as prepropeptides, stored predominantly in a dense subset of the primary granules as propeptides, and released during neutrophil degranulation. Defensins prefer an actively metabolizing target and can kill transformed mammalian cells as well as prokaryotes and yeasts. Defensins and BPI act synergistically against Gram-negative bacteria. Defensins are reduced in CHS but absent in specific granule deficiency.

Proteinase 3 is the antigen against which the antineutrophil cytoplasmic antibody is directed in Wegener granulomatosis (see Chapter 164). It is found predominantly in primary granules but is also in secondary and secretory granules. Synthesis and surface display are upregulated by cytokines such as TNF-α. Elastase is a myeloid serine protease in primary granules that has remarkable roles in host defense. Mice with elastase defects have decreased resistance to Gram-negative bacteria. However, human neutrophil elastase deficiency causes the syndromes of severe congenital neutropenia and cyclic neutropenia. Phospholipase A2

is also found in neutrophil granules, where its various isoforms act both directly and synergistically with BPI to kill intracellular bacteria.

Lactoferrin is an iron-binding protein present in specific granules and in mucosal secretions. When released into the phagolysosome, lactoferrin binds iron and inhibits the growth of phagocytosed bacteria and some fungi. The mechanisms through which lactoferrin exerts its antimicrobial action probably include the depletion of iron from an organism's environment, but iron binding-independent antimicrobial activities and direct immunomodulatory effects are also reported. Lactoferrin is readily released into the circulation after burns and experimental endotoxemia, presumably from neutrophil degranulation.

OXYGEN-DEPENDENT PATHWAYS. Neutrophils can produce toxic oxygen metabolites through the reduced nicotinamide dehydrogenase phosphate (NADPH) oxidase complex, which typically is assembled in the wall of the phagolysosome. The NADPH oxidase catalyses the addition of an electron to molecular oxygen, leading to the formation of superoxide anion. Superoxide in turn is converted to hydrogen peroxide by superoxide dismutase. Inside the phagolysosome, the primary granule component myeloperoxidase converts hydrogen peroxide to hypohalous acid by the addition of a halogen (chloride in neutrophils forms bleach, bromide in eosinophils). The NADPH oxidase is a multiprotein complex, which is maintained in separate membrane-bound and cytosolic compartments. On cell activation, the cytosolic components translocate to the phagolysosome membrane, resulting in an active NADPH oxidase, which can produce the respiratory burst.

The components of the NADPH oxidase are named *phox* (*ph*agocyte *ox*idase) proteins. $p22^{phox}$ and $gp91^{phox}$ are the α and β chains, respectively, of the cytochrome b558 complex, which resides in the wall of the secondary granule. The cytosolic compartment contains three factors, $p47^{phox}$, $p67^{phox}$, $p40^{phox}$ and the small guanine nucleotide (guanine triphosphate) binding protein *rac*. Assembly of the NADPH complex is caused by diverse stimuli. $p47^{phox}$ and $p67^{phox}$ contain *src*-homology type 3 domains (SH3 boxes), which bind to proline-rich targets in themselves and in other members of the NADPH complex. Stimulation leads to structural changes in $p47^{phox}$ that promote its interaction with $p22^{phox}$ through $p47^{phox}$ SH3 domains and $p22^{phox}$ *C*-terminal proline-rich sequences.

Pathologic mutations in the five required components impair the generation of phagocyte superoxide and cause CGD, a disease characterized by recurrent life-threatening infections with bacteria and fungi and exuberant granuloma formation (see Chapter 143).[5]

PHARMACOLOGIC MANIPULATION

When neutrophils are overrecruited into neutrophilic dermatoses, they can produce reactive oxygen intermediates, activate proteinases, and release chemotactic cytokines, which can contribute to tissue injury and inflammation. Therefore, it makes sense to aim treatment to suppress the generation of reactive oxygen intermediates, to inhibit neutrophil adhesion and chemotaxis, and to suppress the release of lysosomal enzymes and chemotactic factors.

Dapsone is often used for chronic neutrophilic dermatoses such as dermatitis herpetiformis, subcorneal pustular dermatosis, or erythema elevatum diutinum (see Chapter 225). Dapsone suppresses neutrophil adherence and subsequent migration, is a successful scavenger of reactive oxygen intermediates, and interferes with the myeloperoxidase-halide system and leukocyte-mediated cytotoxicity. Thalidomide reduces inflammation through inhibition of TNF-α and subsequent neutrophil–endothelial adhesion and reactive oxidant generation (see Chapter 235). Dapsone and thalidomide both inhibit the proinflammatory cytokine TNF-α, which activates neutrophils through upregulation of complement receptors (CR3, CR4) and endothelial adhesion molecules, ICAM-1 and E-selectin. Colchicine inhibits neutrophil chemotaxis, release of lysosomal enzymes, and production of reactive oxidants and is therefore considered for Sweet syndrome and neutrophilic bullous dermatoses. Antibiotics such as tetracyclines, macrolides, and metronidazole also have antioxidant properties and interfere with neutrophil chemotaxis. In addition to its antioxidant activity, sulfasalazine induces neutrophil apoptosis and enhances adenosine release at sites of inflammation, making it especially useful in pyoderma gangrenosum.

KEY REFERENCES

Full reference list available at www.DIGM8.com

DVD contains references and additional content

1. Nathan C: Neutrophils and immunity: Challenges and opportunities. *Nat Rev Immunol* **6**:173, 2006
2. Borreaard N, Sørensen OE, Theilgaard-Mönch K: Neutrophil granules: A library of innate immunity proteins. *Trends Immunol* **28**:340, 2007
3. Heutinck KM et al: Serine proteases of the human immune system in health and disease. *Mol Immunol* **47**:1943, 2010
4. DiStasi MR, Ley K: Opening the flood-gates: How neutrophil-endothelial interactions regulate permeability. *Trends Immunol* **30**:547, 2009
5. Holland SM: Chronic granulomatous disease. *Clin Rev Allergy Immunol* **38**:3, 2010

Chapter 31 :: Regulation of the Production and Activation of Eosinophils

:: Kristin M. Leiferman, Lisa A. Beck, & Gerald J. Gleich

EOSINOPHILS AT A GLANCE

- Eosinophils are bone marrow-derived cells that circulate transiently and normally account for up to 6% (up to 400–600 per mm^3) of circulating blood leukocytes.
- Eosinophils primarily are tissue dwelling cells, but only in certain tissues in humans, with an average tissue life span of 2–5 days that may be increased with eosinophil survival factors for up to 14 days.
- As proinflammatory cells, the presence of eosinophils within most tissues is associated with pathological states that include infections, allergic reactions and atopic diseases, fibrotic disorders, reactive eosinophilias, and hypereosinophilic syndromes.
- Eosinophils play a role in innate and adaptive immune responses, which may explain why they are present in normal, noninflamed tissues such as the gastrointestinal tract and lymphoid tissues.
- This section reviews the biologic actions of eosinophils with particular focus on what controls eosinophil production, activation, and tissue trafficking.
- Pharmacologic manipulation of eosinophil inflammation is possible as new, more specific strategies are emerging.

EOSINOPHILS

ONTOGENY AND DEVELOPMENT

Eosinophils develop in the bone marrow from multipotential, stem cell-derived $CD34^+$ myeloid progenitor cells in response to eosinophilopoietic cytokines and growth factors (see Fig. 31-1). They are released into the circulation as mature cells.[1–3] Important stimulatory cytokines and growth factors for eosinophils include interleukin (IL)-3, granulocyte macrophage colony stimulating factor (GM-CSF), and IL-5. Activated T cells likely are the principal sources of IL-3, GM-CSF, and IL-5 that induce eosinophil differentiation in bone marrow. However, depending on pathogenic stimuli, eosinophilopoietic cytokines may be released by other cell types, including mast cells, macrophages, natural killer cells, endothelial cells, epithelial cells, fibroblasts, and even eosinophils, themselves.[4] IL-3 and GM-CSF are pluripotent cytokines that have effects on other hematopoietic lineages. IL-5 is the most selective eosinophil-active cytokine, but it is relatively late acting. Although it is both necessary and sufficient for eosinophil differentiation, IL-5 demonstrates maximum activity on the IL-5 receptor (IL-5R)-positive eosinophil progenitor pool that first is expanded by earlier acting pluripotent cytokines such as IL-3 and GM-CSF[4]; expression of the high affinity IL-5R is a prerequisite for eosinophil development. Exodus from the bone marrow also is regulated by IL-5. IL-3, GM-CSF, along with IL-5, promote survival, activation, and chemotaxis of eosinophils through binding to receptors that have a common β chain (CD131) with IL-5R, and unique α chains. See eTable 31-0.1 in online edition for designations of many factors involved in eosinophil biology.

INTERACTIONS OF EOSINOPHILIC FACTORS AND CYTOKINES AND INTRACELLULAR SIGNALING

The interactions of eosinophilopoietic factors with their receptors stimulate a cascade of complex biochemical events through signal transduction. Signaling events progress in four steps: (1) juxtamembranous signaling in which membrane-anchored tyrosine kinases and lipid kinases are activated; (2) signal interfacing which serves to transduce juxtamembranous signals to cytosolic signals; (3) mobile signaling in which cytosolic signaling molecules translocate from the receptor site to other cellular compartments including the nucleus, mitochondria, and cytoskeleton; and (4) transcription activation resulting from nuclear translocation and initiation of gene transcription. Studies have shown the pivotal role of IL-5 in immune responses involving eosinophils through receptor-driven signaling.[20] IL-5 binds to the α chain of the IL-5R and induces recruitment of the common β (βc) chain to IL-5R. Janus kinase (JAK)2 tyrosine kinase is constitutively associated with IL-5Rα, and JAK1 tyrosine kinase with IL-5Rβc; both are activated with IL-5 binding as part of the juxtamembranous step. Lyn and Fes are other tyrosine kinases involved in the first step; these tyrosine kinases also are activated by IL-3 and GM-CSF. Adaptor proteins, *src* homologues and

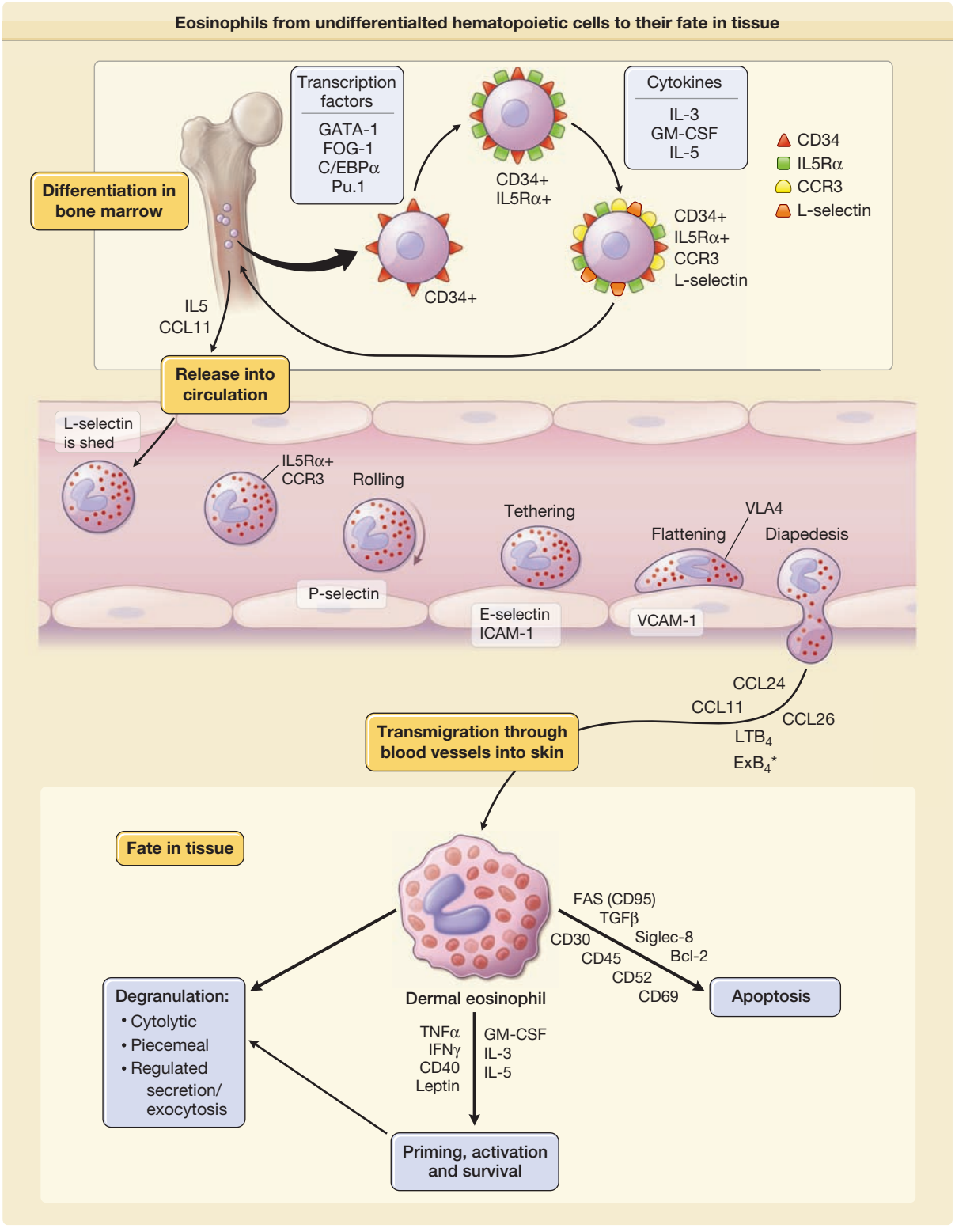

Figure 31-1 Eosinophils from undifferentiated hematopoietic cells to their fate in tissue. The images depict the eosinophil's life from differentiation in the bone marrow to vascular transmigration to their fate in tissue with key factors noted. ExB_4 likely has activities comparable with those of LTB_4.

collagen (Shc), SH2-containing phosphatase-2 (SHP-2), growth factor receptor-bound protein 2 (Grb2), Vav, and lipid kinases, phosphatidylinositol 3-kinase (PI-3K), function in the interfacing step. The activation of JAK2 and signal transducer and activator of transcription (STAT) 5 is essential for IL-5 dependent signal transduction. The Ras GTPase-extracellular signal-regulated kinase (Ras-ERK) and also known as Ras-mitogen-activated protein kinase (Ras-MAPK) pathway, in addition to the JAK2-STAT5 pathway, is important in IL-5 signaling in the mobile step. The JAK-STAT and Ras-MAPK pathways converge at various levels in IL-5 signaling of eosinophils. IL-5 induces the expression of cytokine-inducible SH2 protein (CIS) and JAK-binding protein (JAB), which is one of the negative feedback loops in the regulation of IL-5 signaling. Multiple other interactive signal transduction pathways induce and regulate gene expression for eosinophil growth, development, activation, and survival.[21,22] Much of the discovery in these pathways has been in murine systems with presumed general applicability to humans. However, at least part of the immune response to IL-5 in mice is NOT part of the biological effect in humans, i.e., in mice, IL-5 enhances several functions of B cells, including immunoglobulin production, growth, and differentiation, whereas human B-cells are influenced by IL-5 only in the presence of specific cytokines and under certain conditions.[20] However, human IL-5 does act on T cells by increasing the expression of IL2Rα and augmenting cytotoxic T cell generation.[23]

EOSINOPHIL ULTRASTRUCTURE AND GRANULE CONTENT

(See Fig. 31-2)

Mature eosinophils are 12–17 μm in diameter and, therefore, slightly larger than neutrophils. They typically have a bilobed nucleus with highly condensed peripheral chromatin. Eosinophils have distinctive cytoplasmic granules, demonstrated by their staining properties with acidic dyes such as eosin and by their unique electron microscopic appearance. These specific or secondary granules are composed of an electron-dense core and a less electron dense matrix, the core being a crystalline lattice by electron microscopy. In cross section, the eosinophil contains approximately 30 of these membrane-bound, core-containing, secondary granules.[1] Five highly basic proteins are found within the granules: (1) major basic protein (MBP)-1, (2) MBP-2, (3) eosinophil-derived neurotoxin (EDN) also known as ribonuclease (RNase)2, (4) eosinophil cationic protein (ECP) also known as RNase3, and (5) eosinophil peroxidase (EPO). Several other types of proteins are found in secondary granules and include enzymes, cytokines, growth factors, and chemokines. Eosinophils contain three other types of cytoplasmic granules, referred to as (1) primary granules, (2) small granules, and (3) secretory vesicles. Primary granules are of variable size, round, uniformly dense, present in 1–3 per electron microscopic cross section, and more common in immature eosinophilic promyelocytes. These granules may contain Charcot–Leyden crystal protein (also known as galectin-10), which can be found in neutrophils as well[31]; Charcot–Leyden crystals (CLCs) are characteristically found in asthmatic sputum and in feces from patients with helminth infections or eosinophilic gastroenteritis. Small granules contain acid phosphatase and arylsulfatase and are present at 2–8 per electron microscopic cross section. Secretory vesicles, also referred to as tubulovesicular structures or microgranules, are characterized by their small, dumbbell-shaped appearance and their albumin content. They are the most abundant granules in number, with approximately 160 per electron microscopic cross section. Normal eosinophils contain varying numbers of nonmembrane-bound lipid bodies, which are the principal stores of arachidonic acid. Lipid bodies also contain the enzymes, cyclooxygenase, 5- and 15-lipoxygenase, which are required to synthesize prostaglandins, leukotrienes (LTs), and eoxins (vide infra), and are increased in activated eosinophils.[1]

BIOLOGIC FUNCTIONS

MAMMALIAN STUDIES. In mammals, such as the mouse and humans, the eosinophil is released as a mature cell into the circulation from the bone marrow, but is present in the blood only transiently, ranging from 8–18 hours. Eosinophils comprise a small portion, normally 6% or less, of circulating leukocytes. They are primarily tissue dwelling cells, but only in certain tissues in humans, with an average tissue life span of 2–5 days. This may be prolonged by cytokines that increase eosinophil survival for up to 14 days. Under normal circumstances, a balance exists between bone marrow production and release of eosinophils, their time in circulation, and their entrance into tissues. Changes in any one of the compartments causes an increase or decrease in circulating and tissue eosinophils. Eosinophilia in blood or tissue or both is associated with helminthiasis, allergic hypersensitivity, and other pathological conditions. In humans, bone marrow, spleen, lymph node, thymus, and gastrointestinal tract from the stomach through the colon, sparing the esophagus, are the only tissues in which eosinophils normally reside.[38] Furthermore, the gastrointestinal tract is the only organ other than bone marrow in which extracellular eosinophil granule protein deposition is observed even under homeostatic conditions. Eosinophils and their granule proteins are found in the lamina propria in normal gastrointestinal tract and are not found in Peyer's patches or epithelium. Eosinophils may be important for thymocyte deletion based on the localization of eosinophils within the thymus and the timing of their migration during the neonatal period.[39] Murine observations indicate that eosinophils are also important for postnatal mammary gland and uterine development, and their recruitment into the uterus heralds estrus. Although eosinophils, themselves, are not known to participate in human reproduction, eosinophil proMBP-1 is expressed in the uterus by placental X and giant cells during pregnancy, and its production peaks 2–3 weeks before

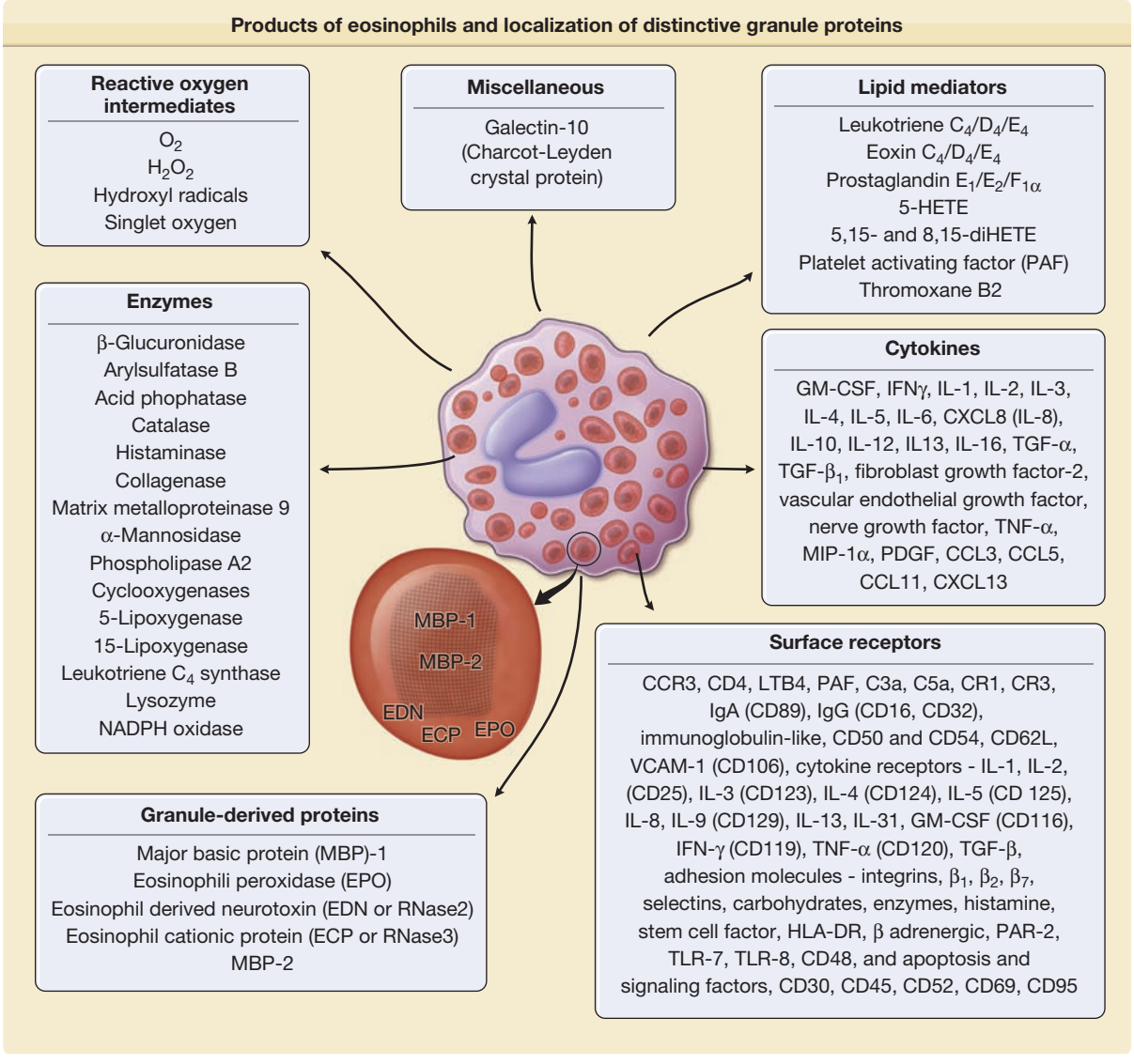

Figure 31-2 Products of eosinophils and localization of distinctive granule proteins. The eosinophil produces myriad products, including toxic granule proteins, which implicate its role in disease pathogenesis. The characteristic eosinophil granules are coarse and, as their name implies, eosinophilic upon staining with eosin. Distinctive granule proteins are localized to core and matrix portions of the specific cytoplasmic granules. **A.** An intact dermal eosinophil with its distinctive granules and typical bilobed nucleus. **B.** Characteristic specific (secondary) eosinophil granule with electron dense crystalline core and radiolucent matrix showing localization of distinctive granule proteins.

parturition.[40,41] The recruitment of eosinophils to the gastrointestinal, thymic, uterine, and mammary tissues is under the control of the CC chemokine, CCL11.[42,43]

Once eosinophils enter tissues, most do not recirculate. Several possible mechanisms exist for removal of tissue eosinophils. These include shedding of the cells across mucosal surfaces into the lumen of the intestinal or respiratory tract, engulfment of apoptotic eosinophils by macrophages, and lysis or degranulation with cellular degeneration. In various inflammatory conditions, including those affecting the skin (Chapter 36), striking numbers of free granules and/or eosinophil granule protein deposition are present in the absence of intact eosinophils.[1] Studies recently have revealed that isolated eosinophil granules express extracellular domains for interferon (IFN)-γ receptor and CCR3 and, upon stimulation, respond independently as organelles by releasing ECP.[44]

ROLE OF EOSINOPHILS IN IMMUNE FUNCTION

Shortly after their discovery by Paul Ehrlich in 1879, eosinophils were observed in association with helminth infections. Theories have been promulgated that eosinophils are important for host defense against parasites spawning numerous studies.[45] For example, in

vitro studies demonstrated that eosinophils are cytotoxic to large nonphagocytosable organisms, such as multicellular helminthic parasites. Eosinophils bind to host-derived immunoglobulins and complement components on the surface of their targets (so-called antibody- or complement-) dependent cytotoxicity. They also bind to carbohydrate ligands expressed on parasites, such as the Lewis^x-related molecules, and cell adhesion molecules similar to selectins. Eosinophils are activated to release their granule products with deposition of these biologically active proteins in and around the parasites causing disruption of the parasite's integument and, ultimately, death of the organism. The granule proteins have different effects. ECP produces fragmentation and disruption whereas MBP-1 produces a distinctive ballooning detachment of the tegumental membrane, and EDN is active only at high concentrations causing crinkling of the tegumental membrane.[46] However, in murine models in which blood, marrow, and tissue eosinophilia is largely abolished by neutralizing IL-5 activity, the intensities of primary or secondary parasitic infection are unchanged indicating that eosinophils have little or no role in parasitic host defense in these models.[1] The results must be interpreted cautiously because mouse and human eosinophils have functional differences, and mice are not natural hosts of many of the parasites tested experimentally.

Eosinophils also release cytotoxic granule proteins onto the surface of fungal organisms and into the extracellular milieu in fungal infections. Eosinophils kill fungi in a contact-dependent manner. Eosinophils adhere to the fungal cell wall component, β-glucan, via a β2-integrin surface molecule, CD11b.[47] Eosinophils do not express other common fungal receptors, such as dectin-1 and lactosylceramide, and, specifically, do not react with chitin. However, chitin, which is a polymer that confers structural rigidity to fungi, helminths, crustaceans, and insects, induces accumulation of eosinophils in tissues through production of LT B4 in mice.[48] Eosinophils also are activated by fungal organisms that release proteases, such as *Alternaria*, through protease-activated receptors (PARs). For example, fungal aspartate protease activates eosinophils through PAR-2 and, thereby, mediates eosinophils' innate responses to certain fungi.[49]

As a granulocyte, the eosinophil is capable of phagocytosing and killing bacteria and other small microbes in vitro, but eosinophils cannot effectively defend against bacterial infections when neutrophil function is deficient. Nevertheless, recent investigations reveal that eosinophils may have a role in innate immunity against bacteria using a unique mechanism, DNA trap.[50] Eosinophils rapidly release mitochondrial DNA when exposed to bacteria, a complement component, C5a, or CCR3 ligands. The traps contain eosinophil granule proteins, ECP and MBP, and have antimicrobial effects. In the extracellular space, the granule proteins and mitochondrial DNA form structures that bind and kill bacteria both in vitro and in vitro. Eosinophils, unlike neutrophils, do not undergo cell death as part of this process. This may be an important innate immune response, particularly in mucosal epithelium.[50]

Another protective function that eosinophils may have is in viral infections. Eosinophils and their granule proteins are increased in the respiratory tracts of patients with respiratory syncytial virus, an RNA-viral infection. EDN (RNase2) and ECP (RNase3), eosinophil granule matrix proteins, are ribonucleases (vide infra). Purified eosinophils, as well as EDN and ECP individually, reduced viral titers when added to respiratory syncytial viral suspensions. In mice, at least 11 eosinophil-associated ribonucleases degrade single stranded RNA containing viruses.[51] Despite divergence of the coding regions, conserved eosinophil ribonuclease activity across species suggests a strong evolutionary pressure to preserve this critical enzymatic activity.[51] In other studies, pretreatment of parainfluenza-infected guinea pigs with anti-IL-5, to reduce numbers of eosinophils, strikingly increased viral load in the airways. Viruses, including parainfluenza virus, respiratory syncytial virus, and rhinovirus, induce the release of another eosinophil granule protein, EPO, when coincubated with antigen-presenting cells and T cells.[52] Paradoxically, eosinophils may be a potential reservoir for the human immunodeficiency virus (HIV)-1.[53]

Eosinophils may have other roles in immune responses as well. Through MHC class II expression and IL-1α production, they can function as antigen-presenting cells for a variety of viral, parasitic, and microbial antigens, including staphylococcal superantigens, and allergens.[54,55] Eosinophils are recruited to secondary lymphoid structures to promote the proliferation of effector T cells although they are unable to affect naïve T cells.[56] Eosinophils, as sources of cytokines, influence T cell-dependent responses.[1] In keeping with the prominence of eosinophils in allergic disorders, eosinophils are involved in T cell polarization favoring Th2 by promoting Th1 apoptosis in addition to their influence via cytokine expression.[54,57–60]

ROLE OF EOSINOPHILS IN DISEASE

The activities of eosinophil-derived products include direct cytotoxic effects on structural cells and microbes, increased vascular permeability, procoagulant effects, innate immune responses to some parasites, viruses, fungi and tumor cells, enhancement of leukocyte migration, amplification of effector T-cell responses and, possibly even mammary gland development. Collectively, these varied biologic actions provide the pathophysiological basis for the signs and symptoms observed in eosinophil-associated diseases.

Eosinophils in lymph nodes and spleen are especially increased after allergen exposures or microbial insults.[61,62] Eosinophils have been found in several cancers, particularly in lymphomas, leukemias, and colon cancer. Clinical studies indicate that certain tumors associated with tissue and/or peripheral eosinophilia have a more favorable prognosis,[63] whereas in other tumors, they are thought to confer a poor prognosis, such as nodular sclerosing Hodgkin disease, Sézary syndrome, and gastric carcinomas. In Sézary syndrome (see Chapter 145), the tumor cells produce IL-5

and, therefore, are responsible for the eosinophilia, which is a reflection of tumor burden.[64] Where eosinophilia is a good prognostic factor, eosinophils are considered to be part of an effective host response to the tumor.[65,66]

EOSINOPHIL CONSTITUENTS AND THEIR ACTIVITIES

The eosinophil contains and produces a myriad of factors that implicate its role in inflammation and tissue destruction and remodeling (see Fig. 31-2).[70] Products released by eosinophils include chemoattractants, colony-stimulating factors, and endothelial-activating cytokines. In addition to toxic cationic proteins from specific granules and oxidative products released into tissues following activation, these factors include arachidonic acid-derived lipids, hydrolytic enzymes, neuropeptides, colony-stimulating factors, and cytokines/chemokines that facilitate further leukocyte recruitment to sites of inflammation (see Fig. 31-2). Surface molecule expression is important in all aspects of eosinophil biology from promoting growth and differentiation to eosinophil trafficking into tissue to activation and/or priming of the cells to senescence. Numerous membrane factors are expressed on eosinophils that further direct eosinophil biological effects. (See eTable 31-0.1 in online edition for designations of various eosinophil factors.)

EOSINOPHIL GRANULE PROTEINS. Among the products of eosinophils that are most damaging to the host are the specific granule's cationic proteins. Furthermore, the granule proteins are markers of eosinophil activity because the eosinophil often loses its characteristic morphology through cytolysis in tissues.[71] Knowledge of their biological actions provides insight into their functions in human disease. Once deposited, the granule proteins persist in tissues for extended times—EPO for 1 week, ECP for 2 weeks, EDN for 2.5 weeks, and MBP-1 for 6 weeks.[72] Each of these proteins have been shown to induce direct tissue damage to both host cells, including myocytes, endothelium, neurons, epithelium, and smooth muscle, and to microbes (vide supra). For example, MBP-1, ECP, or EPO application to airway epithelium in primates produces ciliostasis, desquamation, and hyperreactivity of respiratory smooth muscle mimicking the pathology of asthma.[73,74] Damage to endothelium in eosinophilic endomyocardial disease is thought to be the initiating factor in the cardiomyopathy observed in the hypereosinophilic syndromes (see Chapter 36).[75] All four of the cationic granule proteins [(1) EPO, (2) ECP, (3) EDN, and (4) MBP-1] likely contribute to the edema observed in skin diseases due to their vasodilatory effects with contribution from mast cells and basophil histamine release by MBP-1.[76] Eosinophil granule proteins stimulate various cells in addition to mast cells and basophils, including neutrophils and platelets. Nodules, eosinophilia, rheumatism, dermatitis and swelling (NERDS), episodic angioedema with eosinophilia (Gleich syndrome), urticaria, eosinophilic cellulitis (Wells syndrome), and insect bite reactions demonstrate variable degrees of edema that are probably explained, at least in part, by this mechanism (see Chapter 36). Eosinophil granule proteins injected into skin produce lesions including dose-dependent wheal-and-flare reactions by MBP and ulcerations by ECP and EDN.[77,78] Wound healing is delayed in the presence of eosinophils and eosinophil granule proteins.[79,80] Eosinophils, through activities of granule proteins, have procoagulant activity. Thromboses have developed in the hypereosinophilic syndromes, including several case reports of hepatic vein obstruction (Budd–Chiari syndrome). The thromboses could be the result of direct endothelial damage or due to the ability of MBP and ECP to neutralize heparin. In addition, MBP is a strong platelet agonist, and platelet-activating factor (PAF), which is released by eosinophils, causes platelet aggregation.[1]

MAJOR BASIC PROTEIN

General Characteristics. Major basic protein (MBP) comprises the crystalloid core of the specific eosinophil granule. It was so named because it accounts for a **major** portion, about 55% (in guinea pig), of the eosinophil granule **protein,** and has a high isoelectric point, calculated at greater than pH 11, so strongly **basic** that it cannot be measured accurately. It is now known that MBP is expressed as two homologs, MBP-1 and MBP-2, coded by different genes on chromosome 11.

Tissues Effects of Basic Proteins. MBP-1 directly damages helminths and also lethally damages mammalian cells and tissues, examples of which are its ability to cause exfoliation of bronchial epithelial cells and to kill tumor cells. MBP-1 exerts its effects by increasing cell membrane permeability through surface charge interactions leading to disruption of the cell surface lipid bilayer.[81] MBP-1 and MBP-2, but none of the other eosinophil granule proteins, stimulate histamine and LTC_4 release from human basophils. Further, MBP-1 and MBP-2 stimulate neutrophils, inducing release of superoxide, lysozyme, and IL-8. MBP-1 and EPO are potent platelet agonists causing release of 5-hydroxytryptamine and promoting clotting.

EOSINOPHIL PEROXIDASE. Eosinophil peroxidase (EPO) is highly basic, pI 10.8, localized in the matrix of the specific eosinophil granule and is a key participant in generating reactive oxidants and free radical species in activated eosinophils. EPO consists of a heavy chain and a light chain encoded with a prosequence. The EPO gene is on chromosome 17 and maps closely to myeloperoxidase and lactoperoxidase genes, two other members of the mammalian peroxidase family found in neutrophils and mucosal glands, respectively. Although MBP is present in the highest molar concentration in eosinophil granules, EPO, by weight, is the most abundant protein constituting approximately 25% of the specific eosinophil granule's total protein mass. EPO catalyzes the oxidation of

halides, pseudohalides, and nitric oxide to form highly reactive oxygen species (hypohalous acids), reactive nitrogen metabolites (nitric dioxide), and other oxidants that then oxidize targets on proteins with oxidative stress and subsequent cell death by apoptosis and necrosis. EPO kills numerous microorganisms in the presence of hydrogen peroxide, generated by eosinophils and other phagocytes, and halide. This combination of products also initiates mast cell secretion. As noted, both EPO and MBP induce noncytolytic, dose-dependent 5-hydroxytryptamine release from platelets.[82] Binding of EPO to neutrophils reversibly inhibits EPO peroxidase activity but increases neutrophil aggregation and adhesion to endothelial cells.[83] EPO binding to microbes, including *Staphylococcus aureus*, greatly potentiates their killing by phagocytes. EPO-coated tumor cells are spontaneously lysed by activated macrophages.

EOSINOPHIL CATIONIC PROTEIN AND EOSINOPHIL-DERIVED NEUROTOXIN

General Characteristics. Eosinophil cationic protein (ECP or RNase3) and eosinophil-derived neurotoxin (EDN or RNase2) are homologous proteins with sequence identity in 37 of 55 amino acid residues and are encoded on chromosome 14. ECP also has neurotoxic activity. ECP and EDN play a role in viral host defense to RNA viruses.[51,88,89] New roles for these proteins continue to be identified.[90] EDN induces the migration and maturation of dendritic cells.[91] It also is an endogenous ligand of Toll-like receptor 2 (TLR2) and can activate myeloid dendritic cells by triggering the TLR2-myeloid differentiation factor 88 (Myd88) signaling pathway.[60] Based on its ability to serve as a chemoattractant and activator of dendritic cells along with enhancing antigen-specific Th2-biased immune responses, EDN functions as an alarmin alerting the adaptive immune system to preferentially enhance antigen-specific Th2 responses.[60]

CHARCOT–LEYDEN CRYSTAL PROTEIN

General. Distinctive hexagonal, bipyramidal crystals were initially described in 1853 in a patient with leukemia and later, in 1872, in the sputa of asthmatic patients. Since then, CLCs have been regarded as a hallmark of eosinophilia. CLC protein is an abundant, characteristic, although not unique, protein of eosinophils. It is also found in lesser amounts in basophils. CLC mRNA and EDN mRNA are among the most highly expressed mRNAs in mature peripheral blood eosinophils suggesting de novo synthesis.[1]

CHARCOT–LEYDEN CRYSTALS

REACTIVE OXYGEN METABOLITES. Reactive oxygen species are important mediators of the tissue injury caused by eosinophils. The reactive oxygen intermediates produced by NADPH oxidase during the respiratory burst initiated on eosinophil activation include superoxide, hydroxyl radicals, and hydrogen peroxide. Hydrogen peroxide can generate hypohalous acids through the action of EPO, which are cytotoxic as well. Reactive oxygen species also can augment the inflammatory response by inducing gene expression and T-cell proliferation.[98]

LIPID MEDIATORS

General. Lipid bodies in eosinophils are storage sites for arachidonic acids. Eosinophils produce several arachidonic acid metabolites, including cysteinyl LTs from the 5-lipoxygenase pathway (LTC_4, LTD_4, and LTE_4) and thromboxanes and prostaglandins from the cyclooxygenase pathway [thromboxane B_2, prostaglandin (PG) E_2, and $PGF_1\alpha$].[99,100]

CYTOKINES. Eosinophils are a considerable source of growth factors and regulatory as well as proinflammatory cytokines and chemokines.[1,103] The various growth factors produced by eosinophils include transforming growth factor (TGF)-α, TGF-β, fibroblast growth factor-2, vascular endothelial growth factor, nerve growth factor, and platelet-derived growth factor-β. There is evidence that these growth factors induce stromal fibrosis and basement membrane thickening at sites of chronic eosinophilic inflammation including nasal polyps, asthmatic airways and, likely, in certain skin disorders such as atopic dermatitis.[1] The production and release of nerve growth factor by eosinophils promotes neurites in nerve cells.[104] Another group of cytokines produced by eosinophils modulates other immune cells and includes tumor necrosis factor (TNF)-α, macrophage inflammatory protein (MIP)-1α (CCL3), IL-1α, IL-2, IL-3, IL-4, IL-5, IL-6, CXCL8 (IL-8), IL-10, IL-12, IL-13, IL-16, GM-CSF, and IFN-γ.[103] Additional chemokines produced by eosinophils are CXCL13 (B lymphocyte chemoattractant factor), CCL5 [regulated on activation, normal T cells expressed and secreted (RANTES)], and CCL11, in addition to CCL3 and CXCL8. CCL5 apparently is stored in at least two intracellular compartments, namely, (1) the matrix of specific eosinophil granules and (2) small secretory vesicles. All of these cytokines are constitutively produced in low levels in resting eosinophils and induced in inflammatory conditions with activation of eosinophils by engagement of receptors (vide infra) with immunoglobulins, complement and cytokines, including those produced by eosinophils, themselves, in an autocrine manner. Notably, eosinophils produce the three principal cytokines involved in their own growth and differentiation—(1) IL-3, (2) IL-5, and (3) GM-CSF, as well as chemokines important in their own chemotaxis, CCL5 and CCL11. It is known that eosinophils synthesize and secrete GM-CSF by a peptidyl-prolyl isomerase (PIN1)-dependent mechanism.[105] However, although eosinophils produce quantities of certain cytokines comparable to T cell production,[106] the relative contributions of eosinophil-derived cytokines to inflammation remain to be determined. In summary, the eosinophil-derived cytokines may function in both an autocrine and paracrine fashion and likely have pathophysiological relevance.

SURFACE EXPRESSION. Eosinophils express numerous receptors and other factors on their surface membranes through which they communicate with the extracellular environment, but no single surface protein is uniquely expressed on eosinophils. These receptors have been identified either by flow cytometry or by functional assays, and can be grouped as follows: **chemotactic factor and complement receptors** including chemokine, LT and PAF; **immunoglobulin supergene family member receptors** including immunoglobulins; **cytokine receptors** including those discussed above; **adhesion molecule receptors**; **receptors involved in apoptosis**; and **miscellaneous receptors and surface factors**. Eosinophil membrane proteins are promising targets for therapeutic modulation of eosinophil effects (see section "Pharmacological Manipulation").

CHEMOTACTIC FACTOR AND COMPLEMENT RECEPTORS. Chemotactic factors are important in orchestrating cellular trafficking to sites of inflammation as well as physiologic homing (e.g., eosinophils to gastrointestinal tract). The eosinophil has receptors for many chemotactic agents such as LTB_4, PAF, bacterial products (*N*-formyl-methionyl-leucyl-phenylalanine), complement anaphylatoxins, C3a and C5a. Eosinophils express complement receptor (CR)1 (CD35), a receptor for C1q that also binds C4b, C3b, and iC3b, and CR3 (Mac-1, CD11b/CD18) in addition to receptors for C3a and C5a. These are important receptors in eosinophil effector functions. The binding of chemokines to their respective receptors mediates many biological effects, which, in addition to cell shape change and migration, includes cell activation, receptor internalization, induction of the respiratory burst with generation of toxic oxygen metabolites, and transient activation of integrin adhesiveness. PAF activity on eosinophils is mediated through PAF receptors that have been cloned. PAF is one of the most potent chemoattractants for eosinophils and selectively recruits eosinophils over neutrophils. PAF also induces release of granule proteins, reactive oxygen species, and LTC_4 from eosinophils. LTB_4 through its eosinophil receptor potently stimulates eosinophil chemotaxis and elicits arachidonic acid metabolism and a respiratory burst. It does not induce eosinophil degranulation. Eosinophils also may have LTD_4 receptors.[1] The chemotaxins listed above have potent effects on eosinophils but are nonselective in that they are active on other leukocytes. Because many eosinophil-associated diseases are characterized by tissue eosinophil infiltration with little or no neutrophil infiltration, the identification of the CCR3 receptor and its ligands was an important breakthrough in discovering eosinophil-selective chemotaxins.[107] Specific members of the chemokine family are critical for the cellular trafficking of eosinophils. The major ligands of CCR3, CCL5, CCL11, CCL13 (monocyte chemotactic protein-4), CCL24 (eotaxin-2), CCL26 (eotaxin-3), play a critical role in both the homeostatic and inflammation-induced recruitment of eosinophils to tissue sites.[13,108] Not surprisingly, the most highly expressed chemokine receptor on human eosinophils is CCR3 (40,000–400,000 receptors per cell). CCR3 is a seven-transmembrane spanning G-protein coupled receptor that can deliver both powerful positive and negative signals depending on the interacting ligand.[109]

IMMUNOGLOBULIN SUPERGENE FAMILY MEMBER RECEPTORS. Many of the studies of eosinophil functions, including phagocytosis, antigen-dependent cytotoxicity, oxygen metabolism, LTC_4 production, and eosinophil survival, have been performed using IgG-coated targets. Among eosinophil surface receptors for the immunoglobulin family members, the most highly expressed receptor is FcγRII (CD32), which binds aggregated IgG, particularly of the subclasses IgG_1 and IgG_3. The binding of IgG to this receptor may be important in eosinophil degranulation in parasitic and allergic diseases along with other eosinophil functions.[1] Freshly isolated eosinophils express only FcγRII (CD32) of the IgG receptors, but eosinophils can be stimulated by cytokines, particularly IFN-γ, to express FcγRI (CD64) and FcγRIII (CD16) and augment FcγRII (CD32) expression.

FcαRI (CD89), the IgA receptor, is present on the surface of eosinophils. Eosinophils also possess a binding site for secretory component that may account for the finding that secretory IgA is the most potent immunoglobulin stimulant for eosinophil degranulation. The interaction of eosinophils with IgA is enhanced by Th2 cytokines, IL-4 and IL-5. These observations, coupled with the observation that many eosinophils are found in epithelial tissues such as gastrointestinal tract, suggest that eosinophils and secretory IgA play an important role in mucosal immunity.

Members of the immunoglobulin superfamily are type I transmembrane molecules that share common structural characteristics of the globular domains found in immunoglobulins. Intercellular adhesion molecule (ICAM)-1 (CD54) and ICAM-3 (CD50) are members of this superfamily expressed on eosinophils and are likely important in leukocyte–leukocyte and leukocyte–tissue cell adhesion through leukocyte function-associated antigen (LFA)-1 (αLβ2; CD11a/CD18) as its counterligand (see Fig. 31-1).

CYTOKINE RECEPTORS. Cytokine receptors are present at low levels on the surfaces of eosinophils. Receptors for IL-3 (CD123), IL-5 (CD125), and GM-CSF (CD116) are readily detected and, as noted previously, all share a common β chain (CD132). Eosinophil activation has been observed by a variety of other cytokines through presumed and/or detected receptors. These include: stem cell factor (c-kit receptor; CD117), IFN-γ (CD119), TNF-α (CD120), IL-4 (CD124), IL-9 (CD129 and CD132), IL-13 (gp65), IL-2 (CD25), IL-31, and TGF-β receptors. Many of these receptors are for cytokines that eosinophils produce providing further evidence that they have autocrine functions.

ADHESION MOLECULE RECEPTORS. Adhesion molecule receptors are expressed on the eosinophil cell surface to mediate trafficking to and within tissues, and for general cell–cell interactions.[112] These

receptors fall into three groups: (1) immunoglobulin superfamily (reviewed above), (2) selectins and their glycoprotein counterligands, and (3) integrins. L-selectin (CD62L) and P-SELECTIN glycoprotein ligand-1 (PSGL-1, CD162) are expressed at high levels on eosinophils, whereas E-selectin ligands, as an example, sialyl-Lewis X (CD15s), are expressed at very low levels. P-selectin together with PSGL-1 is the most important selectin pair in eosinophil migration into tissues.

Eosinophils express a variety of integrins (β_1, β_2, and β_7) on their surface, which facilitate their adhesion to extracellular matrix proteins, vascular cellular adhesion molecule (VCAM)-1 (CD106) on activated endothelium, or ICAM-1 present on resting or activated epithelium and activated endothelium. Integrins are composed of two subunits that exist as noncovalently associated heterodimers, with α and β subunits. The β_1 integrins expressed on eosinophils include $\alpha_4\beta_1$ (very late antigen-4 or VLA-4), which binds to VCAM-1 found on activated endothelium and the extracellular matrix protein, fibronectin. Eosinophil adhesion to fibronectin induces the autocrine production of eosinophil-activating survival cytokines, IL-3, IL-5, and GM-CSF. The only other β_1 integrin expressed on eosinophils is $\alpha_6\beta_1$, which mediates the binding to another matrix protein, laminin. Four β_2 integrins are found on eosinophils: (1) $\alpha L\beta_2$ (LFA-1), (2) $\alpha M\beta_2$ (CD11b/CD18 or Mac-1), (3) $\alpha X\beta_2$, and (4) $\alpha D\beta_2$. These integrins bind to ICAM-1, ICAM-2, ICAM-3, VCAM-1, fibrinogen, and the complement fragment, C3bi. Lastly, eosinophils also express $\alpha_4\beta_7$, which is the ligand for the gut mucosal addressin cell adhesion molecule-1 (MAdCAM-1), which is likely important in homing of eosinophils to gastrointestinal mucosa; $\alpha_4\beta_7$ also mediates adhesion to fibronectin and VCAM-1.

RECEPTORS INVOLVED IN APOPTOSIS. Eosinophils express several "death receptors," that are involved in apoptotic pathways, such as Fas receptor (CD95), Siglec-8, CD30, CD45, Campath (CD52), and CD69, along with important intracellular regulators of eosinophil apoptosis such as the members of the B-cell leukemia/lymphoma (Bcl)-2 and inhibitor of apoptosis families.[113] Diseases characterized by eosinophilia likely result, in part, from delayed or defective apoptotic pathways allowing accumulation and persistence of eosinophils in blood and/or tissues.

FACTORS WORKING TOGETHER. The various products elaborated by eosinophils in response to receptor activation do not necessarily function independently but often act in concert to mediate their biological effects. For example, the release of TGF-α, TGF-β, fibroblast growth factor-2, vascular endothelial growth factor, MMP-9, and inhibitors of MMPs from activated eosinophils collectively induce fibroblast proliferation and extracellular matrix protein production. Eosinophils contribute factors of their own and influence factor production from other cells, for example, eosinophil mediators induce platelet release of TGF-β. After intradermal eosinophil infiltration, there is production of extracellular proteins, including tenascin and procollagen 1, as well as myofibroblast formation.[120] Eosinophil-induced fibrosis is observed in the lungs and heart of patients with hypereosinophilic syndrome, in and around organs in other fibrosing/sclerosing disorders and in the skin of patients with eosinophilic fasciitis (Shulman syndrome), eosinophilia–myalgia syndrome, and toxic oil syndrome (see Chapter 36).[121] Eosinophil granule proteins, MBP-1 and EDN, along with other neuroactive mediators produced by eosinophils such as nerve growth factor, vasoactive intestinal peptide, and substance P, likely affect nerve physiology. In fact, eosinophils and eosinophil granule proteins are often observed in close proximity to nerve endings.[122,123] Eosinophil-induced nerve dysfunction is likely an important part of the gastric dysmotility observed in subjects with food allergies, the dysfunction of vagal muscarinic M2 receptors observed in asthmatics, and may also contribute to itch along with other physiological aberrations in atopic dermatitis and other cutaneous diseases.[123,124] Collectively, the eosinophil's response to surface factors determines its role in health and disease.

TISSUE TRAFFICKING

The selective recruitment of eosinophils into sites of inflammation results from interactions among eosinophil-activating cytokines, chemokine-inducing cytokines, and endothelial-activating cytokines (see Fig. 31-1). Similar to other leukocytes, selectin, integrin, and immunoglobulin gene superfamily members contribute to the signaling involved in eosinophil trafficking. In particular, eosinophils constitutively express the integrin, VLA-4, which interacts with its ligand, VCAM-1, induced on endothelial cells by cytokines, especially Th2 cytokines (IL-4 and IL-13).[125] After movement through vessels, eosinophils adhere to extracellular matrix proteins. Here, surface factors, b2 integrins such as CD11b/CD18 (Mac-1), bind to fibrous proteins such as fibronectin, laminin, and collagen, and, not only determine where eosinophils will reside, but likely prolong their survival.[126] In this regard, CD11b/CD18 (Mac-1) integrin is also critical for eosinophil effector functions, including degranulation.[127]

EOSINOPHIL-ACTIVATING CYTOKINES

GENERAL. Eosinophil-activating cytokines can be produced by many cell types in addition to T cells and mast cells, including keratinocytes, endothelial cells, and monocytes, along with eosinophils, themselves. The eosinophil-activating cytokines, IL-3, IL-5, GM-CSF, and others, enhance chemotactic responses, in addition to multiple other effects on eosinophils such as promoting maturation, cell survival, and LT production.[128]

ENDOTHELIAL-ACTIVATING CYTOKINES

(See Chapter 162)

During eosinophil migration, at least three types of endothelial activations occur. The first is the expression of P-selectin, which occurs when Weibel–Palade bodies in endothelial cells are transported to the cell surface rapidly after exposure to histamine, LTs, and a host of other inflammatory mediators. Expression of P-selectin on the endothelial-cell surface initiates leukocyte rolling, via CD162 (PSGL-1), which is the important initial step before firm adhesion and transendothelial migration. A second type of endothelial activation is that induced by nonspecific activators such as IL-1 and TNF-α. These cytokines stimulate endothelial expression of E-selectin, ICAM-1, and VCAM-1, to which eosinophils firmly adhere, or "tether." They also induce production of chemokines by endothelial cells. The third type of endothelial activation is that induced by IL-4 and IL-13. These cytokines selectively induce VCAM-1, which is centrally involved in the recruitment of VLA-4-positive cells, including eosinophils, basophils, and lymphocytes into sites of allergic inflammation.

CHEMOKINES

The transition from rolling to firm adherence is substantially increased by CCR3 ligands, the CC chemokines. Induction of the expression of chemokines by activated endothelial cells results in higher levels of chemokines on or near the endothelial surface, which transiently affect β_1 and β_2 integrin avidity, resulting in firm adhesion of the eosinophil to the endothelial cell. However, chemokines produced by structural cells such as fibroblasts, smooth muscle cells, and epithelium probably are more important in directing migration and activation of eosinophils within tissues than those expressed on endothelial cells.[137]

Tissue chemokine expression forms a gradient signal that guides eosinophils into tissue. CCL11 guides eosinophils into tissue locations in which eosinophils are normally present, thymus, uterus, mammary gland, and gastrointestinal tract.[143] In Th2 disorders, Th2 cytokines induce chemokine expression. In lungs affected by asthma and eosinophilic pneumonia, CCL11, CCL24, and CCL26 are increased along with other chemokines,[144] such as LTB_4 and galectin-9.[145,146] In the intestinal tract, CCL26 plays a key role in eosinophilic esophagitis, whereas CCL11 is involved in lower gastrointestinal eosinophil disorders. In skin, IL-4, IL-13, and TNF-α stimulate CCL11, CCL24, and CCL26 production from mast cell and lymphocyte sources as well as from fibroblasts (CCL11 and CCL26) and keratinocytes (CCL26).[147] As in eosinophilic esophagitis, CCL26 may be important in atopic dermatitis in which serum CCL26 levels correlate with disease activity.[148]

Arachidonic acid metabolites, particularly, the cysteinyl LTs, LTC_4, LTD_4 and LTE_4, and PGD_2, are involved in eosinophil trafficking as evidenced by the observations that LT receptor antagonists reduce blood and lung eosinophilia and that mice, depleted of LTB4 receptors, have markedly reduced lung eosinophilia after allergen exposure. Eosinophil, basophil, and Th2 cell recruitment occurs, to some extent, through CRTH2 (CD294), the high affinity PGD_2 type 2 receptor. Other factors that contribute to eosinophil trafficking are being identified. For example, eosinophils express high levels of histamine 4 receptors that mediate chemoattraction and activation.[149] An extracellular matrix protein, periostin, encoded by an IL-13 inducible gene, likely facilitates eosinophil infiltration into tissues by directly affecting eosinophil adhesion; periostin is overexpressed in eosinophilic esophagitis and correlates with eosinophil numbers in biopsies.[150]

ACTIVATION OF EOSINOPHILS

As reviewed previously, various inflammatory mediators activate eosinophils. In addition to cytokines, TNF-α, GM-CSF, IL-3, and IL-5, these include complement components, C3a and C5a, lipid mediators, LTC_4 and PAF, chemokines, as well as engagement of IgA and IgG Fc receptors. CD11b/CD18 (Mac-1)-dependent cellular adhesion is a critical component for degranulation and superoxide production induced by GM-CSF and PAF eosinophil activation and likely is an in vitro mechanism that results from eosinophil contact with stromal cells and/or proteins.[151] Members of the CC chemokine subfamily, CCL5, CCL7 (MCP-3), CCL11, CCL13 (MCP-4), CCL24 that bind to the chemokine receptor, CCR3, also potently activate eosinophils. Activated eosinophils develop a number of phenotypic changes, including a reduction in granules, vacuolization, and an expansion of their cytoplasm, leading to a reduction in cell density and are referred to as *hypodense*. The number of hypodense cells predicts allergic disease severity. A cell surface marker that distinguishes hypodense from normodense eosinophils has not been identified, but there are several surface markers with enhanced expression on in vitro or in vitro activated or hypodense cells: αM integrin (CD11b), αX integrin (CD11c), FcγR111 (CD16), hyaluronic acid receptor (CD44), ICAM-1 (CD54), CD69, and HLA-DR.[152]

Upon recruitment and activation in tissues, eosinophils have various effects as detailed in previous sections. In tissues, eosinophils release granule contents into their extracellular space via three mechanisms: (1) piecemeal degranulation, (2) regulated secretion (also referred to as regulated exocytosis), and (3) cytolytic degranulation. First, in piecemeal degranulation, eosinophils selectively release specific granule components; as an example, IFN-γ activation promotes mobilization of granule-derived CCL5 to the eosinophil's surface without inducing cationic protein release.[153–155] Second, in regulated secretion, a docking complex forms consisting of soluble *N*-ethylmaleimide-sensitive factor attachment protein (SNAP) receptors (SNAREs) located on the vesicle (vSNAREs) and the target membrane (tSNAREs). Two types of SNAREs have been described based on the presence of a conserved amino acid, arginine (R)

or glutamine (Q). Human eosinophils express the R-SNARE, vesicle-associated membrane protein (VAMP)-2 on cytoplasmic secretory vesicles, and the Q-SNAREs, SNAP-23, and syntaxin-4, on the plasma membrane.[156] VAMP-7 also plays a critical role in both eosinophil and neutrophil mediator release.[157] The current understanding is that receptor-induced eosinophil activation leads to rapid mobilization of cytoplasmic vesicles to the plasma membrane, leading to the formation of a SNARE complex (VAMP-2, -7/SNAP-23/syntaxin-4) and mediator release. Third, cytolytic degranulation occurs in many inflammatory diseases including skin disease, such as atopic dermatitis, eosinophilic esophagitis, and lesions found in affected organs with the hypereosinophilic syndromes. It is characterized by organelle rupture, chromatolysis of nuclei with loss of morphologic integrity and identity of eosinophils, and extensive deposition of eosinophil granules and granule products in tissue.[71] Therefore, it seems somewhat paradoxical that eosinophils from atopic dermatitis patients have prolonged eosinophil survival and yet exhibit such marked cytolytic degranulation in skin lesions. Clearly, there is much more to learn about eosinophil biology and its relevance to human diseases.

PHARMACOLOGICAL MANIPULATION.

Eosinophil-associated disease is a term that, strictly speaking, refers to diseases in which eosinophil numbers or eosinophil granule protein levels (or other eosinophil products) are associated with disease activity. This term encompasses multiple heterogeneous disorders, including skin diseases (see Chapter 36), in which targeting eosinophils and/or their products is a therapeutic goal. Many available treatments reduce eosinophils numbers, thereby inhibiting eosinophilic inflammation, including glucocorticoids, calcineurin inhibitors, IFN-α, IFN-γ, LT antagonists, myelosuppressive/cytotoxic drugs, and, possibly, even antihistamines. However, none is specific for eosinophils. It is only in recent years that selective and direct reduction of eosinophils has been achieved, and these therapies have provided new insight into disease pathogenesis.[9]

Among the nonselective drugs for eosinophil reduction, glucocorticoids generally are very effective. The immediate (within 3 hours) reduction in circulating eosinophils observed after systemic administration of glucocorticoids likely occurs as a consequence of sequestration into extramedullary organs (liver, spleen, and lymph node), as has been shown in rodents. Glucocorticoids affect eosinophil infiltration into tissues by four mechanisms: (1) sequestration into lymphoid tissues, (2) induction of eosinophil apoptosis, (3) reduction of eosinophil production by bone marrow, and (4) alterations in the production of the cytokines/chemokines important in eosinophil trafficking.[158–160] Glucocorticoids suppress the production of several cytokines important for the induction of adhesion molecules on endothelial cells, including IL-1, TNF-α, IL-4, and IL-13, and the release of eosinophil-active chemokines, including CCL5, CCL7, and CCL11. Unfortunately, "steroid resistance" develops in some patients, and long-term administration of glucocorticoids is associated with limiting side effects. The mechanism of glucocorticoid resistance is unclear but, in part, may be explained by decreased numbers of glucocorticoid receptors, and polymorphisms and alterations in transcription factor activator protein-1 (AP-1).[161] Patients who have or who develop glucocorticoid resistance require other therapies. Interestingly, lidocaine and sulfonylureas (such as glyburide) also inhibit cytokine-induced eosinophil survival with glucocorticomimetic effects and may have antieosinophilic effects clinically.[162–164]

Calcineurin antagonists, such as cyclosporine, tacrolimus, and pimecrolimus, broadly inhibit T-cell cytokine release including those that specifically induce eosinophilic inflammation (IL-4, IL-5, and GM-CSF). They also decrease the expression of CCL5, CCL11, and IL-5 with associated decreased tissue eosinophilia as has been shown in atopic dermatitis.[165] Mammalian target of rapamycin (mTOR) inhibitors, including rapamycin, have direct effects on eosinophils, decreasing eosinophil granule protein release after IL-5 activation.[166] The use of these therapeutic agents are limited by their side effects including immunosuppression, as well as other metabolic effects that may be in part genetically determined.[167]

Several myelosuppressive drugs, including hydroxyurea, vincristine sulfate, cyclophosphamide, methotrexate, 6-thioguanine, 2-chlorodeoxyadenosine and cytarabine combination therapy, pulsed chlorambucil, and etoposide, may be beneficial in eosinophil-associated disease alone or as steroid-sparing agents. Hydroxyurea has been particularly effective in decreasing circulating eosinophil numbers.

In myeloproliferative hypereosinophilic syndrome (chronic eosinophilic leukemia) with the *FIP1L1-PDGFRA* mutation that codes for a tyrosine kinase, imatinib mesylate, a tyrosine kinase inhibitor, is approved for the treatment of chronic myelogenous leukemia and the hypereosinophilic syndrome and has produced rapid, complete or near complete remissions.[168] Patients who have features of myeloproliferative HES but who lack *FIP1L1-PDGFRA* still may respond to imatinib (see Chapter 36).[169]

Alemtuzumab is a monoclonal antibody to CD52 that is used to deplete CD52+ lymphocytes in the treatment of chronic (B-cell) lymphocytic leukemia and T-cell lymphoma. Eosinophils, but not neutrophils, also express CD52, and alemtuzumab has been useful in treating patients with refractory hypereosinophilic syndrome, including those with abnormal T cells,[170–172] but has serious limiting side effects from cytopenias, infusion reactions and infections.

Interferons, both IFN-α and IFN-γ, may be therapeutically beneficial in eosinophil-associated disease by inhibiting eosinophil degranulation and inflammatory mediator release. IFN-α may be better tolerated than IFN-γ and is used as a steroid-sparing agent predominantly in patients with lymphocytic variant hypereosinophilic syndrome, but also may be useful in myeloproliferative variant hypereosinophilic syndrome (see Chapter 36).[173,174]

KEY REFERENCES

Full reference list available at www.DIGM8.com

DVD contains references and additional content

1. Kita H, Adolphson CR, Gleich GJ: Biology of eosinophils. In: *Allergy: Principles and Practice*, 6 edition, edited by NF Jr. Adkinson, JW Yunginger, WW Busse, BS Bochner, ST Holgate, FER Simons. Philadelphia, Mosby, 2003, pp. 305-332
2. Blanchard C, Rothenberg ME: Biology of the eosinophil. *Adv Immunol* **101**:81-121, 2009
3. Hogan SP et al: Eosinophils: Biological properties and role in health and disease. *Clin Exp Allergy* **38**(5):709-750, 2008
4. Ackerman SJ, Bochner BS: Mechanisms of eosinophilia in the pathogenesis of hypereosinophilic disorders. *Immunol Allergy Clin North Am* **27**(3):357-375, 2007. [PMCID: 2064859]
9. Bochner BS, Gleich GJ: What targeting eosinophils has taught us about their role in diseases. *J Allergy Clin Immunol* **126**(1):16-25, quiz 6–7, 2010. [PMCID: 2902581]
13. Rothenberg ME, Hogan SP: The eosinophil. *Annu Rev Immunol* **24**:147-174, 2006
61. Adamko D, Lacy P, Moqbel R: Eosinophil function in allergic inflammation: From bone marrow to tissue response. *Curr Allergy Asthma Rep* **4**(2):149-158, 2004
103. Spencer LA et al: Human eosinophils constitutively express multiple Th1, Th2, and immunoregulatory cytokines that are secreted rapidly and differentially. *J Leukoc Biol* **85**(1):117-123, 2009 [PMCID: 2626765]
120. Munitz A, Levi-Schaffer F: Eosinophils: 'New' roles for 'old' cells. *Allergy* **59**(3):268-275, 2004
200. Takatsu K, Kouro T, Nagai Y: Interleukin 5 in the link between the innate and acquired immune response. *Adv Immunol* **101**:191-236, 2009

Chapter 32 :: Acute Febrile Neutrophilic Dermatosis (Sweet Syndrome)

:: Philip R. Cohen, Herbert Honigsmann, & Razelle Kurzrock

ACUTE FEBRILE NEUTROPHILIC DERMATOSIS (SWEET SYNDROME) AT A GLANCE

- Acute febrile neutrophilic dermatosis (Sweet syndrome) is characterized by a constellation of symptoms and findings: the acute onset of fever, neutrophilia, erythematous, and tender skin lesions that typically show an upper dermal infiltrate of mature neutrophils, and the prompt improvement of both symptoms and lesions after initiation of treatment with systemic corticosteroids.
- Cardiovascular, central nervous system, gastrointestinal, hepatic, musculoskeletal, ocular, oral, otic, pulmonary, renal, and splenic organs can be involved by the extracutaneous manifestations of Sweet syndrome.
- Classical Sweet syndrome may be associated with infection of the upper respiratory tract and/or gastrointestinal tract, inflammatory bowel disease, and pregnancy.
- Malignancy-associated Sweet syndrome occurs in individuals with previously undiagnosed or relapsing hematologic malignancies and solid tumors; in these patients, Sweet syndrome appears as a cutaneous paraneoplastic syndrome.
- Drug-induced Sweet syndrome describes the onset of dermatosis in patients following the initiation of certain medications—most commonly granulocyte-colony stimulating factor.
- Cytokines—directly or indirectly—may have an important etiologic role in the pathogenesis of this dermatosis.
- The first-line oral systemic agents for treating Sweet syndrome are corticosteroids, potassium iodide, and colchicine.
- The second-line oral systemic agents for treating Sweet syndrome are indomethacin, clofazimine, cyclosporine, and dapsone.
- Topical application of high-potency corticosteroids or intralesional corticosteroids may be efficacious for treating localized Sweet syndrome lesions.

HISTORY

Acute febrile neutrophilic dermatosis was originally described by Dr. Robert Douglas Sweet in the August–September 1964 issue of the *British Journal of Dermatology*. The cardinal features of "a distinctive and fairly severe illness" that had been encountered in eight women during the 15-year period from 1949 to 1964 were summarized. Although the condition was originally known as the Gomm–Button disease "in eponymous honor of the first two patients" with the disease in Dr. Sweet's department, "Sweet's syndrome" has become the established eponym for this acute febrile neutrophilic dermatosis.[1–10]

EPIDEMIOLOGY

More than 1,000 cases of Sweet syndrome have been reported since Sweet's original paper.[1–509] The distribution of Sweet syndrome cases is worldwide and there is no racial predilection.[1,2,12,16–20,30,31] The dermatosis presents in three clinical settings.[13,15]

Diagnostic criteria for classical or idiopathic Sweet syndrome were proposed by Su and Liu in 1986 and modified by von den Driesch in 1994 (Table 32-1).[11–14] It may be associated with infection (upper respiratory tract or gastrointestinal tract), inflammatory bowel disease, or pregnancy.[13,15] Two studies have noted a seasonal preference for the onset of Sweet syndrome for either autumn or spring in 70% of 42 patients.[416] or autumn.[496]

Classical Sweet syndrome most commonly occurs in women between the ages of 30 to 60 years. However, classical Sweet syndrome also occurs in younger adults and children.[32–48,405,415,445,447,453] The youngest Sweet syndrome patients are brothers who developed the dermatosis at 10 and 15 days of age.[46]

Several investigators consider it appropriate to distinguish between the classical form and the malignancy-associated form of this disease since the onset or recurrence of many of the cases of Sweet syndrome are temporally associated with the discovery or relapse of cancer.[15,49–60] Recently, the investigators of a comprehensive review of 66 pediatric Sweet syndrome patients observed that 44% of 30 children between 3 and 18 years of age had an associated hematologic malignancy.[405,447] Malignancy-associated Sweet syndrome in adults does not have a female predominance and is most often associated with acute myelogenous leukemia.[61,62] In Sweet syndrome patients with dermatosis-related solid tumors, carcinomas of the genitourinary organs, breast, and gastrointestinal tract are the most frequently occurring cancers.[1,2,63–66]

Criteria for drug-induced Sweet syndrome were established by Walker and Cohen in 1996 (Table 32-1).[13] This variant of the dermatosis is most frequently observed to occur in association with the administration of granulocyte-colony stimulating factor (G-CSF).[1,2,13,67,68] However, several other medications have also been implicated in eliciting drug-induced Sweet syndrome (eTable 32-1.1 in online edition).[11,13,17,39,41,69–124,401,402,422,427–429,436,437,439,446,455,456,463,464,468,469 471,474,476,477,482,487, 489,490,492,493,505,506]

TABLE 32-1
Diagnostic Criteria for Classical Sweet Syndrome Versus Drug-Induced Sweet Syndrome

Classical[a]	Drug Induced[b]
(1) Abrupt onset of painful erythematous plaques or nodules	(A) Abrupt onset of painful erythematous plaques or nodules
(2) Histopathologic evidence of a dense neutrophilic infiltrate without evidence of leukocytoclastic vasculitis	(B) Histopathologic evidence of a dense neutrophilic infiltrate without evidence of leukocytoclastic vasculitis
(3) Pyrexia >38°C	(C) Pyrexia >38°C
(4) Association with an underlying hematologic (most commonly acute myelogenous leukemia) or visceral malignancy (most commonly carcinomas of the genitourinary organs, breast, and gastrointestinal tract), inflammatory disease (Crohn's disease and ulcerative colitis) or pregnancy, or preceded by an upper respiratory (streptococcosis) or gastrointestinal (salmonellosis and yersiniosis) infection or vaccination	(D) Temporal relationship between drug ingestion and clinical presentation or temporally related recurrence after oral challenge
(5) Excellent response to treatment with systemic corticosteroids or potassium iodide	(E) Temporally related resolution of lesions after drug withdrawal or treatment with systemic corticosteroids
(6) Abnormal laboratory values at presentation (three of four): erythrocyte sedimentation rate >20 mm/hour; positive *C*-reactive protein; >8,000 leukocytes; >70% neutrophils	

[a]The presence of both major criteria (1 and 2) and two of the four minor criteria (3, 4, 5, and 6) is required in order to establish the diagnosis of classical Sweet syndrome; the patients with malignancy-associated Sweet syndrome are included with the patients with classical Sweet syndrome in this list of diagnostic criteria.
[b]All five criteria (A, B, C, D, and E) are required for the diagnosis of drug-induced Sweet syndrome.
Adapted with permission from Walker DC, Cohen PR: Trimethoprim-sulfamethoxazole-associated acute febrile neutrophilic dermatosis: Case report and review of drug induced Sweet syndrome. *J Am Acad Dermatol* **34**:918-923, 1996.

ETIOLOGY AND PATHOGENESIS

The pathogenesis of Sweet syndrome may be multifactorial and remains to be definitively determined. A condition, similar to Sweet syndrome, presenting as a sterile neutrophilic dermatosis, has been described in a female standard poodle dog after treatment with the nonsteroidal anti-inflammatory drug firocoxib and in multiple dogs temporally associated with the administration of carprofen.[403]

Sweet syndrome may result from a hypersensitivity reaction to an eliciting bacterial, viral, or tumor antigen.[2,127] A septic process is suggested by the accompanying fever and peripheral leukocytosis. Indeed, a febrile upper respiratory tract bacterial infection or tonsillitis may precede skin lesions by 1–3 weeks in patients with classic Sweet syndrome. Also, patients with *Yersinia enterolitica* intestinal infection-associated Sweet syndrome have improved with systemic antibiotics.[2,77,125–127]

The systemic manifestations of Sweet syndrome resemble those of familial Mediterranean fever. Recently, the simultaneous occurrence of both conditions has been observed.[421] Also, in a patient with chronic myelogenous leukemia-associated Sweet syndrome, the causative gene mutation for familial Mediterranean fever was detected.[448] Hence, the pathogenesis for these conditions may be similar.

Leukotactic mechanisms, dermal dendrocytes, circulating autoantibodies, immune complexes, human leukocyte antigen (HLA) serotypes, and cytokines have all been postulated to contribute to the pathogenesis of Sweet syndrome. Complement does not appear to be essential to the disease process. In some patients antibodies to neutrophilic cytoplasmic antigens (ANCAS) have been demonstrated;[430] however, these are likely to represent an epiphenomenon.[2]

Cytokines—directly and/or indirectly—may have an etiologic role in the development of Sweet syndrome symptoms and lesions.[2,21–23] Elevated serum levels of granulocyte-colony stimulating factor and interleukin-6 were detected in a patient with myelodysplastic syndrome-associated Sweet syndrome who was not receiving a drug.[128] Detectable levels of intra-articular synovial fluid granulocyte macrophage-colony stimulating factor has also been observed in an infant with classical Sweet syndrome.[44] Another study demonstrated that the serum G-CSF level was significantly higher in individuals with active Sweet syndrome than in dermatosis patients with inactive Sweet syndrome.[129] And, a recent study showed that the level of endogenous G-CSF was closely associated with Sweet syndrome disease activity in a patient with acute myelogenous leukemia-associated Sweet syndrome and neutrophilic panniculitis.[461]

Significantly elevated levels of helper T-cell type 1 cytokines (interleukin-2 and interferon-γ) and normal levels of a helper T-cell type 2 cytokine (interleukin-4) have been seen in the sera of Sweet syndrome patients.[130] In a patient with neuro-Sweet disease presenting with recurrent encephalomeningitis, serial measurements of cerebral spinal fluid interleukin-6, interferon-γ, interleukin-8, and IP10 [which is also referred to as the chemokine (C–X–C motif) ligand 10 (CXCL10)] were elevated as compared to levels in control subjects with neurologic disorders and also correlated with total cerebral spinal fluid cell counts; this data suggests an important role of the helper T-cell type 1 cell (whose cytokines include interferon-γ and IP10) and interleukin-8 (a specific neutrophil chemoattractant) in the pathogenesis of neuro-Sweet disease.[478] Other studies showed decreased epidermal staining for interleukin-1 and interleukin-6 and postulated that this was due to the release of these cytokines into the dermis.[131] In summary, G-CSF, granulocyte macrophage colony stimulating factor, interferon-γ, interleukin-1, interleukin-3, interleukin-6, and interleukin-8 are potential cytokine candidates in the pathogenesis of Sweet syndrome.[2,13,21–23,44,128–132]

CLINICAL FINDINGS

HISTORY

Sweet syndrome patients may appear dramatically ill. The skin eruption is usually accompanied by fever and leukocytosis. However, the skin disease can follow the fever by several days to weeks or be concurrently present with the fever for the entire episode of the dermatosis. Arthralgia, general malaise, headache, and myalgia are other Sweet syndrome associated symptoms (Table 32-2).[1,2,23]

CUTANEOUS LESIONS

Skin lesions of Sweet syndrome typically appear as tender, red or purple–red, papules or nodules. The eruption may present as a single lesion or multiple lesions that are often distributed asymmetrically (Fig. 32-1).



Figure 32-1 Unilateral lesions of Sweet syndrome around the eye and upper lip consisting of plaques and pseudovesicular papules suggesting herpes simplex.

TABLE 32-2
Clinical Features in Patients with Sweet Syndrome

Characteristic	Clinical Form			
	Classical[a] (%)	Hematologic Malignancy[a] (%)	Solid Tumor[a] (%)	Drug Induced[b] (%)
Epidemiology				
■ Women	80	50	59	71
■ Prior upper respiratory tract infection	75–90	16	20	21
■ Recurrence[c]	30	69	41	67
Clinical symptoms				
■ Fever[d]	80–90	88	79	100
■ Musculoskeletal involvement	12–56	26	34	21
■ Ocular involvement	17–72	7	15	21
Lesion location				
■ Upper extremities	80	89	97	71
■ Head and neck	50	63	52	43
■ Trunk and back	30	42	33	50
■ Lower extremities	Infrequent	49	48	36
■ Oral mucous membranes	2	12	3	7
Laboratory findings				
■ Neutrophilia[e]	80	47	60	38
■ Elevated erythrocyte sedimentation rate[f]	90	100	95	100
■ Anemia[g]	Infrequent	82	83	100
■ Abnormal platelet count[h]	Infrequent	68	50	50
■ Abnormal renal function[i]	11–50	15	7	0

[a]Percentages for classical, hematologic malignancy, and solid tumor associated Sweet's syndrome from Cohen PR, Kurzrock R: Sweet's syndrome and cancer. *Clin Dermatol* **11**:149-157, 1993. Copyright 1993, Elsevier Science Publishing Co., Inc., New York, NY.
[b]Percentages for drug-induced Sweet's syndrome from Walker DC, Cohen PR: Trimethoprim-sulfamethoxazole-associated acute febrile neutrophilic dermatosis: Case report and review of drug induced Sweet's syndrome. *J Am Acad Dermatol* **34**:918-923, 1996. Copyright 1996, American Academy of Dermatology, Inc., Mosby-Year Book, Inc., St. Louis, MO.
[c]Recurrence following oral rechallenge testing in the patients with drug-induced Sweet's syndrome.
[d]Temperature greater than 38°C.
[e]Neutrophil count greater than 6000 cells/uL.
[f]Erythrocyte sedimentation rate greater than 20 mm/hour.
[g]Hemoglobin less than 13 g/dL in men and less than 12 g/dL in women.
[h]Platelet count less than 150,000/uL or greater than 500,000/uL.
[i]This includes hematuria, proteinuria, and renal insufficiency.

The pronounced edema in the upper dermis of the lesions results in their transparent, vesicle-like appearance and has been described as an "illusion of vesiculation" (Fig. 32-2). In later stages, central clearing may lead to annular or arcuate patterns. The lesions may appear bullous, become ulcerated, and/or mimic the morphologic features of pyoderma gangrenosum in patients with malignancy-associated Sweet syndrome.[133,134] The lesions enlarge over a period of days to weeks. Subsequently, they may coalesce and form irregular sharply bordered plaques (Fig. 32-3). They usually resolve, spontaneously or after treatment, without scarring. Lesions associated with recurrent episodes of Sweet syndrome occur in one-third to two-thirds of patients.[1,2,135,136]

Cutaneous pathergy, also referred to as skin hypersensitivity, is a dermatosis-associated feature.[1,2] It occurs when Sweet syndrome skin lesions appear at sites of cutaneous trauma.[458,496] These include the locations where procedures have been performed such as biopsies,[20] injection sites,[431] intravenous catheter placement,[20] and venipuncture.[12,17,20,37,137,138] They also include sites of insect bites and cat scratches,[20] areas that have received radiation therapy,[139–141,138,484] and places that have been contacted by sensitizing antigens.[137,142,420] In addition, in some Sweet syndrome patients, lesions have been photodistributed or localized to the site of a prior phototoxic reaction (sunburn).[13,20,98,143–145] Sweet syndrome lesions have also rarely been located on the arm affected by postmastectomy lymphedema.[100,146,419,505]

Sweet syndrome can present as a pustular dermatosis.[147] The lesions appear as tiny pustules on the tops of the red papules or eythematous-based pustules. Some of the patients previously described as having the



Figure 32-2 Multiple confluent papules and plaques of Sweet syndrome that at first sight give the illusion of vesiculation but are solid on palpation. (From Honigsmann et al: Akute febrile neutrophile Dermatose. *Wien Klin Wochenschr* **91**:842, 1979, with permission.)

"pustular eruption of ulcerative colitis" are perhaps more appropriately included in this clinical variant of Sweet syndrome.[1,148]

"Neutrophilic dermatosis of the dorsal hands" or "pustular vasculitis of the dorsal hands" refers to a localized, pustular variant of Sweet syndrome when the clinical lesions are predominantly restricted to the dorsal aspect of the hands.[3,149–154] The lesions from this latter group of individuals are similar to those of Sweet syndrome in morphology and rapid resolution after systemic corticosteroids and/or dapsone therapy was initiated. In addition, many of the individuals with this form of the disease also had concurrent lesions that were located on their oral mucosa, arm, leg, back, and/or face.[3,155–163,425,435,440,442,457,462,470,495,497]

The cutaneous lesions of subcutaneous Sweet syndrome usually present as erythematous, tender dermal nodules on the extremities.[4,8,12,17,99,119,164–185] When the lesions are located on the legs, they often mimic erythema nodosum.[170] Since Sweet syndrome can present concurrently[21,125,187–189] or sequentially[170] with erythema nodosum,[17,21,187,190,509] tissue evaluation of one or more new dermal nodules may be necessary to establish the correct diagnosis—even in a patient whose Sweet syndrome has previously been biopsy-confirmed.[1,2,4]

RELATED PHYSICAL FINDINGS

EXTRACUTANEOUS MANIFESTATIONS. (eTable 32-2.1 in online edition.) Extracutaneous manifestations of Sweet syndrome may include the bones, central nervous system, ears, eyes, kidneys, intestines, liver, heart, lung, mouth, muscles, and spleen.[12,16,17,20,25,26,32,33,44,73,75,101,117,138,139,165,202,203,205,212–257,407,408,410,433,444,450,452,459,465,468,475,478,481,486,599] The incidence of ocular involvement (such as conjunctivitis) is variable in classical Sweet syndrome and uncommon in the malignancy-associated and drug-induced forms of the dermatosis; however, it may be the presenting feature of the condition. Mucosal ulcers of the mouth occur more frequently in Sweet syndrome patients with hematologic disorders and are uncommon in patients with classical Sweet syndrome[23,26,102,117,203,252]; similar to extracutaneous manifestations of Sweet syndrome occurring at other sites, the oral lesions typically resolve after initiation of treatment with systemic corticosteroids.[1,2] In children, dermatosis-related sterile osteomyelitis has been reported.

ASSOCIATED DISEASES. (eTable 32-2.2 in online edition.) Several conditions have been observed to occur either before, concurrent with, or following the diagnosis of Sweet syndrome. Therefore, the development of Sweet syndrome may be etiologically related to Behcet's disease, cancer, erythema nodosum, infections, inflammatory bowel disease, pregnancy, relapsing polychondritis, rheumatoid arthritis, sarcoidosis, and thyroid



Figure 32-3 Acute febrile neutrophilic dermatosis. Typical lesion consisting of coalescing, plaque-forming papules. **A.** Bright-red lesions on the neck. **B.** Lesion on the dorsum of the right-hand exhibiting the "relief of a mountain range" feature. (From Honigsmann H, Wolff K: Acute febrile neutrophilic dermatosis (Sweet's syndrome). In: *Major Problems in Dermatology, vol 10, Vasculitis*, edited by K Wolff, RK Winkelmann, consulting editor A Rook. London, Lloyd-Luke, 1980, p. 307, with permission.)

disease. The association between Sweet syndrome and the other conditions (eTable 32-2.2 in online edition) remains to be established.[1,2,5,11–20,30,36–43,69–126,158–161,164,166,186–190,195,214,231,236,259–339,400,402,406,410,411,415,417,418,421–424,426–429,434,436–442,445,446,448,449,452–456,459,460,463,464,466–469,471–477,479,480,482,483,487–490,492–494,496,497,500,502–504,508,509]

ASSOCIATED NEUTROPHILIC DERMATOSES.

An inflammatory infiltrate of mature polymorphonuclear leukocytes is the unifying characteristic of neutrophilic dermatoses of the skin and mucosa. Concurrent or sequential occurrence of Sweet syndrome with either erythema elevatum diutinum,[340] neutrophilic eccrine hidradenitis,[6] pyoderma gangrenosum,[9,231,269,341,342,430,483,497] subcorneal pustular dermatosis,[6,9] and/or vasculitis[3,192,231] has been observed. Although these conditions can display similar clinical and pathologic features, the location of the neutrophilic infiltrate helps to differentiate them.[6,120,499]

CONCURRENT LEUKEMIA CUTIS.

In patients with hematologic disorders, Sweet syndrome may present as a paraneoplastic syndrome (signaling the initial discovery of an unsuspected malignancy), a drug-induced dermatosis (following treatment with either all-*trans*-retinoic acid, bortezomib, G-CSF, or imatinib mesylate), or a condition whose skin lesions concurrently demonstrate leukemia cutis.[1] Acute leukemia (myelocytic and promyelocytic) is the most frequent hematologic dyscrasia associated with leukemia cutis (characterized by abnormal neutrophils) and Sweet syndrome (consisting of mature polymorphonuclear leukocytes) being present in the same skin lesion.[1,70,71,93,109,165,205–211,497] Myelodysplastic syndrome and myelogenous leukemia (either chronic or not otherwise specified) are the other associated hematologic disorders that have been associated with concurrent Sweet syndrome and leukemia cutis.[109]

"Secondary" leukemia cutis, in which the circulating immature myeloid precursor cells are innocent bystanders that have been recruited to the skin as the result of an inflammatory oncotactic phenomenon stimulated by the Sweet syndrome lesions has been suggested as one of the hypotheses to explain concurrent Sweet syndrome and leukemia cutis in the same lesion.[165,206,207] Alternatively, "primary" leukemia cutis, in which the leukemic cells within the skin constitutes the bonified incipient presence of a specific leukemic infiltrate is another possibility.[207] Finally, it is possible that the atypical cells of leukemia cutis developed into mature neutrophils of Sweet syndrome as a result of G-CSF therapy-induced differentiation of the sequestered leukemia cells in patients with "primary" leukemia cutis who were being treated with this agent.[205]

LABORATORY TESTS

HISTOPATHOLOGY

Evaluation of a lesional skin biopsy is helpful when the diagnosis of Sweet syndrome is suspected. Lesional tissue should also be submitted for bacterial, fungal, mycobacterial, and possibly viral cultures since the pathologic findings of Sweet syndrome are similar to those observed in cutaneous lesions caused by infectious agents.[1,2]

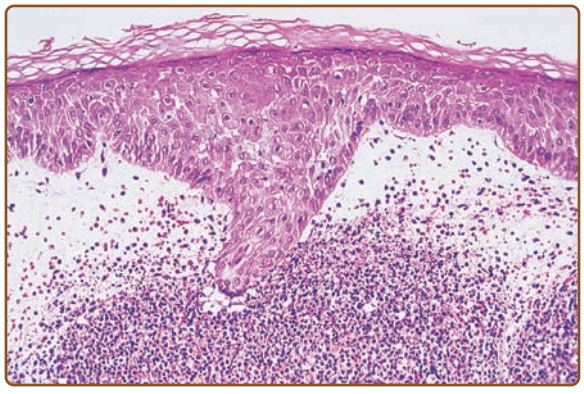

Figure 32-4 Histopathologic presentation of acute febrile neutrophilic dermatosis (Sweet syndrome) demonstrates massive edema of the papillary dermis and a dense diffuse infiltrate of mature neutrophils throughout the upper dermis (hematoxylin and eosin stain). (From Cohen PR et al: Sweet's syndrome in patients with solid tumors. *Cancer* **72**:2723-2731, 1993, with permission.)

A diffuse infiltrate of mature neutrophils is characteristically present in the papillary and upper reticular dermis (Fig. 32-4); however, it can also involve the epidermis or adipose tissue. "Histiocytoid" Sweet syndrome refers to the setting in which the hematoxylin and eosin-stained infiltrate of immature myeloid cells are "histiocytoid-appearing" and are therefore initially misinterpreted as histiocytes.[201,412–414,436,443,445,460,474]

The dermal inflammation is usually dense and diffuse; however, it can also be perivascular or demonstrate "secondary" changes of leukocytoclastic vasculitis believed to be occurring as an epiphenomenon and not representative of a "primary" vasculitis,[3,192,193] Neutrophilic spongiotic vesicles[194] or subcorneal pustules[12,80,167,195,196] result from exocytosis of neutrophils into the epidermis.[12,17,80,167,194,195,197] When the neutrophils are located either entirely or only partially in the subcutaneous fat, the condition is referred to as "subcutaneous Sweet syndrome".[4,8,12,17,99,119,164–184,451,461,493,497]

Edema in the dermis, swollen endothelial cells, dilated small blood vessels, and fragmented neutrophil nuclei (referred to as karyorrhexis or leukocytoclasia) may also be present (Fig. 32-5). Fibrin deposition or neutrophils within the vessel walls (changes of "primary" leukocytoclastic vasculitis) are usually absent and the overlying epidermis is normal.[1,2,23,167,168] However, the spectrum of pathologic changes described in cutaneous lesions of Sweet syndrome has expanded to include concurrent leukemia cutis, vasculitis, and variability of the composition or the location of the inflammatory infiltrate.[3,191,491,496]

Lymphocytes or histiocytes may be present in the inflammatory infiltrate of Sweet syndrome lesi ons.[11,104,167,168,198–200,504] Eosinophils have also been noted in the cutaneous lesions from some patients with either idiopathic[11,167,168,195,202–204,212] or drug-induced[84,107,110,111]

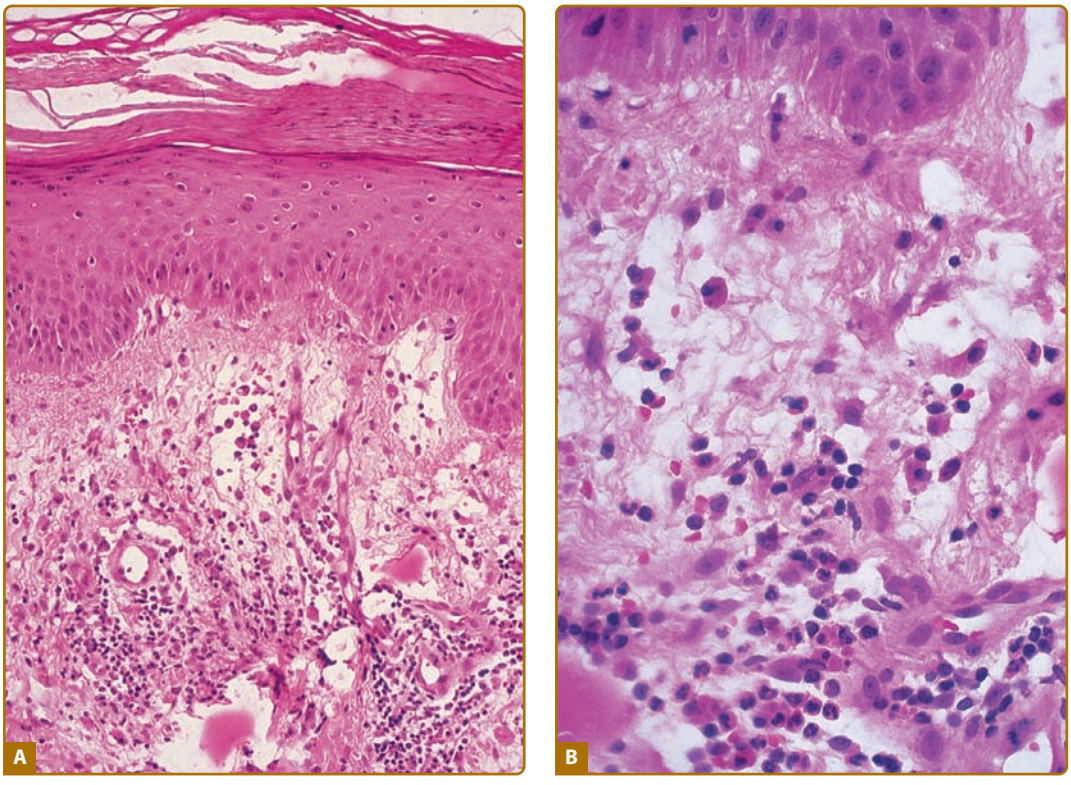

Figure 32-5 Characteristic histopathologic features of Sweet syndrome are observed at low (**A**) and high (**B**) magnification: papillary dermal edema, swollen endothelial cells, and a diffuse infiltrate of predominantly neutrophils with leukocytoclasia, yet no evidence of vasculitis (hematoxylin and eosin stain). (From Cohen PR et al: Concurrent Sweet's syndrome and erythema nodosum: A report, world literature review and mechanism of pathogenesis. *J Rheumatol* **19**:814-820, 1992, with permission.)

Sweet syndrome. Abnormal neutrophils (leukemia cutis)—in addition to mature neutrophils—comprise the dermal infiltrate in occasional Sweet syndrome patients with hematologic disorders.[1,70,71,93,109,165,205–211]

Pathologic findings of Sweet syndrome can also occur in extracutaneous sites. Often, these present as sterile neutrophilic inflammation in the involved organ. These changes have been described in the bones, intestines, liver, aorta, lungs, and muscles of patients with Sweet syndrome.[2]

OTHER LABORATORY TESTS

Peripheral leukocytosis with neutrophilia and an elevated erythrocyte sedimentation rate and are the most consistent laboratory findings in Sweet syndrome.[23] However, leukocytosis is not always present in patients with biopsy-confirmed Sweet syndrome.[26] For example, anemia, neutropenia, and/or abnormal platelet counts may be observed in some of the patients with malignancy-associated Sweet syndrome. Therefore, a complete blood cell count with leukocyte differential and platelet count, evaluation of acute phase reactants (such as the erythrocyte sedimentation rate or *C*-reactive protein), serum chemistries (evaluating hepatic function and renal function), and a urinalysis should be performed. It is also reasonable to perform a serologic evaluation of thyroid function since there appears to be a strong association between thyroid disease and Sweet syndrome.[1,2]

SPECIAL TESTS

EVALUATION FOR EXTRACUTANEOUS MANIFESTATIONS. Extracutaneous manifestations of Sweet syndrome may result in other laboratory abnormalities. Patients with central nervous system involvement may have abnormalities on brain SPECTs (single photon emission computed tomography), computerized axial tomography, electroencephalograms, magnetic resonance imaging, and cerebrospinal fluid analysis. Patients with kidney and liver involvement may demonstrate urinalysis abnormalities (hematuria and proteinuria) and hepatic serum enzyme elevation. And, patients with pulmonary involvement may have pleural effusions and corticosteroid-responsive culture-negative infiltrates on their chest roentgenograms.[2,343]

MALIGNANCY WORKUP. Recommendations for the initial malignancy workup in newly diagnosed Sweet syndrome patients without a prior cancer were proposed by Cohen and Kurzrock in 1993.[15] Their recommendations were based upon the age-related recommendations of the American Cancer Society for

early detection of cancer in asymptomatic persons and the neoplasms that had concurrently been present or subsequently developed in previously cancer-free Sweet syndrome patients. The recommended evaluation included the following:

1. A detailed medical history
2. A complete physical examination, including:
   (a) examination of the thyroid, lymph nodes, oral cavity, and skin;
   (b) digital rectal examination;
   (c) breast, ovary, and pelvic examination in women; and
   (d) prostate and testicle examination in men.
3. Laboratory evaluation:
   (a) carcinoembryonic antigen level;
   (b) complete blood cell count with leukocyte differential and platelet count;
   (c) pap test in women;
   (d) serum chemistries;
   (e) stool guaiac slide test;
   (f) urinalysis; and
   (g) urine culture.
4. Other screening tests:
   (a) chest roentgenograms;
   (b) endometrial tissue sampling in either menopausal women or women with a history of abnormal uterine bleeding, estrogen therapy, failure to ovulate, infertility, or obesity; and
   (c) sigmoidoscopy in patients over 50 years of age.

Since the initial appearance of dermatosis-related skin lesions had been reported to precede the diagnosis of a Sweet syndrome-associated hematologic malignancy by as long as 11 years, they also suggested that it was reasonable to check a complete blood cell count with leukocyte differential and platelet count every 6–12 months.[2,15]

TABLE 32-3
Clinical Differential Diagnosis of Sweet Syndrome

Most Likely
Drug eruptions
Cellulitis
Chloroma
Erysipelas
Erythema nodosum
Leukemia cutis
Leukocytoclastic vasculitis
Panniculitis
Pyoderma gangrenosum
Consider
Acral erythema
Erythema elevatum diutinum
Erythema multiforme
Halogenoderma
Lymphoma
Neutrophilic eccrine hidradenitis
Periarteritis nodosa
Urticaria
Viral exanthem
Always Rule Out
Bacterial sepsis
Behcet's disease
Bowel bypass syndrome
Dermatomyositis
Familial Mediterranean fever
Granuloma faciale
Leprosy
Lupus erythematosus
Lymphangitis
Metastatic tumor
Rheumatoid neutrophilic dermatitis
Rosacea fulminans
Schnitzler's syndrome
Syphilis
Systemic mycosis
Thrombophlebitis
Tuberculosis

Adapted from Cohen PR, Kurzrock R: Sweet's syndrome and cancer. *Clin Dermatol* **11**:149-157, 1993.

DIFFERENTIAL DIAGNOSIS

CLINICAL DIFFERENTIAL DIAGNOSIS

Sweet syndrome skin and mucosal lesions mimic those of other conditions (Table 32-3.)[2,15,23,148,165,202,220,344,345,409,421,448,498] Therefore, infectious and inflammatory disorders, neoplastic conditions, reactive erythemas, vasculitis, other cutaneous conditions, and other systemic diseases are included in the clinical differential diagnosis of Sweet syndrome.

HISTOLOGIC DIFFERENTIAL DIAGNOSIS

The histologic differential diagnosis of Sweet syndrome includes conditions microscopically characterized by either neutrophilic dermatosis or neutrophilic panniculitis (eTable 32-3.1 in online edition).[2–4,6,12,193,346–353,432,451]

The pathologic changes associated with Sweet syndrome are similar to those observed in an abscess or cellulitis; therefore, culture of lesional tissue for bacteria, fungi, and mycobacteria should be considered to rule out infection.[23] Leukemia cutis not only mimics the dermal changes of Sweet syndrome, but can potentially occur within the same skin lesion as Sweet syndrome; however, in contrast to the mature polymorphonuclear neutrophils found in Sweet syndrome, the dermal infiltrate in leukemia cutis consists of malignant immature leukocytes.[354] The pathologic changes in the adipose tissue of subcutaneous Sweet syndrome lesions can be found in either the lobules, the septae, or both; therefore, conditions characterized by a neutrophilic lobular panniculitis also need to always be considered and ruled out.[2,4]

COMPLICATIONS

Complications in patients with Sweet syndrome can be directly related to the mucocutaneous lesions or indirectly related to the Sweet syndrome-associated conditions. Skin lesions may become secondarily infected and antimicrobial therapy may be necessary. In patients with malignancy-associated Sweet syndrome, reappearance of the dermatosis may herald the unsuspected discovery that the cancer has recurred. Systemic manifestations of Sweet syndrome-related conditions—such as inflammatory bowel disease, sarcoidosis and thyroid diseases—may warrant disease-specific treatment.

PROGNOSIS AND CLINICAL COURSE

The symptoms and lesions of Sweet syndrome eventually resolved without any therapeutic intervention in some patients with classical Sweet syndrome. However, the lesions may persist for weeks to months.[10,23,254,355] In patients with malignancy-associated Sweet syndrome, successful management of the cancer occasionally results in clearing of the related dermatosis.[13,15,23] Similarly, discontinuation of the associated medication in patients with drug-induced Sweet syndrome is typically followed by spontaneous improvement and subsequent resolution of the syndrome.[13,15,23] Surgical intervention has also resulted in the resolution of Sweet syndrome in some of the patients who had associated tonsillitis, solid tumors, or renal failure.[1,2,19,315,356,357,507]

Sweet syndrome may recur following either spontaneous remission or therapy-induced clinical resolution.[10] The duration of remission between recurrent episodes of the dermatosis is variable. Sweet syndrome recurrences are more common in cancer patients; in this patient population, the reappearance of dermatosis-associated symptoms and lesions may represent a paraneoplastic syndrome that is signaling the return of the previously treated malignancy.[1,2,15,135]

TREATMENT

Systemic corticosteroids are the therapeutic mainstay for Sweet syndrome (eTable 32-3.2 in online edition).[7,8–10,12,16,17,19,20,23,36,49,50,70,184,223,233,240,250,284,358–361] Initiation of therapy promptly results in improvement of the symptoms and resolution of the mucocutaneous lesions. Daily pulse methylprednisolone administered intravenously may be necessary in patients with refractory disease. Topical (such as 0.05% clobetasol propionate)[13,19–21,30,234,362–365] or intralesional (such as triamcinolone acetonide at a dose between 3.0 and 10.0 mg/cc)[362,366,367] corticosteroids may be effective for treating localized Sweet syndrome lesions.[1,2,7,9]

Potassium iodide and colchicine are also first-line systemic treatments for Sweet syndrome (eTable 32-3.2 in online edition).[10,12,17,20,23,30,49,70,143,184,198,203,221,223,231,240,245,250,259,261,281,284,294,296,329,359–363,368–384,468,496] Vasculitis and hypothyroidism are potential drug-induced side effects of potassium iodide.[385] Gastrointestinal symptoms such as diarrhea, abdominal pain, nausea, and vomiting are potential adverse effects from colchicine which may improve after lowering the daily dose of the drug.[2]

Second-line systemic agents for Sweet syndrome include indomethacin,[259,261,284,378,490] clofazimine,[12,296,379] cyclosporine,[12,30,231,294,380,381] and dapsone[17,20,30,203,221,245,284,372,382–384,459,460,486] (eTable 32-3.2 in online edition). They have all been used as monotherapy either in the initial management of the patient or after first-line therapies has failed. In addition, cyclosporine and dapsone have been used in combination therapy either as a corticosteroid-sparing agent or with other drugs.[1,2,7,303]

There are certain patients whose Sweet syndrome lesions have improved after receiving systemic antibiotics[7,412]: individuals with *Staphylococcus aureus* secondarily impetiginized lesions treated with an antimicrobial agent to which their bacterial strain is susceptible,[23] patients with inflammatory bowel disease treated with metronidazole,[267,387] and persons with dermatosis-related *Yersinia*[125,126] or *Chlamydia*[306,307] infection treated with either doxycycline,[125,389] minocycline,[30,126] or tetracycline.[306,307,388]

In addition, effective treatment of Sweet syndrome has also been described, predominantly in case reports, with other drugs: cytotoxic chemotherapies and antimetabolites (chlorambucil and cyclophosphamide),[30,39,148,200,251,360,390] danazol,[9] etretinate,[361] hepatitis therapy,[9] immunoglobulin,[303] interferon α,[202,366] and tumor necrosis factor antagonists[444] (adalimumab,[501] etanercept,[392,404] infliximab,[264,265,278,266,501] and thalidomide[5,393]). Anakinra (an interleukin-1 receptor antagonist), in combination with oral prednisone, was promptly effective in resolving the symptoms—and subsequently the clinical lesions—of Sweet syndrome in a patient with long-standing disease that was refractory to other therapies.[399] Pentoxifylline was hypothesized to be beneficial for treating Sweet syndrome[394,395]; however, when used as monotherapy, it was not found to be efficacious.[1,2,7,295,362]

KEY REFERENCES

Full reference list available at www.DIGM8.com

DVD contains references and additional content

1. Cohen PR, Kurzrock R: Sweet's syndrome revisited: A review of disease concepts. *Int J Dermatol* **42**:761-778, 2003
2. Cohen PR: Sweet's syndrome—A comprehensive review of an acute febrile neutrophilic dermatosis. *Orphanet J Rare Dis* **2**:34, 2007 (26 July (2007). http://www.ojrd.com/contents/2/1/34
3. Cohen PR: Skin lesions of Sweet syndrome and its dorsal hand variant contain vasculitis: An oxymoron or an epiphenomenon? *Arch Dermatol* **138**:400-403, 2002
4. Cohen PR: Subcutaneous Sweet's syndrome: A variant of acute febrile neutrophilic dermatosis that is included in the histologic differential diagnosis of neutrophilic panniculitis. *J Am Acad Dermatol* **52**:927-928, 2005

5. Cohen PR: Sweet's syndrome and relapsing polychondritis: Is their appearance in the same patient a coincidental occurrence or a bonified association of these conditions? *Int J Dermatol* **43**:772-777, 2004
6. Cohen PR: Neutrophilic dermatoses occurring in oncology patients. *Int J Dermatol* **46**:106-111, 2007
7. Cohen PR, Kurzrock R: Sweet's syndrome: A review of current treatment options. *Am J Clin Dermatol* **3**:117-131, 2002
8. Cohen PR: Iotaderma #120 (Gomm-Button disease: Sweet's syndrome). *J Am Acad Dermatol* **50**:100, 274, 2004
9. Cohen PR: Neutrophilic dermatoses: A review of current treatment options. *Am J Clin Dermatol* **10**:301-312, 2009
10. Cohen PR, Almeida L, Kurzrock R: Acute febrile neutrophilic dermatosis. *Am Fam Physician* **39**(3):199-204, 1989
14. Cohen PR, Kurzrock R: Diagnosing the Sweet syndrome. *Ann Intern Med* **110**:573-574, 1989
15. Cohen PR, Kurzrock R: Sweet's syndrome and cancer. *Clin Dermatol* **11**:149-157, 1993
22. Cohen PR, Kurzrock R: The pathogenesis of Sweet's syndrome [letter]. *J Am Acad Dermatol* **25**:734, 1991
23. Cohen PR, Kurzrock R: Sweet's syndrome: A neutrophilic dermatosis classically associated with acute onset and fever. *Clin Dermatol* **18**:265-282, 2000
26. Cohen PR, Talpaz M, Kurzrock R: Malignancy-associated Sweet's syndrome: Review of the world literature. *J Clin Oncol* **6**:1887-1897, 1988

Chapter 33 :: Pyoderma Gangrenosum

:: Frank C. Powell, Bridget C. Hackett, & Daniel Wallach

PYODERMA GANGRENOSUM AT A GLANCE

- Pyoderma gangrenosum (PG) is a rare inflammatory disease of unknown etiology characterized by sterile neutrophilic infiltration of the skin. Similar neutrophilic infiltrations may occur in other organs. It is considered to be one of the groups of neutrophilic dermatoses and clinical and histological overlap with some of these may occur.
- PG is more frequent in female patients and occurs at any age, but usually between 40 and 60 years.
- The majority of patients with PG have other systemic diseases (such as arthritis, inflammatory bowel disease, hematological dyscrasias, malignant disease, etc.), but PG occurs independently of these disorders.
- PG may present as ulcerative, bullous, pustular, or vegetative variants. Clinical features of different variants sometimes overlap in individual patients but usually one variant dominates the clinical picture.
- There is no laboratory test or investigation that establishes the diagnosis of PG with certainty. The histopathological findings are not diagnostic but can be supportive of the diagnosis of PG in the appropriate clinical setting and are essential to rule out alternative diagnoses.
- Specified criteria (see below) suggest the diagnosis of PG, but other conditions (particularly infection, vascular disease, and malignancy) must be excluded.
- The mainstays of management are systemic immunosuppressive agents together with appropriate local and topical therapy.
- Ulcerative PG is a chronic disease. Remission usually requires months of treatment; maintenance therapy is necessary in many and relapses are common. Significant morbidity and mortality are experienced by patients with ulcerative and bullous PG.

EPIDEMIOLOGY

The prevalence of pyoderma gangrenosum (PG) is unknown. Estimates have suggested that approximately three cases of PG per million of the population occur per year, with most large referral centers seeing one to two cases per year.[1] It has been reported in all age groups but mainly affects adults between the ages of 40 and 60 years.[2] Most reported series of patients with PG indicate a moderate preponderance of females. PG often occurs in patients who have other diseases (arthritis, inflammatory bowel disease, hematologic dyscrasias, etc.), but is not a manifestation or complication of these diseases and its clinical course is usually unrelated to their severity or activity.[3]

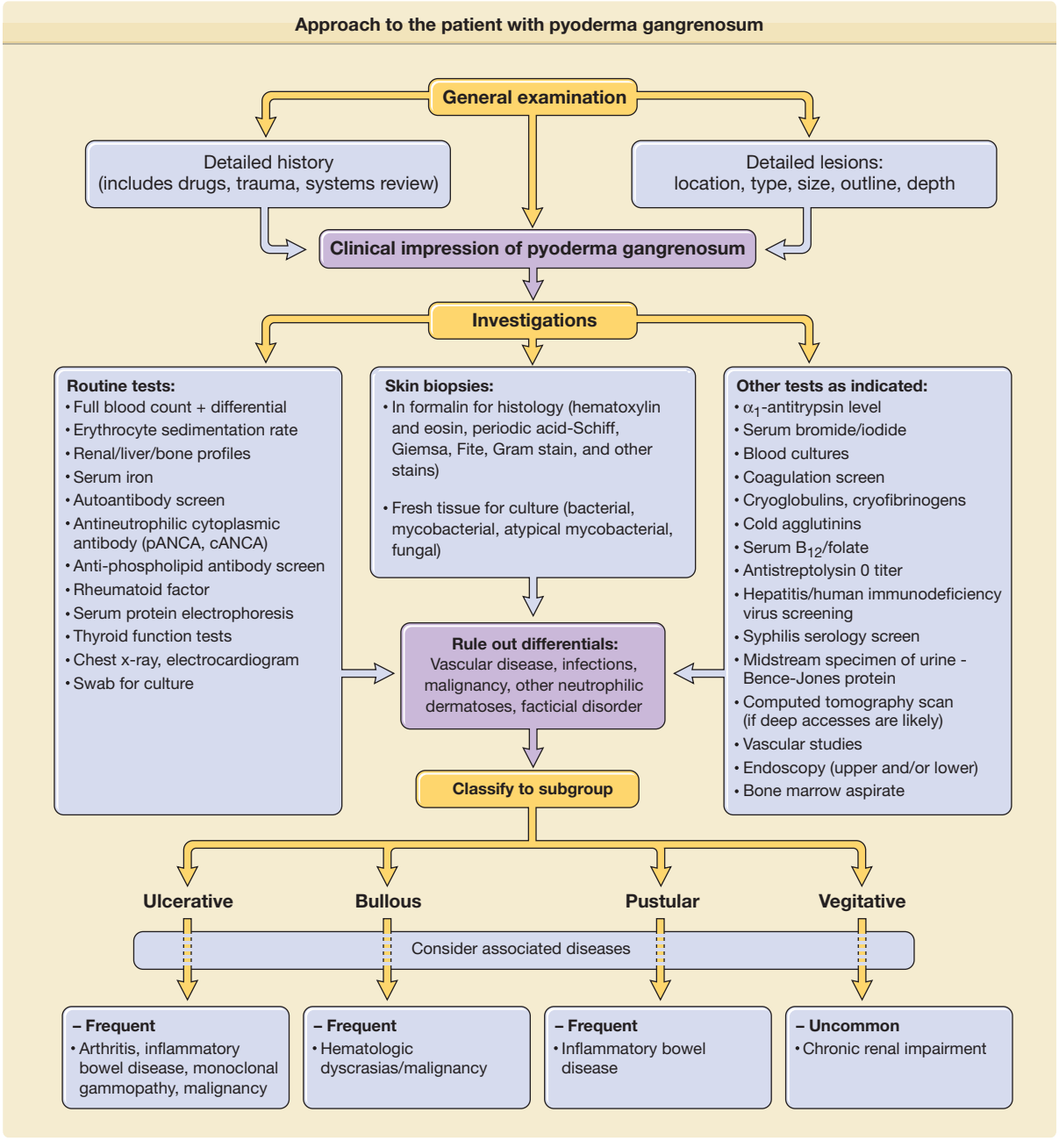

Figure 33-1 Approach to the patient with pyoderma gangrenosum.

ETIOLOGY AND PATHOGENESIS

The etiology of PG is unknown, and its pathogenesis poorly understood. Based on the presence of a lymphocytic infiltrate at the active advancing border of PG lesions, it has been postulated that lymphocytic antigen activation occurs with cytokine release and neutrophil recruitment. This may take place not only in the skin but also in other tissues such as the lung, intestine, and joints. The predominance of the neutrophilic infiltrate in established lesions of PG have led to its classification as one of the neutrophilic dermatoses.[4] Clinical (and to an extent histologic) overlap occurs with the other dermatoses in this category, especially atypical or bullous forms of Sweet syndrome (see Chapter 32). Several of the neutrophilic dermatoses (Sweet syndrome, erythema elevatum diutinum, subcorneal pustular dermatosis, and PG) share an association with immunoglobulin A monoclonal gammopathy, and diseases such as inflammatory bowel disease and hematologic disorders occur more frequently than expected in these patients. The recent description of the PAPA (Pyogenic Arthritis, Pyoderma gangrenosum-Acne) syndrome,[5] a disease considered to be one of the "autoinflammatory"

diseases, raises the possibility that PG may lie within this spectrum.

CLINICAL FINDINGS

The approach to an individual suspected of having PG is outlined in the patient algorithm (Fig. 33-1). The clinical presentation of PG may be diverse and there is neither a diagnostic laboratory test nor pathognomonic histopathologic findings. Therefore, it is important to avoid misdiagnosing other diseases as PG.[6] The most important considerations are the exclusion of infection (bacterial, viral, and deep fungal), vascular disease (stasis, occlusion, and vasculitis), and malignancy in every patient. Close follow-up and reevaluation (with repeated skin biopsies, tissue and swab cultures, and other tests as clinically indicated) is an important part of the ongoing evaluation of patients with suspected PG, particularly those who show a poor response to therapy.

HISTORY

A patient with PG usually complains of severe pain that is out of proportion to the clinical appearance of the lesion. Approximately 25% of patients note the onset of PG at sites of cutaneous trauma (needle stick, inoculation site, insect bites, or surgical procedures). This is called the *pathergic phenomenon* (Fig. 33-2). Lesions progress rapidly (with the exception of vegetative PG) and cutaneous destruction evolves over days rather than weeks. Special inquiry regarding drug intake (especially iodides/bromides, hydroxyurea); exposure to and symptoms of infectious diseases (Box 33-1); symptoms relating to the musculoskeletal system (joint pains, swelling, etc.), the gastrointestinal tract (abdominal pain, diarrhea, constipation, etc.), hematologic disease (tiredness, anemia, bruising, blood clotting disorders, etc.), respiratory disease, and nonspecific but potential malignancy-related symptoms, such as weight loss and fatigue, should be made.



Figure 33-2 Several pathergic pyoderma gangrenosum lesions occurring along a thoracotomy scar site. Note central ulceration, violaceous borders, and peripheral rim of erythema.

CUTANEOUS LESIONS: CLINICAL VARIANTS OF PG

PG is protean in its clinical expression with variable presentation according to the variant and the stage of disease. Lesions can be classified morphologically as being (1) ulcerative (the commonest and originally described variant), (2) bullous, (3) pustular, or (4) vegetative. Although some patients may show more than one variant (e.g., isolated pustular lesions frequently occur in patients with ulcerative PG), usually one variant of PG dominates the clinical picture and the patient should be classified accordingly.

The most common initial clinical lesion in a patient with *ulcerative PG* is an inflammatory pustule or nodular furuncle (these lesions are usually single but may be multiple). They erupt on apparently normal skin (the most common site being the leg), or sometimes at the site of trauma or surgery (Fig. 33-2). The enlarging initial lesion develops a surrounding areola or zone of erythema that extends into the surrounding skin (Fig. 33-3). As it enlarges, the center degenerates, crusts, and erodes, converting it into an eroding ulcer the development of which is accompanied by an alarming increase in the severity of the pain. The ulcer often has a bluish/violaceous edge (due to undermining by the necrotizing inflammatory process) and the base is covered with purulent material. Ulcerative PG may erode deeply with exposure of muscle or tendon in some cases.

Bullous PG (sometimes called atypical PG) presents as a painful, rapidly expanding superficial inflammatory blister that quickly erodes. In the early acute stage, the bullous nature of the lesion is evident, but because the roof of the blister necroses rapidly, close inspection of the border of established lesions is necessary to reveal its bullous nature (Fig. 33-4). Bullous PG is commonly associated with hematologic disease and most



Figure 33-3 Established lesion of ulcerative pyoderma gangrenosum showing well-defined ulceration with surrounding zone of erythema.

BOX 33-1 DIFFERENTIAL DIAGNOSIS OF PYODERMA GANGRENOSUM (PG)

VARIANT SPECIFIC

Ulcerative PG

Most Likely

- Vascular
  - Venous stasis ulceration
  - Occlusive disease/Arteritis
  - Vasculitis
  - Antiphospholipid–antibody syndrome
- Malignancy
  - Primary or secondary
- Infection
  - Bacterial
  - Mycobacterial/Atypical mycobacterial
  - Viral (herpes simplex)
  - Deep fungal infection (*Sporotrichosis*, *Aspergillus*, *Cryptococcus*)
- Other
  - Drugs (halogenoderma/hydroxyurea, etc.)

Consider

- Infection
  - Necrotizing fasciitis
  - Syphilis/Amebiasis/Mucormycosis
  - Histoplasmosis/Rhizopus
- Other
  - Dermatitis artefacta
  - Calciphylaxis/Insect bite (spider)

Bullous PG

Most Likely

- Infection
  - Bacterial (cellulitis/impetigo)
  - Viral (in immunocompromised)
  - Fungal (mucormycosis in diabetics)
- Other
  - Sweet syndrome/Behçet disease

Consider

- Bullous dermatoses
  - Erythema multiforme/Bullous pemphigoid
- Other
  - Insect/Arthropod bite/Malignancy

Pustular PG

Most Likely

- Infection
  - Bacterial/Viral/Fungal
- Vasculitis
  - Pustular vasculitis

Consider

- Other
  - Pustular psoriasis
  - Sneddon–Wilkinson disease
  - Pustular drug eruption
  - Bowel bypass syndrome
  - Pyostomatitis vegetans

SITE SPECIFIC[a]

Parastomal

Most Likely

- Dermatoses (extraintestinal Crohn's)
  - Irritant/Allergic contact dermatitis
  - Other (e.g., psoriasis)
- Infection
  - Bacterial (*Staphylococcus*/*Streptococcus*)/Cellulitis
  - Fungal (*Candida*)
- Other
  - Extraintestinal inflammatory
  - Bowel disease
  - Malignancy

In Wounds

Most Likely

- Infection
  - Bacterial/Cellulitis
  - Fungal (e.g., mucormycosis)
- Breakdown
  - Suture allergy
  - Mechanical

Consider

- Malignancy

Genital

Most Likely

- Infection
  - Bacterial/Viral infection (herpes simplex virus, Epstein–Barr virus, cytomegalovirus)
  - Tuberculosis/Tuberculide
  - Fournier gangrene
- Malignancy
  - Squamous cell/Extramammary
  - Paget disease

Consider

- Infection
  - Syphilis/Lymphogranuloma
  - Venereum/Histoplasmosis
  - Leishmaniasis/Granuloma inguinale
- Other
  - Dermatitis artefacta
  - Behçet disease

Head and Neck

Most Likely

- Infection
  - Bacterial/Viral/Fungal
  - Dissecting cellulitis of the scalp
- Malignancy
  - Squamous cell carcinoma
  - Basal cell carcinoma

Consider

- Vasculitis
  - Granulomatosis with polyangiitis (Wegener's)
  - Malignant pyoderma

(continued)

BOX 33-1 DIFFERENTIAL DIAGNOSIS OF PYODERMA GANGRENOSUM (PG) (Continued)

VARIANT SPECIFIC
Vegetative PG
Most Likely
Infection
Bacterial/Viral/Fungal
Mycobacterial/Atypical mycobacterial
Leishmaniasis
Consider
Blastomycosis-like pyoderma
Dermatitis artefacta/Malignancy
Pyoderma vegetans

SITE SPECIFIC[a]
Other
Dermatitis artefacta

[a]The differential diagnosis of lower limb PG is essentially that delineated for variant-specific ulcerative PG.

often appears on the upper limbs.[2] This variant of PG may show clinical and histological overlap with Sweet Syndrome (one of the neutrophilic dermatoses which is itself often associated with hematologic disease).

Pustular PG (also called the *pustular eruption of inflammatory bowel disease*) is a generalized eruption that occurs almost exclusively in the setting of an exacerbation of acute inflammatory bowel disease (usually ulcerative colitis). Its onset is dramatic, with the rapid development of multiple, large, circular-to-oval, painful pustules on the trunk and, to a lesser extent, the face and limbs (Fig. 33-5). Control of this eruption is difficult without controlling the bowel disease, which in some cases requires extensive resective surgery.

Vegetative PG (or superficial granulomatous pyoderma) usually presents as a single furunculoid nodule, abscess, plaque, or superficial ulcer, typically on the trunk (Fig. 33-6). In contrast to other variants, it is gradual in its onset, mild in the discomfort it generates, and not usually associated with the presence of systemic disease. This form of PG is usually more responsive to localized or mild forms of systemic therapy than the other variants.[7]

Postoperative and *Peristomal* PG are considered to be examples of ulcerative PG demonstrating the pathergic phenomenon, while the PAPA syndrome has recently been reported as an autosomal dominant condition classified as being one of the group of "autoinflammatory" diseases.



Figure 33-4 Bullous pyoderma gangrenosum lesion showing collapsed roof of blister and superficial erosive quality of the subsequent ulceration.

RELATED PHYSICAL FINDINGS

The clinician should be aware that sterile neutrophilic abscesses of internal organs (lung, bone joints, CNS, CVS, intra-abdominal viscera, eye) can occur in association with or even precede the onset of cutaneous PG.[7] In the patient without cutaneous lesions surgical procedures may be undertaken to establish the



Figure 33-5 Pustular pyoderma gangrenosum lesions of the penis in a patient who also had ulcerative pyoderma gangrenosum.

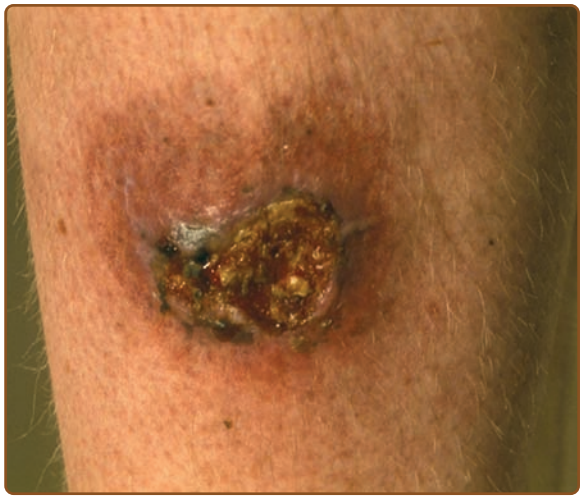

Figure 33-6 Vegetative pyoderma gangrenosum—an indolent area of chronic inflammation and ulceration that was present for months.

diagnosis of the internal neutrophilic infiltration, the wounds of which may subsequently break down and present as postoperative PG. Because many patients with PG also have diseases of other systems (more than 70% of cases), a thorough physical examination is mandatory with particular search for clinical and biological markers of inflammatory bowel disease, arthritis, vasculitis (leukocytoclastic/granulomatous/cryoglobulinemic/Takayasu arteritis), hematologic disease (monoclonal gammopathy and other dyscrasias), and internal malignancy.

LABORATORY TESTS

ROUTINE INVESTIGATIONS

(See Fig. 33-1)

All patients with PG should have the following tests carried out: full blood cell count with differential white cell count and erythrocyte sedimentation rate liver, and bone profiles; autoantibody screen (including anti-Ro/La antibodies, antineutrophilic cytoplasmic antibodies, antiphospholipid antibodies, rheumatoid factor); serum protein electrophoresis; thyroid function studies; chest X-ray (Fig. 33-7), electrocardiogram, and midstream specimen of urine; and swabs from lesions sent for bacterial, fungal, and viral cultures. An incisional, wedge skin biopsy should be taken from the edge of the lesion sampling a portion of normal skin progressing through the border into the area of active inflammation to allow the various histological patterns to be discerned. The excised tissue should then be divided with one section (fresh tissue) sent for bacterial, mycobacterial, and fungal culture, and another portion sent in formalin for histological evaluation requesting hematoxylin and eosin and periodic acid-Schiff, Giemsa, Fite, Gram, and other stains considered relevant. Although immunofluorescent studies may show positive vascular staining in perilesional skin, this is not essential for diagnostic purposes and can be omitted unless vasculitis is suspected in the differential diagnosis.

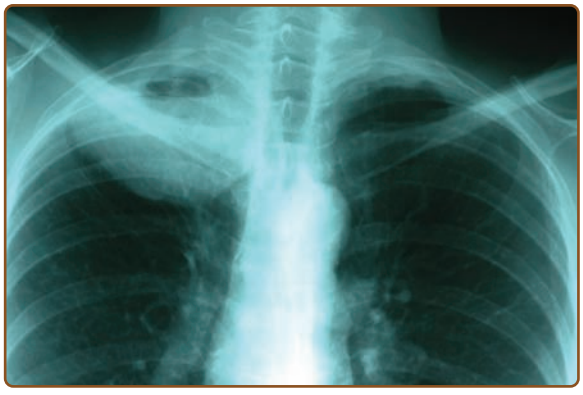

Figure 33-7 Chest X-ray showing neutrophilic abscess in the right upper lung with clear fluid level visible.

HISTOPATHOLOGY

The histopathological changes in the skin are not diagnostic but can be highly suggestive of PG and require experience to interpret. The inflammatory changes that are seen depend on (1) the clinical variant of PG (ulcerative, bullous, pustular, or vegetative), (2) the timing of the biopsy (early lesions show less marked changes than established lesions), and (3) the site of the biopsy relative to the inflammatory process.[8] The site of the biopsy is particularly important because biopsies taken from the center of established ulcerative, bullous, or pustular PG lesions usually show marked neutrophilic infiltration with abscess formation in the mid and deep dermis extending to the panniculus, whereas those taken from peripheral areas (the ulcer edge or inflammatory zone of erythema) show a mixed or predominantly lymphocytic inflammatory infiltrate.

A marked perivascular lymphocytic infiltration is seen in biopsies taken from the "zone" or area of erythema which surrounds active lesions of ulcerative PG. Lymphocytes may be seen to infiltrate vessel walls with intramural and intravascular fibrin deposition indicative of vascular damage (sometimes called lymphocytic vasculitis).[9] Abscess formation with intense dermal neutrophilic infiltration extending to the panniculus and areas of tissue necrosis dominates the histological findings in biopsies taken from central areas of ulcerative PG lesions. Leukocytoclasis is not a prominent finding and although occasionally evidence of leukocytoclastic vasculitis is seen close to the abscess center, this is a minor feature and considered secondary to the intense inflammatory changes rather than the primary event. Histological examination of lesional skin from a patient with bullous PG shows a subepidermal or intraepidermal bulla with overlying epidermal necrosis and marked upper dermal edema with prominence of neutrophils. Biopsy of pustular PG shows a dense dermal neutrophilic infiltration (often centered about a follicle) with subepidermal edema and infiltration of neutrophils into the epidermis with

subcorneal aggregations. Vegetative PG is characterized histologically by the presence of pseudoepitheliomatous hyperplasia, sinus tract formation, and the presence of palisading granulomas in the setting of focal dermal neutrophilic abscesses.

SPECIAL INVESTIGATIONS

In some patients the following additional tests may be warranted: endoscopy (upper and/or lower gastrointestinal); vascular studies; bone marrow aspirate examination; ultrasound of abdomen (including liver/spleen/aorta); computed tomography of the thorax, abdomen, or brain; and other directed investigations as outlined in Fig. 33-1.

DIFFERENTIAL DIAGNOSIS

The differential diagnosis to be considered in a patient with PG is extensive.[6] Different variants of PG (ulcerative, bullous, vegetative, pustular) suggest alternative diagnoses and the occurrence of PG at certain cutaneous sites raises further diagnostic issues for the clinician, as shown in Box 33-1.

Because there is no confirmatory diagnostic test for PG, the following major criteria are proposed which make the diagnosis of PG likely:

1. Major criteria are as follows:
   (a) Sudden onset of a painful lesion fitting the morphologic descriptions outlined above (ulcerative, bullous, pustular, or vegetative) in a (usually middle-aged) apyrexial patient without significant toxemia or relevant drug intake
   (b) Histological evidence of marked tissue neutrophilia in the absence of significant leukocytoclastic vasculitis and histopathological exclusion of malignancy and of infective organisms by special studies and negative tissue culture
   (c) Exclusion of vascular stasis/occlusion/vasculitis by appropriate studies
2. Minor criteria that are supportive of the diagnosis are as follows:
   (a) Localization of lesions at characteristic sites (ulcerative PG on the legs, vegetative on the trunk, bullous PG on the upper limb, pustular PG on the trunk or face) or at a site of cutaneous trauma (postoperative ulcerative PG or peristomal PG).
   (b) Rapid progression of the inflammatory lesion with escalating pain severity (except vegetative PG).
   (c) Occurrence in an individual with systemic disease, such as arthritis, inflammatory bowel disease, or hematological dyscrasias (except vegetative PG).
   (d) Rapid reduction of pain and inflammation on initiation of systemic steroid therapy.

COMPLICATIONS

Active or poorly controlled cutaneous PG causes significant morbidity (loss of mobility, pain, exposure to secondary infection, anemia of chronic disease, etc.). Lack of recognition of the neutrophilic infiltration of internal organs in PG may lead to unnecessary surgical procedures. Many of the treatments for PG must be administered for many months and may have significant side effects. Frequent monitoring and follow-up of patients are necessary. Elective surgery should be undertaken with caution because of the possibility of inducing new PG lesions.

PROGNOSIS AND CLINICAL COURSE

The prognosis depends on the PG variant; the age and sex of the patient; presence of other systemic disease; and the type, dosage, and duration of therapy required to bring the disease under control. Patients with vegetative PG generally have a good prognosis and the skin lesions often heal within 6 months of the initiation of relatively mild forms of treatment.[7] Peristomal PG similarly has a good prognosis often responding to topical or intralesional therapy. Patients with pustular PG often have complete remission of their cutaneous lesions if the severe inflammatory bowel disease that usually accompanies this variant is controlled. Ulcerative PG is a chronic recurrent disease with a significant morbidity and mortality.[2,10] Patients with this variant older than 65 years of age and male patients seem to have a worse prognosis. Patients with bullous PG who have an associated hematological disorder also have a poor prognosis. The onset of bullous PG in a patient with stable polycythemia rubra vera appears to herald the onset of leukemic change in some patients.[11]

TREATMENT

GENERAL MEASURES

The age, mobility, social support networks, pain threshold, extent and severity of disease, and ability to comply with therapeutic measures should be evaluated for each patient and the treatment adapted accordingly. The patient should be given realistic expectations of the speed of recovery likely in this disease. Thus, although lesions develop and evolve within days, the healing process usually takes weeks or even months. Adequate bed rest, efficient pain relief, correction of anemia, and appropriate therapy of any associated disease are pivotal in the overall management strategy of a patient with PG.[12] If other systemic illnesses are present, cooperation with an internal medicine specialist is important, and if surgery is anticipated appropriate measures (such as the use of subcuticular sutures and systemic steroid cover) should be adopted to avoid precipitating new postoperative PG lesions.

The location, morphology, size, and outline of each lesion should be recorded (by photography and by using a calibrated transparent plastic sheet placed over lesions on which the outline is traced) on presentation and subsequent review.

WOUND CARE

The cutaneous lesions of PG are usually extremely tender so cleansing should be carried out daily with tepid sterile saline or a mild antiseptic solution. Potassium permanganate solution diluted 1:2,000 is helpful if there is marked exudation. Silver sulphadiazine 1% cream is usually soothing when applied to the ulcerated lesions of PG and may facilitate granulation tissue formation as well as inhibiting bacterial growth. A nonadhesive dressing should be applied over the lesion and held in place with a crêpe elasticized bandage wound firmly, but not tightly, over it. Some patients, particularly those with superficial lesions, obtain significant relief with the use of hydrocolloid dressings, which can be left on for 2–3 days and "melt" into the lesion. Careful instruction to the patient and nurse is important to ensure compliance and to avoid the use of irritants such as chemical desloughing agents, caustics (such as silver nitrate), or dressings (such as gauze impregnated with soft paraffin and/or antibacterial agents which may adhere to the ulcer base) or pressure dressings as are sometimes prescribed for patients with ulcers due to venous insufficiency. A variety of bacteria may be cultured from the wound surface, but these usually represent contaminants and directed antibiotic therapy is not required unless there are clinical signs of incipient cellulitis around the wound.

TOPICAL TREATMENTS

Topical treatments are important adjuncts to the systemic treatment needed for the management of most PG patients, and may be sufficient to bring the condition under control in those who have vegetative or mild ulcerative PG. Potent topical corticosteroids applied to the periphery of an active PG lesion can reduce inflammation and may be sufficient to heal vegetative or peristomal ulcerative PG.[13] Although topical disodium cromoglycate (with or without occlusion), benzoyl peroxide, nicotine cream or patches, hyperbaric oxygen, and radiotherapy have all been reported as being helpful in individual patients with PG, their effectiveness has not been established. Clinical impression suggests that topical tacrolimus (with or without occlusion) is particularly effective for isolated pustular lesions and for the superficial ulcerations of peristomal PG.

INTRALESIONAL TREATMENTS

Intralesional triamcinolone acetonide (5–10 mg/mL) injected twice weekly into the border of a vegetative or peristomal PG lesion may lead to healing and can also be useful in a patient with ulcerative PG if one section of the ulcer is proving recalcitrant to other therapies. Intralesional cyclosporine and tacrolimus have also been reported to be effective in some PG patients.

SYSTEMIC TREATMENTS

Because PG is a rare disease, most systemic treatment recommendations are based on experience gained from small series of patients studied.[14] The main systemic treatments used for PG with their suggested dosages are listed in Box 33-2. As experience with newer agents is gained, it is likely these recommendations will change.[15] The initiation of systemic therapy is based on the variant of PG (ulcerative and bullous PG usually require systemic therapy), the rapidity of its evolution, the extent of cutaneous involvement, and the general medical status of the patient.

Systemic corticosteroid treatment is probably the initial treatment of choice for most patients with PG. It is important to initiate systemic steroids at a sufficiently high dose to control the disease. Rapid diminution of pain is often recorded by the patient after initiation of therapy and steroids should be continued at this dosage until lesions show evidence of healing, after which gradual tapering of the dose can be undertaken. A steroid-sparing agent should be added as soon as possible, as well as bone protective measures to diminish the risk of osteoporosis because prolonged therapy can be anticipated in most patients. Intravenous corticosteroids in pulsed doses have been used to induce PG remission, but serious potential adverse effects limit their use to exceptional circumstances. Dapsone has been traditionally used in the treatment of PG and remains a useful drug, particularly when used in conjunction with systemic corticosteroids. Dapsone is generally well tolerated, but hematological complications (including agranulocytosis, hemolysis, hemolytic anemia, and methemoglobulinemia) as well as other potentially serious side effects may occur. Other antimicrobial agents reported as successful in

BOX 33-2 SYSTEMIC TREATMENTS FOR PYODERMA GANGRENOSUM

MEDICATION	DOSAGE
Prednisone	0.5–1.5 mg/kg/day PO
Methylprednisolone (pulsed dose)	500 mg–1 g IV
Dapsone	50–200 mg/day PO
Clofazimine	200–400 mg/day PO
Minocycline	50–100 mg twice daily PO
Cyclosporine	3 to 5 mgs/kg/day PO
Tacrolimus	0.1–0.3 mg/kg PO
Mycophenolate mofetil	500 mg–1 g bid PO
Infliximab	5 mg/kg IV

the treatment of PG patients include rifampicin, tetracyclines, vancomycin, mezlocillin, clofazimine, and minocycline. These have usually been prescribed in combination with other systemic therapies and seem to work in PG patients by mechanisms other than their antibacterial properties. Most experience has been with clofazimine and minocycline (100–200 mg daily). The latter agent is well tolerated and often allows for a reduction in systemic corticosteroid dosage and appears to prolong remission in some patients.

Cyclosporine is an alternative first-line therapy of PG[16] or may be used in combination with systemic corticosteroids to achieve rapid control of disease. Doses of 3 to 5 mgs/kg/day have shown efficacy and continued treatment is usually required for 3–4 months. Less risk of serious side effects (such as impairment of renal function and hypertension) is seen at these low doses, but careful monitoring of patients is required and attention should paid to the possibility of other drugs interacting with this medication.

Tacrolimus (FK-506) and mycophenolate mofetil have also been used successfully in the treatment of PG either as monotherapies or in combination with systemic corticosteroids or cyclosporine.[17] Both drugs cause significant immunosuppression with resultant susceptibility of the patient to infection and malignant disease and can have other potentially serious side effects. Infliximab, an antitumor necrosis factor antibody, has been used successfully to treat patients with inflammatory bowel disease and has been reported to be effective in some patients with PG.[18] Other similar drugs that have been reported to be efficacious in the treatment of patients with PG include etanercept and adalimumab. The role of these agents in the management of PG has yet to be fully defined and susceptibility to reactivation of tuberculosis infection and other significant side effects remain a concern. Anakinra, an IL-1 receptor antagonist has been reported to be effective in treating PG of the PAPA syndrome and suggests another possible treatment for this condition.[5] The use of thalidomide in the treatment of PG has probably been superseded by the development of these other agents. Other drugs which have been reported to be helpful in the treatment of PG include azathioprine (thiopurine methyl transferase levels should be checked pretreatment), colchicine,[19] cyclophosphamide, chlorambucil, and melphalan. These agents can have toxic effects and evidence of their efficacy is limited.

Other modalities which have been reported to be useful in the management of individual patients or small series of patients with PG include human intravenous immunoglobulin,[20] interferon-α, nicotine,[21] potassium iodide, leukocytapheresis,[22] and plasma exchange. Skin grafting should be avoided if possible because of the risk of inducing new PG lesions at the donor sites, but cultured tissue allografts/autografts and the use of bovine collagen matrix have been reported to be useful in patients in whom the disease is controlled but reepithelialization incomplete.[23]

The unpredictable nature of PG and its variable aggressiveness in individual patients mean that a flexible approach to treatment is required and the use of therapeutic agents have to be adapted to the patient's physiologic state (childhood, pregnancy, old age). By whichever modality control of PG is achieved, maintenance therapy should be continued until there is complete wound healing. In addition, patients with ulcerative PG have a significant risk of relapse, so long-term follow-up is required.

PREVENTION

A patient who has had a history of PG should be advised to avoid trauma to the skin as there is the possibility of precipitating a new lesion (the pathergic phenomenon). If such patients have to undergo surgery, they should have close supervision by a dermatologist of their postoperative course. Patients with a history of aggressive PG may warrant a course of systemic steroids during and for a period (2 weeks or longer) postoperatively to prevent the development of new PG lesions and subcuticular sutures should be used where possible. Patients with a history of PG and Crohn's disease who are to have an ileostomy should be warned about the possible development of peristomal PG lesions.

KEY REFERENCES

Full reference list available at www.DIGM8.com

DVD contains references and additional content

1. Powell FC, Su WP, Perry HO: Pyoderma gangrenosum: Classification and management. *J Am Acad Dermatol* **34**:395, 1996
2. Bennett ML et al: Pyoderma gangrenosum. A comparison of typical and atypical forms with an emphasis on time to remission. Case review of 86 patients from 2 institutions. *Medicine (Baltimore)* **79**:37, 2000
3. Powell FC et al: Pyoderma gangrenosum: A review of 86 patients. *Q J Med* **55**:173, 1985
4. Wallach D, Vignon-Pennamen MD: From acute febrile neutrophilic dermatoses to neutrophilic disease: Forty years of clinical research. *J Am Acad Dermatol* **55**:1066-1071, 2006
5. Brenner M et al: Treatment of pyoderma gangrenosum in PAPA (pyogenic arthritis, pyoderma gangrenosum and acne) syndrome with the recombinant human interleukin-1 receptor antagonist anakinra. *Br J Dermatol* **161**:1199-1201, 2009
6. Weenig RH et al: Skin ulcers misdiagnosed as pyoderma gangrenosum. *N Engl J Med* **347**:1412, 2002

Chapter 34 :: Granuloma Faciale

:: David A. Mehregan & Darius R. Mehregan

GRANULOMA FACIALE AT A GLANCE

- Granuloma faciale is an uncommon inflammatory dermatosis characterized clinically by reddish brown papules and plaques primarily involving the face.
- The pathology shows changes of a chronic leukocytoclastic vasculitis with a mixed infiltrate containing eosinophils, extensive perivascular fibrin deposition, and dermal fibrosis.
- Etiology is unknown.

EPIDEMIOLOGY

Early cases of granuloma faciale were reported as "eosinophilic granuloma" of the skin. Weidman was the first to separate three cases that had been previously reported in the literature as variants of erythema elevatum diutinum.[1] Lever and Leeper helped to differentiate the lesions from other eosinophil-rich diseases.[2] Cobane, Straith, and Pinkus later stressed the histologic resemblance to erythema elevatum diutinum (EED) and termed the lesions "facial granulomas with eosinophilia" and later granuloma faciale.[3] Granuloma faciale occurs predominantly in adult men and women. There is a slight male predominance, and mean age at presentation is 52 years.[4,5] Granuloma faciale can occur in individuals of any race; however, it is more common in Caucasians. The disease presents most commonly with a single lesion on the face, but extrafacial lesions have been described.[6] Patients with multiple lesions have also been reported.[7] A rare mucosal variant has been described as eosinophilic angiocentric fibrosis, which typically involves the upper respiratory tract.[8]

ETIOLOGY AND PATHOGENESIS

The etiology of granuloma faciale is unknown. The disease can be considered a localized chronic fibrosing vasculitis.[9] Immunofluorescence studies have revealed deposition of immunoglobulins and complement factors in the vessel walls consistent with a type III immunologic response, marked by deposition of circulating immune complexes surrounding superficial and deep blood vessels.[10,11] However, other authors have described negative results with immunofluorescence.[12]

CLINICAL FINDINGS

Granuloma faciale is characterized by solitary papules, plaques, or nodules. The lesions are typically asymptomatic red, brown, or violaceous plaques that are soft, smooth, and well circumscribed, often showing follicular accentuation and telangiectasia (Figs. 34-1 and 34-2). Ulceration is rare. Lesions are most common on the face. Sites of predilection include the nose, preauricular area, cheeks, forehead, eyelids, and ears.[4,12] Rarely, patients may present with multiple lesions or lesions on the trunk or extremities. Extrafacial lesions have been reported both as isolated findings and in conjunction with facial lesions. Lesions may be present for weeks or months and tend to follow a chronic course. Lesions are typically asymptomatic; however, patients may complain of tenderness, burning, or pruritus.[4] Photoexacerbation of lesions has been reported.[13]

LABORATORY FINDINGS

An extensive laboratory evaluation is not required. Peripheral blood eosinophilia is occasionally detected.

The diagnosis may be established by a combination of clinical findings and confirmatory tissue biopsy results. A punch biopsy that includes the full thickness of the dermis is recommended. Histologic examination shows a normal-appearing epidermis, which may be separated from the underlying inflammatory infiltrate by a narrow grenz zone (Fig. 34-3). Within the dermis is a dense and diffuse infiltrate of lymphocytes, plasma cells, eosinophils, and neutrophils with evidence of leukocytoclasis (Fig. 34-4). The inflammatory infiltrate surrounds the blood vessels, which show evidence of fibrin deposition. In later stages, the perivascular fibrin



Figure 34-1 Granuloma faciale. Raised edematous plaques on cheek showing prominent follicular ostia.

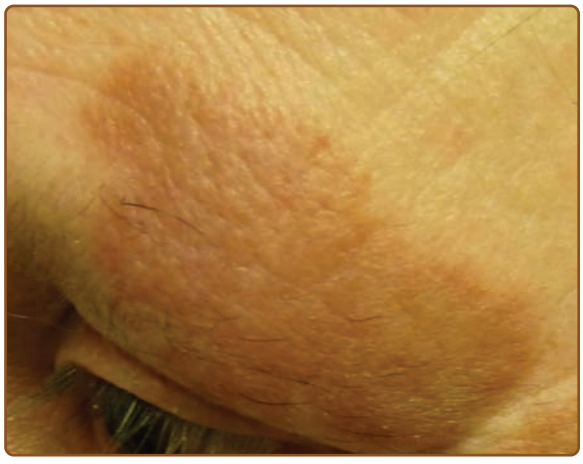

Figure 34-2 Granuloma faciale. Single plaque on the temple showing prominent follicular ostia and central dell.

deposition becomes extensive and dominates the histologic picture. Deposition of hemosiderin may contribute to the brown color seen clinically. Electron microscopic studies confirm the presence of an extensive eosinophilic infiltrate with Charcot–Leyden crystals and numerous histiocytes filled with lysosomal vesicles; however, cases with few eosinophils in the infiltrate have also been described.[14] Immunoglobulins, fibrin, and complement can be found deposited along the dermal–epidermal junction in a granular pattern and around blood vessels by direct immunofluorescence.[10]

DIFFERENTIAL DIAGNOSIS

The clinical differential diagnosis for granuloma faciale includes discoid lupus erythematosus, polymorphous light eruption, fixed drug eruption, benign lymphocytic infiltrate of Jessner, lymphoma cutis, pseudolymphoma, sarcoidosis, granuloma annulare, tinea faciei, insect bite reaction, xanthogranuloma, mastocytoma, basal cell

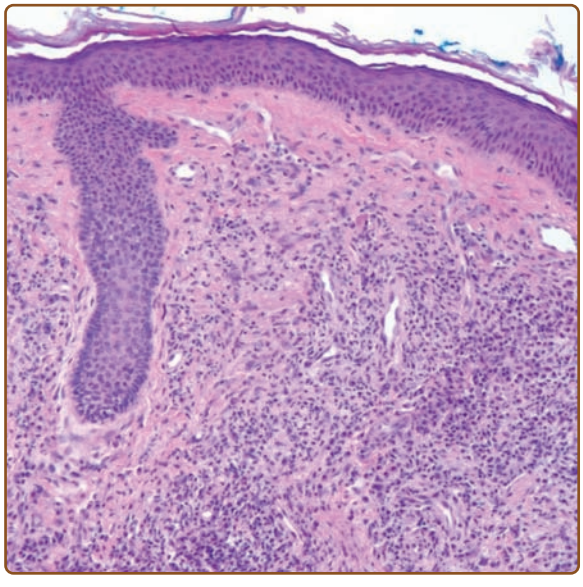

Figure 34-3 Granuloma faciale. This low-power histologic section shows a mixed infiltrate of lymphocytes, histiocytes, neutrophils, plasma cells, and eosinophils. There is sparing of a narrow grenz zone between the inflammatory infiltrate and the overlying epidermis.

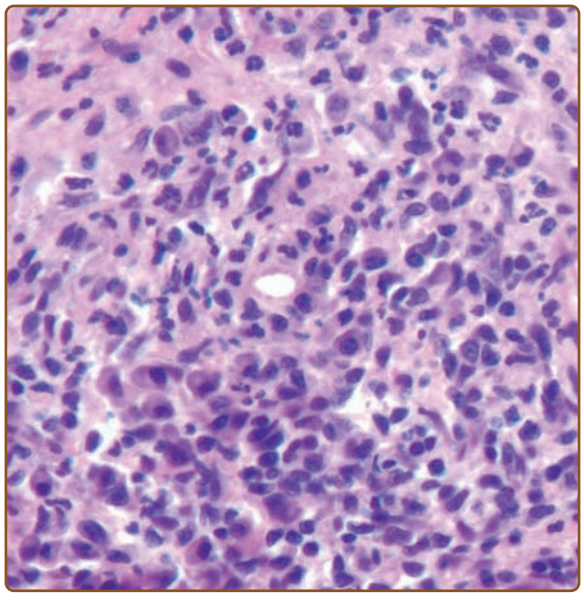

Figure 34-4 Granuloma faciale. This histologic section shows perivascular deposition of fibrin and a mixed infiltrate of lymphocytes, neutrophils, and eosinophils.

BOX 34-1 DIFFERENTIAL DIAGNOSIS OF GRANULOMA FACIALE

Most Likely

- Face
  - Sarcoidosis
  - Benign lymphocytic infiltrate of Jessner
  - Rosacea
- Extrafacial
  - Erythema elevatum diutinum

Consider

- Face
  - Discoid lupus erythematosus
  - Lymphoma cutis
  - Angiolymphoid hyperplasia with eosinophilia
  - Tinea faciei
  - Basal cell carcinoma
  - Xanthogranuloma
  - Mastocytoma
- Extrafacial
  - Granuloma annulare
  - Benign lymphocytic infiltrate of Jessner
  - Fixed drug eruption

Always Rule Out

- Face
  - Discoid lupus erythematosus
- Trunk
  - Erythema elevatum diutinum

BOX 34-2 TREATMENTS FOR GRANULOMA FACIALE

	TOPICAL	PHYSICAL	SYSTEMIC
First-line therapy	Topical corticosteroids	Cryotherapy Intralesional steroids Pulsed dye laser	Dapsone, 50–100 mg/day
Second-line therapy	Topical tacrolimus ointment	Surgical excision	

carcinoma, Langerhans cell histiocytosis, and rosacea (Box 34-1). The diagnosis can be reliably made by histologic examination. Absence of serologic evidence of lupus erythematosus helps to differentiate these lesions from the lesions of discoid lupus erythematosus.

The primary histologic differential diagnosis is EED. Both diseases represent chronic forms of fibrosing small vessel vasculitis and may be related. However, there are several clinical and histologic differences. EED is characterized by multiple lesions, primarily located on extensor surfaces of the extremities in a symmetric acral distribution. The trunk and face are typically spared in EED. Histologically, both show a chronic fibrosing vasculitis.[15] However, a grenz zone of normal collagen beneath the epidermis is not typical of EED. Eosinophils and plasma cells are more prominent in granuloma faciale while neutrophils are more frequently found in EED. EED may be associated with systemic conditions, primarily monoclonal gammopathies, and shows an excellent response to dapsone.[16,17] The histologic and clinical differential may also include angiolymphoid hyperplasia with eosinophilia. However, the lesions of angiolymphoid hyperplasia with eosinophilia contain blood vessels with prominent "hobnail" endothelial cells that protrude into the vascular lumina rather than perivascular fibrin deposition. One case of tinea faciei caused by *Trichophyton rubrum* has been described with clinical and histologic changes consistent with granuloma faciale.[18]

COMPLICATIONS

Granuloma faciale is rarely associated with systemic disease.[19]

PROGNOSIS AND CLINICAL COURSE

Lesions tend to be chronic and resistant to treatment.

TREATMENT

A variety of medical and surgical therapies have been used in the treatment of granuloma faciale (Box 34-2). Because of the small number of patients involved, randomized trials to evaluate these treatments are lacking. Resistance to therapy and cosmetic complications should be discussed with the patient before initiation of therapy. Topical and intralesional steroids have been administered with modest improvement.[4,20] Cryosurgery has been applied with effective results.[21,22] Because the disease is known to be a variant of chronic leukocytoclastic vasculitis, dapsone 25 to 100 mg/day has been used with benefit in a number of patients.[23,24] Topical tacrolimus ointment 0.1% also has been used with success.[25]

Surgical excision may be an option for small lesions. Lesions of granuloma faciale have been treated with a variety of medical lasers. In multiple studies utilizing pulsed dye lasers at 585–595 nm, clinical improvement has been demonstrated.[26–30] A carbon dioxide laser has also been applied with varying success.[31] The use of an argon laser resulted in total resolution of the granuloma faciale with subsequent scarring. The lesions in two patients were reported to respond to the potassium-titanyl-phosphate 532-nm laser in combination with tacrolimus ointment 0.1%.[32] Case studies have suggested a beneficial effect of tacrolimus ointment,[33,34] as well as pimecrolimus cream 1%.[34]

KEY REFERENCES

Full reference list available at www.DIGM8.com

DVD contains references and additional content

3. Cobane JH, Straith CL, Pinkus H: Facial granulomas with eosinophilia: Their relation to other eosinophilic granulomas of the skin and to reticulogranuloma. *Arch Derm Syphilol* **61**:442, 1950
4. Radin DA, Mehregan DR: Granuloma faciale: Distribution of the lesions and review of the literature. *Cutis* **72**:213, 2003
5. Marcoval J, Moreno A, Peyr J: Granuloma faciale: A clinicopathological study of 11 cases. *J Am Acad Dermatol* **51**:269, 2004
9. Carlson JA, LeBoit PE: Localized chronic fibrosing vasculitis of the skin: An inflammatory reaction that occurs in settings other than erythema elevatum diutinum and granuloma faciale. *Am J Surg Pathol* **21**:698, 1997
10. Nieboer C, Kalsbeek GL: Immunofluorescence studies in granuloma eosinophilicum faciale. *J Cutan Pathol* **5**:68, 1978
11. Barnadas MA, Curell R, Alomar A: Direct immunofluorescence in granuloma faciale: A case report and review of literature. *J Cutan Pathol* **33**:508-511, 2006
12. Ortonne N et al: Granuloma faciale: A clinicopathologic study of 66 patients. *J Am Acad Dermatol* **53**:1002, 2005
17. Crowson AN, Mihm MC Jr, Magro CM: Cutaneous vasculitis: A review. *J Cutan Pathol* **30**:161, 2003
19. Dowlati B, Firooz A, Dowlati Y: Granuloma faciale: Successful treatment of nine cases with a combination of cryotherapy and intralesional corticosteroid injection. *Int J Dermatol* **36**:548, 1997
31. Ludwig E et al: New treatment modalities for granuloma faciale. *Br J Dermatol* **149**:634, 2003

Chapter 35 :: Subcorneal Pustular Dermatosis (Sneddon–Wilkinson Disease)

:: Franz Trautinger & Herbert Hönigsmann

SUBCORNEAL PUSTULAR DERMATOSIS AT A GLANCE

- A rare condition with worldwide occurrence.
- A chronic recurrent disorder with a benign course frequently associated with various forms of immune dysfunction [most commonly immunoglobulin (Ig) A monoclonal gammopathy]. Occurrence of intraepidermal deposits of IgA indicates a relationship with IgA pemphigus.
- Crops of flaccid, coalescing pustules; often in annular or serpiginous patterns.
- Usually distributed symmetrically in the axillae, groins, submammary, the flexor aspects of the limbs, and on the abdomen.
- Pathology: subcorneal pustules filled with polymorphonuclear leukocytes.

Subcorneal pustular dermatosis (SPD) is a rare, chronic, recurrent, pustular eruption characterized histopathologically by subcorneal pustules that contain abundant neutrophils. The condition was originally described in 1956 by Sneddon and Wilkinson,[1] who separated SPD from other previously unclassified pustular eruptions. Until 1966, when the first comprehensive review appeared, more than 130 cases had been reported, but not all fulfilled the clinical and histopathologic criteria required for this diagnosis.[2] A considerable number of additional cases have since appeared in the literature, and a subtype with intraepidermal deposits of immunoglobulin (Ig) A directed against desmocollin 1 has been recognized.[3] Today, these cases are usually classified as SPD-type IgA pemphigus and it is a matter of debate whether the finding of epidermal IgA deposits define a subset of SPD or a new pemphigus variant that is otherwise indistinguishable from "classic" SPD.

EPIDEMIOLOGY

There is no racial predilection. Most of the reported cases have been in whites, but the disease has also been observed in Africans, Japanese, and Chinese. The condition is more common in women and in persons older than 40 years of age, but SPD may occur at any age.[2] A pustular eruption that is clinically and histologically similar to the human disease, which also responds to dapsone treatment, has been observed in dogs.[4]

ETIOLOGY AND PATHOGENESIS

The cause of SPD is unknown. Cultures of the pustules consistently do not reveal bacterial growth. The role of trigger mechanisms such as preceding or concomitant infections, though repeatedly discussed, has remained speculative. Immunologic mechanisms have been implicated in the pathogenesis and in a subset of patients, whose disease clinically resembled SPD, intraepidermal IgA deposits have been detected. Some of these patients also had circulating IgA antibodies against the same sites within the epidermis. Desmocollin 1 and in a single case also desmocollins 2 and 3 have been described as autoantigens in these cases and the disease has been classified as a rare pemphigus variant (SPD-type IgA pemphigus).[3,5–7] The pathogenetic role of these antibodies is still to be demonstrated.[8]

The occasional association of SPD with certain other diseases may represent more than a mere coincidence. Increased serum IgA has been detected in a number of patients, and the disease has been reported to occur in cases of IgA-paraproteinemia and IgA multiple myeloma.[9–12] In addition, SPD is associated with pyoderma gangrenosum,[13,14] ulcerative colitis,[15] and Crohn disease.[16] On the other hand, pyoderma gangrenosum is not uncommon in patients with inflammatory bowel disease, paraproteinemia, and myeloma (see Chapter 33). Whether or not the coexistence of these conditions reflects common pathogenetic mechanisms remains to be clarified, but an additional common denominator linking these disorders is their response to sulfone and sulfonamide therapy.

Further associations reported to date include IgG paraproteinemia,[17,18] $CD30^+$ anaplastic large-cell lymphoma,[19] marginal zone lymphoma,[20] nonsmall cell lung cancer,[21] apudoma,[22] rheumatoid arthritis,[23,24] systemic lupus erythematodes,[25] hyperthyroidism[26] and mycoplasma pneumoniae infection.[27]

CLINICAL FINDINGS

The primary lesions are small, discrete, flaccid pustules, or vesicles that rapidly turn pustular and usually arise in crops within a few hours on clinically normal or slightly erythematous skin (Fig. 35-1). In dependent regions, pus characteristically accumulates in the lower half of the pustule (see Fig. 35-1B); as the pustules usually have the tendency to coalesce, they often, but not always, form annular, circinate, or bizarre serpiginous patterns. After a few days, the pustules rupture and dry up to form thin, superficial scales and crusts, closely resembling impetigo. Peripheral spreading and central healing leave polycyclic, erythematous areas in which new pustules arise as others disappear (see Fig. 35-1A).



Figure 35-1 Subcorneal pustular dermatosis. **A.** Typical distribution. Note accentuated involvement of groin and abdomen. Hyperpigmented macules mark previously affected areas. **B.** Close-up showing coalescence of pustules, which form annular and circinate patterns. Lesions of different developmental stages are seen side by side. At the lower right, newly formed pustule with characteristic hypopyon formation.

There is no atrophy or scarring, but an occasional brownish hyperpigmentation may mark previously affected sites. Variable intervals of quiescence, lasting from a few days to several weeks, may be followed by the sudden development of new lesions. The eruptions tend to occur symmetrically, affecting mainly the axillae, groin, abdomen, submammary areas, and the flexor aspects of the limbs. In rare cases, the face,[28] palms, and soles[29] may be involved. Scalp and mucous membranes invariably remain free of lesions. Episodic itching and burning represent subjective symptoms in a small number of patients, but there are no systemic symptoms or abnormalities in routine laboratory parameters.

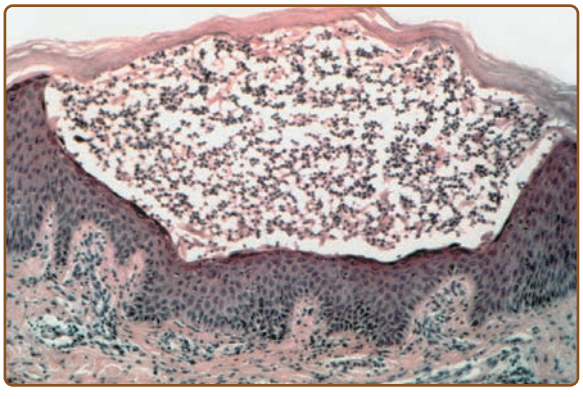

Figure 35-2 Subcorneal pustular dermatosis. Strictly subcorneal pustule filled with polymorphonuclear leukocytes, with the underlying epidermal layers exhibiting only slight edema and some migrating leukocytes. There is a mild inflammatory infiltrate around dermal blood vessels.

HISTOPATHOLOGY

The hallmark of the disease is a strictly subcorneal pustule filled with polymorphonuclear leukocytes,[1] with only an occasional eosinophils.[2] Acantholysis is not involved in pustule formation, but a few acantholytic cells may be found in older lesions (secondary acantholysis). Surprisingly, the epidermal layers underlying the pustule exhibit little pathology, and, apart from a variable number of migrating leukocytes, there is little evidence of spongiosis or cytolytic damage to the epidermal cells. The dermis contains a perivascular infiltrate composed of neutrophils and rarely mononuclear cells and eosinophils (Fig. 35-2).

BOX 35-1 DIFFERENTIAL DIAGNOSIS OF SUBCORNEAL PUSTULAR DERMATOSIS

- Bacterial impetigo
- Dermatitis herpetiformis
- Pemphigus foliaceus
- IgA pemphigus/intraepidermal IgA pustulosis
- Pustular psoriasis
- Necrolytic migratory erythema
- Acute generalized exanthematous pustulosis

BOX 35-2 TREATMENTS FOR SUBCORNEAL PUSTULAR DERMATOSIS

First line	Dapsone Corticosteroids	50–150 mg/day As required
Second line (anecdotally reported beneficial responses)	Retinoids, photochemotherapy, ultraviolet B, colchicine, cyclosporine, infliximab, etanercept	

In a subset of patients, direct immunofluorescence reveals intraepidermal IgA deposits.[17] In these cases, IgA is usually present in a pemphigus-like intercellular pattern, either in the entire epidermis or confined to its upper layers. By indirect immunofluorescence, circulating IgA antibodies directed against the intercellular substance of the epidermis were detected in single cases. Today these cases are usually diagnosed as SPD-type IgA pemphigus (see Chapter 54).

Ultrastructural examination of paralesional skin has shown cytolysis of keratinocytes confined to the granular layer[30]; the formation of pustules has been regarded as a secondary event caused by invasion and subcorneal accumulation of leukocytes.

DIFFERENTIAL DIAGNOSIS

(Box 35-1)

An early localized eruption of SPD may be clinically and histologically indistinguishable from impetigo, but the distribution pattern of the lesions, the absence of bacteria in the pustules, and the ineffectiveness of antibiotic therapy suggest the correct diagnosis. Dermatitis herpetiformis is highly pruritic, affects primarily the extensor surfaces, and has subepidermal vesicles with granular IgA deposits in the dermal papillary tips. Pemphigus foliaceus has acantholysis and a typical immunofluorescence pattern. Generalized pustular psoriasis (von Zumbusch's type) presents with systemic symptoms (fever, malaise, leukocytosis), and spongiform pustules within the epidermis. The necrolytic migratory eruption of glucagonoma syndrome can be differentiated by its distribution, lack of actual pustule formation, erosions of the lips and oral mucosa, and, histologically, necrobiosis of the upper epidermis. Biochemically, hyperglycemia and excess levels of glucagon are diagnostic. Acute generalized exanthematous pustulosis (AGEP) is widespread with an acute febrile onset and histologically exhibits spongiform subcorneal and intraepidermal pustules sometimes with leukocytoclastic vasculitis.

PROGNOSIS AND CLINICAL COURSE

SPD is a benign condition. Without treatment, attacks recur over many years and remissions are variable, lasting from a few days to several weeks. Despite the protracted course the general health of the patient is usually not impaired. However, one of our own cases who had SPD, pyoderma gangrenosum, and IgA paraproteinemia of more than 20 years' duration died of septicemia with staphylococcal abscesses in the lungs, liver, and spleen.

TREATMENT

The drug of choice is dapsone (Box 35-2) in a dose of 50 to 150 mg daily. The response is slower and less dramatic than in dermatitis herpetiformis, but complete remission is most often obtained. In some patients, the treatment may be withdrawn after several months, although in others it may have to be continued for years; the minimal effective dose to suppress disease should be determined in these patients. Systemic corticosteroids are less effective, although they can suppress generalized flares when given in high doses. Responses to retinoids, photochemotherapy, ultraviolet B, colchicine, cyclosporine, and topical tacalcitol (1α-24R-dihydroxyvitamin D_3) have been anecdotally reported.[31–34] More recently antitumor necrosis factor α therapy has been successfully used in single cases. Infliximab was described to induce rapid responses in three recalcitrant cases, with one patient relapsing despite continuing treatment.[25,35,36] In two patients etanercept was able to induce almost complete continuing remissions for 22 and 7 months, in one case combined with acitretin.[37]

KEY REFERENCES

Full reference list available at www.DIGM8.com

DVD contains references and additional content

1. Sneddon IB, Wilkinson DS: Subcorneal pustular dermatosis. *Br J Dermatol* **68**:385, 1956
3. Robinson ND et al: The new pemphigus variants. *J Am Acad Dermatol* **40**:649, 1999
6. Ishii N et al: Immunolocalization of target autoantigens in IgA pemphigus. *Clin Exp Dermatol* **29**:62, 2004
8. Reed J, Wilkinson J: Subcorneal pustular dermatosis. *Clin Dermatol* **18**:301, 2000
36. Bonifati C et al: Early but not lasting improvement of recalcitrant subcorneal pustular dermatosis (Sneddon-Wilkinson disease) after infliximab therapy: Relationships with variations in cytokine levels in suction blister fluids. *Clin Exp Dermatol* **30**:662, 2005
37. Berk DR: Sneddon-Wilkinson disease treated with etanercept: Report of two cases. *Clin Exp Dermatol* **34**:347, 2009

Chapter 36 :: Eosinophils in Cutaneous Diseases

:: Kristin M. Leiferman & Margot S. Peters

EOSINOPHILS IN CUTANEOUS DISEASES AT A GLANCE

- Eosinophils may be seen in skin biopsy specimens from a broad range of cutaneous diseases but are not pathognomonic for any dermatosis.
- Eosinophils are an important component of the characteristic histologic pattern in a limited number of diseases, including the following:
  - Angiolymphoid hyperplasia with eosinophilia
  - Eosinophilic, polymorphic, and pruritic eruption associated with radiotherapy
  - Eosinophilic pustular folliculitis
  - Erythema toxicum neonatorum
  - Eosinophilic ulcer of the oral mucosa
  - Eosinophilic vasculitis
  - Granuloma faciale
  - Hypereosinophilic syndromes
  - Incontinentia pigmenti
  - Kimura disease
  - Pachydermatous eosinophilic dermatitis
  - Wells syndrome (eosinophilic cellulitis)
- Clinical reaction patterns with eosinophil involvement include diseases in which eosinophils probably play a pathogenic role and are a component of the histological pattern, but are not essential for diagnosis.
- Evidence for involvement of eosinophils in cutaneous diseases is provided by observation of intact eosinophils in lesional tissue sections and/or by immunostains for their toxic granule proteins, which are deposited in tissues.

Eosinophils have myriad phlogistic activities that implicate them in disease.[1–3] (See Chapter 31.) Peripheral blood eosinophilia and/or tissue infiltration by eosinophils occur in a variety of common and unusual diseases, including those of infectious, immunologic, and neoplastic etiologies. Organ-specific eosinophil disorders occur in the skin, lung, and gastrointestinal tract.[4–6] Eosinophils are conspicuous in tissue sections stained with hematoxylin and eosin because of their intense avidity for eosin dye. Common dermatoses associated with eosinophils in lesional tissues include arthropod bites and drug eruptions. Parasitic infections, especially those due to ectoparasites and helminthes, typically have a marked host response with eosinophilia.[7,8] Autoimmune blistering diseases, such as bullous pemphigoid and the various forms of pemphigus, often have prominent eosinophil infiltration, including histologic presentation as eosinophilic spongiosis.[9,10] Infiltration of eosinophils in the subcutaneous tissues, so-called eosinophilic panniculitis, is not a specific diagnosis but rather is seen to a variable degree in diverse entities.[11,12] Eosinophils may be found in Langerhans cell histiocytosis,[13] cutaneous epithelial neoplasms,[14] and lymphoproliferative disorders.[15] Although eosinophils constitute one of the histologic features in numerous cutaneous diseases, eosinophil infiltration represents a criterion for histologic diagnosis in relatively few entities (Table 36-1). The absence, presence or number of eosinophils in skin biopsy specimens is often of limited value in reliably choosing among differential diagnoses with different and potentially important implications for clinical management, such as drug reaction versus acute graft-versus-host disease.[16,17] Eosinophils play a role in certain categories of clinical reactions, particularly those characterized by edema.[18] The degree of tissue eosinophil granule protein deposition in such diseases, that exhibit relatively few or no intact eosinophils, suggests that the pathogenic influence of eosinophils may be unrelated to their numbers in tissues. The degree of cutaneous eosinophil infiltration should be taken in the context of other clinical features, other histological features, and knowledge that its diagnostic power has limitations.[19] However, eosinophils do have potent biological activities, particularly imparted by their distinctive granules, and eosinophils may play a pathogenic role in the absence of identifiable cells in tissues.

TABLE 36-1
Eosinophils in Cutaneous Diseases

- Diseases characterized by tissue eosinophils
  - Angiolymphoid hyperplasia with eosinophilia
  - Eosinophilic, polymorphic, and pruritic eruption associated with radiotherapy
  - Eosinophilic pustular folliculitis
    - Classical (Ofugi disease)
    - Infantile/neonatal
    - Human immunodeficiency virus-associated
  - Erythema toxicum neonatorum
  - Eosinophilic ulcer of oral mucosa
  - Granuloma faciale
  - Hypereosinophilic syndromes
  - Kimura disease
  - Pachydermatous eosinophilic dermatitis
  - Wells syndrome (eosinophilic cellulitis)
- Diseases typically associated with tissue eosinophils
  - Arthropod bites and sting reactions
  - Bullous dermatoses
    - Pemphigoid
    - Pemphigus
    - Incontinentia pigmenti
  - Dermatoses of pregnancy
  - Drug reactions
    - DRESS (drug rash with eosinophilia and systemic symptoms)/drug hypersensitivity syndrome
    - Interstitial granulomatous drug reaction
  - Histiocytic diseases
    - Langerhans cell histiocytosis
    - Juvenile xanthogranuloma
  - Parasitic diseases/infestations
  - Urticaria and angioedema
  - Vasculitis
    - Churg-Strauss syndrome
    - Eosinophilic vasculitis
- Histological patterns defined by eosinophils
  - Eosinophilic spongiosis
    - Acute dermatitis
      - Allergic contact dermatitis
    - Arthropod bite
    - Immunobullous diseases
      - Pemphigoid
      - Pemphigus
    - Incontinentia pigmenti
  - Eosinophilic panniculitis
    - Arthropod bite
    - Erythema nodosum
    - Gnathostomiasis
    - Injection granuloma
    - Vasculitis
    - Wells syndrome
- Eosinophils of doubtful, limited or no value in histological diagnosis
  - Drug reaction versus graft-versus-host disease
  - Granuloma annulare
  - Interstitial granulomatous dermatitis
  - Neoplasms
    - Lymphoproliferative disorders (except HES types)
    - Keratoacanthoma

HYPEREOSINOPHILIC SYNDROMES

HYPEREOSINOPHILIC SYNDROMES AT A GLANCE

- Spectrum of entities defined by criteria (Table 36-2).
- Cutaneous lesions are common and may be the presenting sign.
- Two major hypereosinophilic syndromes (HES) subtypes and several variants.
  - Lymphocytic HES characterized by T-cell clones that produce interleukin 5.
    - Variant HES subtypes may evolve into lymphocytic HES.
      - Organ-restricted.
      - Associated with specific disorders such as Churg–Strauss syndrome.
      - Undefined with benign, complex, and episodic presentations.
    - Myeloproliferative HES associated with a deletion on chromosome 4 that produces a tyrosine kinase fusion gene *Fip1-like 1*/platelet-derived growth factor receptor-α or other mutation associated with eosinophil clonality.
      - Responsive to imatinib.
      - Severely debilitating mucosal ulcers portend a grim prognosis unless HES is treated.
      - Overlap with mastocytosis.
  - Familial HES variant, family history of documented persistent eosinophilia of unknown cause.
- Associated embolic events constitute a medical emergency.
- Eosinophilic endomyocardial disease occurs in HES and in patients with prolonged peripheral blood eosinophilia from any cause.

EPIDEMIOLOGY

The hypereosinophilic syndromes (HES) consist of a spectrum of disorders that occur worldwide and span all age groups. Over 90% of patients with myeloproliferative HES and the mutant gene are men, but lymphocytic HES shows equal gender distribution. The relative frequencies of these subtypes are unknown, although up to 25% of HES patients may have lymphocytic HES. Rare familial cases have been reported. A miniepidemic of eosinophilic esophagitis, a subtype of overlap HES with organ-restricted disease, emerged over the last decade with prevalence estimates as high as 1:2,500 among children and 1:4,000 among adults.[31,32]

ETIOLOGY

Eosinophils are implicated as the cause of most end-organ damage in all HES subtypes.[2,33] Clinical improvement usually parallels a decrease in eosinophil count. Patients with lymphocytic HES have abnormal T-cell clones with unusual surface phenotypes, including $CD3^+CD4^-CD8^-$ and $CD3^-CD4^+$. These T cells display activation markers, such as CD25, and secrete T helper 2 cytokines, including high levels of interleukin 5 (IL-5).[23,34] An 800-kilobase deletion on chromosome band 4q12 that codes for a tyrosine kinase has been found in myeloproliferative HES.[26] Patients with this *FIP1L1-PDGFRA* gene mutation form a distinct subset of HES, with cardiomyopathy and endomyocardial fibrosis, that responds to imatinib. Patients in this HES subset have elevated serum tryptase levels and increased atypical spindle-shaped mast cells in bone marrow.[27,28,35] Although they do not have clinical manifestations of systemic mastocytosis or exhibit all its immunological markers, these patients satisfy criteria for mastocytosis.[36] The *FIP1L1-PDGFRA* gene is detected in mast cells,[37] eosinophils, neutrophils, and mononuclear cells. Many HES patients also have marked neutrophilia, likely due to the aberrant gene in the neutrophil lineage. Thus, alteration of several cell lines probably contributes to the pathogenesis of myeloproliferative HES.[38,39] Multiple other chromosomal abnormalities have been identified in myeloproliferative HES, including translocations, partial and complete chromosomal deletions, and trisomies 8, 15, and 21. Myeloproliferative HES with documented mutations also is known as chronic eosinophilic leukemia. The World Health Organization has an updated 2008 classification scheme for myeloid disorders and eosinophilia.[40,41] The etiology of the other HES variants is not well understood, although patients in several HES subtypes, including with episodic angioedema and eosinophilia [Gleich syndrome[42]; see section "Episodic Angioedema Associated with Eosinophilia (Gleich Syndrome)"] and the nodules, eosinophilia, rheumatism, dermatitis, and swelling (NERDS) syndrome,[43] have developed T-cell clones.[30]

TABLE 36-2
Revised Diagnostic Criteria for Hypereosinophilic Syndromes[30]

1. Blood eosinophilia greater than 1500 eosinophils/mm^3 on at least two separate determinations or evidence of prominent tissue eosinophilia associated with symptoms and marked blood eosinophilia
2. Exclusion of secondary causes of eosinophilia, such as parasitic or viral infections, allergic diseases, drug- or chemical-induced eosinophilia, hypoandrenalism, and neoplasms

Original Criteria[21]

- Peripheral blood eosinophilia of at least 1,500 eosinophils/mm^3
  - Longer than 6 months; or
  - Less than 6 months with evidence of organ damage.
- Signs and symptoms of multiorgan involvement.
- No evidence of parasitic or allergic disease or other known causes of peripheral blood eosinophilia.

CLINICAL FINDINGS AND COURSE

Patients satisfying HES diagnostic criteria (Table 36-2) present with signs and symptoms related to the organ systems infiltrated by eosinophils.[44–46] HES often present with skin lesions[47,48] that may be the only manifestations of HES.[49–51] Pruritic erythematous macules, papules, plaques, wheals, or nodules are present in over 50% of patients.[52] Lesions may involve the head, trunk, and extremities. Urticaria and angioedema occur in all HES subtypes and are characteristic of certain variant subtypes. Erythema annulare centrifugum,[53–55] bullous pemphigoid,[56] lymphomatoid papulosis,[57] livedo reticularis, purpura and/or other signs of vasculitis,[58–61] Wells syndrome (eosinophilic cellulitis),[62,63] and multiple other mucocutaneous manifestations[48] may be found in patients with HES (Table 36-3).

In myeloproliferative HES, the usual presenting complex includes fever, weight loss, fatigue, malaise, skin lesions, and hepatosplenomegaly.[29,46,64,65] Mucosal ulcers of the oropharynx or anogenital region (Fig. 36-1) portend an aggressive clinical course; death is likely within 2 years of presentation if the disorder is untreated.[64,66] Cardiac disease occurs frequently.[67] Eosinophils adhere to endocardium and release granule proteins onto endothelial cells, thrombus formation follows, and, finally, subendocardial fibrosis with restrictive cardiomyopathy occurs. Mitral or tricuspid valvular insufficiency results from tethering of chordae tendineae.[67] Cardiac abnormalities that are essentially identical to those of HES but are confined to the intramural regions can occur without appreciable peripheral blood eosinophilia.[68,69] Splinter hemorrhages and/or nail fold infarcts may herald the onset of thromboembolic disease. The central and peripheral nervous system, lungs, and, rarely, kidneys may be affected.[46] Patients with myeloproliferative HES frequently present with clinical features resembling those of chronic myelogenous leukemia and, depending on

TABLE 36-3
Mucocutaneous Manifestations in Hypereosinophilic Syndromes

Angioedema
Bullae (bullous pemphigoid)
Dermographism
Digital gangrene
Eczema
Eosinophilic cellulitis (Wells syndrome)
Erosions
Erythema
Erythema annulare centrifuge
Erythroderma
Excoriations
Livedo reticularis
Lymphomatoid papulosis
Macules
Mucosal ulcers (oral and genital)
Nail fold infarctions
Necrosis
Nodules
Papules
Patches
Pruritus
Purpura
Raynaud phenomenon
Splinter hemorrhages
Ulcers
Urticaria
Vasculitis

(Modified from Leiferman KM, Gleich GJ, Peters MS: Dermatologic manifestations of the hypereosinophilic syndromes. *Immunol Allergy Clin North Am* **27**(3):415-441, 2007 and Stetson CL., Leiferman, KM: Chapter 26, Eosinophilic dermatoses. In: *Dermatology*, 2nd edition, edited by JL Bolognia, J Jorizzo, RP Rapini, TD Horn, AJ Mancini, JM Mascaro, SJ Salasche, J-H Saurat, G Stingl. Mosby, St. Louis 2008. pp. 369-378).

the classification, are regarded as having chronic eosinophilic leukemia. Although chromosomal abnormalities characterize this subtype and the disease may evolve into definite leukemia, the relatively mature nature of the eosinophils and lack of evidence for clonal expansion may preclude such classification.

Lymphocytic HES commonly is associated with severe pruritus, eczema, erythroderma, urticaria, and angioedema, as well as lymphadenopathy and, rarely, endomyocardial fibrosis.[34] In contrast to myeloproliferative HES, lymphocytic HES generally follows a benign course, and T-cell clones can remain stable for years. Patients should be observed closely and regarded as having premalignant or malignant T-cell proliferation, because the disease may evolve into lymphoma.

Churg–Strauss syndrome (see Chapter 164) is a variant HES subtype. Other variant HES subtypes include Gleich syndrome[42] [see section "Episodic Angioedema Associated with Eosinophilia (Gleich Syndrome)"], in which eosinophil counts fluctuate with extreme angioedema.

During the decade or more after diagnosis, HES may evolve into acute leukemia and, less commonly, has been associated with B-cell lymphomas. The overall 5-year survival rate for HES patients is 80%; congestive heart failure from the restrictive cardiomyopathy of eosinophilic endomyocardial disease is a major cause of death, followed by sepsis.

LABORATORY TESTS

A key criterion for diagnosis is marked peripheral blood eosinophilia (see Table 36-2).[44,70–72] Other causes of eosinophilia, including allergic and parasitic diseases, should be excluded. Tests to detect organ involvement, particularly measurement of liver enzyme levels, are important. Because eosinophilic endomyocardial disease can develop in any patient with prolonged peripheral blood eosinophilia, patients should undergo periodic echocardiography along with close observation for signs of thromboembolism. Increased serum levels of immunoglobulin E (IgE) are often present in lymphocytic HES, and levels of vitamin B_{12} and tryptase may be increased in myeloproliferative HES. The Chic2 fluorescent in situ hybridization assay detects the deletion that produces the *FIP1L1-PDGFRA* gene product and should be performed, because patients with this mutation respond to treatment with imatinib.[35,37] Alternatively, the mutant gene can be detected by a polymerase chain reaction assay. Both tests are available commercially. In patients who lack the fusion gene, testing for other clonal



Figure 36-1 Hypereosinophilic syndrome. Mucosal erosions and ulcers of the mouth (**A**) and glans penis (**B**); conjunctival irritation (**C**).

cytogenetic abnormalities or abnormal clonal T-cell populations is warranted.[27] Cytoflow of peripheral blood lymphocytes and immunophenotyping of tissue lymphocytes should be performed for the diagnosis of lymphocytic HES and repeated periodically to detect transformation from a variant HES type to lymphocytic HES or to T-cell lymphoma.[34] An HES evaluation assessment scheme for patients with eosinophilia is presented in Table 36-4.

The cutaneous histopathological features of HES vary with the type of lesion. Skin biopsy specimens from urticarial lesions resemble idiopathic urticaria, with generally mild, nonspecific perivascular and interstitial infiltration of lymphocytes, eosinophils, and, occasionally, neutrophils. Immunostaining reveals extensive deposition of eosinophil granule proteins, in the absence of intact eosinophils, in episodic angioedema with eosinophilia,[42] HES with mucosal ulcers,[73] and in synovial tissues in NERDS.[43] Other than in Churg–Strauss syndrome, vasculitis only rarely has been associated with HES.[58–60]

DIFFERENTIAL DIAGNOSIS

(Box 36-1)

Clinically, parasitic infections and infestations may closely resemble HES.[74] A history of travel to endemic areas or certain dietary exposure implicates helminthiasis. Along with eosinophilia, total serum IgE levels higher than 500 IU/mL commonly are found in helminthic infections. Examination of stool samples for ova and parasites and serologic testing for *Strongyloides* antibodies should be performed. In patients with isolated urticarial plaques with or without angioedema, the differential diagnosis includes common and persistent urticaria,[75,76] but demonstration of multiorgan involvement supports HES. HES with episodic angioedema may resemble hereditary angioedema clinically, although patients with hereditary angioedema often have a family history of the disease rarely have the markedly elevated eosinophil counts that characterize HES, and may be distinguished by complement abnormalities. Pruritic eczematoid lesions of lymphocytic HES may resemble those of atopic dermatitis, contact dermatitis, drug reaction, fungal infection, and T-cell lymphoma. There are multiple diseases in the differential diagnosis of patients with orogenital ulcers,[64] including those associated with thrombosis, such as Behçet syndrome, Crohn disease, ulcerative colitis, and Reiter syndrome. Others considerations are recurrent aphthous stomatitis, immunobullous diseases, erythema multiforme, lichen planus, herpes simplex infection, and syphilis.

TREATMENT

The goal of treatment is to relieve symptoms and improve organ function while keeping peripheral blood eosinophils at 1,000 to 2,000/mm^3 and

TABLE 36-4
Evaluation of Patients with Eosinophilia

- History
  - Attention to travel (parasite exposure)
  - Ingestants (drugs, health foods, food supplements, and food allergy)
  - Close contacts with itch (ectoparasites)
- Physical examination
  - Cutaneous features (see Table 36-3)
  - Cardiovascular signs
    - Murmur of mitral insufficiency
    - Nails for splinter hemorrhage (medical emergency)
  - Hepatosplenomegaly
  - Lymphadenopathy
- Laboratory studies
  - Repeated complete blood counts with differentials
  - Cytogenetics for chromosomal abnormalities to include
    - *FIP1L1-PDGFRA* (*CHIC2* gene) deletional mutation
    - T cell subsets for clonality by cytoflow/T cell receptor gene rearrangement
  - B cell clonality analyses
  - Inflammatory and immunological markers
    - Erythrocyte sedimentation rate
    - C-reactive protein
    - Rheumatoid factor
    - Antiproteinase 3 and antimyeloperoxidase (c-ANCA and p-ANCA)
    - IgE level
    - Strongyloides IgG antibody
    - Interleukin-5 serum level
  - Metabolic parameters
    - Liver function tests to include aspartate aminotransferase and alanine aminotransferase
    - Renal function tests to include creatinine, blood urea nitrogen and urinanalysis for protein and sediment
    - Muscle enzymes to include creatine phosphokinase and aldolase
    - B12 serum level
    - Mast cell/basophil tryptase (protryptase) level
    - Coagulation factors
  - Troponin (before initiation of imatinib treatment)
  - Serum protein analyses
    - Serum protein electrophoresis
    - Quantitative immunoglobulins
    - Immunofixation electrophoresis for monoclonal proteins
- Imaging tests
  - Echocardiography
  - Computerized axiotomography of chest, abdomen, and pelvis
- Gastrointestinal endoscopy, as indicated
- Pulmonary function tests, as indicated
- Bone marrow aspirate and biopsy with staining for tryptase and reticulum (myelofibrosis)
- Tissue biopsy of skin and/or other accessible affected organs
  - Histological examination
  - Direct immunofluorescence for immunobullous disease
  - Immunostaining for eosinophil granule proteins

Modified from Gleich GJ, Leiferman KM: The hypereosinophilic syndromes: Current concepts and treatments. *Br J Haematol* **145**(3):271-285, 2009.

BOX 36-1 DIFFERENTIAL DIAGNOSIS HYPEREOSINOPHILIC SYNDROMES

Parasitic infection	Behçet syndrome
Ectoparasitic infestation	Crohn disease
Urticaria	Ulcerative colitis
Hereditary angioedema	Reiter syndrome
Atopic dermatitis	Recurrent apthous stomatitis
Contact dermatitis	Erythema multiforme
Drug reaction	Lichen planus
Fungal infection	Immunobullous disease
Mycosis fungoides	Herpes simplex infection
Sézary syndrome	Syphilis

minimizing treatment side effects (Fig. 36-2). Recent reviews have delineated evaluation and management of HES.[29,70–72,77] Myeloproliferative HES is responsive to imatinib.[78] In patients with the mutant gene *FIP1L1-PDGFRA*, administration of imatinib mesylate is indicated and usually induces hematologic remission, but endomyocardial disease may worsen during the first several days of treatment. Troponin levels should be monitored before and during imatinib therapy.[79,80] To improve cardiac function, glucocorticoids should be given before and with initiation of imatinib therapy. Imatinib resistance can develop.[81–83] In the absence of the gene mutation, after *Strongyloides* infection has been excluded,[84] first-line therapy is prednisone. Approximately 70% of patients will respond, with peripheral eosinophil counts returning to normal. Patients for whom glucocorticoid monotherapy fails have a worse prognosis generally; in such cases or when long-term side effects become problematic, other treatments should be used. Effective treatment of HES in imatinib-responsive patients results in improvement of associated conditions including cardiac involvement with endocarditis[85] and myelofibrosis[86] and skin disease with bullous pemphigoid.[56] Patients who have features of myeloproliferative HES but who lack *FIP1L1-PDGFRA* still may respond to imatinib.[25] Interferon (IFN)-α has been beneficial in treating myeloid and lymphocytic HES.[87,88] In one patient, loss of the *FIP1L1-PDGFRA* mutation after several years of IFN-α therapy was associated with complete remission.[89] Extracorporeal photopheresis alone or in combination with IFN-α or other therapies represent additional therapeutic options. Other treatments for HES with reported benefit include hydroxyurea, dapsone, vincristine sulfate, cyclophosphamide, methotrexate, 6-thioguanine, 2-chlorodeoxyadenosine and cytarabine combination therapy, pulsed chlorambucil, etoposide, cyclosporine, intravenous immunoglobulin, and psoralen plus ultraviolet A (UVA) phototherapy.[90] Refractory disease may respond to infliximab (antitumor necrosis factor-α)[91] or alemtuzumab (anti-CD52),[92–94] as well as to bone marrow and peripheral blood stem cell allogeneic transplantation.[95,96] Two monoclonal antibodies against human IL-5 have been associated with clinical improvement and reductions in peripheral blood and dermal eosinophils, particularly in patients with lymphocytic HES.[97–101] Treatments targeting IL-5 have provided new insights into understanding eosinophil-associated disease.[33]

WELLS SYNDROME

WELLS SYNDROME (EOSINOPHILIC CELLULITIS) AT A GLANCE

- Single or multiple lesions commonly located on the extremities or trunk.
- Lesions may be painful or pruritic.
- Associated with general malaise but uncommonly with fever.
- Edematous and erythematous lesions evolve into plaques with violaceous borders.
- Blisters may be a prominent feature.
- Individual lesions persist for weeks and gradually change from red to blue–gray or greenish gray, resembling morphea.
- Multiple recurrences.
- Peripheral blood eosinophilia common.
- Histological pattern characterized by dermal infiltration with eosinophils, and flame figures surrounded by histiocytes.
- Systemic glucocorticoids usually therapeutic.

CLINICAL FINDINGS AND COURSE

Cutaneous edema was the common clinical thread in the first four cases reported by Wells.[102] After prodromal burning or itching, lesions begin with erythema and edema (Fig. 36-3A), sometimes in the form of annular or arcuate plaques or nodules. Over a period of days, they evolve into large edematous plaques with violaceous borders. Bullae may develop.[108,109,120,139] Individual lesions gradually change from bright red to brown–red and then to blue–gray or greenish gray, resembling morphea (Fig. 36-3B). Less common clinical presentations include papules, vesicles (Fig. 36-4), and hemorrhagic bullae. The cutaneous lesions may be single or multiple and may be located at any site, but typically involve the extremities and, less often, the trunk.[137] The most frequent systemic complaint in patients with Wells syndrome is malaise; fever occurs in a minority of cases. Lesions resolve without scarring, usually within weeks to months, but multiple recurrences are common.

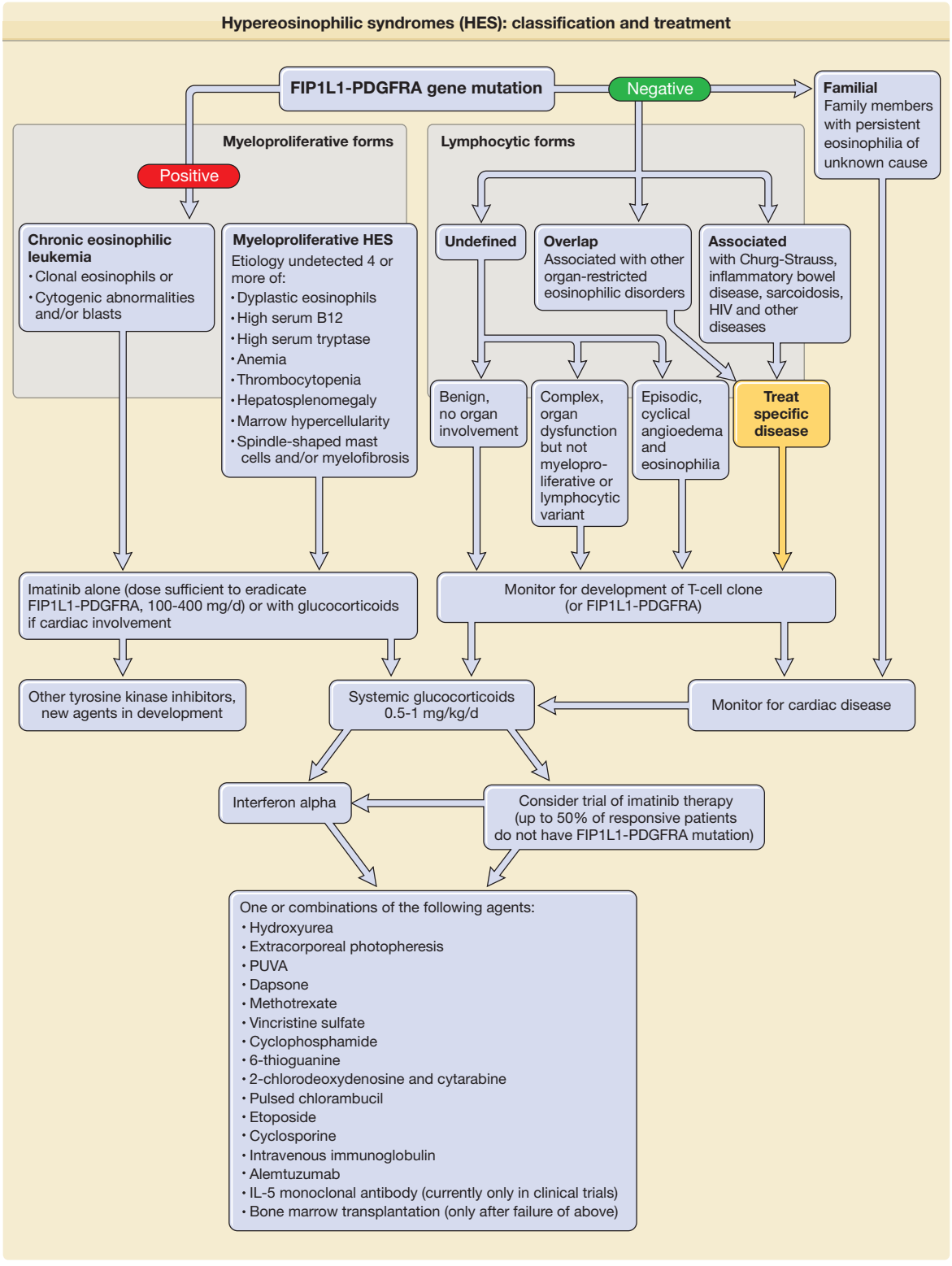

Figure 36-2 Hypereosinophilic syndromes (HES): classification and treatment. Provisional classification consists of myeloproliferative, lymphocytic and familial forms of HES. Chronic eosinophilic leukemia with clonal eosinophilia and myeloproliferative HES with features of the disease but without proof of clonality are included in the myeloproliferative forms of HES; HES with eosinophil hematopoietin-producing T-cells with or without a documented T-cell clone constitute the lymphocytic forms of HES. Further HES classification refinement expected in near future from a multidisciplinary consensus compendium in preparation. *FIP1L1-PDGFRA*, Fip1-like 1/platelet-derived growth factor receptor-α; HIV, human immunodeficiency virus; IL-5, interleukin 5; PUVA, psoralen plus ultraviolet A phototherapy. Further classification revisions likely in near future. (Information from Roufosse F, Weller PF: Practical approach to the patient with hypereosinophilia. *J Allergy Clin Immunol* **126**(1):39-44, 2010; Klion AD: Approach to the therapy of hypereosinophilic syndromes. *Immunol Allergy Clin North Am* **27**(3):551-560, 2007; and Stetson CL, Leiferman KM: Chapter 26: Eosinophilic dermatoses. In: *Dermatology*, 2nd edition, edited by JL Bolognia, J Jorizzo, RP Rapini, TD Horn, AJ Mancini, JM Mascaro, SJ Salasche, J-H Saurat, G Stingl. Mosby, St. Louis, 2008. pp. 369-378.)



Figure 36-3 Wells syndrome. **A.** Early lesion with erythema and edema. **B.** Late lesion resembling morphea.

LABORATORY TESTS AND HISTOPATHOLOGY

Peripheral blood eosinophilia is observed in approximately 50% of patients. Skin lesions histologically are characterized by diffuse dermal infiltration with eosinophils, histiocytes, and foci of amorphous and/or granular material associated with connective tissue fibers, which Wells termed *flame figures*.[102] In the early stages, there also is dermal edema. Later, histiocytes palisade around flame figures. In addition to eight patients with the syndrome, the 1979 report of Wells and Smith includes nine patients with the typical histologic features of eosinophilic cellulitis but in association with a variety of clinical diagnoses, including pemphigoid, eczema, and tinea.[103] This and subsequent reports of flame figures in lesions from patients with a wide spectrum of diseases (see Table 36-5 and referenced above) indicate that the flame figure is characteristic for, but not diagnostic of, Wells syndrome.[105] When examined for eosinophil granule major basic protein by immunofluorescence, flame figures show bright extracellular staining (Fig. 36-5), indicating that extensive eosinophil degranulation has occurred.[113]



Figure 36-4 Familial Wells syndrome. Plaques with erythema, edema, vesicles, and bullae resembling acute dermatitis or pemphigoid. (From Davis MD et al: Familial eosinophilic cellulitis, dysmorphic habitus, and mental retardation. *J Am Acad Dermatol* **38**:919, 1998, with permission.)

TABLE 36-5
Conditions Associated with Wells Syndrome and/or Flame Figures

Arthropod bite
Ascariasis
Bronchogenic carcinoma
Churg–Strauss syndrome
Colonic adenocarcinoma
Dental abscess
Dermographism
Drug reaction
Eczema
Eosinophilic fasciitis
Eosinophilic pustular folliculitis
Herpes gestationis
Herpes simplex infection
Human immunodeficiency virus
Hymenoptera sting
Hypereosinophilic syndromes
Immunobullous diseases
Mastocytoma
Molluscum contagiosum
Myeloproliferative diseases
Onchocerciasis
Vaccinations
Tinea
Toxocariasis
Urticaria
Ulcerative colitis
Varicella

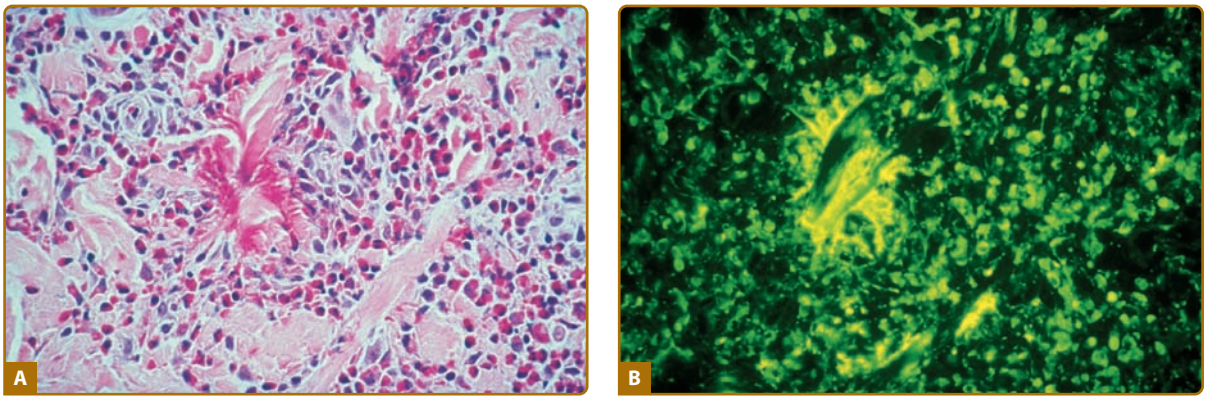

Figure 36-5 Flame figure in familial Wells syndrome. **A.** Hematoxylin- and eosin-stained section. **B.** Eosinophil granule major basic protein immunostain (of serial section to **A**) shows extensive granule protein deposition localized to the flame figure. (Original magnification ×400.)

DIFFERENTIAL DIAGNOSIS

(Box 36-2)

Urticaria, erysipelas, and acute cellulitis should be considered in the differential diagnosis of the early stages of Wells syndrome (see Fig. 36-3A). Later, plaques may resemble morphea (see Fig. 36-3B). The presence of blisters may suggest pemphigoid (see Fig. 36-4). Flame figures are the hallmark of Wells syndrome, but, because they have been identified in biopsy specimens from other dermatoses (Table 36-5), they are not alone sufficient for the diagnosis. However, a diagnosis of Wells syndrome in the absence of flame figures should be met with skepticism, even in the presence of dermal infiltration with eosinophils and histiocytes.[105]

TREATMENT

Wells syndrome usually improves dramatically after administration of systemic glucocorticoids, and tapering of steroid dose over 1 month is well tolerated in most patients. Recurrences may be treated with additional courses of systemic glucocorticoids. For patients who fail to respond, or who experience relapse often enough to raise concerns about the long-term side effects of systemic glucocorticoid therapy, other options such as minocycline, dapsone, griseofulvin, and antihistamines may be beneficial. Cyclosporine and IFN-α also have been used with success. For treatment of mild disease, topical glucocorticoids may be sufficient.

BOX 36-2 DIFFERENTIAL DIAGNOSIS WELLS SYNDROME

Urticaria
Erysipelas
Acute cellulitis
Pemphigoid
Morphea

ANGIOLYMPHOID HYPERPLASIA WITH EOSINOPHILIA (EPITHELIOID HEMANGIOMA)

EPIDEMIOLOGY

Angiolymphoid hyperplasia with eosinophilia (ALHE) occurs in both males and females, but there is a slight female predominance. Patients are generally in the third to fifth decade of life. In contrast to Kimura disease (KD), which develops mainly in patients from Asia, ALHE has no racial predilection.

ETIOLOGY

The pathogenesis of ALHE is unknown, but it has been considered a vascular proliferation arising in response to or in association with underlying vascular malformation. There is a history of trauma in some cases. ALHE has been reported to occur in pregnancy, which implies that sex hormones may be a factor in its development.[145] ALHE also has developed in patients with T-cell clonality, which suggests that it may be an early or low-grade T-cell lymphoma and further highlights a relationship between T-cells and eosinophils, particularly T-cells with the TH2 phenotype.[146,147]

CLINICAL FINDINGS AND COURSE

ALHE shows a predilection for the head and neck area, including the ears,[148] and is characterized by solitary, few, or multiple, sometimes grouped, erythematous, violaceous or brown papules, plaques, or nodules of the dermis and/or subcutaneous tissues (see Chapter 146). Lesions may be associated with pruritus or pain, or may pulsate. Although they are confined to the skin in most patients, mucosal involvement may occur.[149] ALHE tends to be chronic and nonremitting over months to years.

ANGIOLYMPHOID HYPERPLASIA WITH EOSINOPHILIA (EPITHELIOID HEMANGIOMA) AND KIMURA DISEASE AT A GLANCE

- Kimura disease (KD) occurs mainly in Asian males; angiolymphoid hyperplasia with eosinophilia (ALHE) occurs in all races, with a female predominance.
- KD is found in a younger age group than ALHE.
- Characterized by recurrent dermal and/or subcutaneous lesions, primarily of the head and neck area.
  - ALHE lesions tend to be smaller, more superficial, and more numerous than those of KD.
  - KD tends to involve subcutaneous tissues, regional lymph nodes, and salivary glands.
- ALHE may be painful, pruritic, or pulsatile, whereas KD is generally asymptomatic.
- Peripheral blood eosinophilia present in both diseases.
- Increased immunoglobulin E levels are found only in KD.
- Renal disease is associated only with KD (reported incidence of 10% to 20%).
- Histopathological features:
  - Dominant feature of KD is lymphoid proliferation, often with germinal centers, whereas ALHE is characterized by vascular proliferation with numerous large epithelioid or histiocytoid endothelial cells.
  - Fibrosis is characteristic of KD and is limited or absent in ALHE.
  - Inconspicuous to numerous eosinophils in ALHE.
  - Eosinophil abscesses may occur in KD.

LABORATORY TESTS AND HISTOPATHOLOGY

Approximately 20% of patients have peripheral blood eosinophilia; IgE levels are unremarkable. There is no association with renal disease. The dominant histological feature is a well-defined area, in the dermis and/or subcutis, of prominent vascular proliferation with large epithelioid or histiocytoid endothelial cells that contain abundant eosinophilic cytoplasm, often with cytoplasmic vacuoles (see Chapter 147). There are variable numbers of eosinophils and lymphocytes,[150] with an occasional finding of lymphoid nodules. In their report of 116 patients with ALHE, Olsen and Helwig found 53 cases in which "an arterial structure" appeared to be associated with venules or "was the area of endothelial proliferation," which provided evidence that these lesions may represent a form of arteriovenous shunt.[151] The stroma typically is myxoid, and fibrosis is minimal or absent. Mast cells may be a component of the histologic picture.



Figure 36-6 Angiolymphoid hyperplasia with eosinophilia. **A.** Forehead nodule. **B.** Recurrence of lesions in skin graft and adjacent sites 6 years after surgical removal of lesion in **A**.

BOX 36-3 DIFFERENTIAL DIAGNOSIS ANGIOLYMPHOID HYPERPLASIA WITH EOSINOPHILIA

Kimura disease
Pyogenic granuloma
Epithelioid hemangioendothelioma
Epithelioid angiosarcoma
Kaposi sarcoma

DIFFERENTIAL DIAGNOSIS

(Box 36-3)

Lesions of ALHE generally are smaller, more superficial, and more numerous than those of KD, and often are symptomatic. Although lymphoid follicles may occur in ALHE, they represent the dominant characteristic of KD (Table 36-6), and although KD may exhibit some vascularity, it lacks the large epithelioid endothelial cells that are a key feature of ALHE (see Table 36-6). ALHE should be distinguished from a variety of benign and malignant vascular proliferations, including pyogenic granuloma, epithelioid hemangioendothelioma, and Kaposi sarcoma—all of which lack a noticeable eosinophil infiltrate.

TREATMENT

Intervention is dictated in part by the number, location, size of lesions, and the patient's general health.[152] Patients with solitary or a few small lesions may benefit from excision or Mohs surgery, [153] but there may be recurrence at the surgical site (see Fig. 36-6). A variety of other treatment modalities have been used with success, including systemic and intralesional glucocorticoid administration, INF-α therapy,[154] cryotherapy,[155] laser therapy,[156] and topical application of tacrolimus.[157]

BOX 36-4 DIFFERENTIAL DIAGNOSIS KIMURA DISEASE

Angiolymphoid hyperplasia with eosinophilia
Lymphoma

KIMURA DISEASE

(Box 36-4)

TREATMENT

Surgical excision is the treatment of choice when feasible in patients with a single or a limited number of nodules, but lesions may recur.[167,168] Other therapeutic options include systemic glucocorticoids, cyclosporine, and radiation therapy.[169,170] The presence of renal disease may influence or dictate the therapeutic regimen. The finding of platelet-derived growth factor-α and c-kit in tissues from KD patients suggests that imatinib or another tyrosine kinase inhibitor may be effective in the disease.[171]

EOSINOPHILIC PUSTULAR FOLLICULITIS

CLINICAL FINDINGS AND COURSE

Classical EPF presents as recurrent crops or clusters of follicular papules and pustules, which may form an

TABLE 36-6
Comparison of Angiolymphoid Hyperplasia with Eosinophilia (ALHE) and Kimura Disease (KD)

	ALHE	KD
Gender	Typically middle-aged females	Predominantly young adult males
Symptoms	Pruritus, pain, pulsation	Asymptomatic
Lesion type and location	Small and superficial, with overlying erythema; head and neck region	Large, mainly subcutaneous; overlying skin normal; head and neck region; may involve regional lymph nodes and salivary glands
Lymphoid follicles	Uncommon	Prominent lymphoid follicles with germinal centers
Vascular proliferation	Prominent vascular proliferation with large epithelioid/histiocytoid endothelial cells; evidence of underlying vascular malformation may be evident	Some stromal vascularity with unremarkable endothelial cells
Fibrosis	Absent or limited	Prominent
Serum immunoglobulin E level	Normal	Increased
Nephropathy	Absent	Present in up to 20% of patients

EOSINOPHILIC PUSTULAR FOLLICULITIS AT A GLANCE

- Three clinical types, characterized by follicular papules and pustules that may involve the head, trunk, and extremities
  - Classic eosinophilic pustular folliculitis (Ofuji disease)
    - Typically occurs in Japanese patients, who have chronic, recurrent follicular pustules, with a tendency to form circinate plaques, in a seborrheic distribution
  - Eosinophilic pustular folliculitis associated with immunosuppression
    - Most often occurs in patients with human immunodeficiency virus infection, who have severely pruritic papules of the face and upper trunk
  - Eosinophilic pustular folliculitis of infancy/neonatal period
    - Follicular pustules of the scalp
- Tendency for recurrences and chronicity (except eosinophilic pustular folliculitis of infancy)
- Characterized by follicular and perifollicular eosinophil infiltration
- Associated with peripheral blood eosinophilia

annular pattern and usually resolve in 7 to 10 days. Lesions predominantly involve the face and trunk but also may affect the extremities, with involvement of the palms and soles in approximately 20% of patients.[177] In EPF of infancy, lesions typically are located on the scalp but also may be found on the face and extremities. In some neonates who have pustular eruptions that clinically resemble EPF and typically have peripheral blood eosinophilia, the disorder may be classified more appropriately under the term *eosinophilic pustulosis* because the cutaneous infiltrates are not folliculocentric (see Chapter 107).[202] In contrast, HIV-associated EPF tends to manifest as extremely pruritic discrete follicular papules, typically involving the head and neck and often the proximal extremities (see Fig. 198-3, Chapter 198). Rosenthal et al emphasized the urticarial quality of such lesions.[178] EPF of infancy has a good prognosis, whereas classical and HIV-associated EPF are characterized by recurrences. Postinflammatory pigmentation may be seen as lesions resolve, but scarring does not occur.

LABORATORY TESTS AND HISTOPATHOLOGY

Patients suspected of having EPF should be evaluated for underlying immune deficiency, particularly HIV infection. Peripheral blood eosinophilia is a component of all three types of EPF. Although patients with classical EPF usually have eosinophilia with leukocytosis, HIV-positive patients often exhibit eosinophilia with lymphopenia. Low CD4 cell counts and high IgE levels are typical of HIV-associated EPF.[178] Histologically, the most striking feature is the infiltration of eosinophils into hair follicles and perifollicular areas (see eFig. 36-6.2 in online edition), sometimes with follicular damage. The infiltrates also may contain lymphocytes and neutrophils, and may be perivascular as well as follicular.[203] Follicular mucinosis (see Chapter 145) has been noted in association with EPF[204]; however, T-cell clonality is not observed in EPF-associated follicular mucinosis.[205]

DIFFERENTIAL DIAGNOSIS

(Box 36-5)

Folliculitis secondary to bacterial or fungal infection must be kept in mind, particularly in immunosuppressed patients. Based on the distribution of lesions, seborrheic dermatitis should be considered, when there is head and neck involvement, and palmar–plantar pustular psoriasis may also be included in the differential diagnosis when there is hand and foot involvement. Acneiform eruptions may resemble EPF. Erythema toxicum neonatorum, acropustulosis, and acne neonatorum also should be considered in infants. Follicular mucinosis usually is clinically and histologically distinguishable from EPF.

TREATMENT

Topical glucocorticoids and topical calcineurin inhibitors generally are the first approach to the treatment of all types of EPF. Topical tacrolimus is helpful for facial lesions.[206] Nonsteroidal anti-inflammatory drugs, particularly indomethacin, also are recommended as first-line therapy; clinical improvement may be observed within 2 weeks and is associated with a decrease in peripheral blood eosinophil counts.[207–209] A mechanism

BOX 36-5 DIFFERENTIAL DIAGNOSIS EOSINOPHILIC PUSTULAR FOLLICULITIS

Folliculitis, bacterial or fungal
Seborrheic dermatitis
Palmar–plantar pustular psoriasis
Acne, including acne neonatorum
Erythema toxicum neonatorum
Acropustulosis
Follicular mucinosis

for this has been proposed based on the observation that indomethacin, not only inhibits cyclooxygenases and subsequent prostaglandin D2 synthesis, but also is associated with reduction in the prostaglandin D2 receptor (chemoattractant receptor homologous molecule expressed on TH2 cells, CRTH2) on eosinophils and lymphocytes.[210] UV light therapy (UVB or psoralen and UVA) may be beneficial. Topical permethrin, systemic retinoids, systemic glucocorticoids, cyclosporine, itraconazole, metronidazole, cetirizine, minocycline, dapsone, and IFNs have been tried with success.[207,208] Antiretroviral treatment that results in increased CD4 cell counts often is associated with improvement in HIV-associated EPF.

CLINICAL REACTION PATTERNS WITH EOSINOPHIL INVOLVEMENT

There are a variety of diseases in which eosinophils may be present in cutaneous lesions, with or without associated peripheral blood eosinophilia, but either the histologic pattern is unremarkable or eosinophils are not critical for the histological diagnosis of the given entity (see Table 36-1). In many of these dermatoses, the eosinophil loses its morphologic integrity after disruption through cytolysis and is not identifiable histologically.[216] However, toxic granule proteins and other phlogistic eosinophil products are deposited in skin, persist for extended periods of time, and cause tissue effects.[73,217]

EDEMA

Prominent among the eosinophil-associated skin reactions are those manifesting edema, including urticarias.[218–221] In addition to the presence of distinctive, toxic eosinophil cationic granule proteins in lesions, the ability of eosinophils to elaborate vasoactive mediators, induce histamine release from mast cells and basophils, and elicit a cutaneous wheal-and-flare reaction supports a role for the eosinophil as a primary participant in the edema associated with certain cutaneous diseases (see Chapter 31).[2,18]

EPISODIC ANGIOEDEMA ASSOCIATED WITH EOSINOPHILIA (GLEICH SYNDROME).

Episodic angioedema associated with eosinophilia is characterized by recurrent angioedema (with up to 30% increase in body weight), urticaria, fever, increased serum IgM levels, and leukocytosis as high as 100,000 cells/mm^3 with up to 90% eosinophils; disease activity fluctuates with the peripheral eosinophil count.[42,222] Skin biopsy specimens from this disorder[42] and its localized variant, recurrent facial edema with eosinophilia,[223] show few eosinophils, but immunofluorescence staining reveals extracellular deposition of eosinophil granule proteins around collagen bundles and blood vessels. The syndrome is associated with a number of immunologic abnormalities, including increased activated T cells[224,225] and increased serum IL-5 levels.[226,227] Capillary leak syndromes, due to administration of IL-2[228] and granulocyte-macrophage colony-stimulating factor,[229] also are associated with peripheral blood eosinophilia, increased serum IL-5 levels, and eosinophil degranulation.

CHRONIC DERMATITIS/PRURITUS

Although infestations typically are associated with eosinophils, the histologic pattern is nondiagnostic unless a specific organism is identified in tissue sections.[8,230] Infection with *Onchocerca volvulus* causes a pruritic dermatitis with lichenification, associated with slight cutaneous eosinophil infiltration but extensive deposition of eosinophil granule proteins throughout the dermis[231]; after treatment, extracellular deposition of eosinophil granule proteins is located around degenerating microfilaria.[230,232] Although eosinophils are rarely a prominent histological feature of atopic dermatitis, extensive dermal deposition of eosinophil granule proteins is seen in lesions (Fig. 36-7) but not in normal-appearing skin.[231,233] A link between

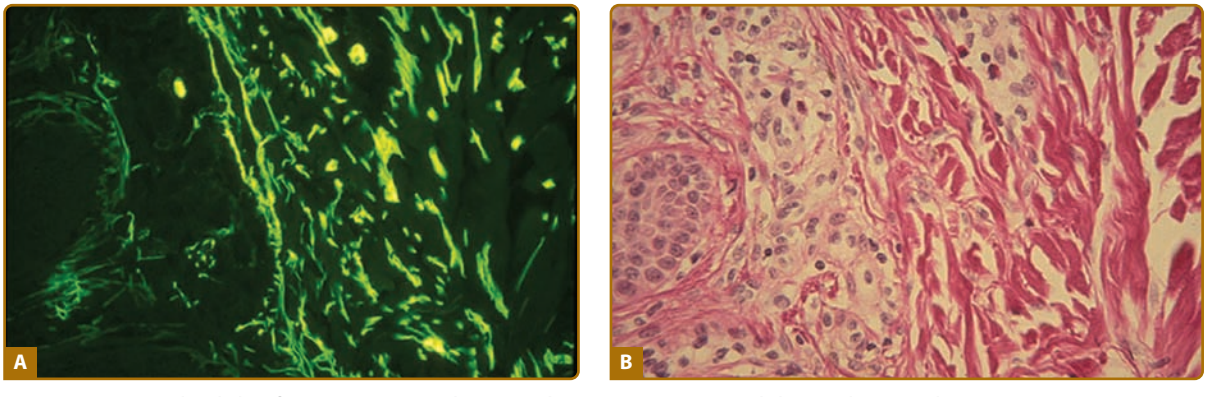

Figure 36-7 Involved skin from a patient with atopic dermatitis. **A.** Eosinophil granule major basic protein immunostain shows extensive extracellular granule protein deposition in the presence of only three intact eosinophils (brightly fluorescent ovals). **B.** Hematoxylin and eosin counterstain of **A** shows minimal nonspecific chronic inflammation. (**A** and **B** ×400, original magnification) (From Leiferman KM et al: Dermal deposition of eosinophil-granule major basic protein in atopic dermatitis. Comparison with onchocerciasis. *N Engl J Med* **313**:282, 1985, with permission).

keratinocytes and eosinophils in atopic dermatitis was reported through activity of a novel TH2 cytokine, IL-31.[234] Prurigo nodularis[235] and pachydermatous eosinophilic dermatitis[236] exhibit a pattern of dermal extracellular eosinophil granule protein deposition similar to that seen in atopic dermatitis and onchocercal dermatitis. In both atopic dermatitis and prurigo nodularis, eosinophil granule products are deposited around cutaneous nerves,[235,237] and there is evidence that eosinophils play a role in itch provocation.[238–242] A particularly difficult clinical presentation is the patient with intractable itching and peripheral blood eosinophilia. Such patients may satisfy criteria for the hypereosinophilic syndromes, but their itch is refractory to most therapies. Understanding the eosinophil's role in the pathogenesis of this disorder may help with identifying effective therapies.

DRUG REACTIONS

Eosinophils are found in all types of drug reactions. There is evidence that, when eosinophils are part of the histologic pattern in leukocytoclastic vasculitis, the eruption is probably drug-induced[243] (see Chapter 41). The drug reaction with eosinophilia and systemic symptoms syndrome, so-called DRESS and also known as drug hypersensitivity syndrome, is a serious multiorgan disorder. Many drugs induce DRESS, and a spectrum of skin lesions may present with DRESS. Eosinophils and other inflammatory cells infiltrate skin, lymph nodes, and organs, including the liver. Fulminant hepatitis is associated with a mortality rate of 10%, and transplanted livers may also be affected. Eosinophil infiltration with and without granulomas with hepatocyte necrosis and cholestasis are prominent in liver failure that occurs with DRESS.[244–246]

BLISTERS

Autoimmune blistering diseases (see Chapters 54 and 56) often are associated with prominent infiltration of eosinophils, including presentation as eosinophilic spongiosis (Fig 36-8), and extracellular deposition of eosinophil granule proteins. IL-5 and eotaxin are present in pemphigoid blister fluid, and eosinophil-derived matrix metalloproteinase 9 that likely cleaves basement membrane zone.[247,248, 249]

In addition to pemphigoid gestationis (which may exhibit eosinophilic spongiosis),[250] other pruritic dermatoses of pregnancy (see Chapter 108) may demonstrate tissue eosinophilia.[251–253]

FIBROSIS

Eosinophils are found in association with fibrotic reactions, including those resulting from parasitic infections, pulmonary and hepatic drug sensitivity reactions, and HES.[254] Eosinophils elaborate mediators (see Chapter 31) that degrade collagen and stimulate dermal fibroblast DNA synthesis and matrix production.[255]

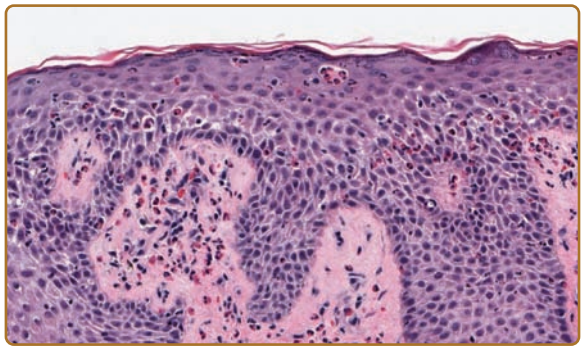

Figure 36-8 Eosinophilic spongiosis. There are eosinophils and intercellular edema within the epidermis. (Hematoxylin and eosin ×400, original magnification)

EOSINOPHILIC FASCIITIS. Eosinophilic fasciitis usually presents with pain, erythema, edema, and induration of the extremities, as well as peripheral blood eosinophilia and hypergammaglobulinemia.[256] Contractures and rippling of the skin may develop (Fig. 36-9). There is infiltration of lymphocytes, plasma cells, mast cells, and eosinophils, as well as increased thickness of the fascia.

EOSINOPHILIA–MYALGIA SYNDROME. Eosinophilia–myalgia syndrome (EMS), historically related to ingestion of certain lots of L-tryptophan,[257] is characterized by marked peripheral eosinophilia, disabling generalized myalgias, pneumonitis, myocarditis, neuropathy, encephalopathy, and fibrosis,[258] a constellation of features that are similar to but distinguishable from eosinophilic fasciitis.[259,260] Cutaneous abnormalities of EMS include edema, pruritus, a faint erythematous rash, hair loss, and *peau d'orange* or morphea-like skin lesions.[261] Lungs, heart, and nervous system may be affected.[262] There



Figure 36-9 Eosinophilic fasciitis. Puckered skin of the thighs.

is a prominent inflammatory infiltrate in the perimysium and fascia, and striking evidence of eosinophil granule protein deposition in skin and around muscle bundles.[257]

TOXIC OIL SYNDROME. Toxic oil syndrome (TOS), which resembles EMS, was linked to consumption of adulterated rapeseed oil distributed in the industrial belt around Madrid.[263] Patients experienced acute respiratory symptoms followed by intense myalgias, thromboembolism, weight loss, and sicca syndrome, followed by a chronic phase characterized by eosinophilic fasciitis-like lesions, peripheral neuropathy, muscle atrophy, and pulmonary hypertension. The cutaneous manifestations of TOS were nonspecific pruritic, erythematous skin lesions that persisted up to 4 weeks, followed over the next 2 months by subcutaneous edema, mainly of the extremities, accompanied by myalgias, arthralgias, contractures, and peripheral blood eosinophilia. Over many years, patients developed indurated plaques of the pretibial areas, and, occasionally, the forearms and abdomen,[263] with marked fibrosis extending into subcutaneous fat. Eosinophil infiltration and degranulation were especially prominent in the acute phase of TOS, and serum eosinophil granule protein levels were elevated during all phases.[264] Potential pathogenic links between TOS and EMS and also eosinophilic fasciitis have been identified.[265,266]

VASCULITIS

In 1951, Churg and Strauss described the complex of systemic vasculitis, asthma, and eosinophilia as *allergic granulomatosis*.[267] Cutaneous lesions develop in approximately two-thirds of cases and are variable consisting of nodules, urticaria, livedo reticularis, purpura, digital gangrene, and blisters. Histologically, the lesions are characterized by eosinophil infiltration, necrotizing vasculitis, and extravascular granulomas with prominent extracellular eosinophil granule protein deposition[268–270] (see Chapter 164). Granuloma faciale is characterized clinically by brown–red infiltrative plaques of the face and represents a localized type of necrotizing vasculitis that contains infiltration of eosinophils as well as neutrophils, lymphocytes, and histiocytes (see Chapter 34). Eosinophilic vasculitis (EV) is associated with peripheral blood eosinophilia and is characterized by chronic, recurrent, widespread pruritic, erythematous, purpuric papules as well as angioedema of face and hands; skin biopsies show necrotizing small vessel vasculitis with prominent infiltration of eosinophils.[271,272] EV may be idiopathic or associated with connective tissue disease,[273] Raynaud phenomenon, or HES.[58]

MALIGNANCY

Eosinophils may be observed in a variety of cutaneous and extracutaneous neoplasms. Their presence in tumors appears to be independent of immune surveillance and likely is part of an early inflammatory reaction at the site of tumorigenesis.[274] Various types of peripheral T-cell lymphomas are eosinophil-rich, including follicular mycosis fungoides and cutaneous anaplastic large cell lymphoma[275–277]; the prognostic significance of tissue eosinophilia in such lesions is not established. Underlying malignancy may prompt lesions associated with eosinophil infiltration, such as the exaggerated arthropod-bite reactions seen in patients with chronic lymphocytic leukemia.[278]

Eosinophilic, polymorphic and pruritic eruption associated with radiotherapy (EPPER) is an uncommon idiopathic disorder that appears in patients undergoing radiation treatment for malignancy. Women are affected more often than men. Onset of the eruption is typically during radiation treatment, but delays up to 7 months are reported.[279,280] Cutaneous findings are not localized to irradiated areas and may include local and generalized pruritus, erythematous papules, wheals, and vesicles and bullae. Eosinophils are prominent in affected skin, but not characteristically in the tumors.

KEY REFERENCES

Full reference list available at www.DIGM8.com

DVD contains references and additional content

1. Leiferman KM: A current perspective on the role of eosinophils in dermatologic diseases. *J Am Acad Dermatol* **24**(6 Pt 2):1101-1112, 1991
4. Simon D, Wardlaw A, Rothenberg ME: Organ-specific eosinophilic disorders of the skin, lung, and gastrointestinal tract. *J Allergy Clin Immunol* 2010
44. Roufosse F, Weller PF: Practical approach to the patient with hypereosinophilia. *J Allergy Clin Immunol* 2010
45. Ogbogu PU et al: Hypereosinophilic syndrome: A multicenter, retrospective analysis of clinical characteristics and response to therapy. *J Allergy Clin Immunol* **124**(6):1319-1325, e3, 2009
137. Moossavi M, Mehregan DR: Wells' syndrome: A clinical and histopathologic review of seven cases. *Int J Dermatol* **42**(1):62-67, 2003
138. Espana A et al: Wells' syndrome (eosinophilic cellulitis): Correlation between clinical activity, eosinophil levels, eosinophil cation protein and interleukin-5. *Br J Dermatol* **140**(1):127-130, 1999
150. Helander SD et al: Kimura's disease and angiolymphoid hyperplasia with eosinophilia: New observations from immunohistochemical studies of lymphocyte markers, endothelial antigens, and granulocyte proteins. *J Cutan Pathol* **22**(4):319-326, 1995
151. Olsen TG, Helwig EB: Angiolymphoid hyperplasia with eosinophilia. A clinicopathologic study of 116 patients. *J Am Acad Dermatol* **12**(5 Pt 1):781-796, 1985
160. Kung IT, Gibson JB, Bannatyne PM: Kimura's disease: A clinico-pathological study of 21 cases and its distinction from angiolymphoid hyperplasia with eosinophilia. *Pathology* **16**(1):39-44, 1984
166. Chong WS, Thomas A, Goh CL: Kimura's disease and angiolymphoid hyperplasia with eosinophilia: Two disease entities in the same patient: case report and review of the literature. *Int J Dermatol* **45**(2):139-145, 2006
176. Nervi SJ, Schwartz RA, Dmochowski M: Eosinophilic pustular folliculitis: A 40 year retrospect. *J Am Acad Dermatol* **55**(2):285-289, 2006
208. Fukamachi S et al: Therapeutic effectiveness of various treatments for eosinophilic pustular folliculitis. *Acta Derm Venereol* **89**(2):155-159, 2009

SECTION 6

Inflammatory Diseases Based on Abnormal Humoral Reactivity and Other Inflammatory Diseases

Chapter 37 :: Humoral Immunity and Complement

:: Lela A. Lee

HUMORAL IMMUNITY AND ANTIBODY STRUCTURE AT A GLANCE

- Humoral immunity, mediated by antibodies produced by B lymphocytes, is a form of specific immunity directed primarily toward extracellular antigens.
- Antibody molecules consist of two identical light chains covalently linked to two identical heavy chains. The variable region of the antibody molecule is responsible for antibody binding, and the constant region mediates most effector functions.
- The five antibody classes serve distinct functions. Immunoglobulin (Ig) M is involved in primary antibody responses, IgD is an antigen receptor on naive B cells, IgA is critical for mucosal immunity, IgG is the major Ig in the circulation and is important in secondary antibody responses, and IgE mediates immunity to parasites.
- An individual is capable of generating millions of distinct antibodies in millions of distinct B-cell clones through the processes of gene rearrangement and junctional diversity.

B LYMPHOCYTES

During evolution, jawed vertebrates developed the capacity to respond with exquisite specificity to foreign organisms.[1] Specific immunity is characterized by an enormous diversity of possible responses and by refinement in the immune response with successive exposures to the organism.[2] The cells that can discriminate with fine specificity through their vast repertoire of receptors are lymphocytes. Specific immunity, also called *adaptive immunity* because it develops as an adaptation to infection, can be segregated into humoral immunity, mediated by antibodies produced by B lymphocytes, and cellular immunity, mediated by T lymphocytes. These two forms of specific immunity developed to serve different functions. Humoral immunity is directed primarily toward extracellular antigens such as circulating bacteria and toxins. Cellular immunity is directed primarily toward antigens that infect or inhabit cells (see Chapter 10). To combat extracellular pathogens, the defending agent needs to be abundant and widely distributed in the body, particularly at its interfaces with the environment. Antibodies fulfill these characteristics by being capable of being secreted in great quantity from the cells that produce them and by being distributed in blood, mucosa, and interstitial fluid. In addition, antibodies can attach through Fc receptors (FcRs) to the surface of certain other cells of the immune system, such as mast cells, conferring antigen specificity to cells that do not have their own endogenously produced antigen-specific receptors. In addition to their major function in humoral immunity as antibody producers, B lymphocytes have a role in antigen presentation, regulation of T-cell subsets and dendritic cells, organization of lymphoid tissues, and cytokine and chemokine production.[3,4]

ANTIBODY STRUCTURE

Antibodies, or immunoglobulins (Ig), are a family of glycoproteins that share a common structure.[2,5,6] The antibody molecule has a symmetric Y-shape consisting of two identical light chains, each about 24 kDa, that are covalently linked to two identical heavy chains, each about 55 or 70 kDa, that are covalently linked to one another (Fig. 37-1). Within the light and heavy chains are variable and constant regions. The major function of the variable region is to recognize antigen, whereas the constant region mediates effector functions. The light and heavy chains contain a series of repeating, homologous units of about 110 amino acids that assume a globular structure and are called *Ig domains*. The Ig domain motif is found not only in antibody molecules but also in a variety of other molecules of the Ig "superfamily," including the T-cell receptor, the major histocompatibility complex (MHC), CD4, CD8, intercellular adhesion molecule 1, among other molecules. The light chain has two major domains, (1) a variable (V_L) and (2) a constant (C_L) domain. The heavy chains have four or five domains, a variable (V_H) and three (in IgA, IgD, and IgG) or four (in IgM and IgE) constant (C_H1–4) domains. In IgA, IgD, and IgG, there is a hinge region

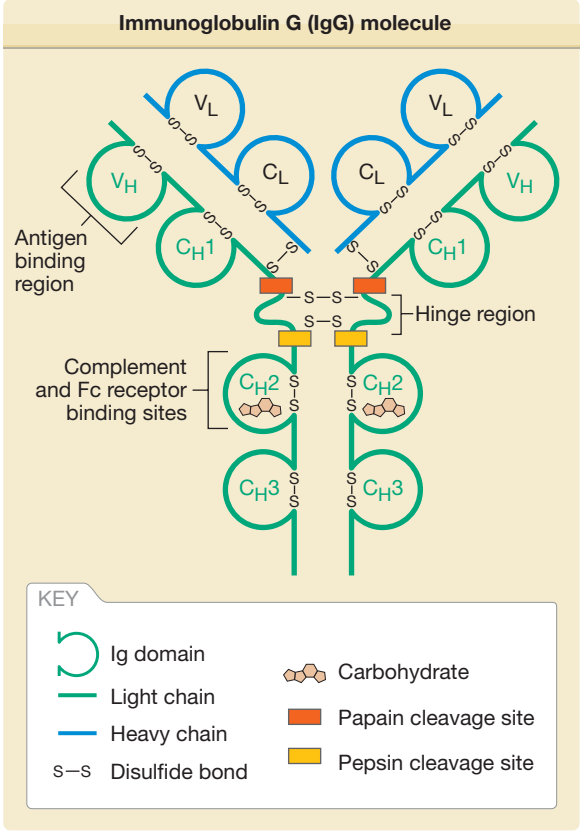

Figure 37-1 Schematic representation of an immunoglobulin G (IgG) molecule.

between C_H1 and C_H2 that confers additional flexibility to the molecule. The variable domains are at the *N*-terminus. At the *C*-terminus are the constant domains and, in the heavy chains of membrane-bound antibodies, the transmembrane and cytoplasmic domains.

Within the variable regions of the light and heavy chains are three areas of intense variability called *hypervariable regions*. These three regions, which are in proximity to one another in the three-dimensional structure of the antibody, are the areas most responsible for binding antigen. Because the hypervariable regions form a shape complementary to that of the antigen, the hypervariable regions are also called the *complementarity-determining regions*. The unique areas formed by the hypervariable regions are present in too low an amount in the individual to generate self-tolerance. Thus, the immune system may not distinguish the unique portion of the antibody as self and may produce antibodies to that region of the antibody. The area of the antibody capable of generating an immune response is called an *idiotope*, and antibody responses to idiotopes result in a network of idiotypic–anti-idiotypic interactions that may help regulate the humoral immune response.[7]

There are two types of light chains, κ and λ, each encoded on different chromosomes. Each antibody molecule has either two κ or two λ chains, never one of each. The functional differences, if any, between κ and λ are not known. There are five types of heavy chains, (1) α, (2) δ, (3) ε, (4) γ, and (5) μ, corresponding to the antibody classes IgA, IgD, IgE, IgG, and IgM, respectively. The different heavy chain classes have significantly different functions, as discussed in Section "Antibody Classes". The IgA and IgG classes contain closely related subclasses, consisting of IgA1 and IgA2, and IgG1, IgG2, IgG3, and IgG4 (Table 37-1).

Enzymatic digestion of IgG molecules by papain results in three cleavage products, two identical Fab fragments consisting of a light chain bound to the V–C_H1 region of the heavy chain and an Fc portion consisting of two C_H2–C_H3 heavy chains bound to each other. *Fab* was so named for its property of antigen binding, and *Fc* was so named for its property of crystallizing. When IgG is digested by pepsin, the *C*-terminal region is digested into small fragments. The remaining product consists of the Fab region along with the hinge region. Fab fragments containing the hinge region are termed Fab'. When the two Fab' fragments in an antibody molecule remain associated, the fragment is called $F(ab')_2$.

ANTIBODY CLASSES

(See Table 37-1)

IMMUNOGLOBULIN M

IgM is evolutionarily the most ancient antibody class and is the first Ig molecule to be expressed during B-cell development.[1] Its secretory form exists mainly as a pentamer consisting of five IgM molecules joined at their *C*-termini by tail pieces and stabilized by a molecule called a *joining (J) chain*. The engagement of membrane-bound IgM by antigen results in the activation of naive B cells. Secreted IgM recognizes antigen, usually through low-affinity interactions, and it can activate complement. IgM is the major effector of the primary antibody response. Although IgM interactions are typically low affinity, IgM can be very effective in responding to a polyvalent antigen (such as a polysaccharide with repeating epitopes) because its pentameric structure allows for multiple low-affinity interactions, resulting in a high-avidity interaction. (*Avidity* refers to the overall strength of attachment, whereas *affinity* refers to the strength of attachment at a single antigen-binding site.)

IMMUNOGLOBULIN D

The IgD molecule exists primarily in a membrane-bound form and is the second antibody class to be expressed during B-cell development. Its function is not completely understood, but in its membrane-bound form it can serve as an antigen receptor for naive B cells.[8] Secreted IgD has been found on the surface of basophils, where it induces production of antimicrobial, opsonizing, inflammatory, and B-cell–stimulating factors.[9]

IMMUNOGLOBULIN A

IgA is the most abundant Ig in the body, being present in large quantity at mucosal sites. It is responsible

TABLE 37-1
Immunoglobulin Classes and Their Functions

A	Subtypes	Secreted Form	Approximate Molecular Weight of Secreted Form (kDa)	Serum Concentration (mg/mL)	Serum Half-Life (Days)	Functions
IgM	None	Pentamer, hexamer	970	1.5	5	Primary antibody response; antigen receptor on naive B cells; complement activation
IgD	None	Monomer	180	Trace	3	Antigen receptor on naive B cells
IgA	IgA1	Monomer, polymer (usually dimer)	160 (monomer), 390 (secretory IgA)	3	6	Mucosal immunity; neonatal immunity
	IgA2	Monomer, polymer (usually dimer)	160 (monomer), 390 (secretory IgA)	0.5	6	
IgG	IgG1	Monomer	150	9	23	Neonatal immunity; opsonization; complement activation (except IgG4); phagocytosis; antibody-dependent cell-mediated cytotoxicity; feedback inhibition of B cells
	IgG2	Monomer	150	3	23	
	IgG3	Monomer	170	1	7	
	IgG4	Monomer	150	0.5	23	
IgE	None	Monomer	190	0.05	2	Immediate hypersensitivity; defense against parasites

Ig = immunoglobulin.

for mucosal immunity and is secreted in breast milk, thus contributing to neonatal immunity. In its secreted form, it exists as a monomer, dimer, or trimer, with the multimers being formed by interactions between tail pieces and stabilized by the J chain. For transport across epithelial surfaces, IgA dimers attach to a type of FcR called the *polymeric Ig receptor*.[10] Once the transport process is complete, the IgA dimers remain attached to the extracellular portion of the receptor, called the *secretory component*, which protects the IgA from proteolysis. Cells of the immune system that have receptors for IgA include neutrophils, eosinophils, and monocytes.

IMMUNOGLOBULIN G

IgG is the most abundant Ig in the circulation. Its secreted form is a monomer. IgG plays an important role in secondary antibody responses, and its interactions with antigen tend to be high affinity, particularly as the immune response matures. A number of cells have FcRs for IgG, including monocytes, neutrophils, eosinophils, natural killer (NK) cells, and B cells. IgG opsonizes (coats) antigen, allowing phagocytosis of the antigen, and activates complement. An exception is IgG4, which does not activate complement. IgG is important in neonatal immunity, as it is the only Ig class to cross the placenta, and it is secreted in breast milk. The interaction of IgG with the MHC class I-related receptor FcRn is involved in the delivery of IgG across the placenta as well as in prolonging its level in the circulation.[11] The serum half-life of IgG is 23 days, considerably longer than that of the other Ig classes.

IMMUNOGLOBULIN E

IgE is found in very small amounts in the circulation. High-affinity receptors for the Fc portion of IgE are present on mast cells, basophils, and eosinophils, and low-affinity receptors are present on B cells and Langerhans cells. In mast cells and basophils, IgE engagement with antigen activates the cells. IgE mediates immediate hypersensitivity, but its principal protective role may be to combat parasites.

MECHANISMS FOR THE GENERATION OF ANTIBODY DIVERSITY

The information encoded by an individual's DNA is limited by the need for the DNA to fit into a package of

the size of a cell. This space is far too small for sufficient DNA to encode billions of different lymphocyte receptors if the genes were encoded separately. Lymphocytes have adapted to this limitation by special mechanisms that increase by orders of magnitude the number of different possible antigen receptors.[12] Each clone of B cells produces identical antigen receptors (i.e., antibodies) with unique specificity. It is estimated that an individual has approximately 10^7 different B-cell clones, resulting in 10^7 distinct antibodies. A major mechanism for generating this enormous diversity is gene rearrangement, whereby segments of DNA within a lymphocyte undergo somatic recombinations.[13] Light chain genes contain three regions, (1) V (variable), (2) J (joining), and (3) C (constant), and heavy chain genes contain four regions, (1) V, (2) D (diversity), (3) J, and (4) C. Within each region are many gene segments from which to select for the final antibody product, which is comprised of one gene segment randomly selected from each region. The initial event in antibody formation is the joining of one D and one J segment from a heavy chain gene, with subsequent deletion of the DNA between the two segments. Next, a V segment is selected to join to the DJ segment, and any remaining D segments are deleted. The VDJ complex has attached 3′ to it any remaining J segments plus the C region. The unused J segments are removed during RNA processing. A similar process occurs in light chain loci; because there are no D segments in light chain loci, a VJ rather than a VDJ complex is formed. (Particularly in the k locus, VJ recombination may occur through a somewhat different mechanism involving inversion of the DNA without deletion of intervening sequences, but the functional result is the same.)

The ability to select one segment each from the many segments available in the V, D, and J regions leads to a vast increase in the repertoire of possible antibodies. Additional diversity is generated by the juxtaposition of a rearranged light chain to a rearranged heavy chain; by the addition, deletion, or transposition of nucleotides at the junctions between V and D, D and J, and V and J segments, a phenomenon called *junctional diversity*; and by somatic hypermutation after antigen stimulation (see below).

B-CELL MATURATION

Cells destined to become mature B cells undergo an orderly progression of events during development, resulting in the formation sequentially of heavy chains, light chains, and whole antibody molecules, with checkpoints to select against cells making unproductive gene rearrangements or autoreactive antibodies, and survival signals to select for cells making potentially useful antibodies. The process of B-cell development occurs in distinct stages, characterized by specific events and identifiable by specific cell surface markers and Ig gene expression.

Bone marrow and fetal liver stem cells that give rise to B cells are initially pluripotent.[2,14] Stem cells developing in the lymphocytic pathway initially become *common lymphoid progenitors*, which can give rise to B, T, or NK cells. B cells originating from fetal liver are mainly B1 cells (see Section "B-Cell Activation and Antibody Function"), whereas B cells originating in the bone marrow are primarily follicular B cells. Cells and extracellular molecules in the stromal microenvironment provide signals required for differentiation of lymphocytes. Induction of the transcriptional regulators EBF, E2A, and Pax-5 leads to the expression of proteins critical to B-cell development. Posttranscriptional regulation of mRNA by RNA-binding proteins and microRNAs provides further control over the process of B-cell differentiation.[15]

The earliest cell committed to the B-cell lineage is called a *pro-B cell*. At the pro-B cell stage, the cell expresses recombination activating gene (RAG) and terminal deoxyribonucleotidyl transferase (TdT) proteins, which will be needed subsequently for somatic recombination and nucleoside transfers involved in junctional diversity, respectively. At the pro-B-cell stage, limited somatic recombination has taken place, and Ig is not yet expressed.

The next stage of B-cell maturation is represented by the *pre-B cell* and is marked by the synthesis of a cytoplasmic μ heavy chain. Because light chains are not yet expressed at this stage, surface Ig is not present. Some of the μ heavy chains associate with invariant molecules called *surrogate light chains* and with the signal transducing proteins Ig α and Ig β to form complexes called *pre-B cell receptors*. Cells that have synthesized heavy chains that are capable of forming part of a pre-B cell receptor are selected for at this stage, as pre-B cell receptors provide important signals for survival, proliferation, and maturation.

The formation of light chains marks the next stage in B-cell maturation, the *immature B-cell* stage. When

B-CELL MATURATION AT A GLANCE

- The pro-B cell expresses enzymes needed for gene rearrangement and junctional diversity, but neither heavy nor light chains are expressed.
- The pre-B cell expresses μ heavy chains in the cytoplasm. On the cell surface, the heavy chains associate with surrogate light chains to form pre-B cell receptors.
- The immature B cell produces light chains and can therefore express antibody molecules on the cell surface. If antigen exposure occurs at this stage, negative selection may take place.
- During the transitional stage, B cells gradually lose sensitivity to negative selection and acquire immune competence.
- The mature B cell expresses both IgM and IgD and is competent to respond to antigen.

light chains join with the μ heavy chains, an IgM molecule results and can be expressed on the cell surface in association with Ig α and Ig β. Although the presence of a B-cell receptor complex confers the ability to recognize specific antigens, at this stage such recognition does not result in proliferation or differentiation. Rather, the cells may undergo negative selection when antigen is encountered. Immature B cells recognizing self-antigen may be negatively selected through deletion,[16] anergy, or receptor editing, a process of secondary gene rearrangement by which a new, nonself specificity is acquired.[17]

The exit of immature B cells from the bone marrow to the spleen marks the beginning of the next stage, the *transitional B-cell* stage.[18] Transitional cells gradually acquire surface IgD, CD21, and CD23 expression and become more immune competent. Alternative splicing of RNA allows the simultaneous expression of IgM and IgD. At the beginning of the stage, cross-linking of the B-cell receptor leads to negative selection. With further maturation, transitional cells become responsive to T-cell help and lose sensitivity to negative selection.

The *mature B cell* expresses IgM and IgD and is competent to respond to antigen. The cell is considered naive because it has not been activated by antigen. The majority of mature B cells circulate through peripheral lymphoid tissues (spleen, lymph nodes, mucosal lymphoid tissue) and are called *follicular B cells*, or recirculating B cells. B cells are recruited to the follicle by the chemokine CXCL13, secreted by follicular dendritic cells, and survive in the follicle with the assistance of a cytokine called BAFF (B-cell activating factor), also known as BLyS (B lymphocyte stimulator). A small percentage of mature B cells home to the marginal zone of the spleen and remain resident there.

The encounter of antigen by mature naive B cells leads to B-cell activation, proliferation, and differentiation (see Section "B Cell Activation and Antibody Function"). A subset of B cells become *memory B cells*, which can persist for long periods apparently without stimulation by antigen, and which respond rapidly if the antigen is encountered subsequently.[19] Another subset of B cells differentiates into cells that make progressively less membrane-bound Ig and more secreted Ig. The terminally differentiated B cells committed to the production of secreted Ig are *plasma cells* and have abundant rough endoplasmic reticulum, consistent with the function of the cells as antibody factories.[20]

ANTIGENS BOUND BY B CELLS

B cells recognize a variety of macromolecules, including proteins, lipids, carbohydrates, and nucleic acids. The portion of the molecule recognized by the antibody is called an *epitope* or *determinant*. B cells recognize both linear epitopes (epitopes formed by several adjacent amino acids) and, quite commonly, conformational epitopes (epitopes present as a result of folding of the macromolecule).[21] In contrast to B cells, T-cell responses are almost entirely restricted to linear epitopes of peptides.

Macromolecules, particularly large proteins, may contain several different epitopes, and a humoral response to a macromolecule typically is comprised of multiple different antibodies. Although each different antibody is specific for a given epitopic configuration, similarities in epitopes may exist such that an antibody to a given epitope on a given macromolecule also may be able to bind a different epitope on a different macromolecule. This phenomenon is called *cross-reactivity*, and may be important in the genesis of autoimmune antibody responses.

Macromolecules that have multiple identical epitopes are classified as being polyvalent or multivalent. Antibodies to these macromolecules or aggregates of macromolecules may form complexes called *immune complexes* with the antigen. At a particular concentration of antibody and antigen, called the zone of equivalence, a large network of linked antigens and antibodies forms. At lower or higher concentrations of antibody or antigen, the complexes are much smaller. Immune complexes, formed in the circulation or in tissue, may be responsible for disease through the initiation of an inflammatory response.

B-CELL ACTIVATION AND ANTIBODY FUNCTION

B-CELL ACTIVATION AND ANTIBODY FUNCTION AT A GLANCE

- When the B-cell receptor (surface antibody) binds antigen, a second signal provided by C3d engagement with complement receptor 2 significantly augments B-cell activation.
- B-cell responses to protein antigens typically involve T-cell help, with resultant antibody class switching and affinity maturation. Activated B cells may become short-lived plasma cells, memory B cells, or long-lived plasma cells. Long-lived plasma cells migrate to the bone marrow, where they may persist indefinitely and are a major source of antigen-specific antibodies in the circulation.
- Effector functions of antibodies include neutralization of antigen, complement activation, cell activation, phagocytosis, and antibody-dependent, cell-mediated cytotoxicity. Most of these are mediated through the binding of Ig to Fc receptors containing an immunoreceptor tyrosine-based activation motif.
- Negative signaling to B cells is provided by binding of IgG to a B-cell Fc receptor that contains an immunoreceptor tyrosine-based inhibition motif. The availability of excess IgG to bind this receptor is an indication that antigen is being successfully eliminated and the immune response is no longer required.

On cross-linking of the mature B-cell receptor by antigen, clustering of receptors initiates signaling transduced by Igα and Igβ. The complex signaling cascade involving the phosphorylation of tyrosine kinases, including Lyn, Fyn, Btk, and Syk, eventuates in the expression of genes involved in B-cell activation.[22] B-cell activation is facilitated by second signals, one of which is provided by the complement protein C3d.[23] Complement fragment C3d is formed as a result of complement activation through any of the complement activation pathways (see Section "Complement"). The B-cell surface contains a coreceptor complex consisting of complement receptor 2 (CR2), CD19, and CD81 (also called TAPA-1, or target for antiproliferative antigen-1). Simultaneous binding of antigen by antibody on the B-cell surface and of C3d by CR2 leads to markedly increased B-cell activation. B-cell activation may also occur through Toll-like receptors that recognize specific microbial products.[24]

The subsequent response to an antigen often involves a complex interaction between B cells and T cells, leading to a fine-tuning of the immune response.[25] Recognition of antigen by both B cells and T cells leads to increased expression of cell surface proteins and cytokines that render these cells increasingly capable of migrating toward and productively interacting with each other. T cells recognizing peptide-class II MHC complexes on dendritic cells receive a primary signal from the complex and a secondary signal from costimulatory interactions involving the binding of B7–1 and B7–2 on dendritic cells to CD28 on T cells.[26] These activated T cells express CXCR5, the ligand for CXCL13, which results in T-cell migration toward the follicle and therefore increasingly toward B cells. In response to a protein antigen, B cells take up the antigen, process it, and present processed antigen on the cell surface in complex with class II MHC. Activated B cells express less CXCR5, which allows them to migrate from the follicle toward the T-cell zone. At the boundary between follicles and T-cell zones, activated T cells interact with B cells and provide signals to the B cells through the binding of CD40 on B cells to CD40 ligand (CD154) on T cells and through the action of cytokines, notably interleukin 2 (IL-2), IL-4, IL-21, BAFF, and APRIL (*a pro*liferation-*i*nducing *l*igand).[2] These signals will be necessary for subsequent class (heavy chain isotype) switching, affinity maturation, and memory B-cell generation. The overall effects on B cells are stimulation of proliferation and differentiation.

At this phase, some of the activated B cells become short-lived plasma cells, which provide a prompt initial response to an antigen, while others migrate back from the periphery of the follicle to proliferate rapidly and form germinal centers. It is primarily in the germinal centers that class switching, affinity maturation, and generation of memory B cells occur. Class switching from IgM to IgA, IgE, or IgG occurs as a result of T cell–B cell interactions.[27,28] The determination of the antibody class selected is based on the site where the antigen is encountered and the cytokine milieu. For example, B-cell responses to antigens encountered on mucosal surfaces characteristically result in class switching to IgA, and transforming growth factor-β is an important contributing cytokine. IL-4 is an important signal for class switching to IgE.

T-cell interaction with B cells also results in affinity maturation, whereby the affinity of antibodies for the antigen progressively increases. During affinity maturation, somatic hypermutations in antibody genes result in antibodies with both greater and lesser affinity for the antigen.[29,30] Those antibodies with greater affinity confer a survival advantage on the B cells that produce them. Progressively, the population of B cells evolves in favor of those producing higher affinity antibodies for the antigen. Both class switching and affinity maturation require the expression of an enzyme called *activation-induced cytosine deaminase* (AID).[31]

The culmination of germinal center activity is the formation of memory B cells and long-lived plasma cells.[32] A number of transcriptional regulators are involved in late B-cell development, including BLIMP1 (B-lymphocyte maturation protein 1), IRF4 (interferon-regulatory factor 4), and XBP1 (X-box-binding protein 1). Plasma cells may arise from and be replenished by memory B cells or may arise from an intermediate cell, the plasmablast. Long-lived plasma cells migrate to and have a survival niche in the bone marrow, where they can persist indefinitely. These bone marrow long-lived plasma cells are the major source of antigen-specific antibody in the circulation.

As noted in Section "Antigens Bound by B Cells," T-cell responses are limited almost entirely to peptides. Thus, B-cell responses to nonprotein antigens may not result in T-cell help through the mechanisms described earlier.[33] In selected cases, T-cell independent nonprotein antigens can induce class switching, but in general, T-cell independent responses are characterized by IgM antibodies of lower affinity. One type of T-cell-independent B-cell response produces so-called *natural antibodies*—IgM antibodies that are largely anticarbohydrate antibodies produced without apparent antigen exposure.[34] These natural antibodies are characterized by a limited repertoire and are produced primarily by B1 peritoneal cells either spontaneously or in response to bacteria that colonize the gut. Marginal zone B cells, located near the marginal sinus in the spleen, may also produce natural antibodies.

Antigen occupation of antibody-binding sites on B cells leads to functional results, called *effector functions*. With the exception of direct neutralization of antigen by antibody binding, effector functions are typically mediated through the binding of Ig to FcRs.[35,36] FcRs can be categorized as those that trigger cell activation and those that do not. Those that can trigger activation contain one or more motifs called *immunoreceptor tyrosine-based activation motifs*. Of those that do not trigger activation, some can inhibit cell activation and contain a motif called *immunoreceptor tyrosine-based inhibition motif*. FcRs that neither activate nor inhibit cell activation are involved in the transport of Ig through epithelia and the prolongation of the half-life of IgG.

The effector functions of antibodies serve to eliminate the antigen that initiated the immune response and also to downregulate the immune response when activation is not required. Effector functions of

antibodies include neutralization of antigen, complement activation, cell activation (of monocytes, neutrophils, eosinophils, and B cells), phagocytosis (by monocytes and neutrophils), and antibody-dependent cell-mediated cytotoxicity (mediated by NK cells and eosinophils). In addition, engagement of IgG by antigen provides a negative signal to B cells, mediated through the binding of the antigen-antibody complex to an immunoreceptor tyrosine-based inhibition motif-containing Fcγ receptor, FcγIIB, on the B cell.[37]

B CELLS AND ANTIBODIES IN DISEASE

Disorders of B cells or antibodies cause or contribute to many diseases of dermatologic relevance. Immunodeficiency diseases may result from abnormalities of B-cell development or activation, or from abnormalities in effector function pathways.[38] B-cell lymphomas may result from failure to regulate proliferation, differentiation, or programed cell death.[39] Ectopic lymphoid aggregates can arise as a result of aberrant chemokine-mediated lymphocyte homing.[40] Antibodies may initiate an inflammatory response that results in injury, as in IgE-mediated allergic reactions or immune-complex diseases.[41,42] In some cases, the antigen may not be obviously harmful, but the response to the antigen is. In other cases, the antigen may be pathogenic, but the character or magnitude of the immune response is inappropriate or inadequately controlled. The regulatory systems that protect an organism from attack by its own immune system occasionally go awry.[43,44] Failure to eliminate autoreactive cells may be a major underlying abnormality in many patients with autoimmunity. In some cases, autoimmunity may be initiated as a result of an immune response to a pathogen.[45] The pathogen may act as a nonspecific activator of the immune system, or may activate the immune response specifically (e.g., by containing an epitope or epitopes that are cross-reactive with an autoepitope). These responses may be particularly difficult to control because the major stimulus for the immune response, the antigen, is a normal component of "self" and cannot be eliminated. As mentioned earlier, B cells have important roles beyond antibody production. Abnormalities or imbalance of immune regulatory functions by B cells may lead to autoimmunity. Thus, through many mechanisms, the normal protective B-cell response, which developed as an elegant means to discriminate very finely among various potential pathogens, can be subverted to result in harm to the organism.

COMPLEMENT

The complement system was discovered through its ability to contribute to, or "complement," bacterial cell lysis by antibodies.[46,47] At physiologic temperatures, serum containing antibacterial antibodies lysed bacteria effectively, whereas serum heated to 56°C (133°F) lost its ability to lyse bacteria. Because antibodies are quite stable at 56°C (133°F), it was postulated that the loss of lytic ability was due to the degradation of heat-labile nonantibody molecules.

Although the complement system was first identified through its role in humoral immunity, a primitive complement system emerged more than 1.3 billion years ago as a component of innate immunity (see Chapter 10).[48] The complement system is constituted in part by a set of plasma proteins that are normally inactive or minimally active. The initial steps of activation involve the cleavage of an inactive protein into a smaller and a larger fragment. The larger fragment, then, is itself able to cleave other proteins in the cascade. Because an activated molecule in one step is capable of generating many activated molecules in the following step, the sequential cleavage and activation of complement proteins result in amplification of the cascade.

COMPLEMENT SYSTEM AND ACTIVATION PATHWAYS AT A GLANCE

- The complement system functions to kill microbes via lysis or phagocytosis, to clear immune complexes and apoptotic debris from the circulation, to promote inflammation, and to stimulate humoral immunity.
- The three pathways of complement activation are the alternative, classical, and lectin pathways.
- The early steps in complement activation are triggered enzyme cascades in which cleavage of an inactive protein into fragments results in cleavage of subsequent proteins in the cascade.
- The alternative and lectin pathways are primarily pathways of innate immunity; the classical pathway is a pathway characteristically initiated by humoral immunity.
- The complement pathways converge at the cleavage of C3 and subsequent cleavage of C5. The final steps of activation consist of the addition of C6–8 to C5b, and polymerization of C9 to form the membrane attack complex.

PATHWAYS OF COMPLEMENT ACTIVATION

The early stages of the activation of complement ultimately result in cleavage of the complement protein C3. This is followed by the cleavage of C5 and initiation of the final steps of complement activation. There are three distinct pathways that lead to the cleavage of C3, the classical, the alternative, and the lectin pathways. Although the classical pathway was the first to be described, the alternative pathway is evolutionarily older.[49]

ALTERNATIVE PATHWAY

(Fig. 37-2)

The first step in the activation of the alternative pathway is the binding of C3b to a cell surface such as a bacterial cell surface. Intact C3 is an inactive molecule, but there is a low-level spontaneous cleavage of C3, called *tickover*, which results in the continuous availability of the C3b fragment. C3b can bind stably to a cell surface through an interaction between a thioester group of C3b and a hydroxyl group of the cell surface. In intact C3, the thioester domain is covered by hydrophobic residues that prevent hydrolysis of the thioester bond. The anaphylatoxin (ANA) domain of C3 stabilizes this inactive conformation. When the ANA domain is cleaved to release C3a, the thioester group is exposed, and conformational change results in its ability to bond to the cell surface.[50,51] If this chemical bonding does not occur, the thioester group is hydrolyzed and C3b is inactivated.

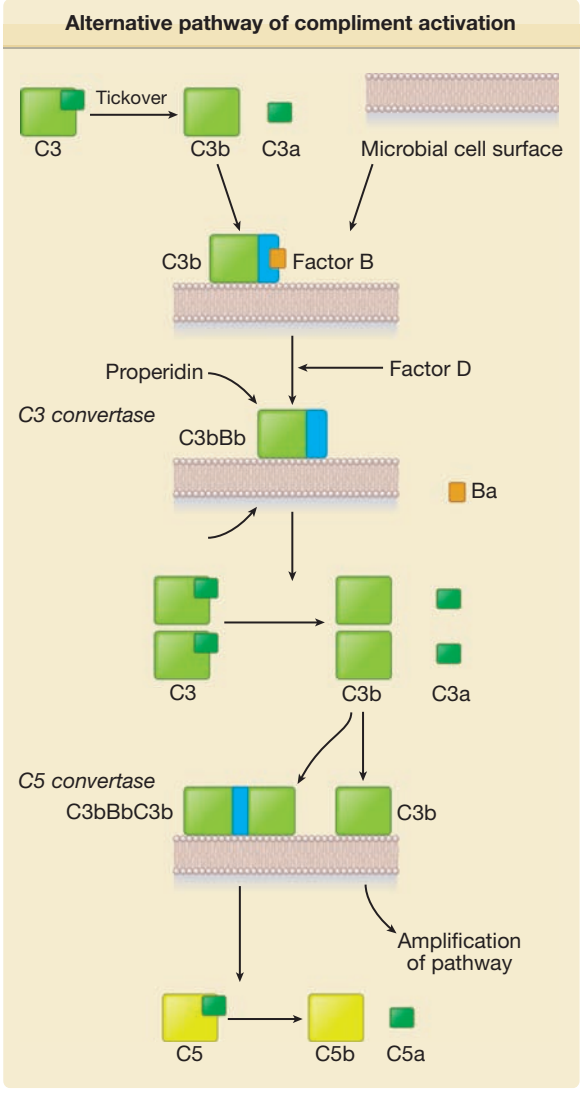

Figure 37-2 The alternative pathway of complement activation. Shown are the steps from the initial attachment of C3b to a microbial cell surface through the cleavage of C5 into C5a and C5b. The final steps of complement activation are shown in Fig. 37-4. See Section "Alternative Pathway" for details.

Once stable attachment of C3b to the cell surface takes place, a plasma protein called *Factor B* binds to C3b. Factor B is in turn cleaved by factor D, generating Bb and Ba. The complex of C3b and Bb, stabilized by the plasma protein properidin, is the alternative pathway C3 convertase (i.e., it cleaves C3 into C3a and C3b). The result of the activity of the C3 convertase is an amplification of the pathway by two or three orders of magnitude. The addition of further C3b to the complex results in C3bBbC3b, which constitutes the alternative pathway to C5 convertase. The late steps of complement activation, after the cleavage of C5, are common to the three pathways and are described in Final Steps of Complement Activation.

Thus, the low level of C3b in the plasma acts as a sentinel for microbes. Once C3b is bound to the cell surface, subsequent molecular interactions result in a substantial amplification of the alternative pathway and cleavage of C5. The requirement for binding of C3b to a structural element serves to limit the effect of complement activation to the area where complement activation is needed. The alternative pathway of complement activation does not require finely specific recognition of antigen and so is considered a component of innate immunity. It follows that if specific recognition is not required, C3b can bind to human cells as well as microbes. However, activation on human cells is generally prevented by the intervention of regulatory proteins present on the surface of human cells, protecting these cells from inappropriate and harmful attack.[52]

CLASSICAL PATHWAY

(Fig. 37-3)

The initial step in the activation of the classical pathway is characteristically the binding of the portion of the C1 complex called *C1q* to IgG or IgM antibodies.[46] The C1q molecule consists of six identical arms attached to a central trunk. The globular ends of the arms attach to the complement-binding regions of the heavy chains of certain Ig classes. In order for C1q to be activated, it must bind simultaneously to at least two Ig heavy chains. This means, in effect, that the Ig must have bound antigen. In the case of IgG, binding of multiple epitopes by antibodies results in close proximity of the antibodies and thus the proper configuration for C1q activation. (As mentioned in Section "Immunoglobulin G," IgG4 is an exception, in that it does not bind C1q or activate complement.) Because IgM exists as a pentamer, theoretically IgM without bound antigen could activate complement. However, when IgM is not bound by antigen, the C1q binding site is not accessible. When antigen is bound, a conformational change results in exposure of the C1q binding site.

The complement component C1 is a complex of C1q, C1r, and C1s. Binding of two or more of the globular heads of C1q results in activation of C1r. Activated C1r is a protease that cleaves and activates C1s, and activated C1s, in turn, cleaves C4 into C4a and C4b.

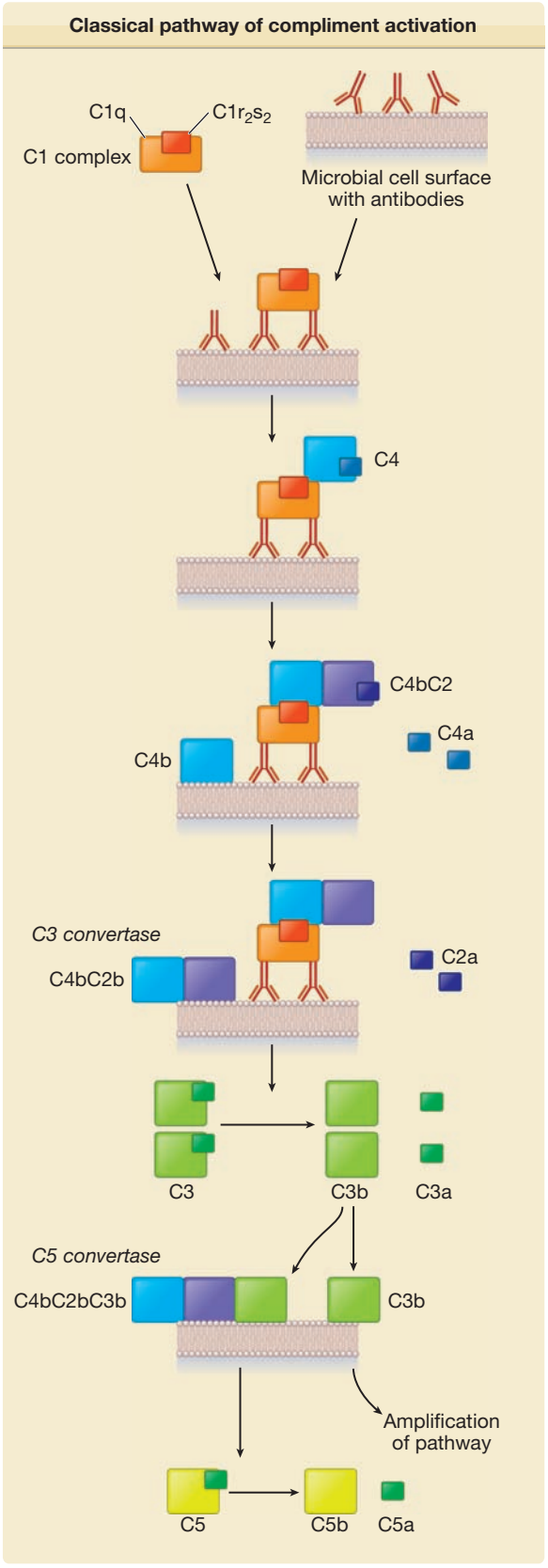

Figure 37-3 The classical pathway of complement activation. Shown are the steps from the initial binding of C1q to antibody–antigen complex through the cleavage of C5 into C5a and C5b. The final steps of complement activation are shown in Fig. 37-4. See Section "Classical Pathway" for details.

(The numbering of the complement proteins differs from their positions in the activation sequence, as components were discovered before the elucidation of their positions in the pathway.) C4b, like C3b, contains a thioester group that can form stable bonds with hydroxyl groups on a particular structure. Bound C4b is then bound by C2, which is cleaved into C2a and C2b. The C4bC2b complex is the classical pathway C3 convertase. (Note: Typically, suffix "a" denotes the smaller and "b" the larger complement fragment. Historically, the exception was C2, where C2a represented the larger and C2b the smaller fragment. Some recent textbooks now identify the smaller fragment as C2a and the larger as C2b, to maintain consistency with the nomenclature of the other complement proteins. However, many recent publications continue to adhere to the historic nomenclature.)

The cleavage of C3 results in C3a and C3b. The C3b fragment may then go on to activate complement by the alternative pathway, or act in concert with C4bC2b to form C4bC2bC3b, the classical pathway C5 convertase.

The major characteristics of the classical pathway are much the same as those of the alternative pathway. Activation of the pathway requires attachment of a complement protein to a structure such as a cell surface or immune complex, so that the effects of complement activation are spatially limited. Initial activation steps result in the formation of a C3 convertase that cleaves C3. Cleavage of C3 leads to the formation of a C5 convertase that cleaves C5 into C5a and C5b. A major difference is the initiation of the classical pathway by specific recognition of antigen by antibodies, in contrast to the less specific binding that occurs to initiate the alternative pathway.

LECTIN PATHWAY

The lectin pathway is very similar to the classical pathway, with the exception of the initiating steps. The first step is the binding of a plasma lectin, mannose-binding protein (MBP), to polysaccharides on microbial cell surfaces.[53] MBP, a member of the collectin (collagenous lectin) family, is structurally similar to C1q and can associate with C1r and C1s. MBP attachment to a microbe can begin the cascade through the activation of C1r and C1s. MBP also interacts with MBP-associated serine proteases (MASPs), which are analogous to C1r and C1s. Binding of MBP to microbial cell surfaces results in cleavage of MBP-associated serine protease and thence cleavage of C4.[54] In either event, the effect is the formation of C4b and its stable binding to a cell surface. As is the case for the alternative pathway, the lectin pathway is a component of innate immunity.

FINAL STEPS OF COMPLEMENT ACTIVATION

(Fig. 37-4)

The alternative, classical, and lectin pathways converge at the cleavage of C5. The C5b fragment remains

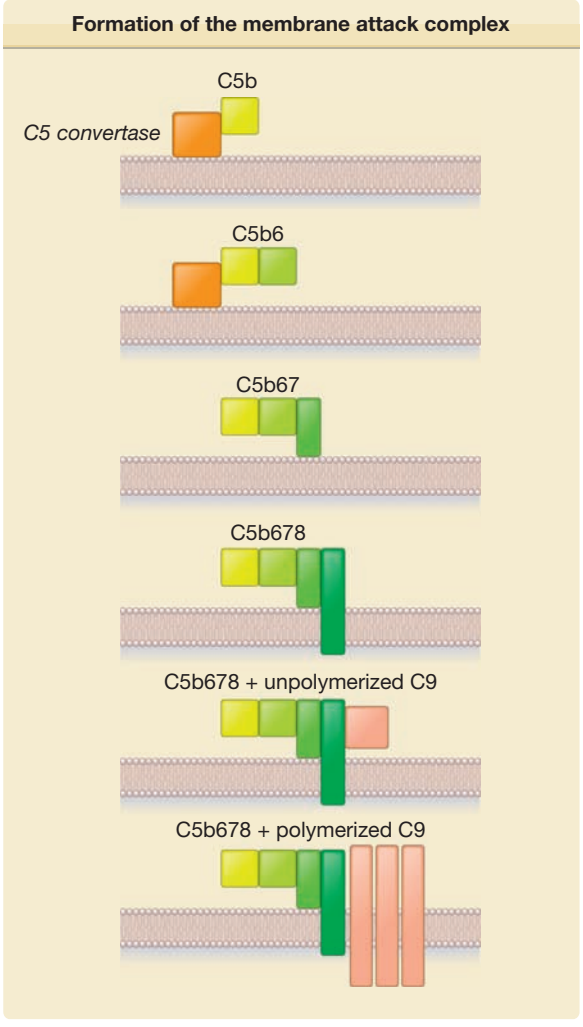

Figure 37-4 Formation of the membrane attack complex. The alternative, classical, and lectin pathways converge at the formation of C5b and its sequential attachment to C6, C7, C8, and C9. The polymerization of C9 results in tubular structures on the cell membrane.

surface bound. The next steps do not involve enzymatic cleavage, but rather the sequential binding of C6, C7, and C8 to C5b. The C5b-8 complex stably bound to a cell membrane becomes an active membrane attack complex (MAC) through the addition of C9. C9 polymerizes around the complex and forms pores in cell membranes. These pores may result in cell death through osmotic rupture, particularly in nonnucleated erythrocytes.

Nucleated cells are more resistant to lysis, but may still exhibit effects attributable to MAC binding.[55] It is quite possible that the nonlytic changes induced by MAC are of more functional and pathologic significance overall than is MAC-induced cell lysis.[56] These nonlytic effects may differ depending on cell type and milieu, and similar effects may lead to different outcomes. For example, MAC insertion into phagocyte cell membranes can lead to the production of inflammatory mediators such as reactive oxygen species and prostaglandins, resulting in phagocyte activation.[57] Glomerular epithelial cells may also exhibit inflammatory mediator production, but, in that setting, the inflammatory mediators may lead to tissue injury.[58] MAC has also been reported to cause proliferation of certain cells, and MAC has been reported to have both apoptotic and antiapoptotic properties.[55]

ADDITIONAL INITIATORS OF COMPLEMENT ACTIVATION

In addition to the characteristic initiators of the three pathways, certain additional structures can trigger complement activation.[59] These include, among others, the following: in the alternative pathway, IgA immune complexes and endotoxin; in the classical pathway, *C*-reactive protein, apoptotic bodies, and serum amyloid P; and in the lectin pathway, serum ficolins (lectins which bind *N*-acetylglucosamine).[53,60]

FUNCTIONS OF COMPLEMENT PROTEINS

As mentioned earlier, the earliest function of the complement system to be discovered was the lysis of bacteria. Killing of microbes through direct lysis is mediated by the MAC, C5b-9. Microbes may also be destroyed through coating, or opsonization, by complement and phagocytosis of the opsonized particles by phagocytic cells. The processes of opsonization and phagocytosis are also mechanisms for another important function of complement—the clearance of immune complexes and apoptotic debris from the circulation.

An ancillary function of complement activation is the induction of inflammation. Inflammation, characterized by vascular changes and ingress and activation of leukocytes and inflammatory proteins, serves to augment the localized immune response in tissue. Three mediators of inflammation initiated by complement activation are the complement fragments C3a, C4a, and C5a. These are called *anaphylatoxins* because of their ability to induce degranulation of mast cells.[61] The most potent of these ANAs is C5a. Receptors for C5a are expressed on endothelial cells, mast cells, eosinophils, basophils, monocytes, neutrophils, smooth muscle cells, and epithelial cells. Binding of C5a to endothelial cells results in increased vascular permeability and expression of P-selectin, both of which promote leukocyte accumulation in tissue. Binding to neutrophils results in increased neutrophil motility, adhesion to endothelial cells, and production of reactive oxygen species. The overall result is the accumulation of inflammatory cells at local sites in tissue where they can phagocytose and efficiently kill microbes.

The activation of complement also results in stimulation of the humoral immune system through the generation of C3d. B cells whose cell surface antibodies recognize complement-bound antigen are upregulated by the concurrent binding of C3d to CR2 on the B-cell surface. Opsonization by complement also facilitates antigen presentation to B cells by follicular dendritic cells.

COMPLEMENT RECEPTORS

COMPLEMENT RECEPTORS AND REGULATORY PROTEINS AT A GLANCE

- Some of the important effects of complement are mediated through binding of complement proteins to complement receptors. CR1 functions in phagocytosis, immune complex clearance, and downregulation. CR2 is important in stimulation of humoral immunity. CR3 and -4 promote phagocytosis.
- Regulation of complement activation is provided by certain serum and cell surface proteins. Many of the regulatory cell surface proteins are expressed on human cells but not microbes, thus protecting human cells from complement damage.
- Some of the regulatory proteins downregulate complement activation by displacing components of the early steps of the cascade. These include C1 inhibitor, factor H, C4 binding inhibitor, decay accelerating factor, membrane cofactor protein, and CR1.

There are several proteins that interact with complement and serve to mediate or regulate its functions. The C5a receptor, which is a member of the seven-transmembrane α-helical G-protein-coupled receptor family, was mentioned in the previous section. Some of the best described of the complement receptors are CR1–CR4.

The type 1 complement receptor, CR1 (CD35), is a member of a family of proteins called *regulators of complement activation* (RCA), which share a common structure consisting of multiple short consensus repeats, also known as *complement control protein repeats*.[52] CR1 binds C3b or C4b and is expressed on peripheral blood cells, including monocytes, B and T lymphocytes, neutrophils, eosinophils, and erythrocytes; on follicular dendritic cells; and on keratinocytes.[62] On phagocytic cells, binding of CR1 to C3b or C4b results in phagocytosis of particles opsonized by complement fragments, as well as activation of microbicidal mechanisms in the phagocytic cells. On erythrocytes, binding of CR1 to C3b- or C4b-coated immune complexes results in transport of the complexes to the spleen and liver, where they are cleared from the circulation by phagocytes. Thus, CR1 serves as an important mediator of complement function. It can also serve as a downregulator of complement activation, as it is involved in the dissociation of C3 convertase complexes.

The type 2 complement receptor, CR2 (CD21), is also a member of the RCA family.[59] CR2 binds C3 fragments iC3b ("i" stands for inactive), C3dg, and C3d, as well as Epstein–Barr virus, interferon-α, and the immunoregulatory protein CD23. CR2 is expressed on subsets of B and T lymphocytes, basophils, mast cells, follicular dendritic cells, and some epithelial cells, including keratinocytes. On B cells, CR2 serves as a coreceptor for B-cell activation. When CR2 is bound by C3d, the level of B-cell activation is increased by orders of magnitude.[63] On dendritic cells, CR2 engagement results in a trapping of immune complexes in germinal centers. CR2 also appears to play a role in antigen presentation to T cells.

The type 3 complement receptor, CR3 (CD11b/CD18, Mac-1), is an integrin cell surface molecule expressed on monocytes, neutrophils, NK cells, and mast cells.[64] It functions to promote phagocytosis of microbes through binding to iC3b and through direct binding to microbes. It interacts with intercellular adhesion molecule 1 expressed endogenously on endothelial cells to stabilize the adhesion of leukocytes to endothelium, facilitating the recruitment of leukocytes from the circulation into tissue.

The type 4 complement receptor, CR4 (CD11c/CD18), is also an integrin cell surface molecule. It is expressed on monocytes, neutrophils, NK cells, and dendritic cells, and probably functions similarly to CR3.

Among the recently described complement receptors are SIGN-R1,[65] which binds C1q and is expressed on splenic marginal zone macrophages, and CRIg (complement receptor of the immunoglobulin family),[66] which binds C3b and iC3b and is expressed on a subset of tissue-resident macrophages.

REGULATION OF COMPLEMENT ACTIVATION

Molecules involved in the regulation of complement activation serve to downregulate the immune response once an immune response is no longer needed and to limit the immune response to the sites required, specifically protecting self from complement attack.

The C1 inhibitor (C1 INH) is a protease inhibitor that inhibits certain plasma serine proteases, including C1, kallikrein, and factor XII.[46] C1 exists as a complex of C1q and a tetramer of two C1r and two C1s fragments. When C1q binds antibody, C1 INH can act to limit complement activation by binding to the C1rC1s tetramer, dissociating it from C1q and preventing downstream activation of the pathway.

Another major point of interaction of regulatory proteins is with bound C3b or C4b.[52] As mentioned earlier, the thioester group of unbound C3b or C4b is rapidly hydrolyzed, rendering these molecules inactive. For surface-bound C3b or C4b, inactivation occurs through the displacement of components of the alternative or classical pathway C3 convertase from C3b or C4b or through proteolysis of C3b or C4b. In the alternative pathway, inactivation of the C3 convertase complex, C3bBb, can take place through the displacement of Bb from C3b by the plasma protein factor H or the cell surface proteins decay accelerating factor (DAF, CD55), membrane cofactor protein (MCP, CD46), and CR1. These three cell surface proteins, all members of the RCA family, are expressed on human cells but not

microbes, thereby allowing complement activation to proceed on microbes while protecting human cells from injury. Factor H preferentially binds cell surfaces with high levels of sialic acid, and the relative abundance of sialic acid on human cells but not microbes further focuses the downregulation of complement activation on human cells. In the classical and lectin pathways, the C3 convertase is C4bC2b. DAF, MCP, and CR1 can displace C2b from C4b, as can the plasma protein C4-binding protein (C4BP). Thus, the cell surface proteins DAF, MCP, and CR1 can dissociate the C3 convertases of both the alternative and the classical/lectin pathways, whereas the plasma proteins factor H and C4BP are specific for alternative or classical/lectin, respectively. Proteolysis of C3b or C4b is mediated by factor I, a plasma protein that requires cofactors for its activity. MCP, CR1, factor H, and C4BP can all serve as cofactors for factor I.

Regulation of complement at the late steps is mediated in part by CD59, a cell surface protein expressed on human cells but not microbes. It binds the C5b-8 complex and inhibits addition of C9, blocking formation of the MAC. Plasma S protein binds the C5b-7 complex and blocks its insertion into the cell membrane and also inhibits C9 polymerization.[67] Intact MACs may be removed from cells through shedding on membrane vesicles or by internalization and degradation.[55]

Carboxypeptidase N can remove the terminal arginine of C3a, C4a, and C5a and has been referred to as *ANA inactivator*.[68] Carboxypeptidase R has also been shown to remove the terminal arginine of C3a and C5a.[69]

COMPLEMENT AND DISEASE

GENETIC ABNORMALITIES OF THE COMPLEMENT SYSTEM

Deficiencies of complement cascade proteins, complement receptors, or complement regulatory proteins can lead to a variety of diseases.[70] Genetic deficiencies of complement have been associated primarily with increased risk for infection or autoimmunity. As examples, deficiencies of many complement components, particularly the early complement components C1–C4, have been associated with early-onset systemic lupus erythematosus (SLE), C3 deficiency has been associated with life-threatening pyogenic infections, and C5–C9 deficiencies have been associated with Neisserial infections (reviewed in Chapter 143). Genetic deficiency of mannose-binding lectin is relatively common, with significantly low levels occurring in about 10% of Caucasians, and is associated with increased risk for infection and autoimmunity, including SLE.[71,72]

Altered expression of CR3 (CD11b/CD18) and CR4 (CD11c/CD18) occurs in leukocyte adhesion deficiency-1, a congenital disorder resulting from mutations in the gene encoding CD18. Mutation in CD18 also affects expression of CD11a/CD18 (leukocyte function-associated antigen-1). Patients with leukocyte adhesion deficiency-1 exhibit significant abnormalities of leukocyte adhesion and have recurrent infections (see Chapter 143).

COMPLEMENT AND DISEASE AT A GLANCE

- Genetic deficiencies of complement components have been associated primarily with susceptibility to infection or autoimmunity. Genetic deficiencies of regulatory complement proteins may result in inappropriately prolonged complement activation, such as occurs with C1 inhibitor deficiency.
- Complement is associated with systemic lupus erythematosus through several possible mechanisms. These include increased risk of autoimmunity conferred by certain complement deficiencies, tissue damage resulting from autoantibody-induced complement activation, ineffective clearance of autoimmunity-promoting apoptotic debris, and failure to eliminate self-reactive B cells.
- Complement activation has been implicated in the pathogenesis of atherosclerosis, reperfusion injury after myocardial ischemia, diabetic microvascular disease, and cerebral infarct in ischemic stroke.
- Certain infectious agents have evolved mechanisms for evasion of destruction by complement, and some use complement receptors or regulatory proteins to gain entry into the cell.

Deficiency of the complement regulatory protein C1 INH causes angioneurotic edema as a result both of poorly regulated classical pathway activation and of excess bradykinin due to the actions of kallikrein and factor XII. Angioedema may also occur if one has markedly reduced levels of the ANA inactivator, carboxypeptidase N[73] (see Chapter 38).

Deficiency of a protein required for the proper expression of DAF and CD59 on the cell surface is associated with paroxysmal nocturnal hemoglobinuria, a disease characterized by complement-mediated erythrocyte lysis.[74] Hemolytic-uremic syndrome has been associated with mutations in MCP, factor H, and factor I.[75] Factor H deficiency has also been associated with membranoproliferative glomerulonephritis.

The risk for developing age-related macular degeneration is affected significantly by the presence of certain polymorphisms in genes of the complement system, particularly complement factor H but also factor B and C2.[76]

COMPLEMENT, SYSTEMIC LUPUS ERYTHEMATOSUS, AND AUTOANTIBODIES

Complement has been closely associated with SLE (see also Chapter 155), albeit in seemingly paradoxical

ways.[77,78] Genetic deficiencies of complement components are associated with SLE, but some of the tissue injury seen in SLE appears to be mediated in part by complement activation. Thus, complement seems to be simultaneously protective and deleterious. These observations underscore the protean roles of complement in the immune system. Complement activation has the potential for causing tissue injury, but complement components may be important in clearance of immune complexes and apoptotic debris. Apoptotic bodies that are not cleared effectively may be able to trigger autoimmunity through presentation of normally sequestered autoantigens to the immune system. It has also been suggested that complement participates in eliminating self-reactive immature B cells, a further mechanism for a protective effect of complement in SLE.[78]

Altered expression of both CR1 and CR2 has been observed in patients with SLE.[79] In murine models of lupus, knockout mice lacking expression of CR1 and CR2 (located on the same gene in mice and produced through alternative splicing) have accelerated autoimmunity if the mice otherwise have the optimal genetic background. These findings indicate that the interaction of CR2 and C3d, important in B-cell response to antigen, is another factor that determines susceptibility to SLE.

Autoantibodies to complement components can result in or exacerbate disease.[80] Autoantibodies to C1q are relatively common in SLE and have been associated with more severe renal disease, possibly through an adverse affect on the clearance of immune complexes or apoptotic bodies.[81] C3 nephritic factor is an autoantibody to the C3 convertase, C3bBb, which acts to stabilize the complex. Its clinical significance is its association with membranoproliferative glomerulonephritis type II and partial lipodystrophy.

COMPLEMENT AND VASCULAR DISEASE

Complement activation has been implicated in the pathogenesis of atherosclerosis, reperfusion injury after myocardial ischemia, and cerebral infarct in ischemic stroke.[82,83] In the microvascular proliferative disease associated with diabetes, glycation, and thereby inactivation of CD59, may result in cellular proliferation due to nonlytic proliferative effects of MAC.[84] Complement activation has also been implicated in hyperacute rejection of xenotransplants due to the presence of natural antibodies to components of the endothelial cells of the transplanted organ, with resultant complement activation, endothelial cell injury, and intravascular coagulation.

EVASION OR SUBVERSION OF COMPLEMENT BY MICROBES

The observation that individuals with deficiencies of components of the late stages of complement activation are at increased risk for only a limited set of infections illustrates that infectious agents have evolved means of evading destruction by complement.[85] Gram-positive bacteria have thick cell walls that are difficult to penetrate by MAC.[46] Group A streptococcus M protein binds factor H, which downregulates complement activation, and many pathogens have evolved mechanisms to attract factor H through the expression of sialic acids on their surfaces. *Staphylococcus aureus* expresses several proteins that inhibit C3 activation. A protein of vaccinia virus (VCP-1, vaccinia virus complement control protein-1) acts as a cofactor for factor I, leading to proteolysis of C3b and C4b. In human immunodeficiency virus (HIV) infection, the inclusion of downregulatory molecules of the complement system into the viral or host cell membrane allows HIV to evade complement-mediated destruction.[86] DAF and CD59 can be subsumed into the HIV virus membrane upon budding from infected human cells, and factor H can bind to HIV surface glycoproteins on infected human cells.

The complement system has been subverted by certain infectious agents for entry into the cell. Epstein–Barr virus penetrates B cells via binding to CR2 on the B-cell surface.[46] Measles virus binds to cells via MCP. *Mycobacteria* make C4-like molecules that bind C2b and then cleave C3. The deposition of C3b on the mycobacterial cell membrane leads to its uptake into macrophages, where it exists as an intracellular parasite. Knowledge of these evasive and subversive strategies of pathogens may be useful in designing vaccines and targeted therapies.[85]

KEY REFERENCES

Full reference list available at www.DIGM8.com

DVD contains references and additional content

1. Flajnik MF, Kasahara M: Origin and evolution of the adaptive immune system: Genetic events and selective pressures. *Nat Rev Genet* **11**(1):47-59, 2010
2. Abbas AK, Lichtman AH, Pillai S: *Cellular and Molecular Immunology*, 6th edition. Philadelphia, Elsevier Saunders, 2010
3. LeBien TW, Tedder TF: B lymphocytes: How they develop and function. *Blood* **112**(5):1570-1580, 2008
13. Jung D et al: Mechanism and control of V(D)J recombination at the immunoglobulin heavy chain locus. *Annu Rev Immunol* **24**:541-570, 2006
20. Fairfax KA et al: Plasma cell development: From B-cell subsets to long-term survival niches. *Semin Immunol* **20**(1):49-58, 2008
46. Walport MJ: Complement. First of two parts. *N Engl J Med* **344**(14):1058-1066, 2001
48. Nonaka M, Kimura A: Genomic view of the evolution of the complement system. *Immunogenetics* **58**(9):701-713, 2006
50. Janssen BJ et al: Structures of complement component C3 provide insights into the function and evolution of immunity. *Nature* **437**(7058):505-511, 2005
52. Kim DD, Song WC: Membrane complement regulatory proteins. *Clin Immunol* **118**(2–3):127-136, 2006
55. Cole DS, Morgan BP: Beyond lysis: How complement influences cell fate. *Clin Sci (Lond)* **104**(5):455-466, 2003

Chapter 38 :: Urticaria and Angioedema

:: Allen P. Kaplan

URTICARIA AND ANGIOEDEMA AT A GLANCE

- Occurs acutely at some time in 20% of the population; incidence of chronic urticaria/angioedema is approximately 0.5%.
- Acute urticaria/angioedema is caused by drugs, foods, occasionally infection in association with immunoglobulin E-dependent mechanisms (allergy), or metabolic factors.
- Chronic urticaria/angioedema is an autoimmune disorder in 45% of patients.
- In the absence of urticaria, angioedema can be due to overproduction or impaired breakdown of bradykinin.
- Treatment of acute urticaria/angioedema relies on antihistamines and short courses of corticosteroids, and identification and elimination of endogenous and exogenous causes.
- Treatment of C1 inhibitor deficiency includes androgenic agents, antifibrinolytic agents, and C1 inhibitor (C1 INH) concentrates, a kallikrein inhibitor, and bradykinin receptor antagonist.
- Treatment of physical urticaria/angioedema includes high-dose antihistamine prophylaxis, except for delayed pressure urticaria.
- Treatment of chronic idiopathic or autoimmune urticaria/angioedema includes antihistamines (nonsedating preparations primarily), low-dose daily or alternate day corticosteroids, or cyclosporine.

Urticaria is defined as a skin lesion consisting of a wheal-and-flare reaction in which localized intracutaneous edema (wheal) is surrounded by an area of redness (erythema) that is typically pruritic. Individual hives can last as briefly as 30 minutes to as long as 36 hours. They can be as small as a millimeter or 6–8 inches in diameter (giant urticaria). They blanch with pressure as the dilated blood vessels are compressed, which also accounts for the central pallor of the wheal. The dilated blood vessels and increased permeability that characterize urticaria are present in the superficial dermis and involves the venular plexus in that location. Angioedema can be caused by the same pathogenic mechanisms as urticaria but the pathology is in the deep dermis and subcutaneous tissue and swelling is the major manifestation. The overlying skin may be erythematous or normal. There is less pruritus (fewer type C nerve endings at the deeper cutaneous levels) but there may be pain or burning.

EPIDEMIOLOGY

Urticaria and angioedema are common. Age, race, sex, occupation, geographic location, and season of the year may be implicated in urticaria and angioedema only insofar as they may contribute to exposure to an eliciting agent. Of a group of college students, 15%–20% reported having experienced urticaria, while 1%–3% of the patients referred to hospital dermatology clinics in the United Kingdom noted urticaria and angioedema. In the National Ambulatory Medical Care Survey data from 1990 to 1997 in the United States, women accounted for 69% of patient visits. There was a bimodal age distribution in patients aged birth to 9 years and 30–40 years.[1]

Urticaria/angioedema is considered to be acute if it lasts less than 6 weeks. Most acute episodes are due to adverse reactions to medications or foods and in children, to viral illnesses. Episodes of urticaria/angioedema persisting beyond 6 weeks are considered chronic and are divided into two major subgroups: (1) chronic autoimmune urticaria (45%) and (2) chronic idiopathic urticaria (55%) with a combined incidence in the general population of 0.5%.[2] Physically induced urticaria/angioedema is not included in the definition. Various types of physical urticaria/angioedema may last for years, but the individual lesions last fewer than 2 hours (except delayed pressure urticaria) and are intermittent. Whereas 85% of children experience urticaria in the absence of angioedema, 40% of adult patients with urticaria also experience angioedema.

Approximately 50% of patients with chronic urticaria (with or without angioedema) are free of lesions within 1 year, 65% within 3 years, and 85% within 5 years; fewer than 5% have lesions that last for more than 10 years. Angioedema alters the natural history, and only 25% of patients experience resolution of lesions within 1 year. There are no data regarding the remission rate in patients with only angioedema. The hereditary group is considered to be life long once the diagnosis becomes clinically manifest.

PATHOGENESIS

MAST CELL AND HISTAMINE RELEASE

The mast cell is the major effector cell in most forms of urticaria and angioedema, although other cell types undoubtedly contribute. Cutaneous mast cells adhere

to fibronectin and laminin through the very late activation (VLA) β_1 integrins VLA-3, VLA-4, and VLA-5 and to vitronectin through the $\alpha_v\beta_3$ integrin. Cutaneous mast cells, but not those from other sites, release histamine in response to compound 48/80, C5a, morphine, and codeine. The neuropeptides substance P (SP), vasoactive intestinal peptide (VIP), and somatostatin, (but not neurotensin, neurokinins A and B, bradykinin, or calcitonin gene-related peptide), activate mast cells for histamine secretion. Dermal microdialysis studies of the application of SP on skin indicate that it induces histamine release only at 10^{-6} M, which suggests that after physiologic nociceptor activation, SP does not contribute significantly to histamine release.[3] Yet it is a major contributor to the flare reaction induced by histamine stimulation of afferent type C fibers (mediating pruritus) with release of SP from adjacent nerve endings by antidromic conduction. Histamine is found associated with the wheal.[4] Recently, the spinal cord afferent fibers mediating pruritis have, for the first time, been distinguished from pain fibers in the lateral spinothalamic tracts.[5]

Not all potential biologic products are produced when cutaneous mast cells are stimulated. For example, SP releases histamine from cutaneous mast cells above 10^{-6} M but does not generate prostaglandin D_2 (PGD_2). Vascular permeability in skin is produced predominantly by H_1 histamine receptors (85%); H_2 histamine receptors account for the remaining 15%.

The current hypothesis regarding cellular infiltration that follows mast cell degranulation suggests that the release of mast cell products (histamine, leucotrienes, cytokines, chemokines) leads to alterations in vasopermeability, upregulation of adhesion molecules on endothelial cells, and rolling and attachment of blood leukocytes, followed by chemotaxis and transendothelial cell migration.

Various forms of physical urticaria/angioedema have provided experimental models for the study of urticaria/angioedema by allowing the observation of the elicited clinical response, examination of lesional and normal skin biopsy specimens, assay of chemical mediators released into the blood or tissues, and characterization of peripheral leukocyte responses.[6,7] The intracutaneous injection of specific antigen in sensitized individuals has provided an experimental model for analysis of the role of immunoglobulin (Ig) E and its interaction with the mast cell. In many subjects, the challenged cutaneous sites demonstrate a biphasic response, with a transient, pruritic, erythematous wheal-and-flare reaction followed by a tender, deep, erythematous, poorly demarcated area of swelling that persists for up to 24 hours. This is the late-phase response with recruitment of variable numbers of neutrophils, prominent eosinophils, monocytes, small numbers of basophils, and CD_4^+ T-lymphocytes of the TH_2 subclass.[8] Chemokines (chemotactic cytokines) strongly associated with Th2 lymphocyte predominance include those reactive with chemokine receptors CCR3, CCR4, and CCR8 on T lymphocytes. Characteristic cytokines produced by Th2 lymphocytes include interleukins (ILs) 4, 5, 9, 13, 25, 31 and 33. The cellular infiltrate seen in biopsy specimens of delayed pressure urticaria is a variant of a late-phase reaction while mast cell degranulation in most other physical urticarias has no associated late phase. These include typical acquired cold urticaria, cholinergic urticaria, dermatographism, and type I solar urticaria.

AUTOIMMUNITY AND CHRONIC URTICARIA

The first suggestion that patients with chronic urticaria and angioedema might have an autoimmune diathesis was the observation that there is an increased incidence of antithyroid antibodies in such patients relative to the incidence in the population at large.[9] These include antimicrosomal (perioxidase) and antithyroglobulin antibodies, as seen in patients with Hashimoto's thyroiditis.[10] Patients may have clinical hypothyroidism, but a small number might be hyperthyroid if inflammation is at an early stage when thyroid hormone is released into the circulation. This atypical presentation should be distinguished from the occasional patient with Grave's disease. Nevertheless, most patients are euthyroid. The incidence of antithyroid antibodies in chronic urticaria, as reported in the literature, varies between 15% and 24%,[11,12] but the most recent data are closer to the latter figure[12] and demonstrate segregation of antithyroid antibodies with chronic autoimmune urticaria rather than chronic idiopathic urticaria. However, the association is not absolute. The incidence in the autoimmune subgroup was 27%, in the chronic idiopathic urticaria subgroup 11%, while in the population at large it is 7%–8%. Gruber et al (1988)[13] considered the possibility that patients might have circulating and anti-IgE antibodies that are functional and did indeed find these in about 5%–10% of patients. Gratten et al[14,15] sought antibodies reactive with skin mast cells by performing an autologous skin test and found a 30% incidence of positive reactions in patients with chronic urticaria. There were only rare positive reactions in healthy control subjects or patients with other forms of urticaria. Subsequently, this level of positivity was shown by Hide et al[16] to be due to an IgG antibody reactive with the α subunit of the IgE receptor; in addition a 5%–10% incidence of functional anti-IgE antibodies was confirmed (eFig. 38-1.1 in online edition).[17]

CELLULAR INFILTRATE

Mast cell degranulation certainly initiates the inflammatory process in autoimmune chronic urticaria and is assumed to also do so in idiopathic chronic urticaria. Evidence for an increased number of mast cells in chronic urticaria has been presented,[36,37] but there are also publications indicating no significant differences from normal;[38] these studies did not discriminate the autoimmune from the idiopathic groups. However, no alternative mechanisms for mast cell degranulation in the idiopathic groups have been suggested to date. Yet the histology of the two groups differs only in minor ways. Common to all biopsy specimens is a perivascular

infiltrate that surrounds small venules within the superficial and deep venular plexus, with a prominence of $CD4^+$ T lymphocytes and monocytes and virtually no B cells.[36,39] Granulocytes are quite variable but are plentiful if the lesion undergoes biopsy early in its development. Neutrophils and eosinophils are both present,[40,41] although the degree of eosinophils accumulation varies greatly.[39] Even when eosinophils are not evident, major basic protein can be identified within lesions (in at least two-thirds of patients), which most likely represents evidence of prior eosinophil degranulation.[42] The presence of basophils has also been recently demonstrated by using an antibody (BB1) that is specific for this cell type.[41] Thus, the infiltrate resembles that of an allergic late-phase reaction, as suggested previously,[43] although the percentage of each cell types differs, with neutrophils and monocytes being relatively more prominent in urticaria. Endothelial cell activation is suggested by the presence of intercellular adhesion molecule 1 and E-selectin in biopsy specimens of urticarial lesions.[44] Sources of chemokines include the mast cell and the activated endothelial cell; the latter cells are stimulated not only by cytokines or monokines, such as IL-4, IL-1, and tumor necrosis factor-α (TNF-α), but also by the vasoactive factors, for example, histamine and leukotrienes released from activated mast cells.[45] Complement activation and the release of C5a results not only in augmented mast cell (and basophil) histamine release, but C5a is also chemotactic for neutrophils, eosinophils, and monocytes. The presence of C5a is one of the factors that would distinguish this lesion from a typical allergen-induced cutaneous late-phase reaction. The particular chemokines released in chronic urticaria have not been studied. The presence of increased plasma IL-4 levels[25] in patients with chronic urticaria provides indirect evidence of lymphocyte activation, basophil activation, or both, and isolated $CD4^+$ lymphocytes of patients were shown to secrete greater amounts of both IL-4 and IFN-γ compared with that seen in healthy control subjects on stimulation with phorbol myristate acetate.

A direct comparison between cutaneous late-phase reactions and the histology of chronic urticaria revealed that infiltrating cells had characteristics of both T_H1 and T_H2 cells, with production of IFN-γ by the former cells and IL-4 and IL-5 by the latter.[46] Alternatively, this might represent activated T_H0 cells (i.e., activated $CD4^+$ lymphocytes that are not differentiated to T_H1 or T_H2 cells). When the histology of autoimmune and idiopathic chronic urticarias was compared,[41] the autoimmune subgroup had greater prominence of granulocytes within the infiltrate, whereas other infiltrating cells were quite similar, with a small increment in cytokine levels in the autoimmune group and greater tryptase positivity (? less degranulation) in the autoantibody-negative group. The patients with autoimmune chronic urticaria generally had more severe symptoms than those with idiopathic chronic urticaria.[47]

BASOPHIL RELEASIBILITY

(Figs. 38-1 and 38-2)

The basophils of patients with chronic urticaria have been shown to be hyporesponsive to anti-IgE, an observation made by Kern and Lichtenstein[48] long before there were any clues to the pathogenesis of this disorder. These findings were confirmed[49] and

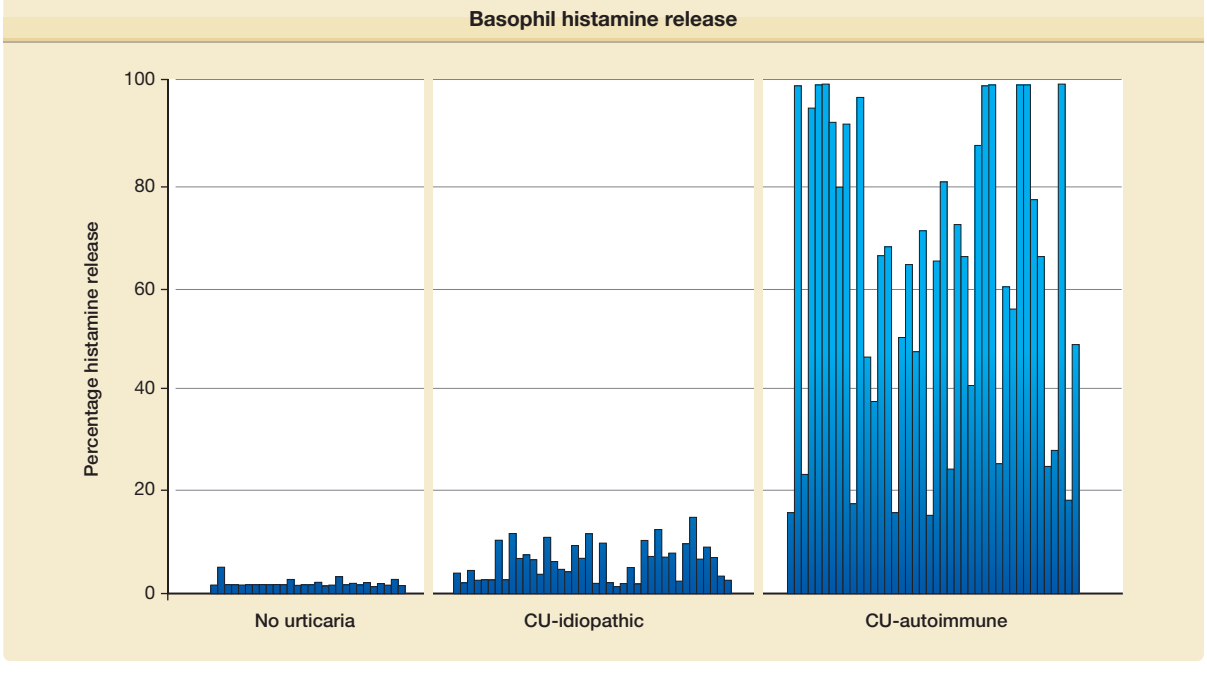

Figure 38-1 Basophil histamine release comparing normal sera (N = 35) with sera from patients with chronic urticaria (N = 104). Those designated as having chronic autoimmune urticaria are shown on the right.

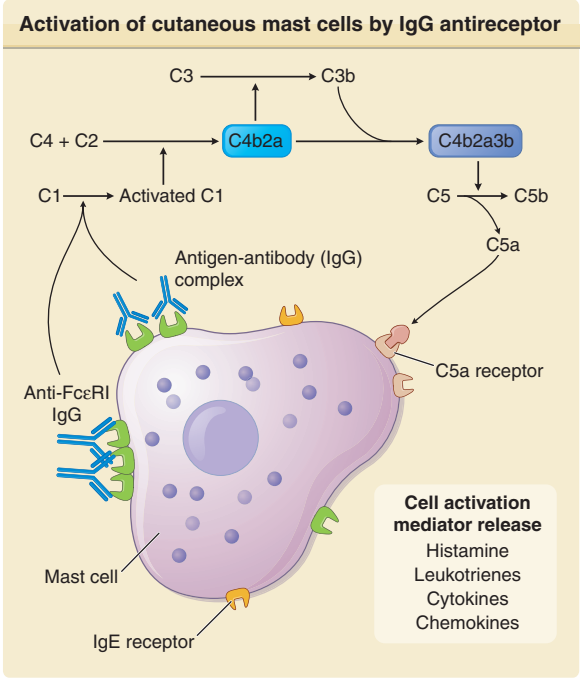

Figure 38-2 Schematic diagram of the activation of cutaneous mast cells by IgG antireceptor antibody, followed by activation of complement, release of C5a, and augmentation of mast cell release.

appeared to be associated with basopenia[50] and to segregate with the autoimmune subgroup. One obvious interpretation is that there is in vivo desensitization of basophils in the presence of circulating anti-IgE receptor. Vonakis et al have demonstrated that patients' basophil hyporesponsiveness to anti-IgE is due to augmented levels of SHIP phosphatase[51] that limits phosphorylation reactions critical for histamine secretion. Although manifest in about half the patients with chronic urticaria (and not segregated with either the autoimmune or idiopathic subgroups), the abnormality appears to reverse when patients remit. Thus, it may be a marker of disease activity. We have found a paradoxical result when the isolated basophils of patients with chronic urticaria were activated and compared with the basophils of healthy control subjects. Although the basophils of the patients with urticaria were clearly less responsive to anti-IgE, they demonstrated augmented histamine release when incubated with serum and it did not matter whether the sera were taken from normal subjects, other patients with chronic urticaria, or was their own.[52]

ROLE OF THE EXTRINSIC COAGULATION CASCADE

Studies of the plasma of patient with chronic urticaria demonstrate the presence of D-dimer and prothrombin 1 and 2 fragments indicating activation of prothrombin to thrombin as well as digestion of fibrinogen by thrombin.[53] The reaction is not specific for chronic urticaria as similar observations have been noted in multiple nonsteroidal hypersensitivity syndrome.[54] Nevertheless, the data are of considerable interest and activation of the coagulation cascade is dependent on tissue factor rather than factor XII, i.e., the extrinsic coagulation cascade. Although activated endothelial cells are a well-known source of the tissue factor, histologic studies suggest that eosinophils are a prominent source.[55] The relationship of these observations to histamine release by basophils or mast cells is not clear. Whereas thrombin activation of mast cells has been reported, the amounts required are large and the observations thus far are confined to rodent mast cells. One publication relating to eosinophil to histamine release found IgG antibody to Fc_eRII in the serum of patients with chronic urticaria which activates eosinophils to release cationic proteins.[56] They propose basophil activation by these eosinophil cationic proteins but do not demonstrate it; however, they offer an additional mechanism for basophil and possibly mast cell histamine release.

BRADYKININ: ROLE IN ANGIOEDEMA

Kinins are low-molecular-weight peptides that participate in inflammatory processes by virtue of their ability to activate endothelial cells and, as a consequence, lead to vasodilatation, increased vascular permeability, production of nitric oxide, and mobilization of arachidonic acid. Kinins also stimulate sensory nerve endings to cause a burning dysesthesia. Thus, the classical parameters of inflammation (i.e., redness, heat, swelling, and pain) can all result from kinin formation. Bradykinin is the best characterized of this group of vasoactive substances.

There are two general pathways by which bradykinin is generated. The simpler of the two has only two components: (1) an enzyme tissue kallikrein[57] and (2) a plasma substrate, low-molecular-weight kininogen.[58,59] Tissue kallikrein is secreted by many cells throughout the body; however, certain tissues produce particularly large quantities. These include glandular tissues (salivary and sweat glands and pancreatic exocrine gland) and the lung, kidney, intestine, and brain.

The second pathway for bradykinin formation is far more complex and is part of the initiating mechanism by which the intrinsic coagulation pathway is activated (eFig. 38-1.2 in online edition).[60] Factor XII is the initiating protein that binds to certain negatively charged macromolecular surfaces and autoactivates (autodigests) to form factor XIIa.[61,62] This is synonymous with Hageman factor as designated in the figure. There are two plasma substrates of factor XIIa, namely (1) prekallikrein[63] and (2) factor XI,[64,65] and each of these circulates as a complex with high-molecular-weight kininogen (HK).[66,67] These complexes also attach to initiating surfaces, and the major attachment sites are on two of the domains of HK, which thereby places both prekallikrein and factor XI in optimal conformation for cleavage to kallikrein (plasma kallikrein) and factor XIa, respectively. It is important to note that plasma kallikrein and tissue kallikrein are

separate gene products and have little amino acid sequence homology, although they have related functions (i.e., cleavage of kininogens). Tissue kallikrein prefers low-molecular-weight kininogen but is capable of cleaving HK, whereas plasma kallikrein cleaves HK exclusively. The two kininogens have an identical amino acid sequence starting at the *N*-terminus and continuing to 12 amino acids beyond the bradykinin moiety[59] but differ in *C*-terminal domains because of alternative splicing at the transcription level.[68,69] Both factor XII and HK bind to endothelial cells (which may function as the "natural" surface in the presence of physiologic zinc ion), thus activation may occur at the cell surface.[70,71]

A scheme for both production and degradation of kinins is shown in eFig. 38-1.2 in online edition. The enzymes that destroy bradykinin consist of kininases I and II. Kininase I is also known as plasma carboxypeptidase N,[72] which removes the *C*-terminal arg from bradykinin or kallidin to yield des-arg[73] bradykinin or des-arg[74] kallidin, respectively.[75] It is the same enzyme that cleaves the *C*-terminal arg from the complement anaphylatoxins C3a and C5a. Kininase II is identical to angiotensin-converting enzyme (ACE).[76] Kininase II is a dipeptidase that cleaves the *C*-terminal phe-arg from bradykinin to yield a heptapeptide, which is cleaved once again to remove ser-pro and to leave the pentapeptide arg-pro-pro-gly-phe.[75] If the *C*-terminal arg of bradykinin is first removed with kininase I, then ACE functions as a tripeptidase to remove ser-pro-phe and to leave the above pentapeptide.[77] Bradykinin and kallidin stimulate constitutively produced B2 receptors,[78] whereas des-arg[73]-BK or des-arg[74] lys-BK both stimulate B1 receptors,[79] which are induced as a result of inflammation. Stimuli for B1 receptor transcription include IL-1 and TNF-α.[80,81]

CLINICAL FINDINGS

Circumscribed, raised, erythematous, usually pruritic, evanescent areas of edema that involve the superficial portion of the dermis are known as *urticaria* (Fig. 38-3); when the edematous process extends into the deep dermis and/or subcutaneous and submucosal layers, it is known as *angioedema*. Urticaria and angioedema may occur in any location together or individually. Angioedema commonly affects the face or a portion of an extremity, may be painful but not pruritic, and may last several days. Involvement of the lips, cheeks, and periorbital areas is common, but angioedema also may affect the tongue, pharynx, or larynx. The individual lesions of urticaria arise suddenly, rarely persist longer than 24–36 hours, and may continue to recur for indefinite periods. They are highly pruritic.

IMMUNOLOGIC: IMMUNOGLOBULIN E- AND IMMUNOGLOBULIN E RECEPTOR-DEPENDENT URTICARIA/ANGIOEDEMA

ATOPIC DIATHESIS. Episodes of acute urticaria/angioedema that occur in individuals with a personal or family history of asthma, rhinitis, or eczema are presumed to be IgE dependent. However, in clinical practice, urticaria/angioedema infrequently accompanies an exacerbation of asthma, rhinitis, or eczema. The prevalence of chronic urticaria/angioedema is not increased in atopic individuals.



Figure 38-3 Urticaria and angioedema. This patient has urticaria occurring on the face, neck, and upper trunk with angioedema about the eyes.

SPECIFIC ANTIGEN SENSITIVITY. Common examples of specific antigens that provoke urticaria/angioedema include foods such as shellfish, nuts, and chocolate; drugs and therapeutic agents notably penicillin; aeroallergens; and Hymenoptera venom (see Fig. 38-3). Urticaria in patients with helminthic infestations has been attributed to IgE-dependent processes; however, proof of this relationship is often lacking. Specific allergens and nonspecific stimuli may activate local reactions termed *recall urticaria* at sites previously injected with allergen immunotherapy.

PHYSICAL URTICARIA/ANGIOEDEMA[5,6]

DERMOGRAPHISM. Dermographism is the most common form of physical urticaria and is the one most likely to be confused with chronic urticaria. A lesion appears as a linear wheal with a flare at a site in which the skin is briskly stroked with a firm object (Fig. 38-4). A transient wheal appears rapidly and usually fades within 30 minutes; however, the patient's normal skin is typically pruritic so that an itch–scratch sequence may appear. The prevalence of dermographism in the general population was reported as 1.5% and 4.2%, respectively, in two studies, and its prevalence in patients with chronic urticaria is 22%. It is not associated with atopy. The peak prevalence occurs in the second and third decades. In one study, the duration of dermographism was greater than 5 years in 22% of individuals and greater than 10 years in 10%.



Figure 38-4 Topical dermatographic response to scratching the skin.

Elevations in blood histamine levels have been documented in some patients after experimental scratching, and increased levels of histamine,[82] tryptase, SP, and VIP, but not calcitonin gene-related peptide, have been detected in experimental suction-blister aspirates. The dermographic response has been passively transferred to the skin of normal subjects with serum or IgE.[83]

In delayed dermographism, lesions develop 3–6 hours after stimulation, either with or without an immediate reaction, and last 24–48 hours. The eruption is composed of linear red indurated wheals. This condition may be associated with delayed pressure urticaria and these two may, in fact, represent the same entity. Cold-dependent dermographism is a condition characterized by marked augmentation of the dermatographic response when the skin is chilled.[84]

PRESSURE URTICARIA. Delayed pressure urticaria appears as erythematous, deep, local swellings, often painful, that arise from 3 to 6 hours after sustained pressure has been applied to the skin.[85,86] Spontaneous episodes are elicited on areas of contact after sitting on a hard chair, under shoulder straps and belts, on the feet after running, and on the hands after manual labor. The peak prevalence occurs in the third decade. Delayed pressure urticaria may occasionally be associated with fever, chills, arthralgias, and myalgias, as well as with an elevated erythrocyte sedimentation rate and leukocytosis. In one study, it accompanied chronic urticaria in 37% of patients. This is far more commonly seen than patients with pressure urticaria and no spontaneously occurring hives. An IgE-mediated mechanism has not been demonstrated; however, histamine and IL-6 have been detected in lesional experimental suction-blister aspirates and in fluid from skin chambers, respectively.[87–89]

VIBRATORY ANGIOEDEMA. Vibratory angioedema may occur as an acquired idiopathic disorder, in association with cholinergic urticaria, or after several years of occupational exposure to vibration.[90] It has been described in families with an autosomal dominant pattern of inheritance.[91] The heritable form often is accompanied by facial flushing. An increase in the level of plasma histamine was detected during an experimental attack in patients with the hereditary form and in patients with acquired disease.[91,92] A typical symptom is hives across the back when toweling off after a shower (in the absence of dermatographism).

COLD URTICARIA. There are both acquired and inherited forms of cold urticaria/angioedema; however, the familial form is rare. Idiopathic or primary acquired cold urticaria may be associated with headache, hypotension, syncope, wheezing, shortness of breath, palpitations, nausea, vomiting, and diarrhea. Attacks occur within minutes after exposures that include changes in ambient temperature and direct contact with cold objects. The elicitation of a wheal after the application of ice has been called a diagnostic cold contact test (Fig. 38-5). This can be performed with thermoelectric elements with graded temperatures so that the temperature threshold for producing a wheal can be determined and a dose-response (sensitivity) in terms of stimulus duration can be readily obtained.[92] If the entire body is cooled (as in swimming), hypotension and syncope, which are potentially lethal events (by drowning), may occur. In rare instances, acquired cold urticaria has been associated with circulating cryoglobulins, cryofibrinogens, cold agglutinins, and cold hemolysins, especially in children with infectious mononucleosis.[93–95]

Passive transfer of cold urticaria by intracutaneous injection of serum or IgE to the skin of normal recipients has been documented.[96,97] Histamine, chemotactic



Figure 38-5 Positive ice cube test in a patient with cold urticaria.

factors for eosinophils and neutrophils, PGD_2, cysteinyl leukotrienes, platelet-activating factor, and TNF-α have been released into the circulation after experimental challenge.[98–104] Histamine, SP, and VIP, but not calcitonin gene-related peptide, have been detected in experimental suction-blister aspirates. Histamine has been released in vitro from chilled skin biopsy specimens that have been rewarmed.[105] Neutrophils harvested from the blood of an experimentally cold-challenged arm manifested an impaired chemotactic response suggesting in vivo desensitization. Whereas complement has no role in primary acquired cold urticaria, cold challenge of patients with cold urticaria who have circulating immune complexes (such as cryoglobulins) can provoke a cutaneous necrotizing venulitis with complement activation.[106–109]

Rare forms of acquired cold urticaria have been described mainly in case reports include systemic cold urticaria,[84] localized cold urticaria,[110] cold-induced cholinergic urticaria, cold-dependent dermographism,[84] and localized cold reflex urticaria.[111,112] Three forms of dominantly inherited cold urticaria have been described. Familial cold urticaria which has been termed *familial cold autoinflammatory syndrome* and is considered a type of periodic fever.[113] It is a disorder showing an autosomal dominant pattern of inheritance with a genetic linkage to chromosomes 1q44. The responsible gene has been identified as *CIASI*, which codes for a protein involved in regulation of inflammation and apoptosis.[114] The eruption occurs as erythematous macules and infrequent wheals and is associated with burning or pruritus. Fever, headaches, conjunctivitis, arthralgias, and a neutrophilic leukocytosis are features of attacks. The delay between cold exposure and onset of symptoms is 2.5 hours, and the average duration of an episode is 12 hours. Renal disease with amyloidosis occurs infrequently. Skin biopsy specimens show mast cell degranulation and an infiltrate of neutrophils. Results of the cold contact test and passive transfer with serum have been negative. Serum levels of IL-6 and granulocyte colony stimulating factor were elevated in one patient. Other studies suggest a pathogenic role for IL-1. Delayed cold urticaria occurs as erythematous, edematous, deep swellings that appear 9–18 hours after cold challenge. Lesional biopsy specimens show edema with minimal numbers of mononuclear cells; mast cells are not degranulated; and neither complement proteins nor immunoglobulins are detected. Cold immersion does not release histamine, and the condition cannot be passively transferred. Recently, a new form of familial cold urticaria with dominant inheritance has been reported with pruritus, erythema, and urticaria with cold exposure that can progress to syncope. The ice cube test is negative and it lacks the fever, and flu-like symptoms associated with familial cold autoinflammatory syndrome.[115]

CHOLINERGIC URTICARIA. Cholinergic urticaria develops after an increase in core body temperature, such as during a warm bath, prolonged exercise, or episodes of fever.[116] The highest prevalence is observed in individuals aged 23–28 years. The eruption appears as distinctive, pruritic, small, 1- to 2-mm wheals that are surrounded by large areas of erythema (Fig. 38-6). Occasionally, the lesions may become confluent, or angioedema may develop. Systemic features include dizziness, headache, syncope, flushing, wheezing, shortness of breath, nausea, vomiting, and diarrhea. An increased prevalence of atopy has been reported. The intracutaneous injection of cholinergic agents, such as methacholine chloride, produces a wheal with satellite lesions in approximately one-third of patients.[117,118] Alterations in pulmonary function have been documented during experimental exercise challenge[119] or after the inhalation of acetylcholine, but most are asymptomatic.



Figure 38-6 Lesions of cholinergic urticaria observed in a patient after 15 minutes of exercise in a warm room.

A major subpopulation of patients with cholinergic urticaria have a positive skin test result and in vitro histamine release in response to autologous sweat.[120] It is not clear whether this is IgE mediated and any antigen present in sweat is unidentified. This is the same subpopulation with a positive methacholine skin test with satellite lesions and a nonfollicular distribution of the wheals. The remaining patients had negative results on autologous sweat skin tests or in vitro histamine release. Results of the methacholine skin test are negative for satellite lesions and the hives tend to be follicular in distribution.

Familial cases have been reported only in men in four families.[121] This observation suggests an autosomal dominant pattern of inheritance. One of these individuals had coexisting dermographism and aquagenic urticaria.

After exercise challenge, histamine and factors chemotactic for eosinophils and neutrophils have been released into the circulation.[99,119] Tryptase has been detected in lesional suction-blister aspirates. The urticarial response has been passively transferred on one occasion; however, most other attempts to do so have been unsuccessful.

Cold urticaria and cholinergic urticaria are not uncommonly seen together[122,123] and cold-induced cholinergic urticaria represents an unusual variant

in which typical "cholinergic" appearing lesions occur with exercise, but only if the person is chilled, for example, with exercise outside on a winter's day. The ice cube test and methacholine skin test are both negative.[124]

LOCAL HEAT URTICARIA. Local heat urticaria is a rare form of urticaria in which wheals develop within minutes after exposure to locally applied heat. An increased incidence of atopy has been reported. Passive transfer has been negative. Histamine, neutrophil chemotactic activity, and PGD_2 have been detected in the circulation after experimental challenge.[125] A familial delayed form of local heat urticaria in which the urticaria occurred in 1–2 hours after challenge and lasted up to 10 hours has been described.

SOLAR URTICARIA. Solar urticaria occurs as pruritus, erythema, wheals, and occasionally angioedema that develop within minutes after exposure to sun or artificial light sources. Headache, syncope, dizziness, wheezing, and nausea are systemic features. Most commonly, solar urticaria appears during the third decade.[126] In one study, 48% of patients had a history of atopy. Although solar urticaria may be associated with systemic lupus erythematosus and polymorphous light eruption, it is usually idiopathic. The development of skin lesions under experimental conditions in response to specific wavelengths has allowed classification into six subtypes; however, individuals may respond to more than one portion of the light spectrum. In type I, elicited by wavelengths of 285–320 nm, and in type IV, elicited by wavelengths of 400–500 nm, the responses have been passively transferred with serum, suggesting a role for IgE antibody. In type I, the wavelengths are blocked by window glass.[127,128] Type VI, which is identical to erythropoietic protoporphyria, is due to ferrochelatase (hemesynthetase) deficiency (see Chapter 132).[74] There is evidence that an antigen on skin may become evident once irradiated with the appropriate wave length of light followed by complement activation and release of C5a.[129–131]

Histamine and chemotactic factors for eosinophils and neutrophils have been identified in blood after exposure of the individuals to ultraviolet A, ultraviolet B, and visible light.[132,133] In some individuals, uncharacterized serum factors with molecular weights ranging from 25 to 1,000 kDa, which elicit cutaneous wheal-and-erythema reactions after intracutaneous injection, have been implicated in the development of lesions.

EXERCISE-INDUCED ANAPHYLAXIS. Exercise-induced anaphylaxis is a clinical symptom complex consisting of pruritus, urticaria, angioedema respiratory distress, and syncope that is distinct from cholinergic urticaria.[134–137] In most patients, the wheals are not punctate and resemble the hives seen in acute or chronic urticaria. The symptom complex is not readily reproduced by exercise challenges as is cholinergic urticaria. There is a high prevalence of an atopic diathesis. Some cases are food dependent, i.e., exercise will lead to an anaphylaxis-like episode only if food was ingested within 5 hours of the exercise. The food dependency is subdivided into two groups: in the first the nature of the food eaten is not relevant, whereas in the second a specific food to which there is IgE-mediated hypersensitivity must be eaten for hives to appear.[138–141] Yet in these cases, eating the food without exercise does not result in urticaria. The food-dependent group is easier to treat because avoidance of food (or a specific food) for 5–6 hours before exercise prevents episodes. Cases not related to food require therapy for acute episodes and attempts to prevent episodes with high-dose antihistaminics or avoidance of exercise. Results of a questionnaire study of individuals who had had exercise-induced anaphylaxis for more than a decade[142] disclosed that the frequency of attacks had decreased in 47% and had stabilized in 46%. Forty-one percent had been free of attacks for 1 year. Rare familial forms have been described. In exercise-induced anaphylaxis, baseline pulmonary function tests are normal. Biopsy specimens show mast cell degranulation, and histamine and tryptase are released into the circulation when symptoms appear.

ADRENERGIC URTICARIA. Adrenergic urticaria occurs as wheals surrounded by a white halo that develop during emotional stress. The lesions can be elicited by the intracutaneous injection of norepinephrine.

AQUAGENIC URTICARIA AND AQUAGENIC PRURITIS. Contact of the skin with water of any temperature may result in pruritus alone or, more rarely, urticaria. The eruption consists of small wheals that are reminiscent of cholinergic urticaria. Aquagenic urticaria has been reported in more than one member in five families.[143] Aquagenic pruritus without urticaria is usually idiopathic but also occurs in elderly persons with dry skin and in patients with polycythemia vera, Hodgkin's disease, the myelodysplastic syndrome, and the hypereosinophilic syndrome. Patients with aquagenic pruritus should be evaluated for the emergence of a hematologic disorder. After experimental challenge, blood histamine levels were elevated in subjects with aquagenic pruritus and with aquagenic urticaria. Mast cell degranulation was present in lesional tissues. Passive transfer was negative.

CONTACT URTICARIA

Urticaria may occur after direct contact with a variety of substances. It may be IgE mediated or nonimmunologic. The transient eruption appears within minutes, and when it is IgE mediated, it may be associated with systemic manifestations. Passive transfer has been documented in some instances. Proteins from latex products are a prominent cause of IgE-mediated contact urticaria.[144] Latex proteins also may become airborne allergens, as demonstrated by allergen-loaded airborne glove powder used in inhalation challenge tests. These patients may manifest cross-reactivity to fruits, such

as bananas, avocado, and kiwi.[145] Associated manifestations include rhinitis, conjunctivitis, dyspnea, and shock. The risk group is dominated by biomedical workers and individuals with frequent contact with latex, such as children with spina bifida. Agents such as stinging nettles, arthropod hairs, and chemicals may release histamine directly from mast cells.

PAPULAR URTICARIA

Papular urticari occurs as episodic, symmetrically distributed, pruritic, 3- to 10-mm urticarial papules that result from a hypersensitivity reaction to the bites of insects such as mosquitoes, fleas, and bedbugs. This condition appears mainly in children. The lesions tend to appear in groups on exposed areas such as the extensor aspects of the extremities.[146]

URTICARIA/ANGIOEDEMA MEDIATED BY BRADYKININ, THE COMPLEMENT SYSTEM OR OTHER EFFECTOR MECHANISMS

KININS AND C1 INHIBITOR DEFICIENCY.

C1 inhibitor (C1 INH) is the sole plasma inhibitor of factor XIIa and factor XIIf,[147,148] and it is one of the major inhibitors of kallikrein[149] as well as factor XIa.[150] Thus, in the absence of C1 INH, stimuli that activate the kinin-forming pathway will do so in a markedly augmented fashion; the amount of active enzyme and the duration of action of the enzymes are prolonged. C1 INH deficiency can be familial, in which there is a mutant *C1 INH* gene, or it can be acquired. Both the hereditary and acquired disorders have two subtypes. For the hereditary disorder, type I hereditary angioedema (HAE) (85%) is an autosomal dominant disorder with a mutant gene (often with duplication, deletions, or frame shifts) leading to markedly suppressed C1 INH protein levels as a result of abnormal secretion or intracellular degradation.[151] Type 2 HAE (15%) is also a dominantly inherited disorder, typically with a point (missense) mutation leading to synthesis of a dysfunctional protein.[152] The C1 INH protein level may be normal or even elevated, and a functional assay is needed to assess activity. The acquired disorder has been portrayed as having two forms, but they clearly overlap and have in common B cell activation that is often clonal. One group is associated with B-cell lymphoma[153–155] or connective tissue disease,[156] in which there is consumption of C1 INH. Examples are systemic lupus erythematosus and cryoglobulinemia, in which complement activation is prominent, and B-cell lymphomas, in which immune complexes are formed by anti-idiotypic antibodies to monoclonal immunoglobulin expressed by the transformed B lymphocytes.[157] A second group has a prominence of a circulating IgG antibody to INH itself,[158–160] but this may be seen with lymphoma or systemic lupus erythematosus as well. Acquired types have depressed C1q levels, whereas hereditary types do not, and depressed C4 levels characterize all forms of C1 INH deficiency. The acquired autoimmune subgroup has a circulating 95-kDa cleavage product of C1 INH because the antibody depresses C1 INH function yet allows cleavage by enzymes with which it usually interacts.[159–162]

It is now clear that depletion of C4 and C2 during episodes of swelling[163,164] is a marker of complement activation but does not lead to release of a vasoactive peptide responsible for the swelling. Bradykinin is, in fact, the mediator of the swelling[165–167]and the evidence in support of this conclusion is summarized below. Patients with HAE are hyperresponsive to cutaneous injection of kallikrein.[168] They have elevated bradykinin levels, and low prekallikrein and HK levels during attacks of swelling.[169–171] The augmentation in complement activation seen at those times may be due to activation of C1r and C1s by factor XIIf.[172] The presence of kallikrein-like activity in induced blisters of patients with HAE also supports this notion,[173] as does the progressive generation of bradykinin on incubation of HAE plasma in plastic (noncontact-activated) tubes[165,166] as well as the presence of activated factor XII and cleaved HK levels seen during attacks.[174] One unique family has been described in which there is a point mutation in the *C1 INH* (A1a 443 → Val) leading to an inability to inhibit complement but normal inhibition of factor XIIa and kallikrein.[175,176] No family member of this type 2 mutation has had angioedema,[175] although complement activation is present. In recent studies plasma bradykinin levels have been shown to be elevated during attacks of swelling in both hereditary and acquired C1 inhibitor deficiency,[169] and local bradykinin generation has been documented at the sites of swelling.[177] It is not known whether bradykinin generation is predominantly seen in the fluid phase, occurs along cell (endothelial) surfaces, or both. A rodent model of HAE demonstrated that angioedema can be prevented by "knockout" of the B-2 receptor.[178] Figure 38-7 depicts a patient with facial swelling due to HAE. Figure 38-8 is a diagram depicting the steps in the bradykinin-forming cascade that are inhibitable by C1 INH.

An estrogen-dependent form of hereditary angioedema has been recognized that is now designated type 3 HAE. One of the first reports involved a single family with seven affected individuals in three generations, which suggests a hereditary (autosomal dominant) pattern.[73] Clinical features include angioedema without urticaria, laryngeal edema, and abdominal pain with vomiting. Attacks occur during pregnancy and with the administration of exogenous estrogen. Numerous subsequent reports support these observations.[179] In one subgroup, there is a mutation in factor XII such that the activated form (factor XIIa) is more potent than normal.[180] These patients all have normal C4 and normal C1 INH protein and function. Bradykinin is the likely mediator; for those with a factor XII mutation, the active enzyme may be less readily inhibited. Although uncommon, a male with the disorder has been described[181] and a bradykinin receptor antagonist (Icatibanit) has provided effective therapy for acute episodes.

ANGIOTENSIN-CONVERTING ENZYME INHIBITORS.

Angioedema has been associated with the administration of ACE inhibitors.[182] The frequency of



Figure 38-7 Hereditary angioedema. Extensive involvement (**A**) is to be contrasted with the patient's normal facies (**B**).

angioedema occurring after ACE inhibitor therapy is 0.1%–0.7%. There is a predilection to ACE inhibitor reactions in the African-American population that may relate to polymorphisms in the genes encoding other enzymes that catabolize bradykinin such as aminopeptidase P or neutral endopeptidase. Low levels of these would predispose to bradykinin accumulation. Angioedema develops during the first week of therapy in up to 72% of affected individuals and usually involves the head and neck, including the mouth, tongue, pharynx, and larynx. Urticaria occurs only rarely. Cough and angioedema of the gastrointestinal tract are associated features. It has been suggested that therapy with ACE inhibitors is contraindicated in patients with a prior history of idiopathic angioedema, HAE, and acquired C1 INH deficiency.[183] It

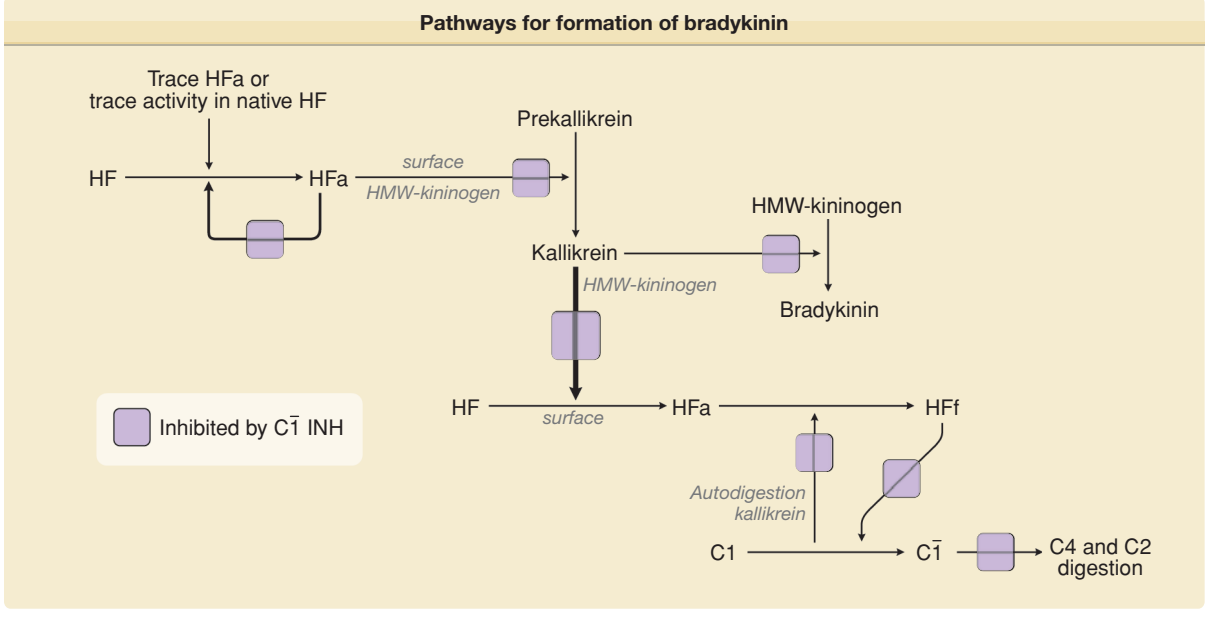

Figure 38-8 Pathways for formation of bradykinin, indicating all steps inhibitable by C1 inhibitor as well as complement activation by means of factor XIIf.

appears that this swelling is also a consequence of elevated levels of bradykinin;[169] however, the accumulation of bradykinin is due to a defect in degradation rather than an excessive production. ACE, being identical to kininase II, is the major enzyme responsible for bradykinin degradation (See eFig. 38-1.2 in online edition) and although it is present in plasma, the vascular endothelium of the lung appears to be its major site of action.[184] The action of ACE always leads to the formation of degradation products with no activity, whereas kininase I alone yields the des-arg products, which are capable of stimulating B1 receptors.

The excessive accumulation of bradykinin implies that production is ongoing, with activation of the plasma cascade or release of tissue kallikrein faulty inactivation of bradykinin then leads to swelling. Continuous turnover of the plasma cascade is implied by data demonstrating activation along the surface of cells and cellular expression or secretion of a prekallikrein activator other than factor XIIa.[185,186]

URTICARIAL VENULITIS

Chronic urticaria and angioedema may be manifestations of cutaneous necrotizing venulitis, which is known as *urticarial venulitis* (See Chapter 163).[187,188] Associated features include fever, malaise, arthralgia, abdominal pain, and less commonly conjunctivitis, uveitis, diffuse glomerulonephritis, obstructive and restrictive pulmonary disease, and benign intracranial hypertension. The term hypocomplementemic urticarial vasculitis syndrome is used in patients with more severe clinical manifestations of urticarial venulitis with hypocomplementemia and a low-molecular-weight C1q-precipitin that has been identified as an IgG autoantibody directed against the collagen-like region of C1q.

SERUM SICKNESS

Serum sickness, which was defined originally as an adverse reaction that resulted from the administration of heterologous serum to humans, but may similarly occur after the administration of drugs. Serum sickness occurs 7–21 days after the administration of the offending agent and is manifested by fever, urticaria, lymphadenopathy, myalgia, arthralgia, and arthritis. Symptoms are usually self-limited and last 4–5 days. More than 70% of patients with serum sickness experience urticaria that may be pruritic or painful. The initial manifestation of urticaria may appear at the site of injection.[189–197]

REACTIONS TO THE ADMINISTRATION OF BLOOD PRODUCTS

Urticaria/angioedema may develop after the administration of blood products. It usually is the result of immune complex formation and complement activation that leads to direct vascular and smooth muscle alterations and indirectly, via anaphylatoxins, to mast cell mediator release. Aggregated IgG may also be responsible for human reactions to immunoglobulins as evidenced by the fact that the administration of IgG from which aggregates have been removed is not associated with urticaria or anaphylaxis.

An uncommon mechanism for the development of urticaria after the administration of blood products is the transfusion of IgE of donor origin directed toward an antigen to which the recipient is subsequently exposed. Another mechanism may be the transfusion of a soluble antigen present in the donor preparation into a previously sensitized recipient.

INFECTIONS

Episodes of acute urticaria can be associated with upper respiratory tract viral infections, most commonly in children.[198] The acute urticaria resolves within 3 weeks. Hepatitis B virus infection has been associated with episodes of urticaria lasting up to 1 week that are accompanied by fever and arthralgias as part of the prodrome. The mechanism is analogous to that seen in serum sickness-like reactions with virus–antibody immune complexes. The mechanism for urticaria occasionally associated with infectious mononucleosis may be analogous.

URTICARIA/ANGIOEDEMA AFTER DIRECT MAST CELL DEGRANULATION

Various therapeutic and diagnostic agents have been associated with urticaria/angioedema. Up to 8% of patients receiving radiographic contrast media experience such reactions, which occur most commonly after intravenous administration. Decreased serum alternative pathway complement protein levels and increased serum histamine levels have been detected in patients receiving radiocontrast media. Opiate analgesics, polymyxin B, curare, and D-tubocurarine induce release of histamine from mast cells and basophils.

URTICARIA/ANGIOEDEMA RELATING TO ABNORMALITIES OF ARACHIDONIC ACID METABOLISM

Intolerance to aspirin manifested as urticaria/angioedema occurs in otherwise normal individuals or in patients with allergic rhinitis and/or bronchial asthma. Urticaria/angioedema in response to aspirin and nonsteroidal anti-inflammatory drugs (NSAIDs) occurred in approximately 10%–20% of individuals referred to a hospital dermatology clinic in the United Kingdom. Patients intolerant of aspirin also may react to indomethacin and to other NSAIDs.

Reactions to aspirin are shared with other NSAIDs because they reflect inhibition of prostaglandin endoperoxide synthase 1 (PGHS-1, cyclooxygenase I)[199] as

well as inhibition of the inducible PGHS-2 (cyclooxygenase 2). Sodium salicylate and choline salicylate generally are well tolerated because of their weak activity against PGHS-1. PGHS-2 inhibitors are generally well tolerated in those with NSAID-induced urticaria.[200,201] Reactions to NSAIDs increase the levels of cysteinyl leukotrienes,[202] which may relate to the appearance of urticaria, although their role in NSAID-induced asthma is better characterized. Prick skin tests are of no diagnostic value, passive transfer reactions are negative, and neither IgG nor IgE antibodies have been associated with clinical disease. The clinical manifestations elicited by aspirin challenge of aspirin-intolerant patients are blocked when such patients are protected with a cysteinyl leucotriene receptor blocker or biosynthetic inhibitor; this finding confirms a pathobiologic role for the cysteinyl leukotrienes.

CHRONIC IDIOPATHIC URTICARIA AND IDIOPATHIC ANGIOEDEMA

Because the clinical entities of chronic idiopathic urticaria (with or without angioedema) and idiopathic angioedema are frequently encountered, have a capricious course, and are recognized easily, they are frequently associated with concomitant events. Such attributions must be interpreted with caution. Although infections, food allergies, adverse reactions to food additives, metabolic and hormonal abnormalities, malignant conditions, and emotional factors have been claimed as causes, proof of their etiologic relationship often is lacking. Among the recent considerations is chronic urticaria as a consequence of infection with *Helicobacter pylori*. Articles both supporting[203–205] and denying[206–209] a relationship are numerous and a definite answer is not available. However, the *H. pylori* infection rate in the population at large is far greater than the incidence of chronic urticaria and in the opinion of this author, the association is spurious. The controversy has been put in perspective by M. Greaves.[210] Idiopathic angioedema is diagnosed when angioedema is recurrent, when urticaria is absent, and when no exogenous agent or underlying abnormality is identifiable. An extensive review of angioedema has been recently published.[184]

Cyclic episodic angioedema has been associated with fever, weight gain, absence of internal organ damage, a benign course, and peripheral blood eosinophilia.[211] Biopsy specimens of tissues show eosinophils, eosinophil granule proteins, and CD4 lymphocytes exhibiting HLA-OR. Blood levels of IL-1, soluble IL-2 receptor, and IL-5 are elevated.

Idiopathic angioedema is characterized by recurrent episodes of angioedema in the absence of any urticaria, which may include the face (lips, tongue, periorbital region, pharynx), extremities, and genitalia, but is not associated with laryngeal edema or massive tongue/pharyngeal swelling that yield airway obstruction. It may not be a continuum with chronic urticaria with or without concomitant angioedema, as is often considered, because the incidence in men and women is about the same and the presence of antithyroid antibodies or anti-IgE receptor antibodies is far less. Extreme cases, particularly if associated with laryngeal edema, could represent type 3 HAE in a patient with a new mutation (i.e., no family history) or a variant of idiopathic anaphylaxis.

MISCELLANEOUS

Muckle–Wells syndrome consists of urticaria, amyloidosis, and nerve deafness and is due to the same gene defect as is seen in familial cold urticaria.[114] Schnitzler syndrome is a chronic urticaria with histology resembling an urticarial vasculitis associated with fever, joint pain, an IgM monoclonal protein, and osteosclerosis. An antibody to IL-1α has been shown to be present.[212]

APPROACH TO THE PATIENT

The evaluation of patients with urticaria/angioedema (Fig. 38-9) begins with a comprehensive history, with particular emphasis on the recognized causes, and a physical examination. Some varieties of urticaria may be identified by their characteristic appearance, such as the small wheals with a large erythematous flare of cholinergic urticaria, the linear wheals in dermographism, and the localization of lesions to exposed areas in light- or cold-induced urticaria. If suggested by the history, the physical examination in all patients with urticaria should include tests for physical urticaria, such as a brisk stroke to elicit dermographism, the use of a weight to elicit delayed pressure urticaria, and application of a cold or warm stimulus for cold-induced urticaria and localized heat urticaria, respectively. Exercise, such as running in place, may elicit cholinergic urticaria and, in some instances, exercise-induced anaphylaxis. Phototests to elicit solar urticaria usually are performed in referral centers, as are challenges for exercise-induced anaphylaxis.

When urticaria has been present for days or weeks at a time (but less than 6 weeks) or occurs recurrently for similar intervals, the main considerations are allergic reactions (IgE mediated) to food or drugs. A careful history regarding possibilities is essential. Skin testing can corroborate IgE-mediated hypersensitivity to foods or can provide suspects when the history is unrevealing. Double-blind placebo-controlled food challenge can demonstrate clinical relevance in cases in which the role of a food is uncertain. Non-IgE-mediated causes of urticaria include adverse reactions to NSAIDs and opiates. Any of these can be associated with concomitant angioedema or, less commonly, present as angioedema in the absence of urticaria. Children may have acute urticaria in association with viral illnesses; it is unclear whether infection with bacteria such as *Streptococcus* can induce urticaria as well, but neither form occurs in adults with the exception of urticaria in association with infectious mononucleosis (Epstein–Barr virus) or as a prodrome to hepatitis B

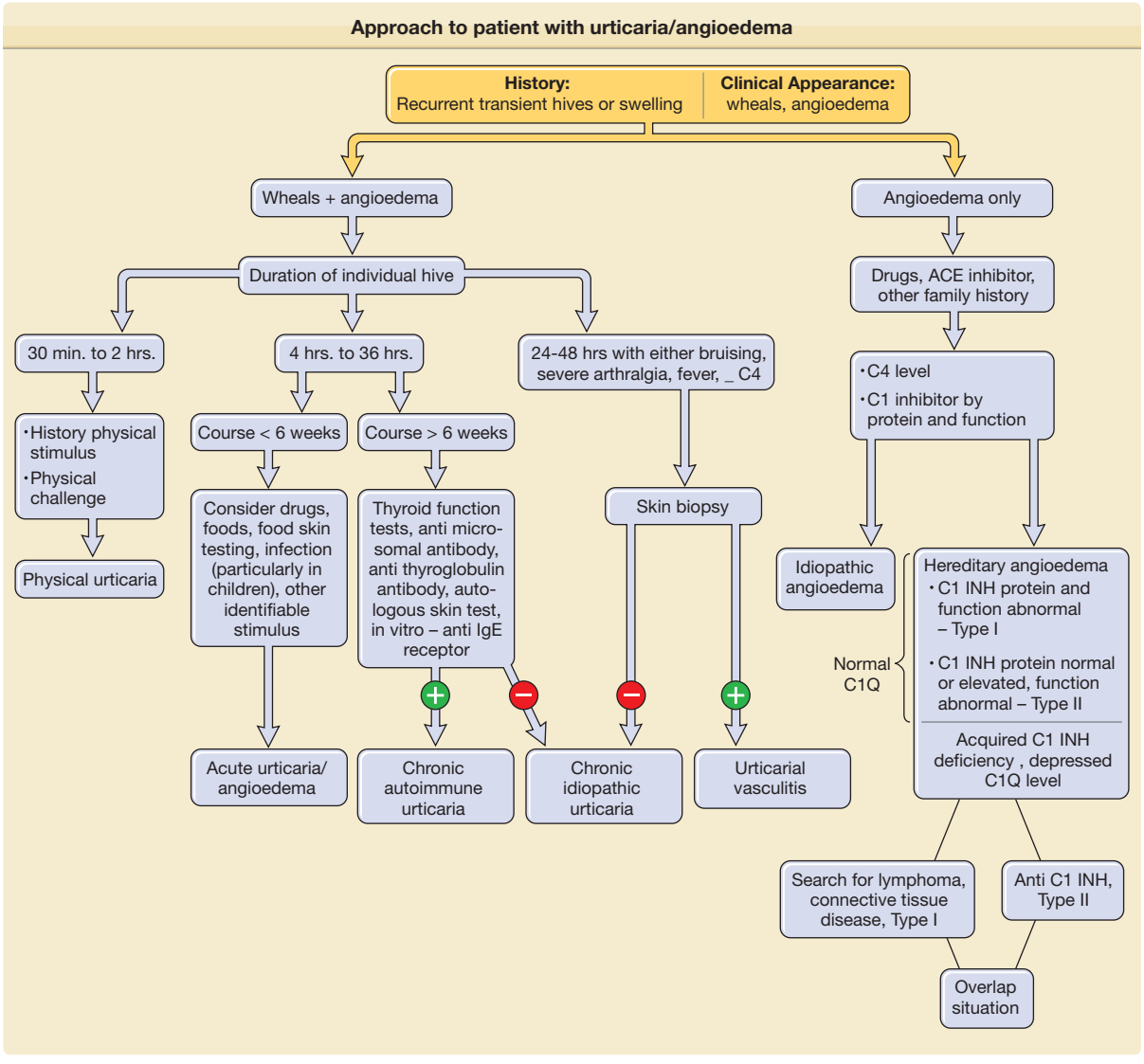

Figure 38-9 Approach to the patient with urticaria/angioedema. ACE = angiotensin-converting enzyme; IgE, immunoglobulin E; INH = inhibitor; ↓ = decreased.

infection. In each of these circumstances, individual lesions last anywhere from 4 hours to 24 hours and fade without associated purpura. If hives last less than 2 hours, the cause is usually physical urticaria, the most common being dermatographism, cholinergic urticaria, and cold urticaria. The main exception is delayed pressure urticaria, in which lesions typically last 12–36 hours and first appear 3–6 hours after the initiating stimuli. Once urticaria continues for longer than 6 weeks (particularly if present for many months or years) chronic urticaria is present. The term chronic spontaneous urticaria has been employed recently to eliminate confusion with physical urticarias. Chronic urticaria is now divided into chronic idiopathic urticaria for which a cause has not yet been found and chronic autoimmune urticaria. Angioedema accompanies chronic urticaria in 40% of cases and is more problematic in the autoimmune subgroup. Swelling in association with chronic urticaria can affect hands, feet, eyes, cheeks, lips, tongue, and pharynx, but not the larynx. When angioedema is present in the absence of an identifiable antigen or exogenous stimulus, the main entities to consider are C1 INH deficiency (hereditary or acquired) and idiopathic angioedema. Approximately 0.5% of patients have an urticarial vasculitis with palpable purpura or other stigmata of a possible vasculitis, such as fever, elevated sedimentation rate, petechiae or purpura, elevated white blood cell count, or lesions of unusual duration (36–72 hours). The differential diagnosis of acute, chronic, and physical urticaria/angioedema is summarized in Box 38-1.

LABORATORY FINDINGS

In most patients with chronic urticaria/angioedema, no underlying disorders or causes can be discerned.

BOX 38-1 DIFFERENTIAL DIAGNOSIS OF URTICARIA/ANGIOEDEMA

ACUTE (<6 WEEK)

- Drug reaction
  - Immunoglobulin E (IgE) mediated
  - Metabolic—idiosyncratic
  - Cellular immunity
- Food reactions
  - IgE mediated
  - Non-IgE mediated (e.g., scombroid poisoning)
- Intravenous administration
  - Blood products
  - Contrast agents
  - Intravenous γ globulin
- Infection
  - Viral in children
  - Infectious mononucleosis or hepatitis B prodrome
  - ? Bacterial in children

PHYSICAL

- Individual lesions last <2 hours
  - Cold urticaria
  - Cholinergic urticaria
  - Dermatographism
  - Local heat urticaria
  - Aquagenic urticaria
  - Cold-induced cholinergic urticaria
  - Cold-dependent dermatographism
- Lesions last >2 hours
  - Delayed pressure urticaria
  - Vibratory angioedema
  - Familial cold-induced syndromes, usually with fever

CHRONIC (>6 WEEK)

- Autoimmune, often with antithyroid antibodies
- Idiopathic
- Urticarial vasculitis
  - Idiopathic—skin only
  - Associated with other connective tissue disease
- Familial febrile syndromes with urticaria-like rash
- Schnitzler's syndrome

Diagnostic studies should be based on findings elicited by the history and physical examination. Evaluation of chronic urticaria/angioedema should include thyroid function tests, assays for antimicrosomal and antithyroglobulin antibodies, and the autologous skin test can be done, even in an office setting.[213] Routine screening laboratory tests are of little value. The histamine release assay for anti-IgE receptor or anti-IgE antibodies are now available in specialized laboratories. Serum hypocomplementemia is not present in chronic idiopathic urticaria or chronic autoimmune urticaria and mean levels of serum IgE in these patients are not different from the general population in which the incidence of atopy is 20%.

Cryoproteins should be sought in patients with acquired cold urticaria. An antinuclear antibody test should be obtained in patients with solar urticaria. Assessment of serum complement proteins may be helpful in identifying patients with urticarial venulitis or serum sickness (C4-, C3-, C1q-binding assay for circulatory immune complexes), as well as those with hereditary and acquired forms of C1 INH deficiency (C4, C1 INH by protein and function, C1q level).

Skin biopsy of chronic urticarial lesions should be undertaken to identify urticarial venulitis or to assess rashes where the urticarial nature is not clear.

There is little role for routine prick skin testing or the radioallergosorbent test in the diagnosis of specific IgE-mediated antigen sensitivity in chronic urticaria/angioedema. Inhalant materials are uncommon causes of urticaria/angioedema, and food skin tests may be difficult to interpret. The tests for drugs are limited to penicillin but cannot be performed in patients with dermographism. The radioallergosorbent test should be reserved for those in whom skin testing is contraindicated, unavailable, or unrevealing despite a highly suspected history.

A finding of the release of histamine from peripheral basophilic leukocytes has supported the diagnosis of anaphylactic sensitivity to a variety of antigens, which include pollens and insect venom.

HISTOPATHOLOGY

Edema involving the superficial portion of the dermis is characteristic of urticaria, whereas angioedema involves the deeper dermis and subcutaneous tissue. Both disorders are associated with dilatation of the venules.

In chronic urticaria, the dermal infiltrating inflammatory cells may be sparse or dense and include more CD4 than CD8 T lymphocytes, neutrophils, eosinophils, and basophils[46,214] without B lymphocytes or natural killer (NK) cells. NKT cells have not been assessed. Increased expression of TNF-α and IL-3 on endothelial cells and perivascular cells was detected in the upper dermis of patients with acute urticaria, chronic idiopathic urticaria, and delayed-pressure urticaria and in one patient with cold urticaria.[215] TNF-α also was detected on epidermal keratinocytes in lesional and nonlesional biopsy specimens. In chronic idiopathic urticaria, CD11b and CD18 cells were detected about the blood vessels in the superficial and deep dermis. Direct immunofluorescence tests for immunoglobulins and complement proteins were negative.

Major basic protein and eosinophil cationic protein, which are derived from the eosinophils granule, are present around blood vessels and are dispersed in the dermis in lesions of acute urticaria, chronic

idiopathic urticaria, delayed-pressure urticaria, cholinergic urticaria, and solar urticaria. In chronic idiopathic urticaria, free eosinophil granules in the dermis were increased in wheals of greater than 24 hours' duration as compared with wheals lasting fewer than 24 hours. The secreted form of eosinophil cationic protein and eosinophil-derived neurotoxin were detected on cells in greater amounts in biopsy specimens from patients with chronic urticaria without autoantibodies than in those with autoantibodies. P-selectin, E-selectin, intercellular adhesion molecules 1, and vascular cellular adhesion molecule 1 have been demonstrated on the vascular endothelium of patients with chronic idiopathic urticaria and dermographism. Major histocompatability complex class II antigen also is upregulated on the endothelial cells of patients with chronic urticaria, and the peripheral blood lymphocytes have increased CD40 ligand expression and higher Bcl-2 expression; these observations suggest an augmentation of autoimmune phenomena.[216]

In papular urticaria, the epidermis is thick with intercellular edema and lymphocytes. In the dermis, there is edema with an infiltrate containing T lymphocytes, macrophages, eosinophils, and neutrophils without B lymphocytes or the deposition of immunoglobulins, fibrin and C3.

TREATMENT

Therapy of acute urticaria uses antihistamines as described in Fig. 38-10; however, the rash can be severe and generalized, and angioedema may be present as well. Thus, if relief provided by nonsedating antihistamines appears insufficient, one can try hydroxyzine or diphenhydramine at 25–50 mg qid.[217] Alternatively nonsedating antihistamines can be tried employing up to 4–6 tablets/day as has been reported for treatment of cold urticaria.[92] A course of corticosteroid can be used, for example, 40–60 mg/day for 3 days and taper by 5–10 mg/day. Epinephrine can relieve severe symptoms of urticaria or angioedema (generalized urticaria, severe pruritus, accelerating angioedema) and is indicated if laryngeal edema is present. Edema of the posterior tongue and/or pharyngeal edema can be confused with it.

The ideal treatment for urticaria/angioedema is identification and removal of its cause. Many patients with acute urticaria and angioedema probably are not treated by physicians because the cause is identified by the individual or the course is limited. Treatment of chronic urticaria focuses on measures that provide symptomatic relief. The physician should provide not only medications but also support and reassurance. In a questionnaire study, patients with chronic idiopathic urticaria considered the worst aspects to be pruritus and the unpredictable nature of the attacks. The presence of facial angioedema can be particularly disconcerting and tongue and/or pharyngeal edema is often considered life threatening. This is not the case and is confused with the potential for laryngeal edema seen with anaphylaxis, or anaphylactic-like reactions, C1 INH deficiency, or reactivity to ACE inhibitors. Affected individuals reported sleep disturbances, diminished energy, social isolation, and altered emotional reactions as well as difficulties in relation to work, home activities, social life, and sex life.[218,219] Another study showed a correlation between the severity of chronic idiopathic urticaria and depression. In a questionnaire study, individuals with delayed pressure urticaria and cholinergic urticaria had the most quality-of-life impairment.[220] Those with cholinergic urticaria suffered in relation to their sporting activities and sexual relationships. Although urticaria/angioedema may be a source of frustration to both physicians and patients, most individuals can achieve acceptable symptomatic control of their disease without identification of the cause. In some individuals, it is important to avoid aspirin and other NSAIDs. Antipruritic lotions, cool compresses, and ice packs may provide temporary relief. H_1-type antihistaminic drugs are the mainstays in the management of urticaria/angioedema. The older H_1-type antihistaminics are known as *classic*, *traditional*, or *first generation* H_1-type antihistamines. Newer, low-sedating, or second- and third-generation H_1-type antihistamines with reduced sedative and anticholinergic side effects have become the initial therapeutic agents of choice. The drug should be taken on a regular basis and not as needed. If the initial drug chosen is ineffective, an agent from a different pharmacological class should be used and nonsedating antihistaminics can be combined or the dose of any one of them increased. When this is ineffective, doses of hydroxyzine or diphenhydramine in the 25–50 mg qid may be tried. The same is true for the treatment of dermatographism when it is particularly severe. It should be noted that if the molar release of histamine in the skin exceeds that of the delivered antihistamine (as can be seen with dermatographism), the histamine will keep the receptors to which it is bound in the active conformation, and therapeutic efficacy with the antihistamine will be achieved only when its molar concentration is much greater than that of histamine. Diphenhydramine is an alternative to hydroxyzine or cetirizine for dermatographism but not for cholinergic urticaria.[221,222] Cold urticaria can be treated with most antihistaminics but cyproheptadine at 4–8 mg tid or qid seems to be particularly effective.[223–226] Excellent results have been recently reported with desloratadine at four times/day.[92] Local heat urticaria is treated with antihistaminics; no regimen is particularly favored. Although anecdotal reports suggest that delayed pressure urticaria will respond to NSAIDs, dapsone, cetirizine, or sulfasalazine, most require corticosteroids (used as in chronic urticaria) to control symptoms and cyclosporine can be a particularly effective alternative. Familial cold autoinflammatory syndrome (urticaria) responds to parenteral IL-1 receptor antagonist (anakinra) as does some cases of Schnitzler syndrome.

Treatment choices for chronic urticaria (idiopathic or autoimmune) have been reviewed[227] and are

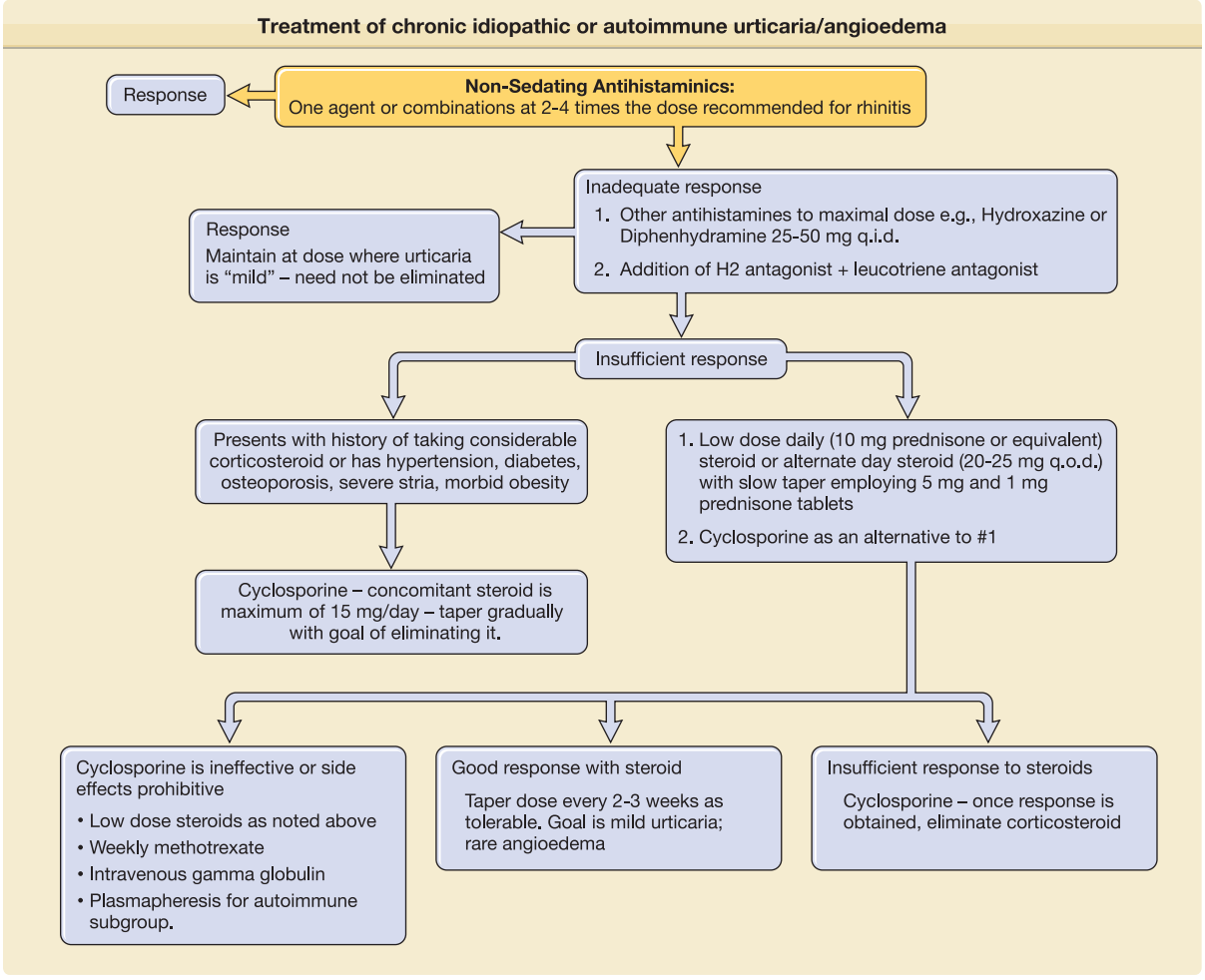

Figure 38-10 Treatment of chronic idiopathic or autoimmune urticaria/angioedema. Note that the following agents are expected to be effective rarely, if ever: hydroxychloroquine, colchicine, dapsone, sulfasalazine, mycophenolate mofetil. Hydroxychloroquine is, however, the drug of choice for the hypocomplementemic urticarial vasculitis syndrome. Urticarial vasculitis may respond to dapsone or colchicine. Omalizumab (IgG anti IgE monoclonal antibody), not yet approved for treatment of chronic spontaneously occurring urticaria and angioedema is as effective as cyclosporine with far less toxicity and when available, will be a major therapeutic advance.

summarized in Fig. 38-10. It is important to use first-generation antihistamines at a maximal dose if nonsedating antihistamines have not been helpful before resorting to corticosteroids or cyclosporine. H_2-receptor antagonists may yield some additional histamine receptor blockade, although their contribution is usually modest. The efficacy of leucotriene antagonists is controversial, with equal numbers of pro and con articles. If steroids are used, this author recommends not exceeding 25 mg q.o.d. or 10 mg daily. With either approach, attempts to slowly taper the dose should be made every 2–3 weeks. One mg prednisone tablets can be very helpful when the daily dose is less than 10 mg. Double-blind placebo-controlled studies of cyclosporine indicate that it is a good alternative to corticosteroid,[228,229] and can be safer when used appropriately. Measurement of blood pressure, blood urea nitrogen level, and creatinine level, and a urinalysis should be done every 6–8 weeks. The starting adult dose is 100 mg bid; it can be slowly advanced to 100 mg tid, but not higher. The response rate is 75% in the autoimmune groups and 50% in the idiopathic group. No comparable studies (or clinical effects) have been obtained with dapsone, hydroxychloroquine, colchicine, sulfasalazine, or methotrexate and only small numbers cases have been treated successfully with intravenous γ globulin or plasmapheresis.[230,231] Successful treatment of chronic autoimmune urticaria has been reported with Omalizumab[232] with results comparable to that seen with cyclosporine. The rate of response can be very striking, for example, remission with a single dose. Additional articles have appeared,[233,234] although uncontrolled.

Urticarial vasculitis is treated with antihistamines and if severe, with low-dose corticosteroid. Here dapsone or hydroxychloroquine may be steroid sparing. When urticarial vasculitis is part of a systemic disease, the treatment will focus on what is needed for the underlying disorders. The drug of choice for the hypocomplementemic urticarial vasculitis syndrome (with circulating immune complexes due to IgG anti-C1q)[195] is hydroxychloroquine.[235]

Angioedema caused by ACE inhibitors can be an acute emergency with laryngeal edema or tongue or pharyngeal edema that is so extensive the patient cannot manage secretions and intubation is necessary. Supportive therapy, epinephrine, and time are needed; there is no response to antihistamines or corticosteroids. Other antihypertensive agents can be substituted, including those that block angiotensin II receptors.

Acute attacks of HAE are unresponsive to antihistaminics or corticosteroid. Epinephrine may be given but a positive response is actually uncommon. Intubation or tracheostomy may be needed when severe laryngeal edema is encountered. Recently, a preparation of C1 INH (Berinert) has been approved in the United States for intravenous infusion to treat acute attacks of HAE. It is effective and has been available and employed in Europe and Brazil for over two decades. Icatibant,[236] a bradykinin B-2 receptor antagonist, has been approved for acute treatment in Europe but not in the United States. It is given by subcutaneous injection. Kalbitor, a plasma kallikrein inhibitor (ecallantide), has been approved for the treatment of acute attacks of HAE in the United States. It too is administered by subcutaneous injection.[237] In the past, fresh frozen plasma was an option. It has been used with excellent success for years, but occasional dramatic worsening of symptoms has been reported because all the plasma factors needed for bradykinin generation are also being infused.

A second C1 INH nanofiltered preparation (Cinryze) has been approved in the United States for prophylactic treatment of AHE types I and II. It is administered by intravenous injection up to twice weekly. Prophylaxis with androgens such as Danazol (200 mg tablets) or Stanazolol (2 mg tablets)[238,239] or antifibrinolytics such as E-aminocaprioc acid or tranexamic acid[240] have been employed (used) successfully for many years.[241,242] The androgens are more commonly used—one watches for hirsutisum, irregular menses, and abnormal liver chemistries, as potential side effects. In the long term, hepatic adenomas may appear. Increased dosages may be used when a patient undergoes elective surgical procedures (e.g., 3 tablets/day for 2–3 days before the procedure, the day of the procedure, and 1 day after). Fresh frozen plasma is a safe alternative given a few hours prior to the procedure and clearly C1 INH concentrate can be used. Acquired C1 INH deficiency can be treated with low-dose androgens in addition to therapy for the underlying condition. C1 INH concentrate may be helpful but the presence of anti-C1 INH will limit responsiveness to reasonable doses. Plasmapheresis and/or cytotoxic agents may be used.

ACKNOWLEDGMENT

I wish to thank Dr Nicholas Soter who reviewed this manuscript, made many helpful suggestions, and contributed two of the photos.

KEY REFERENCES

Full reference list available at www.DIGM8.com

DVD contains references and additional content

6. Gorevic P, Kaplan A: The physical urticarias. *Int J Dermatol* **19**:417, 1980
13. Gruber B et al: Prevalence and functional role of anti-IgE autoantibodies in urticarial syndromes. *J Invest Dermatol* **90**:213, 1988
15. Grattan C et al: A serological mediator in chronic idiopathic urticaria–A clinical, immunological and histological evaluation. *Br J Dermatol* **114**:583, 1986
35. Kikuchi Y, Kaplan A: A role for C5a in augmenting IgG-dependent histamine release from basophils in chronic urticaria. *J Allergy Clin Immunol* **109**:114, 2002
41. Sabroe R et al: Cutaneous inflammatory cell infiltrate in chronic idiopathic urticaria: Comparison of patients with and without anti-FcepsilonRI or anti-IgE autoantibodies. *J Allergy Clin Immunol* **103**:484, 1999
60. Kaplan AP, Joseph K, Silverberg M: Pathways for bradykinin formation and inflammatory disease. *J Allergy Clin Immunol* **109**:195, 2002
166. Fields T, Ghebrehiwet B, Kaplan AP: Kinin formation in hereditary angioedema plasma: Evidence against kinin derivation from C2 and in support of "spontaneous" formation of bradykinin. *J Allergy Clin Immunol* **72**:54, 1983
183. Kaplan A, Greaves M: Angioedema. *J Am Acad Dermatol* **53**:373, 2005
210. Greaves M: Chronic idiopathic urticaria and Helicobacter pylori–Not directly causative but could there be a link. *Allergy Clin Immunol Int* **13**:23, 2001
213. Sabroe R et al: The autologous serum skin test: A screening test for autoantibodies in chronic idiopathic urticaria. *Br J Dermatol* **140**:446, 1999
222. Zuberbier T et al: Double-blind crossover study of high-dose cetirizine in cholinergic urticaria. *Dermatology* **193**:324, 1996
227. Kaplan A: Clinical practice. Chronic urticaria and angioedema. *N Engl J Med* **346**:175, 2002
232. Kaplan A et al: Treatment of chronic autoimmune urticaria with omalizumab. *J Allergy Clin Immunol* **122**:569, 2008

Chapter 39 :: Erythema Multiforme

:: Jean-Claude Roujeau

ERYTHEMA MULTIFORME AT A GLANCE

- Rare cutaneous and/or mucocutaneous eruption characterized by target lesions.
- Benign course but frequent recurrences.
- Most cases related to herpes simplex virus (HSV) infection. Medications are not frequent causes.
- Frequent recurrences can be prevented by long-term use of anti-HSV medications. Thalidomide is usually effective in recalcitrant recurrent cases.

Erythema multiforme (EM) is an acute self-limited, usually mild, and often relapsing mucocutaneous syndrome. The disease is usually related to an acute infection, most often a recurrent herpes simplex virus (HSV) infection. EM is defined only by its clinical characteristics: target-shaped plaques with or without central blisters, predominant on the face and extremities.

The absence of specific pathology, unique cause, and biologic markers has contributed to a confusing nosology. Recent medical literature still contains an overwhelming number of figurate erythema reported as EM, and the International Classification of Diseases (ICD9) still classifies Stevens–Johnson syndrome (SJS) and toxic epidermal necrolysis (TEN) under the heading of EM.

The definition of EM in this chapter is based on the classification proposed by Bastuji-Garin et al.[1] The principle of this classification is to consider SJS and TEN as severity variants of the same process, i.e., epidermal necrolysis (EN), and to separate them from EM (see Chapter 40). The validity of this classification has been challenged by some reports, especially for cases in children and cases related to *Mycoplasma pneumoniae*. It has been confirmed by several others studies however, especially the prospective international Severe Cutaneous Adverse Reactions study.[2] That study demonstrated that, compared with SJS and TEN, EM cases had different demographic features, clinical presentation, severity, and causes.

The original name proposed by von Hebra was *erythema exudativum multiforme*. The term *erythema multiforme* has now been universally accepted (Box 39-1).

EM is usually called minor when mucous membranes are spared or minimally affected, for example, lips, and majus (or major) when at least two mucosal sites are involved.

EPIDEMIOLOGY

EM is considered relatively common, but its true incidence is unknown because largely cases severe enough to require hospitalization have been reported. Such cases are in the range of 1 to 6 per million per year. Even though the minor form of EM is frequent than the major form, many other eruptions (including annular urticaria and serum sickness-like eruption) are erroneously called EM.[3]

EM occurs in patients of all ages, but mostly in adolescents and young adults. There is a slight male preponderance (male–female sex ratio of approximately 3:2). EM is recurrent in at least 30% of patients.

No established underlying disease increases the risk of EM. Infection with human immunodeficiency virus and collagen vascular disorders do not increase the risk of EM, in contrast to their increasing the risk of epidermal necrolysis. Cases may occur in clusters, which suggests a role for infectious agents. There is no indication that the incidence may vary with ethnicity or geographic location.

Predisposing genes have been reported, with 66% of EM patients having HLA-DQB1*0301 allele, compared with 31% of controls.[4] The association is even stronger in patients with herpes-associated EM. Nevertheless, the association is relatively weak, and familial cases remain rare.

ETIOLOGY

Most cases of EM are related to infections. Herpes virus is definitely the most common cause, principally in recurrent cases. Proof of causality of herpes is firmly established from clinical experience, epidemiology,[2] detection of HSV DNA in the lesions of EM,[5,6] and prevention of EM by suppression of HSV recurrences.[7] Clinically, a link with herpes can be established in about one-half of cases. In addition 10% to 40% of cases without clinical suspicion of herpes have also been shown to be herpes related, because HSV DNA was detected

BOX 39-1 ERYTHEMA MULTIFORME SUBTYPES

- Erythema multiforme minor: Skin lesions without involvement of mucous membranes
- Erythema multiforme major: Skin lesions with involvement of mucous membranes
- Herpes-associated erythema multiforme
- Mucosal erythema multiforme (Fuchs syndrome, ectodermosis pluriorificialis): Mucous membrane lesions without cutaneous involvement

in the EM lesions by polymerase chain reaction (PCR) testing.[6] EM eruptions begin on average 7 days after a recurrence of herpes. The delay can be substantially shorter. Not all symptomatic herpes recurrences are followed by EM, and asymptomatic ones can induce EM. Therefore, this causality link can be overlooked by both patients and physicians. HSV-1 is usually the cause, but HSV-2 can also induce EM. The proportion probably reflects the prevalence of infection by HSV subtypes in the population.

M. pneumoniae is the second major cause of EM and may even be the first one in pediatric cases.[8–10] In cases related to *M. pneumoniae*, the clinical presentation is often less typical and more severe than in cases associated with HSV. The relationship to *M. pneumoniae* is often difficult to establish. Clinical and radiologic signs of atypical pneumonia can be mild, and *M. pneumoniae* is usually not directly detected. PCR testing of throat swabs is the most sensitive technique. Serologic results are considered diagnostic in the presence of immunoglobulin (Ig) M antibodies or a more than twofold increase in IgG antibodies to *M. pneumoniae* in samples obtained after 2 or 3 weeks. *M. pneumoniae*-related EM can recur.[11]

Many other infections have been reported to be causes of EM in individual cases or small series, but the evidence for causality of these other agents is only circumstantial. Published reports have implicated infection with orf virus, varicella zoster virus, parvovirus B19, and hepatitis B and C viruses, as well as infectious mononucleosis and a variety of other bacterial or viral infections. Immunization has been also implicated as a cause in children.

Drugs are a rare cause of EM with mucous membrane lesions. Most literature reports of "drug-associated EM" actually deal with imitators, for example, annular urticaria[12] or maculopapular eruption with some lesions resembling targets. "EM-like" dermatitis may result from contact sensitization. These eruptions should be viewed as imitators of EM, despite some clinical and histopathologic similarities.

Idiopathic cases are those in which neither HSV infection nor any other cause can be identified. Such cases are fairly common under routine circumstances. However, HSV has been found in situ by PCR in up to 40% of "idiopathic" recurrent cases.[9] Some such cases respond to prophylactic antiviral treatment and are thus likely to have been triggered by asymptomatic HSV infection; others are resistant.

PATHOGENESIS

The underlying mechanisms have been extensively investigated for herpes-associated EM.[13] It is unknown whether similar mechanisms apply to EM due to other causes.

Complete infective HSV has never been isolated from lesions of herpes-associated EM. The presence of HSV DNA in EM lesions has been reported in numerous studies using the PCR assay. These studies have demonstrated that keratinocytes do not contain complete viral DNA, but only fragments that always include the viral polymerase (*Pol*) gene. HSV Pol DNA is located in basal keratinocytes and in lower spinous cell layers, and viral Pol protein is synthesized. HSV-specific T cells, including cytotoxic cells, are recruited, and the virus-specific response is followed by a non-specific inflammatory amplification by autoreactive T cells. The cytokines produced in these cells induce the delayed hypersensitivity-like appearance in histopathologic evaluation of biopsy sections of EM lesions.

HSV is present in the blood for a few days during an overt recurrence of herpes. If keratinocytes are infected from circulation virus, one would expect disseminated herpes, rather than EM. In fact, HSV DNA is transported to the epidermis by immune cells that engulf the virus and fragment the DNA. These cells are monocytes, macrophages, and especially $CD34^+$ Langerhans cell precursors harboring the skin-homing receptor cutaneous lymphocyte-associated (CLA) marker. Upregulation of adhesion molecules greatly increases binding of HSV-containing mononuclear cells to endothelial cells and contribute to the dermal inflammatory response. When reaching the epidermis the cells transmit the viral *Pol* gene to keratinocytes. Viral genes may persist for a few months, but the synthesis and expression of the Pol protein will last for only a few days. This may explain the transient character of clinical lesions that are likely induced by a specific immune response to Pol protein and amplified by autoreactive cells. To the best of current knowledge, the mechanisms and regulation of this immune response are different from drug reactivity leading to SJS or TEN.[14,15]

Incomplete fragmentation of viral DNA, increased number of circulating $CD34^+$ cells, and/or increased immune response to Pol protein may explain why only a small proportion of individuals with recurrent herpes infections develop EM.

CLINICAL FINDINGS

The first step is to suspect EM, based on clinical features. A skin biopsy and laboratory investigations are useful mainly if the diagnosis is not definite clinically. The second step is to determine whether hospitalization is needed when EM major (EMM) occurs with oral lesions severe enough to impair feeding, when a diagnosis of SJS is suspected, or when severe constitutional symptoms are present. The third step is to establish the cause of EM by identifying a history of recurrent herpes, performing chest radiography, or documenting *M. pneumoniae* infection (Fig. 39-1).

HISTORY

Prodromal symptoms are absent in most cases. If present, they are usually mild, suggesting an upper respiratory infection (e.g., cough, rhinitis, low-grade fever). In EMM, fever higher than 38.5°C (101.3°F) is present in one-third of cases.[2] A history of prior attack(s) is found in at least one-third of patients and thus helps with the diagnosis. The events of the preceding 3 weeks should be reviewed for clinical evidence of any precipitating agent, with a special focus on recurrent herpes.

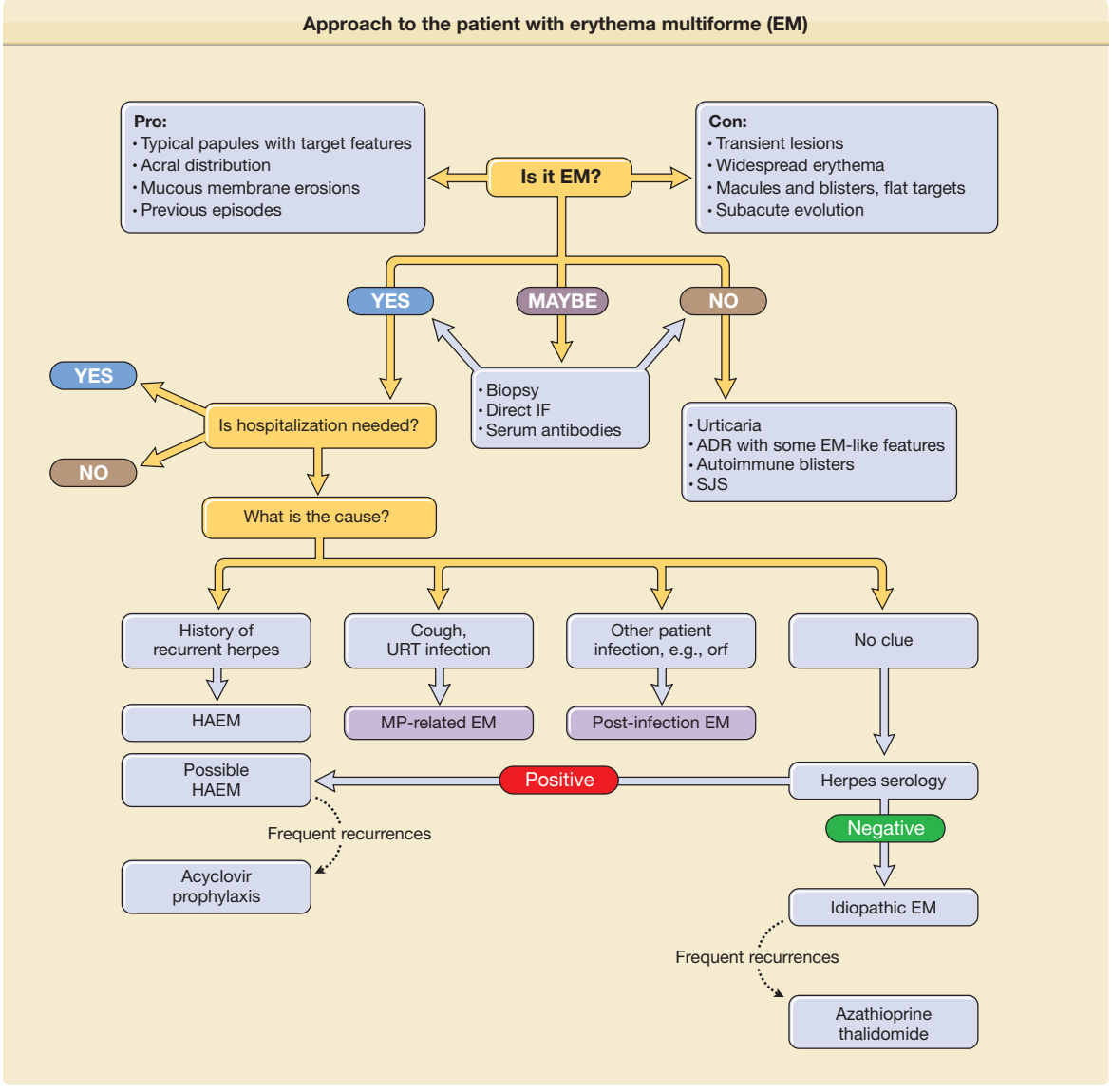

Figure 39-1 Approach to the patient with erythema multiforme (EM). ADR = adverse drug reaction; HAEM = herpes-associated erythema multiforme; IF = immunofluorescence; MP = *Mycoplasma pneumoniae*; SJS = Stevens–Johnson syndrome; URT = upper respiratory tract.

CUTANEOUS LESIONS

The skin eruption arises abruptly. In most patients, all lesions appear within 3 days, but in some, several crops follow each other during a single episode of EM. Often there are a limited number of lesions, but up to hundreds may form. Most occur in a symmetric, acral distribution on the extensor surfaces of the extremities (hands and feet, elbows, and knees), face, and neck, and less frequently on the thighs, buttocks, and trunk. Lesions often first appear acrally and then spread in a centripetal manner. Mechanical factors (Koebner phenomenon) and actinic factors (predilection of sun-exposed sites) appear to influence the distribution of lesions. Although patients occasionally report burning and itching, the eruption is usually asymptomatic.

The diversity in clinical pattern implied by the name *multiforme* is mainly due to the findings in each single lesion; most lesions are usually rather similar in a given patient at a given time. The typical lesion is a highly regular, circular, wheal-like erythematous papule or plaque that persists for 1 week or longer (Fig. 39-2). It measures from a few millimeters to approximately 3 cm and may expand slightly over 24 to 48 hours. Although the periphery remains erythematous and edematous, the center becomes violaceous and dark; inflammatory activity may regress or relapse in the center, which gives rise to concentric rings of color (see Fig. 39-2). Often, the center turns purpuric and/or necrotic or transforms into a tense vesicle or bulla. The result is the classic target or iris lesion.

According to the proposed classification, typical target lesions consist of at least three concentric components: (1) a dusky central disk, or blister; (2) more peripherally, an infiltrated pale ring; and (3) an



Figure 39-2 Mixture of typical targets and papules in a case of EM minor

erythematous halo. Not all lesions of EM are typical; some display two rings only ("raised atypical targets"). However, all are papular, in contrast with macules, which are the typical lesions in epidermal necrolysis (SJS–TEN). In some patients with EM, most lesions are livid vesicles overlying a just slightly darker central portion, encircled by an erythematous margin (Figs. 39-3–39-5, Fig. 39-8). Larger lesions may have a central bulla and a marginal ring of vesicles (herpes iris of Bateman) (Figs. 39-6 and 39-7).

Unusual presentations include cases in which recurrent EM in the same patient produces typical target lesions in one instance but plaques in a subsequent event. Mucous membranes can be severely involved in some episodes and spared in others (see section "Mucous Membrane Lesions").



Figure 39-3 Typical target lesions on the palm.



Figure 39-4 Late lesions of EM with nonspecific blisters and erosions but target shapes still visible.

In most cases, EM affects well under 10% of the body surface area. In 88 hospital cases of EMM prospectively included in the Severe Cutaneous Adverse Reactions study, the median involvement was 1% of the body surface area.[2] Very rare instances of extensive skin lesions with "giant" targets and prominent involvement of several mucous sites may be difficult to distinguish from SJS.

The duration of an individual lesion is shorter than 2 weeks, but residual discoloration may remain for months. There is no scarring.

MUCOUS MEMBRANE LESIONS

Mucosal lesions are present in up to 70% of patients, most often limited to the oral cavity.



Figure 39-5 Typical targets around the knee.



Figure 39-6 Giant targets in a case of recurrent EMM associated to recurrent *Mycoplasma pneumoniae* infection.



Figure 39-7 Multiple concentric vesicular rings (herpes iris of Bateman). This pattern may be more frequent in *Mycoplasma pneumoniae*-related cases of erythema multiforme major.



Figure 39-8 Unusual location of EM.

Predilection sites for mucosal lesions are the lips (eFig. 39-7.1 in online edition), on both cutaneous and mucosal sides, nonattached gingivae, and the ventral side of the tongue. The hard palate is usually spared, as are the attached gingivae. On the cutaneous part of the lips, identifiable target lesions may be discernible (see Fig. 39-9). On the mucosa proper there are erosions with fibrinous deposits, and occasionally intact vesicles and bullae can be seen (Fig. 39-10). The process may rarely extend to the throat, larynx, and even the trachea and bronchi.

Eye involvement begins with pain and bilateral conjunctivitis in which vesicles and erosions can occur (Fig. 39-11).

The nasal, urethral, and anal mucosae also may be inflamed and eroded.



Figure 39-9 Erythema multiforme major. Involvement of the lips with a target pattern.



Figure 39-10 Erythema multiforme major (EMM). Mouth lesions of EMM usually manifest as erosions.

Ectodermosis pluriorificialis (synonym Fuchs syndrome) is a rare occurrence characterized by severe involvement of two or three mucosal sites in the absence of skin lesions. Its often relapsing nature suggests that it is HSV related. Moreover, typical target lesions may arise on the skin with new attacks.

RELATIONSHIP TO RECURRENT HERPES

In more than 70% of patients with recurrent EM, an episode of recurrent HSV infection precedes the rash; the association with herpes labialis predominates over that with genital herpes or herpes in other locations. EM usually follows recurrent herpes but may also occur after primary HSV infection. The average interval is 7 days (range, 2 to 17 days); the duration of the lag period appears to be specific for individual patients. In a small number of patients, HSV recrudescence and EM may occur simultaneously. Not all episodes of EM are preceded by clinically evident HSV infection, and not all HSV episodes are followed by EM. Episodes of recurrent HSV infection may precede the development of HSV-related EM by many years.



Figure 39-11 Erythema multiforme major. Eye lesions. Conjunctivitis with erosions.

RELATED PHYSICAL FINDINGS

Fever and other constitutional symptoms are usually absent in EM minor, and the physical examination is normal. Fever higher than 38.5°C (101.3°F) is present in 32% of cases of EMM. Mouth erosions may be very painful and may impair alimentation. The patient may be unable to close the mouth and may constantly drool bloodstained saliva. Cervical lymphadenopathy is usually present in these patients. The pain of genital erosions may lead to reflex urinary retention. Cough, polypnea, and hypoxia may occur in *M. pneumoniae*-related cases.

LABORATORY FINDINGS

HISTOPATHOLOGIC ANALYSIS

Early lesions of EM exhibit lymphocyte accumulation at the dermal–epidermal interface, with exocytosis into the epidermis, lymphocytes attached to scattered necrotic keratinocytes (satellite cell necrosis), spongiosis, vacuolar degeneration of the basal cell layer, and focal junctional and subepidermal cleft formation (eFig. 39-11.1 in online edition). The papillary dermis may be edematous but principally contains a dense mononuclear cell infiltrate, which is more abundant in older lesions. The vessels are ectatic with swollen endothelial cells; there may be extravasated erythrocytes and eosinophils. Immunofluorescence findings are negative or nonspecific. In advanced lesions subepidermal blister formation may occur, but necrosis rarely involves the entire epidermis (see eFig. 39-11.2 in online edition). In late lesions, melanophages may be prominent.

The histopathologic appearance of EM lesions is different from that of SJS–TEN lesions, in which dermal inflammation is moderate to absent and epidermal necrosis much more pronounced (see Chapter 40). Still, the histopathologic appearances are somewhat overlapping and do not allow the distinction of EM from SJS–TEN in all instances. The main reason for performing a biopsy in EM is to rule out other diagnoses, for example, autoimmune blistering diseases, Sweet syndrome, and vasculitis.

OTHER LABORATORY TESTS

There are no specific laboratory tests for EM. In more severe cases, an elevated erythrocyte sedimentation rate, moderate leukocytosis, increased levels of

acute-phase proteins, and mildly elevated liver aminotransferase levels may occur. In the presence of respiratory symptoms a chest radiograph is needed, and documentation of *M. pneumoniae* infection by PCR assay of a throat swab and serologic testing (a pair at a 2- or 3-week interval) should be sought. Investigations to document causality are important in cases with frequent recurrences when prevention with long-term antiviral treatment is considered and when there is no clinical evidence of association with herpes. HSV can rarely still be isolated from the initial lesion of labial herpes. Amplification of HSV *Pol* gene from biopsy samples of EM lesions is not done routinely. A negative result on serologic testing for HSV may be helpful to exclude the possibility of herpes-associated EM. The positive predictive value of the presence of HLA-DQB1*0301 is too low to have any clinical value.

DIFFERENTIAL DIAGNOSIS

(Table 39-1)

In a retrospective analysis of 66 pediatric cases discharged from hospital with a diagnosis of EM 24 (36%) were clearly not EM.[8] Diseases that had been frequently erroneously called EM were urticaria (eFig. 39-11.3 in online edition) and maculopapular drug eruption (Fig. 39-12).[8,15]

The designation of *Rowell syndrome*[16,17] is used for a variety of cutaneous lupus erythematosus with often erosive circinate lesions resembling those of EM. Subacute evolution, a positive result on direct fluorescence testing, and the presence of antinuclear antibodies exclude EM.

Sweet syndrome can mimic EM minor; biopsy easily distinguishes the two.

Paraneoplastic pemphigus and more rarely other autoimmune blistering diseases occasionally present with target-like lesions that can be confused with those of EM (Figs. 39-13 and eFig. 39-14 in online edition).

Original cases were reported as EMM with anti-desmoplakin antibodies.[18] Clinical features resemble EMM in their acute and recurrent course, but the presence of acantholysis, deposits of IgG around basal cells, and serum antibodies against desmoplakin distinguish such cases from EM.

Better considered a separate disease, SJS should be recognized promptly for three reasons: (1) the possibility of life-threatening complications, (2) the risk of progression to TEN, and (3) the need for urgent withdrawal of suspected causative drug(s) (see Chapter 40). Pain, constitutional symptoms, severe erosions of mucosae, rapid progression, and dusky or violaceous skin lesions are alerting features.

In rare cases of EM affecting only mucous membranes, the diagnosis is especially difficult and often made when further bouts include a few skin lesions. In such cases, pemphigus, cicatricial pemphigoid, allergic or toxic contact stomatitis, toxic erosive stomatitis, aphthous lesions, and lichen planus should be considered.

COURSE AND COMPLICATIONS

EM runs a mild course in most cases, and each individual attack subsides within 1 to 4 weeks. Recovery is

TABLE 39-1
Differential Diagnosis of Erythema Multiforme (EM)

	Mucous Membrane Lesions	Clinical Pattern	Pathologic Findings	Laboratory Testing	Course
Urticaria	No	Circinate, transient	Edema		More acute than EM
Maculopapular drug eruption	Rare (lips)	Widespread polymorphous target-like lesions, macules, papules, plaques	Most often nonspecific		
Lupus (Rowell syndrome)	Possible (mouth)	Face and thorax Large target-like lesions, annular plaques	Interface dermatitis Positive result on DIF ("lupus band")	Antinuclear antibodies present	Subacute
Paraneoplastic pemphigus	Constant; always early and severe	EM-like lesion plus lichenoid papules Positive Nikolsky sign	Acantholysis Positive result on DIF	Antibodies present	Chronic
Cicatricial pemphigoid	Constant	Circinate erythematous patches	Subepidermal blister, Positive result on DIF	Antibodies present	Chronic
Antidesmoplakin "EM major"	Constant	EM-like lesions	Basal acantholysis Positive result on DIF	Antibodies present	Acute relapsing
Stevens–Johnson syndrome	Constant	Widespread small blisters Atypical targets Constitutional symptoms	Interface dermatitis Epidermal necrosis		Acute

DIF = direct immunofluorescence testing.



Figure 39-12 Figurate erythema in a cases of "drug eruption" to amoxicillin. Commonly and erroneously reported as drug-induced EM.

complete, and there are usually no sequelae, except for transient discoloration in some cases.

In rare instances the ocular erosions of EMM may cause severe residual scarring of the eye. *M. pneumoniae*-related EMM may be associated with severe erosive bronchitis that may rarely lead to sequelae.

Recurrences are common and may characterize the majority of cases. In reports of large series of patients with recurrent EM, the mean number of attacks was 6 per year (range, 2 to 36), and the mean total duration of disease was 6 to 9 years. In 33%, the condition persisted for more than 10 years.[19,20] Up to 50 recurrences have been described in a single patient. The severity of episodes in patients with recurrent EM is highly variable and unpredictable. The frequency of episodes and cumulative duration of disease are not correlated with the severity of attacks. The frequency and severity of recurrent EM tend to decrease spontaneously over time (after 2 years or longer), parallel with the improvement of recurring HSV infection when it is the cause. In a substantial proportion of recurrent cases a cause cannot be determined.[20] A small fraction of patients experience a prolonged series of overlapping attacks of EM; this has been labeled *continuous EM* or *persistent EM*.[19]

TREATMENT

The aims of treatment are to reduce the duration of fever, eruption, and hospitalization. Based on retrospective series or small controlled trials, the use of systemic corticosteroids seems to shorten the duration of fever and eruption, but may increase the length of hospitalization because of complications. However, the methodology of most studies was poor, with small series often mixing the various forms of idiopathic and virus-associated EM and drug-induced SJS. The use of systemic corticosteroids cannot be recommended.[21]



Figure 39-13 Figurate blisters, in a case of linear IgA blistering disease.

Several series indicate that administering anti-HSV drugs for the treatment of established episodes of postherpetic EM is useless. When symptomatic, *M. pneumoniae* infection should be treated with antibiotics (macrolides in children, macrolides or quinolone in adults). There is no evidence indicating whether it improves the evolution of the associated EM. Therefore, when asymptomatic infection is suggested by serologic testing, treatment is not mandatory.

Liquid antacids, topical glucocorticoids, and local anesthetics relieve symptoms of painful mouth erosions.

PREVENTION

Continuous therapy with oral anti-HSV drugs (see Chapter 231) is effective to prevent recurrences of herpes-associated EM with or without clinical evidence that herpes is the precipitating factor.[7] Topical acyclovir therapy used in a prophylactic manner does not prevent recurrent herpetic EM.

In a series of 65 patients with recurrent EM, 11 were treated with azathioprine when all other treatments had failed. Azathioprine was beneficial in all 11 patients.[19] Mycophenolate mofetil can be also useful.[20]

Retrospective uncontrolled analyses of thalidomide therapy have indicated that it is moderately effective for the treatment of EM.[22] However, thalidomide is probably the most effective treatment of recurrent/persistent cases when resistant to anti-HSV drugs.

In one randomized controlled trial, levamisole appeared useful. Because agranulocytosis is a severe and not exceptional adverse effect, levamisole use is permitted in only a few countries. The benefit–risk ratio is probably too low to support its use in the treatment of EM.

KEY REFERENCES

Full reference list available at www.DIGM8.com

DVD contains references and additional content

1. Bastuji-Garin S et al: A clinical classification of cases of toxic epidermal necrolysis, Stevens-Johnson syndrome and erythema multiforme. *Arch Dermatol* **129**:92, 1993
2. Auquier-Dunant A et al: Correlations between clinical patterns and causes of erythema multiforme majus, Stevens-Johnson Syndrome and toxic epidermal necrolysis. *Arch Dermatol* **138**:1019, 2002
5. Weston WL: Herpes-associated erythema multiforme. *J Invest Dermatol* **124**:xv, 2005
7. Tatnall FM, Schofield JK, Leigh IM: A double-blind, placebo-controlled trial of continuous acyclovir therapy in recurrent erythema multiforme. *Br J Dermatol* **132**:267, 1995
13. Aurelian L, Ono F, Burnett J: Herpes simplex virus (HSV)-associated erythema multiforme (HAEM): A viral disease with an autoimmune component. *Dermatol Online J* **9**:1, 2003
20. Wetter DA, Davis MD: Recurrent erythema multiforme: Clinical characteristics, etiologic associations, and treatment in a series of 48 patients at Mayo Clinic, 2000 to 2007. *J Am Acad Dermatol* **62**:45, 2010
21. Riley M, Jenner R: Towards evidence based emergency medicine: Best BETs from the Manchester Royal Infirmary. Bet 2. Steroids in children with erythema multiforme. *Emerg Med J* **25**:594, 2008

Chapter 40 :: Epidermal Necrolysis (Stevens–Johnson Syndrome and Toxic Epidermal Necrolysis)

:: L. Valeyrie-Allanore & Jean-Claude Roujeau

EPIDERMAL NECROLYSIS AT A GLANCE

- Rare and life-threatening reaction, mainly drug induced.
- Widespread apoptosis of keratinocytes provoked by the activation of a cell-mediated cytotoxic reaction and amplified by cytokines, mainly granulysin.
- Confluent purpuric and erythematous macules evolving to flaccid blisters and epidermal detachment predominating on the trunk and upper limbs and associated with mucous membrane involvement.
- Pathologic analysis shows full-thickness necrosis of epidermis associated with mild mononuclear cell infiltrate.
  - A dozen "high-risk" drugs account for one half of cases.
  - Up to 20% of cases remain idiopathic.
- Early identification and withdrawal of suspect drugs are essential for good patient outcome.
- Treatment is mainly symptomatic.
  - Sequelae are nearly constant, needing systematic follow-up examinations.

Toxic epidermal necrolysis (TEN) and Stevens–Johnson syndrome (SJS) are acute life-threatening mucocutaneous reactions characterized by extensive necrosis and detachment of the epidermis. Stevens and Johnson first reported two cases of disseminated cutaneous eruptions associated with an erosive stomatitis and severe ocular involvement.[1] In 1956, Lyell described patients with epidermal loss secondary to necrosis and introduced the term *toxic epidermal necrolysis*.[2] Both SJS and TEN are characterized by skin and mucous membrane involvement. Because of the similarities in clinical and histopathologic findings, risk factors, drug causality, and mechanisms, these two conditions are now considered severity variants of an identical process that differs only in the final extent of body surface involved.[3–5] Therefore, it is better to use the designation *epidermal necrolysis* for both, as proposed by Ruiz-Maldonado (acute disseminated epidermal necrosis)[6] and Lyell (exanthematic necrolysis).[7]

EPIDEMIOLOGY

Epidermal necrolysis (EN) is rare. The overall incidence of SJS and TEN was estimated at 1 to 6 cases per million person-years and 0.4 to 1.2 cases per million person-years, respectively.[8,9] EN can occur at any age, with the risk increasing with age after the fourth decade, and more frequently affects women, showing a sex ratio of 0.6. Patients infected with human immunodeficiency virus and to a lesser degree patients with collagen vascular disease and cancer are at increased risk.[10–12] The overall mortality associated with EN is 20% to 25%, varying from 5% to 12% for SJS to more than 30% for TEN. Increasing age, significant comorbidity, and greater extent of skin involvement correlate with poor prognosis. In the United States, evaluation

TABLE 40-1
SCORTEN: A Prognostic Scoring System for Patients with Epidermal Necrolysis

SCORTEN	
Prognostic Factors	**Points**
■ Age >40 years	1
■ Heart rate >120 beats/minute	1
■ Cancer or hematologic malignancy	1
■ Body surface area involved >10%	1
■ Serum urea level >10 mM	1
■ Serum bicarbonate level >20 mM	1
■ Serum glucose level >14 mM	1
SCORTEN	**Mortality Rate (%)**
0–1	3.2
2	12.1
3	35.8
4	58.3
5	90

Data from Bastuji-Garin S et al: SCORTEN: A severity-of-illness score for toxic epidermal necrolysis. *J Invest Dermatol* **115**:149, 2000.

of death certificates suggested a seven time higher risk of dying from EN among blacks than whites.[13]

A prognosis score (SCORTEN) has been constructed for EN,[14] and its usefulness has been confirmed by several teams.[15–18] (See Table 40-1.)

ETIOLOGY

The pathophysiology of EN is still unclear; however, drugs are the most important etiologic factors. More than 100 different drugs have been implicated,[19–21] but fewer than a dozen "high-risk" medications account for about one half of cases in Europe (Table 40-2), as evidenced by two multinational case–control studies.[12,22–25] These high-risk drugs are antibacterial sulfonamides, aromatic anticonvulsants, allopurinol, oxicam nonsteroidal anti-inflammatory drugs, lamotrigine, and nevirapine.[26–27] The risk seems confined to the first 8 weeks of treatment. Slow dose escalation decreases the rate of rash with lamotrigine and nevirapine,[28,29] but there is no evidence that it decreases the risk of EN.[26] Oxcarbazepine, a 10-keto derivative of carbamazepine, which was considered to carry a lower risk, seems to significantly cross-react with carbamazepine.[30] Many nonsteroidal anti-inflammatory drugs (primarily oxicam derivatives and diclofenac) were suspected to be associated with EN.[12,31,32] A significant but much lower risk has also been reported for non-sulfonamide antibiotics such as aminopenicillins, quinolones, cephalosporins, and tetracyclines.[22]Corticosteroids were significantly associated with a high relative risk, but confounding was not excluded.[22]

The role of infectious agents in the development of EN is much less prominent than for erythema multiforme. However, cases of EN associated with *Mycoplasma pneumoniae* infection, viral disease, and immunization have been reported, particularly in children.[33,34] These rare observations underscore the fact that medications are not the only cause of EN, but there is still little evidence that infections can explain more than a very small percentage of cases.

Cases of EN have been reported after bone marrow transplantation. Some are an extreme form of acute graft-versus-host disease (see Chapter 28); others could be drug induced. The relationship between EN and graft-versus-host disease is difficult to assess because clinical and histological skin features are nearly indistinguishable.[35] Lupus erythematosus (systemic LE or subacute cutaneous LE) is associated with an increased risk of EN.[12,22] In such cases, drug causality is often doubtful and necrolysis might be an extreme phenotype of cutaneous lupus.[36] Finally, radiotherapy in addition to treatment with antiepileptic drugs, such as phenytoin, phenobarbital, or carbamazepine, can trigger EN with lesions localized predominantly at sites of radiation treatment.[37,38] In

TABLE 40-2
Medications and the Risk of Epidermal Necrolysis

High Risk	Lower Risk	Doubtful Risk	No Evidence of Risk
Allopurinol	Acetic acid NSAIDs (e.g., diclofenac)	Paracetamol (acetaminophen)	Aspirin
Sulfamethoxazole	Aminopenicillins	Pyrazolone analgesics	Sulfonylurea
Sulfadiazine	Cephalosporins	Corticosteroids	Thiazide diuretics
Sulfapyridine	Quinolones	Other NSAIDs (except aspirin)	Furosemide
Sulfadoxine	Cyclins	Sertraline	Aldactone
Sulfasalazine	Macrolides		Calcium channel blockers
Carbamazepine			β Blockers
Lamotrigine			Angiotensin-converting enzyme inhibitors
Phenobarbital			Angiotensin II receptor antagonists
Phenytoin			Statins
Phenylbutazone			Hormones
Nevirapine			Vitamins
Oxicam NSAIDs			
Thiacetazone			

NSAIDs = nonsteroidal anti-inflammatory drugs.

clinical practice, the causality of a medication can be clearly established in approximately 60% of cases and suspected in 20%. Other causes (infection, GVH, LE) are rarely apparent, about 20% of cases as idiopathic.[39]

PATHOGENESIS

Even if the precise sequence of molecular and cellular events is incompletely understood, several studies provided important clues to the pathogenesis of EN. The immunologic pattern of early lesions suggests a cell-mediated cytotoxic reaction against keratinocytes leading to massive apoptosis.[39–41] Immunopathologic studies have demonstrated the presence within early lesions of cytotoxic cells including natural killer T cells (NKT) and drug-specific $CD8^+$ T lymphocytes; monocytes/macrophages and granulocytes are also recruited.[42–44] However, it is generally accepted that specific and nonspecific cytotoxic cells are too few within the lesions to explain the death of cells on the full thickness and large areas of the epidermis and mucous membranes. Amplification by cytokines has been suspected for years, especially for factors activating "death receptors" on cell membranes, especially antitumor necrosis factor (TNF) α and soluble Fas ligand (Fas-L).[42,45] In the past decade it had been widely accepted that Fas-L was inducing the apoptosis of keratinocytes in EN,[45,46] despite partial evidence and discordant findings.[47–49] An important recent study has challenged this dogma by demonstrating the key role in EN of granulysin.[50] Granulysin was present in the blister fluid of EN at concentrations much higher than those of perforin, granzyme B, or Fas-L. At such concentrations, only granulysin, and to a much lesser degree perforin, were able to kill human keratinocytes in vitro; Fas-L was not. Furthermore injection of granulysin in the dermis of normal mice resulted in clinical and histological lesions of EN.[50]

When combined, the above results strongly suggest that the effector mechanisms of EN have been deciphered. Cytotoxic T-cells develop and are usually specifically directed against the native form of the drug rather than against a reactive metabolite, contrarily to what has been postulated for 20 years. These cells kill keratinocytes directly and indirectly through the recruitment of other cells that release soluble death mediators, the principal being granulysin.[50,51]

These advances on understanding the final steps of the reaction point to inhibition of release and/or blockade of granulysin as major aims of therapeutic interventions.

Little is known on what are the initial and intermediate steps. We still do not understand why very few individuals develop a violent immune response to medications and why effector cells are especially directed to the skin and other epithelia. Actually, most drugs associated with a "high risk" for EN can also induce a variety of milder and more frequent reactions. Drug-specific CD8 cytotoxic T-lymphocytes were also often found in skin reactions with more benign phenotype.[52] Hence, it is tempting to speculate on an abnormal regulation of immune response. Regulatory $CD4^+$ $CD25^+$ T cells have been demonstrated to be potentially important in the prevention of severe epidermal damage induced by reactive cytotoxic T lymphocytes in a mouse model of EN.[53] Similar regulatory cells may play a role in drug eruptions in humans.[54] Altered regulation of the immune response to medications in patients with EN could result from comorbidities that are frequent, for example, cancer, HIV infection, collagen vascular disease; from comedications, for example, corticosteroids; or from genetic background.

Genetic susceptibility plays an important role in the development of EN to a few "high-risk" medications. A strong association was observed in Han Chinese from Taiwan between the human leukocyte antigen HLA-B*1502 and EN induced by carbamazepine, and between HLA-B*5801 and EN induced by allopurinol.[55,56] B*1502 association with carbamazepine-related cases was confirmed in several Asian countries,[57,58] with the remarkable exceptions of Japan and Korea.[59,60] The association between carbamazepine-induced EN and HLA-B*1502 was not present in European patients who do not have Asian ancestry.[61] On the other hand, HLA-B*5801 was confirmed to be associated with allopurinol-related EN in Japan[59] and Europe,[62] but the strength of association was lower than in Taiwan.

CLINICAL FINDINGS

Even in cases requiring immediate referral to specialized wards, the dermatologist will have a specific role in the management of patients with EN (Fig. 40-1).

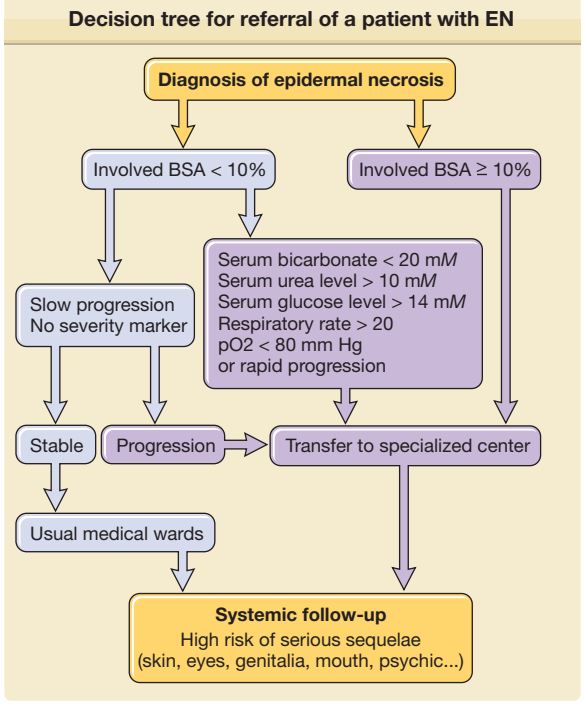

Figure 40-1 Decisional tree for referral of a patient with EN. (Adapted from Ellis MW: A case report and a proposed algorithm for the transfer of patients with Stevens-Johnson syndrome and toxic epidermal necrolysis to a burn center. *Mil Med* **167**:701, 2002)

HISTORY

EN clinically begins within 8 weeks (usually 4 to 30 days) after the onset of drug exposure for the first time. Only in very rare cases with prior reaction and inadvertent rechallenge with the same drug does it appear more rapidly, within a few hours. Nonspecific symptoms such as fever, headache, rhinitis, cough, or malaise may precede the mucocutaneous lesions by 1 to 3 days. Pain on swallowing and burning or stinging of the eyes progressively develop, heralding mucous membrane involvement. About one-third of cases begin with nonspecific symptoms, one-third with symptoms of mucous membrane involvement, and one-third with an exanthema. Whatever the initial symptoms are, their rapid progression, the addition of new signs, severe pain, and constitutional symptoms should alert one to the onset of a severe disease.

CUTANEOUS LESIONS

The eruption is initially symmetrically distributed on the face, the upper trunk, and the proximal part of limbs.[63] The distal portions of the arms as well as the legs are relatively spared, but the rash can rapidly extend to the rest of the body within a few days and even within a few hours. The initial skin lesions are characterized by erythematous, dusky red, purpuric macules, irregularly shaped, which progressively coalesce. Atypical target lesions with dark centers are often observed (Fig. 40-2A). Confluence of necrotic lesions leads to extensive and diffuse erythema. Nikolsky's sign, or dislodgement of the epidermis by lateral pressure, is positive on erythematous zones (Fig. 40-3 and eFig. 40-3.1 in online edition). At this stage, the lesions evolve to flaccid blisters, which spread with pressure and break easily (see Fig. 40-2B). The necrotic epidermis is easily detached at pressure points or by frictional trauma, revealing large areas of exposed, red, sometimes oozing dermis (see Figs. 40-2C and 40-2D). In other areas, epidermis may remain.

Patients are classified into one of three groups according to the total area in which the epidermis is detached or "detachable" (positive Nikolsky): (1) SJS, less than 10% of body surface area (BSA); (2) SJS/TEN overlap, between 10% and 30%; (3) TEN, more than 30% of BSA (eFig. 40-3.2 in online edition). Correct evaluation of the extent of lesions is difficult, especially in zones with spotty lesions. It is helpful to remember that the surface of one hand (palm and fingers) represents a little less than 1% of the BSA.

MUCOUS MEMBRANE INVOLVEMENT

Mucous membrane involvement (nearly always on at least two sites) is observed in approximately 90% of cases and can precede or follow the skin eruption. It begins with erythema followed by painful erosions of the oral, ocular, and genital mucosa. This usually leads to impaired alimentation, photophobia, conjunctivitis, and painful micturition. The oral cavity and the vermilion border of the lips are almost invariably affected and feature painful hemorrhagic erosions coated by grayish white pseudomembranes and crusts of the lips (Fig. 40-4). Approximately 80% of patients have conjunctival lesions,[64,65] mainly manifested by pain, photophobia, lacrimation, redness, and discharge. Severe forms may lead to epithelial defect corneal ulceration, anterior uveitis, and purulent conjunctivitis. Synechiae between eyelids and conjunctiva often occur. There may be shedding of eyelashes (see Fig. 40-4B). Genital erosions are frequent, often overlooked in women, and may lead to synechiae.[66]

Shedding of nails occurs in severe forms.

EXTRACUTANEOUS SYMPTOMS

EN is associated with high fever, pain, and weakness. Visceral involvement is also possible, particularly with pulmonary and digestive complications. Early pulmonary complications occur in approximately 25% of patients and are essentially manifested by elevated respiratory rate and cough, which should prompt strict surveillance.[67,68] Bronchial involvement in EN is not correlated with the extent of skin lesions or with the offending agent. In most cases chest radiographs are normal on admission but can rapidly reveal interstitial lesions that can progress to acute respiratory distress syndrome (ARDS). In all reported cases, when acute respiratory failure developed rapidly after the onset of skin involvement, it was associated with poor prognosis. In the case of respiratory abnormalities, fiberoptic bronchoscopy may be useful to distinguish a specific epithelial detachment in the bronchi from an infectious pneumonitis, which has a much better prognosis.

Gastrointestinal tract involvement is less commonly observed, with epithelial necrosis of the esophagus, small bowel, or colon manifesting as profuse diarrhea with malabsorption, melena, and even colonic perforation.[69,70] Renal involvement has been reported. Proteinuria, microalbuminuria, hematuria, and azotemia are not rare. Proximal tubule damage can result from necrosis of tubule cells by the same process that destroys epidermal cells.[71] Glomerulonephritis is rare.[72]

LABORATORY TESTS

LABORATORY VALUES

There is no laboratory test to support the diagnosis of EN. Laboratory examinations are essential to evaluation of severity and daily management as for all life-threatening conditions in intensive care units.

Evaluation of respiratory rate and blood oxygenation are among the first steps to take in the emergency room. Any alteration should be checked through measurement of arterial blood gas levels. Serum bicarbonate levels below 20 mM indicate a poor prognosis.[14]

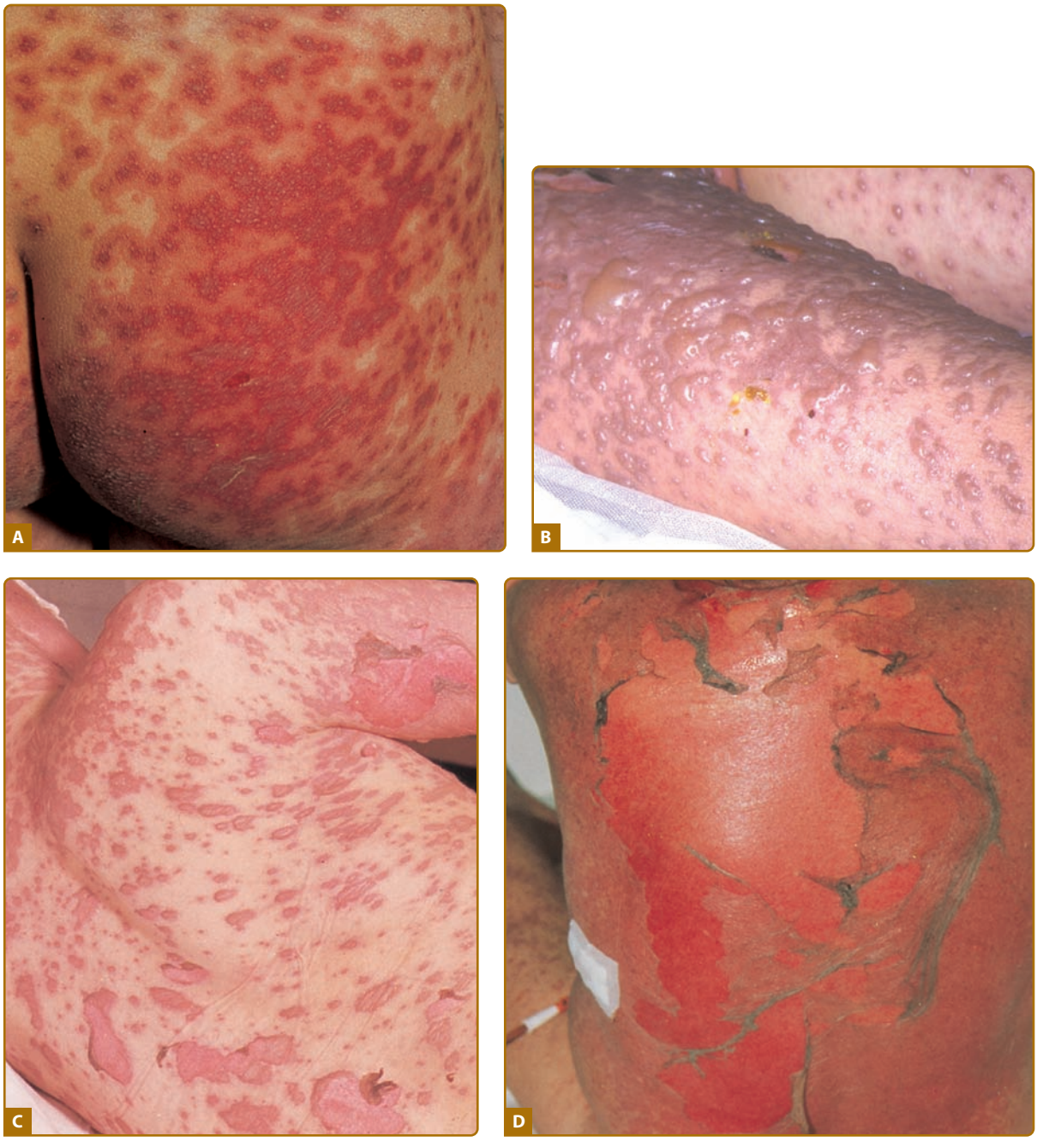

Figure 40-2 **A.** Early eruption. Erythematous dusky red macules (flat atypical target lesions) that progressively coalesce and show epidermal detachment. **B**. Early presentation with vesicles and blisters, note the dusky color of blister roofs, strongly suggesting necrosis of the epidermis. **C.** Advanced eruption. Blisters and epidermal detachment have led to large confluent erosions. **D.** Full-blown epidermal necrolysis characterized by large erosive areas reminiscent of scalding.

They usually result from respiratory alkalosis related to the specific involvement of bronchi and more rarely from metabolic acidosis.

Massive transdermal fluid loss is responsible for electrolyte imbalances, hypoalbuminemia, and hypoproteinemia, and mild and transient renal insufficiency and prerenal azotemia are common. Raised blood urea nitrogen level is one marker of severity. Anemia is usual, and mild leukocytosis as well as thrombocytopenia may occur. Neutropenia is often considered to be an unfavorable prognostic factor but is too rare to have a significant impact on SCORTEN. Transient peripheral $CD4^+$ lymphopenia is nearly always seen and is associated with decreased T-cell function. Mild elevation in levels of hepatic enzymes and amylase (most probably of salivary origin) are frequent but without impact on prognosis. A hypercatabolic state is responsible for inhibition of insulin secretion or insulin resistance, which results in hyperglycemia and occasionally overt diabetes. A blood glucose level above 14 mM is

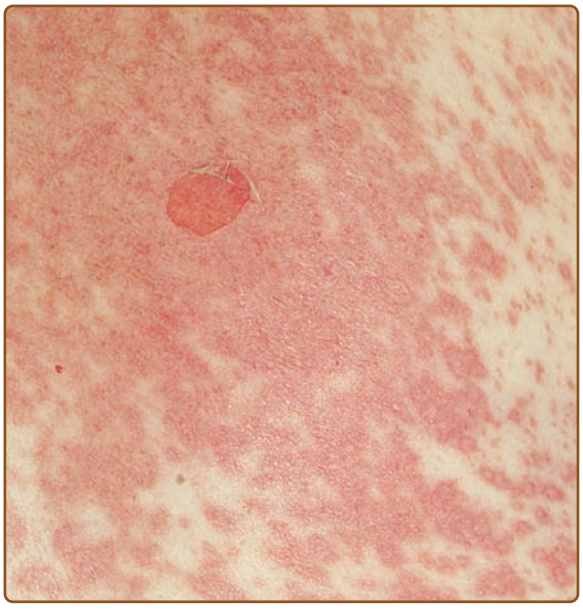

Figure 40-3 Early exanthematous phase with Nikolsky's sign.

one marker of severity.[14] Other abnormalities in laboratory values may occur, indicating involvement of other organs and complications such as sepsis.

HISTOPATHOLOGY

Skin biopsy for routine histologic and possibly immunofluorescence studies should be strongly considered, especially if there are alternative diagnoses to consider. In the early stages, epidermal involvement is characterized by sparse apoptotic keratinocytes in the suprabasal layers, which rapidly evolves to a full-thickness necrosis and subepidermal detachment (Fig. 40-5). Apoptosis of epithelial cells may involve sweat glands and hair follicles. A moderately dense mononuclear cell infiltrate of the papillary dermis is observed, mainly represented by lymphocytes, often $CD8^+$ and macrophages.[73,74] Eosinophils seems to be less common in patients with the most severe form of EN. Results of direct immunofluorescence study are negative. Histopathology of involved mucous membranes, rarely performed, would show similar alterations.[75]

DIFFERENTIAL DIAGNOSIS

(Box 40-1)

Milder presentations of EN must be distinguished from erythema multiforme minor (EMM) (see Chapter 39). Early EN cases are often initially diagnosed as varicella. The rapid progression of skin lesions and the severity of mucous membrane involvement should raise the probability of EN.

The absence of mucous membrane involvement or its restriction to a single site must always raise the suspicion of an alternative diagnosis: staphylococcal scalded skin syndrome in infants; purpura fulminans in children and young adults; acute generalized exanthematous pustulosis, phototoxicity, or pressure blisters in adults. Thermal burns or scalding are occasionally an issue when a transient loss of consciousness occurs.

Linear immunoglobulin (Ig) A bullous disease and paraneoplastic pemphigus present with a less acute progression. Pathologic findings and a positive result on direct immunofluorescence testing are important for these diagnoses.

In all aspects, including pathology, generalized bullous fixed drug eruption (GBFDE) resembles EN. It

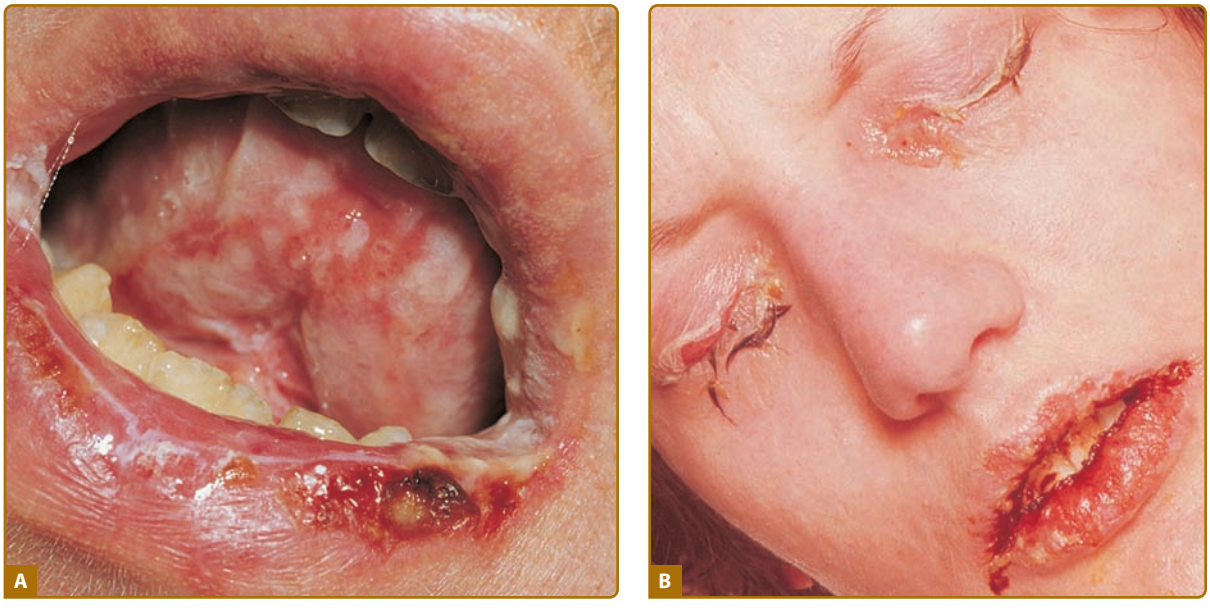

Figure 40-4 **A.** Extensive erosions and necroses of the lower lip and oral mucosa. **B.** Massive erosions covered by crusts on the lips. Note also shedding of eyelashes.

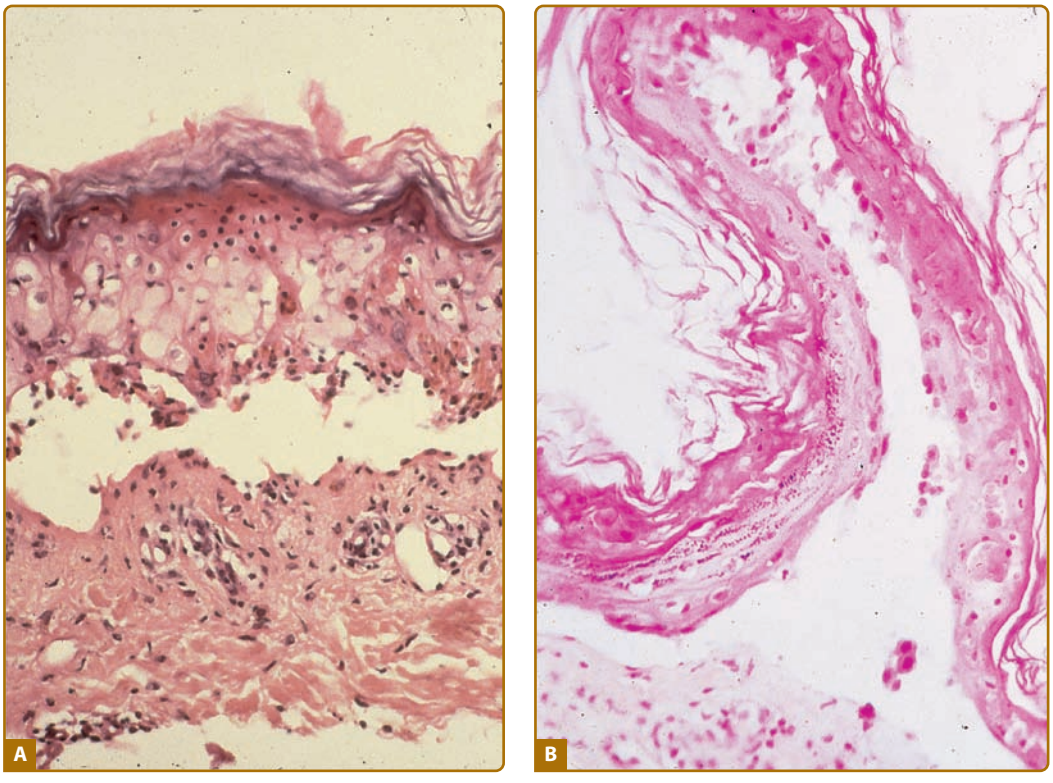

Figure 40-5 Histologic appearance of toxic epidermal necrolysis. **A.** Eosinophilic necrosis of the epidermis in the peak stage, with little inflammatory response in the dermis. Note cleavage in the junction zone. **B.** The completely necrotic epidermis has detached from the dermis and folded like a sheet.

BOX 40-1 DIFFERENTIAL DIAGNOSIS OF EPIDERMAL NECROLYSIS (EN)

Most Likely

- Limited EN (Stevens–Johnson syndrome)
  - Erythema multiforme major
  - Varicella
- Widespread EN
  - Acute generalized exanthematous pustulosis
  - Generalized bullous fixed drug eruption

Consider

- Paraneoplastic pemphigus
- Linear immunoglobulin A bullous disease
- Pressure blisters after coma
- Phototoxic reaction
- Graft-versus-host disease

Always Rule Out

- Staphylococcal scalded skin syndrome
- Thermal burns
- Skin necrosis from disseminated intravascular coagulation or purpura fulminans
- Chemical toxicity (e.g., colchicine intoxication, methotrexate overdose)

may have a similar drug-related mechanism. However, the distinction is worthwhile because GBFDE has a reputation for much better prognosis, probably because of the mild involvement of mucous membranes and the absence of visceral complications. Prior attacks, rapid onset after drug intake, and very large, well-demarcated blisters are the hallmarks of GBFDE.

Toxic destruction of epithelia, whether through contact (fumigants) or ingestion (colchicine poisoning, methotrexate overdose), may result in clinical features of EN, but with skin erosions often predominating in the folds. In these rare cases, causality is generally obvious.

Overreporting of SJS is common. It usually arises from confusion between desquamation and detachment of epidermis, and also between mucous membranes and periorificial skin. Because of such confusion, patients with a desquamative rash and scaly lips are not rarely diagnosed with and reported as having SJS.

COMPLICATIONS AND SEQUELAE

During the acute phase, the most common complication of EN is sepsis. The epithelial loss predisposes these patients to infections, which are the main causes of mortality.[4,63] *Staphylococcus aureus* and *Pseudomonas* are the most frequent pathogens, but about one-third of positive blood cultures contain enterobacteriae not present on the skin, a finding that suggests bacterial translocation from gut lesions.[76] Multisystem organ failure and pulmonary

complications are observed in more than 30% and 15% of cases, respectively.[77]

A very important advance in EN is the recent understanding that sequelae are more frequent and more severe than previously thought.[78] After the well-known risks of the acute stage, EN behaves as a chronic disease. More medical attention should be directed to that phase to better understand the frequency, mechanisms, and evolution of sequelae. Adequate management and prevention of sequelae are as important as saving the life during the acute phase.

A large European cohort has found that 90% of patients who survived EN suffered from sequelae at 1 year, with a mean of three different problems per patient and an important negative impact on the quality of life for about half of them (RegiSCAR group, unpublished data).

Symptoms suggesting posttraumatic stress disorder are not rare. Psychiatric consultation and/or psychological support are probably necessary in a majority of cases. Late ophthalmic complications are reported in 20% to 75% of patients with EN, with a credible figure of about 50% (Fig. 40-6).[64,65,78] The relationship between the initial severity of ocular involvement and the development of late complications seems now to be well established. Late ophthalmic complications are mainly due to functional alteration of the conjunctival epithelium with dryness and abnormal lacrimal film. This leads to chronic inflammation, fibrosis, entropion, trichiasis, and symblepharon. Long-term irritation and deficiency of stem cells in the limbus may result in metaplasia of corneal epithelium with painful ulcerations, scarring, and altered vision. Such severe eye lesions occasionally develop in patients who had no patent ocular signs during the acute phase of EN.[64]

Hypopigmentation and/or hyperpigmentation are most frequent; residual hypertrophic or atrophic scars rarely occur. Nail changes, including change in pigmentation of the nail bed, ridging, dystrophic nails, and permanent anonychia, occur in more than 30% of cases (Fig. 40-7). Mouth sequelae are present in about one-third of patients who complain of dryness, altered taste, and late alterations of teeth.[79]



Figure 40-6 Late ocular complications of SJS. Note opaque corneal epithelium, neovessels, and irritating eyelashes on lower eyelids. (Photograph provided by Julie Gueudry MD and Marc Muraine MD, PhD, Hôpital Charles Nicolle, Rouen, France.)



Figure 40-7 Abnormal regrowth of nails after SJS.

Vulvar and vaginal complications of EN are reported by about 25% of patients.[66] Dyspareunia is not rare and is related to vaginal dryness, itching, pain, and bleeding. Genital adhesions may lead to the requirement for surgical treatment. Esophageal, intestinal, urethral, and anal strictures may also develop in rare cases. Chronic lung disease can be observed after EN, often attributed to bronchiolitis obliterans, and occasionally requires lung transplantation.[68,80] Because these late complications and sequelae may develop insidiously, it is strongly suggested that all patients surviving EN have a clinical follow-up a few weeks after discharge and 1 year later, including examination by an ophthalmologist and by other organ specialist(s) as indicated by abnormal signs and symptoms.

PROGNOSIS AND CLINICAL COURSE

The epidermal detachment progresses for 5 to 7 days. Then, patients enter a plateau phase, which corresponds to progressive reepithelialization. This can take a few days to a few weeks, depending on the severity of the disease and the prior general condition of the patient. During this period, life-threatening complications such as sepsis or systemic organ failure may occur. The overall hospital mortality rate of EN is 22–25%, varying from 5% to 12% for SJS to more than 30% for TEN. The prognosis is not affected by the type or dose of the responsible drug or the presence of human immunodeficiency virus infection (see Table 40-1).[12,14,63,77]

Prospective follow-up has shown an additional abnormally increased mortality in the 3-month period following hospital discharge, which seems to result from the negative impact of EN on prior severe chronic conditions, for example, malignancies (RegiSCAR, unpublished data).

TREATMENT

EN is a life-threatening disease that requires optimal management: early recognition and withdrawal of the offending drug(s) and supportive care in an appropriate hospital setting.

Prompt withdrawal of offending agent(s) is associated with an increased rate of survival in patients with EN induced by drugs with short elimination half-lives.[81] On the other hand, it is preferable to continue every important and nonsuspected medication. That will avoid reluctance on the part of the patient's physicians to prescribe them in the future. In case of doubt, all nonlife-sustaining drugs should be stopped, and particularly those administered within the previous 8 weeks.

SYMPTOMATIC TREATMENT

Only patients with limited skin involvement, a SCORTEN score of 0 or 1, and a disease that is not rapidly progressing can be treated in nonspecialized wards. Others should be transferred to intensive care units or burn centers.[82] There is no "specific" treatment of demonstrated efficacy and supportive measures are the most important.[5] Supportive care consists of maintaining hemodynamic equilibrium and preventing life-threatening complications. The aims are basically the same as for extensive burns.

EN is associated with significant fluid loss from erosions, which results in hypovolemia and electrolyte imbalance. Fluid replacement must be started as soon as possible and adjusted daily. Volumes of infusions are usually less than for burns of similar extent, because interstitial edema is absent. Peripheral venous lines are preferred when possible, because the sites of insertion of central lines are often involved in detachment of epidermis and prone to infection. The environmental temperature should be raised to 28°C to 30°C (82.4°F to 86°F). The use of an air-fluidized bed improves patient comfort.

Early nutritional support is preferentially provided by nasogastric tube to promote healing and to decrease the risk of bacterial translocation from the gastrointestinal tract. To reduce the risk of infection, aseptic and careful handing is required. Skin, blood, and urine specimens should be cultured for bacteria and fungi at frequent intervals. Prophylactic antibiotics are not indicated. Patients should receive antibiotics when clinical infection is suspected. Prophylactic anticoagulation is provided during hospitalization.

We do not recommend extensive and aggressive debridement of necrotic epidermis in EN because the superficial necrosis is not an obstacle to reepithelialization, and might even accelerate the proliferation of stem cells due to the inflammatory cytokines. This is the single noticeable divergence between authors of this chapter and the recommendations of US Burn centers.[5] A few recent series suggest that debridement is necessary neither in superficial burns[81] nor in EN.[84,85] There is no standard policy on wound dressings and the use of antiseptics. It is a matter of experience for each center. Skillfulness on the part of specialized nurses, careful manipulation, and an aggressive protocol of prevention and treatment of pain are essential.

Eyes should be examined daily by an ophthalmologist. Preservative-free emollients, antibiotic or antiseptic eye drops, and vitamin A are often used every 2 hours in the acute phase, and mechanical disruption of early synechiae is indicated. Early graft of cryopreserved amniotic membrane has been proposed as capable to decrease the rate of severe eye sequelae.[64]

The mouth should be rinsed several times a day with antiseptic or antifungal solution.

SPECIFIC TREATMENT IN ACUTE STAGE

Because of the importance of immunologic and cytotoxic mechanisms, a large number of immunosuppressive and/or anti-inflammatory therapies have been tried to halt the progression of the disease. None has clearly proved its efficacy. The low prevalence of the disease makes randomized clinical trials hard to perform.

CORTICOSTEROIDS.

The use of systemic corticosteroids is still controversial. Some studies found that such therapy could prevent the extension of the disease when administered during the early phase, especially as intravenous pulses for a few days.[86] Other studies concluded that steroids did not stop the progression of the disease and were even associated with increased mortality and adverse effects, particularly sepsis. Thus, systemic corticosteroids cannot be recommended as the mainstay treatment of EN,[5] but a large cohort study has suggested a possible benefit that should be explored by a prospective study.[87]

INTRAVENOUS IMMUNOGLOBULIN.

The proposal to use high-dose intravenous Ig was based on the hypothesis that Fas-mediated cell death can be abrogated by the anti-Fas activity present in commercial batches of normal human Ig .[45] Benefits have been claimed by several studies and case reports,[45,88–90] but refuted by several others.[16,87,91,92] Thus, intravenous Ig cannot be considered the standard of care,[5] especially after recent findings that the Fas-L/Fas pathway was not, or only marginally, involved in the mechanisms of EN.[50] If used, a minimal precaution is to avoid preparations that are potentially nephrotoxic.

CYCLOSPORINE A.

Cyclosporine is a powerful immunosuppressive agent associated with biologic effects that may theoretically be useful in treatment of EN: activation of T helper 2 cytokines, inhibition of $CD8^+$ cytotoxic mechanisms, and antiapoptotic effect through inhibition of Fas-L, nuclear factor-κB, and TNF-α. Several case reports and series suggested some efficacy of cyclosporine A in halting the progression of EN without worrisome side effects when administered early.[93,94]

PLASMAPHERESIS OR HEMODIALYSIS.

The rationale for using plasmapheresis or hemodialysis is to prompt the removal of the offending medication, its metabolites, or inflammatory mediators such as cytokines. A small series reported their efficacy and safety in treating EN.[95–98] However, considering the absence of evidence and the risks associated with intravascular catheters, these treatments cannot be recommended.

ANTITUMOR NECROSIS FACTOR AGENTS.

Anti-TNF monoclonal antibodies have been successfully used to treat a few patients. Because a prior

randomized controlled trial of thalidomide, an anti-TNF agent, had to be interrupted due to significantly increased mortality,[99] extreme caution is suggested in the use of anti-TNF agents to treat EN.

TREATMENT OF SEQUELAE

Very promising treatments have now been developed for the ocular sequelae of EN, including gas permeable scleral lenses[100,101] and grafting of autologous stem cells from contralateral limbus or mouth mucosa.[102,103] With the exception of ocular sequelae, the literature contains only case reports related to treating sequelae. Photoprotection and cosmetic lasers may help resolve the pigmentation changes on the skin.

PREVENTION

Primary prevention is only feasible in populations where a strong association has been established between a simple genetic maker and the risk of EN. That is the case for HLAB*1502 and EN induced by carbamazepine. The FDA has issued the recommendation to test patients from "Asian ancestry" for HLAB*1502 before prescribing carbamazepine. This recommendation should be refined to exclude persons of Japanese or Korean origin. In individuals of Han Chinese origin, alternative antiepileptic drugs can be carefully prescribed, although there may be an association of EN with phenytoin and HLAB*1502 as well.[57] The present status of research on the pharmacogenetics of EN (RegiSCAR unpublished data) makes unlikely the finding of other genetic markers useful for primary prevention.

Secondary prevention is important for patients who experienced EN and are reluctant to take any medication. The most important issue is to evaluate drug causality. In vitro tests or patch tests to medications occasionally can be useful in the exploration of drug allergy. When used in EN patients, their sensitivity is low.[104,105] Careful inquiry into all exposures to medications in the few weeks preceding the onset of the reaction leads to the identification of a probable culprit drug in approximately 70% of cases. The most useful clinical criteria are duration of treatment before onset (typically 4 to 30 days), absence of prior intake, and use of a drug known for being associated with a high risk.[39]

The few published cases of recurrent SJS or TEN were always due to inadvertent readministration of the same or a very closely related medication. Epidemiology and in vitro studies suggest that the list of possible cross-reactive medications is rather narrow, based on close chemical similarities. As an example, there is no evidence that patients who experienced SJS or TEN in reaction to an anti-infectious sulfonamide are at increased risk for reaction to sulfonamide-related diuretics or antidiabetic medications. Only anti-infectious sulfonamides should be contraindicated in this situation.

A list of the suspected medication(s) and molecules of the same biochemical structure must be given to the patient on a personal "allergy card." It is also very useful to provide a list of drugs of common use that cannot be suspected. Because of recent indications of genetic susceptibilities to the development of EN, prescription of the offending agent to family members should also be avoided.

KEY REFERENCES

Full reference list available at www.DIGM8.com

DVD contains references and additional content

3. Bastuji-Garin S et al: Clinical classification of cases of toxic epidermal necrolysis, Stevens-Johnson syndrome, and erythema multiforme. *Arch Dermatol* **129**:92, 1993
5. Endorf FW et al: Toxic epidermal necrolysis clinical guidelines. *J Burn Care Res* **29**:706, 2008
22. Mockenhaupt M et al: Stevens-Johnson syndrome and toxic epidermal necrolysis: Assessment of medication risks with emphasis on recently marketed drugs. The EuroSCAR-study. *J Invest Dermatol* **128**:35, 2008
23. Auquier-Dunant A et al: Correlation between clinical patterns and causes of erythema multiforme major, Stevens Johnson and toxic epidermal necrolysis. *Arch Dermatol* **138**:1019, 2002
25. Halevy S et al: Allopurinol is the most common cause of Stevens-Johnson syndrome and toxic epidermal necrolysis in Europe and Israel. *J Am Acad Dermatol* **58**:25, 2008
36. Ting W et al: Toxic epidermal necrolysis-like acute cutaneous lupus erythematosus and the spectrum of the acute syndrome of apoptotic pan-epidermolysis (ASAP): A case report, concept review and proposal for new classification of lupus erythematosus vesiculobullous skin lesions. *Lupus* **13**:941, 2004
44. Nassif A et al: Drug specific cytotoxic T-cells in the skin lesions of a patient with toxic epidermal necrolysis. J Invest Dermatol **118**:728, 2002
50. Chung WH et al: Granulysin is a key mediator for disseminated keratinocyte death in Stevens-Johnson syndrome and toxic epidermal necrolysis. *Nat Med* **14**:1343, 2008
54. Takahashi R et al: Defective regulatory T cells in patients with severe drug eruptions: Timing of the dysfunction is associated with the pathological phenotype and outcome. *J Immunol* **182**:8071, 2009
55. Chung WH et al: Medical genetics: A marker for Stevens Johnson syndrome. *Nature* **428**:486, 2004
56. Hung SI et al: HLA-B*5801 allele as a genetic marker for severe cutaneous adverse reactions caused by allopurinol. *Proc Natl Acad Sci U S A* **102**:4134, 2005
62. Lonjou C et al: A European study of HLA-B in Stevens-Johnson syndrome and toxic epidermal necrolysis related to five high-risk drugs. *Pharmacogenet Genomics* **18**:99, 2008
64. Shay E et al: Amniotic membrane transplantation as a new therapy for the acute ocular manifestations of Stevens-Johnson syndrome and toxic epidermal necrolysis. *Surv Ophthalmol* **54**:686, 2009
87. Schneck J et al: Effects of treatments on the mortality of Stevens-Johnson syndrome and toxic epidermal necrolysis: A retrospective study on patients included in the prospective EuroSCAR Study. *J Am Acad Dermatol* **58**:33, 2008
101. Tougeron-Brousseau B et al: Vision-related function after scleral lens fitting in ocular complications of Stevens-Johnson syndrome and toxic epidermal necrolysis. *Am J Ophthalmol* **148**:852, 2009

Chapter 41 :: Cutaneous Reactions to Drugs

:: Neil H. Shear & Sandra R. Knowles

CUTANEOUS ADVERSE DRUG ERUPTIONS AT A GLANCE

- Drug-induced cutaneous eruptions are common.
- They range from common nuisance rashes to rare life-threatening diseases.
- The spectrum of clinical manifestations includes exanthematous, urticarial, pustular, and bullous eruptions.
- These reactions may mimic other cutaneous diseases such as acne, porphyria, lichen planus, and lupus.
- Fixed drug eruptions are usually solitary dusky macules that recur at the same site.
- Drug reactions may be limited solely to skin or may be part of a severe systemic reaction, such as drug hypersensitivity syndrome or toxic epidermal necrolysis.

Complications of drug therapy are a major cause of patient morbidity and account for a significant number of patient deaths.[1] Drug eruptions range from common nuisance eruptions to rare or life-threatening drug-induced diseases. Drug reactions may be solely limited to the skin, or they may be part of a systemic reaction, such as drug hypersensitivity syndrome or toxic epidermal necrolysis (TEN) (see Chapter 40).

Drug eruptions are often distinct disease entities and must be approached systematically, as any other cutaneous disease. A precise diagnosis of the reaction pattern can help narrow possible causes, because different drugs are more commonly associated with different types of reactions.

EPIDEMIOLOGY

A systematic review of the medical literature, encompassing nine studies, concluded that cutaneous reaction rates varied from 0% to 8% and were highest for antibiotics.[2] Outpatient studies of cutaneous adverse drug reactions (ADRs) estimate that 2.5% of children who are treated with a drug, and up to 12% of children treated with an antibiotic, will experience a cutaneous reaction.[3]

ETIOLOGY

In the evaluation of a patient with a history of a suspected ADR, it is important to obtain a detailed medication history, including use of over-the-counter preparations and herbal and naturopathic remedies. New drugs started within the preceding 3 months, especially those within 6 weeks, are potential causative agents for most cutaneous eruptions (exceptions include drug-induced lupus, drug-induced pemphigus, and drug-induced cutaneous pseudolymphoma), as are drugs that have been used intermittently.

PATHOGENESIS OF DRUG ERUPTIONS

Constitutional factors influencing the risk of cutaneous eruption include pharmacogenetic variation in drug-metabolizing enzymes and human leukocyte antigen (HLA) associations. Acetylator phenotype alters the risk of developing drug-induced lupus due to hydralazine, procainamide, and isoniazid. HLA-DR4 is significantly more common in individuals with hydralazine-related drug-induced lupus than in those with idiopathic systemic lupus erythematosus.[4] HLA factors may also influence the risk of reactions to nevirapine, abacavir, carbamazepine, and allopurinol.[5–7]

Many drugs associated with severe idiosyncratic drug reactions are metabolized by the body to form reactive, or toxic, drug products.[8] These reactive products comprise only a small proportion of a drug's metabolites and are usually rapidly detoxified. However, patients with drug hypersensitivity syndrome, TEN, and Stevens–Johnson syndrome (SJS) resulting from treatment with sulfonamide antibiotics and the aromatic anticonvulsants (e.g., carbamazepine, phenytoin, phenobarbital, primidone, and oxcarbazepine) show greater sensitivity in in vitro assessments to the oxidative, reactive metabolites of these drugs than do control subjects.[9]

Acquired factors also alter an individual's risk of drug eruption. Active viral infection and concurrent use of other medications have been shown to alter the frequency of drug-associated eruptions. Reactivation of latent viral infection with human herpes virus 6 also appears common in drug hypersensitivity syndrome and may be partially responsible for some of the clinical features and/or course of the disease.[10,11] Viral infections may act as, or generate the production of, danger signals that lead to damaging immune responses to drugs, rather than immune tolerance.

Drug–drug interactions may also alter the risk of cutaneous eruption. Valproic acid increases the risk of severe cutaneous adverse reactions to lamotrigine, another anticonvulsant.[12] The basis of these

interactions and reactions is unknown, but they may represent a combination of factors, including alterations in drug metabolism, drug detoxification, antioxidant defenses, and immune reactivity.

The course and outcome of drug-induced disease are also influenced by host factors. Older age may delay the onset of drug eruptions and has been associated with a higher mortality rate in some severe reactions. A higher mortality rate is also observed in patients with severe reactions who have underlying malignancy.[13] The pathogenesis of most drug eruptions is not understood, although the clinical features of most drug reactions are consistent with immune-mediated disease. The immune system may target the native drug, its metabolic products, altered self, or a combination of these factors.[14]

MORPHOLOGIC APPROACH TO DRUG ERUPTIONS

Although there are many presentations of cutaneous drug eruptions, the morphology of many cutaneous eruptions may be exanthematous, urticarial, blistering, or pustular. The extent of the reaction is variable. For example, once the morphology of the reaction has been documented, a specific diagnosis [e.g., fixed drug eruption (FDE) or acute generalized exanthematous pustulosis (AGEP)] can be made. The reaction may also present as a systemic syndrome [e.g., serum sickness-like reaction or hypersensitivity syndrome reaction (HSR)]. Fever is generally associated with such systemic cutaneous ADRs.

EXANTHEMATOUS ERUPTIONS

Exanthematous eruptions, sometimes referred to as *morbilliform* or *maculopapular*, are the most common form of drug eruptions, accounting for approximately 95% of skin reactions[2] (Fig. 41-1). Simple exanthems are erythematous changes in the skin without evidence of blistering or pustulation. The eruption typically starts on the trunk and spreads peripherally in a symmetric fashion. Pruritus is almost always present. These eruptions usually occur within 1 week of initiation of therapy and may appear 1 or 2 days after drug therapy has been discontinued.[15] Resolution, usually with 7–14 days, occurs with a change in color from bright red to a brownish red, which may be followed by desquamation. The differential diagnosis in these patients includes an infectious exanthem (e.g., viral, bacterial, or rickettsial), collagen vascular disease, and infections.

Exanthematous eruptions can be caused by many drugs, including β-lactams ("the penicillins"), sulfonamide antimicrobials, nonnucleoside reverse transcriptase inhibitors (e.g., nevirapine), and antiepileptic medications. Studies have shown that drug-specific T cells play a major role in exanthematous, bullous, and pustular drug reactions.[16] In patients who have concomitant infectious mononucleosis, the risk of developing an exanthematous eruption while being treated with an aminopenicillin (e.g., ampicillin) increases from 3%–7% to 60%-100%.[17] A similar drug–viral interaction has been observed in 50% of patients infected with human immunodeficiency virus (HIV) who are exposed to sulfonamide antibiotics.[14]



Figure 41-1 Exanthematous drug eruption: ampicillin. Symmetrically arranged, brightly erythematous macules and papules, which are discrete in some areas and confluent in others on the trunk and discrete on the extremities.

An exanthematous eruption in conjunction with fever and internal organ inflammation (e.g., liver, kidney, central nervous system) signifies a more serious reaction, known as the *hypersensitivity syndrome reaction*, drug-induced hypersensitivity reaction (DIHS) or drug reaction with eosinophilia and systemic symptoms (DRESS) (Table 41-1). It occurs in approximately 1 in 3,000 exposures to agents such as aromatic anticonvulsants, lamotrigine, sulfonamide antimicrobials, dapsone, nitrofurantoin, nevirapine, minocycline, metronidazole, and allopurinol (Fig. 41-2). HSR occurs most frequently on first exposure to the drug, with initial symptoms starting 1–6 weeks after exposure. Fever and malaise are often the presenting symptoms. Atypical lymphocytosis with subsequent eosinophilia may occur during the initial phases of the reaction in some patients. Although most patients have an exanthematous eruption, more serious cutaneous manifestations may be evident (Fig. 41-3). Internal organ involvement can be asymptomatic.[11] Some patients may become hypothyroid due to an autoimmune thyroiditis approximately 2 months after the first symptoms appear.[18]

The formation of toxic metabolites of the aromatic anticonvulsants may play a pivotal role in the development of HSR.[9] In most individuals, the chemically reactive metabolites that are produced are detoxified by epoxide hydroxylases. However, if detoxification is defective, one of the metabolites may act as a hapten and initiate an immune response, stimulate apoptosis,

TABLE 41-1
Clinical Features of Selected Cutaneous Reactions to Drugs

Clinical Presentation	Drug Eruption	Fever	Internal Organ Involvement	Arthralgia	Lymphadenopathy	Implicated Drugs
Hypersensitivity syndrome reaction	Exanthem, exfoliative dermatitis, pustular eruptions, SJS/TEN	Present	Present	Absent	Present	Aromatic anticonvulsants (e.g., phenytoin, phenobarbital, carbamazepine), sulfonamide antibiotics, dapsone, minocycline, allopurinol, lamotrigine
Serum sickness-like reaction	Urticaria, exanthem	Present	Absent	Present	Present	Cefaclor, cefprozil, bupropion, minocycline, infliximab, rituximab
Drug-induced lupus	Usually absent	Present/absent	Present/absent	Present	Absent	Procainamide, hydralazine, isoniazid, minocycline, acebutolol
Drug-induced subacute cutaneous lupus erythematosus	Papulosquamous or annular cutaneous lesion (often photosensitive)	Absent	Absent	Absent	Absent	Thiazide diuretics, calcium channel blockers, ACE inhibitors
Acute generalized exanthematous pustulosis	Nonfollicular pustules on an edematous erythematous base	Present	Absent	Absent	Absent	β Blockers, macrolide antibiotics, calcium channel blockers

ACE = angiotensin-converting enzyme; SJS = Stevens–Johnson syndrome; TEN = toxic epidermal necrolysis.

or cause cell necrosis directly. Approximately 70%–75% of patients who develop anticonvulsant HSR in response to one aromatic anticonvulsant show cross-reactivity to the other aromatic anticonvulsants. In addition, in vitro testing shows that there is a pattern of inheritance of HSR induced by anticonvulsants. Thus, counseling of family members and disclosure of risk are essential.

Sulfonamide antimicrobials are both sulfonamides (contain SO_2-NH_2) and aromatic amines (contain a benzene ring-NH_2). Aromatic amines can be metabolized to toxic metabolites, namely, hydroxylamines and nitroso compounds.[19] In most people, the metabolite is detoxified. However, HSRs may occur in patients who either form excess oxidative metabolites or are unable to detoxify such metabolite. Because siblings and other



Figure 41-2 Drug hypersensitivity syndrome: phenytoin. Symmetric, bright red, exanthematous eruption, confluent in some sites; the patient had associated lymphadenopathy.



Figure 41-3 Hypersensitivity syndrome reaction, characterized by fever, a pustular eruption, and hepatitis, in a 23-year-old man after 18 days of treatment with minocycline.

first-degree relatives may be at an increased risk (perhaps as high as 1 in 4) of developing a similar adverse reaction, counseling of family members is essential.

Other aromatic amine-containing drugs, such as procainamide, dapsone, and acebutolol, may also be metabolized to chemically reactive compounds. It is recommended that patients who develop symptoms compatible with a sulfonamide-induced HSR avoid these aromatic amines, because the potential exists for cross-reactivity. However, cross-reactivity is much less likely to occur between sulfonamides antimicrobials and drugs that are not aromatic amines (e.g., sulfonylureas, thiazide diuretics, furosemide, celecoxib, and acetazolamide).[20]

Allopurinol is associated with the development of serious drug reactions, including HSR. Active infection or reactivation of HHV-6 has been observed in patients who develop allopurinol HSR.[21] Allopurinol-induced severe adverse reactions, specifically HSR and SJS/TEN spectrum, have been strongly associated with a genetic predisposition in Han Chinese and Thai populations; presence of the HLA-B*5801 allele was found to be an important genetic risk factor.[6,22]

URTICARIAL ERUPTIONS

Urticaria is characterized by pruritic red wheals of various sizes. Individual lesions generally last for less than 24 hours, although new lesions can commonly develop. When deep dermal and subcutaneous tissues are also swollen, the reaction is known as *angioedema*. Angioedema is frequently unilateral and nonpruritic and lasts for 1–2 hours, although it may persist for 2–5 days.[21]

Urticaria and angioedema, when associated with drug use, are usually indicative of an immunoglobulin (Ig) E-mediated immediate hypersensitivity reaction. This mechanism is typified by immediate reactions to penicillin and other antibiotics (see Chapter 38). Signs and symptoms of IgE-mediated allergic reactions typically include pruritus, urticaria, cutaneous flushing, angioedema, nausea, vomiting, diarrhea, abdominal pain, nasal congestion, rhinorrhea, laryngeal edema, and bronchospasm or hypotension. Urticaria and angioedema can also be caused by non-IgE-mediated reactions that result in direct and nonspecific liberation of histamine or other mediators of inflammation.[15] Drug-induced non-IgE-mediated urticaria and angioedema are usually related to nonsteroidal anti-inflammatory drugs (NSAIDs), angiotensin converting enzyme (ACE)-inhibitors and opioids.

Serum sickness-like reactions (see Table 41-1) are defined by the presence of fever, rash (usually urticarial), and arthralgias 1–3 weeks after initiation of drug therapy. Lymphadenopathy and eosinophilia may also be present; however, in contrast to true serum sickness, immune complexes, hypocomplementemia, vasculitis, and renal lesions are absent.

Cefaclor is associated with an increased relative risk of serum sickness-like reactions. The overall incidence of cefaclor-induced serum sickness-like reactions has been estimated to be 0.024%–0.2% per course of cefaclor prescribed. In genetically susceptible hosts, a reactive metabolite is generated during the metabolism of cefaclor that may bind with tissue proteins and elicit an inflammatory response manifesting as a serum sickness-like reaction.[23]

Other drugs that have been implicated in serum sickness-like reactions are cefprozil, bupropion, minocycline, and rituximab[24] as well as infliximab.[25] The incidence of serum sickness-like reactions caused by these drugs is unknown.

PUSTULAR ERUPTIONS

Acneiform eruptions are associated with the use of iodides, bromides, adrenocorticotropic hormone, glucocorticoids, isoniazid, androgens, lithium, actinomycin D, and phenytoin. Drug-induced acne may appear in atypical areas, such as on the arms and legs, and is most often monomorphous. Comedones are usually absent. The fact that acneiform eruptions do not affect prepubertal children indicates that previous hormonal priming is a necessary prerequisite. In cases in which the offending agent cannot be discontinued, topical tretinoin may be useful.[26] An acneiform eruption often occurs during treatment with epidermal growth factor receptor inhibitors (e.g., gefitinib, erlotinib, cetuximab). The acneiform rash is often accompanied by paronychia, dry skin, and skin fissures. The eruption is dose dependent, with respect to both incidence and severity.[27] In a systemic review and meta-analysis encompassing over 1,000 patients receiving cetuximab as a single-agent, the incidence of an acneiform eruption was 81.6%.[28]

AGEP is an acute febrile eruption that is often associated with leukocytosis (Fig. 41-4 and Table 41-1). After initiation of the implicated drug, 1–3 weeks



Figure 41-4 Acute generalized exanthematous pustulosis in a 48-year-old man who developed nonfollicular pustules and fever after 7 days of treatment with diltiazem.

may elapse before skin lesions appear. The lesions often start on the face or major skin creases. Generalized desquamation occurs approximately 2 weeks later. The estimated incidence of AGEP is approximately 1–5 cases per million per year. AGEP is most commonly associated with β-lactam and macrolide antibiotics, anticonvulsants, and calcium channel blockers.[29] Differential diagnosis includes pustular psoriasis, HSR with pustulation, subcorneal pustular dermatosis (Sneddon–Wilkinson disease), pustular vasculitis, or in severe cases of AGEP, TEN. The typical histopathologic analysis of AGEP lesions shows spongiform subcorneal and/or intraepidermal pustules, an often marked edema of the papillary dermis, and perivascular infiltrates with neutrophils and exocytosis of some eosinophils. Discontinuance of therapy is usually the extent of treatment necessary in most patients, although some patients may require the use of corticosteroids. Patch tests have been used in the diagnosis of AGEP.[30]

BULLOUS ERUPTIONS

(Table 41-2)

PSEUDOPORPHYRIA. Pseudoporphyria is a cutaneous phototoxic disorder that can resemble either porphyria cutanea tarda in adults or erythropoietic protoporphyria in children (see Chapter 132). Pseudoporphyria of the porphyria cutanea tarda variety is characterized by skin fragility, blister formation, and scarring in photodistribution; it occurs in the presence of normal porphyrin levels. The other clinical pattern mimics erythropoietic protoporphyria and manifests as cutaneous burning, erythema, vesiculation, angular chicken pox-like scars, and waxy thickening of the skin. The eruption may begin within 1 day of initiation of therapy or may be delayed in onset for as long as 1 year. The course is prolonged in some patients, but most reports describe symptoms that disappear several weeks to several months after the offending agent is withdrawn. Because of the risk of permanent facial scarring, the implicated drug should be discontinued if skin fragility, blistering, or scarring occurs.[31] In addition, the use of broad-spectrum sunscreen and protective clothing should be recommended. Drugs that have been associated with pseudoporphyria include naproxen and other NSAIDs, and voriconazole.[32,33]

DRUG-INDUCED LINEAR IgA DISEASE. Both idiopathic and drug-induced linear IgA diseases (see Chapter 58) are heterogeneous in clinical presentation. Cases of the drug-induced type have morphologies resembling erythema multiforme, bullous pemphigoid, and dermatitis herpetiformis. The drug-induced disease may differ from the idiopathic entity in that mucosal or conjunctival lesions are less common, spontaneous remission occurs once the offending agent is withdrawn, and immune deposits disappear from the skin once the lesions resolve.

Biopsy specimens are necessary for diagnosis. Histologically, the two entities are similar. A study suggests that, as in the idiopathic variety, the target antigen is not unique in the drug-induced disease. Although 13%–30% of patients with sporadic linear IgA have circulating basement membrane zone antibodies, these antibodies have not been reported in drug-induced cases.[34] In patients with linear IgA bullous disease

TABLE 41-2
Drug Eruptions Mimicry

Clinical Presentation	Pattern and Distribution of Skin Lesions	Mucous Membrane Involvement	Implicated Drugs	Treatment
Stevens–Johnson syndrome	Atypical targets, widespread	Present	Aromatic anticonvulsants,[a] lamotrigine, sulfonamide antibiotics, allopurinol, piroxicam, dapsone	IVIg, cyclosporine, supportive care
Toxic epidermal necrolysis	Epidermal necrosis with skin detachment	Present	As above	IVIg, cyclosporine, supportive care
Pseudoporphyria	Skin fragility, blister formation in photodistribution	Absent	Tetracycline, furosemide, naproxen	Supportive care
Linear IgA disease	Bullous dermatosis	Present/absent	Vancomycin, lithium, diclofenac, piroxicam, amiodarone	Supportive care
Pemphigus	Flaccid bullae, chest	Present/absent	Penicillamine, captopril, piroxicam, penicillin, rifampin, propranolol	Supportive care
Bullous pemphigoid	Tense bullae, widespread	Present/absent	Furosemide, penicillamine, penicillins, sulfasalazine, captopril	Supportive care

IVIg = intravenous immunoglobulin.
[a]Aromatic anticonvulsants = phenytoin, carbamazepine, phenobarbital, oxcarbazepine, primidone.

proven by direct immunofluorescence, the index of suspicion of drug induction should be higher in cases with only IgA and no IgG in the basement membrane zone. Several drugs can induce linear IgA bullous dermatosis, the most frequently reported being vancomycin.[35]

DRUG-INDUCED PEMPHIGUS. Pemphigus may be considered as drug-induced or drug-triggered (i.e., a latent disease that is unmasked by the drug exposure; see Chapter 54). Drug-induced pemphigus caused by penicillamine and other thiol-containing drugs (e.g., piroxicam, captopril) tends to remit spontaneously in 35%–50% of cases, presents as pemphigus foliaceus, has an average interval to onset of 1 year, and is associated with the presence of antinuclear antibodies in 25% of patients.

Most patients with nonthiol drug-induced pemphigus manifest clinical, histologic, immunologic, and evolutionary aspects similar to those of idiopathic pemphigus vulgaris with mucosal involvement and show a 15% rate of spontaneous recovery after drug withdrawal. Treatment of drug-induced pemphigus begins with drug cessation. Systemic glucocorticoids and other immunosuppressive drugs are often required until all symptoms of active disease disappear. Vigilant follow-up is required after remission to monitor the patient and the serum for autoantibodies to detect an early relapse.[36]

DRUG-INDUCED BULLOUS PEMPHIGOID. Drug-induced bullous pemphigoid (see Chapter 56) can encompass a wide variety of presentations, ranging from the classic features of large, tense bullae arising from an erythematous, urticarial base with moderate involvement of the oral cavity, through mild forms with few bullous lesions, to scarring plaques and nodules with bullae. Medications that have been reported to cause bullous pemphigoid include furosemide, amoxicillin, and spironolactone. In contrast to patients with the idiopathic form, patients with drug-induced bullous pemphigoid are generally younger. In addition, the histopathologic findings are of a perivascular infiltration of lymphocytes with few eosinophils and neutrophils, intraepidermal vesicles with foci of necrotic keratinocytes, thrombi in dermal vessels, and a possible lack of tissue-bound and circulating anti-basal membrane zone IgG.[37]

In the acute, self-limited condition, resolution occurs after the withdrawal of the culprit agent, with or without glucocorticoid therapy. However, in some patients the drug may actually trigger the idiopathic form of the disease.

STEVENS–JOHNSON SYNDROME AND TOXIC EPIDERMAL NECROLYSIS. SJS and TEN or the SJS/TEN spectra represent variants of the same disease process. Differentiation between the two patterns depends on the nature of the skin lesions and the extent of body surface area involvement (see Chapters 39 and 40).

Recently, the understanding of the pathogenesis of severe cutaneous ADRs has expanded greatly. Various factors including pharmacogenetic and immunogentic determinants may influence the likelihood of a reaction and variability in innate and adaptive immunity may influence the clinical presentation.[38] In addition, the detection of drug-specific T-cell proliferation provides evidence that T cells are involved in severe skin rashes.[39]

Treatment of SJS/TEN includes discontinuance of the suspected drug(s) and supportive measures such as careful wound care, hydration, and nutritional support. The use of corticosteroids in the treatment of SJS and TEN is controversial.[40,41] Intravenous Ig (IVIg, up to 3–4 g over 3 days) has been shown in some reports to halt progression of TEN, especially when IVIg is started early. However, some studies have not found an improved outcome in patients with TEN who are treated with IVIg.[38] A recent study concluded that neither corticosteroids nor intravenous Ig had any significant effect on mortality in comparison to supportive care only.[42] Other treatment modalities include cyclosporine,[43] cyclophosphamide, and plasmapharesis. Patients who have developed a severe cutaneous ADR should not be rechallenged with the drug. Desensitization therapy with the medication may also be a risk.

FIXED DRUG ERUPTIONS

FDEs usually appear as solitary, erythematous, bright red or dusky red macules that may evolve into an edematous plaque; bullous-type lesions may be present, widespread lesions may be difficult to differentiate from TEN. FDEs are commonly found on the genitalia and in the perianal area, although they can occur anywhere on the skin surface (Fig. 41-5). Some

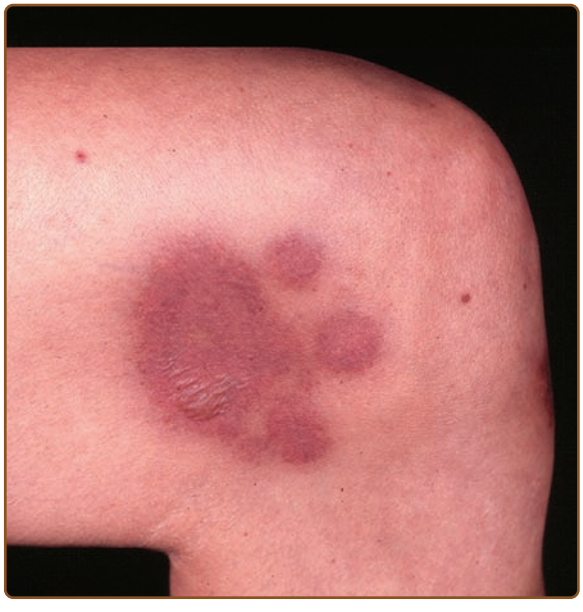

Figure 41-5 Fixed drug eruption: tetracycline. A well-defined plaque on the knee, merging with three satellite lesions. The large plaque exhibits epidermal wrinkling, a sign of incipient blister formation. This was the second such episode after ingestion of a tetracycline. No other lesions were present.

patients may complain of burning or stinging, and others may have fever, malaise, and abdominal symptoms. FDE can develop from 30 minutes to 8–16 hours after ingestion of the medication. After the initial acute phase lasting days to weeks, residual grayish or slate-colored hyperpigmentation develops. On rechallenge, not only do the lesions recur in the same location, but also new lesions often appear.

More than 100 drugs have been implicated in causing FDEs, including ibuprofen, sulfonamides, naproxen, and tetracyclines. A haplotype linkage in trimethoprim–sulfamethoxazole-induced FDE has been documented.

A challenge or provocation test with the suspected drug may be useful in establishing the diagnosis. Patch testing at the site of a previous lesion yields a positive response in up to 43% of patients. Results of prick and intradermal skin tests may be positive in 24% and 67% of patients, respectively.[44,45] Food-initiated fixed eruptions also exist and are important to consider when assessing causation.

ANTICOAGULANT-INDUCED SKIN NECROSIS

Anticoagulant-induced skin necrosis begins 3–5 days after initiation of treatment. The majority of cases of anticoagulant-induced skin necrosis have been attributed to coumarin congeners (bishydroxycoumarin, phenprocoumon, acenocoumarol, and warfarin) (Fig. 41-6). Early red, painful plaques develop in adipose-rich sites such as breasts, buttocks, and hips. These plaques may blister, ulcerate, or develop into necrotic areas. It is estimated that 1 in 10,000 persons who receive the drug is at risk of this adverse event. The incidence is four times higher in women, especially in obese women, with a peak incidence in the sixth and seventh decades of life. Affected patients often have been given a large initial loading dose of warfarin in the absence of concomitant heparin therapy. An accompanying infection such as pneumonia, viral infection, or erysipelas may be seen in up to 25% of patients. An association with protein C and protein S deficiencies exists, but pretreatment screening is not warranted. An association with heterozygosity for factor V Leiden mutation has been reported.



Figure 41-6 Skin necrosis in a patient after 4 days of warfarin therapy.

The pathogenesis of this adverse event is the paradoxical development of occlusive thrombi in cutaneous and subcutaneous venules due to a transient hypercoagulable state. This results from the suppression of the natural anticoagulant protein C at a greater rate than the suppression of natural procoagulant factors.

Treatment involves the discontinuation of warfarin, administration of vitamin K, and infusion of heparin at therapeutic dosages. Fresh frozen plasma and purified protein C concentrates have been used. Supportive measures for the skin are a mainstay of therapy. The morbidity rate is high; 60% of affected individuals require plastic surgery for remediation of full-thickness skin necrosis by skin grafting. These patients may be treated with warfarin in the future, but small dosages (2–5 mg daily) are recommended, with initial treatment under heparin coverage.[46,47]

DRUG-INDUCED LICHENOID ERUPTIONS

Drug-induced lichen planus produces lesions that are clinically and histologically indistinguishable from those of idiopathic lichen planus (see Chapter 26); however, lichenoid drug eruptions often appear initially as eczematous with a purple hue and involve large areas of the trunk. Usually, the mucous membranes and nails are not involved. Histologically, focal parakeratosis, cytoid bodies in the cornified and granular layers, the presence of eosinophils and plasma cells in the inflammatory infiltrate, and an infiltrate around the deep vessels favor a diagnosis of lichenoid drug eruption. Many drugs, including β-blockers, penicillamine, and ACE-inhibitors, especially captopril, reportedly produce this reaction. Lichen planus-like eruptions have also been reported with tumor necrosis factor-α (TNF) antagonists, such as infliximab, etanercept, and adalimumab.[48,49] The mean latent period is between 2 months and 3 years for penicillamine, approximately 1 year for β-adrenergic blocking agents, and 3–6 months for ACE-inhibitors. For anti-TNF treatments, the time to reaction is similar with onset occurring between 3 weeks and 62 weeks. The latent period may be shortened if the patient has been previously exposed to the drug. Resolution usually occurs with 2–4 months. Rechallenge with the culprit drug has been attempted in a few patients, with reactivation of symptoms within 4–15 days.[50]

DRUG-INDUCED CUTANEOUS PSEUDOLYMPHOMA

Pseudolymphoma is a process that simulates lymphoma but has a benign behavior and does not meet

the criteria for malignant lymphoma. Drugs are a well-known cause of cutaneous pseudolymphomas (see Chapter 146), but the condition may also be induced by foreign agents such as insect bites, infections (e.g., HIV), and idiopathic causes.[51]

Anticonvulsant-induced pseudolymphoma generally occurs after 1 week to 2 years of exposure to the drug. Within 7–14 days of drug discontinuation, the symptoms usually resolve. The eruption often manifests as single lesions but can also be widespread erythematous papules, plaques, or nodules. Most patients also have fever, marked lymphadenopathy and hepatosplenomegaly, and eosinophilia. Mycosis fungoides-like lesions are also associated with these drugs.[52]

DRUG-INDUCED VASCULITIS

Drug-induced vasculitis represents approximately 10% of the acute cutaneous vasculitides and usually involves small vessels (see Chapter 163). Drugs that are associated with vasculitis include propylthiouracil, hydralazine, granulocyte colony-stimulating factor, granulocyte-macrophage colony-stimulating factor, allopurinol, cefaclor, minocycline, penicillamine, phenytoin, isotretinoin, and anti-TNF agents, including etanercept, infliximab, and adalimumab.[49] The average interval from initiation of drug therapy to onset of drug-induced vasculitis is 7–21 days; in the case of rechallenge, lesions can occur in less than 3 days.[15]

The clinical hallmark of cutaneous vasculitis is palpable purpura, classically found on the lower extremities. Urticaria can be a manifestation of small vessel vasculitis, with individual lesions remaining fixed in the same location for more than 1 day. Other features include hemorrhagic bullae, ulcers, nodules, Raynaud disease, and digital necrosis. The same vasculitic process may also affect internal organs such as the liver, kidney, gut, and central nervous system and can be potentially life threatening.[53]

Drug-induced vasculitis can be difficult to diagnose and is often a diagnosis of exclusion. In some cases, serologic testing has revealed the presence of perinuclear-staining antineutrophil cytoplasmic autoantibodies against myeloperoxidase. Alternative causes for cutaneous vasculitis such as infection or autoimmune disease must be eliminated. Tissue eosinophilia may be an indicator of drug induction in cutaneous small vessel vasculitis. Treatment consists of drug withdrawal. Systemic glucocorticoids may be of benefit.

DRUG-INDUCED LUPUS

(See Chapter 155)

Drug-induced lupus is characterized by frequent musculoskeletal complaints, fever, weight loss, pleuropulmonary involvement in more than half of patients, and in rare cases renal, neurologic, or vasculitic involvement (see Table 41-1). Many patients have no cutaneous findings of lupus erythematosus. The most common serologic abnormality is positivity for antinuclear antibodies with a homogenous pattern. Although antihistone antibodies are seen in up to 95% of drug-induced lupus, they are not specific for the syndrome and are found in 50%–80% of patients with idiopathic lupus erythematosus. Unlike in idiopathic lupus erythematosus, antibodies against double-stranded DNA are typically absent, whereas antisingle-stranded DNA antibodies are often present.[54] Genetic factors may also play a role in the development of drug-induced lupus. HLA-DR4 is present in 73% of the patients with hydralazine-induced lupus and in 70% of patients with minocycline-induced lupus.[55] Evidence now suggests that abnormalities during T-cell selection in the thymus initiate lupus-like autoantibody induction.[56]

In contrast, drug-induced subacute cutaneous lupus erythematosus is characterized by a papulosquamous or annular cutaneous lesion, which is often photosensitive, and absent or mild systemic involvement. Circulating anti-Ro (Sjögren syndrome A) antibodies have also been identified in many patients.

Many drugs have been implicated in causing drug-induced lupus syndromes, especially hydralazine, procainamide, isoniazid, methyldopa, and minocycline.[57] Drugs that have been associated with subacute cutaneous lupus erythematosus include thiazide diuretics, calcium channel blockers, and ACE inhibitors. The number of patients who develop subacute cutaneous lupus erythematosus during treatment with these medications is very low, and these drugs are thought to have a low risk for causing or exacerbating cutaneous lupus.[58] Other drugs that have been associated with drug-induced lupus include terbinafine, proton pump inhibitors, and anti-TNF treatments.[58]

The identification of minocycline as a cause of drug-induced lupus makes it important for dermatologists to recognize this syndrome. Minocycline-induced lupus typically occurs after 2 years of therapy. The patient presents with a symmetric polyarthritis. Hepatitis is often detected on laboratory evaluation. Cutaneous findings include livedo reticularis, painful nodules on the legs, and nondescript eruptions. Antihistone antibodies are seldom present. A study of HLA class II alleles revealed the presence of HLA-DR4 or HLA-DR2 in many of the patients.[55]

DIAGNOSIS AND MANAGEMENT

The iatrogenic disorders described here are distinct disease entities, although they may closely mimic many infective or idiopathic diseases. A drug cause should be considered in the differential diagnosis of a wide spectrum of dermatologic diseases, particularly when the presentation or course is atypical.

The diagnosis of a cutaneous drug eruption involves the precise characterization of reaction type. A wide variety of cutaneous drug-associated eruptions may also warn of associated internal toxicity (Table 41-3). Even the most minor cutaneous eruption should trigger a clinical review of systems, because the severity of systemic involvement does not necessarily mirror that of the skin manifestations. Hepatic, renal, joint, respiratory, hematologic, and neurologic changes should be sought, and any systemic symptoms or signs investi-

TABLE 41-3
Clinical Features That Warn of a Potentially Severe Drug Reaction

Systemic
- Fever and/or other symptoms of internal organ involvement such as pharyngitis, malaise, arthralgia, cough, and meningismus
- Lymphadenopathy

Cutaneous
- Evolution to erythroderma
- Prominent facial involvement ± edema or swelling
- Mucous membrane involvement (particularly if erosive or involving conjunctiva)
- Skin tenderness, blistering, or shedding
- Purpura

gated. Fever, malaise, pharyngitis, and other systemic symptoms or signs should be investigated. A usual screen would include a full blood count, liver and renal function tests, and a urine analysis.

Skin biopsy should be considered for all patients with potentially severe reactions, such as those with systemic symptoms, erythroderma, blistering, skin tenderness, purpura, or pustulation, as well as in cases in which the diagnosis is uncertain. Some cutaneous reactions, such as FDE, are almost always due to drug therapy, and approximately 40%–50% of SJS/TEN cases are also drug related.[59] Other more common eruptions, including exanthematous or urticarial eruptions, have many nondrug causes.

There is no gold standard investigation for confirmation of a drug cause. Instead, diagnosis and assessment of cause involve analysis of a constellation of features such as timing of drug exposure and reaction onset, course of reaction with drug withdrawal or continuation, timing, and nature of a recurrent eruption on rechallenge, a history of a similar response to a cross-reacting medication, and previous reports of similar reactions to the same medication. Investigations to exclude nondrug causes are similarly helpful.

Several in vitro investigations can help to confirm causation in individual cases, but their exact sensitivity and specificity remain unclear. Investigations include the lymphocyte toxicity and lymphocyte transformation assays.[60] The basophil activation test has been reported to be useful to evaluate patients with possible drug allergies to β-lactam antibiotics, NSAIDs, and muscle relaxants.[14] Penicillin skin testing with major and minor determinants is useful for confirmation of an IgE-mediated immediate hypersensitivity reaction to penicillin.[14] Patch testing has been used in patients with ampicillin-induced exanthematous eruptions, AGEP reactions,[61] abacavir-induced hypersensitivity,[62] and in the ancillary diagnosis of FDEs. Patch testing has greater sensitivity if performed over a previously involved area of skin.

Cutaneous drug eruptions do not usually vary in severity with dose. Less severe reactions may abate with continued drug therapy (e.g., transient exanthematous eruptions associated with commencement of a new HIV antiretroviral regimen). However, a reaction suggestive of a potentially life-threatening situation should prompt immediate discontinuation of the drug, along with discontinuation of any interacting drugs that may slow the elimination of the suspected causative agent. Although the role of corticosteroids in the treatment of serious cutaneous reactions is controversial, most clinicians choose to start prednisone at a dosage of 1–2 mg/kg/day when symptoms are severe. Antihistamines, topical corticosteroids, or both can be used to alleviate symptoms.[63] Resolution of the reaction over a reasonable time frame after the drug is discontinued is consistent with a drug cause but also occurs for many infective and other causes of transient cutaneous eruptions. Drug desensitization, also known as induction of drug tolerance, has been used primarily for IgE-mediated reactions caused by drugs such as penicillin or more recently, monoclonal antibodies such as rituximab and infliximab.[14,64] Patients should not be rechallenged or desensitized if they have suffered a potentially serious reaction.

PREVENTION

Cutaneous reactions to drugs are largely idiosyncratic and unexpected; serious reactions are rare. However, once a reaction has occurred, it is important to prevent future similar reactions in the patient with the same drug or a cross-reacting medication. For patients with severe reactions, wearing a bracelet (e.g., MedicAlert) detailing the nature of the reaction is advisable, and patient records should be appropriately labeled.

Host factors appear important in many reactions. Some of these can be inherited, which places first-degree relatives at a greater risk than the general population for a similar reaction to the same or a metabolically cross-reacting drug. This finding appears to be important in SJS, TEN, and drug hypersensitivity syndrome.

Reporting reactions to the manufacturer or regulatory authorities is important. Postmarketing voluntary reporting of rare, severe, or unusual reactions remains crucial to enhance the safe use of pharmaceutical agents.

KEY REFERENCES

Full reference list available at www.DIGM8.com

DVD contains references and additional content

11. Eshki M et al: Twelve-year analysis of severe cases of drug reaction with eosinophilia and systemic symptoms. *Arch Dermatol* **145**:67-72, 2009
14. Khan D, Solensky R: Drug allergy. *J Allergy Clin Immunol* **125**:S126-S137, 2010
39. Mockenhaupt M: Severe drug-induced skin reactions: Clinical pattern, diagnostics and therapy. *J Dtsch Dermatol Ges* **7**:142-160, 2009
53. Justiniano H, Berlingeri-Ramos A, Sanchez J: Pattery analysis of drug-induced skin diseases. *Am J Dermatopathol* **30**:352-369, 2008

Chapter 42 :: Pityriasis Rosea

:: Andrew Blauvelt

PITYRIASIS ROSEA AT A GLANCE

- Common acute papulosquamous eruption normally lasting 4–10 weeks.
- Most often begins as a single 2- to 4-cm thin oval plaque with a fine collarette of scale located inside the periphery of the plaque ("herald patch").
- Similar-appearing, but smaller, lesions appear several days to weeks later, typically distributed along the lines of cleavage on the trunk ("Christmas tree" pattern).
- Usually asymptomatic, sometimes pruritic with mild flu-like symptoms.
- Occurs most commonly in teenagers and young adults.
- Probably a viral exanthem associated with reactivation of human herpes virus (HHV)-7 and sometimes HHV-6.
- Treatment is usually supportive, although midpotency topical corticosteroids can reduce pruritus; high-dose acyclovir for 1 week may hasten recovery.

The term *pityriasis rosea* (PR) was first used by Gibert in 1860 and means pink (rosea) scales (pityriasis).[1] PR is a common acute, self-limited skin eruption that typically begins as a single thin oval scaly plaque on the trunk ("herald patch") and is typically asymptomatic. The initial lesion is followed several days to weeks later by the appearance of numerous similar-appearing smaller lesions located along the lines of cleavage of the trunk (a so-called *Christmas tree* pattern). PR most commonly occurs in teenagers and young adults, and is most likely a viral exanthem associated with reactivation of human herpes virus 7 (HHV-7) and sometimes HHV-6,[2–5] the viruses responsible for rubeola (see Chapter 192). Possible treatment may focus on associated pruritus. One study suggests that administration of high-dose acyclovir for 1 week, if initiated early in the disease course, hastens recovery from PR.[6]

EPIDEMIOLOGY

PR is reported in all races throughout the world, irrespective of climate.[7–9] The average annual incidence at one center was reported to be 0.16% (158.9 cases per 100,000 person-years).[9] Although PR is usually considered to be more common in the spring and fall months in temperate zones, seasonal variation has not been borne out in studies performed in other parts of the world. Clustering of cases can occur and has been used to support an infectious etiology for PR, although this is not a consistent feature observed in all communities.[8] Most studies have shown a slight female preponderance of approximately 1.5:1.[7,9] PR most commonly occurs between the ages of 10 and 35 years.[9] It is rare before age 2 years and after age 65 years. Recurrences of PR are rare, which suggests lasting immunity after an initial episode of PR.

ETIOLOGY AND PATHOGENESIS

Historically, PR has been considered to be caused by an infectious agent, given (1) the resemblance of the rash to known viral exanthems; (2) rare recurrences of PR that suggest lifelong immunity after one episode; (3) occurrence of seasonal variation in some studies; (4) clustering in some communities; and (5) the appearance of flu-like symptoms in a subset of patients. Numerous studies over the past 50 years have explored various pathogens as possible causes of PR. These pathogens have included bacteria, fungi, and, most notably, viruses. Beginning with a study by Drago and colleagues in 1997,[2] most recent PR etiologic and pathogenic studies have been focused on two ubiquitous viruses: (1) HHV-7 and (2) HHV-6. Critical evaluation of the medical and scientific literature on PR reveals neither credible nor reproducible evidence that PR is associated with any pathogen other than HHV-7 and HHV-6.[10]

Indeed, the best scientific evidence suggesting that PR is a viral exanthem associated with reactivation of either HHV-7 or HHV-6 (and sometimes with both viruses) is strong.[2–5,11–13] The most definitive and compelling study on HHVs and PR was by Broccolo and colleagues in 2005.[4] Using sensitive and quantitative techniques, investigators have collectively shown that (1) HHV-7 DNA, and less commonly HHV-6 DNA, can be readily detected in cell-free plasma or serum samples from many patients with PR, but not in serum or plasma from healthy individuals or patients with other inflammatory skin diseases; (2) HHV-7 messenger RNA and protein, and less commonly HHV-6 messenger RNA and protein, can be detected in scattered leukocytes found in perivascular and perifollicular regions within PR lesions, but not in normal skin or skin from patients with other inflammatory skin diseases; (3) HHV-7- and HHV-6-specific immunoglobulin (Ig) M antibody elevations in the absence of virus-specific IgG antibodies do not occur in PR patients, whereas in primary viral infections elevation of IgM antibodies alone is typical; and (4) HHV-7 and HHV-6 DNA are present in saliva of individuals with PR, which is not observed in those with a primary infection with these viruses. Taken together, these data strongly suggest that PR is

a viral exanthem associated with systemic reactivation of HHV-7 and, to a lesser extent, HHV-6. Patients are viremic, which may explain associated flu-like symptoms in some patients, and they generally do not have infected epithelial cells or large viral loads within skin lesions, which explains the difficulty in detecting these viruses by electron microscopy and by nonnested polymerase chain reaction testing.

Despite these findings, there is still controversy over the role of HHV-7 and HHV-6 in the etiology of PR, because a number of studies with "negative" results have failed to support a causative role for HHV-7 and HHV-6 in this disease.[14–16] Whereas the studies with positive results have used the most sensitive, specific, and calibrated techniques for virologic studies and reports have been published in high-quality journals, the studies with negative results either used laboratory methods that were not particularly sensitive, calibrated, or quantifiable, or focused on peripheral blood mononuclear cells rather than cell-free plasma or serum.

Correct interpretation of the recent viral literature on PR also requires proper understanding of the biology of HHV-7 and HHV-6. HHV-7 and HHV-6 are closely related β-herpes viruses, and the clinical diseases and biology associated with this group of HHVs are not as well studied as those of the α-herpes viruses (herpes simplex virus 1 and 2, varicella-zoster virus) and the γ-herpes viruses (Epstein–Barr virus and Kaposi sarcoma-associated herpes virus). HHV-6 and HHV-7 are ubiquitous, with 90% of the US population infected with HHV-6 by the age of 3 years[17] and 90% of the US population infected with HHV-7 by the age of 5 years.[18] Unlike the α-herpes viruses, HHV-7 and HHV-6 do not infect keratinocytes, but instead infect $CD4^+$ T cells within blood and are retained within these cells in a latent form in most individuals.[10,17–19] These cells are the likely source of cell-free viral DNA found in plasma or serum samples of patients with PR. They are also the likely source of the scattered perivascular and perifollicular virus-positive cells observed within some lesions of PR.[3,4]

It is important to note that the concept that PR represents a reactive viral exanthem containing few infected cells within skin lesions and viral reactivation within circulating blood $CD4^+$ T cells is perfectly analogous to that of the disease roseola, which is well accepted to be caused by primary infection with either HHV-6 or HHV-7[20,21] (see Chapter 192). Children with roseola are viremic and skin lesions generally do not contain infected cells.[22] Complete understanding of the role of HHV-7 and HHV-6 in the pathogenesis of PR is lacking at this time. For example, the mechanisms by which HHV-7 and HHV-6 are reactivated are unknown. As well, the characteristic distribution of lesions and differences in lesional and nonlesional skin are unexplained.

CLINICAL FINDINGS

HISTORY

In classic PR, patients usually describe the onset of a single truncal skin lesion followed several days to weeks later by the onset of numerous smaller lesions on the trunk. Pruritus is severe in 25% of patients with uncomplicated PR, slight to moderate in 50%, and absent in 25%. In a minority of patients, flu-like symptoms have been reported, including general malaise, headache, nausea, loss of appetite, fever, and arthralgias.

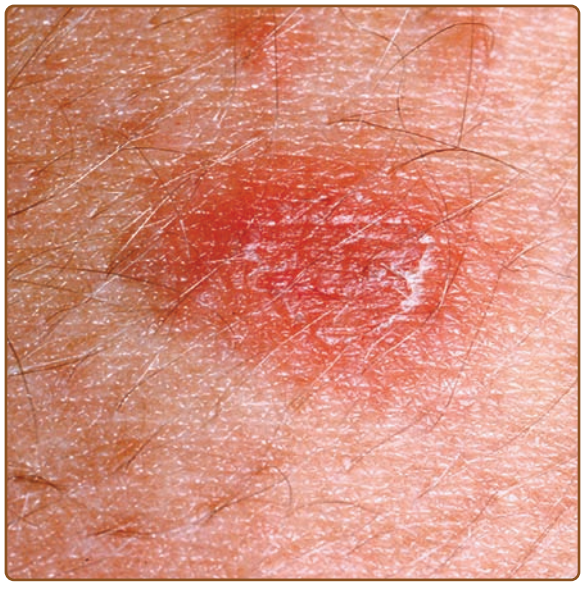

Figure 42-1 A typical primary plaque (herald patch) of pityriasis rosea, demonstrating an oval shape and fine scale inside the periphery of the plaque.

CUTANEOUS LESIONS

The primary plaque of PR, or herald patch (Figs. 42-1–42-3 and see eFigs. 42-3.1 and 42-3.2 in online edition), is seen in 50%–90% of cases. It is normally well demarcated; 2–4 cm in diameter; oval or round; salmon



Figure 42-2 A nonscaly purpuric primary plaque (herald patch) of pityriasis rosea.



Figure 42-3 A double herald patch of pityriasis rosea.

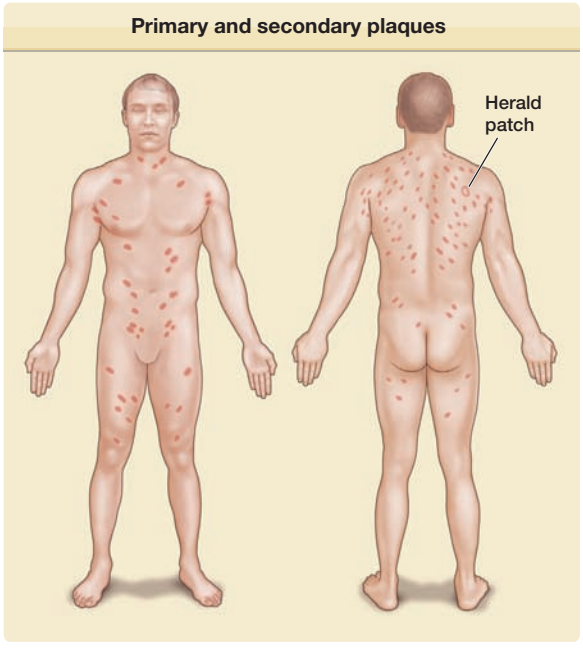

Figure 42-4 Schematic diagram of the primary plaque (herald patch) and the typical distribution of secondary plaques along the lines of cleavage on the trunk in a Christmas tree pattern.

colored, erythematous, or hyperpigmented (especially in individuals with darker skin); and demonstrates a fine collarette of scale just inside the periphery of the plaque. When the plaque is irritated, it may have an eczematous papulovesicular appearance (eFig. 42-3.3 in online edition). The primary plaque is usually located on the trunk in areas covered by clothes, but sometimes it is on the neck or proximal extremities. Localization on the face or penis is rare. The site of the primary lesion does not differ between males and females.

The interval between the appearance of the primary plaque and the secondary eruption can range from 2 days to 2 months, but the secondary eruption typically occurs within 2 weeks of the appearance of the primary plaque. At times, the primary and secondary lesions may appear at the same time. The secondary eruption occurs in crops at intervals of a few days and reaches its maximum in approximately 10 days. Occasionally, new lesions continue to develop for several weeks. The symmetric eruption is localized mainly to the trunk and adjacent regions of the neck and proximal extremities (Fig. 42-4). The most pronounced lesions extend over the abdomen and anterior surface of the chest as well as over the back (Figs. 42-5–42-7 and eFigs. 42-7.1 and 42-7.2 in online edition). Lesions distal to the elbows and knees can occur. Two main types of secondary lesions occur: (1) small plaques resembling the primary plaque in miniature, aligned with their long axes along lines of cleavage and distributed in a Christmas tree pattern, and (2) small, red, usually nonscaly papules that gradually increase in number and spread peripherally. The two types of lesions may coexist.

In approximately 20% of patients, the clinical picture diverges from the classic one described above. The primary plaque may be missing or present as double or multiple lesions (Fig. 42-3 and see eFig. 42-3.1 in online edition), often close together. The primary plaque may be the sole manifestation of the disease or only one of the two lesions (eFig. 42-3.2 in online edition). The distribution of the secondary eruption may be exclusively peripheral. Facial and scalp involvement occurs more commonly in black children. Localized forms of disease may involve

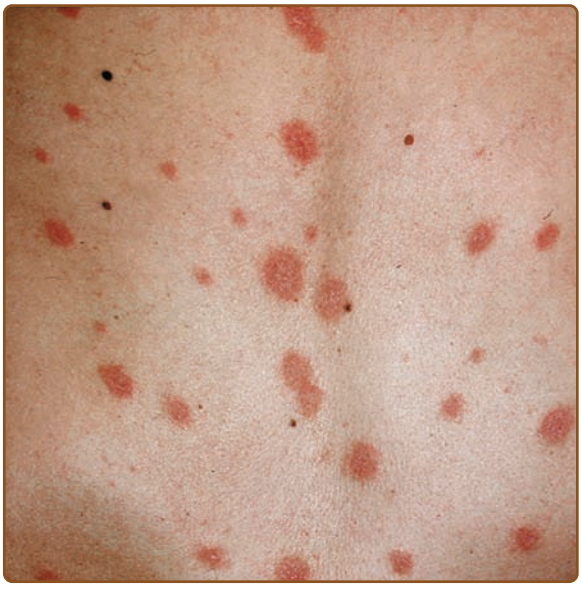

Figure 42-5 Typical distribution of secondary plaques along the lines of cleavage on the back in a Christmas tree pattern.



Figure 42-6 Typical distribution of secondary plaques along the lines of cleavage on the chest of a black individual.

certain body regions such as the palms, soles, axillae, vulva, and groin (eFigs. 42-3.3 and 42-7.1 in online edition) and also may be localized to one side of the body.

The morphology of the secondary lesions may also be atypical, and in these cases, the diagnosis of PR can be more challenging. Macules lacking scales may occur, papules may be follicular, and typical plaques may be absent or resemble psoriasis (eFig. 42-7.3 in online edition). The palms and soles are involved at times, and the clinical picture in these patients may simulate a widespread eczematous eruption. A vesicular type of PR (eFig. 42-3.3 in online edition) uncommonly affects children and young adults. Urticarial, pustular, purpuric (Fig. 42-2 and eFig. 42-7.4 in online edition), and erythema multiforme-like variants of PR also exist. Many patients will have classic PR plaques admixed with the atypical vesicles, follicular papules, and purpura.



Figure 42-7 Vesicular pityriasis rosea, showing typical primary plaque and secondary papulovesicles. Note Christmas tree distribution.

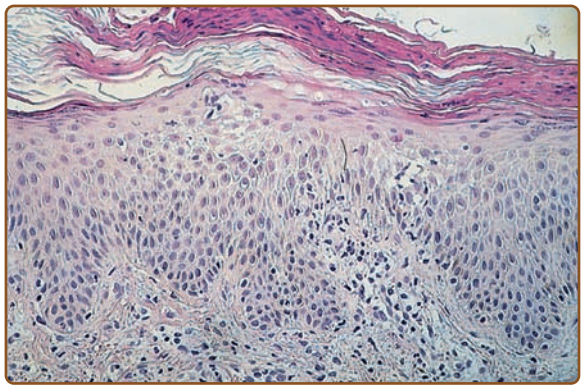

Figure 42-8 Typical nonspecific histologic features of pityriasis rosea, including patchy parakeratosis, absence of a granular cell layer, slight acanthosis, spongiosis, and a lymphohistiocytic infiltrate in the superficial dermis.

RELATED PHYSICAL FINDINGS

In rare cases enanthema may occur with hemorrhagic macules and patches, bullae on the tongue and cheeks, or lesions that resemble aphthous ulcers. Nail dystrophy after PR has also been reported. Lymphadenopathy may occur in patients with PR, especially early in the course of the disease and in association with flu-like symptoms.

In cases of classic PR, most patients do not require skin biopsies because the diagnosis is straightforward on clinical grounds and the histologic findings are nonspecific. Typical histopathologic features include focal parakeratosis, a reduced or absent granular cell layer, mild acanthosis, mild spongiosis, papillary dermal edema, a perivascular and superficial dermal interstitial infiltrate of lymphocytes and histiocytes, and focal extravasation of erythrocytes (Fig. 42-8).[23,24] Similar histologic findings are observed in both primary and secondary plaques. The histologic picture is indistinguishable from that of superficial gyrate erythema. In older lesions, the perivascular infiltrate is often both superficial and deep, with less spongiosis and more pronounced acanthosis. These late lesions may be difficult to distinguish from psoriasis and lichen planus.

LABORATORY TESTS

Routine blood studies usually give normal results and are not recommended. However, leukocytosis, neutrophilia, basophilia, lymphocytosis, and slight increases in erythrocyte sedimentation rate and levels of total protein, α_1- and α_2-globulins, and albumin have been reported.

DIFFERENTIAL DIAGNOSIS

(Box 42-1)

Secondary syphilis may present with slightly scaly lesions and can mimic papular PR with no primary plaque. Mucosal lesions and lymphadenopathy may occur in both PR and syphilis, but as with involvement of the palms and soles, these findings are much more common in the latter. Serologic tests for syphilis will differentiate the two. Tinea corporis may resemble PR, especially when PR occurs as only a primary plaque or when it is localized to the groin area. Scaling will be at the periphery of the plaques in tinea corporis as opposed to inside the periphery of plaques in PR. Mycologic investigation is often necessary to rule out dermatophyte infection. The lesions of nummular dermatitis are usually round, not oval, and pinpoint papules and vesicles are more prominent than in PR. Guttate psoriasis may be difficult to distinguish from PR when only a few lesions are present, when lesions follow lines of cleavage, and when the disease course is chronic. Histologic examination may be useful in these cases. Pityriasis lichenoides chronica may present with a Christmas tree pattern on the trunk, but as a rule, typical lesions will be found on the extremities.

Many drugs have been reported to cause PR-like rashes. Thus, it is always important to obtain a drug history to investigate this possibility. These include arsenic, barbiturates, bismuth, captopril, clonidine, gold, interferon-α, isotretinoin, ketotifen, labetalol, organic mercurials, methoxypromazine, metronidazole, omeprazole, D-penicillamine, salvarsan, sulfasalazine, terbinafine, lithium, and tripelene amine hydrochloride. Of note, more recent additions to this list include imatinib,[25] a drug used in the treatment of chronic myeloid leukemia, and tumor necrosis factor (TNF)-α blockers used to treat psoriasis.[26,27] Drug-induced PR may closely resemble classic PR, but it often shows atypical features, a protracted course, large lesions, subsequent marked hyperpigmentation, and transformation to lichenoid dermatitis.

BOX 42-1 DIFFERENTIAL DIAGNOSIS OF PITYRIASIS ROSEA (PR)

- *Secondary syphilis:* history of primary chancre, no herald patch is present, lesions typically involve palms and soles, condyloma lata may be present, usually more systemic complaints and lymphadenopathy, presence of plasma cells on histology, positive serologic test for syphilis [e.g., a Venereal Disease Research Laboratory (VDRL) test].
- *Tinea corporis:* scale is usually at periphery of plaques, plaques usually not oval and distributed along lines of cleavage, positive KOH examination.
- *Nummular dermatitis:* plaques usually circular and not oval, no collarettes of scale, tiny vesicles common. When in doubt, perform a biopsy.
- *Guttate psoriasis:* plaques usually smaller than PR plaques and do not follow lines of cleavage, scales are thick and not fine. When in doubt, perform a biopsy.
- *Pityriasis lichenoides chronica:* longer disease course, smaller lesions, thicker scale, no herald patch, more common on extremities. When in doubt, perform a biopsy.
- *PR-like drug eruption:* see text for extensive list. When in doubt, obtain a drug history.

COMPLICATIONS

Patients may experience flu-like symptoms, but these are relatively mild if they occur. About one-third of patients with PR experience significant levels of anxiety and depression, mostly centered around uncertainty over the cause of the disease and the length of disease recovery.[28] Reassurance is important for these individuals. No serious complications occur in otherwise healthy PR patients. However, PR during pregnancy is of concern. In one series of 38 pregnant women with PR, Drago and colleagues reported nine premature deliveries, although all babies born to women who had PR during their pregnancy showed no birth defects.[29] Five women had miscarriages, which was most common in the first trimester. Thus, pregnant women who develop PR should warrant careful evaluation and follow-up.

PROGNOSIS AND CLINICAL COURSE

All patients with PR have complete spontaneous resolution of their disease. The disease duration normally varies between 4 and 10 weeks, with the first few weeks associated with the most new inflammatory skin lesions and the greatest likelihood of flu-like symptoms. Both postinflammatory hypopigmentation and hyperpigmentation can follow PR. As with other skin diseases, this occurs more commonly in individuals with darker skin color, with hyperpigmentation predominating.[30] Treatment with ultraviolet light phototherapy may also worsen postinflammatory hyperpigmentation and should be used with caution. Otherwise, patients have no residual effects secondary to the occurrence of PR. Recurrent disease is possible, but it is rare.

TREATMENT

Because PR is self-limited, there is no need to treat uncomplicated cases.[31] Patient education and reassurance is warranted in all cases. Midpotency topical corticosteroids may be used for symptomatic relief of pruritus. Interestingly, Drago and colleagues have

BOX 42-2 TREATMENT OF PITYRIASIS ROSEA

- For all patients, education about the disease process and reassurance.
- For patients with associated pruritus, topical corticosteroids.
- For patients early in the disease course who demonstrate associated flu-like symptoms and/or extensive skin disease, oral acyclovir 800 mg five times daily for 1 week (or equivalent acyclovir derivative) may hasten recovery from disease.
- For selected patients, phototherapy may be useful.

reported that patients given high-dose acyclovir (i.e., 800 mg five times daily for 1 week) experienced more rapid resolution of PR than patients treated with placebo for 1 week.[6] Specifically, 79% of 42 patients had complete resolution of PR within 2 weeks of starting acyclovir therapy, whereas 4% of 45 patients treated with placebo experienced resolution of their disease at 2 weeks. Although patients were blinded to the type of treatment they received, the trial was limited in that the investigators were not blinded and the patients were not randomly assigned to one of the two treatment groups. Given that acyclovir and its derivatives are relatively inexpensive and well-tolerated drugs, this form of therapy should be considered in PR patients presenting early in their disease course who demonstrate associated flu-like symptoms and/or extensive skin disease. Erythromycin was reported to be of benefit to patients with PR,[32] but clinical experience and more recent reports have not confirmed this initial result.[33–35] Some patients with PR may benefit from phototherapy,[36] although this should be used with caution given that it can increase the risk of postinflammatory hyperpigmentation after disease resolution (Box 42-2).

PREVENTION

There are no data on how PR can be prevented.

KEY REFERENCES

Full reference list available at www.DIGM8.com

DVD contains references and additional content

2. Drago F et al: Human herpesvirus 7 in pityriasis rosea. *Lancet* **349**:1367, 1997
3. Watanabe T et al: Pityriasis rosea is associated with systemic active infection with both human herpesvirus-7 and human herpesvirus-6. *J Invest Dermatol* **119**:793, 2002
4. Broccolo F et al: Additional evidence that pityriasis rosea is associated with reactivation of human herpesvirus-6 and -7. *J Invest Dermatol* **124**:1234, 2005
6. Drago F, Vecchio F, Rebora A: Use of high-dose acyclovir in pityriasis rosea. *J Am Acad Dermatol* **54**:82, 2006
10. Drago F, Broccolo F, Rebora A: Pityriasis rosea: an update with a critical appraisal of its possible herpesviral etiology. *J Am Acad Dermatol* **61**:303, 2009
29. Drago F et al: Pregnancy outcome in patients with pityriasis rosea. *J Am Acad Dermatol* **58**:S78, 2008

Chapter 43 :: Erythema Annulare Centrifugum and Other Figurate Erythemas

:: Walter H.C. Burgdorf

ERYTHEMA ANNULARE CENTRIFUGUM AT A GLANCE

- Clinical pattern of annular expanding erythematous rings, which enlarge rapidly, fade, and then disappear, as new lesions appear.
- Diagnosis of erythema annulare centrifugum is one of the exclusions.
- Superficial and deep variants can be separated clinically and histologically. Deep form is usually lupus tumidus or erythema migrans.

The figurate erythemas include a variety of eruptions characterized by annular and polycyclic lesions. Classification of this group has always been controversial; the literature abounds with contradictions, uncertainties, and a bewildering array of synonyms. Darier in 1916 was the first to use the term *erythema annulare centrifugum*[1] (EAC), although similar lesions had been described previously under other names. Table 43-1 lists the figurate erythemas and the differential diagnoses to consider.

EPIDEMIOLOGY

EAC is an uncommon disorder. No epidemiologic data are available. There are only three large series in the literature: (1) 66 cases identified clinically,[2] (2) 73 first

TABLE 43-1
Migratory Erythemas

Disorder	Key Features	
Erythema annulare centrifugum (EAC)	Slowly migrating lesions; often idiopathic.	This chapter
Erythema gyratum repens	Rapidly moving; usually cancer marker.	153
Erythema chronicum migrans	Annular lesions originating from tick bite; skin sign of Lyme borreliosis.	187
Lupus erythematosus	Most deep EAC is lupus tumidus. Annular lesions common in neonatal and subacute cutaneous LE; Ro/La antibodies should be sought; overlaps with Sjögren syndrome (especially in Asians).	155
Urticaria	Giant urticaria is often annular and migratory; patients have ordinary urticaria elsewhere and more pruritus.	38
Pityriasis rosea	Individual lesions closely resemble superficial EAC but pattern and course different	42
Bullous pemphigoid	Early lesions often urticarial and may be annular.	56
Erythema multiforme	Target lesions, usually acral, often mucosal disease; some lesions annular.	39
Dermatophyte infections and tinea versicolor	Many fungal infections are annular (ringworm); the scale contains hyphae or spores.	188
Psoriasis	Pustular and occasionally ordinary psoriasis may have annular lesions.	18
Erythema marginatum	Transient, rapidly spreading annular erythema; specific for rheumatic fever.	160
Necrolytic migratory erythema	Marker for glucagonoma; erosive perioral and acral lesions, but truncal lesions may be polycyclic.	153
Carrier state chronic granulomatous disease	Female carriers may have annular lupus erythematosus-like rash.	143
Hereditary lactate dehydrogenase M-subunit deficiency	Rare genodermatosis with annular erythematous and scaly lesions.	This chapter
Familial annular erythema	Extremely rare.	This chapter
Annular erythema of infancy	Many different disorders; must rule out neonatal lupus erythematosus.	This chapter

diagnosed histologically,[3] and (3) 90 carrying either a clinical or histological diagnosis.[4] EAC appears to have no predilection for either sex or for any age group.

ETIOLOGY AND PATHOGENESIS

Both the annularity and the peripheral spread of EAC have attracted speculation as to a possible mechanism. Most hypotheses have centered on interactions among inflammatory cells, their mediators, and ground substance as foreign antigens diffuse through the skin.[5,6]

While many possible triggers have been suggested, all are common problems and EAC is very rare, so a direct causality is impossible to prove. It is better to view EAC as idiopathic. In one series, 24 patients were closely evaluated, and in none of the cases was any definite cause found.[7] Suspected triggers include bacterial[8] and candidal[9] infections, autoimmune diseases,[10] menses,[11] pregnancy,[12] and even stress.[13] Although medications are often identified as causing EAC in case reports, none regularly induces such lesions. EAC may be coupled with malignant neoplasms, with the eruption disappearing after treatment of the tumor and often returning as the tumor recurs.[14–16] This paraneoplastic marker must be distinguished from metastatic tumors with an annular pattern.[17,18]

CLINICAL FINDINGS

HISTORY

The history is most important in exploring the differential diagnostic considerations. In general, the lesions are asymptomatic but may be cosmetically disturbing.

CUTANEOUS LESIONS

EAC presents as one or more lesions that begin as erythematous macules or urticarial papules and enlarge by peripheral extension to form ringed, arcuate, or polycyclic figures. They are usually asymptomatic. EAC has traditionally been divided into superficial and deep forms. In the superficial form, the bands have fine scales, which are more prominent on the inner aspect rather than the advancing edge. The lesions spread



Figure 43-1 Superficial erythema annulare centrifugum. A large annular plaque with trailing scale behind the advancing erythematous edge.



Figure 43-2 Superficial erythema annulare centrifugum. Multiple lesions, once again demonstrating scale. (Used with permission from Wilfried Neuse and Thomas Ruzicka, Düsseldorf, Germany.)

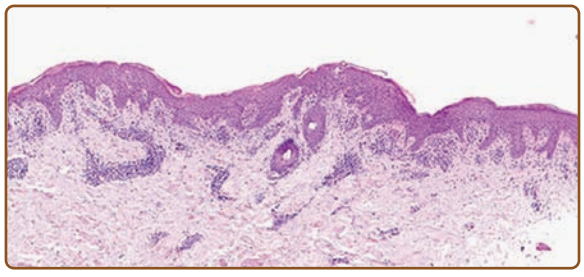

Figure 43-3 Superficial erythema annulare centrifugum showing perivascular lymphocytic infiltrates in papillary dermis. (Used with permission from Heinz Kutzner, Friedrichshafen, Germany.)

gradually to form large rings with central clearing, with the edges of the lesions often advancing several millimeters a day (Fig. 43-1 and Fig. 43-2). After a variable period of time, the lesions disappear, often to be replaced by new ones. In some cases annual recurrence has been described.

In the deep form of EAC, there is no scale and the rings are infiltrated (eFig. 43-2.1 and eFig. 43-2.2 in online edition); almost all these cases represent either lupus erythematosus or erythema migrans caused by infection with *Borrelia burgdorferi*.[4] A few may be drug-induced.

HISTOPATHOLOGY

Superficial EAC has epidermal changes of parakeratosis and spongiosis, with a superficial perivascular infiltrate (eFig. 43-2.1 in online edition, Figs. 43-3 and Fig. 43-4). There is minimal papillary dermal edema and no spongiosis. Thus, there are histological similarities to pityriasis rosea. The deep form has superficial and deep perivascular infiltrates (Fig. 43-5). Histopathology is important in excluding common differential diagnostic considerations; interface change or mucin helps identify lupus erythematosus; a plasma cell infiltrate suggests erythema chronicum migrans; and eosinophils are a possible clue to drug reactions.

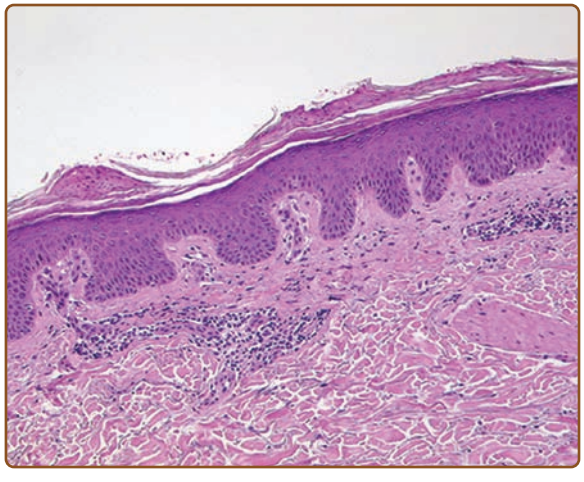

Figure 43-4 Higher view of superficial erythema annulare centrifugum with parakeratosis and focal spongiosis. (Used with permission from Heinz Kutzner, Friedrichshafen, Germany.)

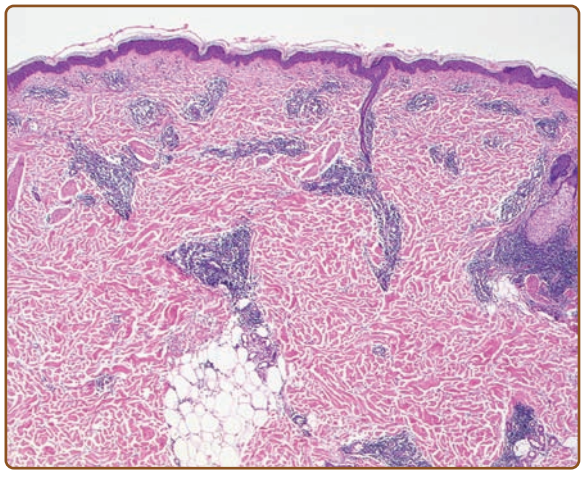

Figure 43-5 Deep erythema annulare centrifugum with normal epidermis and lymphocytic infiltrates about vessels of superficial and deep dermis. Many such lesions are lupus tumidus, so a careful search for mucin is mandatory. None is seen here. (Used with permission from Heinz Kutzner, Friedrichshafen, Germany.)

OTHER LABORATORY TESTS

There are no other laboratory tests diagnostic for EAC.

DIFFERENTIAL DIAGNOSIS

(Box 43-1)

The differential diagnostic challenge in EAC is multiple. First, one must exclude lupus erythematosus and erythema migrans. We view superficial EAC as a specific entity; the annular variants of diseases such as dermatophyte infections, psoriasis, urticaria, bullous diseases, leukocytoclastic vasculitis, secondary syphilis, and sarcoidosis are not EAC. While a relationship to chronic pityriasis rosea has been suggested,[4] there are so many clinical differences that we prefer not to make this association.

There also are a number of rare figurate erythemas that cause problems. Erythema gyratum repens, which is generally more rapidly moving, usually reflects an underlying malignancy (see Chapter 153). Annular erythemas are seen in the carrier state of chronic granulomatous disease or a lactate dehydrogenase M-subunit deficiency. Annular lichenoid dermatitis of youth is clinically similar. Familial EAC, originally described as erythema gyratum perstans, is rare. Finally, there is the broad spectrum of annular erythemas of infancy,[19] including neonatal lupus erythematosus, *Malassezia furfur* infections, and the idiopathic variants which themselves may show eosinophilic or neutrophilic infiltrates, as well as atrophy.

PROGNOSIS AND CLINICAL COURSE

EAC tends to be a chronic disease, which waxes and wanes.

BOX 43-1 DIFFERENTIAL DIAGNOSIS OF ERYTHEMA ANNULARE CENTRIFUGUM (EAC)

Most Likely

- Dermatophyte infections
- Tinea versicolor
- Erythema migrans
- Annular urticaria
- Lupus erythematosus
- Annular psoriasis

Consider

- Erythema multiforme
- Pityriasis rosea
- Granulomatous diseases (granuloma annulare, actinic granuloma, sarcoidosis)
- Bullous pemphigoid (urticarial phase)
- Leukocytoclastic vasculitis (especially in children)
- Erythema marginatum
- Erythema gyratum repens
- Necrolytic migratory erythema
- Hypereosinophilic syndrome
- Carrier state chronic granulomatous disease
- Hereditary lactase dehydrogenase M-subunit deficiency
- Familial annular erythema
- Annular erythemas of infancy

Always Rule Out

- Lupus erythematosus
- Lyme borreliosis
- Underlying tumor or annular metastasis

TREATMENT

Only symptomatic relief is available. Systemic glucocorticoids usually suppress EAC, but recurrence is common when these drugs are stopped. Systemic therapy with antipruritics may help. Topical vitamin D analogs, perhaps combined with ultraviolet irradiation, are another option.[20,21] Empiric use of antibiotic, antifungal, or anticandidal agents has sometimes been useful. Biologics may represent yet another option.[22]

KEY REFERENCES

Full reference list available at www.DIGM8.com

DVD contains references and additional content

2. Kim KJ et al: Clinicopathologic analysis of 66 cases of erythema annulare centrifugum. *J Dermatol* **29**:61, 2002
3. Weyers W, Diaz-Cascajo C, Weyers I: Erythema annulare centrifugum: Results of a clinicopathologic study of 73 patients. *Am J Dermatopathol* **25**:451, 2003

4. Ziemer M, Eisendle K, Zelger B: New concepts on erythema annulare centrifugum: A clinical reaction pattern that does not represent a specific clinicopathological entity. *Br J Dermatol* **160**:119, 2009
7. Mahood JM: Erythema annulare centrifugum: A review of 24 cases with special reference to its association with underlying disease. *Clin Exp Dermatol* **8**:383, 1983
10. Watkins S, Magill JM Jr, Ramos-Caro FA. Annular eruption preceding relapsing polychondritis: Case report and review of the literature. *Int J Dermatol* **48**:356, 2009
18. Patrizi A et al: Neutrophilic figurate erythema of infancy. *Pediatr Dermatol* **25**:255, 2008

Chapter 44 :: Granuloma Annulare

:: Julie S. Prendiville

GRANULOMA ANNULARE AT A GLANCE

- Relatively common disorder; exact prevalence is unknown; favors children and young adults.
- A localized ring of beaded papules on the extremities is typical; generalized, subcutaneous, perforating, and patch subtypes also occur.
- The cause is unknown, and the pathogenesis is poorly understood.
- Pathologic features consist of granulomatous inflammation in a palisaded or interstitial pattern associated with varying degrees of connective tissue degeneration and mucin deposition.
- Most cases resolve spontaneously within 2 years.

Granuloma annulare is a benign self-limited disease, first described by Colcott-Fox[1] in 1895 and Radcliffe-Crocker[2] in 1902.

EPIDEMIOLOGY

Granuloma annulare is a relatively common disorder.[3] It occurs in all age groups, but is rare in infancy.[3–5] The localized annular and subcutaneous forms occur more frequently in children and young adults. The generalized variant is more common in adults. Many studies report a female preponderance,[3] but some have found a higher frequency in males.[6] Granuloma annulare does not favor a particular race or geographic area, with the possible exception of the perforating type, which may be more common in Hawaii.[7]

Most cases of granuloma annulare are sporadic. Occasional familial cases are described with occurrence in twins, siblings, and members of successive generations.[3,8,9] Attempts to identify an associated HLA subtype have yielded disparate results in different population groups.[10,11]

ETIOLOGY AND PATHOGENESIS

The etiology of granuloma annulare is unknown, and the pathogenesis is poorly understood. Most cases occur in otherwise healthy children. A variety of predisposing events and associated systemic diseases is reported, but their significance is unclear. It is possible that granuloma annulare represents a phenotypic reaction pattern with many different initiating factors.[12]

PREDISPOSING EVENTS

Nonspecific mild trauma is considered a possible triggering factor because of the frequent location of lesions on the distal extremities of children. An early study of subcutaneous granuloma annulare found a history of trauma in 25% of children,[3] but this observation has not been replicated. Trauma is also a suspected factor in auricular lesions.[13] Granuloma annulare has occurred after a bee sting,[14] a cat bite,[15] and an octopus bite,[16] and insect bite reactions have also been implicated.[3] There is a report of perforating granuloma annulare in long-standing tattoos.[17] Widespread lesions have developed after waxing-induced pseudofolliculitis[18] and erythema multiforme minor,[19] and in association with systemic sarcoidosis.[3,20] Severe uveitis without other evidence of sarcoidosis has occurred in a few patients with granuloma annulare.[21,22,23]

INFECTIONS AND IMMUNIZATIONS. There are several reports of the development of granuloma annulare within herpes zoster scars, sometimes many years after the active infection.[24] It is also described after chickenpox.[25] Generalized, localized, and perforating forms of granuloma annulare may occur in association with human immunodeficiency virus (HIV) infection (see eFig. 44-0.1 in online edition).[26–31] Adenovirus was isolated from a lesion in one HIV-positive patient.[32] Epstein–Barr virus was excluded as a causative agent in these cases.[26,27] However, in other

instances generalized granuloma annulare has been linked to viral infections, including Epstein–Barr virus infection,[33] chronic hepatitis B,[34] and hepatitis C.[35] Vaccinations for tetanus,[36] diphtheria toxoid,[37] and hepatitis B vaccination[38] have been implicated as triggering factors, although vaccination sites were spared in one case of generalized granuloma annulare.[39]

Lesions compatible with granuloma annulare may occur in patients with active tuberculosis.[12] There are also reports of granuloma annulare after tuberculin skin tests[3] and Bacille Calmette-Guérin immunization.[40] Evidence of *Borrelia burgdorferi* infection was detected in two reports,[41,42] but this association was not confirmed in a serologic study.[43] A case in which chronic relapsing granuloma annulare flared during scabies infestation was attributed to the Koebner phenomenon.[44]

SUN EXPOSURE. Granuloma annulare with a predilection for sun-exposed areas[45–48] and seasonal recurrence[45] has been described. Photosensitive granuloma annulare has been observed in patients with HIV infection.[49] One patient developed generalized disease after psoralen plus ultraviolet A (UVA) light therapy,[50] but it is of note that phototherapy and psoralen/UVA phototherapy have also been used to treat generalized granuloma annulare.[51–54]

Actinic granuloma, also known as *annular elastolytic giant cell granuloma*, develops on photodamaged skin and is believed to represent a granulomatous reaction to actinic elastosis.[55] Its relationship to granuloma annulare is debated.

DRUGS. Granuloma annulare-like drug reactions are reported for gold therapy and treatment with allopurinol, diclofenac, quinidine, intranasal calcitonin, and amlodipine.[56]

An interstitial granulomatous drug reaction linked to the use of angiotensin-converting enzyme inhibitors, calcium channel blockers, and other medications is considered a distinct entity but may mimic granuloma annulare.[57–59]

DIABETES MELLITUS AND THYROID DISEASE. Development of granuloma annulare in patients with diabetes mellitus is extensively documented. Whether this is a true relationship has long been debated. The link is primarily with type 1 insulin-dependent diabetes,[60] but cases are also reported with type 2 noninsulin-dependent disease.[61–63] Localized[60] and generalized[46,63,64] as well as subcutaneous nodular[61,65,66] and perforating[5,7] forms of granuloma annulare have been observed. Granuloma annulare rarely predates the onset of diabetes.[60,66] The histopathologic similarity between granuloma annulare and necrobiosis lipoidica diabeticorum and the coexistence of both conditions in occasional diabetic patients[62] suggest a true association. However, most patients with granuloma annulare do not have diabetes mellitus. Studies attempting to establish a causal correlation have yielded conflicting results.[60,67,68]

Granuloma annulare has also occurred in a number of patients with thyroiditis, hypothyroidism, and thyroid adenoma.[64,69–72]

MALIGNANCY. An association between granuloma annulare and malignancy in adult patients is reported primarily with Hodgkin and non-Hodgkin lymphoma, including mycosis fungoides, Lennert lymphoma, B-cell disease,[73–76] T-cell leukemia/lymphoma,[77,78] and angioblastic T-cell lymphoma.[79] It is reported less commonly with myeloid leukemias[80] and with solid tumors, particularly of the breast.[46,73] The skin lesions of cutaneous lymphoma and other hematologic malignancies can mimic granuloma annulare both clinically and histopathologically.[81,82] It may be difficult to distinguish whether they represent true granuloma annulare with atypical lymphocytes, or cutaneous lymphoma obscured by a granulomatous infiltrate.[75,76]

PATHOGENETIC MECHANISMS

The pathogenetic mechanisms that result in foci of altered connective tissue surrounded by a granulomatous inflammatory infiltrate are not understood. Proposed mechanisms include (1) a primary degenerative process of connective tissue initiating granulomatous inflammation,[83] (2) a lymphocyte-mediated immune reaction resulting in macrophage activation and cytokine-mediated degradation of connective tissue,[30,84–88] and (3) a subtle vasculitis or other microangiopathy leading to tissue injury.[84]

CLINICAL FINDINGS

HISTORY

The typical history is of one or more papules with centrifugal enlargement and central clearing. These annular lesions are often misdiagnosed as tinea corporis and treated unsuccessfully with topical antifungal agents. Subcutaneous nodules may raise suspicion about malignancy or rheumatoid disease.[89]

Granuloma annulare is usually asymptomatic. Mild pruritus may be present, but painful lesions are rare.[90,91] Nodular lesions on the feet may cause discomfort from footwear.[92] Cosmesis is often a concern for adolescent and adult patients, particularly with generalized disease.

CUTANEOUS LESIONS

Clinical variants of granuloma annulare include the localized, generalized, subcutaneous, perforating, and patch types. Linear granuloma annulare,[93,94] a follicular pustular form,[95] and papular umbilicated lesions in children[96] have also been described. There is overlap between the different variants, and more than one morphologic type may coexist in the same patient.

LOCALIZED TYPE. The most common form of granuloma annulare is an annular or arcuate lesion. It may be skin colored, erythematous, or violaceous. It usually measures 1–5 cm in diameter.[3] The annular margin is firm to palpation and may be continuous or

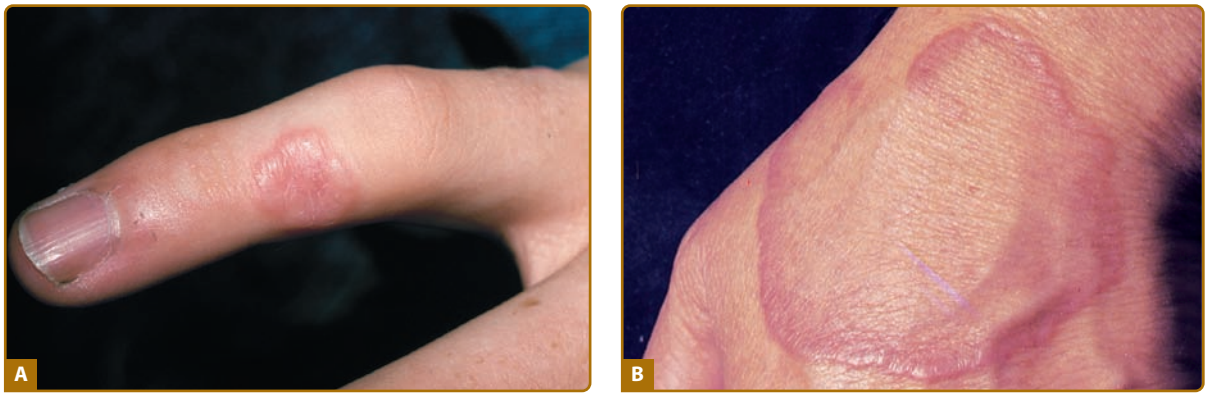

Figure 44-1 **A.** Typical annular lesion of granuloma annulare on a finger. **B.** A larger annular lesion of granuloma annulare on the dorsum of the hand.

consist of discrete or coalescent papules in a complete or partial circle (Fig. 44-1). The epidermis is usually normal, but surface markings may be attenuated over individual papules. Within the annular ring, the skin may have a violaceous or pigmented appearance. Solitary firm papules or nodules may also be present. Papular lesions on the fingers may appear umbilicated.

The dorsal hands and feet, ankles, lower limbs, and wrists are the sites of predilection (see Figs. 44-1 and 44-2). Less commonly, lesions occur at other sites, including the eyelids.[97] The palms and soles are occasionally involved.[90,91] Localized annular lesions may coexist with the subcutaneous or patch forms.

GENERALIZED TYPE. The generalized form of granuloma annulare is said to comprise 8%–15% of cases.[3,46] The majority of patients are adults, but it may also be seen in childhood.[46,98] Unlike in localized disease, the trunk is frequently involved, in addition to the neck and extremities. The face, scalp, palms, and soles may also be affected.[46]

Generalized granuloma annulare presents as widespread papules (Fig. 44-3A), some of which coalesce to form small annular plaques or larger discolored patches with raised arcuate and serpiginous margins (see Fig. 44-3B). Lesions may be skin colored, pink, violaceous, tan, or yellow. An annular or nonannular morphology may predominate.[46] A generalized form of perforating granuloma annulare has also been described.[5,7]



Figure 44-2 Localized granuloma annulare with nodule on the hand of a child.

SUBCUTANEOUS TYPE. The subcutaneous form of granuloma annulare occurs predominantly in children,[89,99,100] but is also described in adult patients.[101–103] It is characterized by firm to hard, usually asymptomatic nodules located in the deep dermis and subcutaneous tissues. They may extend to underlying muscle, and nodules on the scalp and orbit are often adherent to the underlying periosteum.

Individual lesions measure from 6 mm to 3.5 cm in diameter.[100,104] They are distributed most often on the anterior lower legs in a pretibial location.[99] Other sites of predilection are the ankles, dorsal feet, buttocks, and hands.[103,105] Nodules on the scalp,[104,106] eyelids,[107–109] and orbital rim[65,110,111] may present a diagnostic challenge. Subcutaneous granuloma annulare may also be found on the penis.[112–114]

PERFORATING TYPE. The perforating type of granuloma annulare is a rare variant characterized by transepidermal elimination of the necrobiotic collagen. It may be localized, usually to the dorsal hands and fingers (see eFig. 44-3.1 in online edition), or generalized over the trunk and extremities.[5,7] It has been described on the ears,[115] on the scrotum,[116] and within herpes zoster scars and tattoos.[16] Superficial small papules develop central umbilication or crusting, and there may be discharge of a creamy fluid. Lesions heal with atrophic or hyperpigmented scars. In one series, 24% of patients complained of pruritus and 21% of pain.[117] Papular umbilicated granuloma annulare on the hands of children[96] and a generalized follicular pustular type of granuloma annulare[95] may be clinical variants.

PATCH TYPE. Macular lesions that present as erythematous, red–brown, or violaceous patches without an annular rim are reported in adult women.[88,118] An arcuate dermal erythema is also observed. General-



Figure 44-3 **A.** Generalized granuloma annulare. Small papular lesions that are too small to exhibit annular configuration. **B.** Multiple annular lesions on the lower arm.

ized confluent erythema has been described in an HIV-positive patient.[30]

RELATED PHYSICAL FINDINGS

Most patients with granuloma annulare are healthy and have no other abnormal physical findings. Arthralgia is reported in association with painful lesions on the hands.[91] Granuloma annulare-like skin lesions and joint disease characterize a multisystem disorder described as interstitial granulomatous dermatitis with arthritis.[119]

Oral involvement was observed in one patient with HIV-associated disease.[27]

LABORATORY TESTS

A diagnosis of localized granuloma annulare is made on clinical examination, and further evaluation is rarely indicated. Biopsy to obtain a specimen for histopathologic examination is necessary when the presentation is atypical, when lesions are symptomatic, and when the diagnosis is otherwise in doubt. Histopathologic analysis may be required to confirm a diagnosis of generalized granuloma annulare or subcutaneous nodular disease on the head and orbital region.

HISTOPATHOLOGIC FINDINGS

The diagnosis is best made at low magnification. Changes are usually observed in the upper and middle dermis, although any part of the dermis or subcutis can be involved. The characteristic histopathologic finding is a lymphohistiocytic granuloma associated with varying degrees of connective tissue degeneration and mucin deposition. The inflammatory infiltrate may have a palisaded or interstitial pattern, or a mixture of both patterns.[120–122] Occasionally, a sarcoid-like pattern with large epithelioid histiocytes is seen.[120]

The typical appearance is of single or multiple foci of inflammation with a central core of altered collagen (necrobiosis) surrounded by a wall of palisaded histiocytes (Fig. 44-4). The necrobiotic centers are usually oval, slightly basophilic, devoid of nuclei, and marked by a loss of definition of the collagen bundles and diminished or absent elastic tissue fibers. Stains for mucin and lipid often give positive results.

An interstitial, nonpalisaded pattern of inflammation with histiocytes infiltrating among fragmented collagen bundles may be predominant, particularly in the generalized form. This interstitial pattern is also observed in the absence of apparent connective tissue change. Stains for mucin may be helpful in detecting connective tissue alteration within the infiltrate.

Lymphocytes are admixed with histiocytes in the granuloma and in a perivascular distribution. Multinucleated giant cells may be present but are not as numerous as in actinic granuloma.[123] Neutrophils and eosinophils are occasionally seen, but plasma cells are rare. Evidence of vascular reactivity includes variable endothelial cell swelling, red cell extravasation, fibrin, leukocytoclasis, and neutrophilic infiltration in blood vessel walls.[124] When leukocytoclastic vasculitis or nuclear debris is a prominent finding, a diagnosis of palisaded neutrophilic and granulomatous dermatitis of immune complex disease should be considered.[124]

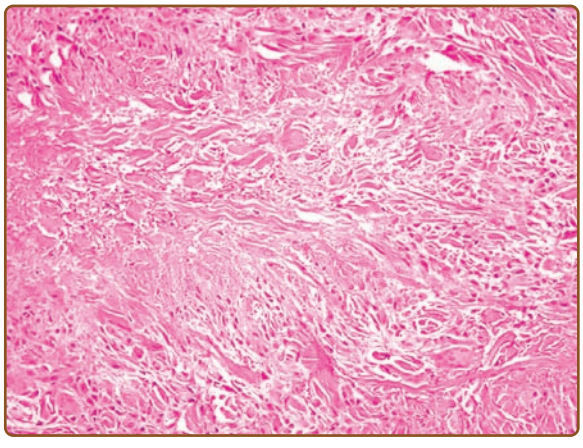

Figure 44-4 Palisading granulomatous inflammation surrounding degenerating collagen within the dermis. (Hematoxylin and eosin stain, ×200.) (Used with permission from Dr. Richard Crawford.)

In subcutaneous granuloma annulare the foci of necrobiosis are larger and lie within the deep dermis and subcutaneous fat. They may be distinguished from rheumatoid nodules by the presence of mucin in the necrobiotic zone.[107] Central ulceration and communication between the area of necrobiosis and the surface are characteristic of perforating granuloma annulare. Examination of serial sections may be necessary to demonstrate the necrobiotic plug. An interstitial pattern of inflammation with diffuse necrobiosis is reported in the patch type of granuloma annulare.[119] Palisaded granulomas have also been observed in macular lesions.[88]

Immunofluorescence testing may show deposition of fibrin, immunoglobulin (Ig) M, and C3 as a variable finding around vessel walls or at the basement membrane zone; IgM cytoid bodies are also reported.[119] Immunohistochemistry may be useful to confirm the histiocytic nature of equivocal disease.[125] Ultrastructural changes in the connective tissue and capillaries have been described.[83]

SPECIAL TESTS

A diagnosis of granuloma annulare is made clinically or by skin biopsy. Special investigations are usually not necessary. Further evaluation to rule out systemic disease such as infection, sarcoidosis, or malignancy may be required in atypical cases of granuloma annulare.[12,77,81,82,118] Investigation for endocrine disease is indicated if the patient has signs or symptoms of diabetes or thyroid dysfunction.

Imaging studies may be performed in subcutaneous granuloma annulare when the clinical features are not recognized or when the presentation is atypical with rapid enlargement or pain.[126] Radiographs show a nonspecific soft tissue mass without calcification

BOX 44-1 DIFFERENTIAL DIAGNOSIS OF GRANULOMA ANNULARE

ANNULAR TYPE

Consider

- Tinea corporis
- Subacute cutaneous lupus erythematosus
- Neonatal lupus erythematosus
- Annular lichen planus
- Acute febrile neutrophilic dermatosis
- Erythema chronicum migrans
- Actinic granuloma/annular elastolytic giant cell granuloma
- Necrobiosis lipoidica diabeticorum

Rule Out

- Infections (e.g., tuberculosis, atypical mycobacteria, syphilis)
- Interstitial granulomatous dermatitis with arthritis
- Interstitial granulomatous drug reaction
- Annular sarcoidosis
- Lymphoma

GENERALIZED TYPE

Consider

- Lichen planus
- Lichen nitidus
- Molluscum contagiosum

Rule Out

- Lichenoid and granulomatous dermatitis of acquired immunodeficiency syndrome
- Infections (e.g., tuberculosis, atypical mycobacteria, syphilis)
- Sarcoidosis
- Blau syndrome (familial granulomatous arthritis, skin eruption, and uveitis)
- Interstitial granulomatous drug reaction
- Lymphoma

SUBCUTANEOUS TYPE

Consider

- Erythema nodosum
- Dermoid cyst
- Rheumatoid nodules

Rule Out

- Epithelioid sarcoma
- Benign or other malignant tumors
- Deep infections

PERFORATING TYPE

Consider

- Molluscum contagiosum
- Insect bites
- Pityriasis lichenoides
- Perforating collagenosis and other perforating disorders
- Foreign body granuloma
- Papulonecrotic tuberculid
- Palisaded neutrophilic and granulomatous dermatitis of immune complex disease

PATCH TYPE

Consider

- Morphea
- Erythema annulare centrifugum
- Parapsoriasis

Rule Out

- Lymphoma

BOX 44-2 TREATMENT OPTIONS FOR GRANULOMA ANNULARE

- Await spontaneous resolution
- Apply topical corticosteroid with or without occlusion
- Administer intralesional triamcinolone 2.5 mg/mL[129]

ANECDOTAL REPORTS OF BENEFIT

- Topical
  - Tacrolimus 0.1% ointment[130]
  - Pimecrolimus cream[131]
  - Imiquimod 5% cream[132,133a]
- Intralesional
  - Interferon-γ[135]
  - Interferon-β[135]
  - Sterile water or saline[129]
- Systemic
  - Antimalarials[98]
  - Retinoids[136–140]
  - Antibiotics[141,142]
  - Corticosteroids[92,108]
  - Cyclosporine[77,143]
  - Zileuton with vitamin E[144]
  - Fumaric acid esters[145,146]
  - Hydroxyurea,[147] chlorambucil, niacinamide, potassium iodide, dapsone[3,46,92]
  - Etanercept[148b]
  - Infliximab[150b]
  - Efalizumab[151b]
  - Adalimumab[152–154]
- Other
  - Phototherapy[51–54]
  - Photodynamic therapy[155,156]
  - Skin biopsy[157]
  - Cryotherapy[158]
  - Pulsed dye, Nd:YAG or CO_2 laser[159–162]

[a]Application of 5% imiquimod cream has been reported to worsen granuloma annulare in a child.[134]
[b]Development of granuloma annulare has been reported during therapy with etanercept, infliximab, and adalimumab.[149]

or bone involvement. Ultrasonographic examination reveals a hypoechoic area in the subcutaneous tissues.[126,127] Magnetic resonance imaging shows a mass with indistinct margins, isointense or slightly hyperintense to muscle with T1-weighted images and with a heterogeneous but predominantly high signal intensity on T2-weighted images.[126,128]

DIFFERENTIAL DIAGNOSIS

See Box 44-1.

TREATMENT

The usual treatment options include awaiting spontaneous resolution, topical steroids and intralesional steroids. These and more anecdotal reports are summarized in Box 44-2.

CLINICAL COURSE AND PROGNOSIS

Most cases of localized granuloma annulare resolve spontaneously without sequelae. Lesions may clear within a few weeks or persist for several years. The majority disappear within 2 years.[92] Recurrent lesions may develop months or even years later, frequently at the same site. Generalized granuloma annulare often runs a more protracted course.[46] Perforating granuloma annulare results in scarring.[117] There are a number of reports of anetoderma or middermal elastolysis following generalized granuloma annulare and annular elastolytic giant cell granuloma.[47,163–166] One case of generalized granuloma annulare in a photosensitive distribution healed with scarring and milia formation.[167]

KEY REFERENCES

Full reference list available at www.DIGM8.com

DVD contains references and additional content

3. Muhlbauer JE: Granuloma annulare. *J Am Acad Dermatol* **3**:217, 1980
43. Halkier-Sorensen L, Kragballe K, Hansen K: Antibodies to the *Borrelia burgdorferi* flagellum in patients with scleroderma, granuloma annulare and porphyria cutanea tarda. *Acta Derm Venereol* **69**:116, 1989
83. Hanna WM, Moreno-Merlo F, Andrighetti L: Granuloma annulare: an elastic tissue disease? Case report and literature review. *Ultrastructural Pathol* **23**:33, 1999
84. Dahl MV: Speculations on the pathogenesis of granuloma annulare. *Australas J Dermatol* **26**:49, 1985
85. Mempel M et al: T-cell receptor repertoire and cytokine pattern in granuloma annulare: defining a particular type of cutaneous granulomatous inflammation. *J Invest Dermatol* **118**:957, 2002
86. Fayyazi A et al: Expression of IFNγ, coexpression of TNFα and matrix metalloproteinases and apoptosis of T lymphocytes and macrophages in granuloma annulare. *Arch Dermatol Res* **292**:384, 2000
100. Felner EI, Steinberg JB, Weinberg AG: Subcutaneous granuloma annulare: a review of 47 cases. *Pediatrics* **100**:965, 1997

SECTION 7

Disorders of Epidermal Differentiation and Keratinization

Chapter 45 :: Epidermal Stem Cells

:: Rebecca J. Morris

EPIDERMAL STEM CELLS AT A GLANCE

- The epidermis is a continually renewing tissue the function of which is maintained by a hierarchy of stem cells, transit amplifying cells, and terminally differentiating cells.
- In the proliferative hierarchy, stem cells have the highest proliferative potential.
- Epidermal stem cells may be identified by their functional characteristics, by distinctive cell cycle patterns, or by characteristic proteins.
- Epidermal stem cells usually exist in characteristic proliferative units with little lateral migration.
- The regulation of epidermal stem cells comprises complex pathways many of which are shared by embryonic, morphogenetic, and homeostatic processes.
- Epidermal diseases are associated with or may arise from proliferative dysfunction in the stem cell or transit amplifying cell compartments.
- Epidermal stem cells are attractive targets for cell and gene therapies.

The cutaneous epithelium is a continually renewing tissue maintained in a dynamic equilibrium of proliferation in the basal layer and loss through terminal differentiation from the suprabasal layers. This process is orchestrated with great elegance by a hierarchy of stem cells, transient amplifying cells, and terminally differentiating cells. These populations of cells work together to maintain lifelong tissue function and to bring about tissue repair. This chapter focuses on the role of stem cells and their identification in the epidermis.

CONCEPT OF STEM CELLS IN RENEWING TISSUES

Proliferation in the cutaneous epithelium begins with the stem cells.[1,2] Stem cells in this regard lack many characteristics of terminal differentiation, and have an intrinsically high proliferative potential relative to the other proliferating cells, but are generally capable of lifelong proliferation.[3] Upon division, a stem cell produces off one daughter that remains a stem cell, and one daughter that goes on to produce a series of transit amplifying cells that serve to magnify or amplify the stem cell's division resulting in the production of many differentiated cells with minimal input from the stem cell. This hierarchical system that usually involves decreasing proliferative potential is illustrated in Fig. 45-1. Stem cells typically interact with their surroundings in a supportive, protective niche.[1]

GENERAL METHODS FOR STEM CELL IDENTIFICATION AND ISOLATION

Stem cells may be studied by the presence or absence of proteins on their surface that distinguish them from other proliferative cells.[2] Such proteins may be internal, or more desirably, proteins on the cell surface that render the cells selective by various methods such as by magnetic bead separation or by fluorescence activated cell sorting (FACS).[2] Stem cells may also be studied by cellular kinetic characteristics such as in slowly cycling label-retaining[4] cells or through their patterns of mitotic activity.[5] Stem cells can sometimes be identified and isolated according to their special physical properties such as cell size or buoyant density,[6] or in conjunction with other properties such as in the so-called "side population" cells[7] that have active Abcg2 transporters. Candidate stem cells identified or isolated by any of these methods may then be characterized by functional tools such as in vitro colony forming assays,[8–10] or in an in vitro or in vivo skin reconstitution assay.[2]

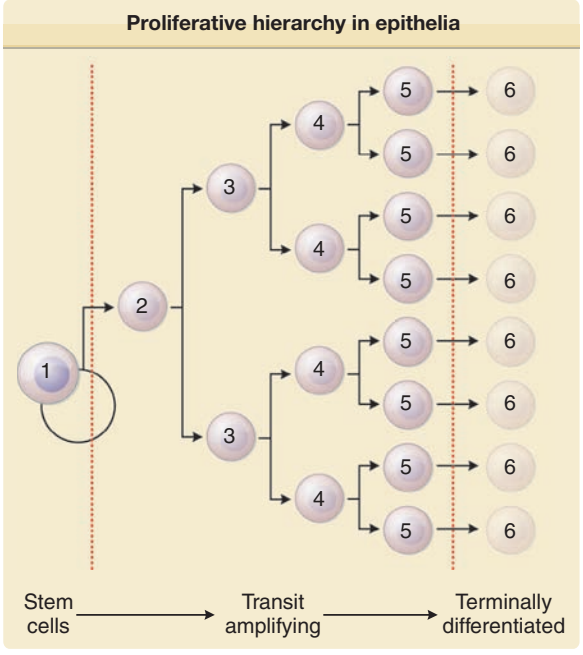

Figure 45-1 The proliferative hierarchy in epithelia: the stem cell concept. The ultimate progenitor cells are termed *stem cells*. They are slow cycling, long-lived, phenotypically undifferentiated, reside in specialized microenvironments, and constitute only a small percentage of the total epithelial cell population. Stem cell division produces transit amplifying or committed progenitor cells, which cycle rapidly and produce a clonal expansion of the offspring arising from an initial stem cell division. These cells eventually become the mature, terminally differentiated cells that constitute the bulk of a given epithelial population. Numbers indicate generation.

ASYMMETRIC DIVISION

The hierarchical model for cell proliferation in the cutaneous epithelium implies some degree of cellular, genetic, or population asymmetry.[3,11] The model of the stem cell hierarchy suggests a level of asymmetry that could be due to infrequent cell division or to chromosomal segregation.[3] As the stem cell mechanism is thought to provide protection for the tissue as well as the cellular DNA, Cairns[12,13] hypothesized that perhaps stem cells have a special mechanism for segregating their DNA and retaining an "immortal strand" at each division. Although there is some fairly convincing evidence that stem cells of the breast[14] and intestinal epithelium[15] may reserve an immortal DNA strand, recent investigation of the multipotential stem cells of the mouse hair follicles suggest that chromosome segregation does not occur.[16,17] Moreover, the Tumbar laboratory developed a method to trace the proliferation history of hair follicle bulge keratinocytes and thus provided direct evidence in support of the infrequent division model for these particular stem cells.[16]

LATERAL MIGRATION

Cellular proliferation and terminal differentiation in the epidermis are usually thought to occur in columns. However, lateral migration is common during wound healing where a tongue of proliferating epithelium migrates over denuded dermis and reestablishes an epithelium complete with vertical proliferative units and terminal differentiation.[18] In addition, Brash and colleagues have suggested that following irradiation of skin with ultraviolet light, clonal patches, each with its own *p53* mutation, might reflect epidermal cell proliferation and differentiation beyond the confines of single proliferative units.[19]

IDENTIFICATION OF STEM CELLS IN THE CUTANEOUS EPITHELIUM

Slowly cycling epidermal stem cells were first identified by of their cell kinetic behavior in the context of the epidermal proliferative units. Hence, Mackenzie identified mitotic basal keratinocytes beneath the edges of the hexagonal squames.[20] In vertical cross sections of skin, Christophers[21] had found that some basal cells in the shape of a hand mirror stained with a fluorescent dye characteristic of suprabasal cells. These studies were quantified by Potten in 1974[22] who called these units of structure epidermal proliferative units (EPUs). He focused on the central basal cells, noting that they were rarely mitotic and also rarely incorporated [3H]thymidine administered as a single pulse, and conjectured that the quiescent central cells might have stem cell activity whereas the peripheral cells may have transit amplifying cell activity. The next major advance in understanding the function of the EPU came with the identification of slowly cycling label-retaining cells in the center of the EPUs. Bickenbach[4] and later Bickenbach and Mackenzie,[23] Morris,[24] and Potten[25] found that administration of [3H]thymidine continuously for 3 days followed by a 4–8 week chase, could identify these central cells in light microscopic autoradiographs. Further characterization of the central stem cells and peripheral transit amplifying cells has been performed by a variety of in vivo and in vitro techniques.[2] The presence of EPUs in some areas of thin human skin has also been noted, and may be as large as 2 millimeters in diameter.[20] The EPU concept in skin is illustrated in Fig. 45-2.

The distribution of stem cells within the epidermis has been a subject of debate. Hence, Lavker and Sun[26] found that mitotic cells and cells that were rarely mitotic (putative stem cells) were located respectively in the upper and lower aspects of the rete ridges. These investigators postulated that the deeper cells were physically more protected than the superficial cells. In contrast, further studies have demonstrated that cells with stem cell characteristics in human epidermis can vary depending upon the site.[27] Ghazizadeh and Taichman[28] used retrovirally marked human epidermal keratinocytes followed by grafting onto athymic nude mice to visualize proliferative units in human skin. These studies found presumptive stem cells to be distributed throughout the epithelium.

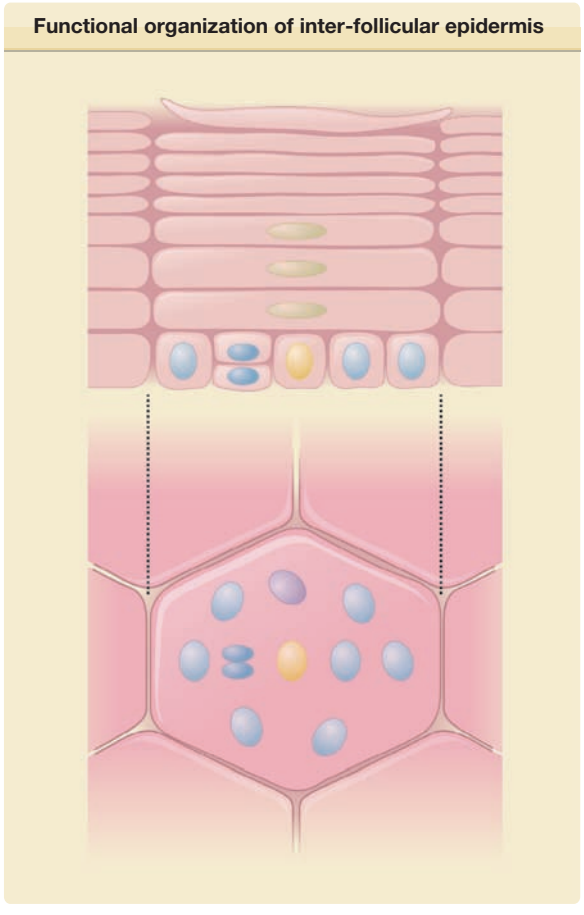

Figure 45-2 Functional organization of interfollicular epidermis: the epidermal proliferative unit (EPU) concept. Interfollicular epidermis of the skin of certain body sites is histologically organized into columns termed *EPUs*; each consists of approximately ten basal cells, including a single putative stem cell (*yellow*), its immediate transit-amplifying cell progeny (*blue*), and early-differentiating cells (*purple*). More differentiated keratinocytes (*green*) and then mature enucleated squames lie directly above them, in an ordered stack rising above the basal layer. EPUs represent functionally independent packets of self-renewing interfollicular epidermis that are ultimately dependent on a single putative stem cell for lifelong cell production. Constant self-renewal within the basal layer of skin compensates for the continual loss of differentiated squames from its surface. (Redrawn from Kaur P: Interfollicular epidermal stem cells: Identification, challenges, potential. *J Invest Dermatol* **126**:1452, 2006.)

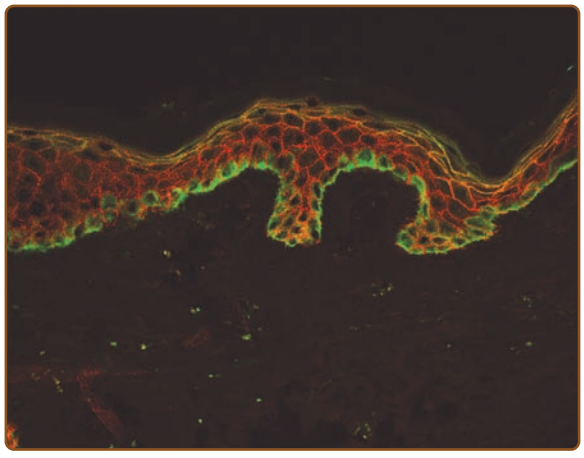

Figure 45-3 A confocal microscopic image of human scalp tissue stained for the EGFR (*red*) and LRIG1 (*green*). Immunostaining such as this has provided valuable information on the role and function of stem cells in the epidermis. The significance of these two markers is reported in Jensen KB, Watt FM: Single cell expression profiling of human epidermal stem and transit amplifying cells. LRIG1 is a regulator of stem cell quiescence. *Proc Natl Acad Sci USA* **103**:11958-11963, 2006 and Jensen KB et al: LRIG1 expression defines a distinct multipotent stem ell population in mammalian epidermis. *Cell Stem Cell* **4**:427-439, 2009. (Used with permission from Drs Kim Jensen and Fiona Watt.)

MARKERS AND SELECTABLE DETERMINANTS

Compared with the plethora of markers and selectable determinants for various hair follicle stem cells, few such markers have been identified in the epidermis. Notable exceptions are β-1 integrin,[10] CD71 (the transferrin receptor),[29] and LRIG1 (Fig. 45-3).[30] β-1 integrin is a cell adhesion molecule and can be used as a selectable determinant to enrich for keratinocytes that have a high proliferative potential in vitro and that can reconstitute a graft. Cells staining brightly with a fluorescently labeled antibody to β-1 integrin keratinocytes are found in human epidermis situated at the bottom of the rete ridges or atop the dermal papillae depending on the location of the skin. CD71 is expressed on all proliferating cells and can be used in conjunction with α-6 integrin (the external component of the hemidesmosomes present on epidermal basal cells) to enrich for a population that reacts with a fluorescently labeled antibody to α-6 integrin, but does not bind to fluorescently labeled CD71. This is enriched for epidermal keratinocytes that have in vitro and in vivo properties of stem cells. In the mouse, cells with this phenotype are located in the hair follicle bulge. LRIG1 is a marker of human interfollicular stem cells and helps to maintain stem cell quiescence.[30] In the mouse, LRIG1 immunoreactive cells are found in the hair follicle junctional zone between the sebaceous glands and the infundibulum.[31]

ALTERNATIVE MECHANISMS FOR REGULATING EPIDERMAL PROLIFERATION

The stem cell concepts presented above have not gone unchallenged. Clayton et al have studied clonal expansion in the mouse tail epidermis together with mathematical modeling.[32] These investigators conclude that the presence of stem cell/transit amplifying cell model in the tails is incompatible with a long-lived stem cell

population and a short-lived transit amplifying cell population. Moreover, this group infers that clones of two basal cells in the tail can adopt any of the three fates: (1) both cells can remain proliferative, (2) both can differentiate and exit the cycle, or (3) that one cell can remain proliferative and the other differentiates. Thus, epidermis from different sites may have different mechanisms for proliferation and terminal differentiation. At the present time, there are no reports of this model being applied to mouse dorsum or human epidermis from any site.

RELATIONSHIPS AMONG VARIOUS EPITHELIAL STEM CELL COMPARTMENTS

Cellular kinetic and labeling data suggest that there are multiple stem and progenitor compartments within the cutaneous epithelium. Under homeostatic conditions, these compartments are stable over intervals with essentially no interactions.[33] Hence, there are multiple proliferative units within the hair follicles: the infundibulum of the follicle, the bulge, the upper isthmus, and the sebaceous gland. The progeny of these follicular and sebaceous proliferative units all appear to be able to contribute to the repair of wounded epidermis.

REGULATION OF EPIDERMAL STEM AND TRANSIT AMPLIFYING CELLS

Identification and functional characterization of molecules regulating epidermal stem cells and transit amplifying cells is currently a subject of intense investigation.[34–37] Mediators under study comprise complex pathways often shared by embryonic, morphogenetic, and adult homeostatic and repair processes. Regulatory "switches"[34] include (1) stimuli that direct progenitor cells toward a particular type of terminal differentiation, (2) molecules and pathways characteristic of the niche and stem cell homeostasis, (3) molecules that differentially alter stem cell and transit amplifying cell proliferation, and (4) positive and negative regulators involved in commitment to terminal differentiation. Examples of such regulatory molecules are given in Table 45-1.

SKIN DISEASES ARISING FROM PROLIFERATIVE DYSFUNCTION

Skin cancer is thought to arise from aberrant proliferation of keratinocyte stem cells.[3,38] In this regard, a stem cell is a candidate for a tumor-initiating cell because of its long-term persistence in the tissue and because of its inherently high proliferative potential. The relationship between the epidermal stem cell and the so-called cancer stem cell is not known at the present time; however, current thinking is that the tissue stem cells, when corrupted, may become cancer stem cells that retain such stem cell properties as long-term self renewal, an ability to cast off transit amplifying cells, and production of terminally differentiated cells. Although stem cells are well protected against carcinogen-induced damage by virtue of being a rare and well-protected population, unlike the relatively short-lived transit amplifying cells, stem cells persist to endure the multiple mutations that lead to malignancy.

Psoriasis is thought to be an example of hyperproliferation of transit amplifying cells, which among inflammatory and dermal changes, is characterized by increased numbers of β-1 integrin dim cells in the suprabasal layers.[39] Additionally, markers of proliferation such as Ki67 and *C*-myc are upregulated.

TABLE 45-1
Examples of "Molecular Switches" that Direct Epidermal Stem Cell Behavior

Stimuli that Direct Progenitor Cells toward a Particular Type of Terminal Differentiation
■ Epithelial to hair follicle: Wnt/β-catenin; Negatively regulated by Dikk1 and Lef1/Tcf
■ Hair follicle stem cells to sebaceous cells: BLIMP1
Molecules and Pathways Characteristic of the Niche and Stem Cell Homeostasis
■ Maintenance of stem cell quiescence in hair follicles: NFATc1, Bmp6
■ Maintenance of stem cell quiescence in the epidermis: Lrig1
Molecules that Differentially Alter Stem Cell and Transit Amplifying Cell Proliferation
■ Stem cell to transit amplifying cell and stem cell renewal: Myc, p63, miR203 microRNA, histone modification
Positive and Negative Regulators Involved in Commitment to Terminal Differentiation
■ Basal to spinous transition and barrier function: turn off K5/K14 and turn on K1/K10
■ Pathways: Notch, MAPK, NFκ-B, p63, AP2 family, EGF receptor signaling
■ Negative regulators of terminal differentiation: extracellular matrix repression, PcG repression

Please see Blanpain C, Fuchs E: Epidermal homeostasis: A balancing act of stem cells in the skin. *Nat Rev Mol Cell Biol* **10**:207-217, 2009; Fuchs E: Finding one's niche in the skin. *Cell Stem Cell* **4**:499-502, 2009; and Watt FM, Jensen KB: Epidermal stem cell diversity and quiescence. *EMBO Mol Med* **1**:260-267, 2009 for more information and additional examples.

EPIDERMAL STEM CELLS AND CELL THERAPY

Epidermal stem cells can be cultivated and expanded in tissue culture.[8,40] This has led to an application of epidermal cells in cell therapy of burn victims. Hence, from a small biopsy from nonaffected skin, skin cells including stem cells can be expanded *ex vivo* and then reapplied to affected skin. The transplanted tissue "takes" to debrided skin regions and ultimately forms a new epithelium with the capacity to persist for many years. This application is now standard therapy in many burn units.[40] In the transplanted epithelium, it is noteworthy that epithelial appendages such as hair follicles, sebaceous glands, or eccrine glands are absent because techniques for in vitro morphogenesis of these tissues have not yet been developed. The lack of skin appendages in the grafted epidermis results in fragility as well as dryness due to lack of sebaceous glands, and poor thermoregulation due to lack of eccrine glands in the transplanted epithelium. These problems highlight the urgent need to develop in vitro methods to recapitulate embryonic morphogenesis of the cutaneous appendages. *Ex vivo* expanded epidermal keratinocytes are also used for treating ulcers and other chronic wounds.[41]

EPIDERMAL STEM CELLS AND GENE THERAPY

The accessibility of skin makes it an attractive target for gene therapy.[42] Here, one goal is to correct mutant genes in the stem cells *ex vivo* and transplant resulting normalized epithelium to patients.[42] Another goal is to correct defective expression of certain secreted proteins in skin stem cells and to apply the corrected epithelium to patients.[43] Although the use of epidermal cells including stem cells was proposed more than a decade ago, these applications still have not been developed for clinical practice. It is possible that the predilection of epidermis to develop into vertical proliferative units rather than to expand laterally precludes these applications. However, the field of gene therapy is still considered to be in its infancy, and identification and targeting of multipotential skin stem cells, as well identification of factors resulting in the lateral migration of epithelium during wound healing will increase therapeutic applications. Additionally, other related means of manipulating the keratinocytes such as siRNA show great promise.[44]

OUTLOOK

In this chapter, I have discussed general properties of epidermal stem cells and some of the techniques for studying them. In this regard, keratinocyte stem cells together with transit amplifying cells and terminally differentiating cells play a role in the normal turnover and repair of the epidermis. Additional studies, perhaps with novel approaches are needed for better identification of epithelial stem and transit amplifying cells. Especially, more investigation is needed for an understanding of the molecular "switches" that regulate stem cell and transit amplifying cell homeostases, fate determination, and repair mechanisms. Moreover, there is a great need for understanding stem cell targeting as well as the lateral migration in wound healing, as these are key questions in making cell and gene therapy a reality. Finally, it must be understood that there will never be a "pure" population of stem cells. Rather, each new marker or selectable determinant discovered, and each new functional assay developed is essential for ultimately designing new treatments for skin diseases and skin cancer.

KEY REFERENCES

Full reference list available at www.DIGM8.com

DVD contains references and additional content

1. Blanpain C, Fuchs E: Epidermal homeostasis: A balancing act of stem cells in the skin. *Nat Rev Mol Cell Biol* **10**:207-217, 2009
2. Kaur P: Interfollicular Epidermal stem cells: Identification, challenges, potential. *J Invest Dermatol* **126**:1450-1458, 2006
3. Lajtha L: Stem cell concepts. *Differentiation* **14**:23-34, 1979

13. Cairns J: Cancer and the immortal strand hypothesis. *Genetics* **174**:1069-1072, 2006
25. Potten CS: Cell cycles in cell hierarchies. *Int J Radiat Biol* **49**:257-258, 1986
34. Fuchs E: Finding one's niche in the skin. *Cell Stem Cell* **4**:499-502, 2009
35. Watt FM, Jensen KB: Epidermal stem cell diversity and quiescence. *EMBO Mol Med* **1**:260-267, 2009
38. Watt FM, Driskell RR: The therapeutic potential of stem cells. *Philos Trans R Soc London B Biol Sci* **365**:155-163, 2010
40. Green H: The birth of therapy with cultured cells. *BioEssays* **30**:897-903, 2008

Chapter 46 :: Epidermal Growth and Differentiation

:: Pierre A. Coulombe, Stanley J. Miller, & Tung-Tien Sun

EPIDERMAL GROWTH AND DIFFERENTIATION AT A GLANCE

- The interfollicular epidermis is maintained by a population of stem cells.
- Slow-cycling stem cells give rise to transit amplifying cells, which yield terminally differentiated cells.
- Abnormalities in epidermal stem cells may be involved in pathogenesis of skin cancers and other proliferative epidermal diseases.
- Epidermal differentiation is accompanied by orchestrated expression of keratins and subunits of cornified envelope.
- Keratins contribute to the mechanical stability and pliability of the epidermis.
- Mutations in major epidermal differentiation products are underlying causes of important skin diseases.

INTRODUCTION

Although thin, human skin is a marvelously resilient and multifunctional organ. It performs immunomodulatory and thermoregulatory functions, is involved in social, cultural, and reproductive behaviors, and provides broad protection against water loss and environmental insults such as trauma, infection, and exposure to radiation or chemicals. The outermost layer of skin, termed the epidermis, consists of a stratified squamous epithelium and its appendages, including hair follicles, sebaceous, apocrine, and eccrine glands. This chapter discusses epidermal differentiation, with the primary focus placed on keratin filaments that are formed as major structural elements within the epidermis. Defects in epidermal keratins are known to play key roles in a number of important blistering epidermal diseases. Additional major epidermal differentiation markers, including keratohyalin granules and the cornified envelope, are also discussed.

KERATINS AND EPIDERMAL DIFFERENTIATION

KERATINS AND THEIR CLASSIFICATION

Keratins (also known as cytokeratins) are structural proteins that belong to the superfamily of intermediate filament (IF) proteins. They are heterogeneous in size (40–70 kDa) and charge (pI 4.7–8.4), and notoriously insoluble. Sequencing the human genome revealed the presence of 54 functional keratin genes that are nearly perfectly conserved in other mammals.[1] The tremendous diversity of keratin genes had not been fully appreciated until the advent of database mining and genomics, and could not be accommodated in the original nomenclature system aptly devised by Roland Moll, Werner Franke and colleagues in 1982.[2] In 2006, an international effort culminated in a revised nomenclature (Table 46-1) that accommodates the newly discovered keratins, adheres to the guidelines of the Human and Mouse Gene Organization Gene Nomenclature Committee, and maintains the original designation of keratins devised by Moll and colleagues.[1]

Sequence homology and gene substructure (number and position of introns) reveal two distinct groups of keratins of roughly equal size, designated type I and II IF genes[1,3] (Fig. 46-1A). In *Homo sapiens*, functional type I and type II keratin genes are clustered on the long arms of chromosomes 17 (Fig. 46-1B) and 12 (Fig. 46-1C), respectively.[1,4] Keratin genes are highly conserved across mammals, at the level of their organization, structure, sequence, and regulation.[5] Mature filaments contain type I and II keratins in a 1:1 molar ratio.[3,6] This requirement underlies the coordinated transcription of type I and II keratin genes. Remarkably, most type I and II keratin genes are regulated in a pairwise, tissue type-related, and differentiation-related fashion.[7–9] This is illustrated particularly well in stratified epithelia such as epidermis (Fig. 46-2). Given their large number, differential regulation, and ease of detection (owing to abundance), keratin mRNAs and proteins represent unparalleled markers for staging the fate and differentiation of epithelial cells, under healthy and diseased conditions.

KERATIN PROTEINS FORM THE INTERMEDIATE FILAMENT NETWORK OF EPITHELIAL CELLS

Despite sequence differences, all keratins display the tripartite domain structure that is typical of IF-forming

TABLE 46-1
Human Keratins and Their Distribution[a]

Type I Keratins			Type II Keratins		
Old Name	**New Name**	**Main Site(s) of Expression**	**Old Name**	**New Name**	**Main Site(s) of Expression**
K9	K9	Epidermis (suprabasal)	K1	K1	Epidermis (suprabasal)
K10	K10	Epidermis (suprabasal)	K2e	K2	Epidermis (suprabasal)
K12	K12	Cornea	K3	K3	Cornea (suprabasal)
K13	K13	Oral mucosa	K4	K4	Oral mucosa (suprabasal)
K14	K14	Complex epithelia	K5	K5	Complex epithelia (basal layer)
K15	K15	Complex epithelia	K6a	K6a	Epithelial appendages
K16	K16	Epithelial appendages	K6b	K6b	Epithelial appendages
K17	K17	Epithelial appendages	K6e/h	K6c	Skin (needs confirm.)
K18	K18	Simple epithelia	K7	K7	Simple epithelia
K19	K19	Broad distribution	K8	K8	Simple epithelia
K20	K20	Gut epithelium			
K23	K23	Pancreas (needs confirm.)			
K24	K24	unknown			
K25irs-4	K25–K28	Inner root sheath (hair follicles)	K6irs1–4	K71–K74	Inner root sheath (hair follicles)
			K6hf	K75	Companion layer (hair follicles)
			K2p	K76	Oral mucosa
			K1b	K77	Sweat gland ducts
			K5b	K78	Tongue
			K6l	K79	Skin
			Kb20	K80	Tongue
Ha1–Ha8	K31–K38	Hair shaft (Hair follicle)	Hb1–Hb6	K81–K86	Hair shaft (hair follicles)
K39	K39	Hair shaft (Hair follicle)			
K40	K40	Hair shaft (Hair follicle)			

[a]Note: A revised keratin nomenclature has been published: see Schweitzer et al., *J Cell Biol* (2006).

proteins (Fig. 46-1D). The central domain consists of an extended α helix featuring long-range heptad repeats that mediate coiled-coil dimerization. This "rod" domain is ~310 amino acids long and is flanked by highly variable sequences at the *N*- terminal head and *C*-terminal tail domains (Fig. 46-1D).[3] Neither terminal domain exhibits known functional motifs other than the glycine loops seen in epidermal keratins.[10] The head and tail domains are readily protease-accessible at the surface of the filament, where they can foster interactions with neighboring filaments, other proteins, or serve as substrates for posttranslational modifications involved in their regulation.[11] Given their heterogeneity of size and primary structure, the head and tail domains are expected to make key contributions to the differential function and regulation of keratin proteins in vivo.[12]

The central rod domain of keratins is the main determinant of self-assembly, with important contributions from the head domain as well.[13] Assembly begins with the formation of heterodimers in which the α-helical central rod domains of type I and II keratins are aligned in parallel and perfect register. Heterodimers interact along their lateral surfaces and in an end-to-end fashion to give rise to the 10–12-nm wide filaments (Fig. 46-2A) which, depending on IF protein type and assembly conditions, may contain a variable number of subunits in cross section.[13] Mature IFs lack a structural polarity, a direct consequence of the antiparallel orientation of their constituent coiled–coiled dimers.

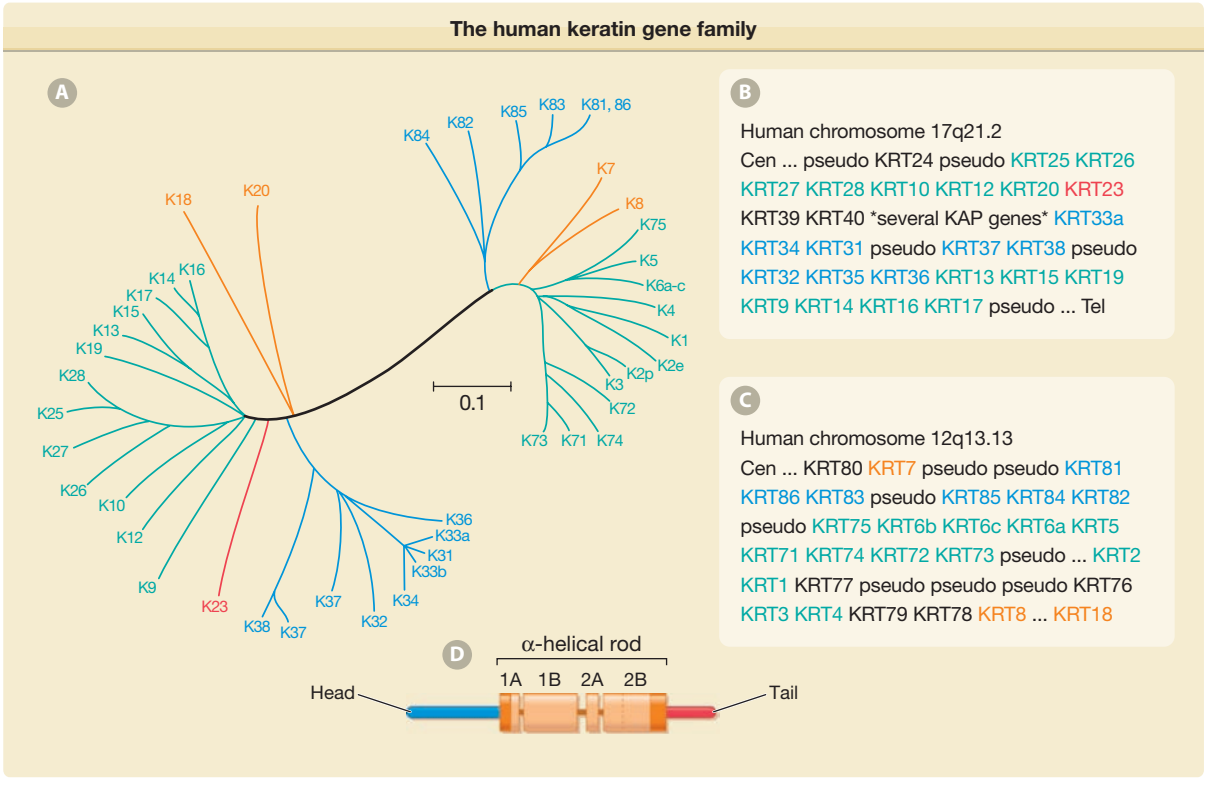

Figure 46-1 The human keratin gene family. **A.** Comparison of the primary structure of human keratins using the publicly available ClustalW and TreeView software. Sequence relatedness is inversely correlated with the length of the lines connecting the various sequences, and to the number and position of branch points. This comparison makes use of the sequences from the head and central rod domain for each keratin. A few keratins were left out for clarity purposes. Two major branches are seen in this tree display, corresponding to type I and type II sequences. Beyond this dichotomy, each subtype is further segregated into major subgroupings (denoted by different colors). **B.** Organization of functional type I keratin genes, all which are clustered on human chromosome 17, with the only exception being *K18* (see "*" in **C**), which is located at the telomeric (Tel) boundary of the type II gene cluster. (Cen = centromere.) A large number of genes encoding keratin-associated proteins (KAP) interrupts the type I gene cluster, between *KRT40* and *KRT33A*. [Pseudo = pseudogene (nonfunctional).] **C.** Organization of functional type II keratin genes, which are clustered on human chromosome 12. The *K8* and *K18* genes are separated by 450,000 bp. **D.** Schematic representation of the tripartite domain structure shared by all keratin and other IF proteins. A central α-helical "rod" domain acts as the major determinant of self-assembly. This rod domain is partitioned into subdomains 1A, 1B, 2A, and 2B, and flanked by nonhelical "head" and "tail" domains at the *N*- and *C*-termini, respectively. Both ends of the rod domain contain 15–20 amino acid regions (*red*) that are highly conserved among all IF proteins.

The extraordinary stability of keratin subunits reflects the tightness of interactions between type I and type II keratins.[14] Most of the intracellular pool of keratin proteins (>95%) is polymerized.[4] There is evidence that keratin IF assembly is initiated at the cell periphery, near the cortical F-actin cytoskeleton, in cultured epithelial cells.[15]

Keratins form the major IF network in all epithelial cells.[2,3,9] The abundance and organization of keratin IFs in vivo differ among epithelia. Keratin proteins are highly abundant (10%–80% of total cellular proteins) in surface-exposed stratified squamous epithelia (e.g., epidermis, oral mucosa, corneal epithelium, etc.).[7] In epithelial cells of such tissues, keratin IFs are organized in a pancytoplasmic network extending from the surface of the nucleus to the cytoplasmic periphery, where they are membrane-anchored at sites of cell–matrix and cell–cell adhesion (hemidesmosomes, desmosomes) (Fig. 46-2B). In simple epithelia (e.g., liver, gut, pancreas, etc.), keratins are less abundant. In such tissues, polarized epithelial cells often feature asymmetrically organized keratin IFs concentrated mostly at the cytoplasmic periphery and, particularly, the apical pole.[4] Several associated proteins contribute to the organization and regulation of keratin IFs in these various settings.[16] Some of these proteins promote the bundling of keratin IFs (e.g., filaggrin, trichohyalin), their association with microtubules and actin microfilaments (e.g., plectin, BPAG isoforms) and/or with desmosomes or hemidesmosomes (desmoplakin, plakophilin, BPAG isoforms, etc.) (Fig. 46-2). Other partners, for example, TRADD, 14–3-3, Akt, reflect the newly discovered participation of keratin IFs in signaling roles.[17]

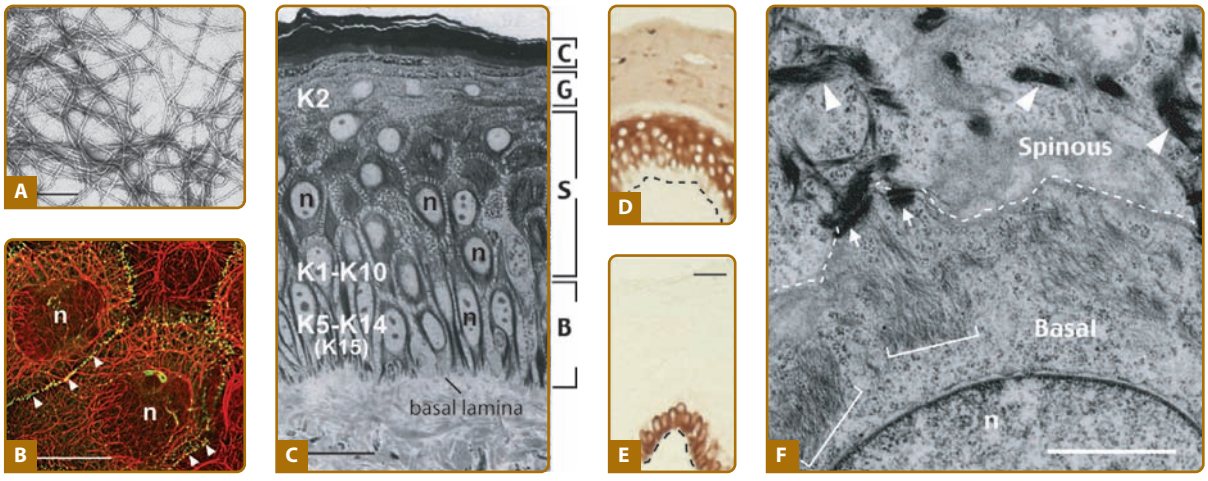

Figure 46-2 Keratin filaments and interfollicular epidermis. **A.** Visualization of filaments, reconstituted in vitro from purified human *K5* and *K14*, by negative staining and electron microscopy. (Bar = 150 nm.) **B.** Double-labeling for keratin (*red chromophore*) and desmoplakin, a desmosome component (*green chromophore*), by indirect immunofluorescence of human epidermal cells in culture. Keratin IFs are organized in a network that spans the entire cytoplasm and are attached at desmosomal cell–cell contacts (*arrowheads*) between cells. (n = nucleus; bar = ~50 µm.) [Micrograph used with permission from Dr Kathleen Green (Northwestern University).] **C.** Histological cross section of resin-embedded human trunk epidermis, revealing the basal (B), spinous (S), granular (G), and cornified (C) cell layers. (Bar = ~50 µm; n = nucleus.) **D** and **E.** Differential distribution of keratin epitopes on human skin tissue cross sections as visualized by an antibody-based detection method. **D.** *K10* is primarily concentrated in the differentiating, suprabasal layers of epidermis. **E.** *K14* occurs in the basal layer, where the epidermal progenitor cells reside. Dashed line indicates the basal lamina. (Bar = ~50 µm.) **F.** Ultrastructure of the boundary between the basal and suprabasal cells in mouse trunk epidermis, as seen by routine transmission electron microscopy. The sample, from which this micrograph was taken, is oriented in the same manner as frame **C**. Organization of keratin filaments as loose bundles correlates with the expression of *K5–K14* in basal cells (*brackets*), whereas the formation of denser, electron-dense filament bundles reflects the onset of *K1–K10* expression in early differentiating cells (*arrowheads*). Arrows point to desmosomes connecting the two cells. (Bar = 2 µm; n = nucleus.)

KERATIN GENE EXPRESSION MIRRORS EPITHELIAL DIFFERENTIATION: THE CASE OF EPIDERMIS

Skin provides a beautiful example of the tight relationship that has evolved between keratin gene regulation and epithelial differentiation. More than half of all known keratin genes are expressed in mature mammalian skin tissue alone. The architectural complexity of adult skin epithelia is achieved through a temporally and spatially regulated expression of keratin genes and a number of other epithelial differentiation-related genes.[7,18] In the clinical setting, keratin typing is often exploited in diagnosing cancer type, its differentiation status (and therefore prognosis), as well as the origin of the cells forming metastatic foci. This strategy is also applied for diseases other than cancer (see below).[4]

In "thin" interfollicular epidermis (e.g., trunk; Fig. 46-2), mitotically active cells of the basal layer act as progenitors, and consistently express *K5* and *K14* as their main keratin pair, along with low levels of *K15*. Onset of differentiation coincides with the appearance of the *K1/K10* pair through a robust transcriptional induction that occurs at the expense of the *K5/K14* genes, which are downregulated.[7,18] Accordingly, *K1/K10* keratins are readily detectable in the lowermost suprabasal layer of epidermis (Fig. 46-2D). The appearance of *K1* and *K10* correlates with a sudden and dramatic shift in the organization of keratin IFs, which now exhibit significant bundling.[19] Another type II gene, *K2e*, is expressed at a later stage of differentiation, i.e., the granular layer.[20]

The epidermis of palm and sole skin is specialized for resisting a high degree of mechanical stress, and thus is markedly thicker. This function is reflected in its architecture of alternating stripes of primary and secondary ridges,[21] and again, in keratin expression. In the thick, stress-bearing, primary ridges, the major differentiation-specific (type I) *K9* is presumed to foster a more resilient cytoskeleton. In the thinner secondary ridges, postmitotic keratinocytes preferentially express the (type II) *K6a* and (type I) *K16* and *K17*.[22] Relative to *K1*, *K9*, and *K10*, the properties of *K6a*, *K16*, and *K17* likely foster greater cellular pliability, thereby providing flexible "hinge" regions between the more rigid, *K1/K9*-rich primary ridges.[22] While this attractive model remains to be supported by direct experimentation, it is consistent with the dramatic upregulation of *K6a*, *K6b*, *K16*, and *K17* that occurs in keratinocytes recruited from wound margins to participate in the restoration of the epidermal barrier following injury.[23,24]

Epidermal disease states are often accompanied by a deviation from normal terminal differentiation and, not surprisingly, they are almost always accompanied by altered keratin gene expression. For instance, *K6a*, *K6b*, *K16*, and/or *K17*, normally restricted to wound repair in trunk epidermis, are ectopically induced in

psoriasis and related hyperproliferative disorders, nonmelanoma skin cancers, viral infections, and other conditions accompanied by inflammation.[23,25,26] Similar "replacement" of the *K1* and *K10* keratin pair by *K6*, *K16*, and *K17* occurs when normal human keratinocytes are placed in culture.[23,25,27] During early progression toward malignancy, cutaneous squamous cell carcinoma progressively shifts from being *K6/K16*-positive while maintaining some degree of *K1/K10* expression, thus reflecting a differentiated state, to being entirely negative for *K1/K10* and positive for the simple epithelial keratins *K8/K18*, indicative of a less differentiated and more aggressive state.[28] These variations in keratin gene expression likely impact the biological properties of keratinocyte in a significant way.

FUNCTION OF KERATIN IN THE EPIDERMIS AND OTHER SKIN EPITHELIA

A major function fulfilled by keratins and all other IF proteins is to enhance the cell's ability to withstand trauma. This structural support function[3,4] is made possible by the unique mechanical properties exhibited by IF networks.[24] This function is enhanced by attachment of IFs to adhesion complexes (desmosomes, hemidesmosomes), and to F-actin and microtubules.[3,4,16] Partial or complete loss of this function, for example, through inherited mutations, underlies a wide variety of rare diseases that render cells fragile and unable to sustain mechanical stress (Table 46-2). In vivo, the mechanical properties of IF networks likely need to be modulated, in a dynamic fashion, to meet the demands placed on cells by changing physiological circumstances. To a degree, varying needs along a continuum of viscoelastic properties likely account, at least in part, for the dynamic regulation of keratin IF genes and their proteins in vivo.[17,24]

The recent discovery of nonmechanical functions for keratin proteins has placed the field on an exciting new path.[17] In hair follicles, *K17* promotes the anagen (growth) phase by attenuating TNF-α-induced apoptosis in matrix keratinocytes.[29] In the epidermis, the suprabasally expressed *K10* regulate proliferation in the basal layer of epidermis and in sebaceous glands, likely through a noncell-autonomous mechanism,[30,31] while *K17* cell autonomously regulates protein synthesis and cell size in wound-proximal keratinocytes.[32] Keratins influence the melanin pigment distribution and, thus, skin pigmentation.[33–35] In polarized epithelia, keratin IFs impact the distribution of organelles, routing of specific outer membrane proteins, and response to stress.[36] These newly defined keratin functions, which are just beginning to be understood, involve regulated interactions between keratin proteins and noncytoskeletal proteins, many exerting key roles in specific signaling pathways.[16,17,24,36] Interference with these functions could play a role in the pathogenesis of disorders linked to IF gene mutations.[4] The discovery of these novel keratin functions provides an opportunity to better understand the diversity and context-dependent regulation of IF genes and their proteins.

MUTATIONS IN EPIDERMAL KERATINS UNDERLIE SEVERAL INHERITED SKIN BLISTERING DISEASES

In the 1980s, ultrastructural studies showed that epidermal basal keratinocytes of patients with the Dowling-Meara form of epidermolysis bullosa simplex (EBS) contained dense cytoplasmic aggregates,[37,38] later shown to contain mispolymerized keratin.[39,40] In parallel, reverse genetic studies showed that expression of dominant-negative keratin mutations cause keratin IF aggregation in cultured cells, and epithelial fragility in vivo.[41,42] In the early 1990s, the first mutations in keratins *K5* and *K14* were linked to EBS.[39,43,44] In EBS, *K5/K14*-expressing basal layer keratinocytes literally rupture in response to mild mechanical trauma to the skin. Fragility is occasionally seen in other sites of *K5/K14* expression, such as the cornea and oral mucosa.[45] Similarly, dominant mutations in the suprabasally expressed *K1*, *K10*, and *K2e* were found to cause epidermolytic hyperkeratosis (EHK),[46,47] ichthyosis bullosa of Siemens,[48] and related diseases (Table 46-2). Such efforts established that compromising keratin function engenders structural failure and fragility. In specific instances, depending on the disorder, this primary defect is accompanied by enhanced proliferation and hyperkeratosis,[4,30] or aberrations in skin pigmentation.[33–35] Since then, a broad range of additional diseases affecting either epidermal appendages (e.g., hair, nail) or nonskin epithelia (e.g., oral mucosa, cornea) have been linked to keratin mutations.[4,49]

The following general principles can be drawn from the large body of data accumulated to date while studying keratin-based disorders. The majority of cases involve single missense mutations acting in a dominant-negative fashion. Small insertions and deletions are also seen with some frequency.[49] In this setting, dominance implies that disease-causing mutant keratin proteins do not markedly alter the early stages of assembly (dimer, tetramer formation) up to the step(s) involving subunit incorporation in a growing IF polymer.[4] Depending on their nature and location within the keratin protein backbone, these mutations exert a wide range of effects on the assembly or organization of IFs in keratinocytes, with a corresponding impact on the severity of clinical presentation. This concept can be readily illustrated for EBS.[50] Mutations altering residues that are highly conserved within the central rod domain tend to dramatically alter the structure of keratin IFs, foster the formation of aberrantly polymerized keratin aggregates, and cause severe disease (as seen in the Dowling-Meara form of EBS). Conversely, mutant proteins that elicit a clinically milder version of the disease (e.g., Weber-Cockayne EBS) affect keratin assembly more subtly, and do not cause keratin aggregation.[50] The extent to which a given keratin mutant compromises the function of the entire IF network is also a function of the number and abundance of potentially redundant IF proteins occurring in a given cell, or its ability to overexpress an alternate IF protein.[4] While it is assumed that these mutations elicit a cell fragility phenotype in part through their ability to alter cellular mechanics,[51–53] there is evidence that they alter

TABLE 46-2
Keratin-based, Inherited Skin Bullous Disease Affecting Primarily the Epidermis[a]

Disease	Relevant OMIM Catalog Number(s)[a]	Target Genes	Affected Cell Type	Comments
Epidermolysis Bullosa Simplex	131800 (Koebner subtype) 131800 (Weber-Cockayne) 131760 (Dowling-Meara)	K5 or K14	Basal keratinocyte	K, WC, and DM correspond to different degrees of severity; the position/nature of the mutation in K5 0r K14 is a key determinant Rare mutations in the same genes result in recessive inheritance (OMIM #60100)
Epidermolysis Bullosa Simplex with mottled pigmentation	131960	K5	Basal keratinocyte	A single dominant allele, K5P28L, has been found in multiple pedigrees. Typified by hyperpigmentation of healed skin blisters
Epidermolysis Bullosa Simplex with limb girdle muscular dystrophy	226670 (also,131950)	Plectin	Basal keratinocyte	Plectin is a cytolinker protein attaching IFs to adhesive complexes and F-actin/microtubules in keratinocytes and myocytes
Dowling-Degos disease	179850	K5 (null)	Basal keratinocyte	Inherited recessively; Features multiple aberrations in skin pigmentation
Epidermolytic Hyperkeratosis	113800	K1 or K10	Spinous keratinocyte	Same as Bullous congenital ichthyosiform erythroderma. As for EBS, there is wide variation in severity of clinical presentation, correlating with position and nature of the mutation affecting either K1 or K10
Ichtyosis hystrix (Curth-Macklin)	146490; 146600	K1 or K10	Spinous keratinocyte	Characteristic ridges or spikes present at the skin surface. Ultrastructurally, presence of large bundles of densely packed IFs around nucleus
Ichtyosis Bullosa of Siemens Palmoplantar keratodermas:	146800	K2e	Granular keratinocyte	Affects primarily flexural areas; Blistering confined to the upper suprabasal layers; Can be confused with mild EHK/BCIE Confined to the epidermis of palms and soles
■ Epidermolytic	144200	K9	Spinous keratinocyte	Reflects the unique distribution of this large type I keratin
■ Non-epidermolytic	139350 (diffuse) 600962 (focal)	K1 K1 or K16	Spinous keratinocyte	This is one of the rare conditions for which the pathogenesis is not indicative of cell fragility; May reflect a non-mechanical role for keratins
■ Striate	607654	DP, Dsg1 or K1	Spinous keratinocyte	Desmoplakin (DP) and desmoglein 1 (Dsg1) are structural components of desmosomes, to which keratin IFs are attached in epidermis

[a]Note: See the Intermediate Filament Database (www.interfil.org) and Online Mendelian Inheritance in Man (www.ncbi.nlm.nih.gov/omim/) websites for further information.

keratin regulation, for example, via posttranslational modifications,[11] and elicit a cellular stress response.[4,54] Treatment options for EBS are currently limited, and are primarily palliative in nature.[50] They consist of supportive care for skin, management of skin blisters as they heal so as to prevent infection, and preventive avoidance of mechanical trauma.

CORNIFIED ENVELOPE

Alongside the substantial build up in keratin IFs inside differentiating keratinocytes, two specializations allow the epidermis to build a remarkably effective and mechanically resilient barrier: (1) the cornified envelope (CE), a covalently cross-linked protein polymer that forms underneath the plasma membrane, and (2) an extracellular hydrophobic phase that is made up of specialized lipids synthesized by terminally differentiating keratinocytes.[55] Epidermal lipids are discussed in detail in Chapter 47, and will not be discussed further here.

The CE represents a complex assembly of covalently cross-linked proteins that forms underneath, and eventually replaces, the outer keratinocyte membrane in the granular layer of epidermis, as part of the final push to complete terminal differentiation. This 20-nm thick sheath, which is so insoluble and stable it resists extended boiling in the presence of strong denaturants, encases the cell's interior, and significantly contributes to the physicochemical properties of the stratum corneum compartment.[56] The extraordinary stability of the CE results in large part from the large number of ε-(-γ-glutamyl)-lysine isopeptide bonds between its primary constituents (see below), which are further reinforced by disulfide bridges. These isopeptide bonds are catalyzed by transglutaminases, a family of calcium-dependent enzymes.[57] The outer aspect of the CE is covalently linked to ceramides and other specialized lipids that are produced by, and secreted from, differentiated granular keratinocytes, whereas large bundles of tightly packed keratin IFs are cross-linked to its inner aspect.

The major protein constituents of the CE are loricrin, involucrin, filaggrin, elafin, cystatin A, cornifelin, several small proline-rich (SPR) proteins and calcium-binding S100 proteins, and "late-envelope proteins" (LEPs). In addition to these proteins, key components of desmosomes (e.g., desmoplakin, envoplakin, and periplakin) and several type II keratins (*K1*, *K2*, *K5*) are also cross-linked into the CE[56–58] (Table 46-3). CE proteins have several interesting features in common. First, many CE proteins are encoded by genes clustered as part of the epidermal differentiation complex (EDC) locus on human chromosome 1q21. In addition to obvious evolutionary implications, this genomic clustering brings up the distinct possibility of coordinated regulation through *cis*-acting determinants.[55,58] Second, many of these proteins are made as precursors that are activated by proteolytic cleavage, calcium binding, or other modifications at the time of CE formation. Third, many CE proteins are made of repeated units that lack an intrinsically defined three-dimensional structure. Fourth, virtually all CE proteins are transglutaminase substrates.[55,57]

Involucrin, loricrin, and filaggrin, in particular, are well-characterized components of the CE.[56,57] Involucrin biosynthesis is initiated in the spinous compartment, soon after the onset of *K1/K10* keratin expression, in differentiating epidermal keratinocytes. It is the first major component to be activated and cross-linked into the emerging CE, possibly reflecting a scaffolding role, and is concentrated in the outermost aspect of the mature CE. Profilaggrin and loricrin are synthesized in precursor forms and stored in keratohyalin granules. Loricrin is the major structural component of the CE (~80% by weight)—this largely unstructured but highly flexible protein features glycine loops as described for type II keratins. Once activated via dephosphorylation and proteolytic cleavage, filaggrin participates in the bundling of keratin IFs in the late granular compartment of epidermis (hence accounting for its incorporation into the CE) and also is degraded to free amino acids that contribute to the cornified cell's ability to retain water. Basic information about other CE components is provided in Table 46-3.[56,57] The protein composition and fine structure of the epidermal CE differs to a degree from those of the other stratified squamous epithelia; the underlying significance of this CE heterogeneity is unclear.[56,57]

The important contribution of the CE toward proper barrier function in epidermis is reflected in the clinical symptoms associated with mutations altering their primary constituents in the context of human diseases[55] (Table 46-3). This is particularly well illustrated by the recently documented role of filaggrin mutations in ichtyosis vulgaris, atopic dermatitis (AD), and AD-associated hay fever or asthma (the so-called atopic march; see Chapter 14).[59–61] The partial or complete loss of filaggrin protein engendered by frameshift mutations in the corresponding gene compromises the epidermal barrier function and allows for the entry of irritants and allergens into the skin,[62] thereby eliciting local (and even systemic) inflammation accompanied by itching, erythema, and flaking reflecting improper cornification (for further information see Chapter 14). Barrier status in the epidermis thus sets our degree of exposure to external elements and contributes to define the relationship that we have with our environment.

CONCLUDING REMARKS

In this chapter, we have discussed epidermal differentiation viewed through the prism of keratin gene regulation and CE formation. While it is well established that specific type I and type II keratins are coexpressed as pairs associated with various stages of normal and pathological epidermal differentiation, and that mutations of major epidermal keratins cause various forms of skin blistering diseases, the functional implications of these different keratins, not only in terms of structural roles, but also in terms of their novel involvements in signal transduction and organelle transport, are just beginning to be understood. Additional studies are needed to better understand the roles of regulatory molecules in epidermal proliferation, homeostasis, and disease; and how the

TABLE 46-3
Protein Composition of the Cornified Envelope (CE)[a]

Protein	Mol. Weight (kDa) (Precursor Form)	Chromos Location	CE Percent Contribution	Comments/Disease Association
Loricrin	26	1q21	80	Rich in Gly, Ser, Cys residues; Contains glycine loops; Flexible; Stored in keratohyalin granules; Mutated in Vohwinkel syndrome, a mutilating keratoderma with ichtyosis, and in progressive symmetric erythrokeratodermia, a related condition.
Involucrin	65	1q21	5	Made up of repeated units; Highly α-helical; Gly-, Asp-rich; Early TG substrate; May act as a scaffold during CE assembly
SPR	6–18	1q21	3–5	SPR: small proline-rich proteins; encoded by 15 genes that are differentially regulated in various stratified epithelia; Great transglutaminases substrates; Influence CE's mechanical properties
Cystatin A	12	3cen-q21	2–5	Cysteine protease inhibitor; Also stored in keratohyalin granules; Mutations in cystatin M/E cause Harlequin ichtyosis
LCEs	9–12	1q21	unknown	LCE: late cornified envelope proteins; Encoded by 18 genes; Synthesized and incorporated at a late stage of CE formation
Profilaggrin/ Filaggrin	>400 36	1q21	<1	Also bundles keratin filaments; Degraded to single amino acids, which markedly contribute to retain H_2O, in stratum corneum layers; Mutated in ichtyosis vulgaris, a mild but very common condition; Risk factor in individuals with atopic dermatitis and asthma
S100A	10–14	1q21	<1	Family of EF-hand containing, calcium binding proteins; Believed to transmit calcium-dependent signals
Proelafin	10	20q12-q13	<1	Elafin is the active entity, and acts as a serine protease inhibitor
Annexin 1	36	9q12-q21	<1	Also known as lipocortin; Interacts with S100A11
Keratins (K1, K2, (K5, K10, K14)	56–70	12q13	<1	Type II keratins are transglutaminase substrates; Keratin IFs become covalently linked to the inner aspect of the CE
Desmosomal proteins	195–330	Various	<1	Includes desmoplakin, envoplakin, periplakin, and others. Assembly of CE is initiated at desmosome cell-cell contacts

[a]Note: A review article by Eckert et al., *J Invest Dermatol.* 124:481-12 (2005) served as a direct inspiration for this Table.

keratin filaments function, at the atomic level, in normal and diseased epidermis. These future studies should lead to new modalities, including cell and gene therapies, for a better treatment of some of the devastating skin diseases.

KEY REFERENCES

Full reference list available at www.DIGM8.com

DVD contains references and additional content

1. Schweizer J et al: New consensus nomenclature for mammalian keratins. *J Cell Biol* **174**:169-174, 2006
2. Moll R et al: The catalog of human cytokeratins: Patterns of expression in normal epithelia, tumors and cultured cells. *Cell* **31**:11-24, 1982
3. Fuchs E, Weber K: Intermediate filaments: Structure, dynamics, function, and disease. *Annu Rev Biochem* **63**:345-382, 1994
4. Omary MB, Coulombe PA, McLean WH: Intermediate filament proteins and their associated diseases. *N Engl J Med* **351**:2087-2100, 2004
7. Fuchs E: Keratins and the skin. *Annu Rev Cell Dev Biol* **11**:123-153, 1995
24. Kim S, Coulombe PA (2007): Intermediate filament scaffolds fulfill mechanical, organizational, and signaling functions in the cytoplasm. *Genes Dev* **21**(13):1581-97
56. Candi E, Schmidt R, Melino G: The cornified envelope: A model of cell death in the skin. *Nat Rev Mol Cell Biol* **6**: 328-340, 2005

Chapter 47 :: Skin as an Organ of Protection

:: Ehrhardt Proksch & Jens-Michael Jensen

SKIN BARRIER AT A GLANCE

- The most important function of the skin is to form a barrier between the organism and the environment.
- The skin barrier prevents excessive water loss (inside–outside barrier) and the entry of harmful substances from the environment (outside–inside barrier).
- The physical barrier is predominantly located in the stratum corneum.
- The stratum corneum barrier is composed of corneocytes and intercellular lipids, cholesterol, free fatty acids, and ceramides.
- Keratins and cornified envelope proteins are important for the mechanical stability of the corneocytes.
- The cornified envelope protein involucrin binds ceramides covalently, forming a backbone for the subsequent attachment of free ceramides.
- The nucleated epidermis through tight junctions and desmosomes also contributes to the barrier.
- Experimental barrier disruption increases epidermal lipids and changes in epidermal differentiation.
- The signals for barrier recovery are cytokines and the calcium ion gradient.
- Several diseases are characterized by a probably genetically disturbed barrier function. The disturbed barrier function contributes to disease pathology, in particular in contact dermatitis, atopic dermatitis, forms of ichthyosis, and psoriasis.
- Lipid or lipid-like creams and ointments can repair disturbed barrier function.

The skin's most important function is to form an effective barrier between the "inside" and the "outside" of the organism. Life on dry land requires the presence of a barrier to regulate water loss and prevent desiccation, commonly referred to as the "inside–outside" barrier. Additionally, skin provides an "outside–inside" barrier to protect against mechanical, chemical, and microbial assaults from the external environment (Fig. 47-1).[1] To perform these functions the epidermis undergoes keratinization, a process in which epidermal cells progressively mature from basal cells with proliferative potential to the lifeless, flattened squames of the stratum corneum (SC) (Fig. 47-2). Both the SC and the deeper skin layers protect the skin from mechanical forces, ultraviolet (UV) radiation, cold and hot temperatures, and invasion of chemicals and microbes. To effectively perform this multiplicity of functions, the skin contains different types of barriers. The physical barrier consists mainly of the SC, but the nucleated epidermis, in particular the tight junctions, provides another important barrier component. The chemical/biochemical (antimicrobial) barrier consists of lipids, acids, lysozymes, and antimicrobial peptides (discussed in Chapter 10). The humoral and cellular immune system provides a barrier to infectious disease, but immune hyperactivity may lead to allergy (Table 47-1).

Although the skin is of central importance for preventing water loss in a dry environment, aquatic animals also require a skin barrier to protect them from the high salinity of their surrounding environment. Terrestrial mammals with dense fur have much thinner skin than animals without this protective coat, demonstrating that fur itself is a considerable barrier. The relatively hairless skin of pigs shows much

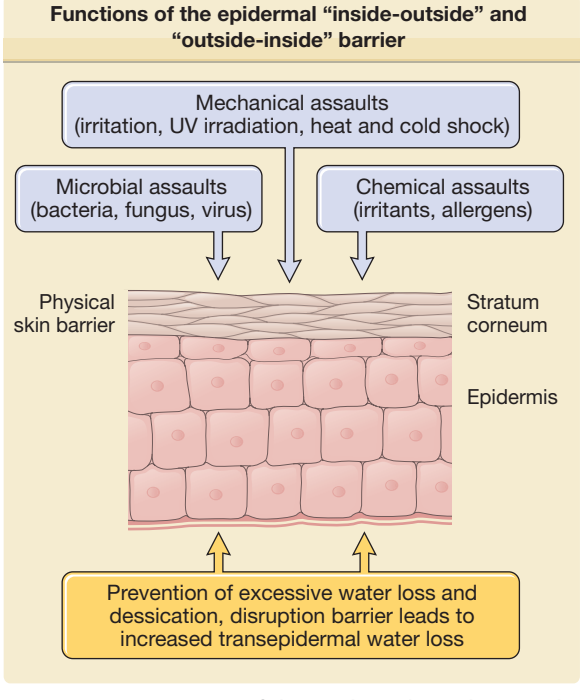

Figure 47-1 Functions of the epidermal "inside–outside" and "outside–inside" barrier.

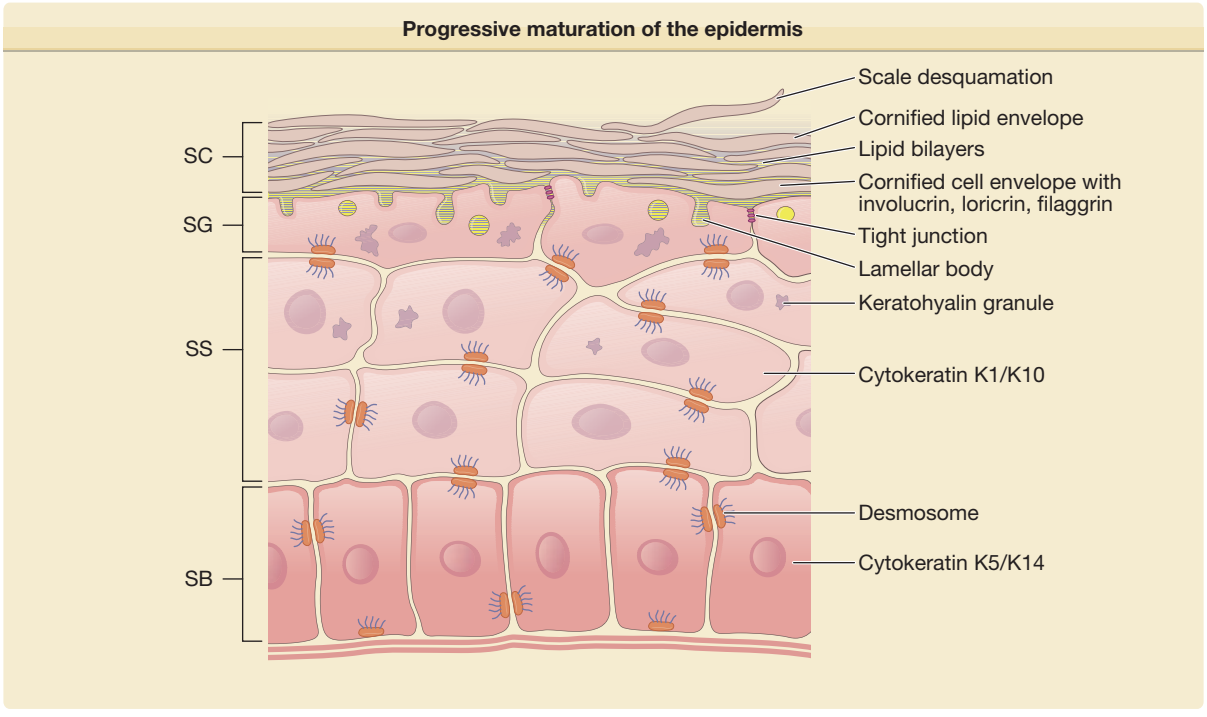

Figure 47-2 The nucleus in the stratum granulosum (SG) should be flattened. In the basal cell layer please add a hemidesmosome towards the basal membrane (please review the former graphic). The lamellar bodies should be hatched (including the membrane fused bag shaped lamellar bodies).

similarity to human skin and is therefore a good model for skin research.

In addition to the SC the entire skin, as a whole, serves a protective function. The innermost region of human skin, the subcutaneous fat layer, offers mechanical shock protection, insulates the body against external heat and cold, and is active in general energy metabolism and storage. The dermis is composed of collagen bundles and elastic fibers and is very important for the mechanical strength of the skin. The epidermis, the skin's outer layer, consisting primarily of stratified nucleated keratinocytes and the SC, is most important for skin protection—the focus of this chapter. Sweat glands and blood vessels regulate body temperature. Sebaceous glands secrete specialized lipids to protect the hair from the environmental stress (see Chapter 79). In animals, these lipids serve as a water repellent for the fur, aiding in buoyancy and temperature regulation, and also preventing desiccation of the body and UV damage. The role of sebaceous lipids for SC barrier function and for dry skin is under active investigation.[2,3] Sebaceous glands also transport glycerol to the skin surface, which is important for SC hydration.[4] Nerve fibers are chemosensitive and act as a warning system against external trauma (see Chapter 102).

TABLE 47-1
Different Skin Barriers

Physical barrier	Stratum corneum (corneocytes, lipid lamellae), nucleated epidermis (desmosomes, tight junctions)
Chemical/biochemical (antimicrobial) barrier (innate immunity)	Lipids, organic acids, lysozymes, antimicrobial peptides
Immune barrier humoral and cellular immune systems	Lymphocytes, neutrophils, monocytes, Langerhans cells

STRUCTURE OF THE STRATUM CORNEUM: THE PHYSICAL PERMEABILITY BARRIER

(Table 47-2)

Research from the 1940s and 1950s established that the SC is the specific location of the physical barrier.[5,6] The SC barrier structure visualized by electron microscopy and ruthenium tetroxide fixation (Fig. 47-3) is a better indicator of its barrier function than the typical "basket-weave" appearance of the SC in routine formalin-embedded tissue sections. Regulation of water permeation is not absolute. The normal movement of water from the SC into the atmosphere is known as transepidermal water loss (TEWL), previously called insensible water loss. The SC serves as the principal barrier against the percutaneous penetration of chemicals and microbes[1] as well.

The 10–20 µm thick SC forms a continuous sheet of protein-enriched cells, embedded in an intercellular matrix, enriched in nonpolar lipids, and organized as

TABLE 47-2
Protection Functions of the Stratum Corneum

Functions	Structural Bases	Biochemical Mechanisms
Permeability barrier	Lamellar bilayers	Hydrophobic lipids
Mechanical integrity/resilience	Cornified envelope, cytosolic filaments	Cross-linked peptides; e.g., involucrin, loricrin. Keratin filaments
Hydration	Lamellar bilayers; corneocyte cytosolic matrix	Sebaceous gland-derived glycerol; filaggrin breakdown amino acids; natural moisturizing factors (NMFs), hornerin
Cohesion/desquamation	Corneodesmosomes	Serine proteases
Antimicrobial defense	Lamellar bilayers; extracellular matrix	Free fatty acids; antimicrobial peptides
UV protection	Corneocyte cytosol	Structural proteins; *trans*-urocanic acid (tUCA)
Antioxidant defense	Corneocytes and extracellular matrix	Keratins; sebaceous gland-derived vitamin E and other antioxidants
Waterproofing/repellence	Lamellar bilayers	Keratinocyte and sebum-derived lipids
Cytokine signaling	Corneocyte cytosol	Storage and release of pro-IL-α; serine proteases
Xenobiotic defense	Lamellar bilayers	Lipid solubility; cytochrome P450 system (outer epidermis)

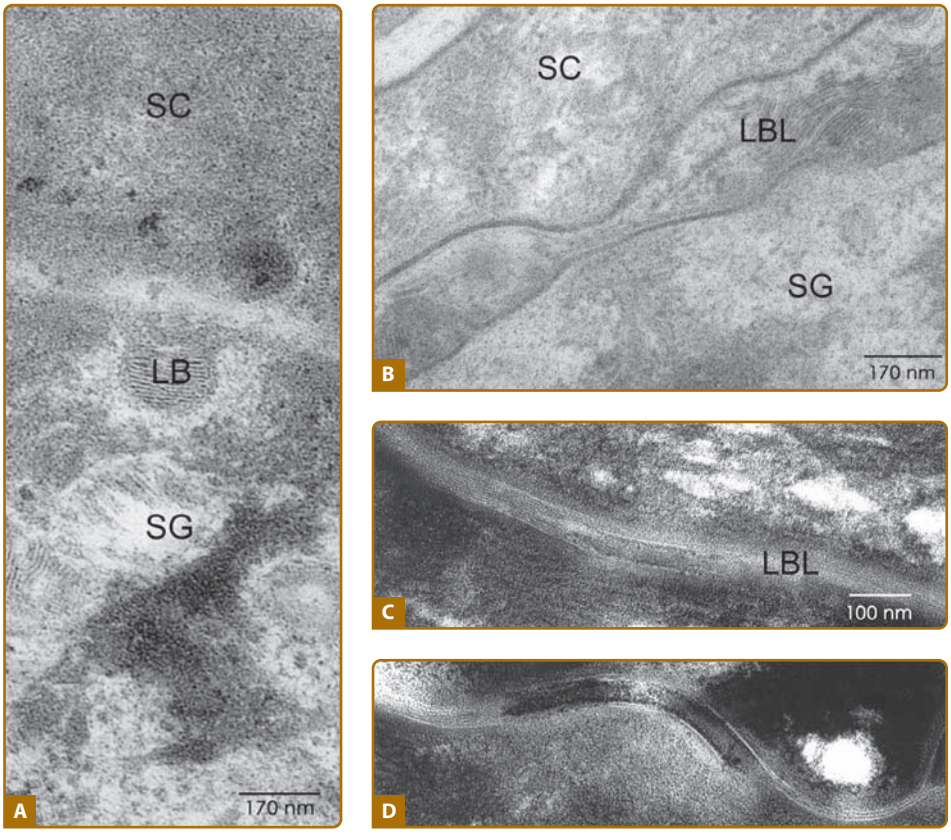

Figure 47-3 Electron microscopy reveals that in the stratum granulosum (SG)–stratum corneum (SC) interface the lamellar bodies (LB) content is extruded to the intercellular space (**A**), thus forming continuous bilayers. (**B** then **C**). Desmosomes are becoming corneosomes in the process of cornification (**D**).

lamellar lipid layers. The viable epidermis is a stratified squamous epithelium, consisting of basal, spinous, and granular cell layers. Upon leaving the basal layer, keratinocytes begin to differentiate and undergo a number of changes in both structure and composition during the apical migration into the stratum spinosum and stratum granulosum (see Chapter 46). Keratinocytes synthesize and express numerous structural proteins and lipids during their maturation. The final steps in keratinocyte differentiation are associated with profound changes in their structure, resulting in their transformation into flat and anucleated squamous cells of the SC, consisting mainly of keratin filaments and surrounded by a cell envelope composed of cross-linked proteins (cornified envelope proteins) as well as a covalently bound lipid envelope (Fig. 47-2). Extracellular nonpolar lipids surround the corneocytes to form a hydrophobic matrix. The cornified envelope proteins as well as the covalently bound lipid envelope are thought to be important for the chemical resistance of the corneocytes (Fig. 47-4). Desmosomes, which interconnect adjacent keratinocytes, are important for SC cohesion and are shed during the desquamation process in the SC. In the upper spinous and granular layers characteristic lamellar vesicles appear, which are called epidermal lamellar bodies (Figs. 47-3 and 47-5). These are enriched in polar lipids, glycosphingolipids, free sterols, phospholipids, and hydrolytic enzymes that deliver the lipids required for the SC's extracellular layers. The lamellar bodies may also contain proteins such as human β-defensin 2.[7] In response to certain signals, for example, an increase in calcium concentration during the transition from the granular layers to the SC, the lamellar bodies move to the apex of the uppermost granular cells, fuse with the plasma membrane, and secrete their content into the intercellular spaces through exocytosis. The lipids derived from the lamellar bodies are subsequently

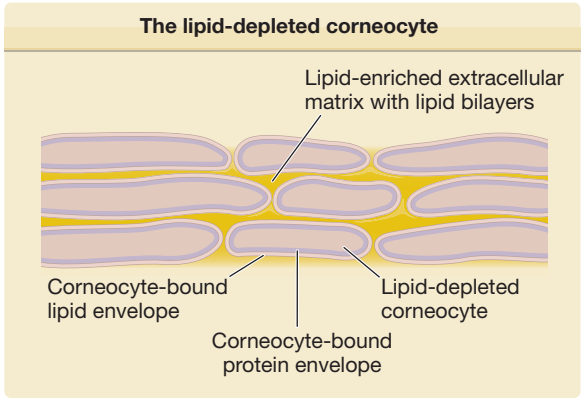

Figure 47-4 The lipid-depleted corneocyte is surrounded by an inner protein envelope and an outer lipid envelope. Special ceramides are covalently bound to cornified envelope proteins, in particularly to involucrin.

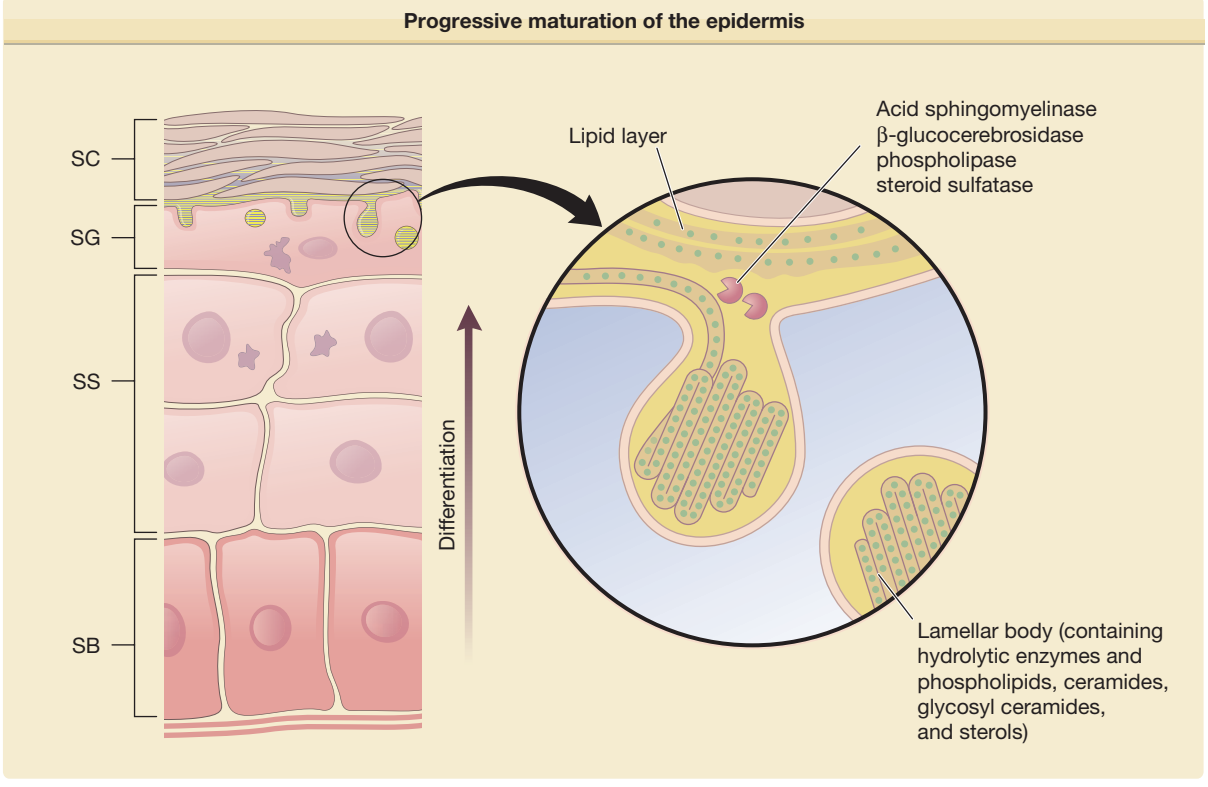

Figure 47-5 During differentiation, the upper stratum spinosum (SS) and the stratum granulosum (SG) cells generate lamellar bodies containing preformed lipid structures and hydrolytic enzymes. Their content is extruded into the SG–stratum corneum (SC) interface and undergoes profound remodeling. SB = stratum basale.

modified and rearranged into intercellular lamellae positioned approximately parallel to the cell surface. The covalently bound lipid envelope acts as a scaffold for this process. After the extrusion of the lamellar bodies into the stratum granulosum–SC interface, the polar lipids are enzymatically converted into nonpolar products. Hydrolysis of glycosphingolipids generates ceramides while phospholipids are converted into free fatty acids. These changes in lipid composition and cell structure result in the formation of a very dense structure packed into the interstices of the SC (Table 47-2).[8]

LIPID COMPOSITION AND ROLE OF LIPIDS IN THE STRATUM CORNEUM PERMEABILITY BARRIER

Confocal laser scanning microscopy and X-ray microanalysis studies have shown that the major route of penetration results in a tortuous pathway between the corneocytes, confirming that intercellular lipids play an irreplaceable role in regulating skin permeability barrier function.[8] The major lipid classes in the SC are cholesterol, free fatty acids, and ceramides (see eFig. 47-5.1 in online edition).[9–11]

CHOLESTEROL. Cholesterol is probably the most abundant lipid in the entire body and part of the plasma membrane, but also part of the intercellular lipid lamellae in the SC. Although basal cells are capable of resorbing cholesterol from circulation, most cholesterol in the epidermis is synthesized in situ from acetate.[12] The epidermal keratinocyte, the main cell type in the epidermis, is highly active in the synthesis of several lipids, including cholesterol and free fatty acids. The rate-limiting step in cholesterol biosynthesis is catalyzed by hydroxymethylglutaryl CoA (HMG CoA) reductase (Fig. 47-6). Epidermal cholesterol synthesis is regulated by these enzymes and increases during permeability barrier repair.[13]

FREE FATTY ACIDS. The skin contains free fatty acids as well as fatty acids bound in triglycerides, phospholipids, glycosylceramides, and ceramides. The chain length of free fatty acids in the epidermis ranges from C_{12} to C_{24}. The rate-limiting enzymes acetyl-CoA carboxylase and fatty acid synthase in the epidermis are largely autonomous (Figs. 47-6 and 47-7).[14] Saturated and monounsaturated fatty acids are synthesized in the epidermis, in contrast to di- and polyunsaturated acids. The nomenclature of the fatty acids is determined from the position of the first double bond in the molecule, starting from the terminal methyl group. In particular, the essential ω-6-unsaturated acids are obtained from food and reach the epidermis by the circulation but can also be obtained by topical treatment. The nonessential monounsaturated fatty acid, the oleic acid, is an ω-9-fatty acid. The most important double unsaturated fatty acid, linoleic acid, is an ω-6 fatty acid. Also of importance is α-linoleic acid (ω-3). No skin changes due to ω-3-fatty acid deficiency are currently known; however, it has been proposed that these fatty acids are important for the resolution of inflammation. ω-3-fatty acids are obtained from fish, whereas ω-6-fatty acids are obtained from plant oils.[15,16] Essential fatty acid deficiency (EFAD) caused by unusual diets or malabsorption in humans or experimentally induced in rats and mice leads to the EFAD syndrome, characterized by profound changes in epithelia including the epidermis.[17] In this condition, the epidermis is rough, scaly, and red and shows a severely disturbed permeability barrier function. In addition, severe bacterial infection, impaired wound healing, and alopecia may occur. Linoleic acid is part of phospholipids, glucosylceramides, ceramide 1, ceramide 4, and ceramide 9.[18] It has been proposed that the linoleic acid metabolite γ-linoleic acid is of special importance for atopic eczema.

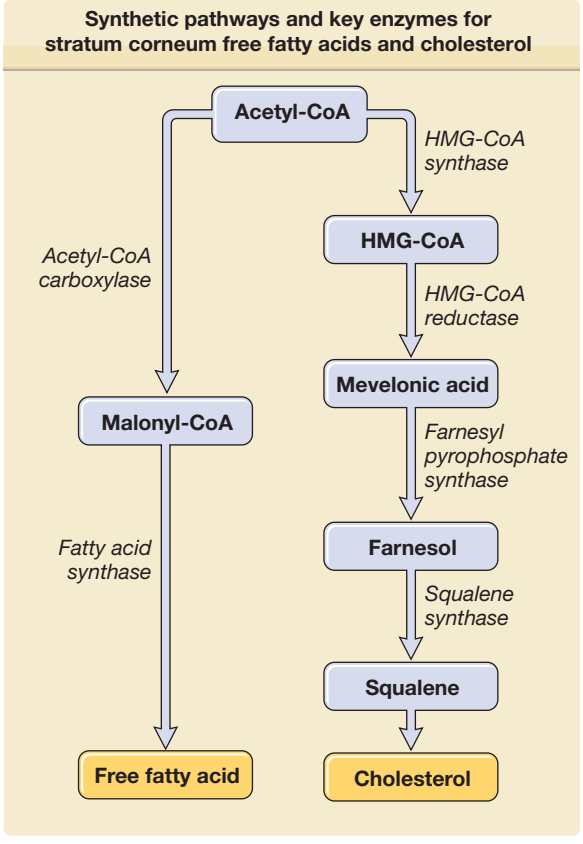

Figure 47-6 Synthetic pathways and key enzymes for stratum corneum free fatty acids and cholesterol. CoA = coenzyme A; HMG-CoA = hydroxymethylglutaryl CoA.

CERAMIDES. Ceramide is an amide-linked fatty acid containing a long-chain amino alcohol called sphingoid base. The carbon chain lengths of amide-linked fatty acids and sphingoid bases in most mammalian tissues are 16 to 26 and 18 to 20, respectively (see eFig. 47-5.1 in online edition). Although sphingolipids, including glycosphingolipids and phosphosphingolipids, are ubiquitously distributed in mammalian tissues, tissue-specific molecular distribution has been described. Glucosylceramide is

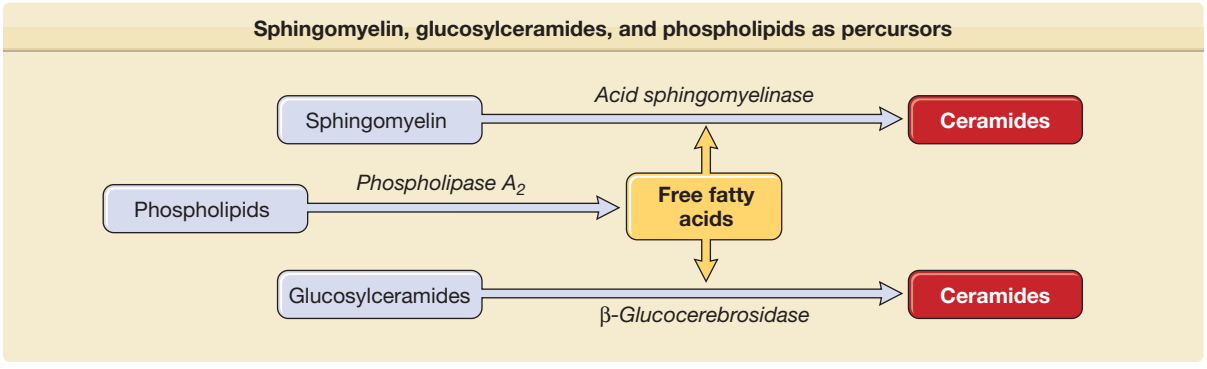

Figure 47-7 Sphingomyelin and glycosylceramides are precursors for ceramide generation, while phospholipids are precursors of fatty acids.

enriched in the epidermis and spleen while galactosylceramide is enriched in the brain, but is not detected in keratinocytes. Whereas ceramide is a minor lipid component, comprising less than 10% of cholesterol or phospholipids in other mammalian tissues, ceramide is a major lipid component in the SC, accounting for 30%–40% of lipids by weight. Moreover, such a high content of ceramides in the SC is not observed in the epidermal stratum granulosum, stratum spinosum, or stratum basale. This also suggests that terminal differentiation is a key factor in accumulating ceramide. The SC contains at least nine different ceramides.[18] In addition, there are two protein-bound ceramides: (1) ceramide A and (2) ceramide B (see eFig. 47-5.1 in online edition).[8] These ceramides are covalently bound to cornified envelope proteins, most importantly to involucrin.

Ceramides are synthesized by serine-palmitoyltransferase as rate-limiting enzyme and by hydrolysis of both glucosylceramide (by β-glucocerebrosidase)[19] and sphingomyelin (by acid sphingomyelinase) (Figs. 47-7 and 47-8).[20] Whereas all kinds of ceramides are derived by synthesis from serine-palmitoyltransferase and from β-glucocerebrosidase, only ceramide 2 and ceramide

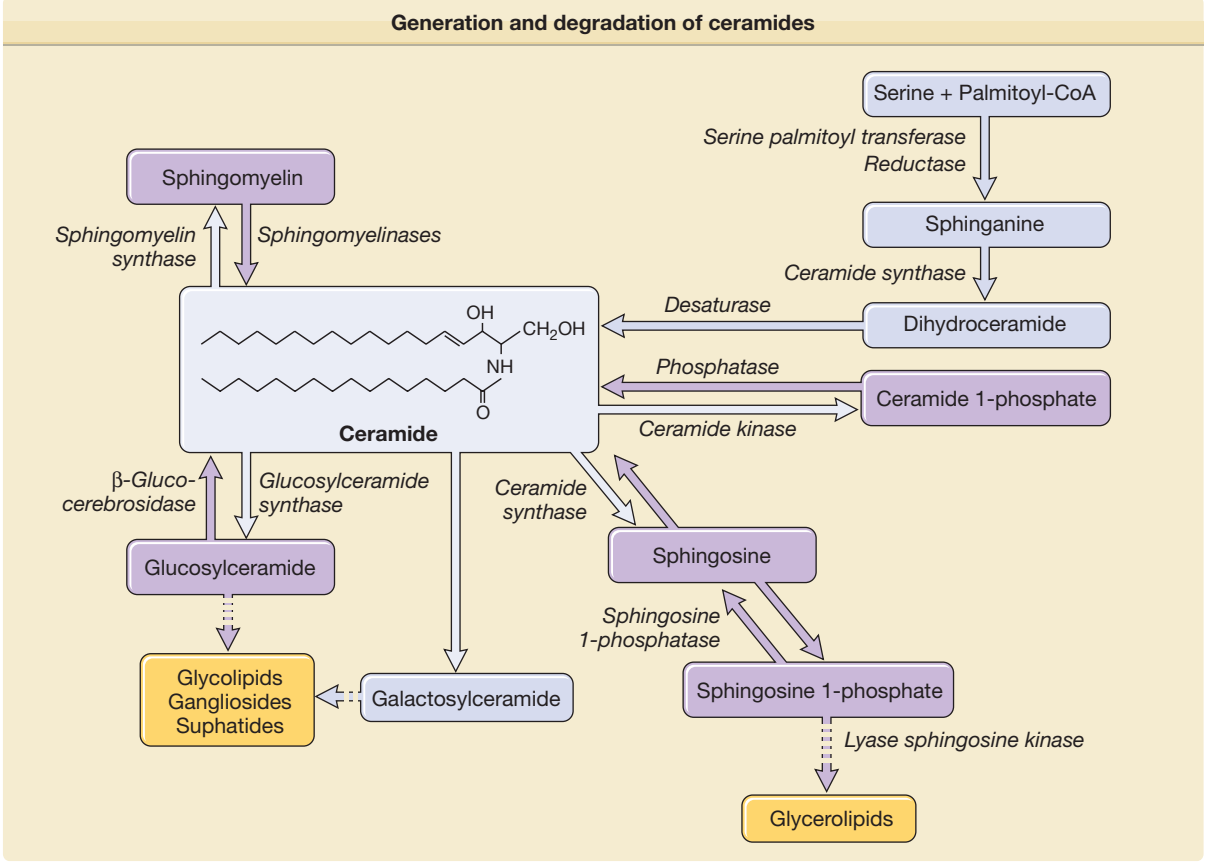

Figure 47-8 Generation and degradation of ceramides.

TABLE 47-3
Additional Protective Functions of the Nucleated Epidermis

Functions	Biochemical Correlates
Antimicrobial systems	Antimicrobial peptides and lipids, iron-binding proteins, complement
Antioxidants	Glutathione, oxidases, catalase, cytochrome P450 system, vitamins C and E
Inflammatory mediators	Prostaglandins, eicosanoids, leukotrienes, histamine, cytokines
UV-absorbing molecules	Melanin, *trans*-urocanic acid, vitamin D, vitamin C metabolites, filaggrin metabolites
Xenobiotic-metabolizing enzymes	Glucoronidation, sulfation, hydroxylation mechanisms

5 are obtained from sphingomyelinase because sphingomyelinase contains nonhydroxy acids.[21]

LIPID TRANSPORT

Keratinocytes require abundant cholesterol for cutaneous permeability barrier function. ABCA1 is a membrane transporter responsible for cholesterol efflux and plays a pivotal role in regulating cellular cholesterol levels. It was demonstrated that ABCA1 is expressed in cultured human keratinocytes and murine epidermis. Liver X receptor (LXR) activation and activation of peroxisome proliferator-activated receptor (PPAR)-α, PPAR-ss/δ, and retinoid X receptor (RXR) increased ABCA1 expression in keratinocyte cultures. Thus, cholesterol levels for permeability barrier function are regulated by ABCA1, LXR, and PPARs.[22] The cellular fatty acid transport and metabolism is regulated by fatty acid-binding proteins (FABPs).[23,24]

Additional protective functions of the epidermis are not discussed in this chapter, but are listed in Table 47-3.

EPIDERMAL PROLIFERATION AND DIFFERENTIATION IN SKIN BARRIER FUNCTION

To provide the physical barrier of the SC, not only intercellular lipids, but also corneocytes are of crucial importance.[25,26] The epidermis undergoes keratinization in which epidermal cells progressively mature from basal cells with proliferative potential to lifeless flattened squames of the SC (Fig. 47-2). Keratinocytes arise from stem cells in the basal layers and transient amplification cells and move to a series of differentiation events until they are finally brought to desquamation.[27] Thus, in the normal epidermis, there is a balance between the processes of proliferation and desquamation that results in a complete renewal approximately every 28 days. In some forms of ichthyosis, the rate of desquamation may be decreased, leading to epidermal cell retention (retention hyperkeratosis).[28] (See Chapter 49.) In inflammatory skin diseases like psoriasis there is an increase in proliferation resulting in a disturbance in differentiation and parakeratotic squames (hyperproliferative hyperkeratosis).[29]

Keratins are major structural proteins synthesized in keratinocytes (see Chapter 46). They assemble into a web-like pattern of intermediate filaments that emanate from a perinuclear ring, extend throughout the cytoplasm, and terminate at junctional desmosomes and hemidesmosomes. During the final stages of normal differentiation, keratins are aligned into highly ordered and condensed arrays through interactions with filaggrin, a matrix protein. In keratin disorders, the filament networks collapse around the nucleus, preventing attachment with the filament-matrix complex and the inner surface of squames, and alter interaction between neighboring cells, thereby affecting desquamation. Filaggrin aggregates the keratin filaments into tight bundles. This promotes the collapse of the cell into a flattened shape, which is characteristic of corneocytes in the cornified layer. Together, keratins and filaggrin constitute 80%–90% of the protein mass of mammalian epidermis.[25,26]

The structural proteins involucrin, loricrin, trichohyalin, and the class of small proline-rich proteins (SPRRs) are synthesized and subsequently cross-linked by transglutaminases to reinforce the cornified envelope just beneath the plasma membrane. The proteins of the cornified envelope constitute about 7%–10% of the mass of the epidermis. These corneocytes provide the bulwark of mechanical and chemical protection, and together with their intercellular lipid surroundings, confer water-impermeability. The cornified cell envelope is a tough protein/lipid polymer structure formed just below the cytoplasmic membrane and subsequently resides on the exterior of the corneocytes (Fig. 47-4). It is resistant to 10% KOH and is the rigid structure seen on KOH skin scrapings. It consists of two parts: (1) a protein envelope and (2) a lipid envelope. The protein envelope contributes to the biomechanical properties of the CE as a result of cross-linking of specialized cornified envelope structural proteins by both disulfide bonds and *N*(ε)-(γ-glutamyl)lysine isopeptide bonds formed by transglutaminases.[26,30] The isopeptide bonds are resistant to most common proteolytic enzymes. The corneocyte-bound lipid envelope is plasma membrane-like structure, which replaces the plasma membrane on the external aspect of mammalian corneocytes.[31] Involucrin, envoplakin, and periplakin serve as substrates for the covalent attachment of ω-hydroxyceramides with very long-chained *N*-acyl fatty acids by ester linkage.[32] These not only provide a coating to the cell, but also interdigitate with the intercellular lipid lamellae (Table 47-2).[26]

EXPERIMENTAL BARRIER DISRUPTION AND GENE MODIFICATION IN EPIDERMAL DIFFERENTIATION

Experimental barrier disruption leads to changes in epidermal differentiation, epidermal lipid keratin, and cornified envelope protein expression and, vice versa, overexpression and deficiency of these lipids and proteins in mice result in barrier defects. A number of diseases displaying defective epidermal barrier function are also the result of genetic defects in the synthesis and metabolism of either lipids, keratins, cornified envelope proteins, or the transglutaminase 1 cross-linking enzyme.

Inhibition of HMG CoA reductase by topical application of the lipid-lowering drug lovastatin in mice resulted in a disturbed barrier function and in epidermal hyperproliferation. Therefore, the specific relationship between barrier function and epidermal DNA synthesis was examined. After acute skin barrier disruption (local acetone treatment or by tape-stripping) (Fig. 47-9) and in a model of chronic barrier disruption (EFAD diet), an increase in DNA synthesis leading to epidermal hyperplasia was noticed.[33] The increase in DNA, and in lipid synthesis, was partially prevented by occlusion.[15,33,34]

Also, the described acute and chronic barrier disruption leads to specific changes in epidermal keratin and cornified envelope protein expression. Increased expression of the basal keratins K5 and K14 and a reduction of the differentiation-related keratins K1 and K10 were noted. In addition, there was expression of the proliferation-associated keratins K6 and K16 as well as the inflammation-associated keratin K17 (see eFig. 47-9.1 in online edition).[35] The importance of keratins for skin barrier function was supported by studies in K10-deficient mice. Heterozygotes and homozygotes showed a mild or severe permeability barrier disruption, respectively. Importantly, homozygous neonatal K10-deficient mice exhibited an extremely delicate epidermis and died a few hours after birth. Heterozygous littermates showed a normal skin at birth but developed increasing hyperkeratosis as they grew up.[36] Barrier repair in heterozygous K10-deficient mice was delayed and skin hydration was impaired.[37] Changes in ceramide composition, a reduced amount of glucosylceramide and sphingomyelin, and reduced acid sphingomyelinase activity, as well as increased involucrin content, were also noted.[38] This shows that genetically determined changes in structural proteins lead to an impaired skin barrier function and changes in differentiation and lipid composition.

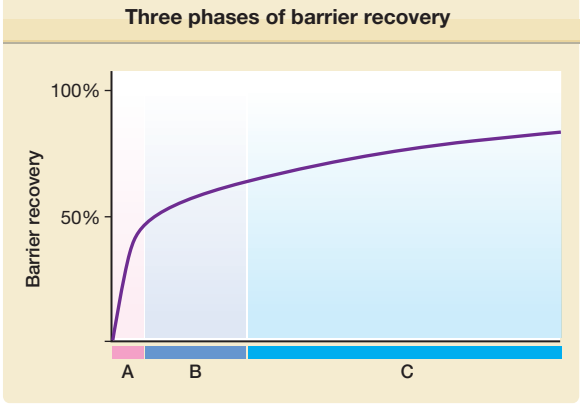

Figure 47-9 Three phases of barrier recovery with distinct metabolic activities occurring after acute barrier disruption. **A** = Secretion of preformed pool of lamellar bodies (0 to 30 minutes). **B** = Increased lipid synthesis (free fatty acids, ceramide, and cholesterol) (30 minutes to 6 hours), accelerated lamellar body formation and secretion (2 to 6 hours). **C** = Increased glucosylceramide processing (9 to 24 hours), increased keratinocyte proliferation and differentiation (16 to 24 hours).

The importance of keratins for skin barrier function is further supported by studies in diseases that are caused by monogenetic defects of these structural proteins. Epidermolysis bullosa simplex (EBS) shows mutation in the basal layer keratins K5 or K14 (details in Chapter 62). Genetic defects in the suprabasal keratins results in hyperkeratosis and a mild barrier defect (details in Chapters 49 and 59). Epidermolytic hyperkeratosis (EHK) has spinous layer K1 or K10 defects, epidermolytic palmoplantar keratoderma (EPPK) has granular layer K9 defects (because this keratin is expressed only in palmar and plantar skin, the disease is restricted to that area), and ichthyosis bullosa of Siemens (IBS) has granular layer defects K2 (formerly K2e) defects.[25]

Experimental permeability barrier disruption leads to a premature expression of involucrin, but not loricrin.[35] Overexpression of filaggrin in mice in the suprabasal epidermis resulted in a delay of barrier repair.[39] Loss of normal profilaggrin and filaggrin is the cause for the flaky tail in an autosomal recessive mutation in mice that results in a dry, flaky skin, and annular tail and paw constrictions in the neonatal period. Targeted ablation of the murine involucrin gene did not show changes in skin barrier function under basal conditions[40] but resulted in a reduced barrier repair. In addition, knockdown of filaggrin was shown to increase UV-sensitivity in a human skin model.[41] Loricrin deficient mice do not show a disturbed barrier function, but a greater susceptibility to mechanical stress which may alter skin barrier function secondarily.[42,43]

Changes in epidermal proliferation and differentiation are also seen in inflammatory skin diseases with a disturbed skin barrier function (see eFig. 47-9.1 in online edition). Increased proliferation is one of the main characteristics of psoriasis, but in atopic dermatitis lesional skin also there is a considerable increase in epidermal proliferation. Also, changes in keratins and cornified envelope proteins occur in inflammatory skin diseases.[44] Overall, this shows that there is undoubtedly a connection between epidermal proliferation, differentiation, and skin barrier function.

FUNCTIONS OF THE SUBCORNEAL EPIDERMAL LAYERS

Although the SC is recognized as the most important physical barrier, the lower epidermal layers are also significant in barrier function. A low-to-moderate increase in TEWL occurs after removal of the SC by tape stripping, whereas loss of the entire epidermis through suction blisters leads to a severe disturbance in barrier function. Loss of the SC and parts of the granular layers in staphylococcal scalded skin syndrome (SSSS) are not usually life-threatening.[45] In contrast, the suprabasal and subepidermal blistering diseases pemphigus vulgaris, toxic epidermal necrolysis and severe burns, respectively, are life-threatening when large areas of the body are involved. Patients die because of extensive water loss or sepsis induced by external bacteria infection—outcomes directly resulting from perturbed barrier function. Survival rates can be greatly improved with application of an artificial barrier in the form of a foil or a grease ointment, often containing active antimicrobial substances. These clinical observations confirm the importance of the nucleated epidermal layers in skin barrier function in both directions, both in preventing excessive water loss and the entry of harmful substances into the skin.[46]

TIGHT JUNCTIONS: A SECOND-LINE EPIDERMAL BARRIER

Tight junctions are cell-junctions connecting neighboring cells sealing the intracellular space and controlling the paracellular movements of molecules (Fig. 47-2). The most important tight junction proteins in the human epidermis are occludin, claudins, and zonal occluding proteins (ZOs). Localization of occludin is restricted to the stratum granulosum, ZO-1 and claudin 4 are found in suprabasal layers, and claudins 1 and 7 are found in all epidermal layers. In various diseases with perturbed SC barrier function, for example, psoriasis vulgaris, lichen planus, acute and chronic eczema, and ichthyosis vulgaris, tight junction proteins that were formerly restricted to the stratum granulosum and upper stratum spinosum, were also found in deeper layers of the epidermis. Claudin 1-deficient mice die within 1 day of birth due to tremendous water loss.[47] Altered barrier function of the skin has also been demonstrated in mice overexpressing claudin 6 in the epidermis.[48,49]

DESMOSOMAL PROTEINS: STRUCTURAL CELL–CELL INTERFACES

A perturbation in SC barrier function has also been found after the alteration of desmosomal proteins. Desmogleins are desmosomal cadherins that play a major role in stabilizing cell–cell adhesion in the living layers of the epidermis (Fig. 47-2, see Chapter 53). Autoantibodies against these transmembrane glycoproteins cause blisters in pemphigus vulgaris due to loss of keratinocyte adhesion. In acute eczema, which shows disturbed skin barrier function a reduction in keratinocyte membrane E-cadherin in areas of spongiosis has been found.[50,51] In transgenic mice in which the distribution of desmoglein 3 in epidermis was similar to that in mucous membrane, a highly increased TEWL resulted in lethality during the first week of life due to dehydration.[52] Mice with conditionally inactivated E-cadherin in the epidermis died perinatally due to the inability to retain a functional epidermal water barrier. Absence of E-cadherin leads to improper localization of key-tight junctional proteins and impermeable tight junctions and thus altered epidermal barrier function.[53,54]

CONNEXINS: INTERCELLULAR GATEKEEPERS

Connexins are transmembrane proteins that homo- or heteromerize on the plasma membrane to form a connexon. Connexons on adjoining cells that associate to form gap junctions and allow the passage of ions and small molecules between cells. Connexin 26 is one of the most highly upregulated genes in psoriatic plaques. Missense mutations in connexin 26 result in five distinct ichthyosis-like skin disorders. In mice overexpressing connexin 26, a hyperproliferative state, infiltration of immunocells, and a delayed epidermal barrier recovery were noted.[55]

PROTEASES

Proteases are important for epidermal differentiation. The characteristic resistance of the cornified envelope is based on the formation of very stable isopeptide bonds that are catalyzed by transglutaminase 1, 3, and 5. Transglutaminase 1-deficient mice showed a defective SC and early neonatal death.[56] Mutations in transglutaminases 1 have been found to be the defect in lamellar ichthyosis.[57] Cathepsin D is involved in the processing of transglutaminase 1. Cathepsin D-deficient mice expressed a defect in barrier function and hyperproliferation.[58] Evidence suggests that cystatin M/E and cathepsin L may be upstream proteases of the cathepsin D–transglutaminase pathway and must exist in a tightly regulated balance in order to ensure tissue integrity in the epidermis, hair follicles, and corneal epithelium.[59] There is further evidence that disruption of the cystatin M/E–cathepsin pathway contributes to the underlying skin barrier dysregulation characteristic of inflammatory dermatoses, such as psoriasis and atopic dermatitis.[60]

Netherton syndrome, a severe autosomal recessive genodermatosis (see Chapter 49) is caused by mutations in SPINK5, encoding the serine protease inhibitor LEKTI. In Netherton syndrome, there is often an atopic eczema-like skin disease with a disrupted permeability barrier. SPINK5$^{-/-}$ mice replicate key features of Netherton syndrome, including altered desquamation, impaired keratinization, hair malformation, and a skin barrier defect. LEKTI deficiency causes abnormal des-

mosome cleavage in the upper granular layer through degradation of desmoglein 1 due to SC chymotryptic enzyme (SCCE)-like hyperactivity. This leads to defective SC adhesion and results in loss of skin barrier function.[61,62]

CYTOKINE SIGNALING: REGULATION OF EPIDERMAL HOMEOSTASIS AND REPAIR

Cytokines are very important for the regulation of wound healing in which reepithelization and differentiation to form a competent barrier are the last steps[63] (see Chapter 248). Besides the immune cells, keratinocytes are able to produce a large variety and amounts of cytokines (Fig. 47-10). Of special importance are the so-called primary cytokines tumor necrosis factor (TNF), interleukin (IL)-1, and IL-6. IL-1, TNF, and IL-6 are potent mitogens and stimulators of lipid synthesis in cutaneous and extracutaneous tissues. After acute permeability barrier disruption, an increase in the expression of TNF, IL-1, and IL-6 on the mRNA and the protein level occurs.[20,64,65,66] In mice deficient in TNF receptor 1 or IL-1 receptor 1/TNF receptor 1-double knockout mice and in IL-6-deficient mice, a delay in permeability barrier occurs.[20,66] Moreover, topical application of TNF enhances permeability barrier repair, and topical application of IL-6 in IL-6-deficient mice restores the normal speed in permeability barrier repair (Fig. 47-10). In TNF-receptor 1-deficient mice, the generation of lipids for skin barrier repair was delayed and the activity of acid sphingomyelinase that generates ceramides for skin barrier repair was reduced.[20] STAT 3 tyrosine phosphorylation was induced after barrier disruption in wild type, but markedly reduced in IL-6-deficient mice. The acute increase in TNF, IL-1, and IL-6 after barrier disruption is crucial for skin barrier repair. However, if barrier disruption is prolonged and a chronic increase in cytokine production occurs, it could have a harmful effect leading to inflammation and epidermal proliferation. This disrupted permeability barrier, epidermal hyperproliferation, and inflammation, and is well known in several diseases like irritant and allergic contact dermatitis, atopic dermatitis, and psoriasis, and could aggravate the disease.

IONIC MODULATIONS: EPIDERMAL CALCIUM AND POTASSIUM LEVELS

A perturbed barrier recovers normally when exposed to an isotonic, hypertonic, or hypotonic external solution instead of air. If the solution contains both calcium and potassium, the barrier recovery is inhibited. Inhibitor studies using both L-type calcium channels and calmodulin and ultrastructural examination by ion-capture cytochemistry showed that there is a calcium gradient in the epidermis. There is a relatively low calcium concentration in the basal epidermis, and an even lower concentration in the spinous layers, while the highest calcium concentrations are found in the granular layers. Calcium in the SC is very low because the relatively dry SC with extracellular lipids is not able to solve the high polar ions. After disruption of the permeability barrier there is influx of water in the SC and the ion gradient is lost (Fig. 47-11). This depletion of calcium regulates lamellar body exocytosis.[67–69] Calcium is a very important regulator of protein synthesis in the epidermis, including regulation of transglutaminase 1 activity.[70] Furthermore, extracellular calcium ions are important for cell-to-cell adhesion and epidermal differentiation. Intracellular calcium is controlled by more than one mechanism as demonstrated by the two genetic diseases discussed below.

Disturbed regulation of calcium metabolism and increased TEWL[71] occur in Darier disease, characterized by loss of adhesion between suprabasal epidermal cells associated with abnormal keratinization, and in Hailey–Hailey disease which shows loss of

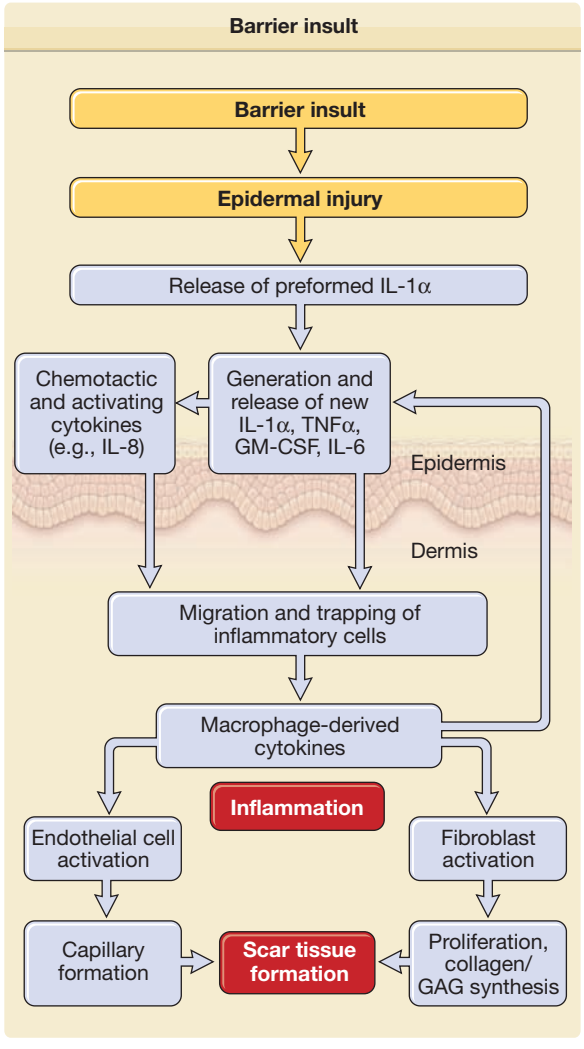

Figure 47-10 A barrier insult from the outside results not only in the release of cytokines for epidermal cell signaling, but also interacts with dermal processes, which may result in inflammation and ultimately scar tissue formation in case of destructions of the dermis. GAG = glycosaminoglycan; GM-CSF = granulocyte macrophage-colony stimulating factor; IL = interleukin; TNF = tumor necrosis factor.

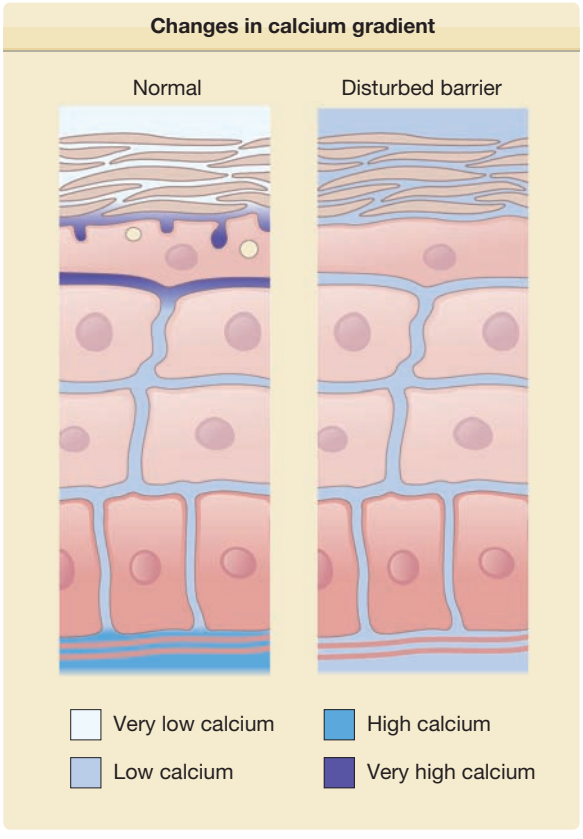

Figure 47-11 Changes in calcium gradient after barrier disruption regulates lamellar body secretion and epidermal differentiation.

epidermal cell-to-cell adhesion (see Chapter 51). The gene for Darier disease (*ATP2A2*) encodes a calcium transport ATPase of the sarco(endo)plasmic reticulum (SERCA2),[72,73] while the gene for Hailey–Hailey disease (*ATP2C1*) codes for a secretory pathway for calcium and manganese transport ATPase of the Golgi apparatus (SPCA1).[74]

NEUROTRANSMITTERS IN THE KERATINOCYTES: COMMON ORIGINS OF THE BRAIN AND SKIN

Neurotransmitters are found in keratinocytes and may regulate skin permeability barrier function. The receptors can be categorized in two groups: (1) ionotropic (calcium or chloride ion) receptors and (2) G-protein-coupled receptors. Topical application of calcium channel agonists delays the barrier recovery while antagonists accelerate barrier repair.

The G-protein-coupled receptors modulate intracellular cAMP level, increase of intracellular cAMP in epidermal keratinocytes delays barrier recovery, while cAMP antagonists accelerate the barrier recovery. Activation of dopamine 2-like receptors, melatonin receptors, or serotonin receptor (type 5-HT 1) decreases intracellular cAMP and consequently accelerates barrier recovery, while activation of adrenergic β2 receptors increases intracellular cAMP and delays the barrier repair. Many agonists or antagonists of neurotransmitter receptors are used clinically to treat nervous disorders. Some of them might also be effective for treating skin diseases.[75]

PATHOLOGICAL SKIN BARRIERS: SKIN BARRIER FUNCTION IN DERMATOSES

Mild impairment of the skin barrier is found in monogenetic diseases expressing an impaired epidermal differentiation or lipid composition without inflammation, for example, ichthyosis vulgaris and X-linked recessive ichthyosis (XLRI).[71] The diseases with a more pronounced barrier disruption are inflammatory diseases, for example, irritant and allergic contact dermatitis, atopic dermatitis, seborrheic dermatitis, psoriasis, and T-cell lymphoma. Also, blistering diseases, most of them inflammation-related, show an increase in TEWL, especially after loosening of the blister roof and the development of erosions (Table 47-4). Since HIV patients are known to display a xerotic phenotype, it seems likely that allergen penetration due to a disturbed skin barrier activates the Th2 pathway and consequently aggravates the underlying skin barrier disturbance (Table 47-4).[76]

Most inflammatory skin lesions are covered with dry scales or scale-crusts due to the disturbed epidermal differentiation and an SC with poor water-holding capacity. Inflammatory skin diseases can be produced by either exogenous or endogenous causes. In contact dermatitis, disruption of the barrier by irritants and allergens (which can also be irritants) is the primary event,

TABLE 47-4
Potential Role of the Cutaneous Barrier in the Pathophysiology of Skin Disorders

Barrier abnormality represents a primary or intrinsic process:
- Irritant contact dermatitis
- Allergic contact dermatitis
- Burns
- Ulcers (ischemic, vascular, diabetic)
- Bullous disorders by friction or keratin abnormalities
- Premature infant's skin
- Ichthyosis, Gaucher's (II), Niemann–Pick (I)

A primary barrier abnormality triggers immunologic reactions, but vice versa primary immunological reactions may trigger barrier abnormalities in yet unknown subgroups of the diseases:
- Atopic dermatitis
- Psoriasis

Immunologic abnormality triggers barrier abnormality:
- T-cell lymphoma (mycosis fungoides)
- Autoimmune bullous diseases
- Lichen planus
- Dry skin in HIV

followed by penetration of the chemicals into the living epidermal layers, irritation of the cell membrane, contact with immune cells, sensitization, inflammation, increased epidermal proliferation, and changes in differentiation. In T-cell lymphoma (mycosis fungoides), an endogenous cause for barrier disruption, changes in epidermal proliferation, and differentiation by expansion of clonal malignant $CD4^+$ T-cells are obvious.[77] In atopic dermatitis and in psoriasis, it is debatable whether permeability barrier disruption is followed by inflammation or whether inflammation leads to epidermal changes including barrier dysfunction. The vast majority of reports on the pathogenesis of atopic dermatitis and even more on psoriasis focused on the primary role of abnormalities in the immune system.[78] However, others have proposed an "outside–inside" pathogenesis for atopic dermatitis and other inflammatory dermatoses with barrier abnormalities,[79–81] as an alternative to the previous "inside–outside" paradigm.[82]

ATOPIC DERMATITIS: THE CONSEQUENCE OF A CHRONICALLY DISTURBED BARRIER

(See also Chapter 14)

The existence of a defective permeability barrier function in atopic dermatitis is now widely accepted. A genetically impaired skin barrier function is already present in nonlesional and more pronounced in lesional skin in atopic dermatitis. Increased epidermal proliferation and disturbed differentiation, including changes in keratins and cornified envelope proteins involucrin, loricrin, and filaggrin, and in lipid composition, cause impaired barrier function in atopic dermatitis (AD) (Fig. 47-12 and see eFig. 47-9.1 in online edition).[81] Mutations in the filaggrin gene have been described by several research groups.[83–85] Two loss-of-function genetic variants in the gene encoding filaggrin are strong predisposing factors for atopic dermatitis in atopic kindreds of European origin.[86] Slightly different mutations are found in Asian patients with atopic dermatitis and ichthyosis vulgaris.[87] These mutations were also significantly associated with asthma, independent of atopic dermatitis, which means that genetic factors that compromise the epidermal barrier could also underlie mucosal atopic diseases (filaggrin is a protein that is unique to keratinizing epithelia). The atopic syndrome represents a genetically impaired skin barrier function as well as impaired nasal, bronchial, and intestinal mucous membrane barriers leading to atopic dermatitis, allergic rhinitis, bronchial asthma, or aggravation of atopic dermatitis. Defective permeability barrier function enables penetration of environmental allergens into the skin and initiates immunological reactions and inflammation (Fig. 47-13). Filaggrin mutation is the first strong genetic factor identified in this complex disease. Filaggrin hydrolysis generates amino acids in their deiminated products that probably serve, together with hornerin, as endogenous humectants.[88,89] This may explain the dry skin of atopic dermatitis. Also, gene polymorphisms in the gene for SPINK5, which encodes the serine protease inhibitor LEKTI, have been reported[90] and variations within two serine proteases of the kallikrein family, the SC chymotryptic enzyme that degrades corneodesmosomal proteins, involved in the cohesion between the corneocytes of the SC, have been found in some cohorts with AD.

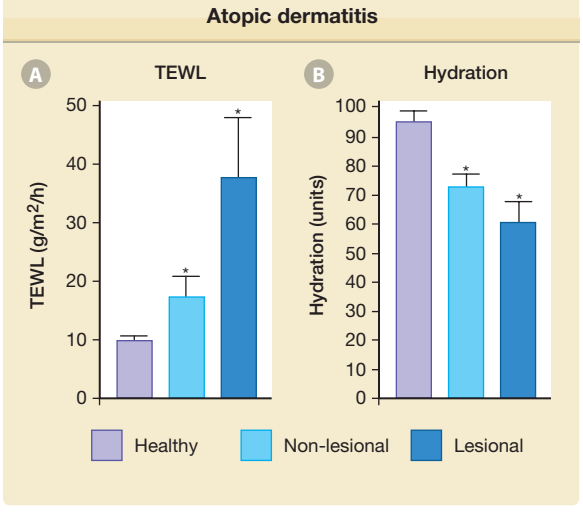

Figure 47-12 Transepidermal water loss (TEWL) (**A**) and stratum corneum hydration (**B**) are impaired in atopic dermatitis. Reduced stratum corneum hydration and enhanced TEWL are already seen in nonlesional skin and are more pronounced in lesional skin in atopic dermatitis.

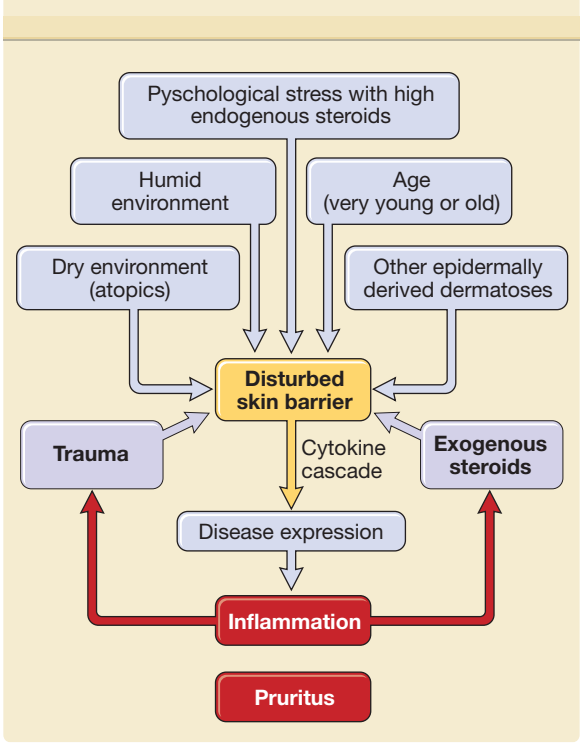

Figure 47-13 Endogenous and exogenous insults lead to a disturbance in skin barrier function, thus inducing or maintaining inflammatory skin diseases in atopic dermatitis.

The impaired skin barrier function in atopic dermatitis is also caused by a reduced lipid content or impaired lipid composition in the epidermis atopic dermatitis. In particular, a decreased content for the total amount and for certain types of ceramides has been described.[80] A decrease in covalently bound ceramides[91] and a reduced sphingomyelinase activity have been found in atopic dermatitis. Also, decreased lamellar body secretion, which is predominantly composed of lipids, with subsequent entombment of lamellar bodies within corneocytes, has been reported.[92]

PSORIASIS: EPIDERMAL HYPERPROLIFERATION AND THE SKIN BARRIER

(See also Chapter 18)

Psoriasis is a chronic, generalized, and scaly erythematous dermatosis that is primarily localized in the epidermis, showing highly enhanced proliferation and disturbed differentiation, which leads to hyperkeratosis and parakeratosis. In addition, there is a neutrophilic infiltrate in the beginning and in particular in severe cases of psoriasis; later on a moderate T-lymphocytic infiltrate is present. Because of this severely disturbed proliferation and epidermal differentiation, there is an impaired barrier function.[93] The level of TEWL is directly related with the clinical severity of the lesion: high TEWL in acute exanthematous psoriasis; a moderate increase in TEWL in the chronic plaque type of the disease. Abnormalities in the SC intercellular lipids, especially a significant reduction in ceramide 1, have been found.[94] Electron microscopy studies disclosed severe structural alteration of the intercellular lipid lamellae.[95] A genetic linkage of psoriasis to the epidermal differentiation complex 1q21 has been found. Within the epidermal differentiation complex, the SPRRs are highly upregulated in psoriasis plaques.[96] Also, the association of psoriasis with cytokeratin K17 has been discussed.

ICHTHYOSIS: THE PATHOLOGICAL LACK OF MOISTURE IN THE EPIDERMIS

(See Chapter 49)

Ichthyosis comprises a group of monogenetic diseases expressing a disturbed desquamation resulting in scales and a mild-to-moderate barrier defect. They are caused either by changes in epidermal lipids or by changes in epidermal differentiation. XLRI is a non-congenital ichthyosis, consisting of a generalized desquamation of large, adherent, and dark brown scales. The metabolic basis of XLRI is an enzymatic lysosomal deficiency of steroid sulfatase or arylsulphatase C. Complete deletions of the *STS* gene mapped to the Xp22.3-pter region have been found in up to 90% of patients. The reduced cholesterol sulfatase activity leads to accumulation of cholesterol sulfate and a reduction of cholesterol and consequent abnormality in the structural organization of the intercorneocyte lipid lamellae.[97–99]

Ichthyosis vulgaris is the most common monogenetic skin disease. Recently, loss-of-function mutations in the gene encoding filaggrin that cause ichthyosis vulgaris have been described. During terminal differentiation, profilaggrin is cleaved into multiple filaggrin peptides that aggregate keratin filaments. The resultant matrix is cross-linked to form a major component of the cornified cell envelope. Reduction of this major structural protein leads to an impaired keratinization and to a moderate defect in skin barrier function.[100]

Transglutaminase 1 is responsible for the cross-linking of several cornified envelope proteins. Therefore, deficiency in transglutaminases 1[57] leads to lamellar ichthyosis which is a more severe disease than ichthyosis vulgaris with a defect in filaggrin only.

TREATMENT IMPLICATIONS AND APPROACHES: RESTORING THE SKIN'S PROTECTIVE FUNCTION

Treatment strategies in inflammatory diseases often address immunogenic abnormalities and barrier function. Treatments with cyclosporine, tacrolimus, pimecrolimus, and UV light have been shown to reduce cell inflammation as well as to improve barrier function, thus helping to normalize proliferation and differentiation. Topical steroids, although clinically effective, do not lead to the repair of the disturbed skin barrier function seen in AD.[101] However, because of their side effects, all of these treatments should be used for a short time only. In contrast, application of bland creams and ointments containing lipids and lipid-like substances, hydrocarbons, fatty acids, cholesterol esters, and triglycerides can be used without side effects for long-term treatment of mild-to-moderate inflammatory diseases. Creams and ointments partially correct or stimulate barrier repair and increase SC hydration,[44,102–104] thus influencing epidermal proliferation and differentiation.[15] It has been proposed that a lipid mixture containing the three key lipid groups [(1) ceramides, (2) cholesterol, and (3) free fatty acids] is able to improve skin barrier function and SC hydration in AD.[105] Also, the efficacy of ceramide 3 in a nanoparticle cream in atopic dermatitis has been described.[106] However, because several research groups and companies report that creams containing ceramides and a mixture of the three key lipids are not superior to "classical" cream or ointment preparations, such preparations have not yet been widely used.

KEY REFERENCES

Full reference list available at www.DIGM8.com

DVD contains references and additional content

8. Bouwstra JA, Pilgrim K, Ponec M: Structure of the skin barrier. In: *Skin Barrier*, edited by PM Elias, KR Feingold. New York, Taylor and Francis, 2006, p. 65
10. Elias PM: Epidermal lipids, barrier function, and desquamation. *J Invest Dermatol* **80**:44s, 1983
25. Roop D: Defects in the barrier. *Science* **267**:474, 1995

30. Candi E, Schmidt R, Melino G: The cornified envelope: A model of cell death in the skin. *Nat Rev Mol Cell Biol* **6**(4):328, 2005
44. Jensen JM, Proksch E, Elias PM: The stratum corneum of the epidermis in atopic dermatitis. In: *Skin Barrier*, edited by PM Elias, KR Feingold. New York, Taylor and Francis, 2006, p. 569
49. Brandner JM, Proksch E: Epidermal barrier function: Role of tight junctions. In: *Skin Barrier*, edited by PM Elias, KR Feingold. New York, Taylor and Francis, 2006, p. 191
81. Proksch E, Foelster-Holst R, Jensen JM: Skin barrier function, epidermal proliferation and differentiation in eczema. *J Dermatol Sci* **43**(3):159-169, 2006
86. Irvine AD, McLean WH: Breaking the(un)sound barrier: Filaggrin is a major gene for atopic dermatitis. *J Invest Dermatol* **126**:1200, 2006

Chapter 48 :: Irritant Contact Dermatitis

:: Antoine Amado, Apra Sood, & James S. Taylor

IRRITANT CONTACT DERMATITIS AT A GLANCE

- Irritant contact dermatitis (ICD) is a nonimmunologic inflammation of the skin caused by contact with a chemical, physical, or biologic agent.
- Up to 80% percent of contact dermatitis is irritant and is commonly related to occupation.
- The most important exogenous factor for ICD is the inherent toxicity of the chemical for human skin.
- Endogenous factors, such as skin barrier function and preexisting dermatitis, play an important role in the pathogenesis of ICD.
- Atopic dermatitis is a major risk factor for irritant hand dermatitis because of impaired barrier function and a lower threshold for skin irritation.
- Patch testing should be performed in cases with suspected chronic irritant dermatitis to exclude an allergic contact dermatitis.
- Identification and avoidance of the potential irritant is the mainstay of treatment.

Dermatitis or eczema is a pattern of cutaneous inflammation that presents with erythema, vesiculation, and pruritus in its acute phase. Its chronic phase is characterized by dryness, scaling, and fissuring. Irritant contact dermatitis (ICD) is a cutaneous response to contact with an external chemical, physical, or biologic agent; endogenous factors such as skin barrier function and preexisting dermatitis also play a role (Figs. 48-1 and 48-2). The spectrum of presentation after contact with an irritant varies from overt dermatitis to subjective symptoms, contact urticaria, caustic and necrotic reactions as well as pigmentary changes and other dermatoses.

EPIDEMIOLOGY

In contrast to allergic contact dermatitis (ACD), no previous exposure to the causative agent is necessary in eliciting irritant reactions.[1] ICD accounts for 80% of all cases of contact dermatitis,[2,3] and is often occupation-related (occupational ICD is discussed in detail in Chapter 211). ICD caused by personal care products and cosmetics is also common; however, very few patients with these irritant reactions seek medical help because they manage by avoiding the offending agent.[4]

The incidence of ICD is difficult to determine because the accuracy of the epidemiologic data is limited. European cross-sectional studies for eczema due to all causes in the general population have shown point prevalence rates of 0.7%–40% and 1-year to lifetime prevalence rates of 7.2%–11.8%.[5] Data from the U.S. Bureau of Labor Statistics show that of the 257,800 cases of nonfatal occupational illnesses reported in 2008 for



Figure 48-1 Irritant contact dermatitis in a welder.

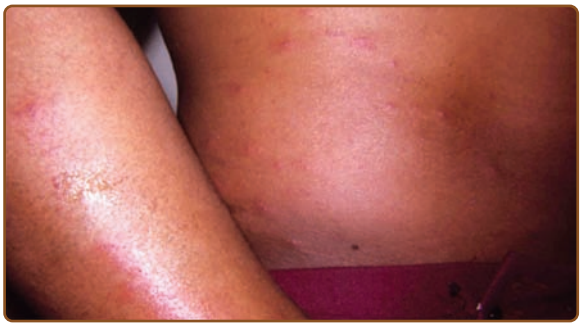

Figure 48-2 Irritant pustular dermatitis from nickel salts.

all industries including state and local government and private industry, 18.9% (48,600 cases) were skin diseases, the second most frequent cause of all occupational illnesses reported.[6] Based also on annual surveys of the Bureau of Labor Statistics incidence rates of occupational diseases in the American working population, contact dermatitis constitutes 90%–95% of all occupational skin diseases, and ICD constitutes about 80% of occupational contact dermatitis.[7]

ETIOLOGY AND PATHOGENESIS

Four interrelated mechanisms have been associated with ICD: (1) removal of surface lipids and water-holding substances, (2) damage to cell membranes, (3) epidermal keratin denaturation,[8–11] and (4) direct cytotoxic effects.[11] There is a clearly demonstrated immunologic-like component to the irritant response,[12] which is characterized by the release of proinflammatory mediators, particularly cytokines, from nonimmune cutaneous cells (keratinocytes) in response to chemical stimuli. This is a process that does not require previous sensitization.[10] Disruption of the skin barrier leads to release of cytokines such as interleukin (IL) 1α, IL-1β, and tumor necrosis factor-α (TNF-α). A tenfold increase in the levels of TNF-α and IL-6, and a threefold increase in the levels of granulocyte-macrophage colony-stimulating factor and IL-2 have been observed in ICD. TNF-α is one of the key cytokines in irritant dermatitis, leading to the increased expression of major histocompatibility complex class II and intracellular adhesion molecule 1 on keratinocytes.[10,13] The chemokine CCL21 that hones naive T-lymphocytes to the skin, has also been shown to be elevated in the skin during irritant reactions.[14]

Loss of function polymorphisms in the filaggrin gene, an important protein for skin barrier function, have been associated with an increased susceptibility to chronic ICD.[15] At the same time, it is hypothesized that upregulation of ceramide 1 synthesis in the epidermis plays a major role in inducing the hardening phenomenon in cutaneous irritation.[16]

INFLUENCING FACTORS

ICD is a multifactorial disease where both exogenous (irritant and environmental) and endogenous (host) factors play a role.

EXOGENOUS FACTORS

(See Table 48-1)

Other than with strong acids and alkalis, it has not been possible to predict the irritant potential of a chemical based on molecular structure. The irritant potential of compounded formulations may be more difficult to predict. Factors to be considered include: (1) chemical properties of the irritant: pH, physical state, concentration, molecule size, amount, polarization, ionization, vehicle, and solubility; (2) characteristics of exposure: amount, concentration, duration and type of contact, simultaneous exposure to other irritants, and interval after previous exposure;[4,17] (3) environmental factors: body region and temperature; (4) mechanical factors such as pressure, friction, or abrasion;[2] and (5) ultraviolet (UV) radiation. Low ambient humidity and cold temperature decrease the water content of the stratum corneum, making it more permeable to irritants. Larmi et al[18] demonstrated that UVB radiation diminished the nonimmunological reactions caused by sodium lauryl sulfate (SLS)-induced irritation, probably as a result of anti-inflammatory effects.

When one or more irritants are combined or used simultaneously, a synergistic or antagonistic effect may occur as a consequence of specific cellular interactions between the compounds, or an alteration in the skin permeability by one or more of the compounds, that would not occur when an irritant is used alone.[4,12] This is known as the *crossover phenomenon*. In a study by Wigger-Alberti et al,[19] concurrent application of SLS and toluene twice daily for 30 minutes to the volar forearms of healthy volunteers induced significantly stronger irritant reactions than those caused by twice-daily application of each chemical alone. This study suggests a crossover phenomenon between the two compounds by which one irritant caused an increased susceptibility to the other. On the other hand, McFadden and

TABLE 48-1
Exogenous Factors Influencing Cutaneous Irritation

Type of irritant (pH, chemical activity)
Cutaneous penetration of irritant
Body temperature
Mechanical factors (pressure, friction, abrasion)
Environment (temperature, humidity)
Other exposure factors: duration, prior or simultaneous exposures, direct versus airborne

Data from Denig NI, Hoke AW, Maibach HI: Irritant contact dermatitis. Clues to causes, clinical characteristics, and control. *Postgrad Med* **103**:199-200, 207-208, 212-213, 1998; Frosch PJ, Jhon SM: Clinical aspects of irritant contact dermatitis. In: *Contact Dermatitis*, 4th edition, edited by PJ Frosh, T Menné, J-P Lepoittevin. Germany, Springer-Verlag Berlin Heidelberg, 2006, pp. 255-294; Weltfriend S, Maibach HI: Irritant dermatitis: Clinical heterogeneity and contributing factors. In: Marzulli *and Maibach's Dermatotoxicology*, 7th edition, edited by H Zhai, K-P Wilhelm, HI Maibach. Boca Raton, CRC Press, 2008, pp. 125-138.

colleagues[20] demonstrated the neutralizing effect of benzalkonium chloride over the irritant effect of SLS.

ENDOGENOUS FACTORS

(See Table 48-2)

GENETIC FACTORS. It has been hypothesized that an individual's ability to quench free radicals, to change the levels of antioxidant enzymes, and the ability to form protective heat shock proteins may all be under genetic control. These factors also determine the variability in responsiveness to irritants.[21] Additionally, a genetic predisposition to irritant susceptibility may be specific for each irritant.[22]

GENDER. The majority of clinical ICD affects the hands, and women account for a majority of these patients.[23] Rather than a gender-related skin susceptibility, this demographic may reflect the facts that women have more extensive exposure to irritants and wet work and are more likely to seek treatment than men.[4,17,24] On the other hand, there are anecdotal reports that suggest that the menstrual cycle can affect the sensitivity of women to primary irritants and can affect their dermatological response.[25] No gender difference for ICD has been established experimentally.

AGE. Children younger than 8 years of age are more susceptible to percutaneous absorption of chemicals and to irritant reactions.[4] Most studies show no compromise in skin barrier permeation with increasing age. Data on the influence of aging on experimental skin irritation are conflicting. Visible skin irritation (erythema) is decreased in older persons while invisible skin irritation (barrier damage) might be increased in the elderly.[26]

ETHNICITY. There are no studies that demonstrate a significant influence of skin types on the development of ICD.[27–29] Because erythema is difficult to measure in dark skin, early studies[30] using erythema as the only parameter to quantify irritation may have led to an erroneous interpretation that black skin is more resistant to irritation than white skin. It is also possible that variations among individuals rather than ethnicity play a role in the intensity of an irritant response.[31]

SKIN SITE. There are significant site differences in barrier function, making the skin of the face, neck, scrotum, and dorsal hands more susceptible to ICD. The palms and soles are comparatively more resistant.[32]

ATOPY. A history of atopy is a well-known risk factor for irritant hand dermatitis (see Chapter 14). A history of atopic dermatitis seems to be linked to an increased susceptibility to irritant dermatitis because of a lower threshold for skin irritation, impaired skin barrier function, and a slower healing process.[33]

In summary, the most important ICD risk factors are the inherent toxicity of the chemical for human skin and its penetration.[34] The most important endogenous factors are an atopic diathesis and skin barrier function.[26]

TABLE 48-2
Endogenous Factors Influencing Cutaneous Irritation

Atopic dermatitis
Skin site
Skin permeability
Individual (genetic) susceptibility
Primary sensitive (hyperirritable) skin
Lack of hardening
Secondary hyperirritability of the skin (status eczematicus)

Data from Denig NI, Hoke AW, Maibach HI: Irritant contact dermatitis. Clues to causes, clinical characteristics, and control. *Postgrad Med* **103**:199-200, 207-208, 212-213, 1998; Frosch PJ, Jhon SM: Clinical aspects of irritant contact dermatitis. In: *Contact Dermatitis*, 4th edition, edited by PJ Frosh, T Menné, J-P Lepoittevin. Germany, Springer-Verlag Berlin Heidelberg, 2006, pp. 255-294, Weltfriend S, Maibach HI: Irritant dermatitis: Clinical heterogeneity and contributing factors. In: *Marzulli and Maibach's Dermatotoxicology*, 7th edition, edited by H Zhai, K-P Wilhelm, HI Maibach. Boca Raton, CRC Press, 2008, pp. 125-138.

CLINICAL TYPES OF IRRITANT CONTACT DERMATITIS

ICD has a spectrum of clinical features, which can be divided into several different categories, depending on the irritant and its exposure pattern.[35] But these manifestations also depend on mechanical, thermal, climatic, and constitutional factors.[17] The clinical types of ICD vary according to the irritant in question: ulceration (e.g., strong acids or alkalis), folliculitis (e.g., oils and greases), miliaria (e.g., aluminum chloride), hyperpigmentation (e.g., heavy metals), hypopigmentation (e.g., *p*-tert-butylphenol),[10] alopecia (e.g., borax), urticaria (e.g., foods and plants), and granulomas (e.g., silica, talc)[36] (see Table 211-1).

At least ten clinical types of ICD have been described. They are listed in Table 48-3 along with a number of clinical subtypes of acute and chronic ICD.

1. *Irritant reaction:* An irritant reaction clinically presents as an acute monomorphic reaction that includes scaling, low-grade erythema, vesicles, or erosions and is usually localized on the dorsum of the hands and fingers. It is often seen in individuals who are exposed to wet work. An irritant reaction can resolve or progress to cumulative irritant dermatitis.[10,12]
2. *Acute ICD:* Acute ICD usually results from a single skin exposure to a strong irritant or caustic chemical, such as alkalis and acids, or as a result of a series of brief chemical or physical contacts. Most cases of acute irritant dermatitis are a consequence of accidents at work. A sensation of burning, itching, or stinging may occur immediately after the exposure to the irritant. The patient may present with erythema,

edema, and vesiculation and with exudation, bullae formation, and tissue necrosis in more severe cases. The healing process of acute ICD occurs as a decrescendo phenomenon, where the irritant reaction quickly peaks and then immediately begins to heal upon removal of the irritant. Complete healing may take 4 weeks, with a good prognosis.[4,12,17]

Other forms of acute irritant reaction have been also described (see Table 48-3), such as airborne contact dermatitis resulting from exposure to irritant volatile substances and fumes or powders and dusts and particles (Table 48-4).[4,17] Irritant cheilitis may result from lip licking or use of cosmetics and medication. Diaper dermatitis and perianal dermatitis may be the result of prolonged or too frequent contact with urine or fecal residues.[17] Dermatitis resulting from sodium azide released by airbag deployment has also been described,[37] causing an alkaline chemical burn; the accompanying talc powder may also contribute to the dermatitis.

3. *Delayed acute irritancy:* The delayed irritant reaction is acute but without visible signs of inflammation appearing until 8–24 hours or more after exposure. Otherwise, the clinical appearance and course are similar to those of an acute ICD.[4,12] The delayed presentation may simulate that of an ACD, sometimes making differentiation of the two disorders difficult, even with patch testing. Substances causing delayed irritancy are listed in Table 48-5. Delayed acute irritancy in general has a good prognosis.[10,12,17]
4. *Chronic cumulative ICD:* This is the most frequent type of contact dermatitis encountered in clinical practice. Also called *traumiterative ICD*, cumulative ICD develops as a result of repeated insults to the skin, where the chemicals involved

TABLE 48-3
Types of Irritant Contact Dermatitis (ICD)

Irritation	Onset
Irritant reaction	Acute, often multiple exposures
Acute ICD	Acute, often single exposure
Delayed acute ICD	Delayed (12–24 hours or longer)
Chronic (cumulative) ICD	Slowly developing (weeks to years)
Subjective (sensory) irritation	Acute
Suberythematous (nonerythematous) irritation	Slowly developing
Frictional dermatitis	Moderate–slow developing (weeks to months)
Traumatic ICD	Slowly developing after preceding trauma
Pustular or acneiform ICD	Moderately slowly developing (weeks to months)
Asteatotic irritant eczema (exsiccation eczematid)	Moderate–slow developing
Other clinical subtypes of acute and chronic ICD	
Interdigital	Slowly developing (days to weeks)
Frictional melanosis	Slowly developing (months to years)
Diaper dermatitis	Acute or delayed
Chemical burns	Acute or delayed
Nonimmunologic contact urticaria	Acute
Airborne	Acute
Scalp irritation	Acute or delayed
Nail irritation	Delayed to slow
Tandem[a]	Acute or delayed
Photoirritation[a]	Acute

[a]Personal communication HI Maibach, June, 2005.

Source: Data from Weltfriend S, Maibach HI: Irritant dermatitis: Clinical heterogeneity and contributing factors. In *Marzulli and Maibach's Dermatotoxicology*, 7th edition, edited by H Zhai, K-P Wilhelm, HI Maibach. Boca Raton, CRC Press, 2008, pp. 125-138; Chew A-L, Maibach HI: Ten genotypes of irritant contact dermatitis. In: *Irritant Dermatitis*, edited by A-L Chew, HI Maibach. Germany, Springer-Verlag Berlin Heidelberg, 2006, pp. 6-9.

TABLE 48-4
Airborne Irritants

Volatile Substances
Acids and alkalis
Ammonia
Anhydrous calcium sulfate
Carbonless copy paper
Dichlorvos
Domestic cleaning products
Epoxy resins
Formaldehyde
Industrial solvents
Powders
Metallic oxide powders
Sawdust from toxic trees
Silver fulminate dust
Wool dust (in atopic patients)
Cement
Calcium silicate
Particles, Salts, Foams
Arsenic
Fiberglass
Phenol formaldehyde resins
Sodium sesquicarbonate
Urea-formaldehyde insulating foam, dust foam

Data from Denig NI, Hoke AW, Maibach HI: Irritant contact dermatitis. Clues to causes, clinical characteristics, and control. *Postgrad Med* **103**:199-200, 207-208, 212-213, 1998; Weltfriend S, Maibach HI: Irritant dermatitis: Clinical heterogeneity and contributing factors. In: *Marzulli and Maibach's Dermatotoxicology*, 7th edition, edited by H Zhai, K-P Wilhelm, HI Maibach. Boca Raton, CRC Press, 2008, pp. 125-138.

TABLE 48-5
Chemicals Causing Delayed Irritant Reactions

Acrylates (some)
  Butanediol diacrylate
  Hexanediol diacrylate
  Tetraethylene glycol diacrylate
Anthralin (Dithranol)
Benzalkonium chloride
Benzoyl peroxide
Bis(2-chloroethyl)sulfide
Calcipotriol
Dichlor(2-chlorovinyl)arsine
Diclofenac
Epichlorhydrine
Ethylene oxide
Fluorohydrogenic acid
Nonanoic acid
Octyl gallate
Podophyllin
Propylene glycol
Sodium lauryl sulfate
Tretinoin

Data from Denig NI, Hoke AW, Maibach HI: Irritant contact dermatitis. Clues to causes, clinical characteristics, and control. *Postgrad Med* **103**:199-200, 207-208, 212-213, 1998; Frosch PJ, Jhon SM: Clinical aspects of irritant contact dermatitis. In: *Contact Dermatitis*, 4th edition, edited by PJ Frosh, T Menné, J-P Lepoittevin. Germany, Springer-Verlag Berlin Heidelberg, 2006, pp. 255-294; Weltfriend S, Maibach HI: Irritant dermatitis: Clinical heterogeneity and contributing factors. In: *Marzulli and Maibach's Dermatotoxicology*, 7th edition, edited by H Zhai, K-P Wilhelm, HI Maibach. Boca Raton, CRC Press, 2008, pp. 125-138.

are often multiple and weak and would not in themselves be strong enough to cause irritant dermatitis.[10,12,17] The most common marginal irritants include soap, detergents, surfactants, organic solvents, and oils,[2] which may also act as perpetuating factors once the dermatitis has become established. Cosmetic cumulative ICD is not infrequent in women, particularly involving the eyelids.[17]

Initially, cumulative contact dermatitis can appear with itch, pain, and a few localized patches of dry skin; then erythema, hyperkeratosis, and fissuring can develop.[2,4,12,17] The symptoms do not immediately follow exposure to the irritant, appearing after days, months, or years of exposure. With extensive and frequent exposure to some irritants, the skin becomes hardened, with better resistance to future irritant exposures. Hardened skin appears coarse and lichenified, which may contribute to resistance. However, even brief periods away from exposure lower the resistance, and with reexposure, patients are once again at risk for irritation. Chronic cumulative ICD can be confused with ACD because of the delayed and variable presentation, and appropriate diagnostic patch testing is indicated to exclude ACD. The prognosis of cumulative ICD is variable.[4,12]

5. *Subjective (symptomatic, sensory) irritancy:* Patients complain of itching, tingling, stinging, burning, or smarting sensation within minutes of contact with an irritant, but without visible cutaneous changes.[12,35] Subjective irritancy usually occurs on the face, head, and neck. Cosmetics, sunscreens, and woolen garments are commonly implicated.[3,4,35] Other common sensory irritants include lactic acid (a model for this phenomenon), propylene glycol, and aluminum salts. Stimulation of cutaneous type C nociceptors has been implicated in this form of irritancy,[12] although recently changes in cutaneous vasculature have been implicated. Some sensory irritation may be nonimmunologic contact urticaria. Screening raw ingredients or final formulations with the guinea pig ear swelling test or the human forehead assay may allow one to minimize subclinical contact urticaria.[38]
6. *Suberythematous (nonerythematous) irritation:* This is a state in which the irritation is not visually apparent, but is histologically visible. Common symptoms include burning, itching, or stinging. Suberythematous irritation has been linked with the use of consumer products containing significant amounts of surfactant.[4,12]
7. *Frictional dermatitis:* Mechanical irritation can result from repeated microtrauma and friction. Nipple dermatitis in patients with ill-fitting bras, and dermatitis from prosthetic limbs, mechanical injury from thorns and spines in plants, adhesive tape, or from handling coarse paper, glass, and rock wool fiber are only some.[10,17] This type of contact irritation usually leads to dry, hyperkeratotic abraded skin, making it more vulnerable to the effects of irritants.[4]
8. *Traumatic reactions:* Traumatic reactions can develop after acute skin trauma as burns or lacerations and most commonly occurs on the hands and persists for about 6 weeks or longer. The healing process in this type of dermatitis is prolonged, and erythema, scaling, papules, or vesicles can appear. The clinical course can resemble that of nummular dermatitis.[4,12]
9. *Pustular or acneiform reactions:* Pustular or acneiform reactions are usually seen after occupational exposures to oils, tars, heavy metals, and halogens but also after the use of some cosmetics. The pustular lesions are sterile and transient and may develop several days after exposure. This type of dermatitis is seen especially among atopic and seborrheic patients.[4,9,12]
10. *Asteatotic irritant eczema (exsiccation eczematid):* Exsiccation eczematid usually occurs in elderly patients who frequently shower without applying moisturizers to their skin. Intense itching, dry skin, and ichthyosiform scaling are clinical features that characterize this irritant reaction.[12]

COMMON IRRITANTS

(Table 48-6)

Water is a hypotonic element that acts as a cytotoxic agent on eroded skin.[17] Hard water has been found to be more irritating than soft water.[39] Skin cleansers cause irritation depending on the chemistry of their constituents. They remove surface lipid film, denature proteins, and damage the cell membrane. Soaps, detergents, and waterless cleansers are the most common irritants. Preservatives, especially quaternary ammonium compounds, have an irritant effect.[17] Löffler and Kampf[40] investigated the biological response of regular human skin to alcohol-based disinfectants and detergents and demonstrated that the degree of skin irritation is significantly lower after application of alcohol in comparison to detergents.

Foods, such as citrus peels, garlic, flour, and spices, can act as irritants.[17] Capsaicin produces hand irritation after handling hot peppers and is also present in some personal defense sprays used by police or by civilians.[1] Pineapple juice contains bromelain, an irritating proteolytic enzyme.[41]

Other potential irritants include animal products from seafood and meat, from caterpillars, carpet beetles, and moths, from insect secretions[42]; cosmetics, especially when applied to the eyelids; alkalis, present in soap, bleaches, detergents, oven cleansers, and toilet bowl cleaners;[1] topical medicaments, such as gentian violet, tar, potassium permanganate, mercury, hexachlorophene, etc.[17] The majority of skin reactions due to transdermal drug delivery systems would be a form of ICD, this may be minimized by rotation of the application site, careful removal of the patch, and appropriate use of moisturizers and topical corticosteroids.[43] Fiberglass dermatitis can develop from wearing clothes that have been washed together with fiberglass-contaminated work clothes or with fiberglass curtains.[44] Other tear gases, [e.g., 2-chlorobenzylidene malononitrile, known as *CS* (pepper spray) and, rarely, 1-chloroacetophenone, known as *CN* (Mace)] are present in a variety of self-defense or riot-control sprays[1] and cause lacrimation, sternutation (sneezing), and, occasionally, cutaneous irritation and sensitization.

TABLE 48-6
Causes of Irritant Contact Dermatitis

Animal products
Cosmetics
Degreasing agents
Detergents
Dusts/friction
Foods
Low humidity
Metal working fluids
Tear gases
Topical medicaments
Solvents
Water/wet work

Data from Contact dermatitis and drug eruptions. In: *Andrews' Diseases of the Skin. Clinical Dermatology*, 10th edition, edited by WJ James, TG Berger, DM Elston. Philadelphia, Elsevier, 2006, pp. 91-94; Wilkinson SM, Beck MH: Contact dermatitis: Irritant. In: *Rook's Textbook of Dermatology*, 7th edition, edited by T Burns, S Breathnach, N Cox, C Griffths. Oxford, Blackwell Publishers, 2004, pp. 19.1-19.30.

DIAGNOSIS

DIFFERENTIAL DIAGNOSIS

(Box 48-1)

ICD is often diagnosed by excluding other causes for the dermatitis, including ACD.[2] A detailed inquiry, including occupational, recreational (hobbies), and past medical histories, and a meticulous clinical examination are important for making the correct diagnosis. History of exposure to friction, wet work, soaps, and detergents or exposure to organic or alkaline solvents; and/or an environmental relative humidity of less than 35% are key factors that support a diagnosis of irritancy.[45] When an allergic component is considered, diagnostic patch testing should be performed.[33] A biopsy often cannot differentiate allergic, irritant, or atopic dermatitis, but may be helpful in excluding psoriasis, in the case of palmar involvement. Measuring transepidermal water loss (TEWL) can indicate barrier impairment but cannot distinguish between ACD and ICD. Rietschel[11] has proposed criteria with subjective and objective features, each with major and minor findings for the diagnosis of ICD. The more features identified, the stronger the case for ICD (Table 48-7).

PREDICTIVE TESTS, GENETICS AND BIOENGINEERING METHODS

In their review of premarket predictive tests for irritants, Basketter and Kimber[46] conclude that except where appropriate human tests, such as the 4-hour prophetic patch test, can be conducted; skin irritation tests, especially in animals, are of limited value in the characterization of the potential effects associated with actual exposure of humans to irritants. In the clinical setting there is likely to be exposure to multiple irritants.

In attempts to predict individual susceptibility to irritants, a number of tests have been studied, including alkali resistance with sodium hydroxide, ammonium hydroxide, dimethyl sulfoxide, threshold response to various irritants (SLS, nonanoic acid, benzalkonium chloride, kerosene, croton oil, and anthralin), lactic acid stinging, minimal erythema dose with UVB radiation, and measurement of TEWL. In their review, Frosch and John[34] conclude that none is so simple and reliable that it can be used on a large scale. A number of these procedures have been used experimentally, usually with individual chemicals, with the results having limited applicability, but they may be of some value in predicting thresholds of irritation. Of the bioengineering methods used, TEWL measurement is the most frequently used procedure to quantify impaired functions of the stratum corneum. Clinically invisible subtle damage, such as by detergents, can be reliably detected by an increase in TEWL.

BOX 48-1 DIFFERENTIAL DIAGNOSIS OF IRRITANT CONTACT DERMATITIS (MAJOR TYPES)

Most Likely

- Localized
  - Atopic eczema
  - Asteatosis
  - Seborrheic dermatitis
  - Stasis dermatitis
- Disseminated
  - Atopic eczema
  - Asteatosis
  - Autoeczematization
  - Tinea corporis

Consider

- Localized
  - Corticosteroid acne
  - Dermatophytosis
  - Factitial dermatitis
  - Herpes simplex
  - Herpes zoster
  - Lichen simplex chronicus
  - Rosacea
- Disseminated
  - Dermatophytosis
  - Drug eruption
  - Nummular eczema
  - Psoriasis
  - Parapsoriasis
  - Polymorphous light eruption

Always Rule Out

- Localized
  - Allergic contact dermatitis
  - Bowen disease
- Disseminated
  - Allergic contact dermatitis
  - Cutaneous T-cell lymphoma

Data from Denig NI, Hoke AW, Maibach HI: Irritant contact dermatitis. Clues to causes, clinical characteristics, and control. *Postgrad Med* **103**:199-200, 207-208, 212-213, 1998; Rietschel RL: Clues to an accurate diagnosis of contact dermatitis. *Dermatol Ther* **17**:224-230, 2004.

A TNF-α gene polymorphism offers a novel approach to detect susceptibility to ICD. In humans, a G to A transition polymorphism has been identified at position P308 within the promoter region of the TNF-α gene. An analysis of different genotypes revealed a correlation between the A allele and a low threshold to irritants.[47]

According to Astner and colleagues,[48] reflectance-mode confocal microscopy facilitates the differentiation of acute ACD from ICD. Stratum corneum disruption, epidermal necrosis, and hyperproliferation were found to be the hallmarks of ICD, whereas ACD was more typically presented with vesicle formation.

A recent study[49] found the use of polarized light as an enhanced visual scoring method to increase the ability to detect low (subclinical) levels of irritation, indicating this noninvasive method has the potential to increase the sensitivity of all clinical dermatological studies.

TABLE 48-7
Diagnostic Criteria of Irritant Contact Dermatitis

Major	Minor
Subjective	
Onset of symptoms within minutes to hours of exposure	Onset of dermatitis within 2 weeks of exposure
Pain, burning, stinging, or discomfort exceeding itching early in the clinical course	Many people in the environment affected similarly
Objective	
Macular erythema, hyperkeratosis, or fissuring predominating over vesiculation	Sharp circumspection of the dermatitis
Glazed, parched, or scalded appearance of the epidermis	Evidence of gravitational influence, such as dripping effect
Healing process begins promptly on withdrawal of exposure to the offending agent	Lack of tendency of the dermatitis to spread
Patch testing is negative	Morphologic changes suggesting small concentration differences or contact time produce large differences in skin damage

Adapted from Rietschel RL: Clues to an accurate diagnosis of contact dermatitis. *Dermatol Ther* **17**:224-230, 2004.

PATCH TESTING

Patch testing is often essential to distinguish ACD from ICD or to diagnose concomitant ICD and ACD. Negative patch tests may favor a diagnosis of ICD "by exclusion" of ACD. A diagnosis of ACD may be missed with false-negative patch test results (see Chapters 13 and 211).[11,33] Conversely, patch testing with obvious irritants, or nonstandard chemicals or mixtures can lead to false-positive patch test results. Irritant patch test reactions may present as erythema with or without papules and often remain confined to the test site and are sharply demarcated. These irritant reactions also show a decrescendo pattern, in which a decreasing severity is seen, although this is not always a reliable indicator.[3,33] Irritant patch test reactions do not equate with ICD but only reflect the irritating patch test concentration or procedure. It is important to perform comprehensive patch testing with the appropriate substances and concentrations to prevent incorrect conclusions.[11]

TREATMENT

Identification and elimination of the irritants and protection from further exposure are important in the management of ICD.[4] Once dermatitis develops, topical treatment is helpful. The role of topical corticosteroids in the management of ICD is controversial, but they may be helpful because of their anti-inflammatory effect.[4,50] However, prolonged use of topical corticosteroids may lead to epidermal atrophy and increased susceptibility to irritants. Emollients or occlusive dressings may improve barrier repair in dry, lichenified skin.[4,17] Traditional petrolatum-based emollients are accessible, inexpensive, and have been shown to be as effective as emollient containing skin-related lipids.[51] Other "barrier creams" are of limited value.[52] Topical calcineurin inhibitors (e.g., pimecrolimus) may be used as an alternative to low-potency topical corticosteroids in chronic ICD.[53,54]

In severe or chronic cases, phototherapy (psoralens with UVA or UVB) or systemic drugs, such as azathioprine and cyclosporine, may be effective.[17,50] Bacterial superinfection can be treated with topical or systemic antibiotics.[17] In sensory irritation, strontium salts act by selectively blocking the activation of cutaneous type C nociceptors.[12]

PREVENTION

ICD is a risk factor for the development of ACD because the impaired skin barrier may facilitate the potential for the induction and elicitation of ACD. Thus, the prevention of irritant dermatitis reduces the risk of ACD.[10,55]

Although long established behavior patterns may be difficult to change,[55] once an irritant has been identified as the causal factor, patients should be educated about irritant avoidance, including everyday practices that may cause or contribute to the ICD.

The use of personal protective equipment, especially in high-risk jobs, is very important. Protective gloves should be worn for any wet work. However, patients should avoid wearing waterproof gloves for long periods of time to help reduce sweating. If prolonged wearing is required, gloves should have a fabric lining or alternatively, thin cotton gloves can be worn inside waterproof gloves.[3] Bock et al[56] evaluated the impact of semipermeable glove membranes (GoreTex® and Sympatex®) on skin barrier repair following SLS-induced irritation and demonstrated an improved barrier recovery and reduced inflammation compared to either occlusive membranes (vinyl) or an uncovered control. These results suggest a unique benefit by semipermeable protective gloves for preventing occupational skin disease by minimizing glove-induced irritation and by enhancing barrier recovery in cases of preexisting minor irritant dermatitis. In another study, the use of gel-filled anti-impaction gloves such as those used for hand-arm vibration exposure, has been shown to aid in the return-to-work process for those patients with occupational frictional hand dermatitis but not with hyperkeratotic hand dermatitis.[57]

If used correctly, protective gloves can reduce or eliminate exposure of the hands to hazardous substances, but if not selected and used properly, gloves can actually cause or worsen ICD of the hands by increasing exposure to hazardous chemicals. Hence, the correct use of gloves is at least as important as selection of gloves made of the appropriate material.[58]

Less irritating substances, such as emollients and soap substitutes, should be used rather than soap when washing. Moisturizers are thought to increase hydration or prevent TEWL, thereby maintaining skin barrier function and reducing the risk of ICD. Care should be taken for several months after the dermatitis has healed, as the skin remains vulnerable to flares of dermatitis for a prolonged period.[3,33,35]

PROGNOSIS

The prognosis for acute ICD is good if the causative irritant can be identified and eliminated. The prognosis for cumulative or chronic irritant dermatitis is guarded and may be worse than that of ACD.[59] An atopic background, lack of knowledge about the disease, and/or a delayed diagnosis and treatment are factors that lead to a worse prognosis.[17] Persistent post-occupational dermatitis has been reported in 11% of individuals.[60]

KEY REFERENCES

Full reference list available at www.DIGM8.com

DVD contains references and additional content

11. Rietschel RL: Clues to an accurate diagnosis of contact dermatitis. *Dermatol Ther* **17**:224-230, 2004
15. de Jongh CM et al: Loss-of-function polymorphisms in the filaggrin gene are associated with an increased susceptibility to chronic irritant contact dermatitis: A case-control study. *Br J Dermatol* **159**:621-627, 2008
23. Lammintausta KH. Gender. In: *Irritant Dermatitis*, edited by AL Chew, HI Maibach. Germany, Springer-Verlag Berlin Heidelberg, 2006, pp. 173-176
34. Frosch PJ, Jhon SM: Clinical aspects of irritant contact dermatitis. In: *Contact Dermatitis*, 4th edition, edited by PJ Frosh, T Menné, J-P Lepoittevin. Germany, Springer-Verlag Berlin Heidelberg, 2006, pp. 255-294
36. Weltfriend S, Maibach HI: Irritant dermatitis: Clinical heterogeneity and contributing factors. In: *Marzulli and Maibach's Dermatotoxicology*, 7th edition, edited by H Zhai, K-P Wilhelm, HI Maibach. Boca Raton, CRC Press, 2008, pp. 125-138
40. Löffler H, Kampf G: Hand disinfection: How irritant are alcohols? *J Hosp Infect* **70**:44-48, 2008
43. Ale I, Lachapelle JM, Maibach HI: Skin tolerability associated with transdermal drug delivery systems: An overview. *Adv Ther* **26**:920-935, 2009
54. Mensing CO, Mensing CH, Mensing H: Treatment with pimecrolimus cream 1% clears irritant dermatitis of the periocular region, face and neck. *Int J Dermatol* **47**:960-964, 2008
58. Kwon S, Campbell LS, Zirwas MJ: Role of protective gloves in the causation and treatment of occupational irritant contact dermatitis. *J Am Acad Dermatol* **55**:891-896, 2006

Chapter 49 :: The Ichthyoses

:: Philip Fleckman & John J. DiGiovanna

ICHTHYOSES AT A GLANCE

- A heterogeneous group of skin diseases characterized by generalized scaling, and often areas of thickened skin.
- Most types are inherited, and these usually present at birth. However, some forms are acquired.
- Scales may vary in size, color, and body site.
- May be accompanied by erythema, abnormalities in other parts of skin and adnexal structures.
- May be associated with systemic findings, such as failure to thrive, increased susceptibility to infection, atopic dermatitis, neurosensory deafness, neurologic and other disease.
- Pathology is usually nonspecific with the exception of epidermolytic hyperkeratosis, neutral lipid storage disease, Refsum disease, and acquired ichthyosis associated with sarcoidosis.

The ichthyoses are a heterogeneous group of skin diseases characterized by generalized scaling. Scaling reflects altered differentiation of the epidermis. In this chapter, the terms epidermal differentiation, keratinization, and cornification will be used synonymously. The name *ichthyosis* is derived from the Greek *ichthys*, meaning "fish," and refers to the similarity in appearance of the skin to fish scale. Both inherited and acquired forms are found. Early reports of ichthyosis in the Indian and Chinese literature date back to several hundred years BC, and the condition was discussed by Willan in 1808.[1]

Ichthyosis can present at birth or develop later in life. It can occur as a disease limited to the skin or in association with abnormalities of other organ systems. A number of well-defined types of ichthyosis with characteristic features can be reliably diagnosed. However, because of the great clinical heterogeneity and the profound effect of the environment on scaling, a specific diagnosis can be challenging in certain patients and families.

Siemens introduced genetic concepts into the ichthyoses.[2] Wells and Kerr classified the ichthyoses on a genetic basis[3] and separated X-linked recessive ichthyosis from ichthyosis vulgaris (IV).[4] Gassman developed the concept of retention versus hyperproliferation hyperkeratosis[5]. Van Scott, Frost, and Weinstein subsequently proposed a classification of the ichthyoses based on differences in rates of epidermal turnover, characterizing them as either disorders of epidermal hyperproliferation or disorders of prolonged retention of the stratum corneum.[6] Subsequently, Williams and Elias proposed a classification that lists the disorders of cornification in which clinical, genetic, or biochemical data suggest a distinct disease.[7] Traupe reviewed the ichthyoses and suggested classification on a clinical level.[5]

Genetic approaches to understanding the ichthyoses have revealed the gene defects underlying many of these genodermatoses.[8] A new classification is evolving based on the underlying molecular and genetic bases of these disorders. Knowing which gene is mutated directs us to the underlying pathophysiologic process. Understanding and describing these disorders on the basis of common molecular processes leads to more rational approaches to understanding their pathophysiology and treatment. A listing of the more common and the better understood hereditary ichthyoses according to pattern of inheritance and clinical features is shown in Tables 49-1 to 49-3. Grouping these disorders according to underlying gene defect (Table 49-4) facilitates understanding of the clinical phenotypes in terms of underlying mechanism. However, further work is necessary to clearly understand how the gene mutations and resultant protein disruptions result in clinical disease, and furthermore, how therapeutic interventions can be creatively developed.

Online Mendelian Inheritance in Man, OMIM,[10] (trademark Johns Hopkins University), a catalog of human genes and genetic disorders, is a useful reference with links to additional resources.

CLINICAL PRESENTATION

A specific diagnosis in an individual or family with ichthyosis can help to predict prognosis, is important for genetic counseling, and may direct treatment. Several features are useful in distinguishing different forms of ichthyosis. These include the age of onset, presence of collodion membrane at birth, quality of scale, presence/absence of erythroderma, abnormalities in other parts of the skin (e.g., palms and soles, ectropion, eclabium) and adnexal structures (e.g., alopecia, hair follicle, or shaft abnormality), and involvement of other organ systems. In different types of ichthyosis, the appearance of the surface of the skin may vary. Visible scaling may be seen in some patients, with flakes of stratum corneum varying in size from fine to coarse. There may also be thickening of the skin with or without visible scale. The term hyperkeratosis has been used clinically to describe thickened skin, with or without scale, that reflects thickening of the stratum corneum. A family pedigree may clarify the pattern of inheritance. However, many autosomal

TABLE 49-1
Features of Selected Ichthyoses, Dominant

A—Autosomal Dominant/Semidominant

Diagnosis	Onset	Characteristic Clinical Features	Associated Features	Gene	Protein	Function	Skin Histopathology
Autosomal Semidominant							
Ichthyosis vulgaris OMIM #146700	Infancy/ childhood	Fine or centrally tacked-down scale with superficial fissuring. Relative flexural sparing; worse on lower extremities. Hyperlinear palms/soles.	Keratosis pilaris; atopy	*FLG*	Absence of filaggrin	Uncertain	Hyperkeratosis; reduced or absent granular layer
Autosomal Dominant							
EHK (bullous CIE) OMIM #113800	Birth	Heterogeneous. May have verrucous, firm, hyperkeratotic (hystrix) spines, often linearly arrayed in flexural creases; blisters; may have erythroderma and/or palmar/plantar keratoderma	Frequent skin infections; characteristic pungent odor	*KRT1, KRT10;* in Vörner type (confined to palms/soles) *KRT 9*	Keratin 1 or 10; in Vörner type, keratin 9	Structural protein abnormality leading to keratin intermediate filament dysfunction—epidermal fragility	Hyperkeratosis; vacuolated degeneration of the epidermal granular (and often deeper) layer; large, irregular keratohyalin granules
Ichthyosis bullosa of Siemens OMIM #146800	Birth	Redness and blistering at birth. Later develop hyperkeratosis, accentuated over flexures. Mauserung (molting): collarette-like lesion where uppermost epidermis has been lost.		*KRT2*	Keratin 2, which is expressed in superficial epidermis	As above for EHK	Similar to epidermolytic hyperkeratosis, but confined to the upper spinous and granular layer
Ichthyosis hystrix of Curth and Macklin OMIM #146590	Birth	Resembles EHK, varies from palmar/ plantar keratoderma to generalized. Thick "porcupine-like" spines. No blistering.		*KRT1*—mutation in variable region	Keratin 1	As above for EHK	Upper epidermal keratinocytes have perinuclear vacuolization/ perinuclear shells of tonofilaments

Annular epidermolytic erythema OMIM #607602 Erythrokeratodermia variabilis— OMIM #133200	Birth/infancy Annular plaques develop later	Severe, intermittent scaling with blisters or pustules. Evolves to widespread, migratory, annular plaques.		*KRT1, KRT10*	Keratin 1 or 10	As above for EHK	As above for EHK
Generalized type	Birth	Generalized hyperkeratosis and figurate, migratory red patches	Red patches move over minutes to hours, may be triggered by changes in temperature	*GJB3* or *GJB4*	Connexin 31 or 30.3; connexins form gap junction channels between cells	Abnormal intercellular communication	Hyperkeratosis, acanthosis, papillomatosis, capillary dilatation; epidermis may have "church spire" appearance
Localized type	Variable	Localized hyperkeratotic plaques with figurate, migratory red patches.	Hyperkeratotic plaques may be induced by trauma. Considerable intrafamilial variability				
Progressive symmetric erythrokeratodermia OMIM #602036	Shortly after birth	Erythematous, scaly plaques, symmetrically distributed over extremities, buttocks, and face; stabilize in early childhood. Trunk tends to be spared.		*LOR or GJB4*	Connexin 30.3	Cornified envelope precursor	Nonspecific
Keratitis–ichthyosis–deafness (KID) syndrome Recessive has been reported OMIM #148210	Birth/infancy	Progressive corneal opacification; either mild generalized hyperkeratosis or discrete erythematous plaques, which may be symmetric; neurosensory deafness.	Follicular hyperkeratosis, scarring alopecia, dystrophic nails, susceptibility to infection	*GJB2, GJB6*	Connexin 26, 30; connexins form gap junction channels between cells	Abnormal intercellular communication	Nonspecific

CIE = congenital ichthyosiform erythroderma; EHK = epidermolytic hyperkeratosis; OMIM = Online Mendelian Inheritance in Man.
Note: These are the predominant modes of inheritance.

TABLE 49-2
Features of Selected Ichthyoses, X-linked

Diagnosis	Onset	Characteristic Clinical Features	Associated Features	Gene	Protein	Function	Skin Histopathology
X-linked recessive ichthyosis OMIM #308100	Birth/infancy	Fine to large scales; comma-shaped corneal opacities on posterior capsule	Cryptorchidism; female carriers may have corneal opacities and delay of onset or progression of labor in affected pregnancies	*STS*	Steroid sulfatase	Lipid metabolism—abnormal cholesterol metabolism with accumulation of cholesterol sulfate	Hyperkeratosis, may have hypergranulosis; nonspecific
Chondrodysplasia punctata X-linked recessive (CDPX) OMIM #302950	Birth	May begin as erythroderma, linear or whorled atrophic areas or hyperkeratosis, alopecia, skeletal abnormalities, short stature	Cataracts, deafness	*ARSE*	Arylsufatase E	Lipid metabolism—ill defined: failure of hydrolysis of sulfate ester bonds	
X-linked dominant chondrodysplasia punctata (Conradi–Hünermann–Happle syndrome) (CDPX2) OMIM #302960	Birth	CIE at birth, clears and is replaced by linear hyperkeratosis, follicular atrophoderma and pigmentary abnormalities, stippled calcifications on radiographs	Occurs almost exclusively in females; hair shaft abnormalities, short stature, cataracts	*EBP*	Emopamil binding protein (EBP)—also known as 3β-hydroxysteroid-$\Delta^{8,7}$-isomerase	Lipid metabolism—abnormal cholesterol biosynthesis	
CHILD syndrome X-linked dominant OMIM #308050	Birth	Congenital hemidysplasia, ichthyosiform erythroderma, limb defects	Almost exclusively in females	*NSDHL*; *EBP* reported	NSDHL (3 β-hydroxysteroid dehydrogenase); EBP reported	Lipid metabolism—postsqualene cholesterol biosynthesis	

CHILD = *c*ongenital *h*emidysplasia with *i*chthyosiform erythroderma and *l*imb *d*efects; CIE = congenital ichthyosiform erythroderma; EBP = emopamil binding protein; NSDHL = *N*AD(P)H steroid *deh*ydrogenase-*l*ike protein; OMIM = Online Mendelian Inheritance in Man.
Note: These are the predominant modes of inheritance.

TABLE 49-3
Features of Selected Ichthyoses, Autosomal Recessive

Diagnosis	Onset	Characteristic Clinical Features	Associated Features	Gene	Protein	Function	Skin Histopathology
ARCI (See Table 49-5)							
ARCI/LI	Birth; often collodion presentation	Large, plate-like, brown scale over most of the body; accentuated on lower extremities. Ectropion; eclabium; alopecia. Palmar/ plantar involvement varies.	Heat intolerance	See Table 49-5	See Table 49-5	See Table 49-5	Hyperkeratosis, acanthosis, may show parakeratosis. Nonspecific.
ARCI/CIE		Fine, white scale; generalized erythroderma. Palmar/plantar involvement varies.					
ARCI/overlap		Varies between "lamellar" and "CIE."					
Harlequin ichthyosis OMIM #242500	Birth	Markedly thickened skin with geometric, deep fissures. Survivors develop severe CIE phenotype.	Restricted respiration, feeding; neonatal sepsis; often leads to neonatal death. Failure to thrive.	*ABCA12*	ATP-binding cassette, subfamily A, member 12	Lipid metabolism—Membrane transport, abnormality of lipid metabolism	Massively thickened, orthokeratotic stratum corneum; variable acanthosis; granular layer variably decreased
Ichthyosis prematurity syndrome OMIM #608649	Birth	Premature delivery of infants with erythrodermic, edematous, caseous scaling skin resembling excessive vernix caseosa, evolves into dry, scaly skin with follicular accentuation with signs of atopy	Respiratory distress, and transient peripheral eosinophilia. The respiratory signs resolve.	*FATP4 (SLC27)*	Fatty acid transport protein 4	Lipid metabolism—fatty acid transport	Trilamellar membrane inclusions are seen in the stratum corneum by electron microscopy.
Netherton syndrome OMIM #256500	Birth	Ichthyosis linearis circumflexa or similar to congenital ichthyosiform erythroderma; trichorrhexis invaginata	Atopy; high serum levels of IgE; may have aminoaciduria; failure to thrive	*SPINK5*	LEKTI (a serine protease inhibitor)	Protein metabolism—may result in premature desmosomal and profilaggrin degradation in stratum corneum.	Nonspecific

(continued)

TABLE 49-3
Features of Selected Ichthyoses, Autosomal Recessive (Continued)

Diagnosis	Onset	Characteristic Clinical Features	Associated Features	Gene	Protein	Function	Skin Histopathology
Sjögren–Larsson syndrome OMIM #270200	Ichthyosis apparent at birth	Generalized fine to coarse hyperkeratosis; spastic diplegia; mental retardation; retinal glistening white dots	Short stature, seizures	*FALDH (ALDH10, ALDH3A2)*	Fatty aldehyde dehydrogenase	Lipid metabolism—Fatty aldehyde metabolism	Nonspecific
Refsum disease OMIM #266500	Ichthyosis develops in adulthood	Progressive neurologic dysfunction; skeletal, cardiac, and renal abnormalities	Retinitis pigmentosa, elevated plasma phytanic acid	Most *PAHX; PEX 7* also reported (see RCPD below)	Phytanoyl-CoA hydroxylase (PhyH)	Peroxisome abnormality—Deficiency of phytanic acid catabolism; results in phytanic acid accumulation.	Lipid-containing vacuoles in basal keratinocytes
Trichothiodystrophy (Tay syndrome; *PIBI(D)*S, *IBI(D)*S, *BI(D)*S) OMIM #278730 OMIM #601675 OMIM #234050	Some have ichthyosis, which may be apparent at birth; may have collodion presentation	*B*rittle hair, *P*hotosensitivity, *S*hort stature, *I*chthyosis, *I*ntellectual impairment, microcephaly, recurrent infections	Abnormally low sulfur content of hair.	Majority have defect in *ERCC2* (XPD). A few have mutations in *ERCC3* (XPB), *GTF2H5* (TTDA), or *TTDN1*.	Most XPD. XPB, TTDA, or TTDN1 in a few	Components of transcription factor TFIIH	Tiger tail banding of shafts under polarizing microscopy; hair shaft abnormalities (trichoschisis, trichorrhexis nodosa-like fraying; ribboning)
Chanarin–Dorfman syndrome (neutral lipid storage disease) OMIM #275630	Birth; may have collodion membrane	Generalized scaling, resembles CIE; variable extracutaneous involvement: cataracts, decreased hearing, psychomotor delay.	Severe pruritus; neurologic abnormalities; hepatic abnormalities; lipid droplets in circulating leukocytes	*CGI-58*	Unknown	Lipid metabolism—Activates adipose-triglyceride lipase for lipolysis of tryglycerides	Lipid droplets in dermal and epidermal cells, and acrosyringia of eccrine ducts
Neonatal ichthyosis–sclerosing cholangitis syndrome #6073718	Birth	Neonatal cholestatic jaundice, mild ichthyosis with fine, white scales.	Scarring alopecia of the scalp and eyebrows, enamel dysplasia	*CLDN1*	Claudin 1	Abnormal tight junction	Intracytoplasmic vacuoles in keratinocytes that do not stain with oil red O

Multiple sulfatase deficiency OMIM #272200	Birth	Ichthyosis resembling X-linked recessive	Neurological deterioration; skeletal abnormalities; facial dysmorphism	*SUMF1*	C_{α}-formylglycine generating enzyme	Generates catalytic residue in active site of eukaryotic sulfatases	Nonspecific
Peeling Skin Syndrome							
Type A (noninflammatory) OMIM #270300	Birth	Generalized peeling in superficial, thin flakes		Unknown	Unknown	Unknown	Intracellular split within corneocytes in stratum corneum
Type A—acral variant OMIM #609796		Limited to over hands and feet		*TGM5*	Transglutaminase 5	Protein cross-linking	Nonspecific
Type B (inflammatory)		Presents as CIE; evolves to migratory, scaling patches	Pruritus, elevated IgE, aminoaciduria, short stature	Unknown	Unknown	Unknown	Intercellular split between stratum corneum and granular layer; between keratinocytes

ARCI = autosomal recessive congenital ichthyosis; ATP = adenosine triphosphate; CIE = congenital ichthyosiform erythroderma; CoA = coenzyme A; LEKTI = *l*ympho-*e*pithelial *K*azal-*t*ype related *i*nhibitor; LI = lamellar ichthyosis; OMIM = Online Mendelian Inheritance in Man.
Note: These are the predominant modes of inheritance.

TABLE 49-4
Ichthyoses Organized by Pathophysiology

Disorder	Protein/Function Abnormality
Structural Proteins	
Ichthyosis vulgaris	Filaggrin
Cytoskeleton	
Annular epidermolytic ichthyosis	Keratins
Epidermolytic hyperkeratosis (EHK)	
Ichthyosis bullosa of Siemens	
Ichthyosis hystrix of Curth and Macklin	
Pachyonychia congenita[a]	
Palmar/plantar keratoderma[a]	
Palmar/plantar keratoderma with EHK	
Cornified Envelope Formation	
ARCI/LI	Transglutaminase 1
Mutilating keratoderma with ichthyosis[a]	Loricrin
(Vohwinkle syndrome without deafness)	
Progressive symmetric erythrokeratodermia	
Intercellular Junctions	
Naxos disease	Plakoglobin
NISCH syndrome	Claudin 1
PPK, wooly hair, cardiomyopathy[a]	
(Carvajal–Huerta syndrome)	Desmoplakin
Striate PPK 1[a]	Desmoglein 1
Striate PPK 2[a]	Desmoplakin
Lipid Metabolism	
ARCI	Hepoxilin pathway
CEDNIK	Lamellar granule maturation and secretion
Maturation and secretion	
Chanarin–Dorfman syndrome	Function unknown
CHILD syndrome	Steroid dehydrogenase
	Sterol isomerase
Conradi– Hünermann–Happle syndrome	Sterol isomerase
Ichthyosis prematurity syndrome	Fatty acid transport
Refsum syndrome	Phytanic acid catabolism
Sjögren–Larsson syndrome	Fatty aldehyde and fatty alcohol metabolism
X-linked recessive ichthyosis	Steroid sulfatase
Intercellular Communication	
Erythrokeratodermia variabilis	Gap junction proteins: Connexins
KID (keratitis, ichthyosis, deafness)	
Progressive symmetric erythrokeratodermia	
PPK with deafness[a]	
Vohwinkel syndrome (classic)	
Protein Metabolism	
KLICK	Proteosome
MEDNIK	Protein trafficking by intracellular vesicles
Netherton syndrome	Protease inhibitor
Papillon–Lefevre syndrome[a]	Protease
Calcium Homeostasis[b]	
Darier disease	Ca^{++} dependent ATPase
Hailey–Hailey disease	
Other	
Cellular Respiration	
PPK with deafness[a]	Mitochondrial serine tRNA
Neurotransmitter	
Mal de Meleda[a]	Function unknown
Nucleotide Excision Repair/Transcription	
Trichothiodystrophy[c]	Transcription

[a]Discussed in Chapter 50.
[b]Discussed in Chapter 51.
[c]Discussed in Chapter 139.

dominant diseases [e.g., *epidermolytic hyperkeratosis* (EHK)] have a high frequency of spontaneous mutation, and the lack of a positive family history does not rule out autosomal dominant inheritance. Alternatively, the presence of parental consanguinity may suggest autosomal recessive inheritance. Light microscopic features are usually diagnostic in epidermolytic hyperkeratosis and can be helpful in selected ichthyoses (e.g., Refsum disease, neutral lipid storage disease, acquired ichthyosis of sarcoidosis and mycosis fungoides), but histopathologic examination may not be useful to distinguish other ichthyoses. In many cases, the clinical diagnosis may be clarified by genetic analysis, although mutations are not always demonstrable. The development of ichthyosis in adulthood may be a marker of systemic disease.

ETIOLOGY AND PATHOGENESIS

The fully differentiated end product of the epidermis is the stratum corneum, which is composed of terminally differentiated keratinocytes, corneocytes ("bricks"), surrounded by an intercellular matrix ("mortar") (see Chapter 47). The corneocyte bricks are protein-enriched, and the intercellular mortar is composed of hydrophobic, lipid-enriched membrane bilayers.[7] The keratin-laden corneocytes are thought to be primarily responsible for the resilience and water retention properties of the stratum corneum, while the matrix forms most of the permeability barrier to water loss. The normal stratum corneum undergoes desquamation in an organized and invisible manner, with individual corneocytes separating from each other and shedding as single cells. Ichthyotic skin has an abnormal quality and quantity of scale, the barrier function of the stratum corneum is compromised, and there may be alterations in the kinetics of epidermal cell proliferation (see Chapter 46). The stratum corneum can be viewed as a compartment, with thickening of the stratum corneum being the result of cells entering the compartment at an increased rate, or leaving (corneocyte desquamation) too slowly, or both.

The process of epidermal differentiation is complex and not completely understood. Defects in many different aspects and steps of this process can lead to a similar end result: abnormal stratum corneum and scale. In some of these disorders, the underlying gene defect has been identified. For example, mutations in the genes that encode the suprabasal epidermal keratins, keratins 1 and 10, cause epidermolytic hyperkeratosis.[11] Mutations in the gene encoding transglutaminase-1, an enzyme that catalyzes the cross-linking of proteins and attachment of ceramides during the formation of corneocytes, are found in up to 55% of patients with *autosomal recessive congenital ichthyosis*.[12–15] The observation that key components of this process cause ichthyosiform disorders highlights the importance and complexity of normal keratinocyte differentiation.

Steroid sulfatase controls the hydrolysis of cholesterol sulfate in corneocytes and is thought to be important in the regulation of corneocyte desquamation. Deficiency of steroid sulfatase causes X-linked recessive ichthyosis.[16,17] The observation that several drugs that lower serum cholesterol (e.g., nicotinic acid, triparanol) can induce ichthyotic skin changes indicates the importance of lipid homeostasis in normal keratinization.[7] Further evidence is the identification of mutations in the genes encoding cholesterol biosynthetic enzymes as a cause of X-linked dominant chondrodysplasia punctata and CHILD (congenital hemidysplasia with ichthyosiform erythroderma and limb defects) syndrome, and genes encoding other aspects of lipid biosynthesis in the autosomal recessive congenital ichthyoses.[18] The identification of mutations in *SPINK5* (*s*erine *p*rotease *in*hibitor, *K*azal type *5*), encoding a serine protease inhibitor, in Netherton syndrome confirms a role for proteolysis and protease inhibitors in normal epidermal differentiation.[19] The discoveries of connexin abnormalities as causes for erythrokeratodermia variabilis, KID (keratitis, ichthyosis, and deafness) syndrome, and other disorders involving ectodermal tissues highlight the role of intercellular communication for properly functioning skin.[20,21] Mutations in the *FLG* gene result in reduced or absent filaggrin and decreased moisture binding in the stratum corneum of patients with IV.[22] Mutations in *FLG* may also result in more severe clinical phenotype in other skin disorders.[23,24]

These examples highlight the complexity of the process of forming a normally functioning stratum corneum and demonstrate that diverse abnormalities can result in similar clinical phenotypes of thickened stratum corneum and scaling. How do diverse processes result in similar phenotype? The answers are unclear, although studies suggest that defects in the barrier may result in inflammation and hyperproliferation.[25] Furthermore, our evolving understanding of these mechanisms continues to clarify the multisystem, clinical phenotypes observed in several ichthyosiform disorders.

ICHTHYOSIS VULGARIS

Ichthyosis vulgaris (OMIM #146700), the most common ichthyosis, is relatively mild. While infants usually have normal skin, the disease often manifests within the first year. The scale of IV is usually most prominent on the extensor surfaces of the extremities, with flexural sparing (Fig. 49-1). The diaper area tends to be spared. There may be fine, white scales over large areas. Particularly on the lower extremities, which are often the most severely involved area, the scales may be centrally attached, with "cracking" (superficial fissuring through the stratum corneum) at the edges. This turning up at the edges can lead to the skin feeling rough.

A number of other findings are commonly observed in association with IV.[26] Hyperlinear palms are usually present, and some patients may have palmar/plantar thickening approaching a keratoderma. Keratosis pilaris is common, even in individuals with mild IV, and usually involves the outside of the arms, extensor thighs, and buttocks. Atopy is also frequently observed and can manifest as hay fever, eczema, or asthma. These findings can confound an accurate diagnosis,



Figure 49-1 Ichthyosis vulgaris. Full presentation of IV in individuals with mutations in both alleles of the profilaggrin gene (**A**, **C**, **E**); milder presentation in an individual with a profilaggrin mutation in a single allele (**B**, **D**, **F**). **A** and **B**. Fine, white scale on lower abdomen. **C**–**F**. Hyperlinear palms. (From Smith FJ et al: Loss-of-function mutations in the gene encoding filaggrin cause ichthyosis vulgaris. *Nat Genet* **38**:337, 2006, with permission.)

because hyperlinear palms and keratosis pilaris may be seen in atopic individuals who do not have IV. Rarely, individuals with IV may have hypohidrosis with heat intolerance. There is great variation in the severity of clinical manifestations between affected individuals in the same family. The condition usually worsens in climates that are dry and cold and improves in warm, humid environments where the disease may clear dramatically.

The disease was thought to be autosomal dominant and in a study of English school children was found to affect 1 in 250.[4] Recently, mutations in the gene encoding profilaggrin have been found to cause IV. Profilaggrin is the precursor protein for multiple copies of filaggrin, which functions during cornification. The inheritance pattern has been clarified to be semidominant; individuals who carry one mutated allele have a mild phenotype, while those with mutations in both

profilaggrin alleles (homozygotes or compound heterozygotes for the mutations) (Fig. 49-1) manifest a severe clinical phenotype. In the Anglo-European population, the prevalence of clinical disease is as high as 1 in 80.[22,27,28]

It is difficult to distinguish some patients with mild IV from simple dry skin (xerosis). Evolving understanding of this very common condition is beginning to clarify how a spectrum of underlying mutations can cause the diverse clinical severity of dry skin from xerosis to severe IV. In addition, on the basis of skin findings alone, males with severe IV may be difficult to differentiate from those affected with X-linked recessive ichthyosis.[26,29] The histopathologic findings of IV (Fig. 49-2A) may, as the clinical severity, be more pronounced, with hyperkeratosis and absent granular layer in individuals with two abnormal alleles.

Filaggrin is an epidermal protein involved in the aggregation of keratin intermediate filaments[30] and retention of moisture in the stratum corneum.[31] Keratin filaments form a network, or cell matrix, that gives structural integrity to the epidermal keratinocytes. As keratinocytes mature into corneocytes, the keratin filaments collapse and are cross-linked to the cornified cell envelope. Filaggrin is synthesized as a high-molecular weight precursor, profilaggrin, that contains multiple filaggrin molecules and is localized to keratohyalin granules. Biochemical studies of epidermis from patients with IV have shown absence of or decrease in filaggrin and its precursor, profilaggrin.[32,33] In the Anglo-European population, null mutations in the gene encoding profilaggrin (*FLG*) are very strong predisposing factors for atopic dermatitis. A strong association is also found with individuals who have sensitivity to common allergens, allergic rhinitis, early onset and persistent eczema, and asthma in the presence of atopic dermatitis.[27,34]

X-LINKED RECESSIVE ICHTHYOSIS

In the 1960s, *X-linked recessive ichthyosis* (OMIM #308100) was distinguished clinically from other ichthyoses.[4] Shortly thereafter, the syndrome of placental steroid sulfatase deficiency was described in pregnancies with failure to initiate labor in association with low maternal urinary estrogens. Because the majority of maternal urinary estrogens are derived from the fetal adrenal and are metabolized by the placenta, low levels can reflect fetal abnormalities or death. However, in this condition low levels do not indicate severe fetal morbidity. The association between failure to

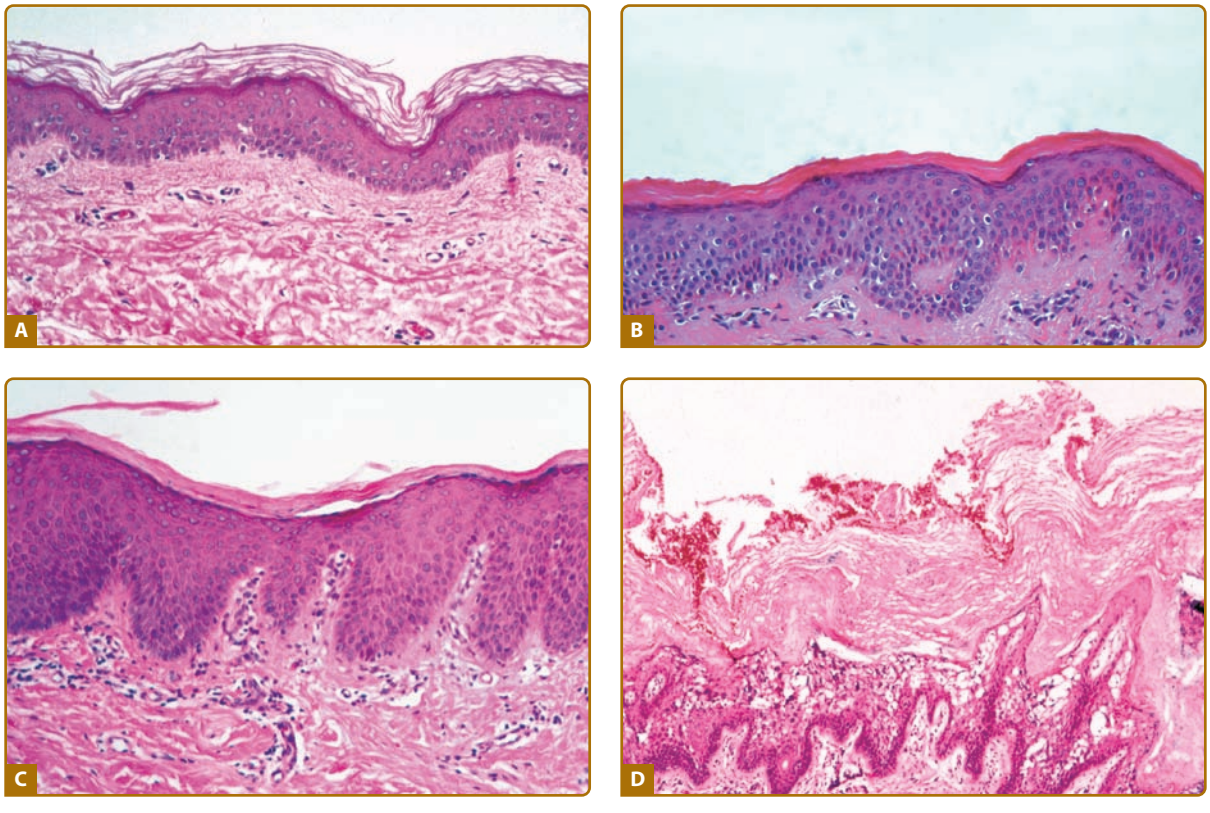

Figure 49-2 Histopathology. **A.** Ichthyosis vulgaris. Note absent granular layer. **B.** X-linked recessive ichthyosis. Note compact hyperkeratosis and accentuated granular layer. (Used with permission from Rob McFarlane, MD). **C.** Autosomal recessive congenital ichthyosis (CIE). Thickened stratum corneum composed of compact hyperkeratosis with foci of parakeratosis. **D.** Epidermolytic hyperkeratosis. The stratum corneum is thickened (hyperkeratosis) and there is prominent vacuolar degeneration of suprabasalar epidermis most marked at the granular layer.

initiate or progress labor and ichthyosis in the male offspring was not appreciated until 1978.[16,17] Steroid sulfatase hydrolyzes sulfate esters, which include cholesterol sulfate and sulfated steroid hormones.[35] Sulfated fetal adrenal hormones undergo desulfation to estrogens, which are excreted in maternal urine. The absence of steroid sulfatase enzyme in the fetal placenta leads to low maternal urinary estrogens, and in some pregnancies, to a failure of labor to initiate or to progress normally. In males with X-linked recessive ichthyosis, steroid sulfatase enzyme activity is decreased or absent in many tissues, including epidermis, stratum corneum, and leukocytes, and in cultured fibroblasts.[36] In addition, cholesterol sulfate, an enzyme substrate, accumulates in serum and in scale. Carrier females have been found to have leukocyte steroid sulfatase levels intermediate between those observed in normal individuals and those in affected males.

X-linked recessive ichthyosis occurs in approximately 1 in 2,000 to 6,000 males.[4,37] Scaling may begin in the newborn period and is usually most prominent on the extensor surfaces, although there is significant involvement of the flexural areas. While the extent and degree of scaling are variable, X-linked ichthyosis can usually be distinguished from IV on clinical criteria.[4,38] The latter tends to be associated with hyperlinear palms and soles, keratosis pilaris, and a family history of atopy. X-linked ichthyosis tends to have more severe involvement with larger scale, and comma-shaped, corneal opacities may be present in half of adult patients[39,40] (Fig. 49-3). Corneal opacities do not affect vision and may be present in female carriers.[40] Affected males have an increased risk of cryptorchidism, and independently they are at increased risk for the development of testicular cancer.[41] Histopathologic examination shows compact orthohyperkeratosis, acanthosis, and papillomatosis. The granular layer is usually thickened (Fig. 49-2).

Cholesterol sulfate levels are elevated in the serum, epidermis, and scale,[42] and there is increased mobility of β-lipoproteins (low-density lipoproteins) on electrophoresis, a feature that can suggest the diagnosis. Steroid sulfatase is one of a group of arylsulfatases located on chromosome Xp22. More than 90% of the mutations in X-linked ichthyosis are deletions that can often be detected by fluorescence in situ hybridization (FISH), available in many clinical laboratories. Confirmation of the diagnosis can also be made by finding an elevation in serum cholesterol sulfate levels. Unfortunately, cholesterol sulfate determination in serum and scale may not be readily available for laboratory confirmation of the clinical diagnosis. In the rare case where deletions are not detected and a clinical diagnosis is necessary, arylsulfatase C (steroid sulfatase) enzyme activity can be measured in cultured fibroblasts. Deletions that include adjacent sulfatases explain the overlap syndromes involving chondrodysplasia punctata and X-linked ichthyosis.[43] The X-linked form of Kallmann syndrome, in which hypogonadotropic hypogonadism and anosmia are found, often with renal abnormalities, obesity, synkinesis (mirror image



Figure 49-3 X-linked recessive ichthyosis. **A.** The scales are large and dark and most evident on the flexural areas in this patient. **B.** The blue arc is a cross-section of the cornea as seen by slit-lamp examination. The opacities appear white.

movements of the extremities), cleft palate, and spastic paraplegia, can also be seen in association with X-linked recessive ichthyosis as part of a contiguous gene deletion syndrome.[43] Because of this, and because of the association with testicular carcinoma, patients with X-linked recessive ichthyosis should be queried about anosmia and have periodic testicular examination.[44]

In the epidermis, steroid sulfatase catalyzes the hydrolysis of cholesterol sulfate. The identification of steroid sulfatase deficiency in X-linked ichthyosis supports the importance of cholesterol sulfate hydrolysis in normal desquamation. Topical application of cholesterol sulfate in mice can induce a scaling disorder, further supporting the role of cholesterol sulfate hydrolysis in corneocyte desquamation.

A family was described with an ichthyosis inherited in an X-linked pattern but with normal steroid sulfatase activity and the absence of corneal opacities.[45] This demonstrates heterogeneity within X-linked ichthyosis. Because of its frequent occurrence, steroid sulfatase deficiency accounts for most cases of X-linked ichthyosis, but a normal steroid sulfatase level in a male with ichthyosis does not rule out an X-linked pattern of inheritance.

AUTOSOMAL RECESSIVE CONGENITAL ICHTHYOSIS

The term *autosomal recessive congenital ichthyosis* (ARCI) is useful to describe a heterogeneous group of disorders that present at birth with generalized involvement of the skin. Autosomal recessive ichthyosis is rare and has been estimated to occur in about 1 in 300,000 persons.[4]

In older literature, *nonbullous congenital ichthyosiform erythroderma* (NCIE) [*lamellar ichthyosis* (LI), with autosomal recessive inheritance] was distinguished from *bullous congenital ichthyosiform erythroderma* (BCIE) (EHK, with autosomal dominant inheritance) based on clinical appearance (bullae) and pattern of inheritance.[6,46] That the term LI was used interchangeably with NCIE and included a spectrum of phenotypes has led to some confusion. Williams and Elias distinguished LI from NCIE [usually called *congenital ichthyosiform erythroderma* (CIE)], a milder erythrodermic form.[47] Some patients with LI can be clearly distinguished from those with CIE on the basis of clinical features. In LI one sees large, dark, plate-like scales, and while infants may be red at birth, adults have little to no erythroderma (Fig. 49-4). In the more severe, classic presentation of LI, tautness of the facial skin leads to traction on the eyelids and lips, resulting in ectropion and eclabium. Scarring alopecia, most prominent at the periphery of the scalp, may be partly due to traction at the hairline. In contrast, CIE has generalized redness and fine, white scales (Fig. 49-5). Patients with classic CIE have little to no ectropion, eclabium, or alopecia. However, many patients do not fit neatly into these two clinical descriptions,[48] in that they have features of both LI and CIE with a clinical phenotype intermediate between both disorders. Therefore, it can be useful to consider these two distinctive presentations as ends of a spectrum, between which lie a



Figure 49-4 Classic lamellar ichthyosis phenotype. **A.** Ectropion. **B** and **C.** Large, brown, plate-like scales. (From Russell LJ et al: Linkage of autosomal recessive lamellar ichthyosis to chromosome 14q. *Am J Hum Genet* **55**:1146, 1994, with permission.)



Figure 49-5 Congenital ichthyosiform erythroderma. Bright, red erythroderma with fine, white scale.

gradation of clinical phenotypes with variable degrees of erythema and coarseness of scale. Individual features such as collodion membrane (discussed below), ectropion, and alopecia can occur across the spectrum. While attempts to refine the categorization of these disorders by biochemical and ultrastructural observations have failed to yield a consistent and replicable classification scheme,[5] identification of the spectrum of specific molecular defects underlying these conditions will undoubtedly help.[49] Identification of mutations has, so far, found ARCI to be caused by six different genes (Table 49-5) which are important for the formation of the intercellular lipid layer or the cornified envelope of keratinocytes.

Most patients with LI or CIE inherit the disease in an autosomal recessive pattern. Rarely, families have been described with similar phenotypes, where the disease is inherited as an autosomal dominant trait.[5] This is an important consideration for genetic counseling.

LAMELLAR ICHTHYOSIS

LI is apparent at birth, and the newborn usually presents encased in a collodion membrane. At this time the skin may be red. Over time, the skin develops large, plate-like scales, which appear to be arranged in a mosaic pattern (see Fig. 49-4). In some areas, the scales are centrally attached with raised borders. The scales tend to be largest over the lower extremities, where the large, plate-like scales separated by superficial fissuring can lead to an appearance similar to that of a dry riverbed. During childhood and into adulthood the degree of erythema may vary, but usually is minimal or absent in the severe presentation of classic LI. Involvement of the palms and soles in LI is variable and ranges from minimal hyperlinearity to severe keratoderma.

The lips and mucous membranes tend to be spared in LI, but the adnexal structures may be compromised by the adherent, firm scales. Thick stratum corneum on the scalp tends to encase hairs, and in conjunction with the tautness of the skin, may lead to a scarring alopecia, most marked at the periphery of the scalp. The hyperkeratosis can interfere with normal sweat gland function, resulting in hypohidrosis, but the degree of impairment varies between patients. Some patients have severe heat intolerance and must be vigilant to avoid overheating. Treatment with oral retinoids can improve or prevent some sequelae of LI. Patients frequently notice an increase in sweating, with improved heat tolerance. While retinoid therapy can cause blepharitis or even conjunctivitis, it is usually well tolerated by patients with LI. Moreover, the ability of systemic retinoid (and in some cases, topical retinoid) therapy to decrease thick periocular scale can decrease the tendency to develop ectropion. Nevertheless, patients with severe, classic LI usually require careful eye maintenance. Because of the ectropion (see Fig. 49-4), the lids

TABLE 49-5
Mutated Genes Identified in ARCI

Gene[a]	Protein	Function
TGM1[b]	Transglutaminase 1	Cornified envelope formation
ABCA12	ATP-binding cassette, subfamily A, member 12	Membrane transport/lipid metabolism
ALOXE3	Arachidonate lipoxygenase 3 (eLOX3)	Hydroperoxide isomerase
ALOX12B	Arachidonate 12-lipoxygenase, R type (12*R*-LOX)	Lipoxygenase
ICHYN	Ichthyin	Trioxilin A3 receptor? Hepoxylin pathway?
FLJ39501 (CYP4F22)	Cytochrome P450, family 4, subfamily F, polypeptide 2	LTB4-ω-hydoxylase?
? (12p11.2-q13)		
? (19p13.1-13.2)		

[a]The same gene may have more than one name.
[b]Approximately one-third of individuals with ARCI have detectable *TGM1* mutations.
From Fischer J: Autosomal recessive congenital ichthyosis. *J Invest Dermatol* **129**:1319, 2009.

may fail to close fully, particularly during sleep; hydration with liquid tears during the day and ophthalmic lubricants at night can prevent exposure keratitis.

Histopathologic examination typically shows orthokeratotic hyperkeratosis with mild to moderate acanthosis. Rates of epidermal proliferation are normal or only slightly elevated in patients with LI, in contrast to those with CIE, which has significantly greater labeling indices.[50]

Mutations in *TGM1*, the gene encoding transglutaminase 1, were found in several families with LI, solidifying the role for transglutaminase 1 in the formation of a normal stratum corneum and its role as a cause of LI.[12,13] The lamellar phenotype is more commonly associated with mutations in *TGM1*.[15,49] The transglutaminases catalyze calcium-dependent cross-linking of proteins through the formation of ε-(γ-glutamyl)lysine isodipeptide bonds. During the formation of the stratum corneum, transglutaminase catalyzes the cross-linking of cellular proteins, including involucrin, loricrin, small proline-rich proteins, and others. The resulting protein complex is deposited on the inner side of the plasma membrane to form the cornified envelope. Transglutaminase also attaches ceramides secreted into the intercellular space by lamellar bodies to cornified envelope proteins, notably involucrin, and thereby is important in the formation of both the protein and lipid components of the stratum corneum.[14]

Bathing suit ichthyosis is an unusual form of LI where affected individuals develop the scaling typical of LI, but limited to the bathing suit area.[51] The distribution correlates with warmer areas of skin. Decreased transglutaminase is found in these areas, and unique, temperature-sensitive mutations in *TGM1* have been identified in affected individuals.[52]

In a human skin/immunodeficient mouse xenograph model, transfer of a transglutaminase-1 gene into transglutaminase-1-deficient keratinocytes from LI patients resulted in normalization of transglutaminase expression and epidermal architecture in addition to restoration of cutaneous barrier function.[53] Additional disease-causing loci have been found (see below).

CONGENITAL ICHTHYOSIFORM ERYTHRODERMA

As with LI, CIE is apparent at birth, and the newborn usually presents with a taut, shiny, collodion membrane. After shedding of the membrane, the skin of infants with CIE remains red, usually with a fine, white, generalized scale (see Fig. 49-5). On the lower legs, the scale may be larger and darker. In contrast to LI, the classic presentation of CIE may have little to no ectropion, eclabium, or alopecia. As in LI, there is a wide variation in the ability to sweat, and patients with CIE may have minimal sweating with severe heat intolerance. Mucous membranes are usually spared. Palm/sole involvement is variable. Nails may have ridging, but they are often spared. As with all the ichthyoses, dermatophyte infection of the skin and nails is common.

Histopathologic examination shows hyperkeratosis, acanthosis, and often parakeratosis (Fig 49-2C). Studies of epidermal proliferation have shown markedly increased epidermal cell turnover, in contrast to LI.[50]

A small subset of patients with CIE have been found to have mutations in *TGM1*, and two siblings with a collodion presentation, CIE, and palmoplantar keratoderma had an autosomal dominant mutation in the cornified envelope protein, loricrin.[54] Further genetic heterogeneity within ARCI has been demonstrated, with exclusion of *TGM1* as the disease-causing gene in families with phenotypes within the spectrum of classic LI and CIE and identification of mutations in other genes. To date, mutations have been identified in five additional genes in ARCI (Table 49-5). In addition, two other genetic loci (12p11.2-q13 and 19p13.1-13.2) have been found to be associated with ARCI; the responsible genes have not been identified. The enzymes coded for by these genes (Table 49-5) are hypothesized to function together to convert arachidonic acid to a specific hepoxilin in a newly described pathway thought to form a common link in ARCI.[18,55]This hypothesis remains to be tested, and how the most common mutation in ARCI, that of *TGM1*, might relate to lipid abnormalities is unclear.

EPIDERMOLYTIC HYPERKERATOSIS

In 1902, Brocq described bullous ichthyotic erythroderma and distinguished the blistering type from the nonblistering type of congenital ichthyotic erythroderma.[56] The original description included three unrelated patients whose clinical manifestations varied. However, this was probably the first description of *epidermolytic hyperkeratosis* (EHK; OMIM #113800). The disease is named for the distinctive histopathologic features of vacuolar degeneration of the epidermis (i.e., epidermal lysis) and associated hyperkeratosis. EHK is also known as BCIE, an earlier descriptive name signifying the blistering, neonatal presentation, scaling, and redness.

EHK is transmitted as an autosomal dominant trait with a prevalence of approximately 1 in 200,000 to 300,000 persons. However, there is a high frequency of spontaneous mutation, and as many as one-half of the cases have no family history[46] and represent new mutational events. The disease usually presents at birth with blistering, redness, and peeling (Fig. 49-6). With time, generalized hyperkeratosis may develop, which may or may not be associated with erythroderma. EHK skin usually has a characteristic pungent odor, thought to be related to superinfection by mixed flora.

In contrast to most other ichthyoses, the histopathologic picture of EHK is almost always distinctive. A tremendously thickened stratum corneum and vacuolar degeneration of the upper epidermis are seen, leading to the histologic term EHK (see Fig. 49-2D). The vacuolar degeneration usually involves the upper epidermis and occasionally all of the suprabasilar keratinocytes. Granular cells exhibit dense, enlarged, irregularly shaped masses that appear to be keratohyalin

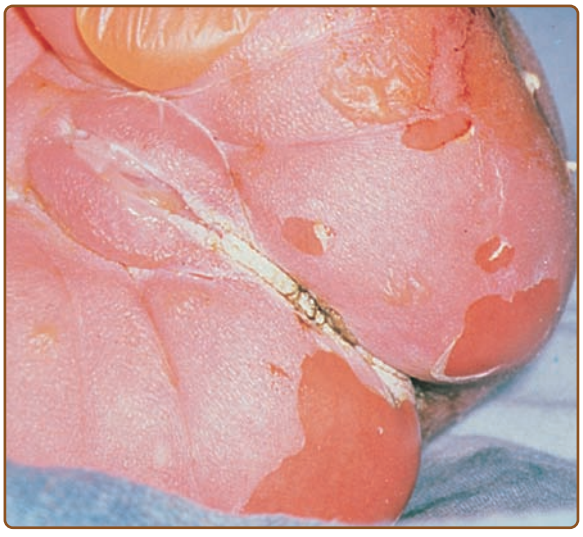

Figure 49-6 Epidermolytic hyperkeratosis. Newborn showing blistering and erosions.

granules.[6] On electron-microscopic examination, clumping of filaments is observed to begin in the first suprabasal layer. These aggregated filaments are clumps of keratin intermediate filaments that contain the suprabasal keratins 1 and 10.[57]

There is striking clinical heterogeneity between EHK families. Six distinctive clinical phenotypes have been described.[58] Several clinical features can be useful to distinguish between the different subtypes, including the presence versus absence of severe palmar/plantar hyperkeratosis and of erythroderma, quality of scale, extent of involvement, presence of digital contractures, and gait abnormality (Table 49-6). Three types without palm/sole hyperkeratosis are called NPS types. Patients with the NPS-1 clinical phenotype have generalized involvement with thick, brown verrucous hyperkeratosis, most prominent over joints. Palms and soles are spared. Cobblestone or hystrix (porcupine-like) spiny papules are characteristic; this severe clinical presentation is one of the more commonly recognized types of EHK (Fig. 49-7A). NPS-2 is similar, but much milder, without the hystrix spines and with relative sparing of the skin between joints (Fig. 49-7B). Generalized exfoliative erythroderma is found in NPS-3 (Fig. 49-7C). Three types with severe palm/sole hyperkeratosis are called PS types. Patients with the PS-1 type have a smooth palmar/plantar hyperkeratosis with a sharp border, often delineated by a red halo. Blisters may be present at the border. There may be limited involvement of the trunk, usually confined to areas over joints (Fig. 49-8A). The PS-2 type is characterized by generalized erythroderma and scaling. Volar involvement may be severe, with contractures of the digits and ainhum-like constricting digital bands (Fig. 49-8B). The PS-3 type has generalized skin involvement with a pebbly hyperkeratosis that is arrayed in a distinctive, cerebriform pattern on the palms and soles (Fig. 49-8C).

Sporadic EHK due to a postzygotic, spontaneous mutation during embryogenesis can present in a mosaic pattern of skin involvement. Areas of hyperkeratosis alternating with normal skin are often distributed in streaks along Blaschko lines (Fig. 49-9A). These may be limited to a few streaks, or there may be many, with widespread, patchy involvement. Unilateral localization can also occur. This clinical mosaic pattern correlates with underlying genetic mosaicism in that keratin mutations characteristic of EHK, which were found in lesional skin, were absent in normal skin.[59] If the germ line is involved, individuals with mosaic EHK can transmit the mutation, which leads to generalized EHK in affected offspring (Fig. 49-9B).[60]

Within keratinocytes, keratin intermediate filaments form an elaborate network that confers structural stability to the cells. In the suprabasilar, differentiating keratinocytes of interfollicular epidermis, this network is formed by keratins 1 and 10. In EHK, failure of this network leads to keratinocyte fragility (particularly of the upper epidermis), easy blistering, altered barrier

TABLE 49-6
Characteristics of Epidermolytic Hyperkeratosis[a]

	NPS-1	NPS-2	NPS-3	PS-1	PS-2	PS-3
Palm/sole hyperkeratosis	–	–	–	+	+	+
Palm/sole surface	Normal	Normal	Hyperlinear, minimal scale	Smooth	Smooth	Cerebriform
Digital contractures	–	–	–	–	+	–
Scale	Hystrix	Brown	Fine, white	Mild	White scale to peel	Tan
Distribution	Generalized	Generalized	Generalized	Localized	Generalized	Generalized
Erythroderma	–	–	+	–	+	–
Blistering	+	+	+	Localized	+	Neonatal
Implied mutation	Keratin 10	Keratin 10	Keratin 10	Keratin 1	Keratin 1	Keratin 1

[a]NPS = types without severe palm/sole hyperkeratosis; PS = types with severe palm/sole hyperkeratosis; minus sign = absent; plus sign = present.



Figure 49-7 Clinical phenotypes of epidermolytic hyperkeratosis. NPS (no severe palm/sole hyperkeratosis) types are shown. **A.** NPS-1 (NPS-type 1): Generalized involvement with thick, brown verrucous hyperkeratosis. Palms are spared. Over the dorsal foot, hyperkeratosis is arrayed in a characteristic cobblestone or hystrix (porcupine-like) pattern. **B.** NPS-2 (NPS-type 2): Brown hyperkeratosis over the trunk, and accentuated over joints. Palms are spared. Compared to the verrucous hyperkeratosis in NPS-1, involvement is much milder. On the lower legs, note the blistering, hypertrichosis, and relative sparing of the skin between the joints. **C.** NPS-3 (NPS-type 3): Generalized erythroderma with white scale and hyperkeratosis.

function,[61] abnormal epidermal kinetics (hyperproliferation), and thickened stratum corneum (hyperkeratosis). Keratin 10 is the coexpressed partner of keratin 1, both of which are required to form keratin intermediate filaments in the cells of the suprabasal layers of the epidermis. Mutations in genes coding for either keratin 1 or 10 have been identified in a number of EHK families.[57,62] In most cases, palmar/plantar involvement implies mutations in K1; this may reflect the "redundancy" of K9 (a keratin that occurs only in the suprabasal epidermis of palmar and plantar skin) and K10 in palmar/plantar epithelium. Mutations in keratin 9 have been found in families with the type of EHK limited exclusively to the palms and soles (Vörner)[63] (see Chapter 50).

DISORDERS RESEMBLING EPIDERMOLYTIC HYPERKERATOSIS

ICHTHYOSIS BULLOSA OF SIEMENS

Ichthyosis bullosa of Siemens (OMIM #146800) is a rare autosomal dominant genodermatosis that is similar in clinical appearance to EHK. Patients are born with redness and blistering. The redness subsides over the subsequent weeks to months, while the skin develops dark gray hyperkeratosis, particularly over flexural areas. In some areas, there may be a lichenified appearance to the skin. As with EHK, the epidermis is fragile;



Figure 49-8 PS (Severe palm/sole hyperkeratosis) types are shown. **A.** PS-1 (PS-type 1): Palmar and plantar hyperkeratosis with sharp border delineated by a red halo. Blisters are present at the border. Note the relatively smooth surface. There is characteristic involvement at the joints but sparing most of the trunk and extremities. **B.** PS-2 (PS-type 2): Hands (left) of a 36-year-old patient with severe palmar hyperkeratosis, contractures, and ainhum-like constricting digital bands. The palmar hyperkeratosis limits spreading of the fingers. Palms (right) of a 15-year-old patient with severe palmar hyperkeratosis and contractures. Flank (lower right) exhibiting generalized erythroderma and scaling. **C.** PS-3 (PS-type 3): Hyperkeratosis in a cobblestone pattern on the knees. Four-year-old patient with hyperkeratosis in a distinctive cerebriform pattern on the palms and soles (not shown). (Adapted from DiGiovanna JJ, Bale SJ: Clinical heterogeneity in epidermolytic hyperkeratosis. *Arch Dermatol* **130**:1026, 1994 with permission.)



Figure 49-9 Mosaic epidermolytic hyperkeratosis. **A.** Streaks of hyperkeratosis distributed along Blaschko's lines in a sporadic case due to postzygotic occurrence of new mutation. **B.** Grandchild of patient shown in Panel **A**. Generalized involvement (in this case the NPS-2 clinical phenotype) is transmitted to subsequent generations in an autosomal dominant inheritance pattern.

however, the fragility is more superficial. This can result in loss of the uppermost epidermis (predominantly stratum corneum), yielding a characteristic, collarette-like depressed area that has been described as "mauserung" (molting). Histologically, the epidermis shows hyperkeratosis and vacuolization similar to EHK, but it may be confined to the granular layer. Mutations have been found in the gene encoding keratin 2,[64] a differentiation keratin of the suprabasilar epidermis that is expressed in the more superficial epidermal layers.

ICHTHYOSIS HYSTRIX OF CURTH AND MACKLIN

Ichthyosis hystrix of Curth and Macklin (OMIM #146590) is a rare, autosomal dominant disorder that clinically resembles EHK. Clinical expression varies, even within families, from palmoplantar keratoderma to severe generalized involvement. There can be widespread patchy, thick, gray–brown hyperkeratosis, most marked on the extensor arms and legs. Patients with extensive involvement resemble those with severe EHK without palmar/plantar involvement, with verrucous or porcupine-like (hystrix) hyperkeratosis. However, in contrast to EHK, blistering does not occur. Histologic examination of the epidermis shows acanthosis, papillomatosis, and severe orthokeratotic hyperkeratosis, with frequent binucleate cells. Keratinocytes within the granular and upper spinous layers may have perinuclear vacuolization, and some have prominent perinuclear shells. On electron microscopy, there are concentric, unbroken shells of tonofilaments surrounding the nucleus. Study of a three-generation family with ichthyosis hystrix of Curth and Macklin identified a mutation in the variable tail domain (V2) of the keratin 1 gene. Structural analyses of the resulting abnormal keratin showed a failure of keratin intermediate filament bundling, retraction of the cytoskeleton from the nucleus, and failure of localization of loricrin to desmosomal plaques.[65]

ANNULAR EPIDERMOLYTIC ERYTHEMA

Annular epidermolytic erythema (cyclic ichthyosis with EHK; OMIM #607602) presents at birth or in the first few months afterward with severe, intermittent scaling and blistering that resolves during puberty.[66] Residual, limited thickened plaques of verrucous scale in linear rows can be seen in flexural and intertriginous skin. In some cases, explosive bouts of widespread erythema with blisters and pustules are seen.[67] Patients subsequently develop widespread, migratory, polycyclic, and annular scaling plaques. Light and electron microscopy reveals findings of EHK. Mutations in keratin 10[68] and keratin 1[67] have been found.

A unifying designation of *keratinopathic ichthyosis* for all ichthyoses with underlying keratin mutations has been suggested recently.[9]

ICHTHYOSIS IN THE NEWBORN

COLLODION BABY

A *collodion baby* is born encased in a translucent, parchment-like membrane that is taut and may impair respiration and sucking. Involvement may vary from mild to severe, but this variation has not been well characterized. In addition, the birth is often premature, which adds to morbidity. During the first 2 weeks of life, the membrane breaks up and peels off, often leaving fissures, with impairment of the barrier to infection and water loss. This can lead to an increased risk of infection, difficulties in thermal regulation, and hypernatremic dehydration.[69] Newborn care should include careful monitoring for infection and of temperature, hydration, and electrolytes, and measures to keep the peeling membrane soft and lubricated to facilitate flexibility and desquamation. Appropriate pain management and eye care should be employed, when indicated. These newborns usually benefit from a humidified incubator where the air is saturated with water; wet compresses followed by bland lubricants can be used to further hydrate the membrane and achieve maximum pliability.[70] If during peeling, residual areas of the membrane are allowed to dry and harden in areas such as the extremities, the taut membrane can constrict and lead to distal swelling. Collodion presentation can develop into a wide spectrum of ichthyotic phenotypes as the child grows (Box 49-1). It is the usual presentation of ARCI (see Fig. 49-10) and is less commonly seen in several other forms of ichthyosis, and rarely Gaucher disease (Box 49-1). In addition, an autosomal recessive, self-healing collodion baby has been described, where the skin greatly clears within the first few weeks and transitions into mildly affected or normal skin.[71] Eleven Swedish and four Danish patients with a self-improving ichthyosis resulting in xerosis, hyperlinear palms, red cheeks, and anhidrosis were found to have mutations in *ALOX12B*, *ALOX3E*, or *TGM1*.[72]



Figure 49-10 Collodion baby. The infant is 36 hours old and is covered with a macerated membrane that shows fissures; note ectropion and eclabium. The condition may develop over time into various clinical phenotypes including ARCI and self-healing collodion baby (Table 49-3).

BOX 49-1 DISORDERS ASSOCIATED WITH COLLODION MEMBRANE

- AEC syndrome
- Autosomal recessive congenital ichthyosis (LI, CIE, overlap)
- Chondrodysplasia punctata
- Gaucher disease
- Loricrin keratoderma
- Neutral lipid storage disease
- Self-healing collodion baby
- Sjögren–Larsson syndrome
- Trichothiodystrophy
- X-linked hypohydrotic ectodermal dysplasia
- Other

Note: This box does not distinguish the frequency in which collodion membrane is found in the different disorders listed. In some cases, severe peeling may be mistaken for collodion membrane. (From Okulicz JF, Schwartz RA: Hereditary and acquired ichthyosis vulgaris. *Int J Dermatol* **42**:95, 2003.)

EPIDERMOLYTIC HYPERKERATOSIS

The newborn affected with one of the more severe, generalized types of *EHK* usually has erythema, blistering, widespread erosions, and denuded skin (see Fig. 49-6). Because there is a high frequency of new mutations, the disease may be unexpected and the diagnosis may be unknown. Epidermolysis bullosa or staphylococcal scalded-skin syndrome may be suspected, and the infant treated with antibiotics. The newborn may require intensive care with fluid and electrolyte monitoring. Specialized skin care can minimize blistering and enhance healing of erosions and may include lubrication to decrease friction and mechanical trauma, protective padding, and specialized wound dressings. The newborn with extensive erosions is prone to bacterial infection and sepsis, and carefully chosen topical and systemic antibiotics can minimize the extent of infection.

HARLEQUIN ICHTHYOSIS

A dramatic, severe, and often fatal presentation of ichthyosis is that of *harlequin ichthyosis* (OMIM #242500) (Fig. 49-11). The child is often premature and born with massive, shiny plates of stratum corneum separated by deep, red fissures that tend to form geometric patterns, as seen in the patched costumes of the harlequin clowns from the Italian Commedia dell'Arte dating from the sixteenth and seventeenth centuries. There are poorly developed or absent ears and marked ectropion and eclabium. The first report is from the diary of Rev. Oliver Hart, of Charleston, South Carolina, who described these features in 1750.[73] These children are at great risk during the neonatal period and often die



Figure 49-11 Harlequin ichthyosis. Note rudimentary ears and the distorted appearance as a result of the thick "plates" of stratum corneum. This baby died a few days after birth.

shortly after birth. Abnormal water loss through the skin and poor temperature regulation lead to risk of fluid and electrolyte imbalance. The infants are also at risk for infection beginning in the skin, but at the same time (because of poor temperature regulation) do not show the usual signs of infection. Normal respiration may be restricted by the taut skin. Treatment with systemic retinoids during the newborn period can facilitate desquamation of the membrane.[74,75] Advances in neonatal intensive care, together with facilitating desquamation by judicious use of systemic retinoid therapy have led to improvements in survival and to the use of the name "harlequin baby" rather than "harlequin fetus." Some babies have suffered from failure to thrive and require tube feeding. The skin of those who survive the newborn period usually resembles the skin of those with a severe phenotype of CIE.[74,75]

In harlequin ichthyosis, normal lamellar granules are not found; instead, there are small vesicles that lack internal structure. There is also no evidence of the lipid lamellae that form between granular and cornified cells as a result of discharge of lamellar granule contents into the intercellular space.[76] The disorder results from autosomal recessive inheritance of mutations in *ABCA12*, which codes for an adenosine triphosphate (ATP)-binding cassette (ABC) transporter involved in lamellar granule secretion and epidermal lipid transport. Premature termination mutations underlie harlequin ichthyosis,[77–79] while missense mutations in *ABCA12* have been identified in a subset of individuals with less severe ARCI[80] (Table 49-5).

NETHERTON SYNDROME

Netherton syndrome (OMIM #256500) is a rare, autosomal recessive disorder characterized by the concurrence of ichthyosis, a structural hair shaft abnormality, and atopy.[81,82] The usual cutaneous manifestation is *ichthyosis linearis circumflexa*, a distinctive condition of generalized hyperkeratosis and polycyclic and serpiginous erythematous plaques with a characteristic, migratory, double-edged scale at the margins (Fig. 49-12A). At birth, affected children may present with generalized erythroderma. Infants and children may have feeding problems, with poor absorption and failure to thrive.[83] With atopic dermatitis, there may be pruritus, and scratching can lead to lichenification at the flexures. In some patients, the ichthyosis resembles LI or CIE.[5,81] Histopathologic examination is not specific and may show features of hyperkeratosis, psoriasis, and atopic dermatitis. Most patients have a specific hair shaft abnormality called *trichorrhexis invaginata*, in which the distal hair segment is telescoped into the proximal one, forming a ball-and-socket-like deformity on microscopic examination (Fig. 49-12B). This is also known as "bamboo hair" and is due to abnormal cornification of the internal root sheath. Hair from multiple areas should be examined, because only 20–50% of hair may be affected; the characteristic abnormality may be more commonly observed on eyebrow hair.[84] Trichorrhexis nodosa and pili torti (see Chapter 88) may also occur. The hair defects may not be detectable at birth, and may disappear with age. Atopy in these patients may manifest as atopic dermatitis asthma, or severe food allergy (particularly to nuts), and marked elevations of serum immunoglobulin (Ig) E may occur. In some patients, generalized aminoaciduria, mild developmental delay, and impaired cellular immunity may also be present.[85]

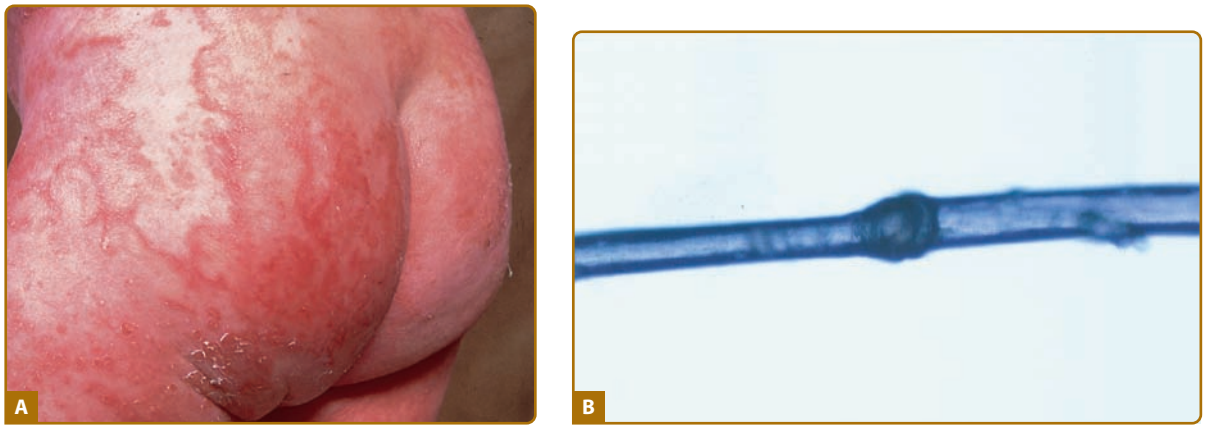

Figure 49-12 Netherton syndrome. **A.** Ichthyosis linearis circumflexa showing typical annular lesions. (Used with permission from James Stroud, A MD.) **B.** Bamboo hair shaft shows features of trichorrhexis invaginata.

Netherton syndrome has been found to be due to mutations in *SPINK5,* a gene encoding LEKTI (*l*ympho-*e*pithelial *K*azal-*t*ype related *i*nhibitor).[19] LEKTI is a serine protease inhibitor that is predominantly expressed in epithelial and lymphoid tissues, and may be important in the downregulation of inflammatory pathways. This discovery highlights the importance of the regulation of proteolysis in the overlap between epithelial barrier function and the hypersensitivity of atopy. Subsequently, LEKTI polymorphisms were associated with common atopy and atopic dermatitis.[86] Prenatal testing for Netherton syndrome using molecular data has been successfully accomplished.[87] Tacrolimus ointment, a topical immunomodulator (see Chapter 221), is effective in common atopic dermatitis with minimal systemic absorption. However, Netherton syndrome is complicated by an abnormal skin barrier, allowing increased percutaneous absorption and associated risk for systemic toxic effects. This should be considered when using topical agents such as tacrolimus, where monitoring of serum levels may be necessary,[88] and topical steroids, where iatrogenic Cushing syndrome has been reported.[89]

LESS COMMON ICHTHYOSES

ARC

ARC (OMIM #208085) is a rare autosomal recessive, multisystem disorder characterized by *a*rthrogryposis, *r*enal tubular dysfunction, and *c*holstasis often with ichthyosis and other abnormalities. Mutations have been found in the *VPS33B* gene that encodes a protein involved in intracellular trafficking pathways.[90]

CEDNIK

*Ce*rebral *d*ysgenesis, *n*europathy, *i*chthyosis, and *k*eratoderma (CEDNIK) syndrome (OMIM #609528) is an autosomal recessive neurocutaneous syndrome characterized by severe psychomotor retardation, ichthyosis, and palmoplantar keratoderma thought to result from abnormal lamellar granule maturation and secretion.[91] In CEDNIK syndrome, lamellar granules are retained within the cornified cell layer resulting in reduced secretion of lipids and proteases into the extracellular space. This results in impaired barrier formation and decreased corneocyte disadhesion.

CHANARIN–DORFMAN SYNDROME

Chanarin–Dorfman syndrome (neutral lipid storage disease; OMIM #275630) is an autosomal recessive disorder characterized by accumulation of triglycerides in the cytoplasm of leukocytes, muscle, liver, fibroblasts, and other tissues. However, blood lipid levels are normal. To date, approximately 30 patients have been reported, mainly from the Mediterranean basin. The ichthyosis is a generalized fine scaling with variable erythema, resembling congenital ichthyosiform erythroderma. Presentation is often that of a collodion baby with ectropion and eclabium. Skin changes may evolve to orange–red with brown scale, and are associated with pruritus. Extracutaneous involvement, which is variable and may be mild, includes cataracts, decreased hearing, hepatosplenomegaly with abnormal liver enzymes and fatty liver, psychomotor delay, myopathy with elevations in serum muscle enzymes, and neurologic abnormalities.

Histopathology of an oil red O or Sudan III stain of frozen sections of the skin shows lipid droplets in dermal cells, in the basal layer (and, to a lesser extent, suprabasally), as well as in the acrosyringia of the eccrine ducts. Examination of peripheral blood smears shows lipid vacuoles within granulocytes, eosinophils, and monocytes, a feature that may also be present in carriers.[92] Mutations in the *CGI-58* gene have been identified.[93] CGI-58 belongs to a large family of proteins, most of which are enzymes, and appears to activate adipose-triglyceride lipase in the initial step in lipolysis of triglycerides. In the absence of CGI-58, triglycerides accumulate.[94]

CHILD SYNDROME

The *CHILD syndrome* (OMIM #308050) is a rare disorder consisting of *c*ongenital *h*emidysplasia, *i*chthyosiform erythroderma, and *l*imb *d*efects, which is found almost exclusively in females.[95] The disorder is related to *X-linked dominant chondrodysplasia punctata* (CDPX2), which also has skin and skeletal abnormalities, but is distinguished by a sharp midline demarcation of the psoriasiform ichthyosis, with minimal linear or segmental contralateral involvement. Involvement of the right side occurs more frequently than the left. There may be bands of normal skin on the affected side. A case with bilateral involvement has been described. Limb defects occur ipsilateral to the ichthyosis and range from digital hypoplasia to agenesis of the extremity. There may be punctate calcification of cartilage. Unilateral hypoplasia can involve the central nervous system and cardiovascular, pulmonary, renal, endocrine, and genitourinary systems. The inheritance pattern is thought to be X-linked dominant, with the condition being lethal in males. Peroxisomal deficiency has been described, and mutations in either of two peroxisomal genes were found to cause CHILD syndrome. One patient was found to have a mutation in the gene encoding EBP (3β-hydroxysteroid-δ8-δ7-isomerase) (the gene underlying CDPX2)[96] and six patients (including one boy) were found to have mutations in *NSDHL* [NAD(P)H *s*teroid *deh*ydrogenase-*l*ike protein] encoding a 3β-hydroxysteroid dehydrogenase.[97] Each enzyme functions in the postsqualene cholesterol biosynthetic pathway, catalyzing intermediate steps in the conversion of lanosterol to cholesterol.[98]

CHONDRODYSPLASIA PUNCTATA

Chondrodysplasia punctata is a clinically and genetically diverse group of rare diseases, first described by

Conradi, that share the features of stippled calcification of the epiphyses and skeletal changes. They are characterized by abnormal deposition of calcium in the areas of enchondral bone formation during fetal development and early infancy. Several forms also include ichthyosiform changes. Clinical severity ranges from severe dwarfism and death during infancy to a self-limited radiographic abnormality in others. An autosomal recessive (rhizomelic) type and both X-linked dominant[99] and recessive forms[100] have been described. The validity of the originally described autosomal dominant Conradi–Hünermann type has been questioned, because some reported cases were later shown to belong to the X-linked dominant type, and occurrences previously considered sporadic have subsequently been recognized as resulting from warfarin (Coumadin) anticoagulant embryopathy.[99,101]

RHIZOMELIC CHONDRODYSPLASIA PUNCTATA. *Rhizomelic chondrodysplasia punctata* (RCDP) (autosomal recessive; OMIM #215100) is also known as peroxisomal biogenesis disorder complementation group 11 (CG11). It is a rare, multisystem developmental disorder characterized by dwarfism due to symmetric shortening of the proximal long bones (i.e., rhizomelia), specific radiologic abnormalities (i.e., the presence of stippled calcifications of cartilage, vertebral body clefting), joint contractures, congenital cataracts, ichthyosis, and severe mental retardation. Skin changes are present in approximately 25% of patients. Patients have low levels of red cell plasmalogens and accumulation of phytanic acid, starting with normal levels at birth and increasing to more than 10 times normal by age 1 year. RCDP is a disorder of peroxisomes, membrane-bound multifunctional organelles found in all nucleated cells. Their functions vary with cell type and include a variety of pathways (e.g., hydrogen peroxide-based respiration, fatty acid β-oxidation, and lipid and cholesterol synthesis) involving the synthesis and degradation of various compounds. Hereditary human peroxisomal disorders are subdivided into disorders of peroxisome biogenesis, in which the organelle is not formed normally, and those involving a single peroxisomal enzyme. RCDP is one of the groups of peroxisome biogenesis disorders, which are characterized by loss of multiple peroxisomal metabolic functions and have been sorted into at least 12 different complementation groups. Many have been found to be due to defects in peroxins, factors required for the import of proteins into the organelle. RCDP is caused by mutations in *PEX7,* a gene that encodes peroxin 7, a receptor required for targeting a subset of enzymes to peroxisomes.[102] Refsum disease, another peroxisome disorder, exhibits genetic heterogeneity. In Refsum disease due to mutations in *PAHX,* the gene for phytanoyl-CoA hydroxylase (PhyH), there is deficiency of the single peroxisomal enzyme PhyH. Refsum disease can also result from mutations in *PEX7;* fibroblasts from those patients show deficiency of several peroxisomal enzymes, similar to fibroblasts from patients with RCDP. It is remarkable that different mutations in the same gene can result in such a wide spectrum of clinical disease.

X-LINKED RECESSIVE CHONDRODYSPLASIA PUNCTATA. *X-linked recessive chondrodysplasia punctata* (CDPX; OMIM #302950) can involve skin (linear or whorled atrophic or ichthyosiform hyperkeratosis, follicular atrophoderma; may begin as erythroderma) (Fig. 49-13), hair (coarse, lusterless, cicatricial alopecia), short stature and skeletal abnormalities, cataracts, and deafness. Curry et al studied a family who had atypical ichthyosis and elevated cholesterol sulfate in two affected males and identified an X chromosomal deletion (Xp22) that included the gene for steroid sulfatase.[100] There is a cluster of arylsulfatase genes at this location. Mutations in *ARSE,* the gene encoding the enzyme arylsulfatase E, were found in five patients; however, it is possible that the disorder may also be caused by mutations in adjacent arylsulfatase genes.[103] The similarity to warfarin embryopathy suggests that warfarin embryopathy may be due to drug-induced inhibition of the same enzyme.

X-LINKED DOMINANT CHONDRODYSPLASIA PUNCTATA. Happle and coworkers identified *X-linked dominant chondrodysplasia punctata* (CDPX2) (Conradi–Hünermann–Happle syndrome; OMIM #302960) as a distinct variant characterized by a mosaic pattern of skin involvement and occurrence almost exclusively in females, with loss of the gene function hypothesized to be lethal to males.[99] Affected females have a normal life expectancy and there may be increased disease expression in successive generations (anticipation). Occurrence in a male has been observed in association with a 47,XYY karyotype. CDPX2 presents at birth as a congenital ichthyosiform erythroderma that clears over months and is replaced by linear hyperkeratosis, follicular atrophoderma, and pigmentary abnormalities. Happle hypothesized that the linear involvement is due to mosaic X-chromosome inactivation (lyonization). Hair shaft abnormalities and cicatricial alopecia can also occur. Stippled calcifications are



Figure 49-13 Erythrokeratodermia variabilis. Generalized type with widespread hyperkeratosis and migratory, figurate, red patches.

seen in radiographs of areas of endochondral bone formation during childhood but may no longer be visible after puberty. Stature may be short, with asymmetric shortening of the legs. Cataracts occur, usually asymmetrically, in about two-thirds of patients. Histochemical staining for calcium may show calcifications within the epidermis, especially within hair follicles in young children, which may not be present in older children.[104] Mutations in the gene encoding the emopamil-binding protein (EBP) cause the Conradi–Hünermann–Happle Syndrome. EBP was first identified as a binding target for the drug emopamil, a calcium-channel blocker. It was later found to be 3β-hydroxysteroid-δ8-δ7-isomerase that catalyses an intermediate step in the conversion of lanosterol to cholesterol.[105] How this defect causes clinical manifestations is unclear.

CONGENITAL RETICULAR ICHTHYOSIFORM ERYTHRODERMA

This rare disorder, also known as *ichthyosis variegata* or *ichthyosis en confetti(s)*, presents as congenital ichthyosiform erythroderma. Small islands of normal appearing skin begin to appear late in childhood. Band-like parakeratosis, psoriasiform acanthosis and vacuolated, binuclear upper epidermal keratinocytes with a filamentous perinuclear shell by electron microscopy and dermal amyloid deposits are seen.[106] Normal areas of skin have been shown to arise from loss of heterozygosity on chromosome 17q via mitotic recombination of disease-causing mutations in the gene encoding keratin 10 (KRT10).[107]

ERYTHROKERATODERMIAS

The *erythrokeratodermias* are a clinically and genetically heterogeneous group of disorders characterized by hyperkeratosis and localized erythema. Within a broad spectrum of phenotypes, at least two disorders can be delineated: (1) erythrokeratodermia variabilis and (2) progressive symmetric erythrokeratodermia. There are overlapping clinical features and phenotypic variability within these two designations.[108]

ERYTHROKERATODERMIA VARIABILIS. *Erythrokeratodermia variabilis* (OMIM #133200), described by Mendes da Costa in 1925, is a rare disorder that usually presents at birth or during the first year of life. Both autosomal dominant and recessive inheritance have been described.[109] At least two distinct clinical presentations can be distinguished. One type (Fig. 49-14) is characterized by generalized, persistent, red–brown hyperkeratotic plaques, and accentuated skin markings. A second, localized type has involvement that is limited in extent and characterized by sharply demarcated, hyperkeratotic plaques; these are symmetrically arrayed and remain relatively fixed for months to years. In the localized type, there may be considerable variability between affected family members, and the disorder may not be apparent until later in life. Both types are characterized by striking, sharply demarcated,



Figure 49-14 KID syndrome. Discrete, symmetric hyperkeratotic plaques are present on the face. There is a scarring alopecia.

migratory red patches, which vary in size from a few to many centimeters. These geographic, figurate red patches appear or regress over minutes to hours; some individuals complain of burning at these sites, while in others they are asymptomatic. The red patches develop independently of the hyperkeratosis. Systemic retinoid treatment clears the hyperkeratotic lesions and may also clear the figurate red patches. The hyperkeratotic skin lesions may be triggered by trauma to the skin and the red patches may be triggered by a change in temperature. Palmoplantar hyperkeratosis may be present in either type, but hair, nails, and mucous membranes are unaffected. Histopathologic features are nonspecific and include hyperkeratosis, acanthosis, papillomatosis, and capillary dilatation. Epidermis involved with severe papillomatosis and suprapapillary thinning may result in a "church spire" appearance.

Several variants have been described. Erythrokeratodermia *en cocardes* was described in a family in which the erythematous component was in a target-like configuration.[110] In a possible clinical variant of erythrokeratodermia *en cocardes*, erythema gyratum repens-like erythema (see Chapter 153) was described in a large kindred.[111] Another family with erythema annulare centrifugum-like lesions (see Chapter 43) has also been described.[112] A child with atypical erythrokeratodermia with neurosensory deafness, bilateral talipes (clubfoot) deformity, and neuropathy was described in which erythematous component changed only slowly over the year.[113] Erythrokeratodermia with ataxia (Giroux-Barbeau type) is an autosomal dominant disorder that presents during infancy with well-defined, symmetric hyperkeratotic plaques, and underlying erythema distributed over the extensor surface of the extremities.[114] Skin lesions regress during adulthood while a progressive spinocerebellar ataxia develops.

Both the localized type of erythrokeratodermia variabilis and erythrokeratodermia with ataxia have been

mapped to a common region (chromosome 1p34-35).[115] Subsequently, mutations in *GJB3*, the gene encoding connexin 31, were identified in four families with erythrokeratodermia variabilis.[116] Connexins are a family of proteins that aggregate to form gap junctions, which are important channels for intercellular communication. This intercellular signaling system is crucial for maintaining tissue homeostasis, growth control, development, and synchronized response of cells to stimuli. The identification of connexin mutations as the cause of erythrokeratodermia variabilis implicates this pathway in epidermal differentiation and in the mechanism of skin response to external factors. Different mutations in the same connexin 31 gene (*GJB3*) have been found in other patients with deafness and also in some with peripheral neuropathy. Mutations in the related connexin 30.3 (*GJB4*) have been found in other families with erythrokeratodermia variabilis[117]; in the variants with erythema gyratum repens-like erythema that have been studied, connexin 30.3 mutations appear to be found exclusively.[109]

PROGRESSIVE SYMMETRIC ERYTHROKERATODERMIA. *Progressive symmetric erythrokeratodermia* (OMIM #602036), first definitively described by Darier in 1911,[118] is characterized by well-demarcated, erythematous, hyperkeratotic plaques that are symmetrically distributed over the extremities and buttocks, and often the face.[119] The trunk tends to be spared, but palms and soles may be involved. The plaques appear shortly after birth, progress slowly during the first few years, and then stabilize in early childhood. The plaques usually remain stable in location and appearance but may undergo partial regression at puberty. The variable, migratory erythema that defines erythrokeratodermia variabilis is absent. The disorder is inherited in an autosomal dominant pattern but with incomplete penetrance and variable expressivity. A mutation in the cornified envelope protein loricrin was found in one family,[120] although the diagnosis (and the distinction from erythrokeratodermia variabilis) has been disputed.[121] Recently, a mutation in *GJB4*, which encodes connexin 30.3, was found in patients from the Netherlands with either progressive symmetric erythrokeratodermia or erythrokeratodermia variabilis, demonstrating that both clinical presentations can arise from the identical mutation.[122]

ICHTHYOSIS FOLLICULARIS, ALOPECIA, AND PHOTOPHOBIA SYNDROME

Noninflammatory follicular hyperkeratosis, total nonscarring alopecia, photophobia, and characteristic facies are seen in the IFAP syndrome (OMIM #308205). Less constant features include recurrent respiratory infections, nail abnormalities, angular cheilitis, keratotic plaques on the extensor surface of the extremities, inguinal hernia, cryptorchidism, short stature, seizures, and psychomotor developmental delay.[123,124] Inheritance is thought to be X-linked recessive, although an autosomal dominant form and a third type, with "psoriasiform plaques," have been postulated.[125] Mutations in the *MBTPS2* gene result in impaired cholesterol homeostasis and ability to cope with endoplasmic reticulum stress.[126]

ICHTHYOSIS PREMATURITY SYNDROME

Polyhydramnion complicates the second trimester in the ichthyosis prematurity syndrome (OMIM #608649), resulting in premature delivery of infants with erythrodermic, edematous, caseous scaling skin resembling excessive vernix caseosa, respiratory distress, and transient peripheral eosinophilia.[127] The respiratory signs, erythema and skin changes resolve, leaving signs of atopy and dry, scaly skin with follicular accentuation more pronounced than is seen in keratosis pilaris. Characteristic trilamellar membrane inclusions are seen in the stratum corneum by electron microscopy. Mutations in the fatty acid transport protein 4 gene, *FATP4* (*SLC27*) have been identified in affected members of one family.[128]

KERATITIS, ICHTHYOSIS, AND DEAFNESS SYNDROME

KID syndrome (OMIM #148210) is a rare disorder characterized by *k*eratitis (with progressive corneal opacification), *i*chthyosis, and *d*eafness (neurosensory). Involvement of multiple ectodermal tissues qualifies KID syndrome as an ectodermal dysplasia. Most cases are compatible with autosomal dominant inheritance. However, occurrence in an inbred sibship suggests the existence of an autosomal recessive form. The disease is characterized by discrete erythematous plaques, and there may be mild, generalized hyperkeratosis. The distinctive plaques may have a discrete border and a verrucous appearance with crusting and may be conspicuously figurate and symmetric on the face (Fig. 49-15).



Figure 49-15 Chondrodysplasia punctata. Newborn child. Generalized erythroderma with scales forming a whorled pattern.

Furrowing about the mouth results in characteristic facies. There may be prominent follicular hyperkeratosis, which can result in a scarring alopecia of the scalp. "Leather-like" palmar/plantar keratoderma is almost always seen.[129] Several authors have suggested that because the plaques do not scale, this disorder is more accurately designated an erythrokeratodermia rather than an ichthyosis.[5,129] Descriptions of nail changes vary from absent, delayed appearance after birth, atrophic, or brittle to thickened, with loss of or "rough" cuticles, subungual hyperkeratosis, and leukonychia. The teeth may be small. Auditory evoked potential studies allow detection of the hearing deficit in infancy. Keratitis may develop. Affected individuals can have an increased susceptibility to bacterial, fungal, or viral infections. Squamous cell carcinoma of the skin and tongue has also been reported. In contrast to many other ichthyotic conditions, treatment of these patients with oral retinoids has been reported to be of little benefit and possibly to exacerbate the corneal neovascularization.

Dominant mutations in *GJB2,* the gene encoding connexin 26, have been detected in sporadic cases and one family with KID syndrome. Functional studies of cells expressing mutated connexin 26 demonstrated failure of a fluorescent tracer to pass through gap junction channels to neighboring cells, consistent with disruption of intercellular communication.[21] Different mutations in the same gene (*GJB2*) encoding connexin 26 have also been found in a family with a mutilating palmoplantar keratoderma (Vohwinkle's disease) and deafness (without ichthyosis)[130] (discussed in Chapter 50), and a mutation in *GJB6*, the gene for connexin 30, has been demonstrated in one child with KID syndrome.[131] The identification of mutations in the genes encoding a variety of connexin proteins has highlighted the role of connexin-mediated intercellular communication through gap junctions in the development and maintenance of ectodermal tissues. Connexins 26, 30, and 31 are expressed in the stratified epithelia of the cochlea and epidermis, and abnormalities in these proteins can cause sensorineural hearing impairment and/or skin disorders.[20]

KERATOSIS LINEARIS WITH ICHTHYOSIS CONGENITA AND SCLEROSIS KERATODERMA

*K*eratosis *l*inearis with *i*chthyosis *c*ongenital and sclerosing *k*eratoderma (KLICK) syndrome (OMIM #601952) is a rare ichthyosis with palmoplantar keratoderma, constricting bands and flexural deformities of the fingers, and linear keratotic papules at the flexures. Mutations in the proteasome maturation protein gene (POMP) suggest a role for the proteasome in the process of cornification.[132]

MEDNIK

*M*ental retardation, *e*nteropathy, *d*eafness, peripheral *n*europathy, *i*chthyosis, and *k*eratodermia (MEDNIK) syndrome is an autosomal recessive disorder described in a Quebec population with a founder mutation in the *AP1S1* gene that encodes a protein involved in protein trafficking by intracellular vesicles.[133]

MULTIPLE SULFATASE DEFICIENCY

Multiple sulfatase deficiency (OMIM #272200) is a rare autosomal recessive disorder that is characterized by a deficiency of several sulfatases, which results in the accumulation of sulfatides, glycosaminoglycans, sphingolipids, and steroid sulfates in tissues and body fluids.[134] The activity of both lysosomal (arylsulfatases A and B) and microsomal (arylsulfatase C/steroid sulfatase of X-linked ichthyosis) arylsulfatases is impaired. The disorder is a composite of the clinical features of both metachromatic leukodystrophy and of a mucopolysaccharidosis. Clinical features include neurologic deterioration, skeletal abnormalities, facial dysmorphism, and ichthyosis resembling that seen in X-linked steroid sulfatase deficiency. This disorder has been proposed to be due to a defect, common to all sulfatases, in posttranslational protein modification that is required for generating a catalytically active enzyme.[135] The gene coding for sulfatase modifying factor 1 (*SUMF1*), which generates a unique amino acid derivative, C_{α}-formylglycine, necessary for catalytic activity of all sulfatases, is mutated in individuals with multiple sulfatase deficiency.[136,137]

NEONATAL ICHTHYOSIS WITH SCLEROSING CHOLANGITIS

Neonatal cholestatic jaundice and mild ichthyosis with fine, white scales are the presenting signs in the NISCH syndrome (OMIM #607626). Hypotrichosis with scarring alopecia affecting the scalp and eyebrows, enamel dysplasia and intracytoplasmic vacuoles within keratinocytes that do not stain with oil red O are also seen.[138] In addition to different staining properties, the syndrome differs from Chanarin–Dorfman syndrome in the absence of ocular or muscle findings and of fatty liver. Mutations in *CLDN1* the gene coding for claudin-1 have been identified.[139]

PEELING SKIN SYNDROME

The *peeling skin syndrome* (OMIM #270300) is an autosomal recessive disorder characterized by lifelong peeling of the stratum corneum. It may be associated with pruritus, short stature, and easily removed anagen hairs. Low plasma tryptophan levels and aminoaciduria have also been reported.[140] Traupe suggested that there are two types of peeling skin syndrome.[5] *Type A*, which is noninflammatory and asymptomatic, is characterized by generalized peeling in thin superficial flakes of differing size and shape. On electron microscopy, the *intracellular* separation occurs in the stratum corneum, within the corneocytes and not between adjacent cells. Intercellular electron-dense globular deposits representing abnormal lipids have

been observed localized to the stratum corneum.[141] An acral variant (OMIM #609796), in which peeling was limited to over the hands and feet, has been described.[142,143] Abnormal keratohyalin granules were seen by electron microscopy. Mutations in the gene coding for transglutaminase 5, a ubiquitously expressed transglutaminase with widespread expression in skin, have been identified in two families with the acral form.[143] In contrast, *type B* presents with congenital ichthyotic erythroderma and evolves into erythematous, scaling, migratory patches. This type is pruritic and may be associated with elevated levels of IgE, aminoaciduria, and short stature. The stratum corneum is easily separated mechanically from the lower epidermis, and histologically the split, which occurs *intercellularly*, is seen between the stratum corneum and the granular layer. On electron microscopy, electron-dense, irregularly vacuolated bodies have been observed in the granular layer, but observations have been variable.[144] Although the type B is clinically similar to Netherton syndrome, mutations in *SPINK5* have not been identified and the protein product of *SPINK5* is overexpressed. Human tissue kallikreins and elevated stratum corneum protease activity have been demonstrated; this is thought to result in excessive desquamation and loss of barrier function.[145] A variant, clinically similar to the inflammatory type B but with associated hair shaft abnormalities, has been described.[144]

REFSUM DISEASE

Refsum disease (heredopathia atactica polyneuritiformis; OMIM #266500) is a rare, progressive, degenerative disorder of lipid metabolism resulting from the failure to break down dietary phytanic acid and its subsequent accumulation in tissues. This autosomal recessive condition affects mostly the Scandinavians and populations originating from Northern Europe. Clinical manifestations include retinitis pigmentosa, peripheral neuropathy, cerebellar ataxia, cranial nerve dysfunction (neural deafness, anosmia), miosis, electrocardiographic abnormalities, cardiomyopathy, renal tubular dysfunction, and skeletal abnormalities (epiphyseal dysplasia). Ichthyosis, which is variable, generally develops in adulthood after the neurologic and ophthalmologic manifestations. Often there are small white scales over the trunk and extremities resembling IV. Routine hematoxylin and eosin histologic examination shows variably sized vacuoles in the epidermal basal and suprabasal cells, which correspond to lipid accumulation seen with lipid stains of frozen sections.[146]

Phytanic acid (a 20-carbon, branched-chain fatty acid) is derived from a variety of dietary sources including dairy products, ruminant fats, and chlorophyll-containing foods, although chlorophyll-bound phytol cannot be absorbed in man. Phytanic acid and other chlorophyll metabolites bind the *retinoid X receptor* (RXR), as does its natural ligand, 9-*cis*-retinoic acid, and they may be physiologically active in coordinating cellular metabolism through RXR-dependent signaling pathways[147]; however, the role of RXR in the pathogenesis of Refsum disease is unclear. The disease is caused by a deficiency of PhyH, a peroxisomal protein that catalyzes the α-oxidation of phytanic acid. This is the first step in the breakdown of phytanic acid, and PhyH deficiency leads to the accumulation of phytanic acid in the serum and tissues, where it substitutes for the fatty acids normally present. While mutations in *PAHX,* the gene encoding PhyH are responsible for most cases of Refsum disease,[148] there is genetic heterogeneity.[149] Some affected patients have mutations in the *PEX7* gene, which is the same gene mutated in RCDP (see above). Refsum disease is distinguished from infantile Refsum disease, a fulminant generalized peroxisomal biogenesis disorder in which young children present with severe neurologic abnormalities, mental retardation, hepatomegaly, and dysmorphic features in addition to the other signs of adult Refsum disease.[150]

The diagnosis can be made by detection of elevated levels of plasma phytanic acid. In children who do not have elevated plasma levels of phytanic acid, the diagnosis may be made by measuring PhyH activity in cultured fibroblasts.[147] Treatment includes dietary restriction of foods containing phytanic acid and its precursors, and can include plasmapheresis or lipapheresis. In the clinical setting of a delayed onset of ichthyosis in association with neurologic impairment, this disease should be considered since therapy can arrest progression.

RUD SYNDROME

Rud syndrome (OMIM #308200) is a poorly characterized disorder, probably of recessive inheritance, that includes epilepsy, mental retardation, infantilism, congenital ichthyosis, and retinitis pigmentosa. Steroid sulfatase deficiency has been reported in some patients. Traupe critically reviewed the literature and suggested that the clinical constellation usually labeled Rud syndrome is associated with steroid sulfatase deficiency (X-linked recessive ichthyosis) and likely reflects a heterogeneous group of disorders; because both the neurologic involvement and the ichthyosis are ill defined, the term *Rud syndrome* should be abandoned.[5]

SJÖGREN–LARSSON SYNDROME

In 1957, Sjögren and Larsson reported on 13 families from north Sweden with a syndrome of congenital ichthyosis, spastic paralysis, and mental retardation. *Sjögren–Larsson syndrome* (SLS; OMIM #270200) is a rare, autosomal recessive disorder that presents at birth with an ichthyosis that may range from fine scaling to generalized hyperkeratosis. Erythema may be present at birth but tends to gradually clear by 1 year of age. Collodion-like membranes are rarely seen. The ichthyosis manifests as fine scale, large scale, or a thickening of the stratum corneum without scale and may be pruritic. Thickened areas may be yellow to brown in color and have a lichenified appearance with



Figure 49-16 Trichothiodystrophy hair shows tiger-tail banding (**A**) under polarization, which is not observed with normal hair (**B**).

accentuated skin markings. The most involved areas are the sides and back of the neck, lower abdomen, and flexures. Hair, nails, and the ability to sweat are generally normal.[151] During the first 2 to 3 years, neurologic manifestations of spastic diplegia or tetraplegia and mental retardation develop and can be accompanied by speech defects and seizures. A characteristic ophthalmologic finding is the presence of glistening white dots in the macula of the retina; these occur after 1 year of age and may not be present in all patients. Histologic findings of hyperkeratosis, papillomatosis, acanthosis, and a mildly thickened granular layer are nonspecific. Electron-microscopic examination of the skin shows lamellar membranous inclusions in the granular and cornified cells.

Rizzo et al linked SLS to *fatty alcohol:NAD oxidoreductase* (FAO) deficiency. FAO is a complex enzyme with two separate proteins that sequentially catalyze the oxidation of fatty alcohol to fatty aldehyde and subsequently to fatty acid. Further work identified the fatty aldehyde dehydrogenase (FALDH) activity in cultured fibroblasts from patients with SLS component as the affected component of FAO in SLS. FALDH is a microsomal enzyme that catalyzes the oxidation of medium- and long-chain aliphatic aldehydes derived from metabolism of fatty alcohol, phytanic acid, ether glycerolipids, and leukotriene B4.[152] Mutations found in the FALDH gene (*FALDH*, *ALDH10*, recently renamed *ALDH3A2*) confirmed the role for this enzyme in the etiology of this disorder and the importance of this pathway for normal desquamation.[153] Most mutations are specific to families, although several common mutations suggest founder effect or favored sites for mutation.[154] The identification of decreased fibroblast FAO activity in a family with atypical cutaneous findings (lack of ichthyosis or discrete plaques rather than generalized ichthyosis) has expanded the spectrum of clinical phenotypes associated with abnormal FAO activity.[155]

TRICHOTHIODYSTROPHY

Trichothiodystrophy (TTD) (OMIM #601675) is an autosomal recessive disorder that includes a broad spectrum of clinical phenotypes linked by the characteristic features of sulfur deficient, brittle hair that exhibits tiger tail banding when viewed under polarizing microscopy (Fig. 49-16).[156] Hair shaft abnormalities include trichoschisis, trichorrhexis nodosa-like defects and ribboning[157,158] (see also Chapter 139). Patients may have photosensitivity, ichthyosis, intellectual impairment, short stature, microcephaly, characteristic facial features (protruding ears, micrognathia) recurrent infections, cataracts, dystrophic nails, and other features.[159] The spectrum of clinical involvement is broad, ranging from only hair to severe multisystem abnormalities. A survey of 112 cases reported in the literature found ichthyosis (65%) as the most common skin finding, followed by photosensitivity (42%). The photosensitivity can range from subtle to severe. Of the patients with ichthyosis, about one-third presented with a collodion membrane at birth. Collodion newborns may have an erythroderma which decreases over weeks with evolution into a generalized ichthyosis, usually without erythema, which varies from fine, translucent scaling to large, dark yellow–brown hyperkeratosis (Fig. 49-17B).[160,161] Some largely resolve and are left with mild ichthyosis. There may be flexural sparing and palmoplantar keratoderma. Nail findings are found in over half of the patients and include dystrophic nails (ridging, splitting) (Fig. 49-17A), hypoplasia, brittle nails, and koilonychia.[159] Ectropion usually does not occur.

A series of mnemonics have been used to describe the constellation of findings as BIDS (*b*rittle hair, *i*ntellectual impairment, *d*ecreased fertility, and *s*hort stature); patients who also have *i*chthyosis have been called IBIDS, and with the addition of *p*hotosensitivity, PIBI(D)S has been used.[162] However, these terms do not account for the other multisystem findings commonly present.

The majority of TTD patients have a defect in XPD (*ERCC2*). A few have mutations in XPB (*ERCC3*) or TTDA (*GTF2H5*), genes which are components of the transcription factor IIH (TFIIH) that regulates both DNA repair and transcription. Some TTD patients have mutations in *TTDN1*.[163] Although many TTD patients have photosensitivity, in contrast to xeroderma pigmentosum, these photosensitive patients have not been observed to be at high risk for the

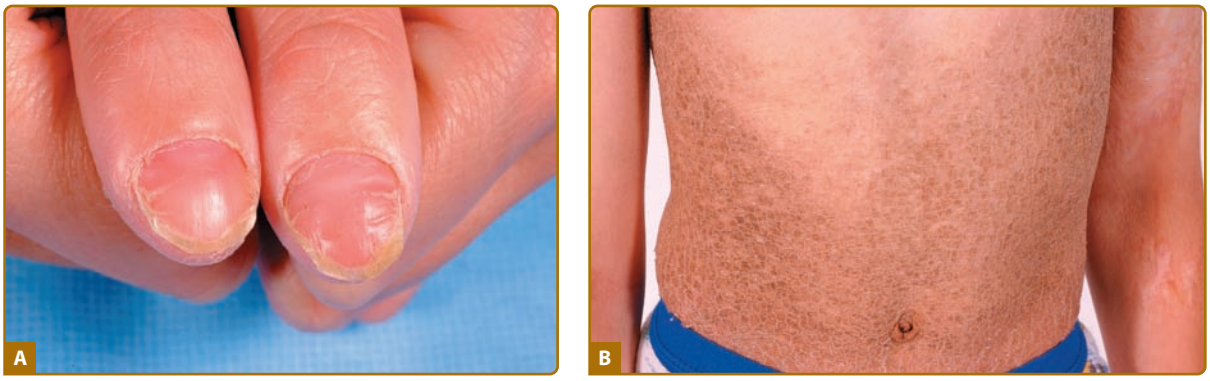

Figure 49-17 Trichothiodystrophy. **A.** The nails are thinned and brittle, with onychoschizia, cracking, and irregular transverse depressions of the dorsal surface. **B.** Skin involvement in TTD can vary from absent to severe ichthyosis. This patient has a more severe ichthyotic involvement with dark colored, adherent scale. Note involvement of the antecubital fossae.

development of skin cancer. Nucleotide excision repair is one normal cellular mechanism by which structural DNA damage (e.g., ultraviolet-induced cyclobutane pyrimidine dimers) is removed and repaired (see Chapters 110 and 139). TFIIH is involved in the initiation of transcription and also in nucleotide excision repair, and consists of a complex of proteins including the XPD and XPB proteins. In the vicinity of the damage, these two helicase subunits of TFIIH unwind the DNA in opposite directions.

ACQUIRED ICHTHYOSIS

The development of ichthyosis in adulthood can be a manifestation of systemic disease, and has been described in association with malignancies, drugs, endocrine and metabolic disease, malnutrition, HIV and other infections, and autoimmune conditions.[164,165] The granular layer is often attenuated in this disorder and the scale often resembles to that seen in mild IV. While Hodgkin disease is the most common malignancy reported with acquired ichthyosis, non-Hodgkin lymphomas and a variety of other malignancies have also been observed.[166] Histology may be diagnostic in acquired ichthyosis associated with mycosis fungoides.[167] Skin involvement may follow the course of malignancy and clear with effective cancer treatment. Acquired ichthyosis is commonly seen in association with AIDS; ichthyotic or xerotic skin has been observed in up to 30% of AIDS patients.[168] A study of HIV-1-positive intravenous drug users found acquired ichthyosis occurred only after profound helper T cell depletion, more frequently with coinfection with human T cell leukemia/lymphoma virus type II (HTLV-II), and suggested that it may be a marker for concomitant infection with both viruses.[169]

In acquired ichthyosis occurring in association with sarcoidosis, skin biopsy can be diagnostic, showing noncaseating granulomas in the dermis.[170] Acquired ichthyosis may be a marker of autoimmune disease, occurring with systemic lupus erythematosus, dermatomyositis, mixed connective tissue disease, and eosinophilic fasciitis.[171,172] It has been described in bone marrow transplant recipients, where it may be related to graft-versus-host disease.[173]

While occurrence in association with cholesterol-lowering agents (nicotinic acid, triparanol) highlights the relationship between cholesterol metabolism and normal desquamation, acquired ichthyosis has been observed with a variety of drugs, including cimetidine, clofazimine, hydroxyurea, cholesterol-lowering agents, and others.[174–178] Kava is a psychoactive beverage made from the root of a pepper plant and used for thousands of years by Pacific Islanders. Heavy kava drinkers can acquire a reversible ichthyosiform eruption called kava dermopathy. In Western nations, kava is sold in health food stores as a relaxant.[179]

PITYRIASIS ROTUNDA

Sharply demarcated, round or oval scaly patches with hypo- or hyperpigmentation are seen in *pityriasis rotunda*. Although this uncommon disorder is usually acquired, occasional familial cases have been described.[180]

RETICULATED PAPILLOMATOSIS OF GOUGEROT AND CARTEAUD

Confluent and reticulated papillomatosis of Gougerot and Carteaud is an uncommon but distinctive acquired ichthyosiform dermatosis seen in young adults and characterized by persistent brown, scaly macules, papules, patches, and plaques. Lesions tend to be localized predominantly on the neck, upper trunk (intermammary and interscapular regions), and axillae where they tend to be confluent and become reticulated towards the periphery (Fig. 49-18). The lesions bear a clinical resemblance to tinea versicolor, a skin infection with *Pityrosporum* species. A variety of treatment approaches have been reported, including topical (keratolytics, derivatives of vitamin A and D, antimicrobials) and systemic (antibiotics, retinoids) agents. Minocycline has been suggested as a first-line treatment; successful retreatment of recurrences supports the concept that this condition is an abnormal response to an infection or inflammation.[181,182]

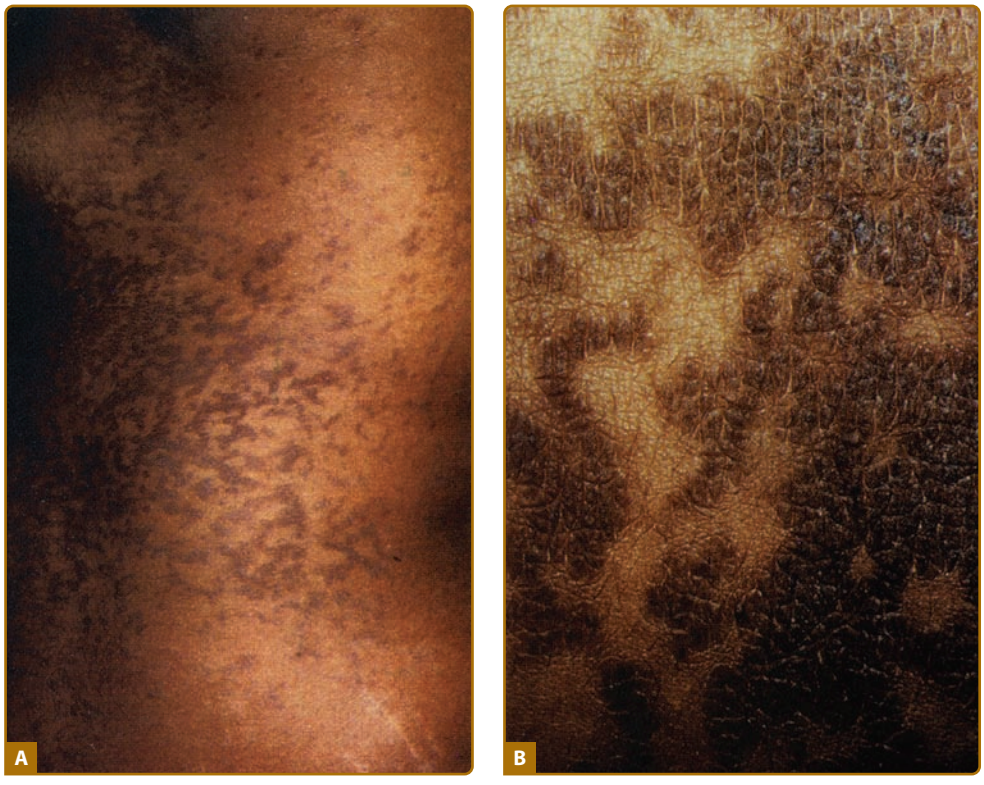

Figure 49-18 Confluent and reticulated papillomatosis of Gougerot and Carteaud. **A.** Dark, scaly papules and plaques on the trunk, which become reticulated towards the periphery. **B.** Close-up view of the distinctive, scaly, reticulated papules and plaques. (Courtesy of Andrew Montemarano, DO, and Stephen Krivda, MD.)

TREATMENT

Current therapies for the inherited ichthyoses are symptomatic and focus on hydration, lubrication, and keratolysis.[183,184] Ichthyotic skin, even if thickened, has a decreased barrier function and increased transepidermal water loss. Because pliability of the stratum corneum is a function of its water content, hydration can soften the surface of the skin. In moist, humid climates, most ichthyoses improve, and mild ichthyoses (e.g., IV) may undergo extensive clearing. Moistening the skin with, for example, long baths can hydrate it. Well-hydrated areas of hyperkeratosis can more easily be thinned with mild abrasives (sponges, buff puffs, pumice stones, etc.). Addition of bath oils or application of lubricants before drying can prolong the hydration and softening. Depending on the ichthyosis and environmental conditions, individual patients may prefer specific lubricating agents, which can take the form of lotions, creams, oils, ointments, or petrolatum. In dry climates and winter months, humidifiers can be used to create a more hospitable environment.

Keratolytic agents are used to enhance corneocyte desquamation and thereby remove scale and thin hyperkeratotic stratum corneum. There are many commercially available keratolytic creams and lotions containing urea, salicylic acid, or α-hydroxy acids (e.g., lactic acid, glycolic acid). Urea may function by its capacity to bind water. Propylene glycol (40–60% in water), with or without occlusion, can also be effective in scale removal. Occlusion can effectively increase skin hydration and facilitate desquamation; it can also enhance the effect of keratolytic agents. Special care should be taken when using extensive areas of occlusion with keratolytic agents and in individuals who may be heat intolerant. Topical retinoid or vitamin D preparations may also be effective but can be irritating in some patients. The markedly impaired barrier function in ichthyosis should be considered when using topical preparations over large areas of body surface. For example, widespread use of topical salicylic acid preparations can lead to significant absorption, intoxication (e.g., nausea, tinnitus, dyspnea, hallucinations), and even death.[185] Children are at greater risk because they have a greater body surface area per unit weight than adults, a situation that effectively heightens the possibility of developing systemic toxicity from topicals. Although the use of topical retinoids in most of the ichthyoses appears to be safe,[186] the abnormal skin barrier should be considered when treating concomitant dermatoses in ichthyosis patients. Topical 0.1% tacrolimus ointment or 1% pimecrolimus cream is effective in atopic dermatitis with minimal systemic absorption. However, the atopic dermatitis of Netherton syndrome is complicated by a defective ichthyotic skin barrier. The defective barrier is associated with increased percutaneous absorption and risk for systemic toxic effects. This should be considered when using topical agents such as tacrolimus, pimecrolimus, or topical steroids, where increased systemic absorption has been observed and monitoring of serum levels may be necessary.[88,89]

Another risk to children is that in several types of ichthyosis nutritional requirements may be high, and inadequate nutrition can lead to failure to thrive. This was thought to be related to the large turnover of scale; however, recent studies suggest energy loss from impaired barrier function is the cause.[187] Some patients with ichthyosis (particularly LI and CIE) have decreased sweating with heat intolerance. It is important for the parents of a newborn with ichthyosis to be aware of the possibility of decreased sweating and to be attentive for signs of heat intolerance, such as flushing and lethargy, particularly during hot weather and, as the child grows, during exercise. Avoiding hot environments, carrying spray bottles with water to moisten the skin and cool it through evaporation, and cooling vests can minimize heat stress.

Systemic retinoid therapy with isotretinoin or acitretin (see Chapter 228) can induce dramatic improvement in many ichthyoses and is particularly useful in LI, CIE, and erythrokeratodermia variabilis. The decision to initiate systemic retinoid therapy should be weighed carefully, because once the drug is started, continued benefit usually requires chronic therapy. Treatment of the harlequin newborn with systemic retinoid therapy during the newborn period can be lifesaving due to enhanced desquamation of a constricting membrane. Retinoic acid metabolism blocking agents, which increase endogenous retinoid levels, offer a possible alternative.[188]

Fungal infections are common, both of skin and nails, and are often undiagnosed because of the generalized scaling. A high index of suspicion can help diagnose tinea corporis, capitis, or versicolor where the only symptom may be localized pruritus and the only sign a difference in the character of scale or a localized area of alopecia.

The management of EHK varies with the clinical type. Areas of thick, hard hyperkeratosis, which are not pliable and have a hard rough surface, are prone to mechanical trauma. In patients with the hystrix type of porcupine-like hyperkeratosis, the rough surface causes high traction with objects moving across the skin surface, which tend to catch on the hyperkeratotic horn and peel it off. Topical agents such as lubricants and keratolytics can reduce the thickened, rough areas and help to minimize blistering and erosion. In contrast, patients with erythroderma and peeling, who do not have the thick areas of hyperkeratotic spines, have less need for keratolytics but still need lubricants. Acute exacerbations may occur from skin infections. Bacterial infection of the skin is common, often leads to enhanced blistering, and may require frequent therapy with topical and oral antibiotics. In patients with extensive involvement, systemic retinoid therapy can be dramatically effective in decreasing the hyperkeratosis and the frequency of infections. Because these drugs can enhance blistering in EHK patients, they should be administered carefully and started at low doses.

PRENATAL DIAGNOSIS

Molecular diagnosis is preferred when possible. Alternative methods, including fetoscopy and fetal skin biopsy, are limited to later times in pregnancy, harbor a risk of fetal mortality, and are rarely performed.[189] When it is possible to do prenatal diagnosis by molecular analysis of a fetal sample, it is optimally performed early in pregnancy. This can be done with chorionic villous sampling in the first trimester (10–12 weeks after last menstrual period) or by amniocentesis in the second trimester[190] in disorders where the underlying genetic defect is known and the specific mutation in the family has been identified. Prenatal diagnosis by mutational analysis has been accomplished in a number of the ichthyoses. If a specific mutation has not been identified, in some circumstances where there is an appropriate family structure, prenatal diagnosis can be done using linkage analysis. Prenatal diagnosis of X-linked recessive ichthyosis by FISH analysis[191] and of TTD by defective DNA repair capacity[192] has been reported. In SLS, the diagnosis can be made by assay of enzyme activity in cultured amniocytes, even if the mutation in the *ALDH10* gene is undefined. Preimplantation genetic diagnosis is a reasonable alternative, and has been accomplished for many inherited disorders, including LI and EHK (S. Bale, personal communication). The procedure requires that the couple undergo in vitro fertilization to obtain embryos. The embryos are then screened by molecular methods to detect the mutation that is segregating in the family. Only those embryos that screen negative for the mutation are selected and then can be used for implantation in the uterus to achieve pregnancy. Noninvasive methods of molecular diagnosis (evaluation of fetal DNA circulating in the mother's blood) offer the potential for the future.[188] For autosomal recessive disorders where the mutation is known (e.g., LI and SLS), carrier detection may be performed for at-risk relatives.

The Foundation for Ichthyosis and Related Skin Types provides support and information for affected individuals, family members, friends, and health care providers. (FIRST, Tel: 800-545-3286; http://www.firstskinfoundation.org/; e-mail: info@ firstskinfoundation.org.)

GeneTests (http://www.genetests.org/) provides disease reviews, genetic testing resources, and educational materials.

Online Mendelian Inheritance in Man, OMIM, (http://www.ncbi.nlm.nih.gov/entrez/query.fcgi?db=OMIM) (trademark Johns Hopkins University), a catalog of human genes and genetic disorders, is a useful reference with links to additional resources.

The National Registry for Ichthyosis and Related Disorders is a resource for investigators to improve diagnosis and treatment of these disorders (University of Washington, Dermatology, Box 356524, 1959 NE Pacific St., Seattle, WA 98195-6524 Tel: 1-800-595-1265; http://www.skinregistry.org/; e-mail: info@skinregistry.org).

KEY REFERENCES

Full reference list available at www.DIGM8.com

DVD contains references and additional content

5. Traupe H: *The Ichthyoses: A Guide to Clinical Diagnosis, Genetic Counseling, and Therapy*. Berlin, Springer-Verlag, 1989

9. Oji V et al: Revised nomenclature and classification of inherited ichthyoses: Results of the First Ichthyosis Consensus Conference in Soreze 2009. *J Am Acad Dermatol* 2010
18. Lefevre C et al: Mutations in a new cytochrome P450 gene in lamellar ichthyosis type 3. *Hum Mol Genet* **15**:767, 2006
21. Richard G et al: Missense mutations in GJB2 encoding connexin-26 cause the ectodermal dysplasia keratitis-ichthyosis-deafness syndrome. *Am J Hum Genet* **70**:1341, 2002
22. Smith FJ et al: Loss-of-function mutations in the gene encoding filaggrin cause ichthyosis vulgaris. *Nat Genet* **38**:337, 2006
33. Sandilands A et al: Filaggrin in the frontline: Role in skin barrier function and disease. *J Cell Sci* **122**:1285, 2009
48. Bernhardt M, Baden HP: Report of a family with an unusual expression of recessive ichthyosis. Review of 42 cases. *Arch Dermatol* **122**:428, 1986
49. Fischer J: Autosomal recessive congenital ichthyosis. *J Invest Dermatol* **129**:1319, 2009
69. Ozturk A et al: A retrospective study on 16 collodion babies. *Turk J Pediatr* **39**:55, 1997
72. Vahlquist A et al: Genotypic and clinical spectrum of self-improving collodion ichthyosis: ALOX12B, ALOXE3, and TGM1 mutations in Scandinavian patients. *J Invest Dermatol* **130**:438, 2010
79. Thomas AC et al: ABCA12 is the major harlequin ichthyosis gene. *J Invest Dermatol* 2006
87. Sprecher E et al: The spectrum of pathogenic mutations in SPINK5 in 19 families with Netherton syndrome: Implications for mutation detection and first case of prenatal diagnosis. *J Invest Dermatol* **117**:179, 2001
98. Herman GE: Disorders of cholesterol biosynthesis: Prototypic metabolic malformation syndromes. *Hum Mol Genet* 12(Spec No. 1):R75-R88, 2003
116. Richard G et al: Mutations in the human connexin gene GJB3 cause erythrokeratodermia variabilis [see comments]. *Nat Genet* **20**:366, 1998
122. van Steensel MA et al: The missense mutation G12D in connexin30.3 can cause both erythrokeratodermia variabilis of Mendes da Costa and progressive symmetric erythrokeratodermia of Gottron. *Am J Med Genet A* **149A**:657, 2009
154. Rizzo WB, Carney G: Sjogren-Larsson syndrome: Diversity of mutations and polymorphisms in the fatty aldehyde dehydrogenase gene (ALDH3A2). *Hum Mutat* **26**:1, 2005
159. Faghri S et al: Trichothiodystrophy: A systematic review of 112 published cases characterises a wide spectrum of clinical manifestations. *J Med Genet* **45**:609, 2008
165. Patel N et al: Acquired ichthyosis. *J Am Acad Dermatol* **55**:647, 2006
184. DiGiovanna JJ, Robinson-Bostom L: Ichthyosis: Etiology, diagnosis, and management. *Am J Clin Dermatol* **4**:81, 2003
187. Moskowitz DG et al: Pathophysiologic basis for growth failure in children with ichthyosis: An evaluation of cutaneous ultrastructure, epidermal permeability barrier function, and energy expenditure. *J Pediatr* **145**:82, 2004

Chapter 50 :: Inherited Palmoplantar Keratodermas

:: Mozheh Zamiri, Maurice A. M. van Steensel, & Colin S. Munro

INHERITED PALMOPLANTAR KERATODERMAS AT A GLANCE[1–8]

- Palmoplantar keratoderma (PPK) is chronic and pathological thickening, predominantly due to hyperkeratosis, of the hairless skin of palms and soles.
- PPK may be acquired in inflammatory skin diseases such as eczema, psoriasis, and lichen planus, and has been reported as a paraneoplastic phenomenon.
- Genetically determined PPKs are a heterogeneous group of individually rare disorders inherited by a variety of mechanisms or occurring sporadically.
- PPK may form part of ectodermal syndromes or be associated with other systemic anomalies. Important associations of specific PPKs include cardiomyopathy, impaired hearing, neuropathy and neurodevelopmental defects, and esophageal cancer.
- The mechanisms of inherited PPK include altered differentiation arising from defects in synthesis, distribution or function of structural components such as intermediate filaments, desmosomes and gap junction proteins, or altered inflammatory responses.
- The severity of palmoplantar hyperkeratosis varies from inconvenience to major functional and social disability. Plantar pain in focal keratoderma is one of the most debilitating features, with hyperhidrosis and secondary dermatophyte infection contributing to symptoms.
- Treatment is unsatisfactory, as it relies largely on physical treatments and appropriate foot care, but oral retinoids are of value in some cases.

EPIDEMIOLOGY

Inherited palmoplantar keratodermas are individually rare; the prevalence of epidermolytic keratoderma in Northern Ireland was 4.4 per 100,000.[9] Autosomal recessive keratodermas may occur with locally high prevalence in sequestered populations or communities amongst whom consanguineous union is common.

ETIOLOGY AND PATHOGENESIS

Palmoplantar skin is structurally specialized,[10] with absence of hair and increased epidermal thickness and rugosity, features necessary to cope with increased friction and mechanical stress. Dermatoglyphics together with eccrine sweat also enhance grip. Localized palmoplantar hypertrophy (callus) is a physiological response to sustained friction, for example, from ill-fitting footwear or manual work. In the inherited PPKs, excessive epidermal thickening is the result of a broad range of pathogenic pathways.

Many keratodermas are associated with defects of keratinocyte structure. The major structural component of keratinocytes is the 10-nm (intermediate) filament cytoskeleton. Keratins are a family of rod-like proteins, expressed in pairs in a tissue and differentiation specific manner, which initially dimerize then assemble to form multimeric intermediate filaments.[7] Defects in individual keratins affect skin in a distribution corresponding to the expression pattern of the particular keratin.[3] Keratin 9 (K9) is specific to palmoplantar skin, although its likely partner in these sites, keratin 1, is also expressed in hair-bearing skin. Other keratins constitutively or facultatively expressed in palmoplantar skin include K6, K16 (also found in mucosa, hair follicles, and nail bed), and K17 (hair follicles and nail bed[11]). There are multiple K6 isoforms,[12,13] and defects in K6a, K6b, and K6c as well as all the other keratins named above can result in keratoderma. The majority of pathogenic mutations in keratins occur in the highly conserved boundary peptides of the α-helical rod domain regions, which are thought vital for end-to-end overlap interactions during the elongation phase of filament assembly.[3] Typically, keratin defects result in a disrupted intermediate filament cytoskeleton. The intermediate filament network is attached to desmosomes, intercellular junctions which in turn form paired plaques with the corresponding structures in adjacent keratinocytes. Defects in desmosomal proteins such as desmoglein 1, desmoplakin 1, plakoglobin, and plakophilin 1 also cause PPK.[6] Structural weakness due to keratin and desmosome defects has the potential to cause epidermolysis or acantholysis of keratinocytes, of which hyperkeratosis may be an indirect consequence, but nonmechanical mechanisms are also probable. Keratins, for example, are also involved in the regulation of proliferation, apoptosis, and skin pigmentation.[14,15] Moreover, cell stress as a nonspecific response to an accumulation of misfolded proteins may contribute to pathogenesis. Mechanically stressed keratinocytes containing mutant keratins of the type which cause severe epidermolysis bullosa simplex show greater resistance to apoptosis than wild-type keratinocytes; the increased resistance was dependant on an increase in extracellular signal-regulated kinase (ERK) and Akt signaling.[16] Keratoderma in tyrosinemia type II may be also due to tonofilament accumulation secondary to excessive intracellular tyrosine.[17]

Another large group of PPK syndromes are due to defects in connexins, the proteins that make up gap junction communication channels between cells.[5] Gap junctions are assembled in plaques containing multiple connexon units, each of which consists of a pair of hemichannels with a central channel through which small molecules (<1 kDa) can pass between the cytoplasm of adjacent cells. Each hemichannel in turn contains six homomeric or heteromeric connexin proteins. The 21 human connexin proteins, like keratins, are expressed in a tissue and differentiation specific manner and the phenotype of gap junction diseases in part reflects their expression pattern. For example, most mutations in the gene (*GJB2*) encoding connexin 26 (Cx26) cause impaired hearing because the gene is expressed in the inner ear where it is necessary for the circulation of endolymph. Cx26 is also expressed in skin, and some Cx26 defects also cause a cutaneous phenotype, such as PPK. PPK is also found in syndromes due to mutations affecting connexin 30 (Cx30, associated with hidrotic ectodermal dysplasia[18,19]) and connexin 43 (Cx43; oculo-dental digital dysplasia[20]). However, point mutations in a single connexin can cause a range of phenotypes depending on the specific amino acid affected. While some pathogenic mutations interfere with the formation of functional gap junctions, others exhibit defects in trafficking to the cell membrane and the connexins instead accumulate within organelles.[21] Recent evidence in erythrokeratoderma variabilis (EKV) suggests that accumulation of mutant proteins causes the unfolded protein response.[22] In the case of connexin mutations associated with palmoplantar keratoderma, this endoplasmic reticulum stress may be responsible for hyperkeratosis and inflammation.

Other mechanisms of PPK are extremely varied. In loricrin keratoderma, a barrier abnormality is associated with a defective CE scaffold that results in increased extracellular permeability defect.[23] The *C*-terminal peptide of the mutant loricrin includes polybasic nuclear recognition signals which cause the aberrant protein to accumulate in the nucleus, which is likely to interfere with terminal differentiation.[24–26] In Papillon–Lefèvre syndrome (PLS), in which PPK is associated with predisposition to pyogenic infection, the cysteine protease cathepsin C is inactive.[27] This lysosomal enzyme is important in intracellular protein degradation[28] and in the activation of neutrophil serine proteases.[29] Its absence may have consequences for the regulation of inflammation,[30] but the mechanism of keratoderma may also relate to aberrant desmosomal cleavage. In Mal de Meleda, a secreted nicotinic acetylcholine receptor ligand, SLURP-1, is deficient. The normally expressed protein may act by modulating

keratinocyte behavior or inflammatory responses.[31–33] Keratoderma is a feature of rare neurodevelopmental syndromes due to defective intracellular vesicle trafficking,[34,35] and of keratosis linearis with ichthyosis congenita and sclerosing keratoderma (KLICK) syndrome where there is a defect in proteasome production.[36]

Known gene defects causing keratoderma are listed in Table 50-1.

TABLE 50-1
Gene Defects in Syndromes Which Include Palmoplantar Keratoderma

Presentation (Syndrome)	Inheritance	Gene(s)/Locus	Protein(s)
Epidermolytic PPK (Vörner)	AD	*KRT9*	Keratin 9
Transgredient epidermolytic PPK	AD	*KRT1*	Keratin 1
Diffuse NEPPK (includes Unna–Thost)	AD	*KRT1*	Keratin 1 (V1 domain)
Ichthyosis hystrix	AD	*KRT1*	Keratin 1
Focal nonepidermolytic PPK	AD	*KRT16, KRT6c*	Keratin 6c, 16
Pachyonychia congenita type 1	AD	*KRT6a, KRT16*	Keratin 6a, 16
Pachyonychia congenita type 2	AD	*KRT6b, KRT17*	Keratin 6b, 17
Ectodermal dysplasia/skin fragility syndrome	AR	*PKP1*	Plakophilin 1
Striate PPK	AD	*DSG1, DSP, KRT1*	Desmoglein 1, Desmoplakin 1, Keratin 1
Keratoderma with cardiomyopathy and wooly hair (Carvajal–Huerta and others)	AR/AD	*DSP*	Desmoplakin 1
Keratoderma with ARVC and wooly hair (Naxos)	AR	*JUP*	Plakoglobin
Keratoderma with hearing loss (Vohwinkel, Bart–Pumphrey, and others)	AD	*GJB2, GJB6*	Connexin 26, 30
Keratitis/Hystrix, ichthyosis, and deafness (KID/HID)	AD	*GJB2*	Connexin 26
Hidrotic ectodermal dysplasia (Clouston)	AD	*GJB6*	Connexin 30
Erythrokeratoderma variabilis	AD/AR	*GJB3, GJB4*	Connexin 31, 30.3
Oculo-dento-digital dysplasia (of the face, eyes, skeletal system, heart, and dentition)	AD	*GJA1*	Connexin 43
Mitochondrial keratoderma with hearing loss	Mito	*MSST1*	Serine transfer RNA
Loricrin keratoderma	AD	*LOR*	Insertion mutation in Loricrin
Keratoderma and periodontitis (Papillon–Lefèvre and Haim–Munk)	AR	*CTSC*	Cathepsin C
Mal de Meleda	AR	*ARSB*	SLURP-1
Tylosis with Oesophageal carcinoma (Howel-Evans)	AD	*RHBDF2*	Inhibitor of active rhomboid protease *RHBDL2*
Odonto-onycho-dermal dysplasia (includes Schöpf–Schultz–Passarge)	AR	*WNT10a*	Signaling molecule implicated in development
Tyrosinemia type 2 (Richner–Hanhart)	AR	*TYR1*	Tyrosinase
KLICK	AR	*POMP*	Proteasome maturation protein
CEDNIK	AR	*SNAP29*	SNARE protein involved in vesicle fusion
MEDNIK	AR	*AP1S1*	Subunit σ1A of adaptor protein-1 complex
Mapped Disorders			
Sclerotylosis (Huriez)	AD	4q23	
Diffuse NEPPK (includes Unna–Thost)	AD	12q11–13	
Punctate PPK	AD	15q22.2–15q22.31	

AD = autosomal dominant; AR = autosomal recessive; ARVC = arrhythmogenic right ventricular cardiomyopathy; CEDNIK = cerebral dysgenesis, neuropathy, ichthyosis, keratoderma; KLICK = keratosis linearis with ichthyosis congenita and sclerosing keratoderma; MEDNIK = mental retardation, enteropathy, deafness, peripheral neuropathy, ichthyosis, keratoderma; NEPPK = nonepidermolytic PPK; PPK = Palmoplantar keratoderma; SLURP1 = Secreted LY6/uPAR domain containing protein 1; SNAP29 = Synaptosomal-associated protein 29kD; WNT10A = wingless-type MMTV integration site family member 10a.

CLINICAL FINDINGS

Clinical findings vary between different genetic forms of PPK. The hyperkeratosis may present as multiple papular lesions (punctate PPK), as callosities localized to points of particular stress (focal/areate, or striate PPK) or may extend over the whole palm or sole (diffuse PPK). The distinction between focal, striate, and diffuse forms is not always easy to make, and the severity of PPK may vary, even within a family. Hyperhidrosis is a common complaint amongst patients with focal or diffuse keratodermas. Corynebacterial overgrowth leading to keratolysis and malodor, and secondary dermatophyte infection, is common. Transgredient keratoderma extends onto the dorsa of the hands and other cutaneous sites; circumferential keratoderma of digits is associated with the formation of constricting bands ("pseudoainhum," see Chapter 68) and sometimes autoamputation (cicatrizing or mutilating keratoderma). It may also cause tapering of the digits (sclerodactyly) with bony atrophy and nail dystrophy. A number of keratoderma syndromes, in particular Huriez and Olmsted syndromes (see below) are characterized by the frequency of squamous cell carcinoma in affected skin; melanoma has also been reported in various PPKs.

APPROACH TO THE PATIENT WITH KERATODERMA

In the history, early age of onset is usual. Punctate keratodermas present in adulthood, but new presentations of diffuse PPK at this age are more likely to be papulosquamous disorders (see Section "Differential Diagnosis"). In inherited PPKs, hyperhidrosis is commonly reported. Pain is a particular feature of focal keratodermas, but in all forms of keratoderma functional, occupational, or social disability should be recorded. A family history, including consanguinity, may be helpful but it is unwise to draw firm conclusions about either clinical type or inheritance patterns without having examined all available members of a pedigree, even if said to be affected. Family history of early onset systemic malignancy or skin cancer should be noted.

The distribution of keratoderma (punctate, focal, striate, or diffuse) is not an absolute guide. Feet tend to be more markedly and diffusely involved, so that in severe cases the underlying pattern may be more obvious on the hands. The appearance of the hyperkeratosis—for example, honeycomb patterned, waxy, or fissured—may be significant. Sharp, livid margins or the presence of transgredient hyperkeratosis on dorsa of hands, feet, and digits should be noted. The possibility of secondary fungal or bacterial infection, and of the development of malignancy, should be considered. It is important to examine the whole skin for signs of other skin diseases such as eczema, psoriasis, and lichen planus. In inherited PPK, mild acral hyperkeratosis may indicate a generalized cutaneous disorder that is locally severe on palms and sole; fissures at the oral commissures and follicular hyperkeratosis are also common. Mild ichthyosis seen in loricrin PPK may be missed if not specifically sought. Many PPKs involve mucosa, including genital mucosa. The presence of other ectodermal abnormalities should be documented, i.e., abnormalities of nails, teeth, hair and hair follicles, sweat glands, and sweating. Finally, specific features associated with syndromic keratoderma should be elicited by history and examination. These include hearing impairment (which may be subtle), neuropathy, and cardiac disease (conduction defects or cardiomyopathy).

A pathway to aid diagnosis (Fig. 50-1) is provided, but is neither comprehensive nor absolute. Individual presentations are discussed in more detail below.

KERATODERMAS WITH MAINLY CUTANEOUS FEATURES

PUNCTATE KERATODERMA. Punctate keratoderma (Buschke–Fischer–Brauer syndrome; MIM 146800) is usually inherited as an autosomal dominant trait.[37] Unlike most other inherited PPKs, punctate PPK presents in adult life as multiple keratinizing papules (Fig. 50-2A). It may be an incidental finding, although plantar lesions can produce significant disability and also cause secondary focal keratoderma. From the gradual accumulation of discrete individual lesions it may be inferred that there is a defect in one inherited allele, and the disease is expressed when the remaining allele is damaged. An association with malignancy of kidney, stomach, breast, and colon, has been reported in a few pedigrees,[38,39] but has not been generally substantiated. In any case, the condition is probably genetically heterogeneous. The size of the papules in different families varies from a few millimeters to tiny filiform lesions (music-box spine keratoderma) (see eFigs. 50-2.1 and 50-2.2 in online edition). Similarly, histology of the lesions may show orthokeratotic or parakeratotic hyperkeratosis. At least two genetic loci have been suggested[40,41] although that at 15q22.2–15q22.31 is most certain. Other clinically similar conditions include punctate keratoderma of the palmar creases, and focal acral hyperkeratosis of the margins of palms and soles, with or without elastoidosis. Papular palmoplantar lesions may be seen in other genodermatoses, notably Darier disease (see Chapter 51), in which the pitted lesions common in younger cases become papular with age. Acquired causes of punctate palmoplantar lesions include dioxin toxicity and chronic arsenicism.

EPIDERMOLYTIC KERATODERMA. An example of uncomplicated diffuse keratoderma is epidermolytic PPK (EPPK; Vörner syndrome; MIM 144200). EPPK is probably the commonest PPK,[9] and is an autosomal dominant trait due to defects in keratin 9, the one keratin specific to palmoplantar skin.[42] It presents in childhood as diffuse PPK with a sharp, livid transition to normal skin at the edge of palms and soles (Fig. 50-2C; see also eFig. 50-2.3 in online edition). Severe cases may be accompanied by blistering,

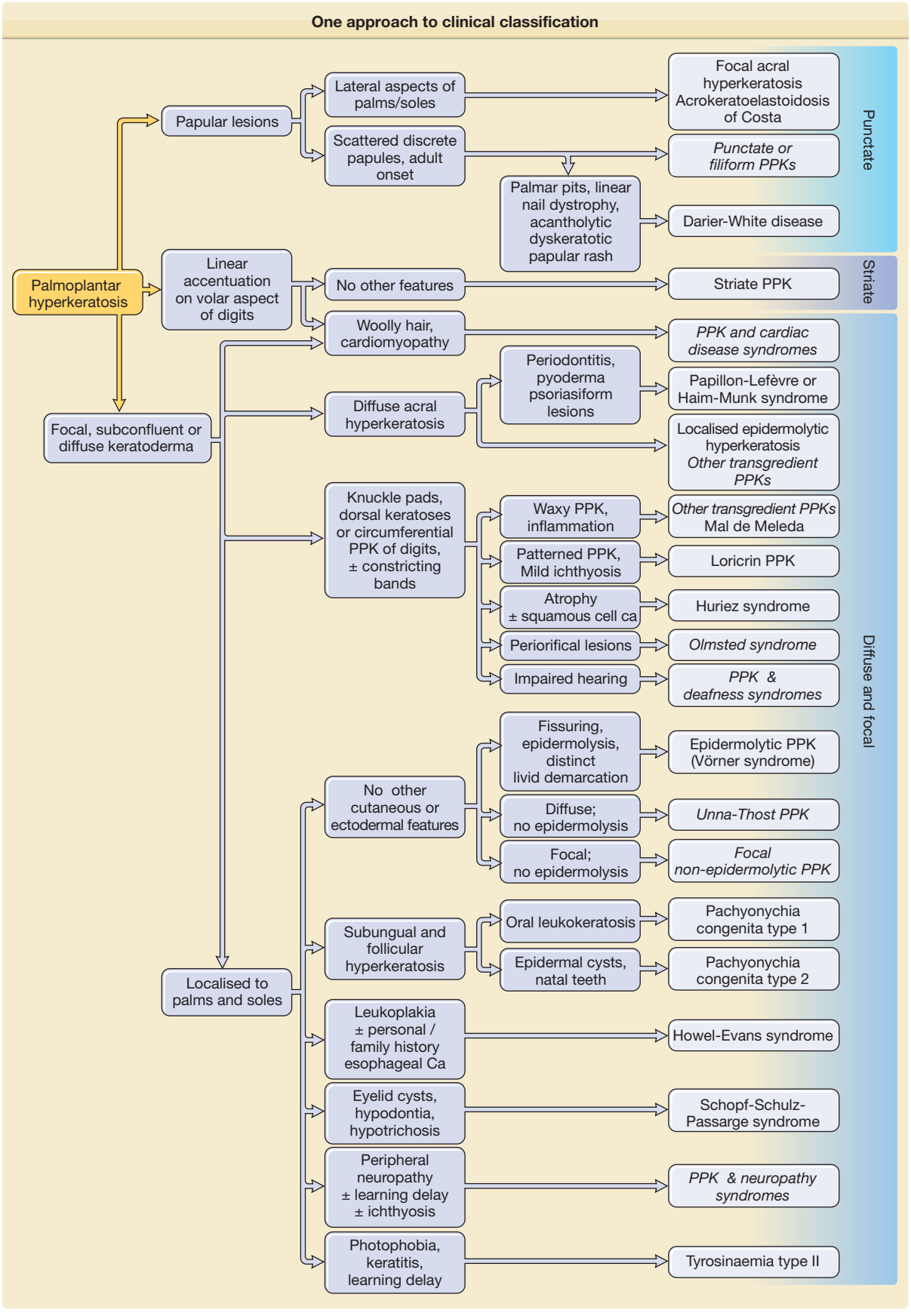

Figure 50-1 One approach to clinical classification. Diagnoses shown in italics are pragmatic groups rather than genetically defined syndromes (see text). It is unwise to use the pattern of keratoderma (i.e., papular, focal, striate, diffuse) as the primary means of classification, since this can vary even within families. It is a good principle to look for ectodermal and syndromic associations in all new cases.



Figure 50-2 Patterns of familial keratoderma. **A.** Punctate, which usually does not appear until adulthood. The lesions have been accentuated by immersion in water for a few minutes. **B.** Striate, often due to desmosomal disorders. **C.** Diffuse, in this case with fissuring and the sharp demarcation typical of keratin 9 defects. **D.** Focal, seen as an isolated finding due to keratin 6c mutations. In practice the distinction between these patterns may not be clear, especially on plantar skin.

although in adults the epidermal weakness is more commonly manifested by fissuring. Histology of the stratum spinosum shows vacuolated keratinocytes with keratin filament aggregates at electron microscopic level, accompanied by orthohyperkeratosis of the stratum corneum. Defects in keratin 1, the presumed partner of keratin 9 in palmoplantar skin, also cause diffuse transgredient keratoderma with epidermolytic hyperkeratosis at other cutaneous sites, but extrapalmoplantar involvement may be subtle (see eFig. 50-2.4 in online edition). A specific defect of the 1B domain of keratin 1 causes tubular tonofilament structures to form in some pedigrees.[43] Keratoderma may also be a feature of epidermolysis bullosa of the severe Dowling–Meara type (MIM 131760; [44]) due to mutations in the basal layer keratins 5 and 14 (see Chapter 62). The mechanism(s) by which keratin gene defects may give rise to the palmoplantar hyperkeratosis are discussed above.

NONEPIDERMOLYTIC DIFFUSE PPK. Nonepidermolytic diffuse PPK restricted to palmoplantar skin is heterogeneous. The term Unna–Thost syndrome (MIM 600962) should probably be discarded, as even the original Thost family in fact had epidermolytic PPK.[45] In one pedigree a diffuse nonepidermolytic phenotype was due to a defect in the variable region of the keratin 1 gene,[46] and in another was mapped to a locus including the type II keratin gene cluster.[47] Another locus proximal to the type II keratin gene cluster has been identified.[48]

FOCAL PPK. Focal PPK (see Fig. 50-2 and eFig. 50-2.5 in online edition) may complicate punctate PPK on the feet, or may occur in isolation; in the latter situation it may be difficult to distinguish from physiological callosities, and indeed the tendency to these may have a genetic basis.[49] Early onset focal keratoderma of whatever cause leads to disability ("hereditary painful callosities"), and patients may be so severely affected as to become wheelchair bound. Autosomal dominant pedigrees of focal PPK are commonly associated with nail dystrophy and mucosal features as part of the pachyonychia spectrum, but even in the absence of nail dystrophy may be due to mutation in keratin 16.[50] In the majority of cases of focal PPK in isolation, genetic causes have not been identified, but in three pedigrees it has been ascribed to mutations in keratin 6c.[49] Painful focal PPK is also found in tyrosinemia type II (see below and Chapter 131).

STRIATE PPK. Striate PPK (SPPK; MIM 148700) is a distinct variant of focal PPK in which there is prominent linear involvement of the volar surfaces of the digits (see Fig. 50-2B) and less distinctly of corresponding areas of the soles. Histology of autosomal dominant inherited striate PPK shows subtle widening of the intercellular spaces (see Fig. 50-5C). [51,52] Most cases

are due to defects in gene encoding desmosomal plaque proteins of which desmoglein 1 (*DSG1*) is most commonly implicated, but mutations in desmoplakin 1 are also reported.[53,54] Keratoderma due to defects in these genes is believed to be due to haploinsufficiency, i.e., reduced amounts of the relevant structural protein expressed in the desmosomal plaque result in mechanical weakness which manifest at points of greatest stress. However, as with keratins, demosomal components are implicated in intracellular signaling and growth regulation. Striate PPK may also be seen with some mutations in keratin 1,[55] and indeed striate accentuation is a nonspecific component of milder diffuse keratodermas. Most cases of autosomal dominant SPPK are simple, but defects in desmoplakin also give rise to syndromes of cardiomyopathy and wooly hair (see below).

LORICRIN KERATODERMA. Loricrin keratoderma (syn. Camisa syndrome; MIM 640117) was described as a variant of Vohwinkel syndrome (VS).[56] It is characterized by a similar "honeycomb" patterned and transgredient keratoderma (Fig. 50-3A; see also eFig. 50-3.1 in online edition), leading to circumferential digital involvement, cicatrizing bands, and sometimes autoamputation. However, there is also a mild generalized ichthyosis, and collodion babies or generalized desquamation at birth are reported.[57,58] Compared with true VS, due to mutations in Cx26, the edge of the keratoderma at the wrists is diffuse, and deafness is not a feature. Multiple mutations are reported of which the most frequent mutation, *730insG*, has been found in families from the United Kingdom, Japan, Germany, and Italy.[24,57,59–64] In all cases they are single nucleotide insertions resulting in a shift of the reading frame and a termination codon delayed by 22 amino acids. In the elongated carboxyl-terminal domain many of the glycine residues are replaced by arginine, drastically altering the properties of the loricrin polypeptide by producing nuclear recognition signals (see above).

HURIEZ SYNDROME. Huriez syndrome (PPK with scleroatrophy, sclerotylosis; MIM 181600), an autosomal dominant disorder, is characterized by diffuse PPK that affects mainly palmar skin (Fig. 50-3C).[65–70] The underlying gene defect is unknown but linkage to chromosome 4q23 has been reported.[71] Sclerodactyly,



Figure 50-3 Rare forms of transgredient PPK. **A.** Patterned keratoderma in a case of loricrin PPK; note circumferential keratoderma and early constricting bands. **B.** Confluent papules in Vohwinkel PPK with impaired hearing due to connexin 26 mutations; honeycomb lesions and circumferential PPK with constricting bands also occur in this syndrome. **C.** Huriez syndrome (sclerotylosis), which carries a high risk of squamous cell carcinoma. (Used with permission from Dr. Cameron Kennedy, Bristol Royal Infirmary, United Kingdom.) **D.** Mal de Meleda due to mutations in ARS component B, with a waxy hyperkeratosis, sclerodactyly, and constricting bands.

brachydactyly, and cutaneous erythema and/or atrophy are typical, as are various nail changes; hypohidrosis is also reported. A deficiency of Langerhans cells in affected skin has been identified.[72] The condition predisposes to squamous cell carcinomas of affected skin, occurring in the third to fourth decade, which are unusually prone to metastasis.[67,68] Causal treatment is not available, but benefit from oral retinoids is recorded.[67]

MAL DE MELEDA. Mal de Meleda (MIM 248300) is a rare autosomal recessive disorder originally described in communities of the Mediterranean littoral. The transgredient (i.e., it extends over the lateral margin of the palms and proximally over the wrists) hyperkeratosis has a waxy ivory to yellow appearance and is typically inflamed or macerated, with a livid margin.[73] Dermatophyte superinfection, to which many keratodermas are prone, may mimic these appearances. Knuckle pads, similar waxy lesions on acral sites, angular cheilitis, and circumferential sclerosing and cicatrizing lesions of the digits are typical (Fig. 50-3D; see also eFig. 50-3.2B in online edition); not surprisingly nails are often dystrophic. The typical Mediterranean disorder is due to mutations in the *ARSB* gene encoding SLURP-1, an acetylcholine receptor analog.[31,74,75]

OTHER TRANSGREDIENT KERATODERMAS. Recessive transgredient and/or mutilating disorders with phenotypes resembling Mal de Meleda are reported,[76,77,78,79,80] but appear to be genetically distinct. A very rare autosomal recessive disorder (KLICK syndrome) has been described in which a cicatrizing PPK is associated with ichthyosis and a bizarre striate hyperkeratosis of flexures.[81,82] This has recently been shown to be due to defects in *POMP* which encodes a protein which is a chaperone for proteasome maturation.[36] Similarly, pedigrees of autosomal dominant transgredient PPKs have been described. The term Greither syndrome has been used,[2,83,84] but may not be a single entity.[85] Some autosomal dominant transgredient keratodermas within this spectrum are due to mutations in keratin 1 (Fig. 50-4A),[86] but other such pedigrees, for example, Sybert syndrome[87] appear not to be keratin disorders.

KERATODERMAS WITH ECTODERMAL DYSTROPHY

PACHYONYCHIA CONGENITA. Pachyonychia congenita (PC) is a spectrum of dominantly inherited disorders associated with focal PPK. In addition to painful focal PPK and hypertrophic dystrophy of the distal nail, there are numerous reported associations[88] (see eFig. 50-4.1 in online edition). Two main syndromes are recognised clinically,[89] in which various associated features can cause significant additional morbidity and disability. PC-1 (Jadassohn–Lewandowsky; MIM 167210) is associated with follicular keratoses, oral leukokeratosis and hoarseness. Severe oral lesions can resemble mucosal candidiasis[90] and laryngeal involvement may produce infantile respiratory obstruction.[91] The rarer PC-2 (Jackson–Lawler; MIM 167210) is distinguished by multiple pilosebaceous cysts, teeth present at birth, and hair changes such as protuberant eyebrows. Extensive and infected flexural, vulval or scrotal cysts can present as hidradenitis suppurativa.[92] PC-1 is typically associated with mutations in *KRT6A* or *KRT16* and PC-2, with mutations in *KRT6B* or *KRT17*, reflecting the expression patterns of the



Figure 50-4 The pattern of plantar PPK is often not diagnostic. **A.** Diffuse fissured PPK due to mutation in keratin 1 but with only localized epidermolytic hyperkeratosis of elbows, knees and flexures. **B.** Similar changes in Papillon-Lefèvre syndrome due to mutation in Cathepsin C. (Used with permission from Barts and the London NHS Trust, United Kingdom.) **C.** Howel–Evans syndrome (PPK with familial esophageal carcinoma) showing subconfluent keratoderma sparing the instep. **D.** Similar changes due to an insertion mutation in keratin 1. **E.** Focal PPK with impaired hearing due to *A7445G* mutation in mitochondrial DNA.

relevant keratins[3]: for example K16 is a major secondary keratin in orogenital epithelia. Severity varies within and between families, and incomplete phenotypes such as PPK without nail dystrophy or steatocystoma multiplex without PPK may be caused by mutations in the same genes. However, detailed analysis of patients with *KRT16* mutations suggests that mutations which predict a more disruptive effect on K16 protein structure produce a more severe phenotype.[93] A recent large study casts doubt on the consistency of the association of clinical syndrome and mutated keratin[94] and it has been proposed instead that PC be designated according to the affected keratin—PC-6a, PC-6b, etc. and PC-U (unknown).[95] Genotypic classification has the aim of individualising targeted molecular therapy, already promising in this disorder.[8]

SCHÖPF–SCHULZ–PASSARGE SYNDROME.

Schöpf–Schulz–Passarge syndrome (SSPS[96]; MIM 227450) appears to be allelic with onycho-odontodermal dysplasia (OODD; MIM 257980), a spectrum of autosomal recessive ectodermal dysplasias with a core phenotype of abnormal nails, oligodontia with abnormal teeth, and hypotrichosis.[97] Dental anomalies may occur in heterozygotes. Features in addition to palmoplantar keratoderma (see eFig. 50-4.2 in online edition) include erythematous facial lesions and atrophic lingual papillae. In SSPS, patients commonly develop benign adnexal tumors. Apocrine hydrocystoma, presenting as eyelid cysts is characteristic of SSPS: eccrine poroma and syringofibroadenoma also occur.[98] Squamous and basal cell carcinomas and porocarcinomas are reported in affected skin. Disorders within the OODD spectrum are due to mutations in *WNT 10a*[97,99–101]; the protein encoded by this gene is a member of a family of secreted signaling molecules which inhibit degradation of the β-catenin complex and hence allow it to modulate gene expression. WNT signaling is important in many developmental pathways, and WNT10a is implicated in dental and hair follicle morphogenesis, and the formation of ectodermal ridges.

OLMSTED SYNDROME.

Olmsted syndrome (mutilating palmoplantar keratoderma with periorificial plaques,[102–105]) is a severe disorder. Congenital diffuse, sharply demarcated, and progressive keratoderma of palms and soles causes flexion deformities, constrictions, autoamputation, and obliteration of digits. Periorificial keratoses are characteristic but associated symptoms include a variety of nail dystrophies and hypotrichosis. The disease usually manifests within the first 6 months of life and is progressive. A number of patients have developed squamous cell carcinoma in affected skin. The genetic basis is unknown. Most cases are sporadic but it may be autosomal dominant. In children, the disorder must be distinguished from recessive transgredient PPKs including Mal de Meleda and, because of the periorificial keratoses, acrodermatitis enteropathica.

OTHER ECTODERMAL SYNDROMES WITH KERATODERMA.

PPK is found in the Naegeli–Franceschetti–Jadassohn syndrome (MIM 161000) and dermatopathia pigmentosa reticularis (MIM 125595), allelic syndromes due to dominant mutations in the nonhelical E1/V1 domains of keratin 14.[106] Other features include absent dermatoglyphics, reticulate pigmentary anomalies, hypohidrosis, and other subtle ectodermal defects. PPK also occurs with keratin 5 and 14 defects in the severe Dowling–Meara form of epidermolysis bullosa simplex[44] in Kindler syndrome, due to mutations in *FERMT1* encoding kindlin-1, a cell adhesion molecule involved in signaling via the actin filament network,[107] and in ectodermal dysplasia with skin fragility due to defects in the desmosomal protein plakophilin 1.[54] PPK is found in hidrotic ectodermal dysplasia (Clouston syndrome, MIM 129500), due to mutations in *GJB6* encoding connexin 30 (Cx30, see Chapter 142),[18] which can mimic PC,[108] and in oculodento-digital-dyplasia (ODDD; MIM 164200) due to mutations in *GJA1* encoding Cx43.[20] Similarly, PPK may be part of the presentation of erythrokeratoderma variabilis (MIM 133200; Chapter 49) which is due to mutations in *GJB3* or *GJB4*.[4]

OTHER KERATODERMAS WITH ORAL OR MUCOSAL FEATURES

HOWEL–EVANS SYNDROME.

Howel–Evans syndrome [Tylosis and (o)esophageal cancer, TOC; MIM 148500] is an exceptionally rare autosomal dominant disorder; only a few families are known. In the original report by Howel–Evans et al,[109] 18 of 48 individuals who had PPK developed squamous cell carcinoma of the esophagus at an average age of 43 years. Palmoplantar hyperkeratosis appeared on average 30 years earlier. The keratoderma is characterized by thick yellow focal hyperkeratosis most prominent on the pressure sites (Fig. 50-4C; see also eFig. 50-4.3 in online edition).[110] Pain is not a major feature, and the palms are only involved in manual workers. Confluent hyperkeratoses over pressure sites on the feet may lead to more diffuse involvement. Oral leukoplakia precedes plantar lesions in children. Follicular hyperkeratosis also occurs and the major differential distinction to be made is with PC or focal PPK with oral leukokeratosis. In the latter disorders, nail abnormalities are usually present, although sometimes subtle. The disorder has long been mapped to chromosome 17q25.[111] Causative mutations have recently been found in RHBDF2.[112] This inactive member of the rhomboid family of intramembrane serine proteases may normally inhibit an active rhomboid protease; mutations may interfere with epidermal growth factor and EphrinB3 signalling.

PAPILLON–LEFÈVRE SYNDROME.

PLS (PPK with periodontitis, MIM 245000) is an autosomal recessive disorder caused by mutations in the *CTSC* gene coding for the proteolytic enzyme cathepsin C.[27,113] PLS is characterized by a diffuse palmoplantar erythematous and fissured hyperkeratosis (Fig. 50-4B) with transgredient erythema, and peridontitis.[114] If untreated, deciduous teeth may be lost by the age of 4–5 years, and subsequently, permanent dentition may

also be lost. Redness and thickening of the palms and soles usually occur in the first years of life, coincidental with eruption of the deciduous teeth.[115] Typically, PLS patients show scaly erythematous psoriasiform lesions over knees, elbows, and interphalangeal joints. Transverse ridging of nails, onychogryphosis, sheeted follicular hyperkeratosis and a subtle, generalized white opalescence of oral mucosa, and dural calcification, have also been reported. Associated plantar hyperhidrosis can cause malodor. Patients are susceptible to skin infections (with *Staphylococcus aureus*) and pyogenic liver abscesses.[116] Loss of permanent dentition will lead to improvement of the periodontitis, but patients benefit greatly from adequate dental hygiene and care. Haim–Munk syndrome (HMS, MIM 245010) is allelic with PLS,[117] but is a distinct disorder which appears to have arisen in the Jewish population of Kochi, Kerala, India. In HMS, the features are more severe and extensive, and there are additional manifestations of arachnodactyly, acroosteolysis, atrophic nails, and pes planus. The recently described autosomal dominant hypotrichosis–acro-osteolysis–onychogryphosis–palmoplantar keratoderma–periodontitis (HOPP) syndrome combines periodontitis, acro-osteolysis, and psoriasiform skin lesions with a unique focal or reticular keratoderma and progressive scarring alopecia[118,119]; *CTSC* mutations have been excluded in the three reported cases.

KERATODERMAS WITH CARDIAC DISEASE

NAXOS DISEASE. Naxos disease (MIM 601214), first reported in pedigrees from the eponymous Greek island, is an autosomal recessive disorder.[120] Patients have a diffuse, gray–yellow fissuring but nonepidermolytic keratoderma, wooly hair, and arrhythmogenic right ventricular cardiomyopathy (ARVC) causing heart failure and sudden death. The disease is due to homozygosity for a deletion mutation in the gene for the desmosomal plaque protein junctional plakoglobin (JUP), which causes a frameshift and premature termination of the protein.[121] More than 90% of homozygous individuals have electrocardiographic abnormalities (mostly T wave inversion in V1–V3 leads), associated with arrhythmias, syncope, heart failure, and sudden death,[122–125] but heterozygotes show no overall increased cardiac morbidity or mortality. Another mutation in *JUP* caused dominant ARVC without cutaneous features.[126] Conversely, in two pedigrees with keratoderma, skin fragility and wooly hair in the absence of cardiac disease, homozygosity for novel recessive mutations in *JUP* has recently been reported.[127]

CARVAJAL–HUERTA SYNDROME. Carvajal–Huerta syndrome (MIM 605676) is the association of striate keratoderma, wooly hair, and dilated left ventricular cardiomyopathy.[128] It is a recessive disorder due to truncating mutations in the desmoplakin gene (*DSP*) which cause the protein to lose its *C*-terminus.[129] Affected family members present with striate PPK, with some extravolar involvement at sites of pressure. The associated dilated left ventricular cardiomyopathy, developing in teenage years, is characterized by cardiac enlargement and disrupted cardiac contraction.[123] A range of phenotypes with right, left, or biventricular arrthymogenic cardiomyopathy in isolation or combined with wooly hair and other ectodermal features including keratoderma, are due to dominant or recessive mutations in desmoplakin.[125,130–132] Larger truncations in *DSP* give rise to lethal acantholytic ectodermal dysplasia.[133]

Mild PPK with ARVC and wooly hair due to recessive mutation in desmocollin-2 has been reported.[134]

KERATODERMAS WITH IMPAIRED HEARING

Many autosomal dominant palmoplantar keratoderma syndromes with sensorineural hearing loss are caused by mutations in the gap junction genes *GJB2* or *GJB6*, encoding the gap junction proteins Cx26 and Cx30, respectively.[4,19,135–138] Mutations in *GJB2*, encoding Cx26, usually cause nonsyndromic deafness, but a minority are responsible for most of the PPK-deafness syndromes. There is a wide range of overlapping phenotypes, and almost every Cx26 mutation associated with PPK has a clinically distinct phenotype.[139,140] Amongst these, VS is most dramatic, with honeycomb patterned keratoderma, "starfish" acral keratoses, constricting bands, and autoamputation[141–143] (Fig. 50-3B; see also eFig. 50-4.4 in online edition). Even in this syndrome the PPK may be focal, papular, or diffuse. Acral hyperkeratosis is found in other Cx26 PPKs; in the case of Bart–Pumphrey syndrome as knuckle pads. Constricting bands around the fingers and autoamputation occur when there is confluent transgredient PPK. The genotype–phenotype correlation is poorly understood, but mutations that cause PPK and deafness tend to cluster in the extracellular domains of Cx26.[5,140] Other mutations in *GJB2* give rise to more severe syndromes in which PPK is part of a generalized oculo-cutaneous disorder: keratitis ichthosis and deafness (KID; MIM 148210) and hystrix ichthyosis and deafness (HID; MIM 602540).[144,145] These disorders are described in Chapter 49.

A specific mutation in mitochondrial DNA, *A7,445G*, has been reported as causing the combination of hearing loss and a variable keratoderma (Fig. 50-4E) with matrilineal inheritance in pedigrees from New Zealand, Scotland, Japan, Portugal, and Hungary.[146–149] This segment of the mitochondrial genome encodes a serine transfer RNA, MTTS1. Penetrance of both features is incomplete, and the same mutation has been reported as a familial cause of impaired hearing in the absence of observed keratoderma.

KERATODERMAS WITH NEUROPATHY OR MENTAL RETARDATION

Two autosomal recessive syndromes with the combination of neuropathy and mental retardation have been

documented genetically. CEDNIK (cerebral dysgenesis, neuropathy, ichthyosis, and keratoderma; MIM 609528) is due to a 1-bp deletion in *SNAP29*, which encodes a SNARE protein involved in vesicle fusion.[34,150] MEDNIK (mental retardation, enteropathy, deafness, peripheral neuropathy, ichthyosis, and keratoderma) is due to a splicing defect in the *AP1S1* gene, encoding a subunit of one of the adaptor protein complexes which regulate vesicle assembly, protein cargo sorting, and vesicular trafficking between organelles.[35] The similarities between the disorders may be explained by the fact that the AP1 complex interacts with the *SNAP29* gene product in the transport vesicles. In other reported pedigrees, PPK was combined with spastic paraplegia or motor and sensory neuropathy,[151–153] but as yet causative mutations have not been identified.

TYROSINEMIA TYPE II. Tyrosinemia type II (Richner–Hanhart syndrome, MIM 276600) is a very rare autosomal recessive disorder[154,155] due to deficiency of tyrosine aminotransferase, leading to accumulation of tyrosine and phenolic acid metabolites[156] (see Chapter 131). Clinical characteristics include painful focal palmoplantar hyperkeratosis, photophobia, and corneal erosions that may cause scarring or glaucoma.[154–159] Eye lesions precede the skin phenotype but the latter may occur in the absence of ocular involvement. Histopathological examination shows eosinophilic inclusions in the basal layer of the epidermis and increased keratohyaline granules. It is suggested that excess tyrosine enhances cross-links between aggregated tonofilaments and stabilizes microtubules.[17] The untreated syndrome causes psychomotor retardation, but a diet low in phenylalanine and tyrosine will both ameliorate cutaneous symptoms and prevent further mental deterioration.

INVESTIGATION OF KERATODERMA

Histologically, keratodermas are characterized by definition by increased stratum corneum thickness often with hypergranulosis but acanthosis, papillomatosis, and increased stratum lucidum vary. Where vacuolar degeneration and epidermolysis are present, it suggests keratin 9 defects (Fig. 50-5A), but it may be necessary to biopsy weight-bearing sites to maximize the chance of finding it. Normal palmoplantar skin contains increased numbers of tonofilaments on electron microscopy.[10] Abnormal aggregated keratin intermediate filaments in EPPK[160] and tonotubular structures in a rare variant form[43,161] are identifiable. Overt epidermolysis is not a major feature of PPK due to defects of other keratins, but prominent eosinophilic cytoplasm and keratin aggregates can be identified in most cases of PC (Fig. 50-5B[52]; Zamiri, unpublished data). Increased tonofilaments and microtubules are also reported in tyrosinemia type II.[17]

In desmosomal disorders, there is increased separation between keratinocytes, although frank acantholysis is unusual with desmoglein mutations (Fig. 50-5C).[51,52] Ultrastructurally, desmosomal plaques may be reduced in number or poorly formed, and keratin aggregation and compaction has also been noted with desmoplakin mutations.[51,162,163] In loricrin keratoderma, retained nuclei may be seen in the stratum corneum in which the mutant loricrin is detectable.[164] In Mal de Meleda, and in PLS, perivascular inflammation may be prominent, although this is a nonspecific finding in other keratodermas. The pathologist should also look for fungal spores or hyphae.

Punctate keratoderma may be orthokeratotic or parakeratotic. The latter in two dimensions resembles

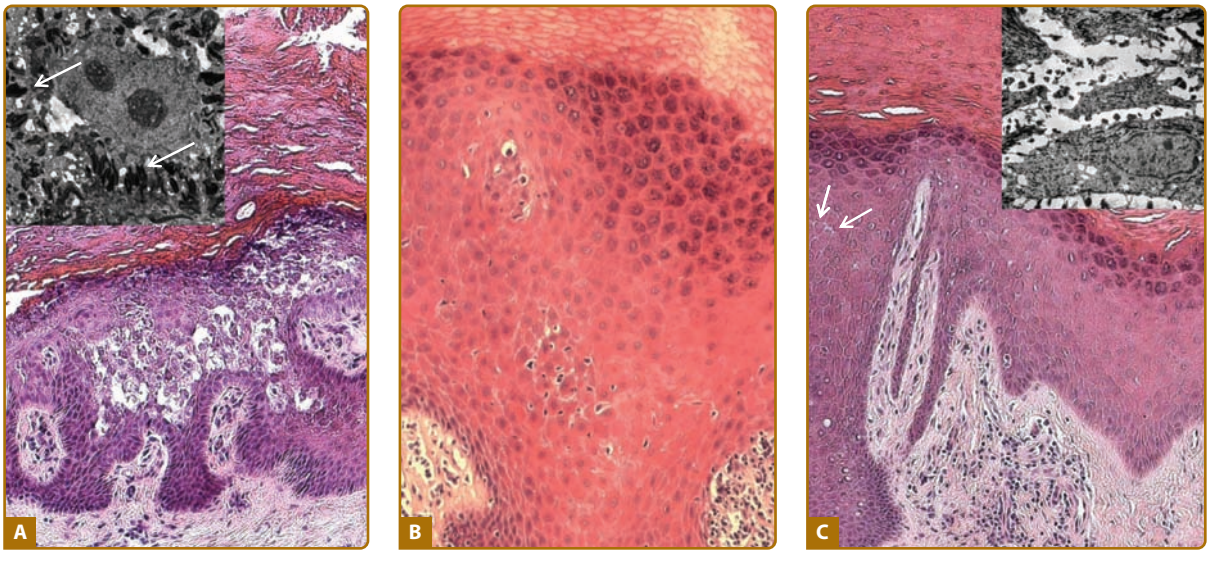

Figure 50-5 Histology of keratoderma. **A.** Vacuolation of spinous layer keratinocytes in epidermolytic PPK due to keratin 9 mutations; inset, tonofilament aggregates (*arrows*), and cytolysis on electron microscopy. **B.** Eosinophilic cytoplasm but without overt epidermolysis and inflammatory infiltrate in pachyonychia congenita due to keratin 17 mutation. **C.** Subtly increased cell separation (*arrows*) in striate PPK due to desmoglein 1 mutation; inset of electron microscopic appearances shows overtly increased cell separation.

the coronoid lamella of porokeratosis, but nonannular lesions are not true porokeratoses. Whether these variations are of nosological significance remains to be determined.

The cysts of PC include epidermoid and vellus hair cysts as well as true steatocysts, and indeed a single cyst may vary in its histology in different sections. The periodontal lesions of PLS show pockets of epithelium with ulceration and a mixed inflammatory cell infiltrate.

It is important to bear in mind the possibility of the development of squamous cell carcinoma or melanoma within keratoderma, and any changing or suspicious area should be biopsied.

Further investigation will be determined by the clinical syndrome; for example, audiometry, cardiac, or esophageal studies. In Olmsted syndrome, acrodermatitis enteropathica should be excluded by measuring serum zinc. Skin scraping for mycology remains the most useful investigation for many patients with keratoderma.

It is increasingly possible to obtain confirmation of the gene defect in familial keratodermas, particularly those involving connexins, by sending DNA to specialist commercial, or academic laboratories, but a reasonably strong clinical suspicion of the gene responsible is usually needed. Molecular diagnosis is particularly useful to distinguish focal PPKs with oral lesions, due for example, to keratin 16 mutations, from Howel–Evans syndrome.

DIFFERENTIAL DIAGNOSIS

See Box 50-1 and eFig. 50-5.1 in online edition.

BOX 50-1 DIFFERENTIAL DIAGNOSIS

- Onset late in life generally indicates acquired keratoderma, although genetic factors may still be relevant. Predisposition to callus formation and hyperkeratosis of the heels is common, exacerbated by obesity. Hypothyroidism should be excluded. The term Haxthausen's disease is used for acquired plantar hyperkeratosis in menopausal women.
- Hyperkeratotic eczema is distinguished by pruritus, erythema, the presence of vesiculation, and response to topical steroid preparations.
- In palmoplantar psoriasis, lesions elsewhere and typical nail changes may help confirm the diagnosis.
- Pityriasis rubra pilaris of the palms is distinguished by characteristic color and associated nail changes.
- Reiter's syndrome is readily distinguished by its acute presentation and associated arthropathy.
- Keratoderma due to chronic dermatophyte infection and in crusted (Norwegian) scabies can be diagnosed by appropriate tests and response to treatment.
- Sudden onset of diffuse keratoderma may be paraneoplastic, particularly carcinoma of the bronchus.
- Keratoderma has been reported in SLE. Autoantibodies to desmocollin 3 were associated with a diffuse acquired PPK.[178]
- Punctate keratoderma of late onset should raise the possibility of arsenical poisoning.

MANAGEMENT OF KERATODERMA

Many patients with PPK, particularly those with diffuse varieties, tolerate the condition without specific treatment. Patient-led self-help groups catering for rare and orphan disorders offer valuable support, but the rarity of individual conditions means that specific advice is difficult to obtain. An important exception is the Pachyonychia Congenita Project (www.pachyonychia.org).

For patients with focal keratoderma, which is often painful and sometimes disabling, regular paring by a podiatrist or the patient him/herself helps to control hyperkeratosis. Topical keratolytic agents such as salicylic acid ointment (5%–20%) or benzoic acid compound ointment help to soften the hyperkeratosis prior to abrasion. Propylene glycol (40%–60% in aqueous cream under occlusion at night) can also soften hyperkeratosis and aid reduction of callosities.

Many patients complain of hyperhidrosis for which simple measures such as topical aluminum chloride hexahydrate may be used. Suitable ventilated footwear, insoles, and "wicking" socks (available from suppliers of outdoor walking equipment) may offer some relief. Botulinum toxin has been successfully used to reduce plantar pain but requires regional anesthesia.[165] Malodor due to keratolytic corynebacterial infection of macerated hyperkeratosis, and fungal superinfection are also common. Where present, topical or systemic antimicrobials produce worthwhile benefit, but need to be repeated.

Oral retinoids are frequently tried but there are few systematic studies. Acitretin (10 mg/day or more), etretinate, or isotretinoin may all help, particularly in keratin, loricrin, or connexin disorders; successful use in PLS and Mal de Meleda is also reported. However, individual dosimetry may need to be adjusted carefully as excessive shedding of hyperkeratosis can cause palmar and plantar skin to become tender. In conditions with painful callosities such as PC, retinoids may reduce the thickness of the hyperkeratoses but aggravate the pain. If successful, lifelong treatment is required, with its associated risks. Oral retinoids have also been used to rescue impending autoamputation due to circumferential constricting bands.[166–168] A few reports suggest topical (or systemic) 5-fluorouracil may benefit punctate or filiform keratoderma.[169–171] Surgical treatment, including excision and grafting, has been reported,[172] most commonly used to prevent permanent contracture in Olmsted syndrome.[173–176] Surgical release of constricting bands has had poor outcomes and asymptomatic lesions are probably best left alone.[177]

For severe disorders where the genetic etiology is known, prenatal diagnosis is technically possible as a preventive strategy. Specific gene therapy is an exciting but still distant prospect for disorders of known etiology. However, a recent study in PC has shown that inhibition of mutant gene expression by repeated

injection of a specific small interfering RNA (siRNA) was effective in reducing hyperkeratosis.[8]

KEY REFERENCES

Full reference list available at www.DIGM8.com

DVD contains references and additional content

1. Irvine AD, McLean WH: Human keratin diseases: The increasing spectrum of disease and subtlety of the phenotype-genotype correlation. *Br J Dermatol* **140**:815, 1999
2. Itin PH, Fistarol SK: Palmoplantar keratodermas. *Clin Dermatol* **23**:15, 2005
3. Lane EB, McLean WH: Keratins and skin disorders. *J Pathol* **204**:355, 2004
4. Richard G: Connexin disorders of the skin. *Clin Dermatol* **23**:23, 2005
5. Laird DW: Life cycle of connexins in health and disease. *Biochem J* **394**:527, 2006
6. Lai-Cheong JE, Arita K, McGrath JA: Genetic diseases of junctions. *J Invest Dermatol* **127**:2713, 2007
7. Moll R, Divo M, Langbein L: The human keratins: Biology and pathology. *Histochem Cell Biol* **129**:705, 2008
8. Leachman SA et al: First-in-human mutation-targeted siRNA phase Ib trial of an inherited skin disorder. *Mol Ther* **18**:442, 2009

Chapter 51 :: Acantholytic Disorders of the Skin

:: Susan Burge & Alain Hovnanian

ACANTHOLYTIC DISEASES AT A GLANCE

- The acantholytic diseases are a heterogeneous group of diseases with overlapping clinical and histological features.
- Darier (or Darier–White) disease (DD) and Hailey–Hailey disease (HHD) are autosomal dominant disorders that are caused by defective calcium pumps—a sarco/endoplasmic reticulum pump in DD and a Golgi apparatus pump in HHD.
- Typical DD presents with greasy keratotic papules in a seborrheic distribution while HHD is characterized by painful oozing erosions in flexures and at sites of trauma.
- Signs in the nails (DD, HHD), flat-topped warty papules on dorsa of hands and feet (DD) and palmar pits (DD, HHD) or palmar keratotic papules (DD) help to confirm the diagnosis.
- Hypertrophic malodorous flexural disease is particularly disabling in DD and HHD.
- Grover disease (GD) is a sporadic papular condition of uncertain etiology that presents most often in sun-damaged skin. Intractable pruritus is common.
- Histopathological examination of involved skin in DD, HH, and GD reveals breakdown of intercellular contacts between suprabasal keratinocytes (acantholysis) with variable dyskeratosis.
- Acrokeratosis verruciformis of Hopf (AKV) is autosomal dominant and characterized by signs that mimic acral DD: flat-topped warty papules on dorsa of hands and feet and nail dystrophy. The histology in AKV is not acantholytic, but some (if not most) cases may be limited variants of DD.
- Treatment options for these diseases include topical corticosteroids (DD, HHD, GD) and topical or oral retinoids (DD, GD, AKV).

DARIER DISEASE

EPIDEMIOLOGY

Darier disease (DD) (OMIM #124200) is an autosomal dominant disease affecting both sexes and all ethnic groups. DD was described independently by Darier and White in 1889 (also known as Darier–White disease or keratosis follicularis).[1] Estimates of prevalence range from 1 in 30,000 (Northeast England, Scotland, Slovenia)[2–4] to 1 in 100,000 (Denmark).[5] Penetrance is complete, but spontaneous mutations are frequent.

ETIOLOGY AND PATHOGENESIS

The gene for DD was mapped by linkage analysis to chromosome region 12q23-24 in 1993[6] and *ATP2A2* was identified as the defective gene in 1999.[7] *ATP2A2*

encodes sarco/endoplasmic reticulum Ca^{2+} adenosine triphosphatase (ATPase) isoform 2 (SERCA2), a calcium pump transporting Ca^{2+} from the cytosol to the lumen of the endoplasmic reticulum (ER).[8–11] DD is caused by mutations inactivating one *ATP2A2* allele.

ATP2A2 spans 76 kilobases (kb), is organized in 21 exons, and encodes a 4.4-kb transcript, which is alternatively spliced into three isoforms: (1) SERCA2a, (2) SERCA2b, and (3) SERCA2c.[12,13] SERCA2a is expressed in the slow-twitch skeletal muscles and cardiac muscle, unaffected in DD.[14,15] SERCA2b and SERCA2c are expressed ubiquitously, but SERCA2b is the major isoform detected in the human epidermis.[16] Mutations specific for SERCA2b are sufficient to cause DD (despite the presence of functional SERCA2a), confirming the important role of SERCA2b in epidermis.[17,18] Most tissues may compensate for deficiencies in SERCA2 by mechanisms such as SERCA3, which is not expressed in keratinocytes.[16]

SERCA2 pumps belong to the P-type Ca^{2+} ATPase family. The pumps catalyze the hydrolysis of adenosine triphosphate (ATP) coupled with the translocation of two Ca^{2+} ions from the cytosol to the ER lumen, where Ca^{2+} is stored at high concentrations. SERCA pumps comprise three cytoplasmic domains [(1) the actuator, (2) phosphorylation, and (3) ATP-binding domains] linked to a transmembrane domain with ten transmembrane helices that contain the two Ca^{2+}-binding sites. After binding of cytosolic Ca^{2+} ions and phosphorylation, the pump undergoes conformational changes and releases Ca^{2+} into the ER lumen.[19]

More than 140 pathogenic *ATP2A2* mutations have been reported, including missense mutations (50%), frameshift mutations (23%), and in-frame deletions or insertions (8%). No consistent correlation has been demonstrated between genotype and phenotype, but missense mutations may be associated with more severe forms.[7,17,18,20–33] The considerable phenotypic variability suggests that other genetic or environmental factors modify the phenotype.

Although the etiology has been explained, the pathogenesis of DD is less clear. High concentrations of Ca^{2+} are required for normal keratinocyte intercellular adhesion and differentiation. Normally, the epidermis displays an increasing epidermal Ca^{2+} gradient from the basal to the superficial layers, but in DD this gradient is disturbed. The level of Ca^{2+} is reduced in basal cells from both affected and unaffected skin.[34]

The earliest ultrastructural change is breakdown of desmosomes with aggregation of keratin filaments around the cell nucleus.[35] Immunohistological studies of acantholytic cells reveal internalization of desmosomal components.[36–38] The dyskeratotic cells in the epidermis (grains, corps ronds) are formed through apoptosis, which appears to be triggered by the loss of adhesion.[39] The expression of antiapoptotic proteins in the *Bcl-2* gene family is reduced in DD, possibly as a secondary phenomenon, but an alteration in Bcl-2 proteins might also contribute to apoptosis.[39–42]

SERCA pumps replenish the ER Ca^{2+} pool from cytosolic Ca^{2+}, but mutations disrupting critical functional domains reduce activity of the pump in DD. A reduced ER Ca^{2+} pool may impair processing of desmosomal proteins by affecting the function of molecular chaperones such as calreticulin and calnexin that prevent protein misfolding and are involved in posttranslational modification.[43] Intracellular signaling through release of ER Ca^{2+} regulates trafficking of proteins to the cell membrane, including those required for the assembly of desmosomes and adherens junctions.[44] The trafficking of desmoplakin to the cell membrane is impaired in cultured DD keratinocytes.[45] Variations in cellular Ca^{2+} concentrations are also likely to have an effect on the expression of Ca^{2+}-dependent genes involved in keratinocyte differentiation and adhesion.

The epidermis is papillomatous and differentiation is abnormal, with the expression of hyperproliferative keratins and premature expression of cornified envelope precursors such as involucrin.[34,38,46–48] Alterations in ATP-mediated signaling may contribute to dyskeratosis and hyperproliferation.[8,34] Extracellular Ca^{2+} binds to purinergic ATP receptors that transmit calcium signals into the cytosol. Activation of the G-protein-coupled ATP receptor (P2Y) generates inositol 1,4,5-tris-phosphate (IP3), a calcium-signaling messenger (Fig. 51-1). Binding of IP3 to surface receptors on the ER and Golgi apparatus triggers release of Ca^{2+} stores and a rise in cytosolic Ca^{2+} which activates a further influx of extracellular Ca^{2+} through plasma membrane Ca^{2+} channels (store-operated Ca^{2+} entry), including transient receptor potential canonical1 (TRPC1). In DD, depleted ER Ca^{2+} appears to upregulate TRPC1 and enhances influx of Ca^{2+}.[8,49]

Elevated cytosolic Ca^{2+} may drive keratinocyte proliferation by activation of Ca^{2+}-dependent messenger systems that regulate cell division and differentiation.[49] Mice with reduced SERCA2 develop papillomas and SCCs.[50] SERCA2 haploinsufficiency in cultured mouse keratinocytes is linked to upregulation of proliferation but downregulation of differentiation.[51] SCC has been reported rarely in DD, sometimes in association with HPV16.[52–56]

Much of the skin may be able to compensate for the deficiency in SERCA2 by increasing the expression of the normal SERCA2 allele or by upregulating other mechanisms such as the human secretory-pathway Ca^{2+}/Mn^{2+} ATPase isoform 1 (SPCA1) in the Golgi (see section "Hailey–Hailey Disease"). However, external factors such as ultraviolet B (UVB) irradiation or friction, which are known to exacerbate DD, may disrupt this subtle balance by downregulating ATP2A2 or by increasing the requirement for SERCA2 until the protein reaches a critical level.[8,57] This hypothesis is supported by the observation that UVB irradiation and proinflammatory cytokines reduce levels of ATP2A2 mRNA in cultured normal keratinocytes and that retinoids and corticosteroids (used in treatment of DD) prevent this reduction.[58] Lithium, another well-known trigger for DD, reduces epidermal expression of SERCA2 in rats.[59]

CLINICAL FINDINGS

HISTORY. (Box 51-1). The first manifestations usually appear between the ages of 6 and 20 years with a peak

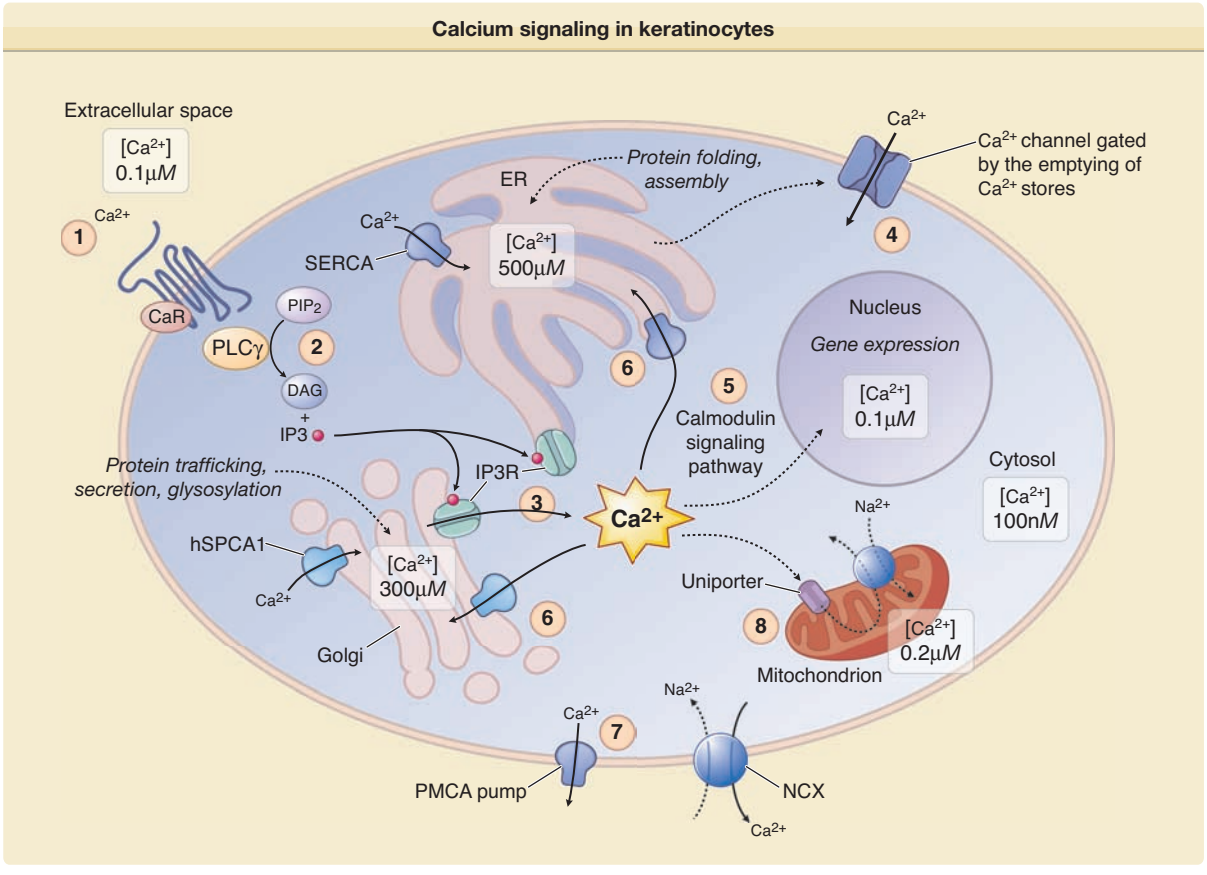

Figure 51-1 A simplified representation of Ca^{2+} signaling in keratinocytes. **1.** Ca^{2+} binding to its plasma membrane receptor (CaR) activates phospholipase Cγ (PLCγ). **2.** This causes the hydrolysis of phosphatidylinositol 4,5-bisphosphate (PIP2) into inositol 1,4,5-tris-phosphate (IP3) and diacylglycerol (DAG). **3.** IP3 binds to its receptor (IP3R) at the surface of the endoplasmic reticulum (ER) and Golgi apparatus, which causes the depletion of intracellular stores and induces an increase in intracellular Ca^{2+} levels. **4.** This increase triggers the opening of Ca^{2+} release-activated channels in the plasma membrane, which leads to a sustained increase in Ca^{2+} intracellular levels. **5.** Ca^{2+} binds to calmodulin; this activates calcineurin and calmodulin-dependent protein kinases, which regulate gene transcription through phosphorylation/dephosphorylation of transcription factors. **6.** Active Ca^{2+} transport by the different sarco/endoplasmic reticulum calcium adenosine triphosphatase (ATPase) pumps (SERCA1 to SERCA3) and human secretory pathway Ca^{2+}/Mn^{2+}–ATPase (SPCA1) pump is essential to replenish ER and Golgi Ca^{2+} stores, respectively. SPCA1 is also required for Mn^{2+} influx into the Golgi apparatus (not indicated here). **7.** Ca^{2+} efflux to the extracellular space involves plasma membrane Ca^{2+}–ATPases (PMCA) and Na^{+}/Ca^{2+} exchangers (NCX). **8.** Mitochondria take up Ca^{2+} released from the internal stores during Ca^{2+} signaling via the Ca^{2+} uniporter and return it to the cytosol through an NCX. Thus, Ca^{2+} homeostasis requires differential Ca^{2+} concentrations in the cytosol, the sarco/endoplasmic reticulum, the Golgi apparatus, the mitochondria, and the nucleus of the cell. The largest store of cellular Ca^{2+} is located in the ER lumen and in Ca^{2+}-binding proteins. Ca^{2+} signaling is highly regulated and generated by influx through Ca^{2+} receptors, release from internal stores (ER, Golgi apparatus, mitochondrion), and sequestration by Ca^{2+} pumps (SERCAs, SPCA1) and Ca^{2+} exchangers. mNCX = mitochondria Na^{2+}/Ca^{2+} exchanger.

BOX 51-1 DARIER DISEASE: WHAT SHOULD I LOOK FOR?

- A family history
- Symptoms such as malodor (many patients are relieved to have an opportunity to discuss this distressing problem) or pain (may indicate infection with *Herpes simplex* virus).
- Exacerbating factors—what happens in heat or sun, for example, summer?
- History of cold sores. Discuss the risk of eczema herpeticum and how to recognize.
- Explore the impact of disease, including mood change. DD is associated with depression including suicidal ideation.

between 11 and 15 years, but DD may develop in infants or old age.[1,60] Symptoms include itch, malodor, and pain. Heat, sweating, friction, and sunlight (UVB) exacerbate the signs that may be noticed for the first time in hot summer months.[1,2,61]

CUTANEOUS LESIONS. The discrete, greasy, yellowish-brown keratotic papules (only some are perifollicular) have a predilection for seborrheic areas: central chest and upper back, scalp (hair growth is not affected), forehead, neck including supraclavicular fossae, ears, and skin creases (axillae, groins, and perineum) (Figs. 51-2 and 51-3). Papules tend to coalesce into crusted plaques (Fig. 51-4). Foul-smelling, hypertrophic disease in the groin is particularly disabling (Fig. 51-5). In 1889, White noted the "intolerable stench" that accompanies severe disfiguring disease.[62] DD may affect schooling, work, and relationships.[1,61,63]

Hands and/or nails are affected in >96% of patients and may show the first signs of disease.[1,2] Look for nail fragility, painful longitudinal splits, or distinctive red and white longitudinal bands terminating in V-shaped nicks (Fig. 51-6). Pits or keratotic papules on palms and, sometimes, soles, help to confirm the diagnosis (Fig. 51-7). Many patients (50–70%) have skin-colored, flat-topped papules on the dorsa of hands and/or feet like those of acrokeratosis verruciformis of Hopf (AKV).[64] Hemorrhagic macules with jagged margins, possibly linked to trauma, are the least common acral sign and may blister (Fig. 51-8). Hemorrhagic DD has been reported in some kindreds as well as individuals.[65–68]

Oral,[1,69–71] esophageal,[72,73] rectal,[74] and cervical[75] mucosa may be affected. Corneal abnormalities have been recorded.[76–78]

CLINICAL VARIANTS. Variants include painful erosive DD,[79] vesiculobullous DD,[80] grossly hyperkeratotic plaques (cornifying DD),[81–83] nipple hyperkeratosis,[84] keratoderma (Fig. 51-9), comedonal DD,[33,85,86] freckled "Groveroid" DD[87] and, in pigmented skin, guttate leukoderma with confetti-like hypopigmented macules, and/or papules.[88,89]

Segmental Disease. Type 1 mosaicism presents with one or more unilateral bands of keratotic papules



Figure 51-2 Hyperkeratotic pigmented papules on the trunk of a patient with Darier disease.



Figure 51-3 Darier disease: inflammatory plaques with fissures and maceration may simulate Hailey–Hailey disease. Note that the fingernails are dystrophic.



Figure 51-4 Malodorous confluent keratotic papules on the chest with fissuring and hyperkeratosis of nipples in Darier disease.



Figure 51-5 Hypertrophic flexural Darier disease may suggest an SCC.



Figure 51-6 Dystrophic fingernails showing fragility, splitting, and red and white longitudinal bands in Darier disease.

following Blaschko's lines. Hands and/or nails may be affected on the same side[90,91] (Fig. 51-8). This distribution reflects a postzygotic somatic mutation in *ATP2A2* early in embryogenesis.[92–94] Theoretically, patients with gonadal mosaicism could transmit generalized disease, but no such cases have been reported. Type 2 mosaicism is rare and characterized by a severely affected linear band of DD, superimposed on generalized disease. A postzygotic mutation causes loss of heterozygosity at the *ATP2A2* locus in the more severely affected skin.[95]

RELATED PHYSICAL FINDINGS

DD has occasionally been reported in association with neuropsychiatric disease including seizures, bipolar disorder, and schizophrenia.[1,32,96–98] Lithium, which may be prescribed for bipolar disorder, exacerbates disease, possibly by suppressing levels of epidermal SERCA2.[59,99–101] The lifetime prevalence of major depression (30%), suicide attempts (13%), and suicidal thoughts (31%) appears higher than in the general population, highlighting the need for careful assessment.[98,102] Reports of cosegregation of DD with bipolar disorder in some families support the existence of a bipolar disorder susceptibility gene in the DD region, but *ATP2A2* has been excluded as a common susceptibility gene for bipolar disease.[103–105] Learning difficulties reported in some patients may be, at least in part, secondary to social handicap caused by disfigurement. Bone changes, particularly bone cysts, have been reported infrequently.[106–108]



Figure 51-7 Keratotic papules of the palms in Darier disease.



Figure 51-8 Hemorrhagic macule and nail dystrophy in Darier disease.

LABORATORY TESTS—HISTOPATHOLOGY

Histologic examination shows downgrowths of narrow cords of keratinocytes, suprabasal acantholysis with suprabasal clefts (lacunae), dyskeratosis (premature and abnormal keratinization), and hyperkeratosis



Figure 51-9 Keratoderma in Darier disease.

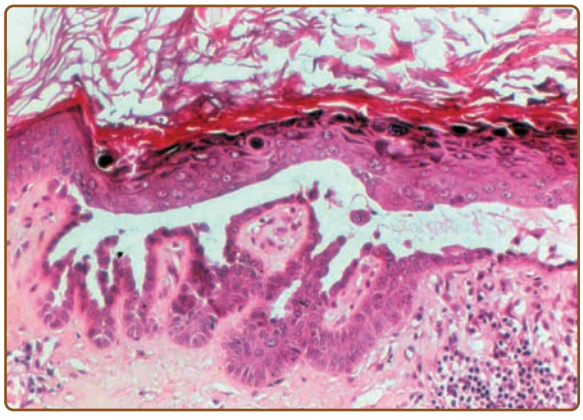

Figure 51-10 Histologic preparation of affected skin in Darier disease showing suprabasal cleft of the epidermis containing acantholytic cells, rounded eosinophilic dyskeratotic cells in the epidermis (corps ronds), hyperkeratosis, and flattened parakeratotic cells in the horny layer (grains).

(Fig. 51-10). Apoptosis results in rounded eosinophilic dyskeratotic cells in the epidermis (corps ronds) and flattened parakeratotic cells in the horny layer (grains).[39] The warty papules on the backs of the hands show the histology of AKV (see below).

DIFFERENTIAL DIAGNOSIS

(Box 51-2)

DD may be misdiagnosed as seborrheic dermatitis or acne, particularly in patients without a family history. Look for signs of DD in the hands or nails. Acneiform facial DD may be confused with familial dyskeratotic comedones[109,110] or comedo-like acantholytic dyskeratosis.[111]

Erosive, bullous, or hypertrophic flexural disease simulates Hailey–Hailey disease (HHD), but HHD tends to present later and patients do not have keratotic papules or nail fragility.[112] Erosive or hypertrophic DD may also resemble pemphigus vulgaris or vegetans (see Chapter 54), but patients do not have mucosal ulcers and intracellular immunoglobulin (Ig) and complement are not detected in the epidermis. Localized hypertrophic DD may suggest malignancy (Fig. 51-5). Freckled or papulovesicular forms may resemble Grover disease (GD),[87] but GD is not familial (see below), or the rare acantholytic variant of Dowling–Degos disease (Galli–Galli disease).[113,114]

Acral papules resemble plane warts or AKV (which may be a form of DD).[64,115,116] Localized papular vulvocrural acantholytic disease may be part of the spectrum of DD or HHD.[117–120]

BOX 51-2 DARIER DISEASE: DIFFERENTIAL DIAGNOSIS

SEBORRHEIC

- Seborrheic dermatitis (scalp, trunk)
- Grover disease (trunk)
- Acne (forehead)
- Confluent and reticulate papillomatosis (trunk)
- *Candida* infection (inframammary)

EROSIVE

- *Herpes simplex* infection
- Bullous impetigo
- Hailey–Hailey disease
- Pemphigus vulgaris

VEGETATING FLEXURAL

- Hailey–Hailey disease
- Pemphigus vegetans
- SCC

COMEDONAL

- Acne
- Familial dyskeratotic comedones
- Comedo-like acantholytic dyskeratosis

ACRAL

- Plane warts
- Acrokeratosis verruciformis of Hopf

FRECKLED

- Grover disease
- Dowling–Degos disease—acantholytic variant (Galli–Galli disease)

GENITAL

- Genital warts
- Vulval intraepithelial neoplasia
- Hailey–Hailey disease
- Papular vulvocrural acantholytic disease

COMPLICATIONS

Impetiginization and eczematization may complicate the picture and patients have an increased susceptibility to widespread infection with *Herpes simplex* (eczema herpeticum) (Fig. 51-11) or *Herpes zoster*.[121,122] Blockage of salivary glands has been reported.[1,69,80,123] SCC (scalp, scrotal, vulval, thigh, subungual) has been recorded infrequently, sometimes linked to the presence of HPV16.[52–56]

CLINICAL COURSE

DD pursues a chronic relapsing course. Severity is unpredictable, but in about 30% of patients disease becomes less severe in old age, while in others DD persists or gradually worsens.[1,61]

TREATMENT

(see Table 51-1)

The physician should take the time to answer questions, explain that treatments may control but not cure



Figure 51-11 Widespread vesicular rash caused by infection with *Herpes simplex* virus in Darier disease.

DD, and offer genetic counseling if appropriate. It is important to discuss how to reduce the impact of triggers such as heat and sun, and use emollients containing urea or lactic acid to reduce hyperkeratosis. Topical antiseptics (washes, bath additives), antibiotics, and antifungals will help to prevent or treat infection. *Herpes simplex* causes painful flares that require oral acyclovir.[121] Topical corticosteroids in combination with antibiotics reduce inflammation. Limited disease may respond to a topical retinoid, for example, 0.1% tazorotene[124,125] or 0.05% isotretinoin,[126] prescribed in combination with a topical corticosteroid to reduce irritation. Other topical agents such as adapalene,[127,128] 5-fluorouracil,[129–131] or tacrolimus[132] have been reported to be effective in small numbers of cases.

Oral acitretin 0.25–0.5 mg/kg or isotretinoin 0.5 mg/kg reduces hyperkeratosis and malodor, but will take 3 to 4 months to achieve maximal effect.[133] Tailor dose to the response and monitor for adverse effects (see Chapter 228). Pregnancy is contraindicated for 2 years after stopping treatment with acitretin and for 1 month after stopping isotretinoin. Oral cyclosporine has been advocated for eczematization[134] and in severe vulval disease,[135] but controlled trials are lacking.

Approaches for severe hypertrophic or erosive disease include dermabrasion, laser ablation, and photodynamic therapy, but controlled studies are needed to evaluate these approaches.[79,133,136,137] Botulinum toxin may control flexural exacerbations by reducing sweating and mammoplasty has been advocated for severe inframammary disease.[138,139]

ACROKERATOSIS VERRUCIFORMIS OR ACRAL DARIER DISEASE

AKV is a rare inherited disease described by Hopf in 1931 that may be a variant of DD.[64,116]

ETIOLOGY AND PATHOGENESIS

AKV (OMIM #101900) is inherited in an autosomal dominant fashion.[115] Sporadic cases have been reported. A missense mutation in *ATP2A2*, the gene that is affected in DD, was identified in a large British pedigree. The heterozygous Pro602Leu mutation caused complete loss of Ca^{2+} transport activity.[116] Thus, in some instances, AKV and DD are allelic disorders, a conclusion that is entirely consistent with the overlapping clinical features. However, mutations in *ATP2A2* were not identified in a Chinese family.[140]

CLINICAL FINDINGS

AKV usually presents at birth or in early childhood. The asymptomatic, skin-colored, flat-topped warty papules are distributed symmetrically on the dorsum of the hands and feet (Fig. 51-12). Papules may also develop on knees, elbows, and extensor aspects of legs

TABLE 51-1
Darier Disease: Treatment

First Line	Second Line	Third Line (Unproven Efficacy)
Discuss how to avoid triggers (heat, sweating, friction) and minimize UVB-induced exacerbations. Emollients containing urea or lactic acid. Soap substitutes and topical antiseptics. Moderate or potent topical corticosteroids with topical antibiotics. Topical retinoids: isotretinoin (0.05%, 0.1%), tretinoin, tazarotene gel, adapalene 0.1% gel.	Oral acitretin 0.25–0.5 mg/kg/day. Takes 3 months to have a maximal effect. Acitretin should be stopped for 2 years before a woman attempts to conceive. Oral isotretinoin 0.5 mg/kg/day. Less effective than acitretin but may be indicated in young women. Isotretinoin should be stopped for 1 month before a woman attempts to conceive.	Topical 5-fluorouracil. Oral cyclosporine for eczematization. Initially 2.5 mg/kg/day. Laser surgery, electrosurgery, or dermabrasion. Photodynamic therapy. Botulinum toxin to reduce sweating in recalcitrant flexural disease. Mammaplasty for severe inframammary disease.



Figure 51-12 Small, flesh-colored papules over the dorsum of the hand in acrokeratosis verruciformis of Hopf.

and forearms.[64] As in acral DD, punctate keratoses and pits may be present on palms and soles, palmar skin may be thickened, and patients may have subungual hyperkeratosis, longitudinal striations, splits, and V-shaped nicks at the free margin of the nail plates. A linear variant with persistent localized unilateral lesions has been reported in two unrelated Saudi patients.[141]

LABORATORY TESTS—HISTOPATHOLOGY

The classic histopathologic findings are hyperkeratosis, hypergranulosis, and acanthosis with papillomatosis. The spiky elevations of the epidermis are said to resemble "church spires" (Fig. 51-13). Epidermis is neither dyskeratotic nor acantholytic.

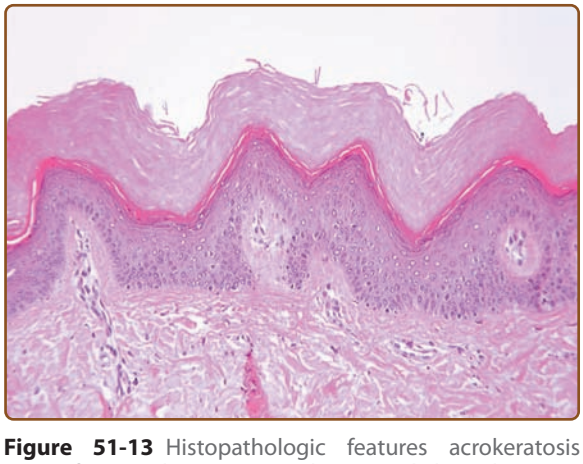

Figure 51-13 Histopathologic features acrokeratosis verruciformis showing acanthosis and hyperkeratosis with "church spike" elevations of the epidermis, but no acantholysis or dyskeratosis. (Used with permission from Dr. Laurence Lamant, Department of Pathology, Purpan Hospital, Toulouse, France.)

DIFFERENTIAL DIAGNOSIS

Acral DD may be indistinguishable from AKV, particularly in childhood, when other features of DD may not be apparent. AKV may resemble plane warts, stucco keratoses, or seborrheic warts, but the family history, symmetrical distribution, and nail changes will suggest the diagnosis.

COURSE

AKV persists and may worsen slowly with age.

TREATMENT

None may be needed. Topical retinoids may flatten lesions. Destruction by cryosurgery, shave, curettage, or laser surgery can be effective. Oral acitretin has been helpful.[142]

HAILEY–HAILEY DISEASE

EPIDEMIOLOGY

HHD (OMIM #169600), also known as familial benign chronic pemphigus, was described by the Hailey brothers in 1939. HHD has an incidence of at least 1 in 50,000, but prevalence may be higher as misdiagnosis is frequent.[112]

ETIOLOGY AND PATHOGENESIS

The discovery of the crucial role of SERCA2 in DD raised the possibility that defects in another calcium pump could underlie acantholysis in HHD. The defective gene, *ATP2C1*, was identified in chromosome region 3q21-24. *ATP2C1* encodes an ATP-powered calcium channel pump on the Golgi membrane, the human secretory-pathway Ca^{2+}/Mn^{2+} ATPase isoform 1 (SPCA1).[143–145] SPCA1 belongs to the family of P-type cation transport ATPases. HHD is dominantly inherited with complete penetrance and is caused by mutations inactivating one *ATP2C1* allele.

The gene spans approximately 30 kb on 3q21 and comprises 28 exons encoding a 4.5-kb transcript. The predicted protein is approximately 115 kDa. Alternative splicing of *ATP2C1* primary transcripts in keratinocytes leads to four splice variants, *ATP2C1a* to *ATP2C1d*, which differ by different splicing of exon 27 and/or 28. *ATP2C1d* is the largest variant, containing exons 27 and 28 in their entirety. The structure of SPCA is similar to that of SERCA (see section "Darier Disease"), but the SPCA-binding site only transports a single Ca^{2+} or Mn^{2+} ion into the Golgi lumen.[19,144,146,147]

Around 100 mutations have been reported in HHD scattered across the *ATP2C1* gene.[143,144,148–161] No correlations have been found between genotype and phenotype; clinical features vary.[149] Mutations predict marked reduction of SPCA1 or cause changes in highly

conserved domains that are critical for function.[143,145,153,162–165] Haploinsufficiency appears to be the mechanism for dominant inheritance, but it is not clear how loss of one functional *ATP2C1* allele causes acantholysis.

Ultrastructural studies of acantholytic cells reveal desmosomal breakdown with retraction of keratin filaments from desmosomal plaques to form perinuclear aggregates.[166,167] Desmosomal components, E-cadherin, and connexins are internalized in acantholytic cells and the expression of keratins is abnormal in lesional skin.[34,36–38,168–172] The abnormality in cell adhesion may be revealed in normal-looking skin in patients with HHD using suction.[173]

Immunohistochemical studies suggest that SPCA1 is localized to the basal layer of normal epidermis.[174] Total [Ca^{2+}] in the epidermal granular layer is reduced and the normal epidermal Ca^{2+} gradient attenuated in both affected and unaffected skin.[143,163] Golgi Ca^{2+} stores are reduced, Ca^{2+} signaling is abnormal and the normal upregulation of transcription of *ATP2C1* mRNA by Ca^{2+}-stimulation is suppressed in HHD keratinocytes.[143,145,163,175–177] Elevated cytosolic Ca^{2+} levels could influence gene expression or alter posttranslational modification of target proteins. Alternatively, low Ca^{2+} or Mn^{2+} concentrations in the Golgi lumen could impair posttranslational modifications (proteolytic processing, glycosylation, trafficking, or sorting) of proteins important in epidermal cell-to-cell adhesion.

Cultured keratinocytes from involved skin display altered patterns of calcium metabolism and reduced proliferative capacity. Increased oxidative stress in HHD keratinocytes may lead to reduced expression of proteins involved in regulation of the balance between proliferation and differentiation such as Itch and Notch1.[161,178] Reorganization of actin is defective, cellular ATP decreased, and synthesis of involucrin is reduced.[161,179–181] Mice deficient for SPCA1 develop squamous cell papillomas and carcinomas similar to those seen in SERCA2 deficient mice (see section "Darier Disease").[176]

Although *ATP2C1* mRNA is expressed ubiquitously, HHD is limited to the skin. Keratinocytes may be more sensitive to levels of SPCA1 than other cells because, unlike most other cells, the Golgi in keratinocytes lack SERCA to compensate for deficient SPCA1.[147] UVB irradiation and proinflammatory cytokines reduce expression of *ATP2C1* mRNA in cultured normal keratinocytes, but suppression is inhibited by retinoids, corticosteroids, cyclosporine, tacrolimus, and vitamin D_3.[58] External factors (UVB, sweating, friction) may reduce the amount of SPCA1 to a critical level leading to the expression of disease.[147]

HISTORY AND CLINICAL FINDINGS

(Box 51-3)

HHD usually presents between the second and fourth decades, predominantly at sites of friction (neck, axillae, inframammary, groin, perineum).[112] The diagnosis is often delayed because HHD simulates common dermatoses such as eczema, tinea, and impetigo.[112] Itch, pain, and malodor are common complaints.

BOX 51-3 HAILEY–HAILEY DISEASE: WHAT SHOULD I LOOK FOR?

Consider the possibility of HHD in any young adult with chronic "eczema" at sites of friction such as the neckline, axilla, or groins. The diagnosis is often missed. Look for:

- Family history
- Exacerbating factors: wearing stiff collars, in heat, or when exercising
- Postinflammatory hyperpigmentation (common)
- Longitudinal white bands in nails (uncommon but very helpful if present)

Signs include crusted weeping erosions, vesicopustules, expanding annular plaques with peripheral scaly borders and vegetating plaques with fissures (rhagades). Postinflammatory hyperpigmentation is frequent (Figs. 51-14 and 51-15). Some patients have longitudinal white lines on the fingernails and these can help to confirm the diagnosis[112,182,183] (Fig. 51-16). Disease may be limited to one or two sites, more widespread or rarely generalized with erythroderma,[184–186] but even mild disease reduces quality of life.[63,187] Painful malodorous inguinal or perineal disease is particularly disabling. HHD koebnerizes into inflammatory dermatoses and has been exacerbated (or diagnosed) after triggers such as contact dermatitis, removal of adherent patch tests, UV irradiation, cutaneous



Figure 51-14 Crusted plaques with postinflammatory hyperpigmentation in a patient with Hailey–Hailey disease.



Figure 51-15 Hailey–Hailey disease with a hypertrophic macerated axillary plaque and painful fissures (rhagades).

infections, and scabies infestation.[173,186,188–196] Generally, HHD does not involve mucosa. Rare instances of conjunctival, oral, esophageal, or vaginal involvement may have been initiated by trauma or infection.[197–203]

SEGMENTAL DISEASE. In Type 1 mosaicism, a postzygotic mutation in ATP2C1 manifests as one or more localized streaks of HHD along Blaschko's lines.[204] Type 2 mosaicism has been confirmed in a patient with severe linear involvement superimposed on symmetrical HHD. In the more severely affected skin, a postzygotic mutation had caused loss of heterozygosity at the ATP2C1 locus.[205]

LABORATORY TESTS—HISTOPATHOLOGY

Involved skin displays widespread partial loss of cohesion (keratinocytes may still be linked together by adherens junctions[206]) between suprabasal keratinocytes with an appearance likened to a dilapidated brick wall (Fig. 51-17). Clusters of loosely coherent cells float in suprabasal clefts or bullae. Dyskeratosis, when present, is usually mild, but changes may resemble those in DD.



Figure 51-16 White longitudinal lines on the nail of a patient with Hailey–Hailey disease.

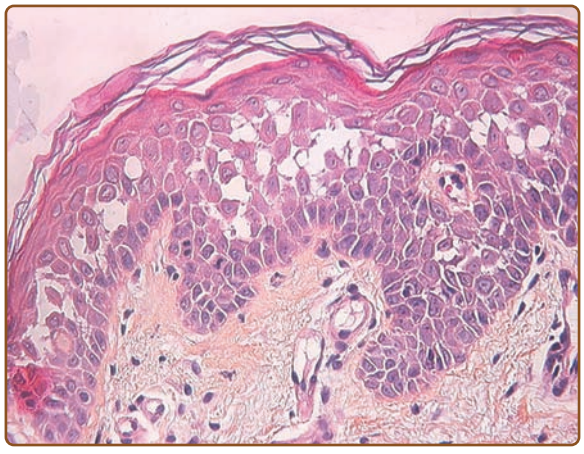

Figure 51-17 Hailey–Hailey disease. Extensive partial loss of intercellular contacts within the epidermis produces the appearance of a "dilapidated brick wall."

DIFFERENTIAL DIAGNOSIS

(Box 51-4)

Eczema or infection (bacterial, fungal, or viral) is the most common misdiagnosis. Hypertrophic flexural

BOX 51-4 HAILEY–HAILEY DISEASE: DIFFERENTIAL DIAGNOSIS

ANNULAR OR CRUSTED PLAQUES

- Eczema including allergic contact dermatitis
- Impetigo
- *Candida* infection
- Tinea corporis
- Darier disease

VESICOPUSTULES

- Eczema
- Bullous impetigo
- *Herpes simplex*
- Grover disease
- Pemphigus vulgaris
- Toxic epidermal necrolysis (if widespread)

VEGETATING FLEXURAL

- Darier disease
- Pemphigus vegetans
- SCC

LOCALIZED GENITAL

- Papular vulvocrural acantholytic disease
- Genital warts
- Darier disease
- Vulval intraepithelial neoplasia

HHD resembles DD, but acantholysis is more widespread and dyskeratosis less prominent in HHD than in DD. Eroded or vesiculobullous HHD may simulate toxic epidermal necrolysis[207] or pemphigus vulgaris (intracellular IgG and complement are not detected in the epidermis). Genital HHD may simulate viral warts[119,208,209] or vulval intraepithelial neoplasia.[210] Papular acantholytic disease limited to the genitalia may be a separate entity, but the identification of an *ATP2C1* mutation in one case suggest that some cases are part of the spectrum of HHD.[117,120,209,211,212]

COMPLICATIONS. Superimposed bacterial or candidal infections are common.[213] *Herpes simplex* causes painful exacerbations, which may disseminate.[214–216] Tinea was a cause of treatment failure in one patient.[217] Allergic contact dermatitis has been described, but the frequency of positive patch tests is probably not increased.[218,219] Skin cancers (SCC more often than BCC) have been reported in association with HHD. SCC may be linked to the presence of human papillomas virus.[220–225] Affective disorder cosegregated with HHD in three families.[226–228]

COURSE

The course is chronic, punctuated by relapses and remissions, but some patients improve in old age.

TREATMENT

(Table 51-2)

Triggers such as heat, sweating, and friction should be minimized. Clothing should be soft, loose-fitting, and cool. Weight loss may be helpful. Patients should be offered genetic counseling.

Treatment is difficult and no controlled trials have been performed. Recommendations in the literature are subject to citation bias and most are based on the response of one or two cases without any long-term follow-up.

It is appropriate to culture skin for bacteria and yeasts, and control infection with antibacterial and/or antifungal agents. It has been suggested that topical gentamicin may be particularly effective in patients harboring a nonsense mutation in *ATP2C1*, because aminoglycosides induce read-through of nonsense mutations in human cells.[229] The role of long-term, low-dose systemic antibiotics is unproven.

Pain may limit application of topical agents, but potent or ultrapotent topical corticosteroids (aqueous lotions, foams, creams, or ointments) can be effective.[112,230] Cutaneous atrophy after prolonged treatment with potent corticosteroids increases skin fragility. Other topical agents that have been recommended include calcitriol,[231,232] tacalcitol,[233] and topical 5-fluorouracil.[234] Tacrolimus helped some cases,[230,235–238] but was ineffective in others.[239] Analgesia is crucial and morphine may be needed in severe disease.

Systemic corticosteroids are a short-term option for widespread disease.[240] Other systemic agents that have been advocated include calcitriol,[241] retinoids,[242,243] methotrexate,[244] cyclosporine,[245,246] dapsone,[247,248] etanercept,[249] and alefacept.[250] Surgical approaches that have been used in recalcitrant disease include excision with or without grafting,[251–253] dermabrasion,[254–256] and laser surgery.[256–259] Other interventions that have been tried include mammoplasty for inframammary disease, superficial X-ray therapy (unhelpful),[260] electron beam therapy,[261] and photodynamic therapy (very painful with variable outcomes).[262,263] Botulinum toxin may help flexural disease by reducing sweating.[256,264,265]

GROVER DISEASE

EPIDEMIOLOGY

Grover disease (GD, transient or persistent acantholytic dermatosis) is an acquired condition, first described in 1970, that is most common in fair skinned men >age 40 years. The male to female ratio is 3:1.[266–269]

TABLE 51-2
Hailey–Hailey Disease: Treatment

First Line	Second Line	Third Line (Unproven Efficacy)
Minimize friction and sweating Emollients containing antibacterials Soap substitutes Antiseptic bath additives Moderately potent or potent topical corticosteroids in combination with topical or oral antibiotics and/or antifungal agents to control secondary infection Pain relief—topical or oral (some patients require morphine)	Ultrapotent topical corticosteroid in combination with topical or oral antibiotics and/or antifungal agents to control secondary infection Prednisolone 20–30 mg/day reduced gradually to control acute exacerbations	Antistaphylococcal antibiotics, e.g., low-dose tetracycline for 6 months or longer Topical tacrolimus Topical tacalcitol or calcitriol Topical 5-fluorouracil Oral cyclosporine 2.5 mg/kg Oral retinoids—start in a low dose to minimize irritation Methotrexate 10–15 mg/week Excision, laser surgery, or dermabrasion Botulinum toxin to reduce sweating in recalcitrant flexural disease Mammoplasty for severe inframammary disease



Figure 51-18 Grover disease. Itchy papules on the trunk resembling folliculitis in a 60-year-old man.



Figure 51-19 Grover disease. Discrete papulovesicular lesions with crusts in a 53-year-old man.

ETIOLOGY AND PATHOGENESIS

Although GD shares clinical, histologic, and ultrastructural features with DD, *ATP2A2* (the defective gene in DD) does not appear to be involved.[270,271] GD may be triggered by factors that promote sweating, for example, febrile illnesses or occlusion,[272–275] but is also common in the winter in elderly men with dry skin.[269,276–278] Other associations include UV or ionizing radiation, inflammatory dermatoses such as atopic eczema, renal failure, HIV infection, malignancies, organ transplants, and some drugs.[268,269,279–283] Electron microscopy shows clumping of keratin filaments with loss of desmosomes and immunostaining reveals that desmosomal components are internalized.[36,37]

CLINICAL FINDINGS

Most often GD presents with an itchy rash on sun-damaged skin of the trunk. Itch may be intense and out of proportion to the signs, which comprise scattered pinkish or red–brown papules with variable hyperkeratosis, papulovesicles (rarely bullae) or, less often, eczematous plaques (Figs. 51-18 and 51-19). Neck and/or proximal limbs can be affected.[269,278,284–287] GD has been described in association with widespread

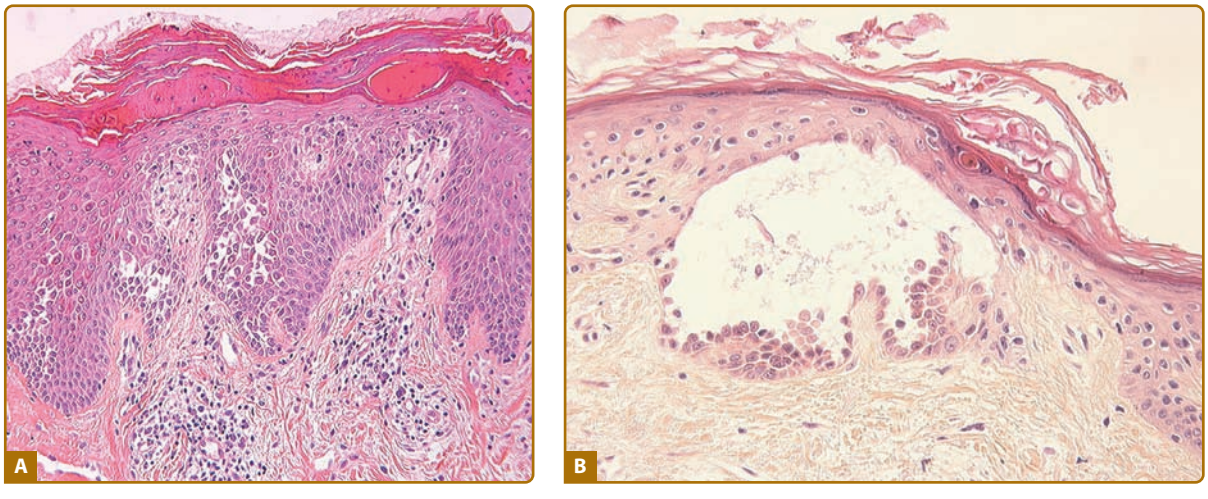

Figure 51-20 **A.** Hailey–Hailey-like histological pattern in Grover disease with detached keratinocytes (acantholysis), focal spongiosis, and epidermal hyperplasia. **B.** Pemphigus-like pattern in Grover disease with suprabasal acantholytic cleavage.

BOX 51-5 GROVER DISEASE: DIFFERENTIAL DIAGNOSIS

- Papular eczema or prurigo
- Folliculitis
- Sun damage with solar lentigines and solar keratoses
- Scabies
- Insect bites
- Miliaria rubra
- Darier disease
- Hailey–Hailey disease
- Pemphigus vulgaris

sun-induced lentigines.[271,288] Guttate leukoderma, similar to that seen in DD, has been observed in dark skin.[289] Unilateral GD has been reported, but this may have been segmental DD.[290,291]

LABORATORY TESTS—HISTOPATHOLOGY

The histological picture is variable and may suggest spongiotic dermatitis, DD, HHD, or pemphigus (no Ig or complement is found in the epidermis). Acantholysis is often subtle and focal.[267,278,285] (See Fig. 51-20).

DIFFERENTIAL DIAGNOSIS

(See Box 51-5)

Other causes of itching such as scabies, insect bites, and eczema should be excluded. Clinicopathological correlation, including family history and examination of nails and mucous membranes, will help to exclude other causes of acantholysis.

COURSE

GD may clear within a few months (transient acantholytic dermatosis), or the itch may persist with fluctuating intensity for years (persistent acantholytic dermatosis), especially in the elderly.[292,293]

TREATMENT

Precipitating factors, including soap and other topical irritants, should be avoided. Emollients, antipruritics, or wet dressings may be soothing. Sometimes topical medicaments such as corticosteroids, retinoids, calcipotriol, or tacalcitol relieve irritation. Oral retinoids, oral corticosteroids, UVB, PUVA, and methotrexate have been advocated for persistent disease, but controlled trials are needed to confirm efficacy. The response to treatment is often disappointing.[269,287,294–298]

KEY REFERENCES

Full reference list available at www.DIGM8.com

DVD contains references and additional content

9. Hovnanian A: SERCA pumps and human diseases. *Subcell Biochem* **45**:337, 2007
17. Dhitavat J et al: Mutations in the sarcoplasmic/endoplasmic reticulum Ca2+ ATPase isoform cause Darier's disease. *J Invest Dermatol* **121**:486, 2003
34. Leinonen PT et al: Reevaluation of the normal epidermal calcium gradient, and analysis of calcium levels and ATP receptors in Hailey-Hailey and Darier epidermis. *J Invest Dermatol* **129**:1379, 2009
49. Pani B et al: Up-regulation of transient receptor potential canonical 1 (TRPC1) following sarco(endo)plasmic reticulum Ca2+ ATPase 2 gene silencing promotes cell survival: A potential role for TRPC1 in Darier's disease. *Mol Biol Cell* **17**:4446, 2006
112. Burge SM: Hailey-Hailey disease: The clinical features, response to treatment and prognosis. *Br J Dermatol* **126**:275, 1992
116. Dhitavat J et al: Acrokeratosis verruciformis of Hopf is caused by mutation in ATP2A2: Evidence that it is allelic to Darier's disease. *J Invest Dermatol* **120**:229, 2003
133. Cooper SM, Burge SM: Darier's disease: Epidemiology, pathophysiology, and management. *Am J Clin Dermatol* **4**:97, 2003
145. Missiaen L et al: Calcium in the Golgi apparatus. *Cell Calcium* **41**:405, 2007
161. Cialfi S et al: Complex multipathways alterations and oxidative stress are associated with Hailey-Hailey disease. *Br J Dermatol* **162**:518, 2010
269. Parsons JM: Transient acantholytic dermatosis (Grover's disease): A global perspective. *J Am Acad Dermatol* **35**:653, 1996

Chapter 52 :: Porokeratosis

:: Grainne M. O'Regan & Alan D. Irvine

POROKERATOSIS AT A GLANCE

- A chronic progressive disorder of keratinization, characterized clinically by hyperkeratotic papules or plaques surrounded by a thread-like elevated border that expands centrifugally.
- At least six clinical variants of porokeratosis have been described.
- The classic form, porokeratosis of Mibelli, presents in infancy or childhood as asymptomatic small brown to skin-colored annular papules with a characteristic raised border.
- Disseminated superficial actinic porokeratosis is the most common type, with multiple papules distributed symmetrically on sun-exposed areas.
- Linear porokeratosis presents at birth or in childhood with lesions distributed along Blaschko's lines.
- Punctate porokeratosis appears during or after adolescence as 1- to 2-mm papules on the palms or soles.
- In all variants, a thin column of parakeratotic cells (*cornoid lamella*) corresponds to the hyperkeratotic border and extends throughout the stratum corneum in histologic sections.
- A genetically heterogeneous disorder; the majority of forms may be inherited as autosomal dominant traits.
- Malignant epithelial neoplasms are reported in all subtypes except the punctate variety.

Porokeratosis is a morphologically distinct disorder of keratinization, characterized clinically by hyperkeratotic papules or plaques surrounded by a thread-like elevated border that expands centrifugally. Histologically, a thin column of parakeratotic cells extends throughout the stratum corneum and is seen in all variants. This distinctive histopathologic feature, known as the *cornoid lamella*, corresponds to the raised hyperkeratotic border evident clinically.

At least six clinical variants of porokeratosis are recognized; however, the clinical distinction between these morphological variants may not be justified (Box 52-1). Reports of one type of porokeratosis coexisting with other forms and different types developing in multiple members of an affected family suggest more similarities than disparities, particularly in the disseminated forms.[1–3]

ETIOLOGY AND PATHOGENESIS

Porokeratosis is a genetically heterogeneous disorder with multiple loci identified to date; however, the pathogenetic mechanisms remain elusive. Loci at chromosome bands 12q23.2–24.1 and 15q25 (DSAP1 and DSAP2) have been reported in familial disseminated superficial actinic porokeratoses; a further locus has been identified for disseminated superficial porokeratosis (DSP) at 18p11.3.[4,5] The locus at DSAP1 corresponds to a candidate gene, *SART3* (squamous cell antigen recognized by T cells 3); this encodes a tumor rejection antigen thought to be involved in the regulation of messenger RNA splicing. Fine mapping of the locus at DSAP1 has also revealed mutations in another potential candidate gene, *SSH1* (slingshot 1), and a variation in the promoter region of *ARPC3*, which play a key role in actin dynamics.[6–8] Missense mutations in *SSH1* in this kindred have been shown to result in loss of heterozygosity in DSAP.[9] However, microarray expression and real time quantative polymerase chain reaction (PCR) profiles of *SART3*, *SSH1*, and *ARPC3* have failed to show differential expression patterns.[10,11] Porokeratosis punctata palmaris et plantaris maps to a

BOX 52-1 CLINICAL VARIANTS OF POROKERATOSIS

Porokeratosis of Mibelli	OMIM #175800
Disseminated superficial actinic porokeratosis (DSAP)	OMIM #175900 and #607728
Disseminated superficial porokeratosis (DSP)	
Porokeratosis palmaris et plantaris disseminata (PPPD)	OMIM #175860
Punctate porokeratosis (PP)	
Linear porokeratosis (LP)	
Syndromic form: CAP (craniosynostosis, anal anomalies, and porokeratosis) syndrome	OMIM #603116

OMIM = Online Mendelian Inheritance in Man.

6.9-centimorgan region at chromosome band 12q24.1–24.2, overlapping with the region identified for DSAP1, suggesting that the two forms may be allelic.[12] The centrifugal expansion of lesions is postulated to reflect the migration of a mutant clone of keratinocytes.[13] Supporting this mutant clone theory are findings of abnormal DNA ploidy and chromosomal abnormalities in lesional keratinocytes.[14] The tumor suppressor proteins p53 and pRb are overexpressed in keratinocytes immediately beneath and adjacent to the cornoid lamella, although to date p53 mutations have not been identified, and there is no significant expression of p53 at an mRNA level.[15–19,11] Cytogenetic abnormalities in fibroblasts, particularly on chromosome 3, have also been documented.[20,21] Decreased mdm2, abnormal expression of psi-3, cytokeratins, filaggrin, and involucrin have also been reported.[22,23] The increased prevalence of porokeratosis in immunosuppressed patients suggests that impaired immunity may be permissive in genetically predisposed individuals.[24–27] Other reported triggering factors such as exposure to ultraviolet (UV) light, together with the increased potential for malignant transformation, highlight the dysplastic potential of affected keratinocytes. Malignant degeneration has been described in all variants of porokeratosis, with the exception of the punctate variety.[28–30]

CLINICAL FINDINGS

POROKERATOSIS OF MIBELLI

Classic porokeratosis of Mibelli begins during infancy or childhood as asymptomatic small brown to skin-colored annular papules with a characteristic annular border (Fig. 52-1). The well-demarcated hyperkeratotic border is usually more than 1 mm in height, with a characteristic longitudinal furrow. The center of the lesion may be hyperpigmented, hypopigmented, depressed, atrophic, or anhidrotic. Lesions range in diameter from millimeters to several centimeters, but giant lesions measuring up to 20 cm may occur. Such giant porokeratoses are rare and occur predominantly on the lower leg and foot. Large lesions are associated with a higher malignant potential.[30] Multiple lesions may arise; however, they are usually regionally localized and unilateral. The condition may be familial and inherited as an autosomal dominant trait. Lesions persist indefinitely.



Figure 52-1 Porokeratosis of Mibelli is characterized by a single large lesion with a clearly defined edge. The scaling is not clearly seen at the border because of the interdigital location of this lesion.

DISSEMINATED SUPERFICIAL ACTINIC POROKERATOSIS

Disseminated superficial actinic porokeratosis (DSAP) is the most common of the porokeratoses. Lesions are characteristically uniformly small, annular, asymptomatic, or mildly pruritic papules ranging from 2 to 5 mm in diameter, distributed symmetrically on the extremities. Lesions are more generalized than other forms of porokeratosis, with typically in excess of 50 lesions located predominantly in sun-exposed sites (Fig. 52-2A and B). Although widespread, lesions typically spare palms, soles, and mucous membranes. Compared with porokeratosis of Mibelli, the hyperkeratotic border is characteristically more subtle. As the lesions progress, the older, central area becomes atrophic and anhidrotic. DSAP tends to be inherited as an autosomal dominant disorder, with the earliest reported age of onset at 7 years, and is usually fully penetrant by the third or fourth decade of life.[5] Initial reports of induction of lesions by exposure to UV light and hypersensitivity of DSAP-derived fibroblasts to X-rays have not been consistently reproduced, and the pathogenesis of DSAP remains unknown.[15,31–33]

DISSEMINATED SUPERFICIAL POROKERATOSIS

DSP also shows an autosomal dominant pattern of inheritance and has its onset in the third or fourth decade of life. Lesions primarily are morphologically identical to those of DSAP, occur on the extremities, and are typically distributed symmetrically, but do not spare sun-protected areas as in DSAP. As with DSAP, in excess of 100 lesions may be disseminated, with a predilection for the extensor surfaces of the extremities. Notably, involvement of the face is rare in both DSAP and DSP. In both disseminated forms, there is a reported female predominance, with a female–male ratio of 3:1.

DISSEMINATED SUPERFICIAL POROKERATOSES OF IMMUNOSUPPRESSION

Disseminated superficial porokeratosis in the context of immunosuppression is recognized following renal, hepatic, and cardiac transplantation, electron beam irradiation,[34] immunosuppressive chemotherapy, and



Figure 52-2 **A.** Disseminated superficial actinic porokeratosis with multiple lesions on the forearm in this severely affected individual. **B.** The characteristic furrowing (*arrows*) is clearly demonstrated on the forearm of this patient.

the use of systemic corticosteroids; with hematopoietic malignancies[35]; and in the setting of human immunodeficiency virus infection.[36] Porokeratosis has also been reported after bone marrow transplantation in the absence of ongoing immunosuppressive therapy, which suggests a more complex association than immunosuppression alone.[37] The distribution and morphology of DSP of immunosuppression are similar to those of DSAP, but a history of sun exposure is less evident.

LINEAR POROKERATOSIS

Linear porokeratosis is an uncommon variant, traditionally categorized as a separate entity, but is increasingly recognized as mosaic manifestation of one of the other types of porokeratosis.[38] Typically, it presents in early childhood, although congenital presentations have been reported.[39] Two distinct clinical variants have been described. The more common presentation consists of a unilateral lesion confined to an extremity following Blaschko's lines (Fig. 52-3). In the rare generalized form, multiple lesions affect several extremities and may involve the trunk. Linear variants have the highest potential for malignant degeneration of all the porokeratoses. It has been postulated that this association can be attributed to allelic loss due to a postzygotic mutation.[40] The proband in Mibelli's original publication most likely had coexistent linear porokeratosis and DSAP, with several subsequent reports confirming this phenomenon.[4,38,41,42] These findings may be explained by the loss of heterozygosity for the DSAP allele and provides an example of the type 2 segmental manifestations of an autosomal dominant disorder.[43,44]

POROKERATOSIS PALMARIS ET PLANTARIS DISSEMINATA

Porokeratosis palmaris et plantaris disseminata (porokeratosis punctata palmaris et plantaris) is a genodermatosis with an autosomal dominant inheritance



Figure 52-3 Linear porokeratosis showing the characteristic distribution along Blaschko's lines.

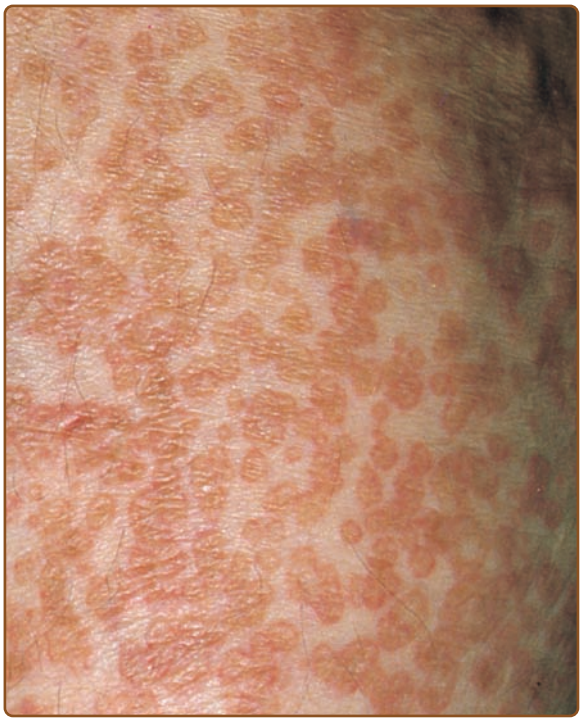

Figure 52-4 Porokeratosis palmaris et plantaris disseminata showing multiple superficial lesions on the calf. Note the similarity to disseminated superficial actinic porokeratosis shown in Fig. 52-2A.

pattern characterized by small, relatively uniform lesions (Fig. 52-4) that initially appear on the palms and soles. Subsequently, lesions spread to involve other parts of the body, including the mucous membranes and nonsun-exposed sites. The palmar and plantar lesions are generally more hyperkeratotic, and the characteristic longitudinal furrow along this ridge may be quite pronounced (Fig. 52-5). Typically, the



Figure 52-5 Sole of the foot in a patient with porokeratosis palmaris et plantaris disseminata. The ridge and furrow are clearly seen.

lesions appear during adolescence or early adulthood and are bilateral and distributed symmetrically. Porokeratosis palmaris et plantaris disseminata affects males twice as often as females.

PUNCTATE POROKERATOSIS

Punctate porokeratosis usually appears during adolescence or adulthood and may be seen concomitantly with other types of porokeratosis. Multiple minute and discrete punctate, hyperkeratotic lesions surrounded by a thin, raised margin are present on the palms and soles. Lesions may occur in a linear arrangement, or they may aggregate to form plaques. Punctate porokeratosis must be differentiated clinically and histologically from punctate keratoderma, also referred to as punctate porokeratotic keratoderma or as porokeratosis punctata palmaris et plantaris (see Chapter 50).

CDAGS SYNDROME

CDAGS syndrome (*c*raniosynostosis and clavicular hypoplasia, *d*elayed closure of the fontanel, *a*nal anomalies, *g*enitourinary malformations, *s*kin eruption), also referred to as *CAP syndrome* (*craniosynostosis*, a*nal anomalies, and p*orokeratosis), is a rare genodermatosis reported in four ethnically diverse families to date.[45,46] The main phenotypic features consist of craniosynostosis and clavicular hypoplasia, anal anomalies, and porokeratosis. It appears to segregate as an autosomal recessive trait, with possible linkage to chromosome band 22q12–13. The cutaneous manifestations are strikingly consistent, with the development of small, widespread porokeratotic papules from 1 month of age in affected individuals, predominantly affecting the face and extremities, with reported photoaggravation of lesions.

HISTOPATHOLOGY

Histopathologic patterns are similar in all forms of porokeratosis, with the characteristic changes evident at the raised and advancing edge of the lesion. The stratum corneum is hyperkeratotic, with a thin column of poorly staining parakeratotic cells, the cornoid lamella, running through the surrounding normal-staining cells (Fig. 52-6). The underlying keratinocytes are edematous with spongiosis and shrunken nuclei, and a striking dermal lymphocytic pattern may be evident. Underlying the cornoid lamella, the granular layer is either absent or markedly reduced but is of normal thickness in other areas of the lesion. The epidermis in the central portion of porokeratosis may be normal, hyperplastic, or atrophic. Although characteristic of porokeratosis, the cornoid lamella is not pathognomonic and may also be found in other conditions, such as viral warts, some ichthyoses, and nevoid hyperkeratoses.

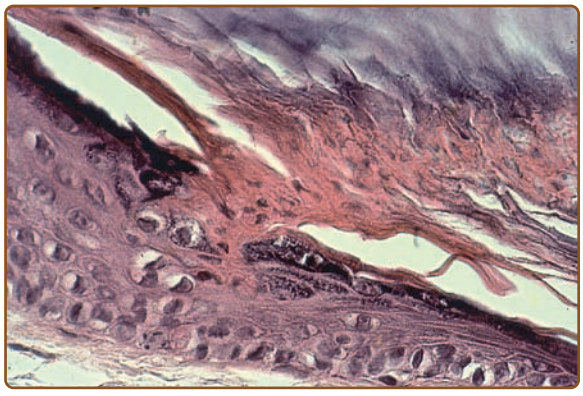

Figure 52-6 The cornoid lamella arises from an indentation of the epidermis and extends as a thin column throughout the stratum corneum. The underlying granular layer is either absent or reduced.

DIFFERENTIAL DIAGNOSIS

The classic lesions of porokeratosis are clinically distinctive, and the diagnosis is usually clinically apparent. However, atypical lesions may require differentiation (Box 52-2). Actinic keratoses, for example, may show cornoid lamellae, but also show cytologic atypia. Verruca vulgaris often shows mounds of parakeratosis that are sometimes identical to cornoid lamellae, but koilocytosis is usually present. Linear porokeratosis may be clinically confused with other linear lesions (Box 52-2), none of which has a cornoid lamella.

BOX 52-2 DIFFERENTIAL DIAGNOSIS OF POROKERATOSIS

LOCALIZED LESIONS

Most Likely

- Granuloma annulare
- Tinea corporis
- Actinic keratosis
- Viral warts

Consider

- Elastosis perforans
- Lichen planus
- Focal dermal hypoplasia (Goltz syndrome)

LINEAR

Consider

- Linear inflammatory verrucous epidermal nevus
- Incontinentia pigmenti (stage II)
- Linear lichen planus
- Ichthyosis linearis circumflexa

TREATMENT

Lesions of porokeratosis are chronic, slowly progressive, and relatively asymptomatic, although intense pruritus has been reported.[47] Intervention is usually unnecessary, and disease surveillance is standard. If the lesions are problematic or cosmetically unacceptable, treatment with potent topical steroids, keratolytics, topical retinoids, topical 5-fluorouracil,[48] imiquimod 5%, calcipotriol,[49] anthralin,[50] cryotherapy,[51] carbon dioxide laser,[52] pulsed dye laser,[53] or neodymium: yttrium-aluminum–garnet laser may be considered (Box 52-3). In order to prevent residual lesions or recurrence, ablative measures that reach the middermis are required. Techniques such as curettage, excision, and dermabrasion,[54] have been used with variable degrees of success. Oral retinoids have been shown to give the most reproducible results, although the disease typically recurs after their discontinuation. Given the association with malignancy, closer disease surveillance and a lower threshold for biopsy of suspicious lesions may be warranted in cases of giant porokeratoses, linear lesions, and in immunosuppressed individuals.

BOX 52-3 TREATMENT FOR POROKERATOSIS

	TOPICAL	SURGICAL	SYSTEMIC
First line	Photoprotection 5-Fluorouracil	Cryotherapy	
Second line	Calcipotriol Imiquimod Topical corticosteroids Topical retinoids	CO_2 laser vaporization	Oral retinoids
Third line	Dermabrasion Neodymium:yttrium-aluminum–garnet laser Grenz ray	Surgical excision	

COURSE AND PROGNOSIS

The porokeratoses are generally chronic and progressive, with lesions increasing in size and number with time. Typically, this process occurs over decades in porokeratosis of Mibelli, but may be rapid in DSAP, particularly after sun exposure. In cases of immunocompromise, fluctuations in severity may parallel the state of immunocompetence, and there are reports of remission after removal of primary malignancy.[27] The disease is generally considered a benign process; however, malignant degeneration may occur. Malignancy is thought to arise in 7% to 11% of individuals, although these figures are likely overestimated. Squamous cell carcinoma is the most frequently associated tumor and may be invasive. Bowen disease and basal cell carcinoma have also been reported. Spontaneous resolution of lesions has been reported, although it is exceptionally rare.[55]

KEY REFERENCES

Full reference list available at www.DIGM8.com

DVD contains references and additional content

1. Lin JH et al: Coexistence of three variants of porokeratosis with multiple squamous cell carcinomas arising from lesions of giant hyperkeratotic porokeratosis. *J Eur Acad Dermatol Venereol* **20**:621, 2006
8. Zhang ZH et al: Loss of heterozygosity analysis on chromosome 12q in disseminated superficial actinic porokeratosis. *J Invest Dermatol* **127**(2):482-5, 2007
9. Zhang ZH et al. Gene expression profiling of porokeratosis. *J Cutan Pathol* **35**:1058, 2008
23. Bencini PL et al: Porokeratosis and immunosuppression. *Br J Dermatol* **132**:74, 1995
32. Schamroth JM et al: Porokeratosis of Mibelli. Overview and review of the literature. *Acta Derm Venereol* **77**:207, 1997
37. Happle R: Mibelli revisited: A case of type 2 segmental porokeratosis from 1893. *J Am Acad Dermatol* **62**(1):136-138, 2010
43. Happle R: Somatic recombination may explain linear porokeratosis associated with disseminated superficial actinic porokeratosis. *Am J Med Genet* **39**:237, 1991

SECTION 8

Disorders of Epidermal and Dermal–Epidermal Adhesion and Vesicular and Bullous Disorders

Chapter 53 :: Epidermal and Epidermal–Dermal Adhesion

:: Leena Bruckner-Tuderman & Aimee S. Payne

EPIDERMAL AND EPIDERMAL–DERMAL ADHESION AT A GLANCE

- The adhesive structures in the skin include desmosomes, focal adhesions, hemidesmosomes, and basement membranes.
- Desmosomes are primarily responsible for epidermal adhesion.
- The major components of desmosomes are the desmosomal cadherins (desmogleins and desmocollins), plakins (desmoplakin, envoplakin, and periplakin), and armadillo family proteins (plakoglobin and plakophilins).
- The hemidesmosomal components comprise plakin homologs, integrins, and collagenous transmembrane proteins.
- All basement membranes contain collagen IV, laminins, nidogens, and perlecan.
- Functional specificity of basement membranes is provided by additional tissue-specific glycoproteins.
- In addition to their structural roles, desmosomes, hemidesmosomes, and the epidermal basement membrane are biologically active in cellular signaling.
- Mutations in the genes encoding the above proteins cause hereditary skin diseases, ranging from hypotrichosis and keratoderma to epidermolysis bullosa and Kindler syndrome.
- Protein components of desmosomes, hemidesmosomes, and epidermal basement membrane are targeted in autoimmune blistering diseases of the pemphigus or pemphigoid group and in epidermolysis bullosa acquisita.

The cell–cell and cell–basement membrane adhesion in the epidermis provides the skin with its resistance against environmental influences; epidermal integrity is required for protection of the entire organism against mechanical, physical, or microbial insults. The major cellular structures involved are the desmosomes at cell–cell junctions in the epidermis and the hemidesmosome–basement membrane adhesion complexes and related structures at the dermal–epidermal junction. Ultrastructurally, the hemidesmosome closely resembles one-half of the desmosome; however, at the molecular level, these two structures are distinct. Both represent specifically organized assemblies of intracellular and transmembrane molecules. The desmosome anchors cytoskeletal filaments to cell–cell junctions, and the hemidesmosome anchors cytoskeletal filaments of basal epithelial cells to the basement membrane. Our knowledge of the desmosomal, hemidesmosomal, and basement membrane molecules has expanded drastically in recent years due to the great power of both molecular genetics and proteomics. After keratinocyte transmembrane proteins were initially identified as autoantigens in pemphigus and pemphigoid, a multitude of molecules have now been characterized at both protein and gene levels, and their expression, regulation, and functions have been discerned. The antigenic epitopes in different autoimmune blistering skin diseases have been carefully mapped and, to date, mutations in at least 24 different genes have been shown to underlie heritable disorders of epidermal or epidermal–dermal adhesion in humans and mice. Morphologic, molecular, and functional aspects of these adhesion structures are delineated in this chapter.

EPIDERMAL ADHESION

ULTRASTRUCTURE OF DESMOSOMES

The desmosome (or *macula adherens*) is the major cell adhesion junction of the epidermis, serving to anchor apposing keratinocyte cell surface membranes to the intracellular keratin intermediate filament network. Desmosomes are present in almost all epithelial tissues, including the oropharynx, gut, liver, heart, lung, bladder, kidney, prostate, thymus, cornea, and central nervous system, although the desmosomal protein isoforms and intermediate filament proteins vary by cell type.[1] The primary role of desmosomes in epidermal cell adhesion is evidenced by the histologic findings in epidermal spongiosis, or intercellular edema, in which adjacent keratinocytes remain attached to each other only at desmosomal junctions (Fig. 53-1). These "intercellular bridges" served as the earliest description of desmosomes in tissues, their observation made possible with the advent of light microscopy in the nineteenth century.[2] The development of electron microscopy techniques in the mid-twentieth century allowed for higher resolution micrographs that revealed the ultrastructure of these intercellular junctions. Even in the twenty-first century, the desmosome still remains best defined by its electron micrographic appearance, with an electron-dense midline

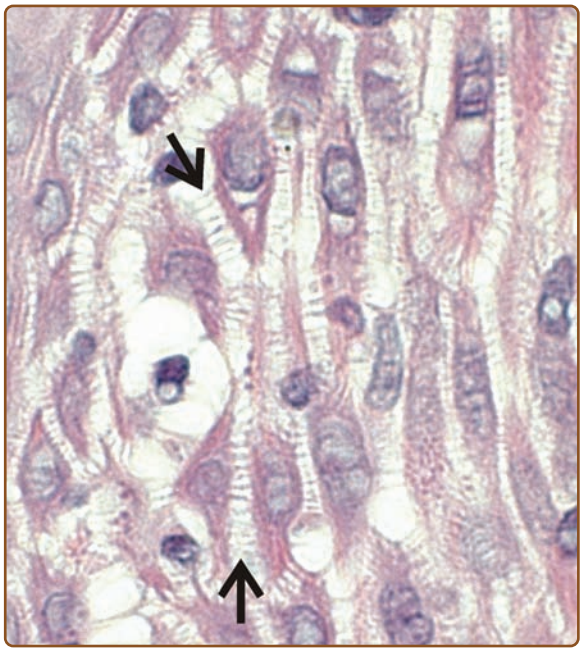

Figure 53-1 Desmosomes are the primary cell adhesion junction in the epidermis. Epidermal spongiosis, or intercellular edema due to inflammation, causes separation of keratinocytes, which remain attached by intercellular bridges representing desmosomal junctions (*arrows*). (Photo used with permission from John Seykora, MD, PhD.)

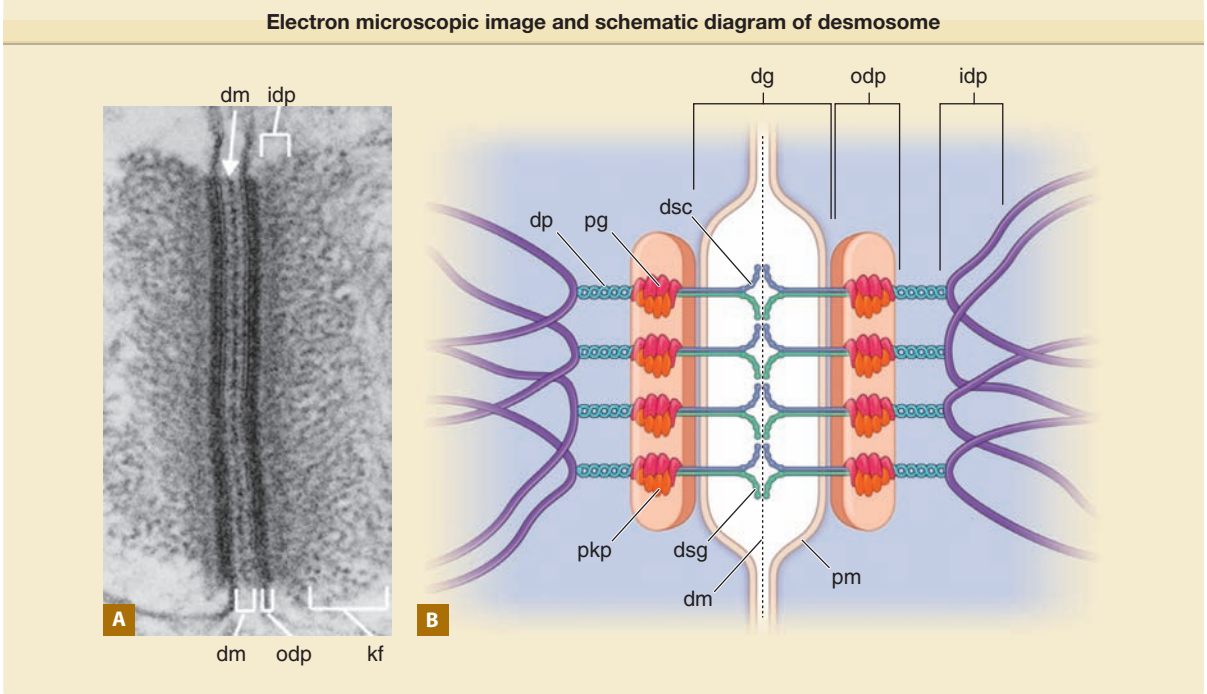

Figure 53-2 Electron microscopic image (**A**) and simplified schematic diagram (**B**) of a desmosome (drawing not to scale). dg = desmoglea; dm = dense midline; dp = desmoplakin; dsc = desmocollin; dsg = desmoglein; idp = inner dense plaque; kf = keratin filaments; odp = outer dense plaque; pg = plakoglobin; pkp = plakophilins; pm = plasma membrane. (Electron micrograph used with permission from Kathleen Green and with permission of Elsevier, adopted from Yin T, Green KJ: Regulation of desmosome assembly and adhesion. *Semin Cell Develop Biol* **15**:665, 2004.)

in the intercellular space halfway between apposing plasma membranes, sandwiched by two pairs of electron-dense cytoplasmic plaques (Fig. 53-2A).[3] The intercellular space between plasma membranes was called the *desmoglea* (from the Greek for "desmosomal glue"), because it was presumed to provide the adhesion that kept cells together.[4]

STRUCTURE AND FUNCTION OF DESMOSOMAL PROTEINS

In anchoring the cell surface to the intermediate filament network, desmosomes create a three-dimensional scaffolding of proteins that extend from the cell surface all the way to the nuclear envelope. This scaffolding is critical to stabilize epithelia in the face of shear stress or external trauma. Early morphologic studies led to the perception of the desmosome as a static structure, a "spot weld" functioning only to maintain intercellular adhesion.[5] Over the last three decades, the individual proteins comprising the desmosome have been biochemically characterized and cloned, shedding light on both the dynamic nature of the desmosome structure and the diversity of desmosomal protein function.

Desmosomal proteins fall into three major categories: (1) desmosomal cadherins (desmogleins and desmocollins), (2) armadillo family proteins (plakoglobin and plakophilins), and (3) plakins (desmoplakin, envoplakin, and periplakin). Additional proteins, such as Perp, ninein, kazrin, and corneodesmosin, have also been localized to epidermal desmosomes.[6–9] Immunogold electron microscopy labeling studies have further refined our understanding of how these molecular components of desmosomes are ordered within the desmosome ultrastructure[10] (Fig. 53-2B). The desmosomal cadherins are transmembrane proteins whose extracellular amino-terminal domains interact to form the trans-adhesive interface between cells, represented by the electron-dense midline of the desmoglea. Intracellularly, approximately 10–20 nm from the plasma membrane, the outer dense plaque contains the desmosomal cadherin cytoplasmic tails, plakoglobin, the desmoplakin amino-terminal domain, and plakophilin. Approximately 40–50 nm from the plasma membrane, the desmoplakin carboxyl-terminus interacts with keratin intermediate filaments, producing the inner dense plaque. The biochemistry, expression pattern, and diseases of each desmosomal component are discussed in further detail below. Although the specific physiologic roles and pathophysiologic mechanisms affecting many of the desmosomal proteins remain under active investigation, current knowledge clearly indicates the importance of desmosomes and their components beyond just cell adhesion.

DESMOSOMAL CADHERINS.

Desmogleins and desmocollins are part of the cadherin superfamily of transmembrane glycoproteins. Members of this superfamily, which includes the adherens junction protein E-cadherin, mediate calcium-dependent adhesion in a variety of epithelial tissues. In humans, there are four desmoglein (Dsg) isoforms and three

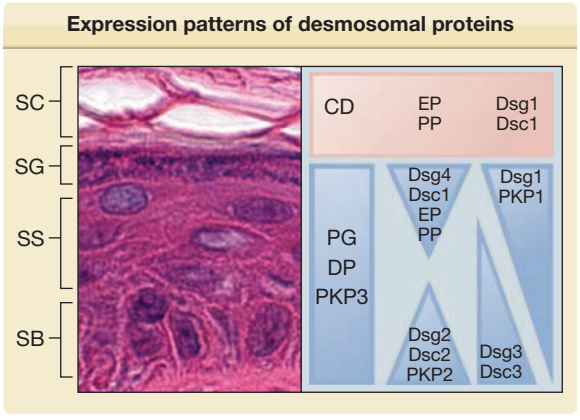

Figure 53-3 Expression patterns of desmosomal proteins in normal human epidermis. SC = stratum corneum, SG = stratum granulosum, SS = stratum spinosum, SB = stratum basale.

desmocollin (Dsc) isoforms, each with varying expression patterns within and among epithelia.[11–13] Within normal human epidermis, Dsg1, Dsg4, and Dsc1 are expressed predominantly in the differentiated cells of the superficial epidermis, while Dsg2, Dsg3, Dsc2, and Dsc3 are expressed more strongly in the basal and/or suprabasal layers[14,15] (Fig. 53-3). Among different epithelial tissues, Dsg1 and Dsg3 expression are largely limited to stratified squamous epithelia in the skin and oropharynx, as well as thymic epithelial cells. Dsg3 is also strongly expressed in squamous cell carcinomas and other head and neck cancers, where it has been proposed as a potential molecular target for therapy.[16] Dsg2 is the major desmoglein isoform in most simple and transitional epithelia, as well as cardiac myocytes.[17] Dsg4 is prominent in desmosomes of the hair follicle, testis, and prostate.[18,19] The expression pattern of the human desmocollins is less well characterized. In normal tissues, Dsc1 expression is largely limited to skin and oral epithelia, while Dsc2 is more widely expressed in most desmosome-containing epithelia and is the only desmocollin isoform in cardiac tissue.[11] Dsc3, like Dsg3, is most strongly expressed in the stratified squamous epithelia of the skin and oropharynx,[20] although UniGene data suggest weaker expression in a variety of other epithelial tissues. Desmocollin switching has been described in colorectal cancer, with downregulation of Dsc2 and upregulation of Dsc1 and Dsc3.[21]

The extracellular domains of the desmosomal cadherins consist of four cadherin repeats plus an extracellular anchor domain, each separated by a calcium-binding motif. All cadherins are synthesized as preproproteins, which include an amino-terminal signal sequence and propeptide. The propeptide is thought to prevent intracellular aggregation of newly synthesized cadherins within the secretory pathway of the cell. Proprotein convertases in the late Golgi network cleave the cadherin propeptide, thereby producing the mature adhesive protein.[22] Although the crystal structure of the desmosomal cadherins remains unsolved, studies comparing the structure of desmosomes analyzed by cryo-electron tomography

of vitreous sections with the solution structure of the classical cadherins suggest common mechanisms of intercellular adhesion, in which a conserved amino-terminal tryptophan residue on one cadherin molecule interacts with a hydrophobic acceptor pocket in the first extracellular domain of another cadherin molecule on a neighboring cell to form the trans-adhesive interface.[23–26] Additionally, cadherins may participate in "cis" interactions with cadherin molecules on the same cell through their membrane proximal domains, which may facilitate desmosome assembly. Desmosomal cadherins can engage in both homophilic (i.e., Dsg–Dsg or Dsc–Dsc) as well as heterophilic (i.e., Dsg–Dsc) interactions, although heterophilic interactions are thought to contribute most to strong intercellular adhesion.[27–29]

The cytoplasmic domains of the desmosomal cadherins are less conserved. Desmocollins have a full length "a" and a shorter "b" splice isoform. The cytoplasmic domains of desmoglein and desmocollin "a" isoforms bind plakoglobin, and some desmoglein and desmocollin isoforms may also directly bind plakophilins[30,31] (Fig. 53-2B). Increasing data suggest that desmosomal cadherins are not just adhesive molecules but may also actively regulate intracellular signaling, transcription, and other cellular processes.[1] Consistent with this, desmocollin 3-deficiency in mice causes embryonic lethality at day 2.5 before implantation, indicating a central role for desmocollin 3 in early tissue morphogenesis independent of its desmosomal adhesive function.[32]

In dermatology, the desmosomal cadherins are best known for their role as autoantigens in the immunobullous disease pemphigus (see Chapter 54). The desmoglein 3 gene was originally discovered and cloned because it was the autoantigen in pemphigus vulgaris[33] (Fig. 53-4A). Since then, all of the desmosomal cadherins have been associated with human autoimmune, infectious, and/or genetic diseases (summarized below and in Table 53-1).

Desmoglein 1 is the target of pathologic proteolytic cleavage in the infectious disorders bullous impetigo and staphylococcal scalded skin syndrome, as well as the inherited ichthyosis associated with Netherton syndrome (see Chapter 49).[34,35] Cleavage of desmoglein 1 by staphylococcal exfoliative toxin occurs between extracellular domains 3 and 4.[36] Pathogenic autoantibodies to desmoglein 1 are found in pemphigus foliaceus, mucocutaneous pemphigus vulgaris, and paraneoplastic pemphigus (see Chapters 54 and 55). Most pathogenic pemphigus foliaceus autoantibodies bind the first two extracellular domains of desmoglein 1, overlapping sites that are critical for desmoglein trans-adhesion.[37–39] Autosomal dominant mutations causing haploinsufficiency of desmoglein 1 result in palmoplantar keratoderma (PPK; see Chapter 50). The PPK is classically striate (Fig. 53-4B), occurring at sites of greatest trauma or friction, but focal and diffuse forms have also been described.[40–42]

Desmoglein 2 has been implicated in human cardiovascular disease as a cause of autosomal dominant arrhythmogenic right ventricular cardiomyopathy (ARVC).[43] The lack of skin phenotypes in affected patients indicates that desmoglein 2 is not required for epidermal adhesion, likely due to compensatory adhesion from other more highly expressed epidermal desmosomal cadherin isoforms.

Desmoglein 3 is the target of pathogenic autoantibodies in mucosal and mucocutaneous pemphigus vulgaris and paraneoplastic pemphigus (see Chapters 54 and 55.) Most pathogenic autoantibodies in pemphigus vulgaris target the amino-terminal extracellular (EC1–2) domains of desmoglein 3.[37,44,45] Because desmoglein 3 deficiency in mice phenotypically resembles autoimmunity to desmoglein 3 in mucosal pemphigus vulgaris with oral suprabasal erosions, pemphigus autoantibodies are thought to cause loss of desmosomal cadherin function.[46] More recent research has focused on signaling pathways activated after binding of pemphigus vulgaris autoantibodies to keratinocytes, as several biochemical inhibitors have been shown to prevent blistering in a neonatal mouse passive transfer model[47] (discussed in further detail in Chapter 54).



Figure 53-4 Desmosomal proteins are pathophysiologic targets in human autoimmune and genetic diseases. **A.** Indirect immunofluorescence on monkey esophagus with pemphigus serum that contains autoantibodies to desmoglein 3. The cell surface–intercellular pattern staining is diagnostic of pemphigus. **B.** Striate palmoplantar keratoderma is associated with haploinsufficiency of desmoglein 1 or desmoplakin.

TABLE 53-1
Desmosomal Targets in Human Disease

	Desmosome Component	Autoimmune Target	Genetic Target
Desmosomal cadherins	Desmoglein 1[a]	Pemphigus foliaceus, pemphigus vulgaris	Striate PPK (AD)
	Desmoglein 2		ARVC (AD)
	Desmoglein 3	Pemphigus vulgaris, paraneoplastic pemphigus	
	Desmoglein 4	Pemphigus foliaceus,[b] pemphigus vulgaris[b]	Hypotrichosis (AR); Monilethrix (AR)
	Desmocollin 1	IgA pemphigus (subcorneal pustular dermatosis)	
	Desmocollin 2		ARVC (AR and AD)
	Desmocollin 3	Pemphigus vulgaris	Hypotrichosis (AR)
Desmosomal plaque proteins	Desmoplakin I/II	Paraneoplastic pemphigus	Striate PPK (AD); Carvajal syndrome (AR): diffuse PPK, wooly hair, left ventricular cardiomyopathy; lethal acantholytic epidermolysis bullosa (AR); skin fragility–wooly hair syndrome (AR): PPK, wooly hair, nail dystrophy
	Other plakins[c]	Paraneoplastic pemphigus	
	Plakoglobin		Naxos disease: diffuse PPK, wooly hair, ARVC (AR)
	Plakophilin 1		Skin fragility and ectodermal dysplasia (AR)
	Plakophilin 2		ARVC (AD)
Stratum corneum desmosome protein	Corneodesmosin		Hypotrichosis simplex of the scalp (AD)

[a]Also targeted by exfoliative toxin in bullous impetigo and staphylococcal scalded-skin syndrome and hyperactive serine proteases in Netherton syndrome.
[b]Desmoglein 4 immunoreactivity is due to cross-reactivity with desmoglein 1 in pemphigus sera.
[c]Including envoplakin, periplakin, and bullous pemphigoid antigen 1.
AD = autosomal dominant; AR = autosomal recessive; PPK = palmoplantar keratoderma; ARVC = arrhythmogenic right ventricular cardiomyopathy.

Desmoglein 4 mutations have been described in rare autosomal recessive forms of hypotrichosis and monilethrix.[48–51] One patient demonstrated transient scalp erosions during the first 2 weeks of life. Most of the mutations in Dsg4 are frameshift or nonsense mutations that would be predicted to lead to haploinsufficiency, although missense mutations have also been reported,[52] Desmoglein 4 immunoreactivity is observed in pemphigus vulgaris and pemphigus foliaceus sera,[51] but subsequent studies have attributed this to cross-reactivity from Dsg1 autoantibodies.[53]

Desmocollin 1 is the target of autoantibodies in the subcorneal pustular dermatosis of IgA pemphigus (see Chapter 54.)

Desmocollin 2, like desmoglein 2, is mutated in both autosomal dominant and recessive forms of ARVC, with no epidermal phenotype in affected patients.[54,55]

Desmocollin 3 mutations were found in one Pakistani kindred with autosomal recessive hypotrichosis.[56] Autoantibodies to desmocollin 3 have also been found in pemphigus vulgaris patients, particularly those with vegetative lesions.[57]

PLAKOGLOBIN. Plakoglobin (also known as γ-catenin) directly binds the cytoplasmic tails of the desmogleins and desmocollin "a" isoforms, as well as E-cadherin, the major transmembrane protein of adherens junctions in epidermal keratinocytes.[58,59] It is expressed throughout all layers of the epidermis and is ubiquitously expressed in all epithelia. Plakoglobin, like plakophilin, is a member of the armadillo gene family, characterized by a conserved protein structure with head and tail domains that flank multiple homologous arm repeats.[60] Various domains of plakoglobin modulate its binding to the desmosomal cadherins.[61–63] Other domains bind to desmoplakin, thus linking desmogleins and desmocollins to desmoplakin.[64] Plakoglobin can also localize to the nucleus, where it may modulate gene transcription by TCF/LEF family members.[65,66] Although most depictions of the desmosome show both plakoglobin and plakophilin binding to desmoplakin, biochemical studies suggest that these interactions are mutually exclusive.[67] Likely, the armadillo family proteins play more dynamic roles in recruitment of desmosomal proteins to the plaque, similar to α-catenin in adherens junctions.[68,69]

Plakoglobin mutations result in Naxos disease, an autosomal recessive syndrome of diffuse PPK, wooly hair, and arrhythmogenic right ventricular cardiomyopathy, the latter of which may present in late childhood to adolescence.[70]

DESMOPLAKIN. Desmoplakin exists in two RNA splice variants, desmoplakin I and II.[71,72] It is unknown whether different isoforms perform different cellular functions, although human disease mutations suggest that desmoplakin I is required for normal desmosomal function.[73] Desmoplakin is part of the plakin gene family,[74] which includes the hemidesmosomal proteins bullous pemphigoid antigen 1 and plectin, as well as envoplakin and periplakin. Similar to other desmosomal components, desmoplakin is a modular protein, with different modules fulfilling different functions. The central part of one desmoplakin molecule coils around the central part of another to form a rod-like center. The amino-terminal head domain binds to plakoglobin,[64] and the carboxyl-terminal tail binds to keratin.[75] Therefore, desmoplakin provides the major link between the keratin filaments and the desmosomal plaque. Desmoplakin also plays a critical role in development independent of its function in desmosomes, as desmoplakin-null mice die early in embryogenesis at E6.5, before desmosomes are formed.[76]

A broad range of desmoplakin mutations have been associated with human disease, leading to variable phenotypic combinations of PPK (striate or diffuse), dilated cardiomyopathy (left or right), wooly hair, nail abnormalities, and/or skin blisters.[52] Haploinsufficiency of desmoplakin leads to autosomal dominant striate PPK.[77] Autosomal recessive mutations in desmoplakin were described in three Ecuadorian families with Carvajal syndrome, consisting of diffuse PPK, wooly hair, and arrhythmogenic *left* ventricular cardiomyopathy.[78] A Naxos-like syndrome of PPK, wooly hair, and ARVC occurs with the p.R1267X nonsense mutation, which affects only the desmoplakin I splice isoform, indicating that desmoplakin II is not sufficient to restore normal desmosomal function in epidermis.[73] Lethal acantholytic epidermolysis bullosa (widespread epidermolysis, generalized alopecia, anonychia, and neonatal teeth) was attributed to compound heterozygous mutations in desmoplakin that caused loss of the desmoplakin tail.[79] Additionally, desmoplakin autoantibodies are observed in paraneoplastic pemphigus sera (see Chapter 55).

PLAKOPHILINS. Plakophilins, like plakoglobin, can localize both to the plasma membrane as well as the nucleus, although their function outside of desmosomal adhesion is not well characterized. Plakophilins directly bind to desmoplakin, and may also directly bind keratins and desmosomal cadherins, which is thought to aid in clustering and lateral stability of the desmosomal plaque.[30,31,67] Plakophilin 1 also associates with the eukaryotic translation initiation factor eIF4A1 in the mRNA cap complex, where it functions to regulate translation and cell proliferation.[80]

Mutations in plakophilin 1 cause ectodermal dysplasia-skin fragility syndrome, suggesting a role for plakophilin 1 in epidermal morphogenesis as well as adhesion.[81] Plakophilin 2 mutations are the most common cause of autosomal dominant ARVC.[82] Currently, there are no known human diseases associated with plakophilin 3.

OTHER DESMOSOMAL PROTEINS. *Envoplakin* and *periplakin* are desmosomal plaque proteins expressed in the superficial layers of the epidermis. Both proteins incorporate into the corneodesmosomes of the stratum corneum. Mice deficient in envoplakin, periplakin, and involucrin do not demonstrate adhesion defects, but instead show impaired desquamation and epidermal barrier function.[83] Envoplakin and periplakin autoantibodies are characteristic of paraneoplastic pemphigus sera (see Chapter 55).

Corneodesmosin is a secreted glycoprotein that incorporates into corneodesmosomes and is also expressed in the inner root sheath of the hair follicle. Heterozygous mutations in corneodesmosin are associated with an autosomal dominant hypotrichosis simplex of the scalp.[84] Loss of cohesion in the inner root sheath and aggregates of proteolytically cleaved corneodesmosin around the hair follicle are observed in scalp biopsies of affected patients.

EPIDERMAL–DERMAL ADHESION

STRUCTURAL AND FUNCTIONAL CHARACTERISTICS OF BASEMENT MEMBRANES

Basement membranes underlie epithelial and endothelial cells and separate them from each other or from the adjacent stroma. Another form of basement membrane surrounds smooth muscle or nerve cells. The physiologic functions of basement membranes are diverse: in the various organ systems they provide support for differentiated cells, maintain tissue architecture during remodeling and repair, and, in some cases, acquire specialized functions, including the ability to serve as selective permeability barriers (e.g., the glomerular basement membrane or the blood–brain barrier) or acquire strong adhesive properties, like the basement membrane at the dermal–epidermal junction, or that surrounding smooth muscle cells, which provide the tissues resistance against shearing forces. All of these characteristics of basement membranes are also used during development and differentiation of multicellular organisms (Box 53-1).

Ultrastructurally, basement membranes most often appear as trilaminar structures, consisting of a central electron-dense region, known as the *lamina densa*, adjacent on either side to an apparently less-dense area, known as the *lamina lucida* or *lamina rara*. The lamina lucida directly abuts the plasma membranes of the adherent cells. The relative size of each of these regions varies in different tissues, among the basement membranes of the same tissue at different ages, and as a consequence of diseases. For example, the trilaminar glomerular basement membrane in humans varies from 240 nm to 340 nm in width, whereas the bilaminar basement membrane of the dermal–epidermal junction measures 50 nm to 90 nm. This ultrastructure demonstrates that basement membranes serve as substrates for the attachment of cells and fix their polarity. Their continuity throughout the various organ systems stabilizes

BOX 53-1 MAJOR FUNCTIONS OF BASEMENT MEMBRANES

- Scaffold for tissue organization and template for tissue repair.
- Selective permeability barriers. The renal basement membranes serve for the ultrafiltration of plasma, and other basement membranes also demonstrate selective filtration.
- Physical barriers between different types of cells or between cells and their underlying extracellular matrix.
- Firmly link an epithelium to its underlying matrix or to another cell layer and provide polarity.
- Regulate cellular functions.

the tissue orientations and provides a template for orderly repair after traumatic injury. Major disruptions in the basement membrane result in the formation of scar tissue and the loss of function in that area.

Different basement membranes contain both common and unique components. All share a basic network structure to which specific macromolecules have been appended. These molecules are responsible for the specialized functions of different basement membranes. The basic constituents of these structures are collagen IV, laminins, nidogens, and proteoglycans of the perlecan type, which all are highly conserved, although the isoforms, the number of the polypeptide subunits, and their individual structures vary among species.[84,85] The nearly ubiquitous distribution of heparan sulfate proteoglycans in all basement membranes suggests that these serve as selective permeability barriers in multiple locations, including the kidney and the blood–brain barrier. Ultrafiltration may be especially important during development and morphogenesis of all tissues.

Basement membranes also provide physical separation between epithelia and their underlying extracellular matrices. This barrier is especially important in the containment of tumors. With the exception of certain cells of the immune system, nonmalignant cells seldom cross a basement membrane. In contrast, malignant cells bind the basement membrane, regionally disrupt its structure, and migrate through the rupture. Laminins and integrins mediate the tumor-cell binding, and the basement membrane dissolution is catalyzed at least in part by metalloproteases produced by the tumor cell. The absence of distinguishable basement membranes in tumor biopsies is used as an indicator of malignancy, and there appears to be a high correlation between metastasis and basement membrane disruption. These observations underline the importance of the basal lamina as an obstacle to cell migration.

By binding biologically active signaling molecules, basement membranes regulate a multitude of biologic events. The constituent proteoglycans can bind growth factors that can be released from the complexes. Thus, the basement membranes are potent regulators of cell adhesion and migration, cytoskeleton and cell form, cell division, differentiation and polarization, and apoptosis.[85]

ULTRASTRUCTURE OF THE DERMAL–EPIDERMAL JUNCTION

The dermal–epidermal junction is an example of a highly complex form of basement membrane,[86,87] which underlies the basal cells and extends into the upper layers of the dermis (Fig. 53-5A). This basement membrane is continuous along the epidermis and skin appendages, including sweat glands, hair follicles, and sebaceous glands. The dermal–epidermal junction can be divided into three distinct zones. The first zone contains the keratin filament–hemidesmosome complex of the basal cells and extends through the lamina lucida to the lamina densa. The plasma membranes of the basal cells in this region contain numerous electron-dense plates known as hemidesmosomes. The intracellular architecture and organization of the basal cells are maintained by keratin intermediate filaments,



Figure 53-5 **A.** Ultrastructure of the human dermal–epidermal junction as visualized by transmission electron microscopy after standard fixation and embedding protocols. af = anchoring filament; AF = anchoring fibril; AP = anchoring plaque; BM = basement membrane; Hd = hemidesmosome; Ld = lamina densa; LI = lamina lucida. (Bar = 200 nm.) **B.** Ultrastructure of the human dermal–epidermal junction by transmission electron microscopy following protocols using high-pressure fixation and embedding techniques. Note the dense character of both the basement membrane and the subjacent papillary dermis. Anchoring filaments, anchoring fibrils, and anchoring plaques are not distinguishable. (Both photos used with permission from Douglas R. Keene, MD, Shriners Hospital, Portland, Oregon.)

7 nm to 10 nm in diameter that course through the basal cells and insert into the desmosomes and hemidesmosomes. External to the plasma membrane is a 25-nm to 50-nm-wide lamina lucida that contains anchoring filaments, 2 nm to 8 nm in diameter, originating in the plasma membrane and inserting into the lamina densa. The anchoring filaments can be seen throughout the lamina lucida but they are concentrated in the regions of the hemidesmosomes. Thus, the anchoring filaments appear to secure the epithelial cells to the lamina densa.

The existence of the lamina lucida in vivo has been questioned.[86,88] When the ultrastructure of the basement membrane is evaluated after high-pressure preservation techniques, the lamina densa appears intimately associated with the epithelial cell surface. When the dermal–epidermal junction is similarly prepared, no distinct lamina lucida is seen (see Fig. 53-5B). This suggests that the lamina lucida may result from shrinkage of the cell surface away from the lamina densa due to dehydration. The appearance of anchoring filaments spanning the lamina lucida may then result from the firm attachment of constituents of the lamina densa at the hemidesmosome that is subsequently pulled from the lamina densa by shrinkage. Other components that are also tightly fixed to the keratinocyte plasma membrane, either at the hemidesmosomes or at other sites along the membrane, may similarly become displaced into the shrinkage space. Regardless of its actual occurrence in vivo, the evaluation of the lamina lucida by standard electron microscopy techniques has allowed identification of specific structures that would otherwise have been difficult to detect. In addition, the morphologic term *lamina lucida* remains practical in the scientific communication and continues to be used.

The second zone, the lamina densa, appears as an electron-dense amorphous structure 20 nm to 50 nm in width. At high magnification, it has a granular–fibrous appearance.[86] The major molecular components of the lamina densa are collagen IV, nidogens, perlecan, and laminins, which all can polymerize to networks of variable thickness.[84,86]

The subbasal lamina contains microfibrillar structures. Two of these are readily distinguishable. *Anchoring fibrils* appear as condensed fibrous aggregates 20 nm to 75 nm in diameter.[89] At high resolution, they appear to have a cross-striated banding pattern (see Fig. 53-5A). The length of the anchoring fibril is difficult to measure because of its random orientation in relation to the plane of the section. In toad skin, these structures have lengths of approximately 800 nm. The anchoring fibrils in human skin appear to be somewhat shorter. The ends of the fibrils appear less tightly packed, giving a somewhat frayed appearance. The proximal end inserts into the basal lamina, and the distal end is integrated into the fibrous network of the dermis.[90] Many of the anchoring fibrils originating at the lamina densa loop back into the lamina densa in a horseshoe-like manner; others insert their opposite ends into amorphous-appearing structures, termed *anchoring plaques*.[90] These structures are believed to be independent "islands" of electron-dense material, although some controversy exists in the literature.[91] Anchoring fibrils are primarily aggregates of collagen VII.

Fibrillin-containing *microfibrils*, 10 nm to 12 nm in diameter, are also localized in the sublamina densa region. These are elastic-related fibers, because elastic components of the dermis are formed from microfibrillar and amorphous components.[92] The microfibrillar component in the presence of abundant amorphous component is known as the *elastic fiber*. In the papillary dermis, the microfibrils insert into the basal lamina perpendicular to the basement membrane and extend into the dermis, where they gradually merge with the elastic fibers to form a plexus parallel to the dermal–epidermal junction. These two elastic components appear to be continuous with the elastic fibers present deep within the reticular dermis.[92]

In summary, the ultrastructure of the dermal–epidermal junction strongly suggests that the lamina densa functions as a structural scaffold for the attachment of the epidermal cells at one surface, secured by anchoring filaments extending from the lamina densa to the hemidesmosomes. The latter also serve as insertion points for intracellular keratin filaments that form scaffolding for the basal cells. On the opposite surface, the extracellular matrix suprastructures of the dermis are firmly attached to the lamina densa. The interaction of collagen-containing dermal fibers with the lamina densa appears to be mediated by the anchoring fibrils. The elastic system of the dermis inserts directly into the basal lamina via the microfibrils. Thus, the dermal–epidermal junction provides a continuous series of attachments between the reticular dermis and the cytoskeleton of the basal cells. These observations suggest four major functions for the epidermal basement membrane: (1) a structural foundation for the secure attachment and polarity of the epidermal basal cells; (2) a barrier separating the epidermis and the dermis; (3) firm attachment of the dermis to the epidermis through a continuous system of structural elements; and (4) modification of cellular functions, such as organization of the cytoskeleton, differentiation, or rescue from apoptotic signaling via outside-in signaling mechanisms.

BIOCHEMICAL CHARACTERIZATION OF THE BASEMENT MEMBRANE

Basement membranes contain collagenous and noncollagenous glycoproteins and proteoglycans. The content of the collagen-specific amino acids hydroxyproline and hydroxylysine suggests that collagens account for 40% to 65% of the total basement membrane protein. All basement membranes contain certain isoforms of collagen IV, laminin, nidogen, and the heparan sulfate proteoglycan perlecan (Box 53-2). For example, the α3 chain of collagen IV is localized in the basement membrane of the kidney and lung, but not in those of the skin and blood vessels. In contrast, collagens VII and XVII are associated with the squamous epithelia of skin but are not found in glomerular and alveolar

BOX 53-2 UBIQUITOUS COMPONENTS OF BASEMENT MEMBRANES

- Collagen IV
- Laminins
- Nidogens
- Perlecan

basement membranes. In addition, many other tissue-specific components are found in basement membranes, including different collagens, laminins, fibulins, and fibronectin.[84,85,92,93] Differences in macromolecular composition are responsible for morphologic and functional variance of basement membranes.

UBIQUITOUS COMPONENTS OF BASEMENT MEMBRANES

COLLAGEN IV. Collagen IV is a heterotrimer of three α chains.[84,94] Each of these contains three distinct domains (Fig. 53-6A): (1) the *N*-terminal cysteine-rich (7-S) domain, (2) a central triple-helical domain, and (3) a *C*-terminal globular domain (NC-l). The trimer composition is determined by the NC-l domains, and the α chains are linked to each other by covalent interactions through these domains.[95] The triple helix of collagen IV is long and contains several discontinuities, which result in increased flexibility in the collagen IV helix, but also render it susceptible to proteases.

The suprastructure of collagen IV has been partially elucidated by rotary shadowing electron microscopy that indicated that the major interactions among collagen IV molecules occur at their amino- and carboxyl-terminal domains, and by lateral association of their triple helices (see Fig. 53-6A).[84,95] Covalent interactions among 7-S regions of different molecules are the basis for the specialized network characteristic of basement membranes (see Fig. 53-6B). The individual 7-S regions overlap in both the parallel and antiparallel directions, producing a characteristic four-legged "spider" form. The NC-l domains at the end of each leg of the spider interact with the NC-l domain of the adjacent aggregates (see Fig. 53-6B). Association is stabilized by covalent bonds. These end-to-end interactions result in an extended two-dimensional network that is the basis of basement membrane organization.

The high flexibility of the basement membrane network structure makes the possibility of interactions with other molecules very attractive. An open meshwork of collagen IV with, for example, laminins or perlecan, can be easily visualized (Fig. 53-7).[85] The implied porosity of this structure would then be limited by the size of the pores in the collagen network and by structural elements associated with it. This model of the basement membrane structure allows considerable mechanical stability while retaining physiologic flexibility. These properties of strength and elasticity would be expected for a dynamic surface, such as that seen in the dermal–epidermal junction and surrounding blood vessels.

Collagen IV molecules in different basement membranes contain genetically distinct but structurally homologous α chains. The α1 and α2 chains are ubiquitous, but the α3, α4, α5, and α6 chains show restricted distribution among tissues.[93] The chain organization and discriminatory interactions between the NC-1 domains govern network assembly in the basement membranes.[95] The six chains of collagen IV are distributed in three major networks, (1) α1–α2, (2) α3–α4–α5, and (3) α1–α2–α5–α6, whose chain composition is determined by the NC-l domains. Two networks, namely α1–α2-containing and α3–α4–α5-containing networks, exist in the glomerular basement membrane. Smooth muscle basement membranes have an α1–α2–α5–α6-containing network in addition to the classic α1–α2 network. Within the dermal–epidermal junction, the α1–α2-containing collagen IV network dominates, but α1–α2–α5–α6-containing network is also likely to be present.[96]

Mutations in the genes encoding the α1 and α2 chains cause pathologies in different organs, ranging from small-vessel disease, which often underlies ischemic strokes and intracerebral hemorrhages to the eye and the HANAC (hereditary angiopathy with nephropathy, aneurysms, and muscle cramps) syndrome.[93,97,98] Interestingly, despite the ubiquitous presence of the α1 and α2 chains of collagen IV in basement membranes, aberrations do not occur in all basement membranes, suggesting varying tissue-specific roles for collagen IV. Structural aberrations in the genes encoding the α3, α4, α5, and α6 chains cause different forms of Alport syndrome, a genetic disease characterized by nephritis and deafness.[93] The α3(IV) chain is the antigen recognized by the circulating autoantibodies in the Goodpasture syndrome.[93]

Laminins. Laminins are very large glycoproteins (600 to 950 kDa) within the lamina lucida/lamina densa of all basement membranes.[99] Three types of subunit chains have been designated α, β, and γ chains, and each laminin is a trimeric aggregate of one α, β, and γ chain. The trimers have semirigid and extended structures, which appear as an asymmetric cross in rotary shadowing electron microscopy (see Fig. 53-6C). The long arm of the cross is approximately 125 nm in length; the short arms are variable. Each laminin molecule contains globular and rod-like domains that have been individually implicated in various functions, such as aggregation with itself and with other components of the lamina densa (Fig. 53-8), cell attachment and spreading, neurite outgrowth, or cellular differentiation.[85,99] The *C*-terminal laminin-type globular (LG) domain of the α chain, at the foot of the long arm of the laminin cross, harbors the binding site for integrins.[99]

To date, 15 laminin isoforms have been identified. These represent different trimeric combinations of five distinct α chains, three β chains, and three γ chains known so far. Historically, laminins were named as *laminin-1* to *laminin-15*, in the order of their discovery, but this classification had grown quite impractical, with the need to memorize the numbers. The current,

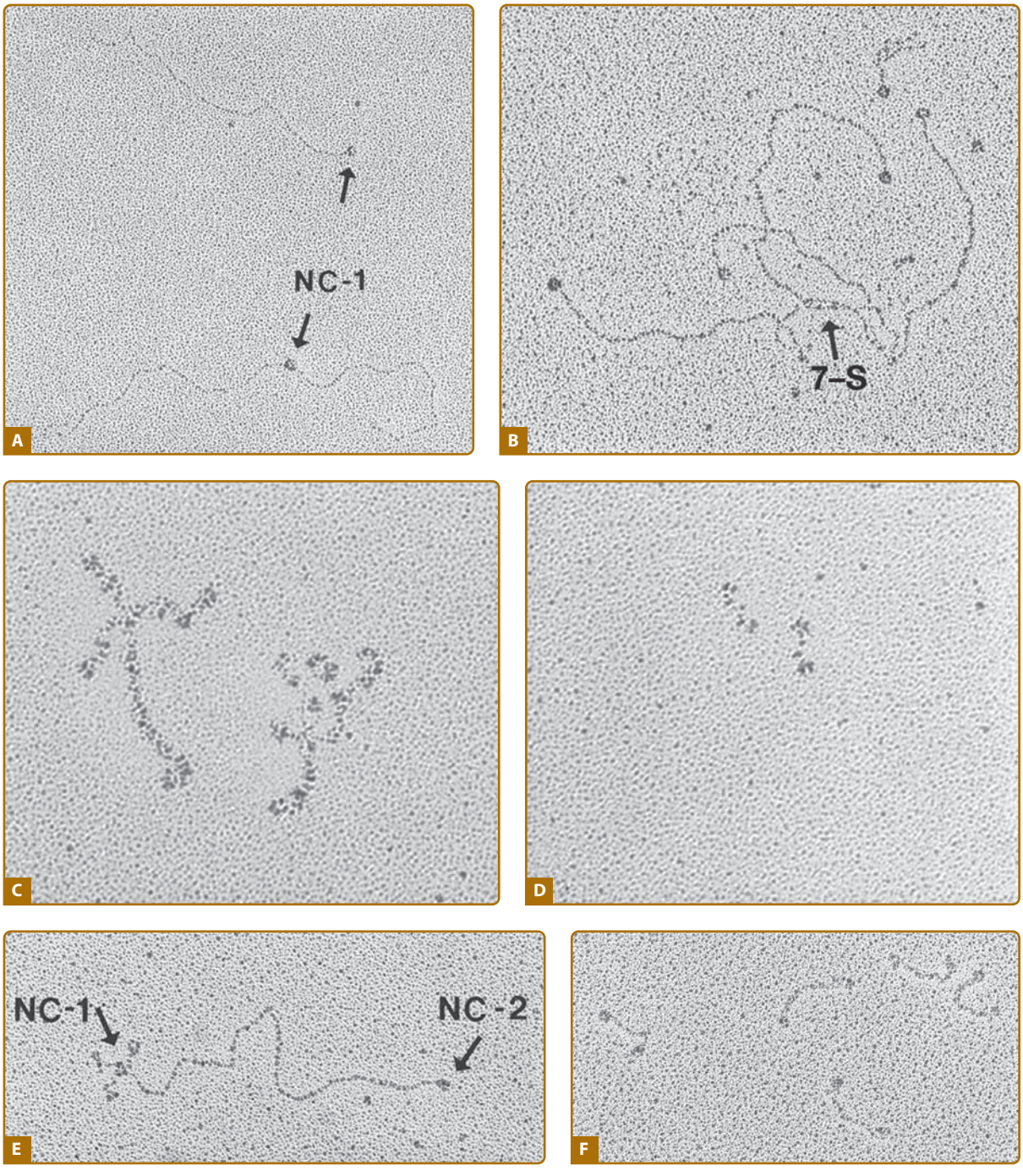

Figure 53-6 Images of basement membrane molecules visualized by rotary shadowing. **A.** Collagen IV monomer and a dimer resulting from aggregation of *C*-terminal NC-1 domains. **B.** Collagen IV tetramer ("spider") demonstrating the 7-S domain with the four protruding molecules and their large terminal NC-1 domains. **C.** Laminin 111 molecules. **D.** Nidogen molecules. **E.** Procollagen VII. The NC-1 and NC-2 regions are indicated. **F.** Laminin 332 molecules. (All micrographs were provided by Douglas R. Keene, MD, Shriners Hospital, Portland, Oregon.)

simplified nomenclature is based on the chain composition and the number of each α, β, and γ chain (Table 53-2).[100] For example, the classic "prototype" laminin-1, with α chain composition α1β1γ1, is now called *laminin 111*. The major laminin of the epidermal basement membrane, the previous laminin-5, with α chain composition α3β3γ2, is now called *laminin 332*.

The α2 chain containing laminins are present primarily within the basement membranes of the muscle fibers, nerves, neuromuscular junction, and glomerulus. The α3 chain is involved in epithelial adhesion, and the α4 and α5 chains are found in a variety of tissues including endothelia, epithelia, neuromuscular junction, and glomerulus.[101] Laminin 511 is present in



Figure 53-7 **A.** Representation of the networks formed by the ubiquitous components of the basement membranes. Monomeric collagen IV (Col-IV) self-assembles into dimers and tetramers that further aggregate into a complex lattice. Laminins self-polymerize into networks. Perlecan can oligomerize in vitro, and the glycosaminoglycan side chains interact with the Col-IV framework. Nidogen is thought to bind components of all three networks and also fibulins. Therefore, nidogen plays a central role as a stabilizer of the lamina densa framework. Individual molecules are not drawn to scale. (Drawing used with permission from Peter Yurchenco, MD, Robert Wood Johnson Medical School, Piscataway, NJ, USA.) **B.** Rotary shadowing image of a quick-freeze, deep-etch replica of Col-IV polymers. The replica shows an extensive, branching, and anastomosing network with occasional globular structures (*arrowhead*), which can be visualized as a model for the structure of the lamina densa. (Photo provided by Toshihiko Hayashi, PhD, University of Tokyo, Japan. See also Nakazato K et al: Gelation of lens capsule type IV collagen solution at a neutral pH. *J Biochem* **120**:889, 1996.)

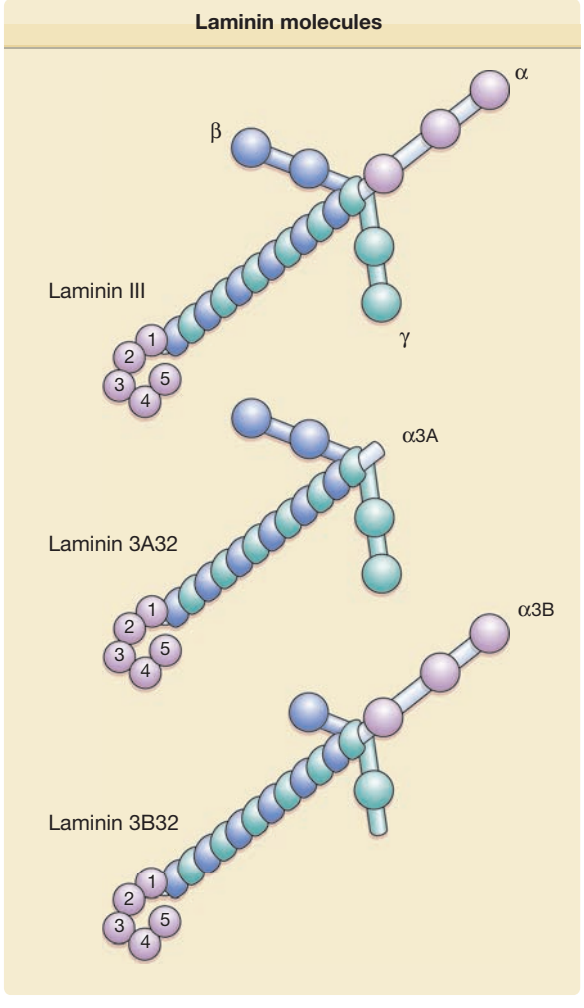

Figure 53-8 A schematic representation of laminin molecules. Each laminin is a heterotrimer of an α, a β, and a γ chain. On the left, the classic prototype laminin 111 consisting of α1β1γ1 chains is shown. The *N*-terminal short arm of each chain is free, the long *C*-termini fold to a coiled-coil and form the long arm. The distal *C*-terminus of the α chain contains five globular LG domains, which harbor the integrin-binding site. Laminin 332 exists in two forms, 3A32 and 3B32. These represent splice variants of the α chain, the short variant is 3A and the "full length" chain 3B. The *N*-termini of the β3 and γ2 chains are proteolytically processed to yield mature laminin 332.

TABLE 53-2
Most Common Laminin Isoforms[a]

Name	Chain Composition	Tissue Distribution
Laminin 111	α1β1γ1	Developing epithelia
Laminin 121	α1β2γ1	Myotendinous junction
Laminin 211	α2β1γ1	Muscle, nerves
Laminin 213	α2β1γ3	Muscle
Laminin 221	α2β2γ1	Neuromuscular junction, glomerulus
Laminin 3A11	α3β1γ1	Stratified epithelia
Laminin 3A21	α3β2γ1	Amnion, maybe other stratified epithelia
Laminin 3A32	α3β3γ2	Stratified epithelia
Laminin 3B32	α3β3γ2	Stratified epithelia, uterus, lung
Laminin 411	α4β1γ1	Endothelia, nerves, smooth muscle, adipose tissue
Laminin 421	α4β2γ1	Endothelia, neuromuscular junction, smooth muscle, glomerulus, adipose tissue
Laminin 423	α4β2γ3	Retina, central nervous system, kidney, testis
Laminin 511	α5β1γ1	Mature epithelia and endothelia, smooth muscle
Laminin 521	α5β2γ1	Mature epithelia and endothelia, smooth muscle, neuromuscular junction, glomerulus
Laminin 523	α5β2γ3	Retina, central nervous system, muscle, kidney

[a]See Durbeej M: Laminins. *Cell Tissue Res* **339**:259-268, 2010.

the basement membrane of the epidermis and the hair follicles, where it is believed to be involved in developmental signaling.[99,100] The distribution of the β2 chain is largely restricted to the neuromuscular junction, but it is also found in nonmuscle tissues such as the kidney glomerulus and the capillary basal lamina.[99] The β3 chain is involved in epithelial adhesion. Three γ chain variants—γ1, γ2, and γ3—are known. The γ2 chain is found only in laminin 332 in the skin. The γ3 chain, a component of laminins 423 and 523, binds nidogens and is localized in basement membrane zones of adult and embryonic brain, kidney, skin, muscle, and testis. It is present in much lower concentrations than the γ1 chain, a fact that may indicate highly specialized functions.[99] The functions of all laminins are not yet fully understood, but by interacting with integrins and other cell surface components laminins control cellular activities such as adhesion, migration, proliferation, and polarity in a wide variety of organs.[99,100]

Several human congenital diseases are caused by mutations in the laminin chains.[99] Since some chains can be components in several different laminins, the mutations can affect functions of multiple laminins in different tissues. For example, mutations in the α2 chain cause congenital muscular dystrophy and a significant decrease in the amount of basement membrane accumulated surrounding muscle cells.[99] The absence of the basement membrane leads to progressive degeneration of the muscle due to cell death. Therefore, the prediction is that laminins, and basement membranes in general, are required to prevent apoptosis by the cell types they surround.[99] Mutations in the α3, β3, or γ2 chains underlie junctional epidermolysis bullosa, and mutations of the α4 chain are associated with cardiomyopathy. Pierson syndrome, a severe congenital condition affecting mainly the kidney and the eye, is caused by mutations of the β2 chain.

Nidogens. Two nidogens, nidogen 1 and 2, previously known as *entactin*, are distinct gene products. Both are relatively small molecules (see Fig. 53-6D), which bind laminins at a specific site within the γ1 and the γ3 chain,[93,102] but also collagen IV, perlecan, and fibulins. Nidogens are likely to act as connecting elements between the collagen IV and laminin networks and integrate other basement membrane components into this specialized extracellular matrix.[84] Targeted ablation of nidogens in mice showed that the loss of either isoform has no effect on basement membrane formation and organ development, but lack of both results in severe defects of the lung and the heart[102] that are not compatible with life. Interestingly, despite the ubiquitous presence of nidogens in basement membranes, aberrations did not occur in all basement membranes, suggesting distinct roles for nidogens in different basement membranes.[102]

Heparan Sulfate Proteoglycans. Another class of ubiquitous integral basement membrane constituents are the proteoglycans. Three proteoglycans are characteristically present in vascular and epithelial basement membranes: (1) perlecan, (2) agrin, and

(3) collagen XVIII.[103] They consist of a core protein of various lengths, and carry primarily heparan sulfate side chains. The name *perlecan* is derived from its rotary shadowing appearance reminiscent of a string of pearls. Perlecan represents a complex multidomain proteoglycan with enormous dimensions and a number of posttranslational modifications. Knockout mice lacking perlecan exhibited abnormalities in many tissues, including basement membranes, and embryonic lethality. The basement membranes deteriorated in regions under increased mechanical stress, such as myocardium or skin, resulting in lethal cardiac abnormalities and skin blistering.[103] Agrin is a major heparan sulfate proteoglycan of neuromuscular junctions and renal tubular basement membranes. Collagen XVIII is considered to be a hybrid collagen—proteoglycan in various organs.[104] In collagen XVIII knockout mice, basement membranes were broadened in different organs, accompanied with mesangial expansion and reduced function of the kidney. The proteoglycans can interact with several other basement membrane components and are believed to contribute to the overall architecture of the basement membrane as well as provide tissue-specific functions. The high sulfate content makes them highly negatively charged and hydrophilic, and the charge density is responsible for providing the selective permeability of the glomerular basement membrane.

Syndecans are transmembrane heparan sulfate proteoglycans present on most cell types, including basal keratinocytes of the epidermis. The extracellular domains have affinity for laminins and, presumably through these interactions, they engage in outside-in signaling and regulate cellular processes ranging from growth factor signaling, cell adhesion, and cytoskeletal organization, to infection of cells with microorganisms.[105]

Fibulins. Fibulins are a family of six highly conserved, calcium-binding extracellular matrix proteins. They are located in vessel walls, basement membranes, and microfibrillar structures and they have overlapping binding sites for a variety of ligands, both basement membrane proteins and components of the interstitial connective tissues.[106] Therefore, fibulins are believed to function as intermolecular bridges that stabilize the supramolecular organization of extracellular membrane structures, such as elastic fibers and basement membranes. Genetic defects of the genes encoding fibulin 4 and 5 cause different forms of cutis laxa.

EPITHELIUM-SPECIFIC BASEMENT MEMBRANE COMPONENTS

The dermal–epidermal junction of skin is an excellent example of specific divergence in basement membrane structure. The structural components of hemidesmosomes, anchoring filaments, and anchoring fibrils in the basement membrane zone are quite well characterized.[84–87,107,108] A cartoon depicting the relative locations of the proteins found at the dermal–epidermal junction is shown in Fig. 53-9. These proteins are listed in Table 53-3 and discussed in the following sections.

HEMIDESMOSOMES

Ultrastructurally, the hemidesmosome closely resembles one-half of the desmosome at cell–cell junctions in the epidermis. However, the components of these two structures are distinct. The 230-kDa BPAG1 (bullous pemphigoid antigen 1, or BP230) is a coiled-coil dimeric protein with homology to plakins, which bind intermediate filaments. BPAG1 is the major component of the hemidesmosomal inner dense plaque. Ablation of BPAG1 is associated with epidermolysis bullosa simplex in mice and humans.[72,109] The 180-kDa BPAG2 or BP180, and the major antigen in bullous pemphigoid (Fig. 53-10), is a transmembrane collagen now known as *collagen XVII*, where the collagenous domain is extracellular. In fact, collagen XVII is a prototype of the novel protein family of collagenous transmembrane proteins, type II transmembrane molecules with one or more collagenous stretches in the extracellular domain.[110] The intracellular ligands of collagen XVII are plectin, BPAG1 and β4 integrin, and the extracellular ligands α6 integrin and laminin 332.[107,108] The 120-kDa ectodomain of collagen XVII is shed from the cell surface by proteinases of the ADAM (a disintegrin-like and metalloproteinase-containing) family through cleavage within the juxtamembranous NC-16 domain (Fig. 53-11).[111] Mutations in collagen XVII cause junctional epidermolysis bullosa (see Chapter 62), indicating that it stabilizes interactions of basal keratinocytes with the basement membrane.[112] Ablation of the mouse *Col17a1* gene resulted in moderate skin blistering, dental anomalies, and graying hair.[113,114] Plectin, another dimeric plakin homolog, is also a component of the hemidesmosome. However, its tissue distribution is not limited to hemidesmosome-containing basement membranes. Mutations of plectin result in epidermolysis bullosa simplex and progressive muscular dystrophy and, in some cases, epidermolysis bullosa simplex with pyloric atresia,[115] indicating a role for plectin in the stability of cell–basement membrane adhesion in a variety of tissues.

One key component of the hemidesmosome is the integrin α6β4.[107] It has a high affinity for laminin 332 and is essential to integration of the hemidesmosome with the underlying basement membrane and stroma.[107,108] Mutations in either the α6 or β4 chains result in junctional epidermolysis bullosa associated with pyloric atresia.[108,112]

A member of the widely expressed cell surface transmembrane proteins of the tetraspanin family, CD151, is also a component of the hemidesmosome. It forms complexes with α3β1 and α6β4 integrins at the basolateral surface of basal keratinocytes and stabilizes their functions.[116] CD151-null mice have apparently normal hemidesmosomes, but exhibit some functional aberrations, for example, poor keratinocyte migration in explant cultures. A very rare human genetic condition delivered indirect information on the functions of CD151. In addition to the expression of CD151 in

Hypothetical relationships of molecules within the dermal-epidermal junction basement membrane

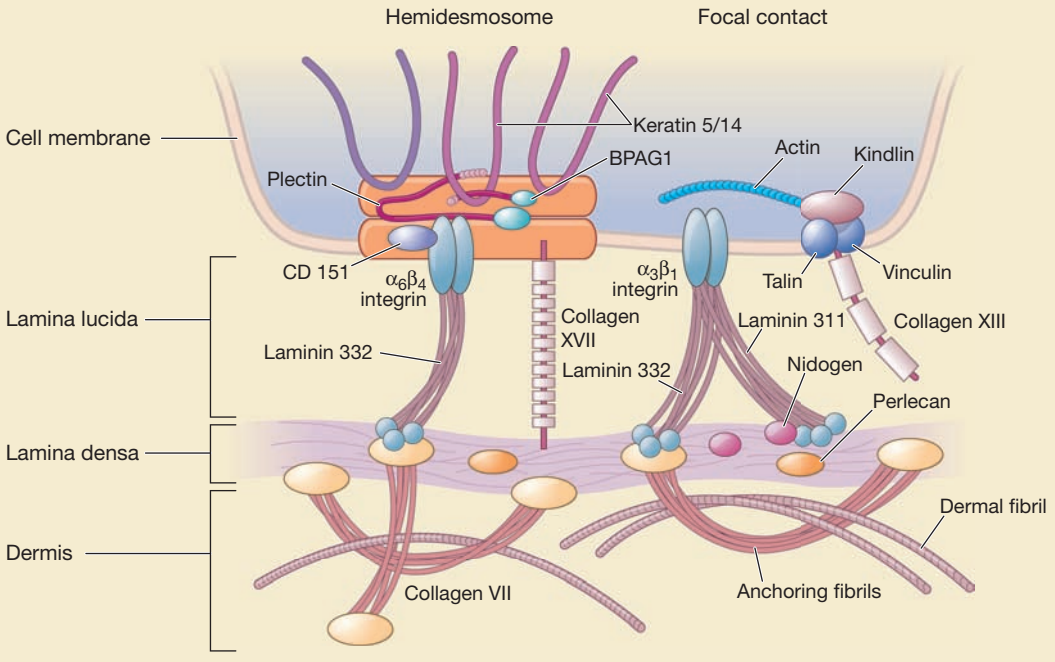

Figure 53-9 Model of the hypothetical relationships of molecules within the dermal–epidermal junction basement membrane. The illustration depicts laminin 332 as the bridge between the transmembrane hemidesmosomal integrin α6β4 and the collagen VII NC-1 domain. The tight binding of laminin 332 to α6β4 and to collagen VII provides the primary resistance to frictional forces. The transmembrane collagen XVII also participates in this stabilization, because its extracellular domain also binds laminin 332. Within the epithelial cell, the transmembrane elements bind the proteins of the hemidesmosomal dense plaque, bullous pemphigoid antigen (BPAG)1 and plectin, which then associate with the keratins. Collagen XVII binds BPAG1, integrin α6β4, and plectin, and integrin α6β4 binds plectin. The laminin 332–311 complex is shown within the basement membrane between hemidesmosomes, bound by integrin α3β1, and associated with the intracellular proteins kindlin-1, talin, and vinculin. This complex presumably maintains basement membrane stability. In vitro, integrin α3β1, kindlin-1, talin, and vinculin, and another transmembrane collagen, type XIII, are localized to the focal contacts, which may function as the link between the basement membrane and the epithelial cortical actin network. In the lamina densa, collagen IV and perlecan networks are stabilized by nidogen. Anchoring fibrils are secured to the lamina densa by the NC-1 domain of collagen VII. The fibrils project into the dermis and either terminate in anchoring plaques or loop back to the lamina densa. The anchoring fibril network entraps dermal fibrils, thus securing the adhesion of the lamina densa to the papillary dermis. None of the molecules is drawn to scale.

several tissues like the kidney and the skin, its gene also encodes the MER2 blood group antigen on erythrocytes. Homozygous CD151-null mutations were identified in three MER2-negative patients, who also presented with hereditary nephritis, sensorineural deafness, pretibial epidermolysis bullosa, and β-thalassemia minor.[117] These symptoms suggest that CD151 is important for the assembly of the basement membrane in the kidney, skin, and inner ear and plays a role in erythropoiesis.

OTHER EPIDERMAL ADHESION COMPLEXES

In addition to the hemidesmosomal components, other adhesion molecules are known to be present at the basolateral aspect of basal keratinocytes, for example, integrin α3β1, the receptor for the laminin 332–311 complex in the basement membrane between the hemidesmosomes,[118] and another transmembrane collagen, type XIII.[94] Since these proteins are localized to focal contacts in vitro, together with vinculin and talin, they are predicted to function as the link between the basement membrane and the epithelial cortical actin network. A novel intracellular component of this complex, kindlin-1, or fermitin-family-homolog 1, was identified by the genetic studies. The kindlin-1 gene, *FERMT1*, is mutated in the Kindler syndrome,[119,120] a disorder with skin blistering in infancy, progressive poikiloderma, skin atrophy, pigment anomalies, and, occasionally, skin cancer. In the epidermis, kindlin-1 is expressed at the basolateral surface of basal keratinocytes and has important functions in β1 integrin-mediated outside-in signaling that regulates cell–matrix adhesions, cell migration, and polarity.[121,122] Thus, kindlin-1 is

TABLE 53-3
Hemidesmosomal and Basement Membrane Zone (BMZ) Targets in Skin Disease

	Hemidesmosome/BMZ Component	Autoimmune Target	Genetic Target
Cytoskeletal proteins	Keratin 5 and 14		EBS
Hemidesmosomal plaque proteins	Bullous pemphigoid antigen 1/BP230 Plectin	BP BP, CP	EBS EBS-MD JEB-PA
Other intracellular adhesion complex proteins	Kindlin-1		KS
Hemidesmosomal transmembrane components	Collagen XVII/BP180 α6β4 integrin CD151	BP, CP, LAD, PG BP, CP	JEB-non-Herlitz JEB-PA Pretibial EB, nephritis, deafness, β-thalassemia minor
Anchoring filament proteins	Laminin 332 Ectodomain of collagen XVII	CP LAD, BP	JEB-Herlitz JEB–non-Herlitz JEB–non-Herlitz
Anchoring fibril proteins	Collagen VII	EBA	DEB

BP = bullous pemphigoid (see Chapter 56); CP = cicatricial pemphigoid (see Chapter 57); DEB = dystrophic EB (see Chapter 62 for all); EB = epidermolysis bullosa; EBA = EB acquisita (see Chapter 60); EBS = EB simplex; EBS–MD = EBS with muscular dystrophy; JEB = junctional EB; JEB–PA = JEB with pyloric atresia; KS = Kindler syndrome; LAD = linear immunoglobulin A dermatosis (see Chapter 58); PG = pemphigoid gestationis (see Chapter 59).

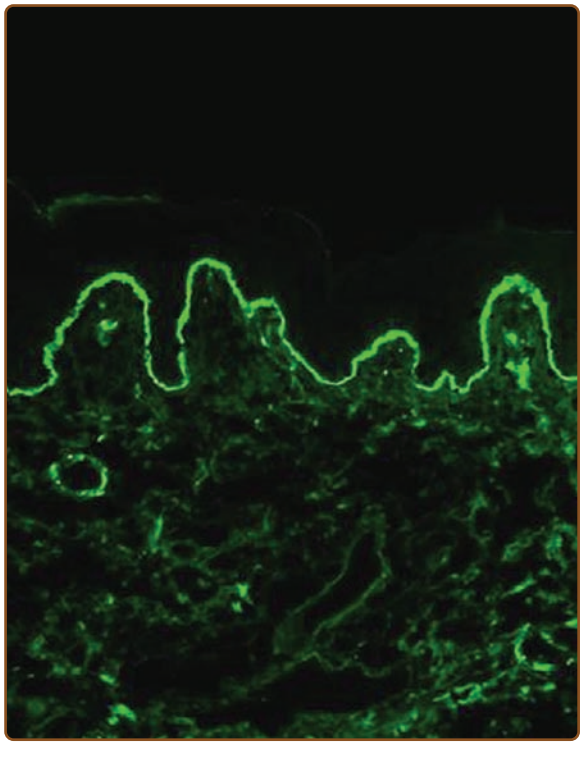

Figure 53-10 Indirect immunofluorescence staining of human skin with a pemphigoid serum that contains autoantibodies to collagen XVII.

necessary for the stability of the dermal–epidermal junction and that, in addition to hemidesmosomes, tethering the actin cytoskeleton to cell–matrix adhesions offers alternative means to anchor basal epithelial cells to the basement membrane.

ANCHORING FILAMENTS

The anchoring filaments contain laminin 332 and the ectodomain of collagen XVII, two ligands that interact with each other through noncovalent bonds.[99,100,108] The ectodomain of collagen XVII, which protrudes from the plasma membrane into the lamina lucida, has a loop structure consistent with its role as an anchoring filament protein.[123] Laminin 332 is a disulfide-bonded complex of α3, β3, and γ2 chains. The two splice variants of the α3 chain, α3A and α3B, associate with the α3 and γ2 chains to form laminin 3A32 and 3B32 (see Fig. 53-8).[99,100] Rotary shadowing imaging indicates that laminin 332 has a rod-like structure terminating in the globular regions (see Fig. 53-6F), a shape consistent with its role as an anchoring filament protein. The individual chains are considerably truncated relative to other laminin chains, and this truncation is reflected in the loss of the structures equivalent to the short arms of other laminins. Additionally, the α3 and γ2 chains are proteolytically processed after secretion from the keratinocyte, further trimming the short arms.[99,100] The

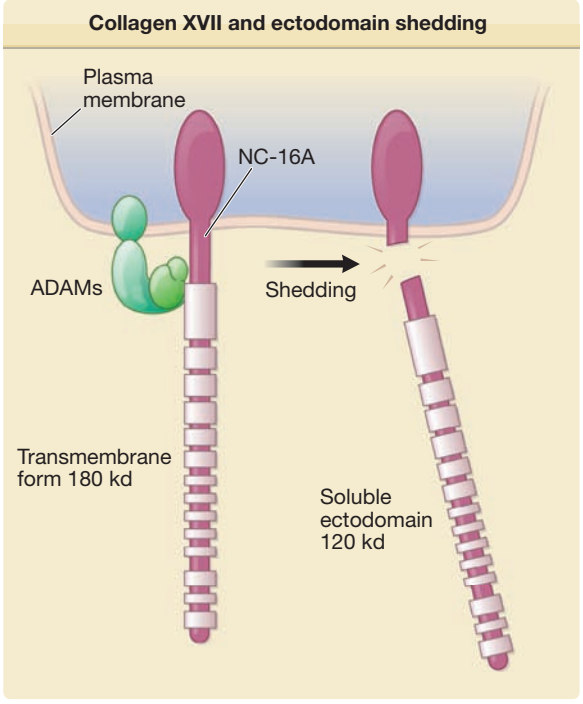

Figure 53-11 Schematic representation of collagen XVII and its ectodomain shedding. Collagen XVII is a hemidesmosomal transmembrane protein with an intracellular *N*-terminus. The extracellular *C*-terminus (ectodomain) contains several collagenous subdomains (*brown*) and intervening noncollagenous sequences (*beige*). The ectodomain can be shed from the cell surface by proteinases of the ADAMs (a disintegrin-like and metalloproteinase-containing) family, themselves transmembrane proteins. Thus, the 180-kDa full-length molecule yields a shorter soluble ectodomain of 120 kDa. The 180-kDa full-length molecule is the classic bullous pemphigoid antigen-2, and the ectodomain is the 120-kDa linear immunoglobulin A (IgA) dermatosis antigen. Further degradation of the *C*-terminus of the ectodomain results in the 97-kDa linear IgA dermatosis antigen.

C-terminus of the α chain, longer than that of the β and γ chains, comprises five globular LG modules, LG1 through LG5, which interact with cell surface receptors. The α3β1 and α6β4 integrins have affinity for the LG1-3 domains, whereas the LG4-5 tandem has affinity for syndecans and β-dystroglycan on the keratinocyte surface.[99,105] The LG4-5 modules are proteolytically cleaved in most laminins, a process which may modulate interactions with cell surface receptors.[99,100] Laminin 332 forms covalent complexes with laminin 311 (α3β1γ1), binds to the NC-1 domain of collagen VII, the anchoring fibril protein.[124] and to the distal ectodomain of collagen XVII.[123] Genetic evidence demonstrates that laminin 332 is essential in keratinocyte adhesion, as null mutations in any of its component α3, β3, or γ2 chains result in severe Herlitz junctional epidermolysis bullosa[112] (see Chapter 62). Targeted disruption of the mouse *lama3* gene prevented the synthesis of both laminin 332 and 311 molecules and resulted in abnormal hemidesmosomes, severe junctional blistering, abnormalities of ameloblast differentiation in developing teeth, and perinatal lethality.[125] Therefore, the severity of the laminin 332 null phenotype indirectly emphasizes its functional importance in bridging the hemidesmosomes and the anchoring fibrils.

EPITHELIAL LAMINA DENSA

The basement membrane beneath and between the hemidesmosomes contains the α1–α2-containing collagen IV network, probably some α1–α2–α5–α6-containing collagen IV network, as well as nidogen, perlecan, and α3 and α5-chain containing laminins.[93] The laminin α3 chain can associate with the β1 and γ1 chains of laminin 311, which has the unique property of forming disulfide-bonded dimers with laminin 332.[99,100] The major α3-containing laminin in the lamina densa between hemidesmosomes is probably the laminin 332–311 complex.[99,100,108] As the laminin α3 chain is a ligand for integrin α3β1 present between hemidesmosomes, binding of laminin 332–311 complex to the intracellular actin cytoskeleton is likely to be mediated by this integrin. This is consistent with studies in mice in which targeted ablation of the integrin α3 chain causes loss of the basement membrane between hemidesmosomes but not beneath them.[93,99] The *N*-termini of laminin 332 bind to collagen VII, the main component of the anchoring fibrils in the sublamina densa, so that anchoring filaments and fibrils are directly connected.[93] The laminin 332–311 complex and laminin 511 (α5β1γ1) contain a γ1 chain and can therefore bind nidogens and the collagen IV network.[93,99] Further, nidogen 1 and fibulin 1 and 2 were shown to be ligands for the laminin γ2 chain.[93] These interactions are important for the integration of laminin 332 into the extracellular matrix before the maturation of the γ2 chain, as a substantial portion of *N*-terminus of the γ2 chain is cleaved in human adult skin.[108] Yet another link, which strengthens dermal–epidermal cohesion, is provided by molecular interactions between perlecan within the lamina densa and fibrillin 1 in the microfibrils.[126]

ANCHORING FIBRILS

Collagen VII is the major component of the anchoring fibrils.[90,124] The collagen VII molecule is distinguished from other collagens in that it has a very long triple-helical domain, 450 nm in length. Globular domains exist at both ends of the triple helix, and the *N*-terminal domain NC-1 is very large and trident-like (see Fig. 53-6E). The smaller *C*-propeptide, NC-2, is believed to facilitate the formation of the antiparallel, centrosymmetric dimers, before it is removed by the metalloproteinase bone morphogenetic protein 1[127] to yield a mature collagen VII. The dimers are covalently cross-linked through disulfide bonds at the carboxyl terminus, and they aggregate laterally to form the anchoring fibrils. The fibrils are further stabilized by tissue transglutaminase, which catalyzes the formation of covalent γ-glutamyl-ε-lysine cross-links.[128]

The NC-1 domain of collagen VII binds to laminin 332 and collagen IV within the lamina densa (see Fig. 53-5A).[124] The triple helical domains of an antiparallel collagen VII dimer make the length of the anchoring fibril. It extends perpendicularly from the lamina densa and either loops back into the lamina densa or inserts into the anchoring plaques.[90,91] The anchoring plaques are electron-dense structures that contain collagen IV and laminin 332, and perhaps other basement membrane components, but which are believed to be independent of the lamina densa itself.[90] They are distributed randomly in the papillary dermis below the lamina densa and are interrelated by additional anchoring fibrils. The anchoring fibril network forms a scaffold that entraps large numbers of dermal fibrils and, most probably, binds them through covalent cross-links between collagen VII and collagen I,[129] thus securing the lamina densa to the subjacent dermis.[124] In the acquired form of epidermolysis bullosa, epidermolysis bullosa acquisita (see Chapter 60), and in bullous systemic lupus erythematosus (see Chapter 155), autoantibodies target mainly the NC-1 domain of collagen VII.[130]

Mutations in *COL7A1*, the gene encoding collagen VII, result in dystrophic epidermolysis bullosa (see Chapter 62). Almost 500 *COL7A1* mutations have been found in both recessive and dominant forms of dystrophic epidermolysis bullosa (Fig. 53-12), and the spectrum of biologic and clinical phenotypes is very broad.[131] In mouse models, complete or partial deficiency of collagen VII recapitulated the clinical and morphologic characteristics of recessive dystrophic epidermolysis bullosa in humans.[132,133] These mice have been useful for testing of molecular therapy strategies for dystrophic epidermolysis bullosa. Both cell therapy approaches using fibroblasts[134] or bone marrow-derived mesenchymal stem cells[135] and protein[136] therapy have shown promise in terms of increasing collagen VII and stabilizing the dermal–epidermal junction. A human clinical trial to treat recessive dystrophic epidermolysis bullosa using bone marrow transplantation is currently ongoing.[137]

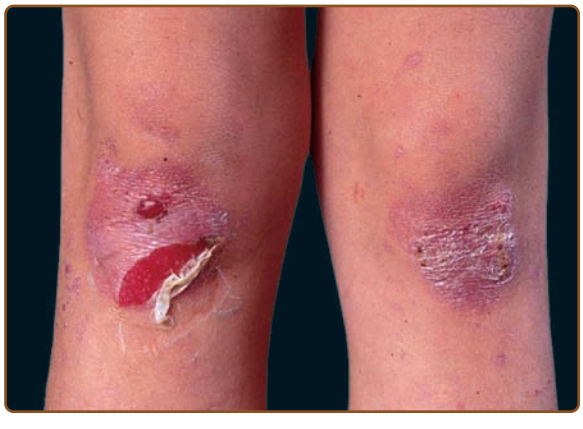

Figure 53-12 Skin fragility and blistering in dystrophic epidermolysis bullosa. Functional deficiency of collagen VII as a result of mutations in the *COL7A1* gene leads to trauma-induced separation of the epidermis and the dermis. The blister roof is below the lamina densa, leading to scar formation on healing of the blisters.

CELLULAR ORIGIN OF THE DERMAL–EPIDERMAL BASEMENT MEMBRANE

The basement membrane constituents are products of both epithelial and mesenchymal cells. In vitro modeling of basement membrane formation using different skin equivalent culture models has demonstrated that a tight interplay between fibroblasts and keratinocytes contributes to the dermal–epidermal basement membrane. Differentiated fibroblasts adjacent to epithelia in vivo produce basement membrane components and assist in basement membrane assembly.[138–141] Of the known basement membrane components, only laminins 332 and 311A are exclusively produced by the epidermis. Conditional knockout of collagen VII has demonstrated that both epithelial and mesenchymal cells manufacture collagen VII,[142] whereas mainly mesenchymal cells synthesize collagen IV, nidogen, perlecan, and the laminin α2 chain.[93] Because the mesenchymal products are translocated to the baso-lateral epithelial surface where they condense, that surface must provide the localization cues. Integrins α6β4 and α3β1 and collagen XVII have been implicated in this process, suggesting that the laminins coordinate basement membrane polymerization.[99] An interesting regulatory step may be added by dermal enzymes (e.g., bone morphologic protein 1), which process epithelial cell products, such as laminin 332 and procollagen VII, to mature basement membrane molecules.[99,127]

KEY REFERENCES

Full reference list available at www.DIGM8.com

DVD contains references and additional content

1. Getsios S, Huen AC, Green KJ: Working out the strength and flexibility of desmosomes. *Nat Rev Mol Cell Biol* **5**:271, 2004
26. Al-Amoudi A et al: The molecular architecture of cadherins in native epidermal desmosomes. *Nature* **450**:832, 2007
45. Payne AS et al: Genetic and functional characterization of human pemphigus vulgaris monoclonal autoantibodies isolated by phage display. *J Clin Invest* **115**:888, 2005
79. Jonkman MF et al: Loss of desmoplakin tail causes lethal acantholytic epidermolysis bullosa. *Am J Hum Genet* **77**:653, 2005
85. Yurchenco PD, Amenta PS, Patton BL: Basement membrane assembly, stability and activities observed through a developmental lens. *Matrix Biol* **22**:521, 2004
90. Keene DR et al: Collagen VII forms an extended network of anchoring fibrils. *J Cell Biol***104**:611, 1987
93. van Agtmael T, BrucknerTuderman L: Basement membranes and human disease. *Cell Tissue Res* **339**:167, 2010
100. Aumailley M, et al: A simplified laminin nomenclature. *Matrix Biol* **24**:326, 2005
109. Groves RW et al: A homozygous nonsense mutation within the dystonin gene coding for the coiled-coil domain of the epithelial isoform of BPAG1 underlies a new subtype of autosomal recessive epidermolysis bullosa simplex. *J Invest Dermatol* E-publication Feb 18, 2010
126. Ramirez F, Dietz HC: Extracellular microfibrils in vertebrate development and disease processes. *J Biol Chem* **284**:14677, 2009

Chapter 54 :: Pemphigus

:: Aimee S. Payne & John R. Stanley

PEMPHIGUS AT A GLANCE

- Two major types: pemphigus vulgaris and pemphigus foliaceus.
- Pemphigus vulgaris: erosions on mucous membranes and skin; flaccid blisters on skin.
- Pemphigus foliaceus: crusted, scaly skin lesions.
- Diagnosis depends on histology showing intraepidermal acantholysis and immunofluorescence studies documenting the presence of cell surface autoantibodies, either bound to patient skin or in the serum.
- Pemphigus vulgaris histology: suprabasal acantholysis.
- Pemphigus foliaceus histology: subcorneal acantholysis.
- Direct immunofluorescence shows immunoglobulin G (IgG) on the keratinocyte cell surface of the patient's skin; indirect immunofluorescence shows IgG in patient serum that binds the cell surface of normal keratinocytes.
- Autoantigens are desmogleins, transmembrane desmosomal adhesion molecules.
- Therapy includes topical and systemic corticosteroids and immunosuppressive agents.

The term *pemphigus* refers to a group of autoimmune blistering diseases of skin and mucous membranes that are characterized histologically by intraepidermal blisters due to acantholysis (i.e., separation of epidermal cells from each other) and immunopathologically by in vivo bound and circulating immunoglobulin (Ig) directed against the cell surface of keratinocytes. The nosology of this group of diseases is outlined in Box 54-1. Essentially, pemphigus can be divided into four major types: (1) vulgaris, (2) foliaceus, (3) paraneoplastic (see Chapter 55), and (4) IgA pemphigus (see Chapter 54). In pemphigus vulgaris (PV), the blister occurs in the deeper part of the epidermis, just above the basal layer, and in pemphigus foliaceus (PF), also called *superficial pemphigus*, the blister is in the granular layer.

The history of the discovery of pemphigus, and its various forms, is covered in Walter Lever's classic monograph *Pemphigus and Pemphigoid*.[1] Both PV and PF display a spectrum of disease. Various points along these spectra have been given unique names, but because the presentation of these diseases is fluid, patients' disease usually crosses these artificial designations over time. Thus, patients with PV may present with more localized disease, one form of which is called *pemphigus vegetans of Hallopeau*. This may become slightly more extensive and may merge into *pemphigus vegetans of Neumann*. Finally, with more severe disease, full-blown PV may appear. Similarly, patients with PF may present with more localized disease, represented by *pemphigus erythematosus*. However, these patients often go on to more widespread PF.

The discovery by Ernst Beutner and Robert Jordon in 1964 of circulating antibodies against the cell surface of keratinocytes in the sera of patients with PV pioneered our understanding that PV is a tissue-specific autoimmune disease of skin and mucosa.[2] Ultimately, their work led the way to the discoveries of autoantibodies in other autoimmune bullous diseases of the skin.

EPIDEMIOLOGY

INCIDENCE AND PREVALENCE

A few prospective and several retrospective surveys of patients with pemphigus clearly indicate that the epidemiology of pemphigus is dependent on both the area in the world that is studied as well as the ethnic population in that area.[3–10] PV is more common in Jews and probably in people of Mediterranean descent and from the Middle East. This same ethnic predominance does not exist for PF. Therefore, in areas where the Jewish, Middle Eastern, and Mediterranean population predominates, the ratio of PV to PF cases tends to be higher. For example, in New York, Los Angeles, and Croatia, the ratio of PV to PF cases is approximately 5:1; in Iran the ratio is 12:1; whereas in Singapore it is 2:1; and in Finland, it is only 0.5:1. Similarly, the incidence of pemphigus varies by region. In Jerusalem, the incidence of PV has been estimated to be 1.6 per 100,000 people per year and in Iran approximately 10.0 per 100,000 people per year. Elsewhere in Europe, the incidences are lower, ranging from a high of 0.7 PV cases per 100,000 person years in the United Kingdom to tenfold less, 0.5–1.0 per million person years, in Finland, France, Germany, and Switzerland.

The prevalence and incidence of PF are also very dependent on its location, as best exemplified by the finding of endemic foci of PF in Brazil, Colombia, and Tunisia. The first recognition of endemic PF was in

BOX 54-1 DIFFERENTIAL DIAGNOSIS OF PEMPHIGUS

PEMPHIGUS SUBTYPES

- Pemphigus vulgaris
- Pemphigus vegetans
- Pemphigus foliaceus
- Pemphigus erythematosus
- Endemic pemphigus foliaceus (e.g., fogo selvagem)
- Immunoglobulin A (IgA) pemphigus
- Subcorneal pustular dermatosis
- Intraepidermal neutrophilic dermatosis
- Paraneoplastic pemphigus

INTRAEPIDERMAL BLISTERING DISEASES WITHOUT AUTOANTIBODIES

- Familial benign pemphigus (Hailey–Hailey disease)
- Bullous impetigo, staphylococcal scalded-skin syndrome
- Blisters from herpes simplex and zoster
- Allergic contact dermatitis (e.g., rhus dermatitis)
- Epidermolysis bullosa simplex
- Incontinentia pigmenti

MOUTH ULCERS/EROSION WITHOUT AUTOANTIBODIES

- Aphthous ulcers
- Candidiasis
- Lichen planus
- Behçet disease

SUBEPIDERMAL BLISTERING DISEASES WITH AUTOANTIBODIES

- Bullous pemphigoid
- Herpes gestationis
- Cicatricial pemphigoid
- Epidermolysis bullosa acquisita
- Linear IgA disease and chronic bullous disease of childhood
- Dermatitis herpetiformis
- Bullous lupus erythematosus

SUBEPIDERMAL BLISTERING DISEASES WITHOUT AUTOANTIBODIES

- Erythema multiforme
- Toxic epidermal necrolysis
- Porphyria
- Junctional or dystrophic epidermolysis bullosa

Brazil and is called *fogo selvagem*, which means "wild fire" in Portuguese. It is a disease that is clinically, histologically, and immunopathologically the same as sporadic PF in any individual patient, but its epidemiology is unique.[11,12] Fogo selvagem is endemic in the rural areas of Brazil, especially along inland riverbeds. The geographic distribution of disease clustering is similar to that of a black fly, *Simulium nigrimanum*, thought by natives to be a vector of this disease. A study of potential environmental risk factors has also implicated the bite of this black fly, showing it to be significantly more frequent among those with the disease compared to an age-, sex-, and occupation-matched control population with unrelated dermatoses.[13] The prevalence on some well-studied Indian reservations in rural Brazil can be as high as 3.4%, with the incidence up to 0.8–4.0 new cases per 1,000 people per year.[12,14] On the reservation in Limao Verde, up to 55% of unaffected individuals have a low-level IgG1 antibody response against desmoglein 1, the PF autoantigen, which becomes an IgG4 response of higher titer against a more pathogenic epitope in disease.[12] These results suggest that some environmental agent (e.g., insects or other infectious disease agent) may trigger a low-level autoantibody response that becomes pathogenic by intramolecular epitope spreading in genetically susceptible individuals. With this theory in mind, it is interesting that 40%–80% of patients from Brazil with the insect-borne diseases onchocerciasis, leishmania, and Chagas disease have low-level antidesmoglein 1 antibodies, but patients with other infectious diseases from Brazil rarely have such antibodies.[15]

Fogo selvagem occurs often in children and young adults, unlike sporadic PF, which is a disease of mostly middle-aged and older patients. Also unlike PF, fogo selvagem occurs not infrequently in genetically related family members, although it is not contagious. This fact probably implies a common exposure, as well as susceptibility. There is no known racial or ethnic predominance, and anyone moving into an endemic area may be susceptible to disease. Again supporting the presence of an environmental trigger, the development of the rural endemic areas of Brazil decreased the incidence of disease. Certainly, this fascinating disease holds clues to understanding how this autoimmune response is triggered.

SEX RATIO

The sex ratio of pemphigus cases is difficult to estimate accurately due to the overall low incidence. Larger epidemiologic studies (i.e., those identifying greater than 100 cases) have shown that the sex ratio of pemphigus in women versus men ranges from 1.33 or 2.25 to 1.[7,9,16–20] Notable exceptions are the predominance of women (4:1) in an endemic focus of PF in Tunisia,[6] and a predominance of men (19:1) in an endemic focus of PF in Colombia.[21]

AGE OF ONSET

The average age of disease onset also varies by region. In Turkey, Saudi Arabia, Tunisia, and Iran, the mean age of onset is approximately 40 years.[6,16,18,22] Studies in the United States and elsewhere in Europe demonstrate an average age of onset between 50 and 70 years.[5,6,9,10,17,19,23,24,25] Pemphigus rarely occurs in children,[26] except in regions of endemic disease.

ETIOLOGY AND PATHOGENESIS

The discovery of pemphigus as an organ-specific, autoantibody-mediated disease of desmosomes highlights the synergy between clinical care and basic science research. The development of light microscopy and electron microscopy allowed dermatologists to identify the morphology and immunopathology of disease. Patient serum IgG served as a key reagent to help identify both the PF and PV antigens.[27–29] The cloning and characterization of the pemphigus antigens have subsequently led to the development of enzyme-linked immunosorbent assay (ELISA) tests to improve the sensitivity and specificity of disease diagnosis, and continued studies on pemphigus pathophysiology aim to develop safer and effective therapies for these potentially fatal diseases.

PEMPHIGUS AUTOANTIGENS

Pemphigus antigens are desmogleins, transmembrane glycoproteins of desmosomes (cell-to-cell adhesion structures, reviewed in Chapter 53).[30,31] Desmogleins are part of the cadherin superfamily of calcium-dependent cell adhesion molecules. The original members of this family (e.g., E-cadherin) demonstrate homophilic adhesive interactions (binding between like molecules). Desmogleins similarly demonstrate homophilic binding but can also participate in heterophilic adhesion by binding desmocollins, the other major transmembrane glycoprotein of desmosomes.[32,33]

The PF antigen (as well as the fogo selvagem antigen) is desmoglein 1, a 160-kDa protein.[27,28,34] The PV antigen is desmoglein 3, a 130-kDa protein that is 64% similar and 46% identical in amino acid sequence to desmoglein 1.[29] All patients with PV have antidesmoglein 3 antibodies, and some of these patients also have antidesmoglein 1 antibodies.[35,36] Patients with mucosal-dominant PV tend to have only antidesmoglein 3 antibodies, whereas those with mucocutaneous disease usually have both antidesmoglein 3 and antidesmoglein 1 antibodies.[37–39] PF patients typically have antibodies against only desmoglein 1.

Several lines of evidence indicate that antidesmoglein 1 and 3 antibodies in pemphigus patients directly cause blisters and hence are the etiologic agents of disease. Passive transfer of PV or PF IgG to neonatal mice or human skin causes blisters that clinically and histologically mimic the corresponding type of pemphigus in patients.[40–42] The antidesmoglein antibodies are responsible for blister formation in the passive transfer model, since affinity purified antidesmoglein 1 and 3 autoantibodies cause PF and PV blisters, respectively, and adsorption of desmoglein-reactive autoantibodies from PF or PV IgG abrogates disease.[43–46] Similar passive transfer "experiments" have been described in humans, where mothers with even mild PV can pass IgG autoantibodies to the fetus, causing blistering oral and skin disease that resolves by approximately 6 months, concurrent with the disappearance of maternal IgG from the circulation.[47]

Desmoglein 4, which is expressed in the developing hair cortex and the superficial epidermis, is a target of some pemphigus antibodies.[48] However, the antidesmoglein 4 antibodies in mucocutaneous PV and in PF have been shown to be a result of cross-reactivity from desmoglein 1 autoantibodies, and the desmoglein 4 reactivity has not been shown to be necessary or sufficient for acantholysis.[49] Other cell surface molecules such as acetylcholine receptors and E-cadherin have also been identified as immunologic targets of pemphigus autoantibodies, although their direct involvement in the pathophysiology of pemphigus is similarly unclear.[50,51]

PATHOPHYSIOLOGY OF ACANTHOLYSIS

Unlike many other autoantibody-mediated diseases, such as pemphigoid and epidermolysis bullosa acquisita, in which the constant region of the antibody is required for blister formation to activate complement or bind antibody receptors on inflammatory cells, in pemphigus the variable region of the antibody is sufficient to cause blisters in neonatal mice or human skin.[42,60–62] For this reason a significant amount of research on disease pathophysiology has focused on the epitopes bound by pathogenic autoantibodies, as these regions are likely critical for maintaining desmosomal cell adhesion.

Epitope mapping studies have shown that pathogenic PV and PF autoantibodies bind calcium-sensitive, conformational epitopes in the amino-terminal extracellular domains of desmogleins, whereas nonpathogenic antibodies tend to bind more membrane proximal extracellular domains.[63–66] The amino-terminal domains bound by pathogenic autoantibodies are the same domains that are predicted to form the key molecular interactions for desmoglein intercellular adhesion, based on studies of cadherin ultrastructure.[67,68] This evidence is the primary basis for the "steric hindrance" hypothesis, which proposes that pathogenic antibodies directly interfere with desmoglein adhesive interactions, causing acantholysis.

Studies on cultured keratinocytes have indicated that loss of intercellular adhesion by pathogenic autoantibodies leads to internalization and degradation of desmogleins,[69–72] indicating that pemphigus antibody binding leads to loss of desmoglein function. If this is the case, then other model systems with loss of desmoglein function should mimic pemphigus. Indeed, mice genetically deficient for desmoglein

3 demonstrate suprabasal blisters in the oral mucosa histologically identical to PV patients.[73] Additionally, cleavage of desmoglein 1 by staphylococcal exfoliative toxin (in bullous impetigo or staphylococcal scalded skin syndrome) causes blisters histologically identical to those seen in PF patients.[74]

If inactivation of desmoglein isoforms results in blistering, then why do blisters in PV and PF have specific tissue localizations that do not necessarily correlate with the sites at which the antibodies bind by immunofluorescence? In PF, for example, the antidesmoglein 1 antibodies bind throughout the epidermis and mucous membranes,[75] yet blisters occur only in the superficial epidermis. This apparent paradox can be explained by desmoglein compensation, as outlined in Fig. 54-1. The concept of desmoglein compensation originates in the assumption that autoantibodies against one desmoglein isoform inactivate only that isoform and that another isoform coexpressed in the same area can compensate in adhesion.[76–78] Desmoglein compensation explains why neonatal PF is so unusual, because even though the maternal antidesmoglein 1 antibodies cross the placenta, in neonatal skin, but not in adult skin, desmoglein 3 is coexpressed with desmoglein 1 in the superficial epidermis, thereby providing protection against the loss of desmoglein 1-based adhesion.[77,79] Desmoglein compensation also offers an explanation for the differing sites of blister formation in PV and PF, both in regard to the histology (i.e., suprabasal or superficial), as well as the areas of involvement (mucosa and/or skin.)

In potential challenge to the steric hindrance hypothesis, several studies have suggested that modulation of cell signaling pathways can prevent blister formation after passive transfer of pemphigus IgG in the neonatal mouse model, including p38 mitogen activated protein kinase (MAPK) and ρ GTPases, among others.[80–82] Whether signaling is upstream or downstream of the loss of intercellular adhesion is controversial. Nevertheless, the current general consensus is that desmosomal adhesion is a dynamic process that is perturbed by pemphigus autoantibodies. Therefore, therapies that aim to strengthen keratinocyte adhesion by modulation of signaling pathways may have a beneficial effect on pemphigus, regardless of whether cell signaling is a primary pathologic cause of disease.

GENETIC RESTRICTION OF THE PEMPHIGUS IMMUNE RESPONSE

Compared to a matched population, patients with PV have a markedly increased frequency of certain class II major histocompatibility complex (MHC) antigens. Among Ashkenazi Jews with PV, the serologically defined HLA-DR4 haplotype is predominant, whereas in other ethnic groups with PV, the DQ1 allele is more common.[83] However, the association with disease susceptibility becomes even more striking in an analysis of these MHC alleles at a genetic level. Patients with the DR4 serotype almost all have the unusual allele DRB1*0402, and patients with the DQ1 serotype almost all have the rare allele DQB1*0503. Similar, but less restricted, HLA-DR alleles are associated with PF.[84] The protein chains encoded by these PV MHC II alleles vary from those found in HLA-DR4 and DQ1 controls without disease by only a few amino acids.

MHC class II alleles encode cell surface molecules that are necessary for antigen presentation to the immune system; therefore, it is hypothesized that PV-associated MHC class II molecules allow presentation of desmoglein 3 peptides to T cells.[85] Consistent with this hypothesis, certain peptides from desmoglein 3, predicted to fit into the DRB1*0402 peptide-binding pocket, were found to stimulate T cells from patients.[86]

Other studies have confirmed that the immune response in pemphigus is restricted to certain desmoglein peptides and MHC class II alleles.[87–89] An unexpected observation was that T cells of normal people with the DRB1*0402 or DQB1*0503 respond just as well as those of pemphigus patients to the same desmoglein 3 peptides,[85,90] indicating that T-cell reactivity to desmoglein 3 peptides is not sufficient for disease onset. The factor that may determine who gets pemphigus and who does not has been proposed to be the presence of regulatory T cells that can suppress the autoimmune response in those who do not.[91]

Cloning of antidesmoglein antibodies from PV and PF patients has indicated a marked restriction of antibody gene usage by the antidesmoglein antibodies, most notably for the heavy chain variable region.[61,62,92] These studies also show that pathogenic antibodies from different patients bind at or near common epitopes on desmogleins and may share common idiotypes. In comparison to the restricted B-cell antibody variable region gene usage, there is more heterogeneity of the T-cell receptor variable gene usage in pemphigus patients.[90,93] If specific antibody or T-cell receptor gene usage patterns are found to be shared among multiple pemphigus patients, these may serve as clinical markers for targeting disease-specific immune cell populations in pemphigus patients.

CLINICAL FINDINGS

PEMPHIGUS VULGARIS

CUTANEOUS LESIONS. The skin lesions in PV can be pruritic or painful. Exposure to ultraviolet radiation may exacerbate disease activity.[94,95] The primary lesion of PV is a flaccid blister, which may occur anywhere on the skin surface, but typically not the palms and soles (Fig. 54-2). Usually, the blister arises on normal-appearing skin, but it may develop on erythematous skin. Because PV blisters are fragile, the most common skin lesions observed in patients are erosions resulting from broken blisters. These erosions are often quite large, as they have a tendency to spread at their periphery (Fig. 54-3).

A characteristic finding in pemphigus patients is that erosions can be extended into visibly normal skin by pulling the remnant of the blister wall or rubbing at the periphery of active lesions; additionally, erosions can be induced in normal-appearing skin distant from

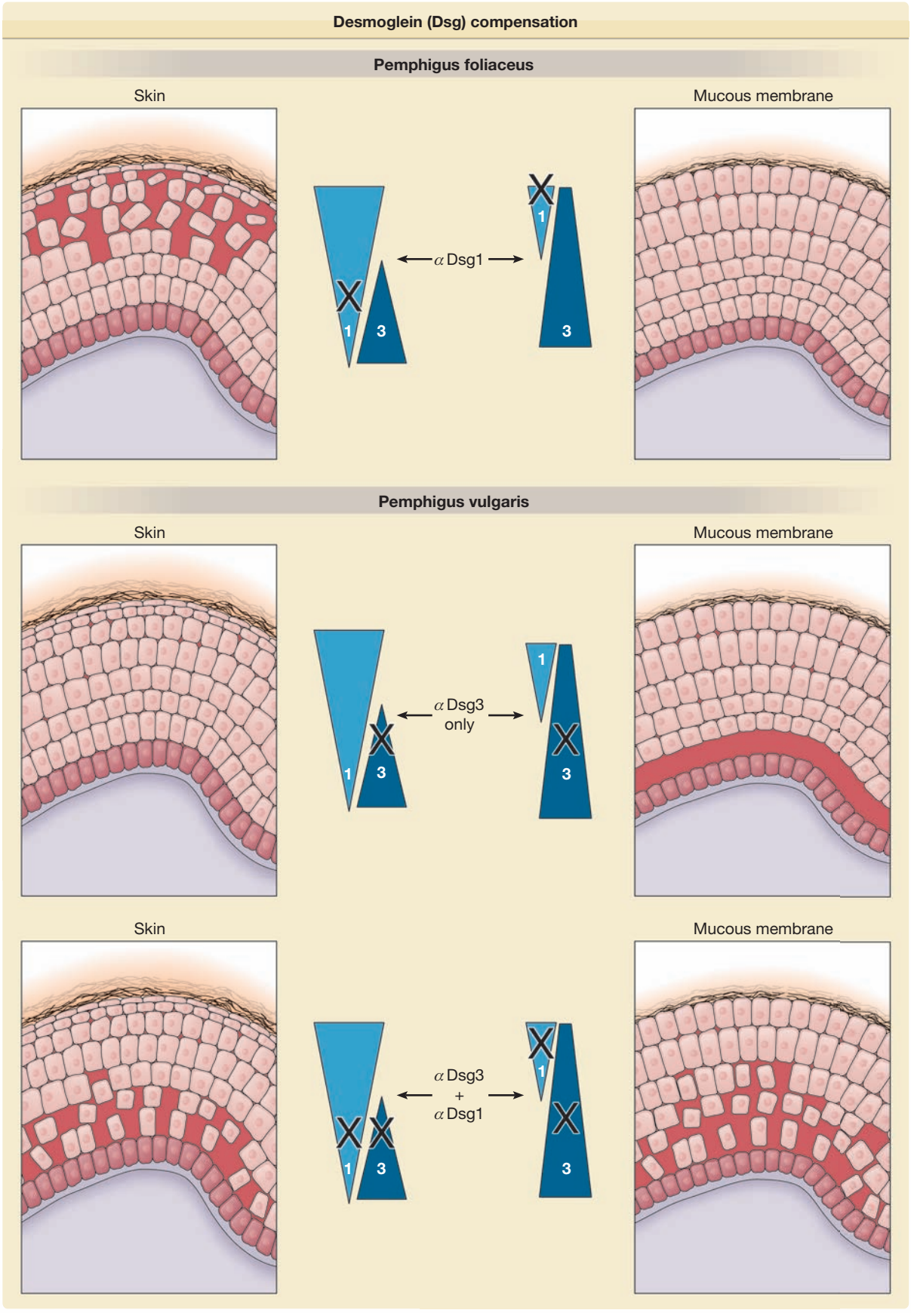

Figure 54-1 Desmoglein (Dsg) compensation. Triangles represent the distribution of Dsg1 and 3 in skin and mucous membranes. Anti-Dsg1 antibodies in pemphigus foliaceus cause acantholysis only in the superficial epidermis of skin. In the deep epidermis and in mucous membranes, Dsg3 compensates for antibody-induced loss of function of Dsg1. In early pemphigus vulgaris, antibodies are present only against Dsg3, which cause blisters only in the deep mucous membrane where Dsg3 is present without compensatory Dsg1. However, in mucocutaneous pemphigus, antibodies against both Dsg1 and Dsg3 are present, and blisters form in both mucous membrane and skin. The blister is deep probably because antibodies diffuse from the dermis and interfere first with the function of desmosomes at the base of the epidermis.

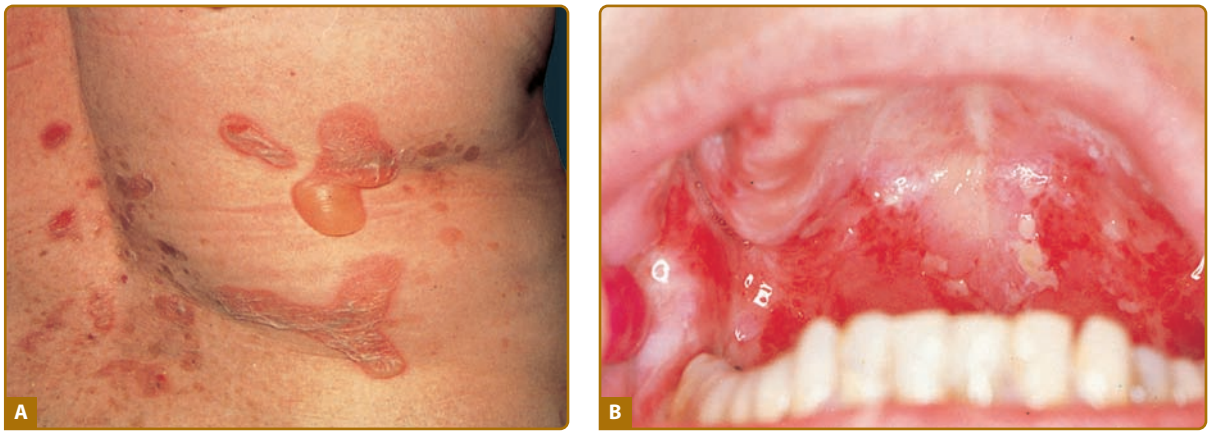

Figure 54-2 Pemphigus vulgaris. **A.** Flaccid blisters. (Used with permission from Lawrence Lieblich, MD.) **B.** Oral erosions.

active lesions by pressure or mechanical shear force. This phenomenon is known as the *Nikolsky sign*.[96] This sign helps differentiate pemphigus from other blistering diseases of the skin such as pemphigoid (Box 54-1); however, similar findings can also be elicited in staphylococcal scalded skin syndrome, Stevens–Johnson syndrome, and toxic epidermal necrolysis.

VEGETATING LESIONS. In certain patients, erosions have a tendency to develop excessive granulation tissue and crusting, referred to as vegetating lesions (Fig. 54-4). This type of lesion tends to occur more frequently in intertriginous areas, in the scalp, or on the face (see Fig. 54-4A). Historically, patients presenting with vegetating lesions have been split out into different disease designations: *pemphigus vegetans of Hallopeau* and *pemphigus vegetans of Neumann*. However, the subsequent analysis of vegetating skin lesions by histology and immunofluorescence suggests that these cases are simply clinical variants of PV.[1,97] In the Hallopeau variant, vegetating and often pustular lesions are present from the outset of disease, are not preceded by bullae, and favor flexural regions (see Fig. 54-4B). Generally, the prognosis for these patients is thought to be better, with milder disease and a higher chance of remission compared to typical PV patients.[98] In patients with the Neumann variant, ordinary PV erosions heal with papillomatous formations, with prognosis related to the extent of disease activity. The vegetating type of response may also appear in certain lesions that tend to be resistant to therapy and remain for long periods of time in one place. Thus, vegetating lesions seem to be one reactive pattern of the skin to the autoimmune insult of PV.



Figure 54-3 Pemphigus vulgaris. Extensive erosions due to blistering. Almost the entire back is denuded. Note intact, flaccid blisters at the lower border of eroded lesions.

MUCOUS MEMBRANE LESIONS. The mucous membranes most often affected by PV are those of the oropharyngeal cavity (see Fig. 54-2B). As with cutaneous lesions, intact blisters are rare. Oropharyngeal erosions can be so painful that the patient is unable to eat or drink. The inability to eat or drink adequately may require inpatient hospitalization for disease control and intravenous fluid and nutrient repletion.

In the majority of patients, painful mucous membrane erosions are the presenting sign of PV and may be the only sign for an average of 5 months before skin lesions develop.[3] However, the presenting symptoms may vary; in a study from Croatia, painful oral lesions were the presenting symptom in 32% of patients.[20] Most of these patients progressed to a more generalized eruption in 5 months to 1 year; however, some had oral lesions for more than 5 years before generalization. On the other hand, in Tehran, 62% of patients presented with oral lesions only.[7] Skin involvement without mucous membrane involvement in PV is less common, accounting in one study for 11% of PV cases.[99]

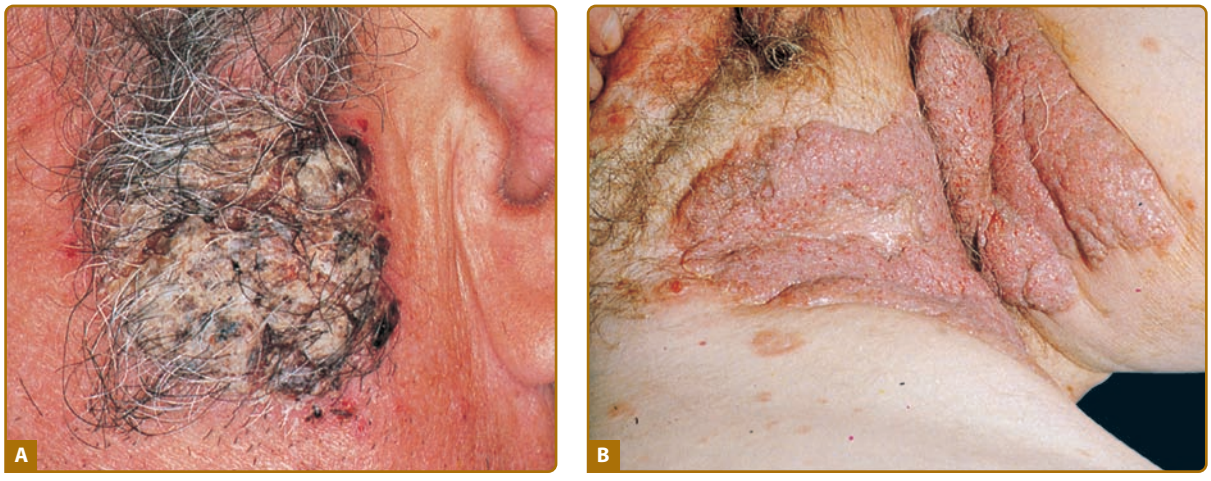

Figure 54-4 **A.** Crusted, vegetating lesions in pemphigus vulgaris. **B.** Extensive, vegetating granulomatous lesions in pemphigus vegetans.

Gastrointestinal tract involvement with PV has been described in the esophagus, stomach, duodenum, and anus, although only biopsies of the esophagus have been proven to be due to suprabasal acantholysis.[7,100,101] Involvement of other mucous membranes can also occur, including the vulvovaginal, nasal, laryngeal, and conjunctival mucosa.[102–106] In women, cervicovaginal lesions may be found in up to 51% of patients with active disease but these lesions may be asymptomatic. Even without obvious lesions, Pap smears may be positive in women with pemphigus and the acantholytic cells may be misinterpreted as indicative of cervical dysplasia.[107,108] There are rare case reports on corneal erosions in PV patients, but no histologic confirmation of acantholysis.[109]

PEMPHIGUS FOLIACEUS

CUTANEOUS LESIONS. The characteristic clinical lesions of PF are scaly, crusted erosions, often on an erythematous base. In more localized and early disease, these lesions are usually well demarcated and scattered in a seborrheic distribution, including the face, scalp, and upper trunk (Fig. 54-5A). The primary lesions of small flaccid blisters are typically not found. Disease may stay localized for years, or it may rapidly progress to generalized involvement, resulting in an exfoliative erythroderma (Fig. 54-5B). Like PV, PF may be exacerbated by ultraviolet radiation.[95,110,111] Patients with PF often complain of pain and burning in the skin lesions. In contrast to patients with PV, those with PF very rarely, if ever, have mucous membrane involvement, even with widespread disease.

The colloquial term for Brazilian endemic pemphigus, fogo selvagem (Portuguese for "wild fire"), takes into account many of the clinical aspects of this disease: the burning feeling of the skin, the exacerbation of disease by the sun, and the crusted lesions that make the patients appear as if they had been burned.

PEMPHIGUS ERYTHEMATOSUS. In 1926, Francis Senear and Barney Usher described eleven patients with features of a pemphigus–lupus erythematosus overlap (*Senear–Usher syndrome*).[112] Over the next several decades, debate over whether these patients had lupus erythematosus, pemphigus, seborrheic dermatitis, or features of all three disorders continued, with Senear concluding that the disease is best considered a variant of pemphigus, termed *pemphigus erythematosus*.[113]



Figure 54-5 Pemphigus foliaceus. **A.** Scaly, crusted lesions on upper back. **B.** Exfoliative erythroderma due to confluent lesions.

As these observations were made prior to the development of immunofluorescence testing for both pemphigus and lupus, the diagnosis was primarily based on the clinical presentation: crusted erosions in a seborrheic distribution, at times concurrent with more lupus-like discoid lesions with "carpet-tack" scale. Walter Lever noted that many patients initially categorized as pemphigus erythematosus went on to develop systemic lupus, or more widespread PF, or even PV, in some cases due to incorrect initial diagnosis. Therefore, rather than perpetuate the use of one term for different diseases, he proposed that pemphigus erythematosus be used to describe a localized form of PF with better prognosis.[1] After the development of immunofluorescence and antinuclear antibody testing for pemphigus and lupus, it was discovered that pemphigus erythematosus patients demonstrate immunologic overlap features; by definition all demonstrate the cell surface staining pattern classic for pemphigus, approximately 30% have positive antinuclear antibody titers, and 80% have positive lupus band tests, although the latter test is only positive in 20%–40% of biopsies on nonsun-exposed skin.[114] As most patients with pemphigus erythematosus do not develop systemic signs or symptoms of lupus, and some may progress from localized disease to generalized PF,[115] the diagnosis of pemphigus erythematosus is largely one of historic, rather than clinical, significance.

NEONATAL PEMPHIGUS

Infants born to mothers with PV may display clinical, histologic, and immunopathologic signs of PV.[47,116] The degree of involvement varies from none to severe enough to result in a stillbirth. If the infant survives, disease tends to remit as maternal antibody is catabolized. Mothers with PF may also transmit their autoantibodies to the fetus, but, as discussed in Section "Pathophysiology of Acantholysis," neonatal PF occurs only rarely.[117–119] Neonatal pemphigus should be distinguished from PV and PF that occur in childhood, which are similar to the autoimmune diseases seen in adults.[120]

DRUG-INDUCED PEMPHIGUS

Although there are sporadic case reports of pemphigus associated with the use of several different drugs, the association with penicillamine, and perhaps captopril, is the most significant.[121] The prevalence of pemphigus in penicillamine users is estimated to be approximately 7%. PF (including pemphigus erythematosus) is more common than PV in these penicillamine-treated patients, although either may occur. The findings of direct and indirect immunofluorescence are positive in most of these patients. Three patients with drug-induced PF and one with drug-induced PV have been shown to have autoantibodies to the same molecules involved in sporadic pemphigus, namely, desmoglein 1 and desmoglein 3, respectively.[122] Therefore, by immunofluorescence and immunochemical determinations, these patients with drug-induced pemphigus resemble those with sporadic disease.

Both penicillamine and captopril contain sulfhydryl groups that are postulated to interact with the sulfhydryl groups in desmoglein 1, 3, or both, thereby causing pemphigus either by directly interfering with these adhesion molecules or, more likely, by modifying them so that they become more antigenic. The use of these drugs may also lead to a more generalized dysregulation of the immune response, allowing production of other autoantibodies such as those resulting in myasthenia gravis. Most, but not all, patients with drug-induced pemphigus go into remission after they stop taking the offending drug.

Additionally, rare anecdotal reports have suggested the association of dietary intake and pemphigus, proposing the hypothesis that thiol-containing foods such as garlic, leeks, and onions may precipitate disease.[123,124] Some patients may note that certain foods aggravate oral lesions, but it is unlikely that dietary intervention alone will remit disease in most patients.

Interestingly, anecdotal case reports have reported improvement of PV with cigarette smoking,[125] as well as with the cholinergic agonists pyridostigmine, carbachol, and pilocarpine.[126,127] Studies suggest that activation of cholinergic receptors may regulate signaling pathways modulated by PV IgG, thereby affecting cell adhesion.[128] These results are intriguing given the clinical benefit of nicotine noted in other inflammatory diseases, such as ulcerative colitis.[129]

ASSOCIATED DISEASES

Myasthenia gravis, thymoma, or both have been associated with PV and PF.[130] Approximately one-half of associated pemphigus cases are vulgaris; one-half, foliaceus or erythematosus. Most of these data, however, were reported before the recognition of paraneoplastic pemphigus as a distinct entity. Therefore, although thymoma may clearly be associated with PV and PF, it may also be associated with paraneoplastic pemphigus (see Chapter 55). Myasthenia gravis is a tissue-specific autoantibody-mediated disease leading to skeletal muscle weakness. Early disease usually affects facial muscles, leading to symptoms of dysarthria, dysphagia, ptosis, or diplopia. Disease may then progress to affect the larger muscles of the trunk and extremities, with potential fatal complications from respiratory muscle involvement. Thymoma, in contrast, is typically asymptomatic in adults. In children, thymomas are more likely to be symptomatic with cough, chest pain, superior vena cava syndrome, dysphagia, and/or hoarseness from localized tumor encroachment.

Myasthenia gravis would be best evaluated by a neurologist, who can complete a full neurologic examination and may test for the presence of serum acetylcholine receptor autoantibodies. The course of myasthenia gravis and pemphigus appear to be independent of each other. Likewise, thymic abnormalities may either precede or follow the onset of pemphigus. Thymic abnormalities include benign or malignant thymoma and thymic hyperplasia. Posteroanterior

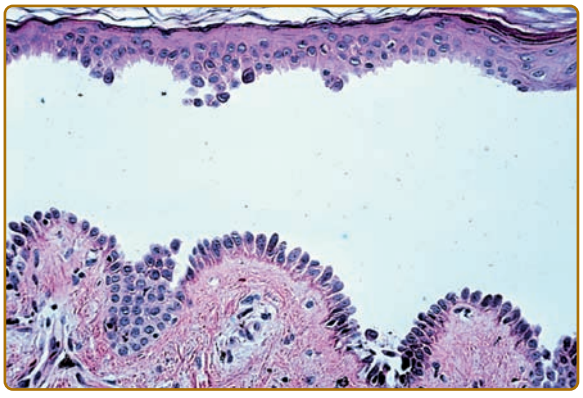

Figure 54-6 Histopathology of pemphigus vulgaris. Suprabasilar acantholysis. The row of tombstones.

and lateral chest radiographs with or without computerized tomography follow-up can detect most thymomas. Irradiation of the thymus or thymectomy, although clearly beneficial for myasthenia gravis, may not improve the pemphigus disease activity. Although this association is reported in at least 30 cases, the finding of thymoma or myasthenia gravis in a patient with PV or PF is still unusual.

LABORATORY TESTS

Diagnosis of pemphigus relies on skin biopsy of a fresh lesion for histology to determine the site of blister formation, as well as a confirmatory immunochemical study to document the presence of skin autoantibodies, either by direct immunofluorescence of perilesional skin, or indirect immunofluorescence or ELISA of patient serum.

HISTOLOGY

The characteristic histopathologic finding in PV is a suprabasal blister with acantholysis (Fig. 54-6). Just above the basal cell layer, epidermal cells lose their normal cell-to-cell contacts and form a blister. Often, a few rounded up (acantholytic) keratinocytes are in the blister cavity. The basal cells stay attached to the basement membrane, but may lose the contact with their neighbors; as a result, they may appear to be a "row of tombstones," symbolic of the potentially fatal prognosis of this disease. Usually, the upper epidermis (from one or two cell layers above the basal cells) remains intact, as these cells maintain their cell adhesion. Pemphigus vegetans shows not only suprabasilar acantholysis, but also papillomatosis of the dermal papillae and downward growth of epidermal stands into the dermis, with hyperkeratosis and scale-crust formation. In addition, pemphigus vegetans lesions may show intraepidermal abscesses composed of eosinophils and/or neutrophils.[131] Early PV lesions may show eosinophilic spongiosis.[132]

The histopathology of early blisters in PF patients demonstrates acantholysis (loss of cell-to-cell contact) just below the stratum corneum and in the granular layer (Fig. 54-7A). The stratum corneum is often lost from the surface of these lesions. The deeper epidermis, below the granular layer, remains intact. Another frequent finding is subcorneal pustules, with neutrophils and acantholytic epidermal cells in the blister cavity (Fig. 54-7B). Histologic findings in PF are often indistinguishable from those seen in bullous impetigo/staphylococcal scalded skin syndrome, because blisters in these latter diseases also result from dysfunction of desmoglein 1, in these cases due to proteolytic cleavage by staphylococcal exfoliative toxins.[31] Therefore, immunochemical studies are essential to confirm a diagnosis of PF, as these would be negative in staphylococcal-mediated skin blisters. The site of blister formation in pemphigus erythematosus is identical to PF. As in PV lesions, very early PF lesions may show eosinophilic spongiosis.[132]

IMMUNOFLUORESCENCE

The hallmark of pemphigus is the finding of IgG autoantibodies against the cell surface of keratinocytes. These autoantibodies were first discovered in patients' sera by indirect immunofluorescence techniques and soon thereafter were discovered by direct immunofluorescence of patients' skin.[133]

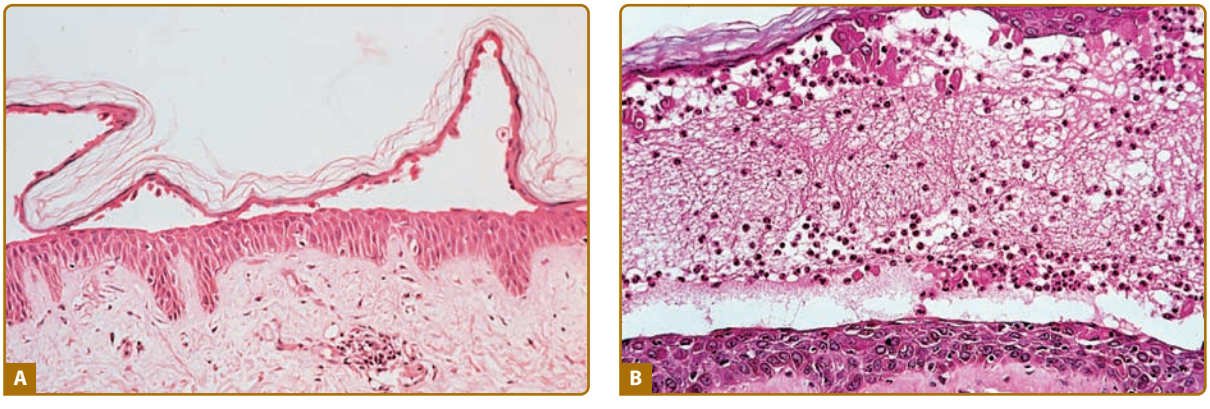

Figure 54-7 Histopathology of pemphigus foliaceus. **A.** Acantholysis in the granular layer. **B.** Subcorneal pustule with acantholysis.

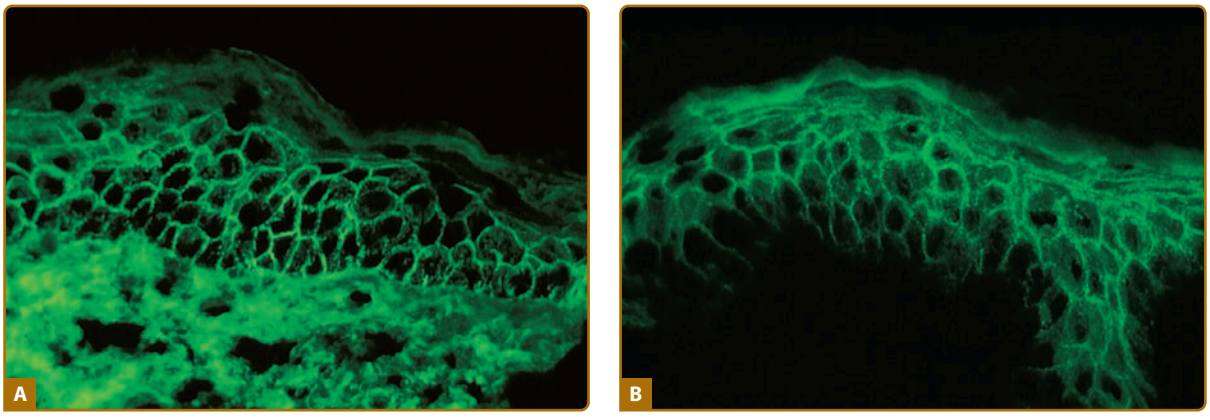

Figure 54-8 Immunofluorescence in pemphigus. **A.** Direct immunofluorescence for immunoglobulin G (IgG) of perilesional skin from a patient with pemphigus vulgaris. Note cell surface staining throughout the epidermis. **B.** Indirect immunofluorescence with the serum from a patient with pemphigus foliaceus on normal human skin. Note IgG on the cell surface throughout the epidermis.

DIRECT IMMUNOFLUORESCENCE. Essentially all patients with active PV or PF have a positive finding on a direct immunofluorescence study, which tests for IgG bound to the cell surface of keratinocytes in perilesional skin (Fig. 54-8A).[134] This is a nonquantitative test (either negative or positive). The diagnosis of pemphigus should be seriously questioned if the test result of direct immunofluorescence is negative. It is important that the biopsy for direct immunofluorescence be performed on normal-appearing perilesional skin, as the immune reactants can be difficult to detect in blistered inflamed epidermis (leading to a false negative result). In some cases of pemphigus erythematosus, IgG and C3 are deposited at the basement membrane zone of erythematous facial skin, in addition to the epidermal cell surface IgG, representing a positive lupus band test in addition to the typical pemphigus intercellular pattern.[135]

INDIRECT IMMUNOFLUORESCENCE. Indirect immunofluorescence is performed by incubating serial dilutions of patients' sera with epithelial substrates. It is reported as a semiquantitative titer (indicating the last dilution at which the serum demonstrates a positive cell surface staining pattern). The test is offered by most major national laboratories and can remain positive for weeks to months after healing of skin lesions, making it a good diagnostic test if a patient should present with no active skin lesions, for example, due to empiric treatment with prednisone by a referring physician. Depending on the substrate used for indirect immunofluorescence, more than 80% of patients with pemphigus have circulating antiepithelial cell surface IgG (Fig. 54-8B).[136] The substrate used to detect pemphigus antibody binding in indirect immunofluorescence greatly influences the sensitivity of the test. In general, monkey esophagus is more sensitive for detecting PV antibodies, and guinea pig esophagus or normal human skin is a superior substrate for detecting PF antibodies. Patients with early localized disease and those in remission are most likely to have negative findings on an indirect immunofluorescence test; for these patients the increased sensitivity of ELISA may help in diagnosis (see below).

Patients with PV and PF usually display similar direct and indirect immunofluorescence findings with IgG on the cell surface of epidermal cells throughout the epidermis, despite the different autoantigen profiles in these two diseases. Therefore, it is usually not possible to differentiate the two diseases by the pattern of immunofluorescence. There is a positive, but imperfect, correlation between the titer of circulating anticell surface antibody and the disease activity in PV and in PF.[137] Although this correlation may hold in general, and although patients in remission often show serologic remission with negative direct and indirect immunofluorescence findings,[138,139] disease activity in individual patients does not necessarily correlate with indirect immunofluorescence titer. Therefore, in the day-to-day management of these patients, following disease activity is more important than following antibody titer.

ENZYME-LINKED IMMUNOSORBENT ASSAY

For diagnosis of disease, antigen-specific ELISAs have been shown to be more sensitive and specific than immunofluorescence, and their titer correlates better than that of indirect immunofluorescence with disease activity.[35,140] Additionally, ELISAs are easier to perform and less subjective than immunofluorescence, and may replace the latter as the preferred first diagnostic test for pemphigus, although currently some major national laboratories do not offer desmoglein ELISA. These assays use desmogleins 1 and 3 bound to plates, which are then incubated with patient sera and developed with antihuman IgG reagents (Fig. 54-9). As an advantage over indirect immunofluorescence, ELISAs can help differentiate between PV and PF due to the different autoantigen profiles in these two diseases.[35,140,141,142] In most cases, ELISA is positive for desmoglein 3 (but not desmoglein 1) in mucosal PV, is

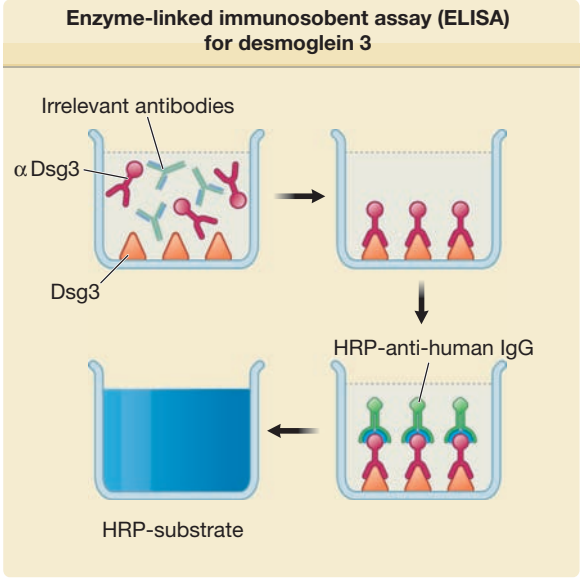

Figure 54-9 Enzyme-linked immunosorbent assay (ELISA) for desmoglein 3. Anti-Dsg3 antibodies (αDsg3) from pemphigus serum binds Dsg3 on the ELISA plate; irrelevant antibodies, that do not bind, are washed off. The plate is then incubated with horseradish peroxidase (HRP) conjugated antihuman IgG, which binds the anti-Dsg3 IgG that is on the plate. HRP is an enzyme that turns a clear substrate blue and the amount of color, read on spectrophotometer, correlates with the amount of pemphigus (i.e., anti-Dsg3) antibody in the patient's serum.

positive for both desmogleins 3 and 1 in PV with both mucosal and significant skin involvement, and is positive for only desmoglein 1 in PF. PV has rarely evolved into PF, and vice versa, as determined by clinical, histologic, and immunochemical criteria.[143–145] A small minority of PF patients may also demonstrate autoantibodies to desmoglein 3[146]; therefore, diagnosis should be made based on the clinical–serologic correlation. Additionally, some patients (e.g., those with bullous pemphigoid) may demonstrate a low level of antidesmoglein 3 autoantibodies,[140] which are detectable due to the high sensitivity of the ELISA. Therefore, a result in the indeterminate range should be interpreted carefully, as this may represent a true positive or a false negative, the latter presumably due to formation of nonpathogenic bystander autoantibodies after epidermal damage. As with indirect immunofluorescence, the correlation of ELISA index value with disease activity is not perfect. In making treatment decisions, a negative result on desmoglein ELISA is more helpful than a positive result, as a patient with the former is more likely to achieve remission off immunosuppressives, whereas a patient with the latter may or may not. In other words, disease activity is the mainstay for determining treatment.

PROGNOSIS AND CLINICAL COURSE

Before the advent of glucocorticoid therapy, PV was almost invariably fatal due to severe blistering of the skin and mucous membranes leading to malnutrition, dehydration, and sepsis. PF was fatal in approximately 60% of patients. PF was almost always fatal in elderly patients with concurrent medical problems; however, in other patients its prognosis, without therapy, was much better than PV.[147,148]

The systemic administration of glucocorticoids and the use of immunosuppressive therapy have dramatically improved the prognosis for patients with pemphigus; however, pemphigus is still a disease associated with a significant morbidity and mortality.[149,150] In the United States, the annual mortality rate from pemphigus (age-adjusted to the standard population) is estimated to be 0.023 deaths per 100,000.[151] A study in the United Kingdom showed that the risk of death in PV patients is 3.3 times greater than for controls.[9] Infection is often the cause of death, and by causing the immunosuppression necessary in the treatment of active disease, therapy is frequently a contributing factor.[152] With glucocorticoid and immunosuppressive therapy, the mortality (from disease or therapy) of PV patients followed from 4 to 10 years is approximately 10% or less, whereas that of PF is probably even less. In a study of 40 patients with PV, two patients (5%) died of sepsis and 17%, after an average of 18 months of therapy, went into a complete and long-lasting (>4 years, average, thought to be permanent) remission requiring no further therapy.[153] Another 37% of patients achieved remission but relapsed at times after therapy was stopped; most of these also eventually achieved long-lasting remissions. The remainder of patients required continual therapy. In a group of 159 patients with PV from Croatia, only approximately 12% went into long-term remission after therapy with glucocorticoids and immunosuppressives, but most relapsed.[20] In a study from Tehran of 1,206 pemphigus patients seen over 20 years, 6.2% of PV and 0.2% of PF patients died, mostly of septicemia; only 9.3% were in complete remission without therapy.[7] In some small studies, higher percentages of patients were reported to go into complete remission (see below). With the advent of rituximab therapy, complete remission in pemphigus may become more common.

TREATMENT

Despite the potentially fatal prognosis, there are currently no FDA-approved treatments. Approach to therapy of pemphigus varies widely, even among experts.[154] It is generally agreed that PV, even if initially limited in extent, should be treated at its onset, because it will ultimately generalize and the prognosis without therapy is very poor. In addition, it is probably easier to control early disease than widespread disease, and mortality may be higher if therapy is delayed.[155] Because PF may be localized for many years, and the prognosis without systemic therapy may be good, patients with this type of pemphigus do not necessarily require treatment with systemic therapy; the use of

topical corticosteroids may suffice. When the disease is active and widespread, however, the therapy for PF is, in general, similar to that for PV.

Recently, a consensus statement on disease definitions and endpoints was proposed by an international committee of pemphigus experts.[156] Additionally, clinical instruments have been developed for tracking disease activity.[157,158] The standardization of disease definitions and activity scoring will facilitate future clinical trials for pemphigus.

CORTICOSTEROIDS

The systemic administration of glucocorticoids, usually prednisone, is the mainstay of therapy for pemphigus. Before adjuvant immunosuppressive therapy was available, very high initial doses of prednisone (>2.0 mg/kg/day) were used for treatment, although such regimens have retrospectively been associated with significant morbidity and mortality from therapy.[152,159,160] In many patients the disease can be brought under control with a 0.5–1.0 mg/kg/day single daily dose, especially if used in combination with adjunctive immunosuppressive therapy, which is thought to result in fewer complications and decreased mortality as compared to higher dose glucocorticoid regimens.[161,162] For patients who do not initially respond or worsen, splitting the dose using a twice or three times daily schedule may achieve disease control. The full systemic dose of glucocorticoids has been defined in the consensus guidelines as 1.5 mg/kg/day of prednisone equivalent for 3 weeks. Therefore, patients whose total daily prednisone dose exceeds approximately 100 mg should be considered for adjunctive treatments, discussed below. Some experts still recommend controlling initial refractive disease with escalating doses of prednisone (increasing by 50% every 1 to 2 weeks until disease control or prohibitive side effects occur), with total daily doses as high as 240 mg.[148,163]

Once disease activity is controlled, tapering prednisone to as low a dose as possible should be the goal. Minimal therapy is defined as 10 mg daily of prednisone equivalent. Although there are no set guidelines, if disease activity can be fully controlled on minimal dose prednisone or lower, then glucocorticoid monotherapy may be feasible depending on the patient's other comorbidities and contraindications to alternative immunosuppressive agents. If patients have continued relapses with daily prednisone doses of 10 mg or higher, adjunctive immunosuppressive agents should be considered.

Interestingly, prednisone can control blistering within days, at a time when the autoantibody titer would be unchanged. A possible explanation is that prednisone may increase the synthesis of desmogleins or other cell adhesion molecules or change their posttranscriptional processing to prolong their half-life.[164] If pemphigus IgG depletes desmosomes of desmogleins, then prednisone could counteract this effect.

Topical corticosteroids may be used as monotherapy in mild forms of disease, or as adjunctive therapy to help heal new lesions. Patients with mucosal disease may benefit from the use of glucocorticoid elixirs as a swish and spit or dental trays to help apply class I corticosteroid gels or ointments to the gingiva. Additionally, class I–IV corticosteroids can be used as topical therapy to help resolve new blisters, even in patients on systemic glucocorticoids.

IMMUNOSUPPRESSIVE AGENTS

When greater than minimal doses of glucocorticoids are required for disease control, or if there are contraindications to oral glucocorticoids, other immunosuppressive agents are used for pemphigus therapy. In many cases, treatment regimens often begin with an immunosuppressive agent and prednisone simultaneously. Prospective randomized studies have shown that immunosuppressive agents such as mycophenolate mofetil, azathioprine, and cyclophosphamide have a steroid-sparing effect; retrospective studies suggest decreased mortality with use of adjuvants plus steroids compared to steroids alone.[147,165,166]

Because patients may die from complications of therapy, it is important to monitor all patients closely for potential side effects, such as blood count, liver and kidney laboratory abnormalities, gastrointestinal ulcer disease, high blood pressure, diabetes, glaucoma, cataracts, osteoporosis, and infection. The decision to use immunosuppressive agents, particularly in young patients, must also take into account the potential incidence of malignancies that might be associated with the long-term use of these drugs, as well as the risks of infertility (for cyclophosphamide) and teratogenicity (for mycophenolate mofetil, azathioprine, and cyclophosphamide, which are all pregnancy category D).

AZATHIOPRINE. Azathioprine has historically been considered as a first-line immunosuppressive agent for pemphigus, with clinical remission rates of approximately 50% in retrospective studies.[139,167] In a prospective randomized trial of high dose methylprednisolone (2.0 mg/kg/day) plus azathioprine (2.0 mg/kg/day), 72% of patients achieved clinical remission within a mean of 74 days, although 33% experienced significant adverse effects of therapy, including hyperglycemia, dizziness, abnormal liver enzyme tests, and infection.[165]

Azathioprine is a prodrug, which is converted to active mercaptopurine, thioguanine, and thioinosine metabolites, in part by thiopurine methyltransferase (TPMT), an enzyme whose levels can vary widely in the population. 89% of Caucasians demonstrate normal to high levels of TPMT, 11% are intermediate, and 0.3% are deficient for TPMT, the latter group representing those who do not tolerate azathioprine therapy.[168] Additionally, 1%–2% of Caucasians may have "super high" levels of TPMT, which is correlated with both treatment resistance as well as increased hepatotoxicity from excessive metabolite production.[169] Altogether, it is estimated that 5% of patients will be azathioprine intolerant, although the genotype–phenotype correlation is imperfect.[170]

In patients with normal TPMT levels, the consensus dosing regimen that defines treatment failure is 2.5 mg/kg/day for 12 weeks.[156] From a practical standpoint however, not all laboratories offer TPMT testing. Additionally, since patients with normal levels of TPMT may also experience azathioprine toxicity, it is reasonable to start all patients at a lower dose (e.g., 50–100 mg daily) and titrate upward until clinical remission, the target dose of 2.5 mg/kg/day, or unacceptable side effects result. Frequent blood and liver monitoring should continue, particularly over the first 8–12 weeks when delayed toxicity from the accumulation of metabolites may emerge.

MYCOPHENOLATE MOFETIL. Mycophenolate mofetil is also considered to be a first-line immunosuppressive agent for pemphigus. In 2006, the FDA granted orphan drug status to mycophenolate mofetil for the treatment of PV, thereby increasing the feasibility of a new drug approval. Typical doses range from 30–40 mg/kg/day dosed twice daily (2.0–3.0 g/day), although certain patients such as the elderly may achieve disease control with doses as low as 1.0 g/day.

In case series, mycophenolate mofetil has been shown to have a rapid effect in lowering pemphigus antibody titers and decreasing disease activity, even in patients whose disease is unresponsive to azathioprine.[171,172] A prospective randomized trial comparing methyprednisolone (2.0 mg/kg/day) with azathioprine (2.0 mg/kg/day) or mycophenolate mofetil (2.0 g/day) in pemphigus patients showed 72% in the azathioprine group and 95% in the mycophenolate mofetil group went in clinical remission in a mean of 74 and 91 days, respectively.[165] 19% of patients experienced significant side effects of mycophenolate mofetil therapy, compared to 33% in the azathioprine group. None of these differences was statistically significant. Another prospective randomized study indicated that azathioprine was significantly more effective than mycophenolate mofetil as a steroid sparing agent, although this study compared a full dose of azathioprine (2.5 mg/kg/day) to a partial dose of mycophenolate mofetil (2.0 g/day).[166] Caution with use of mycophenolate mofetil is warranted, as fatal infection and sepsis occurred in 2%–5% of transplant patients receiving mycophenolate mofetil, and increased risk of infection with or reactivation of cytomegalovirus, herpes zoster, atypical mycobacteria, tuberculosis, and John Cunningham (JC) virus (in progressive multifocal leukoencephalopathy) have been noted in postmarketing surveillance.[173] Interestingly, mycophenolate mofetil may offer protection against *Pneumocystis carinii* infection.[174]

CYCLOPHOSPHAMIDE. Cyclophosphamide, although more toxic than azathioprine or mycophenolate mofetil, is thought to be very effective in controlling severe disease, with one report of 19 of 23 patients with pemphigus achieving complete remission in a median time of 8.5 months.[175] A variety of small case series have evaluated different cyclophosphamide regimens for pemphigus, including daily oral therapy (1.1–2.5 mg/kg/day), daily oral therapy (50 mg) with intermittent high-dose intravenous dexamethasone and cyclophosphamide, and immunoablative intravenous cyclophosphamide.[167,175–179] All methods were effective in the short-term, although none were curative. Significant side effects, including hematuria, infection, and transitional cell carcinoma of the bladder, were observed with higher dose regimens, although one study using a lower daily dose of cyclophosphamide (1.1–1.5 mg/kg/day) did not report a significantly different safety profile compared with other immunosuppressive agents. Together with the risk of infertility, cyclophosphamide is not generally considered a first-line agent in the treatment of PV.

DAPSONE. In a case series and randomized double-blind trial, dapsone demonstrated a trend toward efficacy as a steroid-sparing drug in maintenance phase PV, although these results were not statistically significant.[180,181] Dapsone may be used in conjunction with other immunosuppressive agents, particularly rituximab (discussed below), where it offers the additional benefit of *Pneumocystis* pneumonia prophylaxis.

ADDITIONAL THERAPIES

There are additional therapies that can be used when the more standard treatments, discussed previously, are not effective.

RITUXIMAB. A very effective therapy for pemphigus that is refractory to more standard therapy is a monoclonal anti-CD20 antibody rituximab, approved for therapy of B-cell malignancies. In pemphigus patients, this monoclonal antibody presumably targets B cells, the precursors of antibody-producing plasma cells. The B cell also acts to process autoantigen and present it to T cells that provide "help" in stimulating the autoantibody response.[182] Rituximab is infused intravenously at a dose of 375 mg/m^2 once weekly for 4 weeks. Alternatively, the rheumatoid arthritis dosing regimen can be used (1,000 mg intravenously on day 1 and day 15). The course can be repeated in approximately 6 months for patients with more refractory disease, although a single cycle of rituximab has been shown to be highly effective, with 86% of patients experiencing complete remission lasting 34 months or greater.[183] Disease activity usually begins to remit within 1–2 months after the course of therapy. Some experts consider rituximab the therapy of choice for severe pemphigus uncontrolled by corticosteroids and azathioprine or mycophenolate mofetil or who have contraindications to corticosteroids.[183,184] However, fatal infections with rituximab therapy have been observed, including *Pneumocystis* pneumonia, reactivation of hepatitis B, and JC virus infection or reactivation causing progressive multifocal leukoencephalopathy.[185–188] Although these complications are rare, some experts recommend *Pneumocystis* prophylaxis for 1 year following rituximab infusion.

INTRAVENOUS IMMUNOGLOBULIN. Another method of decreasing serum autoantibodies is the intravenous use of γ-globulin (IVIg) in high doses. IVIg is thought to function by saturating circulating neonatal Fc receptor, thereby increasing catabolism of the patient's serum antibodies, which include the pathogenic autoantibodies.[189–191] It may be useful as adjuvant therapy in those pemphigus patients whose condition does not respond to more conventional therapy.[192,193] A multicenter, randomized, placebo-controlled, double blind study has confirmed its efficacy in pemphigus,[194] but it is expensive and probably requires continued infusions for maintenance of remission. There can also be significant side effects with this therapy, including stroke, deep venous thrombosis, and renal failure with sucrose-containing formulations.[195] Some centers will use IVIg to establish initial control of blistering in severely affected patients because it does not increase risk of infection as much as corticosteroids and immunosuppressants. IVIg has also been used in combination with rituximab,[196] although it is unclear whether the combination is safer or more effective compared to either alone.

PLASMAPHERESIS. Plasmapheresis is sometimes used for severe pemphigus, or for pemphigus that is unresponsive to a combination of prednisone and immunosuppressive agents. Although one controlled study found it to be ineffective,[197] other studies have found that it both reduces serum levels of pemphigus autoantibodies and controls disease activity.[198] Plasmapheresis plus intravenous pulse therapy with cyclophosphamide has been reported to result in remissions of PV.[199] For maximum effectiveness, it is probably necessary to perform plasmapheresis on patients taking immunosuppressive agents to prevent the antibody-rebound phenomenon that can follow the removal of IgG. Protein A immunoadsorption, which removes IgG selectively from plasma, has also been used.[200]

PULSED INTRAVENOUS HIGH-DOSE GLUCOCORTICOIDS. Intravenous, pulse administration of methylprednisolone, 250–1,000 mg given over approximately 3 hours daily for 4–5 consecutive days, can result in long-term remissions and decrease the total dose of glucocorticoids necessary to control disease.[201] Although the purpose of this therapy is to decrease the incidence of complications of long-term steroid use, it can result in all the usual glucocorticoid complications, as well as cardiac arrhythmias with sudden death, and its use is controversial.[202] Furthermore, a controlled trial found that adjuvant oral dexamethasone pulse therapy in addition to standard therapy with prednisolone and azathioprine for PV is not beneficial.[203] It may be that simply giving divided lower doses of prednisone could accomplish the same result with fewer side effects.

All in all, there has been a tremendous advance in the armamentarium of therapies for pemphigus since the time before the development of glucocorticoids when PV was a fatal disease. Thanks to these advances, the "row of tombstones" seen in the pathology of PV no longer alludes to its prognosis.

KEY REFERENCES

Full reference list available at www.DIGM8.com

DVD contains references and additional content

1. Lever WF: *Pemphigus and Pemphigoid*. Springfield, IL, Charles C. Thomas, 1965
12. Aoki V et al: Environmental risk factors in endemic pemphigus foliaceus (fogo selvagem). *J Investig Dermatol Symp Proc* **9**:34, 2004
27. Koulu L et al: Human autoantibodies against a desmosomal core protein in pemphigus foliaceus. *J Exp Med* **160**:1509, 1984
28. Stanley JR et al: A monoclonal antibody to the desmosomal glycoprotein desmoglein I binds the same polypeptide as human autoantibodies in pemphigus foliaceus. *J Immunol* **136**:1227, 1986
41. Anhalt GJ et al: Induction of pemphigus in neonatal mice by passive transfer of IgG from patients with the disease. *N Engl J Med* **306**:1189, 1982
76. Mahoney MG et al: Explanation for the clinical and microscopic localization of lesions in pemphigus foliaceus and vulgaris. *J Clin Invest* **103**:461, 1999
140. Amagai M et al: Usefulness of enzyme-linked immunosorbent assay using recombinant desmogleins 1 and 3 for serodiagnosis of pemphigus. *Br J Dermatol* **140**:351, 1999
165. Beissert S et al: A comparison of oral methylprednisolone plus azathioprine or mycophenolate mofetil for the treatment of pemphigus. *Arch Dermatol* **142**:1447, 2006
183. Joly P et al: A single cycle of rituximab for the treatment of severe pemphigus. *New Engl J Med* **357**:545, 2007
194. Amagai M et al: A randomized double-blind trial of intravenous immunoglobulin for pemphigus. *J Am Acad Dermatol* **60**:595, 2009

Chapter 55 :: Paraneoplastic Pemphigus

:: Grant J. Anhalt & Daniel Mimouni

PARANEOPLASTIC PEMPHIGUS AT A GLANCE

- Rare complication of malignancy, most commonly non-Hodgkin's lymphoma, chronic lymphocytic leukemia, or Castleman disease.
- Painful, erosive stomatitis and polymorphous cutaneous lesions that may be blistering and erosive (resembling erythema multiforme), morbilliform, or lichenoid.
- Serum autoantibodies directed against plakin proteins that are detected by indirect immunofluorescence against rodent bladder epithelium.
- High mortality rate, with death due to sepsis, complications of treatment, or bronchiolitis obliterans.
- No consistently effective therapy, but some success with the combined use of rituximab, systemic corticosteroids, and other immunosuppressive agents.

Paraneoplastic pemphigus (PNP) is an autoimmune disorder that is almost always linked to an underlying lymphoproliferative disorder. The following features define PNP:

1. Painful stomatitis and a polymorphous cutaneous eruption with lesions that may be blistering, lichenoid, or resemble erythema multiforme.
2. Histologic findings that reflect the variability of the cutaneous lesions, showing acantholysis, lichenoid, or interface change.
3. Direct immunofluorescence findings of immunoglobulin G (IgG) and complement deposition in the epidermal intercellular spaces and, often, granular/linear complement deposition along the epidermal basement membrane zone.
4. Serum autoantibodies that bind to the cell surface of skin and mucosae in a pattern typical of pemphigus, but in addition, bind to simple, columnar, and transitional epithelia.
5. The serum autoantibodies identify desmogleins 1 and 3, in addition to members of the plakin family of epithelial proteins, such as desmoplakins, envoplakin, and periplakin.[1]

Non-Hodgkin's lymphoma (NHL), chronic lymphocytic leukemia (CLL), and Castleman disease are the neoplasms most commonly associated with PNP. There is no regularly effective treatment. Most patients die from complications of the disease, including pulmonary involvement with respiratory failure.

EPIDEMIOLOGY

The incidence of PNP is unknown, although it is less common than pemphigus vulgaris or foliaceus (see Chapter 54). In an adverse events reporting analysis including 100,000 patients with known NHL and CLL, 12 were found to have PNP. Only three of them were identified by the reporting physician, and the remainder were identified only by retrospective data analysis, suggesting that the majority of cases of PNP are not being properly diagnosed. In this series, the most common misdiagnoses were erythema multiforme, Stevens–Johnson syndrome, toxic epidermal necrolysis (TEN), and drug reaction.

ETIOLOGY AND PATHOGENESIS

In almost all cases, PNP is associated with a limited number of lymphoproliferative neoplasms. On the basis of 140 cases of PNP confirmed by immunoprecipitation findings of the characteristic autoantibody profile, the estimated frequencies of specific neoplasms are 44% NHL, 19% CLL, 16% Castleman disease (giant follicular hyperplasia), 8% thymoma (malignant and benign), 7% sarcomas that are retroperitoneal and often poorly differentiated, 4% Waldenström's macroglobulinemia, and in 2% the neoplasms were too poorly differentiated to categorize (Fig. 55-1). The



Figure 55-1 Tumors associated with paraneoplastic pemphigus.

disproportionate representation of Castleman disease is notable, given its overall rarity. In children with PNP, Castleman disease is almost always the underlying neoplasm.[2] Before the description of PNP, many cases of Castleman disease associated with atypical forms of pemphigus had been reported, and we suspect that most were PNP. A study of archived clinical material in one such case confirmed the presence of autoantibodies specific for PNP.

With very rare exceptions, more common cancers, such as adenocarcinomas of breast, bowel, and lung, or basal cell and squamous cell carcinoma of skin, have not been associated with PNP. There are a few reports of PNP and squamous cell carcinoma, but in most of them, the diagnosis was made with immunofluorescent techniques only, which have a significant false positive and false negative rate, and were not confirmed immunochemically, so the association remains unproven.

The mechanisms by which these tumors induce autoimmunity against epithelial proteins remain speculative. One hypothesis states that the tumors constitutively or anomalously express epithelial proteins. These proteins are targeted by the antitumor immune response that cross-reacts with normal constitutive epithelial proteins of the host. This mechanism occurs in several neurologic paraneoplastic syndromes.[3] This antitumor immune response may be initiated by reactivity against plakin proteins, and the antitumor immune response may cross-react with normal constitutive proteins of epithelia. However, to date, there are no data to support this hypothesis.

It is more likely that this autoimmune disease is a result of more complex interactions between the tumor cells, the immune system, and specific genetic background. In many autoimmune diseases, specific genetic predispositions have been found, and HLA studies performed on two different series of PNP patients revealed a significant predominance of HLA-class II DRB*03 and HLA-class I Cw*14 genes. It is interesting to note that these two HLA molecules are not those associated with development of pemphigus vulgaris, providing another argument to consider PNP as a distinct entity.[4,5]

There is evidence that dysregulated cytokine production by tumor cells drives the development of autoimmunity. Patients with PNP have evidence of markedly elevated levels of interleukin 6 (IL-6).[6] It has been observed that in a subset of cases of NHLs,[7] CLL, and Castleman tumors, the tumor cells secrete massive amounts of IL-6 in vitro. IL-6 is known to promote B-cell differentiation and to drive immunoglobulin production, and dysregulated IL-6 production has been implicated in certain autoimmune diseases. Castleman tumors are known to be associated with other autoimmune phenomena such as myasthenia gravis and autoimmune cytopenias, and these patients also have high serum levels of IL-6. Symptoms attributable to Castleman tumors are routinely reversed by complete excision of the affected node(s), and, coincidentally, serum IL-6 levels revert to normal. Administration of anti-IL-6 receptor monoclonal antibodies also effectively reverses systemic manifestations of Castleman disease and is currently being studied in clinical trials.[8]

It had also been proposed that the autoantibody may derive from the lymphoid tumor itself. Cultures of Castleman tumors have been shown to contain B cells that produce specific autoantibody.[9] However, Castleman tumors are unique in that they are not clonal neoplasms, and these studies showed the expansion of several immunologically active B-cell clones within the tumors. In Waldenström's macroglobulinemia, the autoantibody is polyclonal and IgG class, not IgM, and therefore, cannot be produced by the tumor cells.

Almost all patients with PNP have autoantibodies against desmogleins, demonstrable by enzyme-linked immunosorbent assay (ELISA), and when the desmoglein autoantibodies from these patients are affinity purified and injected into neonatal mice, acantholytic skin lesions are induced.[10] However, none of features of the disease that appear to be induced by cell-mediated autoimmunity are recreated by the immunoglobulin injections. No internal organs, like the lungs, are involved, and there are no findings of lymphocyte-mediated lichenoid or interface epithelial injury. This is another indication that humoral immunity alone reproduces features of acantholysis, but passive transfer of autoimmune cells from these patients may be necessary to induce the complete spectrum of the disease in animals.

CLINICAL FINDINGS

HISTORY

CUTANEOUS LESIONS. The most constant clinical feature of the disease is the presence of intractable stomatitis (Figs. 55-2A and 55-2B). It is the earliest presenting sign and the one feature that persists throughout the course of the disease, even after treatment and is extremely resistant to therapy. This finding is so consistent that in its absence, PNP should not be considered in the differential diagnosis.

This stomatitis consists of erosions and ulcerations that can affect all surfaces of the oropharynx. The lesions differ from those seen in pemphigus vulgaris in that they show more necrosis and lichenoid change. They also preferentially localize to the lateral borders of the tongue, and characteristically extend onto and involve the vermilion of the lips. Occasionally, oral lesions are the only manifestation of the disease.

The cutaneous lesions of PNP are quite variable, and different morphologies may occur in an individual patient according to the stage of the disease (see Fig. 55-2C and 55-2D). The initial patients reported with the syndrome had episodes of waves of blistering affecting the upper trunk, head and neck, and proximal extremities. These lesions consisted of blisters that ruptured easily, leaving erosions. The blisters on the extremities were sometimes quite tense, resembling those seen in bullous pemphigoid, or they had surrounding erythema, clinically resembling erythema multiforme (see Fig. 55-2D). On the upper chest and



Figure 55-2 **A.** Extensive erosions involving the vermillion of the lips in a patient presenting with paraneoplastic pemphigus and an occult lymphoma. The characteristic severe stomatitis, accompanied by polymorphous cutaneous lesions, is the most consistent feature of the disease. **B.** Painful ulcerations tend to localize to the lateral border of the tongue. **C.** Lesions of the trunk from the same patient pictured in **A.** Erythematous macules and papules coalesce and become erosive on the upper chest as the cutaneous lesions evolve. **D.** Lesions from the forearm of the same patient. These lesions clinically resemble erythema multiforme, but biopsy shows a mix of individual cell necrosis, interface change, and acantholysis.

back, confluent erosive lesions can develop, producing a picture resembling TEN. The similarity of the mucocutaneous features to erythema multiforme and TEN explains why this is the most common differential diagnosis for PNP. However, it is important to note that erythema multiforme and TEN are self-limited events that evolve and resolve over several weeks, whereas PNP is a relentlessly progressive and evolves continuously over months.

Cutaneous lichenoid eruptions are very common, and they may be the only cutaneous signs of the disease, or may develop in lesions that had previously been blistered. When cutaneous lichenoid lesions are present, severe stomatitis is also invariably present. In the chronic form of the disease and after treatment, this lichenoid eruption may predominate over blistering on the cutaneous surface. The common presence of both blisters and lichenoid lesions affecting the palms and the soles as well as the paronychial tissues helps to distinguish PNP from pemphigus vulgaris, in which acral and paronychial lesions are uncommon.

There are a small number of patients who appear to have PNP but who do not have demonstrable circulating autoantibodies.[11] These patients tend to have predominantly lichenoid skin and mucosal lesions, but behave in every other way like antibody-positive patients. They have the same underlying neoplasms, and frequently develop bronchiolitis obliterans. Because the definition of the disease relies so heavily on demonstration of the specific autoantibody markers, further study is required to determine the exact classification of what is presently termed the *lichenoid variant of PNP*.

The disease has also been identified in a horse and two dogs. In animal species, the disease is associated with the same neoplasms and has the same clinical outcomes.[12]

RELATED CLINICAL FINDINGS

PNP is the only form of pemphigus that involves nonstratified squamous epithelium. Approximately 30%–40% of cases develop pulmonary injury, often with a fatal outcome.[13] The earliest symptoms are progressive dyspnea associated initially with an absence of findings on chest radiography. Pulmonary function studies show airflow obstruction in large and small airways. Inflammation of the large airways evolves and is evidenced by endoscopic biopsy showing acantholysis of bronchial respiratory epithelium. Pulmonary function deteriorates in most cases despite immunosuppressive therapy, and radiologic, histologic, and functional changes characteristic of bronchiolitis obliterans develop.

LABORATORY TESTS

The key finding is the serologic identification of polyclonal IgG autoantibodies against plakin proteins and, in most cases, desmogleins 1 and 3. The plakins are a group of sequence-related proteins that form the intracellular plaque of desmosomes and hemidesmosomes, and mediate attachment of cytoskeletal intermediate filaments to transmembrane adhesion molecules such as the desmogleins (see Chapter 53). Autoantibodies against these proteins are the most characteristic surrogate markers for the disease. The pattern of antigens recognized by individual patients shows considerable variability, but the most characteristic and consistently recognized plakin antigens are envoplakin[14] and periplakin[15] (210 and 190 kDa, respectively; Fig. 55-3). The next most frequently detected are antibodies against desmoplakin I and desmoplakin II (250 and 210 kDa, respectively). Less commonly, patients recognize bullous pemphigoid Ag 1 (230 kDa), plectin (400 kDa), and plakoglobin (82 kDa). The identity and frequency of an antigen band at 170 kDa are not well defined. PNP patients may also have clinical and serologic evidence of other autoimmune phenomena such as myasthenia gravis and autoimmune cytopenias (see Fig. 55-3).

To screen for PNP autoantibodies, one can test for IgG autoantibodies by indirect immunofluorescence reactive with rodent urinary bladder epithelium. A positive result implies the presence of plakin autoantibodies; however, the sensitivity and specificity of this serologic test are only approximately 75% and 83%, respectively.[16] Recently, ELISA kits using recombinant proteins containing subdomains of envoplakin and periplakin have been developed and have demonstrated high sensitivity and specificity for the diagnosis of PNP.[17,18] More specific and sensitive tests, which are more time consuming, technically demanding, and of limited availability, include immunoblotting against epidermal cell extracts that can effectively detect antibodies against envoplakin, periplakin and desmoplakin, and immunoprecipitation, using radiolabeled keratinocyte extracts, which can detect antibodies against any of the plakin proteins.

The PNP autoantibody profile is more complex than that observed in pemphigus vulgaris or foliaceus, where there are autoantibodies produced only against the desmogleins. The humoral immunity in PNP may represent an example of epitope spreading in which patients develop autoantibodies against structurally related plakin proteins and structurally unrelated transmembrane cell surface proteins (the desmogleins) that are physically linked to the plakin proteins in the desmosome and hemidesmosome.

HISTOPATHOLOGY

The histopathology of PNP is distinctive from pemphigus vulgaris and foliaceus for two reasons. First, because the lesions can be clinically very polymorphous, there is substantial variability in the histologic findings.[19] Second, findings due to cell-mediated cytotoxicity are frequently observed.

Owing to the severe mucositis, many biopsies of oral lesions yield nonspecific changes of inflammation and ulceration. If one can biopsy perilesional epithelium, a lichenoid mucositis with variable degrees of individual cell necrosis and suprabasilar acantholysis can be observed.

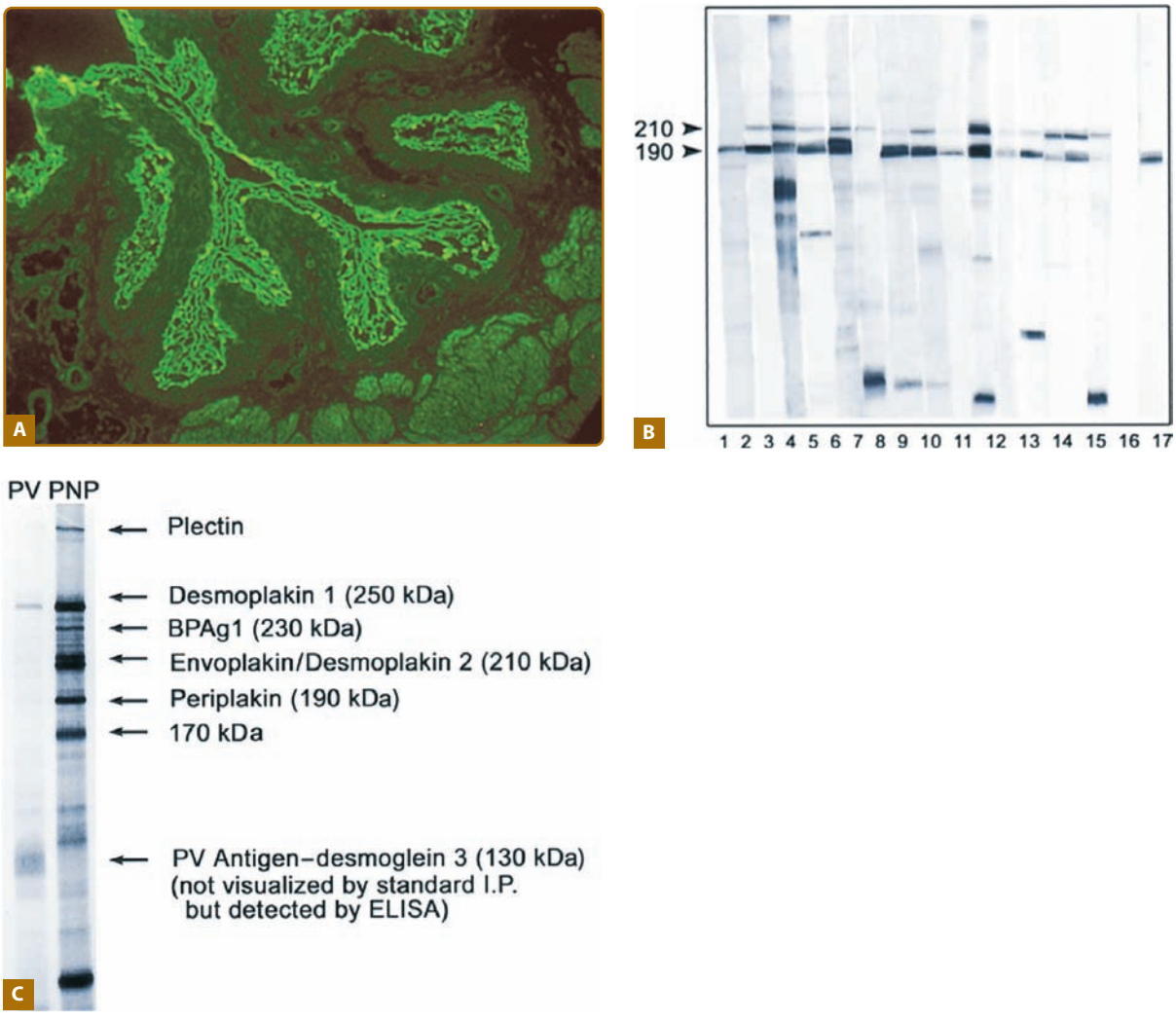

Figure 55-3 Diagnosis of paraneoplastic pemphigus (PNP) depends on the demonstration of antiplakin antibodies. **A.** This can be accomplished by indirect immunofluorescence of patient serum on rodent urinary bladder demonstrating binding of immunoglobulin G to the cell surface of transitional epithelial cells. A positive result implies the presence of antiplakin antibodies. This technique, although easily performed, has the lowest sensitivity and specificity. **B.** Immunoblotting against epidermal cell extracts is much more sensitive and specific. This shows detection of envoplakin (210 kDa) and/or periplakin (190 kDa) in 15 patients with PNP. Lane 16 is a normal control, and lane 17 shows a monoclonal antibody against periplakin. This technique uses denatured antigen extracts, so it does not reliably detect some of the PNP antigens, but antibodies against the most characteristic plakin antigens, envoplakin and periplakin, are easily detected. **C.** Immunoprecipitation using radiolabeled, nondenatured epidermal extracts and serum from a patient with PNP and pemphigus vulgaris (PV). In this case, the PNP patient's serum identifies all of the plakin antigens. Envoplakin and desmoplakin II migrate as a doublet at 210 kDa. This technique is the most sensitive and specific test for demonstration of antiplakin antibodies in PNP, but has limited availability. Although this technique readily detects the antiplakin antibodies, desmoglein 3 is not always efficiently identified, and this is best shown by using enzyme-linked immunosorbent assay (ELISA).

When evaluating biopsies from skin lesions, one must recognize that lesions with different clinical morphologies yield differing histologic findings. In noninflammatory cutaneous blisters, suprabasilar acantholysis is expected to be more prominent than the interface/lichenoid change (Fig. 55-4A). When erythematous macules and papules are sampled, interface and lichenoid dermatitis is predominant (see Figs. 55-4B and 55-4C). Lesions with a mixed clinical pattern also show mixed histologic features of concomitant suprabasilar acantholysis and interface/lichenoid dermatitis.

There is also observed variability of the interface and lichenoid dermatitis. The spectrum of changes can include: (1) individual keratinocyte necrosis with lymphocytic infiltration into the epidermis, reminiscent of that seen in erythema multiforme or graft-versus-host disease; (2) vacuolar interface change with sparse lymphocytic infiltrate of the basilar epithelium, resembling cutaneous lupus erythematosus or dermatomyositis; and (3) a thick lichenoid band along the dermal–epidermal junction similar to that seen in lichen planus. Although most of the specimens show a complex overlap of histologic patterns, there is a relatively good

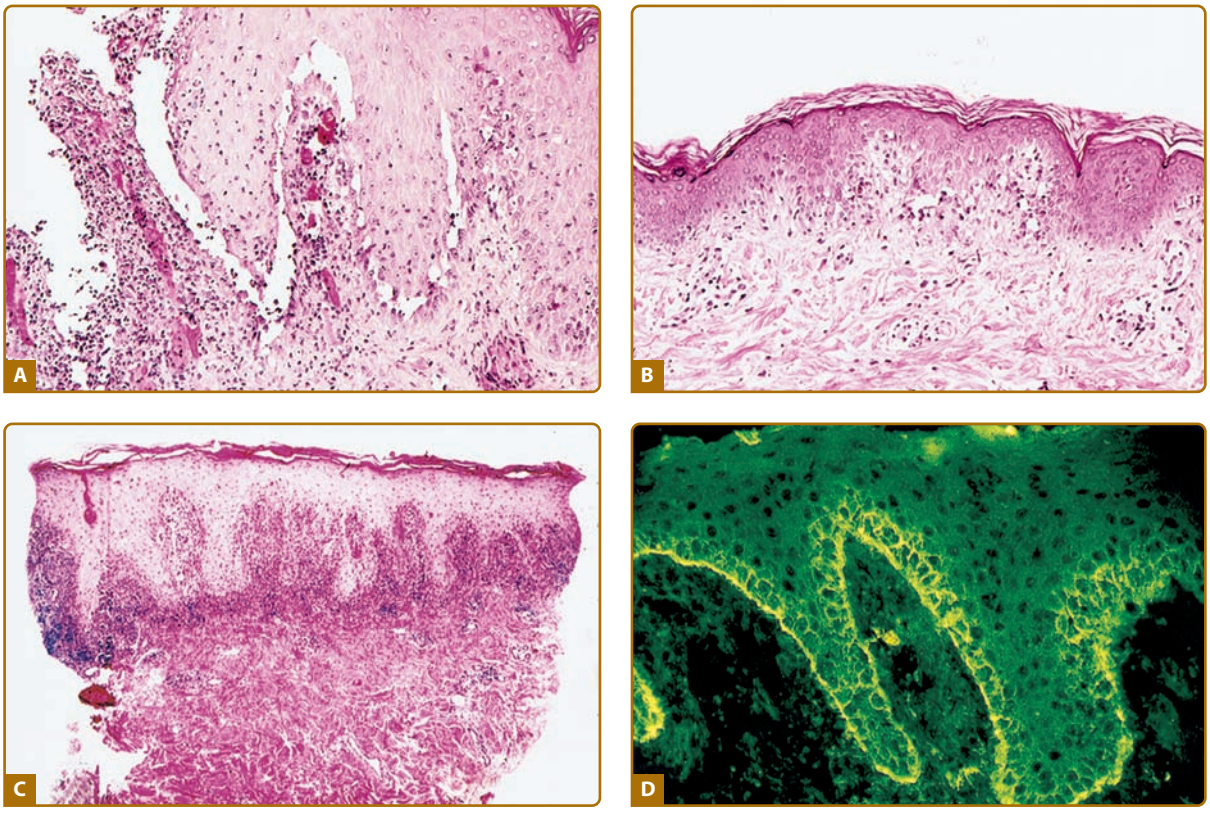

Figure 55-4 **A.** Histopathology of a blistering cutaneous lesion in paraneoplastic pemphigus. This demonstrates the characteristic presence of vacuolar interface change and suprabasilar acantholysis [Hematoxylin and eosin (H&E), 200×]. **B.** Macular and papular lesions may show just vacuolar interface change (H&E, 100×). **C.** Lichenoid lesions demonstrate lichenoid infiltrates on histologic examination (H&E, 40×). The presence of these varied histologic findings help differentiate paraneoplastic pemphigus from pemphigus vulgaris. **D.** Direct immunofluorescence can be negative in a significant number of cases, but when positive, the most characteristic changes are those of deposition of immunoglobulin G and complement components on both the surface of basilar and suprabasilar keratinocytes and along the epidermal basement membrane zone (Immunofluorescence with fluoresceinated anti-immunoglobulin G, 200×).

correlation between the clinical and the predominant histologic pattern.

The histopathologic variability of this disease may be related to the fact that it is a presumed antitumor immune response. If this speculation is correct, one would expect to observe a combination of both humoral and cell-mediated immunity that is aberrantly directed against normal epithelium. In such a setting, one would expect to see changes of the sort described in the previous paragraph. This degree of cell-mediated immunity is not seen in pemphigus vulgaris or foliaceus (see Chapter 54); hence the unique histopathologic features, and, presumably, the unique clinical features as well. The presence of T-cell-mediated epithelial cytotoxicity has been recently demonstrated in histologic studies.[20]

IMMUNOPATHOLOGY

Patients with PNP should have evidence of IgG autoantibodies bound to the cell surface of affected epithelium by direct immunofluorescence. However, false negatives are more common in PNP than in pemphigus vulgaris, and repeated biopsies may be necessary, as well as careful investigation of the adnexal structures which may be the only positive site.[21] In a minority of cases, one might also see a combination of both cell surface and basement membrane zone deposition of IgG and complement components, but the absence of this combined cell surface/basement membrane zone staining does not negate the diagnosis (see Fig. 55-4D).

SPECIAL TESTS

Approximately one-third of patients have an occult malignancy at the time they develop PNP. Neoplasms that would not be detected by routine complete blood count, serum chemistries, and physical examination are most likely to be intra-abdominal lymphoma, intrathoracic or retroperitoneal Castleman tumors, or retroperitoneal sarcomas. The most effective and efficient method for screening for these tumors is either computer-aided tomography or magnetic resonance imaging of the body from the neck to the base of the bladder. If available, Positron emission tomography/ computer tomography (PET/CT) using fluorodeoxyglucose (FDG) as a biologically active molecule can be more specific in the

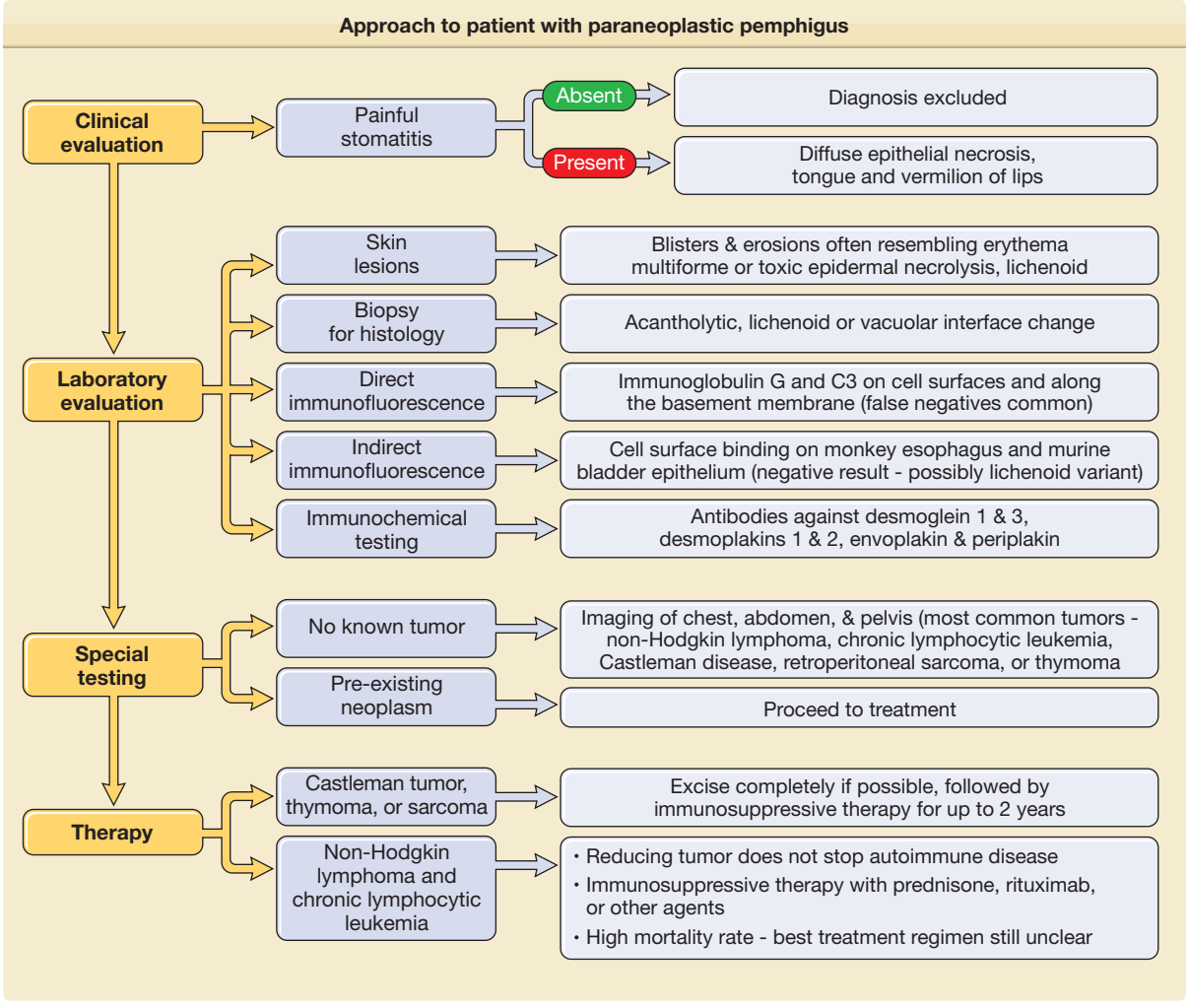

Figure 55-5 Approach to a patient with paraneoplastic pemphigus.

identification of an occult lymphoma. Other studies, such as endoscopy, are not required.

DIAGNOSIS AND DIFFERENTIAL DIAGNOSIS

The diagnosis can best be made if the algorithm shown in Fig. 55-5 is followed. The clinical differential diagnosis is summarized in Box 55-1.

PROGNOSIS AND CLINICAL COURSE

It is not known why PNP is so refractory to the type of immunosuppressive treatments that are usually effective in pemphigus vulgaris and other autoimmune diseases.

In those patients who do succumb, death has been attributed in individual cases to multiple factors,

BOX 55-1 DIFFERENTIAL DIAGNOSIS OF PARANEOPLASTIC PEMPHIGUS

- Oral lesions
  - Pemphigus vulgaris
  - Stevens–Johnson syndrome
  - Mucous membrane pemphigoid
  - Oral lichen planus
  - Chemotherapy-induced stomatitis
  - Major aphthous stomatitis
- Cutaneous lesions
  - Erythema multiforme/Stevens–Johnson syndrome/toxic epidermal necrolysis
  - Pemphigus vulgaris
  - Drug eruption
  - Lichen planus
  - Subepidermal blistering disorders

including sepsis, gastrointestinal bleeding, "multiorgan failure," and respiratory failure. Patients with autoimmune disease associated with B-cell neoplasms are known to have a high frequency of autoimmune cytopenias, and some fatal episodes of sepsis are suspected to have occurred because of sudden and unexplained neutropenia, possibly due to this mechanism. Respiratory failure is a common terminal event. The development of shortness of breath with obstructive disease progressing to bronchiolitis obliterans is a terminal complication in most cases. Because these patients have autoantibodies that react with desmoplakins, and because desmoplakins are present in respiratory epithelium, respiratory failure may be due to autoantibody-mediated injury to bronchial epithelium, with plugging of terminal bronchioles, resulting in airflow obstruction and ventilation/perfusion abnormalities. Additionally, direct damage to alveolar epithelium could cause a diffusion barrier and subsequent intractable hypoxia. One autopsy study showed an absence of autoantibodies and a marked infiltration of bronchioles with cytotoxic T cells in a patient who died from PNP and bronchiolitis obliterans. This shows that there may be similar complex humoral and cell-mediated autoimmune injury to the lung, similar to what is seen in the skin. The pulmonary injury does not respond well to medical treatment, and the development of shortness of breath and hypoxia in a patient with this syndrome is an ominous prognostic sign.

In patients with malignant neoplasms there is no definite correlation between tumor burden and the activity of the autoimmune syndrome. Treatment of the primary malignancy does not affect the activity of the autoimmune disease. It seems that once the process is initiated by the malignancy, the autoimmunity progresses independently. An example of the disconnect between tumor burden and autoimmunity is found in the case reported by Fullerton et al,[22] in which PNP occurred after successful autologous bone marrow transplantation for NHL. This patient was free of detectable tumor burden at the time of his death, but died from pulmonary injury secondary to PNP. It is notable that the patient underwent autologous bone marrow transplantation, and therefore received his own memory T cells, or possibly individual malignant lymphoid cells that were not detectable by routine autopsy methods.

TREATMENT

(See Box 55-2)

Individuals with benign or encapsulated tumors such as Castleman tumors or thymoma should have them surgically excised. If the entire lesion is removed, the disease generally improves substantially or goes into complete remission. The remission of the autoimmune disease may take 1–2 years after surgery, so continued immunosuppression during this period is required. The usual treatment involves combined use of prednisone and rituximab.[23] In pediatric cases with respiratory disease, the persistent autoimmunity immediately after surgery can cause ongoing pulmonary injury, and lung transplantation might be required for long-term survival.[24]

In patients with malignant neoplasms, there is no consensus regarding a therapeutic regimen that is consistently effective. Despite scattered individual reports of long-term survivors, almost all patients with NHL or CLL succumb in a period of 1 month to 2 years after diagnosis. Oral corticosteroids in a dose of 0.5–1.0 mg/kg produce partial improvement, but not complete resolution of lesions. Cutaneous lesions respond quickly to therapy, but the stomatitis is generally quite refractory to any treatment. Systemic corticosteroids and many other agents have been tried in individual cases, but none has proven to be particularly effective. Methods that have been tried and often failed include immunosuppression with cyclophosphamide, mycophenolate mofetil or azathioprine, gold, dapsone, plasmapheresis, and

BOX 55-2 TREATMENTS FOR PARANEOPLASTIC PEMPHIGUS

	DRUG	USUAL DOSE	OTHER DOSING
First line	Prednisone	0.5–1.0 mg/kg	Methylprednisolone, 1,000 mg IV daily × 3 days
	Rituximab	375 mg/m^2 IV weekly × 4 week, repeat every 6 months	1,000 mg IV weekly × 2 week
	Daclizumab	2 mg/kg IV weekly × 4 week, then every other week indefinitely	
	Basiliximab	20 mg IV on day 0 and day 4, repeat every 3–4 months	
Second line	Cyclosporine	5 mg/kg daily	
	Cyclophosphamide	2.5 mg/kg daily	
	Mycophenolate mofetil	1,000 mg PO bid	
	High-dose IV immunoglobulin	2 g/kg IV, repeat q 3–4 week	
	Plasmapheresis	Every other day for six total treatments	

photopheresis. A small number of patients have shown a good response to combination treatment directed at both humoral and cell-mediated autoimmunity. These patients received oral prednisone, rituximab, and daclizumab or basiliximab (both are nondepleting monoclonal antibody against CD25, the high affinity IL-2 receptor of T cells). This appears to be a less toxic way of downregulating both humoral and cell-mediated autoimmunity, with promising early results.

PREVENTION

There is no known intervention that may prevent the development of PNP in a patient with a known lymphoid malignancy. Although there has been individual case reports of PNP perhaps being triggered by certain drugs, radiation therapy, or cytokine administration, it is still not clear that any of these treatments triggered the autoimmune disease, and it appears more likely that the neoplasm itself triggers the autoimmunity.

KEY REFERENCES

Full reference list available at www.DIGM8.com

DVD contains references and additional content

1. Anhalt GJ et al: Paraneoplastic pemphigus: An autoimmune mucocutaneous disease associated with neoplasia. *N Engl J Med* **323**:1729, 1990
3. Posner JB. Immunology of paraneoplastic syndromes: Overview. *Ann N Y Acad Sci* **998**:178, 2003
6. Nousari HC et al: Elevated levels of interleukin-6 in paraneoplastic pemphigus. *J Invest Dermatol* **112**:396, 1999
13. Nousari HC et al: The mechanism of respiratory failure in paraneoplastic pemphigus. *N Engl J Med* **340**:1406, 1999
14. Kim SC et al: cDNA cloning of the 210-kDa paraneoplastic pemphigus antigen reveals that envoplakin is a component of the antigen complex. *J Invest Dermatol* **109**:365, 1997
23. Borradori L et al: Anti-CD20 monoclonal antibody (rituximab) for refractory erosive stomatitis secondary to CD20(+) follicular lymphoma-associated paraneoplastic pemphigus. *Arch Dermatol* **137**:269, 2001

Chapter 56 :: Bullous Pemphigoid

:: Donna A. Culton, Zhi Liu, & Luis A. Diaz

BULLOUS PEMPHIGOID AT A GLANCE

- Usually occurs in elderly patients.
- Yearly mortality varies from 6% to 40%.
- Pruritic urticarial lesions and tense large blisters. Oral mucous membrane erosions in minority of patients.
- Skin pathology shows subepidermal blisters with eosinophils.
- Direct immunofluorescence shows immunoglobulin (Ig) G and C3 at epidermal basement membrane of perilesional skin, indirect immunofluorescence shows IgG antibasement membrane autoantibodies in the serum.
- The autoantigens BPAg1e and the BP180 are proteins of the keratinocyte hemidesmosome, a basal cell–basement membrane adhesion structure.
- Therapy includes topical and systemic corticosteroids and immunosuppressives.

Bullous pemphigoid was originally classified as a unique disease with distinctive clinical and histologic features by Walter Lever in 1953.[1] Its separation from pemphigus was important, because at the time pemphigus vulgaris was often fatal, whereas bullous pemphigoid had a comparatively good prognosis. The separation of bullous pemphigoid from pemphigus was confirmed and fully justified by the characteristic immunopathologic features of these diseases described approximately 12 years later.[2,3]

EPIDEMIOLOGY

Bullous pemphigoid typically occurs in patients over 60 years of age, with a peak incidence in the 70s.[4] There are several reports of bullous pemphigoid in infants and children, although this is rare.[5–8] There is no known ethnic, racial, or sexual predilection for developing bullous pemphigoid. The incidence of bullous pemphigoid is estimated to be 7 per million per year in both France and Germany, and 14 per million per year in Scotland.[4,9–11] A recent large cohort study suggests that the incidence of bullous pemphigoid may be as high as 43 per million per year in the United Kingdom with incidence increasing over the last several years.[12]

ETIOLOGY AND PATHOGENESIS

IMMUNOPATHOLOGY

The hallmarks of bullous pemphigoid include the presence of subepidermal blisters, lesional and perilesional polymorphonuclear cell infiltrates in the upper dermis, and immunoglobulin (Ig) G autoantibodies and C3 bound to the dermal epidermal junction. Remarkable advances have been made in the last decades characterizing the antigens as hemidesmosomal components and developing an animal model that demonstrates the pathogenicity of bullous pemphigoid autoantibodies.

BULLOUS PEMPHIGOID ANTIGENS

Immunofluorescence (IF) techniques demonstrate that patients with bullous pemphigoid exhibit circulating and tissue-bound autoantibodies directed against antigens of the cutaneous basement membrane zone (BMZ).[3] Immunoelectron microscopy studies localize bullous pemphigoid antigens to the hemidesmosome, an organelle that is important in anchoring the basal cell to the underlying basement membrane.[13] These autoantibodies bind to both the intracellular plaque of the hemidesmosome and the extracellular face of the hemidesmosome. Bullous pemphigoid autoantibodies recognize two distinct antigens with molecular weights of 230 kDa and 180 kDa by immunoblot analysis of human skin extracts.[14] The 230-kDa molecule is termed BP230, BPAG1, or BPAG1e.[14–17] BPAG1e belongs to a gene family that includes desmoplakin I, a desmosomal plaque protein that is important in anchoring keratin intermediate filaments to the desmosome.[18,19] By immunoelectron microscopy BPAG1e is located in the intracellular plaque of the hemidesmosome, exactly where keratin intermediate filaments insert.[20] Analysis of BPAG1e-deficient mouse strains generated by transgenic knockout technology further demonstrates that the function of BPAG1e is to anchor keratin intermediate filaments to the hemidesmosome.[21] Mice lacking BPAG1e show fragility of basal cells due to collapse of the keratin filament network, but no epidermal–dermal adhesion defect. Interestingly, an alternatively spliced form of BPAG1e (termed BPAG1n) is expressed in neural tissue. BPAG1n stabilizes the cytoskeleton of sensory neurons,[22,23] just as BPAG1e stabilizes the cytoskeleton of epidermal cells. The lack of dermal–epidermal separation in the BPAG1e-null mice indicates that pathogenic autoantibodies in bullous pemphigoid do not act simply by inhibiting the function of BPAG1e.

The 180-kDa BP autoantigen is termed BP180, BPAG2, or type XVII collagen.[24–26] BP180 is a transmembrane protein with an intracellular amino-terminal domain and an extended carboxyl-terminal domain that spans the lamina lucida and projects into the lamina densa of the basement membrane.[27–31] Its cytoplasmic domain is located in the plaque of the hemidesmosome and its extracellular domain is linked to anchoring filaments.[32–34] The extracellular domain of BP180 contains a series of 15 collagen regions interrupted by 16 noncollagen sequence.[29] The NC16A subdomain, adjacent to the membrane-spanning region, harbors the major autoantibody-reactive epitopes.[35,36] These features make the BP180 antigen a prime target for pathogenic autoantibodies. As discussed in Section "Pathophysiology of Subepidermal Blistering," antibodies against the NC16A domain are capable of inducing subepidermal blisters in mice. Moreover, an enzyme-linked immunosorbent assay (ELISA) to measure antibodies against the BP180 NC16A domain is both sensitive and specific for a diagnosis of bullous pemphigoid[37–39] and its titers correlate with disease activity.[40] Further evidence that BP180 mediates dermal–epidermal adhesion comes from analysis of the gene defect in patients with the junctional subepidermal blistering disease, non-Herlitz junctional epidermolysis bullosa (JEB-nH), previously known as generalized atrophic benign epidermolysis bullosa. These patients have recessively inherited mutations in the *BP180* gene that result in a missing or dysfunctional protein.[41–43]

PATHOPHYSIOLOGY OF SUBEPIDERMAL BLISTERING

Bullous pemphigoid is an autoimmune inflammatory disease. The distinctive feature of bullous pemphigoid is the presence of circulating and tissue-bound autoantibodies against BP180 and BP230. Anti-BP180 autoantibodies of various immunoglobulin isotypes and IgG subclasses are present in bullous pemphigoid sera with IgG being predominant, followed by IgE.[44–46] Serum levels of anti-BP180-NC16A IgG and IgE correlate well with disease activity in bullous pemphigoid patients.[24,26,40] Inflammatory cells are present in the upper dermis and bullous cavity, including eosinophils (the predominant cell type), neutrophils, lymphocytes, and monocytes/macrophages. Both intact and degranulating eosinophils, neutrophils, and mast cells (MC) are found in the dermis.[47–50] Local activation of these cells may occur via the multiple inflammatory mediators present in the lesional skin and/or blister fluid.[51–59] Several proteinases are found in bullous pemphigoid blister fluid, including plasmin, collagenase, elastase, and MMP-9,[60–67] which may play a crucial role in subepidermal blister formation by their ability to degrade extracellular matrix proteins.

Both in vitro and in vivo data demonstrate that autoantibodies, particularly those against BP180, are pathogenic. In vitro studies using normal human skin sections indicate that bullous pemphigoid IgG is capable of generating dermal–epidermal separation in the presence of complement and leukocytes.[68,69] Early attempts to demonstrate the pathogenicity of patient autoantibodies by a passive transfer mouse model were unsuccessful because bullous pemphigoid anti-BP180-NC16A autoantibodies fail to cross-react with the murine BP180.[70] To overcome this difficulty, rabbit antibodies were raised against the epitope on mouse BP180. Passive transfer of these rabbit antibodies to neonatal mice induces blisters that resemble some key

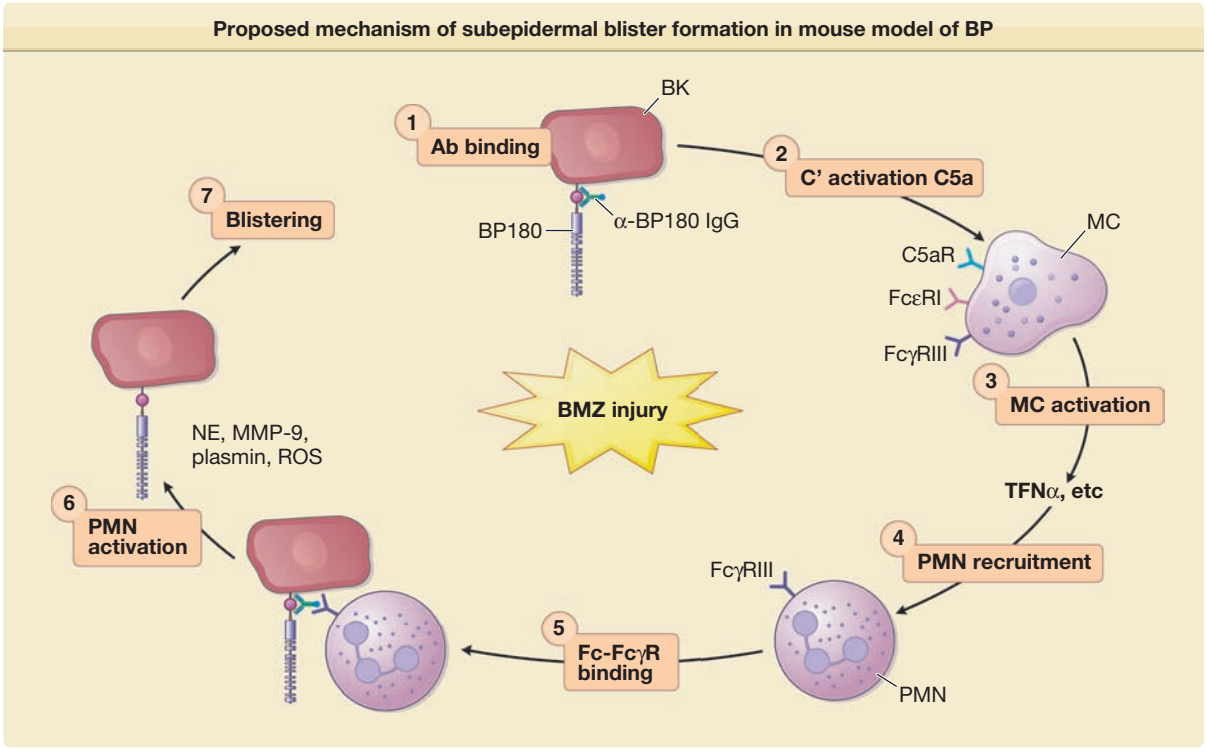

Figure 56-1 Proposed mechanism of subepidermal blister formation in mouse model of BP. Subepidermal blistering is an inflammatory process that involves the following steps: **1**, anti-BP180 IgG binds to the pathogenic epitope of BP180 antigen on the surface of basal keratinocytes (BK); **2**, the molecular interaction between BP180 antigen and anti-BP180 IgG activates the classical pathway of the complement system (C′); **3**, C′ activation products C3a and C5a cause mast cells (MC) to degranulate; **4**, TNF-α and other proinflammatory mediators released by MC recruit neutrophils (PMN); **5**, infiltrating PMNs bind to the BP180–anti-BP180 immune complex via the molecular interaction between Fcγ receptor III (FcγRIII) on neutrophils and the Fc domain of anti-BP180 IgG; **6**, the interaction between Fc and FcγRIII activates PMNs to release neutrophil elastase (NE), gelatinase B (MMP-9), plasminogen activators (PAs), and reactive oxygen species (ROS); **7**, Proteolytic enzymes and ROS work together to degrade BP180 and other extracellular matrix proteins, leading to subepidermal blistering.

features of human bullous pemphigoid, including in situ deposition of rabbit IgG and mouse C3 at the BMZ, dermal–epidermal separation, and an inflammatory cell infiltrate.[70] These studies demonstrate that experimental blistering in animals requires activation of the classical pathway of the complement system, mast cell degranulation, and neutrophil infiltration (Fig. 56-1).[71–75] A well-orchestrated proteolytic event occurs during the disease progression. Plasmin activates proenzyme MMP-9 and activated MMP-9 then degrades α1-proteinase inhibitor, the physiological inhibitor of neutrophil elastase. Unchecked neutrophil elastase degrades BP180 and other extracellular matrix components, resulting in dermal–epidermal junction separation.[76–79] To directly test the pathogenicity of anti-BP180 IgG autoantibodies from bullous pemphigoid patients, humanized BP180 mouse strains were generated, in which the human BP180 or NC16A domain replaces the murine BP180 or corresponding domain.[80,81] These humanized mice, upon injection with anti-BP180 IgG from bullous pemphigoid patients, develop subepidermal blisters.[80,81] Like the rabbit antimurine BP180 IgG-induced model, the humanized NC16A mouse model of bullous pemphigoid also requires complement, MC, and neutrophils (Fig. 56-2).[80]

IgE anti-BP180 autoantibodies may also play a role in blister formation. Human skin grafted onto immune-deficient mice injected with an IgE hybridoma to the extracellular portion of BP180 or total IgE from bullous pemphigoid patients' sera exhibit histological dermal–epidermal separation,[82,83] suggesting that anti-BP180 IgE antibodies may also participate in pathogenesis of bullous pemphigoid through activating MC and recruiting eosinophils.

Although animal model studies clearly show that an inflammatory cascade is triggered by BP180-specific antibodies and is essential for blister formation, direct interference of hemidesmosome-mediated cell–cell matrix adhesion by anti-BP180 autoantibodies may be another disease mechanism.[84] Involvement of anti-BP230 autoantibodies in bullous pemphigoid blistering is also implicated in some animal model studies,[85,86] but direct evidence in humans is lacking.

In addition to the humoral response, bullous pemphigoid patients also mount a cell mediated autoimmune response. Autoreactive T and B lymphocytes recognize BP180.[87–89] These studies suggest that bullous pemphigoid is a T- and B-cell-dependent and antibody-mediated skin autoimmune disease. As in most autoimmune diseases, the initial trigger for induction

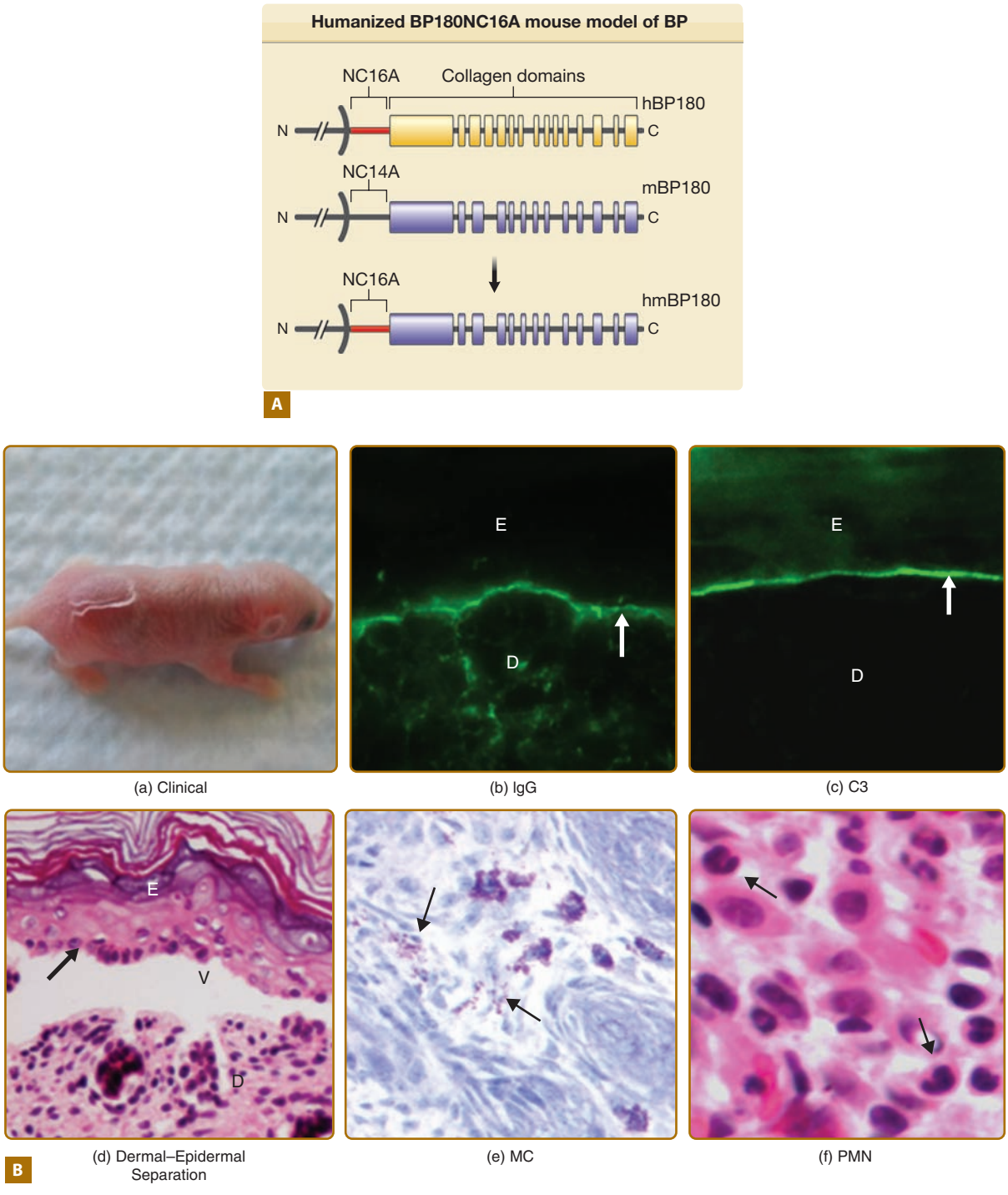

Figure 56-2 Humanized BP180NC16A mouse model of BP. **A.** Human BP180 (*top panel*) is a transmembrane protein of basal keratinocytes. It contains a single transmembrane domain. The extracellular region is consisted of 15 interrupted collagen domains (*yellow bars*) and 16 noncollagen domains (*black lines*). The NC16A domain (*red line*) harbors immunodominant epitopes recognized by BP autoantibodies. The extracellular region of mouse BP180 (*middle panel*) contains 13 collagen domains (*blue bars*) and 14 noncollagen domain (*black lines*). In humanized BP180NC16A mice, the mouse BP180NC14A domain was replaced by the human NC16A domain (*lower panel*). **B.** Neonatal NC16A mice injected i.d. with BP180NC16A-specific IgG autoantibodies developed clinical blistering (a). Direct IF showed BMZ deposition of human IgG (b) and murine C3 (c). Histological sections of lesional skin showed dermal–epidermal separation (d). Examination of toluidine blue-stained skin sections revealed degranulating mast cells (MC) (e). Hematoxylin/Eosin (H/E) staining showed infiltrating neutrophils (PMN) in the upper dermis (400× magnification) (f). E = epidermis; D = dermis; V = vesicle; arrows in panels b–d = basal keratinocytes.

of autoreactive lymphocytes and autoantibody production in bullous pemphigoid remains unknown.

Several other subepidermal blistering diseases also show autoimmune responses to BP180. These include pemphigoid gestationis (or herpes gestationis), cicatricial pemphigoid (or mucous membrane pemphigoid), linear IgA bullous dermatosis, and lichen planus pemphigoid.[90–100] It is possible that they may share some common immunopathological mechanisms with bullous pemphigoid.

CLINICAL FINDINGS

HISTORY

Most cases of bullous pemphigoid occur sporadically without any obvious precipitating factors. However, there are several reports in which bullous pemphigoid appears to be triggered by ultraviolet (UV) light, either UVB or following PUVA therapy, and radiation therapy.[101–103] Certain medications have also been associated with the development of bullous pemphigoid including penicillamine, efalizumab, etanercept, and furosemide.[104–109]

CUTANEOUS LESIONS

The classic form of bullous pemphigoid is characterized by large, tense blisters arising on normal skin or on an erythematous base (Fig. 56-3A).[110,111] These lesions are most commonly found on flexural surfaces, the lower abdomen, and thighs, although they may occur anywhere. The bullae are typically filled with serous fluid, but may be hemorrhagic. The Nikolsky and Asboe–Hansen signs are negative. Eroded skin from ruptured blisters usually heals spontaneously without scarring, although milia can sometimes occur. Once the lesions heal they leave hyperpigmented patches that may last for several months. Pruritus may be intense in some patients, but minimal in others.

Nonbullous lesions are the first manifestation of bullous pemphigoid in almost half of patients.[112] Often, urticarial type lesions precede the more classic tense bullae, and patients may present with these lesions early in the course of disease (Fig. 56-3B). The erythematous component in some bullous pemphigoid patients may appear eczematoid, serpiginous, or targetoid with erythema multiforme-like lesions.

Mucous membrane lesions occur in approximately 10% of patients and are almost always limited to the oral mucous membranes, particularly the buccal mucosa.[110,113–115] Intact oral mucosa blisters are rare, with erosions more commonly seen. The lesions heal without scarring and are fairly limited. Unlike erythema multiforme, the vermillion border of the lips is rarely involved. There are rare reports of esophageal involvement.[116,117] The presence of scarring is more suggestive of cicatricial pemphigoid as discussed in Chapter 57.

In addition to the more classic findings, unusual clinical presentations can be seen.[118] In these cases, the diagnosis is confirmed by IF and ELISA studies. For example, localized bullous pemphigoid often presents as tense bullae restricted to localized areas of involvement, most commonly on the lower legs.[119,120] Patients with localized disease have antibodies against the same pemphigoid antigens as patients with more generalized disease.[119–121] The lesions may remain localized for years or progress to generalized bullous pemphigoid. Childhood bullous pemphigoid often presents as localized disease with acral distribution being common.[5–8,122] Localized vulvar and perivulvar disease has also been described in young girls.[123,124] Other reports of localized bullous pemphigoid suggest that changes induced by radiation, trauma, or surgery (colostomy, urostomy, or skin graft donor site) at a particular site may precipitate disease in these areas.[125–133]

Other less common presentations include erythroderma, prurigo nodularis-like or vegetating lesions, and dyshidrotic dermatitis-like lesions. Again, the antibodies from these patients show typical IF localization and bind the pemphigoid antigens.[121,134–142]



Figure 56-3 Bullous pemphigoid. **A.** Large, tense bullae and erythematous patches studded of small vesicles on the thighs and lower legs. **B.** Urticarial lesions of bullous pemphigoid with overlying tense vesicles and bullae in the axilla.

In addition to atypical clinical presentations, bullous pemphigoid may also coexist with other cutaneous diseases. Lichen planus pemphigoides describes the coexistence of bullous pemphigoid and lichen planus with typical clinical, histologic, and immunopathologic features of both diseases.[143–146] Lichen planus pemphigoides more often presents in middle-aged patients (mean age of onset 35–45 years of age) and is more localized to the extremities with a less severe clinical course when compared to classic bullous pemphigoid. In rare instances, bullous pemphigoid has also been reported to coexist with pemphigus.[147–150]

DISEASE ASSOCIATIONS

Neurological disease is seen more frequently in bullous pemphigoid patients and it appears that patients with neurological disease (especially those over 80 years of age) have a significantly higher risk of developing bullous pemphigoid than those without neurological disease.[151–153] In rare instances, bullous pemphigoid may be seen in association with acquired hemophilia due to acquired Factor VIII inhibitor. Cutaneous clinical manifestations include ecchymoses, hematomas, and hemorrhagic bullae in addition to more systemic findings such as gastrointestinal bleeding.[154–156]

There have been many case reports of bullous pemphigoid associated with malignancy. However, case-control studies suggest that there is no increase, or a very small increase, in the frequency of malignancy in bullous pemphigoid patients compared with age-matched controls.[152,157–159] There may be an increased frequency of malignancy in bullous pemphigoid patients with negative indirect IF studies as compared with those with positive findings.[113,160] The perceived association may be explained by the fact that both bullous pemphigoid and malignancy occur more commonly in elderly patients. While a thorough review of systems and symptom-guided workup is indicated in patients with a new diagnosis of bullous pemphigoid, extensive screening for an asymptomatic malignancy is not warranted.

LABORATORY TESTS

The diagnosis of bullous pemphigoid is made based upon clinical, histologic, and IF features as described below. Other laboratory studies play a small supporting role. Approximately half of patients will have elevated total serum IgE levels, which often correlate with titers of bullous pemphigoid IgG autoantibodies by IF and pruritus.[51,161,162] Approximately one-half of patients have peripheral blood eosinophilia, which does not correlate with serum IgE levels.[162,163]

HISTOPATHOLOGY

Biopsy of an early small vesicle is diagnostic with histology revealing a subepidermal blister with a superficial dermal infiltrate consisting of eosinophils, neutrophils lymphocytes, and monocytes/macrophages (Fig. 56-4).[110] The infiltrate ranges from intense to sparse, but it characteristically contains some eosinophils, which may also be seen in the blister cavity. The blister roof is usually viable without evidence of necrosis. Histology of urticarial lesions may only show a superficial dermal infiltrate of lymphocytes, monocytes/macrophages, and eosinophils with papillary dermal edema. These urticarial lesions may also display degranulating eosinophils at the dermal–epidermal junction, with early separation of individual basal cells from the basement membrane and/or eosinophilic spongiosis.[164]

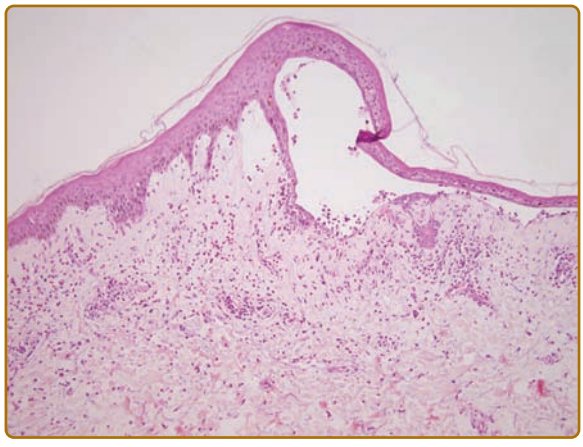

Figure 56-4 Histopathology of bullous pemphigoid. Subepidermal blister with an inflammatory cell infiltrate containing eosinophils in the superficial dermis (100× magnification).

ELECTRON MICROSCOPY

Ultrastructural studies demonstrate that early blister formation in bullous pemphigoid occurs in the lamina lucida, between the basal cell membrane and the lamina densa (Fig. 56-5A and 56-5B).[165] In areas of blister formation, there is loss of anchoring filaments and hemidesmosomes. Degranulation of eosinophils, neutrophils, and MC in the lesional/perilesional skin has also been observed by electron microscopy.[49]

SPECIAL TESTS

Direct IF of perilesional skin shows linear IgG (usually IgG1 and IgG4, although all IgG subclasses and IgE have been reported) and C3 along the basement membrane.[2,3,113,162,166] In approximately 70% of patients, there are circulating IgG and IgE autoantibodies that bind the BMZ on normal human skin or monkey esophagus by indirect IF.[45,113,162,163,166–169] Using 1 M NaCl split skin, which separates the epidermis from the dermis at the lamina lucida, an even higher percentage of patients will have detectable circulating anti-BMZ autoantibodies.[170,171] In addition to being more sensitive, the other

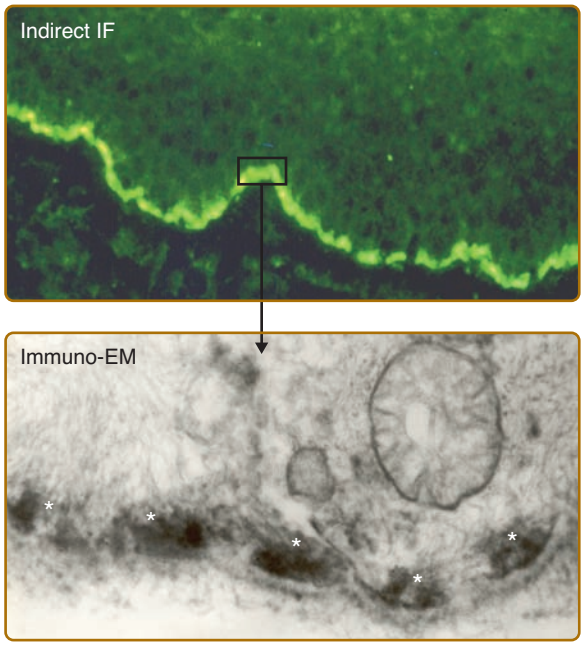

Figure 56-5 **A.** Indirect immunofluorescence of bullous pemphigoid serum shows a linear pattern of immunoglobulin G binding to the epidermal dermal junction of normal skin. **B.** Binding of bullous pemphigoid antibodies to human basal cell hemidesmosomes as described by Mutasim et al: *J Invest Dermatol* **84**:47-53, 1985. A small rectangle of linear indirect IF staining and the arrow depicts the immunolocalization of the reactive antibodies to the hemidesmosome (*white asterisks*).

advantage of the 1 M NaCl-split skin substrate is that bullous pemphigoid antibodies bind the roof of the artificially induced blister (i.e., the bottom of the basal cells). This finding differentiates bullous pemphigoid antibodies from epidermolysis bullosa acquisita (EBA) autoantibodies, which bind the base or the floor of the split skin (i.e., dermal side; Figs. 56-6A and 56-6B). In contrast to pemphigus, in bullous pemphigoid the indirect IF antibody titer does not usually correlate with disease extent or activity.[172]

Recently, ELISA techniques have proven to be useful in both clinical and research settings for the detection of circulating antigen specific IgG and IgE antibodies. Commercial kits are available for detection of both BP-180 (NC16A and total) and BP-230 IgG antibodies. A sensitivity of 89% and specificity of 98% when used with appropriate cutoff values are reported with these assays.[37] As many as 75% of patients also have antigen specific IgE with anti-BP180 and anti-BP230 IgE antibodies detectable by IF and ELISA.[44,46,168,173–176] Those patients with anti-BP180 IgE antibodies may have a more severe form of disease.[174] Antigen specific IgE antibodies may account for the early urticarial type lesions and likely play a role in recruiting eosinophils to skin lesions.[82,173]

Recent studies have shown that approximately 7% of the normal population has anti-BP180 antibodies detectable by ELISA in the absence of clinical and histologic features of disease without age or gender predilection. The predictive relevance of these circulating antibodies in healthy individuals is unknown as long-term follow-up is not available. However, this finding underscores the importance of using the ELISA in appropriate clinical settings and not as a screening tool in patients who lack other features of disease.[177]

DIFFERENTIAL DIAGNOSIS

The differential diagnosis for bullous pemphigoid includes other blistering diseases, such as linear IgA disease, dermatitis herpetiformis, erythema multiforme, EBA, and pemphigus. Histology and IF can easily distinguish bullous pemphigoid from these diseases (Box 56-1). Distinguishing bullous pemphigoid from EBA and cicatricial pemphigoid may be difficult as histology and direct IF may be identical.[115,178] EBA can usually be distinguished from bullous pemphi-

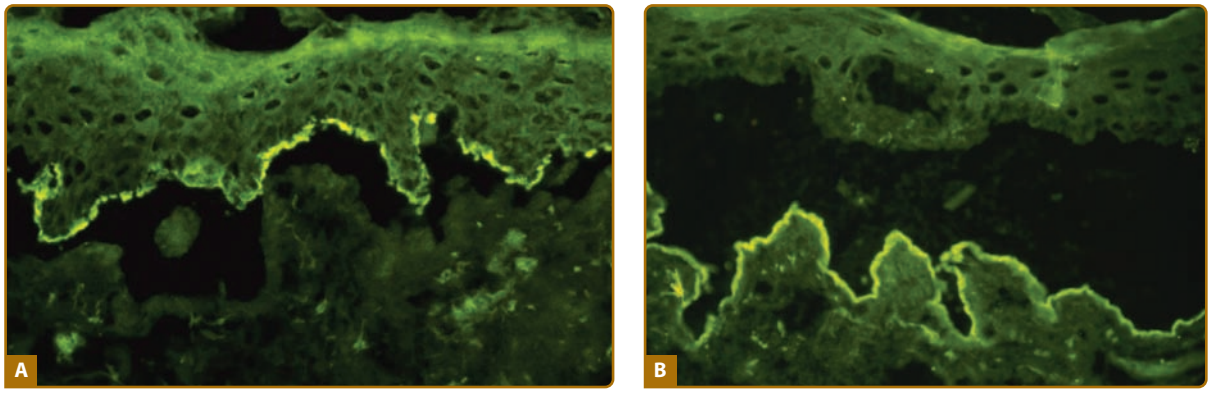

Figure 56-6 Indirect immunofluorescence on normal skin previously incubated in 1 M NaCl to induce a split through the lamina lucida of the dermal–epidermal junction. **A.** IgG antibodies from bullous pemphigoid serum binds to the roof of the artificial blister (hemidesmosomes). **B.** IgG antibodies from epidermolysis bullosa acquisita (EBA) serum binds to the floor of the split (collagen VII of anchoring fibers).

BOX 56-1 DIFFERENTIAL DIAGNOSIS OF BULLOUS PEMPHIGOID

SUBEPIDERMAL BLISTERING DISEASES WITH AUTOANTIBODIES

- Pemphigoid gestationis
- Cicatricial pemphigoid
- Epidermolysis bullosa acquisita (EBA)
- Linear immunoglobulin A disease
- Dermatitis herpetiformis
- Bullous lupus erythematosus, described as an EBA phenotype

SUBEPIDERMAL BLISTERING DISEASES WITHOUT AUTOANTIBODIES

- Erythema multiforme and toxic epidermal necrolysis
- Porphyria
- Epidermolysis bullosa (genodermatoses)

INTRAEPIDERMAL BLISTERING DISEASES WITH AUTOANTIBODIES

- Pemphigus

INTRAEPIDERMAL BLISTERING DISEASES WITHOUT AUTOANTIBODIES

- Allergic contact dermatitis (e.g., rhus dermatitis)
- Bullous impetigo, staphylococcal scalded-skin syndrome
- Friction blisters
- Hailey–Hailey disease
- Incontinentia pigmenti

goid by indirect or direct IF on salt-split skin as stated above.[179] Confirmation of EBA may be accomplished by ELISA assays using type VII collagen, the EBA antigen (discussed in Chapter 60). Immunoelectron microscopy also distinguishes these diseases because the IgG in EBA is below the lamina densa on the anchoring fibrils (type VII collagen), whereas the IgG in bullous pemphigoid is closely associated with the basal cell hemidesmosomes.[180]

As opposed to bullous pemphigoid, cicatricial pemphigoid usually presents with mucosal lesions predominantly, if not exclusively (see Chapter 57). Cicatricial pemphigoid is characterized by desquamative gingivitis as well as inflammation and scarring of conjunctiva. If there is blistering of the skin, it may be transient and may result in scarring. Large, tense blisters, which are characteristic of bullous pemphigoid, are usually not seen in cicatricial pemphigoid.

COMPLICATIONS

Complications in untreated patients include skin infection developing within denuded bullae, dehydration, electrolyte imbalance, and possibly death from sepsis.

PROGNOSIS/CLINICAL COURSE

Bullous pemphigoid is characterized by a waxing and waning course with occasional spontaneous remission in the absence of treatment. Localized disease often resolves spontaneously, but spontaneous remission can even occur in patients with more generalized disease. For example, prior to the availability of systemic corticosteroids, Lever reported that 8 of 30 adults with bullous pemphigoid went into remission after approximately 15 months (range, 3–38 months) of active disease.[110] In treated patients, the length of disease ranges from 9 weeks to 17 years with a median treatment period of 2 years and 50% remission rates in patients followed for at least 3 years.[181] Clinical remission with reversion of direct and indirect IF to negative has been noted in patients, even those with severe generalized disease, treated with oral corticosteroids alone or with azathioprine.[162,182] High ELISA titers and, to a lesser degree, positive direct IF at the time of therapy cessation has been associated with a high risk of relapse within the first year following cessation of therapy.[182] At least one of these tests should be performed before therapy is discontinued.

Old age, poor general health, and the presence of anti-BP180 antibodies have been associated with a poor prognosis.[183–186] Early mortality rates in untreated patients were reported to be 25%.[110] Newer studies have shown the 1-year mortality of patients with bullous pemphigoid to be between 19% and 40% in Europe, but lower (less than 6%–12%) in the United States.[12,183–185,187–190] The factors underlying this discrepancy in mortality rates between Europe and the United States are not clear. While mortality rates remain relatively low in the United States, recent studies have confirmed a slow steady increase in mortality over the last 24 years in the United States.[191]

TREATMENT

Treatment of bullous pemphigoid depends greatly on the extent of disease. Localized bullous pemphigoid often can be treated successfully with topical corticosteroids alone (Box 56-2).[162,166,192] Topical tacrolimus has also been reported to be useful in a few cases of localized pemphigoid.[192–196]

More extensive disease is usually treated with oral prednisone.[192,197,198] Despite the lack of randomized controlled trials, oral prednisone remains the mainstay of therapy. Some recent studies suggest that potent topical steroids, such as clobetasol propionate cream 0.05% applied twice daily, are also effective in both moderate and severe bullous pemphigoid and may be safer than oral prednisone.[189] Thus, these patients received a daily dose of 40 g of clobetasol propionate that was applied twice daily to the entire surface of the body until 15 days after control of the

BOX 56-2 TREATMENTS FOR BULLOUS PEMPHIGOID

CORTICOSTEROIDS

- High potency topical steroids
- Prednisone

OTHER IMMUNOSUPPRESSIVE AGENTS

- Azathioprine
- Mycophenolate mofetil
- Others: methotrexate, cyclophosphamide

MODULATORS OF ANTIBODY LEVELS

- Intravenous γ-globulin
- Plasmapheresis

OTHER

- Tetracycline or erythromycin and nicotinamide
- Dapsone
- Topical tacrolimus

disease had been attained. High-potency topical treatment did result in significant systemic absorption and therefore may act via local and systemic effects.[199] Such topical therapy can be expensive and difficult to apply, which may prove prohibitive in many patients.

In elderly patients, the complications of systemic glucocorticoid therapy (such as osteoporosis, diabetes, and immunosuppression) may be especially severe.[200] Therefore, it is important to try to minimize the total dose and duration of therapy with oral glucocorticoids. Starting doses of prednisone of 0.75–1.0 mg/kg/day or even less may be adequate for disease control.[201] In addition, immunosuppressive agents such as azathioprine, mycophenylate mofetil, and methotrexate (and less often cyclophosphamide) are often used in conjunction with prednisone for their potential steroid-sparing effects,[192,198,202–209] although very few controlled trials have addressed this common approach to therapy. High-dose "pulse" therapy with intravenous methylprednisolone also has been reported to be effective in rapidly controlling active blister formation in bullous pemphigoid.[210] Once the development of blisters has been arrested and the erythema has subsided, a careful tapering of the prednisone is recommended. A weekly lowering of 5 mg to reach 30 mg is commonly used. Lowering this dose must be done according to the clinical response of the patient. The majority of patients may be controlled with small amounts of prednisone and immunosuppressive drugs. Sulfones may be effective in a minority of patients. Dapsone and sulfapyridine have been reported to control disease activity in 15%–44% of bullous pemphigoid patients.[198,211–213]

Reports have described successful treatment of some bullous pemphigoid patients with tetracycline and nicotinamide or variations on this theme, such as erythromycin and nicotinamide or tetracycline alone.[214–216] In small numbers of patients, other therapies reported to be effective include plasmapheresis,[217] intravenous immunoglobulins,[218–220] methotrexate,[205,207,221] leflunomide,[222] and chlorambucil.[223]

KEY REFERENCES

Full reference list available at www.DIGM8.com

DVD contains references and additional content

19. Stanley JR et al: Isolation of complementary DNA for bullous pemphigoid antigen by use of patients' autoantibodies. *J Clin Invest* **82**(6):1864, 1988
28. Diaz LA et al: Isolation of a human epidermal cDNA corresponding to the 180-kD autoantigen recognized by bullous pemphigoid and herpes gestationis sera. Immunolocalization of this protein to the hemidesmosome. *J Clin Invest* **86**(4):1088, 1990
75. Liu Z: Bullous pemphigoid: Using animal models to study the immunopathology. *J Investig Dermatol Symp Proc* **9**(1):41, 2004
165. Lever WF: Pemphigus and pemphigoid. A review of the advances made since 1964. *J Am Acad Dermatol* **1**(1):2, 1979
167. Beutner EH, Jordon RE, Chorzelski TP: The immunopathology of pemphigus and bullous pemphigoid. *J Invest Dermatol* **51**(2):63, 1968
197. Patton T, Korman NJ: Bullous pemphigoid treatment review. *Expert Opin Pharmacother* **7**(17):2403, 2006

Chapter 57 :: Cicatricial Pemphigoid

:: Kim B. Yancey

CICATRICIAL PEMPHIGOID AT A GLANCE

- A chronic autoimmune subepithelial blistering disease characterized by erosive lesions of mucous membranes and skin that result in scarring.
- Lesions commonly involve the oral and ocular mucosae; other sites that may be involved include the nasopharyngeal, laryngeal, esophageal, genital, and rectal mucosae.
- A rare disorder, occurring in one person per million annually; females are affected 1.5–2.0 times as often as males.
- A progressive disorder that may result in serious complications (e.g., blindness, loss of the airway, esophageal stricture formation).
- Immunopathologic studies of perilesional mucosa and skin demonstrate in situ deposits of immunoreactants in epithelial basement membranes; circulating antibasement membrane autoantibodies are detected in sera of some but not all patients.
- A variety of different autoantigens are recognized by autoantibodies from patients, suggesting that cicatricial pemphigoid is not a single nosologic entity but rather a disease phenotype.

Cicatricial pemphigoid (alternate designation: mucous membrane pemphigoid) is a rare chronic autoimmune subepithelial blistering disease characterized by erosive lesions of mucous membranes and skin that result in scarring of at least some sites of involvement.[1–6]

EPIDEMIOLOGY

Cicatricial pemphigoid has been estimated to occur in approximately 1 person per million annually; females are affected 1.5–2.0 times as often as males.[7–9] Cicatricial pemphigoid has a mean age of onset of the early to middle 60s.[9] Although there is no known racial or geographic predilection, the *HLADQB1*0301* allele has been shown to be significantly increased in frequency in patients with oral, ocular, and generalized bullous pemphigoid; amino acid residues at positions 57 and 71 to 77 of the DQB1 protein may represent a disease susceptibility marker.[1,10–14]

ETIOLOGY AND PATHOGENESIS

Autoantibodies directed against autoantigens in epidermal basement membrane are held responsible for the pathogenesis of cicatricial pemphigoid (Fig. 57-1).[15] A variety of different autoantigens are recognized by circulating autoantibodies from these patients.[1,16–31] These and other findings have led to the idea that cicatricial pemphigoid is not a single nosologic entity but rather a disease phenotype. Autoantigens recognized by immunoglobulin G (IgG) autoantibodies from patients with cicatricial pemphigoid are summarized in Table 57-1. While autoantibodies directed against some of these autoantigens have been shown to be pathogenic in vivo (Table 57-1), it is conceivable that other mechanisms may contribute to the pathogenesis of cicatricial pemphigoid. For example, recent studies have demonstrated high stromal expression of IL-13 in $CD3^+$ T cells from patients with ocular cicatricial pemphigoid and that these cells may contribute both profibrotic and proinflammatory stimuli to conjunctival fibroblasts.[39]

Bullous pemphigoid antigen 2 (BPAG2) appears to represent a major cicatricial pemphigoid autoantigen; other autoantigens of particular interest include laminin 332, integrin subunit β_4, integrin subunit α_6, type VII collagen, and bullous pemphigoid antigen 1. Other patients with cicatricial pemphigoid have IgA antibasement membrane autoantibodies (alone or in conjunction with IgG antibasement membrane autoantibodies); the best characterized IgA autoantigen linked to the cicatricial pemphigoid phenotype is bullous pemphigoid antigen 2.[1,40–42]

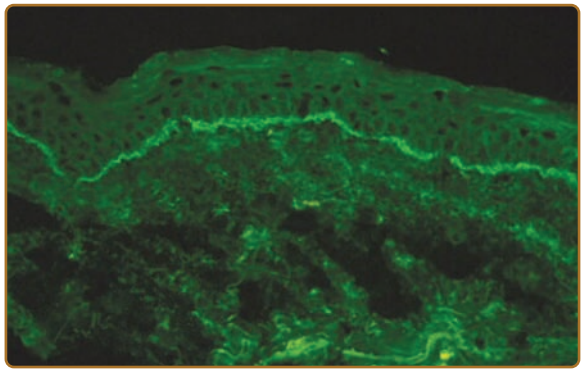

Figure 57-1 Direct immunofluorescence microscopy of normal-appearing perilesional skin from a patient with cicatricial pemphigoid shows continuous linear deposits of C3 in the epidermal basement membrane.

TABLE 57-1
Major Cicatricial Pemphigoid Autoantigens

Autoantigen	MW (kDa)	Location SSS/Ultra	Passive Transfer Studies
BPAG1	230	Epid/HD	
BPAG2	180	Epid/HD–af	IgG vs. the NC16A domain of BPAG2 creates subepid blisters in newborn mice that resemble those seen in patients with BP.[32,33]
Integrin β_4	~205	Epid/HD–af	
Integrin α_6	~120	Epid/HD–af	
Laminin 332	400–440	Derm/LL–LD interface	Exp IgG (intact IgG and Fab fragments alone) vs. laminin 332 create subepid blisters in newborn and adult mice that resemble those seen in patients with AECP.[34] Patient IgG creates subepid blisters in human skin grafts on immunodeficient adult mice that resemble those seen in patients with AECP.[35]
Type VII collagen	290	Derm/AF	Exp and patient IgG vs. the NC1 domain of type VII collagen create subepid blisters in adult mice that resemble those seen in patients with EBA.[36–38]

AECP = antiepiligrin cicatricial pemphigoid; AF = anchoring fibril; BP = bullous pemphigoid; BPAG1 = bullous pemphigoid antigen 1; BPAG2 = bullous pemphigoid antigen 2; Derm = dermal; EBA = epidermolysis bullosa acquisita; Epid = epidermal; Exp = experimental; HD = hemidesmosome; HD–af = hemidesmosome–anchoring filament complexes; IgG = immunoglobulin G; LL–LD interface = lamina lucida–lamina densa interface; Location SSS/Ultra = localization in 1 M NaCl-split skin/ultrastructural localization in epidermal basement membrane; MW (kDa) = molecular weight in kilodaltons; subepid = subepidermal.

CLINICAL FINDINGS

HISTORY

Patients typically describe the onset of painful, erosive, and/or blistering lesions on one or more mucosal surfaces. A few skin lesions on the upper body are also sometimes noted. Associated symptoms are site specific as detailed later.

MUCOSAL AND CUTANEOUS LESIONS

The mouth is the most frequent site of involvement in patients with cicatricial pemphigoid; it is often the first (and only) site affected. Lesions often involve the gingiva, buccal mucosa, and palate (Fig. 57-2); other sites such as the alveolar ridge, tongue, and lips are also susceptible.[9,43] A frequent oral manifestation is desquamative gingivitis. Other lesions may present as tense blisters that rupture easily or as mucosal erosions that form as a consequence of epithelial fragility. Lesions in the mouth may result in a delicate white pattern of reticulated scarring. In severe disease, adhesions may develop between the buccal mucosa and the alveolar process, around the uvula and tonsillar fossae, and between the tongue and the floor of the mouth. Gingival involvement can result in tissue loss and dental complications (e.g., caries, periodontal ligament damage, and loss of bone mass and teeth).

Ocular involvement in patients with cicatricial pemphigoid is common and may become sight threatening (Figs. 57-3 and 57-4). [44,45] Ocular lesions typically manifest as conjunctivitis that progresses insidiously to scarring. Early ocular disease can be quite subtle and nonspecific. Although disease is usually bilateral, it often begins unilaterally and progresses to both eyes within several years. Patients may complain of burning, dryness, or a foreign-body sensation in one or both eyes; frank blisters on conjunctival surfaces are rarely seen. Early disease is best appreciated by slit-lamp examination. Because disease may be localized to the upper tarsal conjunctiva, it may escape detection without eversion of the eyelids. Chronic ocular involvement can result in scarring characterized by shortened fornices, symblepharons (i.e., fibrous tracts between bulbar and palpebral conjunctival surfaces), and, in severe disease, ankyloblepharons (i.e., fibrous tracts fusing the



Figure 57-2 Denuded and inflamed sites on the oral mucosa are seen in association with sites of gingiva recession and loss.



Figure 57-3 The medial aspects of the lower conjunctival fornix and eyelid show shortening, fibrosis, and malaligned eyelashes.



Figure 57-5 Scalloped erosions and sites of denuded vulvar and vaginal mucosae.

superior and inferior palpebral conjunctivae with obliteration of the conjunctival sac). Conjunctival scarring also can cause entropion and trichiasis (i.e., in-turning of the eyelashes) that result in corneal irritation, superficial punctate keratinopathy, corneal neovascularization, corneal ulceration, and/or blindness. Additional ocular complications include scarring of the lacrimal ducts, decreased tear secretion, and loss of mucosal goblet cells leading to decreased tear mucus content and unstable tear films. It is very important for patients with suspected ocular involvement to be examined by an ophthalmologist, because early disease may be subtle, is only identified by slit-lamp examination, and can result in severe complications. Cicatricial pemphigoid may be limited to the eyes.

Other sites that may be affected by cicatricial pemphigoid include the nasopharyngeal, laryngeal, esophageal, and anogenital regions. Nasopharyngeal lesions can result in discharge, epistaxis, excessive crust formation, impaired airflow, chronic sinusitis, scarring, and tissue loss. Laryngeal involvement may present as hoarseness, sore throat, or loss of phonation. Chronic laryngeal erosions, edema, and scarring may result in supraglottic stenosis and airway compromise that eventually necessitates tracheostomy.[46] Esophageal involvement may result in stricture formation, dysphagia, odynophagia, weight loss, and/or aspiration. Moreover, it has been suggested that esophageal dysfunction and gastroesophageal reflux may elicit or exacerbate laryngeal disease and/or bronchospasm in such patients. Although involvement of the genital and/or rectal mucosae in patients with cicatricial pemphigoid is rare, it can be a source of substantial pain and morbidity (Fig. 57-5). Rare cases of urethral stricture, vaginal stenosis, and anal narrowing have developed as a consequence of this disease.

The skin is involved in 25%–35% of patients with cicatricial pemphigoid. The most frequently affected areas are the scalp, head, neck, and upper trunk (Fig. 57-6). Lesions typically consist of small vesicles or bullae situated on erythematous and/or urticarial bases. Lesions rupture easily and are often seen as small, crusted papules or plaques. The extent and number of



Figure 57-4 Ocular involvement has resulted in conjunctivitis, a shortened conjunctival fornix, and symblepharon formation.



Figure 57-6 The scalp displays scarring alopecia and a focal hemorrhagic crust as a consequence of involvement with cicatricial pemphigoid.

cutaneous lesions are generally small; lesions sometimes recur in the same areas.

RELATED PHYSICAL FINDINGS

SYSTEMIC ASSOCIATIONS. A cohort of 35 patients with antiepiligrin cicatricial pemphigoid (also called antilaminin 332 cicatricial pemphigoid) was shown to have an increased relative risk for cancer.[47,48] Ten patients in this cohort had solitary solid cancers (three lung, three gastric, two colon, two endometrial); eight patients developed cancer after the onset of cicatricial pemphigoid (six within a year, seven within 14 months). The time between blister onset and cancer diagnosis was approximately 14 months in nine of the ten patients. Eight patients in this cohort died as a consequence of their cancer. All deaths occurred within 21 months. This form of cicatricial pemphigoid appears to have a relative risk for malignancy that approximates that for adults with dermatomyositis; as is true for the latter, the risk for cancer appears to be particularly high in the first year of disease. Other patients with this form of cicatricial pemphigoid and cancer have been described more recently.[49–57] Interestingly, recent studies have suggested that the relative risk for cancer among patients with ocular or oral cicatricial pemphigoid and autoantibodies versus integrin subunit β_4 or integrin subunit α_6, respectively, may be reduced.[58,59]

BRUNSTING–PERRY PEMPHIGOID. In 1957, Brunsting and Perry described seven patients with locally recurrent and scarring subepidermal blistering lesions of the head or neck that for many years was thought to be a form of cicatricial pemphigoid.[60] Although these patients are typically elderly and demonstrate deposits of immunoreactants in epidermal basement membranes like other patients with cicatricial pemphigoid, Brunsting–Perry pemphigoid predominates in men and lacks mucous membrane involvement. More recently, patients with the same clinical, histologic, and immunopathologic features have been reported to have autoantibodies directed against type VII collagen (or rarely to bullous pemphigoid antigens).[3,61] Identification of similar patients with blister planes beneath the lamina densa further suggests that individuals with this phenotype usually have localized forms of epidermolysis bullosa acquisita.

LABORATORY TESTS

LIGHT MICROSCOPY

Although the findings of light microscopy studies of lesional skin or mucosa from patients with cicatricial pemphigoid often are nonspecific, they characteristically show a subepidermal blister and a dermal leukocytic infiltrate composed of lymphocytes and histiocytes as well as variable numbers of neutrophils and eosinophils.[2,3,62,63] Plasma cells often are seen in mucosal lesions, whereas eosinophils and neutrophils are seen most commonly in skin lesions. Biopsy specimens of older lesions may be relatively "cell poor" and show features that correlate with the noninflammatory character of such sites clinically. Light microscopy studies of older lesions often show fibroblast proliferation and lamellar fibrosis (i.e., fibrosis characterized by collagen bundles ordered parallel to the surface epithelium).

ELECTRON MICROSCOPY

Ultrastructural studies of lesional skin or mucosa from patients with cicatricial pemphigoid show that blisters typically develop within the lamina lucida and eventuate in partial or complete destruction of the basal lamina in older lesions.[62–66] A generally held impression is that blisters form below those of bullous pemphigoid, because scarring is more common in patients with this disease. Reports of patients with blisters in the sublamina densa region are thought to represent mucosa-predominant forms of epidermolysis bullosa acquisita.

IMMUNOFLUORESCENCE MICROSCOPY

Direct immunofluorescence microscopy of normal-appearing perilesional tissue from patients with cicatricial pemphigoid shows continuous deposits of immunoreactants in epithelial basement membranes.[5,66] The most commonly detected immunoreactants are IgG and C3 (see Fig. 57-1); the predominant subclass of these autoantibodies is IgG4.[67] IgA, IgM, and/or fibrin are found in some patients.[68] One study of skin and mucosal samples from ten patients found immunoreactants more commonly in perilesional mucosal biopsy specimens, which suggests that mucous membranes are the preferred biopsy site for direct immunofluorescence microscopy studies.[66] Splitting tissue samples with 1 M NaCl increases the sensitivity of direct immunofluorescence microscopy and facilitates identification of immunoreactants as well as their relative distribution within epithelial basement membranes.[69,70]

Indirect immunofluorescence microscopy studies using intact skin or mucosa often find low-titer IgG (and/or IgA) antibasement membrane autoantibodies in patients with cicatricial pemphigoid.[1,3,5,71] The use of 1 M NaCl-split skin as a test substrate in these studies substantially increases the detection of such autoantibodies.[27,72,73] In such studies, IgG (and/or IgA) binding is usually directed against the epidermal side of 1 M NaCl-split skin, although combined epidermal and dermal or exclusively dermal binding can occur. In fact, this heterogeneity in autoantibody binding patterns was one of the first clues that cicatricial pemphigoid is a disease phenotype that is associated with different autoantigens (see Table 57-1). Although some studies have suggested that the use of human mucosal tissue substrates increases the likelihood of detecting autoantibodies in patients with cicatricial pemphigoid, other studies have not obtained similar results.[6,66] Patients with both IgG and IgA antibasement membrane autoantibodies appear to have a worse prognosis

as defined by requirements for medications to control disease as well as overall clinical severity score.[33,35]

SPECIALIZED TESTS

Selected cases may require specialized immunochemical studies (e.g., immunoblot studies of keratinocyte or skin extracts, immunoprecipitation studies of biosynthetically radiolabeled keratinocytes) to identify the autoantigen targeted by patient antibasement membrane autoantibodies. Perilesional tissue from seronegative patients may be further characterized by immunoelectron microscopy studies to determine if in situ deposits of immunoreactants reside above or below the lamina densa of epidermal basement membrane.

DIFFERENTIAL DIAGNOSIS

The diagnosis of cicatricial pemphigoid is suggested when patients present with bullous or erosive lesions of mucous membranes and continuous deposits of immunoreactants are demonstrated in epithelial basement membranes of perilesional tissue. Distinguishing cicatricial pemphigoid from other autoimmune bullous diseases can be difficult and may require specialized immunopathologic studies and/or immunoelectron microscopy. Disorders that must be differentiated from cicatricial pemphigoid include lichen planus, erythema multiforme, lupus erythematosus, lichen sclerosus, and—in the case of ocular disease—cicatrizing or inflammatory conjunctivitis that results from long-term use of certain ophthalmologic preparations (e.g., pilocarpine, guanethidine, or ephedrine used in the treatment of glaucoma or idoxuridine used as an antiviral) or biologics that inhibit epidermal growth factor receptor tyrosine kinase (Box 57-1).[37,74] It also has been reported that some cases of ocular cicatricial pemphigoid develop after an acute episode of severe ocular inflammatory injury secondary to Stevens–Johnson syndrome[75] (see Chapter 40). Interestingly, the time between the appearance of Stevens–Johnson syndrome and the onset of ocular cicatricial pemphigoid in these patients can range from a few months to more than 30 years.

COMPLICATIONS

Site-specific complications of cicatricial pemphigoid were outlined earlier and are summarized in Table 57-2.

PROGNOSIS AND CLINICAL COURSE

Cicatricial pemphigoid is typically a chronic and progressive disorder, although involvement may be limited to a given anatomic site (e.g., the mouth, the conjunctivae) for many years. Cicatricial pemphigoid rarely goes into spontaneous remission; its treatment is largely determined by its severity and sites of involvement. Scarring can only be prevented in these patients; it cannot be reversed.

BOX 57-1 DIFFERENTIAL DIAGNOSIS OF CICATRICIAL PEMPHIGOID

Most Likely

- Pemphigus
  - Pemphigus vulgaris
  - Paraneoplastic pemphigus
- Other subepidermal immunobullous diseases
  - Epidermolysis bullosa acquisita
  - Bullous pemphigoid
  - Linear immunoglobulin A dermatosis
- Erythema multiforme
- Lupus erythematosus
- Lichen planus

Consider

- Drug-induced hypersensitivity reaction
- Lichen sclerosus (especially in the anogenital area)

Always Rule Out

- Pemphigus (specifically, pemphigus vulgaris, paraneoplastic pemphigus)
- Other subepidermal immunobullous diseases
- Erythema multiforme
- Lupus erythematosus
- Lichen planus

TREATMENT

The following overview (Box 57-2) is representative of most treatment regimens.[4,76–78]

Mild lesions of the oral mucosa and skin can often be treated effectively with topical glucocorticoids (or calcineurin inhibitors such as tacrolimus) in a gel or ointment base applied two to four times each day.[77,79,80] Blotting lesional sites dry with a soft disposable tissue can enhance the adherence and effectiveness of topical agents applied to lesional sites in the mouth. These agents are particularly effective before bed, because oral secretions diminish during sleep. Because it is difficult to maintain contact of topical agents with mucous membranes (and because lesions often are localized to the gingiva), customized delivery trays to occlude topical glucocorticoids over lesional sites in the mouth are also useful.[81] This approach also facilitates interactions with professionals who can manage other complications in these patients (e.g., dental complications). Mouthwash (dexamethasone 100 µg/mL, 5 mL per rinse) used in a "swish-and-spit" regimen for 5 minutes two to three times each day represents another approach for topical therapy. For oral disease resistant to topical glucocorticoids, these agents can (in some instances) be administered intralesionally. In addition to these measures, patients should follow a strict regimen of oral hygiene that includes regular brushing, flossing, and cleaning of teeth. Use of toothpastes and mouthwashes that lack sodium lauryl

TABLE 57-2
Potential Complications of Cicatricial Pemphigoid

Site	Potential Complications
Mouth	
Mucosa	Painful, erosive scarring lesions; adhesions between the buccal mucosa and the alveolar process; the uvula and the tonsillar fossae; the tongue and the floor of the mouth
Gingiva	Loss of gingival tissue, caries, periodontal ligament damage, loss of alveolar bone, loss of teeth
Eyes	
Conjunctivae	Painful, erosive conjunctivitis; foreign-body sensations; photophobia; scarring; shortened fornices; loss of goblet cells; decrease in tear mucus content, unstable tear film; symblepharons; ankyloblepharons
Eyelids	Ectropion, trichiasis, ankyloblepharons
Cornea	Corneal irritation, superficial punctate keratinopathy, corneal neovascularization, corneal ulcers, blindness
Tear ducts	Scarring, occlusion, secondary infection
Nose	Discharge, epistaxis, excessive crust formation, impaired airflow, recurrent and chronic sinusitis, scarring, tissue loss
Larynx	Hoarseness, impaired phonation, loss of voice, scarring, supraglottic stenosis, airway compromise, and loss
Esophagus	Dysphagia, odynophagia, impaired swallowing, aspiration, stricture formation, weight loss
Anogenital region	Painful erosions, stenosis, stricture, secondary infection

sulfate and alcohol, respectively, often facilitates patient compliance with such activities.

A number of reports have suggested that dapsone (50–200 mg by mouth daily) may be effective.[38,82] Others have found that cicatricial pemphigoid does not respond to this agent. Systemic glucocorticoids can be administered alone (e.g., 20–60 mg of prednisone by mouth each morning) or in combination with dapsone. Because of potentially severe complications, ocular, laryngeal, esophageal, and/or anogenital involvement requires aggressive management by teams of physicians familiar with specialized care of these organ systems. For mild or moderate ocular involvement, systemic glucocorticoids (e.g., 20–60 mg of prednisone by mouth each morning) alone or in conjunction with daily dapsone may be effective. Patients whose ocular disease is complicated by trichiasis may benefit from epilation, although this decision is best made by an

BOX 57-2 TREATMENTS FOR CICATRICIAL PEMPHIGOID

MILD INVOLVEMENT

Sites	***Local Care Measures***
Mouth	Topical corticosteroid (gels or ointments) bid/qid; topical corticosteroids under occlusion (e.g., dental trays); topical calcineurin inhibitors; intralesional corticosteroids
Nose	Irrigation with isotonic saline bid/tid; nasal lubricants; topical corticosteroids (e.g., via sprays, inhalers)
Anogenital region	Topical corticosteroids; topical calcineurin inhibitors
Skin	Topical corticosteroids; topical calcineurin inhibitors

MODERATE INVOLVEMENT

Sites	***Therapeutic Options***
Mouth, eyes, nose, larynx, esophagus, anogenital region	Local care measures outlined above plus dapsone 50–200 mg daily, prednisone 20–60 mg each morning, or both of these agents simultaneously

SEVERE INVOLVEMENT

Sites	***Therapeutic Options***
Mouth, eyes, nose, larynx, esophagus, anogenital region	Local care measures outlined above plus prednisone (1 mg/kg each morning), intravenous immunoglobulin (2 g/kg body weight over 2–3 days every 2–6 week for 4–6 months), or both of these agents simultaneously in conjunction with azathioprine (2–2.5 mg/kg/day), mycophenolate mofetil (1–2.5 g/day), cyclophosphamide (1–2 mg/kg/day), or rituximab (375 mg/m^2 weekly × 4 then every 4–6 months as needed, or 1000 mg on days 1 and 15 and then 500 mg at month 6).

ophthalmologist. For severe disease affecting the ocular, pharyngeal, or urogenital epithelia, a combination of systemic glucocorticoids and an additional immunosuppressive is indicated. In such cases, azathioprine (2.0–2.5 mg/kg/day), mycophenolate mofetil (1.0–2.5 g/day), or cyclophosphamide (1–2 mg/kg/day) are often used in conjunction with daily prednisone (1 mg/kg/day).[77,83–86] In this regimen, daily prednisone is tapered gradually over approximately 6 months, and the patient is maintained on the alternate agent alone for an additional 6–12 months. Such combined regimens have had success in halting the progression of severe ocular disease, limiting scarring, and producing long-term remissions. In an effort to avoid adverse effects and complications produced by prolonged treatment with immunosuppressive agents, some groups treat patients with intravenous immunoglobulin (i.e., intravenous immunoglobulin 2 g/kg of body weight administered over 2–3 days every 2–6 weeks for 4–6 months).[87–90] Another emerging trend in the management of patients with particularly severe disease is the use of biologic agents that antagonize tumor necrosis factor-α (e.g., etanercept, infliximab) or bind CD20 (rituximab).[91,92]

Involvement of the nasopharynx or esophagus potentially has severe complications and requires aggressive and specialized care. Nasal lesions often benefit from twice-daily irrigation of the nasal passages with saline or tap water as well as the use of topical emollients. Esophageal involvement requires medical management to avert dysphagia, pain, tissue loss, and secondary complications such as gastroesophageal dysfunction and reflux, stricture formation, aspiration, laryngeal irritation, or bronchospastic pulmonary disease. All patients with cicatricial pemphigoid require long-term follow-up because of the possibility for this chronic disease to relapse.

KEY REFERENCES

Full reference list available at www.DIGM8.com

DVD contains references and additional content

2. Chan LS et al.: The first international consensus on mucous membrane pemphigoid: Definition, diagnostic criteria, pathogenic factors, medical treatment, and prognostic indicators. *Arch Dermatol* **138**:370, 2002
3. Fleming TE, Korman NJ: Cicatricial pemphigoid. *J Am Acad Dermatol* **43**:571, 2000
15. Olasz EB, Yancey KB: Bullous pemphigoid and related subepidermal autoimmune blistering diseases. *Curr Dir Autoimmun* **10**:141, 2008
47. Egan CA et al: Anti-epiligrin cicatricial pemphigoid: Clinical findings, immunopathogenesis, and significant associations. *Medicine (Baltimore)* **82**:177, 2003
76. Kirtschig G et al: Interventions for mucous membrane pemphigoid/cicatricial pemphigoid and epidermolysis bullosa acquisita: A systematic literature review. *Arch Dermatol* **138**:380, 2002

Chapter 58 :: Linear Immunoglobulin A Dermatosis and Chronic Bullous Disease of Childhood

:: Caroline L. Rao & Russell P. Hall III

LINEAR IMMUNOGLOBULIN A DERMATOSIS AT A GLANCE

- Rare blistering disease with onset typically after fourth decade of life.
- Linear band of immunoglobulin A at the dermal–epidermal basement membrane.
- Clinical presentations may mimic dermatitis herpetiformis, bullous pemphigoid, and cicatricial pemphigoid.
- May occur in association with many drugs, including vancomycin.
- May occur in association with inflammatory bowel diseases but only rarely associated with gluten sensitive enteropathy.
- Rarely seen in association with malignancy, specifically lymphoid.
- Histology shows subepidermal collection of neutrophils at the basement membrane, often collecting in papillary tips with subepidermal blisters.
- Most patients respond dramatically to treatment with dapsone; some require adjunctive systemic corticosteroids.
- Prognosis variable with both spontaneous remissions and long-standing disease.

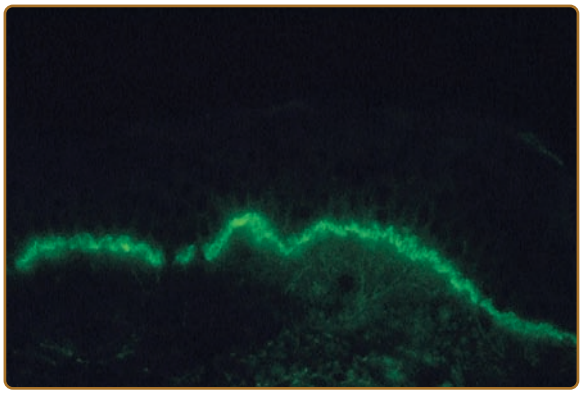

Figure 58-1 Direct immunofluorescence of normal-appearing perilesional skin from a patient with linear immunoglobulin A dermatosis. A homogeneous band of immunoglobulin A is present at the dermal–epidermal junction.

Linear immunoglobulin A (IgA) dermatosis is a rare immune-mediated blistering skin disease that is defined by the presence of homogeneous linear deposits of IgA at the cutaneous basement membrane (Fig. 58-1). Although in the original description of patients with linear IgA dermatosis it was considered to be a manifestation of dermatitis herpetiformis (DH), it has now been clearly separated from DH on the basis of its immunopathology, immunogenetics, and lack of consistent association with a gluten-sensitive enteropathy.[1–4] Patients with linear IgA dermatosis can present with lesions suggestive of epidermolysis bullosa acquisita (EBA), DH, bullous pemphigoid (BP), lichen planus, prurigo nodularis, or cicatricial pemphigoid.[1–6]

Drug-induced linear IgA was initially described in association with vancomycin and has subsequently been associated with a wide variety of drugs.[7–11] Drug-induced linear IgA has been found to differ somewhat from classic linear IgA in clinical presentation with a wider variety of clinical presentations including morbilliform, erythema multiforme like, and toxic epidermal necrolysis like.[7–14]

Chronic bullous disease of childhood (CBDC) is a rare blistering disease that occurs predominantly in children younger than 5 years of age and has an identical pattern of homogeneous linear IgA deposits at the epidermal basement membrane.[15,16] Recent studies have demonstrated that in some patients CBDC and linear IgA dermatosis represent different presentations of the same disease process.[17,18]

EPIDEMIOLOGY

Linear IgA dermatosis occurs most often after puberty, with most patients presenting after the fourth decade of life.[2,4,19] A slight predominance of females has been noted in several studies.[2,4,20] In contrast, CBDC presents most often before the age of 5 years.[20]As in patients with linear IgA dermatosis, there is a slight female predominance in patients with CBDC.[16,20]

Evaluation of the HLA association in patients with linear IgA dermatosis and CBDC has yielded conflicting results. Some investigators have found an increased frequency of the human histocompatibility antigen HLA-B8 in patients with linear IgA dermatosis, whereas others have found no increased frequency.[21–23] In CBDC, an increased frequency of HLA-B8 has been noted, with up to 76% of patients expressing HLA-B8.[20] Collier et al demonstrated an increased frequency of HLA-B8, -DR3, and -DQ2 in CBDC that was not seen in adults with linear IgA dermatosis.[21] These authors suggested that these haplotypes may have a role in earlier disease presentation. In addition, the *TNF2* allele was found with increased frequency in both adults and children with linear IgA disease when compared with unaffected subjects. There was, however, no increase seen in either adults or children when compared with HLA-DR3$^+$ controls.

CHRONIC BULLOUS DISEASE OF CHILDHOOD AT A GLANCE

- Rare blistering disorder of childhood presenting predominantly in children less than 5 years of age.
- Linear IgA at the dermal–epidermal basement membrane.
- Clinical presentation of tense bullae, often in perineum and perioral regions, giving a "cluster of jewels" appearance. New lesions sometimes appear around the periphery of previous lesions with a collarette of blisters.
- Histology shows subepidermal collection of neutrophils at the basement membrane, similar to linear IgA bullous dermatosis.
- Most patients respond dramatically to treatment with dapsone.
- Spontaneous remissions, often within 2 years, are frequent.

ETIOLOGY AND PATHOGENESIS: IMMUNOPATHOLOGY

Linear IgA dermatosis and CBDC are defined by the presence of a homogeneous linear band of IgA at the dermal–epidermal basement membrane zone. A minority of patients in both groups have additional deposits of other immunoreactants, most often IgG and occasionally the third component of complement (C3).[20] Because IgA is the predominant Ig of the secretory immune system, numerous investigators have attempted to determine if the IgA present in the skin of these patients is of mucosal origin. Characterization of the IgA subclass in the skin has revealed almost exclusively IgA1 and not the subclass most often associated

with mucosa, IgA2.[19,24,25] In addition, neither secretory piece nor J chain, both of which are present in secretory IgA, have been found in the IgA present in the skin of patients with linear IgA deposits.[26] Although these data have led to suggestions that the IgA is not of mucosal origin, the true origin of the IgA deposits in the skin of these patients is not known.

Initially it was thought that patients with linear IgA dermatosis and CBDC rarely had circulating IgA antibodies against the epidermal basement membrane. Indirect immunofluorescence, using 1 M NaCl-split normal human skin as a substrate, demonstrates that the majority of patients with CBDC have low-titer circulating antibodies against the epidermal side of the split skin.[19] Circulating low-titer IgA antibodies directed against the epidermal basement membrane also have been found in adults with linear IgA dermatosis.[20,27] Others have reported binding of IgA antibodies from some patients to the dermal side of normal human split skin, suggesting that more than one antigen may be the target for the IgA antibasement membrane antibodies.[27–29] Immunoelectron microscopic studies have been performed to determine the exact location of the IgA in the skin of patients with both linear IgA dermatosis and CBDC. Immunoelectron microscopy of the skin of patients with linear IgA deposits has revealed three distinct patterns of immunoreactants. In some patients with linear IgA dermatosis, the IgA deposits are found in the lamina lucida region of the basement membrane zone, similar to the location of immunoreactants present in the skin of patients with BP.[28,29] A second pattern of IgA deposition has been detected in which the IgA deposits are present at and below the lamina densa in a pattern similar to that seen in EBA.[28–30] Prost et al have described a third pattern of immunoreactants in some patients with linear IgA dermatosis in which the IgA deposits are found both above and below the lamina densa.[29] In a similar manner, immunoelectron microscopic studies of skin of patients with CBDC have shown the IgA immunoreactants to be in either the lamina lucida or a sublamina densa location.[17,30] These findings further support the probability that multiple antigens may be involved as the targets in both adults and children with linear IgA deposits in the skin. Horiguchi et al reviewed 213 cases of linear IgA in Japan and found a strong association between older age of onset and both IgG/IgA type and dermal binding. IgG was found in approximately 9% of patients with the infantile (CBDC) type whereas in adults (>16 years) IgG was found in 24% of patients. Interestingly, when comparing the different groups based on patterns of antigen binding (e.g., dermal vs. epidermal and IgA vs. IgG/A) no significant clinical differences were found.[31]

Although the relatively low titer of IgA antibodies against the basement membrane present in the sera of patients with both linear IgA dermatosis and CBDC has complicated the search for specific antigenic targets for the IgA, several investigators have made significant observations regarding the antigenic targets in these diseases. Zone et al studied sera from patients who had circulating IgA antibodies that bound to the epidermal side of 1 M NaCl-split normal human skin, as shown by indirect immunofluorescence.[32] They found that serum IgA from patients with either CBDC or linear IgA dermatosis bound to a 97-kDa protein. Immunoelectron microscopy revealed that the 97-kDa antigen is present in the lamina lucida, below the hemidesmosome of normal human skin, in a location similar to where the IgA is localized in patients with CBDC and linear IgA dermatosis.[33] Subsequently, Zone et al determined that the 97-kDa linear IgA bullous disease antigen is identical to a portion of the extracellular domain of the 180-kDa BP antigen (BPAG2 or collagen XVII), which is essential in anchoring basal keratinocytes to the epidermal basement membrane.[34] The BP antigen (BPAG2) consists of a 180-kDa transmembrane protein and 120-kDa portion that corresponds to the collagenous ectodomain. Roh et al and Schumann et al have reported that autoantibodies in patients with linear IgA dermatosis recognize the soluble 120-kDa ectodomain of type XVII collagen[35,36] The 120-kDa antigen target is not unique to linear IgA dermatosis because it is also the antigen targeted by autoantibodies in some patients with cicatricial pemphigoid and BP.[35,36] Furthermore, IgA antibodies and T cells from patients with linear IgA bullous dermatosis have been found to be directed against the NC-16A region of collagen type XVII, which is the same region against which the IgG and T cells from patients with BP are directed.[37,38] This may explain in part the overlap in clinical and histologic features of these conditions. Wojnarowska et al have identified another possible target antigen in patients with linear IgA dermatosis and CBDC using sera from patients in whom the IgA bound to the epidermal side of 1 M NaCl-split skin on routine indirect immunofluorescence. They found that IgA in the sera of some patients with these diseases bound to a 285-kDa protein (LAD 285) that was not the 230-kDa BP antigen or type VII collagen, the EBA antigen.[39]Allen and Wojnarowska have analyzed the sera of over 70 patients with both linear IgA dermatosis and CBDC and found that the predominant antigenic target in these patients is the BP180 antigen (collagen XVII), but that some patients react with multiple antigens including the BP230, LAD 285, and other yet to be identified proteins.[40] Ishtii et al described a patient with Linear IgA who had antibodies directed at the NC16a domain of BP180 without evidence of antibody formation to 120-kDa LAD 1.[41] In many patients, IgA appears to bind to several different antigenic targets, suggesting the possibility that there is epitope spreading. The clinical significance of these findings however, has not been established.[40]

CLINICAL FINDINGS

CUTANEOUS MANIFESTATIONS

The clinical manifestations of linear IgA dermatosis are heterogeneous and often indistinguishable from those seen in patients with DH.[2,4,20,42] Patients may present



Figure 58-2 Patient with linear immunoglobulin A dermatosis with crusted erosions, papules, and vesicles on the back and neck.



Figure 58-4 Patient with linear immunoglobulin A dermatosis with grouped urticarial papules on the back with scattered crusted erosions.

with combinations of annular or grouped papules, vesicles, and bullae (Figs. 58-2 and 58-3). Typically, these lesions are distributed symmetrically on extensor surfaces, including elbows, knees, and buttocks. Lesions most often are very pruritic, resulting in numerous crusted papules (Fig. 58-4). The clinical presentation can be difficult to distinguish from that seen in patients with DH. However, the degree of pruritus seen in patients with linear IgA dermatosis is variable and, in general, less severe than that seen in patients with DH. Some patients with linear IgA dermatosis present with larger bullae, in a pattern more consistent with that seen in patients with BP, or occasionally with cutaneous findings similar to those seen in patients with EBA.



Figure 58-3 Patient with linear immunoglobulin A dermatosis with annular erythematous plaques on the thighs.

Patients with drug-induced linear IgA bullous dermatosis have been reported with erythema multiforme-like findings and a toxic epidermal necrolysis-like presentation, with widespread bullae.[7,11,13] Localized palmar and morbilliform variants have also been described.[12,14] While vancomycin is most closely associated with the drug-induced linear IgA, a number of other medications have also been implicated including lithium, phenytoin, sulfamethoxazole/trimethoprim, furosemide, atorvastatin, captopril, and diclofenac.[13] In addition, a localized linear IgA in the setting of an acute contact dermatitis has been reported.[43] Recovery has been reported with discontinuation of the offending agent alone, but these patients may benefit from dapsone therapy (see Section "Treatment and Prognosis").[7,11,44]

The clinical presentation of CBDC is characterized most often by the development of tense bullae, often on an inflammatory base.[15] These lesions occur most frequently in the perineum and perioral region and often may occur in clusters, giving a "cluster of jewels" appearance (Figs. 58-5–58-7). New lesions sometimes appear around the periphery of previous lesions, with a resulting "collarette" of blisters. Patients often



Figure 58-5 Patient with chronic bullous disease of childhood. Tense bullae and crusted papules are present on the abdomen, with a clustering of bullae noted in the perineal region.



Figure 58-7 Extensive chronic bullous disease of childhood. Note tense and flaccid blisters without notable inflammation.

report significant pruritus and/or a burning of the skin with the development of skin lesions. Patients with CBDC often present with the acute development of large numbers of tense blisters, which may rupture and become secondarily infected. CBDC differs from linear IgA bullous dermatosis of adults in its typical clinical appearance, relative paucity of serious mucosal involvement, and good prognosis.[31]

Rarely, patients with linear IgA dermatosis may present with an acute febrile illness with arthritis, arthralgias, and generalized malaise.[45,46] The presence of multiple papules and vesicles in a patient with systemic signs and symptoms has led to the evaluation of these patients for systemic infections, including viral infections. Routine direct immunofluorescence, however, has revealed linear deposits of IgA, and these patients have responded to conventional therapy.



Figure 58-6 Chronic bullous disease of childhood. Tense blisters on erythematous bases in the pubic and inguinal areas.

MUCOSAL INVOLVEMENT

Mucosal involvement is an important clinical manifestation seen in patients with linear IgA dermatosis and CBDC. This involvement can range from largely asymptomatic oral ulcerations and erosions to severe oral disease alone as well as to severe conjunctival and oral disease typical of that seen in cicatricial pemphigoid.[20,47,48] Oral lesions may occur in up to 70% of patients with linear IgA disease.[20] Mucosal invasion with complication is less often seen in CBDC.[31] Although most patients with linear IgA dermatosis and mucosal involvement have significant cutaneous disease, cases have been reported in the literature in which the presenting and predominant clinical manifestations are lesions of the mucous membranes.[48,49] These patients may present with desquamative gingivitis and oral lesions consistent with those seen in patients with cicatricial pemphigoid (see Chapter 57). Patients also may present with conjunctival disease and scar formation typical of that seen in patients with cicatricial pemphigoid (see Chapter 57). Mucosal involvement also appears to be less prominent in patients with drug-induced linear IgA.[13] Patients with linear IgA bullous dermatosis have also been reported to present with severe laryngeal and pharyngeal involvement before the development of more typical cutaneous manifestitations.[50]

DISEASE ASSOCIATIONS

The similar clinical presentation of many patients with linear IgA disease to that seen in patients with DH led to the investigation of patients with linear IgA disease for an associated gluten-sensitive enteropathy. Although some investigators have found evidence of minimal inflammatory changes in the small bowel of patients with linear IgA disease, numerous investigators have been unable to show that the majority of patients with linear IgA disease have significant evidence of the villous atrophy characteristically seen in patients with DH.[3,51] In addition, the clinical manifestations of linear IgA disease have not been controlled by the use of a gluten-free diet.[52] Circulating autoantibodies against tissue transglutaminase, which occur in high frequency in patients with untreated gluten-sensitive enteropathy and DH, have not been found in most patients with linear IgA diseases.[53]

Other conditions have been reported in association with linear IgA disease. One example is ulcerative colitis (UC) and Crohn's disease, which can result in a clinical syndrome where the activity of both diseases is linked (i.e., as one disease flares, so does the other).[54,55] Paige and coworkers reviewed 70 patients with linear IgA bullous dermatosis and found 7.1% had associated UC. The extent and reason for this association has yet to be established. Perhaps, the abnormal mucosal IgA1 production seen in patients with UC may play a role.[55] In patients with CBDC, Horoguchi reported associated systemic disease in only 13 of 213 cases reviewed.[31] CBDC also has been reported in association with acute mononucleosis and *Paecilomyces* lung infection in the setting of chronic granulomatous disease.[56] The relationship between these conditions and CBDC has yet to be established.

The relatively acute onset of clinical, histologic, and immunopathologic findings consistent with linear IgA disease has been seen in patients who have been taking a variety of drugs, including vancomycin, lithium phenytoin, sulfamethoxazole/trimethoprim, furosemide, atorvastatin, captopril, and diclofenac.[7–9,13,44] Vancomycin is the most common drug that is associated with the development of linear IgA bullous dermatosis. Linear IgA dermatosis has similarly been described with interferon α2a and was temporally related to the influenza vaccine. While these may reflect an induction of a previously unrecognized autoimmune process, in both cases the eruption was self-limited, in contrast to classic linear IgA, which follows a chronic, waxing and waning course.[57,58] The mechanism of this interaction is not known; however, a small number of patients with vancomycin-induced linear IgA disease have been reported to have circulating IgA antibodies directed against the BP180, BP230, and LAD 285 antigens.[59,60] In one case of vancomycin-induced linear IgA bullous dermatosis, rechallenge with vancomycin in a gradual manner did not result in a recurrence of the eruption.[61]

Linear IgA disease also has been associated rarely with a variety of malignancies. Patients with linear IgA disease have been reported with both lymphoid and nonlymphoid malignancies.[62,63] Godfrey et al reported three cases of lymphoid malignancies in 70 patients with linear IgA disease followed for a mean of 8.5 years. This represented an increase over the predicted number of 0.2 cases in an age- and sex-matched population.[62] No increase in the rate of nonlymphoid malignancies was seen. These findings suggest a small risk of lymphoid malignancy in these patients. However, larger population-based studies need to be done to confirm these findings.

HISTOPATHOLOGY

Routine histopathology of an early lesion in patients with linear IgA dermatosis and CBDC reveals a subepidermal bulla with collections of neutrophils along the basement membrane, often accumulating at the papillary tips (Fig. 58-8). A mild lymphocytic infiltrate may be present around the superficial dermal blood vessels without any evidence of neutrophilic vasculitis. Occasionally, the inflammatory infiltrate is composed of eosinophils, but most frequently neutrophils are the major component of the subepidermal inflammation.[20,64,65] Electron microscopic examination of the blisters found in patients with both linear IgA dermatosis and CBDC has revealed that the blister forms either within the lamina lucida or in a sublamina densa location.[17,28] Most often the histopathology seen in linear IgA disease is difficult to distinguish from that seen in patients with DH. Smith et al[65] reported that patients with linear IgA disease tended to have fewer papillary microabscesses and a more diffuse infiltrate of neutrophils at the basement membrane zone. However, Blenkinsopp et al found no significant difference between the histopathology found in patients with linear IgA disease and those with DH.[64] In general, the histopathology of blisters in linear IgA disease, CBDC, and DH is virtually indistinguishable.

DIFFERENTIAL DIAGNOSIS

Linear IgA dermatosis often closely mimics the clinical pattern seen in patients with DH. Some patients may

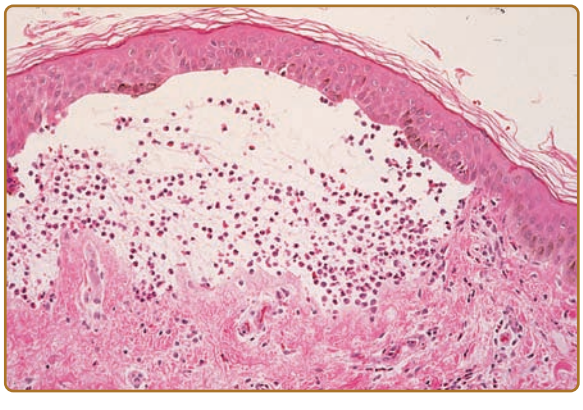

Figure 58-8 Histopathology of lesional skin from a patient with linear immunoglobulin A dermatosis showing a subepidermal blister filled with neutrophils. (Used with permission from Kim B. Yancey, MD.)

BOX 58-1 LINEAR IMMUNOGLOBULIN A BULLOUS DERMATOSIS DIFFERENTIAL DIAGNOSIS

- Dermatitis herpetiformis
- Bullous pemphigoid
- Epidermolysis bullosa acquisita
- Bullous eruption of systemic lupus erythematosus
- Cicatricial pemphigoid
- Lichen planus
- Toxic epidermal necrolysis

have findings that resemble those seen in patients with BP, cicatricial pemphigoid, EBA, and, rarely, toxic epidermal necrolysis. In a similar manner, patients with CBDC must be differentiated from those with DH of childhood and childhood BP. The findings of linear IgA deposits at the basement membrane by direct immunofluorescence, most often in the absence of IgG and the C3, can distinguish this disease from BP, cicatricial pemphigoid, and EBA, whereas granular IgA deposits are found at the basement membrane in patients with DH (Box 58-1).

TREATMENT AND PROGNOSIS

Adults with linear IgA dermatosis have an unpredictable course.[4,20] Many patients have disease that continues for years, with few, if any, episodes of remission. Occasionally, patients may have a spontaneous remission with loss of clinical features of the disease and disappearance of the linear IgA deposits in the skin. Patients with severe mucosal disease, especially of the eyes, may have persistent problems with symblepharon formation and resulting structural problems with the eyelids and cornea, even after active blistering has remitted. Untreated ocular involvement can lead to cicatrix and loss of vision.[66]

Patients with linear IgA disease most often respond dramatically to dapsone or sulfapyridine. This response usually occurs within 24–48 hours, in a manner similar to that seen with DH; as such, it is not a helpful diagnostic sign for linear IgA disease.[2,4,20] Although most patients are well controlled with dapsone or sulfapyridine alone, some patients require low-dose prednisone therapy to suppress blister formation.[20] In patients who are unresponsive or intolerant of these medications, mycophenolate mofetil has been useful as a steroid-sparing agent.[67] Trimethoprim/sulfamethoxazole has been reported to be helpful when used in conjunction with other immunosuppressives.[68] The majority of patients with linear IgA disease cannot control their skin disease with a gluten-free diet.[52]

CBDC is most often a self-limited disease, with most children going into remission within 2 years of the onset of the disease.[15,16,20] Occasionally, the disease persists well into puberty but often is less severe than the initial eruption. Patients with CBDC respond in a similar dramatic fashion to dapsone or sulfapyridine.[15,16,20] Many children, however, require the addition of relatively small doses of prednisone to bring the disease under control.[15,16] Mycophenolate mofetil has been used as a steroid-sparing agent in isolated cases.[69] Intravenous immunoglobulins have also been proposed in the rare patient not responding to, or intolerant of, dapsone therapy.[70,71] Topical tacrolimus may also be a useful tool in minimizing systemic therapy.[72] Several case reports suggest that some patients with CBDC may respond to antibiotics, including sulfonamides, dicloxacillin, and erythromycin.[73,74] In one case series, seven children with linear IgA disease treated with flucloxacillin demonstrated improvement, with four achieving remission within 3 months.[75] However, spontaneous remission in these patients cannot be ruled out.

KEY REFERENCES

Full reference list available at www.DIGM8.com

DVD contains references and additional content

3. Lawley TJ et al: Small intestinal biopsies and HLA types in dermatitis herpetiformis patients with granular and linear IgA skin deposits. *J Invest Dermatol* **74**:9-12, 1980
16. Jablonska S et al: Linear IgA bullous dermatosis of childhood (Chronic bullous dermatosis of childhood). *Clin Dermatol* **9**:393-401, 1992
20. Wojnarowska F et al: Chronic bullous disease of childhood, childhood cicatricial pemphigoid and linear IgA disease of adults: A comparative study demonstrating clinical and immunopathologic overlap. *J Am Acad Dermatol* **19**:792-805, 1988
32. Zone JJ et al: Identification of the cutaneous basement membrane zone antigen and isolation of antibody in linear immunoglobulin A bullous dermatosis. *J Clin Invest* **85**:812-820, 1990
34. Zone JJ et al: The 97 kDa linear IgA bullous disease antigen is identical to a portion of the extracellular domain of the 180 kDa bullous pemphigoid antigen, BPAg2. *J Invest Dermatol* **110**:207-210, 1998
46. Leigh G, Marsden RA, Wojnarowska F: Linear IgA dermatosis with severe arthralgia. *Br J Dermatol* **119**:789-792, 1988
52. Leonard JN et al: Experience with a gluten free diet in the treatment of linear IgA disease. *Acta Derm Venerol (Stockh)* **67**:145-148, 1987

Chapter 59 :: Pemphigoid Gestationis (Herpes Gestationis)

:: Jeff K. Shornick

PEMPHIGOID GESTATIONIS AT A GLANCE

- Acute-onset, intensely pruritic, vesiculobullous eruption of pregnancy or the immediate postpartum period.
- Rare, occurring in roughly 1 in 50,000 pregnancies.
- Histopathology: dermal–epidermal separation with numerous eosinophils.
- Direct immunofluorescence: linear deposition of C3, with or without immunoglobulin (Ig) G, along the basement membrane zone of the epidermal fragment of salt-split skin.
- Enzyme-linked immunosorbent assay for pemphigoid gestationis antibody (BP180) commercially available.
- No significant maternal morbidity or mortality.
- Associated with a slight increase in premature and small-for-gestational-age births.

EPIDEMIOLOGY

Pemphigoid gestationis (PG) is the least common, yet best-characterized, dermatitis specific to pregnancy.[1] It classically presents as an intensely pruritic, urticarial rash during the later part of pregnancy or the immediate postpartum period, then rapidly progresses to a pemphigoid-like, vesiculobullous eruption. The rash may wax and wane during pregnancy, only to flare during labor and delivery. PG appears to be mediated by a specific immunoglobulin (Ig) G directed against the cutaneous basement membrane zone (BMZ).

PG occurs in approximately 1 in 50,000 pregnancies.[2,3] It is associated with HLA-DR3 and -DR4, and it appears likely that the incidence in various ethnic groups parallels the frequency of these genes in different populations.[4]

ETIOLOGY AND PATHOGENESIS

PG appears to be caused by an anti-BMZ antibody that induces C3 deposition along the dermal–epidermal junction. The PG autoantibody (formerly called HG factor) is an IgG that is infrequently found by direct immunofluorescence (IF), although indirect, complement-added IF reveals the circulating IgG in the majority of patients. In salt-split skin, staining remains with the epidermal fragment. An enzyme-linked immunosorbent assay (ELISA) for the PG antibody is commercially available, and when this highly sensitive test is used, antibody titers appear to correlate with disease activity.[5] The PG autoantibody appears to belong to the IgG1 subclass and fixes complement via the classical complement pathway.[6] T cells also show selective NC16A reactivity in PG, although their role in disease development remains to be elucidated.[7]

Nearly all patients with PG [and most patients with bullous pemphigoid (BP)] have demonstrable antibodies to BP180 (type XVII collagen), a 180-kDa transmembrane protein with its *N*-terminal end embedded within the intracellular component of the hemidesmosome and its *C*-terminal end located extracellularly (see Chapter 53). The extracellular section contains a series of 15 collagenous components alternating with 16 short, noncollagenous domains. The sixteenth noncollagenous segment closest to the plasma membrane of the basal keratinocyte is designated NC16A and contains the BP180 immunoreactive site.[8,9] The PG autoantibody is assumed to be pathogenic for several reasons: (1) It is found in essentially all patients. (2) In vitro, purified antibodies to BP180 cause chemoattraction to the dermal–epidermal junction with subsequent degranulation and dermal–epidermal separation.[10] (3) BP180 antibodies cause keratinocytes to lose cell adhesion in tissue culture.[11] (4) Rabbit antibodies to BP180 in animal models induce subepidermal blisters when infused into neonatal mice or hamsters.[12,13]

The BP180 protein differs significantly from the BP230 protein recognized by the majority of BP sera.[14,15] The 230-kDa protein is coded for on the short arm of chromosome 6.[16] Its complementary DNA (cDNA) has been sequenced[17] and codes for an intracellular protein[18] that shows considerable homology with desmoplakin I.[19] The 180-kDa protein is coded on the long arm of chromosome 10.[20] Its cDNA shows no homology with the 230-kDa cDNA but rather encodes a protein with two domains showing the primary structure of trihelical collagen.[21]

What initiates the production of autoantibody remains unclear, but because gestational pemphigoid is exclusively a disease of pregnancy, attention has focused on immunogenetics and the potential for cross-reactivity between placental tissue and skin.

Immunogenetic studies reveal an increase in HLA antigens DR3 or DR4, and curiously, nearly 50% of patients have the simultaneous presence of both.[22] The extended haplotype HLA-A1, B8, DR3 is known to be in linkage disequilibrium with a deletion of C4A (the C4 null allele or C4QO). Indeed, 90% of patients have either a C4AQO or a C4BQO.[23] However, whether the C4QO association is the primary genetic marker for PG

or the presence of a C4QO is even clinically relevant to complement function remains to be shown.

It is worth noting that patients with neither DR3 nor DR4 may have disease clinically indistinguishable from those with classic HLA findings; the presence of HLA-DR3, -DR4, or the concurrent presence of both is neither necessary nor sufficient to produce disease.[22]

Essentially, 100% of women with a history of PG have demonstrable anti-HLA antibodies.[24,25] Because the only source of disparate HLA antigens is typically the placenta (which is primarily of paternal origin), the universal finding of anti-HLA antibodies implies a high frequency of immunologic insult during gestation. Indeed, a slight increase in HLA-DR2 in the husbands of women with PG has been reported.[24] It has been suggested that immunologically primed women may simply react more strongly to tissue with disparate HLA antigens. Whether anti-HLA antibodies represent phenomenon or epiphenomenon remains to be clarified.

The autoantibody of gestational pemphigoid binds to amniotic basement membrane, a structure derived from fetal ectoderm and antigenically similar to skin.[26,27] Women with PG also show an increased expression of major histocompatibility complex class II antigens (DR, DP, DQ) within the villous stroma of chorionic villi but not skin.[28,29] Therefore, it has been proposed that PG is a disease initiated by the aberrant expression of major histocompatibility complex class II antigens (of paternal haplotype) within the placenta that serves to initiate an allogeneic response to placental BMZ, which then cross-reacts with skin.[30]

On the other hand, PG has also been reported in association with hydatidiform moles[31] and choriocarcinomas.[32] This is an intriguing clinical observation, because most hydatidiform moles are produced by a diploid contribution of paternal chromosomes and contain neither fetal tissue nor amnion. There are no case reports of a PG-like rash in males with choriocarcinoma. Unlike its counterpart in women, choriocarcinoma in males is strictly syngeneic tissue. Because choriocarcinoma in women is entirely derived from placental tissue (of paternal derivation), the suggestion is that the development of PG is somehow dependent on the state of partial allograph, not necessarily on the presence of amnion.

CLINICAL FINDINGS

PG is exclusively associated with pregnancy. It typically presents during late pregnancy with the abrupt onset of intensely pruritic urticarial lesions. Fifty percent of patients experience first onset on the abdomen, often within or immediately adjacent to the umbilicus. The other half present with typical lesions, but in an atypical distribution (extremities, palms, or soles). Rapid progression to a generalized, pemphigoid-like eruption, sparing only the face, mucous membranes, palms, and soles is the rule (although any site may be involved). Flares occur with delivery in approximately 75% of patients and may be dramatic. The explosive onset of blistering may occur within hours of delivery, either as a flare of preexisting disease or as presentation de novo. Up to one-quarter of patients initially present during the immediate postpartum period.

Newborns may be affected up to 10% of the time, but the disease is typically mild and self-limited. IF of newborn skin may yield positive findings despite a lack of clinically apparent disease, which suggests that more than C3 deposition alone is required to induce lesions.[33]

Because of clinical and IF similarities with BP, and because of the considerable confusion over the term *herpes gestationis* (particularly outside dermatology), most authors have accepted the revised terminology of PG.[34] However, there are several differences worth bearing in mind: (1) BP is a disease of the elderly and shows no gender bias. PG is exclusively associated with pregnancy. (2) PG shows a strong association with HLA-DR3, -DR4, and a C4 null allele. BP does not. (3) Indirect IF in BP yields positive results in the majority of patients, and the titer of anti-BMZ antibody is often high. The titer of anti-BMZ antibody in PG is usually so low that antibody cannot be detected without the use of complement-added or ELISA techniques. (4) The majority of BP sera react to an intracellular 230- to 240-kDa component of the hemidesmosome. Sera from most PG patients react to a 180-kDa transmembrane protein with a collagenous domain coded for on a different chromosome. Until such time as nosology is driven by pathologic mechanism instead of clinical observation, naming is likely to remain fungible.

CUTANEOUS LESIONS

The typical lesions of PG are urticarial or arcuate plaques that rapidly progress toward a mixed dermatitis, including tense, pemphigoid-like blisters (Figs. 59-1



Figure 59-1 Pemphigoid gestationis. Polymorphic lesions on dorsa of feet.



Figure 59-2 Pemphigoid gestationis. Erythematous urticarial and bullous lesions on the chest and shoulders.

and 59-2, and eFig. 59-2.1 in online edition). Blisters may arise within urticarial plaques or on otherwise normal-appearing skin. Pruritic urticarial papules and plaques of pregnancy (see Chapter 108) can show microvesiculation but not the tense, subepidermal blisters of PG.

RELATED PHYSICAL FINDINGS

PG is seen exclusively in women and only in the presence of pregnancy (or trophoblastic tissue). Any other setting is inconsistent with this diagnosis.

LABORATORY TESTS

Results of routine laboratory investigations are normal. Histopathology classically reveals a subepidermal vesicle with a perivascular infiltrate of lymphocytes and eosinophils (Fig. 59-3). Eosinophils may be lined up along the dermal–epidermal junction and typically fill the vesicular space. However, classic findings are seen only in the minority of cases. A nonspecific mixed cellular infiltrate containing a variable number of eosinophils is more common. The presence of eosinophils is the most constant histologic feature of PG.

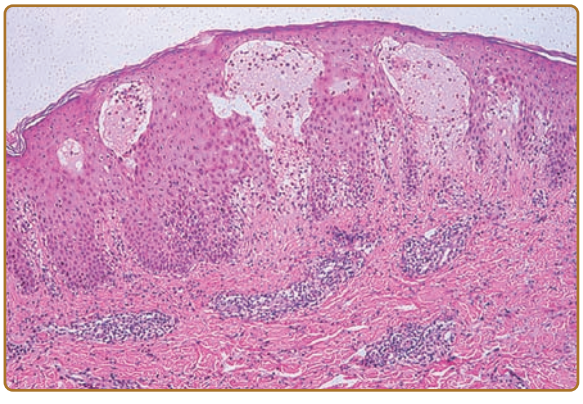

Figure 59-3 Pemphigoid gestationis. Subepidermal vesicle formation; dermal edema; infiltrate consisting of lymphocytes, histiocytes, eosinophils, and a few neutrophils; and focal basal cell necrosis. Note bulbous, teardrop-like vesicles.

SPECIAL TESTS

The sine qua non for a diagnosis of PG is the finding of C3, with or without IgG, in a linear band along the BMZ of perilesional skin (eFig. 59-3.1 in online edition). In salt-split skin specimens, antibody deposition is found along the bottom of the epidermal fragment, a finding similar to that seen in BP. Indirect IF only occasionally detects circulating IgG deposition. However, complement-added indirect IF reveals the circulating anti-BMZ IgG in nearly all patients. The PG ELISA now available may replace IF over time, though not all patients react with the BP180 antibody alone, and such a narrow focus may miss cases where the relevant antigen is outside the NC16A site.

Anti-BMZ antibody titers correlate with the extent and severity of disease, but only if ELISA tests are used.[5] There is no apparent correlation between HLA type and clinical activity.[22] An increased incidence of antithyroid antibodies has been documented in those with a history of PG, but clinically apparent thyroid dysfunction appears rare.[35] Antinuclear antibodies are not seen, and serum complement levels are normal.

DIFFERENTIAL DIAGNOSIS

Since early lesions of PG can be urticarial, the most frequent frustration is differentiating PG from pruritic urticarial papules and plaques of pregnancy, otherwise known as *polymorphous eruption of pregnancy* (see Chapter 108). PG usually progresses rapidly, which makes the clinical diagnosis apparent. Allergic contact dermatitis and drug eruptions might also be difficult to distinguish. Where doubt exists, IF (or ELISA) is the key to differentiation and is particularly relevant in helping patients plan for future pregnancies (Fig. 59-4 and Box 59-1).

COMPLICATIONS

No increase in maternal morbidity or mortality has been documented, although the impression of such remains from a review of published case reports. Cutaneous disease in the newborn is typically self-limited and rarely requires intervention. Although there is an increased risk of premature and small-for-gestational-age births,[33] there are no data to suggest that treatment with systemic corticosteroids alters the risk of premature delivery. That being the case, it is imperative that the risks of therapy be balanced against the severity of the symptoms.

Women with a history of PG appear to be at increased risk for the subsequent development of Graves disease.[35]

PROGNOSIS AND CLINICAL COURSE

The clinical presentation and course of disease may be extremely variable. Many patients experience spontaneous resolution during the later part of gestation

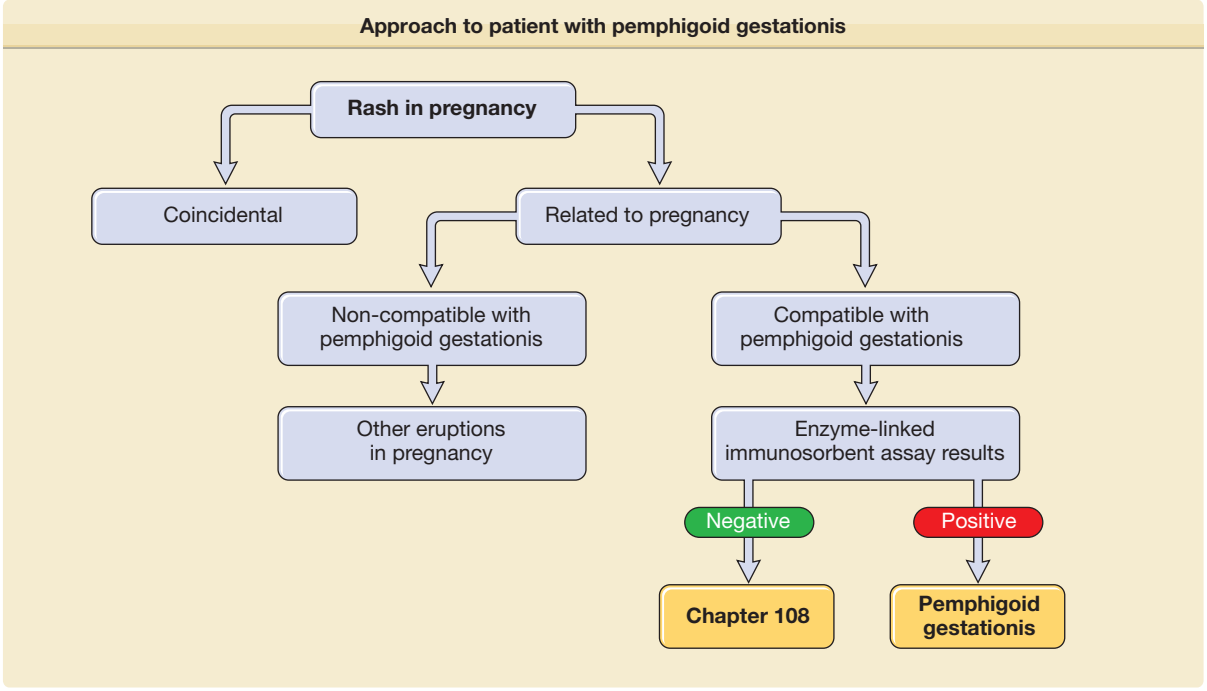

Figure 59-4 Approach to the patient with pemphigoid gestationis.

only to experience a flare, sometimes dramatically, at the time of delivery. Others develop relatively trivial urticarial lesions during one pregnancy, only to suffer characteristic blistering during a subsequent gestation. Still others develop classic disease during one pregnancy, then no disease during the next. The frequency of such "skip pregnancies" approximates 5% to 10%.[36] Recurrences associated with menstruation are common, particularly during the first several months after delivery, and flares during the subsequent use of oral contraceptives occur in at least 25% of patients.

BOX 59-1 DIFFERENTIAL DIAGNOSIS OF PEMPHIGOID GESTATIONIS

Most Likely
- Urticarial pemphigoid gestationis
- Pruritic urticarial papules and plaques of pregnancy
- Other eruptions of pregnancy (see Chapter 108)
- Contact dermatitis
- Drug eruption

Consider
- Urticaria
- Erythema multiforme
- Dermatitis herpetiformis

Rule Out
- Pemphigus vulgaris
- Varicella

Most disease remits spontaneously over weeks to months following delivery, although there are isolated reports of protracted postpartum involvement. It has often been said that once gestational pemphigoid develops, it tends to occur earlier and with greater severity during subsequent gestations, but there are no data to support this contention.

No clear pattern of paternal contribution, if there is one, has yet been elucidated. First onset during both primiparous and multiparous pregnancies has been reported, with and without a change in partners.

TREATMENT

Gestational pemphigoid is sufficiently rare that no controlled studies are available. Nonetheless, there is general consensus that treatment with topical corticosteroids and antihistamines is ineffective. Systemic corticosteroids remain the cornerstone of therapy. Most patients respond to 0.5 mg/kg of prednisone (prednisolone) daily. Maintenance therapy, generally at a lower dosage, may or may not be required throughout gestation. As noted earlier, many patients experience spontaneous disease regression during the third trimester, only to experience flare during parturition.

In individual cases, alternatives to corticosteroids (dapsone, pyridoxine, cyclosporine, rituxan) or adjuvants (gold, methotrexate, cyclophosphamide, plasmapheresis) have been tried. None, with the possible exception of cyclosporine, is useful prior to term, and the experience with each has been variable at best. There are obvious concerns with the use of any of these products during pregnancy.

PREVENTION

Only a small percentage of women who express DR3, DR4, or the combination of DR3 and DR4 ever develop PG, and the role of the paternal tissue in the development of disease (if any) is far from clear. With no predictive test available, prevention is not possible.

Those with a history of PG face the likelihood (but not the assurance) of recurrent involvement during subsequent gestations and are likely to develop symptoms during the use of oral contraceptives. Women who have experienced PG need not avoid additional pregnancies. However, they should be counseled that recurrent disease is the rule.

KEY REFERENCES

Full reference list available at www.DIGM8.com

DVD contains references and additional content

1. Ambros-Rudolph C et al: The specific dermatoses of pregnancy revisited and reclassified: Results of a retrospective two-center study on 505 pregnant patients. *J Am Acad Dermatol* **54**:395, 2006

30. Kelly SE, Black MM, Fleming S: Pemphigoid gestationis: A unique mechanism of initiation of an autoimmune response by MHC class II molecules? *J Pathol* **158**:81, 1989

Chapter 60 :: Epidermolysis Bullosa Acquisita

:: David T. Woodley & Mei Chen

EPIDERMOLYSIS BULLOSA ACQUISITA AT A GLANCE

- Rare, autoimmune subepidermal bullous disease due to immunoglobulin (Ig) G autoantibodies to type VII collagen.
- Etiology is unknown.
- Skin fragility, subepidermal blisters, residual scarring, and milia formation. Common sites are trauma-prone areas such as hands, feet, elbows, knees, sacrum, nails, and mouth.
- Related features may include an underlying systemic disease such as inflammatory bowel disease. May have erosions of the mucosa and esophageal stenosis.
- Pathology shows subepidermal bulla, fibrosis, milia formation, and positive direct immunofluorescence for IgG deposits at the dermal–epidermal junction.
- Treatment options are limited and often difficult.

EPIDEMIOLOGY

Epidermolysis bullosa acquisita (EBA) is a sporadic autoimmune bullous disease of unknown etiology and with no gender, ethnic, or geographic predisposition. Although EBA does not have a Mendelian pattern type of inheritance, there may be some genetic predisposition to EBA and autoimmunity in African-Americans who live in the southeastern part of the United States.[1] African-American patients in the southeastern part of the United States who have either EBA or bullous systemic lupus erythematosus (SLE) have a high incidence of the HLA-DR2 phenotype. The calculated relative risk for EBA in HLA-DR2+ individuals is 13.1 in these patients. These results also suggest that EBA and bullous SLE are immunogenetically related and that either the *HLA-DR2* gene is involved with autoimmunity to anchoring fibril collagen or is some sort of a marker for some other gene that exists in linkage disequilibrium with it.[1]

ETIOLOGY AND PATHOGENESIS

EBA is a chronic, subepidermal blistering disease associated with autoimmunity to the collagen (type VII collagen) within anchoring fibril structures that are located at the dermal–epidermal junction (DEJ). Although the precise etiology of EBA is unknown, most of the evidence suggests an autoimmune etiology. The immunoglobulin (Ig) G autoantibodies to type VII collagen are associated with a paucity of normal-anchoring fibrils at the basement membrane zone (BMZ) separating the epidermis from the dermis and poor epidermal–dermal adherence. Although it is an acquired disease that usually begins in adulthood, it was placed in the category epidermolysis bullosa (EB) approximately 100 years ago because physicians were struck by how similar the clinical lesions of EBA were to those seen in children with hereditary dystrophic forms of EB. Direct immunofluorescence (DIF) of perilesional skin biopsies from EBA patients reveals IgG deposits at the DEJ.[2] EBA antibodies bind to type VII collagen within anchoring fibrils (see Chapter 53).[3,4]

Anchoring fibrils anchor the epidermis and its underlying BMZ to the papillary dermis. Patients with hereditary forms of dystrophic EB (see Chapter 62) and EBA have decreased numbers of anchoring fibrils in their DEJ. This paucity of anchoring fibrils is associated with two similar clinical phenotypes, EBA and dystrophic forms of hereditary EB, because both diseases are characterized by skin fragility, subepidermal blisters, milia formation, and scarring. Although both EBA and hereditary forms of dystrophic EB are etiologically unrelated in terms of their underlying pathogenesis, they share the common feature of decreased anchoring fibrils. In the case of dystrophic forms of hereditary EB, the cause of decreased or absent anchoring fibrils is a genetic defect in the gene that encodes for type VII collagen α chains that ultimately results in small, nonfunctional, or decreased anchoring fibrils.[5,6] The gene coding for type VII collagen is located on the short arm of chromosome 3, approximately 21 cm from zero.[7] The gene defects involved in hereditary forms of dystrophic EB have been identified at variable locations, but the severity of the disease appears to correlate with the degree of type VII collagen and anchoring fibril perturbations.[6] In EBA, the IgG autoantibodies binding to the type VII collagen α chains result in decreased anchoring fibrils, but the pathway leading to this reduction is unknown. It may be that type VII collagen α chains that are newly synthesized but decorated with EBA autoantibodies cannot form triple-helical structures and stable anchoring fibrils. Healed burn wounds that have been covered with cultured keratinocyte sheets also have decreased numbers of anchoring fibrils within the first year after transplantation, and this is associated with spontaneous blister formation, shortened suction blistering times, and skin fragility.[8] These observations provide indirect evidence that anchoring fibrils play a role in maintaining adherence between the epidermis and dermis.

The type VII collagen α chain has a molecular mass between 250 and 320 kDa, and the collagen consists of a homotrimer of three identical α chains (see Chapter 53). Each α chain consists of a large globular noncollagenous amino terminus called the *noncollagenous 1* (NC-1) *domain* that is approximately one-half the entire mass of the α chain. Next, there is a helical domain with typical glycine-X-Y repeats. At the carboxyl terminus is a second globular noncollagenous domain, NC-2, that is much smaller than NC-1.[9] Most EBA autoantibodies recognize four predominant antigenic epitopes within the NC-1 domain and do not recognize the helical or NC-2 domains.[10,11] There may be something intrinsically "antigenic" about the NC-1 domain because the available monoclonal antibodies that have been generated against type VII collagen specifically recognize only NC-1 subdomains.

A reduction in the number of anchoring fibrils is seen in lesional and perilesional skin of EBA patients, but the pathway leading to this reduction is unknown.

Several independent lines of evidence have implicated autoimmune responses as a key element in the pathogenesis of EBA. First, the pathogenic role of EBA antibodies is suggested by the observation that when patients with SLE develop autoantibodies to the EBA antigen, they develop widespread skin blisters and fall into a subset of SLE called *bullous SLE*.[12] This "experiment of nature" suggests that EBA autoantibodies are pathogenic and capable of inducing disadherence between the epidermis and dermis. Secondly, direct proof that EBA autoantibodies are pathogenic comes from recent passive transfer studies. We immunized rabbits and raised a high titer antiserum to the NC-1 domain of human type VII collagen. We injected this antibody into hairless immune competent mice, and the mice developed bullous skin disease with many of the features of EBA in humans.[13] The mice developed subepidermal blisters and lost nails on their feet. They also had circulating NC-1 antibodies in their blood and anti-NC-1 IgG antibody deposits at their DEJ. In addition, the mice had murine complement deposits at the DEJ induced by the autoantibody–antigen complex.[13] Another study by Sitaru and colleagues[14] showed that the injection of rabbit polyclonal antibodies to the NC-1 domain of mouse type VII collagen into mice also induced subepidermal skin blisters that were reminiscent of human EBA.[14] Further, we have also affinity purified human EBA autoantibodies against an NC-1 column and injected them into mice. The mice then developed clinical, histologic, immunologic, and ultrastructural features akin to human EBA.[15] Taken together, these successful passive transfer experiments and the observations with bullous SLE strongly suggest that EBA autoantibodies are "pathogenic" and capable of causing epidermal–dermal separation in skin.

In addition to a passive transfer animal model of EBA, Sitaru and colleagues[16] have established an active EBA animal model by immunizing certain strains of mice with fragments of the noncollagen domain (NC-1) of murine type VII collagen. In these animal models, activation of complement by the alternative pathway and NADPH oxidase for neutrophil action are required for the development of murine EBA.[17,18] The murine models of EBA with these requirements for components of inflammation may better reflect the inflammatory subsets of EBA than the classical noninflammatory mechanobullous EBA phenotype since it is known that not all EBA patients have complement-fixing antibodies or a pathology involving neutrophils. Alternatively, the murine model could reflect early processes in the development of all EBA that is later modulated in certain EBA patients by their intrinsic immune regulatory processes. The next advance in understanding the pathogenesis of EBA will be linking the pathogenic mechanistic steps involved in the disease with the patient's clinical phenotype of disease (see Section "Clinical Findings").

CLINICAL FINDINGS

(Fig. 60-1)

If a patient presents with bullae on the skin with no reasonable explanation despite a thorough history and physical examination, three tests should be done: (1) a skin biopsy for routine hematoxylin and eosin histology, (2) a second biopsy juxtaposed to a

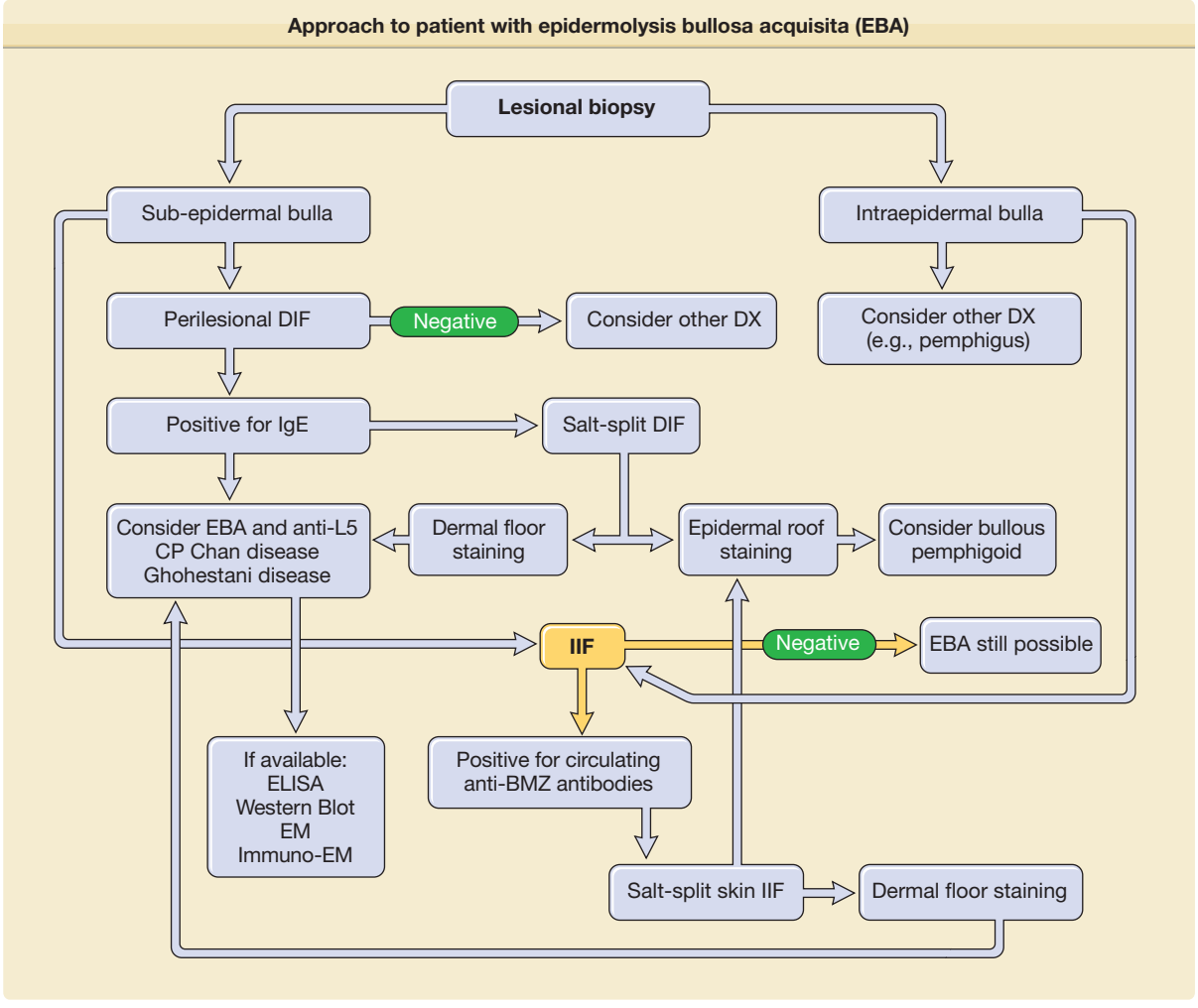

Figure 60-1 Approach to the patient with epidermolysis bullosa acquisita (EBA). BMZ = basement membrane zone; DIF = direct immunofluorescence; DX = diagnosis; ELISA = enzyme-linked immunosorbent assay; IgG = immunoglobulin G; IIF = indirect immunofluorescence.

lesion but on normal-appearing skin for DIF, and (3) a blood draw to test for antibodies against the BMZ and/or type VII collagen by indirect immunofluorescence (IIF) or enzyme-linked immunosorbent assay (ELISA).

HISTORY

CUTANEOUS LESIONS. The cutaneous lesions of EBA can be quite varied and can mimic other types of acquired autoimmune bullous diseases. The common denominator for patients with EBA is autoimmunity to type VII (anchoring fibril) collagen. Although the clinical spectrum of EBA is still being defined, there are at least five clinical presentations: (1) a classic presentation, (2) a bullous pemphigoid (BP)-like presentation, (3) a cicatricial pemphigoid (CP)-like presentation, (4) a presentation reminiscent of Brunsting–Perry pemphigoid with scarring lesions and a predominant head and neck distribution, and (5) a presentation reminiscent of linear IgA bullous dermatosis or chronic bullous disease of childhood.

CLASSIC PRESENTATION. The classic presentation (Figs. 60-2 and 60-3A) is of a noninflammatory bullous disease with an acral distribution that heals



Figure 60-2 Patient with epidermolysis bullosa acquisita who has severe blistering, erosions, scarring, and milia formation on trauma-prone areas of her skin. This is the classic presentation.



Figure 60-3 A. Classic presentation of epidermolysis bullosa acquisita with scarring and milia over trauma-prone areas of skin. **B.** Bullous pemphigoid-like presentation of epidermolysis bullosa acquisita with a widespread inflammatory vesiculobullous dermatosis. **C.** Cicatricial pemphigoid-like presentation of epidermolysis bullosa acquisita with a mucosa-centered bullous scarring eruption. **D.** Brunsting–Perry pemphigoid-like presentation of epidermolysis bullosa acquisita with bullous and scarring lesions predominantly on the head and neck.

with scarring and milia formation. This presentation is reminiscent of porphyria cutanea tarda (PCT; see Chapter 132) when it is mild and of the hereditary form of recessive dystrophic EB when it is severe (see Chapter 62). The classic form of EBA is thus a mechanobullous disease marked by skin fragility. These patients have erosions, tense blisters within noninflamed skin, and scars over trauma-prone surfaces such as the backs of the hands, knuckles, elbows, knees, sacral area, and toes (see Figs. 60-2, 60-3A, and 60-4). Some blisters may be hemorrhagic or develop scales, crusts, or erosions. The lesions heal with scarring and frequently with the formation of pearl-like milia cysts within the scarred areas (see Fig. 60-3A). Although this presentation may be reminiscent of PCT, these patients do not have other hallmarks of PCT, such as hirsutism, a photodistribution of the eruption, or scleroderma-like changes, and their urinary porphyrins are within normal limits. A scarring alopecia and some degree of nail dystrophy may be seen.

Although the disease is usually not as severe as that of patients with hereditary forms of recessive dystrophic EB, EBA patients with the classic form of the disease may have many of the same sequelae, such as scarring, loss of scalp hair, loss of nails, fibrosis of the hands and fingers, and esophageal stenosis.[19]

BULLOUS PEMPHIGOID-LIKE PRESENTATION

(See Chapter 56)

A second clinical presentation of EBA is of a widespread, inflammatory vesiculobullous eruption involving the trunk, central body, and skin folds in addition to the extremities.[20] The bullous lesions are tense and



Figure 60-4 An epidermolysis bullosa acquisita patient with involvement of the leg. Note bullae, erosions, and crusts.

surrounded by inflamed or even urticarial skin. Large areas of inflamed skin may be seen without any blisters and only erythema or urticarial plaques. These patients often complain of pruritus and do not demonstrate prominent skin fragility, scarring, or milia formation. This clinical constellation is more reminiscent of BP (see Figs. 60-3B and 60-4) than a mechanobullous disorder. Similar to BP, the distribution of the lesions may show an accentuation within flexural areas and skin folds.

CICATRICIAL PEMPHIGOID-LIKE PRESENTATION

(See Chapter 57)

Both the classic and BP-like forms of EBA may have involvement of mucosal surfaces. However, EBA also may present with such predominant mucosal involvement that the clinical appearance is reminiscent of CP (see Fig. 60-3C).[24] These patients usually have erosions and scars on the mucosal surfaces of the mouth, upper esophagus, conjunctiva, anus, or vagina with or without similar lesions on the glabrous skin.

BRUNSTING–PERRY PEMPHIGOID-LIKE PRESENTATION

(See Chapter 57)

Brunsting–Perry cicatricial BP is a chronic, recurrent vesiculobullous eruption localized to the head and neck and characterized by residual scars, subepidermal bullae, IgG deposits at the DEJ, and minimal or no mucosal involvement. However, the antigenic target for the IgG autoantibodies has not been defined. Nevertheless, a patient reported with this constellation of findings had IgG autoantibodies directed to anchoring fibrils below the lamina densa.[22] We have seen three additional patients with the features of Brunsting–Perry pemphigoid and autoantibodies directed to type VII collagen (unpublished observations). Therefore, it appears that EBA patients may present with a clinical phenotype of Brunsting–Perry pemphigoid (see Fig. 60-3D).

IMMUNOGLOBULIN A BULLOUS DERMATOSIS-LIKE PRESENTATION

(See Chapter 58)

IgA bullous dermatosis-like presentation of EBA is manifested by a subepidermal bullous eruption, a neutrophilic infiltrate, and linear IgA deposits at the BMZ when viewed by DIF. It may resemble linear IgA bullous dermatosis (LABD), dermatitis herpetiformis, or chronic bullous disease of childhood and may feature tense vesicles arranged in an annular fashion and involvement of mucous membranes.[23] The autoantibodies are usually IgA, IgG, or both.

The diagnosis of these subepidermal blistering cases with IgA antitype VII collagen antibodies showing linear IgA deposition at the BMZ is disputable. Some clinicians regard the patients as having purely LABD, whereas others regard them as having a subset of EBA. Further, the majority of EBA patients have low titer IgA antibodies in their blood directed against type VII collagen.

Childhood EBA is a rare disease. It has a variable presentation, including an LABD-like disease, a BP-like disease, and the classic mechanobullous EBA presentation. Although mucosal involvement is frequent and severe in childhood EBA, the overall prognosis is more favorable than in adult EBA.

INCIDENCE OF THE CLINICAL PRESENTATIONS OF EPIDERMOLYSIS BULLOSA ACQUISITA

According to the authors' experience, approximately 25% of patients with EBA may present with a BP-like clinical appearance. The disease of some of these patients eventually smolders into a more noninflammatory mechanobullous form. However, both the classic and BP-like forms of the disease may coexist in the same patient (Fig. 60-5). The clinical phenotype of EBA that is reminiscent of pure CP occurs in fewer than 10% of all EBA cases.

RELATED PHYSICAL FINDINGS

EBA patients may have many physical findings similar to patients with hereditary dystrophic EB due to gene defects in the type VII collagen gene. These include oral erosions, esophageal strictures, hypo- and hyper-



Figure 60-5 An epidermolysis bullosa acquisita patient demonstrating two presentations of the disease: the classic mechanobullous presentation with erosions, scarring, and milia over the elbows and the more inflammatory bullous pemphigoid-like lesions on her trunk.

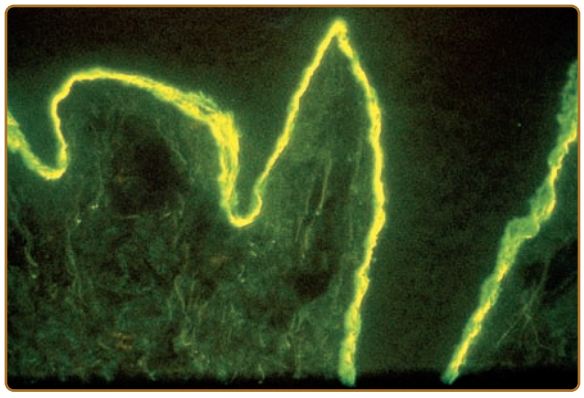

Figure 60-6 Direct immunofluorescence staining for immunoglobulin G deposits in perilesional skin of an epidermolysis bullosa acquisita patient. Note the dense deposits within the dermal–epidermal junction (the epidermis is on top in this section).

pigmentation skin mottling, nail loss, milia formation, scarring, and a degree of fibrosis of the hands.

A number of published reports suggest that EBA may be associated with various systemic diseases[24] such as inflammatory bowel disease, SLE, amyloidosis, thyroiditis, multiple endocrinopathy syndrome, rheumatoid arthritis, pulmonary fibrosis, chronic lymphocytic leukemia, thymoma, diabetes, multiple myeloma, and other diseases in which an autoimmune pathogenesis has been implicated. At the University of North Carolina, University of Stanford, University of Northwestern, and University of Southern California, with a combined experience of following over 62 EBA patients, it appears that inflammatory bowel disease is the systemic disease most frequently associated with EBA.

LABORATORY TESTS

HISTOPATHOLOGY

Routine histologic examination of lesional skin obtained from EBA patients shows a subepidermal blister and a clean separation between the epidermis and dermis. The degree of inflammatory infiltrate within the dermis usually reflects the degree of inflammation of the lesion observed by the clinician. Lesions that are reminiscent of recessive dystrophic EB or PCT usually have a notable scarcity of inflammatory cells within the dermis. Lesions that are clinically reminiscent of BP usually have significantly more inflammatory cells within the dermis, and these cells may be a mixture of lymphocytes, monocytes, neutrophils, and eosinophils. The histology of EBA skin specimens obtained from BP-like lesions may be difficult to distinguish from BP itself.

IMMUNOFLUORESCENCE

Patients with EBA have IgG deposits within the DEJ of their skin.[3,19] This is best detected by DIF of a biopsy specimen obtained from a perilesional site (Fig. 60-6). IgG is the predominant immunoglobulin class, but deposits of complement, IgA, IgM, factor B, and properdin also may be detected. The DIF staining demonstrates an intense linear fluorescent band at the DEJ. Yaoita et al[2] have suggested that a positive DIF and IgG deposits within the sublamina densa zone are necessary criteria for the diagnosis of EBA.

Patients with PCT, which may mimic EBA clinically, frequently have IgG and complement deposits at the DEJ similar to those of EBA patients (see Chapter 132). However, the DIF feature that distinguishes PCT from EBA is that PCT skin also demonstrates immune deposits around the dermal blood vessels.

Patients with EBA may have autoantibodies in their blood directed against the DEJ.[3] These antibodies can be detected by IIF of the patient's serum on a substrate of monkey or rabbit esophagus or human skin and stain the DEJ in a linear fashion that may be indistinguishable from BP sera.[15]

IMMUNOELECTRON MICROSCOPY

The localization of the immune deposits within the DEJ of the skin of EBA patients by immunoelectron microscopy is the "gold standard" for the diagnosis. As demonstrated by Nieboer et al[25] and Yaoita et al,[2] patients with EBA have immune deposits within the sublamina densa zone of the cutaneous BMZ. This localization is clearly distinct from the deposits in BP, which are higher up in the hemidesmosome area or lamina lucida area of the basement membrane. It is also distinct from CP, which has antigenic targets confined to the lamina lucida (see Chapters 56 and 57).

INDIRECT SALT-SPLIT SKIN IMMUNOFLUORESCENCE

When human skin is incubated in 1 M NaCl, the DEJ fractures cleanly through the lamina lucida zone. This

fracture places the BP antigen on the epidermal side of the split and all other basement membrane structures on the dermal side of the separation. Salt-split skin substrate can be used to distinguish EBA and BP sera.[3]

If the serum antibody is IgG and labels the epidermal roof, the patient does not have EBA and BP should be considered. If, on the other hand, the antibody labels the dermal side of the separation, the patient usually has either EBA or bullous SLE. The latter can be ruled out by other serology and by clinical criteria.

DIRECT SALT-SPLIT SKIN IMMUNOFLUORESCENCE

Perilesional skin incubated in cold 1 M NaCl is fractured through the DEJ, which effectively places the BP antigen (and any associated immune deposits) on the epidermal roof and the EBA antigen (and any associated immune deposits) on the dermal floor of the separation.[19] If the patient has EBA, immune deposits are detected on the dermal side of the separation by a routine DIF method using fluorescein-conjugated anti-human IgG.

WESTERN IMMUNOBLOTTING

Antibodies in EBA sera bind to a 290-kDa band in Western blots of human skin basement membrane proteins containing type VII collagen, whereas sera from all other primary blistering diseases do not.[3] This band is the α chain of type VII collagen. Often, a second band of 145 kDa is labeled with EBA antibodies. This band is the amino-terminal globular NC-1 domain of the type VII collagen α chain, which is rich in carbohydrate and contains the antigenic epitopes of EBA autoantibodies, bullous SLE autoantibodies, and monoclonal antibodies against type VII collagen.[10]

ENZYME-LINKED IMMUNOSORBENT ASSAY

Chen et al[26] have produced milligram quantities of recombinant, purified, posttranslationally modified NC-1 in stably transfected human cells and have used this NC-1 to develop an ELISA for autoantibody detection in EBA patients and in patients with bullous SLE. This new ELISA is more sensitive than immunofluorescence and Western blotting, and yet it is very specific for antibodies to type VII collagen.

DIFFERENTIAL DIAGNOSIS

(Box 60-1)

Because EBA has been described in infants and children, it is worth considering that a patient thought to have genetic dystrophic EB just might be a rare childhood patient with EBA. This can be ruled out by the antibody tests outlined in Section "Laboratory Tests." PCT can look clinically very much like classic EBA and can be ruled out by a urine or plasma test for uroporphyrins. Pseudo-PCT, usually caused by drugs such as nonsteroidal anti-inflammatory agents, can look similar to EBA with skin fragility, erosions, and blisters over trauma-prone areas, scarring, and milia formation. Nevertheless, the DIF appears different in that pseudo-PCT, like PCT, shows IgG deposits at both the BMZ at the DEJ and around dermal blood vessels (which are not stained in EBA).

The BP-like EBA can be eliminated by several methods listed above, but the first-line test would be indirect and direct salt-split immunofluorescence.

BOX 60-1 DIFFERENTIAL DIAGNOSIS OF EPIDERMOLYSIS BULLOSA ACQUISITA

Most Likely

- Porphyria cutanea tarda
- Pseudoporphyria cutanea tarda
- Bullous pemphigoid
- Cicatricial pemphigoid

Consider

- Linear immunoglobulin A bullous disease
- Brunsting–Perry pemphigoid
- Bullous systemic lupus erythematosus

DIAGNOSIS

The diagnostic criteria developed by Yaoita et al[2] for the diagnosis of EBA still stand. These criteria, with slightly updated modifications, are shown in Table 60-1.

Alternatives for the last item are indirect or direct salt-split skin immunofluorescence, Western blotting, and ELISA.

COMPLICATIONS

The complications caused by EBA include secondary skin infections, usually due to *Staphylococcus* or

TABLE 60-1
Diagnostic Criteria for Epidermolysis Bullosa Acquisita

- A bullous disorder within the clinical spectrum outlined earlier (see Section "Clinical Findings").
- No family history of a bullous disorder.
- Histology showing a subepidermal blister.
- Deposition of immunoglobulin G deposits within the dermal–epidermal junction (i.e., a positive direct immunofluorescence of perilesional skin).
- Immunoglobulin G deposits localized to the lower lamina densa and/or sublamina densa zone of the dermal–epidermal junction when perilesional skin is examined by direct immunoelectron microscopy.

Streptococcus, because the blisters and erosions compromise the skin's barrier. Scarring and milia formation are naturally occurring complications or sequelae of the deep blistering process. Severe EBA patients may develop significant fibrosis of the hands with decreased range of motion of the palm and digits. Because of wounds and fibrosis of the soles of the feet and toes, some EBA patients have difficulty walking. Many patients with EBA lose their fingernails. EBA patients with significant mucosal involvement may develop esophageal strictures and *even laryngeal scarring*.

TREATMENT

EBA usually responds poorly to treatment. Supportive therapy is warranted in all patients with EBA. This includes instruction in open wound care and strategies for avoiding trauma. Patients should be warned not to over wash or overuse hot water or harsh soaps and to avoid prolonged or vigorous rubbing of their skin with a washcloth or towel. In some patients, it appears that prolonged sun exposure may aggravate or promote new lesions on the dorsal hands and knuckles. Thus, avoidance of prolonged sun exposure and the use of sunscreens are helpful. The patient should be educated to recognize localized skin infections and to seek medical care and antibiotic therapy promptly when they occur.

EBA patients are often refractory to high doses of systemic glucocorticoids, azathioprine, methotrexate, and cyclophosphamide, especially when they have the classic mechanobullous form of the disease. These agents may be somewhat helpful in controlling EBA when it appears as an inflammatory BP-like disease. Some EBA patients improve on dapsone, especially when neutrophils are present in their dermal infiltrate.

Cyclosporine has been shown to be beneficial in EBA.[27] However, the long-term toxicity of this drug limits its use.

There are also independent reports of EBA patients responding to high doses of colchicine.[28] This is often used as a first-line drug because its side effects are relatively benign compared with other therapeutic choices. However, diarrhea is a common side effect of colchicine, which makes it difficult for many patients to achieve a high enough dose to control the disease. Moreover, because of this side effect, we are hesitant to use colchicine in EBA patients who also have inflammatory bowel disease. In addition, there are patients who do not respond to colchicine. Colchicine is a well-known microtubule inhibitor, but it also appears to have properties that have the potential to inhibit antigen presentation to T cells, which could downregulate autoimmunity.

Photopheresis has been used in Sézary syndrome, mycosis fungoides, and a variety of autoimmune bullous diseases (see Chapter 238). Photopheresis improves the clinical features of EBA and remarkably lengthens the suction blistering times of the patients, suggesting an improvement in their epidermal–dermal adherence.[29]

In addition to photopheresis, plasmapheresis and removal of the antibodies to type VII collagen in an EBA patient's plasma is useful for gaining control of EBA patients similar to pemphigus patients. Given that the autoantibodies are pathogenic, this is not surprising, but when plasmapheresis is performed it is necessary to have the patient also treated with a chemotherapy agent (such as azathiaprine, cyclophosphamide, mycotile mofelate, methotrexate).

Intravenous Ig has been used in dermatomyositis, an entity in which autoimmunity may play a role. Intravenous Ig has been reported to be effective in some patients with EBA.[30] The mechanism by which γ globulin may invoke a positive response in EBA is unknown.

The anti-TNF-α biologics (such as infliximab; see Chapter 234) and anti-CD antibodies against B cells have been tried in EBA with some success in limited open trials. Box 60-2 outlines treatment options in EBA that have some support in the medical literature.

Recently, anecdotal reports have also shown that, riuximab, a monoclonal antibody to the CD20 receptor on B lymphocytes is effective in treating recalcitrant patients with EBA.

BOX 60-2 TREATMENTS FOR EPIDERMOLYSIS BULLOSA ACQUISITA (EBA)

MEDICATION	DOSE RANGE
Colchicine[a]	0.6–3.0 mg/day
Cyclosporine A	6 mg/kg/day
Dapsone[b]	100–300 mg/day
Cytoxan	50–200 mg/day
Prednisone[c]	1.0–1.5 mg/kg
Intravenous immunoglobulin[d]	3 g/kg divided over 5 days
Infliximab	5 mg/kg at 0, 2, 4, and 6 week

[a]Must start with 0.4–0.6 mg/day and each 1–2 week double this dose as tolerated. When patient develops diarrhea, back off 1 tablet (0.4–0.6 mg).
[b]Begin at 25 mg/day and double each week after the complete blood count and liver function tests. Most patients need between 100–250 mg/day. Increasing the dose slowly helps the patient tolerate the anemia that develops (i.e., less orthostatic light-headedness, etc.). Expect a 1- to 2-g drop in the patient's hemoglobin on therapeutic doses.
[c]Usually does not help the classic, mechanobullous type of EBA with minimal inflammation. However, it may be somewhat helpful in the bullous pemphigoid-like type of EBA.
[d]Intravenous immunoglobulin is given over 4–5 days every month for 5 or 6 months to give it an adequate trial.

KEY REFERENCES

Full reference list available at www.DIGM8.com

DVD contains references and additional content

2. Yaoita H et al: Epidermolysis bullosa acquisita: Ultrastructural and immunological studies. *J Invest Dermatol* **76**:288, 1981

3. Woodley DT et al: Identification of the skin basement membrane autoantigen in epidermolysis bullosa acquisita. *N Engl J Med* **310**:1007, 1984
12. Gammon WR et al: Evidence that antibasement membrane zone antibodies in bullous eruption of systemic lupus erythematosus recognize epidermolysis bullosa acquisita autoantigens. *J Invest Dermatol* **84**:472, 1985
13. Woodley DT et al: Evidence that anti-type VII collagen antibodies are pathogenic and responsible for the clinical, histological, and immunological features of epidermolysis bullosa acquisita. *J Invest Dermatol* **124**:958, 2005
14. Sitaru C et al: Induction of dermal-epidermal separation in mice by passive transfer of antibodies specific to type VII collagen. *J Clin Invest* **115**:870, 2005
15. Woodley DT et al: Induction of epidermolysis bullosa acquisita in mice by passive transfer of autoantibodies from patients. *J Invest Dermatol* **126**:1324, 2006
16. Sitaru C et al: Induction of complement fixing autoantibodies against type VII collagen results in subepidermal blistering in mice. *J Immunol* **177**:3461-3468, 2006
17. Mihai S et al: The alternative pathway of complement activation is critical for blister induction in experimental epidermolysis bullosa acquisita. *J Immunol* **178**:6514-6521, 2007
18. Chiriac MT et al: NADPH oxidase is required for neutrophil-dependent autoantibody-induced tissue damage. *J Pathol* **212**:56-65, 2007
20. Gammon WR et al: Epidermolysis bullosa acquisita: A pemphigoid-like disease. *J Am Acad Dermatol* **11**:820, 1984
25. Nieboer C et al: Epidermolysis bullosa acquisita: Immunofluorescence, electron microscopic and immunoelectron microscopic studies in four patients. *Br J Dermatol* **102**:383, 1980

Chapter 61 :: Dermatitis Herpetiformis

:: Arash Ronaghy, Stephen I. Katz, & Russell P. Hall III

DERMATITIS HERPETIFORMIS AT A GLANCE

- Intensely itchy, chronic papulovesicular eruption distributed symmetrically on extensor surfaces.
- Characterized histologically by dermal papillary collections of neutrophils (microabscesses).
- Granular immunoglobulin (Ig) A deposits in normal-appearing skin are diagnostic for dermatitis herpetiformis.
- Most, if not all, dermatitis herpetiformis patients have an associated gluten-sensitive enteropathy.
- The rash responds rapidly to dapsone therapy and, in many patients, to strict adherence to a gluten-free diet.

EPIDEMIOLOGY

Dermatitis herpetiformis (DH) is characterized by an intensely itchy, chronic papulovesicular eruption that usually is distributed symmetrically on extensor surfaces. The disease can be clearly distinguished from other subepidermal blistering eruptions by histologic, immunologic, and gastrointestinal criteria. The prevalence of DH in various Caucasian populations varies between 10/100,000 and 39/100,000 persons.[1–3] Some reports suggests a 1.5:1 male to female ratio of DH patients. It may start at any age, including childhood; however, the second, third, and fourth decades are the most common. After presentation, DH persists indefinitely in most patients, although with varying severity. Two long-term studies of immunologically verified patients have suggested that the disease in approximately 10–12% of DH patients eventually remits.[4,5]

Patients with DH have an associated gluten-sensitive enteropathy (GSE) that is usually asymptomatic.

ETIOLOGY AND PATHOGENESIS

In 1884, Louis Duhring first described the clinical features and natural history of a polymorphous pruritic disorder that he called dermatitis herpetiformis; however, the critical elements in the pathogenesis of DH remained unknown until the 1960s.[6] In 1966, Marks et al first noted a gastrointestinal abnormality in patients with DH.[7] Shortly thereafter, it was shown that the lesion was reversible by avoidance of the dietary protein gluten.[8,9] Initially, the intestinal abnormality was thought to be present in 60%–75% of DH patients. However, this view has been modified in two ways. First, the diagnostic criteria for DH have been delineated more precisely, and second, it can be shown that certain patients without apparent gastrointestinal pathology can be "induced" to develop gastrointestinal lesions by subjecting them to a large gluten intake; such patients have been said to have latent celiac sprue.[10]

Thus, most patients with DH have a gastrointestinal abnormality similar (if not identical) to celiac disease, however minimal that may be when the patient is ingesting a normal gluten load. These studies have all confirmed that gluten, a protein found in wheat, barley, and rye, plays a critical role in the pathogenesis of DH. Oats, long thought to contain gluten and play a role in inducing DH lesions, have been shown to be devoid of toxicity in patients with DH.[11,12] As in celiac disease, there is an increased density of small bowel intraepithelial T cells with a γ/δ T-cell receptor in the jejunum of patients with DH.[13] The finding that T-cell lines from patients with DH produce significantly more interleukin 4 (IL-4) than those from patients with GSE and that gut biopsies from symptomatic patients with isolated GSE showed increased expression of interferon-γ suggests that different cytokine patterns may play a role in the varied clinical manifestations of these two diseases.[14,15] Systemic evidence of the gut mucosal immune response has also been found in the serum and the skin of patients with DH. Patients with DH on regular gluten-containing diets have been found to have increased serum IL-2 receptor levels and serum IL-8 levels, increased endothelial cell E-selectin expression in skin, and an increased expression of CD11b on circulating neutrophils.[16–18] These systemic manifestations of the gut mucosal immune response may play a role in creating the proinflammatory environment in the skin necessary for the development of skin lesions. The GSE seen in DH patients probably relates to the immunoglobulin (Ig) A deposits that are found in the skin of these patients, although a direct relationship has not been demonstrated. Patients with a clinical picture consistent with DH and partial IgA deficiency have been reported.[19]

In 1999, Dieterich et al identified antibodies to tissue transglutaminases (Tgases) in the sera from DH patients.[20] Distinguishing various types of Tgases enabled Sardy et al in 2002 to demonstrate that epidermal Tgase is the dominant autoantigen in DH.[21] This was confirmed by a study of nine DH patients by Donaldson et al demonstrating that the dermal deposits of epidermal Tgase colocalized with cutaneous deposits of IgA, in the papillary tips.[22] Because epidermal Tgases were strongly expressed in the upper epidermis, the authors suggested that in regions of trauma they may diffuse through the basement membrane after release from epidermal keratinocytes. Epidermal Tgases were also found in uninvolved skin at least 5 cm away from the lesion suggesting additional factors involved in the production of DH lesions.[22]

It is also known that patients with both GSE and DH have circulating IgA antibodies directed against Tgases.[20,23] There appears to be a predilection for these circulating IgA autoantibodies to bind to epidermal Tgase in DH, whereas the predilection is for autoantibodies to bind tissue Tgase in patients with isolated GSE.[21] The precise role of the circulating IgA antiepidermal Tgase in the development of skin lesions in patients with DH is not known. However, children with celiac disease have lower levels of circulating IgA antiepidermal Tgase when compared to adults with celiac disease, whereas levels of circulating IgA antibodies against tissue Tgase are not significantly different between children and adults with celiac disease.[24] This observation has led to the hypothesis that epitope spread over time results in the development of IgA antiepidermal Tgases and that this late onset of IgA antiepidermal Tgase antibodies may play a role in the typical development of DH in the second to third decade of life.[24]

The mechanism whereby the IgA antiepidermal Tgases bind to skin in patients with DH is not fully understood. One long-standing hypothesis has been that IgA-containing circulating immune complexes are responsible for the IgA deposits in DH skin. The recent discovery of IgA antiepidermal Tgase antibodies has led to the suggestion that IgA–epidermal Tgase immune complexes may be depositing in the skin of DH patients. However, only a minority of DH patients have been found to have IgA and epidermal tissue Tgase deposits colocalized in a perivascular pattern.[22,25] In addition, perivascular neutrophil deposits that are typically found with the perivascular deposition of immune complexes rarely occur in patients with DH.[26] These findings suggest an alternative hypothesis that IgA antiepidermal Tgase may directly bind in the skin to epidermal tissue Tgase. Direct antigen–antibody binding of IgA antiepidermal Tgases to skin also appears unlikely to represent the complete mechanism, since IgA deposits in DH skin cannot be removed using typical techniques for eluting antibody bound directly to antigen. It is possible that the IgA antiepidermal Tgases bind initially via antigen–antibody interactions and that ability of Tgases to cross-link proteins results in the IgA cross-linking to dermal proteins resulting in the stable, long-lasting IgA deposits seen in the skin of patients with DH. This hypothesis awaits confirmation.

Whether the IgA skin deposits play a role in the pathophysiology of blister formation is not known. The finding of IgA and complement in almost all skin sites, not only in lesional skin, makes one postulate that if IgA (either alone or as a part of an immune complex) does play a role, additional factors are still needed to explain the initiation of lesions. Takeuchi et al have demonstrated that minor trauma to skin results in increased expression of IL-8 and E-selectin, both of which may predispose to a neutrophilic inflammatory infiltrate.[27] These findings, coupled with the typical appearance of DH lesions on extensor surfaces at sites of trauma, suggest local cytokine/chemokine production after trauma may be one of the inciting factors of DH skin lesions. It may be that after the initial neutrophilic infiltrate binds to the cutaneous IgA, factors such as cytokines, chemokines, and proteases are released that both directly result in blister formation and induce basal keratinocytes to produce collagenases or stromelysin-1 that further contributes to the formation of blisters.[28,29] Other studies have suggested that T cells may play a role in the pathogenesis of the skin lesions; however, no specific T-cell responses to gluten have been detected.[30,31]

It has been known for some time that iodides, administered orally, can exacerbate or elicit eruptions of DH, and this has, in former times, been used for diagnostic

purposes. The availability of immunopathologic techniques for the detection of IgA deposits in skin has made such provocation tests obsolete.

The absence of animal models of DH, either naturally occurring or developed in the laboratory, has limited advances in our understanding of the pathogenesis of DH. Recently, Marietta and coworkers reported a new mouse model for DH. They reported an HLA-DQ8 transgenic nonobese diabetic mouse that when immunized with gluten developed neutrophilic skin lesions along with cutaneous deposits of IgA. In addition, withdrawal of dietary gluten resulted in resolution of the skin lesions.[32] Further investigation of this mouse model may provide important information regarding the pathogenesis of DH. Finally, there are a few case reports describing the onset of DH with such medication use as interferon, ribavirin, and gonadotropin-releasing hormone analog.[33,34]

CLINICAL FINDINGS

The primary lesion of DH is an erythematous papule, an urticaria-like plaque, or, most commonly, a vesicle (Figs. 61-1–61-3). Large bullae occur infrequently. Vesicles, especially if they occur on the palms, may be hemorrhagic. The continual appearance and disappearance of lesions may result in hyperpigmentation and hypopigmentation. Patients may present with only crusted lesions, and a thorough search may not reveal a primary lesion. The herpetiform (herpes-like) grouping of lesions is often present in some areas (see Figs. 61-1 and 61-3), but patients also may have many individual nongrouped lesions.



Figure 61-1 Dermatitis herpetiformis. Extensive eruption with grouped papules, vesicles, and crusts on the back.



Figure 61-2 Dermatitis herpetiformis. Papules, vesicles, and crusts on knees.

Symptoms vary considerably from the usually severe burning and itching in most patients to the almost complete lack of symptoms in a rare patient. Most patients usually can predict the eruption of a lesion as much as 8–12 hours before its appearance because of localized stinging, burning, or itching.

The usual symmetric distribution of lesions on elbows, knees, buttocks, shoulders, and sacral areas is seen in most patients at one time or another (see Figs. 61-1–61-4). Although these regions are affected most commonly, most patients have scalp lesions



Figure 61-3 Dermatitis herpetiformis. This patient has many firm-topped vesicles and bullae, some erosions, and residual hyperpigmentation. Some of the vesicles are arranged in an annular pattern.

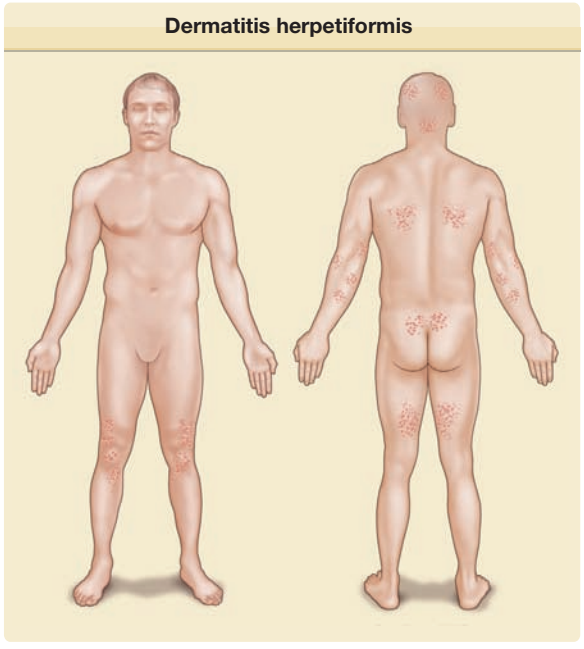

Figure 61-4 Dermatitis herpetiformis. Pattern of distribution.

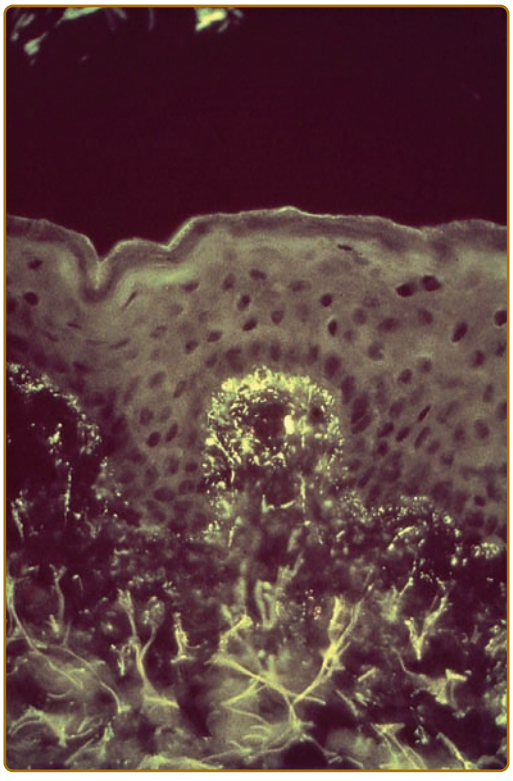

Figure 61-5 Dermatitis herpetiformis. Direct immunofluorescence showing granular dermal papillary deposits of immunoglobulin A.

and/or lesions in the posterior nuchal area. Another commonly affected area is the face and facial hairline. Mucous membrane lesions are uncommon, as are lesions on the palms and soles.

LABORATORY TESTS

IN VIVO–BOUND IMMUNOGLOBULIN A AND COMPLEMENT

After Cormane demonstrated that both perilesional and uninvolved skin of patients with DH contained granular Ig deposits located in dermal papillary tips, van der Meer found that the most regularly detected Ig class in DH skin was IgA (Fig. 61-5).[35,36] Although most patients have granular IgA deposits in their skin, recent studies have suggested that a distinct fibrillar pattern of IgA deposits can be found in some patients with DH.[37] The potential clinical significance of this difference is not known. For the most part IgA deposits have not been seen in the skin of patients with isolated GSE (celiac disease).[38] Recently, however, Cannistraci and coworkers have used confocal microscopy and reported faint colocalization of IgA and epidermal Tgases in the papillary dermis and in a perivascular distribution in the skin of patients with isolated GSE.[39] The significance of these findings in the pathogenesis of DH is not known.

Finding granular IgA deposits in normal-appearing skin is the most reliable criterion for the diagnosis of DH.[26,40] These IgA deposits are unaffected by treatment with drugs, but may decrease in intensity or disappear after long-term adherence to a gluten-free diet.[41,42] The IgA deposits are not uniformly intense throughout the skin and may be detected more easily in normal-appearing skin near active lesions.[43] In DH, other Igs sometimes are bound to the skin in the same areas as the IgA.[40] IgA deposits also may be seen in the skin of patients with bullous pemphigoid, scarring pemphigoid, Henoch–Schönlein purpura, and alcoholic liver disease, although in different patterns of distribution than those seen in DH.

Because of the IgA skin deposits and the association between DH and GSE (celiac disease), several groups have studied the IgA subclasses in DH. IgA1 is the predominant (or exclusive) subclass that has been identified in the skin of DH patients.[44,45] Most IgA1 is produced in the bone marrow, whereas most IgA2 is produced at mucosal sites. This does not negate the possibility that the IgA1 in skin may still be of mucosal origin because IgA1 is the predominant IgA subclass of IgA antibodies directed against dietary proteins produced in gut secretions in patients with DH. [46,47] Recently, Kantele et al reported a DH association with an increase in circulating IgA1-plasmoblasts with skin-homing receptors (CLA) as compared to those with IgA2.[48]

The third component of complement (C3) is frequently found in the same location as IgA. The presence of C3 in both perilesional and normal-appearing skin is not affected by treatment with dapsone (diaminodiphenyl sulfone), but C3 may not be detectable after treatment with a gluten-free diet.[42,49,50] C5 and components of the alternative complement pathway also may be seen in areas corresponding to the IgA deposits. The C5–C9 membrane attack complex, which

is formed as the terminal event in complement activation, is also seen in normal-appearing and perilesional skin of patients.[51]

The exact site of the IgA deposits in DH skin has been studied by immunoelectron microscopy. Early studies indicated that IgA is preferentially associated with bundles of microfibrils and with anchoring fibrils of the papillary dermis immediately below the basal lamina.[52,53] More recent studies, however, have indicated that some or almost all of the IgA deposits are related to nonfibrillar components of skin and other connective tissues.[53–55] There is also no agreement as to whether the IgA deposits in DH colocalize to fibrillin, a major component of the elastic microfibrillar bundles.[55,56]

SERUM STUDIES

Antireticulin antibodies of the IgA and IgG classes have been detected in the sera of 17%–93% of patients with DH and in higher percentages of patients with other diseases, especially celiac disease.[57] Thyroid microsomal antibodies and antinuclear antibodies also have been detected in increased frequency in the sera of patients with DH.[58,59] Putative immune complexes have been detected in the sera of 25%–40% of patients.[60,61]

Chorzelski et al have described an IgA antibody that binds to an intermyofibril substance (endomysium) of smooth muscle.[62] The nature of this antigen has been identified recently by the studies of Sardy et al, who showed that these IgA autoantibodies have specificity for Tgases, particularly epidermis-specific Tgases.[21] Although a majority of DH patients on gluten-containing diets have circulating antiepidermal Tgase antibodies, a significant number of patients do not.[24,63] Therefore, the presence of circulating antiepidermal Tgase antibodies should probably not be considered as a diagnostic test.

IMMUNOGENETIC FINDINGS

There is a marked increase in the incidence of certain major histocompatibility complex antigens in patients with DH. Worldwide studies have found that 77%–87% of DH patients have HLA-B8 (compared with 20%–30% of unaffected individuals).[64–66] In addition, the class II major histocompatibility complex antigens HLA-DR and -DQ are associated with DH even more frequently than is HLA-B8.[67,68] Park et al reported that more than 90% of patients expressed Te24, which was later shown to be similar to HLA-DQw2, and this finding has been confirmed by others.[69] Molecular studies indicate that susceptibility to DH is not associated with a unique HLA-DQw2 molecule.[70,71] Virtually all patients with DH have genes that encode the HLA-DQ (α1*0501, β1*02) or the HLA-DQ (α1*03, β1*0302) heterodimers, a pattern identical to that seen in celiac disease.[70,72] This strong association between susceptibility genes and DH and GSE is important clinically and pathophysiologically in that there is a strong concordance of these two diseases in monozygotic twins.[71] Furthermore, first-degree relatives of both DH and GSE patients are often (4%–5%) affected with one or the other of these diseases.[73]

Nonmajor histocompatibility complex susceptibility genes have been recently associated with DH. The *2 allele of the DNase-hypersensitivity region 1,2 of the Ig heavy chain regulatory region has been found with higher frequency in patients with DH.[74]

HISTOPATHOLOGY

The histology of an early skin lesion (clinically nonvesicular) is characterized by dermal papillary collections of neutrophils (microabscesses), neutrophilic fragments, varying numbers of eosinophils, fibrin, and, at times, separation of the papillary tips from the overlying epidermis (Fig. 61-6). In addition, in such early lesions, the upper and middle dermal blood vessels are surrounded by a lymphohistiocytic infiltrate as well as some neutrophils and an occasional eosinophil.[75,76] At times, early lesions may be difficult or impossible to differentiate from those of linear IgA disease (see Chapter 58), the bullous eruption of lupus erythematosus (see Chapter 155), bullous pemphigoid (see Chapter 56), or the neutrophil-rich form of epidermolysis bullosa acquisita (see Chapter 60). The histology of older lesions shows subepidermal

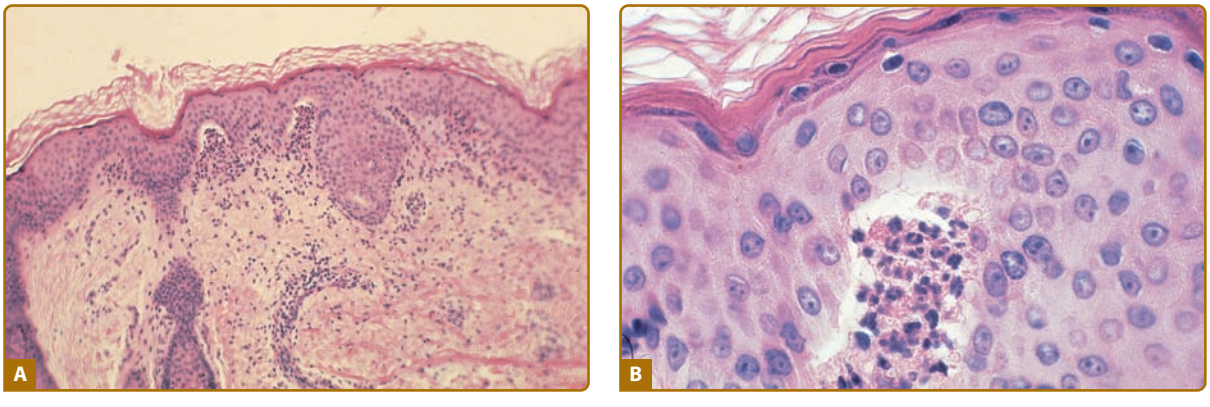

Figure 61-6 Dermatitis herpetiformis. Biopsy of an early lesion showing dermal papillary collections of neutrophils and eosinophils and subepidermal vesiculation at low (**A**) and high (**B**) magnification.

vesicles that may be impossible to differentiate from other subepidermal bullous eruptions, such as bullous pemphigoid, erythema multiforme, bullous drug eruption, and pemphigoid gestationis. Immunofluorescent localization and ultrastructural studies of the site of blister formation in DH have demonstrated that the blister forms above the lamina densa—within the lamina lucida. This is thought to occur because the lamina lucida is the most vulnerable component of the dermal–epidermal junction.[77,78]

ASSOCIATED PROBLEMS

GASTROINTESTINAL MANIFESTATIONS

It is now well accepted that most, if not all, DH patients have an associated gastrointestinal abnormality that is caused by gluten sensitivity.[18,9] The pathology of the GSE associated with DH and that in isolated GSE (GSE unassociated with DH) is essentially the same, although the lesion in the latter is usually much more severe; this applies to the epithelial cell derangement as well as to the character of the lymphoplasmacytic infiltrate. In addition, the distribution of the gastrointestinal lesion in the small intestine is, as a general rule, more widespread in celiac disease. The functional changes in the bowel and clinical sequelae encountered in the GSE associated with DH and those encountered in celiac disease are similar but again differ in degree, those in the latter being more severe. Thus, in DH one observes steatorrhea (20%–30% of patients), abnormal D-xylose absorption (10%–33% of patients), and occasional anemia secondary to iron or folate deficiency. In patients not taking dapsone or related drugs, the latter is usually due to malabsorption. Studies using elemental diets (see Section "Elemental and Other Diet Therapy") in the treatment of DH have questioned the critical role attributed to gluten in the pathogenesis of this disease. In addition to the small intestinal lesion, patients with DH have an increased incidence of achlorhydria and atrophic gastritis.[79,80] Reports of pernicious anemia and antibodies to gastric parietal cells are thus likely to be due to more than chance.

MALIGNANCY

Leonard et al have reported an increased frequency of malignancies, especially gastrointestinal lymphomas, and Collin et al have reported a significant increase in non-Hodgkin lymphomas in patients with DH.[81,82] A combined retrospective study from both these groups suggests a protective role for a gluten-free diet against gastrointestinal lymphomas.[83] Hervonen and coworkers reported that 1% of 1,104 patients with DH developed a lymphoma from 2 to 31 years after the diagnosis of DH.[84] Of interest, only two lymphomas were of the enteropathy-associated type, whereas eight were B-cell type lymphomas and one was unclassified. The patients with DH that developed lymphoma had adhered to a gluten-free diet less strictly than patients without lymphoma.[84] Recently, Viljamaa and coworkers reported on the rate of malignancies and mortality in patients with DH with a 30-year population-based study.[85] They reported no difference in overall malignancy rate in patients with DH from the general population; however, there was an increase in non-Hodgkin lymphomas. Of interest, the mortality rate for patients with DH was lower than in the general population. Lewis et al utilized the General Practice Research Database in the United Kingdom to study a cohort of 846 DH patients and 4,225 matched controls. They report no increased risk of malignancy in the DH patients. The authors suggest a population bias of hospitalized patients in previous smaller studies resulted in either differences in the degree of intestinal inflammation or unrelated illnesses increasing frequencies of malignancy in the DH patients[86] These most recent studies suggest that patients with DH may not have an increased risk of malignancy although further studies are needed.

OTHER DISEASES

In addition to celiac disease, atrophic gastritis, and pernicious anemia (see Section "Gastrointestinal Manifestations"), DH patients have a higher incidence of other autoimmune diseases such as thyroid disease, insulin-dependent diabetes, lupus erythematosus, Sjögren syndrome, and vitiligo.[58,87,88] This predilection for associated autoimmune diseases may be due to the high frequency of the 8.1 ancestral haplotype in these DH patients.[89]

Neurologic disease has been reported in patients with isolated celiac disease, including epilepsy, ataxia, opsoclonus-myoclonus, and dementia; however, confirmation of these findings awaits confirmation with large epidemiologic studies.[90] Some authors have proposed that patients with DH may be at higher risk for these neurologic complications due to long-standing ingestion of gluten; however, Wills and coworkers found no evidence of immune-mediated neurologic disease in their evaluation of patients with DH.[91,92]

Patients with untreated celiac disease have also been found to have an increased frequency of bone loss.[93] Patients with DH frequently continue on gluten-containing diets with a long-standing, albeit low grade, malabsorption. Di Stefano demonstrated a significantly reduced bone mineral density in patients with DH on gluten-containing diets.[94] However, recently Abuzakouk et al in a study of 25 DH patients did not find evidence of bone disease or any relation with bone mineral density and the severity of enteropathy.[95] The authors suggest that the discrepancy between their report and that of Di Stefano may be due to the fact that in the latter study the DH patients were newly diagnosed. These findings suggest that for now patients with DH should be followed closely and those on gluten-containing diets be screened for potential decrease in bone density. If decreased bone mineral density is found, patients should be encouraged to begin a gluten-free diet.

BOX 61-1 DIFFERENTIAL DIAGNOSIS OF DERMATITIS HERPETIFORMIS

Consider

- Eczema
- Atopic dermatitis
- Papular urticaria
- Neurotic excoriations
- Bullous pemphigoid
- Pemphigoid gestationis
- Linear immunoglobulin A dermatosis
- Atopic dermatitis

Rule Out

- Scabies

DIFFERENTIAL DIAGNOSIS

DH may be confused with numerous other conditions because of its pleomorphic manifestations and the occasional lack of diagnostic lesions (Box 61-1). Neurotic excoriations, eczema, papular urticaria, transient acantholytic dermatosis, pemphigoid, pemphigoid gestationis, erythema multiforme, and various other dermatoses can be differentiated easily on the basis of histologic and immunologic criteria. Linear IgA disease may be more difficult to differentiate clinically and histologically, but it is distinctive immunologically. A high index of suspicion is very helpful in that even in the absence of primary lesions, DH can be diagnosed based on the typical in vivo–bound granular IgA deposits in normal-appearing skin.

TREATMENT

SULFONES

Diaminodiphenyl sulfone (dapsone), sulfoxone (diasone—not available in the United States), and sulfapyridine provide prompt improvement in symptoms and signs of the disease. Symptoms may abate in as few as 3 hours or as long as a few days after the first pill is taken, and new lesions no longer erupt after 1–2 days of treatment. Exacerbations occur from hours to days after cessation of treatment. This response to therapy was, for a long time, the most important element in making a diagnosis. The preferred treatment for an adult is dapsone at an initial dosage of 100–150 mg/day (this usually can be taken once a day). An occasional patient may require 300–400 mg of dapsone for initial improvement. Patients should be instructed to take the minimal dose required to suppress signs and symptoms. Not all patients require daily treatment; in rare cases, 25 mg weekly is sufficient. Sulfapyridine, in a dosage of 1.0–1.5 g daily, is particularly useful in patients intolerant of dapsone, in elderly patients, and in those with cardiopulmonary problems. The pharmacology, mechanism(s) of action, adverse effects, and monitoring of dapsone are discussed in Chapter 225. It is important to know that nonsteroidal anti-inflammatory drugs often exacerbate DH, even in patients taking dapsone.[96]

GLUTEN-FREE DIET

EFFECT ON THE SMALL INTESTINE. There is no doubt that the intestinal lesion in DH responds to dietary gluten withdrawal. The time course of the response in adults with DH is the same as that in adults with celiac disease.

EFFECT ON THE SKIN DISEASE. Strict adherence to a gluten-free diet will, after variable periods of time (from 5 months to 1 year), reduce or completely eliminate the requirement for medication in most, but not all, patients. The most extensive early study by Fry et al has been confirmed by several groups.[97] However, it is only the very highly motivated patient who can adhere to the diet, which requires counseling by a dietitian who is very familiar with its use.

ELEMENTAL AND OTHER DIET THERAPY

Studies in small numbers of DH patients have indicated that elemental diets (composed of free amino acids, short-chain polysaccharides, and small amounts of triglycerides) can be very beneficial in alleviating the skin disease within a few weeks.[98,99] The beneficial effect on the skin disease may be achieved even if the patient ingests large amounts of gluten.[98] Unfortunately, elemental diets are difficult to tolerate for long periods. Interestingly, complete resolution of the skin lesions of DH has also been reported by adherence to the high-protein, unlimited fat, low-carbohydrate diet popularized as the "Atkins Diet."[100] Further studies are needed to confirm this report.

KEY REFERENCES

Full reference list available at www.DIGM8.com

DVD contains references and additional content

6. Duhring LA. Dermatitis herpetiformis. *JAMA* **3**:225, 1893
7. Marks J, Shuster S, Watson AJ: Small bowel changes in dermatitis herpetiformis. *Lancet* 1280-1282, 1966
9. Fry L et al: Effect of gluten free-diet on dermatological, intestinal and haematological manifestations of dermatitis herpetiformis. *Lancet* **1**:557-561, 1968
20. Dieterich W et al: Antibodies to tissue transglutaminase as serologic markers in patients with dermatitis herpetiformis. *J Invest Dermatol* **113**:133-136, 1999
21. Sardy M et al: Epidermal transglutaminase (TGase 3) is the autoantigen of dermatitis herpetiformis. *J Exp Med* **195**:747-757, 2002
32. Marietta E FAU - et al: A new model for dermatitis herpetiformis that uses HLA-DQ8 transgenic NOD mice. *J Clin Invest* **114**:1090-1097, 2004
35. van der Meer JB: Granular deposits of immunoglobulins in the skin of patients with dermatitis herpetiformis : An immunofluorescent study. *Br J Dermatol* **81**:493-503, 1969

41. Leonard J et.al: Gluten challenge in dermatitis herpetiformis. *N Engl J Med* **308**:816-819, 1983
64. Katz SI et al: HL-A8: A genetic link between dermatitis herpetiformis and gluten-sensitive enteropathy. *J Clin Invest* **51**:2977, 1972
85. Viljamaa M et al: Malignancy and mortality in patients with coeliac disease and dermatitis herpetiformis: 30-year population based study. *Digestive and Liver Disease* **38**:374-380, 2006
86. Lewis, NR et al: No increase in risk of fracture, malignancy or mortality in dermatitis herpetiformis: A cohort study. *Aliment Pharmacol Ther* **27**(11):1140-1147, 2008
97. Fry L et al: Clearance of skin lesions in dermatitis herpetiformis after gluten withdrawal. *Lancet* **1**:288-291, 1973
98. Kadunce DP et al: The effect of an elemental diet with and without gluten on disease activity in dermatitis herpetiformis. *J Invest Dermatol* **97**:175-182, 1991

Chapter 62 :: Inherited Epidermolysis Bullosa

:: M. Peter Marinkovich

EPIDERMOLYSIS BULLOSA AT A GLANCE

- Family of inherited genodermatoses characterized by blistering in response to minor trauma
- Blistering level categories: simplex, junctional, and dystrophic subtypes
- Cutaneous involvement varies from localized to widespread blistering, depending on subtype
- Extracutaneous involvement varies from none to severely debilitating or lethal
- Oropharynx, trachea, esophagus, eyes, teeth, nails, hair can be involved, depending on subtype
- Diagnosis is made by immunofluorescent and/or electron microscopy followed by DNA analysis

INTRODUCTION

Inherited epidermolysis bullosa (EB), is a family of diseases, with the common feature of blistering in response to mild trauma. Patients with EB can show blistering in the form of small vesicles or larger bullae, which can occur on both the cutaneous surfaces as well as on the mucosal tissues. The fragility of the skin and mucosa and the traumatic production of painful blisters are what all EB cases share in common. However, the distribution of the involvement, the depth of blister formation, any associated extracutaneous involvement and the severity of the blistering process vary with the different EB subtypes and depend on the underlying heritable molecular defect. Different EB subtypes also vary in the way in which blistered areas heal. The wound repair responses are often abnormal and can eventuate into chronic erosions, hypertrophic granulation tissue, scarring, or even invasive carcinoma. While the milder EB subtypes are associated with a normal lifespan and little or no internal involvement, the most severe recessively inherited forms are mutilating, multiorgan disorders that threaten both the quality and length of life.

A number of early studies identified the major subtypes of EB. Studies of von Hebra[1–3] were the first to distinguish pemphigus from inherited blistering and the term epidermolysis bullosa hereditaria was first suggested by Koebner.[4] Hallopeau was the first to distinguish between simplex (nonscarring) and dystrophic (scarring) forms of the disease[5] while Weber[6] and Cockayne,[7] Dowling and Meara[8] and Koebner[4] each described unique forms of epidermolysis bullosa simplex. Hoffman,[9] Cockayne,[10] Touraine,[11] Pasini,[12] and Bart[13] provided much of the information about subtypes of dystrophic epidermolysis bullosa. Herlitz described epidermolysis bullosa letalis,[14] which was later found to be a part of the third major category of epidermolysis bullosa: the junctional form. The application of electron microscopy toward diagnosis of epidermolysis bullosa led to the studies of Pearson[15] and collaborators who classified the patients not only on the basis of clinical findings but also on the existence of ultrastructural changes. A comprehensive classification of epidermolysis bullosa based on a combination of ultrastructural and clinical findings was completed in an early landmark treatise by Gedde-Dahl.[16] Recent major advances have led to the identification of protein and genetic abnormalities in most types of epidermolysis bullosa patients. These studies have led to an improved understanding of the biological basis of epidermolysis bullosa and, finally, a classification of epidermolysis bullosa based on genetic/protein defects, which provides a rational approach to specific molecular therapy.

ETIOLOGY AND PATHOGENESIS

OVERVIEW

Epidermolysis bullosa arises from defects of attachment of basal keratinocytes to the underlying dermis.

These defects can arise from inside the keratinocyte plasma membrane or extracellularly in the dermal–epidermal basement membrane zone (BMZ). Many tissues such as the skin and cornea, which are subjected to external disruptive forces, contain a complex BMZ composed of a group of specialized components that combine together to form anchoring complexes (Fig. 62-1). At the most superior aspect of the BMZ, keratin-containing intermediate filaments of the basal cell cytoskeleton insert upon electron dense condensations of the basal cell plasma membrane termed hemidesmosomes. Anchoring filaments span the lamina lucida connecting hemidesmosomes with the lamina densa and anchoring filaments. At the most inferior aspect of the BMZ, collagen VII-containing anchoring fibrils extend from the lamina densa into the papillary dermis and combine with the lamina densa and anchoring plaques, trapping interstitial collagen fibrils. Thus, the cutaneous BMZ connects the extensive basal cell cytoskeletal network with the abundant network of interstitial collagen fibrils in the dermis.[17,18]

KERATIN FILAMENTS

Keratins are obligate heteropolymers that are composed of pairs of acidic and basic monomers. The keratin pair 5 and 14 assembles together to form the extensive intermediate filament network of the basal cell cytoskeleton.[19] Keratins contain a central α-helical rod with several nonhelical interruptions as well as nonhelical carboxyl and amino-terminal regions. The regions of highest conservation between the keratins are located on the ends of the keratin rod in the helix boundary motifs. Extensive mutagenesis studies suggest that helical regions near the ends of the central rod are important in keratin filament elongation, whereas the nonhelical domains may be important in forming lateral associations.[20]

HEMIDESMOSOMES

Hemidesmosomes contain intracellular proteins, including plectin and BP230. Plectin is a 500-kDa protein, which acts as an intermediate filament-binding protein. It is possible that plectin also interacts with microfilaments, as plectin contains a domain with similarity to the actin-binding domain of spectrin.[21,22] BP230, also known as BPAG1, is a 230-kDa protein which has homology both to desmoplakin[23] and to plectin. Several splicing variants of BP230 are of vital importance in the nervous system.[24–26] BP230 localizes to a region referred to as the inner plate on the cytoplasmic surface of the hemidesmosome and like plectin, functions in the connection between hemidesmosomes and intermediate filaments. BP230 negative transgenic mice lack a hemidesmosomal inner plate and the connection between hemidesmosomes and intermediate filaments is severed, creating a cytoplasmic zone of mechanical fragility just above the hemidesmosomes.

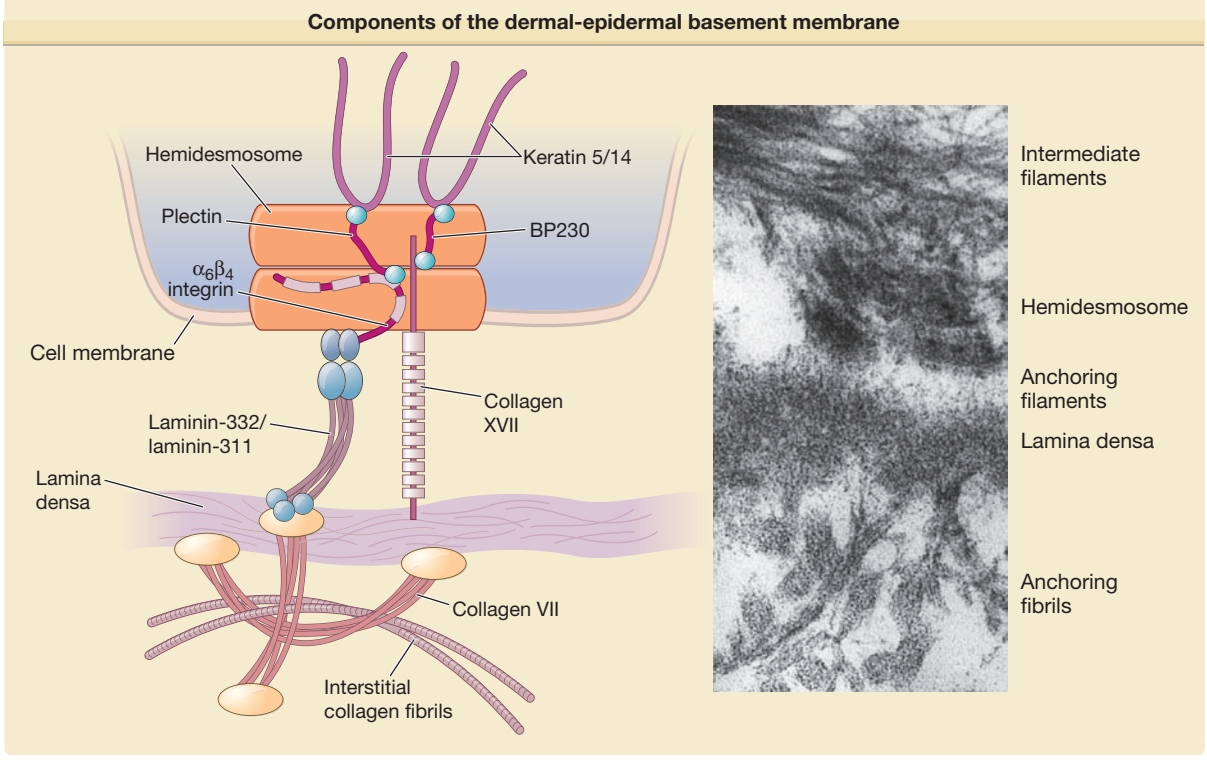

Figure 62-1 Schematic of the components of the dermal–epidermal basement membrane (*left*) compared with ultrastructural appearance of basement membrane morphological entities (*right*).

ANCHORING FILAMENTS

Hemidesmosomes also contain the transmembrane proteins collagen XVII (also termed BPAG2 and BP180)[27] and α6β4 integrin.[28] The cytoplasmic portions of these molecules make up part of the hemidesmosome dense plaque. The extracellular portions of these molecules make up portions of the anchoring filament that probably contribute to the structure known as the subbasal dense plate, which underlies hemidesmosomes in the lamina lucida region. β4 integrin only pairs with the α6 subunit, whereas the α6 subunit can combine either with the β4 integrin or with the β1 integrin. Both the α6β1 or α6β4 integrin combinations have been shown to act as receptors for laminins, but only α6β4 integrin acts as a specific receptor for laminin-332. α6β4 integrin plays a central role in organization of the hemidesmosome. The β4 integrin contains an especially large cytoplasmic domain, which functions in the interaction with other proteins of the hemidesmosomal plaque, including collagen XVII and plectin.[29] Skin from transgenic mice lacking β4 integrin is devoid of hemidesmosomes and shows severe deficits in cell adhesion.[30] Interactions between plectin and α6β4 integrin appear to be critical both in the assembly as well as the disassembly of hemidesmosomes.[31]

Collagen XVII (BPAG2, BP180) is a collagenous protein with a type II transmembrane orientation. Based on electron microscopy and cross-linking studies, collagen XVII assembles into a triple-helical homotrimer and contains three main regions: (1) an intracellular amino-terminal globular head, (2) a central rod, and (3) an extracellular flexible tail.[32] Collagen XVII associates with laminin-332 and α6β4 integrin in adhesion structures termed stable anchoring contacts. These stable anchoring contacts are formed by keratinocytes in vivo, and are thought to represent prehemidesmosomes.[33] The autoantigen in linear immunoglobulin (Ig) A bullous dermatosis, LAD-1[34,35] is a 120-kD protein which has been shown by peptide sequencing to be the cleaved exodomain of collagen XVII.[36] Collagen XVII undergoes processing in keratinocyte cultures and in skin through the action of sheddases, membrane-associated proteases that solubilize cell surface receptors.[37–39]

In addition to α6β4 integrin and collagen XVII, anchoring filaments contain the molecules laminin-332 and laminin-311. Like all members of the family of laminin proteins,[40–42] laminin-332 is a large heterotrimeric molecule, and contains α3, β3, and γ2 chains.[43,44] The first laminins to be described contained three short arms and one long arm, forming a cross shape as shown by rotary shadowing analysis. In contrast, laminin-332 contains truncations of each short arm.[45–47] Because of these short arm truncations, laminin-332 cannot self-polymerize with other laminins or bind to nidogen. Instead, laminin-332 forms a disulfide-bonded attachment to laminin-311,[48] the other known anchoring filament laminin[49] which contains α3, β1, and γ1 chains. Laminin-332 also undergoes processing of its γ2 and α3 chains.[50] While the rat laminin γ2 chain has been previously been shown to be processed by metalloproteinase-2[51] and membrane type metalloproteinase type 1,[52] the predominant site of cleavage by these enzymes is not conserved in human laminin-332.[53] Other studies have shown that processing of laminin γ2 chain takes place through a special class of proteins termed *C*-proteinases which also process *C*-terminal domains of procollagen molecules.[54] While one member of this class of proteins, bone morphogenic protein 1,[55] is capable of performing this action, a splice variant of bone morphogenic protein 1 (mammalian tolloid) is predominantly expressed in keratinocytes and fibroblasts and thus likely performs this function in the skin.[53] Mammalian tolloid also processes the laminin α3 chain,[53] although other enzymes such as plasmin,[56] matrix metalloproteinase 2[51] or membrane type matrix metalloproteinase 1[52] are also capable of this function. The γ2 chain short arm appears important in the assembly of laminin-332 into basement membrane.[57] The antigen recognized by mAb 19-DEJ-1[58] also localizes to anchoring filaments but its molecular identity remains unknown.

ANCHORING FIBRILS

Collagen VII is the major constituent of anchoring fibrils. Analysis of the deduced amino acid sequence of collagen VII[59] reveals the presence of a long central collagenous region characterized by repeating Gly-X-Y sequences that contains a number of noncollagenous interruptions, including a 39 amino acid noncollagenous segment in the center of the helix which corresponds to the "hinge region" predicted by biochemical studies.[60,61] These interruptions account for the flexibility of the collagen VII molecule, and explain its ability to loop around and entrap dermal matrix molecules, thus stabilizing the basement membrane to the underlying papillary dermis.[62] A 50 KDa component of anchoring fibrils has also been identified which appears to localize to the insertion sites of anchoring fibrils to the lamina densa.[63]

The 145-kDa *N*-terminal end of collagen VII contains the largest noncollagenous domain, which inserts onto the lamina densa and anchoring plaques. Collagen IV, the most abundant component of these structures, binds to the collagen VII NC-1 domain. A direct interaction between anchoring filaments and anchoring fibrils exists from a specific interaction between the anchoring filament component laminin-332 and the collagen VII NC-1 domain.[64,65] Collagen VII binds the β3 chain on laminin-332.[64,66–68] This appears to be a critical factor in the maintenance of dermal–epidermal cohesion. Like all collagens, collagen VII assembles into a triple helix. Only one gene and one chain of collagen VII, the α1 chain, have been identified, and thus collagen VII is a homotrimer. Collagen VII triple helices are joined together at their processed NC-2 globular domains to form antiparallel dimers.[62,69] Processing of the NC-2 domains takes place via the same family of *C*-proteinases (bone morphogenic protein 1 and/or mammalian tolloid) that are known to process laminin-332, a closely associated molecule. Anchoring fibrils may derive from lateral associations of collagen VII antiparallel dimers.

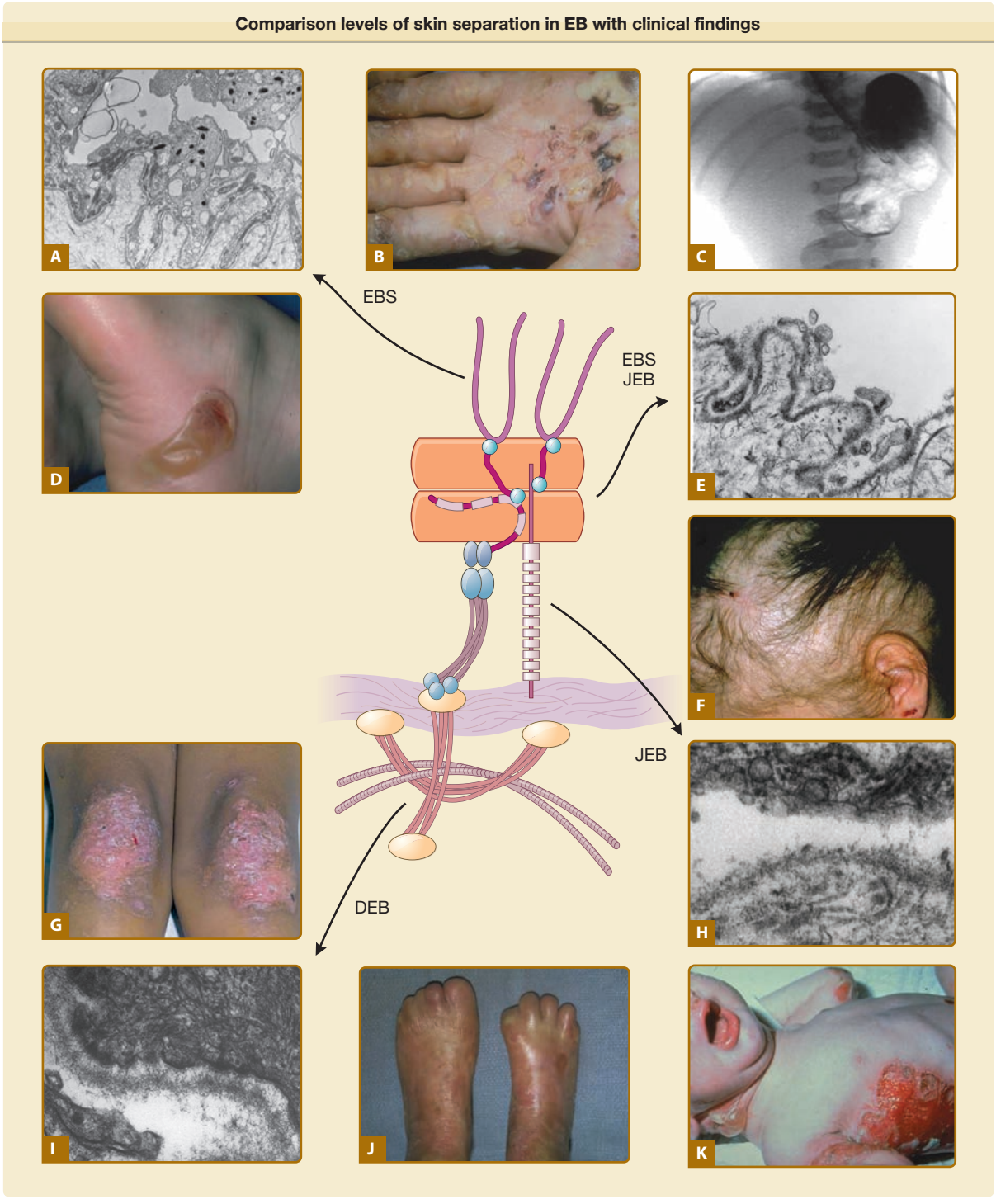

Figure 62-2 Comparison of levels of skin separation in EB with clinical findings. **A.** Transmission electron micrograph showing typical intraepidermal separation in EBS. **B.** Palmar hyperkeratosis and erosions in EB herpetiformis. **C.** Radiograph showing pyloric atresia associated with EB. **D.** Localized blister on heel in EBS Weber–Cockayne. **E.** Transmission electron micrograph showing typical separation at level of hemidesmosome in EB with pyloric atresia, alternatively classified as EBS or JEB. **F.** Nonscarring diffuse alopecia and scalp erosions in generalized atrophic benign epidermolysis bullosa. **G.** Localized dystrophic changes with milia in dominant DEB. **H.** Transmission electron microscopy showing typical intralamina lucida separation in JEB. **I.** Transmission electron microscopy showing typical sublamina densa separation in DEB. **J.** Pseudosyndactly in recessive DEB. **K.** Generalized blistering in Herlitz JEB. EBS = epidermolysis bullosa simplex; DEB = dystrophic epidermolysis bullosa; JEB = junctional epidermolysis bullosa.

CLINICAL FINDINGS

Epidermolysis bullosa has been traditionally classified according to the level of BMZ separation on transmission electron microscopy into simplex, junctional and dystrophic subtypes,[70] (Fig. 62-2). Although this ultrastructural "gold standard" for diagnostic grouping of EB has been electron microscopy, immunomapping of basement membrane antigens as viewed by indirect immunofluorescence can also be quite useful in distinguishing subtypes of EB as well as from other disorders in the differential (see Box 62-1) and is considerably less labor intensive. Within each of these groups there are several distinct types of EB based on clinical, genetic, histologic, and biochemical evaluation.[71] These findings are summarized below (Table 60-1).

BOX 62-1 DIFFERENTIAL DIAGNOSIS OF EPIDERMOLYSIS BULLOSA

Most Likely

- Pompholyx
- Insect bites
- Friction blisters
- Thermal burns
- Bullous impetigo

Consider

- Chronic bullous dermatosis of childhood (linear IgA disease)
- Bullous pemphigoid
- Epidermolysis bullosa acquisita
- Bullous systemic lupus erythematosus
- Cicatricial pemphigoid
- Pemphigus vulgaris

Always Rule Out

- Stevens–Johnson syndrome
- Toxic epidermal necrolysis

EPIDERMOLYSIS BULLOSA SIMPLEX

Epidermolysis bullosa simplex (EBS) is a disease group characterized by intraepidermal blistering and most often is associated with keratin gene mutations. The disease phenotypes range from mild to severe among different subgroups.[72] The common EBS types are dominantly inherited and include Dowling–Meara (Herpetiformis) EBS, generalized (Koebner) EBS, and localized (Weber–Cockayne) EBS. There are several uncommon varieties that include EBS Ogna, EBS with muscular dystrophy, EBS with mottled pigmentation, EBS associated with *BP230/BPAG1* mutation, and a group of suprabasal EBS subtypes. EBS is not usually associated with growth retardation or anemia.

DOWLING–MEARA EBS. This subtype presents at birth, has a generalized distribution and is regarded

TABLE 62-1
Classification of Epidermolysis Bullosa

Level of Separation	Disease	Defect
Simplex	Generalized	KRT5/KRT14
Simplex	Dowling–Meara	KRT5/KRT14
Simplex	Localized	KRT5/KRT14
Simplex	Ogna	KRT5/KRT14/PLEC1
Simplex	Mottled pigmentation	KRT5/KRT14
Simplex	EB with muscular dystrophy	PLEC1
Simplex	Superficialis	KRT5/KRT14
Simplex	Ectodermal dysplasia-skin fragility	PKP1
Junctional[a]	EB with pyloric atresias	ITGB4/ITGA6/PLEC1
Junctional	Herlitz	LAMB3/LAMA3/LAMΓ2
Junctional	Non-Herlitz	LAMB3/LAMA3/LAMG2/COL17A1
Junctional	Localized	COL17A1
Dystrophic	Generalized dominant	COL7A1
Dystrophic	Localized dominant	COL7A1
Dystrophic	Recessive	COL7A1
Variable	Kindler syndrome	KIND1

[a]Alternatively classified as simplex.



Figure 62-3 Characteristic blister formation on trunk and arm in patient with Dowling–Meara EBS.

as the most severe of the EBS subtypes (Fig. 62-3). However, it differs from the Koebner variant in that the oral mucosa is more often involved, occasionally showing extensive erosions. Milium formation may sometimes occur in infancy in patients with this subtype; however, this postwound phenomenon usually resolves after infancy. The disease can often be associated with spontaneous appearance of grouped or "herpetiform" blisters. These occur on the trunk and proximal extremities and heal without scarring. It should be noted that this herpetiform pattern may not be seen when patients show a generalized blistering. Therefore, its absence should not be used as a basis to exclude this EB subtype. Dowling–Meara EBS often shows nail involvement, with shedding and regrowth with dystrophy or long nails with subungual hyperkeratosis. Hyperkeratosis of the palms and soles often develops beginning in early childhood and can progress to confluent keratoderma of the palms and soles. These can be quite painful and, occasionally, interference with ambulation has led to flexural contractures. Esophageal involvement in Dowling–Meara has occasionally been reported, and ranges ranging from erosions to pyloric atresia.[73] The upper respiratory tract can also be affected, including the laryngeal mucosa.[74] Natal teeth have been described.

GENERALIZED EBS. The other common form of generalized EBS is also known as the Koebner EBS. This subtype shows an onset of generalized blistering at birth or at latest during early infancy. The hands, feet, and extremities usually show the most involvement. Lesions often heal with postinflammatory hyper- or hypopigmentation. Atrophy and milia can occur, but are much less frequent than in Dowling–Meara EBS. Palmoplantar hyperkeratosis and erosions may be present (Fig. 62-4). Thickening of the soles is common, but often does not present until later childhood. The oral mucosa sometimes shows mild erosive activity but these usually improve with increasing age.

LOCALIZED EBS. This is the mildest form of EB and is often referred to as the Weber–Cockayne subtype of EBS (Fig. 62-5). This disease is the most common form



Figure 62-4 Widespread blistering in an infant with generalized EBS.

of EB and often presents during infancy or childhood. Occasionally, it presents in early adulthood, such as when blisters are noted following marching during military service. It is speculated that there are a number of undiagnosed cases of this form of EB, as it can be mild enough to escape reporting or detection during clinical visits. Hyperhidrosis of the palms and soles is a common association. Blisters can occasionally become secondarily infected. Postinflammatory pigmentary abnormalities occur with this variant, but milia and scarring as a rule are absent. Blistering activity usually follows areas of trauma, with hands and feet being the most common and the scalp being the least common. Mild oral erosions are present only rarely and usually



Figure 62-5 Trauma-induced blistering from clothing in patient with localized EBS.

resolve with increasing age. Nail involvement is rare with this EB subtype.

ADDITIONAL VARIANTS OF EBS

EBS of Ogna. Onset in infancy is common with seasonal blistering (summer) on the acral areas. Small hemorrhagic and serous blisters occur primarily on the extremities. Healing occurs without scarring. This disease was originally reported in patients from Norway. These patients also show a characteristic onychogryphosis of the great toenails.

EBS with Muscular Dystrophy. This rare clinical entity is an autosomal recessive disorder which consists of generalized blistering of the skin at birth or shortly thereafter. This is accompanied by a progressive muscular dystrophy.[75] It presents with generalized blistering similar to EBS of Koebner clinically. These patients have been shown to harbor mutations in the gene coding for HD1/plectin.[76–78] Mutations in plectin can also cause EB with pyloric atresia (see Junctional EB with Pyloric Atresia) and be difficult to distinguish clinically from disease resulting from integrin mutations.

EBS with Mottled Pigmentation. This form of EB, as its name implies, is characterized by mottled hyperpigmentation of the trunk and proximal extremities. Blistering tends to be mild, and begins at birth or early infancy. Pigmentary alterations appear reticulated and increase with advancing age, as blistering may improve. Mild oral mucosal involvement may be present in infancy. This progressive pigmentation is distinct from the large melanocytic nevi, which can be seen in all three EB types.[79]

Suprabasal EBS Subtypes. *EBS superficialis* is an uncommon form of EBS, named after the subcorneal separation that produces the blisters in this disease.[80] Erosions and crusts, rather than intact bullae, are usually seen in these patients, and heal with postinflammatory pigmentary changes. Despite the superficial cleavage plane, nail involvement. Atrophic scarring and milia have been observed in this disease.

Lethal acantholytic EBS[81] is a rare recessively inherited and lethal disorder characterized by generalized erosions at birth. As in the superficialis subtype, intact blisters are not normally seen, due to the very superficial level of epidermal separation, which appears sheet-like. Nails are dystrophic to absent. Complete alopecia, neonatal teeth, oral erosions, and respiratory involvement distinguish this disorder from other superficial EBS subtypes.

Ectodermal dysplasia skin fragility syndrome is another inherited disorder of suprabasilar epidermal separation, characterized by generalized erosions and sometimes superficial blisters at birth.[82] Alopecia is characteristic, as are palmoplantar keratoderma, painful fissures and nail dystrophy. Patients may sometimes demonstrate failure to thrive, cheilitis, hypohidrosis, and pruritus as well. Like the other superficial EBS subtypes, this disorder is associated with dystrophic nails.

MOLECULAR PATHOLOGY OF EBS. Most of the patients with EB simplex analyzed at the genetic level have been found to be associated with mutations of the genes coding for keratins 5 and 14.[20,72] The level of separation of the skin in these patients is at the midbasal cell, shown in Fig. 62-2A, associated with variable intermediate filament clumping. Hemidesmosomes and other BMZ structures are normal by electron microscopy. The majority of keratin gene mutations associated with epidermolysis bullosa simplex are dominantly inherited due to abnormalities in the multimeric assembly of keratin filaments. There is a smaller subset of patients with recessively inherited disease of varying severity.[83,84]

Mutations coding for the most highly conserved regions of keratins 5 and 14, the helix boundary domains,[85] correlate with the most severe form of EBS, the Dowling–Meara subtype, which exhibits intermediate filament clumping seen by transmission electron microscopy. On the other hand, milder types of disease, such as the Weber–Cockayne subtype, are associated with mutations coding for regions of keratins 5 and 14 that are less conserved. Mutations that code for a specific region of the amino-terminus of keratin 5 are present in patients having EBS with mottled pigmentation.[86] Although significance of this type of mutation and its association with pigmentary abnormalities remains unclear,[87,88] it has been suggested that the keratin 5 globular head domain is responsible for keratin filament insertion onto melanosomes. Recent studies have shown that some mutations of the keratin 5 gene may produce protein which is unstable under increased temperatures.[89] This could help to explain the well-observed exacerbation of some subtypes of EBS to warm temperatures.

The mutations associated with EBS with muscular dystrophy produce premature termination codons, splice site, or other mutations which result in lack of expression or defective expression of plectin.[90] Although the form of EB associated with plectin abnormalities is classified as simplex, it has an identical level of skin separation to that seen in junctional epidermolysis bullosa (JEB) with pyloric atresia. Specifically the separation is present just above the level of the hemidesmosome in the intracellular part of the BMZ. This separation of EBS with muscular dystrophy and JEB with pyloric atresia, diseases with identical levels of separation, into two distinct EB categories illustrates the limitations of the current EB classification system. Plectin defects, like α6β4 integrin defects, can also be associated with pyloric atresia.[90]

Plectin is normally expressed in a wide range of tissues, including muscle.[21] While the mechanism of muscular dystrophy in plectin-deficient patients is unknown, it has been observed that disorganization of muscle sarcomeres occurs in the absence of plectin. It is possible that absence of plectin's spectrin-like domain, which may normally interact with actin filaments in muscle, may be a key factor in the muscle pathology.[91] Interestingly, a case report of autosomal recessive EBS has been recently identified to be associated with both muscular dystrophy and pyloric atresia.[92] This case

was associated with homozygous premature termination codon mutations in the plectin gene causing a significant loss of plectin expression in the skin.[92]

Recently, another unique case of recessive dominant EBS has been identified, this one associated with null mutations of the dystonin gene coding for BP230/BPAG1.[93] Inherited blistering/skin fragility described with this defect was associated ultrastructurally by loss of hemidesmosomal inner dense plate and a concomitant reduction of other hemidesmosomal proteins, presumably by loss of BP230 stabilization. This patient's blistering was also accompanied by a neuropathy, which may be part of the inherited defect, since a splice variant of this molecule has a neural distribution.

The underlying molecular defect of ectodermal dysplasia skin fragility syndrome has been shown to be loss of function of the desmosomal protein plakophilin 1, encoded by PKP1.[94,95–100] Plakophilin is expressed mainly in suprabasilar keratinocytes and outer root sheath cells. Microscopic findings in this disease are usually intraepidermal acantholysis, located in the areas where plakophilin 1 is normally expressed.

JUNCTIONAL EB

All patients with JEB share the common histopathologic feature of blister formation within the lamina lucida of the BMZ due to defects of anchoring filaments located in the lamina lucida and superior lamina densa. This group of diseases is inherited in an autosomal recessive manner and there is considerable variation of the individual clinical phenotypes depending on the molecular defect. Three principal forms of JEB are most common. Herlitz disease, JEB gravis or lethal JEB are each used to describe patients presenting with the most severe and most common phenotype.[14,101]

HERLITZ JEB. Patients with Herlitz JEB, also known as JEB letalis, is one of the most severe EB subtypes and is lethal in most affected children during infancy or early childhood.[102] This disorder is characterized by generalized and often extensive blistering at birth (Fig. 62-6). Later during infancy, a distinctive perioricial granulation tissue begins to manifest, primarily around the mouth, eyes, and nares. The scalp, periauricular areas and, less frequently, locations outside of the head and neck may also be affected. This hypertrophic granulation tissue much less commonly occurs in nonlethal subtypes. Nails are usually severely affected and often are lost during infancy. The presence of nail involvement with periungual hypertrophic granulation tissue during the neonatal period can be a clue to this diagnosis. When nails are still present, they are usually dystrophic. Tooth enamel pitting is characteristic in both primary and secondary teeth, and can progress after tooth eruption. Oropharyngeal mucosal erosions are usually present and may be widespread. Erosions of all stratified squamous epithelial tissues, including nasal, conjunctival, esophageal, tracheal, laryngeal, rectal, and urethral mucosa can be affected. Associated systemic findings in severe cases are important factors in the lethality of this disease. Involvement of the large airways, including tracheolaryngeal stenosis or obstruction, is commonly associated with Herlitz JEB disease and hoarseness in early infancy is an ominous sign. There is a characteristic failure to thrive and growth retardation in this disease, often with a mixed anemia. Sepsis is a common and often lethal complication.

NON-HERLITZ JEB. (Figs. 62-7 and 62-8). Sometimes patients initially presenting with a Herlitz-like phenotype will survive infancy and clinically improve with age. These patients eventually prove to have a severity of blistering and oral erosions less than in the lethal form. In particular, a lack of significant hoarseness is regarded as a favorable prognostic sign, indicative of less severe internal disease manifestations. Scalp and nail lesions, as well as perioricial nonhealing erosions with exuberant granulation tissue are among the most common findings in these patients during childhood. Despite the lack of lethality in infancy, these patients nonetheless can have severe epithelial adhesion abnormalities. Tracheostomies or gastrostomy tubes may help in patient survival. The



Figure 62-6 Widespread blistering at birth in an infant with Herlitz JEB.



Figure 62-7 Perioricial erosions and hypertrohic granulation tissue in a patient with non-Herlitz JEB.



Figure 62-8 Loss of nails and skin atrophy a patient with non-Herlitz JEB/generalized atrophic benign EB.

nonlethal status of these patients distinguishes them from the Herlitz group and the terms nonlethal JEB or JEB mitis have been used in the past to describe these patients. They are much less common than Herlitz EB patients. There are other rare variants of nonlethal JEB that present with localized junctional blistering of the extremities or intertriginous areas.

Interestingly, the association of hypertrophic granulation tissue and laminin-332 defects has been noted in another group of patients with mutations of the laminin α3 (*LAMA3*) gene leading to a small truncation of the *N*-terminal IIIa domain of the laminin α3 chain. This disease, termed laryngo-onycho-cutaneous syndrome, is characterized by a triad of cutaneous erosions, nail dystrophy, and exuberant mucocutaneous granulation tissue, especially in the conjunctiva and larynx.[103] An experimental animal model of engineered laminin-332 deletions has been recently described which recapitulates this hypergranulation tissue phenotype.[104]

Generalized atrophic benign EB (GABEB) is a distinct subset of non-Herlitz JEB that also presents at birth with generalized cutaneous involvement.[105] Despite the widespread cutaneous blistering, there is a relative paucity of oral erosions or other mucosal disease. While enamel pitting is present, resulting in extensive dental caries, and nail dystrophy can often be severe, there is little other extracutaenous involvement noted in these patients. The blisters in these patients, which heal with a characteristic atrophic scarring, are debilitating and can be widespread, but nonetheless these patients generally have a normal lifespan. Blistering improves with age, growth is normal and anemia is uncommon. Some patients with this disease have undergone normal uncomplicated pregnancies and deliveries. One peculiar characteristic of these patients is a progressive alopecia of the scalp and terminal hairs elsewhere in the body. The hair loss starts to become severe after the onset of puberty. While patchy hair loss associated with atrophic scarring has been described, often the alopecia is quite diffuse and scarring is subtle or nonexistent.

LOCALIZED JEB. A very rare subtype of JEB is the localized variant, also known as minimus JEB. These patients generally show mild disease that can be accentuated in localized areas, most often the hands, feet and pretibial regions. Nails can sometimes be shed or become dystrophic, and enamel pitting can occur. Oral or nasal erosions can also occur; however, there is absence of any internal involvement. These patients generally have a favorable prognosis and a normal lifespan.

JEB WITH PYLORIC ATRESIA. These patients exhibit extreme mucosal and cutaneous fragility and may also have various urological abnormalities, including hydronephrosis, and nephritis, and rudimentary ears. Mutations of the genes coding for the β4 and α6 integrin are associated with EB[106] and in which pyloric atresia. Plectin mutations can also be associated with EB and pyloric atresia, although the the integrin mutations are more reliably associated with pyloric atresia. In these patients, hemidesmosomes are usually absent or rudimentary, and the level of separation is intraepidermal at the level of the hemidesmosome as seen in EBS with muscular dystrophy described above. The skin ultrastructure in patients with α6β4 defects is remarkably similar to the β4 integrin knockout mice described above; however, the mice do not show pyloric atresia. These studies illustrate well that there are limitations in the utility of animal models to study human epidermolysis bullosa. Most cases of this disease are quite severe and lethal in infancy, due to extensive extracutaneous epithelial sloughing, in addition to widespread blistering of the skin and mucosa. Rare nonlethal cases of this disease have been characterized which appear to result from a partial loss of function of β4 integrin.[107] Interestingly, nonlethal JEB can sometimes ameliorate itself through alterations in mRNA splicing.[108,109]

MOLECULAR PATHOLOGY OF JEB. JEB can be associated with mutations of the genes coding for any of the α3, β3, or γ2 subunits of laminin-332.[110,111] Absence of any of the three chains results in a lack of trimeric laminin-332 assembly and secretion, which results in a similar blistering phenotype. Patients with mutations of genes coding for the α3 or γ2 laminin subunits will still show normal expression of laminin-311, which contains α3, β1, and γ1 chains.[44] Therefore, positive linear BMZ staining of JEB skin for the α3 chain on immunofluorescence mapping studies with absent expression of the other chains is an indication of either a α3 or γ2 chain defect. Conversely, absence of α3 staining on immunofluorescence can be indicative of a mutation of the α3 gene. About 80% of laminin-332 mutations can be traced to one of two recurrent nonsense mutations in the *LAMB3* gene, making prenatal testing for laminin-332 lesions easier than other EB candidate genes.[112] In the Herlitz patients, all of the mutations so far detected have been those producing

premature termination codons, resulting in absence of expression of laminin-332. While Herlitz cases generally show a complete lack of expression of laminin-332, non-Herlitz patients with abnormal granulation tissue and significant mucosal involvement often show reduced expression of laminin-332. This is due to deletions or missense mutations that result in partial loss of laminin-332 function.[113–115] In some cases, spontaneous amelioration of blistering in severe junctional epidermolysis bullosa cases has taken place, leading to the expression of laminin-332.[109]

In the GABEB variant of non-Herlitz JEB, blistering occurs in the lamina lucida region and abnormalities of hemidesmosomes/anchoring filaments are usually present (Fig. 62-3). While laminin-332 mutations underlie a subset of GABEB patients, the majority of these patients have abnormalities of the hemidesmosomal protein collagen XVII (also known as BP180 or BPAG2). A number of mutations of the gene coding for collagen XVII have been described in GABEB patients, including premature termination codon mutations, missense mutations, splice site mutations, truncations, and a glycine substitution mutation.[111,116] While intralamina lucida/junctional skin separation has been shown in all patients with this disease, one patient was described with a cytoplasmic deletion of collagen XVII who showed intrabasal epidermal skin separation.[117] Localized junctional EB has been shown to be associated with COL17A1 mutations.[118]

Of interest, mosaic GABEB patients have been identified who demonstrate well-defined areas of blistering associated with absence of collagen XVII expression as well as areas of nonblistering skin associated with normal collagen XVII expression. Careful analysis of these patients' keratinocytes revealed reversion of one of the two alleles of the mutation, most likely due to a mitotic gene conversion involving nonreciprocal exchange of parental allele DNA.[119,120] It is possible that this phenomenon of mutational rescue of genes affecting recessive cases of EB is more widespread that currently reported and more careful examination of involved and uninvolved regions of EB skin undoubtedly will reveal more cases. Understanding how epidermolysis bullosa can undergo spontaneous molecular correction (revertant mosaicism) in these cases could help in the design of future molecular therapeutic strategies.

DYSTROPHIC EB

Dystrophic EB (DEB) is characterized by blisters that heal with scarring and milium formation. DEB can be inherited either in an autosomal recessive (RDEB) or dominant fashion (DDEB). One of the most important reasons to distinguish between these two subtypes is the increased prevalence of invasive squamous carcinoma associated primarily with the recessive form. Regardless of the mode of inheritance, DEB is derived from defects of the ultrastructural entity known as the anchoring fibril, which results in sublamina densa separation.

LOCALIZED DDEB. The localized subtype of dominant DDEB (sometimes called the Cockayne–Touraine of DDEB) can present at birth, but occasionally it is not appreciated until childhood. While generalized blistering can take place especially early in life, the blistering usually becomes localized to repetitively traumatized areas such as knees, sacrum, and acral surfaces (Fig. 62-9). These areas show a characteristic scarred, dystrophic appearance. Often the scarring is hypertrophic. Milia are common accompanying features of the healing process in these patients. Nail dystrophy or nail loss with atrophic scarring of the distal digits are common. Occasionally, nail abnormalities can be the only presenting abnormality in DDEB. Oral lesions are not common and teeth are usually unaffected. These patients have a good prognosis and a normal lifespan.



Figure 62-9 Localized trauma-induced blistering with secondary milia in a patient with dominant DEB.

GENERALIZED DDEB. The generalized form of DDEB (sometimes referred to as the Pasini subtype of DDEB) presents at birth with a generally more severe and widespread blistering phenotype compared to the localized subtype. Blisters in generalized DDEB heal with scarring plaques and milia, in a fashion similar to other DEB subtypes. In addition, this disease is sometimes distinguished by the spontaneous appearance of distinctive scar-like flesh colored papules on the trunk. These albopapuloid lesions are not pathognomonic, and can also be seen in other EB subtypes. As the patients get older the generalized blistering may eventually localize to the extremities. Patients often show dystrophic or absent nails. Oral erosions can often be present, but usually are not extensive, and enamel defects can be seen in some patients. A rare variant of self-remitting generalized DDEB, termed bullous dermolysis of the newborn, consists of generalized blistering that gradually recedes after infancy.[121]

RECESSIVE DEB. Recessive DEB (RDEB) can be quite variable in its severity. While the severe subtype is the most common, a localized form can occasionally be seen which has been termed RDEB mitis. Similar to localized DDEB, localized RDEB is usually confined to repetitively traumatized skin surfaces, most often in an acral distribution. Scarring and milium formation

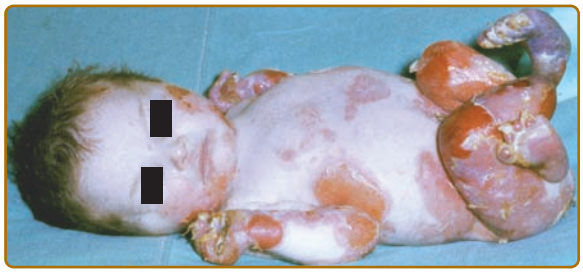

Figure 62-10 Widespread blistering with localized absence of skin at birth in a patient with recessive DEB.

accompany the healing of blisters. Mucosal involvement in localized RDEB, if present, is mild.

Severe RDEB, also known by the eponym the Hallopeau–Siemens, is a devastating disease (Fig. 62-10). This disease presents with generalized blistering at birth. Occasionally, there is extensive denudation of an entire region of skin at birth, often involving one of the limbs. This congenital absence of skin is sometimes termed Bart's syndrome, and has been described with all three major subtypes of EB. In RDEB, healing and blistering cycles occurring during infancy can lead to a progressive scarring which can become quite extensive. Pseudosyndactyly, resulting from a closure of the digits in a "mitten" of skin, is extremely common in this disease (Fig. 62-2J). Scarring can lead to flexion contracture of the hands, as well as the limbs. In contrast to the severe JEB patients, these patients do not show significant periorificial involvement. Instead, the scalp is the most commonly affected area on the head and neck of these patients. Alopecia is progressive, often without significant associated blistering.

The oropharynx can be extensively involved in both dominant and recessive DEB (Fig. 62-11) with generalized erosions evolving into a scarring which limits the movement of the tongue and narrows the opening of the oral cavity. The teeth can show significant enamel pitting, and caries can be extensive, leading to loss of teeth. Involvement of the trachea or larynx can lead to a narrowing of the airway, which can require intervention with a tracheostomy. Mucosal erosions of the esophagus can lead to stricture formation and webbing. The combination of oral lesions, dental caries, esophageal strictures, and increased caloric needs from extensive wound healing can lead these patients toward malnutrition and growth retardation. These patients usually have problems with anemia and may show a deficiency of iron absorption.



Figure 62-11 Oral erosions in a patient with dominant DEB.

In the past, most severe RDEB patients died in infancy of sepsis and other complications of extensive blistering. With improved nutritional, infection, and wound support, these patients now usually can survive into their teens or into adulthood. However, after puberty, another devastating complication, squamous cell carcinoma, can, and often does, appear. It is estimated that 50%–80% of HS-RDEB patients eventually develop these carcinomas and many of these die of metastatic disease. RDEB-associated carcinomas are distinct from other cutaneous squamous cell carcinomas in that they are extremely aggressive with strong tendencies for invasion and metastasis.

MOLECULAR PATHOLOGY OF DEB. Abnormalities of anchoring fibrils are present in DEB patients, ranging from subtle changes in some patients with dominant disease, to absence of anchoring fibrils in patients with RDEB. A sublamina densa plane of blister cleavage is present in all dystrophic blistering (Fig. 62-3). These observations correlate with immunofluorescent microscopic analysis of DEB patients, which demonstrates varying degrees of linear basement membrane staining in dominant patients and total absence of staining in severe recessive patients. In some patients, there is cytoplasmic retention of collagen VII in patient keratinocytes.[122]

Dystrophic EB has been shown to be associated in all cases thus far with mutations of the gene coding for collagen VII (*COL7A1*). In the recessive forms, mutations usually cause premature termination codons, leading to lack of collagen VII in tissue. It is known that mRNAs bearing premature stop codons show accelerated turnover.[123] In addition, truncated proteins that are not secreted or not assembled into anchoring fibrils may also show accelerated turnover. Either or both of these mechanisms can explain the lack of detectable collagen VII in the tissue of individuals with severe RDEB whose mutations lead to premature termination.[62,124,125] Recently, a revertant mosaicism phenotype has also been reported in RDEB.[126]

Generally, *COL7A1* mutations that do not cause premature termination codons produce less severe disease.[110,116] In particular, mutations which produce glycine substitutions of the triple helical region interfere with triple helical assembly of the collagen VII molecule. These types of mutations are present in many patients with milder dominant forms of this disease. In these patients, collagen VII molecules may not be able to assume the proper conformation needed to polymerize into anchoring fibrils. One subtype of DEB

associated with increased pruritus, EB pruriginosa, has also been associated with glycine mutations.[127] Other *COL7A1* mutations have been associated with impaired secretion of collagen VII, resulting in intracellular accumulation of this molecule. In one study, DEB patient mutations that involve the area of the gene coding for the collagen VII NC-2 domain were shown to interfere with NC-2 processing and the assembly of anchoring fibrils.[128]

KINDLER SYNDROME

New advances in our understanding of the molecular pathology of the skin have brought to light the underlying pathophysiology of a disease related to EB, Kindler syndrome. Kindler syndrome was first described by Theresa Kindler in 1954.[129] It is characterized by EB-like trauma-induced blistering at birth and during infancy, with atrophic changes during healing reminiscent of junctional or dystrophic EB.[130–136] However, in later childhood, the blistering usually subsides, and gives way to a progressive poikiloderma which distributes to sun-exposed areas. The poikiloderma may show areas of atrophy and hyperkeratosis, as well as hypopigmentation, hyperpigmentation, and telangiectasias. These patients often show photosensitivity. Nail changes and webbing of the toes and fingers are also sometimes present. Internal complications include oral inflammation, esophageal, or ureteral strictures and ectropion. Ultrastructurally, these patients show reduplication of the basement membrane, which is the most consistent feature seen. While there is often a sublamina densa split with anchoring fibril abnormalities, sometimes lamina lucida or intraepidermal separation can be seen associated with the blistering phenotype. Molecular investigation of this disease led to the discovery of a new epidermal protein, kindlin-1, which shows decreased expression by immunofluorescent microscopy in this disease. Kindlin-1 appears to have some homology to signaling proteins such as talin, which suggests a signaling function.[137] A number of mutations of the gene coding for kindlin-1, *KIND1*, have been described.[138–140] These include nonsense, frameshift, and splice site mutations which underlie the observed decrease in kindlin-1 expression in affected skin. Why the disease evolves from a blistering to a poikilodermatous phenotype and the exact function of kindlin-1 in epidermal homeostasis remain to be fully elucidated.

DIAGNOSIS

The first step toward making the diagnosis of EB begins with a thorough history and physical examination (Fig. 62-12). Useful historical information includes the age of onset of blistering and the presence of blistering in other family members. A review of gastrointestinal, respiratory, ocular, dental, bone, and genitourinary systems is important as is evaluation of general growth and development. Physical examination requires not only a complete skin exam, but a thorough evaluation of mucosal tissues, hair, nails, and teeth. Laboratory measurements of importance in the initial visit include evaluation for anemia, and for measures of nutrition, such as serum albumin.

Skin biopsy is another important diagnostic step. Routine histologic analysis cannot be used to diagnose EB but can be useful for excluding other causes of blistering. The dermal–epidermal BMZ is simply too small to be visualized by light microscopy. To differentiate levels of BMZ separation in skin biopsies, transmission electron microscopy (TEM), and/or indirect immunofluorescent microscopy (IDIF) must be used. While both TEM and IDIF will map the level of skin separation, each test can also provide additional unique diagnostic information, the utility of which depends on the clinical circumstances. For example, in dominant diseases such as EBS and DDEB, there is often not a detectable loss of antigens by IDIF, but ultrastructural abnormalities such as keratin filament clumping or anchoring filament abnormalities can still be seen by TEM. Conversely, in recessive disease, while TEM can detect ultrastructural abnormalities such as rudimentary hemidesmosomes, it cannot distinguish the loss of individual components of hemidesmosomes and other BMZ structures, as IDIF can.

The interior of blisters rapidly reepithelializes, which can obscure correct determination of blister levels. For this reason, it is critical to biopsy a blister that is as fresh as possible. One way to ensure a fresh blister is for the clinician to induce it in the office. This can be accomplished by gently rotating a pencil eraser over an intact area of patient's skin until separation of the epidermis from the dermis can be observed. When actually doing the biopsy, one should place the circular biopsy punch so that only 10% of the punch covers the visible blister with 90% covering intact skin. This is because it is helpful to have both intact and blistered skin on the same biopsy and extension of the blister is likely to occur either during the biopsy process or during shipping.

TEM has been used for decades for determining the level of blistering in EB subtypes. In addition to determining the level of blistering, ultrastructural entities can also be analyzed by TEM for characteristic alterations. For example, clumping of keratin intermediate filaments in basal keratinocyte cytoplasm is a pathognomonic finding for Dowling–Meara EBS. Rudimentary hemidesmosomes can be an important clue to the diagnosis of junctional EB. Absent or altered anchoring fibrils often occur in DEB subtypes especially the recessive forms.

IDDF microscopy has proved increasingly useful in recent years due to the availability of antibody panels directed against all the known EB antigens. In this technique, a panel of antibodies against known BMZ antigens is applied to frozen sections of blistered patient skin. The localization of the antigens to the epidermal or dermal portion of the blister indicates the level of skin separation in the BMZ. In EBS samples, for example, intracellular hemidesmosomal components such as BP230 and a lamina densa protein such as type IV collagen would each localize to the floor of the blister. In JEB cases, BP230 would localize to the roof of

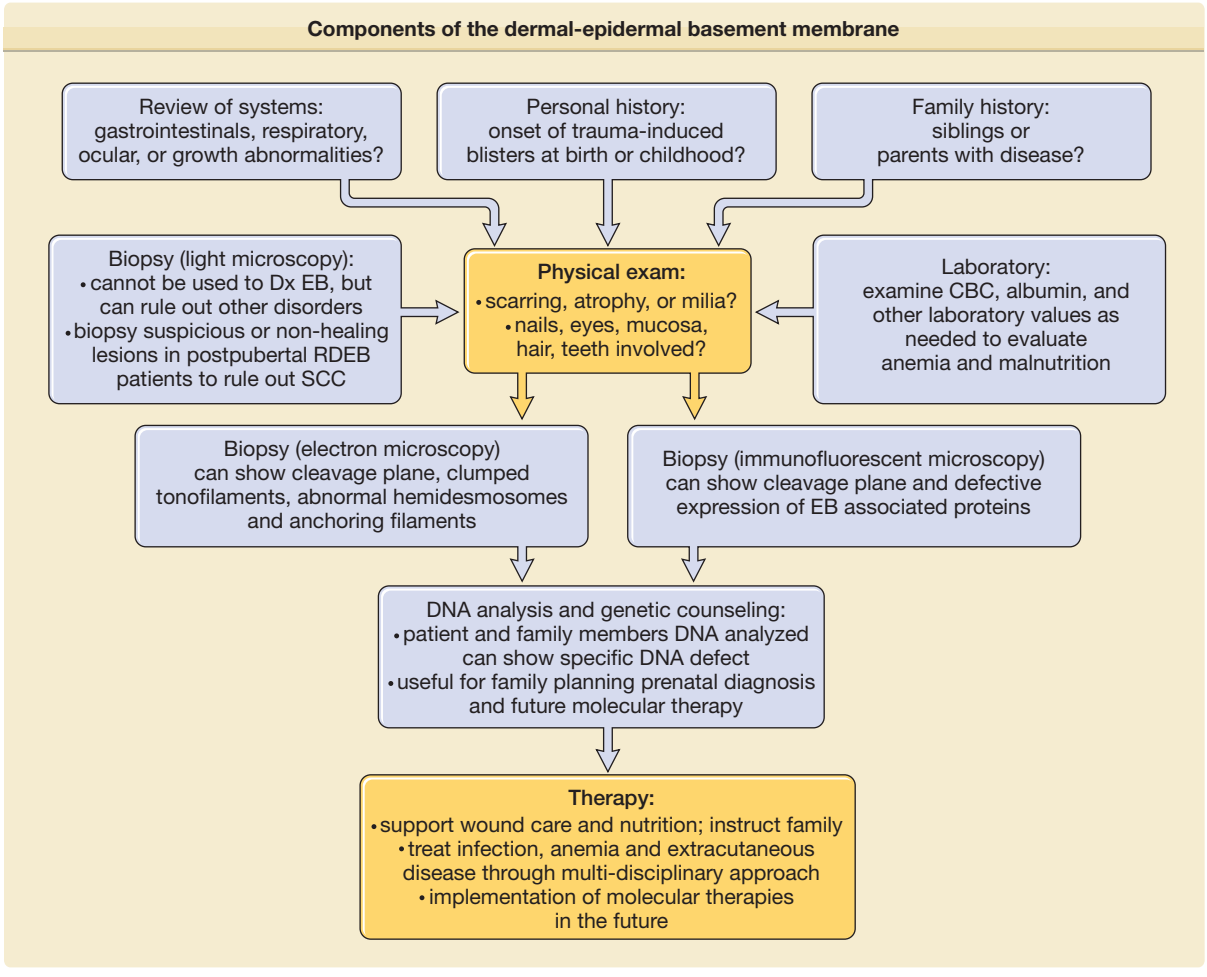

Figure 62-12 Approach to EB patients. A complete history, including family history and review of systems is essential. Physical exam can provide important clues, and laboratory values can help identify associated anemia and malnutrition. Electron microscopy and/or indirect immunofluorescent microscopy are required for diagnosis. DNA analysis is helpful for determining prognosis and family planning. Therapy is mainly supportive. Teaching and working with nursing staff and especially families is critical, as is interdisciplinary interactions with other specialties in the treatment of extracutaneous complications.

the blister while type IV collagen would localize to the floor. In DEB, collagen VII and BP230 would localize to the roof of the blister. The specific absence or presence of staining with a particular antibody in frozen sections of intact portions of patient skin gives important clues to the specific molecular defect. Samples that lack staining with antibodies specific to laminin-332 would further support a JEB diagnosis while a lack of staining for collagen VII would support a DEB diagnosis. Absence of staining for collagen XVII would support a non-Herlitz JEB/generalized atrophic benign EB diagnosis.

A complete panel of antibodies to support IDDF-based diagnosis of EB would include antibodies against laminin-332 (Herlitz and non-Herlitz JEB), as well as antibodies against BP230/BPAG1, BP180/collagen XVII (non-Herlitz JEB/generalized atrophic benign EB), collagen VII (RDEB), α6 and β4 integrins (JEB with pyloric atresia), plectin (EBS with muscular dystrophy), and keratins 5 and 14 (recessive EBS). Antibodies against the individual chains α3, γ2, and β3 chains of laminin-332 are especially helpful.

Its known that laminin-311 (which shares the same laminin α3 chain as laminin-332) is expressed in Herlitz JEB associated with null mutations of genes coding for β3 chain (*LAMB3*) and γ2 chain (*LAMC2*), but not in Herliz JEB associated with null mutations of the α3 chain gene (*LAMA3*).[44] Therefore, if laminin β3 and γ2 antibodies are negative and α3 antibody is positive, this could point the genetic analysis to examine the *LAMB3* and *LAMC2*. Conversely, if all three laminin-332 chains are absent by IDIF, this could point the genetic investigation toward *LAMA3*, saving time and effort in arriving at the final molecular diagnosis.

Gene mutation analysis has revolutionized our understanding of the EB family of diseases and is considered the ultimate final step in arriving at the molecular diagnosis in EB. Concurrent advances in our knowledge of the biochemical structure and supramolecular assembly of BMZ proteins have both facilitated

and complemented the molecular biology studies. Thus, EB patient diagnosis requires both clinical and molecular information. Blood samples or buccal swabs are taken from the patient as well as the parents and siblings for genetic analysis.

GENETIC COUNSELING

DNA mutation analyses can be extremely helpful to EB patients. The prognostic benefit to the patient can often be highly significant. For example, milder recessive DEB cases may have equivalent blistering activity compared to the more severe dominant cases, but their risk of invasive SCC is much greater. Through DNA diagnosis, these two groups can be distinguished, thereby identifying patients potentially at risk for invasive SCC.

Prenatal diagnosis of EB in affected families can be an extremely accurate technique, especially if the original proband has previously had mutational analysis or identification of the defective gene. Fetal skin biopsies and fetoscopy with their increased risk of pregnancy loss can now be avoided by analysis of either chorionic villus sampling as early as 8–10 weeks[141] or amniocentesis in the second trimester.[142] The development of highly informative intragenic and flanking polymorphic DNA markers in EB candidate genes together with rapid screening of genetic "hotspots" makes genetic screening of at risk pregnancies a viable option.[112,143] Coupling of the technique of in vitro fertilization with EB prenatal diagnosis, preimplantation diagnosis has now been successfully performed for EB cases.[144] Another promising area of prenatal diagnosis with potential future applications to EB is the detection and analysis of fetal cells in the maternal circulation.[145]

TREATMENT

Most therapy for epidermolysis bullosa is supportive. The regimen is tailored to the severity and extent of skin and systemic involvement and usually entails a combination of wound management, infection control, surgical management as needed, and nutritional support. Skin care and supportive care for other organ systems in certain EB subtypes is most optimally coordinated through a multidisciplinary approach. Comprehensive topical therapy is a mainstay of treatment in EB, with avoidance of trauma as a primary goal. Wound healing is impaired by endogenous factors, including foreign bodies, bacteria, nutritional deficiencies, anemia, and repeated trauma. Therefore, optimizing wound healing in EB patients involves control of all of these factors.[146]

SUPPORTIVE SKIN CARE

Extensive areas of denuded skin can result in the loss of the barrier provided by the stratum corneum. Subsequent microbial penetration can result in the accumulation of serum and moisture that further enhances bacterial propagation. The above factors combined with immunosuppressive therapy facilitate development of infections. Prevention of infection is obviously the preferred strategy.

A modified Dakin's solution (0.025% w/v sodium hypochlorite) can be helpful in reducing the bacterial load in patient skin. Soaking wounds in this solution for 20 minutes prior to dressing changes also helps to free adherent bandages that have dried onto the wound bed. After soaking, wounds can be dressed with mupirocin or other topical antibiotics, and covered with semiocclusive nonadhesive dressings. Tape causes further blistering and peeling of the skin; thus, it is essential to use self-adhering (clinging) gauze or self-adherent tape to hold nonadherent dressings in place.

For patients with generalized or localized subtypes of EBS, controlling exposure to heat may prove helpful in controlling blister formation. Advising patients to use soft, well-ventilated shoes is also recommended. Herlitz JEB patients, lacking functional laminin-332, an extracellular matrix protein shown to be involved in keratinocyte adhesion and migration, may have especially difficult problems with wound healing. For DEB patients, use of finger splinting or diligent hand wrapping and appropriate hand protection against trauma are helpful, especially following hand surgery (see below).

INFECTION

Management of skin infections is a critical part of EB patient care. Large areas of denuded skin provide an inadequate barrier to microbial penetration. Patients with severe EB subtypes such as recessive DEB may also have immunologic abnormalities including decreased lymphocyte production due to poor nutritional status that lower patients' resistance to infection. *Staphylococcus aureus* and *Streptococcus pyogenes* are common infectious agents. Gram-negative infections with *Pseudomonas aeruginosa* can also occur. Sepsis is a common cause of death in Herlitz JEB patients. Skin cultures and the use of the appropriate systemic antibiotics are indicated for wound infection. To prevent infections in chronic wounds, a regimen entailing regular whirlpool therapy followed by topical antibiotics is the preferred strategy. Rotation of topical antibiotics is also a helpful way to combat resistant bacteria.

SURGICAL TREATMENT

Among the EB patient population, those with the severe recessive DEB (Hallopeau–Siemens) variant are generally the most in need of surgical intervention.[147] Mitten pseudosyndactyly in these patients can be surgically released; however, this procedure may have to be repeated periodically due to the strong tendency of this condition to recur.[148–151] Splinting following surgery is essential to reducing recurrence of hand deformities. Surgery may also be used to correct limb, perioral, and perineal contracture deformities,

but a high rate of recurrence is common. Extra care must be taken to minimize trauma to oral mucosa in EB patients during intubation.

Application of allogeneic skin equivalents has recently demonstrated some promise in wound healing and improvement of quality of life[152] and thus represents an area of future investigation. While long-term benefit or persistence of allografted cells has not been demonstrated, this therapy nonetheless appears to a helpful short-term therapy to help chronic EB wounds to heal.

TUMORS

Squamous cell carcinoma often arises after puberty in patients with recessive DEB. SCC may arise in multiple primary sites, especially in nonhealing areas. Careful surveillance of nonhealing areas is of utmost importance since patients often die from metastatic disease, and the average survival rate after diagnosis of an RDEB-associated squamous cell carcinoma is 5 years. Surgical excision using either Mohs or non-Mohs approaches is an important first-line modality with radiation therapy limited by poor tumor response and impaired site healing.[153] Amputation is often used to control local spread of carcinomas detected on the limbs. Isotretinoin has been used for RDEB patients for chemoprevention of SCC. While it appears well tolerated, it is not clear whether in can increase the overall survival rate of these patients.[154] The epidermal growth factor receptor antagonist cetuximab has also been reported used in RDEB associated with advanced metastatic disease.[155] While the short-term results were positive in the one patient tested, published reports of long-term results and experience with wider groups of RDEB cancer patients are currently lacking.

CARE FOR EXTRACUTANEOUS INVOLVEMENT

GI MANAGEMENT. Esophageal lesions are often the most disabling complication found in recessive DEB and JEB of both the Herlitz and non-Herlitz varieties. Esophageal strictures usually respond to dilatation; however, recurrence of strictures after dilation is common.[156] Colonic interposition has proven effective in advanced cases. Gastrostomy tube insertion has been effective in providing nutrition to individuals with esophageal strictures.[157] Increased fluid and fiber intake and stool softeners may also be of value in EB patients who suffer from constipation.

EYE LESIONS. EBS patients, particularly those with the Dowling–Meara subtype can experience recurrent inflammation of the eyelid, with bullous lesions in the conjunctivae. Junctional EB patients and recessive DEB patients can experience corneal ulcerations with scarring, obliteration of tear ducts, and eyelid lesions.[158] Cicatricial conjunctivitis can also occur in recessive DEB patients. Corneal erosions are treated supportively with application of antibiotic ointments and use of cycloplegic agents to reduce ciliary spasms and provide comfort. Moisture chambers and ocular lubricants are also commonly used. Severely affected upper eyelids may be surgically managed with full-thickness skin grafting. Complete correction of any eye disorder in EB patients is difficult to achieve. Proper management of eye lesions in EB patients must include the assistance of an ophthalmologist to prevent serious visual compromise.[159]

OROPHARYNGEAL LESIONS. Good dental hygiene is essential for EB patients, and regular visits to the dentist are especially important. Enamel defects in JEB and DEB patients often lead to dental carries.[160,161] The softest brush available should be used for regular cleansing. Oral mucosal blistering may also accompany forms of JEB and DEB. Normal saline rinses are effective for gentle cleaning of the mucosal surfaces. Mouthwashes containing alcohol or other harsh agents should be avoided. Erosions and scarring involving the trachea and larynx with resultant narrowing of the airway. In patients with airway involvement, there is danger of pulmonary aspiration.[162]

NUTRITION AND ANEMIA COMPLICATIONS. Nutritional assessment and support can be critical in EB patients[163] for several reasons. Extensive cutaneous injury is associated with marked alterations in hemodynamic and metabolic responses, with increased caloric and protein requirements. Nutritional problems such as low selenium, iron overload, and chronic anemia in the setting of severe blistering may predispose the patient to severe internal complications. Congestive heart failure and cardiomyopathy are prime example of this. This uncommon but nonetheless severe and potentially fatal complication can occur both patients with RDEB or non-Herlitz JEB, becoming more frequent as patients get older.[164]

Oropharyngeal as well as gastrointestinal lesions provide the greatest overall threat to nutritional well-being. These include oral blistering, abnormal esophageal motility, strictures, dysphagia, diarrhea, malabsorption, and dental problems. Nutritional assessment must take into account the above factors in order to develop a supplemental regimen to replenish nutritional deficiencies. Patients are often unable to increase their food intake to balance this increased caloric need. For example, hypoplastic enamel formation in certain subtypes of EB such as GABEB may lead to tooth decay, mucosal blistering, and oral candidiasis. All of these potential complications may compromise patients' ability to eat. Extensive internal mucosal disadhesion in the gastrointestinal tract may cause abnormal GI motility, strictures, and diarrhea—complications that may lead to malabsorption of iron and other nutrients. Anemia of chronic disease can certainly affect all severe EB subtypes. Recessive DEB patients often show a particularly severe defect of iron absorption from the GI tract. In these patients, an iron deficient anemia can develop, which is not responsive to oral supplementation. For these patients, parenteral

iron can be helpful. Furthermore, if a lack of a reticulocyte response to iron supplementation is seen in iron deficient patients, it is helpful to assess the erythropoietin level and to treat with recombinant erythropoietin if necessary.[165] Transfusion is also useful in the treatment of anemia in EB, especially when symptoms require a rapid correction. Deficiencies of other trace minerals and other vitamins such as vitamin D, zinc have also been noted in severe RDEB patients.[166] Osteoporosis and fractures are also a frequent complication of RDEB patients, and bone scans, vitamin D and calcium supplementation may be helpful. Bisphosphonates can be useful in combating this problem.[167]

PSYCHOLOGICAL ASPECTS OF EPIDERMOLYSIS BULLOSA. Patients with EB, especially the severe subtypes, can be plagued with chronic pain and debilitation.[168–170] While many, despite extremely adverse conditions, seem to find a way to maintain a surprisingly positive outlook on life, others lapse into depression.[171,172] Severe epidermolysis bullosa patients can also create stress for their families and loved ones.[173] Thus, it is important to identify the warning signs of depression when they arise and to work in a mutidisciplinary approach with psychiatrists and clinical psychologists as needed. Supportive psychotherapy and patient support group meetings can help patients and their families in this regard. An additional source of support for patients and families include several important patient-based organizations that assist with education and support including Dystrophic Epidermolysis Bullosa Research Association and Epidermolysis Bullosa Medical Research Foundation.

SYSTEMIC THERAPIES

Systemic therapies are not effective in ameliorating the fundamental blistering tendencies in EB patients. Tetracycline and phenytoin have been used in the past for EB but are not currently indicated treatment.[174] Corticosteroids, either topical or systemic, have no beneficial long-term use in inherited EB.

MOLECULAR THERAPY FOR EPIDERMOLYSIS BULLOSA

A number of preclinical models have facilitated the study and development of therapy for epidermolysis bullosa. Some of these models utilize mouse genetic approaches to produce entirely murine tissue models.[175] These include transgenic mouse models with skin targeted expression of trans-dominant molecules including inducible disease phenotype models.[176] These include dominant-negative basal keratins in models of epidermolysis bullosa simplex. Murine knockout models have also been used, including knockout of basal keratin genes in a model of the same disorder and of the α6 and β4 integrins, laminin-332, and types XVII and VII collagens.[177–181] These targeted gene disruptions in mice have accurately recapitulated the blistering phenotype of the corresponding human disorders. These murine genetic models have been of great utility in clarifying our understanding of the pathogenesis of this group of disorders and in providing disease models for development of potential future therapies. Other animal models have also been shown to have the potential to study epidermolysis bullosa pathophysiology and therapy in a preclinical setting. Canine, murine, equine, and feline forms of a number of subtypes of epidermolysis bullosa show promise as preclinical models of molecular therapy.

In addition to such pure animal models, human skin/mouse chimeras have been generated in an attempt to produce true human tissue models of epidermolysis bullosa. These chimeras have either used full thickness grafting of EB patient skin or epidermis regenerated on skin composites and sheets from EB keratinocytes grown in culture.[182] Immune deficient SCID and nude mice readily accept such xenografts and the grafted EB skin retains the clinical and molecular characteristics of the patient donor. This immunodeficient mouse models can be extended to study injections of human cells or proteins as well. This approach has been reported for recessive dystrophic EB due to mutations in collagen VII and for benign junctional EB due to mutations in collagen XVII. Because human epidermis differs dramatically from mouse in tissue architecture, these in vivo models of human tissue in EB may be of special utility in development of models for gene therapy of these disorders.

Potential therapies for EB include protein and gene therapy. In the former case, the missing or defective protein is produced by recombinant methods and applied or injected directly to intact or blistered skin or given intravenously. Recent preclinical studies of collagen VII protein transfer into RDEB-derived skin equivalents have shown successful incorporation of this molecule into anchoring fibrils combined with clinical improvement of skin separation.[183] Collagen VII has a longer in vivo half-life than most molecules. This suggests that protein application or injection could take place at extended intervals, perhaps greater than 3 months, as persistence of exogenous collagen VII protein was detected in animal models at least this long.

In the case of gene therapy, delivery of genes targeted to restore normal protein expression is the goal.[184,185] Successful corrective gene delivery has recently been achieved in human EB tissue in the immune deficient model system described below for both laminin-332 and collagen XVII.[186,187] More recently both viral and nonviral methods of gene transfer have demonstrated successful expression of collagen VII in RDEB skin equivalents on immunodeficient mice[183,188–190] as well as in a canine animal model.[191]

The approach of retroviral ex vivo gene therapy using autologous keratinocytes was recently performed for one patient with junctional epidermolysis bullosa.[192] In this study, a patient with a missense mutation of laminin-332 was grafted with genetically corrected keratinocyte monolayers expressing wild type laminin-332. After over 1 year of post grafting follow up, grafts still showed positive expression of laminin-332 and resistance to blistering. Observations from this study suggested that proper selection of patient skin stem cells were an important part of the success of this study.

This latter study was the first to demonstrate that gene therapy for epidermolysis bullosa can be successfully performed in humans, and opens the door for many new clinical studies in other EB subtypes.

Dermal fibroblasts have long been appreciated as contributors of collagen VII to the dermal–epidermal basement membrane.[193] The technique of injecting collagen VII expressing fibroblasts have proven successful in restoring collagen VII expression and reversing the blistering phenotype in RDEB skin equivalents on immunodeficient mice[189,194] and in a mouse model of RDEB.[195] In addition, allogenic fibroblast-based approaches to the treatment of dystrophic EB have recently found their way into clinical trials, showing some success at delivering collagen VII to deficient RDEB patient skin.[196,197] Although profound immunosupression against a background of extensive skin erosions is not without significant risks, including sepsis and death, new advances in bone marrow transplantation of collagen VII expressing stem cells represents another novel and potentially effective route of cell-based molecular therapy for RDEB.[198–201]

KEY REFERENCES

Full reference list available at www.DIGM8.com

DVD contains references and additional content

16. Gedde-Dahl T: *Epidermolysis Bullosa: A Clinical, Genetic and Epidemiologic Study*. Baltimore, The John Hopkins Press, 1971, pp. 1-180
17. LeBleu VS, Macdonald B, Kalluri R: Structure and function of basement membranes. *Exp Biol Med (Maywood)* **232**:1121-1129, 2007
20. Coulombe PA, Kerns ML, Fuchs E: Epidermolysis bullosa simplex: A paradigm for disorders of tissue fragility. *J Clin Invest* **119**:1784-1793, 2009
70. Smith LT: Ultrastructural findings in epidermolysis bullosa. *Arch Dermatol* **129**:1578-1584, 1993
71. Fine JD et al: The classification of inherited epidermolysis bullosa (EB): Report of the Third International Consensus Meeting on Diagnosis and Classification of EB. *J Am Acad Dermatol* **58**:931-50, 2008
92. Natsuga K et al: Plectin deficiency leads to both muscular dystrophy and pyloric atresia in epidermolysis bullosa simplex. *Hum Mutat* **31**(10):E1687-E1698, 2010
93. Groves RW et al: A homozygous nonsense mutation within the dystonin gene coding for the coiled-coil domain of the epithelial isoform of BPAG1 underlies a new subtype of autosomal recessive epidermolysis bullosa simplex. *J Invest Dermatol* **130**:1551-1557, 2010
103. McLean WH et al: An unusual N-terminal deletion of the laminin alpha3a isoform leads to the chronic granulation tissue disorder laryngo-onycho-cutaneous syndrome. *Hum Mol Genet* **12**:2395-2409, 2003
104. Sakai N et al: Observations of skin grafts derived from keratinocytes expressing selectively engineered mutant laminin-332 molecules. *J Invest Dermatol* **130**:2147-2150, 2010
110. Pfendner EG et al: Basic science of epidermolysis bullosa and diagnostic and molecular characterization: Proceedings of the IInd International Symposium on Epidermolysis Bullosa, Santiago, Chile, 2005. *Int J Dermatol* **46**:781-794, 2007
155. Arnold AW et al: Cetuximab therapy of metastasizing cutaneous squamous cell carcinoma in a patient with severe recessive dystrophic epidermolysis bullosa. *Dermatology* **219**(1):80-83, 2009
164. Lara-Corrales I, Pope E: Dilated cardiomyopathy in epidermolysis bullosa. *Dermatol Clin* **28**(2):347-351, 2010
166. Ingen-Housz-Oro S et al: Vitamin and trace metal levels in recessive dystrophic epidermolysis bullosa. *J Eur Acad Dermatol Venereol* **18**(6):649-653, 2004
167. Martinez AE, Mellerio JE: Osteopenia and osteoporosis in epidermolysis bullosa. *Dermatol Clin* **28**(2):353-355, 2010
170. Tabolli S et al: Quality of life in patients with epidermolysis bullosa. *Br J Dermatol* **161**:869-877, 2009
177. Bruckner-Tuderman L et al: Animal models of epidermolysis bullosa: update 2010. *J Invest Dermatol* **130**:1485-1488, 2010
201. Wagner JE et al: Bone marrow transplantation for recessive dystrophic epidermolysis bullosa. *N Engl J Med* **363**(7):629-639, 2010

SECTION 9

Disorders of the Dermal Connective Tissue

Chapter 63 :: Collagens, Elastic Fibers, and Other Extracellular Matrix Proteins of the Dermis

:: Thomas Krieg, Monique Aumailley, Manuel Koch, Mon-Li Chu, & Jouni Uitto

COLLAGENS, ELASTIC FIBERS AND OTHER EXTRACELLULAR MATRIX PROTEINS OF THE DERMIS AT A GLANCE

- The extracellular matrix (ECM) is a complex network composed of a large number of components, which determines tissue stiffness, compliance, and resilience.
- ECM proteins (i.e., collagens, proteoglycans, glycoproteins) consist of structural domains with different biological functions.
- ECM signals control cell differentiation, polarity, migration, survival, and expression of specific genes.
- There are many ECM-associated heritable diseases. The molecular mechanisms responsible for the resulting phenotypes are often complex and involve several different cellular pathways.
- The dynamic balance between ECM synthesis and degradation is critical for many acquired disease processes, i.e., tumor invasion and metastasis, fibrosis, and inflammatory pathologies.

INTRODUCTION

The extracellular matrix (ECM) is a complex network of different components, responsible for determining and maintaining tissue architecture, and for mediating a number of important biological events. It is composed of a large number of diverse protein families, each constituted by many different individual members. These include the collagens, encoded by 42 different genes, elastin and associated microfibrillar proteins, fibronectin, proteoglycans, and many more molecules. (See Table 63-1.)

Although all of these proteins are genetically, structurally, and biologically diverse, a common denominator is that most of them have a modular structure, and they are composed of one, a few, or several copies of a limited set of individual structural modules, also called domains.[1] These can be combined in multiple ways giving rise to proteins as diverse as fibrillin and laminin (Fig. 63-1). Specific functions have been unraveled for some of these domains, for instance, interaction with other ECM proteins, cell adhesion-promoting activity, cytokine trapping, and regulation. Therefore, the ECM has a critical role for many cellular functions, including proliferation, survival, polarity, differentiation, expression of specific genes, and migration.[2–4] All different cell types, such as mesenchymal, epithelial, and endothelial cells, and also inflammatory and tumor cells, participate in the production of distinct ECM macromolecules, and are all influenced by interactions with these compounds. It is well established that the ECM determines the biophysical properties of connective tissues. More recently it became clear that, conversely, stiffness and compliance of connective tissues are important factors for the regulation of cellular functions.[5–8]

COLLAGENS

The proteins of the collagens family are the main structural components of the connective tissues and the major extracellular proteins of the human body. In human skin, collagens comprises approximately 80% of the dry weight of the dermis. The classical and first recognized physiologic role of collagens in the skin is to provide tensile properties that allow the skin to serve as a protective organ against external trauma. In addition, it is clear that collagens displays important

TABLE 63-1
Major Genes and Proteins of the Extracellular Matrix

Proteins	Number of Genes	Number and Name of Proteins
Collagens	42	28; collagens type I to XXVIII
Elastin	1	Several splice variants
Fibronectin		1; 20 splice variants
Fibulins	7	7; Fibulin 1–7
Fibrillins	3	3; Fibrillin 1–3
Laminins	11	15; LM-111, LM-332, LM-511, etc.
Matrilins	4	4; Matrilins 1–4
Nidogens	2	2; Nidogen 1 and 2
Tenascins	4	4; Tenascin-C, -X, -R, and -W
Thrombospondins	5	5; Thrombospondin 1–5
Vitronectin	1	1

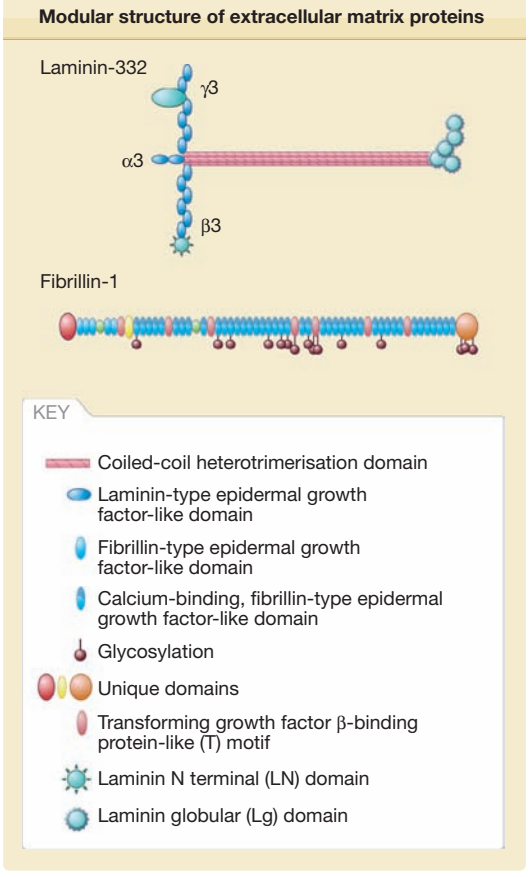

Figure 63-1 Modular structure of extracellular matrix (ECM) proteins. ECM proteins are composed by a few individual structural modules, such as fibrillin- and laminin-type epidermal-growth factor-like modules, von Willebrand factor A domain, follistatin-like and EF-hand Ca^{2+}-binding motif or coiled-coil oligomerization domains. These modules can be combined in multiple ways giving rise to proteins as diverse as fibrillin or laminin displayed here as examples. In addition, ECM proteins can be formed of a single polypeptide chain, as fibrillin, or of several polypeptide chains. For instance, laminin 332 is formed by three polypeptide chains, the a3, b3 and g2 chains.

biological properties regulating multiple cellular and tissue activities.

THE COLLAGENS TRIPLE HELIX

The bulk of collagens in dermis is deposited as large bundles of regularly oriented fibers composed of fibrils that are aligned in a parallel manner, which results in a pattern of cross-striations that can be visualized by electron microscopy (Fig. 63-2). The most prominent cross-striations appear as repeating bands spaced approximately 70 nm apart. The major component of these fibrils is type I collagens, the first identified member of the collagens family and the most abundant collagens in the dermis and most



Figure 63-2 Electron micrograph of collagens fibers demonstrating the regular banding pattern at approximately 70-nm intervals (×45,000).

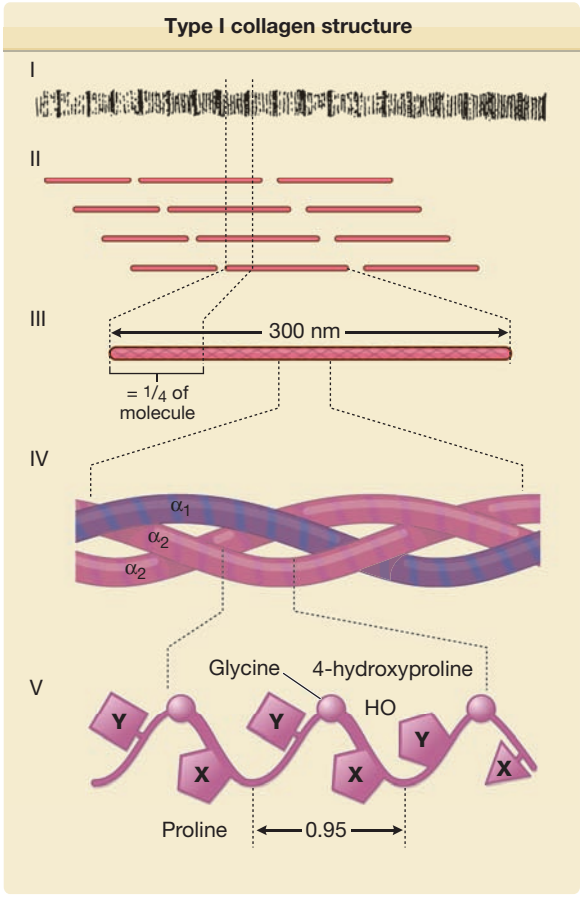

Figure 63-3 Schematic representation of the structure of type I collagens. The collagens fibers (I), which on electron microscopy demonstrate a repeating periodicity (see Fig. 63-2), are composed of individual collagens molecules aligned in a quarter-stagger arrangement (II). Each type I collagens molecule is an approximately 300-nm-long rod-like structure (III) consisting of three individual polypeptides, known as α chains, which are twisted around each other in a right-handed triple helix (IV). Each chain is composed of amino acids in a repeating Gly-X-Y sequence (V); as indicated, the X position is frequently occupied by a prolyl residue and the Y position is frequently occupied by a 4-hydroxyprolyl residue. The individual α chains have a left-handed helical secondary structure with a pitch of 0.95 nm. (From Uitto J et al: Collagens structure, function, and pathology. In: *Progress in Diseases of the Skin*, vol. 1, edited by R Fleischmajer. New York, Grune & Stratton, 1981, p. 103, with permission.)

other connective tissues.[9–11] The characteristic structural features of collagens were deduced from the study of type I collagens, which is therefore considered as the prototype of the collagens family.

The type I collagens molecule has an approximate molecular mass of 290 kDa and is composed of three polypeptide chains, each approximately 94 kDa. These three polypeptides, known as the α chains, are coiled around each other much like strands of rope, so that the collagens monomer has a triple-helical structure. This conformation gives the molecule a rigid, rod-like shape with approximate dimensions of 1.5 × 300 nm (see Fig. 63-3). The special structure of the collagens triple helix is largely explainable by the unusual amino acid composition of the α chains. Specifically, each α chain of type I collagens has approximately 1,000 amino acids, and glycine (Gly), the smallest amino acid, accounts for approximately one-third of the total number of amino acids, evenly distributed along the polypeptide. Consequently, the polypeptide chains of type I collagens can be described as repeating triplets represented as $(Gly\text{-}X\text{-}Y)_{333}$. Although the X and Y positions of the triplets can be occupied by any amino acid, they are often occupied by proline and hydroxyproline, respectively. These two amino acids account for approximately 22% of the total amino acid composition of type I collagens. The relatively high content of these amino acids and the characteristic distribution of glycine in every third position are necessary for the triple-helical conformation of the collagens molecule, and hydroxyproline plays a critical role in stabilizing the triple helix at body temperature. The triple-helical conformation defines the so-called collagenous domain, and it gives type I collagens many of its unique properties.[12] In particular, it is essential for assembly into fibrils. Mutations that affect the formation of the stable triple helix prevent collagens from forming fibers, which results in serious defects of connective tissue function and a spectrum of clinical phenotypes.[13–15]

GENETIC HETEROGENEITY OF COLLAGENS

Collagens comprises a family of closely related yet genetically distinct proteins. In the human genome, there are as many as 42 different genes encoding α chains with variable amino acid sequences. These α chains correspond to at least 28 different types of collagens, which have been assigned Roman numerals I to XXVIII (Table 63-2). These are subdivided into several subfamilies, mainly according to the length and number of collagenous and noncollagenous domains. In addition to well-characterized collagens, short triple-helical collagenous segments are present in other proteins, including acetyl cholinesterase, the C1q component of the complement system, gliomedin, pulmonary surfactant proteins, macrophage scavenger receptors, emilins (elastin microfibril interface-located glycoproteins), and ectodysplasin A, a product of the gene mutated in X-linked anhidrotic ectodermal dysplasia.[16] However, these proteins are not included in the collagens family because the collagenous domains are not a predominant part of the molecules, and the proteins do not function primarily as structural components of the ECM of connective tissue.

The genetically distinct collagens are distributed into several classes, mainly according to the length and number of triple-helical collagenous segments and noncollagenous domains present in the molecule, and on the basis of the architecture of their assembly in tissues (see Table 63-2). A classification and an overview of the major collagens types contributing to skin physiology and pathology are presented in the following paragraphs. Some collagens types are not discussed in detail because they do not appear to be

TABLE 63-2
Genetic Heterogeneity of Collagens

Collagens Type	Gene	Chromosome Localization	α Chains	Comments
I	***COL1A1*** ***COL1A2***	17q21.31–q22 7q22.1	**α1(I)** **α2(I)**	Fibrillar
II	*COL2A1*	12q13.11–q13.2	α1(II)	Fibrillar
III	***COL3A1***	2q31	**α1(III)**	Fibrillar
IV	***COL4A1*** ***COL4A2*** *COL4A3* *COL4A4* ***COL4A5*** ***COL4A6***	13q34 13q34 2q36– q37 2q36– q37 Xq22.3 Xp22.3	**α1(IV)** **α2(IV)** α3(IV) α4(IV) **α5(IV)** **α6(IV)**	Network
V	***COL5A1*** ***COL5A2*** ***COL5A3***	9q34.2– q34.3 2q31 19p13.2	**α1(V)** **α2(V)** **α3(V)**	Fibrillar
VI	***COL6A1*** ***COL6A2*** ***COL6A3*** *COL6A5* *COL6A6*	21q22.3 21q22.3 2q37 3q21 3q21	**α1(VI)** **α2(VI)** **α3(VI)** α5(VI) α6(VI)	Microfibril
VII	***COL7A1***	3p21.3	**α1(VII)**	Anchoring fibril
VIII	*COL8A1* *COL8A2*	3q12– q13.1 1p34.3– p32.3	α1(VIII) α2(VIII)	Network
IX	*COL9A1* *COL9A2* *COL9A3*	6q13 1p33– p32.2 20q13.3	α1(IX) α2(IX) α3(IX)	FACIT
X	*COL10A1*	6q21– q22.3	α1(X)	Network
XI	*COL11A1* *COL11A2*	1p21 6p21.3	α1(XI) α2(XI)	Fibrillar
XII	***COL12A1***	6q12– q13	**α1(XII)**	FACIT
XIII	***COL13A1***	10q22	**α1(XIII)**	Transmembrane
XIV	***COL14A1***	8q23	**α1(XIV)**	FACIT
XV	*COL15A1*	9q21– q22	α1(XV)	Multiplexin
XVI	***COL16A1***	1p34	**α1(XVI)**	FACIT
XVII	***COL17A1***	10q24.3	**α1(XVII)**	Transmembrane
XVIII	***COL18A1***	21q22.3	**α1(XVIII)**	Multiplexin
XIX	*COL19A1*	6q12– q14	α1(XIX)	FACIT
XX	*COL20A1*	20q13.3	α1(XX)	FACIT
XXI	*COL21A1*	6p12.3– p11.2	α1(XXI)	FACIT
XXII	*COL22A1*	8q24.2	α1(XXII)	FACIT
XXIII	*COL23A1*	5q35	α1(XXIII)	Transmembrane
XXIV	*COL24A1*	1p22.3	α1(XXIV)	Fibrillar
XXV	*COL25A1*	4q25	α1(XXV)	Transmembrane
XXVI	*COL26A1*	16p11.2	α1(XXVI)	FACIT
XXVII	*COL27A1*	9q32	α1(XXVII)	Fibrillar
XXVIII	*COL28A1*	7p21.3	α1(XXVIII)	?

FACIT = fibril-associated collagens with interrupted triple helices.
Red: The polypeptide is expressed in the dermis.
Green: The polypeptide is present at the dermal–epidermal junction (basement membrane).

present in the skin in significant quantities, or they do not seem to contribute to the physiologic properties of dermis, or because information is still lacking.

The first class groups the **fibril-forming collagens** types I, II, III, V, XI, XXIV, and XXVII. Except for collagens II, XXIV, and XXVII that were not detected in skin, all other fibril-forming collagens types are expressed in the dermis. These collagens types consist of a single 300-nm long collagenous domain, with very short nontriple-helical extensions (Fig. 63-4), and they assemble into relatively large fibrils.[11,12,17] **Type I collagens**, the most widely distributed and the most extensively characterized form of collagens, accounts for approximately 80% of the total collagens of adult human dermis. It is formed by two identical α chains, designated α1(I), and a third chain, called α2(I), that is clearly different in its amino acid composition. Thus, the chain composition of type I collagens is $[\alpha1(I)]_2\alpha2(I)$. **Type III collagens** represents approximately 10% of the total collagens in the adult human dermis.[18] It is composed of three identical α1(III) chains, distinguished from the chains of type I collagens by a relatively high content of hydroxyproline and glycine and the presence of one cysteine residue. Collagens types I and III form the relatively broad extracellular fibers that are primarily responsible for the tensile strength of the human dermis. Mutations in the type I and III collagens genes can result in connective tissue abnormalities in the skin and joints, among other tissues, in different forms of Ehlers–Danlos syndrome and fragility of bones in osteogenesis imperfecta.[13–15] **Type V collagens** forms a subfamily of similar interrelated collagens resulting from various assemblies of three different types of α chains, α1(V), α2(V), and α3(V). The predominant form in the skin is $[\alpha1(V)]_2\alpha2(V)$, where it represents less than 5% of the total collagens. In dermis, type V collagens is associated with major collagens fibers consisting of type I and III collagens, and type V collagens has been postulated to regulate the fiber diameter during fibrillogenesis. The importance of type V collagens has been demonstrated by the discovery of mutations in type V collagens genes in patients with classical autosomal dominant forms (types I and II) of Ehlers–Danlos syndrome.[19] It is of interest that a clinically similar, classical type of Ehlers–Danlos syndrome can be based on the absence of tenascin-X expression, which leads to an autosomal recessive form of the disease.[20] Tenascin-X is developmentally associated with collagens fibrillogenesis, and its absence could explain the presence of defective collagens fibers similar to those found in patients with mutations in type V collagens genes.

Another class comprises the **network-forming collagens** types IV, VIII, and X, which are, however, very different structurally (Fig. 63-4). **Type IV collagens** is a typical component of basement membranes, where it forms a lattice rather than the fibers characteristic of dermal collagens. Six different α (IV) chains exist, α1(IV) to α6(IV), and participate in the assembly of heterotrimers. In human skin, α1(IV) to α4(IV) chains are present in the basement membrane at the dermal–epidermal junction, with $[\alpha1(IV)]_2\alpha2(IV)$ being the predominant heterotrimer.[17,21] Type IV collagens chains contain imperfect Gly-X-Y triplets, a feature that confers flexibility to the triple-helical domain of the molecule. A noncollagenous globular domain at the amino-terminal part of the molecule mediates dimer formation, while a short segment at the carboxyl-terminal region of the molecule allows for tetramer assembly, altogether resulting in the so-called "chicken-wire" assembly network for collagens type IV.[17] Although

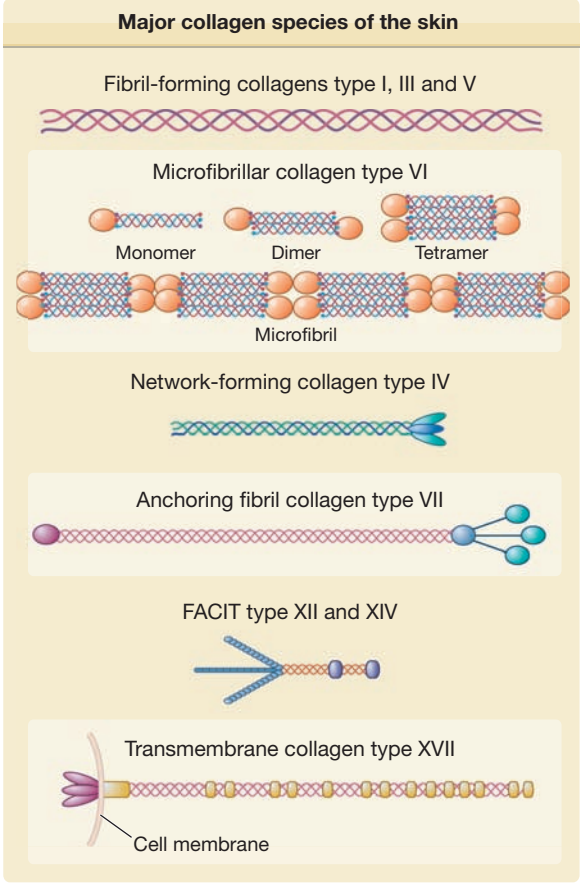

Figure 63-4 The major collagens species of the skin. According to several features, including length and number of collagenous and noncollagenous domains and supramolecular assemblies, the collagens molecules are grouped in different families. Type I, III, and V collagens have the characteristic rod-like structure and form the large collagens fibrils of the dermis. Type VI collagens molecules are arranged following a unique microfibrillar pattern of thin and long aggregates in the dermis. Also present in the dermal extracellular matrix are two FACITs (fibril-associated collagens with interrupted triple helices), type XII and XIV collagens associated to the large collagens fibrils formed by type I, III, and V collagens. Type IV collagens is ubiquitous of basement membranes where it forms large hexagonal networks. Two further collagens, type VII and type XVII, are specific of the dermal–epidermal junction, where type VII collagens is a component of the anchoring fibrils, while the ectodomain of transmembrane type XVII collagens is located in the anchoring filaments anchoring basal keratinocytes of the epidermis to the underlying basement membrane.

skin disorders associated with genetic mutations in type IV collagens have not been described, mutation in the *COL4A1* gene has been identified in a family with autosomal dominant porencephaly and infantile hemiparesis,[22] and mutations in the *COL4A5* gene result in Alport syndrome,[23] an X-linked renal disease. Furthermore, autoantibodies recognizing the collagens α3(IV) chain underlie Goodpasture syndrome,[23] and autoantibodies targeting the collagens α5(IV) chain are associated with a novel autoimmune disease characterized by subepidermal blisters and renal insufficiency.[24]

Two further collagens, **type VI collagens and type VII collagens**, are unique and each has its own distinct molecular structure and supramolecular assembly. Type VI collagens forms specific microfibrils in the dermis, while type VII collagens forms the anchoring fibrils of the dermal–epidermal junction. The microfibril-forming type VI collagens is relatively abundant in a variety of tissues, including skin. In humans, five distinct α chains—α1(VI), α2(VI), α3(VI), α5(VI), and α6(VI)[11]—have been identified (Table 63-2). The α1(VI), α2(VI), and α3(VI) chains fold into a triple-helical domain of approximately 100 nm in length, with globular domains at both ends (Fig. 63-4). The supramolecular assembly involves the formation of antiparallel dimers, then tetramers, which in turn align in rows, leading to relatively thin microfibrils, independently of the broad collagens fibers.[25,26] The microfibrils of type VI collagens may perform an anchoring function by stabilizing the assembly of the broad collagens fibers as well as basement membranes. Studies have now demonstrated that mutations in each of the three type VI collagens genes can lead to different forms of congenital muscular dystrophy, with multiple joint contractures, laxity of distal joints, and characteristic skin involvement.[27]

Type VII collagens, the major, if not the exclusive, component of the anchoring fibrils at the dermal–epidermal junction, has an unusually long triple-helical region of approximately 450 nm.[28] It has only one type of α chain, α1(VII), and the triple-helical collagenous domain is flanked by a large, nonhelical (noncollagenous) domain, NC-1, at the amino terminus and a shorter carboxyl-terminal nonhelical domain, NC-2 (Fig. 63-4). Type VII collagens molecules become organized into anchoring fibrils, which extend from the lower part of the lamina densa to the papillary dermis, through the formation of antiparallel dimers linked through their carboxyl-terminal ends. The large amino-terminal, noncollagenous domains of type VII collagens interact with type IV collagens and laminin 332 components of the dermal–epidermal basement membrane, and it has been suggested that most anchoring fibrils form U-shaped loops that entrap broad dermal collagens fibers consisting of type I and III collagens. Thus, alterations in the expression, structure, or molecular interactions of type VII with other basement membrane components could result in skin fragility. Such a situation is exemplified by dystrophic epidermolysis bullosa (DEB), a group of mechanobullous diseases characterized by blistering of the skin after minor trauma (see Chapter 62). In fact, distinct mutations in the type VII collagens gene, *COL7A1*, have been demonstrated in more than 500 families with different forms of DEB, and none of the families with DEB studied so far has revealed mutations in genes other than that encoding the α1(VII) polypeptide of type VII collagens.[29–31] Furthermore, type VII collagens serves as the autoantigen in the acquired form of epidermolysis bullosa, an autoimmune disorder with circulating antitype VII collagens antibodies (see Chapter 60).

A further class groups the *F*ibril-*A*ssociated Collagens with *I*nterrupted *T*riple helices, in short FACITs, including types IX, XII, XIV, XVI, XIX, XX, XXI, XXII, and XXVI.[11,32] An association with collagens fibers has been demonstrated for several of these collagens, hence the concept that they serve as important molecular bridges for the organization and stability of extracellular matrices. These collagens types form homotrimers with a relatively short triple-helical domain, and 2–4 noncollagenous domains (Fig. 63-4). In the skin, type XII and type XIV collagens associate with the large collagens fibrils of the dermis.

Type XV collagens and Type XVIII collagens are basement membrane-associated collagens. They have been called multiplexins because they contain multiple noncollagenous domains in their collagenous sequences.[33] Interest in these collagens stems from the fact that proteolysis liberates fragments endowed with functions different from those of the original intact molecules.[33,34]

Type XIII, XVII, XXIII, and XXV collagens are transmembrane proteins.[35] Their supramolecular assemblies remain unknown, and, except for types XIII and XVII, their presence in skin has not been established. **Type XVII collagens** (Fig. 63-4) is particularly important for skin physiology and pathology. It is a transmembrane protein anchored in the membrane of basal keratinocytes, with an intracellular domain and a large extracellular domain, or ectodomain, which is a component of the basement membrane at the dermal–epidermal junction. Immunoelectron microscopy has localized type XVII collagens to hemidesmosomes of basal keratinocytes and to the thin anchoring filaments originating from the hemidesmosomes and spanning the lamina lucida toward the lamina densa of the basement membrane.[36] The ectodomain of type XVII collagens consists of 15 collagenous domains with the characteristic repeating Gly-X-Y sequences that form triple helices. These collagenous domains are separated by noncollagenous segments of variable sizes, and consequently type XVII collagens is a protein characterized by alternating collagenous and noncollagenous segments.[37] The ectodomain colocalizes and interacts with laminin 332, also a component of anchoring filaments[36,38] (see also Chapter 53). Type XVII collagens was initially identified as the 180-kDa bullous pemphigoid antigen (*BPAG2*), which was recognized by circulating autoantibodies in the sera of patients with bullous pemphigoid or herpes gestationis.[39] The importance of the type XVII collagens was also shown by mutations in the corresponding gene *(COL17A1)* that underlie a nonlethal variant of junctional

epidermolysis bullosa, generalized atrophic benign epidermolysis bullosa (see Chapter 62). These patients have protracted, lifelong blistering of the skin, atrophic scarring, alopecia, and nail dystrophy.[37,40]

FROM COLLAGENS GENES TO SUPRAMOLECULAR ASSEMBLIES

The collagens genes, like most eukaryotic genes, are large, multiexon genes interrupted at several points by noncoding DNA sequences called *introns*.[41] For expression, the entire gene is transcribed into a high-molecular-weight precursor messenger RNA (mRNA), which undergoes posttranscriptional modifications, such as capping, polyadenylation, and intron splicing to yield a linear, uninterrupted coding sequence with 5′ and 3′ untranslated flanking regions. The mature mRNA is then transported into the cytoplasm and translated to the corresponding polypeptide. Thus, the eukaryotic gene coding for a protein is much larger than would be predicted from the amino acid sequences of the final protein.

With few exceptions, the collagens genes are widely scattered throughout the human genome (see Table 63-2). Knowledge of the precise chromosomal location of the genes coding for collagens in human skin has allowed identification of polymorphic markers within the genes and in the flanking DNA for use in genetic linkage studies. In addition, sophisticated mutation detection strategies, based on scanning of the genes, have led to identification of a large number of mutations in different collagens genes with characteristic phenotypic consequences.

Under physiologic conditions, fibril-forming collagens molecules spontaneously assemble into insoluble fibers.[17] This observation presented a logistic problem, because it was difficult to visualize how a collagens molecule could be synthesized inside the cell and then secreted into the extracellular space without premature assembly of the molecules into insoluble fibers. The solution to this problem was found in the demonstration that fibril-forming collagens, and some other collagens, is initially synthesized as a larger precursor molecule, procollagen, which is soluble under physiologic conditions.

The precursor polypeptides of procollagen, so-called *pre-proα chains*, are synthesized on the ribosomes of the rough endoplasmic reticulum in fibroblasts and related cells (Fig. 63-5). This initial translation product contains an amino-terminal signal (or leader) sequence rich in hydrophobic amino acids. This sequence serves as a signal for attachment of the ribosomes to the membranes of the rough endoplasmic reticulum and vectorial release of the nascent polypeptides into the cisternae of the rough endoplasmic reticulum. During the transmembrane transport of the polypeptides, the signal sequence is enzymatically removed in a reaction catalyzed by signal peptidase, and the polypeptides, termed *proα chains*, are released inside the lumen of the rough endoplasmic reticulum. For some collagens types, in particular the fibril-forming collagens, *proα chains* are larger than collagens α chains because they contain additional peptide sequences at both ends of the molecule.

POSTTRANSLATIONAL MODIFICATIONS OF POLYPEPTIDE CHAINS

After the assembly of amino acids into pre-proα chains on the ribosomes, the polypeptides undergo several modifications before the completed collagens molecules are deposited into extracellular fibers (Fig. 63-5). Most of these posttranslational modifications are catalyzed by specific enzymes (Table 63-3), and include (1) synthesis of hydroxyproline by hydroxylation of selected prolyl residues; (2) synthesis of hydroxylysine by hydroxylation of selected lysyl residues; (3) attachment of carbohydrates, galactose, or glucosylgalactose, onto certain hydroxylysyl residues; (4) chain association, disulfide bonding, and triple-helix formation; (5) proteolytic conversion of procollagens to collagens; and (6) fiber formation and cross-linking. Current evidence indicates that modification reactions (1)–(4) are intracellular events, whereas proteolytic conversion, fiber formation, and cross-linking probably take place extracellularly (see Fig. 63-5).

SYNTHESIS OF HYDROXYPROLINE, HYDROXYLYSINE, AND ATTACHMENT OF CARBOHYDRATES.

A characteristic feature of collagens is the presence of hydroxyproline and hydroxylysine residues.[9] Free hydroxyproline and hydroxylysine are not incorporated into nascent polypeptide chains, but result from the hydroxylation of prolyl and lysyl residues, respectively (Fig. 63-6). The hydroxylation reactions are catalyzed by enzymes belonging to the prolyl and lysyl hydroxylase families.[9,41–45] These enzymes require molecular oxygen, ferrous iron, α-ketoglutarate, and a reducing agent, such as ascorbate as cosubstrates or cofactors for the reactions (Fig. 63-6 and Table 63-3). Hydroxylation begins while the proα chains are growing on the ribosomes, and it is completed soon after the release of full-length polypeptide chains from the ribosomes (Fig. 63-7). The hydroxyproline in collagens is found in two isomeric forms, *trans*-3-hydroxy-L-proline, and the most abundant *trans*-4-hydroxy-L-proline. A critical amount of *trans*-4-hydroxy-L-proline is a prerequisite for the folding of α chains into the triple helix, the conformation required for secretion of procollagens molecules out of the cells. Because triple-helix formation takes place in the cisternae of the rough endoplasmic reticulum, and because prolyl hydroxylases do not hydroxylate prolyl residues if the collagens substrate is in a triple-helical conformation, hydroxyproline formation must be completed before the procollagens molecules leave this cellular compartment. Thus, in the absence of hydroxyproline, the critical triple-helical structure of collagens would not form under physiologic conditions, and no functional collagens fibers would appear in the extracellular space. Also, because prolyl hydroxylase requires a reducing agent, such as ascorbate, for its activity, ascorbic acid deficiency leads to a decreased formation of collagens fibers. This

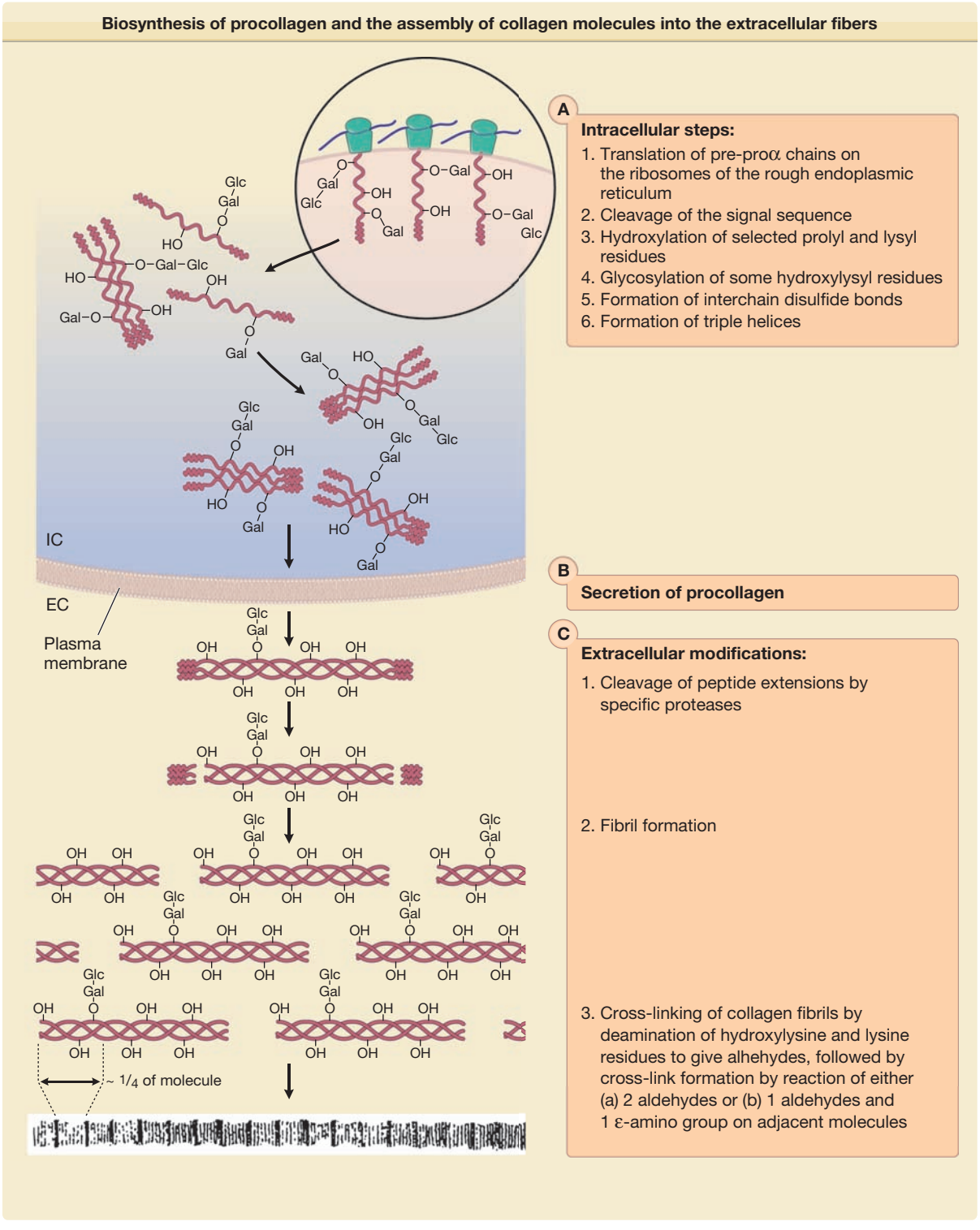

Figure 63-5 Biosynthesis of procollagens and the assembly of collagens molecules into the extracellular fibers. EC = extracellular; Glc-Gal = glucosylgalactose attached to a hydroxylysyl residue; IC = intracellular; mRNA = messenger RNA; –OH = hydroxyl group of hydroxyproline or hydroxylysine; RER = rough endoplasmic reticulum.

explains some of the clinical manifestations in scurvy, such as poor wound healing and decreased tensile strength of the connective tissues.[46] An analogous situation may exist in tissues with hypoxia, because molecular oxygen is a specific requirement for the formation of hydroxyl groups in hydroxyproline. Studies in animal models demonstrate that wound healing is relatively poor under hypobaric conditions, and in such situations the low oxygen levels may limit the synthesis of hydroxyproline.[47] This observation may also explain the

TABLE 63-3
Characteristics of Enzymes Participating in the Biosynthesis of Collagens

Enzyme[a]	Substrate	Product	Co-Factors and Co-Substrates
Signal peptidase	Nascent pre-proα chains	Proα chains	None known
Prolyl-4-hydroxylase	Prolyl residue in X-Pro-Gly sequence in proα chains[b]	4-Hydroxyproline	O_2, Fe^{2+}, α-ketoglutarate, ascorbic acid
Prolyl-3-hydroxylase	Prolyl residue in Pro-Hyp-Gly sequence in proα chains[b]	3-Hydroxyproline	O_2, Fe^{2+}, α-ketoglutarate, ascorbic acid
Lysyl hydroxylase	Lysyl residue in Lys-Gly, Lys-Ser, or Lys-Ala sequence in proα chains[b]	Hydroxylysine	O_2, Fe^{2+}, α-ketoglutarate, ascorbic acid
Collagens galactosyl transferase	Hydroxylysine in proα chains[b]	Gal-*O*-hydroxylysine	Mn^{2+}, UDP-galactose
Collagens glucosyl transferase	Galactosyl-*O*-hydroxylysine in proα chains[b]	Glc-Gal-*O*-hydroxylysine	Mn^{2+}, UDP-glucose
Protein disulfide isomerase[c]	Cysteine residues in the extensions of proα chains	S–S bonds stabilizing the correct protein conformation	Thiols
Procollagen *N*-proteinase (ADAMTS-2)	Procollagen or p_n-collagens	P_c-collagens or collagens[d]	Ca^{2+}
Procollagen *C*-proteinase	Procollagen p_c-collagens	P_n-collagens or collagens[d]	Ca^{2+}
Lysyl oxidases	Lysyl or hydroxylysyl residue in fibrillar collagens	Aldehyde derivatives of lysine or hydroxylysine	Cu^{2+}, O_2

ADAMTS = a disintegrin and metalloprotease with thrombospondin motifs; Ala = alanine; Gal = galactose; Glc = glucosyl; Gly = glycine; Hyp = hydroxyproline; Lys = lysine; p_c-collagens = collagens molecule with the *C*-terminal propeptide still attached whereas the *N*-propeptide has been removed; p_n-collagens= collagens molecule with the *N*-terminal propeptide still attached whereas the *C*-propeptide is cleaved off; Pro = proline; Ser = serine; UDP = uridine diphosphate.

[a]The action of these enzymes (with the exception of signal peptidase) is relatively specific to collagens; the complete sequences of procollagen synthesis and collagens degradation involve additional, less specific enzymes, such as those of transcription and translation.

[b]These reactions are terminated when the proα chains fold into the triple-helical conformation.

[c]It has not been established whether the formation of interchain disulfides in procollagen involves enzymatic catalysis, as occurs in some other proteins, or whether their synthesis takes place spontaneously.

[d]If intact procollagen is used as a substrate, partially modified products are formed; however, if the partially cleaved proteins (p_n-collagens, p_c-collagens) serve as substrates, collagens is produced.

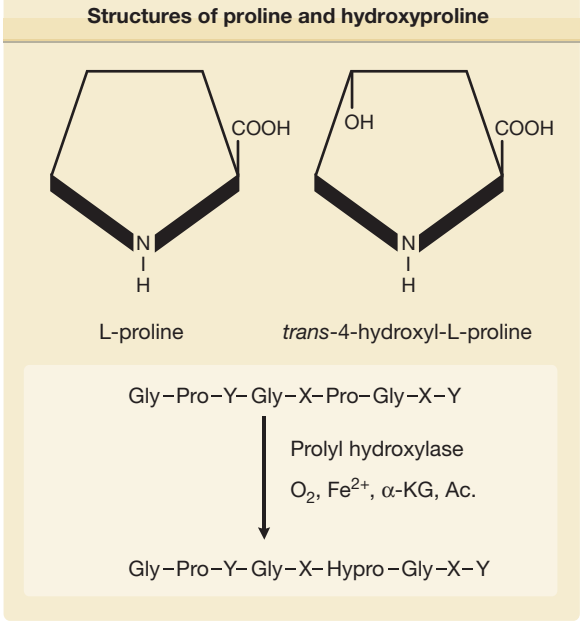

Figure 63-6 Structures of proline (Pro) and hydroxyproline (Hypro), and schematic representation of the enzymatic hydroxylation of prolyl residues in the Y position of the repeating Gly-X-Y sequence of collagens polypeptides. Ac = ascorbic acid; Gly = glycine; α-KG = α-ketoglutarate. (From Uitto J, Prockop DJ: Inhibition of collagens accumulation by proline analogs: The mechanism of their action. In: *Collagens Metabolism in the Liver*, edited by H Popper, K Becker. New York, Stratton Intercontinental, 1975, p. 139, with permission.)

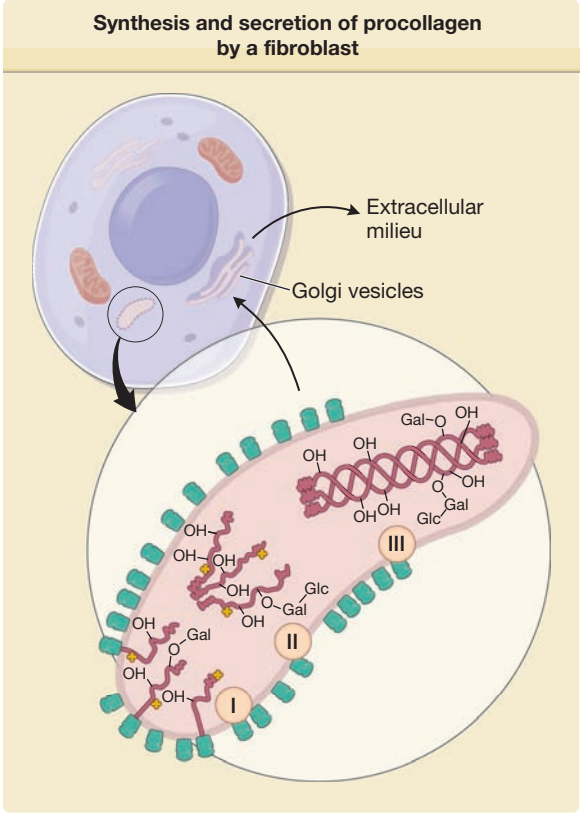

Figure 63-7 Representation of the synthesis and secretion of procollagen by a fibroblast. The enlarged area demonstrates events taking place in the rough endoplasmic reticulum of the cells during the synthesis of procollagen. In the first stage (I), the polypeptide chains of procollagen are synthesized on the membrane-bound ribosomes, and the nascent chains are fed into the cisternae of the rough endoplasmic reticulum. Hydroxylation of prolyl and lysyl residues and glycosylation of hydroxylysyl residues are initiated on the growing polypeptide chains, and these reactions are completed soon after the release of full-size chains from ribosomes (II). Three proα chains are linked together by the formation of interchain disulfide bonds, and the collagenous portions of the polypeptides assume a triple-helical conformation (III). The procollagen molecules are then transferred from the rough endoplasmic reticulum to Golgi vesicles and are secreted from these vesicles into the extracellular milieu. –OH = hydroxyl groups of hydroxyproline and hydroxylysine; –Gal = galactosyl residue attached to hydroxylysine; –Gal-Glc = glucosylgalactosyl residue attached to hydroxylysine in *O*-glycosidic linkage; the cloverleaf-like structures signify the hydroxylating and glycosylating enzymes. (After Prockop DJ et al: Intracellular steps in the biosynthesis of collagens. In: *Biochemistry of Collagens*, edited by GN Ramachandran, AH Reddi. New York, Plenum, 1976, p. 163, with permission.)

decreased healing tendency of wounds and ulcers in peripheral tissues that are anoxic due to relatively poor blood supply. It may also relate to the recent appreciation that prolyl hydroxylases are genuine oxygen sensors. In addition to the prolyl-4-hydroxylase playing a critical role in the hydroxylation of prolyl residues on nascent collagens polypeptide chains, there are additional prolyl-4-hydroxylase isoforms that are responsible for the hydroxylation of two proline residues that earmarks the α subunit of the hypoxia-inducible transcription factor (the master regulator of hypoxia-inducible genes) for proteasomal degradation.[44,48,49]

Lysyl hydroxylation is of critical importance because hydroxylysyl residues serve either as an attachment site for galactosyl and glucosylgalactosyl residues during the intracellular synthesis of procollagen, or to the formation of cross-links that stabilize the collagens matrix in the extracellular space.[9,45,50] The intracellular modification of lysyl residues is a sequential event, with first hydroxylation of lysyl residues, followed by the attachment of galactosyl residue to the hydroxyl group of hydroxylysine with an *O*-glycosidic bond and then a glucose moiety is attached to some of the galactosyl residues (see Figs. 63-5 and 63-7). Therefore, the synthesis of hydroxylysine is a prerequisite for the glycosylation of collagens (see Table 63-3). Three lysyl hydroxylase isoforms exist, and one of them, the lysyl-3-hydroxylase (LH3), displays three activities: (1) lysyl hydroxylase, (2) galactosyltransferase, and (3) glucosyltransfrase activities.[45] The glycosylation reactions use uridine diphosphate sugars as a source of the carbohydrate and require Mn^{2+} as a cofactor. In addition to the glycosylation of hydroxylysyl residues in the triple-helical portion of the molecule, the nonhelical extensions contain complex carbohydrates, consisting mainly of mannose. Deficiency of lysyl hydroxylase has been identified in patients with the scoliotic form (type VI) of Ehlers–Danlos syndrome, characterized by hyperextensible skin, loose-jointedness, severe kyphoscoliosis, and ocular fragility. A connective tissue disorder caused by mutations of the lysyl hydroxylase 3 gene has been recently identified in humans. The disorder is associated with abnormalities in several organs, including skin, and the phenotype has features that overlap with a number of known collagens disorders.[51]

CHAIN ASSOCIATION, DISULFIDE BONDING, AND TRIPLE-HELIX FORMATION

A critical step in the intracellular biosynthesis of procollagens is the association of three proα chains and subsequent folding of the collagens portion of the polypeptides into a triple helix (see Fig. 63-7). The noncollagenous peptide extensions on the individual proα chains assume globular conformations soon after their translation, and this conformation contains the specific information that directs the correct association of the three proα chains. Such a mechanism might explain the association of proα1 and proα2 chains in a proper 2:1 ratio during the synthesis of type I procollagen. It would also explain the rapid and efficient association of the proα chains and folding of the molecule into the triple helix. The association of the extensions at the carboxyl-terminal ends of the polypeptide chains appears to facilitate folding of the molecules into the triple helix, perhaps by providing a nucleation site from which the formation of the triple helix is propagated throughout the collagenous portion of the molecule.

CONVERSION OF PROCOLLAGENSS TO COLLAGENS

After secretion into the extracellular space, procollagens molecules are converted to collagens by limited proteolysis, which removes the extension peptides on the molecule.[52] The conversion of type I procollagens to collagens is catalyzed by two specific enzymes, (1) procollagens *N*-proteinase and (2) procollagens *C*-proteinase, that separately remove the amino-terminal and carboxyl-terminal extensions, respectively (see Table 63-3). Furthermore, the *N*-proteinase catalyzing the conversion of type III procollagens to collagens is a separate, specific enzyme.

The *N*-proteinase capable of cleaving type I procollagens belongs to the ADAMTS (a disintegrin and metalloprotease with thrombospondin motifs) family of extracellular proteases, and is called ADAMTS-2.[53] The activity of this enzyme is dependent on the native conformation of the amino-terminal propeptides in procollagen, because it does not catalyze the removal of the extension peptides from isolated proα chains. Furthermore, partially purified *N*-proteinase is inhibited by metal chelators, which suggests a requirement for divalent cations.

C-proteinase is required for the removal of the carboxyl-terminal extension from type I, II, III, and V procollagen, which allows the fully processed molecules to form functional fibers.[52] Cloning of type I procollagens *C*-proteinase revealed that it is identical to bone morphogenic protein-1, a metalloprotease implicated in pattern formation during development of diverse organisms and also capable of inducing ectopic bone formation.[54] The activity of *C*-proteinase/bone morphogenic protein-1 is stimulated by procollagens *C*-proteinase enhancers, glycoproteins that bind to the *C*-terminal propeptide of type I procollagen.[55] Thus, the conversion of procollagens to collagens is a complex, carefully controlled process, and lack of removal of either the amino- or the carboxyl-terminal extensions results in impaired tensile strength of collagens fibers in the skin. Specifically, deficiency in the removal of the amino-terminal propeptide of type I collagens in vivo causes dermatosparaxis, a disease of fragile skin, originally recognized in various animal species, and more recently recognized in humans.[56] Specifically, the human counterpart is the dermatosparaxis type of Ehlers–Danlos syndrome (type VIIc), caused by deficiency in *N*-proteinase activity. It should be noted that a disease with similar phenotype, the arthrochalasia type of Ehlers–Danlos syndrome (types VIIa and VIIb), can be caused by mutations in the type I collagens genes (*COL1A1* and *COL1A2*, respectively) at the cleavage site for the *N*-proteinase.[57]

COLLAGENS ASSEMBLY AND CROSS-LINKING

Collagens assembly is best defined for fibrillar collagens. After removal of the extension peptides in the extracellular space, the collagens molecules spontaneously align to form fibers. However, these fibers do not attain the necessary tensile strength until the molecules are linked together by specific covalent bonds known as cross-links.[58] The most common forms of cross-links in collagens are derived from lysine or hydroxylysine. The first step in the cross-linking of collagens is the enzymatic conversion of some of the lysyl and hydroxylysyl residues to the corresponding aldehyde derivatives by removal of the ε-amino groups (see Figs. 63-5 and 63-7). The aldehydes then form cross-links by two kinds of reactions. One reaction involves condensation of an aldehyde with an ε-amino group still present in another unmodified lysine or hydroxylysine to form a Schiff base-type of covalent cross-link. The second type of reaction is an aldol condensation between two aldehydes. In addition to these cross-links, collagens contains several more complex cross-links that also involve lysyl or hydroxylysyl residues. The lysine- and hydroxylysine-derived cross-links can be either intramolecular, occurring between two adjacent α chains in the same collagens molecule, or intermolecular, stabilizing the alignment of neighboring collagens molecules along microfibril structures.

The first step in collagens cross-linking, the oxidative deamination of certain lysyl and hydroxylysyl residues, is catalyzed by lysyl oxidase. This enzyme requires copper as a cofactor, and its activity is readily inhibited by nitriles, such as β-aminopropionitrile, which produce lathyrism in animals. Because the cross-links of collagens provide the tensile strength required in certain tissues, a defect in the formation of these covalent bonds can lead to a disturbance in connective tissue function. An example is occipital horn syndrome (previously known as *Ehlers–Danlos syndrome type IX*), which results from reduced lysyl oxidase activity (see Chapter 137). The primary defect resides in perturbed copper metabolism caused by mutations in a copper transport enzyme protein, an adenosine triphosphatase encoded by the gene *MNK-1* that is also involved in Menkes syndrome.[59] As a result, serum copper levels are reduced, which leads to reduced lysyl oxidase activity.

CONTROL OF COLLAGENS AND EXTRACELLULAR MATRIX PRODUCTION

A major question in ECM biology concerns the mechanisms that control the deposition of collagens and other ECM proteins in tissues. Such control must exist in vivo, because the consequences of uncontrolled ECM accumulation are demonstrated by diseases such as progressive systemic sclerosis (see Chapter 157) and various other fibrotic conditions.[60,61]

The accumulation of ECM in tissues can be controlled at several different levels of biosynthesis and degradation. Several observations suggest that an important control mechanism acts at the level of mRNA formation through regulation of the transcriptional activity of gene expression.[62,63] The transcriptional regulation of gene expression involves both *cis*-acting elements and *trans*-acting factors. The *cis*-acting elements are nucleotide sequences in the promoter region of the gene that serve as binding sites for *trans*-acting cellular proteins, which can upregulate or downregulate the transcriptional promoter activity. Some of the *trans*-acting factors are nuclear receptors,

such as the retinoic acid receptors (RAR and RXR)[49] that form a complex with the ligand (a retinoid) and then bind to the retinoic acid-responsive elements (RARE) in the target gene. Retinoids, such as all-*trans*-retinoic acid, modulate type I collagens gene expression both in vitro and in vivo.[64] In particular, quiescent nonproliferating cells can be stimulated by retinoic acid to activate collagens gene expression. This may have relevance to the elevated collagens synthesis observed in photodamaged dermis after topical application of all-*trans*-retinoic acid (see Chapter 109).

Diverse growth factors, cytokines, and chemokines are released into the extracellular space from different types of cells, such as fibroblasts, keratinocytes, and endothelial and inflammatory cells. By both paracrine and autocrine mechanisms these factors elicit intracellular signaling pathways acting on the transcriptional and/or translational levels. One of the most powerful regulators of collagens and ECM production is transforming growth factor β (TGF-β), a member of a family of growth factors involved in many physiological and pathological conditions.[65] Interestingly, TGF-β can induce the expression of other growth factors, in particular the expression of connective tissue growth factor in fibroblasts. Also, cytokines such as platelet-derived growth factor, interleukin-1 and -4, and chemokines, such as monocyte chemotactic protein-1 and -3, are thought to induce collagens production.[66]

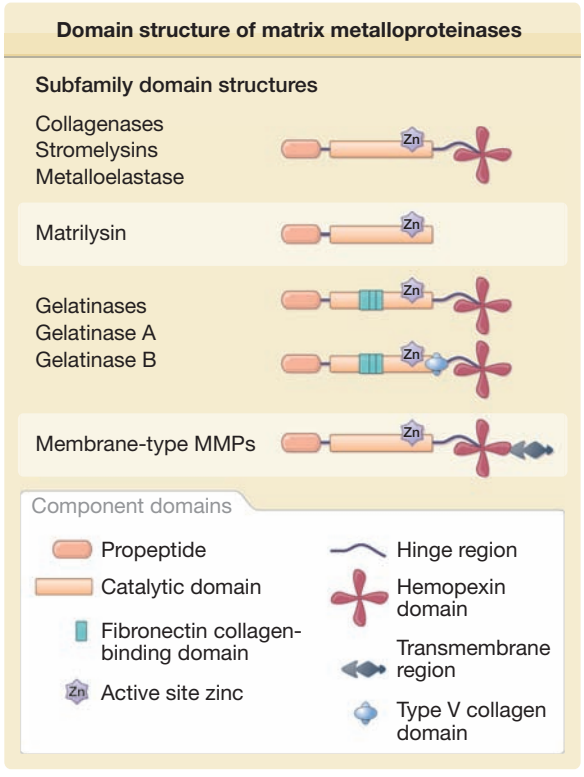

Figure 63-8 Domain structure of matrix metalloproteinases (MMPs).

DEGRADATION AND TURNOVER

In the extracellular space, most collagens form polymers described above, which in turn interact with other proteins of the ECM through multiple protein–protein interactions. It gives rise to large multimolecular assemblies and to the organization of the ECM proteins into specific networks.[17] In addition, many growth factors and cytokines specifically interact with ECM proteins, and they are therefore stored in the networks. There is a continuous remodeling of the multimolecular assemblies, at a rate that can be significantly enhanced during development, wound healing or in certain disease processes. This remodeling results in the release of a large variety of biologically active peptides, including growth factors.[34]

The remodeling of the ECM is a cooperative multistep process involving a variety of molecular pathways and mechanisms. The initial step depends on the presence of proteinases capable of initiating the degradation of the ECM proteins. These enzymes comprise the matrix metalloproteinase (MMP) family,[67–71] which includes collagenases, gelatinases, stromelysins, matrilysins, metalloelastase, enamelysin, and the membrane-type MMPs (Fig. 63-8 and Table 63-4). Interstitial collagenase (MMP-1) was the first enzyme of the MMP family to be discovered and was defined by its ability to break down triple-helical collagens that is resistant to most proteases.[72] Human skin collagenase was initially isolated in active form from the culture medium of skin explants and subsequently as a proenzyme from monolayer fibroblast cultures.[73] Other cell types present in skin, including keratinocytes, endothelial cells, monocytes, and macrophages, express an identical enzyme. Like the other MMPs, MMP-1 contains intrinsic zinc in the active site and requires calcium for its activity and thermostabilization.

MMP-1 degrades some of the collagens present in skin, such as types I, III, and VII, but not others like types IV and V.[74] At physiologic pH and temperature, the enzyme catalyzes a single cleavage three-quarter of the distance from the amino terminus in each of the three α chains comprising the triple-helical, native collagens monomer. Specifically, MMP-1 cleaves the α1(I) chain at a Gly-Ile (glycine-isoleucine) bond (residues 775 and 776) and the α2(I) chain at a Gly-Leu (glycine-leucine) bond in the homologous region. Ten other Gly-Ile or Gly-Leu bonds within the triple-helical domain of interstitial collagens are not cleaved, which suggests that the local conformation of the collagenase cleavage site is a major factor in determining substrate specificity. Indeed, MMP-1 catalyzes multiple cleavages in the denatured chains of all collagens types at Gly-Ile and Gly-Leu bonds. Thus, it appears that the triple-helical conformation of native collagens can drastically alter MMP-1 ability to catalyze cleavages that would be permissible from primary sequence consideration alone.

Human neutrophil interstitial collagenase (MMP-8) attacks collagens at the same site, as does human MMP-1, to produce the characteristic three-quarter/one-quarter collagens fragments. Human MMP-8 is highly homologous to MMP-1, but has a higher degree of glycosylation. It is not immediately secreted but is stored in neutrophil granules and released on stimulation. Although both fibroblast (MMP-1) and neutrophil (MMP-8) collagenases have similar affinities for type I and III collagens, fibroblast collagenase degrades soluble

TABLE 63-4
Matrix Metalloproteinases (MMPs)

Enzyme	MMP Number	Alternate Name	Proenzyme Molecular Weight	Known Matrix Substrates
Interstitial collagenase	MMP-1	Type I collagenase	52,000	Collagens I, II, III, VII, VIII, X, entactin, tenascin, aggrecan, denatured collagens, interleukin-1β, myelin basic protein, L-selectin
Neutrophil collagenase	MMP-8	—	75,000	Collagens I, II, III, V, VII, VIII, X, gelatin, aggrecan, fibronectin
Collagenase-3	MMP-13	—	52,000	Collagens I, II, IV, IX, X, XIV, aggrecan
Gelatinase A	MMP-2	72-kDa type IV collagenase	72,000	Denatured collagens, collagens IV, V, VII, X, XI, XIV; collagens I, species dependent; elastin; fibronectin; laminin; aggrecan; myelin basic protein
Gelatinase B	MMP-9	92-kDa type IV collagenase	92,000	Denatured collagens, collagens IV, V, VII, X, XIV, elastin, entactin, aggrecan, fibronectin, osteonectin, interleukin-1β, plasminogen, myelin basic protein
Stromelysin-1	MMP-3	Proteoglycanase	57,000	Proteoglycan core protein, laminin, fibronectin, collagens I, IV, V, IX, X, XI, gelatin, elastin, tenascin, aggrecan, myelin basic protein, entactin, decorin, osteonectin
Stromelysin-2	MMP-10	Transin-2	55,000	Proteoglycan core protein, collagens III, IV, V, laminin, fibronectin, elastin, aggrecan
Stromelysin-3	MMP-11	—	61,000	α1-proteinase inhibitor
Matrilysin	MMP-7	PUMP, matrilysin-1	28,000	Collagens IV, denatured collagens, laminin, fibronectin, elastin, aggrecan, tenascin, myelin basic protein
Matrilysin-2	MMP-26	Endometase	28,000	Gelatin, α1-proteinase inhibitor
Membrane-type MMP-1	MMP-14	MTI-MMP	63,000	Progelatinase A, denatured collagens, fibronectin, laminin, vitronectin, entactin, proteoglycans
Membrane-type MMP-2	MMP-15	MT2-MMP	72,000	Progelatinase A
Membrane-type MMP-3	MMP-16	MT3-MMP	64,000	Progelatinase A
Membrane-type MMP-4	MMP-17	MT4-MMP	70,000	Unknown
Membrane-type MMP-5	MMP-24	MT5-MMP	73,000	Progelatinase A
Membrane-type MMP-6	MMP-25	MT6-MMP	63,000	Unknown
Metalloelastase	MMP-12	—	54,000	Elastin, collagens IV, vitronectin, plasminogen, laminin, entactin, fibrinogen, fibrin, fibronectin
Enamelysin	MMP-20	—	54,000	Amelogenin, aggrecan
MMP-19	MMP-19	RASI-1	57,000	Gelatin, aggrecan, fibronectin
MMP-21	MMP-21	—	Unknown	Unknown
MMP-22	MMP-22	—	Unknown	Unknown
MMP-23	MMP-23	—	44,000	Unknown
Epilysin	MMP-28	—	56,000	Unknown

PUMP = punctuated metalloproteinase.

type III collagens with a higher turnover rate, whereas neutrophil collagenase degrades soluble type I collagens more rapidly. For both enzymes, the differences in specificity against monomeric collagens are largely abolished when the substrates are reconstituted into the insoluble fibrillar forms found in tissues.[75]

Important mechanistic information on collagens degradation has recently emerged, and specifically, it has been shown[75] that activated collagenase (MMP-1) moves processively on collagens fibrils in which the mechanism of movement is a biased diffusion with the biased component of the motion depending on the proteolysis of collagens and not on ATP hydrolysis. Most importantly, the closely related MMPs, MMP-2 (gelatinase) MMP-9, and the extracellular portion of the membrane-associated metalloproteinase MT1–MMP, can also diffuse on collagens fibrils. These studies also show that a collagenolytic MT1–MMP complex exists at the cell surface. The MT1–MMP complex anchored at the cell surface has profound implications concerning the generation of the forces required for cell locomotion, not only in the normal physiologic processes of tissue remodeling but also in pathologic processes, such as tumor invasion.

Collagenase-3 (MMP-13), first cloned from breast carcinoma, is homologous to rodent collagenase.[69] The purified recombinant enzyme cleaves triple-helical collagens, giving the characteristic three-quarter/one-quarter fragments. However, unlike interstitial and neutrophil collagenases, collagenase-3 acts five to ten times more rapidly on soluble type II collagens, a cartilage-specific collagens, than on types I and III. At physiologic temperature, the collagens cleavage products (i.e., the three-quarter/one-quarter fragments), which are initially triple helical, become soluble, are thermally unstable, and denature spontaneously, forming gelatin (denatured collagens). These denatured gelatin polypeptides are then susceptible to attack by other proteinases. Thus, the interstitial collagenases stand at a key point in connective tissue metabolism: they initiate the proteolytic events that result in the degradation of collagens and overall turnover of the extracellular matrices.

ELASTIN AND ASSOCIATED MICROFIBRILLAR PROTEINS

STRUCTURE AND DEVELOPMENT OF THE ELASTIC FIBERS

Elastic fibers form a network responsible for connective tissue elasticity and resilience specific of various organs.[76,77] The relative concentration of elastic fibers is highest in the aorta and arterial blood vessels and in the lungs, while in the skin they are only a minor component. Specifically, in sun-protected adult human skin, the elastin content is 1%–2% of the total dry weight of dermis.[78] In the papillary dermis, elastic fibers are present either as bundles of microfibrils (oxytalan fibers) or with small amounts of cross-linked elastin (elaunin fibers). In the reticular dermis, the elastic fibers consist primarily of elastin, and they are oriented horizontally in a network with vertical extensions to the papillary dermis in the form of oxytalan fibers. Examination of connective tissues by transmission electron microscopy has demonstrated that mature elastic fibers consist of two distinct components (Fig. 63-9). An amorphous, electron-lucent core consists primarily of elastin, surrounded by distinct electron-dense microfibrillar structures that have a regular diameter of 10–12 nm, and which is composed of a variety of microfibrillar proteins such as fibrillins and fibulins.

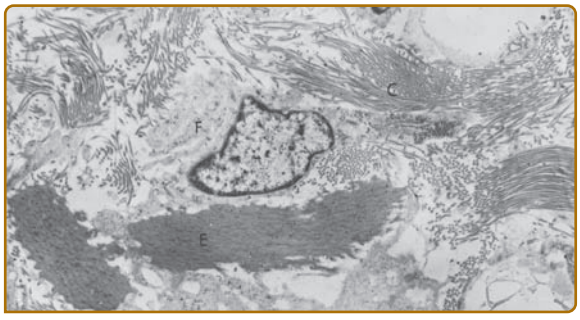

Figure 63-9 Transmission electron microscopy of human skin demonstrating a fibroblast (F) surrounded by elastic structures (E) and collagens fibers (C).

Elastin and the microfibrillar proteins exist in close association in various connective tissues; however, the relative proportions of these components vary during embryonic development. Elastic fibers that form during the first trimester of fetal development consist of bundles of microfibrils, which are thought to form a scaffold into which the elastin molecules will align while fetal age is increasing. Analysis of mature, fully developed elastic fibers suggests that elastin represents well over 90% of the total content of such fibers (see Fig. 63-9). However, it should be noted that skin as well as other tissues contain microfibrils devoid of elastin.

BIOLOGY OF THE ELASTIC FIBERS

Characterization of elastin was hindered for a long time by its extreme insolubility in mature animal tissues. However, it was discovered that this insolubility is attributable to the presence of complex covalent cross-links, known as *desmosines* (see Section "Fibrillogenesis and Cross-Linking of Elastin"), whose formation can be prevented by maintaining the animals on a copper-deficient diet or by feeding them lathyrogens, such as β-aminopropionitrile, which inhibit elastin and collagens cross-linking. Once the formation of the cross-links is prevented, a large fraction of newly synthesized elastin can be extracted from the tissues.[79]

Cloning of cDNAs corresponding to the human elastin mRNA, approximately 3.5 kilobases (kb) in size, has allowed elucidation of the entire primary sequence of tropoelastin[80–84] (Fig. 63-10). The basic molecular unit of elastin is a linear polypeptide, known as *tropoelastin*, that consists of approximately 800 amino acids with a molecular mass of around 70 kDa. Similar to collagens

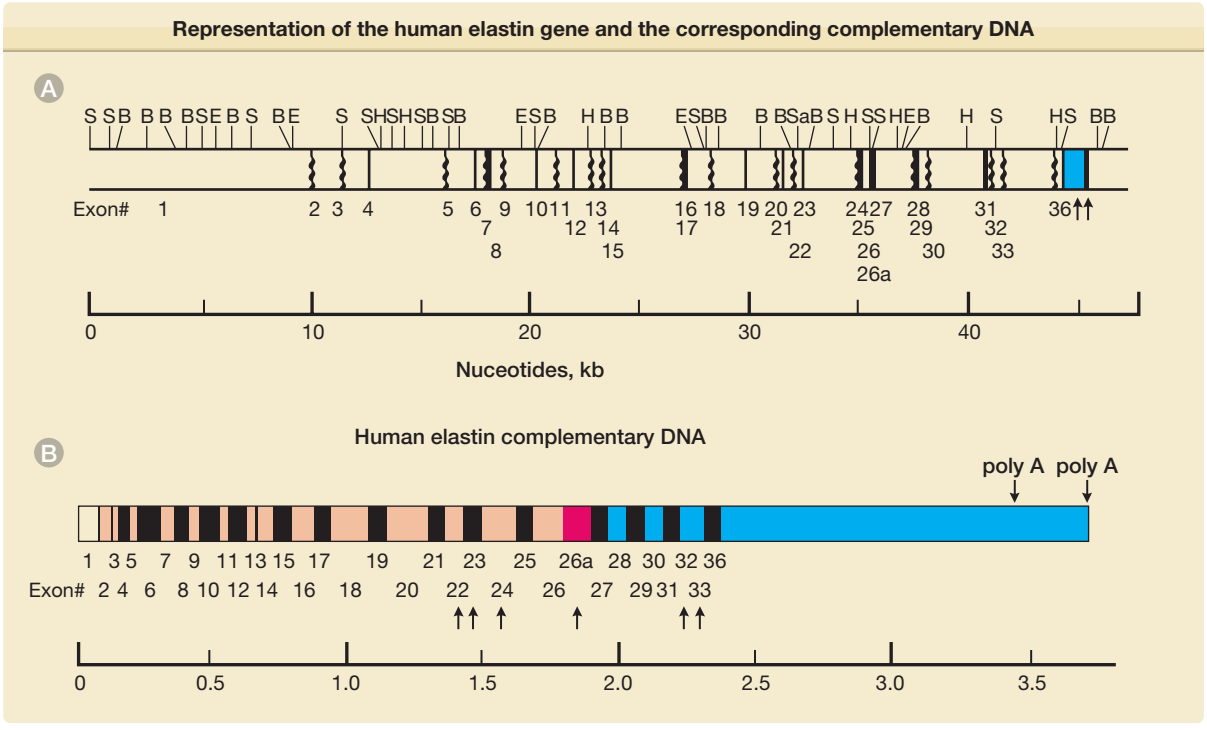

Figure 63-10 Representation of the human elastin gene (**A**) and the corresponding complementary DNA (cDNA) (**B**). **A.** The exons have been numbered starting from the 5′ end of the gene and correspond to those shown in the cDNA (see **B**). The presence of restriction endonuclease cleavage sites: BamHI (B), EcoRI (E), HindIII (H), and SacI (S) are noted on top. **B.** The cDNA, approximately 3.5 kilobases (kb) in size, is divided into separate exons that are numbered from 1 to 36 and drawn to scale. Note that the human elastin gene contains only 34 exons; however, to maintain a consistent numbering system between the bovine and human elastin genes, the last exon is designated as number 36; thus, the human gene is missing the counterparts of bovine exons 34 and 35. The arrows indicate the exons that have been shown to be subject to alternative splicing. The arrows with poly A indicate the polyadenylation sites. (From Uitto et al: Elastic fibers of the connective tissue. In: *Biochemistry and Physiology of Skin*, 2nd edition, edited by L Goldsmith. New York, Oxford University Press, 1991, with permission.)

type I, glycine accounts for about one-third of the amino acid residues in elastin; however, it is not evenly distributed as it is in a typical collagens sequence. Instead, the glycine residues are grouped in valine- and proline-rich regions, which are interspersed with alanine-rich sequences. Elastin also contains some hydroxyproline, but the relative content of this amino acid is considerably lower than that in collagens, and the values for hydroxyproline are variable. Elastin does not contain hydroxylysine or carbohydrate moieties covalently linked to the polypeptide chain.

A characteristic feature of elastic fibers is the presence of cross-links that covalently bind elastin polypeptide chains into a fiber network. The deduced amino acid sequence depicts alternating segments of cross-link domains, characterized by the presence of lysyl residues separated by two or three alanine residues, and hydrophobic domains. The two major cross-link compounds, desmosine and its isomer, isodesmosine, are structures that appear to be unique to elastin.[79] The content of desmosines in various elastin preparations has been shown to be fairly constant, approximately 1.5 residues per 1,000 amino acids. Consequently, assay of desmosine and isodesmosine can provide a quantitative measure of the elastin content in tissues.[79]

CONSTITUTIVE AND ALTERNATIVE SPLICING OF ELASTIN. The human elastin gene consists of 34 separate exons spanning a total of 45 kb of genomic DNA (see Fig. 63-10). The information stored in the DNA sequence is transcribed in the nucleus of the cells to a large mRNA precursor, which undergoes several posttranscriptional modifications, including splicing and polyadenylation. The processed molecules are then transported to the cytoplasm, where the functional mRNAs serve as templates for the synthesis of elastin polypeptides during translation. Several lines of evidence suggest that the rate of elastin biosynthesis is largely regulated by the abundance of the functional mRNA, and consequently, assay of elastin mRNA levels allows measurements of the rate of elastin biosynthesis in tissues and cells.

An early observation during the isolation of human elastin cDNAs was that several overlapping clones were identical, with the exception of short sequences that were absent in some clones but present in others.[81,83,84] Comparison of these sequences in the cDNAs with the corresponding genomic DNA segments indicated that the differences were due to alternative splicing of certain exons during posttranscriptional processing of the elastin pre-mRNA. In fact, at least six

exons in the human gene have been reported to be subject to alternative splicing, and several of the variant mRNAs are translated into protein. This mechanism can provide significant variation in the amino acid composition of individual elastin polypeptides and presumably in the function of the elastic fibers in different tissues. However, the developmental significance and tissue specificity of alternative splicing have not been elucidated in detail.

REGULATION OF ELASTIN GENE EXPRESSION. The elastin promoter contains a remarkable constellation of potential binding sites for transcriptional regulatory factors indicative of complex transcriptional regulation. These include multiple *Sp1* and *AP2* binding sites, putative glucocorticoid-responsive elements, and phorbol ester tumor promoter, 12-*O*-tetradecanoylphorbol and cyclic adenosine monophosphate-responsive elements. The absence of a TATA box in the promoter region suggests that there may be multiple sites of transcriptional initiation, and various molecular tests support this notion.[82] Functional analyses of the human elastin promoter segment have been carried out by constructing a panel of promoter-reporter gene (such as chloramphenicol acetyl transferase) constructs.[85] Use of these constructs in transient transfection of a variety of cultured cells, including human skin fibroblasts, indicated that the core promoter necessary for basal expression of the gene is contained within the region –128 to –1 (in reference to translation initiation site –1, +1), and the upstream sequences contain several upregulatory and downregulatory elements. Development of transgenic mice expressing the human elastin promoter has revealed that 5.2 kb of DNA flanking the human elastin gene contains the elements necessary for tissue-specific expression.[86] In addition to the 5′ upstream sequences, the first introns of both the bovine and human elastin genes contain regions of extremely strong sequence homology. Because it has been demonstrated that the first intron of three different collagens genes contains segments that act as enhancer elements of the promoter activity,[87] the strong conservation within intron 1 of the elastin gene suggests the possible presence of an enhancer in this gene as well.

CYTOKINE AND HORMONAL REGULATION OF ELASTIN SYNTHESIS. The presence of multiple *cis*-acting elements in the elastin promoter region suggests that elastin gene expression is subject to modulation at the transcriptional level by *trans*-acting factors. For example, previous studies have indicated that tumor necrosis factor-α decreases elastin mRNA abundance primarily by suppressing promoter activity.[88] In other studies, TGF-β has been shown to upregulate the abundance of human elastin mRNA by up to approximately 30-fold,[89] but evidence from transient transfection assays suggests that this upregulation is, at least in part, posttranscriptional. In fact, assay of elastin mRNA half-life suggests that TGF-β stabilizes the elastin mRNA, which leads to elevated steady-state levels. These observations collectively suggest that mediators released from inflammatory cells can modulate elastin gene expression, and such modulation may play a role in diseases characterized by altered accumulation of elastic fibers in tissues.

Vitamin D_3 also modulates elastin gene expression. Specifically, incubation of fibroblasts with vitamin D_3 results in an 80%–90% decrease in total accumulation of tropoelastin, accompanied by a parallel decrease in steady-state levels of the corresponding mRNA.[90] At the same time, insulin-like growth factor-1 enhances elastin gene expression at the transcriptional level.[91] Although there is preliminary evidence for modulation of elastin gene expression by selective growth factors and hormone-like substances, the precise details are largely unknown.

ELASTIN BIOSYNTHESIS. Elastin biosynthesis involves several specific steps necessary for the assembly of elastic fibers. Several studies show that smooth muscle cells in culture synthesize relatively large quantities of elastin, which suggests that they may be the major source of elastin in tissues rich in elastic fibers, such as vascular connective tissue.[92,93] The amount of elastin synthesized by cultured human skin fibroblasts is relatively small; nonetheless, fibroblasts may be the primary source of elastin in the dermis. After the completion of translation, newly synthesized polypeptides are translocated into the cisternae of the rough endoplasmic reticulum, and then transferred from the rough endoplasmic reticulum into the extracellular space. Several observations suggest that the secretion of elastin polypeptides is a process that involves the microtubules of the cells and that the molecules may be transferred out of the cells packaged in Golgi vacuoles or related vesicles.

FIBRILLOGENESIS AND CROSS-LINKING OF ELASTIN. The formation of desmosines occurs in the extracellular space, and the first step is the oxidative deamination of lysyl residues to corresponding aldehydes, known as *allysines*. This conversion is catalyzed by copper-requiring enzymes, lysyl oxidases.[94,95] The desmosines are formed by the fusion of three allysines and a fourth unmodified lysyl residue in two adjacent tropoelastin chains. Thus, the desmosines link the individual elastin polypeptides into an insoluble network.

Lysyl oxidases, a group of closely related enzymes, require copper and molecular oxygen as cofactors. It has been shown that the activity of lysyl oxidases is reduced with copper deficiency and that it is associated with a disorder of connective tissue.[96,97] In particular, the individual tropoelastin polypeptides remain soluble and the elastin-rich tissues are fragile.

DEGRADATION AND REMODELING OF ELASTIN. Although the metabolic turnover of elastin is very slow compared with that of proteins in general, a portion of the body's elastin is continuously degraded and may partly be replaced by newly synthesized fibers.[98] In addition, degradation of elastin is markedly increased in a variety of pathologic conditions.[99] Thus, the tissues containing elastin must contain proteolytic enzymes that are capable of degrading elastic fibers.

TABLE 63-5
Microfibrillar Component Proteins

Microfibrillar Protein	Characteristic Features	Human Chromosomal Locus
Fibrillins (FBNs)	350 kDa	
FBN1	Mutations in Marfan syndrome	15q15-q21
FBN2	Mutations in congenital contractural arachnodactyly	5q23-q31
FBN3		19p13.3–13.2
Latent TGF-β-binding proteins (LTBPs)	125–310 kDa	
LTBP1		2p22–24
LTBP2		14q22-q33
LTBP3		11q12
LTBP4		19q13.1–13.2
Fibulins (FBLNs)	60–240 kDa	
FBLN1		22q13.3
FBLN2		3p24-p25
FBLN3		2p16
FBLN4	Mutations in cutis laxa	11q13
FBLN5	Mutations in cutis laxa	14q32.1
Microfibril-associated glycoproteins (MAGPs)		
MAGP1	31 kDa; widely distributed in microfibrils	1p36.1-p35
MAGP2	25 kDa	12p12.3-p13.1
Microfibril-associated proteins (MFAPs)		
MFAP1	Very acidic	15q15-q21
MFAP2		1p36.1-p35
MFAP3		5q32-q33.2
MFAP4	Frequently deleted in Smith–Magenis syndrome	17p11.2
βig-h3		5q31
Lysyl oxidases (LOXs)		
LOX	Probably not structural components	5q23-q31
LOXL1		15q24-q25
LOXL2		8p21.3-p21.2
LOXL3		2p13
LOXL4		10q24
Emilins		
Emilin1 (gp115)		2p23
Emilin2		18p11.3

EGF = epidermal growth factor; TGF-β = transforming growth factor-β; βig-h3 = TGF-β-inducible gene h3.

Evidence for elastase, a specific elastolytic enzyme, was first obtained from study of the pancreas, and since then elastolytic enzymes have been detected in several other tissues, as well as in a variety of cell types, including polymorphonuclear leukocytes, monocytes/macrophages, and platelets.[100] However, elastases from different sources (pancreas vs. polymorphonuclear leukocytes) have different cleavage specificities, as shown by peptide mapping of degradation products.[101]

The classic elastases are serine proteases that degrade insoluble elastic fibers at neutral or slightly alkaline pH. The activity of these enzymes is inhibited by serum factors, such as α_1-antitrypsin and α_2-macroglobulin. In addition to the classic elastases, which are serine proteases, others were shown to be metalloenzymes requiring calcium for their activity. One such enzyme is secreted by macrophages isolated from human alveolar macrophage exudates.[102]

MICROFIBRILLAR PROTEINS

At the electron microscopic level, the microfibrils of the dermis appear in cross section as an outer electron-dense shell surrounding an inner lucid core, and in longitudinal section as a beaded chain, which suggests that they may be composed of more than one protein. Moreover, there is no immunoreactive elastin associated with microfibrils located close to the dermal–epidermal junction, but as microfibrils traverse the dermis, they are associated with an increasing amount of amorphous elastin. Because of their insolubility and apparent complexity, chemical characterization of the microfibrils has progressed slowly until recently. These structural proteins can now be divided into several groups based on their molecular characteristics. Table 63-5 lists these proteins and provides some distinguishing features, including their human chromosomal

localizations. These groups include several gene families that share common structural motifs.

THE FIBRILLINS. The largest, and perhaps the most important microfibrillar proteins for biology and pathology of the dermis, are the fibrillins, 350-kDa glycoproteins that form an integral part of the microfibril structure.[103,104] Electron microscopic images of human monomeric fibrillin synthesized by cultured fibroblasts show an extended flexible molecule, approximately 148-nm long and 2.2-nm wide. Multiple fibrillin molecules align in a parallel head-to-tail fashion to form microfibrils. Molecular cloning studies have so far identified three distinct homologous human genes, (1) *FBN1*, (2) *FBN2*, and (3) *FBN3*, encoding fibrillin-1, -2, and –3, respectively.[104] Analysis of the amino acid sequences deduced from cloned cDNAs showed that these proteins contain multiple repeats of a motif initially observed in epidermal growth factor (EGF) precursor molecule. These motifs have either six or eight conserved cysteines, and many of them contain a consensus sequence for calcium binding.[103,104] Such EGF-like motifs are quite frequent in ECM proteins, and occur as several copies in, for instance, laminins, fibulins, nidogens, agrin, perlecan, tenascins, and latent TGF-β-binding proteins (LTBPs). Besides important structural functions for tissue architecture, it is now clear that fibrillins regulate signaling events and control directly and indirectly cellular activities. Therefore, they play critical roles during development and disease processes.[105–107]

THE LATENT TRANSFORMING GROWTH FACTOR-β-BINDING PROTEINS. It is of interest that LTBPs contain EGF-like motifs similar to those found in fibrillins (Fig. 63-11 provides a comparison of the structures of fibrillins and LTBPs). TGF-β is always secreted as a latent complex with *L*atency-*A*ssociated *P*eptide (LAP) and this complex is bound to an LTBP (Fig. 63-12). To date, four distinct genes (*LTBP1* to *LTBP4*) have been identified, coding for LTBPs ranging in size from 125 to 310 kDa.[108,109] Although LTBPs may facilitate the secretion of TGF-β or association of the inactive complex to the cell surface where activation takes place, they are also found as free proteins associated with components of the ECM. Development of an *LTBP3* knockout mouse revealed craniofacial malformations, perturbed ossification, and development of osteosclerosis and osteoarthritis in the deficient animals. These observations were interpreted to mean that LTBP3 is important for the control of TGF-β action and, specifically, that LTBPs may modulate TGF-β bioavailability. Immunohistologic studies have localized LTBP1 to microfibrils in elastic fibers, which strongly suggests that one or more of the LTBPs may be a component of these fibrils. Furthermore, levels of LTBP1 are altered in a number of pathologic conditions, including solar elastosis.[110]

THE FIBULINS. The fibulins are a family of ECM glycoproteins that contain tandem EGF-like repeats similar to fibrillins and LTBPs, and a common carboxyl-terminal globular domain (see Fig. 63-11).

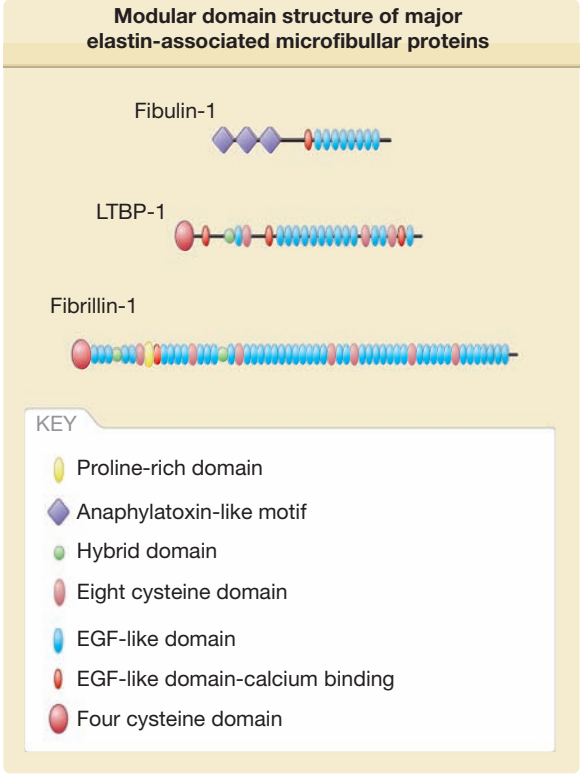

Figure 63-11 Modular domain structure of major elastin-associated microfibrillar proteins, including fibrillin (FBN), latent transforming growth factor-β-binding protein (LTBP), and fibulin (FBLN). The first member of each gene family is represented. The FBN, LTBP, and FBLN families are related because they share common protein motifs. (Adapted from Rosenbloom J, Abrams WR: Elastin and the microfibrillar apparatus. In: *Connective Tissue and Its Heritable Disorders*, 2nd edition, edited by RM Royce, B Steinmann. New York, Wiley-Liss, 2002.)

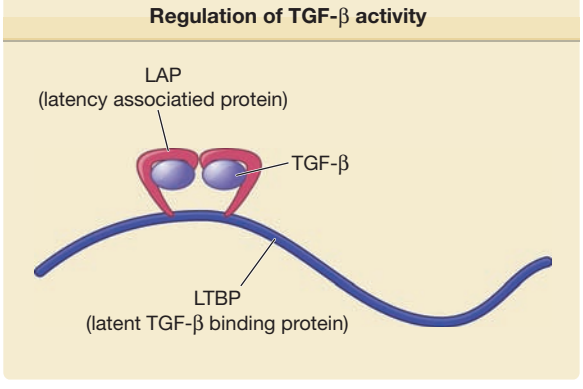

Figure 63-12 Regulation of TGF-β activity. TGF-β is synthesized and secreted in a latent, inactive form in a complex with the latency-associated peptide and the latent TGF-β-binding protein. Therefore, it can be stored in an inactive form in large ECM aggregates. Dissociation of the protein complex leads to activation of TGF-β and a rapid availability, depending on the biological requirements.

Molecular cloning has identified seven fibulin genes (see Table 63-5). Fibulins are widely distributed in connective tissues, including the skin, where they are located within the elastic fibers.[111,112] Fibulin-4- and fibulin-5-deficient mice, developed by targeted ablation of the corresponding genes, demonstrate marked reduction in elastogenesis. Fibulin-4-deficient mice have a severe phenotype that leads to perinatal death, primarily due to pulmonary and cardiovascular abnormalities.[113] Particularly interesting is the phenotype of fibulin-5 knockout mice, which show progressive laxity of skin in addition to vascular abnormalities and emphysematous lung changes.[114,115] The skin changes are reminiscent of those noted in patients with congenital cutis laxa. In fact, mutations in the *FBLN4* and *FBLN5* genes have been documented in some cases of cutis laxa.[116–118]

A number of other proteins unrelated to the fibrillins, LTBPs, and fibulins are constituents of the microfibrils. They include the lysyl oxidases,[94,95] interface proteins called emilins,[119] and several proteins[120] belonging to the families of *M*icrofibril-*A*ssociated *P*roteins (MAP) or microfibril-associated glycoproteins (see Table 63-5). Among the latter, microfibril-associated protein 1 is remarkable in that it is extremely acidic, with glutamic acid comprising 23% and aspartic acid 6% of the residues. The extremely acidic nature of the protein suggests that it may have an important function in the assembly of the very basic tropoelastin molecules. Finally, lysyl oxidases are critical for the cross-linking and stabilization of the elastic fiber structures.

PROTEOGLYCANS AND GLYCOSAMINOGLYCANS

Historically, terms such as *ground substance* or *mucopolysaccharides* were used to describe proteoglycans because of their histologic appearance and their thick and mucinous nature when isolated. Because of these physical properties, proteoglycans were difficult to study. Our understanding of proteoglycans has markedly advanced as a result of increased information about their core proteins and the subsequent use of molecular tools to study the expression and function of both the protein core and glucosaminoglucan (GAG) components. Now, proteoglycans are recognized as a structurally unique and highly diverse group of macromolecules. The most distinguishing structural characteristic of proteoglycans is that they comprise both a core protein and covalently linked linear carbohydrate chains known as GAGs. Proteoglycans constitute an important portion of external cellular membranes and ECM of the skin. Their ability to bind proteins and alter protein–protein interactions or enzymatic activities has identified them as important determinants of cellular responsiveness in development, homeostasis, and disease. Because GAGs are highly polyanionic and bear a high charge density, they are a critical component of the skin, and together with the core proteins, they impart a unique set of functions that are critical to a large number of biologic processes.

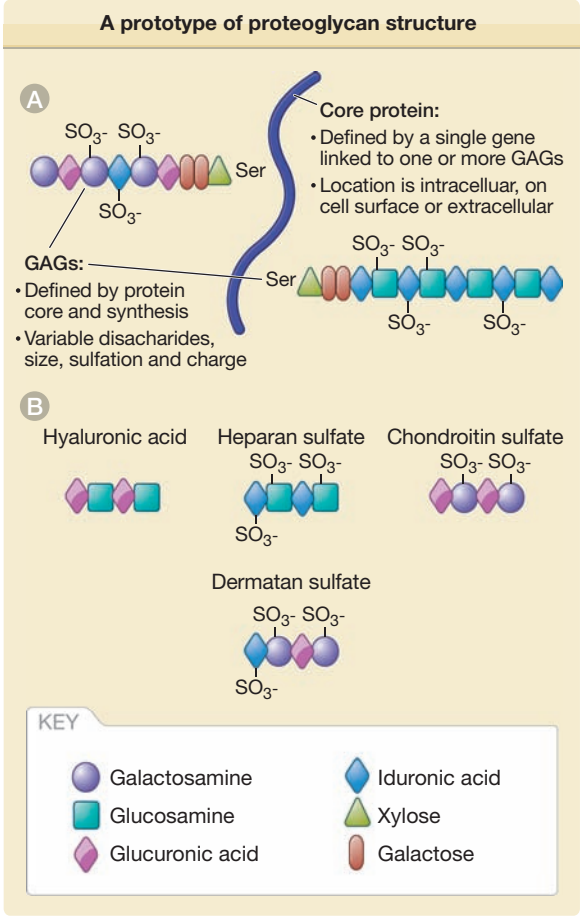

Figure 63-13 A. Prototype of proteoglycan structure. Core proteins may contain from 1 to 100 glycosaminoglycan (GAG) chains, depending on the core protein sequence. Two different GAG chains are shown: dermatan sulfate (*top left*) and heparan sulfate (*bottom right*). Sites of potential sulfation are indicated. Ser represents a serine amino acid residue in the core protein to which GAGs are attached. **B.** Disaccharide repeating units of GAGs shown as tetrasaccharides. Structures of heparan sulfate, dermatan sulfate, chondroitin sulfate A (chondroitin 4-sulfate)/C (chondroitin-6 sulfate), and hyaluronan are shown. Sulfation can vary in heparan sulfate and dermatan sulfate.

STRUCTURE AND SYNTHESIS OF PROTEOGLYCANS

The prototypical proteoglycan consists of a single core protein linked to one or more GAGs (Fig. 63-13). Each core protein has the capacity to accept a variety of GAG chains. Consequently, the nomenclature for proteoglycans is complicated in that individual molecules must be defined based on the core protein and the associated GAGs.

THE GLYCOSAMINOGLYCAN CHAINS

The GAG chains are defined based on the assembly of essential sugar residues.[121,122] These sugars are organized as disaccharide pairs that usually consist of an

acidic sugar that is either an iduronic acid or glucuronic acid alternating with a hexosamine that is either glucosamine or galactosamine. When the chains are assembled as disaccharides, the choice of sugars and the linkage between them is used to assign a name to the GAG chain. Thus, several terms are used to define GAGs (see Fig. 63-13), including *hyaluronic acid*, which contains a glucuronic acid alternating with *N*-acetylglucosamine-linked β1–3 and β1–4; *heparan sulfate*, containing iduronic or glucuronic acids alternating with *N*-acetylglucosamine-linked β1–4; *chondroitin sulfate*, containing glucuronic acid alternating with *N*-acetylgalactosamine-linked β1–3 and β1–4; and *keratan sulfate*, containing galactose alternating with *N*-acetylglucosamine-linked β1–4 and β1–3. A fifth general term used to describe GAGs, and of particular importance to cutaneous biology, is *dermatan sulfate*. This form of GAG (also known as *chondroitin sulfate B*) is similar to other chondroitin sulfates except that it contains a high proportion of iduronic acids in place of glucuronic acid and has more variable sulfation. Dermatan sulfate shares features of both chondroitin sulfate (*N*-acetylgalactosamine) and heparan sulfate (iduronate) (see Fig. 63-13).

The linear chains of linked disaccharide units in a GAG are highly variable in size, ranging from as few as ten disaccharides to several thousand. Thus, the mass of naturally occurring GAGs typically ranges between 5×10^3 Da and 5×10^7 Da for hyaluronic acid. Further variability is introduced into the GAG chain by epimerization reactions and sulfation reactions. The control of these reactions depends on the nature of the GAG, the core protein to which it may be attached, the cell type, and the cell environment. For example, the simplest GAG, hyaluronic acid, is never sulfated, whereas other GAGs can be sulfated to varying degree. The highly sulfated sugars tend to occur in specific regions of the GAG chain and are interspersed with areas of low sulfation. Such discrete domains of low or high sulfation are believed to determine the interactions between proteoglycans and GAGs and their many binding partners. The size, disaccharide composition, and sulfation are of critical importance in understanding GAGs. These parameters influence function and are the mechanism by which instructions are defined within the molecule. Thus, the linear GAG should be considered as a molecule containing information, just as information is encoded in a protein.[121,122]

Synthesis of GAGs (with the exception of hyaluronan) occurs in the Golgi apparatus, and the sequence information is determined by the activity and location of multiple specific enzymes along this pathway. Today, many of the enzymes that control heparan sulfate synthesis and those enzymes responsible for postsynthetic modifications have been identified and characterized. The sulfated GAGs are all synthesized on core proteins. The tetrasaccharide xylose–galactose–galactose–glucuronic acid is first assembled on the core protein by beginning with a xylosyltransferase that forms a linkage between xylose and a serine residue in the core protein. Subsequent elongation reactions that occur in the Golgi apparatus define the nature of the GAG chain. It is appreciated that part of the information necessary to direct synthesis of the GAG is encoded within the core protein sequence itself. The final product, core protein with attached GAG, defines the proteoglycan (see Fig. 63-13). Hyaluronan, the only GAG produced without attachment to a core protein, is synthesized by an enzyme complex at the plasma membrane and then extruded into the extracellular space.

THE VARIETY OF PROTEOGLYCAN CORE PROTEINS

For purposes of organization, it is useful to group proteoglycans according to their site of expression by the cell. Specific proteoglycan core proteins have been identified within the cell, attached to the cell surface, bound within the ECM, and released in soluble form (Table 63-6).

INTRACELLULAR PROTEOGLYCAN: SERGLYCIN. Serglycin is the best-known intracellular proteoglycan and is found within the secretory granules of hematopoietic cells, including mast cells, leukocytes, and eosinophils. The core protein is processed further to contain either heparan sulfate or chondroitin sulfate GAG. The heparan sulfate form is found in serosal mast cells and is a major source from which heparin is pharmacologically derived. The serglycin peptide core is composed primarily of tandem serine–glycine repeats and has an estimated mass of 16–18 kDa before GAG addition and 60–750 kDa after the addition of multiple heterogenous GAG chains.[123] Thus, serglycin is a unique proteoglycan because of its distinctive core protein sequence, and intracellular localization. In the skin, serglycin is found whenever mast cells or eosinophils enter the dermal stroma. On release, serglycin becomes a major source for the delivery of highly sulfated heparan sulfate GAG.

CELL SURFACE PROTEOGLYCANS: SYNDECANS AND GLYPICANS. Several cell surface proteoglycans are very interesting because they act at the interface between the plasma membrane and the extracellular environment. They are attached to the cell surface either by a phospholipid anchor (i.e., glypican family) or as membrane-spanning core proteins (i.e., syndecan family).

The glypicans share the glycophosphatidyl inositol anchorage mechanism and a unique cysteine motif that is likely to impart a compact tertiary structure to the proteoglycans. Consequently, glypicans can be visualized as a compact protein presenting GAG chains in close proximity to the outer surface of the plasma membrane. Six isoforms (glypican-1 to 6) have been described,[124–126] and expression of some glypicans may be altered in inflamed skin and chronic wounds.[127]

The syndecan core proteins consist of a short *C*-terminal cytoplasmic region, a transmembrane domain, and an extracellular region containing attachment sites for GAG chains. Unlike glypicans, syndecans span the plasma membrane and extend beyond the surface of the cell. In this way, syndecans are in a unique position to connect extracellular GAG to structures within the

TABLE 63-6
Core Proteins of Proteoglycans

Core Protein	Location	Usual GAG Component
Intracellular		
Serglycin	Mast cells, basophils	HS, CS
Cell surface		
Syndecan-1	Keratinocytes, other epithelia	HS, CS
Syndecan-2	Fibroblasts, endothelia, bone	HS
Syndecan-3	Neural cells, limbs	HS
Syndecan-4	Ubiquitous, lymphoid	HS, CS
NG-2	Neural, melanoma	CS
Glypican (GPC-1)	Brain, vascular endothelia	HS
Cerebroglycan (GPC-2)	Brain only	HS
OCI-5 (GPC-3)	Intestine and mesenchymal	HS
κ-glypican (GPC-4)	Kidney, brain	HS
Glypican-5 (GPC-5)	Brain, kidney, bone	HS
Glypican-6 (GPC-6)	Intestine, kidney, lung	HS
Epican	Keratinocytes	HS, CS, KS
Betaglycan	Fibroblasts, epithelia	HS
Endocan	Endothelia	DS
Thrombomodulin	Endothelia	DS
Extracellular matrix		
Aggrecan	Cartilage	KS, CS
Versican	Fibroblasts	CS, DS
Brevican	Brain	CS
Neurocan	Brain	CS
Phosphocan	Brain	CS, KS
Decorin	Fibroblasts, others	DS
Biglycan	Bone	DS
Epiphycan	Cartilage	DS
OIF	Cartilage	
Fibromodulin	Fibroblasts	KS
Lumican	Cornea	KS
Agrin	Brain	HS
Perlecan	Basement membranes	HS
Bamacan	Basement membranes	CS

CS = chondroitin sulfate; DS = dermatan sulfate; GAG = glycosaminoglycan; HS = heparan sulfate; KS = keratan sulfate; NG-2 = NG2 proteoglycan; OIF = osteoinductive factor.

cytoplasm.[124,126] The intracellular domain endows syndecans to participate in several signal transduction pathways, including the protein kinase C pathway.[127–129] Syndecan transcripts and proteins are expressed in distinct patterns during development and in mature tissues.[130] Syndecan-1 is particularly abundant on keratinocytes and can vary the nature of attached GAG chains as keratinocytes differentiate.[131] During wound repair, syndecan-1 and syndecan-4 are highly induced in the dermis and granulation tissue.[132] Deletion of syndecan-4 from mice decreases the rate of wound repair.[133] During malignant transformation, syndecan-1 expression decreases in the epidermis,[134] and expression can alter malignant behavior in select cell types.[135] Thus, syndecans have received particular attention as proteoglycans that modify cell function. Because syndecans and other proteoglycans can contain more than one GAG species, either simultaneously or under different cellular circumstances, GAG expression provides another mechanism of regulation in addition to protein expression.

LARGE AGGREGATING EXTRACELLULAR MATRIX PROTEOGLYCANS: AGGRECAN AND VERSICAN. Aggrecan, a large proteoglycan found in cartilage, has a core protein containing a region with over 100 serine–glycine dipeptides that serve as attachment sites for up to 130 GAG chains. As many as 100 aggrecan molecules can bind to a single hyaluronic acid molecule. Thus, the overall proteoglycan aggregate (from which the name *aggrecan* is derived) can have a mass near 200,000 kDa.[135]

In the skin, fibroblasts produce large aggregating proteoglycans similar to aggrecan, the best known being versican.[135,136] The core protein of versican contains attachment sites for 12–15 GAG chains, which are primarily chondroitin sulfate or dermatan sulfate. Versican, like aggrecan, binds hyaluronic acid, which enables it to form large aggregates. In skin, versican has been identified in the dermis (fibroblasts) and epidermis (keratinocytes) and demonstrates selective upregulation in response to TGF-β.[137] Thus, the size, distribution, and abundance of versican in the skin

suggest that it is an important molecule in the regulation of the behavior of the skin.

SMALL EXTRACELLULAR MATRIX PROTEOGLYCANS: DECORIN. Several genes encoding smaller ECM proteoglycans have been identified. One family is characterized by a leucine-rich repeat motif. The prototype of this family is decorin, an approximately 36-kDa secreted proteoglycan.[125,135,136] Decorin is a ubiquitous component of connective tissues and it is found in abundance in skin. The decorin core protein has a single dermatan sulfate chain covalently bound to a serine residue at amino acid position 4 and, like many other proteoglycans, also has *N*-linked oligosaccharides. Thus, after GAG addition, decorin can have a mass of 80 kDa. Decorin received its name from observations that this molecule closely associates with collagens fibrils and can be seen to "decorate" the fibrils in vivo. This interaction is attributed to the ability of the decorin core protein to directly bind to collagens type I.[138] The single GAG chain of decorin also binds to tenascin-X, another ECM protein that colocalizes with collagens fibrils in connective tissues.[139] These binding interactions contribute to collagens fibril formation and influence function. Interestingly, similar phenotypes showing abnormal collagens morphology are seen in a patient deficient in tenascin-X and in the murine decorin knockout model.[140]

FUNCTION OF PROTEOGLYCANS

To understand how proteoglycans function in the skin it is essential to appreciate the basics of their organization: (1) proteoglycans are part protein and part GAG; (2) GAGs are heterogeneous but encode specific information; (3) proteoglycan core proteins are expressed in different cellular compartments; and (4) proteoglycan expression and GAG composition vary according to cellular context. These characteristics are important, because many proteoglycan functions depend on their ability to bind other molecules in the environment, and because both the core protein and GAG chains may be mediating or influencing molecular interactions. Similar GAGs can be attached to diverse core proteins. This ability to interchange GAGs among cores adds complexity to the study of proteoglycan function, and in many cases, proteoglycan properties are defined by the GAG chains. It implies that certain genes encoding different core proteins to which similar GAGs are attached may have a similar function. The list of molecules to which the major skin proteoglycans heparan sulfate and dermatan sulfate bind is quite extensive (Table 63-7). Therefore, several functions for proteoglycans have been proposed that include the particular biologic system in which the ligand is involved.

Some of the most compelling experimental evidence for the functions of heparan and dermatan sulfate proteoglycans identifies the ability to bind several growth factors, cytokines, and components of the ECM.[141] For instance, heparan sulfate is required for the function of growth factors such as several members of the fibroblast growth factor family,[142,143] hepatocyte growth fac-

TABLE 63-7
Binding Interactions of Heparan Sulfate, Dermatan Sulfate, and Heparin

Category	Ligand
Extracellular matrix components	Collagens types I, III, IV, V Fibronectin Laminin Pleiotrophin Tenascin-X Thrombospondin Vitronectin wnt-I wnt-induced secretory protein
Growth factors (GFs)	Fibroblast GF family Hepatocyte GF/scatter factor Heparin-binding epidermal GF Platelet-derived GF Schwannoma-derived GF Vascular endothelial GF
Growth factor binding proteins (BPs)	Follistatin Insulin-like GF BP-3 Transforming GF-β BP
Cytokines	Transforming GF-β Interleukin 8 Interferon-γ-inducible protein-10 Interferon-γ Macrophage inhibitory protein-1α
Cell adhesion molecules (CAMs)	CD45 L-selectin Mac-1 Neural cell adhesion molecule Platelet/endothelial CAM
Proteases/ antiproteases	Elastase Thrombin Tissue plasminogen activator Antithrombin III Heparin cofactor II Leuserpin Plasminogen activator inhibitor-I Protein C inhibitor Protease nexin I
Pathogens	gC and gB of herpes simplex virus gC-11 of cytomegalovirus gp 120 of human immunodeficiency virus *Staphylococcus aureus* surface proteins Penetrin of *Trypanosoma cruzi* *Streptococcus mutans* surface proteins *Neisseria gonorrhoeae* surface proteins Mycobacterial surface proteins Adhesin proteins of *Borrelia burgdorferi*

tor/scatter factor,[144] and vascular endothelial growth factor.[145] In this model, the heparan sulfate proteoglycan is found either at the cell surface or in a soluble form. The molecules then assemble to form a ternary complex at the cell surface between the growth factor, its specific high-affinity signaling receptor, and the proteoglycan.[146] Only after this ternary complex is formed does the cell receive the growth factor signal to begin to proliferate, differentiate, or migrate. Heparan sulfate-dependent growth factors, such as members of the fibroblast growth factor family, are induced in healing wounds and influence the wound repair process through the stimulation of keratinocyte proliferation, fibroblast growth, and angiogenesis. Because dermatan sulfate is the predominant GAG in wound fluid and because it can bind a variety of growth factors, cytokines, and ECM proteins, further study of this GAG and the proteoglycans it comprises promises to be an exciting area for future investigation.

In addition to binding to growth factors, heparan sulfate proteoglycans play an important role in adhesion to the ECM. In the current model, cell surface proteoglycans, in conjunction with other matrix-binding molecules such as the integrins, help the cell adhere to the ECM.[124,126] Furthermore, the formation of these focal adhesions requires heparan sulfate and the subsequent activation of protein kinase C by a domain in the syndecan-4 core protein cytoplasmic tail. In this setting, both the extracellular GAG and intracellular core protein of the proteoglycan have demonstrable signaling function.[128,129]

Other proteoglycans also interact with ECM molecules. Chondroitin sulfate and dermatan sulfate bind fibronectin and laminin. As mentioned earlier, decorin, to which dermatan sulfate is typically attached, is known to associate primarily with type I collagens via its core protein.[138] In mice, selective disruption of the decorin gene leads to abnormal collagens morphology and increased skin fragility.[140] Thus, through targeted disruption of the gene in the mouse, the function of decorin as a stabilizer of collagens fibrils has been directly confirmed.

The function of the large ECM proteoglycans in skin is thought to relate primarily to the physical properties inherent in their large mass and charge density. Hyaluronan has been studied extensively from this perspective because of its extreme hydrophilicity and viscosity in dilute solution. As discussed earlier, hyaluronic acid is pure GAG and is synthesized extracellularly without a core protein. The genes for human hyaluronan synthase have been cloned and identified.[147] The expression of hyaluronan is developmentally regulated in skin and changes during wound repair. It has been proposed that the physicochemical properties of hyaluronan serve to expand the matrix and thus aid cell movements. Other physical properties attributed to GAG and large proteoglycan complexes, such as those formed with versican or basement membrane proteoglycans, include their ability to act as anionic filters and elastic cushions and their function in salt and water balance. In fetal skin, the high relative content of hyaluronan has been associated with the ability of fetal skin to heal without scar.

CELLULAR RECEPTORS FOR PROTEINS OF THE EXTRACELLULAR MATRIX

Many components of the ECM regulate cellular behavior directly and indirectly. An indirect mechanism is provided by the modulation and control of the activity of cytokines, growth factors, and chemokines by proteins in the ECM. A direct and most important mechanism relies on the control of cellular activities through adhesive interactions between cell surface receptors and ECM proteins (Fig. 63-14). Several classes of cell surface receptors have been identified, such as the syndecans,[124,126] DDRs (*D*iscoidin *D*omain *R*eceptors),[148] and integrins.[10,149–152] The latter are noncovalently linked heterodimers of one α and one β subunits. Integrins have a short cytoplasmic domain (except for the 1,000 residue-long intracellular domain of the integrin β4 subunit expressed by keratinocytes), a single stretch transmembrane domain, and a large extracellular domain interacting with specific proteins of the ECM or with counter-receptor present on the surface of circulating cells, including microbial proteins. In human, 18 α and 8 β subunits have been characterized, assembling into 24 different combinations. The integrin cytoplasmic domain lacks enzymatic activity; however, by associating with multiple proteins into signaling platforms,

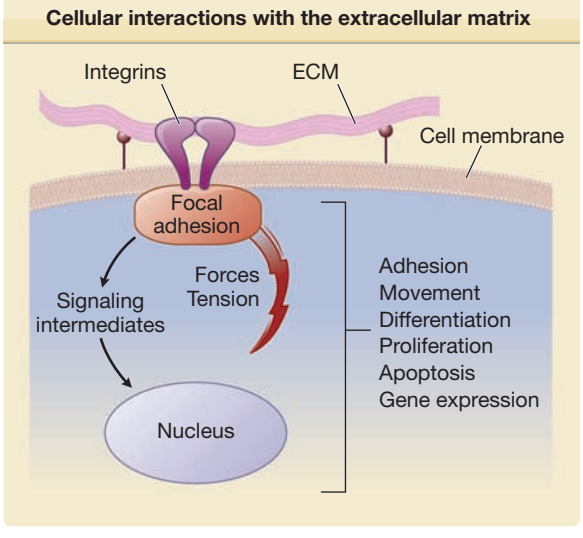

Figure 63-14 Cellular interactions with the extracellular matrix (ECM). The main cellular receptors for ECM constituents are the integrins. They consist of one α and one β subunits noncovalently associated. Together, the large extracellular domains of both subunits provide a binding site for specific ECM ligands. The short intracellular portions of the subunits are devoid of enzymatic activity and recruitment of cytoskeleton-associating and adaptor proteins is required for signal transduction and transmission of forces, both outside-in and inside-out. Through outside-in signaling, the ECM regulates many cellular functions, like adhesion, movement, survival, differentiation, and expression of specific genes. Inside-out transmission of forces is thought to be important for organization of the ECM architecture.

they activate diverse molecular pathways.[151,152] Adhesive interactions between integrins and ECM proteins control many cellular functions, such as migration, survival, differentiation, contraction, transmission of forces, and expression of specific genes.[149,150] Expression of a distinct set of integrins on the cell surface determines specificity, range, and versatility of the interactions with ECM proteins. For instance, fibroblasts express, among others, integrins with the property to interact with native fibril-forming collagens, fibronectin, and vitronectin.[10] In addition, the repertoire of integrins expressed by a given cell type may adapt to the differentiation stage during development and to specific physiological and pathological features of the microenvironment, such as wound healing, aging, inflammation, and fibrosis.[153] Integrins are also expressed by inflammatory cells and control their migration and targeting to specific sites of inflammation.[154] Finally, it has been suggested that integrins cross talk or act in synergy with growth factors, cytokines, and cognate receptors.[155] Together, the many facets of integrins endow these proteins with crucial roles in various physiological and pathological processes such as fibrosis, tissue repair, and carcinoma progression.

DISEASES OF THE DERMAL EXTRACELLULAR MATRIX

The many components of the ECM in the dermal compartment of the skin have an elaborate biosynthesis, maturation, and turnover, often a complex structure, and they are assembled into exquisitely complex networks. Therefore, it is not surprising that many diseases exist due to disturbances in the genetic expression, structure, homeostasis, and assemblies of ECM proteins.

Based on our understanding of the molecular biology and the metabolism of the ECM components, it is now possible to identify discrete points at which defects could occur. These can be located at different levels (Box 63-1). Many mutations in the genes coding for ECM proteins or in the enzymes involved in their posttranslational modifications or their supramolecular assemblies into defined networks have been identified as outlined in preceding paragraphs.

ECM deposition and assembly into insoluble and complex polymers are tightly controlled mechanisms, which undergo substantial variations during development, tissue remodeling, repair, ageing, wound healing, or fibrosis. Several ECM proteins are also targets for circulating antibodies, leading to autoimmune diseases. Most interesting for dermatology are the autoimmune blistering diseases that are discussed in detail in other chapters. There is also accumulating evidence that many ECM proteins manifest regulatory functions, which can be disturbed and lead to disease processes.

BOX 63-1 MOLECULAR MECHANISMS OF EXTRACELLULAR MATRIX-ASSOCIATED DISEASES

- Mutations in genes coding for
  - extracellular matrix (ECM) components
  - enzymes required for posttranslational modifications of ECM components
  - proteins required for folding/assembly of ECM proteins
  - enzymes required for ECM maturation, deposition, turnover, degradation
- Development of autoimmunity (blistering diseases, Goodpasture, etc.)
- Altered regulatory functions of the ECM

CUTANEOUS COLLAGENS DISEASES

The term *collagens disease* implies that a clinical condition involves an abnormality in the structure, synthesis, or degradation of collagens. This term is frequently used to characterize a clinically heterogeneous group of inflammatory diseases, including lupus erythematosus, scleroderma, and dermatomyositis. In the classic nomenclature, the use of the term *collagens disease* for these conditions was based on morphologic changes, known as *fibrinoid degeneration*, that have been interpreted to represent changes in collagens fibers. However, there is currently no evidence for a primary defect in collagens in these diseases. On the basis of available biochemical evidence, scleroderma is the only clinical condition among the classic collagens diseases that involves dysregulation of collagens metabolism (see also Chapter 157).

Collagens is an unusual protein in many respects, and its structure and metabolism involve a number of special features that are critical for deposition of normal collagens fibers. In a primary collagens disease, such a defect could be an inherited abnormality in the structure of the collagens or procollagens or in the enzymes participating in the biosynthesis and degradation of collagens. Indeed, there are many diseases in which a basic biochemical defect in collagens has been described, and several heritable connective tissue diseases with cutaneous involvement are now known to result from specific molecular defects in collagens genes (see Chapter 137). Many of these diseases involve insertions, deletions, or single-base substitutions in the genes that alter the primary structure of the protein.[9,13,14] In several acquired diseases, the regulation of collagens gene expression is disturbed, which leads to altered deposition of collagens in tissues. The diversity of collagens pathology is exemplified by Ehlers–Danlos syndrome and fibrotic skin diseases (see Chapters 137 and 157). Ehlers–Danlos syndrome comprises a group of phenotypically similar conditions that frequently result from abnormalities in the structure of collagens or in enzymes modifying collagens molecules.[19,20,56,57] In contrast, the fibrotic skin diseases exemplify conditions with altered regulation of collagens gene expression that leads to excessive accumulation of collagens in tissues.[61]

PATHOLOGY OF THE ELASTIC FIBERS IN CUTANEOUS DISEASES

Several heritable and acquired connective tissue diseases have been shown to be associated with aberrations in the elastic fibers, including pseudoxanthoma elasticum, cutis laxa, and the Buschke–Ollendorff syndrome (Table 63-8; see Chapter 137). In addition, clinically distinct entities with phenotypes closely resembling pseudoxanthoma elasticum (e.g., elastoderma) or cutis laxa (e.g., wrinkly skin syndrome) can be recognized.

There has been significant progress recently in identifying and understanding the molecular mechanisms associated with mutations in the fibrillin genes.[156] Heterozygous mutations that affect the structure or lead to a reduced synthesis are the cause of the Marfan syndrome. This disease is clinically characterized by abnormalities and disturbances in the ocular, skeletal, and cardiovascular systems. The patients display a thin skin, with extensive striae distensae; some, however, also have contractures. A careful analysis of mouse models with similar molecular defects revealed that the mutations in the fibrillin gene are associated with increased TGF-β signaling. Interestingly, the phenotype presenting with development of a mitral valve prolapse in this mice could be reverted or delayed by addition of TGF-β neutralizing antibodies. These data indicate that fibrillin-1 is likely to be involved in the tight regulation of TGF-β activity. In a clinical study, application of angiotensin II inhibitors to patients with Marfan syndrome consistently and significantly slowed the progression of aortic root dilatation.[157]

DISEASES DUE TO ABNORMAL PROTEOGLYCAN METABOLISM

Multiple cutaneous disorders are associated with abnormal proteoglycan synthesis or deposition. A deficiency of decorin core protein has been described as the cause of a variant form of Ehlers–Danlos syndrome. Even infectious diseases are influenced by proteoglycan expression. A good example is provided by the decorin-deficient mice, which are rather resistant to infection with *Borrelia burgdorferi*. Presumably, the resistance is caused by a partial dependence of the organism on decorin for binding in the dermis.[158] During aging, the composition of GAG in the skin undergoes marked changes and it has been proposed that the decrease in hyaluronic acid explains diminished skin turgor.[159,160] Retinoids also modify this response.[161] In keloids, hyaluronic acid synthesis is elevated.[162] Thyroid hormone also has a marked effect on the synthesis of proteoglycans and GAGs. The manifestation of this response is seen in thyroid dermopathy (Chapter 151), in which the mucinous material deposited is predominantly hyaluronic acid and chondroitin sulfate. Other pathologic skin conditions, including pseudoxanthoma elasticum, scleroderma, psoriasis, a variant form of Ehlers–Danlos syndrome, lichen myxedematosus, and ultraviolet B-irradiated skin, have also been reported to be characterized by abnormal amounts of proteoglycans. These associations do not imply that abnormal proteoglycan metabolism is responsible for these disorders, but they suggest that much of the pathophysiology of skin disease can be influenced by the function of cutaneous proteoglycans.

EMERGING DISEASE MECHANISMS

Mutations in the genes coding for key ECM proteins often lead to functional consequences, which are associated with severe clinical symptoms. Although structural alterations can certainly explain a number of symptoms, it is clear that not all pleiotropic clinical alterations are directly and solely due to the abnormalities in protein structure. Evidence is now accumulating that induction of endoplasmic reticulum stress represents an additional mechanism explaining some of the deleterious effects resulting from mutations in the genes needed for the elaboration of ECM proteins.[22,163–165] For instance, the accumulation of misfolded or unfolded mutant polypeptides in the endoplasmic reticulum induces the so-called "unfolded protein response."[166–168] It results in detrimental processes of diverse severity, ranging from increased protein targeting to the proteasome for destruction, autophagy, general reduction in protein synthesis including that of the abnormal protein, to complete cellular dysfunction with apoptosis of the cells (Fig. 63-15). Such a deleterious outcome has been demonstrated for mutations in several ECM genes, often

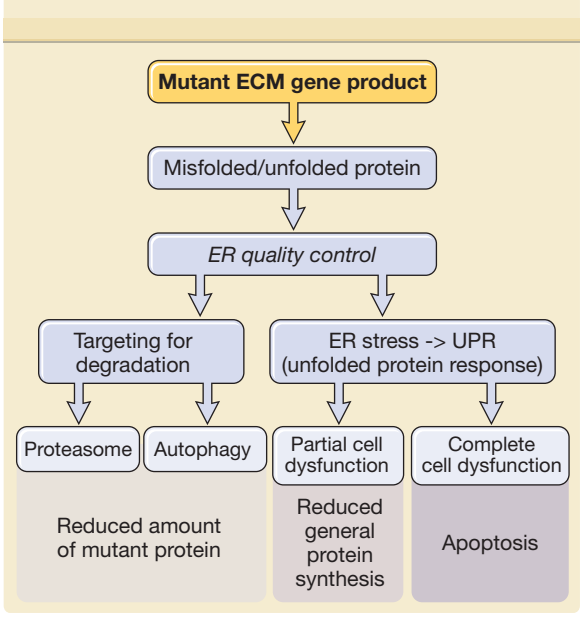

Figure 63-15 The endoplasmic reticulum stress as a mechanism inducing a deleterious function of the extracellular matrix (ECM). Misfolded ECM polypeptide chains harboring mutations, or excess of unfolded polypeptides, are either targeted for degradation or their accumulation within the endoplasmic reticulum induces the unfolded protein response, leading to partial or complete cell dysfunction and apoptosis.

TABLE 63-8
Clinical Features, Histopathology, Inheritance, Associated Biochemical Findings, and Predisposing Clinical Conditions in Cutaneous Diseases with Elastic Fiber Abnormalities[a]

Disease	Inheritance	Clinical Manifestations	Skin Histopathologic Findings	Biochemical Findings[b] Related to Elastic Fibers and Predisposing Clinical Conditions
Pseudoxanthoma elasticum	AR, sporadic[c]	Yellowish papules coalescing into plaques Inelastic skin Cardiovascular and ocular abnormalities	Accumulation of pleomorphic and calcified elastic fibers in the middermis	Deposition of calcium apatite crystals, excessive accumulation of glycosaminoglycans on elastic fibers; D-penicillamine treatment; mutations in the *ABCC6* gene
Buschke–Ollendorff syndrome	AD	Dermatofibrosis lenticularis disseminata and osteopoikilosis	Accumulation of interlacing elastic fibers in the dermis	Increased desmosine content in the skin; mutations in *LEMD3*
Cutis laxa	AR, AD, or NH	Loose, sagging, inelastic skin Pulmonary emphysema Tortuosity of aorta Urinary and gastrointestinal tract diverticuli	Fragmentation and loss of elastic fibers	Decreased desmosine content and reduced elastin mRNA levels; increased elastase activity in some cases; D-penicillamine treatment, inflammatory and urticarial skin lesions (e.g., drug reaction); mutations in the *ELN*, *EBLN4FBLN4*, or *FBLN5*, *LTBP4*, or *PYCR15* gene in limited cases
DeBarsy syndrome	AR	Cutis laxa-like skin changes Mental retardation Dwarfism	Rudimentary, fragmented elastic fibers	Reduced elastin mRNA levels
Wrinkly skin syndrome	AR	Decreased elastic recoil of the skin Increased number of palmar and plantar creases	Decreased number and length of elastic fibers	—
Middermal elastolysis	NH	Fine wrinkling of the skin, primarily in exposed areas	Fragmentation and loss of elastin in the middermis	Inflammatory; sun exposure
Anetoderma	NH	Localized areas of atrophic, sac-like lesions	Loss and fragmentation of elastic fibers in the dermis	Reduced desmosine content in the lesions; often secondary to inflammatory lesions
Elastosis perforans serpiginosa	NH	Hyperkeratotic papules, commonly on the face and neck	Accumulation and transepidermal elimination of elastic fibers	D-penicillamine-induced abnormalities in elastin cross-linking
Elastoderma	Unknown	Loose and sagging skin with loss of recoil	Accumulation of pleomorphic elastotic material without calcification in the mid and lower dermis and the subcutaneous tissue	—
Isolated elastomas	NH	Dermal papules or nodules	Accumulation of thick elastic fibers in the dermis	—
Elastofibroma dorsi	NH	Deep subcutaneous tumor, usually on subscapular area	Accumulation of globular elastic structures encased in collagenous meshwork	Trauma on the lesional area
Actinic elastosis	NH	Thickening and furrowing of the skin	Accumulation of irregularly thickened elastic fibers in upper dermis	Long-term sun exposure
Marfan syndrome	AD	Skeletal, ocular, and cardiovascular abnormalities Hyperextensible skin Striae distensae	Fragmentation of the elastic structures in the aorta	Mutations in the *FBN1* gene
Congenital contractural arachnodactyly	AD	Camptodactyly and joint contractures		Mutations in the *FBN2* gene
Williams syndrome	AD	Supravalvular aortic stenosis Velvety skin Dysmorphic facies	Disruption of smooth muscle and matrix relationship affecting blood vessels	Allelic deletion of the *ELN* gene; contiguous gene deletion syndrome

AD = autosomal dominant; AR = autosomal recessive; NH = not a heritable disease; mRNA = messenger RNA.
[a]Most of these conditions represent a group of diseases with clinical, genetic, and biochemical heterogeneity.
[b]The biochemical abnormalities have been demonstrated in only a limited number of patients in each group, and it is not known whether the biochemical changes are the same in each patient with any given disease.
[c]Rare cases with a distinct acquired form of pseudoxanthoma elasticum have been described.

resulting in severe clinical subsets of osteogenesis imperfecta or some inheritable cartilage diseases. However, it remains to be seen whether these mechanisms could play a much broader role and apply to other inherited or acquired disorders of the ECM.

KEY REFERENCES

Full reference list available at www.DIGM8.com

DVD contains references and additional content

2. Hynes RO: The extracellular matrix: Not just pretty fibrils. *Science* **326**:1216, 2009
8. Eckes B, Krieg T: Regulation of connective tissue homeostasis in the skin by mechanical forces. *Clin Exp Rheumatol* **22**:S73, 2004
9. Myllyharju J, Kivirikko KI: Collagens, modifying enzymes and their mutations in humans, flies and worms. *Trends Genet* **20**:33, 2004
11. Gordon MK, Hahn RA: Collagens. *Cell Tissue Res* **339**:247, 2010
19. Mitchell AL et al: Molecular mechanisms of classical Ehlers-Danlos syndrome (EDS). *Hum Mutat* **30**:995, 2009
34. Ortega N, Werb Z: New functional roles for non-collagenous domains of basement membrane collagens. *J Cell Sci* **115**:4201, 2002
45. Myllylä R et al: Expanding the lysyl hydroxylase toolbox: New insights into the localization and activities of lysyl hydroxylase 3 (LH3). *J Cell Physiol* **212**:323, 2007
48. Myllyharju J: HIF prolyl 4-hydroxylases and their potential as drug targets. *Curr Pharm Des* **15**:3878, 2009
53. Apte SS: A disintegrin-like and metalloprotease (reprolysin-type) with thrombospondin type 1 motif (ADAMTS) superfamily: Functions and mechanisms. *J Biol Chem* **284**:31493, 2009
60. Uitto J, Kouba D: Cytokine modulation of extracellular matrix gene expression: Relevance to fibrotic skin diseases. *J Dermatol Sci* **24**:S60, 2000
61. Gabrielli A, Avvedimento EV, Krieg T: Scleroderma. *N Engl J Med* **360**:1989, 2009
68. Page-McCaw A et al: Matrix metalloproteinases and the regulation of tissue remodelling. *Nat Rev Mol Cell Biol* **8**:221, 2007
69. Kessenbrock K et al: Matrix metalloproteinases: Regulators of the tumor microenvironment. *Cell* **141**:52, 2010
77. Kielty CM: Elastic fibres in health and disease. *Expert Rev Mol Med* **8**:1, 2006
95. Lucero HA, Kagan HM: Lysyl oxidase: An oxidative enzyme and effector of cell function. *Cell Mol Life Sci* **63**:2304, 2006
99. Uitto J: Biochemistry of the elastic fibers in normal connective tissues and its alterations in diseases. *J Invest Dermatol* **72**:1, 1979
104. Ramirez F, Sakai LY: Biogenesis and function of fibrillin assemblies. *Cell Tissue Res* **339**:71, 2010
107. Ramirez F, Rifkin DB. Extracellular microfibrils: Contextual platforms for TGFb and BMP signaling. *Curr Opin Cell Biol* **21**:616, 2009
111. Timpl R et al: Fibulins: A versatile family of extracellular matrix proteins. *Nat Rev Mol Cell Biol* **4**:479, 2003.
141. Iozzo RV: Basement membrane proteoglycans: From cellar to ceiling. *Nat Rev Mol Cell Biol* **6**:646, 2005
167. Bateman JF et al: Genetic diseases of connective tissues: Cellular and extracellular effects of ECM mutations. *Nat Rev Genet* **10**:173, 2009

Chapter 64 :: Morphea

:: Stephanie Saxton-Daniels & Heidi T. Jacobe

MORPHEA AT A GLANCE

- Occurs in children and adults.
  - Linear subtype predominates in children.
  - Circumscribed and generalized predominate in adults.
- A self-limited or chronically relapsing autoimmune disorder targeting the skin with the following major features:
  - Inflammatory, sclerotic, atrophic phases.
  - Thickened sclerotic skin.
  - Systemic disease including arthritis and neurological disorders.
- Differentiated from scleroderma by lack of acrosclerosis/sclerodactyly.
- Complications may cause significant irreversible cosmetic and functional impairment including the following:
  - Atrophy of dermis, fat, and subcutaneous structures.
  - Contracture.
  - Limb length discrepancy.
  - Bony abnormalities.
- Treatment based on the following:
  - Disease subtype.
  - Depth of involvement.
  - Stage (inflammatory, sclerotic, atrophic).
  - Potential for complications.

BOX 64-1 DIFFERENTIAL DIAGNOSIS OF MORPHEA

Most Likely

- Scleroderma (systemic sclerosis)
- Lipodermatosclerosis
- Eosinophilic fasciitis
- Trauma-induced fat necrosis (intramuscular injections)
- Nephrogenic systemic fibrosis
- Chronic graft-versus-host disease

Consider

- Lichen sclerosus
- Pretibial myxedema
- Connective tissue nevi
- Morpheaform basal cell carcinoma
- Chemical mediated sclerosing skin conditions (toxic oil syndrome, rapeseed oil, etc.)
- Lyme disease (acrodermatitis atrophicans)
- Phenylketonuria
- Scleromyxedema, scleroderma chronica, pretibial myxedema
- POEMS syndrome

Always Rule Out

- Carcinoma of the breast metastatic to skin (carcinoma en cuirase)
- Porphyria cutanea tarda

POEMS = *p*olyneuropathy, *o*rganomegaly, *e*ndocrinopathy, *M* protein, and *s*kin changes.

Morphea is a chronic autoimmune disease characterized by sclerosis of the skin. The term "localized scleroderma" is also used in an attempt to highlight the systemic features of morphea. This causes confusion with systemic sclerosis (scleroderma) often resulting in unnecessary evaluation and anxiety. It is the opinion of the authors this term should be avoided. Morphea itself has a spectrum of manifestations ranging from skin only to multiple organ involvement. Of note, organ involvement in morphea is distinctly different from systemic sclerosis (Box 64-1).

EPIDEMIOLOGY

Morphea has an estimated incidence of 2.7 per 100,000 with a female:male ratio of 2 to 3:1.[1] Morphea is more common in Caucasians.[2–5] The relative frequency of the different subtypes varies between studies. This is likely due to use of different classification systems. Twenty to thirty percent of morphea begins in childhood, but it can occur at any age.[2–5] Linear morphea is the most common pediatric subtype (although all subtypes occur at any age).[1,2,6] Twenty-five to eighty-seven percent of pediatric cases are linear morphea, with limb or trunk involvement in approximately 70%–80% and en coup de sabre (ECDS) or progressive facial hemiatrophy (PHA; formerly described as Parry–Rhomberg) in 22%–30%.[1,2,4,5,7,8] In adults, circumscribed and generalized subtypes predominate. Deep morphea/morphea profunda is uncommon in both adults and children with a frequency of 2%–4%.[1,2,4,7,8]

Periods of disease activity vary from 3 to 6 years, but reactivation after periods of remission occurs in 20%.[2,8] (eFig. 64-0.1 in online edition). Others have a chronic course persisting for decades. The prognostic markers for recurrent or chronic disease have yet to be determined.

ETIOLOGY AND PATHOGENESIS

The etiology and pathogenesis of morphea is poorly understood. Most pathologic events ascribed to morphea are extrapolated from studies in systemic sclerosis (assuming the two disorders arise from the same etiology). Morphea probably arises from a genetic background that increases disease susceptibility, combined with other causative factors (infectious, environmental exposures) that modulate disease expression.

Like many autoimmune connective tissue diseases, morphea is likely a complex genetic disease. Familial clustering is rarely seen,[5,9,10] and morphea is also associated with higher than expected rates of familial autoimmune disorders.[5,11,12]

Although there are no definitive associations, development of morphea lesions has been linked to local tissue trauma including radiation (eFig. 64-0.2 in online edition), surgery, insect bites, and intramuscular injections.[13] Although controversial, infectious agents have also been linked to lesion development.

Increasing amounts of evidence support autoimmune-mediated inflammation early in the course of morphea.[14] Early morphea lesions are characterized by the influx of large amounts of mononuclear lymphocytes (usually activated T lymphocytes), plasma cells, and eosinophils.[15] This is likely the result of autoimmunity, as there is widespread autoimmune reactivity in morphea patients (elevated ANAs, cytokines, and adhesion molecules).[5,12,16] Morphea patients also have concomitant autoimmune disease at higher expected frequency than a healthy population.[5,11]

Vessel damage and upregulation of adhesion molecules (ICAM-1, VCAM 1, and E-selectin) occur related to the inflammatory cell infiltrate which facilitates local monocyte recruitment.[17] These adhesion molecules are upregulated by cytokines classically associated with a Th2 immune response (Il-4, Il-1, and TNFs). Cytokines found in the sera and skin of morphea patients in increased concentration include IL-4, IL-6, and IL-8.[18] These cytokines (especially IL-4) upregulate TGF-β, initiating a cascade of events resulting in increased production of collagen and other extracellular matrix components via induction of connective tissue growth factor, platelet-derived growth factor, and matrix metalloproteinases. These cytokines and growth factors inhibit interferon-γ (a suppressor of collagen synthesis and Th1-related cytokine). Chimerism or nonself cells may play a role in the pathogenesis of morphea by initiating a local inflammatory reaction.[19]



Figure 64-1 Lichen sclerosis can overlie morphea lesions. (Reproduced with permission from Jacobe H: Morphea (localized scleroderma) in adults. In: *UpToDate*, edited by DS Basow. Waltham, MA, UpToDate, 2011. Copyright © 2011 UpToDate, Inc. For more information visit www.uptodate.com.)

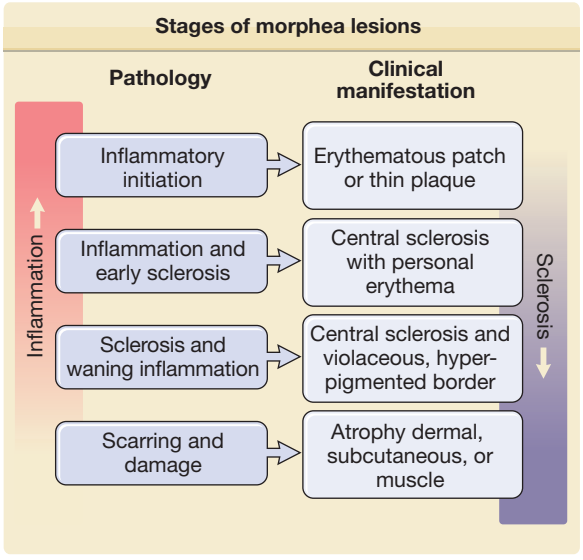

Figure 64-2 Stages of morphea lesions. **A.** Typical active morphea plaque in inflammatory stage, with violaceous border. **B.** Severe atrophy in patient with linear morphea (atrophic stage). (Reproduced with permission from Jacobe H: Morphea (localized scleroderma) in adults. In: *UpToDate*, edited by DS Basow. Waltham, MA, UpToDate, 2011. Copyright © 2011 UpToDate, Inc. For more information visit www.uptodate.com.)

CLINICAL FINDINGS

Morphea is currently divided into five subtypes (Table 64-1).[20] Superficial or deep disease (involving subcutis, fascia, or below) may occur with any subtype. Morphea lesions may also occur with overlying lichen sclerosus change (Fig. 64-1).

CUTANEOUS LESIONS

STAGES OF CUTANEOUS LESIONS. (Fig. 64-2). Morphea begins as erythematous plaques or patches, sometimes with a reticulated appearance. Later hypopigmented sclerotic plaques develop at the center of the lesion, surrounded by an erythematous or violaceous border (inflammatory stage) (Fig. 64-2A). Pain and/or itching can precede the initial skin findings. Sclerosis develops centrally, which turns into a shiny white color, as lesions expand with surrounding hyperpigmentation (sclerotic stage). There is loss of hair follicles, producing alopecia. Over months to years, the sclerotic plaque softens and becomes atrophic with hypo- or hyperpigmentation (atrophic stage) (Fig. 64-2B). The atrophic stage is associated with cigarette paper wrinkling (papillary dermis), cliff drop (dermal), or deep indentions (subcutis or deeper).

TABLE 64-1
Proposed Classification of Morphea Subtypes

Morphea Subtype	Modifiers	Clinical
Circumscribed	Superficial Deep	Single or multiple oval/round lesions limited to epidermis and dermis Single or multiple oval/round lesions involving subcutaneous tissue, fascia, or muscle.
Linear	Trunk/Limbs Head	Linear lesions involving possible primary site of involvement in subcutaneous tissue without involvement of skin, dermis, subcutaneous tissue, muscle, or bone En coup de sabre, progressive facial hemiatrophy, linear lesions of the face (may involve underlying bone)
Generalized 1. Coalescent plaque		More than or equal to four plaques in at least two of seven anatomic sites (head–neck, right/left upper extremity, right/left lower extremity, anterior/posterior trunk); isomorphic pattern: coalescent plaques inframammary fold, waistline, lower abdomen, proximal thighs; symmetric pattern: symmetric plaques circumferential around breasts, umbilicus, arms, and legs
2. Pansclerotic		Circumferential involvement of majority of body surface area (sparing fingertips and toes), affecting skin, subcutaneous tissue, muscle or bone; no internal organ involvement
3. Mixed		Combination of any above subtype: e.g., linear-circumscribed

Adapted from Laxer RM, Zulian F: Localized scleroderma. *Curr Opin Rheumatol* **18**:606-613, 2006.



Figure 64-3 Generalized morphea. **A.** Isomorphic plaques involving bra and waistband areas. **B.** Symmetric plaques on a patient with generalized morphea. (Reproduced with permission from Jacobe H: Morphea (localized scleroderma) in adults. In: *UpToDate*, edited by DS Basow. Waltham, MA, UpToDate, 2011. Copyright © 2011 UpToDate, Inc. For more information visit www.uptodate.com.)

CIRCUMSCRIBED MORPHEA.

Circumscribed morphea represents oval to round lesions undergoing the stages of activity described in the previous section that are not diffuse enough to meet criteria for generalized disease (Table 64-1). Patients with circumscribed morphea should be closely followed, as both linear and generalized morphea may begin with circumscribed lesions.

Atrophroderma of Pasini and Pierini are thought to be the residua of plaque-type morphea. The borders of the atrophoderma lesions have a "cliff-drop" appearance resembling "burnt-out" morphea lesions.

GENERALIZED MORPHEA.

Generalized morphea is characterized by more than or equal to four lesions on at least two of seven different anatomic sites. There are likely three variants of generalized morphea: (1) isomorphic, (2) symmetric, and (3) pansclerotic (Table 64-1; Figs. 64-3 and 64-4).[21,22] In direct contrast to systemic scleroderma, generalized morphea does not



Figure 64-4 Pansclerotic morphea: sclerosis encompassing majority of body surface area (**A**), characteristically sparing the fingertips (**B**). (Reproduced with permission from: Jacobe H: Morphea (localized scleroderma) in adults. In: *UpToDate*, edited by DS Basow. Waltham, MA, UpToDate, 2011. Copyright © 2011 UpToDate, Inc. For more information visit www.uptodate.com.)



Figure 64-5 **A.** Multiple linear lesions involving trunk and extremities. **B.** En coup de sabre. **C.** Multiple hyperpigmented linear morphea lesions on the face. (Reproduced with permission from: Jacobe H: Morphea (localized scleroderma) in adults. In: *UpToDate*, edited by DS Basow. Waltham, MA, UpToDate, 2011. Copyright © 2011 UpToDate, Inc. For more information visit www.uptodate.com.)

present with acrosclerosis or sclerodactyly. Instead, lesions frequently begin on the trunk and spread acrally, sparing the fingers and toes (Fig. 64-4).

LINEAR MORPHEA. Linear morphea usually affects the extremities and face, but it can occur on the trunk (where it is often misclassified as circumscribed) (Table 64-1, Fig. 64-5A). The presence of multiple linear lesions is not uncommon. A recent study suggests that linear morphea may follow Blaschko's lines.[23] Linear morphea may involve the dermis, subcutaneous tissue, muscle, or even underlying bone, causing significant deformities. Bone marrow inflammation has also been reported.[24,25] ECDS "cut of the sword" may present as an atrophic band linear plaque on the forehead (Fig. 64-5B), extending to the scalp (where cicatricial alopecia occurs), brow, nose, and lip. Other linear lesions on the head and neck present on the temple or chin, and are generally hyperpigmented atrophic plaques (Fig. 64-5C). PHF is characterized by a slowly progressive, unilateral atrophy of skin, soft tissues, muscles, and/or bony structures. The atrophy may be accompanied by classic linear morphea lesions on the face or elsewhere.

DEEP MORPHEA. Deep morphea, or morphea profunda, involves the deep dermis, subcutaneous tissue, fascia, and muscle. Plaques are poorly circumscribed



Figure 64-6 Morphea profunda: involved areas have "cobblestone" appearance with subcutaneous atrophy. (Reproduced with permission from Jacobe H: Morphea (localized scleroderma) in adults. In: *UpToDate*, edited by DS Basow. Waltham, MA, UpToDate, 2011. Copyright © 2011 UpToDate, Inc. For more information visit www.uptodate.com.)

and symmetrical (Fig. 64-6). The skin feels thickened and bound down to the underlying fascia and muscle. A "groove sign" (depression) may be present at the site of tendons and ligaments. Deep morphea lesions may underlie any clinical subtype of morphea, particularly linear and generalized, or occur alone.

EF, or Shulman syndrome, is a related disorder presenting with rapid onset of symmetric areas of pain and edema, usually on the extremities. EF may occur with cutaneous induration similar to morphea, or remain without skin involvement.

RELATED PHYSICAL FINDINGS

Extracutaneous manifestations develop in 22%–56% of morphea patients.[1,4,5,7,8,26] Articular and muscular (eFig. 64-6.1 in online edition) involvement (arthritis, myalgias, neuropathies, and carpal tunnel syndrome) is the most common finding (12%) and can occur unrelated to skin lesions.[11,27] Cutaneous disease itself produces limited range of motion, limb length discrepancy, joint deformity, and contracture (45%–56% linear morphea). Patients with lesions crossing joint lines are most at risk.[8,26] ECDS is associated with neurologic and ocular complications (3.6%) including seizures, headaches, adnexal abnormalities (eyelids, eyelashes), uveitis, and episcleritis.[11,27,28] Facial morphea may produce dental malocclusion, altered dentition, and atrophy of the tongue and salivary glands. Another possible finding is Raynaud phenomenon, although more strongly associated with systemic sclerosis.[5]

LABORATORY ABNORMALITIES

SERUM AUTOANTIBODIES. Autoantibodies reported in patients with morphea include ANA, anti-single-stranded DNA, antidouble-stranded DNA, antihistone, antitopoisomerase IIα, antiphospholipid, anticentromere, anti-Scl-70, and rheumatoid factor (MMP-1).[5,16,26,29–34] The clinical and prognostic significance of these autoantibodies remains unclear. ANA occur in 39%–80% of patients and are more common in patients with linear or generalized disease.[5,8,16,26]

OTHER SERUM ABNORMALITIES. Peripheral eosinophilia, hypergammaglobulinemia, and increased ESR/CRP may occur with active disease of any type, but particularly deep morphea (may correlate with disease activity).

IMAGING STUDIES

MRI provides a complete assessment of the extent of disease, including depth of involvement and disease activity.[25] This is especially helpful when deep involvement is suspected. It is also possible to evaluate the response to treatment, although not currently routine practice.

Ultrasonography (US) is a sensitive tool to evaluate or monitor tissue thickness, loss of subcutaneous fat and muscle, or other architectural alterations. Disease activity can be correlated with the detection of hyperemia and echogenicity.[35] Discussion with the radiologist performing the MRI or US studies is crucial to adequately detect and evaluate change related to the morphea.

COMPLICATIONS

Children with morphea can have significant morbidity related to morphea, including effects on growth, function, and quality of life (fewer studies exist in adults). Muscle weakness may occur in affected extremities or face. Behavioral changes, learning disabilities, and seizure (sometimes preceding cutaneous lesions)[36,37] have been reported in children with (and without) facial involvement. In addition, disfigurement and physical symptoms (fatigue, pain, itch) associated with morphea affect psychosocial development and play a substantial role in the quality of life for patients with morphea.

Panscleroticmorphea has been associated with an increased risk of squamous cell carcinoma due to chronic ulcers. The resulting sclerosis of the skin can cause significant contracture, and produces restrictive pulmonary defects and dysphagia. Circumferential sclerosis of the arms or legs may also produce compartment syndrome, bullae, and ulcers.

Morphea may coexist with other autoimmune diseases (systemic lupus erythematosis, vitiligo, primary biliary sclerosis, autoimmune hepatitis, Hashitmoto's thyroiditis, and myasthenia gravis).[38–43] In particular, generalized morphea has been associated with an increased rate of autoimmune disease.[5]

PROGNOSIS AND CLINICAL COURSE

Although morphea causes functional and aesthetic impairment, it is rarely life-threatening. Morphea may be self-limited, but frequently has a remitting relapsing or chronic course producing significant disease burden over time.[12] (eFig. 64-0.1 in online edition)

EVALUATION AND TREATMENT

OVERVIEW

The natural history of morphea is poorly understood. At least some cases undergo spontaneous remission after a few years of activity. However, even when spontaneous remission occurs, residual damage created by active disease remains. In addition, new evidence suggests at least a subset of morphea patients have continued disease activity over many years, ultimately leading to extensive disease burden and related morbidity.[12] Despite the large number of reported treatments, no consistent recommendations exist for therapy. This section aims to provide evidence-based algorithm for the rational evaluation and management of morphea patients (Figs. 64-7A and 64-7B).

PATIENT EVALUATION

In determining which therapy is appropriate, the following must be considered:

- ***Disease Activity and Damage*:** Existing studies indicate that early, active disease is most responsive to any therapy.[44] Indicators of active disease include development of new lesions or extension of existing lesions (photographs are critical), erythema and/or induration of the advancing edge of the lesion, patient reported symptoms such as itch or tingling. Disease damage (reversible or irreversible) includes pigmentary change, induration of the lesion center (controversial), atrophy (dermal, subcutaneous, muscle), contracture, limb length discrepancy, and scarring alopecia. Disease damage is much more difficult to treat and therapy should be aimed at preventing disease damage. Further, patients with

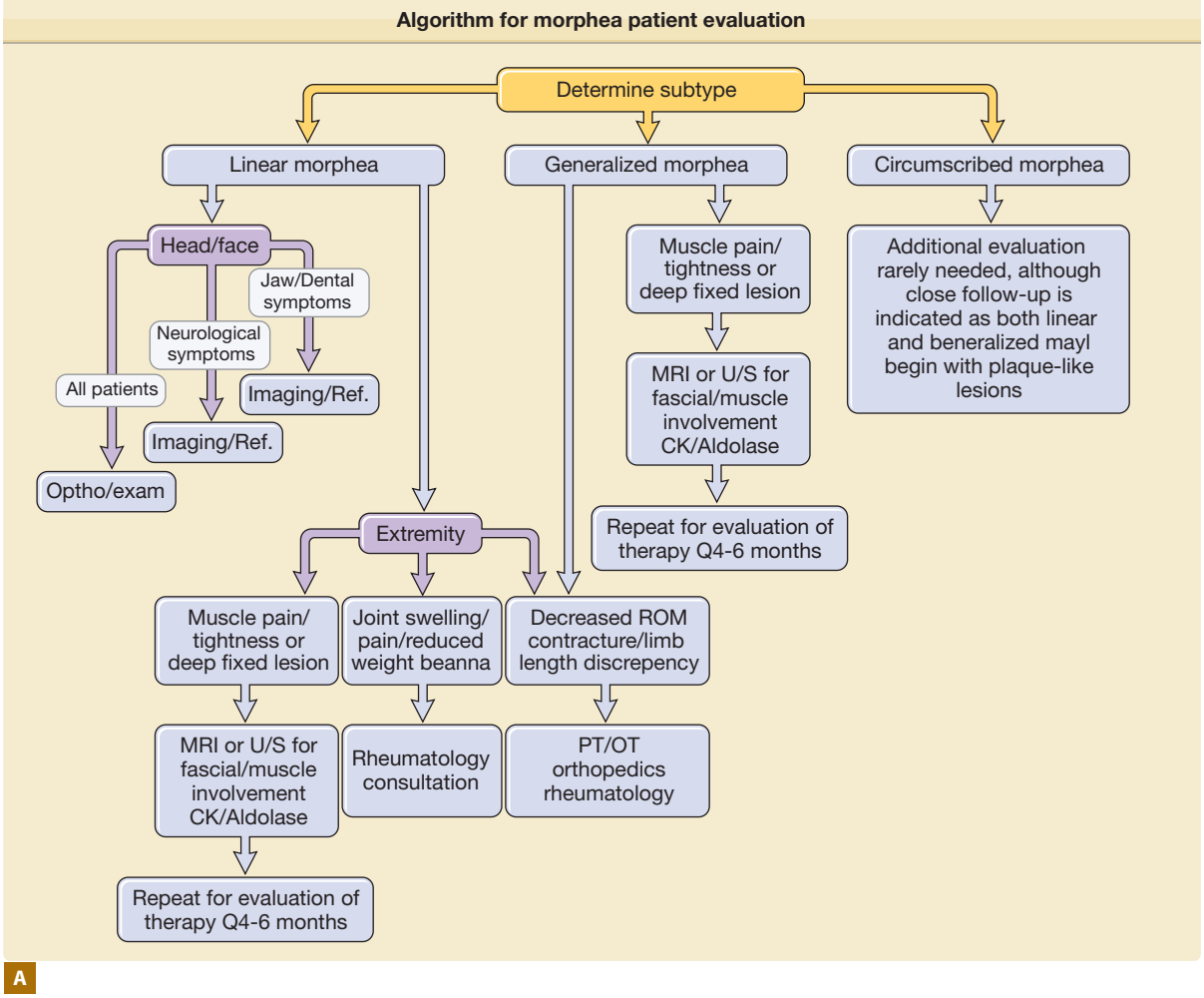

Figure 64-7 **A.** Algorithm for the evaluation of patients with morphea. (*continued*)

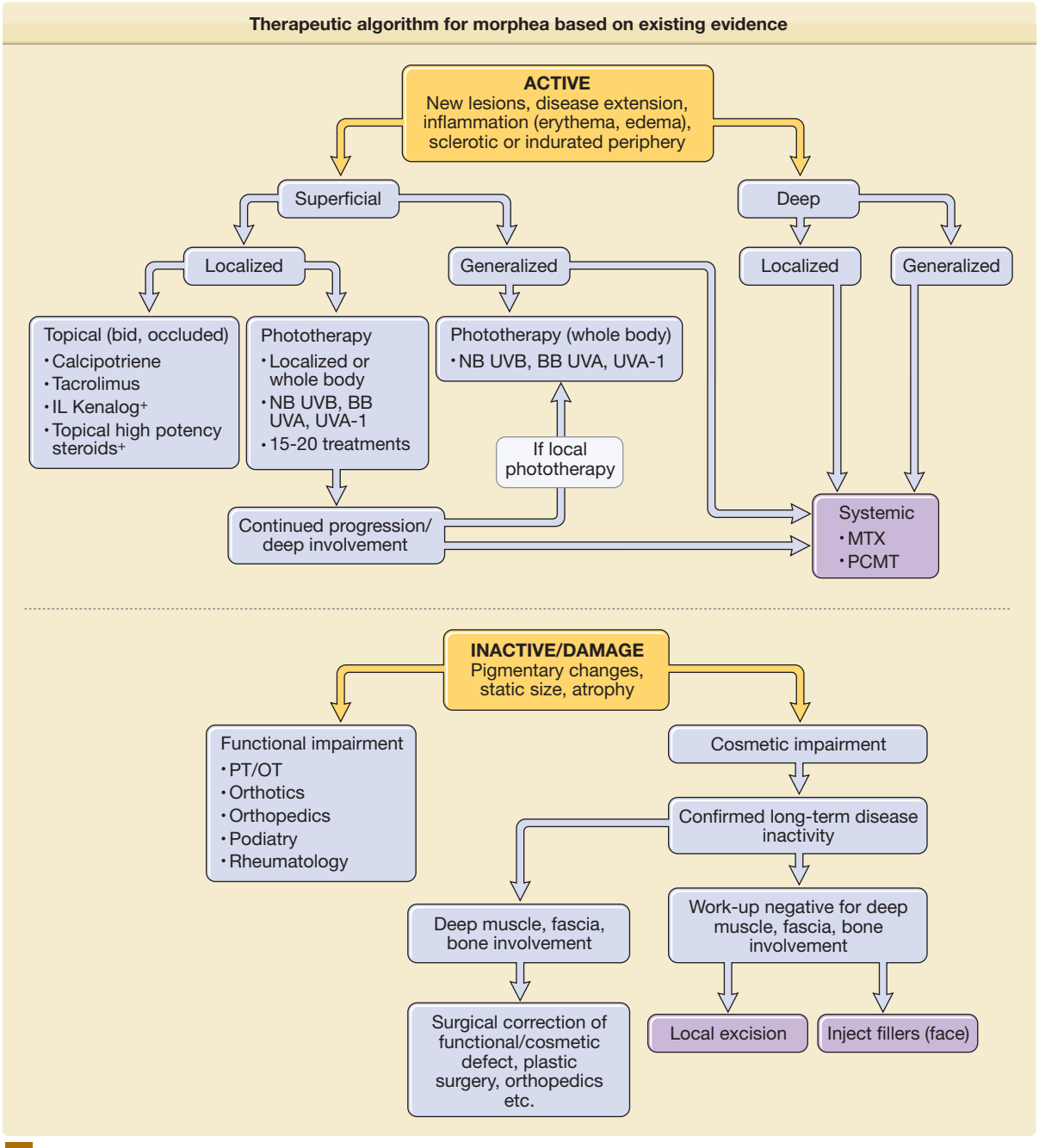

B

Figure 64-7 (*continued*) **B.** Therapeutic algorithm for morphea based on existing evidence. Superficial involvement is defined by histological evidence of papillary dermal involvement. Deep involvement is defined as sclerosis or inflammation of the deep dermis, subcutis, fascia, or muscle. Histological examination and/or MRI are encouraged to evaluate lesions for depth of involvement and, likewise, determine appropriate treatment as well as evaluation of therapeutic efficacy. *There is very little evidence for any therapy addressing disease damage in morphea. The risk of disease reactivation is also unknown, but possible with the use of invasive procedures. Therefore, surgery and the like should only be undertaken after prolonged inactivity of disease. †There is no evidence for efficacy in the literature. (Reproduced with permission from Jacobe H: Morphea (localized scleroderma) in adults. In: *UpToDate*, edited by DS Basow. Waltham, MA, UpToDate, 2011. Copyright © 2011 UpToDate, Inc. For more information visit www.uptodate.com.)

active disease at risk for significant damage (facial lesions, PFH, lesions crossing joint lines, large BSA involvement, rapid progression) likely need aggressive therapy (phototherapy and/or systemic immunosuppresives).

- ***Depth of Involvement*:** Morphea involving the superficial to middermis would logically be amenable to topical therapy or phototherapy; however, involvement of the deep dermis and beyond should be treated systemically. Deep involvement can occur in all subtypes of morphea, but is especially prominent among linear and some generalized patients.
- ***Disease Progression*:** Many generalized and linear morphea patients are initially diagnosed with circumscribed morphea, but progress to have much more extensive disease.[12] Therefore, patients who initially present with 1–3 plaques (which may be amenable to localized therapy) should be closely followed. If these patients progress, therapy should then be aimed at preventing further progression (i.e., phototherapy or systemic therapy).
- ***Systemic Involvement*:** Systemic involvement is usually an indication for systemic immunosuppressive therapy.
- ***Disease Subtype*:** Patients with linear and generalized (particularly those with rapid onset of confluent plaques) are likely at risk for severe, extensive disease and should be treated aggressively either with phototherapy or systemic immunosuppressives depending on the depth of involvement.

ROLE OF HISTOLOGY AND LABORATORY TESTING

The diagnosis of morphea is usually made by the clinical appearance of the lesions. Histological examination may aid therapeutic decision-making because it is sometimes difficult to determine the degree of activity or depth of involvement by clinical examination alone. Biopsy of the advancing edge of a lesion may provide insight into both (eFig. 64-6.2 in online edition). Biopsies should be taken from the inflammatory or indurated border or sclerotic center (indicate on pathology requisition) and include fat. For lesions with minimal clinical change, biopsy of site-matched unaffected skin is helpful. Although a large number of laboratory-based assessments are reported to reflect disease activity and prognosis in morphea, there are no widely accepted biomarkers for morphea. Consequently, laboratory-based tests are not recommended for evaluation morphea in the absence of specific signs and symptoms indicating the need for further assessment. Assessment via MRI and ultrasound is becoming increasingly useful for determination of lesion activity and depth and should be considered when deep morphea is present or suspected.

SPECIFIC TREATMENTS

See Table 64-2.

TABLE 64-2
Morphea Therapy

Treatment	Level of Evidence[a]
BB UVA	1, 2
UVA-1	1, 2
Calcitriol, oral (inefficacy 1)	1, 2
IFN-γ (inefficacy 1)	1
PUVA bath	2
PUVA cream	2
ECP	2
Calcipotriene, topical	2
MTX monotherapy	2
PCMT	2
Tacrolimus, topical	2
Steroids, oral	2
MTX plus oral steroids, hydroxychloroquine, MMF, cyclosporine, Bosentan, infliximab, imiquimod, antimicrobials, D-penicillamine, 585-nm long-pulse laser, wide surgical resection, orthopedic surgery, Apligraf	Minimal evidence (≥level 3)

[a]*Level of Evidence*:
1. Indicates randomized controlled trial
2. Uncontrolled trial
3. Case report, case series

Reproduced with permission from Jacobe H: Morphea (localized scleroderma) in adults. In: *UpToDate*, edited by DS Basow. Waltham, MA, UpToDate, 2011. Copyright © 2011 UpToDate, Inc. For more information visit www.uptodate.com.

PHOTOTHERAPY. Phototherapy has the greatest evidence for efficacy (level 1, randomized controlled trials: broadband ultraviolet (UV) A, narrowband (NB) UVB, and UVA 1; level 2: PUVA systemic and topical).[45–50] NB UVB should be considered for lesions affecting the superficial dermis (relatively thin on palpation or with sclerosis and inflammation in the papillary and superficial reticular dermis). UVA-based therapies are more appropriate for deeper dermal lesions due to greater depth of penetration. UVA-1 in particular has evidence for normalization of dermal collagen and effect on inflammation in morphea so is appropriate for both inflammatory and sclerotic disease.[45] In the absence of access to UVA-1 phototherapy, use of broadband UVA is also supported by the literature.[50] Disease is expected to improve (progression halted and erythema improved) after 10–20 treatments and most trials stopped after 20–30 treatments. Evidence suggests that patients continue to improve after cessation of therapy, and some authors recommend using a greater number of treatments[30–50] for further therapeutic benefit. Uncontrolled trials demonstrated increased benefit with medium to high dose UVA-1

versus low dose, but controlled trials were less convincing. Optimum dose and regimen for UVA-1 phototherapy has yet to be determined. Phototherapy is likely ineffective for deep involvement (subcutis, fascia, muscle), and therefore should not be considered as primary therapy.

VITAMIN D DERIVATIVES. Only one study provides level-1 evidence on the effect of vitamin D derivatives in morphea, and it showed no difference between oral calcitriol and placebo.[51] In fact, placebo and treatment groups improved equally. The authors also point out that the study was underpowered by their own calculations, making definitive conclusions regarding the efficacy of oral calcitriol difficult. The efficacy of topical vitamin D derivatives has been explored via uncontrolled trials and case reports[52] (level-2 evidence) and showed improvement in most or all patients, albeit over several months of therapy (an interval in which lesions might improve independent of therapy). Importantly, calciprotriene was applied under occlusion in these studies.

IMMUNOMODULATORS

Methotrexate With or Without Corticosteroids. The use of methotrexate (monotherapy) and methotrexate combined with systemic corticosteroids is effective based on level-2 evidence.[28,44,53–55] Optimum dose and route, indications for addition of corticosteroids, and duration of therapy have not been determined. In most studies with combined therapy, corticosteroids are used for induction therapy either orally or via intravenous pulse (IVMP 30 mg/kg/day for 3 days per month or 1 mg/kg/day prednisone) over the first 3 months. Methotrexate is used as steroid sparing agent and started simultaneously (0.6 mg/kg/week in children or 15–25 mg/week in adults) and maintained for a prolonged period (1–2 years). Most study participants responded in a mean of 2–5 months. The best responders were all early in their disease course. Importantly, relapse was noted frequently after cessation of therapy, underscoring that therapy likely only suppresses disease activity.

Other Immunomodulators. Level-2 evidence suggests the use of occluded topical tacrolimus 0.1% ointment might be effective for active, inflammatory superficial plaque-type morphea.[56] Recent case series utilizing oral mycophenolate mofetil indicate potential utility in patients refractory to methotrexate or sensitive to corticosteroid side effects.[57] Case reports on the use of oral cyclosporine, bosentan, infliximab, and topical imiquimod have also reported some efficacy, but more definitive studies are lacking.

ANTIMICROBIALS. Despite the widespread use of antimicrobials in morphea (antibiotics and hydroxychloroquine), no published clinical trials exist.[58] Literature supporting the use of antimalarials is limited to a case series in which two patients improved with hydroxychloroquine (while simultaneously receiving oral steroids and methotrexate).[59] In a retrospective review, 7/11 patients continued to have active disease 3–153 months after starting hydroxychloroquine.[4] At this time, the use of these agents in severe morphea is likely not indicated pending more definitive evidence of efficacy.

LACK OF EVIDENCE. The most commonly used treatment for morphea, topical steroids, shows no evidence for efficacy in the literature. There are also no studies investigating the use of intralesional steroids. In the hands of the authors, intralesional steroids have been extremely effective in treating circumscribed plaques or as an adjuvant for recalcitrant areas in patients receiving phototherapy or systemic treatment. Current evidence does not support the use of penicillamine or interferon-γ.[60]

ADJUNCTIVE THERAPY. A significant number of morphea patients suffer irreversible sequelae. When these patients come to medical attention, they may no longer have disease activity, but rather damage from the past or a mixture of active disease and damage. Consequently, every morphea patient should be examined for the presence of limitation in range of motion, contracture, limb length discrepancy, or other functional impairment. In these cases, consultation with rheumatology, physical/occupational therapy, physical medicine and rehabilitation, plastic surgery, orthopedics, and oral maxillofacial surgery is highly recommended to maximize cosmesis, function, and minimize further damage.

KEY REFERENCES

Full reference list available at www.DIGM8.com

DVD contains references and additional content

4. Christen-Zaech S et al: Pediatric morphea (localized scleroderma): Review of 136 patients. *J Am Acad Dermatol* **59**:385, 2008
5. Leitenberger JJ et al: Distinct autoimmune syndromes in morphea: A review of 245 adult and pediatric cases. *Arch Dermatol* **145**:545, 2009
7. Zulian F et al: Juvenile localized scleroderma: Clinical and epidemiological features in 750 children. An international study. *Rheumatology (Oxford)* **45**:614, 2006
12. Saxton-Daniels S, Jacobe HT: An evaluation of long-term outcomes in adults with pediatric onset morphea. *Arch Dermatol* 2010
44. Uziel Y et al: Methotrexate and corticosteroid therapy for pediatric localized scleroderma. *J Pediatr* **136**:91, 2000
46. Kreuter A et al: A randomized controlled study of low-dose UVA1, medium-dose UVA1, and narrowband UVB phototherapy in the treatment of localized scleroderma. *J Am Acad Dermatol* **54**:440, 2006

Chapter 65 :: Lichen Sclerosus

:: Ulrich R. Hengge

LICHEN SCLEROSUS AT A GLANCE

- Infrequent chronic inflammatory dermatosis with anogenital and extragenital manifestations.
- Preferentially affects women in the fifth or sixth decade of life and children younger than the age of 10 years; gender ratio 5:1 female–male.
- Antibodies to extracellular matrix protein-1 and T cells with receptor rearrangement point to an autoimmune pathogenesis.
- Anogenital manifestations cause severe discomfort (pruritus, dyspareunia, dysuria, and painful defecation) and present with polygonal papules and porcelain-white plaques, erosions, and various degrees of sclerosis.
- Vulvar lichen sclerosus is associated with an increased risk of squamous cell carcinoma; the role of human papillomavirus infection or prior radiotherapy remains to be elucidated.
- Potent topical corticosteroids and skin care are the most successful therapeutics; calcineurin antagonists have also recently demonstrated benefit.
- Interdisciplinary management is essential for long-term control.

Lichen sclerosus (LS) is a chronic inflammatory dermatosis of the anogenital area that affects quality of life due to the severe itching. LS may also present with extragenital manifestations that are generally nonpruritic. Of note, vulvar disease seems to have an increased risk of squamous cell carcinoma, but the role of additional cofactors (e.g., human papillomavirus infection or prior radiotherapy) has not been defined.

EPIDEMIOLOGY

The incidence of LS has not been precisely determined. It has been estimated to be in the order of 14 per 100,000 persons per year.[1] LS is more prevalent in females, accounting for a 5:1 gender ratio. It preferentially affects women in the fifth or sixth decade of life and children younger than the age of 10 years.[1,2] Up to 15% of LS cases occur in children, particularly in girls, and one study reported a prevalence of 1 in 900 premenarchal girls.[3] A 0.07% incidence in males has recently been determined in a study of 153,432 male soldiers.[4] Among blacks and Hispanics, the incidence in this group was 1.06%, whereas the incidence was only 0.051% in white soldiers.[4] LS seems to be a prominent cause of phimosis; in one study, 14% of adolescent boys had LS, whereas 40% of phimosis cases in adult men were associated with LS.[5] Similarly, a recent study of foreskins examined after therapeutic circumcision for phimosis confirmed many cases of unrecognized LS.[6] As genital LS in males is almost exclusively seen in uncircumcised men, the rate of circumcision in a given population has a strong impact on the occurrence of the disease.

ETIOLOGY AND PATHOGENESIS

The cause of LS is unknown. While a genetic predisposition has generally not been found,[7] a recent observational cohort study reported a high rate of familial LS cases.[8] Of 1,052 females with LS, 126 (12%) had a positive family history of LS. Vulvar cancer was significantly increased in those patients with a family history of LS compared with those without (4.1% vs. 1.2%).[8] This report proposes a likely genetic component in the etiology of LS. Evidence for the presumed infectious cause, such as acid-fast rods, spirochetes, or *Borrelia*, has not been found.[7] Serologic and clinical evidence of thyroid disease, alopecia areata, pernicious anemia, and vitiligo suggested an association with LS. Extragenital LS is commonly seen in association with plaque-type morphea, and some authors have suggested a common pathomechanism. Recently, low-titer autoantibodies against the extracellular matrix protein-1 (ECM-1) and collagen XVII have been identified in 67% of LS.[9,10] ECM-1 (see Chapter 137) may be involved in basement membrane and interstitial collagenous fiber assembly and growth-factor binding,[11] and may also regulate blood vessel function.[12] In addition, antibodies to the basement membrane protein bp180 have been detected in childhood vulval LS lesions in four of nine children analyzed.[13] All antibodies were IgG-type. There was no clinical and family history of autoimmune diseases or autoantibodies in the children studied. Local irritation also seems to play a role in some cases. The disturbed function of fibroblasts with increased production of collagen has been demonstrated in LS.[14,15]

CLINICAL FINDINGS

CUTANEOUS LESIONS

Polygonal papules and porcelain-white plaques with atrophic fragile skin, fissures, telangiectasias, purpura, erythema, erosions, and different degrees of sclerosis are present in the anogenital area (Figs. 65-1A–65-1F);

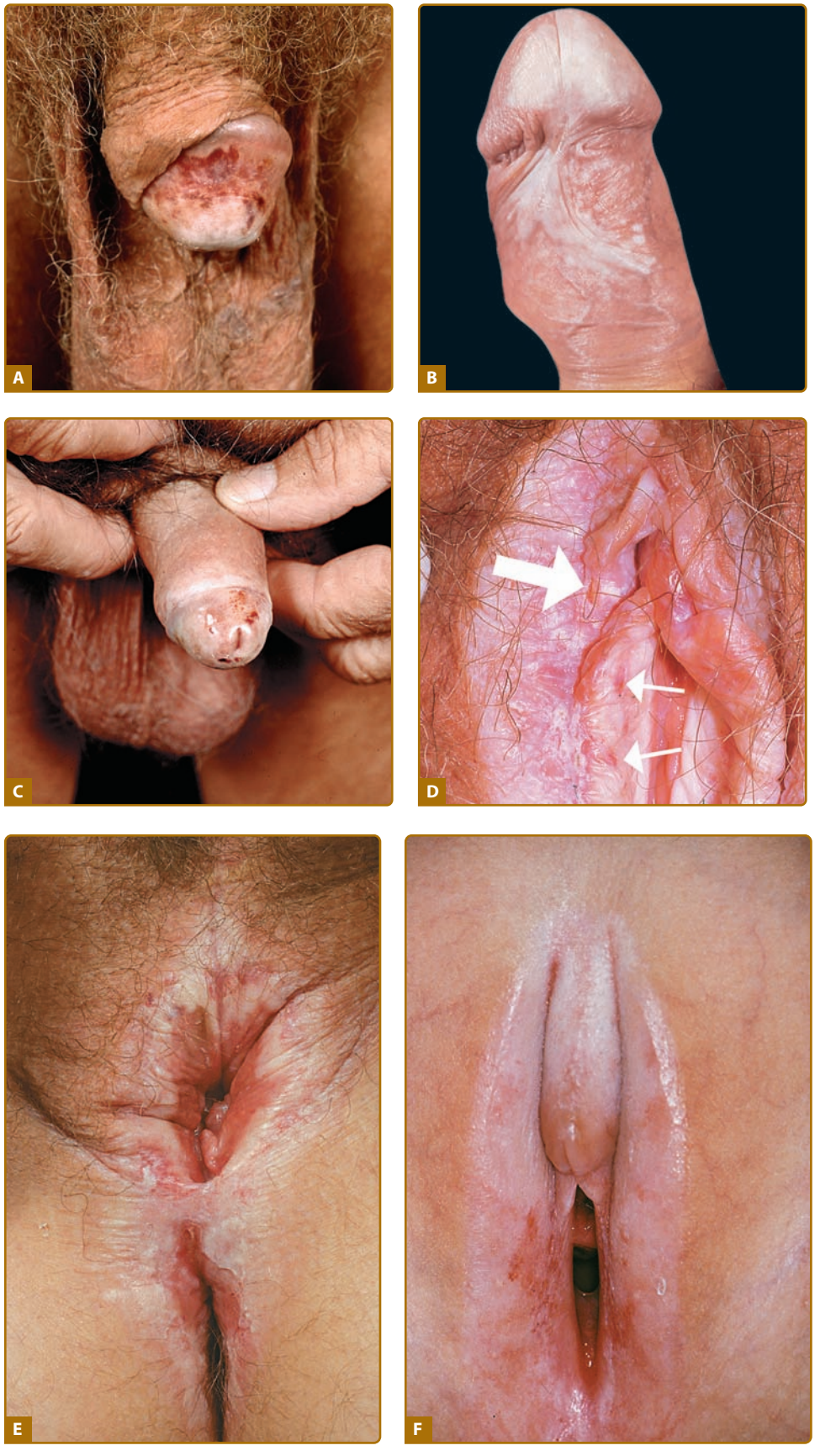

Figure 65-1 **A.** Early sclerosis and significant hemorrhage on the glans in early lichen sclerosus. **B.** Sclerosis of the frenulum and increased vulnerability with bleeding upon sexual intercourse. **C.** Significant sclerosis of the glans and conglutination with the preputium in advanced lichen sclerosus. Note narrowing of the urethral orifice and hemorrhage. **D.** In addition to the well-demarcated white vulvar plaque that is classic for lichen sclerosus, the waxy and crinkled texture, purpura (*small arrows*), and erosions (*large arrow*) are diagnostic. **E.** Sclerotic vulva with disappearance of the smaller labia and shrinkage of the introitus. Significant erythema and erosions are seen on the vulva and the anus in a figure-8 configuration. The patient complained of severe pruritus and dyspareunia. **F.** Erosive, sclerotic vulva in an 8-year-old girl.



Figure 65-2 Extragenital lichen sclerosus with confluent whitish papules and plaques on the skin over the thoracic and lumbar spine.

often the classical figure-8 pattern of the vulva and anus may be observed (see Fig. 65-1E). Blisters (occasionally hemorrhagic) may develop when the lichenoid infiltrate separates epidermis from the sclerotic dermis. The size of LS lesions may vary from a few millimeters to large portions of the trunk. Anogenital LS frequently causes intractable itching and soreness, dyspareunia, dysuria, discomfort with defecation, or genital bleeding and, with time, may lead to destructive scarring (see Fig. 65-1F). Gradual obliteration or synechiae of the labia minora and clitoris, as well as stenosis of the introitus, may also result (see Chapter 78). Male genital LS is usually confined to the glans penis, prepuce, or foreskin remnants (see Fig. 65-1A–65-1C). Penile shaft involvement is less common, whereas scrotal involvement is rare. Many male genital LS cases are simply diagnosed as phimosis. In severe cases, erections may become painful (see Chapter 77). Extragenital manifestations typically affect the thigh, the neck, trunk and lips; lesions are usually asymptomatic (Fig. 65-2). A recent clinical histopathological study has revealed 27 adult cases with lip involvement.[16] Clinical presentation consisted of asymptomatic vitiligo-like lesions in 70% with a variable degree of dermal sclerosis confined to the papillary layer. This was in contrast to genital LS lesions that showed both papillary and reticular dermal sclerosis in the majority of cases. Therefore, the vitiligo-like LS needs to be added to this spectrum of oral lichenoid lesions.

RELATED PHYSICAL FINDINGS

Except for the association with autoimmune thyroid disease, alopecia areata, pernicious anemia, morphea, and vitiligo, which should be ruled out, no additional related findings have been reported. In particular, genital infections by herpes simplex virus or *Candida* do not seem to be increased in LS patients.

LABORATORY TESTS

HISTOPATHOLOGY

Classical LS shows an atrophic epidermis and a lichenoid infiltrate at the dermal–epidermal junction.[17] Papillary edema is usually seen in early LS, but is gradually replaced by fibrosis with homogenization of acid mucopolysaccharides as the lesion matures (Fig. 65-3). The lymphocytic infiltrate in LS contains abundant T cells, B cells, and antigen-presenting dendritic cells that are major histocompatibility complex class II$^+$, CD8$^+$, and CD57$^+$.[18,19] A monoclonal T-cell receptor γ-chain rearrangement has alluded to the existence of an LS antigen, potentially the ECM-1 protein, which is also recognized by the recently described autoantibodies.[8,20] Epidermal hyperplasia and/or dysplasia associated with LS on vulvar specimens are associated with an increased risk of malignant transformation, especially in conjunction with infection by high-risk papillomaviruses.

SPECIAL TESTS

Imaging studies are only needed in special situations (e.g., urinary obstruction secondary to stenosing genital LS). High-resolution ultrasound is occasionally used to document the depth of sclerosis.

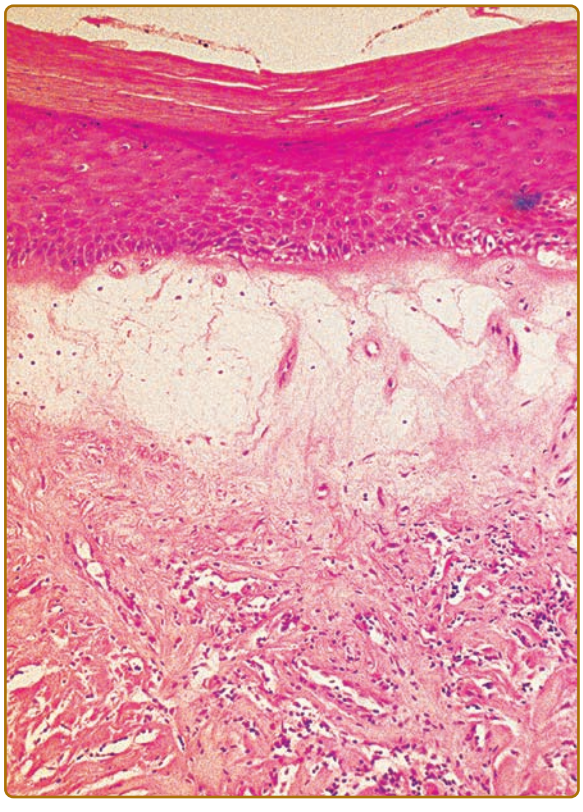

Figure 65-3 Hyperkeratotic epithelium without rete ledges and basal degeneration of keratinocytes. Collagen fibers are homogenized in the papillary dermis, and a lichenoid lymphocytic infiltrate is present. The dermal vessels are dilated.

DIAGNOSIS AND DIFFERENTIAL DIAGNOSIS

A skin punch biopsy of a mature lesion will confirm the diagnosis if the diagnosis is not obvious by clinical examination. ECM-1 autoantibodies may be detected by specialized laboratories; a commercial enzyme-linked immunosorbent assay (ELISA) has recently become available.[21] Despite the described association with autoimmune diseases, an autoimmune workup (e.g., antinuclear antibody, parietal cell antibody, vitamin B_{12} levels, thyroid function tests) is not generally recommended due to their relatively low occurrence.[22] For the same reason, *Borrelia* antibody titers should not be analyzed, as they are not associated with LS.[23] To exclude squamous cell carcinoma, repetitive biopsies may be indicated.

The differential diagnosis of LS and localized scleroderma (morphea) may be difficult (Box 65-1; see Fig. 65-2). Clinically, morphea may be confused with extragenital LS. Morphea represents a circumscribed connective tissue disease with a number of different presentations. Typical early plaque-type lesions show a lilac ring with progressive central induration and whitening and peripheral hyperpigmentation (see Chapter 64). Histologically, early morphea presents as a dense lymphocytic, superficial, and deep perivascular infiltrate with degeneration of collagen fibers. In later stages, inflammation is replaced by dermal fibrosis much like the changes seen in LS. Patients have been described with lesions typical of both plaque-type morphea and the chalky white, atrophic plaques of LS, suggesting that morphea and LS may share a common pathomechanism.[24] Antinuclear antibodies may be positive in either morphea or LS.

Constipation is a common complication in children with anogenital LS.[25] The associated purpura and discoloration often raise concern about child abuse, especially if LS is not recognized (see Chapter 106). LS in children has occasionally been associated with a perineal pyramidal protrusion, a common lesion that can be confused with condyloma and is also associated with constipation. This association further (erroneously) increases the suspicion of sexual abuse.[26,27] It should be noted, however, that LS and child abuse may coexist[28] and that some cases of LS have been linked with trauma of the anogenital region (see Chapter 106). See Box 65-2 for pitfalls in the diagnosis of LS.

BOX 65-1 DIFFERENTIAL DIAGNOSIS OF LICHEN SCLEROSUS

GENITAL MANIFESTATIONS

Consider

- Balanitis plasmacellularis (Zoon disease)
- Child abuse (sexual)
- Complications of dermatologic laser surgery
- Contact dermatitis, including excessive genital hygiene
- Lichen planus
- Lichen simplex chronicus
- Vitiligo

Rule Out

- Cicatricial (scarring) pemphigoid
- Erythroplasia of Queyrat (Bowen disease)
- Leukoplakia
- Squamous cell carcinoma
- Paget disease

EXTRAGENITAL MANIFESTATIONS

Consider

- Anetoderma
- Atrophoderma of Pasini and Pierini
- Idiopathic guttate hypomelanosis
- Lipoid proteinosis (mild forms, see Chapter 137)
- Lichen nitidus
- Lichen planus
- Morphea
- Pinta
- Tinea versicolor

Rule Out

- Discoid lupus erythematosus
- Graft-versus-host disease (scleroderma-like)
- Extramammary Paget disease
- Squamous cell carcinoma

BOX 65-2 PITFALLS IN THE DIAGNOSIS OF LICHEN SCLEROSUS

- Wrong/incomplete diagnosis in the case of squamous cell carcinoma
- Lichen sclerosus, especially when bullous, hemorrhagic, or erosive; may be confused with child abuse
- Inappropriate surveillance for steroid adverse effects
- Irritant dermatitis due to overwashing of the anogenital area may imitate lichen sclerosus and facilitate the occurrence of contact dermatitis

COMPLICATIONS

Besides dyspareunia, urinary obstruction, constipation, secondary infection related to ulceration, and steroid use, squamous cell carcinoma represents the main complication in females (Fig. 65-4). The lifetime risk of developing squamous cell cancer as a complication of long-standing LS has been estimated in the order of 4%–6%.[1,29] Age, long duration of LS, human papillomavirus infection, and

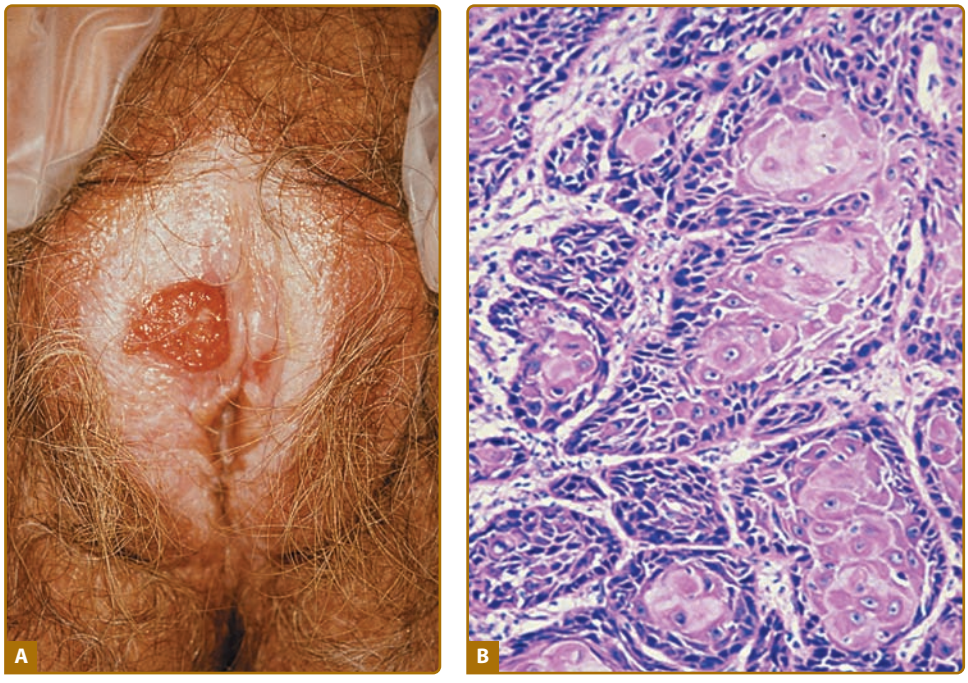

Figure 65-4 **A.** A 1.5-cm, sharply demarcated ulcer of long-standing lichen sclerosus on the right major labium. **B.** Histology reveals squamous cell carcinoma.

evidence of hyperplastic changes represent significant risk factors.[30,31] In males, painful erections and urinary obstruction represent the most frequent complications.

PROGNOSIS AND CLINICAL COURSE

The prognosis of LS is good for most anogenital cases, especially for those in prepubertal children that may resolve spontaneously or may be healed after treatment with ultrapotent topical steroids.[32] However, a recent study reported that childhood onset vulvar LS does not resolve at puberty.[33] The authors prospectively studied 12 cases, of which nine patients, who still had active LS at puberty, continued to require maintenance therapy after menarche. Six of the 12 experienced significant disturbance of the vulvar architecture. Therefore, prepubertal LS does not necessarily resolve at puberty. A further case series reported the efficacy of topical clobetasol propionate 0.05% in childhood LS.[34] Nine of 15 young girls suffered from a relapse about 1 year following the first clearing of the lesions. The authors also concluded that early aggressive treatment with ultrapotent corticosteroids enables the best clinical course of childhood LS.[34] The disease is usually self-limiting, but requires treatment due to the severity of patient discomfort. Recalcitrant chronic LS causing erosions and progressive scarring may result in severe sexual dysfunction. Cosmetic improvement for extragenital cases and for chronic atrophic genital disease is rather poor.

TREATMENT

Various attempts to treat LS have been undertaken. The single most effective treatment of LS is ultrapotent topical corticosteroids such as clobetasol.[20,32–43] However, there is no systematic trial to support this common practice. Due to corticosteroid adverse effects, the treatment period with ultrapotent steroids should be limited, generally to 4–6 weeks. Treatment should be continued, when necessary, with less potent corticosteroids or calcineurin inhibitors (see below).

Case series using topical tacrolimus and pimecrolimus have shown clinical effectiveness.[44–48] Although many of the effects of topical tacrolimus parallel those of corticosteroids,[49] adverse effects such as atrophy, telangiectasias, and pigment changes do not occur. A recent multicenter, phase II trial has assessed the safety and efficacy of twice-daily application of tacrolimus ointment 0.1% in 84 patients (49 women, 32 men, and 3 girls) with longstanding LS (mean duration, 5.8 years), with a follow-up period of 18 months.[50] Clearance of active LS was reached by 42.9% of patients, with at least 50% improvement in an additional 34.3% of patients. However, the duration of treatment to achieve an optimal response was up to 24 weeks.

Systemic therapy with retinoids, including isotretinoin, etretinate, and acitretin and oral tacrolimus, have been useful in small trials. Systemic antibiotics against borreliosis and penicillamine have not proved effective.

Destructive surgical therapies, such as cryotherapy,[51] the tissue-vaporizing carbon dioxide lasers, and nonablative lasers such as the pulsed dye and

Erb:YAG lasers, have been reported to work in LS but should only be used with caution. More recently, PUVA and UVA1 treatment have shown some promising success in LS. Vulvectomy should be limited to cases in which squamous cell carcinoma has been detected.[52–54]

Female LS patients should be particularly monitored for any sign of secondary genital malignancy. Prepubertal LS in girls may resolve spontaneously; however, some of these patients may eventually suffer from vulvodynia in adulthood. In case of LS-associated dyspareunia that interferes with sexual activity, the use of topical anesthetics should be considered.

Circumcision will generally resolve male genital LS and the associated phimosis, although potent topical steroids may obviate the need for surgery. Asymptomatic extragenital LS usually requires no treatment other than cover makeup in selected cases.

PREVENTION

No truly preventive measures of LS have been reported. An interdisciplinary management is essential for the long-term control of LS. Specialists from gynecology, urology, pediatrics, and psychosomatic medicine should be involved in patient care and collaborate to prevent significant complications, including the monitoring for squamous cell cancer and corticosteroid adverse events. It has also been helpful to circulate information via patient organizations for LS.

KEY REFERENCES

Full reference list available at www.DIGM8.com

DVD contains references and additional content

1. Powell JJ, Wojnarowska F: Lichen sclerosus. *Lancet* **353**:1777, 1999
3. Powell JJ, Wojnarowska F: Childhood vulvar lichen sclerosus: An increasingly common problem. *J Am Acad Dermatol* **44**:803, 2001
8. Sherman V et al: The high rate of familial lichen sclerosus suggests a genetic contribution: An observational cohort study. *J Eur Acad Dermatol Venereol* **24**:1031, 2010
9. Oyama N et al: Autoantibodies to extracellular matrix protein 1 in lichen sclerosus. *Lancet* **362**:118, 2003
13. Baldo M et al: Childhood vulval lichen sclerosus: Autoimmunity to the basement membrane zone protein BP180 and its relationship to autoimmunity. *Clin Exp Dermatol* **35**:543, 2010
16. Attili VR, Attili SK: Lichen sclerosus of lips: A clinical and histopathologic study of 27 cases. *Int J Dermatol* **49**:520, 2010
18. Farrell AM et al: Lichen sclerosus: Evidence that immunological changes occur at all levels of the skin. *Br J Dermatol* **140**:1087, 1999
30. von Krogh G, Dahlman-Ghozlan K, Syrjanen S: Potential human papilloma-virus reactivation following topical corticosteroid therapy of genital lichen sclerosus and erosive lichen planus. *J Eur Acad Dermatol Venereol* **16**:130, 2002
33. Smith SD, Fischer G: Childhood onset vulvar lichen sclerosus does not resolve at puberty: A prospective case series. *Pediatr Dermatol* **26**:725-729, 2009
34. Patrizi A et al: Childhood lichen sclerosus: A long-term follow-up. *Pediatr Dermatol* **27**:101, 2010
39. Dahlman-Ghozlan K, Hedblad MA, von Krogh G: Penile lichen sclerosus et atrophicus treated with clobetasol dipropionate 0.05% cream: A retrospective clinical and histopathological study. *J Am Acad Dermatol* **40**:451, 1999
51. Stucker M et al: The outcome after cryosurgery and intralesional steroid injection in vulvar lichen sclerosus corresponds to preoperative histopathological findings. *Dermatology* **210**:218, 2005

Chapter 66 :: Dermal Hypertrophies and Benign Fibroblastic/Myofibroblastic Tumors

:: Christine J. Ko

DERMAL HYPERTROPHIES AND BENIGN FIBROBLASTIC/MYOFIBROBLASTIC TUMORS AT A GLANCE

- Common benign dermal fibrous lesions include hypertrophic scar, keloid, dermatofibroma, and acrochordon.
- Certain benign tumors with a prominent dermal connective tissue component (e.g., angiofibroma, fibrofolliculoma/trichodiscoma, acrochordon-like lesions, and connective tissue nevi) may be associated with genetic disorders.
- Some dermal hypertrophies and tumors (e.g., desmoid tumor, infantile fibromatosis, infantile myofibromatosis) can at times be aggressive with high rates of recurrence.
- Other entities that present in infancy and childhood include fibrous hamartoma of infancy, fibromatosis colli, infantile digital fibromatosis, calcifying aponeurotic fibroma, juvenile hyaline fibromatosis, and infantile systemic hyalinosis.
- Other entities that primarily affect adults include adult fibromatoses (palmoplantar, penile, knuckle pads), pachydermodactyly, reactive lesions (nodular fasciitis, elastofibroma), solitary lesions (acquired digital fibrokeratoma, dermatomyofibroma, pleomorphic fibroma, collagenous fibroma, myofibroma, solitary fibrous tumor), and clinically distinctive hypertrophies (cutis verticis gyrata, pachydermoperiostitis, cerebriform fibrous proliferation).

TABLE 66-1
Fibroblastic/Myofibroblastic Tumors of Infancy and Childhood

Skin Involvement	Entity	Typical Site(s)
Often solitary	Infantile digital fibromatosis Myofibroma Calcifying aponeurotic fibroma Plantar fibromatosis Infantile fibromatosis Fibrous hamartoma of infancy Fibromatosis colli Cranial fasciitis	Digits Head/neck Palms/soles Soles None Upper arm/trunk Clavicle area Head/neck
Often multiple	Juvenile hyaline fibromatosis	Ears/face and other sites
Often multiple with visceral involvement	Infantile systemic hyalinosis Infantile myofibromatosis	Ears/face and other sites None

Dermal hypertrophies and benign fibrous tumors are quite common. Some of the entities described have characteristic clinical presentations and histopathologic features. Many primarily present in infancy and childhood (Table 66-1). A unifying histologic feature of hypertrophic scars and most of the rarer entities described is the presence of myofibroblasts, contractile spindle cells that express smooth muscle actin but not desmin (Table 66-2). Malignant fibrous tumors of the dermis are discussed in Chapter 125.

HYPERTROPHIC SCARS AND KELOIDS

Keloids and hypertrophic scars are related clinical lesions.[1] These lesions present at sites of prior dermal injury and wound repair. They often occur after local skin trauma (e.g. laceration, tattoo, burn, injection, ear piercing, vaccination, or surgery) or inflammatory skin disorders (e.g. acne, bites, or infections). There may be growth of keloids during pregnancy.[2] The predisposition to keloids in darker skin[3] and reports of a familial, autosomal dominant inheritance[4] suggest genetic influences. Hypertrophic scars and keloids show differences morphologically and histologically (Table 66-3),[5,6] suggesting differences in pathogenesis. There also is an apparent association with melanin pigment, as albino and vitiliginous skin do not form keloids.[7] Multiple keloids may also be associated with a genetic syndrome (Table 66-4).

Keloids appear as well-circumscribed pink to purple or hyperpigmented firm nodules (Fig. 66-1) or plaques. The surface of keloids is usually smooth, but can be nodular and borders are often smooth, but can be irregular (Table 66-3). The surface and borders of hypertrophic scars are always smooth and regular. There is a predilection for developing keloids at sites of increased tension, such as the shoulders, sternum, mandible, and arms. Keloids also commonly affect the earlobes. Keloids and hypertrophic scars are often painful, hyperesthetic, or pruritic. Ulceration can occur. Multiple keloids are common, but several rare entities may be considered in the clinical differential diagnosis (see Box 66-1).[8–11] Histopathologically, keloids are composed of thick, haphazard, eosinophilic, collagen bundles. Hypertrophic scars are more cellular with myofibroblasts either in disorganized whorls or sometimes oriented parallel to the epidermis.

Although the exact mechanism of keloid formation is still unclear,[12–19] TGF-beta and its signaling pathway are important (see Table 66-5).[12] Hypertrophic scars are associated with HLA-DRB16.[20] In most studies, keloids

TABLE 66-2
Differences Between Fibroblasts, Myofibroblasts, and Smooth Muscle Cells

	Fibroblast	Myofibroblast	Smooth Muscle Cell
Nucleus	Tapered	Tapered to cigar-shaped	Cigar-shaped
Positive immunohistochemical stains	Vimentin CD34 (sometimes)	Vimentin Smooth muscle actin Muscle specific actin	Vimentin Smooth muscle actin Muscle specific actin Desmin
Negative immunohistochemical stains	Smooth muscle actin Muscle specific actin Desmin	Desmin	

TABLE 66-3
Differences Between Keloids and Hypertrophic Scars

	Keloid	Hypertrophic Scar
Age	Especially third decade	Any
Onset after injury	Delayed[a]	Immediate
Growth beyond border of original wound	Yes	No
Spontaneous regression	Rare	Occasional
Recurrence	Common	Rare
Distorted shape	Common	Rare
Histopathology	Thick, hyalinized collagen	Fascicles of myofibroblasts arranged haphazardly
Treatment response	Poor	Good

[a]May occur spontaneously.

and scars show the same biochemical and pathologic abnormalities. Keloids express increased levels of the gli-1 protein, an oncogene product also present in neoplasms such as basal cell carcinoma.[21] Collagen synthesis and collagenase activity are increased in both keloids and hypertrophic scars. α1-Globulin (a collagenase inhibitor usually not present in normal scars) may contribute to increased collagen deposits. Hypertrophic scars have decreased levels of the profibrotic agent tumor necrosis factor.[22] Keloids contain tenascin C, a protein associated with inflammation and wound healing.[23] Fibroblasts from keloid-prone patients have altered cytokine patterns[24] and increased sensitivity to transforming growth factor- β1 (TGF- β1),[25] TGF-β2,[26]



Figure 66-1 Keloid. Firm, nontender erythematous nodule on the ear that developed after ear-piercing.

TABLE 66-4
Selected Genetic Syndromes Associated with Superficial Dermal Hypertrophies and Fibrous Tumors

	Associated Genetic Syndrome
Keloids	Rubinstein–Taybi Goeminne
Acrochordon-like lesions	Birt–Hogg–Dubé[a] Gorlin (Nevoid basal cell carcinoma)[b]
Fibrous papules/ angiofibromas	Tuberous sclerosis[c] Multiple endocrine neoplasia type I Birt–Hogg–Dubé
Fibrofolliculomas/ trichodiscomas	Birt–Hogg–Dubé
Connective tissue nevus	Tuberous sclerosis[d] Buschke–Ollendorf[e] Familial cutaneous collagenoma Multiple endocrine neoplasia type I Birt–Hogg–Dubé Ehlers–Danlos (hypermobile, type III) Hunter/Hurler
Sclerotic fibroma (circumscribed storiform collagenoma, plywood fibroma)	Cowden
Desmoid tumor	Gardner/Familial adenomatous polyposis[f] Familial infiltrative fibromatosis/ Hereditary desmoid disease
Cutis verticis gyrata	Turner Noonan Fragile X Klinefelter Tuberous sclerosis Beare–Stevenson Ehlers–Danlos Apert
Knuckle pads	Bart–Pumphrey
Cerebriform fibrous proliferation	Proteus
Gardner fibroma	Gardner/Familial adenomatous polyposis

[a]Histopathology is that of a fibrofolliculoma/trichodiscoma.
[b]Histopathology is that of basal cell carcinoma.
[c]Referred to as adenoma sebaceum by some when associated with tuberous sclerosis.
[d]Referred to as a shagreen patch.
[e]Referred to as dermatofibrosis lenticularis disseminata.
[f]Generally tumors are intra-abdominal.

platelet-derived growth factor, and epidermal growth factor.[27] Carbon dioxide laser treatment reduces TGF-β1 levels in keloids.[28] At least, part of the fibroblast stimulation may be secondary to infiltration of the scar by activated T cells.[29] Also, there seem to be decreased

BOX 66-1 CLINICAL DIFFERENTIAL DIAGNOSIS OF MULTIPLE KELOIDAL LESIONS

Keloid
Lobomycosis
Keloidal scleroderma/morphea
Non-Langerhans cell histiocytoses

levels of apoptosis, as shown by terminal transferase dUTP nick end labeling (TUNEL) assays and increased Bcl-2 and p53 expression in keloid-associated fibroblasts.[30]

The treatment of hypertrophic scars and keloids differs slightly.[7,31] Hypertrophic scars tend to be more responsive than keloids and generally flatten with time. Although injection of hypertrophic scars and keloids with intralesional steroids is a first-line treatment in many cases, depending on the situation (e.g. a wound previously infected, a wound across lines of tension or a joint), hypertrophic scars may respond quite well to surgery as an initial treatment. Surgery alone is generally not recommended for keloids, as they often recur as larger lesions. An exception to this may be keloids on the earlobes.[32] An algorithm for treatment is outlined in Treatment Box 66-2.

TABLE 66-5
Factors Associated with Keloids

Increased	Decreased
Transforming growth factor-β	SMAD proteins (e.g., SMAD7)
Platelet-derived growth factor	Apoptosis
Vascular endothelial growth factor	
Collagen	
Cytokines (e.g., IL-1, IL-6)	
Cyclooxygenase 2	
Plasminogen activator inhibitor-1	
Matrix metalloproteinase-2	

DERMATOFIBROMA (FIBROUS HISTIOCYTOMA, SCLEROSING HEMANGIOMA)

Dermatofibroma is a common, benign tumor that has a predilection for the lower legs of women. Any age may be affected, but typically dermatofibromas appear in the 20s and 30s. Dermatofibromas may be solitary or multiple and eruptive (see Box 66-3).[33] Trauma, such as secondary to insect bites, has been thought to induce some lesions, suggesting a reactive/reparative process. The recent demonstration of clonal X-inactivation in some cases of dermatofibroma supports a neoplastic nature.[34,35]

Usually asymptomatic, they occasionally are pruritic or painful. Some tumors grow very rapidly, whereas others remain static for many years. Characteristically, a dermatofibroma is firm, measuring from 0.5 mm to 1 cm in diameter, and lateral compression produces a dimple-like depression in the skin. The surface may be shiny or keratotic, and the color is variable, often brown but sometimes pink, red, tan, or flesh colored (Fig. 66-2A).

Histologically, the epidermis is usually hyperplastic and hyperpigmented. There may be follicular or sebaceous induction. The dermis has fascicles or haphazardly arranged collections of spindle cells that lack atypia in most cases (see Figs. 66-2B and 66-2C). The

BOX 66-2 FOR HYPERTROPHIC SCARS AND KELOIDS

	HYPERTROPHIC SCARS	KELOIDS
First-line	Intralesional steroids or sometimes surgical excision/revision	Intralesional steroids
Potential modalities for use in combination with first-line or second-line treatment	Often not necessary	Cryotherapy Pressure Silicone gel sheeting
Second-line	Often not necessary	Laser therapy Intralesional 5-fluorouracil Surgery[a] Radiation Bleomycin

[a]Often combined with postoperative steroid injections, topical imiquimod application, pressure application, radiation, intralesional verapamil.

BOX 66-3 CONDITIONS ASSOCIATED WITH MULTIPLE (AT LEAST 8[a]) DERMATOFIBROMAS

Systemic lupus erythematosus
Human immunodeficiency virus infection
Immunosuppression of other cause (e.g., immunosuppressive drugs, especially in the setting of patients with autoimmune disease, lymphoma/leukemia, organ transplant)
Case reports of atopic dermatitis, pulmonary hypertension, hydronephrosis, myasthenia gravis, pemphigus, pregnancy, sarcoidosis, hyperlipidemia

[a]Some authors consider 15 to be a cutoff.

BOX 66-4 ATYPICAL,[a] CELLULAR, DEEP, AND INDETERMINATE FIBROUS HISTIOCYTOMAS

Clinical Features

- Often >2 cm in size
- Sometimes facial
- Any age, but some predilection for young adults
- Often recur after incomplete excision
- Rare potential for metastasis

Histologic Features

- Background of dermatofibroma/fibrous histiocytoma
- Variable areas of atypical cells, high cellularity
- May extend deeply into subcutaneous, sometimes in a honeycomb pattern
- May stain with CD34

[a]Occasionally overlaps with aneurysmal variant.

edges of the lesion are poorly defined with individual cells hugging collagen bundles ("collagen entrapment"). Mitotic figures may be present, but atypical forms are not a feature. Dermatofibromas are generally factor XIIIa-positive[36] and CD34$^-$.[37] There are many histologic variants of dermatofibroma, most without clinical significance. Exceptions are in Box 66-4.



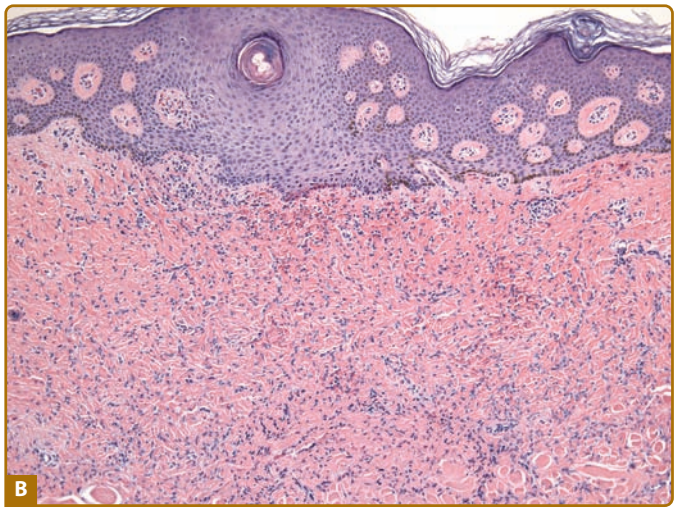

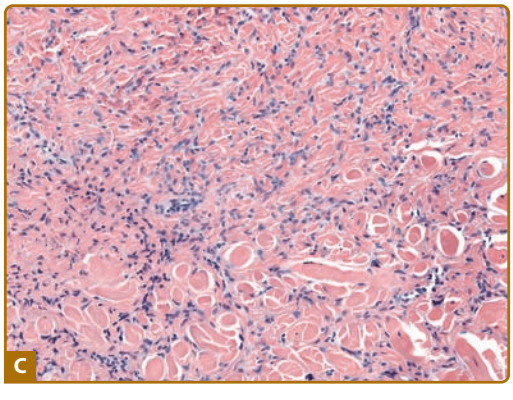

Figure 66-2 **A.** Dermatofibroma on the right thigh of a young man. **B** and **C.** Haphazardly arranged spindle cells in the dermis. The lesion edge is poorly defined with spindle cells infiltrating between thickened collagen fibers [(hematoxylin and eosin 100× magnification (**B**); 200× magnification (**C**)].



Figure 66-3 Soft fibromas or skin tags on the neck overlying acanthosis nigricans.

No treatment is necessary unless symptomatic. A common reason for removal is repeated trauma to the dermatofibroma, often secondary to shaving the lower legs. Cryosurgery may be helpful in flattening out the dermatofibroma but usually is not curative. Lesions termed "atypical," "cellular," "deep," and/or "indeterminate" are generally best treated with complete excision, particularly if clinical size is >2 cm (see Box 66-4).[38–44]

ACROCHORDON (FIBROEPITHELIAL POLYP, SKIN TAG, SOFT FIBROMA)

Acrochordons are pedunculated papules or tumors that are most commonly located on the eyelids, neck, axillae, and groin. There is a familial disposition, and acrochordons are more commonly seen in obese individuals, sometimes overlying acanthosis nigricans (Fig. 66-3). Acrochordon-like clinical lesions may be a feature of a genetic syndrome, although histologically there are differences (see Table 66-4).[45,46] Histologically, an acrochordon is a polypoid lesion with a central collagenous core. Adnexal structures are generally absent. Although usually asymptomatic, lesions can become irritated or necrotic. Patients often request removal for cosmetic reasons.

FIBROUS PAPULE (ANGIOFIBROMA)

A fibrous papule is a common papule on the lower portion of the nose or the central face. It usually presents in adulthood. Multiple lesions are a feature of certain genetic syndromes (see Table 66-4),[47–51] but occasionally may be seen in patients with no other stigmata of a genetic disorder.[52] The fibrous papule is small (2–5 mm), nontender, flesh colored (sometimes pink or slightly hyperpigmented), firm, and dome shaped. It must be differentiated from an early, nodular, basal cell carcinoma, and biopsy may be necessary. Unlike a basal cell carcinoma, it rarely bleeds and stays relatively stable in its smaller size. Histologically, the dermis shows fibrosis with stellate fibroblasts and dilated vessels. Identical histology is seen in pearly penile papules and periungual fibromas (Koenen's tumors) (see Chapter 140). No treatment is necessary, and a simple shave or punch excision is usually curative.

FIBROFOLLICULOMA/ TRICHODISCOMA

Fibrofolliculomas/trichodiscomas are 2- to 4-mm, dome-shaped, yellowish to skin-colored papules located on the head, neck, and upper trunk; multiple lesions may be associated with Birt–Hogg–Dubé syndrome (see Table 66-4).[45]

CONNECTIVE TISSUE NEVUS/ COLLAGENOMA/ELASTOMA

These hamartomas can be divided into familial, those associated with genetic disease (see Table 66-4),[47,50,53–57] and other isolated variants. Connective tissue nevi present as asymptomatic, flesh-colored to yellow–brown papules or plaques that may be solitary or grouped, linear, or irregular in distribution (Fig. 66-4).[58] The overlying epidermis is usually smooth. Histologically, connective tissue nevi show a normal epidermis overlying collagen in the lower dermis. The collagen may be subtly increased, thickened, or oriented vertically to the epidermis, and muscin may be increased. Elastic fibers may also be increased (elastoma).

Familial cutaneous collagenoma is an autosomal dominantly inherited condition of multiple, often papular connective tissue nevi usually appearing postpuberty on the trunk and upper extremities.[59,60] There



Figure 66-4 Cutaneous collagenoma, a connective tissue nevus involving almost the entire back.

may be associated systemic abnormalities such as progressive cardiomyopathy.

DESMOID TUMOR (AGGRESSIVE FIBROMATOSIS)

Desmoid tumors, also known as *deep* or *aggressive fibromatoses*, are a type of fibromatosis. All types (extra-abdominal, abdominal wall, intra-abdominal) may be induced by trauma (Fig. 66-5). Mutations have been found in the adenomatous polyposis coli (APC) gene (*5q21*).[61] Hormonal influences (e.g., pregnancy) are implicated in abdominal wall tumors.[62] Tumors associated with Gardner/Familial adenomatous polyposis (FAP) (see Table 66-4)[63] are often intra-abdominal,[64] may be more aggressive and surgically unresectable, and are associated with a 10% mortality.[65] Extra-abdominal tumors are deep-seated, often located in the area of the shoulder and pelvic girdle, chest wall, or head and neck.[66] Although surgery is widely accepted as first-line treatment,[67] complete surgical excision is difficult to achieve, and recurrences are common. Intra-abdominal tumors, particularly those associated with Gardner/FAP, may be best treated, if symptomatic, with radiation or chemotherapy.[68]



Figure 66-5 Desmoid tumors involving upper chest and epigastric region. These represent recurrences after multiple surgical interventions. This patient also had intra-abdominal desmoid tumors.

INFANTILE FIBROMATOSIS (LIPOFIBROMATOSIS, PEDIATRIC DESMOID TUMOR)

Infantile fibromatosis presents as a rapidly growing nodule on the head and neck, shoulder/upper arm, or thigh; generally before age 2. The lipofibromatosis variant has a predilection for the hands and feet.[69] Histologically, the tumor may have an immature mesenchymal pattern, variable amounts of adipose tissue,[69] or a desmoid tumor-like pattern. Local recurrence is common, but surgery is the treatment of choice.[70,71]

INFANTILE MYOFIBROMATOSIS

Infantile myofibromatosis generally presents before age 2, with many cases being congenital.[72,73] Multiple nodules involving the skin and other organs (gastrointestinal, kidney, lung, heart) are seen, with mortality approaching 75%.[73] Prognosis is generally excellent if only a solitary nodule (then termed *myofibroma*, see below) or multiple nodules limited to the skin are seen. For multiorgan involvement, treatment with surgical resection, chemotherapy and radiotherapy have been described.

Histologic diagnosis relies on the identification of two separate components—a fascicular myofibroblastic pattern at the periphery with a hemangiopericytoma-like pattern in the center. In the past, many cases were considered to be infantile or childhood hemangiopericytomas. Mitotic figures, vascular invasion, and tumor necrosis can be found, but do not predict malignant transformation.[74] Biopsy of these lesions, especially in infants and young children, is important to ensure that the lesions do not represent congenital infantile fibrosarcoma. Histopathologic examination as well as cytogenetic and molecular pathology studies will distinguish myofibromas (chromosome 8 abnormalities) from congenital infantile fibrosarcomas (translocation between chromosomes 12 and 15—*ETV6* and *NTRK3* genes).[75]

FIBROUS HAMARTOMA OF INFANCY

Fibrous hamartoma of infancy is a rare benign tumor that presents before age 2 (up to 25% congenital)[76,77] as a solitary, painless, rapidly growing, flesh-colored, ill-defined, subcutaneous nodule, or plaque. There is a male predominance. The most common locations are the axillary region, upper arm, upper trunk, inguinal region, and external genital region.[76,77] These lesions rarely present with overlying skin changes such as hypertrichosis, alteration in pigmentation, and eccrine gland hyperplasia.[77] Histologic features are characteristic, with an organoid pattern of fibrous trabeculae, myxoid areas with spindle cells, and adipose tissue.[76,78] The treatment of choice is complete excision.[73] An aggressive approach should be avoided because the overall prognosis is excellent.[79]



Figure 66-6 **A.** Well-defined pink nodules of infantile digital fibromatosis in a 9-month-old patient. **B.** The patient at age 2.5 years, with spontaneous resolution of the nodules. (Used with permission from Richard J. Antaya, MD.)

FIBROMATOSIS COLLI (STERNOCLEIDOMASTOID TUMOR OF INFANCY)

Fibromatosis colli is an often self-limiting, rapidly growing tumor, presenting in the first few weeks of life. It is characterized by a benign proliferation of fibroblasts in the lower one-third of the sternocleidomastoid muscle, rarely bilateral, and occasionally associated with torticollis or facial asymmetry.[80] The tumor often resolves within the first year of life.[80] Fine-needle aspiration is the preferred technique for diagnosis.[81,82]

INFANTILE DIGITAL FIBROMATOSIS

Infantile digital fibromatosis is a rare form of superficial juvenile fibromatosis presenting as (an) asymptomatic, flesh-colored, firm nodule(s) on the fingers and toes (tending to spare the thumb or hallux) (Fig. 66-6A), primarily in infants and less commonly in children. One-third of cases are congenital.[83] Histologically, poorly circumscribed, interlacing bundles of myofibroblasts are observed. The pathognomonic finding is eosinophilic, perinuclear inclusion bodies composed of actin filaments, which stain red with Masson trichrome stain and purple with phosphotungstic acid-hematoxylin.[84] Multiple clinically similar tumors, but without inclusion bodies on histopathologic examination, are associated with brachydactyly and facial dyspigmentation.[85] Despite the observation of spontaneous regression over years (Fig. 66-6B) and a high recurrence rate after excision, surgical intervention is common because deformities of the digit and contractures can occur with larger lesions.[83]

CALCIFYING APONEUROTIC FIBROMA

Calcifying aponeurotic fibroma is an uncommon, benign fibrous tumor. It is most commonly found on the palms and soles of male children and young adults (peak incidence between the ages of 8 and 14).[86,87] However, it can present in any area that is closely related to aponeuroses.[86] It is a very slow growing, deep-seated firm proliferation that presents as an asymptomatic infiltrative soft tissue mass, usually measuring less than 3 cm in diameter.[86] If symptomatic, surgical excision may be performed, although there is a 50% local recurrence rate. Local recurrence is more common in children younger than 5 years of age.[86]

On histopathologic examination, it is an ill-defined, poorly circumscribed tumor composed of spindled fibroblasts surrounding central calcified foci. The lesion typically is organized into nodules, with central hyalinization and incipient calcification surrounded by a palisade of chondrocyte-like cells. Less cellular areas contain spindled fibroblastic cells between coalescing calcified nodules. Osteoclastic giant cells may border the calcific deposits. These lesions may demonstrate actin and CD99 and S100 proteins with immunostaining.

JUVENILE HYALINE FIBROMATOSIS/INFANTILE SYSTEMIC HYALINOSIS

Juvenile hyaline fibromatosis (JHF) is a rare, autosomal recessive condition secondary to a defect on chromosome 4q21 associated with the locus of the capillary morphogenesis gene-2 (CMG2).[88] From infancy, subcutaneous, pearly papules and firm, large nodules that progressively enlarge and may ulcerate appear on the nose, chin, ears, scalp, hands (Fig. 66-7), back, and knees.[89] Histologically, cells with perinuclear vacuoles are seen in a hyalinized and chondroid stroma. Patients tend to have gingival hypertrophy, which can result in periodontal disease and caries. Progressive joint contractures, osteolysis, and muscular weakness can result in severe debilitation.

Preliminary genotype–phenotype analyses suggest that abrogation of binding by von Willebrand's factor type A domain of CMG2 results in severe disease



Figure 66-7 Juvenile hyaline fibromatosis. Tumors involving the hand. Both hands were affected.

typical of infantile systemic hyalinosis (ISH), whereas in-frame mutations affecting the highly conserved cytoplasmic domain result in a milder phenotype.[90] Although the fibrous skin lesions, joint contractures, gingival hypertrophy, and osteolysis are shared with JHF, the manifestations of ISH are present within the first months of life and often at birth.[91] Patients may also show diffusely thickened skin, hyperpigmented plaques on bony prominences, visceral involvement, frequent infections, and persistent diarrhea with failure to thrive, leading to death during infancy. The histologic and ultrastructural appearance of biopsied lesional skin resembles that of JHF.

Currently, no widely accepted effective treatment exists for JHF or ISH. Surgical excision is often not feasible due to the number and size of the tumors, and anesthesia can be complicated because of the oral and dental issues.

PALMOPLANTAR FIBROMATOSES

Dupuytren contracture (palmar fibromatosis) is characterized by progressive fibrosis of the palmar fascia, most commonly presenting as one or more nodules over the fourth and fifth metacarpal head. Nodules become cords, and joint contractures and flexion deformities of the fingers may follow.[92] Significant risk factors for development of Dupuytren contracture include old age, male sex, white northern European ancestry, family history, seizures, alcohol-induced liver disease, trauma, smoking, and diabetes mellitus.[93–95] This condition rarely occurs before age 30 and is very rare in children.[93] Concurrent plantar disease, knuckle pads, and/or keloids may be seen.[93,96]

Histologically, there are uniform, spindled fibroblasts separated by collagen.[93] Surgical correction may be the treatment of choice of progressive disease.[92] Recurrence is more common in patients with greater initial deformity, but less common if good surgical correction is achieved and postoperative rehabilitation provided.[97]

Ledderhose disease is characterized by plantar fibrosis especially over nonweight-bearing areas of the sole and has similar features to Dupuytren disease histologically.[93,96] Contractures are uncommon.[96,98] Typically adults are affected, but children can manifest disease.[93] These lesions may be treated with surgical excision.

PEYRONIE DISEASE (PENILE FIBROMATOSIS)

Fibrosis of the dorso-lateral penis, resulting in curvature of the penis and erectile dysfunction, is termed *Peyronie disease*. Risk factors include genetic predisposition, trauma to the penis, smoking, alcohol consumption, and history of diabetes or hypercholesterolemia.[99,100] Over several years, patients may have stabilization and rarely spontaneous regression of the disorder.[101] Conservative management is often recommended.[102] Surgery is reserved for those with compromised sexual function or disabling deformity.[101,103]

KNUCKLE PADS

Knuckle pads are circumscribed, thickened plaques over the dorsal aspects of the interphalangeal joints. Many patients have coexisting palmar, plantar, or penile fibromatosis.[93] Histologically, these lesions are very similar to Dupuytren disease. False knuckle pads are due to repetitive mechanical trauma.

PACHYDERMODACTYLY

Pachydermodactyly is a rare form of benign digital fibromatosis consisting of symmetric, painless, circumscribed swelling of the proximal interphalangeal joints of the fingers, often sparing the thumb.[104] It primarily affects adolescent males. Some consider this a variant of knuckle pads. It may be associated with tuberous sclerosis, atrophia maculosa varioliformis cutis (noninflammatory pitted scarring, usually on the face) and carpal tunnel syndrome. Histologically there is hyperkeratosis, acanthosis, and increased dermal fibrosis.

NODULAR FASCIITIS

Nodular fasciitis is a benign, self-limiting proliferation of fibroblasts of uncertain etiology that often follows trauma, observed most frequently on the upper extremity.[105] Although it is seen most commonly in young adults, it can occur at any age, without racial or sex predilection. It presents as a rapidly growing, painful mass (generally less than 2 cm) in the subcutis, fascia, or muscle. Cranial fasciitis is the most common variant in children and involves the head and neck. Histologically, nodular fasciitis presents as a poorly demarcated nodule in the subcutis, fascia, or dermis that is composed of spindled "tissue-culture"-like

fibroblasts and myofibroblasts in a loose, myxoid, highly vascular stroma that resembles granulation tissue. These lesions often have associated hemorrhage. Mitotic figures are present, but atypia and nuclear polymorphism are not seen. Despite the possibility of spontaneous involution, excision is the treatment of choice, with recurrences being rare.

ELASTOFIBROMA (ELASTOFIBROMA DORSI)

Elastofibroma is a rarely diagnosed, benign, fibroproliferative, soft-tissue tumor that occurs predominantly in the periscapular region of middle-aged to elderly women.[106] Many patients have bilateral involvement. Although the exact etiology is unknown, it is suspected that chronic subclinical microtrauma may lead to reactive hyperplasia of elastic fibers, with consequently increased production of fibrous tissue. Clinically, this tumor presents as a poorly circumscribed, firm, mobile mass; typically, the lesions are concealed with retraction and protuberant with protraction of the shoulders. More than 50% of patients are asymptomatic and present with a painless swelling. Magnetic resonance imaging often shows a characteristic layering of fibrous tissue and adipose tissue.[107] Typical histologic findings are thickened collagen and chenille-like elastic fibers admixed with adipose tissue.

ACQUIRED DIGITAL FIBROKERATOMA (ACRAL FIBROKERATOMA)

This lesion is a keratotic papule acquired in adulthood, often on the digits or occasionally the palms/soles (Fig. 66-8).[108] Histologically, there is overlying hyperkeratosis with abundant dermal collagen that is perpendicular to the epidermis in the papillary dermis.



Figure 66-8 Acquired digital fibrokeratoma. A hyperkeratotic papule with a collarette on the palm, a slightly unusual location.

DERMATOMYOFIBROMA

This is a 1–2 cm, ill-defined, indurated plaque, most commonly seen in young women on the shoulder or upper arm.[109,110] Histologically, in the deep dermis, there are fascicles of slender spindle cells parallel to the epidermis, with sparing of adnexal structures.

PLEOMORPHIC FIBROMA

Pleomorphic fibromas are usually solitary and appear in middle-aged to older individuals. They are generally nondescript, slow-growing, dome-shaped, or polypoid lesions with a predilection for the extremities.[111] Clinical behavior is benign; histologically, a polypoid lesion with a collagenous core has multinucleated cells and scattered large cells with atypical nuclei. Even with incomplete removal, recurrence is uncommon.

COLLAGENOUS FIBROMA (DESMOPLASTIC FIBROBLASTOMA)

Collagenous fibroma usually presents in the fifth to sixth decades with a 5:1 male–female ratio.[112] It is a benign tumor that appears as a slow-growing, painless, mobile mass (1–20 cm) located in the subcutaneous tissue or just deep to skeletal muscle. This tumor has a predilection for the upper arm and shoulder; but may also occur on the posterior neck, upper back, lower extremities, hand, abdominal wall, and hip joint. Histologically, the tumor has an infiltrative appearance into fascia or skeletal muscle and is composed of bland stellate and spindle-shaped fibroblasts and myofibroblasts in a collagenous matrix.

MYOFIBROMA

All ages may be affected by myofibroma. This is a tumor that some consider of vascular origin[113] that is similar histologically to the tumors of infantile myofibromatosis.[72,73] When solitary or multiple in the skin, the prognosis is excellent, with spontaneous regression in some cases.[72] These tumors have a wide distribution, but are often on the extremities in adults (Fig. 66-9), and are painless.[73] Histologic findings are diagnostic, commonly with multiple nodules or poorly circumscribed fascicles of spindle cells that express smooth muscle actin intermixed with thick collagen, sometimes with peripheral cells having a pericytic appearance.

SOLITARY FIBROUS TUMOR

Solitary fibrous tumor is a tumor once thought to only involve the pleural cavity but now known to be a rare



Figure 66-9 Myofibroma. A somewhat ill-defined, focally firm and focally spongy, pink to flesh-colored tumor (with smaller nodules within it) on the ankle. This asymptomatic lesion had been present since at least age 9 and had been growing slowly over the last 15 years.

soft tissue tumor.[114] It usually behaves nonaggressively. Histologically, there are dilated vessels, sometimes staghorn (some consider solitary fibrous tumor and hemangiopericytoma to be part of a spectrum), with interspersed spindle cells that are arranged in a "patternless" pattern. Cells are $CD34^+$. Malignant tumors have been described and should be ruled out when there is increased cellularity, pleomorphism, or mitoses.

CUTIS VERTICIS GYRATA

This rare condition presents on the scalp, often at puberty, and when primary, affects males more commonly. The scalp appears folded, with furrows running anteriorly to posteriorly. Primary disease is idiopathic or associated with neuropsychiatric disorders.[115–117] Histologically, the areas of folded scalp appear normal. Cutis verticis gyrata may also be seen secondarily in association with a variety of inflammatory or neoplastic diseases (see Table 66-4 and Box 66-5).[115] Clues for secondary involvement include early onset of disease (sometimes congenital), asymmetric disease, and disordered furrows that are not oriented anterior to posterior.[115] If the face and acral sites are involved, pachydermoperiostitis should be considered.

BOX 66-5 CONDITIONS ASSOCIATED WITH CUTIS VERTICIS GYRATA

Neuropsychiatric (e.g., schizophrenia, mental retardation, seizures)
Genetic syndromes (see Table 66-4)
Inflammatory (e.g., eczema, psoriasis, folliculitis, impetigo, erysipelas)
Local neoplasms (e.g., congenital melanocytic nevus, neurofibroma, fibroma, hamartoma)
Systemic illness (e.g., myxedema, acromegaly, amyloidosis, syphilis, leukemia, acanthosis nigricans, insulin resistance syndrome)

PACHYDERMOPERIOSTITIS

Pachydermoperiostosis (primary hypertrophic osteoarthropathy) is a rare genetic syndrome with most cases having autosomal dominant transmission.[118] At puberty, there is progressive enlargement of the joints due to pachydermia, periostosis, and clubbing. Other features include thickened skin on the face and scalp (resembling cutis verticis gyrata), palmoplantar hyperhidrosis, and acro-osteolysis. Arthralgias can be quite debilitating. Disease progresses for 5–20 years before stabilizing. Primary hypertrophic osteoarthropathy should be distinguished from secondary hypertrophic osteoarthropathy, which is generally secondary to pulmonary or cardiac disease.

CEREBRIFORM FIBROUS PROLIFERATION

In patients with Proteus syndrome, the soles (and sometimes the palms) have cerebriform overgrowth with gigantism. There is increased dermal fibrosis.

KEY REFERENCES

Full reference list available at www.DIGM8.com

DVD contains references and additional content

13. Seifert O, Mrowietz U: Keloid scarring: Bench and bedside. *Arch Dermatol Res* **301**:259, 2009
31. Wolfram D et al: Hypertrophic scars and keloids—A review of their pathophysiology, risk factors, and therapeutic management. *Dermatol Surg* **35**:171, 2009
41. Horenstein MG et al: Indeterminate fibrohistiocytic lesions of the skin: Is there a spectrum between dermatofibroma and dermatofibrosarcoma protuberans? *Am J Surg Pathol* **24**:996, 2000
43. Guillou L et al: Metastasizing fibrous histiocytoma of the skin: A clinicopathologic and immunohistochemical analysis of three cases. *Mod Pathol* **13**:654, 2000
93. Fetsch JF, Laskin WB, Miettinen M: Palmar-plantar fibromatosis in children and preadolescents: A clinicopathologic study of 56 cases with newly recognized demographics and extended follow-up information. *Am J Surg Pathol* **29**:1095, 2005
116. Polan S, Butterworth T: Cutis verticis gyrata: A review with report of seven new cases. *Am J Ment Defic* **57**:613, 1953

Chapter 67 :: Anetoderma and Other Atrophic Disorders of the Skin

:: Catherine Maari & Julie Powell

ANETODERMA AT A GLANCE

- Circumscribed 1- to 2-cm areas of flaccid skin that may be elevated, macular, or depressed.
- Often circumscribed sac-like protrusions.
- Primary or secondary to a preceding dermatosis in the same location.
- Association with antiphospholipid syndrome.
- Pathology consists of loss of elastic tissue in the dermis.

ANETODERMA

EPIDEMIOLOGY

The lesions in anetoderma usually occur in young adults between the ages of 15 and 30 years and more frequently in women than men. Anetoderma is rare, but the incidence is unknown. Several hundred cases have been reported.[1–4]

PATHOGENESIS

The pathogenesis of anetoderma is unknown. The key defect is damage to the dermal elastic fibers. Anetoderma may be considered to be unusual scars, because scars also have decreased elastic tissue. The loss of dermal elastin could be the result of an impaired turnover of elastin caused by either increased destruction or decreased synthesis of elastic fibers.

CLINICAL FINDINGS

All types of anetoderma are characterized by a circumscribed loss of normal skin elasticity. The characteristic lesions are flaccid circumscribed areas of slack skin with the impression of loss of dermal substance forming depressions, wrinkling, or sac-like protrusions (Fig. 67-1). These atrophic, skin-colored, or blue–white lesions are 5–30 mm in diameter. The number varies from a few to hundreds. The skin surface can be wrinkled, thinned, and often depigmented, and a central depression may be seen. Coalescence of smaller lesions can give rise to larger herniations. The examining finger sinks without resistance into a distinct pit with sharp borders as if into a hernia ring (buttonhole sign). The protrusion reappears as soon as the pressure from the finger is removed.[4]

The most common sites for these asymptomatic lesions are the chest, back, neck, and upper extremities. They usually develop in young adults, and new lesions often continue to form for many years as the older lesions fail to resolve.

Primary anetoderma occurs when there is no underlying associated skin disease (i.e., it arises on clinically normal skin). It is historically subdivided into two types: (1) those with preceding inflammatory lesions, mainly erythema (the Jadassohn–Pellizzari type), and (2) those without preceding inflammatory lesions (the Schweninger–Buzzi type). This classification is only of historical interest, because the two types of lesions can coexist in the same patient; the prognosis and the histopathology are also the same.[4]

True secondary anetoderma implies that the characteristic atrophic lesion has appeared in the exact same site as a previous specific pathology; the most common causes are probably acne and varicella. Numerous and heterogeneous dermatoses have been associated with secondary anetoderma, namely syphilis, Lyme disease, molluscum contagiosum, pilomatricomas, juvenile xanthogranuloma, xanthomas, granuloma annulare, leprosy, discoid lupus, sarcoidosis, and lichen planus, to mention only a few. Anetoderma has also been described in premature infants and, in some cases, it may have been related to the use of cutaneous monitoring leads or adhesives.[5] Both types may be associated with an underlying disease, mainly antiphospholipid syndrome[6] and human immunodeficiency virus. Although most cases are sporadic, rare cases of familial anetoderma have been recently described and are usually not associated with preexisting lesions.[7]

PATHOLOGY

In routinely stained sections, the collagen fibers within the dermis of affected skin appear normal. Perivascular lymphocytes are often present in all types of anetoderma and do not correlate with clinical inflammatory findings.[8]

The predominant defect as revealed by elastic tissue stains is a focal partial or complete loss of elastic tissue in the papillary and/or midreticular dermis. There are usually some residual abnormal, irregular, and fragmented elastic fibers (Fig. 67-2).[9] Presumably, the weakening of the elastic network leads to flaccidity and herniation. Direct immunofluorescence sometimes shows linear or granular deposits of immunoglobulins and complement along the dermal–epidermal junction or around the dermal blood vessels in affected skin.[10]



Figure 67-1 Anetoderma. Primary anetoderma. **A.** Multiple, sharply defined, depressed lesions that look punched out in the supraclavicular region. **B.** Soft, sac-like protrusions on the back. When depressed, there is the buttonhole phenomenon. This is the same patient as in **A**.

Electron microscopy demonstrates that the elastic fibers are fragmented and irregular in appearance and occasionally can be engulfed by macrophages.

DIFFERENTIAL DIAGNOSIS

Anetoderma must be differentiated from other disorders of elastic tissue as well as atrophies of the connective tissue (Box 67-1).

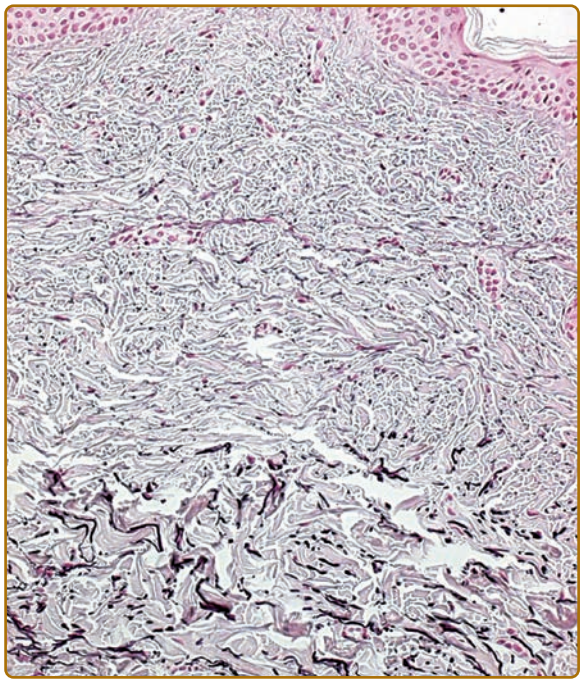

Figure 67-2 Anetoderma. Pathology shows decrease of elastic fibers in the papillary and reticular dermis (Weigert's stain). (Used with permission from Victor Kokta, MD.)

Keloids form nodules that are much firmer on palpation. A history of trauma is often elicited, and the pathology is very distinct.

Glucocorticoid-induced atrophy occurs most commonly over the triceps or buttocks at sites where injections are usually given. Clinically, the lesions resemble atrophoderma. History is obviously most helpful in making the diagnosis. On histopathology, polarization may show the steroid crystals in the dermis.

Nevus lipomatosus superficialis of Hoffman and Zurhelle presents as a clustered group of soft, skin-colored to yellow nodules usually on the lower trunk and buttocks and present since birth. Histology shows ectopic mature lipocytes located in the dermis.

Papular elastorrhexis is an acquired disorder characterized by white, firm nonfollicular papules measuring 1–3 mm, evenly scattered on the chest, abdomen, and back. It usually appears in adolescence or early adulthood. The pathology demonstrates focal degeneration of elastic fibers and normal collagen. There are no associated extracutaneous abnormalities. This is believed by some authors to be a variant of connective tissue nevi[11] or an abortive form of the Buschke–Ollendorff

BOX 67-1 DIFFERENTIAL DIAGNOSIS OF PRIMARY ANETODERMA

ELEVATED	DEPRESSED
Secondary anetoderma	Secondary anetoderma
Acne scars	Glucocorticoid-induced atrophy
Keloids	Acne scars
Nevus lipomatosus superficialis	
Papular elastorrhexis	
Connective tissue nevi	

syndrome,[12] whereas others think that these represent papular acne scars.[13] They are differentiated from anetoderma by being firm noncompressible lesions.

Middermal elastolysis (MDE) usually consists of larger areas with diffuse wrinkling without herniation and with elastolysis limited to the middermis (See below).

TREATMENT

There is no regularly effective treatment. In secondary anetoderma, appropriate treatment of the inflammatory underlying condition might prevent new lesions. In patients with limited lesions that are cosmetically objectionable, surgical excision may be useful. Various therapeutic modalities have been tried but with no improvement of existing atrophic lesions, including intralesional injections of triamcinolone and systemic administration of aspirin, dapsone, phenytoin, penicillin G (benzylpenicillin), and vitamin E. Some authors have reported improvement with hydroxychloroquine.

OTHER ATROPHIC DISORDERS OF THE SKIN

MIDDERMAL ELASTOLYSIS

MDE is a rare acquired disorder of elastic tissue. It is characterized by patches and plaques of diffuse, fine, wrinkled skin, most often located on the trunk, neck, and arms. In 1977, Shelley and Wood reported the first case of "wrinkles due to idiopathic loss of middermal elastic tissue."[14] Since then, fewer than 100 cases have been reported. The vast majority of patients are Caucasian women between the ages of 30 and 50 years.[15,16]

PATHOGENESIS. The pathogenesis of this acquired elastic tissue degeneration is still unknown. Ultraviolet (UV) exposure has been postulated to be a major contributing factor in the degeneration of elastic fibers,[17] including narrowband UVB.[18] Other possible mechanisms include defects in the synthesis of elastic fibers, autoimmunity against elastic fibers, and damage to elastic fibers through the release of elastase by inflammatory cells or fibroblasts. More recent data suggest that inflammatory processes and an altered balance between matrix metalloproteinase and tissue inhibitor of metalloproteinases are possibly involved in the pathogenesis of MDE.[19]

CLINICAL FEATURES. MDE is characterized by asymptomatic, well-demarcated, or diffuse areas of fine wrinkling (Fig. 67-3A). Rarely, erythematous patches, telangiectasias, or a reticular variant can be seen. Discrete perifollicular papules can be seen in some cases, leaving the hair follicle itself as an indented center. Lesions are typically found on the trunk, neck, and upper extremities. They are chronic and give the skin a prematurely aged appearance. There is usually no history of a preceding inflammatory dermatosis, but some patients report mild-to-moderate erythema. There is no associated systemic involvement.

HISTOPATHOLOGY. The pathology shows a normal epidermis and, occasionally, a mild perivascular infiltrate in the dermis. The characteristic histology is seen on elastic tissue stains and reveals a selective band-like loss of elastic fibers in the middermis (see Fig. 67-3B). There is preservation of normal elastic tissue in the superficial papillary dermis above, in the reticular dermis below, and along adjacent hair follicles. Electron microscopy studies have shown phagocytosis of normal as well as degenerated elastic fiber tissue by macrophages.[20]

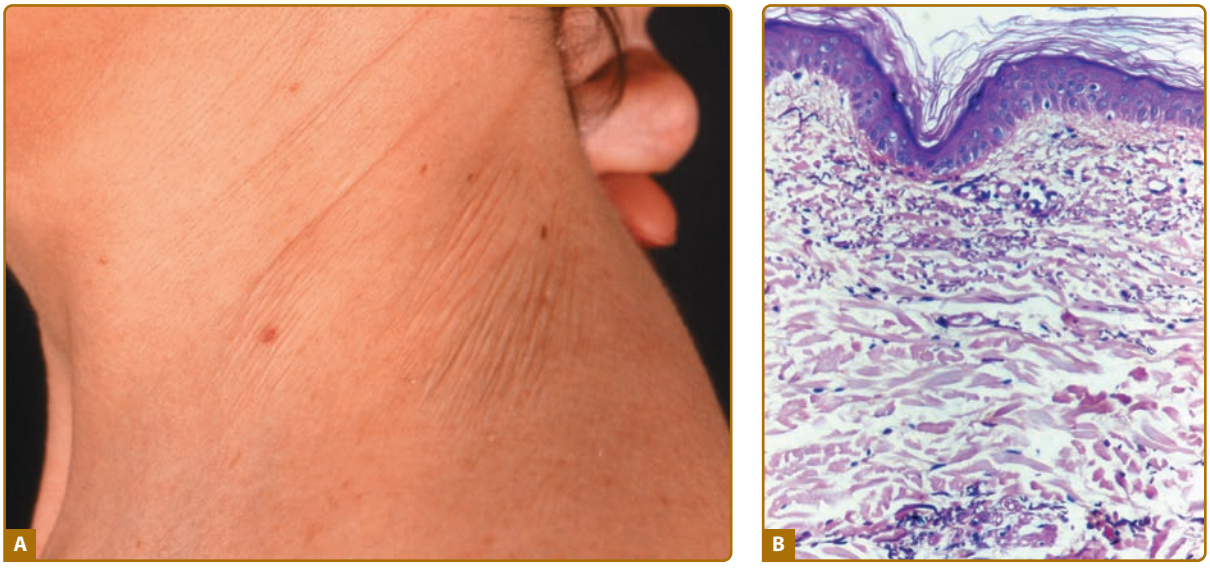

Figure 67-3 Middermal elastolysis. **A.** Well-circumscribed area of fine wrinkling on the neck of a middle-aged woman. (Used with permission from Richard Dubuc, MD.) **B.** Histology of middermal elastolysis. Note selective loss of elastic fibers in the middermis. Normal elastic tissue is preserved in the superficial papillary dermis and in the reticular dermis (Weigert's stain). (Used with permission from Danielle Bouffard, MD.)

DIFFERENTIAL DIAGNOSIS. MDE must be differentiated from the other common disorders of elastic tissue.

Solar elastosis differs by its onset in an older age group, location in only sun-exposed areas, yellowish color, and coarser wrinkling, as well as by hyperplasia and abnormalities of elastic fibers and basophilic degeneration of the collagen in the papillary dermis.

Anetoderma is characterized clinically by smaller soft macules and papules instead of diffuse wrinkling, and histologically by elastolysis that can occur in any layer of the dermis.

Perifollicular elastolysis differs by a selective and almost complete loss of elastic fibers surrounding hair follicles compared with preservation of elastic fibers around follicles in MDE. Elastase-producing *Staphylococcus epidermidis* was found in the hair follicles and is the presumed etiology of this condition.[21]

Postinflammatory elastolysis and cutis laxa were originally described in young girls of African descent. An inflammatory phase, consisting of indurated plaques or urticaria, malaise, and fever, preceded the diffuse wrinkling, atrophy, and severe disfigurement. Insect bites may be the trigger for the initial inflammatory lesions.[22]

TREATMENT

There is no known effective treatment for MDE. Sunscreens, colchicine, and topical retinoic acid have been tried without good success.[15,16]

STRIAE

(See Chapters 108 and 151)

Striae are very common and usually develop between the ages of 5 and 50 years.

They occur about twice as frequently in women as in men. They commonly develop during puberty, with an overall incidence of 25%–35%,[23,24] or during pregnancy, with an incidence of 77%.[25]

The factors leading to the development of striae have not been fully elucidated. Striae distensae are the results of breaks in the connective tissue, resulting in dermal atrophy. Many factors, including hormones (particularly corticosteroids), mechanical stress, and genetic predisposition, appear to play a role.

During puberty, striae appear in areas where there is a rapid increase in size. In girls, the most common sites are the breasts, thighs, hips, and buttocks, whereas in boys, they are seen on the shoulders, lumbosacral region, and thighs. Other less common sites include the abdomen, upper arms, neck, and axillae.

Striae distensae are a common finding on the abdomen, and less so on the breasts and thighs, of pregnant women, especially during the last trimester. They are more common in younger primigravidas than in older pregnant women and are associated with larger weight gain and with babies of higher birth weight. Striae gravidarum can be associated with a higher risk of lacerations during vaginal delivery.[26]

CLINICAL FINDINGS. Striae are usually multiple, symmetric, well-defined linear atrophic lesions that follow the lines of cleavage. Initially, striae appear as red-to-violaceous elevated lines (striae rubra) (see Fig. 107-3). Over time, the color gradually fades, and the lesions become atrophic, with the skin surface exhibiting a fine, white, wrinkled appearance (striae alba).[24] The striae can measure several centimeters in length and a few millimeters to a few centimeters in width. The striae associated with systemic corticosteroid therapy and Cushing syndrome can be larger and more widely distributed.

HISTOPATHOLOGY. Histologic findings show a decrease in dermal thickness and in collagen in the upper dermis. The collagen bundles are thinned and lie parallel to the epidermis, but they are also arranged transversely to the direction of the striae. Alterations in elastic fibers are variable, but dermal elastin can be fragmented, and specific elastin staining can demonstrate a marked reduction in visible elastin content compared with adjacent normal dermis.[27] There is absence of both hair follicles and other appendages.

DIFFERENTIAL DIAGNOSIS. The diagnosis of striae distensae is usually simple, but the differential diagnosis does include linear focal elastosis (elastotic striae) that was first described by Burket et al in 1989.[28] Linear focal elastosis is characterized by rows of yellow palpable striae-like bands on the lower back. Unlike striae, the lesions are raised and yellow rather than depressed and white. Elderly men are most commonly affected, although cases in teenagers have been described. Linear focal elastosis is probably not an uncommon condition. Histologically, there is a focal increase in the number of elongated or fragmented elastic fibers and a thickened dermis. It is postulated that linear focal elastosis may represent an excessive regenerative process of elastic fibers and could be thought of as a keloidal repair of striae distensae.[29]

TREATMENT. Striae distensae have no medical consequences, but they are frequently distressing to those affected. As stretch marks tend to regress spontaneously to some degree over time, the usefulness of treatments that have been tried without case controls is difficult to assess. Topical treatments that have shown some improvement of early stage striae are: tretinoin 0.1% cream,[30] a combination of 0.05% tretinoin/20% glycolic acid, or 10% L-ascorbic acid/20% glycolic acid.[31] Several lasers have been used in treating striae: the 585-nm pulsed-dye laser has been demonstrated to be of some efficacy in improving the appearance of striae rubra but has no effect on stria alba[32]; improvement in the leukoderma of the striae alba was noted with 308-nm excimer laser but maintenance treatment is required to sustain the cosmetic benefit.[33] The long-term future of treatment strategies is encouraging with the advance in laser technologies.

IDIOPATHIC ATROPHODERMA OF PASINI AND PIERINI

EPIDEMIOLOGY AND PATHOGENESIS. Idiopathic atrophoderma of Pasini and Pierini is a form of dermal atrophy that presents as one or several sharply demarcated depressed patches with no outpouching, usually on the back of adolescents or young adults.[34] Whether atrophoderma is a nonsclerotic, primarily atrophic variant of morphea or a separate distinct entity is still debated.[35–39] Its relationship to morphea is favored by its striking clinical and histologic similarities to the atrophy seen at sites of regressing plaques of morphea. Antibodies to *Borrelia burgdorferi* have been reported.[37] Typical lesions of morphea, lichen sclerosus, and atrophoderma have been observed to occur simultaneously in the same patient but in different areas, supporting the view that these conditions are related. In a series of 139 patients, 17% had white induration in the central portions of their atrophic lesions, and 22% had superficial plaques of morphea coexisting in areas outside of their atrophic foci.[35] However, to some, the different course and outcome of atrophoderma of Pierini and Pasini as compared with morphea justifies preservation of a distinct name.

This disorder is more frequently encountered in women than in men, with a ratio of 6:1. It usually starts insidiously in young individuals in the second or third decades of life. A congenital case was recently reported.[40] The lesions usually occur on the trunk, especially on the back and lumbosacral region, followed in frequency by the chest, arms, and abdomen.[37] The distribution is often symmetric and bilateral.

The lesions are single or multiple and usually round or ovoid, ranging in size from a few centimeters to patches covering large areas of the trunk (Fig. 67-4). They are usually asymptomatic and lack inflammation. When lesions coalesce, they can form large, irregular, brown patches but can be hypopigmented.[41] The surface of the skin is normal in appearance, and there is no skin induration or sclerosis.



Figure 67-4 Atrophoderma of Pasini and Pierini. Brownish depressed lesions on the lower back.

The borders or edges of these lesions are sharply defined, and they are usually described as abrupt, "cliff drop" borders ranging from 1 to 8 mm in depth, although they can have a gradual slant.[34] These depressed patches are characteristic and give the impression of inverted plateaus, or, if multiple lesions are present, they can have the appearance of Swiss cheese. They are even more apparent when present on the back because the dermis is thicker in this area. The skin surrounding the patches is normal in appearance, and there is no erythema or lilac ring as in morphea.

COURSE. The course of this benign disease is progressive, and lesions can continue to appear for decades before reaching a standstill. Transformation to generalized morphea has not been observed.

HISTOPATHOLOGY. The histologic picture is generally not diagnostic. The epidermis is usually normal or slightly atrophic. Collagen bundles in the mid- and reticular dermis show varying degrees of homogenization and clumping. Dermal thickness is eventually reduced when compared with adjacent normal skin.[38] Some irregular clumping and loss of elastic fibers were described in earlier case reports,[34] but in most series, no abnormality was seen with elastic tissue stains[35,37]; therefore, this is not of diagnostic value. The appendages are usually preserved. If sclerodermatous changes appear in preexisting patches, the histology reveals varying degrees of collagen sclerosis resembling morphea.

DIFFERENTIAL DIAGNOSIS. The differential diagnosis is to be made with active lesions of morphea that usually present as indurated, often hyperpigmented plaques with a characteristic peripheral lilac rim.

THERAPY. No treatment has been proved effective. Dramatic response to oral hydroxychloroquine was recently reported in one patient.[42]

FOLLICULAR ATROPHODERMA

Follicular atrophoderma refers to dimple-like depressions at the follicular orifices. It can occur as an isolated defect of limited extent, in association with a variety of disorders in which hair follicles are plugged with keratin, or with rare genodermatoses.[43,44]

Distinctive ice-pick depressions around hair follicles can be seen most commonly on the back of the hands or feet and on the cheeks. These pitted scars can present at birth or early in life. A family history may be present. Follicular atrophoderma occurs in the conditions described in the following sections.

ATROPHODERMA VERMICULATUM. Atrophoderma vermiculatum is a term that applies when the lesions are found exclusively on the cheeks. It is a



Figure 67-5 Atrophoderma vermiculatum. Multiple, small, pitted scars on the cheek of a young girl.



Figure 67-6 Ulerythema ophryogenes. Erythematous follicular papules and scarring alopecia of the eyebrow.

condition that can either occur sporadically, be inherited as an autosomal dominant disorder, be part of a group of related diseases including keratosis pilaris atrophicans, or be associated with various syndromes.

Multiple inflammatory symmetric papules on the cheeks, presumably centered around hair follicles, may precede the atrophic lesions. These papules then go on to develop pitted, atrophic, and depressed scars in a reticulated or honeycomb pattern (Fig. 67-5). These lesions can extend to the forehead and preauricular regions. This condition usually has its onset in childhood or, less often, around puberty. Men and women seem to be affected equally.[45] It usually has a slow progressive course.

Keratosis Pilaris Atrophicans. Keratosis pilaris atrophicans[46] can include atrophoderma vermiculatum but also a group of closely related disorders that includes keratosis follicularis spinulosa decalvans and ulerythema ophryogenes. These conditions are characterized by keratotic follicular papules, variable degrees of inflammation, and secondary atrophic scarring. Keratosis follicularis spinulosa decalvans begins in infancy with keratotic follicular papules over the malar area and progresses to involve the eyebrows, scalp, and extremities, with scarring alopecia. This condition is inherited in an X-linked recessive fashion in some patients. Ulerythema ophryogenes (or keratosis pilaris atrophicans faciei) differs from atrophoderma vermiculatum by affecting primarily the lateral portion of the eyebrows (ophryogenes) with erythema, follicular papules, and alopecia (Fig. 67-6).

The underlying pathologic defect in these disorders appears to be abnormal follicular hyperkeratinization of the upper third of the hair shaft leading to obstruction of the growing hair and production of chronic inflammation. The end result of this process is scarring below that level. Histopathology is usually not very helpful and shows dilated follicles, sometimes associated with plugging, inflammation, and sclerosis of dermal collagen.

Associated Syndromes. The various syndromes that include atrophoderma vermiculatum are the Rombo syndrome (milia, telangiectasias, basal cell carcinomas, hypotrichosis, acral cyanosis, and, rarely, trichoepitheliomas), Nicolau–Balus syndrome (syringomas and milia), Tuzun syndrome (scrotal tongue), and finally the Braun–Falco–Marghescu syndrome (palmoplantar hyperkeratosis and keratosis pilaris).

Therapy. These disorders are mainly a cosmetic but vexing problem. Various topical treatments, including emollients, corticosteroids, tretinoin, and keratolytics, have shown no consistent benefit. Systemic isotretinoin has been shown to stop progression and to induce remission in some cases.[46] Dermabrasion as well as carbon dioxide and 585-nm pulsed-dye lasers are other options to improve the appearance of the atrophic scars.[47]

BAZEX–DUPRÉ–CHRISTOL SYNDROME (OMIM #301845).

Bazex–Dupré–Christol syndrome is characterized by follicular atrophoderma, milia, multiple basal cell carcinomas, hypotrichosis, and localized hypohidrosis.[48–50] The follicular atrophoderma described as multiple ice-pick marks or patulous follicles can be found most commonly on the dorsa of the hands. It is inherited in an X-linked dominant fashion, and the gene has been linked to Xq24–q27.[48] Subsequently reported findings include facial hyperpigmentation, hair shaft dystrophy, and multiple genital trichoepitheliomas.

CONRADI–HÜNERMANN–HAPPLE SYNDROME (X-LINKED DOMINANT CHONDRODYSPLASIA PUNCTATA, CDPX2, OMIM #302960)).

Conradi–Hünermann syndrome is an X-linked dominant disorder that occurs only in girls

because it is usually lethal in hemizygous males. The underlying molecular defect consists of mutations in the emopamil-binding protein gene at Xp11.23-p11.22.[50] The clinical manifestations include an ichthyosiform scaling erythroderma patterned along the lines of Blaschko that usually resolves during the first year of life and is replaced by bands of follicular atrophoderma.[43] Hyperpigmentation, cataracts, scarring alopecia, saddle-nose deformity, asymmetric limb reduction defects, and stippled calcifications of the epiphyses can be seen. Ichthyosis with keratotic follicular plugs containing dystrophic calcification in newborns are distinctive histopathologic features.[51]

OTHER ATROPHIES OF THE CONNECTIVE TISSUE

Many systemic conditions [scleroderma (see Chapter 157), lupus erythematosus (see Chapter 155), dermatomyositis (see Chapter 156)], and genodermatoses (poikiloderma congenitale, dyskeratosis congenita, Cockayne syndrome, Hallermann–Streiff syndrome) have skin atrophy as an associated finding and are described in other chapters.

KEY REFERENCES

Full reference list available at www.DIGM8.com

DVD contains references and additional content

4. Venencie PY, Winkelmann RK, Moore BA: Anetoderma: Clinical findings, associations, and long-term follow-up evaluations. *Arch Dermatol* **120**:1032, 1984
7. Thomas JE et al: Familial anetoderma. *Int J Dermatol* **42**:75, 2003
9. Venecie PY, Winkelmann RK: Histopathologic findings in anetoderma. *Arch Dermatol* **120**:1040, 1984
16. Gambichler T: Mid-dermal elastolysis revisited. *Arch Dermatol Res* **302**:85-93, 2010.
24. Ammar NM et al: Adolescent striae. *Cutis* **65**:69, 2000
35. Kencka D, Blaszczyk M, Jablonska S: Atrophoderma Pasini–Pierini is a primary atrophic abortive morphea. *Dermatology* **190**:203, 1995
41. Saleh Z et al: Atrophoderma of Pierini and Pasisni: A clinical and histopathological study. *J Cutan Pathol* **35**: 1108-1114, 2008
45. Frosch P et al: Atrophoderma vermiculatum: Case reports and review. *J Am Acad Dermatol* **18**:538, 1988
46. Callaway SR, Lesher JL: Keratosis pilaris atrophicans: Case series and review. *Pediatr Dermatol* **21**:14, 2004
48. Vabres P et al: The gene for Bazex–Dupré–Christol syndrome maps to chromosome Xq. *J Invest Dermatol* **105**:87, 1995
49. Torrelo A et al: What syndrome is this? Basex-Dupré-Christol syndrome. *Pediatr Dermatol* **23**:286-290, 2006

Chapter 68 :: Ainhum and Pseudoainhum

:: Robert T. Brodell & Stephen E. Helms

AINHUM AND PSEUDOAINHUM ARE SYNDROMES RELATED TO EXTERNAL CONSTRICTING BANDS

- Constricting bands are classified as ainhum and pseudoainhum.
- Ainhum is defined by a constricting band around a digit and is most common in tropic and subtropic latitudes occurring around the fifth toe or toes of people accustomed to walking barefoot.
- Pseudoainhum constrictions clinically mimic ainhum and are much more common in the developed world. It may be caused by (1) amniotic bands; (2) constrictions associated with keratotic disorders or those associated with infections or trauma; and (3) constriction by external forces such as hairs and threads.
- Autoamputation can result from ainhum and pseudoainhum.
- Treatment can simply be the removal of foreign strands wrapped around a digit or limb or surgical intervention in more advanced cases (Z-plasty or amputation).

AINHUM AND PSEUDOAINHUM

Constricting bands are classified as ainhum and pseudoainhum. *Ainhum* describes the development of constricting bands around toes in underdeveloped countries of Africa and may ultimately result in autoamputation. In the African Yorub language, ainhum means "to saw" or "file" and in the Brazilian patois, it means "fissure." In the remainder of the world, constricting bands that mimic ainhum are termed *pseudoainhum*.

EPIDEMIOLOGY

Ainhum (dactylolysis spontanea) is traditionally a disease of middle-aged African males accustomed to going barefoot.[1] In the tropic and subtropic climates, its incidence has been reported as between 0.015% and 2% of the population.[2] This same condition is rarely seen throughout the rest of the world. Occasional isolated cases were reported in the United Kingdom and North America.[1,3] Pseudoainhum of all types is very rare.

ETIOLOGY AND PATHOGENESIS

The pathogenesis of ainhum has not been clearly elucidated. Chronic trauma, infection, hyperkeratosis,

decreased vascular supply, and impaired sensation may produce excessive fibroplasia in a susceptible host.[4] Dent et al described impaired blood supply to the foot proximal to the groove at the plantar digital junction. Poor perfusion was the result of attenuation of the posterior tibial artery and absence of the plantar arterial arch leading to abnormal healing following mechanical trauma. Ainhum has also been blamed on rotational stress applied to the bare, mechanically unstable foot.[5]

There are three pathophysiological categories of pseudoainhum: (1) congenital constricting bands are caused by the umbilical cord; (2) constriction by external forces, such as hairs or threads, which are generally factitial; and (3) constricting bands secondary to other diseases. These may be hereditary or nonhereditary. Hereditary causes include pachyonychia congenita, Mal de Meleda, mutilating keratoderma,[6] lamellar ichthyosis,[7] and psoriasis.[8–10] Nonhereditary diseases include vascular anomalies as seen in Raynaud disease, diabetes mellitus, linear scleroderma, systemic sclerosis. Sensory changes associated with leprosy, tertiary syphilis, syringomyelia, and spinal cord tumors as well as trauma resulting in scar formation from burns, frostbite, and physical trauma can also cause constricting bands to form. When associated with chronic trauma and infection of the extremities, the pathophysiology may be identical to true ainhum.

CLINICAL FINDINGS

Ainhum usually affects the fifth toe; it may be unilateral, but 75% of the cases are bilateral. One or more digits can be involved. All toes can be involved, even the great toe.[11] In early lesions, a groove or sulcus appears at the plantar junction of the toe and the sole. As this sulcus deepens, edema develops distally and roentgenographic examination shows resorption of the underlying bone and ultimately autoamputation.[12]

Congenital constricting bands (Streeter bands) usually involve more than one part of the body (Fig. 68-1) and frequently encircle large structures such as limbs or even the trunk. They persist throughout life and interfere with normal growth of the involved segment unless surgically treated[13] (Fig. 68-2). Autoamputation can occur. More than 50% of cases are associated with other congenital anomalies usually syndactyly or clubfoot when constricting bands are found on the feet.[14]

Factitious pseudoainhum may prove to be a most challenging diagnosis. Strands of hair, fibers, or threads are intentionally wrapped around digits or other body parts such as a nipple or penis. This phenomenon is most commonly encountered in children, but can occur in mentally ill adults.[15] Because of soft-tissue swelling, the ligating band may not be visible and the true cause of the condition may not be immediately recognized.[15]

Acquired constricting bands are associated with a variety of medical and dermatological conditions. In general, pseudoainhum is more likely to involve any

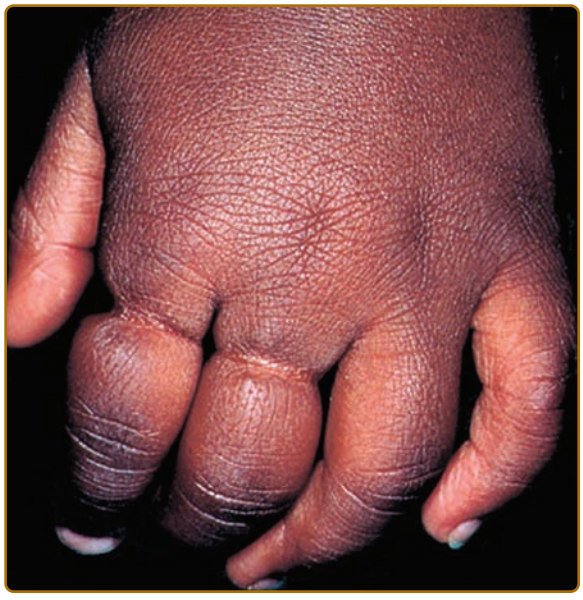

Figure 68-1 Congenital constricting bands about two digits. No etiology was identified.

of the toes or even the hands (Fig. 68-3; eFig. 68-3.1 in online edition). In children, when chronic dermatophyte infection is identified and appropriately treated, complete reversal of the constriction may occur. Severe hyperkeratosis as occurs with Vohwinkel syndrome (keratoderma hereditarium mutilans)[6,16] may show constricting bands due to palmar and plantar hyperkeratoses as well as starfish-like and linear keratoses.



Figure 68-2 Pseudoainhum (congenital constricting band) of the leg in an infant. (Used with permission from Ilona Frieden, MD.)



Figure 68-3 Pseudoainhum of hand with autoamputation due to amniotic bands. (Used with permission from Ilona Frieden, MD.)

The pathology of ainhum and pseudoainhum are similar with fibrotic bands resembling scar tissue.[4,12] The bands in ainhum usually extend deep into the subcutaneous layers and may impinge upon underlying skeletal and vascular structures. Additionally, moderate inflammation and epidermal or verrucous hyperplasia may be present. In pseudoainhum the bands tend to be more superficial. Also, in pseudoainhum there may be histologic clues to the associated disorder, such as dermatophytosis, foreign bodies, or distinct patterns of keratinization.

COMPLICATIONS

The constricting bands of both ainhum and pseudoainhum ultimately produce a dangling, twisted digit, which can become gangrenous or infected. When this tenuous connection produces necrosis, autoamputation occurs.

PROGNOSIS AND CLINICAL COURSE

Diseases caused by constricting bands proceed slowly and often painfully over many years eventuating in autoamputation in severe cases.

TREATMENT

Surgery is the mainstay of therapy and early intervention is important. In most cases of ainhum, prompt amputation may allow the patient to escape pain and infection. Early cases of ainhum or pseudoainhum may respond to conservative plastic repair with a Z-plasty or similar relaxing closure by avoiding further disease progression and damage to underlying structures.[12]

Impending amputation i n Vohwinkel syndrome can sometimes be aborted by therapy with oral etretinate.[16] When chronic fungal or bacterial infections or psoriasis are diagnosed in the early phase of band formation, treatment may reverse the threat to the digit (eFig. 68-3.2 in online edition). Other predisposing causes of underlying diseases should be treated aggressively in the hope of forestalling progression. For example, a case of infantile psoriasis with pseudoainhum was successfully treated with narrowband UVB phototherapy and pimecrolimus.[17]

PREVENTION

Ainhum is rarely seen in people who are protected by wearing shoes. Congenital pseudoainhum cannot be prevented. Psychological counseling may prevent recurrences of pseudoainhum in patients with factitial disease. Control of the underlying disease process may delay progression or prevent recurrence in pseudoainhum of the acquired type.

KEY REFERENCES

Full reference list available at www.DIGM8.com

DVD contains references and additional content

1. Cole GJ: Ainhum: An account of fifty-four patients with special reference to etiology and treatment. *J Bone Joint Surg Br* **47**:43, 1965
2. Carvalho N et al: Ainhum (Dactylolysis Spontanea): A case report. *Foot Ankle* **6**:189-192, 2000
4. Kerhisnik W: The surgical pathology of ainhum (dactylolysis spontanea). *J Foot Surg* **25**:95, 1986
5. Dent DM et al: Ainhum and angiodysplasia. *Lancet* **2**:396, 1981
9. Almond SL et al: Case Report: Pseudoainhum in chronic psoriasis. *Br J Dermatol* **149**:1064-1066, 2003
12. Pickus EJ et al: Digital constriction bands in pseudoainhum: Morphological, radiographic, and histological analysis. *Ann Plast Surg* **47**:194, 2001

Chapter 69 :: Acquired Perforating Disorders

:: Julia S. Minocha & Bethanee J. Schlosser

ACQUIRED PERFORATING DISORDERS AT A GLANCE

- Acquired perforating disorders represent a group of separately identified cutaneous disorders that occur most often in the setting of chronic renal disease or diabetes mellitus.
- The previously recognized Kyrle's disease (KD), acquired elastosis perforans serpiginosa (AEPS), acquired reactive perforating collagenosis (ARPC), and perforating folliculitis (PF) are now classified under the umbrella term of acquired perforating dermatosis.
- Lesions present as umbilicated papules and/or nodules with a central keratotic plug or crust distributed preferentially on extensor surfaces of the extremities.
- Histopathological examination of lesional skin demonstrates invagination of the epidermis with extrusion of dermal material (collagen, elastin, and/or fibrin) through the cup-shaped epidermal depression.
- Treatment is challenging with no universally effective therapy, and patients often exhibit a chronic course.

INTRODUCTION

Acquired perforating disorders represent a group of separately identified cutaneous disorders that occur in adult patients, most often in the setting of chronic kidney disease (CKD) or diabetes mellitus (DM).[1] Kyrle's disease (KD), acquired elastosis perforans serpiginosa (AEPS), acquired reactive perforating collagenosis (ARPC), and perforating folliculitis (PF) were previously considered distinct disorders.[2–5] Given their shared clinical and histopathological characteristics, these four disorders are now classified under the umbrella term of acquired perforating dermatosis (APD).[1] APD is characterized clinically by the presence of umbilicated papules and/or nodules with a central keratotic plug or crust and histologically by the transepidermal extrusion of dermal components (collagen, elastin, and/or fibrin).[6] Although some cases may exhibit clinical and histological characteristics that typify one of the four classically recognized disorders, use of the comprehensive term APD is encouraged.

EPIDEMIOLOGY

Kyrle, in 1916, first described KD in a young diabetic woman and termed it hyperkeratosis follicularis et parafollicularis in cutem penetrans.[5] In 1953, Lutz published the initial description of elastosis perforans serpiginosa (EPS) as keratosis follicularis serpiginosa.[7] The first case of AEPS associated with CKD was identified in 1986 by Schamroth, Kellen, and Grieve.[2] Mehregan, Schwartz, and Livingood reported the earliest description of reactive perforating collagenosis (RPC) in 1967, and the first case associated with DM was recognized by Poliak et al in 1982.[3,8] PF was originally described by Mehregan and Coskey in 1968.[4] In 1989, Rapini, Heber, and Drucker recognized the common clinical and histopathologic characteristics of these disorders and introduced the term acquired perforating dermatosis.[1] Various terminology has been used in the literature to refer to APD (Table 69-1).

APD occurs worldwide without gender predilection.[17] The most common systemic diseases associated with APD are CKD and DM. APD has been documented in 4.5%–10% of hemodialysis patients in North America and in 11% of a dialysis population (both hemodialysis and peritoneal dialysis) in Great Britain.[17,18] APD has also occurred in patients with CKD who are not undergoing dialysis as well as those who have received renal transplants. The most common cause of CKD among APD patients is diabetic nephropathy.[18] Table 69-2 lists less commonly reported associated conditions. APD has rarely been associated with the use of certain therapeutics, including tumor necrosis factor-α inhibitors, indinavir, and sorafenib.[44–46] A predominance of blacks among hemodialysis patients with APD has been reported in one study, but not confirmed in others.[11] AEPS is well recognized as a potential adverse effect of prolonged D-penicillamine therapy.[47] AEPS has also been reported in patients with CKD in the absence of penicillamine exposure or other associations.[2]

ETIOLOGY AND PATHOGENESIS

The precise etiology and pathogenesis of APD are unknown. APD pathology likely involves a complex interaction between the epithelium, connective tissue, and inflammatory mediators. Superficial trauma to the epidermis may be the primary inciting factor in susceptible patients.[8] Predisposing conditions include vasculopathy/angiopathy (related to DM), microdeposition of exogenous materials within the dermis (including calcium salts and silicon, pertinent to the increased frequency of APD in dialysis patients), and epidermal or dermal change related to metabolic derangements including vitamin A deficiency.[13,18,43,48,49]

TABLE 69-1
Synonyms for Acquired Perforating Dermatosis

Acquired reactive perforating collagenosis[9]
Hyperkeratosis follicularis et parafollicularis in cutem penetrans[5]
Hyperkeratosis penetrans[10]
Keratosis follicularis serpiginosa[7]
Kyrle's disease[11]
Kyrle-like lesions[12]
Perforating disorder[13]
Perforating folliculitis[8]
Perforating folliculitis of hemodialysis[14]
Reactive perforating collagenosis of diabetes mellitus (DM) and renal failure[15]
Uremic follicular hyperkeratosis[16]

Given APD's common association with CKD, scratching due to chronic pruritus has been thought to lead to microtrauma and subsequent transepidermal elimination of dermal components. Koebnerization, predominant localization to trauma-prone areas, and resolution of APD lesions with discontinuation of manipulation/trauma support this mechanism.[6] Diabetic vasculopathy has been proposed as an additional predisposing factor for APD in DM patients by creating a relatively hypoxic environment in which trauma from scratching causes dermal necrosis. The finding of PAS-positive thickening of vessel walls in the upper dermis of diabetic patients with APD[48,50] supports this hypothesis, but has not been noted in all studies.[6,51] Imbalances in fibronectin, transforming growth factor-β3 (TGF-β3), and matrix metalloproteinases in APD lesions have also been demonstrated; these molecules are essential to normal epithelial differentiation and wound healing, and their aberration may predispose to the development of APD lesions.[48,51,52] In AEPS, it is hypothesized that penicillamine alters dermal elastic fibers in affected patients.[53] Elastic fiber abnormalities, including "bramble bush-appearing" fibers of variable thickness and increased numbers of fibers in the papillary and reticular dermis, have been described in patients with penicillamine-induced AEPS.[54]

TABLE 69-2
Conditions Associated with Acquired Perforating Dermatosis

Common Associations
Chronic kidney disease
Diabetes mellitus (insulin-dependent and noninsulin-dependent)
Scabies[19,20]

Rare Associations
Acquired immunodeficiency syndrome (AIDS)[21,22]
Arthropod bites[23,24]
Atopic dermatitis[25]
Cutaneous cytomegalovirus infection[26]
Hyperparathyroidism[9]
Liver diseases (hepatitis C, hepatitis B, steatohepatitis, primary biliary cirrhosis)[6,27]
Lupus vulgaris[28]
Myelodysplastic syndrome[29]
Malignancy (Hodgkin lymphoma, mixed histiocytic–lymphocytic lymphoma, hepatocellular carcinoma, pancreatic carcinoma, prostate carcinoma, papillary thyroid carcinoma)[30–37]
Mikulicz's disease[38]
Neurodermatitis[9]
Poland syndrome[39]
Primary sclerosing cholangitis[40]
Pulmonary aspergillosis[41]
Pulmonary fibrosis[25]
Salt water application[13]
Thyroid disease (hypothyroidism, sick euthyroid syndrome, Hashimoto thyroiditis)[9,27,42]
Vitamin A deficiency[43]

CLINICAL FINDINGS

HISTORY

Most patients report lesional pruritus, ranging from mild-to-severe and intractable, of skin lesions. Lesions may also be painful.[6]

CUTANEOUS LESIONS

APD characteristically manifests as round, umbilicated, skin-colored, erythematous or hyperpigmented papules and nodules with a central crust or keratotic plug, predominantly involving the extensor surfaces of the extremities and the trunk (Fig. 69-1). Lesions less commonly involve the face or scalp. In rare cases, purple annular plaques or pustules mixed with papules have been observed. Some lesions may be follicular (PF) (Fig. 69-2). AEPS lesions exhibit papules in a serpiginous configuration, often with central atrophy, and typically occurring on the neck, trunk, and extremities (Fig. 69-3). Scratching can lead to koebnerization with linear umbilicated papules arising in excoriated skin.



Figure 69-1 Acquired perforating dermatosis. Multiple, round, hyperpigmented papules, each with a central keratotic plug, distributed on the extensor aspects of the hand and wrist in a patient with chronic kidney disease.



Figure 69-2 Perforating folliculitis. Multiple follicular, erythematous, firm papules with variable central crusting.

RELATED PHYSICAL FINDINGS

Although most common in patients receiving hemodialysis, especially for diabetic nephropathy,[18] APD has also been seen in CKD patients without hemodialysis or who have undergone renal transplantation. Table 69-2 lists medical conditions that are less often associated with APD.

HISTOPATHOLOGY

The diagnosis of APD is based on clinical and histopathologic findings. Folliculitis and prurigo nodularis may occur concomitantly, especially in patients with CKD; multiple biopsies should be taken if lesions show different clinical morphologies. APD is characterized histologically by transepidermal elimination of dermal material through an epidermal invagination, which may be follicular or perifollicular. Lesions typically demonstrate a central keratotic plug with crusting or hyperkeratosis; parakeratosis is variable. Within the dermis surrounding the perforation, there is often a focal inflammatory infiltrate with neutrophils predominating in early lesions and lymphocytes, macrophages, or multinucleated giant cells present in older lesions.



Figure 69-3 Acquired elastosis perforans serpiginosa in a patient taking penicillamine for Wilson's disease. Annular plaque with variably crusted erythematous papules at the periphery and central cribriform scarring.

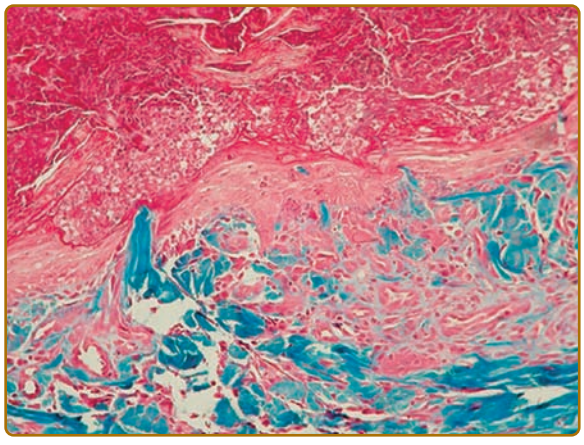

Figure 69-4 Reactive perforating collagenosis. Collagen bundles can be seen crossing from the reticular dermis through the epidermis into an epidermal depression containing necrotic debris. (Hematoxylin and eosin stain.)

The four initially identified acquired perforating disorders [(1) RPC, (2) AEPS, (3) KD, and (4) PF] were classically differentiated histopathologically on the basis of the nature of the eliminated dermal material. In RPC, collagen bundles are detected within the plug (Fig. 69-4); in AEPS, elastic fibers are instead noted (Fig. 69-5). In KD, amorphous dermal material and/or keratin comprise the extruded material. PF is characterized by perforation of the follicular epithelium by degenerating collagen and extracellular matrix (Fig. 69-6). Clear identification of the eliminated material may be impossible and, in addition, multiple substances (i.e., collagen and elastic fibers) may be simultaneously detected, reinforcing the clinical and histopathologic overlap within APD.

LABORATORY TESTS

Laboratory evaluation for comorbidities should include fasting blood glucose, glucose tolerance test, serum creatinine, glomerular filtration rate or creatinine clearance, serum uric acid, liver function tests, and thyroid function tests. A comprehensive past medical history and review of systems should be obtained. Additional diagnostic testing for associated conditions (Table 69-2) should be performed as indicated.

DIFFERENTIAL DIAGNOSIS

(Box 69-1)

The differential diagnosis of APD is broad and includes both infectious and inflammatory disorders, including those that koebnerize (Box 69-1). APD can be especially difficult to differentiate from prurigo nodularis. Perforating pseudoxanthoma elasticum should be distinguished from AEPS.

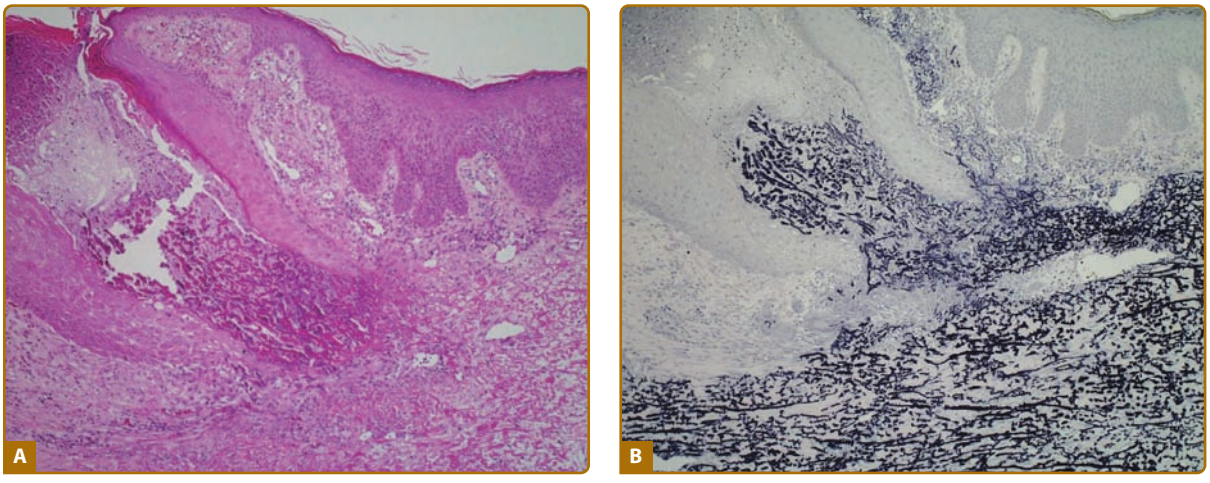

Figure 69-5 Acquired elastosis perforans serpiginosa. **A.** Dilated follicular structure with transepidermal elimination of densely eosinophilic elongated bundles. (Hematoxylin and eosin stain.) **B.** Transepidermally eliminated elongated bundles are elastin fibers (elastin stain).

COMPLICATIONS

Most complications that occur in patients with APD arise from underlying systemic illnesses. However, patients should be monitored for secondary infection (bacterial, fungal, and viral) as well as parasitic infestation. In an attempt to relieve the associated pruritus, patients may apply products to their skin that may result in irritant or allergic contact dermatitis. In darker skinned patients with more excoriations, postinflammatory pigmentary alteration and scarring can be significant.

PROGNOSIS

The prognosis of APD is heavily linked to the presence of underlying diseases. Some studies have shown that APD may improve with successful treatment of the underlying illness.[25] Most cases of APD continue for years unless treated.

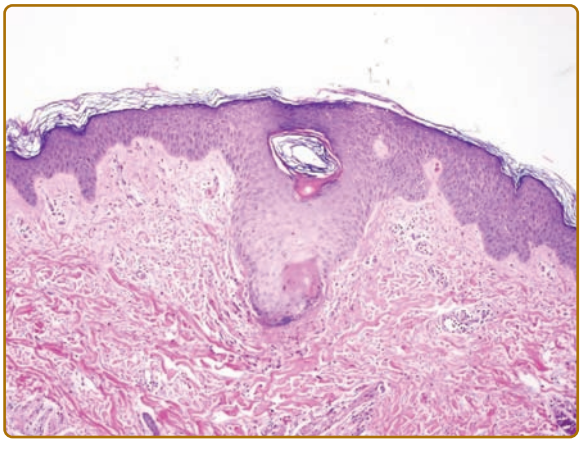

Figure 69-6 Perforating folliculitis. Dilated follicular unit exhibits necrosis and disruption of the epithelium.

TREATMENT

Treatment of APD is difficult. Table 69-3 details the therapeutic options that have been described in the literature to date. There have not been any well-designed clinical trials of APD, and current treatment strategies are based largely on anecdotal reports. In patients with CKD, improvement in APD lesions has been reported after changing the type of dialysis tubing or modification of the dialysis procedure.[18] In a few cases, APD has resolved following renal transplantation.[17,14,80] The most commonly employed treatments for APD include topical and oral retinoids, topical and intradermal

BOX 69-1 DIFFERENTIAL DIAGNOSIS OF ACQUIRED PERFORATING DERMATOSIS

- Actinic granuloma (annular elastolytic giant cell granuloma)
- Arthropod bites
- Discoid lupus erythematous
- Flegel disease (hyperkeratosis follicularis perstans)
- Folliculitis (bacterial, yeast)
- Keratosis follicularis (Darier disease)
- Keratosis pilaris
- Lichen planus
- Multiple keratoacanthomas (Ferguson–Smith familial keratoacanthomas, Grzybowski eruptive keratoacanthomas)
- Perforating granuloma annulare
- Perforating periumbilical calcific elastosis
- Perforating pseudoxanthoma elasticum
- Porokeratosis
- Prurigo nodularis
- Psoriasis
- Sarcoidosis
- Scabies

TABLE 69-3
Treatment of Acquired Perforating Dermatosis

Treatment	Action	Dosing
Topical Therapies		
Retinoic acid[a]	Retinoid	0.025% gel[55]
Tretinoin[a]	Retinoid	0.1% cream one to three times daily[56,57]
Tazarotene[a]	Retinoid	0.1% gel daily[58]
Beclomethasone[a]	Corticosteroid	0.1% cream[17]
Triamcinolone acetonide[a]	Corticosteroid	10 mg/mL intralesional injection[17]
Imiquimod	Immune response modifier	Daily for 6 weeks then three times per week for 4 weeks[59]
Phenol	Antipruritic	0.5% phenol with 10% glycerin in sorbolene cream[60]
Capsaicin	Capsaicinoid	0.025%–0.075% ointment
Systemic Therapies		
Isotretinoin[b]	Retinoid	Isotretinoin 0.5 mg/kg/day[61,62]
Acitretin[b]	Retinoid	25–30 mg/day [60,63]
Prednisolone	Corticosteroid	30 mg daily[64]
Allopurinol[b]	Xanthine oxidase inhibitor	100 mg daily[65,66]
Doxycycline	Antibiotic	100 mg daily[20,67,68]
Metronidazole	Antibiotic	500 mg twice daily[69]
Clindamycin	Antibiotic	300 mg three times daily[70]
Hydroxychloroquine	Antimalarial	200 mg daily[71]
Physical Modalities		
UVB[a]	Phototherapy	MED for 2 minutes every other day with increments of 30 seconds for 2–4 weeks[72]
NUVB[a]	Phototherapy	Three times a week for 2–3 months[60] 400 mJ/cm^2 increased to 1,500 mJ/cm^2, two to three times per week, 10–15 exposures[73]
PUVA[b74]	Phototherapy	Four times per week for total of 326 J/cm^2[75]
Liquid nitrogen	Cryotherapy	10 seconds, on five occasions over 4 months, one occasion 3 months later[76]
Carbon dioxide laser	Laser	Five lesional passes at 300 J (pattern 5, size 7, density 7), followed by three resurfacing passes at 300 J (pattern 2, size 8, density 5), power of 80 W[77]
TENS	Other	1 hour daily for 3 weeks[78]
Surgical debridement[70,79]		

UVB = ultraviolet B; NUVB = narrowband ultraviolet B; PUVA = psoralen and ultraviolet A; TENS = transcutaneous electrical nerve stimulation.
[a]First-line therapy.
[b]Second-line therapy.

corticosteroids, and UVB phototherapy. Phototherapy has been shown to be effective for uremic pruritus and therefore may be particularly beneficial for patients with CKD by reducing koebnerization.[73] Several authors have reported improvement in APD following treatment with allopurinol in cases of elevated or normal uric acid levels.[73] Currently available therapeutic options may not provide complete resolution of APD lesions or associated symptoms.

KEY REFERENCES

Full reference list available at www.DIGM8.com

DVD contains references and additional content

1. Rapini RP, Herbert AA, Drucker CR: Acquired perforating dermatosis. Evidence for combined transepidermal elimination of both collagen and elastic fibers. *Arch Dermatol* **125**(8):1074-1078, 1989
3. Poliak SC et al: Reactive perforating collagenosis associated with diabetes mellitus. *N Engl J Med* **306**(2):81-84, 1982
4. Mehregan AH, Coskey RJ: Perforating folliculitis. *Arch Dermatol* **97**(4):394-399, 1968
5. Kyrle J: Uber einen ungewohnlichen fall von universeller follicularer und parafollikularer hyperkeratose (hyperkeratosis follicularis et parafollicularis in cutem penetrans). *Arch Dermatol Syph* 123, 1916
8. Mehregan AH, Schwartz OD, Livingood CS: Reactive perforating collagenosis. *Arch Dermatol* **96**(3):277-282, 1967
47. Pass F et al: Elastosis perforans serpiginosa during penicillamine therapy for Wilson disease. *Arch Dermatol* **108**(5):713-715, 1973
51. Gambichler T et al: Up-regulation of transforming growth factor-beta3 and extracellular matrix proteins in acquired reactive perforating collagenosis. *J Am Acad Dermatol* **60**(3):463-469, 2009

SECTION 10

Disorders of Subcutaneous Tissue

Chapter 70 :: Panniculitis

:: Iris K. Aronson, Patricia M. Fishman, & Sophie M. Worobec

INTRODUCTION

Inflammation in subcutaneous fat often poses a diagnostic problem for clinician and pathologist alike, since the clinical and histopathological findings in the various inflammatory disorders of adipose tissue (AT) have overlapping features. Specificity in diagnosis is potentially difficult since similar clinical presentations are sometimes associated with disparate histopathological features. Diagnostic problems may also relate to the corollary observation that a range of clinical presentations may have similar histopathologic findings.

There is no universally accepted classification of panniculitis, but from the point of view of many pathologists, a useful classification begins by dividing panniculitis into septal and lobular forms, "septal" signifying inflammation confined predominantly to the septa, and "lobular" indicating inflammation predominantly involving the fat lobule itself. The septal form has been most classically associated with erythema nodosum (EN) and the lobular form with all or most other types of panniculitides. But even this beginning point has not been proven adequate since lobular granulomatous panniculitis may be seen in clinically classic EN,[1] and lobular panniculitides may have mixed lobular and septal inflammation.[2] This classification has been expanded by making note of the presence or absence of vasculitis in the septa or lobules,[3] by the composition of the inflammatory infiltrate, and by additional specific features when present (Fig. 70-1).

Since diverse clinical conditions may be expressed by similar histopathologic features, and the spectrum of histopathologic features in EN and other panniculitides may be variable,[4] it may not be possible to make a specific diagnosis of panniculitis based on histopathology alone. This necessitates correlation with clinical features, including location of lesions, systemic symptoms, laboratory findings, and etiological factors. A significant aid to success in the diagnosis of inflammation in AT is obtaining a tissue sample that will adequately represent the histopathologic changes in the lesion. This can only be done with large excisional biopsies, as small punch biopsies are unlikely to obtain adequate AT, and the inflammatory infiltrate can be missed. An additional consideration is that inflammation in AT is not a static process, and as samples taken at different stages of an evolving lesion will present with different histopathologic features, more than one biopsy may be necessary to come to a conclusive diagnosis.

Under the best of circumstances, with optimal histopathologic sampling and clinical correlation, there may be no specific etiology for many inflammatory reactions in AT. But even with a specific diagnosis or etiology, underlying questions remain. Why were the inflammatory cells accumulating in the AT? What were they doing there?

ADIPOSE TISSUE REGIONAL DIFFERENCES

One of the characteristics of certain types of panniculitides is the preferential localization, such as the pretibial areas for EN, the calf for erythema induratum (EI), and the upper arms, shoulders, and face for lupus panniculitis. Location of panniculitis is a helpful adjunct for differential diagnosis of inflammation in AT and the question of why that occurs may be traced to the origin of the adipocyte regions from different areas of the mesoderm and the varying gene expression in different fat depots.[25] The differences in gene expression between fat depots are large, up to 1,000-fold, and appear to be intrinsic, autonomous, and independent of the tissue microenvironment.[25] Different AT depots may also contain variable percentage of adipocytes of different developmental origins,[25] including brown AT (BAT) that has been observed to be present in white AT depots.[25,26]

The role of AT in innate immunity, inflammation, adaptive immunity, and energy homeostasis places the adipocyte itself centrally in the inflammatory disorders that affect it. The presence of adipocyte transmembrane PRRs, TLRs, and cytosolic PRRs, NLRs, and RLRs and receptors for interaction with macrophages and lymphocytes, as well as production and secretion of multiple cytokines and adipokines reflect the role of

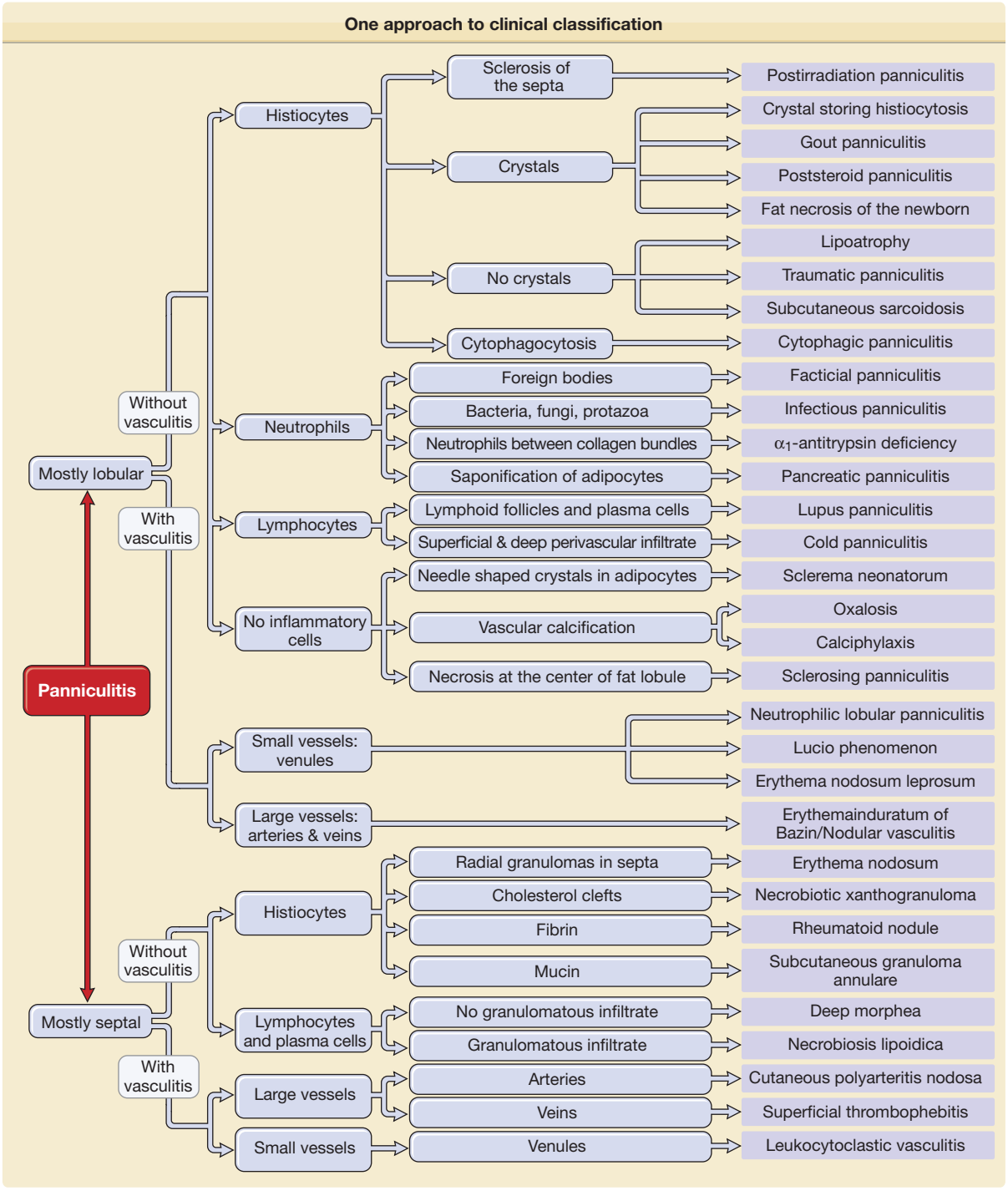

Figure 70-1 Approach to the patient with panniculitis.

the adipocyte in protecting the host from infectious disease and other environmental dangers. The complex interweaving of the adipocyte's role in such numerous and varied spheres may lead to complications should there be a genetic or acquired functional abnormality and/or molecular perturbations, and this may in some instances result in the inflammatory process known as panniculitis.

NODULAR LESIONS OF THE LEGS

Nodular lesions of the legs may represent EN, EI, nodular vasculitis (NV), cutaneous polyarteritis nodosa, or nodules related to vascular disorders. Diagnosis of these disorders often presents difficulties because their clinical manifestations as well as histopathological findings

may overlap. In order to diagnose lesions of the leg, one needs information on the typical as well as unusual manifestations of each disorder, the associated diseases and conditions, and the histopathological presentation.

ERYTHEMA NODOSUM

ERYTHEMA NODOSUM AT A GLANCE

Clinical

- Symmetric, tender, erythematous, warm nodules, and plaques on the anterior aspects of the lower extremities. May become confluent.
- Acute onset; no ulceration or scarring; more common in women.
- Fever, fatigue, arthralgias, arthritis, headache common.
- Lasts from 3–6 weeks, with new lesions appearing for up to 6 weeks.

Histopathology

- Mostly septal panniculitis without vasculitis.
- Thickened septa with inflammatory cells.
- Neutrophils in early lesions and histiocytes and Miescher granulomas in late-stage lesions.

Treatment

- Treatment of the associated disorder.
- Bed rest, aspirin, nonsteroidal anti-inflammatory drugs.
- Systemic corticosteroids are rarely indicated.

EPIDEMIOLOGY. EN may occur in both genders, at any age from childhood to 70 years of age, but is more common in young women in the second to fourth decades of life.[27] There is no gender difference in childhood cases. Prevalence varies from 2.4 per ten thousand population to 52 per million population, and in patient population from 0.38% to 0.5% of patients seen in clinics in Spain and England, respectively.[28,29]

ETIOLOGY AND PATHOGENESIS. EN is a panniculitis that has been reported in association with infections (bacteria, viruses, fungi, and protozoa), medications (antibiotics, oral contraceptives, halides), malignancies (most often leukemias or lymphomas), autoimmune diseases, and other inflammatory disorders, especially sarcoidosis and inflammatory bowel disease (see eTables 70-0.1 and 70-0.2 in online edition). Geographical variations in infectious etiology occur, but streptococcal upper respiratory infections are the most common infectious etiologic factors and the most common causes in childhood.[30] Tuberculosis was a common etiology in the past, and though less frequent now, must always be excluded. Half of all EN cases are idiopathic, without specific etiology, even though in many a viral cause may be suspected.[30]

EN is considered to be a hypersensitivity reaction to the various etiologic factors, but the pathophysiological mechanism of the disorder is not yet understood. Early studies have shown the presence of IFNγ and IL-2, activation of leukocytes, [31] and upregulation of various adhesion molecules,[32,33] and genetic polymorphism in TNF-α promoter, MIF (macrophage migration inhibitory factor), or RANTES (regulated upon activation, normal T-cell expressed, and secreted).[34–36] More recent information identifies AT as an immune organ and adipocytes as cells of the innate immune system, with primary responsibilities and capabilities of activating inflammatory systems and the adaptive immune system to destroy pathogens[37] (see Section "Introduction"). Historically, the primary function of the adipocyte was thought to be protective. However, excessive adipocyte production and secretion of multiple proinflammatory adipokines and adipocytokines is associated with obesity, cardiovascular disease, hypertension, and diabetes.[37] In contrast, the inflammatory reaction of EN is associated with a more limited coccidiomycosis infection[38] and with a less severe and shorter duration of sarcoidosis,[38] especially in those carrying the HLA-DRB1*03-positive leukocyte antigen,[39] which belongs to the "8.1 ancestral haplotype" genes associated with a wide range of immunopathologic diseases.[40] Therefore, it is possible that, especially in AT, certain genetic mutations associated with enhanced inflammatory reactions may confer resistance to certain pathogens, and this may explain the observation that EN, whether in association with coccidiomycosis or sarcoidosis, may be protective against disease dissemination.[38,39]

CLINICAL FEATURES. EN most commonly presents with an acute onset of tender, painful, erythematous, warm nodules and plaques on the anterior and at times the lateral aspect of both lower legs and ankles (Fig. 70-2). Other sites may also be involved, including forearms, thighs, and rarely the trunk or even the face, especially in children.[41,42] The nodules may persist a few days or weeks, may become confluent, and evolve from an erythematous or purple-like hue to a bruise-like pigmentation called erythema contusiforme if hemorrhage is present in the AT. The eruption usually lasts from 3 to 6 weeks, with new lesions appearing for up to 6 weeks, but it may persist longer and may recur.[42] The lesions do not ulcerate, and they resolve without atrophy or scarring.

Systemic symptoms such as fever, fatigue, malaise, arthralgia, arthritis, and headache are common. Abdominal pain, vomiting, diarrhea, and cough are less frequent.[30,42] Ocular manifestations may accompany the cutaneous lesions.[42] Tonsillitis/pharyngitis/upper respiratory infection (URI) preceded the onset in 20%–30% in two series[29,30] and prodromal symptoms may appear 1–3 weeks prior to lesional onset, at which time symptoms may become exacerbated.[43]



Figure 70-2 Erythema nodosum. Erythematous nodules located mainly on the anterior of the legs.

Laboratory abnormalities may include a high ESR, positive throat culture, or high ASO titer in those with a streptococcal etiology and leukocytosis. A positive PPD must be evaluated in the context of prevalence of tuberculosis in the geographical area. Chest X-ray will rule out pulmonary infectious or noninfectious disease (sarcoidosis), and serology or culture for various infectious diseases as well as other testing may be warranted in the appropriate setting (see eTables 70-0.1 and 70-0.2 in online edition).

HISTOPATHOLOGY. Histopathologically, EN is considered the prototype of septal panniculitis, although lobular inflammation may additionally be present. The composition of the inflammatory infiltrate varies according to lesional age, with the earliest lesions demonstrating septal edema, extravasated red blood cells, and scattered neutrophils. More fully developed lesions of EN show widening of the septa and early fibrosis, along with a septal infiltrate that includes lymphocytes, histiocytes, neutrophils, and eosinophils.[27,42,44] There may be extension of the infiltrate into adjacent fat lobules, but centrilobular necrosis of adipocytes is not seen.[27,41,42] Late-stage lesions show widened and fibrotic septa, often containing granulomas (Fig. 70-3A). The fibrosis and inflammation may encroach upon and partially efface fat lobules. Occasionally, predominantly polymorphonuclear cells may be present in typical EN,[45] but this is considered to be part of the early phase of inflammation.[27,41,42]

Miescher's granuloma, a discrete micronodular aggregate of small histiocytes around a central stellate cleft[27,42] (Fig. 70-3B), is considered characteristic of early EN by some, but is not universally found in EN,[41,44] and has been described in other types of panniculitis.[41] The picture of Miescher's granuloma also evolves, as in later-stage lesions, some aggregates of larger histiocytes and multinucleated giant cells retain a central cleft. An overlying superficial and deep perivascular dermal infiltrate is frequently present in EN.[41] Lipomembranous changes have been described in late stages of EN.[27,42] Although by definition, vasculitis is characteristically absent in EN, thrombophlebitis has been emphasized by some as a feature in early EN,[1] and medium vessel arteritis may rarely occur.[4]

DIFFERENTIAL DIAGNOSIS. Differential diagnosis includes cellulitis, infection-induced panniculitis, acute lipodermatosclerosis (LDS), EI/NV, which tends to appear on the calves and ulcerate, other vasculitides which must be differentiated histopathologically, and pancreatic panniculitis, which may occur anywhere on the leg, ulcerate and drain, and which is accompanied by an increase in serum lipase and amylase.

TREATMENT. Treatment of EN primarily focuses on treatment or removal of the etiologic factor. Suspected medications should be discontinued, underlying infections sought and treated if possible, and associated

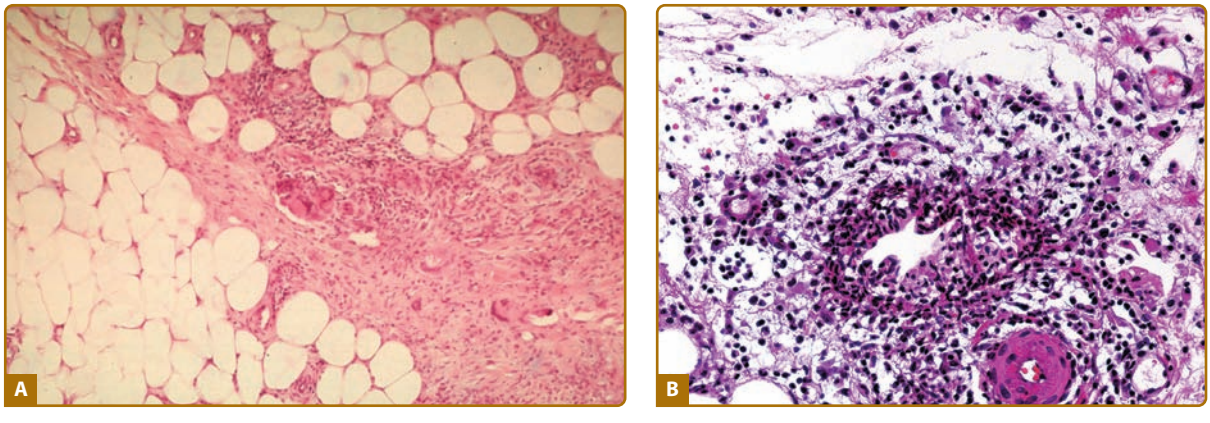

Figure 70-3 Erythema nodosum. **A.** Widened septa with inflammatory infiltrate including multinucleated giant cells. **B.** High magnification of a Miescher's granulomas shows a discrete micronodular aggregate of small histiocytes around a central stellate cleft.

inflammatory disorders or malignancies sought and appropriately treated. The disorder may persist for months before remission, and recurrence is possible, especially if the etiology is unknown.[46] Additional management options include bed rest and leg elevation, aspirin, nonsteroidal anti-inflammatory agents (avoided with IBD). Supersaturated potassium iodide solution (SSKI), 2–10 drops (1 drops = 0.03 mL = 30 mg) three times per day in water or orange juice has been useful, but individuals with thyroid disorders and on certain medications may be at risk for hypothyroidism and goiter as well as toxicity reactions of high potassium involving the heart and lungs.[47] SSKI is contraindicated in pregnancy. Other medications that have been used to treat EN include colchicine (especially for Behcet's disease),[48] corticosteroids (rarely used, especially since an underlying infection must be ruled out), etanercept,[49] and infliximab for IBD-associated EN.[50]

ERYTHEMA INDURATUM AND NODULAR VASCULITIS

EPIDEMIOLOGY AND CLINICAL FINDINGS.

EI is an inflammatory panniculitis, most commonly presenting with ulcerated nodules on the calves, and frequently associated with MTB infection. A similar disorder, without ulceration appearing in calves and other lower extremity sites was subsequently described without MTB association and was called NV. However, with patients presenting with different features in either the same flare or in preceding or subsequent flares, multiple studies have concluded that the clinical and pathological features of the two nodular leg syndromes are so similar that it is impossible to separate them.[51–54] Therefore, at this time the terms are most often used interchangeably. But some still prefer to use EI to denote the MTB-associated panniculitis, and NV for those without MTB association despite the otherwise identical features, to emphasize the need for antituberculosis therapy in the former cases.[55]

EI/NV is seen most commonly in young to middle-aged women, presenting as recurrent erythematous to violaceous nodules and deep plaques on the lower legs that may be tender, or only tender to pressure[52] (Fig. 70-4). Some lesions may heal without scarring, but often ulceration leads to scarring.[52] Surface changes include crusting of the ulcers and a surrounding collarette of scale (Fig. 70-5). The histology is shown in Fig. 70-6. The posterior leg calf region is the most frequent location, but lesions may also appear in the anterolateral areas of the legs, the feet, thighs, and rarely the arms and face.[51] EI lesions develop more frequently during winter, and EI is commonly associated with obesity and venous insufficiency of varying degree and manifestation.[52]

COURSE.

EI/NV can have a protracted course with recurrent episodes over years.[52,53] Patients with EI/NV are for the most part in fairly good health, except for the associated diseases, without the symptoms usually associated with EN. There has been one case report of membranous glomerulonephritis associated with EI/NV[72] and one case of painful peripheral neuropathy in an initially MTB skin test negative patient who was later found to have MTB-positive culture of cervical lymph node.[73]

TREATMENT.

In patients with positive MTB cultures, positive skin test or Quantiferon gold test for MTB, treatment with triple agent antituberculosis therapy is indicated. Patients with hepatitis B or C should

ERYTHEMA INDURATUM OF BAZIN/ NODULAR VASCULITIS AT A GLANCE

Clinical

- Erythematous subcutaneous nodules and plaques of lower legs; common on calves, but also on anterolateral legs, feet, and thighs; rarely elsewhere.
- Commonly associated with venous insufficiency; more frequent in middle-aged women.
- Often, ulceration and scarring, especially on the calves.
- Chronic course.
- Infectious etiology including bacterial [especially *Mycobacterium tuberculosis* (MTB)], fungal, protozoal, and viral should be sought.

Histopathology

- Mostly lobular or mixed lobular and septal panniculitis with vasculitis in 90%.
- Extensive necrosis of the adipocytes in the center of the fat lobule.
- Variable inflammatory infiltrate in the fat lobule: neutrophils in early lesions and epithelioid histiocytes and multinucleated giant cells in fully developed lesions.
- Vasculitis of the small veins and venules of the fat lobule.

Treatment

- With positive MTB microbiological, serological or Mantoux tests, or when MTB DNA is demonstrated: a full course of antituberculosis triple-agent therapy. If other infection proven or suspect: treat specific infection.
- In other cases: potassium iodide, other anti-inflammatory drugs, supporting bandages, support hose, leg elevation, bed rest.



Figure 70-4 Erythema induratum. Erythematous to brown and bluish nodules with ulceration on calves.

receive appropriate intervention for that disorder. Other infectious etiologies including fungi, parasites, and viruses should be sought and treated, if present. Medications that may have incited EI should be discontinued.

Anti-inflammatory treatments that have been used in EI/NV not associated with MBT include super saturated potassium iodide (SSKI), nonsteroidal anti-inflammatory agents (NSAIDS), colchicine, antimalarials, corticosteroids,[55] gold[74] as well as bed rest or leg elevation, and treatment of venous insufficiency with compression and pentoxifylline. Other treatments that have been used include tetracycline and mycophenolate mofetil.[75] If immunosuppressive agents are used, continued monitoring for possible infectious etiology is recommended.

LIPODERMATOSCLEROSIS

LDS (synonyms: sclerosing panniculitis, hypodermitis sclerodermiformis, chronic panniculitis with lipomembranous changes, sclerotic atrophic cellulitis, venous stasis panniculitis) is a form of sclerosing panniculitis involving the lower legs.

EPIDEMIOLOGY

LDS is the most common form of panniculitis, seen by clinicians far more frequently than EN, which has the next highest incidence. LDS occurs in association with venous insufficiency, mostly in overweight women over the age of 40.[76,77] In a review of 97 patients with LDS, 87% were female with a mean age at diagnosis of 62 years; 85% of patients were overweight (BMI >30); and 66% were obese (BMI >34).[78] Comorbidities included hypertension (41% of patients), thyroid disease (29%), diabetes mellitus (21%), prior history of lower extremity cellulitis (23%), deep vein thrombosis



Figure 70-5 **A.** and **B.** Erythema induratum with surrounding collarette of scale.

LIPODERMATOSCLEROSIS AT A GLANCE

Clinical

- Indurated plaques of wood-like consistency on the lower legs, acute and chronic changes, pain frequent.
- Chronic venous insufficiency, higher than normal BMI, female gender, arterial hypertension, arterial ischemia, episodes of thrombophlebitis.
- Pulmonary hypertension in patients with systemic sclerosis and sclerosing panniculitis.

Histopathology

- Background of stasis changes; mostly lobular panniculitis without vasculitis.
- Ischemic necrosis at the center of fat lobule.
- Thickened and fibrotic septa and atrophy of the subcutaneous fat, with marked fibrosis and sclerosis in late-stage severe cases.
- Frequent membranocystic changes.

Treatment

- Compression stockings, ultrasound therapy, pentoxifylline.
- Successful response to anabolic steroids in some cases.

(19%), psychiatric illness (13%), peripheral neuropathy (8%), and atherosclerosis obliterans (5%).[78] Due in part to its placement in the ICD9 classification under "Venous insufficiency with inflammation," and its designation by various medical names (see list of synonyms for LDS above), precise data for prevalence of LDS are not available. With increasing rates of obesity in the United States and the aging of the baby boomer generation, a corresponding increase in incidence and prevalence of LDS will likely follow.

ETIOLOGY AND PATHOGENESIS

Most patients with LDS are female and also have in common venous hypertension and a higher than normal BMI. Additional associated features that have been sought as pathogenetic factors in LDS include the following: elevated hydrostatic pressure-induced increased vascular permeability secondary to down-regulation of tight junctions[79,80] with extravascular diffusion of fibrin[78]; microthrombi[81]; abnormalities in protein S and protein C[82]; hypoxia[83]; damage to endothelial cells by inflammatory cells[84]; upregulation of intercellular adhesion molecule 1 (ICAM-1), vascular cell adhesion molecule 1 (VCAM-1), leukocyte function-associated antigen 1 (LFA-1), platelet- and endothelial-derived factors[85]; and inflammation with wound healing and local collagen stimulation leading to fibrosis and further vascular and lymphatic damage.[78] The fibrosis is accompanied by increased transforming growth factor-β 1 (TGF-β1) gene and protein expression[86] as well as an increase in procollagen type 1 gene expression.[87]

Hypoxia in AT induces chronic inflammation with macrophage infiltration and inflammatory cytokine expression.[88] The adipocyte plays a significant role in extracellular tissue remodeling. For this task, the adipocyte produces multiple matrix metalloproteinases (MMPs) as well as tissue inhibitors of metalloproteinases (TIMPs) and other tissue proteases needed during tissue remodeling,[89] all of which may significantly contribute to the tissue remodeling seen in LDS. Recent studies have linked expansion of AT (as seen in obesity) to resultant hypoxia, causing an increase in hypoxia-inducible factor 1α (HIF1α) expression.[90] This stimulates multiple extracellular factors, including

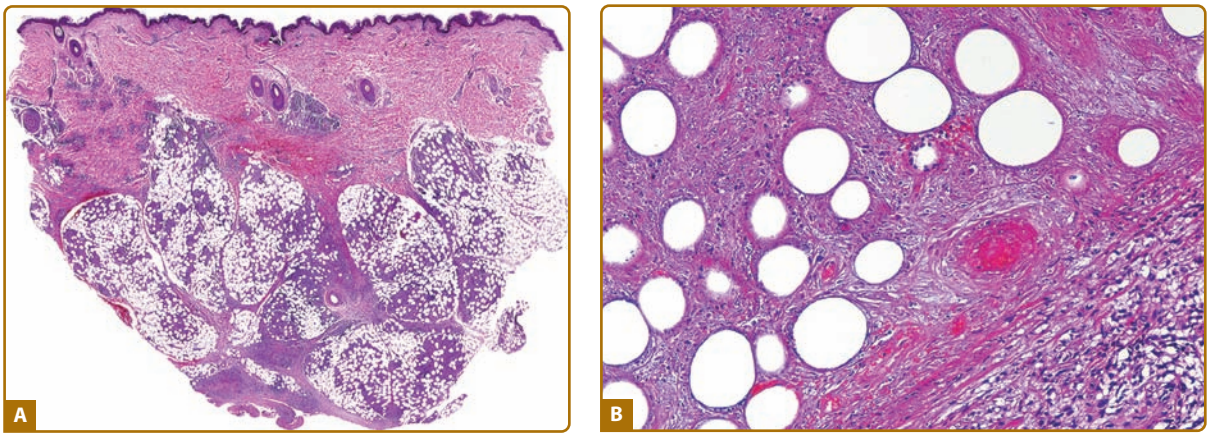

Figure 70-6 Erythema induratum-nodular vasculitis. **A.** Histopathology: scanning power shows a mostly lobular panniculitis. **B.** Higher magnification: extensive adipocyte necrosis and vascular damage-necrotizing vasculitis of small venules in the fat lobule.

collagen I and III, as well as other components involved in remodeling the extracellular matrix, leading to fibrosis as the end result.[91]

A theory regarding an infectious pathogenesis of LDS was advocated by Cantwell and colleagues, who reported the presence of unusual acid-fast bacteria that could not be grown in culture in biopsies of several patients with LDS.[92] This 1979 article dealt with the controversial issue of pleomorphic, nonrod-shaped, acid-fast bacteria being responsible for disease. It is widely accepted that other infections associated with repeated episodes of cellulitis cause lymphatic damage and subsequent changes in the AT.[77] Particularly in the light of more recent discoveries that adipocytes are cells of the innate immune system and possible reservoirs of infectious organisms of all types, the role of infection as a contributing factor to LDS should be reconsidered and explored, perhaps in an analogous manner to that of the process leading to evidence of MTB DNA and dormant MTB in AT of the legs in EI.[58,67]

CLINICAL FINDING'S

LDS has an acute inflammatory stage and a chronic fibrotic stage with a spectrum of intermediate[77] and overlapping presentations. In patients presenting with the acute form (Fig. 70-7A), very painful, poorly demarcated, cellulitis-like erythematous plaques to purple somewhat edematous indurated plaques or nodules are seen on the lower legs, most commonly on the lower anteromedial calf area.[77,93] Scaling may be present in some. The pain can be so intense that patients may not even tolerate a sheet while in bed. In this stage, patients are frequently diagnosed as having EN, cellulitis, or thrombophlebitis,[77,93] and compression may not be tolerated. The acute form may last a few months or even a year.[93] Although patients in this acute phase may present without obvious signs of venous disease,[77] vascular studies show venous insufficiency in the majority.[93] In the remaining group of LDS patients with normal venous studies, most have a high BMI, and given that obesity is usually associated with inactivity, these patients may not exert enough calf muscle contraction to maintain normal venous pressure in the lower extremities[78]; also, obesity is frequently associated with arterial hypertension.

The chronic form of LDS may or may not be preceded by a clinically obvious acute form.[77] Chronic LDS features indurated to sclerotic, depressed, hyperpigmented skin (Fig. 70-7B). These findings occur on the lower portion of the lower leg, predominantly but not limited to the medial aspect, or in a stocking distribution. This is described as having an "inverted champagne bottle" or a "bowling pin" appearance.[76,77,93]

Although some patients may not describe associated pain or tenderness,[93] pain is the most frequent symptom reported by others.[78] Most of the patients are obese or overweight and have hypertension and evidence of venous abnormalities, but only rarely obstruction.[78] Unilateral involvement is seen in 55%, localized plaque in 51%, and ulceration in 13% of cases[78] (Fig. 70-8). Dermatosclerosis in patients with systemic sclerosis has



Figure 70-7 Chronic lipodermatosclerosis (LDS). **A.** Sclerotic hyperpigmented skin on medial lower leg. **B.** Superimposed acute on chronic lipodermatosclerosis with ulceration.



Figure 70-8 Chronic lipodermatosclerosis with champagne bottle/bowling pin deformity.

been associated with pulmonary infarction and hypertension secondary to leg thrombi.[94]

Diagnostic tests to evaluate peripheral vascular disease should include ankle brachial index for arterial evaluation. Also indicated are venous tests: Dopplers to detect thrombi as well as color duplex sonography to detect direction of flow and presence of venous reflux.[93] If the clinical findings are characteristic, biopsy of LDS is usually discouraged, due to the high incidence of subsequent development of ulcers at the biopsy site.[77] But if necessary for diagnosis, a thin elliptical excision from the margin of an erythematous and indurated area, closed primarily with sutures, is recommended.[77]

DERMATOPATHOLOGY

Histopathologic findings reflect the evolution of the disease. Dermal stasis changes are present at any stage, and these include a variable degree of proliferation of capillaries and venules, small thick-walled blood vessels, extravasated erythrocytes, hemosiderin-laden macrophages, lymphohistiocytic inflammation, and fibrosis.[53,95]

In the subcutis, early lesions of LDS show a sparse infiltrate of lymphocytes in the septa, accompanied by central lobular ischemic fat necrosis; the latter is recognized by the presence of pale-staining, small anucleate adipocytes. Capillary congestion is also observed within fat lobules; this may be accompanied by endothelial cell necrosis, thrombosis, red cell extravasation, and hemosiderin deposition.[53,95] Septal fibrosis and small foci of lipomembranous fat necrosis and fat microcysts have also been described to occur in acute lesions.[95] In lipomembranous or membranocystic change, small pseudocystic spaces are formed within necrotic fat. The spaces are lined by a hyaline eosinophilic material believed to be the residue of disintegrated adipocytes and their interaction with macrophages.[96] This distinctive membranous lining is highlighted by periodic acid-Schiff (PAS) staining and may present an arabesque pattern, with intricate undulating papillary and crenulated projections into the cystic spaces. However, membranocystic changes are not exclusive to LDS and may be found in any type of panniculitis.[53,97]

With progression of LDS, the spectrum of histopathologic changes encompasses increasing degrees of membranocystic fat necrosis, septal fibrosis, and thickening; an inflammatory infiltrate comprising lymphocytes, histiocytes, and foamy macrophages; and partial to extensive atrophy of fat lobules.[53,77,95] Advanced lesions show septal sclerosis most prominently, with marked atrophy of fat lobules secondary to lipophagic fat necrosis, accompanied by microcystic and lipomembranous change and a marked reduction in inflammation.[53,95] The most severe LDS shows marked fibrosis and sclerosis in the AT layer with little inflammation.[77] In late stages, with fibrous thickening of the lower dermis and replacement of the subcutis by sclerosis, a punch biopsy of involved skin may not produce any subcutaneous fat.[98]

TREATMENT

Compression therapy is the major universally recommended treatment for LDS.[77,78] Higher compression gradient (30–40 mm Hg) may be more effective, but lower class compression (15–20 mm Hg or 20–30 mm Hg) may be associated with higher rate of compliance, especially in the elderly, and has been shown to be effective in decreasing edema.[99] One mechanism by which compression improves venous return and decreases edema is via tightening of vascular tight junctions, significantly elevating expression of tight junction proteins and inhibiting permeability of fluid into the perivascular tissue, thereby preventing progression of venous insufficiency.[79,80] Stockings must be worn all day and not removed until bedtime, since even a few days without compression may lead to recurrence of the edema and inflammation.[99]

Stanazolol has been shown to be effective in LDS, with decrease in pain, erythema, and induration.[77,100] Patients tolerated the treatment well, but potential side effects of this treatment include hepatotoxicity, and this may preclude its widespread use. In the United States, this drug is no longer distributed. Other anabolic steroids such as oxandrolone and danazol have also been used.[101,102] Pentoxifylline has been successfully used in LDS cases with and without associated ulceration. A Cochrane Database System review of 12 trials involving 864 patients in 2007 concluded the drug was a useful adjunct to compression for treating venous ulcers and may be effective in the absence of compression.[103] Other treatments for chronic venous insufficiency include horse chestnut seed extract,[104,105] oxerutin,[106,107] and flavonoid fraction.[108]

Ultrasound therapy was reported in two studies as being successful in reducing and even resolving hardness, tenderness, and erythema.[109,110] Readily available through physical therapy departments, it is a simple and safe treatment of a painful and refractory condition and may be used along with Grade-2 compression therapy.[109,110]

PREVENTION

Since being overweight and obese are common conditions among affected patients, efforts to reduce weight are prudent.

INFECTION-INDUCED PANNICULITIS

INFECTIOUS PANNICULITIS AT A GLANCE

Clinical

- Caused by wide variety of infectious agents, including bacteria, fungi, parasites, and viruses.
- AT may serve as reservoir for various infections.
- Due to primary inoculation or hematogenous spead; patients may be immunosuppressed.
- Erythematous plaques, nodules, abscesses, ulcers with purulent discharge.

Histopathology

- Suppurative granulomas within fat lobule.
- In primary cutaneous infections, epicenter of inflammation is superficial dermis; in secondary infections, epicenter is deep reticular dermis and subcutaneous fat.
- Special stains, cultures, and serologic studies necessary for detection of microorganisms.

Treatment

- Appropriate antimicrobial therapy selected according to susceptibility tests.

EPIDEMIOLOGY

Infection-induced panniculitis (Infectious panniculitis, infective panniculitis) is panniculitis directly caused by an infectious agent.[62] AT infection can be due to bacteria, mycobacteria, fungi, protozoa, and viruses.[53,62,111] Primary infections produced by direct inoculation at a wound site (injury, surgical procedure, catheter, injection, acupuncture) usually result in a single lesion which may enlarge and spread locally.[53,62,111] Secondary infections caused by sepsis and hematogenous spread may manifest as single or multiple lesions.[53,62,111] In immunosuppressed patients, microorganisms may be numerous and identified on routine histopathology or special stains. In immunocompetent patients, microorganisms may be sparse and not seen on either routine histopathology or special stains, requiring positive cultures or serological studies for identification.[53,62,111] Recent reports of infectious etiologies in association with various autoimmune disorders include *Staphylococcus aureus* panniculitis with juvenile dermatomyositis (DM),[112] *Mycobacterium*- and *Histoplasma*-associated panniculitis with rheumatoid arthritis,[113,114] and diffuse fusariosis with acute lymphobastic leukemia (ALL).[115]

CLINICAL FINDINGS

The clinical appearance of infectious panniculitis varies from fluctuant- or abscess-type lesions with purulent discharge and ulcerations to nonspecific erythematous firm nonfluctuant subcutaneous plaques and nodules, purpuric plaques, and EN-type lesions.[62,111,129] Deep nodules or plaques may not always appear fluctuant, and pustules, fluctuant papules, and ulcers can be superimposed on top of the nodules.[111] The most common sites of infection are the legs and feet, but upper extremities, trunk, and face may also be involved.[62,111] Immunosuppression of varying etiology is the most frequent, but not universal, association.[53,62,111] Immunosuppression is associated with more widespread abscess-type lesions containing nontuberculous mycobacteria, whereas in immunocompetent patients, granulomas are more commonly seen.[111,130] Fungal infections occur in the following clinical settings: (1) localized environmentally injected panniculitis of mycetoma, chromoblastomycosis, and sprorotrichosis; or (2) panniculitis associated with systemic disseminated fungal infection that may be seen in individuals with normal immune functions, or with opportunistic fungal infection seen in immune compromised individuals.[111,129] Clinical features vary with the setting, the infective organism and the underlying state of the individual's immunocompetence or immunosuppression.[111,129]

HISTOPATHOLOGY

Evaluation of panniculitis for infections should include histopathologic studies with special stains for all types of organisms as well as culture and sensitivity testing of biopsy material. In the immunosuppressed patient, microorganisms may be numerous and more readily identified, but in immunocompetent patients, microorganisms may not be seen on either routine histopathology or special stains, requiring positive cultures or serological studies for identification.[53,62,111] The anti-Bacille Calmette-Guérin (BCG) polyclonal antibody immunostain cross-reacts with many bacteria, mycobacteria, and fungi with minimal background staining and is advocated as a good screening tool for detection of microorganisms in paraffin-embedded tissue specimens when conventional stains are negative.[53,111,131] Molecular PCR techniques have been utilized with mycobacterium infections.[56–58,122] Histopathologic features may vary with the organism and its virulence, the host immune status, and the duration of the lesion at time of biopsy.[62] Classified by some as a mostly lobular panniculitis,[53] infection-induced panniculitis often presents a mixed septal and lobular pattern, and a predominantly septal, EN-like neutrophilic panniculitis has also been reported to occur in cases of bacterial as well as fungal etiology.[62] The superficial dermis is the

epicenter of inflammation in infections acquired by direct inoculation or by an indwelling catheter, in contrast to more deeply seated infections secondary to hematogenous spread involving the deep reticular dermis and subcutaneous fat.[53]

Generally, in a typical case, the subcutaneous fat contains a dense infiltrate of neutrophils and some admixed lymphocytes and macrophages, often with extension into the overlying dermis and with abscess formation a common finding.[62,111] Patterson et al additionally noted distinctive subcutaneous features in the majority of 15 reported cases of infection-induced panniculitis of bacterial, atypical mycobacterial and fungal origin, independent of the particular causative microorganism. These features included hemorrhage, vascular proliferation, foci of basophilic necrosis, and sweat gland necrosis. Overlying changes such as parakeratosis, acanthosis, and spongiosis were seen in all cases in which the epidermis was available for examination. All 15 cases also had dermal findings, most commonly upper dermal edema, a diffuse and perivascular inflammatory infiltrate, often with prominent neutrophils, proliferation of thick-walled vessels, and focal or diffuse hemorrhage.[62] With observation of any of these enumerated features, special stains for bacteria, mycobacteria, and fungi are imperative, and additional immunohistochemistry or PCR amplification techniques may be necessary.

Other histopathologic changes may point toward a more particular etiology. Suppurative granulomas formed by epithelioid histiocytes surrounding aggregated neutrophils may occur in panniculitis caused by atypical mycobacteria.[53] Caseating granulomas, though rarely seen, raise suspicion for tuberculous panniculitis.[111] A case of panniculitis secondary to CMV has been reported as a mostly septal panniculitis with many CMV inclusions contained within endothelial cells.[132]

DIFFERENTIAL DIAGNOSIS

Differential diagnosis includes α_1-antitrypsin (α_1AT) panniculitis, pancreatic panniculitis, traumatic, and factitial panniculitis. It is important to recall that presence of one of the above diagnostic types of panniculitis does not exclude infection, as in the case of α_1AT panniculitis associated with lymph node histoplasmosis.[133]

TREATMENT

Treatment will vary and depend on the suspected or known organisms and their cultures and sensitivities. In cases involving bacteria such as MTB and parasites such as *T. cruzi*, their known capability to remain dormant in AT necessitates the use, for adequate treatment durations, of appropriate antibiotics, selected for their abilities to affect nonreplicating organisms.[67,121]

α_1-ANTITRYPSIN PANNICULITIS

α_1-ANTITRYPSIN-DEFICIENCY PANNICULITIS AT A GLANCE

Clinical

- ZZ-, MZ-, MS-, and SS-phenotype-associated panniculitis rare, with higher percentage (>60%) in ZZ cases; low levels of α_1-antitrypsin are associated with emphysema, hepatitis, cirrhosis, vasculitis, and angioedema.
- Subcutaneous nodules mostly located on the lower abdomen, buttocks, and proximal extremities.
- Frequent ulceration and isomorphic phenomenon.

Histopathology

- Mostly lobular panniculitis without vasculitis.
- Necrosis of fat lobules with a dense inflammatory infiltrate of neutrophils.
- Splaying of neutrophils between collagen bundles of deep reticular dermis.
- Large areas of normal fat adjacent to necrotic adipocytes.

Treatment

- Dapsone, doxycycline.
- Homozygous ZZ patients with severe forms of the disease: supplemental intravenous infusion of exogenous α_1-proteinase inhibitor concentrate or α_1-antitrypsin produced by genetic engineering; liver transplantation.

ETIOLOGY AND PATHOGENESIS

α_1AT is a glycoprotein that accounts for 90% of the total serum serine protease inhibitor capacity in humans.[134] It is produced and secreted mainly by hepatocytes, but also in small amounts by monocytes/macrophages and neutrophils,[135–137] and is known to inhibit trypsin, chymotrypsin, leukocyte elastase, kallikrein, collagenase, plasmin, and thrombin among other proteases.[134] α_1AT may also help regulate protease stimulated activation of lymphocytes, phagocytosis by macrophages and neutrophils, and complement activation.[138–141] It is an acute phase reactant, increased in times of stress.

α_1AT deficiency is inherited as a codominant disorder, and more than 100 alleles have been identified.[142,143] The α_1AT phenotypes are classified according to gel



Figure 70-9 α_1-Antitrypsin deficiency associated panniculitis. **A.** Fluctuant abscess type appearance. **B.** Discharge of oily material.

electrophoresis migration/mobility as F (fast), M (medium), S (slow), and Z (very slow), but null variants that do not produce any α_1AT and patients may have dysfunctional α_1AT with normal levels.[144] Homozygous MM, the most common phenotype, is associated with normal levels of α_1AT, whereas those homozygous for ZZ have low levels at 10%–15% of normal, and those heterozygous for S or Z allele have levels in between. MS heterozygous individuals may have low normal serum levels.[145] Due to the complex nature of these proteins, combination protein levels, or phenotyping and genotyping, have been recommended.[144] Estimated prevalence of α_1AT deficiency in Caucasians is 1 per 3,000–5,000 in the United States, with incidence in Caucasian newborns similar to that of cystic fibrosis.[144]

CLINICAL FINDINGS

α_1AT deficiency is most commonly associated with pulmonary and hepatic disease, leading to chronic obstructive pulmonary disease (COPD), hepatic cirrhosis, or hepatocellular carcinoma[144]; the ZZ genotype is at highest risk. There is no association of the null variant with hepatic disease, as it is the accumulation of polymerized α_1AT in the liver that induces damage, and accumulation does not occur in this variant.[144] The exact mechanism of injury is still controversial.[144]

Panniculitis uncommonly occurs in α_1AT deficiency. Less than 50 cases have been reported[146,147] in ZZ, MZ, MS, and SS phenotypes, with higher percentage (>60%) of ZZ cases as well as higher incidence in women (65%).[146] Presenting in an age range from childhood (infancy) to the elderly, panniculitis is most frequently seen between ages 30 and 60.[146,148] Patients present with painful erythematous nodules and plaques, but early lesions may have a cellulitic or fluctuant abscess-type appearance (Fig. 70-9A). Lesions may ulcerate and discharge an oily material or serosanguineous discharge[9] (Fig. 70-9B) and resolve with atrophic scars.[53] The lesions appear most commonly on the lower trunk (buttocks) (Fig. 70-10) and proximal extremities, but lower legs and other sites may be affected.[53,146,150] As trauma or excessive activity may precede the onset of lesions in a third of patients,[53,146] debridement is discouraged.[53] α_1AT panniculitis has occurred in patients with such conditions as hypothyroidism, mixed connective tissue disease, lymphoproliferative disorders, and infections, including a focus of histoplasmosis in a lymph node.[133,149] Therefore, the presence of α_1AT deficiency in association with panniculitis should not

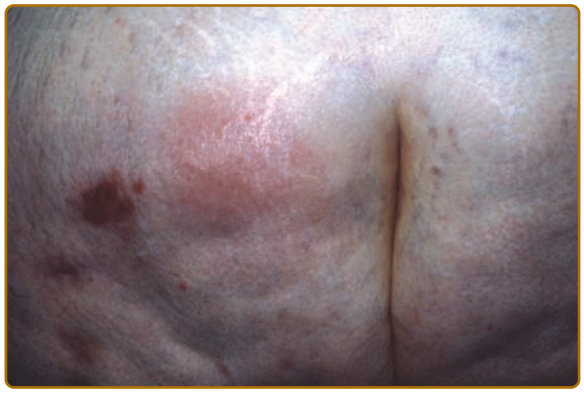

Figure 70-10 α_1-Antitrypsin deficiency associated panniculitis. Nodular lesion on the buttock.

preclude a search for infection or other underlying medical problems such as autoimmune disorders, malignancies, or infections, since they may coexist. Cutaneous and subcutaneous necrosis can develop rapidly. Extensive involvement with α_1AT panniculitis can be life threatening, and fatal cases have been reported.[148,151,152] Erythrophagocytosis was noted in the biopsy of one of the patients with fatal panniculitis.[153]

Possible mechanisms leading to the development of α_1AT panniculitis include lack of interference with the various proteases that lead to activation of lymphocytes, macrophages, complement, and lysis and destruction of connective tissue at sites of inflammation. Trauma to adipocytes may result in their activation, with release of the various adipokines and cytokines that are chemotactic to inflammatory cells, whose released proteases are unopposed due to absence of the α_1AT, leading to severe damage in involved tissue.[154,155] Animal models of soft tissue injury show elevated levels of IL-6 and MCP-1 and increased systemic inflammatory mediators.[154]

PATHOLOGY

Histopathologic findings vary with the age and type of lesion biopsied. Early in their development, nodular lesions may reveal edema and degeneration of adipocytes, with ruptured and collapsed cell membranes and a perivascular mononuclear infiltrate.[153] Also reported at this stage is a mild infiltrate of neutrophils and macrophages in septa and lobules, with foci of early necrosis of subcutaneous fat. This may be accompanied by splaying of neutrophils between collagen bundles throughout the overlying reticular dermis, considered an early and distinctive diagnostic clue.[156] More advanced lesions have masses of neutrophils and histiocytes associated with necrosis and replacement of fat lobules (Figs. 70-11A and 70-11B). A focal pattern of involvement is another distinguishing feature that may be appreciated, manifested by large areas of normal fat in immediate proximity to necrotic septa and fat lobules.[157] Liquefactive necrosis and dissolution of dermal collagen may be accompanied by ulceration, and degeneration of elastic tissue may lead to septal destruction and the appearance of "floating" necrotic fat lobules.[149,158] A rare occurrence is an exclusively septal pattern of mixed inflammatory infiltrate with a predominance of neutrophils.[146,158] Neutrophils and necrotic adipocytes are less prevalent in late stage lesions, with replacement by lymphocytes, foamy histiocytes, and variable amount of fibrosis within fat lobules.[149,159]

DIFFERENTIAL DIAGNOSIS

Differential diagnosis of α_1AT panniculitis includes other panniculitides that may ulcerate and drain such as the spectrum of infections, factitial disease, EI, and pancreatic panniculitis. Subcutaneous Sweet syndrome, rheumatoid arthritis, and myelodysplasia-associated neutrophilic panniculitis do not usually drain and ulcerate.[160,161]

TREATMENT

Many medications have been used in the treatment of α_1AT deficiency panniculitis including colchicine, antimalarials, steroids, immunosuppressive agents, cytotoxic agents, dapsone, doxycyline, plasma infusion and plasma exchange, intravenous α_1AT replacement therapy, and liver transplantation.[148,150,162–167] Steroids, immunosuppressives, and cytotoxic agents were the least successful treatment options. Doxycycline and especially dapsone were very helpful in mild to moderate cases, but severe panniculitis required A1P replacement therapy.[148,149,159,167] Panniculitis resolved with liver transplantation,[168] and panniculitis acquired after liver transplantation was successfully treated with retransplantation.[169]

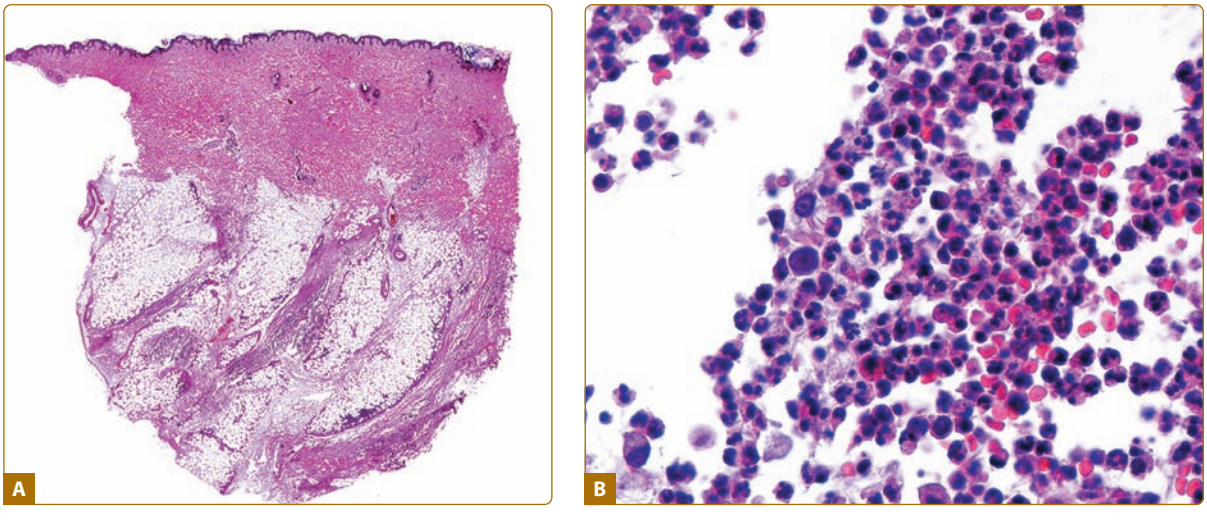

Figure 70-11 α_1-Antitrypsin panniculitis. **A.** Scanning power shows a mostly lobular panniculitis. **B.** Dense inflammatory infiltrate of neutrophils in the fat lobule.

PANCREATIC PANNICULITIS

PANCREATIC PANNICULITIS AT A GLANCE

Clinical

- Erythematous subcutaneous nodules that often ulcerate spontaneously.
- Lower extremities (around ankles and knees) are most frequent sites of involvement.
- Regression of pancreatitis-associated cutaneous lesions, but those associated with pancreatic carcinoma tend to persist; may be fatal.

Histopathology

- Mostly lobular panniculitis without vasculitis.
- Intense necrosis of adipocytes at center of fat lobule.
- Ghost adipocytes with finely granular and basophilic intracytoplasmic material.

Treatment

- Treatment of the underlying pancreatic disease, ocreotide, plasmapheresis.

EPIDEMIOLOGY

Panniculitis in association with pancreatic disease is a rare occurrence, developing in 2%–3% of all patients with pancreatic disorders and appearing in the setting of acute or chronic pancreatitis, pancreatic carcinoma, or pancreatic pseudocysts.[170–172] Although pancreatitis is most commonly due to alcohol abuse, cholelithiasis, or pancreatic calculi, medications and viral infections are also known etiologic factors.[173,174] The cutaneous panniculitis may precede the diagnosis of the associated pancreatic disease by weeks to months in up to 45% of patients.[170,173] Mono- or oligoarticular arthritis secondary to periarticular fat necrosis may be present in over half of patients.[170] This triad of pancreatic disease, panniculitis, and polyarthritis may occur with either pancreatitis or pancreatic carcinoma.[175] and is seen in less than 1% of pancreatitis patients[172]; joint disease may precede the diagnosis of pancreatic disorder.[175] Abdominal symptoms may be mild or absent.[175] Pancreatic panniculitis may also be seen in association with pancreatitis following renal or pancreas renal transplant,[176,177] with SLE,[178] and with hemophagocytic syndrome (HPS).[179] Panniculitis associated with pancreatic disease may be fatal,[170,172,180] with a mortality rate of up to 24% in one series[175] and mortality rates of 100% in those with pancreatic carcinoma and 42% of 19 patients with pancreatitis in another series.[181]

ETIOLOGY AND PATHOGENESIS

Pancreatic panniculitis has generally been attributed to release of pancreatic enzymes such as lipase, amylase, and trypsin into the circulation, promoting vascular permeability, leading to release of fatty acids from adipocytes and subsequent fat necrosis.[172,182] However, there are reports of normal serum levels of pancreatic enzymes in association with typical pancreatic panniculitis.[170] Additionally, incubation of normal AT with amylase and lipase and with pancreatitis patient serum high in those enzymes failed to induce fat necrosis in vitro,[183] leading to suggestions that other mechanisms may be involved in the development of pancreatic panniculitis. Since many of the lesions appear on lower legs, these mechanisms may include venous hypertension, but likely also involve adipocyte generated cytokines and adipokines related to effects of high levels of free fatty acids[170]; resistin and leptin have been shown to be potential markers of extrapancreatic fat necrosis.[184]

CLINICAL FINDINGS

The cutaneous lesions appear most frequently on the lower legs, especially the periarticular areas,[170] but are also found on the arms, thighs, and trunk.[170] Lesions often appear in crops, although single nodule pancreatic panniculitis also occurs.[185] The lesions are ill-defined erythematous to red–brown edematous tender nodules, which in mild cases may involute and resolve with atrophic hyperpigmented scars,[170] may have central "softer" areas or may become fluctuant, abscess-like, and drain oily material similar to lesions of α_1AT deficiency panniculitis (Fig. 70-12A).[170]

Extracutaneous manifestations include periarticular fat necrosis with concomitant arthritis,[170] painful medullary fat necrosis in bone,[172] and pleural effusions and serositis.[172,181] The presence of pleural effusions, alone or with arthritis, is associated with a high mortality rate.[181] Eosinophilia may be seen in both pancreatitis- and pancreatic malignancy-associated pannicultis,[181] and a pancreatic tumor in association with panniculitis, polyarthritis, and eosinophilia (Schmid's triad) imparts a poor prognosis.[186]

HISTOPATHOLOGY

Fully developed lesions of pancreatic panniculitis demonstrate lobular fat necrosis with distinctive qualities (Fig. 70-12B). Adipocytes lose their nuclei but maintain peripheral outlines, forming characteristic "ghost cells" (Fig. 70-12C). With saponification, calcification occurs, producing fine granular basophilic deposits within and around individual necrotic adipocytes. The ghost cells are frequently aggregated in small clusters at the center of fat lobules, with a peripheral inflammatory infiltrate of neutrophils.[53] In older lesions, necrosis and ghost cells are less evident, replaced by foamy histiocytes, multinucleated giant cells, lymphocytes, and eventually, fibrosis.[53,98] Of note,



Figure 70-12 Pancreatic panniculitis **A.** Clinical features: erythematous subcutaneous nodules that ulcerate and exude an oily material. **B.** Scanning power shows a mostly lobular panniculitis with adipocyte necrosis at the center of the fat lobule. **C.** Higher magnification shows ghost adipocytes, necrotic adipocytes without nuclei and with cytoplasmic fine granular basophilic material due to calcification.

pancreatic panniculitis has been reported to originate as a septal inflammatory process similar to EN in its earliest manifestation,[187] and findings mimicking pancreatic panniculitis have been documented at the site of subcutaneous interferon β injections in the course of treatment of multiple sclerosis.[188]

Treatment is supportive and directed at the underlying pancreatic disorder. Since patients may not have abdominal symptoms, pancreatic panniculitis should be considered in the differential diagnosis of any panniculitis. Resolution of the lesions occurs with specific surgical treatment appropriate to the underlying disorder.[173,175,189] Ocreotide, a somatostatin analog, and plasmapheresis have also been associated with resolution of pancreatic panniculitis.[190,191]

LUPUS PANNICULITIS [LUPUS ERYTHEMATOSUS PANNICULITIS (LEP), LUPUS PROFUNDUS, SUBCUTANEOUS LUPUS ERYTHEMATOSUS]

EPIDEMIOLOGY

Lupus erythematosus panniculitis (LEP) is a rare variant of lupus erythematosus (LE), which primarily affects the subcutaneous AT.[192,193] LEP may appear as the sole manifestation of LE or may occur prior to or

LUPUS PANNICULITIS AT A GLANCE

Clinical

- Erythematous nodules on face, shoulders, upper arms, scalp, chest, buttocks; rarely on lower extremities.
- Persistent areas of lipoatrophy in regressed lesions.

Histopathology

- Mostly lobular panniculitis without vasculitis (lymphocytic vasculitis occasionally).
- Lobular lymphocytic infiltrate, with plasma cells in many cases, eosinophils sometimes.
- Lymphoid follicles with germinal centers often.
- Sclerotic collagen bundles within septa.
- Hyaline necrosis and atrophy of entire fat lobule in late-stage lesions.
- Interface changes of discoid lupus erythematosus in 20%–30% of cases (changes at the dermal–epidermal interface may also rarely accompany subcutaneous panniculitis-like T-cell lymphoma).

Treatment

- Antimalarials, thalidomide.
- If active and severely inflamed, short oral courses of corticosteroids.
- Dapsone, cyclosporine, methotrexate, intravenous immunoglobulin, and rituximab.

after the onset of discoid lupus erythematosus (DLE) or systemic lupus erythematosus (SLE).[194,195] The incidence of SLE in patients with LEP has been reported to range from 10% to 41%, with the highest incidence seen in a Japanese series of 44 cases[193,195,196]; LEP occurs in only 1%–5% of patients with SLE.[192,193] Although rare, LEP occurs worldwide, more frequently among women than men, with a female to male ratio of about 4:1.[193,195,197] LEP is most common between the ages of 30 and 60, but may rarely be seen in childhood or even as neonatal lupus.[53,193,194,198] When present in association with SLE, LEP tends to occur in SLE cases of lesser severity.[195,197] There are a few case reports of LEP in more than one family member, or of family members with SLE unaccompanied by LEP.[192,193] Patients with LEP may also have other autoimmune disorders such as Sjögren's syndrome and rheumatoid arthritis.[192,193]

ETIOLOGY AND PATHOGENESIS

While a complete understanding of why LEP develops is still lacking, the innate immune system has been recently recognized to play a significant role in the development of SLE. Adipocytes are important cells of the innate immune system and function in pathogen recognition, activation of adaptive immunity, and as a reservoir for various microbes. All TLRs are expressed in AT. Adipocytes themselves express TLR1, 2, 3, 4, and 6, whereas TLR5, 7, 8, 9, and 10 are expressed on the nonadipocyte stromovascular fraction of AT.[199] The reasons for "lupus panniculitis" may vary from genetic polymorphism of TLRs leading to inappropriate activation of innate immune systems (especially of the type 1 interferon system),[200] to inappropriate interactions of adipocytes with inflammatory cells, to immune responsiveness against microbial and nonmicrobial antigens within AT. The localization of LEP to specific fat depots may be a clue to the functions of those adipocytes, or to a specific genetic aberration, or to the type of lymphocytes that are attracted to those AT depots.

In SLE, TLR7 and TLR9 recognize RNA and DNA patterns, respectively, and appear to provide a mechanism for recognition of self-DNA or self-RNA, with subsequent activation of the adaptive immune system and production of autoantibodies to nucleic acids and proteins bound to nucleic acids.[201–205] Inhibitors of TLR7 and TLR9 can prevent disease in mouse models of autoimmunity,[203] although deletion of TLR9 may enhance disease in some experimental models.[206] Both receptors have been suggested as therapeutic targets.[203,205,206] Genetic variations in TLR9 receptor has been shown to predispose to SLE in a Japanese series[207] and regression of SLE was seen in a patient who developed an acquired TLR7 and TLR9 defect and antibody deficiency.[208] SLE occurs much more commonly in women, and both TLR7 and TLR8 are encoded on the X chromosome, adding another layer of disease association.[209] In addition, hydroxychloroquine, the most common treatment for all variants of SLE and LEP, has been shown to block intracellular TLRs in vitro.[210]

CLINICAL FINDINGS

LEP lesions may be tender and painful and usually appear on the upper arms (lateral aspect), shoulders, face, scalp, hips, buttocks, breasts, and rarely on the lower extremities (Fig. 70-13).[193–195] Orbital/ocular involvement may present with periorbital edema.[211,212] The lesions are deep subcutaneous nodules without any surface changes, or with surface changes including erythema and DLE features such as atrophy, hyperkeratosis, hyper- or hypopigmentation, telangiectasia, follicular plugging, and focal ulceration and necrosis.[193,194] The shoulder and arm sites are frequently associated with surface DLE lesions.[193] Incidence of ulceration varies from <7% (of 44 Japanese cases).[195] to 28% of 40 US cases.[197] Individual lesions may enlarge



Figure 70-13 Lupus panniculitis. **A.** Atrophic upper arm lesion with superficial hyperpigmentation. **B.** With superimposed discoid lupus erythematosus and ulceration.

and/or coalesce to involve large areas with atrophy.[193] Areas of ongoing indurated panniculitis may coexist with DLE, subcutaneous atrophy, and bizarre scar formation.[193] LEP resolves with depressed lipoatrophic areas that may involve much of the upper arms, shoulder, or buttock.[193,194] Facial involvement may result in noticeably atrophic malar areas with severe cosmetic alterations. LEP is a chronic inflammatory disorder with yearly or periodic flares or long remissions.[193] Lesions may appear at sites of trauma, including injections and surgical sites.[193,194] Average disease duration is 6 years, with a range of less than 1 year to 38 years.[197]

Serological findings may be normal[194] or abnormal.[193,195] Patients without associated SLE may have low positive ANA titers and those with SLE tend to have higher positive titers.[195] C4 deficiency may be found.[194,213] Other laboratory findings in some patients may include rheumatoid factor, false positive Venereal Disease Research Laboratory (VDRL), specific ANAs, leucopenia, anemia, or thrombocytopenia.[193]

HISTOPATHOLOGY

Findings may vary, with features of DLE in about 20%–30% of cases. These features include vacuolar alteration of the basal cell layer, thickened basement membrane,[53,193,195] mucin deposition between dermal collagen bundles,[53,193,195] and a superficial and deep perivascular inflammatory infiltrate of lymphocytes.[53] Findings of basement membrane thickening or liquefaction degeneration and/or pigment incontinence may be noted in significant percentages of LEP patients without clinical epidermal changes.[195] The AT shows a mostly lobular or mixed lobular and septal panniculitis, with lymphocytes, often with formation of lymphoid follicles (some with germinal centers), variable hyaline fat necrosis,[53,195] hyalinized, and sclerotic septal collagen bundles associated with an interstitial infiltrate of lymphocytes and plasma cells[53]; occasional lymphocytic vasculitis in small blood vessels of fat lobules, presence of eosinophils in the inflammatory infiltrate in some cases,[53] and membranocystic changes in some late stage lesions.[53] Calcification and/or fibrin thrombi may also be noted in 10% of cases.[195]

In cases with only AT involvement and without other features specific for DLE or SLE, differentiation from subcutaneous T-cell lymphoma, although essential, can be very difficult. There are reports of a spectrum of subcutaneous lymphoid dyscrasias, with lesions originally diagnosed as LEP progressing to indeterminate lymphocytic lobular panniculitis and eventuating in a subsequent diagnosis of subcutaneous panniculitis-like T-cell lymphoma (SPTL).[214] There may also be epidermal involvement in SPTL,[215–217] making the distinction even more difficult; in two cases initially thought to be LEP, one with subcutaneous leg nodules demonstrating

biopsy changes of interface vacuolar alteration and mucin deposition,[218] and the other with vacuolar interface changes,[219] the final diagnosis was fatal SPTL. Multiple wedge biopsies may be necessary to differentiate the αβ TCR-SPTL (SPTL-AB) or the more ominous γδ TCR (SPTL-GD) subcutaneous lymphoma from benign LEP.[214,216,217] Hemophagocytocytic syndrome has been reported in SLE with panniculitis,[220] but is more common in patients with SPTL-AB and SPTL-GD.[216]

Direct immunofluorescence biopsies are very helpful in the diagnosis of LEP, with positive findings in almost all SLE-associated LEP, and a high percentage of positive findings in LEP alone.[193,195] Blood vessel deposition of immunoglobulins and complement varies.[193,195] In those cases in which the histopathology does not provide a specific diagnosis, immunofluorescence biopsies may demonstrate the essential features for diagnosis.[193]

Immunhistochemical studies of LEP show a predominance of lymphocytes, with both αβT helper ($CD4^+$) and cytotoxic ($CD8^+$) lymphocytes mixed with ($CD20^+$) B cells and plasma cells.[196]

Polyclonal findings are seen upon analysis of the TCR-γ gene,[196] although there are additional reports that LEP can also show clonality, respond to antimalarials or corticosteroids, and not progress to clinical lymphoma, suggesting that some cases of LEP may represent an abortive lymphoid dyscrasia.[221]

In one study of biopsies from six patients with active LEP, high levels of type I interferon marker MxA were found in the epidermis and infiltrate of inflamed LEP lesions, along with numerous $CD123^+$ cells with plasmacytoid morphology and expression of interferon inducible protein (IP10)/CXCL10. Sixty to ninety percent of the infiltrating cells in the lobular infiltrates comprised cytotoxic $CXCR3^+$ lymphocytes expressing granzyme B and Tia1, leading to the conclusion that a type 1 interferon-driven immune response was present in active LEP lesions.[222]

In addition to SPTL, the differential diagnosis of LEP includes panniculitis associated with DM or morphea, as well as other panniculitides that may occur in patients with SLE such as pancreatic panniculitis and EN.

TREATMENT

Treatment is challenging and difficult, and there are no easily verifiable assessment tools to judge response to therapy other than clinical assessment of erythema, induration, and tenderness.[223] Antimalarials are usually the first-line treatment for LEP[193,194,197,224] and may be the only medications needed.[193,224] When monotherapy with hydroxychloroquine is ineffective, combination with quinacrine has been used successfully.[194,225] Antimalarials have a lesser effect in smokers,[226–228] requiring at least 3 months to show effectiveness.[194] Antimalarials interfere with inflammatory cytokines[229] as well as TLRs.[210] The effect of cigarette smoking on antimalarial treatment in LE still needs to be better defined, since cigarette smoke may both attenuate and enhance different aspects of the immune system and, in the airways, is considered able to suppress innate immune response to infections.[230,231]

Corticosteroids are effective and useful if the disease is active and severe.[193,195,232] Corticosteroids may be used short term during the period of antimalarial initiation, but long-term use is generally avoided due to the chronic nature of LEP. Intralesional steroids are not recommended currently since they are traumatic and may induce atrophy. Other treatments include dapsone,[233] thalidomide,[223,234] cyclosporine,[235] methotrexate,[236] intravenous immunoglobulin (IVIG)[236] and rituximab.[237]

OTHER CONNECTIVE TISSUE DISEASE-ASSOCIATED PANNICULITIS

PANNICULITIS ASSOCIATED WITH DERMATOMYOSITIS AT A GLANCE

Clinical

- Erythematous painful nodules and plaques on the arms, buttocks, thighs, and abdomen.

Histopathology

- Mostly lobular or mixed septal and lobular panniculitis.
- Lobular lymphocytic and plasma cell infiltrate, hyaline sclerosis of septal collagen bundles, progressive fibrosis of fat lobules.
- Calcification in 25% of cases may have vacuolar alteration at dermal–epidermal junction; membranocystic change may be present in late-stage lesions.

Treatment

- Same as for dermatomyositis.

EPIDEMIOLOGY

Clinical signs of panniculitis in association with DM are very rare, despite histopathological findings of focal nonspecific panniculitis in 9% (5/55) of biopsy specimens from patients with Diabetes Mellitus (DM).[193,238] In a 2009 literature review of clinical panniculitis with nodular and plaque lesions in DM patients, 24 cases were identified, including six in children.[239]

CLINICAL FINDINGS

Panniculitis associated with DM presents as painful indurated erythematous nodules and plaques on the arms, buttocks, thighs, and abdomen; these may ulcerate and result in lipoatrophy.[240,241] The nodules and plaques usually present in association with the characteristic cutaneous manifestations of DM. They are rarely the sole manifestation.[53,242] Juvenile DM is also known to result in lipoatrophy without preceding clinical panniculitis lesions.

HISTOPATHOLOGY

Histopathological features are similar to those of lupus panniculitis,[53] consisting of a mostly lobular panniculitis, or mixed lobular and septal panniculitis, with lymphocytic and plasma cell infiltrates, hyaline sclerosis and fibrosis of septal collagen bundles, progressive replacement of the fat by fibrosis, and calcification in 25% of cases.[53,193,239] Lesions may be associated with vacuolar alteration of the dermal–epidermal junction, and late features may include membranocystic change.[53] Dermal findings include mucin deposition or edema with perivascular lymphocytic inflammation.[243]

DIFFERENTIAL DIAGNOSIS

The main differential diagnoses are cellulitis, infection-associated panniculitis, and lupus panniculitis, which can be distinguished by a combination of clinical, laboratory, and histological findings.

CLINICAL COURSE

The panniculitis may precede, occur with, or appear late in the disease course,[240] and subsides and flares with the overall DM activity.[244] Infection can cause worsening of the panniculitis. Three patients have had infection associated with the panniculitis, two with *S. aureus* [including an immunosuppressed adolescent with both methicillin-resistant *S. aureus* (MRSA) and *Acinetobacter baumanii*] and one with *Mycobacterium chelonae*.[239] Membranocystic changes indicated a worse prognosis.[239]

TREATMENT

As in therapy for DM, treatment for DM-associated panniculitis consists of corticosteroids alone,[239] or corticosteroids and methotrexate,[242,244] or other immunosuppressive therapies such as azathioprine, cyclosporine, or IVIG.[240] Response of panniculitis in juvenile DM to hydroxychloroquine has been variable.[245] Patients with cutaneous calcification may benefit from treatment with IVIG.[246] Infection should be aggressively sought and identified prior to increasing immunosuppressive therapy; concurrent infection may require antibiotic therapy and reduction in immunosuppression.[239]

Panniculitis may also occur in patients with morphea (see Chapter 64) or systemic sclerosis (see Chapter 157).

CYTOPHAGIC HISTIOCYTIC PANNICULITIS

CYTOPHAGIC HISTIOCYTIC PANNICULITIS AT A GLANCE

Clinical findings

- Subcutaneous erythematous to violaceous plaques and nodules on extremities, trunk, less frequently elsewhere; lesions ulcerate.
- Fever, hepatosplenomegaly, two or more cytopenias; hemocytophagocytosis in bone marrow, lymph nodes, liver, or CNS.
- Hypertriglyceridemia, ferritin >500 mg/L; increased soluble CD25, CD163 levels.
- Low or absent NK cell activity, fibrinogen levels.
- Rapidly fatal disease course; intermittent remissions and exacerbations prior to death; or nonfatal acute or intermittent course.

Histopathological findings

- Mostly lobular panniculitis without vasculitis.
- Histiocytes and mature lymphocytes within fat lobules.
- "Bean-bag" cells: macrophages that contain intact or fragmented erythrocytes, leukocytes or platelets within their cytoplasm; may be focal, hard to find.
- Necrosis of adipocytes.

Treatment

- Immunosuppressive therapy: glucocorticosteroids, in combination with cyclosporine or etoposide, combined chemotherapeutic medications, anakinra; supportive care; search for associated malignancies and infections.

SUBCUTANEOUS FAT NECROSIS OF THE NEWBORN

EPIDEMIOLOGY

Subcutaneous fat necrosis of the newborn (SCFN) is a rare panniculitis that occurs in the first few weeks of

SUBCUTANEOUS FAT NECROSIS OF THE NEWBORN AT A GLANCE

Clinical

- Circumscribed, red to violaceous, subcutaneous nodules, or plaques with predilection for buttocks, shoulders, cheeks, and thighs.
- Hypercalcemia in some cases, even presenting much later than acute episode; rarely, hypertriglyceridemia, hypoglycemia, thrombocytopenia, anemia.

Histopathology

- Mostly lobular panniculitis without vasculitis.
- Dense inflammatory infiltrate of lymphocytes, histiocytes, lipophages, and multinucleated giant cells.
- Needle-shaped clefts, often in radial array, within cytoplasm of histiocytes and multinucleated giant cells.

Treatment

- Nodules and plaques usually resolve spontaneously.
- Monitor for hypercalcemia for 6 months following onset, treat if hypercalcemia develops.

life. It presents in full-term newborns with a preceding history of perinatal problems, including meconium aspiration, asphyxia, hypothermia (e.g., for cardiac surgery or ice pack application for supraventricular tachycardia), hypoxemia, seizures, sepsis, preeclampsia, factors requiring cesarean section, forceps delivery, severe neonatal anemia, maternal cocaine use, and/or failure to thrive.[279–287] SCFN may be complicated by hypercalcemia, and rarely, by hypertriglyceridemia, hypoglycemia, thrombocytopenia, and anemia.[282–284]

ETIOLOGY AND PATHOGENESIS

The cause in not known, but hypothermia or hypoxia is presumed to be involved. Possible explanations have included a biochemical defect in the composition or metabolism of neonatal fat, leading to crystallization, fat necrosis, and subsequent inflammation after cold stress.[283,288] The hypercalcemia may be related to increased levels of 25-hydroxyvitamin D3–1α hydroxylase within the granulomatous infiltrate of lesions.[289] Another explanation takes into account the presence of BAT in neonates along with its main function, which is to rapidly convert fat stores to heat under conditions of cold stress.[290] BAT is widely distributed in the early years of life. At its maximal size relative to body weight at birth, when nonshivering heat generation is most needed, the presence and function of BAT relates to the immaturity of the heat regulating mechanism, providing the young with a "thermogenic jacket."[25,290] The BAT cells leak hydrogen ions across the inner membrane of the mitochondria to generate heat instead of creating ATP for other metabolic processes.[291] The mechanism is complex, and uses uncoupling protein isoform 1 (UCP1), found specifically in BAT, cytosolic fatty acids, and Ca^{2+} ions.[292]

CLINICAL FINDINGS

Lesions are sharply demarcated, erythematous to violaceous, firm, indurated nodules, or plaques located on the back, shoulders, arms, buttocks, thighs, or face, but usually not on the anterior trunk[279,283] (Fig. 70-15A). In one case, MRI findings consistent with fat necrosis were seen in the abdominal wall as well as in the fat surrounding the liver, spleen, and a kidney.[293] The subcutaneous nodules range in size from several millimeters to up to 11 cm in greatest dimension,[280,294] may be single or multiple, and may be of irregular shape, although usually well defined.[280] Rarely, fluctuant nodules may drain an oily or chalky white material.[294] Lesions are not warm to touch[280] and may vary from entirely painless[280] to those requiring morphine for control of pain.[284]

HISTOPATHOLOGY

Characteristically, SCFN is a mostly lobular panniculitis (Fig. 70-15B), with focal necrosis of the fat lobule and a dense inflammatory infiltrate of lymphocytes, histiocytes, and foreign body giant cells; a few eosinophils may insinuate between the fat cells. Many adipocytes retain their cellular outlines, but contain fine eosinophilic strands and granules as well as needle-shaped clefts in radial array[53,98,283,295] (Fig. 70-15C). On frozen section, these clefts are occupied by doubly refractile crystals, representing triglycerides. Similar clefts and crystals may also be seen within the cytoplasm of the multinucleated giant cells.[53,98,282,295] Late stage lesions may demonstrate fibrosis and calcified areas within fat lobules; the latter may also be seen radiographically.[53,280]

DIFFERENTIAL DIAGNOSIS

Differential diagnoses include cellulitis, erysipelas, and cold panniculitis (if cold-induced).[285,286] In contrast to SCFN, the histopathology of cold panniculitis does not feature the presence of needle-shaped clefts within the subcutaneous AT.[286] Other childhood panniculitides with the histologic finding of needle-shaped clefts in subcutaneous fat include sclerema neonatorum, which manifests with diffuse skin hardening in stressed infants,[296] and poststeroid

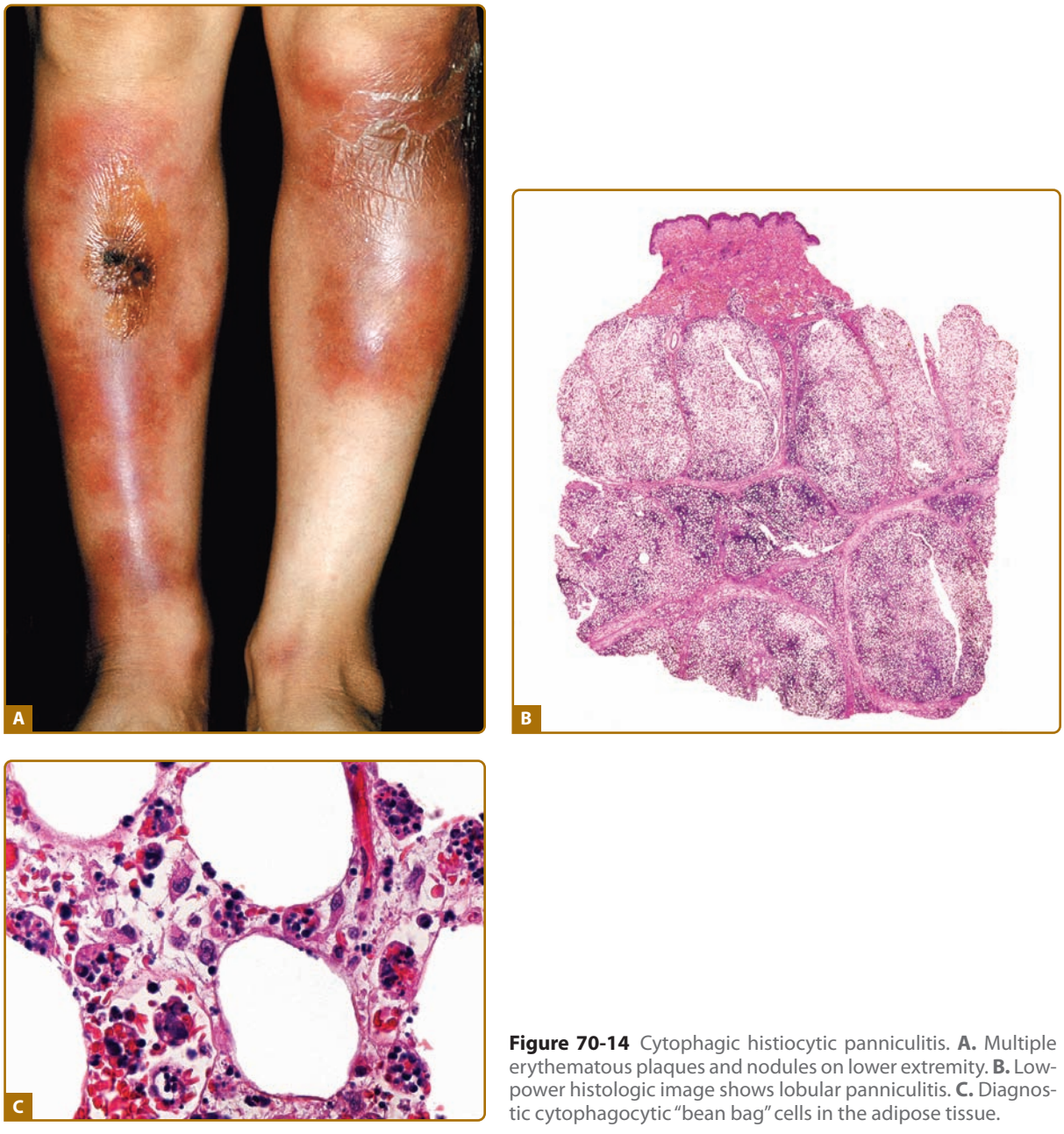

Figure 70-14 Cytophagic histiocytic panniculitis. **A.** Multiple erythematous plaques and nodules on lower extremity. **B.** Low-power histologic image shows lobular panniculitis. **C.** Diagnostic cytophagocytic "bean bag" cells in the adipose tissue.

panniculitis.[297–299] Only one infant with the clinical findings of both the diffuse hardening of the skin of sclerema and the violaceous nodules of SCFN has been described.[300] Poststeroid panniculitis occurs in children, usually within 10 days (range, 1–40 days) after rapid cessation of high-dose systemic corticosteroid therapy.[297,298]

CLINICAL COURSE

SCFN is usually a benign process with an uncomplicated course and excellent prognosis. Lesions regress in a few weeks to 6 months, with some eventuating in atrophy.[283,284,293] However, there are several metabolic complications that may occur during and even after resolution of the panniculitis.[283] These include hypercalcemia,[280,282,284,293,294] thrombocytopenia,[282,283] hypertriglyceridemia, which appears to be related to the fat necrosis[283,284] and anemia.[283] Hypercalcemia may be asymptomatic and uncomplicated,[281,284] or may become symptomatic, with failure to thrive, irritability, fever, vomiting, hypotonia, seizures, polyuria and polydypsia, and even death.[280,294] Soft tissue calcification may occur and resolve without evidence of hypercalcemia,[280] or calcium may deposit in the kidneys and cardiovascular system.[282–284] The hypercalcemia may have a delayed onset up to 6 months after appearance of the skin lesions; therefore, serial monitoring of serum calcium levels is necessary.[283,284]

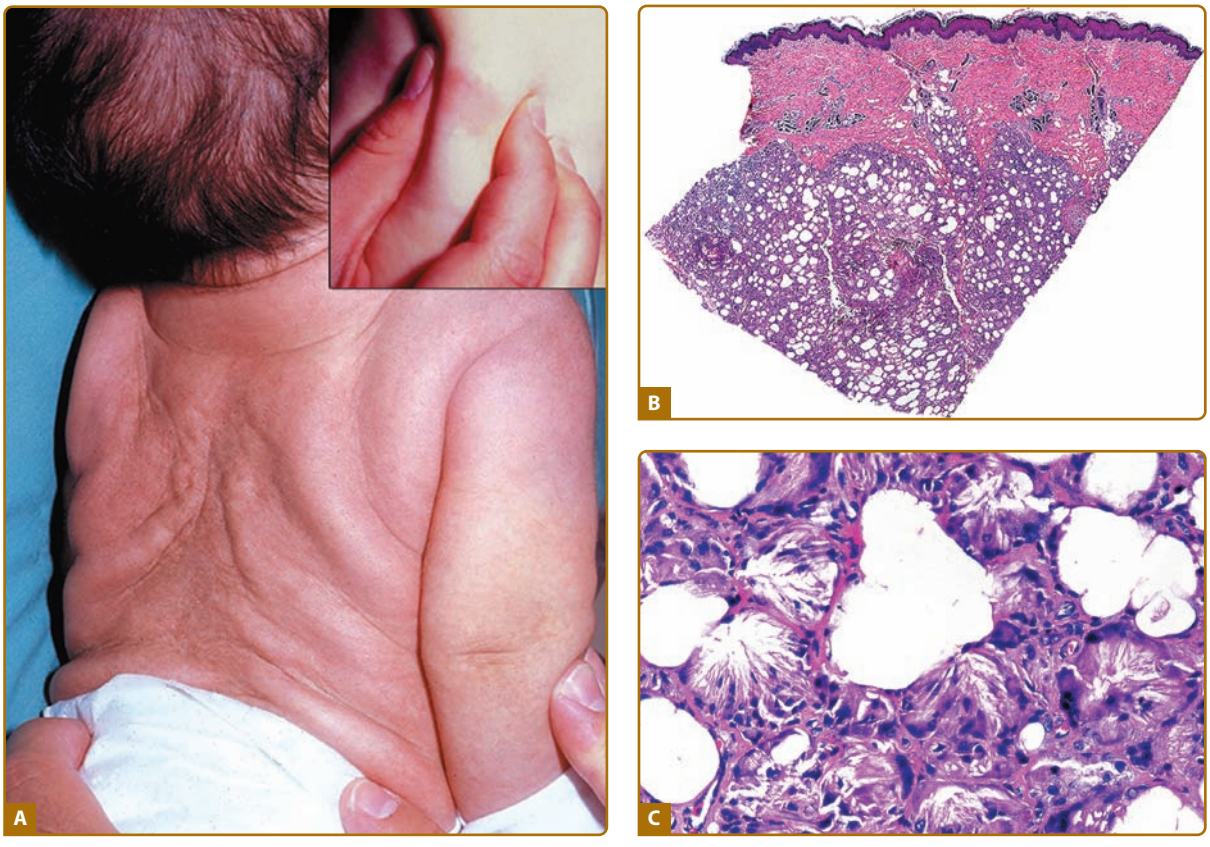

Figure 70-15 Subcutaneous fat necrosis of the newborn. **A.** Circumscribed indurated subcutaneous nodules on the back. **B.** Scanning power shows mostly lobular panniculitis. **C.** Higher magnification shows narrow needle-shaped clefts of adipocytes, histiocytes, and multinucleated giant cells.

TREATMENT

SCFN nodules resolve spontaneously, and treatment should be conservative in most cases, except for fluctuant lesions that may benefit from aspiration to prevent rupture, infections, necrosis, and scarring.[282,283] Serum calcium should be monitored with serial calcium determinations. If hypercalcemia is present, management by a pediatric endocrinologist will include hydration, use of the calcium wasting diuretic furosemide, and a low calcium and vitamin D diet.[283,294] The diuretics that increase calcium excretion may also induce dehydration, requiring careful monitoring. If these measures are insufficient to control hypercalcemia, systemic glucocorticoids are used, as they interfere with vitamin D metabolism and inhibit active vitamin D production by the macrophages in the inflamed AT[279,283,294]; however, nephrocalcinosis may still develop in spite of response to systemic steroids.[301] First and second generation bisphosphonates, including etidronate,[302,303] clodronate,[304] and pamidronate,[305] have been used to treat hypercalcemia in SCFN. However, nephrocalcinosis may develop, despite a rapid response to pamidronate.[306] The degree and duration of hypercalcemia and hypercalciuria may be the important factor in development of nephrocalcinosis; this calls for close early monitoring and recognition of hypercalcemia, since rapid therapeutic intervention to lower serum and urine calcium may be the best treatment modality for prevention of dystrophic calcification.[306]

COLD PANNICULITIS

COLD PANNICULITIS AT A GLANCE

Clinical

- Circumscribed, red to violaceous, subcutaneous nodules or plaques on the face and thighs, and rarely of the scrotal fat in prepubertal boys.
- Follows exposure to cold weather, popsicles, ice packs, and swimming in cold ocean water.

Histopathology

- Mostly lobular panniculitis (lymphohistiocytic or mixed infiltrate) without vasculitis.
- Perivascular lymphohistiocytic infiltrate involving blood vessels at dermosubcutaneous junction and within overlying dermis.
- Findings similar to those seen in perniosis.

Treatment

- Avoid direct ice placement on skin, mucous membranes.
- Spontaneous resolution within 3 months.

FACTITIAL PANNICULITIS

FACTITIAL PANNICULITIS AT A GLANCE

Clinical

- Erythematous nodules with disparate location or appearance in patients with personality aberrations.
- Subcutaneous implantation range from medications, cosmetic fillers, oils, food to human waste.

Histopathology

- Mostly lobular panniculitis without vasculitis.
- Suppurative granuloma involving the fat lobule; requires cultures for various organisms.
- Polarization of the slide may identify the refractile foreign material.
- Panniculitis morphology, such as histiocyte characteristic inclusions, or cystic spaces with foreign substances may vary with type of injected material.

Treatment

- Psychiatric treatment for self-inflicted factitial panniculitis.
- Supportive care and interference with injection of responsible agents.
- In panniculitis induced by cosmetic fillers, intralesional steroids, and often the implanted material must be surgically excised.

Factitial panniculitis is a reaction in AT induced by external factors, usually injection of foreign materials. This may be iatrogenic due to injection of medications or cosmetic fillers, or secondary to cupping and acupuncture,[320] or other means of trauma (accidental or deliberate). Factitial panniculitis is also associated with self-induced injections of various substances due to psychiatric disorder. History obtained from patients of injections of therapeutic agents or cosmetic fillers aids the diagnosis. Self-inflicted factitial panniculitis due to substances that may not necessarily leave a recognizable clinical or histopathologic footprint may be difficult to diagnose and requires a high index of suspicion.[53,320–322] Factitial lesions present a spectrum of clinical findings, from papules and nodules to erosions or ulcerations with perfect round or angulated appearance[322] (Fig. 70-16). Lesions due to blunt trauma will often be ecchymotic, show organized hematomas and hemosiderin deposits.[322] Injections of various oily substances will lead to foreign body reactions with foamy histiocytes and pseudocystic spaces.[53,322] Injection of medication and various other substances such as acids, milk, mustard, acids, alkalis, infected/contaminated materials, urine, and feces have been reported.[53,322] Early lesional histopathology is usually predominantly neutrophilic, and later may show a granulomatous infiltrate.[53,234] Due to the presence of macrophages and lymphocytes in AT, as well as the adipocyte's role as an innate immune cell producing multiple cytokines, materials injected into AT are treated as a foreign agent, with an inflammatory immune response with or without associated fat necrosis.[53,234] Patients with self-induced factitial panniculitis suffer from mental illness and require psychiatric care.[53,234] If iatrogenic, the causative action must cease. Surgical excision of the injected materials may be necessary.[320,322]



Figure 70-16 Factitial panniculitis. Self-induced round and angulated ulceration on the leg at sites of injections and trauma.

KEY REFERENCES

Full reference list available at www.DIGM8.com

DVD contains references and additional content

5. Fantuzzi G: Adipose tissue, adipokines and inflammation. *J Allergy Clin Immunol* **115**:911, 2005
27. Requena L, Sanchez Yus E: Panniculitis. Part I. Mostly septal panniculitis. *J Am Acad Dematol* **45**:163, 2001
52. Segura S et al: Vasculitis in erythema induratum of Bazin: A histopathologic study of 101 biopsy specimens from 86 patients. *J Am Acad Dermatol* **59**:839, 2008

53. Requena L, Sanchez Yus E: Panniculitis. Part II. Mostly lobular panniculitis. *J Am Acad Dermatol* **45**:325, 2001
78. Bruce AJ et al: Lipodermatosclerosis: Review of cases evaluated at Mayo Clinic. *J Am Acad Dermatol* **46**:187, 2002
129. Morrison LK et al: Infections and panniculitis. *Dermatol Ther* **23**(4):328-340, 2010
193. Winkelmann RK: Panniculitis in connective tissue diseases. *Arch Dermatol* **119**:336, 1983
223. Hansen C, Callen J: Connective tissue panniculitis. *Dermatol Ther* **23**(4):341-349, 2010
251. Crotty CP, Winkelmann RK: Cytophagic histiocytic panniculitis with fever, cytopenia, liver failure and terminal hemorrhagic diathesis. *J Am Acad Dermatol* **4**:181, 1981

Chapter 71 :: Lipodystrophy

:: Abhimanyu Garg

LIPODYSTROPHY AT A GLANCE

- Lipodystrophies are genetic or acquired disorders characterized by selective loss of body fat. The extent of fat loss determines the severity of associated metabolic complications such as diabetes mellitus, hypertriglyceridemia, hepatic steatosis, and acanthosis nigricans.
- Four loci have been identified for the autosomal recessive congenital generalized lipodystrophy (CGL), namely, (1) *AGPAT2*, (2) *BSCL2*, (3) *CAV1*, and (4) *PTRF*.
- Four loci have been identified for autosomal dominant familial partial lipodystrophy (FPL), namely, (1) *LMNA*, (2) *PPARG*, (3) *AKT2*, and (4) *PLIN1*.
- *CIDEC* is the locus for autosomal recessive *FPL*, and *LMNA* and *ZMPSTE24* are loci for autosomal recessive mandibuloacral dysplasia-associated lipodystrophy.
- Molecular basis of many rare forms of genetic lipodystrophies remains to be elucidated.
- The most prevalent variety of lipodystrophy develops after prolonged duration of protease inhibitor containing highly active antiretroviral therapy in HIV-infected patients.
- The acquired generalized lipodystrophy and acquired partial lipodystrophy are mainly autoimmune in origin.
- Localized lipodystrophies occur due to drug or vaccine injections, pressure, panniculitis, and other unknown reasons.
- The current management includes cosmetic surgery and early identification and treatment of metabolic and other complications.

Lipodystrophies are a heterogeneous group of disorders characterized by selective loss of adipose tissue.[1] The extent of fat loss varies, with some patients losing fat from small areas (localized lipodystrophy), whereas others may have more extensive fat loss, for example, involving the extremities (partial lipodystrophy) or the entire body (generalized lipodystrophy). Depending upon the extent of fat loss, patients may be predisposed to develop complications associated with insulin resistance such as, diabetes mellitus, dyslipidemia, hepatic steatosis, acanthosis nigricans, polycystic ovarian disease, and coronary heart disease.[2,3] There are two main types of lipodystrophies: (1) genetic and (2) acquired. A detailed classification of various types of lipodystrophies is given in Table 71-1.

GENETIC LIPODYSTROPHIES

In the last decade or so, considerable progress has been made in elucidation of the molecular basis of many types of genetic lipodystrophies. In general, mutations in genes involved in adipocyte differentiation, triglyceride synthesis, lipid droplet formation, and adipocyte survival have been reported to cause lipodystrophies.

EPIDEMIOLOGY

Although the genetic lipodystrophies are rare, recent advances such as improved definition of the phenotypes and elucidation of the molecular defects, have led to increased recognition of these syndromes. Overall, based on literature reports of less than 1,000 patients, the estimated prevalence of genetic lipodystrophies may be less than 1 in a million. The autosomal recessive, congenital generalized lipodystrophy (CGL) has been reported in fewer than 300 patients, with clustering of patients reported from Lebanon and Brazil where there is increased prevalence of consanguinity. The autosomal dominant, familial partial lipodystrophy (FPL) of the Dunnigan variety due to *LMNA* mutations is the most common with ~500 patients being reported; autosomal dominant, FPL due to *PPARG* mutations with ~30 patients; autosomal

TABLE 71-1
Classification of Lipodystrophies

A. **Genetic Lipodystrophies**
1. Autosomal recessive, congenital generalized lipodystrophy (CGL)
   a. Type 1: *AGPAT2* mutations
   b. Type 2: *BSCL2* mutations
   c. Type 3: *CAV1* mutation
   d. Type 4: *PTRF* mutations
   e. Others
2. Autosomal dominant, familial partial lipodystrophy (FPL)
   a. Dunnigan variety: LMNA mutations
   b. PPARG mutations
   c. AKT2 mutation
   d. PLIN1 mutations
   e. Others
3. Autosomal recessive, familial partial lipodystrophy
   a. *CIDEC* mutation
4. Autosomal recessive, mandibuloacral dysplasia (MAD)-associated lipodystrophy
   a. *LMNA* mutations
   b. *ZMPSTE24* mutations
   c. Others
5. Other lipodystrophies associated with *LMNA* mutations
   a. Atypical progeroid syndrome
   b. Hutchinson–Gilford progeria syndrome
6. SHORT syndrome
   a. Autosomal recessive
   b. Autosomal dominant
7. Neonatal progeroid (Weidemann–Rautenstrauch) syndrome
8. Mandibular hypoplasia, deafness, progeroid (MDP) syndrome
9. Joint contractures, microcytic anemia, panniculitis-associated (JMP) lipodystrophy syndrome spectrum
   a. *PSMB8* mutations

9a. Chronic atypical neutrophilic dermatosis with ipodystrophy and elevated temperature (CANDLE) syndrome

B. **Acquired Lipodystrophies**
1. Highly active antiretroviral therapy-induced lipodystrophy in HIV-infected patients
2. Acquired generalized lipodystrophy
   a. Panniculitis-induced
   b. Autoimmune diseases-associated
   c. Idiopathic
3. Acquired partial (Barraquer–Simons) lipodystrophy
   a. Autoimmune diseases-associated
   b. Membranoproliferative glomerulonephritis-associated
   c. Idiopathic
4. Localized lipodystrophies
   a. Panniculitis-induced
   b. Pressure-induced
   c. Drug-induced
   d. Centrifugal
   e. Idiopathic

recessive, mandibuloacral dysplasia (MAD) due to *LMNA* mutations in ~30 patients and due to *ZMPSTE24* mutations in eight patients. Affected females are recognized easily and thus are reported more often than males.

CONGENITAL GENERALIZED LIPODYSTROPHY (CGL, BERARDINELLI–SEIP SYNDROME)

ETIOLOGY AND PATHOGENESIS. This autosomal recessive disorder can be recognized at birth or soon thereafter due to near total lack of body fat. Genome-wide linkage analysis with positional cloning strategy and candidate gene approach have led to the identification of four genetic loci for CGL: (1) 1-acylglycerol-3-phosphate-*O*-acyltransferase 2 (*AGPAT2*) gene on chromosome 9q34,[4,5] (2) Berardinelli–Seip congenital lipodystrophy 2 (*BSCL2*) gene on chromosome 11q13,[6] (3) caveolin 1 (*CAV1*) gene on chromosome 7q31,[7] and (4) polymerase I and transcript release factor (*PTRF*) on chromosome 17q21.[8] AGPAT2 is a critical enzyme involved in the biosynthesis of triglycerides and phospholipids from glycerol-3-phosphate and is expressed highly in the adipose tissue.[9] The *BSCL2*-encoded protein, seipin, plays a role in lipid droplet formation and may also be involved in adipocyte differentiation.[10–12] Caveolin 1 is an integral component of caveolae, specialized microdomains seen in abundance on adipocyte membranes. Caveolin 1 binds fatty acids and translocates them to lipid droplets. *PTRF* is involved in biogenesis of caveolae and regulates expression of caveolins 1 and 3.[8]

CLINICAL FINDINGS. Patients with CGL present with near total loss of body fat, marked muscularity, prominent subcutaneous veins, acromegaloid features, acanthosis nigricans, hepatomegaly, and umbilical prominence or hernia (Fig. 71-1A, Table 71-2). During childhood, they have a voracious appetite, and accelerated linear growth. Females usually have hirsutism, clitoromegaly, oligoamenorrhea, and polycystic ovaries. Only a few women have had successful pregnancies. Fertility is normal in men. Some of them develop hypertrophic cardiomyopathy, mild mental retardation, and focal lytic lesions in the appendicular bones after puberty.[13–15] Metabolic abnormalities related to insulin resistance, such as diabetes mellitus, hyperlipidemia, and hepatic steatosis, may manifest at a young age and are often difficult to control. Patients with *BSCL2* mutations lack mechanical fat located in the retro-orbital region, palm, sole, and in periarticular regions as well as metabolically active adipose tissue located in the subcutaneous (sc), intra-abdominal, intrathoracic, and other areas as compared to those with *AGPAT2*, *CAV1*, and *PTRF* mutations where mechanical fat is preserved.[7,16] The only reported patient with *CAV1* mutation also had short stature and presumed vitamin D resistance.[7] Only 21 patients with *PTRF* mutations have been reported and they have congenital myopathy, increased creatine kinase levels, percussion-induced myoedema, pyloric stenosis, cardiac rhythm disturbances including prolonged QT interval, exercise-induced ventricular tachycardia, and atlantoaxial instability.[8,17,18] Patients of Lebanese origin harbor homozygous c.659delGTATC mutation in *BSCL2*, whereas those of African origin nearly always have either homozygous or compound heterozygous c.IVS4–2A>G mutation in *AGPAT2* gene.[5,6,13]



Figure 71-1 Clinical features of patients with various types of lipodystrophies. **A.** Anterior view of a 33-year-old Hispanic female with congenital generalized lipodystrophy (also known as Berardinelli–Seip congenital lipodystrophy), type 1 due to homozygous c.IVS4–2A>G mutation in *AGPAT2* gene. The patient had generalized loss of sc fat with acanthosis nigricans in the axillae and neck. She has umbilical prominence and acromegaloid features (enlarged mandible, hands, and feet). **B.** Anterior view of a 27-year-old Native American Hispanic female with familial partial lipodystrophy of the Dunnigan variety due to heterozygous p.Arg482Trp mutation in *LMNA* gene. She had marked loss of sc fat from the limbs and anterior truncal region. The breasts were atrophic. She had increased sc fat deposits in the face, anterior neck, and vulvar regions. **C.** Anterior view of an 8-year-old German boy with acquired generalized lipodystrophy. He had severe generalized loss of sc fat with marked acanthosis nigricans in the neck, axillae, and groin. **D.** Anterior view of a 39-year-old Caucasian female with acquired partial lipodystrophy (Barraquer–Simons syndrome). She had marked loss of sc fat from the face, neck, upper extremities, and chest, but had lipodystrophy on localized regions on anterior thighs. She had increased sc fat deposition in the lower extremities. **E.** Lateral view of a 53-year-old Caucasian male infected with human immunodeficiency (HIV) virus with highly active antiretroviral therapy-induced lipodystrophy. He had marked loss of sc fat from the face and limbs, but had increased sc fat deposition in the neck region anteriorly and posteriorly showing buffalo hump. Abdomen was protuberant due to excess intra-abdominal fat. He had been on protease inhibitor-containing antiretroviral therapy for more than 8 years.

FAMILIAL PARTIAL LIPODYSTROPHY (FPL)

ETIOLOGY AND PATHOGENESIS. FPL is an autosomal dominant disorder characterized by fat loss from the limbs with variable fat loss from the trunk and increased sc fat deposition in nonlipodystrophic regions (Fig. 71-1B). It results from heterozygous missense mutations in one of the four genes: (1) lamin A/C (*LMNA*) on chromosome 1q21–22,[19–22] an integral component of nuclear lamina; (2) peroxisome proliferator-activated receptor γ (*PPARG*) on chromosome 3p25,[23–25] a key transcription factor involved in adipocyte differentiation; (3) v-AKT murine thymoma oncogene homolog 2 (*AKT2*) on chromosome 19q13,[26] involved in downstream insulin signaling; and (4) perilipin 1 (*PLIN1*) on chromosome 15q26, a key component of lipid droplets.[27] Adipocyte loss in patients with *LMNA* mutations may be due to disruption of nuclear envelope function and integrity resulting in premature cell death.

CLINICAL FINDINGS. Patients with FPL have normal body fat distribution during early childhood, but around the time of puberty, sc fat from the extremities and trunk is progressively lost (Fig. 71-1B). The face, neck, and intra-abdominal region are spared, and often excess fat accumulates there.[28,29] Affected men are often more difficult to diagnose clinically, as many normal men are also quite muscular. Women are more severely affected metabolically.[30] Some patients with mutations in amino-terminal region of lamin A/C also develop myopathy, cardiomyopathy, and conduction system abnormalities indicative of a multisystem dystrophy.[31] On the other hand, others with mutations in the extreme C-terminal region of lamin A may have mild lipodystrophy.[32]

TABLE 71-2
Clinical Features of Various Types of Congenital Generalized Lipodystrophy (CGL)

	Subtype of CGL			
Characteristic	**CGL1**	**CGL2**	**CGL3**	**CGL4**
Gene	*AGPAT2*	*BSCL2*	*CAV1*	*PTRF*
Loss of metabolically active adipose tissue	+++	+++	++	++
Loss of mechanical adipose tissue	–	+	–	–
Bone marrow fat	–	–	+	+
Lytic bone lesions	++	+	–	–
Mild mental retardation	–	+	–	–
Cardiomyopathy	–	+	–	+
Echocardiogram	Normal	Abnormal	Normal	Normal
Catecholaminergic polymorphic ventricular tachycardia (CPVT)	–	–	–	+
Prolonged QT interval	–	–	–	+
Sudden death	–	–	–	+
Congenital pyloric stenosis	–	–	–	+
Atlantoaxial instability	–	–	–	+
Acanthosis nigricans	+++	+++	++	+/–
Hepatomegaly	+	+	+	+
Congenital myopathy	–	–	–	+
Diabetes mellitus	+	+	+	–
Hypertriglyceridemia	+	+	+	+
Hypocalcemia	–	–	+	–
Hyperinsulinemia	+	+	+	+

Nearly 30 patients with FPL due to heterozygous mutations in *PPARG* gene have been reported so far. They have more marked fat loss from the extremities, especially from distal regions, but the fat from the face, neck, and truncal area is spared. There is increased prevalence of hypertension among the affected subjects. Four subjects from a single family with diabetes and insulin resistance were reported to harbor a heterozygous mutation in *AKT2* gene. The female proband had lipodystrophy of the limbs although detailed studies of body fat distribution were not performed. Recently, five FPL patients were reported to harbor *PLIN1* mutations.[27]

MANDIBULOACRAL DYSPLASIA (MAD) ASSOCIATED LIPODYSTROPHY

ETIOLOGY AND PATHOGENESIS. Mutations in *LMNA* and zinc metalloproteinase (*ZMPSTE24*) on chromosome 1p34 also result in autosomal recessive, MAD-associated lipodystrophies.[33,34] *ZMPSTE24* is involved in posttranslational proteolytic processing of prelamin A to mature lamin A and its deficiency can result in accumulation of prelamin A in cells which is supposed to cause toxicity.

CLINICAL FINDINGS. Patients with MAD have characteristic skeletal abnormalities including hypoplasia of the mandible and clavicles, acroosteolysis, cutaneous atrophy, progeroid features such as thin beaked nose, hair loss, thin skin with prominent superficial vasculature and mottled hyperpigmentation, delayed dentition and closure of cranial sutures, joint stiffness, and lipodystrophy.[35,36] Those with *ZMPSTE24* mutations develop clinical manifestations earlier in life, are premature at birth, and can develop focal segmental glomerulosclerosis and calcified skin nodules.[37,38]

OTHER TYPES

ETIOLOGY AND PATHOGENESIS. Recently, a single patient with autosomal recessive, FPL phenotype was found to harbor a homozygous missense mutation in cell death-inducing DNA fragmentation

factor a-like effector c (*CIDEC*) gene on chromosome 3p25, involved in lipid droplet formation.[39] The histopathology of the sc adipose tissue of the patient revealed multilocular, small lipid droplets in adipocytes. Heterozygous *LMNA* mutations can also cause variable amount of fat loss in patients with atypical progeroid syndrome[40] and generalized loss of sc fat in Hutchinson–Gilford progeria syndrome.[41] Another distinct autosomal recessive autoinflammatory lipodystrophy syndrome with a spectrum of disease manifestations (see JMP and CANDLE syndromes below) results from mutations in proteasome subunit, beta-type, 8 (*PSMB8*).[42,43,44a,44b] *PSMB8* encodes the β5i subunit of the immunoproteasome involved in proteolytic cleavage of immunogenic epitopes presented by major histocompatibility complex, class I molecules.[44c] The molecular genetic basis of many other genetic lipodystrophy syndromes remains unclear (Table 71-1).

CLINICAL FINDINGS. We recently reported a novel autosomal recessive syndrome with mandibular hypoplasia, deafness, progeroid features (MDP)-associated lipodystrophy.[45] All males with MDP had undescended testes and were hypogonadal. One adult female showed lack of breast development. The molecular basis of this syndrome remains unclear. *PSMB8* mutations present as a spectrum of clinical manifestations ranging from onset during the first months of life[46] to later during childhood.[47] Early features are recurrent fevers, annular violaceous plaques, poor weight and height gain, persistent violaceous eyelid swelling, hepatomegaly, arthralgias variable muscle atrophy, and progressive lipodystrophy.[46] Histopathologic examination of lesional skin shows atypical mononuclear infiltrates of myeloid lineage and mature neutrophils, and laboratory abnormalities include chronic anemia, elevated acute-phase reactants, and raised liver enzymes with a cytokine profile showing high levels of IP-1, MCP-1, IL-6, and IL-1Ra, consistent with an IFN signaling signature.[43] This presentation has been called CANDLE syndrome (Chronic Atypical Neutrophilic Dermatosis with Lipodystrophy and Elevated temperature).[46] Older individuals with *PSMB8* mutations show joint contractures, muscle atrophy, microcytic anemia, and panniculitis-induced (JMP) childhood-onset lipodystrophy.[47] Other features of JMP syndrome include hypergammaglobulinemia, elevated erythrocyte sedimentation rate, hepatosplenomegaly, and calcification of basal ganglia.[42,44a,44b,47] Other rare syndromes of lipodystrophy include SHORT syndrome, which is characterized by the constellation of *S*hort stature, *H*yperextensibility or inguinal hernia, *O*cular depression, *R*ieger anomaly, and *T*eething delay.[48,49] This syndrome is reported to have autosomal recessive as well as dominant inheritance patterns and fat loss is usually confined to the face, upper extremities, and trunk, and sometimes the buttocks.[48,49] The autosomal recessive, neonatal progeroid (Weidemann–Rautenstrauch) syndrome presents with generalized loss of body fat and muscle mass and progeroid appearance at birth.[50]

ACQUIRED LIPODYSTROPHIES

Despite recognition of acquired lipodystrophies for more than a century, progress in understanding underlying pathogenetic mechanisms has been slow.

EPIDEMIOLOGY

Acquired partial lipodystrophy was recognized approximately 125 years ago and only ~250 cases of various ethnicities with male-to-female ratio of 1:4 have been reported.[51] Acquired generalized lipodystrophy has been reported in less than 100 cases, mostly Caucasians with a male-to-female ratio of 1:3.[52] The most common type at present is highly active antiretroviral therapy [containing protease inhibitors (PIs)]-induced lipodystrophy in human immunodeficiency virus (HIV)-infected patients, which is estimated to be affecting more than 100,000 patients in the United States and many more in other countries.[53]

ACQUIRED PARTIAL LIPODYSTROPHY (APL, BARRAQUER–SIMONS SYNDROME)

ETIOLOGY AND PATHOGENESIS. The exact pathogenesis of sc fat loss remains unclear but there is strong evidence of autoimmune-mediated adipocyte loss as more than 80% of the patients have low levels of complement 3 (C3) and presence of a circulating immunoglobulin (Ig) G, C3-nephritic factor that blocks degradation of the enzyme C3 convertase.[51] Loss of fat could be due to C3-nephritic factor-induced lysis of adipocytes expressing factor D.[54]

CLINICAL FINDINGS. Acquired partial lipodystrophy develops in most patients before age 15. Patients lose sc fat gradually in a symmetric fashion starting with the face and then spreading downwards. Most of them present with fat loss from the face, neck, upper extremities, and trunk with sparing of sc abdominal fat and lower extremities (Fig. 71-1C). Approximately, 20% of the patients develop mesangiocapillary (membranoproliferative) glomerulonephritis, and some develop drusen.[51] Usually, patients do not develop metabolic complications.

ACQUIRED GENERALIZED LIPODYSTROPHY (AGL, LAWRENCE SYNDROME)

ETIOLOGY AND PATHOGENESIS. The exact mechanisms of fat loss are not known. In approximately 25% of patients, sc fat loss occurs following development of sc inflammatory nodules that on biopsy reveal panniculitis.[52] These lesions initially result in localized fat loss followed by generalized loss of fat. Another 25% of the patients have associated autoimmune diseases such as juvenile dermatomyositis.[52] In the

remaining patients with the idiopathic variety, multiple unknown mechanisms are likely involved.[52] Patients with the panniculitis-associated variety have less severe fat loss and metabolic complications than seen in other types.

CLINICAL FINDINGS. Acquired generalized lipodystrophies present with variable amount of sc fat loss usually during childhood. Although many patients have generalized loss of fat, some areas are spared in some of them (Fig. 71-1D). Usually, intra-abdominal or bone marrow fat is spared.[52] However, patients develop extremely severe hepatic steatosis and fibrosis, diabetes, and hypertriglyceridemia, which are difficult to manage.

HIGHLY ACTIVE ANTIRETROVIRAL THERAPY (HAART)-INDUCED LIPODYSTROPHY IN HIV-INFECTED PATIENTS

ETIOLOGY AND PATHOGENESIS. Drugs such as HIV-1 PIs and nucleoside analogs are implicated in causing lipodystrophy in HIV-infected patients. Many, but not all, PIs may induce lipodystrophy by inhibiting ZMPSTE24, resulting in accumulation of prelamin A.[55] Other mechanisms may include PI-induced alteration of expression of key transcription factors involved in lipogenesis and adipocyte differentiation, such as, sterol regulatory element-binding protein 1c, and PPARG.[56] PIs also reduce glucose transporter 4 expression, which may be a mechanism for inducing insulin resistance.[57] Nucleoside analogs, especially zidovudine and stavudine, may induce fat loss by inhibiting polymerase-γ, a mitochondrial enzyme involved in replication of mitochondrial DNA.[58] Since most patients receive multiple antiretroviral drugs together, the individual effects of PIs or nucleoside reverse transcriptase inhibitors (NRTIs) on the phenotype are not clear.

CLINICAL FINDINGS. Patients infected with HIV usually lose sc fat from the face, trunk, and extremities 2 years or more after receiving PI-containing HAART (Fig. 71-1E; Figs. 71-2A and 71-2B). Fat loss from the face can be so severe as to result in an emaciated appearance. Some of them develop buffalo hump, double chin, and also gain intra-abdominal fat. The fat loss progressively gets worse with ongoing HAART therapy and does not reverse on discontinuation of PIs. Some cases develop diabetes mellitus and many develop combined hyperlipidemia that can predispose the patients to coronary heart disease.[59]

LOCALIZED LIPODYSTROPHY

ETIOLOGY AND PATHOGENESIS. This can occur due to sc injection of various drugs, panniculitis, pressure, and other mechanisms.[2]

CLINICAL FINDINGS. Localized lipodystrophies present with sc fat loss from a focal region resulting in a dimple or a crater with overlying skin usually unaffected. In some patients, large contiguous or anatomically distinct areas on any region of the body may be involved.[2]

APPROACH TO PATIENT ALGORITHM

Lipodystrophies should be strongly suspected in "lean or nonobese" patients who present with premature onset of diabetes, hypertriglyceridemia, hepatic steatosis, acanthosis nigricans, and polycystic ovarian syndrome. These patients should be examined carefully for evidence of loss of sc fat especially from the hips and thighs, as well as excess sc fat deposition in various anatomic regions. For those presenting with generalized lipodystrophy during childhood, pictures at birth should be evaluated for evidence of fat loss. If lipodystrophy phenotype is discovered at or shortly after birth, CGL should be considered; otherwise, the patient may have acquired lipodystrophy.

HISTORY

Patients should be asked about the age of onset and progression of lipodystrophy and other associated manifestations. Taking a detailed family history, including the history of consanguinity, is very important to understand the mode of inheritance of genetic lipodystrophies. Associated autoimmune diseases, especially juvenile dermatomyositis, should be considered in patients with acquired lipodystrophies. Those with localized lipodystrophies should be asked about local injections, trauma, pressure, or other insults. A detailed history of duration and type of antiretroviral therapy should be obtained from HIV-infected patients with lipodystrophy.

CUTANEOUS LESIONS

The most common cutaneous lesion seen in patients with lipodystrophies is acanthosis nigricans in the axillae, groins, neck, and sometimes even on the knuckles, Achilles tendons, and trunk (Figs. 71-3A and 71-3B). Many patients develop clitoromegaly and hirsutism due to associated polycystic ovarian syndrome. Freckles have been noted in a patient with atypical progeroid syndrome (Fig. 71-3C). Thin beaked nose with loss of the scalp, eyebrow, and axillary hair with cutaneous atrophy and mottled hyperpigmentation can be seen in patients with progeroid syndromes and MAD (Fig. 71-3D) along with acroosteolysis (Fig. 71-3E).[35,40,41] Rare patients with MAD develop shiny, taut, atrophic skin with a tendency to breakdown. Eruptive, tuberous, and planar xanthomas are also commonly seen in patients with extreme hypertriglyceridemia (Figs. 71-3F and 71-3G). Loss of sc fat from the soles can result in plantar calluses. Subcutaneous nodules with overlying erythema may be seen in patients with panniculitis.



Figure 71-2 **A.** Highly active antiretroviral therapy-induced lipodystrophy in a patient with human immunodeficiency virus (HIV) infection-associated lipodystrophy in a patient receiving highly active antiretroviral therapy. Loss of buccal fat results in prominence of the zygomatic arch **B.** Highly active antiretroviral therapy-induced lipodystrophy with loss of subcutaneous fat from the lateral buttock and deposit in the trunk, causing an increased waist–hip ratio.

LABORATORY TESTS

Laboratory testing depends upon the type of lipodystrophy. Except for patients with localized lipodystrophies, a serum chemistry profile for glucose, lipids, liver enzymes, and uric acid should be obtained. Measurement of fasting and postprandial serum glucose and insulin during an oral glucose tolerance test can provide some estimate of insulin resistance. Serum leptin measurements are not diagnostic, but can help guide treatment decisions as far as investigational human recombinant leptin replacement therapy is concerned. Serum leptin and adiponectin levels are very low in patients with generalized lipodystrophies.[60] Patients with acquired partial lipodystrophy should be tested for serum C3 and C3-nephritic factor and annually checked for proteinuria. Radiographs can show presence of lytic lesions in appendicular bones in patients with CGL and skeletal defects in those with MAD. Skin biopsy is useful for patients with localized lipodystrophy or panniculitis-associated varieties.

SPECIAL TESTS (INCLUDING IMAGING STUDIES)

Distinction between various types of lipodystrophies can be made by physical examination and supported by anthropometry, including measurement of skinfold thickness with calipers at various sites. For in-depth phenotyping of body fat distribution, dual energy X-ray absorptiometry, and a whole body T-1 weighted magnetic resonance imaging can be conducted. For those genetic lipodystrophies whose molecular basis is known, various commercial and research laboratories offer genetic testing. Prenatal genetic testing is also feasible. FPL patients and CGL, type 4 patients who are predisposed to cardiomyopathy should undergo electrocardiography and Holter monitoring to detect arrhythmias and echocardiography to assess cardiac function.

DIFFERENTIAL DIAGNOSIS

The most important differential diagnosis of generalized lipodystrophies is with conditions presenting with severe weight loss, such as, malnutrition, famine, starvation, anorexia nervosa, uncontrolled diabetes mellitus, thyrotoxicosis, adrenocortical insufficiency, cancer cachexia, HIV-associated wasting, diencephalic syndrome and chronic infections. For partial lipodystrophies, distinction should be made with Cushing syndrome, generalized and truncal obesity, and multiple symmetric lipomatosis (Madelung disease). Patients with MAD and progeroid syndromes-associated lipodystrophies should be differentiated from those with Werner syndrome and leprechaunism (Donahue syndrome).



Figure 71-3 Dermatologic manifestations seen in patients with lipodystrophies. **A.** Acanthosis nigricans (brownish discoloration with thickening of the skin) in the axilla and anterior neck in an 8-year-old Caucasian boy with acquired generalized lipodystrophy. **B.** Acanthosis nigricans in the perineum and medial parts of the proximal thighs in a 37-year-old female with familial partial lipodystrophy (FPL). Multiple, small skin tags accompany increased pigmentation and thick skin. **C.** Multiple, slightly hyperpigmented flat plaques (freckles) in a 7-year-old boy with atypical progeroid syndrome due to heterozygous p.Cys588Arg mutation in *LMNA* gene. **D.** Loss of hair from the posterior scalp region in a 5-year-old girl with severe mandibuloacral dysplasia (MAD) due to homozygous p.Arg527Cys mutation in *LMNA* gene. She had narrow shoulders due to clavicular hypoplasia. **E.** Acroosteolysis in a 20-year-old Hispanic woman with MAD due to homozygous p.Arg527His mutation in *LMNA* gene. The terminal digits appear short and bulbous due to resorption of the terminal phalanges. The skin on the dorsum of the hand is atrophic, especially over the proximal interphalangeal and metacarpophalangeal joints. **F.** Tuberous xanthomas over the middle finger of a 45-year-old Caucasian patient with severe hyperlipidemia associated with FPL of the Dunnigan variety due to heterozygous p.Arg482Gln mutation in *LMNA* gene. **G.** Planar xanthomas on the sole of the patient described in F. (Panel C reproduced with permission from Garg A et al: Atypical progeroid syndrome due to heterozygous missense *LMNA* mutations. *J Clin Endocrinol Metab* **94**:4971-4983, 2009. Copyright 2009, The Endocrine Society. Panel G reproduced with permission from Simha V, Garg A: Lipodystrophy: lessons in lipid and energy metabolism. *Current Opin Lipidol* **17**:162-169, 2006. Wolters Kluwer/Lippincott Williams & Wilkins.)

COMPLICATIONS

Some patients develop extreme hypertriglyceridemia and chylomicronemia, which result in acute pancreatitis and even death. Long-term complications of diabetes such as nephropathy, neuropathy, and retinopathy are frequently seen. Many patients develop coronary heart disease and other atherosclerotic vascular complications.[30,61] Hepatic steatosis can lead to cirrhosis, necessitating liver transplantation. Sudden death has been reported during childhood in CGL, type 4, likely due to arrhythmias.[17] Some patients with APL and membranoproliferative glomerulonephritis may require kidney transplantation.[51] Patients with Hutchinson–Gilford progeria syndrome die of acute myocardial infarction or cerebrovascular accidents during teenage years.[62] Some patients with atypical progeroid syndrome and FPL, Dunnigan develop cardiomyopathy with valvular dysfunction, congestive heart failure, and arrhythmias requiring pacemaker implantation.[31,40] Two adult patients with MAD due to *ZMPSTE24* mutations have died of renal failure due to focal segmental glomerulosclerosis.[37]

PROGNOSIS/CLINICAL COURSE

The prognosis is dependent upon the type of lipodystrophy. Most of the published cases of CGL have been children and thus there is lack of data about their prog-

nosis. In our experience, some have died of complications of acute pancreatitis, cirrhosis, or developed end-stage renal disease, requiring renal transplantation, and blindness due to diabetic retinopathy. Patients with FPL are also predisposed to metabolic complications and die of atherosclerotic vascular and coronary heart disease or cardiomyopathy and rhythm disturbances. Some patients with MAD have reportedly died during childhood and some died later in the 3rd and 4th decades of complications of renal failure.[37,63] Patients with AGL suffer severe metabolic complications. Patients with APL and membranoproliferative glomerulonephritis develop renal failure, but others have normal life span as do those with localized lipodystrophy. HIV-infected patients with lipodystrophy are predisposed to developing coronary heart disease.

TREATMENT

Treatment of various types of lipodystrophies is quite challenging. There is no specific treatment available to reverse the loss of body fat. The mainstay of treatment includes cosmetic surgery and management of complications. Patients with partial lipodystrophies can undergo autologous adipose tissue transplantation or implantation of dermal fillers such as hyaluronic acid, calcium hydroxylapatite, silicone, polyacrylamide gels, or poly-L-lactic acid.[64] Unwanted excess adipose tissue can be surgically excised or removed by liposuction. Those with CGL can undergo reconstructive facial surgery including fascial grafts from thighs, free flaps from anterolateral thigh, anterior abdomen, or temporalis muscle.[1] Support of the parents is critical for preventing unwanted stress and psychological sequelae in children affected with lipodystrophies.

All patients are advised to consume low-fat diets. These diets can improve chylomicronemia in patients with extreme hypertriglyceridemia. However, high carbohydrate intake may also raise very low-density lipoprotein triglyceride concentrations. Increased physical activity should be encouraged to mitigate insulin resistance and its complications except in those with FPL who have cardiomyopathy. Lytic bone lesions in appendicular bones in patients with CGL usually do not pose an increased risk of fractures.

There are no well-controlled trials available to guide treatment decisions about how to manage metabolic complications. For severe hypertriglyceridemia, an extremely low-fat diet along with fibrates and n-3 polyunsaturated fatty acids should be used. Statins can be added if required. Any form of estrogen therapy should be avoided, as it can pose the risk of severe hypertriglyceridemia-induced acute pancreatitis. Diabetes should be managed initially with metformin. Thiazolidinediones should be used with caution in patients with partial lipodystrophies as they can potentially increase unwanted fat deposition in nonlipodystrophic regions.[65] Although thiazolidinediones can be useful in FPL patients with *PPARG* mutations, the data on their efficacy are equivocal.[66] If hyperglycemia persists despite using various combinations of oral antidiabetic drugs, insulin therapy should be initiated. For those with extreme insulin resistance, U-500 insulin should be used. No specific therapy is available at this time for hepatic steatosis. Although, subcutaneous metreleptin replacement therapy has been shown to improve diabetes control, hepatic steatosis, and hypertriglyceridemia in markedly hypoleptinemic patients with generalized lipodystrophies,[67,68] its effects in patients with FPL so far have been equivocal.[69] Metreleptin therapy is investigational and not approved by the Food and Drug Administration of US. Switching PIs and NRTIs strongly associated with lipodystrophy to other regimen may improve dyslipidemia and insulin resistance in HIV-infected patients with lipodystrophy; however, loss of sc fat may not improve.[70]

PREVENTION

With the discovery of the molecular genetic basis of many types of inherited lipodystrophies, prenatal diagnosis can be offered for those families with an affected child. Premarital genetic counseling can be provided to those with high prevalence of consanguinity and CGL such as those from Lebanon and certain regions of Brazil. If the newer HAART regimen (not including PIs) are proven not to be associated with lipodystrophy and are deemed to be efficacious and safe, we may be able to prevent development of lipodystrophy in HIV-infected patients.

KEY REFERENCES

Full reference list available at www.DIGM8.com

DVD contains references and additional content

1. Garg A: Acquired and inherited lipodystrophies. *N Engl J Med* **350**:1220-1234, 2004
2. Garg A: Lipodystrophies. *Am J Med* **108**:143-152, 2000
5. Agarwal AK et al: *AGPAT2* is mutated in congenital generalized lipodystrophy linked to chromosome 9q34. *Nat Genet* **31**:21-23, 2002
6. Magre J et al: Identification of the gene altered in Berardinelli-Seip congenital lipodystrophy on chromosome 11q13. *Nat Genet* **28**:365-370, 2001
7. Kim CA et al: Association of a homozygous nonsense caveolin-1 mutation with Berardinelli-Seip congenital lipodystrophy. *J Clin Endocrinol Metab* **93**:1129-1134, 2008
8. Hayashi YK et al: Human PTRF mutations cause secondary deficiency of caveolins resulting in muscular dystrophy with generalized lipodystrophy. *J Clin Invest* **119**:2623-2633, 2009
19. Cao H, Hegele RA: Nuclear lamin A/C R482Q mutation in Canadian kindreds with Dunnigan-type familial partial lipodystrophy. *Hum Mol Genet* **9**:109-112, 2000
23. Agarwal AK, Garg A: A novel heterozygous mutation in peroxisome proliferator-activated receptor-g gene in a patient with familial partial lipodystrophy. *J Clin Endocrinol Metab* **87**:408-411, 2002
33. Novelli G et al: Mandibuloacral dysplasia is caused by a mutation in LMNA-encoding lamin A/C. *Am J Hum Genet* **71**:426-431, 2002
34. Agarwal AK et al: Zinc metalloproteinase, *ZMPSTE24*, is mutated in mandibuloacral dysplasia. *Hum Mol Genet* **12**:1995-2001, 2003

51. Misra A, Peethambaram A, Garg A: Clinical features and metabolic and autoimmune derangements in acquired partial lipodystrophy: Report of 35 cases and review of the literature. *Medicine (Baltimore)* **83**:18-34, 2004
52. Misra A, Garg A: Clinical features and metabolic derangements in acquired generalized lipodystrophy: Case reports and review of the literature. *Medicine* **82**:129-146, 2003
53. Chen D, Misra A, Garg A: Lipodystrophy in human immunodeficiency virus-infected patients. *J Clin Endocrinol Metab* **87**:4845-4856, 2002
59. Grinspoon S, Carr A: Cardiovascular risk and body-fat abnormalities in HIV-infected adults. *N Engl J Med* **352**:48-62, 2005
67. Oral EA et al: Leptin-replacement therapy for lipodystrophy. *N Engl J Med* **346**:570-578, 2002

SECTION 11

Disorders of Melanocytes

Chapter 72 :: Biology of Melanocytes

:: Hee-Young Park & Mina Yaar

BIOLOGY OF MELANOCYTES AT A GLANCE

- Melanoblasts
  - derive from the neural crest. Their migration/survival in the epidermis is influenced by numerous factors.
- Melanocytes
  - populate the epidermis, hair follicle, eye, cochlea, and meninges.
  - synthesize melanin, an indole derivative of 3,4 di-hydroxy-phenylalanine (DOPA) that is stored in melanosomes.
  - are influenced by endocrine, paracrine, and autocrine factors and by ultraviolet (UV) irradiation.
- Melanosomes
  - display four maturation stages.
  - contain structural matrix proteins, melanogenic enzymes, pH-maintaining proteins, and free-radical scavengers.
  - are transported to melanocyte dendrite tips and transferred to epidermal keratinocytes.
  - in skin, absorb UV radiation and protect against photodamage.

EMBRYONIC DEVELOPMENT

Melanocytes are pigment-producing cells that originate from the dorsal portions of the closing neural tube in vertebrate embryos[1] (eFig. 72-0.1 in online edition). They derive from pluripotent neural crest cells that differentiate into numerous cell lineages including neurons, glia, smooth muscle, craniofacial bone, cartiledge, and melanocytes.[2,3] Progenitor melanoblasts migrate dorsolaterally between the mesodermal and ectodermal layers to reach their final destinations in the hair follicles and the skin as well as inner ear cochlea, choroids, ciliary body, and iris.[2,4] Pigment-producing cells can be found in fetal epidermis as early as the 50th day of gestation.

Melanoblast migration and differentiation into melanocytes are influenced by a number of signaling molecules produced by neighboring cells. These include Wnt, endothelin (ET)-3, bone morphogenetic proteins (BMPs), steel factor (SF) (stem cell factor, c-Kit ligand), and hepatocyte growth factor (HGF/scatter factor).[5–10] By interacting with their specific cell surface receptors, these molecules induce intracellular and intranuclear signaling to influence gene transcription and protein synthesis. Genetic defects in some of these molecules are associated with human genetic diseases: ETs (Waardenburg syndrome and Hirschsprung disease) and c-Kit and stell factor with piebaldism. Detailed discussion of each signaling molecule is available online.

SITE-SPECIFIC MELANOCYTES

MELANOCYTE STEM CELLS

Generally, stem cells are defined by their undifferentiated state and their capacity to develop into several differentiated cell types. They are quiescent, slow-cycling cells that frequently are found in niches where they are surrounded by differentiated cells that affect their behavior through the secretion of cytokines and growth factors.[29,30]

Melanocyte stem cells reside in the hair follicle bulge (Fig. 72-1). They express TRP-2 as well as the neural crest stem cell intermediate filament nestin in addition to other neural crest stem cell markers including the transcription factors Sox10 and Pax5 that participate in the regulation of microphthalmia-associated transcription factor (MITF) and TRP-2. Melanocyte stem cells can leave the bulge region and migrate/differentiate in the epidermis or the hair follicle.

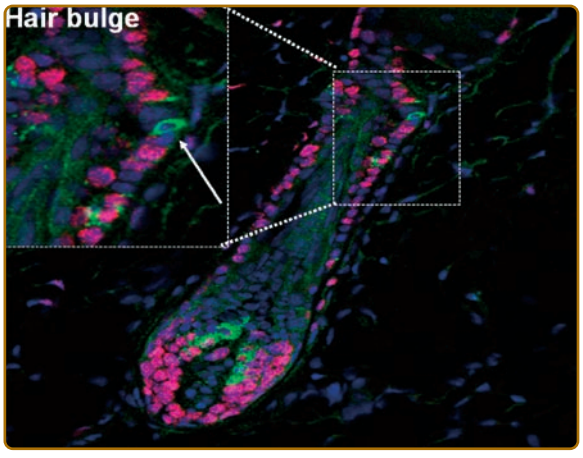

Figure 72-1 Melanocyte stem cells in the hair follicle bulge. A stem cell melanocyte is shown in the hair follicle bulge, indicated by an *arrow* in the high-power insert. These cells stain positive for TRP-2 (*green fluorescence*), an early marker of commitment to the melanocyte lineage, but are negative for the proliferation marker Ki-67 (*red fluorescence*) that characterizes melanocytes migrating down the follicle to the dermal papilla during the anagen phase of the hair cycle. (From Botchkareva NV et al: SCF/c-kit signaling is required for cyclic regeneration of the hair pigmentation unit. *FASEB J* **15**:645, 2001, with permission.)

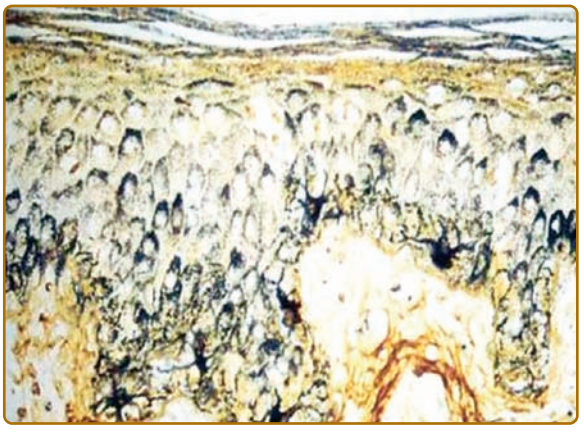

Figure 72-2 Melanosomes are organized into supranuclear "caps" within keratinocytes. Note melanized dendritic melanocytes and adjacent keratinocytes with the supranuclear "caps." Melanin silver-stained (Fontana-Masson) section of a heavily melanized human epidermis. (Bar = 50 µm.) (From Byers HR et al: Role of cytoplasmic dynein in perinuclear aggregation of phagocytosed melanosomes and supranuclear melanin cap formation in human keratinocytes. *J Invest Dermatol* **121**:813, 2003, with permission.)

CUTANEOUS MELANOCYTES

The largest number of melanocytes are present in the skin and hair follicles. While in most furred mammals melanocytes are found only in the hair follicle, in humans, melanocytes are also present in interfollicular epidermis, specifically in the basal layer.[28] There is approximately one melanocyte per five or six basal keratinocytes. Melanocytes synthesize melanin, a pigmented polymer that is stored in cytosolic organelles called melanosomes that are transferred to keratinocytes through melanocyte dendritic processes (Fig. 72-2). As keratinocytes are continuously being desquamated, there is a constant need for synthesis and transfer of melanosomes from melanocytes to keratinocytes in order to maintain cutaneous pigmentation.

The term "epidermal melanin unit" describes a single epidermal melanocyte surrounded by several epidermal keratinocytes[31] (Fig. 72-3). Interestingly, signals from keratinocytes substantially regulate epidermal melanocyte survival, dendricity, melanogenesis and the expression of cell surface receptors[32] (see below). Most keratinocyte-derived signals are induced by ultraviolet (UV) irradiation.

Melanocyte density/mm^2 ranges from approximately 550 to >1,200 with the highest concentrations found in the genitalia and face.[33,34] Melanocyte density is the same in individuals of different racial backgrounds,[34] and thus cutaneous pigmentation does not depend on melanocyte number, but rather upon melanogenic activity within the melanocyte, the proportion of mature melanosomes, and/or their transfer and distribution within the keratinocytes.[35] Indeed, in light-skinned individuals, melanosomes are smaller and are present in clusters within the keratinocytes, while in ethnic groups with darker complexion, melanosomes are larger, darker, and are individually dispersed within the keratinocytes.[36]

HAIR FOLLICLE MELANOCYTES

In contrast with interfollicular epidermal melanocytes, the follicular melanin unit undergoes cyclic modifications in coordination with the hair cycle (Fig. 72-4). Melanocytes are located in the proximal hair bulb during anagen and there is a ratio of 1:5 between melanocytes and keratinocytes and 1:1 between melanocytes and basal layer keratinocytes.[37] Melanocytes proliferate, migrate, and undergo maturation during early to mid anagen. Melanogenesis and melanin transfer to keratinocytes occurs throughout anagen. Melanocytes eventually apoptose during late catagen. In mice, melanocyte proliferation and differentiation during anagen depends on c-Kit expression by melanocytes and SF synthesis by keratinocytes.[38]

Similar to their role in the epidermis, in hair, melanocytes transfer melanin to differentiated keratinocytes that ultimately form the hair shaft. They thus determine hair color by the amount of melanin transferred, as well as by the ratio of eumelanin (black–brown) to pheomelanin (red–yellow) (see below).[39]

In hair, melanin does not appear to have a protective effect, since UV irradiation does not reach the hair follicle. Still, in furry animals hair color plays an important role in camouflage, mimicry, and social communication.[40] It is also speculated that melanocytes restrain keratinocyte proliferation, affect calcium homeostasis, and protect against reactive oxygen species (ROS) during the rapid proliferation and differentiation of the hair follicle.[37]

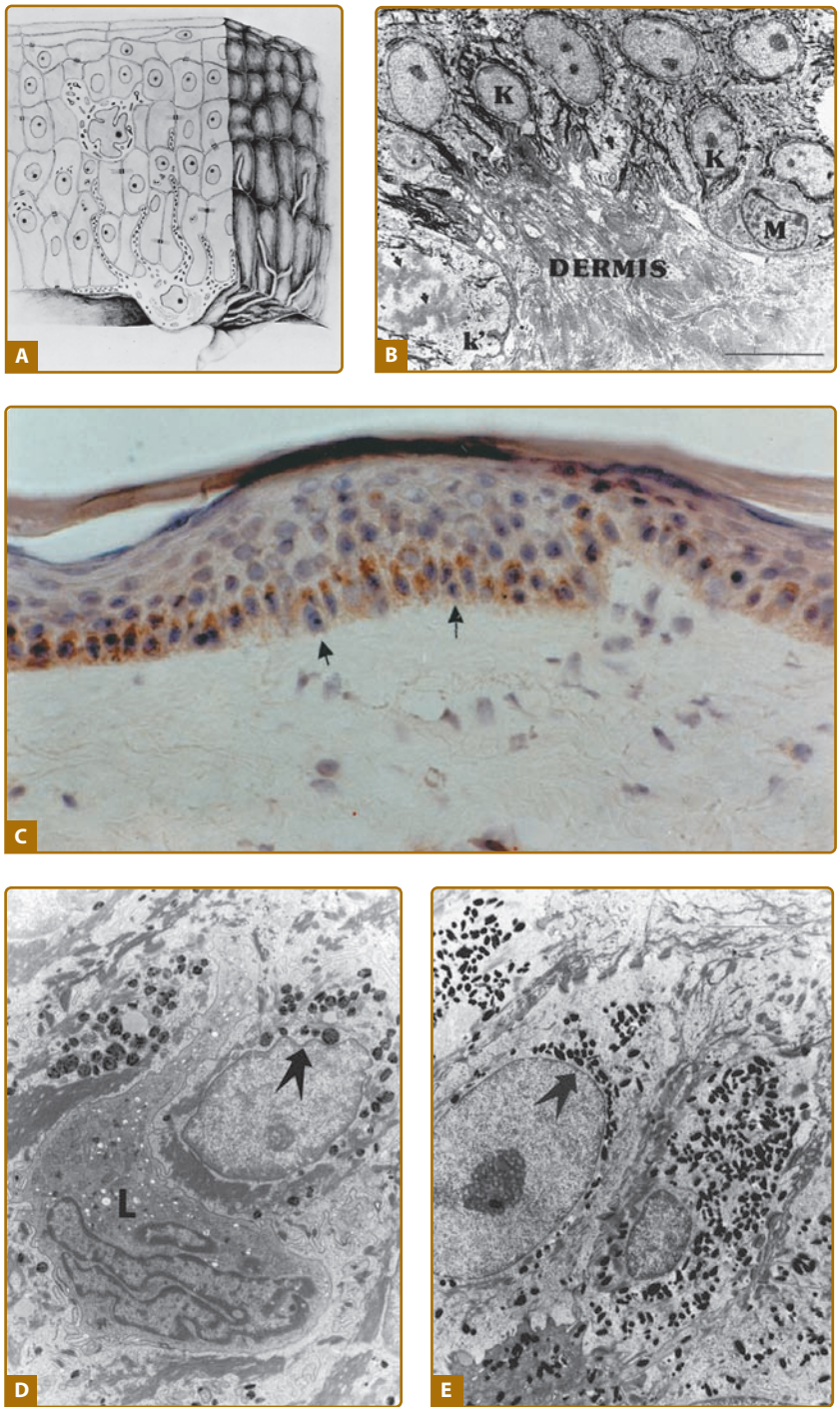

Figure 72-3 The epidermal melanin unit. **A.** Representation showing the relationship between basal melanocytes, keratinocytes, and Langerhans cells, shown at the upper layer of the epidermis. (From Quevedo WC Jr.: The control of color in mammals. *Am Zoology* **9**:531, 1969, with permission.) **B.** Electron micrograph of the dermal–epidermal junction of human skin showing a dendritic melanocyte (M) among the basal keratinocytes (K). k′ represents a basal keratinocyte undergoing mitosis with condensed chromatin (*arrows*). (Bar = 10.0 µm.) (Illustration used with permission from Raymond E. Boissy, Department of Dermatology, University of Cincinnati, Cincinnati, Ohio.) **C.** Human epidermis immunostained for fibroblast growth factor-2 (FGF2). The figure shows basal keratinocytes with peroxidase reaction indicating the presence of immunore-active FGF2. *Arrows* point to melanocytes. (Used with permission from Glynis Scott, MD, Department of Dermatology, University of Rochester School of Medicine and Dentistry, Rochester, NY.) **D** and **E.** Distribution of melanosomes within keratinocytes in lightly pigmented Caucasian and darkly pigmented African-American skin. Melanosomes in lightly pigmented Caucasian skin (**D**) are distributed in membrane-bound clusters. In contrast, in darkly pigmented African-American skin (**E**) the melanosomes are individually distributed throughout the cytoplasm of epidermal keratinocytes. Melanosomes in both skin types are frequently concentrated over the apical pole of the nucleus (*arrows*). L = Langerhans cell. (Bar = 3.0 µm.) (Used with permission from Minwalla L et al: Keratinocytes play a role in regulating distribution patterns of recipient melanosomes in vitro. *J Invest Dermatol* **117**:341, 2001.)

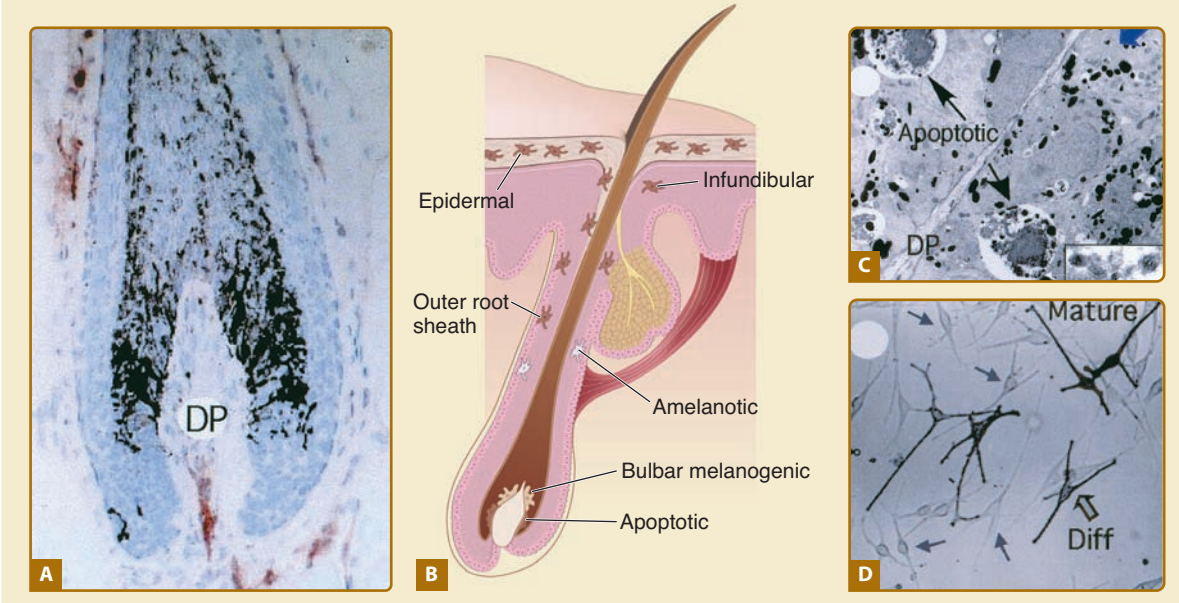

Figure 72-4 Melanocytes in the hair. **A.** Pigmented human scalp hair follicle in full anagen with high levels of hair bulb melanogenesis. Mature melanin granules are transferred into cortical keratinocyte. **B.** Scalp hair bulb. Representation of early catagen hair follicle showing loss of some bulbar melanotic melanocytes via apoptosis. *Arrows* point at melanocytes located in epidermal, infundibular, and outer root sheath regions. **C.** Transmission electron micrograph of section of an early catagen hair bulb showing apoptosis of melanotic melanocytes. *Inset*, high-power view of premelanosomes. **D.** Primary culture of human scalp hair follicle melanocytes. Mature, fully differentiated (Diff; *large arrow*), and less differentiated (*small arrows*) are indicated. DP = dermal papilla. (From Tobin DJ, Paus R: Graying: Gerontobiology of the hair follicle pigmentary unit. *Exp Gerontol* **36**:29, 2001, with permission.)

MELANIZATION

The major differentiated function of melanocytes is to synthesize melanin in specialized organelles within the melanocytes, the melanosomes, and to transfer melanosomes to neighboring keratinocytes in order to provide protection from UV irradiation (Fig. 72-5). Melanogenesis, the synthesis and distribution of melanin in the epidermis, involves several steps: transcription of proteins required for melanogenesis; melanosome biogenesis; sorting of melanogenic proteins into the melanosomes; transport of melanosomes to the tips of melanocyte dendrites and transfer of melanosomes to keratinocytes. Disruption in any of these events results in hypopigmentation.

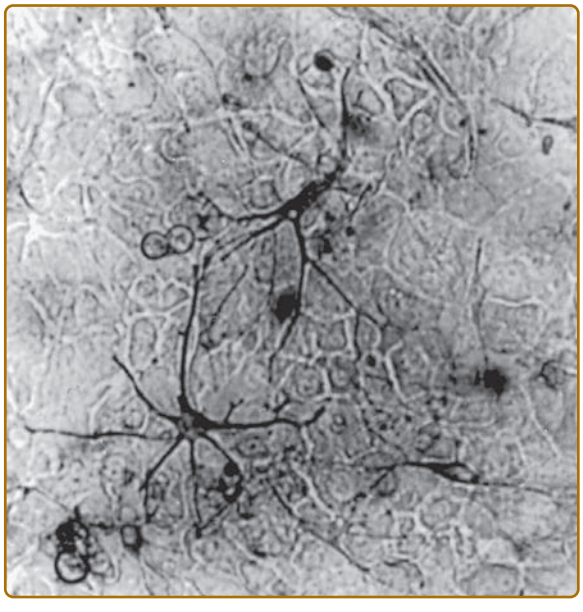

Figure 72-5 Melanocytes cultured on keratinocytes. Light micrograph showing dendritic melanocytes from a black donor loaded with melanin and adjacent pigmented keratinocytes due to transfer of melanosomes.

MELANOSOMES

MELANOSOME BIOGENESIS

The melanosome is a unique membrane-bound organelle in which melanin biosynthesis takes place. Because melanosomes contain enzymes and other proteins also

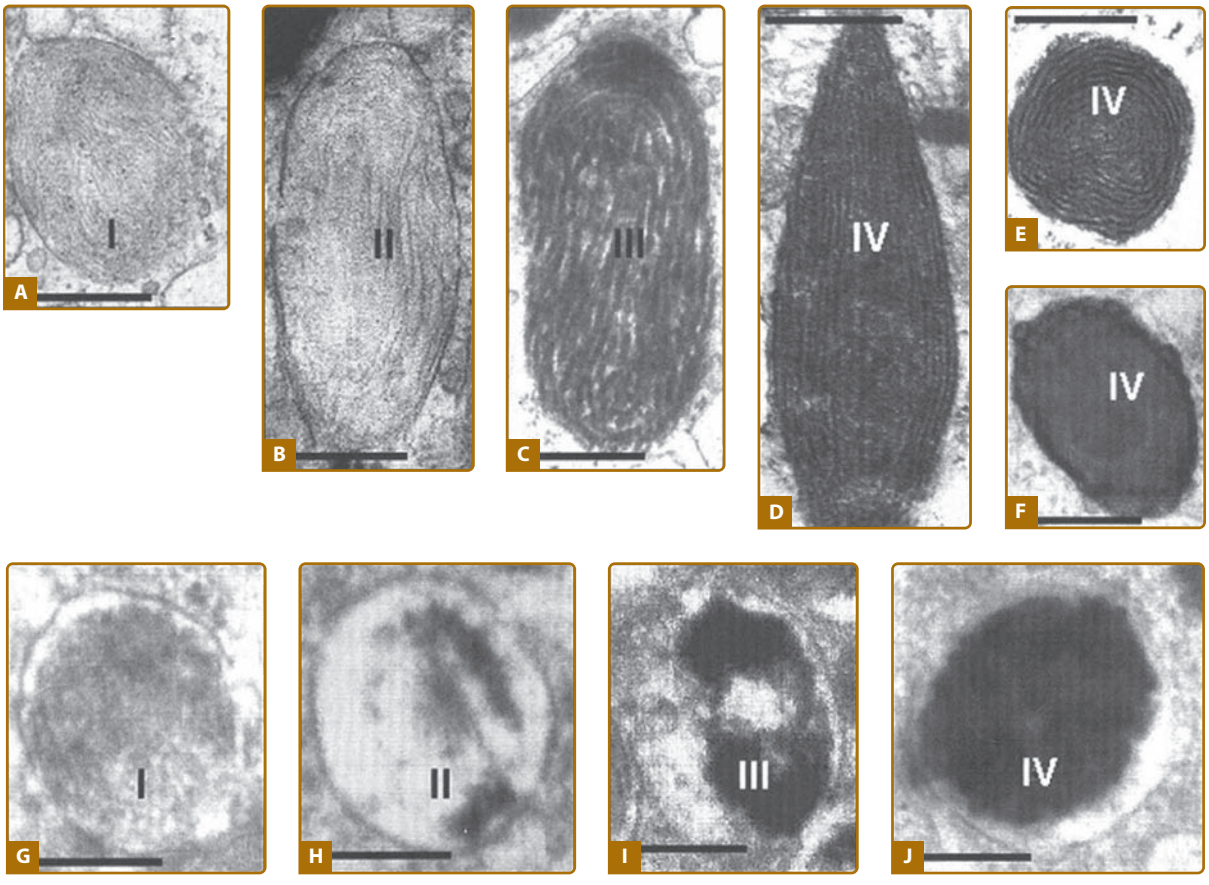

Figure 72-6 Melanosome biogenesis. Electron microscopy of eumelanosome (**A–F**) and of pheomelanosome (**G–J**) development. I, II, III, and IV in **A–J** represent the different maturation stages of melanosomes. [Scale bars are as follows (in µm): a = 0.20; b = 0.23; c = 0.24; d = 0.22; e = 0.20; f = 0.35; h = 0.26; i = 0.26; j = 0.30; k = 0.5.] (From Slominski A et al: Melanin pigmentation in mammalian skin and its hormonal regulation. *Physiol Rev* **84**:1155, 2004, with permission from the American Physiological Society.)

present in lysosomes, they are thought to represent a modified version of the latter. Proteins common to both organelles include the lysosome-associated membrane proteins (LAMPs) that participate in autophagy and regulation of intravesicular pH,[56] as well as acid phophatase, a marker enzyme for lysosomes.[56] Also like lysosomes, melanosomes can endocytose receptors that are targeted for degradation.[56]

Depending on the type of melanin synthesized, melanosomes can be divided into eumelanosomes and pheomelanosomes (Fig. 72-6). Eumelanosomes are large (~0.9 × 0.3 µm), elliptical in shape and contain a highly structured fibrillar glycoprotein matrix required for eumelanin synthesis.[40] Pheomelanosomes are smaller (~0.7 µm in diameter), spherical in shape and their glycoprotein matrix appears disorganized and loose[40] Although both eumelanosomes and pheomelanosomes may be present within a single melanocyte,[57] once committed, they do not change.[58]

Melanosomes display four maturation stages (Fig. 72-6). Stage I melanosomes or premelanosomes likely develop from the endoplasmic reticulum (ER).[40] They have an amorphous matrix and display internal vesicles that form as a result of membrane invagination. Premelanosomes already contain the glycoprotein Pmel17 (gp100) but it requires further processing to become a component of the final fibrillar matrix.[59] Stage II eumelanosomes have organized structured fibrillar matrix, but no active melanin synthesis, whereas in stage II pheomelanosomes melanin synthesis already takes place. Although no active melanogenesis takes place in stage II eumelanosomes, they already contain the enzyme tyrosinase. Deposition of melanin on the fibrillar matrix is found in stage III eumelanosomes, while stage IV eumelanosomes are fully melanized and their internal matrix is masked by melanin deposits.[60,61]

MELANOGENIC PROTEINS

The timely and organized sorting of melanogenic enzymes and structural proteins to melanosomes is an integral part of melanosomal maturation. Melanosome proteins express sorting signals at their amino-terminus and these direct them into the ER and eventually into the melanosomes.[40,60,61]

ENZYMES

Tyrosinase. Tyrosinase is present in plants, insects, amphibians, and mammals. It was initially identified in the early 1900s in mushroom extracts and was subsequently isolated and purified in 1949 from murine

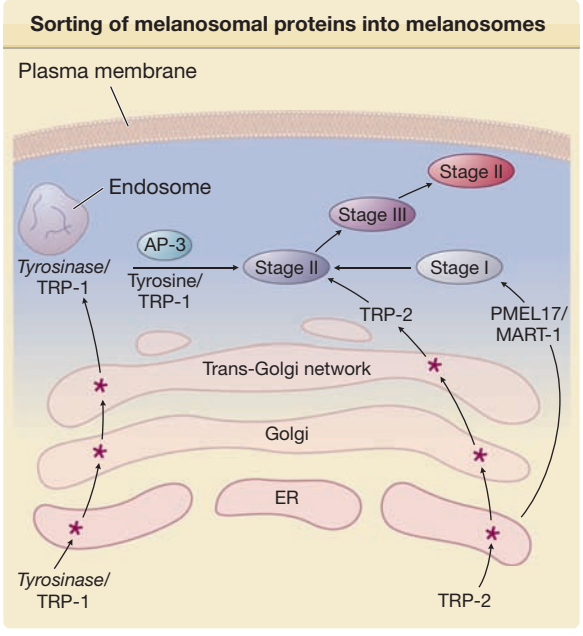

Figure 72-7 Sorting of melanosomal proteins into melanosomes. Tyrosinase and tyrosinase-related protein-1 (TRP-1) are initially synthesized in the endoplasmic reticulum (ER) and, after additional maturation steps (*) in the Golgi and trans-Golgi network, are packaged in endosomes as a complex. TRP-2 follows similar maturation steps. Melanosomes originate in the ER as stage I already containing the melanosomal proteins PMEL17 and MART-1. They then mature to stage II melanosomes and fuse with tyrosinase/TRP-1 in a process directed by the adaptor protein 3 (AP-3). Melanosomes become progressively darker as melanin biosynthesis takes place.

melanoma cells.[62] Mouse and human *tyrosinase* genes are 60–70 kb, and 50 kb long, respectively. The murine *tyrosinase* gene maps to chromosome 7, whereas human *tyrosinase* gene maps to chromosome 11. The human *tyrosinase* gene is composed of five exons and four introns,[63] and tyrosinase mRNA is approximately 2 kb long (genebank access number NM_000372).

Tyrosinase is synthesized in the ER as a precursor protein whose nascent chain is processed in the Golgi complex where sialic acid and neutral sugars are added to the peptide via *N*- and *O*-glycosidic linkages through a process called glycosylation[64] (Fig. 72-7). At least four forms of tyrosinase, all differing with regards to their degree of glycosylation, have been identified. The glycolsylation steps have been shown to be important for proper association of tyrosinase with melanosomes, as well as for its activity.[64] Following the glycosylation steps, mature tyrosinase is folded in the ER, a step required for appropriate trafficking/sorting of tyrosinase into the Golgi apparatus and ultimately into endosomes and finally into melanosomes. A strict control mechanism guarantees the elimination of defective tyrosinase.

Within the melanosome, tyrosinase spans melanosomal outer membrane (eFig. 72-7.1 in online edition). It has three domains: (1) an inner melanosomal domain, (2) a melanosomal transmembrane domain, (3) and a cytoplasmic domain. The inner domain that contains the catalytic region is approximately 90% of the protein. It is followed by a short transmembrane domain, and a cytoplasmic domain composed of approximately 30 amino acids.[65] Histidine residues present in the inner (catalytic) portion of tyrosinase bind copper (Cu) ions and the latter are required for tyrosinase activity.

The biological function of the tyrosinase cytoplasmic domain was not known for a long time. In a mouse model where the entire cytoplasmic domain is missing, tyrosinase protein is inserted into the cellular plasma membrane instead of into the melanosomal membrane, suggesting that tyrosinase cytoplasmic domain is required for proper trafficking of tyrosinase into melanosomes. Indeed, it was found that the motif EXXQPLL (glutamic acid-X-X-glutamine-proline-leucine-leucine, where "X" stands for any amino acid) in the cytoplasmic domain is responsible for tyrosinase trafficking into the melanosomes.[66] In addition, protein kinase C-β (PKC-β) (see below) must phosphorylate two serine residues on this cytoplasmic domain to activate tyrosinase,[65] and in the absence of those phosphorylation events pigmentation does not occur.

Tyrosinase mutations including missense, nonsense frameshift, and deletion mutations that lead to inactivation of the enzyme are found in oculocutaneous albinism type I (see Chapter 73 and Albinism database: http://albinism-db.med.unm.edu/). Such mutations may affect tyrosinase glycosylation interfering with enzyme maturation, or may involve Cu-binding sites disrupting tyrosinase activity or premature termination of tyrosinase protein that causes truncation of cytoplasmic domain.[64]

Tyrosinase-Related Proteins. Two tyrosinase-related proteins, (1) TRP-1 and (2) TRP-2, play important roles in melanogenesis.[67–69] They are structurally related to tyrosinase and share ~40% amino acid homology. Also, similar to tyrosinase, TRP-1 and TRP-2 are glycoproteins located within the melanosomes and span the melanosomal membrane.[70] The conserved nucleotide and amino acid sequences among these three melanogenic enzymes suggest that they originated from a common ancestral gene.[71,72] Mutations of TRP-1 and TRP-2 in mice after coat color ("brown" and "slaty" mice, respectively) and polymorphisms of these gene products are implicated in lighter hair and skin color in European population studies. Their functions are incompletely understood, but the proteins complex with tyrosinase and may stablilize it.

Protein Kinase C-β. PKC constitutes a family of at least 12 isoforms[86] among that PKC-β has been shown to be involved in regulating tyrosinase activity.[87] The mechanisms through which PKC mediates a wide range of membrane generated signals and their relevance to melanocyte biology are further discussed below (see Section "Signaling Pathways Regulating Melanocyte Functions"). PKC-β phosphorylates serine residues on the cytoplasmic domain of tyrosinase, thus activating tyrosinase.[88] Still, the means by which PKC-β-mediated phosphorylation of tyrosinase leads to the enzyme activation is not well elucidated. It has been suggested that phosphorylation of tyrosinase causes a

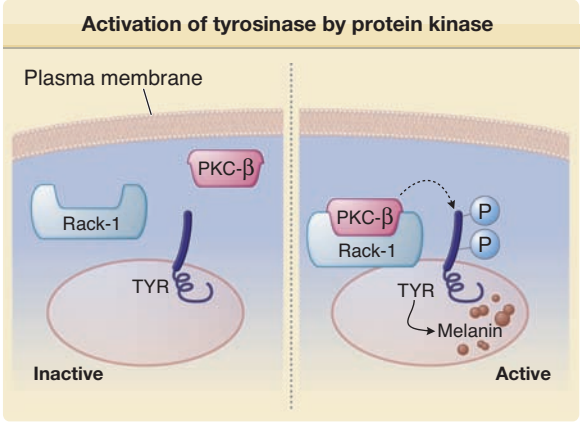

Figure 72-8 Activation of tyrosinase by protein kinase C-β (PKC-β). Under baseline conditions, there is no activation of PKC-β, and tyrosinase (TYR) is not phosphorylated. Activated PKC-β binds receptors for activated C-kinase-I (RACK-I), the complex translocates to the melanosome, and phosphorylates serine residues on the cytoplasmic tail of tyrosinase. Tyrosinase phosphorylation activates the enzyme to catalyze melanin biosynthesis.

complex to form between tyrosinase and TRP-1,[89] an event known to stabilize tyrosinase and increase its enzymatic activity.[79]

In melanocytes, activated PKC-β is associated with melanosomes and the enzyme is found in close proximity to the melanosomal membrane.[88] While structural differences among PKC isoforms may contribute to their associations with particular subcellular fractions, receptors for activated C-kinase (RACK), unique for each PKC isoform, primarily determine the translocation of specific PKC isoforms to specific cellular compartments to activate its target on the membrane[90–92] (Fig. 72-8). RACK-I is the PKC-β partner,[90] and in human melanocytes, the activated PKC-β/RACK-I complex translocates to the melanosome membrane to allow tyrosinase phosphorylation (Fig. 72-8)[93]

STRUCTURAL PROTEINS.

Fibrillar matrix proteins within the melanosomes are required for proper deposition of melanin. Pmel17 and MART-1 are two such melanosomal structural matrix proteins.

Pmel17. Pmel17, also known as gp100 and the silver locus product, is a glycoprotein recognized by the antibodies HMB45, HMB50, and NKI-β.[94] It plays a critical role in fibril matrix formation within eumelanosomes.[59,95] Pmel17 transcription is induced by α-MSH through MITF and it is synthesized as a precursor protein in the ER and the protein undergoes glycosylation and eventual cleavage (Fig. 72-7). After its synthesis, Pmel17 is transported to stage I melanosomes to form a fibrillar structure that is the backbone of eumelanosome matrix,[94] contributes to melanosome ellipsoid shape and promotes melanin polymerization.[94] Melanosomes lacking Pmel17 cannot transit to stage II and have no active melanogenesis.[96] It has been suggested that loss of functional Pmel17 results in melanin cytotoxicity, perhaps through leakage of melanin intermediates from abnormal melanosomes into the cytosol.[94,97] However, there are no known hypopigmentary disorders in humans linked to mutations of *Pmel17*.

MART-1/Melan A. MART-1, also known as Melan A, is a membrane-associated protein[98] that is present in stage I and stage II melanosomes and forms a complex with Pmel17 (Fig. 72-7). MART-1 affects the expression, stability, trafficking, and processing of Pmel17 within the melanosomes.[98] To date, no hypopigmented phenotypes associated with nonfunctional MART-1 have been identified.

TRANSPORT PROTEINS

Heterotetrameric Adaptor Protein Complexes. Sorting of membrane-associated proteins including tyrosinase, TRP-1, TRP-2, and Pmel17 and directing them to the appropriate cytosolic organelles is facilitated by heterodimeric adapter protein complexes (APs).[99,100] AP-3 and possibly also AP-1 facilitate tyrosinase transport from endosomes to melanosomes[101] (Fig. 72-7). Patients with Hermansky–Pudlak syndrome—an autosomal recessive disorder of oculocutaneous albinism, platelet dysfunction, and pulmonary disease (see Chapter 73)—have defects in specific subunits of the AP-3 adaptor protein complex and as a result display several anomalies associated with cellular transport of molecules.[102] Studies suggest that a molecule of the kinesin family, microtubule-associated motor proteins, is involved in endosomal sorting and positioning of melanosomal proteins via interaction with AP-1.[103,104]

P-Protein. The P-protein (pink-eyed dilution) is a transmembrane protein with 12 membrane-spanning domains whose sequence is homologous to that of other transmembrane transport proteins, including anion transporters[97,105,106] thought to function as a transport protein.[107] Studies have identified the protein as an ATP-associated proton pump responsible for maintaining acidic environment within the melanosomes.[108] Other proposed functions of P-protein include stabilizing the tyrosinase/TRP-1/TRP-2 complex and/or transporting tyrosine into the melanosomes.[105] Individuals lacking functional P-protein display oculocutaneous albinism type 2, largely due to improper melanosomal pH.[108–110] Also, Angelman and Prader–Willi syndromes display deletion mutations that include the P-locus on chromosome 15.

SLC24A5. SLC24A5 is a melanosomal protein whose structure and homology to cation exchange proteins suggests that it is a melanosome-associated cation exchanger.[111] Mutations in *slc24α5* in zebrafish lead to hypopigmentation of the organism.[111] The ancestral human homolog is expressed by darker complexioned individuals including Africans and Asians, while lighter complexioned Europeans tend to express a variant allele.[111]

SCAVENGER PROTEIN

Lysosome-Associated Membrane Proteins. LAMPs are linked to melanosome membranes and/or matrix. They are thought to protect melanosomal integrity by acting as scavengers of free radicals that

are produced during melanin biosynthesis.[112] Because LAMPs are also present in lysosomes, it is thought that melanosomes and lysosomes share a common ancestral origin.[112]

REGULATORY PROTEINS

Microphthalmia-Associated Transcription Factor

Gene and Protein. MITF, a basic-helix-loop-helix (bHLH) and leucine zipper transcription factor, has been termed the master gene for melanocyte survival and is a key factor regulating the transcription of the major melanogenic proteins, tyrosinase, TRP-1, TRP-2,[12] PKC-β[113] and MART-1.[114] In melanocytes, it is the MITF-M isoform that stimulates transcription of *tyrosinase* and *PKC-β*.[114] MITF binds to conserved consensus elements in gene promoters, specifically the M-(AGTCATGTGCT) and E- (CATGTG) boxes.[115] It can bind as a homodimer or a heterodimer with another related family member.[116] MITF appears to be a key regulator determining cell fate, as transfection of human MITF cDNA into mouse fibroblasts converts these cells into dendritic cells expressing melanocyte-specific genes.[117]

MITF comprises a family of nine isoforms: (1) MITF-M, (2) -A, (3) -B, (4) -H, (5) -C, (6) -D, (7) -E, (8) -J, and (9) -Mc.[118,119] MITF-M expression is highly specific for melanocytic cells.[120] Melanocytes express in addition other MITF isoforms specifically, MITF-A, -B, and, -E[114]The biologic role of other MITF isoforms in normal melanocytes is not known.

Regulation of MITF Activity and Expression. The activity and stability of MITF are modulated by phosphorylation of the protein. MITF activity is increased upon its phosphorylation by the mitogen-activated protein kinase-2 (MAP kinase-2), whose activity is in turn induced by binding of SF/kit/stem cell factor to c-Kit receptor[121] (Fig. 72-8). Phosphorylated MITF binds to another protein, p300/CBP, which belongs to a coactivator family of proteins and acts to enhance MITF transcriptional activity.[121,122] Another kinase that is activated by SF/c-Kit interaction is p90RSK that also phosphorylates MITF but at a different site from that phosphorylated by MAP kinase-2.[123] These phosphorylation events both activate MITF and at the same time decrease the stability of the protein, as phosphorylated MITF is targeted for degradation by proteosomes (eFig. 72-8.1A in online edition).[123,124]

The expression of MITF is under the control of several transcription factors, including Sox10 (mutated in Waardenburg's syndrome type 4, see Chapter 73) and Pax3. MITF expression is also controlled by the cAMP-response element binding protein (CREB) and Lef1 transcription factor that participates in Wnt-signaling. These transcription factors bind to specific sites within *MITF* promoter regions to induce MITF transcription.[116] The promoter region of the *MITF* gene contains a cAMP-response element (CRE) that interacts with CREB when the cAMP-dependent pathway is activated.[125,126] Therefore, cAMP-elevating agents like α-MSH induce the expression of MITF (eFig. 72-8.1B in online edition).

MITF Role in Melanocyte Proliferation and Survival. MITF promotes melanoycte survival by upregulating the expression of a major antiapoptotic protein BCl2.[127] It is frequently overexpressed or amplified in melanomas, contributing to their increased survival.[128–131] Mutations in *MITF* are found in the pigmentary disorder Waardenburg syndrome type 2[132](see Chapter 73).

A role for MITF in melanocyte proliferation has also been proposed, as under certain conditions, MITF induces the expression of the cell cycle-associated kinase Cdk2 that is involved in the progression of cells from G1 into S phase of the cell cycle.[133] MITF also suppresses the expression of p21, a protein that inhibits Cdk2 activation.[133,134] Conversely, under

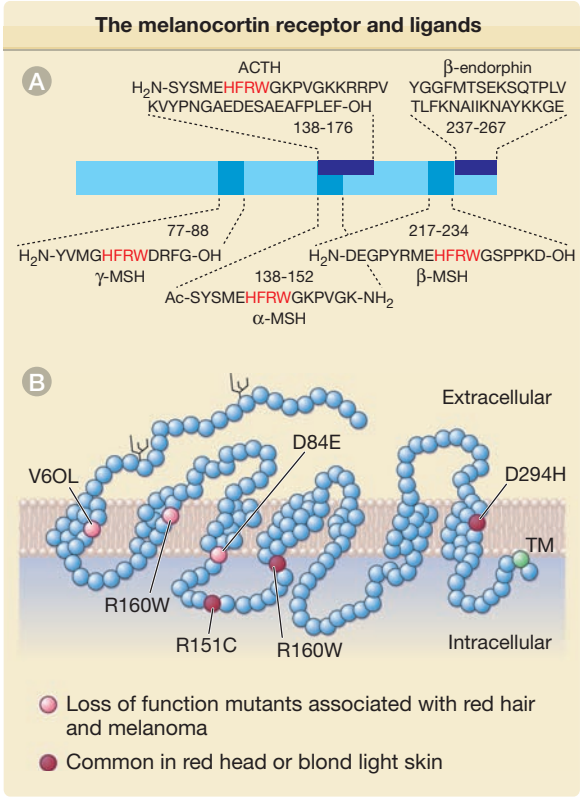

Figure 72-9 The melanocortin receptor (MCR) and its ligands. **A.** Structure of the proopiomelanocortin precursor. Standard abbreviations for amino acids are used. The synthetic superactive α-melanocyte-stimulating hormone (α-MSH) analogue [Nle^4 D-Phe^7]-α-MSH is modified by the exchange of methionine (M) with norleucine and L-phenylalanine (F) with D-phenylalanine. In *red* are critical amino acids required for binding to the MCR. **B.** Schematic representation of the human MC1R receptor. Each of the 318 amino acid residues in the polypeptide chain of the receptor is represented by an empty circle. Branched structures represent *N*-linked glycosylation sites. Reduced function mutants (*red circles*), variants common in red- or blond-haired and fair skinned individuals (*orange circles*), and the conserved *C*-terminal cysteine (*green circle*), the possible site for fatty acid acylation and anchoring to the plasma membrane, are indicated. Ac = acetylated; ACTH = adrenocorticotropic hormone; NH_2 = amidated; TM = transmembrane domain.

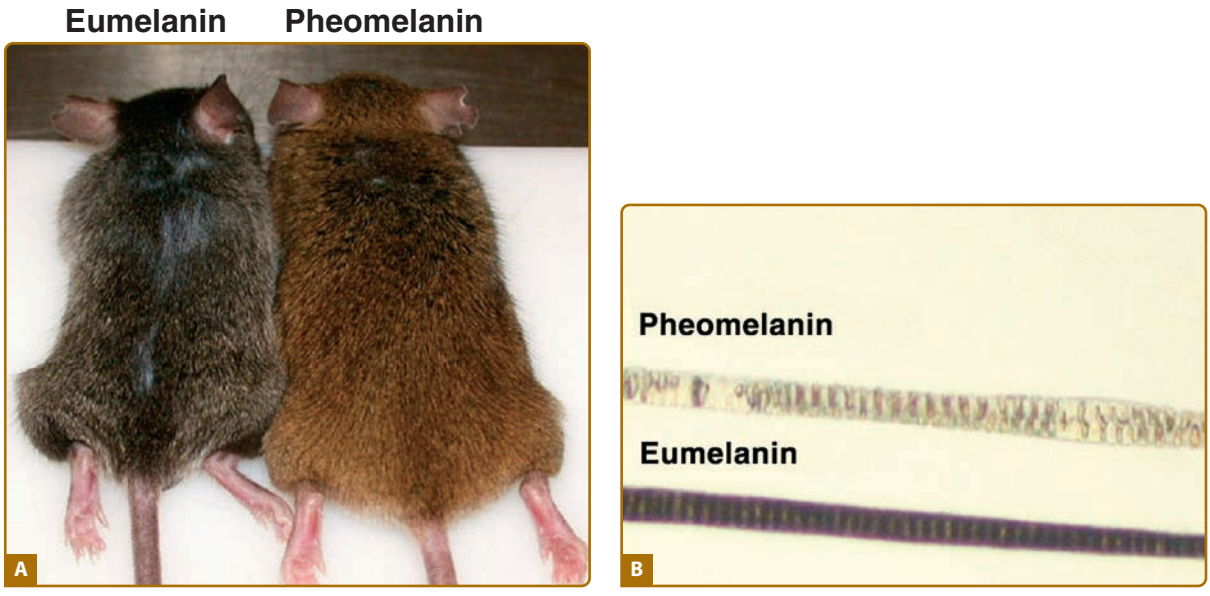

Figure 72-10 Eumelanin and pheomelanin presentation in mice. **A.** Two mice with different coat colors are shown. The one on the left displays brown/black coat color due to eumelanin, and the one on the right displays red/yellow coat color due to pheomelanin. **B.** Representative hair shafts of these mice. (From Sharov et al: Bone morphogenic protein (BMP) signaling controls hair pigmentation by means of cross-talk with the melanocortin receptor 1 pathway. *PNAS* **102**:93, 2004, with permission.)

different conditions, MITF can induce p21 expression and it can also stimulate the expression of $p16^{INK4a}$, a protein that inhibits the activation of kinases required for progression through the cell cycle, thus promoting cell cycle arrest.[135,136] Because MITF cooperates with other transcription factors to induce its effects, it is to be expected that these transcription factors would influence MITF activity, resulting in either stimulation or inhibition of melanocyte proliferation.

Mice bearing null mutations of *MITF* display loss of melanocytes, deafness and failure of differentiation of retinal pigment epithelium.[12]

Melanocortin 1 Receptor. Melanocortin receptors (MCRs) comprise a family of five related receptors (MC1R, MC2R, MC3R, MC4R, and MC5R). Each has seven transmembrane domains and they belong to the G-protein-coupled receptor superfamily.[137] MC3R and MC4R are mainly found in the central nervous system, are absent in melanocytes,[138] and are thought to control energy intake. MC2R is expressed in the adrenal cortex and MC5R is expressed in peripheral adipocytes.[139] MC1R is expressed in a number of cells such as endothelial cells, fibroblasts,[140] and keratinocytes,[140] but the highest expression is found in melanocytes.[140]

α-MSH and adrenocorticotropic hormone (ACTH), a 39 amino acid proopiomelanocortin-derived peptide that contains the α-MSH sequence (Fig. 72-9A),[141–143] activate MC1R (Fig. 72-9B) Receptor–ligand interaction leads to G-protein-dependent activation of the enzyme adenylate cyclase followed by increased intracellular cAMP level[141] inducing MITF transcription and upregulating the level of melanogenic proteins including tyrosinase[40] promoting the synthesis of brown/black eumelanin.[141] Agouti, a protein expressed in both humans and mice, whose expression in mice leads to yellow coat color, antagonizes α-MSH by competitive binding to MC1R. It thus blocks adenylate cyclase activation[144–146] and favors pheomelanin over eumelanin synthesis (Fig. 72-10). However, the role of agouti in human pigmentation is poorly documented.

Polymorphisms within the *MC1R* gene are largely responsible for the different skin/hair color among different racial groups.[147] At least 30 MC1R variants have been identified and nine of them display loss of function[148,149] (Fig. 72-9B), not being able to induce intracellular cAMP production in response to α-MSH despite adequate receptor/ligand binding. Other MC1R variants have reduced affinity for α-MSH.[148,149] Three MC1R variants, each with only a single amino acid substitution, have been associated with red/yellow hair and fair skin[150] of Northern Europeans and Australians.[151–156] Mice expressing a loss-of-function MC1R variant receptor also fail to respond to UV irradiation with increased pigmentation despite an increased level of epidermal α-MSH,[157] but do tan if provided forskolin, a chemical enhancer of pigmentation that bypasses the receptor to directly increase cAMP, demonstrating that the intracellular melanogenic pathway is functional in such individuals.[155]

MELANIN BIOSYNTHESIS

Two types of melanins are synthesized within melanosomes: (1) eumelanin and (2) pheomelanin.[158] Eumelanin is dark, brown–black, and insoluble, whereas pheomelanin is light, red–yellow sulfur-containing, and soluble.[158] Melanins are indole derivatives of 3,4 di-hydroxy-phenylalanine (DOPA) and they are

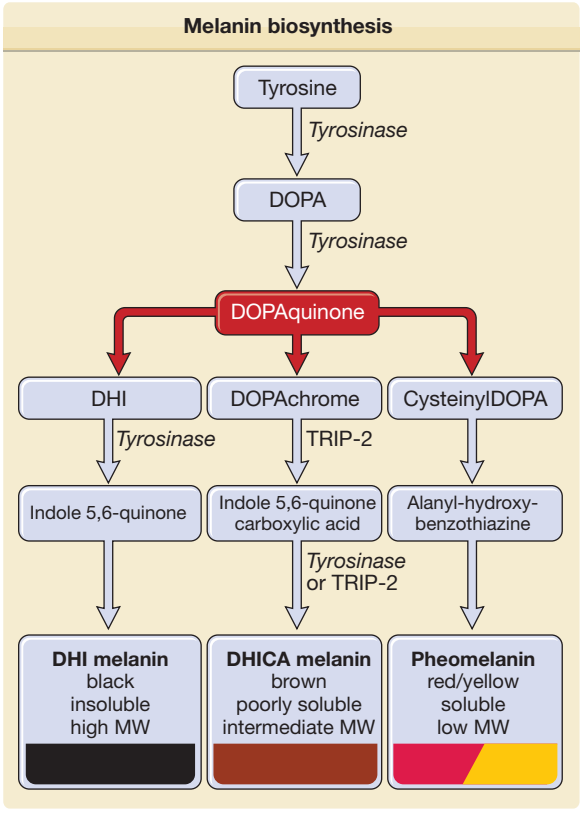

Figure 72-11 Melanin biosynthesis. Melanin biosynthesis begins with the amino acid tyrosine that is converted to DOPA (3,4-dihydroxyphenylalanine) in the rate-limiting step of melanin biosynthesis catalyzed by tyrosinase. DOPA is subsequently converted to DOPAquinone by the same enzyme. DHI (5,6-dihydroxyindole) and DHICA (5,6-dihydroxyindole-2-carboxylic acid) are then formed to produce either black or brown eumelanin. Alternatively, through incorporation of glutathione or cysteine, DOPAquinone can form pheomelanin. MW = molecular weight; TRP = tyrosinase-related protein.

formed in melanosomes through a series of oxidative steps[159] (Fig. 72-11). Melanosomal pH affects the activity of the melanogenic enzymes and influences melanin polymerization.

The synthesis of both types of melanin involves the rate-limiting catalytic step in which the amino acid tyrosine is oxidized by the enzyme tyrosinase (also called tyrosine oxidase, DOPA oxidase, monophenol, DOPA: oxygen oxidoreductase) to DOPA, a first step in a reaction known as the Raper–Mason pathway[160] (Fig. 72-11). Conversion of tyrosine to DOPA is thought to be the critical rate-limiting step in melanogenesis, as inhibition of this reaction blocks melanin synthesis.[161] In both reactions, DOPA acts as a cofactor and also as a substrate for tyrosinase. Although the exact interaction between tyrosinase and its substrates is not completely understood, in vitro kinetic studies suggest that distinct sites mediate tyrosinase binding to tyrosine and to DOPA, and that binding to DOPA causes a conformational change in tyrosinase, resulting in increased affinity for both tyrosine and DOPA.

DOPA is oxidized into DOPAquinone,[162] DOPAquinone is further converted to DOPAchrome and DOPAchrome can be converted to 5,6-dihydroxyindole (DHI) or to 5,6-dihydroxyindole-2-carboxylic acid (DHICA). The latter reaction is catalyzed by the enzyme DOPAchrome tautomeras or TRP-2. The level of brown versus black eumelanin appears to correlate with DHI/DHICA ratio, with a higher ratio leading to the formation of black eumelanin and a lower ratio to brown eumelanin.[163] DOPAquinone can also combine with glutathione or cyteine to form cysteinylDOPA, which then becomes the yellow/red, soluble, low-molecular-weight pheomelanin.[163] Interestingly, tyrosinase also catalyzes a more distant step in melanin biosynthesis, namely DHI conversion to indole-5,6-quinone. In mice, the enzyme TRP-1 (also called DHICA oxidase) converts DHICA to indole-5,6-quinone carboxylic acid. However, the TRP-1 role in human melanin biosynthesis is not well established.

The main function of melanin is to provide protection against UV-induced DNA damage by absorbing and scattering UV radiation (280–400 nm). Accordingly, energy absorption by melanin is maximal in this portion of the electromagnetic spectrum, and decreases gradually across the visible light spectrum. UV absorbed by melanin is converted into heat, a less toxic form of energy.[164] Still, in vitro studies conducted by several investigators suggest that melanin's capacity to act as a sunscreen is limited and that melanin, when incorporated into a cream and spread over the skin, absorbs only 50%–75% of incident sunlight. Naturally, it is possible that in vivo, by virtue of localizing above the nucleus, melanin in melanosomes achieves a higher level of protection.

Melanin intermediates as well as melanin itself can also be harmful to the cell because, depending on their molecular weight and polymerization state, they can promote UVA (320–400 nm)-induced DNA damage, most likely through the generation of ROS.[165] It has been suggested that the increased incidence of UV-induced melanomas in light-skinned, red-hair individuals is not only due to decreased ability of pheomelanin to protect against UV-induced DNA damage, but may also be due to mutagenic capacity of pheomelanin and possibly other melanin intermediates as a result of their pro-oxidant capacity.[166]

MELANOCYTE DENDRITES

Melanocyte dendrites are branching protoplasmic processes that interact with keratinocytes. Actin is a major structural component of melanocyte dendrites, and actin filament disruption leads to dendrite loss.[167] Cocultures of keratinocytes and melanocytes demonstrate that keratinocyte-derived factors play a role in melanocyte dendricity.[168] These factors include ET-1, nerve growth factor (NGF), α-MSH, ACTH, prostaglandins (PGs) E_2 and $F_{2\alpha}$[168] and β-endorphin.[169] Integrins, receptors that mediate actin-extracellular matrix contact are likely to play a role in dendrite formation as well.[170]

Another group of proteins, the Rho family, also plays a role in melanocyte dendrite formation. Rho proteins become active when they bind GTP and inactive when binding GDP.[171,172] It appears that when Rho is activated, dendrites retract; while when its family member Rac is activated, dendrites form.[172] Indeed, it is currently assumed that by increasing cAMP levels, α-MSH inhibits Rho, enhancing melanocyte dendricity. Thus, the equilibrium between Rho and Rac appears to be an important factor influencing melanocyte dendricity.

MELANOSOME TRANSPORT

WITHIN MELANOCYTES

Melanosomes are transferred from their site of origin in melanocyte perikaryon to the tips of melanocyte dendrites. Melanosome transport takes place on microtubules that are arranged parallel to the long axis of the dendrite and is controlled by two classes of microtubule-associated motor proteins: (1) kinesins[173–175] and (2) cytoplasmic dyneins[176–180] (Fig. 72-12). Both motor proteins act as short cross-bridge structures connecting the organelle to the microtubules.

Centrifugal, anterograde organelle movement is mediated primarily by kinesin, whereas centripetal movement is controlled by cytoplasmic dynein. Studies examining melanosomal transport suggest that their microtubule-dependent movement is bidirectional,[181] consistent with a cooperative forward and backward pull of kinesin[173] and dynein,[176] respectively. For melanosomes with net centrifugal movement, the bidirectional movement appears to terminate with myosin-Va (encoded by dilute locus)-dependent melanosomal capture in the actin-rich periphery of the dendrite (Fig. 72-12).[181]

Additional proteins that participate in melanosome transport include Rab27a (encoded by *ashen* locus) that mediates myosin-Va binding to melanosomes through another linker protein-melanophilin (encoded by *leaden* locus) (Fig. 72-12).[182] In the absence of myosin-Va, melanosomes do not collect in dendrite tips.

Mutations in any of the above gene products results in decreased cutaneous pigmentation. Griscelli syndrome, a rare autosomal recessive disorder in which individuals display dilute skin and hair color, is the result of mutations of *myosin-Vα*, *Rab27α*, or *melanophilin*[182] (see Chapter 73). *Myosin-Vα* and *Rab27α* are closely located on chromosome 15.[183–186] Because myosin-Va is also expressed in the brain, mutations of this gene may also cause neurological abnormalities. Rab27a also plays a role in immuno-regulation and individuals with mutations of this gene display abnormalities of the immune system. Mutations of *melanophilin* result only in the distinctive hypopigmentation that characterizes the syndrome.[186]

Melanosome transport across melanocyte dendrites

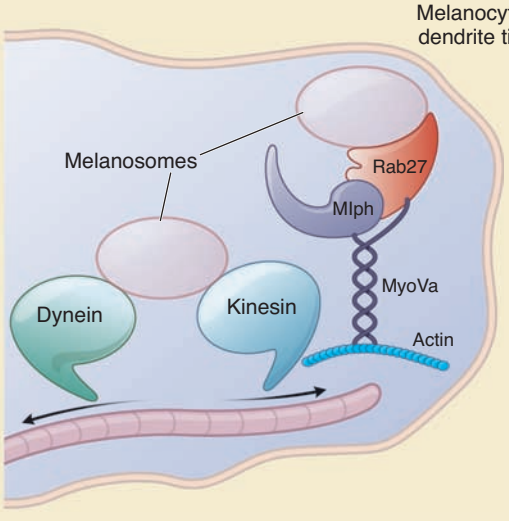

Figure 72-12 Schematic diagram of melanosome transport across melanocyte dendrites. Melanosomes move bidirectionally along melanocyte dendrites. They are attached to microtubules through the motor proteins kinesin (anterograde) and dynein (retrograde). At the tip of the dendrite, melanosomes are captured in the actin-rich periphery. Myosin-Va (MyoVa) mediates melanosome binding to actin through the linker proteins Rab27a and melanophilin (Mlph).

TO KERATINOCYTES

Transfer of melanosomes from melanocytes to neighboring keratinocytes is a critical step in normal pigmentation. Studies suggest several ways for melanosomal transfer, including exocytosis, cytophagocytosis, fusion of plasma membranes, and transfer by membrane vesicles.[187]

The exocytosis pathway of melanosomal transfer involves fusion of the melanosomal membrane with the melanocyte plasma membrane, melanosome release into the intercellular space and phagocytosis by surrounding keratinocytes. Cytophagocytosis is a term indicating the phagocytosis of a live cell or a portion of it. With regard to keratinocytes, they cytophagocytose the tip of a melanocyte dendrite, which then fuses with lysosomes inside the keratinocyte, is transported to a supranuclear location where the phagolysosome membranes break up releasing the melanosomes. Fusion of keratinocyte and melanocyte plasma membranes creates a space through which melanosomes are transferred from the melanocyte to the keratinocyte. Indeed, high-resolution photography shows the presence of filopodia—slender, filliform, pointed cytoplasmic projections at the tip of melanocyte dendrites.[188] These filopodia adhere and fuse with keratinocyte plasma membrane prior to melanosome transfer. Another way of melanosomal transfer involves shedding of melanosome-filled vesicles followed by phagocytosis of these vesicles by keratinocytes, or their fusion with keratinocyte plasma membrane.

The molecular and cellular mechanisms involved in melanosome phagocytosis have been partially elucidated. It appears that keratinocytes express a

seven-transmembrane G-protein coupled receptor called protease activated receptor-2 (PAR-2). PAR-2 is activated when serine proteases cleave the extracellular portion of the receptor, exposing a new segment that acts as a tethered (attached) ligand.[189,190] Activation of PAR-2 increases keratinocyte phagocytic activity.[189,190]

Interestingly, and consistent with its role in melanosome phagocytosis, UV induces the activity and expression of PAR-2.[191] UV effect on PAR-2 activity and expression is more pronounced in individuals with skin phototypes II and III than in those with skin phototype I.[191] Keratinocyte growth factor receptor has also been implicated in enhancing phagocytosis of melanosmes by keratinocytes.[192]

REGULATION OF MELANOCYTE FUNCTION

Melanocyte behavior in skin is largely influenced by signals from neighboring keratinocytes as well as autocrine signals and environmental factors such as UV irradiation (also see Section "UV Irradiation and Melanocytes"). The synthesis and secretion of most keratinocyte-derived factors is increased by UV irradiation, but it is also evident that UV can directly stimulate melanocyte dendricity and melanin production.[171,193] Melanocytes receive both positive and negative paracrine signals that modulate their proliferation and differentiated function.

MELANOGENIC STIMULATORS

PROOPIOMELANOCORTIN AND DERIVED PEPTIDES. It is well documented that MSH and ACTH are potent stimulators of melanogenesis. They belong to a family of peptides derived from the precursor proopiomelanocortin (POMC) that is synthesized, in addition to the pituitary gland, also by epidermal keratinocytes. Interestingly, POMC expression in keratinocytes is induced by UV, phorbol esters, and interleukins.[194,195] In rodents, α-MSH stimulates melanogenesis and favors eumelanin over pheomelanin production, but systemic administration of α-MSH, β-MSH, and ACTH to people increases skin pigmentation predominantly in sun-exposed areas.[196,197] However, in certain disease conditions characterized by abnormally high levels of ACTH, such as Addison disease[198] or Nelson's syndrome[199] (ACTH secreting pituitary adenoma), more generalized hyperpigmentation of the skin has been observed.[200]

Aside from its effect on melanogenic proteins and eumelanin synthesis, α-MSH was also reported to enhance the repair of UV-induced DNA damage in melanocytes, specifically the repair of pyrimidine dimers, and also to reduce the level of UV-induced hydrogen peroxide in the cell.[201] In addition, α-MSH was shown to regulate melanosomal pH.[202] These data suggest a role for POMC-derived peptides beyond merely stimulating melanogenesis.

ENDOTHELIN-1. ET-1 appears to play a role in mature melanocytes, inducing melanogenesis by activating tyrosinase and increasing TRP-1 levels.[203,204] ET-1 also leads to melanocyte proliferation[203,204] and promotes dendrite formation.[205] Cultured keratinocytes synthesize and secrete ET-1,[204–206] and UV irradiation stimulates ET-1 production by keratinocytes.[204,205] ET-1 can also cooperate synergistically with other growth factors/cytokines to further influence melanocyte function.

ET-1 upregulates MC1R level and increases MC1R affinity for α-MSH.[207,208] Similar to α-MSH, ET-1 displays photoprotective effects on melanocytes, enhancing thymine dimer repair, decreasing the level of UV-induced hydrogen peroxide, and inducing the level of antiapoptotic proteins.[201,209]

STEEL FACTOR (SF). Like other keratinocyte-derived factors, SF is induced by UV-irradiation, and in guinea pigs, anti-Kit antibodies block UV-induced tanning. SF can also act synergistically with other cytokines such as IL-3, IL-6, IL-7, IL-9, and granulocyte-macrophage-colony stimulating factor to regulate UV-induced melanogenesis and melanocyte survival.[210,211]

INFLAMMATORY MEDIATORS. Several inflammatory mediators can affect skin pigmentation. PGs—arachidonic acid-derived metabolites, and leukotrienes—lipid compounds related to PGs, both mediators of inflammatory responses, affect melanocyte function. Their level is elevated in sunburned skin[212] and in a variety of inflammatory dermatoses, including atopic dermatitis[213] (see Chapter 14) and psoriasis[214] (see Chapter 18).

Human melanocytes express several PG receptors including the receptors for PGE_2 and $PGF_{2\alpha}$.[215,216] Indeed, $PGF_{2\alpha}$ stimulates melanocyte dendrite formation and activates tyrosinase,[215,216] and UV irradiation upregulates the level of PG receptors on melanocytes.[215,216] Similarly, leukotrienes B_4 and C_4 increase melanin synthesis and stimulate melanocyte proliferation and motility.[217] Interestingly, melanocytes also contribute to cutaneous inflammatory responses, as they synthesize and release IL-8 when stimulated by the proinflammatory cytokines IL-1 and TNF-α.[218]

Melanocytes also respond to histamine released by mast cells during cutaneous inflammation. Histamine binds H_1 and H_2 receptors to induce melanocyte dendricity and upregulate tyrosinase level.[219,220] These effects are decreased when melanocytes are pretreated with the H_2 receptor antagonist famotidine.[220]

NEUROTROPHINS. Neurotrophins (NTs) are a family of molecules that enhance neuronal survival in the central and peripheral nervous systems. They include NGF,[221] NT-3,[222–224] NT-4,[225] and brain-derived neurotrophic factor.[226,227] Melanocytes express the low-affinity receptor common to all NTs, $p75^{NTR}$,[228] as well as the high-affinity receptors for NGF (TrkA) and NT3 (TrkC).[229] Keratinocyte-derived NGF, whose expression is upregulated by UV irradiation, is chemotactic for melanocytes and

induces their dendricity.[230] Both NGF and NT-3, the latter expressed by dermal fibroblasts, increase melanocyte survival. Specifically, after UV irradiation, NGF supplementation increases the level of the antiapoptotic Bcl-2 protein, reducing melanocyte apoptotic cell death.[231,232] Thus, in addition to other keratinocyte-derived cytokines, NGF may help preserve the population of cutaneous melanocytes that would otherwise be depleted by UV damage.

BASIC FIBROBLAST GROWTH FACTOR. Basic fibroblast growth factor (bFGF), named for its ability to stimulate the growth of fibroblasts, was one of the first identified melanocyte mitogens.[233,234] It is produced by keratinocytes, but lacks a secretory signal and hence is presumed to affect melanocytes through cell–cell contact. It binds tyrosine kinase transmembrane receptors to induce its mitogenic effect in the presence of cAMP elevating factors. Like other keratinocyte-derived cytokines, it is upregulated in response to UV irradiation.[234,235] Keratinocyte growth factor, another member of the FGF family of proteins, has been shown to promote melanosome transfer from melanocytes to keratinocytes.[192]

NITRIC OXIDE. Nitric oxide (NO) is a diffusible free radical displaying pleiotropic bioregulatory effects in diverse cells and tissues.[236,237] Melanocytes and keratinocytes produce NO in response to inflammatory cytokines,[238–241] and NO production in keratinocytes is induced by UV irradiation.[242] NO increases tyrosinase activity and melanogenesis[242] and is thus an autocrine as well as paracrine molecule that affects melanocyte behavior in skin.

CATECHOLAMINES. Catecholamines are a group of signaling molecules, primarily functioning as neurotransmitters and as endocrine hormones.[243] Catecholamines bind either α_1-adrenergic receptors (AR) or β_2-AR and can induce melanogenesis through PKC-β or cAMP-dependent pathways.[169,244]

MELANOGENIC INHIBITORS

Numerous reports have suggested the existence of endogenous melanogenic inhibitors,[245,246] but only few specific molecules have been identified. One group of inhibitors includes sphingolipids, a class of membrane-associated lipids[247] that act as signal transducers. Sphingolipids were shown to decrease melanogenesis, at least in part by enhancing MITF degradation via ubiquitin-meditated pathways.[248,249] Another melanogenic inhibitor, BMP-4, downregulates tyrosinase expression in melanocytes,[250] also in part via its effects on MITF.[251] Interestingly, physiologic doses of UV irradiation, a potent melanogenic stimulator, decrease the expression of BMP receptors on melanocytes,[250] presumably eliminating its inhibition during UV-induced tanning. Mice that transgenically overexpress the physiologic BMP antagonist noggin have a darker coat color than wild-type mice and their hairs have a higher eumelanin to pheomelanin ratio.[252]

SIGNALING PATHWAYS REGULATING MELANOCYTE FUNCTION

Growth factors, cytokines, hormones, and other ligands for receptors expressed on melanocytes exert their biologic effect by interacting with their specific cell surface receptors, generating a signaling cascade involving activation or inhibition of protein kinases and leading to distinct patterns of protein phosphorylation. Two types of kinases participate in cellular signaling: (1) serine/threonine kinases and (2) tyrosine kinases that by definition phosphorylate serine and/or threonine residues and tyrosine residues, respectively, on their specific target proteins. This section reviews the major signaling pathways that affect melanocyte behavior in skin.

cAMP/PKA-DEPENDENT PATHWAY

cAMP, one of the first identified intracellular second messengers, plays a key role in diverse biological functions such as cellular metabolism, growth, and differentiation.[253,254] It also mediates α-MSH effect[255] and was one of the first recognized regulators of mammalian pigmentation[256] The intracellular level of cAMP is upregulated by a membrane-associate enzyme called adenylate cyclase that is activated upon receptor–ligand interaction in receptors that are coupled to GTP-binding proteins like MC1R[257] (eFigs. 72-8.1 and 72-12.1 in online edition). cAMP is also elevated by reagents such as choleragen or isobutylmethylxanthine. Providing melanocytes with dibutyryl cAMP, a cAMP analog, increases the intracellular level of cAMP and induces signaling that leads to melanogenesis.[258]

cAMP-dependent protein kinase (PKA) mediates most of the biologic actions of cAMP.[257] PKA is a serine/threonine kinase consisting of two regulatory subunits and two catalytic subunits.[257] It exists in the cytosol in an inactive form and binding of cAMP to its regulatory subunits releases the catalytic subunits, activating the enzyme.[257] PKA phosphorylates the cAMP responsive element-binding protein (CREB) that binds its DNA consensus sequence CRE in the MITF promoter to induce MITF transcription (eFig. 72-8.1 in online edition). cAMP elevation also affects other target genes by increasing or decreasing their transcription[259] (eFig. 72-12.1 in online edition). In vitro, PKA effect can be antagonized by the inhibitor PKI that acts as a pseudosubstrate for the catalytic subunit of PKA and thus prevents it from phosphorylating its endogenous substrates.[260]

PKC-DEPENDENT PATHWAY

PKC is a serine/threonine kinase involved in diverse cellular functions, including growth, transformation, and differentiation.[261] PKC resides as an inactive enzyme in the cytoplasm, and it is activated by diacylglycerol (DAG), a component cleaved from the plasma membrane when cell surface receptors interact with

their ligands. DAG can also be released from the membrane by UV irradiation (eFig. 72-12.1 in online edition). DAG induces PKC translocation to membranes where the latter is activated[261] to induce phosphorylation of serine/theonine residues on target proteins like tyrosinase. Phorbol esters mimic DAG action and initially activate PKC.[261] However, within 24 hours the entire cellular reserves of PKC are depleted, and when melanocytes are treated with phorbol esters they can no longer signal through PKC.[87]

The critical role of PKC in melanogenesis was first suggested by the observation that addition of DAG, the endogenous activator of PKC, to cultured human melanocytes rapidly increased total melanin content,[262] and this increase was blocked by a PKC inhibitor.[262] Moreover, topical application of DAG to guinea pig skin increased epidermal melanin content.[263]

The expression of the 12 PKC isoforms varies among different tissues.[86] Each isoform is thought to carry out a distinct biological function. Human melanocytes express PKC-α, -β, -ε, -δ, and -ς[264,265] and the PKC-β isoform is specifically involved in regulating tyrosinase activity (see above). ET-1 and histamine also utilize the PKC-dependent pathway (in addition to cAMP-dependent pathway) to exert their regulatory effects on melanocyte function.[266,267]

RECEPTOR TYROSINE KINASES

Melanocytes express several distinct tyrosine kinase receptors that bind BMP, bFGF, HGF, and c-Kit ligand. Receptor–ligand interaction activates an intracellular tyrosine kinase domain on the receptor, phosphorylating the receptor and subsequently activating a series of kinases called mitogen-activated protein (MAP) kinases, or other intracellular signaling molecules (eFig. 72-12.1 in online edition). Through a chain reaction involving phosphorylation of proteins like MITF, the signals are transferred to the nucleus to activate or suppress the transcription of genes that participate in melanocyte proliferation, melanogenesis, and/or survival.

β_2- AND α_1-ADRENERGIC RECEPTORS

Studies suggest that pathways that increase intracellular cAMP are also involved in regulation of melanogenesis. POMC-deficient mice (POMC $^{-/-}$) that lack melanocortin ligands still display normal black coat color.[269] Histological and electron paramagnetic resonance spectrometry of the hair follicles showed normal structure and eumelanin pigmentation.[269] This study suggests that either MC1R has adequate basal activity to induce pigmentation or that pathways that do not involve melanocortin can also induce melanogenesis. Indeed, melanocytes express both β_2-AR and α_1-AR, respectively.[270,244] α_1-AR interacts with melanocyte derived-norepinephrine and increases the level of DAG[169,244] inducing melanogenesis in a PKC-β-dependent pathway. Also, keratinocytes produce epinephrine, which then binds to β_2-AR expressed on melanocytes and increases the level of cAMP, leading to melanin synthesis.[244] Therefore, numerous pathways may act in tandem to regulate melanogenesis.

UV IRRADIATION AND MELANOCYTES

TANNING RESPONSE

Melanocyte survival, proliferation, and differentiated function are influenced by environmental factors, the most important of which is UV irradiation. UV irradiation induces tanning, the so-called facultative skin color, an increase above baseline or constitutive skin pigmentation that provides protection against future UV irradiation.[271] Tanning is divided into immediate tanning and delayed tanning.

IMMEDIATE TANNING. Immediate tanning or immediate pigment darkening occurs within 5–10 minutes of exposure and fades within minutes to days depending on the UV dose and the complexion of the individual (Fig. 72-13B). As summarized in Table 72-1, immediate tanning does not provide photoprotection and does not increase epidermal melanin level.[272] It is primarily produced by UVA irradiation, although visible light can also induce immediate tanning.[273] Immediate tanning is only visible in darker individuals, and it is thought to represent melanosomal relocation from the perikaryon to melanocyte dendrites.[274]

DELAYED TANNING. Delayed tanning, summarized in Table 72-1 and shown in Figure 72-13A, occurs within 3–4 days after UV exposure.[271,272] UV is arbitrarily divided into UVC (100–280 nm), UVB (280–320 nm), and UVA (320–400 nm). The UVC portion of the spectrum is generally not present in terrestrial sunlight because it is absorbed by the atmospheric ozone layer. Delayed tanning is affected by both UVB and UVA. The action spectrum that produces delayed tanning is the same as for UV-induced erythema (sunburn), with UVB wavelengths far more effective than UVA.[264] Especially in darker skinned individuals, suberythemogemic UV doses may be effective as well. Delayed tanning peaks between 10 days and 3–4 weeks depending on the absorbed UV dose and the individual's skin type, then fades gradually over a few weeks. Histologically, there are increased epidermal melanocytes, melanocyte dendriticity, and melanosome transfer to keratinocytes with greater melanization of individual melanosomes.[272,274] Overall, total epidermal melanin is increased, providing additional photoprotection from UV irradiation.

DIRECT AND INDIRECT EFFECTS OF UV IRRADIATION

UV irradiation affects melanization, melanocyte proliferation and survival both directly and indirectly through its effect on keratinocytes, inducing the synthesis and secretion of paracrine keratinocyte factors.

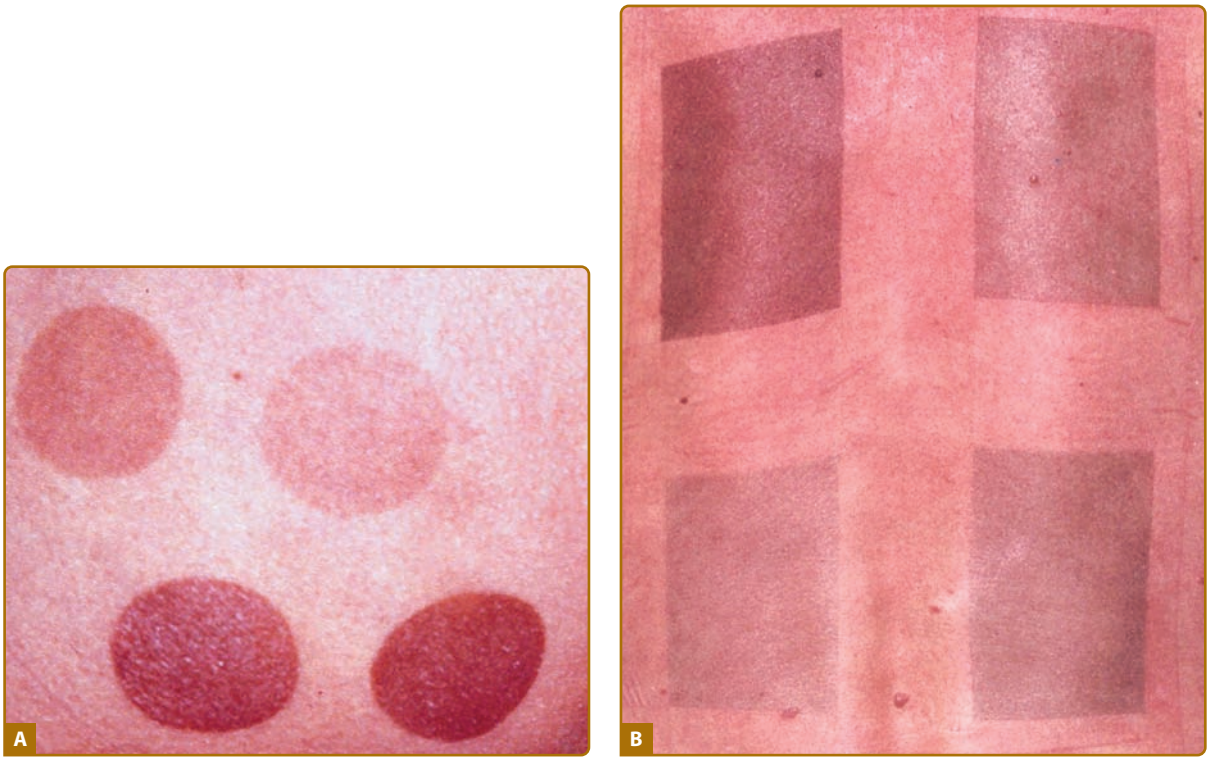

Figure 72-13 **A.** Delayed tanning. Four template test sites in a phototype III individual were exposed to repeated erythemogenic doses of ultraviolet B (UVB) (+UVA) delivered in 24-hour intervals, and the photograph was taken 10 days after the last exposure. The tan in the more heavily pigmented test sites persisted for 2 months. **B.** Immediate tanning in a phototype III individual. Four template test sites were exposed to various doses of UVA, and the photograph was taken 2 hours after the end of exposure. After 48 hours, the tan had almost completely faded.

DIRECT EFFECTS. UV irradiation triggers several biological reactions through its interaction with cellular chromophores that absorb photons. Photochemical reactions affect proliferation, survival, and the differentiated function of melanocytes. Most UVA effects are assumed to be the result of oxidative damage mediated through UVA absorption by cellular chromophores like melanin precursors that act as photosensitizers leading to the generation of ROS and free radicals.[275] UVB irradiation is directly absorbed by cellular DNA, leading

TABLE 72-1
Immediate Tanning versus Delayed Tanning

	Immediate	Delayed
Onset	Minutes	3–4 days
Peak intensity	Minutes to few hours	10–28 days
Fading	Within 24 hours	Weeks
Mechanism	Redistribution of melanosomes	↑Keratinocyte-derived melanogenic cytokines ↑Tyrosinase level and activity ↑Melanin synthesis ↑Melanocyte dendriticity ↑Melanosome number ↑Melanosome transfer ↑Melanocyte proliferation
Photoprotection	Unchanged	Increased
Change in skin color	Undetectable in fair skin Subtle in darker skin	Obvious in most light-skinned and all dark-skinned individuals

From Dillman AM: Photobiology of skin pigmentation. In: *Pigmentation and Pigmentary Disorders*, edited by N Levine. Boca Raton, CRC Press, 1993, pp. 61-94; Gilchrest BA et al: Mechanisms of ultraviolet light-induced pigmentation. *Photochem Photobiol* **63**(1):1-10, 1996; Ortonne JP: The effects of ultraviolet exposure on skin melanin pigmentation. *J Int Med Res* **18**(Suppl. 3):8C-17C, 1990; and Sturm RA: Human pigmentation genes and their response to solar UV radiation. *Mutat Res* **422**(1):69-76, 1998.

to the formation of DNA lesions, mainly cyclobutane dimers and pyrimidine (6–4) pyrimidone photoproducts.[276] DNA damage repair systems are activated, at least in part through the tumor suppressor p53 protein. It has been shown that plasma membrane lipids are also affected by UV irradiation to release DAG,[277] which then activates PKC-β to stimulate melanogenesis by activating tyrosinase (see above).

INDIRECT EFFECTS. Key keratinocyte paracrine factors induced by UV irradiation and their effects on melanocytes are summarized in eTable 72-1.1 in online edition. These factors can act alone and/or synergistically to modulate melanocyte function. Interestingly, UV irradiation also induces the level of TNF-α and IL-1, cytokines that inhibit melanogenesis, suggesting a fine-tuned epidermal equilibrium between melanogenic stimulators and inhibitors after UV irradiation, with the final outcome of increased melanogenesis and melanocyte proliferation.

THE ROLE OF DNA DAMAGE IN MELANOGENESIS

Interestingly, the action spectrum for tanning is virtually the same as that for the formation of thymine dimers,[278,279] and UV-induced melanogenesis can be augmented in pigment cells by treatment with T4 endonuclease V,[276] an enzyme that acts exclusively to enhance the repair of UV-induced DNA damage. Moreover, treatment of melanocytes with agents that act exclusively by damaging DNA, unlike UV that has multiple cellular targets, also stimulates melanogenesis.[280]

A central role for DNA damage and/or its repair in stimulating melanogenesis is further suggested by the fact that p53, a tumor-suppressor protein and transcription factor termed the Guardian of the Genome, when activated, upregulates the level of tyrosinase mRNA and protein, enhancing melanogenesis.[281–284] Thus, tanning may be viewed as part of a p53-mediated DNA damage adaptive response that protects the skin during subsequent exposure to UV irradiation.

p53 IN UV-INDUCED MELANOGENESIS. A central role for DNA damage and/or its repair in stimulating melanogenesis is further supported by the fact that the tumor-suppressor protein p53, when activated, upregulates the level of tyrosinase mRNA and protein, enhancing melanogenesis.[281–285] In p53 knockout mice, it was observed that UV irradiation of the ears (that contain interfollicular melanocytes) minimally stimulates melanogenesis, compared to the far greater "tanning" response in p53 wild-type mice.[282] These findings were expanded by Cui et al,[286] who found a p53 consensus sequence in the POMC gene promoter, thus establishing a continuous signaling pathway from UV-induced DNA damage to the final tanning response. It was shown in mice keratinocytes that following UV irradiation p53 activation stimulates POMC transcription, thereby increasing the release of POMC-derived α-MSH, a key physiologic inducer of melanogenesis. Keratinocyte-derived α-MSH then stimulates MC1R on melanocytes, resulting in increased production of eumelanin.[286]

It has also been shown that p53 transcriptionally upregulates the hepatocyte nuclear factor-1α (HNF-1α) that is a transcription factor for tyrosinase.[287] Thus, even in keratinocyte absence, UV directly activates p53 and HNF-1α in melanocytes to increase tyrosinase transcription. Furthermore, UV is known to increase H_2O_2 that activates p53.[288] Thus, tanning may be viewed as part of a p53-mediated DNA damage adaptive response aimed at protecting the skin from subsequent UV irradiation.[282,283,289]

MELANOCYTE AGING AND PHOTOAGING

Epidermal melanocyte aging is affected by both genetic and environmental factors. With aging, there is a decrease in the density of epidermal melanocytes (number per unit area of skin surface), approximately 10% per decade.[290] However, the number of DOPA-positive melanocytes is greater in chronically sun-exposed skin than in sun-protected skin,[290] possibly due to melanocyte proliferation after sun exposure and/or UV-induced keratinocyte-derived paracrine factors. Melanocyte loss is especially notable in hair follicles with age, with total loss of melanocytes in approximately half of all scalp follicles by middle age.[37] Hair graying (depigmentation) occurs over the entire body but is usually first noted on the scalp, perhaps because of the long anagen (growth) cycle and resulting requirement for melanocyte proliferation and sustained high level of melanogenesis.

In vitro melanocytes derived from older individuals show decreased proliferative capacity compared to those derived from younger individuals. Also, with aging in vitro, there is a general increase in the levels of total melanin as well as in the level differentiation-associated proteins such as MITF, TRP-1, and TRP-2[291,292] and decrease in the level of proliferation-associated proteins such as cyclin D1 and E.[291,292]

KEY REFERENCES

Full reference list available at www.DIGM8.com

DVD contains references and additional content

3. Westerhof W: The discovery of the human melanocyte. *Pigment Cell Res* **19**(3):183-193, 2006
23. Mizoguchi M: Melanocyte development: With a message of encouragement to young women scientists. *Pigment Cell Res* **17**(5):533-544, 2004
39. Ito S: Biochemistry and physiology of melanin. In: *Pigmentation and Pigmentary Disorders*, edited by N Levine. Boca Raton, FL, CRC Press, 1993, pp. 34-59
40. Slominski A et al: Melanin pigmentation in mammalian skin and its hormonal regulation. *Physiol Rev* **84**(4):1155-1228, 2004
65. Park HY, Gilchrest BA: Signaling pathways mediating melanogenesis. *Cell Mol Biol* **45**(7):919-930, 1999
171. Scott G. Rac and rho: The story behind melanocyte dendrite formation. *Pigment Cell Res* **15**(5):322-330, 2002

182. Matesic LA, Copeland, NG, Jenkins, NA: A genetic approach to the study of vesicle transport in the mouse. In: *Mechanisms of Suntanning*, edited by JP Ortonne, R Ballotti. Nice, Martin Dunitz, 2002:199-208
187. Van Den Bossche K, Naeyaert JM, Lambert J: The quest for the mechanism of melanin transfer. *Traffic* **7**(7):769-778, 2006
256. Lerner AB: My 60 years in pigmentation. *Pigment Cell Res* **12**(2):131-144, 1999
271. Gilchrest BA et al: The photobiology of the tanning response. In: *The Pigmentary System: Physiology and Pathophysiology*, edited by JJ Nordlund, RE Boissy, VJ Hearing, RA King, JP Ortonne. New York, Oxford University Press, 1998, pp. 359-372

Chapter 73 :: Albinism and Other Genetic Disorders of Pigmentation

:: Thomas J. Hornyak

ALBINISM AND CONGENITAL DISORDERS OF PIGMENTATION AT A GLANCE

- Worldwide occurrence
- Albinism is usually inherited as a recessive trait, but other congenital disorders of pigmentation are usually inherited as dominant traits. There can be marked differences in penetrance.
- Clinical features of albinism may include lightly pigmented or nonpigmented skin and silvery-white or light hair color.
- Ocular nystagmus and reduced visual acuity are important features of albinism that distinguish albinism from other congenital disorders of pigmentation.
- Clinical features of congenital disorders of pigmentation include patches of white hair (poliosis), variations in iris color, and depigmented patches of white skin.
- The presence of ocular nystagmus is useful for distinguishing albinism from congenital disorders of pigmentation.
- Albino skin contains melanocytes with reduced or absent DOPA-positivity. Depigmented patches in congenital disorders of pigmentation lack melanocytes.

EPIDEMIOLOGY

EPIDEMIOLOGY OF ALBINISM

Oculocutaneous albinism (OCA) is the most common inherited disorder of generalized hypopigmentation, with an estimated frequency of 1 in 20,000 in most populations. Four different types of OCA have been described. OCA1 and OCA2 are the most frequent types and account for approximately 40% and 50%, respectively, of OCA worldwide. OCA2 occurs in approximately 1 in 30,000 to 1 in 36,000 Caucasians and 1 in 10,000 to 1 in 17,000 blacks in the United States,[1–3] but is reported at higher frequencies ranging from 1 in 1,400 to 1 in 7,000 in Sub-Saharan Africa[4,5] and even as high as 1 in 170 individuals in the Kuna population of the Panama coast.[6] OCA3 and OCA4 are far less frequent, although the rufous OCA phenotype, described later, associated with OCA3 in South African blacks has been reported at an incidence of approximately 1/8,500,[7] while OCA4 accounts for 27% of all cases of OCA in Japan.[8]

Hermansky–Pudlak syndrome (HPS) is rare except in the Caribbean island of Puerto Rico, particularly in the northwestern region where the majority of patients are found, with an incidence of 1 in 1,800.[9] Chediak–Higashi syndrome is also quite rare.

BOX 73-1 DIFFERENTIAL DIAGNOSIS OF ALBINISM

- OCA types 1–4
- Hermansky–Pudlak syndrome
- Griscelli syndrome
- Chediak–Higashi syndrome
- Ocular albinism
- Currently unclassified types of albinism
- Tietz syndrome
- Vitiligo (extensive)
- Ziprkowski–Margolis syndrome (X-linked albinism–deafness syndrome)
- Cross (Cross–McCusick–Breen) syndrome (oculocerebral syndrome with hypopigmentation)

TABLE 73-1
Characteristics of Albinism

Disease	Chromosome	Gene Locus	Protein [Biogenesis of Lysosome-Related Organelles Complex (BLOC)]	Distinguishing Signs
Oculocutaneous albinism type 1	11q21	*TYR*	Tyrosinase/TYR	Type 1A—no pigment Type 1B—some pigment
Oculocutaneous albinism type 2	15q11.2-q12	*P*	Pink protein/P	Some pigmentation apparent; nevi and freckles possible
Oculocutaneous albinism type 3	9p23	*TYRP1*	Tyrosinase-related protein-1/TYRP1	Similar to OCA2 phenotype. Includes rufous (red) albinism phenotype.
Oculocutaneous albinism type 4	5p	*MATP*	Membrane-associated transporter protein/MATP	Similar to OCA2 phenotype. Most common in individuals with Asian biogeographic ancestry.
Hermansky–Pudlak syndromes				
Type 1	10q24	*HPS1*	HPS1 (BLOC-3)	Pulmonary fibrosis associated; absent platelet dense granules is a hallmark of all types of HPS
Type 2	15q15	*AP3B1*	β-3 subunit of adaptor protein 3 complex/AP3B1	
Type 3	3q24	*HPS3*	HPS3 (BLOC-2)	
Type 4	22q11.2-q12.2	*HPS4*	HPS4; distant homology with yeast CCZ1 (BLOC-3)	Pulmonary fibrosis associated
Type 5	11p14	*HPS5*	HPS5 (BLOC-2)	
Type 6	10q24.32	*HPS6*	HPS6 (BLOC-2)	
Type 7	6p22.3	*DTNBP1*	Dysbindin (BLOC-1)	
Type 8	?	*BLOC1S3*	BLOC1S3 (BLOC-1)	
Chediak–Higashi syndrome	1q43	*LYST*	Lysosome trafficking/LYST	Giant peroxidase-positive lysosomal granules in neutrophils

EPIDEMIOLOGY OF CONGENITAL DISORDERS OF PIGMENTATION

Waardenburg syndrome (WS) is probably less frequent than OCA. The highest reported incidence is 1/20,000 in Kenya, although most estimates of its incidence in the Netherlands where it was originally reported are in the range of 1/40,000. The incidence of WS with deafness is lower, ranging between 1/50,000 and 1/212,000. WS has been described occurring in a range of frequencies in the congenitally deaf, ranging from 0.9%–2.8% to 2%–5% in different reports. The incidence of piebaldism is estimated to be less than 1/20,000.[10,11]

ETIOLOGY, PATHOGENESIS, AND CLINICAL FEATURES

Awareness of the biologic basis of the distinction between congenital disorders of pigmentation, which are disorders of melanocyte development, and the varieties of albinism, which are disorders of melanocyte differentiation, is important for fully understanding their clinical manifestations. Albinism results from the dysfunction of a normal complement of pigment cells, which results in complete or partial loss of cutaneous pigmentation. The forms of albinism, including the subtypes of OCA as well as albinism syndromes with systemic manifestations, result either from enzymatic defects in the biosynthesis of melanin, from melanosomal defects that interfere with melanin formation, or from problems in the intracellular transport and localization of proteins essential for melanin biosynthesis (Table 73-1; see Chapter 72). Congenital disorders of pigmentation usually result from mutations in genes critical for melanocyte development during embryogenesis. These disorders can also be associated with other systemic problems because of the requirement for these gene products in the development of cell types other than melanocytes. More accurate descriptors of these disorders could be *congenital* (or *genetic*)

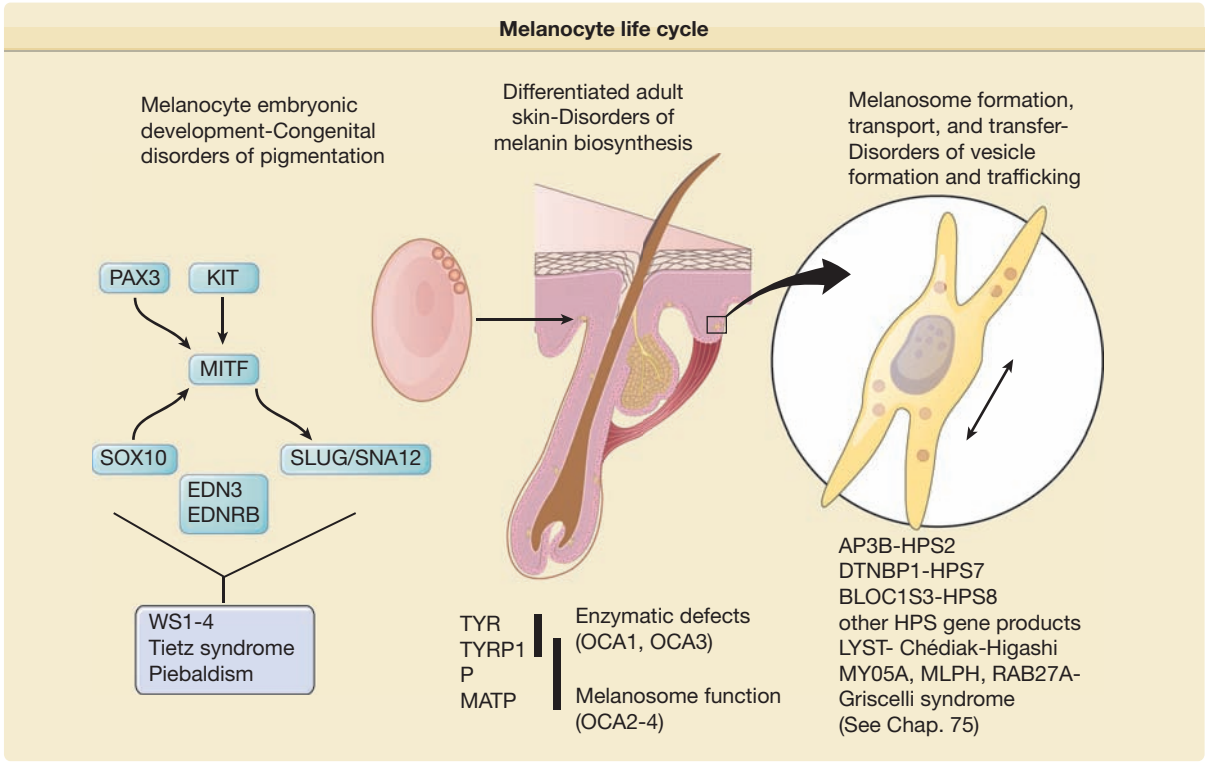

Figure 73-1 Schematic diagram illustrating the steps of the melanocyte life cycle, from development through differentiation, where key genes, altered in the indicated genetic diseases, act to control the function of the melanocyte.

disorders of melanocyte differentiation and *congenital* (or *genetic*) *disorders of melanocyte development*, to reflecting the fact that both categories of conditions, albinism and developmental pigmentary syndromes, are generally inherited but result from different mechanisms of disease (Fig. 73-1).

ETIOLOGY, PATHOGENESIS, AND CLINICAL FEATURES OF ALBINISM

Although the pigmentary abnormalities associated with types of albinism can vary widely, common to all types of albinism is reduced visual acuity and ocular nystagmus, a result of misrouting of the optic nerve at the optic chiasm and foveal hypoplasia. This has been described not only in humans[12] but also in other albino mammals.[13] Experiments using the tyrosinase promoter to express both tyrosinase and tyrosine hydroxylase in albino transgenic mice suggest that the tyrosine hydroxylase activity of tyrosinase is particularly important for ensuring the proper routing of retinal projections at the optic chiasm during development.[14,15] The ocular manifestations of albinism can vary greatly, ranging from severe (20/400) to nearly undetectable, but is often close to 20/80.[16] They also include a reduction in iris pigment, a reduction in retinal pigment, and alternating strabismus.

OCULOCUTANEOUS ALBINISM TYPE 1.

OCA1 [Online Mendelian Inheritance in Man (OMIM) #203100] is caused by loss of function of the melanocytic enzyme tyrosinase resulting from mutations of the *TYR* gene.[17–19] Null mutations are associated with a total loss of function and no pigment formation (OCA1A), whereas "leaky" mutations result in an enzyme that retains some function and is associated with some pigment formation (OCA1B). OCA1 appears to be the most common type of albinism in non-Hispanic Caucasian patients.[20]

Analyses of DNA from individuals with OCA1A have shown a large number of different mutations in the *TYR* gene. These mutations include missense, nonsense, frameshift, splice site, and deletion mutations. Most individuals with OCA1 are compound heterozygotes with different mutant maternal and paternal alleles.[7] Missense mutations in the *TYR* gene are distributed among distinct regions of the coding sequence, which suggests that the encoded protein has multiple functional domains. Two of the clusters are in the copper-binding regions, with a third near the amino-terminus of the mature protein, in the extramelanosomal domain of tyrosinase shown to require phosphorylation for enzyme activation.[21,22] Clustering of mutations in discrete regions of the coding sequence is consistent with these regions' importance either for the melanogenic activity of tyrosinase or for functions related to its maturation or processing.[7,22] Missense mutations at the signal peptide cleavage site[23,24] implicate this cleavage event as an important step in the development of tyrosinase activity. Frameshift mutations near the *C*-terminus of the coding region[25,26] indicate that the cytoplasmic domain of tyrosinase is also important for full activity, possibly because of the presence of protein kinase C-β-dependent



Figure 73-2 OCA1A with no hair or skin pigment, demonstrating iris translucency.



Figure 73-3 OCA1B with golden blond scalp hair and tan.

phosphorylation sites that have been identified at its extreme *C*-terminus.[22]

All nonsense and frameshift mutations are associated with a complete loss of tyrosinase activity, presumably because of the subsequent production of a truncated protein. With missense mutations the picture is more complicated. A set of missense mutations that were associated with OCA1 patients accumulating pigment with age in either OCA1B or temperature-sensitive OCA (OCA1TS) patients[27] were shown to have residual enzymatic activity. Hence, it is likely that a subset of *TYR* missense mutations are responsible for the OCA1B and OCA1TS phenotypes because of the reduced, rather than absent, tyrosinase activity in their melanocytes.[7] However, other missense mutations resulting in the OCA1A and OCA1TS phenotypes result in defective intracellular processing of tyrosinase and retention of the mutant tyrosinase proteins in the endoplasmic reticulum, which suggests that some molecular variants of OCA1 represent an endoplasmic reticulum retention disease.[28–30] Thus, the residual enzymatic activity of a missense tyrosinase mutant cannot fully predict its phenotype, because other, presumably conformational, determinants of nascent mutant proteins may lead to their retention in the endoplasmic reticulum, block transport to the melanosome, and cause a more severe pigmentary phenotype.

In OCA1A, or the classic tyrosinase-negative OCA, there is a complete inability to synthesize melanin in skin, hair, and eyes, resulting in the characteristic "albino" phenotype. Affected individuals are born with white hair and skin and blue eyes, and there are no changes as they mature. The phenotype is the same in all ethnic groups and at all ages (Fig. 73-2). The hair may develop a slight yellow tint due to denaturing of the hair protein due to sun exposure and/or shampoo use. The irides are translucent, appear pink early in life, and often turn a gray–blue color with time. No pigmented lesions develop in the skin, although amelanotic nevi can be present. The architecture of skin and hair bulb melanocytes is normal. The melanosomes show a normal melanosomal membrane, and normal internal matrix formation is observed in stage 1 and 2 melanosomes.

The phenotype of OCA1B can range from minimal hair pigment to skin and hair pigmentation approaching the normal pigmentary phenotype for the individual's genetic composition and continental ancestry. Most individuals with OCA1B have very little or no pigment at birth and develop varying amounts of melanin in the hair and skin in the first or second decade of life (Fig. 73-3). In some cases the melanin develops within the first year. The hair color changes to light yellow, light blond, or golden blond first, as a result of residual pheomelanin synthesis, and eventually can turn dark blond or brown in adolescents and adults. The irides can develop light-tan or brown pigment, sometimes limited to the inner third of the iris, and iris pigment can be present on globe transillumination. However, some degree of iris translucency, as demonstrated by slit lamp examination, is usually present. Many individuals with OCA1B will tan with sun exposure, although it is more common to burn without tanning. Pigmented lesions (nevi, freckles, lentigines) develop in the skin of individuals who have developed pigmented hair and skin. In some patients, the moderate amount of residual tyrosinase activity can lead to near-normal cutaneous pigmentation, so that the clinician may overlook subtle cutaneous pigmentary abnormalities and render instead the mistaken diagnosis of ocular albinism (OA).

One variation of OCA1B is the temperature-sensitive phenotype. In this variation, scalp and axillary hair remain white or slightly yellow, but arm and leg hair pigments. The skin remains white and does not tan. The retention of melanin synthesis in the cooler areas of the body, such as the arms and legs, but not

the warmer areas, such as the trunk and the scalp, is associated with a temperature-sensitive mutation in tyrosinase, which loses activity above 35°C.[27] Similar tyrosinase mutations have been described in the Himalayan mouse[31] and in the Siamese cat with dark "points" at the tips of the ears and on the paws.[32]

OCULOCUTANEOUS ALBINISM TYPE 2.

Mutations of the *OCA2 (P)* gene, which maps to chromosome arm 15q, are responsible for OCA2 (OMIM #203200).[33] OCA2 occurs worldwide, though somewhat more frequently in the African, African-American, and certain Native American populations. Historically, affected individuals have benefited from limiting their sun exposure, especially in desert and equatorial climates. Interesting anthropological studies have described how various societies have differed in their treatment of members with OCA2. For example, the Cuna Indians of Panama actively forbade marriage between female and male albinos, and infanticide against albino infants was common in the early twentieth century. In contrast, no marriage discrimination was practiced in Hopi tribes, whose albinos were not expected to participate in farming activities requiring substantial exposure to sunlight.[34] From the standpoint of melanin synthesis, the defect in OCA2 appears to involve a reduction in eumelanin synthesis primarily, with less effect on pheomelanin synthesis. The predicted structure of the *OCA2* gene, a melanosomal protein, includes 12 transmembrane domains.[35,36] As expected, a number of mutations of the human *OCA2* gene are associated with human OCA2.[37,38]

In Sub-Saharan Africa, a single 2.7-kb deletion allele accounts for 60%–90% of mutant *OCA2* alleles and is associated with a common haplotype, suggesting a common founder.[5,38–40] It has been estimated that this single mutation is associated with 25%–50% of all mutant *OCA2* alleles in African-Americans.[5,38–44] However, other diverse mutant alleles have been described in this population and in Africans. The Brandywine, Maryland, isolate affects an inbred American population, originally located in a rural area east of Washington, DC, that has been studied extensively for its prevalence of albinism, dentinogenesis imperfecta, and other inherited recessive and dominant conditions, with mixed Caucasian, African, and possibly Native American ancestry.[45] In this population, 1 in 85 individuals has OCA2[45,46] and is homozygous for the 2.7-kb deletion allele of *OCA2*.[38] Thus, it is likely that this 2.7-kb deletion allele accounts for the distinct OCA2 phenotype in Africans and African-Americans.[47]

OCA2 also has been reported at relatively high frequencies ranging from 1 in 28 to 1 in 6,500 in specific Native American groups, including those populations in the southwest United States (Hopi population), southern Mexico, eastern Panama (Kuna population), and southwest Brazil.[34] In the Navajo population, a homozygous 122.5-kb deletion has been described in members with OCA2. This mutations results in the loss of exons 10 to 20 of *OCA2*, corresponding to a region containing seven of the transmembrane domains, and appears to be specific for OCA2 within the Navajo population.[48] On the other hand, OCA2 in the Kuna population is caused by a splice site mutation in intron 17 of *OCA2*.[49] Unlike the mutations in *TYR*, the missense mutations described to date in *OCA2* do not seem to cluster in any specific region.



Figure 73-4 OCA2 with yellow hair, white skin, and freckles in an African individual (classic tyrosinase-positive OCA phenotype).

Regarding *OCA2* gene product function, it has been shown that melanosomes from P protein-deficient melanocytes have an abnormal pH. Melanosomes in cultured melanocytes derived from wild-type mice are typically acidic, whereas melanosomes from P protein-deficient mice are nonacidic.[50] Hence, it is likely that the P protein regulates the pH of melanosomes, perhaps by functioning as an anion cotransporter in conjunction with a distinct proton pump on the melanosomal membrane. An alternate possibility is that the acidic conditions mediated by the P protein favor the normal biogenesis of melanosomes, including the correct targeting of other melanosomal proteins such as tyrosinase.[51] Single nucleotide polymorphisms in the first intron of *OCA2* are the major determinant of brown versus blue iris color,[52] and a germ line polymorphism of the *OCA2* gene is associated with favorable survival of estrogen receptor-negative breast cancer.[53] Conceivably this finding may be related to the previously reported enhanced sensitivity of cells overexpressing P protein to cytotoxic agents.[54]

In African and African-American individuals, there is a distinct OCA2 phenotype (Fig. 73-4). Hair is yellow at birth and remains so throughout life, although the color may turn darker. Hair color can turn lighter in older individuals, and this probably represents the normal graying with age. The skin is creamy white at birth and changes little with time. No generalized skin pigment is present, and no tan develops with sun exposure, but pigmented nevi, lentigines, and freckles often develop, since the cutaneous melanocytes in these individuals both remain susceptible to ultraviolet (UV)-induced changes early in life and retain some ability

to synthesize melanin later. The irides are blue–gray or light tan or brown. The development of lentigines or ephelides, well-demarcated pigmented patches usually on sun-exposed areas of the skin, may be evidence of a separate genetic susceptibility because these lesions only develop in some OCA2 families and not in others. The presence versus absence of ephelides is associated with a lower risk of skin cancer in South African albinos,[55] probably because the ability to produce ephelides by albinos in that environment also signifies a greater ability to produce pigment and thus demonstrate increased protection from UV radiation.

In Caucasian individuals with OCA2, the amount of hair pigment present at birth or developing with time varies from minimal in northern Europeans (particularly Scandinavians) to moderate in southern European or Mediterranean individuals. The hair can be very lightly pigmented at birth, having a light yellow or blond color, or more pigmented with a definite blond, golden blond, or even red color. The skin is creamy white and does not tan. The iris color is blue–gray or lightly pigmented, and the amount of translucency correlates with the development of iris pigment. With time, pigmented nevi and lentigines may develop, and freckles are seen in areas with repeated sun exposure. The hair in Caucasian individuals may slowly turn darker through the first two or more decades of life.

The normal delayed maturation of the pigment system and sparse hair early in life can make it difficult to recognize albinism early in northern European individuals. For all types of OCA in northern European families, the cutaneous hypopigmentation at birth or early in life is often similar to that of the parents and relatives, and the first concern is raised when it appears that the child is not tracking well or has developed nystagmus.

PRADER–WILLI AND ANGELMAN SYNDROMES.

Prader–Willi and Angelman syndromes often are associated with hypopigmentation.[57,58] The intragenic deletion encompassing one *P* allele in these patients[59,60] suggests that the observed pigmentary phenotype is related to OCA2 and the *P* gene, even if the details of this association are not fully understood.[47]

PRADER–WILLI AND ANGELMAN SYNDROMES

OCULOCUTANEOUS ALBINISM TYPE 3.

Mutations in the *TYRP1* gene result in OCA3 (OMIM #203290). The first described mutation was in an African-American newborn twin initially classified clinically as brown OCA. Mutation analysis revealed a single-base deletion at codon 368 producing a frameshift and premature stop codon in exon 6 and a slightly truncated TYRP1 molecule.[63] This mutation is shared by a substantial proportion of the rufous ("red") OCA population in southern Africa.[64] Rufous OCA is a distinct OCA phenotype in which the skin color is a mahogany brown with a slight reddish hue, and the hair color varies from deep mahogany to sandy red.[2,64] Additional OCA3-associated *TYRP1* mutations include a single-base substitution at codon 166, resulting in the alteration of a serine to a premature stop codon in exon 3 and a truncated TYRP1 molecule,[64] also identified in the rufous OCA population; and, in a Pakistani kindred, individuals homozygous for a distinct premature termination mutation.[65] A Caucasian male was compound heterozygous for a missense mutation in *TYRP1* located in the second copper-binding domain, inherited from the patient's mother, and a stop codon, which apparently occurred spontaneously.[66] Interestingly, the *p.S166X* mutation in TYRP1 previously associated with rufous OCA[64] was found to modify an OCA2 phenotype to a red-haired variant.[67]

OCA3 has presented with both the brown OCA and the rufous OCA phenotypes in the African and African-American populations. In the two cases of individuals with *OCA3* mutations only, not of African descent, the phenotype has been that of a tyrosinase-positive albinism, such as OCA1B or OCA2. As additional examples of OCA3 are characterized, genotype–phenotype correlation should become clearer.

PATHOGENESIS OF OCA3

HERMANSKY–PUDLAK SYNDROME.

Mutations in eight different genes to date have been associated with types of HPS.[70] Currently, our understanding about the function of their gene products varies greatly. However, a common theme is their functional involvement in trafficking cell type-specific products in cells containing lysosome-related organelles (LROs), including melanosomes in melanocytes.

HPS patients have OCA, with variable hypopigmentation of the skin, hair, and irides, and ocular abnormalities (see Fig. 73-5 and eFigs. 73-4.1, 73-5.1–73-5.3 in online edition). In addition, they lack platelet dense bodies and demonstrate a prolonged bleeding time, mucous membrane bleeding, a predisposition to epistaxis, easy bruising, and metromenorrhagia.[75] Whole-mount electron microscopy is used to provide a definitive determination of the absence of platelet dense bodies.[76]

The greatest clinical experience exists with patients with HPS1 (OMIM #604982), HPS3 (OMIM #606118), and HPS4 (OMIM #606118). Pulmonary fibrosis is a common and severe manifestation of HPS1 and HPS4, generally causing death between the fourth and sixth decades of life.[70,77] However, pulmonary fibrosis appears not to be associated with HPS3, which also features less severe pigmentary abnormalities.[78–80] Among HPS1 and HPS4 patients, a granulomatous colitis is associated, occurring in approximately 15%.[81,77] Ceroid lipofuscin, a complex lipid-protein material, has been reported to accumulate in the cells of HPS patients, predominantly those with HPS1.[75]

Mutations in distinct genes, rather than clinical phenotypes, define the various types of HPS. For example, more than two dozen distinct mutations have been found in *HPS1* that cause disease.[76–78] The most common, found in over 400 Puerto Rican individuals, is a 16-base pair (bp) frameshift duplication in exon 15.[79,80] Although the precise function of HPS1



Figure 73-5 Puerto Rican HPS1 patient. The patient died of pulmonary fibrosis.

protein is not yet known, HPS1 associates with HPS4 in the 200 kDa BLOC-3 (biogenesis of LROs complex-3) complex[81] and has also been found in association with HPS4 in a larger, 500-kDa complex in melanoma cells and fibroblasts.[82–84] In melanocytes cultured from the skin of HPS1 patients, the melanogenic enzymes TYR, TYRP1, and DCT/TYRP2 are found in large vesicular structures in the cell body and dendrites, instead of in the granular pattern typically associated with melanosomal localization,[85,86] suggesting a role in the control of protein trafficking to the melanosome. Mutations in *HPS4* have been described in 15 patients,[76] although its exact cellular role is not yet known. Functionally, the ATP-dependent pump MRP4 (ABCC4), normally localized to platelet granules and the plasma membrane, was found to be greatly reduced in HPS4 platelets.[87]

Mutations or deficiencies in the *AP3B1* gene, encoding the β_{3A} subunit of adaptor complex 3 (AP-3), one of the four known APs, cause HPS2 disease.[88] AP-3 interacts with tyrosinase, which is not targeted properly to melanosomes in *AP3B1*-deficient melanocytes. Hence, AP-3 protein is required for the trafficking of tyrosinase, and possibly other melanosomal proteins, from an intracellular site to melanosomes. Interestingly, the subcellular distribution of TYRP1 is unchanged in HPS2 melanocytes, suggesting that TYRP1 transport, in contrast to tyrosinase, is not entirely dependent upon the AP-3 mechanism.[89] The respiratory infections associated with HPS2 may be due to the abnormal movement of lytic granules in cytotoxic T lymphocytes (CTLs) to the immunologic synapse, leading to impairment of microbial killing.[90]

The most commonly described mutation in *HPS3* is a 3904-bp deletion mutation that includes the entire first exon, found in a Puerto Rican population, which is distinct from the *HPS1* Puerto Rican mutation.[72] In addition, a splice site mutation has been described in Ashkenazi Jews with HPS3 who are either homozygous for this mutation or compound heterozygous for this mutation and other, nonconserved mutations.[73] The HPS3 protein associates with the HPS5 and HPS6 proteins in the 340-kDa BLOC-2 complex.[91,92] Melanocytes from HPS3 patients exhibit defective localization of tyrosinase and TYRP1 in later stage melanosomes, whereas proteins normally incorporated into early-stage melanosomes, such as silver/Pmel17/gp100 and melan-a/MART1, are unaffected.[85,93] These melanocytes exhibited lower levels of melanin than control melanocytes, suggesting that the trafficking defect in tyrosinase, and perhaps also TYRP1, is responsible for the pigmentary dilution that can be observed in these patients.

GRISCELLI SYNDROME. Griscelli syndrome is discussed in Chapter 75.

CHEDIAK–HIGASHI SYNDROME CHS (OMIM #214500). CHS is a rare autosomal recessive disorder characterized by severe immunologic defects, hypopigmentation, bleeding tendency due to absent or reduced platelet dense bodies,[94] progressive neurologic dysfunction, and the presence of giant peroxidase-positive lysosomal granules in peripheral blood granulocytes.[95,96] Mutations in the *LYST* (lysosomal regulator trafficking) gene have been associated with Chediak–Higashi syndrome.[97] Although the precise role of the *LYST* product is not known, structural comparisons and inferences from the cell biology of *LYST* mutant cells suggest it may be important for membrane fusion during vesicular transport from the trans-Golgi network to late endosomes and multivesicular structures.[96,97]

Most patients with CHS have a severe form of the disease, childhood CHS,[98] with early onset of the so-called *accelerated phase*, characterized by fever, anemia, and neutropenia, including a lymphoproliferative syndrome with hemophagocytosis and benign infiltration of most tissues by activated T lymphocytes. This form of the disease is uniformly fatal unless patients undergo allogenic bone marrow transplantation. However, this treatment does not prevent future neurologic complications.[69] Ten percent to 15% of patients exhibit a much milder clinical disease, adult CHS,[98] surviving to adulthood but developing progressive and often fatal neurologic dysfunction in middle age. Very rare patients exhibit the intermediate adolescent CHS phenotype,[98] which presents with severe infections in early childhood but has a milder course by adolescence and no accelerated phase. Interestingly, mutation analysis of patients with the childhood, adolescent, and adult forms of CHS showed that patients with severe childhood CHS had only functionally null mutant *LYST* alleles, whereas patients with the adolescent and adult forms of CHS tended to exhibit missense mutant

alleles that likely encode *LYST* polypeptides with partial function. Furthermore, some patients with the CHS phenotype do not have *LYST* mutations detectable with established techniques.[98]

The hypopigmentation phenotype of CHS is variable and can be quite mild. Hair color is light brown to blond, and commonly has a silvery or metallic sheen.[96] Iris pigment is present, and nystagmus and photophobia may be present or absent. Histologic studies of the eye in CHS have shown reduced iris pigment, a marked reduction in retinal pigment granules, and infiltration of the choroid with reticuloendothelial cells.[99] Cutaneous hypopigmentation is probably a consequence of both the giant, hypopigmented melanosomes clustered around the nucleus within CHS melanocytes, and their inefficient transfer to keratinocytes.[100] Pigment granules in the hair shaft are large and have an irregular shape.[101]

The giant, peroxidase-positive lysosomal granules in neutrophils are a hallmark of the disease. These granules appear to inhibit neutrophil function, which along with neutropenia commonly observed is a likely determinant of the recurrent bacterial infections.[96] CHS natural killer (NK) cells have defective lytic granule secretion,[102] and defective cytotoxic T lymphocyte-associated antigen 4 function has been proposed as a potential mechanism for the accelerated, lymphoproliferative stage of the disease.[103] A reduced number of irregular platelet dense granules in CHS is responsible for the bleeding diathesis component.[69,96]

BOX 73-2 DIFFERENTIAL DIAGNOSIS OF CONGENITAL DISORDERS OF PIGMENTATION

- Waardenburg syndromes types 1–4
- Tietz syndrome
- Piebaldism
- Woolf's syndrome
- Generalized vitiligo
- Segmental vitiligo
- Vogt–Koyanagi–Harada syndrome
- Chemical leukoderma
- Tuberous sclerosis (hypopigmented macules and patches)
- Ziprkowski–Margolis syndrome (X-linked albinism–deafness syndrome)

ETIOLOGY, PATHOGENESIS, AND CLINICAL FEATURES OF CONGENITAL DISORDERS OF PIGMENTATION

WAARDENBURG SYNDROME. WS, described by the Dutch physician Petrus Waardenburg in 1951,[104] is the prototypic congenital disorder of pigmentation. Although it was originally described as a syndrome combining pigmentary defects of the hair (poliosis or white forelock) and iris, congenital deafness, and developmental craniofacial abnormalities, it was subsequently realized that additional phenotypic manifestations could be part of the same syndrome. Four types of WS, WS1 through WS4, have been described.[105–110] The discovery of molecular mutations accounting for the different types of WS has helped to explain its wide variety of manifestations as well as to illuminate the importance of specific genes for the development of different tissues and organs (Table 73-2). While practically all cases of WS1 and WS3 show mutated *PAX3*,[105,105,109,110] WS4 individuals either have homozygous mutations in *EDN3* (the endothelin-3 gene)[111–113] or *EDNRB* (the endothelin-B receptor gene)[114] or heterozygous mutations in *SOX10*.[115] On the other hand, WS2 appears to arise more heterogeneously, as a mutation in *MITF* has been shown in only a small fraction of WS2 patients.[107,108]

Waardenburg Syndrome Type 1. Individuals with WS1 (OMIM #193500) are usually heterozygous for mutations in *PAX3*; hence, WS1 is autosomal dominant in inheritance. Although many different mutations in *PAX3* have been associated with WS1, these mutations are thought either to be functionally

TABLE 73-2
Waardenburg and Tietz Syndrome Characteristics

Disorder	Clinical Signs	Mutated Gene(s)
Waardenburg syndrome (WS) type I	Hypopigmented patches, heterochromia irides, dystopia canthorum, sensorineural deafness (~75%)	*PAX3*
WS type II	Same as type I, but no dystopia canthorum	*MITF* *SNAI2/SLUG* (homozygous)
WS type III	Same as type I with limb abnormalities	*PAX3*
WS type IV	Same as type I with Hirschsprung's disease (congenital aganglionosis of the colon)	*EDN3* *EDNRB* *SOX10*
Tietz syndrome	Generalized hypopigmentation and sensorineural deafness	*MITF*



Figure 73-6 Waardenburg syndrome type 1. Note poliosis (white forelock) and dystopia canthorum (lateral displacement of the medial canthi of the eyes).

null alleles or to abrogate the interactions of PAX3 with DNA.[116]

Individuals with WS1 have pigmentation abnormalities associated with craniofacial abnormalities (see Fig. 73-6). Dystopia canthorum, which is lateral displacement of the medial canthi of the eyes, is the hallmark craniofacial defect found in virtually all cases of WS1. A broadening of the nasal root, the presence of hypoplastic alae nasi, and synophrys are other craniofacial abnormalities associated with WS1. Poliosis, such as the presence of a white forelock, is the most common pigmentation abnormality associated with WS1. Depigmented white spots on the skin occur less commonly, but are often located at the ventral midline reflecting the compromised migration of dysfunctional melanocyte precursors from their origin in the dorsal neural crest. Pigmentary abnormalities of the iris, including complete heterochromia irides (differently colored irises), partial heterochromia irides (variations of color within an iris), or hypoplastic blue irides, can also be associated with WS1. Premature graying may also be observed in WS1. Congenital deafness is present in 57% of cases.[117]

The importance of PAX3 for the expression of MITF,[118,119] with consequent effects upon melanocyte survival during development, is likely to account for the pigmentary defects of WS1. A role for *PAX3* in governing the development of neural crest derivatives that contribute to bony and cartilaginous structures of the face,[120] particularly those contributing to the formation of the frontal bone, explain the craniofacial anomalies observed in WS1. Sensorineural deafness, observed with incomplete penetrance in WS1, results from the variable failure of melanoblasts to migrate to or to survive in the stria vascularis in the lateral wall of the cochlea.[121,122]

Waardenburg Syndrome Type 2. Linkage analysis of families with WS2 (OMIM #193510, 608890, 600193, 606662) identifed the *MITF* locus as a candidate locus for the disease gene. At least nine different of mutations have been found in the coding region of the *MITF* gene in WS2 families.[107,123] However, *MITF* mutations account for only a minor portion (15%) of WS2 cases. A mutation in the transcription factor gene *SLUG/SNAI2* has also been associated with WS2,[124] as have heterozygous deletion mutations in *SOX10*,[125] but mutations in other, as yet undefined genes are likely to be implicated in the future. WS2 is inherited in an autosomal dominant pattern. Since most of the known MITF mutations in WS2 compromise the HLHZip region, thereby interfering with dimerization of mutant MITF with wild-type MITF,[126] the pigmentary developmental pathology in most cases of WS2 probably occurs through haploinsufficiency (reduced gene dosage, expression, or protein activity) rather than through dominant-negative effects.[123] Tietz syndrome, described later, is likely to result from dominant-negative effects of mutant MITF.

That mutations in MITF cause a subtype of WS is mechanistically attractive because of the crucial importance of MITF in melanocyte survival during development. An epistatic relationship exists between PAX3 and SOX10 and MITF in melanocyte development during embryogenesis. PAX3 and SOX10, as transcription factors, synergically transactivate MITF.[33,34] Since mutations of PAX3 and SOX10 also cause auditory-pigmentary symptoms in other types of WS, it is likely that failure of MITF transactivation is the main determinant of pigment cell developmental dysfunction in these other subtypes as well. SLUG/SNAI2, as a transcriptional target of MITF,[35] may act in the same pathway as an important downstream MITF effector in melanocytes whose activity is inhibited in SLUG-associated WS2.

Although all types of WS have skin, hair, and iris pigmentation anomalies and the possibility of hearing loss, WS2 is notable for featuring only these auditory-pigmentary symptoms. Diagnostic criteria for WS2 have previously been defined.[116] Individuals fulfilling two of the following four criteria, in the absence of dystopia canthorum, limb deformity, or Hirschsprung disease, should be counted as affected:

1. Congenital sensorineural hearing loss
2. Pigmentary disturbance of iris
   a. Complete heterochromia irides (two eyes of different color)
   b. Partial or segmental heterochromia (segments of blue or brown pigmentation in one or both eyes)
   c. Hypoplastic blue irides (characteristic brilliant blue, with thin iris stroma, in both eyes)
3. Pigmentary disturbance of the hair
   a. White forelock from birth or in teens
   b. Premature graying before age 30 years
4. A first- or second-degree relative with two or more of criteria 1–3

A survey of 124 cases of WS2 and 270 cases of WS1 revealed differences of phenotypic penetrance between WS2 and WS1: congenital sensorineural hearing loss occurred in 77% and 57%, respectively; heterochromia irides in 48% and 27%, respectively; hypoplastic blue

eye in 9% and 17%, respectively; white forelock in 9% and 17%, respectively; early graying in 23% and 26%, respectively; and white skin patches in 6% and 31%, respectively. The higher incidence of hearing loss in WS2 may be due to the difficulty of diagnosing WS2 in individuals without hearing loss. The hearing loss is congenital, sensorineural, and nonprogressive, showing marked variation between and within families. Among 81 WS2 cases in one series, 84% of patients reported bilateral hearing loss; 40% of patients noted profound loss, whether unilateral or bilateral.[117]

Waardenburg Syndrome Type 3. WS3 (OMIM #148820), also known as *Klein–Waardenburg syndrome*, is regarded as a variant of WS1. Most affected persons are heterozygous for a mutation in *PAX3*, although a few severely affected homozygotes have been described.[109] No specific mutations in *PAX3*, with the possible exception of a missense mutation at Asp47, have been correlated with the WS3 phenotype rather than the WS1 phenotype, although individuals with either homozygous or compound heterozygous mutations in *PAX3* may tend to exhibit a severe WS3 phenotype instead of WS1.[127] In addition to the features of WS1, WS3 patients have musculoskeletal abnormalities, manifested as limb contractures and hypoplasia of the limb musculature. The WS3 phenotype is consistent with the previously described role of PAX3 in the activation of transcription factors that govern muscle and limb development,[128] distinct from its role regulating development of neural crest derivatives.

Waardenburg Syndrome Type 4. WS4 (OMIM #277580), also known as *Shah–Waardenburg syndrome*, is caused by heterozygous mutations in the transcription factor gene *SOX10*, or by homozygous mutations in the gene encoding the peptide ligand endothelin-3, *EDN3*, or its receptor, *EDNRB*.[129] In addition to governing aspects of melanocyte development, these genes are important determinants of the development of the distal aspect of enteric nervous system cells, also neural crest derived, that innervate the distal part of the colon, which explains the association with Hirschsprung's disease or congenital aganglionosis of the colon. WS4 is the combination of the WS1 phenotype with Hirschsprung's disease.

TIETZ SYNDROME.

Tietz syndrome[130] (OMIM #103500) is a hypopigmentation–deafness syndrome resulting, like WS2, from mutations in *MITF.* Tietz syndrome has been described in three families to date. In each case, the mutation is found in the region of the *MITF* gene encoding the DNA-binding domain. In two cases,[131,132] an in-frame deletion mutation (*DelR217*) has been described, which affects the DNA-binding basic domain of MITF, leaving the dimerization HLHZip domain intact and functional. In these heterozygous Tietz syndrome individuals, it is likely that DelR217-MITF binds with wild-type MITF and interferes with the ability of the dimer to bind to DNA, a dominant-negative effect. Indeed, the identical mutation in mice[133] causing a semidominant phenotype, a phenotype that is incomplete in the heterozygous state, in vivo with a mild heterozygous spotting phenotype, but a prominent homozygous phenotype with early embryonic loss of all melanocyte precursors,[134] was shown to have a dominant-negative effect in vitro.[126] In addition, another mutation described in the family originally reported with the syndrome is predicted to exhibit an Asn210Lys substitution in the basic region.[135] The localization of this mutation to the DNA-binding region also suggests that it has dominant-negative effects.

Although sometimes regarded as a variant of WS2A (MITF-associated WS2),[136] Tietz syndrome individuals exhibit generalized cutaneous hypopigmentation similar to that found in OCA2, rather than distinct depigmented patches. Reduced melanosomes in keratinocytes found in one affected individual[132] may account for the generalized hypopigmentation that is observed. Affected individuals invariably exhibit profound hearing loss. Interestingly, a child with a deletion on chromosome arm 3p encompassing the entire *MITF* locus not only exhibits generalized hypopigmentation reminiscent of Tietz syndrome but also mild craniofacial anomalies and retention of some hearing function, as can be seen in types of WS.[137]

PIEBALDISM.

Piebaldism (OMIM #17280) is caused by mutations in the *KIT* proto-oncogene.[138] Stimulation of the KIT receptor tyrosine kinase by its ligand, stem cell factor (SCF)/KIT ligand, results in the phosphorylation of MITF and potentiation of MITF activity.[139] This relationship between the KIT receptor and MITF, as a final common effector of melanocyte survival during development, is likely to explain the developmental patchy loss of melanocytes occurring in human piebaldism when KIT receptor function is compromised.

Patients with piebaldism generally have depigmented patches on the ventral or lateral trunk and/or the mid-extremities, sparing the hands and feet. Poliosis is a common feature. The depigmented patches tend to be larger than those observed in WS. Typically, piebaldism is not associated with deafness, although piebaldism with deafness, otherwise referred to as Woolf syndrome, has been molecularly confirmed.[140]

DYSCHROMATOSIS SYMMETRICA HEREDITARIA.

Dyschromatosis symmetrica hereditaria (DSH; OMIM #127400), an autosomal dominant condition, was recently shown to be caused by mutations in *ADAR1*, formerly known as *DSRAD*, encoding adenosine deaminase acting on RNA 1, an RNA-editing enzyme.[141,142] It is not known how reduced activity of this enzyme results in pigmentary loss at acral sites. Patients exhibit speckled hypopigmentation, which is limited to the dorsa of the hands and feet.

COMPLICATIONS OF ALBINISM AND CONGENITAL DISORDERS OF PIGMENTATION

The complications of albinism revolve around the impact of the reduced visual acuity and hypopigmentation upon the affected individual. The primary medical complications are the early appearance of skin tumors in individuals with inadequate sun protection in equatorial climates. Delayed recognition and management of squamous cell carcinoma and melanoma in this setting can lead to metastasis and early death.

The complications of congenital disorders of pigmentation are more likely to relate to their associated manifestations, such as deafness or aganglionic megacolon, than the pigmentary loss.

PROGNOSIS/CLINICAL COURSE OF ALBINISM AND CONGENITAL DISORDERS OF PIGMENTATION

With the exception of individuals with OCA1A, patients with OCA can realize gradual pigmentation of the skin and hair over the course of their lives, and develop melanocytic nevi.

As long as the life-threatening aganglionic megacolon of WS4 is recognized at birth and corrected surgically, the prognosis of congenital disorders of pigmentation is favorable, with minor long-term health consequences. Spontaneous repigmentation of both the white forelock and white spots has been reported, as has contraction of the white spots.

MANAGEMENT OF ALBINISM AND CONGENITAL DISORDERS OF PIGMENTATION

All individuals with albinism should be under the care of an ophthalmologist and should have annual examinations until adult life. Most are hyperopic or myopic, and many have significant astigmatism; refractive correction aids in their visual attentiveness and performance.

Proper dermatologic care and protection from UV radiation of the sun and care by a dermatologist are strongly advised for individuals with OCA. Precautions include the use of sunscreens, hats, and long sleeves, as well as sun avoidance.

For HPS patients, topical control of bleeding can be achieved with thrombin and Gelfoam. In advance of dental procedures or biopsies, intravenous infusion of 1-desamino-8-D-arginine vasopressin can be used prophylactically.[69] The accelerated phase of CHS is managed initially with multimodal immunomodulatory therapy and maintenance cyclosporine followed by allogeneic hematopoietic cell transplantation.[143]

No treatment has been reported for the pigmentary loss associated with congenital disorders of pigmentation. However, melanocyte grafting, either with epidermal grafts or epidermal cell suspensions as used for the treatment of stable vitiligo,[144–146] might be an option to consider. Cochlear implants in the pediatric population with WS have led to positive outcomes.[147] It is important to recognize the hearing defect early so that proper management, including proper social and mental development and schooling, can be implemented.

Genetic counseling can help affected individuals assess their chances of transmitting the disorder to their progeny.

KEY REFERENCES

Full reference list available at www.DIGM8.com

DVD contains references and additional content

9. Wei ML: Hermansky-Pudlak syndrome: A disease of protein trafficking and organelle function. *Pigment Cell Res* **19**:19-42, 2006. doi:10.1111/j.1600-0749.2005.00289.x
18. Spritz RA et al: Detection of mutations in the tyrosinase gene in a patient with type IA oculocutaneous albinism. *N Engl J Med* **322**:1724-1728, 1990
27. King RA et al: Temperature-sensitive tyrosinase associated with peripheral pigmentation in oculocutaneous albinism. *J Clin Invest* **87**:1046-1053, 1991
47. Brilliant MH: The mouse p (pink-eyed dilution) and human P genes, oculocutaneous albinism type 2 (OCA2), and melanosomal pH. *Pigment Cell Res* **14**:86-93, 2001
96. Introne W, Boissy RE, Gahl WA: Clinical, molecular, and cell biological aspects of Chediak-Higashi syndrome. *Mol Genet Metab* **68**:283-303, 1999
117. Liu XZ, Newton VE, Read AP: Waardenburg syndrome type II: Phenotypic findings and diagnostic criteria. *Am J Med Genet* **55**:95-100, 1995
123. Tassabehji M et al: The mutational spectrum in Waardenburg syndrome. *Hum Mol Genet* **4**:2131-2137, 1995
136. Steingrimsson E, Copeland NG, Jenkins NA: Melanocytes and the microphthalmia transcription factor network. *Annu Rev Genet* **38**:365-411, 2004
141. Miyamura Y et al: Mutations of the RNA-specific adenosine deaminase gene (DSRAD) are involved in dyschromatosis symmetrica hereditaria. *Am J Hum Genet* **73**:693-699, 2003

Chapter 74 :: Vitiligo

:: Stanca A. Birlea, Richard A. Spritz, & David A. Norris

VITILIGO AT A GLANCE

- The most frequent depigmenting disorder, affecting 0.3%–0.5% of the population worldwide
- An acquired disease involving multiple genes and nongenetic environmental factors
- Characterized by progressive autoimmune-mediated destruction of epidermal melanocytes
- Typical presentation: patches of white skin and hair
- Cause of physiological and social stigma among affected individuals
- Increased risk for other autoimmune diseases, unpredictable evolution and unsatisfactory therapeutic outcomes

EPIDEMIOLOGY

The prevalence of vitiligo is reasonably consistent among different populations: ~0.38% in Caucasians,[1] 0.34% in Afro-Caribbeans,[2] 0.46% in Indians,[3] though perhaps somewhat less frequent in Han Chinese, 0.093%.[4] Vitiligo appears to affect both genders equally, though women are overrepresented among patients seeking clinical care. Vitiligo can develop at any age,[5] with a mean age-of-onset in Caucasian patients of about 24 years.[6] The most common subtype, generalized vitiligo (GV), is an autoimmune disease that is associated with other autoimmune diseases in about 20%–30% of patients, most frequently autoimmune thyroid disease (Hashimoto's thyroiditis or Grave's disease), rheumatoid arthritis, psoriasis, type 1 diabetes (usually adult-onset), pernicious anemia, systemic lupus erythematosus, and Addison's disease.[7]

ETIOLOGY AND PATHOGENESIS

Vitiligo is a multifactorial, polygenic disorder, with a complex pathogenesis that is not yet well understood.[8] Of various theories of disease pathogenesis, the most accepted is that genetic and nongenetic factors interact to influence melanocyte function and survival, eventually leading to autoimmune destruction of melanocytes.[7] Other suggested explanations have included defects of melanocyte adhesion,[9] neurogenic damage,[10] biochemical damage,[11] autocytotoxicity,[12] and others.

GENETICS OF VITILIGO

Large-scale epidemiological surveys have shown that most cases of vitiligo occur sporadically, although about 15%–20% of patients have one or more affected first-degree relatives. Typically, familial aggregation of cases exhibits a non-Mendelian pattern suggestive of polygenic, multifactorial inheritance.[8] Concordance in monozygotic twins is 23%,[6] indicating that both genetic and nongenetic (presumably environmental) factors play major roles in disease pathogenesis.

Almost all studies of vitiligo genetics have focused on GV. Several genes involved in immune function, including loci in the MHC, *CTLA4*, *PTPN22*, *IL10*, *MBL2*, and *NALP1* (*NLRP1*), have been implicated in susceptibility to GV on the basis of genetic linkage or association studies.[7] A recent, very large genome-wide association (GWA) study of European Caucasian GV patients and families identified at least ten different loci that contribute to GV risk.[13] Seven of these GV susceptibility loci have also been associated with other autoimmune diseases [(1) *HLA* class I, (2) *HLA* class II, (3) *PTPN22*, (4) *LPP*, (5) *IL2RA*, (6) *UBASH3A*, and (7) *C1QTNF6*], two loci encode proteins involved in immune function [(1) *RERE* and (2) *GZMB*], and another locus, *TYR*, encodes tyrosinase, a key enzyme of melanin biosynthesis and the major GV autoantigen.

Segmental vitiligo (SV) appears to be genetically distinct from GV. Its generally sporadic occurrence and unilateral distribution have led to the suggestion that it might result from somatic mosaicism for de novo mutations,[14,15] perhaps in genes that are critical for melanoblast/melanocyte development or survival, although this hypothesis remains to be confirmed.

AUTOIMMUNE HYPOTHESIS

There is compelling biological evidence supporting an autoimmune basis for GV.[16] GV is epidemiologically associated with a number of other autoimmune diseases,[6,17] both in patients and in their close relatives, indicative of a heritable autoimmune diathesis. Humoral immunity was first implicated by the finding in some cases of circulating antimelanocyte autoantibodies[18] that target various melanocyte antigens, including tyrosinase, tyrosinase-related protein-1, dopachrome tautomerase, and others, and that have the capability to kill melanocytes in vitro[19] and in vivo.[20] Currently, these autoantibodies are thought to reflect secondary humoral responses to melanocyte

destruction rather than a primary cause of GV.[18] A greater role is attributed to the inflammatory infiltrate sometimes seen at the margins of active GV lesions, composed mainly of cytotoxic T lymphocytes. As these T cells express a type-1 cytokine profile and colocalize with epidermal melanocytes, it has been hypothesized that these cells are actively cytolytic toward remaining melanocytes, via the granzyme/perforin pathway.[21]

An immune mechanism has also been suggested to underlie chemical leukoderma.[22] The so-called "occupational vitiligo" may occur in individuals who encounter large doses of phenolic compounds, usually 4-tertiary butyl phenol (4-TBP) and other phenolic compounds that may be contained in cleaning solutions. Occupational vitiligo usually initially involves the hands and forearms (the site of contact with the inciting agent). At present, it is unclear whether these agents are directly toxic to melanocytes, or whether some individuals might be genetically susceptible to melanocyte injury from aliphatic phenolic derivatives, ultimately resulting in melanocyte death, release of antigenic intracellular proteins, loss of tolerance, and autoimmunity.

An immune mechanism has also been proposed for the vitiligo-like depigmentation, which can appear in the course of IL-2 immunotherapy-based treatments for cutaneous melanoma, possibly via the stimulatory effect of IL-2 on T cell growth and activation.[23–25] Some melanoma-associated antigens (e.g., MART-1, gp100, and tyrosinase) are expressed on normal melanocytes, suggesting that the occurrence of treatment-related vitiligo-like depigmentation in melanoma may involve cross-reaction of some antimelanoma immune responses with normal melanocytes.

BIOCHEMICAL HYPOTHESIS

There is some evidence that vitiligo is a disease of the entire epidermis, possibly involving biochemical abnormalities of both melanocytes and keratinocytes.[11] The specific morphological and functional abnormalities observed in vitiligo melanocytes and keratinocytes are thought to have a genetic background.[11] Ultrastructural abnormalities of keratinocytes from perilesional vitiligo skin have been related to impaired mitochondrial activity,[26] and are thought to affect the production of specific melanocyte growth factors and cytokines that regulate melanocyte survival.[11] An essential biochemical finding is elevated levels of H_2O_2 in affected regions of epidermis,[27] that may be caused in part by reduced enzymatic antioxidant capacity of keratinocytes and melanocytes.[11,19] A defective antioxidant defense may confer melanocytes an increased susceptibility both to immunologic cytotoxicity and to cytotoxicity induced by reactive oxygen species.[19]

CLINICAL FEATURES

The principal clinical manifestation of vitiligo is the appearance of acquired milk-white macules with fairly homogeneous depigmentation and well-defined



Figure 74-1 Vitiligo vulgaris in an adult.

borders. On the basis of the polymorphic distribution, extension, and number of white patches, vitiligo is classified into generalized (vulgaris, acrofacial, mixed), universalis, and localized (focal, segmental, and mucosal) types.[28] Vitiligo is also classified as segmental and nonsegmental types, on the basis of distinctive clinical features and natural histories.[29] According to this classification, non-SV includes all cases not classified as segmental, including localized, generalized, and acrofacial.

- Vitiligo vulgaris—multiple scattered lesions distributed in a more or less symmetrical pattern; the most common presentation of GV (Fig. 74-1).
- Acrofacial vitiligo—affects the distal end of fingers and facial orifices in a circumferential pattern; a subtype of GV (Fig. 74-2).



Figure 74-2 Acrofacial vitiligo.



Figure 74-3 Vitiligo universalis.

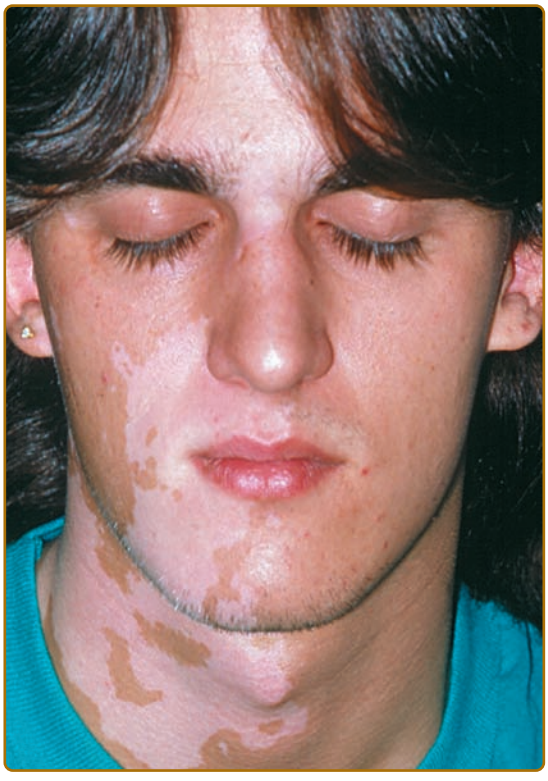

Figure 74-5 Segmental vitiligo of the face and neck.

- Mixed vitiligo—combination of acrofacial and vulgaris, or segmental and acrofacial types.
- Vitiligo universalis—complete or nearly complete depigmentation of the whole body (Fig. 74-3); the most severe form of GV.
- Focal vitiligo—characterized by the presence of one/few macule(s) in one area but not distributed in a segmental pattern (Fig. 74-4); considered a precursor form of GV.
- Mucosal vitiligo—a term reserved for depigmentation of mucous membrane alone.
- SV—characterized by macules having unilateral dermatomal distribution that do not cross the midline (Fig. 74-5). It generally affects young children and typically remains localized, the depigmented lesions persisting unchanged for many years.[30] The occurrence of concomitant other autoimmune diseases is uncommon, compared with GV.[29,31,32]

Vitiligo often demonstrates a predilection for sun-exposed regions, body folds, and periorificial areas, although any part of the body can be affected. Various precipitating factors have been suggested, including physical trauma to the skin, sunburn, psychological stress, inflammation, pregnancy, contraceptives, vitamin deficiency, and many others. However, at this time no specific environmental triggers have been proven.

Vitiligo may appear at sites of skin trauma (Koebner's phenomenon) (Fig. 74-6).

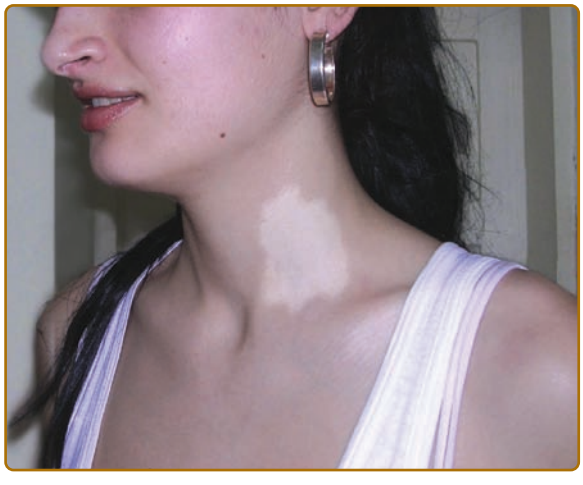

Figure 74-4 Focal vitiligo—unique macule of focal vitiligo.



Figure 74-6 Koebnerization under brassiere.



Figure 74-7 Leukotrichia. (Reprinted with permission from Falabella R: Vitiligo and the malanocyte reservoir. *Indian J Dermatol* **54**(4):313-318, 2009.)

Leukotrichia (depigmentation of hair within vitiligo macules (Fig. 74-7), can be quite variable (10%–60%), and is considered to indicate destruction of the melanocyte reservoir within the hair follicle, therefore, predicting a poor therapeutic response.[28] Premature graying of the hair has been described in up to 37% of patients with vitiligo,[28] although poor definition and quantitation of this feature makes this supposed clinical association uncertain.

SPECIFIC RARE CLINICAL PHENOTYPES

- Trichrome vitiligo is characterized by the presence of patches of intermediate hue (hypopigmentation) between the normal skin and the completely depigmented skin.
- Quadrichrome vitiligo is characterized by the presence of a fourth color (dark brown) at sites of perifollicular repigmentation. It is more often encountered in patients with darker skin phototypes.
- Pentachrome vitiligo—the occurrence of five shades of color: (1) white, (2) tan, (3) medium brown, (4) dark brown, and (5) black.
- Confetti vitiligo or vitiligo ponctué —tiny punctate-like depigmented macules on a hyperpigmented macule or on normal skin.
- Red vitiligo—the depigmented lesions have a raised erythematous border.
- Blue vitiligo—a blue–gray appearance of the skin, which corresponds histologically with the absence of epidermal melanocytes and presence of numerous dermal melanophages.

RELATED PHYSICAL FINDINGS

COMORBID ASSOCIATIONS

GV has been often associated with a variety of other conditions, principally autoimmune diseases.[33] The most prevalent associated autoimmune disease is autoimmune thyroid dysfunction, either hypothyroidism (Hashimoto's thyroiditis) or hyperthyroidism (Grave's disease). Other autoimmune diseases such as rheumatoid arthritis, psoriasis, type 1 diabetes mellitus (usually adult-onset), pernicious anemia, systemic lupus erythematosus, and Addison's disease also occur with increased frequency in patients with GV.[6,17] Most of these disorders, including GV, can occur in various combinations and constitute components of the APECED (APS1) and Schmidt (APS2) multiple autoimmune disease syndromes.

Vitiligo can also be part of the Vogt–Koyanagi–Harada (VKH) syndrome, a multiorgan disorder that affects pigmented structures, such as the eye, inner ear, meninges, and skin.[34] Several clinical and experimental studies have pointed to a role of cell-mediated immunity in VKH, particularly involving $CD4^+$ T cells and Th1 cytokines.[35,36]

Another very rare multiorgan disorder, Alezzandrini syndrome, associates facial skin depigmentation, poliosis, deafness, and unilateral tapetoretinal degeneration of the eye.[37] However, many investigators now believe that VKH and Alezzandrini's syndrome are merely different clinical expressions of the same fundamental disease.[38]

DEPIGMENTATION OTHER THAN VITILIGO

Skin depigmentation may occur in melanoma patients in three different clinical contexts[39]: partial depigmentation ("regression") of the tumor, leukoderma acquisitum centrifugum around the tumor, and vitiligo-like depigmentation, occurring at distant sites. Vitiligo-like depigmentation is thought to be a marker of the patient developing immunity against melanoma cells and to be an indicator of favorable prognosis, especially in advanced stages.[25]

The most common form of leukoderma acquisitum centrifugum appears around pigmented nevi (called halo nevi), and often progress to spontaneous disappearance of the nevus,[39] presumably via lymphocyte-mediated destruction of nevus cells.

DIAGNOSIS

The diagnosis of vitiligo is established principally on clinical grounds, which may include distribution and extent of lesions, and natural history of disease.[40]

LABORATORY. Given the association between vitiligo and other autoimmune diseases, several screening laboratory tests are helpful, including T4 and thyroid-stimulating hormone levels, antinuclear antibodies, and complete blood count. Clinicians should also consider testing for serum antithyroglobulin and antithyroid peroxidase antibodies, particularly when patients have signs and symptoms suggestive of thyroid disease.

HISTOLOGY. A skin biopsy is rarely necessary to confirm the diagnosis of vitiligo. Generally, histology shows an epidermis devoid of melanocytes in lesional areas,[41] and sometimes sparse dermal, perivascular, and perifollicular lymphocytic infiltrates at the margins of early vitiligo lesions and active lesions, consistent with cell-mediated immune processes destroying melanocytes in situ.[42] Some reports[42] have suggested that melanocytes may never be completely absent from the depigmented epidermis and that residual melanocytes maintain the capability of recovering functionality. Further studies are needed to clarify this highly debated issue with obvious therapeutic implications.

Differential diagnosis for vitiligo is presented in Box 74-1 and Box 74-2.[43,44]

BOX 74-1 DIFFERENTIAL DIAGNOSES FOR GENERALIZED VITILIGO

CONDITION	DISTINGUISHING FEATURES
Inherited Hypomelanoses	
Piebaldism	Stable and circumscribed white patches (with absence of melanocytes) affecting anterior body and limbs; white forelock; autosomal dominant.
Waardenburg's syndrome	White forelock, white skin macules, hypertelorism, deafness, ±Hirschsprung disease; multiple genes-autosomal dominant or recessive.
Tuberous sclerosis	Ash leaf hypopigmented macules, facial/periungual angiofibromas, shagreen patches; autosomal dominant.
Ito's hypomelanosis	Linear distribution, unilateral or bilateral pattern of hypopigmented macules; sporadic; chromosomal or genetic mosaicism.
Infectious Disorders	
Tinea versicolor	Hypopigmented lesions, beginning as reddish macules with fine scales upon scraping and seborrheic distribution. At mycologic examination: hyphae and spores.
Secondary syphilis	Depigmented round/oval patches (postinflammatory depigmentation) around the neck (necklace of Venus), trunk, limbs, or depigmented patches with peripheral reticular hyperpigmentation (primary lesion). Serological tests for treponemal infection are positive.
Leprosy (tuberculoid/borderline forms)	Depigmented patches with polymorphic presentation, usually accompanied by localized anesthesia; histology: compact skin granulomas.
Postinflammatory Hypopigmentation	
Discoid lupus erythematosus, scleroderma, lichen sclerosis et atrophicus, psoriasis	Patients have history of preexisting dermatosis.
Paramalignant Hypomelanoses	
Mycosis fungoides	Hypomelanotic macules or diffuse depigmentation especially in darker skin phototypes. Flat skin patch, plaque, and tumors. Histology: epidermal infiltrates with mononuclear cells.
Cutaneous melanoma	Halo depigmentation around or within the tumor.
Autoimmune reactions to advanced melanoma	Depigmentation at a distance from the tumor; the presence of tumor excludes typical vitiligo.
Idiopathic Disorders	
Idiopathic guttate hypomelanosis	Hypopigmented well circumscribed macules, sharply defined and small in size. They are slow progressive and nonconfluent. Histology indicates epidermal atrophy and reduction in melanin content.
Postinflammatory pigment loss	Postburn hypopigmentary lesions, shaped in the form of the burn. Hypopigmenting inflammatory reactions leave ill-defined, poorly circumscribed lesions. The history of preceding eruption/injury excludes vitiligo.
Toxin-Induced Depigmentation	
Drug-induced depigmentation	Vitiligo-like depigmentation generally caused by topical occupational exposure to phenolic–catecholic derivatives, often affecting the hands and forearms. Caused by use of systemic drugs (chloroquine, fluphenazine, physostigmine, imatinib, or topical imiquimod).

From Taïeb A, Picardo M: Clinical practice. Vitiligo. *N Engl J Med* **360**:160, 2009.

BOX 74-2 DIFFERENTIAL DIAGNOSES FOR LOCALIZED VITILIGO

NEVUS DEPIGMENTOSUS	Solitary hypopigmented macule well circumscribed with irregular borders, stable in size, solitary, most often present at birth.
NEVUS ANEMICUS	Hypochromic pale lesion with well-defined borders and irregular margins; often solitary, located on the trunk. Histology and electron microscopic examination reveal no abnormality in melanocytes or melanization.

CLINICAL COURSE AND PROGNOSIS

The clinical course of any given case of GV is unpredictable, but is typically gradually progressive and difficult to control with therapy. Sometimes lesions spread over time, whereas in other cases disease activity stops, persisting in stable status for a long period. Some clinical parameters such as a long duration of the disease, occurrence of Koebner's phenomenon, leukotrichia, and mucosal involvement have been suggested as indicators of relatively poor prognosis.[28]

TREATMENT

FUNDAMENTS OF VITILIGO THERAPY: MELANOCYTE REPOPULATION

The key principle of vitiligo therapy is facilitating repopulation of depigmented patches of the interfollicular epidermis with active melanocytes that are able to migrate, survive to repopulate the depigmented skin, and carry out melanin biosynthesis.[45] Repigmentation may occur spontaneously and may also be therapy-induced. Spontaneous repigmentation is unpredictable, often clinically insignificant, and tends to be cosmetically unacceptable.[46,47] It occurs in fewer than 50% of patients, most commonly in younger patients and in sun-exposed areas, where natural sunlight may act as an inducing agent.[48] In clinical practice, the most frequently encountered pattern of repigmentation is perifollicular (Fig. 74-8), though other patterns, such as marginal, diffuse, or combined also may occur.

The principal source of melanocytes involved in repopulation of vitiligo skin is most likely melanocyte precursors derived from the outer root sheath (ORS) or bulge area of the hair follicle.[49–51] A secondary potential reservoir may be located near lesional borders.



Figure 74-8 Follicular repigmentation in vitiligo after psoralen and ultraviolet A light therapy.

The middle and lower parts of the ORS are populated by L-3,4-dihydroxyphenylalanine (DOPA)-negative, amelanotic melanocytes,[49,50] which may be recruited from the ORS of the hair follicle in response to ultraviolet (UV), corticosteroids, or other stimuli. As a result, the number of melanocytes in the ORS of hair follicles increases significantly and some become active, suggesting that melanocyte precursors proliferate and at least some undergo maturation.[50] Activated ORS melanocytes acquire all of the structural and enzymatic proteins required for melanogenesis, proliferation and maturation as they migrate up the hair follicle into the nearby epidermis, where they spread centrifugally and form perifollicular pigment islands. They then become larger cells, with intense DOPA oxidase activity.

Vitiligo repigmentation is assessed in terms of the proportion of treated subjects in whom a specified degree of repigmentation is achieved; depending on the study, more than 50% or more than 75% repigmentation may be considered a good response.[52] Wood's lamp (UVA) examination is useful to monitor response to therapy. In the absence of epidermal melanin that otherwise absorbs most of the UVA light, more photons reach the dermis, where they are absorbed by collagen that then fluoresces and emits bright visible light. In contrast, visible wavelengths of ambient room light are less well absorbed by melanin in the normally pigmented epidermis than UVA wavelengths and do not produce fluorescence in the dermis. Hence, under Wood's light the vitiligo area appears brighter and the normal skin appears darker than when illuminated with ambient room light (Fig. 74-9).

THERAPEUTIC APPROACHES

Different treatment strategies (Box 74-3) have been designed to inhibit the immune response in vitiligo, thereby reducing melanocyte destruction, and also enhancing epidermal repopulation by melanocytes, both by stimulating recovery of damaged melanocytes in situ and by reactivating residual melanocytes or stimulating melanocyte in-migration from neighboring skin or hair follicles. However, at present it is not clearly understood to what extent treatments must suppress the autoimmune process versus stimulate

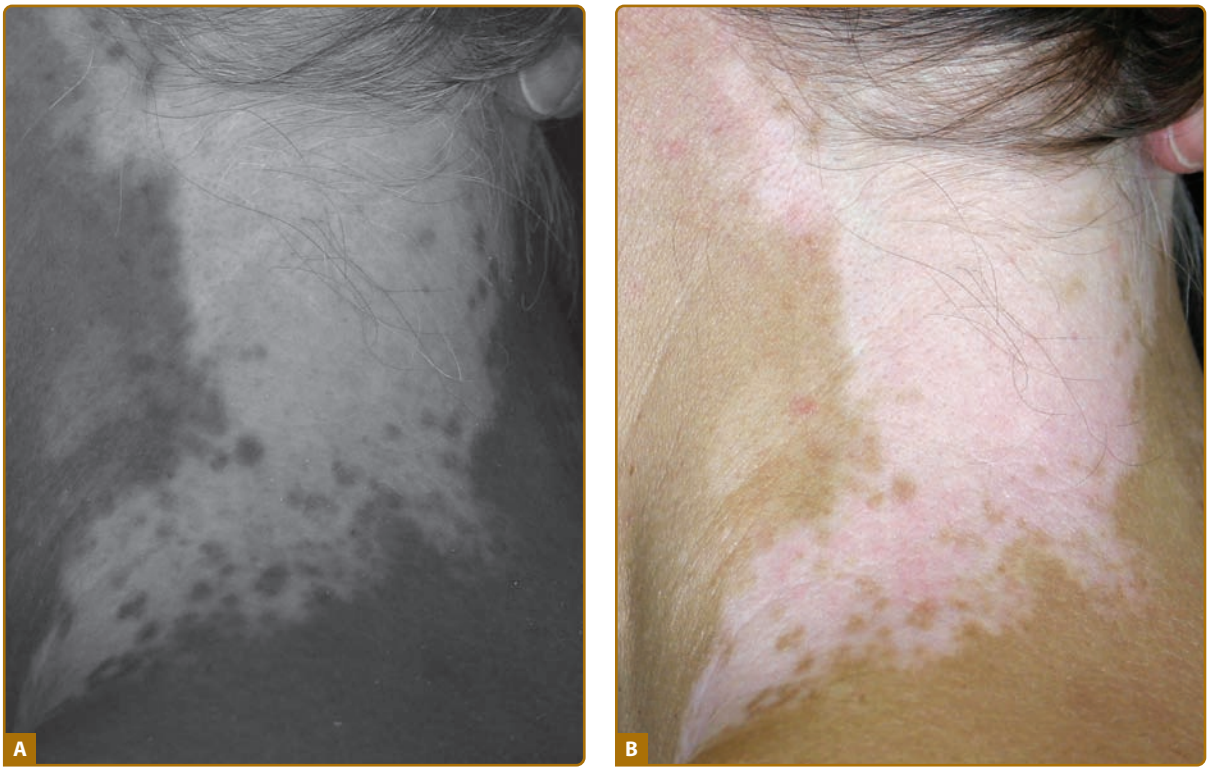

Figure 74-9 Wood's lamp examination. Wood's lamp provides bright reflection of white patches and enhanced details on intermediate pigment tones (**A**), as compared with white light (**B**). (Reprinted with permission from Taieb A, Picardo M: Vitiligo. *NEJM* **260**:160-169, 2009.)

melanocyte repopulation of the epidermis to provide maximum efficacy.

UV radiation therapy includes phototherapy with narrowband UVB (NB-UVB—311 nm) or broadband UVB (BB-UVB—290–320 nm), and photochemotherapy. UV therapy is thought to act as a skin immunomodulator, regulating the activity of inflammatory cytokines, depleting of Langerhans cells, modulating the activity of regulatory T cells, and polarizing the immune response toward the Th2 profile, thereby reducing or stabilizing the depigmentation process in vitiligo.[45] In addition, UV radiation coordinates several of the pathways via which melanogenic cytokines stimulate melanogenesis.[45] Furthermore, UV may also induce the release of epidermal factors that stimulate melanocyte proliferation and migration, although this speculation has not been substantiated in repigmenting vitiligo lesions. The release of several paracrine factors produced by UV-exposed keratinocytes[53] that regulate melanocyte functions is thought to be under p53 regulation,[54] although further studies are needed.

ULTRAVIOLET B NARROWBAND

Narrowband UV (NB-UVB) light, with peak emission at 311 nm, is considered the most effective and safest current therapy for vitiligo, and thus is currently the treatment of choice for patients with moderate-to-severe GV. Recent studies evaluating psoralen and UVA (PUVA) versus NB-UVB indicate that NB-UVB

BOX 74-3 TREATMENTS FOR VITILIGO

	TOPICAL	PHYSICAL	SYSTEMIC	SURGICAL
First line	Corticosteroids Calcineurin inhibitors	Ultraviolet B (narrowband) Systemic psoralen and ultraviolet A light (PUVA)		
Second line	Calcipotriol	Topical PUVA Excimer laser	Corticosteroids (pulse therapy)	Grafting Melanocyte transplant

produces higher repigmentation rates and better color matching).[55] NB-UVB has fewer short-term adverse reactions such as painful erythema and appears to have fewer long-term side effects such as epidermal thickening, atrophy, and photocarcinogenesis than PUVA.[56] Several clinical studies have reported high rates (≥75%) of repigmentation in at least 40% of patients treated with NB-UVB.[57–60]

The most commonly used NB-UVB protocol[43] involves twice-weekly administration of a fixed starting dose of 0.21 J/cm^2, increasing the dose by 20% at each session until the minimal erythema dose (the lowest dose that results in visible erythema on depigmented skin at 24 hours) has been reached. Approximately 9 months of therapy are required to achieve maximal repigmentation; at least 3 months of treatment are warranted before the condition can be classified as nonresponsive.

The most responsive sites are face, trunk, and limbs, and the least responsive sites are the hands and feet.

PHOTOCHEMOTHERAPY (PUVA)

Until recently, PUVA was considered the mainstay of therapy for patients with widespread vitiligo. PUVA consists of a combination of topical or oral 8-methoxypsoralen with UVA (320–400 nm) irradiation. The psoralen of choice, methoxsalen, is given in an oral dose of 0.4-mg/kg body weight, 1–2 hours prior to UVA exposure. For topical PUVA therapy, methoxsalen 0.1% is applied to areas of vitiligo 30–60 minutes before exposure to UV radiation. Topical PUVA is indicated in patients whose vitiligo involves less than 20% of the body surface area, and painful burns (phototoxicity reactions) are unfortunately difficult to avoid. Oral psoralens can be used for patients with more extensive involvement or in patients who do not respond to topical PUVA (see Chapter 237). After oral treatment, patients must wear UVA-blocking glasses, and it is also recommended they use broad-spectrum sunscreens and wear protective clothing. Patients with darker complexions tend to respond best to PUVA, possibly because they tolerate higher PUVA exposures.[61] Potential side effects of PUVA therapy are discussed in Chapter 237. PUVA is not recommended for use in children under the age of 12 years owing to the long-term delayed risks of cataract formation and skin cancer.

CORTICOSTEROIDS

TOPICAL CORTICOSTEROIDS

Topical corticosteroids represent the first-line therapy for localized vitiligo, and are highly recommended for facial or small lesions and for use in children. Advantages include ease of application, high compliance rate, and low cost. Compared with PUVA, which promotes a predominantly perifollicular pattern of repigmentation, topical corticosteroids result in more diffuse repigmentation, which occurs more quickly but is less stable.[62] Light and electron microscopy of skin biopsies from control and steroid-treated areas showed marked repopulation by functional melanocytes in the repigmented vitiliginous skin. In steroid repigmented areas melanocytes appeared dendritic and DOPA-positive, and unlike melanocytes in the pigment margins of untreated areas of vitiligo, contain many melanosomes of normal size and shape.[63] The current trend, based on the results of a large meta-analysis that included randomized controlled trials of 29 patient series, is that class 3 and 4 corticosteroids are the most effective for treatment for localized vitiligo.[52] Thus, localized lesions can be treated with a high-potency fluorinated corticosteroid (e.g., clobetasol propionate ointment, 0.05%) for 1–2 months. Treatment can be gradually tapered to a lower potency corticosteroid (e.g., hydrocortisone butyrate cream, 0.1%). Caution is necessary when using topical steroids on and around the eyelids, as their use can increase intraocular pressure and exacerbate glaucoma. Vitiligo recurrence after cessation of treatment and corticosteroid-induced side effects (i.e., skin atrophy, telangiectases, striae, and, rarely, contact dermatitis) are the limiting factors. Combination therapy (corticosteroids + UVB, corticosteroids + calcineurin inhibitors, corticosteroids + vitamin D analogs) may be beneficial in some cases, as two agents together may act synergistically on pigment restoration and on immune suppression, at lower individual doses, thus, potentially minimizing overall side effects.

SYSTEMIC CORTICOSTEROIDS

Systemic corticosteroids have been used in pulse therapy and for short periods to halt rapid spread of depigmentation in some cases of GV.[61]

CALCINEURIN INHIBITORS

Calcineurin inhibitors can be effective in vitiligo therapy because of their capacity to restore the altered cytokine network. Tacrolimus has been shown to inhibit T cell activation by downregulating transcription of genes encoding proinflammatory cytokines IL-2, IL-3, IL-4, IL-5, interferon-γ (IFN-γ), tumor necrosis factor-α (TNF-α), and granulocyte-macrophage colony-stimulating factor (GM-CSF) in T cells.[64] In addition, a direct effect of tacrolimus on melanocyte growth and migration during repigmentation has been reported.[65] Topical calcineurin inhibitors (e.g., tacrolimus ointment 0.03%–0.1%, pimecrolimus ointment 1%) are generally preferred for treating localized vitiligo lesions of the face and neck,[43] and seem to be more effective in combination with UV radiation delivered by high-fluency UVB devices.[43] Although several reports have emphasized the advantages of calcineurin inhibitors (selective mode of action, absence of skin atrophy, and systemic absorption), additional studies of their effectiveness are needed, as well as more

information about possible risks of cutaneous and extracutaneous cancers.

TOPICAL VITAMIN D DERIVATIVES

Vitamin D analogs—calcipotriol ointment (0.005%) and tacalcitol ointment (20 µg/g)—restore pigmentation in vitiligo by inducing skin immunosuppression, which halts the local autoimmune process, and via direct activation of melanocytic precursors and melanogenic pathways.[66] Some studies report more efficient repigmentation when vitamin D analogs are used in combination therapy, probably because of more complex stimulation of the repopulation process, targeting both melanocyte growth (with corticotherapy or UV) and differentiation (with a vitamin D analog). Vitamin D derivatives are indicated for use in localized disease; benefits include lack of skin atrophy and their easy application. However, their role in vitiligo treatment remains controversial; whereas some studies have reported substantial benefit, others found vitamin D analogs ineffective.[45]

PSEUDOCATALASE

Pseudocatalase has been used to reconstitute deficient activity of catalase in vitiligo epidermis, degrading excessive H_2O_2 and allowing recovery of enzyme activities in vitiligo skin.[67] Pseudocatalase monotherapy or combination with NB-UVB has shown apparent efficacy in repigmentation and prevention of disease progression in uncontrolled trials,[68,69] while in other studies showed no substantial benefit.[70–72] Therefore, its effect in vitiligo needs further validation.

LASER THERAPY

UV B narrowband excimer laser (XeCl) and monochromatic excimer light (MEL) are currently used for treatment of localized vitiligo. These are similar to classical NB-UVB treatments, with the advantage of fewer side effects because only one lesion is treated at a time. These treatments produce optimal aesthetic results, with minor contrast between normal and affected skin.[56] The XeCl has laser-coherent emission of monochromatic rays, whereas the MEL device can generate and selectively deliver 308-nm UVB light. No data for cancer risk and other long-term side effects are available; therefore, caution is currently advised.[73]

SURGICAL TREATMENT

Autologous skin grafts are an option for repigmentation only in patients with stable vitiligo that is refractory or only partially responsive to medical treatment, and in general limited in extent (less than 3% of body-surface area).[43] The most frequent side effects are infection, postinflammatory hyperpigmentation, unaesthetic repigmentation, cobblestoning, and scarring.[55] UV-light therapy generally hastens and improves repigmentation when combined with surgical methods.

Autologous skin graft approaches can be categorized into five principal groups.[55] Of note, in the United States any procedure in which cells are manipulated (e.g., cultured) must be performed in a good manufacturing practices (GMP) facility.

NONCULTURED EPIDERMAL SUSPENSIONS

This technique is performed by grafting noncultured suspensions containing both keratinocytes and melanocytes[74,75] (eFigs. 74-9.1A and 74-9.1B in online edition); suspensions are obtained by 0.25% trypsin digestion of a thin piece of donor skin and are injected into blisters raised by liquid nitrogen freezing or seeded on recipient sites denuded by superficial dermabrasion. An advantage of this method is lack of scarring if recipient and donor sites are carefully manipulated.

THIN DERMAL–EPIDERMAL GRAFTS

Grafts are harvested at a depth of 0.1–0.3 mm, placed directly on recipient abraded areas next to each other, and are secured with surgical dressings under mild pressure for 1 week. Repigmentation occurs during the following weeks. Good results have been reported on dorsal hands and fingers.[76,77]

MINIGRAFTING

Minigrafting represents the most commonly used current surgical method for vitiligo repigmentation (eFigs. 74-9.2A and 74-9.2B in online edition). Multiple perforations are made on recipient sites using 1.0–1.2-mm punches 3–4 mm apart from each other. Next, minigrafts are harvested from the donor site using a similar punch and are transferred to recipient sites with fine forceps or a hypodermic needle.[78] Repigmentation occurs around each minigraft up to 2–5 mm by coalescence of spreading pigment. Good results are achieved in patients with refractory lip leukoderma, although the risk of cobblestoning seems to be high.[76,79] An advantage of this method is its simplicity.

EPIDERMAL GRAFTING

Grafts are harvested at negative pressure using different custom-made suction devices,[55] the preferred donor sites being the inner aspect of the thigh and the flexor aspect of the forearm.[80] Recipient sites are prepared by removing the epidermis using liquid nitrogen freezing or superficial dermabrasion[81] or laser ablation.[55] Epidermal grafts have been successfully used for lip vitiligo.[82] The



Figure 74-10 Treatment with MBEH. Response of disfiguring facial vitiligo to treatment with MBEH (**A**) before, (**B**) after 4 months, (**C**) after 6 months and (**D**) after 8 months.

main advantage is the absence of scarring in donor and recipient sites.

IN VITRO-CULTURED EPIDERMIS WITH MELANOCYTES AND MELANOCYTE SUSPENSIONS[55]

EPIDERMIS WITH MELANOCYTES. An epidermal suspension collected from a small donor skin sample is prepared by 0.25% trypsin digestion and seeded in culture flasks. After 3 weeks, epidermal sheets are harvested from the culture vessel and transplanted onto depigmented recipient sites previously denuded by liquid nitrogen freezing, superficial dermabrasion, lasers, or diatermo surgery. A hyaluronic artificial matrix for growing keratinocytes and melanocytes has also been used with success.[83]

MELANOCYTE SUSPENSIONS. In vitro-cultured melanocyte suspensions are obtained in a similar manner using specific and defined cultured media such as Ham's F12. During subculturing, pigment cells increase in number and may be transplanted onto denuded areas at a density of up to 100,000 melanocytes/cm^2. The suspension spreads onto recipient areas and is covered for a week, providing a good cellular take.[74,84] The large population of cells obtained from a small donor site represents a great advantage for treating extensive vitiligo areas in a single session.

MICROPIGMENTATION

Micropigmentation is useful for vitiligo lesions on mucous and mucocutaneous areas. It is accomplished by tattooing inert pigment granules into the dermis within collagen bundles and extracellularly at a depth of 1–2 mm, delivered by multiple electrically driven needles. Combinations of white, yellow, black, red, and brown pigments are used.[55]

DEPIGMENTATION

Some adult patients with extensive vitiligo may elect to undergo depigmentation of residual pigmented patches on facial and exposed areas. Depigmentation is achieved using 20% monobenzyl ether of hydroquinone (MBEH; monobenzone), which induces melanocyte loss via necrotic death without activating the caspase cascade or DNA fragmentation.[85] MBEH is first applied as a patch test for 48 hours to detect hypersensitivity. Subsequently, twice-daily applications for at least a year are followed by irreversible depigmentation[86] (Figs. 74-10A–D). Sunlight protection of depigmented skin is essential to prevent nonmelanoma skin cancers.[55]

We propose a treatment algorithm for vitiligo, considering the therapeutic approaches presented above (Fig. 74-11).

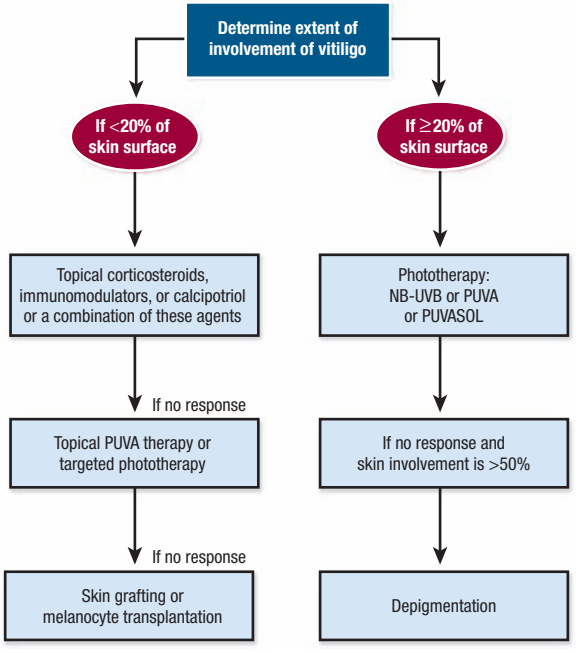

Figure 74-11 Treatment algorithm for vitiligo.

CAMOUFLAGE, SUN PROTECTION, AND PSYCHOLOGICAL SUPPORT

Use of cosmetic camouflage, on the face and other exposed areas, and clothing to conceal affected areas can improve the quality of life for patients with vitiligo. Modern camouflage dyes and creams are waterproof, and the wide range of color and shades available can enable patients to choose the most suitable ones for their own skin color (Figs. 74-12A and 74-12B).

Tanning should be avoided since it enhances the contrast of vitiligo lesions with normally pigmented skin. Moreover, sunscreens are needed to prevent sunburn of depigmented unprotected skin. However, this is somewhat problematic, as moderate sun exposure (heliotherapy) in many cases can induce epidermal repopulation with melanocytes. As well, it has been suggested that skin friction due to repeated application of sunscreen might exacerbate the disease,[43] although there is no evidence to support this hypothesis. Depigmented skin in vitiligo tends to show increased tolerance to UVB light over time (photoadaptation), with the extent of tolerance based in part on skin phototype, supposedly due to both pigmentary and nonpigmentary influences,[87] although the specific mechanism remains unknown.

Psychological support may be beneficial to some patients. Listening to patients' complaints and concerns and providing reassurance with advice about possible treatments and capacity for improvement is usually helpful for patients. Consider psychiatric evaluation for patients with marked low self-esteem and depression.



Figure 74-12 Cosmetic camouflage. Focal vitiligo of chin before (**A**) and after (**B**) application of cosmetic camouflage.

NONTRADITIONAL TREATMENTS

A wide range of nontraditional treatments have been suggested for vitiligo, and some may be considered as alternative approaches for patients who either failed or are unsuitable for the above therapies. The most commonly used include vitamin and nutritional supplements, immunomodulators, human placental extracts, khellin, and topical and systemic phenylalanine, among many others. There is no convincing evidence that any of these nontraditional treatments is effective.

PREVENTION

Patients, patient support groups, and purveyors of alternative medicines have developed extensive and diverse hypotheses regarding vitiligo causation and approaches to its prevention. At present, there is no compelling evidence that any approach to vitiligo prevention is effective. Moreover, there is currently no useful approach to identify individuals at high risk for developing vitiligo.

KEY REFERENCES

Full reference list available at www.DIGM8.com

DVD contains references and additional content

7. Spritz RA: The genetics of generalized vitiligo. *Curr Dir Autoimmun* **10**:244, 2008
13. Jin Y et al: Variant of TYR and autoimmunity susceptibility loci in generalized vitiligo. *New Engl J Med* **362**(18):1686-1697, 2010
16. Ongenae K, Van Geel N, Naeyaert JM: Evidence for an autoimmune pathogenesis of vitiligo. *Pigment Cell Res* **16**:90, 2003
21. Oyarbide-Valencia K et al: Therapeutic implications of autoimmune vitiligo T cells. *Autoimmune Rev* **5**:486, 2006
28. Hann S-K, Nordlund JJ: Clinical features of generalized vitiligo. In: *Vitiligo*, edited by S-K Hann, JJ Nordlund. London, Blackwell Science, 2000, p. 35
43. Taïeb A, Picardo M: Clinical practice. Vitiligo. *N Engl J Med* **360**:160, 2009
45. Birlea SA, Costin GE, Norris DA: New insights on therapy with vitamin D analogs targeting the intracellular pathways that control repigmentation in human vitiligo. *Med Res Rev* **29**:514, 2009
55. Falabella R, Barona MI: Update on skin repigmentation therapies in vitiligo. *Pigment Cell Melanoma Res* **22**:42, 2009

Chapter 75 :: Hypomelanoses and Hypermelanoses

:: Hilde Lapeere, Barbara Boone, Sofie De Schepper, Evelien Verhaeghe, Mireille Van Gele, Katia Ongenae, Nanja Van Geel, Jo Lambert, & Lieve Brochez

HYPOMELANOSES AND HYPERMELANOSES AT A GLANCE

- Pigmentation disorders confront the clinician with a sometimes complex differential diagnosis, but can be approached logically as follows:
  - Congenital or acquired
  - Isolated or part of a syndrome
  - Diffuse or circumscribed
  - Epidermal or dermal
  - With or without inflammation
- Altered skin pigmentation may be caused by the following factors:
  - Increased or decreased melanin
  - Abnormal melanin distribution
  - Decreased hemoglobin
  - Deposition of exogenous pigments

AN ALGORITHMIC APPROACH TO PIGMENTATION DISORDERS

Pigmentation disorders of the skin can either be hypomelanotic, hypermelanotic, or may present with a pattern of mixed hypo- and hypermelanosis. The diagnosis of these disorders can be quite challenging. An algorithmic approach based on clinical features and history of pigmentary disorders is used throughout this chapter and serves as a guide for the clinician' diagnosis and treatment (eFigs. 75-0.1 and 75-0.2 in online edition) (Table 75-1, eTable 75-1.1 in online edition).

HYPOMELANOSIS

Generalized hypopigmentation, including the various defects, classified as "albinism" has been discussed in Chapters 73 and 74. Localized forms of hypomelanosis can be related to defects in melanocyte precursor migration and disordered pigment transfer between melanocytes and keratinocytes, and as a result of postinflammatory changes.

CONGENITAL HYPOMELANOSIS

Some genetic disorders with reduced skin and hair pigmentation are caused by impaired melanocyte migration/differentiation or melanosome abnormalities.[1] Piebaldism, Waardenburg syndrome, and Tietze syndrome, characterized by a localized absence of melanocytes resulting in "white-patch" patterns, belong to the first group whereas oculocutaneous albinism (OCA), Griscelli syndrome (GS), Elejalde syndrome (ES), Chédiak–Higashi syndrome (CHS), and Hermansky–Pudlak syndrome (HPS) belong to the second group. OCA, CHS, and HPS are discussed in Chapter 73; GS and ES are discussed here. They are rare autosomal recessive disorders with abnormal biogenesis or transport of "lysosome-related organelles" (a group of specialized cytoplasmic organelles including melanosomes, platelet dense bodies, and lymphocyte lytic granules).[2] GS, ES, and CHS are termed "silvery hair syndromes" because hair of these patients has a particular silver–gray hue.[3]

GRISCELLI SYNDROME. Three types of GS [GS types I–III (GS1–3)] are known. The phenotype of the patients is characterized by various degrees of skin hypopigmentation and hair with a silvery shine (Fig. 75-1), usually lighter than in unaffected family members. Furthermore, neurological signs and symptoms and/or immunologic impairment with "accelerated phases" of uncontrolled lymphocyte and macrophage activation with lymphohistiocytic infiltration of the central nervous system (CNS) are associated.[4] This lymphoproliferative syndrome is similar to that observed in, for example, virus-associated hemophagocytic syndrome.[5]

Briefly, patients with GS type I (GS1) are characterized by primary and severe neurological symptoms

TABLE 75-1
Differential Diagnosis and Management of Dermal Melanocytosis

	Nevus of Ota	Nevus of Ito	Mongolian Spot	Nevus of Hori	Dermal Melanocyte Hamartoma
Epidemiology	▪ Mostly congenital ▪ Sporadic (rare familial cases) ▪ Asian and female predominance	▪ Mostly congenital ▪ Sporadic (rare familial cases) ▪ Asian and female predominance	▪ Congenital ▪ Often familial ▪ Asian, African, and Hispanic population with slight male predominance	▪ Acquired ▪ Familial or sporadic ▪ Asian and female predominance	▪ Congenital
Clinical presentation	▪ Blue to slate-gray mottled macular hyperpigmentation	▪ Blue to slate-gray mottled macular hyperpigmentation	▪ Uniform blue to slate-gray macular hyperpigmentation	▪ Brown–blue progressing to slate-gray mottled macular hyperpigmentation	▪ Mottled hyperpigmentation with small blue–gray macules in a diffuse pigmented patch
Distribution	▪ Trigeminal nerve	▪ Acromioclavicular nerve	▪ Lower back and sacrum	▪ Especially malar region of the cheek (also forehead, upper eyelids, temple)	▪ Dermatomal distribution
Histology	▪ Spindle-shaped melanocytes diffusely throughout the dermal layers. Sometimes more band-like melanocytic proliferation and stromal fibrotic reaction.	▪ Spindle-shaped melanocytes diffusely throughout the dermal layers. Sometimes more band-like melanocytic proliferation and stromal fibrotic reaction	▪ Spindle-shaped melanocytes diffusely throughout the dermal layers	▪ Dermal melanocytes in the upper and middermis	▪ Dermal melanocytes in the upper two-thirds of the dermis (including subpapillary layer)
Therapy	▪ Q-switched laser ▪ Cryotherapy ▪ Surgery	▪ Q-switched laser ▪ Cryotherapy ▪ Surgery	▪ Usually spontaneous regression during childhood	▪ Q-switched laser in combination with bleaching cream and chemical peels	▪ None
Associated features	▪ Rare malignant transformation	▪ No associated features of medical concern	▪ Possible association with inborn errors of metabolism	▪ No associated features of medical concern	▪ None

occurring early in life or even at birth without signs of an accelerated phase. These symptoms can include seizures, spasticity, psychomotor retardation, peripheral facial palsy, hemiparesis, encephalopathy, and hypotonia. CNS disorder is pertinent and never regresses with time.

Immunological and hematological manifestations are only observed in GS type II (GS2) and include: anemia, neutropenia, and lack of natural killer cell function, with development of an accelerated phase of the disease with fever, jaundice, hepatosplenomegaly, lymphadenopathy, pancytopenia, and generalized lymphohistiocytic infiltrates of various organs, including the CNS. Onset of the accelerated phase seems to be associated with viral or bacterial infections. When a remission occurs, recurrent accelerated phases with increasing severity will be observed.

Neurological problems may also occur in GS2 patients and are related to lymphocyte infiltration of the CNS. Associated symptoms are, for example, hyperreflexia, seizures, signs of intracranial hypertension (e.g., vomiting), hypertonia, nystagmus, and ataxia. Psychomotor development is normal at onset, and regression of CNS signs, at least in part, can be observed during remission, although some sequelae may be irreversible. Skin hypopigmentation and silvery-grey hair in Griscelli patients are not caused by deficient melanosome biogenesis but by impaired intramelanocytic melanosome transport. Murine models with autosomal recessive mutations on the dilute (d), ashen (ash), and leaden (ln) locus present a phenotype close to that of their human GS counterparts.[6] These loci respectively encode three molecules, myosin Va, Rab27a, and melanophilin (Mlph) that act as a tripartite complex linking the melanosome to subcortical actin. When MYO5A (GS1), RAB27A (GS2), or MLPH (GS3) is mutated in human melanocytes, the tripartite complex fails to form and melanosomes can no longer be tethered near the plasma membrane for transfer to keratinocytes, leading to a pigmentary defect.[7]



Figure 75-1 A Griscelli patient with silvery gray eyebrows/eyelashes.

The prognosis for patients with GS is generally bad. They usually die in the first or second decade of their life if accelerated phases are not treated adequately. As for GS2 therapy, allogeneic bone marrow transplantation has appeared to be successful in some cases, especially when carried out at an early age.[8–11] Palliative therapy consists of suppressing the accelerated phases with immunosuppressive therapy (high-dose corticosteroids, cyclosporine) and chemotherapeutic agents (methotrexate, etoposide, cytosine arabinoside). For GS1 there is no therapy. Palliation consists of treating infections with antibiotics.[12]

The hematologic, immunologic, and neurologic findings in GS1–3 presumably relate to organelle transport difficulties in the respective organ systems.

ELEJALDE SYNDROME (OMIM #256710).

ES, also referred to as *neuroectodermal melanolysosomal disease*, is another autosomal recessive pigment mutation with silvery hair, pigment abnormalities, and severe CNS dysfunction[21,22] similar to those of GS1. ES patients do not manifest the hemophagocytic syndrome or immunological impairment associated with GS2.[23,24]

Certain patients with ES have clinical and histologic features suggestive of GS1, indicating that these are other cases of *MYO5A* mutations.[25,26] Further work will be required to define the molecular basis of ES and to group all patients with these rare disorders correctly.

ACQUIRED LOCALIZED HYPOMELANOSIS

PITYRIASIS VERSICOLOR.

(See Chapter 189). Pityriasis versicolor is characterized by slightly scaling macules that can either be hypopigmented, pink or salmon-colored, or hyperpigmented (Fig. 75-2); variants with red and black macules have also been described. The prevalence of pityriasis versicolor is very high in hot and humid climates.

This superficial mycosis is caused by *Malassezia* species of which *M. globosa*, *M. sympodialis*, and *M. Furfur* are most frequently identified in lesional scales. *M. Furfur* cultures produce a wide range of fluorochromes and pigments that appear to lead to depigmentation, high resistance to ultraviolet (UV)-induced tanning, and lack of inflammation observed in pityriasis versicolor.[27] In approximately one out of three patients, a yellow–green fluorescence is visible using Wood's light. It should be differentiated from the nonscaling depigmented lesions of vitiligo that frequently affect hands and feet, whereas pityriasis versicolor is mainly located on the trunk. The slightly scaling patches of pityriasis alba (PA) usually occur on the face and limbs and are nonfluorescent. Many local and systemic antifungal preparations are effective but relapses often occur.[28,29]

PIGMENTARY DEMARCATION LINES.

Originally described in Japanese patients as a line present on upper and lower extremities corresponding to a border of transition between the more deeply pigmented skin of the outer (dorsal) surfaces and the lighter inner (ventral) surfaces, the concept of



Figure 75-2 Pityriasis versicolor. **A.** Typical macules are round, very well circumscribed, have fine scale, and are off-white to tan colored. Typical distribution involves the upper back and upper chest. Involvement of the lower arms and legs and of the face is unusual. **B.** Confluent macules create scalloped borders. This is a characteristic pattern of macules of pityriasis versicolor.



Figure 75-3 Pigmentary demarcation line (Futcher line). These lines are often barely perceptible but common in darker skinned phototypes.

pigmentary demarcation lines was expanded to include five specific patterns, labeled A–E, with A: upper anterolateral arms, across pectoral area (Fig. 75-3), B: posteromedial portion of lower limb, C: vertical hypopigmented line in pre- and parasternal area, D: posteromedial area of spine, and E: bilateral aspect of chest, marking from midthird of clavicle to periareolar skin. In a population survey of black and white patients it was determined that these lines appeared in early childhood. They are present in the majority of female black adults, with types A and B being most prevalent. Seventy-five percent of black adult males had at least one type of pigmentary demarcation line, with type C the most prevalent. Fifteen percent of white female adults had at least one line, and 14% of black women saw type B lines appearing during pregnancy.[30] The lines of pigmentation are often called Futcher's lines in the United States.

The pathogenesis of pigmentary demarcation lines is uncertain. Some authors believe that these lines coincide with lines of Blaschko and are secondary to a form of pigmentary mosaicism. Others suggest that there is no true genetic difference but hypothesize that the difference between cells on the dark, posterior side versus the light, anterior side are due to the normal function of genes, such as the agouti locus.[31]

According to some reports, pigmentary demarcation lines do not follow lines of Blaschko but have a pattern similar to lines of Voigt, which separate dermatomes arising from nonconsecutive dorsal roots. The difference in melanogenesis would be explained by a strict territorial control by different homeobox genes during development.[32]



Figure 75-4 Pityriasis alba.

PITYRIASIS ALBA. PA is a common benign condition mainly affecting the head and neck region of preadolescent children. Although the disease is more noticed in darker skin types, there is no predilection for either sex or skin type. The etiology and pathogenesis remain poorly understood. PA is widely understood to represent mild atopic dermatitis. Unprotected sun exposure, frequent bathing, and hot baths are strongly related to the development of PA. Lower serum levels of copper, a cofactor for tyrosinase, could also play a role in the pathogenesis of this condition.

PA may present as a pink patch with an elevated border, fading after several weeks into a paler spot covered with powdery white scale (Fig. 75-4). The lesions progress to nonscaly hypopigmented macules persisting for months or years. The three stages may occur simultaneously.

Histologically, there is markedly reduced pigment in the epidermis of lesional skin, but no significant difference in melanocyte count was found between lesional and normal skin. Ultrastructurally, degenerative changes in melanocytes and a reduced number of melanosmes within keratinocytes were seen.[33] Extensive PA often also involves the inferior torso in a symmetric pattern. The lack of a preceding inflammatory phase and spongiosis differentiate extensive PA from the classic form. This particular form of PA may overlap with progressive macular hypomelanosis (PMH), a condition mainly described in young female adults, characterized by relapsing hypopigmented, nonscaling patches involving the back, particularly after summer.[34]

Pigmenting PA is a variant associating classic PA with a superficial dermatophyte infection, almost always affecting the face. It is clinically characterized by a bluish hyperpigmentation, attributed to melanin deposits in the dermis surrounded by a hypopigmented scaly area. One-third of patients have concurrent classic PA.

Differential diagnosis includes any localized form of hypopigmentation, especially inflammatory skin conditions associated with postinflammatory hypopigmentation, such as psoriasis, but also with fungal infection, nevus depigmentosus, nevus anemicus, tuberous sclerosis, mycosis fungoides (MF), or vitiligo.

The disease is self-limited and treatment is often not completely successful. Topical steroids and emollients are helpful. Topical tretinoin has also been used with success, but may be irritating. Extensive PA and pigmenting PA have also responded to UV therapy and oral antifungals, respectively. Supportive measures such as decreasing sun exposure, use of sunscreens, and reducing frequency and temperature of baths should be recommended.

The pathogenesis of pigment loss is unclear.[34–38]

SARCOIDOSIS. (See Chapter 152). Hypopigmentation is a rare manifestation of sarcoidosis. Hypopigmented macular lesions scattered over the trunk and extremities but also papular or nodular lesions may be present. The presence of noncaseating dermal granulomas, usually most evident in biopsies of indurated lesions, reinforce the diagnosis. A reduction in melanin content of the epidermis with preservation of melanocytes has been demonstrated.

The pathogenesis of pigment loss is unclear.[39–41]

SCLERODERMA. (See Chapter 157). Hypopigmentation has been described as a pigmentary change in morphea (localized scleroderma) (Fig. 75-5) and scleroderma (progressive systemic sclerosis). Localized hypopigmentation and/or hyperpigmentation are seen in areas of localized sclerosis. Focal depigmentation with perifollicular hyperpigmentation ("salt and pepper pigmentation") especially on upper trunk and extremities, mimicking vitiligo, is reported in up to 30% of patients with scleroderma. The coexistence of scleroderma/morphea and vitiligo has also been reported.[42–44]

LUPUS ERYTHEMATOSUS. (See Chapter 155). Pigment alterations are frequently seen in discoid lupus erythematosus. Hypopigmented patches result from interface dermatitis with destruction of the epidermal basal layer containing melanocytes. "Burned out" lesions are atrophic and depigmented and may be surrounded by hyperpigmentation. Cutaneous depigmentation is also reported in systemic lupus erythematosus, usually localized to inflammatory skin lesions. Biopsy specimens in depigmented skin feature degeneration of the basal layer with epidermal atrophy, a variable number of melanocytes, and pigmentary incontinence in the superficial dermis. The mechanism of hypopigmentation in lupus is not known but could be postinflammatory or cicatricial.

Vitiligo has also been reported in association with lupus erythematosus.[45] A shared genetic predisposition may explain the association of these two autoimmune disorders.[46]

MYCOSIS FUNGOIDES. (See Chapter 146). MF, the most common type of cutaneous T-cell lymphoma, is clinically characterized by three cutaneous phases: (1) the patch phase, (2) the plaque phase, and (3) the tumor phase. Several pigmentary changes have been described in MF.

In poikiloderma vasculare atrophicans, a variant of the patch stage, mottled pigmentation, atrophy and telangiectasia of the involved skin are observed. A mix of hyper- and hypopigmentation may remain after regression of the skin lesions following treatment.

Hypopigmented MF is an uncommon variant of this lymphoma. It mainly develops before the fourth decade, predominantly in juvenile-onset cases and in dark-skinned individuals, without sex predilection. Irregular hypopigmented patches with variably distinct borders are preferentially located on trunk and extremities. Erythema, scaling, and infiltration may be present. A central area of normal pigmentation may be observed. These lesions may also be associated with the more typical lesions of the three cutaneous phases. The hypopigmentation develops without preceding skin changes and occasionally complete depigmentation is observed.

Histopathologically, hypopigmented MF is characterized by minimal dermal involvement, lack of epidermal atrophy, and moderate to marked exocytosis. Pigment incontinence and decrease or absence of melanin may be observed. Infiltrating lymphocytes often have a T-suppressor cell $CD8^+$ phenotype, but a $CD4^+$ phenotype has also been reported.

Electron microscopy may disclose degenerative changes in melanocytes. Melanocytes may be incompletely melanized or occasionally reduced in number. The number of melanosomes within keratinocytes is normal or decreased and melanin-containing macrophages can be observed in the papillary dermis. T-cell receptor gene rearrangement analysis may help to confirm the diagnosis but is often negative, as in early stage MF.

The pathogenesis of hypopigmented MF is not clear. At least in cases showing a $CD8^+$ phenotype, hypopigmentation could be due to the melanocytotoxic effect of nonneoplastic $CD8^+$ lymphocytes, as hypothesized in vitiligo.

Hypopigmented MF responds well to treatment, particularly psoralen and UVA light (PUVA) or



Figure 75-5 Morphea. Note the discrete hyperpigmentation in the area of localized sclerosis.

narrowband UVB therapy. It has a relatively benign course, although recurrences are common. Hypopigmented MF should be distinguished from other causes of diffuse hypopigmentation, especially vitiligo, tinea versicolor, PA, or postinflammatory hypopigmentation.[47–51]

INFECTIONS

Treponematoses. (See Chapters 200 and 201). Nonvenereal treponematoses are currently endemic in parts of Central and South America, Africa, Asia, and the Pacific Islands and can be severely disfiguring. Depigmentation is seen in several stages of yaws, bejel, and pinta. When the primary lesion of yaws disappears, a typical depigmented and pitted scar remains. In the tertiary stage of bejel, gummatous nodules develop in the skin and in other organs. Most skin lesions regress, leaving depigmented, noncontracted scars. Pinta is the only treponematosis that only affects the skin and causes pigmentary abnormalities in the first, second, and third stages of the disease. The sentinel lesion of pinta may heal at the end of the primary stage, leaving a macular dyschromia. The secondary stage is characterized by the appearance of the so-called *pintids*, which are initially red but often turn brown, slate-blue, gray, or black. This stage can last several years, leading to a mix of depigmentation and hyperpigmented lesions. Generalized pigmentary abnormalities develop during the tertiary stage. A symmetrical pattern of vitiligo-like lesions and brown, gray or blue and black lesions is seen over bony prominences (Fig. 75-6).[52]

Onchocerciasis. (See Chapter 207). Several different skin manifestations can become apparent during the course of onchocerciasis. Onchocercal depigmentation or "leopard skin" is rarely associated with itch and is one of the most common skin manifestations of onchocerciasis. Hypopigmented patches with perifollicular spots of normally pigmented skin, typically occur symmetrically on the pretibial area of older people in endemic areas.[53] (Fig. 75-7).

Post-kala-Azar Dermal Leishmaniasis (PKDL). (See Chapter 206). Post-kala-azar dermal leishmaniasis develops in insufficiently treated kala-azar or visceral leishmaniasis, which is caused by *Leishmani. donovani*. Skin manifestations of PKDL are nodules and plaques, facial erythema, and hypopigmented macules. Nodules and plaques typically develop around the mouth and spread to the face, arms and chest, but the macules may occur more generalized over the whole body. Mild disease can resolve spontaneously, but severe forms require systemic treatment.[54,55]

Leprosy. (See Chapter 186). The presence of a hypopigmented lesion with reduced sensation is the hallmark of leprosy and is one of the diagnostic criteria (Fig. 75-8). Indeterminate leprosy, frequently the first manifestation of leprosy, is characterized by the presence of a few such lesions. Tuberculoid leprosy usually manifests as a limited number of well-defined,



Figure 75-6 Pinta. The hypomelanosis in pinta is a vitiligo-like hypomelanosis that occurs later in the disease and is associated with deep blue to slate-gray areas of hyperpigmentation.

depressed, hairless lesions occur that appear hypopigmented in black patients and erythematous in white patients.[56]

CHEMICAL AND PHARMACOLOGIC AGENTS.

The potential for chemicals to induce hypopigmentation was discovered in the first half of the twentieth century. Leukoderma was noticed in rubber workers exposed to



Figure 75-7 Onchocerciasis.



Figure 75-8 Leprosy. A characteristic off-white hypomelanotic and anesthetic macule.

the monobenzylether of hydroquinone (MBEH), a frequently used antioxidant in the rubber industry. Since then, depigmenting properties have been attributed to many chemicals and new therapeutic depigmenting agents have been developed.[57]

Occupational exposure to chemicals that have a destructive effect on melanocytes can result in chemical leukoderma. Agents such as *para*-tertiary butylphenol, *para*-tertiary butyl catechol, MBEH, and hydroquinone can cause permanent depigmentation. The depigmentation caused by chemicals is difficult to distinguish from idiopathic vitiligo. The former usually starts at the hands and forearms, presumptive sites of contact, but depigmentation at a distance is also possible (Fig. 75-9). Chemical leukoderma spreads by coalescence of small macules, whereas the sudden appearance of large patches with perifollicular sparing is more suggestive of vitiligo. Chemical leukoderma is very likely if several exposed workers develop depigmentation. However, not all exposed individuals develop leukoderma and it is hypothesized that the individual susceptibility is variable.[57,58]

Chemicals are also employed therapeutically or cosmetically to lighten skin color. There are three main mechanisms of action for bleaching agents. Some act before melanin is synthesized by inhibiting tyrosinase transcription and glycosylation. Other agents act during melanin synthesis by inhibiting enzymes such as tyrosinase or peroxidase or act as reducing agents or radical oxygen species scavengers. Finally, some agents act after melanin synthesis because they are responsible for tyrosinase degradation, inhibition of melanosome transfer, or acceleration of skin turnover, leading to depigmentation.[59]

MBEH was used as a lightening agent until its ability to cause total permanent and often confetti-like depigmentation became apparent. It should be used only to produce total depigmentation in patients with diffuse vitiligo. A formulation with 20% MBEH is usually prescribed for that purpose. Hydroquinone is one of the most popular depigmenting substances and is frequently used for the treatment of melasma in concentrations between 2% and 5%. Concentrations higher than 5% incur a risk of permanent depigmentation. Adverse effects are irritation, postinflammatory pigmentation, and exogenous ochronosis.[57,59–61]

PHYSICAL AGENTS. Heat, freezing, X-ray, ionizing radiation, UV irradiation, and laser light can cause hypopigmentation or permanent depigmentation by damaging melanocytes, leading to destruction or impaired function.[62]

LICHEN SCLEROSUS. (See Chapter 65). Lichen sclerosus typically presents as a pruritic erythematous patch in the early stage, evolving to a depigmented atrophic plaque with porcelain white appearance.

Mechanisms believed to play a role in this idiopathic leukoderma include decreased melanin production, blocked transfer of melanosomes to keratinocytes, and loss of melanocytes.

MELANOMA-ASSOCIATED LEUKODERMA. (See Chapter 124). Regression in a primary melanoma lesion typically causes a depigmented scar-like area within the lesion.

Melanoma-associated hypo- or depigmentation, also known as leukoderma acquisitum centrifugum, can occur around the primary melanoma or metastases or at distant sites. The latter is often called vitiligo, although the resemblance is limited. Whereas vitiligo depigmentation is usually symmetric and spreads centripetally to the trunk, melanoma-associated hypo- or depigmentation tends to be extensive, patchy, and asymmetric. The lesions may be mottled (hypomelanotic) or milk white (amelanotic). In most cases, leukoderma appears simultaneously with the finding of metastases. Histologic examination of lesions shows a decrease or complete absence of melanocytes. Macromelanocytes with stubby dendrites can also be observed. Melanoma with associated leukoderma may be associated with a better survival rate than comparably advanced lesions without epidermal pigment loss. Strong evidence suggests that melanoma-associated leukoderma results from host immune reaction against the malignancy, involving humoral and cellular mechanisms. Both passive and active immunotherapeutic strategies used in the treatment of melanoma have been associated with leukoderma (Fig. 75-10).[63,64]

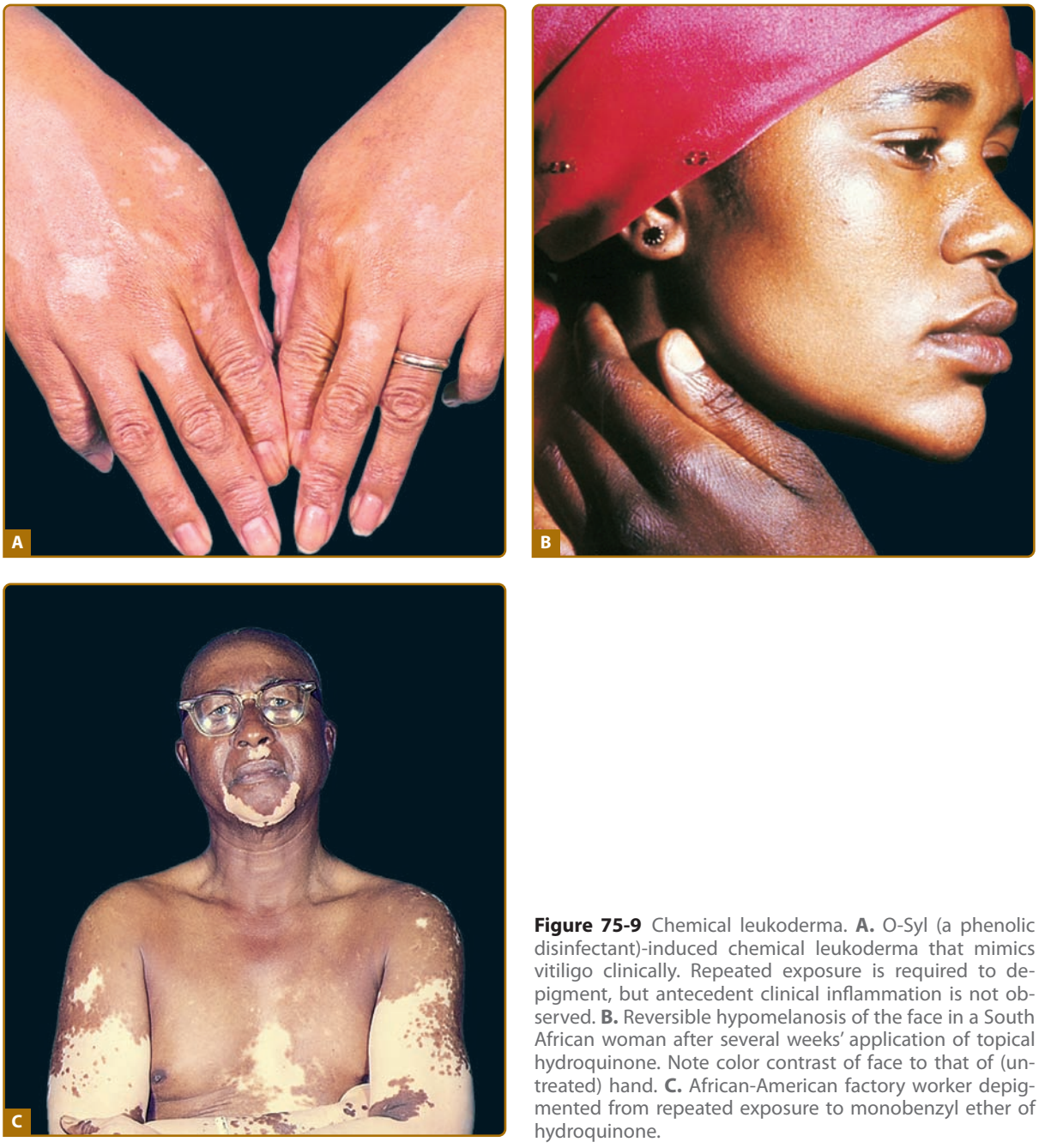

Figure 75-9 Chemical leukoderma. **A.** O-Syl (a phenolic disinfectant)-induced chemical leukoderma that mimics vitiligo clinically. Repeated exposure is required to depigment, but antecedent clinical inflammation is not observed. **B.** Reversible hypomelanosis of the face in a South African woman after several weeks' application of topical hydroquinone. Note color contrast of face to that of (untreated) hand. **C.** African-American factory worker depigmented from repeated exposure to monobenzyl ether of hydroquinone.

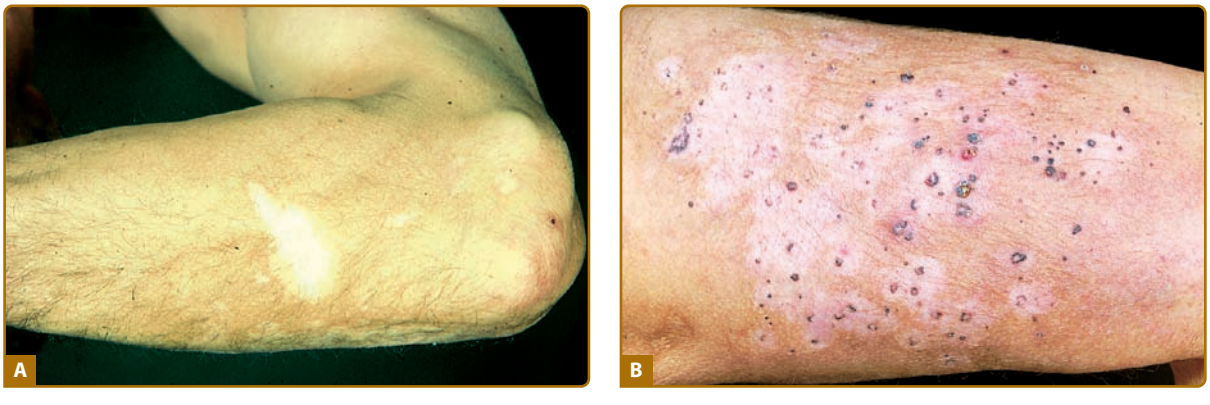

Figure 75-10 Melanoma-associated leukoderma. **A.** This hypomelanosis may resemble vitiligo clinically and be characterized by an absence of melanocytes. It may be associated with a favorable prognosis. **B.** These macules in a different patient developed after the patient developed metastases to the skin. They surround the individual metastases.

ACQUIRED DIFFUSE HYPOPIGMENTATION

Nutritional disorders and endocrinopathies mainly cause hyperpigmentation. Diseases such as copper deficiency, vitamin B_{12} deficiency, kwashiorkor, Addison disease, hyperthyroidism, and diabetes can also be associated with hypopigmentation, but are discussed under Section "Hypermelanosis" because hyperpigmentation is their main feature.

HYPOTHYROIDISM. (See Chapter 151). Hypothyroidism is frequently associated with cutaneous alterations. The skin is pale due to anemia and vasoconstriction. Yellowish discoloration of the palms, soles, and nasolabial folds is caused by an accumulation of carotene in the stratum corneum. The associated hypercarotinemia results from reduced capacity of the liver to convert β-carotene to vitamin A. Vitiligo has been associated with autoimmune hypothyroidism.[65–67]

HYPOPITUITARISM. Panhypopituitarism results from a variety of conditions that compromise the anterior pituitary. As a consequence, release of pituitary-derived factors including melanocyte-stimulating hormone (MSH), thyroid-stimulation hormone, adrenocorticotrophic hormone, luteinizing hormone, follicle-stimulating hormone, growth hormone, and vasopressin is decreased. Due to the reduction of circulatory pituitary hormones, production of cortisol, thyroxine, estrogens, and testosterone in target organs is lowered.

Patients suffering from panhypopituitarism look pale due to anemia and decreased cutaneous blood flow. As well, generalized hypopigmentation results from decreased adrenocorticotrophic and MSH that stimulate epidermal melanogenesis.[66]

HYPOGONADISM. Castrated human males are characteristically pale and their genital skin is not hyperpigmented as in normal men. An impaired tanning response to UV radiation has been described. Administration of testosterone makes the skin turn darker and restores the tanning response.[68]

SELENIUM DEFICIENCY. Loss of hair and skin pigmentation due to selenium deficiency has been described in children receiving long-term total parenteral nutrition. After selenium supplementation, skin and hair darken.[69]

COPPER DEFICIENCY. Acquired copper deficiency occurs in severely malnourished infants. Hypopigmentation of the hair is attributed to copper deficiency, presumably because tyrosinase is a copper-dependent enzyme, but as multiple nutritional deficiencies tend to coexist pathogenesis is difficult to confirm.[70]

IDIOPATHIC GUTTATE HYPOMELANOSIS. Idiopathic guttate hypomelanosis (IGH) is an acquired leukoderma, characterized by discrete, round, or oval porcelain-white macules of approximately 2–5-mm diameter, which increase in number with aging

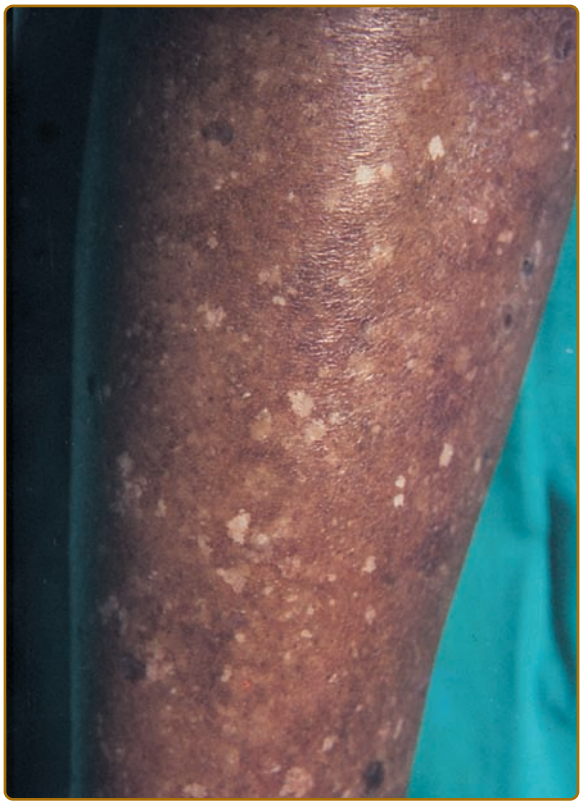

Figure 75-11 Idiopathic guttate hypomelanosis. Lesions on the leg of an African-American individual.

(Fig. 75-11). Any associated hairs often remain pigmented. Lesions are found in a photodistribution and tend to occur in chronically sun-damaged skin. They are often seen pretibially and on the forearms, although they may also arise on other sun-exposed areas, including the face, neck, and shoulders. IGH has been hypothesized to be UV-induced, although controversy exists. Some suggest that IGH may reflect the normal aging process.[71]

Histologically, IGH lesions are characterized by slight basket-weave hyperkeratosis with epidermal atrophy and flattening of the rete pegs. Lesions show a decrease in melanocytes and melanin content of the affected epidermis and pigment granules are irregularly distributed.

A variety of therapies with variable success are described, including cryotherapy, superficial dermabrasion, topical steroids, and topical retinoids.[72,73]

LEUKODERMA PUNCTATA. Leukoderma punctata was first described by the development of multiple punctiform hypopigmented and achromic spots after several months of PUVA treatment.[74] Later, similar cases were described after UVB therapy for psoriasis and after topical PUVA in one case of segmental vitiligo.[75]

Lesions are predominantly present on the extremities, upper back and chest. They are round or oval, sharply demarcated, and small (0.5–1.5 mm), without follicular distribution. Spontaneous reduction of the leukodermic lesions has been observed.[74]

It has been suggested that phototoxicity damage to keratinocytes and melanocytes is the etiologic factor. Leukoderma punctatum is suggested to be distinct from IGH on the basis of the clinical and histologic features. In IGH, lesions are larger and spontaneous resolution is not reported. Ultrastructurally, leukoderma punctata demonstrates slight-to-severe damage of keratinocytes and melanocytes not reported in IGH.

CANITIES. Hair graying or canities is a process of chronological aging and occurs regardless of gender or race.[76] The age of onset, which appears to be hereditary, is usually in the fourth decade. The average age for whites is mid-30s, for Asians late 30s, and for Africans mid-40s. Premature canities (before 20s or 30s) can be associated with pernicious anemia, hyper/hypothyroidism, osteopenia, and several rare syndromes like progeria and pangeria (Werner syndrome). Graying usually appears at the temples first, then the vertex, and, finally, the occiput. Beard and body hair are affected later. Gray hairs seem to be thicker and longer than normally pigmented hairs. The perception of "gray hair" derives in large part from the admixture of pigmented and white hair, but individual hair follicles can indeed exhibit pigment dilution or suboptimal melanocyte–cortical keratinocyte interactions during the graying process.[77–79] An acute episode of alopecia areata may result in a very sudden "overnight" graying (so-called *canities subita*) that is caused by the preferential loss of pigmented hair in this immune-mediated disorder.

HEMODIALYSIS. Chronic hemodialysis patients frequently show disorders of skin pigmentation, primarily involving hyperpigmentation of sun-exposed body areas. Hypopigmentation of skin and hair is rather exceptional but occurs, possibly due to a disturbance of phenylalanine metabolism.

PROGRESSIVE MACULAR HYPOMELANOSIS. PMH is an entity that affects the trunk with nummular, hypopigmented nonscaly macules. It affects young adults, mainly women. Although described in people of mixed racial ancestry (known as *Creole dyschromia*),[80] it is seen in all races. It can be mistaken for PA and pityriasis versicolor. Topical and systemic antifungal treatment and topical steroids are ineffective, but the disorder may resolve, sometimes temporarily, after sun exposure or phototherapy.

ACQUIRED DIFFUSE HYPOPIGMENTATION WITH VASCULAR CAUSES

ANEMIA. The color of the skin is determined by several chromophores, usually predominantly melanin pigment, but the hemoglobin content of the skin also contributes to the skin color. The pale skin color observed in anemia is due to decreased levels of circulating oxyhemoglobin and is proportional to the severity of the anemia.

BIER SPOTS. Bier spots are small, irregular apparently hypopigmented areas, usually on arms and legs in young adults, resulting in a reticulated appearance. The surrounding skin is erythematous and blanches with pressure causing the "hypopigmented" macules to disappear. The condition is a vascular anomaly with vasoconstriction in the pale areas and venodilatation in erythematous skin.[81,82]

WORONOFF'S RING. (See Chapter 18). Woronoff's ring represents a blanched halo surrounding a psoriatic lesion. It is observed after UV treatment or topical steroid treatment, but may also occur in untreated psoriasis. The pathogenesis is not clear. A decreased melanin content has been found in both psoriatic and halo epidermis suggesting a true hypomelanosis. A local decreased prostaglandin synthesis with decreased vasodilatation or a diffusion of anti-inflammatory mediators from the psoriatic lesion to the halo is also postulated.

CUTANEOUS EDEMA. Cutaneous edema produces an appearance of leukoderma that is not true hypomelanosis. Decreased absorption of light, reduced capillary blood flow, and increased dermal thickness may contribute to the pale appearance of the skin.

HYPERMELANOSIS

CONGENITAL DIFFUSE HYPERMELANOSIS

CONGENITAL DIFFUSE LINEAR HYPERMELANOSIS

Linear and Whorled Nevoid Hypermelanosis. Linear and whorled nevoid hypermelanosis (LWNH) is characterized by hyperpigmented macules in streaky configuration along the lines of Blaschko without preceding inflammation or atrophy.[89] Similar cases have been described under different descriptive names (*zosteriform hyperpigmentation*, *zosteriform lentiginous nevus*, *zebra-like hyperpigmentation*). Lesions are typically located on the trunk and limbs and do not cross the midline. Face, palms, soles, eyes, and mucous membranes are spared. Kalter et al described LWNH as having onset within a few weeks of age and progression during the initial years of life.[89] The pigmentation can fade gradually with increasing age. Several cases have been reported with both hyper- and hypopigmentations. Pigmentary mosaicism is a useful term to encompass all these different phenotypes.[90]

The presence of mosaicism has been confirmed in a few cases (mosaic trisomy 7, 14, 18, 20, and X-chromosomal mosaicism) by chromosomal analysis on lymphatic cultures or dermal fibroblasts.[91]

LWNH may be differentiated from incontinentia pigmenti (IP) and epidermal nevus.[89]

Extracutaneous abnormalities have been observed in a number of LWNH cases, including developmental and growth retardation, facial and body asymmetry, ventricular septal defect, and pseudohermaphroditism.

Histologic examination reveals increased pigmentation of the basal layer and prominence or vacuolization of melanocytes. Pigment incontinence is usually but not always absent.[92]

Incontinentia Pigmenti. IP, also known as *Bloch–Sulzberger syndrome*, was first described by Garrod et al in 1906. It is an X-linked, dominantly inherited disorder, reported primarily in females, and believed to be embryonic lethal in the majority of males. In most cases, IP is due to a mutation in the gene *NEMO* [nuclear factor κB (NF-κB) essential modulator] on the X chromosome at Xq28.[93–96] In IP females, inactivation of one of the two X chromosomes through a process termed lyonization occurs during embryogenesis. Epidermal cells expressing the defective *NEMO* gene give rise to typical skin lesions along the lines of Blaschko, reflecting the embryonic migration path of the affected keratinocytes. Lesions usually proceed through four cutaneous stages, sometimes with some overlap: (1) vesicular stage (from birth or shortly thereafter), (2) verrucous stage (between 2 and 8 weeks of age), (3) hyperpigmented stage (several months of age into adulthood), followed by (4) hypopigmentation stage (from infancy through adulthood) (Fig. 75-12). A significant percentage of IP patients have ocular, dental, skeletal, and CNS anomalies.[97]

The cutaneous lesions in the first stage represent the population of NEMO-deficient cells that fail to activate NF-κB, leading to apoptosis, as NF-κB normally protects against tumor necrosis factor-induced apoptosis. The number of NEMO-deficient cells decreases secondary to apoptosis and is replaced by cells expressing the normal allele. Subsequently, the inflammatory and vesicular stage ends. The hyperproliferation in the second stage is likely due to compensatory proliferation of normal NEMO keratinocytes. Hyperpigmentation in the third stage results from incontinence of melanin pigment from the destroyed epidermis into the dermis.

The hyperpigmentation appears in streaks and whorls along the lines of Blaschko and is usually most pronounced on the trunk, but can also appear on the extremities. The degree of hyperpigmentation varies among individuals. Histologically, the areas of pigmentation show many melanin-laden melanophages, extensive deposits of melanin in the basal cell layer and dermis. There is vacuolization and degeneration in the epidermal basal cell layer. Usually, the hyperpigmentation fades gradually after several years and the skin can become hypopigmented (stage 4), which represents postinflammatory dermal scarring. The hypopigmentation stage is characterized by linear, atrophic, hairless scars following the Blaschko's lines.

Histologically, the number of melanocytes seems to be normal, although a reduced number of melanocytes also has been reported. The epidermis is thinner and there is an absence or reduction of skin appendages in the dermis that may contribute to the impression of hypopigmentation.[98]

A beneficial effect of topical steroids and topical tacrolimus in the vesicular stage has been described.[99,100]

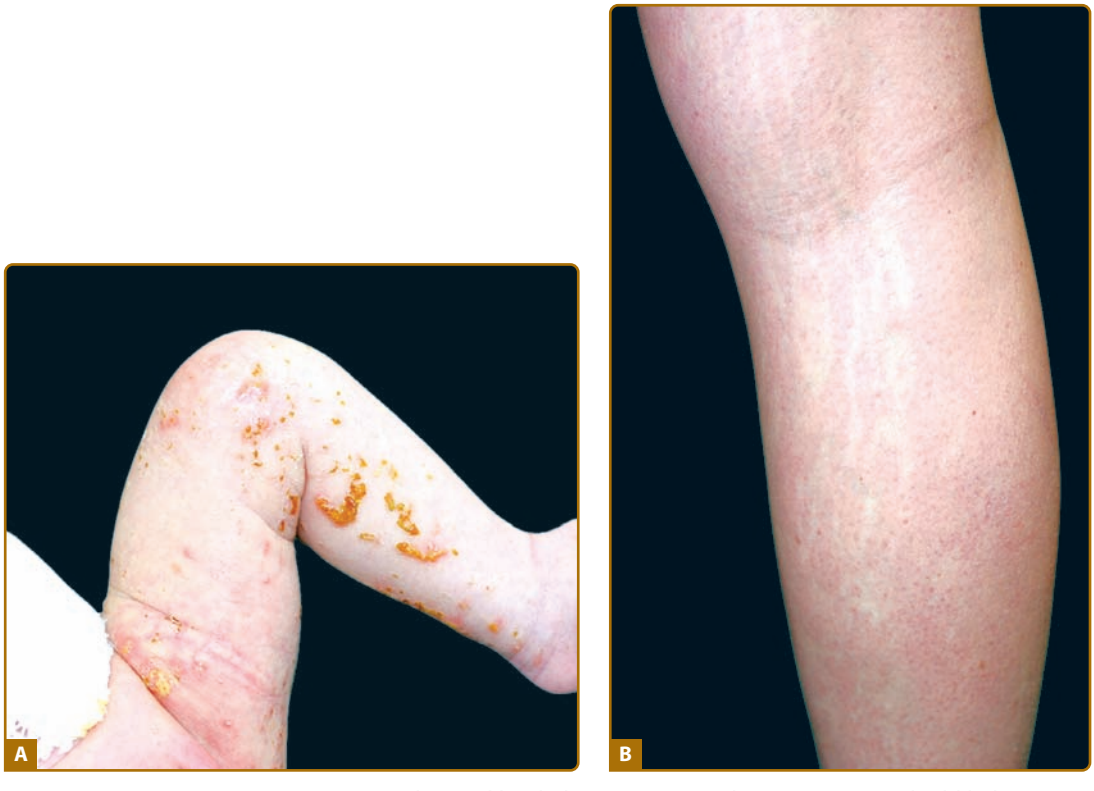

Figure 75-12 Incontinentia pigmenti in a mother and her baby. **A.** Verrucous lesions in a 2-week-old baby. **B.** Hypopigmented atrophic lesions following the Blaschko's lines.

CONGENITAL DIFFUSE RETICULAR HYPERMELANOSIS

Dyskeratosis Congenita. Dyskeratosis congenital (DKC) or *Zinnser–Engmann–Cole syndrome* is characterized by reticulate skin pigmentation, nail atrophy, leukoplakia, and bone marrow failure. Bone marrow failure and malignancy develop in the second and third decades. In all characterized cases of DKC, the causative mutations are present in components of the telomerase complex. Rapidly dividing somatic cells express low but detectable levels of telomerase activity that slows the otherwise progressive telomere shortening that occurs with each cycle of DNA replication and eventually leads to cellular senescence (permanent loss of proliferative capacity). It is now thought that DKC is due to defective telomere maintenance, limiting the proliferative capacity of hematopoietic and epithelial cells. Increased melanin synthesis is now recognized to occur in senescent melanocytes, likely accounting for the pigmentary phenotype of DKC; and critically short telomeres may force cells into "replicative crisis," at which time activation of an alternative "ALT" mechanism for lengthening telomeres in the absence of telomerase may lead to development of malignancies. The finding of shortened telomeres in DKC was indeed the first evidence of the role of telomeres in cell biology (cellular aging).[101]

X-linked DKC is caused by mutations in the *DKC1* gene located at Xq28, encoding for dyskerin. Females carrying one mutated allele are protected by expression of normal telomerase on the unaffected allele. In autosomal dominant DKC the majority of cases are due to mutations in TERC, the RNA component of the telomerase complex. TERT (telomerase reverse transcriptase) is affected much less often in autosomal dominant DKC. The autosomal dominant form has the better prognosis, presumably because some telomerase activity is preserved, due to the presence of an unaffected allele.

In the autosomal recessive form of DKC, mutations in telomerase-associated proteins such as NOP10, NHP2, and TINF2 are involved.[102–104] Skin biopsy of hyperpigmented skin shows nonspecific changes, including epidermal atrophy, a chronic inflammatory infiltrate with numerous melanophages in the upper dermis. DKC may be confused with Fanconi's syndrome, characterized by short stature, hypoplastic or aplastic thumbs, and a reduced number of carpal bones. Here, there is a patchy hyperpigmentation of the trunk, neck, groin, and axillary region that manifests itself earlier than in DKC, i.e., in the first few years of life.

For a discussion of Naegeli–Franceschetti–Jadassohn syndrome, dermatopathia pigmentosa reticularis, Dowling–Degos disease, Galli–Galli disease, Kitamura reticular acropigmentation, Haber's syndrome, and Partington syndrome, see online edition.

CONGENITAL CIRCUMSCRIBED HYPERMELANOSIS

CONGENITAL CIRCUMSCRIBED HYPERMELANOSIS WITH DERMAL MELANOCYTOSIS. Dermal melanocytoses or dermal dendritic melanocytic proliferations are characterized by the presence of melanin-producing dendritic melanocytes in the dermis. They include the nevus of Ito, nevus of Ota, and Mongolian spot and dermal melanocyte hamartoma (Table 75-1). Associated vascular malformation has been described in phakomatosis pigmentovascularis (Port-wine stain type, Klippel–Trenaunay or Sturge–Weber syndrome).[111]

Nevus of Ota. Ota's nevus (nevus fuscocaeruleus ophthalmomaxillaris) was first described by Ota in 1939.[112] It is characterized by blue–black or gray–brown dermal melanocytic pigmentation and typically occurs in areas innervated by the first and second branches of the trigeminal nerve. Mucosal pigmentation may occur involving conjunctiva, sclera, and tympanic membrane (oculodermal melanocytosis), (Fig. 75-13) or other sites. It is most frequently seen in the Asian population, has a female predominance, and is usually congenital, although appearance in early childhood or at puberty has been described. Nevus of Ota is now subclassified as mild (type 1), moderate (type 2), intensive (type 3), and bilateral (type 4). Bilateral cases should be differentiated from Hori nevus, which is acquired, does not manifest mucosal involvement and is less pigmented (see Table 75-1).[113]

Malignant melanoma may rarely develop in a nevus of Ota. This necessitates careful follow-up of the lesion, especially if it occurs in Caucasian patients, in whom malignant degeneration seems to be more frequent. Malignant melanocytic tumors in association with nevus of Ota have been shown to arise in the chorioidea, brain, orbit, iris, ciliary body, and optic nerve.[114,115] In addition, association with ipsilateral glaucoma and intracranial melanocytosis has been described.[116]

Nevus of Ito. Nevus of Ito is a congenital dermal melanocytosis first described by Ito in 1954 as nevus fuscocaeruleus acromiodeltoideus.[117] It can be considered as a variant of nevus of Ota but with involvement of the acromioclavicular and deltoideal region. Clinical, demographical, and histological characteristics are similar to nevus of Ota and both lesions can occur simultaneously (see Table 75-1).

Mongolian Spots. Mongolian spots are congenital, benign hyperpigmentations preferentially occurring in the African, Asian, and Hispanic population and only rarely seen in Caucasians.[118] They occur in both sexes but with a slight male predominance,[119] usually in the sacral area. (Fig. 75-14) They can also be found in the gluteal and lumbar region and on the thorax, abdomen, arms, legs, and shoulders. In most cases Mongolian spots spontaneously regress during childhood, but persistence into adulthood has been described.[120] Histologically, these macules consist of spindle-shaped melanocytes in the lower dermis that have failed to migrate to the dermal–epidermal junction during fetal life. Several cases are described with extensive Mongolian spots involving large areas of the trunk and extremities, associated with inborn errors of metabolism such as GM1 gangliosidosis and mucopolysaccharidosis.[121,122] Laser treatment in childhood or adolescence can give favorable results with sacral Mongolians spots being more laser-resistant than extrasacral ones.

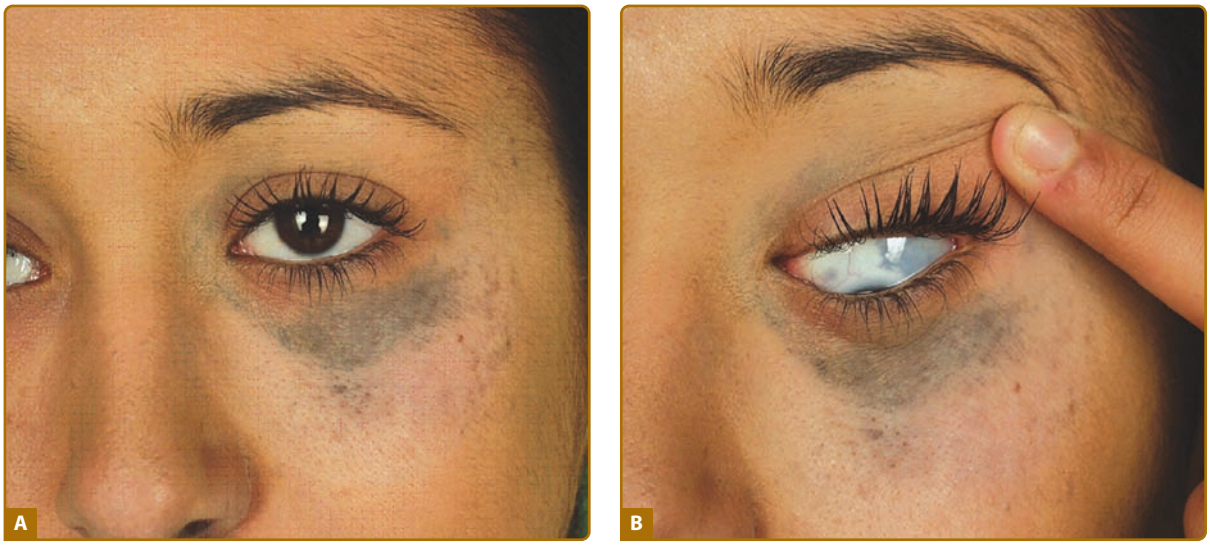

Figure 75-13 Nevus of Ota in a 20-year-old woman. **A.** Hyperpigmentation around the orbita. **B.** The hyperpigmentation extends into the sclera.

Dermal Melanocyte Hamartoma. Dermal melanocyte hamartoma is a distinctive form of congenital dermal melanocytosis first described by Burkhart et al in 1981.[123] Gray–blue pigmentation, caused by melanocytes residing in the dermis, occurs in a dermatomal pattern.

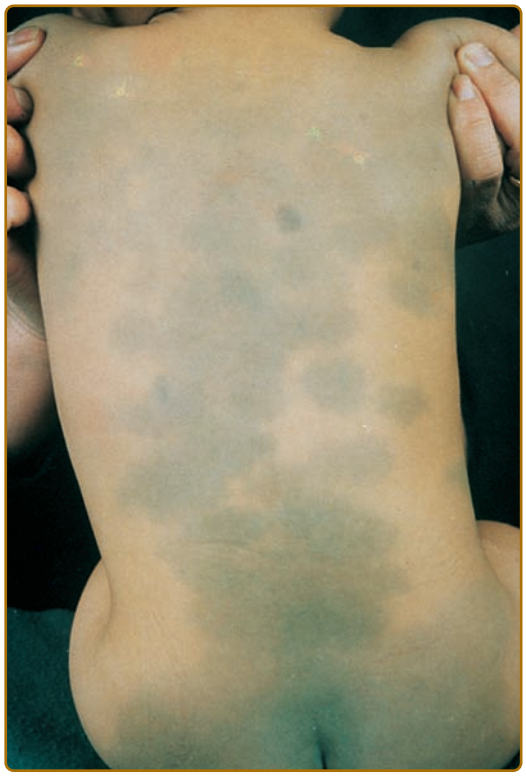

Figure 75-14 Classic Mongolian spot in the lumbosacral region and aberrant or extrasacral Mongolian spots on the back.

CONGENITAL CIRCUMSCRIBED HYPERMELANOSIS WITH LENTIGINOSIS

Familial Lentiginosis Syndromes. Familial lentiginosis syndromes are characterized by the presence of lentigine-circumscribed brown macules (usually <5 mm in diameter), which display an increased number of melanocytes in the epidermis (epidermal melanocytic hypermelanosis) and an increased incidence of cardiovascular, endocrine, or gastrointestinal neoplasias. They include Carney complex, Peutz–Jeghers syndrome (PJS), LEOPARD syndrome (LS) (lentigines, electrocardiogram conduction defects, ocular hypertelorism, pulmonary stenosis, abnormalities of genitalia, retardation of growth, and sensorineural deafness), arterial dissection and lentiginosis, Laugier–Hunziker disease, familial benign lentiginosis, Bannayan–Ruvalcaba–Riley syndrome (BRSS), centrofacial lentiginosis, and segmental and agminated lentiginosis.[124] (See Fig. 75-16.) Genetic loci and gene mutations have been identified for Carney complex, PJS, and BRRS.

Peutz–Jeghers Syndrome. PJS is an autosomal dominant cancer predisposition syndrome first described by Peutz (1921) and Jeghers (1949).[125] Mucocutaneous pigmentation and intestinal hamartomatous polyposis are hallmarks of the disease. (See Fig. 75-15.) The pigmentary lesions resemble those of Carney complex, with small hyperpigmented macules typically appearing in childhood (not present at birth) on the lips and buccal mucosa, but they may also involve the eyelids, hands, and feet.[124]

The most common malignancies associated with PJS are gastrointestinal (small intestine, colorectal, stomach, pancreas). In addition, nongastrointestinal neoplasms such as breast, cervix, and endocrine tumors (thyroid, testicular, ovarian) have been described. More than half of all cases of PJS can be attributed to a mutation in the serine/threonine kinase 11 (*STK 11*



Figure 75-15 Peutz–Jeghers syndrome. **A.** Lentigines, which are dark-brown to gray–blue, appear on the lips, around the mouth, and on the fingers. Lip macules may, overtime, disappear. **B.** Macules of the buccal mucosa are blue to blue–black and are pathognomonic; unlike lip lesions, these do not tend to disappear with time.



Figure 75-16 **A** and **B.** A 27-year-old woman with LEOPARD (lentigines, electrocardiogram conduction defects, ocular hypertelorism, pulmonary stenosis, abnormalities of genitalia, retardation of growth, and sensorineural deafness) syndrome. Note the characteristic widespread lentigines and several café-au-lait macules.

or *LKB 1*) gene,[126] which is therefore thought to act as a tumor-suppressor gene. Close surveillance of PJS patients from a young age is warranted.

LEOPARD Syndrome. LS is an autosomal dominant genodermatosis[124] The characteristic lentigines usually develop during childhood and in the first months of life. Clinical diagnosis is primarily based on the typical facial features and the presence of hypertrophic cardiomyopathy and/or café-au-lait macules (CALMs). The disorder is caused by mutations in the *PTPN11* gene, coding for the protein tyrosine phosphatase SHP-2 and situated on chromosome 12. LS is allelic to Noonan syndrome and shares several clinical features (Fig. 75-16).[127] Recently missense mutations in the *RAF1* gene were found in two LS patients in whom no *PTPN11* mutations could be discovered.[128]

For Carney complex, BRSS, and centrofacial lentiginosis, see online edition.

CONGENITAL CIRCUMSCRIBED HYPERMELANOSIS WITH CAFÉ-AU-LAIT MACULES. CALMs consist of sharply bordered hyperpigmented patches of skin, varying in size from 0.5 cm to more than 20.0 cm. They are often present at birth or appear in the early months of life. Between 0.3% and 18% of all newborns display isolated CALMs.[137] Histologically, isolated CALMs show a normal number of melanocytes but increased epidermal melanin (epidermal melanotic hypermelanosis). Multiple CALMs are well-known markers for several multisystem disorders.

Neurofibromatosis Type 1. Neurofibromatosis type 1 (NF1) was first recognized by Friedrich von Recklinghausen in 1882 and is therefore also called von Recklinghausen's disease (see Chapter 141 for detailed discussions).

NF1 is an autosomal dominant disease caused by a mutation in the *NF1* gene, situated on chromosome 17q11.2 and encoding the neurofibromin protein. Neurofibromin takes part in several signaling pathways and exhibits multiple isoforms through alternative splicing mechanisms. The most important neurofibromin function involves downregulation of the Ras signal transduction pathway and it is, therefore, considered a tumor-suppressor gene.[124,138]

NF1 has been considered as a neurocristopathy and is characterized by a number of cutaneous and noncutaneous pigment cell-related manifestations such as CALMs, intertriginous freckling, and iris Lisch nodules.[138,139] In 1987, the US National Institutes of Health Consensus Development Conference established clinical diagnostic criteria for NF1 (see Chapter 141). The presence of six or more CALMs greater than 5 mm in greatest diameter in prepubertal individuals or greater than 15 mm after puberty is one of the hallmarks of the disease. NF1-associated CALMs, contrary to isolated CALMs, contain a significantly increased number of melanocytes in the epidermis.[140] Intertriginous freckles, pathognomic for NF1, also display increased numbers of epidermal melanocytes, which differentiates them from ordinary freckles (ephelides). (See eFig. 75-16.1 in online edition.)

Mccune–Albright Syndrome. McCune–Albright syndrome (MAS) was first described by McCune (1936) and Albright (1937) as a triad of poly/monostotic fibrous dysplasia, CALMs, and hyperfunctioning endocrinopathies, including precocious puberty, hyperthyroidism, hypercortisolism, hypersomatotropism, and hypophosphatemic rickets.[141,142] The CALMs are fewer in number and have more irregular borders than those seen in NF1. They are classically demarcated at the midline. MAS is caused by a postzygotic activating mutation of the α subunit of the cAMP-regulating Gs protein. Consequently, a mosaic distribution of MAS cells bears the constitutively active adenylate cyclase.[143]

For Bloom, Watson, and Silver–Russel syndromes, see online edition.

ACQUIRED DIFFUSE NONFIGURED HYPERMELANOSIS

ENDOCRINOPATHIES

Addison's Disease. (See Chapter 151). Addison's disease is a clinical syndrome characterized by salt-wasting and skin hyperpigmentation, associated with adrenal deficiency with inadequate secretion of corticosteroid and androgenic hormones, leading to compensatory overproduction of adrenocorticotropic hormone (ACTH) secretion by the pituitary gland.[157]

In the developed world, Addison's disease is usually autoimmune in etiology.

Hyperpigmentation is the most striking cutaneous sign of patients with chronic Addison's disease and is the consequence of ACTH binding to the melanocortin-1 receptor (see Chapter 72). The hyperpigmentation is diffuse and occurs preferentially on sun-exposed areas (face, neck, hands), on sites of trauma, scars, or chronic pressure (knees, spine, knuckles, elbows, shoulders), in the palmar creases, and on nipples, areolae, axillae, perineum, and genitalia.[157]

Cushing's Syndrome. (See Chapter 151). Cushing syndrome is characterized by clinical signs and symptoms due to chronic glucocorticoid excess.

Various degrees of hyperpigmentation can be seen, usually most severe in patients with the ectopic ACTH syndrome. As in Addison disease, hyperpigmentation is generalized, but most prominent in sun-exposed areas such as face, neck, and dorsal hands, as well as in areas subject to chronic mild trauma or pressure (shoulders, midriff, waist, elbows, knuckles, spine, knees) and on mucosal surfaces.[158,159]

Nelson's Syndrome. Nelson's syndrome comprises an enlarging pituitary tumor associated with elevated fasting plasma ACTH levels, hyperpigmentation, and neuro-ophthalmological symptoms in patients with Cushing's disease after bilateral adrenalectomy and inadequate hormonal replacement.[160]

Pheochromocytoma. Pheochromocytoma is a tumor derived from chromaffin cells of the adrenal medulla with associated excessive production of catecholamines. Pallor of the face due to vasoconstriction may be observed. In contrast, addisonian-like hyperpigmentation has been reported and is probably due to ectopic ACTH and MSH production by the tumor. Pigmentation rapidly fades after surgical treatment.[161]

Carcinoid Syndrome. Diffuse hyperpigmentation due to MSH-producing tumors, such as gastric or thymic carcinoid tumors, have been described in carcinoid syndrome. Carcinoid syndrome can also be accompanied by a pellagra-like rash occurring on light-exposed skin. The rash is secondary to a tryptophan deficiency, as a large amount of dietary tryptophan is diverted to serotonin by the tumor.

Hyperthyroidism. (See Chapter 151). Thyrotoxicosis has multiple causes. The most common cause is Grave's disease, characterized by circulating antibodies against thyroid-stimulating hormone receptors.

The occurrence of hyperpigmentation in thyrotoxic patients has been estimated from 2% to as high as 40% in large series. The increased cutaneous pigmentation can be localized or generalized and is more common in dark-skinned people. The distribution of hyperpigmentation is often similar to that in Addison's disease with pigment deposition in the creases of the palms and soles. However, several features distinct from that of Addison's disease have been noted. Involvement of the mucous membranes is uncommon and pigmentation of the nipples and genital skin is less striking. Hyperpigmentation associated with thyrotoxicosis is thought to be due to an increased release of pituitary ACTH, compensating for accelerated cortisol degradation. The response of hyperpigmentation to therapy for the hyperthyroidism is reported to be poor.[162–164] Autoimmune Grave's disease has been reported in association with vitiligo.

Melasma. Melasma is a common hypermelanosis that typically occurs on sun-exposed areas in the face. The pathogenesis is poorly understood, but genetic and hormonal influences in combination with UV radiation are important. Specific precipitants include birth-control pills, estrogen replacement therapy, mild ovarian or thyroid dysfunction, ovarian tumors, cosmetics, nutrition, phototoxic and photoallergic medications, phototoxic drugs, and medication for epilepsy.

Melasma is rarely reported before puberty and is far more common in women, especially those of reproductive age and often begins or is exacerbated during pregnancy, explaining the common appellation "mask of pregnancy." People with darker skin types are more frequently affected. The lesions are brownish macules with irregular borders and symmetric, photodistribution usually on the face (Fig. 75-17), often coalescing in a reticular pattern. Sun exposure intensifies the lesions. There are three major patterns of distribution of the lesions: (1) centrofacial (63%: forehead, nose, chin, and upper lip), (2) malar (21%: nose and cheeks), and (3) mandibular (16%: ramus mandibulae). The anterior chest and dorsal forearms may also be affected.



Figure 75-17 Melasma. Typical yellowish to brownish macules with irregular borders on the forehead of a young woman.

From its appearance under Wood's lamp, melasma is classically classified into epidermal, dermal, and mixed. (Epidermal pigmentation is accentuated under Wood's lamp, whereas dermal pigmentation is less apparent.)

Sun protection is central to management. Epidermal pigmentation is known to be more responsive to topical treatment than dermal pigmentation. Hypopigmenting agents such as hydroquinone, tretinoin, azelaic acid, rucinol, and kojic acid are helpful when used for prolonged periods. The so-called Kligman formula is a popular combination of hydroquinone, tretinoin, and a mild topical corticoid. Chemical peels and laser therapy may be helpful in the treatment of melasma, but can also result in further unwanted hyperpigmentation. Sometimes, melasma slowly disappears after discontinuation of the hormonal stimulus and/or careful sun avoidance.[165–167]

Pregnancy. During pregnancy increased pigmentation occurs in 90% of women and is most prominent in darker skin types. Preexisting pigmented lesions such as nevi and ephelides become darker. Also, recent scars often darken. In normally pigmented areas, such as nipples, areolae, and genitalia, the pigmentation becomes more intense. The linea alba, the median line on the anterior abdominal wall, often becomes hyperpigmented during pregnancy and is then called linea nigra. In a small proportion of pregnant women, hyperpigmentation occurs in the axillae or the inner upper thighs. Melasma or "mask of pregnancy" (see Section "Melasma") occurs in more than 50% of pregnant women (see Chapter 108).[168,169]

Acanthosis Nigricans. Acanthosis nigricans is discussed in Chapters 151 and 153.

Diabetes. (See Chapter 151.) A higher vitiligo prevalence has been reported in patients with diabetes type I and II compared to the general population. Diabetic dermopathy is characterized by asymptomatic, irregular, light brown, depressed patches on the anterior lower legs,[65] but the pathogenesis is not known.

NUTRITIONAL CONDITIONS.

(See Chapter 130 and online text). Pigmentary changes can be secondary to nutritional conditions such as kwashiorkor, vitamin B_{12} deficiency, folic acid deficiency, or pellagra. The skin changes are reversible on correction of the nutritional deficiency.

METABOLIC CONDITIONS

Porphyria Cutanea Tarda. (See Chapter 132.) Porphyria cutanea tarda is a metabolic disorder that has been associated with diffuse brown hypermelanosis accentuated in sun-exposed areas. In females, a melasma-like hyperpigmentation of the face can be observed.

Hemochromatosis. Hereditary hemochromatosis is an autosomal recessive disorder associated with increased intestinal absorption of iron and deposition of excessive amounts of iron in the liver, pancreas, and other organs, including the skin. In the past, hemochromatosis was usually diagnosed at an advanced stage by the classic triad of hyperpigmentation, diabetes mellitus ("bronze diabetes"), and hepatic cirrhosis. Darkening of the skin was present in 70% of the patients due to two different mechanisms: (1) hemosiderin deposition causing a diffuse, slate-gray coloring and (2) increased epidermal melanin production. Because hemochromatosis is now usually diagnosed early, hyperpigmentation is less frequently observed. The pigmentation is usually generalized, but may be more pronounced in sun-exposed areas, genitalia, and scars. Skin bronzing is reversible by phlebitic therapy.[178–180]

TUMORAL CONDITIONS

Mast Cell Disorders and Melanoma. Mast cell disorders and melanoma can lead to hyperpigmentation and are discussed in Chapters 149 and 124, respectively. Diffuse, generalized melanosis associated with advanced metastatic melanoma is a rare, although well-documented, event. It is characterized by a slate bluish-gray to brown discoloration of the skin (Fig. 75-18). Histology reveals melanin particles and melanin-containing histiocytes and dendritic cells in the dermis and subcutaneous fat. No melanoma cells can be detected in the skin, and there is no increase in epidermal melanin pigment or number of melanocytes. Melanosomes circulating in the blood have been detected, supporting the hypothesis that diffuse melanosis may result from tumor lysis[183] with release of their organelles into the circulation and subsequent deposition in the skin.



Figure 75-18 Metastatic melanoma-associated, slate-gray, dermal pigmentation involving the entire body. There was melanogenuria and at autopsy all internal organs were found to be black.

PHYSICAL AGENTS

Ultraviolet Radiation. (See Chapter 90.) A major acute effect of UV radiation on normal human skin is tanning.

Ionizing Radiation. (See Chapter 240.) Exposure of skin to ionizing radiation during accidents, such as in Chernobyl, or after local fractionated radiotherapy can give rise to a cutaneous radiation syndrome characterized by fibrosis, keratosis, telangiectasias, and sharply demarcated lentiginous hyperpigmentation, resembling UV-induced lentigines (radiation dermatitis). Small hypopigmented spots can be intermingled with zones of hyperpigmentation. Skin biopsy shows altered melanin content in melanocytes and basal keratinocytes, corresponding to the clinical appearance. Electron beam therapy has been reported to induce tan-like transient hyperpigmentation and transverse melanonychia.[184–189]

Thermal Radiation. In superficial thermal burn injuries, when the melanocyte-bearing basal epidermis has not been destroyed, various degrees of hyperpigmentation result, depending on the skin color and time after the injury. Thermal injury resulting from laser therapy with intense, high-dose visible light also can give rise to hyperpigmentation, especially in dark-skinned patients. Cryotherapy, tissue destruction by application of cold, commonly causes (sometimes permanent) hypopigmentation in combination with

peripheral hyperpigmentation in treated skin due to melanocyte injury.[190–193]

Trauma. Friction melanosis in an acquired pigmentary disorder due to repeated rubbing of the skin [194]

TOXIN- AND MEDICATION-INDUCED HYPERPIGMENTATION

Hyperpigmentation caused by toxic agents or medication accounts for 10%–20% of all cases of acquired hyperpigmentations. CNS drugs, antineoplastic agents, anti-infectious drugs, antihypertensive medications, and hormones are most commonly responsible (eTable 75-1.1 in online edition).

In the majority of cases of medication-induced hyperpigmentation, the underlying pathogenetic mechanism involves one of the following.

Hyperpigmentation can be due to deposition of melanin in the dermis, usually in macrophages. Sometimes this melanin is complexed to the drug [drug-pigment complex (e.g., hydroxychloroquine)]. Accumulation of melanin can occur after cutaneous inflammation (postinflammatory) and/or DNA damage (e.g., carmustine). This type of hyperpigmentation is often increased by UV exposure and is usually more pronounced in sun-exposed areas.

Some substances (e.g., carotene, heavy metals) are directly deposited in the skin. Sometimes this type of pigmentation is also accentuated in sun-exposed areas as UV can induce a transformation in the deposited drugs, which may then become more visible.

In other cases, the dyschromia is caused by nonmelanin pigments synthesized or produced under the direct or indirect influence of the drug.

Clinical features vary with characteristic sites, patterns, and shades of discoloration. The forms associated with melanin accumulation are often worsened by sun exposure. Sometimes, the manifestation is more or less specific for the responsible drug, although the mechanism is often poorly understood. For example, a linear, sometimes flagellate hyperpigmentation can be observed in patients taking bleomycin or zidovudine. A diffuse hyperpigmentation on the palms and soles may be present in patients taking cyclophosphamide or doxorubicin. Bleomycin and doxorubicin may produce localized hyperpigmentation around small joints. Estrogen-related hormonal substances and phenytoin-like medication may cause melasma-like pigmentation. Nail unit involvement can be observed with some medications, most frequently chemotherapeutic agents, zidovudine, psoralens, minocycline, antimalarials, and gold. Mucosal hyperpigmentation has been reported with cyclophosphamide, doxorubicin, zidovudine, minocycline, and some heavy metals.

Amiodarone can produce blue–gray pigmentation in sun-exposed areas due to accumulation of a lipid-like substance in macrophages. Some of these patients display photosensitivity (Fig. 75-19). (Hydroxy) chloroquine may give rise to a yellow–brown to bluish-gray pigmentation on the face, neck, lower extremities, and forearms after several years of intake, due to deposition of a drug–melanin complex in the dermis (eFig. 75-19.1 in online edition). The nail unit and hard palate may also be involved. Exogenous ochronosis has been reported after chronic hydroquinone use (see Section "Ochronosis").



Figure 75-19 Amiodarone hyperpigmentation. This patient exhibits a striking amiodarone-induced, slate-gray pigmentation of the face. The blue color (ceruloderma) is due to the deposition of a brown pigment in the dermis, contained in macrophages and endothelial cells (Lindall effect).

Chlorpromazine and related phenothiazines can produce a bluish-gray pigmentation, especially in sun-exposed areas, and pigmentation of the conjunctivae. Minocycline can induce skin hyperpigmentation, as well as pigmentation of the nails, sclerae, oral mucosa, thyroid, bones, and teeth. Skin hyperpigmentation may present as a blue–black discoloration, especially at sites of inflammation, but also in noninflamed sites, especially the anterior legs. In some patients, there is a dull brown discoloration, especially in sun-exposed areas. Argyria patients present with a generalized grayish-blue pigmentation; the nails and the sclerae may also be involved.

Treatment of toxin- and medication-induced hyperpigmentation involves discontinuation of the responsible agent, if possible. In a small subset of patients, the hyperpigmentation persists even after discontinuation, particularly the bluish or gray pigmentation characteristic of dermal deposition. Sun protection should be advised, especially in forms entailing melanin accumulation. Laser treatment has been reported to be successful in some cases (e.g., amiodarone).[195]



Figure 75-20 Exogenous ochronosis. Hyperpigmentation on the nose and cheeks after the use of a hydroquinone cream.

OCHRONOSIS

Endogenous Ochronosis/Alkaptonuria. Endogenous ochronosis/alkaptonuria is discussed in Chapter 131.

Exogenous Ochronosis. Exogenous ochronosis results from the use of certain medications, which form a homogentistic acid polymer-like substance during their metabolism. It presents as asymptomatic hyperpigmentation of the face, sides and back of the neck, back, and extensor sites of the extremities (Fig. 75-20). Histopathologically, there is a collection of yellowish-brown (ochronotic) globules in the papillary dermis. There is no articular, renal, or cardiovascular involvement. It has been most frequently reported in association with hydroquinone (bleaching creams), usually in skin phototype VI patients, although it has been described in other skin types. Exogenous ochronosis has also been noticed after the use of antimalarials and products containing resorcinol, phenol, mercury, and picric acid. Treatment is rarely helpful, but the offending drug should be stopped to prevent progression.[196]

For POEMS syndrome and Cronkhite–Canada syndrome, and zidovudine-induced hyperpigmentation see online edition. The hyperpigmentation associated with the following disorders is discussed briefly online and/or the other indicated chapters: systemic sclerosis (Chapter 157), pinta (Chapter 201), onchocerciasis (Chapter 207), phytophotodermatitis (Chapter 90), flagellate pigmentation due to bleomycin (Chapter 227).

SYSTEMIC SCLEROSIS. (See Chapter 157.) Different types of abnormal pigmentation have been described in systemic sclerosis. A diffuse, generalized hyperpigmentation similar to Addison's disease but with normal levels of MSH can be observed in severe systemic sclerosis.

Focal depigmentation with perifollicular hyperpigmentation may occur, especially on friction sites (e.g., shins, elbows, and dorsum of the hands). There can be localized hyper- and hypopigmentation.

A streaky hyperpigmentation over blood vessels on a background of depigmentation has been reported. Diffuse reticulated hyperpigmentation accentuated on the trunk has been reported in one case.[43]

INFECTIONS. (See Chapter 201.) Erythematous, scaling papules termed pintids develop during the secondary stage of pinta. These initially red lesions can turn brown, slate-blue, black, or grayish.[52]

Chronic papular onchodermatitis is one of the skin manifestations of onchocerciasis. It is characterized by a severely pruritic maculopapular rash with hyperpigmented macules, most often occurring on shoulders, buttocks, and extremities (see Chapter 207).[53]

ACQUIRED CIRCUMSCRIBED HYPERMELANOSIS

PHYTOPHOTODERMATITIS. Contact with plants containing phototoxic agents such as psoralens, with subsequent UV exposure, may lead to phytophotodermatitis, which is followed by patterned hyperpigmentation.

FLAGELLATE PIGMENTATION DUE TO BLEOMYCIN. (See Chapter 227.)

FLAGELLATE MUSHROOM DERMATITIS. Flagellate mushroom dermatitis is characterized by linear grouped, erythematous, and intensely pruritic papules, a clinical pattern very similar to bleomycin-induced flagellate dermatitis. It is caused by eating raw or insufficiently boiled shiitake mushrooms (*Lentinus edodes*) and is not elicited by topical contact or ingestion of well-boiled shiitake. The pathogenesis is not yet known, but it is hypothesized that a thermolabile polysaccharide is responsible.[199–201]

HYPERMELANOSIS—ACQUIRED DIFFUSE PATTERNED OR RETICULAR

ERYTHEMA AB IGNE. Erythema ab igne is caused by a chronic exposure to moderate heat. The reticular erythema can be accompanied by epidermal atrophy, scaling, and hyperpigmentation. It was seen in the past in people who frequently sat in front of open fires or stoves for warmth, but it occurs less often since the introduction of central heating. Nevertheless, it is still seen after local application of heating pads, hot water bottles, or heating blankets. Modern appliances that have been reported to elicit erythema ab igne are furniture with built-in heaters, car heaters, and laptop computers (Fig. 75-21).[204–206]

PRURIGO PIGMENTOSA. Approximately 200 cases of prurigo pigmentosa have been published in the international literature since it was first described

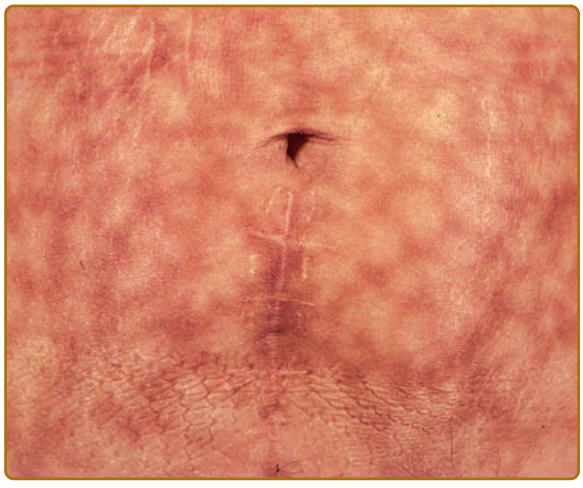

Figure 75-21 Reticular hyperpigmentation (erythema ab igne) resulting from repeated applications of a heating pad over several years.

in 1971 by Nagashima. Prurigo pigmentosa presents itself as intensely pruritic erythematous papules, papulovesicles, and vesicles that involute in several days. The lesions develop symmetrically on the back, chest, neck, and lumbosacral region. The papulovesicular lesions heal spontaneously, leaving a nonpruritic reticular hyperpigmentation (see eFig. 75-21.1 in online edition). The disease has a fluctuating course with exacerbations and recurrences. It is twice as frequent in females as in males. The eruption and pruritus respond well to minocycline and dapsone but the pigmentation does not and must resolve spontaneously. Environmental and metabolic factors have been suggested as causative agents but the pathogenesis remains unknown.[207]

ACQUIRED CIRCUMSCRIBED HYPERMELANOSIS

NEVUS OF HORI. Nevus of Hori was first described in 1984 as acquired, bilateral nevus of Ota-like macules termed ABNOM.[208] It consists of blue–brown to slate-gray mottled hyperpigmentation on the face with predilection for the malar regions. Similar to nevus of Ota, it typically affects the Asian population and has a female predominance. However, the lack of ocular and mucosal membrane involvement and the acquired bilateral character distinguish the entities. Histologically, melanocytes with stage III or IV melanosomes reside in the upper and middle layers of the dermis. Sun exposure and hormonal changes during pregnancy have been described as triggering factors.[209] Hori described three possible mechanisms for the pathogenesis of ABNOM: (1) "dropping" of epidermal melanocytes into the dermis, (2) migration of melanocytes from hair bulbs, and (3) reactivation of preexisting latent or immature dermal melanocytes.[208] The latter has been suggested as being the most probable mechanism with UV-radiation and sex hormones as activating factors. In some cases, ABNOM can occur simultaneously with other pigmentary abnormalities such as melasma, freckles, solar lentigines, and nevus of Ota.[113,209]

Combination treatments of pigment-specific laser (Q-switched lasers) with chemical peels and topical bleaching agents have been used with variable results.[210]

BECKER'S NEVUS (BECKER HAMARTOMA, BECKER MELANOSIS). This acquired hyperpigmented epidermal nevus was first described in 1949 (Fig. 75-22). It preferentially occurs in the scapular region, although it has been described in any area of the body, and classically after an intense sun exposure. The lesion is androgen-dependent and becomes more prominent in adolescence, especially in the male population. Hypertrichosis in the lesion is often associated. Associated anomalies, such as ipsilateral breast hypoplasia, musculoskeletal abnormalities (scoliosis, ipsilateral limb hypoplasia, etc.), maxillofacial abnormalities, and additional cutaneous hypoplasias, occur in the rare Becker's nevus syndrome. Microscopic examination demonstrates normal numbers of melanocytes, but increased levels of melanin in the basal epidermal layer (epidermal melanotic hypermelanosis). The epidermis is acanthotic with variable hyperkeratosis and elongation of the rete ridges. In the dermis, the number of arrector pili muscles is increased, making it difficult to differentiate from the related smooth muscle hamartoma. Good therapeutic results have been reported using a long-pulsed alexandrite laser.[215]



Figure 75-22 Becker's nevus on the upper arm and shoulder of a young man. Note the typical localization and marked hypertrichosis.

Becker's nevus is suggested to follow a paradominant inheritance pattern, which means it (almost) always occurs sporadically. The rare familial cases that have been described (especially in Becker's nevus syndrome) can be explained by a somatic mutation during embryogenesis, resulting in loss of heterozygosity and formation of a mutant cell population. This hypothesis is supported by the identification of chromosomal mosaicism in fibroblasts derived from a Becker's nevus.[216–218]

EPHELIDES. Ephelides or freckles are small light brown macules appearing in sun-exposed skin of fair-skinned individuals, often those with red or blond hair and Celtic ancestry. They are more pronounced during spring and summer and fade during the winter period. They appear in early childhood and often regress later in life. Histopathologic examination shows a normal to reduced number of sometimes hypertrophic melanocytes but increased melanin in the basal epidermal layer.

POSTINFLAMMATORY HYPERPIGMENTATION. Postinflammatory hyperpigmentation (PIH) is a common condition caused by numerous preceding cutaneous insults such as drug and phototoxic reactions, infections, physical injury or trauma, allergic reactions, and inflammatory diseases. Clinically, PIH consists of a macular hyperpigmentation at the site of inflammation (Fig. 75-23).[179] It is far more common and persistent in darker skin types (Fitzpatrick types III–VI) and can be characterized by epidermal as well as dermal melanotic hypermelanosis. A Wood's lamp examination can determine depth of the hyperpigmentation (see Section "Melasma"). Histologic features include pigment incontinence with accumulation of melanophages and increased melanin in dermal or epidermal layers.[219] Management of PIH remains difficult,[220–222] although epidermal PIH often shows slow spontaneous fading.

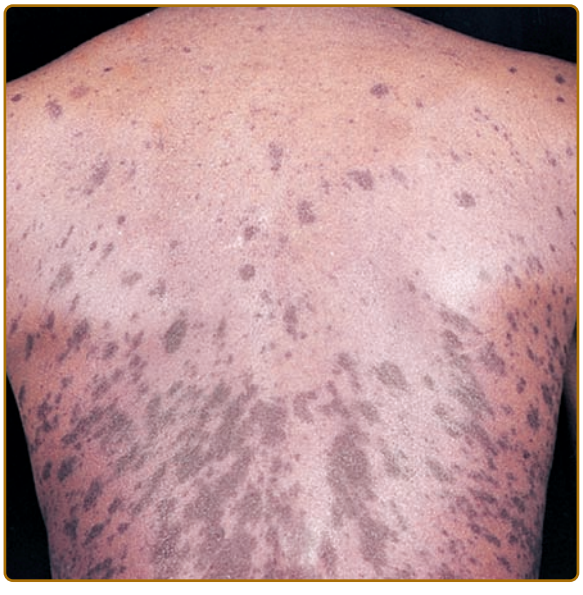

Figure 75-23 Postinflammatory hyperpigmentation. May follow a drug eruption, psoriasis, or lichen planus, especially in skin phototypes V and VI as was the case in this middle-aged East Indian woman. Postinflammatory hyperpigmentation is a major problem in young women with skin phototypes V and VI.

FAMILIAL PERIORBITAL HYPERPIGMENTATION. Increased pigmentation of the upper and lower eyelids has been described in a number of families. Histologically, increased basal pigmentation and dermal melanophages are seen. However, inflammation does not appear to precede the hyperpigmentation.[223]

PARTIAL UNILATERAL LENTIGINOSIS. Partial unilateral lentiginosis (PUL) is also known as unilateral lentigines, lentiginous mosaicism, zosteriform lentiginous nevus, segmental lentiginosis, and agminated lentiginosis.

RIEHL MELANOSIS. Riehl melanosis, also known as female facial melanosis, is mostly seen in middle-aged women, especially in darker skin types, such as Mexicans and Asians (see eFig. 75-23.1 in online edition).

It is characterized by a rapid onset of a reticular gray–brown to almost black hyperpigmentation.

The face (especially the forehead, zygomatic area, and temples) and the neck are principally involved, but the hands, forearms, and trunk can also be affected. Inflammatory findings such as erythema and pruritus are usually absent.

The main histopathologic feature is liquefactive degeneration of the basal layer of the epidermis, resulting in pigment incontinence in the dermis. The pathogenesis is not understood.[226,227]

The hyperpigmentation has been postulated to be induced by repeated contact with threshold doses of a contact sensitizer such as fragrances, some pigments, and bactericides used in cosmetics and optical whiteners, but is poorly documented in most cases.

CUTANEOUS AMYLOIDOSIS. Macular amyloidosis presents as brown to gray–brown macules, mainly on the back (see Chapter 133).

ATROPHODERMA OF PASINI–PIERINI. (See Chapter 67). The cutaneous lesions of atrophoderma of Pasini–Pierini can be described as single or multiple gray to violaceous-brown atrophic patches from 1 cm to more than 10 cm in diameter with slight depression with a characteristic "cliff drop" border.

FIXED DRUG ERUPTION. Fixed drug eruption can cause hyperpigmentation (see Chapter 41).

ERYTHEMA DYSCHROMICUM PERSTANS. Erythema dyschromicum perstans, also known as ashy dermatosis, dermatosis cenicienta, and erythema chronicum figuratum melanodermicum, was first described by Ramirez in 1957. Patients with this eruption were labeled as los cenicientos, the ashy ones.[229]

The disease is characterized by hyperpigmented macules and patches of variable shape and size with an ashen-gray to brown–blue color. They may have a thin, raised erythematous border in the early stage that later can be absent or, mainly in darker skin types, evolve into a hypopigmented border that accentuates the hyperpigmentation. The eruption can also be polymorphic, presenting simultaneously hypo- and hyperpigmented macules. Lesions occur primarily on the face, the neck, the trunk, and the proximal part of the arms. The lesions are usually asymptomatic, although slight pruritus can be present. There is a slow progression of the lesion over several years, usually without spontaneous regression.

Erythema dyschromicum perstans is mainly observed in intermediate skin types. It is a disease of young adults, although there are small series reporting the disease in prepubertal children. There is no clear sexual predilection.[230]

Histologic examination of the inflammatory border may demonstrate lichenoid dermatitis with vacuolization of the basal cell layer, occasional colloid bodies, and increased epidermal melanin. The dermal changes are edema of the papillary dermis, a moderate or mild lymphohistiocytic infiltrate, and dermal melanophages. The pathogenesis of erythema dyschromicum perstans is unclear and likely influenced by many factors. An HLA-DR-associated susceptibility to develop erythema dyschromicum perstans has been described in a Mexican population.[231]

In inactive lesions, there is no vacuolization of the basal cell layer, a diminished dermal infiltrate, and an increased number of dermal melanophages. There is no effective treatment.[229,230]

IDIOPATHIC ERUPTIVE MACULAR HYPERPIGMENTATION

Idiopathic eruptive macular hyperpigmentation is an uncommon disorder of pigmentation characterized, as the name suggests, by an eruption of asymptomatic, brown macules (5 mm to several cm in diameter) involving the trunk, neck, and proximal extremities in children and adolescents. No previous drug exposure has been implicated, and the lesions disappear gradually over several months to years.

Histopathologically, there is hyperpigmentation of the basal layer of the epidermis and prominent dermal melanophages. The number of mast cells is normal.[232]

MIXED HYPO- AND HYPERMELANOSIS

DYSCHROMATOSIS HEREDITARIA UNIVERSALIS

Dyschromatosis hereditaria universalis is an autosomal dominant disorder that usually presents in infancy or early childhood in Asian families and is characterized by pinpoint to pea-sized hypo- and hyperpigmented macules, distributed in a reticulated pattern over the trunk, abdomen, and limbs, usually sparing the face and palmoplantar surfaces.[233]

RETICULATE ACROPIGMENTATION OF DOHI

Reticulate acropigmentation of Dohi is a localized form of dyschromatosis universalis hereditaria, also called dyschromatosis symmetrica hereditaria. It is characterized by small, symmetric hyper-, and hypopigmented macules on the dorsal hands and feet, and is mainly seen in young children in South American and Asian families.

WESTERHOF SYNDROME

Westerhof syndrome, described in three generations of one family, displays congenital hypo- and hypermelanotic macules. There is also small stature and mental retardation.[234]

VAGABOND LEUKODERMA

Vagabond leukoderma is a condition found in persons living in poor hygienic conditions. Many abuse alcohol, live on an inadequate diet, and are infested with lice and/or scabies. Diffuse light-brown hyperpigmentation is present at the shoulder and waist girdle, and the neck and back are dotted with depigmented macules. The condition improves on institutions of a healthier lifestyle and likely represents a coexistence of many of the disorders.[235]

KEY REFERENCES

Full reference list available at www.DIGM8.com

DVD contains references and additional content

1. Dessinioti C et al: A review of genetic disorders of hypopigmentation: Lessons learned from the biology of melanocytes. *Exp Dermatol* **18**:741-749, 2009
3. Van Den Bossche K, Naeyaert JM, Lambert J: The quest for the mechanism of melanin transfer. *Traffic* **7**:769-778, 2006
26. Bahadoran P et al: Comment on Elejalde syndrome and relationship with Griscelli syndrome. *Am J Med Genet A* **116A**:408-409, 2003
48. El-Shabrawi-Caelen L et al: Hypopigmented mycosis fungoides: Frequent expression of a CD8+ T-cell phenotype. *Am J Surg Pathol* **26**:450-457, 2002
55. Zijlstra EE et al: Post-kala-azar dermal leishmaniasis. *Lancet Infect Dis* **3**:87-98, 2003
56. Ramos-e-Silva M, Rebello PF: Leprosy. Recognition and treatment. *Am J Clin Dermatol* **2**:203-211, 2001
61. Engasser PG, Maibach HI: Cosmetic and dermatology: Bleaching creams. *J Am Acad Dermatol* **5**:143-147, 1981
72. Kumarasinghe SPW: 3–5 second cryotherapy is effective in idiopathic guttate hypomelanosis. *J Dermatol* **31**:437-439, 2004
83. Braun RP et al: Dermoscopy of pigmented skin lesions. *J Am Acad Dermatol* **52**:109-121, 2005
88. Zanardo L et al: Progressive hyperpigmentation and generalized lentiginosis without associated systemic symptoms: A rare hereditary pigmentation disorder in south-east Germany. *Acta Derm Venereol* **84**:57-60, 2004

103. Vulliamy TJ et al: Very short telomeres in the peripheral blood of patients with X-linked and autosomal dyskeratosis congenita. *Blood Cells Mol Dis* **27**:353-357, 2001
116. Sinha S, Cohen PJ, Schwartz RA: Nevus of Ota in children. *Cutis* **82**:25-29, 2008
126. Jenne DE et al: Peutz-Jeghers syndrome is caused by mutations in a novel serine threonine kinase. *Nat Genet* **18**:38-43, 1998
133. Gorlin RJ et al: Bannayan-Riley-Ruvalcaba syndrome. *Am J Med Genet* **44**:307-314, 1992
158. Slominski A et al: Melanin pigmentation in mammalian skin and its hormonal regulation. *Physiol Rev* **84**:1155-1228, 2004
172. Lechner K et al: [Vitamin B12 deficiency. New data on an old theme]. *Wien Klin Wochenschr* **117**:579-591, 2005
188. Steinert M et al: Delayed effects of accidental cutaneous radiation exposure: Fifteen years of follow-up after the Chernobyl accident. *J Am Acad Dermatol* **49**:417-423, 2003
203. Greenberg RG, Berger TG: Nail and mucocutaneous hyperpigmentation with azidothymidine therapy. *J Am Acad Dermatol* **22**:327-330, 1990
212. Hidano A, Kaneko K: Acquired dermal melanocytosis of the face and extremities. *Br J Dermatol* **124**:96-99, 1991
215. Choi JE et al: Treatment of Becker's nevi with a long-pulse alexandrite laser. *Dermatol Surg* **35**:1105-1108, 2009

SECTION 12

Disorders of the Oral and Genital Integument

Chapter 76 :: Biology and Pathology of the Oral Cavity

:: Sook-Bin Woo

ORAL MUCOSAL DISEASE AT A GLANCE

- Idiopathic recurrent aphthous ulcers affect 15%–20% of the population; severe cases can be debilitating.
- Oral ulcers may also be associated with Crohn disease and other gastrointestinal disorders or due to herpes simplex, other viral infections, vasculitis, or other autoimmune disorders.
- Candidiasis of the oral cavity is common and painful. Predisposing factors include immunosuppression, hyposalivation, and use of steroids or antibiotics.
- Hair leukoplakia is due to Epstein–Barr viral infection and may be the presenting sign of HIV/AIDS.
- Oral lichen planus (LP) and lichenoid reactions affect 1%–2% of the population and are the most common cause of desquamative gingivitis; LP probably reflects a hypersensitivity response to endogenous or exogenous antigens.
- Leukoplakia is a premalignant condition associated with smoking and/or alcohol ingestion that must be distinguished from LP and benign frictional keratoses.
- Bullous diseases that affect the mouth include pemphigus, pemphigoid, and lupus erythematous.
- Intraoral pigmented lesions include nevi, postinflammatory hyperpigmentation, drug reactions, tattoos, and rarely melanoma.

INTRODUCTION

The mouth is the beginning of the aerodigestive tract and an extension of the skin barrier. It plays an important role in mastication, deglutition and digestion, speech, and immunologic defense. The oral mucosa, salivary glands (both major and minor), jawbones, and teeth are frequently the site of primary inflammatory or neoplastic disease. However, the oral cavity may present with manifestations of systemic disease and in some cases, oral findings may precede systemic signs and symptoms by months or years. Lesions in the maxillary sinus and nasal cavity may lead to pain in the upper teeth or may extend inferiorly and present in the maxilla or palate. Metastatic lesions may present as nodules on the gingiva or masses in the jawbones.

This chapter focuses only on the more common mucosal and salivary gland diseases encountered in dermatology practice.

EVALUATION OF THE PATIENT

As with evaluation of the skin, obtaining a comprehensive medical and medication history and careful inquiry into current symptoms are essential. The extraoral examination should begin with an examination of the skin of the face and in particular the perioral region, palpation of the submandibular and submental lymph nodes, and palpation of the temporomandibular joints for clicking or pain on opening. Clicking with no pain occurs in 20%–30% of the population and is of no clinical significance but should be noted. Clicking with pain and/or limitation of opening may indicate temporomandibular joint myofascial pain syndrome and requires referral to a dental specialist for management.

The intraoral examination should be directed to the following areas:

1. The mucosal surfaces as outlined above, taking note of where the lesions are located, and in particular, whether they are on the keratinized or nonkeratinized sites.



Figure 76-1 Fordyce granules.

2. The presence or absence of saliva in the floor of mouth and whether the saliva is of the usual watery consistency or whether it is ropey.
3. The dentition and whether there are grossly carious teeth.
4. The use of a removable prosthesis (upper and/or lower dentures—complete or partial); this is particularly important for some mucosal diseases caused by denture trauma and for the diagnosis and treatment of candidiasis since the denture acts as a fomite.

NORMAL ANATOMIC STRUCTURES

There are several structures in the oral mucosa that are considered variations of normal. These include:

1. *Fordyce granules*: These are sebaceous glands that present as painless yellow papules, 1–2 mm in diameter located in a bilateral symmetric fashion on the posterior buccal mucosa, and lips (usually vermilion) (Fig. 76-1). Sebaceous hyperplasia of these glands may form discrete larger yellow papules several millimeters in size.
2. *Linea alba*: This is a linear keratosis located on the buccal mucosa bilaterally where the upper and lower teeth meet. It is a form of frictional keratosis and exaggeration of this is seen in patients who habitually chew the buccal mucosa, a condition known as morsicatio mucosae oris (MMO) (see below).
3. *Palatal and mandibular tori*: These are benign, usually symmetric exostoses that are present in the midline of the hard palate or bilaterally on the lingual aspect of the mandible (Fig. 76-2). They may be large and multilobated, but patients are usually unaware of their presence.

PRESCRIBING TOPICAL MEDICATIONS

TOPICAL STEROIDS

Topical steroids are the mainstay of treatment for many inflammatory and autoimmune mucosal diseases.[1] The only topical steroid that is FDA-approved for intraoral use is Kenalog-in-Orabase dental paste (0.1% triamcinolone; Apethecon, Princeton, NJ). This is a Class IV steroid and is weakly efficacious as an anti-inflammatory agent in the oral cavity, although the Orabase (methylcellulose) is useful and soothing as a covering agent in some conditions. In general, most oral medicine specialists use fluocinolone, fluocinonide, clobetasol, and topical tacrolimus for the management of mucosal disease. Principles applying to use of these medications in the oral cavity regardless of specific diagnosis are found in Table 76-1 and eBox 76-0.1 in online edition.

TOPICAL ANALGESICS

Viscous lidocaine (2%) may be used alone or combined with diphenhydramine, Kaopectate (Pfizer, NY), or Maalox (Novartis, NJ) in equal volumes as a swish and spit out preparation for pain control. This is particularly useful for diffuse painful lesions, acute or chronic.

Localized ulcers may be treated with over-the-counter benzocaine preparations, or covering agents such as methylcellulose (Orabase; Colgate-Palmolive, NY).

As with any disease condition, provision of up-to-date information on the disease allays many fears and misconceptions, empowers patients, and helps patients to better understand their condition. Information on the nature, management, and prognosis of common mucosal conditions are available on the Web

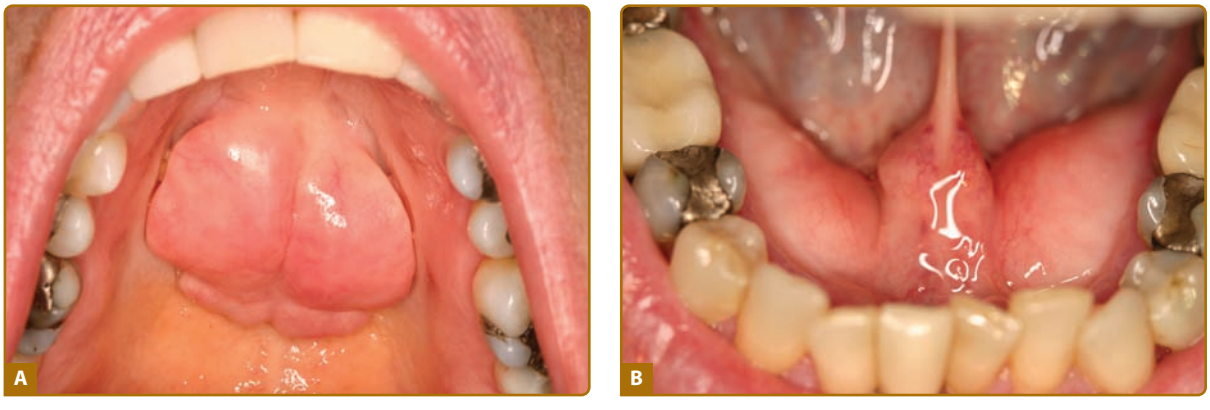

Figure 76-2 **A.** Palatal torus. **B.** Mandibular tori.

TABLE 76-1
Commonly-Used Medications for Oral Lesions

Medication	How to Prescribe
Topical immunosuppressive agents	
Triamcinolone 0.1% dental paste	5-mg tube; apply to affected site tid or qid (this forms a barrier)
Fluocinolone 0.05% gel	15-60 g tube dry area, apply to affected site tid or qid; no food or drink for 30 minutes after OR
Clobetasol 0.05% gel	
Betamethasone 0.05% gel	Place gel in stent and wear for 30 minutes, bid or tid
Dexamethasone elixir 0.5 mg/5 mL	Dispense 300–500 mL; swish 5 mL. (dexamethasone, tacrolimus, or cyclosporine) or 5–10 mL. (prednisolone) for 3 minutes (timed) and spit out tid or qid; no food or drink for 30 minutes after
Prednisolone syrup (15 mg/5 mL)	
Tacrolimus solution (5 mg/mL)	
Cyclosporine (100 mg/mL)	
Nasal sprays used orally (such as fluticasone and budesonide)	1–2 puffs 2–3 times a day
Intralesional steroid injection with triamcinolone	1–5 mg triamcinolone per cm^2 of ulceration
Antifungal therapy	
Nystatin 1:100,000 units/mL[a]	Dispense 300–500 mL; swish and spit out (or swallow) 5 mL tid or qid
Clotrimazole 10 mg troches[a]	Suck on one troche tid or qid
Fluconazole 100 mg	Take one tablet in the morning qd × 3–10 days (depending on the severity of the infection)
Mycostatin/triamcinolone cream	Apply to corners of mouth tid or qid for angular cheilitis Paint onto denture base tid and wear denture
Denture treatment in patients with candidiasis	Soak denture in solution overnight.
Denture soaks such as:	
Nystatin 1:100,000 units/mL	
Chlorhexidine digluconate 0.12%	
3% sodium hypochlorite diluted in water (1:10)	
2% sodium benzoate	
Topical pain medications	
Viscous lidocaine 2%	Swish and spit out tid or qid for pain
Benzydamine hydrochloride 0.15%	
Dyclonine hydrochloride 1%	
Systemic immunosuppressive therapy	Topical therapy should be started concomitant with systemic therapy.
Prednisone	0.5–1.0 mg/kg to begin for 7–10 days with a rapid taper over 2–3 weeks
Pentoxifylline	400 mg three times a day or 800 mg twice a day
Hydroxychloroquine	200–400 mg daily
Dapsone	25 mg to begin, increasing to 75–100 mg/day
Mycophenolate mofetil	1000–3000 mg daily
Colchicine	0.6 mg once or twice a day
Azathioprine	50–100 mg daily
Thalidomide	50–100 mg tid to begin; begin taper to maintenance dose (which may be weekly) or discontinue completely

[a]Formulations contain cariogenic sugars that may lead to caries if used for months.

sites of the American Academy of Oral and Maxillofacial Pathology (www.aaomp.org) and the American Academy of Oral Medicine (www.aaom.com). These can be modified to suit your practice needs.

ORAL MANIFESTATIONS OF SYSTEMIC DISEASE AND SYNDROMES

Systemic diseases often have distinctive presentations in the oral cavity and many skin conditions also have concomitant oral findings. eTable 76-1.1 in online edition provides a list of some of the more common systemic diseases and syndromes that present with oral findings. Some are discussed in greater detail below.

DISEASE CLASSIFICATION

The disease entities to be described are those normally treated by the dermatologist and are divided primarily into how the lesions present clinically (e.g., ulcers, nodules, or red and white lesions). However, there is also a section based on lesions that are site-specific. Pathogenetic mechanisms for diseases such as the autoimmune bullous disorders will not be discussed

in any detail since they are presented elsewhere in this book.

ULCERATIVE CONDITIONS

The oral ulcer appears as a yellow–white papule or plaque of fibrin (often referred to as a "pseudomembrane"), usually with a surrounding red rim. It does not appear crusty because of the wet environment. Such lesions are always painful unless the ulcer represents a squamous cell carcinoma (SCC), which is often painless. Several conditions fall into this category and only the most common will be discussed here (eTable 76-1.2 in online edition).

RECURRENT APHTHOUS ULCERS/STOMATITIS ("CANKER SORES"). Recurrent aphthous ulcer (RAU) is a T-cell-mediated disorder and tumor necrosis factor (TNF)-α plays an important role in its occurrence.[2] There is usually a family history of aphthous ulcers and there is a significant association with a number of HLA-haplotypes.[3] Stress, systemic illness, and local trauma predisposes to their occurrence in susceptible individuals.

Aphtheiform ulcers are aphthous-like in their appearance and history but they may occur sometimes on the dorsum of the tongue if they are a result of hematinic deficiency or inflammatory bowel disease. RAU are seen in all patients with Behçet disease and may precede other findings by years. Behçet disease, a vasculitic disorder, has a predilection for Turkish and Japanese populations and is associated with an increase in HLA-B51.[4] In periodic fever-adenopathy, pharyngitis, aphthae (PFAPA) syndrome, ulcers are often so severe that children miss days at school.[5,6] Patients with other systemic or skin conditions and aphthous ulcers form part of the "complex aphthosis" syndrome and include those with MAGIC (mouth and genital ulcers with inflamed cartilage) syndrome (eTable 76-1.2 in online edition). Approximately 3% of patients with RAU have gluten-sensitive enteropathy[7] and some show sensitivity to foods and sodium lauryl sulfate.

Clinical Findings. Idiopathic RAU occurs in 15%–20% of the population beginning in the second decade of life and the disease generally becomes less severe over the age of 50. Patients often report the sensation of a small nodule beneath the epithelium before the ulcer appears. The painful yellow–white ulcers are surrounded by an erythematous halo.

There are four clinical forms of RAU and these are always painful:

a. *Minor* ulcers (<1 cm, 1–10 at each episode lasting 1–2 weeks) (Fig. 76-3A); this is by far the most common form.
b. *Major* ulcers (>1 cm lasting several weeks and healing with scarring) (Fig. 76-3B).
c. *Herpetiform* ulcers (<1 cm, usually 0.1–0.5 cm each, >10 clustered ulcers at each episode, lasting 1–2 weeks (Fig. 76-3C).
d. *Severe* aphthous ulcers where patients have minor ulcers but with continuous ulcerations with minimum or no ulcer-free days for months.



Figure 76-3 **A.** Recurrent aphthous minor. **B.** Recurrent aphthous major. **C.** Recurrent herpetiform aphthous ulcers.

Idiopathic RAU are almost always confined to the nonkeratinized mucosa. They may occur on the nonattached gingiva, but generally do not cross the mucogingival junction onto the attached gingiva, except in some cases of RAU major.

Differential Diagnosis and Laboratory Studies. Traumatic lesions must be considered because the oral cavity is subject daily to mechanical trauma (such as mastication) (eTable 76-1.2 in online edition). However, traumatic ulcers are not the same as RAU, although patients with RAU readily develop ulcers at sites of trauma. A history of trauma and the nonepisodic nature of the condition help to differentiate between traumatic ulcers and those of RAU. Chemotherapy-associated ulcers are not generally considered aphthous ulcers but rather chemotherapy- and neutropenia-associated (similar to cyclic neutropenia); they also tend to occur on the nonkeratinized mucosa. Herpetic ulcers in healthy patients occur intraorally on the keratinized mucosa of the gingival margin and the palate. However, in immunocompromised patients, they may resemble RAU, especially RAU major in patients with HIV disease. Culture and biopsy (Box 76-1) are indicated in such patients. Lesions of chronic recurrent oral erythema multiforme must also be considered in the differential diagnosis. Oral manifestations of Crohn disease and other gastrointestinal conditions are discussed below.

The biopsy is nonspecific and shows only a fibrin membrane with acute and chronic inflammation and granulation tissue, but may exclude an infectious etiology.

Management and Prognosis. Any positive findings should be followed up. For example, it may be useful to keep a food diary and to change toothpaste to one that does not contain sodium lauryl sulfate. In most cases, the work-up is negative.

The treatment for minor RAU is topical steroids (Table 76-1) or intralesional steroid injection if the ulcers are large and persistent, especially those of aphthous major or in patients with HIV disease. Topical agents that may be useful include cyanoacrylate (Soothe-N-Seal; Colgate Palmolive, NY) and anti-inflammatory agents such as amlexanox 5% paste (Aphthasol, Uluru, Texas), 2 mg amlexanox mucoadhesive disc (Oradisc, Uluru, Texas), or tetracycline oral rinse. Lesions may also be cauterized with 28%–50% sulfuric acid and sulfonated phenolics (Debacterol, Epien Medical Inc.) or with silver nitrate (shaving sticks). Topical anesthetics in paste form are available over-the-counter, in particular benzocaine of varying strengths. Systemic therapy with prednisone for a few weeks and maintenance with pentoxifylline may reduce the number, duration and size of ulcers, and reduce the number of episodes. In appropriate patients, thalidomide therapy is extremely effective, although patients often develop irreversible neuropathy with long-term use. Other agents that are variably efficacious include colchicine and azathioprine.

BOX 76-1 OBTAINING A BIOPSY

A biopsy of any mucosal condition is readily performed with a skin punch (3–5 mm in diameter). Here are a few helpful suggestions:

1. Use a local anesthetic such as 2% lidocaine with 1:50,000 epinephrine instead of 1:100,000 epinephrine if possible. Since only a small volume is used, this should not cause problems even with hypertensive patients, but will reduce the amount of bleeding encountered during the biopsy.
2. Punch biopsies of the attached gingiva and hard palate are not readily closed with sutures and the use of silver nitrate or aluminum chloride is preferable.
3. Labial, buccal mucosa, and tongue biopsies should be closed in an anteroposterior direction.
4. Excision using an elliptical incision is preferable to a shave biopsy in most cases, unless the lesion is small, exophytic, and obviously benign (e.g., small fibroma or papilloma).

ORAL ULCERATIVE LESIONS ASSOCIATED WITH GASTROINTESTINAL DISEASE

Clinical Findings. The most common bowel diseases associated with oral ulcers are Crohn disease, ulcerative colitis, malabsorption syndromes leading to hematinic deficiency, and celiac disease.[8]

Oral lesions are seen in up to 20% of patients with Crohn disease if nonspecific mucogingivitis is excluded.[9] Ulcers of Crohn disease typically present as linear lesions along the maxillary and mandibular vestibule/sulcus (Fig. 76-4A). In addition, patients often also present with papulous folds of tissues, swelling of the lips (indistinguishable from cheilitis granulomatosa), and cobblestoning of the mucosa.[10] Other manifestations of Crohn disease include severe and diffuse erythema and inflammation of the mucosa, sometimes associated with *Staphylococcus aureus* infection (Fig. 76-4B).[11] A reliable finding is a dusky-red firm area of the perivermilion skin that has a slight pitted, "orange peel" appearance.

Pyostomatitis vegetans (oral analog of pyoderma gangrenosum) associated with inflammatory bowel disease presents as "snail-track" ulcers of the oral mucosa.[12] Dental enamel defects (enamel hypoplasia) are associated with celiac disease in children.[13]

Differential Diagnosis and Laboratory Studies. Oral ulcers ultimately associated with inflammatory bowel disease may predate gastrointestinal lesions by years in up to 60% of patients,[10] so that absence of gastrointestinal symptoms does not exclude this etiology. Elevated tissue transglutaminase and the presence of endomysial antibodies support the diagnosis of celiac disease.

A biopsy of oral lesions of Crohn disease shows granulomatous inflammation or while pyostomatitis vegetans shows acantholysis.

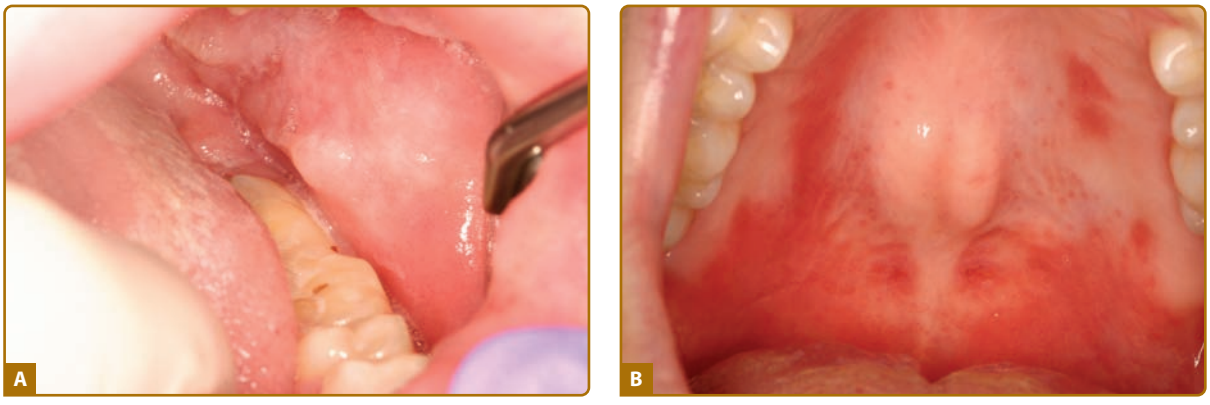

Figure 76-4 **A.** Aphtheiform ulcer in Crohn disease. **B.** Mucosal erythema in Crohn disease.

Management and Prognosis. In the absence of gastrointestinal findings, treatment is with topical steroid therapy and in severe cases, prednisone for rapid control of lesions with maintenance on topical steroids or other anti-inflammatory agents similar to the protocol for management of idiopathic aphthous ulcers.[14] If gastrointestinal disease is active, this should be brought under control first and oral ulcers may then resolve.

Oral manifestations generally wax and wane with the severity of systemic disease.

CHEMOTHERAPY-ASSOCIATED ULCERATIVE MUCOSITIS.

Damage from chemotherapy agents is mediated via production of cytokines, cytokine modulators, and stress responders, leading to apoptosis of dividing epithelial cells.[15] Ulcers are potential portals for bacteremia and septicemia, particularly because patients are also often neutropenic. Depending on the regimen, 25%–30% of patients develop this complication. Agents often associated with such lesions include cytarabine and cisplatin, especially when combined with radiation.

Clinical Findings. These ulcers are generally located on the nonkeratinized sites and in particular the buccal mucosa and ventral tongue. They begin within 3–5 days of the start of chemotherapy and generally resolve when absolute neutrophil counts recover, usually a course of 7–10 days. Lesions are extremely painful and may measure several centimeters in size.[16]

Differential Diagnosis and Laboratory Studies. Recrudescent herpes simplex virus (HSV) infection is common in immunocompromised patients such as patients with cancer and, unlike in healthy hosts, often occurs on nonkeratinized sites. Hence, patients who undergo hematopoietic stem cell transplantation, if seropositive for HSV antibodies, are prophylactically placed on antiviral agents during their hospital course. However, a positive culture may represent shedding of HSV in the oral fluids and saliva rather than true recrudescence within the ulcers.

Deep fungal infections and cytomegalovirus infection may all present with large ulcers on the mucosa, but these generally do not heal with recovery of neutrophil counts.

Radiation to the head and neck leads to severe erythema, inflammation, and ulceration (radiation mucositis).[17,18]

In patients who have received allogenic hematopoietic transplants, persistence of oral ulcers after engraftment may herald the development of acute graft-versus-host disease. In such situations, involvement of the keratinized tissues of the tongue dorsum and hard palate is not uncommon.

Management and Prognosis. Ulcers are self-limiting and therapy is directed toward pain control and prevention of septicemia from bacterial ingress into the oral wounds.[19] Patients are often treated with granulocyte-colony-stimulating factor to reduce the period of neutropenia and this has reduced the frequency of such ulcers.

Topical analgesia such as viscous lidocaine and systemic analgesia (especially narcotics) is the mainstay of pain control. Although chlorhexidine is often used for decontamination, its high alcohol content makes patient compliance poor. Other oral decontamination rinses contain nystatin and antibiotics.

DEEP FUNGAL INFECTIONS.

Zygomycosis is a broad term used to describe fungal infections caused by organisms in the phylum Zygomycota. These include infections caused by organisms in the family Mucorales with organisms in the genera *Mucor* and *Rhizopus*. These are unusual infections, seen usually in patients who have diabetes mellitus (usually ketoacidotic) or are immunocompromised, and are often life threatening. Organisms are inhaled and spread into the adjacent sinuses, eroding through the bone, sometimes presenting on the palate as a necrotic ulcer, a condition also referred to as rhinocerebral zygomycosis.[29] *Aspergillus* infections are seen in neutropenic patients, especially those with leukemia and tend to present as necrotic soft tissue and bony lesions of the gingiva, while histoplasmosis, coccidioidomycosis, blastomycosis, and paracoccidioidomycosis are seen in areas where such infections are endemic such as in South America and in patients with HIV/AIDS.[30–33]

Clinical Findings. Unlike candidiasis, deep fungal infections usually present as necrotic ulcers because they are angioinvasive organisms that cause vascular

TABLE 76-2
Herpes Virus and Oral Lesions

HHV1 (herpes simplex-1)	(a) Primary gingivostomatitis, usually in first to third decades of life (b) Herpes labialis and recrudescent herpetic ulcers on the attached mucosa in healthy patients; in adults (c) Ulcers on any oral mucosal site in immunocompromised patients
HHV2 (herpes simplex-2)	May present with oral ulcers similar to HSV-1; young adults
HHV3 (varicella zoster)	Primary infection may or may not have oral ulcers; recrudescent with unilateral ulcers along distribution of V_{II} or V_{III}; adults and immunocompromised patients
HHV4 (Epstein–Barr)	Oral ulcers in infectious mononucleosis in young adults; nasopharyngeal carcinoma in older adults, hairy leukoplakia in patients with HIV/AIDS
HHV5 (cytomegalovirus)	Oral ulcers; may be seen associated with HSV ulcers; usually in immunocompromised patients
HHV6	Unlikely to have oral manifestations
HHV7	Unlikely to have oral manifestations
HHV8	Kaposi sarcoma; usually seen in patients with HIV/AIDS
HHV 9 (simian)	Unlikely to be seen in humans

thrombosis and ischemia. The most common location for rhinocerebral zygomycosis is the palate, although fungal infections in immunocompromised patients may occur at any site in the mouth.

Differential Diagnosis and Laboratory Studies. Deep fungal infections involving the palate or maxilla are an important differential diagnosis for the clinical entity "midline destructive disease." Other conditions that fall into this category include NKT-cell lymphoma, other infections such as tertiary syphilis, granulomatosis with polyangiitis (Wegener disease), cocaine use, and epithelial malignancy of surface or salivary gland origin.[34] A biopsy readily distinguishes among these entities.

Because these are deep infections, a swab culture may not capture any organisms. A biopsy shows the presence of hyphae. It is useful to submit part of the harvested tissue in saline for speciation in a microbiology laboratory.

A biopsy shows necrosis and inflammation. The morphology of hyphae seen on special stains, together with culture results, confirms the diagnosis.

Management and Prognosis. Treatment is with systemic antifungal agents such as liposomal amphotericin and triazole antifungal agents such as fluconazole, itraconazole, and posaconazole, often with surgical debridement.[35] Mortality is often high in poorly controlled infection. Reducing environmental exposures is a particularly important prophylactic measure for immunocompromised patients.

WHITE LESIONS

It is important to distinguish truly white lesions from ulcerated or necrotic lesions that usually have a creamy-yellow color.

Many well-recognized oral lesions are white, ranging from developmental lesions such as white sponge nevus, to infections such as candidiasis, to immune-mediated disorders such as lichen planus (LP) and to frictional keratoses such as morsicatio mucosae oris (Table 76-3). Such lesions, with specific clinical and histologic findings, are not properly termed "leukoplakia."

True leukoplakias tend to be well demarcated at least around part of the lesion, are frequently dysplastic at first biopsy, and carry a significant potential for developing into SCC over time. White sponge nevus and reactive white lesions are discussed online.

WHITE SPONGE NEVUS.

White sponge nevus is an extremely rare condition, inherited in an autosomal dominant fashion. It affects the oral and genital mucosa, usually in a symmetric and often multifocal pattern, due to mutation in keratin K4 or K13 that results in keratin instability and abnormal keratin aggregation.[53] Spontaneous mutations have been reported.

Clinical Findings. Patients develop poorly demarcated, diffuse, painless white plaques on the oral mucosa, usually the buccal mucosa and tongue, usually within the first two decades of life.[21,54]

Differential Diagnosis and Laboratory Studies. Other conditions that may appear similar clinically include hereditary benign intraepithelial dyskeratosis, another rare mucosal disorder that occurs in a racial isolate in South Carolina,[55–57] and pachyonychia congenita.[58–60] Oral lesions of dyskeratosis congenita are true leukoplakias occurring in approximately 65% of patients and are usually dysplastic.[61,62]

Biopsy or exfoliative cytology is always indicated and shows perinuclear eosinophilic condensations (representing abnormal keratin aggregation) and distinguishes it from other mucosal disorders discussed below.

Management and Prognosis. There is no treatment for white sponge nevus, although some have

TABLE 76-3
Oral White Lesions

Developmental (Often Part of a Genodermatosis)
- White sponge nevus
- Hereditary benign intraepithelial dyskeratosis
- Pachyonychia congenita

Reactive
- Frictional keratoses
  - Morsicatio mucosae oris
  - Benign alveolar ridge keratosis
  - Other nonspecific
- Chemical injury
  - Leukoedema
  - Contact desquamation
  - Smokeless tobacco keratosis
  - Submucous fibrosis (scarring and fibrosis, not keratotic)*
- Retention of secretions and debris
  - Hairy tongue
  - Retention on other surfaces
- Unknown
  - Uremic stomatitis

Infectious
- Candidiasis
- Hairy leukoplakia

Immune-mediated
- Lichen planus
- Chronic graft-versus-host disease
- Lupus erythematosus
- Psoriasis
- Migratory glossitis/stomatitis

Neoplastic
- Leukoplakia
  - Verrucous leukoplakia
  - Proliferative leukoplakia
- Squamous cell carcinoma
- Verrucous carcinoma

reported resolution with antibiotics, in particular tetracycline.[63] It is postulated that tetracycline affects the keratinization process and inhibits epithelial proliferation.

REACTIVE WHITE LESIONS.

These very common conditions are caused by very mild topical injury caused by smoking or other mild contact injury such as strong toothpastes and alcoholic mouth rinses. The following white lesions are in ascending order of severity of injury beginning with changes caused by intracellular edema and swelling to those resulting in keratoses.

Leukoedema.

Many dentists classify leukoedema as a developmental malformation but it is likely a reactive lesion. It occurs in 20%–70% with habits such as using tobacco, coca, or marijuana to >90% of dark-skinned individuals mainly because the whiteness of the lesion shows up more clearly on pigmented mucosa.[54,64]

Clinical Findings. Lesions are usually bilateral on the buccal mucosa or ventral tongue and consist of painless, fine grayish white, opalescent reticulations. They are not well demarcated, but diffuse. Stretching the mucosa completely eliminates these fine lines since this is not a keratotic lesion, but rather caused by intracellular edema of damaged superficial keratinocytes.[21]

Differential Diagnosis and Laboratory Findings. Reticular LP may look similar but they are more densely white and do not disappear on stretching the mucosa.

A biopsy shows typical findings of keratinocyte edema or hydropic degeneration.

Management and Prognosis. No treatment is necessary since these lesions are benign although advice on smoking cessation may be warranted.

Contact Desquamation.

This is a common oral condition, where the injury to the tissue is slightly more severe than in leukoedema causing actual degeneration and detachment of the superficial keratinocytes. The offending agents are mouthwashes and toothpastes that are caustic [in particular Listerine (Pfizer Pharmaceutical, NY) mouthwash that contains 27% alcohol as well as eucalyptol and menthol].

Clinical Findings. This is generally a condition of adults. Patients will often report that their mouth is "peeling." Lesions present as painless sloughs of desquamated tissue that lie in thin ribbons on the mucosa and can be removed without pain or discomfort to the patient, with normal-appearing, pink underlying tissue.[65] Since the keratinized tissues are somewhat protected from the adverse effects of such topical agents, it is generally the nonkeratinized tissues that are involved. A helpful sign is a background of leukoedema with faint reticulations.

Differential Diagnosis and Laboratory Studies. While some bullosing disorders may form such sloughs, those lesions are almost always painful or sensitive, and may bleed. Lack of symptoms is key to the diagnosis of this condition coupled with the typical history.

A biopsy shows desquamating strips of surface keratinocytes.

Management and Prognosis. Patients should discontinue the use of the offending dentrifrice, or change to a less caustic agent.

Morsicatio Mucosae Oris (Pathominia Mucosae Oris, Chronic Bite Injury).

This is a yet more intense local factitial injury to the oral mucosa, caused by a chewing habit, leading to reactive keratosis and benign epithelial hyperplasia. It occurs in 3% of the population.[66] Any other factitial injury either from an unusual habit, or the rough edge of an appliance may lead to a similar lesion.

Clinical Findings. MMO appears as white papules and plaques on either side of the linea alba on the buccal mucosa, lower labial mucosa, or the lateral tongue, usually caused by raking of the teeth over the mucosa[67] Patients may or may not be aware of this habit (especially if this is a nighttime habit). Lesions have a shaggy, rough surface, are poorly demarcated, and



Figure 76-5 Primary herpes simplex virus (HSV) gingivostomatitis with involvement of gingiva and left upper labial mucosa.

occasionally may show evidence of erythema and/or ulceration where the "chewing" has been more intense (eFig. 76-5.3A and 76-5.3B in online edition).

Differential Diagnosis and Laboratory Studies. Candidiasis, some lesions of LP, hairy leukoplakia, and some leukoplakias and erythroleukoplakias may look similar but a biopsy will provide a definitive diagnosis. Such factitial injury may be superimposed upon an underlying condition such as dysplasia or LP, making the diagnosis even more challenging.

A biopsy shows varying degrees of parakeratosis with impetiginization and benign epithelial hyperplasia.

Management and Prognosis. No further management is necessary. These lesions are benign and have no malignant potential. The use of night guards or appliances to break the habit has not been shown to be helpful.

Benign Alveolar Ridge Keratosis (BARK, Oral Lichen Simplex Chronicus). BARK is a very common condition that was recently defined histologically. It occurs primarily on the keratinized mucosa of the gingiva and hard palate as a reaction to frictional trauma. It is the oral equivalent of lichen simplex chronicus.

Clinical Findings. BARK presents as poorly demarcated, painless white papules and plaques, often with a rough surface, usually less than 1 cm in greatest dimension (eFig. 76-5.4 in online edition). The most common location is the retromolar pad (at the site of previously extracted wisdom teeth) and other areas where teeth have been extracted.[68,69] It is not necessary for the opposing teeth to contact the mucosa, since crushing of food against the alveolar ridge that had been previously protected by a tooth is sufficient.

Differential Diagnosis and Laboratory Studies. Leukoplakia, especially verrucous leukoplakia is a very important differential diagnosis and a biopsy should always be performed if the lesion shows signs of sharp demarcation or is extensive. More worrisome, verrucous leukoplakia, a dysplastic lesion, also has a rough surface and is usually greater than 1 cm.

A biopsy shows typical features of lichen simplex chronicus. BARK is closely related to MMO (described above), another frictional keratosis. It is possible that BARK being located on the keratinized mucosa that is closer in histology to the skin, takes on the more typical histologic characteristics of lichen simplex chronicus (LSC).

Management and Prognosis. No treatment is necessary once the histopathologic diagnosis has been established. If a denture is the source of frictional irritation, this should be adjusted accordingly.

Nicotinic Stomatitis. Nicotinic stomatitis is not caused by nicotine as its name suggests but rather by heat, usually from pipe smoking. A similar condition may be seen in patients who reverse smoke, that is, hold the lighted end of the cigarette in the mouth, as is the habit in some South Indian and Southeast Asian populations. It has also been noted in patients who habitually drink very hot beverages.

Clinical Findings. The palate of adult patients is the site most often affected. It is diffusely white with red, punctuate areas representing the openings of salivary ducts. It is usually not a painful lesion although severe cases may be sensitive to hot and spicy foods, and lesions are usually symmetric and diffuse.[21,54]

Differential Diagnosis and Laboratory Studies. Leukoplakia and candidiasis of the palate may both mimic nicotine stomatitis.

A biopsy shows hyperkeratosis with benign epithelial changes and importantly, inflammation of excretory salivary ducts that exhibit squamous metaplasia. This diagnosis is difficult if the ducts are not included in the biopsy specimen.

Management and Prognosis. Lesions may resolve if the habit is discontinued. The risk for malignant transformation has not been well documented. However, the development of raised, indurated areas should raise suspicion for malignant transformation.

Smokeless Tobacco Keratosis. This is a lesion that results from a combination of direct contact toxicity of the smokeless tobacco on the mucosa (early lesions), and from effects of carcinogens within the snuff, namely tobacco-associated nitrosamines (late lesions that represent true leukoplakias). Not all smokeless tobaccos are alike. Snuff may be moist or dry and in general moist Swedish snuff ("snus") is lower in nitrosamines than moist and dry snuff from the United States.[70] Toombak, snuff from Ethiopia, has the highest levels of nitrosamines of all.[71] In many Asian countries, snuff and smokeless tobacco is mixed with other substances such as spices and importantly areca nut, which contains another potent carcinogen, the alkaloid arecoline.[72]

Over the last 10–15 years, there has been increased interest in using smokeless tobacco as a risk reduction measure in subjects who have difficulty discontinuing cigarette smoking because the risk of developing cancer (oral and other cancers) is reduced.[73,74]

Clinical Findings. The lesions are located where the snuff is placed, usually the mandibular sulcus/vestibule, between the teeth and the buccal mucosa. The area looks grayish white, opalescent, and wrinkled, often with fissures.[21,54]

Lesions are generally painless and poorly demarcated (eFig. 76-5.5 in online edition).

Differential Diagnosis and Laboratory Studies. The diagnosis includes leukoplakia, candidiasis, and BARK. Aspirin is much more caustic and causes necrosis and ulceration, rather than this delicate white lesion.

Biopsy reveals thin parakeratosis, intracellular edema, and devitalization of superficial keratinocytes. Any other agent that is locally irritating and slightly caustic may cause this clinical appearance.

Management and Prognosis. Most early lesions are primarily caused by contact injury and are reversible if the habit is discontinued. However, the development of a dense white plaque or erythema may signal transformation to malignancy and these areas should be biopsied. The rate of malignant transformation is only 1%–2% compared with cigarette smoking.

INFECTIOUS LESIONS

Candidiasis. Fungal infections are extremely common in the oral cavity and the most common causative agent is *Candida albicans*. Approximately 20%–30% of the population are carriers. In immunocompromised hosts, other species such as *C. tropicalis, C. dubliniensis, C. glabrata, and C. kruseii* should also be considered, as some of these may be resistant to conventional therapy. Predisposing factors include hyposalivation (see Section "Xerostomia" and "Hyposalivation" in online edition), immunocompromise, topical steroid therapy (for treatment of oral lesions or as inhalers), and antibiotic therapy.

Clinical Findings. Oral candidiasis may present in various forms (Table 76-4) (Figs. 76-6A–76-6E).[1,21] Lesions are almost always painful and dentures act as fomites.[75] Although *C. albicans* is the most common pathogen in denture-associated candidiasis, *C. glabrata* is found in 30% of cases.[76]

Differential Diagnosis and Laboratory Studies. An important differential diagnosis is hairy or coated tongue. This is not a candidal infection, although cultures may grow *Candida* in carriers. These lesions are almost always painless and do not involve mucosa other than tongue dorsum, unusual for candidiasis. It is caused by hyperplasia and hypertrophy of the filiform papillae of the tongue, with retention of keratinaceous debris as a result of hyposalivation and poor oral intake. Patients therefore are often ill, dehydrated, and on antibiotic therapy, further adding to the suspicion that the lesions represent candidiasis.

Culture is not particularly useful for diagnostic purposes since many individuals are carriers. However, culture is important if speciation or sensitivity is required,

TABLE 76-4
Presentation and Management of Oral Candidiasis

Type	Clinical	Treatment
Thrush/Pseudomembranous candidiasis	Curdy yellowish-white papules or plaques; may or may not scrape off Often synchronously on dorsum or tongue and palate so-called "kissing lesions"	Nystatin 1:100,000 iu/mL; swish and spit out 5 mL tid or qid Clortrimazole troche[a] 10 mg; suck on 1 troche tid or qid Ketoconazole 200 mg qd × 7-14 days Fluconazole 100 mg; take one tablet once a day × 3–10 days
Erythematous/Atrophic candidiasis	1. Erythematous areas under a denture 2. Linear gingival erythema in HIV/AIDS	1. Mycostatin and triamcinolone cream on worn denture ("under occlusion"); treat denture with dilute bleach (1:10), sodium benzoate or other antimicrobial soaks 2. See Thrush above
Hyperplastic candidiasis	Primarily white papules and plaques with minimal erythema; associated with mucocutaneous disease or hairy leukoplakia	See Thrush above
Angular cheilitis	Fissured, weepy lesions at the corners of the mouth; often associated with *Staphylococcus aureus*	Mycostatin and triamcinolone cream; may need topical erythromycin
Median rhomboid glossitis	Rhomboidal area in posterior midline of tongue, anterior to circumvallate papillae; maybe slightly depressed and erythematous, or raised	See Thrush above

[a]Troches do not dissolve well in patients with hyposalivation.

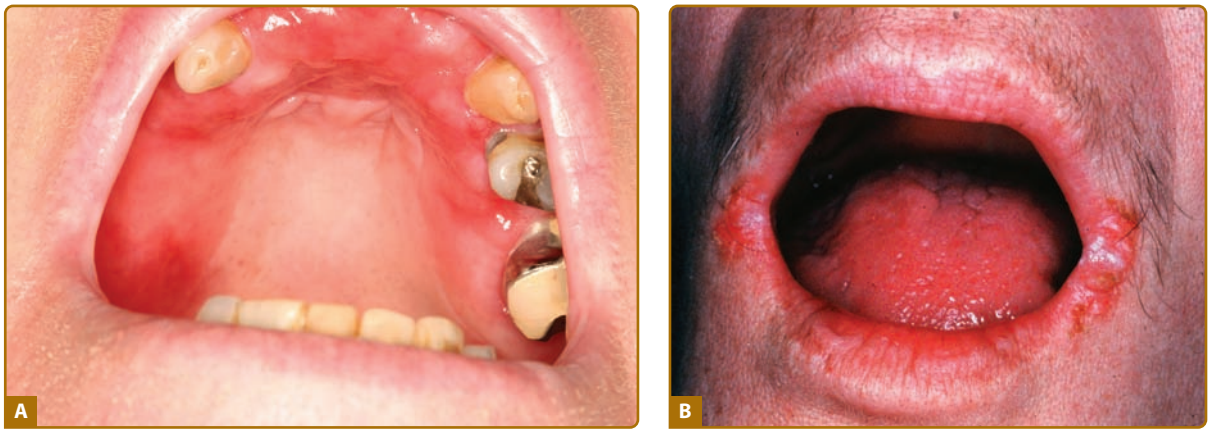

Figure 76-6 **A.** Erythematous candidiasis. **B.** Angular cheilitis.

or to identify carriers prior to the start of long-term steroid therapy. A potassium hydroxide preparation using scrapings from oral lesions is a good way to identify infection. Biopsies show typical candidal organisms.

Management and Prognosis. Patients who have dry mouths from polypharmacy or substantial damage to salivary glands (such as from radiation) are prone to develop recurrent candidiasis and are particularly difficult to manage. Nystatin rinses and clotrimazole troches contain caries-inducing sugars and should be used long-term only with careful monitoring by the dentist. The use of cholinergic agents such as pilocarpine or cevimeline helps to restore some secretory function of salivary glands and may reduce the frequency of candidiasis.

Hairy Leukoplakia. Epstein–Barr virus (EBV) infections in the oral cavity may present as a primary infection (infectious mononucleosis). Hairy leukoplakia is an unusual presentation of recrudescent EBV in the oral cavity, where this normally lymphotropic virus is present within the epithelium.

Clinical Findings. This manifests as a painless, white plaque usually located on the lateral border of the tongue in immunocompromised patients, and in particular, those with HIV/AIDS and after organ transplantation.[77,78]

Typically, these present as white linear lesions running perpendicular to the long axis of the tongue but when more advanced, may extend onto the dorsum and present as a plaque (Fig. 76-7). Lesions are usually asymptomatic and usually superinfected with *Candida*. Infrequently, hairy leukoplakia has been reported in healthy individuals.[79]

Differential Diagnosis and Laboratory Studies. Lesions of MMO and candidiasis often occur on the lateral tongue and may appear similar.

Both cytologic smears and biopsies show characteristic findings and the presence of EBV can be confirmed by in situ hybridization.

Management and Prognosis. The presence of hairy leukoplakia may be the first indication that a patient is infected with HIV. In patients with established HIV/AIDS, hairy leukoplakia is usually associated with a low CD4 count and high viral load.[77] Treatment with an antifungal medication (see Section "Candidiasis") will resolve the associated candidiasis and treatment with antiretroviral therapy results in resolution.

ORAL LICHEN PLANUS

Oral LP is an immune-mediated disorder and an interface stomatitis characterized by T-cell destruction of the basal cells of the epithelium, possibly as a result of altered antigen presentation on these cells, mediated by TH1 cytokines. Interferon-α production is thought to mediate lesions involving the oral cavity only while TNF-α may mediate systemic disease.[80] Whether this is a disease in and of itself or whether it represents a "final common pathway" of mucosal reaction is unclear at this time. Many local and systemic conditions predispose to the development of such "lichenoid lesions" in the oral cavity. The term "lichenoid" used here to describe reticulated, often erythematous and/or ulcerated lesions, usually bilateral and symmetric. Unfortunately, many erythroleukoplakias that are by definition red and white lesions but usually without significant reticulation are also clinically described as "lichenoid"



Figure 76-7 Early hairy leukoplakia (Used with permission from Dr. Mark Lerman, Harvard School of Dental Medicine).

by some investigators, causing confusion and leading to the concept of LP as a premalignant lesion.

Local lichenoid reactions may develop as a result of contact injury to amalgam restorations or cinnamic aldehyde from chewing gum. Medications implicated in the development of oral LP include antihypertensive agents (especially hydrochlorthiazide), some hypoglycemic agents, allopurinol, sulfasalazine, carbamazepine, and the new biological agents.[80–82] It is often impossible to differentiate either clinically or histologically, between lesions of idiopathic LP and lichenoid hypersensitivity reactions.[83]

Other conditions associated with oral lichenoid lesions include hepatitis C in Mediterranean races and this is associated with HLA-DR6[84,85]; chronic graft-versus-host disease, and lupus erythematosus.[86,87]

CLINICAL FINDINGS. Oral LP occurs in 1%–2% of the population in the United States and affects females more than males, usually those in the fifth decade of life and older. Three clinical forms are noted—(1) keratotic/reticular, (2) erythematous/erosive, and (3) ulcerative—and these often occur in combination.[21,54] The most recognizable is the keratotic/reticular form (Wickham striae) that is usually not painful. This is symmetric in distribution and reticulations almost always occur on the buccal mucosa and tongue although any oral mucosal site may be affected (Figs. 76-8A and 76-8B). Lesions on the dorsum of tongue tend to be subtle and more papular with atrophy of filiform papillae giving the tongue a white cast and smooth appearance (Fig. 76-8C). The erythematous or erosive form is usually painful and this is particularly common as a primary presentation on the gingiva (clinically desquamative gingivitis).[88] LP on the gingiva is also noted in the gingival–genital syndrome.[89] Ulcerative LP usually occurs in association with the other two forms. The finding of intact blisters (bullous LP) is rare in the oral cavity because it is a trauma-intense environment. Concomitant skin involvement is noted only in 10%–15% of patients.

A controversial entity is the so-called "plaque-type LP." If this lesion occurs as a unilateral plaque without reticulations, it should be considered a leukoplakia. If it occurs within an established, typical symmetric oral LP, it should be considered "leukoplakia developing within LP." In either case, biopsy is indicated to exclude dysplasia or malignancy.

Several scoring systems have been developed for evaluating the severity of disease but none are universally accepted.[90–92]

DIFFERENTIAL DIAGNOSIS AND LABORATORY STUDIES. Many conditions may result in the development of LP and lichenoid reactions. However, the most important is erythroleukoplakia. It can be differentiated from oral LP in that it is not usually definitively reticulated (although it may have subtle linear areas), is



Figure 76-8 **A.** Reticular lichen planus (LP) of right buccal mucosa. **B.** Reticular, erythematous and ulcerative LP of left buccal mucosa in same patient as 76-8A. **C.** LP of dorsum of tongue; **D.** LP of gingiva.

usually asymmetrically distributed, and often presents at a high-risk site for cancer such as the ventral tongue unilaterally. It is strongly associated with dysplasia and carcinoma (see below). Other lesions include candidiasis and contact stomatitis such as to chewing gum.

Chronic ulcerative stomatitis is an entity that resembles erythematous/erosive LP but is associated with antibodies directed against δNp63α.[93] Direct immunofluorescence studies reveal nuclear binding of keratinocytes in the basal and lower one-third of the epithelium. Serum immunoglobulin (Ig) G can be detected using guinea pig esophagus as substrate and an ELISA is now available.[94]

The reticulated white areas on the buccal mucosa may sometimes resemble MMO. Erythematous LP lesions on the gingiva are often indistinguishable from other diseases presenting as desquamative gingivitis such as mucous membrane pemphigoid, hypersensitivity reaction, or plasma cell gingivitis. Pure ulcerative lesions without reticulations are more likely to be aphthous ulcers.

Diagnostic histopathologic findings for oral LP, are squamatization of basal cells and a lymphocytic band at the interface. Direct immunofluorescence studies show shaggy fibrinogen and often IgM at the interface and IgM staining of colloid bodies.

MANAGEMENT AND PROGNOSIS. Management of oral LP and lichenoid lesions involves pain control and treatment with topical steroids and other anti-inflammatory agents (Table 76-1).[95] Gingival lesions are effectively treated with topical steroids held in a stent. Systemic therapy with prednisone (at 1 mg/kg for 1 week with a fairly rapid taper) or hydroxychloroquine should be instituted in severe cases and topical therapy started concomitantly.

Localized, unliateral lesions may respond to removal of dental restorations and a short course of topical steroids. Disease remission occurs in <10% of cases.

The rate of malignant transformation (often given as 1% every 5 years) is controversial because some studies do not correct for confounding factors such as smoking, while other included erythroleukoplakias, leukoplakias (diagnosed as "plaque-type" LP), and proliferative leukoplakia in the group of "lichenoid" lesions. Classic, bilaterally symmetric, reticulated LP has a very low malignant potential.[96]

LEUKOPLAKIA AND ERYTHROPLAKIA

This is one of the more challenging diagnostic entities of oral mucosal disease. Leukoplakia is defined as a "white plaque of questionable risk having excluded other (known) diseases or disorders that carry no increased risk for cancer."[97] It is a clinical diagnosis only and modified once the histopathologic diagnosis is known. For example, what may appear to be a provisional diagnosis of leukoplakia on the buccal mucosa may histopathologically prove to be MMO as a final definitive diagnosis. Frictional keratosis is NOT a leukoplakia and the only two histologically well-defined frictional keratoses are (1) MMO and (2) BARK. Because frictional injury is very common in the oral cavity and usually presents as a hyperkeratosis, it is likely that many so-called leukoplakias actually represent nonspecific frictional keratoses that are not MMO or BARK.

Leukoplakias occur in 2%–4% of the population.[98] Any lesion that carries a provisional diagnosis of leukoplakia must be biopsied because approximately 20%–50% of these lesions are dysplastic or cancerous at the time of biopsy.[99,100]

Leukoplakia is strongly associated with smoking and/or alcohol ingestion. Other predisposing factors are similar to those for oral cancer and will be discussed below.

CLINICAL FINDINGS. Leukoplakia is more common in adult males. It presents as a painless, white plaque that may be homogenous or nonhomogenous.[97] It may occur anywhere in the oral cavity and generally shows areas that are sharply demarcated from the surrounding mucosa (Fig. 76-9). Homogenous leukoplakia may show areas of fissuring. Nonhomogenous leukoplakia have areas of erythema (erythroleukoplakia), rough, warty areas (verrucous leukoplakia), or nodular areas; they have a higher association with dysplasia and carcinoma, as do lesions on the floor of mouth, ventral tongue, and soft palate.[101,102]

Proliferative verrucous leukoplakia (PVL)[103,104] tends to occur in middle-aged females and, as its name suggests, tends to spread or proliferate over the mucosa over time, and is usually multifocal (eFigs. 76-9.1A–76-9.1C in online edition). It is associated with smoking in less than 30% of cases. Patients are usually diagnosed with this condition one to two decades after the first appearance of the white lesion. Areas of it may become verrucous, although not invariably, and other areas may appear red, in which case the term proliferative erythroleukoplakia may be appropriate. Approximately 70%–100% of cases develop SCC over time.[103,105] These lesions are particularly difficult to diagnose because patients often have had multiple biopsies over many years, and each time, the diagnosis is one of "hyperkeratosis" only without evidence of dysplasia.

Oral *erythroplakia*, although a red lesion, will be discussed here because of its high associated dysplasia. It is an uncommon lesion and in its pure form



Figure 76-9 Leukoplakia of tongue (dysplasia).

presents as a painless, red, sometimes velvety plaque of the oral mucosa (eFig. 76-9.2 in online edition). More than 90% of cases are associated with dysplasia or carcinoma at the time of diagnosis.[106,107] It is much more common to see it in combination with leukoplakia (erythroleukoplakia).

DIFFERENTIAL DIAGNOSIS AND LABORATORY STUDIES. The clinical differential diagnosis list for leukoplakia is long (Table 76-3). However, sharp demarcation at least one border is a helpful finding and usually excludes an inflammatory/reactive lesion. A biopsy should be performed for any white lesion if the etiology cannot be established with confidence on clinical grounds.

Approximately 20%–50% of leukoplakias are dysplasias or carcinoma at the time of biopsy.[100,101,106,108] However, 5%–18% of lesions diagnosed as "benign hyperkeratosis," when followed over time, transform to carcinoma.[99,102,108] This is particularly true of lesions of proliferative leukoplakia where multiple biopsies show "benign hyperkeratosis" until many years later when overt dysplasia or carcinoma develops.

Research using microarrays and other techniques to better characterize the genome of these lesions will shed light on this in coming years. The concept of "oral" or "squamous intraepithelial neoplasia" similar to "cervical intraepithelial neoplasia" has not received acceptance although it is likely a useful concept to adopt.

Management, prognosis, and risk of progression to oral SCC are discussed online.

There is controversy as to whether leukoplakias should be excised.[109] Some suggest that small leukoplakias should be excised, while extensive lesions could be managed with multistage stripping.[110] While some clinicians and pathologists believe that mild dysplasias may just be observed since some of these regress, it is likely that some of these "regressing mild dysplasias" represent only keratotic lesions with reactive atypia. True dysplasias are intraepithelial neoplasias that have not yet become invasive. If such lesions can be removed without excessive morbidity, this seems prudent.

Options for the 50%–80% of cases diagnosed as "benign hyperkeratosis," include periodic rebiopsy or excision. It is suggested that "benign hyperkeratoses" that are not clearly frictional or reactive in nature and are in high-risk sites be narrowly excised and followed and that recurrent lesions be excised with a margin of several mm. Because leukoplakia is a clinicopathologic entity, it is important that the clinician work with a pathologist who is experienced in the diagnosis of reactive and nonreactive oral keratotic lesions.

Smoking cessation counseling should always be part of the overall management strategy for patients who smoke.

ORAL SQUAMOUS CELL CARCINOMA

Head and neck cancer is the 11th most commonly occurring cancer in the United States, and there are approximately 35,000 cases per year, with one-third of these occurring in the oropharynx.[111] Risk factors include smoking cigarettes, excessive use of alcohol, chewing areca nut, a past history of cancer and/or immunosuppression, family history of cancer, exposure to high-risk forms of human papilloma virus (HPV) (especially for carcinomas of the posterior oral cavity and oropharynx), age, and for lip cancer, sunlight.[112,113]

CLINICAL FINDINGS. Oral SCC affects males more often than females in a 2:1 ratio and usually affects older adults. Excluding the lip, the most common sites are the ventral tongue, gingiva, and floor of mouth. It may present as a leukoplakia, erythroplakia, proliferative leukoplakia, a nonhealing ulcer or ulcerated nodule, or a mass.[112] The tumor may have a verrucous or papillary surface (eFig. 76-9.3 in online edition). Pain may or may not be present and there may be paresthesia. Advanced lesions infiltrate the underlying bone or muscle and may lead to difficulty with movement of the tongue, adversely affecting speech and eating. Metastases to the submandibular and upper cervical lymph nodes are common, and nodes should be palpated in patients with suspicious lesions.

DIFFERENTIAL DIAGNOSIS AND LABORATORY STUDIES. The differential diagnose for leukoplakia are presented in Table 76-3. Traumatic ulcerative granuloma (see above) may be mistaken for oral carcinoma because it is often on the lateral/ventral tongue, may not be particularly painful and is often present for weeks. Benign neoplasms of soft tissue or salivary gland origin may be traumatized and present as an ulcerated nodule, raising the suspicion of oral carcinoma.

A biopsy shows a proliferation of malignant epithelial cells infiltrating the stroma as single cells or in a bluntly invasive fashion. The latter is a particular feature of verrucous carcinoma that tends not to metastasize.

MANAGEMENT AND PROGNOSIS. Management and prognosis is dependent on the stage. Most Stage I and II lesions are treated with surgical excision (usually en bloc resection) with an objective of obtaining clear margins.[114] Some Stage II lesions are treated with a supraomohyoid neck dissection. Studies on sentinel node biopsy have shown metastatic lesions in 20%–30% of patients.[115,116] Stage III and IV tumors may be treated with surgery, radiation or chemoradiation (the chemotherapy being a radiation sensitizer) for organ-sparing purposes.[117] The use of cetuximab, a monoclonal antibody against the epidermal growth factor receptor, which is highly expressed in many oral cancer, has resulted in improved disease control.

Five-year survival for patients with local disease only, locoregional disease and distant metastases are 81%, 50%, and 14%, respectively.[114]

BULLOUS DISORDERS/RED LESIONS

Many autoimmune bullous disorders present as erythematous and/or ulcerative lesions. It is rare for intact bullae to be present in the oral cavity.

MUCOUS MEMBRANE PEMPHIGOID

Mucous membrane pemphigoid is a heterogeneous group of disorders characterized by subepithelial blistering and antibodies, usually IgG or IgA, directed against a variety of antigens such as BP230, BP-180, laminin-332, laminin-331, Type XVII collagen, Type VII collagen, or β 1 integrin subunit,[121] to name a few.

CLINICAL FINDINGS. This is a disease of middle aged and older adults with a slight female predisposition. The most common presentation for mucous membrane pemphigoid is desquamative gingivitis. This presents as a band of bright red, painful gingiva, often denuded of epithelium, with areas that are ulcerated or with necrotic epithelium lying on the surface (Fig. 76.10). Patients have difficult eating coarse, acidic, or spicy foods and the gingiva bleed readily on brushing. Oral mucosa lesions rarely cause scarring and most patients who present with oral lesions initially do not usually develop skin lesions. It is uncommon to see lesions on sites other than the gingiva in the oral cavity.

DIFFERENTIAL DIAGNOSIS AND LABORATORY FINDINGS. LP is the most common disease (70%–75%) presenting as desquamative gingivitis, with mucous membrane pemphigoid representing 9%–14% of cases.[122,123] Other conditions include hypersensitivity reactions such as plasma cell gingivitis and less commonly other autoimmune bullous disorders such as pemphigus vulgaris, linear IgA disease, and epidermolysis bullosa acquisita. LP may or may not show reticulations on the gingiva or elsewhere in the oral cavity and pemphigus vulgaris almost always involves mucosal sites other than the gingiva. Linear IgA disease and epidermolysis bullosa acquisita always present with concomitant skin lesions. Granulomatosis with polyangiitis (Wegener disease) produces a granular, erythematous gingivitis.

All patients with a clinical diagnosis of desquamative gingivitis should have a biopsy both for routine histology and for direct immunofluorescence studies. The presence of linear IgG, IgA, and/or C3 at the basement membrane zone on direct immunofluorescence testing is strongly suggestive of pemphigoid. The diagnosis of linear IgA disease should not be made in patients with mucosal disease alone. Indirect immunofluorescence using salt-split skin may also be helpful.[121]



Figure 76-10 Mucous membrane pemphigoid.

MANAGEMENT AND PROGNOSIS. The most effective way to treat mucous membrane pemphigoid presenting as desquamative gingivitis is with a topical steroid gel held in a soft stent (similar to a bleaching or fluoride tray extended over the gingiva) for 30 minutes twice a day. Clobetasol may be used for the first few months, switching to fluocinonide when disease is better controlled. Application may also be reduced to 10–15 minutes once a day for maintenance. Prednisone and dapsone may be used if lesions are recalcitrant.[124] Azathioprine and cyclophosphamide are also effective in some cases.[121] It is unclear whether patients with IgA on direct immunofluorescence studies have more recalcitrant disease. Some cases may respond to etanercept.[125]

This disease is chronic and the disease rarely remits completely. Since ocular complications may be severe, all patients with oral lesions are referred for baseline ophthalmologic examination. Long-term topical steroid therapy may lead to hypertension, hyperlipidemia, and poor control of diabetes mellitus, so periodic blood pressure measurements, ACTH and cortisol levels, and lipid and glucose levels are indicated.

PEMPHIGUS

The oral cavity may be involved by pemphigus vulgaris and paraneoplastic pemphigus. There is a predilection for this condition among Ashkenazi Jews and those living around the Mediterranean and South Asia and a strong association with HLA-DR4, Drw14, and DQB1*503.[126] The antigen is desmoglein 3.

CLINICAL FINDINGS. Pemphigus vulgaris is an uncommon condition, most often seen in adults. Patients may present with lesions in the mouth before developing skin lesions. Lesions may present as desquamative gingivitis, but almost invariably, other mucosae are involved, in particular the hard and soft palate. Oral lesions are denuded and erythematous, painful, and slightly depressed. Remnants of the bullae or necrotic debris may overlie the erosion, or be heaped up at the edges (eFig. 76-9.4 in online edition). Some patients have lesions limited to the oral cavity and never develop skin lesions.

In addition to the erosions and ulcers present intraorally, patients with paraneoplastic pemphigus (also known as paraneoplastic autoimmune multiorgan syndrome) present with hemorrhagic crusting of the lips. It is usually associated with a lymphoid malignancy.[127]

DIFFERENTIAL DIAGNOSIS AND LABORATORY FINDINGS. Large ulcers of Behçet disease and recurrent aphthae major may look similar to pemphigus vulgaris. Stevens–Johnson syndrome and the more severe toxic epidermal necrolysis may resemble lesions of paraneoplastic pemphigus.



Figure 76-11 Lupus erythematosus of buccal mucosa.

The biopsy for pemphigus vulgaris shows suprabasilar acantholysis and direct immunofluorescence studies show intercellular deposition of IgG. Paraneoplastic pemphigus shows deposition of IgG and C3 both intercellularly and at the basement membrane zone. Patients with only oral lesions of pemphigus usually do not exhibit elevated serum IgG.

MANAGEMENT AND PROGNOSIS. Treatment for pemphigus vulgaris is with topical steroids in mild cases with the use of a stent for gingival lesions. More severe cases can be successfully treated with prednisone and mycophenolate mofetil in conjunction with topical steroids.

LUPUS ERYTHEMATOSUS

Patients with systemic and discoid lupus erythematosus present with oral findings in up to 25% of cases.[128]



Figure 76-12 Plasma cell gingivitis.

CLINICAL FINDINGS. Patients may present with erythematous and eroded mucosa, especially on the buccal mucosa and palate with a hint of white reticulations. Ulcers may be present (Fig. 76-11).

DIFFERENTIAL DIAGNOSIS AND LABORATORY FINDINGS. LP can usually be differentiated by well-formed reticulations of the buccal mucosa. Patients with lupus erythematosus usually have an established diagnosis and present for management of painful oral lesions.

The biopsy shows an interface stomatitis with linear IgG deposition along the basement membrane zone on direct immunofluorescence.

MANAGEMENT AND PROGNOSIS. The mainstay of treatment is topical steroid therapy. Symptoms usually wax and wane with systemic and skin disease.

PIGMENTED LESIONS

The two most common pigments of exogenous origin are amalgam and graphite from pencil lead. Pigmented lesions of endogenous origin are usually caused by melanin or hemosiderin.

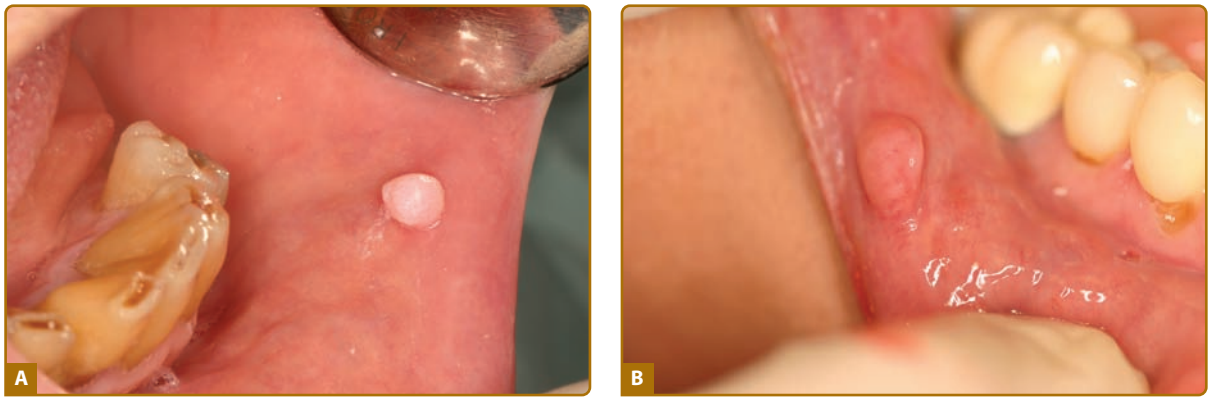

Figure 76-13 **A** and **B.** Fibroma.



Figure 76-14 Gingival nodule.

AMALGAM TATTOO

Dental amalgam restorations are primarily composed of silver and mercury with smaller amounts of other elements such as tin. The silver particles stain the reticulin fibers leading to the tattoo.[165]

CLINICAL FINDINGS. This presents in adults usually, as a discrete, nontender, slate-gray, or black macule of the oral mucosa that is usually less than 1 cm.[166–168] The patient is usually unaware of the lesion. When it is noted adjacent to a silver or amalgam restoration because of leaching out of particles, the diagnosis is straightforward. However, if it is located at a site away from the restoration, such as the buccal mucosa, tongue, sulcus, or palate, the diagnosis may not be as obvious (Fig. 76-15).

DIFFERENTIAL DIAGNOSIS AND LABORATORY FINDINGS. Any other dark foreign material such as graphite may look similar. Melanotic lesions especially the oral melanotic macule and postinflammatory hypermelanosis may look similar although in general these are more tan and dark brown rather than dark blue. Dysplastic melanocytic lesions and melanoma usually have less uniform pigmentation and irregular borders. A vascular lesion such as a varix or venous lake may look similar, although those intend to appear as blebs or papules and blanch with pressure.

The histopathology is distinctive. Pigmentation by other materials not containing silver such as graphite does not cause staining of the reticulin fibers.

MANAGEMENT AND PROGNOSIS. A biopsy is usually not required if the lesion is adjacent to a restoration. However, if there is any doubt about the diagnosis, a biopsy is recommended.



Figure 76-15 Amalgam tattoo in floor of mouth.



Figure 76-16 Physiologic pigmentation.

PHYSIOLOGIC PIGMENTATION (RACIAL PIGMENTATION)

This is very common in dark-skinned individuals of African, South and Southeast Asian, and Mediterranean descent.

CLINICAL FINDINGS. Physiologic pigmentation presents asymptomatic diffuse, even or patchy, brown-to-black macular pigmentation of the oral mucosa and in particular the attached gingiva (Fig. 76-16). This usually has a symmetric distribution.[21]

DIFFERENTIAL DIAGNOSIS AND LABORATORY STUDIES. The patient is usually unaware of this. Postinflammatory hypermelanosis from diffuse and symmetric involvement by oral LP may also have a similar appearance. However, the pigmented areas tend to be located where the obvious white reticulations are present. Cosmetic tattooing of the gingiva is a prevalent practice in some African cultures and this may lead to extensive and symmetric pigmentation.

The biopsy shows the presence of melanin within basal cells in the absence of melanocytic hyperplasia.

MANAGEMENT AND PROGNOSIS. Recognition of the condition is sufficient and a biopsy is seldom necessary.

ORAL MELANOTIC MACULE

The etiology of the solitary melanotic macule is unclear. It is possible that at some of the lesions may have an inflammatory etiology.

CLINICAL FINDINGS

The most common sites of involvement are the lower lip vermilion, gingiva, and hard palate.[169,170] They are asymptomatic, discrete, tan, brown, or black macules, usually less than 1 cm with even pigmentation (eFig. 76-16.1 in online edition). Unlike ephelis, they do not darken in summer or lighten in winter. While most lesions are solitary, multiple macules are not uncommon in dark-skinned individuals, and they may proliferate in middle age.

DIFFERENTIAL DIAGNOSIS AND LABORATORY STUDIES

Multiple oral melanotic macules are seen in idiopathic lenticular mucocutaneous pigmentation (Laugier–Hunziker syndrome) associated with melanonychia.[171] Multiple melanotic macules are often seen neurofibromatosis, McCune–Albright syndrome, Peutz–Jeghers syndrome, LAMB (lentigenes, atrial myxoma, blue nevus) syndrome, and the associated Carney syndrome.[21]

The sudden onset of melanotic macules should raise the possibility of Addison disease and ACTH levels should be measured. History and clinical examination usually exclude the other syndromes.

Multifocal oral melanosis is also associated with postinflammatory conditions such as LP and the so-called "smoker's melanosis" that occurs on the gingiva around the canine teeth (see below).

Biopsy reveals increased melanin pigment in the basal cells in the absence of melanocytic hyperplasia, and many melanophages in the lamina propria.

MANAGEMENT AND PROGNOSIS

No treatment is necessary. Laser therapy may be useful in patients who are concerned with the esthetic appearance of the macules.[172]

POSTINFLAMMATORY HYPERMELANOSIS

These pigmented lesions occur in particular in dark-skinned patients, similar to lesions of postinflammatory hyperpigmentation on the skin. They may be localized or diffuse depending on the underlying inflammatory process.

CLINICAL FINDINGS

LP is often associated with postinflammatory hypermelanosis and the pigmentation underlies the reticulations of the disease (Fig. 76-17). Smoker's melanosis is often described as a separate entity but likely represents a postinflammatory hypermelanosis occurring in approximately 20% of subjects who smoke. It tends to occur on the buccal gingiva around the canine teeth or on the buccal mucosa.[173,174] Resolution of these lesions after smoking cessation supports an inflammatory etiology.[175]



Figure 76-17 Postinflammatory hypermelanosis from lichen planus.

DIFFERENTIAL DIAGNOSIS AND LABORATORY FINDINGS

Oral melanotic macules may resemble melanoacanthosis, another likely inflammatory reactive disorder in which there is proliferation of dendritic melanocytes throughout acanthotic epithelium.

Biopsy helps exclude a dysplastic melanocytic lesion.

MANAGEMENT AND PROGNOSIS

No treatment is necessary unless the patient is concerned about esthetics. Lesions generally fade over time if the inflammation resolves.

MEDICATION-INDUCED HYPERPIGMENTATION

The medications most commonly associated with oral pigmentation do so via several different mechanisms.[176] Minocycline and tetracycline chelate to apatite crystals in bones and teeth and their metabolic products chelate iron and melanin in the soft tissues.[177] The latter mechanism is also seen during therapy with antimalarial drugs. Pegylated interferon used with ribavirin may stimulate melanin production by stimulating production of α-melanocyte stimulating factor.[178,179] Heavy metals such as lead is secreted into the gingival fluids and likely chelate with sulfides (usually black) produced by plaque bacteria.[180] Bismuth subsalicylate ingestion is also associated with pigmentation of the tongue either from systemic ingestion and tissue deposition, or direct conversion of the compound to bismuth sulfide from oral bacteria.[181,182]

CLINICAL FINDINGS

The most common site of pigmentation caused by minocycline and antimalarial medications is the palatal mucosa, which assumes a slate-gray to blue diffuse macular discoloration that is generally bilateral and symmetric. The lesions are asymptomatic.

Tongue pigmentation caused by pegylated interferon accentuates the papillae in a punctate configuration; this has been reported mainly in dark-skinned individuals.[178] Heavy metals deposit on the gingiva in linear fashion (Burton line in plumbism).[180]

DIFFERENTIAL DIAGNOSIS AND LABORATORY FINDINGS

The history of ingestion of the drug followed by the appearance of a diffuse pigmentation of the oral mucosa and sometimes skin after several months or years is diagnostic.

Biopsy shows pigment granules that stain for both iron and melanin.

MANAGEMENT AND PROGNOSIS

Depending on the length of exposure, discontinuation of the drug may or may not result in eventual complete resolution of the lesion.

MELANOACANTHOSIS

This is an uncommon inflammatory condition of the oral mucosa. Although this condition is also reported under the term "melanoacanthoma," melanoacanthosis is preferred because this is a macular lesion, may be multifocal and is not a tumor-like lesion. Many cases of multifocal melanoacanthoma and melanoacanthosis reported in the literature represent either multiple melanotic macules or postinflammatory hypermelanosis. This raises the question as to whether oral melanotic macules and melanoacanthosis are just two manifestations of postinflammatory hypermelanosis.

CLINICAL FINDINGS

Black females in the second to fourth decades are most often affected. The lesion starts as a brown macule, usually on the buccal mucosa, that over days and weeks spreads rapidly, but still in a macular fashion.[183,184]

DIFFERENTIAL DIAGNOSIS AND LABORATORY STUDIES

While dysplastic nevi and melanoma may grow rapidly, the rate of expansion of the lesion is so fast that an inflammatory condition is more likely.

A biopsy shows acanthosis with benign melanocytes throughout the full thickness of the epithelium.

MANAGEMENT AND PROGNOSIS

No treatment is necessary; this condition regresses over time.

NEVOMELANOCYTIC NEVI

CLINICAL FINDINGS

The most common is the intramucosal nevus that accounts for two-thirds of cases, followed by the compound nevus and the blue nevus (17%) each; junctional nevus constitute only 3% of lesions.[168] The most common location is the palate (40%) followed by the buccal mucosa (19%).[185] Most were identified in the third and fourth decades of life.

Intramucosal and compound nevi tend to be nodular, while junctional and blue nevi tend to be macular. Most nevi are pale-tan to dark-brown or black while blue nevi are slate-blue in color. Approximately 15%–20% of intramucosal nevi are nonpigmented clinically.[185]

DIFFERENTIAL DIAGNOSIS AND LABORATORY STUDIES

Intramucosal and compound nevi may be mistaken for fibromas or any other benign mesenchymal tumor. Blue nevi resemble melanotic macules, amalgam tattoo, or even a varix. Intraoral Spitz nevi are rare but have been reported.

A biopsy shows the presence of nevomelanocytic cells in nests in the lamina propria and/or the epithelial–connective tissue interface. Blue nevi consist of spindled melanocytes in the lamina propria.

MANAGEMENT AND PROGNOSIS

In general, nodular lesions are excised or shaved.

MELANOMA

Intraoral melanomas constitute 0.7% of all melanomas and occur on average 20 years later than cutaneous melanomas.[186,187] The etiopathogenesis in this UV-protected site is unknown and lesions behave similarly to acral lentiginous melanoma.

CLINICAL FINDINGS

Oral melanomas are tumors of adults in the fifth to seventh decades of life with a male predilection and usually evolve from preexisting dysplastic melanocytic lesions.[188,189] They are more frequent in black and Japanese patients and the most common site is the palate or maxillary gingiva. By the time they are diagnosed, they are fairly large, asymmetric, and unevenly pigmented. Areas of ulceration and bleeding may be present. Approximately 40% are amelanotic.[188]

DIFFERENTIAL DIAGNOSIS AND LABORATORY FINDINGS

Kaposi sarcoma tends to be purple or bluish-red, while melanomas tend to be brown-to-black. A large pyogenic granuloma or other vascular lesion with a dark coloration may resemble a melanoma, although a surrounding macular dysplastic melanocytic lesion would be absent.

A biopsy shows an invasive proliferation of melanocytes from an intraepithelial component.

MANAGEMENT AND PROGNOSIS

Five-year survival is approximately 20%–30%.[190,191] Excision with clear margins is the treatment of choice and survival is closely related to the depth of invasion.[192] Surgery with radiotherapy greatly reduces local relapse and metastasis to lymph nodes, although it may not improve survival.[190,193]

DISORDERS OF THE LIPS

Disorders of the lips including actinic cheilitis, orofacial granulomatosis,[200,204] angular cheilitis, and lip nodules are discussed online.

ACTINIC CHEILITIS

Some use the term actinic cheilitis to encompass atrophy of the lips caused by actinic damage without evidence of dysplasia. Here, it will be defined as actinic keratosis of the lip, a dysplastic lesion.

CLINICAL FINDINGS

Because the etiology is related to sun-damage, patients are generally adults in the sixth decade and beyond.[194,195] There is usually a background of chronic actinic damage and atrophy of the lip with blurring of junction of the vermilion and the skin, predominantly involving the lower lip. Actinic cheilitis presents as single or multiple crusted or scabbing, slightly scaly lesions and plaques on the vermilion of the lip, usually several millimeters in size, that heal and then break down. These occur on a whitish, keratotic background. Fissuring and erosions of the vermilion may be present. Discomfort is variable.

DIFFERENTIAL DIAGNOSIS AND LABORATORY STUDIES

An early SCC, traumatized adnexal or salivary gland tumor, or recrudescent herpes simplex infection should be considered in the differential diagnosis.

A biopsy is diagnostic and shows keratinocytic dysplasia.

MANAGEMENT AND PROGNOSIS

Several treatment options are available depending on the size of the lesion and patient preference. Lesions may be surgically excised, treated with cryotherapy or carbon dioxide laser,[196] or managed with topical agents such as 5-fluorouracil or 5% imiquimod for 4–6 weeks.[197,198] In patients prone to herpes simplex recrudescence, antiviral prophylaxis should be considered. More recently, the use of photodynamic therapy with 5-aminolevulinic acid has shown complete clinical response in two-thirds of cases and partial response in one-third; follow-up revealed recurrence in approximately one-third of cases.[199]

CHEILITIS GRANULOMATOSA (OROFACIAL GRANULOMATOSIS)

This is the best known of the noninfectious granulomatous diseases that affects the orofacial region. Like other granulomatous disease, it likely represents a delayed-type hypersensitivity reaction to antigens.[200] Elimination diets and removal of amalgam restorations have resulted in complete remission of some cases, but no obvious etiologic agents is identified in many cases. There may be a genetic predilection and the reaction is mediated via Th1 pathways.[201,202]

Patients with orofacial granulomatosis who present only with lip involvement have cheilitis granulomatosa. The term Melkersson–Rosenthal syndrome refers to the triad of fissured tongue, facial palsy, and cheilitis granulomatosa, but it is rare to see the triad fully expressed clinically. It is also unclear whether fissured tongue, a fairly common condition, is truly part of the syndrome.

CLINICAL FINDINGS

Most patients are young adults and the presentation is variable. Some present with unilateral, soft (early lesions), or firm-rubbery (more established lesions) painless swelling of the lip, and others present with symmetric swelling of the upper or lower lips or, less frequently, both (eFig. 76-17.1 in online edition). Periorbital or zygomatic swelling are atypical presentations.[203] The swelling is originally relapsing–recurring and then becomes persistent, often with fissuring of the lips. There may also be a history of facial swelling, VII nerve palsy (uncommon), and gingival involvement. The last presents as nodular swellings on the gingiva or a cobblestoning of the buccal mucosa. While some also include linear ulcers in the maxillary and mandibular vestibule/sulcus as part of orofacial granulomatosis, such ulcers are more typical of Crohn disease (see Section "Differential Diagnosis and Laboratory Findings").

DIFFERENTIAL DIAGNOSIS AND LABORATORY FINDINGS

Early Crohn disease and sarcoidosis are indistinguishable from lesions of orofacial granulomatosis, both

clinically and histopathologically. Therefore, patients should be questioned regarding gastrointestinal symptoms such as cramping, diarrhea, and blood in stools. Endoscopy is often uninformative in asymptomatic patients since gastrointestinal manifestations may occur years later. Patient should be made aware that this may represent early Crohn disease so that they can self-monitor for gastrointestinal symptoms. In sarcoidosis, angiotensin-converting enzyme levels are often elevated and hilar lymphadenopathy may be present.

Angioedema is never persistent, but rather shows complete resolution between acute episodes; and patients may show increased levels of C1 esterase inhibitor. Cellulitis from infections of the anterior teeth may lead to lip swelling, but these are acute and painful and the offending tooth is always identified.

Biopsy reveals the presence of nonnecrotizing granulomas without foreign material or identifiable infectious agent.

MANAGEMENT AND PROGNOSIS

Topical and intralesional steroid injections are the mainstay of treatment.[204] The dose depends on the severity of swelling and usually patients are treated every week for 2–3 weeks.[205] Systemic therapy in recalcitrant or severe disease includes the use of prednisone (1 mg/kg), thalidomide, minocycline, and more recently, monoclonal antibodies against TNF-α.[206,207]

Less than 50% of patients are in remission on follow-up.[204] In long-standing cases, fibrosis from the inflammation may lead to cosmetic problems that can only be corrected with cheiloplasty.

ANGULAR CHEILITIS

In most cases, this represents a form of candidiasis (see Section "Candidiasis") often with concomitant *S. aureus* infection.[21] The prevalence is approximately 1% in the general adult population and 28% in denture wearers.[211,212] Drooping of the corners of the mouth with drooling and retention of saliva in the creases leading to candidiasis, often associated with wearing of full dentures that do not provide adequate soft tissue support is a major predisposing factor. Patients with hematinic deficiencies or who are immunocompromised are also prone to developing this condition.[213]

CLINICAL FINDINGS

There is painful, usually bilateral maceration of the corners of the mouth with ulceration, crusting, cracking, and, in severe cases, fissuring.[214] Lesions may heal and recur within days or weeks. Some patients develop a diffuse cheilitis due to candidiasis.[215]

DIFFERENTIAL DIAGNOSIS AND LABORATORY STUDIES

Recrudescent HSV infection in immunocompromised patients may lead to bilateral ulcers and maceration of the corners of the mouth, although usually other intraoral sites are also involved. A culture or direct fluorescent antibody testing will establish the diagnosis.

Patients should have bloodwork to rule out a hematinic deficiency.

MANAGEMENT AND PROGNOSIS

Antifungal creams with topical steroid therapy (see Table 76-4) are particularly useful in the treatment of this condition. The usual anticandidal regimens employing nystatin, clotrimazole, and chlorhexidine are also effective.[216] If lesions only partially resolve, *S. aureus* infection should be suspected and treatment with topical erythromycin usually resolves the residual lesion.[217,218]

If there is a hematinic deficiency, repletion should be undertaken and dentures may need to be relined or remade to better support the soft tissues.

EXFOLIATIVE CHEILITIS

This is a rare inflammatory condition of the lip and some cases are associated with factitial injury and lip licking or picking, sometimes associated with psychological distress; however, many cases are of unknown etiology. It is seen in approximately 25% of patients with HIV infection.[219]

CLINICAL FINDINGS

The lip is covered by fine or thick scales and crusts that can be peeled away, leaving an erythematous, raw area (eFig. 76-17.1 in online edition). Patients will report that within a few hours, a new scale or crust forms.[220,221] The lips may also appear cracked, fissured, and chapped. Some patients admit picking at the lesions while others deny this.[222] Cultures in patients with HIV disease yield *Candida* in 50% of cases.[219]

DIFFERENTIAL DIAGNOSIS AND LABORATORY STUDIES

Actinic keratosis is an important consideration and this also causes scaly plaques but these do not tend to peel and recur as quickly. Plasma cell cheilitis should be considered although this presents as an erythematous rather than scaly lesion.[223,224]

A biopsy shows parakeratosis, acanthosis, and chronic inflammation, either somewhat consistent with factitial injury or nonspecific in nature.

MANAGEMENT

Some patients have been at least partially successfully treated with antidepressants, suggesting that factitial

injury associated with psychological distress plays a role.[221,225] Other treatment modalities include mupirocin and tacrolimus.[222]

LIP NODULES

On the lower lip nodules usually result from trauma and include bite or irritation fibromas and mucoceles (both discussed above under Nodular Lesions). The upper lip is traumatized much less frequently and mucosal nodules at this site usually represent one of the following:

1. Benign salivary gland neoplasm (such as pleomorphic adenoma or canalicular adenoma)
2. Malignant salivary gland neoplasm (such as mucoepidermoid carcinoma)
3. Benign nerve sheath tumor (such as solitary circumscribed neuroma)
4. Benign vascular tumor (such as pyogenic granuloma)
5. Nasolabial cyst, a developmental malformation

All require excisional biopsy. Histopathology is diagnostic for each condition.

TONGUE

ATROPHIC GLOSSITIS

Atrophy of the filiform and fungiform papillae of the tongue leads to a bald shiny, erythematous tongue dorsum. Such atrophy is often seen in hematinic deficiencies and in patients with prolonged hyposalivation such as those with Sjögren syndrome or after head and neck radiation therapy.[213]

CLINICAL FINDINGS. The tongue presents with a smooth, bald appearance and papillae are atrophic (Fig. 76-18). Patients often complain of a burning sensation and experience sensitivity when eating acidic, salty, or crunchy foods.[21] They may have associated angular cheilitis if there is a hematinic deficiency. Patients who develop malabsorption after intestinal surgery are prone to developing atrophic glossitis.[226]



Figure 76-18 Atrophic glossitis.

LABORATORY STUDIES AND DIFFERENTIAL DIAGNOSIS. Patient should have blood work to rule out hematinic deficiencies, in particular iron and vitamins B6 and B12 deficiency. For the last, assay of methyl malonic acid may be more sensitive than just a B12 level alone.

MANAGEMENT AND PROGNOSIS. Treatment is with repletion of deficient elements. Topical anesthetics help to control symptoms.

HAIRY TONGUE (BLACK HAIRY TONGUE, COATED TONGUE)

This is an extremely common condition that causes much confusion. There is generally an antecedent history of illness and antibiotic use, leading to a common misdiagnosis of candidiasis. There are usually no other lesions on other oral mucosal sites and no pain, which would be highly unusual for candidiasis. To further add to the confusion, a small number of such patients will grow *Candida* on culture because they are carriers.

Hairy tongue is caused by retention of keratinaceous debris on the tongue dorsum resulting from two factors acting alone or in combination: (1) dehydration (leading to more sticky and mucous rather than serous saliva) and (2) poor oral intake (eating a soft diet or one low in fresh fruits and vegetables).[54] Since most patients have an antecedent history of illness or are hospitalized, they often are dehydrated and have poor appetite. Chromogenic bacteria that reside in the tongue produce metabolic by-products that sometimes stain the tongue, as do food dyes.

CLINICAL FINDINGS. The tongue presents with a matted or coated appearance that is usually symmetric (Fig. 76-19). If located on the posterior midtongue, patients may experience gagging if the "hairs" are long. The thickened matte of keratin on the tongue leads to increased bacterial colonization and their metabolic products (often sulfides) may lead to a foul or stale breath. Such metabolic products may stain the tongue a variety of colors such as brown or black.

DIFFERENTIAL DIAGNOSIS AND LABORATORY STUDIES. Candidiasis involving the dorsum of the tongue is an important differential diagnosis, but has more patchy distribution of the curdy plaques, associated erythema, a less symmetric distribution, and involvement of other parts of the oral cavity by similar candidal papules and plaques. Ingestion of bismuth subsalicylate may transiently lead to a black tongue.[182]

There is no test that is useful. Rare cases have been biopsied and show only elongated filiform papillae. Cultures for *Candida* are positive in 20%–30% of patients and likely indicate carrier status.

MANAGEMENT AND PROGNOSIS. Vigorous hydration and return to a normal diet with fresh fruits and vegetables generally resolve the lesions.



Figure 76-19 **A.** Hairy tongue. **B.** Brown hairy tongue.

The tongue may be brushed as part of the daily oral hygiene regimen to help to dislodge loose keratin squames and reduce discoloration. Hairy tongue is not harmful to the patient.

FISSURED TONGUE

This is a common condition that occurs in 1%–2% of the population and is generally believed to be developmental in etiology.[211]

CLINICAL FINDINGS. It is fairly uncommon in the first and second decade of life and usually seen in adults. Some believe that *Candida* reside within the fissures and cause symptoms.

There are two main patterns. The first consists of a central fissure, either alone or with smaller fissures radiating from it at right angles (Fig. 76-20A). The second pattern is one of short fissures distributed evenly throughout the tongue without the central fissure (Fig. 76-20B). Some patients report some sensitivity of the tongue with spicy or acidic foods, although in general, this condition is asymptomatic.[21] Approximately one-third of patients with migratory glossitis (see below) have concomitant fissured tongue.

DIFFERENTIAL DIAGNOSIS AND LABORATORY STUDIES. The clinical presentation is striking and a biopsy is not useful. The presence of sensitivity should prompt a careful examination for the presence of migratory glossitis, atrophic glossitis, or even candidiasis within the fissures.

MANAGEMENT AND PROGNOSIS. Most lesions are noted on routine examination, are asymptomatic and do not require therapy. Some patients who are symptomatic show resolution of symptoms with a short course of antifungal therapy, but predisposing factors for candidiasis must be addressed or the lesions will recur.

In general, fissured tongue is a permanent condition. However, some patients report that fissures are evanescent.

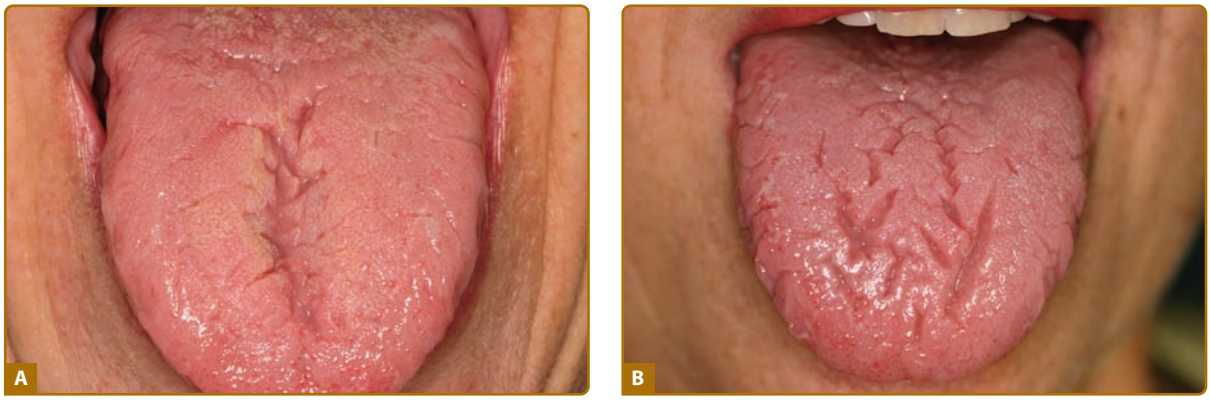

Figure 76-20 **A.** Fissured tongue. **B.** Fissured tongue with migratory glossitis on right.



Figure 76-21 Typical migratory glossitis.

BENIGN MIGRATORY GLOSSITIS/ STOMATITIS (GEOGRAPHIC TONGUE)

CLINICAL FINDINGS. This occurs in 1%–2% of the population and is associated with a fissured tongue in about 30% of cases.[211,227] There is an area of atrophy of the tongue dorsum leading to loss of filiform papillae and a slightly depressed erythematous area that is usually sensitive or painful, especially when acidic foods come in contact with it (Figs. 76-21 and 76-22A and B). Such demarcated areas rimmed by a raised white border that is circinate or serpiginous are diagnostic.[228] Waning lesions are often merely well-demarcated erythematous patches. A history of atopy is often elicited from such patients or from immediate family members.[227] Approximately 13% of patients with psoriasis develop this tongue condition.[229] Flare-ups are associated with both physical and psychological stress.

Infrequently, other mucosal sites such as the palatal mucosa, floor of mouth or buccal mucosa may be involved. In such cases, the term "migratory stomatitis" should be applied.[230]

DIFFERENTIAL DIAGNOSIS AND LABORATORY STUDIES. Erythematous candidiasis may cause depapillation of the tongue dorsum and cause some soreness and sensitivity.[231] Identification of candidal hyphae via cytology distinguishes the two. LP and MMO on the lateral tongue are white lesions that are sometimes mistaken for this condition, but biopsy showing a psoriasiform pattern with many spongiotic pustules in the absence of candidal hyphae is diagnostic.

MANAGEMENT AND PROGNOSIS. Patients should be reassured that this is not infectious in etiology, a common concern. Diphenhydramine used as a swish and spit preparation or 2% viscous lidocaine may reduce symptoms. If severe, topical steroids (especially dexamethasone) are helpful. However, patients need to realize that this is an evanescent lesion that tends to recur.

Macroglossia, hyperplastic lingual tonsil, papillitis of the tongue, and tongue nodules are discussed online.

CLINICAL MACROGLOSSIA

Macroglossia refers to the diffuse enlargement of the tongue that may be symmetric or asymmetric. Patients report that the tongue seem enlarged and is more readily traumatized by biting since it may now overly the mandibular teeth. Mild symmetric enlargement is usually caused by loss of muscle tone such as in aging or with some systemic conditions such as amyloidosis.

Loss of muscle tone ("flabby tongue") is particularly obvious in older patients who have lost all their teeth so that there is concomitant loss of bone height in the mandible. The tongue appears to "spread" over the edentulous mandibular ridge and this also makes it difficult for the lower denture to stay in place. Patients with trisomy 21 often have such flabby tongues.

Asymmetric enlargement is usually caused by the presence of a tumor, in particular a vascular malformation of either lymphatic (lymphangioma) or blood vascular origin (venous malformation) that tends to insinuate between the muscle fibers rather than produce an encapsulated mass.

DIFFERENTIAL DIAGNOSIS AND LABORATORY STUDIES. In cases of amyloid deposits or a



Figure 76-22 **A.** Migratory glossitis presenting with mostly erythema and atrophy. **B.** Subtle migratory glossitis.

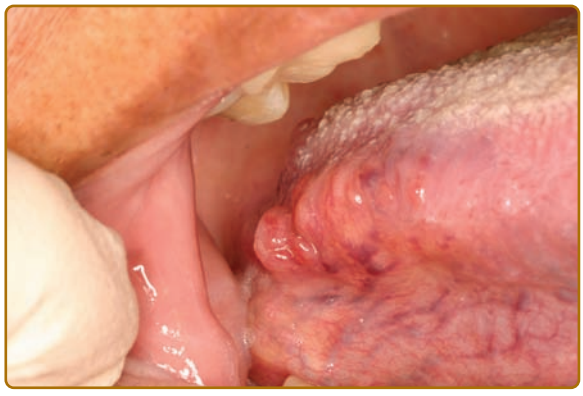

Figure 76-23 Hyperplastic lingual tonsil.



Figure 76-24 Fungiform papillitis.

neoplasm, a biopsy is diagnostic. An MRI study is usually helpful for soft tissue tumors in the tongue that present with asymptomatic enlargement.

MANAGEMENT AND PROGNOSIS. The diagnosis relies on a careful clinical history and examination, with biopsy as necessary. For symmetric lesions, there is no treatment unless the patient resorts to a surgical recontouring of the tongue.

For patients with amyloidosis, a work-up for plasma cell dyscrasia is indicated. For patients with other tumors, excision with/out the use of embolization in the case of vascular tumors is the treatment of choice.

HYPERPLASTIC LINGUAL TONSIL

The lingual tonsil is located on the posterolateral aspects of the tongue bilaterally and is part of Waldeyer ring. In its healthy form, it lies below the foliate papillae (Fig. 76-23). Inflammation of this tissue from trauma or upper respiratory tract infection leads to hyperplasia. Although the term "foliate papillitis" is often used for this condition, the more accurate term is "hyperplastic lingual tonsil."

CLINICAL FINDINGS. The hyperplastic lingual tonsil, when inflamed, protrudes as a fleshy, soft area with a slightly irregular surface (because of the crypts in the overlying foliate papillae), which then becomes more readily traumatized that then makes it even more inflamed and protuberant.[21]

DIFFERENTIAL DIAGNOSIS AND LABORATORY FINDINGS. This posterolateral tongue is a common site for SCC and the fairly rapid appearance of this lesion may mimic cancer. Lymphomas may also develop in this area.

Biopsy shows benign hyperplasia of lymphoid tissue.

MANAGEMENT AND PROGNOSIS. Excision is curative. Intralesional steroid injections may reduce the size of the lesion so that it is no longer traumatized.

There are several forms of papillitis and they represent irritation of the tongue papillae either from local trauma, dryness, or a hypersensitivity reaction (possibly to a contactant).

CLINICAL FINDINGS. One form is transient lingual papillitis that presents as multiple enlarged white papillae scattered over the surface of the tongue that tends to be relapsing–recurring.[232–234] Another form presents as reddened and enlarged fungiform papillae on the dorsum of the tongue (Fig. 76-24). A rare form is eruptive papillitis with intrafamilial transmission.[235]

MANAGEMENT AND PROGNOSIS. Dexamethasone mouth rinse reduces inflammation. However, the inciting factor must be addressed to prevent recurrence.

TONGUE NODULES

As with the lip, nodules on the lateral tongue tend to have a traumatic etiology and include fibromas (and its variant giant cell fibroma) and traumatic neuroma. More common tumors of the tongue include benign nerve sheath tumors, granular cell tumors, oral lymphoepithelial cyst, vascular lesions such as pyogenic granulomas or venous malformations, and osseous and cartilaginous hamartomas.

All require excisional biopsy and have diagnostic histopathology.

KEY REFERENCES

Full reference list available at www.DIGM8.com

DVD contains references and additional content

1. Bruch JM, Treister NS: *Clinical Oral Medicine and Pathology*, 1st edition. New York, Humana Press, 2009
2. Jurge S et al: Mucosal disease series. Number VI. Recurrent aphthous stomatitis. *Oral Dis* **12**(1):1-21, 2006

83. Thornhill MH et al: The role of histopathological characteristics in distinguishing amalgam-associated oral lichenoid reactions and oral lichen planus. *J Oral Pathol Med* **35**(4):233-240, 2006

88. Casiglia J, Woo SB, Ahmed AR: Oral involvement in autoimmune blistering diseases. *Clin Dermatol* **19**(6):737-741, 2001
93. Solomon LW: Chronic ulcerative stomatitis. *Oral Dis* **14**(5):383-389, 2008
97. Warnakulasuriya S, Johnson NW, van der Waal I: Nomenclature and classification of potentially malignant disorders of the oral mucosa. *J Oral Pathol Med* **36**(10):575-580, 2007
121. Chan LS et al: The first international consensus on mucous membrane pemphigoid: Definition, diagnostic criteria, pathogenic factors, medical treatment, and prognostic indicators. *Arch Dermatol* **138**(3):370-379, 2002
184. Fornatora ML et al: Oral melanoacanthoma: A report of 10 cases, review of the literature, and immunohistochemical analysis for HMB-45 reactivity. *Am J Dermatopathol* **25**(1):12-15, 2003
190. Mendenhall WM et al: Head and neck mucosal melanoma. *Am J Clin Oncol* **28**(6):626-630, 2005
193. Meleti M et al: Head and neck mucosal melanoma: Experience with 42 patients, with emphasis on the role of postoperative radiotherapy. *Head Neck* **30**(12):1543-1551, 2008
200. Grave B, McCullough M, Wiesenfeld D: Orofacial granulomatosis—a 20-year review. *Oral Dis* **15**(1):46-51, 2009
204. Al Johani KA et al: Orofacial granulomatosis: Clinical features and long-term outcome of therapy. *J Am Acad Dermatol* **62**(4):611-620, 2010

Chapter 77 :: Diseases and Disorders of the Male Genitalia

:: Christopher B. Bunker

DISEASES AND DISORDERS OF THE MALE GENITALIA AT A GLANCE

- Men with genital skin problems can present to physicians who are not trained or experienced in the diagnosis and management of these problems.
- Skin problems of the male genitalia may be any of the following:
  - Normal variants.
  - Manifestations of sexually transmitted diseases.
  - Dermatoses that may be generalized or found at extragenital sites but that have a predilection for the genitalia.
  - Dermatoses that are specific to the genitalia.
- Much dermatologic disease of the male organ can be linked to the causes or consequences of preputial dysfunction.
- The guiding philosophy behind diagnosis and management is to exclude sexually transmitted disease and to minimize or abolish sexual and urinary dysfunction and the risk of cancer of the penis.
- Circumcision is controversial, but it is indispensable in the management of some diseases of the penis and foreskin.

EPIDEMIOLOGY

The incidence and prevalence of male genital dermatoses are not known with accuracy, but most, like sexually transmitted diseases, are more common and more severe in the uncircumcised; these include psoriasis, seborrheic dermatitis, and lichen planus (LP).[1] The global prevalence of circumcision is estimated at 25%–33% and in the United States, 85%.[1–5] Religious and cultural practices and medical intervention account for these rates. Circumcision has been adopted as a measure to reduce human immunodeficiency virus (HIV) transmission.[6–17] Neonatal circumcision is a topic that evokes controversy, but some benefits are accepted (Table 77-1).[1,2,3,10,18–41] Although there is little evidence of significant adverse effects on health and psychosexual function, circumcision can have side effects and complications, especially when performed "ritually."[3,5,17–19,42–47] Although views of circumcision range from prophylaxis to child abuse, the rational stance is that nontherapeutic circumcision of male infants should be left to parental discretion.[3,48–50]

ETIOLOGY AND PATHOGENESIS

Etiologic and pathogenetic factors have to be understood in relationship to structure, function, and micro-

TABLE 77-1
Benefits of Circumcision

Reduced or abolished risk of penile cancer
Decreased risk of cervical cancer in partners
Protection from sexually transmitted infections, including human immunodeficiency virus infection (controversial)
Reduced risk of urinary tract infections (controversial)
Reduced risk of inflammatory genital skin diseases

ecology.[3] Obviously the genital area differs between the sexes, but it also provides a good example of regional human variation.

Although the whole organ of the skin is concerned with sexual expression and activity, the penis is the male structure most intimately involved in sexual intercourse. It is also the conduit for urinary excretion. The scrotum is the extracorporeal sack that maintains the testes at the ideal temperature for spermatogenesis. The essential structures of the penis and its important landmarks are illustrated in Figure 77-1.[3] As at other sites, topographical and regional anatomic nomenclature is an essential part of the vernacular for a dermatologist. The anatomic position is that of full penile erection.

The perineal area is abundant in eccrine and apocrine (some functionless) sweat glands and holocrine sebaceous glands, usually in association with hair follicles as pilosebaceous units but also occurring as free glands at some sites such as the anal rim or around the coronal sulcus (Tyson glands). Adnexal secretions lubricate the hinge between limb and torso, lubricate hair, lubricate the mucocutaneous junctions to assist in the voiding of excreta, and protect the epithelia from irritation and lubricate the penis for the retraction of the foreskin during sexual activity. The pattern of keratinization differs throughout the male genital tract area, most markedly so at the mucosal junctions, the prepuce and distal penile shaft, especially the

Anatomy and landmarks of the penis

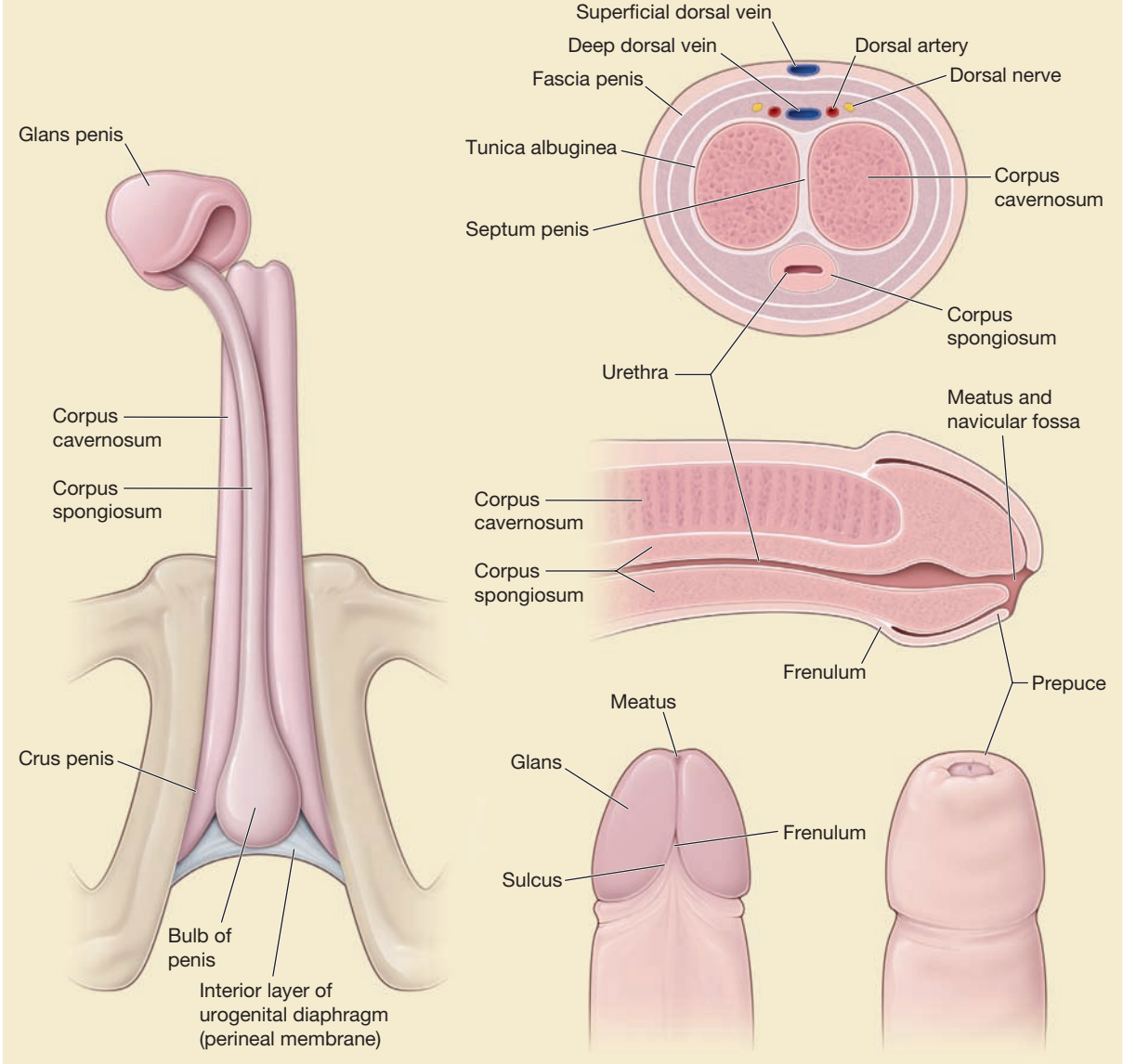

Figure 77-1 Anatomy and landmarks of the penis. (Adapted from Bunker CB: *Male Genital Dermatology.* London, Saunders, 2004.)

glans in the circumcised individual. The detritus of mucosal turnover combines with adnexal secretions to produce smegma that can accumulate in the preputial sac of the uncircumcised individual, especially if hygiene is poor. There is wide normal variation in the anatomy of the penis (particularly the urethral meatus) and its relationship to the prepuce, which perhaps reflects susceptibility to minor embryologic anomalies; the embryogenesis of the anogenital structures is complex.[3] The foreskin is a delicate, busy tissue that is in close contact with urine and exposed to sexual secretions, detergents, and infectious agents, especially opportunistic organisms and those that are sexually transmitted. Of the latter, human papillomavirus (HPV) is the most important known from the point of view of precancerous dermatoses and invasive squamous carcinoma. All these congenital and acquired factors can conspire to produce a dysfunctional foreskin,[51] often clinically expressed as male sexual dysfunction in the form of male dyspareunia. The genitals may be a site of predilection or exclusive manifestation of disorders often encountered extragenitally (e.g., vitiligo, psoriasis, and LP), in part due to the Koebner phenomenon.[3]

CLINICAL FINDINGS

The algorithm shown in Box 77-1 emphasizes the need to obtain a complete history, perform an adequate examination, and construct a differential diagnosis. Initiating investigations to exclude sexually transmitted disease or performing a biopsy may be indicated. Occasionally, a trial of treatment may help crystallize a diagnosis.

The responsibility for the elucidation of anogenital symptoms may need to be shared with the genitourinary physician, pediatrician, urologist, or colorectal surgeon.

HISTORY

Although classic dermatologic symptoms (itch, rash, lumps or bumps, or ulceration) may be present, the physician must be alert to symptoms of sexually transmitted disease (e.g., discharge, dysuria), urologic disease (e.g., pain, hematuria, dysuria), and male sexual dysfunction. Symptomatic male sexual dysfunction equates with male dyspareunia, that is, painful or

BOX 77-1 CLINICAL APPROACH TO MALE GENITAL DERMATOLOGY

HISTORY

- Age
- Job
- Symptoms
  - Itchiness, soreness, pain
  - Rash
  - Lump, bump, ulcer, blister
- History of presenting complaint
- Time and space relationships, especially to sexual activity
- Personal and family history
  - Circumcision
  - Atopy
  - Psoriasis
- Drugs and allergies
  - Systemic medication
  - Topicals
  - Over-the-counter medication
- Sexual history
  - Single/married
  - Heterosexual/homosexual/bisexual
  - Regular partner
  - Last sexual activity
    - When
    - How (vaginal, oral, anal)
  - Contraception
  - Partner symptomatology
- Urologic history and symptomatology
- Smoking

EXAMINATION

- Complete
- Mucous membranes
- Hair, nails, and teeth
- Inguinal folds and nodes
- Scrotum and contents
- Perineum and anus
- Prepuce
  - Circumcised/uncircumcised
  - Retractibility
  - Phimosis, paraphimosis
- Penis
  - Navicular fossa
  - Glans
  - Coronal sulcus
  - Frenulum
  - Shaft
- Signs
  - Pigmentary change
  - Purpura
  - Red patches
  - Balanitis/posthitis/intertrigo
  - Scaly patches
    - Eczematous/psoriasiform/lichenoid
  - Erosions/blisters/ulcers
  - Papules/nodules
  - Swelling
  - Urinalysis

DIFFERENTIAL DIAGNOSIS

- Normal variant
- Sexually transmitted disease
- Systemic disease (e.g., diabetes)
- Genital manifestation of extragenital dermatosis
- Primary genital dermatosis
- Precancer (penile carcinoma in situ: PCIS)
- Cancer



Figure 77-2 Phimosis. Foreskin unretractable. Lichen sclerosus. (© Medical Illustration UK.)



Figure 77-3 Paraphimosis. Foreskin fixed in retraction. (From Bunker CB: *Male Genital Dermatology*. London, Saunders, 2004. © Medical Illustration UK.)

difficult sexual intercourse. Many men will not volunteer such information, so specific inquiry should be tactfully made. The components of normal male sexual function are libido, erection, ejaculation, and orgasm.

CUTANEOUS LESIONS

A systematic approach to the penis and prepuce is summarized in the algorithm (see Box 77-1). The foreskin (if present) should be gently retracted, the gluteal and crural folds and the meatal lips parted, and the rectum examined digitally. Site, distribution, and morphology of lesions should be conventionally noted and analyzed. Specific male genital signs include phimosis (nonretractable foreskin; Fig. 77-2), paraphimosis (foreskin fixed in retraction; Fig. 77-3), balanitis (inflammation of the glans penis), posthitis (inflammation of the prepuce), and dorsal perforation of the prepuce (glans and shaft of penis ulcerated through the prepuce, which lies ventrally as an empty sleeve). Phimosis should be regarded as a sinister situation and impedes complete inspection and palpation of the glans and coronal sulcus. The causes of phimosis are listed in Table 77-2. Paraphimosis is rarer and is usually an acute emergency presentation caused by vigorous sexual activity, acute contact urticaria, acute allergic contact dermatitis, and lichen sclerosus (LSc). Chronic paraphimosis is increasingly recognized in India and is due to chronic inflammation and fibrosis of the foreskin in the retracted state. *Balanitis* and *posthitis xerotica (obliterans)* can be confusing terms, used to signify the end stage of all chronic cases of balanitis and posthitis (e.g., scarring dermatoses such as LP and cicatricial pemphigoid), but these conditions are usually due to LSc and are therefore considered synonymous by some. Dorsal perforation of the penis is very rare and is caused by gross penile disease such as hidradenitis suppurativa, pyoderma gangrenosum, florid condylomata, chancroid, herpes simplex, idiopathic balanoposthitis, and podophyllin misuse.[3,53,54]

RELATED PHYSICAL FINDINGS

The algorithm (see Box 77-1) underlines the necessity to examine patients conventionally, systematically, and completely, because important signs will be found at nongenital sites.

LABORATORY TESTS

The most commonly required special investigational procedures are taking a swab or smear for microbiologic

TABLE 77-2
Causes of Phimosis

Lichen sclerosus
Nonspecific balanoposthitis (e.g., in diabetes)
Lichen planus
Hidradenitis suppurativa
Crohn disease
Cicatricial pemphigoid
Chronic penile lymphoedema
Kaposi sarcoma

or virologic analysis, obtaining scrapings for fungal microscopic examination and culture, taking scrapings for mite identification, and performing a skin biopsy. Wood's light examination is helpful in the clinical diagnosis of vitiligo, erythrasma, and fungal infections. The investigations pertinent to the diagnosis of sexually transmitted disease are discussed in Section 32 (see Chapters 200, 202, 203, 204 and 205).

A genital skin biopsy is informative under selected clinical conditions. It is important to obtain the right specimen from the right site at the right time (the most floridly inflamed areas may not be the best from which to obtain a specimen and histologically often show nonspecific or zoonoid features) and to provide the pathologist with a differential diagnosis. Examination of biopsy specimens should not be regarded as a substitute for clinical diagnosis. It is safe and helpful to use small amounts of adrenaline—the region is highly vascular. Knowledge of anatomy is crucial: ventrally, the urethra can lie very close to the surface in the coronal sulcus. It is not often necessary to suture a preputial punch biopsy site.[3,55]

SPECIAL TESTS

Diagnostic imaging of the penis, scrotum, and perineum by ultrasonography or magnetic resonance can be helpful under some circumstances.[56–58] Patch testing is sometimes indicated.[3]

DIFFERENTIAL DIAGNOSIS

The principal presenting scenarios are tabulated in Box 77-2.

NORMAL VARIANTS

PEARLY PENILE PAPULES (ANGIOFIBROMAS)

Pearly or pink penile papules,[3] which may be found in between 15% and 48% of men, are flesh-colored, smooth, rounded papules (1–3 mm) occurring predominantly around the coronal margin of the glans, rarely on the glans. Often there are rows or rings of the papules. They are commoner in the uncircumcised male and regress with age.[59] Ectopic lesions, for example, on the penile shaft, have been reported. They are frequently mistaken for warts or Tyson "ectopic" sebaceous glands (of Tyson) and sometimes cause anxiety in adolescents. The histologic findings are those of angiofibroma, and the lesion is analogous to other acral angiofibromas such as adenoma sebaceum, subungual and periungual fibromas, fibrous papule of the nose, acquired acral angiofibroma, and oral fibroma. Reassurance should suffice, but cryotherapy and laser treatment have been used.[3]

SEBACEOUS GLAND PROMINENCE

Sebaceous gland prominence, Tyson glands, sebaceous hyperplasia, and "ectopic" sebaceous glands (Fordyce condition) are all essentially equivalent, common, normal variants of the skin of the scrotal sac and penile shaft, analogous to the situation on the vermillion of the lips. Nevoid linear lesions on the penile shaft and lesions on the glans have been reported. Reassurance is usually adequate, but patients can be inordinately distressed.[3]

MELANOCYTIC NEVI

It is possible that nevi on the penis occur more frequently in patients with the atypical nevus syndrome.[3] A divided or "kissing" nevus is a lesion with one-half located on the glans and the other half located on the distal penile shaft separated by uninvolved skin across the coronal divide; an analogous nevus affects the eyelids.[60] Epithelioid blue nevus of the genitals is very rare.[61]

PROMINENT VEINS

Prominent veins are common and very occasionally give rise to concern but very rarely cause complications.[3]

ANGIOKERATOMA

Angiokeratomas are more common in white men and are common on the genitalia (where, confusingly, together with prominent sebaceous glands they have attracted the eponymous epithet of *Fordyce spots*). Angiokeratomas are blue to purple, smooth, 2–5-mm papules on the scrotum, penile shaft, or glans. They generally appear and multiply during life but occasionally present as singletons. They may bleed after trauma and may be mistaken for a nevus, melanoma, or Kaposi sarcoma. The angiokeratomas of Fabry disease (see Chapter 136) are smaller than common angiokeratomas, presenting as less hyperkeratotic pinhead lesions, and are found more extensively around the lower limb girdle and upper thighs from the navel to the knees. Angiokeratoma circumscriptum very, very rarely may affect the penis (see Chapter 172).

Electrocautery or laser ablation can be offered, but the lesions may recur.

CONGENITAL ABNORMALITIES

The complicated embryogenesis of the anogenital region involving sexual differentiation and pubertal determination of secondary sexual characteristics means that congenital and developmental anomalies are common. Consequent anatomic and functional

BOX 77-2 DIFFERENTIAL DIAGNOSIS OF MALE GENITAL DERMATOSES

MALE GENITAL PRURITUS

Most Likely
- Eczema/dermatitis
- Psoriasis
- Lichen sclerosus
- Lichen planus
- Herpes simplex
- Candidosis
- Scabies
- Pediculosis
- Dysesthesia syndromes

Consider
- Insect bite/papular urticaria
- Hirsutism
- Hyperhidrosis
- Fox–Fordyce disease
- Urticaria and dermatographism
- Dermatitis herpetiformis
- Trichosporosis
- Larva currens/cutaneous larva migrans
- Onchocerciasis
- Drugs and foods

Always Rule Out
- Sexually transmitted diseases
- Bowen disease
- Erythroplasia of Queyrat
- Extramammary Paget disease
- Langerhans cell histiocytosis

MALE GENITAL HYPOPIGMENTATION/LEUKODERMA/PLAQUES

Most Likely
- Scar
- Vitiligo
- Postinflammatory
- Lichen sclerosus
- Viral warts

Consider
- Bier's spots
- Striae
- Cicatricial pemphigoid
- Pityriasis versicolor

Always Rule Out
- Squamous hyperplasia
- Extramammary Paget disease
- Mycosis fungoides

MALE GENITAL HYPERPIGMENTATION

Most Likely
- Hyperpigmentation of median raphe
- Postinflammatory hyperpigmentation
- Lentigines
- Melanosis

Consider
- Tattoos
- Purpura
- Addison and Nelson syndromes
- Laugier–Hunziger syndrome
- Peutz–Jeghers syndrome
- LAMB (*l*entigines, *a*trial *my*xoma, *b*lue nevi) syndrome
- LEOPARD (multiple *l*entigines, *e*lectrocardiographic abnormalities, *o*cular hypertelorism, *p*ulmonary stenosis, *a*bnormalities of the genitalia, growth *r*etardation, *d*eafness) syndrome
- Ruvalcaba–Myhre–Smith syndrome
- Pseudoacanthosis nigricans
- Drugs and metals

Always Rule Out
- Acanthosis nigricans
- Acral lentiginous melanoma

MALE GENITAL POSTINFLAMMATORY HYPOPIGMENTATION

Most Likely
- Postcryotherapy
  - Electrotherapy
  - Chemocautery
- Lichen sclerosus
- Lichen planus

Consider
- Contact dermatitis
  - Condom leukoderma
- Systemic sclerosis
- Cicatricial pemphigoid
- Gonococcal dermatitis
- Herpes simplex
- Pityriasis versicolor
- Onchocercal "leopard skin"
- Peyronie disease

Always Rule Out
- Leprosy
- Syphilis
  - Leukoderma—postsecondary syphilide gumma
- Pseudoepitheliomatous and micaceous keratotic balanitis

MALE GENITAL POSTINFLAMMATORY HYPERPIGMENTATION

Most Likely
- Posttraumatic
- Lichen planus
- Herpes simplex

Consider
- Fixed drug eruption

Always Rule Out
- Bowenoid papulosis

MALE GENITAL PURPURA

Most Likely
- Physical (e.g., from suction)
- Zoon balanitis
- Lichen sclerosus

Consider
- Henoch–Schönlein purpura

Always Rule Out
- Amyloidosis

(*continued*)

BOX 77-2 DIFFERENTIAL DIAGNOSIS OF MALE GENITAL DERMATOSES (*Continued*)

MALE GENITAL RED SCALY PATCHES

Most Likely
- Eczema/dermatitis
- Psoriasis
- Lichen sclerosus
- Lichen planus
- Erythrasma
- Candidosis
- Scabies
- Bowen disease

Consider
- Inflammatory linear verrucous nevus
- Reiter syndrome
- Pityriasis rosea
- Acrodermatitis enteropathica
- Hailey–Hailey disease
- Darier disease
- Kawasaki syndrome
- Primary and secondary syphilis
- Pityriasis versicolor
- Tinea
- Porokeratosis
- Fixed drug eruption

Always Rule Out
- Psudoepitheliomatous and micaceous keratotic balanitis
- Mycosis fungoides
- Extramammary Paget disease
- Langerhans cell histiocytosis

MALE GENITAL RED PLAQUES

Most Likely
- Psoriasis
- Lichen planus
- Bowen disease and bowenoid papulosis
- Fixed drug eruption

Consider
- Giant lichen simplex (of Pautrier)
- Inflammatory linear verrucous nevus
- Leishmaniasis

Always Rule Out
- Extramammary Paget disease
- Kaposi sarcoma
- Carcinoma erysipeloids
- Langerhans cell histiocytosis

BALANOPOSTHITIS AND INTERTRIGO

Most Likely
- Eczema/dermatitis
  - Contact, seborrheic
- Psoriasis
- Zoon balanitis
- Nonspecific balanoposthitis
- Lichen sclerosus
- Candidosis

Consider
- Reiter syndrome
- Acrodermatitis enteropathica
- Hailey–Hailey disease
- Darier disease
- Crohn disease
- Streptococcal dermatitis
- Staphylococcal cellulitis
- Nonsyphilitic spirochetal ulcerative balanoposthitis
- Tinea
- Amebiasis
- Myiasis
- Scabies
- Eccrine syringofibroadenomatosis
- Chronic lymphatic leukemia
- Fixed drug eruption

Always Rule Out
- Sexually transmitted disease
  - Gonorrhea
  - Syphilis
  - Chancre with balanitis
  - Human papillomavirus infection
  - Herpes simplex
  - Mycoplasma infection
  - Trichomonas vaginalis infection
  - Lymphogranuloma venereum
- Leprosy
- Erythroplasia of Queyrat
- Squamous carcinoma
- Carcinoma erysipeloides
- Extramammary Paget disease
- Kaposi sarcoma

MALE GENITAL EROSIONS

Most Likely
- Trauma
  - Excoriated pruritic dermatoses (e.g., scabies)
- Inverse pattern psoriasis
- Zoon balanitis
- Lichen sclerosus
- Lichen planus
- Herpes simplex
- Candidosis
- Erythroplasia of Queyrat

Consider
- Autoimmune bullous diseases
  - Pemphigus
  - Bullous pemphigoid
  - Cicatrizing pemphigoid
  - Linear immunoglobulin A disease
  - Dermatitis herpetiformis
- Streptococcal dermatitis
- Gonorrhea
- Secondary syphilis
- Herpes zoster
- Acute primary human immunodeficiency virus (HIV) infection
- Cytomegalovirus in HIV infection
- Tinea
- Paracoccidioidomycosis
- Pediculosis
- Porokeratosis
- Topical steroids
- Fixed drug eruption

Always Rule Out
- Kaposi sarcoma
- Langerhans cell histiocytosis

BOX 77-2 DIFFERENTIAL DIAGNOSIS OF MALE GENITAL DERMATOSES (*Continued*)

MALE GENITAL VESICLES AND BLISTERS

Most Likely

- Erythema multiforme/Stevens–Johnson syndrome
- Lichen sclerosus
- Bullous impetigo
- Herpes simplex
- Fixed drug eruption

Consider

- Acute contact dermatitis (e.g., phytophotodermatitis)
- Lichen planus
- Autoimmune bullous diseases
  - Bullous pemphigoid
  - Cicatrizing pemphigoid
  - Linear IgA disease
  - Dermatitis herpetiformis
- Herpes zoster

PENILE NECROSIS

Most Likely

- Decubitus ulcer
- Spider bite
- Strangulation/tourniquet syndromes
- Vacuum erection device use
- Priapism
- Embolism
- Pyoderma gangrenosum
- Coagulopathy
- Warfarin

Consider

- Chronic renal failure
- Diabetes mellitus
- Thrombocytopenia
- Polycythemia
- Cryoglobulinemia
- Vasculitis
- Calciphylaxis
- Ecthyma gangrenosum
- Herpes simplex

Always Rule Out

- Fournier gangrene
- Leukemia

MALE GENITAL ULCERS

Most Likely

- Trauma
- Aphthae
- Erythema multiforme
- Ulcerative sexually transmitted disease
  - Chancre of primary syphilis
  - Chancroid
  - Donovanosis
  - Lymphogranuloma venereum
  - Syphilis
- Squamous carcinoma

Consider

- Dermatitis artefacta
- Spontaneous scrotal ulceration
- Hidradenitis suppurativa
- Crohn disease
- Sarcoid
- Behçet disease
- Autoimmune bullous diseases
  - Bullous pemphigoid
  - Cicatrizing pemphigoid
  - Linear immunoglobulin A disease
- Necrobiosis lipoidica
- Hypereosinophilic syndrome
- Gonorrhea
- Tuberculosis and tuberculids
- Leprosy
- Yaws
- Nonsyphilitic spirochetal ulcerative balanoposthitis
- Herpes simplex (e.g., in HIV)
- HIV giant aphthae
- Deep fungal infections
  - Histoplasmosis
  - Blastomycosis
  - Paracoccidioidomycosis
  - Cryptococcosis
- Actinomycosis
- Leishmaniasis
- Amebiasis
- Filariasis
- Porokeratosis
- Basal cell carcinoma
- Drug reaction

Always Rule Out

- Embolization
- Penile necrosis
- Pyoderma gangrenosum
- Necrotizing vasculitis
  - Granulomatosis with polyangiitis (Wegener)
  - Systemic lupus erythematosus
  - Polyarteritis nodosa
  - Idiopathic systemic vasculitis
- Hereditary spherocytosis and vascular necrosis
- Degos malignant atrophic papulosis
- Calciphylaxis
- *Pseudomonas* infection
  - Ecthyma gangrenosum
  - Necrotizing anorectal ulcer in leukemia
- Fournier gangrene
- Sweat gland carcinoma
- Kaposi sarcoma
- Langerhans cell histiocytosis
- Extramammary Paget disease
- Leukemia
- Lymphoma

MALE GENITAL FLESH-COLORED PAPULES AND MICROPAPULES

Most Likely

- Scrotal calcinosis
- Lichen nitidus
- Viral warts
- Secondary syphilis
- Mollusca
- Acrochordons (skin tags)
- Angiofibroma (pearly penile papules)

Consider

- Median raphe cyst
- Mucoid cyst
- Tick bite/tick in situ
- Sclerosing lymphangitis
- Lichen nitidus and lichen planus
- Mucinous syringometaplasia
- Demodicidosis

Always Rule Out

- Amyloidosis
- Squamous hyperplasia
- Amelanotic malignant melanoma
- Malignant schwannoma

(*continued*)

BOX 77-2 DIFFERENTIAL DIAGNOSIS OF MALE GENITAL DERMATOSES (*Continued*)

MALE GENITAL FLESH-COLORED PAPULES AND MICROPAPULES

Most Likely	*Consider*	*Always Rule Out*
■ Fordyce spots (ectopic sebaceous glands) ■ Seborrheic keratosis ■ Epidermold cyst	■ Syringoma ■ Leiomyoma ■ Genital smooth muscle hamartoma ■ Neurofibroma ■ Lymphangioma circumscriptum ■ Lipoid proteinosis	

MALE GENITAL RED OR PIGMENTED PAPULES AND MICROPAPULES

Most Likely	*Consider*	*Always Rule Out*
■ Angioma/angiokeratoma ■ Lichen planus and nitidus ■ Inflamed viral wart ■ Secondary syphilis ■ Inflamed mollusca ■ Melanocytic nevus ■ Seborrheic keratosis ■ Scabies ■ Venous varicosities ■ Bowenoid papulosis	■ Tick bite/tick in situ ■ Insect bite ■ Granuloma annulare ■ Sarcoid ■ Primary granuloma inguinale (donovanosis) ■ Primary lymphogranuloma venereum ■ Tuberculide (lichen scrofulosorum) ■ Leprosy ■ Early chancre of primary syphilis ■ Superficial phaeohyphomycosis ■ Schistosomiasis ■ Inflamed epidermoid cyst ■ Dermatofibroma ■ Acanthosis nigricans ■ Nevus comedonicus ■ Syringoma ■ (Juvenile) xanthogranuloma ■ Pseudo-Kaposi sarcoma	■ Amyloidosis ■ Angiokeratoma corporis diffusum ■ Carcinoma erysipeloids ■ Kaposi sarcoma ■ Malignant melanoma ■ Langerhans cell histiocytosis ■ Xanthoma disseminatum ■ Metastases

MALE GENITAL PUSTULES

Most Likely	*Consider*	*Always Rule Out*
■ Penile acne ■ Candidosis ■ Folliculitis (e.g., occlusional) ■ Gonorrhea ■ Herpes simplex	■ Herpes zoster ■ Steroid acne	■ Behçet disease ■ Tuberculide (acne scrofulosorum)

MALE GENITAL PLAQUES

Most Likely	*Consider*	*Always Rule Out*
■ Lichen sclerosus ■ Confluent condylomata ■ Secondary syphilis ■ Seborrheic keratosis ■ Bowen disease and bowenoid papulosis	■ Halogenoderma ■ Granuloma inguinale ■ Atypical mycobacterial infection ■ Yaws ■ Leprosy ■ Herpes simplex (e.g., in HIV infection/immune restoration disease) ■ Candidosis ■ Deep mycoses (e.g., blastocytosis) ■ Epidermal nevus ■ Verruciform xanthoma	■ Secondary syphilis ■ Squamous hyperplasia ■ Squamous carcinoma ■ Buschke–Lowenstein tumor ■ Extramammary Paget disease ■ Xanthoma disseminatum

MALE GENITAL LYMPHEDEMA

Most Likely	*Consider*	*Always Rule Out*

■ Idiopathic penile edema
■ Postinfectious
■ Cellulitis and erysipelas
■ Chancroid
■ Granuloma inguinale
■ Lymphogranuloma venereum
■ Syphilis
	■ Idiopathic congenital lymphedema (Milroy disease)
	■ Lipogranuloma and silicone granuloma
	■ Iatrogenic
	  ■ Radical abdominopelvic surgery
	  ■ Radiotherapy
	■ Granulomatous lymphangitis
	■ Tuberculosis
	■ Leprosy
	■ Filariasis/onchocerciasis
		■ Strangulation of the penis
		■ Carcinomatosis
		■ Lymphatic involvement
		■ Lymphatic blockage
		■ Lymphoma
		■ Fournier gangrene

BOX 77-2 DIFFERENTIAL DIAGNOSIS OF MALE GENITAL DERMATOSES (*Continued*)

MALE GENITAL CYSTS OR NODULES

Most Likely
- Median raphe cysts
- Scrotal calcinosis
- Sclerosing lymphangitis
- Hidradenitis suppurativa
- Crohn disease
- Scabies
- Epidermoid cyst
- Pilar cyst
- Squamous cell carcinoma

Consider
- Segmental urethral hypospadias
- Urethral/mucoid cysts
- Hernias and herniation
- Foreign body
- Lipogranuloma
- Keloid
- Scrotal fat necrosis
- Sarcoid
- Amyloid
- Granuloma inguinale
- Penile acne
- Bacillary angiomatosis
- Leprosy
- Histoplasmosis
- Paracoccidioidomycosis
- Schistosomiasis
- Onchocerciasis
- Benign appendageal tumors
- Myxoma
- Dermoid cyst
- Granular cell tumor
- Giant cell fibroblastoma
- Connective tissue nevus
- Fibrous hamartoma of infancy
- Leiomyoma
- Neurofibroma
- Hemangioma
- Masson tumor (intravascular papillary endothelial hyperplasia)
- Epithelioid hemangioma
- Angiolymphoid hyperplasia with eosinophilia/Kimura disease
- Lymphangioma circumscriptum
- Solitary reticulohistiocytic granuloma
- Penile horn
- Keratoacanthoma
- Basal cell carcinoma

Always Rule Out
- Buschke–Lowenstein tumor/giant condyloma
- Extramucosal anorectal carcinoma
- Malignant melanoma
- Merkel cell carcinoma
- Malignant eccrine poroma
- Sarcoma
- Malignant schwannoma
- Kaposi sarcoma
- Chronic lymphocytic leukemia
- Langerhans cell histiocytosis
- Metastases

PENOSCROTAL SWELLING

Most Likely
- Paraphimosis
- Foreign body
- Strangulation of the penis
- Iatrogenic
  - Continuous ambulatory peritoneal dialysis
  - Raised right heart filling pressure in intensive therapy unit
  - Postsurgery
  - Postradiotherapy
- Varicocele
- Hydrocele
- Priapism
- Peyronie disease
- Epididymitis and orchitis
- Cellulitis
- Idiopathic penile edema
- Testicular tumors

Consider
- Idiopathic congenital lymphedema
- Giant hemangioma
- Urethral diverticulum
- Segmental urethral hypospadias
- Accessory scrotum
- Herniation of scrotal contents into penile shaft
- Foreign body
- Lipogranuloma/silicone granuloma
- Scrotal fat necrosis
- Henoch–Schönlein purpura
- Familial Mediterranean fever
- Acute hemorrhagic edema of childhood
- Granulomatous lymphangitis
- Sarcoid
- Infected cyst
- Tuberculosis
- Paracoccidioidomycosis
- Giant scrotal tumor (e.g., neurilemoma)
- Epithelioid hemangioma
- Epithelioid hemangioendothelioma
- Drugs (e.g., angioedema due to lisinopril)

Always Rule Out
- Aortic aneurysm
- Abscess of corpus cavernosum
- Kaposi sarcoma
- Lymphoma
- Sarcoma
- Fournier gangrene

abnormality may increase the vulnerability of the area to dermatoses (such as LSc) and infections.

Common abnormalities include meatal pit, hypospadias, median raphe cysts, canals and sinuses, and ambiguous genitalia. Rarer anomalies include hypospadias variants, meatal stricture, mucoid or urethral cysts, dermoid cysts, buried penis, urethral atresia, penoscrotal transposition, congenital lymphedema, giant preputial sac, megaprepuce, accessory scrotum, hemangiomas, strawberry nevus, os penis, and true aposthia. These entities may be features of congenital syndromes.[3]

SEXUALLY TRANSMITTED DISEASES

VENEREAL DISEASES

The clinical manifestations on the male genitals of syphilis, chancroid, lymphogranuloma venereum, granuloma inguinale, gonorrhea, and other venereal diseases as well as their pathogenesis, diagnosis, treatment, and complications are discussed in depth in Chapters 200, 202–205). Here it may suffice to remind the physician that any inflammatory, papulonodular, or ulcerative genital presentation requires consideration and exclusion of sexually transmitted diseases.

PEDICULOSIS

(See Chapter 208)

Pediculosis pubis, or lice infestation ("crabs"), can cause severe genital itching with few physical signs unless the hairs are examined assiduously for nits and the base of individual hairs is scrutinized with a hand lens for the crab lice (1–2 mm), which will be tightly adherent to the skin because their mouth parts are embedded in perifollicular blood vessels. Sometimes gray–blue macules (tache bleu, maculae caeruleae) are seen on the affected sites.

SCABIES

(See Chapter 208)

Scabies is a cause of intense itching that characteristically keeps patients awake at night. Usually there is a rash of diagnostic distribution and morphology. Some patients with scabies—who may have been infested for a long time, have had it before, have been inadequately treated, or have been adequately treated but develop secondary eczema or nodules—may have itch in the anogenital region only.

VIRAL WARTS

(See Chapter 196)

CLINICAL FINDINGS. Genital HPV infection can usually be diagnosed with certainty on clinical grounds (Figs. 77-4 and 77-5). Morphology is described in Chapter 196. Clinically inapparent penile warts may present as balanoposthitis.[62–64]



Figure 77-4 Viral warts. Condyloma acuminata. (© Medical Illustration UK.)

DIFFERENTIAL DIAGNOSIS. Disorders from which viral warts must be differentiated are listed in Box 77-3.

COMPLICATIONS. HPV infection is a risk factor for anogenital cancer, particularly of the cervix and anus. HPV is associated with the clinical expressions of penile carcinoma in situ (PCIS), or Bowen disease of the penis, erythroplasia of Queyrat (EQ), or bowenoid papulosis (BP) and approximately 50% of cases of



Figure 77-5 Viral warts. Confluent plaque. No histologic dysplasia. Patient with diabetes. (© Medical Illustration UK.)

BOX 77-3 DIFFERENTIAL DIAGNOSIS OF VIRAL WARTS

Most Likely
- Pearly penile papules
- Seborrheic keratoses
- Nevi
- Mollusca

Consider
- Lichen planus
- Lichen nitidus
- Bowenoid papulosis

Always Rule Out
- Condylomata lata (secondary syphilis)
- Squamous carcinoma (and variants)

BOX 77-4 TREATMENT FOR GENITAL WARTS

Cryotherapy
Surgical/scissor excision
Electrocautery/electrotherapy
Loop electrosurgery
Laser surgery
Interferons
  Intralesional
  Systemic
  Topical
Podophyllin/podophyllotoxin
Trichloroacetic acid
5-Fluorouracil
Imiquimod

squamous carcinoma of the penis.[65,66] Infection with HIV may alter and worsen the expression and consequences of anogenital HPV infection: high-grade dysplasia associated with high-risk HPV types have been found in the urothelium and genital warts from HIV-positive individuals and the penis cancer risk is increased three- to sixfold (the anal cancer risk may be increased by as much as 100).[3,67–75]

TREATMENT. Patients presenting with warts, as well as their sexual partners, should be counseled and screened for HPV, other sexually transmitted diseases including HIV infection, and cervical neoplasia.

HPV infection may be very difficult to treat. Subclinical infection is very common, difficult to detect, and virtually untreatable, so there is divergence between ambitions for treatment and achievability. The principles of management are based on diagnosing and treating relevant lesions that are causing personal genital morbidity or psychosexual stress or long-term risk to the patient or his partner. Reasonable goals include (1) inducing cure or wart-free periods, (2) relieving or improving symptoms such as dyspareunia, (3) ensuring that side effects or complications of the treatment are no worse than the symptoms or risks of the warts, (4) minimizing morbidity and mortality from cervical cancer in female partners, (5) minimizing mortality and morbidity from PCIS and frank cancer in the patient especially those with HIV.[62,69,72,73]

Treatments are listed in Box 77-4.[3,62,69,76,77]

MOLLUSCA

(See Chapter 195)

Mollusca may be sexually acquired, as in adult men, but genital lesions caused by autoinoculation are common in children. Classically small, flesh-colored, monomorphic, dome-shaped papules indented by a central dell or umbilicus are seen. Multiple lesions are usually present. Giant and polypoidal lesions may occur in the setting of HIV infection. Inflammation and purulence may be due to infection but are a common phenomenon when individual lesions spontaneously involute. Condylomata lata (secondary syphilis) and LP enter the differential diagnosis of mollusca, as do simple HPV infection and BP. Treatment may not be necessary especially in children. Options are similar to those for viral warts.[3,77]

DERMATOSES WITH A PREDILECTION FOR THE MALE GENITALIA

VITILIGO

(See Chapter 74)

Vitiligo commonly affects the genitalia in men and may be the only site to be affected. Perianal involvement is also common.[3] Other organ-specific autoimmune diseases should be excluded. Vitiligo has been reported after treatment of genital warts with imiquimod.[78,79] An important rare differential diagnosis is depigmented extramammary Paget disease (EMPD).[80] Phototherapy of vitiligo might lead to squamous cell carcinoma (SCC).[81]

SEBORRHEIC DERMATITIS

(See Chapter 22)

A diagnosis of seborrheic dermatitis is made when a nonspecific psoriasiform or eczematous balanitis or balanoposthitis is found in conjunction with classic symptoms and extragenital manifestations of the diathesis.[3]

No treatment other than reassurance may be required. However, treatments that diminish the commensal pityrosporum load and reduce irritation and eczematization can be very successfully and safely used long term. These include topical antifungals (such as clioquinol, nystatin, and imidazoles) in the



Figure 77-6 Psoriasis. Circumcised glans penis. (© Medical Illustration UK.)

form of ointments, creams, lotions, or shampoos and mixtures of the same agents with mild and moderately potent topical corticosteroids used alongside emollients and soap substitutes. In severe cases, such as with concomitant seborrheic folliculitis or in acquired immunodeficiency syndrome (AIDS), treatment with an oral imidazole might be indicated.

PSORIASIS

(See Chapter 18)

Psoriasis is probably the most common dermatosis of the male anogenitalia, either in isolation or in association with frank or mild, subtle extragenital disease.[3] The Koebner phenomenon is a likely factor in site predilection. Drugs such as lithium, β blockers, antimalarials, and angiotensin-converting enzyme inhibitors may be responsible for the onset or exacerbation of psoriasis.

In circumcised men, genital psoriasis presents with variably itchy, silvery-scaled, erythematous patches or plaques (Fig. 77-6). On the glans or in the preputial sac of the uncircumcised patient, scale is absent from the patches or plaques because of the mucosal site (Fig. 77-7). The scalp, ears, umbilicus, and face (in sebopsoriasis) may be involved, and there may be variable additional anogenital involvement, especially of the sacrum, buttocks, intergluteal cleft, pubic mound and groin, perianal skin, and, less commonly, the scrotum. Psoriatic balanoposthitis can be part of the spectrum of inverse-pattern psoriasis and may be associated with intertriginous disease of the axillae, intergluteal cleft, gluteal folds, and groin.

Patients with the reactive arthritis syndrome (see Chapter 20) may sometimes have involvement of the penis with circinate balanitis or small, flat pustules. These penile lesions have the same histopathology and ultrastructure as psoriasis. Sometimes this morphology is seen clinically with no background urethritis, gastroenteritis, or arthritis (Fig. 77-8).



Figure 77-7 Psoriasis. Uncircumcised glans penis and prepuce. (© Medical Illustration UK.)

Usually the diagnosis of psoriasis is clinical. Soreness might indicate superinfection, especially with *Candida*. Inordinate itch would make one suspect another dermatosis such as an eczematized dermatitis or tinea. A biopsy



Figure 77-8 Circinate balanitis. HLA-B27 positive. No background urethritis, gastroenteritis, or arthritis. (© Medical Illustration UK.)

may be necessary if there are solitary mucosal lesions in the uncircumcised to exclude Zoon balanitis (ZB), LP, EQ, and Kaposi sarcoma. Bowen disease and EMPD may be misdiagnosed as psoriasis when there are single or several foci on the penile shaft and/or in the groin.

Topical treatment is based on the use of emollients, soap substitutes, corticosteroids combined with antibiotic and antifungal agents, or weak tar solutions. Atrophy is a risk with long-term use of potent topical steroids, and anogenital skin has a heightened tendency to absorb topical agents. Strong crude tar preparations should also therefore be avoided at this site because of the risk of genital cancer. Dithranol application may lead to burning and so is usually avoided in this region. Vitamin D analogues and calcineurin inhibitors seem safe, but with the latter, the prescriber must be certain of the absence of PCIS. Severe anogenital inverse psoriasis can be an indication for systemic treatment. Phototherapy is conventionally contraindicated because of the risk of anogenital cancer. It is possible that chronic anogenital psoriasis and its treatment may create a risk for anogenital squamous cancer.

LICHEN PLANUS

(See Chapter 26)

LP has a particular predilection for the mucosa, which is perhaps partly explained by the Koebner phenomenon. LP can present in, and remain focalized to, the pelvic girdle, the genital area including the groin, and the perianal skin. Alternatively, symptoms and morphology of the classic disease—lilac papules and plaques with white lacy scale—may be present at other sites (Fig. 77-9). However, it may affect the penis (like the mouth, vulva, and anus) in isolation as the cause or consequence of foreskin dysfunction (by "koebnerization") and so present as dyspareunia and a nonspecific dermatosis.[3]

The differential diagnosis includes eczema, psoriasis, seborrheic dermatitis, nonspecific balanoposthitis, ZB, LSc, drug eruption, porokeratosis, viral warts, penile precancer, and frank SCC. LP can cause phimosis; the differential diagnosis of phimosis is given in Table 77-2.



Figure 77-9 Lichen planus. Annular plaque. Circumcised glans penis. Coronal rim. (From Bunker CB: *Male Genital Dermatology*. London, Saunders, 2004. © Medical Illustration UK.)



Figure 77-10 Lichen planus. Erosions on glans penis and prepuce. Severe dyspareunia. (© Medical Illustration UK.)

Just as extragenital disease, for example, on the palms and soles, may be erosive in rare cases, occasionally an erosive form of genital disease is encountered (Fig. 77-10). A male equivalent of the vulvovaginal syndrome of Hewitt with chronic erosive gingival and genital lesions (genito-gingival syndrome) has been described.[82] Bullous penile LP has also been reported.[83]

Although LP is self-limiting, some patients experience relapses and remissions. Adhesions can form. Postinflammatory hyperpigmentation can persist for months or years.

Chronic mucosal erosive LP is associated with a risk of SCC, although most reports linking the two concern oral LP. SCC may complicate chronic hypertrophic LP of the lower leg but has also occurred in the context of hypertrophic LP of the glans penis.[3,84,85]

A biopsy is frequently necessary for diagnostic purposes but, more importantly, is performed in following up the rare cases of chronic anogenital disease in which the appearance of ulcero-erosive or verrucous features leads to concern about the development of SCC. The classic histologic findings are discussed in Chapter 114.

Potent or very potent topical corticosteroids usually produce remission. Patients should be warned about postinflammatory hyperpigmentation. Systemic corticosteroids are sometimes indicated for severely symptomatic disease, erosive orogenital involvement, and scarring of the scalp and nails. Topical and systemic cyclosporin has been used. Circumcision may be necessary if there is phimosis and should be seriously considered in cases of refractory disease, especially the erosive form, because the removal of "koebnerizing" influences may allow the LP to remit. The toxicity and the lack of efficacy of systemic therapy in treating this distressingly symptomatic situation are other powerful arguments in favor of circumcision.[3,86]

LICHEN NITIDUS

(See Chapter 27)

Lichen nitidus is sometimes held simplistically and controversially to be a micropapular variant of LP. It has an affinity for the penis and can be difficult to diagnose because the signs may be subtle, even when the lesions are widespread. Also, when the lesions are very pruritic, the signs due to excoriation and eczematization may eclipse those due to the lichen nitidus.[3]

GRANULOMA ANNULARE

(See Chapter 44)

Erythematous smooth, ovoid nodules of granuloma affecting the penis have been described. They are perhaps related to trauma and koebnerization, because circumcision can be curative.[87]

NECROLYTIC MIGRATORY ERYTHEMA

Necrolytic migratory erythema can be focalized to the male genitalia as a sore or painful annular erythematous eruption with a central glassy appearance and serpiginous border surrounded by scaling. It is a characteristic cutaneous manifestation of the glucagonoma syndrome (see Chapter 153).[88]

APHTHAE

The diagnosis of aphthous ulceration of the genitalia requires the exclusion of sexually transmitted diseases and other causes of genital ulceration, especially Behçet disease. This is in contradistinction to oral ulceration, in which a clinical diagnosis is acceptable practice.[3] The causes of aphthae are obscure. The histologic findings of idiopathic aphthous ulceration are nonspecific. Aphthae and idiopathic orogenital ulceration are more common and are worse, symptomatically and morphologically, in HIV-infected individuals. In patients with AIDS, biopsy must be performed on all mucocutaneous ulcers and specimens must be cultured; several pathologies may coexist. Treatment of simple aphthae is with topical corticosteroid/antibiotic/anticandidal combinations. In patients with AIDS, thalidomide may be efficacious.

BEHÇET DISEASE

(See Chapter 166)

The genital ulcers in men are painful, sometimes very painful, and this distinction may be helpful. They occur anywhere on the anogenitalia, including the scrotum and perianal skin. They are said to be bigger, deeper, fewer, and less recurrent than those in the mouth.

To diagnose Behçet disease according to strict diagnostic criteria, oral ulceration must be present; then patients must also either manifest genital ulceration and ophthalmic involvement or genital ulceration and skin signs (or a positive pathergy test result). In practice, there are many patients who have an incomplete syndrome. Although their disease does not satisfy these rigid diagnostic criteria, "possible" or "probable" Behçet disease is an acceptable label for everyday practical purposes. Essentially, Behçet disease is a systemic vasculitis that may involve many organs, so that protean presentations and complications are possible. Patients with relapsing polychondritis (see Chapter 159) and Behçet disease have been reported, and the term *MAGIC* (*m*outh *a*nd *g*enital ulcers with *i*nflamed *c*artilage) *syndrome* applied.[89,90] Histologic findings are usually nonspecific and do not distinguish idiopathic aphthae, although sometimes necrotizing vasculitis can be seen. Topical treatment with corticosteroid/antimicrobial combinations may suffice. Topical interferon α lozenges have been advocated.[91] However, some patients will require systemic treatment with colchicine, prednisolone, azathioprine, cyclosporin, thalidomide, infliximab, or etanercept.[3,92,93] (See Chapter 166).

MUCOUS MEMBRANE PEMPHIGOID

(See Chapter 57)

Mucous membrane (cicatricial) pemphigoid is a rare disease that must be in the differential diagnosis of blistering, erosions, ulcers, transcoronal adhesions, scarring, and phimosis.[3,94] These manifestations can occur in isolation, but ophthalmic, oropharyngeal, and cutaneous lesions are more common than genital involvement. Direct immunofluorescence usually yields positive results, but indirect immunofluorescence does not. Topical and oral steroids may be ineffective. Dapsone, sulphamethoxypyridazine, mycophenolate, and biological therapies may be used.

PYODERMA GANGRENOSUM

(See Chapter 33)

Pyoderma gangrenosum is a rare event but is frequently misdiagnosed or diagnosed late while infections and cancer are pursued diagnostically (Fig. 77-11). It may represent a pathergic reaction after urologic surgery or complicate inflammatory bowel disease or leukemia. Treatment must be aggressive to avoid permanent damage to the urethra and erectile tissues.[3]

DRUG ERUPTIONS

(See Chapter 41)

The penis is a classic site of predilection for fixed drug eruptions.[3] Clinically, fixed drug eruption is characterized by the acute eruption of itchy, painful, swollen plaques, sometimes with central blister formation, erosion, and ulceration. Postinflammatory hyperpigmentation can be persistent. On first exposure to the drug the eruption can take 1–2 weeks to appear but subsequently appears just a few hours after administration. Recurrence is at the same site(s) each time the drug is encountered, and rechallenge/provocation can be used as a diagnostic test. For causes, see Chapter 41.

Ulceration due to papaverine can occur when the drug is inadvertently injected subcutaneously for the treatment of erectile impotence.[95] Heparin and warfarin have induced skin necrosis of the genitalia.[3] All-*trans* retinoic acid has been reported to induce genital



Figure 77-11 Pyoderma gangrenosum. Most of the shaft of the penis, but not the glans, has been destroyed. (© Medical Illustration UK.)

ulceration in patients with hematologic malignancy.[96] Foscarnet can create genital ulceration in HIV-infected patients due to the high urinary concentrations of the drug.[97] Nicorandil is a newly-appreciated cause of anogenital and peristomal ulceration.

Lisinopril has been associated with genital angioedema.[98] The cutaneous side effects of topical steroids are well known: striae, atrophy, erythema, telangiectasia, erosion, and modification of cutaneous, bacterial, viral, and fungal infections occur commonly. Drugs can also cause pruritus and urticaria.

STREPTOCOCCAL DERMATITIS

(See Chapter 176)

Streptococcal dermatitis causing a perianal cellulitis is a recognized syndrome in children, but a similar clinical situation occasionally occurs in adults and might affect the genitalia alone.[3] It is much more common in boys, and if the penis is involved, there may be dysuria, erythema, swelling, and balanoposthitis. Group A β-hemolytic streptococci can be isolated, and the lesions may be associated with streptococcal infection of the upper respiratory tract in other members of the family. Treatment is generally with systemic penicillin.

HERPES ZOSTER (SHINGLES)

(See Chapter 194)

Sacral herpes zoster is relatively rare but can be associated with severe morbidity due to nocturia, dysuria, acute urinary retention, constipation, and fecal retention.[3] When the pain precedes the rash, the differential diagnosis of an acute surgical emergency is evoked. Painful, grouped, crusting, vesicopustular lesions may be found unilaterally on the buttock, in the perineum, on the scrotum and penis, in the groin, and on the upper thigh. Hospitalization, urologic assessment, observation, possibly catheterization and sigmoidoscopy, and possibly assisted fecal extraction are indicated. Treatment should be with intravenous acyclovir.

TINEA

(See Chapter 188)

Tinea of the penis or scrotum is not common, and when it occurs it is usually associated with crural disease. Rarely encountered is tinea that occurs on the glans penis as a seat of itch or pain and produces an erythematous patch or a crop of scaly papules.[3] In India, it is associated with penile lesions due to the wearing of a langota, an occlusive T-shaped loincloth.[99]

SCHISTOSOMIASIS

(See Chapter 207)

Perineal granulomatous lesions are a rare manifestation of schistosomiasis (infection with *Schistosoma haematobium*).[3,100] Rarely genital skin lesions may lead to the diagnosis. They occur because of ova shed by worms that have entered the perineal vessels from the pelvic venous plexuses. Papules and nodules may be itchy; may be skin-colored, pink, or brown; may be scattered or grouped; and may affect the penis and scrotum. They can spread onto the perineum and around the anus and may develop into soft, warty, vegetating lesions but remain relatively asymptomatic. Ulceration is rare and carcinoma even rarer. Diagnosis is by biopsy (see Chapter 207). Ova may be recovered from urine or stool.

ONCHOCERCIASIS

(See Chapter 207)

The dermatologic genital consequences of onchocerciasis are pruritus, "leopard skin" hypopigmentation (on shins and scrotum), nodules (on ileal crests, scrotum, and ribcage), dermatitis, including "lizard skin" lichenification, "hanging groin," and scrotal enlargement.[3] The differential diagnosis of the scrotal enlargement includes bancroftian filariasis. The diagnosis is made by demonstrating microfilariae in skin snips.

POROKERATOSIS

Genital porokeratosis of Mibelli (see Chapter 52) is rare.[3,101] Annular raised (double-rimmed) lesions have been found in the intergluteal cleft, on the scrotum, and on the penis, including the glans. Rarely lesions may be ulcerative. Porokeratosis may be misdiagnosed clinically as psoriasis, Bowen disease, granuloma annulare, or LP but histologic examination of the margin shows the characteristic cornoid lamella. Cryotherapy and topical 5-fluorouracil can be used for treatment.

KAPOSI SARCOMA

(See Chapter 128)

Solitary Kaposi sarcoma of the penis was recognized, if rarely, before the HIV epidemic, and cases are still occasionally seen in HIV-negative patients.[3] AIDS-related Kaposi sarcoma is usually multicentric and often involves the face, oral mucosa, palate, and penis (20%). A solitary lesion is not unusual. It can present as a dull red patch or plaque on the glans penis or in the preputial sac and can also affect the penile shaft, scrotum, and perianal skin in one of its more classic manifestations—namely, purple, slightly scaly patches or plaques, nodules, and ulcerative lesions. An engorged, "hypervascular" presentation has been described, as has penile lymphedema, acute phimosis, and rectourethral fistulation. Odd morphology should arouse suspicions of mixed pathology.

LYMPHOMA, LEUKEMIA, METASTASES

Ulceration of the penis in chronic lymphocytic leukemia and scrotal ulceration in acute myelogenous leukemia due to leukemic infiltration have been reported.[3] Pyoderma gangrenosum, *Pseudomonas* infection, and Fournier gangrene can be associated with hematologic malignancy. Although the groin is a classic site of involvement in Langerhans cell histiocytosis (see Chapter 147), involvement of the penis is very rare. Metastases to the penis and scrotum occur uncommonly.[102] They are usually secondary to cancer of the urogenital tract or gastrointestinal system (e.g., rectum) or complicate other common cancers such as those of the lung. They may present with pain, swelling, priapism, urinary symptoms, or hematuria. A cutaneous nodule or nodules may be seen or infiltration of the deeper penile structures palpated.

PRIMARY MALE GENITAL DERMATOSES

PENILE MELANOSIS AND LENTIGINOSIS

Several terms have been coined to describe benign pigmented macules of the penis such as penile melanosis, penile melanotic macules, and atypical pigmented penile macules: penile melanosis, vulvovaginal melanosis, and the predominantly oral mucosal hyperpigmentation of Laugier–Hunziker syndrome (see Chapter 75) may be grouped under the umbrella of essential melanotic hyperpigmentation of the mucosa.[3,103] Some if not all cases may represent postinflammatory hyperpigmentation from previous disease or insult [e.g., phimosis, balanoposthitis, topical treatment, LSc (Fig. 77-12), LP, circumcision]. It has been suggested that adjacent depigmentation is an essential element of the condition.[104] Although *penile melanosis* is a good term for lesions without lentiginous hyperplasia on histologic examination, there may be increased basal epidermal pigmentation with or without benign lentiginous melanocytic hyperplasia, including ultrastructurally. The possibility of Addison or Nelson syndrome should be entertained, as should the possibility of a lentiginosis syndrome [Peutz–Jeghers, LAMB (*l*entigines, *a*trial *m*yxoma, *b*lue nevi), LEOPARD (multiple *l*entigines, *e*lectrocardiographic abnormalities, *o*cular hypertelorism, *p*ulmonary stenosis, *a*bnormalities of the genitalia, growth *r*etardation, *d*eafness), or Bannayan–Riley–Ruvalcaba syndrome (see Chapter 75)], although idiopathic lentigines of the penis are recognized.



Figure 77-12 Penile melanosis. Glans penis. Postlichen sclerosus. (© Medical Illustration UK.)

If lesions are large or enlarging, with irregular edges and multifocal and variegated pigmentary patterns, concern may be raised about atypical melanocytic proliferation and acral lentiginous melanoma.

Despite being benign, penile melanosis can be cosmetically disturbing. Laser treatment may be helpful.

ZOON BALANITIS

ZOON BALANITIS AT A GLANCE

- Zoon plasma cell balanitis (ZB; properly balanoposthitis) affects the middle-aged and older uncircumcised male.
- ZB is a chronic, reactive, irritant mucositis.
- ZB is characterized by silent symptomatology and florid signs.
- Zoonoid inflammation is a common corollary of other dermatoses that cause a dysfunctional prepuce. Asymmetric, atypical, or unusual morphology should be viewed with suspicion.
- Circumcision is the definitive treatment in the majority of cases.

ETIOLOGY AND PATHOGENESIS. The evidence indicates that ZB is a chronic, reactive, principally



Figure 77-13 Zoon balanitis. Symmetric red patches. Glans penis and prepuce. (© Medical Illustration UK.)



Figure 77-14 Zoonoid inflammation. Florid zoonoid balanoposthitis complicating lichen sclerosus. (© Medical Illustration UK.)

irritant mucositis that causes, or is due to, a dysfunctional foreskin.[3,51] Irritation is induced by retention of urine and squames between two tightly apposed and infrequently and inadequately separated and/or infrequently or inappropriately bathed, commensally hypercolonized, desquamative, secretory epithelial surfaces.

CLINICAL FINDINGS. An asymptomatic presentation with little or no dyspareunia is classic. Conversely, the signs can be florid. Well-demarcated, glistening, moist, shiny, bright red, or autumn brown patches symmetrically involve the glans and inner prepuce, sparing the keratinized penile shaft or foreskin (Fig. 77-13). Other signs include dark red stippling or "cayenne pepper spots" due to hemosiderin deposition and solitary or multiple lesions of differing sizes (guttate or nummular), characteristically "kissing." Rarely, erosive and vegetative presentations have been reported, but lesions with asymmetric, atypical, or unusual morphology should be viewed with great suspicion and the organ inspected diligently for other, less florid signs. ZB may be secondary and may thus conceal more subtle evidence of underlying preputial disease such as LSc, precancer, or frank cancer that might have induced the manifest zoonoid changes. Overt cases of other dermatoses such as contact dermatitis, psoriasis, LSc, LP, penis precancer, and penile cancer may appear to have zoonoid changes on clinical and histologic examination (Fig. 77-14). It is possible that some of the clinical and histologic variants that have been reported and the dubious claim that ZB per se is a premalignant condition are a consequence of this phenomenon.[105]

LABORATORY TESTS. On histologic examination the epidermis is attenuated with absence of the granular and horny layers, sparse dyskeratosis and spongiosis, and diamond- or lozenge-shaped basal cell keratinocytes. In the dermis there are variably seen a band of plasma cells infiltration, extravasated erythrocytes, hemosiderin, fibrosis, and vascular proliferation.[106]

DIFFERENTIAL DIAGNOSIS. Disorders from which ZB must be differentiated are listed in Box 77-5.

TREATMENT. Although the condition may be ameliorated by improvement in washing habits and micturition

BOX 77-5 DIFFERENTIAL DIAGNOSIS OF ZOON BALANITIS

Most Likely
- Psoriasis
- Seborrheic dermatitis
- Lichen sclerosus
- Nonspecific balanoposthitis

Consider
- Contact dermatitis
- Erosive lichen planus
- Viral warts
- Herpes simplex
- Fixed drug eruption

Always Rule Out
- Erythroplasia of Queyrat
- Kaposi sarcoma

practices and by the intermittent application of mild or potent topical corticosteroids (with or without antibiotics and anticandidals) and topical tacrolimus, ZB usually persists or relapses. Definitive curative treatment is surgical circumcision.[3,107,108]

LICHEN SCLEROSUS

LICHEN SCLEROSUS AT A GLANCE

- Male genital lichen sclerosus (LSc) is an idiopathic inflammatory fibrosing dermatosis.
- It is principally a disease of uncircumcised men, although it can persist or recur after circumcision.
- LSc can be the cause of significant morbidity expressed as preputial dysfunction and male dyspareunia.
- Between one-fourth and one-half of cases of squamous cell carcinoma (SCC) of the penis may be preceded by LSc. SCC complicating LSc carries a high mortality.

(See Chapter 65)

EPIDEMIOLOGY. Genital LSc is more common than extragenital disease, but there may very occasionally be involvement in both areas. In adults, anogenital LSc is said to be about ten times more common in women than in men. Perianal disease is very rarely, if ever, encountered in the male. LSc may be much more frequent than is generally supposed in young boys. In boys, persistent primary phimosis or the secondary development of phimosis in a previously retractable foreskin should be viewed with suspicion: some, many, or most of such cases will be due to LSc.[3,51,107,109]

ETIOLOGY AND PATHOGENESIS. The pathogenesis of LSc, particularly the role of autoimmunity, is discussed in Chapter 65. Antiextracellular matrix protein 1 antibodies have been found in the sera of male and female patients with genital LSc.[110,111] In male genital LSc, roles seem likely for trauma (as suggested by cases in which the development of LSc was related to injury or surgery[112]) and contact with urine (as suggested by the association of genital LSc with anatomic abnormality, particularly hypospadias,[113] and the striking differences in the pattern of distribution between the sexes) but not for infection (men with genital LSc rarely if ever have sexual partners with LSc[3,107]). It is likely that chronic exposure of susceptible epithelium to urine due to a dysfunctional naviculomeatal valve accounts for most cases in men.[114]

CLINICAL FINDINGS. LSc is discussed in detail in Chapter 65. The symptoms and signs of male genital LSc are summarized in Table 77-3 and partially illustrated in Figs. 77-15 and 77-16. The principal presentation in men is of dyspareunia. The classic genital morphologic manifestations of LSc are of atrophic white patches or plaques or lilac, slightly scaly patches with telangiectasia and sparse purpura, like those of

TABLE 77-3
Symptoms and Signs of Male Genital Lichen Sclerosus

Asymptomatic
Spontaneous
Itching, burning, soreness, pain, adhesions, blisters, white patches, purpura, balanoposthitis, phimosis
Dyspareunia
Itching, burning, soreness, pain, bleeding, tearing, splitting,
Effacement of normal architectural features
Phimosis, narrow meatus, dissolution of frenulum, short frenulum, broad frenulum, "bunched" frenulum, white papules and patches, loss of coronal definition, adhesions, telangiectasia, scarring, fibrotic band ("waisting" or "bunching"), constrictive posthitis
Posthitis and balanitis xerotica
Dysuria, voiding difficulties, urinary retention
Renal failure
Cancer



Figure 77-15 Lichen sclerosus. Constrictive posthitis and tight fibrotic band causing "waisting" or "bunching." (© Medical Illustration UK.)

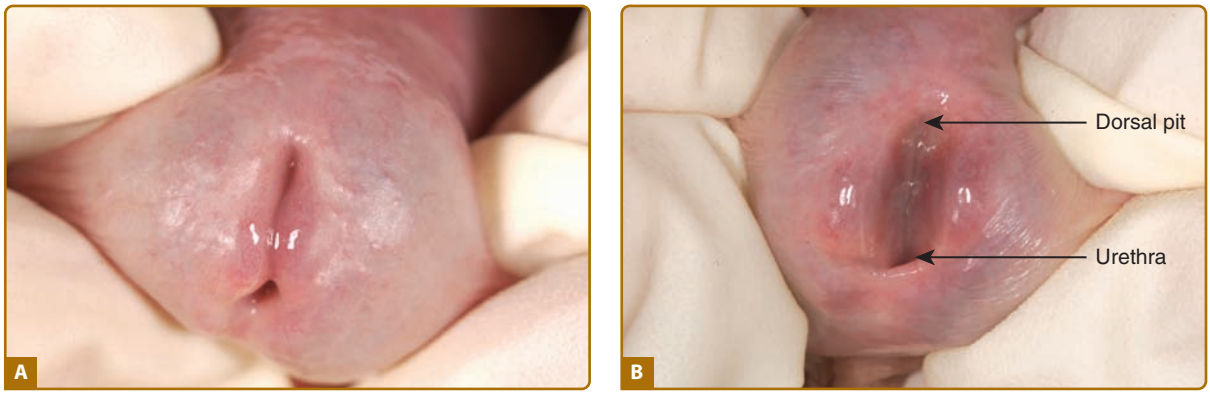

Figure 77-16 Lichen sclerosus affecting the glans penis. Etiolation (washed out appearance) is apparent. **A.** Apparent partial hypospadias. **B.** Meatal lips parted to reveal the deep navicular fossa with dorsal pit. This naviculomeatal architecture leads to an incompetent valve and urinary dribbling postmicturation. (© Medical Illustration UK.)

the classic clinical manifestations of extragenital LSc, may be seen. A constrictive lichenoid posthitis is commonly seen associated with a fibrotic preputial band causing "hourglass" "waisting" of the penile shaft.[3] Urethral involvement may be more common and extensive than hitherto supposed.[115,116]

Most cases of LSc can be diagnosed clinically. If there is clinical doubt, then a biopsy should be performed. The histologic findings are discussed in Chapter 65.

DIFFERENTIAL DIAGNOSIS. Disorders from which LSc must be differentiated are listed in Box 77-6.

COMPLICATIONS. The urological morbidity due to urethral disease can be severe.[116] The psychological consequences of sexual dysfunction for men and their partners are frequently overlooked. SCC of the penis is the most worrying complication of LSc: the published risk is 2%–12.5% and the latent period may be 10–30 years.[3,51,117–126] Involvement of the glans with LSc is a significant risk.[126] Carcinoma complicating LSc constitutes approximately 25%–50% of all cases of penile cancer.[3,107,120,127–130] LSc is histologically associated with differentiated PCIS, basal epithelial atypia and 'usual' or verrucous (rarely pseudohyperplastic) SCC.[131]

BOX 77-6 DIFFERENTIAL DIAGNOSIS OF LICHEN SCLEROSUS

Most Likely
- Lichen planus
- Nonspecific balanoposthitis

Consider
- Cicatricial pemphigoid

Always Rule Out
- Child sexual abuse
- Squamous carcinoma

TREATMENT. Treatment of extragenital LSc[132] is discussed in Chapter 65. The aims in male genital disease are to minimize or abolish male sexual dysfunction (dyspareunia), urinary dysfunction, and the risk of penis cancer.[114] Avoidance of contact with soap and urine are essential. Very potent topical steroids acheive remission in 50%–60% and the majority of the remainder are cured by circumcision.[133] Topical steroids are safe but occasionally HPV may be reactivated.[134,135] Topical calcineurin inhibitors should not be used.[136,137] Some men require sophisticated urethromeatal surgery.[116,125,138]

NONSPECIFIC BALANOPOSTHITIS

Nonspecific balanoposthitis is viewed either as a diagnosis of exclusion or as a descriptive term that indicates the limitations of diagnostic acumen.[3,51,107,] Sexually transmitted disease, immunosuppression, and diabetes or an identifiable primary dermatosis such as psoriasis, seborrheic dermatitis, ZB, LSc, LP, warts, or carcinoma in situ must be sought. A biopsy is essential. When patients present with symptoms and signs of balanoposthitis, nonspecific histopathologic features are found in approximately 10% of biopsy specimens.[139] Genitourinary physicians frequently diagnose candidosis, but dermatologists believe that *Candida* infection may complicate any inflammatory mucocutaneous dermatosis and is found as a secondary opportunistic phenomenon rather than as a primary cause of disease.[3] Phimosis may be the end stage situation including in diabetes.[140] Preputial dysfunction is the cause or consequence ofprobably all cases of nonspecific balanoposthitis, and many patients probably have LSc as the underlying morbid state. Treatment[141] can be very difficult, and the disease may fail to respond to local hygienic measures, soap substitution, topical steroids, and topical and systemic antibiotics.

The ultimate recourse is circumcision, which is curative in most instances. Histologic examination of the whole prepuce may substantiate the presence of an underlying genital dermatosis such as LSc. However, in a significant number of patients the circumcision histologic findings will be nonspecific, even after review

with the pathologist for early signs of LSc and even if there had been either hard or soft signs of an underlying dermatosis such as LSc on clinical evaluation on one or more occasions. These observations imply that such patients have nonspecific preputial dysfunction due to nonspecific irritation, trauma, and secondary candidosis such that a genuine nonspecific balanoposthitis ensues, with the pace of normal preputial repair and regeneration being exceeded by the pace of day-to-day attrition or wear and tear.[3,51,107]

DERMATOLOGIC NONDISEASE, DYSESTHESIA, AND CHRONIC PAIN SYNDROMES

Dermatologic nondisease[142] should be considered when florid symptomatology is accompanied by a paucity or complete absence of any primary dermatologic signs.[143] Patients with symptoms of itching, burning, redness, and pain focalized to the penis or scrotum, in some cases so severe as to prevent the patient from sitting down, are not uncommonly encountered. The chronic urogenital and rectal pain syndromes are described by the terms *penodynia*, *scrotodynia*, *orchialgia*, *prostatodynia*, *coccygodynia*, *proctalgia fugax*, *perineal pain*, *descending perineum syndrome*, and *vulvodynia*.[144–147]

The red or burning scrotum syndrome has been defined as "persistent redness of the anterior half of the scrotum that may involve the base of the penis… usually accompanied by a persistent itching or burning sensation and hyperalgesia."[148] Accompanying the erythema there may be telangiectasia. It is a chronic condition that is resistant to treatment and its cause is unknown.[143,148]

The neuroanatomy of the pelvis is complicated, and the neuropathophysiologic basis of these syndromes is poorly understood. They seem to share features of neurogenic inflammation and neuropathic pain.[149] Although their clinical presentations are well recognized by physicians in many specialties, these diagnoses should be arrived at after comprehensive clinical assessment, contemplation of the differential diagnosis, and a process of exclusion based on suitable investigations and response to treatment.[150] Localized dermatographism should be sought by stroking the inside of the thigh. Contact urticaria, irritant and contact dermatitis, and scrotal rosacea due to topical steroid application should be considered. Tinea and candidosis must be excluded. Intercurrent herpes simplex or postherpetic neuralgia might mislead. Angiokeratoma corporis diffusum and multiple sclerosis are causes of odd sensory symptoms. Zinc deficiency and migratory necrolytic erythema could be entertained. Penile sensitivity is reduced in diabetic patients, and this may correlate with erectile dysfunction in some of these men.[151] The drug chart should be reviewed. Some men with "idiopathic" anogenital pruritus may be found to have lumbosacral radiculopathy if investigations such as plain radiography, nerve conduction studies, computerized tomography, and needle electromyography are performed, and significant improvement may be obtained by paravertebral injections of triamcinolone and lidocaine.[152]

A diagnosis of a chronic pain syndrome carries the possibility of considerable psychological morbidity. Dysmorphophobia, depression, and psychosis may be present, and attempted or completed suicide is a real risk in such patients.[14]

Scrotal rosacea (see Chapter 81) should be treated with oral tetracycline's and these (e.g., doxycycline) may be effective in the red scrotum syndrome.[153] If anogenital dermatographism and/or urticaria is suspected, oral antihistamines can be prescribed. Prednisolone and antidepressants such as doxepin, amitriptyline, and paroxetine can afford some relief. Neuromodulation by sacral root stimulation might be tried.[96] However, treatment is generally problematic and at best only empiric. Invasive and irreversible procedures should be avoided if at all possible. Multidisciplinary management is the ideal.[3,107]

PENILE ACNE

Penile acne is an poorly-documented entity occasionally encountered in clinical practice.[3] Young men complain of penile spots or boils or blackheads and on examination have comedones, papules, pustules, and inflammatory nodules of the proximal penile shaft. An important differential diagnosis of acneiform disease presenting at any site is chloracne caused by occlusion of the skin with machine oil. Conventional treatment for acne is prescribed in a hierarchical manner: topical keratolytics, antibiotics, and retinoids; oral antibiotics; and isotretinoin (see Chapter 80).

CHRONIC "IDIOPATHIC" PENILE EDEMA

Chronic idiopathic penile edema is a rare, ill-understood condition.[3,154] It is the cause of significant morbidity, sexual dysfunction, and phimosis. Patients present with swelling and intercurrent attacks of cellulitis and lymphangitis of the penis, scrotum, and pelvic girdle. Recurrent sexually transmitted diseases, a chronic dermatosis, and hypoplastic lymphatics are sometimes incriminated. The antistreptolysin-O titer may be elevated, and a biopsy specimen may show granulomatous lymphangitis, and Crohn disease (Fig. 77-17) should be sought even if the patient has no gastrointestinal symptoms. Sarcoidosis should be excluded. Treatment has to be aggressive to prevent intercurrent infection and further lymphatic damage and scarring. Long-term treatment with oral antibiotics such as erythromycin, clarithromycin, clindamycin, trimethoprim, cotrimoxazole, or ciprofloxacin is advocated. Occasionally, a short cause of oral prednisolone is helpful. The goal should be to reduce the preputial edema to allow circumcision.

SPONTANEOUS SCROTAL ULCERATION

Rare cases of spontaneous scrotal ulceration in young, previously fit men have been described.[155] Histologic examination showed nonspecific vasculitis and



Figure 77-17 Chronic penile edema. Crohn disease. Histologic examination showed a granulomatous lymphangitis. (© Medical Illustration UK.)

spontaneous resolution occurred. A related entity may be idiopathic scrotal panniculitis and fat necrosis,[156] because trauma, extreme cold, and Fournier gangrene were excluded.

FOURNIER GANGRENE

(See Chapter 179)

Fournier gangrene is a medical and surgical emergency.[3] Patients present with systemic upset and painful erythematous swelling of the genital, perianal, or lower abdominal skin and may be in urinary retention. An ominous black spot may appear on the scrotum. There is gross systemic toxicity (peculiarly, sometimes absent in children) and no suppuration. Necrosis of skin and deeper tissues rapidly supervenes and death ensues (the mortality may be higher than 50%) unless diagnosis is prompt and radical management is instituted. In its clinical picture Fournier gangrene overlaps with necrotizing fasciitis and Meleney gangrene. Risk factors are presented in Table 77-4.

The process probably begins with appendageal or urethral infection, and polybacterial infection develops. Most of the organisms isolated from cases prove to be resident urethral or lower gastrointestinal flora, and most patients have mixed infections. What then follows is a necrotizing cellulitis, perhaps exotoxin mediated that affects skin, subcutis, fascia, and muscle—the human counterpart of the local Shwartzman phenomenon. In children, the most commonly isolated pathogens are staphylococci and streptococci. Radiologic studies may show soft tissue gas.

Disorders from which Fournier gangrene must be differentiated are listed in Box 77-7.

If the clinical diagnosis of Fournier gangrene is entertained, then drastic emergency management is required. Surgical and microbiologic expertise, often in an intensive care setting, may be required. Radical surgical débridement of all affected tissue is undertaken and broad systemic antibiotic therapy initiated. If the patient survives, then plastic surgical repair can be performed.[157] Hyperbaric oxygen treatment has been advocated, as has high-dose systemic corticosteroid treatment. Children can be treated with more conservative surgery, and the mortality rate is lower.[158]

In adults, the mortality is around 25% and is highest in disease of anorectal rather than urogenital origin, which likely reflects a less typical presentation and longer delay in diagnosis.[3]

TABLE 77-4
Risk Factors for Fournier Gangrene

Debilitation
Diabetes mellitus
Alcoholism
Anogenital infection
Chemotherapy
AIDS
Postinstrumentation
Postsurgery (urologic and colorectal)
Heroin addiction
Trauma
Unconventional sexual practices

BOX 77-7 DIFFERENTIAL DIAGNOSIS OF FOURNIER GANGRENE

Most Likely
- Trauma
- Herpes simplex
- Cellulitis
- Gonococcal balanitis and edema

Consider
- Migratory necrolytic erythema
- Allergic vasculitis
- Polyarteritis nodosa
- Ecthyma gangrenosum
- Warfarin necrosis

Always Rule Out
- Necrotizing fasciitis
- Vascular occlusion syndromes

NONSYPHILITIC SPIROCHETAL ULCERATIVE BALANOPOSTHITIS

Nonsyphilitic spirochetal ulcerative balanoposthitis is recognized in the tropics and South Africa and presents as large, serpiginous, foul-smelling ulcers in uncircumcised men, associated in some with nontender inguinal lymphadenopathy.[159] Treatment is with penicillin or metronidazole.

SCROTAL CALCINOSIS

Scrotal calcinosis is a relatively common, benign idiopathic disorder presenting as rock-hard smooth white papules or nodules on the scrotum, multiple or

solitary.[3] Occasionally, the lesions may become secondarily inflamed or infected after trauma. Rarely, a lesion or lesions occur on the penis. The differential diagnosis includes epidermoid cyst. Indeed, it is debatable whether the lesions are indeed idiopathic or whether they arise from epidermoid cysts, eccrine duct milia, eccrine epithelial cysts, dystrophy of the dartos muscle, trauma, or foreign bodies (e.g., thorn or even *Onchocerca* organisms). Cold, trauma, and the thinness and specialization of scrotal skin are thought to be etiologic factors. Treatment is by surgical excision, but the lesions recur.

SCLEROSING LYMPHANGITIS

Nonvenereal sclerosing lymphangitis [there are a confusing number of synonyms: *penile venereal edema*, *Mondor phlebitis*, *localized penile (venereal) lymphedema*, *penile lymphocele*] is increasingly recognized.[3] Patients present with a serpiginous mass in the coronal sulcus, spreading sometimes onto the dorsal penis. The lesion may appear for the first time or become tender and enlarge after prolonged or frequent sexual intercourse. In circumcised men the circumferential scar may be a predisposing factor. It has not been established whether this entity represents a posttraumatic lymphangitis or phlebitis. The problem may resolve spontaneously or surgical excision may be required.

True thrombophlebitis of superficial penile and scrotal veins is analogous to Mondor phlebitis of the chest wall. Herpes simplex virus infection, polyarteritis nodosa, and thromboangiitis obliterans may initiate it. Penile thrombophlebitis has been seen as the initial presentation of a paraneoplastic migratory thrombophlebitis caused by pancreatic cancer.

VERRUCIFORM XANTHOMA

Verruciform xanthoma is a rare entity that principally involves the mouth. Genitalia are the next most frequently affected area, where it presents as a painless, yellow–brown or red, verrucous, sessile, or papillary plaque.[3] Histologically there is hyperkeratosis, focal parakeratosis, and irregular epidermal acanthosis. Rete ridges are lengthened and extend into the dermis, forming areas called *dermal papillae* and which enclose capillary vessels surrounded by foam cells that are $CD68^+$ but $S100^-$. It is thought that the lesion results from epidermal degeneration and that keratinocyte lipid is taken up by dermal macrophages or fibroblasts to form the foam cells. HPV-6 DNA has been found in one case. SCC may arise within the lesion. Treatment is by surgical excision.

PENILE CARCINOMA IN SITU AND SQUAMOUS CELL CARCINOMA

EPIDEMIOLOGY.

SCC of the penis accounts for 0.3%–0.6% of cases and less than 1% of cancer deaths in the United States.[3,51,65,107,160] One hundred deaths and 400 cases are seen per year in the United Kingdom.[161,162] It is estimated that penile SCC represents 10%–20% of tumors seen in males in the developing world, where neonatal or infantile circumcision is not part of the culture.[163] However, in developed countries such as Japan and Denmark where circumcision is not routinely practiced, penile cancer incidence is falling and is approximating that in the United Kingdom and United States.[164,165] The epidemiology of PCIS is not well established; it is probably underdiagnosed and underreported.[161,166]

ETIOLOGY AND PATHOGENESIS.

(See Chapters 114). The precise causes of the different types of PCIS and SCC of the penis are unknown. Acknowledged risk factors for SCC are presented in Table 77-5.

HPV (high-risk and mixed infections), LSc, and immunoincompetency are the most important considerations.[65,66,74,75,107,129,130,167–169]

CLINICAL FINDINGS.

EQ manifests as bright red, shiny patches, or plaques of the mucosal sites, the glans, and prepuce of the uncircumcised (Fig. 77-18

PENILE CARCINOMA IN SITU AND SQUAMOUS CELL CARCINOMA AT A GLANCE

- Erythroplasia of Queyrat (EQ), Bowen disease of the penis (BDP), urethral disease and bowenoid papulosis (BP) are synonymous in describing clinical situations in which histologically carcinoma in situ (CIS) is present.
- *Penile carcinoma in situ* (PCIS) is a better term than *penile intraepithelial neoplasia* or PIN (corresponding to cervical intraepithelial neoplasia, vulval intraepithelial neoplasia, and anal intraepithelial neoplasia) because of the potential for confusion with prostatic intraepithelial neoplasia.



Figure 77-18 Erythroplasia of Queyrat. (© Medical Illustration UK.)

TABLE 77-5
Risk Factors for Penile Cancer

Uncircumcised state
Phimosis
Poor hygiene
Chronic irritation and inflammation
Scarring
Smoking
Alcohol
Lichen sclerosus
Lichen planus
Squamous hyperplasia
Bowen disease of the penis
Erythroplasia of Queyrat
Bowenoid papulosis
Warts and Human papillomavirus infection
Other sexually transmitted diseases
Age of first sex
Multiple sexual partners
Oral sex
Never having used a condom
Human immunodeficiency virus infection
?Psoriasis
Photochemotherapy
Iatrogenic immunosuppression

and eFig. 77-18.1 in online edition). Bowen disease of the penis (BDP) is characterized by red, scaly patches and plaques of the keratinized penis (Fig. 77-19 and eFig. 77-19.1 in online edition). Both affect the older male. BP presents as multiple warty lesions rather than as erythematous patches or red, scaly plaques



Figure 77-19 Bowen disease. (© Medical Illustration UK.)



Figure 77-20 Bowenoid papulosis. Red papules, distal penile shaft. (© Medical Illustration UK.)

(Fig. 77-20). BP is pigmented in keratinized sites, and lesions are multiple and more inflamed in mucosal sites; lesions are more polymorphic, more coalescent, less papillomatous, and smoother topped than common genital viral warts. BP is seen in younger, sexually active men. Pseudoepitheliomatous micaceous and keratotic balanitis is probably not a separate entity but a clinical variant of PCIS, probably associated with LSc and conferring a risk of development of invasive SCC.[3,65]

In SCC irregular nodular and ulcerative morphology is encountered (Fig. 77-21). Clinically, there may be evident background PCIS and/or LSc (or even LP). Inguinal lymphadenopathy may be present, although in penile cancer only 50% of enlarged glands will be found to contain tumor. Verrucous carcinoma, warty carcinoma, Buschke–Lowenstein tumor (BLT), and giant condyloma may be dramatic clinical lesions, often polypoid or cauliflower-like. Although locally deeply invasive, they are well demarcated from surrounding tissue. These terms are often used synonymously to describe rare, low-grade, well-differentiated squamous carcinomas.[170–177] The potential for aggressive behavior, mortality risk, and clinical, histologic, and virologic differences may distinguish them. Giant condyloma and BLT are thought likely to have their origin from common genital warts. BLT has also been associated with LSc.[178]

DIFFERENTIAL DIAGNOSIS (Box 77-8). A biopsy is indicated in most instances.



Figure 77-21 Squamous carcinoma. HIV-positive patient. (© Medical Illustration UK.)

BOX 77-8 DIFFERENTIAL DIAGNOSIS OF PENILE CARCINOMA IN SITU AND SQUAMOUS CELL CARCINOMA

BOWEN DISEASE OF THE PENIS/ERYTHROPLASIA OF QUEYRAT

Most Likely
- Psoriasis
- Zoon balanitis
- Nonspecific bowenoid papulosis
- Lichen sclerosus

Consider
- Extramammary Paget disease
- Kaposi sarcoma
- Erosive lichen planus

Always Rule Out
- Squamous cell carcinoma

BOWENOID PAPULOSIS

Most Likely
- Viral warts
- Seborrheic keratosis
- Lichen planus

Consider
- Mollusca
- Nevi

Always Rule Out
- Condylomata lata

SQUAMOUS CELL CARCINOMA

Most Likely
- Ulcerative sexually transmitted disease
- Lichen sclerosus
- Erosive lichen planus

Consider
- Artifact
- Behçet disease

Always Rule Out
- Fournier gangrene
- Pyoderma gangrenosum

HISTOLOGY. The histopathology of mucosal PCIS is generally that of a bowenoid pattern of dysplasia with dysmaturation and atypical cells and increased mitoses at different levels of the epithelium. This is often accompanied by HPV-related cytopathic changes in the upper layers of the epithelium, but there is as yet no formal consensus on clinicopathologic classification and clinical utility. Increasingly encountered are the terms *squamous hyperplasia* and *squamous intraepithelial lesion* of squamous, basaloid, or warty type and low or high grade to describe the histologic findings of epithelial lesions associated with penile SCC.[179,180] Differentiated PCIS and basal epithelial atypia are associated with LSc and full thickness, undifferentiated bowenoid dysplasia with HPV.[131]

In SCC, tongues of invasive atypical keratinocytes invade the lamina propria or deeper structures and contain foci of aberrant and ectopic keratinization (squamous pearls). Penile SCC is morphologically and histologically heterogenous.[65,128,131,181–186] The frequency of occurrence of different types in 61 U.S. cases was 59% usual (squamous), 15% papillary (not otherwise specified), 10% basaloid, 10% warty (condylomatous), 2% verrucous, and 2% sarcomatoid.[181] Usual or verrucous (rarely pseudohyperplastic) SCC are associated with LSc whereas warty, basaloid or mixed types are associated with HPV.[131]

Suspected verrucous carcinoma demands a deep surgical biopsy. Verrucous carcinoma has different pathologic features from typical squamous carcinoma, showing well differentiated and maturing squamous epithelium with very little atypia or pleomorphism and few mitoses. The diagnosis of verrucous carcinoma in biopsy specimens may be difficult to establish because it relies very much on the depth of invasion of the lesion in relation to surrounding epidermis, and the growth pattern is of a "pushing" margin rather than infiltration. Warty carcinoma, BLT, and giant condyloma differ further in having marked squamous proliferation with HPV-related changes; they are not associated with bowenoid dysplasia but do have more atypia and mitoses than classic verrucous carcinoma.

PROGNOSIS. Quantifying the malignant potential of BDP/EQ/BP/PCIS is not easy. EQ is probably more dangerous than BDP in terms of risk of progression to invasive SCC. BP may remit spontaneously and probably has less malignant potential than EQ or BDP.[3,14,16] The prognosis of established, thick, invasive SCC remains poor, but that of early thin disease is much better. HPV status does not correlate with survival.[187] In the United States, previously or currently married men present earlier and have increased survival overall; African-Americans present later and do less well.[188] In India late presentation is common.[189]

The histologic type of SCC has a bearing on prognosis: low mortality risk is associated with mixed, papillary, and warty types, intermediate risk with usual and basaloid types and high risk with sarcomatoid cancers.[65,181,182,185,186,190,191] The prognosis is also related to the depth of invasion of crucial anatomic landmarks. Features imparting a poor prognosis include perineural invasion and vascular invasion and high histological grade.[192]

The role of SCC antigen as a biomarker for penile cancer remains speculative.[193,194]

TREATMENT. There are several approaches to the treatment of PCIS, summarized in Box 77-9. The guiding principle is to be conservatively ablative.[65,107,161] A rational initial step is to recommend circumcision. Patients presenting with these conditions (and their sexual partners) should be counseled and screened

BOX 77-9 TREATMENTS FOR PENILE CARCINOMA IN SITU

- Circumcision
- Cryotherapy
- Salicylic acid
- Podophyllin/podophyllotoxin
- Curettage and cautery
- Simple excision
- Mohs micrographic surgery
- Laser therapy
- Photodynamic therapy
- Radiotherapy (not advised)
- 5-Fluorouracil
- Imiquimod

for HPV and other sexually transmitted diseases, including HIV infection. Smoking should be discouraged. Follow-up should be long term, and the focus should include the whole perineum, anus, and perianal skin.

For SCC, adequate surgical excision is required. This may need to be radical (i.e., penile amputation), depending on location and extent, but the trend is toward tissue-conserving techniques for functional and cosmetic reasons.[107,162] Mohs micrographic surgery and laser procedures have their proponents. Local staging to inform management decisions is achieved by clinical evaluation, histologic analysis, sonography, and magnetic resonance imaging. The histologic grade helps predict proximal histologic extent beyond grossly visible tumor margin. Sentinel node biopsy has been advocated, but the management of ilioinguinal lymphadenopathy is controversial. Established lymphatic or hematogenous dissemination requires individualized multidisciplinary management. Combination chemotherapy has been used for palliation and proposed for adjuvant treatment but is of uncertain value. Brachytherapy or external beam radiotherapy and chemoradiotherapy have their proponents.

PREVENTION. Chronic disease and dysfunction of the foreskin confer a significant risk of PCIS or frank SCC. The "field changes" due to LSc and HPV create situations of multifocality or multicentricity and a temporal dynamic, contributing to long-term risk even if corrective treatments have been initiated. Feasible measures for penile cancer prophylaxis are treatment of chronic inflammatory conditions such as LSc, LP, and nonspecific balanoposthitis; prevention of phimosis; limitation of psoralen and ultraviolet A treatment; smoking cessation; and prophylaxis for HPV infection.[165,195]

MELANOMA

(See Chapter 124)

Melanoma is a rare neoplasm of the penis, but the prognosis is poor because of late diagnosis and early lymphovascular invasion. It should always enter the differential diagnosis of penile melanosis and lentiginosis as well as genital papules, nodules, and ulcers.[3]

EXTRAMAMMARY PAGET DISEASE

(See Chapter 121)

EMPD[3] presents as an irritating, itchy, burning, red scaly patch or plaque and may be multicentric. It can be found anywhere around the anogenital area, including the glans penis. An "underpants" pattern of erythema has been described in some patients. EMPD is frequently misdiagnosed as an inflammatory dermatosis, such as psoriasis, eczema, or Bowen disease. Subclinical EMPD disease occurs, in which the skin looks normal macroscopically but is involved microscopically. The disease behaves indolently, spreading by local extension and metastasis. The combination of genital and extragenital EMPD is rare but overt, and latent axillary EMPD disease may coexist. Axillary macular lesions that changed shape and color daily have been reported in association with penile and pubic Paget disease. Very rarely, depigmented EMPD disease presents as a pale patch in the genital area, evoking a differential diagnosis of vitiligo, hypopigmented mycosis fungoides, and LSc.[80]

EMPD has been treated with cryotherapy and topical 5-flurouracil, but wide excisional surgery (e.g., Mohs), with plastic repair if needed, is probably the treatment of choice. Radiotherapy is controversial. Photodynamic therapy is under evaluation. Topical imiquimod holds promise.[196]

KEY REFERENCES

Full reference list available at www.DIGM8.com

DVD contains references and additional content

1. Mallon E et al: Circumcision and genital dermatoses. *Arch Dermatol* **136**:350, 2000
3. Bunker CB: *Male Genital Dermatology*. London, Saunders, 2004
51. Porter WM, Bunker CB: The dysfunctional foreskin. *Int J STD AIDS* **12**:216, 2001
65. Micali G et al: Penile cancer. *J Am Acad Dermatol* **54**:369, 2006
107. Bunker CB: Management of penile dermatoses. *Expert Rev Dermatol* **1**:241, 2006
114. Bunker CB et al: Re: Lichen sclerosus: Review of the literature and current recommendations for management. Pugliese JM et al. *J Urol* **178**:2268-2276, 2007. *J Urol* **181**:1802-1803, 2009
132. Neill SM et al: Guidelines for the management of lichen sclerosus. *Br J Dermatol* **147**:640, 2002
139. Alessi E, Coggi A, Gianotti R: Review of 120 biopsies performed on the balano-preputial sac. From Zoon's balanitis to the concept of a wider spectrum of inflammatory non-cicatricial balanoposthitis. *Dermatology* **208**:120, 2004
161. Bunker CB: Diagnosis and management of penile precancer: Combined clinics and topical chemotherapy. In: *The Effective Management of Urological Malignancies*, edited by J Anderson, RTD Oliver, A Miles. London, Aesculapius Medical Press, 2005

Chapter 78 :: Diseases and Disorders of the Female Genitalia

:: Lynette J. Margesson & F. William Danby

VULVOVAGINAL DISEASES AT A GLANCE

- Common problems, including the following:
  - Infections
  - Inflammatory dermatoses
  - Bullous and erosive diseases
  - Ulcers
  - Vulvodynia
- Evaluation, diagnosis, and management are challenging because:
  - Normal vulvar anatomy is often unfamiliar to the physician.
  - Morphology and histologic features of dermatoses are often nonspecific.
  - Causes are often multiple and complex.
  - Patient anxiety and depression are often severe and can worsen symptoms.

EPIDEMIOLOGY

The incidence and prevalence of dermatoses affecting the female genitalia are generally not well established. The vulva has been referred to as "the forgotten pelvic organ." Despite being the visible female genital structure, it is least described in the medical literature.[1] Teaching about vulvar conditions and even the normal vulva is sadly lacking for most medical practitioners, so it is not surprising that vulvar conditions are both underreported and underdiagnosed. Approximately 16% of women report undiagnosed chronic vulvovaginal pain at some time in their lives.[2,3]

ETIOLOGY AND PATHOGENESIS

The etiology and pathogenesis of many diseases of the female genitalia are likewise not well understood. Those that also affect other areas of the body are better characterized, but the environment of the vulva strongly affects the course of disease.

CLINICAL FINDINGS

HISTORY

The approach to the patient with vulvar complaints requires directed history taking, as outlined in Box 78-1.

CUTANEOUS LESIONS AND SYMPTOMS

The warm moist environment of the vulva often alters disease morphology or symptomatology. For example, usually scaling dermatoses may lack clinically obvious scale, and in diseases that usually exhibit well-demarcated plaques, the lesions may be less distinct. In addition, diseases that normally do not produce scarring of keratinized skin or oral mucosa can induce resorption of the labia minora, narrowing of the introitus, and

BOX 78-1 ELEMENTS OF HISTORY TAKING FOR PATIENTS WITH VULVOVAGINAL COMPLAINTS

- Symptoms: onset, initial trigger, duration, alleviating, and exacerbating factors
- Previous treatments: duration and effectiveness
- Copies of previous physicians' evaluations, culture, and biopsy reports
- Daily cleansing and care practices
- Contactants: tampons, pads, lubricants, deodorants, fragrances
- Gynecologic history
- Menstruation/menopause/estrogen and other hormone replacement
- Pap test results
- Contraception
- Pregnancy
- Sexual activity
- Sexually transmitted diseases
- Surgeries
- Urologic history
- Continence/incontinence
- Surgery
- Gastrointestinal history
- Diarrhea
- Constipation
- Psychiatric history

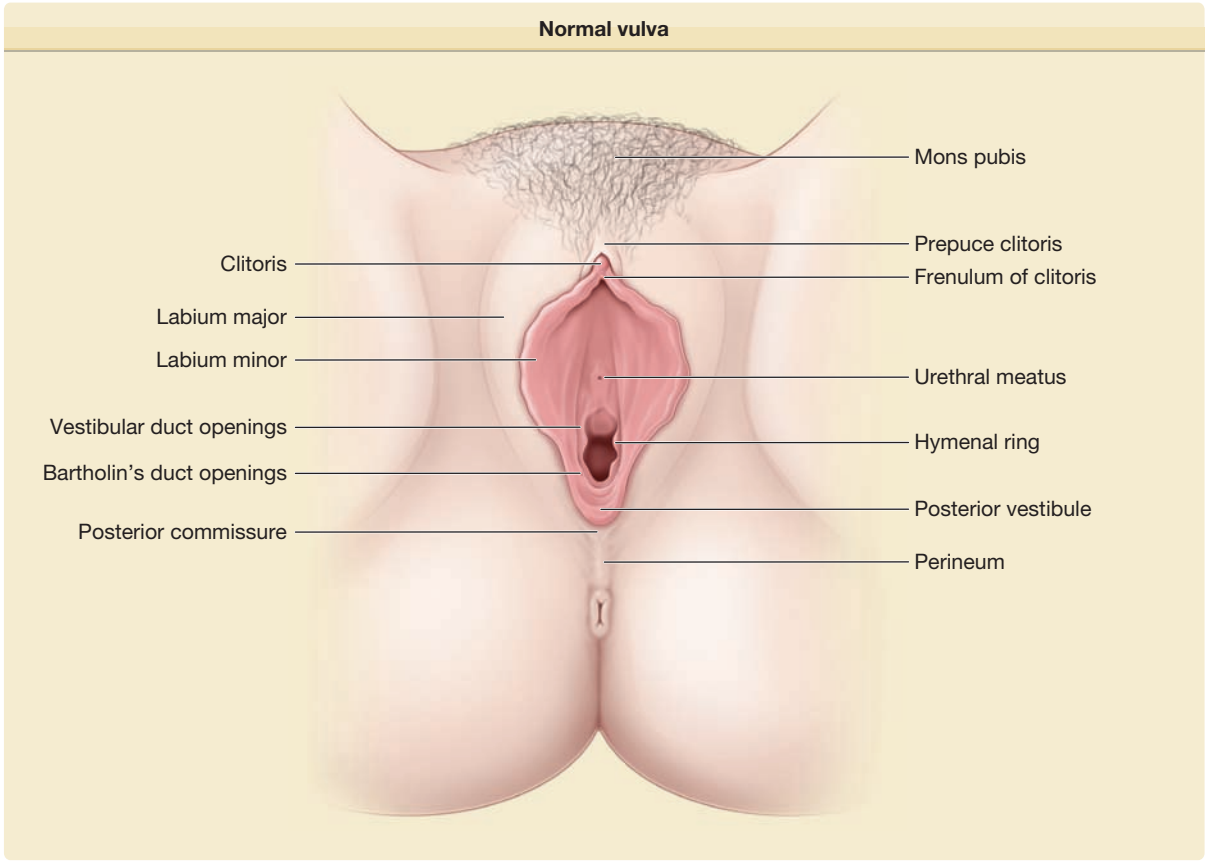

Figure 78-1 Normal vulva.

scarring of the clitoral hood. Vulvar scarring can occur from any inflammatory condition.[4]

When examining the vulva, it is important to make sure there are no physical abnormalities, particularly, that all normal anatomy is present. Using a diagram can help and this also can be shared for patient education (Fig. 78-1). Unimpressive physical findings are sometimes associated with severe itching and vulvar pain. Lichenification manifested only by a slight change in texture can present with severe pruritus deserving of and responsive to aggressive therapy. Finally, a complete mucocutaneous examination is crucial, because extragenital findings can assist in the diagnosis of several genital conditions.

RELATED PHYSICAL FINDINGS

Skin disease affecting the vulva more often has a multifactorial etiology, compared to other areas of the body. The primary skin disease is often accompanied by and driven by a secondary yeast infection, bacterial colonization, or lack of estrogen, even in the absence of obvious clinical findings. The infection can be purely cutaneous, purely vaginal, or both. Irritant contact dermatitis from topically applied agents often exacerbates both signs and symptoms. Such contributors need to be constantly sought.

Vulvar symptoms cannot be divorced from vaginal abnormalities. Irritating or infected vaginal secretions are a common cause of vestibular (introital) symptoms, which makes a speculum examination highly advisable in many instances.

LABORATORY TESTS

Skin biopsy specimens for hematoxylin and eosin staining and direct immunofluorescence testing may be required. Sometimes multiple biopsy samples are required to establish a specific histologic diagnosis. When previously well-controlled dermatoses flare, repeat biopsy may be needed to rule out squamous cell carcinoma or a second disease process. When doing a vulvar biopsy, preanesthetizing the area with a topical anesthetic can be very helpful.

Culture of cutaneous swab samples, for *Candida* and bacteria, is indicated when concurrent infection is considered. Infection can complicate treatment at any point in the course of a disease.

A microscopic evaluation of vaginal smears allows inspection for yeast (see Chapter 189), *Trichomonas*, and bacterial vaginosis (see Chapter 205). Abnormalities such as an increased number of white blood cells or the presence of immature epithelial cells may be seen as well and may be markers for inflammatory skin diseases, estrogen deficiency, foreign body, or pyogenic bacterial infection. Vaginal cultures, done in addition, can identify infection caused by a nonalbicans *Candida*

organism, a pathogen difficult to see on microscopic smears but occasionally a cause of significant symptoms.

Patch testing is important if allergic contact dermatitis is suspected (see Chapter 13). Consultation with specialists in gynecology, urology, or urogynecology may be necessary to assist with diagnosis, management, or treatment. This is particularly true in the setting of multifactorial processes (e.g., incontinence as a contributing factor) or diseases requiring surgical intervention (e.g., posterior fourchette fissuring).

DIFFERENTIAL DIAGNOSIS

Because of the varied morphologies and frequent multifactorial presentations, the differential diagnosis of a vulvar condition can be quite broad (Box 78-2). Normal variants can be confusing as well. The diseases discussed in this chapter are grouped into the categories of inflammatory dermatoses, bullous and erosive diseases, ulcers, abscesses, and vulvodynia.

BOX 78-2 DIFFERENTIAL DIAGNOSIS OF VULVOVAGINAL DISORDERS

INFLAMMATORY DERMATOSES

- Lichen simplex chronicus
- Irritant contact dermatitis
- Allergic contact dermatitis
- Psoriasis
- Lichen sclerosus
- Vulvar fissures

BULLOUS AND EROSIVE DISEASES

- Lichen planus
- Erythema multiforme major
- Toxic epidermal necrolysis
- Cicatricial pemphigoid
- Pemphigus vulgaris
- Fixed drug eruption
- Herpes simplex
- Extramammary Paget disease
- Vulvar carcinoma

ULCERS

- Aphthous ulcers
- Crohn disease
- Syphilis
- Chancroid
- Other in sexually transmitted diseases

ABSCESSES

- Bartholin gland abscess
- Hidradenitis suppurativa

PROGNOSIS AND CLINICAL COURSE

Women with vulvovaginal symptoms assume they have a curable, infectious disease. Patients need to be counseled that many genital dermatoses are controllable but not curable. These women cannot be evaluated and treated in a 10-minute office visit; they require adequate time for education and reassurance. Frequently they need to be followed long term.

TREATMENT

Several factors need to be considered when treating most dermatoses of the female genitalia.

Many women are unfamiliar with their genital anatomy and do not have the vocabulary to accurately discuss their problem or follow instructions for applying topical medications. Diagrams and/or a use of a hand-held mirror are extremely helpful for patient education. The vulvar diagram (Fig. 78-1) can be very important here.

An ointment is generally the most comfortable vehicle for delivering medication to the modified mucous membranes of the vulva. Ointments spread easily, require very small volumes per application, are less sensitizing and generally cause less burning.

Irritant contact dermatitis is a common complicating factor in any genital dermatosis. Aggressive washing and use of soaps, topical medications, and home remedies are the most common offenders. Because soaps, douches, disinfectants, and very hot or cold water often are not considered relevant by patients, information regarding their use is often not volunteered, and very careful questioning is warranted. Gentle cleansing of the area can be accomplished by flushing once a day with water (or mild cleanser and water) and patting dry. Washcloths for washing and towel rubbing while drying must be avoided.

Superpotent glucocorticoids such as clobetasol propionate are often required to treat dermatoses of the female genitalia. Fortunately, glucocorticoid atrophy is surprisingly uncommon on the modified mucous membranes of the vulva. Nonetheless, patients should be reevaluated monthly during periods of daily use and warned about side effects due to spread of medication to the surrounding areas where atrophy is more likely to occur such as the inguinal crease, proximal medial thighs, and perianal skin. Limit the amount of topical steroid prescribed.

Tacrolimus or pimecrolimus can be used as steroid-sparing medications on vulvar skin. Stinging or burning frequently occurs with initial application. This is especially true for very inflamed or eroded areas. These agents are often less effective than glucocorticoids and their long-term safety is still in question. Despite these issues they are a useful second line option.[5] (For efficacy and side effects, see Chapter 221.)

Warmth and moisture of the genital area are unavoidable and promote infection and maceration. Bacterial

superinfection can be treated with oral antibiotics. Yeast infections are especially common, particularly when patients are treated with topical glucocorticoids and/or oral antibiotics. The identification of infection on red, scaling, and often exudative skin can be difficult and should be pursued actively in patients with recalcitrant symptoms.

COMMON NORMAL VARIANTS

There is great variety in normal vulvovaginal anatomy. Vulvar and vaginal erythema of varying degrees is present in most asymptomatic premenopausal women, but this redness is rarely noticed before the onset of discomfort. Architecturally, the labia minora exhibit a wide range of asymmetry and sizes. Normal but very small labia minora may be difficult to differentiate from scarring produced by inflammatory skin disease. Sebaceous glands may be prominent on the inner labia minora. Harmless, soft, finger-like, skin-colored, monomorphous papules called vulvar papillomatosis can be seen around the hymenal ring. (See eFig. 78-1.1 in online edition) These can be confused with genital warts.

INFLAMMATORY DERMATOSES

Clinically subtle inflammation of the vulva sometimes produces remarkable symptoms. Therefore, a very careful examination with a high index of suspicion for a dermatosis is required.

LICHEN SIMPLEX CHRONICUS

(See Chapter 15)

Vulvar lichen simplex chronicus is most often seen in atopic individuals with sensitive skin. It can complicate other vulvar dermatoses, especially contact dermatitis, lichen sclerosus and, less frequently, lichen planus.

The morphologic manifestations of lichen simplex chronicus when it occurs on the vulva vary from minimal hyperpigmentation and dullness of texture of the modified mucous membranes to remarkable lichenification and edema (see Fig. 78-2 and eFigs. 78.2.1–78.2.5 in online edition). Erythema can be subtle on the labia majora because hair obscures the skin. Excoriations and fissures within skin folds are common but heal quickly and may not be seen in the office. Sometimes hydrated, thickened lichen simplex chronicus appears white, mimicking lichen sclerosus, or the leukoplakia of intraepithelial neoplasia.

Although the histologic findings, differential diagnosis, and therapy are similar for lichen simplex chronicus affecting the vulva as for that involving other parts of the body, there are several notable modifications.[6] Contact dermatitis needs to be recognized and treated as it frequently confounds management. Women overwash and especially scrub the area and also may apply topically whatever they can find. Topical glucocorticoid therapy is a mainstay, but prompt alleviation of symptoms often requires a higher potency preparation than is standard for intertriginous skin. Those with significant lichenification do well with a superpotent preparation such as clobetasol propionate for the first few weeks. The potency or frequency can be decreased as the patient improves. Nighttime sedation is often required to interrupt the itch–scratch cycle.[7] Skin and vaginal infections, often subclinical, are extremely common and often drive lichen simplex chronicus. Therefore, skin and vaginal cultures for yeast, and especially to rule out methicillin-resistant *Staphylococcus aureus* (MRSA), should be performed, especially since treatment will normally require potent topical glucocorticoid therapy for control. Treat bacteria and *Candida* infections orally because topical treatment can irritate and intensify pruritus. Proper hydration is essential for healing. Patients with lichen simplex chronicus that is intensely inflamed, excoriated, or eroded generally require medications in an ointment base, to avoid additional sensitizers and the drying effects of cream and lotion bases. A plain water soak in a tub for 5 minutes three times a day, followed by gentle patting of excess moisture and the application of a Class 3–1 corticosteroid ointment is the best approach for initial therapy, and must be done under cover of an appropriate oral antibiotic and fluconazole. Sedation is very helpful initially to stop scratching, with hydroxyzine or doxepin at night to tolerance. Systemic corticosteroids should be used for short periods of time for severe pruritus. Follow-up to prevent and manage relapse is essential.



Figure 78-2 In this case of lichen simplex chronicus of the vulva there is thick dramatic whitening bilaterally and symmetrically around the vulva and perianal area.

IRRITANT AND ALLERGIC CONTACT DERMATITIS

(See Chapters 48 and 13)

Vulvar skin is thin, damp, and permeable. It is exposed to a wide range of insults from washcloths and vigorous scrubbing to caustic, irritating or allergenic cleansers, and topical products applied to alleviate symptoms. Irritant vulvar dermatitis is common, ranging from the diaper dermatitis seen in infants and elderly incontinent ladies to the chapped, sore vulva of the overzealous scrubbers. Allergic vulvar contact dermatitis is less common, with relevant allergens found in 30% of those tested.[8]

Irritant and allergic contact dermatitis of the vulva can be either a primary or secondary diagnosis, acute or chronic. Either or both may commonly complicate any vulvar dermatosis. A patient with acute irritant contact dermatitis experiences burning on contact with the offending substance. Deep erythema is common. Vesiculation, rare, can occur on keratinized skin, whereas erosion is usual on modified mucous membranes (Fig. 78-3). Therapies such as fluorouracil, imiquimod, podophyllin resin, benzocaine, some topical antifungal creams, and topical gentian violet can produce a brisk reaction.[9] Chronic irritant contact dermatitis is characterized by poorly demarcated erythema or hyperpigmentation that can be difficult to appreciate because the vulva normally is pink or dusky (eFig. 78-3.1 in online edition). Lichenification and scale, when present, make diagnosis easier. Pruritus can be intense.



Figure 78-3 Patchy erythema, superficial desquamation, and small erosions are often seen with an irritant contact dermatitis such as this eruption caused by benzocaine and resorcinol.

Although the British have found allergic contact dermatitis to be a common finding on the vulva, American physicians report few relevant positive results on patch tests for patients with eczematous vulvar skin.[8–11]

Nevertheless, women with refractory vulvar symptoms should be evaluated clinically and a thorough history taken to identify allergic contact dermatitis. In acute allergic contact dermatitis of the genital area, vesicles erode as quickly as they form, producing painful exudative erosions and plaques. Chronic allergic contact dermatitis is manifested more often by mild erythema and subtle edema. Notable scale is infrequent. Scratching in more severe and chronic cases induces lichenification. Common allergens include diphenhydramine, neomycin, polymyxin, sulfonamides, benzocaine, some antifungal creams, spermicides, glucocorticoids, some antiseptics, fragrances, and preservatives (see Chapter 13). As can occur with eyelid dermatitis, allergens can be carried inadvertently from fingertips to the vulva during the course of scratching or wiping. In addition, the habits of sexual partners can be important (consort dermatitis).

The therapy for vulvar contact dermatitis is the same as for this disease occurring in other areas and hinges most importantly on avoidance of irritants and allergens. Irritant, and to a lesser extent allergic, contact dermatitis can be a complicating factor in most vulvar conditions.[12] It can also obscure underlying disease. Women with chronic symptoms often are well served by discontinuing all topical therapies (eFigs. 78-3.2 and 78-3.3 in online edition). For a severe or extensive eruption, use systemic steroids, avoiding topicals except for a bland emollient like petrolatum. Be sure to stop all offending hygiene practices and control secondary infection and pruritus. For a mild-to-moderate eruption a Class II–IV topical steroid ointment applied twice daily can hasten improvement. Reevaluation 1 or 2 weeks later may reveal an underlying primary process.

PSORIASIS

(See Chapter 18)

Vulvar psoriasis is too often missed. Women are embarrassed to mention it to their dermatologist. They show it to the gynecologist, unfamiliar with skin conditions, who cannot help with recognition and management. Dermatologists need to ask female psoriatics if they have genital rashes. Although vulvar psoriasis generally is accompanied by psoriasis in other typical locations, the vulva is a common site of Koebnerization. Vulvar psoriasis usually affects only fully keratinized skin, sparing the modified mucous membrane of the inner labia majora and the labia minora. Vulvar psoriasis typically exhibits dusky red, well-demarcated plaques. Rather than thick, silvery scale, the moistness of inverse psoriasis or a glazed, shiny surface texture is seen (Fig. 78-4, eFigs. 78-4.1–78-4.3 in online edition).

Genital psoriasis often responds well to topical therapy. A mid- or high-potency glucocorticoid ointment generally is required for significant clinical or symp-

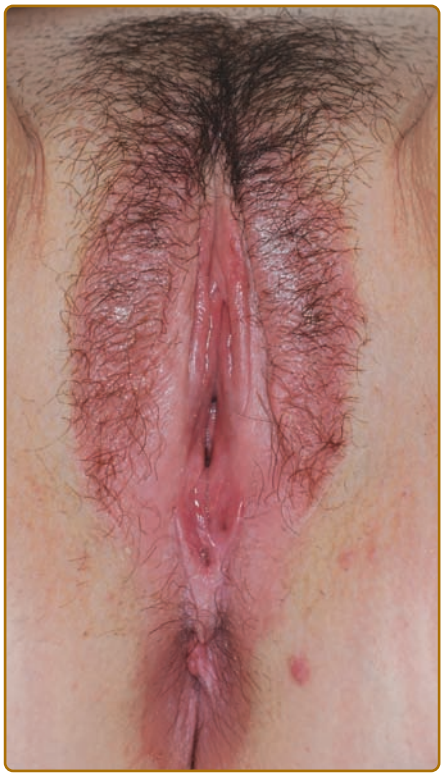

Figure 78-4 Psoriasis of the vulva with symmetrical, papulosquamous, scaling, and erythema typically seen on the hairy area of the labia majora with a thin pink plaque extending to the perianal area.

tomatic improvement. Calcipotriene ointment, tacrolimus ointment, or pimecrolimus cream can be tried as well, but some patients find these too irritating. For extensive psoriasis, methotrexate, oral retinoids, cyclosporine, or the newer biologics are required.

LICHEN SCLEROSUS AT A GLANCE

- Inflammatory condition of the vulva occurring at any age.
- Most symptomatic in childhood and postmenopausal years (low estrogen levels).
- Cellophane paper-like texture to the white plaques classically.
- Chronic, long-term disease leads to scarring and resorption.
- Chronic active disease increases risk of vulvar squamous cell carcinoma.
- Treatment is with superpotent steroid (clobetasol propionate) ointment.
- Maintenance therapy is needed for long-term control.

LICHEN SCLEROSUS

(See Chapter 65)

Lichen sclerosus is the commonest cause of chronic vulvar dermatosis. The prevalence is 1:300–1:1,000. The onset is bimodal in premenarchal girls and perimenopausal women.

CLINICAL FINDINGS. Lichen sclerosus begins asymptomatically in most patients. Women often tolerate their disease comfortably until they develop a superimposed complicating event, such as candidiasis or atrophic vaginitis that produces itching, followed by scratching, and the process becomes self-perpetuating. At presentation, the most common symptom of lichen sclerosus is pruritus (mild or severe). Because vulvar skin affected by lichen sclerosus is fragile, scratching often produces painful erosions. Many women, by the time they come for treatment, exhibit late signs of lichen sclerosus, including remarkable textural changes and scarring with loss of normal vulvar architecture. Scarring and narrowing of the introitus may make intercourse painful, even intolerable.

Lichen sclerosus begins with white papules or plaques that often occur first on the anterior vulva and periclitorally. Although these papules and plaques are sometimes smooth and somewhat waxy, especially when they occur on moist skin, the classic presentation is one of a hypopigmented, well-demarcated plaque with a shiny, crinkled cellophane-like surface



Figure 78-5 Hypopigmentation, crinkled texture, and purpura are classically seen in lichen sclerosus.

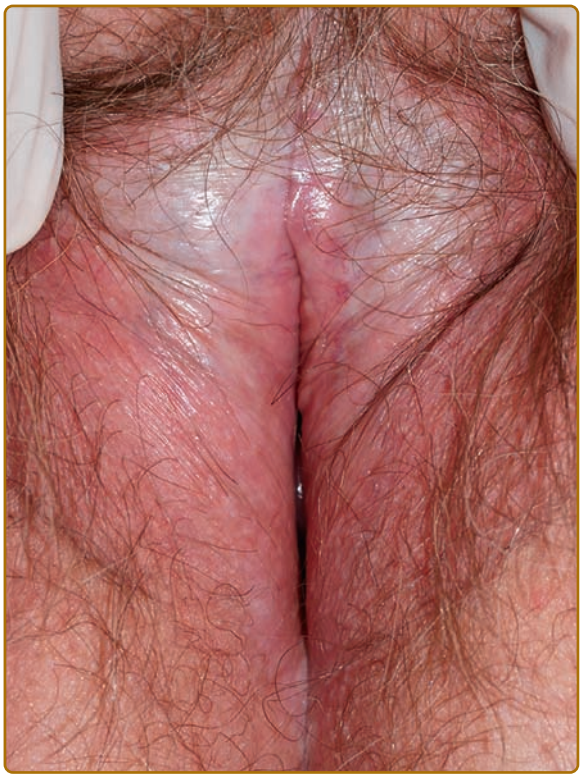

Figure 78-6 Occasionally, the texture of lichen sclerosus can be waxy or even thin and smooth, as seen here, rather than crinkled. The loss of labia minora and midline agglutination of the clitoral hood are also seen commonly in late lichen sclerosus.

(Fig. 78-5 and eFigs. 78-5.1–78-5.4 in online edition). Generally, the skin is quite thin and fragile, with erosions and purpura being common manifestations. Some women, particularly those who experience intolerable itchiness, exhibit thickened hyperkeratotic skin with extensive secondary changes, including fissuring, crusting, and even bleeding (eFig. 78-5.5 in online edition). Many patients with lichen sclerosus experience progressive scarring (eFig. 78-5.6 in online edition). Resorption of the labia minora and scarring of the clitoral hood, which buries the clitoris, are common in long-standing disease (Fig. 78-6). Extragenital lichen sclerosus of keratinized skin occurs in a minority of women with vulvar lichen sclerosus and is most often located on the upper trunk and arms (see Chapter 65). Usually, extragenital lesions are asymptomatic.

An association of lichen sclerosus with circulating autoantibodies has been reported, but the only association with autoimmune disease sufficient to justify laboratory testing is with hypothyroidism.[13]

DIFFERENTIAL DIAGNOSIS.

Fully developed lichen sclerosus with hypopigmentation and distinctive shiny or crinkled textural changes is easily recognized. Unfortunately, lichen sclerosus is sometimes subtle or mimics other diseases (Box 78-3).

COMPLICATIONS.

Sexual dysfunction results from scarring and introital narrowing. Four to five percent of patients are reported to develop squamous cell carcinoma in the natural course of lichen sclerosus.[4,15] Squamous cell carcinomas occurred primarily in patients with chronic hyperkeratosis or erosions. With effective topical therapy, this risk is understood to be lower.

BOX 78-3 DIFFERENTIAL DIAGNOSIS OF LICHEN SCLEROSUS OF THE VULVA

Most Likely
- Lichen simplex chronicus
- Lichen planus
- Vitiligo

Consider
- Immunobullous disease
- Contact dermatitis

Always Rule Out
- Squamous cell carcinoma

TREATMENT.

Although topical glucocorticoids reduce symptoms, they do not always normalize the skin texture or prevent scarring. The application of a superpotent topical preparation once or twice a day alleviates symptoms within a few days, but several months of therapy is required for resolution of the clinical findings.[14,15]

Most patients require 3–5 months of once- or twice-daily application to achieve maximal improvement. Patients should be followed monthly during periods of daily treatment to monitor the skin for steroid side effects and for improvement so that the frequency of application can be decreased.[16] As an adjunct therapy for the first week or two to control scratching and hasten healing, sedating dosages of an antihistamine or a tricyclic antidepressant are helpful. Any infection must be controlled.

Lichen sclerosus usually is not eliminated permanently by therapy. One survey showed an 84% recurrence rate among patients off therapy.[17] Despite the frequent requirement for long-term maintenance therapy, however, there is no proven optimal schedule. Most patients do well with two to three carefully localized weekly applications of a superpotent glucocorticoid on an ongoing basis.

No other treatments for lichen sclerosus produce the striking and prompt benefit of a topical superpotent glucocorticoid. Intralesional triamcinolone is used in resistant areas. In addition, other medical therapies generally have shown benefit only in open-label series. Tacrolimus and pimecrolimus (see Chapter 221) have been reported effective.[18]

Beneficial effects have also been described historically with topical testosterone, progesterone, and estrogen, but the benefit is minimal and equivalent to that of vehicle or lubrication alone.[19–21]

Topical tretinoin 0.025% and calcipotriol sometimes produce improvement, but their usefulness is limited because they can cause irritation.[22,23]

Oral retinoids have been reported to be helpful for some.[24] The Chinese literature abounds with reports of benefit from traditional Chinese herbs and acupuncture for lichen sclerosus.[25]

Surgical therapies, including cryotherapy, vulvectomy, carbon dioxide laser vaporization, pulsed dye laser therapy, and photodynamic therapy have been advocated for the treatment of lichen sclerosus.[26–30]

VULVAR FISSURES

Small, linear fissures on the vulva are common causes of itching, stinging, and dyspareunia.[31] Sometimes these fissures present clinically as painful, erythematous lines in skin folds and at other times they present as obvious linear erosions.

Most well recognized are fissures at the posterior fourchette that split during intercourse (Fig. 78-7 and eFig. 78-7.1 in online edition). These produce tearing pain initially, followed by burning and stinging when alkaline semen touches the area. The skin heals quickly, but splits recur with intercourse. The cause is unknown. The condition usually occurs suddenly, after years of comfortable coitus. Adequate lubrication and positioning of the woman on top can minimize tearing. Otherwise, surgical excision (perineoplasty) is required, with the vertical fissure excised and the skin closed front to back with advancement of the vaginal mucosa to cover the area.[32]

Recurrent fissuring within skin folds, especially in the interlabial sulci of the vulva, is a common cause of stinging and irritation of the vulva. Women typically complain of a sensation of "paper cuts." Intercourse and tight clothing are often precipitating events. Isolated acute fissuring is associated most often with *Candida* colonization or infection. Skin fold fissures can result from any inflammatory dermatosis, including psoriasis, lichen sclerosus, and lichen simplex chronicus. When one of these factors is identified, treatment is directed toward its correction. When no specific underlying cause is found, a topical glucocorticoid ointment combined with an oral antibiotic and anticandidal medication often eliminates the fissuring. However, almost immediate recurrence is common, and prolonged therapy may be required to break the cycle.



Figure 78-7 Recurrent fissuring of the posterior fourchette with intercourse is a commonly recognized phenomenon of unknown cause that often requires perineoplasty, a type of excisional surgery.

BULLOUS AND EROSIVE DISEASES

LICHEN PLANUS

(See Chapter 26)

Vulvovaginal lichen planus is much less common than vulvar lichen sclerosus with a likely prevalence of 1 in 2,500–4,500. It is often misdiagnosed as lichen sclerosus.[33]

CLINICAL FINDINGS. Vulvovaginal lichen planus has a wide variety of clinical manifestations. Erosive vulvovaginal lichen planus is most common and is generally very symptomatic. It presents with burning, rawness, and dyspareunia with variable itching. Nonerosive lichen planus of the vulva may appear bland with mainly itching and irritation, but it can be very symptomatic and be accompanied by serious accompanying erosive vaginal disease. Irritating inflammatory vaginal secretions can produce symptoms of introital burning and stinging. Disease may be restricted to the vagina with no vulvar manifestations. Rectal and perianal disease is common and often produces pain.

White, lacy, reticulate striae resembling papular oral lichen planus sometimes occur on the modified mucous membranes of the vulva (Fig. 78-8 and eFig. 78-8.1 in online edition). Less easily recognized are solid, uniformly hypopigmented, flat white plaques that mimic lichen sclerosus except for the absence of crinkled cellophane paper-like texture (eFig. 78-8.2 in online edition). Erosive lichen planus is manifested by a glazed erythema and variable red, painful erosions that are either nonspecific or surrounded by typical white, often scalloped, epithelial changes (eFigs. 78-8.3 and 78-8.4 in online edition). Erosive vulvovaginal lichen planus is often accompanied by erosive buccal and gingival oral disease.[34,35]

Lichen planus, especially when erosive, produces remarkable scarring (eFig. 78-8.5 in online edition). Resorption of the labia minora and obliteration of the clitoris under an agglutinated clitoral hood are very common. Narrowing of the introitus occurs more often and more severely than with lichen sclerosus, and vaginal adhesions can close the vagina, preventing both intercourse and introduction of a speculum (eFig. 78-8.6 in online edition).

Vaginal erosions are often obvious, appearing as bright red, often raw, patches, but sometimes equally painful disease can be subtle and show only mild erythema on a speculum examination. Scarring may vary from a minor synechia, slight narrowing or vaginal



Figure 78-8 Although these white, well demarcated linear papules are typical for papular lichen planus, they are often accompanied by nearby erosive disease.

shortening to vaginal obliteration. Vaginal discharge can be light to heavy and bloody. An examination of vaginal smears is a sensitive test for the presence of vaginal inflammation. Large, flat, cuboidal, mature desquamated vaginal epithelial cells are replaced by smaller, rounded basal cells shed from erosions and rapidly proliferative inflamed vaginal epithelium and sheets of leukocytes are seen. Up to 77% of patients with oral lichen planus have vulvovaginal lichen planus, but are often unaware and should be examined for asymptomatic involvement.[36,37]

The diagnosis of lichen planus is made either by biopsy or by the identification of classic lacy lesions in association with other typical mucous membrane lesions. Biopsies are often nonspecific and a negative biopsy does not rule out this diagnosis.

DIFFERENTIAL DIAGNOSIS.

When lichen planus presents classically and involves oral and genital mucosa, it is easy to diagnose. Unfortunately, lichen planus on the vulva alone can be indistinguishable from other diseases (Box 78-4).

COMPLICATIONS.

The inflammation, pain, and scarring commonly cause sexual dysfunction, and at times, anger and depression. Vulvar squamous cell carcinoma has been well described in patients with erosive genital lichen planus. The magnitude of this risk is not known, but patients should be evaluated for this condition regularly.

BOX 78-4 DIFFERENTIAL DIAGNOSIS OF VULVAR LICHEN PLANUS

Most Likely
- Lichen sclerosus
- Immunobullous disease
- Stevens–Johnson syndrome

Consider
- Fixed drug eruption
- Contact dermatitis

Always Rule Out
- Squamous cell carcinoma

TREATMENT.

The aggressive treatment of vaginal lichen planus is crucial for patient comfort. Meticulous local care with early treatment of infection, minimization of external irritants, and attention to any underlying atrophy of estrogen deficiency are important measures. A vaginal dilator should be used daily to prevent adhesions of the vaginal walls. Emotional support and careful patient education regarding the nature of the disease, its prognosis, and its therapy are vital.

Pruritic, noneroded vulvar lichen planus is usually quite well managed simply by the application of a potent topical glucocorticoid ointment. Severe erosive vulvovaginal lichen planus can present a difficult therapeutic problem. A superpotent glucocorticoid ointment applied to the vulva is standard first-line therapy. For mild-to-moderate disease, a gram of the glucocorticoid ointment can be inserted into the vagina as well, or hydrocortisone acetate 25 mg rectal suppositories can be inserted nightly into the vagina.[38]

For severe disease, use a compounded 100-mg/g hydrocortisone acetate vaginal cream, 3–5 g nightly for 2 weeks, decreasing to three times a week as maintenance. Systemic steroids are also used and the least toxic is deep intramuscular triamcinolone 1 mg/kg up to 80 mg/dose. This may be repeated monthly for 3 months and limited to four doses per year (personal experience). Patients are warned about adrenal suppression and given fluconazole 150 mg weekly to prevent candidiasis. Any patient with vulvar disease receiving an intravaginal glucocorticoid should be told of her increased risk for yeast infection. There is little tendency for erosive vulvovaginal lichen planus to remit, but it can be well controlled. The severity tends to wax and wane, sometimes as a result of secondary infections, exposure to irritants, or stress but more often for no identifiable cause. Bursts of oral predniso(lo)ne or intramuscular triamcinolone can be helpful for flares.

Topical tacrolimus and pimecrolimus have been reported to be useful in the treatment of vulvar lichen planus, but these medications are irritating.[39,40] They can be used as "steroid sparers" once the inflammation is controlled.

Other medications that have been reported primarily in open trials as useful for the treatment of erosive mucous membrane lichen planus include hydroxy-

chloroquine, methotrexate, retinoids, azathioprine, cyclophosphamide, mycophenolate mofetil, and thalidomide.[41–45]

ERYTHEMA MULTIFORME MAJOR, STEVENS–JOHNSON SYNDROME, AND TOXIC EPIDERMAL NECROLYSIS

(See Chapters 39 and 40)

Erythema multiforme major, Stevens–Johnson syndrome, and toxic epidermal necrolysis all lead to erosive vulvar disease. One retrospective survey of 40 women with toxic epidermal necrolysis revealed that 28 had vulvovaginal involvement with severe erosions, of whom five experienced permanent scarring.[46] These patients were unable to engage in intercourse, even after corrective surgery. Local care during the serious phase of the illness can prevent long-term dysfunction due to scarring. Prompt treatment of secondary bacterial or *Candida* infection may be important. In addition, daily insertion of a vaginal dilator (such as an inexpensive syringe cover) is important to ensure patency.

CICATRICIAL PEMPHIGOID

(See Chapter 57)

Cicatricial pemphigoid regularly produces multiple mucosal erosions. The nonspecific, painful erosions of the vulva and surrounding epithelium can be clinically indistinguishable from lichen planus and lichen sclerosus. Vulvar erosions generally are accompanied by nonspecific vaginal erosions that can result in significant vaginal scarring. Management consists of both local glucocorticoid therapy and systemic treatments.[47] Vaginal treatment is the same as for erosive vaginal lichen planus. Again, local care, the use of vaginal dilators, and secondary infection control are important factors in management.

PEMPHIGUS VULGARIS

(See Chapter 54)

Pemphigus vulgaris often presents with mucosal erosions on the vulva. Although pemphigus vulgaris is usually considered to be a nonscarring disease, vulvovaginal involvement can lead to scarring, with vaginal adhesions and obliteration of vulvar architecture. As with cicatricial pemphigoid, a high index of suspicion and confirmatory biopsies are important in reaching the correct diagnosis. For treatment, see Chapter 54.

FIXED DRUG ERUPTION

(See Chapter 41)

Erosions due to fixed drug eruption sometimes occur on the vulva. Common offenders include acetaminophen, hydrochlorothiazide, nonsteroidal anti-inflammatory medications, oral contraceptives, sulfa drugs, penicillin, tetracyclines, allopurinol, barbiturates, and furosemide.[48,49] Lesions are most often located in the vestibule or on the modified mucous membranes of the labia minora or medial labia majora. Unlike the classic, round, edematous plaques or blisters seen on keratinized skin, the erosions of a fixed drug eruption on the vulva are often irregular, sometimes with a slightly shaggy border. Often there are one or a few typical lesions on keratinized skin, or there are oral erosions. The deepening hyperpigmentation seen on keratinized skin affected by recurrent fixed drug eruptions is usually absent on the modified mucous membranes of the vulva (Fig. 78-8.7 and eFig. 78-8.8 in online edition).

HERPES SIMPLEX

(See Chapter 193)

EXTRAMAMMARY PAGET DISEASE

(See Chapter 121)

VULVAR CARCINOMA

(See Chapters 113 and 114)

ULCERS

APHTHAE

(See Chapters 76 and 166)

Aphthae, "canker sores," common in the oral cavity, are often misdiagnosed on the vulva where they occur more frequently than the few literature reports would suggest. These are acute, painful ulcers that can be single or multiple (Fig. 78-9).

They typically affect girls 9–19 years of age and present with the sudden onset of painful, punched-out,



Figure 78-9 Aphthae of the vulva are characterized by large size, punched-out borders, and a white fibrin base as seen on the medial labium minus of this patient with concomitant vaginal candidiasis.

well-demarcated vulvar ulcers, usually less than a centimeter (range 0.5–5 cm). The ulcers are most often found on the vulvar trigone, the labia, and less frequently the lower vagina. Typically there is a prodrome with flu-like symptoms of mild fever, headache, and malaise. There may be a past history of oral aphthae. The ulcers last 1–3 weeks and resolve. Scarring is variable. Usually there is just one episode but these can recur. The pathogenesis probably involves the interaction of genetic factors with infection as a trigger. The hypothesis is that microbial antigens with molecular mimicry induce a reactive process directed at host antigens. Commonly the antigenic agent is unknown, but a number of cases have been associated with Epstein–Barr virus, a few cases with *Mycoplasma pneumoniae*, HIV, or cytomegalovirus[50–52] (eFig. 78-9.1 and 78-9.2 in online edition). The combination of recurrent oral plus genital ulcers is complex aphthosis.[53] This pattern is seen most commonly with inflammatory bowel disease, Crohn disease and ulcerative colitis and, less commonly with, celiac disease. It also can occur infrequently with medications, myeloproliferative diseases, neutropenia, lymphopenia, and some rare syndromes like FAPA syndrome (fever, aphthae, pharyngitis, and adenitis). Rarely, in North America, these ulcers are associated with Behçet's disease. This is a frequent association in the Middle East.

Diagnosis is one of exclusion. Biopsies are often taken but are usually nonspecific. For acute ulcers, test for Herpes simplex, sexually transmitted diseases including HIV, Epstein–Barr virus, and *Mycoplasma*. For chronic recurrent ulcers investigate for inflammatory bowel disease and the less common causes above. The differential diagnosis includes herpes simplex, other sexually transmitted infections (syphilis, chancroid), and pyoderma gangrenosum.

A short course of prednisone is best for acute disease. For recurrent aphthae, colchicine, dapsone, colchicine combined with dapsone, cyclosporine, and thalidomide have been used.[53]

CROHN DISEASE

(See Chapter 150)

Crohn disease is a noninfectious granulomatous inflammatory disorder that primarily involves the bowel, but vulvar and perianal skin are sometimes affected. Vulvar involvement is underrecognized and misdiagnosed.[54] Only 55 cases are reported in the literature, but most vulvar specialists have managed vulvar Crohn cases.

The average age is 34 years. Metastatic spread is the most common presentation (91%). Symptoms include swelling (62%) and pain (20%). Examination usually shows swelling and induration in the labia majora with or without ulcers that extend to the groin. The ulcers occur in 41% and can be the classic "knife-cut" type in the skin folds, aphthous ulcers, or both[55] (Fig. 78-10 and eFigs. 78-10.1–78-10.3 in online edition).

The diagnosis is made on the basis of biopsy results and identification of the bowel disease, but 25% of vulvar Crohn disease patients have no gastrointestinal symptoms. The primary disease to be differentiated from anogenital Crohn disease is hidradenitis suppurativa (see Section "Hidradenitis Suppurativa"), which is said to coexist in 17% of cases of Crohn disease. Other diseases to rule out are sarcoidosis, tuberculosis, lymphogranuloma venereum, and atypical pyogenic infections. Treatment is with systemic therapy for the underlying intestinal Crohn disease.[56,57]



Figure 78-10 Diffuse firm vulvar edema is a common presentation of Crohn disease.

Topical and intralesional glucocorticoids and local care can help to induce healing of ulcerations.

SYPHILIS

(See Chapter 200)

CHANCROID

(See Chapter 202)

OTHER ULCERATIONS IN SEXUALLY TRANSMITTED DISEASES

(See Chapters 203 and 204)

ABSCESSES

Abscesses occur in Crohn disease (see Section "Crohn Disease"), gonorrhea (see Chapter 205), hidradenitis suppurativa (see Section "Hidradenitis Suppurativa"), and Bartholin gland (see below).

BARTHOLIN'S CYST AND ABSCESSES

The Bartholin's glands are the largest of the vulvar vestibular glands. They secrete mucus-like material for

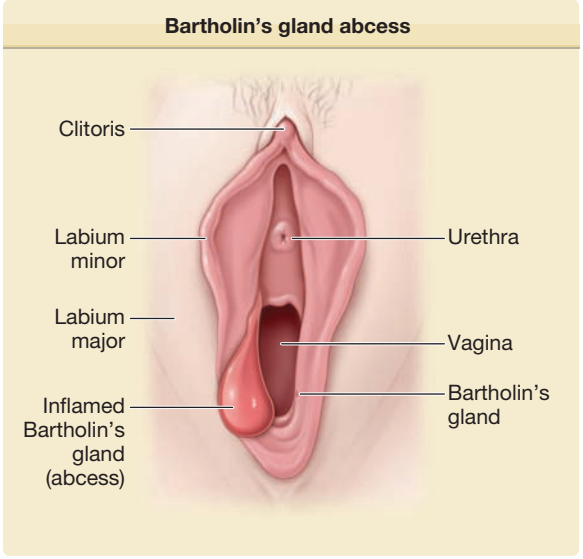

Figure 78-11 Bartholin's gland abscess. This schematic drawing shows the exact location of Bartholin's gland and abscess. (Used with permission from Petra Kohlberger, MD.)

lubrication during sexual activity. Cysts form due to occlusion of the opening ducts. They are located on the lower labia minora at 5 and 7 o'clock just lateral to the hymenal ring. Cysts can range from 1–3 cm in size and are often asymptomatic.[58]

Diagnosis is clinical with the typical nodule of varying size lying in the posterior vestibule with the labium minus classically "transecting" the cyst (Fig. 78-11). No treatment is necessary for asymptomatic Bartholin's cysts unless the patient is over 40 and there is concern about carcinoma.

Bartholin's duct abscesses develop as an infected obstruction of the Bartholin's duct. Infection is typically from *Escherichia coli*, *Staphylococcus*, or *Streptococcus*.[59,60] Occasionally, it is a sexually transmitted infection. Patients present with severe pain and swelling and sometimes an inability to sit or walk. The cyst is warm, swollen, and tender with a varying degree of surrounding edema and erythema. Treatment is with incision and drainage and for complicated infections appropriate antibiotics. Recurrent lesions require specific surgery.

HIDRADENITIS SUPPURATIVA

(See Chapter 85)

Hidradenitis suppurativa is a chronic, inflammatory, recurrent, debilitating, follicular disorder predisposed to involve intertriginous areas.[61–64] It presents with painful, deep seated, inflamed lesions, note that the newest classification makes no mention of apocrine gland involvement.

The Second International Hidradenitis Suppurativa Research Symposium (San Francisco; March, 2009) adopted the following diagnostic criteria that must be met to establish the diagnosis:

1. Typical lesions—i.e., deep-seated painful nodules: blind boils in early lesions; abscesses, draining sinuses, scars, and "tombstone" open comedones in secondary lesions.
2. Typical topography—i.e., axillary, groin, perineal and perianal lesion, buttocks, infra and intermammary folds.
3. Chronicity and recurrence.

Most commonly the axillary, inguinal, inframammary, and anogenital regions. This disease is more common in women than men, with a ratio of 3.3 to 1 and affects 1% of the general population. It is frequently misdiagnosed as "boils," delaying diagnosis, and leading to fragmented care and progression to a chronic, disabling condition that has a profoundly negative impact on quality of life.[62] Onset is usually in a woman's twenties with remission after menopause. The course varies from intermittent and benign to continuous and severe.

In women these "boils" present classically in the groin and around the hair-bearing areas of the vulva, less often on the modified mucous membranes, but commonly in the axillae and under the breasts (Fig. 78-12).

The nodules can be extremely painful nodules and very debilitating. Rupture and drainage of malodorous purulent material can be very distressing. Lesions vary from a few acneform nodules that last 7–15 days to persistent chronic hypertrophic scars, with dense fibrosis forming linear rope-like bands with varying degrees of drainage from interconnecting sinuses. In more severe cases, hidradenitis suppurativa results in chronic erosions from draining ulcerations and lymphedema from lymphatic obstruction. It can be difficult to differentiate from Crohn disease and they can coexist.[65]

The Second International Hidradenitis Suppurativa Research Symposium (San Francisco; March, 2009) adopted the following diagnostic criteria that must be met to establish the diagnosis:



Figure 78-12 Hidradenitis suppurativa (Hurley's Stage III) of the vulva with chronic interconnecting draining sinuses, painful swelling and discharge for years.

1. Typical lesions—i.e., deep-seated painful nodules: blind boils in early lesions; abscesses, draining sinuses, scars, and "tombstone" open comedones in secondary lesions.
2. Typical topography—i.e., axillary, groin, perineal and perianal lesion, buttocks, infra and intermammary folds.
3. Chronicity and recurrence.

Treatment depends on severity, using the Hurley classification.[66]

At all stages, if appropriate, androgen blockade with nonandrogenic birth control pills, spironolactone, and/or finasteride are used.[67] Smoking must cease. All friction or trauma to the areas of involvement must be avoided. Oral zinc has been used as an anti-inflammatory.[68]

STAGE I (ABSCESS FORMATION WITHOUT SINUS TRACTS). Treatment is aimed at reducing flares using topical clindamycin lotion, courses of antibiotics for 7–10 days (tetracycline, doxycycline, clindamycin), oral zinc gluconate, and intralesional triamcinolone or a short oral course of predniso(lo)ne. Low-dose isotretinoin is useful in a minority of cases.[69]

STAGE II (RECURRENT ABSCESSES WITH SINUS TRACTS AND SCARRING, SINGLE OR MULTIPLE WIDELY SEPARATED LESIONS). (eFig. 78-12.1 in online edition). Management requires the above medical therapy as baseline plus surgical treatment to reduce activity to Stage I and also to prepare for wide unroofing of sinuses and persistent cysts. Antibiotics such as the tetracyclines or clindamycin and rifampicin are used in combination for 3 months.[70,71] At times dapsone may be helpful. Intralesional triamcinolone and short courses of predniso(lo)ne are used to quickly control swelling and inflammation.

STAGE III (DIFFUSE OR EXTENSIVE INVOLVEMENT, OR MULTIPLE INTERCONNECTING TRACTS AND ABSCESSES ACROSS THE ENTIRE AREA). This is a surgical disease. Medical treatment is essential in preparation for surgery.[72] Anti-inflammatories may be necessary. The biologics can provide dramatic preoperative improvement but are not a cure.[73,74]

Surgical management need not be heroic and widely ablative in Stage II and early Stage III. The preferred technique is to unroof the sinuses as early as possible, to include a thorough exploration and exposure of any secondary sinuses and cysts, and then eradicate to the extent possible inflammatory masses responsible for perpetuating the lateral extension of lesions.[75,76]

VULVODYNIA

Vulvodynia is chronic vulvar pain *with no identifiable cause*. Vulvar pain is a challenging problem for caregivers and, too often, a very difficult problem for women. Pain can seriously impact their lives, affecting not only their sexuality but also their daily activities, even what they can wear. Vulvar pain and vulvodynia have been defined and classified by the International Society for the Study of Vulvovaginal Disease.[77] (Box 78-5). Vulvodynia is defined as vulvar pain in the absence of relevant, visible physical findings or a specific clinically identifiable neurological disorder. All vulvar pain conditions due to specific disorders, infections, inflammatory disorders, neoplastic conditions, or neurological conditions must be excluded.[78–80]

Vulvodynia is divided into localized (formerly vulvar vestibulitis) (eFig. 78-12.2 in online edition) and generalized (formerly dysesthetic vulvodynia). Both of these groups can be further divided into those who experience provoked (brought on by touch), unprovoked (spontaneous), or mixed (both provoked and unprovoked) pain. Localized vulvodynia can be primary as in pain present with first tampon use or vaginal entry, or secondary, as in acquired after some years of no pain on touching/vaginal entry.

BOX 78-5 CLASSIFICATION OF VULVAR PAIN

SECONDARY VULVAR PAIN (RELATED TO A SPECIFIC DISORDER)

1. Infectious, e.g., candidiasis
2. Inflammatory, e.g., erosive lichen planus
3. Neoplastic, e.g., squamous cell carcinoma
4. Neurologic, e.g., postherpetic neuralgia

PRIMARY VULVAR PAIN (WITHOUT VISIBLE LESIONS)

1. Localized vulvodynia (formerly vulvar vestibulitis)
2. Generalized (formerly dysesthetic or essential vulvodynia)

EPIDEMIOLOGY

Unexplained vulvar pain is highly prevalent among women of reproductive age with lifetime prevalence estimates ranging from 16%–28%. The prevalence of true vulvodynia is unknown because careful clinical evaluation is required for a definitive diagnosis.[3,81,82] Localized provoked vulvodynia usually affects younger women and is more common than generalized vulvodynia.[83]

ETIOLOGY AND PATHOGENESIS

The etiology of vulvodynia is unclear. It is likely multifactorial with both organic and functional components. Etiological factors being studied range from neuropathic mechanisms, neural hyperplasia, neurogenic inflammation, abnormal nociception, and neurotransmitter and neuropeptides anomalies, to pelvic floor muscle dysfunction. There are localized processes in the vulva that can trigger pain and changes centrally

in the dorsal root ganglia and in the brain, changes that keep the pain active. The result is abnormal pain perception so that light touch causes pain (allodynia).

More work has been done on localized vulvodynia. Patients are overly sensitive to pain and cannot downregulate it. They have increased nerve fibers, inflammatory cells, and mediators in the vulvar vestibule along with a poor ability to modify pain. The pelvic floor muscles are dysfunctional, tight, and weak, and play an important role in causation or perpetuation (and are not just a consequence) of vulvodynia. Underlying psychosexual issues or personality traits, such as somatization disorder, can be important.[84] Depression and anxiety have been reported. These patients may have other comorbid hypersensitivity syndromes with centralized pain such as migraines, irritable bowel syndrome, and fibromyalgia.[85,86] Very few studies have looked at generalized vulvodynia, and it may represent pudendal neuralgia or a regional pain syndrome.

CLINICAL FINDINGS

Patients with localized vulvodynia are usually between the ages of 20–50. Typically there is pain on touch or attempted vaginal entry (referred to as provoked pain). This may be with the first use of a tampon or sexual intercourse (primary vulvodynia) or after years of no discomfort (secondary vulvodynia). The patient complains of burning, stinging, irritation, or a raw sensation at the vaginal entrance (hymenal ring area).[87–89] The pain can be moderate-to-severe. Sexual intercourse is difficult to impossible. They may complain of constant vaginal infections despite negative tests or that their partner is too big. They are often distressed, anxious, and/or depressed. Patients with generalized vulvodynia, usually over 40 years old, have constant or episodic vulvar pain. They complain of burning, soreness, rawness, stabbing pain, irritation, aching, or stinging, but they usually can have sexual intercourse. They are hyperaware of their genital area. They often complain of "constant yeast." These patients have often seen many caregivers, had multiple incorrect diagnoses, and tried many treatments.

On examination there is no visible abnormality. The pelvic floor muscles may be tight and sensitive. Q-tip sensitivity (see below) may be prominent in localized vulvodynia.

DIFFERENTIAL DIAGNOSIS

The diagnosis of vulvodynia is one of exclusion. The diagnosis of localized vulvodynia is made on history and the demonstration of pain on Q-tip touching around the hymenal ring. Patients with vulvodynia should be examined carefully for any underlying skin disease, infection, neoplasm, or well-defined neurologic disorder. Irritant contact dermatitis, vulvar fissures, and lichen planus are the most common skin diseases to be mistaken for vulvodynia. Painful vaginitis from nonalbicans *Candida* infection or a noninfectious inflammatory vaginitis (desquamative inflammatory vaginitis) can be confused with vulvodynia. Desquamative inflammatory vaginitis is manifested by grossly and microscopically purulent vaginal secretions and immature epithelial cells similar to those seen in lichen planus. Nonalbicans *Candida* infections, such as *C. glabrata*, *C. krusei*, and *Saccharomyces cerevisiae* infection also can cause chronic vulvovaginal pain. These infections are easily missed unless a culture is performed, and they can be resistant to therapy. Finally, neurologic disorders such as postherpetic neuralgia, pudendal nerve entrapment, pudendal neuralgia, and spinal compression need to be addressed through history and imaging studies when appropriate.

TREATMENT

Vulvodynia is complex, and with multiple possible contributing factors many medical/surgical, psychological, and alternate approaches have been used. The different aspects of vulvodynia therapy are ideally addressed simultaneously using a multidisciplinary approach.

Education and support are vital. There are excellent resources through the National Vulvodynia Association (http://www.nva.org).

All irritating hygiene practices must stop. Good education here is needed to avoid laundry detergents, cleansers, pads, ill-fitting clothing, etc., that could cause local harm. Activities that hurt, like bike riding, must stop. Sexual intercourse should be avoided when there is pain.

For topical pain control lidocaine 5% ointment has decreased pain up to 50%. Topical 6% compounded gabapentin cream has been helpful for over 50% of generalized vulvodynia patients. Topical estradiol cream has been used for cases of localized vulvodynia. Other local treatments with a few reports include topical capsaicin, and local injections (as pain blocks) using lidocaine with methylprednisolone.

Systemic medications are often used as pain modulators. Tricyclic antidepressants such as amitriptyline or desipramine, beginning at very low dosages and increasing up to 150 mg or until the patient is comfortable, are first-line.[90] For women who do not tolerate tricyclic antidepressants or who experience suboptimal improvement, gabapentin has been used.[91] The newer antidepressants venlafaxine and duloxetine have been used effectively as well. Pregabalin provides yet another possible option. Combinations of these medications can be used.

Pelvic floor dysfunction needs to be addressed with the help of a pelvic floor physiotherapist who can also assess the back and hips to make sure no other confounding biomechanical problems are present. Treatments to normalize pelvic floor function include myofascial release, trigger-point pressure, biofeedback, vaginal dilation, and exercises.

Attention to depression and sexual dysfunction is mandatory. Most patients benefit from referral for counseling to help them cope with their debilitating symptoms. Behavior and cognitive-behavior therapy

can reduce the fear of pain and improve sexual functioning with good results.

For localized vulvodynia, surgical vestibulectomy has been successful in over 60% of cases. It is best for secondary vulvodynia, especially when combined with pelvic floor therapy. It is usually chosen only when conservative treatment fails.

For generalized vulvodynia with neuralgia, management in a pain clinic using nerve blocks and interventional devices (sacral nerve root stimulators) may be needed.

However, improvement is usually slow and trial-and-error therapy with support by the physician is required.[85,86,83,92,93]

PRURITUS VULVAE

Pruritus vulvae is common, affecting perhaps 10% of women. It can be acute or chronic, minor, or debilitating. The most common cause is candidiasis. Irritant contact dermatitis is next, due to overwashing and topical irritants, particularly urine, feces, and sweat, as well as various topical medications.

The commonest chronic vulvar conditions are lichen simplex chronicus and lichen sclerosus and, less frequently, lichen planus and psoriasis. Often there is a combination of infection, contact dermatitis, and one or more dermatoses. Rarely the problem is due to a neuropathy or underlying malignancy. Investigation and treatment is directed at the individual causes. It is always important to eliminate all irritants and control infection. Sedation to stop scratching is often imperative. Topical or at times systemic corticosteroids can be very effective for inflammation. The calcineurin inhibitors can be used as "steroid sparers."

There is a group of women in whom it is very difficult to pinpoint a cause for the itching. The majority of these have some degree of neuropathy with or without anxiety or depression. Treatment is with neurotropic agents as used for vulvodynia; anxiety andor depression must be addressed.[94–96]

KEY REFERENCES

Full reference list available at www.DIGM8.com

DVD contains references and additional content

6. Lynch PJ: Lichen simplex chronicus (atopic/neurodermatitis) of the anogenital region. *Dermatol Ther* **17**(1):8-19, 2004
8. Margesson LJ: Contact dermatitis of the vulva. *Dermatol Ther* **17**(1):20-27, 2004
16. Smith YR, Haefner HK: Vulvar lichen sclerosus: Pathophysiology and treatment. *Am J Clin Dermatol* 2004;**5**(2):105-125.
33. Moyal-Barracco M, Edwards L: Diagnosis and therapy of anogenital lichen planus. *Dermatol Ther* **17**(1):38-46, 2004
74. Revuz J: Hidradenitis suppurativa. *J Eur Acad Dermatol Venereol* **23**(9):985-998, 2009
85. Damsted-Petersen C, Boyer SC, Pukall CF: Current perspectives in vulvodynia. *Womens Health (Lond Engl)* **5**(4):423-436, 2009

Disorders of the Skin Appendages

PART 3



Disorders of the Sebaceous Glands

Chapter 79 :: Biology of Sebaceous Glands

:: Amanda M. Nelson & Diane M. Thiboutot

SEBACEOUS GLANDS AT A GLANCE

- Sebaceous glands are unilobular or multilobular structures that consist of acini connected to a common excretory duct and are usually associated with a hair follicle.
- Sebaceous glands vary considerably in size, even in the same individual and in the same anatomic area.
- The sebaceous glands exude lipids by disintegration of entire cells, a process known as *holocrine secretion*.
- Human sebum, as it leaves the sebaceous gland, contains squalene, cholesterol, cholesterol esters, wax esters, and triglycerides.
- Sebaceous glands are regulated by androgens and retinoids.
- Other factors, such as melanocortins, and peroxisome proliferator-activated receptors (PPARs), may regulate sebaceous gland activity as well.

ANATOMY OF THE SEBACEOUS GLAND

HISTOLOGY

Sebaceous glands are unilobular or multilobular structures that consist of acini connected to a common excretory duct, which is composed of stratified squamous epithelium. Sebaceous glands are composed of lipid-producing sebocytes and of keratinocytes that line the sebaceous ducts and are usually associated with a hair follicle. The periphery of the sebaceous gland is a basal cell layer composed of small, cuboidal, nucleated, highly mitotic sebocytes. Cells progress toward the middle of the gland and accumulate lipid droplets as they terminally differentiate. These fully differentiated sebocytes are full of lipid and lack all other cellular organelles (Fig. 79-1). Surrounding the glands are connective tissue capsules composed of collagen fibers that provide physical support.[1]

LOCATION

Sebaceous glands are associated with hair follicles all over the body. A sebaceous gland associated with a hair follicle is termed a *pilosebaceous unit*. The glands may also be found in certain nonhairy sites, including the

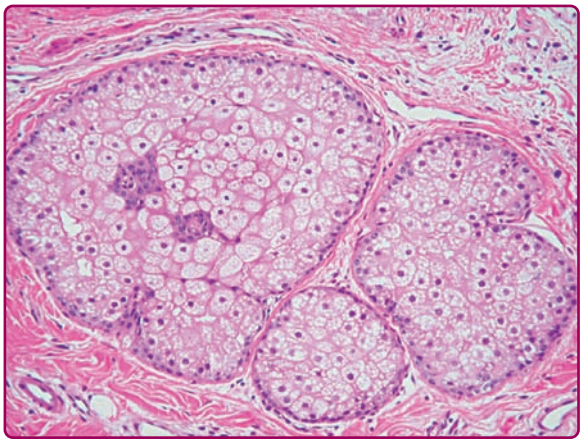

Figure 79-1 Hematoxylin and eosin-stained section of the human sebaceous gland showing its multilobular structure.

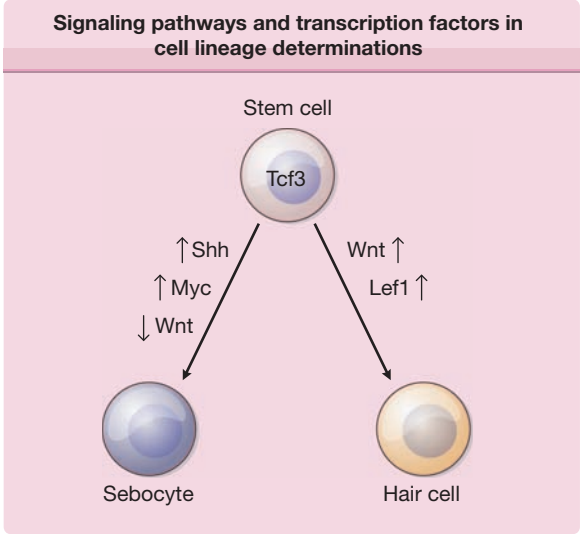

Figure 79-2 Signaling pathways and transcription factors that are involved in cell lineage determinations. As daughter cells migrate from the bulge region, changes in the expression patterns of numerous transcription factors determine their final cell lineage. Data is far from complete in this area; it is very likely that other pathways and transcription factors will play a significant role in determining each cell lineage. Lef1 = lymphoid enhancer binding factor 1; Myc = myelocytomatosis oncogene; Shh = Sonic Hedgehog; Tcf3 = transcription factor 3; Wnt = wingless (wg)/int.

eyelids (Meibomian glands), the nipples (Montgomery glands), and around the genitals (Tyson glands). Only the palms and soles, which have no hair follicles, are totally devoid of sebaceous glands. Sebaceous glands vary considerably in size, even within the same individual and within the same anatomic area. On the external body surface, most glands are only a fraction of a millimeter in size. The largest glands and greatest density of glands (up to 400–900 glands/cm^2) are located on the face and scalp.[1–3] The hairs associated with these large glands are often tiny, and it has been suggested that the total structures be more properly termed *sebaceous follicles* rather than hair follicles.

In the oral epithelium, sebaceous glands known as *Fordyce spots* are sometimes present. Fordyce spots are visible to the unaided eye because of their large size (up to 2–3 mm) and the transparency of the oral epithelium. In this location, the sebaceous ducts open directly to the surface.

EMBRYOGENESIS AND MORPHOGENESIS

In the human fetus, sebaceous glands develop in the 13th to 16th week of gestation from bulges (epithelial placodes) on the developing hair follicles. The bulge region of the follicle contains the epidermal stem cells that generate multiple cell lineages, including epidermal and follicular keratinocytes, as well as sebaceous glands. As daughter cells migrate from the bulge region, changes in the expression patterns of numerous transcription factors determine their final cell lineage. Wnt/wingless (Wnt) and Sonic Hedgehog (Shh) signaling pathways are intricately involved in embryonic patterning and cell fate decisions. Cells destined to become sebocytes have increased Shh and Myc signaling and decreased Wnt signaling (Fig. 79-2). In transgenic mouse models, intact Wnt signaling promotes hair follicle differentiation, whereas inhibition of Wnt signaling by preventing the Lef1/B-catenin interaction leads to sebocyte differentiation.[4] Loss-of-function and gain-of-function transgenic mouse models demonstrated that blocking Shh signaling inhibited normal sebocyte differentiation and constitutively activating Shh signaling increased the number and size of sebaceous glands in skin.[5] When fully formed, the glands remain attached to the hair follicles by a duct through which sebum flows into the follicular canal and eventually to the skin surface.

PHYSIOLOGY OF THE SEBACEOUS GLAND

HOLOCRINE SECRETION

The sebaceous glands exude lipids by disintegration of entire cells, a process known as *holocrine secretion*. The life span of a sebocyte from cell division to holocrine secretion is approximately 21–25 days.[6] Because of the constant state of renewal and secretion of the sebaceous gland, individual cells within the same gland are engaged in different metabolic activities dependent upon their differentiation state.[7] The stages of this process are evident in the histology of the gland.[8] The outermost cells, basal cell layer membrane, are small, nucleated, and devoid of lipid droplets. This layer contains the dividing cells that replenish the gland as cells are lost in the process of lipid excretion. As cells are displaced into the center of the gland, they begin to produce lipid, which accumulates in droplets. Eventually the cells become greatly distended with lipid droplets and the nuclei and other subcellular structures disappear. As the cells approach the sebaceous duct, they

disintegrate and release their contents. Only neutral lipids reach the skin surface. Proteins, nucleic acids, and the membrane phospholipids are digested and apparently recycled during the disintegration of the cells.

LIPID COMPOSITION OF SEBUM

Human sebum, as it leaves the sebaceous gland, contains squalene, cholesterol, cholesterol esters, wax esters, and triglycerides (Fig. 79-3). During passage of sebum through the hair canal, bacterial enzymes hydrolyze some of the triglycerides, so that the lipid mixture reaching the skin surface contains free fatty acids and small proportions of mono- and diglycerides, in addition to the original components. The wax esters and squalene distinguish sebum from the lipids of human internal organs, which contain no wax esters and little squalene. However, human sebaceous glands appear to be unable to cyclize squalene to sterols such as cholesterol. The patterns of unsaturation of the fatty acids in the triglycerides, wax esters, and cholesterol esters also distinguish human sebum from the lipids of other organs. The "normal" mammalian pathway of desaturation involves inserting a double bond between the ninth and tenth carbon of stearic acid (18:0) to form oleic acid (18:1Δ9). However, in human sebaceous glands, the predominant pattern is the insertion of a Δ6 double bond into palmitic acid (16:0). The resulting sapienic acid (16:1Δ6) (Fig. 79-3) is the major fatty acid of adult human sebum. Elongation of the chain by two carbons and insertion of another double bond gives sebaleic acid (18:2Δ5,8), a fatty acid thought to be unique to human sebum.[9]

Sebaceous fatty acids and alcohols are also distinguished by chain branching. Methyl branches can occur on the penultimate carbon of a fatty acid chain (iso branching), on the third from the last (antepenultimate) carbon (anteiso branching), or on any even-numbered carbon (internal branching). Examples of these unusual unsaturated and branched-chain moieties are included in the lipid structures in Fig. 79-3.

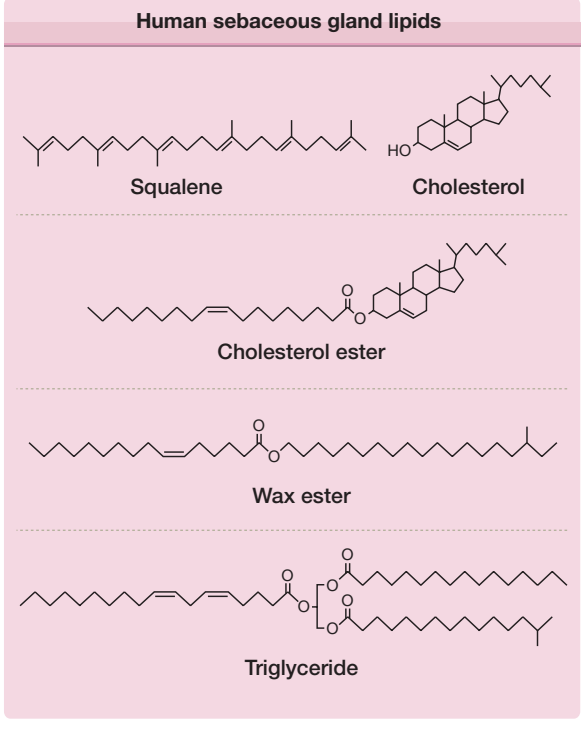

Figure 79-3 Human sebaceous gland lipids. The structures of the cholesterol ester, wax ester, and triglyceride are representative of the many species that are present. Two sebaceous-type unsaturated fatty acid moieties are shown: sapienic acid (16:1Δ6) (in the wax ester structure) and sebaleic acid (18:2Δ5,8) (in the triglyceride structure). Anteiso branching is shown in the alcohol moiety of the wax ester, and iso branching is shown in the triglyceride.

FUNCTION OF SEBUM

The precise function of sebum in humans is unknown. It has been proposed that its solitary role is to cause acne.[10] It has been suggested that sebum reduces water loss from the skin's surface and functions to keep skin soft and smooth, although evidence for these claims in humans is minimal; however, as demonstrated in the sebaceous gland-deficient (Asebia) mouse model, glycerol derived from triglyceride hydrolysis in sebum is critical for maintaining stratum corneum hydration.[11] Sebum has been shown to have mild antibacterial action, protecting the skin from infection by bacteria and fungi, because it contains immunoglobulin A, which is secreted from most exocrine glands.[12] Vitamin E delivery to the upper layers of the skin protects the skin and its surface lipids from oxidation. Thus, sebum flow to the surface of the skin may provide the transit mechanism necessary for vitamin E to function.[13]

INNATE IMMUNITY

Antimicrobial peptides, including cathelicidin, psoriasin, β-defensin 1, and β-defensin 2 are expressed within the sebaceous gland. Functional cathelicidin peptides have direct antimicrobrial activity against *Propionibacterium acnes*, but also initiate cytokine production and inflammation in the host organism.[14,15] In addition, free fatty acids in human sebum is bactericidal against Gram-positive organisms as a result of its ability to increase β-defensin 2 expression.[16] Innate immune Toll-like receptors 2 and 4 (TLR2, TLR4), CD1d and CD14 molecules are also expressed in sebaceous glands and immortalized human sebocytes. With the expression of innate immune receptors and antibacterial peptides, the sebaceous gland may play an important role in pathogen recognition and protection of the skin surface.

FACTORS REGULATING SEBACEOUS GLAND SIZE AND SEBUM PRODUCTION

Serum production is continuous and is not controlled by neural mechanisms. The exact mechanisms

underlying the regulation of human sebum production are not fully defined.

A variety of experimental models are used to study the factors involved in sebaceous gland regulation, including cell culture of isolated human sebaceous glands, primary sebocytes, and immortalized sebocyte cell lines; as well as mouse and hamster animal models. Results from these investigations clearly indicate that sebaceous glands are regulated by androgens and retinoids. Recent evidence suggests that melanocortins, peroxisome proliferator-activated receptors (PPARs), and fibroblast growth factor receptors (FGFRs) play a role as well.

ANDROGENS

Sebaceous glands require androgenic stimulation to produce significant quantities of sebum. Individuals with a genetic deficiency of androgen receptors (complete androgen insensitivity) have no detectable sebum secretion and do not develop acne.[17] A question still exists about which androgen is physiologically important. Although the most powerful androgens are testosterone and its end-organ reduction product, dihydrotestosterone (DHT), levels of testosterone do not parallel the patterns of sebaceous gland activity. For example, testosterone levels are many fold higher in males than in females, with no overlap between the sexes. However, the average rates of sebum secretion are only slightly higher in males than in females, with considerable overlap between the sexes. Also, sebum secretion starts to increase in children during adrenarche, a developmental event that precedes puberty by about 2 years.

The weak adrenal androgen, dehydroepiandrosterone sulfate (DHEAS), may be a significant regulator of sebaceous gland activity through its conversion to testosterone and DHT in the sebaceous gland. Levels of DHEAS are high in newborns, very low in 2- to 4-year-old children, and start to rise when sebum secretion starts to increase. In adulthood, DHEAS levels show considerable individual variation, but are only slightly higher in men than in women on the average. There is a decline in DHEAS levels in both sexes starting in early adulthood and continuing throughout life; this decline parallels the decline of sebum secretion. DHEAS is present in the blood in high concentration. The enzymes required to convert DHEAS to more potent androgens are present in sebaceous glands.[18] These include 3β-hydroxysteroid dehydrogenase, 17β-hydroxysteroid dehydrogenase, and 5α-reductase. Each of these enzymes exists in two or more isoforms that exhibit tissue-specific differences in their expression. The predominant isozymes in the sebaceous gland include the type 1 3β-hydroxysteroid dehydrogenase, the type 2 17β-hydroxysteroid dehydrogenase, and the type 1 5α-reductase.

RETINOIDS

Isotretinoin (13-*cis*-retinoic acid, 13-*cis*-RA) is the most potent pharmacologic inhibitor of sebum secretion. Significant reductions in sebum production can be observed as early as 2 weeks after use.[19] Histologically, sebaceous glands are markedly reduced in size and individual sebocytes appear undifferentiated lacking the characteristic cytoplasmic accumulation of sebaceous lipids.

Isotretinoin does not interact with any of the known retinoid receptors. It may serve as a prodrug for the synthesis of all-*trans*-retinoic acid or 9-*cis*-retinoic acid, which do interact with retinoid receptors. However, it has greater sebosuppressive action than do all-*trans*- or 9-*cis*-retinoic acid.[20] The mechanism by which 13-*cis*-RA lowers sebum secretion is currently under investigation. Experimental evidence shows that 13-*cis*-RA inhibits the 3α-hydroxysteriod activity of retinol dehydrogenase leading to decreased androgen synthesis.[21] In addition, isotretinoin triggers cell cycle arrest in human sebocytes and immortalized cell culture models of human sebocytes (SZ95 and SEB-1), as well as induces apoptosis in SEB-1 sebocytes.[22,23,24] Inhibition of androgen synthesis, cell cycle arrest, and apoptosis by 13-*cis*-RA may explain the reduction of sebaceous gland size after treatment.

MELANOCORTINS

Melanocortins include melanocyte-stimulating hormone (MSH) and adrenocorticotropic hormone (ACTH). In rodents, melanocortins increase sebum production. Transgenic mice deficient in the melanocortin-5 receptor have hypoplastic sebaceous glands and reduced sebum production.[25] The melanocortin-5 receptor has been identified in human sebaceous glands, where it may play a role in the modulation of sebum production.[26] Further experimentation is required to test this hypothesis.

PEROXISOME PROLIFERATOR-ACTIVATED RECEPTORS

PPARs are orphan nuclear receptors that are similar to retinoid receptors in many ways. Each of these receptors forms heterodimers with retinoid X receptors in order to regulate the transcription of genes involved in a variety of processes, including lipid metabolism and cellular proliferation and differentiation. PPAR-α, -δ, and -γ receptor subtypes have been detected in basal sebocytes. PPAR-γ is also detected within differentiated sebocytes. In patients receiving fibrates (PPAR-α ligands) for hyperlipidemia or thiazolidinediones (PPAR-γ ligands) for diabetes, sebum secretion rates are increased.[27] Rat preputial cells serve as a model for human sebocytes in the laboratory.[28] In rat preputial cells, agonists of the PPAR-γ receptor, such as drugs of the thiazolidinedione class, increase lipid accumulation.[29]

FIBROBLAST GROWTH FACTOR RECEPTORS

FGFR1 and FGFR2 are expressed in the epidermis and skin appendages. Expression of FGFR3 and FGFR4 are

localized to dermal vessels and microvessels and are notably absent in epidermis and appendages.[30] FGFR2 plays an important role during embryogenesis in skin formation.[31] Germ line mutations in FGFR2 lead to Apert syndrome, which is commonly associated with acne. In addition, somatic mutations in the same location can lead to acne, but how this receptor is involved in sebaceous gland development and how its mutation leads to acne is unknown.[32,33]

CONCLUSION

The regulation of sebaceous glands and human sebum production are complex. Advances are being made in this area, which may lead to alternative therapies for the reduction of sebum and improvement in acne.

KEY REFERENCES

Full reference list available at www.DIGM8.com

DVD contains references and additional content

1. Downie MMT, Guy R, Kealey T: Advances in sebaceous gland research: Potential new approaches to acne management. *Int J Cosmet Sci.* **26**:291-311, 2004
4. Merrill B et al: Tcf3 and Lef1 regulate lineage differentiation of multipotent stem cells in skin. *Genes Dev* **15**:1688-1705, 2001
9. Nicolaides N: Skin lipids: Their biochemical uniqueness. *Science* **186**:19-26, 1974
15. Lai Y, Gallo RL: AMPed up immunity: How antimicrobial peptides have multiple roles in immune defense. *Trends in Immunology* **30**(3):131-141, 2009
18. Chen W, Thiboutot D, Zouboulis C: Cutaneous androgen metabolism: Basic research and clinical perspectives. *J Invest Dermatol* **119**:992-1007, 2002
27. Trivedi NR et al: Peroxisome proliferator-activated receptors increase human sebum production. *J Invest Dermatol* **126**(9):2002-2009, 2006

Chapter 80 :: Acne Vulgaris and Acneiform Eruptions

:: Andrea L. Zaenglein, Emmy M. Graber, & Diane M. Thiboutot

ACNE AT A GLANCE

- Common disorder of the pilosebaceous unit.
- Four key elements of pathogenesis: (1) follicular epidermal hyperproliferation, (2) excess sebum production, (3) inflammation, and (4) the presence and activity of *Propionibacterium acnes*.
- Comedones, papules, pustules, nodules on face, chest, and back.
- Treatment often includes combinations of oral and topical agents such as antimicrobials, retinoids, and hormonal agents. Laser and light sources are additional treatment options.
- Acne variants and acneiform eruptions also exist, many of which have an identifiable and reversible etiology.

ACNE VULGARIS

Acne vulgaris is a self-limited disorder of the pilosebaceous unit that is seen primarily in adolescents. Most cases of acne present with a pleomorphic array of lesions, consisting of comedones, papules, pustules, and nodules with varying extent and severity. While the course of acne may be self-limiting, the sequelae can be lifelong, with pitted or hypertrophic scar formation.

EPIDEMIOLOGY

Acne is sufficiently common that it often has been termed physiologic. Mild degrees of acne are frequently seen at birth, probably resulting from follicular stimulation by adrenal androgens, and may continue into the neonatal period. However, in the vast majority of cases it is not until puberty that acne becomes a more significant problem. Acne often heralds the onset of puberty. In girls, the occurrence of acne may precede menarche by more than a year. In these very young patients, the predominant lesions are comedones. Acne prevalence hits its peak during the middle-to-late teenage period, with more than 85% of adolescents affected, and then steadily decreases. However, acne may persist through the third decade or even later, particularly in women. One study demonstrated a prevalence of facial acne in women between ages 26 and 44 to be 14%.[1] Acne severity seems to be familial. The prevalence of high school students with moderate-to-severe acne was 19.9% in those students with a family history of acne and 9.8% in those students without a family history of acne.[2] In twin studies, 81% of the population variance in acne was found due to genetic factors (vs. 19% environmental

factors).[3] Nodulocystic acne has been reported to be more common in white males than in black males, and one group of investigators has found that acne is more severe in patients with the XYY genotype.[4,5]

ETIOLOGY AND PATHOGENESIS

Understanding the underlying basis for acne, and the mechanisms of action of the multitude of therapeutic options in treating acne will assure better therapeutic results. The pathogenesis of acne is multifaceted, but four basic steps have been identified. These key elements (Fig. 80-1) are: (1) follicular epidermal hyperproliferation, (2) excess sebum production, (3) inflammation, and (4) the presence and activity of *Propionibacterium acnes*. Each of these processes are interrelated and under hormonal and immune influence.

Follicular epidermal hyperproliferation results in the formation of a microcomedo. The epithelium of the upper hair follicle, the infundibulum, becomes hyperkeratotic with increased cohesion of the keratinocytes. The excess cells and their tackiness result in a plug in the follicular ostium. This plug then causes downstream concretions of keratin, sebum, and bacteria to accumulate in the follicle. These packed concretions cause dilation of the upper hair follicle producing a microcomedo.

The stimulus for keratinocyte hyperproliferation and increased adhesion is unknown. However, several proposed factors in keratinocyte hyperproliferation include: androgen stimulation, decreased linoleic acid, increased interleukin-1 (IL-1) α activity, and effects of *P. acnes*. Dihydrotestosterone (DHT) is a potent androgen that may play a role in acne. Fig. 80-2 demonstrates the physiologic pathway for dehydroepiandrosterone sulfate (DHEA-S) conversion to the androgen DHT. 17-β hydroxysteroid dehydrogenase (HSD) and 5-α reductase are enzymes responsible for converting DHEA-S to DHT. When compared to epidermal keratinocytes, follicular keratinocytes have increased 17-β HSD and 5-α reductase, thus enhancing DHT production.[6,7] DHT may stimulate follicular keratinocyte proliferation. Also supporting the role of androgens in acne pathogenesis is the evidence that individuals with complete androgen insensitivity do not develop acne.[8] Follicular keratinocyte proliferation may also be regulated by linoleic acid. Linoleic acid is an essential fatty acid in the skin that is decreased in subjects with acne. The quantity of linoleic acid normalizes after successful treatment with isotretinoin. Subnormal levels of linoleic acid may induce follicular keratinocyte hyperproliferation and produce proinflammatory cytokines. It has also been suggested that regular quantities of linoleic acid are actually produced but are simply diluted by increased sebum production.[9] In addition to androgens and linoleic acid, IL-1 α may also contribute to keratinocyte hyperproliferation. Human follicular keratinocytes demonstrate hyperproliferation and microcomedone formation when IL-1 α is added. IL-1 receptor antagonists inhibit microcomedone formation providing additional support for the cytokine's role in acne pathogenesis.[10,11] Fibroblast growth factor receptor (FGFR)-2 signaling may also be involved in hyperkeratinization. There is a long established relationship between acne and Apert syndrome, a complex bony malformation syndrome, due to a gain in function mutation in the gene encoding FGFR-2. Mutations in FGFR-2 in a mosaic distribution underlie a nevus comedonicus-like lesion.[12] The FGFR-2 pathway is androgen dependent and proposed mechanisms in acne include an increased production of IL-1 α and 5-α reductase.[13,14]

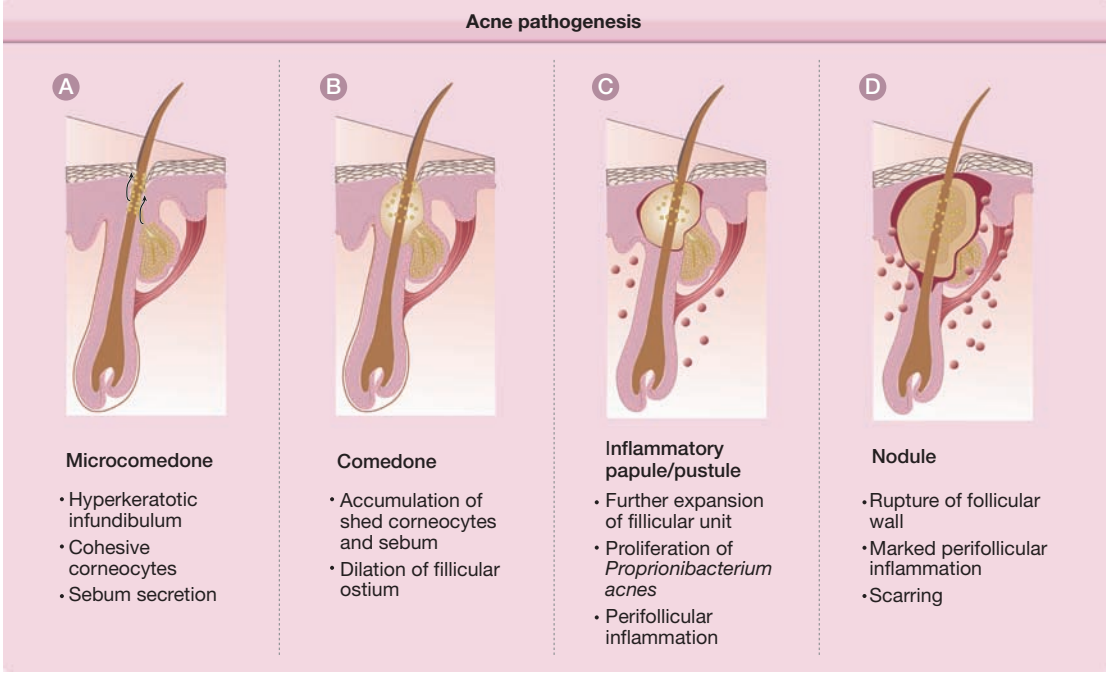

Figure 80-1 **A–D.** Acne pathogenesis.

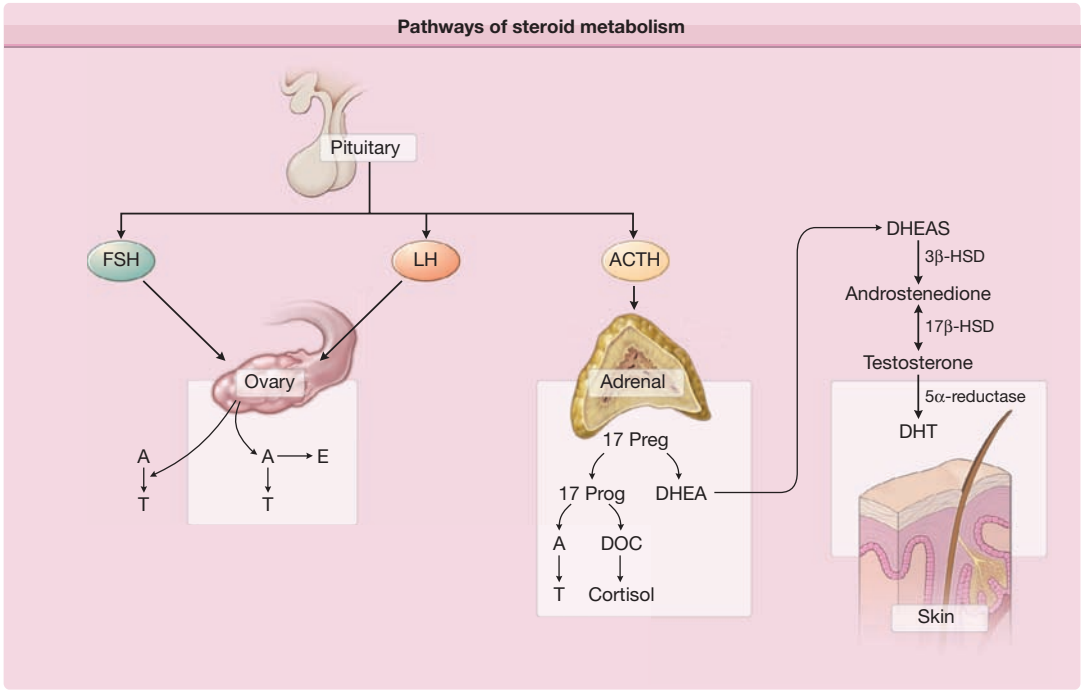

Figure 80-2 Pathways of steroid metabolism. Dehydroepiandrosterone (DHEA) is a weak androgen that is converted to the more potent testosterone by 3β-hydroxysteroid dehydrogenase (HSD) and 17β-HSD. 5-α reductase then converts testosterone to dihydrotestosterone (DHT), the predominant hormonal effector on the sebaceous gland. The sebaceous gland expresses each of these enzymes. A = androstenedione; ACTH = adrenocorticotropin-stimulating hormone; DHEAS = dehydroepiandrosterone sulfate; E = estrogen; FSH = follicle-stimulating hormone; LH = luteinizing hormone; T = testosterone; DOC = deoxycortisol.

The second key feature in the pathogenesis of acne is excess sebum production from the sebaceous gland. Patients with acne produce more sebum than those without acne, although the quality of sebum is the same between the two groups.[15] Components of sebum—triglycerides and lipoperoxides—may play a role in acne pathogenesis. Triglycerides are broken down into free fatty acids by *P. acnes*, normal flora of the pilosebaceous unit. These free fatty acids promote further bacterial clumping and colonization of *P. acnes*, incite inflammation, and may be comedogenic.[16] Lipoperoxides also produce proinflammatory cytokines and activate the peroxisome proliferator-activated receptors (PPAR) pathway, resulting in increased sebum.[17,18]

Androgenic hormones also influence sebum production through actions on sebocyte proliferation and differentiation. Similar to their action on the follicular infundibular keratinocytes, androgen hormones bind to and influence sebocyte activity.[19] Those with acne have higher average serum androgen levels (although still within normal range) than unaffected controls.[20,21] 5-α reductase, the enzyme responsible for converting testosterone to the potent DHT, has greatest activity in areas of skin prone to acne, the face chest and back.[14]

The role of estrogen on sebum production is not well defined. The dose of estrogen required to decrease sebum production is greater than the dose required to inhibit ovulation.[22] The mechanisms by which estrogens may work include: (1) directly opposing the effects of androgens within the sebaceous gland; (2) inhibiting the production of androgens by gonadal tissue via a negative feedback loop on pituitary gonadotropin release; and (3) regulating genes that suppress sebaceous gland growth or lipid production.[23]

Corticotropin-releasing hormone may also play a role. It is released by the hypothalamus and increased in response to stress. Corticotropin-releasing hormone receptors are present on a vast number of cells, including keratinocytes and sebocytes, and are upregulated in the sebocytes of patients with acne.[24]

The microcomedo will continue to expand with densely packed keratin, sebum, and bacteria. Eventually this distension will cause follicular wall rupture. The extrusion of the keratin, sebum, and bacteria into the dermis results in a brisk inflammatory response. The predominant cell type within 24 hours of comedo rupture is the lymphocyte. $CD4^+$ lymphocytes are found around the pilosebaceous unit, while $CD8^+$ cells are found perivascularly. One to two days after comedo rupture, the neutrophil becomes the predominant cell type surrounding the burst microcomedo.[25]

It was originally thought that inflammation follows comedo formation, but there is evidence that dermal inflammation may actually precede comedo formation. Biopsies taken from comedo-free acne-prone skin, demonstrate increased dermal inflammation compared to normal skin. Biopsies of newly formed comedos demonstrate even greater inflammation.[26] This may suggest that inflammation actually precedes comedo formation, again emphasizing the interplay between all of the pathogenic factors. As mentioned above, *P. acnes* also plays an active role in the process

of inflammation. *P. acnes* is a Gram-positive, anaerobic, and microaerobic bacterium found in the sebaceous follicle. Adolescents with acne have higher concentrations of *P. acnes* compared to nonacne controls. However, there is no correlation between the raw number of *P. acnes* organisms present in a sebaceous follicle and the severity of the acne.[27] Sebocyte differentiation and proinflammatory cytokine/chemokine responses are varied depending on the strain of *P. acnes* predominating within the follicle.[28]

The cell wall of *P. acnes* contains a carbohydrate antigen that stimulates antibody development. Those patients with the most severe acne have the highest titers of antibodies.[29] The antipropionobacterium antibody enhances the inflammatory response by activating complement initiating a cascade of proinflammatory events.[30] *P. acnes* also facilitates inflammation by eliciting a delayed type hypersensitivity response and by producing lipases, proteases, hyaluronidases, and chemotactic factors.[31,32] Reactive oxygen species and lysosomal enzymes are released by neutrophils and levels may correlate with severity.[33] Additionally, *P. acnes* has been shown to stimulate expression of cytokines by binding to toll-like receptor 2 (TLR-2) on monocytes and polymorphonuclear cells surrounding the sebaceous follicle.[34] After binding TLR-2, proinflammatory cytokines such as IL-1α, IL-8, IL-12, and TNF-α are released.[35,36] The antimicrobial peptides, histone H4 and cathelicidin, are also secreted locally in response to *P. acnes.* Histone H4 exerts direct microbial killing, while cathelicidin interacts with components of the innate immune system, such as β defensins and psoriasin, in response to *P. acnes*.[37,38] Another indicator of the role of innate immunity in the pathogenesis of acne is the differentiation of peripheral blood monocytes to $CD209^+$ macrophages and $CD1b^+$ dendritic cells in response to *P. acnes*.[39]

The impact of diet on acne is an emerging area of interest, particularly relating to glycemic index and dairy consumption. Both are thought to increase insulin-like growth factor (IGF)-1 with possible proacne effects and an increase in androgen activity.[40,41]

CLINICAL FINDINGS

HISTORY. Most patients with acne vulgaris report gradual onset of lesions around puberty. In other cases, acne can be seen in the neonatal or infantile age. Neonatal acne appears at about 2 weeks of age and infantile acne develops at 3–6 months of age (see Chapter 107). Since classic acne vulgaris is usually gradual in onset, patients describing an abrupt onset of acne should be questioned to possibly discover an underlying etiology, such as an androgen-secreting tumor.

Hyperandrogenism should be considered in the female patient whose acne is severe, sudden in its onset, or associated with hirsutism or irregular menstrual periods. The patient should be asked about the frequency and character of her menstrual periods and whether her acne flares with changes in her menstrual cycle. Hyperandrogenism can also result in deepening of the voice, an increase in libido and hirsutism. A complete medication history is important, as some medications can cause an abrupt onset of a monomorphous acneiform eruption. Drug-induced acne may be caused by: anabolic steroids, corticosteroids, corticotropin, phenytoin, lithium, isoniazid, vitamin B complexes, halogenated compounds, and certain chemotherapy medications, particularly with epidermal growth factor receptor (EGFR) inhibitors.

CUTANEOUS LESIONS. The primary site of acne is the face and to a lesser degree the back, chest, and shoulders. On the trunk, lesions tend to be concentrated near the midline. The disease is characterized by several clinical lesion types (Fig. 80-3). Although one type of lesion may predominate, close inspection usually reveals the presence of several types of lesions. The lesions may be either noninflammatory or inflammatory. The noninflammatory lesions are comedos, which may be either closed (whiteheads; Fig. 80-3A) or open (blackheads; Fig. 80-3B). The open comedo appears as a flat or slightly raised lesion with a central dark-colored follicular impaction of keratin and lipid (Fig. 80-4). Closed comedones, in contrast to the open comedones, may be difficult to visualize. They appear as pale, slightly elevated, small papules, and do not have a clinically visible orifice (Fig. 80-3A). Stretching of the skin is an aid in detecting the lesions.

The inflammatory lesions vary from small papules with a red border to pustules and large, tender, fluctuant nodules (see Figs. 80-3C and 80-3D and Figs. 80-4–80-6). Some of the large nodules were previously called "cysts" and the term *nodulocystic* has been used to describe severe cases of inflammatory acne. True cysts are rarely found in acne; this term should be abandoned and substituted with *severe nodular acne* (see Figs. 80-3D and 80-6). Whether the lesion appears as a papule, pustule, or nodule depends on the extent and location of the inflammatory infiltrate in the dermis.

Scarring can be a complication of both noninflammatory and inflammatory acne. There are four general types of acne scars: (1) ice pick, (2) rolling, (3) boxcar, and (4) hypertrophic[42] (Fig. 80-7). Ice pick scars are narrow, deep scars that are widest at the surface of the skin and taper to a point in the dermis. Rolling scars are shallow, wide scars that have an undulating appearance. Boxcar scars are wide sharply demarcated scars. Unlike ice pick scars, the width of boxcar scars is similar at the surface and base. In rare instances, especially on the trunk, the scars may be hypertrophic.

Acne vulgaris is usually an isolated cutaneous finding, other than in the presence of hyperandrogenism. Such cases may have associated hirsutism, precocious puberty, and other signs of hyperandrogenism.

LABORATORY TESTS

In general, laboratory workup is not indicated for patients with acne unless hyperandrogenism is suspected. There are numerous clinical studies relating acne to elevated serum levels of androgens in both adolescents and adults. Among 623 prepubertal girls, girls with acne had increased levels of DHEAS as compared



Figure 80-3 Clinicopathologic correlation of acne lesions. **A.** Closed comedone. The follicular infundibulum is distended, filled with keratin and sebum, and the follicular epithelium is attenuated. The follicular ostium is narrow. **B.** Open comedone. Resembles the closed comedone with the exception of a patulous follicular ostium. **C.** Inflammatory papule. Acute and chronic inflammatory cells surround and infiltrate the follicle, which shows infundibular hyperkeratosis. **D.** Nodule. The follicle is filled with acute inflammatory cells. With the rupture of the distended follicle, there is a foreign body granulomatous response.



Figure 80-4 Acne vulgaris mild. **A.** A 13-year-old girl with mild acne vulgaris. Scattered comedones and/or inflammatory lesions are seen, usually limited to less than half of the face. The T-zone of the face is commonly involved. No nodules are present. **B.** An adult female with primarily inflammatory acne. Note the typical involvement of the jawline.



Figure 80-5 Acne vulgaris moderate. **A.** A 15-year-old male with moderate acne is seen. Typically more than half of the face is involved with increasing numbers of lesions, usually a mix of lesions is seen: papules, pustules, and comedones. Infrequent and limited nodules may be present. Chest and back involvement may also be moderately affected. **B.** A 16-year-old female with open and deep closed comedones is pictured. Scarring and postinflammatory changes are possible sequelae.



Figure 80-6 Acne vulgaris severe. **A.** A 17-year-old female with extensive acne is seen. Numerous pustules and nodular lesions admixed with comedones and smaller papules cover the entire face. **B.** Deep, friable nodules that coalesce into pseudocysts are seen in acne conglobata. **C.** Chest and back involvement can be extensive and severe. Scarring is a common complication in severe acne.



Figure 80-7 Acne vulgaris, scarring. **A.** Honeycomb scarring is seen in this young girl with mild-to-moderate inflammatory acne. **B.** Extensive keloidal scarring occurring as sequelae of acne fulminans. **C.** Rolling scars.

to age-matched controls without acne.[43] DHEAS can serve as a precursor for testosterone and DHT. Elevated serum levels of androgens have been found in cases of severe cystic acne and in acne associated with a variety of endocrine conditions, including congenital adrenal hyperplasia (11β- and 21β-hydroxylase deficiencies), ovarian or adrenal tumors, and polycystic ovarian disease. However, in the majority of acne patients serum androgens are within the normal range.[44,45]

Excess androgens may be produced by either the adrenal gland or ovary. The laboratory workup should include measurement of serum DHEAS, total testosterone, and free testosterone. Additional tests to consider include the luteinizing hormone (LH) to follicle-stimulating hormone (FSH) ratio or serum 17-hydroxyprogesterone to identify an adrenal source of androgens in cases where testing does not clearly indicate an adrenal or ovarian source of androgens. Testing should be obtained just prior to or during the menstrual period, not midcycle at the time of ovulation. Patients on contraceptives that prevent ovulation will need to discontinue their medication for at least 1 month prior to testing. Values of DHEAS in the range of 4,000–8,000 ng/mL (units may vary at different laboratories) may be associated with congenital adrenal hyperplasia. Patients with a serum level of DHEAS >8,000 ng/mL could have an adrenal tumor and should be referred to an endocrinologist for further evaluation. An ovarian source of excess androgens can be suspected in cases where the serum total testosterone is >150 ng/dL. Serum total testosterone in the range of 150–200 ng/dL or an increased LH/FSH ratio (>2.0) can be found in cases of polycystic ovary disease. Greater elevations in serum testosterone may indicate an ovarian tumor, and appropriate referral should be made. There is a significant amount of variability in individual serum androgen levels. In cases in which abnormal results are obtained, it may be wise to repeat the test before proceeding with therapy or additional testing.

Many patients report that their acne flares during periods of stress. Although objective data are limited, stress is known to increase the output of adrenal steroids, which may affect the sebaceous gland.[46] It has been shown that patients with acne have a greater increase in urinary glucocorticoid levels after corticotropin administration.[47]

DIFFERENTIAL DIAGNOSIS

Although one type of lesion may predominate, acne vulgaris is diagnosed by a variety of acne lesions (comedones, pustules, papules, and nodules) on the face, back, or chest (see Box 80-1). Diagnosis is usually easy, but inflammatory acne may be confused with folliculitis, rosacea, or perioral dermatitis. Patients with

BOX 80-1 DIFFERENTIAL DIAGNOSIS OF ACNE

Most Likely

- Closed comedonal acne
  - Milia
  - Sebaceous hyperplasia
- Open comedonal acne
  - Dilated pore of Winer
  - Favre–Racouchot syndrome
- Inflammatory acne
  - Rosacea
  - Perioral dermatitis
- Neonatal acne
  - Miliaria rubra

Consider

- Closed comedonal acne
  - Osteoma cutis
  - Trichoepitheliomas
  - Trichodiscomas
  - Fibrofolliculomas
  - Eruptive vellus hair cysts, steatocystoma multiplex
  - Colloid milia
  - Flat warts
- Open comedonal acne
  - Trichostasis spinulosa
  - Nevus comedonicus
- Inflammatory acne
  - Pseudofolliculitis barbae, acne keloidalis nuchae
  - Keratosis pilaris
  - Neurotic excoriations/factitial
  - Lupus miliaris disseminatus faciei
- Neonatal acne
  - Sebaceous hyperplasia
  - Milia

Always Rule Out

- Closed comedonal acne
  - Acne due to systemic agents (e.g., corticosteroids)
  - Contact acne (e.g., occupational acne)
  - Chloracne
- Open comedonal acne
  - Acne due to systemic agents
  - Contact acne
  - Chloracne
- Inflammatory acne
  - Acne due to systemic agents
  - Staphylococcal folliculitis
  - Gram-negative folliculitis
  - Eosinophilic folliculitis
  - Furuncle/carbuncle
  - Angiofibromas of tuberous sclerosis
- Neonatal acne
  - Candidal infections
  - Benign neonatal cephalic pustulosis

tuberous sclerosis and facial angiofibromas have been misdiagnosed as having recalcitrant midfacial acne. Facial flat warts or milia are occasionally confused with closed comedones.

Acne can be seen in association with endocrinologic abnormalities. Patients with hyperandrogenism may have acne plus other stigmata of increased androgen levels (i.e., hirsutism, deepened voice, irregular menses). Endocrinologic disorders such as polycystic ovarian syndrome (including HAIR-AN syndrome), congenital adrenal hyperplasia, and adrenal and ovarian neoplasms often have accompanying acne.

Variants of acne must also be differentiated from typical acne vulgaris in order to guide treatment. These types of acne include: neonatal acne, infantile acne, acne fulminans, acne conglobata, acne with solid facial edema, and acne excoriée des jeunes filles. These variants are discussed in detail later in the chapter.

There are several less common acneiform eruptions that can be confused with acne vulgaris. These mimickers include: medication-induced acne, halogen acne, chloracne, acne mechanica, tropical acne, radiation acne, and other various miscellaneous acneiform disorders that are discussed subsequently.

COMPLICATIONS

All types of acne lesions have the potential to resolve with sequelae. Almost all acne lesions leave a transient macular erythema after resolution. In darker skin types, postinflammatory hyperpigmentation may persist months after resolution of acne lesions. In some individuals, acne lesions may result in permanent scarring.

Acne vulgaris may also take a psychological toll on many patients. It is estimated that 30%–50% of adolescents experience psychiatric disturbances due to acne.[48] Studies have shown that patients with acne have similar levels of social, psychological, and emotional impairment as those with asthma and epilepsy.[49] Additional studies have also shown that unemployment rates are higher among adults with acne than those without.[50] When appropriate, patients should be referred for psychiatric counseling.

PROGNOSIS AND CLINICAL COURSE

The age of onset of acne varies considerably. It may start as early as 6–8 years of age or it may not appear until the age of 20 or later. The course is one of several years' duration followed by spontaneous remission in the majority of cases. While most patients will clear by their early twenties, some have acne extending well into the third or fourth decades. The extent of involvement varies, and spontaneous fluctuations in the degree of involvement are the rule rather than the exception. In women there is often a fluctuation in association with menses, with a flare just before the onset of menstruation. This flare is not due to a change in sebaceous gland activity as there is no increase in sebum production in the luteal phase of the menstrual

cycle. It has been shown that prepubescent females with comedonal acne and those females with high DHEAS levels are predictors of severe or long-standing nodulocystic acne.[51]

TREATMENT

Tailoring a patient's acne regimen with the knowledge of the pathogenesis of acne and the mechanism of action of the available acne treatments will ensure maximum therapeutic response. Treatment regimens should be initiated early and be sufficiently aggressive to prevent permanent sequelae. Often multiple treatments are used in combination so as to combat many factors in the pathogenesis of acne (Table 80-1). The mechanism of action of the most common treatments for acne can be categorized in the following categories as they relate to the pathophysiology:

1. Correct the altered pattern of follicular keratinization.
2. Decrease sebaceous gland activity.
3. Decrease the follicular bacterial population, particularly *P. acnes*.
4. Exert an anti-inflammatory effect.

LOCAL THERAPY

Cleansing. The importance of cleansing in the treatment of acne is generally intuitive. Twice daily washing with a gentle cleanser followed by the application of acne treatments may encourage a routine and therefore better compliance. Overcleansing or using harsh alkaline soaps are likely to increase the

TABLE 80-1
Treatment Algorithm for Acne Vulgaris

	Mild	Moderate	Severe		
	Comedonal	Papular/ Pustular	Papular/Pustular	Nodular	Conglobata/ Fulminans
First	Topical retinoid or combination[a]	Topical retinoid + topical antimicrobial or combination[a]	Oral antibiotic + topical retinoid ± BPO or combination[a]	Oral antibiotic + topical retinoid ± BPO	Oral isotretinoin ± oral corticosteroids
Second	Topical dapsone or azelaic acid or salicylic acid	Topical dapsone or azelaic acid or salicylic acid	Oral antibiotic + topical retinoid ± BPO or combination[a]	Oral isotretinoin or oral antibiotic + topical retinoid ± BPO/azelaic acid or combination[a]	High-dose oral antibiotic + topical retinoid + BPO or combination[a]
Female	—	—	+ Oral contraceptive/ antiandrogen	+ Oral contraceptive/ antiandrogen	+ Oral contraceptive/ antiandrogen
Additional options	Comedone extraction	Laser/light therapy, photodynamic therapy	Comedone extraction, laser/light therapy, photodynamic therapy	Comedone extraction; intralesional corticosteroid, laser/light therapy, photodynamic therapy	Intralesional corticosteroid, laser/light therapy, photodynamic therapy
Refractory to treatment	Check compliance	Check compliance Exclude Gram-negative folliculitis Females: Exclude polycystic ovary syndrome, adrenal or ovarian tumors, congenital adrenal hyperplasia Males: Exclude congenital adrenal hyperplasia			
Maintenance	Topical retinoid ± BPO, or combination[a]	Topical retinoid ± BPO, or combination[a]	Topical retinoid ± BPO, or combination[a]	Topical retinoid ± BPO, or combination[a]	

BPO = benzoyl peroxide.
[a]Manufactured combination products include BPO/erythromycin, BPO/clindamycin, adapalene/BPO, tretinoin/clindamycin.
Adapted from Gollnick H et al: Management of acne: A report from a Global Alliance to improve outcomes in acne. *J Am Acad Dermatol* **49**:1, 2003.

skin's pH, disrupt the cutaneous lipid barrier, and compound the irritancy potential of many topical acne treatments. Use of a syndet (synthetic detergent) will allow cleansing without disruption of the skin's normal pH. Antibacterial soaps, containing agents such as triclosan, inhibit Gram-positive cocci but may increase Gram-negative rods; their overall affect on acne is unclear. Medicated cleansers, containing benzoyl peroxide or salicylic acid, offer convenience as a wash and are excellent for hard to reach areas like the back.

Topical Agents. (See Table 80-2)

Sulfur/Sodium Sulfacetamide/Resorcinol. Products containing sulfur, sodium sulfacetamide, and resorcinol, once favored treatments for acne, are still found in several over-the-counter and prescription niche formulations. Sulfonamides are thought to have antibacterial properties through their inhibition of *para*-aminobenzoic acid (PABA), an essential substance for *P. acnes* growth.[52] Sulfur also inhibits the formation of free fatty acids and has presumptive keratolytic properties. It is often combined with sodium sulfacetamide to enhance its cosmetic tolerability due to sulfur's distinctive odor. Resorcinol is also indicated for use in acne for its antimicrobial properties. It is generally found in 2% concentration in combination with 5% sulfur.

Salicylic Acid. Salicylic acid is a ubiquitous ingredient found in over-the-counter acne preparations in concentrations ranging from 0.5% to 2%. This lipid soluble β-hydroxy acid has comedolytic properties, though somewhat weaker than those of a retinoid. Salicylic acid also causes exfoliation of the stratum corneum though decreased cohesion of the keratinocytes. Mild irritant reactions may result.

Azelaic Acid. Azelaic acid is available by prescription in a 20% cream or 15% gel. This dicarboxcylic acid has both antimicrobial and comedolytic properties.[53] It is also a competitive inhibitor of tyrosinase and thus may decrease postinflammatory hyperpigmentation.[54] It is generally well tolerated, though transient burning can occur, and is safe in pregnancy.

Benzoyl Peroxide. Benzoyl peroxide preparations are among the most common topical medications prescribed by dermatologists and are also readily available over-the-counter. Benzoyl peroxide is a powerful antimicrobial agent through decreasing both the bacterial population and the hydrolysis of triglycerides. Benzoyl peroxide preparations are available in creams, lotion, gels, washes, and pledgets. Products that are left on the skin, such as a gel, are generally considered more effective. Benzoyl peroxide can produce significant dryness and irritation. Allergic contact dermatitis has been uncommonly reported. Of significance, bacteria are unable to develop resistance to benzoyl peroxide, making it the ideal agent for combination therapy.[55]

Topical Antibiotics. (See Chapter 218). Erythromycin and clindamycin are the most commonly used topical antibiotics for the treatment of acne. These two agents have also been used in combination preparations with benzoyl peroxide. Increased levels of *P. acnes* resistance have been reported in patients who are being treated with antibiotics. However, the development of resistance is less likely in patients who are treated with a combination of benzoyl peroxide/erythromycin or clindamycin.[56] Therefore, the combination of these two products is preferable over monotherapy with topical antibiotics. Topical dapsone is the most recently approved topical antibiotic for acne. With twice daily application topical dapsone has shown better efficacy in controlling inflammatory lesions (58%) versus non-inflammatory lesions (19%).[57,58] Unlike oral dapsone, topical dapsone is safe for use even in patients with a G6PD deficiency.[59] It is generally well tolerated but should not be applied concomitantly with benzoyl peroxide or it may impart an orange color on the skin.[60]

Retinoids. (See Chapter 217). Retinoids are defined by their ability to bind to and activate retinoic acid receptors (RAR) and in turn activate specific gene transcription resulting in a biologic response. Some have chemical structures similar to tretinoin (all-*trans*-retinoic acid), but they may be entirely dissimilar, such as adapalene or tazarotene, and still potentiate a retinoid effect. In general, the binding of these agents to nuclear RAR affects the expression of genes involved in cell proliferation, differentiation, melanogenesis, and inflammation.[61,62] The result is modification of corneocyte accumulation and cohesion, and inflammation. Thus, retinoids have both comedolytic and anti-inflammatory properties.[62]

Tretinoin is commercially available in several strengths and formulations. Having both potent comedolytic and anti-inflammatory properties, it is widely used. In general, all retinoids can be contact irritants, with alcohol-based gels and solutions having the greatest irritancy potential. Some newer formulations utilize a microsphere delayed-delivery technology (Retin A Micro® 0.04% or 0.1% gel) or are incorporated within a polyolprepolymer (PP-2) (Avita® cream) to decrease the irritancy potential of tretinoin while allowing greater concentration of medication. Advising patients to apply tretinoin on alternate nights during the first few weeks of treatment can help ensure greater tolerability. Patients must also be cautioned about sun exposure due to thinning of the stratum corneum, especially those with any irritant reaction. Regular use of a sunscreen should be advised. The comedolytic and anti-inflammatory properties of topical retinoids make them ideal for maintenance therapy of acne. Generic tretinoin is inactivated by concomitant use of benzoyl peroxide and is photolabile. Therefore, patients should be counseled to apply tretinoin at bedtime.

Adapalene is a synthetic retinoid widely marketed for its greater tolerability. It specifically targets the RARγ receptor. It is both photostable and can be used in conjunction with benzoyl peroxide without degradation. Adapalene 0.1% gel has been shown in clinical trials to have greater or equal efficacy to tretinoin 0.025% gel with greater tolerability.[63,64] It is available at a 0.1% concentration in both a nonalcohol gel and

TABLE 80-2
Commonly Available Prescription Acne Preparations—Topical

Generic	Trade	Vehicle	Concentration	Size
Retinoids—Topical				
Tretinoin	Retin-A	Cream	0.025%, 0.05%, 0.1%	20 g, 45 g
		Gel	0.01%, 0.025%	15 g, 45 g (0.025% only)
		Liquid	0.05%	28 mL
	Retin-A micro	Gel with microsponge	0.04%, 0.1%	20 g, 45 g
				50-g pump
	Avita	Cream	0.025%	20 g, 45 g
		Gel	0.025%	20 g, 45 g
	Refissa	Cream	0.05%	40 g
	Tretin-X	Cream	0.025%, 0.05%, 0.1%	35 g (kit with cleanser)
		Gel	0.025%, 0.1%	35 g (kit with cleanser)
	Generic	Cream	0.025%, 0.05%, 0.1%	20 g, 45 g
		Gel	0.025%, 0.1%	15 g, 45 g
Adapalene	Differin	Cream	0.1%	15 g, 45 g
		Gel	0.1%, 0.3%	15 g, 45 g
		Lotion	0.1%	2 oz
	Generic	Gel	0.1%	45 g
Tazarotene	Tazorac	Cream	0.1%	30 g, 60 g
		Gel	0.1%	30 g, 60 g
Retinoid Combinations—Topical				
Tretinoin/clindamycin	Ziana	Gel	0.025%/1.2%	30 g, 60 g
Adapalene/benzoyl peroxide	Epiduo	Gel	2.5%/0.1%	45 g
Antimicrobials—Topical				
Benzoyl peroxide	Benzac AC	Gel	2.5%, 5%, 10%	60 g
		Wash	2.5%, 5%, 10%	240 mL (2.5%), 226 mL
	Benzac W	Gel	2.5%, 5%, 10%	60 g
		Wash	5%, 10%	226 mL
	Benzashave	Cream	5%, 10%	113.4 g
	Benziq LS	Gel	5.25%	50 g
		Wash	5.25%	175 g
	Brevoxyl	Gel	4%, 8%	42.5 g
		Creamy wash	4%, 8%	170 g (kit with cleanser)
	Clinac	Gel	7%	45 g
	Desquam E	Gel	2.5%, 5%, 10%	42.5 g
	Triaz	Gel	3%, 6%, 9%	42.5 g
		Cleanser	3%, 6%, 9%	6 oz, 12 oz
		Pads	3%, 6%, 9%	1 g (30 or 60/box)
		Foaming cloths	3%, 6%, 9%	3.2 g (30 or 60/box)
	Zoderm	Cleanser	4.5%. 6.5%, 8.5%	400 mL
		Pads	4.5%. 6.5%, 8.5%	6 mL (30/box)
		Hydrating wash	5.75%	400 mL
	Generic	Gel	5%, 10%	45 g, 60 g, 90 g
		Wash	2.5%, 5%, 10%	142 g, 227 g
Erythromycin	Generic	Gel	2%	30 g, 60 g
		Ointment	2%	25 g
		Solution	2%	60 mL
		Pledget	2%	(60/box)
Clindamycin	Cleocin T	Gel	1%	30 g, 60 g
		Lotion	1%	60 mL
		Solution	1%	30 mL, 60 mL
		Pledget	1%	(60/box)
	Evoclin	Foam	1%	50 g, 100 g
	Clindagel	Gel	1%	40 mL, 75 mL
	ClindaMax	Gel	1%	30 g, 60 g
		Lotion	1%	60 mL
	Clindets	Pledget	1%	60 s
	Generic	Gel	1%	30 g, 60 g
		Lotion	1%	30 g, 60 g
		Solution	1%	30 g
Dapsone	Aczone	Gel	5%	30 g
Benzoyl peroxide/ erythromycin	Benzamycin	Gel	5%/3%	46.6 g, 60/box
	Benzamycin Gel Pak			
	Generic	Gel	5%/3%	23.2 g, 46.6 g
Benzoyl peroxide/clindamycin	Benzaclin	Gel	5%/1%	25 g, 50 g
				50-g pump
	Duac	Gel	5%/1%	45 g
	Acanya	Gel	2.5%/1.2%	50 g
	Generic	Gel	5%/1%	50 g
Benzoyl peroxide/ hydrocortisone	Vanoxide HC	Lotion	5%–0.5%	25 mL
Miscellaneous				
Sodium sulfacetamide	Klaron	Lotion	10%	4 oz
Sodium sulfacetamide/sulfur	Sulfacet-R	Lotion	10–5%	25 g
	Rosula	Gel	10%–5% in 10% urea	45 mL
		Cleanser	10%–5% in 10% urea	355 mL
Azeleic acid	Azelex	Cream	20%	30 g, 50 g

cream and as a 0.3% gel. The 0.3% adapalene gel has been shown to have similar efficacy to tazarotene 0.1% gel with increased tolerability.[65] A combination topical agent containing 0.1% adapalene and 2.5% benzoyl peroxide is also available.[66,67]

Tazarotene, also a synthetic retinoid, exerts is action through its metabolite, tazarotenic acid, which in turn inhibits the RARγ receptor. It is a potent comedolytic agent and has been show to be more effective than tretinoin 0.025% gel and tretinoin 0.1% microsphere gel.[68,69] Both the 0.1% cream and gel formulations are approved for the treatment of acne. The irritant properties of tazarotene can be minimized by the use of short-term contact therapy. In this regimen, the medication is applied for 5 minutes then washed off with a gentle cleanser. Tazarotene has been given a pregnancy category X rating and female patients of childbearing age should be adequately counseled.

An overview of topical agents for acne treatment is outlined in Table 80-2.

SYSTEMIC THERAPY

Antibiotics and Antibacterial Agents. (See Chapter 230).

Tetracyclines. Broad-spectrum antibiotics are widely used in the treatment of inflammatory acne. The tetracyclines are the most commonly used antibiotics in the treatment of acne. Although the oral administration of tetracyclines does not alter sebum production, it does decrease the concentration of free fatty acids while the esterified fatty acid content increases. Decreases in free fatty acid formation also have been reported with erythromycin, demethylchlortetracycline, clindamycin, and minocycline. The free fatty acids are probably not the major irritants in sebum, but their level is an indication of the metabolic activity of the *P. acnes* bacteria and its secretion of other proinflammatory products. The decrease in free fatty acids may take several weeks to become evident. This, in turn, is reflected in the clinical course of the disease during antibiotic therapy, as several weeks are often required for maximal clinical benefit. The effect, then, is one of prevention; the individual lesions require their usual time to undergo resolution. However, the fact that a decrease in free fatty acids does occur strengthens the rationale for the use of tetracycline. Tetracycline may also act through direct suppression of the number of *P. acnes,* but part of its action may be due to its anti-inflammatory activity. In clinical practice, tetracycline is usually given initially in dosages of 500–1,000 mg/day. Higher doses of up to 3,500 mg/day have been used in severe cases, but prudent monitoring of liver functions is warranted. Tetracycline should be taken on an empty stomach, 1 hour before or 2 hours after meals, to promote absorption; thus, compliance by adolescents with its administration can be challenging. Gastrointestinal (GI) upset is the most common side effect, with esophagitis and pancreatitis possible. Uncommon side effects include hepatotoxicity, hypersensitivity reactions, leukocytosis, thrombocytopenic purpura, and pseudotumor cerebri. Tetracyclines should be used with caution in patients with renal disease as they may increase uremia. Tetracyclines have an affinity for rapidly mineralizing tissues and are deposited in developing teeth, where they may cause irreversible yellow–brown staining; also, tetracyclines have been reported to inhibit skeletal growth in the fetus. Therefore, they should not be administered to pregnant women, especially after the fourth month of gestation and are not recommend for use in children younger than 9 years of age in the treatment of acne.

The tetracycline derivatives, doxycycline and minocycline, are also commonly used in the treatment of acne. They have the distinct advantage of being able to be taken with food without impaired absorption. Doxycycline is administered in dosages of 50–100 mg twice daily. Its major disadvantage is the potential risk of photosensitivity reactions, including photo-onycholysis, and patients may need to be switched to another antibiotic during summer months. Minocycline is given in divided dosages at a level of 100–200 mg/day. Patients on minocycline should be monitored carefully, as the drug can cause blue–black pigmentation, especially in the acne scars, as well as the hard palate, alveolar ridge, and anterior shins. Vertigo has occasionally been described. Minocycline-induced autoimmune hepatitis and a systemic lupus erythematosus-like syndrome have been reported during minocycline therapy, but these side effects are very rare.[70,71] Of note, patients who develop lupus-like reactions can be safely switched to an alternative tetracycline. Serum sickness-like reactions and drug reaction with eosinophilia and systemic symptoms (DRESS) syndrome have also been reported with minocycline use.

Macrolides. Due to the prevalence of erythromycin-resistant strains of *P. acnes*, the use of oral erythromycin is generally limited to pregnant women or children. Azithromycin has been used more often for acne, typically at dosages of 250–500 mg orally three times weekly.[72] Azithromycin undergoes hepatic metabolism with GI upset and diarrhea as the most common side effects.

Trimethoprim–Sulfamethoxazole. Trimethoprim–sulfamethoxazole combinations are also effective in acne. In general, because the potential for side effects is greater with their use, they should be used only in patients with severe acne who do not respond to other antibiotics. GI upset and cutaneous hypersensitivity reactions are common. Serious adverse reactions, including the Stevens–Johnson syndrome-toxic epidermal necrolysis spectrum (see Chapter 40) and aplastic anemia, have been described. If trimethoprim–sulfamethoxazole is used, the patient must be monitored for potential hematologic suppression approximately monthly.

Cephalexin. Cephalexin, a first generation cephalosporin, has been shown in vitro to kill *P. acnes*. However, because it is hydrophilic and not lipophilic it penetrates poorly into the pilosebaceous unit. Success with oral cephalexin[73] is most likely due to its anti-inflammatory rather than antimicrobial properties. Due to the risk of promoting the development of bacterial resistance,

particularly to *Staphylococcus*, the authors discourage the use of cephalexin for acne.

Clindamycin and Dapsone. Less commonly used antibiotics include clindamycin and dapsone. Oral clindamycin had been used more readily in the past, but because of the risk of pseudomembranous colitis, it is now rarely used systemically for acne. It is still commonly used topically, however, often in combination with benzoyl peroxide. Dapsone (see Chapter 225), a sulfone often used for cutaneous neutrophilic disorders, may be beneficial in severe markedly inflammatory acne and select cases of resistant acne. It is used at doses of 50–100 mg daily for 3 months. G6PD levels should be examined prior to initiation of therapy and regular monitoring for hemolysis and liver function abnormalities is warranted. While not as reliably effective as isotretinoin, it is relatively low cost and should be considered in severe cases where isotretinoin is not an option.

Antibiotics and Bacterial Resistance. Antibiotic resistance is a growing concern worldwide and should be suspected in patients unresponsive to appropriate antibiotic therapy after 6 weeks of treatment. Increasing propionobacterium resistance has been documented to all macrolides and tetracyclines commonly used in the treatment of acne. A prevalence rate of 65% was documented in one study performed in the United Kingdom.[74] Overall, resistance is highest with erythromycin and lowest with the lipophilic tetracyclines, doxycycline, and minocycline.[75] The least resistance is noted with minocycline. To prevent resistance, prescribers should avoid antibiotic monotherapy, limit long-term use of antibiotics and combine usage with benzoyl peroxide whenever possible.[55]

HORMONAL THERAPY OF ACNE.

The goal of hormonal therapy is to counteract the effects of androgens on the sebaceous gland. This can be accomplished with the antiandrogens, or agents designed to decrease the endogenous production of androgens by the ovary or adrenal gland, including oral contraceptives, glucocorticoids, or gonadotropin-releasing hormone (GnRH) agonists.

Oral Contraceptives. Oral contraceptives can improve acne by four main mechanisms. Firstly, they decrease the amount of gonadal androgen production by suppressing LH production. Secondly, they decrease the amount of free testosterone by increasing the production of sex hormone binding globulin. Thirdly, they inhibit the activity of 5-α reductase activity, so as to prevent the conversion of testosterone to the more potent DHT. Lastly, progestins that have an antiandrogenic effect can block the androgen receptors on keratinocytes and sebocytes. The third-generation progestins—gestodene (not available in the United States), desogestrel, and norgestimate, have the lowest intrinsic androgenic activity.[76] Two progestins have demonstrated antiandrogenic properties: (1) cyproterone acetate (not available in the United States) and (2) drospirenone. There are three oral contraceptives currently Food and Drug Administration (FDA) approved for the treatment of acne: (1) Ortho Tri-Cyclen, (2) Estrostep, and (3) Yaz. Ortho Tri-Cyclen is a triphasic oral contraceptive comprised of a norgestimate (180, 215, 250 mg)–ethinyl estradiol (35 μg) combination.[77] In an effort to reduce the estrogenic side effects of oral contraceptives, preparations with lower doses of estrogen (20 μg) have been developed for the treatment of acne. Estrostep contains a graduated dose of ethinyl estradiol (20–35 μg) in combination with norethindrone acetate (1 mg).[78] Yaz contains ethinyl estradiol (20 ug) and the antiandrogen drospirenone (3 mg). Drospirenone is a 17 α-spironolactone derivative that has both antimineralocorticoid and antiandrogenic properties, which may improve estrogen-related weight gain and bloating.[78] An oral contraceptive containing a low dose of estrogen (20 μg) in combination with levonorgestrel (Alesse) has also demonstrated efficacy in acne.[79] Side effects from oral contraceptives include nausea, vomiting, abnormal menses, weight gain, and breast tenderness. Rare but more serious complications include thrombophlebitis, pulmonary embolism, and hypertension. With the use of estrogen–progestin-containing oral contraceptives rather than estrogen alone, side effects such as delayed menses, menorrhagia, and premenstrual cramps are uncommon. However, other side effects such as nausea, weight gain, spotting, breast tenderness, amenorrhea, and melasma can occur.

Glucocorticoids. Because of their anti-inflammatory activity, high-dose systemic glucocorticoids may be of benefit in the treatment of acne. In practice, their use is usually restricted to the severely involved patient, often overlapping with isotretinoin to limit any potential flaring from at the start of treatment. Furthermore, because of the potential side effects, these drugs are ordinarily used for limited periods of time, and recurrences after treatment are common. Prolonged use may result in the appearance of steroid acne. Glucocorticoids in low dosages are also indicated in those female patients who have an elevation in serum DHEAS associated with an 11- or 21-hydroxylase deficiency or in other individuals with demonstrated androgen excess. Low-dose prednisone (2.5 mg or 5 mg) or dexamethasone can be given orally at bedtime to suppress adrenal androgen production.[44] The combined use of glucocorticoids and estrogens has been used in recalcitrant acne in women, based upon the inhibition of sebum production by this combination.[80] The mechanism of action is probably related to a greater reduction of plasma androgen levels by combined therapy than is produced by either drug alone.

Gonadotropin-Releasing Hormone Agonists. GnRH agonists, such as leuprolide (Lupron), act on the pituitary gland to disrupt its cyclic release of gonadotropins. The net effect is suppression of ovarian steroidogenesis in women. These agents are used in the treatment of ovarian hyperandrogenism. GnRH agonists have demonstrated efficacy in the treatment of acne and hirsutism in females both with and without endocrine disturbance.[81] However, their use is limited

by their side effect profile, which includes menopausal symptoms and bone loss.

Antiandrogens. Spironolactone is an aldosterone antagonist and functions in acne as both an androgen-receptor blocker and inhibitor of 5-α reductase. In doses of 50–100 mg twice a day, it has been shown to reduce sebum production and to improve acne.[82] Side effects include: diuresis, potential hyperkalemia, irregular menstrual periods, breast tenderness, headache, and fatigue. Combining spironolactone treatment with an oral contraceptive can alleviate the symptoms of irregular menstrual bleeding. Although hyperkalemia is a risk of spironolactone, this risk has shown to be minimal, even when spironolactone is administered with other aldosterone antagonists (such as drospirenone containing oral contraceptives).[83] As an antiandrogen, there is a risk of feminization of a male fetus if a pregnant female takes this medication. Long-term studies in rats receiving high doses of spironolactone demonstrated an increased incidence of adenomas on endocrine organs and the liver. These findings recently led to a black box warning by the FDA.[84]

Cyproterone acetate is a progestational antiandrogen that blocks the androgen receptor. It is combined with ethinyl estradiol in an oral contraceptive formulation that is widely used in Europe for the treatment of acne. Cyproterone acetate is not available in the United States.

Flutamide, an androgen receptor blocker, has been used at doses of 250 mg twice a day in combination with oral contraceptives for treatment of acne or hirsutism in females.[85] Liver function tests should be monitored, as cases of fatal hepatitis have been reported.[86] Pregnancy should be avoided. Use of flutamide in the treatment of acne may be limited by its side effect profile.

Isotretinoin. (See Chapter 228). The use of the oral retinoid, isotretinoin, has revolutionized the management of treatment-resistant acne.[87] It is approved for use in patients with severe recalcitrant nodular acne. However, it is commonly used in many other acne scenarios, including any significant acne that is unresponsive to treatment with oral antibiotics and acne that results in significant physical or emotional scarring. Isotretinoin is also effective in the treatment of Gram-negative folliculitis, pyoderma faciale, and acne fulminans.[88] The remarkable aspects of isotretinoin therapy are the complete remission in almost all cases and the longevity of the remission, which lasts for months to years in the great majority of patients. However, due to its teratogenicity its use has become highly regulated in the United States with the initiation of the iPledge program in March 2006 to insure that pregnancy-prevention procedures are followed.

The mechanism of action of isotretinoin is not completely known. The drug produces profound inhibition of sebaceous gland activity, and this undoubtedly is of great importance in the initial clearing.[89,90] In some patients, sebaceous gland inhibition continues for at least a year, but in the majority of patients, sebum production returns to normal after 2–4 months.[89] Thus, this action of the drug cannot be used to explain the long-term remissions. The *P. acnes* population is also decreased during isotretinoin therapy, but this decrease is generally transient.[90,91] Isotretinoin has no inhibitory effect on *P. acnes* in vitro. Therefore, the effect on the bacterial population is probably indirect, resulting from the decrease in intrafollicular lipids necessary for organism growth. Isotretinoin also has anti-inflammatory activity and probably has an effect on the pattern of follicular keratinization. These effects also are temporary, and the explanation for long-term remissions remains obscure.

Given the ubiquitous distribution of RAR, isotretinoin almost always causes side effects, mimicking those seen in the chronic hypervitaminosis A syndrome.[92] In general, the severity of side effects tends to be dose dependent. The most common side effects are related to the skin and mucous membranes. Cheilitis of varying degrees is found in virtually all cases. Other side effects that are likely to be seen in over 50% of patients are dryness of the mucous membranes and skin. An eczematous dermatitis is occasionally seen, particularly in cold, dry weather. Thinning of hair and granulomatous paronychial lesions are less common. Ophthalmologic findings include xerophthalmia, night blindness, conjunctivitis, keratitis, and optic neuritis. Corneal opacities and hearing loss (both transient and persistent) have also been reported with isotretinoin use. Pseudotumor cerebri, also known as benign intracranial hypertension, is evidenced by severe headache, nausea, and visual changes. The risk of pseudotumor cerebri may be increased with concomitant use of tetracyclines and isotretinoin; therefore, these two medications should not be used together without careful prior consideration. If symptoms suggest benign intracranial hypertension, prompt neurological evaluation for evidence of papilledema is required. Vague complaints of headache, fatigue, and lethargy are also not infrequent.

The relationship between isotretinoin use and psychiatric effects is currently being examined. Risk of depression, suicide, psychosis, and aggressive and/or violent behavior are all listed as possible side effects. While no clear mechanism of action has been established, some evidence for biologic plausibility does exist. Psychiatric adverse events are described with high-dose vitamin A and etretinate. Also, retinoids have the demonstrated ability to enter the central nervous system (CNS) of rats and mice. And finally, there are documented case reports and studies linking isotretinoin use to depression in certain individuals.[93] A meta-analysis of nine studies looking at the possible link between isotretinoin and depression found that the incidence of depression in patients on isotretinoin ranged from 1%–11%.[94] The authors importantly pointed out that this range is similar to control group patients on oral antibiotics. Another author examining case-control studies on isotretinoin and depression found the relative risk to range from 0.9 to 2.7 with wide confidence intervals.[95] Some studies demonstrate that those on isotretinoin have an overall improvement in mood.[96] Retinoids have not been shown to activate genes to induce behavioral/psychiatric changes. Nor

is there evidence demonstrating functionality of retinoid signaling pathways in the mature CNS. Large population-based studies have not supported causality. As dermatologists are often on the front line seeing adolescents at risk for depression, careful screening of adolescents is particularly needed, since the risk of depression in this population is 10%–20%.[97]

GI symptoms are generally uncommon, but nausea, esophagitis, gastritis, and colitis can occur. Acute hepatitis is rare but liver function studies should be regularly monitored, as elevation in liver enzymes can occur in 15% of patients, sometimes necessitating dose adjustments. Elevated levels of serum triglycerides occur in approximately 25% of patients on isotretinoin. This elevation, which is dose-related, typically occurs within the first 4 weeks of treatment and is often accompanied by an overall increase in cholesterol with a decrease in the high-density lipoprotein levels. The effect of this transient alteration on overall coronary artery health is unclear. Acute pancreatitis is a rare complication that may or may not be related to triglyceride levels. There are case reports documenting a potential link between isotretinoin and new-onset or flared inflammatory bowel disease. However, a study that critically examined these case reports found no grounds for a causal relationship between isotretinoin use and inflammatory bowel disease.[98] A recent population-based case-control study found that patients with inflammatory bowel disease were no more likely to have used isotretinoin than those without inflammatory bowel disease.[99] Patients with a family history of inflammatory bowel disease, or those with a preexisting inflammatory bowel disease, should be counseled regarding the possibility of isotretinoin-induced inflammatory bowel disease.

Isotretinoin has effects on bone mineralization as well. A single course of isotretinoin was not shown to have a significant effect on bone density.[100] However, chronic or repeated courses may result in significant osteopenia. Osteoporosis, bone fractures, and delayed healing of bone fractures have also been reported. The significance of reported hyperostosis is unclear, but the development of bony hyperostoses after isotretinoin therapy is more likely in patients who receive the drug for longer periods of time and in higher dosages, such as for disorders of keratinization.[101] Serial bone densitometry should be done in any patient on long-term isotretinoin. Myalgias are the most common musculoskeletal complain, seen in 15% of patients. In severe cases, creatine phosphokinase levels should be evaluated for possible rhabdomyolysis.

Other laboratory abnormalities that have been reported with isotretinoin use are an elevated erythrocyte sedimentation rate and platelet count. Alterations in the red blood cell parameters with decreased white cell counts can occur. White blood cells in the urine have rarely been linked to isotretinoin use. Most laboratory changes are mild and spontaneously resolve upon discontinuation of medication use.

The greatest concern during isotretinoin therapy is the risk of the drug being administered during pregnancy and thereby inducing teratogenic effects in the fetus.[102,103] The drug is not mutagenic; its effect is on organogenesis. Therefore, the production of retinoic embryopathy occurs very early in pregnancy, with a peak near the third week of gestation.[102,103] A significant number of fetal abnormalities have been reported after the use of isotretinoin. For this reason, it should be emphasized that isotretinoin should be given only to patients who have not responded to other therapy. Furthermore, women who are of childbearing age must be fully informed of the risk of pregnancy. The patient must employ two highly effective contraception techniques such as the use of an oral contraceptive and condoms with a spermicidal jelly. Contraception must be started at least 1 month before isotretinoin therapy. Female patients must be thoroughly counseled and demonstrate an understanding of contraception techniques before starting isotretinoin. Two forms of contraception should be used throughout the course of isotretinoin and for 1 month after stopping treatment. No more than 1 month's supply of isotretinoin should be given to a female patient so that she can be counseled on a monthly basis on the hazards of pregnancy during isotretinoin therapy. A pregnancy test must be repeated monthly. Abstinence as a form of birth control should only be allowed in special instances. Because the drug is not mutagenic, there is no risk to a fetus conceived by a male who is taking isotretinoin. Although it may seem obvious, it is important to remind men who are taking isotretinoin not to give any of their medication to female companions under any circumstances.

The recommended daily dosage of isotretinoin is in the range of 0.5–1 mg/kg/day. A cumulative weight-based dosing formula may also be used with a total dose of 120–150 mg/kg of isotretinoin during a course of therapy.[104] This dosing regimen is of particular use in patients who have variable dosages or interrupted periods of treatment as achieving the total dose will ensure the greatest chance of long-term remission. Because back and chest lesions show less of a response than facial lesions, dosages as high as 2 mg/kg/day may be necessary in those patients who have very severe truncal involvement. Patients with severe acne, particularly those with granulomatous lesions, will often develop marked flares of their disease when isotretinoin is started. Therefore, the initial dosing should be low, even below 0.5 mg/kg/day. These patients often need pretreatment for 1–2 weeks with prednisone (40–60 mg/day), which may have to be continued for the first 2 weeks of therapy. A typical course of isotretinoin is 20 weeks, but the length of the course of treatment is not absolute; in patients who have not shown an adequate response, therapy can be extended. Additional improvement may be seen for 1–2 months after discontinuation, so that complete clearance may not be a necessary endpoint for determining when to discontinue therapy. Low-dose regimens, 0.1–0.4 mg/kg/day, have shown efficacy. However, with such dosages, the incidence of relapses after therapy is greater. Approximately 10% of patients treated with isotretinoin require a second course of the drug. The likelihood for repeat therapy is increased in patients younger than 16–17 years of age. It is standard

practice to allow at least 2–3 months between courses of isotretinoin.

Furthermore, laboratory monitoring is indicated. It is appropriate to obtain a baseline complete blood count and liver function tests, but the greatest attention should be paid to following serum triglyceride levels. Baseline values for serum triglycerides should be obtained and repeated at 3–4 weeks and 6–8 weeks of therapy. If the values are normal at 6–8 weeks, there is no need to repeat the test during the remaining course of therapy unless there are risk factors. If serum triglycerides increase above 500 mg/dL, the levels should be monitored frequently. Levels above 700 to 800 mg/dL are a reason for interrupting therapy or treating the patient with a lipid-lowering drug. Eruptive exanthemas or pancreatitis can occur at higher serum triglyceride levels.

DIET. Several articles suggesting a role for diet in acne exist.[105,106] A recent review of these studies concluded that there may be some link between milk and acne as well as between high-glycemic index foods and acne.[107] Yet, overall the implications of these studies is not clear and the role of chocolate, sweets, milk, high-glycemic index foods, and fatty foods in patients with acne requires further study. There is no evidence to support the value of elimination of these foods. However, restricting a food firmly thought by the patient to be a trigger is not harmful, as long as the patient's nutritional well-being is not compromised.

ACNE SURGERY. Acne surgery, a mainstay of therapy in the past used for the removal of comedones and superficial pustules, aids in bringing about involution of individual acne lesions. However, with the advent of comedolytic agents, such as topical retinoids, its use is primarily restricted to those patients who do not respond to comedolytic agents. Even in those patients, the comedones are removed with greater ease and less trauma if the patient is pretreated with a topical retinoid for 3–4 weeks. Acne surgery should not be performed at home, as inaccurate placement of the comedo extractor may rupture the follicle and incite an inflammatory reaction. The Unna type of comedo extractor, which has a broad flat plate and no narrow sharp edges, is preferable. The removal of open comedones is desirable for cosmetic purposes, but does not significantly influence the course of the disease. In contrast, closed comedones should be removed to prevent their rupture. Unfortunately, the orifice of closed comedones is often very small, and usually the material contained within the comedo can be removed only after the orifice is gently enlarged with a no. 25 needle or other suitable sharply pointed instrument.

INTRALESIONAL GLUCOCORTICOIDS. Intralesional injection of glucocorticoids can dramatically decrease the size of deep nodular lesions. The injection of 0.05–0.25 mL per lesion of a triamcinolone acetate suspension (2.5–10 mg/mL) is recommended as the anti-inflammatory agent. This is a very useful form of therapy in the patient with nodular acne, but it often has to be repeated every few weeks. A major advantage is that it can be done without incising or draining the lesions, thus avoiding the possibility of scar formation. Hypopigmentation, particularly in darker skinned patients, and atrophy are risks.

PHOTOTHERAPY AND LASERS. Various forms of phototherapy are under investigation for their use in treating acne vulgaris. Ultraviolet (UV) light has long been thought to be beneficial in the treatment of acne. Up to 70% of patients report that sun exposure improves their acne.[108] This reported benefit may be due to camouflage by UV radiation induced erythema and pigmentation, although it is likely that the sunlight has a biologic effect on the pilosebaceous unit and *P. acnes*. Although ultraviolet B (UVB) can also kill *P. acnes* in vitro, UVB penetrates poorly to the dermal follicle and only high doses causing sunburn have be shown to improve acne.[109,110] UV radiation may have anti-inflammatory effects by inhibiting cytokine action.[111] Twice-weekly phototherapy sessions are needed for any clinical improvement. The therapeutic utility of UV radiation in acne is superseded by its carcinogenic potential.[112–116]

Other types of phototherapy for acne treatment utilize porphyrins. Treatment of acne with phototherapy works either by activating the endogenous porphyrins of *P. acnes* or by applying exogenous porphyrins. Coproporphyrin III is the major endogenous porphyrin of *P. acnes*. Coproporphyrin III can absorb light at the near-UV and blue light spectrum of 415 nm.[117] Irradiation of *P. acnes* with blue light leads to photoexcitation of endogenous bacterial porphyrins, singlet oxygen production, and subsequent bacterial destruction.[118] A visible light source, either blue or red, or both may be used to excite the endogenous porphyrins. The high intensity, enhanced, narrow-band (407–420 nm) blue light known as ClearLight (Lumenis) is currently FDA approved for the treatment of moderate inflammatory acne.[116] Red light too may be beneficial, as it penetrates deeper into the dermis and has greater anti-inflammatory properties, but causes less photoactivation of the porphyrins. Therefore, the combination of blue and red light may prove the most beneficial. Treatments should be given twice weekly for 15-minute sessions for the face alone, and 45 minutes for the face, chest, and back. A multicenter study has shown that 80% of patients treated with the ClearLight for 4 weeks had a 60% reduction in acne lesions. There was a gradual return of lesions over 3–6 months.[119]

The most consistent improvement in acne after light treatment has been demonstrated with photodynamic therapy.[120] Photodynamic therapy involves the topical application of aminolevulinic acid (ALA) 1 hour prior to exposure to a low-power light source. These sources include the pulsed dye laser, intense pulsed light, or a broadband red light source. The topical ALA is taken up by the pilosebaceous unit and metabolized to protoporphyrin IX.[121] The protoporphyrin IX is targeted by the light and produces singlet oxygen species, which then damage the sebaceous glands.[122] Several studies utilizing ALA-PDT maintained clinical improvement for up to 20 weeks.[123,124]

Although lasers are beginning to find a role in the treatment of acne, the authors consider them inferior to the traditional medical treatments. They work by emitting minimally divergent, coherent light that can be focused over a small area of tissue. The pulsed KTP laser (532 nm) has demonstrated a 35.9% decrease in acne lesions when used twice weekly for 2 weeks. Although there was no significant decrease in *P. acnes*, there was significantly lower sebum production even at 1 month.[125] The pulsed dye laser (585 nm) can also be used at lower fluences to treat acne. Instead of ablating blood vessels and causing purpura, a lower fluence can stimulate procollagen production by heating dermal perivascular tissue.[122] The beneficial effects of a single treatment can last 12 weeks.[126] Some of the nonablative infrared lasers, such as the 1,450 nm and 1,320 nm laser, have shown to be helpful in improving acne.[127,128] These lasers work by causing thermal damage to the sebaceous glands. The concurrent use of a cryogen spray device protects the epidermis while the laser causes necrosis of the sebaceous gland.[129] In a pilot study, 14 out of 15 patients treated with the 1,450 nm laser had a significant reduction in inflammatory lesions that persisted for 6 months. The 1,320 nm Nd:Yag and the 1,540 erbium glass lasers have also been demonstrated to improve acne.[130,131] Multiple treatments are needed with either of these lasers to lessen acne lesions. These treatments tend to be painful and show a gradual modest improvement, limiting their utility.

One of the newer uses of light for treating acne is with a photopneumatic device (Isolaz, Solta Medical). This photopneumatic device has a handpiece that applies negative pressure (i.e., suction) to the skin and then delivers a broadband-pulsed light (400–1,200 nm). The suction is employed to unplug the infundibulum of the pilsebaceous unit and the light is delivered to activate the *P. acnes* porphyrins, thus releasing singlet oxygen species. Patients treated with this device may experience some posttreatment erythema or purpura. Results are modest and temporary and the device is best for inflammatory lesions.[132,133] Although the light-based treatments are beneficial in that they avoid some of the side effects of the oral medications, the cost of these light and laser treatments tends to be prohibitive.

ACNE VARIANTS

NEONATAL ACNE

Neonatal acne can occur in up to 20% of healthy newborns. Lesions usually appear around 2 weeks of age and resolve spontaneously within 3 months. Typically, small, inflamed papules affect the nasal bridge and the cheeks. Because comedone formation is absent, many consider neonatal acne a variant of neonatal cephalic pustulosis. However, it has been shown that sebum excretion rates in newborns are transiently elevated in the perinatal period.[134] Additionally, *Malassezia sympodialis*, a normal commensal on human skin, may also play a role. Some reports have demonstrated positive cultures of the pustules with *Malassezia* and improvement with ketoconazole cream.[135] While there appears to be a strong association between *Malassezia* and neonatal acne, definite causality has not yet been proven.[136]

INFANTILE ACNE

Infantile acne presents at 3–6 months of age and typically shows comedones. Papules, pustules, and nodules can also present on the face and scarring may occur even with relatively mild disease. Infantile acne is caused in part by the transient elevation of DHEA produced by the immature adrenal gland. Additionally, during the first 6–12 months of life boys may also have an increased level of LH that stimulates testosterone production. Around 1 year of age, these hormone levels begin to stabilize until they surge again during adrenarche. As a result, infantile acne usually resolves around 1–2 years of age. Treatment generally consists of topical retinoids and benzoyl peroxide. Oral therapy with erythromycin, trimethoprim, or isotretinoin can be used in severe or refractory cases.[136]

ACNE CONGLOBATA

This severe form of nodular acne is most common in teenage males, but can occur in either sex and into adulthood. Acne conglobata (*conglobate* means shaped in a rounded mass or ball) is a mixture of comedones, papules, pustules, nodules, abscesses, and scars. It can be on the back, buttocks, chest, and, to a lesser extent, on the abdomen, shoulders, neck, face, upper arms, and thighs (Fig. 80-6). The comedones often have multiple openings. The inflammatory lesions are large, tender, and dusky-colored. The draining lesions discharge a foul-smelling serous, purulent, or mucoid material. Subcutaneous dissection with the formation of multichanneled sinus tracts is common. Healing results in an admixture of depressed and keloidal scars. The management of these patients is very difficult and the effect of treatment is often temporary. Several medications have been used, including intensive high-dose therapy with antibiotics, intralesional glucocorticoids, systemic glucocorticoids, surgical debridement, surgical incision, and surgical excision. The use of isotretinoin has produced dramatic results in some of these patients. In severe cases, dosages as high as 2 mg/kg/day for a 20-week course may be necessary. However, because severe flares may occur when isotretinoin is started, the initial dose should be 0.5 mg/kg/day or less, and systemic glucocorticoids are often required either before initiating isotretinoin therapy or as concomitant therapy.

ACNE FULMINANS

Acne fulminans (also known as acute febrile ulcerative acne) is the most severe form of nodular acne and is accompanied by systemic symptoms. The sudden appearance of massive, inflammatory, tender, oozing, friable plaques with hemorrhagic crusts characterize acne fulminans. The lesions predominate on the chest



Figure 80-8 Acne fulminans. An eruptive form of acne with extensive inflammatory papules and nodules on the chest (**A**) and back (**B**). Systemic symptoms may accompany this extreme form of acne and scarring is usually quite extensive.

and back (Figs. 80-8A and 80-8B) and rapidly become ulcerative and heal with scarring. The disease is reported to occur primarily in teenage boys. The face is often uninvolved. The patients are febrile, have a leukocytosis of 10,000–30,000/mm^3 white blood cells, and usually have polyarthralgia, myalgia, hepatosplenomegaly, and anemia. Bone pain is common, especially at the clavicle and sternum. Radiologic examination may demonstrate lytic bone lesions. Occasionally there is accompanying erythema nodosum. Although this disease is often classified with acne conglobata, there are basic differences. The onset of acne fulminans is more explosive; nodules and polymorphous comedones are less common; the face is not involved as frequently and the neck is usually spared; ulcerative and crusted lesions are unique; and systemic symptoms are more common. Systemic glucocorticoid therapy, along with oral antibiotics and intralesional glucocorticoids, is the treatment regimen required for these patients. Isotretinoin is also of benefit in these patients, but in order to prevent explosive flares, systemic glucocorticoids must be started before isotretinoin and continued during the first few weeks of isotretinoin therapy. The initial dosing of isotretinoin must also be lowered accordingly in the initial weeks of therapy until the inflammation is controlled. The daily dose of glucocorticoids should be slowly decreased as tolerated. Dapsone in conjunction with isotretinoin has been reportedly beneficial in the treatment of acne fulminans associated with erythema nodosum.

SAPHO SYNDROME

SAPHO syndrome is manifested by synovitis, acne, pustulosis, hyperostosis, and osteitis. It is predominantly associated with hyperostosis of the anterior chest, palmoplantar pustulosis, hidradenitis suppurativa, and acne fulminans. Its etiology is unknown. Reported successful treatments for SAPHO syndrome are NSAIDS, sulfasalazine, and infliximab.[137] The bisphosphonates are beneficial for treating the associated bone pain.[138]

PAPA SYNDROME

PAPA syndrome, another acne variant with systemic symptoms, is marked by sterile pyogenic arthritis, pyoderma gangrenosum, and acne. Patients with PAPA syndrome may also give a history of sterile cutaneous abscesses, inflammatory bowel disease, and pancytopenia following administration of sulfa-containing medications.[139] It is an autoinflammatoy disorder inherited in an autosomal dominant manner. Due to mutations in the CD2 binding protein-1 gene (also known as the protein serine–threonine phosphatase interacting protein), there is an increase in IL-1β production.[140] There have been reports of successful treatment with infliximab and anakinra.[139,140]

ACNE EXCORIÉE DES JEUNES FILLES

Acne excoriée des jeunes filles, as the name suggests, occurs primarily in young women who are picking at their skin. Mild acne may be present and is accompanied by extensive excoriations. Comedones and papules are systematically and neurotically excoriated leaving crusted erosions that may scar. Often the lesions that are excoriated are minute. This condition may suggest underlying depression, anxiety, obsessive–compulsive disorder, or a personality disorder. Antidepressants and psychotherapy can be helpful in treating these patients.

ACNE MECHANICA

Acneiform eruptions have been observed after repetitive physical trauma to the skin such as rubbing. This can occur from clothing (belts and straps) or sports equipment (football helmets and shoulder pads). Occluding the skin with adhesive tape can also produce acne mechanica. Obstruction of the pilosebaceous gland results in comedo formation. It presents as a well-defined, lichenified, hyperpigmented plaque interspersed with comedones. A classic example of

acne mechanica is fiddler's neck, produced where the violin pad repetitively rubs against the player's lateral neck.

ACNE WITH SOLID FACIAL EDEMA

A rare and disfiguring variant of acne vulgaris is acne with solid facial edema, also known as Morbihan's disease. There is a woody edema of the midthird face with accompanying erythema and acne. Similar changes have been reported with rosacea, Melkerson–Rosenthal syndrome, and rosacea. There may be fluctuations in the severity of the edema, but spontaneous resolution does not occur. Oral antibiotic treatment is ineffective. Treatment with low dose isotretinoin (0.2–0.5 mg/kg/day) alone or in combination with oral glucocorticoids, ketotifen (1–2 mg/day), or clofazimine for 4–5 months has been reported to be beneficial.[141,142]

ACNE WITH ASSOCIATED ENDOCRINOLOGY ABNORMALITIES

Although the majority of cases of acne vulgaris occur in patients without endocrinologic disturbances, there is a certain population whose acne is driven or worsened by endocrine abnormalities. As mentioned previously, it is important to screen patients for such abnormalities by taking a thorough history. In addition to the presence of acne, endocrinologic disturbances may be marked by irregular menstrual cycles, deepened voice, increased libido, and hirsutism. Laboratory work can help define an endocrinologic problem causing acne.

POLYCYSTIC OVARY SYNDROME. Polycystic ovary syndrome (PCOS) occurs in roughly 3%–6% of the general population. Patients with PCOS, also called Stein–Leventhal syndrome, ovulate infrequently or not at all, have multiple cysts on their ovaries, and often have irregular menses, obesity, androgenic alopecia, hirsutism, and acne. There is an increased risk of diabetes mellitus and endometrial carcinoma in patients with PCOS.[143] Serum total testosterone in the range of 150–200 ng/dL or an increased LH/FSH ratio (greater than 2.0) can be found in cases of PCOS. Patients with signs of hyperandrogenism should also be asked about insulin resistance, since acne can occur with the HAIR-AN syndrome, a subset of PCOS. Hyperandrogenism, acne, insulin resistance, and acanthosis nigricans are markers of this syndrome. It is important to identify these patients because they are at increased risk for accelerated cardiovascular disease and diabetes mellitus.

CONGENITAL ADRENAL HYPERPLASIA. Congenital adrenal hyperplasia, usually caused by defects in the adrenal enzyme 21β-hydroxylase, occurs as both a classic severe type and as a nonclassic mild type. Neonates are screened at birth for the classic type and typically present with ambiguous genitalia and salt-wasting. The nonclassic type is not identified at birth and can present throughout childhood and adolescence. The prevalence of the nonclassic type in the white population is 1 in 1,000. Patients with this type of congenital adrenal hyperplasia have normal cortisol levels but increased androgens. Female patients present with precocious puberty, irregular menses, polycystic ovaries, hirsutism, and acne.[144] Values of DHEAS in the range of 4,000–8,000 ng/mL are suggestive of congenital adrenal hyperplasia. Findings of CAH in males are often subtle, as acne may be the only sign, but CAH should be considered in patients who do not respond to treatment.[145] Treatment of congenital adrenal hyperplasia consists of low dose replacement of glucocorticoids, as well as oral contraceptives, spironolactone, or flutamide in females.

ACNEIFORM ERUPTIONS

STEROID FOLLICULITIS

Following administration of systemic glucocorticoids or corticotropin, folliculitis may appear. This is very uncommon in children but may occur in any adult as early as 2 weeks after steroids are started. Similar lesions may follow the prolonged application of topical glucocorticoids to the face. For this reason, topical glucocorticoids have no place in the treatment of acne, and their use on the face, in general, should be limited. The pathology of steroid acne is that of a focal folliculitis with a neutrophilic infiltrate in and around the follicle. This type of acne clearly differs from acne vulgaris in its distribution and in the type of lesions observed. The lesions, which are usually all in the same stage of development, consist of small pustules and red papules. In contrast to acne vulgaris, they appear mainly on the trunk, shoulders, and upper arms, with lesser involvement of the face. Postinflammatory hyperpigmentation may occur, but comedones, cysts, and scarring are unusual. Treatment consists primarily of stopping any corticosteroid use. Typical acne treatments such as topical retinoids and antibiotics may also be helpful.

DRUG-INDUCED ACNE

In addition to glucocorticoids, other medicines can also cause a monomorphic, diffuse popular eruption that mimics steroid folliculitis. Such drugs include: phenytoin, lithium, isoniazid, high doses of vitamin B complexes, halogenated compounds, and certain chemotherapy medications (see Box 80-2). Halogenated compounds containing either bromides or iodides are often found in cold and asthma remedies, sedatives, radioopaque contrast material, kelp (in many fad diet pills), and other vitamin–mineral combinations. With iodides, in particular, inflammation may be marked.[146,147] The iodine content of iodized salt is low and, therefore, it is extremely unlikely that enough iodized salt could be ingested to cause this type of acne.

BOX 80-2 DRUG-INDUCED ACNEIFORM ERUPTIONS

- Glucocorticoids
- Phenytoin
- Lithium
- Isoniazid
- High-dose vitamin B complex
- Halogenated compounds
- Epidermal growth factor receptor inhibitors

EPIDERMAL GROWTH FACTOR RECEPTOR INHIBITOR ASSOCIATED ERUPTION

A newer class of chemotherapy medicine, known as the EGFR inhibitors, may also cause a follicular-based eruption. EGFR inhibitors are primarily used to treat nonsmall-cell lung cancer, colorectal cancer, and breast cancer. Some of the EGFR inhibitors include: gefitinib (Iressa), cetuximab (Erbitux), erlotinib (Tarceva), and trastuzumab (Herceptin). In treatment responsive patients, the EGFR inhibitors are indefinitely administered for their long-term ability to inhibit tumor growth, progression, cell proliferation, and angiogenesis. A frequent side effect of the EGFR inhibitors is a perifollicular, papulopustular eruption distributed on the face and upper torso. The eruption occurs in up to 86% of patients treated with EGFR inhibitors. An associated lateral paronychia may also occur. Histopathological sections of lesional skin show a noninfectious perifolliculitis.[148] The etiology of the acneiform eruption is not clear, but it may occur because EGFR is highly expressed in the basal cell layer of the epidermis, follicular keratinocytes, and the sebaceous epithelium. The presence and severity of the eruption correlates with a positive treatment response. If the eruption is absent, dosing may be inadequate or the patient's tumor may be unresponsive to EGFR inhibitor therapy.[149]

OCCUPATIONAL ACNE AND CHLORACNE

Several different groups of industrial compounds encountered in the workplace may cause acne. These include coal tar derivatives, insoluble cutting oils, and chlorinated hydrocarbons (chloronaphthalene, chlorobiphenyls, and chlorodiphenyloxide). Chloracne is the term that is used to describe occupational acne caused from chlorinated hydrocarbons. Occupational acne tends to be quite inflammatory and, in addition to large comedones, is characterized by papules, pustules, large nodules, and true cysts. Tar acne is often accompanied by hyperpigmentation. The lesions of occupational acne are not restricted to the face and, in fact, are more common on covered areas with intimate contact to clothing saturated with the offending compound. Because the cutting oils are so widely used, they are the most common cause of industrial acne. However, the chlorinated hydrocarbons, which cause chloracne, have posed a more difficult problem because of the severity of the disease induced with these compounds. Exposure can cause comedones, cysts, and pigmentary changes of the skin but can also affect the ophthalmic, nervous and hepatic systems.[150] Many cases have occurred as the result of massive exposure in industrial accidents.[151] Chlorinated hydrocarbons are found in fungicides, insecticides, and wood preservatives. Chloracne classically affects the malar, retroauricular, and mandibular regions of the head and neck, as well as the axillae and scrotum (see eFig. 80-7.1 in online edition), Pathology demonstrates multiple tiny infundibular cysts.[152] In 2,004, Ukrainian President Viktor Yushchenko was poisoned with dioxin, causing severe chloracne. Most chloracne lesions clear up within 2 years, providing exposure to the chemical has stopped. Treatment with topical or oral retinoids and oral antibiotics may be beneficial.

GRAM-NEGATIVE FOLLICULITIS

Gram-negative folliculitis may occur in patients with preexisting acne vulgaris treated with long-term oral antibiotics, especially the tetracyclines. Patients usually give a history of initial success with oral tetracyclines followed by a worsening of their acne. Gram-negative folliculitis may appear as either papulopustules concentrated around the nose or as deep-seated nodules. Culture of these lesions may reveal *Enterobacter*, *Klebsiella*, or *Escherichia* in the papulopustules or *Proteus* in the nodules. An appropriate antimicrobial agent with adequate Gram-negative coverage should be used. In recalcitrant cases, Gram-negative folliculitis improves with oral isotretinoin for 4–5 months. Gram-negative bacteria require a moist environment for survival and the drying action of isotretinoin will kill the bacteria.

RADIATION ACNE

Different types of radiation such as ionizing radiation and UV radiation may induce acneiform eruptions. Previous sites of therapeutic ionizing radiation (e.g., external beam) can develop comedo-like papules. These lesions begin to appear as the acute phase of radiation dermatitis is resolving. The ionizing rays induce epithelial metaplasia within the follicle, creating adherent hyperkeratotic plugs in the pilosebaceous unit. These keratotic plugs are resistant to extraction. Excessive exposure to UV radiation may produce a yellow, atrophic plaque studded with large open comedones. This condition is known as Favre–Racouchot, but has also been called solar comedones, senile comedones, nodular cutaneous elastosis with cysts and comedones, and nodular elastoidosis with cysts and comedones. It has been estimated to occur in 6% of persons above age 50.[153] The lesions are usually

symmetrically distributed on the temporal and periorbital areas. The exact pathogenesis of Favre–Racouchot is unknown, but it is suggested that extensive UV exposure as well as exposure to harsh climates and smoking may be risk factors. It can be treated with oral or topical retinoids as well as extraction.[154]

TROPICAL ACNE

In extreme heat, a severe acneiform folliculitis may develop. This can be seen in tropical climates or in scorching occupational environments, as in furnace workers. This acneiform eruption is a major cause of dermatologic disability in military troops serving in tropical climates. Tropical acne occurs mainly on the trunk and buttocks. It has many deep, large, inflammatory nodules with multiple draining areas, resembling acne conglobata. The pathogenesis of this type of acne is unknown, although secondary infection with coagulase-positive *Staphylococci* almost always ensues. Systemic antibiotics must be given, but often more important is removing the patient to a cooler environment.

ACNE AESTIVALIS

This monomorphous eruption consists of multiple, uniform, red, papular lesions seen after sun exposure. It is referred to as *Mallorca acne* because it occurred in many Scandinavians after they had been on a sunny vacation in Mallorca in southern Europe after a long, dark winter. Almost all cases have occurred in women, mainly 20–30 years old. The lesions are common on the shoulders, arms, neck, and chest. Histologically, the lesions resemble steroid acne in that they show a focal follicular destruction with neutrophilic infiltrate. Comedones are not part of the clinical or histologic picture. The eruption is due to the effects of UV radiation, primarily ultraviolet A (UVA). Rarely, a similar clinical picture can be observed after starting psoralen and UVA (PUVA) treatment. The eruption will subside if the patient is protected from UV light for several months. Oral antibiotics are ineffective in speeding up the resolution, but topical retinoids and benzoyl peroxide may be helpful. Like polymorphous light eruption, patients with acne aestivalis will flare on reexposure to UV light.[147]

PSEUDOACNE OF THE NASAL CREASE

The transverse nasal crease is an anatomic variant that appears as a transverse linear groove across the middle of the nose. Preadolescent patients have been described to develop acneiform red papules within the nasal crease along with milia (Fig. 80-9). Histologic examination of the papules reveals keratin granulomas that may be derived from ruptured, inflamed milia. Due to its similarity in clinical appearance to acne, but deviation from acne histologically, it has been termed "pseudoacne of the nasal crease."[155]



Figure 80-9 Pseudoacne of the nasal crease. Open and closed comedones and small papules line up along the transverse nasal crease.

APERT SYNDROME

Apert syndrome, also known as acrocephalosyndactyly, is an autosomal dominant disorder marked by synostoses of the cranium, vertebral bodies and hands and feet. It is caused by a mutation in the gene encoding FGFR-2. These patients have a diffuse acneiform eruption that often involves the arms, buttocks, and thighs. It is typically very resistant to treatment but excellent responses to isotretinoin have been reported. Patients with Apert syndrome may also present with severe seborrhea, nail dystrophy, and cutaneous and ocular hypopigmentation.

KEY REFERENCES

Full reference list available at www.DIGM8.com

DVD contains references and additional content

3. Bataille V et al: The influence of genetics and environmental factors in the pathogenesis of acne: A twin study of acne in women. *J Invest Dermatol* **119**:1317-1322, 2002
12. Munro CS, Wilkie AO: Epidermal mosaicism producing localised acne: Somatic mutation in FGFR2. *Lancet* **352**:704-705, 1998
26. Jeremy A et al: Inflammatory events are involved in acne lesion initiation. *J Invest Dermatol* **121**:20-27, 2003
35. Kim J et al: Activation of toll-like receptor 2 in acne triggers inflammatory cytokine responses. *J Immunol* **169**:1535-1541, 2002
49. Mallon E et al: The quality of life in acne: A comparison with general medical conditions using generic questionnaires. *Br J Dermatol* **140**(4):672-676, 1999
53. Gollnick H, Schramm M: Topical therapy in acne. *J Eur Acad Dermatol Venereol* **11**(1), 1998
75. Ross JI et al: Antibiotic-resistant acne: Lessons from Europe [see comment]. *Br J Dermatol* **148**(3):467-478, 2003
94. Marqueling AL et al: Depression and suicidal behavior in acne patients treated with isotretinoin: A systematic review. *Semin Cutan Med Surg* **26**(4):210-220, 2007
99. Bernstein CN et al: Isotretinoin is not associated with inflammatory bowel disease: A population-based case-control study. *Am J Gastroenterol* **104**(11):2774-2778, 2009
100. DiGiovanna JJ et al: Effect of a single course of isotretinoin therapy on bone mineral density in adolescent patients with severe, recalcitrant, nodular acne [see comment]. *J Am Acad Dermatol* **51**(5):709-717, 2004

Chapter 81 :: Rosacea

:: Michelle T. Pelle

ROSACEA AT A GLANCE

- Rosacea affects all races, but is most common in fair-skinned individuals.
- Triggers of rosacea may include hot or cold temperature, sunlight, wind, hot drinks, exercise, spicy food, alcohol, emotions, cosmetics, topical irritants, menopausal flushing, and medications that promote flushing.
- There are four rosacea subtypes: erythematotelangiectatic, papulopustular, phymatous, and ocular.
- The primary clinical features of rosacea include flushing, inflammatory papules, pustules, and telangiectases.
- Secondary features of rosacea may include facial burning and stinging, edema, plaques, a dry appearance, phyma, peripheral flushing, and ocular manifestations.
- Sun protection and trigger avoidance are important for prevention in all types of rosacea.
- Rosacea therapy may include barrier protection practices, topical antimicrobials, oral antibiotics, retinoids, intense pulsed light, and vascular laser modalities for adequate long-term control of symptoms.

ROSACEA

Despite universal recognition, rosacea is clinically varied and of uncertain pathophysiology. Practitioners and the public can easily identify the prototypical red face of rosacea; however, confusion arises when photodamage, perioral dermatitis, postadolescent acne, and topical steroid overuse present in a similar guise. Recent theory has shifted conceptually from staged progression of rosacea signs and symptoms to a new classification that defines four subtypes with variable severity and potential overlap.

Rosacea is characterized by erythema of the central face that has persisted for months or more. The convex areas of the nose, cheeks, chin, and forehead are the characteristic distribution. Primary features of rosacea, which may be observed but are not required for the diagnosis, include flushing, papules, pustules, and telangiectases. Secondary features include facial burning or stinging, edema, plaques, a dry appearance, phyma, peripheral flushing, and ocular manifestations. Erythema in peripheral locations (the scalp, ears, lateral face, neck, and chest) can be observed in rosacea, but is also a common feature of physiologic flushing and chronic sun damage, and therefore must be interpreted carefully.[1]

SUBTYPE CLASSIFICATION

The subtypes of rosacea were defined provisionally by the National Rosacea Society (NRS) Expert Committee in 2002 and include erythematotelangiectatic, papulopustular, phymatous, and ocular subtypes.[1] These represent the most common groupings of rosacea signs and symptoms. The subtypes coincide with the first rosacea "staging" classification devised by Plewig and Kligman.[2] The erythematotelangiectatic subtype is analogous to Plewig–Kligman stage I disease, the papulopustular subtype to Plewig–Kligman stage II, and the phymatous subtype to Plewig–Kligman stage III. In contrast, the NRS classification maintains that progression of rosacea in stages (from one subtype to another) does not occur, but that subtypes may overlap in the same individual. A provisional grading system was also incorporated by the NRS Expert Committee to standardize the clinical assessment of rosacea.[3] Rosacea severity assessments must additionally include consideration of the psychological, social, and occupational impacts of this disorder and individual responsiveness to treatment.

EPIDEMIOLOGY

Although the prevalence of rosacea is unknown, the vast majority of cases occur in fair-skinned populations and it is common. However, persons of African and Asian descent may also develop rosacea.[2,4] The NRS has estimated that rosacea affects 14 million Americans. Rosacea occurs in both men and women, with onset typically after age 30.[1,5] However, children, adolescents, and young adults may develop rosacea.[6–8]

ETIOLOGY AND PATHOGENESIS

Because of prominent clinical variation among the rosacea subtypes, it has been hypothesized that etiologic and pathophysiologic differences may exist. Such differences may involve facial vascular reactivity, dermal connective tissue structure or composition, matrix composition, pilosebaceous structure, microbial colonization, or a combination of factors that alter the cutaneous response to rosacea trigger factors.[9] Rosacea is unmasked or induced by chronic, repeated trigger exposure, in particular by triggers of flushing that may

include hot or cold temperature, sunlight, wind, hot drinks, exercise, spicy food, alcohol, emotions, cosmetics, topical irritants, menopausal flushing, and medications that promote flushing.[10] Both neural and humoral mechanisms produce flush reactions that are visibly limited to the face. Facial prominence occurs because baseline facial blood flow is increased compared with other body sites,[11,12] and the facial cutaneous vasculature is more superficial and comprised of larger and more numerous vessels when compared with other sites.[13]

New investigations have demonstrated that exacerbation of the innate immune response occurs in rosacea.[14,15] Individuals with rosacea express high levels of cathelicidin peptides, and those peptides are processed atypically compared to normal skin. Cathelicidin peptides appear to enable stratum corneum tryptic enzyme (SCTE)-mediated inflammation in the epidermis.[14,15]

Dermal factors also play a role in rosacea pathogenesis. Matrix degeneration and endothelial damage have been demonstrated histologically in rosacea specimens.[16,17] Factors that contribute to matrix degeneration include inherent problems with vessel permeability and/or delayed clearance of inflammatory mediators and waste products. Alternatively, photodamaged connective tissue may alter vascular and lymphatic structure and support within the dermis.[18] In either case, chronic and persistent dermal inflammation may occur and ultimately manifest as erythema of the facial convexities in predisposed individuals.[19]

Sun damage is considered a contributing etiologic factor, and solar elastosis is a common background on which rosacea histologic features are superimposed. However, rosacea prevalence is not increased in outdoor workers, sun damage in nonfacial locations does not progress to a rosacea phenotype, and photoprovocation studies in rosacea patients have not demonstrated increased cutaneous sensitivity to acute ultraviolet exposure.[9,17,20,21]

It has long been debated whether oral and topical antimicrobial agents for rosacea exert their effects by anti-inflammatory or antimicrobial mechanisms. The concept of microbe-induced, follicle-based inflammation in rosacea is controversial. It is unclear whether commensal organisms such as *Propionibacterium acnes* and *Demodex folliculorum*, which reside in hair follicles and sebaceous glands, trigger folliculocentric inflammatory papules in rosacea patients.[9] Alternatively, a hypersensitivity reaction may be triggered by these microbes or by mite-associated bacteria such as *Bacillus oleronius*.[22] Compelling arguments in favor of a microbe-induced mechanism for papulopustular rosacea (PPR) include the observation that nonsteroidal anti-inflammatory drugs and corticosteroids do not clear rosacea papules and pustules as effectively as oral tetracyclines. Furthermore, benzoyl peroxide is quite effective for papules and pustules in rosacea patients who tolerate this drug.[10] It remains unclear whether clinical improvement of PPR requires a quantitative reduction of *P. acnes*.

CLINICAL FEATURES

Erythematotelangiectatic rosacea (ETR) is characterized by persistent facial erythema and flushing along with telangiectases, central face edema, burning and stinging, roughness or scaling, or any combination of these signs and symptoms (Fig. 81-1). Mild, moderate,

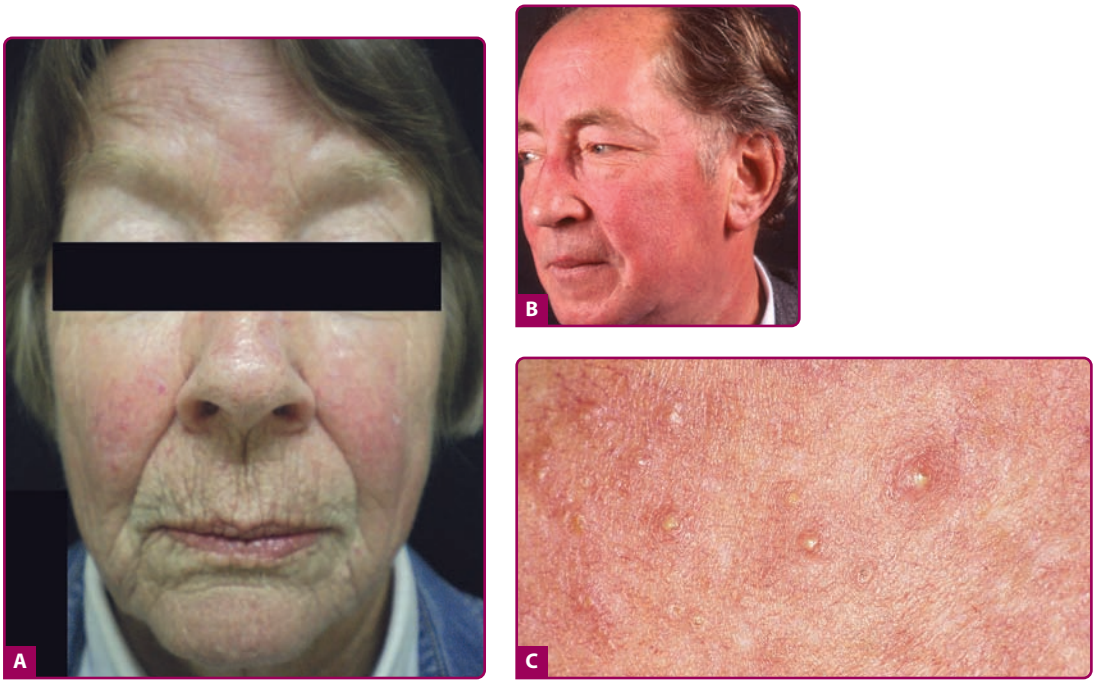

Figure 81-1 **A.** Erythematotelangiectatic subtype, mild. **B.** Erythematotelangiectatic subtype, severe. **C.** Close-up detailing the common occurrence of erythematotelangiectatic and papulopustular subtype overlap.



Figure 81-2 **A.** Papulopustular subtype. There is persistent erythema with papules and tiny pustules. Mild subtype. **B.** Severe form of the papulopustular subtype.

and severe subtypes are recognized. In contrast, PPR manifests as persistent, central-face erythema with papules and pustules that predominate in convex areas (Fig. 81-2).[9] Again, mild (see Fig. 81-2A), moderate, and severe forms (see Fig. 81-2B) are distinguished. Burning and stinging of the facial skin may occur in PPR, but occurs less commonly compared with ETR. Flushing is often less severe in PPR compared with ETR. In both subtypes, erythema spares the periorbital areas. Edema can be mild or severe. Severe edema may take on the plaque morphology of solid facial edema.[1,23] This occurs most often on the forehead and glabella and it less commonly affects the eyelids and upper cheeks.

Phymatous rosacea is characterized by patulous follicular orifices, thickened skin, nodularities, and irregular surface contours in convex areas (Fig. 81-3). Here also, mild, moderate, and severe subtypes are distinguished.



Figure 81-3 **A.** Phymatous subtype. Moderate subtype with patulous follicular orifices, thickened skin, and nodularities on nose and cheeks. **B.** Severe rhinophyma.

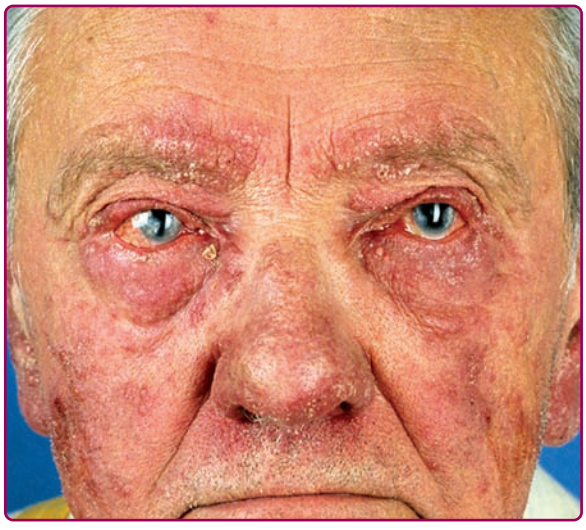

Figure 81-4 Ocular subtype, severe. This patient has blepharitis, conjunctivitis, and keratitis.

Phyma most often occurs on the nose (rhinophyma), but may also develop on the chin (gnathophyma), forehead (metophyma), eyelids (blepharophyma), and ears (otophyma).[24] Women with rosacea do not develop phyma, perhaps for hormonal reasons, but they can manifest sebaceous or glandular features characterized by thickened skin and large follicular orifices.[9]

Ocular rosacea may develop before cutaneous symptoms in up to 20% of affected individuals[25] (Fig. 81-4). In half of patients, ocular symptoms develop after skin symptoms. In a minority, skin and eye symptoms present simultaneously.[26] Ophthalmic rosacea severity does not coincide with cutaneous rosacea severity. Ocular involvement may manifest as blepharitis, conjunctivitis, iritis, scleritis, hypopyon, and keratitis; mild, moderate, and severe subtypes are recognized (see Fig. 81-4).[26] Blepharitis is the most common feature, characterized by eyelid margin erythema, scale, and crust, with the variable presence of chalazia and staphylococcal infections due to underlying meibomian gland dysfunction.[25] Photophobia, pain, burning, itching, and foreign body sensation may be part of the ocular symptom complex. In severe cases, rosacea keratitis may lead to vision loss.

Granulomatous rosacea is considered the only true rosacea variant.[1] Granuloma formation is a histologic feature of the condition; the clinical features of granulomatous rosacea include yellow–brown or red papules or nodules that are monomorphic and located on the cheeks and periorificial facial skin[27] (Fig. 81-5). Upon diascopy, these papules reveal apple-jelly-like change in color similar to sarcoidosis or lupus vulgaris. The background facial skin is otherwise normal. Other signs and symptoms of rosacea are not required to make a diagnosis of granulomatous rosacea.

HISTOPATHOLOGY

Rosacea is a clinical diagnosis; histology may be helpful when the facial distribution is atypical or when



Figure 81-5 Granulomatous rosacea. There are multiple monomorphic red and yellow brown papules that, on diascopy, show apple-jelly-like color.

granuloma formation is suspected. In ETR, a sparse, perivascular lymphohistiocytic infiltrate is accompanied by dermal edema and ectatic venules and lymphatics.[16] Severe elastosis may be present. Similar features are found in the papulopustular subtype, but the inflammatory infiltrate also surrounds hair follicles and sebaceous glands. Phymatous rosacea is characterized by prominent elastosis, fibrosis, dermal inflammation, sebaceous hyperplasia, and hypertrophy of sebaceous follicles.[16,28] Epithelialized tunnels undermine the hyperplastic tissue and are filled with inflammatory debris. *D. folliculorum* mites may be found in all types of rosacea within the follicular infundibula and sebaceous ducts.[28]

DIFFERENTIAL DIAGNOSIS

(Fig. 81-6)

Systemic diseases that must be differentiated from rosacea include polycythemia vera, connective tissue disorders (lupus erythematosus, dermatomyositis), carcinoid syndrome, mastocytosis, and neurologic causes of flushing. Neurologic causes include brain tumors, spinal cord lesions, orthostatic hypotension, migraine headaches, and Parkinson disease.[29] Unilateral auriculotemporal flushing may follow parotid gland injury or surgery.[30]

Medication-induced flushing has been associated with all vasodilators, calcium channel blockers, nicotinic acid (niacin), morphine, amyl and butyl nitrite, cholinergic drugs, bromocriptine, thyroid releasing hormone, tamoxifen, cyproterone acetate, systemic steroids, and cyclosporine.[29,31] The flush associated with nicotinic acid may be blocked with aspirin or indomethacin.[32] Disulfiram, chlorpropamide,

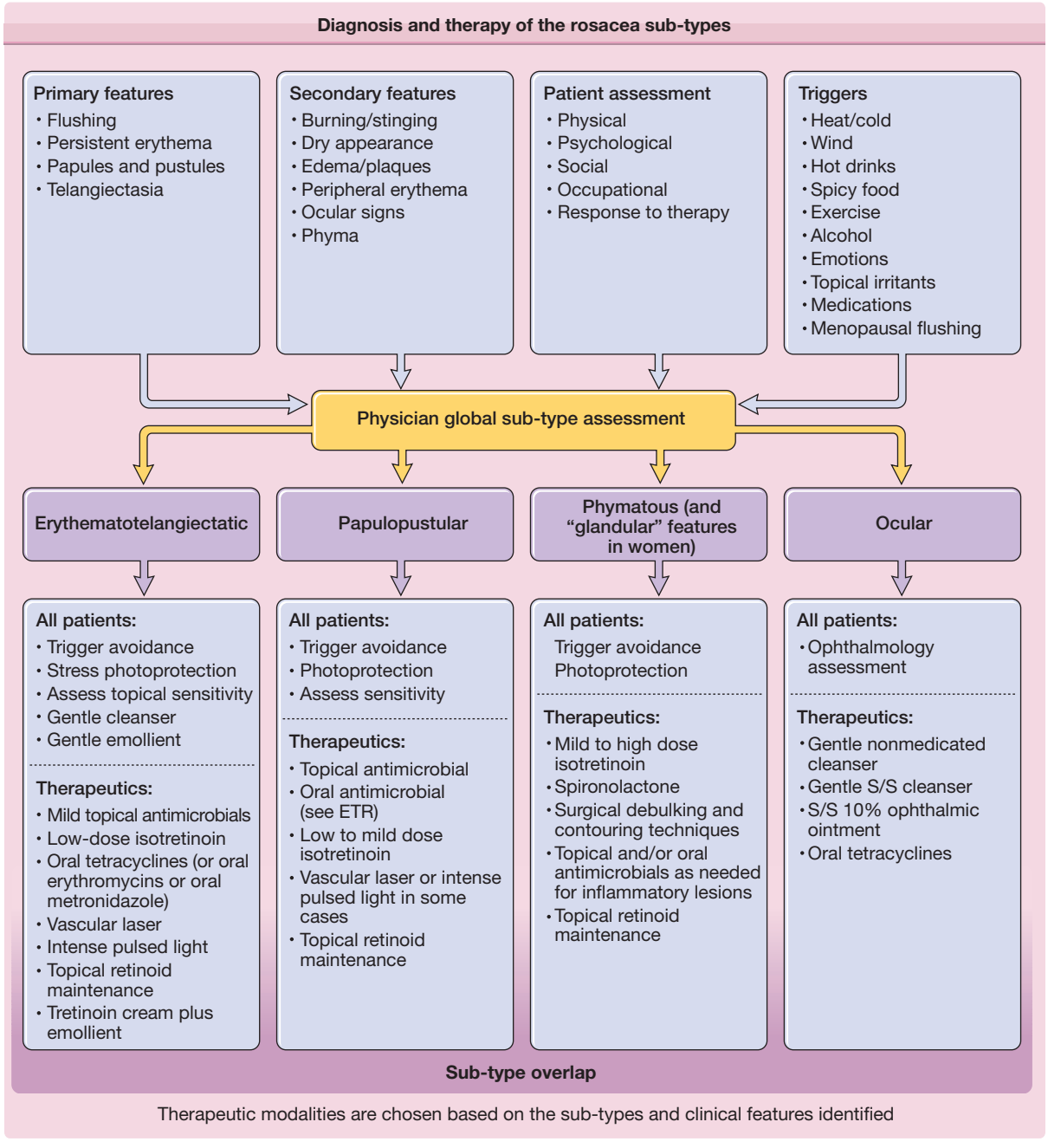

Figure 81-6 Approach to patient. Diagnosis and therapy of the rosacea subtypes. [a]Regimen recommendation based on author experience. ETR = erythematotelangiectatic; S/S = sodium sulfacetamide/sulfur.

metronidazole, phentolamine, and cephalosporins induce flushing when they are combined with alcohol.[29] Amiodarone has induced rosacea and multiple chalazia.[33] Food additives, including sulfites, sodium nitrite, nitrates, and monosodium glutamate, may also cause flushing.[29] Dumping syndrome following gastric surgery is characterized by flushing, sweats, tachycardia, and abdominal pain.

Cutaneous conditions that may mimic rosacea include topical steroid-induced acneiform eruption (formerly steroid-induced rosacea), acne vulgaris, perioral dermatitis, inflammatory keratosis pilaris, and chronic photodamage. In particular, acne vulgaris (see Chapter 80) and rosacea may coexist, although rosacea most often begins and reaches its peak incidence in the decades after acne declines. The primary differentiating feature between acne vulgaris and rosacea is the presence of open and closed comedones in acne alone.[2]

Rosacea fulminans, also known as *pyoderma faciale* and *rosacea conglobata*, occurs mainly in women in their 20s.[2,34,35] It is characterized by the sudden onset of confluent papules, pustules, nodules, and draining sinuses on the chin, cheeks, and forehead within a background of diffuse facial erythema. Rosacea fulminans has proved controversial in its classification and

was not included as a rosacea subtype or variant by the NRS Expert Committee.[1,2]

Perioral dermatitis (see Chapter 82) differs from rosacea in its facial distribution, signs, symptoms, and patient demographic. It is characterized by perioral, and sometimes periorbital, microvesicles, micropustules, scaling, and peeling. It affects younger women and also occurs in children. Central face erythema and inflammatory papules are not features of perioral dermatitis.[9] Therapy includes topical and oral antimicrobials. Perioral dermatitis is exacerbated by topical steroid use.

Steroid-induced acneiform eruption (see Chapter 80) can mimic PPR. With prolonged use of topical steroids on the face, monomorphic inflammatory papules may develop.[1] The treatment is discontinuation of the topical corticosteroid and initiation of an oral tetracycline, a topical antimicrobial, a topical calcineurin inhibitor, or a combination of these agents.[36,37] This regimen is generally continued for 1 to 3 months, and relapse does not tend to occur as long as topical steroids are not reintroduced.

In chronic photodamage (see Chapter 90), telangiectases and erythema are prominent features. However, unlike rosacea, actinic damage affects the periphery of the face and neck, the upper chest, and the posterior auricular skin. Hyperpigmentation and hypopigmentation are additional feature of sun damage not observed in rosacea. Chin involvement is both mental and submental in rosacea, while in chronic photodamage there is submental sparing.[9]

THERAPY

Before implementing therapy, rosacea trigger factors specific to each individual must be identified (see Fig. 81-6).[10] Patient education should stress trigger avoidance. Other key aspects of prevention include the daily application of gentle, broad-spectrum ultraviolet A and ultraviolet B sunscreen, hat use, avoidance of midday sun, and seeking shade. Physical sunscreens (zinc or titanium based) are best tolerated. Chemical sunscreens are better tolerated when barrier protective silicones (dimethicone, cyclomethicone) are included.[38]

Cosmetic intolerance and facial skin sensitivity are common features of the erythematotelangiectatic and papulopustular subtypes, perhaps due to inherent barrier dysfunction or facial vascular hyperreactivity.[39] As many as 75% of these individuals may experience burning, stinging, pruritus, or dryness and scaling in affected areas. Avoidance of harsh products and ingredients, including astringents, toners, menthol, camphor, and sodium lauryl sulfate, is important when sensitivity is present.[40] A soap-free cleanser applied with the fingers is best tolerated. A protective, gentle emollient should be applied once or twice daily before application of other products. Light liquid foundation makeup is the best choice for patients with sensitivity. Green-tinted makeup can be applied before foundation to further mask red areas.[40]

TOPICAL THERAPY

The topical agents approved by the US Food and Drug Administration (FDA) for rosacea include 15% azelaic acid gel, 0.75% and 1% metronidazole (available in cream, gel, and lotion vehicles), and 10% sodium sulfacetamide with 5% sulfur (available in cleanser, cream, suspension, and lotion vehicles). Each has proved effective for clearance of inflammatory papules and pustules and for erythema reduction when applied once daily.[41] Twice-daily application or combinations of these agents may be necessary when topical monotherapy is inadequate. Metronidazole and azelaic acid are pregnancy category B, whereas sodium sulfacetamide and sulfur is category C. Azelaic acid may be associated with initial tingling or burning that can disappear with continued use. Sodium sulfacetamide/sulfur medicated cleansers are better tolerated in sensitive patients compared with "leave-on" topical formulations that may increase burning and stinging.[42] Daily use of a barrier repair emollient is important in these patients.

Off-label topical formulations used for rosacea include benzoyl peroxide, clindamycin, erythromycin, calcineurin inhibitors, and topical retinoids.[10] Benzoyl peroxide is effective for clearance of papules and pustules, but should be avoided in sensitive patients.[10] Twice-daily topical clindamycin was more effective than oral tetracycline for the eradication of pustules in one series.[43] Tacrolimus ointment and pimecrolimus cream are most beneficial for topical, steroid-induced acneiform eruptions, but they may offer a useful therapeutic alternative in some patients with rosacea. Niacinamide-containing facial emollients may improve stratum corneum barrier function and hydration, and have shown benefit as adjunctive topical therapy in rosacea.[44]

"Manual" therapy should also be considered adjunctively in rosacea patients. Facial massage is performed in the direction of the lymphatic flow, according to Soybe's technique, beginning at a central location on the face (the glabella and nose) and pressing the fingers in a sweeping motion toward the inferolateral face (the mandibles and lateral neck).[17] This can help to mobilize edema and speeds clearance of dermal inflammation.

Tretinoin cream promotes connective tissue remodeling and minimizes dermal inflammation with long-term use.[45–47] Topical retinoids have demonstrated benefit for rosacea in small clinical series.[48,49] The clinical response to retinoids is delayed in the rosacea setting; generally 4 to 6 months of use is required to see significant effects. Because of their potential for irritation and concerns regarding promotion of angiogenesis, retinoids are often avoided for rosacea. However, their long-term use does not appear to promote the development of telangiectasia. Retinoids inhibit vascular endothelial growth factor production by cultured human skin keratinocytes via their anti-AP1 transcription factor activity.[50,51] The use of barrier emollients in conjunction with gradual introduction of topical retinoids allows them to be tolerated early on in treatment when retinoid dermatitis is a problem. Topical retinoids are especially useful for long-term maintenance in rosacea.

α-Adrenergic receptor agonist topical therapies (brimonidine, oxymetazoline) require further study

to characterize their efficacy and safety for ETR; however, their vasoconstrictive properties represent a novel approach for the treatment of telangiectasia and erythema.[52,53]

ORAL THERAPY

Topical management of rosacea is possible and generally preferable, especially when considering issues of antimicrobial resistance and the risks associated with long-term use of oral antibiotics. Furthermore, because rosacea is photoaggravated in many affected individuals, photosensitizing oral agents must be used with caution in this population. Oral antimicrobials in particular are useful short-term tools that can achieve rapid control of symptoms, but long-term topical maintenance should be the eventual therapeutic goal. In 2006, Oracea (doxycycline, USP, 40 mg) became the first oral therapy to be FDA-approved for rosacea.

For moderate to severe flushing or erythema, short-term oral therapy (2 to 4 months) with a tetracycline or isotretinoin may be useful for initial control. Tetracyclines achieve faster reduction of papules, pustules, and erythema when compared with isotretinoin, and since the 1950s, rosacea has been treated and maintained with both antimicrobial and subantimicrobial dosages of the tetracyclines.[54,55] Relapses occur in approximately one-fourth of patients after 1 month off tetracycline, and in over one-half of patients at 6 months off therapy.[55] Therefore, topical maintenance therapy is advised. Oral tetracyclines should be avoided in pregnant women and in those contemplating pregnancy.

In one small series, a significant reduction of facial cutaneous blood flow, measured by laser-Doppler, was achieved in isotretinoin-treated patients (30 mg daily for 10 weeks), whereas no significant change in facial blood flow was observed in those treated with 250 mg of tetracycline twice daily for 10 weeks.[56] Low-dose isotretinoin (10 to 40 mg daily or less than 0.5 mg/kg/day) can be effective and is better tolerated in rosacea patients.[57–59] Isotretinoin is teratogenic, and its use is strictly monitored in women of child-bearing potential.

Other oral agents used for rosacea include macrolides, metronidazole, antiandrogenic agents (oral contraceptives, spironolactone, and cyproterone acetate), β blockers, clonidine, naloxone, and selective serotonin reuptake inhibitors.[10,60–66] In patients with a history of acne vulgaris or overlap of acne vulgaris with rosacea, spironolactone in low doses (25 to 50 mg daily) and/or oral contraceptive pills may prove helpful. When high levels of *Demodex* exacerbate rosacea, or in cases refractory to tetracyclines, ivermectin may be a useful adjunctive therapy. It can be given as a single 0.2 mg/kg dose repeated once weekly or once monthly as needed for symptom control.[67]

LASER AND LIGHT THERAPY

(See Chapter 239)

Vascular lasers and intense pulsed light (IPL) therapy are useful alternatives to oral rosacea therapies; they may be used adjunctively with topical and oral rosacea regimens for faster and more complete symptom resolution. These nonablative modalities can eliminate telangiectasia, reduce or eliminate erythema, reduce papule and pustule counts, and they appear to extend the duration of remission. Their drawbacks are cost and side effects, which may include transient erythema, edema, purpura, blistering, dyschromia, burns, and, rarely, scarring.

Vascular lasers include short and long wavelength devices with a variety of pulse durations. Short wavelength lasers emit light that is selectively absorbed by oxyhemoglobin absorption peaks that occur at 541 nm and 577 nm. This allows for superficial vessel destruction without collateral tissue damage. Short wavelength lasers include the pulsed dye laser (585 nm or 595 nm), long pulsed dye laser (595 nm), the potassium-titanyl-phosphate laser (532 nm), and the diode-pumped frequency-doubled laser (532 nm).[68–70] Long wavelength vascular lasers can eradicate deeper and larger vessels by targeting the oxyhemoglobin spectral peaks at 800 nm and above 1,000 nm. These lasers include the long pulsed Alexandrite (755 nm), the diode laser (810 nm), and the neodynium:yttrium-aluminum-garnet laser (1,064 nm).[10]

The success and tolerability of laser therapy for rosacea have been improved by modified pulse duration parameters and by advances in epidermal cooling mechanisms. Longer pulse durations can deliver equivalent energy at a slower rate to heat vessels uniformly and gently, minimizing tissue trauma and purpura. Epidermal cooling gels and sprays prevent epidermal damage and can help to minimize pain, erythema, and edema and help to ensure safe delivery of laser energy. Generally, two to four laser treatments are required to achieve best outcomes for rosacea; purpuric treatment settings may eradicate telangiectasia more quickly. Multiple laser passes and pulse-stacking on larger vessels may improve treatment outcomes when subpurpuric settings are utilized.[71]

Unlike laser devices that emit a single wavelength, IPL (broadband light) emits a broad wavelength spectrum, ranging from approximately 550-nm visible light to 1,200-nm infrared light. Filters are used to establish the short end of the spectrum, which varies depending on the device. Fluence and pulse width also vary with the system used. IPL may cause transient erythema, transient hyperpigmentation, or hypopigmentation, and, rarely, purpura, burns, and scarring.[72] Epidermal cooling mechanisms are necessary to protect the epidermis. IPL effectively reduces facial erythema and telangiectases and is generally well tolerated.[72–74] Vascular lasers and IPL may also impact rosacea by inducing fibroblasts to increase dermal collagen production, perhaps achieving some degree of dermal remodeling and rejuvenation.[75–77]

TREATMENT OF PHYMA

Oral isotretinoin monotherapy is beneficial for early to moderate phymatous change.[24] Advanced phyma is treated with surgical therapy or the combination

of surgery followed by isotretinoin therapy. Surgical approaches to the reshaping of rhinophyma have included cold scalpel tangential excision, heated scalpel excision, electrocautery, dermabrasion, laser ablation, tangential excision combined with scissor sculpturing, radiofrequency electrosurgery, or a combination of these approaches.[24,78–83] Techniques that use partial thickness tangential excision and contouring with preservation of the underlying sebaceous glands allow spontaneous reepithelialization within 2 to 3 weeks, result in minimal scarring, and give an excellent aesthetic result with a low risk of recurrence.[83]

TREATMENT OF OCULAR ROSACEA

Ophthalmologic referral should be made for patients with ocular symptoms. For mild blepharitis, careful use of a gentle nonmedicated or sodium sulfacetamide/sulfur cleanser may be used once to twice daily as initial therapy. Sodium sulfacetamide 10% ophthalmic ointment is also effective for control of blepharitis. When topical management is inadequate, oral tetracyclines are generally effective.[7,25,26]

SUMMARY

To effectively treat rosacea, practitioners must recognize the clinical spectrum of rosacea phenotypes and what lies outside that spectrum. Subtyping of rosacea is a useful guide to establish a multimodality approach to therapy. Therapeutic success is achieved by inducing remission of signs and symptoms, and by minimizing and controlling relapses. Ultimately, early recognition of this disorder, some key behavioral modifications, and the combination of sunscreen and topical agents can achieve safe, effective, and long-term control of rosacea, while avoiding the risks of oral pharmaceuticals and the financial strain of laser and light therapies.

KEY REFERENCES

Full reference list available at www.DIGM8.com

DVD contains references and additional content

1. Wilkin J et al: Standard classification of rosacea: Report of the National Rosacea Society Expert Committee on the classification and staging of rosacea. *J Am Acad Dermatol* **46**:584, 2002
2. Plewig G, Kligman A: *Acne and Rosacea*, 3rd edition, Berlin, Springer-Verlag, 2000, p. 455
3. Wilkin J et al: Standard grading system for rosacea: Report of the National Rosacea Society Expert Committee on the classification and staging of rosacea. *J Am Acad Dermatol* **50**:907, 2004

10. Pelle M, Crawford G, James W: Rosacea: II. Therapy. *J Am Acad Dermatol* **51**:499, 2004

16. Marks R, Harcourt-Webster J: Histopathology of rosacea. *Arch Dermatol* **100**:683, 1969

83. Bogetti P et al: Surgical treatment of rhinophyma: A comparison of techniques. *Aesth Plast Surg* **26**:57, 2002

RECOMMENDED READING

Rosacea Symposium, ESDR 2009 and 2010. *J. invest. Dermatol Symp Proc* **15**(1):1-62, 2011

Chapter 82 :: Perioral Dermatitis

:: Leslie P. Lawley & Sareeta R.S. Parker

PERIORAL DERMATITIS AT A GLANCE

- Inflammatory skin disorder of young women and children.
- Small papules, vesicles, and pustules in perioral, periorbital, and/or perinasal distribution.
- Treatment: stop topical corticosteroid use; initiate 2- to 3-month course of systemic antibiotics (tetracycline family or erythromycin) and/or topical metronidazole.

Perioral dermatitis is characterized by small, discrete papules and pustules in a periorificial distribution, predominantly around the mouth. Because this condition can involve areas other than the perioral region, the term periorificial dermatitis has been proposed for this disorder.[1,2] The classic presentation is an eruption with overlapping features of an eczematous dermatitis and an acneiform eruption. Although initially described in young women of 15–25 years of age, perioral dermatitis is now recognized to occur in children as well.[3] A subset of perioral dermatitis shows granulomas when lesional skin is examined histologically. Several names have been used to describe this granulomatous form of perioral dermatitis, including granulomatous perioral dermatitis, facial Afro-Caribbean childhood eruption, and granulomatous periorificial dermatitis.[2,4,5]

HISTORICAL ASPECTS

The first reports describing perioral dermatitis appeared in the 1950s; various names were given to the condition, however, there was a lack of defining clinical criteria. In 1957, Frumess and Lewis described a "light sensitive seborrheid" that is generally accepted as the first account of what was later termed *perioral dermatitis* by Mihan and Ayres in 1964.[6,7] Later descriptions

by Cochran and Thomson[8] and Wilkinson, Kirton, and Wilkinson[9] further defined this disorder, and more recently the term *periorificial dermatitis* has been proposed.[2] The condition was first described in children in the late 1960s.

EPIDEMIOLOGY

Adult perioral dermatitis predominantly affects women. Pediatric perioral dermatitis may have a slight female preponderance and is seen equally among those of different races.[1,10] The granulomatous form of perioral dermatitis has been reported mostly in children of prepubertal age.[5] Perioral dermatitis can occur as early as 6 months.[1] An increased prevalence in African-American children has been reported, but more recent reviews do not support this finding.[2,11]

ETIOLOGY AND PATHOGENESIS

A relationship of perioral dermatitis to the misuse of topical corticosteroids (fluorinated or nonfluorinated) has been well established.[12] Patients often reveal a history of an acute steroid-responsive eruption around the mouth, nose, and/or eyes that worsens when the topical corticosteroid is discontinued. Dependency on the use of the topical corticosteroid may develop as the patient repeatedly treats the recurrent eruption. In other cases, the condition may worsen with the application of topical corticosteroids, especially in the granulomatous variant of perioral dermatitis, which usually occurs in prepubertal children.[2] Perioral dermatitis has been reported in patients using inhaled corticosteroids[13] and with inadvertent facial exposure to topical corticosteroids.[14] However, perioral dermatitis is not always linked to topical corticosteroids.[9] The exact cause of perioral dermatitis in these other cases is unclear. Although isolated reports of affected siblings exist,[2,15] no clear genetic predisposition has been noted, nor have specific environmental exposures been consistently implicated. Of note, the disease is predominant in young women, yet no link to hormonal causes has been found. The initial reports of photosensitivity by Frumess and Lewis[6] were not further substantiated, nor were theories of microbiologic causes such as infection with *Candida*, fusiform bacteria, or *Demodex folliculorum*.[16] Cases of allergic contact with fluorides or other components in toothpaste and dentifrices have also been reported, however, use of these agents after clearing of the perioral dermatitis without further eruption has also been described. Patch testing in a small series of patients led to few positive results, and these were not considered relevant.[9]

In the past, authors have considered the relationship of perioral dermatitis to acne rosacea, however, the clinical features are distinct (see Section "Differential Diagnosis"). In perioral dermatitis, the histopathologic findings are variable and are dependent on the form of perioral dermatitis. In a histopathologic review of 26 patients with the nongranulomatous form, follicular spongiosis and eczematous changes were prominent features, suggesting that perioral dermatitis is distinct from rosacea.[17] A lymphohistiocytic infiltrate and occasional plasma cells were noted in a perifollicular and perivascular distribution in this series. In granulomatous perioral dermatitis, histopathology demonstrates follicular hyperkeratosis, edema and vasodilatation in the papillary dermis, perivascular and parafollicular infiltrates of lymphocytes, histiocytes, and polymorphonuclear leukocytes with occasional epithelioid granulomas and giant cells, similar to the histopathologic changes in acne rosacea.[5,18]



Figure 82-1 Typical perioral dermatitis. The eruption is confined to the nasolabial folds and the skin of the chin.

CLINICAL FINDINGS

The primary lesions of perioral dermatitis are discrete and grouped erythematous papules, vesicles, and pustules (Figs. 82-1 and 82-2). The lesions are often symmetric but may be unilateral and appear in the perioral, perinasal, and/or periocular regions (Figs. 82-2 and 82-3 and eFigs. 82-3.1 and 82-3.2 in online edition). In a retrospective review of 79 children with perioral



Figure 82-2 Perioral (granulomatous periorificial) dermatitis. This child shows the typical small papules studding the area around the mouth and eyes.



Figure 82-3 Perioral dermatitis, granulomatous form: child with densely aggregated periorificial erythematous and edematous papules.

dermatitis, isolated perioral involvement was present in only 39%, and in rare cases nonperioral regions were involved exclusively.[1] Background erythema and/or scale may be present. A distinct 5-mm clear zone at the vermilion edge is well described (Fig. 82-2). The granulomatous variant of perioral dermatitis presents with small flesh-colored, erythematous, or yellow–brown papules, some with confluence, and shares the distribution of perioral dermatitis in adults (Fig. 82-3). In addition, lesions have been reported to appear on the ears, neck, scalp, trunk, labia majora, and extremities.[1,11]

Occasionally, an associated burning sensation or itching is reported, and intolerance to moisturizers and other topical products is described.[1,9] In a few cases of granulomatous perioral dermatitis, an associated blepharitis or conjunctivitis has been reported.[11] Systemic findings and regional lymphadenopathy are absent.

DIFFERENTIAL DIAGNOSIS

(Box 82-1)

The differential diagnosis of nongranulomatous and granulomatous perioral dermatitis is outlined in Box 82-1.[19–24] Both forms of perioral dermatitis lack systemic symptoms and a thorough history and physical examination are generally sufficient to establish the diagnosis. However, in some cases histopathological evaluation of lesional skin, chest radiography, and/or

BOX 82-1 DIFFERENTIAL DIAGNOSIS OF PERIORAL DERMATITIS

DISORDER	DISTINGUISHING CLINICAL FEATURES
Nongranulomatous Perioral Dermatitis	
Most Likely	
Rosacea	Involves the nose, facial convexities; persistent erythema, and telangiectasias
Seborrheic dermatitis	Accentuated at nasolabial folds; scale
Allergic contact dermatitis	Consider musical instruments, toothpaste/dentrifices, latex gloves, dental appliances, and lipstick
Irritant contact dermatitis	Common in children (from saliva, foods)
Lip-licking cheilitis	Common in children; scale, well demarcated border
Consider	
Acne vulgaris	May involve chest and back; comedones
Gram-negative folliculitis	Predominance of pustules
Demodex folliculorum infestation	Pustules, pruritus; often immunocompromised host[19]
Acrodermatitis enteropathica	Infants with acral and/or diaper dermatitis; zinc deficiency
Tinea facei	KOH positive for hyphal elements
Psoriasis	Involvement of other cutaneous sites common
Impetigo	Honey-colored crusts
Eosinophilic folliculitis-HIV related	Immunocompromised host
Granulomatous Perioral Dermatitis	
Most Likely	
Granulomatous rosacea	Flushing, telangiectases, pustules, and edema; similar histopathologic features
Consider	
Familial juvenile systemic granulomatosis (Blau syndrome)	Synovial cysts, uveitis, granulomatous arthritis, camptodactyly, papular rash
Fungal or mycobacterial infection	
Lupus miliaris disseminatus faciei	
Benign cephalic histiocytosis	Diffuse distribution on the face
Sarcoidosis	Rare in children; reported cases may represent Blau syndrome
Zirconium dermatitis	May involve axillae

BOX 82-2 TREATMENT FOR PERIORAL DERMATITIS

	TOPICAL	DOSE	SYSTEMIC	ADULT DOSE
First line	Metronidazole	Apply bid	Tetracycline	250–500 mg p.o. bid
			Doxycycline	50–100 mg p.o. bid
			Minocycline	50–100 mg p.o. bid
Second line	Erythromycin or clindamycin	Apply bid	Erythromycin	400 mg p.o. tid
				Or
	Sulfur preparations	Apply bid		30–50 mg/kg/day p.o.
	Azelaic acid	Apply bid		divided tid[a]

[a]Pediatric dose

ophthalmologic examination may be necessary, particularly with the granulomatous variant.[11] Sarcoidosis in young children is rare and often accompanied by systemic signs and symptoms such as weight loss, fatigue, joint pains, lymphadenopathy, and uveitis.[5,25] At least some of the reported cases of sarcoidosis in young children represent Blau syndrome with underlying mutations in *CARD15/NOD2* (see Chapter 134).[11,26]

COMPLICATIONS

The majority of cases of perioral dermatitis and granulomatous perioral dermatitis resolve without sequelae or relapse. However, there are rare reports of scarring.[5]

PROGNOSIS AND CLINICAL COURSE

Perioral dermatitis is usually a self-limited disorder that evolves over a few weeks and resolves over months or rarely years. The condition may take on a waxing and waning course, often with a tendency to progress (granulomatous form). If treated with topical corticosteroids alone, recurrent episodes on withdrawal of therapy or with continuing therapy are typical. With appropriate intervention the condition resolves with rare recurrences.

TREATMENT

(Box 82-2)

If topical corticosteroids are being used, they should be discontinued. If fluorinated corticosteroids are being applied, initial substitution with a low-potency hydrocortisone cream may minimize a flare of the dermatitis. Patients should be educated about the link between application of topical corticosteroids and exacerbation of the dermatitis.

In most cases, effective therapy is oral tetracycline, doxycycline, or minocycline, for a course of 8 to 10 weeks, with a taper over the last 2 to 4 weeks. In children under 8 years of age, nursing mothers, or tetracycline-allergic patients, oral erythromycin is recommended. Not uncommonly, patients require continued low-dose systemic antibiotic therapy for months or sometimes years to maintain control. In recalcitrant cases, isotretinoin may be considered.[27]

Topical antibiotic therapy, most commonly with topical metronidazole, should be initiated concurrently with the systemic antibiotic. For milder cases, topical metronidazole alone may suffice.[1,28,29] In a retrospective review of 79 children, best outcomes were associated with the use of topical metronidazole, oral erythromycin, or both.[1] Response is generally noted within 2–3 months. Other options include topical clindamycin or erythromycin, topical sulfur-based preparations, and topical azelaic acid.[30] Reports of successful use of topical calcineurin inhibitors exist, particularly in adults; however, caution is advised given the occasional reports of granulomatous eruptions after the use of these agents.[31–35] Ointment preparations should generally be avoided in the treatment of perioral dermatitis. Photodynamic therapy with topical 5-aminolevulinic acid has shown promise for treating perioral dermatitis in one report.[36]

PREVENTION

The only widely accepted factor that may predispose to the development of perioral dermatitis is the use of topical corticosteroids. Avoiding facial skin exposure to these products may prevent the eruption in some cases.

KEY REFERENCES

Full reference list available at www.DIGM8.com

DVD contains references and additional content

1. Nguyen V, Eichenfield LF: Periorificial dermatitis in children and adolescents. *J Am Acad Dermatol* **55**:781, 2006
3. Manders SM, Lucky AW: Perioral dermatitis in childhood. *J Am Acad Dermatol* **27**:688, 1992
5. Frieden IJ et al: Granulomatous perioral dermatitis in children. *Arch Dermatol* **125**:369, 1989
9. Wilkinson DS, Kirton V, Wilkinson JD: Perioral dermatitis: A 12-year review. *Br J Dermatol* **101**:245, 1979
12. Weston WL, Morelli JG: Identical twins with perioral dermatitis. *Pediatr Dermatol* **15**:144, 1998

SECTION 14

Disorders of the Eccrine and Apocrine Glands

Chapter 83 :: Biology of Eccrine and Apocrine Glands

:: Theodora M. Mauro

SWEATING AT A GLANCE

- Humans have 2–24 million sweat glands.
- Up to 10 L/day of sweat is produced by acclimatized individuals.
- The three eccrine cell types are (1) clear (secretory), (2) dark (mucoid), and (3) myoepithelial (contractile).
- Hypothalamic temperature is the strongest stimulus for sweating.
- Acetylcholine is the major stimulus secreted by sympathetic nerves.
- Botulinum toxin inhibits sweating by preventing acetylcholine release.
- Oxidative metabolism of glucose is a major source of eccrine gland adenosine triphosphate.
- Ductal reabsorption conserves NaCl.
- In individuals with cystic fibrosis, mutated chloride channels increase NaCl loss.
- Bacteria are necessary for apocrine odor.
- Odiferous precursors secretion is controlled by the MRP8 encoded by *ABCC11*.
- Adrenergic stimulation controls apocrine gland secretion.

In humans, sweat glands generally are found as two types, (1) eccrine and (2) apocrine. Eccrine-gland sweat allows the body to control its internal temperature in response to thermal stress. Apocrine gland function is more obscure but likely includes pheromone production.

DEVELOPMENT OF ECCRINE SWEAT GLANDS

Humans have approximately 2–4 million sweat glands.[1] Sweat glands are found over nearly the entire body surface, and are especially dense on the palms, soles, forehead, and upper limbs.[2] Analgen of eccrine sweat glands first appear in the 3.5-month-old fetus on the palms and soles (see Chapter 7), then develop in the axillary skin in the fifth fetal month, and finally develop over the entire body by the sixth fetal month.[3] The analog of the eccrine sweat gland, which developed from the epidermal ridge, is double layered, and develops a lumen between the layers between the fourth and eighth fetal months. By the eighth fetal month eccrine secretory cells resemble those of the adult; by the ninth fetal month myoepithelial cells form.

ANATOMY AND FUNCTION OF ECCRINE SWEAT GLANDS

Two distinct segments, the secretory coil and the duct, form the eccrine sweat gland. The secretory coil secretes an isotonic sweat, while the duct resorbs Na^+ and Cl^-, thus producing sweat to cool the body while preserving Na^+ and Cl^- body stores.

SECRETORY COIL

The secretory coil contains three distinct cell types: (1) clear (secretory), (2) dark (mucoid), and (3) myoepithelial.[4] The clear and dark cells occur in approximately equal numbers but differ in their distribution (Fig. 83-1). While the dark cells border the apical (luminal) surfaces, the clear cells rest either directly on the basement membrane or on the on the myoepithelial cells. The clear cells directly access the lumen by forming intercellular canaliculi (Fig. 83-2). Spindle shaped contractile myoepithelial cells lie on the basement membrane and abut the clear cells. The adult secretory coil is approximately 2–5-mm long, and approximately 30–50 μm in diameter. Heat accumulation results in larger sweat glands and ducts, and their dimensions,

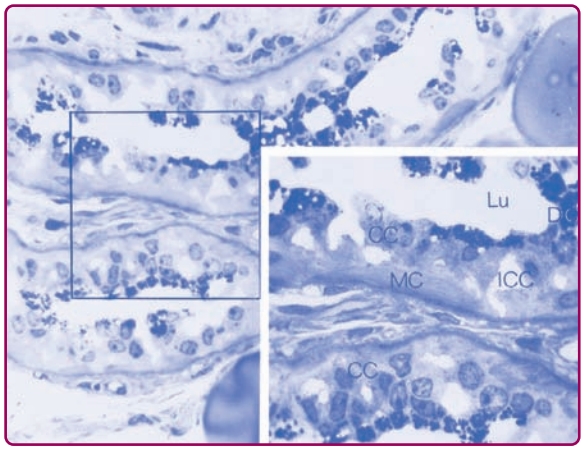

Figure 83-1 Light photomicrograph of the secretory coil of an acetylcholine-stimulated monkey palm eccrine sweat gland. A 1-m thick section was cut from an Epon-embedded specimen and stained with methylene blue. Inset: A higher-power view of the area marked by the square. CC = clear cell; DC = dark cell; ICC = intercellular canaliculi; Lu = lumen; MC = myoepithelial cell.

in turn, correlate with enhanced sweat output.[5] Clear cells contain abundant mitochondria and an autofluorescent body, called the lipofuscin granule, in the cytoplasm. The clear cell plasma membrane forms many villi. The clear cell secretes water and electrolytes. Dark cells have a smooth cell surface and contain abundant dark cell granules.[4] The function of dark cells are unknown. Myoepithelial cells contain actin filaments[6] and are contractile,[7,8] producing pulsatile sweat.

DUCT

The eccrine sweat duct consists of an outer ring of peripheral or basal cells and an inner ring of luminal

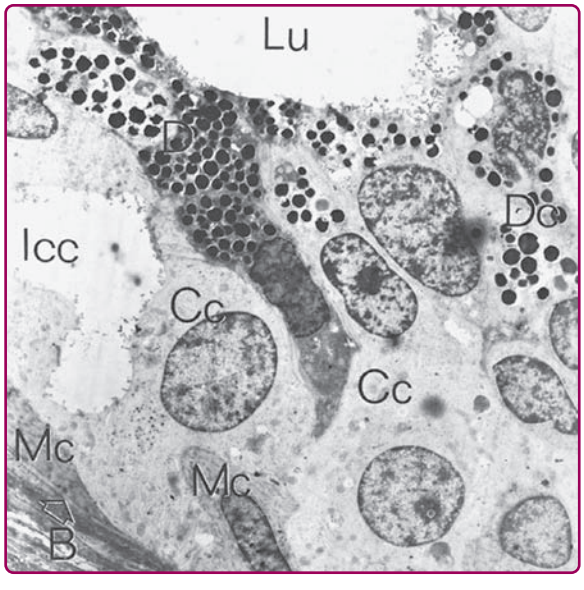

Figure 83-2 Electron micrograph of the secretory coil of a human eccrine sweat gland. B with arrow = basal lamina; other symbols are the same as in Fig. 83-1.

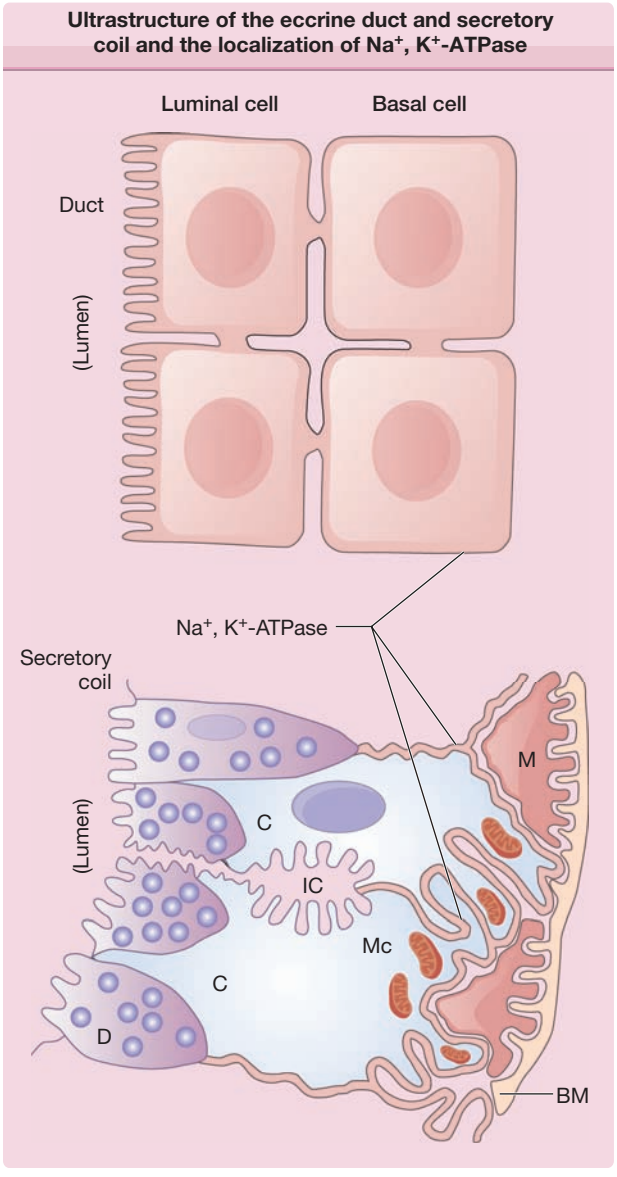

Figure 83-3 Drawing of the ultrastructure of the eccrine duct and secretory coil and the localization of Na^+, K^+-adenosine triphosphatase (ATPase). The thick lines indicate the localization of Na^+, K^+-ATPase. BM = basement membrane; C = clear cell; D = dark cells; IC = intercellular canaliculi; M = myoepithelial cell; Mc = mitochondria.

or cuticular cells. It seems that the proximal (coiled) duct is functionally more active than the distal straight portion in pumping Na^+ for ductal Na^+ reabsorption, because Na^+, K^+-adenosine triphosphatase (ATPase) activity and the number of mitochondria are higher in the proximal portion (Fig. 83-3).[4,7,9,10] In contrast, the luminal ductal cells have fewer mitochondria, much less Na^+, K^+-ATPase activity, and a dense layer of tonofilaments near the luminal membrane, which is often referred to as the *cuticular border*. The cuticular border provides structural resilience to the ductal lumen, which may dilate whenever ductal flow of sweat is blocked. The entire structural organization of the duct is well designed for the most efficient Na^+ absorptive

function. The luminal membrane serves as the absorptive surface by accommodating both Na^+ and Cl^- channels, and the basal ductal cells serve in Na^+ pumping by providing maximally expanded Na^+ pump sites and efficient energy metabolism. The lumen and the duct contain β-defensin, an antimicrobial, cysteine-rich, low-molecular-weight peptide.[11,12] In the epidermis, the duct spirals tightly upon itself.

NEURAL CONTROL OF ECCRINE SWEATING

The preoptic hypothalamic area plays an essential role in regulating body temperature: local heating of the preoptic hypothalamic tissue activates generalized sweating, vasodilatation, and rapid breathing, whereas local cooling of the preoptic area causes generalized vasoconstriction and shivering. The elevation of hypothalamic temperature associated with an increase in body temperature provides the strongest stimulus for thermoregulatory sweating responses, while cutaneous temperature exerts a weaker influence on the rate of sweating.[13] On a degree-to-degree basis, an increase in internal temperature is about nine times more efficient than an increase in mean skin temperature in stimulating the sweat center. The local temperature effect is speculated to be due to increased release of periglandular neurotransmitters.

The sweating in menopausal "hot flashes" reinforces the concept of a central hypothalamic mechanism for thermal sweating, but also shows that the response of individuals to the same changes in core temperature can vary. Although hormonal factors influence sweating during menopause, excessive sweating does not correlate simply with hormonal levels. Instead, menopausal hot flashes seem to be due to a hypersensitive brain response (particularly the hypothalamus, but perhaps the insula, anterior cingulate, amygdala, and primary somatosensory cortex as well). In asymptomatic menopausal women and premenopausal women, the core temperature can change up to 0.4°C (33°F) without eliciting a response. In symptomatic postmenopausal women, changes as small as 0.1°C (32°F) trigger peripheral vasodilation and sweating. Why the brain is hypersensitive to small changes in core temperature is poorly understood, but increased levels of brain norepinephrine appear to influence the response to small changes in core temperature through their action on α_2-adrenergic receptors in the brain; higher levels of the norepinephrine metabolite 3-methoxy-4-hydroxyphenylglycol have also been found in symptomatic menopausal women than in asymptomatic women. Decreased norepinephrine release is postulated as the mechanism by which clonidine relieves hot flashes in symptomatic women. Decreased core temperature may be the reason that women with decreased body mass index tend to have fewer symptoms, even though their estrogen levels probably are lower than those in women with increased body mass index. Levels of estrogen, luteinizing hormone, and β-endorphins also were originally thought to influence hot flashes, but later studies have suggested no association.[14]

INNERVATION. Efferent nerve fibers originating from the hypothalamic preoptic sweat center descend through the ipsilateral brainstem and medulla and synapse in the intermediolateral cell columns of the spinal cord without crossing (although sympathetic vasomotor fibers may partially cross).[15] The myelinated axons rising from the intermediolateral horn of the spinal cord (preganglionic fibers) pass out in the anterior roots to reach (through white ramus communicans) the sympathetic chain and synapse. Unmyelinated postganglionic sympathetic class C fibers arising from sympathetic ganglia join the major peripheral nerves and end around the sweat gland. The supply to the skin of the upper limb is commonly from T2 to T8. The face and the eyelids are supplied by T1 to T4, so that resection of T2 for the treatment of palmar hyperhidrosis is likely to cause Horner syndrome. The trunk is supplied by T4 to T12 and the lower limbs by T10 to L2. Unlike the sensory innervation, a significant overlap of innervation occurs in the sympathetic dermatome because a single preganglionic fiber can synapse with several postganglionic fibers.

The major neurotransmitter released from the periglandular nerve endings is acetylcholine (Ach), an exception to the general rule of sympathetic innervation, in which noradrenaline is the peripheral neurotransmitter. In addition to ACh, adenosine triphosphate (ATP), catecholamine, vasoactive intestinal peptide, atrial natriuretic peptide, calcitonin gene-related peptide, and galanin have been localized in the periglandular nerves. The significance of these peptides or neurotransmitters in relation to sweat gland function is not fully understood.

Botulinum toxin interferes with ACh release. Its heavy chain binds the neurotoxin selectively to the cholinergic terminal and the light chain acts within the cells to prevent ACh release. Type A toxin cleaves sensory nerve action potential-25, a 25-kDa synaptosomal-associated protein; the type B light chain cleaves vesicle-associated membrane protein (also called *synaptobrevin*). Botulinum toxins are used for symptomatic relief of hyperhidrosis.[16] A more detailed description can be found in Chapters 84 and 255.

DENERVATION. In humans, the sweating response to intradermal injection of nicotine or ACh disappears within a few weeks after denervation of the *postganglionic* fibers,[17] while the sweating response to heat ceases immediately after resection of the nerves. In contrast, after denervation of *preganglionic* fibers (due to spinal cord injuries or neuropathies), pharmacologic responsiveness of the sweat glands is maintained from several months to 2 years, even though their thermally induced sweating is no longer present.[18]

EMOTIONAL SWEATING

Sweating induced by emotional stress (emotional sweating) can occur over the whole skin surface in some individuals, but it is usually confined to the palms, soles, axillae, and the forehead. Emotional sweating on the palms and soles ceases during sleep,

whereas thermal sweating occurs even during sleep if the body temperature rises. Because both types of sweating can be inhibited by atropine, emotional sweating is cholinergically medicated.

PHARMACOLOGY OF THE ECCRINE SWEAT GLAND AND SWEATING RATE

Sweat glands respond to cholinergic agents, α- and β-adrenergic stimulants, and other periglandular neurotransmitters, such as vasoactive intestinal peptide and ATP. Periglandular ACh is the major stimulant of sweat secretion, and its periglandular concentration determines the sweat rate in humans. When dissociated clear cells are stimulated in vitro by cholinergic agents, they lose K^+ & Cl^-, increase intracellular Ca^{2+}, and shrink, mimicking actions seen in vivo.[19] Striking individual differences exist in the degree of sweating in response to a given thermal or physical stress. In general, males perspire more profusely than females.[20] The sweat rate in a given area of the skin is determined by the number of active glands and the average sweat rate per gland. The maximal sweat rate per gland varies from 2 to 20 nL/min^2. Sweat rate increases during acclimatization, but the morphologic and pharmacologic bases of the individual and regional differences in sweating rate during acclimatization are still poorly understood (Fig. 83-4). In thermally induced sweating, the sweat rate can be mathematically related to the body and skin temperatures in a given subject only in the low sweat rate range. Cholinergic stimulation yields a five to ten times higher sweating rate than does β-adrenergic stimulation. α-Adrenergic stimulation (by phenylephrine) is no more potent than isoproterenol (ISO) (a β-adrenergic agonist) in humans in vivo.[21] Whereas cholinergic sweating begins immediately on intradermal injection, β-adrenergic sweating requires a latent period of from 1 to 2 minutes, which suggests that the intracellular mechanism of sweat induction may be different for methacholine and for ISO. Because the sweat rate in response to adrenergic agents is rather low, it may be reasonable to surmise that adrenergic stimulation in periglandular nerves may be involved in the regulation of sweat gland function but not in the induction of sweat secretion. One consequence of dual cholinergic and adrenergic innervation is to maximize tissue accumulation of cyclic adenosine monophosphate, which may be instrumental in stimulating the synthesis of sweat and glandular hypertrophy of the sweat gland. The possibility that periglandular catecholamine is directly involved in emotional sweating or sweating associated with pheochromocytoma[22] may be ruled out, because these sweating responses can be blocked by anticholinergic agents.

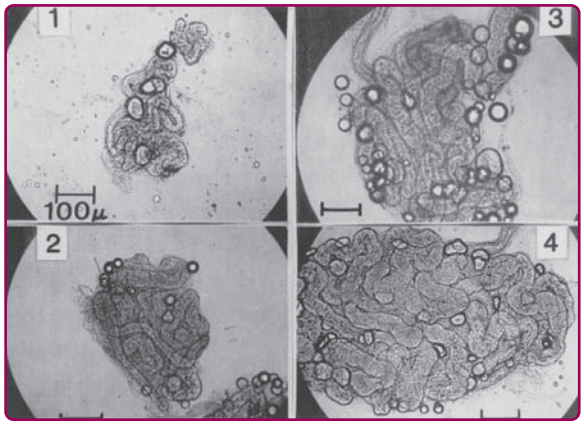

Figure 83-4 Individual variation in the size of the sweat gland in four male adults, aged 22–28 years. Sweat glands were isolated from skin biopsy specimens obtained from the upper back behind the axilla. Subject 1 is a sedentary man who does not exercise regularly, whereas subject 4 is a well-acclimatized athletic individual.

PHARMACOLOGY AND FUNCTION OF ECCRINE MYOEPITHELIUM

The periodicity of sweat secretion in vivo is caused by the periodicity of central nerve impulse discharges, which occur synchronously with vasomotor tonus waves. Myoepithelial contraction occurs with cholinergic stimulation, but neither α- nor β-adrenergic agents induce tubular contraction.[23] While the myoepithelium may contribute to sweat production via pulsatile contractions, it also seems to provide structural support for the secretory epithelium, especially under conditions in which stagnation of sweat flow (due to ductal blockade) results in an increase in luminal hydrostatic pressure.[8]

ENERGY METABOLISM

Sweat secretion is mediated by the energy (i.e., ATP)-dependent active transport of ions, so a continuous supply of metabolic energy is mandatory for sustained sweat secretion. Endogenous glycogen stored in the clear cells can sustain sweat secretion for less than 10 minutes; thus the sweat gland must depend almost exclusively on exogenous substrates for its energy metabolism. Mannose, lactate, and pyruvate are used nearly as readily as glucose; other hexoses, fatty acids, ketone bodies, intermediates of the tricarboxylic acid cycle, and amino acids are either very poorly used or not used as substrates. The physiologic significance of lactate or pyruvate utilization by the sweat gland is not yet clear. However, because the plasma level of glucose (5.5 mM) is much higher than that of lactate (1–2 mM) or pyruvate (less than 1 mM), glucose may play a major role in sweat secretion. Oxidative metabolism of glucose is favored as the major route of ATP formation for secretory activity.[23]

COMPOSITION OF HUMAN ECCRINE SWEAT

INORGANIC IONS. Sweat is formed in two steps: (1) secretion of a primary fluid containing nearly isotonic NaCl concentrations by the secretory coil, and

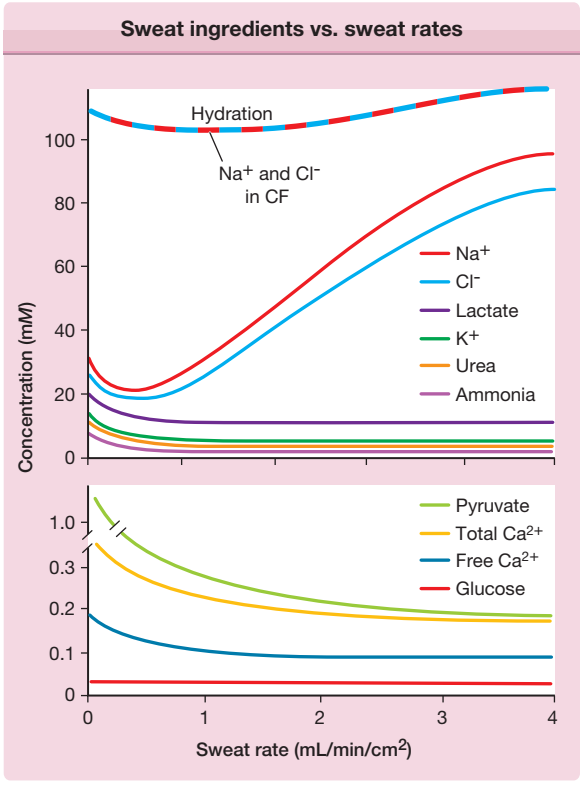

Figure 83-5 Relationship between the concentration of sweat ingredients and the sweat rate in thermally induced human sweat in normal individuals and in persons with cystic fibrosis (CF).

(2) reabsorption of NaCl from the primary fluid by the duct. Although a number of factors affect ductal NaCl absorption, the sweat rate (and thus the transit time of sweat) has the most important influence on final NaCl concentration. Sweat NaCl concentration increases with increasing sweat rate to plateau at around 100 mM (Fig. 83-5). Potassium (K^+) concentration in sweat is relatively constant. It ranges from 5 to 10 mM, which is slightly higher than plasma K^+ concentration. HCO_3^- concentration in the primary sweat fluid is approximately 10 mM, but that of final sweat is less than 1 mM, which indicates that HCO_3^- is reabsorbed by the duct, presumably accompanied by ductal acidification.[24] Sweat NaCl concentration is increased in individuals with cystic fibrosis. Aquagenic wrinkling of the palms (whitened, wrinkling, and papillation of the palms after brief water exposure) is seen more frequently in carriers and patients with cystic fibrosis (see Chapter 84).

LACTATE. The concentration of lactate in sweat usually depends on the sweat rate. At low sweat rates, lactate concentration is as high as 30–40 mM, but it rapidly drops to a plateau at around 10–15 mM as the sweat rate increases. Acclimatization is known to lower sweat lactate concentrations, whereas arterial occlusion rapidly raises sweat NaCl and lactate concentrations and reduces the sweat rate.[23] Sweat lactate is probably produced by glycolysis of glucose by the secretory cells.[25]

UREA. Urea in sweat is derived mostly from serum urea.[26] Sweat urea content is usually expressed as a sweat–plasma ratio (S/P urea). S/P urea is high (2–4) at a low sweat rate range but approaches a plateau at 1.2–1.5 as the sweat rate increases.

AMMONIA AND AMINO ACIDS. Ammonia concentration in sweat is 0.5–8 mM,[27] which is 20–50 times higher than the plasma ammonia level. The concentration of sweat ammonia is inversely related to the sweat rate and sweat pH. Free amino acids are present in human sweat,[27] although it is not clear what proportion of measured amino acids derive from epidermal contamination.

PROTEINS INCLUDING PROTEASES. The concentration of sweat protein in the least contaminated, thermally induced sweat is approximately 20 mg/dL, with the major portion being low-molecular-weight proteins (i.e., MW <10,000). Because sweat samples collected by simple scraping, and even those collected with a plastic bag, can be massively contaminated with plasma or epidermal proteins, previous reports on the presence of α- and γ-globulins, transferrin, ceruloplasmin, orosomucoid, and albumin[28,29] and immunoglobulin E must be carefully reexamined. The sweat samples collected over an oil barrier placed on the skin (the least-contaminated sweat) contain no or trace of γ-globulin and a very small amount of albumin. Yokozeki et al[30] also reported the presence of cysteine proteinases and their endogenous inhibitors in sweat and the sweat gland. Dermcidin is an antimicrobial peptide produced and secreted in sweat.[31] Other organic compounds reported to be present in sweat include histamine,[32] prostaglandin,[33] and vitamin K-like substances.[34] Sweat also contains traces of pyruvate and glucose. Sweat glucose increases concurrently with a rise in plasma glucose level. Some orally ingested drugs, including griseofulvin,[35] ketoconazole,[36] amphetamines,[37] and various chemotherapeutic agents,[38] are secreted in sweat.

MECHANISMS OF SWEAT SECRETION

Several distinct sequential processes lead to eccrine gland sweat production[39]: (1) stimulation of the eccrine sweat gland by ACh via increased intra cellular Ca^{2+}; (2) Ca^{2+}-stimulated loss of cellular K^+, Cl^-, and H_2O, which leads to eccrine gland cell shrinkage; and (3) volume-activated transcellular plus paracellular fluxes of Na^+, Cl^-, and H_2O, which leads to net flux of largely isotonic NaCl solution into the glandular lumen. These processes are illustrated in Fig. 83-6.

Sweating initially is stimulated when ACh is released from periglandular cholinergic nerve endings in response to thermal or emotional stimuli. ACh binds to cholinergic receptors on the clear cell plasma membrane, stimulating intracellular Ca^{2+} release and influx, and increasing cytosolic Ca^{2+} concentrations. Increased intracellular Ca^{2+}, in turn, opens Ca^{2+}-sensitive Cl^- and K^+ channels in the clear cell basolateral membrane, which allows Cl^- and K^+ to escape. Because H_2O follows K^+ and Cl^-, to maintain cell iso-osmolarity, the cell shrinks.[39,40]

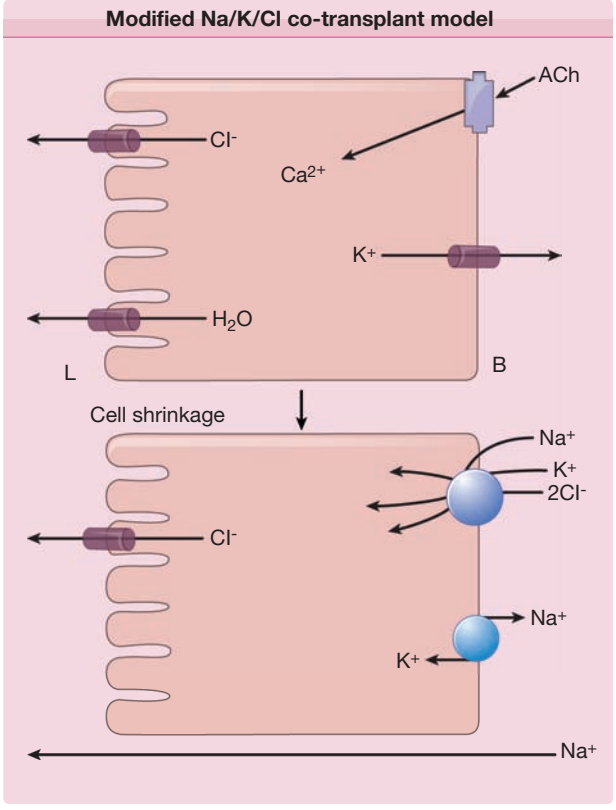

Figure 83-6 Modified Na/K/2Cl cotransport model for the ionic mechanism of cholinergic eccrine sweat secretion. Periglandular neurotransmitters, such as acetylcholine (ACh), bind to receptors on the basolateral membrane, which leads to increased intracellular Ca^{2+}; this in turn activates K^+ and Cl^- channels, mediating K^+, Cl^-, and H_2O efflux from the cell. The resulting cell shrinkage activates the basolateral $Na^+/K^+/2Cl$ antiporter, which leads to Na^+, K^+, and Cl^- influx. The Na^+ and K^+ fluxes are recycled across the basolateral membrane by the Na^+, K^+-adenosine triphosphatase. In contrast, Cl^- fluxes flow unopposed into the lumen, causing an electrical gradient that drives Na^+ exit from the tissue into the lumen via a paracellular pathway. Net fluxes: H_2O, Cl^-, and Na^+ (isotonic) flow into the lumen. pH of the secreted fluid is neutral. Paracellular Na^+ fluxes across the cell junction are indicated with an arrow at the bottom of the figure. B = basolateral membrane; L = luminal or apical membrane; arrows = conductive flux of ions through ionic channels.

This decrease in cell volume sets off a second cascade of cell signaling events. First, decreased cell volume stimulates the NKCC1[41] class of Na/K/2Cl cotransporters, which carry Na^+, K^+, and $2Cl^-$ into the cell in an electrically neutral fashion (i.e., two cations and two anions cancel out net charges). The resulting increase in cytosolic Na^+ activates the Na^+, K^+-ATPase, located in the basolateral membrane, which recycles Na^+ and K^+ across the basolateral membrane. The net movement of the negatively charged Cl^- ion across the apical membrane into the lumen in turn drives the positively charged Na^+ ion into the lumen as well, along a paracellular pathway. Therefore, the final product of glandular secretion is the net movement of Na^+, Cl^-, and H_2O into the glandular lumen to form the isotonic NaCl precursor of sweat.

ACh-induced sweating, which constitutes the bulk of sweat production, appears to be mediated by intracellular Ca^{2+}, as detailed earlier. In contrast, adrenergic-induced sweating appears to be mediated by increased intracellular cyclic adenosine monophosphate.[41]

MECHANISM OF DUCTAL REABSORPTION

Because the production of large sweat volumes could lead to dangerous losses of NaCl, the sweat duct has evolved to reabsorb NaCl, which minimizes electrolyte loss, even at high sweat volumes (Fig. 83-7).

Ductal Na^+ reabsorption is accomplished through the coordinated activities of intracellular enzymes and plasma membrane ion channels, pumps, and exchangers. These mechanisms not only reabsorb electrolytes but also acidify the sweat, which results in a final sweat product that is hypotonic and acidic. Na^+ reenters the duct cells through the apical membrane via amiloride-sensitive[42] epithelial Na^+ channels (ENaC)[42] and is transported across the basolateral membrane by ouabain-sensitive[10] Na^+, K^+-ATPase pumps. Cl^- transport appears to be both transcellular and paracellular, with the cystic fibrosis transmembrane regulator (CFTR) Cl^- channels playing an important role in transcellular fluxes.[43] In cystic fibrosis, CFTR Cl^- channels are mutated, and eccrine duct Cl^- reabsorption is defective, although not completely abolished.[24] Na^+ is increased in the duct and the sweat at the skin surface.[44] Unlike in the lung, CFTR mutations do not lead to increased ENaC-mediated Na^+ influx, which suggests that the CFTR–ENaC interactions seen in other tissues differ from that in the eccrine duct. Sweat acidification appears to be mediated via the enzyme carbonic anhydrase, the HCO_3^-/Cl and Na^+/H^+ exchangers, and the V-type H^+ ATPase. The intracellular enzyme carbonic anhydrase catalyzes HCO_3^- and H^+ production. Intracellular HCO_3^- is cleared via the HCO_3^-/Cl antiporter, whereas H^+ is pumped into the luminal sweat by the V-type H^+ ATPase.[45] The Na^+/H^+ antiporter NHE1 (Na^+/H^+ exchanger isoform 1)[44,46] found in the basolateral membrane, is important in intracellular pH regulation.

Several drugs are known to modify ductal NaCl reabsorption. When aldosterone is injected systemically or locally, the Na/K ratio in sweat begins to decrease within 6 hours, reaching a nadir at 24 hours and returning to the preinjection level in 48–72 hours.[44] Na^+ deprivation stimulates both renin and aldosterone secretion, but high thermal stress per se [a single 1-hour exposure of humans to a temperature of 40°C (104°F)] is a potent stimulator of renin and aldosterone secretion in either the presence or absence of sodium deprivation. In an in vitro sweat gland preparation, neither acetazolamide (a carbonic anhydrase inhibitor) nor antidiuretic hormone changed ductal or secretory function. However, more potent carbonic anhydrase inhibitors, such as topiramate,[47] have been reported to induce oligohidrosis.

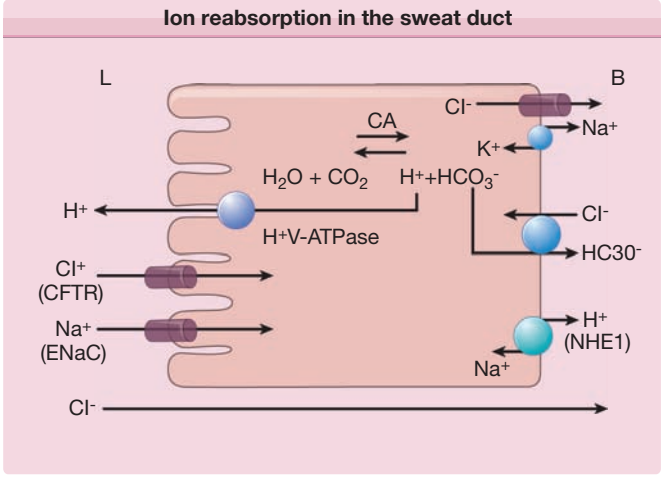

Figure 83-7 Illustration of ion reabsorption in the sweat duct. Na^+ enters the apical (luminal) membrane through epithelial Na^+ channels (ENaC) and is transported across the basolateral membrane by Na^+, K^+-adenosine triphosphatase (ATPase). Cl^- enters the cell through the cystic fibrosis transmembrane regulator Cl^- channel (CFTR) and also is transported across the lumen via a paracellular pathway. H^+ generated by the enzyme carbonic anhydrase (CA) is pumped into the lumen by a V-type H^+ ATPase (H^+ V-ATPase). Intracellular pH homeostasis is maintained by parallel HCO_3^-/H^+ and Na^+/H^+ (NHE1) exchangers. The activity of these enzymes, transporters, and channels results in H^+ secretion and Na^+ and Cl^- reabsorption, which produces a final sweat that is hypotonic and acidic. Paracellular Cl^- fluxes across the cell junction are indicated with an arrow at the bottom of the figure. B = basolateral membrane; L = luminal or apical membrane; arrows = conductive flux of ions through ionic channels.

APOCRINE SWEAT GLAND

In addition to the eccrine sweat glands, described earlier, apocrine sweat glands are found in humans, largely confined to the regions of the axillae and perineum.[48] They do not become functional until just before puberty; thus, it is assumed that their development is associated with the hormonal changes at puberty, although the exact hormones have not been identified.

ANATOMY

Apocrine glands are coiled and localized in the subcutaneous fat near the dermis. The gland consists of a single layer of cuboidal or columnar cells. These secretory cells rest on a layer of myoepithelial cells.[49] The duct is composed of a double layer of cuboidal cells, and empties into hair follicle infundibulum.

Like the eccrine gland, the myoepithelium fulfills dual functions in both providing structural support and pumping out preformed sweat.

β-adrenergic receptors and purinergic receptors have been identified on apocrine glands. However, nerve fibers and muscarinc receptors have not been identified, suggesting that any cholinergic stimulation acts humorally.[50]

FUNCTIONS

A number of functions have been attributed to the apocrine glands, including roles as odoriferous sexual attractants, territorial markers, and warning signals. These glands play a role in increasing frictional resistance and tactile sensibility as well as in increasing evaporative heat loss in some species. The production of pheromones by the apocrine glands of many species is well established.[51]

Because the apocrine glands of humans do not begin to function until puberty and are odor producing, it is attractive to speculate that they have some sexual function, which may now be vestigial. There are high levels of 15-lipoxygenase-2 in the secretory cells of the apocrine gland. Its product, 15-hydroxyeicosatetraenoic, a ligand for the nuclear receptor peroxisome proliferator-activated receptor-γ, may function as a signaling molecule and in secretion or differentiation.[51] For nonhuman furred primates, apocrine glands may have a purpose in thermoregulation as well.

COMPOSITION OF SECRETION

When it is first secreted, the apocrine sweat of humans is milky, viscid, and without odor. Apocrine sweat contains three types of precursors: fatty acids, sulfanyl alkanols and odiferous steroids, which are converted by bacteria on axillary skin, particularly corynebacterium striatum, into odiferous substances. Secretion of amino acid and steroid precursors is controlled by an ATP-dependent efflux pump multidrug resistance protein 8 (MRP8), encoded by the gene *ABCC11*, which is expressed in apocrine sweat glands. Axillary odor is significantly reduced in Asian populations that carry a single nucleotide polymorphism (SNP) in this gene, which also affects earwax characteristics.[52]

MODE OF SECRETION

Apocrine (decapitation), holocrine and merocrine types of secretion have been reported in apocrine glands. Cannulation of the duct of the human apocrine sweat gland has shown that secretion is pulsatile, and it is assumed that contractions of the myoepithelial cells surrounding the secretory cells are responsible for these pulsations.[53]

CONTROL OF SECRETION

The apocrine sweat glands of humans respond to emotive stimuli only after puberty. They can be stimulated by either epinephrine or norepinephrine given locally or systemically. Studies have shown that the apocrine glands are controlled mainly by adrenergic agonists[52]; although some cholinergic control also has been reported.[49,54] This is in contrast to the eccrine glands, which are under cholinergic control.

Although an intact nerve supply is a functional requirement of apocrine sweating, the demonstration of nerve endings or varicosities in close proximity to the glands has been difficult.[49,55] Local capillary circulation likely assists in conveying transmitter substance to the sweat gland cells, a form of neurohumoral transmission.

As would be expected, drugs that affect adrenergic systems also have an effect on apocrine sweat glands. Adrenergic neuron-blocking agents inhibit sweating, as do drugs that deplete the stores of transmitter substance in adrenergic neurons. Drugs that block specific adrenergic receptors also inhibit sweating, but the types of receptors that must be blocked differ in various species. The type of receptor that mediates the response of the apocrine glands of humans has not been elucidated.

KEY REFERENCES

Full reference list available at www.DIGM8.com

DVD contains references and additional content

12. Murakami M et al: Postsecretory processing generates multiple cathelicidins for enhanced topical antimicrobial defense. *J Immunol* **172**(5):3070-3077, 2004
13. Nadel ER, Bullard RW, Stolwijk JA: Importance of skin temperature in the regulation of sweating. *J Appl Physiol* **31**(1):80-87, 1971
17. Coon J, Rothman S: The sweat response to drugs with nicotine-like action. *J Pharmacol Exp Ther* **23**:1, 1941
23. Sato K: The physiology, pharmacology, and biochemistry of the eccrine sweat gland. *Rev Physiol Biochem Pharmacol* **79:**51-131, 1977
38. Bolognia JL, Cooper DL, Glusac EJ: Toxic erythema of chemotherapy: A useful clinical term. *J Am Acad Dermatol* **59**(3):524-529, 2008
46. Nejsum LN, Praetorius J, Nielsen S: NKCC1 and NHE1 are abundantly expressed in the basolateral plasma membrane of secretory coil cells in rat, mouse, and human sweat glands. *Am J Physiol Cell Physiol* **289**(2):C333-C340, 2005
47. de Carolis P et al: Transient hypohidrosis induced by topiramate. *Epilepsia* **44**(7):974-976, 2003

Chapter 84 :: Disorders of the Eccrine Sweat Glands and Sweating

:: Robert D. Fealey & Adelaide A. Hebert

HYPERHIDROSIS AND ANHIDROSIS AT A GLANCE

- Primary focal (essential) hyperhidrosis:
  - Affects over 6 million young people worldwide.
  - Excessive palmar sweating affects quality of life.
  - Effective treatments (stratified to match the severity) include topical agents, iontophoresis, oral anticholinergics, and botulinum toxin.
  - Endoscopic thoracic sympathetic surgery is a last-line choice for severe hyperhidrosis.
- Localized, large areas of hyperhidrosis may be compensatory.
  - Clue to loss of sweating elsewhere.
  - Determine location of sudomotor lesion and underlying cause by thermoregulatory sweat testing combined with direct and axon reflex sweat evaluation.
- Patterns of anhidrosis provide objective evidence of small nerve fiber and/or eccrine gland involvement in many neurologic and dermatologic disorders.
- Analysis of sweat composition continues to be diagnostic in cystic fibrosis.
- Determination of sweat-derived antimicrobial peptides may provide evidence of impaired innate defense in skin disorders such as atopic dermatitis and neutrophilic eccrine hidradenitis.

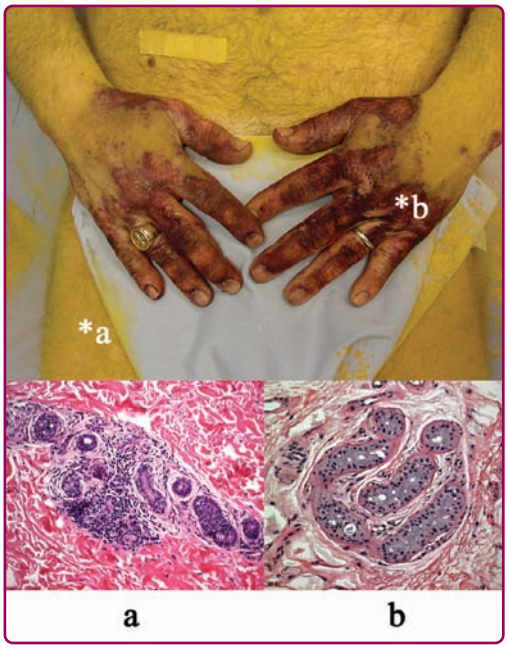

Figure 84-1 A patient with an acquired idiopathic anhidrosis shows anhidrotic (*yellow*) and sweating (*purple*) staining of sodium alizarin sulfonate (alizarin Red S) indicator powder. Punch skin biopsy from an anhidrotic skin site (a) shows marked perieccrine lymphocytic infiltration of sweat gland secretory coils, whereas sweating skin (b) shows normal sweat gland morphology. The presence of perieccrine inflammation prompted immunomodulatory therapy with corticosteroids and pulsed methotrexate and a trial of topical tacrolimus.

Disorders of eccrine sweating can occur for many different reasons, including dysfunction of the thermoregulatory centers in the brain's central autonomic network, changes in the spinal sympathetic preganglionic, ganglionic, or postganglionic neurons/axons or in the muscarinic (M3) cholinergic synapse on sweat glands. Abnormalities of eccrine sweat formation by the secretory coil and sweat ductal cells may occur or ductal disruption or occlusion may develop, preventing delivery of sweat to the skin surface.

A review of the normal anatomy and physiology of eccrine sweat glands and sweating may be found in Chapter 83. This chapter focuses on neurologic and dermatologic disorders that cause focal or generalized abnormalities of sweating, highlighting an exciting interface where disorders are better understood, diagnosed, and treated based on recognition of the integrated function of nerves, skin, and the immune system (Fig. 84-1). There are a variety of techniques that can be used clinically and in research of sweating that are discussed online. Table 84-1 is a comprehensive table based on disorders with increased or decreased sweating—some diseases are discussed in this text–the others are discussed online. Many are disorders related to nervous system structural, functional and inherited disorders; therefore any patient with a sweating disorder should be evaluated carefully for internal medicine diseases and neurologically by consultants in some cases.



Figure 84-2 A patient with segmental anhidrosis (*yellow*) with compensatory left-sided hemihyperhidrosis (*purple*) due to a right greater than left-sided upper thoracic spinal cord injury (sodium alizarin sulfate indicator powder).

VISUAL EXAMINATION OF THE SKIN

The physical examination continues to be important in the diagnosis of sweating disorders. For example, the skin of an infant with cystic fibrosis is much saltier than infants without cystic fibrosis and when collected sweat is dried, it forms fern-like crystals. Infants with widespread sweat loss may present with "fever of unknown origin." Taking note of the beads of sweat on the palms and soles of a young adult goes a long way to making a diagnosis of primary focal (essential) hyperhidrosis. In uremia, the evaporation of sweat with high urea concentrations results in the deposition of urea on

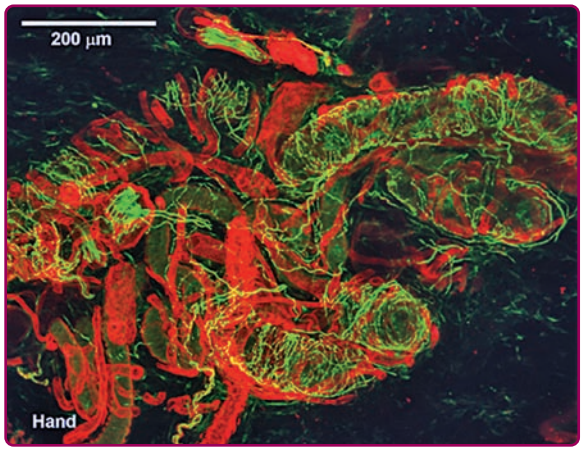

Figure 84-3 Secretory tubules, nerve fibers, and blood vessels in a normal human sweat gland fluorescently stained by immunohistochemical and lectin methods and visualized via laser scanning confocal microscope. Immunoreactive staining of nerves with protein gene product 9.5 antibody (*green staining*) shows axons wrapped around secretory tubules. (Photo used with permission from Dr. William Kennedy, MD, Minneapolis, MN.)

TABLE 84-1
Classification of Disorders of Eccrine Sweating

Primary Focal (Essential) Hyperhidrosis
Palmoplantar, axillary, craniofacial, generalized hyperhidrosis

Secondary Causes of Focal Hyperhidrosis

Due to cerebral infarction
- Frontal opercular infarct
- Brainstem stroke

Associated with spinal cord injury
- Autonomic dysreflexia
- Posttraumatic syringomyelia
- Orthostatic hypotension triggered

Associated with other central nervous system disorders
- Chiari type I and II malformation
- Myelopathies due to infarction, syringomyelia, tumor
- Cold-induced sweating syndrome
- Olfactory hyperhidrosis

Associated with peripheral nervous system disorders
- Peripheral motor neuropathy with autonomic dysfunction
- Dermatomal or focal hyperhidrosis due to nerve trunk irritation
- Compensatory segmental hyperhidrosis (postsympathectomy, Ross syndrome, pure autonomic failure)
- *Gustatory sweating*
- *Physiologic*
- *Idiopathic*
- *Postherpetic*
- *Post nerve injury (postsurgical, diabetic autonomic neuropathy, postinfectious, tumor invasion)*
- Lacrimal sweating
- Harlequin syndrome
- Idiopathic, localized hyperhidrosis
- Idiopathic unilateral circumscribed hyperhidrosis
- Postmenopausal localized hyperhidrosis

Associated with local skin disorders
- Blue rubber bleb nevi
- Eccrine angiomatous hamartoma
- Tufted angioma
- Glomus tumor
- Burning feet syndrome
- Pachydermoperiostosis
- Granulosis rubra nasi
- Pretibial myxedema
- POEMS (polyneuropathy, organomegaly, endocrinopathy, M protein, and skin changes) syndrome

Secondary Causes of Generalized Hyperhidrosis

Associated with central nervous system disorders
- Episodic hypothermia with hyperhidrosis (Hines–Bannick or Shapiro syndrome)
- Posttraumatic or posthemorrhagic "diencephalic epilepsy"
- Fatal familial insomnia and Parkinson disease

Associated with fever and chronic infection
- Tuberculosis, malaria, brucellosis, endocarditis

Associated with metabolic and systemic medical diseases
- Hyperthyroidism, diabetes mellitus, hypoglycemia, hypercortisolism, acromegaly

Associated with malignancy
- Leukemia, lymphoma, pheochromocytoma, Castleman disease, carcinoids, renal cell cancer

Medication-induced
- See Table 84-3
- Neuroleptic malignant syndrome
- Serotonin syndrome, other medications

Toxic syndromes
- Alcohol, opioid withdrawal, delirium tremens

Associated with central and peripheral nervous system disorders
- Familial dysautonomia (Riley–Day), Morvan fibrillary chorea

Primary Autonomic Disorders with Acquired Anhidrosis

Isolated sudomotor disorders
- Progressive isolated segmental anhidrosis
- Idiopathic pure sudomotor failure
- Chronic idiopathic anhidrosis

Sudomotor plus other autonomic disorders
- Ross syndrome
- Pure autonomic failure
- Autoimmune autonomic neuropathy

Secondary Autonomic Disorders Associated with Anhidrosis

Central nervous system lesions (stroke, tumor, infection, infiltration, trauma, etc.)
- Hypothalamic lesions
- Brainstem lesions
- Spinal cord lesions

Degenerative disorders
- Multiple system atrophy, dementia with Lewy body disease, Parkinson disease—autonomic failure

Peripheral Nerve Lesions Causing Anhidrosis
- Hereditary sensory and autonomic neuropathy types I, II, IV (congenital insensitivity to pain with anhidrosis)
- Guillain–Barré syndrome (acute inflammatory demyelinating polyneuropathy)
- Diabetic autonomic neuropathy
- Amyloidosis
- Lepromatous neuropathy
- Lambert–Eaton myasthenic syndrome
- Alcoholic neuropathy
- Fabry disease
- Idiopathic small-fiber neuropathy
- Erythromelalgia
- Sympathectomy and other surgical lesions
- Harlequin syndrome

Anhidrosis due to toxins, pharmacologic agents and heat exposure
- *Botulism*
- Ganglionic blockers, anticholinergics, carbonic anhydrase inhibitors
- Opioids
- Heat hyperpyrexia and heat stroke

Anhidrosis Associated with Diseases of Skin and Sweat Glands

Anhidrosis due to physical agents damaging skin
- Trauma, burns, pressure, scar formation, radiation therapy

Anhidrosis due to congenital and acquired skin diseases
- Fabry and other congenital metabolic diseases
- Congenital ectodermal dysplasia
- Ichthyosis
- Neutrophilic eccrine hidradenitis
- Sjögren syndrome
- Systemic sclerosis (scleroderma)
- Incontinentia pigmenti
- Segmental vitiligo
- Bazex–Dupre–Christol syndrome

Disorders affecting the sweat duct
- Miliaria
- Palmoplantar pustulosis
- Psoriasis
- Lichen planus
- Atopic dermatitis

Disorders with abnormal sweat composition
- Atopic dermatitis (reduced dermcidin levels)
- Cystic fibrosis (increased chloride concentration)

the skin, referred to as *uremic frost*. Patients with craniofacial hyperhidrosis may develop a darkened hue to their skin known as *chromhidrosis*. Focal or segmental compensatory hyperhidrosis may be apparent on examination. Dry, atrophic skin may be seen in areas affected by small-fiber neuropathy. Disorders affecting the sweat duct (miliaria or psoriasis, for example) are often diagnosed via visual inspection of the skin.

DISORDERS OF SWEATING

Table 84-1 organizes disorders of sweating into the six categories discussed in this chapter.

PRIMARY FOCAL (ESSENTIAL) HYPERHIDROSIS

CLINICAL MANIFESTATIONS AND PATHOMECHANISM

Primary focal (essential) hyperhidrosis is one of the most common disorders of eccrine sweating.[16] This condition is defined as focal visible, excessive sweating of at least 6-months' duration without apparent cause with at least two of the following characteristics: (1) bilateral and relatively symmetric sweating; (2) the sweating impairs daily activities; (3) a frequency of at least one episode per week; (4) an age of onset before the age of 25 years; (5) a positive family history; (6) cessation of sweating during sleep.[17] A national survey estimated that hyperhidrosis affects 2.8% of the US population, and that half of those affected experience excessive sweating of the axillae.[18] Hyperhidrosis of the palms, soles, axillae, and, to a lesser extent, craniofacial and groin regions may occur at any time irrespective of temperature, stress, or pleasure. Primary focal hyperhidrosis does not manifest when the patient undergoes general anesthesia and augmentation with thermal stimuli and physical exertion is not uncommon. Sweating may be continuous or phasic; when continuous, sweating is most troublesome in summer. Phasic outbursts with minor emotional activity are similar year round.

Severe primary focal hyperhidrosis interferes with many activities of daily living and patients report a reduced quality of life[19] Avoiding a handshake can lead to professional embarrassment, and avoidance of touch can lead to social or interpersonal seclusion and other symptoms of social anxiety disorder. Symptoms begin in childhood or around puberty and affect either sex equally. A family history is present in approximately one-fourth of patients. The disorder persists for years with occasional spontaneous improvement after 35 years of age.

The central autonomic network control of emotional sweating is distinct from the preoptic-anterior hypothalamic controller of thermoregulatory sweating. The anterior cingulate cortex, which orchestrates the sweat response from the palms and soles, may modulate hypothalamic output inappropriately. These patients have less reflex bradycardia than control subjects in response to the Valsalva maneuver or facial immersion, but a higher degree of cutaneous vasoconstriction in response to finger immersion in cold, suggesting that they have increased sympathetic outflow passing through the T2–T3 ganglia.[20] Ventilated capsule recordings of palmar sweating provide further evidence of emotionally triggered, centrally derived sweat output. Such sweating is augmented at rest, bilaterally synchronous, and pulsatile (eFig. 84-3.1 in online edition).

The severity of primary focal hyperhidrosis ranges from intermittent, slightly moist palms and soles to daily sweat drippage from hands and feet, requiring the frequent use of towels.

TREATMENT

Treatment involves determining the severity and distribution of the disorder, ruling out other causes of hyperhidrosis, and selecting a modality of therapy appropriate to age of the patient and severity of the disorder. Some current treatment methods are shown in Box 84-1. Treatment begins with discussing the nature of the disorder and discerning patient wishes and expectations. Mild cases of axillary and palmar sweating are controlled via topical application of aluminum chloride hexahydrate or glycopyrrolate, an anticholinergic agent. Care should be taken to have the aluminum chloride applied to completely dry skin as use of the agent on moist skin can result in the formation of a weak hydrochloric acid that can result in discomfort, and burning and peeling of the skin surface. This irritation can be managed by cessation of therapy for a few days and the use of a class VII topical steroid cream. Oral glycopyrrolate, oral or transdermal clonidine, transdermal scopolamine, or oral topiramate[21] can be administered if topical agents alone are not helpful or are too irritating. Control of palmar-plantar sweating is sometimes possible using tap water (or a solution of glycopyrrolate) iontophoresis. Intradermal injection of botulinum toxin (BTX), (onabotulinumtoxinA) is appropriate for treatment of focal areas, such as axillae, palms of hands, soles of feet and groin, and is effective for 2–8 months per treatment.[22] Facial hyperhidrosis can be treated with oral or topical[23] glycopyrrolate.

Immunohistochemical studies show sweat glands appear structurally normal in hyperhidrotic patients before BTX therapy, whereas after therapy the luminal area of the gland and protein gene product 9.5 (neural marker) staining is diminished. This suggests that BTX therapy induces long-standing functional denervation of the sweat glands. However, growth-associated protein 43, indicative of axonal sprouting, is increased, suggesting reinnervation may eventually take place.[24]

Repeat BTX injections do not demonstrate a diminished duration of efficacy.[25] Pain with palmar botulinum injections is common and several techniques are in use to minimize this.[26,27] Iontophoresis of BTX in solution has been successfully tried with better control

BOX 84-1 TREATMENTS FOR HYPERHIDROSIS

TYPE OF HYPERHIDROSIS	TREATMENT	FORMULATION	ROUTE OF ADMINISTRATION AND DOSAGE
Craniofacial, gustatory	Glycopyrrolate	0.5%–2% Vanicream base or roll-on lotion; 1- to 2-mg tablet	Topical, once to twice daily. Tablet started at 1 mg bid; increase prn up to 2 mg three to four times daily.
	Clonidine	0.1-mg tablet, 0.1–0.3 mg/day, transdermal patch	Oral incremental increases up to 0.6–1.2 mg/day in two or three divided doses; 0.1 mg/day patch first week increased weekly up to two 0.3 mg/day patches.
Craniofacial, gustatory Paroxysmal localized	Donnatal extend tab	Phenobarbital, USP (3/4 gr.) 48.6 mg Hyoscyamine Sulfate, USP 0.3111 mg Atropine Sulfate, USP 0.0582 mg Scopolamine Hydrobromide, USP 0.0195 mg	One tablet orally every 12 hr.
	Topiramate	25-mg tablet	Begin 25 mg twice daily; increase each dose weekly by 25 mg up to 100–200 mg daily in two divided doses.
Axillary, palmar-plantar, craniofacial	Aluminum chloride	20% aluminum chloride in anhydrous ethyl alcohol; 12% aluminum chloride in sodium carbonate water	Topically, nightly, until desired sweat reduction achieved. Then taper to once weekly; follow *Physicians' Desk Reference* directions carefully for each body region to maximize effect and minimize skin irritation.
Axillary	Over the counter clinical strength antiperspirant	Aluminum Zirconium Trichlorohydrex Gly 20% anhydrous	Apply to axillae twice a day
Palmar–plantar	Iontophoresis unit	Patient-controlled current, 15–30 mA using tap water; glycopyrrolate can be added, making a 0.1% solution	Immerse hands, feet for 30 min once or twice daily, or 20 min at each site every 2–3 days, or 10 min at each site three to five times weekly; anode site is most effective so switch sides after one-half of each treatment; direct current more effective, but AC current less painful and may be used part of time; glycopyrrolate solution enhances effect. Most modern iontophoresis unit do not require switching of anodes.
Palmar–plantar, axillary, gustatory, recalcitrant	Botulinum toxin A injection	2–5 units of botulinum toxin	Given via high intradermal injections to ~1 cm^2 iced/anesthetized skin areas; for botulinum toxin A, total of 12–20 injections (50 units total) given per axilla, 50–75 injections in the palm/each foot; benefit lasts 2–8 months; reinjection is effective.
	Glycopyrrolate	1- to 2-mg tablet	Tablet started at 1 mg bid; increase 1 mg each week as tolerated up to 2 mg three to four times daily.
Axillary	Local incision	Liposuction and curettage of sweat glands in dermis	Define area of involvement with starch-iodide Minor test or equivalent; small incisions with sharp suction-curettage cannula; usually permanent, 40%–70% reduction in sweating achieved.
Palmar, axillary; documented severely affected cases resistant to other treatment modalities	Sympathetic surgery	Various procedures affecting the T2, T3, and/or T4 sympathetic ganglia and connections	Invasive, video-assisted endoscopic thoracic procedure preferred; intraoperative monitoring of hand/finger skin blood flow/temperature suggested; sympathotomy (disconnection of sympathetic chain between T2 and stellate ganglia done to minimize compensatory hyperhidrosis; selective T3 sympathectomy may have less compensatory hyperhidrosis; T2–T4 sympathectomy done for axillary hyperhidrosis has high incidence of compensatory hyperhidrosis on trunk and gustatory hyperhidrosis.

of sweating than with water alone.[28,29] However, the cost effectiveness of this has been questioned.

Only the most severe cases of palmar hyperhidrosis not responding to conservative treatment may be considered for surgical management. Many patients have been successfully treated with endoscopic, upper thoracic sympathectomy[30] (eFig. 84-3.2 in online edition); however, the best procedure to use is still being investigated.[10,30–36] These surgical procedures carry the risk of creating minor to severe compensatory hyperhidrosis in body segments below the treated area (see eFig. 84-3.3 in online edition) as well as much less common surgical complications of wound infection, Horner's syndrome, pneumo- or hemothorax, and atelectasis. Long-term surveys of patients having undergone thoracic sympathectomy for treatment of palmar hyperhidrosis have illustrated that many patients wish they had not undergone the procedure due to the compensatory sweating that developed after the surgery.[37,38]

Another surgical option for axillary hyperhidrosis is tumescent suction curettage, which is performed in an outpatient setting. In one limited study of 63 subjects, greater than 75% were still satisfied with their reduction in sweating 2 years after treatment.[39]

(Secondary causes of localized hyperhidrosis are discussed online only.)

SECONDARY CAUSES OF LOCALIZED HYPERHIDROSIS

GUSTATORY SWEATING

Localized sweating on lips, forehead, scalp, and nose while eating hot and spicy foods occurs physiologically in many people via a trigeminovascular reflex. Pathologic gustatory hyperhidrosis is asymmetric, intense, and may produce patches of sweating on the trunk and even extremities. The cause is aberrant regeneration of damaged and undamaged facial parasympathetic fibers, destined for salivary glands, which instead supply facial sweat glands that have been sympathetically denervated. Thus, gustatory stimuli that previously caused parotid, salivary gland, or gastric secretion now also cause sweating in the distribution of the damaged sympathetic nerve. The most common occurrence is in Frey syndrome, in which sweating occurs in the distribution of the auriculotemporal nerve after an injury, abscess, or surgery in the parotid region.[50] Frey syndrome can be seen in infants and children, often following birth trauma with forcep delivery, but two cases of familial, bilateral Frey syndrome without birth trauma have also been reported.[51] Gustatory sweating may follow upper thoracic and cervical sympathectomy,[50,52–54] facial herpes zoster, or chorda tympani injury and has been reported in cluster headache, diabetic neuropathy,[55–57] encephalitis, syringomyelia, and invasion of the cervical sympathetic trunk by a tumor.[58] The exact distribution can be delineated with indicator powder on the face, neck, and upper trunk while the subject chews and is photographed. Treatment with topical scopolamine, clonidine,[53] glycopyrrolate,[59,60] aluminum chloride, or BTX injection[61,62] can be effective; rarely, intracranial section of the glossopharyngeal nerve or tympanic neurectomy is needed.

FEVER AND CHRONIC INFECTION

Malaria, tuberculosis, brucellosis, and subacute bacterial endocarditis may present with fever and generalized hyperhidrosis due to exogenous bacterial pyrogens that stimulate phagocytic leukocytes to produce endogenous pyrogen [interleukin 1 (IL-1) and IL-6, tumor necrosis factor (TNF), and γ-interferon]. These cytokines act not only as circulating hormones, but also as intrinsic modulators in the brain. Signals that stimulate IL-1 production in the brain include humoral factors, such as circulating IL-6 and activation of peripheral C fibers and vagal afferents. These effects can raise "set-point" temperature (producing fever), while simultaneously activating antipyretic mechanisms (eventually producing drenching sweats).[75]

METABOLIC AND SYSTEMIC MEDICAL PROBLEMS

Increased sweating has been reported in diabetes mellitus, hypoglycemia, congestive heart failure, thyrotoxicosis, hyperpituitarism, dumping syndrome, carcinoid syndrome, and alcohol and drug withdrawal. Sweating is increased (especially in males) in acromegaly (in which the size of sweat gland acini and the density of innervation to the sweat glands is greater than in controls) and is decreased in growth hormone deficiency (GHD).

Some studies of GHD pre- and posttreatment, using histochemistry for acetylcholinesterase and immunohistochemistry for the neuropeptide vasoactive intestinal polypeptide and protein gene product 9.5, a general neural marker, have shown increased sweat gland acinar size and periacinar innervation and pilocarpine iontophoresis sweat rate after GH therapy. However, other studies have shown that even treated GHD subjects still sweat less than controls implying permanent eccrine gland hypofunction and androgen deficiency as a cofactor of reduced sweating.

HYPERHIDROSIS AND MALIGNANCY

Hodgkin disease is characterized by the triad of fever, sweating, and weight loss; night sweats may be the only symptom and 31 of 100 patients present with "B"-cell symptoms (fever, weight loss, sweating).[76] The excessive production of IL-1 by activated macrophages is implicated as the cause of temperature instability.[77] IL-1 is known to induce an abrupt increase in the synthesis of prostaglandin E_2 in the preoptic anterior hypothalamic region, causing an elevation of the temperature "set point." Excessive production of IL-6 by Hodgkin lymphoma cells[78] is also implicated as cause

of fever and subsequent night sweating. Advanced solid tumors may also cause sweating via immunologic mechanisms relating to TNF-α and effect of ILs on central thermoregulation.

The symptomatic triad of excessive and inappropriate paroxysmal sweating, tachycardia, and pounding headaches (associated with increased blood pressure) almost assures the diagnosis of pheochromocytoma as the cause of hyperhidrosis. Anti-α- and β-adrenergic therapy is a mainstay of this disorder, with a rare patient developing sweat gland necrosis during preoperative therapy.

GENERALIZED HYPERHIDROSIS DUE TO MEDICATIONS/TOXINS

Hyperhidrosis is frequently associated with serotonin (5-hydroxytryptamine) reuptake inhibitors, opioids, and sometimes with prostaglandin inhibitors (naproxen). The serotonin syndrome and the neuroleptic malignant syndrome include hyperthermia, labile blood pressure, hyperhidrosis, rigidity, agitation and confusion. The mechanisms may relate to 5-hydroxytryptamine (2A) and dopamine receptor antagonism. The hyperhidrosis that commonly occurs during acute and chronic administration of opioids is mainly due to stimulation of mast cell degranulation, resulting in the release of histamine.[79] Excessive sweating can occur in as much as 45% of patients taking methadone.[80] Hyperhidrosis is also a recognized side effect of transdermal fentanyl.[81] Sweating in combination with hypertension, nausea, and mydriasis characterizes acute opioid and alcohol withdrawal. Despite their well-recognized anticholinergic effects, tricyclic antidepressants occasionally cause hyperhidrosis due to their sympathomimetic effect. The presumed mechanism is inhibited reuptake of norepinephrine, leading to stimulation of peripheral adrenergic receptors and a generalized diaphoretic response. Cholinergic agonists such as pilocarpine and bethanechol and reversible cholinesterase inhibitors such as pyridostigmine can increase sweating directly or indirectly via activation of M3 cholinergic receptors on sweat glands. See Table 84-2 for an abbreviated listing by drug class, example, and mechanism of hyperhidrosis and Table 84-3 for a complete listing of medications reported to cause hyperhidrosis.

TABLE 84-2
Some Drugs that can Cause Hyperhidrosis

Class	Examples	Probable Mechanism
Anticholinesterases	Pyridostigmine	Cholinesterase inhibition
Antiglaucoma agents	Physostigmine Pilocarpine	Cholinesterase inhibition for physostigmine; muscarinic cholinergic agonism for pilocarpine
Bladder stimulants	Bethanechol	Muscarinic cholinergic agonist
Opioids	Fentanyl Hydrocodone Methadone Morphine Oxycodone	Histamine release; alteration of central thermoregulation
Serotonin-selective reuptake inhibitors	Citalopram Duloxetine Escitalopram Fluoxetine Fluvoxamine Mirtazapine Paroxetine Trazodone Venlafaxine	Serotonergic effect on hypothalamus or spinal cord
Sialogogues	Cevimeline Pilocarpine	Muscarinic cholinergic agonist
Tricyclic antidepressants	Amitriptyline Desipramine Doxepin Imipramine Nortriptyline Protriptyline	Norepinephrine reuptake inhibition with stimulation of peripheral adrenoreceptors

TABLE 84-3
Some Drugs that can Cause Hypohidrosis

Class	Common Examples	Mechanism
Anticholinergics	Glycopyrrolate Hyoscyamine Scopolamine Propantheline Dicyclomine Belladonna Atropine	Antimuscarinic effect
Antiepileptics	Topiramate Zonisamide Carbamazepine	Carbonic anhydrase inhibition for topiramate and zonisamide; central anticholinergic effect for carbamazepine
Antihistamines	Cyproheptadine Diphenhydramine Promethazine	Antimuscarinic effect
Antihypertensives	Clonidine	Central antiadrenergic effect
Antipsychotics and antiemetics	Chlorpromazine Clozapine Olanzapine Thioridazine Quetiapine	Antimuscarinic effect
Antivertigo	Meclizine Scopolamine	Antimuscarinic effect
Bladder antispasmodics	Darifenacin Oxybutynin Solifenacin Tolterodine	Antimuscarinic effect
Gastric antisecretory	Propantheline	Antimuscarinic effect
Muscle relaxants	Cyclobenzaprine Tizanidine	Uncertain, possibly inhibition of spinal excitatory interneurons; possible central and peripheral antimuscarinic effect
Neuromuscular paralytics	Botulinum toxins	Cleavage of synaptosomal-associated protein-25 (SNAP-25) inhibiting presynaptic release of Ach
Opioids	Fentanyl Hydrocodone Methadone Morphine Oxycodone	Elevation of hypothalamic set point; calcium channel antagonism
Tricyclic antidepressants	Amitriptyline Desipramine Doxepin Imipramine Nortriptyline Protriptyline	Antimuscarinic effect (marked for amitriptyline, doxepin; moderate for imipramine and protriptyline; low for nortriptyline)

ANHIDROSIS DUE TO TOXINS AND PHARMACOLOGIC AGENTS

BOTULINUM TOXIN. BTX type A (onabotulinumtoxinA) and B both exhibit a dose-responsive suppression of sweating when injected intra- and subcutaneously (see Chapter 255). This chemodenervation of sweat glands is caused by the structural architecture of BTX with its heavy chain binding to the nerve cell, and its light chain catalyzing the proteolysis of one of the three SNARE (soluble *N*-ethylmaleimide-sensitive factor-attachment protein receptor) proteins preventing vesicle membrane fusion and therefore the release of ACh and transmission of the nerve impulse. This unique property has made BTX (especially type A) very popular for the treatment of localized hyperhidrosis of the axilla and palms and skin areas affected by gustatory sweating. More widespread anhidrosis can occur with BTX as well as organophosphate ingestion as a consequence of bioterrorism.[114]



Figure 84-4 Thermoregulatory sweat test (*left inset*) in a patient with lepromatous leprosy. Note the well-defined anhidrotic areas of the extremities (*yellow*) with greater involvement distally in cooler body regions. The patient's skin (*right inset*) showed ill-defined, scaling, and erythematous to hyperpigmented patches. Patchy loss of pinprick sensation in the distal feet and toes was noted. Skin biopsy from the right forearm (*background photo*) shows numerous acidfast bacilli (*red staining*) in a background of lymphohistiocytic inflammation. (Fite, ×600.) (Fite stain and skin photo used with permission from the Mayo Clinic Department of Dermatology.)

PHARMACOLOGIC AGENTS. Many pharmacologic agents can cause anhidrosis, especially those that are anticholinergic and interfere with the binding of ACh at M3 muscarinic receptor on sweat glands. Blockade at the sympathetic ganglionic level can inhibit sweating and cause orthostatic hypotension. Recently, oligohidrosis in children has been reported in those taking the carbonic anhydrase (CAII) inhibitors zonisamide and topiramate and studies show reduction in axon reflex-mediated sweating compatible with an effect on the sweat gland. Such observations and the location of CAII in the secretory coil clear cells and at the apex of the ductal cells suggest that the formation of HCO_3^- and H^+ by CAII plays a significant role in sweat fluid secretion.[115,116]

μ-OPIOID AGONISTS. μ-Opioid agonists (e.g., morphine) tend to inhibit warm-sensitive neurons in the hypothalamus. This action raises the body's set-point temperature, allowing core temperature to rise substantially. This results in anhidrosis even in a hot environment. After opioid drug levels drop, set-point temperature drops below the elevated core temperature, producing profuse sweating.[79] Clonidine and α_2-adrenergic agonists can suppress sweating, probably by reducing norepinephrine's effect on hypothalamic thermoregulatory neurons. The drug can be effective in Shapiro syndrome, essential hyperhidrosis, and postmenopausal sweating.

HEAT HYPERPYREXIA AND HEAT STROKE

Heat hyperpyrexia and heat stroke are states of thermoregulatory failure of sudden onset that are characterized by general anhidrosis, hyperpyrexia [rectal temperature greater than 40.5°C (105°F)], and disturbances of the central nervous system. The exact cause of this disorder is unknown. The picture is generally one of environmental stress, too severe for the thermoregulatory system, which suddenly collapses. In the early stages, sweating may still be present and the patient rational, but the rectal temperature may be greater than 40.5°C (105°F). Within minutes, anhidrosis, mental confusion, coma, and/or seizures may appear. The diagnosis should be suspected from the clinical setting of activity in extreme heat and rectal temperature greater than 40.5°C (105°F); it should be accepted with the additional presence of anhidrosis, hot, dry skin, and any degree of central nervous system manifestations. If untreated, the disorder is uniformly fatal. In treated cases, the mortality is approximately 35%.

ANHIDROSIS ASSOCIATED WITH OTHER DISORDERS OF SKIN AND SWEAT GLANDS

ANHIDROSIS DUE TO DAMAGE FROM PHYSICAL AGENTS

Localized anhidrosis can occur whenever sweat glands are damaged by surgery or trauma, scar formation, cutaneous neoplasms, radiation therapy, infection, inflammation of the skin, granulomatous lesions, scleroderma, or vasculitis. Delivery of sweat to the skin surface may be impaired in a variety of dermatoses and papulosquamous diseases, presumably because of poral occlusion. Blister formation with sweat gland necrosis has been reported during intoxication with barbiturates, methadone, diazepam, carbon monoxide, amitriptyline, and clorazepate. Similar changes may occur in coma induced by hypoglycemia and other neurologic events, suggesting the changes are due in part to pressure over skin areas not usually subject to pressure. Radiation-induced dermatitis can abolish eccrine function in a dose-dependent fashion. Mantle irradiation (usually in the 25- to 50-Gy range) often produces a permanent loss of eccrine gland function, which tends to be discovered incidentally when previously treated patients undergo autonomic testing (see eFig. 84-4.2 in online edition). Keratotic changes blocking the eccrine duct with or without syringoma-like ductal

proliferation have been described. Similar changes have been noted with breast cancer radiation therapy. Congenital ectodermal dysplasia (see Chapter 142), acantholytic dermatosis (Grover disease; see Chapter 51), cholinergic urticaria (see Chapter 38), and various forms of ichthyosis (see Chapter 49) may also be associated with altered sweating.

ANHIDROSIS DUE TO CONGENITAL AND ACQUIRED SKIN DISEASES

STORAGE DISEASES. Sweat gland cellular inclusions that can be identified on skin biopsy include membrane-bound vacuoles in secretory cells in the mucopolysaccharidoses, intracytoplasmic lipid in Niemann–Pick and Sandhoff storage diseases, inclusions in adrenoleukodystrophy, maltase deficiency, and periodic acid-Schiff (PAS)-positive granules in the outer duct cells in Lafora myoclonic epilepsy.

NEUTROPHILIC ECCRINE HIDRADENITIS. Lesions are most often painful, pruritic, erythematous plaques or papules developing on the limbs, trunk, neck, face, and ears. Most commonly reported is chemotherapy-associated neutrophilic eccrine hidradenitis (NEH), typically occurring within 2 weeks of initiation of multiagent antineoplastic therapy. Fever and neutropenia may occur and the disorder is usually self-limited (lasting several weeks). Necrosis of eccrine secretory coils and associated epithelium with surrounding dense neutrophilic neutrophilic infiltrate that characterizes NEH is seen histologically (see eFig. 84-4.3 in online edition). A direct toxic effect of the drug on eccrine glands is suspected and recurrences with repeated chemotherapy may occur. Treatment with colchicine and dapsone has been beneficial. Another category of NEH appears due to bacterial infection. Biopsied lesions have grown *Serratia, Staphylococcus, Enterococcus, Pseudomonas*, and *Nocardia*.[117] Community outbreaks due to swimming pool water contamination with *P. aeruginosa* have been described. Spontaneous resolution in weeks is common, although some patients receive antibiotics. It is not known whether susceptible individuals have deficient innate dermcidin antimicrobial peptide secretion in sweat (see Section "Disorders Affecting the Sweat Duct") or if changes in sweat duct structural proteins produce reduced barrier protection against infection.

A recent case of NEH due to *Streptococci* showed the presence of human β-defensin 2, an epithelial antimicrobial peptide, in lesional epidermis and the eccrine duct; however, levels of dermcidin, a recently discovered antimicrobial peptide constitutively expressed in human eccrine sweat glands and secreted into sweat, were not determined. Dermcidin levels have been reported to be reduced in atopic dermatitis and have recently been shown to activate normal human keratinocytes.[118]

Recurrent, palmoplantar NEH has been increasingly reported in otherwise healthy children between 1 and 15 years of age. Vigorous exercise with heavy sweating and damp, occlusive footwear are possible risk factors.[119] Spontaneous resolution in 3–4 weeks is common, but repeated bouts with subsequent exercise occur. Treatment with cool compresses and topical steroids and rest has provided symptomatic relief. NEH has been described in association with Behçet disease[120] and human immunodeficiency virus infection. A possible treatment for NEH-Behçet is an anti-TNF-α agent, such as infliximab, which has been effective for other manifestations of Behçet disease[121,122] (see eTable 84-1.1 in online edition for summary of NEH).

SJÖGREN SYNDROME AND SCLERODERMA. Variable degrees of anhidrosis can occur in Sjögren syndrome (see Chapter 161). Most often patchy areas of anhidrosis occur on proximal and/or distal limbs, compatible with a small-fiber neuropathy. Case reports of widespread anhidrosis and heat intolerance associated with dry eyes and dry mouth, positive extractable nuclear antigen panel, and lymphocytic infiltrates of minor salivary glands exist.[123,124] Skin biopsies have shown perieccrine infiltrates in some patients, but not in others. The failure of the anhidrotic skin on TST to respond to ACh/pilocarpine iontophoresis in one report suggests that autoantibodies to the muscarinic (type 3, M3) cholinergic receptor interfere with eccrine gland function.[125–128] M3 cholinergic receptors predominate on salivary glands and sweat glands, which further supports an association. The stage of the immune-mediated response may determine whether lymphocytic infiltration is present or not.[129]

The aquaporin 5 (AQP5) water channel has been identified in the apical plasma membrane of sweat gland cells,[130] and mobilization of these channels may influence sweat production.[131] The effects of drugs or disease on these channels at this time are speculative with regard to sweat gland disorders. Preliminary evidence of autoantibody-mediated alterations in M3 cholinergic receptor activation and AQP5 expression in salivary gland cells of Sjögren's syndrome patients raises the possibility that some patients with disturbances of sweating may turn out to have AQP5 channelopathies.[21]

Atrophic sweat glands and focal anhidrosis have been noted in patients with linear scleroderma. The forehead is most commonly affected.[132]

INCONTINENTIA PIGMENTI. Hypohidrosis has also been noted in the hypopigmented streaks and patches on the legs, arms, and scalp of ten women with incontinentia pigmenti.[133] Skin biopsies reveal a lack of eccrine sweat glands and hair follicles at these sites. Hypohidrosis has also been described in segmental vitiligo, but not the generalized or acrofacial types.[134,135] Anhidrosis of the face and neck has also been reported in members of a family with "follicular atrophoderma, basal cell carcinoma, and hypotrichosis," a rare X-linked, dominantly inherited syndrome (Bazex–Dupre–Christol syndrome). Milia and sweat duct occlusions may occur, but are inconstant features of the disease.[136]

DISORDERS AFFECTING THE SWEAT DUCT

MILIARIA. Miliaria results from disruption of sweat ductal integrity[137] with consequent sweat secretion into layers of the epidermis. Ultraviolet light exposure, resident organisms on skin, and repeated sweating episodes are facilitating factors. Focal anhidrosis can occur and persist for several weeks, much longer than the miliaria in affected skin regions. Based on clinical and histopathology findings, miliaria is subdivided into four groups: (1) miliaria crystallina; (2) miliaria rubra; (3) miliaria pustulosa; and (4) miliaria profunda.

Miliaria crystallina (sudamina) consists of superficial, subcorneal, noninflammatory vesicles that easily rupture when rubbed with a finger (Fig. 84-5). They are common in infants in warmed environments, including in intensive care units where medications employed (cholinergic and adrenergic agents) may be stimulating sweating and aggravating the problem.[138,139]

Miliaria rubra (prickly heat) results when obstructed sweat migrates into the epidermis as well as the upper dermis, causing pruritic inflammatory papules around the sweat pores (see eFig. 84-5.1 in online edition). This disorder is common in infants, but also occurs in children and adults after repeated episodes of sweating in a hot, humid environment. The eruption usually subsides within a day after the patient moves to a cool environment. However, anhidrosis associated with miliaria takes 2 weeks (the time needed to repair the affected epidermal sweat duct unit by epidermal turnover) to recover completely. Some of the eruptions of miliaria rubra become pustular, resulting in miliaria pustulosa. Miliaria profunda results when the sweat leaks into the deeper dermis. During exposure to intense heat or after local injection of cholinergic agents, the affected skin can be uniformly covered with multiple discrete, flesh-colored papules that resemble gooseflesh. Ductal blockade at various levels is the immediate cause of miliaria. However, investigators do not agree on why the sweat escapes the duct at different levels (causing different subgroups of miliaria) nor on what causes the ductal blockade and/or ductal leakage at different levels.



Figure 84-5 Miliaria crystallina. Note the delicate, drop-like vesicles without erythema.

It is puzzling that the morphologic evidence of ductal blockade, such as keratin rings, PAS-positive proteins, or clusters of microorganisms, is rarely seen by light microscopic observation of miliarial lesions. Thus, Holzle and Kligman speculated that the keratin rings and PAS-positive proteins are the consequence but not the cause of ductal damage. The role of resident organisms especially *Staphylococcus epidermidis* has been proposed as a leading predisposing factor in miliaria.[140,141] Indeed, there was a linear correlation between the severity of miliaria rubra and the number of cocci in experimental miliaria under a plastic film. The development of experimental miliaria could be markedly suppressed by pretreatment of the skin with hexachlorophene or pyrithione.[140]

OTHER DISORDERS AFFECTING THE SWEAT DUCTS. Abnormalities of the epidermal portion of the spiraling sweat duct (acrosyringium) with altered sweat delivery to the skin surface are present in several disorders with immunohistologic evidence of neurogenic inflammation of skin. The presence of vanilloid receptors and neuropeptide fibers containing substance P and calcitonin-gene related protein in the acrosyringium may explain the presence of mast cell and other mediators of inflammation with subsequent impairment of sweating.[142–144]

DISORDERS WITH ALTERED COMPOSITION OF SWEAT

ATOPIC DERMATITIS. Dermcidin is a recently discovered antimicrobial peptide with a broad spectrum of activity. It is constitutively expressed in human eccrine sweat glands and secreted into sweat. Recent evidence suggests deficient amounts of sweat-derived antimicrobial peptides may play a role in skin inflammatory disorders characterized by increased bacterial colonization of the skin, such as atopic dermatitis.[143,145] Dermcidin and other antimicrobial proteins and peptides may have a therapeutical potential as topical anti-infectives in several skin diseases because of their broad spectrum of antimicrobial activity, the low incidence of bacterial resistance and their function as immunomodulatory agents.[118,146,147]

CYSTIC FIBROSIS. Sweat chloride ion concentration can determine the integrity of the CFTR Cl^- channel and provide diagnostic information for cystic fibrosis.[15] This in vivo assay may prove useful in studying the effectiveness of CF gene therapy. In vitro studies of the CFTR Cl^- activity from sweat glands obtained via skin biopsy are presently under evaluation as markers of the efficiency of CF-gene delivery and expression in sweat gland epithelial cells.[148] The saltier sweat may be responsible for the frequent observation of the aquagenic wrinkling of the palms (AWP) syndrome in CF patients.[149,150]

AQUAGENIC WRINKLING OF PALMS (AWP) SYNDROME. AWP is an uncommon disease characterized by the rapid and transient formation of edematous whitish plaques on the palms on

exposure to water.[151] Although the exact cause of this condition is unknown, hyperplastic glandular epithelium and aberrant AQP5 staining in the patient's sweat glands suggest that AWP stems from dysregulation of sweating.

KEY REFERENCES

Full reference list available at www.DIGM8.com

DVD contains references and additional content

3. Fealey RD: Thermoregulatory sweat test. In: *Clinical Autonomic Disorders*, 3rd edition, edited by PA Low, EE Benarroch. Philadelphia, PA, Lippincott Williams & Wilkins, 2008, pp. 244-263
13. Morgan CJ et al: Cutaneous microdialysis as a novel means of continuously stimulating eccrine sweat glands in vivo. *J Invest Dermatol* **126**(6):1220-1225, 2006
14. Kennedy WR, Wendelschafer-Crabb G, Brelje TC: Innervation and vasculature of human sweat glands: An immunohistochemistry-laser scanning confocal fluorescence microscopy study. *J Neurosci* **14**(11 Pt 2):6825-6833, 1994
16. Eisenach JH, Atkinson JL, Fealey RD: Hyperhidrosis: Evolving therapies for a well-established phenomenon. *Mayo Clin Proc* **80**(5):657-666, 2005
17. Hornberger J et al: Recognition, diagnosis, and treatment of primary focal hyperhidrosis. *J Am Acad Dermatol* **51**(2):274-286, 2004
33. Miller DL et al: Effect of sympathectomy level on the incidence of compensatory hyperhidrosis after sympathectomy for palmar hyperhidrosis. *J Thorac Cardiovasc Surg* **138**(3):581-585, 2009
36. Atkinson JL, Fode-Thomas NC, Fealey RD, Eisenach JH, Goerss SJ: Endoscopic transthoracic limited sympathotomy for palmar-plantar hyperhidrosis: Outcomes and complications during a 10-year period. *Mayo Clin Proc* **86**(8):721-729, 2011
38. Weksler B et al: Transection of more than one sympathetic chain ganglion for hyperhidrosis increases the severity of compensatory hyperhidrosis and decreases patient satisfaction. *J Surg Res* **156**(1):110-115, 2009
61. Kreyden OP, Scheidegger EP: Anatomy of the sweat glands, pharmacology of botulinum toxin, and distinctive syndromes associated with hyperhidrosis. *Clin Dermatol* **22**(1):40-44, 2004
90. Nolano M et al: Ross syndrome: A rare or a misknown disorder of thermoregulation? A skin innervation study on 12 subjects. *Brain* **129**(Pt 8):2119-2131, 2006
107. European Federation of Neurological Societies/Peripheral Nerve Society Guideline on the use of skin biopsy in the diagnosis of small fiber neuropathy. Report of a joint task force of the European Federation of Neurological Societies and the Peripheral Nerve Society. *J Peripher Nerv Syst* **15**(2):79-92, 2010
130. Horsefield R et al: High-resolution x-ray structure of human aquaporin 5. *Proc Natl Acad Sci U S A* **105**(36):13327-13332, 2008
143. Jarvikallio A, Harvima IT, Naukkarinen A: Mast cells, nerves and neuropeptides in atopic dermatitis and nummular eczema. *Arch Dermatol Res* **295**(1):2-7, 2003
145. Rieg S et al: Deficiency of dermcidin-derived antimicrobial peptides in sweat of patients with atopic dermatitis correlates with an impaired innate defense of human skin in vivo. *J Immunol* **174**(12):8003-8010, 2005

Chapter 85 :: Disorders of the Apocrine Sweat Glands

:: Christos C. Zouboulis & Fragkiski Tsatsou

Apocrine glands are adnexal glands that are distributed in the scalp, the axillae, the anogenital region, the eyelids (Moll's glands), the external auditory meatus (ceruminous glands), and the mammary glands. Apocrine glands can also be found in a more limited distribution on the face and abdomen. Apocrine glands are quiescent until puberty. Embryologically, apocrine glands develop from the upper bulge of the hair follicle late in the fourth month of gestation, with continued development as long as hair follicles develop. A primary epithelial germ (hair germ) grows down from the epidermis and forms an apocrine gland, sebaceous gland, and hair follicle. Apocrine glands are composed of three components: (1) the intraepithelial duct, (2) the intradermal duct, and (3) a coiled gland in the deep dermis or at the junction of the dermis and subcutaneous fat, which contains the secretory portion. The coiled gland consists of one layer of secretory cells around a lumen that is about ten times the diameter of its eccrine counterpart. Contractile myoepithelial cells, a hyaline basement membrane, and connective tissue surround the coiled gland. The predominant mode of apocrine secretion is decapitation, a process where the apical portion of the secretory cell cytoplasm pinches off and enters the lumen of the gland. Apocrine sweat consists mainly of sialomucin. Apocrine sweat is more viscous and produced in much smaller amounts than eccrine sweat (which actually is the wet portion of axillary sweat). The exact function of apocrine glands is unclear, although they are thought to represent scent glands. Their primary sympathetic stimulation is adrenergic.[1]

Four disorders are considered in this chapter: two primary disorders of the apocrine glands, namely (1) apocrine bromhidrosis and (2) apocrine chromhidrosis; and two secondary disorders, (1) Fox–Fordyce disease and (2) hidradenitis suppurativa (acne inversa), in which apocrine glands become secondarily affected.

APOCRINE BROMHIDROSIS

APOCRINE BROMHIDROSIS AT A GLANCE

- *Apocrine bromhidrosis* refers to an offensive or unpleasant body odor arising from apocrine gland secretions.
- Chronic disorder, most often developing in the axillae, but may also involve the genitals or plantar aspect of the feet.
- The best-characterized short chain fatty acid causing odor is ε-3-methyl-2-hexenoic acid.
- Should be distinguished from eccrine bromhidrosis.
- Surgical removal of affected glands may be effective.

Body odor, *osmidrosis*, is a common phenomenon in a postpubertal population. *Bromhidrosis* refers to body odor, which is excessive or particularly unpleasant and *apocrine bromhidrosis* to such an offensive odor that arises from apocrine glands. It is most often mentioned in the axillae. This condition may contribute to impairment in an individual's psychosocial functioning. The terminology in the literature is sometimes confusing, using *osmidrosis* to imply offensive odor, and *bromhidrosis* to imply osmidrosis in the setting of concomitant hyperhidrosis.[2]

EPIDEMIOLOGY

Disease onset after puberty is common and tends to be more prevalent in African-American populations. There is no geographic predilection, although summer months or warm climates may aggravate the disease. Poor personal hygiene may also be a contributing factor.[3]

ETIOLOGY AND PATHOGENESIS

Apocrine secretions are responsible for odor production, primarily through bacterial action on its components. It is accepted that the odorous steroids, the so-called pheromones, among them 16-androstenes, 5α-androstenol, and 5α-androstenone, contribute to osmidrosis.[4,5] 5α-Reductase type I is expressed in apocrine glands. Individuals with osmidrosis have increased levels of 5α-reductase in their apocrine glands. Because this enzyme catalyzes the conversion of testosterone to 5α-dihydrotestosterone, levels of 5α-dihydrotestosterone may be greater than testosterone in the skin of affected individuals.[6] The biotransformation of these steroids is complex and further research is required to delineate these pathways.

Moreover, the axilla hosts many different bacteria, most of which are Gram-positive ones. Bromhidrosis has been particularly associated with the action of aerobic *Corynebacterium* species. Eccrine bromhidrosis may develop from the action of bacteria on keratin that has been softened by eccrine secretions. In addition, the bacterial action on apocrine secretions produces ammonia and short chain fatty acids. The best-characterized short chain fatty acid is ε-3-methyl-2-hexenoic acid.[7] This acid is delivered to the surface of the skin on two binding proteins, apocrine-secretion binding proteins (ASOB1 and ASOB2). ASOB2 has been identified as apolipoprotein D.[8]

The effect of hyperhidrosis (excessive eccrine sweat secretion) on osmidrosis and bromhidrosis is unclear. Some have advocated that excessive eccrine sweat improves apocrine bromhidrosis by flushing away excessive apocrine secretions. Others have postulated that eccrine sweat augments apocrine bromhidrosis by encouraging local spread of apocrine sweat components and enhancing the moist environment in which bacteria flourish.[3]

CLINICAL FINDINGS

HISTORY. Patients complain of an unpleasant body odor. The axillae are the most common affected site, although the genitals or plantar feet may also be affected. The diagnosis is usually clinical. What constitutes a "normal" amount of body odor varies considerably among individuals and ethnic groups. In Asian populations, only slight odor is often considered diagnostic.[9,10]

CUTANEOUS LESIONS. Physical examination of the affected individual is usually unremarkable.

LABORATORY TESTS. There are no associated laboratory abnormalities.

PATHOLOGY. Although some reports do not reveal any abnormalities in the apocrine glands of affected individuals, an increase in the numbers and size of apocrine glands has also been reported.[9]

DIFFERENTIAL DIAGNOSIS

Apocrine bromhidrosis should be distinguished from eccrine bromhidrosis, which is far less common (see Chapter 84). Eccrine secretions are distributed in a generalized fashion, are usually odorless, and serve a thermoregulatory function. A plantar location is characteristic for eccrine bromhidrosis. Certain foods (garlic, curry, alcohol), drugs (bromides), toxins, or metabolic causes (disorders of amino acid metabolism) may result in eccrine bromhidrosis (Box 85-1).

TREATMENT

GENERAL MEASURES. Frequent washing of the axillae, use of a deodorant or antiperspirant

BOX 85-1 DIFFERENTIAL DIAGNOSIS OF APOCRINE BROMHIDROSIS

- Eccrine bromhidrosis
  - Fish odor syndrome (trimethylaminuria)
  - Phenylketonuria
  - Sweaty feet syndrome
  - Odor of cat syndrome
  - Isovaleric acidemia
  - Hypermethioninemia
  - Food, drug, toxin ingestion
- Liver failure (fetor hepaticus)
- Renal failure
- Nasal foreign body in children
- Poor hygiene
- Olfactory hallucinations
- Body dysmorphic disorder

From Rehmus W et al: Bromhidrosis. In: *emedicine*, edited by T McCalmont et al (http://www.emedicine.com), 2005.

(aluminum chloride), perfumes, and changing of soiled clothing can help. Removal of axillary hair may minimize odor by preventing bacteria and sweat accumulation on the hair shafts. Antibacterial soaps or topical antibacterial agents may also be of benefit.

NONSURGICAL THERAPY. The injection of botulinum toxin A has been reported to successfully treat genital[11] and axillary bromhidrosis.[12] The frequency-doubled, Q-switched Nd:YAG laser has also been reported to be an effective noninvasive therapy for axillary bromhidrosis.[13]

SURGERY. Several surgical measures have been investigated in the treatment of apocrine bromhidrosis. Patient selection is important because surgery is potentially associated with postoperative scar formation, prolonged healing times, infection, and other complications. Upper thoracic sympathectomy has been successful in treating apocrine bromhidrosis either in isolation or in association with palmar hyperhidrosis.[2] Surgical removal of the culprit apocrine glands can be achieved either by the removal of subcutaneous tissue in isolation or in combination with axillary skin.[14–16] Surgical subcutaneous tissue removal has also been used in association with CO_2 laser ablation.[17] Although surgical excision may be highly efficacious, depending on the depth of tissue removed and surgical technique used, regeneration and return of apocrine function/osmidrosis and bromhidrosis may develop. Superficial liposuction,[18] tumescent superficial liposuction with curettage,[19] and ultrasound-assisted liposuction[20] have efficacy in the management of apocrine bromhidrosis. In a series of 375 patients, more than 90% reported a satisfactory reduction in odor.[20] Another technique with reported efficacy is ultrasonic surgical aspiration of axillary apocrine glands with endoscopic confirmation.[21] This technique uses ultrasound to liquefy fat and sweat glands. In contrast, laser hair removal may be associated with intensification of bromhidrosis.[22]

PROGNOSIS AND CLINICAL COURSE

Apocrine bromhidrosis is a chronic and nonremitting condition. Patients with apocrine bromhidrosis often feel self-conscious and embarrassed by their condition and may develop impairment with psychosocial functioning.

APOCRINE CHROMHIDROSIS

APOCRINE CHROMHIDROSIS AT A GLANCE

- Rare, chronic condition characterized by the secretion of colored sweat.
- Axillary and facial involvement is most common. Areola involvement has been reported.
- Caused by an increased number of lipofuscin granules in the luminal secretory cells of the apocrine glands.
- Secretions may be yellow, blue, green, brown, or black.
- Wood's light examination may demonstrate fluorescence of secretions and stained clothes.
- Adequate therapy is lacking. Reports of efficacy with manual expression, capsaicin, and botulinum toxin.

Apocrine chromhidrosis is a rare condition characterized by the secretion of colored apocrine sweat. Two variants of apocrine chromhidrosis are recognized: (1) axillary and (2) facial. Involvement of the mammary areola has also been described.[23,24] Yonge first recognized facial chromhidrosis in 1709. Shelley and Hurley described this entity in 1954 and associated it with an increased number of lipofuscin granules in apocrine glands.[25]

EPIDEMIOLOLGY

Apocrine chromhidrosis is a rare disease. The worldwide prevalence is unknown. Onset of apocrine chromhidrosis is usually at puberty, at the time of increased apocrine gland activity. The disease persists throughout life, improving in the aged. It is reported most commonly in African-Americans.[26] Geographic predilections have never been described. Most of the

cases reported in the literature involve women; however, there is a lack of sound scientific evidence supporting a female preponderance.

ETIOLOGY AND PATHOGENESIS

The pigment responsible for causing apocrine chromhidrosis is lipofuscins that are produced in the apocrine secretory cells and excreted to the skin surface. Lipofuscin is a golden-colored pigment that is not specific to apocrine glands. In apocrine chromhidrosis, the lipofuscin granules are in a higher state of oxidation, thereby imparting various colors of pigment, such as yellow, green, blue, or black. Higher states of oxidation produce darker colors.[23] It is uncertain why this only develops in some individuals.[27]

One case of facial chromhidrosis was successfully treated with capsaicin. Nerve endings with receptors for substance P have been found around eccrine sweat glands, suggesting that substance P, a potent vasodilator, may play a role in sweat production and apocrine chromhidrosis.[28]

CLINICAL FINDINGS

HISTORY. Individuals with apocrine chromhidrosis often describe a sensation of warmth, a prickling sensation, or tingling feeling before apocrine gland secretion. Triggers for colored sweating are usually emotional or physical stimuli.[26] The morbidity associated with apocrine chromhidrosis stems from the emotional distress experienced by affected individuals.[29] Staining of undershirts and handkerchiefs are common complaints.

CUTANEOUS LESIONS. Individuals with apocrine chromhidrosis develop colored sweat in the axillae or face (Fig. 85-1). Mammary areolar involvement has also been described.[23] The pigment produced ranges in color from yellow, blue, green, brown, to even black. The quantity of pigmented sweat produced is usually quite small (approximately 0.001 mL at each follicular orifice).[30] The droplets are odorless and dry quickly. Dried secretions appear as dark flecks within affected areas. Axillary involvement causes staining of shirts and undergarments. Facial chromhidrosis commonly develops close to the lower eyelid, including the malar cheeks, and occasionally the forehead.[29,30] Colored sweat can also be manually expressed by squeezing in the affected area. Such a maneuver may also be therapeutic.[26]

SPECIAL TESTS. An examination of yellow, blue, or green secretions using a Wood's light (360 nm) produces a characteristic yellow fluorescence. Black or brown pigment rarely autofluoresces.[26] Secretions can be manually expressed if not present at the time of examination. Stained clothing may also fluoresce with Wood's lamp examination.[31] Apocrine glands can be stimulated to produce colored secretions by the injection of epinephrine or oxytocin.

LABORATORY TESTS. It is reasonable to check a complete blood cell count to exclude a bleeding diathesis, homogentisic levels in urine to exclude alkaptonuria, and bacterial and fungal cultures of affected areas to exclude pseudo-eccrine chromhidrosis.[27]



Figure 85-1 (**A**) Blue-black sweat produced in a patient with facial apocrine chromhidrosis after gentle squeezing of the cheeks (Reproduced with permission from Chang YC, Anderson N, Soeprono F. Bilateral facial pigmentation. *Dermatology Online J*. **13**(3):16, 2007), (**B**) blue-black apocrine pigmentation of the axilla and the inflammatory boils of a male patient with hidradenitis suppurativa.

PATHOLOGY

The luminal cells of the apocrine sweat glands have an eosinophilic cytoplasm, a large nucleus, and may contain lipofuscin, iron, lipid, or periodic acid-Schiff-positive and diastase-resistant granules.[32] Under light microscopy using hematoxylin–eosin staining, an increased number of (yellow–brown) lipofuscin granules may be present in the apical portion of luminal secretory cells of the apocrine glands. The number of granules varies. Additionally, autofluorescence of paraffin-embedded nonstained sections can be demonstrated using a 360-nm wavelength.[31] The granules are positive on periodic acid-Schiff stains. Schmorl stain may also be weakly positive.[33]

DIFFERENTIAL DIAGNOSIS

Apocrine chromhidrosis must be distinguished from eccrine chromhidrosis (Box 85-2; see Chapter 84). True eccrine chromhidrosis is very rare and occurs when water-soluble pigments are excreted from eccrine glands after the ingestion of certain drugs, such as quinines. *Pseudo-eccrine chromhidrosis* refers to the development of colored sweat when surface compounds or molecules mix with sweat to produce pigment. A classic example of this type is the formation of blue sweat in copper workers.[33] Extrinsic dyes, paints, fungi, and chromogenic bacteria (e.g., *Corynebacterium* species) are other causes of pseudochromhidrosis.[27]

TREATMENT

Adequate therapy for chromhidrosis is lacking. Manual expression of colored secretions may result in a temporary improvement in symptoms for the following 48–72 hours.[28] Botulinum toxin type A has reported to be successful in one patient with facial chromhidrosis. This patient experienced a substantial reduction in pigmented sweat and the results were sustained for 4 months.[34] Capsaicin is a topical cream that depletes and prevents reaccumulation of substance P levels in unmyelinated, slow-conducting type C sensory fibers. Case reports have demonstrated efficacy of capsaicin in the treatment of facial chromhidrosis.[28]

BOX 85-2 DIFFERENTIAL DIAGNOSIS OF APOCRINE CHROMHIDROSIS

- Eccrine chromhidrosis
  - Quinine ingestion
- Pseudo-eccrine chromhidrosis
  - Blue sweat with copper exposure
  - Extrinsic dyes, paints
- Alkaptonuria (ochronosis)
- Hyperbilirubinemia
- Hematohidrosis (bleeding diathesis)
- Chromogenic bacteria (e.g., *Corynebacterium* species), pseudomonas

From June K et al: Chromhidrosis. In: *emedicine*, edited by G Burg et al (http://www.emedicine.com), 2005.

PROGNOSIS AND CLINICAL COURSE

Apocrine chromhidrosis is a chronic disease that improves in old age as apocrine gland activity diminishes. Disease-associated morbidity is a result of psychosocial dysfunction experienced by affected individuals.

FOX–FORDYCE DISEASE

FOX–FORDYCE DISEASE AT A GLANCE

- An uncommon eruption characterized by pruritic skin-colored to pink papules localizing mainly to axillae and genitofemoral area.
- More than 90% of patients are female, and onset tends to be after puberty.
- Likely a result of intraluminal plugging of follicular infundibula, causing apocrine duct obstruction, rupture, and inflammation.
- The most consistent pathologic finding is hyperkeratosis and plugging of the follicular infundibula.
- Topical clindamycin, surgery, or other treatments may be of benefit.

Fox–Fordyce disease is an uncommon eruption characterized by pruritic follicular papules that localize to anatomic regions that bear apocrine glands.[35] George Henry Fox and John Addison Fordyce originally described it in 1902 in two patients with axillary involvement.[36] In 1925, Fischer hypothesized that Fox–Fordyce was a disease of the apocrine glands.[37] Shelley and Levy introduced the term *apocrine miliaria* as a synonym for this disease.[38]

EPIDEMIOLOGY

Approximately 90% of patients with Fox–Fordyce disease are female. Age of onset tends to be after puberty, with most patients between 13 and 35 years of age.[38] The incidence of this disorder is unknown. There is no reported ethnic or racial predilection.

ETIOLOGY AND PATHOGENESIS

FOLLICULAR PLUGGING. The triggers for the development of Fox–Fordyce disease are largely

unknown. Shelley and Levy hypothesized that the clinical manifestations of this disease are a result of intraluminal keratin plugging of the follicular infundibula, causing obstruction of the apocrine duct, rupture, and inflammation.[38] Although blockage of the apocrine duct seems important in disease development, experimentally plugging the duct has not clinically reproduced disease manifestations.[39] One case report detailed the development of Fox–Fordyce disease associated with obstruction of apoeccrine sweat glands.[40]

GENETICS. Genetics likely plays a role in disease development. This disease has been reported in two patients with Turner syndrome[41] and one patient with a small deletion on chromosome 21.[42] The disease has also been reported in identical male twins,[43] one set of siblings,[44] and in father and daughter.[45]

HORMONES. Hormonal influences on disease have been debated. Disease onset after puberty and improvement with pregnancy and estrogens lends support to a hormonal influence.[36,46] However, hormonal studies in one patient with Fox–Fordyce did not reveal any abnormalities.[47] Additionally, development before puberty has also been described.[48]

CLINICAL FINDINGS

HISTORY. Patients describe the development of pruritic papules at the time of puberty with gradual worsening. Pruritus can be triggered by emotional excitement or sweating.

CUTANEOUS LESIONS. Fox–Fordyce disease manifests as numerous symmetrically distributed skin-colored to slightly yellow or red follicular, dome-shaped papules that are equidistant from one another and characteristically intensely pruritic (Fig. 85-2). These papules may resemble lichen planus, lichen nitidus, folliculitis, or syringomas (Box 85-3). Excoriations may be prominent. Apocrine-rich areas are affected, most commonly the axillae. Other areas involved include the pubic area and perineum, mammary areola,[7] presternal area, periumbilical area, and upper inner thighs. Only sparse hair growth is seen in the affected area. Apocrine sweat is not produced in affected areas.

BOX 85-3 DIFFERENTIAL DIAGNOSIS OF FOX–FORDYCE DISEASE

- Lichen planus
- Lichen nitidus
- Folliculitis
- Multiple syringomas



Figure 85-2 Numerous skin colored to browning papules involving the axilla a woman with Fox-Fordyce disease (Reproduced with permission from Chae KM, Marschall MA, Marschall SM. Axillary Fox-Fordyce disease treated with liposuction-assisted curettage. *Arch Dermatol*. **138**:452-454, 2002.)

PATHOLOGY

Although the clinical features in patients with Fox–Fordyce disease are quite uniform, pathologic findings can vary considerably. The most distinct, relatively consistent pathologic finding is perifollicular foamy macrophages (xanthomatous infiltrates).[49] These cells expressed CD68 but lack expression of carcinoembryonic antigen, gross cystic disease fluid protein 15, and periodic acid-Schiff with diastase digestion. Perifollicular mucin, fibrosis, and mast cells in the infiltrate can also be observed. Dilation and hyperkeratosis of the follicular infundibula can also be seen and were previously considered as a histological sign of Fox–Fordyce disease. Other findings include spongiosis and solitary dyskeratotic cells throughout the infundibular epidermis, vacuolar changes at the dermal–epidermal junction in conjunction with some lymphocytes, cornoid lamella in the follicular infundibula with eosinophilic keratinocytes directly below the parakeratotic column, and few lymphocytes in the dermis surrounding the infundibula.[35] It has been suggested that transverse histologic sectioning of the specimen is the most effective and efficient method to demonstrate the characteristic pathologic features of Fox–Fordyce disease.[50]

TREATMENT

NONSURGICAL THERAPY. Treating Fox–Fordyce disease is difficult. Avoidance of excessive sweating or heat may minimize symptoms and flares. Clindamycin with propylene glycol has demonstrated efficacy in small case series in both eliminating symptoms and resolving papules.[44,51] Topical tretinoin 0.1%, although potentially irritating, has also demonstrated efficacy.[52] Topical pimecrolimus ointment has been shown effective.[53] Systemic isotretinoin led to almost complete clearance of lesions, but lesions recurred within 3 months after isotretinoin discontinuation.[42] Other reported medical therapies include oral contraceptives,[54] testosterone,[55] topical or intralesional corticosteroids,[56] ultraviolet light,[57] and X-rays.[47]

SURGERY. Electrocoagulation,[58] surgical excision,[59] and liposuction-assisted curettage[60] have all demonstrated efficacy.

PROGNOSIS AND CLINICAL COURSE

Fox–Fordyce disease is a chronic disease characterized by intermittent flares. It rarely remits. Infection or folliculitis may develop secondary to trauma caused by scratching.

HIDRADENITIS SUPPURATIVA/ ACNE INVERSA

HIDRADENITIS SUPPURATIVA AT A GLANCE

- Common disorder with a point prevalence of 1.0% and female preponderance.
- A chronic and recurrent disorder, usually developing after puberty and most commonly involving the genitofemoral area or axillae.
- Primary pathogenic event is believed to be follicular occlusion with subsequent inflammation, secondary adnexal gland involvement, fibrosis, and scarring.
- Pathologic features may include follicular hyperkeratosis, folliculitis, abscess formation, sinus tract formation, fibrosis, and granuloma formation.
- Surgery may sometimes be curative; clindamycin/rifampicin, hormonal treatments, some immunosuppressive medications and certain biologics (infliximab, adalimumab) may benefit some patients.

Hidradenitis suppurativa/acne inversa (HS) is a rather common, multifactorial, chronic and debilitating inflammatory skin appendage disorder with a notoriously underestimated burden of disease. The first International Hidradenitis Suppurativa Research Symposium (2006, Dessau, Germany) formulated the following definition: HS is a chronic, inflammatory, recurrent, debilitating skin disease (of the hair follicle) that usually presents after puberty with painful, deep-seated, inflamed lesions in the apocrine gland-bearing areas of the body, most commonly the axillary, inguinal, and anogenital regions.[61]

EPIDEMIOLOGY

Conflicting reports have provided a varying assessment of HS epidemiology. A current study recorded an HS prevalence of 1% in a representative sample of the French population (n = 10,000).[62] In a previous study, a point prevalence of up to 4.1% based on objective findings, and a 1-year prevalence of 1% based on patient recall was found.[63] It seems to be more common in females, with reported female–male ratios ranging from 2:1 to 5:1. The reason for female preponderance is unknown. HS rarely develops before puberty or after menopause, although persistence into menopause is not uncommon.[64] The average age of onset is 23 years.[65] Although the disease may develop in any apocrine gland-bearing skin, genitofemoral lesions are more prevalent in women, whereas axillary involvement does not demonstrate a gender predilection.[63,66,67]

ETIOLOGY AND PATHOGENESIS

HS is a disease of the terminal hair follicle associated with lymphohistiocytic inflammation, granulomatous reactions, sinus tracts, and scarring.[61,68] A consistent finding in histological studies of HS is a follicular occlusion due to hyperkeratosis, regardless of disease duration, whereas an isotopic hyperplasia of follicular epithelium is evident.[69] This leads to occlusion of the apocrine gland with subsequent follicular rupture, perifollicular inflammation and possible secondary infection, giving rise to clinical findings.[69–71] The concept of the follicular occlusion tetrad stems from the concept that HS, acne vulgaris, pilonidal sinus, and dissecting cellulitis share follicular occlusion as an inciting event that eventually leads to disease expression.

ADNEXAL STRUCTURES. Classically, HS was thought to represent a primary disorder of apocrine glands, and was also referred to as *apocrinitis*.[72] The anatomic location of disease in apocrine-bearing skin has supported this concept. Shelley and Cahn provided additional support of this concept by hypothesizing that poral occlusion of the apocrine duct reproduced the clinical and pathologic lesions using their experimental model.[73] More recent publications have refuted the concept that this primary event in HS

is apocrine gland inflammation and postulate that apocrine glands become secondarily affected.

GENETIC FACTORS. A family history of HS may be elicited in 26% of patients.[74] Several studies have not demonstrated HLA associations.[75,76] Others studies have suggested an autosomal dominant mode of inheritance with single gene transmission.[77–89] The group of experts, who participated at the first International Symposium has accepted that HS has to be a polygenic disease with sporadic cases having defects in a number of critical genes involved in its pathogenesis and familial cases with probably highly penetrant defect(s) in one of these genes.[61] A genome-wide scan in a four-generation Chinese family identified a first locus for HS at chromosome 1p21.1–1q25.3 into a 76-Mb region flanked by the markers *D1S248* and *D1S2711*.[90] This locus could not be confirmed by others groups.[68,91]

In a study of six Han Chinese families with familial disease, frameshift or termination mutations in the γ-secretase complex were identified at 19p13 suggesting that haplosufficiency might play a role in HS in familial cases.[92]

ASSOCIATED DISEASES. The coexistence of HS and Crohn disease, particularly with perianal involvement, has been associated with a more fulminant course.[80–83] Perianal Crohn disease may be clinically indistinguishable from perianal HS. A pilot study carried on ten HS patients detected no CARD15/NOD2 polymorphisms, found to be associated with Crohn disease.[93] This finding adds evidence to the fact that HS has to be distinguished from Crohn disease and its HS-like cutaneous manifestations.[94] Other reported associations include pyoderma gangrenosum,[84] nephrotic syndrome, and amyloidosis,[85] Dowling–Degos disease,[86] and arthropathy.[87–89] A current systematic literature review reported that follicular occlusion disorders, inflammatory bowel diseases, especially Crohn disease, spondyloarthropathy, other hyperergic diseases, genetic keratin disorders associated with follicular occlusion and squamous cell carcinoma are the most common HS comorbid diseases. A first classification of these major comorbidities and their possible genetic background revealed a list of chromosome loci and genes, which could be HS candidates. Most of these diseases belong to the group of autoinflammatory disorders, where Th17 cell cytokines seem to play a central role.[95]

HORMONES AND ANDROGENS. The tendency of HS to develop at puberty or postpuberty suggests an androgen influence. Additionally, disease flares have been reported postpartum,[86,96] in association with the oral contraception pill, and in the premenstrual period (approximately 50% of patients).[97] Antiandrogen therapy has also demonstrated therapeutic benefit in some studies.[98–101] However, no biochemical evidence of hyperandrogenism was found in 66 women with HS.[102] Additionally, unlike the sebaceous glands, the apocrine glands are not affected by androgens. Thus, the influence of androgens on HS is unclear.

OBESITY. Obesity is unlikely to be a causal factor in HS but is often regarded as an exacerbating factor by increasing shearing forces, occlusion, keratinocyte hydration, and maceration.[86,103,104] Obesity may also exacerbate disease by creating a state of androgen excess.[77] Weight reduction is recommended for overweight patients and may help to control disease.[66] A current multivariate analysis showed a strong association with body mass index [odds ratio = 1.1 (1.1–1.2)].[62]

BACTERIAL INFECTION. The role of bacterial infection in HS is unclear. It is believed that the pathogenic role is indirect, similar to the role of bacteria in acne. Bacterial involvement is thought by some authors to occur secondarily. Routine cultures are often negative, but numerous bacteria have been recovered from lesions. *Staphylococcus aureus* and coagulase-negative *Staphylococci* are most frequently isolated.[105,106] However, other bacteria, including *Streptococci*, Gram-negative rods, and anaerobes, have also been identified. These are likely to be colonizing bacteria rather than causative bacteria,[86,107] a concept that could explain the increased expression of Toll-like receptor 2 as well as of β-defensin 2 and psoriasin in HS lesions.[108,109]

SMOKING. The use of tobacco products is more common in HS patients than in healthy controls.[110,111] One study determined that 70% of their 43 patient cohort with perineal HS were smokers.[112] It is postulated that smoking affects polymorphonuclear cell chemotaxis.[64] Multivariate analysis showed a strong association with current smoking (odds ratio = 12.6, 95% CI 8.6–18.4).[62] Smoking cessation may improve the clinical course of the disease.

CLINICAL FINDINGS

HS is a chronic disease with a variable clinical course.[113–115] The diagnosis of HS is clinical, and a biopsy is rarely needed (Box 85-4). Clinical diagnostic criteria are wide and include recurrent disease, scarring, and multifocal location.[66]

One of the most obvious hallmarks of the disease is the restriction to the skin areas affected.[113–115] The disease is essentially limited to the intertriginous areas, although aberrant lesions may occur. The sites affected in order of decreasing frequency include: axillary, inguinal, perineal and perianal, mammary and inframammary, buttocks, pubic region, chest, scalp, retroauricular, and eyelid.[64] HS is not acne: closed comedones are not seen, since the deep part of the follicle appears to be involved and not its superficial compartments, as seen with acne affecting convex skin surfaces. HS inflammatory lesions are initially transient, but gradually become intransigent and associated with significant scarring.[61,115]

SEVERITY. Three stages of disease are recognized and named after Hurley (I–III)[116] In the primary stage, abscesses develop in isolated locations. The secondary

BOX 85-4 DIFFERENTIAL DIAGNOSIS OF HIDRADENITIS SUPPURATIVA

- Abscesses (including from methicillin-resistant *Staphylococcus aureus*)
- Furuncles/carbuncles
- Actinomycosis
- Cat scratch disease
- Donovanosis
- Lymphogranuloma venereum
- Lymphadenitis
- Infected Bartholin cyst
- Crohn disease
- Ulcerative colitis
- Tuberculosis
- Tularemia
- Ruptured epidermal cyst

From Jovanovic M et al: Hidradenitis suppurativa. In: *emedicine*, edited by D Siegel et al (http://www.emedicine.com), 2006.

stage involves the development of sinus tracts with scars bridging individual lesions. The tertiary stage shows coalescing lesions with scarring and sinus tracts, inflammation, and chronic discharge.

The disease onset is insidious and shows variable severity. Otherwise healthy postpubertal individuals initially may experience slight discomfort or pruritus. After this, a tender papule or deep-seated nodule (0.5 to 2.0 cm) ensues (eFig. 85-2.1 in online edition). Pustules may also be visualized (eFig. 85-2.2 in online edition). This nodule may slowly resolve or may expand and coalesce with surrounding nodules to form large painful inflammatory abscesses. These abscesses are rounded without central necrosis and may resolve or rupture spontaneously, producing a purulent discharge (Fig. 85-3). Eventual healing may result in scarring with fibrosis (Fig. 85-4), dermal contractures and rope-like elevation of the skin (Fig. 85-5), and double-ended comedones (eFig. 85-5.1 in online edition). Sinus tracts may also develop (Fig. 85-6). Sinuses have been



Figure 85-3 A ruptured draining abscess involving the groin of a male patient with hidradenitis suppurativa.



Figure 85-4 Area of scarring with associated fistules involving the axilla of a male patient with hidradenitis suppurativa.

reported to involve deep tissue, including muscle and fascia, urethra, and bowel. The process then recurs in an adjacent area or different apocrine-bearing site.[66]

LABORATORY TESTS. Patients with acute lesions of HS may demonstrate an increase in the erythrocyte sedimentation rate or *C*-reactive protein. If there is any concern over infection, then deep cultures (not skin surface) from lesions should be conducted and submitted for bacterial, tuberculosis, and fungal cultures.[117]



Figure 85-5 Large scars and fistule pseudo-comedones at the buttocks of a male patient with severe hidradenitis suppurativa involving the anogenital area.



Figure 85-6 Sinus tract formation developing in the vulva of a woman with hidradenitis suppurativa. (Used with permission from Dr. L. Edwards.)

SPECIAL TESTS. Ultrasonography of the follicles and dermis may reveal abscess formation and abnormalities in the deep part of the follicle, but is rarely indicated.[117] Magnetic resonance imaging features of the skin and subcutaneous tissue have been described. Such features included marked thickening of the skin, induration of the subcutaneous tissues, and multiple subcutaneous abscesses.[118]

PATHOLOGY

The early lesions of HS demonstrate follicular hyperkeratosis. Epidermal psoriasiform hyperplasia and subepidermal interfollicular inflammatory infiltrate have been additionally observed in a current report.[69] The deep part of the follicle appears to be involved. Dermal features include perifolliculitis, active folliculitis or abscess, sinus tract formation, fibrosis, and granuloma formation. There is evidence of an inverse relationship between fibrosis and inflammation, supporting the concept that fibrosis corresponds to areas of chronic involvement.[119] Histologic feature examination of adnexal structures reveals inflammation of the apocrine glands in only one-third of cases. Interestingly, involvement of eccrine glands (25%) has been reported to be more common than apocrine glands (12%).[120,121] Poral occlusion or cyst formation may be noted. The subcutis may demonstrate some fibrosis, fat necrosis, or inflammation.[70,71]

A reduction in the percentage of NK cells over time and a lower monocyte response to triggering by bacterial components was observed in patients with HS.[122] Compared with normal skin, increased numbers of TLR2-expressing infiltrating macrophages ($CD68^+$) and dermal dendrocytes ($CD209^+$) was detected in HS lesions.[108] In addition, a striking $CD8^+$ lymphocyte epitheliotropism was identified.[69]

COMPLICATIONS

QUALITY OF LIFE. Patients with HS experience a significant degree of morbidity when quality of life is measured by the Dermatology Life Quality Index.[123] The highest scores relate to disease-associated pain. Quality of life measurements are lower than other dermatologic diseases that have been investigated using this tool.[124] Loss of workdays is a socioeconomic consequence. Women lose significantly more days of work (mean, 2.9 days) than men (mean, 1.7 days).[117] A significant positive correlation of fair degree between HS severity and life quality index was detected.[125]

SYSTEMIC COMPLICATIONS. Local infection may develop and lead to septicemia. A case of lumbosacral epidural abscess has been reported.[126] Anemia or leukocytosis may be detected, but does not tend to be significant clinically.[127,128]

LOCAL COMPLICATIONS. Scarring may limit mobility. Anal, urethral, or rectal strictures may develop from chronic genitofemoral inflammation. Urethral fistulas have also been reported.[129] Additionally, disfiguring persistent penile, scrotal, or vulvar lymphedema due to blockade or destruction of local lymph drainage routes subsequent to chronic and recurrent inflammation may develop,[130] giving rise to significant functional impairment. Once this complication appears, no medical treatment is effective and surgical reconstruction may be necessary.[131] Squamous cell carcinoma (SCC) may rarely develop in chronically inflamed and scarred areas in individuals with long-standing disease.[132,133] SCC has been reported in 3.2% of patients with perianal HS lasting 20–30 years. Malignant transformation affects mainly men with a long-term history of genitoanal HS, whereas HPV has been detected in these genitoanal tumoral lesions, principally HPV-16.[133] These carcinomas tend to be more aggressive locally and are associated with a high incidence of metastatic disease and mortality (up to 50%). One case of paraneoplastic neuropathy has been described in association with SCC complicating severe perineal HS.[134] Clinicians should have a low threshold for biopsying any nonhealing lesion localizing to an area of chronic HS. One case-controlled Swedish study found that the overall incidence of malignancy, including nonmelanoma skin cancer, is increased in patients with HS.[135]

TREATMENT

The objective of patient management is prevention of the development of primary lesions as well as resolution, amelioration, or regression of secondary disease features such as scarring or sinus tract formation. The literature reveals only few randomized controlled studies, several case series, and a plethora of case reports.

Assessing severity is a prerequisite to manage individual patients; the classification of Hurley[113] is still useful: stage I is manageable with systemic drugs, stage II may benefit from medical treatment and from limited excisions of locally recurring lesions, stage III requires radical surgery (Box 85-5). On the other hand, the modified Sartorius score is more sensitive and

BOX 85-5 PROPOSAL FOR A GLOBAL ALGORITHM OF TREATMENT OF HIDRADENITIS SUPPURATIVA/ACNE INVERSA

HS STAGE	TREATMENT
Hurley stage I	Clindamycin 300 mg 2–3×/day (alternatively minocycline 100 mg/day) and rifampicin 300 mg 2×/day p.o. for 4–12 week (to potentate: clindamycin 300 mg 2–3×/day iv during the first 5 days of treatment) For females with signs of hyperandrogenism/hyperandrogenemia (additionally): hormonal antiandrogen with cyproterone acetate (up to 100 mg/day)
Hurley stage II	Step 1: As stage I Step 2: Limited excisions of locally recurring lesions
Hurley stage III	Step 1: As stage I Step 2: Infliximab (5 mg/kg) (alternatively adalimumab 40 mg) once or twice (Step 3: Ultrasonography of the area to be excised) Step 4: Wide excision of the involved area

useful in evaluating disease severity in clinical studies[125] (Box 85-6).

MEDICAL TREATMENT. Treatment is often disappointing, which has a significant negative impact on the patient's quality of life. Although topical and systemic antibiotics are effective, supportive evidence for bacterial etiology is lacking. In an evidence-based analysis of standard treatments and recent advances in the therapy of HS, only treatment with topical clindamycin 1% solution,[136] oral clindamycin and rifampicin, or with the hormonal antiandrogen cyproterone acetate 100 mg/day achieved an evidence level 2 and a recommendation grade B.[137] In three retrospective studies, 164 HS patients have received clindamycin 300 mg 2×/day and rifampicin 300 mg 2×/day for 10–12 weeks.[138–140] Thirty-two experienced complete remission of HS of between 1 and 4 years after only one course of treatment, and further two patients achieved remission after substituting clindamycin with minocycline (100 mg/day) because of transient diarrhea. Twenty-one patients were unable to complete the course of treatment because of side effects, mostly diarrhea. Most responders have not subsequently relapsed. A randomized controlled study comparing topical clindamycin with systemic tetracycline did not reveal a statistical difference.[141]

Intralesional corticosteroids may be of benefit for patients with an isolated number of tender lesions.[142] Practically, such treatment may not be appropriate for individuals with extensive disease and is not appropriate for areas of chronic inflammation.

Oral isotretinoin is ineffective in the treatment of HS. In a study with 358 HS patients interviewed and

BOX 85-6 MODIFIED SARTORIUS SCORE FOR EVALUATION OF DISEASE SEVERITY

	NUMBER	FACTOR	TOTAL
1. Number of regions involved, namely axillary area, (right/left), groin (right/left), gluteal area (right/left), other	_____	× 3 =	_____ _____
2. Number of lesions (per region)			
▪ Number of nodules (painful or sensitive)	_____	× 1 =	_____ _____
▪ Number of fistules (all purulent lesions, spontaneously or after pressure)	_____	× 6 =	_____ _____
3. Longest distance between two relevant lesions (per region) <5 cm = 1; 5–10 cm = 3; >10 cm = 9	_____	=	_____
4. All lesions are separated by normal skin (per region) yes = 0; no (Hurley III) = 9	_____	=	_____
TOTAL			_____ _____ _____

From Sartorius K, Emtestam L, Jemec GB, Lapins J: Objective scoring of hidradenitis suppurativa reflecting the role of tobacco smoking and obesity. *Br J Dermatol* **161**:831, 2009.

examined for the effect of previous treatment with oral isotretinoin, only 16.1% declared an improvement.[143] In a previous study with 68 patients, 23.5% were cleared during therapy, whereas only 16.2% maintained improvement during a follow-up period of up to 6 months.[144] One case report described an individual with severe vulvar HS who, after treatment with prednisolone and then long-term isotretinoin (more than 1 year), remained disease free at 10 months posttreatment.[145] The other systemic retinoids, acitretin and etretinate, have also demonstrated limited efficacy in disease management.[146,147]

Hormonal therapy does have some reported success. In a double-blinded study, the antiandrogen, cyproterone acetate (50 mg), in conjunction with ethinyl estradiol (50 µg), resulted in complete or partial clearance at 18 months posttreatment in 50% of patients.[99,100] In a retrospective study with 64 female HS patients antiandrogen therapy was superior to oral antibiotic therapy (55% vs. 26%). Female patients presenting with HS should prompt investigations for underlying PCOS and insulin resistance.[148] The 5α-reductase inhibitor, finasteride (1 mg), may also have a weak limited effect on disease management.[101,149]

Intramuscular human immunoglobulin (HIG; 1,320–1,980 mg sc/m) administered in five HS patients led to >50% improvement in four patients.[150]

In a pilot study, 22 patients with Hurley's grade I and II were treated with 90 mg/day zinc gluconate; 8 complete remissions (CR) and 14 partial remissions were observed. When CR was obtained, the treatment was progressively decreased; 4 out of 22 patients experienced side effects, mainly gastrointestinal.[151]

Emerging data on the efficacy of biologics as monotherapy[152–154] did not fulfill the expectations initially, since etanercept and efalizumab showed a minor effectiveness in a few open and was ineffective in one controlled study (Box 85-7).[155–160] In contrast, infliximab, a chimeric monoclonal antitumor necrosis factor antibody, has demonstrated efficacy in several case reports with severe HS patients in both open and a controlled study, although the results seem transient and

BOX 85-7 TREATMENT OF HIDRADENITIS SUPPURATIVA/ACNE INVERSA WITH BIOLOGIC AGENTS (STUDIES WITH ≥3 PATIENTS; PATIENTS WITH CROHN'S DISEASE WERE EXCLUDED)

				RESULT		
				Improvement ≥50%		Relapse after A Discontinuation or Surgical Treatment Required
AGENT REFERENCE	NO. OF PATIENTS	SCHEMA	DURATION	No	Yes	
Adalimumab[168–171]	12	40 mg/2nd week-40–80 mg/week		0	12 (100%)	5/6 (83%)
Efalizumab[160]	5	1.0 mg/kg/week	3 months	5	0 (0%)	
Etanercept[155–158]	34	25 mg sc 2×/week	3–10 months	19	15 (44%)	10/14 (71%)
Infliximab[161–167]	40	5–10 mg/kg 0, 2, 6 week	2.5–72 months	21	19 (48%)	11 (53%)

Randomized, Prospective, Double-Blind, Placebo-Controlled Studies

				RESULT		
				Improvement ≥50%		Relapse After A Discontinuation or Surgical Treatment Required
AGENT REFERENCE	NO. OF PATIENTS	SCHEMA	DURATION	No	Yes	
Etanercept[159]	20 (crossover)	50 mg sc 2×/week	3	No significant difference compared with placebo		
Infliximab[168]	33 (crossover)	5 mg/kg 0, 2, 6 week	2.5	Significant improvement under infliximab ($p < 0.001$) (27% >50% improvement under infliximab: 5% under placebo)		Yes

are associated with significant toxicity as long-term treatment.[161–168] Small case series with adalimumab exhibited even more promising results but controlled studies are still missing.[169–171]

Case reports or small case series have also shown therapeutic success with other systemic therapies, including systemic corticosteroids, azathioprine, cyclosporine, dapsone, and methotrexate.[86,172–176]

Local therapies have also been recently examined. A single patient with aggressive perianal HS has responded favorably to wide surgical excision in conjunction with perilesional granulocyte-macrophage colony-stimulating factor injections.[177] A small case series demonstrated the efficacy of treatment of persistent painful nodules with cryotherapy. Healing time in these patients was lengthy (18–42 days).[178] Finally, the first case of botulinum toxin A successfully treating HS has been reported. In this case, injections into the axillae resulted in a 10-month remission.[179] Topical 15% resorcinol peel in 12 women with HS Hurley stage I or II led to a significant decrease in pain and a reduction in mean duration of the painful abscesses.[180]

Photodynamic therapy (PDT) as treatment for HS has recently been described in three small case series, but is neither established nor has been standardized.[181–184] Moreover, pulsed dye laser-mediated photodynamic therapy was not successful in a pilot study with four self-controlled cases.[185]

SURGERY. Surgical removal of all involved tissue, beyond clinically involved margins, is an effective treatment modality.[186–190] Postoperative recurrences may occur. Some authors have advocated the use of CO_2 laser[191,192] or the neodymium-doped yttrium aluminum garnet laser[193,194] for surgical ablation of tissue. The modality of closure has been a topic of debate. Overall, healing by secondary intent is thought to provide the best outcome. Primary closure, grafting, or flaps have been extensively used, but may be associated with poorer results.[195–201] In one series of 106 patients, there was a 70% recurrence rate requiring subsequent operation in the primary closure cohort and no recurrence in the split-thickness graft and flap groups.[202] A more limited surgical approach also plays a role in disease management. Deroofing or marsupializing of recurrent troublesome lesions or sinus tracts may aid with local control.[203] Lancing an inflammatory lesion is of limited benefit and should be discouraged.[195,204,205] A study with 200 patients has shown that enclosure of gentamicin after primary excision of HS lesions can reduce the number of complications 1 week postoperatively but it was ineffective on the long-term recurrence rate.[206] Ultrasonography can identify the true extent of lesions in HS, which may be of use in the preoperative planning.[207,208]

RADIOTHERAPY. Several authors have reported radiotherapy to be successful in the treatment of HS. Given the often young patient population with HS, long-term side effects must be considered.[209,210]

BIOMARKERS. Soluble interleukin-2 receptor (sIL-2R) and tumor necrosis factor-α serum levels were found increased in HS and especially sIL-2R correlated well with Hurley's grade.[211,212] Both serologic markers may be used as a valuable marker for disease staging and evaluation of treatment in patients with HS.

KEY REFERENCES

Full reference list available at www.DIGM8.com

DVD contains references and additional content

12. Heckmann M, Teichmann B, Pause BM: Amelioration of body odor after intracutaneous axillary injection of botulinum toxin A. *Arch Dermatol* **139**:57, 2003
34. Matarasso SL: Treatment of facial chromhidrosis with botulinum toxin type A. *J Am Acad Dermatol* **52**:89, 2005
49. Bormate AB Jr, Leboit PE, McCalmont TH: Perifollicular xanthomatosis as the hallmark of axillary Fox-Fordyce disease: An evaluation of histopathologic features of 7 cases. *Arch Dermatol* **144**:1020, 2008
61. Kurzen H et al: What causes hidradenitis suppurativa? *Exp Dermatol* **17**:455, 2008
62. Revuz JE et al: Prevalence and factors associated with hidradenitis suppurativa: Results from two case-control studies. *J Am Acad Dermatol* **5**:596, 2008
95. Fimmel S, Zouboulis CC: Comorbidities of hidradenitis suppurativa (acne inversa). *Dermatoendocrinol* **2**:9, 2010
113. Alikhan A, Lynch PJ, Eisen DB: Hidradenitis suppurativa: A comprehensive review. *J Am Acad Dermatol* **60**:539, 2009
114. Revuz J: Hidradenitis suppurativa. *J Eur Acad Dermatol Venereol* **23**:985, 2009
125. Sartorius K et al: Objective scoring of hidradenitis suppurativa reflecting the role of tobacco smoking and obesity.*Br J Dermatol* **161**:831, 2009
152. Haslund P, Lee RA, Jemec GB: Treatment of hidradenitis suppurativa with tumour necrosis factor-alpha inhibitors. *Acta Derm Venereol* **89**:595, 2009
186. Kagan RJ et al: Surgical treatment of hidradenitis suppurativa: A 10-year experience. *Surgery* **138**:734, 2005

SECTION 15

Disorders of the Hair and Nails

Chapter 86 :: Biology of Hair Follicles

:: George Cotsarelis & Vladimir Botchkarev

BIOLOGY OF HAIR FOLLICLES AT A GLANCE

- The primary purpose of hair in humans is to influence social interactions.
- Hair follicle development depends on interactions between epithelial and mesenchymal cells. The genes important for this interaction are slowly being elucidated.
- Genes important for hair follicle development also play a role in hair follicle cycling.
- The hair follicle bulge possesses stem cells important for the continual regeneration of the follicle during cycling.
- Hair pigmentation depends on melanocyte stem cells and differentiated cells in the follicle. Many genes important for melanocyte behavior and hair pigmentation have been defined.

EVOLUTION AND FUNCTION OF HAIR

Hair is found only in mammals, where during the course of evolution its primary roles were to serve as insulation and protection from the elements. However, in contemporary humans, hair's main purpose revolves around its profound role in social interactions. Loss of hair (alopecia) and excessive hair growth in unwanted areas (hirsutism and hypertrichosis) can lead to significant psychological and emotional distress that supports a multibillion-dollar pharmaceutical and cosmetic effort to reverse these conditions.

Fundamental understanding of hair growth and its controls is increasing and result in new treatments for alopecia.[1,2] These advances resulted from the interest of developmental biologists and other investigators in the hair follicle as a model for a wide range of biologic processes. As each hair follicle cyclically regenerates, it recapitulates its initial development. Many growth factors and receptors important during hair follicle development also regulate hair follicle cycling.[3–10] The hair follicle possesses keratinocyte and melanocyte stem cells (MSCs), nerves, and vasculature that are important in healthy and diseased skin.[11–13] To appreciate this emerging information and to properly assess a patient with hair loss or excess hair (see Chapter 88), an understanding of the anatomy and development of the hair follicle is essential.

EMBRYOLOGY

Morphologically, hair follicle development has been divided into eight consecutive stages, several of which are illustrated in Fig. 86-1. Each stage is characterized by unique expression patterns for growth factors and their receptors, growth factor antagonists, adhesion molecules, and intracellular signal transduction components.[14–16] Promising advances in understanding the molecular mechanisms behind hair follicle development arose through the discovery that mammalian counterparts (homologs) of genes important for normal *Drosophila* (fruit fly) development also affect hair follicle development. *Decapentaplegic [Dpp/bone morphogenetic protein (BMP)], Engrailed (en), Homeobox (hox), hedgehog/patched (hh/ptc), notch, wingless/armadillo (wg/wnt/catenin) genes are all critical for hair follicle and vertebrate development in general.*[17–19] These genes were all first discovered in *Drosophila*, thus, most of the names assigned to them describe the peculiar appearance (phenotype) of the flies carrying mutations in these genes.[20]

Follicle formation begins on the head, and then moves downward to the remainder of the body in utero. The first hairs formed are lanugo hairs, which are nonpigmented, soft, and fine. Lanugo hair is typically shed between the 32nd and 36th weeks, although approximately one-third of newborns still retain their lanugo hair for up to several weeks after birth.

Patterning genes, called *homeobox genes*, which are precisely organized in the genome so that they are

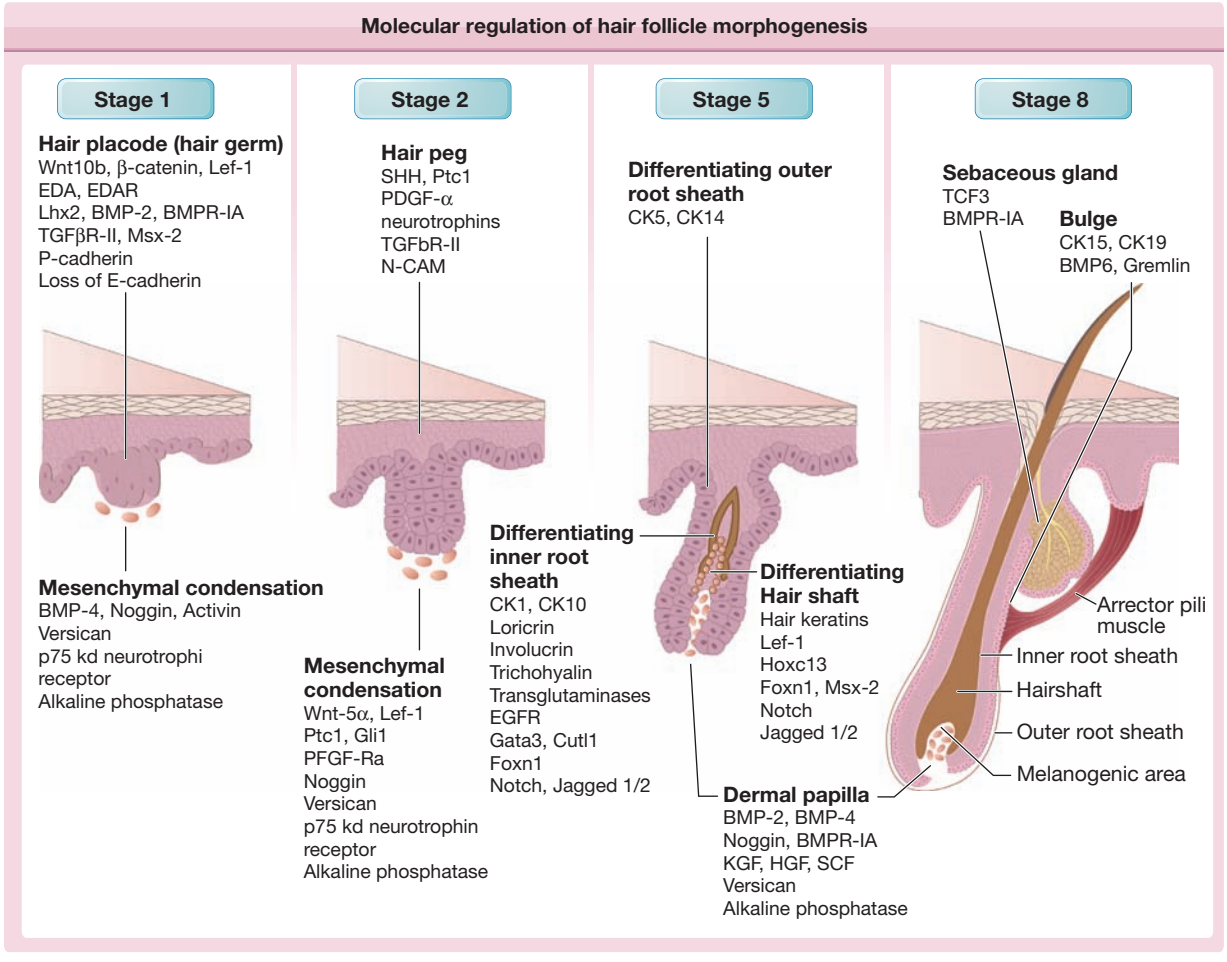

Figure 86-1 Molecular regulation of hair follicle morphogenesis. The scheme shows the expression of different growth factors, their receptors, adhesion, and cell matrix molecules, transcriptional regulators in hair follicle epithelium, and mesenchyme during distinct stages of hair follicle development. BMP = bone morphogenetic protein; BMPR-IA = bone morphogenetic protein receptor, type IA; CK = keratin 5; Cutl1 = cut-like 1; E-cadherin = epithelial cadherin; EDA = ectodysplasin; EDAR = ectodysplasin receptor; EGFR = epidermal growth factor receptor; Foxn1 = forkhead box N1; Gata3 = GATA binding protein 3; Gli1 = glioma-associated oncogene homolog 1; HGF = hepatocyte growth factor; Hoxc13 = homeobox C13; KGF = keratinocyte growth factor; Lef-1 = lymphoid enhancer factor 1; Lhx2 = LIM homeobox 2; N-CAM = neural cell adhesion molecule; P-cadherin = placental cadherin; PDGF-α = platelet-derived growth factor α polypeptide; PFGF-Rα = platelet-derived growth factor receptor α; Ptc1 = patched1; SCF = stem cell factor; Shh = sonic hedgehog; TCF3 = transcription factor 3; TGF-βR-II = transforming growth factor-β receptor 2.

expressed in strict temporal sequences and spatial patterns during development, likely are responsible for the nonrandom and symmetric distribution of hair follicles over the body.[21,22] In adult mice, homeobox gene expression reappears in hair follicles and serves to maintain normal hair shaft production.[6] *Engrailed*, a type of homeobox gene, is responsible for dorsal–ventral patterning, and mice lacking *engrailed* develop hair follicles on their footpads.[23]

Although hair follicles and hairs all share the same basic anatomy, their growth, size, shape, pigmentation, and other characteristics differ widely, based on body location and variation among individuals. Many of these characteristics are established during development but are then profoundly altered by hormonal influences later in life. We are beginning to understand the genes controlling hair length, curl and distribution because of elegant genetic studies on dogs. These studies reveal that fibroblast growth factor-5 (FGF-5), Keratin 71, and R-spondin 2 influence length, curl and distribution respectively.[24] In humans, thicker hair found in Asians is associated with increased activity of *ectodysplasin receptor (EDAR)*,[25] the receptor of ectodysplasin (*EDA*) (see below).

The size of many types of follicles changes drastically several times throughout life. For example, lanugo hair follicles, which produce hair shafts several centimeters long, convert to vellus follicles that produce small hairs that protrude only slightly from the skin surface. Later in life, vellus follicles on the male beard enlarge into terminal follicles that generate thick, long hairs. On the scalp of genetically

predisposed individuals, terminal follicles miniaturize and form effete, microscopic hairs.

EPITHELIAL PLACODE OR PRIMARY HAIR GERM

In the human fetus, hair follicles develop from small collections of cells, called *epithelial placodes*, which correspond to stage 1 of hair follicle development and first appear around 10 weeks' gestation (see Fig. 86-1). The epithelial placode then expands to form the "primary hair germ" whose progeny eventually generate the entire epithelial portion of the hair follicle.[26]

The cells of the hair placode and germ express placental cadherin and become oriented vertically, losing their desmosomes, hemidesmosomes, and epithelial cadherin, which decreases their adhesion to their neighbors.[27–29] Dermal cells beneath the hair placode form a cluster (or condensate), which later develops into the dermal papilla.[30]

Hair follicle formation depends on a series of mesenchymal/epithelial interactions.[30] An initial signal arises in the mesenchyme (primitive dermis) and instructs the overlying epithelium to form an appendage, indicated by the appearance of regularly spaced placodes (see Fig. 86-1). The second signal arises from the epithelial placode and causes an aggregation of cells in the underlying mesenchyme that will eventually form the dermal papilla. Finally, a signal from this primitive dermal papilla initiates proliferation and differentiation of placode cells, ultimately leading to formation of a mature follicle. These reciprocal signals pass through the intervening basement membrane, which undergoes alterations in its morphology and chemical composition that may alter its ability to sequester growth factors and binding proteins, thus possibly modulating the epithelial/mesenchymal interactions.

Many of these regulatory molecules important for the formation of the hair follicle have been defined, but how they interact to generate hair follicles in an otherwise homogeneous epithelium is yet to be determined. In one model, the spacing and size of placodes are regulated by a dermal signal, which varies in character in different body regions. The dermal signal occurs uniformly within each body region and triggers the activation of promoters and repressors of follicle fate in the epithelium that then compete with one another, resulting in the establishment of a regular array of follicles.[15,31] Differences in the levels of promoter and repressor activation could account for regional differences in the size and spacing of follicles. Consistent with this model, several positive and negative regulators of hair follicle fate are initially expressed uniformly in the epidermis and subsequently become localized to placodes.

One of the earliest molecular pathways that positively regulates hair follicle initiation is the WNT/β-catenin pathway. β-Catenin is the downstream mediator of WNT signaling. WNT proteins bind to receptors on the cell membrane and, through a series of signals, inhibit the degradation of cytoplasmic β-catenin. β-Catenin then translocates to the nucleus, forming a complex with the LEF/TCF family of transcription factors and resulting in expression of downstream genes.[15,31] Activation of this β-catenin pathway appears necessary for establishing epithelial competence—a state in which the epithelial tissue has the potential to form a hair follicle. Normally, the β-catenin pathway is inactive in the adult epidermis, but by artificially activating β-catenin in epidermal basal cells of adult transgenic mice, hair follicles develop de novo.[32] This remarkable finding could eventually have therapeutic implications, although constant activation of this pathway in the hair follicle also results in pilomatricomas and trichofolliculomas, two types of relatively rare cutaneous tumors.[32,33]

EDA, a molecule related to tumor necrosis factor, and its receptor (*EDAR*) also are part of another major pathway that stimulates early follicle development in both mice and humans.[34] *EDA* gene mutations cause X-linked anhidrotic ectodermal dysplasia, a syndrome associated with decreased numbers of hair follicles, and defects of the teeth and sweat glands (see Chapter 142).[35] The *EDAR* gene is mutated in autosomal recessive and dominant hypohidrotic ectodermal dysplasias, causing identical phenotypes to those resulting from *EDA* mutations. The mouse *Edar* gene is expressed ubiquitously in the epithelium before placode formation, and then becomes restricted to placodes, whereas the *Eda* gene is ubiquitously expressed even after placode formation.[36] Mice with mutations in these genes have the same phenotype as humans with similar mutations, and mice overexpressing Eda in the epidermis show formation of the "fused" follicles due to the loss of proper spacing between neighboring hair placodes.[37,38] Humans with more active *EDAR* genes have thicker hair.[25]

In contrast to EDA and EDAR, which promote hair follicle development, members of the BMP family inhibit follicle formation. *Bmp2* is expressed diffusely in the ectoderm, but then localizes to the early placode and underlying mesenchyme, while *Bmp4* is expressed in the early dermal condensate.[39,40] BMP signaling inhibits placode formation, whereas neutralization of BMP activity by its antagonist Noggin promotes placode fate, at least in part via positive regulation of lymphoid enhancer factor 1 (Lef-1) expression.[39,41–43] Mice lacking Noggin have fewer hair follicles than normal and retarded follicular development.[43] The Notch pathway also appears to play a role in determining the follicular pattern. The Notch ligand Δ-1 is normally expressed in the mesenchyme underlying the placode[44–46] and, when misexpressed in a small part of the epithelium, promotes and accelerates placode formation while suppressing placode formation in surrounding cells.[44,47]

Another secreted protein present in the follicular placode that plays a major role in epithelial-mesenchymal signaling is sonic hedgehog (Shh).[48,49] Skin from mice lacking Shh have extremely effete hair follicles with poorly developed dermal papillae.[50–52] Patched1 (Ptc1), the receptor for Shh, is expressed in the germ cells and the underlying dermal papilla, suggesting that Shh may have both autocrine and paracrine inductive properties necessary for hair

germ and dermal papilla formation.[53] Patched is the gene deficient in basal cell nevus syndrome (see Chapter 116).[19]

THE BULBOUS PEG OR HAIR BUD

In the next stage of development, the bulbous peg or hair bud (or stage 2 of hair follicle development, see Fig. 86-1) is formed by elongation of the hair germ into a cord of epithelial cells. The mesenchymal cells at the sides of the peg will develop into the fibrous sheath of the hair follicle, and those at the tip of the peg will develop into the dermal papilla. The deepest portion of the follicle peg forms a bulbous structure that surrounds the underlying mesenchymal cells destined to become the dermal papilla. These epithelial cells will become the matrix of the hair follicle, which gives rise to the hair shaft and inner root sheath. The outer root sheath forms two bulges on the side of the hair follicle forming an obtuse angle with the surface of the skin. The superficial bulge will develop into the sebaceous gland. The deeper bulge serves as the future site of epithelial stem cells that generate the new lower follicle during hair follicle cycling. The arrector pili muscle usually attaches in the bulge area, and contraction of the muscle causes a more vertical orientation of the hair shaft leading to "goose bumps." In the axillae, anogenital region, areolae, periumbilical region, eyelids (the specialized glands of Moll), and external ear canals, a third bulge develops superficial to the sebaceous gland bud and gives rise to the apocrine gland.

As the hair follicle bulb appears during the bulbous peg stage, at least eight different cell layers constituting all of the components of the mature hair follicle are formed. Understanding which genes determine specific cell lineages within the follicle is an important question. GATA-3 is important in inner root sheath differentiation.[54] Notch1, a membrane protein involved in determining cell fate through cell–cell interactions and intracellular signal transduction, and its ligands Serrate1 and Serrate2 are expressed in matrix cells destined to form the inner root sheath and hair shaft.[46,55] Notch1 appears to control the phenotype of keratinocytes as they leave the bulb matrix and differentiate into specific cell types.[56]

MATURE HAIR FOLLICLE

The central lumen where the hair shaft will emerge is formed by necrosis and cornification of epithelial cells in the infundibulum. As the hair shaft is produced, several signaling pathways are involved in the control of its differentiation. Wnt/β-catenin/Lef-1 signaling plays an important role in hair shaft formation, and ectopic expression of Wnt3 in the hair follicle outer root sheath causes hair shaft fragility.[57,58] Hair shaft keratin genes contain binding sites for Lef-1,[59] which translocates to the nucleus after activation of the WNT/β-catenin pathway. WNT signaling probably regulates expression of hair shaft keratin genes, because nearly all of these genes contain Lef-1 binding sites in their promoter regions.[60]

BMP signaling is also essential for proper differentiation of the inner root sheath and hair shaft, because conditional deletion of BMP receptor type 1A in keratinocytes results in profound alterations of the inner root sheath and hair shaft formation.[61–63] Several other putative transcription factors control hair shaft differentiation, including HOXC13,[6] a homeobox protein, and the WHN gene,[64–66] which is mutated in nude mice and rarely in humans with hair, nail, and immune defects.[67,68]

This process of hair follicle formation is repeated in several waves, with the formation of secondary follicles alongside the initial follicle. The follicles are primarily clustered into groups of three and possess an oblique orientation with a similar angle to their neighbors.

ANATOMY

HAIR TYPES

After formation of the lanugo hair that is characteristic of the prenatal period, there are two major types of hair classified according to size (Table 86-1). Terminal hairs are typically greater than 60 µm in diameter, possess a central medulla, and can grow to well over 100 cm in length. The duration of the growing stage (anagen) determines the length of the hair. The hair bulb of terminal hairs in anagen is located in the subcutaneous fat. In contrast, vellus hairs are typically less than 30 µm in diameter, do not possess a medulla, and are less than 2 cm in length. The hair bulb of vellus hairs in anagen is located in the reticular dermis. Terminal hairs are found on the scalp, eyebrows, and eyelashes at birth. Vellus hairs are found elsewhere, and, at puberty, vellus hair follicles in the genitalia, axillae, trunk, and beard area in men transform into terminal hair follicles under the influence of sex hormones. Terminal hair follicles in the scalp convert to vellus-like or miniaturized hair follicles during androgenetic alopecia (see Chapter 88).[1,69]

The curvature of the hair varies greatly among different individuals and races, and ranges from straight to tightly curled. Curved hair shafts arise from curved hair follicles. The shape of the inner root sheath is thought to determine the shape of the hair. Curled

TABLE 86-1
Hair Types and Characteristics

Type of Hair	Anagen Duration	Size (Diameter, Length)
Lanugo	1–3 months	40 µm, 1–2 cm
Vellus	1–2 weeks	<30 µm, <2 cm
Terminal	>1 year	>60 µm, 10–>100 cm
Miniaturized	<1 week	<30 µm, <2 cm

hair in cross section is more elliptical or flattened in comparison with straight hair, which is more round. Several genes influencing hair shape have been identified. Mutations in the epidermal growth factor receptor (EGFR) pathway and in insulin-like growth factor binding protein 5 result in curly hair in mice.[70,71]

MICROSCOPIC ANATOMY

The upper follicle consists of the infundibulum and the isthmus, and the lower follicle consists of the suprabulbar and the bulbar areas (Fig. 86-2).[14,66] The upper follicle is permanent, but the lower follicle regenerates with each hair follicle cycle. The major compartments of the hair from outermost to innermost include the connective tissue sheath, the outer root sheath, the inner root sheath, the cuticle, the hair shaft cortex, and the hair shaft medulla, each characterized by distinct expression of the hair follicle-specific keratins (Table 86-2).[72,73]

OUTER ROOT SHEATH. The outer root sheath is continuous with the epidermis (see Fig. 86-2) at the infundibulum and continues down to the bulb. The cells of the outer root sheath change considerably throughout the follicle. The outer root sheath in the infundibulum resembles epidermis and forms a granular layer during its keratinization. In the isthmus, the outer root sheath cells keratinize in a trichilemmal fashion, lacking a granular layer. Trichilemmal keratinization occurs where the inner root sheath begins to slough. Desmoglein expression markedly changes here as well and trichilemmal or pilar cysts retain these characteristics.[74] Keratinocytes in the outer root sheath form the bulge at the base of the isthmus (see Section "Hair Follicle Stem Cells"). These cells generally possess a higher nuclear to cytoplasmic ratio compared with other areas of the follicle. Moving downward, the outer root sheath cells become much larger and contain abundant glycogen in the suprabulbar follicle. In the bulb, the outer root sheath consists of only a single,

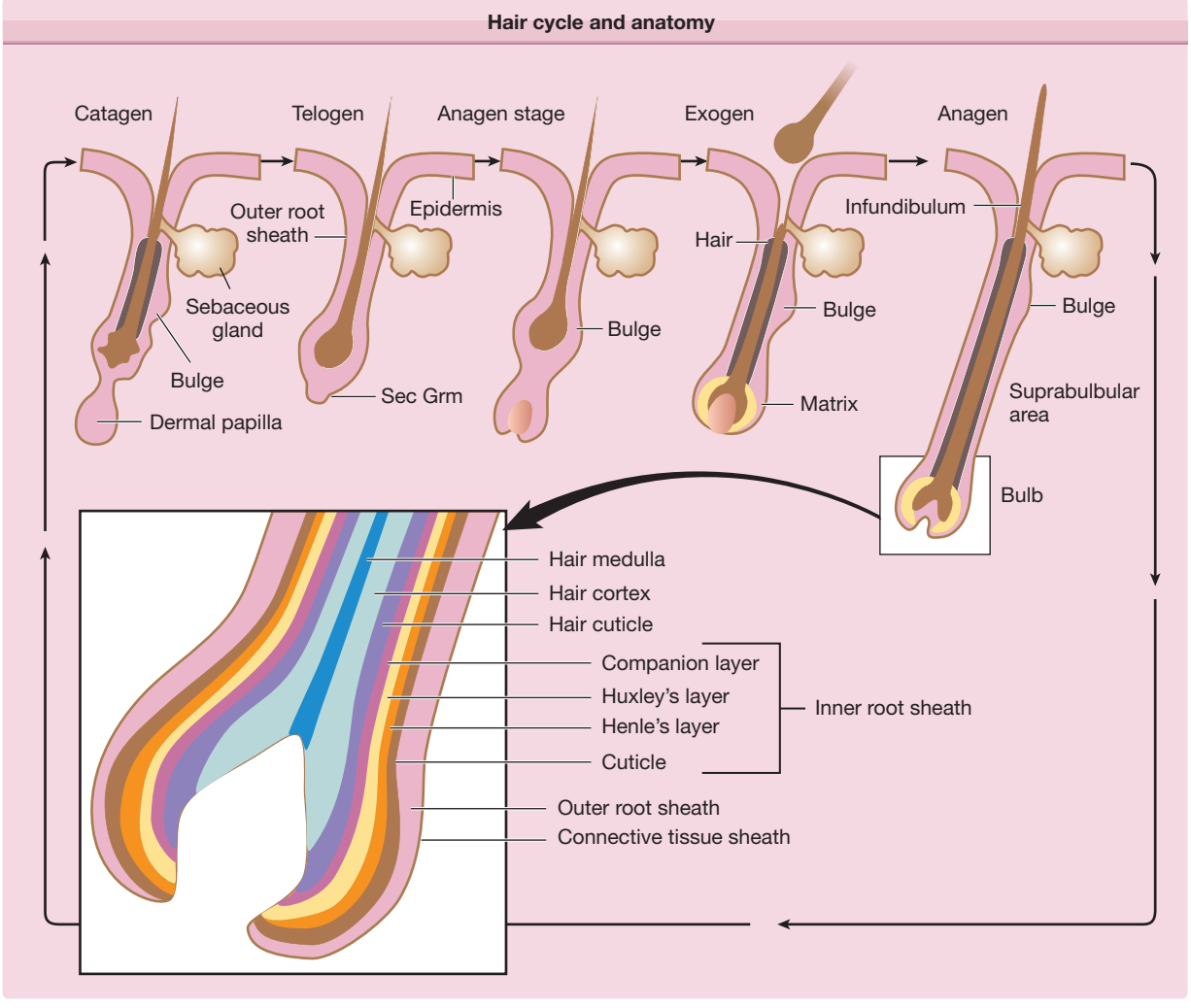

Figure 86-2 Hair cycle and anatomy. The hair follicle cycle consists of stages of rest (telogen), hair growth (anagen), follicle regression (catagen), and hair shedding (exogen). The entire lower epithelial structure is formed during anagen and regresses during catagen. The transient portion of the follicle consists of matrix cells in the bulb that generate seven different cell lineages, three in the hair shaft and four in the inner root sheath. B = bulge; E = epidermis; DP = dermal papilla; H = hair shaft; M = matrix; ORS = outer root sheath; S = sebaceous gland; Sec Grm = secondary germ.

TABLE 86-2
Expression of Keratin Genes in Distinct Hair Follicle (HF) Compartments

HF Compartments	Type I Keratins, New Nomenclature (Old Nomenclature)	Type II Keratins, New Nomenclature (Old Nomenclature)
Outer root sheath	K14 (K14), K15 (K15), K16 (K16), K17 (K17), K19 (K19)	K5 (K5)
Inner root sheath, companion layer	K16 (K16), K17 (K17)	K75 (K6hf), K6 (K6)
Hair matrix/precortex	K35 (Ha5)	K85 (Hb5)
Inner root sheath, Henle's layer	K25 (K25irs1), K27 (K25irs3), K28 (K25irs4)	K71 (K6irs1)
Inner root sheath, Huxley's layer	K25 (K25irs1), K27 (K25irs3), K28 (K25irs4)	K71 (K6irs1), K74 (K6irs4)
Inner root sheath, cuticle	K25 (K25irs1), K26 (K25irs2), K27 (K25irs3), K28 (K25irs4)	K71 (K6irs1), K72 (K6irs2), K73 (K6irs3)
Hair, cuticle	K32 (Ha2), K35 (Ha5)	K82 (Hb2), K85 (Hb5)
Hair, mid-/upper cortex	K31 (Ha1), K33a (Ha3-I), K33b (Ha3-II), K34 (Ha4), K35 (Ha5), K36 (Ha6), K37 (Ha7), K38 (Ha8)	K81 (Hb1),[a] K83 (Hb3), K85 (Hb5), K86 (Hb6)[a]
Hair, medulla	K16 (K16), K17 (K17), K25 (K25irs1), K27 (K25irs3), K28 (K25irs4), K33 (Ha3), K34 (Ha4), K37 (Ha7)	K5 (K5), K6 (K6), K75 (K6hf), K81 (Hb1)[a]

[a]Autosomal dominant mutations of K81 and K86 lead to monilethrix (alopecia due to increased hair fragility).
Data from Langbein L et al: K25 (k25irs1), K26 (k25irs2), k27 (k25irs3), and k28 (k25irs4) represent the type I inner root sheath keratins of the human hair follicle. *J Invest Dermatol* **126**:2377, 2006; and Langbein L, Schweizer J: Keratins of the human hair follicle. *Int Rev Cytol* **243**:1, 2005.

flattened cell layer that can be traced to the base of the follicle.

INNER ROOT SHEATH. The inner root sheath extends from the base of the bulb to the isthmus and contains four parts from outermost to innermost: companion layer, Henle layer, Huxley layer, and the inner root sheath cuticle. The companion layer (see Fig. 86-2) has been referred to as the innermost layer of the outer root sheath, but recent evidence indicates that it is more like inner root sheath than outer root sheath.[75] The companion layer attaches to Henle layer and moves upward with the rest of the inner root sheath; thus, it provides a slippage plane between the outer root sheath, which is stationary, and the inner root sheath.[76] The companion layer is prominent in some follicles (e.g., the beard) compared with others. The cells of the companion layer are flat compared to the cuboidal outer root sheath cells and express a type II cytokeratin, K6hf.[75] Henle layer is one-cell-layer thick and is the first to develop keratohyalin granules and the first to keratinize. Huxley layer is two to four cell layers thick and keratinizes above Henle layer at the region known as *Adamson fringe*. Some cells within Huxley's layer protrude through Henle layer and attach directly to the companion layer. These cells are called *Fluegelzellen* or *wing cells*.[77] The cells of the inner root sheath cuticle partially overlap, forming a "shingled roof" appearance, and they intertwine precisely with the cuticle cells of the hair shaft. This association between the two cuticles anchors the hair shaft tightly to the follicle. The inner root sheath, composed of hard keratins and associated proteins (see Table 86-2), is thought to dictate hair shape by funneling the hair shaft cells as they are produced. The transcription factor, GATA-3, is critical for inner root sheath differentiation and lineage. Mice lacking this gene fail to form an inner root sheath.[54]

HAIR SHAFT. The hair shaft (and inner root sheath) arises from rapidly proliferating matrix keratinocytes in the bulb, which have one of the highest rates of proliferation in the body. The cells of the future hair shaft are positioned at the apex of the dermal papilla and form the medulla, cortex, and hair shaft cuticle (see Fig. 86-2). Immediately above the matrix cells, hair shaft cells begin to express specific hair shaft keratins in the prekeratogenous zone. The differentiation of hair shaft cells in this zone is dependent on the Lef-1 transcription factor. Lef-1 binding sites are present in most hair keratin genes. BMP receptor type 1a is also critical for matrix cell differentiation into the hair shaft, because loss of this receptor prevents hair shaft differentiation.[61–63]

The hair shaft cuticle covers the hair, and its integrity and properties greatly impact the appearance of the hair. Once the hair exits the scalp, the cuticle endures weathering, and it is often completely lost at the distal ends of long hairs. Inside the cuticle, the cortex comprises the bulk of the shaft and contains melanin. The cortex is arranged in large cable-like structures called *macrofibrils*. These, in turn, possess microfibrils that are composed of intermediate filaments. The medulla sits at the center of larger hairs, and specific keratins expressed in this layer of cells (see Table 86-2) are under the control of androgens.[78]

DERMAL PAPILLA. The dermal papilla (see Fig. 86-1) is a core of mesenchymally derived tissue enveloped by the matrix epithelium. It is comprised of fibroblasts, collagen bundles, a mucopolysaccharide-rich stroma, nerve fibers, and a single capillary loop. It is continuous with the perifollicular sheath (dermal sheath) of connective tissue that envelops the lower follicle.

Tissue recombination experiments have shown that the dermal papilla has powerful inductive properties, including the ability to induce hair follicle formation when transplanted below nonhair-bearing footpad epidermis.[76,79] This shows that the tissue patterning established during the fetal period can be altered under appropriate conditions. In human follicle, the volume of the dermal papilla correlates with the number of matrix cells and the resulting size of the hair shaft.[80] In mice, sizes of the hair bulb and hair diameter strongly depend of the proliferative activity of the matrix keratinocytes.[81]

Many soluble growth factors that appear to act in a paracrine manner on the overlying epithelial matrix cells originate from the dermal papilla. Specifically, keratinocyte growth factor (KGF) is produced by the anagen dermal papilla, and its receptor, FGF receptor 2 (FGFR2), is found predominantly in the matrix keratinocytes. Injections of KGF into nude mice produce striking hair growth at the site of injection,[82] suggesting that KGF is perhaps necessary for hair growth and cycling. However, surprisingly, KGF knockout mice develop morphologically normal hair follicles that produce "rough" or "greasy" hair; thus, KGF's effects on hair follicle morphogenesis and cycling appear dispensable or replaceable by other growth factors with redundant functions.[83]

HAIR FOLLICLE INNERVATION. Myelinated sensory nerve fibers run parallel to hair follicles, surrounding them and forming a network.[84] Smaller nerve fibers form an outer circular layer, which is concentrated around the bulge of terminal follicles and the bulb of vellus follicles. Several different types of nerve endings, including free nerve endings, lanceolate nerve endings, Merkel cells, and pilo-Ruffini corpuscles are found around hair follicles.[85] Each nerve ending detects different forces and stimuli. Free nerve endings transmit pain, lanceolate nerve endings detect acceleration, Merkel cells sense pressure, and pilo-Ruffini structures detect tension. Perifollicular nerves contain neuromediators and neuropeptides, such as substance P or calcitonin gene-related peptide, that influence follicular keratinocytes and alter hair follicle cycling.[86–90] Conversely, hair follicle keratinocytes produce neurotrophic factors that influence perifollicular nerves and stimulate their remodeling in hair cycle-dependent manner.[90,91] Merkel cells that are considered neuroendocrine cells also produce neurotrophic factors, cytokines, or other regulatory molecules. Because Merkel cells are concentrated in the bulge area, some have postulated that these secreted factors may influence the cycling of the hair follicle.[92]

PERIFOLLICULAR SHEATH. The perifollicular sheath envelops the epithelial components of the hair follicle and consists of an inner basement membrane called the *hyaline* or *vitreous (glassy) membrane* and an outer connective tissue sheath. The basement membrane of the follicle is continuous with the interfollicular basement membrane. It is most prominent around the outer root sheath at the bulb in anagen hairs. During catagen, the basement membrane thickens and then disintegrates.

Surrounding the basement membrane is a connective tissue sheath comprised primarily of type III collagen. Around the upper follicle, there is a thin connective tissue sheath continuous with the surrounding papillary dermis and arranged longitudinally. Around the lower follicle, the connective tissue sheath is more prominent, with an inner layer of collagen fibers that encircle the follicle surrounded by a layer of longitudinally arranged collagen fibers.[66]

When transplanted under the skin, this perifollicular connective tissue has the remarkable ability to form a new dermal papilla and induce new hair follicle formation.[93] Even when the connective tissue sheath is transplanted to another individual, these follicles survive without evidence of immunologic rejection.

HAIR FOLLICLE CYCLE

Each individual hair follicle perpetually traverses through three stages: (1) growth (anagen), (2) involution (catagen), and (3) rest (telogen).[12] The length of anagen determines the final length of the hair and thus varies according to body site; catagen and telogen duration vary to a lesser extent depending on site. Scalp hair has the longest anagen of 2 years to more than 8 years. Anagen duration in young males at other sites is shorter: legs, 5–7 months; arms, 1.5–3.0 months; eyelashes, 1–6 months; and fingers, 1–3 months. In contrast to most mammals, including mice and newborn humans, in the adult human the hairs of the scalp grow asynchronously. Approximately 90%–93% of scalp follicles are in anagen and the rest primarily in telogen.[94] Applying these figures to the 100,000–150,000 hairs on the scalp indicates that approximately 10,000 scalp hairs are in telogen at any given time. However, because we lose only 50–100 hairs per day, this indicates that telogen is a heterogenous state. The follicles that are shedding their hair shaft are thus in "exogen," which comprises approximately 1% of the telogen hair follicles (see Fig. 86-2 and below). Hair on the scalp grows at a rate of 0.37–0.44 mm/day or approximately 1 cm/month.

HAIR FOLLICLE STEM CELLS

Because the lower portion of the follicle cyclically regenerates, hair follicle stem cells were thought to govern this growth. Historically, hair follicle stem cells were assumed to reside exclusively in the "secondary germ" (see Fig. 86-2), which is located at the base of the telogen hair follicle. It was thought that the secondary

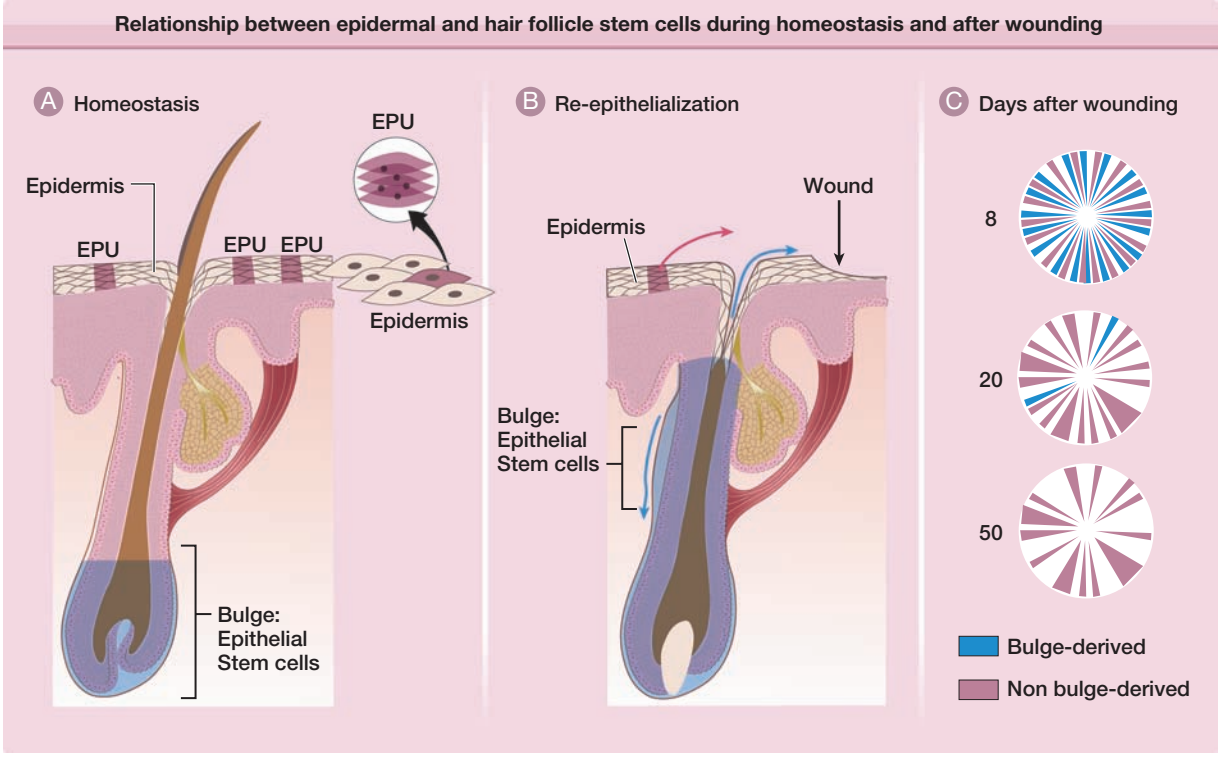

Figure 86-3 Relationship between epidermal and hair follicle stem cells during homeostasis and after wounding. **A.** During normal conditions, epidermal renewal is dependent on cell proliferation within epidermal proliferative units (EPUs), which are clonal populations of cells roughly arranged in hexagonally shaped columns that produce a single outer squame. Epithelial stem cells in the hair follicle bulge do not contribute to epidermal renewal. **B.** After full-thickness wounding, bulge cells contribute cells to the epidermis for immediate wound closure (*blue upward arrow*). Bulge cells also are required for hair follicle cycling (*blue downward arrow*) **C.** Over time, bulge-derived cells diminish, whereas nonbulge-derived cells (from the interfollicular epidermis and infundibulum) appear to predominate in the reepithelialized wound.

germ moved downward to the hair bulb during anagen and provided new cells for production of the hair. At the end of anagen, the secondary germ was thought to move upward with the dermal papilla during catagen to come to rest at the base of the telogen follicle. This scenario of stem cell movement during follicle cycling was brought into question when a population of long-lived presumptive stem cells was identified in an area of the follicle surrounding the telogen club hair.[95] Subsequently, it was shown that the secondary germ is a transient structure that forms at the end of catagen from cells in the lower bulge.[96] The concept that hair follicle stem cells are permanently located in the bulge has now been confirmed using lineage analysis, which showed that the bulge cells give rise to all epithelial layers of the hair follicle.[11,97,98] In line with this, ablation of bulge cells results in destruction of the follicle.[96] These findings support the notion that loss of hair follicle stem cells in the bulge leads to permanent or cicatricial types of alopecia (see Chapter 88).

Progress has been made in defining subsets of cells within the hair follicle that serve as different stem and progenitor populations. Markers that have been shown through genetic lineage analysis to contribute to the perpetual cycling of the hair follicle, include cytokeratin 15 and Lgr5.[96,99] Lgr5, although sometimes touted as an exclusive marker of secondary germ cells, also marks bulge cells. Lgr6, a gene related to Lgr5, is expressed in an area above the bulge in the upper isthmus. The cells marked by Lgr6 migrate to the epidermis during homeostasis and after wounding.[100] In addition to these markers, several others demonstrate the heterogeneity of the hair follicle epithelium.[101]

Are bulge cells the "ultimate" stem cells within the skin epithelium? For example, do they generate epidermis and sebaceous glands during homeostasis and after wounding? To answer these questions, lineage analysis and transgenic techniques were again used. As illustrated in Fig. 86-3, bulge cells do not normally move to the epidermis, but after full-thickness excision of the skin, bulge cell progeny migrate into the wound during reepithelialization.[11,96] These cells comprise approximately 30% of the cells in the regenerated epidermis. The role of bulge cells in sebaceous gland maintenance is still not clear, but is under investigation.

ANAGEN

The formation of a new lower follicle and hair at anagen onset recapitulates folliculogenesis in the fetus. Anagen can be divided into seven stages: (1) stage I—growth of the dermal papilla and onset of mitotic

activity in the germ-like overlying epithelium; (2) stage II—bulb matrix cells envelop the dermal papilla and begin differentiation, evolving bulb begins descent along the fibrous streamer; (3) stage III—bulb matrix cells show differentiation into all follicular components; (4) stage IV—matrix melanocytes reactivate; (5) stage V—hair shaft emerges and dislodges telogen hair; (6) stage VI—new hair shaft emerges from skin surface; and (7) stage VII—stable growth.[102]

During proliferation and migration of keratinocytes into the dermis to reform the new lower follicle, enzymes such as proteases and collagenases appear at the leading edge of the downgrowth, and growth factors and their receptors are upregulated similar to an epithelial wound.[12] Pathways of keratinocyte differentiation that are seen in the epidermis during wound healing, such as expression of keratin 6, are activated. Mice lacking Stat3, a regulator of cell migration in the cutaneous epithelium, show defects in wound healing and a failure of hair follicles to enter anagen,[103] thus further illustrating the similarity between wound healing and the early events of anagen. Remarkably, the dermal papilla in the midst of this degradative milieu survives and moves downward. Neurocutaneous and vascular networks are remodeled.[91,95] Melanocytes proliferate and repopulate the new hair bulb.[104] Finally, a burst of endothelial proliferation and angiogenesis in the dermal papilla marks the time point when the lower follicle is completely restored and is actively producing the new hair shaft.[105]

CATAGEN

The onset of catagen is marked by cessation of the mitotic activity of the matrix cells and by well-coordinated apoptosis in the cyclic portion of the hair follicle.[12,106] Pigment production by melanocytes ceases before matrix cell proliferation stops, thus leading to a nonpigmented proximal end in the telogen club hair (see Fig. 86-2). Melanin is often found in the surrounding dermis and papilla where it is engulfed by macrophages. The perifollicular sheath collapses, and the vitreous or glassy membrane thickens. The lower follicle retracts upward with the dermal papilla. The perifollicular sheath forms a fibrous streamer comprised of fibroblasts, small blood vessels, and collagen.[1] Eventually, the dermal papilla becomes situated immediately below the bulge at the lower portion of the isthmus.

During catagen, the largest follicles, on the scalp for example, shorten their length from 2- to 5-mm-long structures whose deepest portion, the bulb, extends down into the subcutaneous fat to truncated 0.25- to 0.5-mm follicles in telogen. As the basement membrane around the lower follicle thickens, the dermal papilla, protected from the surrounding apoptosis and destruction (perhaps because it expresses Bcl-2, an antiapoptotic factor[12]) condenses and begins to move upward to come to rest below the bulge during telogen. The migration of the dermal papilla from the subcutaneous fat to the dermis during catagen is necessary for continued follicle cycling. This is illustrated by the syndrome of atrichia with papules.[107,108] These patients have mutations in either their hairless gene or in their vitamin D receptor gene, in which case they also have rickets. Mice with similar mutations have the hairless phenotype. We know from these mice that folliculogenesis is normal; however, when the follicles enter catagen for the first time, the lower portion of the follicle does not involute and contract properly, and the dermal papilla remains stranded in the subcutaneous fat.[95] Although bulge cells are still present, no new anagen follicles ever form, presumably because the stem cells cannot interact with the dermal papilla.[95]

The study of mouse mutants has also resulted in several key findings that have increased our understanding of the molecular events at catagen onset. Specifically, Hebert et al[3] discovered that mice lacking the *Fgf5* gene have hair that is 50% longer than their wild-type litter mates, and that mutations in this gene are responsible for the angora phenotype that was described more than 30 years ago. Although these findings were rather unexpected, careful evaluation of *Fgf5* expression throughout the normal hair cycle demonstrated that its expression was upregulated in the outer root sheath and hair matrix cells just before the onset of catagen, suggesting that *Fgf5* may trigger catagen onset. Interestingly, the follicle still eventually entered catagen, even in the absence of FGF-5, suggesting redundancy in the FGF-5 pathway or an intrinsic finite proliferative capability of the matrix cells.[95] Further studies also demonstrated that other FGF family members and their receptors are expressed during anagen, and probably also play a role in the hair follicle cycle.[109] The hair phenotype of FGF-5-deficient mice is substantially reversed by ectopic expression of the antiapoptotic gene *bcl-xL*$_x$ in the outer root sheath, suggesting that regulation of cell survival in the outer root sheath may play a role in control of the hair growth cycle.[110]

Although it has been known for many years that exogenous EGF administered to sheep results in catagen induction,[111] only through more recent transgenic and knockout studies in mice has the importance of the EGFR system in hair cycle regulation been realized.[70,112] For example, knockout mice lacking transforming growth factor-α (TGF-α), the major ligand for EGFR, have abnormal hair follicle development and manifest the waved hair phenotype.[4,5] When EGFR is functionally downregulated in the basal layer of the epidermis and hair follicle using a dominant negative transgenic strategy, the resulting hair is not only waved, but also longer than normal.[70] The transition of the hair follicles from anagen to catagen is delayed in these mice. Hair follicles in mouse skin that completely lack EGFR also do not progress from anagen to telogen.[112] Thus, EGFR and its ligand are required for normal hair follicle development and cycling. Given the complexity of the EGFR family, which includes four receptors (ErbB1–4) and at least six ligands, future studies are needed to clarify the role of individual family members in hair follicle cycling.[113]

In addition to FGF-5 and EGF, neurotrophins and TGF-β1 induce premature catagen. Neurotrophin-3 and brain-derived neurotrophic factor transgenic mice show premature catagen development, and brain-derived neurotrophic factor overexpression leads to

the shortening of hair length by 15%, most likely via stimulation of proapoptotic signaling through p75 kDa neurotrophin receptor.[114,115] TGF-β1 induces premature catagen in isolated human hair follicles and in mouse skin in vivo, and TGF-β1 knockout mice display delay in catagen onset.[116–118]

TELOGEN AND EXOGEN

Once the involution of catagen is complete and a club hair is formed (see Fig. 86-2), the hair follicle prepares the hair for expulsion from the scalp. About 1% of telogen follicles are shed each day. Milner et al[119] have proposed distinguishing hair shedding as a separate phase called *exogen*. Exogen is a highly controlled and timed event in mammals that shed on a seasonal basis. That exogen is an active stage is supported by Headington's description of one type of telogen effluvium he termed *immediate telogen release*.[120] This type of hair loss can be seen soon after starting medications, such as minoxidil, or in response to rapid fluctuations in light/dark cycles. It consists of an increase in shedding of club hairs within weeks of the precipitating event (too soon to be caused by follicles prematurely entering telogen from anagen), suggesting that club hairs that are normally retained in the follicle can be actively shed. The heterogeneity of telogen is further supported by the work of Guarrera and Rebora,[121] who followed individual hairs in situ using macrophotographs for more than 2 years and showed that several months could transpire between hair shedding and regrowth. This "lag period" is normally not present or is very short, but often lasts several months in patients with androgenetic alopecia.

HAIR PIGMENTATION

Hair becomes pigmented as a result of a tightly coordinated program of melanin synthesis and transport from the hair bulb melanocytes to differentiating hair shaft keratinocytes.[122–124] This process is strictly coupled to anagen and ceases during catagen and telogen. Numerous signaling molecules, structural proteins, enzymes, cofactors, and transcriptional regulators control hair pigmentation (Figs. 86-4 and 86-5).[122,124,125]

HAIR MELANOCYTE DEVELOPMENT

Melanoblasts can be identified in the epidermis of human embryos at 50 days of estimated gestational age before the onset of hair follicle morphogenesis.[126–128] These follicular melanocytes originate in the neural crest and migrate first to the dermis and then epidermis.[129] New data reveal that melanocytes in the skin arise from two sources: from neural crest cells migrating in the dorsolateral pathway and from Schwann cell progenitors located in cutaneous nerves.[129a] Commitment of neural crest cells to the melanocyte lineage is regulated by Pax3 and microphthalmia transcription factors (Mitf), which stimulate the expression of dopachrome tautomerase [or tyrosinase-related protein 2 (Trp2)], an enzyme involved in melanin biosynthesis that also functions as an early melanoblast marker.[128] Subsequent steps of melanoblast development (migration into the dermis and epidermis) are controlled by signaling mechanisms activated through endothelin receptor type B and c-kit oncogene (c-kit) receptor, which are mutated in humans with Hirschprung disease and piebaldism, respectively, resulting in formation of unpigmented hairs[129] (see also Chapter 72).

After entering the placode of the developing hair follicle, melanoblasts proliferate and become melanogenically active synchronously with the onset of hair fiber formation.[130] Experimental and genetic data suggest that migration of melanoblasts into the hair follicle and their development toward melanogenically active forms depend on stem cell factor (SCF)/c-kit signaling. SCF is a ligand that binds to its receptor, c-kit. Pharmacologic blockade of c-kit during embryogenesis, as well as genetic ablation of SCF or c-kit in corresponding mouse mutants results in unpigmented hairs.[131–133]

HAIR FOLLICLE MELANOCYTE STEM CELLS AND PIGMENT-PRODUCING MELANOCYTES

MSCs located in the hair follicle bulge generate progeny that repopulate the melanocytes in the new hair bulb formed at the onset of anagen.[103,134] MSCs express Trp2, Bcl-2, Pax3, while other melanogenic enzymes (tyrosinase, Trp1) and signaling molecules (c-kit, endothelin receptor type B, SOX10, Mitf and Lef-1)[135] are expressed at low levels. MSCs can be first detected in the bulge area during late stages of hair follicle morphogenesis and similarly to epithelial stem cells they are quiescent.[134–136] TGF-β signaling plays an important role in controlling MSCs entering into a noncycling (dormant) state during hair follicle (HF) morphogenesis.[137]

Maintenance of MSCs during hair follicle cycling is controlled by TGF-β and Notch-signaling pathways. Notch signaling plays a crucial role in the survival of melanocyte stem cells and immature melanoblasts by preventing apoptosis.[138] Crosstalk between the TGF-β pathway and Bcl2 is also important for maintenance of MSCs, and Bcl2 knockout mice show progressive hair graying due to their depletion.[135–138] Bcl-2 plays a key role in maintenance of MSCs, and Bcl-2 knockout mice show progressive hair graying due to the depletion of MSCs.[139–141] However, Bcl-2 deficiency may be compensated by overexpression of SCF, which rescues loss of MSCs in the hair follicle bulge of Bcl-2 knockout mice.[135]

Melanogenically active melanocytes are located in the hair bulb above the dermal papilla.[104,124] These cells synthesize and transport melanin to hair shaft keratinocytes and express a full set of enzymes and other proteins involved in melanin biosynthesis including tyrosinase, Trp1, Trp2 (in mice), and pMel17 (in humans).[105,135] Keratinocytes, as pigment recipient cells, produce Foxn1 and its target Fgf2 to identify themselves as the targets for pigment transfer.[142]

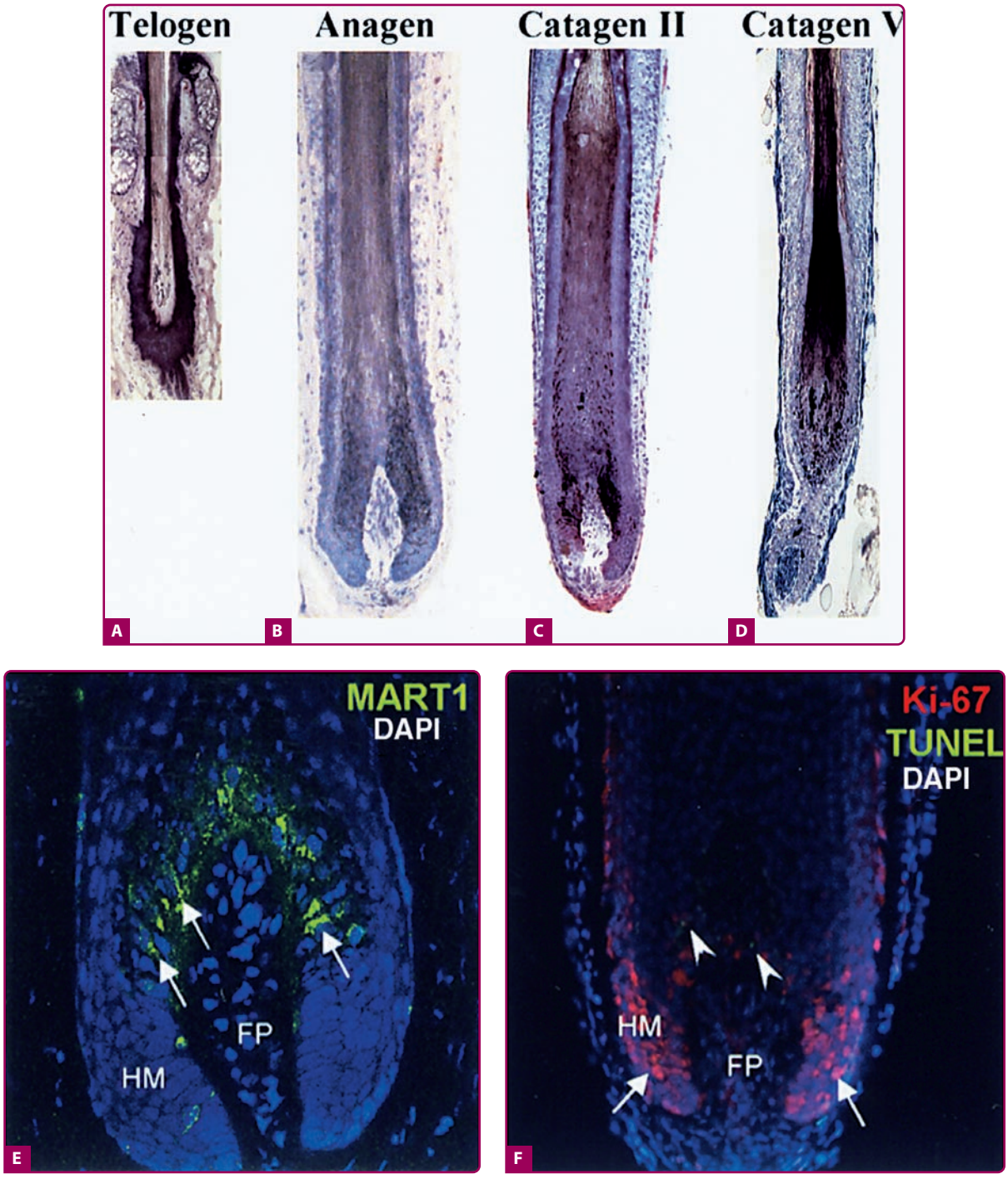

Figure 86-4 Morphology and fluorescent microscopy of human hair follicle at distinct hair cycle stages. **A–D.** Morphology of human hair follicle during telogen (**A**), late anagen (**B**), and early and late catagen (**C, D**). **E.** Immunofluorescent visualization of the melanocytes (*arrows*) in the hair bulb of late anagen hair follicle with antimelanoma-associated antigen recognized by T cells antibody. **F.** Immunofluorescent detection of proliferative marker Ki-67 (*arrows*) and apoptotic TUNEL+ cells (*arrowheads*) in early catagen hair follicle. FP = follicular papilla; HM = hair matrix.

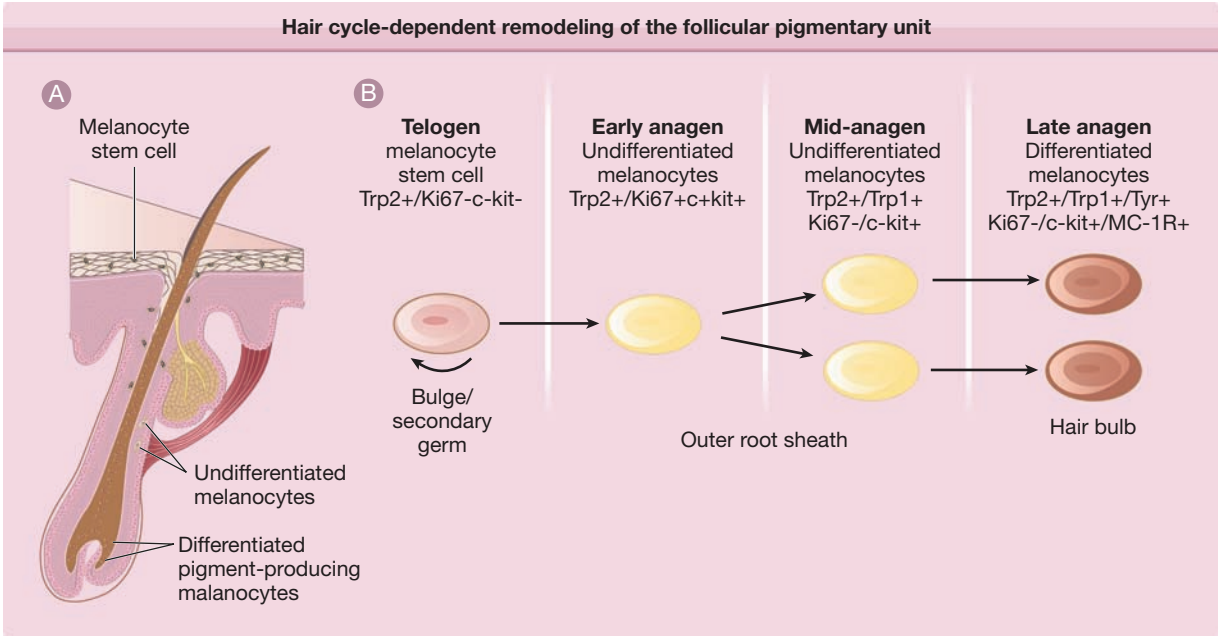

Figure 86-5 Hair cycle-dependent remodeling of the follicular pigmentary unit. **A.** Scheme illustrating localization of distinct subpopulations of melanocytes in anagen hair follicle. **B.** Dynamics of the follicular melanocytes during anagen. Expression of melanogenic markers and growth factor receptors indicated is based on the data obtained from murine hair follicles. Note that human follicular melanocytes do not express tyrosinase-related protein 2 (Trp2). c-kit = c-kit oncogene. (From Ando H et al: Fatty acids regulate pigmentation via proteasomal degradation of tyrosinase: A new aspect of ubiquitin-proteasome function. Botchkareva NV, Botchkarev VA, Gilchrest BA: Fate of melanocytes during development of the hair follicle pigmentary unit. *J Investig Dermatol Symp Proc* **8**:76, 2003 .

HAIR CYCLE-DEPENDENT CHANGES IN MELANOCYTES

Hair follicle melanocytes undergo substantial remodeling during hair follicle cycling.[104,124] In telogen, hair follicle melanocytes are found in the bulge, secondary hair germ, and connective tissue.[104] In humans, melanocytes in the telogen hair follicle do not express Trp1 or tyrosinase and do not proliferate. Melanocytes can be visualized by expression of pMel17.[141] Some of these cells also express c-kit receptor, whereas others remain c-kit-negative and represent MSCs.[104,134,135] TGF-β signaling is activated in MSCs when they reenter the quiescent noncycling state during the hair cycle and this process requires Bcl2 for cell survival.[137]

During early anagen, resting melanocytes proliferate, differentiate, and migrate within the hair follicle synchronously with regeneration of the hair follicle bulb. Hair follicle melanocytes are maximally proliferative during early and midanagen, and their transition to melanogenic competence is accompanied by the appearance of Trp1 and tyrosinase proteins.[104,143] However, this process is stringently controlled, and Notch signaling is necessary to prevent differentiation of melanoblasts into pigment-producing melanocytes before they reach the hair bulb, as well as for their proper positioning in the hair matrix.[144]

Similar to embryonic and early postnatal development, SCF/c-kit signaling plays a critical role in repopulation of the bulb with pigment-producing melanocytes. C-kit is expressed on proliferating, differentiating, and melanogenically active melanocytes, whereas overexpression of SCF in the epidermis of transgenic mice significantly increases the number of hair follicle melanocytes and their proliferative activity.[104] Similarly, administration of the ACK45 antibody blocking c-kit signaling dramatically reduces melanocyte number in anagen hair follicles, resulting in hair depigmentation.[104] However, in the next hair cycle, the previously treated animals grow fully pigmented hairs with the normal number and distribution of melanocytes, suggesting that MSCs are not dependent on SCF/c-kit.[104]

During catagen, melanogenic activity in the follicular melanocytes abruptly ceases. Immunohistochemical and electron microscopic data suggest that some pigment-producing melanocytes located above the follicular papilla undergo apoptosis, while others drop into the dermal papilla of the follicle and migrate into the dermis.[145,146]

MOLECULAR CONTROL OF HAIR COLOR

Follicular melanocytes synthesize pigment via a cascade of enzymatic conversions of phenylalanine or tyrosine into brown–black eumelanin or yellow pheomelanin that requires melanogenic enzymes (tyrosinase, Trp1/2, γ-glutamyl transpeptidase,

peroxidase) and essential cofactors, such as 6-tetrahydrobiopterin.[122] The balance between black and yellow pigment synthesis (eumelanin and pheomelanin, respectively) is regulated by signaling through the melanocortin type 1 receptor (MC-1R) that has long been implicated in the control of hair color.[147,148] (See Chapter 72.)

After binding to MC-1R, α melanocyte-stimulating hormone (α-MSH) stimulates adenylyl cyclase, resulting in elevation of intracellular cyclic adenosine monophosphate levels. This leads to increase of transcriptional activity of Mitf that stimulates synthesis of melanogenic enzymes (tyrosinase, Trp1/2) involved in eumelanin formation.[149,150] Pheomelanin synthesis in the hair follicle melanocytes of mice occurs when MC-1R signaling is inhibited by Agouti signal protein (ASP) that competes with α-MSH in binding to MC-1R.[148,149] In mice, ASP expression is positively regulated by BMP signaling, and transgenic mice overexpressing BMP antagonist Noggin show hair darkening.[151] Although ASP is expressed in human skin, its role in human pigmentation remains unclear.[150]

Recent data also demonstrate existence of fully functional proopiomelanocortin/MC-1R system in human hair follicles: MC-1R is expressed by hair follicle melanocytes, whereas its ligands α-MSH and adrenocorticotropic hormone are able to promote proliferation, dentricity, and melanogenesis.[152] Similar effects are seen with another proopiomelanocortin-derived peptide, β-endorphin that interacts with μ-opiate receptor expressed by hair follicle melanocytes.[152] However, signaling through the μ-opiate receptor may regulate hair pigmentation via modulating the activity of protein kinase C-β, a known positive regulator of melanogenesis.[153]

Follicular melanocytes are sensitive to aging, which results in their premature loss and hair graying.[154] In contrast to normally pigmented hair follicles, fewer melanocytes are found in the bulbs of gray hairs; however, these melanocytes still express tyrosinase, synthesize and transfer melanin to keratinocytes.[146] In addition, a population of melanogenically inactive melanocytes (melanoblasts including stem cells) in the outer root sheath is markedly reduced in the follicles producing gray hairs compared to pigmented follicles (Commo et al, 2004). The fact that MSCs are damaged in hair follicles producing gray hairs was confirmed in mice by applying ionizing radiation, which triggered premature differentiation of MSCs in the follicular bulge into mature, pigment-producing melanocytes followed by their depletion and irreversible hair graying.[155] Deficiency of ATM-kinase, a central transducer of the DNA-damage response, sensitizes MSCs to ectopic differentiation, demonstrating its role in protecting MSCs from their premature differentiation.[155]

However, hair graying is also mediated by H_2O_2-induced oxidative damage in the entire hair follicle including the hair shaft, which does not exclusively affect follicle melanocytes, thus suggesting that accumulation of hydrogen peroxide in both keratinocytes and melanocytes is one of the critical factors that underlie biochemical changes in the follicular pigmentary unit of graying hairs.[156]

CONCLUSION

The hair follicle is formed as the result of a complex interplay of signals between epithelium and mesenchyme. The nature of these signals is just now being elucidated, with many molecular pathways important in development also playing roles in hair follicle formation. The product of this process is a miniature organ with distinctive vertical and concentric divisions. Both epithelial stem cells and MSCs in the follicle are important for the constant regeneration of the follicle.

KEY REFERENCES

Full reference list available at www.DIGM8.com

DVD contains references and additional content

1. Cotsarelis G, Millar SE: Towards a molecular understanding of hair loss and its treatment. *Trends Mol Med* **7**:293, 2001
11. Cotsarelis G: Epithelial stem cells: A folliculocentric view. *J Invest Dermatol* **126**:1459, 2006
12. Stenn KS, Paus R: Controls of hair follicle cycling. *Physiol Rev* **81**:449, 2001
15. Millar SE: Molecular mechanisms regulating hair follicle development. *J Invest Dermatol* **118**:216, 2002
16. Schmidt-Ullrich R, Paus R: Molecular principles of hair follicle induction and morphogenesis. *Bioessays* **27**:247, 2004
30. Hardy MH: The secret life of the hair follicle. *Trends Genet* **8**:55, 1992
73. Langbein L, Schweizer J: Keratins of the human hair follicle. *Int Rev Cytol* **243**:1, 2005
84. Paus R et al: Neural mechanisms of hair growth control. Review. *J Invest Dermatol Symp Proc* **2**:61, 1997
106. Botchkareva NV, Ahluwalia G, Shander D: Apoptosis in the hair follicle. *J Invest Dermatol* **126**:258, 2006

Chapter 87 :: Keratosis Pilaris and Other Inflammatory Follicular Keratotic Syndromes

:: Paradi Mirmirani & Maureen Rogers

KERATOSIS PILARIS AT A GLANCE

- Common condition of keratotic follicular plugging with variable erythema.
- Mainly involves cheeks and extensor arms and thighs.
- Two main patterns—(1) early childhood onset and (2) adolescent onset.
- Usually improves gradually over years.
- Nonspecific histology of follicular orifice distended by keratin plug.
- Variable response to keratolytics.
- Variants:
  - Erythromelanosis follicularis faciei et colli (EFFC): marked erythema and hyperpigmentation.
  - Keratosis rubra pilaris (KRP): erythema not limited to perifollicular area, may be same as EFFC.

Follicular keratosis refers to orthokeratosis involving the follicular ostium and infundibulum. Horny plugs protrude from the orifices, producing a rough sensation on palpation of the skin. It may be isolated [keratosis pilaris (KP)] or associated with other pathologic processes, including follicular inflammation, atrophy, scarring, and alopecia [keratosis pilaris atrophicans (KPA)]. These are reaction patterns that occur alone or as part of a wide variety of syndromes.

KERATOSIS PILARIS

Typical KP is a common condition of keratotic follicular plugging with varying degrees of surrounding erythema. Sometimes, the erythema is so striking that it is the main complaint. The clinical expression of KP varies from subtle to conspicuous, which, along with possible racial differences, may explain the great range of reported prevalences, from 1% to 42%.[1–4] It involves most commonly the extensor aspects of the upper arms (Fig. 87-1) and thighs as well as the face but may rarely be more extensive, extending to the distal limbs and the trunk. There seem to be two patterns. In early childhood, the face and arms are mainly affected and gradual improvement is seen in most cases by later childhood or adolescence. In the other pattern, the onset is in teenage years, and the extensor arms and legs are predominantly involved. It usually improves by the mid-20s. However, in both patterns, the condition may be persistent into later adult life.[5] The histopathologic pattern in skin biopsy specimens is nonspecific, simply showing the follicular orifice distended by a keratin plug.

Treatment is usually with various keratolytics, from simple urea, lactic acid, or salicylic acid preparations to topical retinoids and tazarotene.[6,7] These preparations may aggravate associated erythema, limiting their value.

ASSOCIATIONS OF KERATOSIS PILARIS. Clinical ichthyosis vulgaris (see Chapter 49) is associated with KP[8]; in one series KP was found in 74.3% of patients (Fig. 87-1).[2] Other conditions in which KP is more prevalent or more prominent are atopic disorders, hypothyroidism, Cushing syndrome, insulin dependent diabetes, obesity or high body mass index, and Down syndrome.[9] Follicular keratosis, which may simulate KP, can occur in several nutritional deficiencies, although vitamin A deficiency is most commonly cited (see Chapter 130).[10]

KERATOSIS PILARIS VARIANTS

ERYTHROMELANOSIS FOLLICULARIS FACIEI ET COLLI

Erythromelanosis follicularis faciei et colli (EEFC) is a condition probably related to KP.[11] The suffix "colli"



Figure 87-1 Keratosis pilaris in a characteristic distribution on upper outer arm in a patient with ichthyosis vulgaris.

refers to the neck. EEFC It is seen primarily in adolescents and young adults, most commonly in males. Well-demarcated erythema, hyperpigmentation, and follicular papules involve the preauricular and maxillary areas, usually in a symmetric distribution, with spread in some cases to the temples and sides of the neck and trunk. Atrophy is not a feature. Histopathology is nonspecific, demonstrating a variable degree of follicular hyperkeratosis, dilation of upper dermal vessels, some perivascular inflammatory infiltrate, and hyperpigmentation of the basal layer. There are few reports of EEFC in the literature, however it may be underreported.

KERATOSIS PILARIS RUBRA

Although erythema is often present in typical KP, it is usually mild and limited to the perifollicular skin. When perifollicular erythema is more noticeable, the disorder has been called keratosis pilaris rubra (KPR) or less commonly keratosis follicularis rubra.[12] These findings are usually limited to the cheeks, forehead, and neck (Fig. 87-2). Features that differentiate EFFC from KPR are a lack of reported involvement on the torso and the presence of hyperpigmentation. However the hyperpigmentation noted in EFFC may, at least in part, be related to skin pigmentation type, with darker skin types showing more evidence of hyperpigmentation. Thus it is likely that KPR and EFFC are variants of the same clinical spectrum.



Figure 87-2 Keratosis pilaris rubra with dramatic perifollicular erythema on the cheeks.

KERATOSIS PILARIS ATROPHICANS

KERATOSIS PILARIS ATROPHICANS AT A GLANCE

- A group of rare follicular keratosis conditions with variable degrees of inflammation, and secondary atrophic scarring/and or alopecia.
- Ulerythema ophryogenes (Keratosis pilaris rubra atrophicans faciei) predominantly affects eyebrow area, causing scarring alopecia; occurs with Noonan, cardiofaciocutaneous and other syndromes.
- Atrophoderma vermiculatum—predominantly involves cheeks and leads to a striking honeycomb-like atrophy; mosaic forms described.
- Keratosis follicularis spinulosa decalvans—predominantly involves scalp, leading to severe cicatricial alopecia; associated features include plantar keratoderma and photophobia.

The general term *keratosis pilaris atrophicans* is a group of rare genodermatoses in which the clinical hallmarks is follicular keratosis with variable degrees of inflammation, and secondary atrophic scarring and/or alopecia.[13–15] Three distinct clinical entities that fall under the umbrella of keratosis pilaris atrophicans include ulerythema ophryogenes [UO or keratosis pilaris atrophicans faciei (KPAF)], atrophoderma vermiculatum, and keratosis follicularis spinulosa decalvans (KFSD).

ULERYTHEMA OPHRYOGENES (KERATOSIS PILARIS RUBRA ATROPHICANS FACIEI)

The prefix 'ophryo-' refers to the eyebrow. UO is a form of KPA affecting particularly and initially the eyebrow areas, in some cases extending later to the cheeks and forehead.[13] Scalp and eyelash hair is normal. The onset is within months of birth, with erythema and small keratotic follicular papules involving the lateral one-third of the eyebrows. It may slowly progress through childhood to involve more of the eyebrows and sometimes beyond, leading to alopecia (Fig. 87-3). Progression usually ceases after puberty but the sequelae are permanent. The condition is frequently associated with standard KP that may involve the arms and legs or may be more generalized. The term keratosis pilaris rubra atrophicans faciei is used interchangeably with UO, however some prefer this diagnosis for patients in whom the initial erythema starts on the cheeks as opposed to the eyebrows.

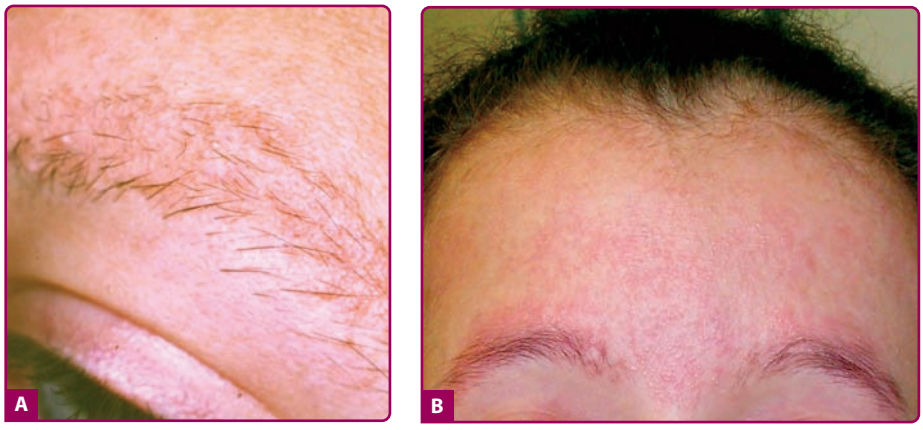

Figure 87-3 **A.** Ulerythema ophryogenes involving eyebrow area with scarring alopecia. **B.** Ulerythema ophryogenes involving the upper face in a patient with Noonan syndrome.

Most cases have followed an autosomal dominant inheritance pattern, with incomplete penetrance.[13] Response to topical corticosteroids, topical retinoids, and keratolytics has been poor. There is one report of a good response to several months' therapy with oral isotretinoin, with lessening of the horny plugs and the erythema.[16] The improvement was maintained for some months after therapy had ceased. Some improvement in erythema was reported with the pulsed tunable dye laser at 585 nm, but the follicular plugging was unchanged.[17]

SYNDROMES ASSOCIATED WITH ULERYTHEMA OPHRYOGENES. UO has been reported in association with isolated woolly hair,[18,19] Noonan syndrome,[19,20] cardiofaciocutaneous (CFC) syndrome,[21,22] Rubenstein–Taybi syndrome,[23] Cornelia de Lange syndrome,[24] and 18p deletion.[25,26] CFC and Noonan syndrome have overlapping clinical features, and both have mutations in genes of the Ras pathways.[27,28] In CFC, mutations have been described in *BRAF*, *KRAS*, *MEK1*, and *MEK2* genes.[27] Whereas in Noonan syndrome, there is primarily mutations of *PTPN11*, but also *KRAS* and *SOS1* genes.[29,30]

Follicular keratosis in Noonan syndrome, if present, is usually limited to the face (Fig. 87-3B) and resembles UO with loss of eyebrow hairs.[19,20] In CFC syndrome, follicular keratosis is often much more extensive, and there may be striking alopecia involving the scalp.[22] The remaining scalp hair in CFC syndrome is brittle and curly.

ATROPHODERMA VERMICULATUM (FOLLICULITIS ULERYTHEMATOSA RETICULATA)

AV is a form of KPA in which the cheeks are predominantly involved, with follicular plugs and pit-like depressions up to 1.5 mm in diameter and a background of erythema. Alopecia and follicular papules are not features of the condition,[22,31] but sparse open and closed comedones and milia may be found.[32] The depressions merge into each other, producing a "worm-eaten," "honeycombed," or reticular appearance (Fig. 87-4). Involvement of the forehead, arm, and leg, as well as the typical cheek area, has been described.[14] However, in general, it is rare for the condition to involve the limbs, and eyebrow involvement does not occur. Standard KP of the extensor aspects of arms and legs is a common associated finding.[31] Unlike the other KPA disorders in which the onset is in infancy, AV usually starts in childhood, between 5 and 12 years old, although later onset has been described[14]; the course is usually one of inexorable worsening. The condition is often sporadic but, in some cases, appears to be inherited as an autosomal dominant trait.[33] Several more or less linear unilateral cases have been described,[34] suggesting a possible mosaic form of the condition.[35] However, it is possible that at least some of these cases may represent examples of nevus comedonicus.[35]

Histopathologic evaluation demonstrates atrophic pilosebaceous units with mild perifollicular and



Figure 87-4 Atrophoderma vermiculatum demonstrating honeycomb atrophy on the cheek of an adolescent girl.

TABLE 87-1
Syndromes with Follicular Atrophoderma as a Feature

Condition	Inheritance	Main Features	Comments
Bazex syndrome (Bazex–Dupre—Christol syndrome)[41]	X-linked dominant	Hypotrichosis, pili torti, hypohidrosis, milia, development of basal cell carcinomas in adolescence.	—
Rombo syndrome[38]	Autosomal dominant	Hypotrichosis, especially of eyelashes, peripheral cyanosis, basal cell carcinomas, and trichoepitheliomas.	—
X-linked dominant chondrodysplasia punctata (Conradi–Hünermann syndrome)[39]	X-linked dominant, lethal in males	Congenital Blaschko-distributed red scaly lesions that resolve in months, replaced by follicular atrophoderma. Cataracts, shortening of limbs, frontal bossing, saddle nose, low-set ears.	Mutation in emopamil binding protein gene, relevant in cholesterol biosynthesis
Congenital ichthyosis, follicular atrophoderma, hypotrichosis, and hypohidrosis[42,43]	Probably autosomal recessive	Congenital, diffuse ichthyosis, hypohidrosis, hypotrichosis. Woolly hair in one pedigree.	Only described in two families so far
Hereditary perioral pigmented follicular atrophoderma associated with milia and epidermoid cysts[40]	Autosomal dominant	Epidermoid cysts and milia.	Follicular atrophoderma limited to face, especially periorally
Nevus comedonicus[44]	Somatic mutation	Blaschko-distributed comedo-like plugs in dilated follicular orifices. Cribriform atrophy follows extrusion of comedones.	Due to somatic mutation of fibroblast growth factor receptor 2, identical to that, which, if present in the germline, causes Apert syndrome

perivascular inflammation. The follicular orifices are dilated and filled with keratin plugs. Numerous dermal horn cysts may be found. There is perifollicular fibrosis and a decrease in elastic fibers in the dermis.[31,36]

Therapy is uniformly unsuccessful and has included topical steroids, topical retinoids, cryotherapy, and derm-abrasion. Favorable results have also been described with carbon dioxide laser in a case in which atrophy was prominent, and pulsed dye laser in a case with a marked erythematous component.[32] Oral isotretinoin suppressed the inflammation in one patient.[37]

SYNDROMES ASSOCIATED WITH FOLLICULAR ATROPHODERMA. Follicular atrophoderma occurs as a feature of several rare syndromes[38–43] and in nevus comedonicus (Table 87-1).[44] As such, these conditions may come into the differential diagnosis of atrophoderma vermiculatum.

KERATOSIS FOLLICULARIS SPINULOSA DECALVANS

The term *KFSD* was first used by Siemens in 1926 who described a scarring follicular condition in 20 members of a large family.[45] The condition begins in infancy with noninflammatory, flesh-colored, spiny lesions affecting hair-bearing areas, especially the scalp (Fig. 87-5) and later eyebrows, eyelashes, and the dorsal of the hands and fingers. Sometimes, more proximal limbs and even the trunk become involved.[45–47] An associated plantar keratoderma may occur, especially over the heels.[15] By puberty, many of the follicular spines have disappeared and are replaced by atrophy. Scarring alopecia of scalp (see Fig. 87-5), eyebrows, and eyelashes becomes apparent in childhood and progresses till puberty. It is often patchy and is rarely total. Facial lanugo hair is absent, and axillary and pubic hair is often thinned.

Photophobia is seen in many patients, and punctate corneal epithelial defects have been seen in some.[47] It is unclear whether there is a primary epithelial defect or whether the corneal changes occur as a result of irritation from distorted remnant lashes and keratotic plugs in eyelash follicles. There are rare reports of other ophthalmologic abnormalities, including cataract and retinal detachment.[48]

Biopsy specimens show follicular based hyperkeratosis, perifollicular and dermal inflammation, fibrosis, and distorted follicles at different stages of the condition.[46] Family studies suggest an X-linked dominant inheritance pattern,[45,47–49] with men often more severely

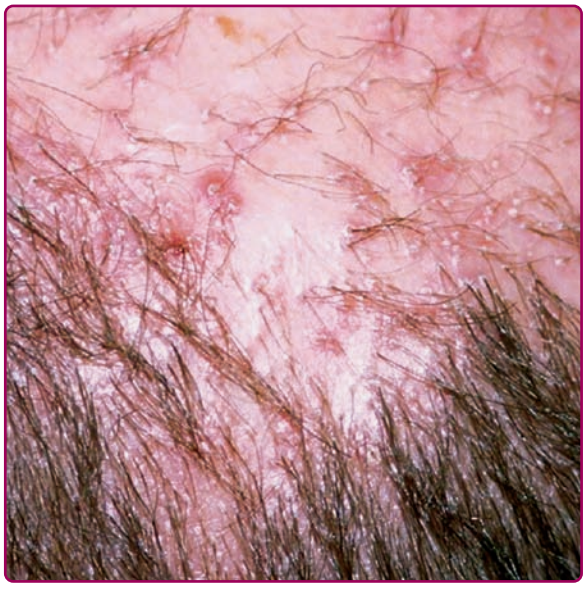

Figure 87-5 Keratosis follicularis spinulosa decalvans with severe scarring alopecia of scalp. (Photograph used with permission from Dr. Peter Hogan.)

affected than women. A mutation in the gene encoding spermidine/spermine *N*(1)-acetyltransferase (SSAT) has been noted in these patients and has been localized to Xp22.13-p22.2.[50] However clinical heterogeneity is likely as there have been identification of pedigrees unlinked to this region as well as rare instances of male to male transmission suggesting an autosomal dominant form.[51,52] In the differential diagnosis of KFSD is ichthyosis follicularis with alopecia and photophobia (IFAP) syndrome [see Section "Ichthyosis Follicularis, Alopecia (Atrichia), and Photophobia Syndrome"].[53] However, features in KFSD not shared by IFAP are involvement of the fingers, late atrophy, and scarring of involved follicles, and the development in some patients of a red–brown telangiectatic pigmentation of cheeks and brows.

In general, treatment of KFSD is unsatisfactory; however, there are isolated reports of improvement in photophobia with oral vitamin A,[47] as well as conflicting reports on the results of dapsone,[51,54] and oral retinoids.[46,55,56]

FOLLICULITIS SPINULOSA DECALVANS

A variant of KFSD has been called *folliculitis spinulosa decalvans* (acknowledging that this name may lead to confusion with the separate entity of folliculitis decalvans).[15,57] This variant is characterized by persistent pustule formation, especially on the scalp. Unlike the typical variant of KFSD, there is more severe inflammation, and it is progressive, rather than stable or remitting after puberty. In addition, the inheritance appears to be autosomal dominant rather than X-linked recessive. Treatment response to isotretinoin has been unsuccessful.[57]

OTHER SYNDROMES WITH FOLLICULAR KERATOSIS AS A SIGNIFICANT FEATURE

Apart from the conditions described in the preceding sections in association with UO, there are other conditions that have follicular keratosis as a significant feature (Table 87-2).

MONILETHRIX

(See Chapter 88)

Monilethrix is an autosomal dominant condition producing a beaded appearance of the hair.[58] Mutations in the human basic hair trichocyte keratins K81, K83, and K86 (formerly hHb1, hHb3, and hHb6, respectively) have been reported.[59–61] However, the failure to demonstrate these mutations in one family suggests the possibility of genetic heterogeneity.[62] A striking follicular keratosis is associated in some pedigrees and may involve the scalp (Fig. 87-6), face, and limbs. Nail onychodystrophy or koilonychia are also variably reported. Genotype/phenotype correlation is not obvious in reported cases in which mutations have been identified.[63,64] The clinical phenotype of autosomal recessive hypotrichosis resembles that of monilethrix. In these patients, there is a defect of the *desmoglein 4* gene, which belongs to the desmosomal cadherin superfamily and is also expressed in the cortex of the hair follicle.[65–67]

KERATOSIS PILARIS AND HEREDITARY KOILONYCHIA

A family has been described with koilonychia and widespread KP, involving all areas of trunk and limbs. Affected family members also showed eyebrow involvement with alopecia, simulating UO/KPAF.[68] The inheritance pattern appeared to be autosomal dominant. Unlike previous cases, there was no monilethrix in this pedigree.

KERATITIS, ICHTHYOSIS, AND DEAFNESS SYNDROME

(See Chapter 49)

TABLE 87-2
Syndromes That May Feature Follicular Keratosis

- Monilethrix
- Keratosis pilaris and hereditary koilonychia
- Hereditary mucoepithelial dysplasia
- Ichthyosis follicularis, alopecia, and photophobia syndrome
- Keratitis, ichthyosis, and deafness syndrome
- Cardiofaciocutaneous syndrome
- Noonan syndrome
- Rubenstein–Taybi syndrome
- Cornelia de Lange syndrome
- 18p deletion



Figure 87-6 Striking follicular keratosis of the scalp in a patient with monilethrix.

Widespread spiny follicular keratosis is a striking feature of keratitis, ichthyosis, and deafness syndrome, a connexin/gap-junction disorder. This autosomal dominant disorder is also characterized by alopecia of scalp, body, eyebrow, and eyelash hair, vascularizing keratitis, and a profound sensorineural hearing loss.[69]

HEREDITARY MUCOEPITHELIAL DYSPLASIA

The characteristic features of hereditary mucoepithelial dysplasia (HMD) are follicular keratosis, nonscarring alopecia with some coarse abnormal hairs remaining, fiery-red palatal and gingival mucosae, photophobia with demonstrable keratitis and corneal vascularization, and psoriasiform hyperkeratotic lesions in the perineal area and often also on the extensor limbs.[70–72] The condition occurs in both sexes, and family studies suggest both autosomal dominant and autosomal recessive patterns of inheritance may be possible. Light microscopic evaluation of skin and mucosae shows dyskeratotic cells in the spinous layer, vacuolated basal cells, and lack of epithelial maturation.[70,72] Electron microscopy shows paucity of desmosomes, cytoplasmic vacuolization, and presence of multilaminar bands and wheat sheaf-like collections of filamentous fibers in the cytoplasm, resembling gap-junction material, and suggesting a disorder of desmosomal or gap junction proteins.[72] However, subsequent studies of several characteristic cases in one pedigree found normal expression of gap junction proteins (connexins 26, 32, and 43), desmosomal proteins (desmogleins 1 and 2, plakoglobin, desmoplakins I and II, and plakophilin 1), adherens junction proteins (β-catenin and E-cadherin), and cytoskeleton proteins (keratins, β-tubulin, vimentin, and actin).[70] Genetic analysis in the studied family excluded the desmosomal cadherins in chromosome 18q12 as candidate genes and ruled out a mutation in connexin 26.[70]

ICHTHYOSIS FOLLICULARIS, ALOPECIA (ATRICHIA), AND PHOTOPHOBIA SYNDROME

The association of ichthyosis follicularis, alopecia, and photophobia was first reported as a syndrome by McLeod in 1909,[73] and for many years additional reported cases of what came to be designated *IFAP syndrome* occurred in males. Affected individuals demonstrate widespread, flesh-colored, spiny, follicular projections with minimal, if any, inflammation (except for inflammatory palmoplantar keratoderma with advancing age), severe alopecia, often total atrichia involving eyebrows and lashes as well as scalp hair, and severe photophobia, often with demonstrable corneal vascularization.[53,74–76] The condition was postulated to be inherited as an X-linked recessive trait, which is supported by the report of the mother and sister of a male patient with classical features of IFAP syndrome having linear lesions of hyperkeratosis, hypohidrosis, and atrophy and a patchy scalp alopecia, distributed along Blaschko's lines.[77] Recently, the gene defect has been mapped to Xp22.11-p22.13 and a missense mutation of the gene, *MBTPS2*, which codes for an intramembrane zinc metalloprotease, has been identified.[78] This gene is essential for cholesterol homeostasis and endoplasmic reticulum stress response.

Patients may have only cutaneous features, but neurologic and skeletal anomalies and recurrent infections have occasionally been described.[44,79–82] Atypical cases have included females with generalized involvement and transmission from mother to daughter[83,84–86]; psoriasiform patches,[80,85,86] particularly involving the perineal area; and hypotrichosis rather than complete atrichia.[86] Some patients with psoriasiform plaques lack the typical spiny follicular projections[80,81] and may represent a different entity,[76] or even a variant of HMD.[86] In support of the latter is the ultrastructural finding of reduced numbers of desmosomes in one patient with IFAP and psoriatic lesions, analogous to what is seen in HMD.[85] Patients with documented mutations in *MBTPS2*, have reportedly had spiny follicular projections during infancy, and the later progressive development of psoriasiform plaques. Treatment of IFAP is usually unsatisfactory, but there are reports of temporary flattening of the follicular keratotic papules and plaques and regrowth of eyelashes with oral acitretin.[87,88]

KEY REFERENCES

Full reference list available at www.DIGM8.com

DVD contains references and additional content

12. Marqueling AL et al: Keratosis pilaris rubra: A common but underrecognized condition. *Arch Dermatol* **142**:1611-1616, 2006
13. Callaway SR, Lesher JL Jr: Keratosis pilaris atrophicans: Case series and review. *Pediatr Dermatol* **21**:14-17, 2004
15. Oranje AP, van Osch LD, Oosterwijk JC: Keratosis pilaris atrophicans. One heterogeneous disease or a symptom in different clinical entities? *Arch Dermatol* **130**:500-502, 1994

52. Castori M et al: Clinical and genetic heterogeneity in keratosis follicularis spinulosa decalvans. *Eur J Med Genet* **52**:53-58, 2009
70. Boralevi F et al: Hereditary mucoepithelial dysplasia: Clinical, ultrastructural and genetic study of eight patients and literature review. *Br J Dermatol* **153**:310-318, 2005
78. Oeffner F et al: IFAP syndrome is caused by deficiency in MBTPS2, an intramembrane zinc metalloprotease essential for cholesterol homeostasis and ER stress response. *Am J Hum Genet* **84**:459-467, 2009

Chapter 88 :: Hair Growth Disorders

:: Nina Otberg & Jerry Shapiro

APPROACH TO THE PATIENT WITH HAIR GROWTH DISORDERS AT A GLANCE

- Take patient with hair growth disorders serious and provide emotional support.
- Classify hair disorder based on patient's history and clinical pattern (see eTable 88-0.2 in online edition).
- Exclude or confirm common hair growth disorders based on clinical assessment and diagnostic tools (see Table 88-1).
- Find the right treatment for confirmed diagnosis.
- Dispel misconceptions on treatment options and results, and educate patient.

INTRODUCTION

The importance of human hair in view of social communication and sexual attraction is enormous. Thus, diseases that lead to hair loss (alopecia), structural hair shaft defects or excessive hair growth on the body are often accompanied by diminished sense of personal well-being and self-esteem, leading to depressive moods and withdrawal from social interims.

In this chapter, we discuss the biologic basis and clinical presentation of hair growth disorders, give definitions (eTable 88-0.1 in online edition), explain key management principles, and provide practical advice for diagnosis, therapy and patient management.

Two frequently applied terms of alopecia and effluvium need to be characterized. While effluvium typifies the process of hair shedding, alopecia characterizes the final result of this. Both terms are nonspecific; they do not give etiological information of the underlying hair loss (see eTable 88-0.1 in online edition).

Disorders that result in alopecia can be grouped into diffuse, patterned and focal hair loss as well as into scarring (synonym: cicatricial) and nonscarring forms. Scarring forms are characterized by permanent destruction of hair follicular stem cell structure resulting in loss of hair producing capabilities. In contrast, in nonscarring alopecia the hair follicle is not ultimately destroyed and subsequent hair regrowth follows periods of hair shedding. In both, scarring and non scarring alopecia, distribution of hair loss can occur in a diffuse pattern over the whole scalp or be circumscribed, affecting only a few, more or less demarcated areas. Alopecia can also be due to improper or missing follicle development. These rare inherited hair abnormalities can be focal (e.g., aplasia cutis congenita, see Chapter 107) or diffuse (e.g., ectodermal dysplasia, see Chapter 142).

Hair growth disorders caused by structural hair shaft defects can be acquired or inherited. While acquired hair shaft defect are accompanied by increased hair breakage and are usually due to hair grooming practices, inherited hair shaft defects can be grouped into disorders with or without increased hair breakage. Acquired hair shaft disorders are reversible when trigger factors are stopped. Inherited hair shaft disorders cannot be cured, but tend to improve as the patient ages.

PRINCIPLES OF HAIR FOLLICLE BIOLOGY

(See Chapter 86)

TABLE 88-1
Diagnostic Procedures[a]

- Essential procedures
  - Hair pull test to assess scalp hair cycling
  - Hair shaft microscopy
  - Dermatoscope
  - Biopsy (mandatory if scarring alopecia is suspected)
- Additional useful tests
  - Trichogram (hair pluck test)
  - Hair shedding count
  - Potassium hydroxide stain (for suspected fungal infection)
  - Laboratory tests
    - Most commonly performed for hair loss: complete blood cell count, ferritin or iron/total iron binding capacity, thyroid-stimulating hormone, and thyroxine

[a]See online Table 88-1.1 for additional diagnostic procedures.
Data from Olsen EA: Current and novel methods for assessing efficacy of hair growth promoters in pattern hair loss. *J Am Acad Dermatol* **48**:253, 2003.

DIAGNOSTIC TECHNIQUES FOR EVALUATING HAIR GROWTH DISORDERS

HISTORY

A thorough patient history is critical for the development of an initial differential diagnosis and for the relationship with the patient. The patient should be asked about the duration and pattern of the hair problem. Was the problem present at birth, did it evolve gradually over time starting at a certain age or was there a rapid onset? A hair problem that is present at birth leads more to a genetic disorder; certain conditions are more common in children, such as tinea capitis, alopecia areata, or trichotillomania. For example, a rapid onset of hirsutism can lead to the diagnosis of an androgen-secreting tumor. A gradual thinning of fronto-parietal scalp hair fits more to the diagnosis of androgenetic alopecia (AGA) (see eTable 88-0.2 in online edition). Patients with hair loss should be asked if the hair is shedding or thinning and if the hair is coming out "by the root" or if it is breaking off. A patient history includes the family history as well as questions about current and past medication, pregnancy, menses, menopause, thyroid function, diet, past and present health, surgeries, accidents, physical or emotional stress events and hair care practices.

GLOBAL ASSESSMENT AND IMAGING

The global examination of the scalp should first of all assess the overall pattern of the hair problem. It is important to determine density and distribution and if the hair loss is focal or global. Furthermore, the presence of scaling, erythema, erosions, crust or pustules and the presences or absence of follicular ostia should be noted. The clinical examination should also involve the nails, since some disorders, for example alopecia areata, lichen planopilaris (LPP), or ectodermal dysplasia can also affect finger and toe nails. Excessive body hair is oftentimes shaved or epilated. The extent of unwanted terminal hair growth can be evaluated by a patient self-assessment with the help of images (see Section "Hirsutism").

PULL TEST

The pull test is a useful ancillary, qualitative test for the assessment of the ongoing activity of hair loss. The examiner grasps approximately 50–60 hairs and tugs at them from proximal to distal end. Removal of six hairs indicates a positive pull test and active shedding. However, the test can be considered positive if three hairs can be pulled out in several different areas of the scalp. The proximal ends can be examined against a white (for dark hair) or black (for light hair) background. A blunt tip indicates hair breakage; a tapered tip can indicate regrowth or miniaturized hairs. The proximal end of the hair shafts may also be examined with a light microscope to determine, if the hairs break off (blunt ends) or came out as club hairs (telogen hair).

BIOPSY

A scalp biopsy is necessary, particularly when confirming the diagnosis of scarring alopecia. A scalp biopsy should also be considered for the differential diagnosis of TE, diffuse alopecia areata and AGA. The following recommendations were developed at the consensus meeting on cicatricial alopecia in February 2001: one 4-mm punch biopsy including subcutaneous tissue should be taken from a clinically active area, processed for horizontal sections and stained with hematoxylin and eosin. Elastin (acid alcoholic orcein), mucin, and periodic acid-Schiff (PAS) stains may provide additional information. A second 4-mm punch biopsy from a clinically active disease affected area should be cut vertically into two equal pieces. One-half provides tissue for transversely cut routine histological sections; the other half can be used for direct immunofluorescence (DIF) studies.[1,27] Usually only one biopsy from the affected area is necessary for the diagnosis of a nonscarring alopecia; the samples are preferably processed with horizontal sections.

TRICHOGRAM

This technique is a simple method of quantifying hair loss by comparing the proportion of anagen to catagen and telogen hairs. For accurate measurement, patients should avoid washing their hair 3–4 days prior the test. Also perms, dyes, or straightening of hair can alter results and have to be avoided at least 6 weeks prior. A group of about 25–50 hairs should be grasped with a needle holder close to the scalp and plucked sharply in the direction of the hair. The proximal ends of the hair shafts are place on a glass slide in a drop of water and covered with a cover slip. Alternatively, a solution of 1% dimethylcinnamaldehyde in 0.5 N hydrochloric acid can be used, which stains the anagen hairs red due to the presence of protein bound citrulline in the inner root sheath. The roots are than examined by light microscopy with 100-fold magnification. Ten to twenty percent of telogen hair can be regarded as normal (the percentage of anagen hairs is slightly higher in women and children compared to men); a telogen count over 35% is highly suspicious for a TE. By repeating the trichogram over a time period, a hair loss condition can be followed and treatment results can be measured[28] (Fig. 88-1).

Investigation of plucked hairs for spores allows establishing the diagnosis of tinea capitis. In this case the hair should be mounted in 5% potassium hydroxide and gently heated.

ANDROGENETIC ALOPECIA

AGA or pattern hair loss is by far the most common type of hair loss in men and women. Male pattern hair

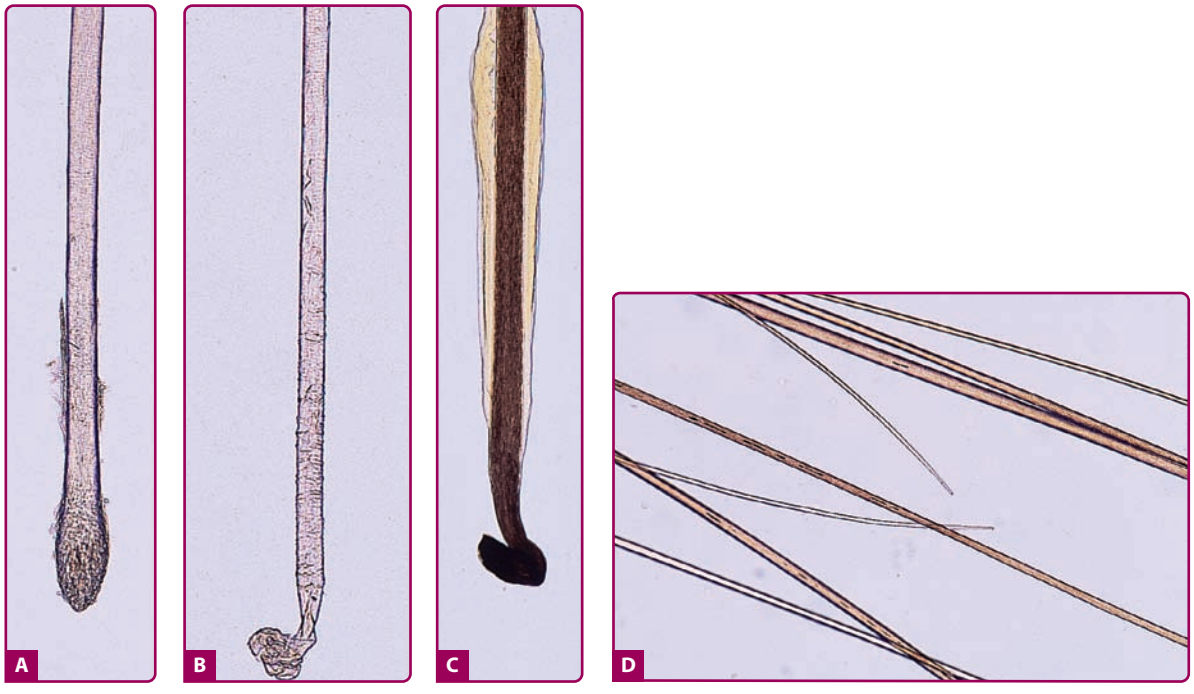

Figure 88-1 **A.** Telogen club hairs have a cornified, depigmented, rounded-up bulb without an attached root sheath. **B.** Loose anagen hair obtained by hair pull: Ruffled cuticle and no attached root sheath. Anagen hairs are recognized clinically by their pigmented, somewhat distorted, malleable bulb. Anagen hairs should not normally be found in a hair pull in patients with alopecia areata. **C.** Comparison with a normal anagen hair obtained by hair pluck. **D.** A newly growing anagen hair has a tapered distal tip rather than the blunt distal end of hairs that have been cut or trimmed or ends that are intrinsically broken. (From Ralf Paus, Elise A. Olsen, Andrew G. Messenger: Fitzpatrick's Dermatology in General Medicine. 7th ed. Copyright © The McGraw-Hill Companies, Inc. All rights reserved, with permission.)

ANDROGENETIC ALOPECIA (AGA) AT A GLANCE

- Most common form of human hair loss.
- Presents as a nonscarring hair loss condition under the influence of androgens (dihydrotestosterone, DHT); androgen susceptibility of the follicles plays an important role.
- Clinical characteristics include a reduction of terminal hair density on the scalp that follows a typical pattern in both genders, with a conversion of terminal to vellus-like hairs and an increase of telogen hair (in an episode of active shedding).
- Classification with gender-specific features (Norwood–Hamilton classification for men and Ludwig classification in women) with clinical overlap.
- FDA approved therapeutic options are: topical minoxidil 2% (women) and 5% (men), oral finasteride 1 mg daily (men), hair restoration surgery, and low laser light.

loss (MPHL) (also known as male AGA, male balding) is an androgen-dependent, genetically determined trait. Female pattern hair loss (FPHL) (or female androgenetic alopecia) is believed to be the same entity. However, the requirement of androgens is less clear-cut than in men and the distribution of hair loss is generally different.[35,36] In both, men and women, AGA is characterized by a progressive decline in the duration of anagen, an increase in the duration of telogen and miniaturization of scalp hair follicles.

EPIDEMIOLOGY

MEN

Estimates of the prevalence of AGA vary widely. Most men will develop some degree of recession of the hairline during their lifetime. A progression to at least type III (see Fig. 88-2) is seen in around 50% of men and women beyond 40 years of age.[37–40,41] The risk of male pattern baldness depends on the family history in the father, the mother, or the maternal grandfather.[42,43] Men whose father had hair loss were twice as likely to have hair loss as men whose father showed no hair loss.

Ethnic variation in the incidence of AGA has been reported. AGA seems to be four times less frequent in men of African ancestry,[44] around three times less frequent in Korean men[45] and approximately 1.5 times



Figure 88-2 Patient with male pattern hair loss, Norwood–Hamilton class III.

less frequent in men originating form China, Japan or Thailand.[46,47]

WOMEN

FPHL is less common than MPHL but shows a similar age-related increase in frequency and severity. However, the condition can start as early as the prepubertal period both in men and women (Fig. 88-3). Around 40% of Caucasian women have developed some degree of FPHL at age 70.[35,48] FPHL seems to be less frequent in Asian woman.[45]



Figure 88-3 Patient with female pattern hair loss, Ludwig typ II.

ETIOLOGY AND PATHOGENESIS

The underlying causes of patterned hair loss have yet to be determined. In men, MPHL appears to result from a combination of androgen hyperactivity, a genetic predisposition to hair loss-related sensitivity to androgen action as well as an androgen-independent genetic predisposition. For females, the condition known as female pattern hair loss (FPHL) may have a more complex etiology. However, androgen action combined with genetic sensitivity to those actions seems to play a dominant role in most cases, and indeed these factors may be present generally in FPHL.

In AGA, large, pigmented hairs, called terminal hairs, are gradually replaced by fine (nearly invisible) colorless vellus hairs.[1,39] This transformation follows a progressive course with each hair cycle in the following manner. Scalp hair develops in three phases[40,49]: (1) a growth phase, or anagen, of approximately 2–6 years; (2) a short (2–3 weeks) phase, catagen, which actually represents the termination of anagen; and (3) transition to the telogen phase. A telogen hair does not grow and is shed from the follicle after about 12 weeks. The transition to catagen results in decreased levels of anagen-maintaining cytokines within the hair follicle. MPHL and FPHL exhibit a progressive decrease in anagen duration with each cycle, producing shorter, thinner hairs.[38] Finally, the interval between late telogen hair shedding (exogen) and new hair growth with initiation of anagen increases, resulting in more follicles without hair and an apparent reduction in scalp hair density.[37]

CLINICAL FINDINGS

The identification of AGA is usually not difficult if the alopecia occurs in a classical clinical pattern. In 1951, Hamilton produced the first grading scale for MPHL. The Hamilton scale ranges from type I to VIII. Whereas type I represents the prepubertal scalp with terminal hair growth on the forehead and all over the scalp, type II and III show gradual frontal mostly M-shaped recession of the hairline, type IV, V and VI show additional gradual thinning in the vertex area, type VII and VIII show a confluence of the balding areas and leave hair only around the back and the sides of the head.[50,90] In 1975 Norwood modified the classification, and included variations on the middle grades III a, IV a and V a, that show a more prominent gradual receding of the middle portion of the frontal hairline and type III vertex which is characterized by a loss of hair mainly in the tonsure area and a frontotemporal recession which never exceeds that of type III.[91] (Fig. 88-4). In 1977, Ludwig introduced a classification for pattern of AGA in women, characterized by a diffuse loss of hair on the crown and persistence of the frontal hairline.[92] In 1994, Olsen noted that women with AGA did not necessarily present with diffuse hair loss over the entire top but rather may have increasing hair loss towards the front, called frontal accentuation or Christmas tree pattern (Fig. 88-5). Women can also

Hamilton-Norwood classification of pattern hair loss in men

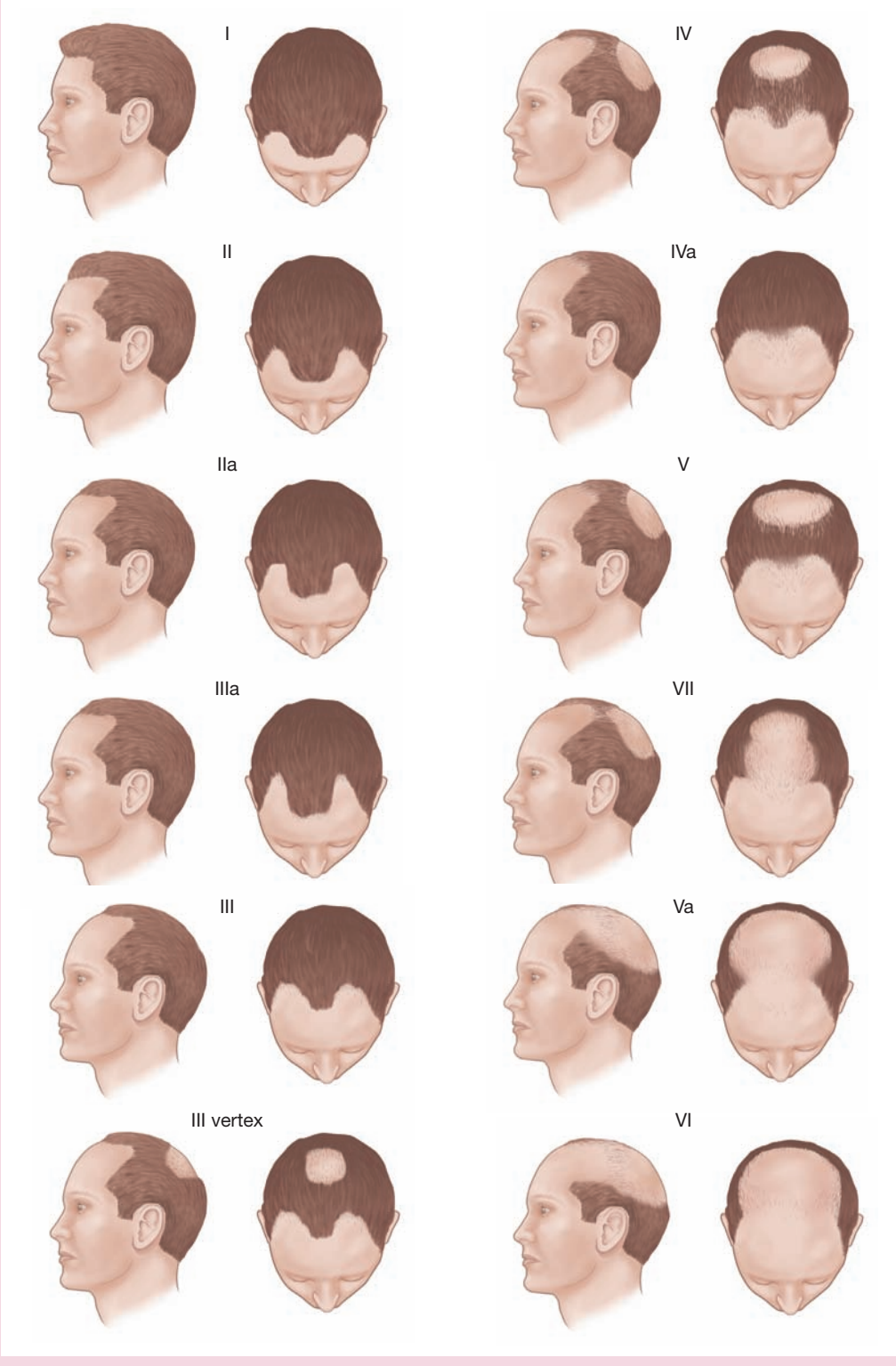

Figure 88-4 Hamilton–Norwood classification of pattern hair loss in men. (From Olsen EA: Female pattern hair loss. *J Am Acad Dermatol* **45**:S70, 2001.)

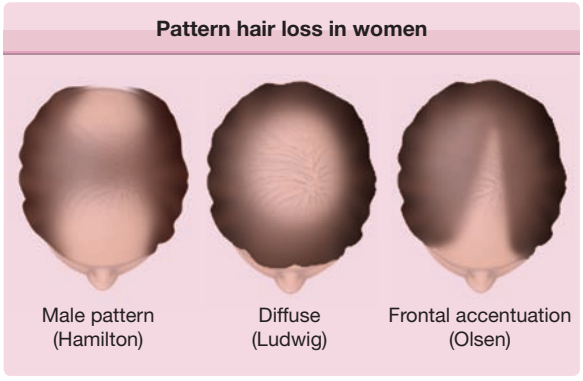

A

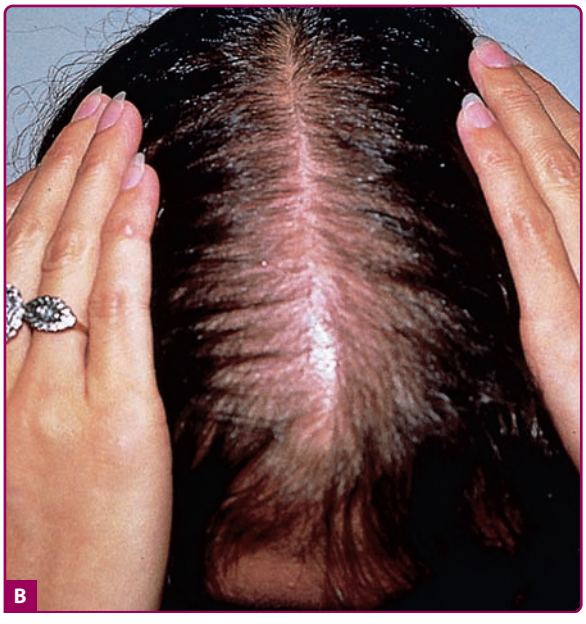

B

Figure 88-5 Pattern hair loss in women. **A.** Different phenotypic expressions. **B.** Characteristic frontal accentuation (widened hair part). (From Wolff K, Goldsmith LA, Katz SI, Gichrest BA, Paller AS: Fitzpatrick's Dermatology in General Medicine. 7th ed. Copyright © The McGraw-Hill Companies, Inc. All rights reserved, with permission.)

show a male pattern of distribution, as well as men can show a more female pattern.[1]

A thorough scalp exam together with the patient history usually allows a definitive diagnosis.

Standardized global scalp photography, especially of the part area, is very helpful as a qualitative assessment of the progression of the hair loss and as therapy control. A pull test and a trichogram can give information on the ongoing activity of the condition. Videodermoscopy and phototrichogram techniques can be used for therapy control.

The diagnosis can be more difficult if the hair loss is more diffuse over the entire scalp or if it occurs together with other hair loss conditions such as TE, diffuse alopecia areata or mild forms of cicatricial alopecias. A scalp biopsy allows a definitive diagnosis, since it provides information on histological features, the number of terminal and vellus hair per area and the number of anagen and telogen hair.

BOX 88-1 ANDROGENETIC ALOPECIA DIFFERENTIAL DIAGNOSIS

- Telogen effluvium
- Diffuse Alopecia areata
- Trichotillomania
- Secondary syphilis

In women, a laboratory test for ferritin and thyrotrophin-stimulating hormone (TSH) are recommended to rule out sources for and underlying TE. An extensive laboratory workup for androgens is not recommended for a routine visit. Women with irregular periods and/or other signs of androgen excess should be at least checked for free and total testosterone as well as DHEA-S. The best time for the blood work is in the morning of one of the days of her menstrual cycle. She also must be off the pill for at least one cycle.

RISK FACTOR AND ASSOCIATION WITH OTHER DISEASES

An increased risk of coronary heart disease and insulin resistance has been correlated for early vertex balding, especially in young men with hypertension, obesity, and dyslipidemia.[93–95] Early vertex balding has also been correlated with an increased risk of prostate cancer.[96,97]

DIFFERENTIAL DIAGNOSIS

(Box 88-1)

TREATMENT

AGA is a progressive condition with a decrease in hair density of approximately 6% of hair fiber per year.[40] However, increased shedding can occur periodically and the extent of hair loss depends on the genetic predisposition. Currently two pharmaceutical treatments are approved for the therapy of AGA in men: oral finasteride and topical minoxidil.

MINOXIDIL

Minoxidil is a biologic response modifier, which has been shown to halt AGA in many patients and regrow hair to a certain extent. Minoxidil, a piperidinopyrimidine derivative, was noted to cause hypertrichosis when administered orally as an antihypertensive. It is now used as a 2% and a 5% topical treatment in a lotion or foam preparation.

The mechanism of action is not fully understood. A direct effect on the hair follicle cells may be responsible for the effects of minoxidil. It has been shown to have a mitogenic effect on epidermal cells leading to prolonged survival time and induced increased proliferation

of hair follicles in vitro.[98–100] A possible mechanism of action involves a change in calcium homeostasis of cells, as minoxidil is converted to minoxidil sulfate, a potassium channel agonist. Increased potassium channel permeability leads to impaired entry of calcium into cells, thus decreasing epidermal growth factors and enhancing hair growth.[101]

Several clinical trial have shows the efficacy of topical minoxidil. An increase in hair counts probably reflects reversal of miniaturized hairs to thicker, more highly visible terminal hairs. Although studies have been performed on the vertex scalp, the drug also works on the frontal scalp, especially if hairs have not completely miniaturized to vellus-like hairs. Moderate to dense regrowth could be seen in up 30%–45% of patients.[41] Some patients experience an increased shedding in the first 4–6 weeks of application. This positive sign seems to indicate anagen induction with earlier "molting" of telogen hairs from the follicles. The patient should be educated and prepared for this possible side effect to improve compliance. Observed side effects include contact dermatitis in 6.5% of patients and facial hypertrichosis in 3%–5% of women.[102] Most patients do not have a true contact allergy to minoxidil but an irritation from propylene glycol. The 2% lotion with less propylene glycol, other vehicles with butylene glycol or the foam may then be used. To discriminate, which component causes the dermatitis, a patch test or testing the product on the volar forearm (repeated open application test) may be helpful.

Only minimal amounts of minoxidil are systemically absorbed and serum levels are too low to have hemodynamic effects in normotensive or hypertensive patients. Nevertheless, less than one in thousand patients may experience tachycardia and decreased blood pressure. Patients with hypotension or heart problems should be cautious and use the medication with approval from their cardiologist. The cardiac effects suggested in earlier studies could not definitely be linked to minoxidil and may be due to increased incidence of coronary artery disease in subsets of men with AGA.[93]

Topical minoxidil solution is used twice daily (1ml or 25 drops bid). It is also available in a 5% foam. If the hair has been shampooed, the hair and scalp should be at least towel-dry. The lotion or foam should stay on the scalp for at least 4 hours before the next shampoo. The patient should be informed that this is a lifelong treatment. It takes 4–6 months before the medication starts working and that the maximum effect can be expected after 1 year.

FINASTERIDE

Finasteride is a synthetic azo-steroid that has been used for the treatment of AGA in men since 1997. It is a potent and highly sensitive selective 5α-reductase type-2 inhibitor.[59] It binds irreversibly to the 5α-reductase isoenzyme 2 and inhibits the conversion of testosterone to DHT. Finasteride has a pharmacological half-life of around 8 hours. The administration of 1 mg finasteride daily reduces the concentration of DHT in scalp skin by 64%, serum DHT is reduced by 68%.[59] The dose response curve is nonlinear and therefore higher doses do not lead to significantly increased suppression of DHT or greater clinical benefits.[103] In placebo-controlled studies, a significant hair count increase in men with vertex alopecia or frontal AGA could be shown after 6 and 12 months.[104,105] Finasteride stabilizes hair loss in 80% of patients with vertex hair loss and 70% of patients with frontal hair loss. The chance of mild to moderate regrowth is 61% on the vertex and 37% on the frontal scalp.[106] After 24 months of continuous use, 66% of the patients experienced a certain amount of hair regrowth in the vertex area (approximately 10%–25% of the hair the patient lost previously).[107] Most of the patient showed no further hair loss and only a few patients continued to lose hair. Continued use beyond 2 years does not promote continued hair regrowth. Instead the hair density stabilizes with the retention of the newly acquired hair.[107] If successful, the treatment should be continued indefinitely because the balding process continues once treatment ceases.[38] Finasteride was found to be well tolerated with side effects occurring in fewer than 2% of patients. The side effects included decreased libido in 1.8% of the recipients versus 1.3% in the placebo group, erectile dysfunction in 1.3% of the recipients versus 0.7% in the placebo group and decreased ejaculate volume in 0.8% of the recipients versus 0.4% in the placebo group.[108,109] Finasteride 1 mg daily does not affect spermatogenesis or semen production in men aged 19–41 years of age.[110] The effect on prostate volume and serum prostate specific antigen (PSA) in younger men was small and reversible after discontinuation of the drug.[110] Finasteride can decrease PSA levels by 50% in older men.[111] Therefore a baseline PSA should be taken in men over 40 and the family doctor should be advised to double the PSA value while patients are taking finasteride.[106] Long term side effects of 1 mg finasteride daily are yet unknown. A placebo controlled study over 7 years carried out in 9,060 men 55 years of age or older, taking 5mg finasteride per day or placebo, showed that finasteride prevents or delays the appearance of prostate cancer, but a slightly higher risk of high-grade prostate cancer.

Finasteride is not approved for the use in women and its efficacy in FPHL is still controversial. A multicenter double-blind, placebo-controlled, randomized study of finasteride 1 mg/day in postmenopausal women with FPHL showed no differences in anagen:telogen ratio and the terminal hair:miniaturized hair ratio. However, Camacho et al reported hair regrowth using finasteride 2.5 mg/day in 41 women with FPHL and SAHA (seborrhea, acne, hirsutism, and alopecia).[39,49]

DUTASTERIDE

Dutasteride is an inhibitor of type I and II 5α-reductase. It is approved at a dose of 0.5 mg daily for the treatment of symptomatic benign prostatic hyperplasia. Some studies have shown great efficacy in the treatment of MPHL and FPHL.[112–115] However, dutasteride is not FDA approved for use in androgenetic alopecia. More studies are necessary for the evaluation of the safety profile of this drug.

CYPROTERONE ACETATE

The antiandrogen cyproterone acetate (CPA) is a synthetic derivative of 17-hydroxyprogesterone. It acts as an AR antagonist with weak progestational and glucocorticoid activity.[62] It also inhibits the steroidogenic enzyme 21-hydroxylase, reducing the production of aldosterone and to a lesser extent 3-β-hydroxysteroid dehydrogenase, both of which are needed to synthesize cortisol. CPA is available in Europe, Canada and South America. It is usually combined with ethinyl estradiol as a birth control pill. CPA is not approved by the FDA for the treatment of AGA. For the treatment of FPHL a regimen with 100 mg CPA daily on days 5–15 of the menstrual cycle and 50 µg of ethinyl estradiol on days 5–25 or 50 mg CPA daily on days 1–10 of the cycle and 35 µg of ethinyl estradiol on days 1–21 have been suggested.[116] In a randomized 12 months clinical trial in 66 women, 33 women with FPHL used topical minoxidil 2% plus combined oral contraceptive whereas 33 women received CPA 52 mg daily plus ethinyl estradiol 35 µg for 20 days of the cycle. The later combination result in greater hair density in women with hyperandrogenism.[117] Side effects from CPA are irregular menstrual cycles, weight gain, breast tenderness, loss of libido, depression, nausea. Since CPA is an antiandrogen, its use in men is obsolete, unless a gender change is desired.

SPIRONOLACTONE

Spironolactone is a synthetic 17-lactone drug, which is a renal competitive aldosterone antagonist with a mild antiandrogenic effect by blocking the AR and preventing its interaction with DHT. The maximum androgen suppression is reached after 4–12 months; dosages of 200 mg daily are required. Spironolactone may have a preventative effect in FPHL and may reduce shedding in individuals without hyperandrogenism.[118] However, Spironolactone is not approved by the FDA for the treatment of FPHL and, sd sn antiandrogen, should not be used in men. The main side effect is menstrual irregularities, which may be mitigated by decreasing the dose to 50–75 mg/day and adding oral contraceptives or after 2–3 months of therapy. Spironolactone is contraindicated in patients with renal insufficiency, hyperkalemia, pregnancy, abnormal uterine bleeding, and women with genetic predisposition of breast cancer.[116,118]

17α- AND 17β-ESTRADIOL

In Europe topical 17α- or 17β-estradiol are commercially available for the treatment of FPHL. Studies showed an increased in anagen and decreased telogen rates after topical treatment compared with placebo treatment.[119] The underlying pathways of 17α-estradiol induced hair regrowth are unknown. Niiyama et al showed that 17α-estradiol is able to diminish the amount of DHT formed by human hair follicles after incubation with testosterone while increasing the concentration of weaker steroids.[119,120] Recently, it has been shown that hair follicles in women with FPHL express more aromatase activity as compared to male hair follicles. Under the influence of 17α-estradiol, an increased conversion of testosterone to 17β-estradiol and androstenedione to estrone takes place in hair follicles derived from the occiput, which might explain the beneficial effects of estrogen treatment in FPHL. Woman who were taking aromatase inhibitors were shown to develop FPHL more rapidly.[121] Another theory about the effectiveness of estradiol is the systemic induction of SHBG and therefore the reduction of free, bioavailable testosterone.[63] Since estradiol is absorbed through the scalp skin, systemic side effects must be considered, and it cannot be used in men.

LOW-LEVEL LIGHT THERAPY

Laser sources have become very popular in medical and nonmedical areas. Manufacturers and suppliers often guarantee hair regrowth and various devices are available without prescription. The only FDA approved low-fluence laser light device is the Hair Max Laser Comb® (Lexington international, LLC, Boca Raton, FL, United States of America) (FDA approval as a medical device). Paradoxical hair growth has occurred in patients undergoing laser hair removal when relatively low energy fluences were used. The mechanism of action of this phenomenon is unknown. One theory suggests an increase in blood flow in the dermal papilla.[122–124] Low-level laser light sources appear to be safe to use in the treatment of hair loss. More studies are necessary to understand the mechanism of action and to evaluate the efficacy of these devices.

HAIR RESTORATION SURGERY

Hair restoration is the most successful and permanent treatment for AGA in suitable candidates. It includes hair transplantation (HT) and, in skillful hands, scalp-reduction surgery. Suitable candidates for HT are those with reasonable expectations, a donor supply that is adequate to cosmetically improve the recipient area coverage and those without contraindications for surgery. The most dramatic change in cosmetic appearance is achieved in patients with stages Hamilton–Norwood VI and VII, and in patients with anterior accentuation of balding (subtypes IIIa and IVa, "Christmas tree pattern").

With recent advancements in technique and combination with medical treatment, more patients may benefit from the surgical option. Larger numbers of smaller grafts are moved per session, and results have thus become very natural.[125,126] It is possible and advisable to distribute small grafts in between preexisting hairs and thus account for future hair loss. Rational use of the donor area with strip harvesting or FU extraction makes several sessions possible in many patients if they experience progressive hair loss.

HT is based on the principle of donor dominance as shown by androgen-independent follicles retaining their properties when they are transplanted into

androgen-dependent areas. The donor supply is limited by the area of the strip (size of the "safe zone," scalp elasticity) and the density of donor hair.

HT is an outpatient procedure and may take up to 10 hours, depending on various factors, especially the number of grafts. Tumescence anesthesia is used for the donor and recipient areas, sometimes combined with nerve blocks. The most commonly used technique is strip harvesting. It allows for a relatively fast removal of large numbers of hairs leaving a fine line as a scar, which can be minimized with special harvesting and wound closure techniques. The strip is dissected into FUs ("families" of hairs growing together in one connective tissue sheath) under magnification these grafts are then carefully and strategically placed in the balding areas. The recipient side is prepared with small needles or spears, according to the size of the graft. A recent technique involves separately harvesting individual FUs using very small blunt punches (follicular unit extraction (FUE). This procedure is usually more time consuming but avoid a long scar in the occipital area. Follicular unit extraction is indicated in patients who desire to wear a very short hairstyle.

WIGS AND HAIRPIECES

Scalp prostheses are practical for patients who are not candidates for hair restoration surgery, women with extensive hair loss and/or patients without satisfying improvement after using medical therapy. Wigs and hairpieces can provide excellent cosmetic results, especially when they are custom made. It is usually easier to overcome the reluctance to wear a scalp prosthesis if the hair piece blends in nicely with the preexisting hair and is comfortable to wear. Women tend to be less reluctant to wear a wig or hairpiece, especially if the patient is exposing her natural hairline (Figs. 88-6 and 88-7).

DIFFUSE HAIR LOSS

GENETIC

HYPOTRICHOSIS SIMPLEX. Hypotrichosis simplex is characterized by progressive global loss of scalp hair starting during childhood. This autosomal dominant disorder affects both sexes equally; eyebrows and body hair is unaffected by the condition. The pathogenesis is of hypotrichosis simplex is not fully understood. In two families with hypotrichosis simplex, a gene defect in the corneodesmosin gene (adhesin protein) was found[84,127] (Fig. 88-8).

REDUCED OR ABSENT HAIR GROWTH ASSOCIATED WITH ECTODERMAL DYSPLASIA

A failure in normal follicle development in utero can results in a reduction or absence of hair follicles. These developmental disorders are often associated with ectodermal defects. These hereditary syndromes, most frequently show abnormalities of bones, central nervous system, teeth or eyes (see Chapter 142). The most common ectodermal dysplasia, hypohidrotic ectodermal dysplasia, which is characterized by sparse hair,

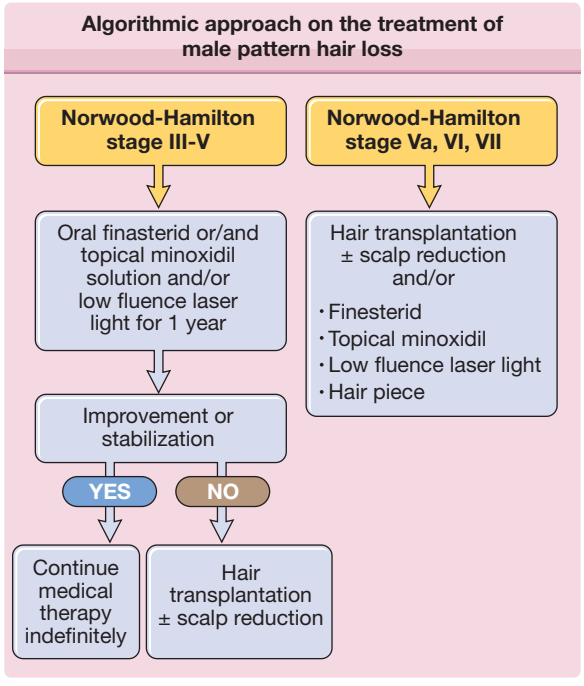

Figure 88-6 An algorithmic approach on the treatment of male pattern hair loss.

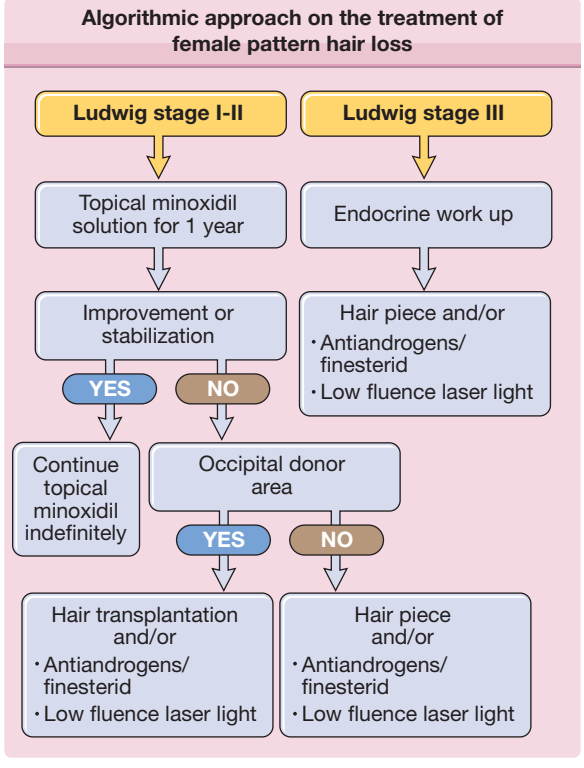

Figure 88-7 An algorithmic approach on the treatment of male pattern hair loss.



Figure 88-8 Hypotrichosis simplex in a 35-year-old woman.

abnormal teeth and reduced or absent sweating, is due to a mutation in the ectodysplasin signaling pathway.[128] This pathway is involved in the early embryogenic formation of the hair follicle.[129–131] Ectodermal dysplasias with hair disorders are discussed in Chapter 142.

ATRICHIA WITH PAPULAR LESIONS

Atrichia with papular lesions is an autosomal dominant hair disorder that presents in infancy. Hair is usually present at birth but alopecia develops within the first year of life. Several years after the development of alopecia, papular follicular cysts often appear.[132] Mutations either in the *hairless* gene or the gene encoding the vitamin D receptor can lead to this phenotype. Hair follicle formation in utero appears to be normal, but massive apoptosis in the hair bulb during the first catagen phase leads to a separation of the dermal papilla from the base of the hair follicle and consequent failure to reenter anagen. The follicular epithelium than undergoes a cystic change. If universal hair loss occurs during the first month of life, atrichia with popular lesions and alopecia areata universalis should be considered as differential diagnosis. If universal alopecia is seen in the family, gene testing and genetic counseling should be considered.

SHORT ANAGEN SYNDROME

The term short anagen hair syndrome applies to a poorly understood clinical presentation of short fine hair in children.[87] The hair fails to grow long due to a shortened anagen phase. Hair density and hair shafts seem to be normal. The condition may improve after puberty. Short anagen hair can be inherited autosomal dominant or can occur sporadically.

LOOSE ANAGEN SYNDROME

Loose anagen syndrome is characterized by an easy epilation of anagen hair. The hair appears to grow slowly and can be pulled out without pain. Hair density can appear normal or reduced and some children may display demarcated areas of incomplete alopecia. The typical patient with loose anagen hair syndrome is 2–5 years of age. The condition more frequently affects girls and hair is most often light blond. The hair loss tends to get better without any treatment once the child grows older. Microscopic examination of gently pulled hair can make the diagnosis; 80%–100% of the hairs are anagen hairs with a ruffled cuticle and no inner root sheath. However, the hair loss can cycle, and it may be hard to gather enough hair with a gentle pull, necessitating collection by the parent at home and later microscopic evaluation. Loose anagen hair syndrome can be familial, sporadic or associated with other developmental defects such as Noonan syndrome or hypohidrotic ectodermal hyperplasia.[133] It is also seen in association with HIV.[134] Hair shaft abnormalities, alopecia areata and trichotillomania have to be considered in the differential diagnosis. (See Fig. 88-9.)

TELOGEN EFFLUVIUM

EPIDEMIOLOGY

The second most common cause of hair loss in women after FPHL is TE. The latter presents as a nonpatterned increase in shedding of terminal hairs, diffusely over the entire scalp, and can produce an apparent thinning of hair in severe cases.[135] While both genders can experience TE, attitudes toward hair loss result in a greater proportion of females who complain. TE can copresent with AGA, particularly in early-onset situations, and this can complicate diagnosis and treatment. TE differs from AGA in that it is not androgen-sensitive,



Figure 88-9 Loose anagen hair syndrome with diffuse hair loss. (From Olsen EA et al: The presence of loose anagen hairs obtained by hair pull in the normal population. *J Investig Dermatol Symp Proc* **4**:258, 1999, with permission.)

does not appear to be inherited and, since it does not involve a terminal- to vellus-hair transition, does not decrease matrix cell volumes or hair shaft diameters.[136] TE also tends to be related to external causes and is often reversed when the exogenous stimuli are removed.

ACUTE TELOGEN EFFLUVIUM

ACUTE TELOGEN EFFLUVIUM AT A GLANCE

- Nonscarring alopecia.
- Sudden conversion of large numbers of actively growing anagen to telogen hair leads to diffuse hair shedding.
- Seen after severe illness, surgery, nutritional deficiency, iron deficiency, childbirth, in association with medications and in patients with thyroid disease.
- Reversible once the initiating factor is eliminated.

ETIOLOGY AND PATHOGENESIS. The pathophysiology underlying TE is best characterized as a premature shift of hairs from the anagen (growth) phase into the catagen (resting) and telogen (terminal) phases. However, there are variants: anagen may be prolonged, or telogen may instead be shortened or prolonged. Which type of shift occurs depends on the stimulus producing the shift, with the main clinical difference being the latency of effluvial onset following the stimulus.

The hair loss that commonly occurs following pregnancy is generally seen 2 or 3 months postpartum, although some individuals can exhibit longer times to onset. While this is classic TE, the mechanism has been shown to involve a delayed transition from anagen to catagen/telogen, which results in a simultaneous shedding of large numbers of terminal hairs.[137] This hair does eventually regrow; however, the returning hair may show changes in texture, color and curliness, and may not attain its previous length. As such, pregnancy (parturition or abortion) may in some cases produce permanent changes in anagen length.[136]

Other perturbations can produce TE, usually involving premature termination of the anagen phase. Some women experience transient TE 2–3 months after discontinuing or changing oral contraceptive medication; the delayed onset of TE in these cases distinguishes it from the anagen effluvium (AE) initiated by certain drugs (see below). In the 1970's, the popularity of fad "crash" diets resulted in many cases TE about 3 months after initiation of these spartan regimens, depending on the severity of weight loss. Sudden deprivation of amino acids and other dietary factors most likely produced the condition, and the hair tended to regrow following cessation of the diets.[136] Surgical procedures, psychological traumas, and febrile illness have all been reported to produce TE events.

Drugs are widely reported to produce temporary hair loss. This is usually, but not necessarily, of the AE variety, since, depending on the causal agent, the time course and severity may suggest a diagnosis of TE to be appropriate. Agents producing TE include cimetidine, enalapril and captopril, imiquimod, metoprolol and propranolol,[138–141] lithium,[142] L-dopa[143] trimethadione,[144] and bromocriptine.[145] The hair loss from administration of etretinate[146] and isotretinoin are problems, more of the AE, as is hair loss that sometimes follows renal dialysis, possibly with hypervitaminosis A.[136] Finally, hair loss occurring following environmental contamination or poisoning, for example with selenium, arsenic, thallium, mercury, and lead, displays an AE-like rapid onset, probably involving a cytotoxicity mechanism.

CLINICAL FINDINGS. TE is characterized by a fairly sudden onset of massive shedding. Anagen hairs are prematurely shifted into telogen hairs and the normal anagen/telogen ratio of 90:10 can switch to 70:10. Women often present with the "bag sign": bringing in bags with hair that they have collected every day or over a couple of days (Fig. 88-10). More than 300 telogen hairs can be shed every day. The global examination of the scalp may show a reduction in hair density especially in the temporal area. The pull test is usually positive (3 or more hairs can be pulled out on different parts of the scalp). A trichogram or phototrichogram can be use to quantify the amount of telogen hair. A scalp biopsy may be helpful to distinguish the condition from diffuse alopecia areata or AGA.

CHRONIC TELOGEN EFFLUVIUM

ETIOLOGY AND PATHOGENESIS. Chronic Telogen Effluvium (CTE) was first proposed in 1996 as a means of distinguishing the abrupt-onset, short-acting



Figure 88-10 Diffuse thinning in a female patient with acute telogen effluvium.

BOX 88-2 CAUSES OF TELOGEN EFFLUVIUM

- Endocrine
  - Childbirth, miscarriage, abortion
  - Hypo- and hyperthyroidism
  - Discontinuation of estrogen-containing drugs
- "Stressful" events
  - Febrile illnesses
  - Catabolic illnesses (e.g., malignancy, "consumptive" chronic infection)
  - Major surgery
  - Major trauma
  - Acute or chronic psychological stress
- Nutritional
  - Rapid weight loss (e.g., "crash dieting")
  - Caloric or protein deprivation
  - Chronic iron deficiency
  - Excessive vitamin A ingestion
- Intoxication
  - Thallium
  - Mercury
  - Arsenic
- Drugs
  - Anticoagulants (including heparin)
  - β Blockers (propanolol)
  - Captopril
  - Cholesterol-lowering drugs
  - Colchicine

type TE, usually caused be exogenous triggers or parturition, from a more durable condition (CTE) that may not be so clearly related to any external event.[147]

A few conditions have been proposed to be underlying stimuli for CTE. While "crash" diets have been pinpointed as potential triggers for acute TE, chronic malnutrition can analogously lead to CTE. Protein deficiency is the likely mechanism in this type of balding. It is less clear whether zinc[148] or biotin deficiencies are also correlated with chronic diffuse hair loss. Although controversial, iron deficiency, as evidenced by decreased serum ferritin and anemia, may be a trigger for CTE.[27,149,150,151] Hypothyroidism has also been associated with CTE (Box 88-2).

CLINICAL FINDINGS. CTE can most commonly be seen in women. Patients report ongoing massive shedding or recurrent episodes of shedding. As a rule of thumb, any diffuse hair shedding lasting longer than 6 months after any triggering event, or after withdrawal from suspected causal drugs, should be considered CTE. The clinical examination can show a normal or reduced hair density. Regrowth of tapered new anagen hair can usually be found. The pull test may be moderately positive. A trichogram or phototrichogram can be used to confirm and quantify the diagnosis. A scalp biopsy is very helpful for the confirmation of the diagnosis and to distinguish the condition other forms of alopecia. Since other types of hair loss disorders, chiefly FPHL/MPHL and alopecia areata, may copresent with TE and CTE, clinicians may be advised to assay serum iron and thyroid hormone concentrations in order to eliminate iron deficiency and hypothyroidism as treatable causes for the patient's baldness.[152]

BOX 88-3 ACUTE TELOGEN EFFLUVIUM DIFFERENTIAL DIAGNOSIS

- Androgenetic alopecia
- Diffuse Alopecia areata
- Trichotillomania
- Anagen effluvium
- Secondary syphilis

DIFFERENTIAL DIAGNOSIS. (Box 88-3)

PROGNOSIS AND CLINICAL COURSE. Both acute and CTE usually resolve once trigger factors are eliminated. However, in CTE triggers may be difficult to identify. Women with TE are often most concerned about complete baldness. The patient has to be reassured that the condition does not lead to complete baldness and that the hair likely grows back around 6 months after removal of the initiating trigger. The patient should understand that the condition is reversible, but that the shedding may persist for a few weeks or months once the initiation factor is eliminated.

TREATMENT

The removal of the cause is the major goal in the treatment of TE. Iron supplementation is recommended if the ferritin level is less than 70 ng/mL.[150,153] Borderline hypothyroidism can be difficult to identify. Women, who complain about hair loss, depression, lack of energy, mental fatigue, cold intolerance, weight gain or/and constipation are suspicious for the diagnosis of hypothyroidism. TSH levels may fluctuate but are usually elevated, with normal or reduced thyroid hormone levels. If a thyroid dysfunction is suspected, the patient should be closely followed by an endocrinologist. Topical 2% or 5% minoxidil solution 1 mL twice daily can be helpful, especially in women with prolonged hair loss with unknown triggers or in patients with drug related hair loss who are unable to discontinue the initiating medication.

ANAGEN EFFLUVIUM

AE is a result of a disturbance of hair follicle matrix cells. The anagen phase is interrupted and the hair falls out 7–14 days after the initiating event without entering catagen or telogen. Two different types of AE can be distinguished: Dystrophic AE and Immediate anagen release. Dystrophic AE can be caused by

chemotherapy, radiation, toxins or alopecia areata. Microscopic investigation of the hair bulbs, obtained from a hair pull test or trichogram, usually shows a tapered tip with the weakened hair shaft broken shortly above the bulb ("dystrophic hair").[1]

Drugs used in chemotherapy quickly produce severe hair loss and even total baldness. A rapid onset undoubtedly indicates an immediate release from anagen hair. Immediate anagen hair release is characterized by an easy release of anagen hairs after gentle pulling. The anagen hair has a broom-shaped, pigmented bulb. Therapeutic agents that can cause immediate anagen hair shedding include vincristine, vinblastine, methotrexate, doxorubicin, and fluorouracil.

Normal appearing anagen hair with inner and outer root sheath can be found to some extent in every AE, but especially in bullous dermatosis of the scalp with sub- or intraepidermal blisters.

Once the initiating trigger is removed, the hair usually regrows after around 120 days. Cases of incomplete recovery following multiagent chemotherapy have been reported.[1] Patients should be advised about scalp prostheses and other forms of head covering.

NONSCARRING FOCAL HAIR LOSS

ALOPECIA AREATA AT A GLANCE

- Nonscarring hair disorder.
- Occurs in both genders equally and can affect every age group, although incidence at younger age is higher.
- Most common form of hair loss in children.
- Clinically presents with well-demarcated round or oval bald spots on the scalp or other parts of the body.
- 5% develop hair loss of their entire scalp hair (alopecia areata totalis), 1% develop alopecia areata universalis (loss of total body hair).
- Nail changes include pitting or sandpaper nails.
- Thought to be an autoimmune disease with a possible heredity component.
- Usually without associated disorders, but can coexist with other autoimmune disorders such as Hashimoto thyroiditis or vitiligo.

ALOPECIA AREATA

EPIDEMIOLOGY. At any given time, approximately 0.2% of the world population is suffering from alopecia areata with an estimated lifetime risk of 1.7%.[154,155] It is a common cause of abrupt-onset hair loss, but occurs less frequent than androgenic alopecia or TE. Both sexes are affected equally. Although it may occur at any age, incidence at younger age is higher. Alopecia areata is the most common form of alopecia seen in children. The familial occurrence is around 15% but expression of the disorder is variable among different family members. 5% of patients suffering from alopecia areata develop hair loss of their entire scalp hair (alopecia totalis), and 1% of patients develop loss of total body hair (alopecia universalis) at some point.

ETIOLOGY AND PATHOGENESIS. Alopecia areata is a chronic, organ-specific autoimmune disease, mediated by autoreactive $CD8^+$ T-cells, which affects hair follicles and sometimes nails.[156–159] Alopecia areata is thought to be an autoimmune disease with inappropriate immune- response to hair follicle associated antigens. A collapse of the normal immune privilege of the anagen hairbulb, probably induced by interferon-γ, may play a key role in the pathogenesis of this disease.[156,159] Melanogenesis-associated autoantigens, which are normally sequestered from immune recognition by a functional hair follicle immune privilege, may be one key target of autoaggressive inflammation in alopecia areata.[160] There is a high frequency of a positive family history of alopecia areata in affected individuals, ranging from 10% up to 42% of cases,[161] and a much higher incidence of a positive family history in early onset alopecia areata.[162] Many patients report the experience of major emotional stress prior to the onset of alopecia. A genome-wide association studies recently showed several loci linked to alopecia areata containing genes controlling both innate and acquired immunity, as well as genes expressed in the hair follicle itself.[163]

Histologically, alopecia areata is characterized by an inflammatory infiltrate, comprised mainly of T-cells, in and around the bulbs of anagen hair follicles ("swam of bees"). However, the classic inflammatory infiltrate may be missing in subacute or chronic forms. Alopecia areata should be in the differential diagnosis whenever high percentages of telogen hairs or miniaturized hairs are present, even in the absence of peribulbar inflammation.

CLINICAL FINDINGS. Alopecia areata is characterized by an acute onset. It typically presents with oval or round, well-circumscribed, bald patches with a smooth surface in a diffuse distribution (Fig. 88-11). Alopecia totalis results in the loss of the entire scalp hair and may occur suddenly or follow partial alopecia (Fig. 88-12). Partial alopecia may be observed in other areas of the body as well. Loss of total body hair is called alopecia universalis and may also occur suddenly or follow of long-standing partial alopecia.

Characteristic hallmarks of alopecia areata are "black dots" (cadaver hairs, point noir), resulting from hair that breaks before it reaches the skin surface. Exclamation point hairs, with a blunt distal end and taper proximally, appear when the broken hairs (black dots) are pushed out of the follicle. Localization of the initial patch is most frequently on the scalp, but may occur on



Figure 88-11 Patient with patchy alopecia areata.

any hair-bearing part of the body. Patches are usually without further symptoms, but may show mild itching and erythema in some cases. Alopecia areata can less commonly present in a diffuse generalized pattern that resembles androgenic alopecia or TE. In the acute stages, gentle pulling from the periphery of bald areas will yield more than 10 hairs. Involvement of nails is common with nail pitting and a sandpaper-like appearance. The disease has been described in association with a variety of other disorders, such as cataracts, thyroid disease, vitiligo, atopic dermatitis, psoriasis, and immunodysregulation polyendocrinopathy enteropathy X-linked syndrome (IPEX), Cronkhite–Canada, and Down syndromes.[164,165]

Clinical features, such as shape and look of the patches, presents of exclamation point hair, nail changes (pitting or sandpaper nails) lead to the diagnosis of alopecia areata. In most patients the physical findings are so characteristic that the diagnosis is obvious. Moreover, positive family history and/or the presence of associated diseases may give further evidence in cases of doubt. Scalp biopsy reveals a generalized miniaturization and a marked increase in catagen and telogen hair follicles. In the acute phase, a peribulbar lymphocytic infiltrate, which has been described as a "swarm of bees" may be found. Sometimes mast cell, plasma cells and eosinophils can also be seen. Laboratory tests to rule out thyroid dysfunction should be performed.



Figure 88-12 Patient with alopecia areata totalis showing some regrowth of fine hair.

BOX 88-4 NONSCARRING FOCAL HAIR LOSS DIFFERENTIAL DIAGNOSIS

- Temporal triangular alopecia
- Tinea capitis
- Early scarring alopecia
- Trichotillomania
- Secondary syphilis (alopecia areolaris)
- Androgenetic alopecia
- Telogen effluvium
- Anagen effluvium

DIFFERENTIAL DIAGNOSIS. (Box 88-4)

COMPLICATIONS.

A relapsing course and progression of hair loss to severe forms of alopecia totalis or universalis are dreaded complications. Missing hair on the scalp and face, including nasal hair and eye lashes/brows can increase the incidence of sunburn and skin cancer, as well as nasopharyngeal and ophthalmologic inflammation. Although the condition is not life threatening, changes in appearance frequently cause a diminished sense of personal well-being and self-esteem, leading to severe depression and withdrawal from social situations.

PROGNOSIS AND CLINICAL COURSE.

The course of the disease is very variable and characterized by an irregular relapsing course, with about 25% of affected individuals having a solitary episode. Spontaneous regrowth of hair is common. Different body areas appear to regrowth independently. About 60% of patients have at least a partial regrowth by 1 year, but this is often followed by repeated episodes of hair loss. About 40% of the relapses occur within the first year, but a large percentage of patients may relapse after 5 years. Hair can regrow white but may change to the patient's natural color over time. Poor prognosis is linked to involvement of the occiput and/or hairline (called the ophiasis pattern if sweeping around the periphery of the scalp), a chronic relapsing course, the presence of nail changes, and onset during childhood.[166–168] The number of patients progressing to alopecia totalis also higher in patients with hair loss from the trunk and extremities.

TREATMENT.

Very little evidence-based data is available for the treatment of alopecia areata;

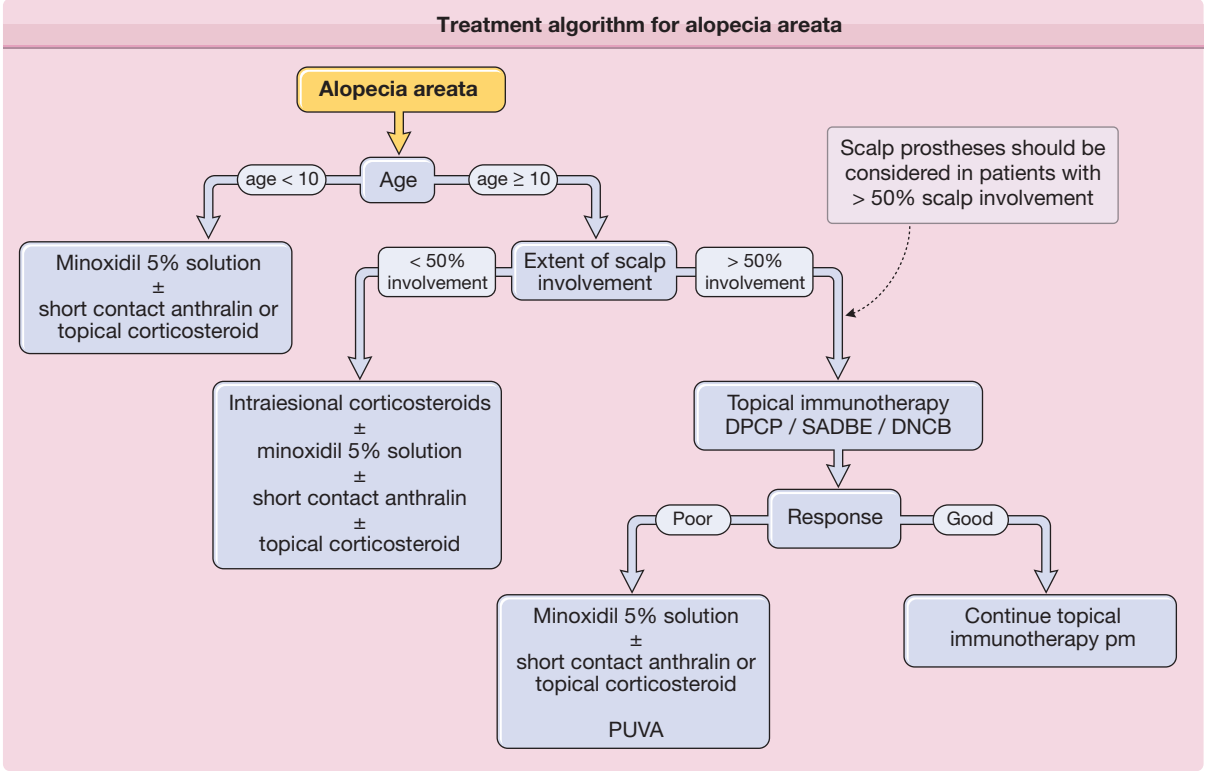

Figure 88-13 Treatment algorithm for alopecia areata. (Copyright © by Jerry Shapiro, Vera Price and Harvey Lui).

recommendations are mainly based on case series and clinical experience. At this time all available treatments for alopecia areata are palliative, only controlling the ongoing episode of hair loss and not curing the condition itself. However, helpful treatment guidelines have been published.[166–168] Fig. 88-13 shows an algorithm for treating alopecia areata based on age and scalp involvement.

CONSERVATIVE MANAGEMENT.

Alopecia areata shows a high rate of spontaneous remission, especially in those patients with a short history and limited scalp involvement. On the other hand, in alopecia totalis and universalis, treatments have a high failure rate. After the discussion of possible risks and benefits of all options, "no treatment" may be a legitimate option for some patients.

Topical Corticosteroids. Superpotent (class I) and potent (class II) topical corticosteroids are widely used to treat alopecia areata. Evidence of efficacy has been proven for class I corticosteroids when applied under occlusion[169] and for class II corticosteroids when used in combination with minoxidil.[170]

Intralesional Corticosteroids. Intralesional corticosteroid (triamcinolone acetonide or triamcinolone hexacetonide) injection is first line therapy for adult patients with less than 50% scalp involvement. Triamcinolone acetonide is used at concentrations from 2.5–10 mg/mL. Treatment are repeated every 4 to 6 weeks, and the total amount injected per session varies from 15–40 mg.[109,166–168,171] An initial response is often seen after 4–8 weeks. Some patients experience indentation of the scalp skin in the injection sites due to a nonpermanent atrophy of the subcutaneous fat. Permanent skin atrophy can occur if the same skin area is injected repeatedly over months and years. If no regrowth can be seen after 4 months of treatment, other treatment options should be considered. Intralesional corticosteroids injections are usually used on the scalp, eyebrows and beard area and can be combined with topical treatment.

Systemic Corticosteroids. Systemic corticosteroids are effective in the treatment of alopecia areata. However, the regrown hair frequently falls out again when the treatment is discontinued. The use of systemic corticosteroids is controversial and largely used on a short-term basis with rapidly advancing hair loss. They should not be used as routine treatments because they do not alter the long-term prognosis and can cause side effects such as striae, acne, obesity, cataracts and hypertension. Dosages vary from initial 20–40 mg prednisone daily tapered down to 5 mg daily in a few weeks or different pulse therapies regiments with short-term high doses of oral prednisolone (100–300 mg) or i.v. methylprednisolone (250 mg).[109,166–168]

Topical Minoxidil. There is some evidence of clinically acceptable hair regrowth using topical minoxidil 5% solution.[172,173] Better results can be achieved when minoxidil is used in combination with class II topical

corticosteroids or anthralin.[170] Minoxidil shows little efficacy in alopecia totalis and universalis.

Anthralin. Anthralin is an irritant that may have a nonspecific immunomodulating effect and is primarily used in the treatment of psoriasis (Chapter 18).[174] Several studies have shown efficacy in the treatment of alopecia areata with cosmetically acceptable improvement varying from 20% to 25% for patchy alopecia areata.[175,176] Anthralin is used as a 0.2%–1.0% cream or ointment. It is usually applied daily to the affected scalp areas and left on for 20–30 minutes for the first 2 week, and then 45 minutes daily for 2 week, up to a maximum of 1 hour daily. Some patient may tolerate overnight therapy.[109,175] When therapy is effective, new hair growth can usually be seen after 2–3 months of treatment. Because of its good safety profile, anthralin can be used safely in affected children. Side effects of anthralin are irritation, scaling, folliculitis and regional lymphadenopathy. Anthralin is not suitable for the treatment of eyebrows and beard area. Patients should be cautious not to get anthralin in the eyes and to protect the treated skin areas from UV irradiation. Brown discoloration of the treated skin and brown staining of clothes and linen may occur. The patient should be advised to rinse off the anthralin with cool or luke-warm water, since hot water increases the likelihood of brown stains of tiles and bathtub.

Topical Immunotherapy. Although not approved by the FDA, topical immunotherapy seems to be the most effective therapeutic option with the best safety profile in the treatment of chronic severe alopecia areata. The exact mechanism of action is not fully understood. A decrease in the peribulbar $CD4^+/CD8^+$ lymphocyte ratio and a shift in the position of T-lymphocytes from the perifollicular area to the interfollicular area and dermis are believed to be responsible for the immunomodulating effect.[177–179] The desired effect of the treatment is the creation of a contact dermatitis. Diphenylcyclopropenone (DPCP) and squaric acid dibutyl ester (SADBE) are the most commonly used contact sensitizers. DPCP and SADBE are compounded in an acetone base and stored in opaque bottles to protect the solution from photodegradation. Applying a small amount of a 2% solution to a small scalp or other area (often the arm) one week prior to treatment initiation sensitizes the patient. The DPCP or SADBE solution is then applied weekly to the scalp, starting at a concentration of 0.0001%. The scalp should not be washed for 48h post treatment and should be protected from UV radiation. Every week the concentration is carefully increased until the patient develops a mild erythema and mild itching. The treatment is continued with this concentration; the highest concentration used is 2%. Success rates vary from 17%–75% with the lowest success rates in patients with alopecia totalis and universalis.[20] Side effects include lymphadenopathy in 100% of patients, severe contact eczema, discoloration of the skin including vitiliginous patches and hyperpigmentation on the scalp and other arts of the body. Greater caution is indicated in patients with atopic dermatitis and dark skin types.

Photo(chemo)Therapy. Ultraviolet B light has been reported to be useful in some patients with alopecia areata.[180] Further therapeutic options include both oral and topical administration of psoralen followed by UVA irradiation (PUVA-therapy). PUVA may affect T cell function and antigen presentation, and possibly inhibits the local immunologic attack against the hair follicle by depleting Langerhans cells.[181] Photo(chemo)therapy shows a very high relapse rate especially after tapering the treatment. The major concern about long term UV irradiation of any kind is its promotion of all types of skin cancer, including melanoma. Therefore phototherapy should only be considered in exceptional cases.[20]

Cyclosporine. Systemic cyclosporine at doses of 4–6 mg/kg/day has been shown to have a beneficial effect in some patients with alopecia areata.[20,182] Side effect of oral cyclosporine include elevated serum transaminases and cholesterol levels, as well as headaches, dysesthesia, fatigue, diarrhea, gingival hyperplasia, flushing and myalgias. Cyclosporine can be combined with low dose oral prednisone and may be considered in patients with severe atopic dermatitis and alopecia areata. However, due to its side effect profile and the high recurrence rate observed after discontinuation, cyclosporine seems to be a relatively impractical treatment for alopecia areata.

Camouflage, Wigs, and Hairpieces. When alopecia is progressive despite treatment and sometimes during treatment for improved cosmesis, extensive alopecia areata of the scalp can be camouflaged with wigs. In women with alopecia areata of the eyebrows, permanent makeup may be considered.

The treating physician should provide psychological support. Local and national alopecia areata support groups (National Alopecia Areata Foundation, www.naaf.org) can be very helpful for patients and their relatives.

TEMPORAL TRIANGULAR ALOPECIA

Temporal triangular alopecia (TTA) is a nonscarring, noninflammatory alopecia that presents with one or more roughly triangular, oval, or lancet-shaped alopecic patches in the fronto-temporal area.[183–185] A few terminal hairs or vellus-like hairs can often be found in the periphery of the affected area and the scalp is normal.[186–190] The lesions are usually asymptomatic and the hair elsewhere on the scalp is of normal density. The patches are mostly unilateral (80%) but can occur bitemporally as well (20%)[34,185,190] (Fig. 88-14). A strip of hair of normal density can be seen between the affected patch and the forehead. Lesions can be present at birth or first appear before school age. TTA has been reported in Asian and Caucasian patients with no sexual predilection. TTA seems to be unresponsive to medical treatment. Hair transplantation or excision is reasonable therapeutic approaches.[191] TTA is often misdiagnosed as alopecia areata.



Figure 88-14 Temporal triangular alopecia.

SYPHILIS

Hair loss is a common symptom of secondary or tertiary syphilis. In its classical form, the hair loss is an irregular, patchy loss of hair scattered throughout the scalp, which has been described as "moth eaten" (Fig. 88-15). Eyebrows may be shed and patchy alopecia may occur in the beard or other hair-bearing areas of the body. Syphilitic alopecia can be very difficult to distinguish from alopecia areata. The presence of plasma cells, lack of peribulbar eosinophils, and abundant lymphocytes in the isthmus are histological features of syphilitic alopecia. Essential syphilitic alopecia occurs in the absence of any other cutaneous sign of secondary syphilis,[192] and is characterized by a diffuse shedding, thereby resembling TE.

CICATRICIAL ALOPECIA

Cicatricial or scarring alopecias comprise a diverse group of scalp disorders that result in permanent hair loss. The destructive process can occur as a primary or secondary cicatricial alopecia. Primary cicatricial alopecia refers to a group of idiopathic inflammatory diseases, characterized by a folliculocentric inflammatory process that ultimately destroys the hair follicle. Secondary cicatricial alopecias can be caused by almost any cutaneous inflammatory process of the scalp skin or by physical trauma, which injures the skin and skin appendages. Regardless of whether a cicatricial alopecia is primary or secondary in nature, all scarring alopecias are characterized clinically by a loss of follicular ostia and pathologically by a replacement of hair follicles with fibrous tissue. Cicatricial alopecias are psychosocially distressing for the affected patient and medico-surgically challenging for the treating physician.



Figure 88-15 Alopecia secondary to syphilis. (From Wolff K, Goldsmith LA, Katz SI, Gichrest BA, Paller AS: Fitzpatrick's Dermatology in General Medicine. 7th ed. Copyright © The McGraw-Hill Companies, Inc. All rights reserved, with permission.)

PRIMARY CICATRICIAL ALOPECIAS

CICATRICIAL ALOPECIA AT A GLANCE

- Scarring alopecia occurs in a heterogeneous group of hair disorders of a wide variety of causes.
- The inflammatory process leads to permanent destruction of hair follicular stem cell structure and subsequent replacement with fibrous tissue.
- The destructive process can occur as a primary or secondary cicatricial alopecia
- In each case, the differential diagnosis includes alopecia areata, an alternative form of cicatricial alopecia, temporal triangular alopecia, trichotillomania, and secondary syphilis (alopecia areolaris).
- Loss of hair ultimately occurs with permanent alopecia.
- No evidence-based treatment is available.

EPIDEMIOLOGY. Inflammatory cicatricial alopecias are rare.

ETIOLOGY AND PATHOGENESIS. The mechanisms causing the follicle stem cell destruction are not completely understood, and there is no cure to date. Primary cicatricial alopecias are characterized by an inflammatory infiltrate affecting the upper, permanent portion of the follicles referred to as the infundibulum, and below it, the isthmus of the follicle. The isthmus is the home of pluripotent hair stem cells, which are found in the bulge region where the arrector pili muscle attaches to the outer root sheath. Pluripotent hair follicle stem cells are responsible for the renewal of the upper part of the hair follicle and sebaceous glands,

BOX 88-5 FORMS OF PRIMARY CICATRICIAL ALOPECIA

LYMPHOCYTIC	Chronic cutaneous lupus erythematosus (discoid lupus erythematosus, DLE) *Lichen planopilaris (LPP)* ▪ Classic LPP ▪ Frontal Fibrosing Alopecia ▪ Graham–Little syndrome Classic Pseudopelade of Brocq (PPB) Central centrifugal cicatricial alopecia (CCCA) Alopecia mucinosa
NEUTROPHILIC	Keratosis follicularis spinulosa decalvans Folliculitis decalvans Dissecting cellulites/folliculits (perifolliculitis abscedens et suffodiens)
MIXED	Folliculitis (acne) keloidalis Folliculitis (acne) necrotica Erosive pustular dermatosis

Source: Olsen EA et al: Summary of North American Hair Research Society (NAHRS)-sponsored Workshop on Cicatricial Alopecia, Duke University Medical Center, February 10 and 11, 2001. *J Am Acad Dermatol* **48**:103-110, 2003.

and for the restoration of the lower cyclical component of the follicles at the onset of a new anagen period.[27,193] Damage to the bulge area and the sebaceous gland with the isthmus, affected either stem cells or sebaceous glands, may result in an incomplete hair cycle and can be associated with chronic follicular inflammation and foreign body reaction.[194] Scarring hair loss is the consequence.[5,195–197]

A working classification on the basis of pathology of scalp biopsy was suggested by the North American Hair Research Society in 2001[27] (Box 88-5).

CLINICAL FINDINGS. Primary cicatricial alopecia usually affects the central and parietal scalp before progressing to other sites of the scalp. Isolated alopecic patches showing atrophy and a lack of follicular ostia with inflammatory changes such as diffuse or perifollicular erythema, follicular hyperkeratosis, pigment changes, tufting, and pustules provide hints to the diagnosis.[20,198] However, clinically visible inflammatory change might be absent in the affected lesions and may present histologically as inflammatory infiltrates in the deep dermis and subcutaneous tissue. Diagnostic tools such as a tenfold magnifying dermatoscope with and without polarized light can help to identify the presence or absence of follicular ostia, perifollicular erythema and follicular hyperkeratosis in the affected areas.

A thorough examination of the entire scalp, a detailed clinical history, and skin biopsies of an active lesion are crucial in the correct diagnosis of cicatricial alopecia. Patient-reported symptoms such as itching or pain might be used as approximate indicators of disease activity but can also be completely absent. The presence of other indirectly related symptoms, such as sun sensitivity, can also help support a particular diagnosis [e.g., discoid lupus erythematosus (DLE)]. A scalp biopsy is necessary to confirm the diagnosis of scarring alopecia, and should be taken as described in Section "Diagnostic Techniques for Evaluating Hair Growth Disorders" under "Biopsy."[1,27,199,200] Keratoses follicularis spinulosa decalvans is a form of cicatricial alopecia associated with follicular plugging that is more fully described in Chapter 87 as well as online.

LYMPHOCYTIC PRIMARY CICATRICIAL ALOPECIAS

CHRONIC CUTANEOUS LUPUS ERYTHEMATOSUS (DISCOID LUPUS ERYTHEMATOSUS).

(See also Chapter 155). Discoid lupus erythematosus (DLE), together with LPP, is the most common cause of inflammatory cicatricial alopecia.[198] Women are more often affected than men and the disease is more common in adults (with first onset typically at the age of 20–40 years) than in children.[201–203]

Systemic lupus erythematosus (SLE) will develop in 26%–31% of children and approximately 5%–10% of adult patients with DLE.[203,204] Patients with DLE are found to have a higher incidence of concurrent alopecia areata. Moreover, DLE has also been associated with verruciform xanthoma and papulonodular dermal mucinosis.[205]

Clinical Presentation. DLE usually presents with one or more erythematous, atrophic, and alopecic patches on the scalp (Fig. 88-16). Follicular hyperkeratosis, hyperpigmentation, hypopigmentation and telangiectasia can be present.[194,206] Hyperpigmentation is frequently found in the center of the lesion. Active lesions can be sensitive or pruritic, and the patient might report a worsening after UV exposure.

Pathology. Characteristic features of early, active DLE lesions are lymphocyte-mediated interface



Figure 88-16 Discoid lupus erythematosus.

dermatitis with vacuolar degeneration of the basal cell layer and necrotic keratinocytes, a thickening of the basement membrane and destruction of sebaceous glands. Elastic fibers are frequently destroyed throughout the reticular dermis.[1,195] The lymphocytic infiltrate is predominantly found in the upper part of the follicle, but can also be found in deeper parts of the follicle, in the interfollicular epidermis and around the periadnexal vessels.[18,207–209] DIF typically shows a linear granular deposition of IgG and C3 at the dermal–epidermal junction. IgM, C1q, and rarely IgA can also be found.

Management and Treatment. Hydroxychloroquine at a dose of 200–400 mg daily in adults or 4–6 mg/kg in children has been shown to be highly effective. A baseline ophthalmologic examination and complete blood count is required before the therapy is started.[201,203] Bridge therapy with oral prednisone (1 mg/kg) tapered over the first 8 weeks of treatment might be helpful in adult patients with rapidly progressive disease.[20,198]

In limited or slowly progressive DLE, intralesional triamcinolone acetonide should be used at a concentration of 10 mg/cc every 4–6 weeks, alone or in addition to oral therapy.[198] Intralesional triamcinolone acetonide can be used with or without topical class I or class II corticosteroids. Topical corticosteroids alone have also been shown to be effective in milder forms of DLE,[1,18,20,203] and oral acitretin and isotretinoin have shown some efficacy.[210,211] Immunosuppressive therapies such as mycophenolate mofetil, methotrexate, or azathioprine should only be considered if the above therapies fail. Multimodal aggressive therapy in rapidly progressive DLE might reverse early alopecic patches and save hair follicles from the destructive process.[212]

LICHEN PLANOPILARIS.

LPP is a follicular variant of lichen planus. Together with DLE, this is the most common cause of primary cicatricial alopecia. LPP can be divided in classic LPP, frontal fibrosing alopecia (FFA), and Graham–Little syndrome. The typical age of onset of classic LPP is around the fifth decade, and women are more often affected than men. Extracranial lichen planus may occur in up to 28% of patients.[196,213,214] FFA predominantly affects postmenopausal women. Graham–Little–Piccardi–Lassueur Syndrome is a very rare condition that predominantly affects female adults. It is characterized by LPP of the scalp, noncicatricial of the eyebrows, axilla, and groin and keratosis pilaris.

Lichenoid drug eruptions can be triggered by many drugs and might present as LPP. Some of the most common drugs, causing lichenoid drug eruption are gold, antimalarials and captopril. Actinic lichenoid drug eruption is confined to sun exposed sites. The most likely drugs to cause this are quinine, and thiazide diuretics.[215–217]

Clinical Presentations of LPP. Classic LPP typically starts at the crown and vertex area. In classic LPP, the affected areas usually show perifollicular erythema and follicular hyperkeratosis. The alopecic areas of LPP are often smaller, irregularly shaped and interconnected, which can lead to a reticulated clinical pattern as compared to DLE. However, overlapping clinical features with those of DLE are frequently seen. Patients complain about itching, burning sensations and sensitivity of the scalp (Fig. 88-17).



Figure 88-17 Extensive lichen planopilaris.

FFA is characterized by a frontal, band-like, or circumferential scarring alopecia.[195] In some cases a few hairs are spared in the original frontal hairline. Follicular hyperkeratosis and perifollicular erythema may be found in a band-like pattern in the frontal hairline. Alopecia of the eyebrows is also frequently seen in FFA (Fig. 88-18). Graham–Little syndrome presents with lesions of classic LPP on the scalp, nonscarring alopecia of axillae, pubic area, and eyebrows as well as keratosis pilaris of the trunk and extremities.

Pathology. The three subgroups of LPP show similar histopathological features. A lymphocytic infiltrate and interface dermatitis are predominantly found in and around the upper permanent part of the hair follicle. Unlike DLE, the vascular plexus is not affected by inflammation and mucin deposits are absent.[195] DIF typically shows globular cytoid depositions of IgM, and rarely IgA, IgG or C3, in the dermis around the infundibulum.[218]



Figure 88-18 Frontal Fibrosing alopecia.

Management and Treatment. First line treatment for moderately active classic LPP lesions is intralesional triamcinolone acetonide at a concentration of 10 mg/cc every 4–6 weeks or in combination with topical class I or class II corticosteroids.[198,211] Literature on the efficacy of oral medication is limited. Oral cyclosporine, retinoids, antimalarials and griseofulvin[194,206,219–222] have been shown to have a positive effect in patients with rapidly progressive LPP. Oral corticosteroids in the first weeks of treatment as bridge therapy might be considered in very active cases. In FFA, a lower dose of intralesional triamcinolone acetonide (2.5–5 mg/cc), or topical application of minoxidil or tacrolimus can be considered, although no effective treatment has been reported yet. The treatment of Graham–Little syndrome is typically similar to the management of classic LPP.

CLASSIC PSEUDOPELADE OF BROCQ.

PPB is classified as an idiopathic lymphocytic primary cicatricial alopecia that predominantly affects the scalp. It is the second most common cause of primary cicatricial alopecia.[196] Women between 30 and 50 years of age are most frequently affected.

Clinical Presentation. Pseudopelade of Brocq usually affects the vertex and occipital area of the scalp. It presents with small flesh-toned alopecic patches with irregular margins. This pattern has been described as "footprints in the snow."[223] PPB can also present as a non-inflammatory centrifugally spreading patch of alopecia, which might be seen as a variant of central centrifugal cicatricial alopecia in Caucasians. Follicular hyperkeratosis and perifollicular or diffuse erythema is mostly absent.[206] Clinically the features may overlap with LPP.

Pathology. Early PPB lesions typically show a sparse to moderate lymphocytic infiltrate around the follicular infundibulum with a complete destruction of the sebaceous glands.[176] In later disease stages, hair follicles are completely replaced by fibrous tracts. Unlike DLE and LPP, interface dermatitis is usually absent and the elastic fibers are preserved and thickened in PPB.[224]

Management and Treatment. Intralesional triamcinolone acetonide at a concentration of 10 mg/cc every 4–6 weeks in combination with topical corticosteroids is the treatment of first choice. Hydroxychloroquine, oral prednisone, and isotretinoin have shown some effectiveness in treating PPB.[196,206,225,226]

CENTRAL CENTRIFUGAL CICATRICIAL ALOPECIA.

CCCA is classified as a lymphocytic primary cicatricial alopecia, primarily affecting women of color. It remains unclear which of the following contribute most to its formation: chemical processing, heat, traction or other traumas.[1,18] CCCA can rarely be seen in Caucasians (sometimes called "central elliptical pseudopelade") and African-American men. Due to clinical and histopathological similarities, it has been debated whether CCCA is a variant of PPB.

Clinical Presentation. CCCA presents with a skin colored patch of scarring alopecia on the crown, gradually progressing centrifugally to the parietal areas. Perifollicular hyperpigmentation and polytrichia might be present.[198] Patients may complain about itching, tenderness and "pins and needle" sensations[227] (Fig. 88-19).



Figure 88-19 Central centrifugal cicatricial alopecia.

Pathology. Limited studies suggest that histopathological features of CCCA seem to be similar to those of PPB.[18,194]

Management and Treatment. Topical corticosteroids and tetracycline have shown to be effective in active progressive cases.[18] Since a multifactorial etiology is debated for CCCA, some dermatologists recommend a switch to more natural, less traumatizing, hair care practices.[1,206,228] Wigs and hairpieces can help camouflage the alopecia and are frequently used by women with CCCA.

ALOPECIA MUCINOSA.

Alopecia mucinosa (AM) can present as indurated, well-demarcated erythematosus or skin colored patches of scarring or nonscarring alopecia that can be accompanied by diffuse hair loss[229] and alopecia of the eyebrows.[230] Grouped follicular papules, follicular cysts and follicular hyperkeratosis may be present in some cases. Early lesions of AM show mucin deposition in the outer root sheath and replacement of the entire pilo-sebaceous unit by pools of mucin in more advanced lesions.[195,230] AM strictly speaking it is not a primary cicatricial alopecia because the hair follicle is not replaced by a true scar.[195] AM can occur idiopathically or in the setting of cutaneous T-cell lymphoma or mycosis fungoides.[231] Cell atypia and monoclonal populations of T-lymphocytes can be present in the idiopathic form of AM as well as in the latter form.[231]

Management and Treatment. A complete workup is necessary to rule out an underlying malignancy such as mycosis fungoides and Sézary syndrome, its advanced endpoint. Oral corticosteroids, minocycline and isotretinoin have been shown to be

effective. Topical and intralesional corticosteroids, dapsone, indomethacin and light therapy have also been used with variable outcomes.[232]

NEUTROPHILIC PRIMARY CICATRICIAL ALOPECIA

FOLLICULITIS DECALVANS. Approximately, 11% of all primary cicatricial alopecia cases are diagnosed with folliculitis decalvans (FD).[194,196] FD predominantly occurs in young and middle-aged adults with a slight preference of the male gender. A bacterial infection involving *S. aureus*, in combination with hypersensitivity reaction to "superantigens" and defect in host cell-mediated immunity have all been suspected as possible pathogenetic factors.[194,234,235]

Clinical Presentation. FD frequently starts at the vertex area of the scalp with erythematous alopecic patches, follicular pustules and follicular hyperkeratosis. Tufted folliculitis is typically found in FD, but can also occur in other cicatricial inflammatory alopecias. Tufted folliculitis is characterized by multiple hairs (5–15) emerging from one single, dilated follicular orifice. In older lesions pustules might be absent but progressive scarring may still continue (Fig. 88-20). An overlap with acne keloidalis is possible since some patients with acne keloidalis not only develop cicatricial lesion on the nape of the neck but also develop progressive cicatricial alopecia that resembles FD in other areas of the scalp. Patients frequently complain about pain, itching and/or burning sensations.

Pathology. Early lesions are characterized by keratin aggregation in the infundibulum with numerous intraluminal neutrophils, as well as an intrafollicular and perifollicular neutrophilic infiltrate.[194,195,206] Sebaceous glands are destroyed early. In advanced lesions, the infiltrate may consist of neutrophils, lymphocytes, and plasma cells and extend into the dermis.[198,206] Hair shaft granulomas with foreign-body giant cells can frequently be found.[194,206] In end-stage lesions, follicular and interstitial dermal fibrosis as well as hypertrophic scarring can be observed.[206]

Management and Treatment. Treatment of FD in general is difficult and disease activity can be noted over many years. Bacterial cultures with the testing of antibiotic sensitivities are recommended. Eradication of *Staphylococcus aureus* with minocycline, erythromycin, cephalosporines, and sulfamethoxazole-trimethoprim has shown some effectiveness. Relapse can often be observed after the antibiotics are discontinued.[20,234,236] If so, the patient might have to stay on low dose antibiotics for many years. Rifampin in combination with clindamycin has shown good response; however, this combination shows a higher incidence of side effects.[234,237] Oral fucidic acid alone or in combination with other agents has also shown to be effective in some patients.[238] Oral therapy should be combined with topical antibiotics such as mupirocin, 1.5% fusidic acid and 2% erythromycin[237,238] and antibacterial cleansers. Intralesional triamcinolone acetonide at a concentration of 10 mg/cc every 4–6 weeks might help to reduce the inflammation and reduces symptoms such as itching, burning, and pain.[20,196] Intranasal eradication of *S. aureus* with topical antibacterial agents have been described to be useful.[206]

DISSECTING FOLLICULITIS. Dissecting folliculitis (DF) (or dissecting cellulites or perifolliculitis capitis abscedens et suffodiens of Hoffman) is related to acne conglobata and hidradenitis suppurativa. These three diseases have been described as follicular occlusion triad. DF predominantly occurs in young men between 18 and 40 years of age.[198] African-American men seem to be more commonly affected compared to Caucasian men. The pathogenesis of DF may include follicular occlusion, seborrhea, androgens and secondary bacterial overpopulation as well as an abnormal host response to bacterial antigens.[239–246]

Clinical Presentation. DF typically presents with fluctuating nodules, abscesses, and sinuses, which frequently show spontaneous discharge of pus, as well as with erythematous, follicular papules and pustules. Initial lesions are mostly found on the vertex and occipital scalp. Multifocal lesions can form an intercommunicating ridge and sero-purulent exudates can be discharged when pressure is applied to one region of the scalp (Fig. 88-21). The lesions can be pruritic and tender. Chronic and relapsing courses result in cicatricial alopecia, which can show hypertrophic or keloidal scars.[246]



Figure 88-20 Folliculitis decalvans.

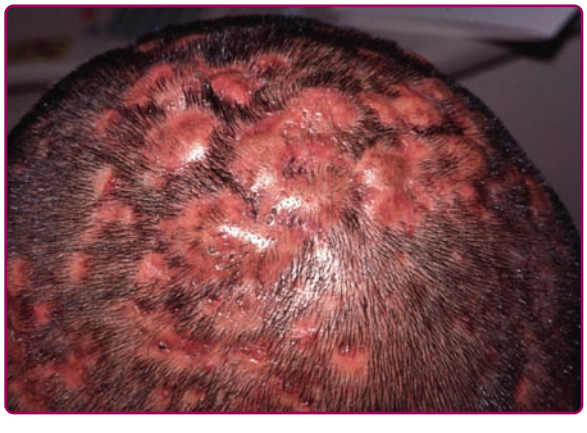

Figure 88-21 Dissecting cellulitis.

Pathology. The main histological feature is an intrafollicular and perifollicular neutrophilic infiltrate with follicular occlusion in early lesions.[195] In more advanced stages, interconnecting sinus tracts lined by squamous epithelium, follicular perforation, perifollicular and deep dermal abscesses are typical findings.[195,206,209]

Management and Treatment. Multimodal treatment has been reported with successful results, such as systemic antibiotics (minocycline, tetracycline, cloxacillin, erythromycin, cephalosporin or clindamycin), intralesional corticosteroids, and oral prednisolone.[247,248] The benefits of systemic antibiotics are most likely due to their antiinflammatory effects rather than to their antibacterial action. Isotretinoin at a dose of 0.5–1 mg/kg/d has shown prolonged remission.[249,250] Incision and drainage of therapy resisted, painful nodules, marsupialization with curettage of the cyst wall, complete scalp extirpation with skin grafting have been reported, but should be an exception for extreme and therapy refractory cases.[250–252]

MIXED PRIMARY CICATRICIAL ALOPECIAS

ACNE KELOIDALIS NUCHAE. Acne keloidalis nuchae (AKN) predominantly occurs in African-American men age 14 to 25. This idiopathic primary cicatricial alopecia might be triggered by trauma (shirt collars) or infection (Demodex or bacteria). Clinically AKN presents with skin-colored follicular papules, pustules and plaques as well as keloid-like scarred lesions in the occipital scalp (Fig. 88-22). Histologically, acne keloidalis is characterized by an acute inflammation with neutrophilic or lymphocytic infiltration and chronic granulomatous inflammation around the isthmus and the lower infundibulum. Treatment is usually difficult and protracted. Monthly intralesional triamcinolone acetonide (10–40 mg/mL) alone or combined with topical 2% clindamycin or oral (tetracyclines) antibiotics is the treatment of first choice.[1,18,194,253,254] Class I or II topical steroids alone or in combination with topical antibiotics for mild cases of AKN as well as cryotherapy and laser therapy have shown some success. Surgical excision of extensive keloidal lesions may be considered but should be reserved for therapy refractory, extensive and symptomatic cases.



Figure 88-22 Acne keloidalis nuchae.

ACNE NECROTICA (VARIOLIFORMIS). Acne necrotica varioliformis is a very rare, chronic condition, which predominantly occurs in adults. Frontal and parietal scalp as well as seborrheic areas of the face are most commonly affected. Acne necrotica presents with umbilicated, pruritic or painful papules that undergo central necrosis. The condition leaves varioliform, or smallpox-like scars.[255,256] Histology shows a suppurative, necrotic, infundibular folliculitis with lymphocytic or mixed inflammatory infiltrate.[256] Oral antibiotics, isotretinoin, intralesional or topical corticosteroids have shown success.[257] Excision of larger scarred areas can be considered.

EROSIVE PUSTULAR DERMATOSIS. Erosive pustular dermatosis is an uncommon disorder predominantly occurring in elderly women.[258,259] The characteristic lesion is a suppurative, necrotic, erosive papule or plaque.[258,260] Histology of early lesions is nonspecific, but older lesions show an extensive, chronic mixed inflammatory infiltrate the dermis and later dermal fibrosis. Treatment include class I or II topical steroids with or without topical antibiotics, systemic antibiotics, and oral isotretinoin.[258,260]

DIFFERENTIAL DIAGNOSIS

(Box 88-6)

PROGNOSIS AND CLINICAL COURSE

Once the hair follicle is destroyed and replaced by fibrous tissue, there is no hope for hair regrowth. Various medical treatment options may fail and the inflammatory process may continue and leave the patient with a disfiguring permanent alopecia.

TREATMENT

The main goal in treating primary cicatricial alopecia is to stop the inflammation and therefore further progression of the disease. If hair loss is already extensive and/or medical treatment fails, patients should be advised about camouflage techniques, hairpieces and wigs. Women with extensive LPP lesion on the crown and vertex benefit highly from a well designed hair piece, which can look very natural, particularly if the

BOX 88-6 DIFFERENTIAL DIAGNOSIS

- Alopecia areata
- Secondary cicatricial alopecia
- Temporal triangular alopecia
- Trichotillomania
- Secondary Syphilis (alopecia areolaris)

frontal hairline is preserved and is usually more comfortable to wear compared to a full wig. Hair restoration surgery including HT and scalp reduction can be an option for burnt out cicatricial alopecia. No disease activity should occurs on the scalp for at least 1 year without therapy. The patient has to be warned about a possible limited graft survival and disease recurrence, which seems to be higher in neutrophilic primary.

SECONDARY CICATRICIAL ALOPECIA

ETIOLOGY AND PATHOGENESIS. In secondary cicatricial alopecias, permanent hair loss is caused by various other scalp conditions not related to the hair follicle. In these conditions, the primary event develops outside the FU and this leads to incidental destruction of the follicle. Possible causes are congenital defects, trauma, inflammatory conditions, infections, neoplasms, and rarely drugs (eBox 88-6.1 in online edition). Permanent, chronic traction alopecia and scars from surgery can be considered secondary scarring alopecias as well.[261]

CLINICAL FINDINGS. A thorough clinical history is crucial in the diagnosis of secondary cicatricial alopecia. Diagnosis in early stages can sometimes be made based on specific clinical and histological features of the underlying disorder. Follicular orifices are lost clinically, and histology shows extensive scarring with fibrosis, loss of elastic fibers and adnexal structures.[261]

DIFFERENTIAL DIAGNOSIS. (Box 88-7)

PROGNOSIS AND CLINICAL COURSE. Prognosis and clinical course of secondary cicatricial alopecia depend on the underlying disease. Once scar tissue has formed and the adnexal structures are destroyed no hair regrowth can be expected.

TREATMENT. Treatment is specific in active conditions, while in localized end-stage lesions, specific medical treatment is no longer efficient and hair restoration surgery techniques become the mainstay of therapy.

TRAUMATIC HAIR LOSS

An acute or chronic mechanical insult to the scalp hair may lead to reversible or irreversible alopecia of the scalp. Traumatic alopecias are usually of three types: (1) acute trauma, (2) prolonged traction, and (3) pressure.

BOX 88-7 DIFFERENTIAL DIAGNOSIS BOX

- Primary cicatricial alopecia
- Alopecia areata
- Temporal triangular alopecia
- Trichotillomania
- Secondary Syphilis (alopecia areolaris)

TRAUMATIC INJURIES

Minimal or severe injuries to the scalp can result in alopecia. It usually presents with fine streaks of hair loss in the injured scalp area, but if the wound borders undergo contusion or destruction, this may result in irregular and large patches of hair loss. Traumatic hair loss can occur after scalp surgery, especially after extensive scalp reduction or large donor strip harvesting in hair restoration surgery, if too much tension is applied with wound closure. This type of hair loss is usually reversible but can also be permanent. Traumatic birth induced alopecia is infrequent; causes include mechanical extractor marks, tears or contusions or resulting infections. Aplasia cutis congenita should be considered in the differential diagnosis of cicatricial alopecia at birth.[1]

TRACTION ALOPECIA

Prolonged traction of the hair may lead to transient or if continued over a period of time, may lead to follicular atrophy, resulting in cicatricial alopecia. Chronic traction can be caused by tight ponytails, braids, heavy dead locks, or extensive use of rollers. Due to ethnic differences in hair fragility and cultural differences in hair styling practices, marginal traction alopecia is more commonly seen in African-American women due to hair braiding and weaving procedures[1] (Fig. 88-23). Patchy traction alopecia in the frontal hairline or temples is commonly seen in Sikh boys, whose hair is usually tight up in a "topknot."[270] Cicatricial alopecia caused by prolonged traction can be treated with HT, if the patient discontinues the injuring hairstyles and sufficient donor hair supply is available.



Figure 88-23 Traction alopecia. (From Wolff K, Goldsmith LA, Katz SI, Gichrest BA, Paller AS: Fitzpatrick's Dermatology in General Medicine. 7th ed. Copyright © The McGraw-Hill Companies, Inc. All rights reserved, with permission.)

TRICHOTILLOMANIA

Trichotillomania (Greek: *tricho* = hair, *tillo* = pull, *mania* = excessive excitement) is a form of traumatic alopecia caused by an irresistible compulsion to pull out or twist or break of one's own hair. Trichotillomania is relatively common with an estimated incidence of 1 million Americans.[1] Two forms of trichotillomania can be distinguished: (1) infantile trichotillomania or (2) early onset trichotillomania, which starts in early childhood is typically of short duration and may resolve spontaneously or with simple interventions.[271,272] Childhood trichotillomania may be seen analogous to other habitual infantile behaviors such as thumb sucking. Boys are more frequently affected. Trichotillomania, which starts around or after puberty, shows a more chronic course and is usually a sign of a more severe underlying psychopathology. It is classified as an impulse control disorder.[273–275] Women are far more often affected than men. The clinical presentation is usually quite distinctive with a single or multiple asymmetrical, occasionally geometrically shaped areas of hair loss on the scalp or other areas of the body (Fig. 88-24). The areas are not smoothly devoid of hairs, as seen in alopecia areata but display short or bristly anagen hair. Telogen hair in the involved area is usually plugged out easily; anagen hair may be plucked out, twisted and broken at various lengths. Regrowing anagen hair needs to reach a certain length before it can be plugged out again. Alopecia areata and tinea capitis should be considered as differential diagnosis. Where doubt remains, a scalp biopsy can be diagnostic, showing a characteristic increase in catagen hair, trichomalacia and pigment casts within the follicular canal secondary to traumatic hair removal. Most important in the therapy of trichotillomania is the education of patient and/or parents and in late onset trichotillomania the treatment of the underlying psychopathology. Especially if patients deny the self-inflicting nature of their hair loss, a referral to a psychiatrist or psychologist is usually refused and treatment becomes difficult.



Figure 88-24 Trichotillomania.

PRESSURE ALOPECIA

Pressure alopecia can occur after a patient was unconscious and completely immobile for a certain length of time. Hair loss is presumably due to ischemia caused by the pressure of the body weight to a certain scalp area. The ischemic injury may lead to permanent hair loss.

HAIR SHAFT ABNORMALITIES

Hair shaft abnormalities are structural defects of the hair shaft. They can be inherited or acquired. Inherited hair shaft abnormalities can be associated with increased hair breakage or can lead to unruliness of the scalp hair.

HAIR SHAFT ABNORMALITIES WITH INCREASED HAIR BREAKAGE

TRICHORRHEXIS NODOSA. Trichorrhexis nodosa can be inherited or acquired. Affected hair shafts develop a breach in the cuticle with separation and fraying of the exposed cortical fibers, which leads to a node-like swelling.[142] The fibers then fracture and the shaft breaks with the resultant appearance of a splayed paint brush or fan-like array (Fig. 88-25). Congenital trichorrhexis nodosa can be present at birth or may develop in the first months of life. In rare cases, Trichorrhexis nodosa can be associated with teeth and nail defects or hyperkeratosis[1] and with metabolic disorders such as argininosuccinic aciduria (see Chapter 131), Menkes syndrome, and trichothiodystrophy.

Acquired trichorrhexis nodosa is much more common. Hair breakage may either occur in the proximal or distal hair shaft. Proximal trichorrhexis nodosa is more commonly seen in African-American women usually after repetitive chemical or hot-comb straightening. Distal trichorrhexis nodosa is mostly secondary



Figure 88-25 Trichorrhexis nodosa. (From Wolff K, Goldsmith LA, Katz SI, Gichrest BA, Paller AS: Fitzpatrick's Dermatology in General Medicine. 7th ed. Copyright © The McGraw-Hill Companies, Inc. All rights reserved, with permission.)

to excessive brushing, teasing or chemical treatment such as bleaching or permanent waves. Patients with trichorrhexis nodosa should be advised to avoid any harsh chemical or physical hair styling practice. Proximal trichorrhexis nodosa may take month to year to resolve even if the initiating hair care is avoided.

TRICHOSCHISIS AND TRICHOTHIODYSTROPHY. Trichoschisis is characterized by a clean transverse fracture of the hair shaft in an area of a focal absence of the cuticle. It is usually, but not specifically, a marker for sulfur-deficient hair in trichothiodystrophy, in which the scalp hair, eyelashes and eyebrows are short and brittle (see Chapter 139). The hair cysteine content is less than one-half normal, primarily from a major reduction and altered composition of the ultrahigh-sulfur matrix proteins.[276] Microscopic examination with polarized light characteristically shows a "tiger tail" pattern with altering light and dark bands, secondary to alterations in the sulfur content[1] (eFig. 88-25.1 in online edition). Various structural abnormalities can be detected by confocal and scanning electron microscopy. These complex alterations make hair shafts in trichothiodystrophy excessively prone to breakage and weathering.[1] Sulfur and amino acid analysis of the hair is diagnostic. Hair shaft abnormalities in trichothiodystrophy identify a group of autosomal recessive disorders that are associated with neuroectodermal abnormalities (eTable 88-1.2 in online edition).

TRICHOCLASIS. Trichoclasis is the common "greenstick" fracture of the hair shaft. It is characterized by a transverse fracture of the shaft, which is splinted partly or completely by intact cuticle. Cuticle, cortex and sulfur content are normal. Trichoclasis does not indicate any specific underlying disease. It can occur in normal hair or may be associated with pili torti.[1]

PILI TORTI AND MENKES SYNDROME

In pili torti, the affected hair shafts are flattened and twisted on their axis, usually through an angle of 180°, with a range of 90°–360° (Fig. 88-26). The twisting occurs in multiple irregular intervals along an otherwise straight hair shaft. Pili torti do not signify a particular abnormality but can be seen in many different syndromes and in the presence of other hair shaft disorders.[277] The way of inheritance in pili torti is mostly autosomal dominate, but can also be autosomal recessive or sporadic. Clinically, the patients may present with patchy alopecia with coarse stubble or longer broken hairs. Hair fragility usually improves after puberty.

Pili torti occurs in combination with trichorrhexis nodosa, trichoclasis, and trichoptilosis in Menkes kinky hair syndrome, also called steely hair syndrome or trichopoliodystrophy. Menkes syndrome is an X-linked recessive multisystem disease, which begins in infancy. It is associated with depigmented hairs, hypopigmentation of the skin, metal retardation, neurologic impairment secondary to degeneration of cerebral, cerebellar, as well as bone and connective tissue degeneration. The clinical features result from a defective copper transport and an accumulation of intracellular copper, which results in a functional deficiency of copper-dependent enzymes. Most patients die by the age of 3 years. In Menkes' syndrome, copper uptake is normal, therefore copper supplementation is ineffective, but copper-histidin given immediately postpartum may prevent or ameliorate the severe neurodegeneration. Low serum concentrations and ceruloplasmin levels are diagnostic.[1]

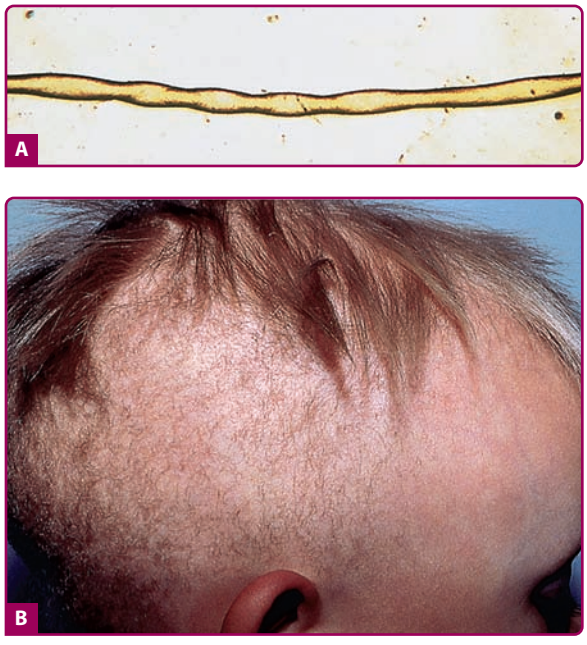

Figure 88-26 Pili torti. **A.** Irregularly spaced 180° twists in hair shaft. (From Whiting DA: Hair shaft defects. In *Disorders of Hair Growth: Diagnosis and Treatment,* edited by EA Olsen. New York, McGraw-Hill, 2003, with permission.) **B.** Brittle broken hair typical of congenital pili torti.

TRICHORRHEXIS INVAGINATA ("BABOO HAIR") AND NETHERTON SYNDROME

Trichorrhexis invaginata is a diagnostic marker for Netherton syndrome, although it also may occur sporadically and in association with other hair shaft abnormalities. Netherton syndrome is an autosomal recessive inherited disorder, characterized by a triad of atopic diathesis, ichthyosiform skin changes and trichorrhexis invaginata (see Chapter 49). The primary hair defect appears to be abnormal keratinization of the hair shaft in the keratogenous zone, allowing intussusception of the fully keratinized and hard distal shaft into the incompletely keratinized and soft proximal portion of the shaft.[278] This leads to the typical "ball-and-socket" deformity (Fig. 88-27). Once the hair fractures, it shows a typical golf tee-shaped the distal end. Affected short, brittle hairs can be distributes over the scalp, which may result in sampling errors. Retinoids and phototherapy may be considered as therapy,



Figure 88-27 Trichorrhexis invaginata (light micrograph ×400). (From Whiting DA: Hair shaft defects. In: *Disorders of Hair Growth: Diagnosis and Treatment,* edited by EA Olsen. New York, McGraw-Hill, 2003, with permission.)

although the condition frequently improves, as the patient gets older.

MONILETHRIX

Monilethrix present with extremely short, brittle, fragile, beaded hairs emerging from a hyperkeratotic follicular orifice. Monilethrix hair shafts show elliptical nodes, 0.7–1 mm apart, with intervening, tapered constrictions that are nonmedullated (Fig. 88-28). These internodes are the predetermined breaking points and often present with longitudinal ridges. Most cases of monilethrix are of autosomal dominant inheritance, with variable expression. In rare cases it is autosomal recessive. It is caused by one of the three genes encoding type II hair keratin (KHb1 or *KRT81*, KHb3 or *KRT83*, and KHb6 or *KRT86*). In the case of autosomal recessive inheritance, the underling gene encodes desmoglein 4 (DSG4). In mildest cases monilethrix is localized to the occiput or the nape of the neck. The hair shaft defect may occur alone or in association with keratosis pilaris, nail and teeth abnormalities, syndactyly, cataracts and physical retardation. Retinoids and topical minoxidil may improve the condition, although monilethrix frequently improves spontaneously with age.[1,279,280]

LOCALIZED AUTOSOMAL RECESSIVE HYPOTRICHOSIS. This rare autosomal recessive disorder present with localized sparse broken hair involving scalp and eyebrows. The gene defect lies in a



Figure 88-28 Monilethrix. Typical beaded appearance of hair as seen under light microscopy (×40). (From Wolff K, Goldsmith LA, Katz SI, Gichrest BA, Paller AS: Fitzpatrick's Dermatology in General Medicine. 7th ed. Copyright © The McGraw-Hill Companies, Inc. All rights reserved, with permission.)



Figure 88-29 Uncombable hair syndrome.

mutation in the gene for desmoglein 4 (DSG4). Unlike Monilethrix, the hair does not present with beading.[281]

HAIR SHAFT ABNORMALITIES ASSOCIATED WITH UNRULY HAIR

Uncombable Hair Syndrome. Uncombable hair syndrome, also known as spun glass hair or pili trianguli et canaliculi is an inherited autosomal dominant trait or a sporadic structural hair abnormality.[282] This unique syndrome is characterized by rigid hair shafts with a triangular or kidney bean-shaped cross section, but irregular forms, such as flattened, heart-shaped and longitudinal grooves may be present. Clinically, the hair is dry, coarse, usually blond to light brown, and with a spangled appearance. The scalp hair is frizzy, unruly, kinky and unmanageable from infancy, grows in multiple directions and cannot be combed flat (Fig. 88-29). Male and female individuals are equally affected. It first occurs more often during early childhood, but it can develop as late as age 12 years. Microscopic analysis of hair samples under polarized light shows a homogeneous band on one edge caused by the shadow thrown as light passes over the pili canaliculi.[283] There is no definitive therapy, but uncombable hair syndrome may improve over time without treatment.[284]

Wooly Hair. Wooly hair is a rare congenital structural anomaly of scalp hair. It is marked by an extreme kinkiness of the hair in Caucasians. Wooly hair can be present at birth or appear in the first months of life. The curls, which have an average diameter of only 0.5 cm, lie closely together and usually make the hair difficult to comb. In addition, the hairs may be more fragile than usual. Hair growth rate is usually normal but the anagen phase may be truncated, with the result that the hairs do not grow to be long. The hair shaft exhibits an elliptical cross section, an axial rotation and a kinked formation. A circumscribed occurrence of wooly hair in the form of a wooly hair nevus[285] is distinguished from the forms that affect the entire scalp. The latter forms are: autosomal dominant wooly hair (hereditary wooly hair) and, the much rarer form, autosomal recessive hereditary wooly hair (familial wooly hair).[286] Autosomal recessive hereditary wooly hair can be syndromic and accompanied by palmoplantar hyperkeratosis and heart anomalies (Fig. 88-30). No treatment is currently available. Harsh physical and chemical



Figure 88-30 Sporadic recessive wooly hair. (From Wolff K, Goldsmith LA, Katz SI, Gichrest BA, Paller AS: Fitzpatrick's Dermatology in General Medicine. 7th ed. Copyright © The McGraw-Hill Companies, Inc. All rights reserved, with permission.)

cosmetic treatments should be avoided. Wooly hair is most pronounced during childhood; the manifestation often becomes less severe in adulthood.

MARIE–UNNA HYPOTRICHOSIS.

Marie–Unna hypotrichosis is of autosomal dominant inheritance and is characterized by sparse or absent hair at birth and variable coarse, wiry hair growth during childhood, affecting scalp and eyebrows. Once the child grows older, scalp hair is lost in a pattern, resembling AGA with scattered thick hair in the balding areas. Body hair is sparse or absent. Male and female individuals are equally affected. Light and electron microscopic examination shows irregular twisting, longitudinal ridging and cuticle peeling. Diffuse follicular hyperkeratosis and facial milia-like lesions may be present. Marie–Unna hypotrichosis results from mutations in the upstream untranslated open reading frame region of the *hairless* gene,[287] which maps to chromosome 8p21.[288] There is no known treatment.

HAIR SHAFT ABNORMALITIES UNASSOCIATED WITH BREAKAGE OR UNRULINESS

Pili Annulati. Pili annulati or ringed hairs occur as an autosomal dominant or sporadic hair shaft abnormality without increased hair breakage. Pili annulati can be present at birth or develop during infancy. It is characterized by altering light and dark bands, which are secondary to air-filled cavities in the cortex.[289] The ringed appearance is clinically only detectable in blond or light brown hair. The gene locus for pili annulati maps to chromosome 12q24.[290,291] No treatment is necessary, although hair care practices should be gentle.

HIRSUTISM

Hirsutism is defined as excessive growth of terminal hair in a male distribution in women.[292] Hirsutism is indicated by a hirsutism score of 8 or more on the Ferriman–Gallwey scale (Fig. 88-31).[61] It must be distinguished from hypertrichosis, generalized excessive hair growth that may be hereditary or result from certain medications in men and women. Hypertrichosis is distributed in a generalized, nonsexual pattern and is not caused by excess androgen (although hyperandrogenism may aggravate it).

HIRSUTISM AT A GLANCE

- Defined as terminal body hair growth in women in a male distribution
- Women with a Ferriman–Gallwey score 8 or higher are considered hirsute
- Women with mild to moderate hirsutism and regular menstrual cycles are most likely diagnosed with idiopathic hirsutism; hormone testing is not necessary
- Hormone testing is necessary in women with moderate to severe hirsutism and all women with hirsutism and irregular menstrual cycles or sign of virilization
- Therapy should always consist of direct hair removal with or without medical therapy

EPIDEMIOLOGY

Approximately 5% of women of childbearing age are suffering from mild to severe hirsutism (Ferriman–Gallwey score 8 or higher).

ETIOLOGY AND PATHOGENESIS

Prior to puberty, body hair is vellus (small, straight, and fair), and the sebaceous glands are small. In response to the increased levels of androgens at puberty, vellus follicles in specific areas develop into terminal hair follicles (larger, curlier, and darker). The growth of terminal body hair (sexual hair) is entirely dependent on the presence of androgens, especially testosterone.[292] Higher androgen levels are required for the growth of beard hair than for pubic and axillary hair. In other areas of the body (for example, the forehead and cheeks), the increased androgen levels dramatically increase the size of the sebaceous glands while the hair remains vellus.

Hirsutism results from an interaction between the androgen level and the sensitivity of the hair follicle to androgens. Some women have hirsutism without evidence of androgen excess ("idiopathic hirsutism").

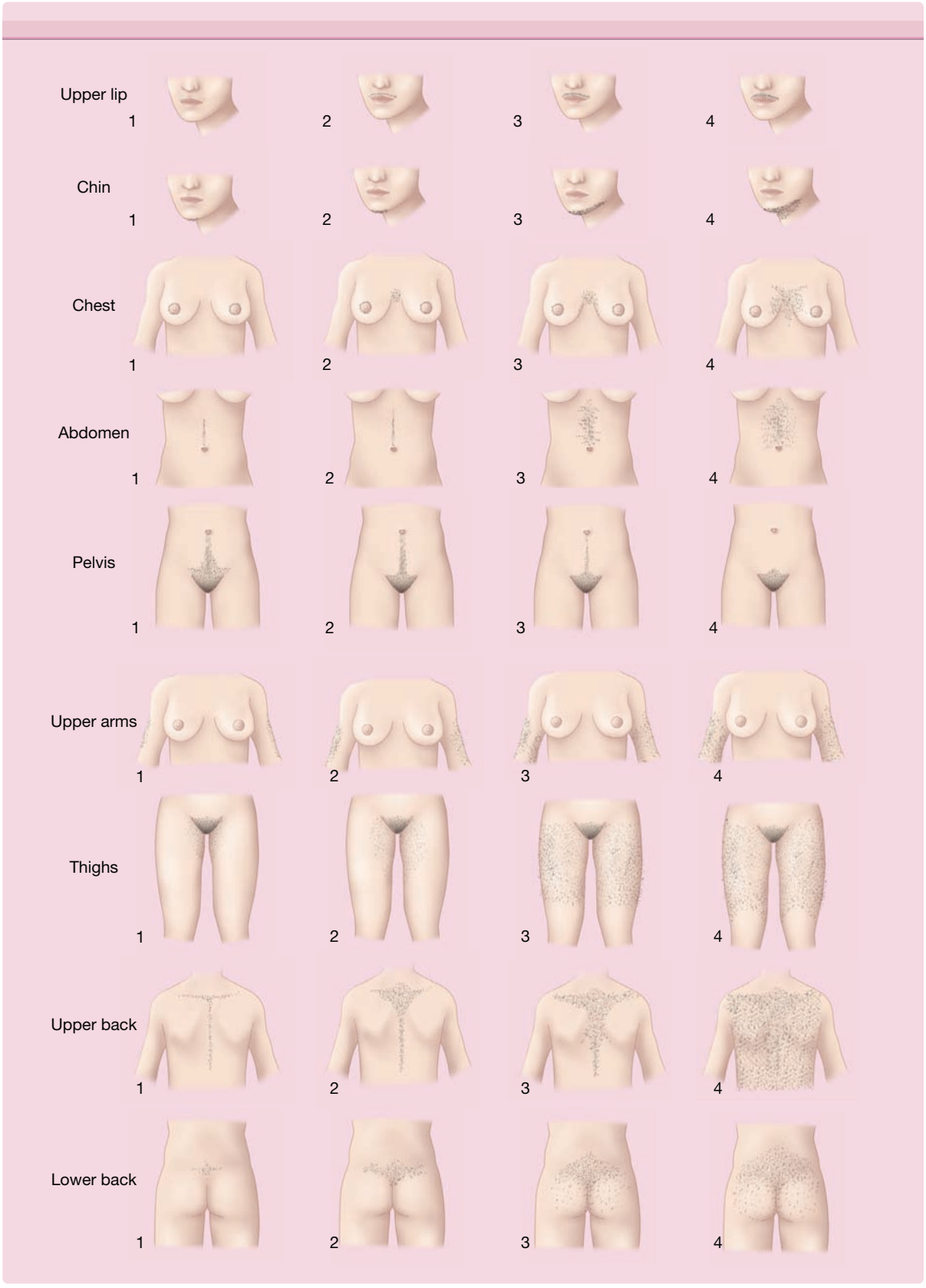

Figure 88-31 Ferriman–Gallwey scale.

Most women with a twofold or greater elevation of androgen levels have some degree of hirsutism, but in others these levels are associated with a "hirsutism equivalent" (acne vulgaris, seborrhea, pattern alopecia, hidradenitis suppurativa, or hyperhidrosis).[292]

Androgen excess relates to an increase in bioactive free testosterone plasma levels. Total testosterone includes the albumin bound and SHBG (sex hormone binding globulin) bound testosterone. Hirsute women commonly have a relatively low level of SHBG and therefore more bioactive testosterone.[62,293,294] Thus, the free testosterone level may be elevated when the total testosterone level is normal. SHBG levels are suppressed by the hyperinsulinemia of insulin-resistance and by androgen excess itself.[62,295] The level of SHBG is also low in persons with hypothyroidism; rarely, it is congenitally absent.[296]

CLINICAL FINDINGS AND DIAGNOSIS

Clinical diagnosis and scoring can be difficult since most women with hirsutism will practice various hair removal techniques. Therefore, it is useful to let the patient rate her degree of hair growth is different skin areas according to the Ferriman–Gallwey score (upper lip, chin and checks, chest, abdomen, pubic area and lower abdomen, arms, legs, upper back and lower back, and buttocks) with the help of images.

LABO RATORY TESTS

If hirsutism is mild (Ferriman–Gallwey score 8–15) and menses are regular with no evidence of risk factors that would suggest a secondary cause, it is reasonable not to pursue laboratory evaluation, given the very high likelihood of idiopathic hirsutism. If hirsutism is moderate or severe (Ferriman–Gallwey score over 15), or there are features to suggest an underlying disorder (Box 88-8), androgen excess must be ruled out. An onset or progression of hirsutism or evidence of virilization (such as clitoromegaly or increasing muscularity) would raise concern for an androgen-secreting neoplasm.[62,297] Since most androgenic drugs are not detected by testosterone assays, the history is particularly important. Medications that cause hirsutism include anabolic or androgenic steroids; thus, whether the patient is an athlete or has endometriosis or sexual dysfunction heightens this risk. Valproic acid is unique in raising plasma testosterone.[298] The high frequency of PCOS as a cause of hirsutism warrants attention to evidence for anovulation (such as menstrual irregularity), obesity, metabolic syndrome, or insulin resistance (acanthosis nigricans or a family history of type 2 diabetes mellitus). If risk factors like menstrual irregularity are present, even normal degrees of focal hirsutism are usually associated with androgen excess.[299] Other disorders to be considered include various endocrinopathies. Cushing syndrome is suggested by the development of truncal obesity, moon facies, buffalo hump, purple striae, or proximal muscle weakness; virilizing congenital adrenal hyperplasia or PCOS by a history of the premature development of pubic hair or acne; hyperprolactinemia by the presence of galactorrhea; and acromegaly by coarsening of the facial features or hand or foot enlargement.[292]

BOX 88-8 HIRSUTISM

- Androgen-secreting tumors
- Adrenal
- Adenoma
- Adenocarcinoma (rare)
- Ectopic adrenocorticotropic hormone-secreting tumor (rare)
- Ovarian
- Gonadal stromal tumor
- Thecoma
- Lipoid tumor
- Functional androgen excess
- Adrenal enzyme deficiencies (congenital adrenal hyperplasia)
- Early onset 21-hydroxylase deficiency
- Late-onset 21-hydropxylase deficiency
- 11β-hydroxylase deficiency
- 3β-ol dehydrogenase deficiency
- Cushing syndrome
- Polycystic ovarian disease
- With or without adrenal contribution
- Hyperthecosis
- "Idiopathic" hirsutism
- Medication/drug use

Hughes CL: Hirsutism. In: *Disorders of Hair Growth: Diagnosis and Treatment*, edited by EA Olsen. New York, McGraw-Hill, 1994, p. 344, Table 14-2.

SPECIAL TESTS

Once androgen excess is confirmed, further tests should be considered such as pregnancy test (if the patient has amenorrhea), pelvic ultrasonography (if an ovarian neoplasm or PCOS is suspected) and measurement of dehydroepiandrosterone sulfate and early morning 17-hydroxyprogesterone (if congenital adrenal hyperplasia or adrenal neoplasm is suspected), and a prolactin level. It may include measurement of thyroid function, adrenocortical function, and IGF-I. Further workup typically begins with dexamethasone suppression testing to determine the source of androgen. If androgen excess is not suppressible by dexamethasone, the presence of Cushing's syndrome, neoplasm, and PCOS must be considered. If androgen excess is dexamethasone-suppressible, an adrenocorticotropic hormone (ACTH) test for congenital adrenal hyperplasia is indicated. If an undetected neoplasm is suggested, further imaging studies may be warranted, such as abdominal computed tomography for adrenal neoplasm.[300]

PROGNOSIS AND CLINICAL COURSE

Hirsutism tends to get more severe as the patient gets older. Underlying disorders associated with hyperandrogenemia as mentioned earlier have to be ruled out.

TREATMENT

The main treatment goals are to remove the existing terminal hair and to prevent further vellus-to-terminal hair transformation. Direct hair removal should be considered for all women with hirsutism. In patients with moderate to severe hirsutism and women with androgen access additional medical therapy is necessary. Direct hair removal can be achieved with nonpermanent techniques such as shaving, depilatories (lasts 12 hours to a few days), waxing, threading and sugaring (lasts up to 4 weeks), or permanent hair removal techniques such as electrolysis (for white and blond hair) and photoepilation (intense pulsed light or laser). Several sessions of photoepilation at intervals of 4–6 weeks are necessary to achieve a satisfying result, since only anagen hair follicles with dark bulb areas can be destroyed by the light source. Topical eflornithine has been shown to slow down the hair cycle and can be used in combination with every hair removal technique.

The first line medical therapy is oral contraceptives, eventually in combination with antiandrogens. Glucocorticoids can be considered for women with hirsutism due to nonclassic congenital adrenal hyperplasia who have a suboptimal response to oral contraceptives and/or antiandrogens, cannot tolerate them, or are seeking ovulation induction. GnRH agonists in women with severe forms of hyperandrogenemia, such as ovarian hyperthecosis, who have a suboptimal response to oral contraceptives and antiandrogens.

HYPERTRICHOSIS

Hypertrichosis is defined as an androgen-independent generalized, increased growth of hair on the body. The hair can be terminal or lanugo. Hypertrichosis can be acquired or inherited. Congenital hypertrichosis lanuginosa is characterized by a generalized overgrowth of silvery blonde to gray lanugo hair at birth or in early childhood. This rare condtion is thought to be of autosomal dominant inheritance with variable expressivity. Most patients display anomalous dental eruptions. Lanugo hair may persist, increase or decrease with age.[301,302] Autosomal dominant Ambras syndrome or Hypertrichosis universalis congenita is characterized by much longer thicker hair distributed over the entire body with accentuation over the face ears and shoulders. Ambras syndrome can be associated with facial dysmorphism and dental anomalies.[303–305] An X-linked dominant congenital generalized Hypertrichosis has been described in a five-generation family with an accentuation on the face and upper body.[302,306] Patients with autosomal dominant or recessive gingival fibromatosis frequently display hypertrichosis, mostly on the face, eyebrows limbs and upper back, which may be associated with seizures and oligophrenia. Hypertrichosis may show a delayed onset until puberty although gingival fibromatosis usually appear with the emergence of the primary teeth[1] (eBox 88-8.1 in online edition).

ACKNOWLEDGMENT

Thanks to Dr. Elise Olsen, an active investigator of hair diseases, and author of this chapter in three previous editions for her contributions to hair research and to this text.

KEY REFERENCES

Full reference list available at www.DIGM8.com

DVD contains references and additional content

27. Olsen EA et al: Summary of North American Hair Research Society (NAHRS)-sponsored Workshop on Cicatricial Alopecia, Duke University Medical Center. *J Am Acad Dermatol* **48**:103-110, 2003
34. Tosti A, Gray J: Assessment of hair and scalp disorders. *J Investig Dermatol Symp Proc* **12**:23-27, 2007
43. Otberg N, Finner AM, Shapiro J: Androgenetic alopecia. *Endocrinol Metab Clin North Am* **36**:379-398, 2007
62. Zouboulis CC et al: Sexual hormones in human skin. *Horm Metab Res* **39**:85-95, 2007
102. Shapiro J, Price VH: Hair regrowth. Therapeutic agents. *Dermatol Clin* **16**:341-356, 1998
109. Price VH: Treatment of hair loss. *N Engl J Med* **341**:964-973, 1999
115. Rogers NE, Avram MR: Medical treatments for male and female pattern hair loss. *J Am Acad Dermatol* **59**:547-566, 2008
166. Alkhalifah A et al: Alopecia areata update: Part I. Clinical picture, histopathology, and pathogenesis. *J Am Acad Dermatol* **62**:177-188, 2010
167. Alkhalifah A et al: Alopecia areata update: Part II. Treatment. *J Am Acad Dermatol* **62**:191-202, 2010
199. Otberg N et al: Diagnosis and management of primary cicatricial alopecia: Part I. *Skinmed* **7**:19-26, 2008
200. Wu WY et al: Diagnosis and management of primary cicatricial alopecia: Part II. *Skinmed* **7**:78-83, 2008

Chapter 89 :: Biology of Nails and Nail Disorders

:: Antonella Tosti & Bianca Maria Piraccini

BIOLOGY OF NAILS

The nail apparatus consists of a horny "dead" product, the nail plate, and four specialized epithelia: (1) the proximal nail fold, (2) the nail matrix, (3) the nail bed, and (4) the hyponychium (Fig. 89-1A). The nail apparatus develops during the 9th embryonic week from the epidermis of the dorsal tip of the digit as a rectangular area, the nail fold that is delineated by a continuous groove.[1] The proximal border of the nail fold extends downward and proximally into the dermis to form the nail matrix primordium. By the 15th week the nail matrix is completely developed and starts to produce the nail plate, which will continue to grow until death. The nail apparatus lies immediately above the periosteum of the distal phalanx. The intimate anatomic relationship between the nail and the bone is responsible for the common occurrence of bone alterations in nail disorders and vice versa. The shape of the distal phalangeal bone also determines the shape and the transverse curvature of the nail.

Fingernails usually present a longitudinal major axis and toenails a transverse major axis. The ratio between length and width is important for the aesthetic appearance of the nails. The size of the nails varies in the different digits. The biggest nail is that of the first toe, which covers approximately 50% of the dorsum of the digit.

Nails have numerous functions. Fingernails not only contribute to the pleasing appearance of the hands, but are very important in protecting the distal phalanges and enhancing tactile discrimination and the capacity to pick up small objects. They are also widely used for scratching and grooming and are an efficient natural weapon. Toenails protect the distal toes and contribute to pedal biomechanics.

NAIL PLATE

(See Fig. 89-1A)

The nail plate is a fully keratinized structure that is continuously produced throughout life (see Fig. 89-1B). It results from maturation and keratinization of the nail matrix epithelium and is firmly attached to the nail bed, which partially contributes to its formation. Proximally and laterally the nail plate is surrounded by the nail folds, which cover its proximal third and lateral margins. At the tip of the digit, the nail plate separates from the underlying tissues at the hyponychium. The nail plate is rectangular, translucent, and transparent. It is curved in both the longitudinal and transverse axes, especially in the toes. The nail plate surface is smooth but frequently shows mild longitudinal ridges that increase with aging (Fig. 89-2). The pattern of these ridges can be used for forensic identification. The bottom of the nail plate shows longitudinal ridges that correspond to the rete ridges of the nail bed. The nail plate is homogeneously pink, except for its free edge, which is white. The pink color of the nail plate is due to the nail bed blood vessels.

The proximal part of the fingernails, especially of the thumbs, shows a whitish, opaque, half-moon-shaped area, the lunula that is the visible portion of the nail matrix. In this area the nail plate attachment to the underlying epithelium is loose. More than 90% of fingernails show a thin distal transverse white band, the onychocorneal band, better defined as the isthmus, which marks the most distal portion of firm attachment of the nail plate to the nail bed.[2,3] This area represents an important anatomic barrier against environmental hazards, and its disruption produces nail plate detachment with onycholysis. The onychocorneal band is separated from the nail plate white free edge by a 1.0–1.5-mm pink band called the onychodermal band.

In transverse sections, the nail plate consists of three portions: (1) dorsal nail plate, (2) intermediate nail plate, and (3) ventral nail plate.[4] The dorsal and the intermediate portions of the nail plate are produced by the nail matrix, whereas its ventral portion is produced by the nail bed. Above the lunula the nail plate is thinner and consists only of the dorsal and intermediate portions. There is a natural line of cleavage between the dorsal and the intermediate nail plate.

The nail plate progressively thickens from its emergence to its distal margin. The mean toenail thickness at the distal margin is 1.65 ± 0.43 mm in men and 1.38 ± 0.20 mm in women. Fingernails are thinner; the mean thickness is 0.6 mm in men and 0.5 mm in women. There is an increase in nail thickness with age, particularly in the first two decades. Nail thickness depends on the length of the nail matrix and nail bed.[5] Thinning of the nails is usually a sign of nail matrix disorders, whereas nail thickening is most commonly a consequence of nail bed disorders.

PROXIMAL NAIL FOLD

(See Fig. 89-1A)

The proximal nail fold is a skin fold that consists of a dorsal and a ventral portion. The dorsal portion is anatomically similar to the skin of the dorsum of the digit but thinner and devoid of pilosebaceous units. The ventral portion, which cannot be seen from the exterior and proximally continues with the germinative matrix, covers approximately one-fourth of the nail plate. It closely adheres to the nail plate surface and keratinizes with a granular layer. The limit between the proximal nail fold and the nail matrix can be histologically established at the site of disappearance of the granular layer.

The horny layer of the proximal nail fold forms the cuticle, which is firmly attached to the superficial nail plate and prevents the separation of the plate from the nail fold. The integrity of the cuticle is essential for maintaining the homeostasis of this region.

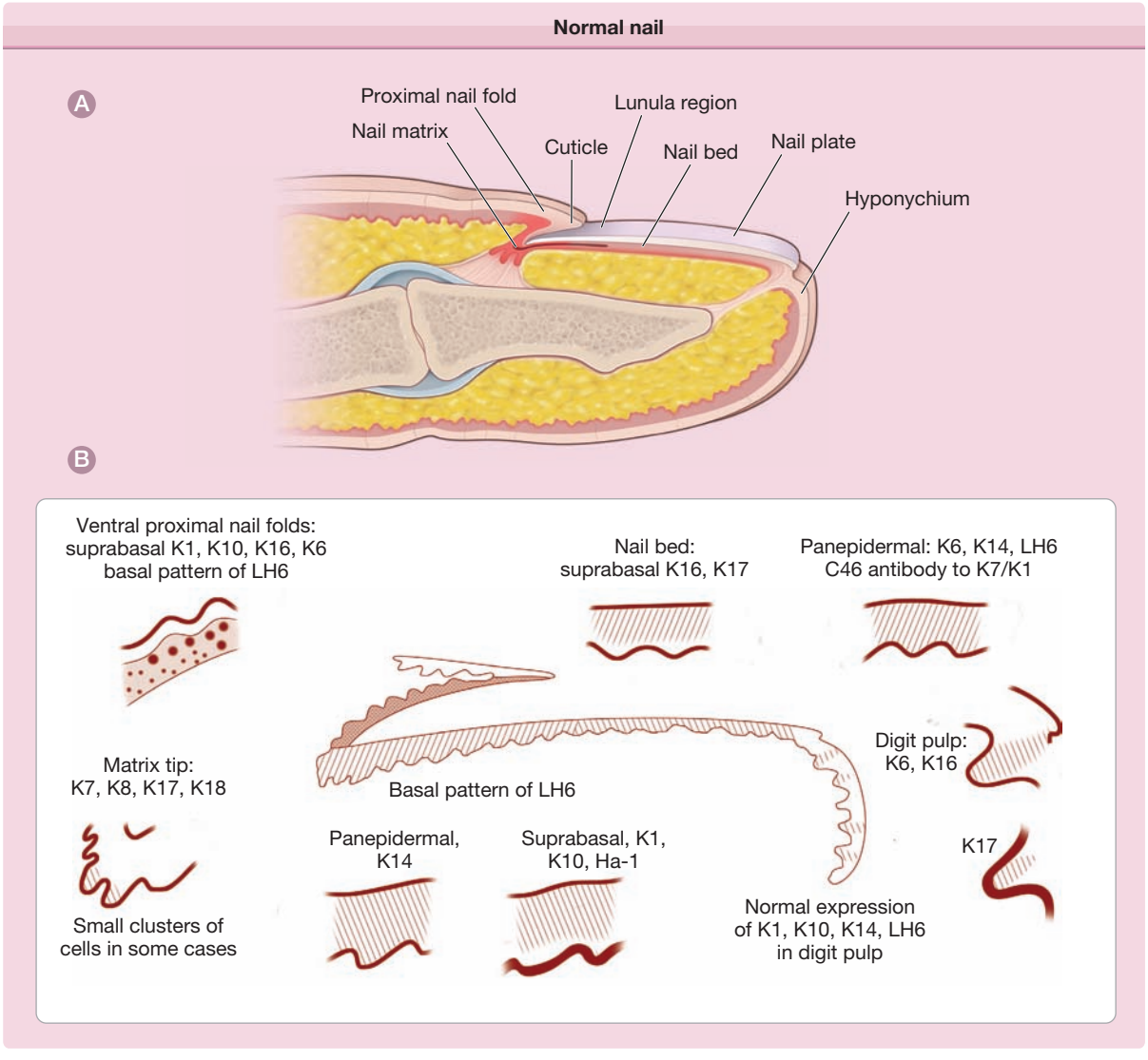

Figure 89-1 **A.** Diagrammatic drawing of a normal nail. **B.** Keratin gene expression at different locations within the nail. (From De Berker D et al: Keratin expression in the normal nail unit: Markers of regional differentiation. *Br J Dermatol* **142**:89, 2000, with permission.)



Figure 89-2 Longitudinal ridging of the nail plate surface. This is commonly observed in the elderly.

The dermis of the proximal nail fold contains numerous capillaries that run parallel to the surface of the skin and may easily be observed in vivo by capillary microscopy. This permits the observation of both the arterial and the venous limbs of the capillaries, which are arranged in parallel rows and appear as fine regular loops with a small space between the afferent and efferent limbs. The morphology of proximal nail fold capillaries is typically altered in connective tissue diseases.[6–8]

NAIL MATRIX

(See Fig. 89-1A)

The nail matrix is a specialized epithelial structure that lies above the mid portion of the distal phalanx.

After elevation of the proximal nail fold, the matrix appears as a distally convex crescent with its lateral horns extending proximally and laterally.

In longitudinal sections the matrix has a wedge-shaped appearance and consists of a proximal (dorsal) and a distal (ventral) portion. Nail matrix keratinocytes divide in the basal cell layer and keratinize in the absence of a granular zone. The site of keratinization (keratogenous zone) of nail matrix onychocytes can be clearly distinguished in histological sections as an eosinophilic area where cells show fragmentation of their nuclei and condensation of their cytoplasm.[1] In this area, nuclear fragments are destroyed by deoxyribonuclease and ribonuclease enzymes. In some conditions nuclear fragments may persist within the intermediate nail plate, producing leukonychia spots. However, these frequently disappear before reaching the nail-free edge, due to the persistence of active DNA and RNA lytic enzymes within the horny nail plate.

Maturation and differentiation of nail matrix keratinocytes do not follow a vertical axis, as in the epidermis, but occur along a diagonal axis that is distally oriented. For this reason, keratinization of the proximal nail matrix cells produces the dorsal nail plate and keratinization of the distal nail matrix cells produces the intermediate nail plate.

In some fingers the distal matrix is not completely covered by the proximal nail fold but is visible through the nail plate as a white half-moon-shaped area, the lunula. The white color of the lunula results from two main anatomic factors: (1) the keratogenous zone of the distal matrix contains nuclear fragments that cause light diffraction, (2) nail-matrix capillaries are less visible than nail bed capillaries because of the relative thickness of the nail-matrix epithelium.[9]

NAIL MATRIX KERATINOCYTES. (See Fig. 89-1B). The nail matrix cells are able to synthesize both "soft" or skin-type and "hard" or hair-type keratins.[10–12] Evaluation of keratin expression in the different constituents of the nail apparatus showed that the nail matrix is the sole site of expression of hard keratin proteins, particularly Ha1 keratin.[13] Data indicate that fibroblasts derived from the nail matrix may induce hard keratin expression in nonnail-matrix keratinocytes.[14]

MELANOCYTES. (See Chapter 72). Nail matrix melanocytes are usually quiescent and therefore not detectable in pathologic sections. However, they possess the key enzymes that are necessary for melanin production, and may become activated by a large number of physiologic and pathologic conditions.[15] Nail matrix melanocyte activation produces diffuse or banded nail pigmentation and is more common in blacks and Japanese than in Caucasians. DOPA-negative (inactive) melanocytes are sparsely present in the nail matrix and in the nail bed.[16] DOPA-positive, activable melanocytes are especially seen in the distal nail matrix, where they are frequently arranged in small clusters among the suprabasal layers of the nail matrix epithelium.[17]

LANGERHANS CELLS. (See Chapter 10). Langerhans cells are more numerous in the proximal than in the distal nail matrix. As in normal epidermis, Langerhans cells are predominantly found in the suprabasal layers. However, they may occasionally be seen within the basal layer of the nail matrix epithelium.

MERKEL CELLS. The presence of Merkel cells in the nail matrix has been demonstrated. Their density is possibly influenced by age, with these cells being more numerous in fetus than in adult nails.[18]

NAIL BED

(See Fig. 89-1A)

The nail bed extends from the distal margin of the lunula to the isthmus and is completely visible through the nail plate. The nail bed epithelium is so adherent to the nail plate that it remains attached to the undersurface of the nail when the latter is avulsed.

The nail bed epithelium is thin and consists of two to five cell layers. Its rete ridges, which are longitudinally oriented, interdigitate with the underlying dermal ridges in a "tongue-and-groove"-like fashion. The nail bed epithelium is a specialized epithelial structure with a horny layer that interlocks to of the inferior border of the nail plate and is responsible for the strong attachment between the two tissues. Nail bed horny layer forms the ventral nail plate, which corresponds to approximately one-fifth of the terminal nail thickness and mass.[19] In pathologic sections, the ventral nail plate is easily distinguishable because of its light eosinophilic appearance. Nail bed keratinization is not associated with the formation of a granular layer. This may appear, however, when the nail bed becomes exposed after nail avulsion.[1]

The nail isthmus is a thin transverse distal band that represents a transitional zone between the nail bed and the hyponychium and exhibits a unique pattern of keratinization, the onycholemmal keratinization, with pale, nucleated keratinocytes. The cornified layer of the nail isthmus closely adheres to the undulating inferior surface of the nail plate preventing onycholysis; the two grow forward together.[3] Keratin expression in the nail bed differs form that of the nail matrix since keratins K6, K16, and K6hf are only expressed in the nail bed.[20] The isthmus differs from nail bed because of a strong suprabasal expression of K10. Transition from isthmus to hyponychium is marked by the disappearance of expression of K6hf and K6/16, and return to expression of K5/17.

HYPONYCHIUM

The hyponychium marks the anatomic area between the nail bed and the distal groove, where the nail plate detaches from the dorsal digit (see Fig. 89-1A). Its anatomic structure is similar to that of plantar and volar skin, and keratinization occurs through the formation of a granular layer. The horny layer of the

hyponychium partially accumulates under the nail plate free margin. The hyponychium is normally covered by the distal nail plate, but it may become visible in nail biters. The architecture of the capillary network of the hyponychium dermis consists in regular capillary loops arranged perpendicularly to the skin, visible as red dots with dermoscopy.

BASEMENT MEMBRANE ZONE

The antigenic structure of the basement membrane zone of the nail is identical to that of the epidermis, and there are no differences in the antigenic composition of the basement membrane zone in the different portions of the nail apparatus.[21] This may explain the involvement of the nails in conditions characterized by mutations of basement membrane-associated genes as well as in autoimmune skin diseases involving the basement membrane zone antigens.[22]

DERMIS

(See Fig. 89-1A)

The nail apparatus is devoid of subcutaneous tissue, and its dermis does not contain pilosebaceous units. The arrangement of the rete ridges varies in the different portions of the nail apparatus. The dermis beneath the proximal nail matrix consists of condensed connective tissue that forms a tendon-like structure connecting the matrix to the periosteum of the proximal phalangeal bone (posterior ligament). A small amount of subdermal fat tissue is present close to the periosteum of the base of the phalanx.[23] The close connection between the lateral horns and the periosteum is possibly responsible for the nail plate's lateral convexity. The rete ridges of the dermis underneath the nail matrix are characteristically long and root-like in shape. The dermis under the distal matrix consists of a loose network of connective tissue containing numerous blood vessels and rare glomus bodies.

The dermis of the nail bed has a unique arrangement with longitudinal grooves and ridges that run from the lunula to the hyponychium.[1] The longitudinal orientation of the capillary vessels within the nail bed grooves explains the linear pattern of nail bed hemorrhages (splinter hemorrhages). The nail bed dermis contains abundant connective tissue networks with connective tissue bundles radiating to the phalangeal periosteum. It contains numerous glomus bodies.

BLOOD AND NERVE SUPPLY

The nail apparatus has an abundant blood supply provided by the lateral digital arteries. These run along the sides of the digits and produce both branches that supply the matrix and the proximal nail fold and arches that supply the matrix and the nail bed. The nail matrix, therefore, has two different sources of blood supply. The nail bed is richly supplied (10–20 cm^2) by encapsulated neurovascular structures containing one to four arteriovenous anastomoses and nerve endings. These glomus bodies are arteriovenous shunts involved in the regulation of the blood supply to the digits related to thermoregulation. The cutaneous sensory nerves, which originate from the dorsal branches of the paired digital nerves, run parallel to the digital vessels.

CHEMICAL PROPERTIES

(See Fig. 89-1B)

The nail plate, like hair, consists mainly of low-sulfur filamentous proteins (keratins) embedded in an amorphous matrix composed of high-sulfur proteins rich in cysteine. Other nail constituents include water, lipids, and trace elements. Nail keratins consist of 80%–90% hard hair-type keratins and 10%–20% soft skin-type keratins. Hard keratins have been identified as the acidic 44K/46K and basic 56K/60K keratins. Soft keratins have been identified as the 50K/58K and 48K/56K keratin pairs.[24] Keratin filaments have a transverse orientation that is parallel to the nail surface. This explains why the nail plate is more susceptible to transverse fractures than to longitudinal fractures. Specific keratins are expressed only in some compartments of the nail unit; for instance, K6a and K6b, K16, and K17 are not expressed in the nail matrix.[13,25,26] Mutations of the genes encoding for these keratins are associated with nail thickening due to nail bed hyperproliferation, as is seen in pachyonychia congenita (PC).[27,28] Nail keratin content and composition, measured as the quantity of carbon (C), nitrogen (N), and sulfur (S) in the fingernails, vary between sexes and in relation to the aging process. Sulfur content is higher in female than in male nails and the opposite is for nitrogen. Carbon content is equal in the two sexes. The carbon content increases with aging, possibly due to loss of inorganic material, and the nitrogen content decreases, while the sulfur content remains stable.[29]

Under normal conditions, the water content of the nail plate is 18%, and most of the water is in the intermediate nail plate.[30] The average water content of the nail plate is significantly lower in winter than in summer.[31)] and varies significantly in time, due to the high porosity of the nail plate, which allows it to be rapidly hydrated and dehydrated. Dehydration is faster when the nails are kept long. When the water content decreases below 18%, the nail becomes brittle; when it increases above 30%, it becomes opaque and soft.[32]

The nail contains less than 5% lipids, mainly cholesterol; the nail plate lipid content is under hormonal control and decreases after menopause.[33] The nail plate also contains traces of several inorganic elements, particularly iron, zinc, and calcium. However, these do not contribute to nail hardness.

PHYSICAL PROPERTIES

The nail plate is hard, strong, and flexible. The hardness and strength of the nail plate are due to its high content of hard keratins and cysteine-rich high-sulfur

proteins, whereas its flexibility depends on its water content and increases with nail plate hydration.[34,35]

The double curvature of the nail plate along its longitudinal and transverse axes enhances nail plate resistance to mechanical stress.[36]

The physical properties of the nail also depend on the arrangement and adhesion of onychocytes in the different portions of the nail plate, as well as on the orientation of the keratin filaments within the nail plate onychocytes.[36] At the ultrastructural level, the corneocytes of the dorsal nail plate are flat, with their shorter diameter perpendicular to the nail plate surface. The average sizes of these cells are 34 µm in length, 64 µm in width, and 2.2 µm in height.[37] Cell adhesion is strong. This portion of the nail is responsible for nail plate hardness and sharpness. The onychocytes of the intermediate nail plate show multiple interdigitations of their cell membranes. The average dimensions of these cells are 40 µm in length, 53 µm in width, and 5.5 µm in height. Cell adhesion is provided by desmosomes. This part of the nail plate is responsible for nail pliability and elasticity. The ventral nail plate is thin and consists of soft keratins. It provides adhesion to the underlying nail bed.

NAIL GROWTH

The nail plate grows continuously in a proximal to distal manner throughout life. The nail plate is "pushed" out by two factors: (1) matrix keratinocytes proliferation and differentiation which makes a new plate, (2) the nail bed which moves slowly, parallel to the direction of the nail growth, toward the inferior border of the nail plate.[3]

Fingernails grow two times faster than toenails, with a mean growth rate in adults of 3.5 mm/month for fingernails and 1.5 mm/month for toenails. The 5th fingernail growth rate is significantly slower than other fingernails and the growth rate of the great toenail significantly faster than other toenails.[38]

Complete replacement of a fingernail requires 100–180 days (6 months). When the nail plate is extracted, it is approximately 40 days before the new fingernail first emerges from the proximal nail fold. After a further 120 days it will reach the fingertip.[39] The total regeneration time for a toenail is 12–18 months. As a consequence of the slow nail growth rate, diseases of the nail matrix only become evident a considerable time after their onset and require a long time to disappear after treatment.

Nail growth rate varies among different individuals and among the different digits of the same individual. It depends on the turnover rate of the nail matrix cells and is influenced by several physiologic and pathologic conditions. Nail growth rate is slow at birth, increases slightly during childhood, and usually reaches its maximum between the second and the third decades of life. It sharply decreases after the age of 50 years.[39]

Conditions that have been associated with a slow growth rate include systemic illness, malnutrition, peripheral vascular or neurologic diseases, and treatment with antimitotic drugs. Nails affected by onychomycosis frequently exhibit a slow growth rate. An arrest of nail growth is a typical feature of yellow nail syndrome. Conditions that have been associated with accelerated nail growth include pregnancy, finger trauma, psoriasis, and treatment with oral retinoids or itraconazole. Accelerated nail growth may cause longitudinal ridging of the nail plate (nail beading).

Due to their slow growth rate, the nails may provide information on pathologic conditions that have occurred up to several months before the time of observation. Drugs, chemicals, and biologic substances accumulate in nails, where they can be detected and measured. Advantages of analyzing nail samples include the ease and noninvasiveness of their collection, the small sample size required for analysis, and the ease of storage at room temperature. The nail of the big toe is the best site for investigation because of its size (big toenail length of an adult: 20 mm) and slow growth rate (about 2 mm/month) permitting to obtain data on exposure to drugs and chemicals over a period of 10 months.[40]

NAIL SIGNS AS A FUNCTION OF THE SITE OF PATHOLOGY[1,32]

(See Table 89-1)

BEAU'S LINES AND ONYCHOMADESIS (NAIL SHEDDING)

Beau's lines result from a temporary arrest of proximal nail matrix proliferation and appear as transverse grooves, often deeper in the central nail plate, that move distally with nail growth. Onychomadesis also results from a temporary arrest in nail matrix activity,

TABLE 89-1
Relation Between Resultant Clinical Manifestations and Location of Pathologic Change

Proximal Matrix	Beau's Lines Pitting Longitudinal striations Longitudinal fissures Longitudinal grooves Trachyonychia
Distal matrix	True leukonychia
Proximal and distal matrix	Koilonychia Onychomadesis
Nail bed	Longitudinal erythronychia Onycholysis Splinter hemorrhages Apparent leukonychia
Nail bed and hyponychium	Subungual hyperkeratosis
Proximal nail fold	Paronychia Periungual erythema

BOX 89-1 CAUSES OF BEAU'S LINES AND ONYCHOMADESIS

- Trauma
  - Manicure
  - Onychotillomania
- Dermatologic diseases
  - Eczema
  - Erythroderma
  - Paronychia
- Systemic conditions
  - Use of certain drugs
  - High fever
  - Viral illness (hand-foot-and-mouth disease; measles)
  - Diarrhea
  - Kawasaki syndrome
  - Peripheral ischemia

and the proximal nail plate is detached from the proximal nail fold by a whole-thickness sulcus. Causes of onychomadesis are the same as those for Beau's lines but are more severe (Box 89-1). Multiple Beau's lines or onychomadesis in the same nail indicates repetitive insults. Measuring the distance of the groove from the proximal nail fold can date the time of the insult leading to Beau's lines. Local trauma, such as from manicures or onychotillomania, or related to local cutaneous disease, particularly dermatitis, periungual erythema, and paronychia, are causes of Beau's lines. Beau's lines or onychomadesis at the same levels in several nails suggest a systemic cause (Fig. 89-3). Most common among these are drugs (especially chemotherapy), high fever, viral illness,[41,42] surgery, and peripheral ischemia. Onychomadesis in children often relates to recent coxsackievirus infection (hand-foot-mouth disease).[41,43]

PITTING

Pits result from small areas of abnormal keratinization of the proximal nail matrix that produce foci of parakeratotic cells in the superficial nail plate. They appear as small punctate depressions of the superficial nail plate, which progress distally and often become more evident with nail growth. Deep and irregularly distributed pits are seen in psoriasis (Fig. 89-4) and atopic dermatitis; geometric and superficial pits are typical of alopecia areata (see Chapters 14, 18, and 88).

ONYCHORRHEXIS (LONGITUDINAL STRIATIONS AND FISSURING)

Onychorrhexis results from diffuse defective keratinization of the proximal nail matrix. The nail plate is usually thinned and presents multiple longitudinal ridges and fissures. Onychorrhexis is a sign of severe nail fragility and typical of lichen planus (see Chapter 26).



Figure 89-3 Beau's lines of several nails after systemic illness. Note involvement of all the nails at the same level.

LONGITUDINAL GROOVES

Longitudinal grooves are usually single and appear as a longitudinal depression of the nail plate (1–2 mm large) due to compression of the nail matrix by tumors of the proximal nail fold.

TRACHYONYCHIA

Trachyonychia results from multiple foci of defective keratinization of the proximal nail matrix. The nails are rough due to excessive longitudinal ridging.

TRUE LEUKONYCHIA

True leukonychia results from defective keratinization of the distal matrix with persistence of parakeratotic



Figure 89-4 Pitting: small punctate depressions of the superficial nail plate. In psoriasis, pits are irregularly distributed and often associated with onycholysis and splinter hemorrhages.



Figure 89-5 Punctate leukonychia due to microtraumas in a child.

cells in the ventral nail plate. The superficial nail plate is structurally normal, but the nail presents opaque white patches or striae, which often disappear before reaching the distal edge of the nail. Punctate leukonychia is due to microtrauma and is typically seen in the fingernails of children (Fig. 89-5). Striate leukonychia of fingernails is a consequence of aggressive manicure. Total or subtotal leukonychia is rare and usually hereditary.

KOILONYCHIA

In koilonychia the nail plate is thin and spoon shaped. Koilonychia is physiologic in the toenails of children. In adults it can be a sign of iron deficiency or occupational damage to the nail plate.

MELANONYCHIA[44]

Melanonychia describes a brown to black color of the nail due to the presence of melanin in the nail plate. It can be caused by activation or proliferation (benign or malignant) of nail matrix melanocytes. The pigmentation may involve the whole nail (total melanonychia) or may be banded, as in transverse melanonychia (rare) or in the most common longitudinal melanonychia (LM). LM may appear as a single band involving one digit, or as multiple bands affecting several digits, which are usually due to melanocyte activation, as is seen in dark-skinned individuals, pregnant women, inflammatory nail disorders, individuals with Laugier–Hunziker syndrome, and those taking certain medications (Box 89-2). LM has also been described in individuals with a variety of systemic disorders, particularly human immunodeficiency virus infection and Addison syndrome. In Laugier–Hunziker syndrome, melanonychia begins during adolescence, affects several digits, and is associated with the presence of lip and/or genital pigmented macules[45,46] (see Chapter 78). Melanonychia due to melanocyte activation may in some cases involve a single digit, as in patients with onychotillomania, with frictional melanonychia of the 4th or 5th toenails (Fig. 89-6), with inflammatory nail diseases, such as psoriasis or lichen planus, or with nail tumors, such as Bowen's disease. A single band of melanonychia deserves a careful evaluation, since it may be a sign of a nail matrix nevus or melanoma (see Chapters 122 and 124). LM of a single nail often deserves biopsy.

BOX 89-2 CAUSES OF LONGITUDINAL MELANONYCHIA

- Race
- Acquired immunodeficiency syndrome
- Inflammatory nail disorders
- Use of certain drugs
- Addison disease
- Pregnancy
- Laugier–Hunziker syndrome
- Trauma

LONGITUDINAL ERYTHRONYCHIA[47]

Longitudinal erythronychia reflects a nail bed disorder and appears as a pink–red longitudinal band of various width extending from the proximal nail to the distal edge. A single band of longitudinal erythronychia is most commonly caused by an onychopapilloma or by another benign or malignant subungual tumor (Fig. 89-7). Multiple bands of longitudinal erythronychia are seen in lichen planus. In Darier's disease bands of longitudinal erythronychia alternate with white longitudinal bands and V-shaped indentations of the nail-free margin (see Chapter 51).

ONYCHOLYSIS

Onycholysis is detachment of the nail plate from the nail bed and can be caused by traumatic, inflammatory, infectious, or neoplastic nail bed disorders. See Section "Onycholysis under Environmental Nail Disorders."

SPLINTER HEMORRHAGES

Splinter hemorrhages appear as red to black small thin longitudinal lines under the nail plate. They are more commonly located in the distal nail plate and represent



Figure 89-6 Frictional melanonychia of the 4th and 5th toenails.

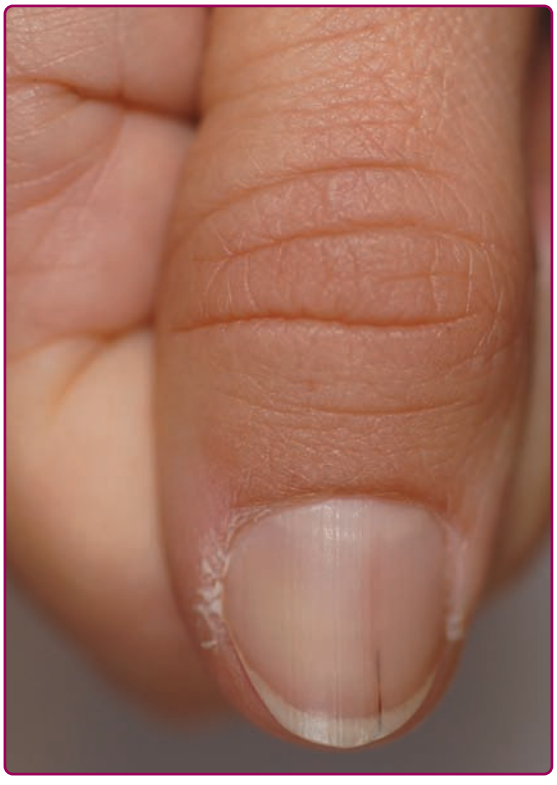

Figure 89-7 Longitudinal erythronychia. The nail plate shows a narrow longitudinal pale pink band that ends with a dark red steak corresponding to a splinter hemorrhage. This clinical feature is typical of onychopapilloma.

rupture of the longitudinally oriented nail bed capillaries (Fig. 89-8). Causes include trauma and inflammatory nail disorders, such as psoriasis.

APPARENT LEUKONYCHIA

In apparent leukonychia the nails are pale white due to nail bed discoloration that fades with pressure.



Figure 89-8 Multiple distal splinter hemorrhages in a manual worker with mild nail psoriasis.

SUBUNGUAL HYPERKERATOSIS

Subungual hyperkeratosis is due to inflammatory disorders that cause an abnormal keratinization of the distal nail bed and hyponychium with accumulation of scales under the distal nail plate. The most common causes include psoriasis, onychomycosis, trauma, contact and atopic dermatitis (see Chapters 13, 14, and 18).

PARONYCHIA

Paronychia is inflammation of the proximal nail fold and presents as painful periungual erythema, sometimes with associated purulence. Acute paronychia is usually caused by infection (see Section "Infectious Nail Disorders"). Chronic paronychia is most commonly due to mechanical or chemical factors. If the periungual area is fluctuant or shows purulence, it should be drained to avoid matrix damage. Topical and/or systemic antibiotics should be administered if bacterial infection is suspected.

NAIL PIGMENTATION

Nail pigmentation is most commonly due to exogenous staining of the nail plate. In this case the proximal margin of the pigmentation follows the shape of the proximal nail fold. Exogenous nail pigmentation is most commonly due to occupational exposures or nail cosmetics. Nail pigmentation due to endogenous causes is rare. The proximal margin of the pigmentation follows the shape of the lunula. Possible causes include drugs, argyria, hemochromatosis, alkaptonuria, and Wilson disease.

HEREDITARY AND CONGENITAL NAIL DISORDERS[48]

(See Table 89-2)

ECTODERMAL DYSPLASIAS

(See Chapter 142)

Nail changes may be associated with hypotrichosis, hypodontia, and hypohidrosis. Most commonly the nails are short, thickened, and hypoplastic.

EPIDERMOLYSIS BULLOSA

(See Chapter 62)

Nail abnormalities are a common feature in most subtypes of epidermolysis bullosa (EB) and have recently been included among the criteria for scoring EB severity.[49] Trauma undoubtedly contributes to the development of nail dystrophy and for this reason the great toenails are more often severely affected. Pachyonychia of the toenails be the first or the only symptom of dominant dystrophic EB (DDEB) in some families (eFig. 89-8.1 in online edition). Junctional and dermolytic EB may produce anonychia.[50]

TABLE 89-2
Hereditary and Congenital Nail Disorders

Ectodermal Dysplasias	Atrophy/Thickening
Epidermolysis bullosa	Partial or total anonychia Pachyonychia Subungual/periungual hemorrhagic blisters Periungual erosions with granulation tissue
Pachyonychia congenita	Onychogryphosis Severe thickening Yellow–brown discoloration
Iso-Kikuchi syndrome	Micronychia/anonychia Hemionychogryphosis
Nail patella syndrome	Hypoplasia/aplasia Triangular lunulae
Congenital malalignment of the hallux	Lateral deviation of the nail plate Lateral/distal embedding of nail Nail thickening Yellow–brown discoloration Transverse ridging

PACHYONYCHIA CONGENITA

(See Chapter 50)

PC is an autosomal dominant genodermatosis characterized by painful keratoderma, nail thickening, oral leukokeratosis, and epidermal cysts. The severity of PC can vary greatly among patients and the most problematic aspect of PC, the painful palmoplantar keratoderma (PPK), have vary in extent from focal to a severe, diffuse PPK.[51] The International Pachyonychia Congenita Research Registry (IPCRR) has compared the PC phenotype with genotype in hundreds of individuals, and have found issues with the classical division into PC1 (Jadassohn-Lewandowski type) and PC2 (Jackson-Lawler). A new molecular classification has been proposed, in which subtypes of PC refer to the mutated keratin gene.[52] Mutations in *KRT6A* account for almost 50% of known cases, while 24% have mutations are in *KRT16*, 23% in *KRT17*, and 3% in *KRT6B*.[53] In contrast to the old classification, in which PC1 was thought to result from mutations in *KRT6a* or 16, and PC2 from mutations in *KRT6b* or 17, the clinical features of the former subtypes overlap. For example, cysts (a feature of PC2 and not PC1) most commonly occur in individuals with either a *KRT17* mutation or *KRT6a* mutation.

Nail abnormalities are a constant feature and develop during infancy to early childhood, although a late-onset variety of PC has been described.[54] In typical cases the 20 nails are thickened, very difficult to trim, darkened, and with an increased transverse curvature. Nail thickening is a consequence of nail bed hyperkeratosis and is more evident on the distal half of the nails, which have an upward angling. Recent evidence indicates that PC may also present with very subtle nail changes and that there is not a good correlation between mutations detected at molecular level and clinical phenotype. Severity may even vary among family members with the same gene mutation.[55,56]



Figure 89-9 Nail patella syndrome: nail hypoplasia of the 1st and 2nd fingers.

NAIL PATELLA SYNDROME

Nail abnormalities in nail patella syndrome may involve all fingernails or may be limited to the thumbs, which are always the most severely affected digits (Fig. 89-9). Nail hypoplasia is usually more marked in the medial portion of the nail. The shape of the lunula is typically triangular.[48]

CONGENITAL MALALIGNMENT OF THE HALLUX

Congenital malalignment of the hallux is the most common cause of ingrowing (ingrown) nails and is usually diagnosed when the child starts to walk. The great toenail shows a lateral deviation that produces embedding of the lateral side of the nail plate (Fig. 89-10). The digit is painful and the toenail often shows Beau's lines and



Figure 89-10 Congenital malalignment of the big toenail associated with mild disto-lateral ingrowing on the medial side.

TABLE 89-3
Infectious Nail Disorders

Bacterial	
Staphylococcus aureus	Acute paronychia
Streptococcus pyogenes	Acute paronychia
Viral	
Herpes simplex	Acute paronychia
	Onycholysis
	Periungual vesicles
Warts	Periungual/subungual papules
Fungal	
Dermatophytes	DSO
	PSO
	WSO
Nondermatophytes	PSO + periungual inflammation
	Deep WSO
Candida sp.	TO + paronychia

DSO = distal subungual onychomycosis; PSO = proximal subungual onychomycosis; WSO = white superficial onychomycosis; TO = total onychomycosis.

onycholysis. Congenital malalignment may be unilateral or bilateral. Spontaneous improvement may occur, and most children do not have symptoms by the age of 2 years.[57] Inflammation due to lateral ingrowing can be managed by daily massaging of the lateral nail fold with creams containing steroids, antibiotics, and urea. Surgical treatment may be necessary if nail symptoms are severe and do not subside with growth.[58,59]

INFECTIOUS NAIL DISORDERS

(See Table 89-3)

ACUTE PARONYCHIA

Acute paronychia is most commonly due to *Staphylococcus aureus* infection and typically affects a child's fingernail. Predisposing factors include nail biting or sucking and occupational traumas. The proximal nail fold is painful, erythematous, and swollen. Pus may be discharged after pressure (see Chapter 176). The differential diagnosis includes herpes simplex virus infection (see Chapter 193) and Hallopeau's acrodermatitis (see Chapter 21), both of which have a typical relapsing course. Suspicion of *Herpes simplex*-virus infection should arise when the pain intensity is disproportionate to the clinical symptoms and the disease is recurrent. The treatment of choice depends on the extent of the infection. If diagnosed early, acute paronychia without obvious abscess can be treated nonsurgically, often with topical antibiotics alone. If an abscess has developed, incision and drainage must be performed. Oral antibiotics with Gram-positive coverage against *S. aureus*, such as cephalexin, amoxicillin with clavulanic acid, and clindamycin, are effective.

GREEN NAILS

Bacteria are not capable of attacking a healthy nail plate. The Gram-negative bacterium *Pseudomonas aeruginosa* may colonize the dorsal or ventral nail plate under propitious conditions, such as chronic paronychia or onycholysis. The presence of *Pseudomonas* is revealed by characteristic green–black nail pigmentation due to pyocyanin staining. Topical application of a few drops of diluted bleach or chlorhexidine solution two or three times a day clears the pigmentation in a few weeks. Administration of systemic antibiotics is unnecessary.

ONYCHOMYCOSIS[60,61]

For a detailed description of the onychomycoses, see Chapter 188. Onychomycosis is a common toenail disease, and its prevalence increases with age.

Clinical features depend on type of nail invasion (Table 89-4). The possibility of mold onychomycosis should be suspected when proximal subungual onychomycosis (PSO) is associated with periungual inflammation, or when white superficial onychomycosis is severe and involves the entire nail plate (Fig. 89-11). Nondermatophytic onychomycoses are becoming more frequent worldwide and represent a clinical problem, because they usually respond poorly to systemic treatment.

TABLE 89-4
Clinical Presentations of Onychomycosis (See Chapter 188)

Distal subungual onychomycosis[a]	*Trichophyton rubrum*, *Trichophyton interdigitale*	Onycholysis associated with subungual hyperkeratosis, patchy or linear yellow discoloration
Proximal subungual onychomycosis	*T. rubrum*[b]	Proximal leukonychia with normal nail plate surface
	Fusarium sp. *Aspergillus* sp. *Scopulariopsis* sp.	Associated with periungual inflammation and purulent discharge
White superficial onychomycosis	*Trichophyton interdigitale*[a]	Multiple superficial areas of friable opaque leukonychia
	Fusarium sp. *Aspergillus* sp.	Involvement more diffuse and deeper

[a]Associated with tinea pedis.
[b]Possible marker of human immunodeficiency virus infection.

ONYCHOMYCOSIS AT A GLANCE

- Fifteen percent of the general population and 40% of individuals older than 60 years are affected.
- Clinical presentation reflects the route of nail invasion.
- Dermatophytes account for 85% of cases, nondermatophyte fungi for 15%.
- Infection with human immunodeficiency virus should be suspected with proximal subungual onychomycosis (PSO) due to *Trichophyton rubrum*.
- Mold fungal infection should be suspected when PSO is associated with acute periungual inflammation or when white superficial onychomycosis involves most of the nail plate.
- *Candida* sp. is the causative agents only in immunosuppressed individuals.
- Toenails are involved in most cases; tinea pedis is usually associated.
- The cure rate for toenail onychomycosis is approximately 80% with the use of systemic antifungals, but recurrences are frequent (up to 20%). Mold infections respond poorly to systemic treatment.

ENVIRONMENTAL NAIL DISORDERS

NAIL FRAGILITY[62]

(Box 89-3)

With nail fragility, the nails are brittle and show distal lamellar splitting (onychoschizia) (Fig. 89-12). Several fingernails are usually affected. The nail plate margin is irregular due to distal splitting. Idiopathic nail fragility usually affects middle-aged women who are exposed to water and chemicals that dehydrate the nail plate. Aging also is associated with increased nail fragility. The risk of nail fragility from trauma is increased by manicures, onychotillomania, and certain occupations, especially those that involve frequent exposure to water and chemicals. Fragile nails can be a feature of several dermatologic disorders, such as lichen planus, alopecia areata, psoriasis, and onychomycosis. In addition, nutritional deficiency, peripheral neuropathies, peripheral vascular disease, and use of certain medications increase the risk of nail fragility. Management includes protection of the hands by the use of cotton gloves under rubber gloves and frequent application of topical moisturizers.[61] Oral biotin, 5 mg/day, can be helpful.[63]

BOX 89-3 CAUSES OF NAIL FRAGILITY

- Idiopathic
  - Aging
  - Exposure to water and chemicals
- Traumatic
  - Occupational injury
  - Manicure
  - Onychotillomania
- Dermatologic diseases
  - Lichen planus
  - Alopecia areata
  - Psoriasis
  - Onychomycosis
- Systemic conditions
  - Use of certain drugs
  - Peripheral vascular diseases
  - Peripheral neuropathies
  - Nutritional deficiencies

CHRONIC PARONYCHIA[64–66]

Chronic paronychia is an inflammatory disorder that almost exclusively involves the fingernails of adult women. Mechanical or chemical traumas damage the cuticle and permit penetration of irritant and allergenic environmental substances under the proximal



Figure 89-11 White superficial onychomycosis due to *Fusarium* sp. Note diffuse and "deep" nail invasion.



Figure 89-12 Onychoschizia lamellina: lamellar exfoliation of the distal nail plate.

CHRONIC PARONYCHIA AT A GLANCE

- Occurs most commonly in food handlers and housecleaners.
- Associated with mechanical or chemical cuticle damage.
- Characterized by eczematous inflammation of the proximal nail fold and matrix.
- Secondary colonization by bacteria and yeasts usually occurs.
- First, second, and third digits of the dominant hand are most often affected.
- Management includes protective measures, topical and/or systemic steroids, and topical antimicrobials.
- Systemic antifungals are not effective.

nail fold, causing an inflammatory reaction of the nail folds and matrix. Secondary colonization with *Candida* sp. and/or bacteria occurs in most cases, causing self-limited episodes of painful acute inflammation (see Chapter 189). Chronic paronychia most commonly affects the first, second, and third fingers of the dominant hand. Clinically, the proximal and lateral nail folds show mild erythema and swelling, and the cuticle is absent. The nail plate may show superficial abnormalities and green discoloration due to *Pseudomonas* invasion. Hand protection from the environmental hazards is mandatory for remission of chronic paronychia, which can be considered cured only when the cuticle has regrowth. Systemic antifungals are not effective. Chronic paronychia should be treated as contact dermatitis, with topical steroids or tacrolimus associated with topical antiseptics to prevent secondary microbial colonization.

IDIOPATHIC ONYCHOLYSIS[65]

IDIOPATHIC ONYCHOLYSIS AT A GLANCE

- Occurs in homemakers and those in certain occupations.
- Caused by mechanical or chemical damage.
- Follows asymptomatic and slowly progressive nail plate detachment.
- Management includes taking protective measures, trimming the onycholytic nail plate, and applying topical antiseptics.

BOX 89-4 ONYCHOLYSIS

- Primary
  - Idiopathic
  - Fingernails: women (mechanical/chemical damage)
- Trauma
  - Fingernails: occupational injury
  - Toenails: podiatric abnormalities, improper shoes
- Secondary
  - Vesiculobullous disorders
    - Contact dermatitis
    - Pompholyx
    - Herpes simplex
  - Nail bed hyperkeratosis
    - Onychomycosis
    - Psoriasis
  - Nail bed tumors
    - Drugs (often hemorrhagic)

Idiopathic onycholysis usually affects the fingernails of women and is a consequence of mechanical and chemical damage of the nail bed isthmus (Box 89-4). The detached nail plate is white due to the presence of air and frequently presents areas of green–brown discoloration due to bacterial colonization (Fig. 89-13). The use of sharp tools to clean the nail plate free margin produces roller coaster onycholysis (manicure onycholysis). Traumatic onycholysis of the fingernails is usually occupational and is more commonly observed in butchers, slaughterhouse workers, chicken processing workers, and workers lifting heavy bags. Traumatic onycholysis of the toenails most frequently affects the big toe, often bilaterally. It is usually a consequence of anatomic abnormalities (overlapping of the second toe on the first toe) or poorly fitting shoes. Subungual hematoma is frequently associated. Secondary onycholysis is seen in several dermatologic disorders. When only one nail is affected, it is important



Figure 89-13 Idiopathic onycholysis: note areas of green discoloration of the onycholytic space due to *Pseudomonas* colonization.

to explore the nail bed after cutting the onycholytic nail to rule out a nail tumor. Patients with idiopathic onycholysis should be instructed to keep the nail dry, trim the onycholytic nail plate, and wear cotton gloves under rubber gloves. Application of topical 4% thymol in chloroform solution on the exposed nail bed can accelerate cure.

NAIL TUMORS[67]

Tumors of the nail usually affect one digit and are associated with symptoms that depend on tumor localization: nail plate furrows or grooves are due to tumors in the proximal nail fold, while onycholysis or subungual nodule are a consequence of nail bed tumor. The nail plate may be altered both in its shape and thickness and in color.

BENIGN TUMORS

FIBROMA/FIBROKERATOMA. Fibroma/fibrokeratoma appears as a nodular or filiform growth that often has a keratotic surface. Most fibromas originate in the proximal nail fold and extend to the nail plate surface, where the tumor presents as a longitudinal furrow or groove. Subungual lesions are uncommon. Tuberous sclerosis should be considered, especially if multiple lesions are present (see Chapter 140).

SUBUNGUAL EXOSTOSIS.[68] Subungual exostosis appears as a subungual hard nodule that detaches and lifts the nail plate. The toenails of young adults are usually affected, and a history of trauma is not unusual. Radiography confirms the diagnosis.

MYXOID CYST.[69] Myxoid cyst appears as a nodule of the proximal nail fold associated with a longitudinal groove in the correspondent nail plate. Because the cyst often drains spontaneously, the shape of the groove is irregular. Myxoid cysts usually affect the fingernails of middle-aged women and are associated with osteoarthritis of the interphalangeal joints.

GLOMUS TUMOR. Glomus tumor may hardly be seen, appearing as a small red patch under the nail plate and usually affecting the hand. The minimal clinical appearance is disproportionate to the intense pain, which is usually accentuated by cold and radiates to the limb. Due to the small size of the tumor, preoperative assessment with MRI or high-variable frequency ultrasound is advisable to improve the out come of surgery.

ONYCHOMATRICOMA.[70] Onychomatricoma is a rare benign fibroepithelial tumor that originates from the nail matrix and produces typical clinical features: the whole or part of the nail is thickened, overcurved, with a yellow–white discoloration and multiple longitudinal tunnels (hollows) that end in the distal nail producing a beehive appearance of the free margin.

BOX 89-5 CLINICAL SIGNS THAT REQUIRE HISTOLOGIC EVALUATION OF LONGITUDINAL MELANONYCHIA

- Periungual pigmentation
- Adult age
- Change in color/width of the band
- Hyperpigmented lines within the band
- Proximal portion of the band wider than distal
- Thumb, index finger, or toe involvement
- Blurred margins

NAIL MATRIX NEVI.[71,72] Nail matrix nevi produce a band of LM and usually appear in childhood. The color and width of the band are variable, and modification of the pigmentation (fading or darkening) with time is common (eFigs. 89-13.1 and 89-13.2 in online edition). Pigmentation of the periungual tissues (Hutchinson's sing) is commonly associated with congenital nevi. Clinical management of nail matrix nevi in children is often problematic as lesions frequently show signs (Box 89-5) that are indicative for nail melanoma in adults.[73,74] Excision of the lesions that show rapid increase in size is probably the best option, to exclude the possibility of a melanoma, which is rare but can occur.

MALIGNANT TUMORS

SQUAMOUS CELL CARCINOMA. (See Chapter 114). *In situ* squamous cell carcinoma (Bowen's disease) usually manifests in fingernails, with a lesion that clinically, closely resembles a wart. Associated melanonychia or paronychia may be a diagnostic clue (Fig. 89-14).



Figure 89-14 Bowen's disease. Verrucous lesion of the nail bed, associated with onycholysis and melanonychia.



Figure 89-15 Subungual squamous cell carcinoma: ulcerated subungual nodule.

Human papillomavirus (HPV) 56 has been detected in tumoral cells of cases of Bowen's diseases associated with LM, indicating that the virus may be involved in the carcinogenesis of these cases.[75] Squamous cell carcinoma presents as a slowly growing subungual nodule that eventually ulcerates (Fig. 89-15) or a warty periungual growth. The underlying bone is commonly involved. It is more common in the fingernails and after the fifth decade of life, and the diagnosis is often delayed, since the tumor simulates other benign nail lesions and is frequently not recognized until it ulcerates.[76] Oncogenic HPV may be isolated from fingernail lesions. Surgical excision with Mohs surgery is the best treatment for squamous cell carcinoma without bone involvement.

MELANOMA.[77–79] (See Chapter 124)

MELANOMA AT A GLANCE

- Involvement of nails is rare (0.7%–3.5% of melanomas).
- Thumb or hallux is most often affected.
- Longitudinal melanonychia and Hutchinson sign are classic.
- Lesion is amelanotic in 25% of cases.
- Only 15% of patients survive 5 years or longer.

Nail melanoma is an uncommon form of acral melanoma that arises within the nail matrix or bed. The incidence for acral melanomas is similar worldwide, but the proportion is higher in dark-skinned individuals. It represents about 2% of cutaneous melanomas in Caucasians, and up to 25% in Africans and 10% in Japanese. Nail melanoma most commonly affects the thumb or great toe of middle-aged or elderly patients and is usually an acral lentiginous melanoma. Melanoma of the nail matrix presents as a band of LM, usually dark in color and with irregular border. Periungual brown–black pigmentation (Hutchinson nail sign) indicates superficial spreading of the tumor and is a diagnostic clue (Fig. 89-16). Although dermoscopy is increasingly utilized in the evaluation of nail pigmentation, the experience in this field is still limited and there are no data showing that dermoscopy is superior to clinical evaluation in early detection of nail melanoma. Recent evidence indicate that dermoscopy should not be considered a substitute for pathology in the differential diagnosis of doubtful cases of LM and an excisional biopsy is recommended in all cases of LM showing suspicious features (Box 89-5).[74]



Figure 89-16 Nail melanoma: note Hutchinson's sign of the hyponychium.

Up to 33% of subungual melanomas are amelanotic, and they are often misdiagnosed as pyogenic granuloma or squamous cell carcinoma, because the tumor appears as a nail bed growth that first detaches the nail plate and then destroys the epithelium with erosion and bleeding. The low survival rate of patients with nail melanoma is related mainly to the delay in diagnosis.

NAIL PSORIASIS

(See Chapter 18)

NAIL PSORIASIS AT A GLANCE

- Present in up to 50% of patients with skin psoriasis and up to 83% of those with psoriatic arthritis.
- Isolated nail psoriasis is not rare.
- Nail matrix and nail bed are most commonly affected.
- Most often precipitated or worsened by trauma.
- Most common signs are onycholysis, salmon patches, subungual hyperkeratosis, and irregular pitting.
- Fingernails and/or toenails may be affected. Several nails are involved in most cases.
- Treatment is often unsatisfactory.

Up to 50% of patients with psoriasis have concurrent nail psoriasis, which can occur in the absence of skin lesions. Up to 30% of patients with skin psoriasis also have psoriatic arthritis and of these, approximately 80% have nail disease. It has been recently understood that the close proximity of the nail unit to the distal phalanx and the joint has important functional and pathological consequences.[80] The fibers of the extensor tendon of the digit insert to the periosteum and then are directed to the nail matrix, which they envelop and link to the bone. The collateral ligaments of the digit anchor the lateral sides of the nail to the interphalangeal joint. Thus, any acute inflammatory process affecting the interphalangeal joint necessarily affects the nail and vice versa.

Psoriasis limited to the nails can be easily diagnosed when it produces typical signs, usually detectable only in the fingernails: psoriatic pitting, onycholysis with erythematous border and salmon patches of the nail bed.[81] Psoriatic pits are large, deep, and irregular (see Fig. 89-4), and represent psoriatic involvement of the proximal nail matrix. Onycholysis is actually the most common manifestation of nail psoriasis and may affect both fingernails and toenails. In fingernails the presence of an erythematous border along the onycholytic area is diagnostic for nail psoriasis (Fig. 89-17). In toenails, onycholysis is usually combined with subungual hyperkeratosis and may closely resemble onychomycosis (Fig. 89-18). Salmon patches (oil drop sign) appear as yellow–red areas of discoloration in the center of the nail or bordering an onycholytic area. Rarely, nail psoriasis may produce severe nail plate abnormalities such as trachyonychia or crumbling. Other common but rather aspecific signs include splinter hemorrhages and paronychia.

DIFFERENTIAL DIAGNOSIS

The differential diagnosis of nail psoriasis is summarized in Box 89-6.

Pathology of nail clipping can be helpful for diagnosis and to rule out onychomycosis.[82] When typical symptoms are not present, diagnosis of nail psoriasis may rely on videodermoscopy of the hyponychium (magnification 40×), which shows dilated, tortuous, elongated, and irregularly distributed capillaries, a finding typical of nail psoriasis (eFig. 89-18.1 in online edition). The capillary density positively correlates with disease severity and decreases with the response to treatment.[83]



Figure 89-17 Nail psoriasis: onycholysis surrounded by an erythematous border and salmon patches of the nail bed.



Figure 89-18 Psoriasis of the toenails producing subungual hyperkeratosis and onycholysis.

TREATMENT

Treatment of psoriasis affecting only the nails is often unsatisfactory and should be limited to patients who experience functional impairment or severe cosmetic problems. It is important to instruct patients to avoid trauma and to refer the patient to a rheumatologist if digital pain is described.

Systemic treatments for skin and joint psoriasis are generally effective for nail psoriasis (methotrexate, cyclosporine A). Since the advent of biologic therapies for severe skin and joint psoriasis, their effects on nails symptoms has been investigated and infliximab 5 mg/kg appears to be the most effective to date. Statistically significant mean percent improvement in the Nail Psoriasis Severity Index (NAPSI) score over placebo was obtained at both week 10 and week 24.[84] Phototherapy is not effective.

Intralesional steroids (triamcinolone acetonide 2.5–5.0 mg/mL in saline) are the best treatment for nail

BOX 89-6 DIFFERENTIAL DIAGNOSIS OF NAIL PSORIASIS

- Onycholysis
  - Onychomycosis (usually associated with subungual hyperkeratosis): up to 21% of psoriatic nails have secondary onychomycosis
  - Idiopathic onycholysis (fingernails): usually seen with other nail changes
  - Trauma (toenails): psoriasis usually affects several nails, not just the great toenails
- Pitting
  - Eczema: often has periungual scaling and Beau's lines
  - Alopecia areata: different morphology of pits

matrix psoriasis limited to a few fingernails, for which they can be injected in the proximal nail fold every 4–8 weeks. Acitretin at low dosages (0.2–0.3 mg/kg/day) for 4 to 6 months is an effective option in severe nail psoriasis.[85] In nail bed psoriasis, topical treatment with calcipotriol, combination of calcipotriol and betamethasone, or tazarotene may be effective after removal of the detached nail plate.[86–88]

PUSTULAR PSORIASIS

(See Chapters 18 and 21)

The diagnosis of Hallopeau' acrodermatitis is suggested by a clinical history of relapsing periungual and subungual pustules with onycholysis (Fig. 89-19). The patient is most commonly seen when the acute episode has subsided; at this time the affected digit shows onycholysis with nail bed and periungual erythema and scaling. Low-dose acitretin (0.3 mg/kg/day) may be useful.



Figure 89-19 Hallopeau acrodermatitis continua.

LICHEN PLANUS[81]

(See Chapter 26)

NAIL LICHEN PLANUS AT A GLANCE

- Nail lichen planus is seen in approximately 10% of patients with skin lichen planus.
- Nail involvement is not associated with oral, skin, or scalp lesions in most cases.
- Nail matrix lichen planus produces nail thinning, with longitudinal fissuring, dorsal pterygium, and trachyonychia.
- Nail bed lichen planus is frequent, but clinical signs are not specific (onycholysis and mild subungual hyperkeratosis).
- Several nails are involved in most cases. Scarring of the nail matrix with dorsal pterygium is a possible sequela.
- Diagnosis should be confirmed by nail biopsy, and systemic treatment is necessary to avoid scarring.

Nail lichen planus is not rare, and nail lesions may occur in the absence of cutaneous or mucosal involvement. Nail localization of lichen planus should be taken seriously, because it may destroy the nails. Therefore, it is important to diagnose and treat the disease as soon as possible. Although lichen planus often affects both the nail matrix and the nail bed, clinical suspicion should be aroused by nail matrix signs, particularly nail thinning with longitudinal ridging and fissuring (Fig. 89-20). Dorsal nail pterygium formation is not common. It results from nail matrix destruction and appears as a V-shaped extension of the skin of the proximal nail fold that adheres to the nail bed. Idiopathic atrophy of the nails is a rare variety of nail matrix lichen planus characterized by acute and progressive painless nail destruction leading to diffuse nail atrophy with and without pterygium. Onycholysis is quite frequent in both fingernails and toenails. Severe toenail involvement causes features that resemble yellow nail syndrome, with thickened, yellow–brown toenails. More rarely, nail lichen planus may present with erosive lesions of the nail bed and periungual tissues. Other possible clinical presentations include trachyonychia and nail plate thickening.

DIFFERENTIAL DIAGNOSIS

(Box 89-7)

In patients with brittle nails, the nail abnormalities are milder. The nails are thin and ridged, but fissuring at multiple sites is not observed. Onychoschizia is frequently associated. Trauma that produces damage to the matrix in an area wider than 3 mm causes permanent thinning and fissuring. Only one nail is



Figure 89-20 Nail matrix lichen planus: note longitudinal ridging and fissuring of the nail plate.

BOX 89-7 DIFFERENTIAL DIAGNOSIS OF LICHEN PLANUS

- Longitudinal fissuring
  - Brittle nails
  - Trauma (single fissure)
  - Systemic amyloidosis
  - Lichen striatus
  - Graft-versus-host disease
- Pterygium
  - Trauma
  - Bullous diseases
  - Digital ischemia
  - Dyskeratosis congenita
  - Graft-versus-host disease

usually affected, and it may show a single fissure. Nail abnormalities may be the first sign of systemic amyloidosis, with nail thinning, ridging, and fissuring closely resembling mild nail matrix lichen planus. In amyloidosis, nail bed hemorrhages are common. Diagnosis depends on nail biopsy. Lichen striatus may manifest as nail thinning and fissuring limited to one or two adjacent digits. Skin changes that course from the affected nail in a linear configuration are typical. Inherited (EB) and acquired (e.g., bullous pemphigoid) bullous diseases can produce pterygium. Skin and mucosal lesions are usually present. Digital ischemia is distinguished in that the digit is cold and shows skin signs of impaired vascular skin supply.

TREATMENT

Nail matrix lichen planus requires oral or intramuscular treatment with systemic steroids, which induce remission of the disease in 2/3 of the cases (Figs. 89-21 and 89-22). Intralesional (vs. systemic) corticosteroid injections should be considered in patients with involvement of fewer than three digits. Relapses are not uncommon, but usually respond to treatment.



Figure 89-21 Nail matrix lichen planus before and after treatment with systemic steroids.



Figure 89-22 Nail matrix lichen planus before and after treatment with systemic steroids.

Dorsal pterygium is not reversible and when it is the sole manifestation, should not be treated. Solitary nail lichen planus presenting as trachyonychia does not lead to nail scarring and therefore does not necessarily require treatment.

PARAKERATOSIS PUSTULOSA

Parakeratosis pustulosa is a rather common condition that occurs only in children. The disease is limited to one nail in most cases (usually the thumb or index finger) with a clinical picture that closely resembles that of psoriasis. Characteristics are distal onycholysis, fingertip desquamation, and mild subungual hyperkeratosis. Spontaneous regression usually occurs after puberty.

TRACHYONYCHIA (TWENTY-NAIL DYSTROPHY)

TRACHYONYCHIA (TWENTY-NAIL DYSTROPHY) AT A GLANCE

- Idiopathic but likely reflects alopecia areata, psoriasis, dermatitis, or lichen planus of the nail. More common in children.
- Characterized by nail roughness due to excessive longitudinal ridging (sandpaper nails).
- Several nails are involved in most cases; involvement of 20 nails is not necessary for diagnosis.
- Nail changes often regress spontaneously.
- Treatment is not required.



Figure 89-23 Trachyonychia.

Trachyonychia (twenty-nail dystrophy) is a nail sign that can be caused by several inflammatory disorders that produce a mild disturbance of nail matrix keratinization. These include alopecia areata, psoriasis, lichen planus, and eczema. The nail is rough and opaque due to excessive longitudinal ridging (Fig. 89-23). The disease occurs most commonly in children. Trachyonychia does not produce nail scarring, even in cases due to lichen planus.

DARIER DISEASE[1]

(See Chapter 51)

The nail abnormalities noted in Darier disease are diagnostic but are not seen in all patients). Key features are longitudinal erythronychia, longitudinal leukonychia associated with distal nail plate nicking (V shaped), and subungual hyperkeratotic papules.

ALOPECIA AREATA

(See Chapter 88)

Nail involvement is seen in approximately 20% of adults and 50% of children with alopecia areata and is most common in male patients with severe involvement. Geometric pitting is most typical. Pits are small, superficial, and regularly distributed in a geometric pattern along longitudinal and transverse lines. Trachyonychia is quite common in children affected by alopecia totalis or universalis. Other nail abnormalities include punctate leukonychia, mottled lunulae, and acute onycholysis. Nail abnormalities may improve with systemic steroid treatment or spontaneously; they respond poorly to application of topical medications.

ATOPIC DERMATITIS

(See Chapter 14)

Nail abnormalities associated with atopic dermatitis are nonspecific in most cases. Manifestations are most commonly Beau's lines, irregular pitting, and chronic paronychia. Onycholysis and subungual hyperkeratosis are seen in severe cases, especially those triggered by occupational exposure.

YELLOW NAIL SYNDROME

YELLOW NAIL SYNDROME AT A GLANCE

- In the typical syndrome, nail changes are associated with respiratory disorders and lymphedema.
- Arrested nail growth is diagnostic.
- Nails are overcurved and thickened, the cuticle is absent, and nail color varies from pale yellow to green. Onycholysis is often associated.
- Most or all nails are usually involved.

Yellow nail syndrome may or may not be associated with a systemic disorder and is occasionally familial.[88,89] However, it is important to refer patients to a pneumologist to exclude respiratory tract involvement. Other conditions that may be associated with yellow-nail syndrome include rheumatoid arthritis and internal malignancies. The history is the most important clue to diagnosis, because patients always claim that their nails have stopped growing (Fig. 89-24).

The nail changes may benefit from treatment with high oral dosages of vitamin E. Spontaneous improvement is possible. Topical vitamin E and systemic antifungal medications (itraconazole, fluconazole) do not appear to be effective.[89–91]

NAIL SIGNS OF SYSTEMIC DISEASES

(Table 89-5)

In systemic diseases, nail manifestations usually involve most or all nails. The diagnosis is suggested by clinical history, morphology, and distribution of



Figure 89-24 Yellow nail syndrome.

TABLE 89-5
Nail Signs of Systemic Disease

Beau's lines/onychomadesis	See Box 89-1
Koilonychia	Sideropenic anemia
Proximal splinter hemorrhages	Bacterial endocarditis Trichinosis Antiphospholipid syndrome Altitude sickness
Periungual erythema	Collagen disorders Infection with human immunodeficiency virus or hepatitis C virus
Lichenoid nail changes with hemorrhages	Systemic amyloidosis
Apparent leukonychia Half-and-half nails Terry's nails Banded nails (Muehrcke's lines)	 Renal disorders Hepatic disorders Systemic chemotherapy Hypoalbuminemia
Clubbing	See Box 89-8
Melanonychia	See Boxes 89-2 and 89-5

the nail abnormalities. Beau's lines located at the same level in all digits or onychomadesis occurring simultaneously in all digits is strongly diagnostic for nail matrix damage from a systemic cause.

Examination and capillaroscopy of the proximal nail fold are very important for the diagnosis of connective tissue diseases. Patients with scleroderma and dermatomyositis show enlarged capillary loops with reduced capillary density and avascular areas. In systemic lupus, erythematous, periungual erythema and telangiectasia are typical; although periungual vessels can be tortuous, the capillary density tends to be normal. Cuticular hyperkeratosis and hemorrhages are seen in systemic lupus erythematous and dermatomyositis. Pterygium inversum unguium is typical of scleroderma; in this condition the nail plate adheres to the fingertip skin, which makes nail trimming very painful.

The diagnosis of systemic amyloidosis can be suggested by nail symptoms, which sometimes precedes skin and mucosal changes. The nails are thinned, longitudinally fissured, and show subungual hemorrhages.

Mild leukonychia is often seen in normal individuals and therefore does not represent a specific sign of systemic disorders. Clinical patterns include half-and-half nails (leukonychia affects the proximal half of the nail bed), Terry's nails (leukonychia affects the entire nail bed except for its 2-mm distal margin), and Muehrcke's lines (narrow paired transverse bands parallel to the lunula).

Clubbing may or may not be associated with cyanosis (Box 89-8). In clubbing the angle between the proximal nail fold and nail plate is greater than 180 degrees. The digit has a bulbous appearance, and the nail plate is enlarged and excessively curved.

Melanonychia can be associated with a variety of systemic disorders and conditions, particularly human immunodeficiency virus infection, adrenal disease, pregnancy, and certain drugs (Box 89-9).

BOX 89-8 CAUSES OF CLUBBING

- Cardiovascular disorders
  - Aortic aneurysm[a]
  - Congenital/acquired cardiovascular disease[b]
- Bronchopulmonary conditions[c]
  - Intrathoracic neoplasms
  - Chronic intrathoracic suppurative disorders
- Gastrointestinal disorders
  - Inflammatory bowel disease
  - Gastrointestinal neoplasms
  - Hepatic disorders
  - Multiple polyposis
  - Bacillary dysentery
  - Amoebic dysentery
- Chronic methemoglobinemia

[a]Unilateral.
[b]Associated with cyanosis.
[c]Associated with hypertrophic osteopathy.

DRUG-INDUCED NAIL ABNORMALITIES[92]

A few nail abnormalities are highly likely to have resulted from administration of medication (see

BOX 89-9 DRUG-INDUCED NAIL CHANGES

- Chemotherapy
  - Beau's lines
  - Onychomadesis
  - Muehrcke's lines
  - Hemorrhagic onycholysis
  - Pyogenic granulomas
  - Melanonychia
- Antiretrovirals
  - Azathioprine
    - Melanonychia
  - Indinavir
    - Pyogenic granuloma
- β Blockers
  - Digital ischemia
- Bleomycin
  - Digital ischemia
- Psoralen plus ultraviolet A phototherapy
  - Photo-onycholysis
  - Melanonychia
- Retinoids
  - Nail fragility
  - Pyogenic granuloma
  - Paronychia



Figure 89-25 Hemorrhagic onycholysis due to taxanes

Box 89-9). Pyogenic granulomas involving several nails are an occasional side effect of treatment with retinoids, indinavir, and antiepidermal growth factor receptor chemotherapeutic agents, often leading to drug discontinuation. Retinoids have also been associated with nail fragility and paronychia. Taxanes (docetaxel and paclitaxel) frequently induce painful onycholysis with subungual hemorrhage and abscess formation (Fig. 89-25). The nail lesions resemble a subungual infection and are reversible after drug discontinuation. Both β blockers and bleomycin may lead to digital ischemia. Therapy with psoralen plus ultraviolet A light has been associated with photo-onycholysis and melanonychia. Photo-onycholysis has recently been seen after photodynamic therapy.[93] and can rarely follow the intake of tetracycline derivatives, psoralens, and fluoroquinolones. It may be associated with a photosensitivity reaction in the skin and typically affects the central part of the nail plate of one or more fingernails (Fig. 89-26). Onycholysis is painful and often hemorrhagic.[94]

TRAUMATIC NAIL DISORDERS

NAIL BITING

Nail biting is common in children and may encourage spreading of subungual warts (Fig. 89-27). When nail biting is associated with picking and chewing of the cuticle and periungual skin, the nail plate often shows superficial abnormalities and melanonychia due to melanocyte activation.



Figure 89-26 Photo-onycholysis: note the presence of nail bed hemorrhages.

HABIT TIC DEFORMITY (ONYCHODYSTROPHIA MEDIANA CANALIFORMIS)

In habit tic deformity the thumb shows a central longitudinal furrow with multiple transverse parallel lines (Fig. 89-28). The nail deformity is due to the nervous tic of pushing back the cuticle and the proximal nail fold of the thumb with the index finger.

SUBUNGUAL HEMATOMA

Subungual hematoma may be caused by a single acute trauma or by repeated microtraumas (see Chapter 99). Nail hematomas last several months because part of the blood is incorporated into the nail plate. Very dark lesions require differentiation from melanotic pigmentation. Dermoscopy shows rounded red–black globules (eFig. 89-28.1 in online edition).[74] Acute hematomas require immediate drainage to avoid matrix compression.

ONYCHOLYSIS

Traumatic onycholysis of the great toenails is frequent in athletes, in women wearing high-heeled shoes,



Figure 89-27 Subungual warts in a nail biter.



Figure 89-28 Longitudinal furrow of the nail plate due to habit tic.

and in individuals with podiatric abnormalities. Nail detachment is not associated with nail bed hyperkeratosis.

ONYCHOGRYPHOSIS

Onychogryphosis is common in the elderly and neglected individuals .The nail is thickened, distorted, opaque, and yellow–brown, and tends to have an oyster shell appearance.

PINCER NAILS

Pincer nails is a painful abnormality that usually affects the toenails and may be associated with subungual exostosis. The distal nail plate is overcurved and compresses the subungual soft tissues (Fig. 89-29).

INGROWING TOENAILS

Ingrowing toenails most commonly affect young adults with congenital malalignment of the great toenails. Improper nail cutting may lead to embedding of a nail edge, causing inflammation and granulation tissue formation. Hyperhidrosis is frequently associated. The aim of treatment for ingrowing toenails is to extract the nail edge that is ingrowing and prevent further penetration of nail fragments into the lateral



Figure 89-29 Pincer nails.



Figure 89-30 Retronychia: proximal ingrowing of the nail plate.

folds. To accomplish this, the lateral nail plate can be lifted by using a cotton pack or by inserting a gutter splint along the lateral nail margin.[95] The width of the nail plate can also be reduced by surgical or chemical (phenolization) removal of the lateral nail matrix.[96,97]

RETRONYCHIA

Retronychia describes the ingrowth of the proximal nail plate into the proximal nail fold associated with multiple generations of nail plate misaligned beneath the proximal nail.[98] It involves 1 or both the first toenails and starts as an onychomadesis (posttraumatic) not followed by nail shedding. The persistence of the partially detached plate under the proximal nail fold, associated with the growth of new nail plates underneath it, results in inflammation with pain and granulation tissue formation (Fig. 89-30). Nail plate avulsion leads to a slow regrowth of a normal nail.

KEY REFERENCES

Full reference list available at www.DIGM8.com

DVD contains references and additional content

1. Zaias N: *The Nail in Health and Disease*, 2nd edition. Norwalk, CT, Appleton & Lange, 1990
16. Perrin C et al: Anatomic distribution of melanocytes in normal nail unit: An immunohistochemical investigation. *Am J Dermatopathol* **19**:462, 1997
28. McGowan KM, Coulombe PA: Keratin 17 expression in the hard epithelial context of the hair and nail, and its relevance for the pachyonychia congenita phenotype. *J Invest Dermatol* **114**:1101, 2000
32. Runne U, Orfanos CE: The human nail. Structure, growth and pathological changes. *Curr Probl Dermatol* **9**:102, 1981

38. Yaemsiri S et al: Growth rate of human fingernails and toenails in healthy American young adults. *J Eur Acad Dermatol Venereol* 2009 Sept (epub ahead of print)
40. Daniel CR, Piraccini BM, Tosti A: The nail and hair in forensic science. *J Am Acad Dermatol* **50**:258, 2004
44. Baran R, Kechijian P: Longitudinal melanonychia (melanonychia striata): Diagnosis and management. *J Am Acad Dermatol* **21**:1165, 1989
47. De Berker DA, Perrin C, Baran R: Localized longitudinal erythronychia: Diagnostic significance and physical explanation. *Arch Dermatol* **140**:1253, 2004
48. Fistarol SK, Itin PH: Nail changes in genodermatoses. *Eur J Dermatol* **12**:119, 2002
64. Tosti A, Piraccini BM: Paronychia. In: *Contact Urticaria Syndrome*, edited by S Amin, A Lahti, HI Maibach. Boca Raton, CRC Press, 1997, p. 267
67. Tosti A, Richert B, Pazzaglia M: Tumors of the nail apparatus. In: *Nails: Diagnosis, Therapy, Surgery*, 3rd edition, edited by KR Scher, CR Daniel III. Philadelphia, WB Saunders, 2005, p. 195
73. Levit EK et al: The ABC rule for clinical detection of subungual melanoma. *J Am Acad Dermatol* **42**:269, 2000
74. Tosti A, Piraccini BM, de Farias DC: Dealing with melanonychia. *Semin Cutan Med Surg* **28**:49, 2009
80. McGonagle D, Tan AL, Benjamin M: The nail as a musculoskeletal appendage- implications for an improved understanding of the link between psoriasis and arthritis. *Dermatology* **218**:97, 2009
92. Piraccini BM, Iorizzo M: Drug reactions affecting the nail unit: Diagnosis and management. *Dermatol Clin* **25**:215, 2007

PART 4 Disorders Due to the Environment



Disorders Due to Ultraviolet Radiation

Chapter 90 :: Fundamentals of Cutaneous Photobiology and Photoimmunology

:: Irene E. Kochevar, Charles R. Taylor, & Jean Krutmann

FUNDAMENTALS OF CUTANEOUS PHOTOBIOLOGY AND PHOTOIMMUNOLOGY AT A GLANCE

- When radiation enters the skin, it is scattered or absorbed. Only light absorbed by molecules (chromophores) in the skin can cause a photobiologic response.
- Electromagnetic radiation can be conceptualized either as a wave or as packets of energy called *photons*.
- An action spectrum indicates which wavelengths produce a photobiologic response most effectively and is plotted as the reciprocal of the minimum effective fluence versus wavelength.
- The most erythemogenic wavelengths present in sunlight are in the ultraviolet B (UVB) range. Ultraviolet A (UVA) is roughly 1000-fold less effective than UVB.
- Prostaglandins and nitric oxide appear to be the major mediators for UVB erythema.
- When certain drugs and dyes absorb UV/visible light, inflammation ensues. This is called *photosensitization*.
- Photosensitivity responses are usually mediated by reactive oxygen species.
- Blocked by sunscreen use, cutaneous vitamin D production is mediated by wavelengths from 295–300 nm. Optimal vitamin D blood levels are essential for good bone health and increasingly associated with a myriad of other potential health benefits.
- Ultraviolet radiation is immunosuppressive. Local and systemic immunosuppressions are recognized.
- Pyrimidine dimers, reactive oxygen species and urocanic acid initiate UV-induced immunosuppression.
- Interleukin-10 (IL-10), tumor necrosis factor (TNF)-α, platelet-activating factor, platelet-activating factor-like lipids and other molecules mediate photoimmunosuppression.
- The major cellular players in UV immunosuppression are Langerhans cells, keratinocytes, macrophages, and T cells.
- UV radiation impairs T helper 1-mediated cellular immune response.

Knowledge of the interaction of sunlight with the skin is fundamental to understanding the pathogenesis, diagnosis, and treatment of more than 100 cutaneous disorders. Whenever ultraviolet (UV) or visible radiation is used to diagnose or treat a skin condition, important principles of photophysics involving absorption and emission of light underlie the success of the therapy. Sunscreen recommendations rely on an understanding of solar UV radiation and the ways in which the causative wavelengths can be minimized. Skin cancer is an epidemic clinical problem, whose pathophysiology necessitates comprehension of the photophysical, photochemical, and photobiologic events described in this chapter.

Almost every ancient civilization worshipped a god of the sun whose healing powers were believed to be broad reaching. Even today, sun exposure is widely felt to induce a sense of well-being. In addition, sunlight is important for the synthesis of vitamin D_3 and the setting of internal clocks. On the negative side, sunlight causes deleterious acute and chronic inflammatory skin reactions, skin cancer, and photoaging, and can elicit adverse reactions to certain drugs (see Chapters 91, 92, 109, 112). Although the sun is a major source of the UV and visible radiation that interacts with human skin, UV and/or visible radiation are also emitted from common sources such as fluorescent lights, incandescent bulbs, photocopy machines, and phototherapy lamps. Tanning salons are another familiar example. Thus, UV and visible radiation are a constant part of the human environment and play a role in health, disease, and therapy. Photodermatology is the study of this interaction between human skin and UV and visible radiation. To understand the responses of skin to UV and visible radiation, it is essential to be acquainted with the principles governing the interaction of these wavebands with biomolecules in the skin.

When UV and visible light photons reach the skin surface the energy of the radiation is transformed into an observable response as shown schematically in Figure 90-1. First, the radiation must penetrate to the appropriate level in the skin where it is absorbed by molecules in the skin, termed *chromophores*. Photochemical reactions then convert the chromophores into new molecules, the photoproducts. These photoproduct molecules stimulate cellular signal transduction pathways leading to biochemical changes that culminate in cellular effects, such as the proliferation, secretion of cytokines, and apoptosis that are responsible for the observed acute skin responses.

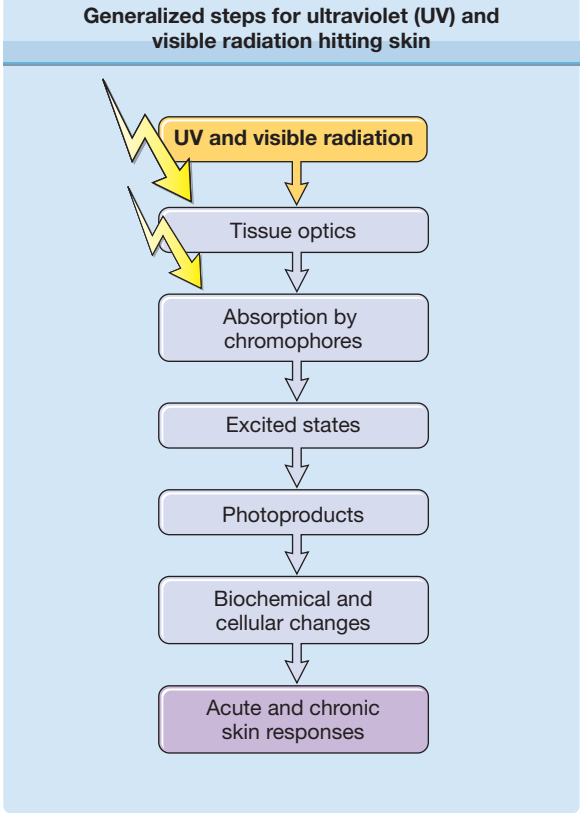

Figure 90-1 Generalized steps from ultraviolet (UV) and visible radiation hitting the skin to observation of clinical responses.

ULTRAVIOLET AND VISIBLE RADIATION

UV radiation and visible light are portions of the electromagnetic (EM) spectrum, which includes a wide range of wavelengths, from high-energy X-rays to low-energy microwaves and radio waves (Table 90-1; Fig. 90-2). The UV waveband is of special interest because dozens of skin disorders are aggravated by these wavelengths and, many popular therapies, such as UVB phototherapy (see Chapter 237) and psoralen and ultraviolet A light (PUVA) photochemotherapy (see Chapter 238), use sources emitting UV radiation. Visible light encompasses those wavelengths perceived as color by the human eye and is also frequently used in therapies, such as blue-light amino levulinic acid–photodynamic therapy (PDT; see Chapter 238), and is emitted by several lasers intended to target cutaneous chromophores (see Chapter 239).

ULTRAVIOLET RADIATION

For medical photobiology, the UV range (200–400 nm) is subdivided into UVA, UVB, and UVC (see Table 90-1 and Fig. 90-2). A division was made at 290 nm because wavelengths from the sun shorter than 290 nm are absorbed by ozone in the stratosphere and do not reach the earth's surface at sea level. Wavelengths in the range of 200 to 290 nm are referred to as *UVC* or *germicidal radiation*. These wavelengths are strongly absorbed by DNA and therefore can be lethal to viable cells of the epidermis or to bacteria. UVC lamps emit at 254 nm and are used for air and water purification. Care must be taken to avoid exposure of eyes and skin to UVC radiation because of the danger of UV keratitis and mutation.

The range 290 to 320 nm is known as *UVB* and is often referred to as *mid-UV* or *sunburn spectrum*. It includes the biologically most active wavelengths

TABLE 90-1
Electromagnetic Radiation According to Wavelength

Waveband	Wavelength Range (nm)
X-ray	0.1–10
Vacuum ultraviolet	10–200
Ultraviolet C	200–290
Ultraviolet B	290–320
Ultraviolet A (UVA)	320–400
UVA I	340–400
UVA II	320–340
Visible	400–760
Violet	400
Blue	470
Green	530
Yellow	600
Red	700
Near infrared	760–1000
Far infrared	1000–100,000
Microwaves and radio waves	$>10^6$

reaching the earth's surface. The UVB constitutes only approximately 5% of the UV and 0.5% of total radiation reaching the earth's surface; the exact amount varies markedly with the time of day, season, cloud conditions, and other factors. Ordinary window glass blocks UVB. Most sunscreens efficiently reflect or absorb these wavelengths, and the sun protection factor (SPF) is primarily based on testing against this waveband. However, it is important to note that different wavelengths within these subdivisions can elicit greatly varying biologic responses. For example, consider the response of skin to two wavelengths in the UVB range, 297 and 313 nm. Radiation at 297 nm is nearly 100 times more erythemogenic than 313-nm radiation[1] and more effectively causes DNA damage and photocarcinogenesis.[2] An example relevant to phototherapy is the great efficacy of certain UVB wavelengths for treatment of full UVB spectrum.[3,4] Narrowband UVB (311 nm) and excimer laser (308 nm) are used to treat psoriasis because these wavelengths are more effective than other portions of the UVB spectrum.[3,4]

Long-wave UV or UVA (320–400 nm) is sometimes referred to as *black light* because it is not visible to the human eye but causes certain substances to emit visible fluorescence. Approximately 95% of the UV radiation reaching the earth's surface is UVA. As described for UVB radiation, the response of skin to UVA is not constant across all wavelengths from 320 to 400 nm.[3] In fact, UVA has been divided into UVA I (340–400 nm) and UVA II (320–340 nm) because the latter band is more damaging to unsensitized skin than the longer wavelengths. Although most sunscreens offer their greatest protection against UVB wavelengths, those products said to be "broad-spectrum" indeed have considerable ability to protect against UVA wavelengths, although no widely used formal measure equivalent to the SPF rating yet exists. Generally, the higher the SPF, for example, 45 or greater, the more likely one is going to find some UVA protection in that preparation. Newer sunscreen agents enhance protection against damaging UVA rays (see Chapter 223). Because of its predominance in the UV radiation reaching the earth's surface, protection against UVA is quite important for minimizing adverse cutaneous effects such as photoaging and carcinogenesis.

VISIBLE RADIATION

The visible spectrum (400–760 nm) is defined by the wavelengths that are perceived as color by the retina.

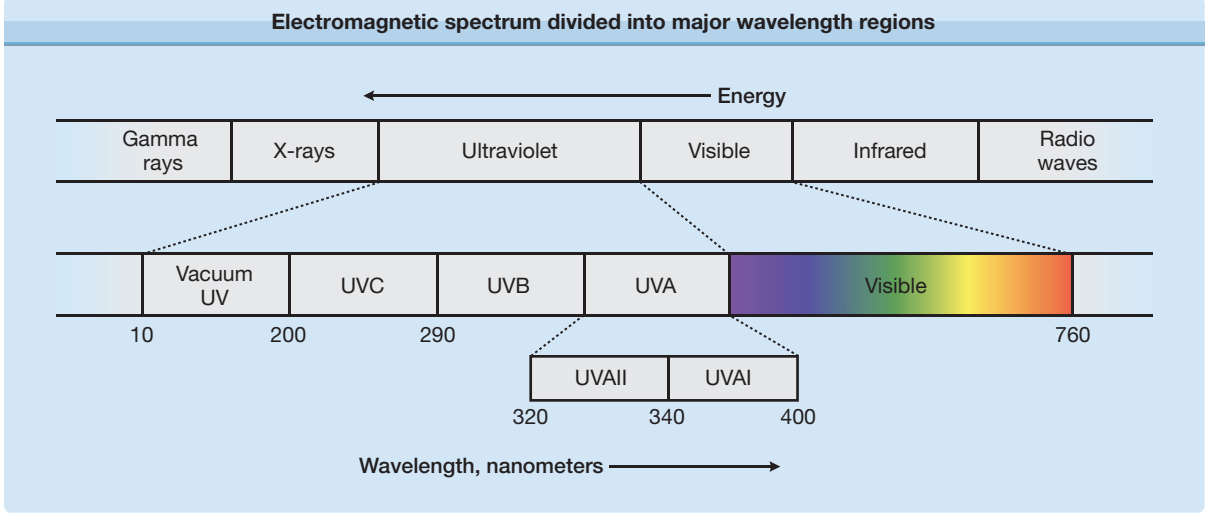

Figure 90-2 Electromagnetic spectrum divided into major wavelength regions. The lower band emphasizes the ultraviolet (UV) and visible bands that are important for photobiologic responses in human skin.

Specific colors are associated with different wavelengths, as shown in Fig. 90-2. Skin responses to visible light generally require photosensitization. For example, in PDT, dyes absorbing long wavelength visible light (red) are used (see Chapter 92). Because they take advantage of the absorption spectra of endogenous chromophores, intense pulsed visible light sources such as lasers are used to treat vascular, pigmented and other lesions without application of a photosensitizing dye (see Chapter 239).

OTHER WAVEBANDS OF ELECTROMAGNETIC RADIATION

X-rays and γ rays occupy the short wavelength (high energy) end of the EM spectrum, and infrared radiation (IR) is found at longer wavelengths (lower energy) than visible radiation (see Table 90-1). X-ray and γ rays ionize molecules (remove electrons) indiscriminately and are known as *ionizing radiation*, the subject of radiobiology (see Chapter 240). In radiation therapy of tumors, these wavelengths kill tumor cells by ionizing water molecules and producing free radicals that damage DNA. IR has lower energy than visible light. It is subdivided into IR-A (760–1,440 nm), IR-B (1,440–3,000 nm), and IR-C (3,000 nm–1 mm). IR-A penetrates into the dermis and causes skin damage whereas IR-B and IR-C are felt as heat. Recent studies suggest that IR-A wavelengths might also be therapeutic.[5]

PROPERTIES OF ELECTROMAGNETIC RADIATION

Certain principles are better illustrated by conceptualizing EM radiation as waves, whereas others are better understood by thinking of it as packets of energy called *photons*. These two descriptions are complementary.

When considering EM radiation as a wave, it is described as oscillating electric and magnetic fields at right angles to each other and to the direction of propagation. Consequently, it may be described either by its frequency (number of oscillations per second) or by its wavelength (distance traveled per oscillation). Frequency and wavelength have an inverse relationship, which is expressed as: $\nu = c/\lambda$, where ν = frequency (number of oscillations per second), c = speed of light (3×10^8 m/s), and λ = wavelength in meters.

EM radiation also may be described as a stream of discrete packets of energy known as *quanta* or *photons*. The amount of energy in a photon (quantum) is directly proportional to the frequency of the radiation and inversely proportional to its wavelength, as expressed by Planck's law: $E = hc/\lambda$, where E = the energy of the photon in joules (J), h = Planck's constant (6.626×10^{-34} J/s), c = speed of light, and λ = wavelength in meters. This relationship shows that the energy of the photon increases when the wavelength is shorter and decreases when the wavelength is longer. For example, a 300-nm UVB photon has twice the energy of a 600-nm yellow photon.

SOURCES OF ULTRAVIOLET AND VISIBLE RADIATION

SUNLIGHT

The shortest wavelength of the solar spectrum reaching the earth's surface at sea level is approximately 290 nm, although slightly shorter wavelengths are detected at high altitudes. Depending on the geographic location and the season, it has been estimated that sunlight produces between 2 and 6 mW/cm^2 of UV radiation between 290 and 400 nm. Filtering of wavelengths less than 290 nm by ozone is a very important process because the shorter UVC wavelengths are highly damaging to animals and plants. Because the transmission of solar UVC and UVB through the atmosphere varies exponentially with ozone concentration, small changes in the ozone layer may result in hazardous increases in UV irradiance at the earth's surface.[6] For example, calculations of the effects of ozone depletion predicted a doubling of skin cancer incidence by 2,100 AD even if the Montreal Protocol restrictions on ozone-depleting substances were followed.[7]

The UV Index developed by the National Weather Service and the US Environmental Protection Agency represents an attempt to quantify the risks attendant with solar radiation at a given time and place. Among other factors, the effects of altitude, latitude, season, and clouds are considered. The scale goes up to 15, and any UV Index greater than 10 is considered a high-risk day for possible overexposure in that locale.

ARTIFICIAL SOURCES OF ULTRAVIOLET AND VISIBLE RADIATION

Skin is exposed to UV and visible radiation from a wide variety of sources in daily life and from a different set of light sources for therapy and diagnosis. Specific information should be obtained from the manufacturer before using a new light source.

INCANDESCENT SOURCES. Incandescent light sources include conventional electric light bulbs, flood lamps, and some quartz iodide bulbs. In these lamps, an electric current passing through a metal filament heats the filament, causing it to emit mostly visible and IR. Only the occasional patient with solar urticaria, chronic actinic dermatitis, or some porphyrias is bothered by the output of ordinary incandescent sources. Tungsten-halogen incandescent lamps, often used as flood lamps, emit UVA and visible radiation. Some quartz iodide incandescent lamps produce significant UVA and some UVB emission.

ARC SOURCES. Arc sources include xenon lamps, medium- and high-pressure mercury (hot quartz) lamps, fluorescent lamps, and halide lamps. In arc lamps, electrons are driven through a gas by a potential difference between two electrodes. The gaseous

molecules are ionized and subsequently release EM radiation. Radiation is emitted preferentially at specific wavelengths (emission lines) as well as in a continuum, that is, all wavelengths are emitted rather than just specific wavelengths. The wavelengths and relative power at each wavelength depend on the gas used, the arc temperature, the pressure within the lamp, and the lamp wall material.

Xenon arc lamps emit both UV and visible radiation and are now the most common sources used in solar simulators. Photoprovocation testing for polymorphic eruption is often done with such sources using filters to limit the wavelengths. Xenon arcs are also used in some phototherapy and photobiologic research applications. In a xenon lamp, xenon gas under 20–40 atmospheres (atm) of pressure produces intense visible and UV radiation. At these pressures, the xenon spectrum becomes a continuum.

The wavelengths emitted by mercury arc lamps are strongly influenced by the pressure of the gas within the envelope. Low-pressure mercury germicidal lamps emit 85% of the radiant energy at 254 nm. Because the operating temperature is low, they are also known as *cold quartz lamps*. With increasing pressure (1 atm), the primary 254-nm emission is absorbed by other mercury atoms within the lamp and reemitted at longer wavelengths (297, 302, 313, 334, and 365 nm, and visible wavelengths). With further pressure increases (2–100 atm), these spectral lines broaden and decrease relative to the intensity of the continuous spectral background. In medical practice, medium- and high-pressure mercury (hot quartz) lamps are generally used as sources of UVB, although their spectral power distribution is mainly in the UVA and visible range.

The commonly used UVB sunlamps (see Chapter 237) and UVA lamps for PUVA therapy (see Chapter 238) are fluorescent lamps. They are, in essence, modified low-pressure mercury arc lamps. The inner surface of the glass tube is coated with a phosphor, which absorbs the 254-nm radiation and reemits the energy at longer wavelengths. The chemical composition of the phosphor determines which wavelengths are reemitted. In general, fluorescent lamps have a relatively wide, bell-shaped emission spectra, with emission lines of mercury superimposed, and are referred to as *broadband light sources*.

Fluorescent sunlamps (type FS) emit mainly in the UVB range (Fig. 90-3). They are often referred to as *UVB lamps*, even though they emit a portion of UVA radiation, because the therapeutically significant radiation is in the UVB range (Table 90-2). A fluorescent lamp with a major emission peak at 311 nm (Philips TL01) was developed for use in phototherapy (see Fig. 90-3).[8,9] This lamp is an efficient source for psoriasis phototherapy because, compared to a conventional UVB lamp, the energy emitted almost entirely overlaps with the action spectrum for clearance of psoriasis.[3] Interestingly, this lamp has also been successfully used for the treatment of vitiligo, atopic dermatitis, and polymorphic light eruption, all of whose action spectra are unknown and may possibly differ from that for psoriasis.

High-intensity, UVA-emitting fluorescent lamps are most often used in PUVA therapy of psoriasis, vitiligo,

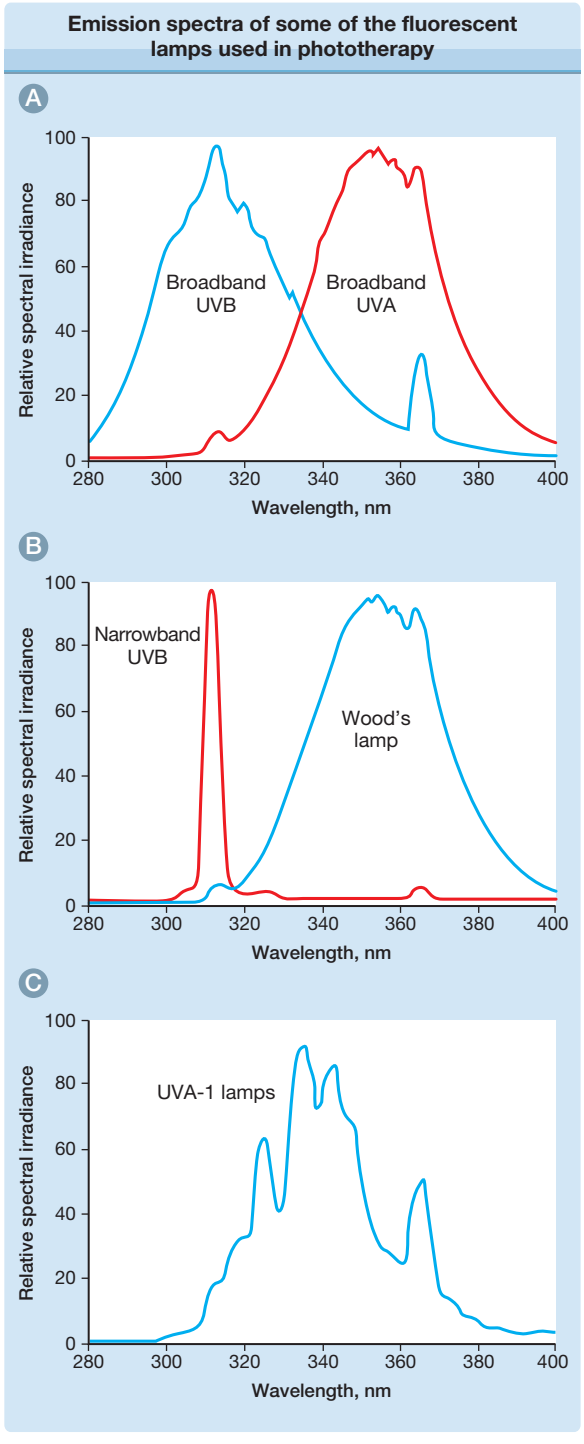

Figure 90-3 Emission spectra of some of the fluorescent lamps used in phototherapy. **A.** Broadband ultraviolet B (UVB) fluorescent lamps and UVA (black light) fluorescent lamps. **B.** Narrowband (Phillips TL01) fluorescent lamp with a maximum at 311 nm and a fluorescent lamp with a Wood's glass filter. **C.** UVA I halide lamps (Sellamed 24,000 bed system). Emission spectra were measured with a Luzchem model SPR-4001 spectroradiometer.

TABLE 90-2
Approximate Spectral Power Distribution of UVB and UVA Radiation Expressed as Percentage of Total Emission in the UV Waveband in Common Phototherapy Sources

	% UVB	% UVA
Broadband UVB (Westinghouse Sunlamp)	60	40
Narrowband UVB[a] (Phillips Fluorescent UVB, TL01, 311 nm)	80	20
Broadband UVA (Houva Lite; Black Light by Sylvania, Westinghouse, and General Electric; Sylvania Puva Life Line; Dermalight Metal)	2	98
UVA I[b] (Dermalight UltrA1, Dr. K. Hönle Medizintechnik GmbH)	0	100
Wood's light[c] (RA Fisher; Spectronics)	0	100
Halide lamps[d] (Dermalight Systems, Dr. K. Hönle Medizintechnik GmbH)	0	100

[a]Most (~95% of the UVB emission of the typical narrowband UVB source is centered around 311 nm).
[b]This UVA emission is above 340 nm.
[c]The filter used (so-called *Wood's filter*) is glass with nickel oxide phosphor. Consequently, UVB is screened. A moderate amount of visible light is produced.
[d]The actual amount depends on the model purchased and the filters used (glass vs. quartz). Some models allow the operator to change the filters readily and thus increase the amount of UVB to >50% of the irradiance.

and other skin diseases. The most efficient UVA source for PUVA therapy would maximize the emission of 320- to 360-nm radiation for photoactivation of psoralen molecules, while minimizing the UVB emission. Table 90-2 shows the percentage of total emission that is in the 320–360-nm range from several UVA-emitting light sources that are used in phototherapy units.

Wood's lamps are small, low-pressure, UVA-emitting fluorescent lamps with a UVA-transmitting, visible-absorbing glass envelope. They are useful in clinical practice because, after UVA absorption, the fluorescent emission from normal and abnormal components of skin, hair, teeth, and urine may be diagnostic (e.g., in porphyria, vitiligo, and fungal infection).

Halide lamps emit a high-intensity continuum in the UVB and especially the UVA range. With appropriate filters, this lamp is used increasingly as a UVB, as well as a UVA, source for phototherapy (in particular, UVA I therapy) and photochemotherapy. The metal halide lamp usually consists of a high-pressure mercury lamp with metal halides as additives. The continuous range of wavelengths emitted from halide lamps differentiates them from medium-pressure mercury arc lamps that emit in narrow wavelength ranges. Approximately 20% of the emission spectrum can be UVA radiation.

LASERS. (See Chapter 239.) Lasers produce intense beams of monochromatic (single wavelength) radiation. The laser operates by exciting molecules to a metastable excited state from which photon emission is stimulated by a subsequent photon incident on the excited molecule. The emitted photon and the stimulating photon are then each capable of stimulating emission of yet other excited molecules, eventually producing an avalanche of photons of the same wavelength, phase, and direction of propagation. Different lasers emit UV, visible, or infrared wavelengths and may operate as either continuous or pulsed sources.

ULTRAVIOLET AND VISIBLE RADIATION DOSIMETRY

To treat patients with the appropriate amount and wavelengths of UV or visible radiation, it is important to become acquainted with how the radiation is quantified and related to the exposure time. The basic unit of EM energy is the joule (J). Power is the rate of energy flow, joules per second (J/s), usually expressed as watts (W). The rate at which the radiant energy is delivered to a surface, such as skin, is expressed as the power delivered per unit area of surface (power/area; W/cm^2). This quantity is called *irradiance*. The total radiant energy delivered per unit area of skin surface over a period of time is called the *exposure dose* or *fluence* and is the product of irradiance and time:

$$\text{Irradiance } (w/cm^2) \times \text{time (s)} = \text{Exposure dose or fluence } (J/cm^2)$$

For most responses to UV and visible radiation, it is the fluence at particular wavelengths that determines the magnitude of the response. The irradiance generally does not affect the response using conventional light sources.

The irradiance delivered by a source as a function of wavelength is called the *spectral irradiance* and is expressed as units of irradiance per nanometer [$(W/cm^2)/nm$]. A spectroradiometer is used to measure the spectral irradiance of a light source. When measuring a light source's irradiance over a given spectral region, a detector weighted to the wavelengths of interest is most useful. For example, a broadband radiometric measurement of wavelengths less than 315 nm provides a rough indication of the erythemally effective wavelengths emitted by a source of UV radiation.

There is, however, no substitute for knowing the full spectral irradiance delivered by a source, as determined by a spectroradiometer. For example, in phototesting, only the wavelengths of interest should be

used. To assess endogenous UVA sensitivity, the UVB portion of a source's emission, if present, must be filtered out so that the more erythemogenic UVB wavelengths do not lead to a falsely lower determination of erythema threshold in the UVA range.

OPTICAL PROPERTIES OF SKIN

When UV and visible radiation strike the skin, part is remitted (reflected and scattered), part is absorbed by chromophores in various layers, and part is transmitted inward to successive layers of cells until the energy of the incident beam has been dissipated (Figs. 90-4 and 90-5). The two major processes limiting the penetration of UV and visible radiation into skin, absorption and scattering, vary with wavelength.[10]

UV wavelengths less than 320 nm are readily absorbed by proteins, DNA, and other components of epidermal cells. Along with scattering, this absorption accounts for the low penetration of these wavelengths into skin (see Fig. 90-4). For example, approximately 10% of 300-nm radiation and 50% of 350-nm radiation reaches the dermal–epidermal junction in fair skin. Between 5% and 10% of incident light is reflected by the outer surface of the stratum corneum. This surface or so-called *specular reflectance* is relatively constant for all visible wavelengths and accounts for the surface appearance of skin, which is especially glossy if the surface is smooth, wet, or oily. In contrast, if the surface is irregular, the light is scattered and the skin appears dull or "rough." Moisturizers applied to the skin reduce this rough appearance by smoothing out the many air–surface interface irregularities and making the skin look shinier.

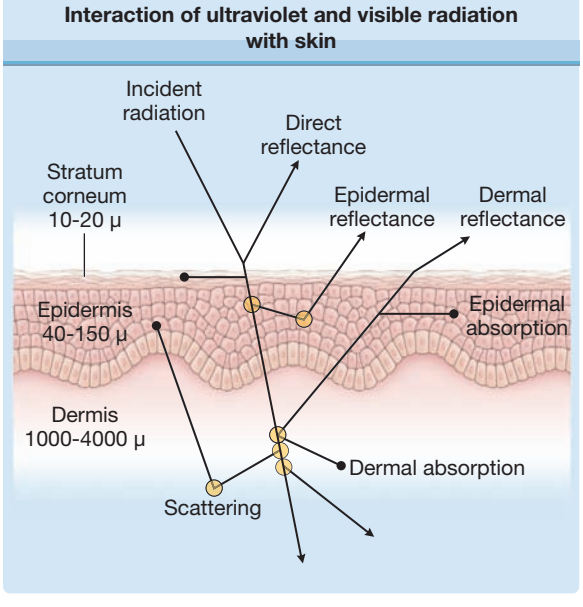

Figure 90-4 The interaction of ultraviolet and visible radiation with skin. The incident radiation is reflected from the surface, scattered (*circles*), and absorbed (*black dots*) as it travels through the skin.

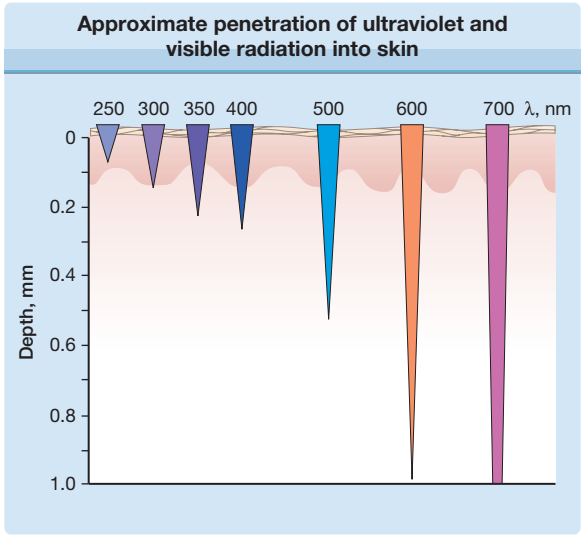

Figure 90-5 Illustration of the approximate penetration of ultraviolet and visible radiation into skin. λ = wavelength.

Scattering includes any process that deflects the path of optical radiation. For example, skin with scales, as in psoriasis, scatters more light than does normal skin. During phototherapy, application of emollients to the psoriatic plaques helps reduce the scattering of UV radiation and allows more of the effective wavelengths to penetrate into the viable tissue.

Melanin, which absorbs relatively uniformly over the visible wavelengths and is normally present only in the epidermis, acts largely as a neutral density filter to diminish remittance from the dermis. The greater overall melanin content in darker skin absorbs more visible light and therefore causes the skin to appear darker as there is less light remitted back to the observer. Blood (hemoglobin) within the dermis absorbs the shorter (blue) visible wavelengths, diminishing these spectral regions, and giving a reddish hue to our perception of the total remittance. Abnormal location and quantity of these or other pigments account for the appearance of the skin in pathologic conditions (e.g., melasma with extra pigment in the epidermis and/or dermis, vitiligo with an absence of epidermal melanin).

ABSORPTION OF ULTRAVIOLET AND VISIBLE RADIATION BY MOLECULES IN SKIN

When a photon is taken up by a chromophore, it is said that absorption has occurred. The specific wavelengths absorbed by each molecule (called an *absorption spectrum*) are characteristic of the structure of the molecule (i.e., the arrangement of the nuclei and electrons). Only radiation that is absorbed by the chromophores can initiate biologic responses.

The absorption spectrum of a compound is a plot of the probability of absorption of photons of a specific wavelength on the *Y*-axis against wavelength on the

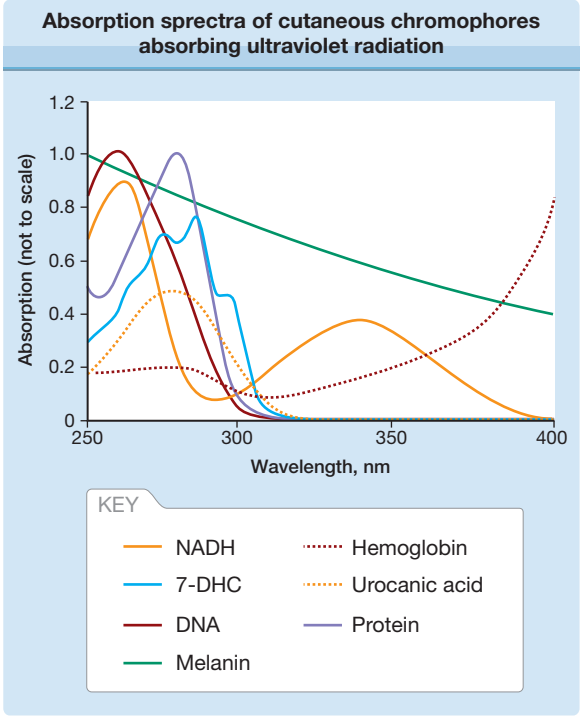

Figure 90-6 Absorption spectra of cutaneous chromophores absorbing ultraviolet radiation. Note that the relative amounts of ultraviolet radiation absorbed by these chromophores in skin depend on the heights of the absorption peaks as shown in this figure, the amount of each chromophore in skin, and the penetration of each wavelength into skin. 7-DHC = 7-dihydrocholesterol; NADH = reduced nicotinamide adenine dinucleotide.

X-axis (Fig. 90-6). The wavelengths that have the highest probability of absorption are called *absorption maxima*, λ_{max}, (e.g., DNA, λ_{max} = 260 nm; porphyrins, λ_{max} = 400–410 nm). Many of the biomolecules that absorb in the UVB spectrum actually have absorption maxima at shorter wavelengths in the UVC range (see Fig. 90-6). These include the purine and pyrimidine bases in DNA and RNA (λ_{max} ~260 nm) and 7-dehydrocholesterol (λ_{max} = 285 nm). Many endogenous cutaneous chromophores absorb UVA or a combination of UVA and visible radiation, including hemoglobin (λ_{max} = 410 nm) and bilirubin (λ_{max} = 450 nm). Melanin absorbs throughout the UV, visible, and near IR spectra without a distinct absorption maximum wavelength. The absorption spectra of few chromophores extend into the IR-A waveband, an exception being cytochrome c oxidase, which is last enzyme in the mitochondrial respiratory electron transport chain.

PHOTOCHEMICAL REACTIONS LEADING TO SKIN RESPONSES

After absorbing the energy of a photon, the chromophore is in an "excited state," which exists for only a very short time before reacting with nearby molecules. The products of these reactions initiate signal transduction processes that lead to the observed responses in skin.

EXCITED STATE MOLECULES

Normally, molecules are in the so-called *ground state* and have a certain distribution of electrons in space around the nuclei of their atoms. For each molecule, a series of electronic states with higher energies and different distributions of electrons also exist; these are called *excited states*. When a molecule in the ground state absorbs the energy of a UV or visible photon, the molecule is promoted to an excited electronic state (Fig. 90-7). According to quantum mechanics, only certain energy gaps are allowed to exist between electronic states. Consequently, a molecule can absorb photons only with certain energies; this results in a unique absorption spectrum for each molecule.

A molecule exists in this first excited state formed for a very brief period. It is called a *singlet excited state* and exists for a few nanoseconds. The molecule may return to the ground state by emitting light (fluorescence) or releasing the energy as heat by a process called *internal conversion* (see Fig. 90-7). Alternatively, the singlet excited state may undergo a chemical reaction to form a photoproduct, or it may convert into another excited state with lower energy, the triplet excited state, by a process called *intersystem crossing* (see Fig. 90-7). Singlet and triplet excited states differ in the spins of a pair of electrons in an orbital. The ground state is almost always a singlet state. The triplet excited state may exist for a longer time (i.e., a few microseconds). It may emit light (phosphorescence), undergo a chemical reaction, or return to the singlet ground state by intersystem crossing (see Fig. 90-7).

These excited state processes are responsible for the effectiveness of light for diagnosis and therapy. For example, fluorescence occurs every time a Wood's light is used. UVA emitted from this lamp causes autofluorescence of dermal collagen fibers. To the examining physician, this fluorescence is viewed through

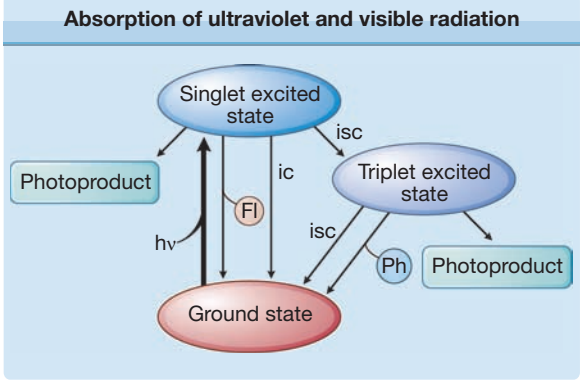

Figure 90-7 Absorption of ultraviolet and visible radiation (hν) by molecules and the dissipation of the absorbed energy by fluorescence (Fl), internal conversion (ic), intersystem crossing (isc), phosphorescence (Ph), and photochemistry to form photoproducts.

the overlying epidermis. Thus, any epidermal lesions such as lentigines tend to have their borders accentuated by contrast because the fluorescence is observed most brightly around the lesion. The heat generated by internal conversion is responsible for the effects of pulsed lasers (see Chapter 239).

PHOTOPRODUCTS

During a photochemical reaction, the excited state molecule is transformed into a new, stable molecule called the *photoproduct*. Photoproducts in DNA are important for UVB-induced responses in skin. The photoproduct molecule may be produced entirely by rearrangement of the bonds in the chromophore, for example, the formation of previtamin D3 from 7-dehydrocholesterol or in DNA of a four-membered ring structure called a *cyclobutyl pyrimidine dimer (CPD)* from adjacent thymines or cytosines. These DNA photoproducts lead to mutations and development of nonmelanoma skin cancers (see Chapter 112). Alternatively, the chromophore may form covalent bonds with another molecule in the cell, for example, the formation of covalent adducts between psoralen and DNA. The phototherapy of diseases such as psoriasis makes use of this photochemical reaction (see Chapter 238). In addition, many skin responses to UV and visible light are initiated when the excited state chromophore transfers its energy to oxygen to form singlet oxygen or transfers an electron to form superoxide anion. These forms of oxygen react with cellular molecules, which often initiates intracellular signal transduction leading to the inflammation seen in sunburn and drug phototoxicity.

Photochemical reactions vary in efficiency. Not every chromophore molecule that absorbs a photon undergoes a photochemical reaction because the excited states may fluoresce or follow other pathways (see Fig. 90-7). The term *quantum yield* indicates the likelihood that one of these processes occurs. For example, the quantum yield for forming a certain photoproduct is:

$$\text{Photoproduct quantum yield} = \frac{\text{Number of photoproduct molecules formed}}{\text{Number of photons absorbed}}$$

PHOTOSENSITIZATION

When certain drugs (e.g., tetracyclines, fluoroquinolones, psoralens) and dyes absorb UV and/or visible radiation, delayed erythema or inflammation is observed (see Chapter 92). This phenomenon is called *photosensitization*, and the dyes and drugs are called *photosensitizers*. Photosensitization requires the presence of oxygen in most cases and the initial photoproducts are reactive oxygen species (ROS). ROS are small molecules and free radicals including singlet oxygen, hydrogen peroxide, superoxide anion and hydroxyl radical. These ROS oxidize unsaturated lipids in membranes, certain amino acids in proteins (histidine, methionine, tryptophan, cysteine), and guanine in nucleic acids. The oxidized products initiate signal transduction processes leading to inflammatory mediators, for example, prostaglandin E_2 (PGE_2) and tumor necrosis factor (TNF)-α, that produce the inflammation observed as erythema.

A photosensitizer molecule in an excited triplet state can transfer its energy to an oxygen molecule, thereby generating the ROS called singlet oxygen ($^1O_2$). Singlet oxygen is relatively long-lived for a singlet state (<4 microseconds) and reacts with other cellular molecules to generate additional ROS. The skin photosensitization produced by PDT drugs and by protoporphyrin IX, the porphyrin that accumulates to abnormally high levels in red blood cells of patients with erythropoietic protoporphyria (EPP), involves initial formation of singlet oxygen. Oxidation of membrane lipids is believed to initiate the signal transduction processes, leading the wheal and flare response observed in EPP photosensitivity. Singlet oxygen is also involved in the phototoxicity mechanisms for some phototoxic drugs. However, the observed skin phototoxicity responses often differ from that seen in EPP photosensitivity, possibly because of the presence of the photosensitizing agents in different tissue locations (e.g., epidermis, dermis, or vasculature). The photosensitizers may also be in different locations in the cells (i.e., nucleus, mitochondria, or cell membranes), which would influence the photoproducts formed and the subsequent cutaneous effect observed. Endogenous UVA-absorbing chromophores generate singlet oxygen in keratinocytes and fibroblasts and in skin.[11]

Endogenous chromophores and some exogenous photosensitizers generate other ROS.[12] For example, hydrogen peroxide and superoxide anion are produced after photosensitized and direct photon damage to mitochondria. The UVB or UVA radiation also activates ROS-producing enzymes such as nicotinamide adenine dinucleotide phosphate (NADPH) oxidase in keratinocytes and fibroblasts.[13,14] The UVA-induced responses in normal skin and in photosensitivity conditions are generally dependent on production of ROS. Recent studies suggest that ROS are important in the development of many UVB-initiated responses. Antioxidants act by quenching (i.e., chemically reacting with and removing) ROS and other free radicals before they can damage cellular molecules.

ACUTE RESPONSES TO UV RADIATION

Sunburn and tanning are the most obvious responses elicited by exposure of skin to a single dose of UV radiation. Many other responses are less visually apparent, but have important physiologic effects including formation of vitamin D3, altered immune responses, production of antimicrobial peptides and disruption of the epidermal barrier function. In addition, the cumulative effect of repetitive exposures gives rise to chronic skin changes including skin cancer development and photoaging. All of these responses result from a complex burst of UV-induced activity in the epidermis and dermis involving cytokines, neuropeptides, prostaglandins, ROS, and altered expression of at least 600 proteins.[11,15–17]

This section centers on three different parts: (1) UV-induced inflammation (sunburn), (2) vitamin D synthesis, and (3) altered immune responses. Two other acute responses to UV, (1) tanning (melanogenesis) and (2) abnormal acute responses to UV, are described in Chapters 72 and 91, respectively.

ACUTE INFLAMMATION—SUNBURN

Erythema is the most visually apparent indicator of UV-induced skin inflammation. Increased blood flow in the superficial and deep vascular plexus is responsible for the appearance of erythema and also may increase skin temperature. Two other classical signs of inflammation, swelling caused by increased vasopermeabilty and pain caused by released mediators on nerve endings, may also occur. Both UVB and UVA radiations elicit inflammation although the initiating photochemistry, cell signaling processes, and biochemical pathway processes involved are not identical. Erythema has been used as the endpoint for measuring the relative effects of different wavelengths in the UVB and UVA, usually expressed as an action spectrum.

ACTION SPECTRA. An action spectrum indicates which wavelengths most effectively produce a skin response. It is used to understand the basic science of a photobiologic as well as a therapeutic response because phototherapy is most efficient when the emission of the lamp matches the action spectrum for the beneficial response. An action spectrum is most accurately plotted as the reciprocal of the number of incident photons required to produce a given effect (*Y*-axis) against wavelength (*X*-axis). Conventionally in dermatology, the reciprocal of the minimum fluence (exposure dose) to produce the response is plotted versus wavelength. In an ideal case, the action spectrum corresponds to the absorption spectrum for the chromophore and can be used to identify the chromophore for a given photobiologic reaction. For example, an action spectrum for wheal formation in a patient with EPP showed a maximum at 400 nm, close to the maximum of protoporphyrin IX, which supports biochemical evidence for this porphyrin as the chromophore.[18] Another example involves the action spectrum for the clearance of psoriasis, which was found to peak around 313 nm.[3] This insight has led to the development of so-called "narrowband" UVB sources with peak output at 311 nm, and the use of the excimer 308-nm laser for the efficacious treatment of psoriasis. Absorption in this range suggests that DNA is a punitive chromophore, but given the different depths of penetration of the two wavelengths into skin and the varying clinical responses, it is possible the relevant chromophore for the therapeutic effect of UVB on psoriasis is not exclusively DNA. Moreover, in some cases, the action spectrum for a response may not directly correlate to the absorption spectrum of the responsible chromophore because the wavelengths actually reaching the chromophore are distorted by absorption and scattering of light by tissue above the level of the chromophore.

The action spectrum for erythema indicates that the most effective wavelengths present in sunlight are in the UVB range.[1,19] UVA is roughly 1,000-fold less effective than UVB. The time in the sun required to produce sunburn is strongly influenced by many factors including skin pigmentation, season, geographical location, cloud cover and time of day. The relative contributions of UVB and UVA radiation from the sun to a sunburn response are not constant because the UVB to UVA ratio in the solar spectrum varies with the time of day, the season and other factors.

UVB-INDUCED INFLAMMATION

Erythema is usually apparent 3–5 hours after UVB exposure, reaches a maximum intensity at 12–24 hours and generally resolves by 72 hours. However, when the UVB dose is high, erythema appears sooner, reaches a maximum at a later time and is more persistent, and the response is more likely to include pain or swelling. The minimal erythema dose or MED is the fluence that elicits minimal erythema at 24 hours. The UVB MED for fair skin (Fitzpatrick type I–II) using fluorescent UVB bulbs is about 30 mJ/cm^2 (300 J/m^2). Many biochemical and cellular events occur before the erythema is evident including increased blood flow, endothelial cell activation and elevated inflammatory mediator levels.[20,21]

HISTOLOGY—UVB. The extent and time course of the histological changes observed after UVB varies with the magnitude of the exposure dose.[22,23] Dyskeratotic cells, so-called "sunburn cells," may appear in the epidermis as soon as 30 minutes after a 3 MED exposure. Sunburn cells are apoptotic keratinocytes that show condensed nuclear chromatin and eosinophilic cytoplasm. They increase in number with a maximum at about 24 hours and eventually (by 72 hours) form a band at the stratum corneum. Intercellular edema occurs early and may persist to 72 hours.

Dermal changes include early (30 minutes) and persistent (up to 72 hours) endothelial cell swelling, perivenular edema and degranulated mast cells.[22] Neutrophils appear perivascularly shortly after UVB and the influx peaks at about 14 hours. A later mononuclear (macrophage) infiltrate persistes at least 48 hours.

MECHANISM—UVB. Absorption of UVB photons by chromophores in skin leads to the production of inflammatory mediators and cytokines that characterize the sunburn response. The action spectrum for erythema closely correlates with the absorption spectrum of DNA suggesting that DNA is one of the important chromophores and that DNA photoproducts initiate at least partially the biochemical pathways leading to UV-induced inflammation.[1,24] A role for DNA photoproducts is further supported by the observation that xeroderma pigmentosum patients, who have low ability to repair DNA, demonstrate prolonged UVB-induced erythema that can be reduced by treatment with a DNA repair enzyme.[25] The biochemical pathways linking the DNA photoproducts with inflammatory mediators are still unclear. However, an action

spectrum for TNF-α followed the DNA absorption spectrum suggesting formation of this proinflammatory cytokine is initiated by DNA photoproducts.[26]

In addition to DNA, other UVB-absorbing chromophores initiate formation of inflammatory mediators.[27,28] A UVB-induced photoproduct of tryptophan initiates signaling events leading to expression of cyclooxygenase-2 (COX-2), which catalyzes formation of prostaglandins, which are associated with erythema.[29] UVB exposure rapidly generates ROS that oxidize membrane lipids leading to proinflammatory cytokines.[27,28,30] The role of ROS is supported by the ability of topical antioxidants to modulate UVB-induced erythema.[12,31]

INFLAMMATORY MEDIATORS—UVB. Prostaglandins and nitric oxide appear to be the major mediators for UVB-induced inflammation. Early studies showed that PGE_2 levels in suction blister fluid increased before the appearance of erythema and continued to rise at least until 24 hours.[22] More recently, numerous proinflammatory and anti-inflammatory eicosanoids were identified in suction blister fluid over a 72 hours period after UVB exposure.[15] Prostaglandins with vasodilatation activity (PGE_2, $PGF_{2\alpha}$, and PGE_3) appeared at 24–48 hours, and the species with leukocyte chemoattractant activity [11-, 12-, and 8-monohydroxy-eicosatetraenoic acid (HETE)] were present to later times (4–72 hours). Interestingly, an anti-inflammatory species, 15-HETE, was maximally present at 72 hours. The first UVB-induced step in the formation of these eicosanoids is a rapid (<30 minutes) increase in the activity of phospholipase A_2, which liberates arachidonic acid from cell membranes. Arachidonic acid is then acted on by cyclooxygenases and lipoxygenases to produce the eicosanoids. Inhibiting cyclooxygenases with indomethacin applied after UVB suppressed erythema.[21,32]

A role for nitric oxide in UVB-induced inflammation was established using NG-nitro-L-arginine methyl ester (L-NAME), a specific inhibitor of nitric oxide synthase, which suppressed erythema.[21,33] Interestingly, L-NAME effectively suppressed erythema even when injected 48 hours after UVB indicating that nitric oxide was continuously synthesized. Histamine, however, which can trigger an inflammatory response, does not appear to be a major contributor to the UVB-induced sunburn[34] even though it rises after UVB.[22]

Several proinflammatory cytokines, including TNF-α, IL-1, IL-6, and IL-8, are elevated after UVB exposure of human skin.[35–38] The IL-1-like activity was detected by 1 hour after UVB[36] and TNF-α was elevated by 4 hours, maximal at 15 hours, and then declined.[35] Cytokines may play several roles in UVB-induced inflammation including recruiting leukocytes from the vasculature by acting as chemoattractants and as inducers of endothelial cell adhesion molecules that facilitate movement of cells across the capillary walls.

UVA-INDUCED INFLAMMATION

Sunburn elicited by UVA has been much less thoroughly examined than UVB-induced erythema even though the amount of UVA in sunlight vastly exceeds (~19-fold) the UVB portion. UVB and UVA contribute significantly to the effects of chronic sun (and tanning bed) exposure. Erythema is usually present at the end of the UVA exposure using clinical or laboratory light sources. This immediate response may fade or merge into a delayed erythema with a maximum between 6 and 15 hours depending on the fluence, irradiance and spectrum of the light source.[20,39] The UVA MED in fair skin is generally 30–75 J/cm^2.[20,23,40]

HISTOLOGY—UVA. In contrast to UVB-induced erythema, the major histological changes after UVA exposure occur in the dermis. Most notably, the sunburn cells that characterize UVB-exposed epidermis are not apparent after UVA.[23,39] Epidermal intercellular edema was present for at least 48 hours, and LCs decreased over 48 hours. In the dermis, neutrophils peaked at 3 hours, earlier than after UVB, and remained present for at least 48 hours. A lymphocytic infiltrate was also apparent throughout the dermis at all times after irradiation.[39]

MECHANISMS—UVA. The differences in time course and histology between UVB and UVA-induced responses suggest that different mechanisms are involved. The erythema action spectrum supports this concept; the slope of the curve decreases at wavelengths longer than about 330 nm and a small shoulder is seen at about 360 nm.[1,19] In addition, UVA-induced erythema was suppressed when the skin oxygen level was reduced whereas the UVB erythema was not affected.[40] Although several UVA chromophores are present in skin (Fig. 90-6), the identity of the light absorber for UVA sunburn is still unidentified.

ROS play a significant role in UVA-induced inflammation, as suggested by the oxygen dependence of UVA erythema.[40] Singlet oxygen and other ROS are detected by spectroscopy when skin is exposed to UVA.[11,41] These reactive species are responsible for activating phospholipase A_2, which releases arachidonic acid from membrane lipids and makes it available for enzymatic conversion into proinflammatory eicosanoids. ROS also initiate intracellular signal transduction pathways that activate the synthesis of proinflammatory cytokines. In addition, UVA has been shown to liberate nitric oxide very rapidly from storage forms in skin.[42]

INFLAMMATORY MEDIATORS—UVA. Exposure of skin to UVA increased the levels of proinflammatory prostaglandins as measured in suction blister fluid.[43] A study in keratinocytes indicated that increased prostaglandin levels were caused by UVA-induced activation of PLA_2.[44] In vivo UVA stimulated an increase in the levels of PGD_2, PGE_2, and 6-keto-$PGF_{1\alpha}$ at 5–9 hours, which returned to normal by 24 hours.[43] Histamine also increased by 9–15 hours and returned to baseline by 24 hours. UVB, but not UVA, stimulated production of TNF-α from keratinocytes and in human skin.[45,46]

VITAMIN D PHOTOBIOLOGY

In 1928, Adolf Windaus garnered the Nobel prize in chemistry for his studies on the constitution of sterols and their connection with vitamins.[47] The fat-soluble substance under his investigation was vitamin D; however, the story of vitamin D and rickets, its deficiency, actually dates back to antiquity based on careful study of writings and paintings. Conducting dietary studies with cod-liver oil on dogs in 1919, Mellanby first concluded that rickets stems from the absence of an "accessory food factor."[48] Three years later McCollum et al found that heated, oxidized cod-liver oil could cure rickets in rats.[49] They named the new factor vitamin D because it was the fourth vitamin discovered.

Concurrently, an entirely different remedy for rickets appeared in the form of UV light. By the late nineteenth and early twentieth centuries, lack of fresh air and sunshine or lack of exercise was implicated in the etiology or rickets.[50] In 1921, Hess and Unger observed that seasonal incidence of rickets seemed to parallel seasonal variations of sunlight.[51] Chick independently observed that sunlight would cure rickets just as well as cod-liver oil.[52] In 1919, Huldschinsky reasoned that artificial sunlight might well do the same as natural sunlight.[53] Controlling for dietary intake and ambient UV exposure, he irradiated severely rachitic children with a UV-emitting quartz-mercury lamp and observed remarkable clinical and radiographic improvement, including fresh calcium deposition.

From cottonseed oil in 1925, Hess and his team isolated sitosterol, which was inactive against rickets in rats until it was irradiated by UV light.[54] The discovery that irradiation of food, in particular of whole milk, could impart antirachitic potency led to tremendous advances in public health, producing a rapid decline in the prevalence of rickets in children. With amazing foresight, Hess hypothesized that cholesterol in skin is activated by UV-irradiation and rendered antirachitic. The complete photochemical and thermal reaction steps in the vitamin D pathway were finally elucidated in 1955 by Velluz.[55] The exact sequence of steps leading to the cutaneous photoproduction of cholecalciferol was reported in a comprehensive paper by Holick in 1980.[56]

FUNCTIONS OF VITAMIN D. Vitamin D regulates calcium and phosphorus metabolism.[56] Its major role is to increase the flow of calcium into the bloodstream, by promoting absorption of calcium and phosphorus from the intestines, and reabsorption of calcium in the kidneys, thus enabling normal mineralization of bone and muscle function. It affects serum alkaline phosphatase level. Vitamin D also inhibits the proliferation of T-cells and the maturation of dendritic cells (DCs) along with affecting keratinocyte function.

Vitamin D deficiency results in impaired bone mineralization that leads to bone softening diseases, rickets in children and osteomalacia in adults, and possibly contributes to osteoporosis.[57] Deficiency can arise from inadequate intake coupled with inadequate sunlight exposure, disorders that limit its absorption, or conditions that impair conversion of vitamin D into active metabolites, such as liver or kidney diseases. Most vulnerable to low vitamin D levels are elders, individuals living at high latitudes with long winters, obese persons, and all individuals with dark skin pigmentation living at high latitudes.[58–65]

Toxicity from excess vitamin D may manifest itself as hypercalciuria or hypercalcemia, the latter causing muscle weakness, apathy, headache, confusion, anorexia, irritability, nausea, vomiting, and bone pain, and potentially leading to complications such as kidney stones and kidney failure. Chronic toxicity effects include the aforementioned symptoms along with constipation, anorexia, abdominal cramps, polydipsia, polyuria, backache, and hyperlipidemia. Findings may also include calcinosis, followed by hypertension and cardiac arrhythmias (due to shortened refractory period). Although information about the effects of high doses of vitamin D is limited, 10,000 IU daily is a safe upper limit for adult intake.[66] Chronic toxic dose is more than 50,000 IU/day in adults.

There are two major sources of vitamin D, one is diet and the other is skin. When obtained exogenously from food or supplements, vitamin D is absorbed in the small intestine. Natural food sources rich in vitamin D include certain oily fish such as salmon, mackerel, tuna, herring, catfish, cod, sardines and eel, butter, margarine, yogurt, liver, liver oil, and egg yolks, but at least in the United States, most dietary vitamin D comes from the fortification of food like cereal, milk, and orange juice.[67] Fortified milk, for example, typically provides 100 IU per 8 oz glass, or only a quarter of the estimated adequate daily intake for adults. To get the recommended daily allowance, most Americans have to take supplemental vitamin D either alone, or with calcium or in a multivitamin.

BIOCHEMICAL PATHWAY. (Fig. 90-8.) As a result of UVB exposure on the skin, provitamin D3 (7-dehydrocholesterol, a precursor of cholesterol) is rapidly converted to previtamin D3, which spontaneously isomerizes to vitamin D3, entering the circulation on a binding protein and joining dietary D2 (or ergocalciferol) and D3 (cholecalciferol) absorbed from the gut.[56] Once reaching the liver, these undergo passive hydroxylation in the endoplasmic reticulum of the hepatocytes, a process that requires NADPH, O_2 and Mg^{2+}. The product 25-hydroxyvitamin D_3 [25(OH)D_3 (calcidiol)] is stored in the hepatocytes until it is needed when it can be released into the plasma to make its way to the proximal tubules of the kidneys, where it is acted upon by 25(OH)D-1-α-hydroxylase, an enzyme whose activity is increased by parathyroid hormone and low PO_4^{2-}. People with kidney disease may not be able to convert vitamin D to its active form. Following this conversion, 1,25-hydroxyvitamin D_3 [1,25$(OH)_2D_3$ (calcitriol)] is released into the circulation, and by binding to a carrier protein in the plasma, vitamin D-binding protein (VDBP), it is transported to various target organs.

ACTION SPECTRUM FOR VITAMIN D FORMATION IN SKIN. Action spectra studies show that wavelengths the most effective at bringing about the

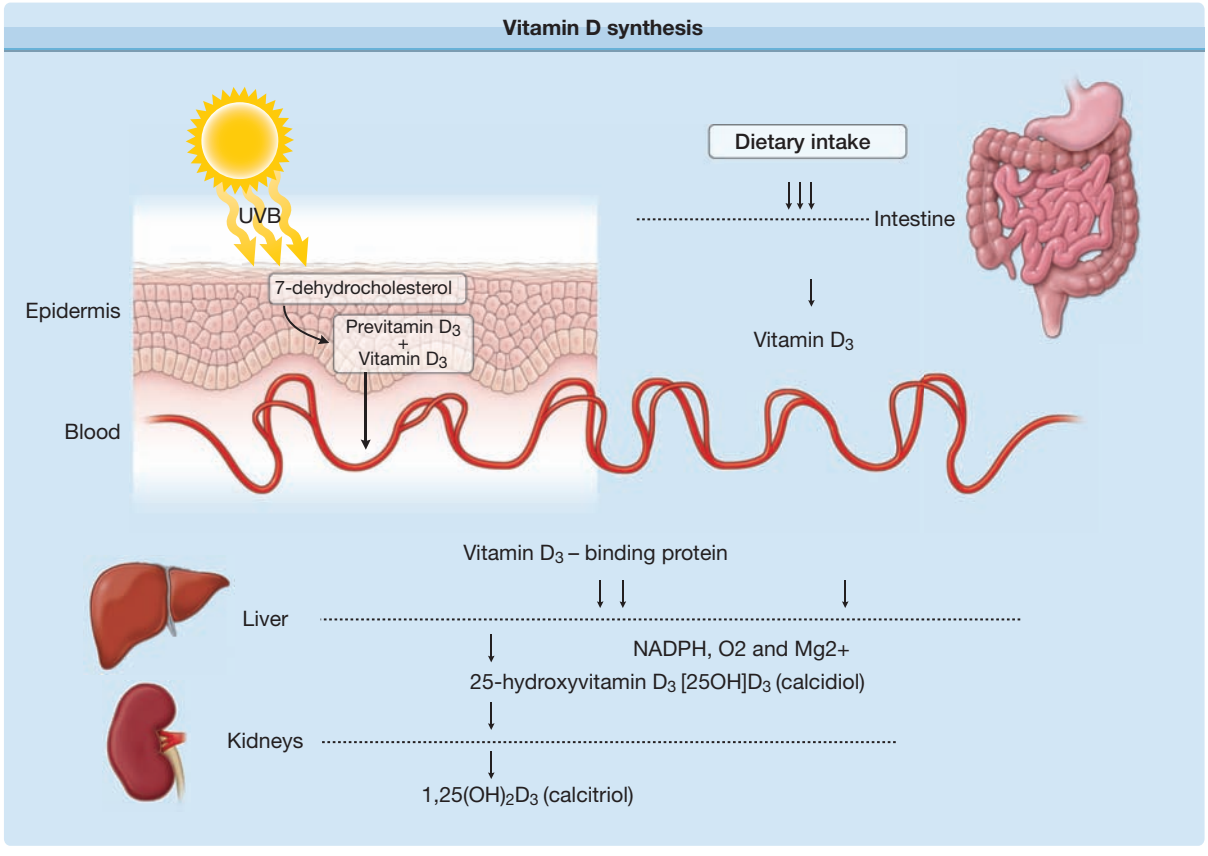

Figure 90-8 Vitamin D synthesis: Vitamin D is synthesized in the epidermis in response to UVB and is also absorbed from the intestine. It is then transported on a binding protein to the liver, where it undergoes 25-hydroxylation. This metabolite calcidiol is the major circulating form of Vitamin D. The final step occurs mainly in the proximal tubules of the kidneys, where it is acted upon by 25(OH)D-1-α-hydroxylase, an enzyme whose activity is increased by parathyroid hormone and low PO_4^{2-}. This l-α-hydroxylation is also believed to occur peripherally such as in the skin, where Vitamin D promotes differentiation.

photosynthesis of cutaneous vitamin D lie in the range of 295 nm to 315 nm, which ironically are some of the same wavelengths most responsible for photocarcinogenesis.[68] Optimal synthesis occurs in a very narrow band of UVB spectra between 295–300 nm with peak isomerization at 297 nm.[68,69] With a UV Index of at least 3, which occurs daily in the tropics and almost never at high latitudes, adequate amounts of vitamin D_3 can be made in the skin after 10–15 minutes of sun exposure at least two times per week to the face, arms, hands, or back without sunscreen. In Boston, sunlight exposure from November through February is inadequate to result in significant cutaneous vitamin D production.[65] The available flux of UVB for the synthesis of vitamin D depends on all the factors that determine the UV Index, including time of day, cloud cover, smog, shade, reflection from nearby water, sand or snow, latitude, altitude, and season of the year. Of course, individual factors such as age (vitamin D production decreases when older[70]), body mass index, clothing worn, amount of skin exposed also have an effect.[71] Individuals with higher skin melanin content require more time in sunlight to produce the same amount of vitamin D as individuals with lower melanin content.

According to Holick, human beings make at least 10,000–25,000 units of vitamin D upon full body exposure to the sun at one minimal erythemal dose.[72,73] Vitamin D production in the skin occurs within minutes and is already maximized before your skin turns pink. Exposure to sunlight for extended periods of time does not normally cause vitamin D toxicity. Within 20 minutes of sun exposure in fair-skinned individuals (1–3 hours for pigmented skin) the concentration of vitamin D precursors produced in the skin reaches an equilibrium, and excess vitamin D simply degrades as fast as it is generated.

OPTIMAL LEVELS OF VITAMIN D. Ninety years after its discovery, vitamin D has become a subject of intense interest to dermatologists in part due to the fact that its deficiency is being increasingly recognized and that its deficiency may well have important health consequences beyond those related to bone health. As dermatologists counsel patients to employ sunscreens in order to minimize subsequent risk of skin cancer, they should be aware that sun protection recommendations may impede the efficacy of vitamin D photosynthesis in the skin.[74] Several studies have all shown that most people, even those living in year-round sunny locations such as Florida and Australia have low vitamin D levels.[75–79] In addition, other studies have demonstrated that minimal or even moderate UVB exposures may

not be sufficient to maintain 25-hydroxy vitamin D [25(OH)D] levels at the now widely quoted "sufficient level" of 30 ng/mL.[75,80] Consequently, relying solely on ambient exposure appears not to be sufficient as a means to obtain adequate vitamin D. Nearly all randomized trials that have proven the beneficial effects of increased vitamin D have achieved that increase by oral supplementation. It seems most likely that skin cancer prevention recommendations in the form of sunscreen use and judicious use of protective clothing did not cause the problem of low vitamin D levels and equally unlikely that urging unprotected ambient exposure will not fully solve this year-round problem either unless dietary vitamin D supplementation is recommended.

Low levels of vitamin D are clearly associated with falls and fractures in the elderly.[81–86] As to whether vitamin D supplementation can reduce these complications, there is controversy with reports showing a benefit while others do not. Capturing more attention as of late is the mounting evidence that vitamin D plays a role in preventing colorectal cancer and to a lesser extent cancers of the breast and prostate.[87–92] Other malignancies have been associated with vitamin D insufficiency in observational studies. Moreover, multiple other health problems have been shown to be inversely correlated in frequency with vitamin D levels in some studies. Examples include diabetes mellitus,[93,94] multiple sclerosis,[95] hypertension,[96] myocardial infarction,[97] cardiovascular,[98] seasonal affective disorder,[99] chronic pain,[100] peripheral artery disease,[101] cognitive impairment, which includes memory loss,[102] and infections,[103,104] among others. There is an association between low vitamin D levels and Parkinson's disease.[105] Current evidence is simply insufficient to infer a causal relationship in any of these conditions.

What is an optimal level of vitamin D? Risk of cardiovascular events in the Framingham Offspring cohort study suggested levels as low as about 20–25 ng/mL.[106] The national representative National Health and Nutrition Examination Survey data suggested that overall mortality was minimized at levels of about 30–40 ng/mL.[101] Given concerns about potential confounding factors, we cannot be certain about these estimates of optimal levels, but the preponderance of published evidence would support values of 25–40 ng/mL.[107] Thirty ng/mL (75 nmol/L) is a common estimate given current knowledge.[108]

Clinicians can measure individual levels and recommend supplementation accordingly. Common guidelines include 400–1,000 IU daily with or without calcium or in a multivitamin, 10,000 IU weekly or every 10 days, or 50,000 IU every month. After correction of their vitamin D status with oral vitamin D, patients should have a repeat test of their 25(OH)D level to confirm that they are in the normal range. Such measurement is necessary since there is great variation in the increment of 25(OH)D achieved from a given dose of vitamin D supplement. If a patient remains persistently low, despite several attempts at correction with oral vitamin D, there may be malabsorption and referral to a gastroenterologist is in order. A trial of UVB light therapy may be considered to improve vitamin D status. For patients with 25(OH)D levels less than 15 ng/mL, one usually prescribes oral supplements of 50,000 IU vitamin D weekly for 8 weeks and then switches to standard maintenance doses. Efficacy of vitamin D supplementation is dependent on body mass index (BMI).[57] Overweight and obese patients with hypovitaminosis D require higher doses of vitamin D to achieve vitamin D repletion compared to individuals with normal body weight.

In short, we can conclude that vitamin D supplementation appears to enhance musculoskeletal health and may possibly reduce mortality in some groups. We have evidence that vitamin D may have an influence on cancer, cardiovascular disease, autoimmune disease, and infection, but this evidence, although suggestive, is quite variable in strength and does not allow the conclusion that any of these associations are proven. These are subjects of ongoing investigation.

PHOTOIMMUNOLOGY

Skin cancer is caused largely by direct damage to DNA, leading to specific gene mutations. However, for the development of clinically apparent skin cancer, a second UVB-induced mechanism is required, namely, UVB-induced immunosuppression.[109,110] The connection between sun exposure and skin cancer was realized first in the beginning of the last century when physicians observed skin tumors that grew preferentially at sites that had been extensively sun exposed. This was followed in the 1970s by a seminal study by Kripke,[111] who discovered a connection between immunosuppression and photocarcinogenesis. In a series of experiments, she demonstrated that UV-induced tumors, which had been transplanted onto syngeneic recipient mice, were rejected if the recipient mice had not been exposed to UVB. This result implies that UV-induced tumors have a highly antigenic phenotype[111] and can be rejected by a functioning immune system. Treatment with known immunosuppressive drugs, or—this was the novel finding—with low doses of UVB, led to failure of tumor rejection.[112,113] Both aspects (i.e., the strong antigenicity of UV-induced tumors and the immunosuppression by UVB) have triggered vigorous research activities in the field now termed *photoimmunology*. Numerous studies tried to clarify the cellular and molecular mechanisms.[114] These have turned out to be highly complex (see Fig. 90-9). Results sometimes appear contradictory, likely due to use of various experimental approaches and model systems.

MODEL SYSTEMS FOR ULTRAVIOLET B-INDUCED IMMUNOSUPPRESSION

The standard model for studying UVB-induced immunosuppression is the delayed-type hypersensitivity (DTH) to antigens and the contact hypersensitivity reaction (CHS). The ability of UVB irradiation to block either induction or elicitation of allergic sensitization can then be quantified; typically a hapten such as dinitrofluorobenzene or oxazolone is applied to the skin as the stimulus and intensity of the subsequent immune response is measured as tissue swelling. DTH responses have become the model of choice to study

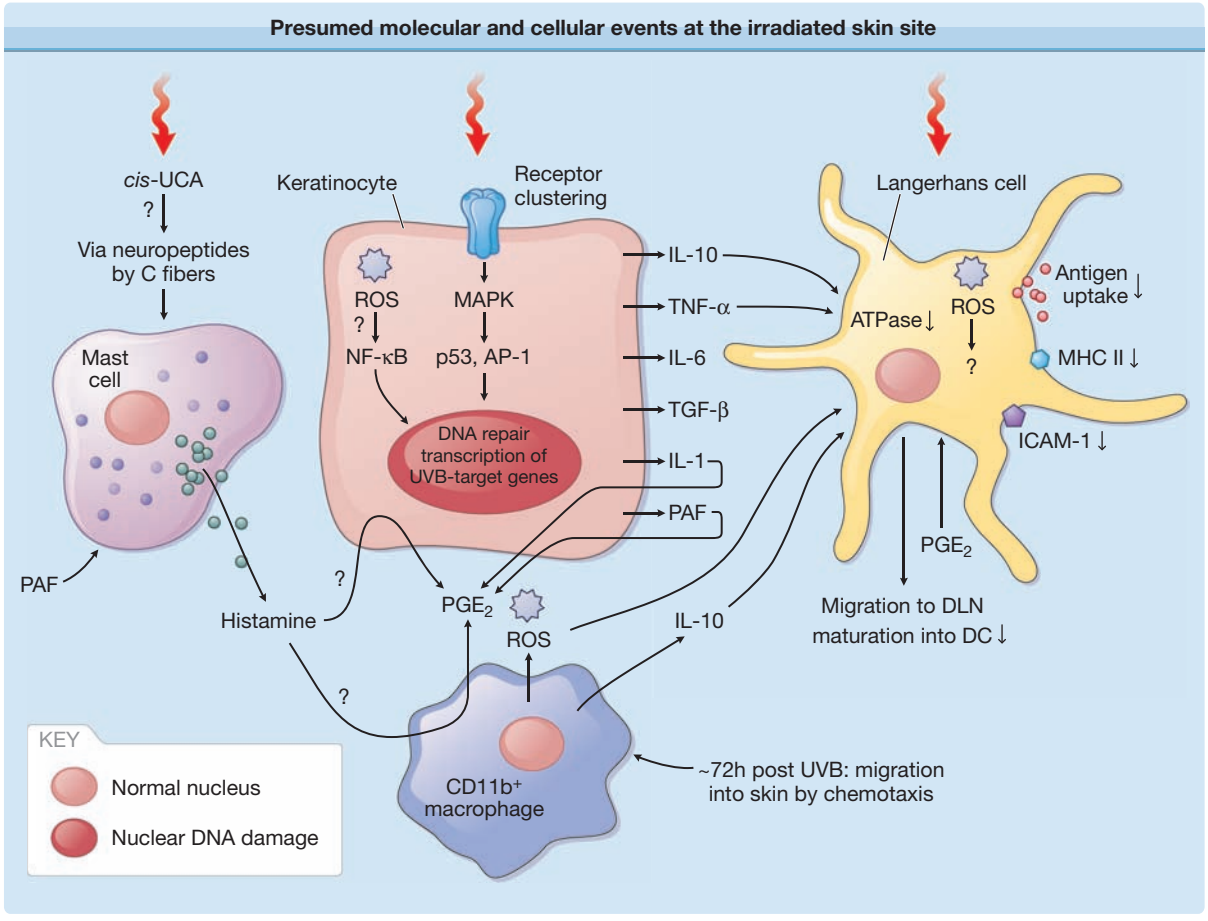

Figure 90-9 Ultraviolet B (UVB) radiation-induced immunosuppression: Illustration of the presumed molecular and cellular events at the irradiated skin site. ATPase = adenosine triphosphatase; DC = dendritic cell; DLN = draining lymph node; IL = interleukin; ICAM = intercellular adhesion molecule; MAPK = mitogen-activated protein kinase; MHC = major histocompatibility complex; NF-κB = nuclear factor κB; PAF = platelet-activating factor; PGE_2 = prostaglandin E_2; ROS = reactive oxygen species; TGF = transforming growth factor; TNF = tumor necrosis factor; UCA = urocanic acid.

the immunosuppressive effects of UVB radiation, as the tumor-associated antigens of UVB-induced tumors are only poorly characterized and testing DTH responses is less time-consuming and less laborious than examining photocarcinogenesis. UVB radiation has also been shown to affect immune responses involved in the pathogenesis of viral, parasitic, fungal, and bacterial infections. UVB-mediated immunosuppression is of two types: (1) local immunosuppression in which the immune response to antigens applied at the irradiated site is abrogated, and (2) systemic immunosuppression in which the immune response to antigens applied to unexposed sites is impaired (Fig. 90-10).[115] However, some mice are more susceptible to UVB-induced immunosuppression than others, with the genetic loci for lipopolysaccharide, *Lps*, and tumor necrosis factor, *Tnf*, strongly influencing the response.[116]

MOLECULAR TARGETS IN PHOTOIMMUNOSUPPRESSION

DNA is a chromophore for UVB radiation and can be a direct target (see Fig. 90-6). UVB radiation generates a variety of photoproducts, most commonly CPDs[6–4] and photoproducts. Pyrimidine dimer formation is a direct cause of UV-induced immunosuppression (Fig. 90-9). The cells of the opossum *Monodelphis domestica* contain endogenous photoreactivating enzymes, which are capable of repairing CPDs, and UVB does not induce immunosuppression in these animals on exposure to photoreactivating light immediately after irradiation.[117] Also in mice, a correlation between CPDs and UVB-induced systemic immunosuppression exists.[118]

UVB irradiation leads to CPDs in antigen-presenting cells (APCs) and impairment of their antigen-presenting capacity. The damage persists for several days, and the damaged cells migrate from the skin to lymph nodes. Treatment at the site of UVB irradiation with liposomes containing the DNA repair enzyme T4 endonuclease V prevents the impairment in antigen presentation.[119] The role of DNA damage in UVB-induced immunosuppression was also confirmed in human skin, in which topical application of photolyase-containing liposomes to UVB-exposed sites prevents UVB-induced immunosuppression.[120]

In addition to direct DNA damage, the generation of ROS is likely to be involved in photoimmunosuppression (see Fig. 90-9). Accordingly, topical application of a polyphenolic fraction isolated from green tea before

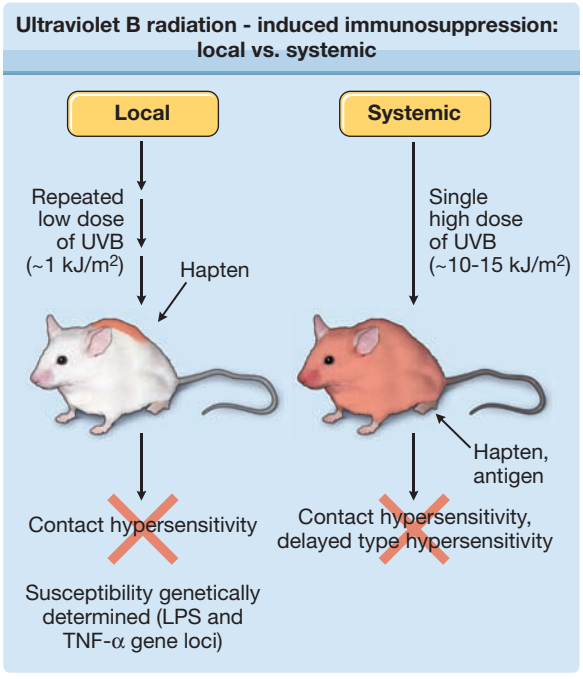

Figure 90-10 Ultraviolet B (UVB) radiation-induced immunosuppression: local versus systemic. TNF = tumor necrosis factor.

and after UVB irradiation to mouse skin protects against UV-induced immunosuppression,[121] an effect most likely mediated by the antioxidant epigallocatechin-3-gallate, the component of extract that has the ability to reduce oxidative stress, inflammatory responses, and skin cancer. It should be noted that such secondary plant metabolites affect cell signaling, however, so that protection against UVB-induced events may not exclusively be explained by antioxidant effects.

The cell membrane of immunocompetent skin cells is another target for UV radiation. An important function of the cell membrane is to transfer signals from outside into the cell via membrane receptors. UVB exposure leads to clustering and internalization of cell surface receptors for epidermal growth factor, TNF, and IL-1 in the absence of the respective ligands. Clustering results in strong activation of stress-induced c-Jun NH_2-terminal kinases, which are members of the mitogen-activated protein kinase family[122] (see Fig. 90-9). Conceivably, such aberrant receptor clustering may subvert signaling pathways normally used by growth factors and cytokines, eventually contributing to the immunological response. The chromophore for these UVB-induced membrane alterations is cytoplasmic tryptophan. The resulting tryptophan photoproduct(s) bind to the transcription factor arylhydrocarbon receptor (AhR), which in its inactive form is part of a cytoplasmic complex including c-src and the heat shock protein Hsp90. Upon binding of the tryptophan photoproduct to the AhR, the complex dissociates and the AhR translocates into the nucleus whereas c-src translocates to the cell membrane where it subsequently causes the previously mentioned cell membrane/surface receptor activation.[29]

UVB radiation can lead to lipid peroxidation, including cell membrane lipids. Phosphatidylcholine, an important membrane lipid, can be oxidized to platelet-activating factor(PAF)-like lipids that bind to PAF receptors and activate cytokine synthesis. A role of UVB-induced PAF formation in photoimmunosuppression is suggested by the observation that comparable immunosuppression can be induced in mice when they are irradiated with UVB, injected with carbamyl-PAF, or injected with phosphatidylcholine that had been exposed to UVB under atmospheric oxygen. The immunosuppressive properties of all three treatments were equally blocked by specific PAF receptor antagonists, indicating that UVB-induced PAF-like lipids can trigger the PAF receptor in a way similar to PAF. In turn, PAF receptor activation stimulates a variety of downstream effects, including the activation of mitogen-activated protein kinase pathway and synthesis of immunosuppressive cytokines (see Fig. 90-9).[123] Interestingly, UVB radiation-induced immunosuppression as well as formation of PAF were enhanced in mice, which were unable to take up the osmolyte taurine. Thus, similar to nucelotide excision repair, taurine uptake is critically involved in protection of the skin against UVB radiation-induced immunosuppression.[124]

An extracellular chromophore that mediates UVB-induced immunosuppression is UCA (see Fig. 90-6).[125] UV radiation isomerizes *trans*-UCA to *cis*-UCA dose-dependently until a balanced photostationary state is reached. A number of independent studies confirmed the importance for *cis*-UCA in UVB-induced immunosuppression, although the exact mechanism of action is not clear at present.

CELLULAR EVENTS INVOLVED IN PHOTOIMMUNOSUPPRESSION

UVB radiation of keratinocytes alters their expression of surface molecules and induces the synthesis and secretion of a whole set of immunomodulatory soluble factors, including IL-1, IL-6, IL-8, TNF-α, and PGE_2 (see Fig. 90-9).[126] Evidence for keratinocyte-derived soluble factors with immunosuppressive function came from experiments showing that either serum factors from UVB-exposed mice or supernatants from UVB-irradiated murine epidermal cells suppressed hypersensitivity reactions in mice. Subsequently, it was found that TNF-α and IL-10, two potent immunosuppressive cytokines, are produced by UVB-irradiated keratinocytes as well.[125,128] IL-10 is also released by $CD11b^+$ macrophages in human skin.[129] Injection of TNF-α mimics UVB-induced alterations on Langerhans cells (LCs). The administration of a neutralizing antibody to TNF-α before irradiation abrogates partially UVB-induced accumulation of DCs in draining lymph nodes (DLNs) and suppression of contact hypersensitivity. The release of TNF-α is of special importance for local immunosuppression, and, as mentioned above, the *Tnfa* gene locus contributes to UVB susceptibility.

IL-10 is a T-helper cell type 2 (Th2) cytokine and abrogates the production of Th1 cytokines, in particular, interferon-γ (IFN-γ). UVB-induced IL-10 production

by keratinocytes in murine or macrophages in human skin[130] shifts the immune response from a Th1 to a Th2 type. This can explain why Th1-mediated cellular immune reactions are impaired by UV radiation.

The interactions between the different cytokines are not fully understood, but IL-10 certainly is a major player. For instance, anti-IL-10 antibodies neutralize the suppressive effects of supernatants from UVB-irradiated keratinocytes on DTH in mice.[127] The main mechanism of IL-10 is probably inhibiting the antigen-presenting capacity of LCs. In parallel, UV-exposed keratinocytes release PAF and PAF-like lipids, which trigger the PAF receptor, as described in Section "Molecular Targets in Photoimmunosuppression."[29] Presumably, PAF and its receptor enhance the production of COX-2, PGE_2, IL-4, and IL-10. IL-10 production can be reversed by IL-12. Incidentally, IL-12 can restore UV-impaired CHS.[130] Injection of mice with IL-12 after UVB exposure prevented UVB-induced immunosuppression and suppressed partially UVB-induced tolerance obtained by resensitization 14 days after the UV irradiation. This IL-12 effect is most likely linked to the capacity of this cytokine to enhance the repair of UVB radiation-induced DNA photoproducts, which form the molecular basis for IL-10 production by irradiated keratinocytes.

CELLULAR MEDIATORS OF PHOTOIMMUNOSUPPRESSION: LANGERHANS CELLS, MACROPHAGES, AND T CELLS

LCs, 2%–5% of epidermal cells, are a DC subset that originates from bone marrow precursors and populates the epidermis. They are the "professional" skin-specific APCs and ingest antigen locally in the skin, but lack costimulatory capacity. After antigen uptake, LCs migrate to the DLN, where they mature to potent stimulators for antigen-specific T cells, expressing high levels of major histocompatibility complex molecules and costimulatory molecules B7.1 and B7.2 and intercellular adhesion molecule-1 on their cell surface (see Chapter 10).

In the 1980s, it was demonstrated that epidermal LCs play a pivotal role in the induction and regulation of CHS reactions. LC density is an important factor for the induction of CHS responses, and UV radiation leads to the disappearance of LC from irradiated sites.[131] In these studies, mice were sensitized with the hapten dinitrofluorobenzene either on skin with typical amounts of LC or on LC-deficient skin. A significantly impaired CHS response was observed when the mice were sensitized on LC-deficient skin. The capacity to deplete LCs temporarily from the skin appears to be an important feature of UVB irradiation. Moreover, UV exposure results in reduced surface expression of costimulatory molecules Ia, B7.1, B7.2, and intercellular adhesion molecule-1 (see Fig. 90-9).[132,133] The depletion of these molecules might account for or contribute to immunosuppression. The loss of LCs in the skin is accompanied by an increase in DCs in the DLN. [134] Fluorescein isothiocyanate+ Ia+ CPD+ cells in the DLNs were found after painting the skin with fluorescein isothiocyanate and irradiating subsequently with UV. This demonstrates that LCs indeed leave the skin after UV exposure. UVB possibly induces LC migration in the absence of exogenous antigen, although the migratory effect is enhanced by sensitization with antigen. The ultimate fate of chronically irradiated LCs remains to be examined. UVB-induced LC migration was also observed in human skin in vivo.[135]

In addition to reducing the number of LCs in the skin, UVB radiation affects LC function by impairing the antigen-presenting capacity in DTH and CHS. UVB-irradiated LCs activate preferentially $CD4^+$ Th2 cells.[136] In contrast, they do not activate $CD4^+$ T cells of the Th1 subset, but induce clonal anergy.[137] Another cellular player in UV-induced immunosuppression is $CD11b^+$ macrophages, which infiltrate UVB-irradiated human skin (see Fig. 90-9). These cells produce IL-10, and their deletion by antibodies makes UV-irradiated mice permissive again for CHS.[138]

In addition to immunologic unresponsiveness to haptens applied after irradiation, UVB exposure-induced hapten-specific tolerance (i.e., resensitization with the same hapten at later time points) likewise fails.[139] In adoptive transfer experiments, it was shown that UVB induces T-suppressor cells. Elmets et al[140] prepared single cell suspension of the spleen and lymph nodes from UVB-exposed and hapten-treated mice, injecting the cell suspension into naive mice. When the recipient mice were sensitized and challenged with the same hapten that was used for the donor mice, they showed significantly impaired CHS responses.

The phenotype of the regulatory T cells and their mechanism of action are not well understood (Fig. 90-11). Results obtained so far are difficult to compare. Different experimental setups yielded partly contradictory results. There is evidence to suggest that $CD8^+$ T cells are important mediators of UVB-induced immunosuppression in the local immunosuppression.[141] In addition, T cells (not defined by CD4 or CD8) that express cytotoxic T lymphocyte antigen (CTLA)-4 on their surface transfer UV-induced tolerance.[142] CTLA-4 appeared to be of functional relevance, because in vivo injection of anti-CTLA-4 antibodies blocked transfer of suppression. The physiologic function of CTLA-4 is to end immune responses by shutting down activated T cells, so CTLA-4 is an important molecule in immune regulation. On stimulation with antigen-bearing DCs, $CTLA\text{-}4^+$ T cells secrete high levels of IL-10, transforming growth factor-β, and IFN-γ, but low levels of IL-2 and no IL-4. Other studies showed that $CD4^+$ T cells from UV-exposed mice are capable to suppress CHS when injected into untreated recipient mice.[143] These $CD4^+$ T cells produce IL-10, but no IL-4 and IFN-γ on APC coculture and inhibit IL-12 production by APCs.

Apart from $CD4^+$ regulatory T cells, natural killer T cells with regulatory capacities were found in UVB-induced systemic immunosuppression (see Fig. 90-10). In particular, $CD3^+$, $CD4^+$, and $DX5^+$ CD1-restricted natural killer T cells have been described, which secrete IL-4 and can adoptively transfer suppression of tumor rejection as well as DTH responses.[134]

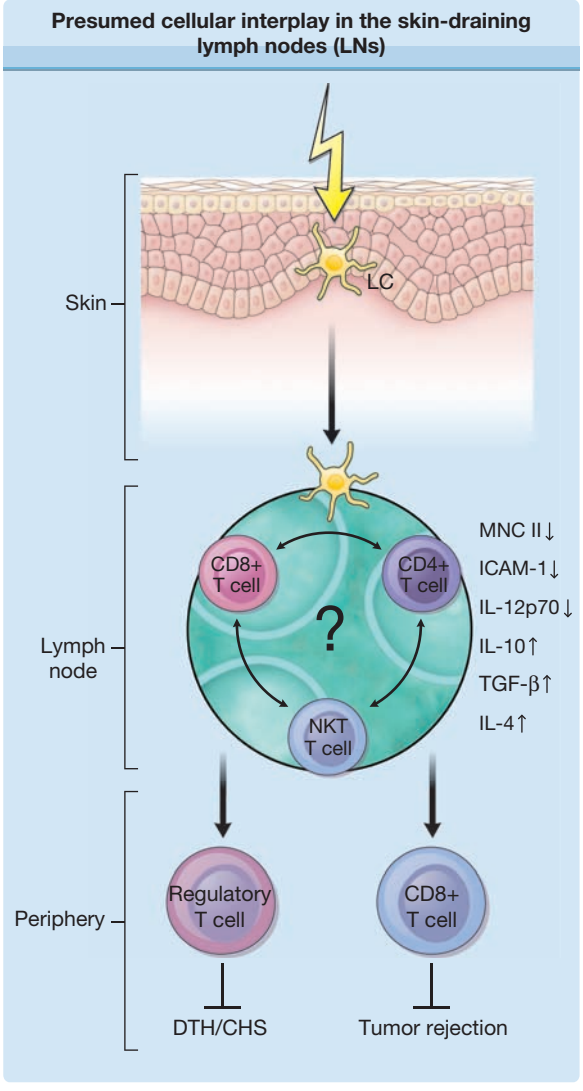

Figure 90-11 Ultraviolet B radiation-induced immunosuppression: illustration of the presumed cellular interplay in skin-draining lymph nodes (LNs). CHS = contact hypersensitivity reaction; DC = dendritic cell; DTH = delayed-type hypersensitivity; ICAM = intercellular adhesion molecule; IL = interleukin; LC = Langerhans cell; MHC = major histocompatibility complex; NKT = natural killer type; TGF = transforming growth factor.

ULTRAVIOLET RADIATION EFFECTS ON INNATE IMMUNITY

In the skin, in addition to slow but specific adaptive immune responses, the more primitive innate immune response can be generated as well. Essential components of the innate immune response are neutrophils, eosinophils, natural killer cells, mast cells, cytokines, complement, and, in particular, amtimicrobial peptides and proteins. It is important to note that the immunosuppressive properties of UV radiation refer exclusively to the adaptive immune response. In contrast, UV radiation has been shown to induce rather than suppress the innate immune response by increasing the production of the antimicrobial peptides human β-defensin (HBD)-2, -3, ribonuclease 7 and psoriasin in human keratinocytes and skin in vitro and in vivo.[144] This may explain why T-cell-mediated immune reactions are suppressed on UV exposure but not host defense reactions against bacterial attacks.

PHOTOIMMUNOLOGY: CONCLUDING REMARKS

UV radiation is a permanent environmental threat, and adaptive responses against its damaging effects have been developed in all living organisms. From a theoretic point of view, it is therefore tempting to speculate that photoimmunosuppression serves a physiologic role as an adaptive response of the skin to UV-induced modifications of proteins and an immunologic response to so-called *neoantigens* and, as a consequence, chronic inflammation. Under these conditions, the higher risk of skin cancer that appears to accompany UV-induced immunosuppression appears of less significance in evolutionary terms, as skin cancers occur principally in late life, after the reproductive period. From a practical point of view, however, photocarcinogenesis poses a serious health problem. Accordingly, modern approaches to prevent UV-induced immunosuppression include broad-spectrum UV filters, liposomally encapsulated DNA repair enzymes, antioxidants, and osmolytes.[145]

KEY REFERENCES

Full reference list available at www.DIGM8.com

DVD contains references and additional content

6. de Gruijl FR et al: Health effects from stratospheric ozone depletion and interactions with climate change. *Photochem Photobiol Sci* **2**:16, 2003
12. Pinnell SR: Cutaneous photodamage, oxidative stress, and topical antioxidant protection. *J Am Acad Dermatol* **48**:1, 2003
15. Rhodes LE et al: The sunburn response in human skin is characterized by sequential eicosanoid profiles that may mediate its early and late phases. *FASEB J* **23**:3947, 2009
29. Fritsche E et al: Lightening up the UV response by identification of the arylhydrocarbon receptor as a cytoplasmatic target for ultraviolet B radiation. *Proc Natl Acad Sci USA* **104**:8851, 2007
72. Holick MF: Environmental factors that influence the cutaneous production of vitamin D. *Am J Clin Nutr* **61**:638S, 1995
80. Rhodes LE et al: Recommended summer sunlight exposure levels can produce sufficient (>20 ng ml-1) but not the proposed optimal (>32 ng ml-1) 25 (OH)D levels at UK latitudes. *J Invest Dermatol* **130:**1411, 2010
107. Bischoff-Ferrari HA et al: Estimation of optimal serum concentrations of 25-hydroxyvitamin D for multiple health outcomes. *Am J Clin Nutr* **84**:18, 2006
118. Kripke ML et al: Pyrimidine dimers in DNA initiate systemic immunosuppression in UV-irradiated mice. *Proc Natl Acad Sci USA* **89**:7516, 1992
131. Schwarz A et al. Interleukin-12 suppresses ultraviolet radiation-induced apoptosis by inducing DNA repair. *Nat Cell Biol* **4**:26, 2002

Chapter 91 :: Abnormal Responses to Ultraviolet Radiation: Idiopathic, Probably Immunologic, and Photoexacerbated

:: Travis W. Vandergriff & Paul R. Bergstresser

ABNORMAL RESPONSES TO ULTRAVIOLET RADIATION: IDIOPATHIC, PRESUMED IMMUNOLOGIC, AND PHOTOEXACERBATED

Abnormal responses to ultraviolet radiation (UVR) exposure divide into four categories (Table 91-1): (1) acquired idiopathic, presumed immunologic; (2) DNA repair defect disorders; (3) chemical and drug photosensitivity, including the porphyrias; and (4) photoexacerbated dermatoses not caused directly by UVR. The first and last categories and an approach to assessing photosensitivity are covered in this chapter. The other categories are covered in other chapters in this book. Diagnosis of photodistributed eruptions is discussed in Box 91-1 and Figure 91-1, and the entities are discussed in the following sections.

ACQUIRED IDIOPATHIC, PROBABLY IMMUNOLOGIC PHOTODERMATOSES

POLYMORPHIC (POLYMORPHOUS) LIGHT ERUPTION

EPIDEMIOLOGY. Polymorphic light eruption (PMLE) is common worldwide, but thought to occur more frequently in temperate latitudes and rarely in equatorial latitudes. However, a large-scale cross-sectional study has revealed no latitudinal gradient

BOX 91-1 DIFFERENTIAL DIAGNOSIS OF POLYMORPHIC LIGHT ERUPTION

USUAL ACUTE FORM

- Photoexacerbated dermatoses such as atopic or seborrheic dermatitis or acne
- Solar urticaria
- Erythropoietic protoporphyria
- Xeroderma pigmentosum

RARE PERSISTENT FORM

- Jessner lymphocytic infiltrate

POLYMORPHIC LIGHT ERUPTION AT A GLANCE

- A common acquired sunlight-induced disorder typically presenting in the spring.
- Clinical presentation: a pruritic, erythematous, symmetrically distributed, papulovesicular eruption, usually on exposed areas, within hours of exposure to ultraviolet radiation, most commonly sunlight, with full resolution in days to several weeks.
- Histopathology: epidermal spongiosis with a superficial and deep dermal, perivascular, mainly mononuclear cell infiltrate and papillary dermal edema.
- Genetics: most likely a genetically determined delayed-type hypersensitivity reaction against UVR-induced cutaneous antigen(s).
- Therapy: responds to broad-spectrum sunscreen use, oral or topical steroids, and prophylactic low-dose immunosuppressive phototherapy.

TABLE 91-1 Abnormal Responses to Ultraviolet Irradiation

- Acquired idiopathic, presumed immunologic photodermatoses
- Polymorphic light eruption
- Actinic prurigo
- Hydroa vacciniforme
- Chronic actinic dermatitis
- Solar urticaria
- DNA repair defect disorders
- Xeroderma pigmentosum
- Cockayne syndrome
- Trichothiodystrophy
- Bloom syndrome
- Rothmund–Thomson syndrome (probable)
- Chemical and drug photosensitivities
- Exogenous
- Systemic
- Topical
- Endogenous
- The porphyrias
- Photoexacerbated dermatoses

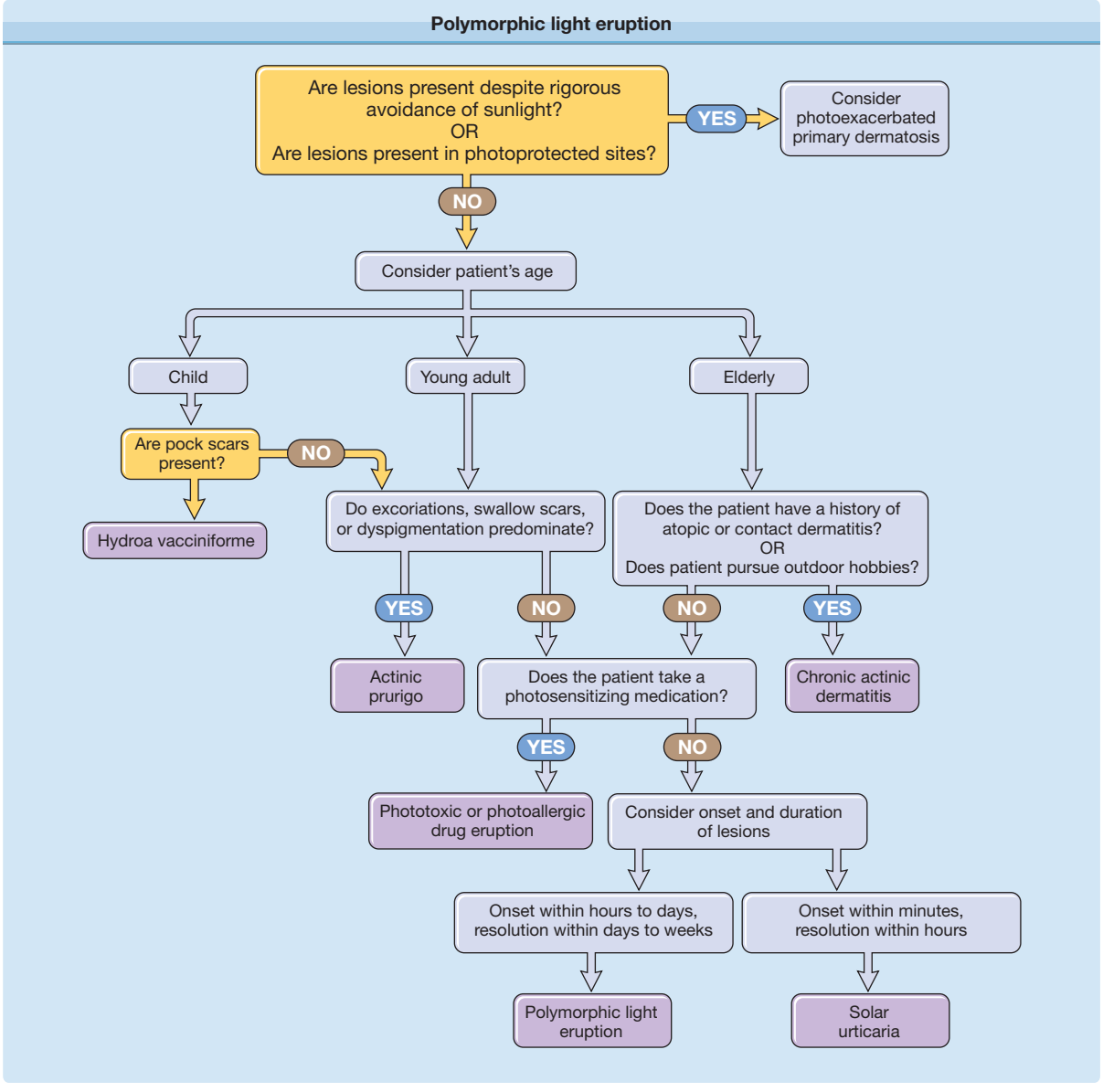

Figure 91-1 Diagnostic algorithm for abnormal responses to ultraviolet radiation.

in Europe.[1] This study estimated an overall suspected lifetime prevalence of 18% among Europeans. Previous reports indicate a prevalence of 10%–15% among North Americans[2] and southern Britons,[3] and 5% among southern Australians.[3] Women are affected more than twice as frequently as men.[1] Fitzpatrick skin type also influences the risk of developing PMLE, with the highest prevalence in people with skin type I and the lowest prevalence in people with skin type IV or higher.[1]

ETIOLOGY AND PATHOGENESIS.

A delayed-type hypersensitivity (DTH) response to a sunlight-induced cutaneous photoantigen was first suggested as the cause of PMLE in 1942, based on the delay between UVR exposure and onset of the eruption, as well as on its lesional histologic features.[4] In normal skin, UVR is known to induce a transient state of immunosuppression by depleting epidermal Langerhans cells and by promoting the release of immunosuppressive cytokines, including IL-4 and IL-10. In patients with PMLE, the immunosuppression normally associated with UVR is diminished substantially. It is thought that this creates an environment in which hypersensitivity responses to one or more photoinduced neoantigens is permissible. The notion that PMLE represents a DTH response is supported by histopathologic, molecular, and epidemiologic data.

Histopathologic examination of biopsy specimens from lesions of PMLE induced by solar-simulated radiation demonstrates the consistent appearance within hours of a T-cell dominated perivascular infiltrate that peaks by 72 hours. $CD4^+$ T cells are most numerous in early lesions, whereas by 72 hours $CD8^+$ T cells predominate, perhaps abolishing the response.[5] Increased

numbers of epidermal Langerhans cells and dermal macrophages are also present. Additionally, it has been demonstrated that neutrophil infiltration into the skin following UVB irradiation is deficient, leading to impaired IL-4 and IL-10 release.[6] Whereas a Th2 cytokine milieu is favored in normal skin following irradiation, a Th1 cytokine profile is favored in patients with PMLE.[7]

Molecular studies have revealed increased intercellular adhesion molecule-1 expression on keratinocytes overlying the perivascular infiltrate in PMLE,[8] as has been noted in DTH reactions but not in irritant contact dermatitis or after the UVB (290–320 nm) irradiation of normal skin.[9]

More recently, the induction of allergic contact sensitivity to dinitrochlorobenzene after solar-simulated irradiation of sensitization sites has been shown to occur more easily in PMLE patients than in normal individuals,[10,11] which suggests that sensitization to a putative UVR-induced cutaneous antigen may also be easier during disease-inducing exposure. On the other hand, elicitation of allergic contact responses to dinitrochlorobenzene in previously sensitized PMLE patients and normal individuals were equally suppressed by irradiation,[12] which explain the frequent development of immunologic tolerance, often called *hardening* or *desensitization*, as summer progresses or during prophylactic phototherapy. In fact, normalization in the depletion of epidermal Langerhans cells in response to UVR has been observed in patients with PMLE after undergoing therapeutic hardening.[13]

Finally, epidemiologic studies also point to hypersensitivity in patients with PMLE. The prevalence of PMLE is much lower in patients with skin cancer, suggesting that UVR-induced immunosuppression that may allow the persistence of malignant cells also inhibits hypersensitivity to photoantigens.[14] Also, PMLE is quite uncommon in iatrogenically immunosuppressed transplant recipients, occurring in only 2% of this population.[15]

The photoinduced neoantigens that initiate PMLE have not been identified, but several molecules may play roles, even in a single patient. The altered molecule(s) itself may hypothetically become antigenic directly by UVR, or secondarily through UVR-induced free radicals that modify nonantigenic peptides in such a way that they become antigenic. Of course, both mechanisms may even take place simultaneously.

UVA radiation (320–400 nm) usually seems more effective than UVB (290–320 nm)[12,16] at initiating PMLE. In one study, UVA irradiation elicited the eruption successfully in 56% of patients exposed to UVA or UVB daily for 4–8 days, in 17% of those exposed to UVB, and in 27% of those exposed to both.[17] However, other reports have suggested that UVB radiation may be implicated in up to 57% of patients. Therefore, it could broadly be said that approximately 50% of PMLE patients seem sensitive to UVB radiation and 75% to UVA, including in each case approximately 25% who are sensitive to both. Even visible light may be responsible on rare occasions.[18] As a result, paradoxically, patients may note that the use of sunscreens, which tend preferentially to remove UVB while transmitting some UVA and all visible light, may even have a PMLE-enhancing effect if exposure times are lengthened. There is most likely genetic predisposition to PMLE,[19] but the intensity of initial UVR exposure may also be important in such predisposed individuals.

CLINICAL FEATURES

History. PMLE usually has onset within the first three decades of life and affects females two to three times more often than males. It occurs in all skin types and racial groups, but is more common in Caucasians. A positive family history is present in about a fifth of patients.[19]

The typical PMLE eruption (Fig. 91-2) occurs each spring or on sunny vacations after the first substantial UVR exposure following a prolonged period with little exposure. It can also occur after recreational sunbed use or, very rarely, after exposure to visible light,[18] and it often abates with continuing exposure. It is rare in winter except after extended outdoor recreational activities. Sufficient exposure may also occur through window glass. The threshold required to trigger PMLE varies from patient to patient and is usually from 30 minutes to several hours, although it may occur several days into a vacation. Lesions appear in hours to days following exposure, but usually in not less than 30 minutes. Patients may note itching as the first sign of an impending PMLE eruption. Once UVR exposure ceases, all lesions gradually resolve fully without scarring over one to several days, occasionally taking a week or two. In any given patient, PMLE outbreaks always tend to affect the same exposed sites. The distribution is generally symmetric. Only some of the exposed skin is usually affected, particularly skin that is habitually covered, and large areas may be spared. An apparent extreme example of PMLE is juvenile spring eruption,[20] which tends to affect boys in the



Figure 91-2 Polymorphic light eruption. Papular lesions of exposed sites.



Figure 91-3 Polymorphic light eruption. Papulovesicular lesions on the arm.

spring and is characterized by pruritic papules and vesicles on their ear helices, although typical PMLE sometimes coexists. Systemic symptoms in PMLE are rare, but malaise and nausea may occur.

Cutaneous Lesions. PMLE has many morphologic forms, all probably with similar pathogenesis and prognosis. The term "polymorphous" describes the variability in lesion morphology observed among different patients with the eruption. In fact, the lesions are usually quite monomorphous in an individual patient. Papular, papulovesicular (Fig. 91-3), plaque (Fig. 91-4), vesiculobullous, insect bite-like, and erythema multiforme-like forms have been described, and pruritus alone may even occur, albeit rarely.[21] The papular form, characterized by large or small separate or confluent erythematous and edematous papules that generally tend to form clusters, is most common. Papulovesicular and plaque variants occur less frequently, and the other forms are rare. An eczematous form has been claimed but probably refers to mild chronic actinic dermatitis or photoexacerbated seborrheic or atopic dermatitis.



Figure 91-4 Polymorphic light eruption. Variably sized itchy plaques on the cheek.

Small papular PMLE, generally sparing the face and occurring after several days of continuing exposure, has been designated *benign summer light eruption* in Europe.[22]

LABORATORY TESTS

Histology. The histologic features of PMLE are characteristic but not pathognomonic,[23] and they vary with clinical presentation. There is generally a moderate to dense perivascular infiltrate in the upper and mid dermis in all forms. The infiltrate consists predominantly of T cells, with neutrophils and infrequent eosinophils. Other common features are papillary, dermal and perivascular edema with endothelial cell swelling. Epidermal change, not always present, may include variable spongiosis and occasional dyskeratosis, exocytosis, and basal cell vacuolization.

Blood Tests. Assessment for circulating antinuclear antibodies (ANA) and extractable nuclear antibodies (ENA) is advisable to exclude subacute cutaneous or other form of cutaneous lupus erythematosus (LE), and, if there is uncertainty, red blood cell protoporphyrins should be assessed to exclude erythropoietic protoporphyria (EPP). Approximately 11% of patients with PMLE have been found to have a positive ANA, with the vast majority having insignificant titers of less than 1:160.[24] An even smaller fraction (less than 1%) of patients with PMLE have anti-Ro antibodies.[24] Clinical correlation is necessary in these patients to exclude the possibility of cutaneous LE.

Phototesting. Cutaneous phototesting with a monochromator confirms photosensitivity in up to half of cases,[25] but usually does not differentiate PMLE from other photodermatoses. However, provocation testing with a solar simulator or other broadband source, sometimes repeated over 2 or 3 successive days, may induce the eruption, allowing a subsequent skin biopsy. This is most appropriate when the history and clinical features are not diagnostic.

DIFFERENTIAL DIAGNOSIS. (See Box 91-1)

COMPLICATIONS.

A very few patients with PMLE may develop LE, as there is a higher than normal prevalence of prior PMLE in patients with LE.[26] However, the presence of autoantibodies does not portend development of LE. Patients with PMLE may also experience significant disease-related psychosocial morbidity. The rate of both anxiety and depression in patients with PMLE are twice that of the general population, and these rates are similar to those observed in patients with psoriasis and atopic dermatitis.[27]

PROGNOSIS AND CLINICAL COURSE.

Over 7 years, 57% of 114 patients reported steadily diminishing sun sensitivity, including 11% in whom the condition cleared.[28]

PREVENTION.

PMLE may often be avoided by moderating sunlight exposure, wearing protective clothing,

and applying broad-spectrum high-protection-factor sunscreens regularly. Sunscreens with UVA and UVB protection may prevent PMLE eruptions in photoprovocable patients,[29] but sunscreens without UVA protection are generally ineffective. Prophylactic phototherapy each spring or before sunny vacations tends to prevent attacks.

TREATMENT. The first goal in treating PMLE is to prevent it. As noted above, one should advise restricting midday sunlight exposure and employing frequent applications of broad-spectrum, high-protection sunscreens. If this is not fully effective, patients who have outbreaks only infrequently, such as on vacations, usually respond well to short courses of oral steroids that are prescribed and taken with them to use in the event of an eruption.[30] If PMLE does develop, approximately 20–30 mg prednisone taken at the first sign of pruritus and then each morning until the eruption clears usually provides relief within several days, and recurrences are then uncommon during the same vacation. This treatment, if well tolerated, may be repeated safely every few months.

More severely affected individuals who experience repeated attacks of PMLE throughout the summer may require prophylactic courses of low-dose photochemotherapy (psoralen and UVA radiation: PUVA) in the spring. This appears to be more effective than broadband UVB radiation, controlling symptoms in up to 90% compared to approximately 60% of cases.[31] Narrowband (311-nm) UVB phototherapy, effective in 70%–80% of cases, is now probably the treatment of choice, because of ease of administration.[32] Prophylactic PUVA or UVB irradiation may sometimes trigger the eruption, particularly in severely affected patients, in which case a brief course of oral steroid therapy is indicated.

Various other therapies have also been tried but appear largely ineffective. These include hydroxychloroquine,[33] which is perhaps occasionally useful; β-carotene,[34] which is rarely effective; nicotinamide,[35] which is usually ineffective; and ω-3 polyunsaturated fatty acids, which are perhaps of moderate assistance in some patients.[36]

A small percentage of patients remain who are unsuitable for, unable to tolerate, or not helped by any of these measures. For these patients, when severely affected, oral immunosuppressive therapy, usually intermittent, with azathioprine or cyclosporine can be helpful.[37,38]

ACTINIC PRURIGO

EPIDEMIOLOGY. Actinic prurigo (AP) occurs throughout much of the world. Native North and South Americans are particularly affected. The disease is estimated to occur in 2% of the Canadian Inuit population.[39] In Mexico, AP is seen most commonly in the indigenous and Mestizo populations living at altitudes greater than 1,000 m.[40] Less commonly, inhabitants of Europe, United States, Australia, and Japan are reported to develop AP.

ACTINIC PRURIGO AT A GLANCE

- A rare, persistent, pruritic and excoriated papular or nodular eruption of sun-exposed and, to a lesser extent, nonexposed skin.
- Beginning in childhood, it may remit at puberty, exacerbate most often in summer, and fade in winter.
- A persistent variant of the sometimes coexistent polymorphic light eruption.
- Similar to the hereditary or familial variant of PMLE that affects native North and South Americans predominantly but which is usually more severe, persisting into adulthood.
- Prevention through avoidance of sunlight is the first line therapy; thalidomide or other immunosuppressive agents may be required.

PATHOGENESIS. AP appears to be UVR-induced in that it is more severe in spring and summer and often demonstrates abnormal skin phototest responses to UVB and/or UVA radiation.[41] UVA is implicated more often than UVB.[42] The cytokine TNF-α is overexpressed by keratinocytes in lesions of AP, creating a proinflammatory environment.[40] Sunlight exposure and solar simulating irradiation may sometimes induce an eruption resembling PMLE in patients with AP, and many patients have close relatives with PMLE.[19] A dermal, perivascular mononuclear cell infiltrate similar to that of PMLE may be seen in early lesions.

Therefore, AP may be a slowly evolving, excoriated variant of PMLE, and thus also a DTH reaction. The human leukocyte antigen (HLA) DRB1*0407 (DR4) is found in 60%–70% of patients with AP but in only 4%–8% of normal DR4 positive controls.[42] Additionally, HLA DRB1*0401 is found in approximately 20% of affected individuals.[42] These immunogenetic features may well be responsible for modulating conventional PMLE into AP. In addition, in some patients, AP appears to transform into PMLE and, in others, PMLE appears to transform into AP,[43] all of which suggests a relationship between the two disorders. The cutaneous UVR chromophores responsible for the eruption are not known, but they are likely to be diverse.

CLINICAL FEATURES

History. AP occurs more commonly in females, with a female to male ratio of about 2:1.[42] The eruption has its onset in childhood, usually present by age 10 years.[41] A positive family history of either AP or PMLE is present in about a fifth of patients.[19] The eruption is often present all year round, but it is commonly worse in summer. Very rarely it is worse in winter or both spring and



Figure 91-5 Actinic prurigo. Papules and nodules on the legs of a 15-year-old girl.

fall, with immunologic tolerance presumably developing during the summer. Exacerbations tend to begin gradually during sunny weather in general rather than after specific sun exposure, although PMLE-like outbreaks may also occur.

Cutaneous Lesions. The primary lesion of AP is a pruritic papule or nodule that occurs singly or in clusters (Fig. 91-5). Papules and nodules are often excoriated and crusted, and plaques may assume a lichenified or eczematous appearance. Vesicles are not seen unless superinfection is present.[42] Sun-exposed areas are most often affected, particularly the forehead, chin, cheeks, ears, and forearms. There is a gradual fading toward habitually covered skin, and the sacral area and buttocks may be mildly affected. Lower lip cheilitis and conjunctivitis are also possible, particularly in Native Americans[44] (Figs. 91-6, and 91-7). Healed facial lesions may leave dyspigmentation and sall pitted or linear scars.

LABORATORY TESTS

Histology. Early papular lesions show changes similar to those of PMLE, namely, mild acanthosis, exocytosis, and spongiosis in the epidermis and a moderate lymphohistiocytic superficial and middermal perivascular infiltrate.[23] A dense dermal lymphoid infiltrate and lymphoid follicles may be seen in lesions from the lip.[40] In persistent lesions, however, excoriations, more acanthosis, variable lichenification, and a dense mononuclear cell infiltrate produce a nonspecific appearance.



Figure 91-6 Cheilitis of actinic prurigo seen in a Mexican landscape gardener.

Blood Tests. Assessment of ANA and ENA should be undertaken to exclude subacute cutaneous or other forms of cutaneous LE. The finding of HLA type DRB1*0401 (DR4) or DRB1*0407, especially the latter, supports the diagnosis of AP.

Phototesting. Cutaneous phototesting with a monochromator confirms light sensitivity in up to half of cases,[41] but, as in PMLE, does not differentiate other photodermatoses. Most patients with positive monochromator testing have reduced minimal erythema doses (MED) in the UVA spectrum or in the combined UVA/UVB spectra.[42] Provocation testing with a solar simulator or other broadband sources induces typical lesions of AP in about two-thirds of patients.[42]

DIFFERENTIAL DIAGNOSIS. (See Box 91-2)

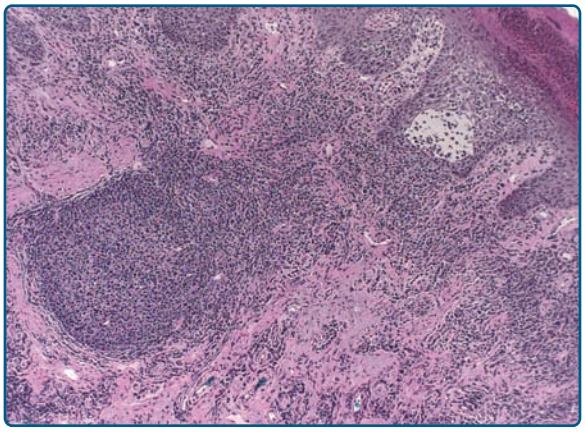

Figure 91-7 Lip biopsy from a patient with actinic prurigo shows a dense lymphohistiocytic infiltrate as well as a lymphoid follicle in the lamina propria.

BOX 91-2 DIFFERENTIAL DIAGNOSIS OF ACTINIC PRURIGO

Most Likely

- Polymorphic light eruption
- Atopic eczema
- Photoexacerbated atopic or seborrheic eczema
- Insect bites
- Prurigo nodularis

Always Rule Out

- Scabies

COMPLICATIONS. Mild scarring, especially on the face, and hypopigmentation may result from excoriations associated with AP. Additionally, two cases of primary cutaneous B-cell lymphoma arising on the face in patients with AP have been reported.[45]

PROGNOSIS AND CLINICAL COURSE. AP commonly arises in childhood and often improves or resolves in adolescence, although persistence into adult life is possible. Persistent cases may assume features of PMLE in adulthood. More rarely, the disorder arises in adulthood and persists indefinitely.[46]

PREVENTION. Prevention begins by restricting midday sunlight exposure and the compulsive use of broad-spectrum sunscreens.[46] In addition, topical calcineurin inhibitors tacrolimus and pimecrolimus may be effective in preventing recurrences in patients with previously documented disease. Of course, there is no known way to prevent its initial onset.

TREATMENT. In less severe cases of AP, sufficient relief may be achieved by restricting sun exposure and by using broad-spectrum, high-protection-factor sunscreens alone.[47] Higher potency topical corticosteroids may be used to relieve the inflammation and pruritus associated with the disease. Phototherapy with narrowband UVB or PUVA may occasionally help,[48] perhaps more reliably if the skin is cleared first with oral steroids. Topical tacrolimus or pimecrolimus may also help, again if the skin is cleared first. The treatment of choice in more severe or recalcitrant cases is thalidomide, with initial doses of 50–100 mg daily, preferably given intermittently. Responses to thalidomide are evident in most patients within several weeks. The most serious complication associated with thalidomide is teratogenicity, so pregnancy must be rigorously avoided. Other potential adverse effects are typically mild, including drowsiness, headache, constipation, and weight gain. An increased risk of thromboembolism and dose-related peripheral (mostly sensory) neuropathy are other potential adverse effects of thalidomide. In cases where thalidomide is unavailable or otherwise not appropriate, oral immunosuppressive therapy with azathioprine or cyclosporine may also be considered.

HYDROA VACCINIFORME

HYDROA VACCINIFORME AT A GLANCE

- A rare, chronic, scarring photodermatosis sometimes associated with Epstein–Barr virus infection
- Characterized by recurrent sunlight-induced crops of papulovesicles and vesicles, most commonly on the face and dorsa of the hands.
- Onset commonly in childhood, remitting most often at puberty.
- May be a scarring variant of polymorphic light eruption.
- Focal intraepidermal vesiculation, reticular keratinocyte degeneration, epidermal and upper dermal necrosis, and sometimes ulceration are virtually pathognomonic histologic changes.
- Avoidance of ultraviolet radiation, including the use of broad-spectrum high-protection-factor sunscreens, is the only established therapy.
- Prophylactic immunosuppressive phototherapy, administered with great care to avoid induction of new lesions, may help.

EPIDEMIOLOGY. Hydroa vacciniforme (HV) occurs in North America, Europe, Japan, and very likely elsewhere. However, its rarity and lack of universally acknowledged diagnostic criteria may make the diagnosis difficult to establish.

ETIOLOGY AND PATHOGENESIS. The pathogenesis of HV is not known. No chromophores have been identified, and although UVB minimal erythemal dose responses are normal in most patients, some have increased UVA sensitivity.[49] Blood, urine, and stool porphyrin concentrations are normal, as are all other laboratory tests. Nevertheless, its clear relationship to sunlight exposure, its distribution, and its early clinical appearances are all similar to that of PMLE, which suggests a relationship. On the other hand, fully developed HV eruptions are more severe than those found in PMLE, are associated with permanent scarring, and are unresponsive to treatments ordinarily effective in PMLE, apart perhaps from sunscreens and occasionally prophylactic phototherapy. Reports from Asia and Mexico have linked HV to chronic Epstein–Barr virus (EBV) infection,[50,51] although a relationship

between EBV and HV in all populations has not been established. Japanese reports indicate that EBV nucleic acids are found in the cutaneous lesions of HV in 85%–95% of patients but not in lesional skin of control patients.[51,52] A recent report from France has now provided substantial evidence that EBV infection persists in adult patients with HV and that it plays an important pathogenic role.[53]

CLINICAL FINDINGS

History. HV commonly develops in early childhood and resolves spontaneously by puberty, although, in some patients, it is lifelong. There is male predominance for severe forms, whereas milder disease is more common in females.[49,54] Familial incidence is exceptional. One estimate of the prevalence of HV is 0.34 cases per 100,000 with an approximately equal sex ratio; males had a later onset and longer duration of the disorder than females.[54]

HV eruptions typically occur in summer,[41] often with an intense burning or stinging sensation followed by the appearance of individual or confluent papules and then vesicles, all within hours of sunlight exposure (Fig. 91-8). This is followed by umbilication, crusting, and progression to permanent pock scarring within weeks. The eruption affects the cheeks and, to a lesser extent, other areas of the face as well as the backs of the hands and outer aspects of the arms. The distribution tends to be symmetrical.

Cutaneous Lesions. HV is characterized by initial erythema, sometimes with swelling, followed by symmetrically scattered, usually tender papules within 24 hours; vesiculation, occasionally confluent and hemorrhagic (Fig. 91-9); umbilication; then crusting and detachment of the lesions with permanent, depressed, hypopigmented scars within weeks. These scars are invariably present. Oral ulcers and eye signs also occur rarely.[55,56]



Figure 91-8 Hydroa vacciniforme. Vesicular, bullous, and crusted facial lesions, which are precursors of vacciniform scars.

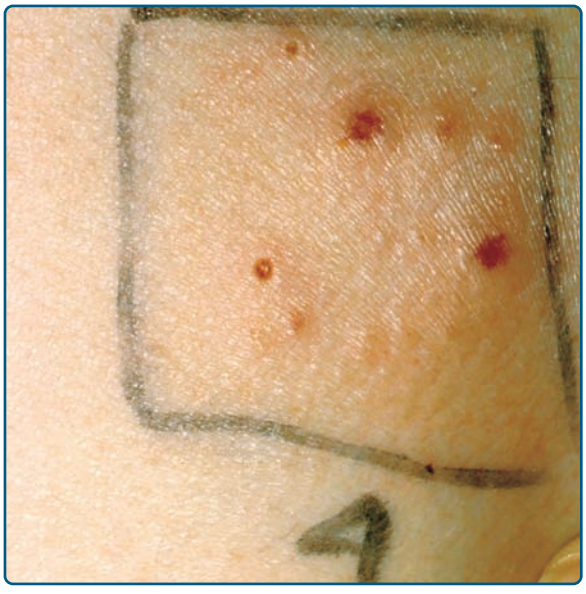

Figure 91-9 Typical hydroa vacciniforme lesions provoked by repeated ultraviolet A irradiation.

LABORATORY TESTS

Histology. Early histologic changes include intraepidermal vesicle formation with subsequent focal epidermal keratinocyte necrosis and spongiosis. There is a dermal perivascular neutrophil and lymphocyte infiltrate.[23] Older lesions show necrosis, ulceration, and scarring. Vasculitic features have been reported.[49]

Blood Tests. Blood, urine, and stool porphyrin concentrations should be assessed to exclude cutaneous porphyria, and an ANA and ENA to exclude the small possibility of cutaneous LE.

Phototesting. Phototesting may show increased sensitivity to short-wavelength UVA in some patients, but phototesting usually does not discriminate HV from other photodermatoses. Simulated solar irradiation may also induce erythema at reduced doses or occasionally provoke the typical vesiculation of HV (see Fig. 91-7).

Other Tests. Viral studies for herpes infection or other viral disorders should be undertaken if photoexacerbation or photoinduction of these other disorders seems at all possible.

DIFFERENTIAL DIAGNOSIS.

(See Box 91-3). There are reports of severe HV-like eruptions occurring in patients with chronic EBV infection and other associated disorders such as hypersensitivity to mosquito bites and the hemophagocytic syndrome. HV-like eruptions are distinguished from true HV by the development of lesions in both exposed and sun-protected skin and by the presence of systemic symptoms such as fever, hepatosplenomegaly, and wasting.[51,57]

BOX 91-3 DIFFERENTIAL DIAGNOSIS OF HYDROA VACCINIFORME

- Photoexacerbated viral dermatoses such as herpes simplex
- Erythropoietic protoporphyria
- Polymorphic light eruption
- Subacute cutaneous lupus
- Xeroderma pigmentosum

The distinction between an HV-like eruption and true HV is important because patients with a severe HV-like eruption may rarely go on to develop potentially fatal hematologic malignancy.[56–59] Finally, a recent quality-of-life study indicates that HV causes embarrassment and self-consciousness among children with the disease.[60] The negative impact of HV on quality of life exceeds previously reported indices for atopic dermatitis and psoriasis.[60]

COMPLICATIONS. Pock scarring is an inevitable sequela of HV. Cases of severe HV-like eruption may progress to lymphoproliferative disease.

PROGNOSIS AND CLINICAL COURSE. HV often resolves in adolescence but may occasionally persist into adult life.

PREVENTION. Sun avoidance and sunscreen use, as well as prophylactic phototherapy annually in spring, tend to prevent HV in some patients.

TREATMENT. Treatment of HV consists of restricting sunlight exposure and use of high-protection-factor broad-spectrum sunscreens. Occasionally, antimalarials appear to have helped, but their true value has not been established. As with PMLE, prophylactic phototherapy with narrowband UVB or PUVA, particularly the latter, may be helpful but must be administered with care to avoid disease exacerbation.[49,53,61] If conservative measures are ineffective, however, as often occurs, topical or intermittent oral steroids, topical calcineurin inhibitors, or even oral immunosuppressive medication may be tried if clinically appropriate, though these agents too are usually ineffective. In patients with chronic EBV infection, antiviral therapy with acyclovir and valacyclovir was reported in a small series of patients to reduce the frequency and severity of eruptions.[62]

CHRONIC ACTINIC DERMATITIS

EPIDEMIOLOGY. Chronic actinic dermatitis (CAD) has regularly been diagnosed in Europe, North America, Africa, Australia, New Zealand, Japan, and India. The disorder therefore appears to have worldwide distribution, affecting all skin types, although it is perhaps more common in temperate regions.

CHRONIC ACTINIC DERMATITIS AT A GLANCE

- A rare acquired persistent eczematous eruption of exposed skin, sometimes having pseudolymphomatous features.
- Commonly affects older men, but sometimes young atopic patients and rarely patients with hydroa vacciniforme or human immunodeficiency virus infection.
- Histologic features are eczematous, but pseudolymphomatous forms may be virtually indistinguishable from cutaneous T-cell lymphoma.
- Ordinarily induced by small amounts of ultraviolet B radiation, often with ultraviolet A radiation, and sometimes even visible light; in rare cases, induced by UVA radiation or visible light alone.
- Persistent light reaction, actinic reticuloid, photosensitive eczema, and photosensitivity dermatitis are all considered clinical variants.
- Very likely due to a delayed-type hypersensitivity reaction against an endogenous photoinduced epidermal antigen(s).
- Therapy consists of strict avoidance of ultraviolet radiation, along with topical and intermittent oral steroids, topical calcineurin inhibitors, or prolonged low-dose immunosuppressive phototherapy. Oral immunosuppression with cyclosporine or azathioprine is often required.

ETIOLOGY AND PATHOGENESIS. Studies of the clinical, histologic, and immunohistochemical features of CAD all show it to resemble the DTH reaction of allergic contact dermatitis,[73–75] even in its severe pseudolymphomatous form (formerly called *actinic reticuloid*), in which the clinical and histologic features duplicate those seen in long-standing allergic contact dermatitis.[76] It is therefore highly probable that CAD is an allergic reaction. In addition to hypersensitivity to cutaneous photoantigens, patients with CAD often have concomitant allergic contact dermatitis to airborne or other ubiquitous allergens, including plant compounds, fragrances, and medicaments.[77] Commonly implicated allergens include sesquiterpene lactone from plants of the Compositae family and sunscreens. A recent study indicates that sesquiterpene lactone remains the most common allergen in patients with CAD, with positive and clinically relevant photopatch testing to this allergen documented in approximately 20% of patients.[78]

TABLE 91-2
Original Criteria for the Eczematous Photosensitivity Disorders

- Persistent light reaction[62]: Eczema of predominantly light-exposed skin sensitive to UVB ± UVA following acute photoallergic contact dermatitis
- Actinic reticuloid[63]: Infiltrated papules and plaques of mainly light-exposed skin with lymphoma-like histologic features and sensitivity to UVB + UVA ± visible light; negative results on photopatch testing
- Photosensitive eczema[64]: Morphologic and histologic eczema of mainly light-exposed skin with photosensitivity only to UVB; negative results on photopatch tests
- Photosensitivity dermatitis[65]: Morphologic and histologic eczema of mainly light-exposed skin with photosensitivity to UVB ± UVA; positive results on photopatch testing in some of the patients
- Chronic actinic dermatitis[66]: Syndrome encompassing photosensitive eczema, photosensitivity dermatitis, and actinic reticuloid; persistent light reaction also now included

UVA = ultraviolet A radiation; UVB = ultraviolet B radiation.

In addition, cc has emerged as an increasingly common antigen in CAD[78] as has balsam of Peru.[79]

When CAD occurs in the absence of an obvious epicutaneous contact allergen, the relevant novel antigen must be either directly radiation-induced or formed indirectly as a result of secondary oxidative metabolism. Important support for the latter possibility comes from the fact that albumin can become antigenic in vitro through photooxidation of its histidine moieties.[80] There is no evidence for a genetic susceptibility to CAD; however, one stimulus for the acquisition of skin reactivity may be concurrent allergic contact dermatitis to recognized exogenous sensitizers or photosensitizers,[81,82] often airborne, which may predispose by altering cutaneous immunity, and thus permitting immunological recognition of an endogenous photoantigen. Long-standing endogenous eczema,[68,69,83,84] drug-induced photosensitivity,[85] human immunodeficiency virus infection,[86] and possibly PMLE[75] may also play similar roles. On the other hand, in addition or instead, chronic photodamage in frequently sun-exposed elderly outdoor enthusiasts, those who most often develop CAD,[75] may impair normal UVR-induced skin immunosuppression sufficiently for endogenous UVR-induced photoantigens to be recognized, as apparently also occurs for genetic reasons in PMLE.[19] Clearly, there is much work left to be done to identify the immunologic mechanisms that account for CAD.

Determining the action spectrum for CAD should theoretically help identify the postulated antigens, and the action spectra for CAD have been shown to resemble that of sunburn in many patients.[87] However, the eruption in CAD is eczematous, and much lower doses of UVR are required to evoke CAD than to produce erythema. In any event, the UVR chromophore for some patients may be the same as that of sunburn, namely DNA,[87] with UVR-damaged DNA serving directly as an antigen in CAD. In other patients with CAD, however, the photoallergen must be different, because these patients react only to UVA radiation,[88] and some patients react only to visible light.[89]

In summary, CAD appears to be an allergic contact dermatitis-like reaction against UVR-altered DNA or similar or associated molecules, perhaps as a result of enhanced immune reactivity due to concomitant airborne contact dermatitis or a reduced immunosuppressive capacity in photodamaged skin. The eruption occurs most often in patients with long-standing exposure to sunlight and airborne contact allergies.

CLINICAL FEATURES

History. CAD may arise de novo in apparently normal skin or in the skin of patients with previous endogenous eczema, photoallergic or allergic contact dermatitis, or rarely PMLE.[75,90] Concurrent allergic contact sensitivity to plant allergens, fragrances, or sunscreens is common.[82] The condition usually affects middle-aged or elderly men,[75] as CAD is rarely seen in patients under 50 years of age, except for those with prior atopic eczema.[83,84] The disorder is worse in summer, developing within minutes to hours after sunlight exposure and producing a pruritic confluent erythematous eruption that occasionally remits over several days with scaling, if exposure ceases and if the reaction is mild. However, severely affected patients frequently do not even recognize that exacerbations are related to sunlight exposure, especially when affected all year round.

Cutaneous Lesions. The lesions of CAD are eczematous, patchy or confluent, and acute, subacute, or chronic (Figs. 91-10 and 91-11). In severe cases, lichenification is common. Less commonly, scattered or widespread erythematous, shiny, infiltrated pseudolymphomatous papules or plaques are present on a background of erythematous, eczematous,

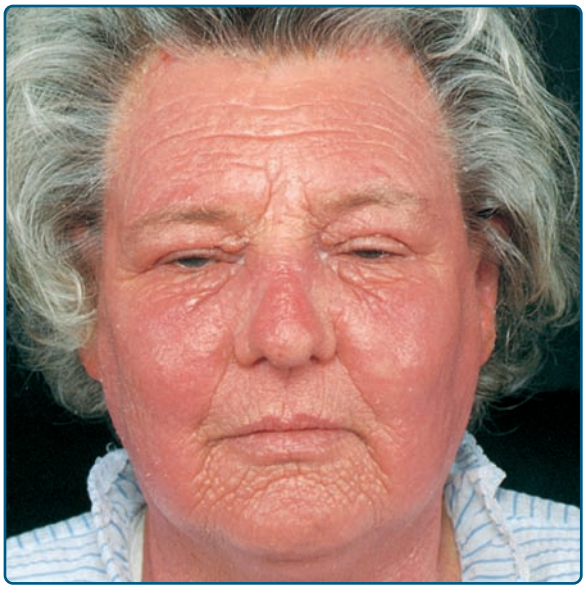

Figure 91-10 Chronic actinic dermatitis. Infiltrated eczematous eruption on the face.



Figure 91-11 Chronic actinic dermatitis. **A, B.** Severe light-induced eczema of the face and neck. **C, D.** Patient in full remission after low-dose psoralen plus ultraviolet A irradiation over weeks, with initial high-dose oral steroid cover to prevent initial exacerbation.

or normal skin.[75] Habitually exposed areas are most often affected, commonly with sharp cutoff at lines of clothing. There is sparing of deep skin creases, upper eyelids, finger webs, and skin behind the earlobes. In severe disease, eczema of the palms and soles may also be found. Eyebrows, eyelashes, and scalp hair may be stubbly or altogether lost from constant rubbing and scratching. Erythroderma, usually but not always accentuated on exposed sites, supervenes rarely. Variable, sometimes geographic, sparing of exposed areas of the face or elsewhere, as well as irregular hyperpigmentation and hypopigmentation, sometimes vitiligo-like,[91] may also occasionally be found.

LABORATORY TESTS

Histology. Histologic features include epidermal spongiosis and acanthosis, sometimes with hyperplasia. There is usually a predominantly perivascular lymphocytic cellular infiltrate confined to the upper dermis that in milder cases may resemble chronic eczema.[23] Severe CAD, however, may mimic cutaneous T-cell lymphoma (CTCL), on occasion being virtually indistinguishable. Features mimicking CTCL include epidermal Pautrier-like microabscesses and deep, dense epidermotropic mononuclear cell infiltration, sometimes with atypia. Typically, there is no marked increase in mitoses. T-cell receptor gene rearrangement studies should be undertaken if there is suspicion of CTCL. However, T-cell receptor clonality may also be observed in benign dermatoses.

Blood Tests. Assessment of the ANA and ENA is advisable in all patients to exclude the unlikely possibility of cutaneous LE. In severe or erythrodermic CAD, there may be large numbers of circulating $CD8^+$ Sézary cells without other suggestions of malignancy.[92,93] Human immunodeficiency virus status should be assessed if there is suspicion that this may be a predisposing factor.[86] Serum IgE may be elevated,

with higher levels of IgE correlating with more severe disease.[79]

Phototesting. Phototesting is essential, if available, to confirm the diagnosis of CAD. Almost invariably one finds low erythemal thresholds and eczematous or pseudolymphomatous responses after irradiation with UVB, usually with UVA, and rarely with visible wavelengths.[75] A small number of patients react only to UVA,[88] and fewer still only to visible light,[89] in which case, drug photosensitivity must be excluded. Testing should be done on uninvolved skin of the back with no topical or systemic steroid therapy for at least the preceding few days to avoid false-negative results.[94] Monochromatic and broad-spectrum sources both induce abnormal responses, with the former determining the action spectrum for disease induction and the latter tending to demonstrate acute eczema.

Patch and Photopatch Testing. Patch and photopatch testing is also essential in suspected CAD, because contact sensitivity to airborne allergens such as Compositae oleoresins, phosphorus sesquisulfide, and colophony alone may resemble CAD or even coexist. In addition, occasional secondary contact or photocontact sensitivity to sunscreens or other topical therapies may complicate the clinical picture further. Positive results with photopatch testing are found in approximately 80% of patients.[78,79]

DIFFERENTIAL DIAGNOSIS. (See Box 91-4)

COMPLICATIONS.

A relationship to CTCL seems likely to be coincidental, especially because results of T-cell receptor, immunoglobulin gene rearrangement, and other studies are negative in CAD.[92,95,96] In addition, CAD gradually resolves in many patients, there is no higher incidence of malignancies, and life expectancies are thought to be normal.[97] However, CTCL itself may present very rarely with severe CAD-like photosensitivity, and careful investigation to exclude CTCL is necessary when the disease suspected.[98]

PROGNOSIS AND CLINICAL COURSE.

Once established, CAD usually persists for years before resolving gradually.[98]

TREATMENT.

Treatment of CAD is often difficult and not fully effective. Rigorous avoidance of UVR and exacerbating contact allergens is essential, along with regular application of high protection-factor broad-spectrum topical sunscreens of low irritancy and allergenic potential. Strong topical steroids such as clobetasol propionate are also often needed and frequently produce marked symptomatic relief without adverse effects, even after long-term use, if confined to affected skin. Occasional oral steroid use is often helpful for disease flares. In more resistant disease, the topical calcineurin inhibitors—tacrolimus and pimecrolimus—sometimes produce good results if tolerated.[99,100] For refractory CAD, however, oral immunosuppressive therapy is almost always necessary and generally helpful if tolerated. Azathioprine 1.5–2.5 mg/kg/day often produces remission in months,[101] after which it may be reduced in dosage, or perhaps discontinued in the winter. Cyclosporine 3.5 to 5.0 mg/kg/day is usually rapidly effective,[102] but is more likely to produce adverse effects, which sometimes necessitate withdrawal. Mycophenolate mofetil is less often useful. Finally, long-term low-dose phototherapy with PUVA, usually several times weekly initially followed by maintenance exposures about every 3 weeks may be helpful,[103] generally accompanied initially by oral and topical steroid therapy to avoid disease flares.

PREVENTION.

The risk of CAD can probably be reduced by moderating outdoor pursuits, especially those associated with plant allergen exposure such as gardening, even more so for individuals who already have a tendency to develop eczematous eruptions in exposed areas. Avoidance of UVR is critical, and patients should be aware that indoor lighting may also be a source of UVA exposure. Compact fluorescent lamps even emit UVR at wavelengths as low as 254 nm, and some patients with CAD appear to be susceptible to disease flares after exposure to such lamps.[104]

BOX 91-4 DIFFERENTIAL DIAGNOSIS OF CHRONIC ACTINIC DERMATITIS

- Photoexacerbated atopic or seborrheic eczema
- Drug or chemical photosensitivity
- Cutaneous T-cell lymphoma
- Eczematized actinic prurigo

SOLAR URTICARIA

EPIDEMIOLOGY.

Solar urticaria (SU) has been reported in Asia, Europe, and the United States, and, thus, probably occurs worldwide. Perhaps 3 per 100,000 are affected.[105] Ultraviolet and visible radiation are causes of this form of urticaria, but SU accounts for less than 0.1% of all cases of chronic urticaria.[106]

ETIOLOGY AND PATHOGENESIS.

Primary SU is an immediate type I hypersensitivity response against a cutaneous or circulating photoallergen(s) generated from a precursor at the time of irradiation. Both circulating photoallergens and relevant IgE antibodies have been demonstrated. This has been termed primary SU, for which no genetic basis has been identified. Very rarely, SU may occur in association with drug photosensitivity, such as chlorpromazine and coal tar,[106] cutaneous porphyria, or LE. This has been termed secondary SU.

Two types of primary SU have been proposed, both involving immunoglobulin E-mediated hypersensitivity against a neoantigen that is photoinduced. In type 1, the photoallergen is the chromophore, which is generated only in patients with SU. Type 2 is mediated by circulating antibodies found only in patients and

SOLAR URTICARIA AT A GLANCE

- An uncommon sunlight-induced whealing disorder that occurs more often in females.
- Rarely is secondary to phototoxic drug use or with cutaneous porphyria.
- Onset within 5 to 10 minutes of sunlight exposure. Resolves in an hour or two; may be disabling and, rarely, life threatening.
- An immediate type I hypersensitivity response against a cutaneous or circulating photoallergen(s).
- Clinical and histologic features are those of urticaria.
- Phototesting may confirm the diagnosis and identify the action spectrum.
- Sensitivity may be to ultraviolet B, ultraviolet A, visible light, and/or any combination, but most commonly to ultraviolet A and visible light.
- Sunlight avoidance prevents solar urticaria, and high protection-factor broad-spectrum sunscreens and antihistamines may help.
- When necessary, phototherapy, plasmapheresis, or oral immunosuppressive drugs may be helpful in management.

directed against a common chromophore-generated antigen.[106] The wide range of inducing wavelengths is attributed to the unique action spectra of different photoallergens (chromophores). Patients with type 1 SU appear to have photoallergens of molecular mass 25–34 kilodaltons (kDa) and action spectra within the visible region, whereas type 2 SU has photoallergens of 25–1,000 kDa and variable action spectra.[107] The range of eliciting wavelengths can narrow or broaden over months or even years, suggesting that the relevant choromophores may vary over time.

Exposure to visible or UVA irradiation before, during, or after the urticaria-inducing irradiation inhibits whealing in some patients, possibly by inactivation of the initial photoproduct or the inhibition of subsequent reactions.[108,109]

CLINICAL FEATURES

History. Primary SU is slightly more common in females and may arise at any age, although most patients develop the disease in childhood or young adulthood.[106] The first episode typically occurs after prolonged sunlight exposure or occasionally following tanning bed use. It also seems to be associated with other photosensitive skin disorders more often than expected.[110] Typically, 5–10 minutes or, rarely, 20–30 minutes of exposure leads to itching and erythema, followed by patchy or confluent urticarial whealing, with gradual resolution within 2 hours. Rarely, patients report itching alone, and the onset of symptoms may be delayed for up to several hours.[111] A rare variant termed "fixed solar urticaria" has been reported and is characterized by urticarial lesions that are induced repeatedly in the same location.[112] In patients with mild disease, or in those who quickly recognize their SU onset and avoid further exposure, whealing may not be reported, even if it may be elicited during phototesting. Patients having extensive whealing may also describe headache, nausea, bronchospasm, and syncope, which rarely may be life threatening. Angioedema and anaphylaxis are exceedingly rare but have been reported. Secondary SU should be excluded by ruling out drug photosensitivity, cutaneous porphyria, and LE.

Cutaneous Lesions. SU usually affects all exposed skin with an initial macular erythema, followed by whealing and a surrounding patchy erythematous flare (Fig. 91-12), often with clear demarcation at lines of clothing. Rarely, there is sparing of the face and hands, perhaps as a result of UVR-induced tolerance. In some patients, specific sites may be affected repeatedly.

LABORATORY TESTS

Histology. There is dermal vasodilation, edema, and predominantly perivascular neutrophil and eosinophil infiltration at 5 minutes and at 2 hours, but not 24, hours.[23] Endothelial cell swelling occurs early on, with mononuclear cell infiltration later following higher irradiation doses. Extensive eosinophil granule major basic protein deposition is also present in the dermis at 2 and 24 hours, which suggests eosinophil degranulation.[113] Histologic features do not distinguish SU from other causes of urticaria.



Figure 91-12 Solar urticaria. Pruritic wheals with a surrounding patchy flare occurring within 15 minutes of sun exposure after irradiation of the patient's back through a template.

Blood Tests. Tests for an ANA and ENA should be employed to exclude cutaneous LE, as should the blood, urine, and stool porphyrins to exclude cutaneous porphyria.

Phototesting. Phototesting with a monochromator, broad-spectrum source, or sunlight allows confirmation of the diagnosis of SU and identification of the inducing wavelengths. However, negative phototest results do not exclude the disorder, because the ease of SU induction, particularly when mild, may vary. If no monochromator is available, appropriately filtered broadband sources can be used, and minimal urticarial dose estimation may help in assessing treatment efficacy. Patients with SU may have a biphasic response to phototesting whereby wheals develop in response to one action spectrum but are inhibited by another action spectrum.[114] Most commonly, shorter wavelengths induce wheals on phototesting while longer wavelengths may inhibit wheal formation.[114]

DIFFERENTIAL DIAGNOSIS. (See Box 91-5)

COMPLICATIONS.

Severe primary SU may lead to anaphylactic shock, which is rarely fatal. The rare secondary SU related to drug or chemical photosensitivity, cutaneous porphyria, or cutaneous lupus may be associated with the complications of the primary conditions.

COURSE AND PROGNOSIS.

SU often persists indefinitely, sometimes with deterioration but also sometimes with improvement, with the probability of clinical resolution at 5, 10, and 15 years of 12%, 26%, and 46%, respectively.[105,106]

TREATMENT.

Restricting sun exposure and using high protection-factor broad-spectrum sunscreens and appropriate clothing may be helpful in preventing SU. Sunscreens with UVA and UVB protection effectively increase the minimal urticarial dose on phototesting.[115] Antihistamines have been demonstrated to suppress wheal and itch formation in patients with SU, and, when combined with sunscreens, the increase in UV tolerance may be remarkable.[115] Phototherapy may be helpful in those patients who commonly develop SU tolerance as summer advances and also sometimes in those with persistent disease. Unfortunately, phototherapy usually needs to be continued to maintain its effect, and, consequently, carries the usual risks of long-term phototherapy. In addition, phototherapy should be undertaken with caution early on to avoid the risk of anaphylaxis, particularly in severely affected individuals.[113] Multiple UVA exposures with increasing doses during the same day (so-called *rush hardening*) have helped some patients.[116] Others with recalcitrant disease have been reported to respond to plasma exchange, or plasmapheresis, particularly if they are found to have circulating SU-associated serum factors; these remissions may be long-lived.[117,118] Intravenous immunoglobulin has also been helpful on occasion,[119] as has oral cyclosporine. Partial improvement has recently been reported with omalizumab, a monoclonal antibody directed against IgE.[120]

BOX 91-5 DIFFERENTIAL DIAGNOSIS OF SOLAR URTICARIA (SU)

- Polymorphic light eruption[a]
- Subacute cutaneous lupus[a,b]
- Photoexacerbated dermatoses such as atopic or seborrheic eczema
- Erythropoietic protoporphyria[b]
- Hepatic porphyrias[b]
- Drug or chemical photosensitivity[b]

[a]Rarely may coexist with SU.
[b]A rare cause of secondary SU.

PHOTOEXACERBATED DERMATOSES

Several dermatoses that are not caused by UVR may be worsened by it (Table 91-3). Mechanisms of this phenomenon, termed photoexacerbation, have rarely been studied. The initial condition may be severely worsened even if it was originally only mild or subclinical.[121,122] These disorders are relatively common and account for a significant percentage of all photodermatoses. Such conditions, especially the eczemas, psoriasis, and acne, improve with UVR exposure in most patients, perhaps because cutaneous reactivity is reduced, but in a small proportion of individuals, it is instead aggravated. If photoexacerbation does occur, the new eruption generally develops or worsens initially at sites typical of the basic disorder (Fig. 91-13), followed at times by extension to other areas. In photoexacerbated

TABLE 91-3
Selection of Diseases Sometimes Exacerbated by Ultraviolet Irradiation

- Acne
- Atopic eczema
- Carcinoid syndrome
- Cutaneous T-cell lymphoma
- Dermatomyositis
- Disseminated superficial actinic porokeratosis
- Erythema multiforme
- Familial benign chronic pemphigus (Hailey–Hailey disease)
- Keratosis follicularis (Darier disease)
- Lichen planus
- Lupus erythematosus
- Pellagra
- Pemphigus foliaceus (erythematosus)
- Pityriasis rubra pilaris
- Psoriasis
- Reticulate erythematous mucinosis syndrome
- Rosacea
- Seborrheic eczema
- Transient acantholytic dermatosis (Grover disease)
- Viral infections



Figure 91-13 Photo-exacerbated seborrheic dermatitis, affecting the face only at sites of predilection for the seborrheic eruption.

seborrheic eczema, however, an unpleasant sensation at the exposed sites may be the first or only feature. Treatment consists of minimizing UVR exposure, protection with suitable clothing, application of high protection-factor broad-spectrum sunscreens, and careful treatment of the underlying disorder. Taking these steps alone, frequently, if perhaps surprisingly, even may abort the photosensitivity.[121] If these actions are inadequate, low-dose phototherapy, as for PMLE, can sometimes help, for example, in seborrheic or atopic eczema and psoriasis, but its use is contraindicated in cutaneous LE or dermatomyositis, in which aggravation of the systemic disease is a risk. Photoexacerbated acne commonly requires treatment with oral isotretinoin.

Individual diseases for which photoexacerbation may occur are discussed in more detail in the online sections of this chapter include the disorders many of the disorders in Table 91-3.

APPROACH TO THE PATIENT WITH ABNORMAL SKIN PHOTOSENSITIVITY

CLINICAL FEATURES

Patients with abnormal photosensitivity present in three ways: (1) sporadic or (2) persistent eruptions in sunlight-exposed areas, or, infrequently, (3) erythroderma. When sporadic, the patient usually considers sunlight exposure to be responsible; when persistent, the physician often must identify the association. However, careful history taking is essential, first to confirm that sunlight exposure is responsible and then to make a diagnosis. Information of considerable importance are age at disease onset, gender, family history, previous sunlight sensitivity, occupation, leisure pursuits, and systemic and topical drug (or chemical) use. Additional relevant details include distribution of lesions, effects of season, exposure times required for induction, time between exposure and the appearance of lesions, duration of the eruption after exposure ceases, effects of sunlight received through window glass (implicating UVA and visible light), presence of systemic symptoms, and patient-assessed morphologies (progression of the disease before the clinic visit).

In terms of age and sex, young woman are more likely to develop PMLE; women or girls more commonly develop AP; children of either gender may have HV, xeroderma pigmentosum (XP), or EPP; elderly men or younger individuals with a history of eczema most often develop CAD.

A family history of sunlight sensitivity may be present in patients with PMLE, AP, XP, and the porphyrias. CAD is more common in outdoor enthusiasts exposed to both sunlight and airborne allergens, although exacerbations of disease, despite sunscreen use, invoke the possibility of sunscreen allergy. On the other hand, exacerbations with sunscreens may even occur in the absence of allergy in PMLE. An eruption appearing in minutes and remitting within 2 hours suggests SU or occasionally photosensitivity to drugs, such as amiodarone. Onset within 20 minutes to several hours, with resolution over days suggests PMLE, HV, EPP, cutaneous LE or other photoexacerbated dermatoses, or other drug photosensitivities, such as to thiazides. Systemic malaise is uncommon in PMLE, HV, and SU. Development of lesions after exposure through window glass suggests an inducing spectrum that includes UVA, although it may occur in virtually all of the photodermatoses.

The eruption described by patients with PMLE is generally that of small or large, elevated, pruritic, red or skin-colored, and often clumped spots of blisters, sometimes confluent, that usually involve several, but not all exposed sites. In HV, blistering with scar formation occurs, and in SU, elevated pruritic wheals are often confluent. In EPP and amiodarone drug photosensitivity, a marked burning sensation, without visible change, has been reported. In EPP, relatively lengthy exposure may lead to firm, colorless or pink, diffuse swelling, rarely with scattered blisters. In most drug photosensitivity reactions and in XP, an exaggerated sunburn-like reaction is possible, which is often maximal in XP at 2–3 days. Finally, in photoexacerbated dermatoses, the eruption resembles that of the primary disorder.

Photosensitivity eruptions are usually present on some, and occasionally all, of the forehead, nose, upper cheeks, tip of the chin, rims of the pinnae, back and sides of the neck, upper chest, backs of the hands and feet, and extensor aspects of the limbs. Covered areas may also be involved, but to a lesser extent. On the other hand, portions of the face protected by hair or customarily shown in shadow such as upper eyelids, finger webs, skin creases and skin under the nose, lower lip, chin, and earlobes are frequently unaffected, except when there is associated airborne contact dermatitis.

Excoriated papules suggest AP, whereas eczematous lesions, or very rarely light-associated erythroderma, suggest CAD or photoexacerbated atopic or seborrheic eczema. Finally, skin fragility, bulla formation, and atrophic superficial scarring suggest hepatic porphyria or pseudoporphyria, especially if there has been drug or excessive alcohol intake.

Clinical appraisal along with the history usually results in a diagnosis, although for complete certainty, several of the studies listed below may be appropriate.

LABORATORY STUDIES

If the diagnosis is not certain, appropriate additional studies include an assessment of the ANA and ENA. If present at significant titers, cutaneous LE should be considered. In addition, examination of blood, urine, and stools for porphyrins should be considered.

Biopsies may be helpful. Lesional histologic features are characteristic in several photodermatoses, especially PMLE, HV and CAD. However, with the exception of HV, histopathologic changes in photodermatoses are rarely entirely diagnostic. These are reviewed in the preceding disease descriptions.

Phototesting of normal back skin with a monochromator in CAD and SU often produces the papules or wheals of the condition itself, frequently at low irradiation doses, and this also may identify the action spectrum. Phototesting also helps to confirm XP through the delayed development of erythema over 2–3 days, with an abnormally low-dose threshold, often eventuating in blister formation (Table 91-4). In eczematous photosensitivity, patch and photopatch testing are also essential to identify relevant allergens. Finally, special techniques such as the assessment of DNA excision repair or of RNA synthesis recovery rate in cultured fibroblasts after UVR exposure are essential for the diagnoses of certain genophotodermatoses.

PHOTOTESTING. Techniques of phototesting vary greatly from country to country and from center to center. Although it is the investigational technique of choice for photodermatoses when the diagnosis is uncertain or when details of the inducting action spectrum are required, it remains primarily a research tool employed in a limited number of clinical centers. The cost of the equipment and its infrequent use in most clinical practices means that patients should be referred for consultation to such centers whenever indicated.

Phototesting falls into two categories: (1) Monochromatic phototesting, usually of the upper back with selected wavelengths and selected doses to identify the action spectrum for the disorder and (2) photoprovocation with a broad-spectrum source to induce the eruption for its clinical appearance and subsequent biopsy if indicated. Table 91-4 lists the disorders for which monochromatic testing may be helpful.

For precise characterization of the wavelength dependency of a disorder, monochromatic testing, preferably with a xenon arc irradiation monochromator, should be employed. For photoprovocation, the favored device is a solar simulator, usually a xenon arc-filtered source that produces a spectrum that resembles the terrestrial sunlight spectrum at noon on a midsummer's day in temperate regions of the world. Keep in mind that the terrestrial spectrum at noon in June varies considerably between Iceland and Kenya, as it also does between high elevations and sea level. Several suitable protocols have also been described for using simple broad-spectrum metal halide or fluorescent light sources with filters if necessary. In some parts of the world, sunlight with filters has also been used, although this method is generally too unpredictable for clinical use.[148,149]

The mainstay of phototesting is a monochromator. It is composed of a high-pressure xenon arc source that emits radiation along a pathway incorporating a diffraction grating angled to produce the required waveband at the exit slit. Such equipment needs regular calibration of output and wavelength. Because even large centers cannot always afford such equipment, lesser alternatives have been created, for example, metal halide or fluorescent light sources of sufficient output intensity. With such sources, the UVB, UVA, and visible light components of patient photosensitivity can be studied, based on deviation from normal erythemal reactions throughout the UVR spectrum.

Monochromatic phototesting is preferably performed on unaffected skin of the upper back, lateral

TABLE 91-4
Usual Monochromatic Phototest Responses in Idiopathic, Probably Immunologic Photodermatoses

Disease	Action Spectrum	Frequency of Abnormal Findings
Polymorphic light eruption	UVA more often than UVB	Only sometimes
Actinic prurigo	UVA more often than UVB	Only sometimes
Hydroa vacciniforme	More often UVA	Only sometimes
Chronic actinic dermatitis	UVB ± UVA ± visible light	Virtually always
Solar urticaria	UVB, UVA, or visible, or combination	Usual
Xeroderma pigmentosum	UVB	Usual
Photoexacerbated dermatoses	UVB, UVA, or combination	Rare

UVA = ultraviolet A radiation; UVB = ultraviolet B radiation.

to the paravertebral groove whereas lesion induction, except when done relatively easily with the monochromator, as in SU and CAD, is best undertaken using broadband sources with output directed over larger areas of skin known to be susceptible to the eruption. PMLE, AP, and HV are conditions in which repeated irradiation with UVA- or UVB-emitting or combined sources is often required to reproduce the disease.

It is important that the use of potent topical and systemic steroids be avoided when possible for at least several days before phototesting to prevent false-negative results. It is not certain how much the other oral immunosuppressive agents affect testing, but they should be stopped whenever possible, as well. False-positive results may also occur in patients with widespread disease, and the eruption should first be well controlled whenever possible, if necessary by keeping the patient in a reduced-light environment. However, it is often difficult to fulfill these requirements if the eruption is active, and in such circumstances, testing may need to be undertaken with knowledge of its limitations.

All phototesting should be undertaken at carefully standardized sequential doses (often a geometric series) and wavelengths, and the results read at consistent times after exposure in carefully controlled conditions of light and temperature. Furthermore, because testing involves UVR exposure, potentially noxious to both skin and eyes, the patient and the investigator should be protected with appropriate clothing, shielding and goggles.

PHOTOPATCH TESTING. (See Chapter 92.) Photopatch testing is an established investigational tool designed to identify photoallergic contact dermatitis, although it can also be employed to help identify phototoxic agents. It is essentially a more complex version of patch testing, and it is used in patients with exposed-site eczema, whether or not they also have another photodermatoses, to determine whether photoallergy is also present.

The methodology of photopatch testing has received less attention than allergen testing or phototesting, as it resides between the two specialty areas of photodermatology and contact dermatology. However, consensus methodology is now available.[150]

Using this approach, test materials (usually sunscreens, topical nonsteroidal and anti-inflammatory agents, and other possible causative agents) are applied in duplicate for 24–48 hours to normal skin. One set of test sites is then uncovered and irradiated with a broad-spectrum UVA source, usually at 5 J/cm^2 from fluorescent PUVA lamps, and the results read 24 and 48 hours later. Strongly positive reactions at sites exposed to both chemical agent and UVA, with no reactions at the covered control sites, confirms a diagnosis of photoallergy. Occasionally, however, contact irritation or contact allergy occurs in both sites, making a diagnosis of photoallergy uncertain. One should also be alert to the possibility that all irradiated sites may become positive, suggesting that underlying widespread UVA photosensitivity is responsible. Furthermore, the identification of potential photoallergens is still primitive, often with separation of phototoxicity from photoallergy uncertain. Once again, testing for photoallergy is best conducted in regional centers or by physicians with appropriate experience.

The current authors (Travis W. Vandergriff and Paul R. Bergstresser) are grateful to the authors of this chapter in the previous edition for leaving behind an outstanding framework that we employed as our starting point for this updated edition. Special thanks go to John L. M. Hawk and James Ferguson.

KEY REFERENCES

Full reference list available at www.DIGM8.com

DVD contains references and additional content

1. Rhodes LE et al: Polymorphic light eruption occurs in 18% of Europeans and does not show higher prevalence with increasing latitude: Multicenter survey of 6,895 individuals residing from the mediterranean to scandinavia. *J Invest Dermatol* **130**(2):626-628, 2010 [Epub Aug 20, 2009]
6. Wolf P et al: New insights into the mechanisms of polymorphic light eruption: Resistance to ultraviolet radiation-induced immune suppression as an aetiological factor. *Exp Dermatol* **18**:350, 2009
9. van de Pas CB et al: Walker SL: Ultraviolet-radiation-induced erythema and suppression of contact hypersensitivity responses in patients with polymorphic light eruption. *J Invest Dermatol* **122**:295, 2004
10. Palmer RA, Friedmann PS: Ultraviolet radiation causes less immunosuppression in patients with polymorphic light eruption than in controls. *J Invest Dermatol* **122**:291, 2004
19. McGregor JM et al: Genetic modeling of abnormal photosensitivity in families with polymorphic light eruption and actinic prurigo. *J Invest Dermatol* **115**:471, 2000
23. Hawk JLM, Calonje E. The photosensitivity disorders. In: Lever's Histopathology of the Skin, 9th ed, edited by DE Elder et al. Philadelphia, Lippincott Williams & Wilkins, 2005, p. 345
27. Richards HL et al: Evidence of high levels of anxiety and depression in polymorphic light eruption and their association with clinical and demographic variables. *Br J Dermatol* **159**:439, 2008
41. Hönigsmann H, Hojyo-Tomoka MT. Polymorphic light eruption, hydroa vacciniforme, and actinic prurigo. In: *Photodermatology*, edited by HW Lim, H Hönigsmann, JLM Hawk. New York, Informa Healthcare, 2007 p. 149
43. Grabczynska SA, McGregor JM, Kondeatis E, Vaughan RW, Hawk JL: Actinic prurigo and polymorphic light eruption: common pathogenesis and the importance of HLA-DR4/DRB1*0407. *Br J Dermatol* **140**:232, 1999
60. Huggins RH et al: Quality of life assessment and disease experience of patient members of a web-based hydroa vacciniforme support group. *Photodermatol Photoimmunol Photomed* **25**:209, 2009
75. Hawk JLM, Lim HW: Chronic actinic dermatitis. In: *Photodermatology*, edited by HW Lim, H Honigsmann, JLM Hawk. New York, Informa Healthcare, 2007 p. 169
120. Waibel KH et al: Partial improvement of solar urticaria after omalizumab. *J Allergy Clin Immunol* **125**:490, 2010
142. Orteu CH, Sontheimer RD, Dutz JP: The pathophysiology of photosensitivity in lupus erythematosus. *Photodermatol Photoimmunol Photomed.* **17**:95, 2001
148. Neumann NJ, Lehmann P. Photodiagnostic modalities. In: *Dermatological Phototherapy and Photodiagnostic Method*, edited by J Krutmann et al. Berlin, Springer-Verlag, 2001, p. 329
150. Bruynzeel DP et al: Photopatch testing: A consensus methodology for Europe. *J Eur Acad Dermatol Venereol* **18**:679, 2004

Chapter 92 :: Abnormal Responses to Ultraviolet Radiation: Photosensitivity Induced by Exogenous Agents

:: Henry W. Lim

ABNORMAL RESPONSES TO ULTRAVIOLET RADIATION AT A GLANCE

- Photosensitivity is broadly divided into phototoxicity and photoallergy, caused by topical or systemic agents that absorb ultraviolet A (UVA) energy.
- Phototoxicity occurs in anyone exposed to sufficient phototoxic agent and UV radiation and usually manifests as an exaggerated sunburn reaction.
- Photoallergy is an immune reaction to a UVA-modified chemical, commonly topical sunscreen agents and antimicrobials in the United States and the United Kingdom and topical nonsteroidal anti-inflammatory agents in Europe. It presents as eczematous eruption on sun-exposed areas.
- History taking is an important part of the evaluation; phototesting and photopatch testing are sometimes helpful.
- Differential diagnosis includes contact allergic or contact irritant dermatitis, airborne contact dermatitis, and other photodermatoses.
- Management consists of identification and avoidance of the precipitating agent, photoprotection, and symptomatic therapy.

Photosensitivity may be caused by exogenous or endogenous agents. It occurs when a compound, classically one with unsaturated double bonds in a six-carbon ring, absorbs radiation energy in its action spectrum, usually ultraviolet A (UVA) wavelengths. Exogenous photosensitizers can be agents administered systemically or applied topically. Well-characterized examples of photosensitivity induced by endogenous photosensitizers are the cutaneous porphyrias, which are associated with enzymatic defects in heme biosynthetic pathways that result in elevated levels of porphyrins, known phototoxic agents (see Chapter 132).

Photosensitivity induced by exogenous agents can be divided into phototoxicity and photoallergy. Phototoxicity is the result of direct tissue injury caused by the phototoxic agent and radiation. It can occur in all individuals exposed to adequate doses of the agent and the activating wavelengths of radiation (Table 92-1). In contrast, photoallergy is a type IV delayed hypersensitivity response to a molecule that has been modified by absorption of photons. It has a sensitization phase, occurs only in sensitized individuals, and requires only a minimal concentration of the photoallergen (see Table 92-1).

INCIDENCE

Over 350 medications in the United States have been reported to cause photosensitivity.[1] Only a small number of them, however, induce reactions frequently or have been well studied (Tables 92-2, 92-3, 92-4, and 92-5). In evaluations performed at photodermatology centers in New York City, Melbourne, Singapore, and Detroit, photosensitivity induced by a systemic drug was documented in 5% to 15% of the referred patients.[2–5] In studies performed in the United States, United Kingdom, Europe, and Australia, the percentage of photopatch-tested patients who had clinically relevant reactions leading to a diagnosis of photoallergic contact dermatitis ranged from 1.4% to 12.0%, with the value in most series being around 10%.[2,5–11]

PHOTOTOXICITY

PATHOPHYSIOLOGY

Several pathways eventuate in the development of phototoxic tissue damage, and for many phototoxic agents more than one pathway is responsible.

PHOTODYNAMIC PROCESSES. On absorption of radiation energy by the photosensitizer (P) at its ground state, formation of an excited (usually triplet) state (^3P) molecule occurs. The excited state molecule may then participate in oxygen-dependent processes (i.e., photodynamic processes) via two major pathways, type I and type II reactions, both of which result in cytotoxic injury.[12]

The type I reaction involves transfer of an electron or a hydrogen atom to the excited state photosensitizer (^3P), which results in the formation of free radicals [Eq. (92-1)]. These may then participate in an oxidation–reduction reaction that results in peroxide formation and subsequent cell damage [Eqs. (92-2) and (92-3)].

$$^3P + RH \rightarrow PH\cdot + R\cdot \quad (92\text{-}1)$$

$$PH\cdot + PH\cdot \rightarrow P + PH_2 \quad (92\text{-}2)$$

$$PH_2 + O_2 \rightarrow P + H_2O_2 \quad (92\text{-}3)$$

TABLE 92-1
Characteristics of Phototoxicity and Photoallergy

	Phototoxicity	Photoallergy
Clinical presentation	Exaggerated sunburn reaction: erythema, edema, vesicles, and bullae; burning, stinging; frequently resolves with hyperpigmentation	Eczematous lesions; usually pruritic
Histologic features	Eosinophilic keratinocytes, epidermal necrosis, dermal edema, sparse dermal infiltrate of lymphocytes, macrophages, and neutrophils	Spongiotic dermatitis, dermal lymphohistiocytic infiltrate
Pathophysiology	Direct tissue injury	Type IV delayed hypersensitivity response
Occurrence after first exposure	Yes	No
Onset after exposure	Minutes to hours	24 to 48 hours
Dose of agent needed for reaction	Large	Small
Cross-reactivity with other agents	None	Common
Diagnosis Topical agent Systemic agent	 Clinical Clinical + phototests	 Photopatch tests Clinical + phototests; possibly photopatch tests

Alternatively, interaction of ^3P with ground state oxygen could result in the formation of superoxide anion (O_2^{-}), which, in turn, can be converted into highly reactive and cytotoxic hydroxyl radicals (OH·).

The type II reaction is also known as an *energy transfer process*. Transfer of energy to ground state oxygen results in the formation of singlet oxygen ($^1O_2$), which is highly reactive and has a lifetime of 50 ns [Eq. (92-4)]:

$$^3P + 0_2 \rightarrow P + {}^1O_2 \qquad (92\text{-}4)$$

Cytotoxic injury occurs upon singlet oxygen-induced oxidation of amino acids and unsaturated fatty acids; interaction with the latter results in the formation of hydroperoxides, which initiate lipid and protein oxidation.

Phototoxicities induced by porphyrins,[12] quinolones,[13] nonsteroidal anti-inflammatory agents, tetracyclines, amitriptyline, imipramine, sulfonylureas, hydrochlorothiazide, furosemide, and chlorpromazine[14] are examples of photodynamic phototoxic reactions.

TABLE 92-2
Topical Phototoxic and Photosensitizing Agents

Agent	Exposure
Fluorescein	Used topically to visualize the anterior surface of the eye
Fluorouracil[a]	Topical treatment of actinic keratoses
Furocoumarins	Occur naturally in plants (especially Compositae species), including fruits and vegetables (lime, lemon, celery, fig, parsley, and parsnip); used in topical photochemotherapy
Retinoids[a]	For treatment of acne and photoaging
Rose Bengal	Used in ophthalmologic examinations
Tar	Used as topical therapeutic agent; found in roofing materials

[a]Induces exaggerated UV response due to skin irritancy.

GENERATION OF PHOTOPRODUCTS. Exposure to radiation may result in the generation of stable photoproducts that are responsible for tissue injury. Phototoxic products have been demonstrated on irradiation of phenothiazines, chlorpromazine, tetracyclines, quinolones, and nonsteroidal anti-inflammatory agents.[15]

BINDING TO SUBSTRATE. Another mechanism of phototoxicity is radiation-mediated binding of the photosensitizer to its biologic substrate. A photoaddition reaction occurs when the excited state molecule covalently binds to a ground state molecule. An example is the covalent binding of 8-methoxypsoralen to pyrimidine bases of the DNA molecules, which results in the formation of a cross-link between the DNA strands.

INFLAMMATORY MEDIATORS. Mediators of inflammation and inflammatory cells participate in phototoxic tissue injury. Biologically active products of complement activation, mast cell-derived mediators, eicosanoids, proteases, and polymorphonuclear leukocytes contribute to the development of phototoxicity induced by porphyrins, demeclocycline, and chlorpromazine.[16]

APOPTOSIS. Photodynamic therapy (PDT) involves the use of a photosensitizer and electromagnetic

TABLE 92-3
Systemic Phototoxic Agents

Class	Generic Name (Common US Trade Names)[a]
Antifungal	Griseofulvin (Fulvicin, Grifulvin V, Gris-PEG)[b] Voriconazole (Vfend)
Antimalarials	Chloroquine (Aralen) Quinine[b]
Antimicrobials	Sulfonamides Tetracyclines Demeclocycline (Declomycin)[c] Doxycycline (Adoxa, Doryx, Monodox, Periostat, Vibra-Tabs, Vibramycin)[c] Minocycline (Arestin, Dynacin, Minocin) Tetracycline (Helidac, Sumycin) Trimethoprim (Bactrim, Polytrim, Primsol, Septra) Quinolones Ciprofloxacin (Cipro) Enoxacin (Penetrex)[b] Gemifloxacin (Factive) Lomefloxacin (Maxaquin)[b,c] Moxifloxacin (Avelox) Nalidixic acid (NegGram)[b,c] Norfloxacin (Chibroxin, Noroxin) Ofloxacin (Floxin, Ocuflox) Sparfloxacin (Zagam)[c]
Cardiac drugs	Amiodarone (Cordarone, Pacerone)[c] Quinidine (Quinaglute, Quinidex)[b]
Diuretics	Furosemide (Lasix)[c] Thiazides Bendroflumethiazide (Corzide) Chlorothiazide (Aldoclor, Diuril)[c] Hydrochlorothiazide (Accuretic, Aldactazide, Aldoril, Atacand, Avalide, Capozide, Diovan, Dyazide, Hyzaar, Inderide, Lopressor, Lotensin, Maxzide, Micardis, Microzide, Moduretic, Prinzide, Teveten HCT, Uniretic, Vaseretic, Zestoretic, Ziac)[c]
Dyes	Fluorescein (AK-Fluor, Fluorescite) Methylene blue
Furocoumarins	Psoralens 5-Methoxypsoralen[c] 8-Methoxypsoralen (Oxsoralen-Ultra)[c]
Hypoglycemics	Sulfonylureas Acetohexamide (Dymelor) Chlorpropamide (Diabinese) Glipizide (Glucotrol, Metaglip) Glyburide (DiaBeta, Glucovance, Glynase PresTab, Micronase) Tolazamide (Tolinase) Tolbutamide (Orinase)[c]
Immunosuppressant	Azathioprine (Azasan, Imuran)
Nonsteroidal anti-inflammatory drugs	Acetic acid derivative Diclofenac (Arthrotec, Cataflam, Voltaren) Alkanone derivative Nabumetone (Relafen)[c] Anthranilic acid derivative Mefenamic acid (Ponstel) Cyclooxygenase-2 inhibitor Celecoxib (Celebrex) Enolic acid derivative Piroxicam (Feldene)[b,c] Propionic acid derivatives Ibuprofen (Advil, Motrin, Nuprin, Vicoprofen) Ketoprofen (Orudis, Oruvail) Naproxen (Aleve, Naprelan, Naprosyn)[c] Oxaprozin (Daypro) Tiaprofenic acid Salicylic acid derivative Diflunisal (Dolobid)
Oncologic drugs	Dacarbazine (DTIC-Dome) Docetaxel (Taxotere) Fluorouracil (Adrucil) Methotrexate (Rheumatrex)[d] Paclitaxel (Taxol) Vinblastine (Velban)
Photodynamic therapy agents	Porfimer (Photofrin)[c] Verteporfin (Visudyne)[c]
Psychotropic drugs	Alprazolam (Xanax) Chlordiazepoxide (Librax, Librium, Limbitrol) Clozapine (Fazaclo) Phenothiazines Chlorpromazine (Thorazine)[c] Perphenazine (Triavil, Trilafon) Prochlorperazine (Compazine)[c] Thioridazine (Mellaril) Trifluoperazine (Stelazine) Tricyclics Amitriptyline (Elavil, Limbitrol, Triavil) Desipramine (Norpramin) Imipramine (Tofranil)
Other	Dapsone Flutamide (Eulexin) Hypericin (St John's wort) Pyridoxine (vitamin B_6) Ranitidine (Zantac)

[a]Although it is the policy not to use trade names in this book, exceptions are made in cases in which we consider this information highly useful.
[b]Also reported as a systemic photoallergen.
[c]Commonly reported.
[d]Induces erythema on previously UV-exposed sites.

TABLE 92-4
Topical Photoallergens

Group	Chemical Name Trade Name[a]
Sunscreens (see Chapter 223)	Benzophenones Benzophenone-3 (oxybenzone)[b] Benzophenone-4 (sulisobenzone) PABA derivatives Ethylhexyl dimethyl PABA (padimate O)[b] PABA[b] Cinnamates Ethylhexyl methoxycinnamate (octinoxate) Cinoxate (cinoxate) Others Butyl methoxydibenzoylmethane (avobenzone, Parsol 1789)[b] Octocrylene (octocrylene) Octyl triazone Phenylbenzimidazole sulfonic acid (ensulizole)
Fragrances	6-Methylcoumarin[b] Musk ambrette[b] Sandalwood oil
Anti-infective agents	Surface disinfectants: halogenated salicylanilides Dibromosalicylanilide (dibromsalan, DBS)[b] Tetrochlorosalicylanilide (Irgasan BS200)[b] Tribromosalicylanilide (tribromsalan, TBS)[b] Skin cleansers Chlorhexidine (Hibiclens) Hexachlorophene (pHisoHex) Pesticides Bithionol (thiobis-dichlorophenol)[b] Dichlorophene (G4, Korium, Teniatol) Dimethylol dimethyl hydantoin Fenticlor (bis-hydroxy-chlorophenyl sulfide)[b] Personal care products Triclosan (Irgasan DP300, Microban, Lexol 300) Topical antifungals Buclosamide (Jadit, butylchlorosalicylamide) Multifungin (bromochlorosalicylanilide, BCSA)
Others	Antibiotic for cattle Olaquindox[b] Nonsteroidal anti-inflammatory agents (topical) Etofenamate Fepradinol Flufenamic acid Ketoprofen[b] Phenothiazines Chlorpromazine (Thorazine)[b] Promethazine (Phenergan)[b] Miscellaneous Acyclovir cream (Zovirax) Clioquinol (Vioform, iodochlorhydroxyquin) Cadmium sulfide Cinchocaine (Dibucaine) Thiourea (thiocarbamide, sulfourea)

PABA = *para*-aminobenzoic acid.
[a]Although it is the policy not to use trade names in this book, exceptions are made in cases in which we consider this information highly useful.
[b]Commonly reported to be photoallergens.

TABLE 92-5
Systemic Photoallergens

Property	Generic Name (US Trade Name[a])
Antifungal	Griseofulvin (Fulvicin, Grifulvin V, Gris-PEG)
Antimalarial	Quinine
Antimicrobials	Quinolone Enoxacin (Penetrex)
Cardiac medication	Quinidine (Quinaglute, Quinidex)
Nonsteroidal anti-inflammatory drugs	Ketoprofen (Orudis, Oruvail) Piroxicam (Feldene)
Vitamin	Pyridoxine hydrochloride (vitamin B_6)

[a]Although it is the policy not to use trade names in this book, exceptions are made in cases in which we consider this information highly useful.

radiation in the presence of oxygen to treat premalignant and malignant skin conditions. In addition to generating reactive oxygen species, which results in cytotoxicity, PDT also is a potent inducer of apoptosis.[12]

CLINICAL MANIFESTATIONS

ACUTE PHOTOTOXICITY. (See Table 92-1.) Acute phototoxicity occurs within hours of exposure to the phototoxic agent and UV radiation. Symptoms are drug-dose and UV-dose dependent—usually asymptomatic, but at sufficient doses, the patient complains of a burning and stinging sensation on exposed areas, such as forehead, nose, V area of the neck, and dorsa of the hands (Fig. 92-1). Erythema and edema may appear within hours of exposure; in severe cases, vesicles and bullae may develop accompanied by pruritus. Protected areas, such as nasolabial folds, postauricular and submental areas, and areas covered by clothing, are spared. A notable exception to these kinetics is psoralen-induced phototoxicity, in which often the acute response first appears after 24 hours, and peaks at 48–72 hours, which is the rationale for administering psoralen plus UVA (PUVA) photochemotherapy doses 48–72 hours apart. The phototoxic response resolves with a varying degree of hyperpigmentation, which may last for months. At lower drug/UV doses, gradual tanning only, without preceding sunburn-like reaction, can be seen.

PHOTO-ONYCHOLYSIS. Separation of the distal nail from the nail bed, usually painful, is a manifestation of acute phototoxicity, with the nail plate serving as a lens to focus UV energy on the nail bed. It has been reported with doxycycline and other tetracyclines, fluoroquinolones, psoralens, benoxaprofen, clorazepate dipotassium, olanzapine, aripiprazole, indapamide, and quinine (Fig. 92-2).[17]

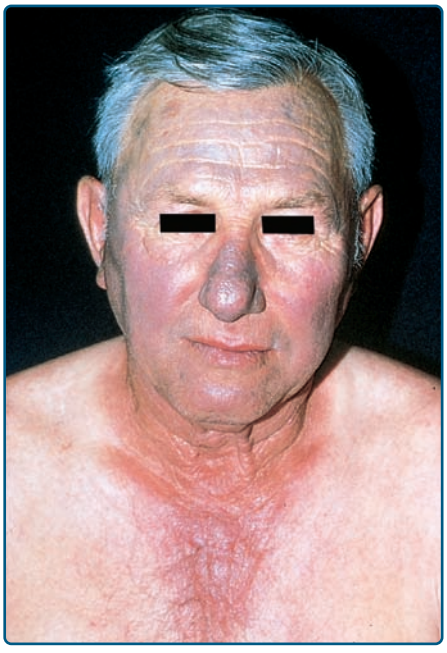

Figure 92-1 Amiodarone-induced phototoxicity. Note the erythema and slate-gray pigmentation (nose, forehead) on the sun-exposed area.

SLATE-GRAY PIGMENTATION. Asymptomatic blue–gray pigmentation on sun-exposed areas has been associated with exposure to several agents.[18,19] One percent to ten percent of patients taking amiodarone develop this side effect (Fig. 92-1). Chlorpromazine and clozapine can induce a similar change. The tricyclic antidepressants imipramine and, less commonly, desipramine have also been reported to cause slate-gray pigmentation. A drug metabolite–melanin complex has been postulated to be the cause of this alteration. Minocycline can induce blue–gray pigmentation on the face (Fig. 92-3), frequently on sites of acne scars, although similar pigmentation on forearms and shins can also occur. Chronic exposure to diltiazem, a benzothiazepine calcium channel blocker, has resulted in photodistributed, reticulated, slate-gray pigmentation. Slate-gray pigmentation seen in argyria involves the nail lunulae, mucous membranes, and sclerae. A photochemical reaction, in which silver granules are deposited in the dermis, results in these pigmentary alterations.



Figure 92-2 Distal onycholysis in a patient receiving psoralen plus ultraviolet A therapy.

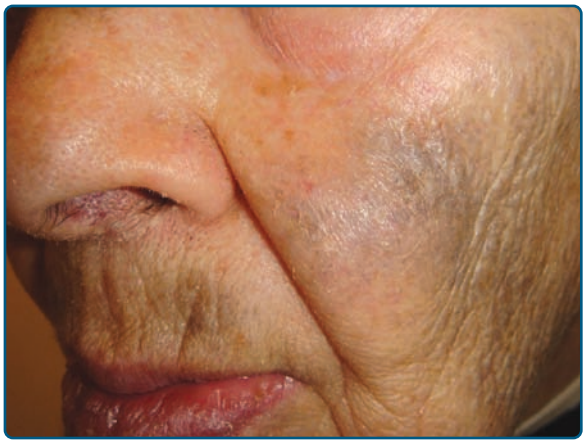

Figure 92-3 Minocycline-induced blue–gray pigmentation on cheeks and upper lip.

LICHENOID ERUPTION. Lichenoid eruption has been reported as a form of phototoxicity, but is controversial.

PSEUDOPORPHYRIA. The development of porphyria cutanea tarda-like cutaneous changes of skin fragility, vesicles, and subepidermal blisters is associated with several phototoxic agents (Fig. 92-4). Although histologic and immunofluorescence findings are similar to those of porphyria cutanea tarda, the porphyrin profile is normal or in the upper range of normal in these patients. Naproxen is the most commonly reported causative agent. Other drugs incriminated include amiodarone, β-lactam antibiotics, celecoxib, ciprofloxacin, cyclosporine, diflunisal, etretinate, furosemide, imatinib, nabumetone, nalidixic acid, narrowband UVB, oral contraceptives, oxaprozin, ketoprofen, mefenamic acid, the tetracyclines, tiaprofenic acid, torsemide, and voriconazole.[20,21]

ACCELERATED PHOTO-INDUCED CHANGES. This has been uniquely described with voriconazole, a broad spectrum antifungal agent. Immunosuppressed patients receiving voriconazole for >12 weeks can develop photosensitivity, pseudoporphyria, photoaging, lentigines, premature dermatoheliosis; in addition, squamous cell carcinoma and melanoma have been described in this group of patients who were on voriconazole for >12 months.[21]

PHOTODISTRIBUTED TELANGIECTASIA. Telangiectasia on sun-exposed areas has been reported with calcium channel blockers, including nifedipine, amlodipine, felodipine, and diltiazem, with the



Figure 92-4 Pseudoporphyria. Note subtle erosions on dorsum of hand and at the base of the index finger, and crusting on the knuckle.

antibiotic cefotaxime, and with antidepressant venlafaxine. In some of these patients, provocation with UVA resulted in the development of telangiectasia.[22]

PERSISTENCE OF PHOTOSENSITIVITY AND EVOLUTION TO CHRONIC ACTINIC DERMATITIS. Although phototoxicity usually resolves after discontinuation of the causative agent, there are reports of persistence of photosensitivity for many years after the cessation of exposure, which results in the development of chronic actinic dermatitis (Fig. 92-5). The condition presents with pruritus and lichenification and excoriation on sun-exposed sites; it has been reported with thiazides, quinidine, quinine, and amiodarone.[23]

CHRONIC EFFECTS. Cutaneous effects of long-term, repeated phototoxic tissue injury are best exemplified by the manifestations in patients who have received long-term PUVA photochemotherapy, which is known to affect DNA. These effects include premature aging of the skin, lentigines, squamous cell and basal cell carcinomas, and melanoma. These are discussed in greater detail in Chapter 238.

PHOTOTOXIC AGENTS

TOPICAL AGENTS. Table 92-2 lists the major topical phototoxic and photosensitizing agents. It should be noted that fluorouracil and retinoids induce exaggerated UV response due to their irritant effect on the skin. Therapeutic or occupational exposures to these agents are the common route of contact.

Furocoumarins. Topical exposures to furocoumarins may occur in individuals in certain occupations (bartenders, salad chefs, gardeners) and in patients receiving topical photochemotherapy with psoralens.

Tar. Crude coal tar, although no longer commonly used in dermatologic therapy, is well documented to produce a burning and stinging sensation on exposure to UVA ("tar smarts"). In addition to phototoxicity, occupational exposure to tar is associated with increased risk of nonmelanoma skin cancers.



Figure 92-5 Chronic actinic dermatitis. Note the lichenification and hyperpigmentation on sun-exposed areas, and sparing of skin folds.

SYSTEMIC AGENTS. Table 92-3 lists the major systemic phototoxic agents.[24–28] They commonly produce an exaggerated sunburn reaction but, like most phototoxins, may also induce an eczematous photoallergic response in a small percentage of users, especially after topical exposure. As a rule, the action spectra are in the UVA range; notable exceptions are the porphyrins, fluorescein, and other dyes, whose action spectra are in the visible light range.

HISTOPATHOLOGY

Acute phototoxicity is characterized by individual necrotic keratinocytes and, in severe cases, epidermal necrosis (see Table 92-1). There may be epidermal spongiosis, dermal edema, and a mild infiltrate consisting of neutrophils, lymphocytes, and macrophages. Slate-gray pigmentation is associated with increased dermal melanin and dermal deposits of the drug or its metabolite.[18,19] Histologic features of lichenoid eruptions are similar to those of idiopathic lichen planus; however, there may be a greater degree of spongiosis and dermal eosinophilic and plasma cell infiltrates, and a larger number of necrotic keratinocytes and cytoid bodies. In pseudoporphyria, as in porphyria cutanea tarda, there is dermal–epidermal separation at the lamina lucida and deposits of immunoglobulins at the dermal–epidermal junction and surrounding blood vessel walls.[20,21]

MANAGEMENT

Identification and avoidance of the causative phototoxic agent are the most important steps in management.

Beyond this or if the agent cannot be removed, sun avoidance is essential. Because the action spectrum for most agents is in the UVA range, high sun protection factor, broad-spectrum sunscreens containing efficient UVA filters should be used (see Chapter 223). Acute phototoxicity can be managed with topical corticosteroids and compresses; systemic corticosteroids should be reserved for only the most severely affected patients. Management of patients with slate-gray pigmentation, lichenoid eruption, pseudoporphyria, and photodistributed telangiectasia is symptomatic only, and patients should be advised that it will take months after the discontinuation of the offending agent for the condition to resolve. Patients with nonsteroidal anti-inflammatory drug-induced (NSAID-induced) pseudoporphyria who require NSAIDs should be switched to a different class of agents or to those that are less photosensitizing, such as indomethacin or sulindac.[29]

PHOTOALLERGY

PATHOPHYSIOLOGY

Photoallergy is a type IV delayed hypersensitivity response requiring the presence of both photoallergen and the activating wavelengths of radiation, which for most agents are in the UVA range.[30] After the absorption of UV energy, a photoallergen may be converted to an excited state molecule, which subsequently reverts to ground state by releasing the energy. In this process, the molecule may conjugate with a carrier protein to form a complete antigen. This is thought to be the mechanism of photoallergy induced by halogenated salicylanilides, chlorpromazine, and *para*-aminobenzoic acid (PABA). Alternatively, a photoallergen may form a stable photoproduct on exposure to radiation, which in turn may conjugate with a carrier protein to form a complete antigen. Sulfanilamide and chlorpromazine have both been shown to participate in this reaction.

Once the complete antigen is formed, the mechanism of photoallergy is identical to that of contact allergy. The antigen is taken up and processed by Langerhans cells, which then migrate to regional lymph nodes to present the antigen to T lymphocytes. Cutaneous lesions develop when the activated T lymphocytes circulate to the exposed site to initiate an inflammatory response.

CLINICAL MANIFESTATIONS

In sensitized individuals, exposure to the photoallergen and sunlight results in the development of a pruritic, eczematous eruption within 24 to 48 hours after exposure (see Table 92-1). Although the morphology is clinically indistinguishable from that of allergic contact dermatitis, the distribution of the eruption in photoallergy is predominantly confined to sun-exposed areas; however, in severe cases, it may spread to the covered areas, albeit at a lower intensity. Unlike the lesions in phototoxicity in fair-skinned individuals, those in photoallergy usually resolve without significant postinflammatory hyperpigmentation. Lichenoid eruption has also been reported.

Currently, in the United States, United Kingdom, and France, UV filters in sunscreen products (especially benzophenone-3) and antimicrobial agents are the most common cause of photoallergy, whereas NSAIDs are the leading topical photoallergens in Europe.[10,11,30–32] Although there have been reports of systemic agents inducing a photoallergic response, the evidence of such response remains unclear.[30]

As with phototoxicity, persistence of photosensitivity and evolution to chronic actinic dermatitis (see Chapter 91) have been reported after exposure to photoallergens, including chlorpromazine, dioxopromethazine, halogenated salicylanilides, ketoprofen, musk ambrette, olaquindox, and quinidine.[33,34] The mechanism is not completely understood. One possible explanation is that UV radiation alters the carrier protein that originally binds the photoallergen; this results in the formation of a neoantigen that stimulates the immune system over the long term. This hypothesis is supported by the observation that the histidine moiety in albumin can undergo oxidation in the presence of salicylanilide, which binds to albumin.

PHOTOALLERGENS

TOPICAL AGENTS. Topical exposure is the most common route of sensitization to photoallergens.[30,35] Table 92-4 lists the common groups of photoallergens.

SYSTEMIC AGENTS. Photoallergy caused by systemic agents is much less frequent, and not as well documented, than that induced by topical agents. All but one of these photoallergenic agents (pyridoxine) are also phototoxic and have been discussed previously in this chapter (see Section "Systemic Agents" under Section "Phototoxic Agents" and Table 92-3).

HISTOPATHOLOGY

The histologic features of photoallergy are similar to those of allergic contact dermatitis. There is epidermal spongiosis associated with infiltrate of mononuclear cells in the dermis (see Table 92-1).

MANAGEMENT

Management is identical to that of phototoxicity: identification and avoidance of the photoallergen, sun-protective measures, and symptomatic therapy.

EVALUATION OF PATIENTS WITH PHOTOTOXICITY AND PHOTOALLERGY

The evaluation of patients with phototoxicity and photoallergy is similar to the evaluation of patients

with other photosensitivity disorders and is described in greater detail in Chapter. A history of exposure to known photosensitizers is most important. It is also helpful to ascertain whether window glass-filtered sunlight can induce the cutaneous eruption, because UVB is filtered out by window glass. Distribution of the cutaneous eruption is a helpful clue to the type of photosensitizer responsible. Widespread eruption suggests systemic photosensitizers, whereas topical photosensitizers produce lesions only in areas that have been exposed to both sensitizers and radiation. Vesicular and bullous eruptions are most commonly associated with phototoxicity, whereas eczematous eruptions strongly suggest photoallergy; usually, the former is associated with a burning sensation, the latter with pruritus. Skin biopsy findings may also be helpful in differentiating these two conditions: necrotic keratinocytes are commonly seen in phototoxicity, whereas spongiotic dermatitis is associated with photoallergy (see Table 92-1).

Phototests and photopatch tests are an integral part of the evaluation of photosensitivity when history and physical examination alone are insufficient to determine the responsible agent. Approximately 10% of patients who undergo photopatch testing have clinically relevant positive results, which leads to the diagnosis of photoallergic contact dermatitis.[2,11]

The procedures for phototesting and photopatch testing are generally as follows, although there are variations in testing methods.[5,10] On day 1, exposure to UVB and UVA to determine minimal erythema dose (MED) is carried out, and duplicate sets of photoallergens are applied symmetrically to another site on the back and covered by an opaque tape. On day 2, the MEDs are determined. One of the duplicate set of photoallergens is exposed to 10 J/cm^2 of UVA or 50% of the MED to UVA, whichever is lower. After irradiation, the exposed site is covered again with an opaque tape. On day 3, both irradiated and nonirradiated test sites are uncovered, and the reactions are graded. On day 5 or day 8, the irradiated and nonirradiated sites are evaluated for delayed reactions. Reaction only at an irradiated site indicates photoallergy. Reaction of equal intensity at both irradiated and covered sites indicates allergic contact dermatitis. Reaction at both sites, but with higher intensity at the irradiated site, signifies both photoallergy and allergic contact dermatitis. Well-defined erythema that resolves promptly indicates an irritant dermatitis.

DIFFERENTIAL DIAGNOSIS OF PHOTOTOXICITY AND PHOTOALLERGY

Airborne allergic contact dermatitis is characterized by involvement of skinfolds on exposed areas, such as the nasolabial folds, and the eyelids that receive minimal direct sunlight. It also involves exposed areas that are relatively sun protected, such as the postauricular areas and area under the chin. Allergic contact dermatitis and irritant contact dermatitis occur at sites of contact, in both sun-exposed and in sun-protected areas.

Other photodermatoses can be differentiated from phototoxicity and photoallergy by their characteristic time course and morphology and lack of a compatible exposure history. Polymorphous light eruption manifests itself within a few hours of sun exposure as pruritic papules, plaques, and, uncommonly, vesicles on sun-exposed sites and resolves in a few days. Chronic actinic dermatitis presents as chronically lichenified plaques on sun-exposed areas. Lesions of solar urticaria appear within minutes of sun exposure as mildly pruritic urticaria and resolve within a few hours.

OTHER EXOGENOUS AGENT-INDUCED PHOTODERMATOSES AND PHOTOEXACERBATED DERMATOSES

PORPHYRIA CUTANEA TARDA

(See Chapter 132)

Ingestion of wheat treated with hexachlorobenzene (HCB) as a preservative resulted in an outbreak of a porphyria cutanea tarda-like syndrome in Turkey in the 1950s.[36] Inhibition of the enzyme uroporphyrinogen decarboxylase by HCB was thought to be responsible for the clinical manifestations. However, a study of adults highly exposed to HCB in Catalonia, Spain, and of children from the same area, did not show any increase in prevalence of porphyria cutanea tarda or increased urinary concentrations of porphyrins.[37]

LUPUS ERYTHEMATOSUS

(See Chapter 155)

Drug-induced systemic lupus erythematosus present with purpura, erythema nodosum, urticarial and necrotizing vasculitis, and/or photosensitivity. It is most commonly associated with exposure to hydralazine, procainamide, isoniazid, and minocycline; antinuclear antibody (ANA) test is positive and antihistone antibodies are characteristically present.[38]

Drug-induced subacute cutaneous lupus erythematosus (SCLE) presents with similar cutaneous lesions as idiopathic SCLE, although blisters and targetoid lesions may occur, and lower extremities may be involved. Antinuclear antibody and anti-Ro/SSA antibodies are frequently present, while antihistone antibodies are usually absent. Drugs associated with this condition include calcium channel blockers, angiotensin-converting enzyme inhibitors, thiazide diuretics, terbinafine and tumor necrosis factor(TNF)-α antagonists.[38]

Drug-induced discoid lupus erythematosus is very rare; it has been reported with exposure to fluorouracil and TNF-α antagonists.

Identification and avoidance of the precipitating agent is the treatment of drug-induced lupus erythematosus.

KEY REFERENCES

Full reference list available at www.DIGM8.com

DVD contains references and additional content

5. Kerr HA, Lim HW: Photodermatoses in African Americans: A retrospective analysis of 135 patients over a 7-year period. *J Am Acad Dermatol* Oct;**57**(4):638-43, 2007
10. Victor FC, Cohen DE, Soter NA: A 20-year analysis of previous and emerging allergens that elicit photoallergic contact dermatitis. *J Am Acad Dermatol*Apr **62**(4):605-10, 2010
13. Ferguson J, DeLeo VA: Drug and chemical photosensitivity: Exogenous. In: Photodermatology, edited by HW Lim, H Hönigsmann, JLM Hawk. New York, Informa Healthcare, 2007, p. 199-218
14. Moore DE: Drug-induced cutaneous photosensitivity: Incidence, mechanism, prevention and management. *Drug Saf* **25**:345-72, 2002
30. Kerr A, Ferguson J: Photoallergic contact dermatitis. *Photodermatol Photoimmunol Photomed* **26**(2):56-65, 2010
35. Scheuer E, Warshaw E. Sunscreen allergy: A review of epidemiology, clinical characteristics, and responsible allergens. *Dermatitis* **17**(1):3-11, 2006

SECTION 17

Skin Changes Due to Other Physical and Chemical Factors

Chapter 93 :: Thermoregulation

:: Dean L. Kellogg, Jr.

HUMAN THERMOREGULATION AT A GLANCE

- Thermoregulatory reflexes involve changes in skin blood flow and sweating that act to preserve thermal balance with an internal temperature of approximately 37°C (98.6°F).
- Thermal balance is determined by metabolic heat production; evaporative heat loss; heat gain or loss through radiant, convective, and conductive mechanisms; and useful mechanical work done.
- Dermal papillary loops, arteriovenous anastomoses, and sweat glands are the major skin effectors of thermoregulation.
- Heat stress evokes large increases in skin blood flow and sweating through cholinergic cotransmitter and nitric oxide-dependent mechanisms to facilitate heat dissipation.
- Local skin heating causes a local vasodilation through antidromic neurotransmitter release from afferent skin nerves and increased nitric oxide generation.
- Cold stress evokes reduced skin blood flow through noradrenergic cotransmitter mechanisms to facilitate heat conservation.
- Local skin cooling causes a local vasoconstriction through noradrenergic and afferent neural mechanisms as well as nonneural mechanisms.

THE ROLE OF SKIN IN HUMAN THERMOREGULATION

Human beings are homeotherms: we maintain our internal, or core temperature of the body within a narrow range despite thermal stresses. Thermal stress can arise from variations in environmental temperature or from the human body itself, as with heat generation by skeletal muscle during dynamic exercise. When thermal stresses arise from the environment, changes in skin temperature occur prior to any change in internal temperature. When thermal stresses arise from the body itself as with exercise, changes in core temperature occur prior to any change in skin temperature. In either case, thermal gradients are established between the skin and the body core. If skin temperature is lower than core temperature, heat will be lost from the body unless skin blood vessels constrict. If skin temperature is greater than core temperature, the body will gain heat, unless skin vessels dilate and sweat glands produce perspiration. The skin is thus a crucial component of human thermoregulation.

Human thermoregulation is achieved through an integration of several physiological processes. These integrated processes make up thermoregulatory reflexes that maintain a stable internal temperature at a "set point" of 37°C (98.6°F) despite thermal stresses. The set point is not invariant and may fluctuate as much as 0.5°C–1.0°C (0.9°F–1.8°F) according to circadian rhythms and during the menstrual cycle in females. The thermoregulatory reflexes designed to preserve internal temperature at the set point are coordinated by thermally sensitive neurons in the anterior hypothalamic–preoptic area and spinal cord, which respond to the changes in internal and skin temperatures. For example, cold-sensitive neurons in the anterior hypothalamic–preoptic area and spinal cord integrate afferent sensory inputs and activate heat-conserving mechanisms that include cutaneous vasoconstriction and increased metabolic heat production (shivering). Conversely, the stimulation of heat-sensitive neurons in the anterior hypothalamic–preoptic area and spinal cord integrate afferent sensory inputs and activate heat-dissipating mechanisms that include cutaneous vasodilation and sweat production.

HEAT TRANSFER

To maintain thermal balance, heat gained or lost by the body must equal heat dissipated from, or produced

by the body. This concept can be mathematically expressed as:

$$\Delta S = M - E \pm R \pm C \pm K - W$$

where

- ΔS = change in heat storage by the body
- M = metabolic heat production and is defined as the rate of transformation of chemical energy into heat and mechanical work
- E = evaporative heat loss and is defined as the rate of heat loss by evaporation of water from skin and surfaces of the respiratory tract. E is dependant on (1) rate of sweat secretion, (2) water vapor pressure of the environment, and (3) the area of evaporative surface.
- R = radiant heat gain or loss and is defined as heat exchange by emission and absorption of electromagnetic (infrared) radiation. This component accounts for 50%–60% of the heat loss in a thermally comfortable (thermoneutral) individual, but can easily become a net heat gain as when one is in direct sunlight.
- C = convective heat gain or loss and is defined as heat exchange due to forced movement of a fluid, either liquid or gas. This component is responsible for the transfer of heat to the skin through skin blood flow and transfer from the skin to the environment by air or water movement. Within the body, the cardiovascular system is the major mediator of convective heat transfer. C is dependent on (1) body surface area, (2) temperature differences, and (3) fluid (or air) movement.
- K = conductive heat gain or loss and is defined as heat transfer by flow down a temperature gradient, as between tissues and blood, between blood and skin, and between skin and the environment. This is usually combined with convective heat transfer.
- W = useful mechanical work

The sum of R, C, and K is determined by the temperature gradient between the skin and the environment. If ΔS is zero, the body is in heat balance. This "thermoneutral" condition is characterized as having low skin blood flow of approximately 5% of cardiac output. Sweating does not occur during thermoneutrality.

If $\Delta S < 0$, the body is losing heat, core temperature is falling, and thermoregulatory reflexes are evoked to conserve heat. Thermal stability is maintained through reduction of skin blood flow that can approach zero during maximal vasoconstriction. Reduction in skin blood flow increases the thermal insulation between the body and the environment by minimizing losses through conductive (K), convective (C), and radiant (R) mechanisms. If heat loss continues despite low skin blood flow, metabolic generation of heat (M) through the shivering of skeletal muscle is initiated to restore and maintain core temperature. Brown adipose tissue can also be a source of metabolic heat generation through nonshivering thermogenesis.[1] Although originally thought to be important only in human neonates where brown adipose tissue is 2%–5% of body weight, some brown adipocytes persist into adulthood.[2] These adipocytes can directly generate heat (M) to maintain core temperature.[3] If, despite all these mechanisms, ΔS remains negative, core temperature will fall and life-threatening hypothermia may result.

If $\Delta S > 0$, the body is gaining heat and core temperature is rising. Under this circumstance of heat stress, thermal stability is maintained by increases in skin blood flow to facilitate heat loss through K, C, and even R losses. If heat gain continues despite these mechanisms, sweating is evoked to increase heat loss through evaporation (E) of perspiration. If ΔS remains positive, blood flow is diverted from skeletal muscle and gastrointestinal beds, providing for dramatic increases in skin blood flow. Sweat rate will also increase until maximal levels are achieved. If, despite maximal skin blood flow and maximal stimulation of sweating, ΔS remains positive, core temperature will rise and life-threatening hyperthermia, i.e., heat stroke, will occur.

THERMOREGULATION AND THE SKIN

ANATOMIC CONSIDERATIONS

The critical role of the skin in human thermoregulation is well understood: thermoregulation is achieved through variations in blood flow and sweat production so as to maintain thermal stability.[4] Without these variations, thermal stability cannot be maintained resulting in risk of hypothermia or hyperthermia (see Chapters 94 and 95). Under normothermic conditions, skin blood flow ranges from 30–40 mL/min/100 g of skin in resting humans. However, the cutaneous vasculature is exceedingly compliant so that skin blood flow can vary from nearly zero during cold stress periods with maximal vasoconstriction to 8 L/min over the body's surface during maximal vasodilation in heat stress.[5]

Blood vessels in the skin are arranged in several plexuses in superficial and deep layers parallel to the skin surface. Most vessels are in the superficial layer and consist of high-resistance terminal arterioles, papillary loops, and postcapillary venules. Papillary loops are true capillaries. Blood flow through the loops is controlled by highly innervated arterioles. The loops are located near the dermal–epidermal junction, a region characterized by a maximal thermal gradient because of its proximity to the skin surface. Since the papillary loops also have a large surface area, blood flow through these vessels is a major determinant of heat exchange through vasodilation during heat stress and vasoconstriction during cold stress.

While papillary loops are found in both glabrous (palms, plantar aspect of feet, and lips) and nonglabrous skin (most of the body's surface, including the limbs, head, and trunk), arteriovenous anastomoses (AVAs) are found mainly in glabrous skin. They represent direct connections between arterioles and venules that bypass the high-resistance arterioles and capillaries of the papillary loops. AVAs have thick muscular walls with rich noradrenergic innervation and lie deep

to papillary loops.[6] Because of their deeper location in the dermis and smaller surface area, AVAs are less efficient in heat transfer than papillary loops. While AVAs dilate in response to heat stress and constrict during mild-to-moderate cold stress, their major role is to mediate local vasodilation during prolonged cold exposure. AVA vasodilation delivers warm blood to maintain tissue temperature and thus tissue viability through "cold-induced vasodilation."[7]

Sweat glands also play a major role in human thermoregulation (see Chapter 83). The critical thermoregulatory role of the eccrine sweat glands that are found over most of the body surface is well known. Clearly, the main function of eccrine sweat glands is to increase heat loss through the evaporation of sweat. The density of these glands varies from 700 glands per cm^2 in planar and plantar skin to 64 glands per cm^2 on the back[8]; these glands may hypertrophy with repeated heat exposure.[9] Each gland is made up of a secretory coil found in the dermis with a duct that extends through the dermis and epidermis to the surface of the skin. Sweat is secreted as an isotonic fluid by the coils. NaCl is reabsorbed within the ducts so sweat that is finally delivered to the surface is hypotonic.[10] Each liter of sweat evaporated is capable of removing 580 kcal from the body. Although apocrine sweat glands have been dismissed as "atavistic scent glands," this has recently been questioned.[11] Apocrine glands are usually associated with hair follicles and are most developed on the scalp, face, upper back, and chest. It has been proposed that sebum from apocrine glands acts as a surfactant at high temperatures and, thus, facilitates dispersion of eccrine sweat over the skin's surface. At low temperatures, sebum may function to repel water from the skin and, thus, reduce heat loss.

CUTANEOUS THERMOREGULATORY MECHANISMS

Cutaneous circulation is a major effector of human thermoregulation.[4] During heat stress, elevated internal temperature and skin temperature lead to cutaneous vasodilation through neural mechanisms and the local effect of higher temperatures on the skin vessels themselves. During the periods of cold stress, reduced temperatures mediate a cutaneous vasoconstriction through neural as well as local vascular effects. Under normothermic conditions, skin blood flow averages approximately 5% of cardiac output; however, the absolute amount of blood in the skin can vary from nearly zero during periods of maximal vasoconstriction in severe cold stress to as much as 60% of cardiac output in severe heat stress.[5]

SWEATING

Heat dissipation through the secretion and evaporation of eccrine sweat is critical to maintaining thermal stability in hot environments or during heat stress induced by strenuous dynamic exercise. Indeed, when environmental temperature exceeds blood temperature, the evaporation of sweat is the sole mechanism for heat dispersal. Sweat secretion is controlled primarily by sympathetic cholinergic nerves that release acetylcholine (Ach) to activate muscarinic receptors on the glands. Sweat secretion can be augmented by local production of nitric oxide near sweat glands.[12] Stimulated glands produce an isotonic fluid that becomes progressively hypotonic as the Na^+ is reabsorbed in the sweat gland duct by active ion transfer (see Chapter 84).

NEURAL CONTROL MECHANISMS OF THE CUTANEOUS VASCULATURE

In glabrous skin, cutaneous arterioles are innervated by sympathetic vasoconstrictor nerves that release norepinephrine and other cotransmitters.[7,13–16] All thermoregulatory reflex changes in blood flow in these areas are caused by changes in noradrenergic vasoconstrictor activity and the effects of local temperature on the skin blood vessels themselves (Fig. 93-1).[4,7,17]

In nonglabrous skin, changes in skin blood flow are mediated by two branches of the sympathetic nervous system: (1) noradrenergic vasoconstrictor nerves as found in glabrous skin and (2) a cholinergic active vasodilator system.[4,7,17] These dual sympathetic neural control mechanisms are the major effectors of thermoregulatory responses. Vessels in nonglabrous skin also respond to the effects of local temperature changes (Fig. 93-2).[4,7,17]

In normothermia, cutaneous arterioles are under little neural tone. During cold stress, reduction of skin temperature and/or internal temperature cause a thermoregulatory reflex-mediated reduction in skin blood flow to conserve body heat. Enhanced noradrenergic vasoconstrictor tone mediates an arteriolar vasoconstriction and, thus, decreases skin blood flow.

Conversely, during heat stress, thermoregulatory reflexes that facilitate body cooling are affected. As internal temperature continues to rise over a threshold value of approximately 37°C (98.6°F), a cutaneous vasodilation begins. At this threshold, active vasodilator tone to the cutaneous arterioles is enhanced. At rest, sweating also begins at the same internal temperature threshold. Vasodilator tone increases as internal temperature increases. Enhanced vasodilator activity decreases smooth muscle tone, leading to an arteriolar vasodilation, and, thus, an increase in skin blood flow, especially through the papillary loops. High skin blood flow delivers heat to the body surface where it is dissipated to the environment in conjunction with the evaporation of sweat. Overall, the active vasodilator system is responsible for 80%–95% of the elevation in skin blood flow that accompanies heat stress. A small, but significant portion of the vasodilation is mediated by the direct vasodilator effects of local heat on the cutaneous vessels.[18]

Dual vasoconstrictor nerves and vasodilator nerves in skin were first suggested in 1931 by Lewis and Pickering[19] and confirmed by Grant and Holling.[20] They measured skin temperature as an index of blood flow in the human forearm and found that large increases in response to heat stress could be abolished by sympathectomy or nerve blockade. They noted that while sympathectomy or nerve blockade caused only a slight

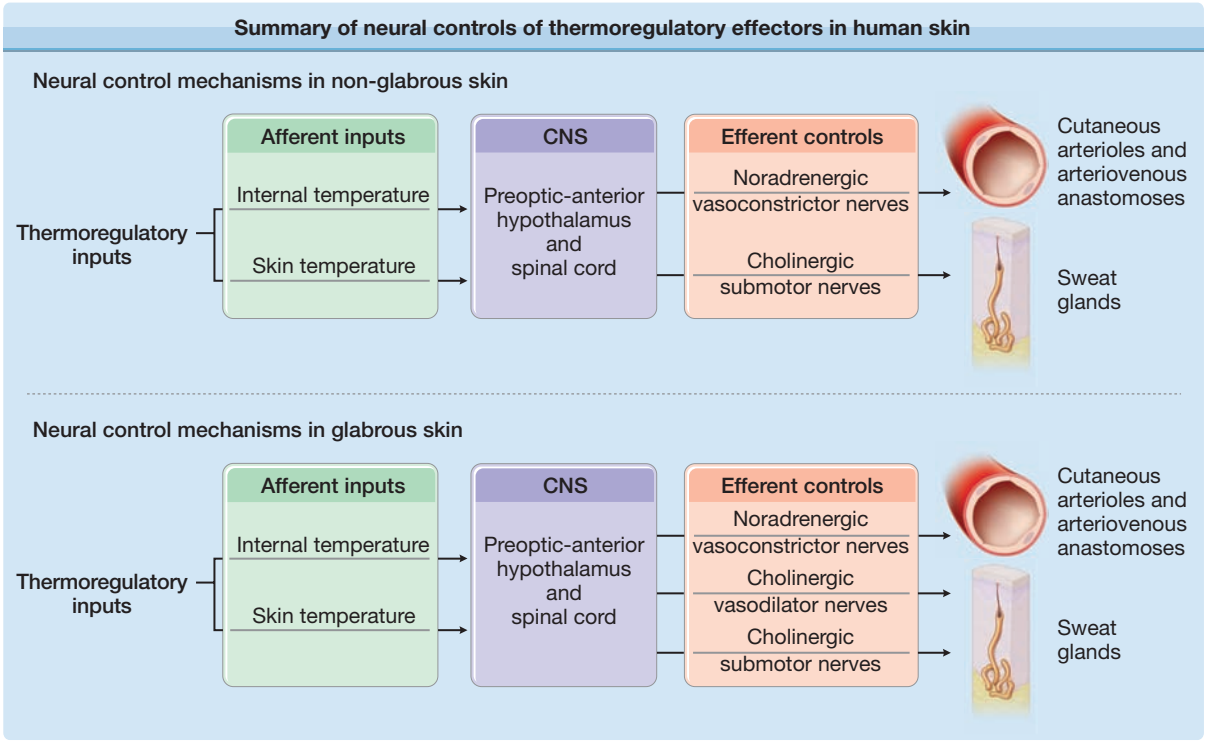

Figure 93-1 Summary of neural controls of thermoregulatory effectors in human skin: Thermoregulatory reflexes are mediated by the afferent inputs of internal and skin temperature. These afferent inputs are integrated in the preoptic anterior hypothalamus and spinal cord areas of the central nervous system. Efferent control of blood vessels and sweat glands in glabrous skin is mediated by noradrenergic vasoconstrictor nerves and cholinergic sudomotor nerves, respectively. In nonglabrous skin regions, efferent control of blood vessels is effected through a system of dual sympathetic innervation, noradrenergic active vasoconstrictor nerves and cholinergic active vasodilator nerves. Sweat glands also receive cholinergic sympathetic innervation; however, whether cholinergic active vasodilator nerves and cholinergic sudomotor nerves are one and the same is not known.

cutaneous vasodilation during normothermia, heat stress elicited a much greater increase in skin blood flow. In addition, nerve blockade during established heat stress abolished any cutaneous vasodilation. These results suggested that cutaneous vessels in nonglabrous skin are innervated by sympathetic active vasodilator as well as sympathetic vasoconstrictor nerves. In the 1950s, their findings were confirmed by Edholm et al[21] and by Roddie et al.[22] In addition, it has been shown that bretylium tosylate (a prejunctional noradrenergic neuronal blocking agent) abolishes the cutaneous vasoconstriction induced by cold stress, but does not alter the vasodilator responses induced by heat stress.[23] This confirmed that dual efferent neural systems control the cutaneous arterioles: a noradrenergic vasoconstrictor system and a nonadrenergic active vasodilator system.

FACTORS THAT ALTER RESPONSES TO HEAT AND COLD

Thermoregulatory responses undergo physiological acclimatization after repeated thermal challenges over a prolonged (2-week) time period. After repeated exposure to a hot environment, sweat glands hypertrophy to produce more sweat and cutaneous active vasodilation begins at lower internal and skin temperatures to facilitate long-term thermal stability by favoring earlier and greater heat dissipation.[87] Humans also acclimate to cold environments after repeated exposure by increasing metabolic heat generation (in part through increased amounts of brown adipose tissue) and habituating to cold. These adaptations are less effective in promoting thermal stability than adaptations to heat.[88]

Acute and chronic dermatological disorders can impair thermoregulation. For example, sunburn compromises sweat production, thus impairing evaporative cooling and reducing heat tolerance. At the same time, the inflammatory vasodilation that accompanies sunburn can compete against thermoregulatory reflex vasoconstriction during cold exposure. This will compromise the ability to reduce skin blood flow to conserve body heat, thus reducing cold tolerance.[87] Other inflammatory skin conditions, of which erythroderma is the most extreme, have the same effect.

Medications can alter thermal tolerance, especially during heat exposure. Numerous medications have anticholinergic effects. Since the cutaneous active vasodilator system and sweat glands are both controlled by cholinergic sympathetic nerves, it is not surprising that such agents have deleterious thermoregulatory consequences. Examples of commonly used medications that can compromise heat stress responses include first generation antihistamines, H_2-receptor antagonists, and tricyclic antidepressants. These systemic agents

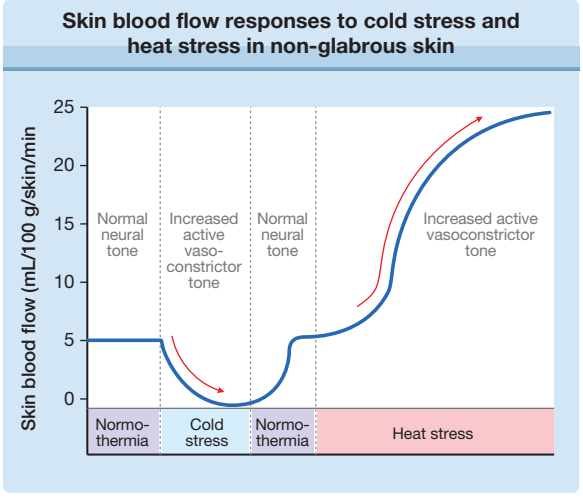

Figure 93-2 Skin blood flow responses to cold stress and heat stress in nonglabrous skin: under normothermic conditions, skin blood flow is relatively low (approximately 5% of cardiac output) and skin vessels receive relatively minor neural inputs from active vasoconstrictor and vasodilator nerves. During cold stress, reductions of skin and internal temperatures lead to reflex increases in sympathetic noradrenergic vasoconstrictor nerve activity. Increased vasoconstrictor system tone reduces skin blood flow, thus increasing thermal insulation and conserving body heat. During heat stress, increasing skin and internal temperatures lead to reflex increases in sympathetic cholinergic active vasodilator nerve and cholinergic sudomotor activity. Increased activity of the vasodilator system leads to potentially dramatic increases in skin blood flow that can reach 60% of cardiac output. High skin blood flow delivers heat to the skin surface where it is removed to the environment primarily through evaporation of sweat.

(and many others) can reduce sweat secretion, attenuate cutaneous active vasodilation, and increase the risk of thermoregulatory failure.[17]

Aging also modifies thermoregulatory reflexes. Relative to younger subjects, in healthy older persons, noradrenergic mechanisms are more important than cotransmitter mechanisms in vasoconstricting skin during cold stress.[89] During heat stress, older subjects show a delay in the onset and reduced magnitude of cutaneous vasodilation.[90] These alterations in cutaneous responses to thermoregulatory challenges contribute to increased morbidity and mortality during thermal stresses in older persons.

KEY REFERENCES

Full reference list available at www.DIGM8.com

DVD contains references and additional content

4. Kellogg DL, Jr: In vivo mechanisms of cutaneous vasodilation and vasoconstriction in humans. *J Appl Physiol* **100**:1709-1718, 2006
7. Johnson JM, Proppe DW: Cardiovascular adjustments to heat stress. In: *Handbook of physiology—environmental physiology*, edited by M Fregly, and C Blatteis. New York, Oxford University Press, 1996, p. 215-243
19. Lewis T, Pickering GW: Vasodilation in the limbs in response to warming the body; with evidence for sympathetic vasodilator nerves in man. *Heart* **16**:33-51, 1931
20. Grant RT, Holling HE: Further observations on the vascular responses of the human limb to body warming; evidence for sympathetic vasodilator nerves in the normal subject. *Clin Sci* **3**:273-285, 1938
22. Roddie IC, Shepherd JT, Whelan RF: The vasomotor nerve supply of the human forearm. *Clin Sci* **16**:67-74, 1957
37. Kellogg DL, Jr. et al: Cutaneous active vasodilation in humans is mediated by cholinergic nerve co-transmission. *Circ Res* **77**:1222-1228, 1995

Chapter 94 :: Cold Injuries

:: Gérald E. Piérard, Pascale Quatresooz, & Claudine Piérard-Franchimont

COLD INJURIES AT A GLANCE

- Skin is important for maintaining core body temperature within a narrow physiologic range.
- Cold weather, wind, humidity, dampness, and altitude combine to inflict skin damage.
- Nonfreezing and freezing conditions can both produce cold injuries.
- Frostbite occurs after exposure to intensely cold air, liquids, or metals. Several degrees of frostbite are recognized.
- Winter xerosis and acrocyanosis are common consequences of prolonged exposure to cold.
- Erythrocyanosis tends to occur over skin areas with thick adipose tissue, whereas chilblain is more frequently seen in lean persons.
- Cold urticaria is rare and occurs at the sites of localized cooling.
- Primary erythromelalgia is a rare neuropathic disorder to which there is a genetic predisposition.

The human capacity for physiologic adaptation to cold is minimal. This deficiency may cause problems, because seasonal changes in the outdoor environment are quite prominent, even in the temperate zones of the world. In this context, skin is important in thermoregulation, and cutaneous blood flow and the resulting skin temperature may vary widely to help preserve the core body temperature.[1–3] Physiologic, behavioral, and environmental factors modulate skin responses to cold exposure.

PHYSIOLOGIC RESPONSE TO COLD

Core body temperature is maintained within a narrow range by thermoregulatory mechanisms that rely largely on control of the cutaneous blood flow. Arteriovenous anastomoses are abundant in acral areas, and they regulate the volume of blood that passes through the skin. When the skin is cooled, there is usually an immediate acute reduction in the amount of blood that flows to the surface. These events alter skin temperature, heat loss, and color. Skin reactivity and the anatomic pattern of blood supply differ in the skin of newborns, adults, and older people. For instance, a reticulate appearance of cooled skin is a common finding in young infants (Fig. 94-1).

The parallel arrangement of large arteries and veins in the limbs allows countercurrent exchange of heat. Vasoconstriction due to cold results in shunting of blood from the superficial to the deep venous system, and heat is transferred from arteries to veins. Thus, the blood going to the acral part of the limbs is precooled, and less heat is lost to the environment. With such thermoregulation, the body can maintain a constant core temperature of approximately 37°C (98.6°F) over a range of external temperatures between 15°C and 54°C (59°F and 129.2°F).

Normally, the skin is to some extent adapted to a cooler environment than the 37°C (98.6°F) of internal organs. Given the presence of many cold-adapted enzymes, the skin may even function more effectively when slightly cooled. In the case of adipose tissue, mild long-term exposure to cooling may lead to progressively better insulation. Habitually cold-exposed skin also develops a more efficient system for shunting blood away from the surface. These adaptive mechanisms are most flexible during the first years of life. Tissues in the aged are less able to develop new shunts.



Figure 94-1 Reticulate appearance of cooled skin in the newborn due to the anatomic pattern of the blood supply and factors influencing flow such as arteriolar vasoconstriction and the increased viscosity of cooled blood.

The effect of swimming in cold water after extreme heating—for example, after using a sauna[4]—is somewhat comparable to accidental cold water immersion. Well-being depends substantially on the degree of subcutaneous insulation, so that overweight persons, as well as those who are well clothed, can survive prolonged accidental cold-water exposure.[5]

Viscosity of fluids generally increases as temperature decreases. However, blood is a non-Newtonian fluid that exhibits thixotropy, i.e., it becomes less viscous with increasing flow velocity, independent of temperature. This effect is strongly influenced by hematocrit and by packing of erythrocytes. Macrophages also can block capillaries when they develop pseudopods as a result of reduced flow. The combination of slow flow and leukocyte conformational changes is, in part, a physiologic process that enables these cells to migrate through the endothelial lining.[6] Other factors affecting blood viscosity include increased platelet adhesiveness, changes in concentrations of proteins, and the presence of abnormal proteins. Fibrinogen level is particularly important.

THERMOREGULATION AND HUNTING REACTION

Local and systemic thermoregulation is complex. A group of neurons in the hypothalamus responds directly to temperature. When the temperature decreases, the rate of discharges decreases. From this temperature-sensitive area, signals radiate to various other portions of the hypothalamus to control either heat production or heat loss. Stimuli that influence the autonomic nervous system, such as painful stimuli, mental stress, arousal stimuli, and deep breaths, can all produce cutaneous vasoconstriction in warm subjects but vasodilation in cold subjects.[7,8]

Cold exposure produces an initial massive cutaneous vasoconstriction, which results in a fall in skin temperature. This change serves to maintain core temperature, but at the expense of the skin. Conversely, cold-induced vasodilation represents a protective mechanism to prevent skin necrosis. This physiologic reflex, known as the *hunting reaction of Lewis*, involves transient cyclic vasodilation caused by the opening of arteriovenous anastomoses.[9,10]

A chilling effect is produced by applications of dedicated hydrogel pads or cushions previously stored in a refrigerator.[11,12] This biothermal procedure is commonly used during laser therapy. It also serves to achieve a sustained removal of heat from the skin and its underlying tissues. It produces discrete skin hemodynamic changes and may relieve pain.

COLD, WIND, HUMIDITY, AND ALTITUDE

Outdoor work and winter sports are common risk situations for cold damages. A cold environment can be a threat to the skin, leading to a subsequent fall in core body temperature. Many physiologic, behavioral, and environmental factors predispose to the global effects of cold injuries. Marked increases in convective, conductive, or radiant heat loss are responsible for the immediate effects of cold exposure. For instance, touching cold metal objects considerably increases conductive cooling (Fig. 94-2). Other predisposing factors increasing heat loss and/or decreasing heat production and insulation from clothing make people especially susceptible to cold.[13]

There is ample evidence that the effect of low temperature on skin biology is, in part, a function of environmental humidity, wind speed, and altitude. In this respect, the wind chill index is indicative of the convective heat loss. Wind chill affects the gradients of temperature and water content across the stratum corneum, which result in an imbalance in condition between outer and deeper epidermal layers.[14] High altitude, which reduces the oxygen supply to tissues, also contributes to increase the skin damage induced by cold.[15]

Transepidermal water loss (TEWL) plays a prominent role in evaporative thermal loss. The skin temperature and the relative and absolute environmental humidity are key factors affecting cold injuries. The ambient humidity indicates the mass of water vapor present in a unit volume of the atmosphere. An accurate representation of the amount of moisture in the air as a function of temperature is given by the calculation of the dew point,[11,16] which is defined as the temperature of the air at which the gaseous moisture begins to condense, that is, the temperature at which relative humidity reaches 100%.

Poor clothing insulation is a common reason for cold injuries. The insulation is insufficient when clothing is too light, wet, tight, permeable to wind, or inadequate to cover the cold sensitive body parts. Individual factors predisposing to cold injuries are physical injuries, leanness, low physical fitness level, fatigue, dehydration, previous cold injuries, sickness, trauma, poor peripheral circulation, the wearing of tight constrictive clothing, and old age.[13] Newborns, the elderly, and individuals with impaired mental faculties remain the most vulnerable. Injury is often increased by alcohol, smoking, and psychotropic drug use.



Figure 94-2 Bullous frostbite following contact with a cold steel sheet.

Severe cold injuries have historically influenced the outcome of battles and wars.[17,18] Peacetime military operations also impose risks.[19–22] However, cold injuries are becoming more prevalent among the general population.[21] Many cases are associated with alcohol consumption, homelessness in urban centers, and car breakdown. Frostbite also prevails among winter sport enthusiasts such as cross-country skiers and backpackers who get lost or trapped in a snowstorm.[2,22–26] Accidental exposure to liquefied gas is another cause of severe cold injuries.[27]

Adaptation to cold protects one from responding inappropriately, and a moderate degree of exposure to cooling might be health promoting by stimulating a responsive and protective vasculature. In contrast, individuals who have experienced severe cold injury may have a profoundly delayed or abolished hunting reaction in the affected limbs.[28] They are rendered more susceptible to recurrent cold injury with pain, hyperesthesia, or paresthesia.[29] Some of these individuals also have coldness of the skin, which is very persistent and probably related to a functional imbalance in the sympathetic nervous system that results from increased α-adrenergic receptor density or affinity for norepinephrine.[30] In addition, altered vascular structure may reduce vasocompliance after cold exposure. There may also be impairment of normal vascular reflexes to various stimuli, including deep inspiration, venous occlusion, neck cooling, and ipsilateral skin cooling.[30]

CLASSIFICATION OF SKIN COLD INJURIES

Freezing and nonfreezing injuries can be distinguished according to the severity and duration of chilling. However, the damage caused depends on many variables other than the actual temperature. Recognition is generally easy at a clinical level, but awareness of potential uncommon underlying disorders is important. Treatment, both physical and pharmacologic, is aimed at keeping the body warm and maintaining vasodilation.

Frostbite is the consequence of extreme and prolonged freezing conditions. In addition, the whole body may cool down so much that life-threatening hypothermia may ensue. This is an important concern for people who enjoy cold weather sports, particularly in mountains and circumpolar regions. Prompt recognition and treatment are of paramount importance, because many hypothermia victims can recover from very low body temperatures. Treatment in an adequate medical facility can make the difference between full recovery and lifelong problems. Even if the victim appears to be dead from exposure to cold, resuscitative efforts should be started and continued until the proper core body temperature is reached.[31]



Figure 94-3 Hemorrhagic bulla and necrosis of the skin induced by freezing a wart with liquid nitrogen.



Figure 94-4 Facial redness in a person exposed to cold winters in a temperate climate.

Extreme and often conductive heat loss at a given body site freezes the tissues and results in localized blistering and necrosis (Fig. 94-3). Several cutaneous disorders also occur when the tissue temperature is maintained just above freezing for long periods. These conditions include chilblains, cold urticaria, cold panniculitis, erythrocyanosis, and acrocyanosis, among others. These disorders may be a consequence of impaired blood flow, reduced sensory perception, or a change in the physical properties of the tissues, such as in adipose tissue.

Minor but long-term cold exposure combined with environmental desiccation may have profound effects on the biology of the epidermis, leading, for example, to winter xerosis.[32,33] Persistent erythema of the face and the hands is not a rare finding (Fig. 94-4).

FROSTBITE

Frostbite occurs when tissue freezes after exposure to extremely cold air, liquids, or metals. The clinical effects of accidental injury that leads to the death of tissues are similar to those caused by cryosurgery.[34] The components of tissue that may lead to damage when frozen are water, with formation of ice crystals at 0°C (32°F), and lipids such as fat globules or cell membrane constituents.

Contrasting with damaging cryoinjuries, cryopreservation is used to preserve or "to freeze" in vitro most of the biomolecules present in tissues.[35] Any metabolic activity is blocked in these circumstances. Cryoscopy is a diagnostic procedure applicable in vivo.[36] It relies on an acute but short icing of the stratum corneum in order to disclose some structures exhibiting different capacities of thermal conductivity.

The rate of freezing determines the site of injury at the cellular level.[37] Extracellular formation of ice occurs most commonly with slow freezing, whereas fast freezing tends to produce intracellular ice. The formation of ice crystals in the extracellular space alters the osmotic properties of the tissues and disturbs the flow of water and electrolytes across the cell membranes. Thawing may be as damaging as the freezing itself, and repeated freeze and thaw cycles, as may occur in accidental injury, compound the damage, making more water available, which rapidly leads to intracellular flooding. The rewarming rate is also important. In slow rewarming, ice crystals become larger and more destructive. Cells are also exposed to a high concentration of electrolytes for a longer period than with rapid rewarming.

As the body cools, there is a reflex constriction of the arteries and veins in the extremities.[31] This results in increased venous pressure, decreased capillary perfusion, and sludging. Cooling also creates a leftward shift in the oxygen dissociation curve, and hemoglobin gives up its oxygen less readily. These two conditions result in hypoxia and damage to the capillaries and surrounding tissue. Oxygen tension is further decreased by thrombus formation in the microvasculature, which results in arteriovenous shunting. Arterial and arteriolar constriction, mediated by sympathetic outflow, initiates and probably maintains circulatory impairment. In addition, segmental vascular necrosis occurs in areas of erythrostasis, which suggests that ultimate damage may depend more on insufficient clearance of toxic substances than on initial vasoconstriction.

Cell types vary in their susceptibility to cold injury. Melanocytes are very sensitive to cold, and irreversible damage may occur at –4°C to –7°C (24.8°F–19.4°F). This sensitivity explains the hypopigmentation that often follows cryotherapy. In addition, it appears that black persons are more susceptible to frostbite than whites. Nerve axons are also easily damaged by cold,

TABLE 94-1
Consequences of Cold Injuries

Arterial and arteriolar vasoconstriction
Excessive venular and capillary vasodilation
Increased endothelial leakage
Erythrostasis
Arteriovenous shunting
Segmental vascular necrosis
Massive thrombosis

and nerve injury may occur with axonal degeneration of large myelinated fibers. Autonomic fibers are also affected, and this may account for the abnormal sweating and cold sensitivity that follow nonfreezing cold injury.[38,39] Nerve sheaths are quite resistant to cold, as are bone and cartilage.[28] Desolidification of lipids in adipose tissue and disruption of endothelial cells lining blood vessels and lymphatics, with secondary disturbances of permeability and blood flow, are other consequences of severe cold. In the overall assessment, there are marked similarities in the pathologic processes to those seen in thermal burns and in ischemia-perfusion injuries.

Three stages of cooling are recognized. The first is massive vasoconstriction, which causes a rapid fall in skin temperature. In a second step, the hunting reaction follows with a cyclic rise and fall in skin temperature. If cold exposure continues, the third stage of freezing occurs as the skin temperature falls to approach ambient temperature. The events that ensue in freezing and nonfreezing cold injuries are similar.[17,40] Consequences of cold injuries and their classification are presented in Tables 94-1 and 94-2, respectively.

Frostbite commonly affects fingers, toes, ears, nose, and cheek.[41,42] The clinical presentation of frostbite falls into three categories corresponding to mild frostbite or frostnip, superficial frostbite, and deep frostbite with tissue loss.

TABLE 94-2
Classification of Nonfreezing Cold Injuries to the Skin

Vasoconstriction
Hunting reaction
Immersion foot
Pulling-boat hands
Acrocyanosis
Chilblains
Cold urticaria
Cold panniculitis
Erythromelalgia
Raynaud phenomenon
Sclerema neonatorum
Subcutaneous fat necrosis of the newborn
Livedo reticularis
Cryoglobulinemia
Cold agglutinins
Cryofibrinogenemia

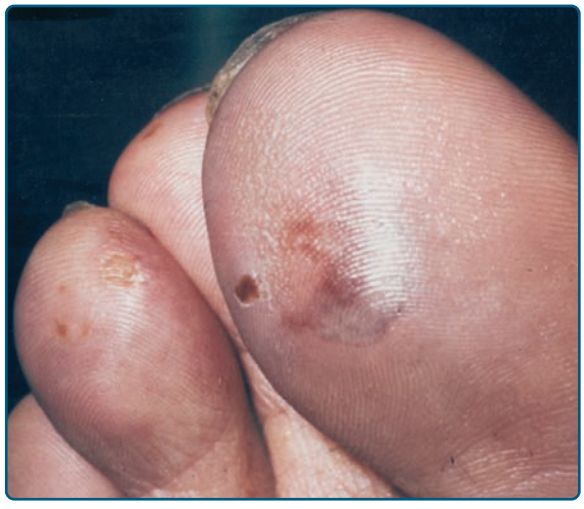

Figure 94-5 Frostnip.

Frostnip involves only the skin and causes no irreversible damage. There is a sensation of severe cold progressing to numbness followed by pain. Erythema is usually present on the cheeks, ears, nose, fingers, and toes (Fig. 94-5). There is no edema or bleb formation. Frostnip is the only form of frostbite that can be treated safely in the field with first aid measures.

Superficial frostbite involves the skin and immediately subcutaneous tissues. It includes the previously described signs but with the pain subsiding to feelings of warmth. This is a sign of severe involvement. The skin has a waxy appearance, but deeper tissues remain soft and resilient. Clear blebs form, accompanied by edema and erythema within 24–36 hours after thawing. Lesions may become eroded (Fig. 94-6).

Deep frostbite extends to the deep subcutaneous tissue. The injured skin becomes white or bluish white with a variable degree of anesthesia. Most often the affected skin becomes deceptively pain free, and the discomfort of feeling cold vanishes. The tissue is



Figure 94-6 Superficial frostbite.



Figure 94-7 Deep frostbite after rewarming. Large blisters have formed. Note cyanosis of toes as a sign of developing necrosis. This cold injury occurred in a homeless person who was found on the street after heavy alcohol consumption and overnight snowfall.



Figure 94-8 Dry gangrene of all fingers in a mountain climber 5 weeks after being caught in a snowstorm.

totally numb, indurated with immobility of joints and extremities. Muscles may be paralyzed. Nerves, large blood vessels, and even bone may be damaged. Large blisters form 1 to 2 days after rewarming, and they can be classified according to depth, as in heat-induced burns (Fig. 94-7). Frostbite blister fluid contains high amounts of prostaglandins, including prostaglandin $F_{2\alpha}$ and thromboxane A_2. These mediators may contribute to increased vasoconstriction, platelet aggregation, leukocyte adhesiveness, and ultimately progressive tissue injury. The blister fluid begins to be resorbed within 5 to 10 days, which leads to the formation of hard, black gangrene. Weeks later, a line of demarcation occurs, and the tissues distal to the line undergo autoamputation (Fig. 94-8).

PREVENTION

Prevention is key to protecting individuals from the effects of cold weather; and frostbite, frostnip, and hypothermia always should be taken seriously. Prognostic factors[25,43–46] are listed in Table 94-3. Wearing protective clothing, warm hat, earflaps and scarf together with preventive behavior such as turning bare areas away from the wind are the most important procedures for preventing frostbite. Nonmedicated waterless ointments are traditionally used for protection against facial frostbite, but their benefit is undocumented. The thermal insulation they provide is indeed minimal.[41,42] The use of protective emollients seems to cause a false sensation of safety, which leads to an increased risk of frostbite, probably through neglect of other, more efficient protective measures.[47,48] In less extreme conditions, however, some specific topical formulations bring beneficial effects.[49] The most effective products are those reducing TEWL and perspiration because these biological functions cause emission of body thermal energy and thus cool the skin.

MANAGEMENT

The first consideration in frostbite treatment is to be aware that the victim may be suffering from hypothermia.[25,31,50,51] Because of the difficulty in assessing the depth of frostbite injury, conservative waiting after the frostbite episode is often encouraged in an attempt to delineate the extent of tissue loss. Beyond this, the main principles are to avoid trauma, friction, pressure, massaging with snow, and refreezing. Slow rewarming increases tissue damage, and therefore rapid rewarming is the keystone of treatment.[20] It should be performed in a

TABLE 94-3
Prognostic Signs of Frostbite

Good prognostic signs	Large, clear blebs extending to the tips of the digits Rapid return of sensation Rapid return of normal (warm) temperature to the injured area Rapid capillary filling time after pressure blanching Pink skin after rewarming
Poor prognostic signs	Hard, white, cold, insensitive skin Cold and cyanotic skin without blebs after rewarming Dark hemorrhagic blebs Early evidence of mummification Constitutional signs of tissue necrosis, such as fever and tachycardia Cyanotic or dark red skin persisting after pressure Freeze–thaw–refreeze injury

water bath no warmer than 40°C–42°C (104°F to 107.6°F) until the most distal parts of the body are flushed. Large amounts of analgesics may be required. The damaged part should be elevated, and blisters should be left intact. Surgical debridement is often best delayed until 1 to 3 months after demarcation. However, triple-phase bone scans, magnetic resonance imaging, and magnetic resonance angiography can be used to predict ultimate tissue loss and to assess the possibility of earlier surgical intervention.[40,52,53]

There is no uniformly accepted protocol for other measures allegedly beneficial in the treatment of frostbite injury.[51] Intra-arterial reserpine and sympathectomy have been used to reverse vasospasm, which may contribute to tissue loss. Their role is controversial, although some patients have benefited from this therapy. To counteract vasoconstriction caused by local release of inflammatory mediators, the use of topical aloe vera, which inhibits thromboxane synthetase, and systemic ibuprofen, which inhibits cyclooxygenase, have been advocated. Oxpentifylline has been presented as an advanced therapy.[54] In addition, several adjunctive therapies, including vasodilators, thrombolysis, and hyperbaric oxygen, are sometimes useful.[55] Tetanus toxoid should be given in the case of open wounds. Surgery and amputation remain the ultimate strategies to help the victims.[56]

SEQUELAE

Sequelae of frostbite include permanent hypersensitivity to cold and, less often, hyperhidrosis.[38] Squamous cell carcinoma is a rare outcome, usually occurring on the heel 20–30 years later.[57] Epiphyseal plate damage or premature fusion may occur in children. Premature fusion can result in shortened digits, joint deviation, and dystrophic nails. In addition, frostbite arthritis, resembling osteoarthritis, may occur weeks to years later.

NONFREEZING COLD INJURY AND DAMPNESS

Nonfreezing cold injury occurs when tissues are cooled to temperatures between approximately 15°C (59°F) and their freezing point for prolonged periods. This type of injury, which is exacerbated by dampness, has claimed numerous casualties in warfare. Nonfreezing cold injury may be followed by cold sensitivity and hyperhidrosis, which may persist for years.

During World War I, trench foot was identified as a separate entity. Wet conditions at temperatures above freezing and limb dependency due to immobility and constrictive footwear were important pathogenic factors. Three stages were described. Stage I consisted of initial erythema, edema, and tenderness. Stage II followed within 24 hours with paresthesia, marked edema, numbness, and sometimes blisters. Stage III corresponded with progression to a usually superficial gangrene. Immersion foot, similar to trench foot, was described in shipwreck survivors during World War II.

Tropical immersion foot was described during the Pacific campaign in World War II. Occurring after exposure to the warm, wet conditions of jungle warfare, this condition differed from classic trench foot and immersion foot in that it caused less tissue destruction, numbness, and anesthesia and was followed by more rapid complete recovery. The role of temperature in tropical immersion foot is unclear and may not be important.[58] As with trench foot and immersion foot, prevention is most important.

Another specific condition known as *pulling-boat hands* was described, characterized by the presence of erythematous macules and plaques on the dorsum of the hands and fingers of sailors aboard rowboats.[59] Small vesicles developed later, accompanied by itching, burning, and tenderness. These individuals were exposed to long periods of high humidity, cool air, and wind, an ideal setting for the development of nonfreezing cold injury. In addition, hours of vigorous rowing daily produced repetitive hand trauma.

WINTER XEROSIS

Many individuals present with dryness of the skin, particularly on the lower extremities, during wintertime. The hands, forearms, cheeks, lips, and trunk also may be affected. Itching, a dry appearance, chapping, and cracking of the stratum corneum are more or less prominent. The condition is markedly influenced by cold environments, especially in combination with low humidity.[38,39] Predisposing factors include atopic dermatitis, ichthyosis, and increasing age. Excessive washing exacerbates winter xerosis. Indeed, irritant dermatitis of the hands worsens in a cold and dry environment.[60] Emollients and improvement in the environmental temperature and humidity are helpful in controlling this condition.

ACROCYANOSIS

Acrocyanosis is a bilateral dusky mottled discoloration of the hands, feet, and sometimes the face. It is persistent and accentuated by cold exposure. When the temperature is very low, the skin may be bright red. Trophic changes and pain do not occur, and pulses are present. This condition must be distinguished from Raynaud phenomenon (see Chapter 170), which is clearly episodic, often segmental, and painful, as well as from obstructive arterial disease (see Chapter 173).

Acrocyanosis is genetically determined and usually starts in adolescence. Chronic vasospasm of small cutaneous arterioles or venules with a secondary dilatation of the capillaries and subpapillary venous plexus has been postulated. Stasis in the papillary loops with aneurysmal dilatation at the tips redistributes blood flow to the subpapillary venous plexus. The blood flow may be compromised by altered erythrocyte flexibility, increased platelet adhesiveness, and other plasma viscosity factors. Cold agglutinins may exacerbate the acrocyanosis manifestations.[61,62] The "puffy hand

syndrome" is defined by the presence of hand edema superposed on acrocyanosis.[63]

Tissues are less sclerotic in acrocyanosis than in Raynaud phenomenon. They contain twisted collagen fibrils and large pericytes. In cases developing for the first time late in life, an underlying myeloproliferative disorder should be excluded. Remittent necrotizing acrocyanosis is associated with enhanced susceptibility to cooling and pain, as well as ulceration and gangrene of the fingers. Arteriolar occlusion by thrombi or intimal proliferation may occur. Cold pain should be distinguished from cold allodynia and cold hyperalgesia.

There is no effective treatment for acrocyanosis. Supportive measures to keep the skin warm are helpful.

ERYTHROCYANOSIS

Erythrocyanosis is a dusky cyanotic discoloration, worse in winter, which occurs over areas with a thick layer of subcutaneous fat (Fig. 94-9). The condition is seen most often on the lower legs and thighs of adolescent girls and middle-aged women. Nodular lesions similar to chilblains may occur and have been described in women with severe erythrocyanosis and paraplegia. Keratosis pilaris, angiokeratomas, and telangiectasia are commonly associated. Spontaneous improvement often occurs after a few years. However, the disease may persist with long-standing edema and fibrosis.

The wearing of warm clothes and weight reduction are important to decrease the insulating effect of the subcutaneous fat, which is responsible for a chronically low skin temperature. The outcome remains unpredictable.

CHILBLAINS

Chilblains, also called *pernio* or *perniosis* (Fig. 94-10), are localized inflammatory lesions caused by continued exposure to cold above the freezing point.[64,65] Dampness and wind that increase thermal conductivity and convection play a part. Absolute temperature is less important than the cooling of nonadapted tissue. The condition shows a genetic predisposition. It has been described most often in temperate regions, where winters are occasionally cold and damp. Chilblains are seen less often in very cold climates, where well-heated houses and warm clothing are available. Both acrocyanosis and chilblains appear to be more common in children, women, and persons with low body mass index. Spontaneous remission is common when spring arrives, and relapse is frequent during the following winters. However, chilblains do not always occur at the time of maximum cold.

Chilblains develop acutely as single or multiple, burning, erythematous, or purplish swellings (see Fig. 94–10A and C). Patients may complain of itching, burning, or pain. In severe cases, blisters (see Fig. 94-10B), pustules, and ulceration may occur. Characteristic locations include the proximal fingers and toes, plantar surfaces of the toes, heels, nose, and ears, but other sites like the calves and thighs can be affected[66,67] (see Fig. 94-10C). Lesions usually resolve in 1 to 3 weeks but may become chronic in elderly people with venous stasis. Tight garments such as gloves, stockings, and shoes are especially to be avoided in cases in which there is also peripheral vascular disease. A papular form of chilblains resembles erythema multiforme and occurs at all times of the year, usually in crops on the sides of the fingers,[68] often superimposed on a background of acrocyanosis.



Figure 94-9 Erythrocyanosis of plump upper arms of a woman.



Figure 94-10 Chilblains are common at such sites as the hands and feet when they are exposed to both cooling and tight garments. **A.** Chilblains on the toes. **B.** Chilblains on the dorsum of the foot. Children and the elderly are most commonly affected, perhaps, because they take less care to protect themselves from cooling. **C.** Equestrian chilblains from horse riding on a cold morning with inadequate clothing.

A peculiar clinical presentation may occur in young women riding horses for several hours daily during winter.[69,70] Indurated red-to-violet tender plaques develop on the lateral calves and thighs (see Fig. 94-10C). The condition is quite similar to the nodular perniotic lesions described in adolescent girls with erythrocyanosis. For prophylaxis, experienced riders usually wear baggy breeches that provide insulation and are not tight enough to compromise the circulation.

Perniotic lesions have been described in association with myeloproliferative disorders,[71] probably as a consequence of blood flow changes, presence of cold agglutinins, and altered inflammatory response on cooling.

Idiopathic perniosis is characterized histologically by edema of the papillary dermis and by the presence of superficial and deep perivascular lymphocytic infiltrates. Necrotic keratinocytes and lymphocytic vasculitis also have been reported. Thickening of blood vessel walls with intimal proliferation may lead to obliteration of the vascular lumen.[72–74]

Chilblain lupus is a distinct disease and is similar to discoid lupus erythematosus.[75,76] Lupus pernio is a variant of sarcoidosis (see Chapter 152) and is unrelated to cold injuries.

The unfamiliarity of physicians with chilblains sometimes gives rise to unnecessary hospital admissions with expensive laboratory and radiologic evaluations and, at times, hazardous therapy. The most important point in management is prophylaxis through the use of adequate, loose, insulating clothing and appropriate warm housing and workplace. Maintaining the blood circulation by avoiding immobility is also helpful. A short course of ultraviolet light therapy at the beginning of winter was a recommendation but has been challenged.[77] Once chilblains occur, treatment is symptomatic with rest, warmth, and topical antipruritics. Calcium channel-inhibiting drugs may be effective in the treatment of severe recurrent perniosis,[78] although they may cause headache and flushing that are troubling to some patients. In cases of crippling severity, thyrocalcitonin and hemodilution may be helpful.

COLD URTICARIA AND POLYMORPHOUS COLD ERUPTION

Acquired cold urticaria is a form of physical urticaria (Fig. 94-11). Lesions occur at sites of localized cooling, usually when the area is rewarmed. The disease is recognized by wheal and flare-type reactions and/or angioedema. The condition may be idiopathic or associated with some serologic abnormality.[79–83] It accounts for approximately 2% of cases of urticaria (see Chapter 38).

Most cases fall into the group of essential cold urticaria. They can be subdivided into a rare familial type and an acquired form. Immunoglobulin E and, more rarely, immunoglobulin M have been implicated in the pathogenesis. The antigen is likely a normal metabolite produced on exposure to cold. Histamine is one of the most important mediators, but leukotrienes, platelet-activating factor, and others have been incriminated. In this disease, exposure to cold causes prolonged



Figure 94-11 Cold urticaria induced by the application of ice to the skin.

edematous papules and plaques, often with headache, fever, arthralgia, and leukocytosis. Swelling of the oral mucosa and esophagus may occur on ingestion of cold liquids. A rather distinctive combination of cold urticaria and dermographism or cholinergic urticaria is not uncommon. Alarming signs resembling those of histamine shock may lead to loss of consciousness. Death while swimming in cold water has been reported.

Familial cold urticaria is a rare autosomal dominant condition with onset at an early age.[84,85] A mutation in the gene responsible for the cold-induced autoinflammatory syndrome-1 (CIAS1) has been identified.[85] Urticaria develops when the patient is exposed to generalized cooling, particularly chilling wind, rather than local cold application. The delayed type of familial cold urticaria is characterized by localized angioedema developing 9 to 18 hours after cold exposure.

Cold urticaria may occur in 3%–4% of patients with cryoglobulinemia, and it also may be associated with cold agglutinins, cryofibrinogens, and cold hemolysins. Cold urticaria has been reported in cases of infectious mononucleosis in association with either cryoglobulins or cold agglutinins, but such occurrences are rare. Cold urticaria may also be a sign of the Muckle–Wells syndrome that associates urticaria, deafness and amyloidosis.[86] In this rare genetic disorder recurrent bouts of urticaria, fever, chills and malaise may occur from birth and persist throughout life. *Helicobacter pylori* has been suggested as a causative agent in some cases of acquired cold urticaria.[87]

Diagnosis of cold urticaria is confirmed by a cold challenge induced by an ice cube wrapped in a plastic bag placed on the skin of the forearm for periods varying from 30 seconds to 10 minutes (see Fig. 94-11). Wheals form on rewarming. Sometimes water at 7°C (44.6°F) is more effective, presumably because it causes less severe vasoconstriction. Peltier effect-based temperature challenge appears to be an improved method for diagnosis.[88] The Peltier effect relies on using two different heat-transferring metals to generate a precise skin surface temperature, sufficiently cold, to induce lesions. The temperature is regulated by a microprocessor control unit monitoring the actual temperature at the test site.

Cold erythema seems to be a related disorder with erythema and pain but without urticaria. Familial polymorphous cold eruption is a rare autosomal dominant disease characterized by childhood onset of nonpruritic,

erythematous patches often accompanied by influenza-like symptoms and leukocytosis after generalized exposure to cold. Results of the ice cube test are negative. The pathogenesis remains unknown. The disease frequently has been referred to as *familial cold urticaria*, although the skin lesions are not urticarial.[89]

Avoiding cold wind exposure and swimming in cold water are important preventive measures. Antihistamines reduce clinical signs and symptoms. Desensitization to cold is possible by immersing one arm into water at 15°C (59°F) for 5 minutes daily.

COLD PANNICULITIS AND RELATED ENTITIES

Cold injuries may affect the subcutaneous tissue in different ways. The freezing injury in deep frostbite results in tissue gangrene. Nonfreezing injuries also can alter the hypodermis. Among them, cold panniculitis is more common in children than in adults. It affects the cheeks and legs most commonly. Tender erythematous subcutaneous nodules appear 1 to 3 days after exposure and subside spontaneously within 2 to 3 weeks. Ice cube challenge to the child's skin for 10 minutes results in the development of an erythematous plaque 12 to 18 hours later.

A perivascular mixed infiltrate with neutrophils, lymphocytes, and histiocytes is present at the dermal–subcutaneous junction after 24 hours, followed by a well-developed panniculitis at 48 to 72 hours. Some adipocytes are necrotic and rupture to form cystic spaces. The reaction subsides completely in 2 weeks. Infants have a higher content of saturated fatty acids in adipose tissue than do adults, and this may result in solidification at higher (less cold) temperatures.[90,91] Cold panniculitis should be distinguished from other related disorders, including erythrocyanosis with nodules, sclerema neonatorum, and subcutaneous fat necrosis of the newborn.

SCLEREMA NEONATORUM AND SUBCUTANEOUS FAT NECROSIS OF THE NEWBORN

(See Chapters 70 and 107)

Sclerema neonatorum and subcutaneous fat necrosis of the newborn are distinct disorders involving the subcutaneous fat of the newborn. As noted in the prior paragraph, infant fat differs from adult fat in that it has a higher saturated–unsaturated fatty acid ratio, which results in solidification at a higher temperature. Prematurity and immaturity of enzyme systems may result in a relative inability to desaturate fatty acids, which alters the ratio further. Sepsis, dehydration, chilling, infection, and other stresses also may inhibit the enzyme system. Thus, infants in general, and premature or otherwise compromised newborns in particular, are susceptible to such disorders.

Sclerema neonatorum is a rare disorder characterized by diffuse, rapidly spreading hardening of the skin and subcutaneous tissue in infants.[92] It starts on the buttocks and trunk, usually in the first week of life. Palms, soles, and scrotum are spared. Fifty percent of affected infants are premature. They have difficulty feeding and are lethargic, and many are otherwise debilitated. Septicemia is frequent, and the prognosis is poor. Cold exposure does not seem to be important in the etiology of sclerema neonatorum; however, similar clinical findings have been seen in cases of primary cold injury.[93] Histologically, the subcutaneous layer is greatly thickened by enlarged fat cells and wide, fibrous bands. There is no fat necrosis, and many of the fat cells contain fine needle-like clefts.[94]

Treatment of sclerema neonatorum involves correcting dehydration and electrolyte imbalance and treating septicemia if present. The value of systemic glucocorticoids is controversial. Successful treatment with exchange transfusions has been reported.[95]

Subcutaneous fat necrosis of the newborn is characterized by discrete red to violaceous mobile plaques and nodules that usually appear within a few days of birth. The back, thighs, and cheeks are most commonly affected. Fat necrosis and crystallization are the hallmarks of the disease. There may be a granulomatous inflammatory response with foci of calcification. In most cases, the condition is benign and self-limited, although it has been associated with hypercalcemia and death.[96]

As in sclerema neonatorum, there is no clear etiologic relationship to cold, and the cause is likely multifactorial. It has been postulated that an underlying defect in fat composition, poor nutrition, and various physical stresses such as hypothermia may be important.

ERYTHROMELALGIA

Erythromelalgia or erythermalgia is a rare chronic cutaneous disorder characterized by erythema, burning discomfort, and warmth of the extremities.[97,98] Primary erythromelalgia is an autosomal dominant neuropathic disorder involving a mutation in a voltage-gated sodium channel subunit.[99–106] Vasoconstriction apparently precedes reactive hyperemia, similar to that seen in Raynaud phenomenon. An early-onset type and an adult-onset type have been recognized. When the extremity is lowered or heat is applied, the pain is intensified. The application of cold or elevation of the extremity has the opposite effect of decreasing the pain. Idiopathic erythromelalgia may involve increased thermoregulatory arteriovenous shunt flow. Secondary erythromelalgia is associated commonly with myeloproliferative syndrome-related thrombocythemia and is mostly evident in the adult-onset type.

Treatment for adults with erythromelalgia includes a single daily dose of acetylsalicylic acid (aspirin), but children who have no associated underlying disorder obtain little to no relief from the drug. Other drugs including mexiletine[107] and venlafaxine[108] may also help. Pain may be decreased by topical amitriptyline combined with ketamine.[109] Lidocaine in patches[110] or

administered intravenously in combination with oral mexiletine[111] may also alleviate pain. Sympathectomy in the upper extremities is another option for treating refractory primary erythromelalgia.[112]

RAYNAUD PHENOMENON

(See Chapter 170)

CRYOGLOBULINEMIA

(See Chapter 169)

LIVEDO RETICULARIS

(See Chapter 173)

KEY REFERENCES

Full reference list available at www.DIGM8.com

DVD contains references and additional content

22. Long WB 3rd et al: Cold injuries. *J Long Term Eff Med Implants* **15**:67, 2005
32. Middleton JB, Allen BM: The influence of temperature and humidity on stratum corneum and its relation to skin chapping. *J Soc Cosmet Chem* **24**:239, 1974
33. Piérard-Franchimont C, Piérard GE: Beyond a glimpse at seasonal dry skin: A review. *Exog Dermatol* **1**:3, 2002
46. Daanen HA, van der Struijs NR: Resistance index of frostbite as a predictor of cold injury in arctic operations. *Aviat Space Environ Med* **76**:1119, 2005
83. Buss YL, Sticherling M: Cold urticaria; disease course and outcome – An investigation of 85 patients before and after therapy. *Br J Dermatol* **153**:440, 2005
91. Quesada-Cortés A et al: Cold panniculitis. *Dermatol Clin* **26**:485, 2008
98. Davis MD, Rooke T: Erythromelalgia. *Curr Treat Options Cardiovasc Med* **8**:153, 2006

Chapter 95 :: Thermal Injuries

:: Robert L. Sheridan

THERMAL INJURIES AT A GLANCE

- Burns are common; most are small and managed in the outpatient setting.
- Serious burns require inpatient care, ideally in a verified burn center.
- Large burns are managed in four general phases:
  - Initial evaluation and resuscitation.
  - Wound excision and biologic closure.
  - Definitive wound closure.
  - Rehabilitation and reconstruction.
- Styles of outpatient burn care are variable, but proper patient selection and monitored wound healing are essential.
- Long-term outcome quality tends to be very good in patients surviving large burns.

EPIDEMIOLOGY

The very young and very old are at increased risk of domestic burns.[1,2] Active young adults in industrial jobs are at modest increased risk. In developed countries, about 70% of pediatric burns are caused by hot liquid. Flame injuries are more common in older children and young working adults. Scalding and flame injuries each account for approximately half of burn injuries in the elderly, with kitchen and bathing accidents being predominant. Approximately 20% of burns in younger children involve abuse or neglect.

ETIOLOGY AND PATHOGENESIS

The development of an envelope of cornified skin was a crucial component of the adaptation of aquatic sea animals to the land environment. The vapor and fluid barrier created by the epidermal layer facilitates the maintenance of fluid and electrolyte homeostasis within very narrow limits. The dermis provides strength and flexibility, and the reactive dermal vasculature facilitates control of internal body temperature within very narrow limits. The appendages provide lubrication and prevent desiccation. All of these critical functions are lost when substantial areas of the skin are burned.

There is both a local and a systemic response to the burn wound.[3,4] The local response consists of coagulation of tissue with progressive thrombosis of surrounding vessels in the zone of stasis over the first 12–48 postinjury hours. An ability to truncate this secondary microvascular injury and its associated tissue loss is a major area of ongoing investigation. In larger burns, a systemic response develops that is driven initially by release of mediators from the injured tissue, with a secondary diffuse loss of capillary integrity and accelerated

transeschar fluid losses. This systemic response is subsequently fueled by by-products of bacterial overgrowth within the devitalized eschar.

Burn wounds are initially clean but are rapidly colonized by endogenous and exogenous bacteria.[5] As bacteria multiply within the eschar over the days following injury, proteases result in eschar liquefaction and separation. This leaves a bed of granulation tissue or healing burn, depending on the depth of the original injury. In patients with large wounds involving 40% or more of the body surface, the infectious challenge generally cannot be localized by the immune system, leading to systemic infection. This explains the rare survival of patients managed in an expectant fashion with burns of this size.

The systemic response to injury is characterized clinically by fever, a hyperdynamic circulatory state, increased metabolic rate, and muscle catabolism.[6] This stereotypical response to injury has been retained by all mammalian species. It is effected by a complex cascade of mediators, including changes in hypothalamic function resulting in increases in glucagon, cortisol, and catecholamine secretions; deficient gastrointestinal barrier function with translocation of bacteria and their by-products into the systemic circulation; bacterial contamination of the burn wound with systemic release of bacteria and bacterial by-products; and some element of enhanced heat loss via transeschar evaporation. It is likely that this response has significant survival value, but control of some of the adverse aspects of this response, particularly muscle catabolism, is an active area of ongoing investigation.[7,8]

BOX 95-1 ESSENTIALS OF BURN MANAGEMENT

- Burn size, extent, depth, and circumferential components influence decisions regarding outpatient care, hospitalization or transfer.
- Burn extent is best estimated using the Lund–Browder diagram that compensates for the changes in body proportions with age (see eFig. 95-4.1 in online edition). An alternative is a "rule-of-nines" for adults and children (see eFig 95-5.1 in online edition).
- In the adult rule-of-nines, the head and neck is given 9%, each lower extremity is given 18%, each upper extremity is given 9%, and the anterior and posterior torso are each given 18%.
- In the pediatric rule-of-nines, the head and neck is given 18%, each lower extremity is given 15%, each upper extremity is given 10%, and the anterior and posterior torso are each given 16%.
- For scattered or irregular burns, the entire palmar surface of the patient's hand represents approximately 1% of the body surface over all ages.

CLINICAL FINDINGS

(See Box 95-1)

Burns are classified by depth:

- First degree: Red, dry, and painful and are often deeper than they appear, sloughing the next day (Fig. 95-1A).
- Second degree: Red, wet, and very painful with enormous variability in their depth, ability to heal, and propensity to hypertrophic scar formation (see Fig. 95-1B).



Figure 95-1 Burn depth is classified as first, second, third, or fourth degree. **A.** First-degree burns are red, dry and painful and are often deeper than they appear, sloughing the next day. **B.** Second-degree burns are red, wet and very painful. There is an enormous variability in their depth, ability to heal, and propensity to hypertrophic scar formation. **C.** Third-degree burns are leathery, dry, insensate, and waxy. **D.** Fourth-degree burns involve underlying bone and/or muscle.

- Third degree: Leathery, dry, insensate, and waxy (see Fig. 95-1C).
- Fourth degree: Involve underlying subcutaneous tissue, tendon, or bone (see Fig. 95-1D).

Circumferential burns require special monitoring and possible surgical decompression. If across the torso, they will interfere with ventilation. If they involve an extremity, limb-threatening ischemia may occur during resuscitation.

LIGHTNING STRIKES

Although lightning strikes carry large amounts of energy, measured in millions of volts, human injuries are rare, with only about 50 people so injured annually in the United States and a fatality rate of only about 10%. Injury can rarely occur from direct strike, and is usually fatal. More commonly, people are injured by current flow around the skin envelope, or side flash, when a nearby object is struck. Destructive burns are unusual. Serious injury is more often the result of associated blunt trauma or occasional cardiac arrest. In most survivors, lingering symptoms are nonfocal, neurologic in nature, often preceded by an immediate but transient loss of consciousness.[9] The most common physical finding in those injured by side flash is an evanescent serpiginous cutaneous erythema, as noted in Figure 95-2.



Figure 95-2 (**A** and **B**) An evanescent serpiginous cutaneous erythema is characteristic of lightning injury.

TABLE 95-1
Burn Wound Complications

Common Outpatient Burn Complications
- Wound sepsis, usually streptococcal cellulitis
- Excessive pain and anxiety
- Underestimation of burn depth

Common Inpatient Burn Complications
- Wound sepsis, often invasive
- Septic shock and organ failures
- Inadequately controlled pain and anxiety
- Compartment syndromes
- Ocular exposure
- Respiratory failure
- Gut failure
- Pancreatitis
- Cholecystitis
- Urosepsis
- Donor site infection
- Soft-tissue contractures

COMPLICATIONS

In the outpatient setting, patient selection should ensure that major complications are few (Table 95-1). The most common issues that arise are wound sepsis, excessive pain and anxiety, and underestimation of burn depth.[10] The most common wound infection in this setting is streptococcal cellulitis, which presents initially with surrounding erythema that progresses to lymphangitis and systemic toxicity (Fig. 95-3). These patients often need admission for antibiotics, observation, and sometimes surgery. In some situations, adequate pain and anxiety management is very difficult in the outpatient setting, especially around dressing changes. This can be addressed with judicious medication and sometimes carefully monitored membrane dressings. Some patients will require admission. It is common for burn depth to be underestimated initially, with areas of full-thickness injury not appreciated for several days. These patients may require admission for surgery.

As burns increase in size and depth, the local injury is accompanied by an increasing degree of systemic derangement. Classically, this response has two phases. An initial "ebb" phase of reduced perfusion and metabolic rate, which lasts 24–48 hours, is followed by a "flow" phase of protein catabolism and a hyperdynamic circulation.[11] This later phase lasts until well after wound closure. Management of this physiology is an essential part of inpatient burn care. Those with large burns are susceptible to a host of other complications



Figure 95-3 The most common wound infection in this setting is streptococcal cellulitis, which presents initially with surrounding erythema that progresses to lymphangitis and systemic toxicity.



Figure 95-4 Some burn patterns are very suggestive of possible abuse. Here is illustrated flexor sparing in an immersion injury.

related to sepsis and organ failure. Careful monitoring and early intervention are essential to successful outcomes (Table 95-1).

PROGNOSIS AND CLINICAL COURSE

PATIENT EVALUATION AND TREATMENT PLANNING

In both outpatient and inpatient settings, a careful evaluation of the patient is essential for treatment planning. Patient evaluation is organized into a primary and a secondary survey, following the guidelines of the American College of Surgeons Committee on Trauma and the Advanced Burn Life Support Course of the American Burn Association. As in trauma, the primary survey begins with an assessment, and control if necessary, of the airway. Deeper burns of the face and neck can result in progressive airway edema. Occasionally, a child will aspirate hot liquids resulting in very severe upper airway edema mandating urgent intubation.

A burn-specific survey evaluates the issues uniquely associated with burn injury (eTable 95-1.1 in online edition). This may take just a few seconds if the burn is small, but will be much more time consuming in the more seriously injured.[12] In those with small injuries, essentials include a detailed determination of the mechanism of injury, a screen for associated trauma, consideration of the possibility of abuse (Fig. 95-4), and a detailed assessment of the burn wound. Delayed presentation for care, confusing stories, sharply demarcated margins, immersion patterns, and contact injuries are physical findings suggesting for abuse or neglect.[13] All such children should be admitted for evaluation.

After the patient has been evaluated, the burn wound should be examined for size, extent, depth, and circumferential components.[14] Burn extent is best estimated using a chart based on the Lund–Browder diagram that compensates for the changes in body proportions with age (eFig. 95-4.1 in online edition). An alternative is a modified "rule-of-nines," in which the head and neck is given 18% (instead of the adult 9%), each lower extremity is given 15% (instead of the adult 18%), each upper extremity is given 10% (instead of the adult 9%), and the anterior and posterior torso are each given 16% (instead of the adult 18%). For scattered or irregular burns, the entire palmar surface of the patient's hand represents approximately 1% of the body surface over all ages.

Burn depth is classified as first, second, third, or fourth degree (Fig. 95-1A–D). First-degree burns are red, dry and painful and are often deeper than they appear, sloughing the next day. Second-degree burns are red, wet and very painful. There is an enormous variability in their depth, ability to heal, and propensity to hypertrophic scar formation. Third-degree burns are leathery, dry, insensate, and waxy. Fourth-degree burns involve underlying subcutaneous tissue, tendon, or bone.

Near or completely circumferential burns should be identified for special monitoring, as they may need to be decompressed in the hours following injury to avoid ischemia (extremities) or failure of ventilation (torso).

The majority of burns can be successfully managed in the outpatient setting. However, poorly provided outpatient burn care can be frustrating and painful for patients and providers. The key is careful patient selection (eTable 95-1.2 in online edition) and a detailed care plan, especially an inpatient care plan (eTable 95-1.3 in online edition).

PATIENT OUTCOMES

Burn wounds and grafts typically develop some degree of hypertrophic scarring.[15] This involves a gradual increase in vascularity and collagen deposition in the months following healing. Some wounds will demonstrate significant contracture formation, with important functional and esthetic consequences (Fig. 95-5). Many patients will have bothersome pruritus and sometimes temporary neuropathic pain if burns are deep. A



Figure 95-5 Hypertrophic scarring and contracture formation can become difficult problems after serious burns (**A**), but are often amenable to surgical improvement (**B**).

long-term follow-up plan, consisting of scar management strategies, rehabilitation, reconstructive surgery, and emotional support will facilitate optimal outcomes. This care is best provided in a multidisciplinary burn clinic, ideally part of a comprehensive burn program. With such supports in place, the long-term outcome for most patients is surprisingly good. When managed in a comprehensive follow-up program, even those who have suffered devastating burns tend to become happy and productive again.[16,17]

TREATMENT

OUTPATIENT BURNS

Practice patterns vary widely, but certain characteristics are universal.[18] The wound should be kept generally clean and regularly inspected for infection. Desiccated exudates and topical medications should be periodically cleansed. Burns selected for outpatient management tend to be small and superficial with a corresponding low risk of infection, so clean rather than sterile technique is reasonable. If topical agents rather than membrane dressings are used, wounds may be cleansed with lukewarm tap water and a bland soap. Soaking adherent dressings prior to removal will decrease the pain associated with daily wound care. The wound is gently cleansed with a gauze or clean washcloth, inspected for any sign of infection, patted dry with a clean towel and redressed. It is important to instruct each patient to return promptly if they notice erythema, swelling, increased tenderness, lymphangitis, odor, or drainage so that infectious complications can be addressed early. Most small burns are adequately managed with a daily cleansing and dressing change. In some cases, a membrane dressing is applied once it is clear that early surgery is not needed, early infection is unlikely, and wounds are superficial. Pain and anxiety can be an issue for many. Some will benefit from an oral narcotic given 30–60 minutes prior to a planned dressing change. If dressings are occlusive, pain between dressing changes tends to be modest.

Increasing pain and anxiety associated with dressing changes; inability to keep scheduled follow-up appointments; delayed healing; signs of infection or a wound, which appears deeper than appreciated at the time of the initial examination, should prompt early return and specialty evaluation. Wounds selected for outpatient management are usually fairly superficial and heal within two weeks, but patients with mid and deep dermal injuries may have a deeper component with resulting scarring that may benefit from specialty evaluation. Finally, wounds of the face, ears, hands, genitals, and feet have functional and cosmetic importance out of proportion to their wound size. In some cases, early specialty evaluation may be prudent, as initial care can have an impact on long-term outcome.[19]

INPATIENT BURNS

A system of burn center verification has evolved to ensure that the patients requiring care of more

serious injuries receive coordinated efforts by experienced providers. Burn center referral criteria can be found at www.ameriburn.org (eTable 95-1.4 in online edition). Care of severe burns can be divided into phases, each with important objectives (eTable 95-1.3 in online edition).[20] Critical care is an important component, especially in the first three phases. Verified burn programs are required to have embedded burn intensive care units.

TOPICAL MEDICATIONS AND MEMBRANES

There is an increasingly confusing array of wound medications and membranes available for burn wounds. Wound medications and membranes provide three benefits: (1) pain control, (2) prevention of wound desiccation, and (3) reduction of wound colonization.

Topical wound medications range from aqueous solutions through antibiotic-containing ointments and debriding enzymes. Most topical agents in outpatient use have a viscous carrier that prevents wound desiccation and a more or less broad antibacterial spectrum that reduces wound colonization. A gauze wrap minimizes soiling of clothing and protects the wound from trauma. Silver sulfadiazine is in common use because it is painless on application and has a broad spectrum of antibacterial activity. Superficial burns are commonly treated with a clear, viscous antibacterial ointment containing low concentrations of various antibiotics. Wounds around the eyes can be treated with topical ophthalmic antibiotic ointments. Significant ear burns should be treated with mafenide acetate, as it is the only agent that will penetrate the relatively avascular cartilage.

Wound membranes provide transient physiologic wound closure while the underlying wound heals.[21] Physiologic closure implies a degree of protection from mechanical trauma, vapor transmission characteristics similar to skin, and a physical barrier to bacteria. The major benefit of wound membranes is that, when successful, they minimize wound manipulations. These membranes help create a moist wound environment with a low bacterial density and are generally intended for use on selected clean superficial wounds and donor sites. Occlusive synthetic membranes must be used with caution if wounds are not clearly clean and superficial, as submembrane infection can occur, deepening underlying wounds and causing systemic infection and toxicity.

PREVENTION

There have been a plethora of burn prevention efforts, which have met with mixed success. They can be based on (1) public education, (2) legislation, or (3) engineering.[22] Public education campaigns depend for their success on an educated literate community. The "stop, drop, and roll" campaign in elementary schools is an excellent example. Legislation is often more effective. Examples include safe factory set points for home water-heaters and flammability standards for children's bedclothes. Engineering solutions are perhaps the most effective. Examples are common in industry, and include physical isolation of high-power lines and "child-proof" cigarette lighters. Often all the three are combined, a current example being the fire-safe cigarette. A self-extinguishing cigarette has been engineered and, in some places, its sale is mandated after public education influenced the legislative process.

KEY REFERENCES

Full reference list available at www.DIGM8.com

DVD contains references and additional content

1. Fagenholz PJ et al: National study of Emergency Department visits for burn injuries, 1993 to 2004. *J Burn Care Res* **28**(5):681-690, 2007
10. Sheridan R: Outpatient burn care in the emergency department. *Pediatr Emerg Care* **21**(7):449-656, 2005
12. Sheridan RL: Comprehensive management of burns. *Curr Probl Surg* **38**(9):641-756, 2001
13. Chester DL et al: Non-accidental burns in children—Are we neglecting neglect? *Burns* **32**(2):222-228, 2006
14. Sheridan RL: Evaluating and managing burn wounds. *Dermatol Nurs* **12**(1):17-31, 2000
16. Sheridan RL et al: Longterm outcome of children surviving massive burns. *JAMA* **283**(1):69-73, 2000
20. Sheridan RL: Burn care: Results of technical and organizational progress. *JAMA* **290**(6):719-722, 2003

Chapter 96 :: Skin Problems in Amputees

:: Calum C. Lyon & Michael H. Beck

SKIN PROBLEMS OF AMPUTEES AT A GLANCE

- Skin problems under limb prosthesis result from:
  - Trauma.
  - Heat.
  - Pressure.
  - Occlusion and maceration.
- Physical trauma, disturbances of tissue fluid dynamics may cause other distinctive skin changes.
- Microclimate under prosthesis promotes bacterial and fungal infections.
- Irritant and allergic contact dermatitis occurs due to materials applied to skin, worn, or used in construction of the prosthesis.
- Koebner phenomenon may occur in skin under prosthesis.
- Management: most important are basic hygiene measures.
- Early medical intervention and collaboration with prosthetist are essential to address problems.

TECHNICAL BACKGROUND: LIMB PROSTHESES

In most centers, artificial limbs are constructed in a modular fashion.[1] The stump is placed in a thermoplastic socket that is then fitted into the main body of the limb. The bulk of the prosthesis comprises a metal frame with articulations and an outer casing of acrylic resin or carbon composite material. Before fitting the limb, many patients place their stump in a liner designed to reduce friction on the skin. This may be an expanded plastic cup, a silicon/mineral oil sleeve, or a cotton or nylon sock. The prosthetic limb, once fitted, is held in position by one of a range of suspension elements. In above-knee (Fig. 96-1) or proximal arm amputations, this is usually a fabric belt arrangement worn around the waist or shoulders, respectively. Below-knee amputees require a different system using either a butyl rubber sleeve or corset to hold the appliance firmly onto the thigh (Fig. 96-2). Many patients with above-knee amputations now use a suction socket device that provides sufficient suspension by holding the prosthesis in place through negative pressure without the need for additional belts (see Fig. 96-1).

Limb prostheses are the subject of continual technological development particularly in the field of bionics. Myoelectric devices, for example, rely on skin contact with electrodes to detect neuromuscular signals that can be converted to artificial limb movement. Neuroprosthetic devices involve implantation of electrodes into neural tissue usually through the skin, for example, cochlear implants. Such devices are under development for prosthetic limbs. These devices thus have the potential for causing skin problems.

DERMATOLOGIC PROBLEMS IN AMPUTEES

The skin of an amputation stump is not designed to withstand the physical insults it encounters within a prosthetic limb. For example, although some adaptation to friction or pressure occurs, some skin problems are inevitable. If these dermatoses cannot be prevented or rapidly resolved by prosthesis adjustment or medical intervention, they can incapacitate the patient, particularly those who have lower limb, weight-bearing prostheses. As a result, patients may suffer social isolation,

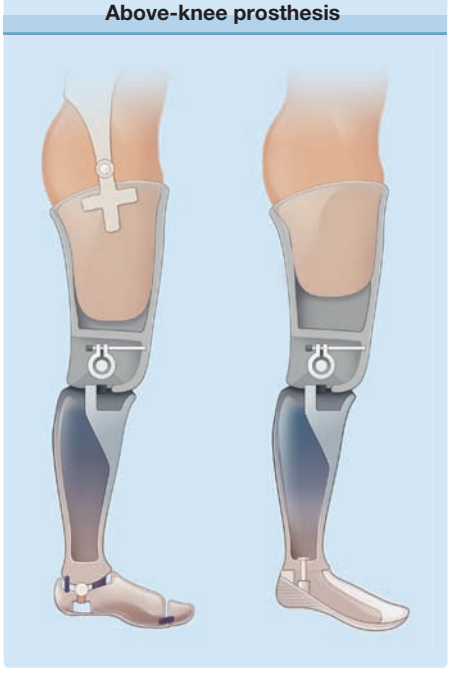

Figure 96-1 Above-knee prosthesis. Suction-socket prosthesis.



Figure 96-2 Below-knee prosthesis. Patellar tendon-bearing cuff suspension.

emotional distress, or even financial deprivation if they are unable to work.

Skin problems may occur because of allergy or chemical irritation to materials in contact with the skin, as well as from trauma and occlusion. Examples of physical stresses on the skin include shearing and friction from elements in the socket and pressure on load-bearing areas, especially on the tibial tuberosity in below-knee amputations and the ischial tuberosity, adductor region, or groin in above-knee amputations. In all cases, the occlusion results in increased humidity from trapped perspiration, increasing the likelihood of irritation, allergy, and infection.

The common skin disorders in amputation stumps can be classified into diseases related to the reasons for the amputation, physical effects of a prosthesis, infection, contact dermatitis, and other cutaneous disorders.

EPIDEMIOLOGY

The great majority of artificial limb wearers are amputees, although a small proportion are people with congenital limb malformations. Lower limb amputees are the most numerous and are also the group at greatest risk of skin problems. Traumatic amputations are possibly more likely to be associated with a dermatosis[2] although the commonest problems encountered are the same as for all amputees.[3] Modern limb prostheses allow many of today's amputees to lead an active life with good mobility. Nevertheless, as many as 73% of one cohort of lower limb amputees reported at least one skin disorder.[2] In a further group of 745 lower leg amputees, 40.7% had at least one skin problem. Further analysis identified four factors independently associated with dermatologic disorders, namely transtibial amputation, employment status, type of walking aid used, and peripheral vascular disease.[4] A more recent questionnaire-based study of 805 lower limb amputees[5] suggests that the factors more likely to be associated with skin problems are, smoking, younger age, female sex, washing the stump frequently and the use of antibacterial soaps. Overall one-third of amputees, either upper or lower limb, experiences a skin problem that significantly interferes with the normal use of the artificial limb.[6]

DERMATOSES RELATED TO THE REASONS FOR AMPUTATION

Several disorders resulting in the need for amputation can have a significant impact on skin integrity. In general, younger patients require artificial limbs because of traumatic amputations, congenital abnormalities, or malignancy, whereas in the older age group, arterial disease and vascular complications of diabetes mellitus predominate. Amputations after trauma or severe vasculitis may be associated with scarring that makes for a suboptimal prosthesis fit (Fig. 96-3). Stump dermatoses appear to be more likely in patients following traumatic amputations. Koc et al[2] found a skin problem in nearly three quarters of amputees most of whom had lost a limb as a consequence of mine explosions. The nature of current conflicts means that, presently, such amputations are unfortunately common amongst both service personnel and civilians. Vasculitis resulting in amputation may be ongoing and cause problems in the skin of amputation stumps (Fig. 96-4). However, it is diabetes mellitus that is particularly associated with protracted skin problems (Chapter 151) as a result of impaired wound healing, susceptibility to infection, abnormal sensory nerve function, and disruption of normal tissue fluid balance.[7] Diabetic amputees as a group require more frequent clinical review to prevent complications. Treatment of the diabetic amputee not only requires good control of the blood glucose level but possibly a change of the stump environment through adjustment or redesign of the artificial limb. The diabetic amputee highlights the need for close links with a prosthetics department, which allow rapid referral of patients for assessment.



Figure 96-3 Scarring of the stump after amputation for severe postinfective vasculitis.



Figure 96-4 Patient with vasculitis resulting in ischemia (**A**) that required amputation (**B–C**). This recurred on the amputation stump (**D**) but fortunately responded to systemic therapy.

PHYSICAL DERMATOSES

The physical effects of wearing a prosthesis are the most common causes of skin problems.[6,8] These can be divided into those resulting from repeated direct trauma and those secondary to disturbance of tissue fluid dynamics.

DIRECT PHYSICAL TRAUMA

Ulceration. Ulceration and callus formation are seen where there is chronic pressure or repeated frictional forces on stump skin. Ulceration may also be caused by infection or poor cutaneous nutrition, particularly secondary to diabetes mellitus (Figs. 96-5 and 96-6). Stump ulcers should be treated early as malignancy may develop in long-standing ulceration.[9] With repeated infection and ulceration, an amputation scar on the distal stump skin can erode further. In some cases, the skin may become completely adherent to bone and develop thick, callus-like hyperkeratosis (Fig. 96-7), which may necessitate revision of the distal bony surface. Ulceration or other injuries incurred while putting on artificial limb components may be particularly associated with poor manual dexterity consequent on neurological disorders or arthritic changes.[10,11] Incorrect use of some appliance components can also result in injury.[12] Patient selection and access to follow-up advice is therefore important in reducing such injuries. Apparently spontaneous ulceration at unexpected sites is occasionally seen (Fig. 96-8). In every instance, the cause of the ulceration must be determined to resolve a chronic process that can become totally disabling. However, a recent study

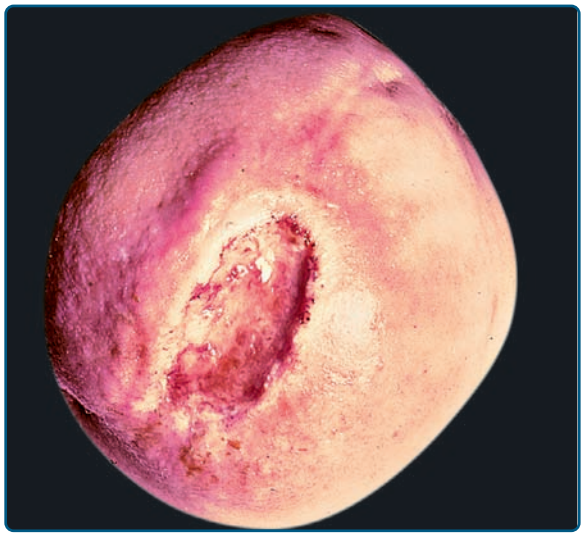

Figure 96-5 Chronic ulcer of stump skin.

examining 102 patients over 4 years suggests that the majority of patients with delayed wound healing or secondary ulcers will experience healing despite continuing to use their prosthesis, provided they are carefully monitored.[13]

Physical Dermatitis. In some patients, eczema may be caused by a poorly fitted or misaligned prosthesis or by edema and congestion of the terminal portion of the stump; only with alleviation of these problems does the condition clear.

Epidermoid Cysts and Follicular Keratoses. Epidermoid cysts and follicular keratoses are two ends of a spectrum of the same disorder. Repeated pressure and friction from the prosthesis appears to cause



Figure 96-6 Ulceration associated with infection in a diabetic man with an amputation for ischemia.



Figure 96-7 Chronic ulceration resulting in thick hyperkeratosis and scab formation adherent to the underlying bone.

invagination of keratin around hair follicles, which then results in a foreign-body reaction. Follicular keratoses are therefore the earliest changes.[14] These are very common, often multiple, and distributed at sites of weight bearing such as the anterior tibial area, popliteal fossa, and the adductor or inguinal areas of the thigh (Fig. 96-9A). Fortunately, they cause little trouble in many cases, but they can become inflamed and painful particularly if the patient picks at them to extract



Figure 96-8 Ulceration in a patient receiving nicorandil for angina. The ulcer appeared spontaneously and not at a site of friction. It resolved slowly over 3 months after nicorandil was stopped suggesting the drug may have been involved.



Figure 96-9 Epidermoid cysts in different stages. **A.** Early follicular keratoses in the popliteal fossa of a man with below-knee amputation. **B.** Hemorrhagic and inflamed large epidermoid abscess in a man with an above-knee prosthesis. Note the follicular hyperkeratosis. **C.** Inflamed epidermoid cysts in the groin of a man with an above-knee prosthesis.

the keratin plug or if they become infected. Inflamed follicular keratoses can have an acneiform appearance, leading some to suggest that they represent a form of acne mechanica. When the continued pressure and friction causes the keratin to extend deeper into the dermis, larger cystic lesions, 1–3 cm in diameter, form; these are commonly termed *posttraumatic epidermoid cysts*. Meulenbelt et al[15] described a case of follicular keratoses of a transfemoral amputation stump in a patient who did wear an appliance at all. These lesions recurred after resection and were associated with retention of vellus hairs. This raises the possibility that, in some individuals, mechanisms other than just friction may be involved. Deeper cysts can be very tender when compressed by the prosthesis. Some cysts have an obvious punctum and patients may express keratinous material from them. Large cysts can be so painful that the patient can no longer wear a weight-bearing prosthesis each day (see Fig. 96-9B and 96-9C). Distention of the overlying epidermis can occur, followed by spontaneous rupture. A serous, purulent, or hemorrhagic fluid is then discharged. The resulting sinus is difficult to occlude and the discharge continues as long as the prosthesis is worn. Intercommunicating sinuses can appear and spontaneous ruptures may occur. In advanced cases, a granulomatous reaction occurs around the cyst with considerable capillary dilation, vascularization, and a heavy inflammatory infiltrate progressing to abscess formation (see Fig. 96-9B).

Management of this condition can be difficult. Clearly, prevention is the ideal but is not always possible despite regular prosthetic assessments. The fit of the prosthesis is the single most important method of preventing cyst formation. The problem can sometimes be improved or successfully eliminated by proper fitting and aligning of the prosthesis and continued adjustment by the prosthetist. Rough surfaces in areas of increased contact pressure in the socket, particularly the suction socket, tend to catch the skin, increasing the shearing forces. For this reason, the lining of the socket should be kept smooth. With the idea of inserting a buffer between the skin and the socket, protective devices such as liners and stump socks are used. Various synthetic films and adhesives, such as Teflon, have been found satisfactory as liners. They allow for a smooth, gliding action of the prosthetic socket wall or brim against the skin. Applying a vapor-permeable adhesive membrane to the skin before fitting the appliance can

also help reduce frictional trauma. Topical glucocorticoids can be used at night to reduce inflammation and provide symptomatic relief. Intralesional injection of glucocorticoids into the cysts and their channels also results in temporary improvement.

Surgical intervention is useful in cases with a few lesions that are not infected. Lesions can be surgically incised and drained. In other instances, removal of the prosthesis is sufficient to cause the lesion to involute, provided that the cyst has not become too large. However, spontaneous rupture, incision, and drainage, and even spontaneous resorption of the lesion are of only temporary benefit. When the prosthesis is worn again, these cysts can recur so that surgical excision is not always the treatment of choice, especially in continually rubbed areas.

In selected cases, systemic retinoid therapy may be appropriate to minimize hyperkeratosis. One author found oral isotretinoin to be effective in a patient described as having acne mechanica.[16]

DISTURBANCES OF TISSUE FLUID DYNAMICS

Edema. Amputation of a lower extremity greatly disturbs the normal pattern of blood and lymph channels, as well as the relationship of pressure both inside the vessels and in the surrounding tissues of the stump. An important feature of care during convalescence after amputation is the reduction of edema and stabilization of new circulatory patterns in the stump. Swelling can be partially prevented by gradual compression of the stump tissues with an elastic bandage or "shrinker" sock before fitting the prosthesis and socket.

When an amputee begins to wear a suction-socket prosthesis, the skin must adapt to an entirely new environment. The patient can expect edema, reactive hyperemia for days or weeks, a reddish-brown pigmentation resulting from capillary hemorrhage, and, occasionally, serous exudation and crusting of the skin of the distal portion of the stump. These changes are relatively innocuous, usually short lived, and do not usually require therapy.

The extent to which edema may persist or recur in the healed stump depends on many factors.[17] Edematous portions of the skin of the distal part of the stump may become pinched and strangulated within the socket (Fig. 96-10). Such areas may ulcerate if they catch in the spring-valve opening and become gangrenous as a result of the impaired blood supply. Therapy includes eliminating all mechanical factors contributing to the edema, such as choking by the socket, poor fitting, and misalignment. Excessive negative pressure in a suction-socket prosthesis also contributes to circulatory congestion and edema. Treatment should be directed toward better support of the distal soft tissues. Occasional use of an oral diuretic sometimes allows the edema to resolve.

Verrucous Hyperplasia. *Verrucous hyperplasia* refers to a reactive hyperplastic condition, characterized morphologically by numerous, coalescent warty papules (Fig. 96-11). It occurs when the chronic pressure effects of a poor prosthetic fit disrupt vascular and lymphatic channels, resulting in chronic tissue edema. The same appearance is seen around longstanding leg ulcers where there is an element of lymphedema (see Chapter 174). Histologic examination can show evidence of pseudoepitheliomatous hyperplasia, although the condition itself is benign and potentially reversible. However, in neglected cases, malignant change can occasionally occur (see Fig. 96-11C). Bacterial infection may play a role in the development of pseudoverrucous hyperplasia, as secondary mixed flora infections are common because of the poor superficial blood flow and the convoluted surface (Fig. 96-12). External compression is the best method of treatment, in combination with topical control of bacterial infection. In below-knee amputees, the distal part of the stump is edematous; the stump dangles freely in the socket or has no distal support or partial end-bearing. When the stump end is supported in the socket by a temporary cushion or platform, compression gradually reduces and slowly clears the verrucous condition. The greater the compression on the distal stump, the more immediate and lasting is the improvement. The use of compression bandaging, shrinker socks and other pads, and partial end-bearing all have a definite place in therapy and can be skillfully applied by the prosthetist. Short courses of oral diuretics may be indicated to reduce edema of the stump. The medication can be gradually decreased when the stump and its skin return to normal.



Figure 96-10 Dependent edema/early verrucous hyperplasia in a man with multiple amputations after severe peripheral vasculitis and necrosis.

Acroangiodermatitis. Acroangiodermatitis occurs when the chronic pressure changes result in vessel proliferation in the upper- and middermis. There is also extravasation of red blood cells and these features combine to give a purplish hue to the papules and plaques that appear on a background of edematous skin. The appearance may mimic Kaposi sarcoma.[18] Some authors suggest that acroangiodermatitis occurs in above-knee amputees who use a suction socket prosthesis that exerts negative pressure.[19] However, there are reports of acroangiodermatitis in below-knee amputees,[20] and the same condition is seen in chronic venous insufficiency and in the patients with arteriovenous



Figure 96-11 Verrucous hyperplasia of the distal stump skin. **A.** Before compression therapy. **B.** Total resolution after compression therapy. **C.** Malignant degeneration into squamous cell carcinoma.

shunts (acroangiodermatitis of Mali). Management of this condition is the same as for stump edema and verrucous hyperplasia.

BACTERIAL AND FUNGAL INFECTIONS

The bacterial flora of amputation stumps have been examined in small groups of patients,[21,22] and the most common species encountered are *Staphylococcus epidermidis*, *S. aureus*, and *Streptococcus* sp. (see Chapter 176). The moist, occluded environment under a prosthesis is ideal for fungal and bacterial growth so that minor skin infections occur fairly frequently. In one study, *S. aureus* folliculitis or *Trichophyton rubrum* infection was identified in 3% of the study population.[6] Infections are more common during hot weather and in those amputees who pay insufficient attention to stump hygiene, partly because in these situations the skin becomes macerated more readily and follicular infections become more likely. Although folliculitis (Fig. 96-13) and furuncles are more common, superficial infections of the skin itself may also occur (see Chapter 176). Superficial dermatophyte and candidal infection (see Chapters 188 and 189) are also common and may be difficult to eradicate because of the ideal environment for fungal growth within a prosthesis.

The diagnosis of infection is usually obvious when the rash extends onto skin not covered by the prosthesis. Underneath the prosthesis, any superficial infection may present as a nonspecific scaling erythema indistinguishable from that caused, for example, by chronic irritation. All stump rashes should be swabbed and scraped for bacterial and fungal culture.

In the management of bacterial infections, oral antibacterial therapy should be directed by bacterial culture and sensitivity. Topical antiseptics or antibacterials can be used but some antiseptic preparations can cause irritation and there is also the potential for sensitization.



Figure 96-12 This man developed postinfectious purpura fulminans after varicella-zoster infection as a child in the 1960s and lost both legs as a consequence. He presented with infected verrucous hyperplasia having lived a reclusive life in a cabin in the woods wearing an old-fashioned unadjusted aluminum prosthesis for many years. The infection was treated with new hygiene measures, and he was fitted with a modern modular prosthesis. The skin rapidly resolved, although some of the verrucous hyperplasia changes persisted.



Figure 96-13 Folliculitis of stump skin showing the typical distribution in the occluded area.

Superficial fungal infections respond to appropriate topical therapy (see Chapters 188 and 189) but can be hard to completely eradicate because of the favorable conditions for fungal growth. In this situation, systemic antifungal therapy is useful.

CONTACT DERMATITIS

(See Chapters 13 and 48)

The clinical presentations of irritant and allergic contact dermatitis affecting amputation stumps are indistinguishable (Fig. 96-14), ranging from dry, scaling erythema to weeping dermatitis.[6] Indeed, the morphologic features may be the same as nonspecific eczematization where no irritant, allergic, or infectious cause is found, and where there is no history of eczema or atopy. Consequently, a careful history and examination is essential if one is to identify irritant or allergic causes (Table 96-1). This includes accurate timing of the onset of dermatitis in relation to changes in the patient's appliance routine or the composition of the prosthesis. The distribution of rash typically matches the site of the contactant. To identify a primary irritant or allergen, it is particularly important for the dermatologist to observe the patient removing and refitting their limb, making note of its construction and any medicaments or other agents such as cleansers, talcs, and creams that the patient uses. These products may contain allergens such as fragrances or preservatives. Colored stump socks may contain potentially allergenic nylon dyes.

Knowledge of the materials used in prosthesis manufacture is also necessary when considering potential sensitizers and irritants. This is best achieved by liaison with the local prosthetist, as different construction techniques may be used in different areas. In general,



Figure 96-14 Allergic contact dermatitis to formaldehyde-releasing biocides in a lubricating "baby oil." Note the nonspecific, dry, eczematous appearance.

TABLE 96-1
Causes of Dermatitis on Amputation Stump

- Traumatic
- Irritant
  - Soaps and washing materials
  - Topical applications, including medicaments
  - Solvents in glues and resins used to make prosthesis
- Allergic
  - Active ingredients, perfume, and excipients of topically applied materials (e.g., deodorizers, cleansers, topical medicaments, and moisturizers)
  - Acrylic, epoxy, polyester, and formaldehyde resins
  - Resin hardeners
  - Other plastic additives (e.g., *para*-tertiary butylphenol catechol)
  - Nickel
  - Rubber accelerators and antioxidants
  - Chromate (leather)
  - Nylon dyes

modern modular prostheses are fabricated with sockets, liners, and casings that may contain acrylic resins, carbon composites, and thermoplastics. Epoxy and, occasionally, polyester resins are still used by some manufacturers. Acrylate-based thread sealants are commonly used in socket bolts and metalwork. Butyl or black rubber material may be used to conceal access points to the metal frame. Rubber materials can also be found in some suction socket valves (Fig. 96-15). Accelerators used in the manufacture of natural or synthetic rubbers are potential allergens, for example, dialkyl thiourea used in chloroprene rubber.[23] Suspension elements often include chrome-tanned leather and sometimes have metal fastenings, rivets, or screws containing nickel. Glues containing *para*-tertiary butylphenol formaldehyde resins are often used.

Repairs or adjustments to prostheses can introduce new irritants and allergens. For example, sockets sometimes have additional leather linings cemented to points of friction or pressure.

Irritant dermatitis (see eFig. 96-15.1 in online edition) can be due to occluded contact with volatile solvents in glues or resins and from fragrances and detergents in topical medicaments or lubricants. Soaps and other washing materials used to clean appliances can cause irritation if they are not removed by proper washing (see Table 96-1). Burns from a malfunctioning electrode used in a myoelectric prosthesis have been reported.[24]

Contact allergy should always be considered as a cause of inflammatory and dermatitic disorders affecting the stump, especially if there is secondary spread (see Table 96-1). In addition to standard series patch testing, the authors recommend an extra series of allergens to include components of plastic, including acrylic, epoxy, and polyester resin systems, as well as an azo dye series. It is important to test with pieces of the prostheses and all materials applied to the stump skin including emollients, cleansers, powders, medicaments, and cosmetics. In our experience, the most common relevant allergens are nickel, acrylates, rubber, chromate (in leather), *para*-tertiary butylphenol formaldehyde resin, and components of topical applications.[6]

OTHER CUTANEOUS DISORDERS

Common skin diseases, for example, eczema (see eFig. 96-15.2 in online edition) and psoriasis (see eFig. 96-15.3 in online edition), may affect amputation stumps. Those



Figure 96-15 Allergic contact dermatitis to rubber materials in a suction socket from an arm prosthesis. **A.** The prosthesis fitted. **B.** The dermatitis is worst around the areas where the pressure is released on removing the limb.

diseases that exhibit the Koebner phenomenon, especially psoriasis or lichen planus, have been reported on amputation stumps with little involvement of other areas of skin. Treatment should always take into account the implications of an occluded environment.

Hyperhidrosis can be a problem in some patients resulting in maceration of the skin increasing the risk of erosions and even ulceration. Standard topical antiperspirants can be irritating under occlusion and one novel approach is to use intradermal botulinum toxin A.[25]

Benign keratoses, warts, nevi, and a variety of cutaneous papillomas may occur on stump skin and occasionally cause discomfort when a prosthesis is worn. Malignancies have also been described and squamous cell carcinoma (Marjolin's ulcer)[9] may develop in nonhealing chronic stump ulcers or verrucous hyperplasia (see Fig. 96-11). The patients who have amputations for lymphangiomas may develop the Stewart–Treves syndrome and metastatic lymphangiosarcoma (see Chapter 128). There is a risk that such malignancies may not be recognized as an ulcer might be wrongly blamed entirely on trauma from a poorly fitting prosthesis. A biopsy of persistently ulcerated areas should be undertaken.

Treatment of these benign and malignant tumors is the same as when they occur elsewhere on the skin. Healing after tumor excision may take weeks, during which time the artificial limb may not be worn.

GENERAL MANAGEMENT CONSIDERATIONS

Many of the more common skin problems can be prevented or controlled by adherence to an appropriate hygiene and skin-care regimen in conjunction with regular prosthetics reviews, which ensure that the prosthesis remains appropriate and correctly adjusted. To this end, it is important that good communication exists between the dermatologist and prosthetist, which permits rapid referral of patients before skin disorders become established.

As a general routine, the stump skin should be washed at night rather than in the morning because newly washed skin is hydrated and swollen, thereby increasing the likelihood of friction and shearing trauma. Nonperfumed soap should be used to minimize contact with potential sensitizers and fully removed with tepid water and gentle rubbing with a nonabrasive towel.

Antibacterial soaps and washes can reduce the possibility of infection in addition to their cleansing action. However, these antiseptic preparations can cause irritation or allergy in a small number of cases and patients should be warned about this. If a stump sock is worn, it should be changed daily and washed and rinsed fully as soon as it is taken off, before perspiration is allowed to dry within it. Silicone liners should be washed every day.

KEY REFERENCES

Full reference list available at www.DIGM8.com

DVD contains references and additional content

1. Marks LJ, Michael JW: Science, medicine, and the future: Artificial limbs. *BMJ* **323**(7315):732-735, 2001
4. Dudek NL et al: Dermatologic conditions associated with use of a lower-extremity prosthesis. *Arch Phys Med Rehabil* **86**(4):659-663, 2005
6. Lyon CC et al: Skin disorders in amputees. *J Am Acad Dermatol* **42**(3):501-507, 2000
8. Levy SW: Skin problems of the leg amputee. *Prosthet Orthot Int* **4**(1):37-44, 1980

Chapter 97 :: Skin Problems in Ostomates

:: Calum C. Lyon & Michael H. Beck

SKIN PROBLEMS IN STOMA PATIENTS AT A GLANCE

- Peristomal skin is chronically occluded and subject to pressure, shearing forces, and fecal/urine soiling. Some skin problems are therefore inevitable.
- Two-thirds of ostomates develop dermatological problems. Irritant reactions, common skin diseases, and infections are the most common.
- The occlusion under a stoma appliance can result in unusual clinical appearances of common dermatoses. All rashes should be swabbed to exclude primary or secondary infection.
- Allergic contact dermatitis is relatively uncommon. Nonetheless patients should be advised to minimize exposure to potential allergens especially fragrances and preservatives.
- Some dermatoses are commoner than expected around stomas, particularly psoriasis, pyoderma gangrenosum, and lichen sclerosus.
- Liaison with stoma nurses (ET therapists) and surgeons is essential to provide an effective service for patients with peristomal dermatoses.

SKIN PROBLEMS IN PATIENTS WITH ABDOMINAL STOMAS (OSTOMATES)

A stoma is a surgically created opening onto the skin of part of the gastrointestinal or urinary tract in order to drain the effluent from that viscus. The most frequently performed stomas are ileostomies, colostomies, and ileal conduits (urostomies or urinary diversion). The commonest indications for stoma surgery are inflammatory bowel disease, malignancy and neurological problems. A patient with a stoma is usually termed an "ostomist" or "ostomate."

EPIDEMIOLOGY

There are estimated to be more than 1.4 million ostomates in the United States and 100,000 in the United Kingdom and Ireland. Some stomas are temporary, with surgical anastomosis delayed, pending resolution of the acute disorder. Temporary stomas are often "loop stomas" where a loop of bowel is brought to the skin surface and part of the wall removed to allow preferential drainage into a stoma pouch in order to relieve a distal problem, for example, perianal ulceration. Such stomas are more frequently associated with skin problems secondary to leaks.[1] Many stomas formed for malignant indications can be seen as palliative procedures.

A stoma appliance is essentially a device for collecting stoma effluent with a high degree of comfort and security until it can be disposed of. There continues to be promising advances in the design of stoma bags. Essentially, the device is a pouch or bag held in place over the stoma by an adhesive skin barrier made solely or partly from hydrocolloid. Many ileostomists and urostomists use two-piece appliances where the barrier remains on the skin for 2–4 days and is detachable; disposable bags are changed as necessary. Appliances with convexity on the surface next to the skin are available for patients with short or buried stomas (Fig. 97-1). Useful recent innovations include softer convex appliance that apply less pressure on the skin and collars or sleeves that fit snugly around the stoma before applying the bag thereby reducing the chance of leaks of effluent or intestinal mucus under the barrier.



Figure 97-1 A typical drainable stoma bag with a convex barrier.



Figure 97-2 Peristomal dermatitis due to fecal irritation. The skin beneath the stoma was chronically exposed to feces because a bag with too large an aperture was used.

As many as two-thirds of ostomates experience skin problems that interfere with the normal use of their stoma appliance,[2,3] and such dermatoses are the commonest reasons for a visit to outpatient stoma services.[4,5] The majority of these problems are irritant reactions, usually dermatitis secondary to leaks from the stoma; however, there are also a number of other well-defined irritant reactions. Common coincidental dermatoses, particularly psoriasis and constitutional eczema, account for around 15% of the diseases seen.[2,6] An approach to diagnosing peristomal dermatoses is given in eFigure 97-1.1 in online edition.

IRRITANT REACTIONS

DERMATITIS. Dermatitis most frequently results from the chronic leakage of effluent onto the skin because the patient is using an inappropriately shaped appliance or one with too large a hole for their stoma. The most common cause is the remodeling of the stoma and abdominal wall that occurs in the months after surgery, whereby a stoma usually becomes a little shorter and thinner, resulting in leaks unless a correctly fitting appliance is selected (Figs. 97-2–97-6). Leaks will also occur when patients gain a lot of weight after surgery and the effective length of their stoma diminishes because it becomes buried by subcutaneous fat.[7] Irregular scarring after surgery or retraction of the stoma, may also be associated with chronic leakage. Such irregularities can be corrected with topically applied pastes. One effective alternative is to use collagen fillers (Porcine collagen Permacol™)[8] to recontour the skin surface. Short stomas (<2 cm long), loop ileostomies and stomas formed as emergency procedures are more likely to be associated with skin problems.[1,9] Chronically irritated skin can become markedly hyperkeratotic and acanthotic



Figure 97-3 Irritant contact dermatitis circumferentially around an ileostomy because the bag aperture was cut too big thereby allowing soiling of the skin around this short stoma.



Figure 97-5 A short ileostomy where recurrent soiling has led to irritation and hypertrophic changes due to massive hyperkeratosis and acanthosis similar to chronic papillomatous dermatitis.

(Fig. 97-7). These problems can be prevented and resolved by careful postsurgical follow-up by the enterostomal therapist (ET; stoma nurse specialist) to ensure that the correct appliance is being used. Severe, acute irritant dermatitis can be effectively treated with a short course of topical corticosteroid while longer term appliance modifications are being undertaken (Table 97-1).

Anxieties about possible leaks and odors can lead to excessively frequent bag changing, which may cause an irritant dermatitis by stripping the skin. Patients may, for the same reasons, wear waist belts too tightly thereby causing pressure damage even ulcers (eFig. 97-7.1 in online edition) and occasionally necrosis. Whatever the cause of skin inflammation, a vicious cycle can develop when the damaged skin prevents proper bag adhesion necessitating more frequent bag changes.[12] Careful counseling is usually necessary in order to reassure the patient regarding leaks.

Approximately 15% of ostomates with skin problems suffer from a chronic or recurrent dermatitis for which no irritant, allergic, or infective cause can be found, and where primary skin disease is ruled out.[2] In the absence of a primary treatable cause, the use of topical corticosteroid lotions is appropriate. Most patients



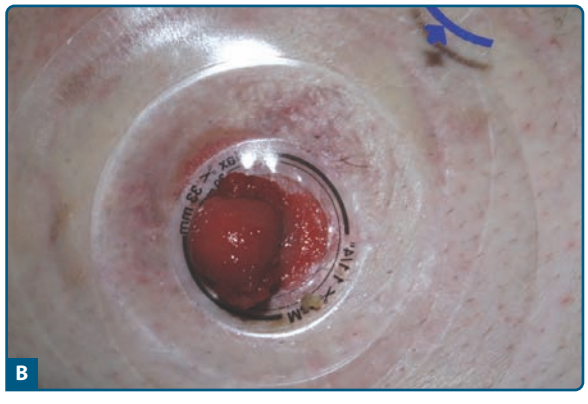

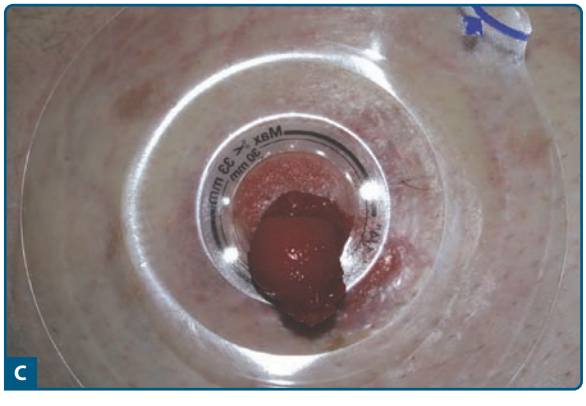

Figure 97-4 **A.** Eroded irritant dermatitis in two places around an ileostomy. **B** and **C.** show the release film from the bag in the two positions that the patient was accustomed to place the appliance, accounting for the fecal soiling and the dermatitis seen.



Figure 97-6 Irritant contact dermatitis from leaks occurring when reclining at night resulting in a cycle of poor bag adhesion and further leaks. Patient was unable to sleep sitting up and the rash did not respond to barriers or steroid tape. It eventually responded to applications of beclomethasone via a metered dose inhaler allowing proper bag adhesion and less leakage.

require only occasional short courses for a maximum of 4 weeks' duration (Table 97-1). A small number of patients require intermittent applications longer term. Provided that the frequency of application is no more than once every 10 days, steroid atrophy of the skin appears to be unusual.

In ileostomy patients with short bowel, the output may be very high and corrosive due to the enzyme and bile salt content. In this situation, some leaks are inevitable, despite the use of proprietary barrier preparations or soothing lotions. Where the irritation has resulted in an eroded dermatitis, sucralfate powder applied at every stoma bag change can be very effective. In addition to forming a sticky barrier, the preparation is thought to promote healing.[13] Surgical scars and even large striae (eFig. 97-7.2 in online edition) can lead to ulcerations and bag failures, which may respond to topical carmellose sodium or sucralfate powders. Wound dehiscence can cause severe difficulties for bag adhesion (eFig. 97-7.3 in online edition) and

TABLE 97-1
Topical Corticosteroid Treatment of Inflammatory Peristomal conditions

1. Good adhesion between the appliance and the skin is essential. Ointments, creams, and greasy lotions will cause a bag to lift so that most patients will not use them.
2. One approach tolerated by some patients is to use dressings such as thin hydrocolloid or vapor-permeable membranes placed over the cream preparation and before applying a stoma bag.
3. Another approach is to apply a cream preparation for 1–3 hours per day before wiping off and applying a stoma bag. While the cream is in place, a nonadhesive bag can be worn, held in place with a waist belt, provided that the patient is sedentary during this time.
4. A number of alternative vehicles for delivering topical corticosteroid are available although none is ideal nor designed for stoma use.
   a. Adhesive tapes impregnated with fludroxycortide 4 mcg/cm^2.
   b. Scalp lotions (oil-free; 40% isopropyl alcohol) betamethasone valerate 0.1%, clobetasol propionate 0.05%. These will sting on broken skin and can be applied to the bag adhesive and allowed to dry before applying to the stoma.[10]
   c. Scalp gels flucinolone acetonide 0.025%. This preparation contains propylene glycol that may impair bag adhesion a little.
   d. Steroid asthma inhalers beclomethasone dipropionate 250-µg/metered dose. Several activations are used to the affected area (Fig. 97-6)
   e. Carmellose sodium oral pastes are especially useful in ulcerative conditions such as mild pyoderma gangrenosum, e.g., triamcinolone acetonide 0.1% in carmellose sodium paste (this product needs to be compounded).
   f. Alternative nongreasy steroid sprays are available in some regions.[11]
5. With each of these preparations, the steroid is under occlusion and, therefore, effectively more potent. Skin atrophy and absorption, particularly in children must be considered. The authors limit initial courses to a maximum of 4 weeks and thereafter one to two times per week if needed.



Figure 97-7 **A.** Ulcerated hyperkeratotic dermatitis due to leaks. **B.** Three weeks after leakage was reduced using a combination of convex barrier and filler pastes around the stoma.

presents particular challenges for nursing management where the dermatologist may be called upon for advice as part of the multidisciplinary team.[14]

CHRONIC PAPILLOMATOUS DERMATITIS. This term refers to clinical appearance of warty excrescences around urostomies resulting from leaks and pooling of urine on the peristomal skin (eFig. 97-7.4 in online edition). Recurrent urinary tract infections appear to increase the likelihood of chronic papillomatous dermatitis (CPD) probably due to the presence of ammonia from urea-splitting bacteria. Histologically, there is massive hyperkeratosis and acanthosis. Pseudoepitheliomatous hyperplasia may also be a feature but is not universal. The histology is therefore not specific and comparable to that of other irritant reactions. Verrucous lesions with similar appearances are occasionally seen affecting ileostomies[15] (Fig. 97-5). In severe cases, the lesions can encroach on the stoma and cause stenosis (Fig. 97-8). When the leaking of urine is caused by a receding stoma, CPD will resolve rapidly if a convex-backed appliance is used to increase the effective length of the urostomy and thereby stop leaks. Acetic acid soaks (10% domestic vinegar in water)[16] at each bag change are effective in some cases (eFig. 97-8.1 in online edition). Larger excrescences may be shaved off under local anesthetic to allow a bag with a smaller aperture to be used. In severe cases, surgical revision of the stoma may be required.

GRANULOMAS. The term *granuloma* is commonly used for a range of papular lesions, which are almost all secondary to irritation. The authors have only seen the condition affecting ileostomies or colostomies and not urostomies. They may affect the stoma itself (inflammatory colonic or ileal polyps) or the mucocutaneous junction, or may be found more widely,



Figure 97-8 Chronic papillomatous dermatitis affecting a urostomy in a patient who is using a bag with too large an aperture. The red area is stoma and is becoming stenosed by the warty papules. The brown pigmentation is a typical finding in long-standing urostomies in all races. (Courtesy of Anita Eriksson, Karolinska Institute, Stockholm, Sweden.)

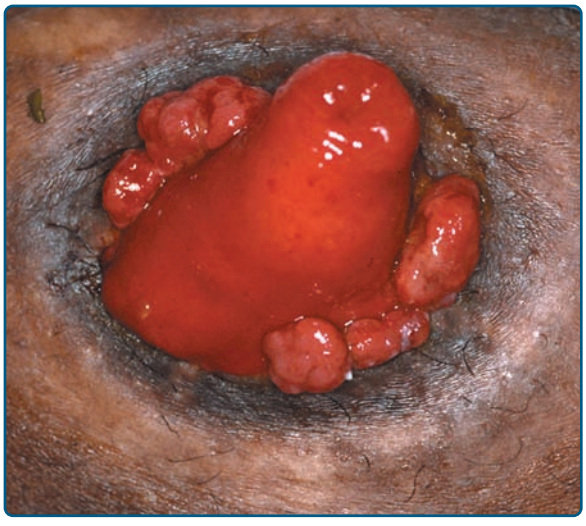

Figure 97-9 Granulomas around a colostomy. The patient has cut the bag aperture larger to accommodate the original lesion, and the area thus exposed is seen as a ring of postinflammatory hyperpigmentation in which new lesions developed.

extending onto the peristomal skin (Fig. 97-9). The latter is more frequent in patients with colostomies, and in this situation, the papules may become very extensive. This occurs when the patient enlarges the stoma bag aperture to accommodate a papule, thereby exposing normal skin to fecal irritation, which precipitates further lesions and prompts the patient to enlarge the aperture still further (eFig. 97-9.1 in online edition). Histologically, the lesions contain a chronic inflammatory infiltrate, granulation tissue, and sometimes metaplastic bowel mucosa where the metaplasia is probably a response to fecal irritation. Comparable lesions occur around ileostomies (eFig. 97-9.2 in online edition) but are generally flatter and may even present as sheets of cherry-red granulation tissue. These lesions are sometimes caused by seeding mucosa at the time of surgery.[17] The majority, however, probably represent mucosal metaplasia as a consequence of persistent fecal contact with the skin. In long-standing ileostomies (greater than 10 years), there is a small risk of malignant change *analogous to* Barrett esophagus.[18] A biopsy to rule out malignant change should be considered for unusual lesions particularly ulcerative changes in existing granulomas around ileostomies.

Asymptomatic, solitary lesions can be left. Where they are painful[19] or bleed easily leading to poor stoma bag adhesion, they can be destroyed by cautery (thermal or silver nitrate) or by cryotherapy, using a liquid nitrogen spray. Larger and proliferating lesions especially around colostomies are best removed by shave and cautery under local anesthetic and an appliance with a correctly sized aperture fitted in order to prevent massive proliferation. Laser ablation is increasingly regarded as a first-line treatment being less painful and possibly more effective.[20]

PSORIASIS. Psoriasis is a common cause of peristomal skin disease because it may appear in irritated

or traumatized skin (Koebner's phenomenon) and because it is associated with inflammatory bowel disease (Chapter 18). Peristomal psoriasis presents as a glazed erythema similar to flexural psoriasis (eFig. 97-9.3 in online edition) and can be treated in the same way with topical corticosteroids although, at the peristomal site, a nongreasy base should be selected (Table 97-1). The diagnosis is usually unmistakable being part of more generalized involvement (eFig. 97-9.4 in online edition) but localized peristomal involvement is described.[21] Resolution of psoriasis under hydrocolloid occlusion has been described,[22] which is of relevance to stoma patients because 50% of cases of peristomal psoriasis will resolve if a bag is selected with a thicker, hydrocolloid-only barrier. Where the patient can tolerate the stoma being temporarily unprotected from leaks, ultraviolet (UV) phototherapy is effective as for psoriasis elsewhere. The mucous membranes of the stoma should be protected from UV light. Although irritating topical psoriasis treatments are not usually tolerated, some patients have had success with creams containing hydrocortisone 1% and coal tar 3%, the application being left on the skin for 1 hour each day (Table 97-1, Point 3). Superficial X-ray (Grenz-ray) therapy has been used in recalcitrant cases.

INFECTIONS. The most frequent peristomal skin infection is staphylococcal folliculitis, usually, but not exclusively, in those individuals with hairy abdomens who shave regularly to help the bags stick (eFig. 97-9.5 in online edition). It responds to oral antibiotics and to a reduction in shaving frequency to no more than once per week. Although antiseptic washes can be a useful additional therapeutic measure, they can cause irritant reactions if the skin is not correctly rinsed before being occluded by the stoma bag. Localized skin infections, usually staphylococcal or streptococcal, can produce a rash indistinguishable from irritant dermatitis or primary skin disease such as psoriasis or eczema. Furthermore, preexisting psoriasis or eczema can become secondarily infected under occlusion (eFig. 97-9.6 in online edition). Therefore, all peristomal rashes should be swabbed for microbiological investigation and appropriate antibiotics prescribed based on microbiological sensitivities. In tropical climates, cutaneous fungal infections are common, whereas in more temperate regions, *Candida albicans* is an occasional problem and dermatophyte infection is rare. Viral warts are occasionally seen and can present as verrucous lesions solely affecting the stoma itself (eFig. 97-9.7 in online edition). Despite the body site and the presence of skin trauma herpes zoster is surprisingly uncommon around stomas. Nonetheless viral infections should be considered in the differential diagnosis of vesicular eruptions and where there are peristomal erosions because vesicles and bullae are typically deroofed by removing stoma bags and, therefore, are not commonly observed (eFig. 97-9.8 in online edition).

PYODERMA GANGRENOSUM. This rare, inflammatory, ulcerative neutrophilic dermatosis (see Chapter 33) is more common in peristomal skin than would be expected from its frequency in the general population.[23,24] Clearly, this is partly due to its strong association with inflammatory bowel disease. There is some evidence, however, that the increased use of convex-backed appliances may contribute to the incidence via the pathergic effect of increased pressure on the skin. We have seen a decline in incidence of peristomal PG in the last 5 years associated with reduced use of deeply convex appliances and the introduction of softer convex materials. Although some cases of pyoderma gangrenosum (PG) are associated with active inflammatory bowel disease,[25] the association is not universal; indeed, peristomal PG occurs in ostomates who have no history of inflammatory bowel disease.[26] Peristomal PG presents as a painful papule or pustule, often hemorrhagic, which then ulcerates and is usually very painful (eFigs. 97-9.8 and 97-9.9 in online edition). The pain and the ulceration can have profound effects on the patient's ability to wear a bag and, therefore, on their quality of life. The ulcers heal with cribriform scarring (eFigs. 97-9.10 and 97-9.11 in online edition) that can itself impair bag adhesion so that rapid, effective treatment of PG is essential.

Management is similar to that for PG elsewhere (Chapter 33) although small, superficial, and solitary ulcers respond very rapidly to topical therapy alone (eFig. 97-9.12 in online edition). Because of the problems with greasy preparations causing lifting of stoma bags, alternative vehicles are usually necessary (Table 97-1). There are no randomized controlled trials of treatment for this rare condition and some current evidence has recently been reviewed.[27] The author's approach is detailed in Table 97-2.

CONTACT ALLERGY

Modern stoma bags are made largely from food-grade materials and those with a low potential for sensitization. Nonetheless, there are case reports of sensitivities to individual ingredients including Gantrez® (GAF

TABLE 97-2
Management of Peristomal Pyoderma Gangrenosum

- The majority of smaller and superficial PG ulcers respond to potent or superpotent topical corticosteroid in a suitable base (Table 97-1).[23,28]
- Larger, deeper, or multiple lesions and those not responding to steroid alone may require topical tacrolimus 0.3% in carmellose sodium paste.[29,30] Fludroxycortide impregnated tape used in conjunction with topical tacrolimus may hasten improvement; it also serves to reduce the overgranulation typically seen when topical tacrolimus is associated with rapid healing of a PG ulcer.[30]
- Systemic treatment may be indicated from the outset for very multiple, circumferential or rapidly progressing PG as well as for where topical therapy has failed. These agents are as described for PG elsewhere (Chapter 33). Those specifically reported for peristomal PG include cyclosporin, mycophenolate mofetil,[31] infliximab,[32] and adalimumab.[33]
- With all treatments the first sign of improvement is reduction of pain and tenderness usually seen within 48 hours with effective therapies.

Corporation. Wayne NJ) resins and acrylate adhesive systems (eFig. 97-9.13 in online edition). Furthermore, there is a potential for contact allergy from deodorizers and topically applied preparations. These case reports of peristomal allergic contact dermatitis have recently been the subject of a literature review.[34] Despite the fact that contact allergy is a relatively uncommon cause of peristomal dermatitis most patients and many health professionals regard contact hypersensitivity to their appliance as the likely cause of a peristomal rash. Patch testing is indicated in patients with persisting problems where infection, irritation, and constitutional skin disease has been ruled out.[35] We have patch tested well over 100 such patients and relevant positive allergic reactions were found in only three cases of topically applied materials including fragrance in a deodorizer and biocides in wet wipes.

OTHER CONDITIONS

In theory, almost any of the multitude of skin disorders might affect a stoma. In clinical practice, the common disorders (e.g., psoriasis predominate and others) are more common than expected (e.g., PG). Some less common peristomal dermatoses are worthy of note either because they present practical difficulties such as pemphigoid and nicorandil ulceration, or in the case of lichen sclerosus because they have an unusual predilection for this site. The authors have managed five patients with pemphigoid affecting the skin around stomas (eFig. 97-9.14 in online edition); in all cases, the principal problems are pain and the failure of stoma bag adhesion (eFig. 97-9.15 in online edition). This necessitates a low threshold for rapidly effective systemic therapy (Chapter 56) otherwise the patient is rendered immobile in order to reduce the effect of a leaking stoma. Cecchi et al have summarized the clinical features and therapy of their own plus five previously published cases.[36]

Nicorandil, a potassium channel activator with nitrate activity is used in the management of angina. It has been associated with mouth ulceration as well as perianal,[37] peristomal and even small bowel ulceration.[38] It presents as rather indolent ulcers with minimal inflammation clinically or histologically. In a patient with pericolostomy ulcers that has had the stoma formed because of intractable perianal ulcers, for example, the diagnosis is usually straightforward. There are, however, a range of differential diagnoses for nonspecific ulceration including simple trauma such as one sees in patients with parastomal hernias that cause stretching and tearing of the skin. The diagnosis should be considered in patients receiving nicorandil with otherwise unexplained ulceration around a stoma. In most cases, the ulceration resolves within a month or two of stopping the drug (eFig. 97-9.16 in online edition).

Lichen sclerosus affecting peristomal skin is an enigmatic condition as it can present in the absence of genital involvement and affect any type of stoma.[39–41] In the authors' experience of six cases (eFig. 97-9.17 in online edition), the condition is painful and readily ulcerates. Topical corticosteroid therapy may be ineffective and intralesional steroid may be required (eFig. 97-9.17 in online edition). Stoma surgery is avoided if at all possible in patients with inherited conditions that are associated with skin fragility or blistering. These conditions together with the more severe congenital ichthyoses can cause significant difficulties with proper stoma bag adhesion.

Benign tumours, particularly seborrheic keratoses, sometimes cause problems if they become inflamed or infected under the occlusion of a stoma appliance. In these circumstances, ablative treatment with simple curettage and cautery is effective.

Other conditions occasionally seen around stomas include Crohn disease, metstatic ulcerative colitis,[42] basal cell carcinoma,[43] squamous carcinoma,[44] and metastatic adenocarcinoma.[45]

KEY REFERENCES

Full reference list available at www.DIGM8.com

DVD contains references and additional content

2. Lyon CC et al: The spectrum of skin disorders in abdominal stoma patients. *Br J Dermatol* **143**(6):1248-1260, 2000
7. Nybaek H et al: Skin problems in ostomy patients: A case-control study of risk factors. *Acta Derm Venereol* **89**(1):64-67, 2009
14. Braun K: Managing a highly exudative wound adjacent to an ileostomy. *J Wound Ostomy Continence Nurs* **30**(3):159-164, 2003
18. Al-Niaimi F, Lyon CC: Primary adenocarcinoma in peristomal skin: A case study. *Ostomy Wound Manage* **56**(1): 45-47, 2010
21. Moriyasu A, Katoh N, Kishimoto S: Psoriasis localized exclusively to peristomal skin. *J Am Acad Dermatol* **54**(Suppl. 2):S55-S56, 2006
24. Hughes AP, Jackson JM, Callen JP: Clinical features and treatment of peristomal pyoderma gangrenosum. *JAMA* **284**(12):1546-1548, 2000
33. Fonder MA et al: Adalimumab therapy for recalcitrant pyoderma gangrenosum. *J Burns Wounds* **5**:e8, 2006

Chapter 98 :: Corns and Calluses

:: Thomas M. DeLauro & Nicole M. DeLauro

CORNS AND CALLUSES AT A GLANCE

- Corns and calluses result from prolonged application of forces to the skin and produce painful symptoms.
- Every weight-bearing human being is vulnerable.
- Lesions occur in predictable pedal locations.
- Corns and calluses show changes within the epidermis, dermis, and adipose layer.
- There are no associated systemic abnormalities.
- Treatments are available and vary in aggressiveness.

EPIDEMIOLOGY

Every human being, with the exception of the non-weight-bearing infant, is vulnerable to the development of corns and calluses, because the skin is subjected to regular mechanical stress. The prevalence of corns and calluses can be readily appreciated by the number of nonprescription products aimed at reducing or preventing them—a billion-dollar market annually.

The earliest known discussion of these lesions can be found in the writings of Cleopatra, who authored a textbook on cosmetics.[1] Corns and calluses have plagued humankind since antiquity, affecting those at all socioeconomic levels.

Certain foot types and regions are prone to mechanically induced skin thickening, regardless of race, gender, or age.

ETIOLOGY AND PATHOGENESIS

Corns and calluses result from the prolonged application of excessive mechanical shear or friction forces to the skin. In theory, these forces induce hyperkeratinization, which leads to a thickening of the stratum corneum, although the precise mechanism by which this occurs remains unknown. If the abnormal forces are distributed over a broad area (i.e., more than 1 cm^2), a callus develops. In contrast, a corn will form if the same forces are applied to a focused location, with the lamellae of the stratum corneum becoming impacted to form a hard central core known as the *radix* or *nucleus* (Fig. 98-1).

Mechanical keratoses are not determined genetically. Heredity does play a role, however, in configuring the individual's skeletal architecture. A family history of bony abnormality or ligamentous laxity predisposes the person to the presence of sites of increased cutaneous friction or shear. The prevalence of these lesions has also proven to be significantly higher in females, certain ethnic groups, and mentally ill patients.[2,3]

CLINICAL FINDINGS

HISTORY

Corns and calluses produce painful symptoms often described as burning, especially when the affected area is weight bearing and/or shoes are worn. This discomfort is thought to result from microtearing of the thickened, inflexible skin.

CUTANEOUS LESIONS

Corns [clavi or helomata (singular: clavus or heloma)] and calluses [tylomata (singular: tyloma)] are, respectively, keratotic papules and plaques that occur in areas that are subject to sustained excessive mechanical shear or friction forces.

RELATED PHYSICAL FINDINGS

The lesions occur in predictable pedal locations, corresponding to a structural deformity or biomechanical fault. Crookedness of the lesser toes leads to prominence of the proximal and/or distal interphalangeal joints. Keratoses can therefore form either dorsal to those joints, between the toes, at the distal end of the toe, or on the lateral aspect of the fifth toe and/or



Figure 98-1 A simple corn beneath the fifth metatarsal head. Note the white central radix or nucleus, which has been partially pared. This radix must be pared to provide comfort.

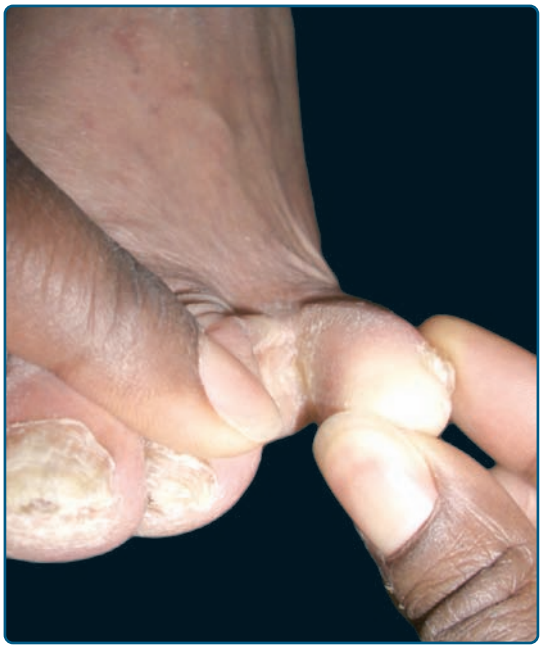

Figure 98-2 A soft corn (also known as a *heloma molle*) located deep within the fourth interdigital space.



Figure 98-3 A large callus beneath the fifth metatarsal head in a postpoliomyelitis patient whose foot is now in rigid adductovarus.

toenail (lateral toenail corn, also known as *Durlacher's corn*; see eFig. 98-1.1 in online edition). Interdigital corns can be hard when they are adjacent to the interphalangeal joint(s) (see eFig. 98-1.2 in online edition) or soft when deep within the fourth interdigital space. The softness of latter last corn results from trapped perspiration, which leads to maceration of the keratotic tissue (Fig. 98-2).

In patients with bunions (hallux valgus), a callus usually forms at the medioplantar aspect of the hallux. During gait, the individual rolls off that portion of the great toe because of its incorrect position. The skin is subsequently pinched to form a "pinch callus" (see eFig. 98-2.1 in online edition). In addition, the first metatarsal often does not bear its fair share of the weight-bearing load. Weight is therefore transferred laterally to the second metatarsal head, which usually leads to the development of an additional corn or callus beneath that bone.

Other favored locations for lesser metatarsal head keratosis include the following:

- Beneath the first and fifth metatarsal heads in cavus foot types
- Beneath the fifth metatarsal head alone in persons with tailor's bunions (bunionette)
- Erratic locations (e.g., beneath the third and fifth metatarsal heads, isolated third or fourth metatarsal head, second and fourth metatarsal heads) in individuals with structural abnormalities such as brachymetatarsia or dislocated metatarsophalangeal joints, as in rheumatoid arthritis or neuroarthropathy (Fig. 98-3)
- Beneath the second through fourth metatarsal heads when multiple hammertoes, hallux valgus, or an equinus deformity coexists (Fig. 98-4)

Another variant of corn is that referred to as *heloma miliare* or *seed corn*. This title is derived from the clinical appearance of these corns: multiple guttate keratoses that are easily pared. When seamed nylon hosiery was fashionable, this garment was considered the causative factor. However, patients still present with seed corns even though they have never worn seamed stockings.



Figure 98-4 A large callus beneath the second metatarsal head in a patient with concomitant hallux valgus. Usually, the hallux valgus segment causes a lateral shift in weight bearing to the second metatarsal.

HISTOPATHOLOGY

In contrast to nonmechanically induced keratoses, corns and calluses exhibit changes within the epidermis, dermis, and adipose layer. Corns demonstrate a parakeratotic plug within the stratum corneum, with a pressure-related loss of the stratum granulosum as well as atrophy of the stratum malpighii. The dermis displays significant fibrosis, dilated eccrine ducts and blood vessels, hypertrophied nerves, and scar tissue replacement of subcutaneous fat. Overall, the histologic changes in calluses are less pronounced, and include a thickened stratum corneum but intact stratum granulosum.[4]

Because corns and calluses are the result of mechanical friction and shear alone, there are no associated hematologic, chemical, serologic, or immunohistochemical abnormalities.

BOX 98-1 DIFFERENTIAL DIAGNOSIS OF CORNS AND CALLUSES

Most Likely (Secondary to Structural Deformity)

Deformity	Corn or Callus Location
Pronation	Medioplantar heel
Pes planus foot type	Medioplantar heel
Charcot neuroarthropathy	Midsole
Cavus foot type	Submetatarsal heads 1 and 5
Tailor's bunion	Submetatarsal head 5
Hallux valgus	Submetatarsal head 2 Medioplantar hallux
Brachymetatarsia	Submetatarsal heads 3, 5
Dislocations as in rheumatoid arthritis and other structural abnormalities	Submetatarsal heads 3, 4 Submetatarsal heads 2, 4
Transmetatarsal amputation without tendo-Achilles lengthening	Stump of amputation

Consider

- Multiple guttate keratoses
  - Heloma miliare
- Painful corns
  - Intractable plantar keratoses
- Neurofibrous or neurovascular corn
- Porokeratosis plantaris discreta

Always Rule Out

- Lesions not associated with bony prominences
  - Verruca
  - Genokeratoses
  - Cutaneous neoplasms
  - Neuroborreliosis

DIAGNOSIS AND DIFFERENTIAL DIAGNOSIS

(See Box 98-1)

PROGNOSIS AND CLINICAL COURSE

If left untreated, corns and calluses result in painful ambulation and also in subhelomal bursitis and blistering that can rupture to the surface. Because of the close proximity of some corns to joints and bone, septic arthritis and/or osteomyelitis can ensue. The mechanical forces that cause corns and calluses can also rupture portions of the subcutaneous vascular plexus, which leads to hemorrhage into keratotic tissue. In healthy patients, such findings are of minor significance, but in other cases (e.g., in diabetic patients and patients with connective tissue disease), they may herald extensive skin ulceration or vasculitis.

The need for lower extremity amputation is a dominant fear in most diabetic patients. Such amputations are most often preceded by a history of foot ulceration (see Chapter 151). Although a number of comorbidities contribute to the development of ulceration (e.g., peripheral vascular disease, neuropathy, and limited joint mobility), minor trauma via repetitive pressure is the pivotal precipitating event. As markers of repetitive friction and shear, corns and calluses in the diabetic foot are of special significance. Simple débridement of these hyperkeratotic lesions decreases peak plantar pressures by as much as 26%.[5] In a retrospective review of more than 200 diabetic foot ulcerations, patients who had their corns and calluses pared frequently experienced a statistically significant decrease in the incidence of foot ulceration, hospitalization, and surgical intervention.[6] Hemorrhage within a corn or callus is an especially ominous sign, indicating subcutaneous breakdown with a strong potential for ulceration. Therefore, ulcer care should include paring of calluses. The use of proper footwear by the diabetic as well as the nondiabetic patient may also play a role in not only preventing but also reducing the development of callosities. Shoes should be correctly sized to accommodate the width and length of the patient's foot, and the heel should be elevated minimally, if at all, to prevent pathology and pain.[7,8]

TREATMENT

(See Box 98-2)

PREVENTION

Corns and calluses can be prevented only by reducing or eliminating the mechanical forces that created

BOX 98-2 TREATMENT

	PHYSICAL		TOPICAL		SURGICAL
First line	Paring Padding	Central radix of corn requires débridement	Keratolytics[a]	40% salicylic acid or 40% urea cream used as directed	
Second line	Injections[b]	4% alcohol mixed with local anesthetic	Lipid extract with garlic[c]		Osseous and/or soft-tissue procedures[d]
Under investigation	Injections[e]	Botulinum toxin to reduce digital contractures and thereby reduce the increased local skin pressures that lead to hyperkeratosis[13]			

[a]Keratolytics are to be used with caution. Their use is contraindicated in patients with comorbid peripheral neuropathy or arterial disease.
[b]Injections are useful for soft corns and intractable plantar keratoses. Typically up to seven injections may be required, with darkening and thrombosis of the lesion heralding a cure.[9,10]
[c]Newer modality under research. Side effects include blistering, redness, burning, and hyperpigmentation.[11]
[d]Osseous procedures are designed to redistribute weight-bearing pressures, whereas soft-tissue procedures (i.e., adipofasciocutaneous flaps[12]) are used to eliminate cicatrix (fifth digit) secondary to the use of medicated padding.
[e]Newer modality under research. Efficacy undetermined.

them. Usually, this is a daunting, if not impossible, task. Repetitive occupational motions are often unavoidable, patients are commonly reluctant to alter shoe styles, and osseous architecture is predetermined through heredity.

KEY REFERENCES

Full reference list available at www.DIGM8.com

DVD contains references and additional content

2. Dunn JE et al: Prevalence of foot and ankle conditions in a multiethnic community sample of older adults. *Am J Epidemiol* **159**:491, 2004
4. Lemont H: Histologic differentiation of mechanical and non-mechanical keratoses of the sole. *Clin Dermatol* **1**:44, 1983
6. Sage RA, Webster JK, Fisher SG: Outpatient care and morbidity reduction in diabetic foot ulcers associated with chronic pressure callus. *J Am Podiatr Med Assoc* **91**:275, 2001
9. Costello MJ, Gibbs RC: *The Palms and Soles in Medicine.* Springfield, IL, Charles C Thomas, 1967
10. Dockery GL, Nilson RZ: Intralesional injections. *Clin Podiatr Med Surg* **3**:473, 1986
13. Radovic PA, Shah E: Nonsurgical treatment of hallux abductovalgus with botulinum toxin A. *J Am Podiatr Med Assoc* **98**:61, 2008

Chapter 99 :: Sports Dermatology

:: Dirk M. Elston

SPORTS DERMATOLOGY AT A GLANCE

- Forty percent of all athletes develop skin problems.
- Infections are highly prevalent.
- Community-acquired methicillin-resistant *Staphylococcus aureus* (CAMRSA) has emerged as the most important pathogen among athletes.
- MRSA typically presents as an abscess or folliculitis.
- The most important intervention for a CAMRSA abscess is drainage.
- Control of MRSA outbreaks requires treatment of fomites and skin colonization.
- Infections with *Pseudomonas*, *Vibrio*, and atypical mycobacteria are frequently associated with water sports.
- Heat and cold injury remain important problems in athletes.

EPIDEMIOLOGY

Skin problems are common among athletes.[1,2] During an 8-week survey of university athletes, 40% reported skin problems.[3] In a study of mountain biking injuries, skin lesions accounted for 75% of all injuries.[4] Skin lesions account for 35% of all in-line skating injuries.[5] Skin infections are more prevalent in athletes than in the general population.[6] Skin-related complaints are especially common in warm, humid climates. During the 1993 Central American and Caribbean Games, held in Puerto Rico, one out of every hundred athletes had a skin-related complaint severe enough to require medical care.[7] Similarly, sports that involve repeated immersion in water are associated with an increased incidence of skin injury and infection.[8] Winter sports often involve short periods of repetitive injury resulting in a high frequency of injuries.[9]

Table 99-1 lists some unique sports-associated skin conditions that are worthy of mention but are not discussed further in this chapter (Figs. 99-1 and 99-2).

PYOGENIC SKIN INFECTIONS

EPIDEMIOLOGY

Cutaneous community-acquired methicillin-resistant *Staphylococcus aureus* (MRSA) has emerged as the most important pathogen among athletes.[10–13] Athletes at risk include weight lifters, wrestlers, and members of competitive sports teams.[14–16] During an outbreak of MRSA in a college football team, linemen had the highest attack rate (18%). Preexisting cuts or abrasions and sharing bars of soap were important risk factors associated with infection. Nasal carriage was associated with sharing towels, living on campus, having a locker near a teammate.[17] Cosmetic body shaving has also been identified as a risk factor for MRSA infection.[18] Data

TABLE 99-1
Sports-Associated Skin Conditions

Bikini bottom: bacterial folliculitis on the buttocks of swimmers
Jazz ballet bottom: buttock cleft abscess
Jogger's nipples: painful, swollen, eroded or hyperkeratotic nipples
Karate cicatrices: linear scars on the dorsal aspects of the hands
Mogul skier's palm: traumatic hypothenar ecchymosis
Painful piezogenic pedal papules: transdermal fat herniations
Ping-pong patches: traumatic ecchymotic patches
Pool palms: smooth, shiny, tender palms secondary to rough pool surfaces
Pulling-boat hands: pernio-like condition produced by friction and damp cold
Rower's rump: lichenification
Runner's nail: multiple Beau's lines or periodic shedding of the nail plate (see Fig. 99-1)
Runner's rump: ecchymoses of the superior gluteal cleft
Stingray hickey: bite ecchymosis
Stretcher's scrotum: scrotal hematoma
Swimmer's shine: facial oiliness seen in swimmers
Swimmer's shoulder: abrasion of the shoulder by the beard during crawl stroke
Talon noir (black heel): intradermal hemorrhage
Tennis toe: subungual hematoma with or without subungual hyperkeratosis or nail dystrophy (jogger's toe, hiker's toe, skier's toe are similar) (see Fig. 99-2)
Turf toe: metatarsophalangeal joint sprain



Figure 99-1 Runner's nail. In this case there are multiple Beau's lines with onychoschizia.

from an outbreak of MRSA abscesses among members of a professional football team (St. Louis Rams) indicates that most infections developed at turf-abrasion sites. Infection was significantly associated with the lineman or linebacker position as well as a higher body mass index. MRSA was cultured from whirlpools and taping gel as well as from 35 of the 84 nasal swabs from players and staff.[19] In competitive male athletes, abscesses generally occur at sites of minor abrasions. In weightlifters, abscesses favor the axillae. Abscesses among female athletes favor the thighs and buttocks. Folliculitis and abscesses noted during an outbreak of MRSA in a saturation diving facility involved the nose, external ear canal, necks, back, extremities, and buttocks.[20]



Figure 99-2 Tennis toe. Subungual hemorrhage seen in runners and basketball and tennis players that produces anxiety because of fear of melanoma. It can be easily differentiated from melanoma by dermoscopy.

ETIOLOGY AND PATHOGENESIS

MRSA isolates usually contain the type IV staphylococcal chromosomal cassette (SCC)*mec* coding for methicillin resistance, as well as the Panton-Valentine leukocidin virulence factor. There is a high risk of colonization in close contacts of individuals with MRSA, and those who are colonized commonly progress to clinical infection.[21,22] Sharing of towels and higher body mass index are independent risk factors for MRSA infection.[23]

CLINICAL FINDINGS

MRSA infection in athletes typically presents as folliculitis or spontaneous abscess (see Chapters 176 and 177). Abscesses may begin as furuncles but rapidly evolve to fluctuance with surrounding cellulitis.

TREATMENT

Like other abscesses, MRSA abscesses respond to drainage. Surveillance data from Baltimore, Atlanta, and Minnesota including 1,647 cases of CAMRSA infection show that therapy to which the strain was resistant was not associated with adverse patient-reported outcomes if the abscess was incised and drained.[24] Other data also suggest that many MRSA abscesses respond to drainage alone.[25,26] Failure to drain MRSA abscesses may have catastrophic results, even if effective antibiotic therapy is prescribed. In one report, bilateral blindness resulted.[27]

Although the SCC*mec* type IV gene cassette present in most *MRSA* strains codes only for methicillin resistance, an isolate from a Japanese athlete also contained a transmissible plasmid coding for multiple-drug resistance.[28] Other MRSA isolates have emerged that are resistant to multiple antibiotics. Some MRSA isolates from Taipei carry a distinct SCC*mec* cassette (type VT) that codes for resistance to multiple antibiotics.[29] While drainage will cure many MRSA abscesses, some athletes will require antibiotic therapy. Of the inexpensive oral agents available to treat MRSA infections, sulfa drugs consistently show the best mean inhibitory concentrations. Tetracyclines are good alternative agents, although only about 80% of MRSA will be sensitive in many locations. Lincosamide resistance is increasing.[30–32] Inducible resistance, related to the *erm* gene, results in strains that test clindamycin-susceptible in vitro, but may be resistant in vivo. A D-test can be used to determine the presence of inducible resistance. In the D-test, clindaymcin and erythromycin disks are placed close together on a culture plate. If inducible lincosamide resistance is present, the zone of inhibition around the clindamycin disk is flattened on the side towards the erythromycin disk, resembling a capital letter D. Rates of inducible lincosamide

resistance vary from 8% in Houston to 94% in Chicago.[33–37] In some areas in the United States, MRSA strains were less likely than methicillin-sensitive strains to demonstrate inducible resistance.[38] In contrast, some locations in Asia report that 100% of tested MRSA strains demonstrate the *ermB* gene.[39]

Some serious MRSA infections will require the use of linezolid, vancomycin, fluoroquinolones, daptomycin, quinupristin/dalfopristin, or newer generation carbapenems. Fluoroquinolones and linezolid, have the advantage of oral administration. In some groups of severely ill patients, linezolid has proved superior to vancomycin.[40–42] Daptomycin has been used effectively in serious MRSA infections, but resistance has been reported, and disk diffusion testing may not predict clinical outcome.[43,44] A new cephalosporin, ceftobiprole medocaril appears to offer a good balance of efficacy and tolerability.[45]

PREVENTION

Nasal colonization correlates poorly with cutaneous MRSA infection, suggesting that other sites of carriage and close physical contact with carriers are important in disease transmission.[46] Cutaneous carriage and fomites are important in the spread of MRSA infection among athletes, and preventive measures directed only at nasal decolonization are frequently ineffective.[47,48] Topical antiseptics such as chlorhexidine, povidone iodine, quaternary ammonium compounds, triclosan, and Dakin's solution play an important role in management.[49] Chlorhexidine gluconate is widely used and generally has good activity against staphylococci. Some MRSA isolates are less sensitive to chlorhexidine than methicillin-sensitive *Staphylococcus aureus* (MSSA) isolates.[50,51] Some chlorhexidine-resistant isolates also exhibit resistance to quaternary ammonium compounds. Resistance can be overcome by using disinfectants containing both alcohol and chlorhexidine.[52] Seventy percent ethanol alone is an effective agent for fomite sterilization if contact can be maintained for 3 minutes.[53] Povidone iodine has shown good activity against both MRSA and MSSA isolates.[81] Triclosan-based products are readily available as "no-wash" hand sterilizers. Some triclosan resistance has been documented, and some MRSA isolates are less sensitive than MSSA isolates.[54,55] Mupirocin is commonly used to treat staphylococcal nasal carriage, but resistant strains have emerged.[56] In one double-blind, placebo-controlled trial, successful nasal eradication was only 44%.[57]

OTHER PYOGENIC SKIN INFECTIONS AMONG ATHLETES

Group A streptococcal infections may also spread rapidly among athletes. Pyoderma with a nephritogenic *Streptococcus* can cause epidermic glomerulonephritis. *Streptococci* also produce erysipelas and lymphangitis (see Chapters 177 and 178).

Pseudomonas infections are commonly associated with water. *Pseudomonas* folliculitis, green nails, and *Pseudomonas* webspace infection are the most common (see Chapter 180 and online edition).

VIRAL SKIN INFECTIONS

Herpes simplex virus (see Chapter 193) can be transmitted by skin-to-skin contact during any contact sport. Herpes gladiatorum is recognized as a major problem among wrestlers. Attack rates as high as 34% have been reported. Ocular involvement is a serious complication. Wrestlers with active infections are barred from participation. The use of abrasive shirts may contribute to the spread of herpes simplex virus infection among wrestlers. They should be avoided. Oral antiviral drugs such as acyclovir, valacyclovir, and famciclovir can be used to shorten the course of an outbreak. It is likely that all three of these drugs can prevent outbreaks of herpes gladiatorum when given as long-term or periodic prophylaxis.

FUNGAL INFECTIONS

(See Chapter 188)

Cutaneous fungal infections are more common among athletes than in the general population, and are particularly common among swimmers and soccer players.[58,59] Tinea facei and tinea capitis are particularly common among wrestlers and others who engage in close contact sports.[60,61] During an outbreak of *Trichophyton tonsurans* tinea in Japan, 52% of the patients were Judo participants and 39% were wrestlers.[62] Asymptomatic carriage and poor compliance with eradication regimens is common in this setting and contributes to the spread of the disease.[63–65] Many of the implicated strains were recently imported to Japan, spread first through martial arts, then to the community at large.[66] Tinea pedis may be spread by floors around swimming pools. Prevalence among runners increases with age, and asymptomatic carriers are common. Periodic prophylactic treatment of carriers with topical agents to prevent clinical disease may be possible, and oral prophylaxis with 100 mg of fluconazole daily for 3 days twice during the season has been shown to be effective in reducing the incidence of fungal infections among high-school wrestlers. In one study, the incidence rate of tinea gladiatorum dropped from 67.4% to 3.5% as a result of intervention.[67]

TRANSMISSION OF BLOOD-BORNE PATHOGENS

There is growing concern about possible transmission of blood-borne pathogens during contact sports. Minor cuts and abrasions are both a source of contamination and a portal of entry for human immunodeficiency virus and hepatitis viruses. Lacerations can be covered with self-adherent biosynthetic dressings to prevent blood transmission from minor wounds during contact sports.

HEAT AND COLD INJURY

Heat injury is a common cause of morbidity during sports. The skin serves as the major organ of thermal regulation. Regular exercise modifies the responsiveness of cutaneous vessels, increasing cutaneous perfusion during periods of activity.[68] The duration of exercise can be safely increased in hot environments if a volume of fluid at least equal to that lost in sweat is ingested within 60 minutes prior to and during exercise.[69] Uniforms promote heat retention, and adequate skin surface must be exposed during exercise in order to reduce the risk of heat stress injury. Evaporative cooling from forearm skin is more efficient than that from the upper trunk; therefore, short sleeve uniforms are helpful in hot climates.[70] Clothing should be lightweight and have high water permeability in order to facilitate evaporative cooling. At high humidity, evaporative cooling from skin is inefficient and the risk of heat stress increases. Spraying of water on the skin during exercise can reduce skin temperature, but results in vasoconstriction and does not reduce core body temperature.[71] Cooling vests can improve athletic performance in hot weather.[72,73] Harlequin syndrome is a disorder of the sympathetic nervous system with diminished sweating and flushing in response to exercise.[74]

Younger athletes have a greater skin surface area, which places them at greater risk for hypothermia in cold environments. Skin injury, such as frostbite and perniosis, are seen in sports enthusiasts who engage in cold weather sports. Frostbite is a common problem among joggers, and may involve the face, hands, feet and penis. The decreased oxygen tension at high altitudes contributes to peripheral vasoconstriction, decreasing peripheral blood flow and increasing the risk of frostbite.[75] Clothing must remain dry in order to retain its insulating properties. Frequent changes of socks and periodic breaks in a warm environment are important safeguards. If frostbite occurs, rapid rewarming should be accomplished as soon as the individual is in a safe environment with no risk of refreezing.

SKIN INJURIES

Skin and soft tissue injuries are common among athletes.[76,77] New treatments, including hydroactive wound dressings, have advanced the treatment of superficial wounds. Application of a hydroactive dressing can provide a protective barrier that can allow an athlete to return to training. Cold gel application has been shown to provide effective symptomatic relief for sports-related soft tissue injuries.

FRICTION BLISTERS

Friction blisters occur as a result of midepidermal necrosis (Fig. 99-3). Proper fitting of footwear and the use of gloves and chalk can reduce the incidence of blistering. Heat, sweating, and maceration increase the risk of blistering. Antiperspirants have been used in an attempt to reduce the incidence of blistering, but results have been mixed, and they may cause irritant dermatitis. Attempts to reduce the incidence of irritant dermatitis through the addition of emollients reduce the efficacy of the antiperspirant. In a study of cross-country hikers, use of a 20% solution of aluminum chloride hexahydrate in anhydrous alcohol reduced the rate of blister formation from 48%–21%, but the incidence of irritant dermatitis was high and noncompliance with the treatment regimen was common. The use of closed-cell neoprene insoles, acrylic socks, or thin polyester socks combined with thick wool or polypropylene socks that maintain their bulk can reduce the incidence of blisters. The use of mesh-top footwear can decrease the risk of blistering by providing a cooler, dryer environment without the use of antiperspirants. A unique form of friction dermatitis occurs in Sumo wrestlers.[78]

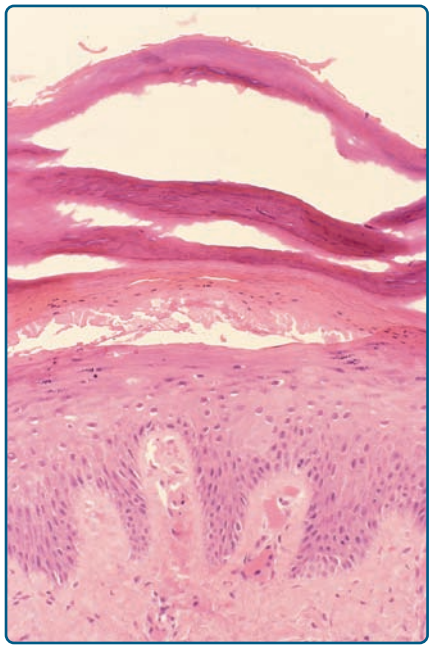

Figure 99-3 Friction blisters are a manifestation of intraepidermal necrosis.

LIME BURNS

The use of calcium oxide (quicklime) or calcium hydroxide (slaked lime) instead of calcium carbonate (chalk) to line sports fields may result in chemical burns, especially in wet weather. Second- and third-degree burns may occur. Lime use may also result in severe inhalation and ocular injury.

ATHLETE'S NODULES

Collagenous "surfer's nodules" are a well-described complication of surfboarding. Boxers, marbles players, and football players are also prone to collagenous nodules. Surgical excision may be required.

ACTINIC DAMAGE

(See Chapters 90 and 113)

Actinic irradiation can cause burns and a risk of skin cancer in later life. Even relatively short periods of exposure during sports are associated with an increased risk of basal cell carcinoma. Sweating alters hydration of the stratum corneum and lowers the minimal erythema dose of ultraviolet (UVB) light by as much as 40.9% after just 15 minutes of jogging. Actinic exposures are particularly high during nautical and mountain sports and participation in water sports and marathons are independent risk factors for both melanoma and nonmelanoma skin cancer.[79–82] Athletes should be advised to reduce UV exposure by choosing training schedules with lower sun exposure, wearing UV-protective clothing, and using water-resistant sunscreens.

ALLERGIC CONTACT DERMATITIS

(See Chapter 13)

Rubber allergens are the most common cause of sports-associated allergic contact dermatitis (Fig. 99-4).[83] Rubber adhesives and rubber chemicals in the box toe and cushioning materials can cause dermatitis from footwear. Contact dermatitis can also result from equipment, swimming-pool chemicals, athletic tape, epoxy resins associated with golf clubs or bowling balls, and topical creams and sprays.[84–86] Wetsuit dermatitis is usually related to thioureas but may also be caused by *p*-tert-butylphenol formaldehyde resin and zinc diethyldithiocarbamate.[87] Clothing dermatitis in athletes may relate to fabric softener, textile finishes, dyes, or designs applied to the fabric. Textile dye penetration of skin is more closely related to the degree of sweating rather than the duration of contact between fabric and skin.[88] Dermatitis under soccer shin guards more commonly represents irritant dermatitis related to sweating and friction rather than allergic contact dermatitis.[89]



Figure 99-4 Athletic shoe allergic contact dermatitis.

BITES AND STINGS

Unexpected bites and stings are frequent while playing sports and may result in both local injury and anaphylaxis (see Chapter 210).

SKIN PROBLEMS RELATED TO WATER SPORTS

Skin eruptions account for almost half of all illnesses related to recreational water. Monitoring of water for fecal coliforms has been practiced for years and has proved to be a better predictor of the risk of skin disease than of the risk of gastrointestinal disease. Contamination by storm runoff results in a predominance of organisms linked to skin infections. Water and activity can rapidly reduce the effect of many sunscreens, although some newer formulations retain their efficacy better under these conditions.[90]

Exposure to the rough surfaces of diving boards can result in a chronic plantar dermatosis. The fingers can also be affected. Some individuals with this disorder have a history of atopic dermatitis, psoriasis, or juvenile plantar dermatosis. The rough interior of swimming pools can result in "pool palms." The skin appears taut, shiny, and erythematous with loss of dermatoglyphics (Fig. 99-5). Green hair is related to the presence of copper in pool water. Copper pipes or algicides may be the source of the high copper levels. Acidic pH, fluoridation of water, and swimming pool chlorination all contribute to the release of copper into pool water. Green hair has been treated with penicillamine shampoo, hot vegetable oil, hydrogen peroxide, edetic acid, and 1-hydroxyethyl diphosphonic acid.

Swimming pool water may be treated with chlorine, bromine, or ozone ionization. All three methods are acceptable, although the use of bromine with ozone may be associated with a slightly lower risk of cutaneous reactions.



Figure 99-5 Finger dermatitis in this diver paralleled the intensity of her training. It resolved during breaks from training.

SWIMMER'S ITCH

(See Chapter 209)

Swimmer's itch is related to avian schistosome cercariae.[91] Newly created bodies of water, such as recently abandoned quarries, are associated with a lower incidence of swimmer's itch. Administration of praziquantel to ducks inhabiting a lake can reduce the incidence of swimmer's itch. Chemical control or mechanical removal of snails can also be effective. The rash heals spontaneously in 2–3 weeks. Topical steroids and antihistamines may be beneficial. Topical antipenetrants have been evaluated, but an ointment based on IR3535 (ethyl butylacetylaminopropionate) failed to prevent an outbreak of cercarial dermatitis during swimming races across Lake Annecy in France.

SEA BATHER'S ERUPTION

(See Chapter 209 and online edition)

OTHER SKIN PROBLEMS RELATED TO OCEAN SPORTS

(See also Chapter 209)

Jellyfish stings result in immediate pain and may produce delayed immune-mediated reactions. *Cyanea* and *Chrysaora* sea nettles are the most common causes of jellyfish dermatitis. *Chrysaora* jellies are especially common off Atlantic beaches. *Physalia physalis*, the Portuguese man-of-war, is common in the southeastern United States and the Gulf of Mexico. *Physalia utriculus*, the blue bottle jellyfish, is native to the Pacific. Stings of *Chironex fleckeri*, the Pacific box jellyfish or sea wasp, may result in shock or death. Victims of any marine envenomation should immediately be removed from the water. Administration of antivenin can prevent cardiovascular collapse. Verapamil shows little effect in experimental animals and may negate some of the beneficial effect of antivenin. Unlike verapamil, $MgSO_4$ has been shown to prevent cardiovascular collapse in test animals. First aid includes mechanical removal of tentacles by seawater and sand. Most northern sea nettle nematocysts are inactivated in alkaline conditions, and most man-of-war nematocysts are inactivated in acidic conditions; however, the use of either acid or alkaline solutions can be complicated by the release of venom in some species. Application of ice can provide analgesia. Most marine venoms are inactivated by heat, and hot water immersion [40°C–41°C (104°F–105.8°F)] generally results in better pain relief. Jellyfish sting inhibitors can be added to sunscreen lotions. *Haloclava producta*, the "ghost anemone," is responsible for summer outbreaks of dermatitis off the coast of Long Island, New York.

Stingray injury usually occurs when a swimmer accidentally steps on a ray. Roughly 750 stingray stings are reported each year off the US coast. Stings are associated with severe pain, hyperhidrosis, hypotension, muscle cramps, and dysrhythmia. Tissue necrosis can be extensive, and surgical exploration is commonly required. Hot water immersion is effective in the control of acute pain but may not prevent skin necrosis. Lionfish are most common in the subtropical waters of the Pacific but are increasingly being reported off the coast of the United States. Stings cause pain, swelling, redness, bleeding, and mild systemic symptoms. Hot water immersion generally produces pain relief. Surgical exploration may be prudent for injuries involving the hands.

Corals, especially fire coral, can produce contact dermatitis in divers. Their stinging cells produce a powerful irritant that can produce severe local reactions, including reactions that resemble full-thickness burns. Contact with seaweed has been implicated in vesiculobullous reactions. Algal organisms in seaweed can cause "stinging seaweed dermatitis" and pustular folliculitis.

Mycobacterium marinum can cause epidemics of swimming pool granuloma (see Chapter 184). Mycobacterial infections are also commonly acquired in brackish coastal waters. Marine *Vibrio* infections (see Chapter 180) also occur with exposure to brackish coastal waters. Necrotizing fasciitis and sepsis may occur. Culture of specimens from wounds contaminated with seawater has a greater yield if thiosulfate-citrate-bile-sucrose agar is used, and the cultures are incubated both at room temperature and at 30°C (86°F).

Decompression injury may affect the skin of divers. Livedo reticularis is commonly noted. In a porcine model of decompression injury, vascular congestion and vasculitis were common findings in skin biopsy specimens.

HISTAMINE-MEDIATED REACTIONS

Exercise-associated urticarial reactions include cholinergic urticaria, solar urticaria, symptomatic dermatographism, pressure-induced urticaria, cold urticaria, aquagenic urticaria, latex-induced contact urticaria, and exercise-induced anaphylaxis. These entities are discussed in Chapter 38.

ACNEIFORM LESIONS

Acne mechanica is common among athletes, occurring under chinstraps, helmets, and shoulder pads. The lesions may respond better to keratolytics than to antibacterial agents. Severe acne may be a sign of anabolic steroid use.[92] The use of these drugs is widespread among athletes of all ages. Some studies suggest that healthcare providers provide illegal androgens to up to 48.1% of abusers, and physicians are involved in illegal prescription of anabolic steroids in 32.1% of cases.[93] There is an alarming trend to combine anabolic steroids with human growth hormone, insulin, and insulinotropic milk protein-fortified drinks to potentiate the effect of each agent.[94] Although the standard in drug testing is immunoassay screening followed by gas chromatography–mass spectrometry of urine samples to provide confirmation, newer technology may allow reliable detection of anabolic steroids in hair.

DERMATOLOGIC PROBLEMS OF SPECIAL ATHLETES

Patients with preexisting dermatoses may experience koebnerization or pathergy following cutaneous injuries related to sports.[95] Athletes with atopic eczema may experience bouts of pruritus with exercise. However, there is evidence that the sweating and vascular response improve with athletic training and that athletics may not interfere with treatment of atopic dermatitis.[96,97] Application of an emollient after showering and short periods of rest can inhibit sweat-induced itching in atopic athletes, and regular moderate exercise does not cause deterioration in the condition of their skin.[98]

The athlete treated with oral retinoids also faces special problems. Arthralgia, staphylococcal colonization, photosensitization, and fatigue may result in lost training time or lost seasons. Retinoids cause disruption of epidermal integrity and skin fragility. Greater trochanter enthesopathy (pain at the site of tendon insertion) may be a complication of short-term oral retinoid therapy in athletes.[99] When possible, retinoid treatment should be planned between seasons.

KEY REFERENCES

Full reference list available at www.DIGM8.com

DVD contains references and additional content

1. Cordoro KM, Ganz JE: Training room management of medical conditions: Sports dermatology. *Clin Sports Med* **24**(3):565-599, 2005
2. Pecci M, Comeau D, Chawla V: Skin conditions in the athlete. *Am J Sports Med* **37**(2):406-418, 2009
10. Redziniak DE et al: Methicillin-resistant *Staphylococcus aureus* (MRSA) in the Athlete. *Int J Sports Med* **30**(8):557-562, 2009
14. Cohen PR: Cutaneous community-acquired methicillin-resistant *Staphylococcus aureus* infection in participants of athletic activities. *South Med J* **99**(6):596-602, 2005
16. Centers for Disease Control and Prevention (CDC): Methicillin-resistant *Staphylococcus aureus* infections among competitive sports participants—Colorado, Indiana, Pennsylvania, and Los Angeles County, 2000-2003. *MMWR* **52**(33):793-795, 2003
19. Kazakova SV et al: A clone of methicillin-resistant *Staphylococcus aureus* among professional football players. *N Engl J Med* **352**(5):468-475, 2005
23. Centers for Disease Control and Prevention (CDC): Methicillin-resistant *Staphylococcus aureus* among players on a high school football team—New York City, 2007. *MMWR Mortal* **58**(3):52-55, 2009
24. Fridkin SK et al: Active Bacterial Core Surveillance Program of the Emerging Infections Program Network. Methicillin-resistant *Staphylococcus aureus* disease in three communities. *N Engl J Med* **352**(14):1436-1444, 2005
41. Sharpe JN, Shively EH, Polk HC Jr: Clinical and economic outcomes of oral linezolid versus intravenous vancomycin in the treatment of MRSA-complicated, lower-extremity skin and soft-tissue infections caused by methicillin-resistant *Staphylococcus aureus*. *Am J Surg* **189**(4):425-428, 2005
47. Garza D et al: Ineffectiveness of surveillance to control community-acquired methicillin-resistant *Staphylococcus aureus* in a professional football team. *Clin J Sport Med* **19**(6):499-501, 2009
49. Elston DM: Handling a community-acquired methicillin-resistant *Staphylococcus aureus* outbreak: Emerging data. *Cutis* **82**(2 Suppl. 2):13-17, 2008
67. Brickman K et al: Fluconazole as a prophylactic measure for tinea gladiatorum in high school wrestlers. *Clin J Sport Med* **19**(5):412-414, 2009

Chapter 100 :: Decubitus (Pressure) Ulcers

:: Jennifer G. Powers, Lillian Odo, & Tania J. Phillips

PRESSURE ULCERS[1,2] AT A GLANCE

- Commonly known as *decubitus ulcers*, *pressure sores*, and *bedsores*.
- Affect approximately 0.5% to 2.2% of the population.
- Tend to occur over bony prominences, more common from the waist down.
- Etiologic factors include pressure, shearing, frictional forces, and moisture.
- Related risk factors are prolonged immobilization, sensory deficit, impaired consciousness, circulatory disturbance, poor nutrition, and chronic diseases.
- Staged according to the degree of tissue damage observed (I to IV); pathologic findings depend on the stage of evolution.
- No specific laboratory findings. The diagnosis is made clinically.

EPIDEMIOLOGY

Estimates are that between 1.5 and 3 million people in the United States have pressure ulcers. Hospital stays with pressure ulcers listed as a diagnosis increased by nearly 80% in the United States between 1993 and 2006. These chronic wounds cost approximately $5 billion annually to treat, and Center for Medicaid and Medicare Services (CMS) no longer reimburses for additional costs arising from nosocomial stage III or IV pressure ulcers.[1–6]

The prevalence and incidence of pressure ulcers varies with the clinical setting. In acute care, the incidence ranges from 0.4% to 38%; in long-term care, from 2.2% to 23.9%; and in home care, from 0% to 17%. Most pressure ulcers develop during the first few weeks of hospitalization. The prevalence of pressure ulcers in acute care settings is approximately 15%, in long-term care settings from 2.3% to 28%, and in home care from 0% to 29%.[1–4]

Pressure ulcers are more common in the elderly, especially those over the age of 70, in patients who have had surgery for hip fracture, and in patients with spinal cord injury. A multicenter study of 3,233 elderly admitted from the emergency demonstrated a pressure-ulcer incidence (mostly stage II) of 6.2% on hospital day 3, with significant associations to advanced age, male gender, dry skin, urinary and fecal incontinence, difficulty turning in bed, and poor nutritional status.[7]

The majority of pressure ulcers occur on the lower part of the body, 65% in the pelvic area and 30% on the lower limbs, though other locations include the scalp in infants with neurological injury or the face from endotracheal tubes during long surgeries or intensive care unit (ICU) stays.[1–4]

ETIOLOGY AND PATHOGENESIS

The main etiologic factors contributing to pressure ulcer development include pressure, shearing forces, friction, and moisture.

Pressure or force per unit area is considered to be the most important factor in pressure ulcer formation. Normal tissue pressure is between 12 and 32 mm Hg. Pressures higher than this upper limit can compromise tissue circulation and oxygenation. When a patient lies immobile on a hospital bed, pressures as high as 150 mm Hg can be generated, especially over bony prominences. At pressures of 70 mm Hg or more, there is an inverse time–pressure curve with rapid pressure ulcer formation.[2] Sitting positions can also generate elevated pressure over precise body surfaces. The duration as well as degree of pressure is important. If pressure is relieved regularly, tissue recovery can occur, whereas constant pressure can lead to tissue death (Fig. 100-1). Often, damage occurs deep at the bone–muscle interface, in which the limited cutaneous injuries may be only the "tip of the iceberg" of deeper, more extensive damage (eFig. 100-1.1 in online edition). Patients who are immobile should therefore be turned regularly to prevent pressure ulceration. The pathophysiology of pressure ulcer formation is summarized in eFigure 100-1.2 in online edition, and common sites of pressure ulcers are shown in Figure 100-2.



Figure 100-1 Pressure ulcer, stage IV. (From Wolff K and Johnson RA. Fitzpatrick's Color Atlas, 2009.)

Shear force results from the motion of bone and subcutaneous tissues relative to the skin when the skin is fixed (e.g., when the upper body of a supine patient is raised to an angle above 30° and the skin remains in contact with the bed). Shearing forces are parallel to the tissue surface, and the subsequent sliding pressure is transmitted to deeper tissues, which can become angulated and occlude the blood vessels (Fig. 100-3A). Spinal cord injury patients develop such shearing forces with muscle spasms, which may be controlled with muscle relaxants.[8]

Friction is the force that resists the relative motion between two surfaces that are in contact. This causes damage to the superficial layers of the skin (e.g., when a patient is dragged across the bedsheets) (Fig. 100-3B).

A moist environment from urinary or fecal incontinence, perspiration, or excessive wound drainage can cause maceration of the skin, which increases the risk of pressure ulcer formation fivefold (Fig. 100-4). Other risk factors for pressure ulcer development include prolonged immobilization, sensory deficit, circulatory disturbances, poor nutrition, acute illness, advanced age, and a previous history of pressure ulcers as well as fecal and urinary incontinence, hip fractures, smoking, and dry skin. Concomitant use of medications such as corticosteroids, which can impair healing; sedatives and analgesics, which can impair consciousness; and drugs that can cause alterations in cutaneous blood flow, such as antihypertensive medications, can also increase pressure ulcer risk, and such drugs should be used with care (Table 100-1).

CLINICAL FINDINGS

(See eFig. 100-4.1 in online edition)

HISTORY

History taking and physical examination for pressure ulcer patients should incorporate a risk assessment scale.

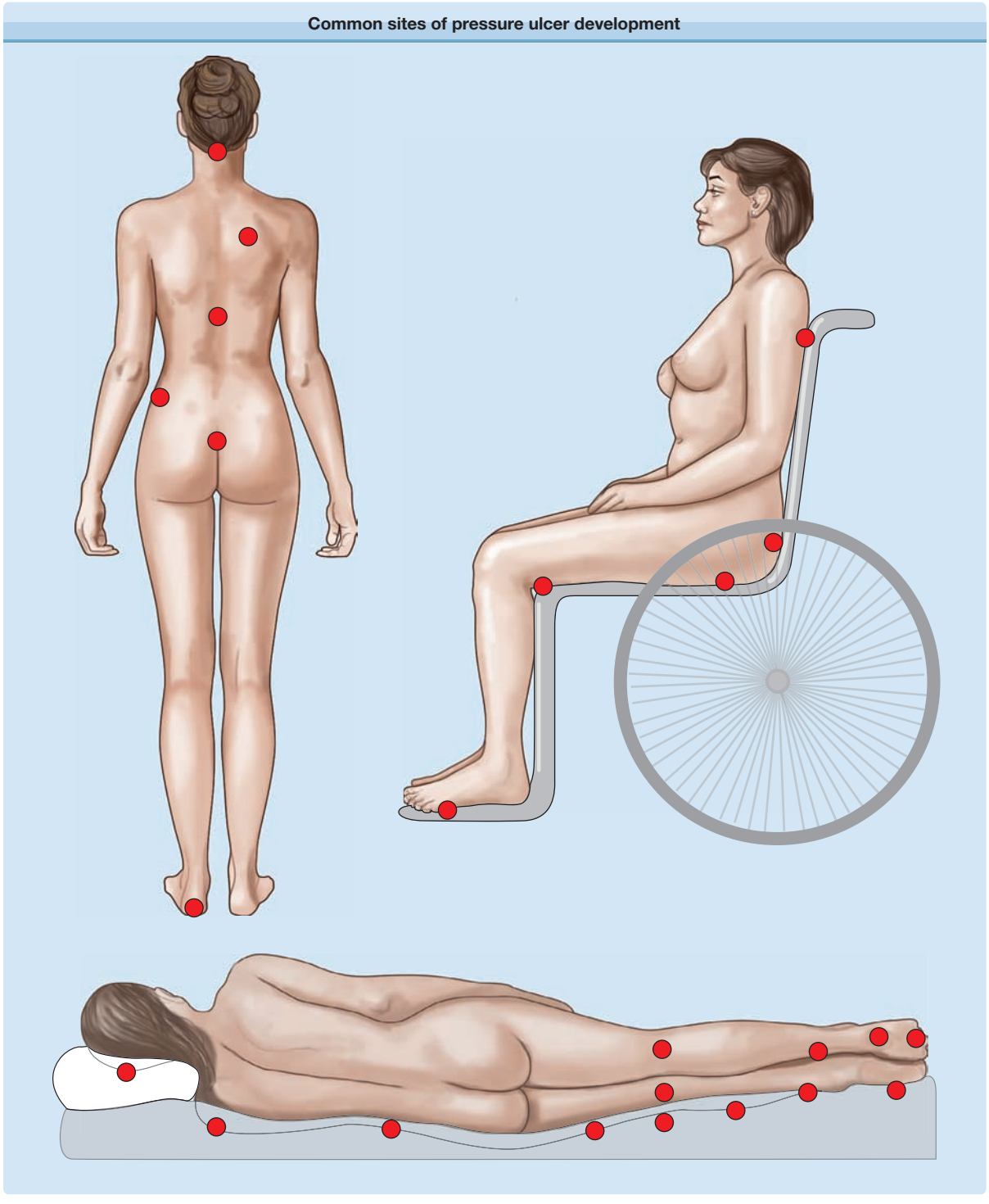

Figure 100-2 Common sites of pressure ulcer development. (From *Preventing Pressure Ulcers: A Patient's Guide*. Washington, DC, US Department of Health and Human Services, USGPO 617-025/68298, 1992.)

A number of risk assessment tools have been devised in an attempt to identify persons at risk for pressure ulcers. The Braden, Waterlow, and Norton scales have been extensively tested for reliability and validity and have been recommended by the Agency for Healthcare Research and Quality for predicting the risk of developing pressure sores. Currently, best practices in acute care, long-term care, and home-health care dictate that such risk assessments be performed initially at admission and at subsequent precise intervals. Components of these scales assess the following risk factors: mobility, activity level, nutritional status, mental status, incontinence/moisture conditions, general physical condition, skin appearance, medication use, friction and shear, weight, age, predisposing diseases, and prolonged pressure (eTable 100-1.1 in online edition).

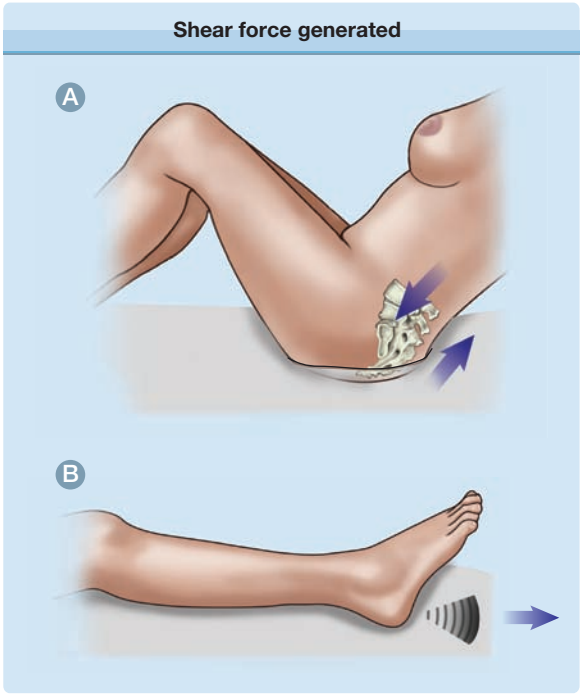

Figure 100-3 Shear force generated when a patient slides down a bed, for example, in the sacral region (**A**) or on the heels (**B**). (From Grey JE, Harding KG, Enoch S: Pressure ulcers. *BMJ* **332**:472, 2006, with permission of Blackwell Publishing.)

CUTANEOUS LESIONS

Staging is an assessment system that classifies pressure ulcers based on anatomic depth of soft-tissue damage. Pressure ulcers often progress from lower to higher stages, and any small pressure ulcer should be considered as the possible "tip of an iceberg." Table 100-2 shows the clinical appearance of pressure lesions and ulcers and their histopathologic correlates as defined by the National Pressure Ulcer Advisory Panel (NPUAP). Palpation is important to assist visual evaluation. Ulcers that initially appear superficial can end up being classified as stage III or IV after débridement reveals their true depth. The epidermis may be hypertrophic at the ulcer margin with varying degrees of pigmentation.[10]

There are several staging systems for classifying pressure ulcers. The most commonly used include the NPUAP, Shea, and Yarkony et al systems. In February 2007, the NPUAP redefined the stages of pressure ulcers established in 1989 by preserving the four original stages and adding two new stages of deep tissue injury and unstageable pressure ulcers. The unstageable category was created to avoid unnecessary removal of slough or eschar simply for the purpose of staging, which might hinder ulcer healing (Fig. 100-5). eTable 100-2.1 in online edition compares these four classification systems.[2,10–13]

TABLE 100-1
Major Risk Factors for Developing Pressure Ulcers

Alteration in Sensation or Response to Discomfort
■ Degenerative neurologic disease
■ Cerebrovascular disease
■ Central nervous system injury
■ Depression
■ Drugs that adversely affect alertness
Alteration in Mobility
■ Neurologic disease or injury
■ Fractures
■ Pain
■ Use of restraints
Significant Changes in Weight (≥5% in 30 days or ≥10% in previous 180 days)
■ Protein–calorie undernutrition
■ Edema
Incontinence
■ Bowel and bladder

Excerpted from American Medical Directors Association: *Clinical Practice Guideline: Pressure Ulcers*. Columbia, MD, American Medical Directors Association, 2008. © 2008 American Medical Directors Association.



Figure 100-4 Pressure ulcer, stage III, complicated by fecal incontinence.

RELATED PHYSICAL FINDINGS

All pressure ulcer patients should undergo a full physical examination to identify systemic disease contributing to wound development, such as anemia, chronic cardiac or respiratory disease, and neurologic disorders.

Tenderness, erythema, edema and warmth of surrounding skin, exudate, and foul odor are symptoms and signs of infection. Fever and declining mental or physical status should raise suspicion of bacteremia or osteomyelitis.

Spasticity secondary to inflammation and infection may trigger muscle contractures and joint deformity

TABLE 100-2
Comparison of Clinical and Histologic Findings by Ulcer Stage

Classification/Stage[9]	Clinical Findings	Histopathologic Description
Stage I 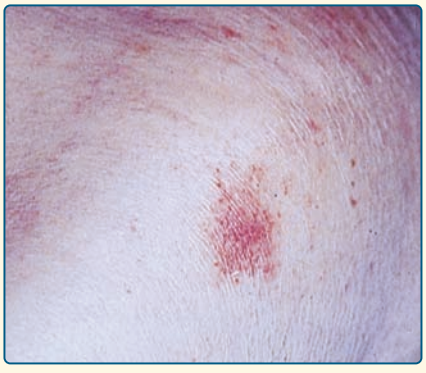	Nonblanchable erythema of intact skin	Epidermis appears normal. Striking red blood cell engorgement of capillaries and venules, mainly in papillary dermis with platelet thrombi and hemorrhage. Degeneration of sweat glands and subcutaneous fat is often seen.
Stage II 	Partial-thickness skin loss involving epidermis, dermis, or both	Epidermis is lost. Dermal papillae are often identifiable. Acute inflammation of papillary and reticular dermis is found. In addition to a perivascular lymphocytic infiltrate, neutrophils are seen. Necrotic changes in the appendages and fat are more pronounced.
Stage III 	Full-thickness skin loss involving damage to or necrosis of subcutaneous tissue that may extend down to, but not through, underlying fascia.	Hemorrhagic crust containing acute inflammatory cells or a thin zone of coagulation necrosis on the surface. Diffusely fibrotic dermis. Loss of appendageal structures.
Stage IV 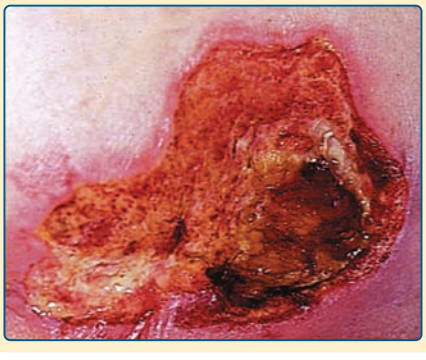	Full-thickness skin loss with extensive necrosis of or damage to muscle, bone, or supporting structures.	Full-thickness destruction of skin. The tissue appears basophilic with obliteration of cellular detail, although the general dermal architecture is preserved. Inflammatory infiltrate is often not seen.

NPUAP = National Pressure Ulcer Advisory Panel.

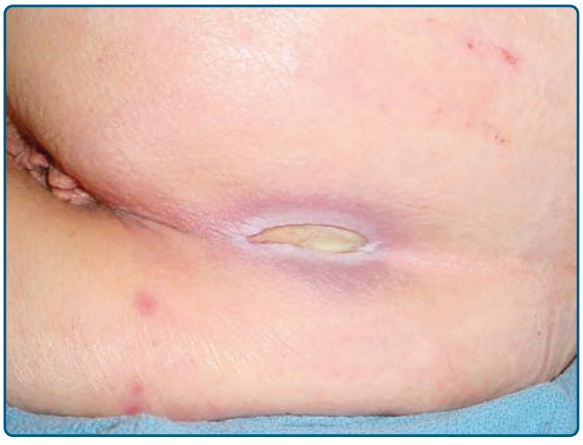

Figure 100-5 Unstageable pressure ulcer covered with slough. (Used with permission from Mary Gloeckner, RN, MS, CWOCN.)

that can limit motion, which complicates positioning. Weakness and signs of anemia and dehydration can be found secondary to profound loss of fluid and protein from these open, draining wounds.

LABORATORY TESTS

The diagnosis is made clinically. However, anemia, leukocytosis, hypoproteinemia, hypoalbuminemia, elevated ESR, or reduced serum iron levels may be present. It is important to exclude other diseases that can cause skin ulcers, including calciphylaxis, vasculitis, and connective tissue diseases.

SPECIAL TESTS

BIOPSY. Histologic analysis may be helpful to diagnose the pressure ulcer stage when clinical findings are insufficient to determine depth and exclude other diseases that can present with skin ulcers such as collagen vascular diseases. In long-standing pressure ulcers, squamous cell carcinoma can develop (Marjolin's ulcer). Histologic findings in pressure ulcers are described in Table 100-2.

IMAGING STUDIES. Radiology is most useful to identify complications, particularly of deep pressure sores. Plain radiographs can identify ectopic bone, air in the ulcer cavity, and sclerotic or destructive changes in the underlying bony prominence. Ectopic bone can cause a pressure sore by altering the patient's posture and locally increasing pressure over soft tissue.[14] When there is clinical uncertainty about the size or extent of a pressure ulcer, sinography can be performed. Direct magnification radiography of sacral areas is useful when plain radiographs leave doubt about the condition of the bony cortex adjacent to a pressure sore. If the cortex is intact, osteomyelitis is unlikely.

Computed tomographic scanning is useful to determine the extent of a pressure ulcer and its anatomic relation to surrounding structures. It is helpful in assessing large, complicated lesions with associated sinus tracts or extensive undermined margins. Computed tomography is the only radiographic modality that can define the external margin of the lesion.

Magnetic resonance imaging (MRI) is helpful in determining the depth and extent of soft-tissue involvement underlying decubitus ulcers. It can also be a useful tool for identifying osteomyelitis, fluid collections, abscesses, and sinus tracts.[15,16] The gold standard for the diagnosis of osteomyelitis is histologic/microbiologic analysis of surgical biopsy specimens, but MRI is accurate in the diagnosis of osteomyelitis (sensitivity, 98%; specificity 89%) and associated soft-tissue abnormalities. It also can delineate the extent of infection to assist in guiding limited surgical resection and preserving viable tissue.[14]

TREATMENT

Therapy should be individualized for each patient and involves more than simple wound management. Pressure ulcers are frequently a clinical sign of underlying medical conditions which should be treated to facilitate healing. Treatment takes great coordination by inpatient facilities such as nursing homes, where caretakers often use the NPUAP-designed PUSH (Pressure Ulcer Scale for Healing) tool or the Bates–Jensen Wound Assessment Tool (BWAT) to document wound healing.[23,24] Photography can also be an important means of documenting improvement and should include dimensions, date, and wound location.[25] Few controlled trials have evaluated specific treatment modalities for pressure ulcers, but reasonable interventions include use of basic support surfaces, repositioning the patient, optimizing nutritional status, and moisturizing sacral skin with expectations of some improvement within 2 weeks.[26] The general principles of therapy for pressure ulcers are as follows.

TABLE 100-3
Complications of Pressure Ulcers

- Local infections
- Bacteremia
- Osteomyelitis
- Sinus tracts
- Malignancies
- Necrotizing fasciitis
- Myonecrosis
- Metabolic alterations
  - Hypercalcemia
  - Hypoproteinemia
  - Anemia
- Postsurgical complications
  - Hematoma
  - Seroma
  - Wound dehiscence
  - Abscess
- Amyloidosis and others
- Death

RELIEF OF PRESSURE, SHEAR, AND FRICTIONAL FORCES

POSITIONING. Positioning techniques are critical in the management of tissue loads.

While in bed, patients should be positioned to avoid pressure over existing ulcers or over bony prominences, especially the trochanter. Pillows or foam wedges can be used to raise a pressure ulcer off its support surface or to prevent direct contact between bony prominences, such as knees or ankles. It is important to limit the amount of time the head of the bed is elevated and to maintain the head of the bed at the lowest possible level of elevation tolerable to reduce shearing forces at sacral tissues. Immobilized patients are usually placed in a 30° oblique position to the left or right, which should be alternated every 2 hours at a minimum. International best practices have validated this approach though controlled studies are still needed.

The patient and caregivers must learn appropriate transfer or mobilization techniques to avoid friction. The patient should be lifted rather than dragged across the bedsheets, using lifting devices such as a trapeze or bed linen.[27] Repositioning should be done as frequently as warranted by the patient's condition.

Moisture from urinary or fecal incontinence, perspiration, or wound drainage should be minimized, and the skin should be kept clean. Absorbing underpads or briefs, diapers, and occasionally urinary catheters or rectal tubes may be required to help manage incontinence. Skin barrier creams can help protect the skin from maceration.

Patients, who are sitting, may select a pressure-relieving cushion based on specific needs. Donut-type devices should be avoided because they result in venous congestion and may worsen ulcers. Patients should be encouraged to reposition themselves frequently.

SUPPORT SURFACES. Support surfaces can be used on top of or instead of standard mattresses. They distribute pressure over a large surface area, and the type of support surface used will depend on the patient's needs and abilities. Support surfaces are typically divided into static and dynamic, the latter powered by electricity (eTable 100-3.1 in online edition).

Static support surfaces are recommended for patients who can assume several positions without bearing weight on an ulcer. These include specialized foam mattresses and mattresses with various fillings. They may also be overlays used atop of a base mattress.

"Low-tech" foam mattresses are the most commonly used material for pressure reduction, given their ease of use, affordability, and evidence base. A Cochrane Systematic Review examined five trials comparing foam alternatives with standard hospital mattresses, demonstrating a relative risk reduction of 60% in pressure ulcer incidence with the use of foam mattresses.[28] Foam slabs should be 3–4 inches thick to effectively reduce pressure. A trial with 70 intensive care unit patients in France showed 85% risk reduction in heel ulcers in patients using a total foam body support system compared to control groups receiving standard pressure ulcer protocol including a water mattress.[29]

Other "low-tech" pressure supports include static supports filled with air, water, gel, silicone, polyvinyl, heel elevators, and sheepskins. Most of them permit a high degree of immersion, allowing the body to sink into the surface as it conforms to the bony prominences. This increases the surface pressure distribution area and lowers the interface pressure by transferring the pressure to adjacent areas. Unfortunately, many of the water-filled and bead-filled mattresses that demonstrated success in clinical trials are no longer available. A Cochrane Systematic Review of two trials examining the effects of sheepskins showed relative risk of 0.42 for pressure ulcer development compared to standard low-tech support surfaces.[28]

Patients who cannot tolerate frequent turning, immobile patients, those with large or multiple ulcers, and patients with unresponsive ulcers may require dynamic support surfaces, which are electrically powered. These provide cyclical, alternating pressure relief, and include air-fluidized, low-air-loss, and/or alternating-air beds.

Air-fluidized beds contain microspheric silicon-coated beads encased in an air-permeable fabric (polyester or Gore-Tex). The beads are suspended by pressurized streams of warmed air, which allows patients to "float" and decreases pressure through the principle of immersion while simultaneously reducing shear. Feces and body fluids flow freely through the sheet; thus, the skin is kept dry.

Low-air-loss systems use a series of connected, air-filled cushions that are inflated to specific pressures. Some have alternating and pulsating pressure features. A prospective, randomized trial demonstrated that the use of low-air-loss beds resulted in threefold faster wound healing than use of a foam mattress.[30] Unlike with air-fluidized beds, urine and feces do not pass through the fabric of low-air-loss beds.

Alternating-pressure systems distribute pressure by shifting the body weight to different surface contact areas. The air is pumped into the chambers at periodic intervals to inflate and deflate them in opposite phases, which thereby changes the location of contact pressure. Though alternating-pressure systems have not been proven more efficacious than low-tech supports, a cost effectiveness analysis by the UK National Health Service associated them with 80% probability of being cost saving due to shorter hospital stays and delay in ulceration.[28,31]

Other pressure supports that may be of modest benefit include kinetic turning beds, operating table overlays, and seat cushions. Kinetic turning beds are primary used in ICU settings for pulmonary concerns. Operating table overlays may decrease postoperative pressure ulcer incidence and should be employed with high-risk patients undergoing long procedures.

WOUND MANAGEMENT

CLEANSING. Cleansing should be performed gently to minimize mechanical and chemical trauma to healing tissues. Normal saline is preferred because it

is most physiologic in relation to the wound. Safe and effective irrigation pressures for ulcers range from 4 to 15 psi; higher pressures than this may cause trauma and drive bacteria into the wound tissue. Certain skin cleansers and antiseptics such as povidone iodine, sodium hypochlorite solution, hydrogen peroxide, acetic acid, and liquid detergents should be avoided, because these agents are cytotoxic and may retard epithelialization.

DÉBRIDEMENT. Ulcers with devitalized, necrotic tissue should be débrided, because necrotic tissue supports the growth of pathogenic organisms. Mechanical débridement techniques include application of moistened saline or wet-to-moist dressings, hydrotherapy (whirlpool), wound irrigation, and application of dextranomers. Wet-to-dry dressings changed every 4 to 6 hours are painful and are nonselective for necrotic tissue. Whirlpool devices can be considered for pressure ulcers with thick exudate, slough, or necrotic tissue. For wound irrigation, a large 35-mL syringe and 19-gauge angiocatheter can be used to provide adequate pressure.[1]

Sharp débridement involves the use of a scalpel, scissors, or other sharp instrument to remove devitalized tissue and is generally indicated in cases in which there is eschar. For smaller ulcers, local anesthesia can be used, whereas larger stage III or IV ulcers may require extensive surgical débridement under general anesthesia. Enzymatic débridement can be used in patients who cannot tolerate surgery. Topical agents such as sutilains, collagenase, fibrinolysin, and deoxyribonuclease can be used. Papain was removed from the market due to hypersensitivity reactions.[32] Dressings should be changed once to several times daily. Contact dermatitis can sometimes occur, and these agents should not be used if tendon is exposed.[2]

Autolytic débridement involves the use of synthetic dressings to cover the wound, which allows digestion of necrotic tissue by enzymes normally present in wound fluids.

In addition to traditional débridement methods, the use of sterile fly larvae (maggots) to clean necrotic tissue is gaining popularity and appears to be safe and effective.

DRESSING PRODUCTS. Dressings can help protect the wound from the environment, reduce or prevent wound infection, stimulate autolytic débridement, reduce wound pain, and stimulate the development of granulation tissue. It has been demonstrated experimentally that wounds maintained in a moist environment heal 40% faster than air-exposed wounds. Control of moisture and drainage from the wound helps provide an optimum wound environment for healing. There are several types of dressings, each one of which has specific properties, advantages, and disadvantages (eTable 100-3.2 in online edition). Higher stage ulcers usually require more absorptive dressings to maintain a moist environment. A variety of specialized dressings may be helpful for pressure ulcer management, including a bilayer matrix wound dressing, pig-derived acellular small intestine submucosa, and natural latex biomembrane. Both the NPUAP and the EPUAP (European Pressure Ulcer Advisory Panel) state in their international pressure ulcer guidelines that gauze dressings should be avoided in clean, open pressure ulcers since they may stick to wounds, causing pain with dressing changes.[24] In fact, a systematic review of 29 studies demonstrated hydrocolloid dressings to be superior to gauze in terms of pressure ulcer healing, pain associated with dressing change, absorption capacity, side effects, and cost.[33]

Intact skin surrounding the ulcer should always be assessed for signs of inflammation and infection. Irritation of surrounding skin may result from epidermal skin stripping during dressing changes or maceration secondary to contact with feces, urine, or wound drainage. Periwound skin must be adequately moisturized but neither macerated nor eroded.[28] A randomized clinical trial of 331 patients over a 30-day period demonstrated pressure ulcer incidence was 7.32% in a group of patients treated twice daily over high-risk sites with Mepentol, a hyperoxygenated fatty acid preparation, compared with 17.37% in the placebo group treated with a generic greasy product. In addition, Mepentol, comprised of such compounds as oleic acid, linoleic acid, arachidonic acid, and eicosenoic acid was found to be cost effective.[34] Creams or gels containing metronidazole, balsam of Peru, trypsin, and recombinant human platelet-derived growth factor are also available.

BACTERIAL COLONIZATION AND INFECTION MANAGEMENT

Ulcer cleansing and débridement are important to control microbial burden in pressure sores. Systemic antibiotic therapy is not recommended for contamination or minor localized infections but is indicated when bacteremia, cellulitis, or osteomyelitis is present.

Topical antibiotics are used to prevent or treat wound infection, reduce bacterial load, or reduce odor and signs of inflammation. Topical antibiotics such as neomycin and bacitracin are common allergens and can cause contact dermatitis and, rarely, anaphylaxis. Topical formulations of antibiotics that are used systemically (e.g., gentamicin) should be avoided because bacterial resistance may develop. However, the Agency for Healthcare Research and Quality guideline recommends a short 2-week course of topical antibiotics for a clean ulcer that is not healing or that is producing a moderate amount of exudate despite appropriate care.[35] The use of topical metronidazole 1% solution or 0.75% or 0.80% gel has gained popularity in reduction of wound odor, though randomized controlled trials are still needed to prove efficacy.[36]

PAIN MANAGEMENT

Pain management requires a combination of conservative measures, medications, and appropriate wound care. Muscle relaxants and physical and occupational therapy may be helpful to decrease muscle spasm in the area of ulceration. Transcutaneous electrical nerve

TABLE 100-4
Preventive Measures

Maintain personal hygiene. Consider topical lotions containing fatty acids.
Try to assure adequate nutrition and hydration.
Evaluate and manage urinary and fecal incontinence.
Position to alleviate pressure over bony prominences and shearing forces over heels and elbows, base of head, and ears.
Try to reposition every 2 h when in bed and every hour when in a chair; if alert and capable, the patient should be taught to shift his or her weight every 15 min while in a chair.
Use appropriate positioning devices and foam padding; do not use donut-shaped devices. Consider dynamic supports in high-risk patients.
Try to avoid placing the patient on his or her trochanters or directly on the wound.
Maintain the lowest head elevation possible (no greater than 30°)
Use lifting devices such as draw sheets or a trapeze.
Try to prevent contractures.
Do not massage reddened areas over bony prominences.

Modified from American Medical Directors Association: *Clinical Practice Guideline: Pressure Ulcers*. Columbia, MD, American Medical Directors Association, 2008. © 2008 American Medical Directors Association.

stimulation may help relieve acute and chronic pain. The use of topical anesthetics such as lidocaine-prilocaine cream on wounds 30 minutes before débridement significantly reduces pain associated with wound care procedures. An opiate diamorphine gel was also shown to significantly reduce pain with dressing changes in a small randomized controlled trial of patients with stage II and III ulcers.[37]

Nonopioid analgesics (aspirin, other nonsteroidal anti-inflammatory drugs) are first-line systemic therapy, followed by stronger medications such as opioids. Adjuvant medications such as tricyclic antidepressants can be used to enhance analgesia.[37] They can also improve depression in some chronic pain states and have sedative, sleep-enhancing qualities.

PREVENTION

Preventive actions can decrease the patient's risk of developing pressure ulcers. These steps can also keep pressure ulcers from getting worse. Preventive measures are listed in Table 100-4.

KEY REFERENCES

Full reference list available at www.DIGM8.com

DVD contains references and additional content

2. Kanj LF, Wilking SVB, and Phillips TJ: Pressure ulcers. *J Am Acad Dermatol* **38**:517, 1998
9. Shea JD: Pressure sores: Classification and management. *Clin Orthop Relat Res* **112**:89, 1975
26. Reddy M, Gill SS, Rochon PA: Preventing pressure ulcers: A systematic review. *JAMA* **296**:974, 2006
28. McInnes E et al: Support surfaces for pressure ulcer prevention. *Cochrane Database Syst Rev* **4**:CD001735, 2008
38. Langer G et al: Nutritional interventions for preventing and treating pressure ulcers. *Cochrane Database Syst Rev* **4**:CD003216, 2003

Chapter 101 :: Body Art

:: Anne Laumann

BODY ART AT A GLANCE

- Tattoos are common: 24% of the US 18- to 50-year-olds in 2004, equal numbers of men and women.
- Tattooing medical complications are rare: mainly related to pigment ingredients, but include viral, bacterial, fungal, and transfusion-transmitted diseases.
- Tattoo social associations and difficulties are significant.
- Piercing: soft earlobes 37% and body piercing excluding the soft earlobe 14% of the US 18- to 50-year-olds in 2004, mainly women; 46% of women aged 16–24 in the United Kingdom in 2005. Body piercing fashion started in the late 1980s.
- Piercing medical complications are common: metal-induced contact allergic dermatitis, broken teeth, anesthetic risks, and infections of all types.
- The relationship of body art to hepatitis is unclear.

DEFINITIONS

Body art is art made on, with, or consisting of, the human body. The most common forms of body art are tattoos, body piercings, and body painting, but other types include scarification, branding, tongue splitting, subdermal and extraocular implants. *Tattooing* is the practice of producing an indelible mark or figure on the human body by inserting pigment under the skin using needles or other sharp instruments.[1] *Body piercing* refers to the cosmetic piercing of body parts for the implantation of objects such as rings, studs, or pins.[2] *Body painting* is the application of paint on to the skin and includes face painting, the application of *mehndi* and temporary tattoos. *Scarification* is a means of permanently marking the skin by cutting alone, without the use of pigments. This includes the deliberate formation of keloids. When purposeful third-degree burns are used to induce a scar, the procedure is called branding.[3] *Tongue splitting* is the bisection of the tongue from the tip toward the back for about 3–5 cm leading to an appearance similar to the tongue of a lizard.[4,5] *Subdermal implantation* is the placing of a foreign body under the skin so that none of the object remains outside of the body. A three-dimensional effect is seen on the surface. Materials used are silicone, Teflon, or metal.[6]

Extraocular implantation is the placing of sterile nonpyrogenic platinum jewelry inside the interpalpebral conjunctiva of the eye.[7]

TATTOOING

EPIDEMIOLOGY AND BACKGROUND

The word "tattoo" is said to come from Captain Cook after he saw markings on the bodies of the Polynesian people during his 1769 South Pacific voyage. "Ta-Tu" means "to mark" in Tahitian and is associated with the sound made by the Tahitian tattoo instrument.[8] However, tattoos have probably been performed since the beginning of humanity. The famous Ice Man dating from 3300 BC found in the mountains of Europe was covered in tattoos, and they are seen on Egyptian mummies dating from 2000 BC. Tattoos were a sign of nobility, bravery and beauty. They are forbidden in the Old Testament in both Leviticus and Deuteronomy and in the Koran. Despite this, the practice has persisted and has been popular in Europe and America. During the Depression, the prevalence of tattooing declined as incomes shrank. Nondecorative tattoos were used to identify slaves, criminals and internees in prisoner of war and concentration camps during the Second World War. Military personnel often had tattoos with patriotic designs, together with hearts and the names of loved ones. With the advent of peace, the popularity of tattoos decreased, although they were still seen in close-knit group situations. They became associated with marginalized groups, signaling time spent in jail, "punk" status, membership in a motorcycle gang or a traveling circus. In recent times, images have become increasingly eclectic and the practice has become mainstream.[9]

Studies performed in 2008,[10] 2006,[11] and 2004[12] found that 14% of 18- to 64-year-olds in the United States have tattoos, including approximately 30% of those under the age of 40. They are equally common among men and women and are seen in all ethnic groups. They are still found more commonly in those with a military association and in those of low educational and socioeconomic backgrounds. They are associated with the abuse of alcohol, the taking of illicit drugs and having spent significant time in prison.[13] They are inversely associated with having a religious affiliation and having never drunk alcohol. Most tattoos are done in a dedicated studio, but approximately a quarter of people with tattoos have had at least one tattoo done elsewhere.

PROCESS

A handheld device, powered by low-voltage direct current, holds solid needles placed singly or in groups of up to fourteen on an oscillating bar (Fig. 101-1). The needles are dipped into colored inks and then moved across the skin in the desired pattern, penetrating rapidly and vertically 0.5–2.0 mm into the skin, depositing the pigment into the dermis. A thin layer of petroleum jelly is applied to the skin prior to and during the procedure to minimize blood loss and prevent spatter. After the tattoo is finished, the area is cleaned with a mixture of alcohol and water, and more ointment is applied. Sometimes, the ink is spread over an area of skin and the needles made to penetrate through it to carry the particles into the skin. Amateur tattooers often do it this way using handheld needles wound round with thread to prevent too deep penetration. Other instruments used may be pencils, pens, and straight pins.



Figure 101-1 Tattooing with a handheld electric tattoo machine.



Figure 101-2 Four days after the application of this tattoo, much of the inserted pigment is extruding.



Figure 101-4 This Tattoo is 35 years old and the image has blurred. From the top down: Mom in heart, a wreath, an eagle, a peace arrow, God Bless America.

Much of the pigment is extruded through the epidermis during the first 10 days (Fig. 101-2). The final location of the pigment is in the mid-to-lower dermis (Fig. 101-3), but the pigment in amateur tattoos tends to be more superficially and more variably placed. The particles are membrane bound (in secondary lysosomes) within fibroblasts, macrophages and occasionally mast cells around blood vessels. They may also be seen around hair follicles and sebaceous glands. Many of the pigment conglomerations are too large to traverse the vessel walls and leave the area of original deposition, but with time pigment diffusion from the site may lead to blurring of the visible design as well as pigment deposition in the draining lymph nodes (Fig. 101-4).[14,15]

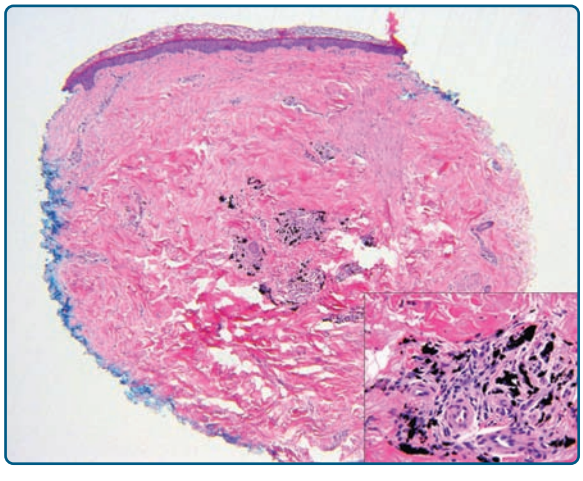

Figure 101-3 Tattoo pigment is seen in the reticular dermis. The particles are within fibroblasts, macrophages, and occasional mast cells around blood vessels.

PIGMENTS

Tattoo pigment composition, as obtained from the manufacturer, and possibly further mixed by the artist, is complex, usually nonsterile, unregulated, variable and changing. In recent times, industrial organic pigments, including azo and polycyclic compounds, sandalwood and brazilwood, as well as aluminum, cadmium, calcium, copper, iron, phosphorus, silica, and sulfur have been identified.[16] In addition, titanium dioxide and barium sulfate are often used to lighten the color. The 1976 Food, Drug and Cosmetic Act limited the content of lead and mercury in cosmetics for application to the skin so that now these two elements are rarely found.[17–19] The pigment in amateur tattoos is usually black and carbon based, often deriving from India ink, charcoal, soot, or mascara[20] (Table 101-1).

COMPLICATIONS

Medical complications are unusual in developed countries. Clearly, there is a real risk of contracting a contagious disease, but most recent reports are anecdotal. These include reports of verrucae, molluscum contagiosum, and atypical mycobacterial infections in the area of the tattoo, methicillin-resistant staphylococcal infections spreading from the area of the tattoo and bacterial endocarditis within a week of tattoo application.[21–26] There has been more than one report of cutaneous leishmaniasis in a tattoo site among HIV-infected individuals with visceral leishmaniasis.[27] Inoculation leprosy is common in parts of the world where leprosy is endemic.[28,29] (See Table 101-2.)

There have been outbreaks of hepatitis B traced to tattoo parlors in the past, but currently there is a

TABLE 101-1
Tattoo Pigments

Red	Mercuric sulfide (cinnabar); cadmium selenide; ferric hydrate (sienna); sandalwood; brazilwood; aromatic azo compounds including naphthol-AS; quinacridone
Green	Chromium oxide; lead chromate; copper or aluminum phthalocyanine; malachite (contains copper); ferrocyanides and ferricyanides
Purple	Manganese ammonium pyrophosphate; aluminum salts; quinacridone; dioxazine/carbazole
Blue	Cobalt aluminum oxide; chromium oxide; copper phthalocyanine
Yellow	Cadmium sulfide; curcuma (from the ginger plant family); chrome yellow (lead chromate mixed with lead sulfide)
Black	India ink; ferrous oxide; magnetite (Fe_3O_4); carbon; logwood (a heartwood extract from *Haematoxylum campechianum* found in Central America and the West Indies)
Brown	Iron oxides
White	Zinc oxide; titanium dioxide; lead carbonate; barium sulfate

controversy as to how often hepatitis C in the United States is transmitted this way. During the same time that the prevalence of tattoos has increased, the absolute numbers of reported acute hepatitis B and C cases have fallen. The numbers were at a nadir for hepatitis B in 2007 (1.5/100,000), in contrast to a high of 11.5/100,000 in 1985; for hepatitis C, the numbers are stable at 0.3/100,000 since 2003, from a high of 2.4/100,000 in 1992.[30] Most hepatitis C infection is asymptomatic. The sources of approximately 65% of the cases of hepatitis C are unidentified. Cross-sectional data from a number of population groups, for example, veterans,[31] attendees in an orthopedic practice,[32] hospital outpatients,[33] have been inconsistent in identifying tattoos as an independent risk factor for the presence of Hepatitis C. Variables such as getting the procedure in a dedicated studio or in a penitentiary[34,35] may be relevant and the confusion may relate to the fact that, in some people, tattoos are a marker for other unconventional or socially disapproved behaviors.[36,37] The American Association of Blood Banks recommends that blood for donation not be taken from anyone within a year of a tattoo or a body piercing, unless applied by a state-regulated entity with sterile needles and ink that have not been reused.[38] In 2005, the Canadian Blood Services decreased the deferral period from 12 to 6 months. Donor deferral rates were assessed before and after the change. Remote tattooing was associated with increased hepatitis C risk, but this did not hold true for recent tattooing nor piercing. There was no measurable adverse effect on safety and a positive but less than expected effect on blood availability.[39]

Many, but not all, of the pigment-based reactions are in the red areas of tattoos (Fig. 101-5). Now that cinnabar, vermilion or other pigments containing mercuric sulfide, are rarely used, other culprits have been identified. These include cadmium selenide and quinacridone.[40] Reactions may be photosensitive and histology may be pseudolymphomatous, lichenoid,[41] or granulomatous, either (1) foreign body type with numerous giant cells containing pigment or (2) hypersensitivity type with dense aggregates of epithelioid cells, a thin peripheral ring of lymphocytes and few giant cells.[42] Hypersensitivity reactions may be localized or generalized,[43] but standard epicutaneous patch testing is not often helpful, presumably related to the dermal placement or the rapid decomposition of the tattoo antigen.[44] The social implications of tattooing are protean and may alert the onlooker to other risk-taking behaviors.[45]

TABLE 101-2
Known Infectious Complications of Tattooing

Bacterial	Viral
■ Impetigo	■ Warts
■ Ecthyma	■ Molluscum contagiosum
■ Furunculosis	■ Herpes simplex
■ Erysipelas	■ Herpes zoster
■ Tuberculosis cutis	■ Vaccinia
■ Atypical mycobacterial infection	■ Rubella
■ Syphilis	■ Viral hepatitis
■ Leprosy	■ HIV possible but no case reports
■ Endocarditis (rare)	

TATTOO REMOVAL

Most people are proud of their tattoos, but approximately 17% desire removal. In addition, 5% opt for and 8% are considering further tattooing to cover a disliked or faded image. Often these people have obtained their tattoos at a young age and want them



Figure 101-5 Red tattoo reaction.

TABLE 101-3
Tattoo Removal Methods

Excision with primary closure or grafting	For grafting, to avoid donor site scars, techniques may be used that enzymatically separate the excised epidermis from the underlying, excised, pigment-containing dermis and grafting this epidermis to the original tattoo site.[48]
Mechanical dermabrasion	May use a handheld mechanical unit or sterile sandpaper to abrade the skin to the reticular dermis. Rotating (up to thousands of rpm) wire brushes, diamond fraises, or serrated wheels attached to compact electric machines are available.
Salabrasion	First described by Aetius, a Greek physician in 543AD, tap water dipped in salt is rubbed vigorously to abrade the skin overlying the tattoo.
Chemical extraction using a remover paste	The remover paste, made with deionized water, zinc oxide, magnesium oxide, calcium oxide, triethanolamine, isopropanol, and benzoic acid[49] is applied. A superficial microtattoo process is used to puncture the skin over the tattoo and the paste is reapplied. Inflammation ensues and the pigment is extruded.[50]
Cryosurgery	Salt/ice (–20°C) or dimethyl ether/propane (–50°C) mixtures, solid carbon dioxide (–79°C), nitrous oxide (–70°C), or liquid nitrogen (–196°C) may be used.
Application of caustic chemicals	These include phenol, trichloroacetic acid, tannic acid, or oxalic acid with silver nitrate.[51]
Argon and carbon dioxide lasers	These were the early tattoo removal lasers but nowadays mainly used for the removal of tattoo granulomas as healing times are prolonged. Significant thermal damage and hypertrophic scarring often ensue.
Q-switched lasers	These produce nanosecond pulses similar to the Tr[a] of the target pigment. Each pulse has a very high peak power. Surface cooling may be used to prevent epidermal damage.

[a]Tr is the thermal relaxation time, the time it takes for the target chromophore to lose 50% of its incident heat without conducting heat to the surrounding tissue.

removed or changed to enhance self-esteem, or for social, domestic, and family reasons.[46,47] Many tattoo removal methods have been documented (Table 101-3), but most are only partially effective, and leave scarring and pigmentary changes (Fig. 101-6). With the advent of the theory of thermal relaxation, lasers with very short (nanosecond) high-energy pulses have been designed, which are less likely to heat the surrounding tissue leaving scars (Table 101-4). On the horizon, are lasers (titanium:sapphire) with picosecond pulse durations which may be even more effective but potentially more destructive to surrounding tissue. The laser energy photoacoustically explodes the pigment particles. Some of these may be allergenic or carcinogenic. Macrophages engulf the fragments so that they are removed via the draining lymphatics, and some may be extruded through the epidermis. Lightening may take several weeks. In general, proximally placed and old tattoos are easier to remove than distally placed and more recent ones.[20]

Removal of tattoos in dark-skinned individuals is difficult. A long wavelength laser (Q-switched Nd:YAG) may be used together with skin freezing to cause lightening of the epidermis so that the laser light not only penetrates deeply enough but also bypasses the melanin in the epidermis to avoid a permanent pigment change. Red, white, and flesh-tone tattoos, which often contain ferric and/or titanium oxides, may darken with laser treatment related to chemical reduction by the laser beam (See Chapter 239).



Figure 101-6 Scarring related to tattoo removal by acid 50 years previously.

TEMPORARY TATTOOS

Traditional henna tattooing, practiced throughout Africa, the Middle East, and India (mehndi) for thousands of years, very rarely causes hypersensitivity reactions. Henna is made from the leaves of the plant *Lawsonia inermis*, a member of the Loosestrife family, and is a reddish brown color. Recently, the application of temporary tattoos has become popular in the developed world. Some of these are made with "black henna," which contains up to 16% *para*-phenylenediamine (PPD) used as a darkening agent. Concentrations of PPD as high as this commonly cause sensitization and lead to contact allergic dermatitis (see Chapter 13).

TABLE 101-4
Use of Lasers for Tattoo Removal

Q-Switched[a] Laser	Wavelength (nm)	Pulse Duration (ns)	Fluence (J/cm^2)	Used for This Color
Nd:YAG	1,064	10	6–12	Black, blue
Frequency-doubled Nd:YAG	532	10	2–12	Red, orange, purple
Ruby	694	~ 25	8–10	Black, blue, green
Alexandrite	755	50–100	4.5–8	Black, blue, green

[a]A Q-switch is an electro-optical device that concentrates laser energy into a single, intense nanosecond pulse.

BODY PIERCING

EPIDEMIOLOGY AND BACKGROUND

Body piercing has been practiced in almost every society and on every continent, not only for beautification but also for ritual, religious and status reasons. Usually, only the ears, mouth, and nose were pierced, although penile piercing was described in detail in the Kama Sutra (4th century BC). More recently there have been many myths propagated by the promoters of body art in order to stimulate interest in the practice.[52] For instance, it is a myth that a nipple piercing could support the weight of a Roman centurion's toga. In the United States, piercing of the soft earlobes has been common in women since the 1960s, but the body piercing fashion appears to have taken off in the late 1980s.

A US cross-sectional study of 18- to 50-year-olds in 2004 found that 19% of men and 49% of women had soft earlobe piercings and 8% of men and 21% of women had body piercings in other parts of the body. Of 18- to 29-year-olds, 32% had body piercings, not including the soft earlobe.[12] Similarly, a 2005 UK study found that 46% of 16- to 24-year-old females and 13% of males had body piercings other than the soft earlobes.[53] Other studies in teens and young adults have shown body piercing outside the earlobe in 27%–51%.[54,55] Women are more likely to have body piercings than men, and more than 50% of those with body piercings have more than one. Most piercings are done in tattoo or dedicated shops, but soft earlobe piercings are often done in department or specialty stores. Important behavioral and social associations in the young include some cultural normative attributes, for example, being of Hispanic or South Asian heritage, but they also include the participation in a number of risk-taking behaviors such as being a drinker, having used illicit drugs, having spent time in jail, having limited religious affiliation, and having early and multiple sex partners. It may also be a marker for depression.[56,57]

PROCESS

A hollow 12–16 gauge needle is passed through the body part and body jewelry is inserted in the hole. A piercing gun is often used for soft earlobe piercings,

TABLE 101-5
Complications Related to Infection of Piercings

Complication	Reported Organisms
Loss of ear cartilage	*Staphylococcus aureus* *Pseudomonas aeruginosa*
Endocarditis: usually superimposed on a known underlying cardiac abnormality, but occasional reports without prior cardiac abnormality	Skin piercing: *Staphylococcus aureus* Group A β-hemolytic *Streptococcus* *Staphylococcus epidermidis* Mucosal piercing: *Streptococcus viridans* *Neisseria mucosa* *Haemophilus aphrophilus* *Haemophilus parainfluenzae*
Septic arthritis	Group A β-hemolytic *Streptococcus*
Osteomyelitis	*Staphylococcus aureus*
Toxic shock syndrome	*Staphylococcus aureus*
Lymphadenitis	*Lactobacillus*
Cephalic tetanus	*Clostridium tetani*
Acute glomerulonephritis (may lead to acute renal failure)	Group A β-hemolytic *Streptococcus*
Ludwig's angina	Oral piercing: *Streptococcus viridans* *Neisseria mucosa* *Haemophilus aphrophilus* *Haemophilus parainfluenzae*
Fournier gangrene	Male genital piercing: Group A *Streptococcus* and mixed Gram-negative bacilli and anaerobic organisms
Brain abscess	Tongue piercing resulting in a mixed infection: *Streptococcus viridans* *Peptostreptococcus micros* *Actinomyces* species *Eikenella corrodens*
Lupus vulgaris	*Mycobacterium tuberculosis* inoculation at time of nose piercing (India)

but these are difficult to sterilize, can lead to crush injuries, and, if used in a cartilaginous area, to loosening of the perichondrium. Swelling occurs immediately so that the jewelry inserted has to be long and fine enough to allow for this. It should be made of titanium, niobium, ≥14-karat yellow gold, or stainless steel in order to avoid the induction of nickel and/or cobalt delayed type hypersensitivity. Postoperative healing times, from 2 weeks for clitoris to 9 months for navel piercings, vary with the site. There are two types of bead closures. The captive bead ring is held closed by pressure. The bead screw is similar to any other screw mechanism and is often part of hoops, barbells, and circular barbells.

COMPLICATIONS

These vary with the site on the body of the piercing as well as with the place the procedure is done, for example, at home or in a commercial studio. Bleeding may occur during or immediately following the procedure, and bacterial, fungal, or viral diseases may be transmitted, especially if nonsterile instruments are used[58] (Table 101-5). However, most infection comes from the subject's own flora often related to poor hygienic practices during the healing period leading to localized infection (erythema, edema, purulent drainage). Rates as high as 35% after ear cartilage piercings have been reported, sometimes leading to loss of ear cartilage and, rarely, endocarditis (Fig. 101-7).[59,60] Other high-risk areas include the navel, with its propensity for movement, and any intraoral site.[61] Jewelry may be left in place to facilitate drainage and prevent sac formation. In addition, local hygiene should include compresses, a topical antibiotic, and, if necessary, an oral antibiotic. If pseudomonas is suspected a fluoroquinolone, which will also cover most species of *Staphylococcus* and *Streptococcus*, including many β-lactam-resistant strains, is a good choice. Importantly, viral hepatitis may be transmitted through the piercing needle. This includes hepatitis C and less often hepatitis B and D, although this uncommonly occurs in modern America,[62] where disposable or sterilized piercing equipment is used.[63] Transmission of HIV is another risk that has not been proven to occur.

Other complications are protean (Table 101-6). In view of the high and increasing prevalence of nickel



Figure 101-7 Early upper ear cartilage infection following the insertion of metal jewelry.

TABLE 101-6
Noninfectious Complications Related to Piercings

Bleeding
- Usually at time of or immediately after procedure. This may lead to significant blood loss.

Avulsion Injuries
- Earlobe tear, urethral rupture, splitting of urinary stream, rejection of jewelry near the eyebrow, navel, or nipple.

Scarring
- May lead to phimosis or strictures.
- Keloid formation.
- Cyst related to tract closure.

Neurological Damage
- Loss of taste, increased salivary flow, clitoral numbness.

Anesthetic Risks
- Interference with free access to the airway[a], postoperative laryngospasm, pressure on area during surgery, electrosurgical burns, problems with catheterization.

Intraoral
- Aspiration of jewelry ball.
- Broken teeth and gingival recession.
- Speech impairment.
- Loss of taste.
- Increased salivary flow.
- Embedding of jewelry in tongue.

Nipples
- Galactorrhea related to hyperprolactinemia due to nipple stimulation.

Penis
- Priapism related to entrapment of penis in a scrotal-piercing hole.
- Paraphimosis related to inability to replace the prepuce over jewelry in the glans.
- Glanular hypospadias.
- Split urinary stream.

Jewelry-induced Contact Allergy
- Nickel and cobalt are the most likely allergens (Type IV delayed hypersensitivity)
  - In the US
    - 12% jewelry allergy in those without piercings
    - 31% in those with piercings: 48% in those with three piercings
- Gold and palladium rarely cause delayed reactions which may be of granulomatous (sarcoidal) type.[64]

[a]To avoid problems, remove tongue, lip, or cheek jewelry before anesthesia and insert a nonreactive thread to preserve tract patency.

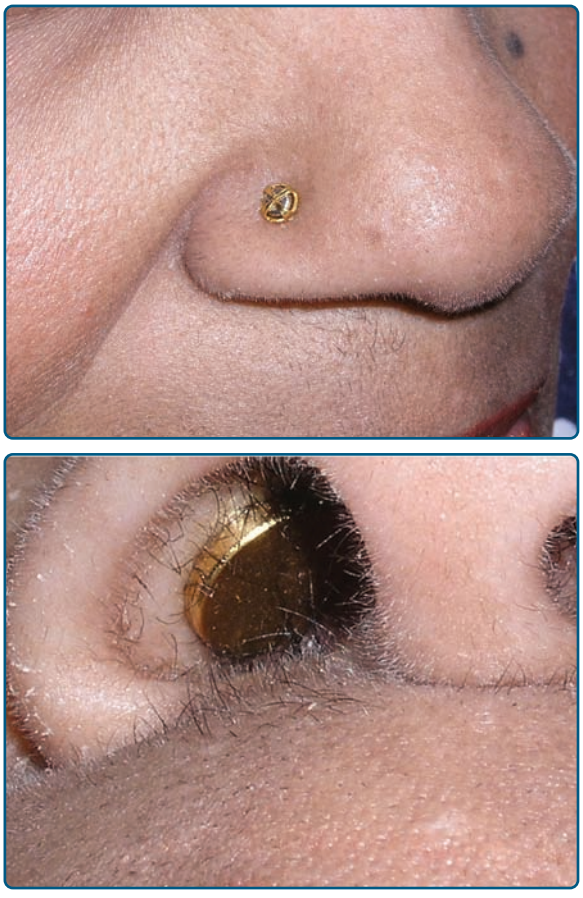

Figure 101-8 Magnetic jewelry avoids a piercing but still can be inhaled accidentally or become embedded in the tissue.

allergy, European nations implemented legislation to limit the release of nickel from objects intended to be in prolonged contact with the skin. This legislation was first passed in Denmark in 1976 and went into full effect in 1992. The European Union (EU) adopted the EU Nickel Directive in 1994. It went into full effect in all EU nations in 2001. Nickel content of piercing post assemblies was initially set at ≤0.05%. In 2004, this was changed to ≤0.2 μg/cm^2/week of nickel release, and it appears that the incidence of new sensitization is falling.[65]

Piercing tracts are not necessarily permanent as they may close if the jewelry is removed. This is common with tongue piercings as the epithelium in the depths of the tract is thin and possibly missing.[66] Replacement of tongue jewelry prior to anesthesia can be done with a fine inert flexible catheter.

MAGNETIC JEWELRY

This is occasionally used to avoid piercing (Fig. 101-8). Aspiration of the magnetic back of the jewelry is a possible complication.

KEY REFERENCES

Full reference list available at www.DIGM8.com

DVD contains references and additional content

1. Sperry K: Tattoos and tattooing. Part I: History and methodology. *Am J Forensic Med Pathol* **12**(4):313-319, 1991
2. Stirn A: Body piercing: Medical consequences and psychological motivations. *Lancet* **361**(9364):1205-1215, 2003
9. De Cuyper C, Pérez-Cotapos M, eds: *Dermatologic Complications of Body Art*. Heidelberg, Springer, 2009
12. Laumann AE, AJ Derick: Tattoos and body piercings in the United States: A national data set. *J Am Acad Dermatol* **55**(3):413-421, 2006
30. Daniels D et al: Surveillance for acute viral hepatitis—United States, 2007. *MMWR Surveill Summ* **58**(3):1-27, 2009
65. Schram SE et al: Nickel hypersensitivity: A clinical review and call to action. *Int J Dermatol* **49**(2):115-125, 2010

Neurocutaneous and Psychocutaneous Aspects of Skin Disease

PART 5



Neurocutaneous and Psychocutaneous Skin Disease

Chapter 102 :: Neurobiology of the Skin

:: Martin Steinhoff & Thomas A. Luger

NEUROBIOLOGY OF SKIN AT A GLANCE

- In an interactive network, cutaneous nerves communicate with various skin cells, the endocrine system, and the immune system.
- Neurocutaneous interactions influence a variety of physiological and pathophysiological functions such as thermoregulation, cell growth, inflammation, host defense, apoptosis, pruritus, pain, metastasis, and wound healing.
- Primary afferent as well as autonomic nerves release neuromediators and activate specific receptors on many target skin cells.
- Cutaneous cells express a variety of specific receptors tightly controlled by upregulatory or downregulatory signals, peptidases, or neighboring receptors.
- Many mediators (peptides, proteases, cytokines, kinins, prostanoids, opioids, cannabinoids, neurotrophins, etc.) are critically involved in physiological and pathophysiological conditions in the skin by activating neuronal receptors.
- The spinal cord and CNS modulate transmitted signals from the peripheral nerves with respect to the perception of pain or itch, and—vice versa—modulate skin function.
- New pathways are being defined for the treatment of various skin diseases in which the neuro-immuno-endocrine axis is implicated.

THE NERVOUS SYSTEM AND SKIN

This chapter discusses the structural basis and the specific molecules involved in the interactions between the skin and different portions of the nervous system.

The peripheral nervous system provides essential information to the rest of body during injury of "danger signals" such as parasites, UV radiation, toxins, allergens, pH changes, or "stress". This information can be modulated at various levels including the brain, spinal cord, dorsal root ganglia (DRG), peripheral sensory nerve endings, autonomic nerves and neurons, etc; and through specialized structures like Pacini bodies or specialized cells such as Merkel cells. This closely woven group of structures and their molecules are ultimately and critically involved in normal

cutaneous biology and skin diseases (eTable 102-0.1 in online edition). In conjunction with the spinal cord and the brain, peripheral sensory nerves have afferent functions; their endings detect physical stimuli such as touch, heat or cold, and chemical mediators into the skin from nerve endings and also have efferent functions in the skin. (eFig. 102-0.1 in online edition). These sensory nerves critically contribute to skin development before birth and to protection and homeostasis after birth. In addition, autonomic nerves modulate both physiological and pathophysiological functions as part of the stress response to external or endogenous stimuli, and form a vital link communicating with the vascular, endocrine, and immune systems (eTable 102-0.1 in online edition).

PERIPHERAL NERVES

Sensory as well as autonomic (in the skin predominantly cholinergic sympathetic) nerves influence a variety of physiologic and pathophysiologic functions of the skin such as embryogenesis, vasoconstriction, vasodilation, body temperature, erector pili movement, regulation of the function of the pilosebaceous unit, sensing physical, chemical and biological stimuli on the skin surface; modulating epidermal barrier function, cell secretion, cell growth and differentiation, cell nutrition and apoptosis, nerve growth, inflammation, immune defense, and wound healing, respectively (eTable 102-0.1 in online edition).

In unstimulated cutaneous nerves, neuromediators are stored in cytoplasmic vesicles. On direct or indirect activation through physical, mechanical, electrical, chemical or biologic or endogenous inflammatory processes lipids, cytokines or neurotrophins (NT), a significant increase of regulatory neuropeptides, or oxygen products can be detected at the site of inflammation within seconds to hours. Thus, mediators derived from sensory or autonomic nerves may play an important regulatory role in the skin under many physiologic and pathophysiologic conditions. However, in addition to neuroimmunomodulation in the periphery, a subtle and complex communication network also exists between the spinal cord, the central nervous system (CNS), and the immunoendocrine system that also modulates skin function. In addition, neuropeptides and NTs can be upregulated and released by nonneuronal cells under certain circumstances that may amplify or counterregulate the neurogenic stimulus. While certain neuropeptides [e.g., substance P (SP)] exert clear-cut proinflammatory effects during inflammation, others such as calcitonin-gene-related protein (CGRP) may be acutely released to induce vasodilatation (proinflammatory), but in addition counterregulate inflammatory responses like antigen presentation and immunosuppression in order to reestablish skin homeostasis at the later stage of inflammation.

The skin expresses a variety of receptors for these neuromediators, such as G protein-coupled receptors, ion channels and certain cytokine receptors (see Tables 102-1 and 102-2). This neuromediator–receptor interaction is controlled by endopeptidases [neutral endopeptidase (NEP), angiotensin-converting enzyme (ACE), endothelin-converting enzyme (ECE)], which terminate neuropeptide-induced inflammatory or immune responses.[1–3] A close multidirectional interaction between neuromediators, high-affinity receptors, and regulatory peptidases is critical to maintain or reestablish tissue integrity and regulating pathophysiologic conditions in the skin. Ion channels are promiscuous and can be activated by physical stimuli (heat, cold), chemicals (e.g., capsaicin, menthol, protons) as well as lipid metabolites like prostaglandins. Activation of ion channels by cannabinoids (CB) has been also recently described.

From this background, it is clear that a better cellular and molecular understanding of the complex skin–nervous system interactions opens an avenue for future therapeutic approaches to skin disease.

Taken as a whole, present information clearly indicates a crucial role for the neuronal skin network in influencing a variety of physiologic and pathophysiologic functions such as host defense, inflammation, pruritus, pain, burning, wound healing, and probably cancer (e.g., by modulating angiogenesis).

BRAIN–SKIN AXIS

The CNS proper is connected to skin either directly via efferent nerves or CNS-derived mediators, or indirectly via the adrenal glands or immune cells.[1] Cutaneous nerves also respond to internal stimuli from the circulation (e.g., pH changes, osmotic changes, bradykinin, cytokines) or the skin itself and to emotions (internal trigger factors).[2] Under normal circumstances, the sensory and the autonomic nervous systems modulate important biologic functions such as body temperature, blood flow, and cell growth. Mechanically induced nerve impulses transmit information such as pressure to the CNS. Chemical- or heat-responsive afferent nerve fibers are involved in recognizing dangerous signals. Thus, normally the innervated skin is a crucial barrier in protecting the body from danger from the external environment. This is also supported by the finding that not only the dermis but also the epidermis is highly innervated.[4] Interactions between the central and peripheral nervous system have been implicated to play a role in thermoregulation,[1,5] the pathophysiology of various skin diseases such as psoriasis,[6–8] atopic dermatitis,[9] acne,[10] wound healing,[11] as well as hair loss and regrowth.[12–14]

SPINAL CORD

Our knowledge about the involvement of the spinal cord in regulating specific chronic pain sensations in human skin, its role in modulating pruritus, or modulating inflammatory stimuli transduced from the periphery to the brain is very limited. We know that μ-opioids such as morphine can induce pruritus while being analgesic when injected intrathecally. In contrast, κ-opioids exert antipruritic effects, probably by the inhibition of the μ-opioid receptor. These results strongly indicate a role of opioids in the regulation of

TABLE 102-1
Role of Nerves in Inflammation, Immunomodulation, Pruritus and Pain

Pruritogenic Stimuli (In Alphabetic Order)	Receptors	Sources, Receptors by which Expressed	Comments
Acetylcholine (ACh)	Nicotinergic (nAChR) and muscarinergic (mAChR) ACh receptors	Autonomic cholinergic nerves, keratinocytes, lymphocytes, melanocytes, dermal fibroblasts, endothelial cells	Mediates itch in atopic dermatitis; mAChR3 is probably involved in itch.
Calcitonin gene-related peptide (CGRP)	CGRP receptors	Sensory nerve fibers	Expressed on central terminals; sensitizes receptive endings. Associated with increased pain transmission, prolongation of itch latency after substance P injection (inhibitory effect on itching). Involved in itchy skin diseases. Regulates antigen presentation on Langerhans cells; involved in drug-induced adverse reactions, atopic dermatitis and contact dermatitis. Downregulates NF-κB
Cannabinoids	CB1, CB2 receptors	Nerves, keratinocytes, immune cells	Involved in antinociception (peripheral and central), anti-fibrotic; anti-inflammatory (contact dermatitis); regulates cell growth, differentiation, apoptosis. Involved in thermoregulation.
Corticotropin-releasing hormone (CRH) and proopiomelanocortin (POMC)	CRH receptors (CRHR1, CRH-R2)	CRH-R1: keratinocytes, mast cells CRH-R2: bone marrow mast cells	Induces release of histamine, cytokines, TNF-α, VEGF from mast cells. CRH-like immunoreactivity seen on sensory nerves (rat).
Cytokines	Cytokine receptors (e.g., IL-2, IL-31)	Leukocytes, keratinocytes, endothelial cells, nerves	T cells release IL-31 during inflammation and activate monocytes and keratinocytes via the IL-31 receptor (IL-31R). IL-31R is upregulated in atopic dermatitis and prurigo.
Endocannabinoids	Cannabinoid receptors (CB1, CB2)	Nerves, immune cells, keratinocytes, hair follicles	Antipruritic in the periphery.
Endothelins (ETs)	Endothelin receptors (ET_A, ET_B)	Endothelium, mast cells	Induces burning itch. Degraded by chymase via ET_A-receptor activation.
TRP channels and agonists (heat, cold, acidosis, osmolar changes, capsaicin, menthol, camphor, eicosanoids, bradykinin, prostaglandins, various neurotrophins; aldehydes, formalin, nicotine, etc.)	Activation of transient receptor potential vanilloid 1 (TRPV1) sensitization of TRPV1 via activation of specific receptors (see in this table)	TRPV1 is expressed on sensory neurons, mast cells, epidermal and hair follicle keratinocytes, Langerhans cells, smooth muscle, and sebocytes TRPV2 expressed by sensory nerves and murine macrophages TRPV3 and TRPV4: expressed by sensory nerves and keratinocytes. TRPV6: keratinocytes. TRPA1: expressed by sensory nerves and keratinocytes	Short-term TRPV1 activation: induces pain and itch, depletes neuropeptides from sensory neurons. Long-term antipruritic effect of TRPV1 agonists (e.g., capsaicin): Suspend interplay between sensory neurons and mast cells. Affects epidermal and hair follicle proliferation, differentiation, apoptosis, and cytokine release. Increased expression in epidermal keratinocytes of prurigo nodularis patients. TRPV2: role in antigen presentation in mice. TRPV3 and TRPV4: role in sensory and keratinocyte function. TRPA1: role in pain, hypernociception, vasoregulation, barrier function. TRPV6: keratinocyte differentiation
Gastrin-releasing peptide	Activates GRPR	GRP: sensory nerves. GRPR: superficial dorsal horn of spinal cord	GRP mediates itch but not pain (histamine dependent and independent).

(continued)

TABLE 102-1
Role of Nerves in Inflammation, Immunomodulation, Pruritus and Pain (Continued)

Pruritogenic Stimuli (In Alphabetic Order)	Receptors	Sources, Receptors by which Expressed	Comments
Histamine	Histamine receptors (H_1R to H_4R)	Sensory fibers	In humans, histamine induces itch by stimulating specific sensory fibers, whereas H_1 (and to a lesser extent H_2) antagonists reduce itch in numerous clinical trials. In mice, H_3 antagonists induce scratching behavior, whereas H_1 and H_4 antagonists effectively suppress pruritus.
Proteases, kallikreins, tryptase, trypsins, cathepsins, (MMP1)	Partly proteinase-activated receptors (PARs), tryptic enzymes	Keratinocytes, endothelial cells, mast cells, platelets	Massive itch behavior in mice overexpressing epidermal kallikrein-7. Potential role of other kallikreins. Chymase degrades pruritic and antipruritic peptides. Tryptase, trypsin and cathepsin S induce inflammation and itch by a neurogenic mechanism via PAR-2. Microbial proteases may induce itch and inflammation via PAR-2. PAR1 and PAR4 involved in pain.
Kinins	Bradykinin receptors (B1R, B2R)	Endothelial cells, immunocytes	Bradykinin induces pain rather than pruritus. B2R antagonists reduce itch.
Leukotriene B_4	Leukotriene receptors	Sensory nerves fibers, keratinocytes	Leukotriene B_4 induces itch and is also involved in the substance P- and nociceptin-mediated induction of itch.
Neurokinin A (NKA) and substance P (SP)	Tachykinin (neurokinin) receptors (NKRs)	Sensory nerve fibers	NKA: upregulates keratinocyte nerve growth factor expression. SP: at low (physiologically relevant) concentrations, primes mast cells. Mediates release of TNF-α, histamine, leukotriene B_4, and prostaglandins from mast cells (agents involved in pruritus and burning).
Nerve growth factor (NGF), brain-derived neurotrophic factor (BDNF), neurotrophins (NT-3, NT-4)	Specific receptors TrkA: NGF TrkB: NT-4, BDNF TrkC: NT-3	Keratinocytes, mast cells, fibroblasts, eosinophils	NGF levels enhanced in atopic dermatitis. Induces tryptase release from mast cells. Inducible by histamine. TrkA: enhanced in keratinocytes during inflammation. NT-4: enhanced in atopic dermatitis and induces sprouting of sensory nerves. BDNF: increases eosinophil chemotaxis levels in atopic dermatitis and inhibits apoptosis. Neurotrophins sensitize receptive nerve endings and upregulate neuronal neuropeptides and TRPV1.
Opioids	μ, κ, δ opioid receptors (partly receptor-independent cell activation)	Nerves, keratinocytes	Antipruritic effect of μ-opioid antagonists (central effect) and κ-opioid agonists (spinal cord level). Opioid agonists do not provoke itch on injection or intradermal application. μ-Opioid receptor upregulated in atopic dermatitis.
Pituitary adenylate cyclase-activating polypeptide (PACAP) and vasoactive intestinal peptide (VIP)	VPAC receptors	Autonomic and sensory nerve fibers, lymphocytes, dermal endothelial cells, Merkel cells	PACAP: involved in flush, vasodilation, pain, neurodegeneration. Induces release of histamine from mast cells. VIP: Histamine release from mast cells, allodynia (no allodynia in atopic dermatitis) intensifies ACh-induced itch in atopic dermatitis patients (together with ACh).
Prostaglandins	Prostanoid (P) receptors	Sensory nerve fibers, keratinocytes	Prostaglandin E_2 induces itch sensitization in humans but not in mice. Prostaglandin D_2 reduces immunoglobulin E-mediated scratching in mice. Thromboxane A2 induces itch in mice.

ATP = adenosine triphosphate; IL = interleukin; TNF-α = tumor necrosis factor-α; VEGF = vascular endothelial growth factor.

TABLE 102-2
Role of Nerves in Inflammation

Neuromediator	Receptor	Source	Target Cells/Function
Acetylcholine	Nicotinergic and muscarinergic acetylcholine receptors	Autonomic cholinergic nerves, keratinocytes, lymphocytes, melanocytes	Innervation of sweat glands and arteriovenous anastomoses; keratinocyte and lymphocyte differentiation, proliferation, adhesion, migration. α_7-Nicotinergic receptor modulates keratinocyte function, modulates skin microcirculation; involved in atopic dermatitis.
Adenosine, ATP	Purinergic receptors	Nerves, keratinocytes, endothelial cells, immune cells	Involved in pain and hypernociception; neuronal cell death; involved in vasoregulation and immune response (cytokine release, cell adhesion molecules).
Catecholamine, noradrenaline	Adrenergic receptors	Autonomic adrenergic nerves, keratinocytes, melanocytes	Innervation of blood vessels, erector pili muscles; pain transmission; regulation of activity in natural killer cells and monocytes; induction of apoptosis in lymphocytes. Regulate dendritic cell function. β-Adrenergic-induced inhibition of keratinocyte migration.
CGRP			Involved in sweating.
Galanin and galanin-like peptides	Galanin receptors (GPCRs)	Sensory nerves	Inhibit inflammatory edema by reduction of microvascular blood flow via Gal3R.
Substance P	Tachykinin (neurokinin) receptor	Sensory nerve fibers, keratinocytes (inducible)	Mediation of skin edema, pruritus; upregulation of cell adhesion molecule expression on keratinocytes and endothelial cells; induction of release of IL-8, TNF-α, histamine, tryptase, leukotriene B_4, prostaglandin D_2; regulation of sebaceous glands; involved in inflammatory pain, contact dermatitis, immunomodulation, tumorigenesis and metastasis. Released by proteinase-activated receptor 2 (PAR-2) agonists.
Neurokinin A	Tachykinin (neurokinin) receptor	Sensory nerve fibers	Upregulation of keratinocyte nerve growth factor expression.
Vasoactive intestinal peptide	VPAC receptors	Sensory nerve fibers, Merkel cells	Sweat secretion, vasodilation; proliferation, migration of keratinocytes; histamine release from mast cells. Downregulation of VPAC2 receptor in mast cells in atopic dermatitis.
Pituitary adenylate cyclase-activating polypeptide	VPAC receptors	Autonomic and sensory nerve fibers, lymphocytes, dermal endothelial cells	Vasodilatation, immunomodulation; effect on T cells and macrophages; modulation of mast cell function; inhibition of antigen-induced apoptosis of mature T lymphocytes; downregulation of proinflammatory cytokines and chemokines in T cells; upregulation of cytokines and cell adhesion molecules in dermal microvascular endothelial cells; nociception.
Calcitonin gene-related peptide (CGRP)	CGRP receptors	Sensory nerve fibers	Keratinocyte and endothelial cell proliferation; stimulation of cytokine production. Increased CGRP nerves in atopic dermatitis and nummular eczema; released by PAR-2 stimulation.
Pro-opiomelanocortin (POMC)	Melanocortin receptors	Melanocytes, keratinocytes, endothelial cells, Langerhans cells, mast cells, fibroblasts, monocytes, macrophages	Antagonism of effects of proinflammatory cytokines (IL-17α, IL-1β, IL-6, TNF-α, endotoxins); upregulation of IL-10; induction of release of histamine from mast cells; inhibition of nuclear factor κ B. Thioredoxin regulates *POMC* genes. MSH-induced exocytosis from melanosomes. Melanocortin 1 receptor expressed on human keratinocytes. Antioxidative and cytoprotective.

IL = interleukin; MSH = melanocyte-stimulating hormone; TNF-α = tumor necrosis factor-α.

pain and pruritus on the spinal cord level. Moreover, gastrin-releasing peptide (bombesin) released to the central nerve endings in the spinal cord activates the gastrin-releasing peptide receptor (GRPR) on postsynaptic spinal neurons, thereby regulating selectively itch transduction but not pain.[15,16] Together, these data implicate the spinal cord as an important regulator of skin–nervous system interactions as observed during inflammation, pruritic diseases, and pain, and may be a target for future therapies.

ANATOMY AND PHYSIOLOGY OF THE SKIN NERVOUS SYSTEM

SENSORY NERVES

Most nerve fibers are found in the middermis and the papillary dermis. Region-specific differences can be observed with respect to the mucocutaneous border, glabrous skin, and hairy skin.[17] In the epidermis, sensory nerves are linked to keratinocytes, melanocytes, Langerhans cells (LC), and Merkel cells. Cutaneous nerve fibers are principally sensory, with an additional complement of autonomic nerve fibers.[18,19] In contrast to sensory nerves, autonomic nerves never innervate the epidermis in mammals. Sensory nerves innervate the epidermis and dermis as well as the subcutaneous fatty tissue[20–22] (see eFig. 102-0.1 in online edition).

Sensory nerves are categorized into two groups: (1) the epidermal and (2) the dermal skin nerve organs. The epidermal skin nerve organs consist of free nerve endings or nerve organs (e.g., Merkel cells). In the dermis, there are free sensory nerve endings, the hair nervous network (Pinkus discs), and the encapsulated endings [Ruffini, Meissner, Krause, and Vater–Pacini (vibration) corpuscles, and mucocutaneous end organ]. These can be subdivided into four groups: (1) A-α fibers (12–22 nm) are highly myelinated, show a fast conduction velocity (70–120 m/second), and are associated with muscular spindles and tendon organs. (2) A-β fibers are moderately myelinated (6–12 µm) and innervate touch receptors. (3) A-δ fibers have a thin myelin sheath (1–5 µm), show an intermediate conduction velocity (4–30 m/second), and are generally polymodal. (4) The slow-conducting C fibers (0.5–2.0 m/second) are unmyelinated and thin (0.2–1.5 µm) (nociceptors). A-β and A-δ fibers are mostly mechanically sensitive afferents (type I) localized on hairy and glabrous skin and show a long latency to heat. A subpopulation of A-δ fibers on hairy skin are mechanically insensitive (type II). A-δ fibers constitute approximately 80% of primary sensory nerves sprouting from DRG, whereas C fibers make up approximately 20% of the primary afferents.[23,24]

C-fibers are either polymodal nociceptors, which can respond to chemical (c^+), temperature changes (h^+) or mechanical (m^+) stimuli, or more specialized, which only respond to a combination ($C\text{-}c^+h^+m^-$) or a single stimulus ($C\text{-}c^-h^-m^+$). Among human peripheral nerves, 45% of the cutaneous afferent nerves belong to a subtype of sensory nerves that are both mechano- and heat-responsive C-fibers ($C\text{-}c^-m^+h^+$).[25] However, 13% of these nerves are only mechanosensitive ($C\text{-}m^+$), 6% only heat sensitive ($C\text{-}h^+$), 24% are neither heat nor mechanoresponsive ($C\text{-}m^-h^-$), and approximately 12% are of sympathetic (cholinergic) origin. Fifty-eight percent of $C\text{-}m^+h^+$ respond to mustard oil, whereas 30% of $C\text{-}m^+$ or ($C\text{-}m^-h^-$) do so indicating the existence of chemosensitive fibers among the other subtypes.[25]

Sensory nerves percept cutaneous stimuli such as warmth, cold, or touch. The nerves for warmth are predominantly unmyelinated C-fibers, a subpopulation of A-δ fibers respond to gentle cooling, whereas selective C-fibers become activated during noxious cold. Many subtypes of cells respond to touch and play an important role in mechanically induced pain. Thus, our body system has designed less selective as well as highly specialized nociceptors in order to guarantee body integrity and survival.[26]

A specific receptor distribution on these different sensory nerve subtypes appears to be important for the various functions (temperature, chemical, mechanical) and the sensations, which may derive thereof (prickling, stinging, burning, pain, itch). For example, mechanoreceptors exclusively express the T-type calcium channel Ca(v)3.2 in the dorsal root ganglion of D-hair receptors. The sodium channels Nav1.8 (SNS/PN3) and Nav1.9 (SNS/SNS2) are expressed by both peptidergic as well as nonpeptidergic $IB4^+$ (isolectin B4 from Griffonia simplicifolia) neurons and have been shown to be critically involved in certain subtypes of pain.[27] Only certain small-diameter primary afferents express the transient receptor potential vanilloid-1 (TRPV1) receptor which is critically involved in heat sensation.[28] Only nonpeptidergic (poor peptidergic) sensory fibers express the purinergic P2×3 receptor. Exogenous factors like trauma, UV-radiation, temperature changes, microbial agents, toxins, or allergens, as well as endogenous inflammatory triggers such as pH changes or stress hormone responses are able to stimulate the activation and/or sensitization of certain sensory nerves. The cellular events that transmit a stimulus (e.g., UV radiation) to a certain response (burning pain) via activation of a certain pathway (activation of pain fibers but not itch fibers and vice versa) are only poorly understood.[29,30]

AUTONOMIC NERVES

Compared to sensory nerves, autonomic nerves represent only a minority of cutaneous nerve fibers. In human skin, autonomic nerve fibers are derived almost completely from sympathetic (cholinergic) and rarely from parasympathetic (also cholinergic) neurons.[31] The distribution of autonomic nerves is restricted to the dermis, where they innervate blood vessels, arteriovenous anastomoses, lymphatic vessels, erector pili muscles, eccrine glands, apocrine glands, and hair follicles.[32]

Postganglionic autonomic nerves in the skin predominantly generate acetylcholine, although observations have revealed an additional role for neuropeptides. For example, neuropeptide Y (NPY)

and atrial natriuretic peptide[33] are expressed solely by autonomic nerve fibers.[34]

The cutaneous autonomic nervous system adjusts sweat gland function, thereby regulating body temperature, and modulates water and electrolyte balance in various organs. Under pathophysiologic conditions, autonomic nerves are involved in hyperhidrosis or hypohidrosis, congenital sensory neuropathy type IV, progressive segmental hypohidrosis, diabetic neuropathy, syringomyelia, lepra, and dysfunction after sympathectomy.[35–38]

Autonomic nerves exert their effects mainly by releasing classical neurotransmitters (noradrenaline, acetylcholine) or—to a lesser extent—certain neuropeptides like vasoactive intestinal peptide (VIP). In contrast, primary afferent (sensory) nerves release different classes of molecules such as neuropeptides, prostanoids, or nitric oxide (NO).[1]

Autonomic nerve fibers are crucially involved in the regulation of vascular effects in the skin. Sympathetic nerve fibers release noradrenalin and/or NPY to innervate arterioles, arteriovenous anastomoses, and venous sinusoids, which results in vasoconstriction, whereas parasympathetic nerves mediate vasodilation through activation of venous sinusoids by the release of acetylcholine and vasoactive intestinal peptide (VIP)/peptide histidine methionine[39–42] (eTable 102-0.1 and Table 102-1 in online edition). Of note, C-fiber nociceptors can develop responsiveness to adrenergic neurotransmitters by upregulating the corresponding receptors during trauma or inflammation. Thus, the sensory and the autonomic nervous systems communicate and interact in disease on the molecular level.

Small arteries, arterioles, and the arteriovenous anastomoses are richly supplied with noradrenergic nerves.[43] Previous studies suggested that this system is cholinergic and involves a cotransmitter, possibly VIP.[44] Cholinergic sympathetic nerves are also known to stimulate eccrine sweat glands via muscarinic receptors,[31] whereas higher concentrations of acetylcholine induce an axon-reflex flare mediated via nicotinic receptors. In the vasoconstrictor system, the transmitter appears to be norepinephrine along with one or more cotransmitters. The best-characterized sympathetic cotransmitters that participate in the regulation of blood flow include adenosine triphosphate[45] and NPY.[46]

Interestingly, even without intact sensory or autonomic function the skin reveals a nonneurogenic vasodilator and nonneurogenic vasoconstriction response. The mechanisms for the nonneurogenic vasodilator and vasoconstrictor components of the response to direct cooling are poorly understood but may involve several pathways including cholinergic stimulation, NO and neuropeptides.[5,47]

BIOCHEMISTRY AND CELL BIOLOGY OF THE CUTANEOUS NERVOUS SYSTEM

As outlined above, many subtypes of nerve fibers exist to cover the multiple functions of the skin nervous system to maintain or reestablish body integrity. This chapter focuses on the role of neuropeptides, TRP channels, and cytokines in the skin (Table 102-1).

SKIN NEUROPEPTIDES AND NEUROPEPTIDE RECEPTORS

Classically, neuropeptides range from as few as 4 to more than 40 amino acids. Because they are released by nerve endings and modulate various biologic functions, they were originally defined as neuropeptides. Later, these molecules were also found to be generated by nonneuronal cells (e.g., epithelial cells and immune cells). Therefore, the designation *regulatory peptide* may be more appropriate.[48] These peptides mainly activate members of the G protein-coupled receptor superfamily with seven transmembrane domains. To date more than 20 neuropeptides, including SP, neurokinin A (NKA), neurotensin, CGRP, VIP, pituitary adenylate cyclase-activating polypeptide (PACAP), peptide histidine-isoleucinamide, NPY, somatostatin (SST), dynorphin, β-endorphin, enkephalin, galanin, secretoneurin, melanocyte-stimulating hormone (MSH), thyroid-stimulating hormone (TSH), or corticotropin-releasing hormone (CRH), have been detected in the skin.[1,2,49] Table 102-1 lists the neuropeptides, ion channels, and other molecules like NO involved in pruritus, pain, and inflammation. eFigure 102-0.1 in online edition and Fig. 102-1 depict the basic concepts and knowledge concerning these neuropeptides.

Various neuropeptides are produced and released by a subpopulation of unmyelinated afferent neurons (C fibers) known as *C-polymodal nociceptors*. In addition, it has been shown that cutaneous cells themselves, such as keratinocytes, microvascular endothelial cells, Merkel cells, fibroblasts, and leukocytes, are capable of releasing regulatory peptides under physiologic or pathophysiologic circumstances.

In the skin, nerves are necessarily closely linked to the vascular system. Dermal blood vessels are tightly associated with sensory and autonomic nerve fibers, they also synthesize neuropeptides and they express receptors for neuropeptides. Arterial sections of arteriovenous anastomoses, precapillary sphincters of metarterioles, arteries, and capillaries appear to be the most intensely innervated regions. Large increases in skin blood flow provide the necessary augmentation of convective heat loss during environmental heat exposure and/or exercise, and the reflex cutaneous vasoconstriction is key to preventing excessive heat dissipation during cold exposure. Sensory nerves are important for vasodilation and neuropeptides from sympathetic neurons such as NPY mediate vasoconstriction, which supports an important role for neuropeptides in thermoregulation, blood flow during inflammation or tumorigenesis, as well as activation of endothelial cells and smooth muscle cells. Both endothelial cells and smooth muscle cells respond to neuronal modulation in inflammatory diseases such as atopic dermatitis and rosacea and during host defense, neovascularization, and wound healing. Sensory as well as autonomic nerves modulate the function of sweat glands, sebaceous glands, apocrine glands, and

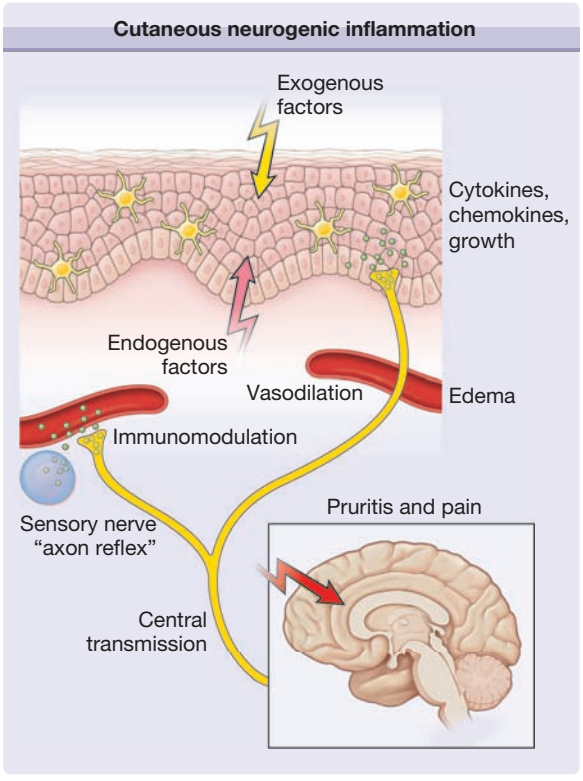

Figure 102-1 Cutaneous neurogenic inflammation. Exogenous trigger factors (heat, scratching, irritants, allergens, ultraviolet light, microbiologic agents) or endogenous trigger factors (pH changes, cytokines, kinins, histamine, proteases, neurotransmitters, hormones, stress) may directly or indirectly stimulate nerve endings from primary afferent neurons. Signals are transmitted to the central nervous system and thereby affect regions involved in pruritus, pain, somatosensory reactions (scratching), and probably emotional responses. In addition, peripheral nerve endings stimulate neighboring afferent nerve fibers in the dermis and epidermis in a process known as *axon reflex*. Stimulated release of neuropeptides results in vascular responses (triple response of Lewis, erythema by vasodilation, and edema by plasma extravasation), modulation of immunocyte function (e.g., mediator release from mast cells), and regulation of mediator release (cytokines, chemokines, growth factors) from keratinocytes and Langerhans cells.

the pilosebaceous unit. In the following, we emphasize the biological role of certain neuromediators and neurohormones in more detail.

CYTOKINES AND CHEMOKINES FROM A NEURONAL PERSPECTIVE

Cytokines are capable of inducing pruritus, and, conversely, cytokine inhibitors have been demonstrated to reduce neurogenic inflammation, pain, and pruritus. Thus, cytokines and chemokines may communicate with sensory nerves via high-affinity receptors[269–274] (see eFig. 102-0.1 in online edition and Table 102-1).

"Neurophilic" cytokines include IL-1, IL-6, IL-8, and IL-31.[48,52] Of note, transgenic mice overexpressing IL-31 released by T cells and macrophages developed a chronic inflammatory skin disease characterized by a T-cell infiltrate and pruritus, similar to atopic dermatitis in humans. IL-31 activates the IL-31 receptor (IL-31R), a heterodimeric receptor composed of the IL-31R A subunit and the oncostatin M receptor subunit. Whether IL-31 exerts its pruritic effects via direct activation of IL-31R on sensory nerves or indirectly (e.g., via keratinocytes) is currently unknown. The finding that keratinocytes express IL-31R suggests that IL-31 may induce pruritus through the induction of a yet unknown keratinocyte-derived mediator that subsequently activates unmyelinated C fibers in the skin. Therefore, one may speculate that IL-31 is upregulated in pruritic forms of cutaneous inflammation.[275,276] These findings were confirmed in mice: the expression of cutaneous IL-31 messenger RNA was significantly higher in NC/Nga mice with scratching behavior than in NC/Nga mice without scratching behavior.[277] Therefore, IL-31 may participate in causing an itch sensation and promoting scratching behavior.[278,279] In addition, IL-31 may be also a link in the communication between eosinophils and keratinocytes in pruritic inflammatory skin diseases.[280–282] Primary cutaneous amyloidosis (PCA) is an itchy skin disorder associated with amyloid deposits in the superficial dermis. A gene mutation has been recently described in PCA, a pruritic skin disorder associated with amyloid deposits in the superficial dermis.[283] Together, IL-31 may serve as a link between the immune and neural systems by regulating inflammation as well as itch. For this reason, IL-31 and the IL-31R are promising targets for the treatment of inflammatory and itchy dermatoses such as atopic dermatitis, urticaria, and other genetically associated pruritic diseases. Various antagonists such as the OSMR-L-GPL fusion protein are currently under investigation.[284]

ROLE OF THE NERVOUS SYSTEM IN SKIN PATHOPHYSIOLOGY

A number of human clinical diseases or symptoms, appear to have a significant neurogenic component, including atopic dermatitis, prurigo, pruritus-associated diseases, psoriasis, rosacea, urticaria, herpes zoster, or inflammatory arthritis (see Table 102-0.1).[1] The peripheral nervous system also modulates inflammatory responses or symptoms in other organs, such as eye inflammation, asthma, inflammatory bowel syndrome, and transmits pain. Moreover, neuronal mediators play a role during wound healing by regulating growth, proliferation, and angiogenesis.

The ability of neuropeptides to activate human mast cells and induce urticaria has been appreciated for a number of years.[285] For example, chronic idiopathic urticaria and, to a lesser extent, pressure urticaria showed enhanced SP- and CGRP-induced wheal-and-flare reactions (see Fig. 102-1). Certain transient receptor potential ion channels are expressed by sensory nerves as well as by mast cells that can be activated by trigger factors of urticaria like heat, cold, pressure, or food ingredients.

A neurogenic component in the pathophysiology of psoriasis is suggested based on clinical obser-

vation (e.g., stress induction) and is supported by experimental studies.[286–289] Data suggest a role for NGF as a mediator of inflammatory responses in psoriasis, although its significance remains to be established.[290]

In acute as well as lichenified lesions of atopic dermatitis, increased staining of cutaneous nerves or concentrations of neuropeptides has been observed.[80,139,291–297] Also, characteristics of the triple response (erythema, wheal, flare) of neurogenic inflammation as well as pruritus have been observed after injection of neuropeptides into human skin.[298,299] The lesions of patients with atopic dermatitis show enhanced concentrations of mast cell tryptase, a ligand for the proteinase-activated receptor-2 (PAR-2), which is upregulated in atopic dermatitis and mediates pruritus, inflammation, and upregulation of intercellular cell adhesion molecule 1 or nuclear factor κB.[300–303] A role for proopiomelanocortin peptides in the pathogenesis of atopic dermatitis is supported by the in vitro observation that α-MSH modulates immunoglobulin E production and the finding of increased levels of proopiomelanocortin peptides in the skin of patients with atopic dermatitis.[304,305] Some studies also suggest that NTs such as NGF or NT-3 may participate in the pathophysiology of atopic dermatitis (Table 102-2).[306]

Neuropeptides such as CGRP, PACAP, or α-MSH, are obviously involved in the regulation of epidermal antigen presentation.[307–310] Also, pretreatment of the skin with capsaicin enhances contact hypersensitivity (CHS) at the site of treatment. It has been suggested that capsaicin-sensitive neurons modulate this reaction via the release of neuropeptides.[114,311] Studies also indicate that SP agonists can prevent impaired CHS and tolerance after UVB irradiation.[191] CGRP significantly inhibited antigen presentation to antigen-specific T cells.[114,312] The effect of CGRP on murine LCs is probably mediated by a specific CGRP receptor, which leads to intracellular increase in cyclic adenosine monophosphate.[113] Accordingly, IL-10 can be upregulated by CGRP.[313] α-MSH is one of the most powerful neurohormones in terms of its ability to modify CHS reactions.[314–316] PACAP is also able to inhibit CHS reactions.[310]

The skin nervous system also plays a crucial role during wound healing and impaired wound healing processes. Released neuropeptides participate in inflammation, cell proliferation, cytokine, and growth factor production, and neovascularization.[317,318] Of note, delayed wound healing occurred in animal models after surgical resection of cutaneous nerves.[319–323] For instance, decreased concentrations of SP, SST, and CGRP were observed in wounds in rats[324]; elevated levels can be observed in other wound models.[321,324] CGRP promotes proliferation and migration of human keratinocytes[325–327] and stimulates proliferation of human dermal endothelial cells.[328] VIP has both inhibitory and stimulatory effects on the proliferation of keratinocytes.[325,326,329] Angiotensin II appears to influence tissue repair via activation of the angiotensin I receptor in fibroblasts, which leads to collagen remodeling, collagen gel contraction, and upregulation of collagen-binding integrins in vitro.[330] NGF induces human skin and lung fibroblast migration but not proliferation.[331] In a mouse model, it could be observed that NGF accelerated the rate of wound healing.[332] These findings have encouraged successful treatment of leg ulcers in humans with topical NGF.[333,334] Parathyroid hormone-related protein expression is temporarily upregulated in migratory keratinocytes, myofibroblasts, and infiltrating macrophages in guinea pig skin, although topical application of a parathyroid hormone-related protein agonist did not change the healing rate or morphology in these wounds.[335,336]

NEP expression appears to be both increased and redistributed in the wound environment during wound healing, which indicates a role for neuropeptide-degrading enzymes in this process.[337] In normal skin, NEP immunoreactivity was restricted to the basal layer, whereas during wound healing, NEP was also detected in the suprabasal layer of human skin. Future studies using transgenic and knockout animals, in which certain components of the neurologic system are overexpressed or deleted by homologous recombination, may make it possible to examine the role of the cutaneous nervous system in normal and delayed wound healing.[338]

Pruritus is one of the most frequent symptoms of skin diseases and derives from stimulation of sensory nerve endings, spinal cord modulation, or dysfunction of certain areas in the CNS (see Table 102-0.1).[48,65,222,339] Polymodal C fibers, stimulated by chemicals or heat, transmit signals to the spinal cord and CNS, which results in itching. Accordingly, both the peripheral cutaneous system and the CNS coordinate the sensation of itch, which leads to the autonomic reflex of scratching. Histamine is the best-studied, albeit definitely not the only, mediator of pruritus. New histamine receptors (e.g., histamine receptor-3, histamine receptor-4) have now been cloned; their role in human itch is poorly understood.[212] Another important mediator of pruritus in patients with atopic dermatitis may be IL-31 (see Table 102-1, eFig. 102-0.1 in online edition).[275,279,340,341] In notalgia paresthetica, a neuropathy characterized by pruritus, pain, and hyperalgesia, immunostaining for several neuropeptides revealed that affected areas had a significant increase in intradermal nerve fibers as well as epidermal dendritic cells, which suggests that sensory nerve fibers are involved in the pathogenesis of this disease. Agents such as capsaicin that deplete neuropeptides from sensory neurons have been shown to have a therapeutic effect in diseases associated with pruritus and pain. Other neuromediators such as opioids seem to be involved in the pathophysiology of cholestatic pruritus.[342,343] Cholestatic pruritus can be significantly reduced by application of an antagonist to 5-hydroxytryptamine.[344] Like opioids, endogenous CB appear to be implicated in itching.[48,65,261,345] Under inflammatory conditions,[346] CB are capable of activating and sensitizing the TRPV1 receptor.[347,348] Cannabinoid receptors also induce release of analgesic β-endorphin from murine keratinocytes.[149] Aprepitant, a selective NK1R antagonist, which has been recently demonstrated to be beneficial for the treatment of pruritus and prurigo,[75] may also be beneficial for the treatment of other pruritic skin diseases.

SUMMARY AND PERSPECTIVES

In many ways, the nervous system modulates (and eventually "manipulates") the function of the skin, which under physiological conditions leads to control of skin homeostasis. However, under pathophysiological conditions, neuromediators can either aggravate (proinflammatory) or ameliorate (anti-inflammatory) disease development. The bidirectional interaction of the skin with the peripheral nervous system as well as the CNS plays a crucial role in skin homeostasis and disease states, as seen for inflammation, pain, or pruritus. Recent discoveries have increased our knowledge about the molecular mechanisms regulating the function of neuromediators, their receptors, and controlling enzymes. The development of modern techniques including proteomics, genomics, metabolics, and molecular imaging of neuronal structures offer exciting insights into the complex network between skin, nerves, and immune system during inflammation, tumorigenesis, pruritus, or chronic pain. Various applications like TRPV1 channel agonists/antagonists or neuropeptide receptor antagonists are currently in clinical or preclinical trials for the treatment of various skin diseases including atopic dermatitis, rosacea, viral infection, pruritus, or pain. Using novel technical approaches and understanding new pathways of neuro-immuno-endocrine communication, it will be possible to learn how neuromedicine can contribute to treat skin diseases and symptoms such as inflammation, cancer, pigmentation disorders, allergic reactions, endocrine disregulation, painful skin diseases, or pruritic diseases.

KEY REFERENCES

Full reference list available at www.DIGM8.com

DVD contains references and additional content

1. Roosterman D et al: Neuronal control of skin function: The skin as a neuroimmunoendocrine organ. *Physiol Rev* **86**:1309-1379, 2006
26. Basbaum AI et al: Cellular and molecular mechanisms of pain. *Cell* **139**:267-284, 2009
28. Caterina MJ et al: The capsaicin receptor: A heat-activated ion channel in the pain pathway [see comments]. *Nature* **389**:816-824, 1997
30. Slominski A et al: Corticotropin releasing hormone and proopiomelanocortin involvement in the cutaneous response to stress. *Physiol Rev* **80**:979-1020, 2000
52. Steinhoff M et al: Modern aspects of cutaneous neurogenic inflammation. *Arch Dermatol* **139**:1479-1488, 2003
65. Paus R et al: Frontiers in pruritus research: Scratching the brain for more effective itch therapy. *J Clin Invest* **116**:1174-1186, 2006
168. Brzoska T et al: Alpha-melanocyte-stimulating hormone and related tripeptides: Biochemistry, antiinflammatory and protective effects in vitro and in vivo, and future perspectives for the treatment of immune-mediated inflammatory diseases. *Endocr Rev* **29**:581-602, 2008
303. Buddenkotte J et al: Agonists of proteinase-activated receptor-2 stimulate upregulation of intercellular cell adhesion molecule-1 in primary human keratinocytes via activation of NF-kappa B. *J Invest Dermatol* **124**:38-45, 2005
341. Homey B et al: Cytokines and chemokines orchestrate atopic skin inflammation. *J Allergy Clin Immunol* **118**:178-189, 2006

Chapter 103 :: Pathophysiology and Clinical Aspects of Pruritus

:: Gil Yosipovitch & Tejesh S. Patel

PRURITUS AT A GLANCE

- Pruritus is the predominant symptom of skin disease.
- May originate in the skin or nervous system.
- Clinical classification of itch includes:
  - pruritus on diseased (inflamed) skin
  - pruritus on nondiseased (noninflamed) skin
  - pruritus presenting with severe chronic secondary scratch lesions
- Chronic itch consists of multidimensional phenomena including sensory, emotional, and cognitive components.
- Central and peripheral mediators in humans include histamine, proteinases, opiates, substance P, nerve growth factor, interleukins, and prostaglandins.
- Treatment should address the multifactorial nature of pruritus including central pathways and peripheral mediators.

INTRODUCTION

Pruritus (itching) is the predominant symptom of skin disease and can best be defined as a sensation that leads to a desire to scratch. All human beings experience this sensation in the course of their lifetime; therefore, it is important to make a distinction between acute itch, which is of a limited period of time ranging from seconds to a week such as the itch related to acute insect bite reaction, and chronic itch, which lasts for months and is the focus of this chapter.[1] Chronic itch is a multidimensional phenomenon consisting of sensory, emotional, and cognitive components. In most cases, chronic itch results from interaction of the brain-skin axis. Although itch and pain are separate and distinct sensations, itch has many similarities to pain.[2,3] Both itch and pain are unpleasant sensory experiences, follow similar neural pathways, and can severely impair patients' quality of life. However, the behavioral response patterns differ—pain elicits a reflex withdrawal, whereas itch leads to a scratch reflex.

The limited understanding of itch results from the subjective nature of itching, the absence of specific and sensitive investigational methods to study the neuropathophysiology and molecular basis of itch in humans, the lack of convincing animal models and incomplete knowledge of pharmacologic mediators of pruritus. However, significant progress has been made in the past decade with the discovery of new neural pathways (both histaminergic and nonhistaminergic) as well as novel receptors in humans and animals. The concept that itch is transmitted to the central nervous system (CNS) and processed in the brain should lead to new approaches to antipruritic therapy.[4]

EPIDEMIOLOGY

Itch is a symptom rather than a specific disease entity; therefore, epidemiologic data for itch are limited. Nevertheless, itch has been found to be the dominant skin complaint among all age groups.[5] In a large cross-sectional study in Norway, the prevalence of pruritus was approximately 8% among adults.[6] Itch is a primary symptom in a diverse range of skin diseases as well as in systemic diseases. The prevalence of pruritus in different dermatologic and systemic diseases is outlined in Tables 103-1 and 103-2.

TABLE 103-1
Prevalence of Itch in Skin Disorders and Infectious Skin Diseases

Cause	Estimated Prevalence of Pruritus
Skin disease	
Atopic dermatitis	100%
Contact dermatitis	Unknown
Poison ivy	Unknown
Elderly idiopathic xerosis	30%–60%[7]
Urticaria	97%
Extensive psoriasis	80%
Pityriasis rosea	Unknown
Seborrheic dermatitis	Unknown
Neurodermatitis: lichen simplex chronicus, prurigo nodularis, lichen amyloidosis	Unknown
Burns	67%–87%[8]
Pityriasis rubra pilaris	Unknown
Dermatitis herpetiformis	Unknown
Acne	50%–70%[9,10]
Linear immunoglobulin A disease	Unknown
Bullous pemphigoid	Unknown
Collagen disease	
Dermatomyositis	38%
Sjögren syndrome	Unknown
Scleroderma	45%[11]
Infection	
Varicella	Unknown
HIV disease	HIV-associated folliculitis in 25%–50% of HIV patients; nonspecific pruritic eruption in 11%–46% of HIV patients
Onchocerciasis	5%–67%[12]
Scabies	100% (except Norwegian scabies)[13]
Superficial fungal infections	Unknown

HIV = human immunodeficiency virus.
Adapted from Yosipovitch G: Epidemiology of itching in skin disease. In: *Itch: Basic Mechanisms and Therapy*, edited by G Yosipovitch et al: New York, Marcel Dekker, 2004, with permission.

ETIOLOGY AND PATHOGENESIS

Pruritus may originate in the skin or in the CNS. There is no single, definitive classification of pruritus. The International Forum for the Study of Itch (IFSI) has proposed a classification that distinguishes three clinical groups of patients as follows[14]:

Group I: Pruritus on diseased (inflamed) skin
Group II: Pruritus on nondiseased (noninflamed) skin
Group III: Pruritus presenting with severe chronic secondary scratch lesions, such as prurigo nodularis

The first group includes underlying dermatological diseases, while the second and third group includes patients with systemic diseases including diseases of pregnancy and drug-induced pruritus as well as neuropathic and psychiatric diseases. In some patients, more than one cause may account for pruritus (category "mixed") while in others no underlying disease can be identified (category "others").[14] It is also important to differentiate acute itch from chronic itch because therapies that provide transient itch relief often do not address the pathological processes underlying chronic itch.[1] Moreover, the biologic function of nerve fibers most probably differs in chronic itch than acute itch.

ITCH–SCRATCH CYCLE

Itch and scratching are interwoven together in both acute and chronic itch conditions. Phylogenetically,

TABLE 103-2
Prevalence of Pruritus in Systemic Disease

Disease	Estimated Prevalence of Pruritus
■ Chronic renal failure, end stage	25%–85%
■ Hepatic	
■ Cholestatic jaundice	20%–25%
■ Primary biliary cirrhosis	100%
■ Hepatitis C	4%
■ Cholestasis of pregnancy	Unknown
■ Hematopoietic	
■ Polycythemia vera	48%
■ Iron deficiency anemia	Unknown
■ Multiple myeloma	Unknown
■ Mastocytosis	Unknown
■ Hodgkin lymphoma	30%
■ Non-Hodgkin lymphoma	Unknown
■ Endocrine	
■ Hyperthyroidism	60%
■ Hypothyroidism	Unknown
■ Carcinoid syndrome	Unknown
■ Diabetes	11%
■ Anorexia nervosa	58%

itch is probably a mechanism for animals to remove parasites residing in the hairy skin. Scratching is also a behavioral response. A study in humans has shown that repetitive scratching activates the prefrontal cortex in particular, an area of the brain implicated in goal-directed and habit-learning systems.[15] It is thus possible that activity induced by scratching in the prefrontal cortex may serve to drive the compulsion to continue scratching and could also account for the highly rewarding aspects of scratching. Furthermore, the hedonic experience of scratching may be associated with release of endogenous opioids. Repetitive scratching in chronic conditions such as atopic dermatitis and psoriasis further damages the skin and causes secretion of neuropeptides and opiates that may further augment the vicious itch-scratch cycle (Fig. 103-1).

ALLOKNESIS: "ITCHY SKIN"

Alloknesis is a phenomenon in which a normally innocuous stimulus induces itch. For example, application of a fine brush to an itchy site induces itch. Alloknesis is analogous to the better-known allodynia (defined as pain due to stimuli, which does not normally provoke pain). This type of itch is mediated by mechanical mechanoreceptor units as well as an ongoing activity of afferent C nerve fibers and is considered a central neural sensitization response. Alloknesis is common in chronic atopic dermatitis; sweating or slight mechanical stimulation associated with wearing wool exacerbates itch. The exact role of central sensitization in pruritus associated with specific diseases is unknown.[3]

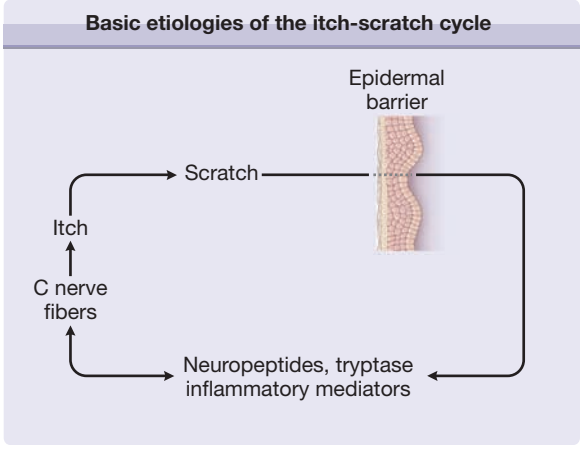

Figure 103-1 Basic etiologies of the itch-scratch cycle.

ITCH TRANSMISSION IN THE SKIN

The only peripheral tissues from which itch can be evoked are skin, mucous membranes, and cornea. Interestingly, the nerves in the deeper layer of the reticular dermis and subcutaneous fat do not transmit itch and inflammatory skin diseases affecting these areas, such as panniculitis, cause pain but not itch. Removal of the epidermis abolishes perception of pruritus, suggesting that pruritus receptor units are located predominantly within this layer.[16] We suspect that the epidermis acts as a receptor for itch, but a specific receptor has not yet been identified. Light microscope and ultrastructural studies of human skin have shown the existence of intraepidermal nerve fibers with "free" nonspecialized nerve endings extending to the stratum granulosum.[17] Many epidermal nerve fibers stain positively for neuropeptides implicated in itch transmission. It has recently been shown that Mrgprs, a family of G protein-coupled receptors expressed exclusively in peripheral sensory neurons, function as itch receptors.[18]

Keratinocytes express a variety of neural mediators and receptors, all of which appear to be involved in the itch sensation.[19] Mediators include opioids, proteases, substance P (SP), nerve growth factor (NGF), and neurotrophin 4 whereas receptors include μ- and κ-opioid receptors, proteinase activated receptor-2 (PAR-2), vanilloid receptors, tropomyosin-related kinase A (TRKA), transient receptor potential vanilloid (TRPV) ion channels, gastrin releasing peptide receptor, and cannabinoid receptors 1 and 2. Keratinocytes also have voltage-gated adenosine triphosphate channels and adenosine receptors similar to C nerve fibers. Because these channels have a role in pain,[20] these findings suggest that keratinocytes may act as itch receptors.

DEDICATED ITCH-TRANSMITTING C NERVE FIBERS

Significant advances in our understanding of itch neurophysiology have been achieved in the past decade.

Microneurography has helped to disprove the historic concept that pruritus and pain are simply responses of the same neurons to mild versus intense stimuli, respectively. Studies using electric field stimulation coupled with microneurography have identified individual histamine-sensitive C nerve fibers that transmit itch.[21] The C nerve fibers have exceptionally slow conduction velocity, unusually wide innervation territories, and represent no more than 5% of total C fibers. These neurons are sensitive to pruritogenic and thermal stimuli as well as capsaicin, but not mechanical stimuli. The co-responsiveness of this subset of C neurons to temperature change as well as pruritic stimuli is of interest because raising the temperature of skin lowers the threshold of receptors to pruritic stimuli[22] and most pruritic patients complain of aggravation of pruritus in a warm environment. In chronic itch, spontaneous activity in these C fibers occurs.[23] In contrast, the vast majority of C fibers are sensitive to mechanical and heat stimuli and are entirely insensitive to histamine.[24]

The existence of a subset of dedicated itch-transmitting C neurons receives further support from studies of spinal-cord pathways. Itch-transmitting primary afferent C neurons synapse with secondary transmission neurons that cross over to the contralateral spinothalamic tract and ascend to the thalamus. In the cat, microneurography identified lamina 1 neurons in the lateral spinothalamic tract that selectively responded to histamine, suggesting a central dedicated nerve pathway for itch.[25] Other C nerve fibers transmit itch as well. Mechanically induced itch is commonly observed clinically; for example, itch associated with contact with wool cannot be explained by histamine-sensitive nerve fibers. Moreover, in patients with chronic pruritus, electrical or painful stimuli can also induce itch.[26–28] Oral antihistamines are ineffective in the treatment of most types of itch, suggesting that nonhistamine-mediated fibers also play an important role. A separate nonhistaminergic itch processing pathway activated by cowhage (Mucuna pruriens) was discovered in peripheral nerve fibers of humans as well as in the spinothalamic tract in primates.[29,30] The active ingredient inducing itch by cowhage has been found to be a cystine protease which acts through PAR-2 and PAR-4.[31] Therefore, two parallel subpopulations of primary afferent C-fibers and spinothalamic tract neurons transmit itch in humans. Both of these pathways are most probably not itch specific since they also transmit burning sensations and respond to the algogen, capsaicin. In addition, gastrin-releasing peptide (GRP) receptor positive neurons were recently found to constitute a dedicated neuronal pathway for itch in the spinal cord of mice.[32] The role of these neurons and their interaction with both histaminergic and nonhistaminergic pathways in humans remains to be elucidated.

The perceived sensation of pruritus can vary greatly in quality. Patients may experience sensations of burning or pricking but the neurophysiologic and psychologic correlates of these differences have not yet been elucidated. Information obtained from itch questionnaires based on previously developed pain questionnaires has enabled us to better understand the different characteristics of itch.[7,33–35]

THE CENTRAL PROCESSING OF ITCH

The central processing of itch has been demonstrated using the neuroimaging techniques of positron emission tomography and functional magnetic resonance imaging in healthy humans and patients with atopic dematitis. In these studies, histamine-induced itch activated various brain areas implicated in sensory and motor function as well as emotion—reflective of the multidimensional aspects of this distressing symptom. A recent study showed that that the central processing of itch in atopic dermatitis is different from that of healthy subjects. The anterior and posterior cingulate cortex as well as the dorsal lateral prefrontal cortex, which are involved in emotions, reward, and memory of negative experiences were significantly activated in patients with atopic eczema but not in healthy subjects.[36] The activation of the precuneus, which is located in close proximity to the posterior cingulate cortex seems unique in itch and has rarely been reported in pain imaging. The precuneus is involved in episodic memory retrieval and could be associated with the affective components involved in itch.[36,37]

CLINICAL FINDINGS

HISTORY

It is of prime importance to determine whether the cause is related to a primary skin disease or systemic disease. Diseases such as skin dryness or scabies may exhibit few primary skin lesions; therefore, careful history and laboratory evaluation can be particularly important. It is important to differentiate between generalized pruritus and localized itch. Careful history, including a full drug history, and physical examination including lymph nodes, are the starting points. The history should take into account the multidimensional nature of itching and should include details of quality, distribution, and timing. Any patient referred with generalized pruritus in the setting of other family members with pruritus should be assumed to have scabies until proved otherwise—skin signs may be clinically inapparent, perhaps confined to a few small nodules on the genitalia. In addition, patients with localized pruritus, especially in a dermatomal distribution, that present with other sensory complaints such as a burning sensation, loss of sensation or increased pain should be evaluated carefully for neuropathic itch. Figure 103-2 is an algorithm showing the approach to a patient with pruritus.

CUTANEOUS LESIONS

Secondary skin lesions characteristic of pruritus include excoriations, lichenification, and hyper- or hypopigmentation. Lichenification results from continuous

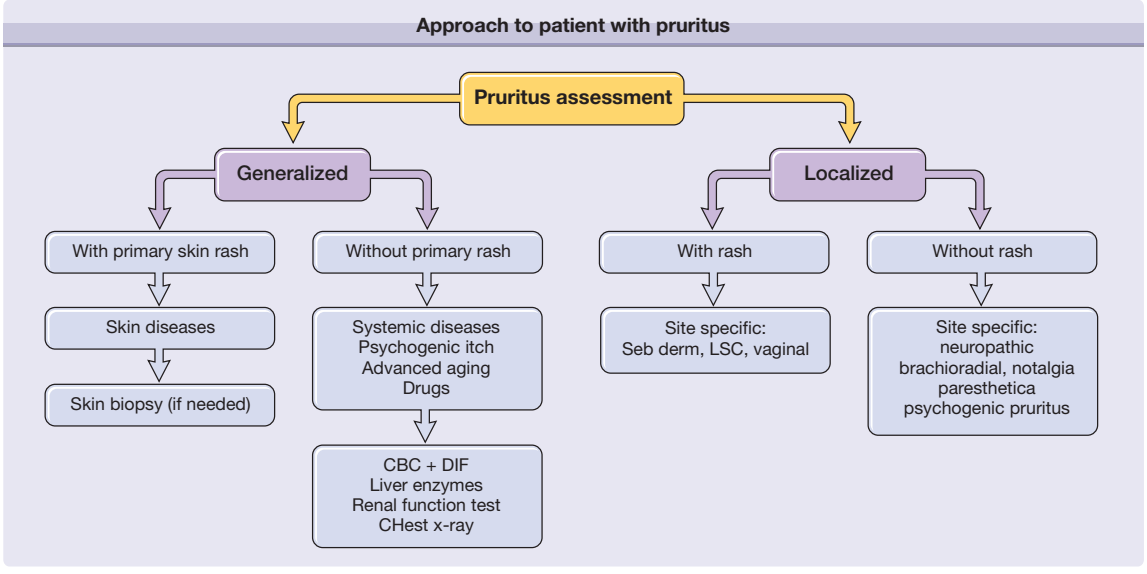

Figure 103-2 Approach to a patient with pruritus. CBC = complete blood cell count; DIF = differential; LSC = lichen simplex chronicus; Seb derm = seborrheic dermatitis.

rubbing or scratching and consists of well-developed, thickened plaques with marked accentuation of skin creases (see Chapter 14). Post-inflammatory hyperpigmentation or hypopigmentation is common in patients with skin phototypes 4 through 6 (see Chapter 75). Lichenified plaques are most commonly distributed in areas the patient can easily scratch or rub (i.e., nape of neck, below the elbow, ankle, buttock, and genitalia). The butterfly sign consists of normal-appearing skin in the middle of the back outlined by a butterfly pattern of contrasting hyperpigmentation in areas subjected to persistent scratching, resulting from the patient's inability to reach the middle of the back. Shiny fingernails may result from prolonged rubbing. Prurigo nodules are excoriated papules that form nodules in patients with chronic pruritus (see Chapter 15). In many cases, this type of itch is accompanied by a painful, burning sensation suggestive of a neuropathic component. Prurigo nodules are frequently associated with emotional stress and obsessive-compulsive disorder; however, they can be also be a manifestation of itch in patients with atopic dermatitis or chronic renal failure. Such nodules are usually distributed over extensor aspects of the limbs.

Some pruritic states have specific clinical patterns. Despite severe pruritus, chronic urticaria usually does not show secondary skin lesions associated with scratching. Neuropathic itch in disease entities, such as postherpetic neuralgia, brachioradial pruritus, and notalgia paresthetica, is typically associated with pain and burning sensation. Atopic dermatitis may also be associated with burning sensation after scratching.[89]

LABORATORY TESTS AND SPECIAL TESTS

Laboratory tests to be considered in the evaluation of generalized pruritus are outlined in Box 103-1. Secondary laboratory considerations may include stool examination for ova and parasites, screening for hepatitis B or C, plasma protein electrophoresis, and immunoelectrophoresis. A computed tomography scan of the chest and abdomen may be justifiable to help rule out lymphoma. A skin biopsy is not warranted and only useful to exclude clinically inapparent cutaneous mastocytosis, bullous pemphigoid or cutaneous T cell lymphoma.

DIFFERENTIAL DIAGNOSIS

(Box 103-2)

COMPLICATIONS

Pruritus can significantly impair patients' quality of life and have an effect on prognosis. Patients with chronic pruritus often have difficulty sleeping, difficulty concentrating, decreased sexual desire and sexual function, agitation, and depression.[7,90] In addition, eczematous

BOX 103-1 RECOMMENDED LABORATORY TESTS FOR INVESTIGATION OF PATIENTS WITH GENERALIZED PRURITUS

- Recommended
  - Complete blood cell count with differential
  - Chemistry profile: urea, creatinine, liver enzymes
  - Thyroid function tests
  - Chest radiograph
- Optoinal
  - Stool Examination for parasites
  - Human immunodeficiency virus testing with other associated symptoms and signs

BOX 103-2 DIFFERENTIAL DIAGNOSIS OF GENERALIZED PRURITUS WITHOUT PRIMARY SKIN DISEASE

- Chronic renal disease
- Cholestasis
- Hyperthyroidism
- Pruritus in hematologic disease and lymphoreticular malignancy
  - Hodgkin disease and non-Hodgkin lymphoma
  - Polycythemia vera
  - Myeloid and lymphatic leukemia
  - Myelodysplasia
  - Mastocytosis
- Solid malignant tumors (paraneoplastic manifestation)
- Human immunodeficiency virus-associated pruritus
- Itching in advanced age
- Aquagenic pruritus
- Itching as a manifestation of psychiatric disease
  - Delusions of parasitosis
  - Itch associated with obsessive-compulsive disorder
  - Itch associated with fibromyalgia and depression
  - Pruritus of anorexia nervosa
- Neuropathic itch
  - Postcerebrovascular accident pruritus
  - Multiple sclerosis-associated pruritus
  - Pruritus of Creutzfeldt–Jakob disease ("prion pruritus")
- Drug-induced pruritus
  - Opiate-associated pruritus
  - Hydroxyethyl starch-induced pruritus

lesions resulting from scratching can become secondarily infected, particularly in patients with atopic dermatitis. Moreover, in a large multinational study in hemodialysis patients, pruritus was associated with a 17% higher mortality risk.[91]

CLINICAL COURSE

Generalized pruritus can wax and wane. Changes in the clinical presentation may be associated with seasonal changes, such as exacerbation of atopic dermatitis in the winter, or changes between dry and humid environments. Pruritus associated with underlying internal disease is often multifactorial, involving both systemic and external factors, including ambient temperature and humidity. Chronic itch associated with skin disease may also include central neural sensitization.[28,36]

ITCH CAUSED BY SKIN DISORDERS

PRURITUS IN ATOPIC DERMATITIS. (See Chapter 14.) Pruritus in atopic dermatitis remains a controversial area and the molecular basis of pruritus in atopic dermatitis remains largely unexplained.[92] Whether itch precedes skin lesions or vice versa is also an unresolved issue. What is certain is that a vicious itch-scratch cycle (see Fig. 103-1) exists in atopic patients, in which scratch damage enhances pruritus. Itching is particularly acute in response to punctate stimuli such as wool fibers. Alloknesis (see Section "Alloknesis: Itchy Skin") is a prominent feature of the itch of atopic dermatitis and explains the bouts of intense itching associated with sweating, sudden changes in temperature, dressing, undressing, and direct contact with wool.

A central (neurogenic) component to the itch of atopic dermatitis is suggested by the poor response to low sedation H_1 antihistamines.[93] The intensity of itch in atopic dermatitis has been related to mental factors, and itch may be induced by cognitive stress, such as anxiety, as well as depression.[94–97] Of note, itch intensity and disease severity were significantly correlated with brain activity in the anterior cingulate cortex as well as the insula in atopic dermatitis patients.[36] Opioid peptides may serve as central and peripheral mediators because opioid antagonists acting at these levels are effective in some patients.[98] Interestingly, there is a significant downregulation of μ-opioid receptor expression in the epidermis of atopic dermatitis patients.[99] Nocturnal scratching is a major problem in atopic dermatitis, occurs during superficial sleep, and occupies 10%–20% of the total sleeping time, leading to tiredness and irritability.

PSORIASIS. Itch in psoriasis is a significant but underrecognized problem in dermatology. Several studies have demonstrated that itch is a principal symptom of psoriasis.[100–104] Among psoriasis patients, 77% experience pruritus on a daily basis.[90] Dermatologists emphasize observable criteria of psoriasis, such as visible lesions; however, itching frequently occurs in areas of the body where no psoriasis plaques are visible. Scalp itching, in particular, is specific to psoriasis and may require different therapies than pruritus in other areas of the body.[103,105]

NEUROPATHIC ITCH

POSTHERPETIC NEURALGIA. Postherpetic neuralgia commonly has neuropathic pain; and often, associated neuropathic itch in 30%–58% of such patients. Pruritus commonly accompanies both acute zoster and postherpetic neuralgia, particularly lesions affecting the head, face, and neck.[106,107]

BRACHIORADIAL PRURITUS. Brachioradial pruritus, a localized pruritus, is becoming increasingly common. Patients, usually fair skinned, affluent, and middle aged, habitually indulge in golf, tennis, sailing, or other leisure outdoor activities in sunny climates.[108,109] They develop persistent pruritus of the outer surface of the upper arm, elbow, and forearm, associated with clinical evidence of chronic sun damage and xerosis. The itch is often accompanied by a

burning sensation. The itch may gradually become more widespread. The pathophysiology is believed to involve compression of spinal nerve roots in C4–C6 and in rare cases it has been associated with spinal nerve tumors.[110] Of note, exposure to UV light has been an eliciting factor.[111] (See Chapter 90.)

NOTALGIA PARESTHETICA. Notalgia paresthetica is a chronic localized itch, affecting mainly the interscapular area especially the T2–T6 dermatomes, but occasionally with a more widespread distribution, involving the shoulders, back, and upper chest. The sensation perceived by the patient is part itch, part paraesthesia. There are no specific cutaneous signs, apart from those attributed to scratching and rubbing. Amyloid deposition in skin biopsies is a secondary event. The current view on etiology is that it is a neuropathic itch due to nerve entrapment of the posterior rami of spinal nerves arising at T2–T6.[112,113]

SYSTEMIC ITCH

PRURITUS OF CHRONIC KIDNEY DISEASE. (See Chapter 150.) Pruritus is one of the most distressing symptoms of chronic kidney disease (CKD). It affects 42% of patients on hemodialysis as reported by the Dialysis Outcomes and Practice Pattern Study (DOPPS).[91] The DOPPS report and a large study in Japan showed that CKD-associated itch induces depression, sleep disturbance and increased mortality.[91,114] Scratching is common and patients may be heavily excoriated or the skin may appear lichenified or present with prurigo nodules. The back is invariably affected, and the arm bearing the arteriovenous fistula is also a common site in dialysis patients. Patients with CKD associated-pruritus often have dry skin, but correction of this by emollients usually provides minimal relief.

The pathophysiology of CKD-associated pruritus remains poorly understood. Current understanding points towards central roles for the immune and opioidergic systems. It is postulated that the itch associated with CKD is a manifestation of an immune system derangement that results in a proinflammatory state. In line with this theory, immunomodulators such as ultraviolet B light,[115] tacrolimus[116] and thalidomide[117] have been shown to alleviate CKD-associated pruritus. An imbalance of the endogenous opioidergic system has also received recent attention in terms of the pathophysiology of CKD-associated pruritus.[118] An increased ratio of serum β-endorphin to dynorphin A has been reported in HD patients compared with healthy controls, and the ratio increased with the increased intensity of itch.[119] Moreover, a kappa-receptor agonist, nalfurafine, was shown to significantly decrease itch intensity and excoriations in HD patients.[120,121] Other proposed etiologic factors may include elevated calcium levels, release of pruritogenic cytokines during hemodialysis, damage to C nerve fibers, proliferation of sensory nerve endings in skin, increased numbers of dermal mast cells, elevated plasma histamine levels, secondary hyperparathyroidism and abnormal levels of divalent cations.[118,122,123] Secondary hyperparathyroidism, though common in patients with renal failure, is a rare cause of renal pruritus. The proliferation of nerve endings in skin is most likely a response to incessant scratching and rubbing, rather than the primary cause of pruritus. Elevation of histamine levels, with or without increased population density of dermal mast cells, is also unlikely to be important because antihistamines are rarely effective.

PRURITUS OF CHOLESTASIS. (See Chapter 150.) Pruritus of cholestasis is highly distressing. The unique feature of cholestatic pruritus is that the itch initially starts and is most intense in the palms and soles, which is usually not reported in other diseases and later becomes more generalized. Of note, intractable itch in chronic liver disease may be an indication for liver transplantation even in the absence fulminant liver failure.[124] Both peripheral and central mechanisms are important. Cholestatic pruritus is associated with high plasma levels of bile salts; however, there is little or no evidence of a correlation between skin or serum concentrations of bile salts and itching[125] although administration of cholestyramine, which lowers bile salt levels, does provide some relief. Patients also have elevated plasma opioid levels,[126] and pruritus has been shown to improve with treatment with opioid antagonists including naloxone, naltrexone, and butorphanol.[127–129] In addition, animal models of cholestasis are associated with elevated levels of opioid peptides and scratching, relieved by naloxone.[130,131] Thus, combination of both bile salt-lowering and opioid-directed strategies appear reasonable in the management of pruritus of cholestasis.

Furthermore, recent studies have shown that patients with cholestatic pruritus have elevated serum levels of autotoxin and its substrate lysophosphatidic acid (LPA) a signaling phospholipid. The activity of autotaxin in cholestatic patients' sera correlated with the intensity of pruritus. LPA and autotaxin may therefore be potential targets in the treatment of cholestatic pruritus.[132]

PRURITUS OF ENDOCRINE DISEASE. (See Chapter 151.) Generalized intractable itching is a recognized feature of thyrotoxicosis and may be a presenting symptom.[133] This may be due to increased blood flow, which raises the skin temperature, which, in turn, reduces the threshold to itching.[22] Hypothyroidism is less frequently associated with itch. Generalized itching is not a feature of diabetes mellitus.[134] However, anogenital itching is a common presenting feature, and is due to mucocutaneous candidiasis. Localized itching of the scalp and lower extremities in the form of lichen simplex chronicus can also be a manifestation of diabetic neuropathy,[135] which may respond to topical capsaicin treatment.[136] In addition, truncal pruritus of unknown origin has been recently reported to be associated to diabetes and diabetic neuropathy.[137]

PRURITUS IN HEMATOLOGIC DISEASE AND LYMPHORETICULAR MALIGNANCY. (See Chapters 144 and 145.) Itch is common in hematologic

disorders. In widespread cutaneous T-cell lymphoma, and erythrodermic forms of cutaneous T-cell lymphoma including Sézary syndrome (T-cell leukemia), intractable itch is difficult to manage. In polycythemia vera, it occurs in approximately 50% of patients, is often precipitated by contact with water ("bath itch"), and is associated with raised blood histamine levels.[138,139] In other lymphoproliferative diseases, itch can also be precipitated by contact with water. In Hodgkin disease, it may be a presenting symptom and occurs in between 15%–19% of patients.[124,140] It can a be a presenting sign in non-Hodgkins lymphoma also. Of note, recent data has shown functional abnormalities of mast cells in patients with myeloproliferative disease with an increased release of pruritogenic factors, such as histamine, leukotrienes, and IL-31, when compared to normal mast cells.[141] In cutaneous mastocytosis (see Chapter 149), itching occurs locally following rubbing the skin, although it can be widespread in severely affected patients, when it is usually associated with systemic symptoms. Itching may occur in patients with myeloid and lymphatic leukemia and myelodysplasia.

PARANEOPLASTIC PRURITUS. (See Chapter 153). Chronic itch could be a presenting sign of both hematologic malignancies as well as solid tumors. It may occasionally be present years before the tumor becomes clinically detectable. It could also be present as part of a primary epidermal or dermal skin disease associated with malignancy such as eruptive seborrheic keratosis, malignant acanthosis nigricans, erythroderma, transient acantholytic dermatosis (Grover disease) and dermatomyositis.[142] Traditionally, the onset of pruritus in a middle-aged or elderly patient with an otherwise normal-looking skin prompts a thorough investigation for underlying systemic causes, including internal neoplasia, although the latter is an uncommon cause. Full investigation for a causative solid tumor is probably not worthwhile in the absence of other skin or systemic findings suggestive of malignancy even if resources are available.[143,144]

PRURITUS OF HUMAN IMMUNODEFICIENCY VIRUS INFECTION. (See Chapter 198.) Itch is an early symptom of human immunodeficiency virus (HIV) disease and may be associated with skin disease or a result of systemic disease (e.g., hepatic, renal, adverse drug reactions, lymphoma, and systemic and skin infections including *Staphylococcus aureus* and *Pityrosporum*). However, it may occur as a primary symptom of HIV.[145] The most common example is eosinophilic folliculitis. Other common types of itch in HIV are insect bite hypersensitivity reaction, pruritic papules other than eosinophilic folliculitis, and itch associated with skin xerosis and lichenoid dermatitis, as well as exacerbation of seborrheic dermatitis and psoriasis.

PSYCHOGENIC ITCH

(See Chapter 104)

The prevalence of pruritus among psychiatric inpatients is as high as 42% and appears related to psychosocial stress.[146,147] Patients with depression, fibromyalgia, and other somatoform disorders can suffer from severe itch that responds well to selective serotonin reuptake inhibitors (SSRIs). Of importance, delusions of parasitosis is one of the more challenging types of itch that dermatologists encounter. The patient holds a false belief that they are infested with parasites, although careful inspection reveals no supporting clinical findings. The patient often brings "evidence" in the form of collected fragments, although on examination the material proves to be nonspecific debris. The patients often refuse to see a psychiatrist. Delusions of parasitosis is classically treated with typical antipsychotic agents; pimozide is most commonly used by dermatologists. Olanzapine (5 mg/day) is another option to treat this severe type of psychogenic itch. Localized pruritus in the form of prurigo nodularis or anogenital pruritus could be a manifestation of obsessive-compulsive disorders and anxiety.

MISCELLANEOUS TYPES OF ITCH

ADVANCED AGE AND ITCH. Itch is the most common dermatologic symptom among people over 65 years of age.[148,149] At least 50% of persons aged 70 years or older suffer from prolonged bouts of troublesome pruritus. Idiopathic itch in the elderly, sometimes referred to inappropriately as *senile pruritus*, is common and presents a diagnostic and therapeutic challenge. Itch in senescent skin can result from a variety of causes including dry skin, inflammatory skin diseases such as low-grade eczema and scabies, as well as underlying systemic disease, especially cholestasis and renal failure. Several drugs can induce pruritus without a rash including opioids and angiotensin converting enzyme inhibitors. However, in many instances, no cause is found. Although dry skin is probably the most common associated factor, it may not be the cause of pruritus; many elderly patients have senescent skin without xerosis. Other factors may play important roles, such as age-related changes in nerve fibers and loss of input from pain fibers leading to central disinhibition of itch. Additional skin changes in elderly patients that may contribute to itch include decreased skin surface lipids, decreased clearance of transepidermally absorbed materials from the dermis, decreased sweat and sebum production, and diminished barrier repair.[150]

ITCH ASSOCIATED WITH BURNS AND SCARS. (See Chapters 66 and 95.) Burn scars are common in both children and adults and are associated with significant pruritus. The reported prevalence rates of mild to severe itching were as high as 87%, 70% and 67% at 3, 12, and 24 months post burn respectively.[8] Compared to healthy skin, burn-graft skin displays significantly elevated SP nerve fibers as well as significantly elevated thresholds for pinprick, warming, touch, and vibration.[151] Keloids are frequently associated with itch at the periphery of the keloid lesion and less frequently pain in the center of the keloid.[152] These

findings probably result from entrapment of small nerve fibers.

AQUAGENIC PRURITUS. Originally described by Shelley[153] and subsequently characterized by Greaves et al,[154] aquagenic pruritus is a rare, intractable pruritus of unknown etiology found mainly in the middle-aged and elderly.[155] Characteristically, local itching without visible skin signs is provoked by contact with water. Notably, aquagenic pruritus can be associated with lymphoproliferative disorders such as polycythemia vera.[139,156]

TREATMENT OF PRURITUS

Unfortunately, there are no general-purpose antipruritic drugs. Treatment of pruritus depends on identifying and removing the cause, whether systemic or cutaneous. False hopes of highly effective treatment for those patients in whom no cause can be found should not be raised. Recently, a kappa opioid receptor agonist, nalfurafine, was officially approved in Japan for clinical use as an antipruritic for CKD-associated pruritus. The antipruritic effects of this drug on other forms of itch still need to be elucidated. It is important to obtain a detailed history, including the precise quality, timing, and distribution of the itch, so that more focused therapy can be instituted. The sensation of itching is heightened if the skin is warm,[22,157] therefore measures should be taken to cool the skin down, including tepid showering, light clothes, and air conditioning where appropriate. Cooling lotions, such as calamine lotion or menthol 1%, may help. Of note a subset of chronic itch patients report that hot showers alleviate their itch for several hours.[35,90]

A general therapeutic ladder for generalized pruritus is presented in Fig. 103-3.

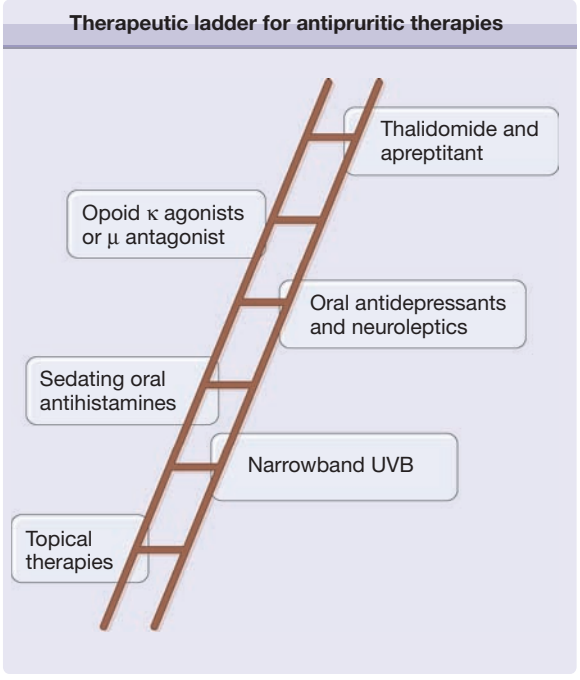

Figure 103-3 Therapeutic ladder for antipruritic therapies. UVB = ultraviolet B.

TOPICAL ANTIPRURITIC TREATMENTS

There is a lack of controlled studies for most topical antipruritic treatments. Many topical agents are claimed to be effective for pruritus; however, few claims are supported by more than anecdotal evidence. Although capable of relieving pruritus due to inflammatory skin disease, corticosteroids are not intrinsically antipruritic. Antihistamines are only antipruritic if the pruritus is caused by histamine, as in urticaria. However, a number of pharmacologic mechanisms offer promising avenues for treatment of itch. A summary of topical antipruritic treatments is given in Table 103-3.

BARRIER CREAMS AND COMBINATION THERAPIES. Emollients and barrier repair creams often reduce pruritus through improved barrier function. They help the stratum corneum to retain water and provide an exogenous barrier to prevent transepidermal water loss. Such barrier creams are often effective treatments for itch associated with dry skin and atopic dermatitis; however, the mechanism of their antipruritic effects are not fully understood. Restoration of the barrier minimizes fissuring and reduces exposure of C nerve fibers. Atopic dermatitis patients treated with ceramide-dominant emollients demonstrate improved transepidermal water loss and overall severity of skin disease. Lipids, occlusives, and humectants also reduce damage to skin by decreasing contact between skin proteins, lipids, and surfactants. Acidifying the stratum corneum may also reduce itch. High pH solutions increase the swelling of the stratum corneum, change lipid rigidity, and increase secretion of serine proteases, suggesting that neutral or acidic pH solutions are less damaging.[158]

TOPICAL SALICYLATES. Clinical trials have shown that applying a topical salicylic acid solution to the skin relieves itch. Topical salicylic acid is a common keratolytic agent and may also increase hydration and soften the stratum corneum by decreasing its pH (see Chapter 222). Topical aspirin significantly reduced pruritus in patients with lichen simplex chronicus—a form of localized itch[85]; however, oral salicylates do not relieve pruritus except in polycythemia vera.

TOPICAL IMMUNOMODULATORS. (See Chapter 221.) Although topical immunomodulators, such as tacrolimus and pimecrolimus, are used primarily for atopic dermatitis, these medications are promising antipruritic treatments in other dermatologic diseases as well. Other pruritic dermatoses treated successfully with topical calcineurin inhibitors include chronic irritative hand dermatitis, seborrheic dermatitis, graft-versus-host disease, lichen sclerosus, anogenital pruritus and prurigo nodularis. Tacrolimus and pimecrolimus have both been shown to directly affect C nerve fibers.[159,160]

TABLE 103-3
Topical Antipruritic Treatments

Medication	Dose	Indication	Notes
Barrier repair creams	N/A	Atopic dermatitis, dry skin	—
Salicylic acid	2%–6%	Lichen simplex chronicus	Stinging
Tacrolimus	0.03%–0.1% ointment	Atopic eczema, contact dermatitis	Stinging, burning sensation
Pimecrolimus	1% cream	Atopic eczema, contact dermatitis	Stinging, burning sensation
Menthol	1% cream	Patients who respond well to cold showers	Skin irritation
Capsaicin	0.025%–0.1% cream	Neuropathic itch (notalgia paresthetica, postherpetic itch), uremic itch, psoriasis, atopic dermatitis	Poor compliance due to transient burning sensation
Pramoxine	1.0%–2.5%	Facial eczema, atopic eczema	Particularly effective for pruritus of face
Polidocanol	5% urea + 3% polidocanol (Lauromacrogol)	Atopic dermatitis, contact dermatitis, psoriasis, uremic pruritus	—
Doxepin	5% cream	Atopic dermatitis	Drowsiness in 25% of patients; allergic contact dermatitis
Cannabinoids		Atopic dermatitis, uremic pruritus	Combine with a barrier cream

COOLANTS AND COUNTER-IRRITANTS. A distinct subset of sensory neurons may directly sense changes in temperature via receptors of TRP ion channels on cutaneous nerve endings. These include vanilloid receptors, such as TRPV1, which respond to warmth and capsaicin. These receptors act synergistically with other receptors involved in itch, such as PAR-2 and SP receptor (Neurokinin 1). These receptors are targets for treatment of itch. Other receptors from the same family include cold receptors, such as TRPM8. Menthol has been used as a symptomatic topical treatment for pruritus for centuries and relieves itch in some patients by activating nerve fibers that transmit a cool sensation. Menthol may reduce itch via TRPM8 receptors in keratinocytes and nerve fibers.[161,162] Menthol 1% cream is popular with patients who have pruritic skin; however, higher concentrations can induce skin irritation.[163] Those patients who report that cold showers and ice relieve their itch tend to respond extremely well to treatment with menthol.

CAPSAICIN. Topical capsaicin, the active compound in the chili pepper, causes release of neuropeptides, including SP, from C nerve fibers. The exact mechanism is not fully understood; however, prolonged application of capsaicin to the skin depletes stores of SP, desensitizes neurons, and abolishes pruritus at the site of application. Capsaicin activates the vanilloid receptor TRPV1, which is abundant in the epidermal layer of the skin.[17] Several reports have supported capsaicin's value for localized, chronic pruritic disorders, particularly those of neuropathic origin, including brachioradial pruritus, notalgia paresthetica, postherpetic itch as well as pruritus associated with CKD, psoriasis and atopic dermatitis.[164,165] Unfortunately, compliance is poor because initial application causes an intense, transient burning sensation at application sites; however, this usually resolves after using the medication for a few days or with application of a topical anesthetic.[107]

TOPICAL ANESTHETICS

Pramoxine. Pramoxine is a topical anesthetic that reduces itch, especially when applied to facial areas, by blocking the transmission of nerve impulses. Double-blind studies have shown that pramoxine inhibits histamine-induced itch in humans and CKD-associated pruritus.[166,167]

Polidocanol. Polidocanol is a nonionic surfactant with both local anesthetic properties and moisturizing effects. In an open-label study, a combination of 5% urea and 3% polidocanol (Lauromacrogol) was found to significantly reduce pruritus in patients with atopic dermatitis, contact dermatitis, and psoriasis.[168]

TOPICAL ANTIHISTAMINES. Doxepin is a tricyclic antidepressant with potent H_1- and H_2-antihistamine properties and significant atropine-like (anticholinergic) side effects. Doxepin 5% cream has been shown to relieve pruritus in patients with atopic dermatitis in a large placebo-controlled, double-blind study.[169] However, percutaneous absorption of doxepin, causing drowsiness, occurs in approximately 25% of patients, limiting its usefulness. Allergic contact dermatitis is also a recognized adverse effect.

TOPICAL CANNABINOIDS. Uncontrolled trials have shown that topical cannabinoids combined with

a barrier cream have an antipruritic effect in patients with atopic dermatitis and uremic pruritus.[170]

FUTURE TOPICAL THERAPIES. Although none are currently available, topical drugs that inhibit serine proteases may be an additional mechanism for future antipruritic therapies. Drugs that act in a similar manner to prostaglandin (PG) D_2 are currently being tested in humans and may also have a potential therapeutic role in itch.

SYSTEMIC ANTIPRURITIC TREATMENTS

ANTIHISTAMINES. (See Chapter 229.) Pruritus due to histamine is mediated exclusively via H_1 receptors; H_2 antihistamines are ineffective in relieving pruritus. First-generation (classic) H_1 antihistamines have marked sedative and atropine-like (anticholinergic) actions. Second generation (minimal- or low-sedation) H_1 antihistamines have lower lipophilicity and consequently are associated with less drowsiness and other unwanted side effects. Sedative (first-generation) antihistamines are useful in severe chronic urticaria with or without angioedema because they suppress pruritus and alleviate associated anxiety. Hydroxyzine is especially valuable in this context along with doxepin. Second-generation H_1 antihistamines are suitable in the daytime for relief of pruritus due to urticaria; however, the role of these nonsedating antihistamines is limited in other pruritic disorders. A summary of systemic antipruritic treatments is given in Table 103-4.

OPIATE ANTAGONISTS AND AGONIST–ANTAGONISTS. As previously mentioned, μ-opioid receptor agonists can cause generalized pruritus.[67,69–71] μ-Opioid antagonists, such as naloxone and naltrexone, have been used for the treatment of pruritus associated with cholestasis, uremia, and dermatologic diseases. The efficacy of such opioid antagonists is supported by data from controlled clinical trials.[64,127,129,171–173] Naltrexone was effective in the treatment of some cases of severe, intractable pruritus.[174] However, such μ-antagonists are associated with significant side effects including hepatotoxicity, nausea and vomiting, difficulty sleeping, and reversal of analgesia, among others. κ-Receptor agonists also inhibit μ-receptor effects. In animal models, κ-opioid receptor agonists inhibit pruritus and scratching induced by SP or histamine.[68,69] The novel κ agonist, nalfurafine (TRK-820), has been shown to be effective in treatment of severe uremic pruritus.[121] Thus, κ agonists are a promising treatment for severe itch.[120]

Butorphanol is a commercially available opioid agonist-antagonist analgesic with both κ-agonist activity and μ-antagonist activity. Previous studies have found that epidural butorphanol was effective in relieving pruritus associated with epidural morphine.[175,176] Intranasal butorphanol is an effective treatment for many patients with chronic, severe, and intractable pruritus due to systemic diseases and inflammatory skin diseases.[177]

ANTIDEPRESSANTS. The oral antidepressant and selective noropinephrine re-uptake inhibitor, mirtazapine, has been shown to relieve itch in some patients.[178,179] Unlike other SSRIs, mirtazapine is a central presynaptic α_2 noradrenergic inhibitor and specific serotonergic antidepressant. Mirtazapine is a safe medication without serious side effects and may be an effective alternative for the treatment of nocturnal pruritus.[179] It has been shown to be effective when used to treat systemic pruritus as well as pruritus of inflammatory skin diseases and in particular nocturnal itch using a low dose of 15 mg at night. A recent open-labeled study showed paroxetine and fluvoxamine, both selective serotonin reuptake inhibitors, to be efficient in the treatment of chronic itch.[180]

THALIDOMIDE. (See Chapter 235.) Thalidomide has shown antipruritic efficacy in treatment of inflammatory skin diseases, such as prurigo nodularis, actinic prurigo, eczema, and idiopathic elderly pruritus. It is especially useful in pruritus associated with multiple myeloma and lymphoproliferative disease. Thalidomide has been used for years as an immunomodulatory agent whose spectrum of activity is not fully characterized. The antipruritic activity could be related to several mechanisms, including inhibition of TNF-α synthesis. Although TNF-α does not have any direct pruritogenic effect, it is elevated in many pruritic dermatoses. Thalidomide may also act directly as a peripheral and central nerve depressant. The major adverse effects of thalidomide are peripheral neuropathy and teratogenicity.

NEUROLEPTICS. Gabapentin is a structural analog of the neurotransmitter γ-aminobutyric acid and has been used as an anticonvulsant; however, its mechanism of action in the CNS is poorly understood. Studies have shown that gabapentin is effective for treatment of brachioradial pruritus, multiple sclerosis-induced itch, other types of neuropathic itch as well as uremic itch. Gabapentin appears to alter sensation and pruritus associated with itch related to nerve damage in dermatologic and systemic disease. Gabapentin may inhibit central itch pathways, as it does in pain. Pregabalin is a neuropathic pain medication that has a similar structure and function to gabapentin with fewer side effects and can reduce neuropathic itch or alter the sensation of itch in systemic diseases.[113,181]

SUBSTANCE P ANTAGONIST. Aprepitant, an oral drug that antagonizes the effect of SP on neurokinin type 1 receptor has recently been shown to be effective against pruritus associated with the Sézary syndrome in a case series of 3 patients.[182]

NONPHARMACOLOGIC TREATMENTS FOR ITCH

PHOTOTHERAPY. (See Chapter 237.) Phototherapy has been used for more than three decades to treat different types of itch. Reports have suggested that narrow band UVB may be as effective for treatment

TABLE 103-4
Nonclassical Systemic Antipruritic Treatments

Medication	Dose	Indication	Notes
Doxepin	25–100 mg PO qd	Chronic urticaria	Drowsiness, dry mouth; abrupt withdrawal may cause confusion; should not be coadministered with other antidepressants
Hydroxyzine	25–100 mg PO qd	Nocturnal pruritus, atopic dermatitis, chronic urticaria	Drowsiness, dry mouth; abrupt withdrawal may cause confusion
Naloxone	0.002 µg/kg/min increased gradually up to 0.2 µg/kg/min over 24 h	Cholestatic pruritus, uremic pruritus	Hepatotoxicity, nausea and vomiting, difficulty sleeping, reversal of analgesia
Naltrexone	12.5–50 mg PO qd	Cholestatic pruritus, uremic pruritus	Hepatotoxicity, nausea and vomiting, difficulty sleeping, reversal of analgesia; contraindicated in patients with liver dysfunction
Nalfurafine	2.5–5 µg PO qd	Useful in CKD-associated pruritus	May cause insomnia, approved in Japan only
Butorphanol (intranasal)	1–4 mg inhaled qhs	Intractable pruritus due to systemic and some inflammatory skin disease	Drowsiness, dizziness, nausea and vomiting
Mirtazapine	7.5–15 mg PO qhs	Systemic and inflammatory skin disease	Drowsiness, increased weight and appetite, dry mouth
Paroxetine	10–40 mg PO qd	Generalized pruritus	Insomnia, sexual dysfunction
Thalidomide	100 mg PO qd	Pruritus in multiple myeloma and lymphoproliferative disease	Teratogenic, peripheral neuropathy, drowsiness, expensive
Gabapentin	300–3,600 mg PO qd	Neuropathic itch	Drowsiness, constipation
Pregabalin	75–300 mg PO qd	Neuropathic itch	Drowsiness and weight gain
Aprepitant	80 mg PO qd	Purigo nodularis, recalcitrant atopic dermatitis, pruritus associated with malignancy and epidermal growth factor inhibitors	Alopecia, nausea

of pruritus as broadband UVB or psoralen and UVA light. Phototherapy decreases the population density of mast cells by inducing apoptosis, causes peripheral nerve dysfunction, and reduces divalent cations in the skin. Phototherapy is an effective treatment for itch associated with atopic dermatitis, psoriasis, and CKD. Remissions may last for as long as 18 months.

CUTANEOUS FIELD STIMULATION AND ACUPUNCTURE. Cutaneous field stimulation (CFS) is a new technique that electrically stimulates afferent fibers, including nociceptive C fibers. CFS has similarities to transcutaneous electrical nerve stimulation, which activates large myelinated nerve fibers; however, CFS more specifically targets unmyelinated C nerve fibers. CFS may act through endogenous central inhibitory mechanisms that are normally activated by scratching.[183] In patients with localized itching, CFS significantly reduces patient-reported itch and causes degeneration of epidermal nerve fibers.[184] However, CFS is only practical for localized disease. In addition, acupuncture at the correct points showed a significant reduction in type I hypersensitivity itch in both healthy volunteers and patients with atopic eczema.[185,186]

BEHAVIORAL THERAPY TARGETING THE CENTRAL NERVOUS SYSTEM. Stress and other psychogenic factors are important in chronic itch.[187,188] Atopic dermatitis patients have been shown to demonstrate an abnormal sympathetic and parasympathetic response to itch and mental stres.[189] Studies have shown that behavioral modification therapy reduces both itching and scratching.[190] Other possible behavioral interventions include stress reduction and biofeedback.[188] Stress reduction using holistic approaches such as meditation, yoga and mindfulness may have adjunctive role in reducing itch intensity.

KEY REFERENCES

Full reference list available at www.DIGM8.com

DVD contains references and additional content

2. Davidson S, Giesler GJ: The multiple pathways for itch and their interaction with pain. *Trends Neurosci* **33**(12):550-558, 2010
4. Patel T, Yosipovitch G: Therapy of pruritus. *Expert Opin Pharmacother* **11**(10):1673-1682, 2010
5. Weisshaar E, Dalgard F: Epidemiology of itch: Adding to the burden of skin morbidity. *Acta Derm Venereol* **89**(4):339-350, 2009
14. Stander S et al: Clinical classification of itch: A position paper of the International Forum for the Study of Itch. *Acta Derm Venereol* **87**(4):291-294, 2007
70. Yosipovitch G et al: Itch. *Lancet* **361**(9358):690-694, 2003
113. Yosipovitch G, Samuel LS: Neuropathic and psychogenic itch. *Dermatol Ther* **21**(1):32-41, 2008
124. Wang H, Yosipovitch G: New insights into the pathophysiology and treatment of chronic itch in patients with end-stage renal disease, chronic liver disease, and lymphoma. *Int J Dermatol* **49**:1-11, 2010

Chapter 104 :: Psychocutaneous Skin Disease

:: Evan Rieder & Francisco A. Tausk

PSYCHOCUTANEOUS DISEASES AT A GLANCE

- **Primarily Psychiatric Disorders**
  - **Delusional:** Delusions of Parasitosis, Body Dysmorphic Disorder.
  - **Factitial:** Dermatitis Artefacta, Dermatitis Para-Artefacta (Trichotillomania, Skin Picking), Malingering.
  - **Somatoform:** Body Dysmorphic Disorder, Atypical Pain/burning, Hypochondriasis, Somatization.
  - **Obsessive Compulsive Disorders.**
- Affecting approximately 5% of dermatology patients.
- Variable degree of insight, mostly poor.
- Mostly self-induced lesions.
- Poor prognosis if untreated.
- Quality of life severely deteriorated.

Scientific advances are shedding new light on the understanding and treatment of long-recognized conditions located at the interface of dermatology and psychiatry. Both arising from ectoderm, the skin and the nervous system are connected by more than just their common origins. The skin is one of the major avenues by which humans perceive the world, and, in turn, are perceived by it. When these perceptions go awry, great distress may result. When the skin is markedly affected by a primary dermatologic condition, psychological sequelae in the form of comorbidity often follow, greatly impacting patient quality of life.

The central nervous system (CNS) can influence the health of other organ systems, including the skin. Psychophysiologic mechanisms for this interaction range from the stress responses mediated by neuroadrenal connections and associated changes in immunologic function, to the systemic and local action of various neuropeptides and neurohormones.[1,2]

ROLE OF THE DERMATOLOGIST

Between 20% and 40% of patients seeking treatment for skin complaints have some type of psychiatric or psychological problem causing or complicating the presenting symptoms.[3,4] A large number of these patients lack insight into the possible psychogenic origin of their symptoms and are often reluctant to accept any kind of psychiatric referral. Therefore, in the absence of a psychiatry liaison clinic in the dermatologic setting,[4] the dermatologist must be familiar with the most common of these diagnoses, their clinical manifestations (both psychological and dermatologic), and the basic principles of treatment. When approaching these issues, it is important to explore psychiatric, and particularly psychotic, symptoms as well as compliance with medications. Collateral informants such as family members can be quite helpful if the patient grants permission. Lastly, the effects of patient symptoms on familial and social life can be of much assistance in understanding the issues to be addressed.

CLASSIFICATION OF PSYCHOCUTANEOUS DISEASES

Following the original description of C. Koblenzer,[5] psychocutaneous diseases can be classified on the basis of their primary etiology as:

- *Primary psychogenic* disorders, which can present with a variety of symptoms and behaviors, usually characterized by self-injury, that can lead to perceived or actual dermatologic conditions, or
- *Primary dermatologic* disorders that can be either triggered or amplified by contextual causes (e.g., life stresses or interpersonal relationships) that may lead to psychiatric comorbidities such as, anxiety, depression, and distress through their impact on physical appearance and well being. In some instances, the psychiatric comorbidities are not merely the result of the detrimental aspects of skin, but are associated to the pathophysiology of the dermatological disease itself. An example of the latter is the association of psoriasis with depression, in which both conditions share common inflammatory pathways.

The classification can guide in implementing an effective treatment approach including dermatologic, psychiatric, and contextual aspects of the disease aimed to interrupt the circular reinforcement of pathology. In this chapter, we focus on the description of the most frequent *primary psychogenic disorders* that present to the dermatologist, and require acknowledgement and treatment.

BOX 104-1 CLASSIFICATION OF THE PRIMARY PSYCHOCUTANEOUS DISEASES[6]

DELUSIONAL	Delusion of parasitosis
	Body odor delusion
	Hypochondriacal syndrome
	Body dysmorphic disorders (BDD[a])—somatic form
FACTITIOUS	Dermatitis para-artefacta syndrome
	Dermatitis artefacta syndrome
	Malingering
SOMATOFORM	BDD
	Cutaneous dysesthesias
	Somatization syndrome
COMPULSIVE	Compulsive washing
	Lichen simplex chronicus
	BDD

[a]BDD is classified by the DSM-IV as a somatoform disorder, although some patients may be classified as having obsessive-compulsive disorders (OCD) and others as delusional.

PRIMARY PSYCHOGENIC DISORDERS

Frequently, these diseases are manifested by self-inflicted dermatosis. The most significant difference between them is the degree of insight or conscious perception of autoinjury. The classification of these disorders as *delusional, factitial, somatoform, or compulsive* is adapted for the clinical dermatological practice, following the one described in *Clinical Management in Psychodermatology*[6] with the understanding that in many instances, disorders may span through various categories (Box 104-1), and may differ conceptually from the DSM-IV (*Diagnostic and Statistical Manual of Mental Disorders*, published by the American Psychiatric Association), which is directed towards the psychiatric practitioners[7] and clinical studies.

DELUSIONAL DISORDERS

DELUSION OF PARASITOSIS

Subjects with delusional disorders present with somatic complaints, no insight into the involved psychological issues, and encapsulated monosymptomatic delusions. Delusions are fixed, false beliefs that are not endorsed by the larger cultural, ethnic, or religious community. Patients' unshakeable beliefs frequently coexist with a fairly intact character and personality structure. The most frequent form of this condition seen by dermatologists is *delusion of parasitosis*[8] in which patients manifest the belief of being infested with parasites. Because this is frequently the only overt manifestation of the subject's psychosis, these patients most often present to dermatologists and entomologists rather than to psychiatrists. Although we will describe below the more common form of *delusions of parasitosis*, there are other more rare forms of delusions such as hypochondriacal, where patients believes that they are afflicted by a particular disease (such as AIDS, cancer, etc.), or delusions of body odor. In many instances, patients with body dysmorphic disorder (BDD) may have the unshakeable delusional conviction that they have a severe physical disfigurement.

EPIDEMIOLOGY. This disease predominates in middle aged to elderly females with premorbid social isolation. In approximately 12% of patients, the delusion of infestation is shared or at least endorsed by a family member (*folie a deux*).[9,10]

CLINICAL FINDINGS. Patients with delusional parasitosis frequently present to the clinician in an anxious, ruminative, overwhelmed state, with a history of visits to multiple physicians without satisfaction. In addition to proffering a long and detailed history that includes visual or tactile hallucinations of the organisms, the patient also frequently provides "evidence" of the parasitic infection in the form of clothing lint, skin crusts, or other debris, the so-called "matchbox sign"[11] (these items are collected in a matchbox to be presented to the physicians), which is

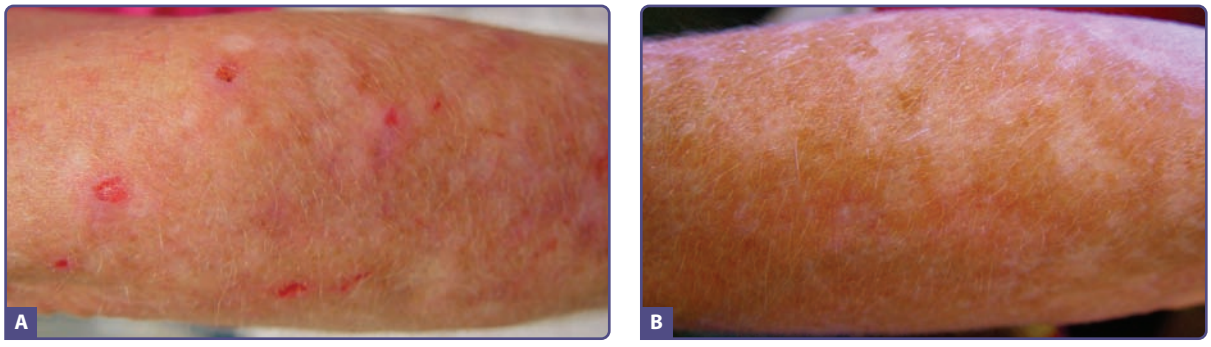

Figure 104-1 Delusions of parasitosis. **A.** Excoriations secondary to the attempt to provide an exit route for the parasites. **B.** After 2 months of treatment with aripiprazole.

delusionally misinterpreted as entire organisms, body parts, larvae, or ova. Skin manifestations can be quite variable, if present. Lesions ranging from mild excoriations (Fig. 104-1A) to large ulcers may reflect patients' unsuccessful attempts at treating the perceived infestation.[12] Because this is a monosymptomatic delusional disorder, some patients have a well-organized train of thought and normal outward appearance and behavior, resulting in the conviction by those surrounding them that the subject has a true infestation. The delusion becomes apparent to the physician when the subject is approached.

DIFFERENTIAL DIAGNOSIS. Actual infestation and underlying skin or systemic disorders must be ruled out (see Box 104-2). Subsequently, the differential diagnosis of psychosis must be considered, distinguishing between the primary psychiatric conditions that manifest with delusions of infestation. True monosymptomatic hypochondriasis represents a form of delusional disorder characterized by a discrete, circumscribed delusional belief with possible associated hallucinations without clear syndromic changes in affect or personality.[7] On the contrary, patients with uni- or bipolar depressive psychosis will describe predominantly classic changes in mood, motivations, sleep, and appetite. Schizophrenic patients may have a history of previous psychotic episodes and often show deterioration in global functioning, impaired social relatedness, thought disorder, paranoid traits, and more bizarre and extensive delusions and hallucinations. In arriving at the diagnosis, it is critical that the clinician differentiate true delusions of parasitosis from formication, which involves the cutaneous sensation of crawling, biting and stinging, but lacks the fixed unshakeable conception that the skin sensations are induced by parasites.

PROGNOSIS AND CLINICAL COURSE. Although often regarded as chronic, unremitting, and difficult to treat, these patients have an improved recovery rate following appropriate pharmacologic therapy.

TREATMENT. The critical tenet of treatment is to keep the patient engaged. Empathetic listening, statements of concern, and examinations of the material that patients brings in help to establish rapport. Because these patients will frequently reject psychiatric referrals,[13] various authors have suggested means of increasing trust, thus paving the road towards psychiatric evaluation.[13,14] It is critical that the dermatologist avoids confronting the patient directly, and exhibits interest in the chief complaint patiently. After a few visits, the physician may carefully introduce the notion that the parasites may not be present, or that the patient is so distressed by this condition, that the prescription of psychotropic medication could be warranted. Targeted therapy is undertaken with antipsychotic medications (Fig. 104-1B).[15] Pimozide has been used historically as the drug of choice,[16,17] although it is now being replaced by atypical antipsychotics, which are associated with a more favorable side effect profile (eBox 104-2.1 in online edition).[14,18] The clinician needs to be aware of the need for monitoring for metabolic syndrome characterized by abdominal obesity, insulin resistance and impaired glucose tolerance, disturbance in lipid metabolism, hypertension, and weight gain.

BOX 104-2 DIFFERENTIAL DIAGNOSIS OF DELUSIONS OF PARASITOSIS

DERMATOLOGIC	SYSTEMIC	PSYCHIATRIC
Chronic folliculitis	Dementia	Cocaine use
Insect bite reactions	Malignancy (brain)	Amphetamine use
Dermatitis artefacta	Cerebrovascular disease	Psychotic-spectrum illness
Dermatitis para-artefacta	Vitamin B12 deficiency	Affective disorders

In many instances, the psychotropic medication needs to be introduced by the dermatologist, and only when the patient begins to respond favorably is it possible to obtain a referral to a psychiatrist.

FACTITIOUS DISORDERS

This group of syndromes is characterized by self-inflicted dermatological disease; they are mostly differentiated based on the degree of insight or consciousness of their behavior.

DERMATITIS ARTEFACTA

Dermatitis artefacta is a form of factitious disorder in which patients intentionally feign symptoms and produce signs of disease in an attempt to assume the patient role.[6] Unlike patients with malingering who engage in similar behavior for external or "secondary gain" (such as monetary reward or relief from occupational or other social responsibilities), the factitious patient seeks the "primary gain" of the emotional and psychological benefits that accrue to those who are "ill." Patients with borderline personality disorder also frequently exhibit self-mutilatory behavior[19] as do patients who consume cocaine or methamphetamine. However, their reasons for self-mutilation are variable, and are not usually consistent with efforts for primary or secondary gain. Occasionally, a psychologically disturbed adult will induce skin lesions in their children.[20]

EPIDEMIOLOGY. Predominating in females, the age of onset varies significantly from adolescence through adulthood.[21] Comorbid depressive and personality disorders may also be seen coexisting with this rare syndrome.[6]

CLINICAL FINDINGS. Although it has long been observed that patients with dermatitis artefacta may present with lesions in virtually all areas of the body that can mimic most dermatoses, some common elements may hint at this diagnosis. Lesions are often in areas readily accessible to the patient, and may have geometric patterns or angulated borders surrounded by completely healthy skin. Morphology is often bizarre and does not conform to typical presentations of known dermatoses (Figs. 104-2 and 104-3). Patients are often unable to provide a clear history of the initial appearance or evolution of the process, typically deny any role in the production of the lesions, and may self-induce the lesions in a dissociated state.[22] Characteristically, the histopathology is unrevealing.

DIFFERENTIAL DIAGNOSIS. As in all cases of factitious disease, the clinician must rule out possible disease entities that are consistent with the history and clinical findings. Unusual presentations of common illnesses and rare conditions must be entertained. However, exhaustive searches for primary skin pathology without supporting clinical evidence may compound the problem and actually perpetuate the patient's factitious behavior. Occlusive dressings (e.g., an Unna boot) or other means of preventing manipulation by the patient lead to healing of the lesions and are often helpful strategies in clarifying the diagnosis.



Figure 104-2 Dermatitis artefacta. Linear, sharply bordered ulcer.

TREATMENT. A supportive, nonconfrontational, empathic approach to the patient is indicated initially. Immediate confrontation regarding the suspicion that the patient's lesions are self-induced can be counterproductive in that the patient often flees from treatment. Frequent visits and symptomatic topical treatments are initially useful.[23] However, the clinician must be careful not to collude in the patient's abnormal illness behavior. Ultimately, the recognition of the patient's role in the production of the lesions must be broached. The goal is to establish a trusting relationship such that the patient will accept a psychiatric referral. Antidepressants (eBox 104-2.2 in online edition) and low-dose atypical antipsychotics (eBox 104-2.1 in online edition) have been reported to be useful adjunctive therapies.[24,25] In the case of inflicted lesions in a child protective services or equivalent agencies must be alerted immediately to safeguard the welfare of the child.



Figure 104-3 Dermatitis artefacta. Part of the nasal cartilage has been manually destroyed.

COURSE AND PROGNOSIS. These are fundamentally determined by the underlying psychopathology. In those patients with severely disturbed personalities, the recurrent self-defeating and destructive behaviors are likely to continue.

DERMATITIS PARA-ARTEFACTA SYNDROME

These are a group of factitious diseases, where problems of *impulse control* play a significant role; the patients are conscious or semiconscious of manipulating their skin, but are unable to stop this behavior.

Trichotillomania is an impulse control disorder,[7] characterized by repetitive pulling of hair, resulting in alopecia. Strict criteria also include a build up of tension before hair pulling or when resisting an urge to do so, pleasure or relief after pulling out the hair, and significant functional impairment and distress in the patient.

EPIDEMIOLOGY. Prevalence rates are estimated to be between 0.5% and 3.5% with a mean age of onset between 10 and 13 years. Despite its current classification, there are marked similarities with obsessive-compulsive disorder (OCD), which may have important treatment implications.[26–28] Comorbid psychiatric disorders are depression, anxiety, and OCD.

CLINICAL FINDINGS. Trichotillomania presents clinically with nonscarring alopecia, most commonly with hairs broken at different lengths, normal overall hair density (Fig. 104-4), and a negative pull test[29]; occasionally, repeated trauma may result in some scarring. Body areas involved typically include the scalp, eyelashes, eyebrows, and pubic hair, with a majority of patients pulling hair from more than one site. Rarely, this is followed by the ingestion of the hair, leading to the potentially dangerous complication of trichobezoar.[30] Awareness of the behavior is partial to complete in a vast majority of patients, and frequently occurs while patients are engaged in isolated, sedentary activities. Attempts to resist the behavior and to disguise its cosmetic sequelae are common. Typical histopathologic findings that may be helpful in confirming the diagnosis in questionable cases include catagen and telogen hairs, pigment casts, and traumatized hair bulbs without significant inflammation or scarring.[31] Perifollicular hemorrhage near the hair bulb is diagnostic.



Figure 104-4 Trichotillomania. Hairs broken off at different lengths.

DIFFERENTIAL DIAGNOSIS. When patients do not have awareness of pulling their own hair and present with alopecia, other etiologies of hair loss must be ruled out.

TREATMENT. Because of trichotillomania's similarities to OCD, the use of selective serotonin reuptake inhibitors (SSRIs) and clomipramine, as well as combinations with atypical antipsychotics have received much attention (eBoxes 104-2.1 and 104-2.2 in online edition).[28,32–37] However, psychopharmacologic data have been conflicting, and the best-designed studies have not demonstrated superiority of psychotropics over nonpharmacologic interventions. Nonpharmacologic treatment of trichotillomania relies heavily upon behavioral therapies, especially habit reversal, which entails engaging the patient in a behavior incompatible with hair pulling when the urge appears. The addition of cognitive-behavioral or insight-oriented psychotherapy have good results; hypnotherapy may also be very useful, particularly in children.[38]

PROGNOSIS AND CLINICAL COURSE. Trichotillomania is a chronic disorder and data on long-term success of pharmacologic and psychotherapeutic interventions are inconclusive. Though children typically have a benign course, adult-onset trichotillomania is often associated with other psychiatric conditions and sustained improvement has yet to be shown convincingly.

SKIN PICKING (NEUROTIC EXCORIATIONS)

This is also a condition in which patients induce skin lesions through repetitive, compulsive excoriation of their skin. However, unlike patients with dermatitis artefacta syndrome, these patients admit their role in the production of the lesions.

EPIDEMIOLOGY. This is the most common psycho-cutaneous disorder, reported in up to 2% of dermatology clinic patients[39] with a predominance in middle-aged females, and are frequently associated with compulsivity–impulsivity spectrum and mood disorders.[40,41]



Figure 104-5 Dermatitis para-artefacta: skin picking on the breast of a 16-year-old girl.

CLINICAL FINDINGS. Patients with skin picking often describe significant itch leading to persistent scratching, which is frequently antedated by considerable psychological stressors. The development of this disorder has also been noted to be associated with the marked limitation in activity seen in illness or senescence.[42] The repeated excoriation can lead to the development of an "itch–scratch cycle," perpetuating the behavior. Patients present with multiple excoriations in various stages of evolution and healing, with postinflammatory hyperpigmentation and frequent scarring (Fig. 104-5). The distribution of the lesions reflects their self-inflicted nature with most being on the extensor surfaces of the extremities, upper back, and face, sparing unreachable areas such as the central mid-upper back. Frequently, patients develop excoriations overlying preexisting dermatosis, such as folliculitis and acne; excessive manipulation of the latter leads to the condition known as "acne excorieé". These patients often spend many hours each day in front of the mirror injuring the skin with instruments such as tweezers. The trauma often results in temporary relief of anxiety. Prurigo nodularis can be considered an extreme variant of this entity, characterized by severely pruritic nodules varying from a few millimeters to 1–2 cm in diameter, preferentially located on the extremities (Fig. 104-6) (see also Chapter 15).

DIFFERENTIAL DIAGNOSIS. The clinician must evaluate the patient for causes of pruritus (see Chapter 103) and rule out possible internal diseases including neoplasms, in particular, lymphomas. The differential for the underlying psychiatric disorder,[43] if present, must include depressive and anxiety disorders and, more rarely, excoriations secondary to delusions of parasitosis.



Figure 104-6 Prurigo nodularis.

TREATMENT. Work-up for pruritus should be instituted in those patients that present significant itch. In the absence of organic cause, these patients may improve with phototherapy. Additional treatment should be directed at underlying psychopathology when identifiable. Antidepressants, helpful in both depressive and anxiety disorders including OCD,[44] are very useful. Subsequent addition of low-dose atypical antipsychotics has been found effective. Supportive psychotherapeutic approaches and behavioral interventions as those used to treat self-injurious behaviors in Tourette's syndrome may be helpful.[45]

COURSE AND PROGNOSIS. This can be a chronic condition whose prognosis depends on the underlying psychiatric illness.[46] With appropriate therapy, patients with affective and anxiety disorders may have excellent outcomes, with a symptom-free, normally functioning state.

MALINGERING

Malingerers intentionally induce skin lesions in order to obtain secondary gains, often workman's compensation or disability. Since there is no patient motivation for therapy, treatment is not possible.[6,47]

SOMATOFORM DISORDERS

This is a group of heterogeneous disorders where the patients complain of a variety of symptoms that cannot

be objectively verified by the physician, but they share similar psychiatric underlying problematics.

BODY DYSMORPHIC DISORDER

BDD is a chronic condition characterized by an excessive preoccupation or concern with a presumed defect in physical appearance despite normal or minimally objective anomalous findings.[48] Also known as *dysmorphophobia*,[49,50] this is a psychological experience that also results in functional impairment, poor quality of life, and low treatment response.

The nosological classification of BDD revolves around the intensity with which patients hold on to their abnormal beliefs. Those with unshakeable convictions are currently diagnosed as having a delusional disorder.[7] However, there appears to be a continuum of intensity and insight from preoccupations, through overvalued ideas to clear delusions.[51] Those patients that retain a certain degree of insight evidence characteristics more similar to the obsessive–compulsive spectrum of disorders,[51,52] a finding that has significant potential treatment implications. BDD patients have obsessive thoughts about their "flaws" and engage in compulsive behaviors related to how they perceive their appearance, similar to behavior seen in obsessive–compulsive disorder.[53]

EPIDEMIOLOGY. The prevalence of BDD, is estimated to be from 0.7% to 2.4% in the general population to 12% in dermatology clinic patients, often in association with mood disorders such as major depressive disorder (MDD) (37%), social phobia (33%) and OCD (26%).[54,55] Improvement of MDD and BDD seems to be closely related, with the improvement of each disorder significantly predicting the remission of the other. Improvement of OCD significantly predicts remission of BDD, but not vice versa. Approximately 80% of patients report a history of suicidal ideation and 24%–28% have attempted suicide.[56–58]

CLINICAL FINDINGS. Patients present with intensely articulated distress about various body parts. Most patients also develop ideas of reference in which they think or are convinced that others notice and comment upon the presumed defect. Time-consuming, compulsive behaviors often accompany the worrisome thoughts, including repeated examination in mirrors, covering up defects, and asking others for reassurance. Consultations with other physicians and past operations on the perceived defect are common. Marked restriction in social and occupational functioning is seen in up to 98% of individuals, and 30% of patients have been described as housebound.[59] Thoughts and attempts of suicide are frequent. Thus, current or past suicidal ideation should be routinely assessed by the practitioner. Particular monitoring may be needed with younger patients as antidepressant action may increase impulsivity and likelihood of suicidal attempts.[58]

TREATMENT. Many patients with BDD will seek dermatologic or surgical treatment over the course of their illness. Evidence suggests that if patients receive such treatment they do not improve, are usually disappointed with the results, and may even experience an exacerbation of their symptoms. It is strongly recommended that cosmetic lines of treatment be avoided. BDD is a severe and complex disorder that often requires multimodal treatment using cognitive behavioral therapy (including exposure response prevention) and medication.[60,61]

Pharmacologic trials show a good response to SSRIs (see eBox 104-2.2 in online edition), improving insight while decreasing distress, compulsions, and frequency and intensity of obsessions about perceived defects. Interestingly, SSRIs appear equally effective for delusional as well as nondelusional patients. Efficacy usually requires 12–16 weeks of relatively high dosages. Issues of compliance require close monitoring, since they are a frequent cause of treatment failure. A significant proportion of patients who fail one adequate SSRI trial respond favorably to a second SSRI, suggesting that serial trials of similarly acting agents should be administered in initially refractory cases. Lack of clear success has been noted with other agents such as antipsychotics, tricyclic antidepressants (TSA) (other than clomipramine), benzodiazepines, and anticonvulsants.[62–67] Similar to patients with OCD, cognitive-behavioral therapy is strongly recommended.

PROGNOSIS AND CLINICAL COURSE. BDD is a chronic illness without clear evidence for spontaneous remission without treatment. Pharmacotherapy with appropriate medications may lead to improvement in a considerable number of patients. However, effective doses of SSRIs are usually beyond those approved by the FDA; the data also indicate high recurrence rates with discontinuation of treatment.[64] Thus patients may require long-term treatment, including adjunctive insight oriented psychotherapy.[57,60]

SOMATIZATION DISORDER

These patients present to the physician with multiple significant physical complaints and the belief that their symptoms are due mostly to exposure to environmental causes. This disorder includes Gulf War syndrome, multiple chemical sensitivity syndrome, amalgam related syndrome, chemical or detergent allergies, "sick building syndrome," food intolerances, and "candida hypersensitivity syndrome," among many others. There is no medical proof of a direct causal relationship between exposure and the extent of complaints. The widespread dissemination of information through the Internet as well as the insistence of self-proclaimed experts reinforces the patients' misinterpreted beliefs.

HYPOCHONDRIACAL DISORDERS

Typically these patients express the conviction or fear of suffering from a serious illness (such as AIDS, venereal diseases or cancer) despite the lack of medical evidence.

CUTANEOUS DYSESTHESIAS (ATYPICAL CHRONIC PAIN/BURN SYNDROME)

Occasionally, patients will present to dermatologists with complaints of burning, pain, or dysesthesias in the skin or mucus membranes for which no identifiable pathology can be found. This can be a frustrating situation for patient and clinician alike. A psychiatric approach to these patients may offer a means of understanding the complex factors underlying this syndrome, such as comorbid affective disorders, personality vulnerabilities, behavioral problems, and life circumstances that may perpetuate the pain cycle and maintain the patient in an illness role.

There is a significantly increased rate of depression in patients with chronic pain syndromes and a clear relationship between lifetime depression and the development of medically unexplained symptoms, including pain.[68] Depression not only worsens the experience of pain by psychologically magnifying negative perceptions, but may also interfere with the function of descending monoaminergic neurons that dampen nociceptive transmission.[69,70] Other complicating factors include anxiety, which is also commonly seen in patients with chronic pain.[68] Personality disorders influence all aspects of patients' lives and may make the burden of a chronic condition more challenging. At times, family or social environments may unwittingly play a role in undermining the chronic pain patient's rehabilitation by rewarding illness behaviors with well-meaning, yet oversolicitous, attention. Pain states can further be complicated if the patient develops an inappropriate pattern of using prescribed analgesics. For all of these reasons, the best course of action for patients presenting with poorly explained chronic pain is to refer them to a multidisciplinary pain center for thorough evaluation and treatment. The presence of burn syndrome may occasionally respond to the administration of gabapentin (see eBox 104-2.2 in online edition). Milnacipran, an SNRI approved for fibromyalgia (eBox 104-2.2 in online edition), also may be effective for chronic pain/burn/dysesthesia syndrome. Extreme forms of chronic dysesthesia can resolve with the administration of antipsychotic medication, suggesting that it represents a form of delusion.

PSYCHOGENIC PRURITUS

Psychogenic pruritus and itch in general are discussed in Chapter 103.

OBSESSIVE-COMPULSIVE DISORDERS (OCD)

These include dermatological findings that are the result of disorders such as compulsive washing (xerosis, eczema) or rubbing (lichen simplex chronicus). OCD is also related to BDD as well as some factitious conditions such as trichotillomania or skin picking (see above).

PSYCHOTROPIC MEDICATIONS USED IN DERMATOLOGY

Dermatologists who elect to treat psychocutaneous disorders routinely use a number of different classes of psychotropic medications. Knowledge of the drugs and their actions, indications, side effects, therapeutic doses, and potential drug interactions is critical.[71] These drugs are classified according to their clinical utility (e.g., antidepressants or antipsychotics) and further identified by their chemical structure and/or mechanism of action. All of the drugs discussed in this section exert their clinical effects through modulation of neurotransmitter function in the CNS by altering presynaptic reuptake of the transmitters, blocking their pre- and/or postsynaptic receptor binding, stimulating those receptors, or some combination thereof. The most appropriately used in each of the following three major classes are discussed: antipsychotics, antidepressants, and anxiolytics.

For a detailed discussion of these drugs, their side effects, and precautions, see online edition of the book.

NONPHARMACOLOGIC TREATMENTS FOR PSYCHOCUTANEOUS DISORDERS

The dermatologist should request a consultation with a psychiatrist or a liaison clinic during the treatment of patients with psychocutaneous disorders as soon as it is amenable to the patient. Although dermatologists are becoming more comfortable with the use of certain psychotropic medications, they generally do not have the time or the training to use effectively nonpharmacologic modalities. Therefore, it is sufficient that the practicing dermatologist be aware that a variety of adjunctive, stress-reducing approaches are available, including hypnosis, biofeedback, progressive muscle relaxation, and psychotherapy (Box 104-3). Although no modality has been demonstrated to be superior to another, certain types of therapies may be more effective for a given condition. Diagnosis should drive choice of therapy.

BOX 104-3 NONPHARMACOLOGICAL TREATMENTS

- Cognitive-behavioral therapy
- Insight-oriented psychotherapy
- Hypnosis
- Mindfulness-based cognitive therapy
- Biofeedback
- Family therapy

KEY REFERENCES

Full reference list available at www.DIGM8.com

DVD contains references and additional content

3. Gupta MA: Psychocutaneous disease. *Dermatol Clin* **4**:591-745, 2005
5. Koblenzer C: *Psychosomatic Concepts in Dermatology*. Orlando, FL, Grune & Stratton, 1987
6. Harth W et al: *Clinical Management in Psychodermatology*, 1st edition. New York, Springer, 2008
14. Sandoz A et al: A clinical paradigm of delusions of parasitosis. *J Am Acad Dermatol* **59**(4):698-704, 2008
59. Phillips KA: *Understanding Body Dysmorphic Disorder*. New York, Oxford University Press, 2009
72. Koo JYM, Lee CS: *Psychocutaneous Medicine*. New York, Marcel Dekker, 2003

Chapter 105 :: Cutaneous Manifestations of Drug Abuse

:: Haley Naik & Richard Allen Johnson

MUCOCUTANEOUS MANIFESTATIONS OF DRUG ABUSE AT A GLANCE

- The morphology and arrangement of skin lesions can identify persons with former and current drug dependency.
- Skin lesions associated with drug use can be related directly to the drug itself, mode of drug delivery, and/or adulterants or infectious agents mixed with the drug.
- Drug addiction-related bacterial infections predominantly involve the skin and soft tissue. Culture-guided antibiotic therapy is essential because infection with unusual organisms, antibiotic-resistant strains, and polymicrobes is more common.
- Behavioral effects of drug use can lead to the transmission of sexually transmitted diseases and blood-borne pathogens including *Treponema pallidum*, hepatitis B virus, hepatitis C virus, human immunodeficiency virus, and human T-lymphotropic viruses 1 and 2.

INTRODUCTION

Drug abuse and addiction can be suspected or diagnosed on the basis of mucosal and cutaneous findings. The administration of drugs may cause cutaneous stigmata and eruptions predominantly through local or systemic, toxic or hypersensitivity-induced effects as a result of the drug itself, adulterants, infectious agents, or the mode of drug delivery.

DEFINITIONS

Illicit drug use is a maladaptive pattern involving self-administration of prescribed or recreational drugs. *Chipping* is a lay term used to describe a pattern of drug use in which the user is not physically dependent, but rather sustains "controlled use" of a drug. A certain percentage of users will progress to *drug dependence*, a physical and/or psychological need for the effects of a chemical in order to avoid withdrawal symptoms associated with abstinence (Box 105-1). Drug dependence often leads to *drug abuse*, an intense desire to recurrently obtain increasing amounts of one or more chemical substances to the exclusion of all other activities, resulting in

BOX 105-1 CRITERIA FOR DRUG DEPENDENCE

The presence of three or more of the following, occurring any time in the same 12-month period:

- Tolerance
- Withdrawal symptoms
- Sustained intent or unsuccessful efforts to abate drug use
- Administration of drug in higher doses and longer duration than initially intended
- Significant time devoted to obtaining the drug or recovering from its effects
- Relinquishment or reduction of social, occupational or recreational activities because of drug abuse
- Continued drug use despite awareness of the presence of a persistent or recurrent physical or psychological problem caused or exacerbated by the drug

Adapted from American Psychiatric Association: *Diagnostic and Statistical Manual of Mental Disorders IV-TR*, 4th edition. Washington DC, American Psychiatric Press, 2000.

BOX 105-2 CRITERIA FOR DRUG ABUSE

The presence of one or more of the following, occurring within a 12-month period:

- Recurrent substance use resulting in a failure to fulfill major role obligations at work school, or home
- Recurrent substance use in physically hazardous situations
- Recurrent substance-related legal problems
- Continued substance use despite having persistent or recurrent substance-related social or interpersonal problems

Adapted from American Psychiatric Association: *Diagnostic and Statistical Manual of Mental Disorders IV-TR*, 4th edition. Washington DC, American Psychiatric Press, 2000.

clinically significant physical, emotional or social distress (Box 105-2). *Tolerance* defines a physiologic state in which progressive increases in the dose of a drug are needed to achieve the effects previously experienced at smaller doses. Some drugs chiefly induce physical dependence, while cause predominantly psychological dependence.[1]

The National Institute of Drug Abuse (NIDA) (http://www.drugabuse.gov/)[2] considers the following agents to be drugs of abuse in the United States:

- Alcohol
- Club drugs
- Cocaine
- Heroin
- Inhalants
- Lysergic acid diethylamide (LSD)
- Marijuana
- 3,4-Methylenedioxymethamphetamine (MDMA, Ecstasy)
- Methamphetamine
- Phencyclidine (PCP)
- Prescription medications
- Steroids (anabolic)
- Tobacco

Betel is widely used in South Asia, Southeast Asia and the South Pacific.

EPIDEMIOLOGY

In 2004, the United Nations' World Drug Report estimated that between 3% and 5% of the global population used illicit drugs.[3] In 2008, the National Survey on Drug Use and Health in the United States estimated that:

- 20.1 million Americans aged 12 or older (8% of that population) were currently using illicit drugs including marijuana/hashish, cocaine, crack, heroin, hallucinogens, inhalants or prescription-type psychotherapeutics.
- Marijuana was the most commonly used illicit drug (15.2 million past month users).
- The most commonly injected drugs were heroin and cocaine.
- Almost 2 million current cocaine users, comprising 0.7% of the population, were estimated.[4]
- The actual number of individuals who use heroin is difficult to determine because there has been a growing tendency to sniff, snort or smoke rather than to inject heroin intravenously or subcutaneously.
- An estimated 70.9 million Americans (28.4%) aged 12 or older were current users of tobacco in any form.
- Of Americans aged 12 and older, 51.6% had consumed alcohol at least once in the 30 days prior to being surveyed; 23.3% reported drinking heavily (>5 drinks on >5 occasions).

The drugs most commonly associated with emergency department visits in 2001 included cocaine, marijuana, benzodiazepines and heroin, in that order (Fig. 105-1).

PATHOGENESIS

Studies in concordant twins have shown a strong influence of genetic inheritance on the susceptibility to drug use.[5] The potential of a drug to cause addiction varies. The processes by which genes regulate physical reactions to addictive drugs have not been clearly elucidated. Repeated exposure to cocaine causes a change at the level of gene expression that leads to altered levels of the specific brain protein called *cyclin-dependent kinase-5*. This protein regulates the action of dopamine, which potentiates the euphoric effects of cocaine and other drugs.[6] Narcotics disable the neurons that normally inhibit the release of dopamine while amphetamines and cocaine increase dopamine signaling, either by directly stimulating its release, or by blocking its absorption. Environmental factors such as history of sexual abuse during childhood, severe family dysfunction with drug abusing, detached or mentally ill parents, poor social skills, and drug-using peers are also clearly important.

The mechanisms of addiction, tolerance and dependence are complex. Addictive drugs flood the synapses of the mesolimbic system, especially the nucleus accumbens, with excessive amounts of dopamine, augmenting the hedonic tone and producing a euphoric state. The subsequent pleasurable reactions of the frontal cortex, amygdala, and hippocampus are exaggerated. The association of drug use and euphoria in these brain areas is reinforced with each exposure until the user no longer controls behavior, at which point addiction has resulted.[7] Chronic users have sustained activation of the cAMP response element-binding (CREB) protein, a trigger for the production of dynorphin and other proteins that shut off dopamine release, preventing the individual from finding pleasure in usually enjoyable activities and requiring subsequent fixes with higher doses of drug to overcome the effects of

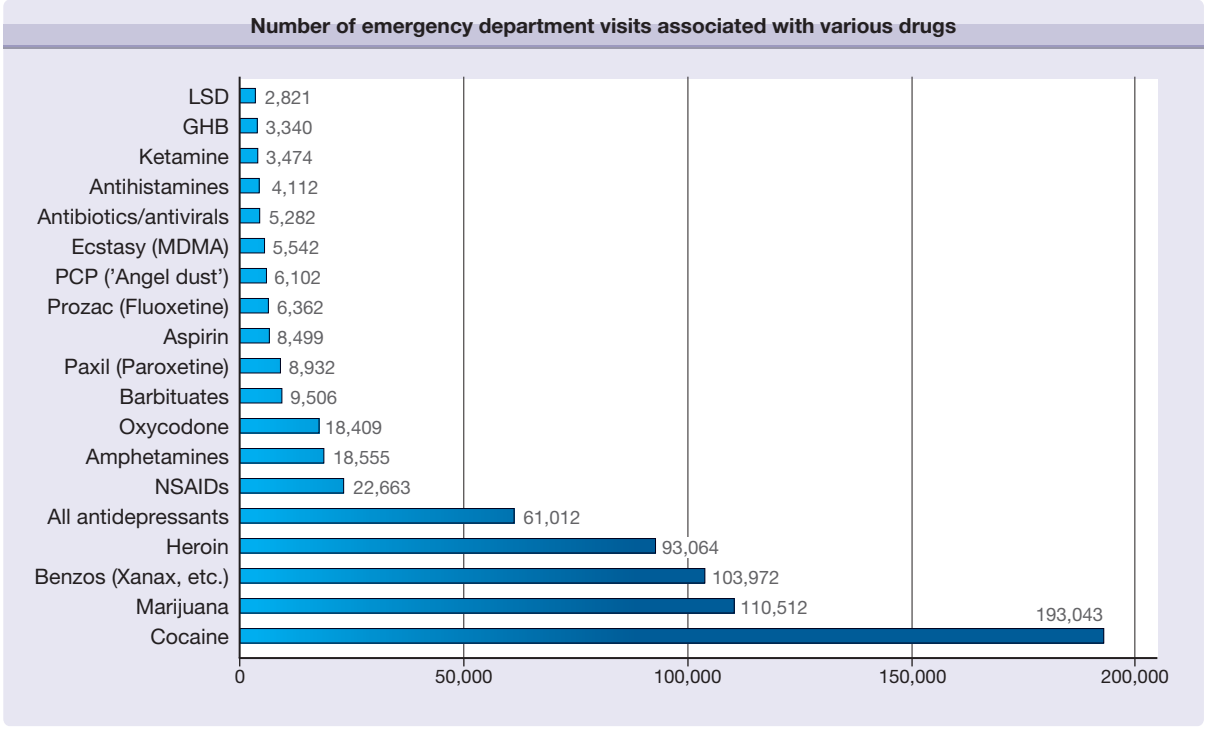

Figure 105-1 Number of emergency department visits associated with various drugs. Cocaine, marijuana and benzodiazepines were the most common drugs associated with emergency department visits in 2001. Data from the United States Substance Abuse and Mental Health Services Administration, 2001, http://thedea.org/statistics.html.[158]

tolerance. Addictive drugs also inhibit or excite neuronal activity in various areas of the nervous system. To compensate for these alterations, neuroadaptation develops with either formation of new neuroreceptor sites or diminished synthesis and sensitivity of neurotransmitters and neuroreceptor sites. Discontinuation of the drug reverses the neuroadaptation process and results in an exaggerated neural response that produces withdrawal symptoms.

CLINICAL FINDINGS ASSOCIATED WITH COMMONLY USED DRUGS

ALCOHOL

Ethyl alcohol, or ethanol, is the intoxicating ingredient found in alcoholic beverages. It is a central nervous system depressant that impairs brain function and motor skills and is rapidly absorbed from the stomach and small intestine into the bloodstream. Heavy use can increase the risk of liver disease, stroke and certain cancers.

Direct liver toxicity of alcohol can cause hepatomegaly, jaundice, shrunken liver in the setting of cirrhosis, and hypoalbuminemia leading to Muehrcke lines and Terry nails (see Chapter 89). Hyperestrogenemia can lead to gynecomastia, palmar erythema, spider angiomata, and testicular atrophy. Portal hypertension secondary to alcohol-induced liver cirrhosis can lead to an enlarged spleen, ascites, variceal bleeding, hemorrhoidal bleeding and caput medusae. Dupuytren contractures due to fibroblastic proliferation and disorderly collagen deposition may be seen in 66% of alcohol abusers. Asterixis and confusion are seen in patients with hepatic encephalopathy. Alcohol withdrawal delirium, also known as delirium tremens, is characterized by tachycardia, hypertension, body temperature elevation and delirium. Ataxia, confusion and lateral gaze palsy are indications of Wernicke encephalopathy. Wernicke encephalopathy followed by anterograde and retrograde amnesia along with confabulation characterize Korsakoff syndrome.

CLUB DRUGS

Club drugs include γ-hydroxybutyric acid (GHB, date rape drug), flunitrazepam (Rohypnol®, roofies), ketamine, MDMA, and LSD (Table 105-1). These drugs tend to be used by teenagers and young adults in social settings. In 2008, NIDA showed that among 12th graders, 1.3% had abused flunitrazepam, 1.2% had abused GHB and 1.5% had abused ketamine at least once in the year prior to their being surveyed.[8] GHB is sedating and can cause coma and seizures. It is being used increasingly by bodybuilders, who believe that it helps to metabolize fat and build muscle. Flunitrazepam is also sedating and can incapacitate users and cause amnesia; when combined with alcohol, this drug can be lethal. Ketamine distorts perception and produces feelings of detachment from the environment and self.

TABLE 105-1
Drugs: Street Names and Routes of Administration

Drug	Street Names[a]	Route of Administration
Alcohol	Booze Brew Juice	Ingestion
Anabolic steroids	Gym candy Juice Pumpers Stackers	Ingestion Injection
Betel	Bunga (Tagalog) Cau (Vietnamese) Jambe (Javanese) Kunya (Burmese) Paan (Sanskrit) Supadi (Nepali) Shupari (Bengali)	Chewed
Tobacco	Bogie, cancer stick, cigs (cigarettes) Chaw, snuff, chew (smokeless tobacco)	Chewed Smoke inhalation
Club Drugs		
GHB	Fantasy G Georgia Home Boy Liquid ecstasy Soap	Ingestion
Flunitrazepam	Roofies	Ingestion
Ketamine	Jet Special K Vitamin K	Ingestion
Cocaine	Blow Coke Crack Flake Snow	Nasal inhalation Injection Transdermal application
Heroin	H Junk Ska Smack	Injection Smoke inhalation
Inhalants	Poppers Snappers Whippets	Inhalation
Club Drugs		
LSD	Acid Blotter Dots	Ingestion
Marijuana	Ganga Grass Mary Jane Pot Reefer Weed 420	Smoke inhalation Ingestion
MDMA	Adam E Ecstasy Love X XTC	Ingestion
Methamphetamine	Chalk Crystal Glass Ice Meth Speed	Ingestion Injection Nasal inhalation Smoke inhalation
Phencyclidine	Angel dust Fuel Ozone PCP Rocket Wack	Ingestion Nasal inhalation Smoke inhalation
Prescription medications: Opioids, CNS depressants, stimulants	Dust, dillies (dilaudid) Emsel, God's drug (morphine) Oxy, cotton (oxycontin) Rids, vitamin R (Ritalin)	Ingestion

[a]More terms at NIDA (National Institute of Drug Abuse) http://www.drugabuse.gov and Office of National Drug Control Policy website http://www.whitehousedrugpolicy.gov.[2,159]

COCAINE

Cocaine (benzoylmethylecgonine) is an alkaloid extracted from the leaves of the coca plant *Erythroxylon coca*.[9–15] It is a powerful sympathomimetic, vasoconstrictor, local anesthetic, and stimulant. Cocaine hydrochloride is a powder that can be can be nasally inhaled or injected intravenously or subcutaneously, also known as "skin popping" (Fig. 105-2). Crack cocaine or "crack," the freebase rock crystal form of cocaine hydrochloride, is smoked (Table 105-1). *Freebase* refers to the pure basic form of an amine, as



Figure 105-2 Skin popping scars. Multiple white angular atrophic scars on the dorsal forearms and hands.

opposed to its salt form. The amine is usually a natural alkaloid product.

Cocaine can produce intense vasoconstrictive effects by directly stimulating the central nervous system and increasing peripheral catecholamines. The vasospastic action of cocaine is greatest at one hour after use and can be associated with ischemia, infarction and hemorrhagic injuries of most organ systems including the skin.[16–18] The ischemic effects of cocaine in the skin can lead to acute multifocal skin necrosis,[19] chronic skin ulcers,[20] cutaneous fibrosis,[21] blackened hyperkeratotic "crack hands"[22] and claw-like "parrot beak" curvature of the nails. These changes are commonly found in association with pernio and some atrophy of the distal portions of the digital pulp secondary to ischemia. At skin-popping sites, there may be central pallor surrounded by ecchymosis due to the vasoconstrictive properties of cocaine acting locally at the injection site with hemorrhage occurring in the surrounding tissue. *Skin popping* is a method of drug administration whereby a substance is injected subcutaneously or intradermally, but not intravenously and not typically intramuscularly. Individuals with vasomotor instability are more susceptible to these types of reactions.[23]

Inadvertent or deliberate direct intraarterial injection of cocaine can cause severe tissue ischemia and necrosis via direct vasoconstriction. Individuals experience an initial intense burning pain, followed by cyanosis and marked edema. Compartment syndrome may also result. In the most severe cases necrosis leads to amputation.[24,25] Skin popping also puts one at risk for developing secondary amyloidosis.

Cocaine-induced vasospasm may cause major internal organ injury including acute myocardial ischemia, cerebrovascular accidents, renal infarction[26] and splenic infarction.[18,27] Vasoconstriction of mesenteric vessels and the direct toxic effect of cocaine on gastrointestinal mucosa can result in acute abdominal crises (known as *crack belly*) secondary to perforations, intestinal ischemia and infarction.[28,29]

Various vasculitic and vasculopathic processes have been associated with cocaine use including pseudovasculitis,[30] urticarial vasculitis,[31] Churg–Strauss vasculitis,[32] Raynaud phenomenon,[33,34] Henoch–Schonlein purpura, necrotizing vasculitis[35,36] and Buerger disease (see Chapters 163, 164, and 173).[37,38]

The local anesthetic properties of cocaine make it difficult for individuals to feel traumatic injury. This leaves users prone to repetitive trauma from the irritant properties of the drug itself and implements of drug delivery, thus exposing them to an increased risk of infection.[39] Missing a vein and injecting into the surrounding tissue creates a niche environment in which bacteria can thrive.[40] Repeated needlesticks increase the likelihood of cutaneous infection and transmission of blood-borne viruses.[41]

Mucosal manifestations of ischemia secondary to cocaine inhalation or smoking include dental caries,[42] gingival recession,[43] oral blisters[44] and nasal and palatal perforation.[45] Insufflating (snorting) cocaine may lead to recurrent epistaxis, intranasal crusting, rhinitis and chronic sinusitis.[42,46] Inhalation utensils themselves can act as vectors for viruses and may induce "snorter's warts." Nasal septum perforation reduces nasal support and results in a broad, flat nose or "saddle nose deformity."[46–49] Nasal septum perforation typically occurs prior to development of palatal perforation. Cocaine burns of the upper airway are associated with hoarseness, dysphonia, odynophagia, dysphagia and stridor.[23,26,50–53] Crack cocaine smoke has a direct toxic effect on the corneal epithelium of the eye. Repeated exposure to the alkaloid smoke may cause an irritant effect leading to excessive eye rubbing and subsequent infectious complications, and chemical burns.[51]

Drug reactions including acute generalized exanthematous pustulosis[54] and Stevens–Johnson syndrome [55] have also been reported.

The stimulant properties of cocaine are associated with increased metabolism and dramatic weight loss.[56] Psychiatric conditions, most commonly delusions of parasitosis and subsequent formication are experienced approximately 20% of the time in cocaine users (also known as *coke bugs*)[57] (see Chapter 104). Recent reports have emerged of febrile agranulocytosis and often vasculitis with prominent involvement of the ear lobes secondary to cocaine adulterated with levamisole, an anthelmintic medication used in veterinary medicine to control parasites in livestock.[58,59]

HEROIN

Natural and semisynthetic derivatives of the opium poppy are known as opiates. Biologically natural opiates include morphine and codeine, while semisynthetic opiates such as heroin and hydromorphone are derived from biologically active opiates. Diacetylmorphine, or heroin, crosses the blood–brain barrier and binds opioid receptors in the brain, resulting in its euphoric, analgesic and anxiolytic effects. Heroin

is the most common parenterally injected illicit drug, either by intravenous or subcutaneous (*skin popping*) administration. Heroin may also be inhaled. With a peak "rush" at 7–8 seconds, it is the fastest-acting and via smoking most potent opiate, accounting for up to 90% of opiate use in the United States.

Scarring is the primary cutaneous stigma of injection drug use. The antecubital fossa is the usual starting point of intravenous drug use, followed sequentially by the upper arms, hands, neck, feet, legs, groin and digits.[60] Linear cord-like scars along a vascular distribution (*track-marks*), are formed after repeated injections along a superficial vein, resulting in venous thrombosis and subsequent fibrosis.[61] (Fig. 105-3) Skin popping scars are irregular round hypopigmented or hyperpigmented, atrophic or hypertrophic scars or keloids.[62] (see Fig. 105-2) *Soot tattoos* or *shooting tattoos* result from soot deposition or the introduction of foreign materials in the dermis after "cooking" of the drug and/or flaming of needles (Fig. 105-4).[63]

Diluting or "cutting" heroin to retail "street strength" is a common practice. Common diluents for white powder heroin include quinine, lactose, lidocaine, caffeine, lemon juice, inositol, dextrose, sucrose, procaine, starch, magnesium silicate and mannitol.[64] Diluents may cause lymphatic destruction, foreign body granulomas, cutaneous nodules, ulcerations, panniculitis and dermal sclerosis secondary to irritation and dermal inflammatory processes (Fig. 105-5).[65–67] The subsequent vascularized granulation tissue in and around chronic ulcers may be used as a site for drug injection.[20] (see eFig. 105-5.1 in online edition) *Black tar heroin* is a dark, gummy form of heroin that is less refined and cheaper than the white powder variant. It is mixed with a variety of diluents including dextrose, burnt cornstarch, instant coffee and dirt.[68] The mixture may



Figure 105-3 Track marks formed after repeated intravenous drug injections. (**A**) Inflammatory tracks of the dorsal hand, (**B**) inflammatory tracks with associated ulcers, nodules and abscesses on the hands and forearms, and (**C**) fibrotic tracks on the dorsal forearms.



Figure 105-4 "Soot tattoo." Soot tattoos result from the deposition of soot and other foreign materials in the dermis. Foreign materials may be introduced via adulterated drugs and/or introduction of needles with adherent soot after flaming for sterilization.

also contain dust and pathogens introduced during the process of manufacturing or storage.[64,66] Irritant substances can also cause sterile chemical cellulites and abscesses.

Cutaneous infections are common in injection drug users (Table 105-1). Skin popping and black tar heroin use are associated with cutaneous necrosis and necrotizing ulcers.[69–72] An increase in *Clostridial* infections including wound botulism due to *Clostridium botulinum*, tetanus due to *Clostridium tetani*, and rapidly progressive myonecrosis with a fulminant shock syndrome due to *Clostridium sordellii* have been observed with the use of black tar heroin in California.[73–76]

Fungi have been cultured from confiscated heroin specimens.[77] Systemic candidosis characterized by painful nodules and pustules on the scalp and hair-bearing areas, chorioretinitis or uveitis, and costochondritis has been described in individuals injecting brown heroin diluted with lemon juice.[78]



Figure 105-5 Foreign body response and cellulitis. Angular ulcerations, firm erythematous nodules, and warm tender induration at the site of subcutaneous and intravenous injection of adulterated heroin.

Inhaling smoke and then exhaling it into another individual's mouth (known as *shotgunning*) is associated with efficient transmission of respiratory pathogens. [79]

Opiates induce histamine release that results in subsequent pruritus that starts almost immediately after heroin injection and can last 10 minutes to 24 hours.[80] Urticaria, severe angioedema and bronchospasm have also been reported with heroin use.[80]

Rare morbilliform eruptions, fixed drug eruptions and a case of toxic epidermal necrolysis have also been reported.[62,64,81] Adulterants are thought to be responsible for most of these reactions.

Secondary systemic amyloidosis is an important cause of renal disease in heroin users. Its pathogenesis is thought to be associated with chronic antigenic stimulation and prolonged inflammation secondary to cutaneous infections. Patients were observed to progress to end stage renal disease over several months to 3 years.[82]

3,4-METHYLENEDIOXYMETHAMPHETAMINE

3,4-methylenedioxymethamphetamine (MDMA, ecstasy), along with lysergic acid diethylamide (LSD) and hallucinogenic mushrooms, is one of the most commonly used illicit hallucinogens (Table 105-1). More than 7 million persons have tried MDMA at least once in their lifetime. MDMA is a synthetic stimulant with psychoactive properties that acts both by causing a massive synaptic release of serotonin, and to a lesser extent dopamine and norepinephrine, as well as inhibiting the reuptake transporters within the synapse. Its short-term effects include inducing euphoria, a sense of enhanced intimacy with others, and diminished anxiety and depression. Adverse health effects can include nausea, chills, sweating, teeth clenching, muscle cramping, and blurred vision. MDMA is usually ingested, but may be injected or inhaled with effects lasting for 3–6 hours. It is frequently used in combination with alcohol, cannabis, amphetamine or cocaine, resulting in unpredictable effects.[83]

MDMA is associated with xerostomia and is therefore often coupled with soft drinks, which may lead to dental caries. The neurotransmitter release associated with MDMA induces bruxism, trismus and teeth grinding that can wear down tooth enamel. Direct application of MDMA to the gums may cause necrotizing gingivitis and widespread perioral and intraoral swelling. MDMA can also interfere with systemic temperature regulation that can, rarely, be lethal.

METHAMPHETAMINE

Methamphetamine is a very addictive synthetic stimulant that affects the brain and central nervous system through the release of dopamine, norepinephrine, and serotonin. By concurrently blocking reuptake of these neurotransmitters, sensations of euphoria, lowered inhibitions, feelings of invincibility, and hyperactivity are produced.[84] Metamphetamine a white, odorless,

bitter-tasting powder that can be ingested orally, snorted or injected. It may also be smoked in its rock "crystal" form.[85] Short-term effects include feelings of euphoria, decreased fatigue associated with difficult life situations, headache, difficulty concentrating, diminished appetite, abdominal pain, vomiting, diarrhea, disordered sleep, paranoid or aggressive behavior, and psychosis. Long-term use of methamphetamine use is associated with anorexia, neurotoxicity, neurodegeneration, and clinical depression that may lead to homicidal and suicidal ideation and action.[85]

An increased rate of skin and soft tissue infections have been reported in methamphetamine users, including increased rates of methicillin-resistant *Staphylococcus aureus* (MRSA) infections in noninjection drug users. Methamphetamine use is associated with formication that can lead to subsequent skin picking, skin breakdown, and portals of infection (see eFig. 105-5.2 in online edition). Use of methamphetamine and other sexually stimulating drugs can also increase direct skin-to-skin sexual contact and transmission of MRSA[86] (Table 105-1).

Methamphetamine users are at risk for developing *meth mouth*, or oral decay characterized by poor oral hygiene, xerostomia and rampant caries typically on the smooth surfaces of teeth, and excessive tooth wear.[87] Methamphetamine use has also been associated with psychosis and subsequent self-injurious behavior including genital mutilation.[88]

SEDATIVES

Sedatives as a class of drugs includes benzodiazepines, hydroxybutyrate, flunitrazepam and cannabis. Cutaneous manifestations and reactions to this group of drugs is quite rare, however drug reactions have been rarely associated with benzodiazepines, including type IV morbilliform drug hypersensitivity eruptions,[89] acute generalized exanthematous pustulosis to tetrazepam[90] and erythema multiforme to clonazepam.[91]

ANABOLIC STEROIDS

Most anabolic steroids are synthetic substances similar to the male sex hormone testosterone. They may be ingested or injected, and are used especially by athletes to build muscle and enhance athletic performance. In 2000, approximately 3.6% of male and 0.9% of female twelfth graders in the United States had used anabolic steroids. Their abuse is most commonly associated with acne vulgaris, striae formation and alterations in hair growth.

Anabolic steroids induce sebaceous gland enlargement and the development of comedones through abnormal follicular keratinization.[92,93] Steroid-associated acne is characteristically distributed on the face, shoulders, chest and back.[93] It can progress to acne conglobata and fulminans secondary to the brisk immune response to *Propionibacterium acnes* in individuals who have never even had acne.[94] Steroid-associated acne does not always respond to routine therapy and may persist for weeks to months following discontinuation of the drugs (see Chapter 80).[93,95]

Anabolic steroid use is also associated with alterations in hair growth, including hirsutism and androgenic alopecia, both of which are often more noticeable in women and may not be reversible with discontinuation of the drug.[93,96,97] Males can develop testicular atrophy, gynecomastia and infertility. Women may experience menstrual changes, male-pattern alopecia, and deepening of the voice. Teenagers risk permanently stunted height and accelerated pubertal changes.

Steroid use is associated with striae formation secondary to dramatic hypertrophy of muscle tissue.[98] Gingival enlargement has also been observed in those using anabolic steroids for greater than one year. Systemic effects of steroid abuse include hepatic damage, jaundice, hypertension and dyslipidemia.

Bacterial abscesses may occur at steroid injection sites secondary to nonsterile injection techniques.[93,96] Repeated injection into the same site can result in inflammation and oil-induced granuloma formation.[99] Soft tissue pseudotumors[100] and rhabdomyolysis[101] have also been reported in injectors.

In addition to causing de novo conditions, anabolic steroid use is also associated with exacerbation of existing acne and psoriasis.[93] Case reports have described exacerbation of angiolipomas[102] and latent acute hereditary coproporphyria as well.[103]

TOBACCO

Through the use of tobacco, nicotine is one of the most heavily used addictive drugs in the United States. Cigarette smoking accounts for 90% of lung cancer cases in the US. Tobacco is an agricultural product processed from the leaves of plants in the genus *Nicotiana*, which can be smoked or chewed (more precisely, placed between gingival and buccal mucosa) to allow nicotine absorption via oral mucosa. Nicotine in the tobacco leaves is responsible for the vasoconstrictive effects of smoking via increased vasopressin secretion and stimulation of the sympathetic nervous system, thereby causing peripheral vasoconstriction.[104–108] Smoking a single cigarette can produce cutaneous vasoconstriction for up to 90 minutes.[109] Smoking decreases tissue oxygenation via vasoconstriction and by increasing carboxyhemoglobin, thereby limiting the blood's oxygen carrying capacity.[110] Smoking also increases platelet aggregation[111] and blood viscosity,[112] and decreases prostacyclin formation.[113] This combination of mechanisms also leads to impaired postoperative wound healing in smokers.[114,115] The tar in cigarettes increases a smoker's risk of lung cancer, emphysema, and bronchial disorders. The carbon monoxide in smoke increases the chance of cardiovascular diseases.

Although the mechanism is unknown, smoking tobacco has also been linked with premature aging and rhytid formation. Elastin from photoprotecting skin in smokers is thick and fragmented, resembling that of sun-damaged skin but involving the reticular rather than the papillary dermis. Chronic dermal ischemia of as well as



Figure 105-6 The "nicotine sign." The orange hue of tobacco can lead to yellow–orange discoloration of the fingertips and fingernails in chronic cigarette smokers. Clubbing of the distal digits indicates the presence of chronic lung disease.

the decreased collagen synthesis likely play roles in the damaging elastic fibers.[116] Increased plasma neutrophil elastase activity secondary to smoking may contribute to abnormal elastin.[117] Smoking also causes a yellow–brown discoloration of the fingers and fingernails of digits habitually holding the cigarette (Fig. 105-6).[118]

Cigarette smoking and chewing tobacco use are associated with a number of mucosal conditions. *Leukokeratosis nicotinica palati* (nicotine stomatitis, smoker's palate) is characterized by uniform keratosis of the hard palate with multiple tiny umbilicated erythematous papules representing the inflamed orifices of minor salivary glands.[119] This benign oral lesion is seen exclusively in smokers and is caused by the tars and heat in tobacco smoke. Resolution is usually complete within 2 weeks of smoking cessation. All forms of tobacco use play a significant causative role in the development of leukoplakia.[120] *Leukokeratosis nicotinica glossae* (also known as tongue) is a homogeneous leukoplakia affecting the anterior two-thirds of the dorsal tongue.[121] Acute necrotizing ulcerative gingivitis "trench mouth," Vincent disease is caused by bacteria but is not communicable. Smokers tend to have fewer oral aphthous ulcers than nonsmokers due to decreased mucosal blood flow resulting from the vasoconstrictive effect of nicotine. Yellow discoloration of teeth secondary to tar deposition is also commonly observed.

Oral verrucous carcinoma, black hairy tongue, oral melanosis and oral warty dyskeratoma have been linked to tobacco use, but the connection is not as strong as in the aforementioned conditions.[122,123]

All forms of tobacco are associated with an increased risk of oral cancer.[124–127] Cigarette smoke may act as a direct carcinogen or via systemic absorption.[128,129] Smokers are also at an increased risk of developing squamous cell carcinomas at sites other than the oral mucosa, likely because of the immunosuppressive effects of smoking.[130–132] Immune dysregulation associated with smoking is thought to be the reason that smokers with melanomas present with more advanced lesions and have a poorer disease prognosis.[133,134]

Thromboangiitis obliterans (Buerger disease) is an obstructive vascular disease that is indisputably associated with heavy cigarette smoking in young men. Cutaneous manifestations include blanching, cyanosis, burning, tingling, ulceration, necrosis, and gangrene (see Chapter 170).

Cigarette smoking has been shown to exacerbate and possibly induce palmoplantar pustulosis.[135,136]

Both allergic and irritant contact dermatitis characterized by itching and burning, have been documented to nicotine patches.[137] Allergic contact dermatitis to the tobacco leaf has also been reported in tobacco harvesters and factory workers.[138,139]

BETEL

Betel (*Piper betle*) belongs to the *Piperaceae* family; its leaf has an important social and cultural role in South Asia, Southeast Asia and the South Pacific. Betel leaves are chewed with the areca nut (also known as *betel nut*), calcium hydroxide, Acacia catechu bark, and occasionally tobacco in a wrapped package known as "betel quid." Betel leaves are used as a stimulant, antiseptic and breath freshener. The areca nut contains the alkaloid and stimulant arecoline which promotes salivation and stains saliva and teeth dark red to rust-colored. Calcium hydroxide keeps the active ingredients alkaline, thereby enabling its sublingual absorption and entry into the bloodstream.

Continuous chewing of betel quid maintains constant moisture at the oral commissures which, when coupled with continuous friction of opposing surfaces, causes maceration, erosion and fissures. These lesions can be mistaken for angular cheilitis, candidiasis or vitamin-deficiency associated perleche.[140] The mixture is usually kept between the teeth and lip and may thus cause burning and erosions of the buccal mucosa.[140] *Chewer's mucosa* results from the direct chemical action of the quid and/or traumatic effect of chewing, and is characterized by a brownish–red discoloration of the buccal mucosa with an irregular desquamative epithelial surface. These mucous membrane findings are not thought to be malignant or premalignant.[141] Oral lichenoid lesions regress with decrease in frequency, duration or change in site of placement of the quid.[142]

Oral submucous fibrosis is directly related to betel quid chewing and affects the buccal mucosa, lips, retromolar areas, soft palate and occasionally the pharynx and esophagus.[143] It is characterized by prodromal oral dysesthesia aggravated by spicy foods, followed by early blanching mottled mucosal lesions and subsequent late development of palpable vertical fibrous bands in the buccal mucosa and around the mouth opening requiring surgical release for sufficient opening of the mouth.[144] Trismus, dysphagia, xerostomia, rhinolalia and tongue stiffening present late in the disease course. Mucosal petechiae, leukoplakia and epithelial dysplasia are also seen.[145,146] The most serious complication of oral submucous fibrosis is the development of oral carcinoma, which can be seen in up to 10% of users and is typically localized to the buccal tongue and labial mucosa.[147] Of all oral cancers in Taiwan, as many as 86.2% of cases have been reported to be in betel quid chewers.[148]

POLYSUBSTANCE ABUSE

Polysubstance abuse, the concurrent use of several drugs with different pharmacologic effects, is becoming increasingly common. The diversity of reported drug use combinations suggests that achieving some perceptible change in state may be the primary motivator driving this practice. One drug may be used to enhance the effects of another, as with the combined use of benzodiazepines and methadone or cocaine and heroin (*speedballs*). Polysubstance abuse can cause adverse health consequences, such as pulmonary disease, reproductive dysfunction and immunosuppression in chronic cocaine and psychostimulant abuse. It may also exacerbate preexisting conditions such as hypertension and cardiac disease. The concurrent use of some drugs, including cocaine and opiates, is frequently associated with deleterious behavior such as needle sharing by injection drug users.

COMPLICATIONS

In addition to the local reactions and systemic effects of specific drugs themselves complications of drug use must also be considered.

Injection drug use is associated with inoculation and transmission of infectious agents leading to local skin and soft tissue infections and abscesses, as well as the subsequent hematogenous spread of microbes. Gram-positive cocci including *Staphylococcus aureus*, group A β-hemolytic streptococcus and other streptococci are the most commonly observed microbial agents.[149–151] Anaerobes are the second most common group of bacteria to be isolated, while Gram-negative bacteria are less commonly isolated. The source of the pathogens is variable, but most originate from the flora of the skin and oropharynx secondary to needle-licking practices and use of saliva to clean or moisten skin and injection implements.[149] Abscesses and cellulitis occur in 22%–65% of drug users[152] (Fig. 105-7). Irritant substances including the drug or its diluents may cause sterile chemical cellulitis and abscesses. Systemic infections including bacteremia, endocarditis, osteoarthritis, and systemic candidosis may result. Systemic candidosis is the most common systemic fungal infection in injection drug users (Table 105-2).

Direct intra-arterial injection of drugs may cause severe ischemia and necrosis. Early intense burning is noted in the injected area, followed by marked edema, compartment syndrome, cyanosis, and livedoid patches of the affected limb within a few hours. Distal necrosis may occur in the most severe cases, and has been seen with the use of drugs such as cocaine, heroin, pentazocine, diazepam, amphetamine and others[25,153,154] The local cytotoxicity of a drug may cause a chemical endarteritis resulting in vasospasm and thrombosis.

The behavioral effects of injection drug use has been associated with an increased risk of sexually transmitted diseases as well as blood-borne diseases transmitted through unsterilized needles including hepatitis B virus (HBV), hepatitis C virus (HCV), human immunodeficiency virus (HIV) and human T-lymphotropic virus (HTLV) (Table 105-2).



Figure 105-7 Cellulitis at the site of repeated drug injection. Tender warm erythema and induration surrounding a chronic ulceration at the site of routine drug injection. Secondary infections at injection sites can be caused by introduction of pathogens via unsterilized needles, adulterated drugs, and at sites of compromised skin integrity. *S. aureus* infectious endocarditis occurred following bacteremia from this site.

The repeated trauma of venipuncture, local infections and the irritant drugs and adulterants can lead to superficial and deep venous thrombosis. Chronic venous insufficiency can result from vein trauma, necrotic ulcers at sites of past subcutaneous injection, vein thrombosis and blockage of the lymphatic system.[155,156]

Other noninfectious diseases associated with drug use include psychiatric disease, accidental injury due to altered mental status and trauma due to criminal violence or domestic abuse.

TABLE 105-2
Common Infectious Agents Associated with Drug Abuse and Addiction

Class	Infectious Agent
Bacterial	*Staphylococcus aureus* *Streptococcal* species *Pseudomonas aeruginosa* *Clostridium botulinum* *Eikenella corrodens* Anaerobes Unusual organisms
Fungal	Dermatophytes *Candida* *Aspergillus* *Mucor*
Viral	Herpatic viruses Human T-cell lymphotropic virus Human immunodeficiency virus Hepatitis B virus Hepatitis C virus
Sexually transmitted	*Chlamydia trachomatis* *Neisseria gonorrhoeae* Human immunodeficiency virus Human papilloma viruses *Molluscum contagiosum* *Treponema pallidum*

TABLE 105-3
Drug Detection in Body Fluids and Hair

Substance	Blood/Saliva	Urine	Hair
Alcohol	12–24 hours	6–24 hours	Up to 90 days
Amphetamines (except meth)	12 hours	1–3 days	Up to 90 days
Methamphetamine	1–3 days	3–5 days	Up to 90 days
MDMA (Ecstasy)	25 hours	24 hours	Up to 90 days
Benzodiazepines	6–48 hours	Therapeutic use: 0–7 days Chronic use (>1 year) 4–6 weeks	Up to 90 days
Cannabis	2–3 days, up to 2 weeks in heavy users	3–7 days, up to >30 days after heavy use and/or in users with high body fat	Up to 90 days
Cocaine	2–5 days	2–5 days with exceptions for certain kidney disorders	Up to 90 days
Codeine		2–3 days	
Cotinine (break-down product of nicotine)	2–4 days	2–4 days	Up to 90 days
Morphine	1–3 days	2–4 days	Up to 90 days
Heroin	1–2 days	3–4 days	Up to 90 days
LSD	0–3 hours	24–72 hours (tests for LSD are very uncommon)	Up to 3 days
Methadone	24 hours	3 days	Up to 90 days
PCP	1–3 days	3–7 days for single use; up to 30 days in chronic users	Up to 90 days

Urine data from Labcorp I. Drugs of Abuse Reference Guide, 2004, https://www.labcorp.com/pdf/doa_reference_guide.pdf. accessed May 1, 2011.

DIAGNOSIS

While mucocutaneous findings can be suggestive of drug use drug testing is needed to identify the agents used. Bodily fluids including saliva, blood, urine and hair can be used in drug detection. Urinalysis for qualitative detection of psychoactive substances and their metabolites is often the fastest way to determine ingestion of a substance (Table 105-3).

Systemic conditions secondary to the effects of substance abuse should also be part of the evaluation of these patients. Cutaneous infections at sites of trauma, ulcers, or necrosis should be swabbed or biopsied for culture to identify and treat causative organisms. Thorough evaluation and imaging may be required to rule out injury to or involvement of vital organs and bony structures. In injection drug users, thorough cardiac evaluation and examination of mucocutaneous and acral surfaces should be undertaken to access for embolic phenomenon. Evaluation for transmitted infections such as HIV, hepatitis and sexually transmitted diseases may be required.

DIFFERENTIAL DIAGNOSIS

It is imperative to rule out primary infectious causes of ulcers, nodules, skin and subcutaneous infections in suspected drug users. Inflammatory and vasculopathic processes such as pyoderma gangrenosum, livedoid vasculopathy and medium vessel vasculitides must be considered in the setting of ulcers and nodules. Evidence of distal vascular compromise can be seen in pernio, thromboembolic phenomenon and Raynaud phenomenon. The edematous phase of scleroderma, eosinophilic fasciitis and secondary lymphatic obstruction are rare entities to consider the setting of distal extremity swelling. Infectious and noninfectious granulomatous diseases [including tuberculosis, leishmaniasis, granulomatosis with polyangiitis (Wegener's) and sarcoidosis] can present with nasopalatal infiltration and perforation. Patients with pruritus and formication may require evaluation for infestation, metabolic or psychiatric etiologies of their symptoms.

TREATMENT

A detailed discussion of the treatment of drug abuse and dependence is beyond the scope of this chapter, but it is essential to recognize that these are chronic illnesses that require long-term strategies. Combined medical and behavioral therapy are important elements of a therapeutic process comprising detoxification, treatment and relapse prevention. Amelioration of withdrawal symptoms is key to initiation of therapy. A multidisciplinary approach including addiction

counseling, social work support and management of associated infectious, vascular, cardiac and hepatic complications is critical to comprehensive care.

Potential therapies for opiate dependence include drug detoxification (office-based, inpatient or ultra rapid under anesthesia), agonist maintenance (injectable diacetylmorphine, methadone, levomethadyl or buprenorphine), antagonist maintenance (naltrexone) and pharmacologic treatment of withdrawal symptoms (clonidine, lofexidine or guanfacine).

Treatment options for tobacco addiction include nicotine replacement therapies (patch, spray, gum and lozenges). Bupropion and varenicline have been approved by the Food and Drug Administration for management of nicotine addiction. Behavioral interventions include group and individual therapies, and telephone quitlines.

Outpatient and residential treatment centers can provide environments in which individuals can participate in therapeutic communities and benefit from behavioral therapy and peer support. Alternative therapies including acupuncture may also prove useful in combination with medical and behavioral therapeutic interventions. Although relapses are common, successful outcomes are accomplishable, indicating the importance of candid, supportive, nonjudgmental, care-facilitating discussions in patients whose drug use has been revealed through skin examination.

The transmission of infectious disease via injection drug use can be addressed by encouraging physicians to prescribe sterile injection equipment, setting up injection rooms staffed by healthcare personnel who can provide advice on safe injection techniques and instituting strictly supervised heroin, diamorphine or buprenorphine prescription programs for long-term injectors.[157] This may help reduce the risk of life-threatening infection from nonsterilized drugs, prevent overdose from drugs of unknown purity, break the link between drug use and criminal activity to acquire drugs and decrease the number of injections in public places.

KEY REFERENCES

Full reference list available at www.DIGM8.com

DVD contains references and additional content

2. Abuse NIoD: 2010, http://www.drugabuse.gov, accessed Jun 2010
23. Payne-James JJ, Munro MH, Rowland Payne CM: Pseudosclerodermatous triad of perniosis, pulp atrophy and 'parrot-beaked' clawing of the nails—A newly recognized syndrome of chronic crack cocaine use. *J Forensic Leg Med* **14**(2):65-71, 2007
58. Zhu NY, Legatt DF, Turner AR: Agranulocytosis after consumption of cocaine adulterated with levamisole. *Ann Intern Med* **150**(4):287-289, 2009
66. Heng MC, Feinberg M, Haberfelde G: Erythematous cutaneous nodules caused by adulterated cocaine. *J Am Acad Dermatol* **21**(3 Pt 1):570-572, 1989
86. Cook HA, et al: Heterosexual transmission of community-associated methicillin-resistant Staphylococcus aureus. *Clin Infect Dis* **44**(3):410-413, 2007
145. Pindborg JJ et al: Oral submucous fibrosis as a precancerous condition. *Scand J Dent Res* **92**(3):224-229, 1984

Chapter 106 :: Skin Signs of Physical Abuse

:: Howard B. Pride

ABUSE AT A GLANCE

- Child abuse, elder abuse, and domestic violence are common.
- Abuse is a problem of all socioeconomic classes and races.
- Bruising on soft padded areas of the body and patterned bruising that are multiple and in different stages of healing are suspicious of abuse.
- Burns that are bilateral and uniform are suspicious of abuse.
- Law mandates the reporting of all suspected cases of child abuse and, in some states, elder abuse.

CHILD ABUSE

Child abuse is an uncomfortable topic for most practitioners and is a source of anxiety, anger, and confusion among those who care for children. True incidence statistics are difficult to determine, but each year in the United States, of the approximately three million children referred to child protective services, approximately one million are determined to be the victims of abuse and neglect (or about 12 cases per 1,000 children) and approximately 1,500 die from abuse or neglect.[1] Clearly, those whose practices involve the dermatologic care of children encounter real or suspected child abuse. Practitioners must have some basic knowledge of abuse and its evaluation to appropriately manage these cases.

Because many forms of physical abuse have external manifestations, the skin examination may serve as the first clue that abuse is taking place. Conversely, a broad knowledge of skin diseases provides a unique

TABLE 106-1
Conditions Mistaken for Abusive Bruising

- True petechiae and purpura
  - Disorders of coagulation
  - Ehlers–Danlos syndrome
    - Infections
    - Rocky Mountain spotted fever
    - Meningococcal infections
    - Group A streptococcal infections
- Palpable purpura of vasculitis
- Valsalva petechiae
- Lichen sclerosus
- Folk remedies
  - Cao gio: rubbing vigorously with a hard object such as a coin
  - Cupping: suction mark left by the cooling of a warm metal cup
- Nodular lesions mimicking deep bruises
  - Neuroblastoma
  - Vascular malformations
  - Dermatomyositis-associated nodules
  - Erythema nodosum
  - Discolorations that look like bruises
  - Phytophotodermatitis
  - Maculae coeruleae from lice infestation
  - Mongolian spots
  - Dye from blue jeans
- Inflammatory conditions that mimic bruising
  - Urticaria/angioedema/urticarial vasculitis
  - Pernio
- Conditions that mimic whip marks
  - Incontinentia pigmenti
  - Striae
  - Phytophotodermatitis

insight into those diagnoses that may mimic various forms of child abuse (Tables 106-1 and 106-2). The literature is rich in examples in which an astute clinician averted the disastrous results of a false claim of abuse by correctly diagnosing a dermatologic condition.

True abuse must be reported and a thorough evaluation conducted. It is essential that practitioners develop a relationship with the institution or individual in their area who is best able to manage these difficult cases. Ideally there should be an abuse team consisting of a dermatologist, pediatrician, social worker, medical photographer, and, when needed, pediatric subspecialists such as orthopedists, hematologists, psychologists, and gynecologists. The need for specialization in this field is highlighted by the institution in the United States of pediatric subspecialty board certification in child abuse, beginning in 2010. It is most helpful if one's relationship is forged with the abuse team before an abuse incident and a set protocol for dealing with alleged or suspected abuse is established in the practitioner's office. Local emergency phone numbers for reporting abuse can be obtained from the Child Welfare Information Gateway or Childhelp National Headquarters (Table 106-3).

Child abuse spans all ages with 32% of abused children being younger that 4 years of age, 24% being 4–7 years of age, and 19% being 8–11 years of age. Typical children who suffer abuse have emotional or behavioral problems, have special medical needs, have several siblings, live in single-parent households, or live at or below the poverty level. Abuse is approximately

TABLE 106-2
Conditions Mistaken for Nonaccidental Burns

- Phytophotodermatitis
- Folk remedies (Maquas, or moxibustion): burns delivered near diseased organs or therapeutic sites as in acupuncture
- Impetigo/ecthyma
- Epidermolysis bullosa
- Immunobullous diseases
- Sunburn/xeroderma pigmentosum
- Burns from objects heated by sun
- Electric burn from an enuresis blanket
- Chemical burn from use of undiluted acetic acid
- Chemical burn from Icy Hot balm
- Chemical burn from calcium chloride
- Diaper dermatitis
- Pernio
- Fixed drug eruption

TABLE 106-3
Helpful Agencies for Information on Abuse and Domestic Violence

- Child Welfare Information Gateway, 1250 Maryland Avenue, SW, Eighth Floor, Washington, DC 20024, Ph: (800) 394-3366, email: info@childwelfare.gov, http://www.childwelfare.gov/
- Childhelp National Headquarters, 15757 N. 78th Street, Suite B, Scottsdale, AZ 85260, Ph: (480) 922-8212, http://www.childhelpusa.org
- Domestic Violence International Resources, http://www.vachss.com/help_text/domestic_violence_intl.html
- International Network for the Prevention of Elder Abuse, http://www.inpea.net, e-mail contactus@inpea.net
- International Society for Prevention of Child Abuse and Neglect, 13123 E. 16th Ave, B390, Aurora CO 80045, Ph: (303) 864-5220, Fax: (303) 864-5222, email: ispcan@ispcan.org, http://www.ispcan.org
- National Adult Protective Services Association, 920 S. Spring Street, Suite 1200, Springfield, IL 62704, Ph: (217) 523-4431, Fax: (217) 522-6650, http://www.apsnetwork.org
- National Center on Elder Abuse, c/o Center for Community Research and Services, University of Delaware, 297 Graham Hall, Newark, DE 19716, Ph: (302) 831-3525, Fax: (302) 831-42525, e-mail ncea-info@aoa.hhs.gov, http://www.elderabusecenter.org
- National Committee for the Prevention of Elder Abuse, 1612 K Street, NW, Suite 400, Washington, DC 20006, Ph: (202) 682-4140, Fax: (202) 223-2099, email: ncpea@verizon.net, http://www.preventelderabuse.org
- National Coalition Against Domestic Violence, 1120 Lincoln Street, Suite 1603, Denver, CO 80203, Ph: (303) 839-1852, Fax: (303) 831-9251, email mainoffice@ncadv.org, http://www.ncadv.org
- National Resource Center on Domestic Violence, 6400 Flank Drive, Suite 1300, Harrisburg, PA 17112, Ph: (800) 537-2238 ext. 5, Fax (717) 545-9456, http://www.nrcdv.org

two times more common in Pacific Islanders, American Indians, Native Alaskans, and African American children compared to the average American population. Perpetrators tend to have emotional or psychological problems, have frequently been victims of abuse themselves, abuse drugs or alcohol, are perpetrators of spousal abuse or have a history of marital discord, have marginal parental skills or knowledge, and have poor self-esteem. Parents are the perpetrator 80% of the time.[2] Although these profiles are helpful, it is important to remember that any child may be the victim of abuse.

THE BATTERED CHILD

Bruising is the result of blunt trauma, delivered either accidentally or intentionally. Active children, particularly toddlers, are prone to multiple bruises, and the identification of abusive injury is fraught with difficulty. The size, shape, color, and feel of a bruise varies on the basis of anatomic site, the degree of force used, the firmness of the object delivering the force, and the underlying health of the injured individual. Great care and attention to detail must be exercised when evaluating these children who likely have been brought to the office for some other complaint. The history should include as much detail as possible and inconsistencies in the parent's story clearly documented in the medical record (eTable 106-3.1 in online edition).[3] It is essential to perform a total body, skin, and mucous membrane examination. It is also important to note the child's behavior and parent–child interactions.

The color of all bruises should be noted and clearly documented. This may aid in determining the age of a bruise and may point out inconsistencies in the caretaker's history. Multiple bruises of differing colors may indicate ongoing trauma rather than one isolated incident. Caution must be exercised in dogmatically, stating the time of injury based on bruise characteristics because color depends on the intensity, depth, and location of the injury. There is good evidence that a bruise with any yellow color must be older than 18 hours, but a bruise may be red, blue, or purple/black throughout its life span, from beginning to resolution. Bruises of identical age and cause on the same person may not appear as the same color and may not change at the same rate.[4] It is most prudent to document color without alluding to a specific age of a bruise in the medical record. Faint bruised might be more easily visualized with the use of a Wood's lamp.

Although there are no absolute differentiating features, certain aspects of an intentionally inflicted bruise may suggest abuse. Because young children tend to explore in a forward direction, accidents are more frequent on the distal arms and legs, knees, elbows, and forehead. Soft, padded, posterior, and protected areas of the body are far less likely to be accidentally injured. Bruises on the abdomen, buttocks (Fig. 106-1), thighs, genitalia, ear lobes, and cheeks are uncommon, so marks in these areas should raise concern.

Inflicted bruises often leave patterned imprints of a hand, whip, or hard object. Linear purpura, with a small triangle at the base (Fig. 106-2) representing the interdigital and finger web spaces, occurs after a slap injury. Grab or pinch marks can be recognized by their location on soft padded areas and their unusual patterning. Circumferential purpura or hemosiderin pigmentation (Fig. 106-3) suggests a ligature injury, which would be difficult to explain as accidental. Bite marks (Fig. 106-4) are always inflicted, although they are sometimes from siblings or other children. The shape and size of the marks can identify an adult mouth versus a bite from a child. It is helpful to include a ruled measuring scale in any photographs to help forensic identification at a later date.

The head is the most common target of physical abuse (see eFig. 106-4.1 in online edition). Black eyes are common accidental injuries but are more suspicious if they are bilateral or are unaccompanied by evidence of trauma to the nose or superior orbital ridge. Subconjunctival hemorrhages can be seen in 0.5%–13.0% of typical newborns, but a large subconjunctival hemorrhage beyond 1 and 2 weeks of life is suspicious of abuse. Petechiae in the periorbital region



Figure 106-1 Purpura and erosions on the soft, padded areas of the buttock and thighs, representing very obvious abuse. (Used with permission from Paul Bellino, MD.)



Figure 106-2 Linear purpura representing the interdigital spaces from a hand slap. Note the inferior triangular shape that corresponds to the finger web space. (Used with permission from Paul Bellino, MD.)



Figure 106-3 Linear, circumferential hyperpigmentation at the site of previous ligature. (Used with permission from Paul Bellino, MD.)

have been seen in children with abuse related retinal hemorrhages. Accidental bruising or other injuries to the oral mucous membranes are unusual and should be considered as suspect (see eFig. 106-4.2 in online edition).

Any bruises in a young infant who is not yet pulling to a stand should raise concerns of abuse or of an unsafe environment (see eFig. 106-4.3 in online edition). A shaken infant may have bruising on the hands because he or she is liable to be flailing during the shaking incident (see eFig. 106-4.4 in online edition). Concern should be raised whenever the history of an accident is inconsistent with the developmental level of the child.

INFLICTED BURNS

The most common agent involved in childhood burns, both accidental and inflicted, is hot liquid. Accidents such as inadvertently stepping into a hot tub or pulling a hot liquid off a table counter or stove leave irregular or geographic burn patterns that lack symmetry. By contrast, inflicted scalds tend to be symmetric, with sharply demarcated edges and an absence or paucity of splash marks. In one study, all the children whose bathtub burns were inflicted had associated features of abuse, including bruises, fractures, or evidence of neglect.[5] Stocking and glove burns result when the feet or hands are forcibly held under hot water. The uniformity of the burn indicates that the child was not able to reflexively withdraw from the scalding water as would happen with accidental immersion. A common pattern of inflicted immersion burn involves the buttocks, low back, and thighs. The child is flexed at the waist and dipped into the hot water, frequently as a punishment for a toilet training accident. The resultant pattern may give "zebra stripes" on the abdomen due to sparing of the flexural skin that is protected from the scald when bent forward. A "donut hole" pattern of sparing might be seen on the buttock if the child is pushed forcibly to the bottom of the tub that is cooler than the scalding water.[6] Inflicted splash burns are much more difficult to differentiate from accidents. A careful history is needed to detect inconsistencies between the proposed injury and the physical examination. When doubt exists, it is mandatory that child protective services be contacted.

An inflicted contact burn can be recognized by the pattern that duplicates the object creating the injury (see eFig. 106-4.5 in online edition). Accidental contact burns tend to be smaller, less severe, less patterned, and of irregular depth. When a child is held against a hot object, the depth is more uniform, the pattern is more clearly defined, and the burn is more severe. Irons, curling irons, hot plates, and cigarettes are objects commonly used to inflict burns.[7] Some burns may, in fact, be accidental but represent inadequate supervision and neglect. This situation is also harmful to children and needs to be reported to the appropriate agencies.



Figure 106-4 Human bite marks. (Used with permission from Paul Bellino, MD.)

SEXUAL ABUSE

It is estimated that more than 300,000 children suffer from sexual abuse each year in the United States. The lifetime risk of sexual abuse is approximately 25%–40% for girls and approximately 10% for males. *Sexual abuse* is defined by the American Academy of Pediatrics as the engaging of a child in sexual activities that the child cannot comprehend, for which the child is developmentally unprepared, and cannot give informed consent and violate the social taboos of society.[8] This broad definition includes inappropriate touching, genital penetration, fondling, and sexual kissing, but also includes noncontact activities such as exhibitionism, voyeurism, and the involvement of a child in verbal sexual propositions or the making of pornographic pictures or movies. Clearly, many forms of sexual abuse leave no physical examination findings.

Girls are more likely than boys to suffer sexual abuse and the risk rises in preadolescence (Fig. 106-5). Most abuse is at the hands of someone known to the child



Figure 106-5 Sexual abuse. Perianal wound in a 3-year-old girl after anal penetration. (Used with permission from Dr. Francesca Navratil, Zurich, Switzerland.)

and only 10% is carried out by strangers. Victims and perpetrators span all racial, religious, and socioeconomic spectrums but risk factors for sexual abuse include the presence of a stepfather, single-parent families, children whose mothers are extensively out of the home, a history of parental violence, parents who have suffered abuse themselves, parental substance abuse, and low household income level.

Most victims of sexual abuse have no physical findings.[9,10] Pregnancy, positive cultures for sexually transmitted diseases, presence of sperm or acid phosphatase, acute genital or anal injuries without plausible explanation, and marked hymeneal opening enlargement with associated hymeneal disruption are very definitive signs of abuse. However, it is very seldom that such signs are present. The American Academy of Pediatrics Committee on Child Abuse and Neglect recommends that certain findings are consistent with, but not diagnostic of, abuse. These include chafing, abrasions or bruising of the inner thighs and genitalia, scarring, tears or distortion of the hymen, a decreased amount or absent hymeneal tissue, scarring of the fossa navicularis, injury to or scarring of the posterior fourchette, scarring or tears of the labia minora, and enlargement of the hymeneal opening, even without disruption of the hymen.[8]

The child's spoken word is the most valuable piece of evidence in establishing sexual abuse. All historical information must be very well documented and preserved with the same care as any piece of forensic evidence. It is immensely important to enlist the help of an experienced abuse team in obtaining the history and completing an appropriately thorough physical examination with the aid of colposcopic observations.

The skin examination's greatest contribution may be in correctly diagnosing those dermatoses that may look similar to sexual abuse but are not. Irritant dermatitis, atopic dermatitis, psoriasis, seborrheic dermatitis, pinworms, candidiasis, scabies, and other common dermatoses tend to cluster in the diaper region and should be easily diagnosed with a critical eye. Other conditions that have been reported as mimickers of sexual abuse are listed in Table 106-4.

TABLE 106-4
Conditions Mistaken for Sexual Abuse

- Lichen sclerosus
- Crohn disease
- Localized vulvar pemphigoid
- Langerhans cell histiocytosis
- Perianal streptococcal dermatitis
- Hemangiomas
- Urethral prolapse
- Entities that look like condylomata acuminata
  - Focal epithelial hyperplasia
  - Darier disease
  - Lymphangioma circumscriptum
  - Pigmented vulvar hamartomas
  - Pseudoverrucous papules
  - Epidermal nevus and inflammatory linear verrucous epidermal nevus
- Entities that look like herpes simplex
  - Localized varicella/zoster
  - Allergic contact dermatitis

Genital warts pose a particularly difficult problem for practitioners. They certainly can be sexually transmitted to children, and the possibility of sexual abuse needs to be discussed with parents. However, there is much evidence that genital warts can be acquired perinatally from an infected mother, through autoinoculation from warts on other parts of the body or through nonsexual contact with caretakers.[11] Children younger than 3 years of age at the onset of warts are least likely to have acquired their warts from sexual contact, whereas children with onset after 5 years of age have a much greater risk of having suffered sexual abuse. The ages in between represent a gray zone. Other signs of abuse will seldom be present to aid in the diagnosis, and human papillomavirus typing is not helpful. History provides the most valuable insight into the correct diagnosis; again, it is imperative that an abuse team be involved. At the author's institution, all children with perianal or genital warts are referred, in a nonaccusatory and nonjudgmental fashion, to the hospital's abuse social worker and pediatrician as routine protocol.[12]

ELDER ABUSE

Elder abuse is one of the fastest growing forms of abuse. Although statistics vary, the National Center on Elder Abuse in Washington, DC, estimates that 1 to 2 million Americans 65 years of age or older are victims of various forms of abuse each year. Abuse may affect a range of 2%–10% of the elderly population. Those older than age 80 years are two to three times more likely to suffer abuse, and the American population in this age range continues to increase each year. For every case of reported elder abuse, at least another five cases go undetected.[13] All segments of society are affected. Although there is inherent inaccuracy in these statistics, it is readily apparent that elder abuse is common enough for a busy dermatologist to encounter a few abused patients every week.

TABLE 106-5
Types of Elder Abuse

- Neglect: 55%
- Physical abuse: 15%
- Financial and material abuse: 12%
- Emotional or psychological abuse: 8%
- Sexual abuse: 1%
- Unspecified forms of abuse: 9%

The US National Academy of Sciences has defined *elder abuse* as:

> *(a) intentional actions that cause harm or create a serious risk of harm (whether or not harm is intended) to a vulnerable elder by a caregiver or other person who stands in a trust relationship to the elder, or (b) failure by a caregiver to satisfy the elder's basic needs or to protect the elder from harm.*

Acts of commission and omission are thus included in the definition. Types of abuse and their respective incidence rates are listed in Table 106-5. More than one type of abuse can occur simultaneously.[14,15]

Abuse most often occurs at the hands of caregivers or family members who have frequent close contact with patients and often may live with them. Historically, adult children of the abused patient have been the most common perpetrators, but most recent data show that spouses now account for the majority of abuse cases. Men are more likely to abuse than women. The abuser is often financially dependent on the victim, and they are usually in a shared living situation. However, financial abuse is more common among those who live alone. Risk factors for abuse are listed in Table 106-6. Note that the risk factors have far more to do with the caretaker than the abused patient. In particular, the level of debility or health status of the patient does not predict abuse.

Physical abuse is defined as the intentional application of any force that causes bodily injury, pain, or impairment to an elderly individual. It may include acts such as hitting, beating, shaking, kicking, slapping, pushing, pinching, burning, overly aggressive force-feeding, and the improper use of physical or chemical restraints. The signs discussed in Section "Child Abuse" above apply to elder abuse as well and include multiple bruises or fractures in different stages of healing, bruises in normally well-protected areas such as the inner thighs, odd-shaped injuries such as from pinching or slapping, belt marks or patterned bruising (see eFig. 106-5.1 in online edition), unusual welts or puncture wounds, cigarette burns, rope marks that might indicate restraints, bed sores, strangely patterned alopecia, attempts to hide part of the body, and signs of malnutrition or dehydration. Because many of these signs, particularly multiple bruises, can occur normally in elderly individuals, detection of abuse can be very challenging. Unexplained repetitive injuries or explanations by caretakers that do not match the pattern of injury are concerning. Caretakers who act withdrawn, infantilize the patient, or insist on providing the medical history should alert the clinician.

TABLE 106-6
Risk Factors for Elder Abuse

- Older age
- Lack of access to resources
- Low income
- Social isolation
- Minority status
- Low level of education
- Functional impairment
- Substance abuse by elder or caregiver
- Previous history of family violence
- History of psychological problems
- Caregiver stress
- Cognitive impairment

It is important to interview by directing questions to the patient rather than the caregiver, and it is prudent to try to arrange a time to confer with and examine the patient alone. Repetitive follow-up visits help develop a rapport with the patient and allow serial observation of past and ongoing injuries. The assurance of confidentiality facilitates garnering sensitive information.

Once abuse is suspected, most states mandate that physicians contact the appropriate authorities. Information on a particular state's laws can be obtained from the National Center on Elder Abuse (see Table 106-3). The nearest medical center's social service department is well equipped to offer guidance, but the agencies listed in Table 106-3 are also helpful resources. Treatment, support, and counseling may be needed for the perpetrator as well.

DOMESTIC VIOLENCE

Domestic violence is a pattern of coercive behaviors that may include repeated battering, psychological abuse, sexual abuse, social isolation, deprivation, and intimidation perpetrated by someone who is or was involved in an intimate relationship with the victim. Conservative estimates say that in the United States approximately 1 million people suffer domestic violence each year, but the actual number likely approaches 4 million. Women comprise approximately 90%–95% of all victims, and men 95% of all perpetrators. Forty percent to 60% of men who abuse their partner or spouse are also abusing their children. In the United States, approximately one in three women suffers a least one physical assault during her life, and 1,500 women are murdered by their husbands or boyfriends each year.[16,17] Domestic violence is a devastatingly common problem.

The profiles of domestic abuse are similar to child and elder abuse. Women ages 19–29 years are the most common victims, with other risk factors being low income, mental health issues, alcohol or substance abuse by the victim or the perpetrator, pregnancy, large age difference between partners, separated or divorced status, and a family history or personal past history of abuse and violence. Women with educational or occupational levels above that of their partners may be at

higher risk. Abusers are typically underachievers with occupational status below their educational level.[16,17]

Whenever possible, the patient should be interviewed alone, without the partner's presence. A thorough examination should be done with a nurse chaperone, but not the partner, in the room. Repeat visits may be used to document new or progressing skin findings and to build trust with the patient. Statements such as "Because domestic violence is such a prevalent problem, we have begun to ask about it routinely" may open the door to more discussion regarding difficulties at home. Literature and posters in the clinic setting with information and hotline numbers for abuse victims indicate the common reality of abuse and may facilitate disclosures.

For various reasons, a victim may not want to reveal abuse. Implausible explanations for an injury or a delay in seeking medical attention may be clues of abuse. Signs of depression, excessive use of sedatives, chronic pain disorders, or vague stress-related symptoms may be subtle signs of abuse.[17]

Physical examination findings are the same as outlined for child and elder abuse. The distribution of injuries tends to be central, and the perpetrator may choose to injure hidden areas, such as the breast or genitals, to deter detection. Unlike infants or debilitated adults, blows to a young adult may be to areas suggesting a defensive posture and might include purpura, sprains, dislocations, and fractures to the wrist or forearms, palms, and soles.

The social service department at the local medical center is a good resource for information and help on domestic violence. The National Domestic Violence hotline (800–799-7233) is a 24-hour resource for women who need to find a local shelter. Other helpful organizations can be contacted (see Table 106-3).

KEY REFERENCES

Full reference list available at www.DIGM8.com

DVD contains references and additional content

1. Legano L, McHugh MT, Palusci VJ: Child abuse and neglect. *Curr Probl Pediatr Adolesc Health Care* **39**:31e1, 2009
6. Kos L, Shwayder T: Cutaneous manifestations of child abuse. *Pediatr Dermatol* **23**:311, 2006
7. Swerdlin A, Berkowitz C, Craft N: Cutaneous signs of child abuse. *J Am Acad Dermatol* **57**:371, 2007
14. Abbey L: Elder abuse and neglect: When home is not safe. *Clin Geriatr Med* **25**:47, 2009
16. Zolotor AJ, Denham AC, Weil A: Intimate partner violence. *Prim Care Clin Off Pract* **36**:167, 2009
17. Toohey JS: Domestic violence and rape. *Med Clin N Am* **92**:1239, 2008

This page intentionally left blank

PART 6 Skin Changes across the Span of Life



From Birth to Old Age

Chapter 107 :: Neonatal, Pediatric, and Adolescent Dermatology

:: Mary Wu Chang

NEONATAL, PEDIATRIC, AND ADOLESCENT DERMATOLOGY AT A GLANCE

- Many dermatologic diseases exhibit different manifestations in newborns, infants, and children.
- Some dermatoses are encountered only in neonates and infants and therefore require special attention.
- Obtaining a history and methods of clinical examination in infants and children differ from the approaches chosen for adults. In adolescents, different skills are required to enhance compliance.
- Many outpatient procedures in pediatric dermatology can be done easily with appropriate planning and age appropriate techniques. Necessary biopsies should not be avoided simply because of a patient's young age.
- The infant has increased risk for systemic toxicity from topically applied substances; the risk is even greater in premature infants. Children with disorders of barrier function are at high risk of excess percutaneous absorption and toxicity as well.
- Drug labeling for pediatric patients is different from that in adults and most therapeutic agents are prescribed off-label.

Just as dermatology cannot be separated from internal medicine, pediatric dermatology is inseparable from general pediatrics. Since most dermatologists have experience and training in internal medicine but less exposure to pediatrics and neonatology, an introduction to the special issues that can arise in pediatric dermatology is presented herein. As it is impossible to discuss all of pediatric dermatology in one chapter, the focus is instead on certain methods, diseases, and issues divided by three age divisions: neonates and infants, children, and adolescents. Topics of special importance such as pediatric medication use and biopsy pitfalls are discussed. Methods to enhance success in outpatient procedures in pediatric dermatology are also reviewed.

TABLE 107-1
Ten Helpful Tips in Pediatric Dermatology

1. The child is the patient, not the parents.
2. Biopsy when indicated, regardless of age. (Refer if necessary)
3. Be aware of the family situation: Does the child live in two homes? Are the parents going through a divorce?
4. Be aware of the parents' perception of the child: Was there difficulty in conceiving? Prematurity? Significant early illness?
5. A team approach with the pediatrician, neonatologist, or family physician is most efficient. Psychiatrist comanagement may be indicated (e.g., isotretinoin issues or trichotillomania).
6. Chronic illness in one person affects the entire family (e.g., severe atopic dermatitis).
7. Guide parents and patients to appropriate Internet resources, but always review materials for accuracy beforehand.
8. Obtain consent from parents, and assent from children, for procedures and photos.
9. An adolescent's confidentiality must be maintained unless there is a danger of harm to the patient, or others. Consider interviewing patient alone without parents for a portion of the visit. Consider a chaperone in the office for full skin exams.
10. Remember the aphorism, "To cure sometimes, to relieve often, to comfort always."

Successful care of the pediatric patient is best achieved via comanagement with the neonatalogist, pediatrician, or primary care physician. In addition, an understanding of the parental or family situation is important. For example, children living in two households (due to divorced parents) may do best with two sets of medications, one in each home, to enhance compliance. Table 107-1 reviews ten helpful tips in practicing pediatric dermatology. As an example, if Internet access exists, patients or parents will likely search online for medical information before or after the office encounter. Parents and patients should be warned that medical information on the Internet is often inaccurate.[1] It is wise to direct them to specific Internet Web sites, support groups, or pamphlets, but these resources should be reviewed before recommending them.

Lastly, the aphorism, "To cure sometimes, to relieve often, to comfort always," should always be kept in mind when delivering pediatric care. Parents often have higher expectations, and a heightened level of worry and concern for their children and the office visit cannot be rushed.

NEONATES AND INFANTS

The neonatal period is defined as the first 30 days of life. Neonatal skin diseases evolve much more rapidly than adult skin diseases, and some conditions that initially appear to be serious turn out to be trivial, whereas in others, the opposite is true. Infancy is defined as beginning after the first 30 days of life.

NEONATAL SKIN

After birth, the neonate's skin undergoes a series of changes in adaptation to the extrauterine environment. In utero, the skin of the fetus is protected by the vernix caseosa and is immersed in amniotic fluid. After birth, the vernix is wiped off, and the skin is exposed and adapts to the dry ambient air. For example, desquamation of the upper layers of the stratum corneum occurs normally in all infants and is believed to be a normal adaptive process.

Research regarding the maturation of the neonatal stratum corneum in neonates has produced varying results, and the question of when full barrier function is achieved is not fully answered. Barrier stabilization appears to be a dynamic process, one dependent upon a balance between different biologic and environmental parameters. Postnatal life is believed to accelerate stratum corneum maturation in premature and term infants. Parameters such as skin thickness, skin pH, and stratum corneum hydration indicate that neonatal skin is continuously adjusting to the extrauterine environment, in contrast to the adult skin, which remains in a steady state.[2]

In vivo studies of human skin show that infant stratum corneum and epidermis is thinner than adult skin and has higher transepidermal water loss (TEWL) rates, but infant stratum corneum has higher water content. Infant corneocytes and granular cells are smaller than adult corneocytes suggesting a more rapid cell turnover than in adults.[3]

Infants have an increased risk for systemic toxicity from topically applied substances. This is due in large part to the great surface area–body mass ratio in the infant. In addition, the infant's metabolism, excretion, distribution, and protein binding of substances can be significantly different from those of an adult and add to increased risk of toxicity.[4]

The postmature infant (>40 weeks' gestation) typically has dry and cracked or peeling skin noted soon after birth (Fig. 107-1). Shedding of the dry peeling skin of postdates infants occurs spontaneously in the first month of life, leaving normal, healthy skin. Topical care should include moisturizers and avoidance of overbathing.

Premature infants, particularly those born before 34 weeks of gestation, have markedly decreased epidermal barrier function and an even greater surface area–body mass ratio than term infants. In addition, the immature organs of the premature infant may affect the metabolism, excretion, distribution, and protein binding of chemical agents. Local or systemic toxicity can occur in the premature infant not only from topical medications, but also soaps, lotions, or other cleansing solutions.[4,5]

Increased skin fragility is a hallmark of prematurity (gestational age less than 37 weeks). Epidermal and dermal injury may lead to significant cutaneous pain even with routine handling and nursing care. The premature infant is at risk for infection and sepsis from skin-associated organisms entering through breaks in the thin and fragile skin and via iatrogenic portals of entry. Sweating



Figure 107-1 The feet of a postmature newborn. The dry, hyperlinear, and scaly skin is typical of a postdates baby. There are also pustules of transient neonatal pustular melanosis.

in the premature infant is functionally reduced and contributes to poor thermal regulation. Heat regulation is dysfunctional due to a thin subcutaneous fat layer for insulation, poor autonomic control of cutaneous vessels, and a large surface–body ratio. In the nursery, the premature infant is usually placed in a temperature and humidity-controlled isolette until the infant matures and temperature and fluid regulation stabilizes.

In the 1990s researchers reported application of petrolatum-based emollient therapy to be beneficial in hospitalized preterm infants, decreasing transepidermal water loss.[6] Subsequently, various emollients and regimens have been tested in infants of variable prematurity and birthweight. Improved skin integrity consistently improved in these studies, however, a threefold increase in the incidence of systemic candidiasis was reported after emollient therapy was implemented in extremely low birthweight (≤1,000 g) premature infants in one neonatal intensive care unit.[7] Another outbreak of systemic candidiasis occurred in very low birthweight neonates (≤1,500 g) in a different neonatal intensive care unit.[8] A 2004 Cochrane review concluded that prophylactic application of topical ointments increased the risk for nosocomial infection and advised against their routine use in preterm infants. In contrast, randomized, controlled studies in impoverished Bangledeshi preterm neonates have demonstrated decreased mortality rates when sunflower seed oil or Aquaphor ointment was applied by massage, compared to premature infants not receiving massage or emollients.[9] Until prospective, controlled trials are performed, neonates receiving petrolatum-based emollient therapy should be carefully monitored for infections, particularly those infants with birthweights less than 1,500 g.

Once at home, bathing once or twice a week in plain water is sufficient for most infants; if bathing is more frequent, moisturization with unscented, simple emollients is recommended. The face, hands, and diaper area may be cleansed daily using a small amount of a mild, unscented, pH-neutral cleanser. Well-meaning parents often bathe their infants too frequently and use a multitude of products on their infant's skin. In addition to irritation and asteatosis, these practices may increase the risk of allergic contact dermatitis in infants. It has been estimated that the average newborn is exposed to approximately 10 skin care products in the first month of life, leading to exposure to more than 50 different chemicals ranging from mildly toxic to toxic.[10] Parents should be taught that "less is best."[11]

EXAMINATION TECHNIQUES

A complete history includes gestational and birth history as well as family history. Exposures during pregnancy, including medications, illicit drugs, and infectious diseases such as varicella and sexually transmitted diseases, should be reviewed. Obstetric data, including placental appearance and cultures, can be invaluable. In examining an infant, the most important element is thoroughness. Whether the infant is examined in the lap of the parent or on the examination table, all surfaces, including the creases and valleys of body folds and the diaper region (including the genitalia), deserve close examination. A vascular stain, vasoconstricted macule, or erosion can be the presenting sign of a hemangioma.[12] A stray hair may later strangulate an appendage and should be removed. Infants with digital tourniquet (pseudoainhum) and clitoral tourniquet have been described.[13,14] Congenital lesions of all classifications (e.g., pigmented, vascular, aplasias) warrant closer inspection to rule out associated findings. Midline lesions on the face, scalp, or spine may have central nervous system (CNS) connections and should not be biopsied without proper evaluation (see Table 107.7). The diaper area has its own unique set of problems and deserves examination at every visit.

The infant is vulnerable and completely dependent on the caretakers. The social support system and family structure must be considered when implementing a medical plan. There are times when the parents' desire for treatment may not be in the best interest of the patient.

Medical and surgical decision making for the infant is based primarily on function rather than cosmesis. For example, extraction of a natal tooth is indicated if breast-feeding is impaired; whether or not the tooth is a component of a genetic syndrome is a separate issue.

DISEASES OF NEONATES AND INFANTS

TRANSIENT DERMATOSES OF THE NEONATE.

Skin conditions encountered in newborns that tend to resolve by 30 days of age are considered to be transient. They are very common and many are expected in newborns.

Caput Succedaneum and Cephalohematoma. Caput succedaneum is subcutaneous edema over the presenting part of the head and is a common occurrence in newborns. Cephalohematoma is a subperiosteal collection of blood and is less common. Both lesions are due to shearing forces on the scalp skin and skull during labor.

Caput succedaneum is soft to palpation, and borders are ill-defined. Cephalohematoma is bounded by the suture lines of the skull and often feels fluctuant. If purpura is extensive, it can lead to hyperbilirubinemia. Congenital lymphedema or lymphatic malformations (such as in Turner syndrome) can mimic caput succedaneum. Both caput succedaneum and cephalohematoma resolve spontaneously; however, caput usually fades in 7–10 days, whereas cephalohematoma slowly resolves over several weeks.

Milia. Milia are multiple pinpoint- to 1-mm papules representing benign, superficial keratin cysts. They are seen most commonly on the nose of infants and may be present in the oral cavity as well, where they are called *Epstein's pearls*. They are expected findings in the newborn and resolve spontaneously within a few weeks of life.

Sebaceous Gland Hyperplasia. At least 50% of normal newborns have sebaceous gland hyperplasia (Fig. 107-2). Tiny (<1-mm) yellow macules or papules are seen at the opening of each pilosebaceous follicle over the nose and cheeks of term newborns. It is a benign condition that clears spontaneously by 4–6 months of age.

Erythema Toxicum Neonatorum. Erythema toxicum neonatorum (ETN) is an idiopathic, common condition seen in up to 75% of term newborns. It is rarely seen in premature infants. Blotchy erythematous macules 1–3 cm in diameter with a 1–4-mm central vesicle or pustule are seen in ETN (Fig. 107-3). They usually begin at 24–48 hours of age, but delayed eruption as late as 10 days of age has been documented.[15] These follicular-based lesions can be located anywhere but tend to spare the palms and soles. A smear of the central vesicle or pustule contents will reveal numerous eosinophils on Wright-stained preparations. A peripheral blood eosinophilia of up to 20% may be associated, particularly in infants, with numerous lesions. Transient neonatal pustular melanosis (TNPM) lesions conrail neutrophils rather than eosinophils, and individual lesions heal with residual pigmentation, which is not seen in ETN. Bacterial infections, *Pityrosporum* folliculitis, and congenital candidiasis also may mimic ETN. Bacterial and fungal culture of lesions and Gram staining will help differentiate among these entities. ETN is benign and clears spontaneously by 2–3 weeks of age without residua.



Figure 107-2 Sebaceous hyperplasia on the nose of a 1-day-old infant.



Figure 107-3 Erythema toxicum neonatorum. Erythematous macules, some with a tiny central papule or pustule, on the arm of a 1-day-old newborn.

Transient Neonatal Pustular Melanosis. TNPM is an idiopathic pustular eruption of the newborn that heals with tiny brown-pigmented macules (Fig. 107-4). It is less common than ETN and is more prevalent among newborns with darkly pigmented skin. Lesions are usually present at birth or shortly thereafter, but may appear as late as 3 weeks of age, as superficial vesicles and pustules, with ruptured lesions evident as collarettes of scale. Pigmented macules are also often present at birth or develop at the sites of resolving pustules or vesicles within hours or during the first day of life; occasionally babies are born with the tiny melanocytic macules, suggesting in utero vesiculation. Lesions can occur anywhere but are common on the forehead and mandibular area. The palms and soles may be involved. Smear of the vesicle or

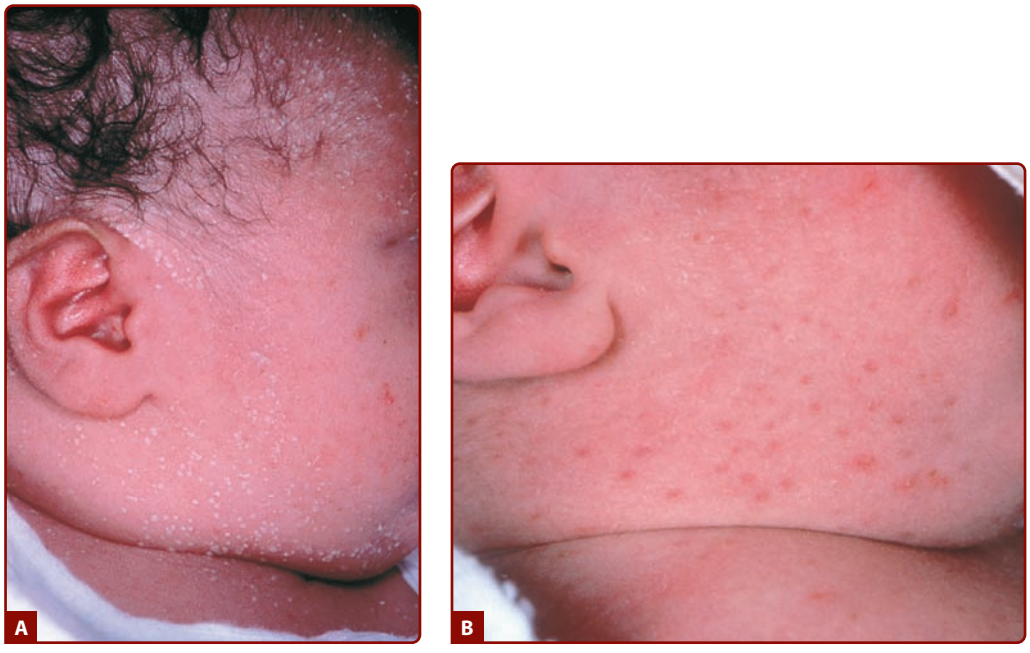

Figure 107-4 Transient neonatal pustular melanosis. **A.** A newborn with congenital, thin-walled pustules that rupture easily. **B.** Hyperpigmented macules appeared by 10 hours of age.

pustule contents will reveal a predominance of neutrophils with occasional eosinophils on Wright-stained preparations.[16]

Miliaria rubra is frequently confused with ETN and TNPM. The erythema around miliaria rubra is small in area (1–2 mm versus 20–30 mm in ETN). The central pustule of TNPM may mimic congenital candidiasis, *Pityrosporum* folliculitis, or bacterial folliculitis lesions. Herpes simplex should be considered if lesions are vesicular. A Gram-stained slide of the pustules of ETN or TNPM will not show organisms. A Wright-stained slide usually will show a predominance of neutrophils. TNPM is a harmless condition that requires no treatment. The pustules usually disappear within 5–7 days of age, leaving residual pigmented macules that resolve over 3 weeks to 3 months.

Mottling. Mottling is a blotchy or lace-like pattern of dusky erythema over the extremities and trunk of neonates that occurs with exposure to cold air. Virtually all babies demonstrate mottling at some time during the newborn period due to immaturity of the autonomic control of the cutaneous vascular plexus. This physiologic mottling disappears on rewarming, differentiating it from cutis marmorata telangiectatica congenita and livedo reticularis. Normal mottling resolves spontaneously by 6 months of age.

Harlequin Color Change. Harlequin color change is a rare vascular phenomenon occurring in low-birthweight infants. When the infant is placed on one side, an erythematous flush with a sharp demarcation at the midline develops on the dependent side, and the upper half of the body becomes pale. The color change usually subsides within a few seconds of placing the baby in the supine position but may persist for as long as 20 minutes. The exact mechanism of this unusual phenomenon is not known, but it may be due to immaturity of autonomic vasomotor control. Harlequin color change is seldom seen after 10 days of age.

Sucking Blisters. Sucking blisters may be present at birth as the result of intrauterine sucking, but are more commonly seen during the first weeks of life. Sucking blisters are usually solitary, intact oval or linear blisters, erosions, or drying crusts, arising on noninflamed skin of the dorsal-radial aspect of forearms, wrists, or fingers or on the upper lip. They resolve within a few days. If the affected extremity is brought up to the infant's mouth, the infant will often commence sucking at the site, confirming the diagnosis. Herpesvirus infection is often considered when sucking blisters are encountered, but lesions of *Herpes simplex* infection are grouped vesicles occurring on an erythematous base or punched out, hemorrhagic erosions.

Benign Cephalic Pustulosis. Neonatal acneiform facial lesions usually develop within the first 30 days of life and are estimated to occur in 50% of newborns (Fig. 107-5). This benign eruption appears to be hormonally mediated (see Chapter 80) and has been attributed to overgrowth of *Malassezia* sp., and termed "benign neonatal cephalic pustulosis."[17] Most cases resolve spontaneously, but the eruption can be treated topically with ketoconazole, benzoyl peroxide, or erythromycin. True neonatal acne is probably much less common than benign cephalic pustulosis and can be distinguished by the presence of comedonal lesions. Similarly, infantile acne usually shows true comedones, sometimes with papules, pustules, and even cysts. An example of infantile acne is seen in Figure 107-6.



Figure 107-5 Benign cephalic pustulosis. Tiny papulopustules on the cheeks of a 3-week-old infant.

HAIR LOSS IN THE INFANT[18]

Telogen Effluvium. Telogen effluvium occurs frequently in newborns and is often overlooked. The hair loss may be gradual or sudden, and may occur as soon as the first few days of life, with the telogen hairs shed by 3–4 months of age. No treatment is indicated as spontaneous resolution is the rule.

A transient circumscribed patch of nonscarring alopecia develops at the occiput in many infants. Thought to be due to a combination of physiologic telogen effluvium and localized pressure from lying in the supine position, occipital alopecia spontaneously resolves.

Triangular Temporal Alopecia. Triangular temporal alopecia is a form of nonscarring hair loss noted at 2–5 years of age as a triangular-, oval-, or lancet-shaped area of alopecia at the frontotemporal scalp. Often, a thin row of hair separates the affected area from the forehead. The terminal hairs are replaced by vellus hair. The condition is often mistaken for alopecia areata; however, distinguishing features include the typical location and shape, the presence of vellus hairs, and the absence of exclamation point hairs or histologic findings of alopecia areata. There is no known treatment, and the condition persists unchanged. However, triangular temporal alopecia is benign and will not expand.



Figure 107-6 Infantile acne. True comedones and inflammatory papules are noted on the cheeks of a healthy 10-month-old girl.

Alopecia Areata. Alopecia areata occurs in all ages (see Chapter 88). All forms of alopecia areata occur in infants and children (patchy, universalis, etc.), with the same disease presentation and treatment challenges as in adults. Onset at younger than 2 years of age is estimated to occur in 1%–2% of alopecia areata patients; however, it may be under-recognized and more common. Several cases of congenital alopecia areata have been documented. Early onset is considered to be a poor prognostic marker. Total alopecia during the first year of life after having hair at birth should be distinguished from genetic disorders, such as congenital atrichia with papular lesions and vitamin D resistance.

Tinea Capitis. Tinea capitis can occur at any age, including infancy (see Chapter 188). Hair loss associated with scaling, broken hairs, pustules, or black dots should prompt a potassium hydroxide scraping and fungal culture to confirm the diagnosis. Just as in older children, *Trichophyton tonsurans* is the most common dermatophyte, and oral griseofulvin is the treatment of choice. Tinea capitis and fungal infections are discussed in Chapter 188.

BIRTHMARKS.

Birthmarks represent an excess of one or more of the normal components of skin per unit area: blood vessels, lymph vessels, pigment cells, hair follicles, sebaceous glands, epidermis, smooth muscle, collagen, or elastin. Although most birthmarks are of little medical or psychosocial consequence, the social and cultural impact of a disfiguring birthmark should not be underestimated, from both the patient's and the parents' perspectives.[19] The age-old theory of maternal imprinting is still widely accepted in many countries, including the United States, and the mother may be subtly or actively blamed for congenital conditions in the newborn. With selective photothermolysis offered by lasers and advances in surgical and topical therapies, therapeutic options are increasing.

The two most common birthmarks are the nevus simplex (see Chapter 172) and Mongolian spots (see Chapter 122). Nevus simplex (also known as salmon patch, nevus flammeus, angel's kiss, or stork bite) represents a capillary malformation of the skin. It occurs most commonly on the glabella, upper eyelids, and nuchal area. Nevus simplex appears with high frequency in all races, occurring in 70% of white infants and 59% of black infants. Mongolian spots, which represent collections of dermal melanocytes, are seen in 80%–90% of infants of color but in only 5% of white infants.[20,21] Solitary café-au-lait macules are extremely common and benign, however, the appearance of multiple café-au-lait macules raises the possibility of neurofibromatosis type 1 (see Chapter 141). Other common birthmarks are listed in Table 107-2.

HEMANGIOMAS.

Infantile hemangiomas are the most common tumors of infancy. They must be differentiated from vascular malformations and other vascular anomalies. Hemangiomas are discussed in detail in Chapter 126.

TABLE 107-2
Common Birthmarks in the Newborn

- Mongolian spots
- Nevus simplex (nevus flammeus, salmon patch, "stork bite," "angel's kiss")
- Port-wine stain
- Hemangioma of infancy (infantile hemangioma)
- Epidermal nevus, including nevus sebaceus
- Congenital nevocellular nevi
- Congenital melanocytic nevi
- Nevus depigmentosus
- Café-au-lait spots

LYMPHANGIOMAS. Both types of lymphatic malformations, microcystic (lymphangiomas) and macrocystic (cystic hygromas), are discussed in Chapter 172.

UNCOMMON DERMATOSES OF THE NEONATE. Selected dermatoses of the neonate are discussed in the following sections. Table 107-3 lists differential diagnoses for selected cutaneous conditions encountered in neonates and infants.

Cutis Marmorata Telangiectatica Congenita. Cutis marmorata telangiectatica congenita is characterized by persistent coarse cutis marmorata, telangiectasia, and sometimes associated underlying cutaneous atrophy and ulceration (Fig. 107-7). Its incidence is sporadic, and its etiology is obscure. Theories of vascular malformation are currently favored. Diagnosis is usually evident on clinical examination. Usually a lower extremity is involved, but location on the trunk or upper extremity is not uncommon. A multitude of associated anomalies can occur, including limb asymmetry, hemangiomas, other vascular birthmarks, pigmented nevi, and aplasia cutis congenita (ACC). However, the majority of patients have a good prognosis, with half demonstrating improvement of the mottled appearance over the first 2 years.[22]



Figure 107-7 Cutis marmorata telangiectatica congenita. Note the atrophic, dusky, stellate patches with overlying telangiectasias.

TABLE 107-3
Selected Differential Diagnosis of Neonates and Infants

- Pustules
  - Erythema toxicum neonatorum
  - Transient neonatal pustular melanosis
  - Congenital candidiasis
  - Pustular psoriasis
  - Langerhans cell histiocytosis
  - Neonatal cephalic pustulosis
  - Bacterial sepsis
  - Herpes simplex infection
- Blisters
  - Sucking blisters
  - Herpes simplex virus
  - Aplasia cutis congenital
  - Cutaneous mastocytosis
  - Epidermolysis bullosa
  - Neonatal pemphigus
  - Varicella
  - Impetigo
  - Incontinentia pigmenti
  - Epidermolytic ichthyosis
- The red scaly baby
  - Physiologic scaling and redness (postdates) infant
  - Psoriasis
  - Atopic dermatitis
  - Scabies
  - Seborrheic dermatitis
  - Immunodeficiency
  - Hypohidrotic ectodermal dysplasia
  - Netherton syndrome
  - Acrodermatitis enteropathica
- The collodion baby
  - Lamellar ichthyosis
  - Congenital ichthyosiform erythroderma
  - Gaucher syndrome
  - X-linked ichthyosis
  - Epidermolytic ichthyosis
- The "blueberry muffin" baby
  - TORCH infections
  - Congenital leukemia
  - Congenital self-healing reticulohistiocytosis
  - Blue rubber bleb nevus syndrome
  - Twin-twin transfusion

TORCH = *t*oxoplasmosis, *o*ther agents, especially syphilis, but also hepatitis B, *c*oxsackie virus, Epstein-Barr virus, varicella-*z*oster virus, and human parvovirus, *r*ubella, *c*ytomegalovirus, *h*erpes simplex virus.

Subcutaneous Fat Necrosis of the Newborn. Subcutaneous fat necrosis of the newborn is characterized by firm, circumscribed, reddish or purple subcutaneous nodules or plaques that appear over the back, cheeks, buttocks, arms, and thighs (Fig. 107-8; see Chapter 70). The lesions usually begin within the first 2 weeks of life and resolve spontaneously over several weeks.[23]



Figure 107-8 Subcutaneous fat necrosis of the newborn. This infant developed an erythematous firm mass on the back by 2 weeks of age. She later developed hypercalcemia.

Sclerema Neonatorum. Sclerema is diffuse hardening of the skin in a sick premature newborn that is now rare because of improved neonatal care. The onset is characteristically after 24 hours of age. The skin feels hard and immobile and looks yellow and shiny. The trunk is always involved. Severely ill premature newborns that have suffered sepsis, hypoglycemia, metabolic acidosis, or other severe metabolic abnormalities are at risk. Biopsy sections show edema of fibrous septa surrounding fat lobules, but no fat necrosis, differentiating it from subcutaneous fat necrosis of the newborn. The etiology of this rare condition is unclear, and infant mortality is high.

Aplasia Cutis Congenita (ACC). ACC represents a failure of skin to fully develop, most often on the scalp, and less commonly elsewhere (Fig. 107-9). It is often an isolated finding, but a multitude of associated conditions have been described. ACC has no single underlying cause. Some cases may represent a forme fruste of a neural tube defect.[24] In the most common form of ACC, oval, sharply marginated atrophic macules are seen on the midline of the posterior scalp. They are usually solitary, but may be multiple. Aplasia cutis is always hairless, and may appear vesicular, ulcerated, or covered by a thin epithelial membrane. When healed, lesions are usually atrophic scars, but sometimes develop a keloidal scar. Epidermis, dermis, and fat all may be missing, or a single layer may be absent. Lesions may range from a few millimeters to many centimeters in diameter. Lesions at birth of epidermolysis bullosa (see Chapter 62) may resemble ACC, especially on one or both legs. Scalp ulcers at birth of aplasia cutis may be mistaken for obstetric trauma. Other forms of congenital circumscribed hair loss should be considered. Midline blisters or erosions should not be biopsied, scraped for herpes cultures, or otherwise traumatized. After a careful examination to rule out associated malformations, ACC is treated conservatively to allow healing. Surgical revision of the scar later in childhood or adolescence can be done electively to improve cosmesis.

Hair Collar Sign. The "hair collar sign" is a ring of darker and/or coarser terminal hairs on the scalp, typically surrounding ACC, dermoid cyst, encephalocele, meningocele, or heterotopic brain tissue.[25] The hair collar sign itself is a marker of cranial dysraphism and its presence, like aplasia cutis, mandates careful examination of the infant, particularly of midline structures and fusion planes.

Anetoderma of Prematurity. A specific form of iatrogenic anetoderma (see Chapter 67) has been described in extremely premature infants (born at 24–30 weeks' gestation) with very low birthweight and prolonged neonatal intensive care hospitalization.[26]

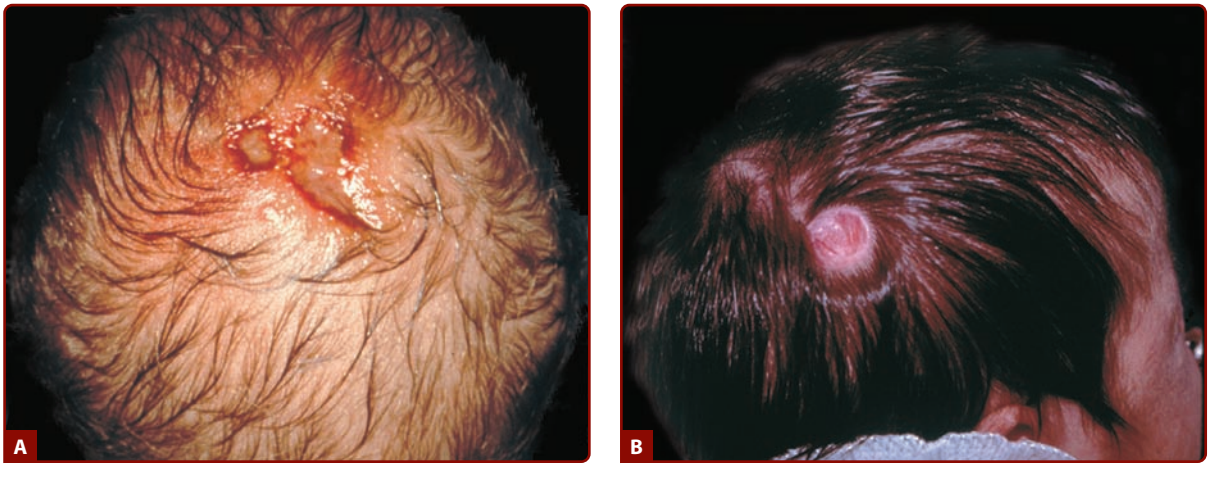

Figure 107-9 Two infants with aplasia cutis congenita. **A.** Scalp erosions grouped at the vertex scalp. Scraping or biopsy is contraindicated. **B.** An atrophic, well-circumscribed round patch with visible capillaries on the scalp of an infant. (**A** used with permission from 1991 Yale Resident Photograph Collection.)

A retrospective review of 11 cases noted the appearance of round, flat atrophic patches on the chest and abdomen (including the periumbilical region), developing at age 6 weeks to 5 months. Eight patients had lesions at sites where adhesive monitoring leads had been removed, and five patients had circular ecchymotic patches from removal of adhesive monitoring leads prior to the occurrence of the anetoderma. The anetoderma did not improve with time. One child underwent surgical excision of the disfiguring lesions at age 7 years. Given the presumed relationship of the development of anetoderma and skin trauma mainly from adhesive leads, avoidance of pressure (e.g., placing leads on the ventral chest when the infant slept on the back) markedly reduced the risk of occurrence.[27]

INFECTIONS OF THE NEONATE

Infants younger than the age of 2 months are less able to localize infection due to immature immunologic function, and life-threatening sepsis can develop insidiously. Subtle clues such as a decrease in body temperature, poor feeding, or other nonspecific signs are taken seriously by the pediatrician, and a "rule out sepsis" admission is implemented when suspicions are high. At a minimum, blood, cerebrospinal fluid, and urine cultures are obtained, and intravenous antibiotic therapy begun pending cultures.

CONGENITAL VIRAL INFECTION. Petechiae, purpura, jaundice, hepatomegaly, splenomegaly, microcephaly, encephalopathy, ocular abnormalities, anemia, thrombocytopenia, conjugated hyperbilirubinemia, or elevated serum hepatic transaminases should prompt the consideration of congenital viral infection, particularly if these signs arise in combination. Cutaneous infections of the neonate are listed in Table 107-4. Bacterial infections, such as staphylococcal scalded skin syndrome; and viral infections, such as varicella, are discussed in Chapters 193 and 194.

TABLE 107-4
Selected Cutaneous Infections in the Neonate

- Staphylococcal infections
- Impetigo
- Staphylococcal scalded-skin syndrome
- Omphalitis
- Breast abscess (usually due to *Staphylococcus aureus* and Gram-negative organisms)
- Viral infections
- Varicella
- Herpes simplex virus
- Fungal/candidal infections
- Scabies

NEONATAL HERPES SIMPLEX VIRUS INFECTION. (See Chapter 193.) It is estimated that untreated neonatal herpes simplex virus (HSV) has a 50% mortality rate, with three-fourths of survivors suffering neurologic sequelae. The greatest risk of neonatal herpes occurs when the delivery is vaginal and the mother has primary genital herpes (as opposed to recurrent herpes, in which the mother has antibodies protective to the neonate), the herpes infection involves the cervix, and the infant is premature and delivered with instrumentation (e.g., scalp electrodes).

The vast majority of cases are due to HSV type 2. The typical lesions of herpes are present in the skin, eye, or mouth in a large majority of infected neonates, but some patients with CNS or disseminated disease never have skin lesions (Fig. 107-10).[28] Vesicles present during the first 24 hours of life suggest in utero acquisition of HSV, but onset during the first week to 10 days of life is more common, representing exposure to the virus during the delivery.[28]

A high index of suspicion should be maintained even in the absence of maternal infection or history of genital herpes. Specimens for Tzanck smear, direct

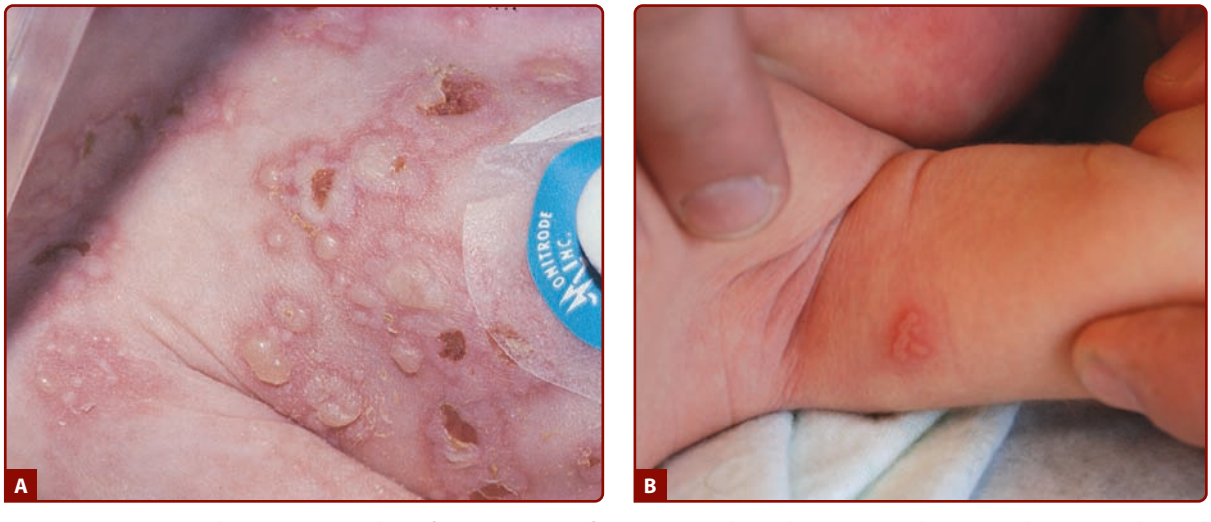

Figure 107-10 **A** and **B.** Herpes simplex infection in two infants. Grouped vesicles on an erythematous base. Pustules and erosions are also present. (A used with permission from Alvin H. Jacobs, MD.)



Figure 107-11 Supernumerary digit, a common minor malformation.

fluorescent antibody assays, and/or viral cultures for HSV should be obtained. Cultures require 12–120 hours to grow, and in all infected or suspected neonates, cultures of skin lesions, urine, nasopharynx, eyes, and cerebrospinal fluid are indicated. If available, a polymerase chain reaction test can be very helpful in rapid diagnosis. Intravenous acyclovir should be instituted as soon as possible after specimens are collected to minimize the chance of replication of virus in the CNS and systemic dissemination of HSV. Prompt recognition and early therapeutic intervention lead to an improved outcome in the HSV-infected infant.[28]

CONGENITAL MALFORMATIONS OF THE SKIN

MINOR ANOMALIES. Congenital malformations are developmental defects and are frequently observed



Figure 107-12 **A** and **B.** Nasal glioma initially thought to be a hemangioma of infancy. A firm, reddish slightly pedunculated was noted off of the midline of the nasal root. The MRI showed no intracranial connection. **C.** Nasal glioma. Firm subcutaneous mass noted at birth.

in newborns. Single minor anomalies occur in approximately 15% of all newborns and are, by definition, of no functional significance. The supernumerary digit (Fig. 107-11), supernumerary nipple and the accessory tragus are common examples of minor malformations. The occurrence of two is less common, however, and the presence of three or more is unusual; a complete thorough physical examination is indicated to rule out other congenital abnormalities.[29,30]

CUTANEOUS MARKERS OF DYSRAPHISM.

The skin and the nervous system are both derived from the ectoderm. The neural ectoderm separates from the epithelial ectoderm during the third to fifth week of gestation, occurring simultaneously with the formation and closure of the neural tube. Hence, errors in neural tube development [i.e., dysraphism (incomplete fusion)] can be associated with cutaneous lesions. Midline facial lesions, such as dermoid cysts, nasal gliomas (Fig. 107-12), and ACC (Fig. 107-9), can be markers of cranial dysraphism, whereas cutaneous lesions seen on the lumbosacral midline can signify underlying spinal dysraphism (Fig. 107-13). Imaging studies should be considered for midline nasal lesions before biopsy to rule out intracranial connections.[31]

A retrospective review of 54 cases of congenital lumbosacral skin lesions (including deviated gluteal cleft)[32] demonstrated that the highest risk of occult spinal dysraphism occurs with the presence of two or more congenital midline lumbosacral skin lesions, or if spinal cord dysfunction exists in the presence of one lumbar skin lesion. In addition, lumbosacral lipoma, human tail, and dermal sinus (as isolated findings) were highly associated with occult spinal dysraphism. Lumbosacral magnetic resonance imaging is indicated when these high-risk congenital lesions are present. An intermediate risk of occult spinal dysraphism was associated with atypical sacral dimple (≥5-mm diameter, or location ≥2.5 cm away from the anus), ACC, overlying hamartoma, or deviated gluteal cleft. In the presence of any of these lesions, ultrasound can be used to screen for occult spinal dysraphism if the infant is less than 4 months of age. If the infant is older, magnetic resonance imaging is needed to rule out dysraphism. Low-risk lesions that do not require imaging include isolated lumbosacral hemangioma, port-wine stain, focal, mild hypertrichosis, pigmented nevus, Mongolian spot, or simple sacral dimple (≤5-mm diameter and location 2.5 cm or closer to the anus).[32] These findings are summarized in Table 107-5.



Figure 107-13 A large, wide tuft of thick terminal hair on the lumbosacral spine noted at birth. She had underlying tethered cord (note midline scar due to surgical repair).

TABLE 107-5
Congenital Lumbosacral Midline Skin Lesions and Risk of Occult Spinal Dysraphism

Risk of Occult Spinal Dysraphism	Congenital Lumbosacral Midline Lesion
High	Group 1: MRI indicated ■ Two or more lesions of any kind ■ One lesion + spinal cord dysfunction ■ Lipoma ■ Tail ■ Dermal sinus
Intermediate	Group 2: Ultrasound if younger than age 4 month (then MRI if ultrasound is abnormal), MRI indicated for age >4 month, or if sonographic expertise unavailable ■ Atypical sacral dimple (deep, farther than 2.5 cm from the anus, size ≥5 mm) ■ Unclassified hamartoma ■ Aplasia cutis congenita ■ Deviation of gluteal crease
Low	Group 3: No imaging needed ■ Port-wine stain ■ Hypertrichosis (unless large and/or unusual) ■ Pigmented nevus ■ Simple sacral dimple (<5-mm diameter, 2.5 cm or closer to the anus) ■ Mongolian spot

MRI = magnetic resonance imaging.
Adapted from Guggisberg D et al: Skin markers of occult spinal dysraphism in children: A review of 54 cases. *Arch Dermatol* **140**:1109, 2004, with permission.

INFANCY AND CHILDHOOD

EVALUATION TECHNIQUES

Observing the play of a child allows for a quick assessment of his or her neurologic development. Interactions between caregivers and child are also informative. Early prolonged or intense eye contact with the young child should be avoided because this can be threatening to the child. If an elective biopsy or procedure is needed, it is often more acceptable for the parent (especially if a neonate) or child if the procedure is scheduled for a second visit rather than the initial one.

If a language barrier exists between the parents and physician, one should resist the urge to have the bilingual patient serve as interpreter for the parents. This

practice places an inappropriate burden of responsibility on the child and may increase fear and anxiety in the child. In addition, inaccurate transmission of information may occur.

Examination of young children may be performed with the child on the parent's lap or while playing with toys on the examination table. If needed, examination of the perineum and genitalia can be accomplished with the child in the knee-chest position on the examination table (eFig. 107-13.1 in online edition) or the parent's lap. Alternatively, the child may sit on the parent's lap with legs held apart by the parent. eFig. 107-13.2 in online edition illustrates anatomic terminology of the young female genitalia for accurate documentation, and can be helpful in conditions such as lichen sclerosus. Caution must be used in interpreting the genital examination in the young female so as not to underdiagnose or overdiagnose disease or abuse. For example, the presence of labia minora adhesions is not diagnostic of trauma or abuse because they occur in as many as one-third of girls who are not abused.[33] The diastasis ani is a normal structure that can be mistaken for perianal scarring.[34] The infantile perianal pyramidal protrusion may be mistaken for condyloma acuminata but is a harmless normal finding (discussed later in this chapter in Infantile Perineal Protrusion).[35,36] Child abuse is discussed in Chapter 106.

PERFORMING PROCEDURES ON THE YOUNG CHILD

Historically, there has been a widespread reluctance to biopsy skin lesions in infants and children. This often leads to a delay in diagnosis in conditions such as childhood melanoma, for example. In addition, many skin conditions in children have a paucity of dermatopathologic information in the literature due to this reluctance. Parents may be anxious about causing pain or scarring, and children may be fearful because of their experience with immunizations, or an age-appropriate fear of bodily mutilation. However, with proper preparation of the parent and child, skin biopsies and other outpatient procedures are easily performed (see Table 107-6). Note that there are certain situations in which a biopsy can be detrimental; examples of these "biopsy pitfalls" are outlined in Table 107-7.

Eutectic mixtures of lidocaine and prilocaine (EMLA cream) or lidocaine alone (LMX cream) are useful in minimizing the pain of intralesional injections or local anesthetic injections for biopsies. As EMLA use has become widespread, reports of toxicity in children have appeared, including methemoglobinemia and seizures. The maximum dose, body surface area exposed to drug, and application time should not be exceeded; these parameters are age dependent and are 1 g for 1–3 month old, 2 g for a 3–12 month old, 10 g for a 1–6 year old, and 20 g was a 7–12 year old.[40] The application of ice or anesthetic cryospray is another option to numb the skin before injections.

Before and during procedures, young infants can be soothed with a pacifier dipped in a sucrose solution. A randomized, controlled, double-blinded study of 201 newborns found that orally administered glucose solution was superior to topical EMLA cream in reducing pain with venipuncture.[41] Infants may be swaddled with a blanket for comfort and immobilization. The young child can be effectively immobilized and comforted with a restraining "hug," by a parent or assistant. Distraction techniques are invaluable as well. For example, instructing the child to blow a colorful toy windmill, blow soap bubbles, or "wiggle" his or her toes during an injection or procedure helps to decrease pain. Older children may be effectively soothed by listening to music with headphones or by watching a movie during procedures.

Alkalinizing local anesthetics to a pH of 7.0 (0.1 mEq/mL sodium bicarbonate or a 1:10 bicarbonate–anesthetic ratio by volume) minimizes the pain of cutaneous infiltration without limiting anesthetic effects.[42] Alkalinization decreases the solution's shelf life to approximately 1 week [43] due to more rapid oxidation of epinephrine. Warming lidocaine also lessens the pain of injection.[42]

Vibrational motions applied with the surgeon's nondominant hand adjacent to injection site and infiltrating slowly are additional helpful techniques to reduce the pain of injection of anesthetic.

Instruments and materials should be laid out ahead of time to ensure rapid performance of the procedure, and are less frightening if kept out of sight by covering with a drape. Needles, instruments, and blood-stained gauze should be kept out of view and out of reach of the patient.

Children sense their parents' anxiety and nervous energy. Parents who are overly anxious can be asked to sit farther away from the operating table, or sometimes are best positioned outside the procedure room.

TABLE 107-6
The ABC's of Successful Outpatient Procedures in Pediatric Dermatology

- **A**: **A**nesthesia techniques: EMLA or ice prior to injection, buffer the lidocaine, apply vibration next to injection site, and infuse slowly. **A**ppointment times in the morning are best for procedures on young children. If they are tired they are less able to focus and cooperate.
- **B**: **B**lood: keep bloody gauze and instruments out of sight of patient and parents.
- **C**: **C**alm parents = calm child. **C**onsent by parents is required if patient is a minor.
- **D**: **D**istraction techniques are essential: MP3 player, DVD player, Where is Waldo? books, and I-Spy books are all very helpful.
- **E**: **E**xpedite the procedure by preparing all instruments and materials before starting.
- **F**: Four hands (minimum) are needed—have at least one assistant to help, preferably not the parent.
- **G**: **G**o to a day surgery setting if patient is unable to participate in local anesthesia due to patient's age or abilities.
- **H**: **H**overing parents—keep them seated and calm, with surgical site out of view.
- **I**: **I**nvest the time, do not rush.

TABLE 107-7
Biopsy Pitfalls in Pediatric Dermatology

Age Group	Lesion and Site	Diagnosis	Danger	Proper Management
Newborn	Erosion or vesicle on the scalp	Aplasia cutis congenita Differential diagnosis: herpes, fetal scalp electrode trauma	Possible intracranial connection, risk of meningitis with biopsy or scraping	Protect site; do not scrape lesion or biopsy, consider ultrasound or MRI of head if a typical
Infant	"Hair collar" sign surrounding lesion on scalp or midline lesion	Encephalocele, spina bifida occulta, meningomyelocele	Possible intracranial connection; risk of meningitis	Preoperative imaging; consider neurosurgical consultation
Infant	Tuft of hair over midline spine	Spina bifida occulta, meningomyelocele	Possible intracranial connection; risk of meningitis	Preoperative imaging; consider neurosurgical consultation
Infant	Preauricular "tag"	Accessory tragus	Risk of chondritis if removed by shave or snip excision or if ligated with suture[37]	Appropriate closure when excised, if cartilaginous component present
Infant or child	Mass along midline scalp, glabella, side of forehead, or other embryonic fusion plane	Dermoid cyst	Intracranial connection in up to 25% for midline dermoids; risk is higher if sinus present[38]; dermoids near the lateral eyebrows rarely have intracranial connections[39]	Consider MRI and neurosurgical consultation
Infant, young child	Nasal midline mass	Nasal glioma, encephalocele, or other dysraphic state Differential diagnosis: "hypertelorism," hemangioma	Intracranial connection in 100% of encephaloceles; gliomas may extend into oropharynx or have intranasal connections[38]	Consider MRI and neurosurgical consultation
Infant, young child	Vascular mass with greatly increased warmth, often with pulsation or bruit	Arteriovenous malformation Differential diagnosis: hemangioma	Uncontrolled bleeding, problematic bony or soft tissue hypertrophy	Consider Doppler studies, MRI, and surgical consultation

MRI = magnetic resonance imaging.

The use of general anesthesia for dermatologic procedures in healthy pediatric patients is very safe when properly performed. Fears of general anesthesia should not be a barrier to delivering necessary surgical or laser procedures to healthy children.[44]

DISEASES OF INFANCY AND CHILDHOOD

INFANTILE PERINEAL PROTRUSION. Also known as *infantile pyramidal protrusion*, infantile perineal protrusion (IPP) is a benign condition that occurs almost exclusively in female prepubertal girls. It appears as a pyramidal, soft-tissue, "tongue-like," smooth, or velvety pink protrusion. It is usually located in the midline just anterior to the anus. IPP is usually asymptomatic, but painful defecation has been reported. It occurs in three settings: constitutional, functional (after constipation, diarrhea, or other irritant exposure), or associated with lichen sclerosus et atrophicus. Often, IPP is misdiagnosed as condyloma acuminatum, hemorrhoids, or as a sign of trauma. Conservative management is indicated. Spontaneous resolution as well as resolution following high-fiber diet to relieve constipation has been noted.[35,36]

DIAPER DERMATITIS. Diaper dermatitis, like hand dermatitis, denotes a group of region-specific dermatoses. Diaper dermatitis is one of the most common dermatologic conditions in infants and children, noted in approximately 1 million pediatric outpatient visits each year.[45] With the advent of superabsorbent disposable diapers in the last decade, severe forms of diaper dermatitis have diminished in incidence. Irritant and candidal diaper dermatitis comprises the vast majority of diaper dermatitides in diaper-wearing individuals of all ages.

The etiology of diaper dermatitis is multifactorial. The initiating factor is prolonged and increased wetness to the skin. This leads to increased frictional damage, decreased barrier function, and increased reactivity to irritants. Other interrelated etiologic factors include contact with urine and feces, fecal proteolytic and lipolytic digestive enzymes, increased skin pH, and superinfection with *Candida* and, less commonly, bacteria.[46]

Irritant Diaper Dermatitis. By far the most common type of diaper dermatitis is irritant diaper dermatitis. This dermatitis occurs in any person who wears diapers, regardless of age. Irritant diaper dermatitis appears as erythematous, moist, and sometimes scaly patches on the convexities of the genitalia and buttocks, beginning in areas in closest contact with the diaper. Shallow erosions are sometimes present on the convex surfaces. It can be asymptomatic or tender.

Candida Diaper Dermatitis. (See Chapter 189). *Candida* diaper dermatitis is the second most common type of diaper dermatitis and presents with bright red erythematous, moist papules, patches, and plaques that tend to involve body folds as well as convex surfaces. Satellite lesions are very characteristic. Oral thrush can be associated. *Candida* from intestinal flora frequently contaminates any type of diaper dermatitis present for greater than 3 days, and *Candida* levels increase with the clinical severity of the dermatitis.[47]

Miliaria Rubra ("Heat Rash"). (See Chapter 84.) Miliaria rubra tends to occur at sites where plastic components of the diaper cause occlusion of eccrine ducts of the skin. It is also seen in the folds of the neck and upper torso, and is particularly common when there is a rapid shift to warm weather, and the child is overdressed.

Pseudoverrucous Papules and Nodules. Pseudoverrucous papules and nodules occur in the diaper and perianal areas in patients of any age with exposure to prolonged wetness. Children who wear diapers due to chronic urinary incontinence are prone to this type of dermatitis for example.

Infantile Granular Parakeratosis. Infantile granular parakeratosis represents an idiopathic form of retention keratosis in diaper-wearing infants. There are two clinical patterns: bilateral linear plaques in the inguinal folds and erythematous geometric plaques underlying pressure points from the diaper. A thick, flake-like scale is present in both forms and is characteristic. Therapeutic responsiveness to topical agents is ambiguous; however, spontaneous clearance after months to 1 year appears to be the rule.[48]

Jacquet Erosive Dermatitis. Jacquet erosive dermatitis is an uncommon, severe diaper dermatitis that can occur at any age. It is characterized by well-demarcated, punched-out ulcers, or erosions with elevated borders. Prolonged contact with urine and feces under occlusion leads to this condition.[49] It is seen less commonly since the advent of superabsorbent disposable diapers.

Granuloma Gluteale Infantum. Granuloma gluteale infantum is an uncommon condition characterized by reddish purplish nodules of different sizes (0.5–3.0 cm) occurring on the convexities of the diaper area in 2- to 9-month-old infants. It arises within preexisting diaper dermatitis. Biopsy shows dense dermal infiltrates of lymphocytes, plasma cells, neutrophils, and eosinophils, but no true granulomas. It appears to be an unusual reaction to the usual irritant factors, candidal infection, and, in some cases, topical steroid use in the diaper region.[49] Treatment consists of avoidance of irritants, use of barrier pastes, and avoidance of topical steroids. Resolution occurs over several months.

Dermatoses Not Etiologically Related to Diaper Wearing. Seborrheic dermatitis, atopic dermatitis, psoriasis (Fig. 107-14), bullous impetigo, acrodermatitis enteropathica, scabies, hand-foot-and-mouth disease, herpes simplex infections, and Langerhans cell histiocytosis are conditions that occur in the diaper region but are not primarily due to the wearing of diapers and should be considered in the differential diagnosis. Skin biopsy is indicated to rule out Langerhans cell histiocytosis (see Chapter 147) if nonhealing erosions or petechiae are seen in the diaper area (Fig. 107-15).

Treatment of Diaper Dermatitis. The treatment of diaper dermatitis is outlined in Table 107-8.[50] Irritant diaper dermatitis and *Candida* diaper dermatitis (or a combination of both) comprise the vast majority of diaper rashes. *Candida* is more likely to complicate diaper rash if present for more than 3 days.

Education of parents and primary care physicians should include instructions regarding the use of topical steroids in the diaper area. Because of greatly increased percutaneous absorption of steroids from

TABLE 107-8
ABCs in the Treatment of Diaper Dermatitis

A = Air. The diaper should be left open as much as possible when the infant sleeps to allow drying of the skin.
B = Barrier ointments. Zinc oxide pastes, petrolatum, and other bland, unmedicated barrier preparations are mainstays of therapy. A continuous layer of barrier paste or ointment should be maintained, reapplying with every diaper change, if necessary. Baby powder on the diaper area offers no antimicrobial benefit to the infant and adds a risk of aspiration.
C = Cleansing and anticandidal treatment. Gentle cleansing with plain water, mineral oil, or unscented gentle cleanser is recommended. Avoidance of friction or rubbing is important. A topical anticandidal agent should be added for any signs of candidiasis. Oral nystatin is indicated if oral thrush is present.
D = Diapers. Diapers should be changed as frequently and as soon after soiling as possible, especially if cloth diapers are used.
E = Education of parents and caregivers.

Modified from Boiko S: Making rash decisions in the diaper area. *Pediatr Ann* **29**:50, 2000.



Figure 107-14 **A.** Infantile psoriasis with involvement in the diaper region. **B.** Infantile psoriasis. This generalized eruption responded well to topical steroids initially and topical tacrolimus later.

moisture and occlusion from diapers, topical steroid use in this anatomic region should be limited to a short course (3–7 days) of hydrocortisone (1% or 2.5%) ointment. This is effective in nearly all cases when a topical steroid is needed. Similarly, use of the combination products containing steroids, such as nystatin plus triamcinolone, and clotrimazole plus betamethasone dipropionate, should be avoided due to increased risks of steroid atrophy and hypothalamic–pituitary axis suppression when used in the diaper area.

Last, parents will be reassured by the fact that even the most problematic diaper dermatitis will resolve when toilet training is achieved, and diapers are not worn.

TINEA CAPITIS. (See Chapter 188.) Scrapings for potassium hydroxide examination and fungal culture should be obtained before administration of systemic antifungal therapy. In children, collection of specimens for tinea capitis may be accomplished by the use of a toothbrush, ring curette, moistened cotton swab, a scalpel, or by collection of infected hairs. Alternatively, a media plate with nonslanted agar may be applied directly to the infected areas of the scalp to collect material.



Figure 107-15 **A** and **B.** Langerhans cell histiocytosis with petechiae and erosions of the skin. This patient also had hepatosplenomegaly.

ADOLESCENT DERMATOLOGY

Dermatologic diagnoses of adolescents overlap with those of general adult dermatology; however, caring effectively for the adolescent patient requires different interviewing skills and strategies to enhance compliance.

EVALUATION TECHNIQUES

Greeting the adolescent first and the parents second, and interviewing the adolescent patient alone at the beginning of the visit help to earn the patient's trust.[51] The confidentiality laws of each state should be considered and the patient's right to privacy respected. Many states protect the adolescent's right to confidential medical care for problems such as drug abuse, sexually transmitted diseases, contraception, pregnancy, and abortion.

The open-ended questioning style used for adults frequently fails with adolescents. Phrasings using the third person and giving choices when asking questions are more effective techniques to obtain information. For example, "Many women on oral contraceptives forget to take their pill once in a while. How often do you forget to take your birth control pills: often, sometimes, or almost never?" will yield a more accurate reply than, "Do you take your birth control pills every day?"

Adolescents lack a well-developed sense of future time and long-term consequences are less valued than immediate outcomes. Goals should be concrete, short term, and relevant to the present. Rather than using goals related to more distant benefits, such as the reduction of potentially serious disease complications (e.g., smoking causes increased risk of lung cancer), emphasis should be placed on immediate and concrete effects (e.g., smoking causes your clothes, hair, and breath to smell bad and your teeth to turn yellow). Body image is a more powerful motivator, and messages such as "tanning salons cause premature wrinkles and ugly skin" are more effective than future health concerns (e.g., "tanning salons increase your risk of skin cancer"). Any treatment that is disfiguring or has visible side effects will meet with resistance.[51]

Physical and psychosocial development may not be congruent. An adolescent should not be expected to shoulder all medical responsibilities for himself or herself or for younger siblings. The physician's role is not to befriend, nor is it to parent the adolescent patient, but rather it is to be a trusted, valuable authority.

ACNE AND THE ADOLESCENT

(See Chapter 80.)

Acne vulgaris is an extremely common and variable disorder that can have far-reaching detrimental effects on self-image and self-esteem. Increased unemployment has been documented among patients with a history of severe acne.[52] For adolescents, a single- or two-drug regimen will optimize compliance and cost-effectiveness.

Females with treatment resistant acne, signs of virilization (including irregular menstrual cycles, hirsutism, and/or obesity) should have evaluation for androgen excess states including polycystic ovary syndrome (see Chapters 80 and 151).

Several oral contraceptives (Yaz®, Yazmin®, and Ortho-Tricyclen®) have Food and Drug Administration (FDA) labeling for the treatment of acne and are an important therapeutic option for adolescent females with recalcitrant acne. The effectiveness of oral contraceptives often allows discontinuation of chronic oral antibiotic therapy. Patients should be counseled that adherence to three cycles of oral contraceptives are often needed to establish treatment efficacy for acne. Oral contraceptives with a higher androgenic component and lower estrogenic component tend to worsen acne. Topical acne medications such as retinoids may need to be continued for best results.

Isotretinoin has been a valuable, unique, and effective agent for nodulocystic acne since 1982. Isotretinoin's teratogenicity is well known. The question of psychopathology induced by isotretinoin is more controversial. The Adverse Drug Event Reporting System of the United States FDA has received reports of depression, suicide, and other psychiatric side effects (e.g., aggression, psychosis) in patients using isotretinoin. The question of isotretinoin-induced depression is complicated by the high baseline incidence of depression and suicide in the adolescent population and by the depression and stress associated with severe acne.[53,54] Case reports, including positive cases of positive dechallenge and rechallenge, have suggested that isotretinoin may induce depression and other psychiatric adverse effects, but larger retrospective and prospective studies have not demonstrated causation.[55] In some studies, depression scores improved when patients' acne improved with isotretinoin therapy.[56] Double-blind, placebo-controlled isotretinoin studies have not yet been done. To date, animal studies have shown conflicting results. Although a causal link has not been established between isotretinoin and depression/suicide at this time, it is likely that uncommon idiosyncratic psychiatric reactions to isotretinoin may occur in predisposed individuals. Pretreatment evaluation and, if cleared to proceed, subsequent comanagement by a psychiatrist or psychologist should be considered for vulnerable patients. If mood changes arise, the drug should be stopped until the patient is evaluated by the pediatrician or psychiatrist. If deemed appropriate, a rechallenge can be done cautiously.

A second unanswered question is whether the risk of inflammatory bowel disease increases with isotretinoin use. Studies have shown conflicting results thus far. It is possible that isotretinoin may trigger inflammatory bowel disease in predisposed individuals. Until we have better data, patients and parents should be counseled that a rare but potentially real risk might exist. If bowel symptoms develop, discontinuation of isotretinoin is advisable until the patient is evaluated by a gastroenterologist.[57,58]

AXILLARY HYPERHIDROSIS

Idiopathic focal hyperhidrosis is a common condition that has been long been under recognized. Axillary hyperhidrosis is much more common but palmar and/or facial sites can be affected as well. It can be familial or sporadic. Although all ages may be affected, patients commonly present during adolescence when the condition becomes socially troubling and impacts significantly on quality of life. The management of focal idiopathic hyperhidrosis is similar to that of adults. If topical and oral treatments fail, injection of botulinum toxin A should be considered. Hyperhidrosis is reviewed in Chapter 84.

INDOOR TANNING

The WHO Cancer Group has classified tanning beds as "carcinogenic to humans." Extensive evidence has linked sunlamp or sun bed exposure to increased risk of melanoma and nonmelanoma skin cancers. Nevertheless, approximately 50,000 tanning salons exist in the United States and tanning bed use is increasing among adolescents and young adults. In addition to the desire for tanned skin and the socialization of the tanning salon, some individuals feel more relaxed, and have improved mood following tanning. Evidence is mounting that tanning bed use is physiologically and psychologically addictive. A study demonstrated that frequent tanners developed a preference for functional UV beds compared to otherwise identical sham light beds.[59] In addition, physiologic withdrawal symptoms arose in some subjects who were given naltrexone prior to their tanning sessions, suggesting that an opioid-mediated mechanism of dependency may exist in frequent tanners.[60]

Psychiatric studies, using modified tools originally used for substance abuse screening, confirm addictive behaviors of people who frequent tanning salons. Among 229 college students who had used indoor tanning facilities, 90 (39.3%) met diagnostic and statistical manual of mental disorders IV-TR criteria and 70 (30.6%) met CAGE (Cut down, Annoyed, Guilty, Eye-opener) criteria for addiction to indoor tanning. In addition, these students also reported greater symptoms of anxiety and greater use of alcohol, marijuana, and other substances than those who did not meet these criteria.[61]

The fight against indoor tanning is becoming similar to the fight against the tobacco industries. Stronger legislation banning tanning bed use in minors, control of false safety claims in advertisements, and extensive education of parents and our youth are needed to wage this war.

SPECIAL TOPICS IN PEDIATRIC DERMATOLOGY

DRUG LABELING FOR PEDIATRIC PATIENTS

The lack of FDA labeling for pediatric use does not imply that a drug is contraindicated or disapproved; it simply means that insufficient data are available to grant approval status. Although attempts have been made to equate off-label prescribing with recklessness in the medical malpractice arena, the American Academy of Pediatrics has stated that failure to prescribe medications for off-label uses when the medication is appropriate under standard of care may constitute malpractice.

The thalidomide tragedy (see Chapter 235) led to more stringent regulation of drugs in the early 1960s, and manufacturers began omitting drug studies in infants and children. In the 1970s, pediatric dosage information in package inserts tended to exclude children from therapeutic benefit. Performing research in healthy children is problematic because of ethical and logistic questions, medicolegal risk, and cost. It has been estimated that approximately 50%–75% of drugs used in pediatrics have not been studied adequately to provide accurate labeling information, and the younger the patient, the more likely the lack of information.[62] Safety and effectiveness information for drug use in children under 2 years of age is particularly lacking. The absence of pediatric testing and labeling poses significant safety risks for children. Additionally, children may be denied the benefits from therapeutic advances because physicians choose to prescribe existing, less effective medications in the face of insufficient pediatric information about new medications. In 1997, as part of the FDA Modernization Act, Congress enacted a law known as the *Pediatric Exclusivity Provision* that provides marketing incentives (i.e., 6 month extension of patent protection) to manufacturers who conduct studies of drugs in children. This law was effective in generating pediatric studies on many drugs, and an increase in labeling information has occurred for some. Unfortunately, many studies have centered on children greater than 6 years of age, and many drug studies were stimulated by market concerns rather than medical need.

Hopefully, with new incentives such as the Pediatric Research Equity Act of 2003, significantly more pediatric drug research will proceed forward. Ideally in the future, physicians caring for children will no longer need to prescribe drugs "off label," and children will no longer be "therapeutic orphans."

TOPICAL MEDICATIONS

While topical medications often have excellent safety and efficacy profiles, one must be aware that infants and young children are at increased risk for toxicity from topically applied agents because of increased surface area:body mass ratio compared to adults. In addition, at times infants and children have altered metabolism of drugs compared to adults. Patients with disorders of cornification (e.g., lamellar ichthyosis) or other forms of skin barrier disruption (e.g., Netherton syndrome) have a much higher risk of toxicity due to increased percutaneous absorption. Patients with Netherton syndrome treated with topical tacrolimus may develop immunosuppressive or toxic blood levels of tacrolimus, without clinical signs or symptoms

TABLE 107-9
Topical Medications Reported to Cause Systemic Toxicity in Children

Topical Medication	Complication	Reference
Tacrolimus 1% ointment	Three children with Netherton syndrome found to have blood levels of tacrolimus in the range of organ transplant requirements	63
Hydrocortisone 1% ointment	Cushing syndrome developed in an 11-year-old boy with Netherton syndrome receiving topical application to extensive areas for over one year	64
Benzocaine, 3% (Lanacane)	Methemoglobinemia in a 2-year-old child	65
Iodoquinol, clioquinol (Vioform)	Neurotoxicity when used as treatment for diaper dermatitis	66,67
Lindane	Neurologic toxicity in children with disrupted epidermal barrier and/or excessive topical application or ingestion	68,69
N, *N*-diethyl-*m*-toluamide (DEET)	Slurred speech, tremors, seizures, and death in children after repeated and extensive application of high concentrations of DEET	70
Povidone-iodine (Betadine)	Hypothyroidism in infants with spina bifida	71
Povidone-iodine (Betadine)	Decreased free thyroxine and elevated iodine levels in infants treated with diluted povidone-iodine during *Staphylococcus aureus* epidemic	72
Salicylic acid	In a 7-yr-old boy treated for ichthyosis vulgaris, life-threatening salicylism occurred with neurologic sequelae lasting 6 month	73
Saline, sodium chloride	Fatalities in infants and children following ancient Turkish custom of "salting"	74
Viscous lidocaine, 2%	Lidocaine overdose following frequent application to oral lesions	75

of toxicity.[63] A heightened awareness of this problem is important because Netherton syndrome is often misdiagnosed as atopic dermatitis, and both conditions often improve with topical tacrolimus therapy. In addition, a patient with Netherton syndrome developed Cushing syndrome after application of hydrocortisone 1% ointment for over 1 year.[64] Examples of inadvertent percutaneous poisoning from topical agents are listed in Table 107-9.

SYSTEMIC MEDICATIONS

DRUG DOSAGES. Pediatric doses of systemic medications are calculated according to body weight (mg/kg) or body surface area to account for size variations between patients of the same age and to account for a child's growth. Prescriptions for liquid medications (syrups or suspensions) must indicate concentration (e.g., milligrams per 5 mL, or teaspoon) to avoid serious error. In addition, the appropriate measuring instrument should be dispensed, along with education on its use. One study demonstrated that dosing cups (commonly provided in OTC children's medications) were associated with a large error in one in four doses—some of which were overdoses of 100%–300%.[76]

For guidelines on indications and dosing of antimicrobials and other medications, the reader is directed to excellent references including the *Red Book*[77] published by the American Academy of Pediatrics, and *The Harriet Lane Handbook*.[78]

SYSTEMIC GLUCOCORTICOIDS. Hypothalamic–pituitary axis suppression, osteonecrosis, and other adverse effects of systemic glucocorticoid therapy affect patients of all ages and are reviewed in Chapter 224. The potential risk of growth suppression is unique to childhood. Exogenous glucocorticoids disrupt the secretion of growth hormone (GH), causing abnormal spontaneous GH secretion with reduced pulse amplitude of GH release and reduced response to provocative stimuli.[79,80] There is also decreased local production of insulin-like growth factor 1. These and other effects of glucocorticoids act to cause delayed growth at the bony epiphyses, with the most noticeable reduction in growth velocity occurring during early childhood and adolescent growth spurts. There is a linear relation between the daily dose and growth suppression. Alternate-day dosing, with single morning doses, may decrease the risk of glucocorticoid growth suppression. Most children will have adequate catch-up growth eventually with reduction of doses, alternate-day therapy, or cessation of therapy.[81] For the pediatric patient on long-term systemic steroid therapy, charting height and weight on a standardized growth curve is the best method for the pediatrician to screen for decreasing growth velocity.

Children taking immunosuppressive doses of systemic glucocorticoids should not be vaccinated with live-virus vaccines (e.g., measles, oral polio, varicella). A dosage equivalent to 2 mg/kg/day or greater of prednisone or a total of 20 mg/day or greater for children weighing more than 10 kg, when given for more than 14 days, is sufficient to warrant withholding immunization with live-virus vaccines.[82] Systemic steroids should not be given to a healthy child if he or she has had recent varicella exposure and is not varicella-immune because varicella infection can be fatal in this situation. In addition, children with ocular herpes simplex and untreated tuberculosis should not be given systemic steroids, and patients with

underlying diabetes, hypertension, peptic ulcer disease, renal insufficiency, or psychosis should be treated with great caution or with an alternative agent.[77]

ANTIMICROBIALS. Use of tetracycline family medications is contraindicated in children younger than 8 years of age because it causes brown discoloration of developing teeth and decreased bone growth. Ciprofloxacin and quinolone use in children younger than 18 years of age is restricted because the fluoroquinolones have been shown to cause cartilage damage in juvenile animal models at therapeutic doses. The mechanism is unknown. It is recommended that its use be restricted to relatively serious infections for which no other oral agent is available or intravenous antibiotics would be impractical and for certain pathogenic infections or situations such as multidrug resistance.[78]

Griseofulvin doses of 20 mg/kg/day of the (125 mg/5 mL) liquid and 15 mg/kg/day of the ultramicrosized tablets for 6–8 weeks have long been considered first-line therapy for tinea capitis. In 2007, terbinafine oral granules (sprinkled on nonacidic food) were approved for the treatment of tinea capitis in children age 4 years and older. Currently, griseofulvin and terbinafine are the only FDA-approved agents for tinea capitis in children. Griseofulvin appears to be superior against *M. Canis* however if access and/or cost prevent the use of the oral granule form of terbinafine, crushed generic terbinafine tablets off-label can be substituted. Although further studies are needed, itraconazole also appears to be effective with a good safety profile. Fluconazole was not very effective in pediatric tinea capitis in a large multicenter, double-blinded randomized trial of 880 children.[83]

CHILD ABUSE

In the United States in 2003, 906,000 children were determined to be victims of child abuse and neglect by child protective agencies; an estimated 1,500 children died of child abuse. Ninety percent of all abused children are said to have suggestive or confirmative dermatologic findings.[84] Ideally, due to the sensitive medical and legal aspects of this important problem, any case of suspected child abuse should be referred to a specialized team specializing in pediatric abuse, however, appropriate evaluation should not be delayed in the absence of such a resource. Child abuse is discussed in Chapter 106.

KEY REFERENCES

Full reference list available at www.DIGM8.com

DVD contains references and additional content

1. Scullard P, Peacock C, Davies P: Googling children's health: Reliability of medical advice on the internet. *Arch Dis Child* 2010 Apr 6; [e-pub ahead of print]
2. Chiou YB et al: Stratum corneum maturation. A review of neonatal skin function. *Skin Pharmacol Physiol* **17**:57, 2004
6. Nopper AJ et al: Topical ointment therapy benefits premature infants. *J Pediatr* **128**:660, 1996
7. Campbell JR et al: Systemic candidiasis in extremely low birth weight infants receiving topical petrolatum ointment for skin care: A case-control study. *Pediatrics* **105**:1041, 2000
16. Van Praag MC et al: Diagnosis and treatment of pustular disorders in the neonate. *Pediatr Dermatol* **14**:131, 1997
17. Niamba P et al: Is common neonatal cephalic pustulosis (neonatal acne) triggered by Malassezia sympodialis? *Arch Dermatol* **134**:995, 1998
18. Lenane P et al: Congenital alopecia areata. *J Am Acad Dermatol* **52**:S8, 2005
23. Burden AD, Krafchik BR: Subcutaneous fat necrosis of the newborn: A review of 11 cases. *Pediatr Dermatol* **16**:384, 1999
24. Frieden IJ: Aplasia cutis congenita: A clinical review and proposal for classification. *J Am Acad Dermatol* **14**:646, 1986
25. Drolet B et al: "Membranous aplasia cutis" with hair collars: Congenital absence of skin or neuroectodermal defect? *Arch Dermatol* **131**:1427, 1995
26. Prizant TL et al. Spontaneous atrophic patches in extremely premature infants. Anetoderma of prematurity. *Arch Dermatol* **132**:671, 1996
27. Goujon E et al: Anetoderma of Prematurity: An iatrogenic consequence of neonatal intensive care. *Arch Dermatol* **146**:565-566, 2010
31. Drolet B: Birthmarks to worry about: Cutaneous markers of dysraphism. *Dermatol Clin* **16**:447, 1998
32. Guggisberg D et al: Skin markers of occult spinal dysraphism in children: A review of 54 cases. *Arch Dermatol* **140**:1109, 2004
36. Khachemoune A et al: Infantile perineal protrusion. *J Am Acad Dermatol* **54**:1046, 2006
43. Proudfoot J: Analgesia, anesthesia, and conscious sedation. *Emerg Med Clin North Am* **13**:357, 1995
48. Chang MW et al: Infantile granular parakeratosis: Recognition of two clinical patterns. *J Am Acad Dermatol* **50**:S93, 2004
50. Boiko S: Making rash decisions in the diaper area. *Pediatr Ann* **29**:50, 2000
53. Wysowski DK et al: Depression and suicide in patients treated with isotretinoin. *N Engl J Med* **344**:460, 2001
54. Wysowski DK et al: An analysis of reports of depression and suicide in patients treated with isotretinoin. *J Am Acad Dermatol* **45**:515, 2001
55. Kontaxakis VP et al: Isotretinoin and psychopathology: A review. *Ann Gen Psychiarty* **8**:2-9, 2009
56. Chia CY et al: Isotretinoin therapy and mood changes in adolescents with moderate to severe acne: A cohort study. *Arch Dermatol* **141**:557, 2005
57. Crockett SD et al: Isotretinoin use and the risk of inflammatory bowel disease: A case-control study. *Am J Gastroenterol* 2010 Mar 30; [e-pub ahead of print]
58. Shale M et al: Isotretinoin and intestinal inflammation: What gastroenterologists need to know. *Gut* **58**:737, 2009
60. Kaur M et al: Induction of withdrawal-like symptoms in a small randomized, controlled trial of opioid blockade in frequent tanners. *J Am Acad Dermatol* **54**:709-117, 2006
77. American Academy of Pediatrics: Antimicrobial agents and related therapy. In: *2009 Red Book: Report of the Committee on Infectious Diseases*, 28th edition, edited by L Pickering. Elk Grove Village, IL, American Academy of Pediatrics, 2009, 737
78. *The Harriet Lane Handbook*, 19th edition, edited by Kristen Arcara and Megan Tschudy. Mosby, Johns Hopkins Hospital, 2012

Chapter 108 :: Skin Changes and Diseases in Pregnancy

:: Julie K. Karen & Miriam Keltz Pomeranz

CUTANEOUS CHANGES COMMONLY ASSOCIATED WITH PREGNANCY AT A GLANCE

- Cutaneous changes result from the altered endocrine, metabolic, and immunologic milieus that characterize pregnancy.
- Pigmentary disturbances, including hyperpigmentation, darkening of the linea alba, and melasma are the changes most commonly observed.
- Significant change in nevi size is not a feature of most pregnancies.
- Structural changes known to occur during pregnancy include, most commonly, striae distensae.
- Pruritus is a common complaint during pregnancy and may be related to flare of a preexisting dermatosis or onset of a specific dermatosis of pregnancy.

CHANGES COMMONLY ASSOCIATED WITH PREGNANCY

Pregnancy is characterized by altered endocrine, metabolic, and immunologic milieus. These dramatic alterations result in multiple cutaneous changes, both physiologic and pathologic. A comprehensive list of physiologic alterations within the skin and appendages is provided in Table 108-1.[1–3]

Pigmentary disturbances are the most common of these physiologic changes (see Table 108-1). Hyperpigmentation of the areola, axillae, and genitalia is well documented in pregnancy. *Linea nigra* refers to the typically reversible darkening of the linea alba, a hypopigmented linear patch extending from the pubis symphysis to the xiphoid process of the sternum (Fig. 108-2). Melasma or chloasma is a related finding comprising irregular, blotchy, facial hyperpigmentation that occurs in up to 70% of pregnant women (see eFig. 108-2.1 in online edition). This tendency is aggravated by sun exposure and by oral contraceptive intake by nonpregnant women. Melasma may regress postpartum, but oftentimes persists, posing a therapeutic challenge.[1]

Changes in melanocytic nevi were historically deemed "normal" during pregnancy. However, few studies have objectively studied whether and how nevi evolve during pregnancy. Pennoyer et al[4] photographically monitored 129 melanocytic nevi throughout the pregnancies of 22 healthy Caucasian women. Only eight nevi (6.2%) changed in diameter from the first to third trimester, with a mean change in size of zero. The authors concluded that significant change in nevus size (excluding nevi on the pregnant abdomen) does not appear to be a feature of most pregnancies.[4] Until further controlled studies are performed, any pigmented lesion in a pregnant woman that undergoes change in morphology (size, color, or shape) or symptomatology (begins to itch, bleed, or scale) should be considered for histopathologic review. Recently, Chan et al identified characteristic histologic features unique to nevi excised during pregnancy, including increased mitotic index.[5]

The most common structural change during pregnancy is striae distensae, also known as *striae gravidarum* or *stretch marks* (Fig. 108-3). Sites of predilection for striae include those areas most prone to stretch, including the abdomen, hips, buttocks, and breasts. Genetic factors as family history, personal history, and race are the strongest predictors of an individual's risk of developing striae distensae, surpassing pregnancy



Figure 108-1 Spider angiomata on the arm of a pregnant woman. These spider nevi, as they are also called, have a central "body" and small vessels (legs) extending out from it. In this example, they are part of a unilateral nevoid telangiectasia, linear grouping of spider angiomata that can become more prominent during pregnancy.

TABLE 108-1
Physiologic Skin Changes during Pregnancy

Pigmentary
- Diffuse hyperpigmentation
- Selective hyperpigmentation (genitalia, axillae, recent scars)
- Secondary areolae
- Linea nigra
- Melasma (chloasma, mask of pregnancy)
- Darkening of ephelides and melanocytic nevi[a]

Hair
- Hirsutism
- Thickening of scalp hair
- Postpartum telogen effluvium
- Postpartum androgenetic alopecia

Nail
- Subungual hyperkeratosis
- Distal onycholysis
- Transverse grooving
- Brittleness
- Accelerated growth

Glandular
- Increased eccrine function (except palms) (miliaria, dyshidrotic eczema, hyperhidrosis)
- Elevated thyroid activity with resultant relative iodine deficiency
- Increased sebaceous function (growth in Montgomery's tubercles) (see eFig. 108-0.1 in online edition)
- Decreased apocrine function

Structural Changes
- Striae distensae (striae gravidarum)
- Molluscum fibrosum gravidarum (acrochordons)

Vascular
- Spider angiomas (spider nevi, nevi aranei) (Fig. 108-1)
- Palmar erythema (see eFig. 108-0.2 in online edition)
- Nonpitting edema (hands, ankles, feet, face)
- Varicosities
- Cutis marmorata
- Vasomotor instability
- Dermographism/pruritus
- Purpura
- Gingival hyperemia or hyperplasia
- Pyogenic granuloma (granuloma gravidarum, pregnancy epulis)
- Hemorrhoids
- Hemangiomas, hemangioendotheliomas, glomangiomas
- Unilateral nevoid telangiectasia (unilateral dermatomal superficial telangiectasia)

Mucosa
- Gingivitis (marginal gingivitis, papillomatous hypertrophy of the gums)
- Jacquemier–Chadwick sign (bluish discoloration of vagina and cervix)
- Goodell's sign (cervical softening)

[a]Although some degree of darkening of nevi during pregnancy may be physiologic, any pigmented lesion noted to change should be evaluated in a pregnant woman, as in nonpregnant women.
Data from Elling SV, Powell FC: Physiological changes in the skin during pregnancy. *Clin Dermatol* **15**:35, 1997; Kroumpouzos G, Cohen LM: Dermatoses of pregnancy. *J Am Acad Dermatol* **45**:1, 2001; and Muzaffar F, Hussain I, Haroon TS: Physiologic skin changes during pregnancy: A study of 140 cases. *Int J Dermatol* **77**:429, 1998.



Figure 108-2 Linea nigra. A hyperpigmented line extends from the pubis symphysis to the xiphoid process of the sternum. Hyperpigmentation is often more pronounced inferior to the umbilicus.

weight gain or changes in body mass index.[6] These findings strongly support a genetic predisposition to this condition.

Pruritus, a common complaint during pregnancy, may be physiologic, but may herald a flare of a preexisting dermatosis or onset of a specific dermatosis of pregnancy. The remainder of this chapter outlines the relatively rare conditions that may be specific to pregnancy. An overview of these conditions is provided in Table 108-2.

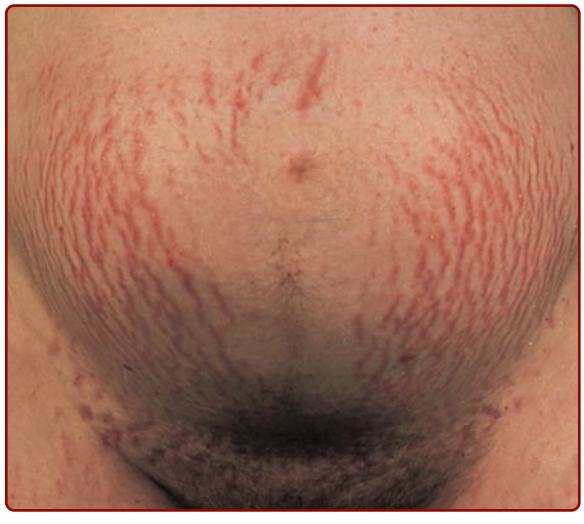

Figure 108-3 Striae distensae.

TABLE 108-2
Summary of Dermatoses of Pregnancy

	Morphology	Distribution	Usual Onset	Fetal Risk	Synonym(s)
Pemphigoid (Herpes) gestationis	Urticarial papules and plaques progress to vesicles and bullae	Begins on trunk, then progresses to generalized eruption Spares face, mucus membranes, palms, soles	Second or third trimester, or immediately postpartum	Small-for-gestational age births Preterm delivery Neonatal pemphigoid gestationis	Herpes gestationis
Intrahepatic cholestasis of pregnancy	Excoriations and excoriated papules ± jaundice	Localized to palms and soles or generalized	Third trimester	Preterm delivery Fetal distress Fetal death	Cholestasis of pregnancy Obstetric cholestasis Recurrent jaundice of pregnancy Cholestatic jaundice of pregnancy Idiopathic jaundice of pregnancy Prurigo gravidarum Icterus gravidarum
Pustular psoriasis of pregnancy	Erythematous patches with subcorneal pustules at their margins	Begins in flexures Generalizes demonstrating centrifugal spread	Third trimester	Placental insufficiency may lead to stillbirth or neonatal death	Impetigo herpetiformis
Pruritic urticarial papules and plaques of pregnancy	"Polymorphous" including urticarial papules and plaques ± vesicles	Begins within abdominal striae Spreads to remainder of trunk and then extremities Spares umbilicus	Third trimester or immediately postpartum	None	Polymorphic eruption of pregnancy Bourne's toxemic rash of pregnancy Nurse's late onset prurigo of pregnancy Toxemic erythema of pregnancy (Holmes)
E-type Atopic eruption of pregnancy	Eczematous patches and plaques	Face, neck, chest, flexural extremities	Second or third (less commonly) trimester	None	Eczema in pregnancy[a]
P-type Atopic eruption of pregnancy	Excoriated or crusted papules	Extremities, occasionally trunk	Second or third (less commonly) trimester	None	Prurigo of pregnancy[a] Besnier's prurigo gestationis Nurse's early onset prurigo of pregnancy Papular dermatitis of Spangler Atopic eruption of pregnancy[a]

NA = not applicable.
[a]A newly proposed classification by Ambros-Rudolph et al[41] combines the previously distinct entities prurigo of pregnancy and pruritic folliculitis of pregnancy into a single entity, atopic eruption of pregnancy, which also includes eczema in pregnancy.

DERMATOSES ASSOCIATED WITH FETAL RISK IN PREGNANCY

DERMATOSES ASSOCIATED WITH FETAL RISK IN PREGNANCY AT A GLANCE

- Pemphigoid gestationis is an immunologically mediated, intensely pruritic, vesiculobullous eruption of mid- to late pregnancy that is associated with fetal risk.
- Intrahepatic cholestasis of pregnancy represents a reversible form of cholestasis in late pregnancy associated with biochemical abnormalities and a risk of fetal complications, but invariably lacking primary cutaneous lesions. Symptoms remit within 2–4 weeks of delivery, but recurrences in subsequent pregnancies are common.
- Pustular psoriasis of pregnancy is a rare, acute, pustular eruption often accompanied by fever, leukocytosis, and an elevated erythrocyte sedimentation rate. This is generally regarded as a variant of psoriasis.

PEMPHIGOID (HERPES) GESTATIONIS

Pemphigoid (herpes) gestationis (PG; see Chapter 59) is an intensely pruritic, vesiculobullous eruption of mid- to late pregnancy and the immediate postpartum period. PG classically begins during the second or third trimester, and is manifest by the abrupt appearance of severely pruritic urticarial lesions on a background of normal or erythematous skin. PG is associated with an increased incidence of small-for-gestational age births and premature delivery. PG is immunologically mediated, and linear deposition of C3 with or without IgG are found at the dermal–epidermal junction by direct immunofluorescence (DIF).[7]

INTRAHEPATIC CHOLESTASIS OF PREGNANCY

NOMENCLATURE AND EPIDEMIOLOGY.

The terms *obstetric cholestasis*, *cholestasis of pregnancy*, *recurrent jaundice of pregnancy*, *cholestatic jaundice of pregnancy*, *idiopathic jaundice of pregnancy*, *prurigo gravidarum*, and *icterus gravidarum* all refer to the same clinical entity, intrahepatic cholestasis of pregnancy (ICP), characterized by a reversible form of cholestasis in late pregnancy. Svanborg and Ohlsson first recognized ICP as a distinct entity, separate from other causes of jaundice during pregnancy in 1939.[8] Jaundice develops in approximately 1 in 1,500 pregnant women. With an estimated incidence of 70 cases per 10,000 pregnancies in the United States, ICP ranks second only to viral hepatitis in terms of etiology of jaundice in pregnant women.[9] Mild cases of ICP, in which pruritus is not accompanied by jaundice, were previously referred to as prurigo gravidarum.

ICP is most common in Scandinavia and South America. The highest reported incidence rates are in Chile (14%–16%), whereas much lower rates are seen among pregnant women in the United States (less than 0.1%–0.7%), Canada (0.1%), Australia (0.2%–1.5%), and Central Europe (0.1%–1.5%).[9]

ETIOLOGY

Although the precise pathogenesis remains unclear, the interplay of hormonal, genetic, environmental, and alimentary factors is thought to induce a biochemical cholestasis in susceptible individuals. A prominent role for hormonal alterations is suggested by the following observations: (1) ICP is a disease of late pregnancy (corresponding to the period of highest placental hormone levels); (2) ICP spontaneously remits at delivery when hormone concentrations normalize; (3) twin and triplet pregnancies, characterized by greater rises in hormone concentrations, have been linked to ICP; and, (4) ICP recurs during subsequent pregnancies in an estimated 45%–70% of patients.[9,10]

Geographic variation and familial clustering indicate a genetic predisposition. ICP appears to be a polygenetic condition. Candidate genes include those mutated in a variety of other forms of inherited cholestasis: *ABCB4* (multidrug resistance gene3), *ABCB11* (Bsep), and *ATP8B1* (*FIC1*). A recent decline in prevalence rates in Chile, reports of higher incidence rates during the winter months, and reports of relative reductions of selenium levels in some ICP patients all point toward etiologic roles for environmental and alimentary factors.[9,11] At least one study confirmed a higher risk of hepatitis C virus infection among women with ICP.[12]

CLINICAL FEATURES. Patients classically present during the third trimester with moderate-to-severe pruritus, which may be either localized to the palms and soles or generalized. Pruritus begins during the first and second trimester in 10% and 25% of cases, respectively. Intense pruritus is oftentimes associated with secondary excoriations, although primary cutaneous lesions are invariably absent. Initially, patients may complain of nocturnal pruritus only, and symptoms generally are more severe at night throughout the course of illness. Constitutional symptoms such as fatigue, nausea, vomiting, or anorexia may accompany the pruritus. Progression to clinical jaundice, dark urine, or lightly colored stools occurs in approximately one in five patients. Pruritus generally precedes the onset of these symptoms by 1–4 weeks.[9]

COURSE. A hallmark of ICP is that symptoms and associated biochemical abnormalities typically resolve within 2–4 weeks of delivery. Recurrences during subsequent pregnancies occur in an estimated 45%–70% of

patients. Some women experience recurrent ICP after exposure to oral contraceptives or to contraceptive aids, such as synthetic estrogens and progestational agents.

Maternal outcomes are generally favorable, although women with severe cases are predisposed to postpartum hemorrhage secondary to vitamin K depletion. Additionally, affected women have a tendency toward the later development of cholelithiasis or gallbladder disease. Fetal risks in ICP include increased rates of prematurity, intrapartal fetal distress, and fetal death. These complications generally correlate with higher bile acid levels and are thought attributable to acute placental anoxia and an increased incidence of meconium-stained amniotic fluid. Such fetal complications may be reduced with treatment and induction of labor after fetal pulmonary maturation has been documented.[9]

LABORATORY STUDIES. Elevation in serum bile acids is the single most sensitive indicator of ICP. In healthy pregnant women, total bile acids (TBAs) are slightly elevated above baseline and levels as high as 11.0 μM are accepted as normal in late pregnancy. Clearly defined biochemical indices of ICP have not yet been established. However, Brites et al[13] identified the following common features of ICP: (1) serum TBA concentrations greater than 11.0 μM (normal range, 4.6–8.7 μM); (2) cholic acid–chenodeoxycholic acid ratio greater than 1.5 (normal range, 0.7–1.5) or cholic acid proportion of TBAs greater than 42%; (3) glycine conjugates–taurine conjugates of bile acids ratio less than 1.0 (normal range, 0.9–2.0) or glycocholic acid concentration greater than 2.0 μM (normal range, 0.6–1.5 μM).[13] Degree of pruritus and disease severity generally correlate with bile acid concentrations.

Mild perturbations in liver function tests, including elevated transaminases, alkaline phosphatase, 5′-nucleotidase, cholesterol, triglycerides, phospholipids, and lipoprotein X are commonly found. Among these parameters, alanine transaminase is particularly sensitive, as an elevation in this enzyme is not a feature of healthy pregnancies, but is commonly seen in ICP. γ-Glutamyl transferase, which is generally low in late gestation, is typically normal or slightly elevated in ICP. Direct (or conjugated) fractions of bilirubin are most commonly elevated in ICP. Albumin may be slightly reduced, whereas α_2-globulins and β-globulins are appreciably elevated. However, routine liver tests alone are not a sufficient basis for the diagnosis of ICP.[13]

Cutaneous biopsy does not aid in the diagnosis of ICP. Although generally unnecessary, hepatic biopsy reveals intrahepatic cholestasis with dilated, plugged bile canaliculi and deposits of bile pigment in centrilobular hepatocytes.[9]

DIFFERENTIAL DIAGNOSIS. Distinction from other causes of pruritus in the pregnant woman can be challenging. The presence of primary lesions points away from a diagnosis of ICP, which lacks primary lesions. Other causes of liver derangement and jaundice, such as viral and nonviral hepatitis, medications, hepatobiliary obstruction, and other intrahepatic diseases (i.e., primary biliary cirrhosis) must be ruled out. Finally, it must be remembered that hyperthyroidism, allergic reactions, polycythemia vera, lymphoma, pediculosis, and scabies may each manifest as generalized pruritus in pregnant as in nonpregnant women.

TREATMENT. Therapy aims to reduce serum bile acid levels and thereby prolong pregnancy, ameliorate maternal symptoms and reduce fetal risks. An interdisciplinary approach characterized by intense fetal surveillance is essential to the management of ICP. Although obstetric management varies, the need for weekly fetal monitoring beginning by the thirty-fourth week of gestation is widely accepted. Additionally, most authors recommend early induction of labor, commonly at 37–38 weeks' gestation, but as soon as there is evidence of fetal pulmonary maturity in severe cases.[9]

In mild cases, adequate relief of maternal symptoms can be achieved with bland emollients and topical antipruritic agents. Antihistamines and Ultraviolet B (UVB) phototherapy are variably effective.[7] Several uncontrolled trials have suggested that the anion exchange resin, cholestyramine, may effectively reduce symptoms in up to 70% of patients with mild ICP. However, the lack of randomized, placebo-controlled cholestyramine trials precludes definite conclusions about the efficacy of this agent. Furthermore, cholestyramine must be administered for several days before taking effect. Its efficacy in treating severe cases has been disappointing, and, importantly, it may precipitate vitamin K and thereby trigger a coagulopathy.[14,15] Other systemic therapies such as dexamethasone, *S*-adenosylmethionine, and plasmapheresis have been reported to sometimes reduce maternal symptoms.[7,9,16,17] However, these agents do not reverse the associated biochemical abnormalities, and thus, do not reduce fetal risks.

Ursodeoxycholic acid (UDCA), a naturally occurring hydrophilic bile acid, is the only treatment that has been shown to reduce maternal symptoms and fetal risk. UDCA exerts a hepatoprotective effect through augmentation of the excretion of hydrophobic bile acids, sulfated progesterone metabolites, and other hepatotoxic compounds. UDCA decreases bile acid levels in colostrum, cord blood, and amniotic fluid. The results of several small, randomized, placebo-controlled trials demonstrate that when administered at doses between 450 mg and 1,200 mg daily, UDCA is well tolerated and highly effective in controlling the clinical and liver function abnormalities that define ICP.[15] Enhanced efficacy may be achieved by coadministration with *S*-adenosylmethionine.[18] Randomized, controlled trials comparing UDCA head-to-head with either dexamethasone[19] or cholestyramine[20] demonstrated UDCA's superior efficacy.

PUSTULAR PSORIASIS OF PREGNANCY (IMPETIGO HERPETIFORMIS)

NOMENCLATURE. Von Hebra first used the designation *impetigo herpetiformis* in 1872 to describe an

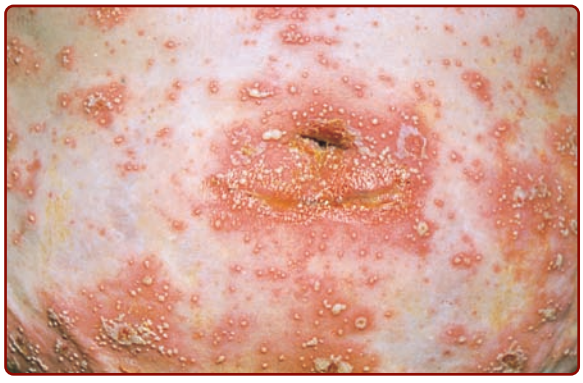

Figure 108-4 Pustular psoriasis of pregnancy. Erythematous patches are studded with subcorneal pustules.

acute pustular eruption with usual onset during the third trimester of pregnancy. It is now generally regarded as a variant of pustular psoriasis attributable to hormonal alterations during pregnancy; however, some authors maintain that it is a distinct clinical entity.[21,22]

CLINICAL FEATURES. Pustular psoriasis of pregnancy is characterized by an acute eruption occurring as early as the first, but generally during the third, trimester of an otherwise uneventful pregnancy. The condition manifests as erythematous patches whose margins are studded with subcorneal pustules (Fig. 108-4). The eruption typically originates in flexural areas but spreads centrifugally and sometimes generalizes. Subungual lesions may result in onycholysis. Rarely, mucous membrane involvement may lead to painful erosions. The face, palms, and soles are commonly spared. The rash may be pruritic or painful. Onset of the eruption is accompanied by such constitutional symptoms as fever, chills, malaise, diarrhea, nausea, and arthralgias. Rarely, tetany, delirium, and convulsions occur if hypocalcemia is severe.[1]

Although generally regarded as a form of pustular psoriasis (see Chapter 18), absence of a positive family history, abrupt resolution of symptoms at delivery, and a tendency to only recur during subsequent pregnancies distinguish this entity from generalized pustular psoriasis. Moreover, factors known to trigger pustular psoriatic flares, such as infection, exposure to culprit drugs, or abrupt discontinuation of systemic corticosteroids are lacking in virtually all patients with pustular psoriasis of pregnancy.[1,22]

LABORATORY STUDIES. Histopathologic examination reveals classic features of pustular psoriasis (see Chapter 18). The most common laboratory derangements include leukocytosis, neutrophilia, an elevated erythrocyte sedimentation rate, hypoferric anemia, and hypoalbuminemia. Less commonly, calcium, phosphate, and vitamin D levels are decreased. Serum parathormone levels are rarely decreased. Cultures of pustule contents and peripheral blood are negative unless secondarily infected.[1]

COURSE. Pustular psoriasis of pregnancy classically presents during the last trimester, but there are reports of cases occurring as early as the first trimester, during the puerperium, in nonpregnant women taking oral contraceptives, and in postmenopausal women. Symptoms are invariably progressive throughout pregnancy. A cardinal feature of this disorder is the rapid resolution of symptoms after delivery. Recurrences in subsequent pregnancies are common and characteristically are more severe with onset earlier in gestation.[1] Several reports of subsequent menstrual exacerbation occurring either during or immediately preceding menses exist in the literature.[23]

More widespread disease generally portends a worse prognosis. Life-threatening maternal complications are infrequent today, but may result from profound hypocalcemia and bacterial sepsis. The most feared complications are placental insufficiency and consequent stillbirth or neonatal death. For these reasons, early induction of labor is often contemplated.[21]

DIFFERENTIAL DIAGNOSIS. Box 108-1 outlines the differential diagnosis of pustular psoriasis of pregnancy.

TREATMENT. Resolution after delivery is the norm. However, given its consistently progressive course, treatment is indicated to reduce the risk of fetal and maternal complications during pregnancy. Topical treatments include wet dressings and topical corticosteroids, but are rarely effective as monotherapy. Systemic corticosteroids are the mainstay of therapy during pregnancy. Cyclosporine, which is categorized as pregnancy category "C," has been successfully used at doses between 5 mg/kg and 10 mg/kg daily to treat cases refractory to high-dose systemic corticosteroids.[24,25] Narrowband UVB combined with topical steroids has been reported to be successful.[26] Infliximab, a TNF-α blocking agent has been successfully used without adverse effect on the fetus.[27] Although

BOX 108-1 DIFFERENTIAL DIAGNOSIS OF PUSTULAR PSORIASIS OF PREGNANCY

Most Likely
- Pustular drug eruption (acute generalized exanthematous pustulosis)
- Pemphigoid gestationis

Consider
- Pemphigus vulgaris
- Dermatitis herpetiformis
- Subcorneal pustular dermatosis
- Pustular eruption in inflammatory bowel disease

Always Rule Out
- Infectious causes of pustular eruptions

careful consideration of the benefits and risks of TNF-blockade during pregnancy must be considered, these agents (including etanercept, infliximab, and adalimumab) are Class B and may have a role in the management of cases refractory to other therapies.

In all, cases, fluid status and electrolytes should be monitored with rapid correction of imbalances. Fetal monitoring is essential as decelerations in fetal heart rate may be the earliest sign of fetal hypoxemia. Maternal cardiac and renal functions may be compromised with disease progression and therefore should be monitored as well. Induction of labor is an option when symptoms do not remit despite supportive and pharmacologic therapy. The therapeutic armamentarium available after pregnancy termination or after delivery in a non-nursing mother can be extended to include oral psoralen and ultraviolet A (PUVA), oral retinoids, clofazimine, methotrexate, sulfapyridine, and sulfones.[28]

DERMATOSES NOT ASSOCIATED WITH FETAL RISK IN PREGNANCY

DERMATOSES NOT ASSOCIATED WITH FETAL RISK IN PREGNANCY AT A GLANCE

- Pruritic urticarial papules and plaques of pregnancy is a common, self-limited, intensely pruritic dermatosis that occurs almost exclusively in primigravidas during late pregnancy. The term *polymorphic eruption of pregnancy* appropriately encompasses the wide spectrum of clinical presentations.
- Atopic eruption of pregnancy represents a newly introduced complex comprising pruritic folliculitis of pregnancy, prurigo of pregnancy, and eczema of pregnancy. Lesions typically appear before the third trimester and may resemble classic atopic dermatitis (AEP, E-type) or be papular (AEP, P-type).

PRURITIC URTICARIAL PAPULES AND PLAQUES OF PREGNANCY (POLYMORPHIC ERUPTION OF PREGNANCY)

NOMENCLATURE AND EPIDEMIOLOGY. Pruritic urticarial papules and plaques of pregnancy (PUPPP) is a common benign intensely pruritic dermatosis that occurs almost exclusively in primigravidas during late pregnancy. The term *PUPPP*, introduced by Lawley et al in 1979[29] is synonymous with Bourne's toxemic rash of pregnancy, Nurse's late onset PP, toxic erythema of pregnancy, and polymorphic eruption of pregnancy (PEP).[30] *Polymorphic eruption of pregnancy*, a more recent term, best describes the clinical spectrum of this entity, and is favored throughout Europe.[31] The incidence of PUPPP ranges between 1 in 300 pregnancies and 1 in 130 pregnancies.[32]

ETIOLOGY. The pathogenesis remains unknown. An association between PUPPP and multiple gestation is suggested by the higher than expected rates of twin and triplet pregnancies in most published series.[32–34] An unexplained association with male fetuses and delivery by cesarean section has been reported.[32,34] Reports linking PUPPP to increased maternal–fetal weight gain[32,35] are contested. Some postulate that increased abdominal cutaneous distension leads to altered collagen and/or elastic tissue, thereby triggering maternal immune-reactivity to previously non-antigenic stimuli.[32] Additionally, fetal DNA has been detected in involved maternal skin and is hypothesized to be etiologically linked to this condition.[36] Increased progesterone receptor immunoreactivity has been detected in lesional PUPPP, leading some to posit a role for progesterone activation of keratinocytes.[37]

CLINICAL FEATURES. PUPPP typically occurs in primigravidas during the last trimester of pregnancy (mean onset, 35 weeks); however, cases of otherwise classic PUPPP have occurred earlier in pregnancy and in the immediate postpartum period. Polymorphous in nature, lesions may be urticarial (most commonly), vesicular, purpuric, polycyclic, targetoid, or eczematous in appearance (Fig. 108-5).[38] Typical lesions are 1- to 2-mm erythematous urticarial papules surrounded by a narrow pale halo. The eruption begins on the abdomen, classically within the striae gravidarum, and demonstrates periumbilical sparing. Pruritus generally parallels with the eruption and is localized to the involved skin. Rapid spread to the thighs, buttocks, breasts, and arms is the norm. Involvement of the palms, soles, or skin above the breast is exceptional.[1] Severe pruritus may disturb sleep, but no other systemic symptoms are reported.

LABORATORY STUDIES. Laboratory investigations reveal no abnormalities. Histopathologic findings, although nonspecific, generally include parakeratosis, spongiosis, and occasional exocytosis of eosinophils (eosinophilic spongiosis). The adjacent dermis may be edematous and contains a perivascular infiltrate of lymphocytes admixed with variable numbers of eosinophils and neutrophils. DIF studies reveal no specific immunoreactants and indirect immunofluorescence studies are negative.[1]

COURSE. PUPPP mostly affects primigravidas in the last trimester, although it may occur as early as the first trimester. There are several reports of cases occurring in the immediate postpartum period as well. Duration of symptoms is typically brief, averaging 6 weeks. However, severe symptoms rarely persist for more than 1 week. Spontaneous remission within days of delivery is the rule. Recurrences in subsequent pregnancies or with exposure to oral contraceptives are unusual. Fetal and maternal prognoses



Figure 108-5 Pruritic urticarial papules and plaques of pregnancy. **A.** The earliest lesions are 1- to 2-mm, erythematous, urticarial papules localized within and around the striae distensae and sparing the umbilicus. **B.** The papules coalesce to form erythematous plaques that spread to involve the buttocks and thighs. **C.** Urticarial plaques on the breasts. Of note, the breasts also show a "secondary areola," the physiologic darkening, and reticular expansion of the areolar pigmentation. There are also striae distensae visible on the breast as well as Montgomery tubercles on the areolae.

are unaltered.[1] There is a single report of involvement of a newborn.[39]

DIFFERENTIAL DIAGNOSIS. Box 108-2 outlines the differential diagnosis of PUPPP.

BOX 108-2 DIFFERENTIAL DIAGNOSIS OF PRURITIC URTICARIAL PAPULES AND PLAQUES OF PREGNANCY

Most Likely
- Pemphigoid gestationis
- Atopic eruption of pregnancy
- Contact dermatitis

Consider
- Drug eruption
- Viral exanthema
- Pityriasis rosea
- Exfoliative or eczematous dermatitis

Always Rule Out
- Scabies

TREATMENT. Although harmless to the mother and fetus, pruritus is often intense and unremitting. Symptomatic relief of pruritus can usually be achieved with topical antipruritics, antihistamines, and topical corticosteroids. A brief course of oral corticosteroids is rarely required, but effectively controls symptoms in most cases refractory to topical treatment. Early induction of labor has been rarely considered in instances in which severe pruritus is unrelenting, but is generally considered unnecessary.[1,40] Patient reassurance regarding the self-limited nature of PUPPP can help to assuage unnecessary anxiety.

ATOPIC ERUPTION OF PREGNANCY

NOMENCLATURE AND EPIDEMIOLOGY. Ambros-Rudolph et al have proposed the term *atopic eruption of pregnancy* (AEP) to denote the disease complex comprising the previously distinct entities prurigo of pregnancy (PP) and pruritic folliculitis of pregnancy (PFP), as well as *eczema in pregnancy* (EP), which has not previously been considered a specific dermatosis of pregnancy.[41] PFP includes Besnier's prurigo gestationis, and Nurse's early onset PP and papular dermatitis of Spangler are now considered subset of AEP as well.[7]



Figure 108-6 Atopic eruption of pregnancy, P-type (formerly, prurigo of pregnancy). Multiple discrete, excoriated papules demonstrate a predilection for extensor surfaces.

AEP is a benign pruritic condition of pregnancy characterized by an eczematous (AEP, E-type) and/or papular (AEP, P-type) eruption in individuals with a personal and/or familial atopic background and/or elevated serum immunoglobulin E (IgE) levels. AEP comprises about 50% of all pregnancy dermatoses. AEP is thought to be triggered by pregnancy-related shifts in cytokine profile expression leading to preferential expression of T-helper 2 cytokines.[41]

CLINICAL FEATURES. Whereas 20% of AEP patients present with a flare of preexisting atopic dermatitis, the remaining patients experience an atopic eruption for the first time ever (or after a long remission). A classic eczematous eruption primarily affecting flexural surfaces and the face occurs in two-thirds of affected individuals (AEP, E-type). The remaining third present with papular lesions (AEP, P-type) and would previously have been classified as PP. Papular or P-type lesions are discrete, pruritic, excoriated papules with a predilection for extensor surfaces (Fig. 108-6), with truncal involvement less common. Minor features of eczema, including xerosis or hyperlinear palms, may be noted in patients with either subtype. Distinguishing features of AEP include onset early in pregnancy (before the third trimester) and a personal and/or family history of atopy.[41]

LABORATORY STUDIES. Total serum IgE is elevated in 20%–70% of individuals with AEP.[41] Serologic tests reveal no other abnormalities. Histopathologic features are nonspecific. Direct and indirect immunofluorescence studies are negative.[1]

COURSE. Onset is typically during the second trimester. Lesions respond quickly to therapy; however, recurrence with subsequent pregnancies is common, consistent with an atopic diathesis. Maternal and fetal prognoses are excellent, even in severe cases.[1]

DIFFERENTIAL DIAGNOSIS. Other specific dermatoses of pregnancy, especially ICP and PUPPP should be ruled out, as should microbial folliculitis or allergic contact dermatitis occurring in a pregnant woman.

TREATMENT. Treatment seeks to ameliorate pruritus and includes emollients, midpotency topical corticosteroids and antihistamines. Benzoyl peroxide may be helpful for truncal, follicular lesions and UVB phototherapy can be used in severe cases.[1,42,43]

KEY REFERENCES

Full reference list available at www.DIGM8.com

DVD contains references and additional content

4. Pennoyer JW et al: Changes in size of melanocytic nevi during pregnancy. *J Am Acad Dermatol* **36**:378, 1997
7. Kroumpouzos G, Cohen LM: Specific dermatoses of pregnancy: An evidence-based systematic review. *Am J Obstet Gynecol* **188**:1083, 2003
9. Lammert F et al: Intrahepatic cholestasis of pregnancy: Molecular pathogenesis, diagnosis and management. *J Hepatol* **33**:1012, 2000
13. Brites D et al: Relevance of serum bile acid profile in the diagnosis of intrahepatic cholestasis of pregnancy in an high incidence area: Portugal. *Eur J Obstet Gynecol Reprod Biol* **80**:31, 1998
21. Heymann WR: Dermatoses of pregnancy update. *J Am Acad Dermatol* **52**:888, 2005
41. Ambros-Rudolph CM et al: The specific dermatoses of pregnancy revisited and reclassified: Results of a retrospective two-center study on 505 pregnant patients. *J Am Acad Dermatol* **54**:395, 2006

Chapter 109 :: Aging of Skin

:: Mina Yaar & Barbara A. Gilchrest

SKIN AGING AT A GLANCE

- Intrinsic (chronologic) aging occurs throughout the skin and causes primarily functional losses.
- Caused by oxidative damage, cell senescence, amino acid racemization, nonenzymatic glycosylation of proteins.
- Displays flattening of the dermal–epidermal junction, decreased cellularity, decreased dermal thickness, loss of vascular and lymphatic beds.
- Photoaging is the superposition of chronic ultraviolet-induced damage on intrinsic aging and accounts for most age-associated changes in skin appearance.
- Triggered by receptor signaling, mitochondrial damage, and protein oxidation.
- Displays variable epidermal thickness, dermal elastosis, decreased/fragmented collagen, increased matrix degrading metalloproteinases, inflammatory infiltrate, and vessel ectasia.
- Dermatologic problems with increased incidence in the elderly include skin cancer, xerosis, pruritus, varicella-zoster infection, ulcers, bullous pemphigoid, and drug eruptions.

EFFECTS OF AGING

In both developed and developing nations, the number and proportion of older people are increasing. In 2008, 23% of the US population was 55 years of age or older.[1] The number of persons aged ≥65 years is expected to increase to an estimated 71 million in 2030.[1,2] This demographic shift compels health care providers and government officials to confront the pathophysiology of aging and associated health issues.

Aging is a process of progressive decreases in the maximal functioning and reserve capacity of all organs in the body, including the skin. This naturally occurring functional decline in the skin is often compounded and accelerated by chronic environmental insults, such as ultraviolet (UV) and infrared (IR) irradiation as well as environmental carcinogens present in polluted air of major urban centers.

Aging occurs at the cellular level and reflects both a genetic program and cumulative environmentally imposed damage. Mammalian cells can undergo only a limited number of cell divisions and then arrest irreversibly,[3–5] in a state known as *replicative senescence*, after which they are refractory to mitogenic stimuli. This fact has led to the perception that aging evolved in multicellular organisms as a cancer prevention mechanism[6] because it prevents the unlimited and possibly unregulated growth of cells whose DNA has been progressively damaged over their life span. Of note, in general the more proficient the DNA repair mechanisms of the organism, the longer its life span.[7] Furthermore, there is an inverse correlation between the organism's life span and metabolic rate,[8] consistent with the understood role of cumulative oxidative DNA damage, due to aerobic metabolism, in the aging process.[7]

AGING MECHANISMS

TELOMERES AND AGING[9]

Telomeres, the terminal portions of eukaryotic chromosomes, consist of up to many hundreds of tandem short sequence repeats (TTAGGG in all mammals). During mitosis of somatic cells, DNA polymerase cannot replicate the final base pairs of each chromosome, resulting in progressive shortening with each round of cell division. A special reverse transcriptase, telomerase, can replicate these chromosomal ends, but, with the exception of stem cells and germline cells, the enzyme is normally expressed at extremely low levels. Telomeres of patients with premature aging syndromes, such as Werner syndrome also termed "adult progeria" and associated in addition with increased risk of cancer,[10] progeria,[11] and dyskeratosis congenita,[12] are shorter than those of age-matched controls. Also, most of the DNA repair deficiency diseases, such as xeroderma pigmentosum show varying degrees of "accelerated aging," or cancer or both.[13]

Although at low levels, telomerase is expressed in epidermal cells in vivo. In skin, the relatively quiescent fibroblasts and melanocytes have longer telomeres than keratinocytes, but the three cell types exhibit only minor age-dependent telomere shortening of 11–25 bp (base pairs) per year. Some investigators believe that telomerase helps in telomere maintenance of keratinocytes, while dermal fibroblasts and melanocytes maintain their long telomeres due to their low proliferation rate.[14,15] Critically short telomeres signal for proliferative senescence or apoptosis, depending on cell type, and appear to compromise DNA stability and transcription of subtelomeric genes,[16] presumably contributing to the aged phenotype. Thus, telomeres appear to serve as a biologic

clock that determines proliferative life span and functional level of the cell.

DNA DAMAGE AND AGING[17]

In humans, the only genes implicated in the rate of aging are those in which mutations are responsible for premature aging syndromes. For example, Cockayne syndrome patients display mutations in DNA helicases, enzymes that participate in the repair of DNA damage[18]; ataxia telangiectasia is caused by a mutation in the *ATM* gene,[19] encoding a kinase that detects DNA damage; and Werner syndrome is caused by mutation in a protein with DNA helicase and exonuclease domains.[20] Progeria, a disease that leads to death from atherosclerotic heart disease often in the first decade of life, is caused by mutations in lamin A, a protein important in maintaining chromatin organization in the nucleus for transcriptional control and for DNA damage repair.[21,22] These human premature aging diseases suggest that decreased DNA repair capacity is associated with accelerated aging and that cumulative DNA damage plays a major role in the aging process. Still, the role of these genes in normal aging is not established, as patients with so-called *premature aging syndromes* display some manifestations of aging at an accelerated rate but lack other features of normal aging and have characteristic findings that differ greatly from those of normal aging.

Even in DNA repair proficient individuals, throughout life DNA damage accumulates in cells, interfering with cellular metabolism and function. One system that is particularly susceptible to DNA damage is that of growth hormone and insulin growth factor. It is thought that shifting the energy utilization of the cell from growth and proliferation of a damaged cells to preserving the somatic functions of the individual cell has evolved as a way of ensuring the well-being of the organism as a whole and as a cancer preventing mechanism.[23] Epigenetic events also play a role in aging. For example, DNA methylation is likely affected with aging and may result in silencing of tumor-suppressor and repair genes resulting in cellular senescence and increasing cancer incidence.[24]

However, in other species so-called longevity genes have been identified whose mutation or overexpression increase life span. However, in lower organisms all characterized longevity genes encode proteins that assist in control of environmental stress such as starvation, UV irradiation, oxidative damage, and heat shock. Silent information regulator proteins, sirtuins are a class of protein deacetylases implicated in slowing the aging process. Although it is still unclear how they affect aging, it is suggested that they maintain telomere structural integrity, induce transcriptional silencing of genes that promote aging, and/or modulate mitochondrial function in response to caloric restriction.[25] Resveratrol, a phenolic substance present in red wine is thought to be sirtuin activator.[26] A recently identified transcription factor family of proteins, FoxO, regulates cellular metabolism, stress resistance, and life span extension in mammals.[27,28] In addition, FoxO induces the transcription of procollagen I and decreases the transcription of the matrix degrading metalloproteinases (MMP) -1 and -2.[28] Mice with extended life spans show high expression of a small number of gene loci that control immune responses, a critical mammalian defense against environmental insults. In the aggregate, these studies strongly support a role of cumulative cellular damage, particularly DNA damage, in the aging process; and proficient repair of such damage in longevity.

AGING AND THE IMMUNE SYSTEM[29]

The immune system has two major roles: defense against external insults and internal immunologic surveillance. Decreased T cell memory, loss of the naïve T cell population, defective humoral, and cellular immunity characterize the aging immune system. Chronic inflammatory state, decreased immunity to exogenous antigens, and increased autoreactivity compromise the ability to sustain environmental insults.[30,31] With aging, increased reactive oxygen species (ROS) within cells leads to oxidative stress and contributes to low-grade inflammation. Additionally, mitochondrial electron transfer during oxidative phosphorylation is compromised with aging and results in leakage of proinflammatory ROS into the cytoplasm. This ROS imbalance contributes to immune senescence beginning with decline in the innate immune response and culminating with impaired adaptive immune responses.[31] These changes contribute to the increased incidence of infections and malignancies in the elderly.[32]

SKIN AGING

Cutaneous aging includes two distinct phenomena. Intrinsic aging is a universal, presumptively inevitable change attributable to the passage of time alone; extrinsic aging is the superposition on intrinsic aging of changes attributable to chronic environmental insults, sun exposure, which are neither universal nor inevitable. Extrinsic skin aging is also commonly termed photoaging, reflecting the large and well-studied role of chronic sun exposure. The former is manifested primarily by physiologic alterations with subtle but undoubtedly important consequences for both healthy and diseased skin. The latter has major morphologic as well as physiologic manifestations and corresponds more closely to the popular notion of old skin.

INTRINSIC SKIN AGING

The skin changes that occur with aging (Table 109-1) lead to a gradual physiologic decline (Table 109-2).[33] Major age-related changes in the skin's appearance include dryness (roughness), wrinkling, laxity, and a variety of benign neoplasms. Aged skin is inelastic and recovers more slowly after injury.

TABLE 109-1
Histologic Features of Aging Human Skin

Epidermis	Dermis	Appendages
Flattened dermal–epidermal junction	Atrophy (loss of dermal volume)	Depigmented hair Loss of hair
Variable/decreased thickness	Fewer fibroblasts	Conversion of terminal to vellus hair
Variable cell size and shape	Fewer mast cells	Abnormal nail plates
Occasional nuclear atypia	Fewer blood vessels	Fewer glands
Fewer melanocytes	Shortened capillary loops	
Fewer Langerhans cells	Abnormal nerve endings	

MECHANISMS OF INTRINSIC SKIN AGING.

A major aging theory[34] suggests that cumulative damage to biomolecules, including DNA as a result of continuous generation of free radicals, results in increased cellular vulnerability and eventually terminates in senescence or apoptosis. The skin, like other bodily systems, is continuously exposed to ROS generated during aerobic metabolism (eFig. 109-0.1 in online edition). Although the skin contains a network of antioxidant enzymes (superoxide dismutases, catalase, and glutathione peroxidase) and nonenzymatic antioxidant molecules (vitamin E, coenzyme Q10, ascorbate, and carotenoids), this system is less than completely effective and tends to deteriorate with aging.[35]

Oxidative stress upregulates the level of stress regulatory proteins, including hypoxia-inducible factors (HIFs) and nuclear factor κB (NFκB). HIFs influence the expression of genes that regulate cellular metabolism, survival, motility, basement membrane integrity, angiogenesis, hematopoiesis, and other functions.[36] Both HIFs and NFκB induce the expression of proinflammatory cytokines like interleukin (IL)-1 and IL-6, vascular endothelial growth factor (VEGF), and tumor necrosis factor (TNF)-α. These proteins are involved in immunoregulation and cell survival,[37] stimulate the expression of matrix-degrading metalloproteins,[38] and are believed to play a central role in the aging process. Furthermore, HIFs stabilize subpopulations of malignant cells with stem cell properties (cancer stem cells) and induce their self-renewal by stimulating the expression of signaling pathways critical for survival and proliferation. This suggests that age-associated cellular hypoxia could be involved in cancer stem cell maintenance.[36]

TABLE 109-2
Functions of Human Skin That Decline with Age

Barrier function
Cell replacement
Chemical clearance
DNA repair
Epidermal hydration
Immune responsiveness
Mechanical protection
Sebum production
Sensory perception
Sweat production
Thermoregulation
Vitamin D production
Wound healing

Oxidative damage also affects telomeres. A recent hypothesis suggests a common cellular signaling pathway activated by DNA damage and involving the terminal portion of the telomeres.[39,40] The terminal portion of the 3′ telomeric strand extends beyond the complementary 5′ strand (Fig. 109-1), leaving a single stranded G-rich overhang. It is suggested that during both telomere shortening and repair of telomere damage, such as that encountered during oxidative stress, the normal loop structure at the end of telomeres is disrupted, exposing the 3′ overhang that under baseline conditions is "buried" in the loop structure.[39,40] Exposure of the TTAGGG tandem repeat sequence then appears to activate p53[41] and to stimulate responses known to include proliferative senescence and apoptosis.[40,41] Thus, the intrinsic component of skin aging involves progressive oxidative stress and telomere signaling as telomeres shorten during serial cell division and in response to oxidative DNA damage.[39]

Oxidative damage also affects cellular proteins, leading to the formation of multiple carbonyl groups (C = O). Such proteins are typically targeted for degradation by proteasomes whose function declines with age, leading to the accumulation of damaged proteins that interfere with proper cellular function.[42]

Another mechanism that plays a role in intrinsic aging is cellular senescence, the limited capacity of cells to divide. It is regarded by some as having evolved in multicellular organisms as a cancer-prevention mechanism.[6] Senescent cells display critically short telomeres, irreversible growth arrest,

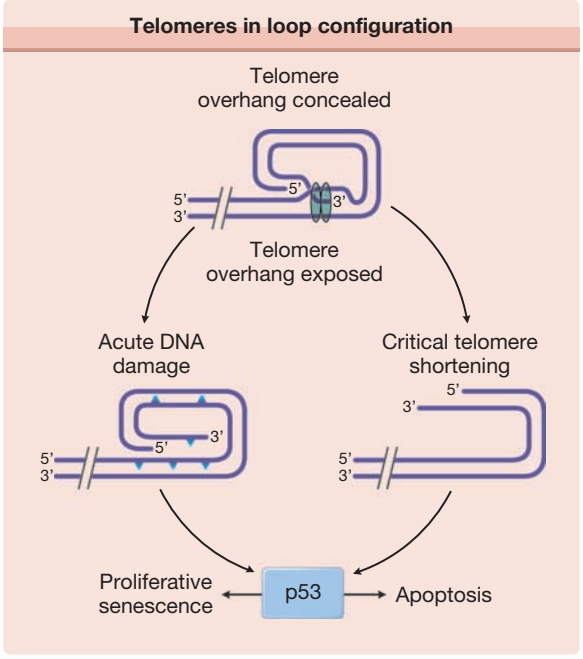

Figure 109-1 Telomeres normally exist in a loop configuration, held in place by the final 150–200 bases (TTAGGG repeats) on the 3′ strand that forms a single-stranded overhang. When the loop is disrupted when telomeres become critically short (e.g., after repeated cell divisions or when telomeres are damaged as a result of UV irradiation or oxidative damage), the overhang becomes exposed, activating the tumor suppressor protein p53 to induce proliferative senescence or apoptosis, depending on the cell type. IL = interleukin. (From Yaar M: Clinical and histological features of intrinsic versus extrinsic skin aging. In: *Skin Aging*. Springer, 2006, p. 9, with permission.)

resistance to apoptosis, and altered differentiation. They also overexpress genes that block progression into the cell cycle[43–45] as well as genes encoding proteins such as fibronectin and proteases involved in modulation of extracellular matrix, such as collagenase and stromelysin. In addition, the levels of certain tissue inhibitors of MMPs are decreased.[46]

Additional mechanisms include amino acid racemization, a process that substitutes D-amino acids for L-amino acids within proteins, affecting protein function and rendering them less susceptible to degradation. Finally, nonenzymatic glycosylation of proteins occurs when reducing sugar aldehydes condense with protein amino groups, resulting in brown discoloration, loss of function, and altered degradation. Glycosylation of extracellular matrix proteins, such as dermal collagen, leads to cross-linking with trapping and sequestration of other unaffected proteins.

EPIDERMIS. Many of the morphologic and functional age-associated changes in skin were documented many years ago[47] and are not specifically referenced here. The most striking and consistent histologic change is flattening of the dermal–epidermal junction with effacement of both the dermal papillae and epidermal rete pegs.[48] This results in a considerably smaller surface between the epidermis and dermis and presumably less communication and nutrient transfer. Dermal–epidermal separation has been demonstrated to occur more readily in old skin, undoubtedly explaining the propensity of the elderly to torn skin and superficial abrasions after minor trauma.

There is an age-associated epidermal thinning of 10%–50% between the ages of 30 years and 80 years.[49] Variability in epidermal thickness and individual keratinocyte size increases, including those of the basal layer. Evidence suggests that epidermal keratinocytes senesce and senescent cells are more resistant to apoptosis. Therefore, such keratinocytes are more likely to accumulate mutations, increasing their risk for malignant transformation. Epidermal stem cells are a population of cells responsible for epidermal maintenance. It is unclear whether there is an age-associated decrease in epidermal stem cells. Some studies also show loss of epidermal stem cell population in aged skin as determined by the loss of cells expressing CD71 (transferrin receptor) and α_6 integrin, accepted markers for keratinocyte stem cells,[50] while others claim that unlike stem cells from other tissues, epidermal stem cells maintain their number and functionality with age and do not display ROS increases.[51,52] The latter has been attributed to high levels of antioxidant enzymes particularly superoxide dismutase-1.[53] At the electron microscopic level, sun-protected old skin is characterized by some widening of interkeratinocyte spaces, by reduplication of the lamina densa and anchoring fibril complex in the basement membrane zone, and by loss of the numerous microvillous projections of basal cell cytoplasm into the dermis.[49]

Average thickness and degree of compaction of the stratum corneum appear constant with increasing age, although individual corneocytes become larger. The skin surface pattern, a patchwork of fine lines possibly determined by papillary dermal architecture, reveals slight age-associated loss of regularity. There is an overall decreased lipid content in the stratum corneum of the elderly as well as decreased water content in part as a result of decrements in cholesterol synthesis.[54] Age-associated increase in stratum corneum pH impedes lipid-processing enzyme activity.[55] Age effects on percutaneous absorption depend in part on drug structure, with hydrophilic substances such as hydrocortisone and benzoic acid being less well absorbed through the skin of old versus young individuals but with hydrophobic substances such as testosterone and estradiol being equally well absorbed.[56] Of perhaps greater clinical importance, aging markedly delays the recovery of barrier function in damaged stratum corneum, apparently because of slow replacement of neutral lipids, leading to decreased amount of lipids in the newly formed lamellar bodies.[57] Lipid synthesis and activities of enzymes required to generate stratum corneum lipids decrease with age possibly because of aberrations in elements that regulate enzyme transcription, or abnormal autocrine/paracrine signaling.[58]

In the elderly, the skin often appears dry and flaky, especially over the lower extremities, an area in which a remarkable age-associated decrease in the content of epidermal filaggrin has been reported.[59] Filaggrin,

required for binding of keratin filaments into macrofibrils, is also decreased in the skin of patients with ichthyosis vulgaris, and its lack has been postulated to cause the increased scaliness in both conditions.[59] Barrier function also may be affected by this structural change.

Epidermal turnover rate and thymidine-labeling index decrease approximately 30%–50% between the third and eighth decades, with a corresponding prolongation in stratum corneum replacement rate. Linear growth rates also decrease for hair and nails. Epidermal repair rate after wounding likewise declines with age.

A decrease in the number of enzymatically active melanocytes per unit surface area of the skin, approximately 10%–20% of the remaining cell population each decade, has been documented repeatedly, presumably reducing the body's protective barrier against UV radiation. Age-associated decline in DNA repair capacity compounds the loss of protective melanin and increases the risk for skin cancer development. The number of melanocytic nevi also decreases progressively with age, from a peak of 15 to 40 in the third and fourth decades to an average of four per person after age 50 years; such nevi are rarely observed in persons beyond age 80.

Between early and late adulthood there is a 20%–50% reduction in the number of morphologically identifiable epidermal Langerhans cells, the skin's immune effector cells responsible for antigen presentation. The remaining cells display morphologic abnormalities, including less and shorter dendrites, and they display reduced antigen-presenting capacity.[60] These changes, compounded by decreases in cytokine production by keratinocytes and lymphocytes and failure of migration through the lymphatic system, presumably contribute to the observed age-associated decrease in cutaneous immune responsiveness.

An endocrine function of human epidermis that declines with age is vitamin D production.[61] Vitamin D, by binding its nuclear receptor, induces the transcription of numerous genes.[62] Vitamin D deficiency in adults leads to osteomalacia and low levels have been implicated in epidemiologic studies as contributing to diabetes, hypertension, and prevalent tumors.[63] Aside from its well-studied role in calcium homeostasis, vitamin D, when bound to its nuclear receptor (1,25D-VDR) influenced transcription of numerous genes including those that encode proteins of the Wnt signaling pathway affecting the formation of the cornified epithelium as well as hair growth. 1,25D-VDR also activates genes that encode proteins that participate in the innate and adaptive immune responses and repress IL-17, a major inducer of autoimmune disorders such as type I diabetes mellitus, multiple sclerosis, lupus, and rheumatoid arthritis. 1,25D-VDR is also anti-inflammatory, as it decreases NFkB and COX2 activation. Finally, 1,25D-VDR induces the activity of the tumor suppressor p53 and p21 proteins and the activity of FoxO, preventing oxidative damage and inducing DNA repair enzymes in skin.[64] Elderly individuals frequently have reduced serum levels of vitamin D. Although avoidance of dairy products (the principal dietary source of vitamin D), insufficient sun exposure, and sunscreen use undoubtedly contribute to vitamin D deficiency in the elderly, the level of epidermal 7-dehydrocholesterol per unit skin surface area also appears to decrease linearly by approximately 75% between early and late adulthood,[61] suggesting that lack of its immediate biosynthetic precursor also may limit vitamin D production. Together these observations suggest that age-associated decrease in Vitamin D could accelerate the aging process and argue for use of vitamin D dietary supplements in the elderly.[65]

With regard to susceptibility to oxidative damage, there is progressive accumulation of damaged cellular proteins and lipids with aging.[49,66] Furthermore, antioxidant defense systems decline with age, and, in addition, there is a decrease in DNA damage repair capacity.[49] These changes in combination increase cellular mutability or their tendency to become senescent, or both.

DERMIS. Loss of dermal thickness approaches 20% in elderly individuals, although in sun-protected sites significant thinning occurs only after the eighth decade.[67] Old dermis is relatively acellular and avascular, and there is age-related loss of normal elastic fibers and dermal collagen.[68,69]

Decreased inflammatory responses in the elderly are the result of decreased synthesis and secretion of keratinocyte-derived cytokines and inflammatory mediators in addition to decreased endothelial response. The dermal microvasculature in middle-aged or elderly subjects also may show mild vascular wall thickening, especially in the lower legs as a result of gravitational forces[70]; vascular wall thinning to less than one-half the normal young adult measurement, associated with absent or reduced perivascular veil cells, has been reported in skin of very elderly subjects and probably contributes to vascular fragility. Loss of elastin contributes to vascular rigidity. Electron microscopic studies show focal degeneration of the elastic component of dermal arterioles. The striking age-associated loss of vascular bed, especially of the vertical capillary loops that occupy the dermal papillae in young skin, and increased distance from the epidermis of existing loops, is thought to underlie many of the physiologic alterations in old skin, including pallor, decreased skin temperature, and the approximately 60% reductions in basal and peak induced cutaneous blood flow.[71]

VEGF of epidermal origin appears to play a major role in maintaining dermal vasculature, inducing the expression of antiapoptotic proteins in endothelial cells,[70] and decreased VEGF level shown in aged mice and rabbits skin probably contributes to endothelial cells apoptosis.[72,73] Also, evidence suggests that there is an age-associated decline of both angiogenic and anti-angiogenic factors, disrupting cutaneous angiogenic homeostasis.[74] Decreased endothelial cell permeability response and decreased capacity to induce white cell adhesion[75] contribute to the compromised immune response. When exposed to intense heat or cold, aging vessels demonstrate reduced ability to constrict, dilate, or shunt.[70] Compromised thermoregulation, which predisposes the elderly to sometimes fatal heat stroke

or hypothermia, may be due in part to reduced vasoactivity of dermal arterioles and, in the latter instance, to loss of heat-conserving subcutaneous fat as well. Reduction in the vascular network surrounding hair bulbs and eccrine, apocrine, and sebaceous glands may contribute to their gradual atrophy and fibrosis with age.

Age-associated decreases in wheal resorption and dermal clearance of transepidermally absorbed materials have been reported,[56] probably due to alterations in both the vascular bed and the extracellular matrix. Conversely, the time required for development of a tense blister after topical ammonium hydroxide application is nearly twice as long in older individuals, suggesting a decreased transudation rate with age in injured skin. Impaired transfer of cells as well as solutes between the extravascular and intravascular dermal compartments is suggested by several studies; multiple factors undoubtedly contribute.

With aging there is a decrease in the density and lumen size of lymphatic vessels accompanied by increased rigidity and decrements in lymphatic drainage, affected by decreased surrounding elastic fibers.[70] The ability to effectively pump lymph from interstitial spaces into the lymphatics is impaired with aging in part because of decreased activity of enzymes that catalyze the production of nitric oxide.[76]

Biochemical changes in collagen, elastin, and dermal ground substance lead to increased skin rigidity primarily due to modifications in collagen. Collagen content per unit area of skin surface decreases approximately 1% per year throughout adult life,[77] and the remaining collagen fibrils appear disorganized, more compact, and granular, and they display increased collagen cross-links.[78–80] The latter is the result of decreased collagen I and III synthesis; decrements in enzymatic processing of collagen as well as nonenzymatic glycosylation, a process that leads to molecular damage of proteins with a long half-life such as collagen[49]; and increased collagenase levels. Such changes almost certainly contribute to impaired wound healing in the elderly.[79]

Beginning in early adulthood, elastic fibers decrease in number and diameter; by old age, they often appear fragmented, with small cysts and lacunae, especially near the dermal–epidermal junction[81] most likely due to enzymatic degradation of elastin. Elastic fibers also show progressive cross-linkage and calcification with age. At the biochemical level, there is an age-associated decrease in numerous elastic fiber components, including elastin, fibrillin, and fibulin-2. With aging, the level of fibulin-5, an extracellular matrix protein that functions as a scaffold for elastic fibers, appears to decrease before other changes are observed, suggesting that loss of fibulin-5 is a marker for skin aging.[82]

The ground substance mucopolysaccharides, glycosaminoglycans (GAGs), and proteoglycans are decreased relative to dry weight or collagen content of the skin, especially hyaluronic acid,[83] possibly due to decreased hyaluronan secretion or due to decreased hyaluronic acid extractability.[84] Aging also affects GAG composition and binding to elastin, impeding the drainage of molecules into lymphatic vessels.[70] These changes may adversely influence skin turgor because proteoglycans bind 1,000 times their own weight in water and also impact collagen fiber deposition, orientation, and size.[85]

Changes with age in the mechanical properties of the skin during adulthood include progressive loss of elastic recovery, consistent with gradual destruction of the dermal elastic network, and marked prolongation of the time required for excised skin to return to its original thickness. In vivo ultrasound studies also show age-associated differences in water distribution in the dermis,[86] no doubt affecting dermal pliability, resilience, and elasticity. Overall, a picture emerges of aging dermis as an increasingly rigid, inelastic, and unresponsive tissue that is less capable of undergoing modifications in response to injury or stress.

SUBCUTANEOUS TISSUE, MUSCLES, AND BONE. Like other striated muscles, facial muscles show accumulation of the "age pigment" lipofuscin, a marker of cellular damage. Compounded by diminished neuromuscular control, this deterioration contributes to wrinkle formation.[87] In addition, subcutaneous fat is depleted from distinct facial regions, including the forehead, preorbital, buccal, temporal, and perioral regions. In contrast, there is a prominent increase in fatty tissue in other areas, including the submental regions, the jowls, the nasolabial folds, and the lateral malar areas. In contrast to the young face in which fat is diffusely dispersed, fat in the aged face, subject to the force of gravity, contributes to sagging and drooping of the skin.[88]

Finally, like other parts of the skeleton, facial bones display reduced mass with age. Bone resorption affects particularly the mandible, maxilla, and frontal bones. Bone loss in these areas enhances the sagging of facial skin and contributes to the obliteration of the demarcation between the contour of the jaw and the neck that is so distinct in young adults.[89]

HAIR. By the end of the fifth decade, approximately half the population has at least 50% gray (white) scalp hair, and virtually everyone has some degree of graying due to progressive and eventually total loss of melanocytes from the hair bulb.[90] Loss of melanocytes is believed to occur more rapidly in hair than in skin because the cells proliferate and manufacture melanin at maximal rates during the anagen phase of the hair cycle, whereas epidermal melanocytes are comparatively inactive throughout their life span. More specifically, hair graying reflects loss of the melanocyte stem cell population in hair follicle bulge due, at least in part, to compromised interaction between two transcription factors, microphthalmia-associated transcription factor (Mitf) and Pax3 (see Chapter 72).[91] Faulty migration of melanocyte stem cells into the bulb area of the hair[92] has also been suggested to contribute. Additionally, high levels of H_2O_2 in the millimolar range have been reported in gray/white scalp.[93] By oxidizing methionine, tryptophan, and cysteine residues on enzymes, H_2O_2 likely to interferes with the activity of tyrosinase as well as antioxidant enzymes by altering their

tertiary structure and may thus affect melanogenesis in the human hair follicle.[93]

Scalp hair may gray more rapidly than other body hair because its anagen to telogen ratio (see Chapter 86) is considerably greater than that of other body hair. Advancing age is also accompanied by a modest decrease in number of hair follicles, due in part to atrophy and fibrosis. In addition, with aging there is an increase in the proportion of telogen hair follicles. Remaining hairs may be smaller in diameter and grow more slowly. One hypothesis suggests that melanocyte loss and lack of melanosomal transfer may increase oxidative stress level in highly metabolic hair follicle keratinocytes, affecting their function and viability.[94]

The process termed *balding* results primarily from the androgen-dependent conversion of the relatively dark, thick, terminal scalp hairs to lightly pigmented short, fine, vellus hairs similar to those on the ventral forearm. Women are affected less often and far less severely than men. However, in postmenopausal women, hair loss is also the result of decreased estrogen levels and estrogen to androgen ratio.[95,96] Besides hair loss, almost 50% of women older than age 60 years display mild facial hirsutism, presumably attributable to the same hormonal changes as scalp hair loss. In susceptible women, testosterone and/or progestin derivatives that are present in some hormone replacement regimens may exacerbate these changes.

CUTANEOUS GLANDS AND NERVES. Eccrine glands decrease by approximately 15% in average number during adulthood in most body sites. Spontaneous sweating is further reduced by more than 70% in healthy older subjects compared with younger controls, attributable primarily to a decreased output per gland, predisposing the elderly to heat stroke. Apocrine gland size and function also decrease with aging. Sebaceous gland size and number appear not to change with age, but there is an exponential decrease in sebum production in both men and women most likely due to a decrease in production of gonadal or adrenal androgens.[97]

Pacinian and Meissner's corpuscles, the cutaneous end organs responsible for pressure perception and light touch, progressively decrease to approximately one-third their initial average density between the second and ninth decades of life and display greater size variation and structural irregularities.

Decreased sensory perception in old skin encompasses optimal stimulus for light touch, vibratory sensation, and corneal sensation; ability to discriminate two points; and spatial acuity.[98,99] Cutaneous pain threshold increases up to 20% with advancing adult age, and compromised arteriolar constriction on changing position from supine to standing is reflective of decreased responsiveness of the sympathetic nervous system.

EFFECTS OF MENOPAUSE. Estrogens play a critical role in female development and reproduction and also influence skin and hair. Not surprisingly, their influence decreases dramatically after menopause. Menopause typically occurs in a woman's early 50s, so that, with life expectancy in the developed world approaching 80 years,[100] women are postmenopausal for approximately one-third of their lives. In premenopausal women, the predominant estrogen is estradiol, which is produced by the ovaries,[101] and after menopause levels decrease by more than 90%,[102] with estron, a less active estrogen, becoming the predominant form.[103] Progestin and androgen levels also fall markedly after menopause.[103] The reduced levels of estrogen underlie many physiologic effects, including hot flashes, atrophy of reproductive tissue, and changes in nonreproductive tissues that are estrogen sensitive.[103] Age-associated decrements in keratinocyte barrier function, immune-regulation, and wound healing appear to be compounded by decreased estrogen levels and/or decreased responsiveness of cells to existing estrogens. Because both estrogen and androgen receptors are expressed by skin-derived cells, both hormones are likely to play a role in skin structure and function.

Structural and Functional Changes in Postmenopausal Skin. Decreased circulatory levels of estrogens are associated with reduced dermal collagen content,[104–106] increased cutaneous extensibility,[107,108] and decreased elasticity.[109] Also, decreased water-holding capacity, increased dryness, and increased fine wrinkling are reported after menopause,[110] as are decreased sebum levels.[111] These changes are related more to menopause than to chronologic age alone,[112] and wrinkling is reported to be more pronounced in postmenopausal women who are not taking hormone replacement therapy than in treated women.[113]

After menopause, the decreased rate of wound healing is associated with reduced levels of collagen I.[114] Estrogen and progesterone are also reported to modulate cutaneous inflammation, enhance keratinocyte proliferation and collagen synthesis, decrease the activity of MMPs, and increase the synthesis of dermal mucopolysaccharides and hyaluronic acid.[96,115]

PHOTOAGING

Clinical and histologic features of actinically damaged skin are listed in Table 109-3. A prominent feature of photoaged skin is elastosis, a process characterized clinically by yellow discoloration and a sometimes pebbly surface (Fig. 109-2) and histologically by tangled masses of degraded elastic fibers that further deteriorate to form an amorphous mass composed of disorganized tropoelastin and fibrillin (eFig. 109-2.1A in online edition). Although fibrillin is abundant in the elastotic material deeper in the dermis, in the upper portions of the dermis at the dermal–epidermal junction, fibrillin is reduced.[116] In addition, the amount of ground substance, largely composed of glycosaminoglycans (GAGs) and proteoglycans, increases in photodamaged skin, whereas the amount of collagen decreases, in part because of increased metalloproteinase activity. In contrast with aged sun-protected skin that demonstrates hypocellularity, photodamaged skin frequently displays an increased number of hyperplastic fibroblasts

TABLE 109-3
Features of Photoaged Skin[a]

Clinical	Histologic
Dryness (roughness)	Increased compaction of stratum corneum, increased thickness of granular cell layer, reduced epidermal thickness, reduced epidermal mucin content
Actinic keratoses (see Chapter 113)	Nuclear atypia, loss of orderly, progressive keratinocyte maturation; irregular epidermal hyperplasia and/or hypoplasia; occasional dermal inflammation
Irregular Pigmentation	
Freckling	Reduced or increased number of hypertrophic, strongly DOPA-positive melanocytes
Lentigines (see eFig. 109-2.2 in online edition)	Elongation of epidermal rete ridges; increase in number and melanization of melanocytes
Guttate hypomelanosis	Reduced number of atypical melanocytes
Diffuse irreversible hyperpigmentation (bronzing) (see eFig. 109-2.3 in online edition)	Increased number of DOPA-positive melanocytes and increased melanin content per unit area and increased number of dermal melanophages
Wrinkling	
Fine surface lines	None detected
Deep furrows (see Figs. 109-2 and 109-3)	Contraction of septae in the subcutaneous fat
Stellate pseudoscars (see eFig. 109-2.4 in online edition)	Absence of epidermal pigmentation, altered fragmented dermal collagen
Elastosis (fine nodularity and/or coarseness) (see Fig. 109-3)	Nodular aggregations of fibrous to amorphous material in the papillary dermis
Inelasticity	Elastotic dermis
Telangiectasia	Ectatic vessels often with atrophic walls
Venous lakes	Ectatic vessels often with atrophic walls
Purpura (easy bruising)	Extravasated erythrocytes and increased perivascular inflammation
Comedones (maladie de Favre et Racouchot) (see eFig. 109-2.5 in online edition)	Ectasia of the pilosebaceous follicular orifice
Sebaceous hyperplasia	Concentric hyperplasia of sebaceous glands

[a]Basal cell carcinoma and squamous cell carcinoma also occur in photoaged skin but, unlike the table entries, affect only a minority of individuals.

as well as increased inflammatory cells (eFig. 109-2.1B in online edition), including mast cells, histiocytes, and other mononuclear cells, giving rise to the term *heliodermatitis* (literally, "cutaneous inflammation due to sun"; Fig. 109-3). Immunohistologic studies show

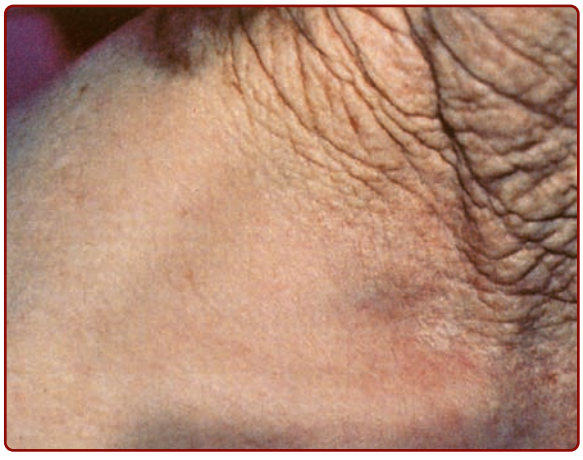

Figure 109-2 Photoaged versus intrinsically aged skin of an elderly man. Habitually sun-exposed skin above the collar line is prominently wrinkled and lax, in contrast with the equally chronologically aged but sun-protected skin of the lower neck and shoulder. Despite the striking difference in appearance, both areas manifest age-associated functional decrements.

increased $CD4^+$ T cells in the dermis. Dermal vasculature in mildly photodamaged skin displays venule wall thickening; in severely photodamaged skin, thin vessel walls with compromised perivascular veil cells display dilations (telangiectases).

In contrast with chronologically aged skin, photodamaged epidermis is frequently acanthotic, although severe atrophy also can be seen in addition to loss of polarity and cellular atypia. Also, there is a more profound decrease in the number and function of Langerhans cells. Additional changes are described in Table 109-3.

The relative severity of sun-induced cutaneous changes varies considerably among individuals, undoubtedly reflecting inherent differences in vulnerability and repair capacity for the solar insult. Photoaging occurs not only in fair-skinned individu-



Figure 109-3 Photoaging: heliodermatitis. Pronounced furrowing, yellow discoloration, and pebbly surface (solar elastosis) with plugged follicles on the neck. *Arrows* denote small actinic keratoses.

als (skin phototypes I and II) but also in individuals with darker skin phototypes III and IV with a history of ample past sun exposure. It usually involves the face, neck, or extensor surfaces of the upper extremities most severely. Interestingly, the gross appearance of photodamaged skin of individuals with skin phototypes I and II differs from that of individuals with darker skin types. The former generally show atrophic and dysplastic skin changes with actinic keratoses and epidermal malignancies, whereas the latter manifest hypertrophic responses such as furrowing, lentigines, and coarseness (eFig. 109-3.1 in online edition).[39] One study noted that patients presenting with basal cell carcinoma (BCC) are less wrinkled than peers of similar complexion and degree of photodamage,[117] suggesting that certain phenotypes of photoaging correlate with a predisposition to mutation and carcinogenesis.

Photoaging is most apparent in whites but also occurs in Asians, Hispanics, and Africans. The differences in clinical appearance of photoaged skin between whites and other groups is primarily due to differences in their UV defense systems. In the latter three groups, melanin is a major form of protection, whereas in whites, melanin plays a lesser role, and stratum corneum thickening is relatively more important.[118] One study reported a sun protection factor for black epidermis of 13.4, compared to 3.4 for white epidermis.[119] Black epidermis transmitted approximately 6% of ultraviolet B (UVB) to the dermis, compared to almost 30% transmission through white epidermis.[119] Similarly, only ~18% of ultraviolet A (UVA) was transmitted into black dermis, compared to more than 55% to white dermis.[119]

Major clinical features of photoaging in Asian skin are solar lentigines and mottled pigmentation.[120] Moderate-to-severe wrinkling occurs in Asians but only in the sixth decade and only in individuals who regularly spent ample time in the sun.[121]

There are no specific studies addressing photoaging in Hispanics, and studies on photoaging of black skin have been published only in African-Americans. As expected, fairer skinned Hispanics and Africans display clinical photoaging signs earlier and more prominently than those with very dark skin.[98] Changes include fine wrinkling and mottled pigmentation.[116,120]

MECHANISMS OF PHOTOAGING.

Mechanisms involved in intrinsic aging also play a role in photoaging.[122] Additional mechanisms are discussed below.

Membrane and Nuclear Signaling. UV irradiation, in part through ROS generation that inhibits phosphatases whose function is to maintain receptors in their inactive state,[123] activates (phosphorylates) cell surface receptors, including receptors for epidermal growth factor, IL-1, and TNF-α, to induce intracellular signaling culminating in activation of the nuclear transcription complex activator protein (AP)-1, composed of the proteins c-Jun and c-Fos.[124] In intact human skin, even suberythemogenic doses of UVB [~0.1 minimal erythema dose (MED)] transcriptionally upregulate and activate AP-1.[125] Increased AP-1 activity interferes with synthesis of the major dermal collagens I and III by blocking the effect of transforming growth factor (TGF)-α, a cytokine that enhances collagen gene transcription.[124,125] AP-1 also decreases the level of TGF-β receptors, further inhibiting collagen transcription,[126] and also antagonizes intrinsic retinoid effects in skin, leading to a functional retinoid deficiency and reducing collagen synthesis normally promoted by retinoic acid bound to its nuclear receptors. Additionally, UV induces the synthesis and secretion of a cysteine-rich growth regulatory factor (CYR61) that reduces type I procollagen synthesis, increases MMP-1 levels, decreases TGF-β receptor level, and induces AP-1 activation.[127] Hence, in habitually UV-irradiated photodamaged skin there is an overall reduction in collagen synthesis.[128] Increased AP-1 activity also increases the levels and activity of several enzymes that degrade extracellular matrix components, notably the MMP-1 (collagenase), MMP-3 (stromelysin-1), and MMP-9 (92-kd gelatinase).[77,124] UV also activates the nuclear factor κB transcription factor that induces the expression of multiple proteins as discussed in Section "Mechanisms of Intrinsic Skin Aging"24 and aggravates the degradation of dermal matrix by increasing the levels of MMP-1 and MMP-9.[125] Matrix degradation is further exacerbated by MMP-8 (collagenase) of neutrophil origin after neutrophil infiltration into UV-irradiated skin.[129] Although there is also a concomitant upregulation of tissue inhibitors of metalloproteinases (TIMPs) that limit matrix degradation, TIMPs presumably are not completely effective in blocking cumulative damage to dermal collagen.[130] UV also decreases FoxO mRNA level further compromising collagen I synthesis and increasing the transcription of MMP-1 and -2 (18C).

UV-induced collagen degradation is generally incomplete, leading to accumulation of partially degraded collagen fragments in the dermis, thus reducing the structural integrity of the skin.[124] In addition, the large collagen degradation products inhibit new collagen synthesis,[131] and, thus, collagen degradation itself negatively regulates new collagen synthesis. Interestingly, increased stress-associated AP-1 activity, increased CYR61 and MMP levels, and reduced collagen production have been documented in intrinsically aged skin,[127,132] suggesting that similar mechanisms may contribute to chronologic aging, perhaps again through the generation of ROS, as discussed in Section "Mechanisms of Intrinsic Skin Aging."

UV radiation, both directly and through generation of ROS induces the transcription of tropoelastin, a component of the mature elastic fibers.[133] Fibulins 2 and 5 and fibrillin-1, components of the microfibrillar fraction of the dermal elastic fiber are also increased in the elastotic material.[82] Furthermore, increased elastase levels are present in photodamaged skin as a result of elastase synthesis and secretion by neutrophils that are attracted to the area by inflammatory mediators.[134] Thus, excessive unbalanced synthesis of elastic fiber components that undergo partial degradation results in the formation of amorphous elastotic material.

Mitochondrial Damage. Mitochondria are cellular organelles that produce energy (adenosine triphosphate) by consuming oxygen. Although equipped with antioxidant defense systems, continuous generation of ROS damages mitochondrial DNA (mtDNA). To date, machinery to remove bulky DNA lesions has not been identified in mitochondria, although they display capacity for base excision repair relevant to repair of oxidative damage. Still, mtDNA mutation frequency is approximately 50-fold higher than that of nuclear DNA, and photodamaged skin has higher mtDNA mutation frequency than sun-protected skin, displaying large DNA deletions[135–138] and resulting in decreased mitochondrial function, leading to further accumulation of ROS and compromising the cell's ability to generate energy. Also, a correlation was noted between decreased mitochondrial function and increased MMP-1 levels without concomitant increase of MMP-1-specific TIMP,[136] exacerbating collagen degradation[135–138] and aggravating skin photoaging.

Protein Oxidation. Proteins are affected by oxidative damage, and photodamaged skin shows accumulation of oxidized, damaged proteins in the upper portions of the dermis.[139] In vitro studies suggest that UVA is a major contributor and the accumulation of such proteins further inhibits proteasomal function and the ability of the cell to successfully degrade additional damaged proteins.[140]

Basement Membrane Damage. In sun-exposed skin, the basement membrane becomes thicker and multilayered in part as a result of damage through MMP activation, affecting molecular transfer between the epidermis and the dermis and compromising epidermal health.[141]

ACTION SPECTRUM.

The action spectrum for human photoaging has not been determined, but many studies have explored the relative contribution of the various spectral bands within sunlight, using animal models.

Despite the well-documented affects of UVB, UVA is suspected of playing a proportionately larger role in photoaging because of its minimally 10-fold greater abundance in terrestrial sunlight, far greater year-round and daylong average irradiance, and greater average depth of penetration into the dermis compared to UVB.

In rodent skin, an elastosis-like condition can be produced by prolonged intense irradiation with either a predominantly UVB or UVA source.[142,143] UVB photons are on average 1,000 times more energetic than UVA photons and are overwhelmingly responsible for sunburn, suntanning, and photocarcinogenesis after sun exposure.[144] UVB is the major cause of direct DNA damage and induces inflammation and immunosuppression, as well as synthesis and release of prostaglandins (PGs), particularly PGE_2, through induction of the enzyme cyclooxygenase-2. UVB also induces ornithine decarboxylase, the rate-limiting enzyme in the biosynthesis of polyamines that stimulates cellular proliferation (contributing to cancer formation) and contributes to cutaneous angiogenesis by decreasing the expression of the angiogenic inhibitor thrombospondin-1 and inducing the expression of VEGF and platelet-derived endothelial cell growth factor, two angiogenic factors.[145,146] UVB also triggers the penetration of elastase-producing leukocytes into the skin, aggravating elastin degradation.

Moreover, human skin exposed daily for only 1 month to suberythemogenic doses of UVA alone demonstrates epidermal hyperplasia, stratum corneum thickening, Langerhans cell depletion, and dermal inflammatory infiltrates with deposition of lysozyme on the elastic fibers.[147] UVA also induces the synthesis and release of cytokines and MMPs, particularly collagenase (MMP-1) and elastase, and triggers mtDNA mutations.[148–151] Both UVA and UVB lead to the generation of ROS that damage cellular lipids, proteins, and DNA.[152,153] Studies using laser-capture microdissection of human skin show that p53-mutant keratinocytes of the basal layer, in addition to UVB signature mutations, have more mutations associated with UVA (and primarily 8-OXO-dG photolesions), suggesting that UVA is an important etiologic factor in the generation of BCC.[42] UVA is more effective than UVB in inducing oxidative damage. Indeed, the degree of solar elastosis and cutaneous photoaging appear to correlate with the level of accumulated dermal protein oxidation[139] but not epidermal oxidation, suggesting a superior antioxidant network and/or better repair capacity in the epidermis.

Sunlight also contains IR (760 nm to 1 mm).[154] Wavelengths of 760–1,400 nm can penetrate the skin to reach the subcutaneous tissue without inducing a significant increase in skin temperature. In contrast, wavelengths of 1,400 nm to 1 mm are primarily absorbed in the epidermis and considerably increase skin temperature.[155] IR is particularly important in regions of high insulation and aggravates UVA-induced dermal changes, producing severe elastosis. Even when delivered without UV, IR affects dermal elastic fibers and increases the amount of dermal ground substance.[155] In the hairless mouse model, IR contributes to UV-induced thickening of the epidermis and dermis and alone induces the expression of MMP-3 and the mouse equivalent of MMP-1.[154] Furthermore, in human skin, the expression of tropoelastin, a major component of elastic fiber that associates with microfibrils, is increased as a result of IR, and IR induces the expression of fibrillin-1, a component of the microfibrils.[156] In addition, the level of MMP-12, the enzyme that degrades elastin, is increased.[156] Thus, IR appears to contribute to UV-induced photoaging.

Many of the age-associated physiologic decrements, such as slowed wound healing and loss of immunoresponsiveness, also appear to be accelerated in sun-exposed skin. Furthermore, cells cultured from chronically sun-exposed skin sites differ from cells cultured from sun-protected sites of the same donors in having shortened culture life spans, slower growth rates, lower saturation densities, and altered responsiveness to retinoic acid,[157] all changes also observed as a function of advanced chronologic donor age. Several of the mechanisms known to be involved in UV-mediated

cellular damage are also postulated to underlie chronologic aging,[158,159] although the changes only appear after the seventh decade.[132] These include DNA injury and/or decreased DNA repair, oxidative damage, lysosomal disruption, elevated MMPs, reduced collagen production, and connective tissue damage.

OTHER CONTRIBUTORS TO EXTRINSIC AGING

Cigarette smoking exacerbates photoaging, particularly in women, with a direct correlation between the number of pack-years smoked and the severity of wrinkling and grayish discoloration.[160,161] Histologic analysis of "smoker's skin" reveals elastic fiber thickening and fragmentation, similar to that found in sun-damaged skin.[162] However, whereas solar elastosis is restricted in the papillary dermis, elastic fiber changes in smoker's skin also occur in the reticular dermis. This dermal elastosis has been suggested to result from increased elastase activity in neutrophils,[163] chronic dermal ischemia, and the pro-oxidant effects of cigarette smoke compounded by decreased levels of vitamin A, which reduce the capacity to quench free oxygen radicals and increase DNA damage.[160,161] Smoking also has been associated with decreased stratum corneum water content[160,161] and accelerated hydroxylation of estradiol, leading to decreased estrogens in the skin that may in turn contribute to dryness and atrophy.[161] Smokers display poor wound healing capacity[164] and increased incidence of skin cancers as well as increased severity of photoaging-like changes compared with nonsmokers who have otherwise similar risk factors,[165] consistent with the possibility that mutagens present in cigarette smoke directly affect cells in the dermis and epidermis. By increasing oxidative stress, cigarette smoke impairs collagen synthesis and induces the synthesis and release of MMPs.[166] Also, the polycyclic aromatic hydrocarbons that are present in cigarette smoke bind to the cytoplasmic aryl hydrocarbon receptor. When activated, the receptor translocates to the nucleus to induce the transcription of xenobiotic-metabolizing genes that encode ptoeins involved in growth control, cytokines, nuclear transcription factors and regulators of extracellular matrix proteolysis.[166]

RELEVANCE TO SKIN DISEASE IN THE ELDERLY

Closely associated with aging is increased vulnerability to disease and injury. Disorders of the skin are known to be common and bothersome in the elderly, and some occur predominantly in this age group.[1] Such disorders often appear to be the consequence of age-associated intrinsic losses of cutaneous cellular function. However, many dermatoses observed more commonly in the elderly reflect the higher prevalence of systemic diseases, such as diabetes, vascular insufficiency, and various neurologic syndromes, that compound physiologic changes in the skin itself. The increased prevalence of some disorders also may reflect reduced local skin care due to immobility or neurologic impairment rather than changes in the skin itself. As well, subtle age-associated changes in immune status may contribute, in analogy to the increased prevalence and severity of skin disease in patients with acquired immunodeficiency syndrome.

Reduced tolerance to systemically administered drugs is well documented in the elderly[167] due to decrements in lean body mass, metabolism, and renal excretion of the active ingredients. Comparable data for topically applied medications do not exist, but it is tempting to postulate that retarded dermal clearance of absorbed material, reduced dermal mass and cellularity, and, possibly, altered metabolic capacity may render old skin more susceptible to both beneficial and adverse effects of topical medications or may at least alter the optimal therapeutic schedule. In the case of glucocorticoid preparations, relative vascular unresponsiveness may render blanching of erythema an unreliable indicator of other effects in old skin.

Selected common cutaneous disorders in the elderly are discussed briefly in the following sections, with special emphasis on their pathogenesis and clinical presentation in this population (Table 109-4). Most of these entities are covered more comprehensively in other chapters.

TUMORS

Benign proliferative growths are especially characteristic of aging skin. Acrochordons, cherry angiomas, seborrheic keratoses, and lentigines begin to appear in middle age and are numerous in nearly every adult beyond age 65 years.

SEBORRHEIC KERATOSES

Seborrheic keratoses are benign papules or plaques that are highly variable in size and color. Because their number increases with aging, independent of sun exposure, they are considered by some as a biomarker of intrinsic aging (see Chapter 118).[168] Seborrheic keratoses represent clonal proliferations of both keratinocytes and melanocytes,[169] presumably the result of focal epidermal homeostatic loss. They have no malignant potential. Although the pathogenesis of these keratoses is not completely understood, lesional keratinocytes express high levels of endothelin-1 and lesional melanocytes have increased tyrosinase expression,[170] leading to the hypothesis that dysregulation of endothelin-1, an inducer of melanogenesis, dendriticity, and proliferation in melanocytes,[171,172] plays an etiologic role in seborrheic keratoses.

SKIN CANCER

(See Chapters 113–115.)

TABLE 109-4
Presumptive Pathophysiology of Common Cutaneous Disorders in the Elderly

Disorder	Pathophysiology
Benign neoplasia	
Seborrheic keratosis	Focal epidermal homeostatic loss leading to increased endothelin-1
Malignant neoplasia	
Squamous cell carcinoma and actinic keratosis	Ultraviolet-induced DNA damage
Basal cell carcinoma	Decreased DNA damage repair capacity
Malignant melanoma	Cumulative age-associated DNA damage
Merkel cell carcinoma	Decreased DNA damage repair capacity; polyoma virus
Angiosarcoma	
Papulosquamous disorders	
Psoriasis	Changes in patient's environment leading to Koebnerization Systemic medications
Xerosis/asteatotic dermatitis	Disturbance of epidermal maturation (decreased filaggrin production and/or altered lipid profile) Decreased water content in outer layers of stratum corneum Slower corneocyte transit
Pruritus	Penetration of irritants through damaged stratum corneum (?) Altered sensory threshold (neuropathy) (?) Metabolic disorder Endocrine disorder Malignant neoplasm Adverse drug reaction Parasitic infestation
Infections	Compromised local cutaneous health predisposing to growth of infective organism Age-associated decreased immune function Underlying systemic disorder associated with decreased immune function
Ulcers	Impaired wound healing capacity (decreased levels of growth factors, decreased cellular proliferative capacity, increased perivascular fibrin deposition) Decreased mobility Underlying systemic disorder Compromised local cutaneous health (venous stasis, arteriosclerosis, hypertension)
Bullous pemphigoid	Flattening of the dermal-epidermal junction Increased circulating autoantibodies
Photosensitivity reactions	Medications with unsaturated ring structures

The age-specific incidence of skin cancer, including melanoma, increases exponentially with age,[148] presumably due in part to cumulative exposure to carcinogens over a lifetime interspersed with cell division, with the attendant risk of mutation. There are also well-documented age-associated decreases in DNA repair capacity[66,173] and immunosurveillance,[174] as well as subtle loss of proliferative homeostasis.

The major etiologic factor for skin cancer is UV irradiation. Habitual sun exposure of fair-skinned individuals induces squamous cell carcinoma as well as actinic keratoses, a premalignant lesion that may evolve into squamous cell carcinoma in a direct dose-response relationship.[175] In contrast, the risk of BCCs and particularly malignant melanoma is related not only to total sun exposure but also to intense intermittent sun exposure.[176] The mechanism underlying these different epidemiologic patterns is unknown, although inducible protective responses and relative resistance of the responsible cell types to apoptosis may contribute.[177]

The elderly, particularly men, present with melanomas (see Chapter 124) that are thicker than those of young adults, presumably in part because of failure to properly examine their skin, poor vision, and other medical problems; and their melanomas arise on a background of multiple benign cutaneous lesions. Presumably because of delayed diagnosis, men older than age 50 years have an increased mortality risk from melanoma compared with women or younger men.[178] Although all types of melanoma have increased age-specific incidences,[179] lentigo maligna melanoma overwhelmingly develops in the 60s or later in habitually sun-exposed skin.[180] Reflectance confocal microscopy is a novel approach to distinguish in vivo between lentigo maligna and lentigo maligna melanoma.[181]

Merkel cell carcinoma (trabecular carcinoma) (see Chapter 120) is a rare cutaneous tumor thought to arise from a pluripotential cell that displays neuroendocrine differentiation.[182,183] It is seen most often in sun-exposed areas of the head, neck, or extremities and presents as a rapidly growing nodule with a poor prognosis. More than 90% of patients diagnosed with this tumor are older than age 50, with the mean age of onset being 68 years. Polyomavirus sequences found integrated within the DNA of tumor cells are likely the etiologic agent for Merkel cell carcinoma,[184] and age-associated subtle losses in cellular immunity may well account for the demographics of this malignancy.

The most common form of angiosarcoma (see Chapter 128) occurs overwhelmingly on the head and neck of the elderly. Its rapid growth, associated with early metastasis, usually results in death within 2 years of diagnosis.[185] Immunohistochemical analysis shows high levels of VEGF and its receptor, VEGF receptor-2, as well as cell cycle-associated proteins in cutaneous angiosarcoma explaining in part the rapid growth of these vascular tumors.[186]

PAPULOSQUAMOUS DISORDERS

XEROSIS AND ASTEATOTIC DERMATITIS

Xerosis is a dry, rough quality of skin that is almost universal in the elderly and may be attributed to a subtle disturbance of epidermal maturation, such as inadequate filaggrin production[59] or altered lipid profile.[57,190] Histologic studies reveal little alteration of either the viable epidermis or the stratum corneum with age. Available data fail to demonstrate an overall decrease in stratum corneum lipids[54,57] or altered amino acid composition as etiologic factors.[191] Water content of the viable epidermis is normal, but there is some reduction in the outermost layers of the stratum corneum.[54] The surface irregularity may be attributed simply to slower transit of corneocytes through the stratum corneum, allowing accumulation of damage in situ. There is no explanation for the pruritus that often accompanies xerosis.[192] Speculations include frequent penetration of irritants through an abnormal stratum corneum and an altered sensory threshold due to subtle neuropathy.

Asteatotic eczema, a condition frequently found in the elderly during the wintertime, is dermatitis superimposed on xerosis. It is often caused by low humidity in a heated environment. It manifests by dry, fissured skin with fine scale and is usually localized to the pretibial region. This condition, which may be extremely pruritic, responds to application of medium-potency topical steroid ointments and/or liberal application of emollients.

PRURITUS[162]

(See Chapter 103.)

Pruritus is perhaps the most common skin-related complaint of the elderly. In a majority of cases, pruritus is attributable only to xerosis, often exacerbated by low humidity, frequent bathing, or application of irritants to the skin. However, in up to 10%–50% of patients in some series, pruritus may have other etiologies. These include metabolic or endocrine disorders, such as diabetes mellitus, renal failure, thyroid disease, or hepatic disease, in particular the obstructive type. Pruritus can be a manifestation of a malignant neoplasm, in particular lymphoma or leukemia, or the result of a hematologic disease such as polycythemia vera. Adverse drug reactions can manifest predominantly or exclusively as pruritus and always should be considered in this segment of the population. Finally, infestations such as scabies lead to intense pruritus, and associated primary skin lesions may be overlooked.

INFECTIOUS PROCESSES

BACTERIAL[193]

Impetigo and folliculitis in the elderly are usually caused by *Staphylococci*, in contrast to impetigo in the pediatric population, which usually is caused by *Streptococci* (see Chapter 176). Hence, in the older age group, impetigo should be treated with penicillinase-resistant semisynthetic penicillin or erythromycin until culture confirms the identity of the organism.[194]

Cellulitis is an infectious inflammatory process that involves the subcutaneous tissue and is caused most frequently by *Streptococci* or *Staphylococci*. Like other inflammatory conditions in the elderly, cellulitis may present with only subtle rubor, tumor, calor, and dolor. Predisposing factors with increased prevalence in the elderly include chronic edema, compromised circulation, diabetes mellitus, surgical sites, and asteatotic eczema.

Distinct forms of cellulitis (see Chapter 178) preferentially affect older individuals. These include orbital cellulitis that is caused by *Streptococcus viridans* alone or in combination with gram-negative bacteria. Another form of cellulitis that is relatively rare in the younger population is *Pseudomonas* cellulitis of the ear, an infectious process that affects elderly diabetic individuals. Erysipelas, a β-hemolytic streptococcal infection of the skin, is more common in the elderly and tends to spread more readily in this age group, creating a life-threatening situation.

Necrotizing fasciitis (see Chapter 179), caused by a strain of *Streptococcus*, is a rare cutaneous infection, but it is more frequent in the elderly and is associated with increased morbidity and mortality in this age group.

Methicillin-resistant *Staphylococcus aureus* (MRSA) has become an increasingly important pathogen in hospital and community acquired infections, and age >80 years is significantly associated with MRSA carriage.[164] Because community-associated MRSA infection most often presents as skin and soft tissue infections, dermatologists should be aware of this possibility when managing infections in the elderly.

PARASITIC[195]

(See Chapter 208.)

Scabies can occur in any age group, but nursing homes provide a fertile ground for rapid spread of the infestation. In the elderly, in part because of their decreased immunity, lesions may be atypical and display less inflammation and pruritus. In addition, the elderly frequently have xerosis, and their pruritus at times may be attributed to this etiology.

DERMATOPHYTES AND YEASTS[196]

(See Chapters 188 and 189.)

Onychomycosis is present in approximately 40% of patients after age 60 years, and tinea pedis is present in approximately 80% of this patient population. Although usually present for decades, tinea pedis may exacerbate with age. Indeed, in elderly diabetic patients, interdigital tinea pedis may ulcerate and predispose to bacterial cellulitis, a presentation that is relatively rare in the young adult immunocompetent patient.

Cutaneous infections due to *Candida albicans* are common in the elderly. When recurrent or difficult to control, candidiasis may be a sign of poorly controlled diabetes, an endocrinopathy, malnutrition, or malignancy.

VIRAL (VARICELLA-ZOSTER VIRUS)[163]

(See Chapter 194.)

The incidence of herpes zoster peaks at approximately 1,500 cases per 100,000 persons annually at age 75 years. Postherpetic neuralgia, uncommon in patients younger than 40 years old, occurs in more than 40% of patients aged 60–69 years and 50% of patients 70 years of age or older.[100] A number of patients older than 60 years also experience paresthesias and muscle weakness. Decreased cellular immunity and impaired wound healing in the elderly may account for slower resolution of the acute eruption, but the pathogenesis of their postherpetic neuralgia is unclear. A new vaccine composed of live, attenuated *varicella zoster* virus is now available and reported to reduce the incidence of postherpetic neuralgia by 66.5%.[197]

ULCERS[198]

Chronic ulcers of all etiologies are more common in the elderly than in younger individuals, presumably due to a combination of impaired wound healing and higher prevalence of underlying diseases. The most common are leg ulcers, usually in the setting of chronic venous insufficiency leading to venous hypertension (see Chapter 174). Exudation of macromolecules such as fibrinogen into the dermis may block the passage of oxygen and nutrients and sequester cytokines and growth factors required for tissue homeostasis, maintenance, and repair. The sclerotic indurated quality of affected skin, termed *lipodermatosclerosis*, is postulated to further impair healing. In addition, diseases such as diabetes mellitus and atherosclerotic peripheral vascular disease may contribute to ulcer evolution.

Decubitus ulcers (see Chapter 100) are proportionately far more common in elderly hospitalized patients than in younger patients, as the former tend to be less mobile, needing help turning in bed, and have additional aggravating disorders such as dry skin over bony prominences, incontinence, sensory deficiency, and/or poor nutritional state.[199,200]

BULLOUS PEMPHIGOID

(See Chapter 56.)

Bullous pemphigoid is far more common after age 60 years than in younger persons, a predilection that may be explained in part by the age-associated increases in circulating autoantibodies and ease of dermal–epidermal separation,[201] although many other autoimmune and blistering dermatoses are not more common in old age. Possibly, age-associated changes in the basement membrane itself render it specifically vulnerable to this disease process. Bullous pemphigoid is a self-limited condition that frequently resolves within 6–12 months, but elderly patients may experience increased morbidity and mortality because of debilitated general health or as a side effect of treatment.

DRUG ERUPTIONS

Adverse drug reactions of all kinds increase with age, in part because the elderly consume more medications than younger age groups and in part because of medical conditions, including impaired renal, cardiac, or hepatic function, that compromise drug metabolism or excretion. The most frequently observed adverse cutaneous drug reactions are pruritus, exanthems, and urticaria, but drug-induced autoimmune reactions, including pemphigus, bullous pemphigoid, and lupus erythematosus, also occur in the elderly. A careful history to elicit all prescription medications as well as over-the-counter preparations is critical to diagnosis and optimal patient care.

KEY REFERENCES

Full reference list available at www.DIGM8.com

DVD contains references and additional content

6. Campisi J: Replicative senescence: An old lives' tale? *Cell* **84**:497-500, 1996
29. Weng NP: Aging of the immune system: How much can the adaptive immune system adapt? *Immunity* **24**:495-499, 2006
34. Harman D: Free radical theory of aging: An update: Increasing the functional life span. *Ann N Y Acad Sci* **1067**:10-21, 2006
39. Kosmadaki MG, Gilchrest BA: The role of telomeres in skin aging/photoaging. *Micron* **35**:155-159, 2004
65. Wolpowitz D, Gilchrest BA: The vitamin D questions: How much do you need and how should you get it? *J Am Acad Dermatol* **54**:301-317, 2006
94. Van Neste D, Tobin DJ: Hair cycle and hair pigmentation: Dynamic interactions and changes associated with aging. *Micron* **35**:193-200, 2004
96. Verdier-Sevrain S, Bonte F, Gilchrest B: Biology of estrogens in skin: Implications for skin aging. *Exp Dermatol* **15**:83-94, 2006

Neoplasia

PART 7



Carcinogenesis

Chapter 110 :: Genome Instability, DNA Repair, and Cancer

:: Thomas M. Rünger & Kenneth H. Kraemer

GENOME INSTABILITY, DNA REPAIR, AND CANCER AT A GLANCE

- DNA can be damaged by physical agents (ultraviolet or ionizing radiation) or chemical agents in the environment.
- DNA damage may lead to mutations (changes in DNA sequence).
- The ability of cells to repair DNA damage and to maintain genome stability is of utmost importance to prevent malignant transformation.
- Different agents induce different types of DNA damage, which in turn require different responses and repair pathways.
- A number of hereditary disorders are characterized by genome instability due to defects in genes involved in DNA repair or DNA damage signaling.
- Many different laboratory tests can be used to diagnose genome instability and/or DNA repair defects.
- Inherited or acquired genome instability is associated with an increased cancer risk.

INTRODUCTION

The integrity of the genome of all living organisms is constantly threatened by exogenous and endogenous DNA-damaging agents. Exogenous DNA-damaging agents include physical agents, such as ultraviolet (UV) or ionizing radiation (IR), and a wide variety of chemical agents, such as components of cigarette smoke. Endogenous DNA damage arises from regular metabolic processes within the cell, mediated, for example, by reactive oxygen species. Maintaining the stability of the genome is of utmost importance to all living organisms. Therefore, since early evolution, all organisms ranging from prokaryotes to eukaryotes

TABLE 110-1
Cellular Damage Induced by Physical and Chemical Agents

Agent	Damage
Ultraviolet (UV) radiation	Dipyrimidine cyclobutane dimers (TT, TC, CT, or CC), pyrimidine-pyrimidone (6–4) photoproducts (mostly TC), DNA-protein cross-links
X-irradiation	DNA single- and double-strand breaks, oxidative base damage
Psoralens plus UVA	DNA-psoralen monoadducts, DNA interstrand cross-links (binds to T at TA sequences)
Mitomycin C	DNA interstrand cross-links
Benzo-[a]-pyrene	Bulky adducts
Reactive oxygen species	Oxidative base damage (8-oxo-deoxyguanine, thymine glycol), cyclopurines (A or G) making bulky lesions

have been equipped with mechanisms that react to and repair DNA damage and thereby maintain genomic stability. The types of damage produced include alterations in the structure of nucleotides, DNA strand breaks, DNA cross-links, and DNA adducts. Different types of DNA-damaging agents induce different types of DNA damage (Table 110-1), which in turn require different responses and repair pathways for processing (Table 110-2).[1]

TABLE 110-2
Types of DNA Damage and Associated DNA Repair Pathways

Type of DNA Damage	DNA Repair Pathway
DNA photoproducts (CPDs, 6,4-PP)	Nucleotide excision repair (NER)
Oxidative base modifications (e.g., 8-oxoG)	Base excision repair
Incorrect DNA base pairing	Mismatch repair
DNA double-strand breaks	Nonhomologous end joining, homologous recombination (i.e., recombination repair)
DNA adducts	NER
DNA cross-links (interstrand and intrastrand)	Recombination repair
Persistent DNA lesions	Translesion (bypass) DNA synthesis

CPDs = cyclobutane pyrimidine dimers; 6, 4-PP = 6, 4-pyrimidine–pyrimidone photoproducts; 8-oxoG = 8-oxo-deoxyguanine.

If DNA damage is not repaired adequately, it may lead to altered cell function, cell death, or the formation of mutations (alterations of the DNA sequence) in the damaged cells. These DNA damage-induced mutations will persist as long as the affected cell survives. At a cellular level, mutations in vital genes can lead to alterations of cell functions or malignant transformation. Accumulation of mutations may lead to organ dysfunction, aging, and cancer. Although most DNA damage is adequately repaired, none of the cellular responses is 100% effective in repairing all DNA damage under all circumstances.

A hereditary or acquired impairment in the way cells respond to DNA damage may result in genome instability with an increased rate of mutation formation. Numerous hereditary disorders are characterized by such genome instability (reviewed in Chapter 139). Many, but not all, of those are associated with an increased cancer risk and/or accelerated aging.

Exposure of the skin to UV radiation has multiple cellular and clinical effects, including an increase in skin cancer risk. The photocarcinogenesis cascade of events (Fig. 110-1) exemplifies the link between genome instability, DNA repair, and cancer. UV light produces a type of DNA damage involving the generation of photoproducts, which are alterations in the structure of nucleotides. The major DNA photoproducts are cyclobutane pyrimidine dimers (CPDs; Fig. 110-2) and 6,4-pyrimidine–pyrimidone dimers. Unrepaired CPDs or 6,4-pyrimidine–pyrimidone dimers may result in characteristic mutations: C to T single base and CC to

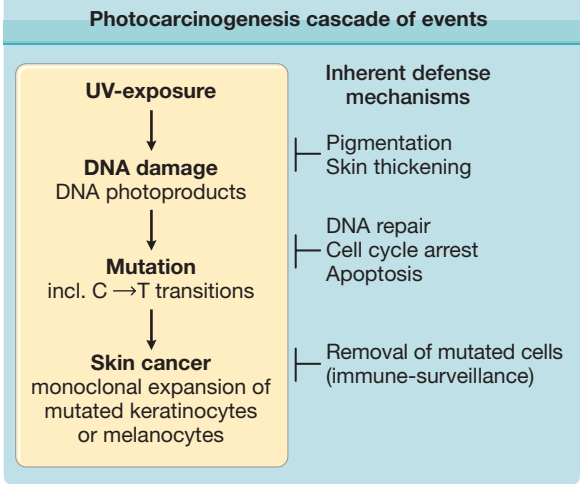

Figure 110-1 Photocarcinogenesis cascade of events. Exposure to ultraviolet (UV) light induces typical types of DNA damage, namely, cyclobutane pyrimidine and 6,4-pyrimidine–pyrimidone photoproducts. These often generate single and tandem base substitution mutations (C→T and CC→TT) that are typical for UV light exposure and are therefore termed *UV-signature mutations*. With sufficient numbers of inactivating mutations in crucial genes (tumor suppressor genes), individual cells may undergo malignant transformation, clonally expand, and form skin cancers. Several inherent defense mechanisms counteract this chain of events (see text).

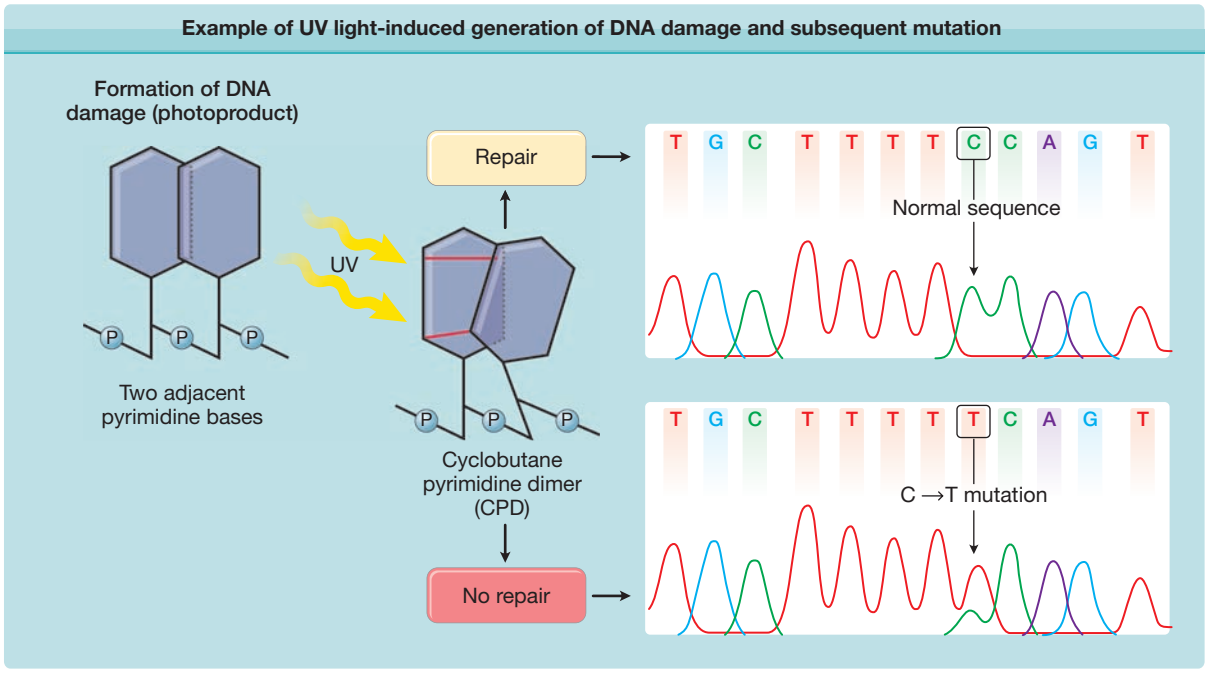

Figure 110-2 Example of ultraviolet (UV) light-induced generation of DNA damage and a subsequent mutation. On direct excitation of the DNA molecule by UV light, adjacent pyrimidine bases (cytosine or thymine) may form covalent bonds between them, which lead to creation of pyrimidine dimers. The illustration shows an example in which two covalent bindings generate a tricyclic cyclobutane ring between two pyrimidines. Hence, this type of UV light-induced DNA damage is called a *cyclobutane pyrimidine dimer*, a common type of DNA photoproduct. The nucleotide excision repair DNA repair system functions to remove this damage, which results in the normal DNA sequence (*upper box*). If the damage is not repaired, this type of DNA photoproduct can lead to formation of a typical C→T single base substitution mutation (*lower box*). This is most likely to occur on replication of damaged DNA and misincorporation of adenine opposite the cytosine-containing photoproduct. An example of such a UV-signature mutation is shown on the right.[4] Note that the mutation is located within a run of seven pyrimidines, a common location for UV-signature mutations.

TT tandem base substitution mutations.[2–4] Such mutations are typical for UV light exposures and only rarely are induced by other mutagens. They have therefore been termed *UV-signature mutations* (see Fig. 110-2). Pleasance et al.[5] sequenced all the genes in cells from a melanoma metastasis and reported that they harbor approximately 25,000 such mutations, accounting for about 70% of all mutations found. This clearly links the mutation burden in this cancer to prior UV-exposures.

DNA repair is an important cellular defense mechanism that prevents mutation formation at sites of DNA damage after UV exposure. However, it is not the only defense mechanism (see Fig. 110-1). Most mutations are generated during replication of damaged DNA. Therefore, a damage-induced arrest in cell cycling, which allows more time for repair, is another important cellular damage response that prevents mutation formation.[6,7] Furthermore, programmed cell death (apoptosis) prevents the survival of cells with overwhelming DNA damage, and through that mechanism the frequency of cells with UV-induced mutations is also reduced.[8] Other inherent defense mechanisms against the ultimately carcinogenic properties of UV light include increased melanogenesis and thickening of the epidermis and stratum corneum, which protect from future DNA damage. Other protection includes removal of mutated cells through host immune responses (see Fig. 110-1).

DNA DAMAGE AND REPAIR

More than 100 DNA repair genes have been identified (http://sciencepark.mdanderson.org/labs/wood/DNA_Repair_Genes.html). The nucleotide excision repair (NER) pathway acts on DNA damaged by UV radiation, repairing CPDs and other photoproducts, as well as on DNA damaged by certain carcinogens (such as benzo-[a]-pyrene) (see Table 110-2). In NER, the damaged nucleotide is removed and replaced with undamaged DNA. A simplified schema of the NER system describing some of the many proteins that act in concert to repair UV-induced DNA damage is shown in Fig. 110-3. Defects in these repair genes can cause human diseases (Table 110-3), including xeroderma pigmentosum (XP), Cockayne syndrome (CS), and trichothiodystrophy (TTD) (for details on these disorders, see Chapter 139). For instance, XP can be caused by a defect in any one of several genes involved in NER. Cells/patients with defects in the same gene are considered to be in the same complementation group, and in different complementation groups if different genes are affected. The term "complementation group" is based on cell fusion experiments, in which cells from different XP patients are fused to investigate if the DNA repair defect in the fused cells is corrected. If DNA repair in the fused cell is increased, each cell

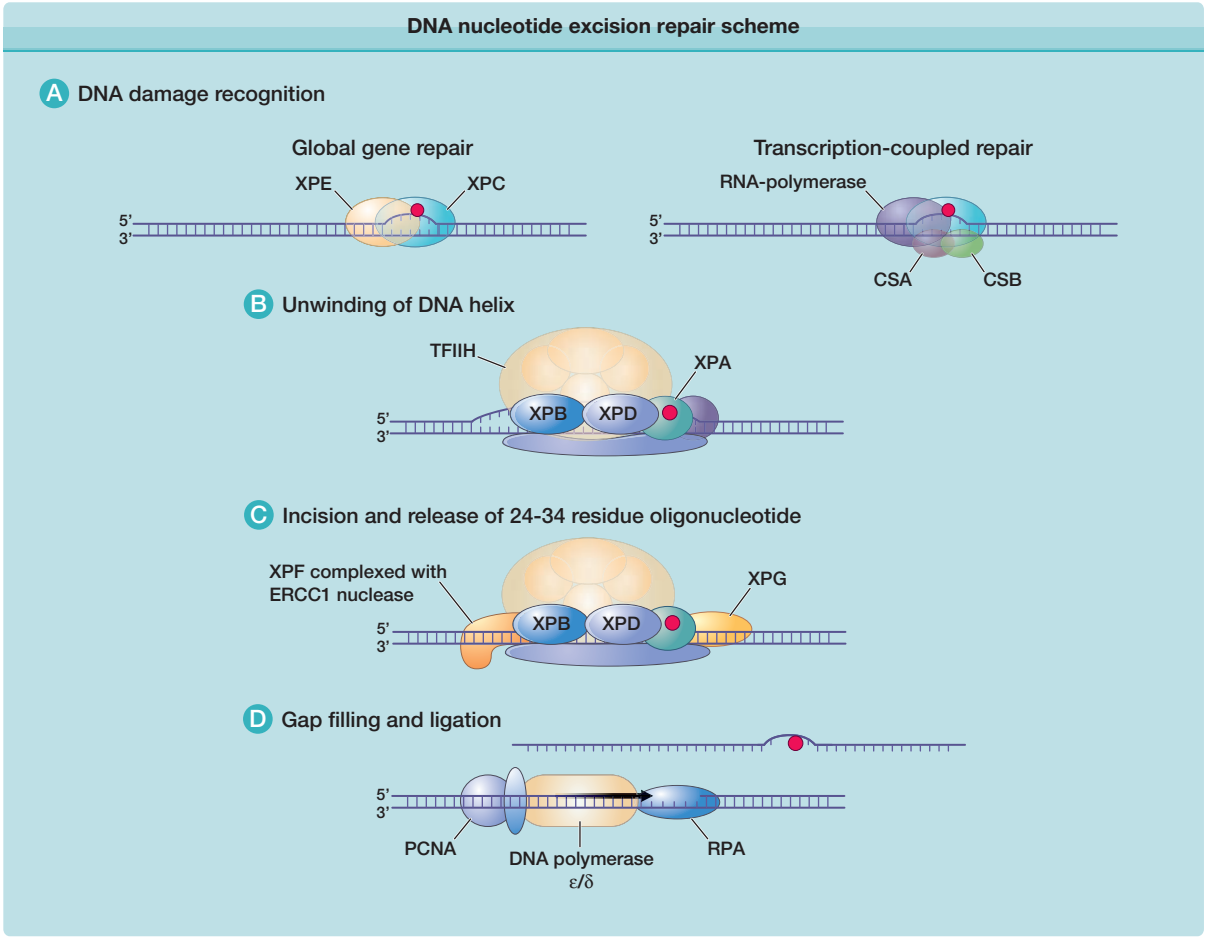

Figure 110-3 DNA nucleotide excision repair scheme. **A.** *Right:* Damaged DNA in actively transcribed genes results in stalling of the RNA polymerase in a process that involves the CSA and CSB proteins. This serves as a signal to initiate transcription-coupled DNA repair. *Left:* Damaged DNA in the remainder of the genome is bound by the XPE and XPC gene products. This serves as a signal to initiate global genome repair. **B.** A portion of the DNA, including the damage, is unwound by a complex of proteins including the XPB and XPD gene products. These proteins are also part of the 10-subunit basal transcription factor IIH (TFIIH). The XPA protein may stabilize the unwound DNA. **C.** The XPF and XPG nucleases make single-strand cuts on either side of the damage, releasing a 24- to 34-residue segment of DNA. **D.** The resulting gap is filled by DNA polymerase in a process that includes the proteins proliferating cell nuclear antigen (PCNA) and replication protein A (RPA). CSA, CSB = Cockayne syndrome complementation groups A and B; ERCC1 = excision repair cross-complementing gene 1; LIG1 = ligase 1; XPA, XPC, etc. = xeroderma pigmentosum complementation groups A, C, etc.

provides proteins that the other is lacking and the cells "complement" each other and are in different complementation groups. If DNA repair in the fused cells is not normalized, the cells do not "complement" each other, meaning that both cells harbor mutations in the same DNA repair gene. Seven such complementation groups have been identified (XP-A to XP-G), which correspond with mutations in seven distinct genes that can cause XP.

Transcribed genes are repaired faster than the rest of the genome. In the NER pathway, the first steps involving DNA damage recognition are different in nontranscribed (global genome NER) and transcribed genes (transcription-coupled NER). In nontranscribed genes and noncoding areas, which represent most of the genome, the *XPE* and *XPC* gene products bind to UV-damaged DNA, marking it for further processing. In contrast, DNA damage in transcribed genes appears to be sensed by a stalled RNA polymerase acting in conjunction with the CS complementation groups A and B (CSA and CSB) gene products. After the DNA damage recognition steps, global genome NER and transcription-coupled NER follow the same pathway. The *XPA* gene product functions in conjunction with replication protein A (RPA), the transcription factor IIH (TFIIH), XPF, and excision repair cross-complementing gene 1 (ERCC1). The following steps occur in both nontranscribed and transcribed gene repair:

- The *XPB* and *XPD* gene products partially unwind the DNA in the region of the damage, thereby exposing the lesion for further processing. These proteins are part of the TFIIH basal transcription factor (see Fig. 110-3B).
- The *XPF* gene product, in a complex with ERCC1, makes a single-strand nick at the 5′ side of the lesion, whereas the *XPG* gene product makes a similar nick on the 3′ side, which results in the

TABLE 110-3
DNA Repair and Telomere Maintenance Genes Associated with Human Diseases[a]

Gene[b]	Chromosome Location	Repair Pathway	Function
XPA	9q22.3	NER	Binding of damaged DNA
XPB (ERCC3)	2q21	NER	DNA helicase, part of TFIIH
XPC	3p25	NER	Binding of damaged DNA, global genome repair
XPD (ERCC2)	19q13.3	NER	DNA helicase, part of TFIIH
XPE (DDB2)	11p12-p11	NER	Binding of damaged DNA, global genome repair
XPF (ERCC4)	16p13.3-p13.11	NER	DNA endonuclease
XPG (ERCC5)	13q22	NER	DNA endonuclease
TTDA (GTF2H5)	6p25.3	NER	Part of TFIIH
CSA (ERCC8)	5q12	NER	Transcription-coupled repair
CSB (ERCC6)	10q11	NER	Transcription-coupled repair
XPV (polymerase eta)	6p21.1-p12	Bypass	DNA damage bypass polymerase
MSH2	2p22-p21	MMR	Mismatch repair (Muir–Torre syndrome, HNPCC)
MLH1	3p21.3	MMR	Mismatch repair (Muir–Torre syndrome, HNPCC)
PMS1	2q31-q33	MMR	Mismatch repair (HNPCC)
PMS2	7p22	MMR	Mismatch repair (HNPCC)
MSH6	2p16	MMR	Mismatch repair (HNPCC)
MLH3	14q24.3	MMR	Mismatch repair (HNPCC)
DKC1	Xq28	Telomere maintenance	Dyskerin, Posttranscriptional pseudouridylation, forms a ribonucleoprotein complex with NOP10 (gene name NOLA3) and NHP2 (gene name NOLA2)
TERT	5p15.33	Telomere maintenance	Telomerase, extends nucleotide repeats at chromosome ends
TERC	3q21-q28	Telomere maintenance	RNA template for telomerase
TINF2	14q12	Telomere maintenance	Part of protein complex shelterin, regulates telomere length
NOLA2	5q35.3	Telomere maintenance	See dyskerin
NOLA3	15q14-q15	Telomere maintenance	See dyskerin

ERCC = human excision repair cross-complementing genes that correct defects in cultured hamster cells; HNPCC = hereditary nonpolyposis colon cancer; NER = nucleotide excision repair; MMR = mismatch repair; TFIIH = transcription factor IIH.
[a]More than 100 DNA repair genes have been identified. An updated list can be found at (http://sciencepark.mdanderson.org/labs/wood/DNA_Repair_Genes.html).
[b]The genes designated XP are defective in the corresponding xeroderma pigmentosum complementation group, and those designated CS are defective in the corresponding Cockayne syndrome complementation group.

release of a region of approximately 30 nucleotides containing the damage (see Fig. 110-3C).
- The resulting gap is filled by DNA polymerase using the other (undamaged) strand as a template in a process involving proliferating cell nuclear antigen (PCNA). DNA ligase 1 seals the region, restoring the original undamaged sequence (see Fig. 110-3D).

Other DNA repair pathways include base excision repair, recombination repair, and mismatch repair. Defects in mismatch repair are also associated with human diseases—Muir–Torre syndrome and human nonpolyposis colon cancer.[1,9–11]

REGULATION OF CELLULAR RESPONSES TO DNA DAMAGE

Several cellular responses to DNA damage contribute to the maintenance of genome integrity, including: cell cycle arrest, apoptosis (programmed cell death), and DNA repair.[6,12–19] These responses need to be carefully

orchestrated, and there are many proteins involved in the signaling of DNA damage and the regulation of DNA damage responses. Different types of DNA-damaging agents and different types of DNA damage require different DNA damage responses. A simplified version of this complex pathway is presented in Figure 110-4. As with defects in DNA repair genes (see Table 110-3), defects in many of these DNA damage-signaling genes (boxed in Fig. 110-4) are also implicated in hereditary disorders of genome instability (Table 110-4; for further details see Chapter 139). These disorders are characterized by an increased cancer risk, which is due to the genome instability from impaired DNA damage signaling.

The tumor suppressor gene p53, termed the *guardian of the genome*,[20] plays a pivotal role in regulating and orchestrating these responses and is mutated in many cancers, including cutaneous squamous cell carcinomas. Upstream regulators of p53 in the cellular DNA damage response pathway are ataxia telangiectasia mutated (ATM) and ataxia telangiectasia- and Rad3-related (ATR) genes. One of p53's several functions is the regulation of the cell cycle in response to DNA damage. After cell division (mitosis), cells have 23 pairs of chromosomes and are in the G_1 phase of the cell cycle. The chromosomes then replicate during DNA synthesis, or S phase, and as a result have twice the number of chromosomes (G_2 phase) just before mitosis (M phase). In response to damage, the cell may stop cycling (arrests) in specific cell cycle phases called *cell cycle checkpoints*. An important downstream effector in preventing cells from entering S phase (G_1/S checkpoint) is p21.[6,12] p53 also induces NER by transcriptionally inducing XPC, XPE/p48, and GADD45.[21,22] This indicates that a cell's capacity to repair DNA damage can be upregulated in response to DNA damage.

If cells enter S phase with unrepaired DNA damage, or if cells are UV exposed during S phase, regular DNA polymerases stall at DNA photoproducts and fall off the DNA strand. For these instances, cells are equipped with several specialized DNA polymerases for translesional

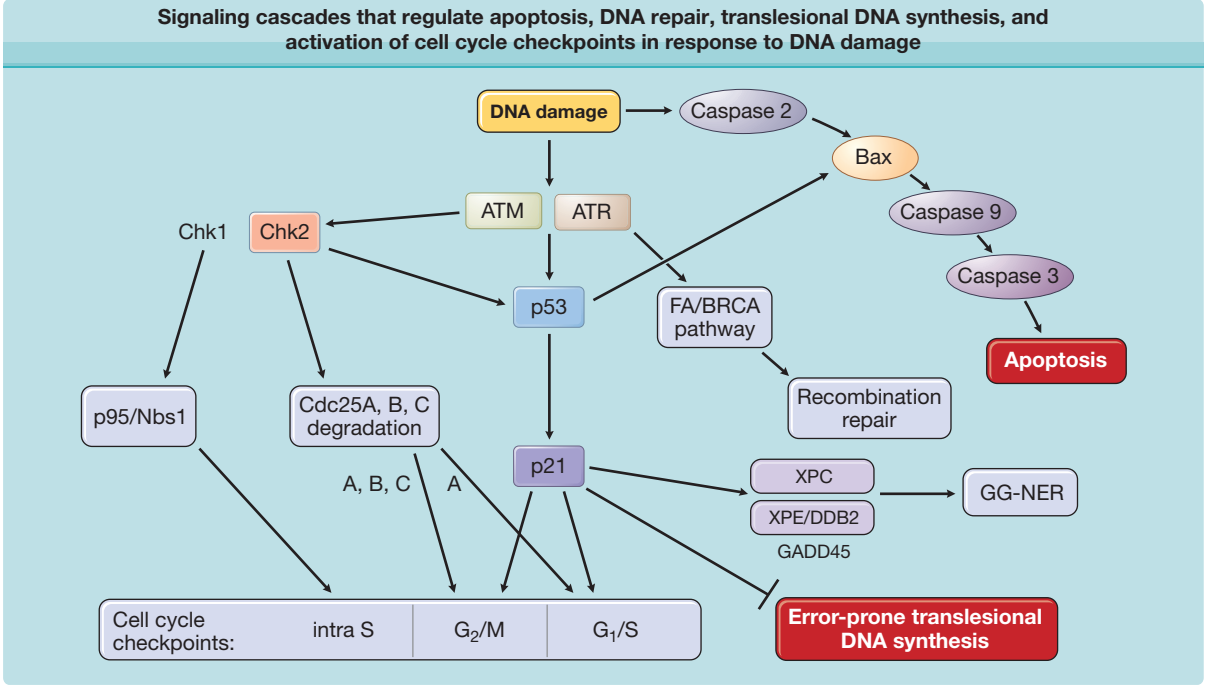

Figure 110-4 Signaling cascades that regulate apoptosis, DNA repair, translesional DNA synthesis, and activation of cell cycle checkpoints in response to DNA damage. This is a highly simplified diagram that depicts only the most important players in the intricate and interwoven DNA damage-signaling networks. The traditional thinking was that ataxia telangiectasia mutated (ATM) gene is activated (phosphorylated) in response to ionizing radiation (IR) and ATR (ataxia telangiectasia- and Rad3-related gene) is activated in response to ultraviolet (UV) radiation, but newer data indicate that both are activated by IR and UV. ATM/ATR can activate (i.e., phosphorylate) p53 either directly or indirectly through activation (phosphorylation) of Chk2 (an ATM target) or Chk1 (an ATR target). Through transcriptional activation of p21 and subsequent inhibition of cyclin-dependent kinases, which usually drive cells from the G_1 into the S phase of the cell cycle, activated p53 activates the G_1/S checkpoint (i.e., arrests cells in G_1). The G_1/S checkpoint is also activated by Chk1/Chk2-induced phosphorylation and then degradation of Cdc25A and subsequent failure to activate cyclin-dependent kinases. Phosphorylation and subsequent degradation of Cdc25A, Cdc25B, and Cdc25C also mediate the G_2/M arrest, as does p21. Intra-S-phase arrest is mediated through activation (phosphorylation) of p95/Nbs1. p53 also induces global genome nucleotide excision repair (GG-NER) through transcriptional activation of XPC, XPE/p48, and GADD45. Translesional DNA synthesis has been shown to be downregulated by p53 via p21. Recombination repair is mediated through the Fanconi anemia (FA)/BRCA pathway, which in turn is dependent on ATR activation. The mitochondrial pathway of apoptosis is activated through activation of Bax by caspase 2 and p53, the initiator caspase 9, and the effector caspases 3, 6, and 7 (for references, see text). Gene products that are defective in hereditary human diseases are boxed. DDB2 = DNA damage binding protein 2; XPC, XPE = xeroderma pigmentosum complementation groups C and E.

TABLE 110-4
DNA Damage-Signaling Genes Associated with Human Diseases[a]

Gene	Chromosome Location	Hereditary Disorder
ATM	11q22.3	Ataxia telangiectasia
ATR	3q22–24	Seckel syndrome
FANCA	16q24.3	Fanconi anemia
FANCB	Xp22.31	Fanconi anemia
FANCC	9q22.3	Fanconi anemia
FANCD1/BRCA2	13q12.3	Fanconi anemia, familial breast cancer
FANCD2	3p25.3	Fanconi anemia
FANCE	6p21-p22	Fanconi anemia
FANCF	11p15	Fanconi anemia
FANCG	9p13	Fanconi anemia
FANCI	15q25-q26	Fanconi anemia
FANCJ	17q22	Fanconi anemia
FANCL	2p16.1	Fanconi anemia
FANCM	14q21.3	Fanconi anemia
FANCN	16p12.1	Fanconi anemia
BRCA1	17q21	Familial breast cancer
p53	17p13.1	Li–Fraumeni syndrome
Chk2	22q12.1	Li–Fraumeni syndrome
CDKN2A ($p16^{INK4}$)	9p21	Familial malignant melanoma
CDK4	12q14	Familial malignant melanoma
Nbs1 (p95)	8q21	Nijmegen breakage syndrome
Rb	13q14.1–14.2	Bilateral retinoblastoma

[a]Please see Fig. 110-4 for the function of these genes in the DNA damage-signaling cascade and Chapter 139 for a clinical descriptions of these disorders.

DNA synthesis.[23] DNA polymerase eta is one of these; it is specialized to bypass DNA photoproducts but may introduce mutations while doing so.[24] It is mutated in XP variant patients, who are clinically indistinguishable from other XP patients with defects in NER (see Table 110-3, Chapter 139).[25,26] This demonstrates the importance of this second line of defense against the mutagenic and carcinogenic consequences of DNA photoproducts. p53 and p21 also downregulate the activity of this translesional DNA synthesis to maintain a low mutagenic activity at the price of reduced damage bypass.[27]

If this translesional DNA synthesis fails, cells can use recombination repair to resolve stalled replication forks.[28] When invoked in response to damage from UV light, this third line of defense is mediated by activation of the Fanconi anemia/BRCA DNA damage response pathway.[29] The exact mechanisms that initiate these DNA damage response signaling cascades is under investigation. Telomeres, which are repeats of TTAGGG that cap the ends of chromosomes and whose ends form a loop structure, are suggested to be important players in sensing DNA damage, for example, through opening of the telomere loop.[30] Other sensors may be stalled DNA or RNA polymerases, or proteins that detect bending of the DNA helix at sites of DNA damage.

Apoptosis is a regulated physiologic process leading to cell death characterized by cell shrinkage, membrane blebbing, and DNA fragmentation. A group of cysteine proteases called *caspases* are central regulators of apoptosis. Triggers may be extrinsic or intrinsic to the cell (e.g., DNA damage) and involve separate initiator caspases (e.g., caspase 2 in response to DNA damage) but share the same downstream effector caspases.[8]

APPROACHES TO DIAGNOSIS OF GENOME INSTABILITY AND/OR DNA REPAIR DEFECTS

When a disorder of genome instability is suspected, the clinician is challenged with choosing the appropriate laboratory tests to secure a diagnosis and to provide

TABLE 110-5
Hallmark Clinical Features That May Indicate a Disorder of Genome Instability or DNA Repair and Prompt Clinicians to Initiate Testing[a]

Disorder	Clinical Features
Xeroderma pigmentosum	Burning or blistering on minimal sun exposure (some patients), childhood freckling, early or multiple skin cancers
Cockayne syndrome	Burning on minimal sun exposure, postnatal growth failure, sensorineural deafness
Trichothiodystrophy	Burning on minimal sun exposure (some patients), brittle hair, ichthyosis
Ataxia-telangiectasia	Telangiectasias, ataxia, leukemias or lymphomas
Bloom syndrome	Photosensitivity, malar erythema, growth retardation, infections, cancers
Fanconi anemia	Aplastic anemia, growth retardation, café-au-lait spots, thumb abnormalities, acute myelogenous leukemia
Dyskeratosis congenita	Triad of reticulated hyperpigmentation, nail dystrophy, and mucosal leukoplakias
Muir–Torre syndrome	Sebaceous tumors, keratoacanthomas, personal or family history of colon cancer

[a]Refer to Chapter 139 for more information.

guidance for affected patients and families. Table 110-5 lists some hallmark clinical features that may indicate the presence of such disorders and should prompt clinicians to initiate testing. Various laboratory tests for genome stability, DNA repair, and response to physical and chemical agents are listed in Table 110-6.

USE OF CULTURED CELLS

Cells obtained directly from patients and grown in culture medium are termed *primary cultures*. Dermal fibroblasts generally grow easily in culture and can generally be established from a 2- to 4-mm sterile skin punch biopsy specimen. The inner surface of the upper arm has proven to be a suitable biopsy site because this area heals easily, the resulting scar is not readily visible, the site is shielded from UV radiation, and attempts to establish cultures from specimens are generally successful. The tissue is placed in sterile culture medium (or sterile saline) with antibiotics and transported to a cell culture laboratory at room temperature.

Human cell cultures are made available for research by the National Institutes of Health-funded Human Genetic Mutant Cell Repository (401 Haddon Ave, Camden, NJ 08103; telephone: 856–966-7377; http://ccr.coriell.org).

TABLE 110-6
Diagnostic Tests of Genome Stability, DNA Repair, and Response to Physical or Chemical Agents[a]

- Intact cell function (proliferation or cell death)
  - Cell counts (growth in mass culture)
  - Thymidine incorporation
  - Colony-forming ability
- Chromosome integrity and breakage
  - Giemsa-stained metaphase karyotype analysis
  - G_2 chromosome breakage
  - Sister chromatid exchanges
  - Fluorescent in situ hybridization
  - Microsatellite instability testing
  - Telomere length
- DNA repair
  - Unscheduled DNA synthesis
  - RNA synthesis inhibition
  - Host cell reactivation
  - Comet assay
  - Immunological analysis of DNA damage and removal (enzyme-linked immunosorbent assay, slot blot)
  - Microsatellite instability testing
- Characterization and expression of defective genes
  - Real-time polymerase chain reaction
  - Western blotting
  - DNA sequencing

[a]Agents are listed in Table 110-1.

DIAGNOSTIC TESTS OF GENOME INSTABILITY AND DNA REPAIR

Tests to assess genome instability and/or DNA repair capacity may be divided into tests of intact cellular function and tests of chromosome integrity and breakage in response to DNA-damaging agents. Other tests measure the mechanism of impairment of a cell function such as DNA repair or characterize or determine the expression of defective genes (see Table 110-6).

TESTS OF INTACT CELL FUNCTION.

Tests of cellular function measure the capacity of the intact cell to recover from DNA damage. These tests do not provide information regarding the specific type of damage resulting in cellular injury or the mechanism of cellular recovery, but they do form the basis for identifying cells as hypersensitive to DNA-damaging agents and are often used as simple screening tests.

Cell Counts or Thymidine Incorporation. One of simplest tests after exposure to UV radiation or X-rays is the assessment of the growth rate in mass culture by using a microscope or an automated cell counter to count the number of cells or by measuring incorporation of radioactive thymidine into newly synthesized DNA (see Tables 110-6 and 110-7).

Colony-Forming Ability. A test of colony-forming ability assesses the capacity of a single cell to proliferate enough to form a visible colony (Fig. 110-5).

TABLE 110-7
Suggested Sequence of Diagnostic Testing for Diseases of Genome Instability or DNA Repair[a]

Disease	Step 1	Step 2	Step 3	Step 4	Testing Available[b]
Xeroderma pigmentosum	Post-UV hypersensitivity	Post-UV DNA repair	DNA sequencing	—	CLIA/R
Xeroderma pigmentosum variant	Post-UV hypersensitivity (with caffeine)	Post-UV DNA repair (normal)	DNA sequencing	—	R
Cockayne syndrome	Post-UV hypersensitivity	Post-UV inhibition of RNA synthesis	DNA sequencing	—	CLIA
Trichothiodystrophy[c]	Post-UV hypersensitivity	Post-UV DNA repair	DNA sequencing	—	CLIA/R
Ataxia telangiectasia	Chromosome breakage	X-ray hypersensitivity	Western blotting for level of protein	DNA sequencing	CLIA/R
Bloom syndrome	Chromosome breakage	Sister chromatid exchange	DNA sequencing	—	CLIA
Fanconi anemia	Chromosome breakage	Hypersensitivity to DNA cross-linking agents	Western blotting for FANCD2	DNA sequencing	CLIA/R
Dyskeratosis congenita	Telomere length	DNA sequencing			
Muir–Torre syndrome	Microsatellite instability	Western blotting for level of protein	DNA sequencing	—	CLIA

CLIA = testing available by laboratories certified under the Clinical Laboratory Improvement Act; R = research testing available; UV = ultraviolet radiation.
[a]These are suggestions only and may change based on availability of different assays or new scientific information. In recent years, sequencing has become much easier and cheaper through automated processes. Thus, DNA sequencing may be considered as a first diagnostic test, in particular for diseases with no or few complementation groups. However other tests (e.g., of cell function or protein levels) may be required to exclude a diagnosis if no mutation is identified.
[b]Testing laboratories are listed on the National Institutes of Health-funded Web site http://genetests.org.
[c]Screen by polarizing microscopic examination of hair followed by measurement of sulfur-containing amino acids in the hair (see Chapter 139).

TESTS OF CHROMOSOME INTEGRITY AND BREAKAGE.

Chromosome breakage is usually assessed in primary cultures of mitogen-stimulated peripheral blood leukocytes or in long-term cultures of fibroblasts or lymphoblastoid cell lines. Cell cycle progression is stopped at metaphase by treatment of the cells with an inhibitor of mitosis such as colchicine. In this procedure, the 23 pairs of metaphase chromosomes from a single cell are spread over a discrete area of the slide and stained (usually with Giemsa stain). Preparations may be analyzed for the number of chromosomes per metaphase, the morphology of the individual chromosomes, and the attachments or rearrangements of chromosomes in relation to each other.

Sister Chromatid Exchange. During DNA replication, chromatids occasionally exchange positions along the arms of a chromosome. This sister chromatid exchange (SCE) may be detected by permitting the cells to grow through two cycles of replication in medium containing the nucleic acid analog bromodeoxyuridine (BrUdR) (Fig. 110-6). SCEs are thought to be related to DNA recombination repair, although their precise significance is not understood.

Telomere Length. Shortened telomeres characterize cells from patients with dyskeratosis congenita. Several methods can be used to measure telomere length, including terminal restriction fragment (TRF) measurement on Southern blots, fluorescence in situ hybridization (FISH) with immunostaining, quantitative polymerase chain reaction (PCR), single telomere length analysis, and flow-cytometry with FISH (flow-FISH).[31] Those tests are usually done on freshly isolated white blood cells, not cultured cells.

TESTS OF DNA REPAIR

Unscheduled DNA Synthesis. One of the most commonly used tests of NER is unscheduled DNA synthesis. This test has been used to measure DNA repair in intact human skin, in cultured epidermal or dermal cells, and in blood cells, and for prenatal diagnosis using amniotic fluid cells. Unscheduled DNA synthesis testing measures the repair-associated DNA synthesis in G_1 or G_2 cells (which usually do not synthesize DNA). Cells are treated with UV radiation or another DNA-damaging agent and then incubated in medium containing radioactive thymidine. During the

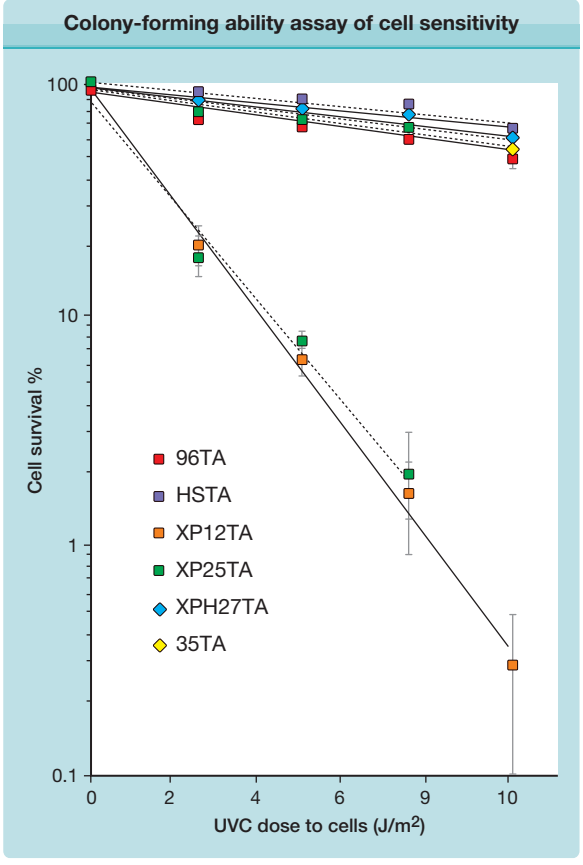

Figure 110-5 Colony-forming ability assay of cell sensitivity. Xeroderma pigmentosum (XP) fibroblasts from two affected siblings (XP12TA and XP25TA), their father (XPH27TA), and an unaffected brother (35TA) as well as normal fibroblasts (96TA and HSTA) were treated with 254-nm ultraviolet C (UVC) radiation and colony-forming ability was determined. The XP complementation group C (XPC) fibroblast strains from the affected siblings were much more sensitive than the normal strains and showed similar post-UVC hypersensitivity. Cells from the unaffected brother and the clinically normal father, a heterozygous carrier of the XPC defect, had normal post-UVC survival. (Modified from Slor H et al: Clinical, cellular, and molecular features of an Israeli xeroderma pigmentosum family with a frameshift mutation in the XPC Gene: Sun protection prolongs life. *J Invest Dermatol* **115**:974, 2000.)

process of NER, the damage is removed and the radioactive thymidine is incorporated into the repaired region. The cells are treated with fixative, coated with autoradiographic (photographic) emulsion, and kept in the dark for an appropriate interval, and then the emulsion is developed. UV radiation of normal fibroblasts results in a large increase in the number of grains seen over all the nuclei. In marked contrast, irradiation of the XP fibroblasts that cannot repair DNA damage results in very few grains over the nuclei.

RNA Synthesis Inhibition. After exposure to UV radiation, normal cells temporarily reduce RNA synthesis from active genes. Synthesis resumes when the damage is repaired. This resumption of RNA synthesis is delayed in cells from patients with CS and some forms of XP.

Host Cell Reactivation. The host cell reactivation assay relies on the fact that plasmids do not have the ability to repair damage to their DNA but depend on cellular repair systems. Thus, when transfecting plasmids with DNA damage into host cells, the DNA repair enzymes of the host cells need to repair the damage before the plasmids' genes can be expressed. Therefore, damaged plasmids would be expected to be expressed at a higher level in cells with normal repair capacity. A nonreplicating plasmid that contains the gene for the firefly enzyme luciferase, constructed to permit expression in human cells,[32] is widely used; generation of light provides a quantitative endpoint for its repair (Fig. 110-7).

Comet Assay. The comet assay is a single cell-based technique that allows detection and quantitation of DNA damage, in particular DNA strand breaks that were either introduced directly by the DNA-damaging agent or by repair endonucleases at sites of other types of DNA damage. For this assay, damaged cells are embedded in agarose, lysed, and exposed to an electric field. In the electrical field, the DNA migrates out of the nucleus forming a "comet" when stained. In presence of DNA strand breaks, DNA migrates out of the nucleus faster and with that generates a longer comet. Thus, the length of the comet is proportional to the fragmentation of the nuclear DNA. This assay can be modified for detection of single-strand or double-strand DNA breaks, UV damage, or oxidative DNA damage. Cells from patients with XP have defective repair in the post-UV comet assay.

Microsatellite Instability. Normal DNA has tens of thousands of regions with repeats of the dinucleotide CA or other short motifs up to five nucleotides long. In normal individuals each of these microsatellites (also called *simple sequence repeats* or *short tandem repeats*) has a uniform size. However, these sizes are highly variable among different individuals and are often used for DNA "fingerprinting." The appearance of abnormally longer or shorter simple sequence repeats in different tissues or tumors from a patient is called *microsatellite instability*. This can be associated with a defect in mismatch repair genes.

CHARACTERIZATION AND EXPRESSION OF DEFECTIVE GENES

Real-Time Polymerase Chain Reaction. Many disease-causing mutations, including those responsible for disorders of genome instabilty disrupt the gene product's function by changing its amino acid sequence. In some genome instability genes, disease-causing mutations create premature stop codons for protein synthesis. These mutations result not only in truncated but also in low levels of messenger RNA (mRNA) for the gene product through a process called *nonsense-mediated message decay*. The mRNA levels can be accurately measured by the use of quantitative reverse transcriptase real-time polymerase chain reaction. For example, low

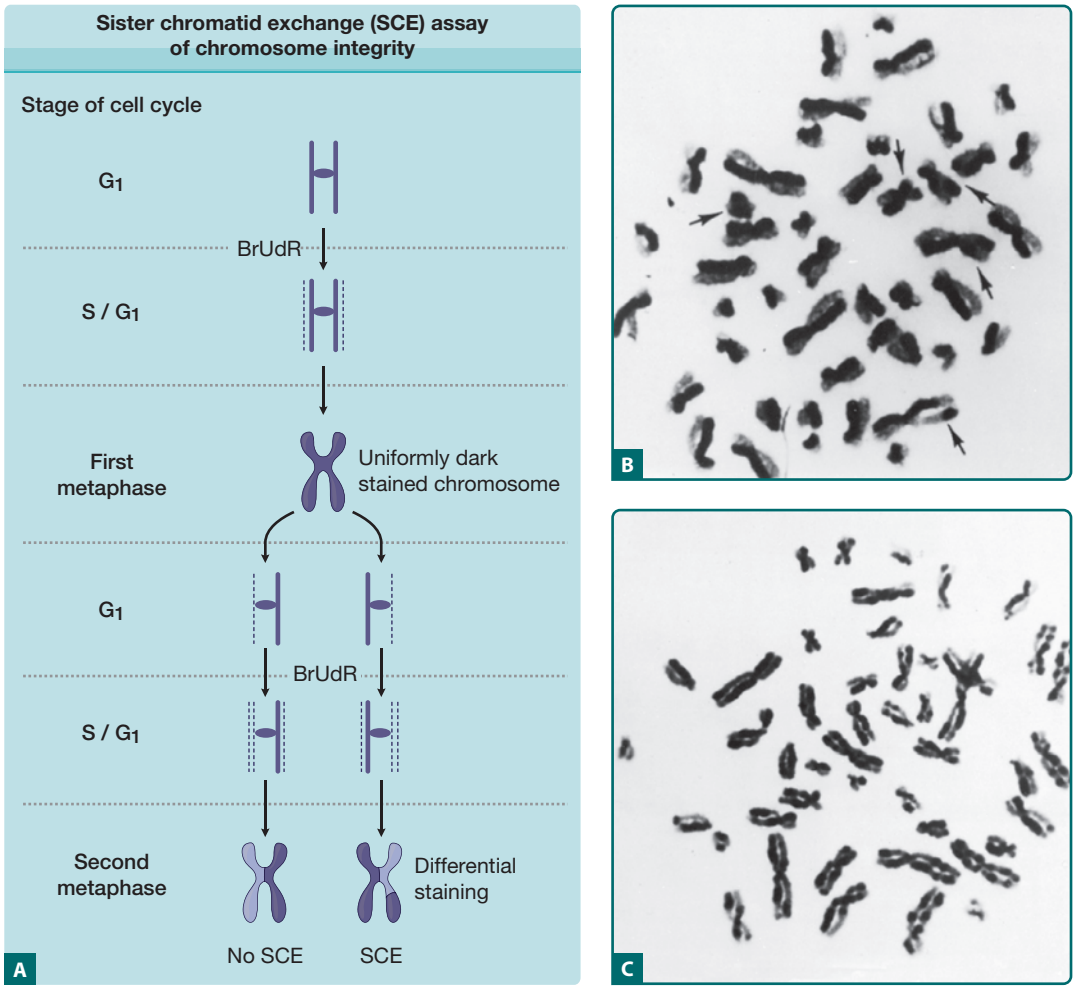

Figure 110-6 **A.** Sister chromatid exchange (SCE) assay of chromosome integrity. After the first cycle of replication, the DNA of the newly synthesized strand is labeled with bromodeoxyuridine (BrUdR), whereas the older strand is unlabeled. Such chromosomes appear uniformly dark with Giemsa stain. After a second cycle of replication in BrUdR-containing medium, one arm of a chromosome will contain two labeled chromatids, whereas the other will contain one labeled and one unlabeled chromatid. The doubly substituted arm will stain lightly, whereas the singly substituted arm will stain darkly. If an SCE occurred during replication, a portion of each chromosome arm will be doubly substituted and the remainder singly substituted with BrUdR. **B.** Undamaged normal cultured peripheral blood lymphocytes have approximately ten SCEs per metaphase. **C.** Cultured peripheral blood lymphocytes from a patient with Bloom syndrome have a manifold increase in SCEs. (From Chaganti RS, Schonberg S, German J: A manyfold increase in sister chromatid exchanges in Bloom's syndrome lymphocytes. *Proc Natl Acad Sci U S A* **71**:4508, 1974, with permission.)

XPC mRNA levels have been found in cells from most XP patients with defects in this gene.[33]

Western Blotting. Some mutations result in reduced levels or size of encoded proteins, often through creation of premature stop codons.[33] Reduced protein levels are most commonly detected by Western blotting. Cells are lysed and the proteins are extracted and separated by gel electrophoresis. The separated proteins are transferred to a membrane and probed with an antibody that is specific for the protein of interest. The intensity of the antibody staining reflects the amount of protein in the cells, and its location on the membrane is an indication of the size of the protein molecules. For example, undetectable or low levels of polymerase eta protein are present in cells from most XP variant patients.[34]

DNA Sequencing. Direct sequencing of defective genes is the gold standard for determination of the presence of a mutation. The final step in confirmation of a diagnosis may be DNA sequencing to determine the disease-causing mutation. By definition, disease-causing mutations alter the function of genes. However, not every alteration in the sequence of a gene alters the function of the encoded protein. In the human genome there are millions of single nucleotide polymorphisms, or changes in one nucleotide, that are not associated with disease and may not even change the amino acid composition of the encoded protein. In recessive disorders, each clinically unaffected parent has one normal allele and one potentially disease-causing mutation in the other allele. The affected child receives an allele with a disease-causing mutation from each parent. The

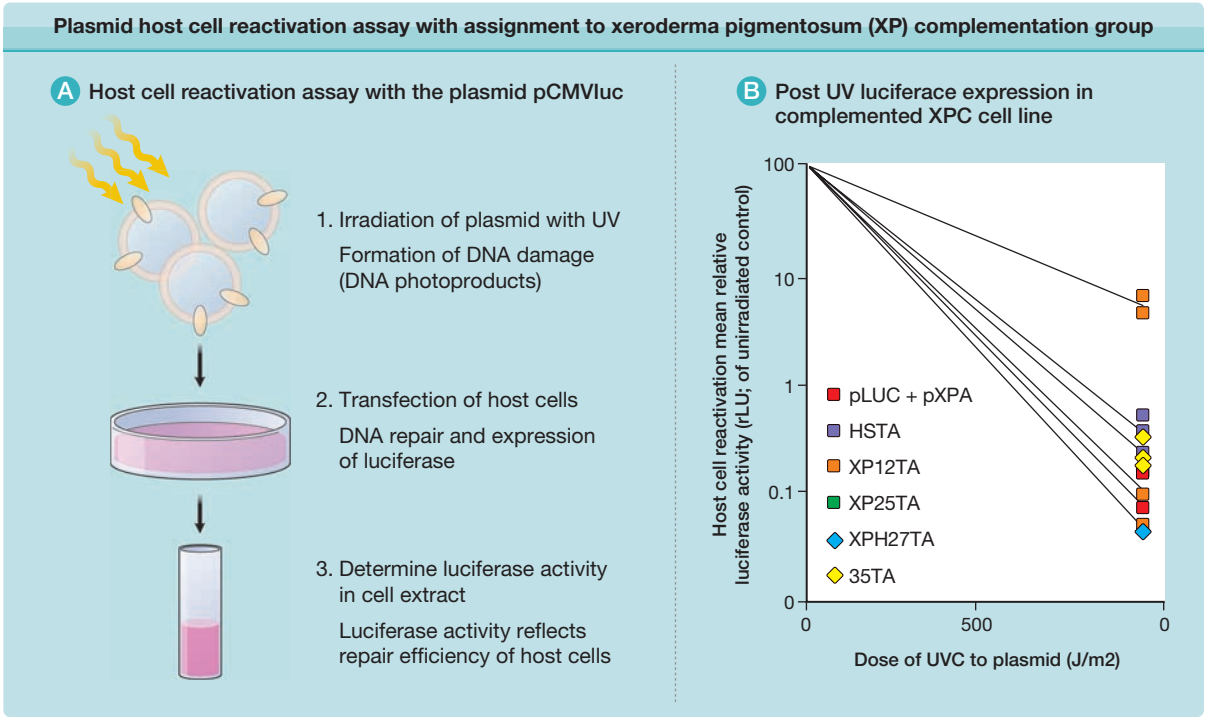

Figure 110-7 Plasmid host cell reactivation assay with assignment to xeroderma pigmentosum (XP) complementation group. **A.** The plasmid is damaged by ultraviolet (UV) radiation and introduced into cultured human cells by a transfection technique. The cells' DNA repair enzymes repair the damage in a manner similar to the repair of cellular DNA. Repaired DNA will then function to transcribe the plasmid-encoded luciferase gene in the human cell. The amount of luciferase activity within the host cells therefore reflects the efficiency of the cellular DNA repair system. This assay can also be used to determine the complementation group by cotransfecting UV-treated plasmid plus plasmids expressing wild-type XP complementary DNA (cDNA). **B.** The results of plasmid host cell reactivation experiments and complementation group assignment with DNA excision repair-deficient XP46DC cells. UV-treated plasmid showed low expression in the XP65BE cells that was increased only by cotransfection with a plasmid expressing the wild-type XPC cDNA. This result indicates that XP65BE cells are in XP complementation group C (XPC). rLU = relative light units; pCMVluc and pLUC = plasmids containing gene for luciferase; pXPA–pXPG = plasmids expressing xeroderma pigmentosum complementation groups A–G.

two mutations must be in the same gene, although they need not necessarily be identical to each other.

CONSIDERATIONS IN DIAGNOSTIC TESTING

Diagnosis of disorders of genome instability or DNA repair is often a multistep process. A suggested sequence of steps is listed in Table 110-7. As new tests are developed and new information is obtained about these disorders, testing procedures may change accordingly. In addition, decisions regarding the extent of testing performed may be made with consideration of how much the tests cost and whether additional information would alter treatment. For example, DNA sequencing is rarely required for establishment of a diagnosis of XP in a child with classical clinical features and cells that are hypersensitive to killing by UV and have defective DNA repair. But if a family has one child affected with XP and is considering having additional children, DNA sequencing might offer them the possibility of prenatal diagnosis through DNA sequencing of a trophoblast biopsy specimen.

Genetic counseling is an important component of patient management for these genetic diseases. This function may be performed by the treating physician or by a trained genetic counselor.

In the United States, only laboratories certified in accordance with the Clinical Laboratory Improvement Act (CLIA) are allowed to perform these specialized tests in the context of patient care. Tests performed in research laboratories generally have limited use in clinical practice. However, a research laboratory may identify a disease mutation in cells from a patient that could then be confirmed in a CLIA-certified laboratory and used in clinical practice. A current listing of laboratory testing facilities for these diseases may be found at the Web site http://genetests.org, funded by the National Institutes of Health.

KEY REFERENCES

Full reference list available at www.DIGM8.com

DVD contains references and additional content

1. Friedberg EC et al: *DNA Repair and Mutagenesis*. Washington, DC, ASM Press, 2006

2. Wikondahl NM, Brash DE: Ultraviolet radiation induced signature mutations in photocarcinogenesis. *J Invest Dermatol Symp Proc* **4**:6, 1999
9. Bootsma D et al: Nucleotide excision repair syndromes: Xeroderma pigmentosum, Cockayne syndrome, and trichothiodystrophy. In: *The Genetic Basis of Human Cancer*, 2nd edition, edited by B Vogelstein, KW Kinzler. New York, McGraw-Hill, 2002, p. 211
22. Hanawalt PC: Subpathways of nucleotide excision repair and their regulation. *Oncogene* **21**:8949, 2002
23. Lehmann AR: Replication of damaged DNA by translesion synthesis in human cells. *FEBS Lett* **579**:873, 2005
33. Khan SG et al: Reduced XPC DNA repair gene mRNA levels in clinically normal parents of xeroderma pigmentosum patients. *Carcinogenesis* **27**:84, 2006

Chapter 111 :: Chemical Carcinogenesis

:: Adam B. Glick & Andrzej A. Dlugosz

CHEMICAL CARCINOGENESIS AT A GLANCE

- In 1775, Sir Percivall Pott's report of scrotal cancer in chimney sweeps established a link between environmental exposure and cutaneous malignancy.
- Over 200 chemicals have been linked to human cancer development, according to the National Toxicology Program's 11th Report on Carcinogens (2005).
- Chemicals implicated in human skin cancer development include polycyclic aromatic hydrocarbons and arsenic.
- Studies in mouse skin have defined operational stages of epithelial carcinogenesis: initiation, promotion, and malignant progression. Chemicals linked to human cancer are classified as tumor initiators, promoters, or "complete" carcinogens.
- Tumor initiation, associated with gene mutations that permanently alter the cell's biological responsiveness, is irreversible; tumor promotion a nonmutagenic process that provides a selective growth advantage to initiated cells, is reversible at early stages; agents that facilitate malignant progression are generally genotoxic.
- Most carcinogens must undergo metabolic activation, which involves enzymes involved in xenobiotic metabolism, including cytochrome p450 enzymes and glutathione S-transferase.
- An individual's likelihood of developing chemically induced skin cancer is a function of exposure history; presence of additional risk factors (e.g., UV exposure); and genetic background, including gene polymorphisms that influence susceptibility.

CUTANEOUS CANCER AND PUBLIC HEALTH

According to the *American Cancer Society*, it is estimated that over 2,000,000 cases of basal cell carcinoma (BCC) and squamous cell carcinoma (SCC), 46,770 cases of melanoma in situ, and 68,130 cases of invasive melanoma will be diagnosed that in the year 2010.[1] The precise number of nonmelanoma skin cancers is unknown since they are not routinely reported to registries, but recent data suggest that previous approximations are likely to have been underestimates.[2] Although only a small fraction of patients with nonmelanoma skin cancer will die as a result of their cancer, which is SCC in nearly all cases, the frequency of these cancers nonetheless results in an estimated 1,000 and 2,000 deaths per year. In contrast, although much less common than nonmelanoma skin cancer, melanoma has a continually rising death rate now estimated at 8,700 per year, and it is currently predicted that the lifetime risk in Caucasians of developing melanoma is a staggering 1 in 37 for males and 1 in 56 for females.[1] Because they are so common, cutaneous cancers have a major impact on health care costs: in addition to the mortality burden, treatment is associated with considerable morbidity and cosmetic defects. For these reasons, understanding the etiology and pathogenesis of these malignancies is a significant public health goal, and development of rational nondeforming therapies to reduce morbidity and mortality is urgently needed. The high prevalence of skin cancer, the external location of the tumors, and well-defined preneoplastic lesions all provide an excellent opportunity for studying the factors regulating cutaneous cancer induction in humans. Those qualities that facilitate the study of cutaneous neoplasms in human populations have also been useful in establishing relevant animal models. Advances in molecular genetics, keratinocyte cell culture, and development of genetically altered mice and reconstructed human skin models have greatly facilitated the analysis of basic mechanisms of cutaneous carcinogenesis. Our main focus in this chapter will be on nonmelanoma skin cancer: the reader is referred to Chapter 124 for further discussion of melanoma.

AGENTS ASSOCIATED WITH SKIN CANCER INDUCTION IN HUMANS

The ultraviolet radiation (UVR) in sunlight is the primary etiologic agent for all skin cancers, and thus UVR is the major carcinogen in the human environment. The powerful carcinogenic activity of UVR is attributable to its ability to damage DNA and cause mutations, its capacity to clonally expand incipient neoplastic cells whose altered signaling pathways provide a survival advantage in the face of ultraviolet-induced cytotoxicity, its ability to induce reactive oxygen species, and its activity as an immune suppressant (see Chapter 112). The association of UVR with skin cancer is so strongly supported by clinical, epidemiologic, and experimental data that it represents the most clear-cut etiologic factor in human malignancy.

Also implicated in the development of human skin cancer are various chemicals, as a result of environmental, occupational, or medicinal exposures (Table 111-1). In 1775, Sir Percivall Pott[3] attributed the increased incidence of scrotal cancer in chimney sweeps to repeated exposure to soot. This report provided the first link between occupational exposure and the development of cancer as well as the first example of chemical carcinogenesis. According to the National Toxicology Program's 11th Report on Carcinogens, published in 2005 (http://ntp.niehs.nih.gov/ntp/roc/toc11.html), 246 agents are listed as known or likely human carcinogens, and the great majority of these are chemicals. In the last 35 years, the mechanisms by which chemicals cause cancer have been unraveled, and reveal striking similarities to the properties responsible for UVR carcinogenicity, namely DNA damage, selective cytotoxicity, and immune suppression.

The carcinogenic potential of coal and petroleum derivatives is now firmly established as a result of experimental animal studies and epidemiologic reports. Petroleum products, grease as well as insecticides, herbicides, and fungicides are particularly pathogenic for SCC, while fiberglass and dry-cleaning agents increase the incidence of BCC.[4] Cigarette and pipe smokers have an overall twofold increased risk for cutaneous SCC, and the risk increases with the intensity of the tobacco use.[5] Arsenic exposure is associated with the development of premalignant keratoses, Bowen's disease, SCC, and BCC, as well as a number of internal malignancies.[6] While Fowler's solution (1% potassium arsenite) is no longer used in medical practice, certain herbal medicines are still a source of arsenic exposure. Occupational exposures to arsenic as a component of agricultural pesticides, sheep and cattle dip, mining and smelting, glass manufacturing, and other industries are well documented. A more insidious source of environmental arsenic exposure is contaminated drinking water or shellfish, and analysis of affected populations shows a dose-dependent increase in skin cancer.[7] Mouse models have provided evidence for an interaction of ingested arsenic acting as a cocarcinogen with solar radiation to

TABLE 111-1
Environmental Agents Associated with the Development of Human Skin Cancer

Agent	Individual at Risk	Route of Exposure	Tumor Types
UV radiation	General population	T	BCC, BD, SCC, M
Cigarette smoke	Smoker	T or S	SCC
Soot	Chimney sweep	T	SCC
Coat tar, pitch	Coker of coal, steel worker	T	SCC
Petroleum oils	Machinist, textile worker	T and S	SCC
Arsenic	Agriculture worker, living in areas of high groundwater and soil contamination	S and/or T	BD, SCC, BCC
4,4′-Bipridyl	Pesticide manufacturer	T	SCC, BD
Polychlorinated biphenyl	Petrochemical worker	T or S	M
Dry cleaning reagents	Dry cleaner	T or S	BCC
Fiberglass	Insulator	T	BCC
Psoralen (PUVA)	Psoriasis patient	T and S	SCC, BCC, M
Nitrogen mustard	CTCL patient	T	SCC
Immunosuppressants	Transplant recipient, etc.	S	SCC, BCC
Ionizing radiation	Cancer therapy patient	T	BCC, SCC

Abbreviations: T = topical; S = systemic; SCC = squamous cell carcinoma; BD = Bowen's disease; BCC = basal cell carcinoma; PCB = polychlorinated biphenyl; M = melanoma; CTCL = cutaneous T-cell lymphoma.

Source: Modified from Dlugosz A, Merlino G, Yuspa SH: Progress in cutaneous cancer research. *J Invest Dermatol Symp Proc* **7**:17, 2002, with permission of Nature Publishing Group, London, UK.

increase the frequency and size of cutaneous carcinomas and reduce the latency period.[8,9]

A variety of medications have been associated with the development of skin cancer. Systemic treatment with immunosuppressive agents results in an increased incidence of both benign and malignant skin lesions,[10] which is generally attributed to reduced immune-surveillance of nascent tumor cells. However, a more specific mechanism predisposing to skin cancer has been proposed for azathioprine, which may sensitize DNA to ultraviolet A (UVA) radiation via its metabolite 6-thioguanine, leading to the production of mutagenic reactive oxygen species.[11] In addition, cyclosporine A inhibits DNA repair and cell death in UVB-irradiated keratinocytes,[12] raising the possibility that this compound may also increase photocarcinogenesis. Topical nitrogen mustard also increases the risk of developing skin cancer.[13] Despite the clear-cut association between occupational exposure to tars and skin cancer, the use of coal tar in patients with psoriasis or eczema does not appear to increase the risk of developing skin cancer, based on a large study including over 13,000 patients.[14] In contrast, the use of ionizing radiation to treat a variety of skin diseases increases the risk of BCC in all treated patients, and SCC in individuals with sun-sensitive skin.[15]

Systemic administration of 8-methoxypsoralen combined with UVA treatments (PUVA) is associated with a dose-dependent increase in the risk of developing cutaneous SCC that persists following discontinuation of therapy.[16] Patients receiving high-level exposures (≥337 PUVA treatments) had over a 100-fold increase in SCC incidence while those receiving <100 treatments had a fivefold higher than expected incidence. 3.8% of individuals with PUVA-associated SCC developed metastases, and SCCs developed on the male genitalia much more frequently than in the general population.[17] The incidence of BCC and melanoma is also increased in PUVA patients.[18,19] PUVA is thus a potent stimulus for the induction of epithelial skin cancer in humans and also induces SCC in mice.[20] While this implies that PUVA is a complete carcinogen by virtue of its DNA damaging properties, the frequent detection of human papilloma virus DNA in PUVA-induced cancers suggests that immunosuppression may also contribute to carcinogenesis in this setting.[21] In contrast to PUVA, UVB phototherapy does not appear to be associated with an increased risk of developing nonmelanoma skin cancer.[22] There is strong evidence implicating the use of tanning beds in the development of both nonmelanoma skin cancers and melanoma.[23] The World Health Organization now places tanning beds in the category of group I carcinogens,[24] which will hopefully help bring about policy changes leading to strict regulation of the tanning bed industry.[25]

THE NATURE OF CHEMICAL CARCINOGENS: CHEMISTRY AND METABOLISM

How can such a diverse group of chemical and physical agents contribute to cutaneous cancer when the great majority of environmental agents to which humans are exposed are not carcinogenic? We now know that carcinogens can be genotoxic, nongenotoxic, or both.[26] Genotoxic carcinogens have high chemical reactivity (such as alkylating agents like nitrogen mustard) or can be metabolized to reactive intermediates by the host (such as petroleum products). They form covalent adducts with macromolecules and target DNA in the nucleus and mitochondria.[27] Since there is a good correlation between the ability to form covalent DNA adducts and the potency to induce tumors in laboratory animals, DNA is considered the ultimate target for most genotoxic carcinogens. The interaction with DNA is not random, and each class of agents reacts selectively with purine and pyrimidine targets.[27] Furthermore, targeting of carcinogens to particular sites in DNA is determined by nucleotide sequence, by host cell, and by selective DNA repair processes making some genetic material at risk over others. As expected from this chemistry, genotoxic carcinogens are potent mutagens, particularly adept at causing base mispairing or small deletions, leading to missense or nonsense mutations. Others may cause macrogenetic damage such as chromosome breaks and large deletions. In all cases, mutations detected in tumors represent a combination of the effect of the mutagenic change on the function of the protein product and the effect of the functional alteration on the behavior of the specific host cell type.

A number of chemicals that cause cancers in laboratory rodents and contribute to human skin cancer incidence are not demonstrably genotoxic.[28] Synthetic pesticides and herbicides, dry-cleaning reagents, and arsenic may fall within this group. The mechanism of action by nongenotoxic carcinogens is controversial and may be related in some cases to toxic cell death and regenerative hyperplasia. Induction of endogenous mutagenic mechanisms such as DNA oxyradical damage,[29] depurination of DNA, and deamination of 5-methylcytosine may contribute to carcinogenicity of these agents. Nongenotoxic carcinogens may interfere with host protective mechanisms as has been suggested for the action of arsenic in suppressing DNA repair or inhibiting the activity of tumor suppressor genes.[8] Thus, nongenotoxic carcinogens may serve as modifiers in concert with genotoxic agents such as UVR.

While a number of carcinogens can directly interact with DNA, many require bioactivation by cellular metabolic enzymes to form a compound that can react and form adducts with DNA. In general, these reactive intermediates are inadvertent byproducts of xenobiotic detoxification pathways. These pathways are complex and interactive,[30] and genetic polymorphisms both in animal models and humans contribute to cancer susceptibility.[31] This genetic variation in metabolic enzymes leading to differing rates of biotransformation and detoxification among individuals provides an approach to estimate individual risk profiles for particular chemical exposures. Initial stages in metabolic activation are most often carried out by cytochrome P450s, a class of heme containing monooxygenases, although other enzymes can be involved.[32,33] Oxidation

of carcinogens at carbon–carbon double bonds or saturated carbon atoms, or oxidation or reduction at nitrogen moieties, yields reactive intermediates that can be further metabolized and detoxified or can bind to DNA. Further biotransformation involves enzymatic conjugation of one of several different chemical groups such as glucuronide, glutathione, acetyl, or sulfate to reactive intermediates to enhance elimination. However, these conjugation reactions can also activate as well as detoxify carcinogens.[30] A number of metabolic pathways and enzymes such as cytochrome P450s are induced by carcinogen or other chemical exposures through interaction of these xenobiotics with the aryl hydrocarbon receptor (AhR) a cytoplasmic receptor that functions as a transcription factor for detoxifying enzymes.[34] Thus, carcinogen exposure induces detoxifying enzymes, which in turn increase cancer risk through biotransformation. Expression of these metabolic pathways can be modified by diet and hormones, thus, adding further complexity to the process and determination of relative risk of carcinogenesis.

ONCOGENES, TUMOR SUPPRESSOR GENES, AND HEREDITARY CANCER SYNDROMES

If DNA is the target for carcinogens and mutagenesis is the underlying mechanism of cancer pathogenesis, how do we identify the genes that when mutated are responsible for tumor formation? Studies on the molecular basis of cancer development in the last 30 years have revealed two classes of genes, oncogenes and tumor suppressor genes that play a key role in the pathogenesis of cancer. An oncogene is any gene that can transform normal cells in culture and induce cancer in animals. Most oncogenes are derived from proto-oncogenes: normal cellular genes that are critical positive regulators of cell proliferation or inhibitors of apoptosis. Conversion to an oncogene can occur through point mutations resulting in a constitutively active protein, through DNA amplification, or through chromosomal translocations that link a highly active promoter with the proto-oncogene. Both of these later two mechanisms cause increased or inappropriate expression of a proto-oncogene and altered growth regulation of the normal cell. Tumor-suppressor genes normally function to negatively regulate cell proliferation, cause apoptosis, repair damaged DNA, or induce cellular differentiation. In contrast to oncogenes, both copies of a tumor suppressor gene must be inactivated to promote tumor development. Frequently, inactivating point mutations occur in one copy of a tumor suppressor gene, and the remaining normal copy is lost through a process of chromosomal missegregation during mitosis that leads to loss of heterozygosity.[35,36]

Which oncogenes and tumor suppressors contribute to development of cutaneous neoplasms? Considerable insight into the genetic basis of sporadic skin cancers has come from the elucidation of specific genes or genetic loci that define hereditary skin tumor syndromes (Table 111-2).[37] In particular, the importance of DNA as a target for carcinogenesis was strongly supported by the discovery of defects in DNA repair genes that comprise the complementation groups of skin cancer prone xeroderma pigmentosum (XP) patients (Chapters 110 and 139).[38,39] At least six independent genes, on distinct chromosomal loci, define proteins involved in nucleotide excision repair, a process critical for the protection of DNA against both UVR and chemical carcinogen-induced damage.[40] Among these are proteins that recognize and bind to sites of DNA damage (XPA, XPC, XPE), helicases (XPB, XPD) and endonuclease components (XPG, XPF, defects in any of which give a skin cancer-prone phenotype. Potential polymorphisms with functional consequences in these and other DNA repair genes may contribute to susceptibility states in the general population as well.[41–43] Examination of SCCs and BCCs from XP patients has also revealed potential target genes for cancer induction since signature mutations in *PTCH1*, *RAS*, *p53*, and *INK4a-ARF* ($p16^{INK4a}$ and *ARF*) have been found with high frequency.[44]

Chromosomal mapping studies in the basal cell nevus syndrome (Chapter 116), coupled with genetic and functional studies in *Drosophila* and mice, implicated mutations in the *PTCH1* gene and other defects in the Hedgehog (Hh) signaling pathway in the development of hereditary and sporadic BCCs[45] and a variety of internal malignancies.[46] All of these tumors are characterized by elevated Hh signaling activity (Chapter 115). The *INK4a-ARF* locus, specifically mutations in the *p16(INK4A)* gene, was identified in the etiology of melanoma[47] through mapping of the inheritance pattern of familial melanoma. Oncogenic mutations in *BRAF* were discovered in a high proportion of melanoma by systematically screening for alterations in genes in the Ras/MAP kinase signaling pathway,[48] an important growth regulator in many cell types. Detection of specific mutations in Cowden syndrome (*PTEN*),[49,50] Muir–Torre syndrome (*MSH2, MLH1*),[50,51] multiple cylindroma (*CYLD1*),[52] multiple trichoepithelioma (*CYLD1*),[53] Birt–Hogg–Dube syndrome (*FLCN*),[54] and sporadic pilomatricomas (*CTNNB*)[55] and sebaceous tumors (*LEF1*)[56] have illuminated genetic defects associated with the development of adnexal tumors. The delineation of the specific genes mutated in other syndromes where locus mapping is confirmed (Table 111-2) should provide even more insight into the molecular pathogenesis of a broader spectrum of skin neoplasms.

ANIMAL MODELS VERIFY THE GENETIC BASIS FOR CUTANEOUS NEOPLASMS

Using human hereditary cancer syndromes as a guide, genetically based animal models have been developed that validate the contribution of individual genes to human cancer susceptibility by prospective experimental analysis.[57] These models have also contributed to the understanding of gene–environment interactions

TABLE 111-2
Oncogenes and Tumor Suppressor Genes in Human Skin Cancers

Gene	Type	Function	Locus	Tumor Type	Syndrome	Spontaneous
TP53	Tumor suppressor	DNA repair, apoptosis, cell cycle regulation	17p13.1	BCC, SCC	Li Fraumeni (but no increase in skin cancers)	Yes
XPA, XPB *XPC, XPD* *XPF, XPG* PolH (XPV)	Tumor suppressor	DNA repair	9q22.3, 2q21 3p25, 19q13.2-q13.33 16p13.3-p13.13, 13q33 6p21.1	BCC, SCC, melanoma	Xeroderma pigmentosum	Possible
PTCH1	Tumor suppressor	Hedgehog receptor	9q22.3	BCC, trichoepithelioma	Nevoid basal cell carcinoma	Yes
SMO	Oncogene	Hedgehog effector	7q31-q32	BCC	Unknown	Yes
p16(INK4A)	Tumor suppressor	Cyclin-dependent kinase inhibitor	9p21	Melanoma, SCC	Familial melanoma	Yes
BRAF	Oncogene	Cell cycle, survival	7q34	Melanoma	None	yes
HRAS, NRAS	Oncogene	Cell cycle, survival	11p15.5, 1p13.2	SCC, melanoma	None	Yes
CTNNB1	Oncogene	Cell–cell adhesion, transcription factor	3p22-p21.3	Pilomatricoma	Unknown	Yes
LEF1	Oncogene	Transcription factor	4q23-q25	Sebaceous tumors	Unknown	Yes
CYLD	Tumor suppressor	NF-κB inhibitor	16q12-q13	Cylindroma	Multiple cylindroma, multiple trichoepithelioma	Yes
PTEN	Tumor suppressor	Phosphatase	10q23.3	Trichilemmoma melanoma	Cowden's	Unknown
MSH2 *MLH1*	Tumor suppressor	Mismatch repair	2p22-p21 3p21.3	Sebaceous gland carcinoma	Muir–Torre	Unknown
FLCN	Tumor suppressor	Ribosomal protein S6 modulator	17p11.2	Fibrofolliculoma	Birt–Hogg–Dube	Unknown
Unknown		Unknown	9p21	Trichoepithelioma	Multiple trichoepithelioma	Unknown
Unknown		Unknown	Xq24-q27	BCC	Bazex	Unknown
Unknown		Unknown	9q31	Keratoacanthoma	Ferguson-Smith	Unknown

Modified from Dlugosz A, Merlino G, Yuspa SH: Progress in cutaneous cancer research. *J. Invest. Dermatol Symp Proc* **7**:17, 2002 with permission of Nature Publishing Group, London, UK.

by testing the influence of chemical and physical carcinogens on tumor development in the setting of an altered genetic makeup. The discovery of inactivating *PTCH1* mutations and activating *SMO* mutations in BCCs (see Chapters 115 and 116) led to the development of several mouse models exploring the role of deregulated Hh signaling in BCC tumorigenesis.[45] Keratinocyte-targeted overexpression of SHH[58,59] or an activated form of the Hh pathway signaling molecule SMO (M2SMO)[60,61] resulted in the development of basal cell-like proliferations or follicular hamartomas in mouse skin. Overexpression of SHH in human keratinocytes grafted onto immune-deficient mice also resulted in BCC-like lesions.[62] Mice with heterozygous disruption of the *Ptch1* gene have features in common with basal cell nevus syndrome patients,[63,64] including

microscopic hair follicle-derived tumors and various macroscopic skin tumors, including BCCs, after treatment with UVR or ionizing radiation.[65,66] When GLI1 or Gli2 transcription factors, which are nuclear effectors of Hh signaling are targeted to mouse keratinocytes, multiple skin tumors develop. GLI1 mice display a variety of follicle-derived tumors with relatively few BCCs,[67] while Gli2 mice develop BCCs exclusively.[68] Interestingly, when Gli2 expression was extinguished in gene-switch mice, BCCs regress but leave behind a subset of residual tumor cells, at least some of which may be able to form growing tumors when the Hh pathway is reactivated.[69] Collectively, these findings provide strong evidence supporting the notion that constitutive Hh signaling plays a key role in, and may be sufficient for, BCC development.

The multistage induction of cutaneous SCC (Fig. 111-1)[70] and the absence of a hereditary syndrome

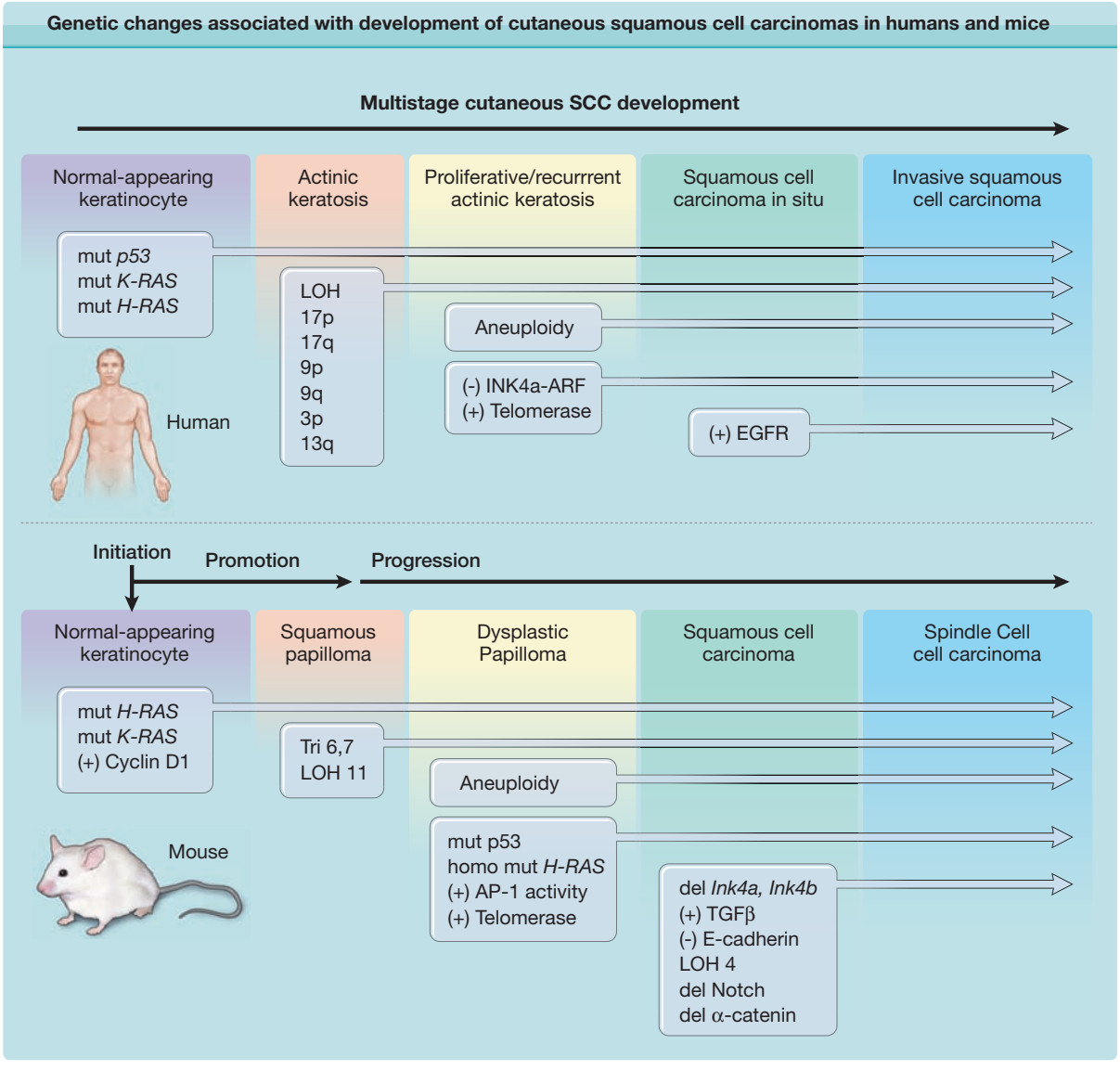

Figure 111-1 Genetic changes associated with development of cutaneous squamous cell carcinomas (SCC) in humans and mice. The multistage evolution of invasive squamous cell cancer in humans is depicted schematically with frequently associated genetic changes. Single base mutations in early lesions frequently are characteristic of ultraviolet light-induced damage, while later changes are associated with genomic instability. Increased activity of telomerase (deletion of inhibitor) or epidermal growth factor receptor (EGFR) tyrosine kinase (gene amplification) may also result from epigenetic changes. In chemically induced mouse cutaneous SCC, the multistage evolution to spindle cell tumors in this model is highly ordered both temporally and genetically. Operationally defined stages include initiation, promotion, and progression. *Ras* mutations are characteristic of chemical mutagens used to initiate tumor formation. Early upregulation of Cyclin D1 and later upregulation of TGFβ1 occur through epigenetic mechanisms and appear to be important components of carcinogenesis. Note that while p53 alterations are seen at early stages of human SCC development and ultraviolet radiation (UVR)-induced mouse SCC development (not shown), p53 mutations occur at later stages during mouse chemical carcinogenesis. (Modified from Dlugosz A, Merlino G, Yuspa SH: Progress in cutaneous cancer research. *J Invest Dermatol Symp Proc* **7**:17, 2002, with permission of Nature Publishing Group, London, UK.)

that specifically imparts uniquely high susceptibility to this lesion have made the delineation of specific genetic loci involved in SCC induction more complex. Nevertheless, the analysis of genetic defects in human SCCs has focused attention on specific targets such as DNA repair genes, *RAS*, *p53*, *p16(INK4A)*, and the epidermal growth factor receptor (EGFR) pathway. Significant progress has been made in defining pathways capable of driving nonmelanoma skin cancer development using reconstructed human skin, comprising genetically altered primary human keratinocytes on architecturally intact dermis, grafted onto immune-deficient mice.[71] Using this powerful system for modeling human skin cancer in mice, it has been shown that coexpression of oncogenic Ras and either Cyclin-dependent kinase 4 (Cdk4), or the NF-κB inhibitor IκB, in human keratinocytes, rapidly leads to invasive SCC development in reconstructed skin grafts.[72,73]

Mouse models for XPA, XPC, and XPE deficiency have been constructed, and all show sensitivity to UVR and enhanced development of SCC after either UVR or chemical carcinogen exposure.[39] A number of other DNA repair-deficient mutant mice are also being tested for cancer susceptibility and may reveal the mechanistic basis for new clinical syndromes by reverse genetics.[74] Mouse mutants targeting the *Ras* gene have revealed important information concerning the contribution of the Ras pathway to particular stages of SCC development. Heterozygous activating *Ras* gene mutations are sufficient to induce a benign squamous papilloma, the precursor to SCC, and the yield of chemically induced tumors in mice genetically deleted in the *H-ras* allele is markedly reduced.[75] Homozygosity of a mutant *ras* gene is associated with progression to SCC,[76] suggesting that high penetrance of the Ras pathway can recruit additional changes required for progression. Transgenic targeting of oncogenic *Ras* to suprabasal epidermis produces terminally benign tumors, while mosaic targeting to basal cells or hair follicle outer root sheath cells encourages progression to SCC,[77] indicating the target cell for early mutations may also determine the tumor phenotype.[78] While heterozygous p53 inactivation is detected early in human SCC, p53 deletion in mice enhances malignant progression but does not increase benign tumor formation.[79] This may be analogous to the common loss of heterozygosity seen at the *p53* locus later in human SCC development.[80] Of particular interest for human tumor development is the frequent observation that double heterozygotes for p53 deletion and other cancer-prone phenotypes (such as DNA repair deficiency) further sensitize mouse skin to tumor induction by UVR or chemical carcinogens. Mice with genetically defined defects in the $p16^{Ink4a}$ locus or its downstream target Cdk4 are sensitive to both squamous tumor and melanoma induction after treatment with carcinogenic chemicals, consistent with defects in this pathway detected in both melanoma and nonmelanoma human skin cancers.[81,82] Elegant mouse modeling studies have confirmed the importance of Braf mutations, when combined with alterations in the tumor suppressor Pten, in the development of metastatic melanoma in mice.[83]

TUMOR BIOLOGY AND BIOCHEMISTRY

GENERAL PRINCIPLES

Malignant tumors exhibit fundamental alterations in behavior that distinguish them from the normal tissues in which they arise. These differences include a reduced requirement for growth stimuli, impaired response to growth inhibitory/differentiation signals, alterations in apoptosis, delayed or blocked senescence, prolonged angiogenesis, and the capacity for invasion and metastasis.[84] Although one or more of these abnormalities can be detected at different stages of tumor progression and may thus be seen in premalignant lesions, all are present in advanced cancers. The driving force behind many of these changes is genomic instability, which facilitates the accumulation of mutations in both oncogenes and tumor suppressor genes that contribute to the observed aberrations in cell function.[85] While some of these changes are cell-autonomous and can be studied in purified populations of tumor cells, others depend on various additional cell types recruited to participate in the development and progression of cancer in intact organisms. Both the intrinsic alterations in neoplastic keratinocytes and the influence of collaborating cell types in skin tumor biology are being elucidated through the use of powerful experimental models.

From analyses of both human SCC pathogenesis and experimental skin tumor induction by chemical carcinogens, specific premalignant and malignant stages have been identified that have typical phenotypic, genetic, and biochemical characteristics (Fig. 111-1).[86,87] Note that in contrast to SCCs and most other cancers, BCCs do not appear to have precursor lesions or give rise to more aggressive cancers. This is likely related to the observation that the genomic instability that fuels neoplastic progression in other tumor types is largely missing in BCCs, even though a substantial proportion of these tumors harbor p53 mutations that would be expected to facilitate the accumulation of additional genetic defects. SCC starts as a single or small number of specific mutations in a cell that has the capacity to cycle, a change understood as the "initiation" of carcinogenesis. Upon clonal expansion, initiated cells form a premalignant lesion, such as a squamous papilloma in the mouse or an actinic keratosis in the human. Agents that enhance clonal expansion of initiated cells are called tumor promoters. Tumor promotion may occur as a consequence of exogenous exposures such as UVR, topical chemicals or medications, infections, or wound healing. Promotion may be an endogenous process influenced by diet, smoking, or immune suppression. The acquisition of additional mutations that provide a growth advantage to the incipient cancer cell may also serve as an autonomous promoting stimulus. Premalignant lesions undergo further phenotypic changes, often in a predictable sequence and commonly multifocal

within a single lesion.[88] Some foci or lesions progress at a faster rate than others, and these are at highest risk for malignant conversion.[89] Premalignant progression encompasses the majority of the tumor latency period prior to malignant conversion, when the lesion shows invasive properties.

Initiation is usually a low frequency genetic event and is directly dependent on carcinogen dose. A large variety of carcinogen classes can initiate skin tumors in rodents (Table 111-3). The phenotype of initiated epidermal cells as defined from in vitro analysis includes a defect in maturation, escape from senescence, and an enhanced growth potential, but initiated cells are still responsive to negative regulation, for example by TGFβ. At the molecular level, initiation involves an alteration in signal transduction pathways that regulate cellular responses to extracellular signals, and these are internally regulated by proto-oncogenes and tumor suppressor genes.[84,90] Tumor promotion is generally a nongenotoxic stimulus that results in a disturbance of tissue homeostasis.[88] Multiple classes of agents have promoting properties in experimental skin carcinogenesis (Table 111-3). The mechanisms of tumor promotion include activation of cell surface receptors, activation or inhibition of cytosolic enzymes, and nuclear transcription factors, stimulation of proliferation, inhibition of apoptotic cell death, and direct cytotoxicity. Chronic inflammation is linked with tumor promotion, and agents that suppress inflammation reduce tumor formation in experimental models.[91] Genotoxic carcinogens also can have promoting properties, and repeated exposures to low concentrations of genotoxic carcinogens can induce tumors more effectively than fewer exposures to the same total dose in experimental carcinogenesis.[92] Exogenous tumor promoters can determine the target site for tumor formation, and the promoting action of UVR may in part contribute to skin targeting for tumors when germ-line mutations produce an initiated state in multiple cell types. In general, initiated cells respond differently to promoters than normal cells, allowing for clonal selection of an initiated population.[93] Premalignant progression in an initiated cell clone occurs spontaneously but is accelerated by additional exposures to genotoxic agents including some cancer chemotherapeutic drugs.[94] Premalignant progression in chemically induced mouse skin carcinogenesis is associated with nonrandom, sequential chromosomal aberrations, including amplifications, duplications, deletions, and loss of heterozygosity,[95] suggesting repeated episodes of cell selection, producing specific chromosomal aberrations that become modally dominant within the progressing focus. Thus, at least one function of the relevant genetic events in premalignant progression must result in a growth advantage for the affected cell. Epigenetic changes are also associated with malignant conversion, and upregulation of AP-1 transcriptional activity, alterations in cell cycle regulatory genes and secreted proteases, changes in gene splicing and expression of modified cell surface molecules have all been reported. Together these changes could facilitate migration and invasion that characterize the malignant phenotypes. Alterations in methylation of DNA in tumor cells could also contribute to this stage of carcinogenesis.[96]

TABLE 111-3
Examples of Agents Capable of Inducing Skin Cancer in Rodents

Initiating Agents	Promoting Agents
Polycyclic Aromatic Hydrocarbons	**Phorbol Esters**
Benzo[a]pyrene[a]	12-*O*-Tetradecanoylphorbol-13-acetate
7,12-Dimethylbenz[a]anthracene	Croton oil[a]
3-Methylcholanthrene	**Aromatics**
Tobacco tar[a]	Phenol[a]
Dibenz(a,h)anthracene[a]	Anthralin[a]
Aromatic Amines	7-Bromomethylbenz[a]-anthracene
2-Acetylaminofluorene	**Other**
Alkylating Agents	Dihydroteleocidin (fungal product)[a]
β-Propriolactone[a]	Wounding[a]
4-Nitroquinoline-*N*-oxide	Abrasion[a]
Bis(chloromethyl)ether[a]	Cigarette smoke condensate[a]
Nitrogen mustard[a]	Benzoyl peroxide[a]
Cisplatin[a]	2,3,7,8-Tetrachlorodibenzo-*p*-dioxin[a]
Nitrosamines and Nitrosamides	Diacylglycerols
N,N'-Dimethylnitrosourea[a]	Ultraviolet radiation[a]
N-Methyl-*N'*-nitro-*N*-nitrosoguanidine[a]	Dodecane
Other	
Urethane[a]	
Dinitropyrene[a]	
Ionizing radiation[a]	
Ultraviolet radiation[a]	

Documented activity of these agents in rodent carcinogenesis models does not necessarily indicate they also contribute to skin cancer development in humans.
[a]Known human exposure.

THE PATHOGENESIS OF BASAL CELL CARCINOMAS

Animal models for induction of skin tumors by chemical and physical agents have been extremely valuable for exploring mechanisms of carcinogenesis in an experimental setting (Table 111-4). Rats exposed to chemical carcinogens (methylcholanthrene, dimethylbenzanthracene) or ionizing radiation preferentially develop BCCs[97] that are phenotypically similar to human BCCs. In contrast, mice are resistant to BCC induction unless they are genetically modified in the laboratory, although one study reported mouse BCC development following either subcutaneous or topical exposure to dehydroretronecine.[98]

As noted in Section "General Principles," BCCs represent an intriguing exception to the rule of multistage cancer development. Individual tumors typically consist of homogeneous, slowly growing cells that very rarely metastasize, although they can cause extensive

TABLE 111-4
Animal Models of Cutaneous Cancer Induction By Exogenous Agents

Agent	Species	Comments
Basal Cell Carcinoma		
3-Methylcholanthrene	Rat	Also other skin tumors
DMBA	Rat	SCC > BCC; lower DMBA doses may increase BCC incidence
Ionizing radiation	Rat	Also other skin tumors
Dehydroretronecine	Mouse	BCC > SCC, also internal tumors
Squamous Cell Tumors		
(PAH, NA, AA) + promoter	Mouse, rat	Predominantly papilloma
(PAH, NA, AA) repeated	Mouse, rat	Predominantly SCC
Ultraviolet B	Mouse	*p53* mutations, immune suppression, SCC
Ultraviolet A	Mouse	Papillomas and SCC

DMBA = 7,12-Dimethylbenz[a]anthracene; PAH = polycyclic aromatic hydrocarbons; NA = nitrosamines; AA = aromatic amines.

local damage. Even those rare BCCs exhibiting cellular atypia generally have a benign course,[99] suggesting that the full complement of factors driving malignant progression in SCCs and other neoplasms is not operating in these tumors. BCC cells exhibit abnormalities in growth control and terminal differentiation, induce clinically apparent angiogenesis, and invade their immediate surroundings. However, transplantation studies using human BCCs or transgenic mouse skin with BCC-like lesions[58] suggest that the tumor cells are critically dependent on adjacent stroma for survival. This property may help explain both the lack of BCC metastases and the difficulty in establishing BCC cell lines. Interestingly, in a recent study in which global gene expression profiling was performed on stromal cells derived from tumors versus normal tissue, the bone morphogenetic protein (BMP) antagonist, GREMLIN 1, was found to be highly expressed in BCC stroma but not normal skin.[100] BCCs express BMP 2 and 4, and GREMLIN 1 stimulates growth of cultured BCC cells in vitro, suggesting that GREMLIN 1 may be a stromal factor needed to support BCC proliferation in vivo, by antagonizing growth-inhibitory effects of BMPs.

Studies performed using human and rodent BCCs have identified additional candidate molecules that may be important in the biology of these tumors. Upregulation of various matrix metalloproteases (MMPs), both in tumor cells and stroma, is likely to be important in the local invasion of BCC, and may impact on growth control and other cellular functions given the emerging role of MMPs in regulating signaling at multiple levels.[101] Expression of several adhesion molecules is downregulated in BCCs, and this may account for the characteristic appearance of artifactual clefts between tumor cells and stroma in histological sections, but the functional significance of this finding in BCC biology has not been established. The antiapoptotic molecule BCL2 is consistently upregulated in BCCs probably because *BCL2* is an Hh target gene,[102,103] but this does not appear sufficient to block apoptosis in these tumors as it does in other settings. Indeed, the remarkably slow growth rate of BCCs has been attributed in part to baseline apoptotic cell loss. Expression studies in human BCCs and experimental models suggest the involvement of growth factor signaling pathways such as PDGF[104,105] and EGFR.[106] Several lines of evidence point to components of the cell cycle machinery as potentially critical targets in mitogenic responses to Hh signaling. Keratinocytes overexpressing Shh have enhanced proliferative potential and fail to undergo growth arrest in response to the cell cycle inhibitor p21[107]; in the absence of Shh, Ptch1 interacts with and may sequester Cyclin B1, a component of M-phase promoting factor which is required for mitosis and cell cycle progression[108]; and Shh can drive proliferation of immature cerebellar cells by causing prolonged induction of Cyclins D1, D2, and E.[109] In skin, Hh-driven proliferation of hair follicle epithelium is likely to be mediated by Cyclin D2 and N-Myc.[110] Oncogenic Hh signaling in skin leads to activation of the Wnt/β-catenin pathway; remarkably, signaling via this additional pathway is required for Hh pathway-driven skin tumor development.[111] The discovery of key molecules and other pathways required for Hh-driven tumorigenesis will provide additional targets for therapy.

THE PATHOGENESIS OF SQUAMOUS CELL CARCINOMAS

Both mice and rats are sensitive to SCC induction by a variety of chemical and physical agents (Table 111-4), and the induction of SCC in mice by UVR mimics the pathogenesis of SCC in human skin (Chapter 114). Multistage chemical carcinogenesis in mouse skin has been a powerful tool for delineating many of the fundamental concepts underlying epithelial carcinogenesis in other organs. Inbred strains of mice differ in their sensitivity to tumor induction using chemical carcinogens and tumor promoters, and extensive genetic analysis has led to identification of loci that confer sensitivity or resistance to induction of either benign and malignant tumors.[112–114] Interestingly, benign tumors that develop in FVB/n mice have a high frequency of conversion to SCC, and this is due to a polymorphism in the FVB/n Ptch allele which enhances Ras-induced SCC development.[115]

Building on the association of deregulated EGFR signaling in human cancer, mouse models suggest that constitutive EGFR activation is an important component of skin tumor formation. Transgenic epidermal targeting of TGFα, which activates the EGFR, can produce a benign tumor phenotype in the absence of activating *Ras* mutations.[116,117] However, activation of the EGFR by ligand overexpression alone is not an

efficient stimulus for autonomous tumor formation, since many of these tumors regressed. Loss of function studies also point to an important role for EGFR in squamous tumorigenesis in skin. Transformation of *Egfr* null keratinocytes with oncogenic *ras*, followed by transplantation onto immune-deficient mice, results in the formation of smaller benign tumors that those arising from *ras*-expressing control keratinocytes. These data imply point to an important role for EGFR signaling in squamous tumors, but suggests that an alternative, *ras*-induced pathway for tumor growth exists in the early, premalignant tumor.[18]

Additional evidence implicating enhanced growth factor signaling in SCC is provided by transgenic studies using a dominant form of SOS, an adapter molecule involved in transducing growth-stimulatory signals from receptor tyrosine kinases like EGFR, which resulted in spontaneous development of papillomas in mouse skin.[119] Overexpression of ErbB2, a receptor tyrosine kinase related to and capable of interacting with EGFR, results in spontaneous skin tumor development in transgenic mice.[120] Insulin-like growth factor 1 (Igf1), when overexpressed in mouse skin, also triggers development of squamous papillomas, some of which progressed to carcinomas.[121] While most of these studies invoke an autocrine mechanism for growth stimulation of tumor cells, factors produced by cells in the tumor stroma may supply mitogenic signals to keratinocytes or angiogenic signals as well.[122] Additional studies performed in mice suggest that specific components of the cell cycle machinery, including E2F1,[123] Cyclin D1,[124] and Cdk4,[125] can contribute to SCC development and/or progression.

The TGFβ signaling pathway is an additional growth factor pathway that contributes to SCC development but in contrast to the EGFR it functions as a negative regulator of epidermal proliferation and to maintain epidermal homeostasis.[126] Reduced levels of intracellular mediators of TGFβ signaling, Smad2 and Smad4, are observed in human SCC,[127,128] suggesting that loss or disruption of this growth control pathway is important in tumor development. Interestingly, SCC that develop in organ transplant recipients receiving antirejection drugs exhibit significant activation of the TGFβ pathway. Thus, in this context the TGFβ pathway may enhance tumor susceptibility.[128]

In addition to deregulated growth control, there is a progressive loss in the capacity for terminal differentiation during SCC progression (Fig. 111-1), culminating in a tumor with a spindle cell morphology that is indistinguishable from malignancies originating in mesenchymal tissues. Although the mechanisms responsible for defective differentiation at different stages of human skin cancer are not known, there is evidence that deregulation of the protein kinase C (PKC) family of enzymes plays a role in aberrant differentiation of mouse skin keratinocytes expressing the Ras oncogene.[88] PKCδ, which has been implicated in terminal differentiation of normal epidermal keratinocytes, is rendered inactive as a result of tyrosine-phosphorylation in ras-transformed keratinocytes. Restoring PKCδ to its native, nontyrosine phosphorylated state reversed the block to terminal differentiation in ras-transformed keratinocytes. In addition, overexpression of PKCδ in the skin of transgenic mice inhibits the development of squamous papillomas and carcinomas.[129] In contrast, skin-targeted overexpression of PKC ε resulted in less differentiated SCCs that rapidly metastasized to regional lymph nodes.[130] Additional work is needed to better understand the mechanism by which SCC tumor cells evade signals that trigger differentiation of normal keratinocytes.

Prostaglandin metabolism is activated by UVR and is constitutively induced in human SCCs, probably due to overexpression of the enzyme cyclooxygenase 2 (COX-2). Although the mechanism by which changes in prostaglandins influence skin cancer is not clear, they appear to operate at the tumor promotion stage. Telomerase activity is detected in a substantial proportion of human skin cancers, suggesting that these tumor cells are capable of evading cellular senescence, and telomerase-deficient mice are resistant to chemical carcinogenesis.[131] Additional contributors that are likely to be involved in SCC development and progression include mediators of angiogenesis, MMPs, and integrins, as well as other molecules involved in cellular adhesion and migration.

Spontaneous or carcinogen-induced tumor formation in genetically modified mice has revealed genes and pathways that appear to be important in skin cancer induction but would not have been apparent from hereditary cancer syndromes or analysis of human skin cancers. Suprabasal targeting of c-Myc in transgenic mice permits suprabasal cells to cycle and produces the papilloma/actinic keratosis phenotype while basal cell targeting of c-Myc is not oncogenic.[132,133] Deletion of the Cyclin/CDK inhibitor $p21^{waf1}$, a downstream effector of p53, increases the number of benign tumors but not the rate of premalignant progression.[134,135] Inactivation of TGFβ signaling enhances premalignant progression while overexpression blocks papilloma outgrowth and promotes invasion and metastasis of established tumors and progression from SCC to a spindle cell phenotype.[136–139] Surprisingly, reduction of cutaneous TGFβ1 also suppresses papilloma formation indicating a critical role for physiological levels of this growth factor in supporting tumor outgrowth.[140] Two AP-1 transcription factors influence distinct stages of skin tumor development, where c-Jun is essential for papilloma and c-Fos is essential for SCC development.[141,142] Inhibition of AP-1 activity in benign papillomas prevents progression to carcinomas, but instead, converts these lesions into benign sebaceous adenomas,[143] supporting the concept that squamous tumors are derived from progenitor cells with multilineage potential. Additional molecules now implicated in SCC development are ornithine decarboxylase, $p16^{Ink4a}$, $p15^{Ink4b}$, E-cadherin, STAT3, c-Myc, Notch, α–catenin, NF-κB, and Smad3.[144–152]

CONSTITUTIONAL MODIFIERS OF CARCINOGENESIS

Inbred mouse strains differ in susceptibility to particular carcinogenic exposures by several orders of magnitude, and transplantation studies indicate sensitivity resides in the target tissue rather than systemically.

Genomic scans of backcrossed mice among sensitive and resistant mouse strains indicate that constitutional determinants are multigenic and distinct for squamous tumor formation or progression.[113,153] Similar studies indicate genetic loci determine the survival potential for tumor bearing animals.[154] Classical genetic approaches are frequently difficult and complex because multiple interacting loci are typically involved in defining cancer susceptibility.[155] However, the study of skin cancer susceptibility may uncover genes of broad relevance to oncology. For example, the identification of a low-penetrance susceptibility gene for mouse skin cancer, *Stk6*,[156] fueled investigation of the human homologue *AURKA* which is now implicated in the development of multiple tumor types. More recently, studies examining the susceptibility of different mouse strains to cutaneous SCC uncovered, surprisingly, an alteration in the *Ptch1* gene,[115] which is strongly implicated in the development of a BCC.[45] Thus, alterations in the same gene can promote either SCC or BCC development, and this may in part be determined by influencing a cell's decision to enter either the squamous or basal cell lineage.

Analysis of genetically modified mouse models has also revealed pathways associated with skin tumor susceptibility. Alterations in p53,[79] drug metabolizing enzymes,[157] T cell function[158] and DNA repair[74] modify risk for experimental skin cancer induction. Remarkably, polymorphisms in drug metabolizing enzymes and DNA repair pathways,[159,160] and variable responses in the p53 tumor suppressor pathway or in T cell immunity after exposure to skin carcinogens[161,162] modify the human risk for skin cancer.

EXOGENOUS MODIFIERS OF CARCINOGENESIS

In experimental models, antioxidants and agents that alter microsomal metabolism of carcinogens can reduce or prevent tumor initiation by inhibiting the formation of ultimate carcinogens or accelerating their detoxification (Table 111-5). Similar mechanisms may influence ultraviolet light or ionizing radiation mutagenesis through inhibition of mutagenic oxyradicals produced endogenously following exposure. Scavengers prevent reactive mutagens from reaching critical targets. Cell cycle inhibitors prevent fixation of mutations, allowing for DNA repair while cytotoxic agents kill initiated cells prior to their expansion into a tumor mass.

A number of agents are effective in the postinitiation phase of experimental tumor development, and some are being clinically evaluated.[163] Inhibitors of COX-2 (celecoxib, indomethacin) and ornithine decarboxylase (difluoromethylornithine) prevent both UVR and chemically induced tumors.[164,165] While the mechanism of action of retinoids as modifiers of tumor development is not clear, retinoids are effective inhibitors of benign tumor formation in mouse skin carcinogenesis studies. Low-dose systemic retinoids also reduce SCC development in organ transplant recipients,[166] but additional studies are needed to assess whether they will be useful in long-term chemoprevention in certain high-risk populations. Predictable and parallel alterations in retinoid receptors in mouse and human cutaneous SCC indicate that the retinoid pathway must be central to cancer development in epidermis.[167,168] Considerable interest has developed in dietary factors that modify skin carcinogenesis. Restricted fat/energy diets reduce papilloma incidence in mouse models[169] and decrease the frequency of actinic keratoses in human populations.[170] Diverse dietary or natural factors such as green tea, caffeic acid phenethyl ester from honey bee hives, resveratrol from grapes, silymarin from milk thistle, ginger extract, crocetin, and ursolic acid from the rosemary plant are among natural products shown to be effective inhibitors of skin tumor formation by topical application or systemic exposure.[171] Several of these agents are believed to be antioxidants, but the precise mechanism of inhibition and their effectiveness as chemopreventive agents for human skin cancer remain to be established. Finally, immune response modifiers such as imiquimod may

TABLE 111-5
Modifiers of Carcinogenesis

Inhibitor Class	Examples
Inhibitors of Initiation	
Antioxidants, scavengers	Butylated hydroxyanisole; butylated hydroxytoluene; selenium; vitamin C; vitamin E; ellagic acid
Inducers of mixed function of oxidase	Polycyclic aromatic hydrocarbons; TCDD; PCB
Inhibitors of mixed function oxidase	α-napthoflavone; glucocorticoids;
Cytotoxic agent	Sulfur mustard
Suppressor of tumor development	Retinoids
Inhibitors of Promotion	
Antiproliferative	Anti-inflammatory steroids: dexamethasone, fluocinolone acetonide; inhibitors of arachidonic acid metabolism: indomethacin, celecoxib; inhibitors of polyamine metabolism: α-difluoromethylornithine
Antioxidant	Antioxidants: tert-butylhydroxyanisole, selenium; protease inhibitors: leupeptin, tosyl lysine chloromethylketone; superoxide dismutase; copper (II) 3,5-diisopropylsalicyclic acid
Natural products and dietary factors	Retinoic acid; vitamin D; green tea; silymarin; resveratrol; ursolic acid; caffeic acid phenethyl ester; curcumin; 1,25-dihydroxyvitamin D_3

TCDD = 2,3,7,8-tetrachlorodibenzo-*p*-dioxin; PCB = polychlorinated biphenyl.

be effective for treating some types of skin cancer by modulating cytokine expression.[172]

NOVEL THERAPEUTIC TARGETS BASED ON MECHANISTIC DATA

The substantial progress in our understanding of factors involved in skin tumor pathogenesis holds the promise of new approaches to treatment and prevention. In addition to the identification of new therapeutic targets, improved strategies are being developed for altering gene and protein function in skin with great selectivity. The abundance and unrivaled accessibility of skin cancers and precancers makes them prime targets for rigorous translational studies and clinical trials. On the basis of the basic research studies outlined above, potential therapeutic targets include p53; COX-2; telomerase; EGFR or other receptor tyrosine kinases, and intracellular signaling elements such as SOS; Ras; ornithine decarboxylase; the DNA repair machinery; MMPs; PKC; molecules involved in cell cycle progression, such as Cyclins D1 and D2, CDK4, p16INK4a, and E2F1; retinoid receptors; and c-Fos. In all cases, the potential efficacy of the proposed treatments would need to be carefully evaluated in animal models or human tissues grown in immune-deficient mice. Although the great majority of cutaneous SCCs are effectively treated using surgery or radiation therapy it is likely that dermatology patients would benefit from agents, which could prevent appearance of premalignant lesions, block neoplastic progression to SCC or cause tumor ablation with minimal invasive methods especially in cosmetically sensitive sites. This is likely to be especially true for genetically predisposed individuals or organ transplant recipients that are prone to multiple aggressive SCC. Along these lines, a double-blind study reported a significant reduction in the development of actinic keratoses and BCCs in XP patients treated topically with the DNA repair enzyme T4 endonuclease V, administered over a 1-year period.[173] Pathogenic mutations in *BRAF* have recently been exploited for the treatment of melanoma, and in a promising phase I trial using a mutated BRAF inhibitor, the majority of individuals with melanomas carrying the V600E BRAF mutation exhibited either a partial or complete response.[174]

In contrast to the multiple genetic and biochemical changes associated with SCC development, the majority of BCCs have mutations in *PTCH1* or *SMO* and essentially all of these tumors exhibit uncontrolled activation of the Hh pathway. Since several experimental models suggest that deregulated Hh signaling plays a central role in BCC development and maintenance, this pathway is a prime target for mechanism-based drug development. Cyclopamine is a natural product which blocks Hh signaling by inhibiting the function of SMO,[175] a pivotal effector of Hh signaling. Cyclopamine and other Hh pathway inhibitors targeting SMO have been shown to effectively inhibit growth of BCC-like cancers and other Hh-activated tumors in preclinical studies.[176] In a phase I clinical trial, a systemic Hh pathway antagonist showed promising results in patients with advanced and metastatic BCC,[177] raising hopes that these cancers, and multiple other malignancies linked to deregulated Hh signaling, may be amenable to treatment with Hh pathway antagonists.[178] BCC is rarely lethal, but its common occurrence on sun-exposed, cosmetically-sensitive sites makes a medical approach to treatment highly desirable, particularly if a topical Hh pathway antagonist is effective in treating tumors or preventing their appearance in high-risk individuals, including those with Nevoid BCC syndrome. Additional trials are currently underway in BCC patients using both systemic and topical Hh pathway antagonists, and if they establish efficacy with an acceptable safety profile, they may change our approach to treating these extremely common cancers. Given the fundamental advances in our understanding of nonmelanoma skin cancer, we can look forward to additional, rationally designed therapeutics to complement and perhaps in some cases replace, surgical management.

KEY REFERENCES

Full reference list available at www.DIGM8.com

DVD contains references and additional content

26. Luch A: Nature and nurture—Lessons from chemical carcinogenesis. *Nat Rev Cancer* **5**:113, 2005
37. Somoano B, Niendorf KB, Tsao H: Hereditary cancer syndromes of the skin. *Clin Dermatol* **23**:85, 2005
45. Saran A: Basal cell carcinoma and the carcinogenic role of aberrant Hedgehog signaling. *Future Oncol* **6**:1003, 2010
57. Dlugosz A, Merlino G, Yuspa SH: Progress in cutaneous cancer research. *J Investig Dermatol Symp Proc* **7**:17, 2002
155. Quigley D, Balmain A: Systems genetics analysis of cancer susceptibility: From mouse models to humans. *Nat Rev Genet* **10**:651, 2009
163. Wright TI, Spencer JM, Flowers FP: Chemoprevention of nonmelanoma skin cancer. *J Am Acad Dermatol* **54**:933, 2006

Chapter 112 :: Ultraviolet Radiation Carcinogenesis

:: Masaoki Kawasumi & Paul Nghiem

ULTRAVIOLET RADIATION CARCINOGENESIS AT A GLANCE

- Ultraviolet radiation (UVR) from the sun is the most prevalent carcinogen in humans, particularly among Caucasians.
- Annual increases continue in the incidence of all types of skin cancer.
- The importance of exposure timing, dose rate, and total UVR exposure differ between the types of skin cancer.
- Sunlight leaves characteristic mutations that identify key molecular and cellular steps in skin tumor development.
- DNA repair, apoptosis, and cell signaling pathways are critical to preventing skin cancer, and UVR affects each of these processes.
- Genetic polymorphisms in genes for DNA repair, melanin, and free radical scavenging affect skin cancer risk.
- Novel, pathway-based approaches to prevent or treat skin cancer are being developed.
- Educational and behavioral approaches are key to minimizing skin cancer rates in the future.

ULTRAVIOLET RADIATION AS A CARCINOGEN

Skin cancer offers a very clear picture of how a carcinogen causes human neoplasia. The basic principles of carcinogen exposure and slow development were discovered when Sir Percivall Pott traced scrotal cancers in adults to childhood employment as a chimney sweep[1] and they also apply to sunlight-induced cancers.[2,3] The process begins with carcinogen exposure, DNA damage, and failure to repair DNA or failure to apoptotically eliminate a damaged cell.[4–7] A mutant gene arises in a single cell which then expands into a mutant clone.[8] Rare cells of the clone repeat this carcinogenesis cycle to generate mutations in additional genes. Sunlight acts at each of these steps.

EPIDEMIOLOGIC OBSERVATIONS

The lifetime expectation of skin cancer in Australia is ~60%.[9] In the southern United States and Hawaii, nonmelanoma skin cancers exceed all other cancers combined.[10–12] Basal and squamous cell carcinomas (BCC and SCC), and an SCC precursor, actinic keratosis (AK), are most frequent on sun-exposed skin, in outdoor workers, and at lower latitudes.[13–16] SCCs increase more quickly with dose of sun exposure or nearness to the equator than BCCs, and occur later in life, implying that SCC requires more sun-related steps.[16–20] In contrast, one-third of BCCs occur on body sites having only intermittent sun exposure, such as the trunk and legs.[16,21]

Melanoma also depends on sunlight. The relation to latitude is clear,[22–25] yet it is often stated that the predilection for the back and lower legs makes the relation to sunlight uncertain. This predilection likely reflects the large surface area of back and legs. When expressed as lesions per unit area, melanomas are 10–20-fold more frequent on the ears of males and face than on intermittently exposed sites such as the lower legs in women, shoulders, back, or neck.[25,26] Melanomas are rare on the buttocks and soles. Melanoma appears to have two distinct origins:

1. A chronic sun damage (CSD) etiology affects the head and neck and is associated with chronic elastosis—a classic indicator of CSD—as well as gene amplification of the cell cycle genes *CDK4* and *CCND1*.[27] The slow-growing lentigo maligna melanoma and its precursor, lentigo maligna occur on habitually exposed body sites of light-skinned individuals.[28]
2. A non-CSD route involves intermittent sun exposure of sites such as the trunk. Non-CSD melanomas carry mutations in the *BRAF* or *NRAS* oncogene—upstream regulators of cell cycle genes—and the patients have variant alleles of the melanocortin 1 receptor.[27,29,30] Intermittently exposed body sites are the main locations of melanoma increases in recent decades, melanomas in patients younger than age 50 years, and the additional melanomas seen near the equator.[23,25,31] Recreational sunburn may explain these and the twofold higher melanoma incidence in office workers compared to outdoor workers.[32,33]

Sunlight is also implicated by the susceptible population: both classes of skin cancer are more frequent in light-skinned individuals with blonde or red hair who burn rather than tan.[13,34] Compared to dark-skinned individuals, nonmelanoma skin cancer risk rises ~10-fold in Asians and ~100-fold in Caucasians, with a further 2–12-fold risk for people with blonde or, especially, red hair.[13,34–37] The divergence is less for melanoma,

about 1:1:15 (Blacks:Asians:Caucasians).[38] In black skin, BCC is rare even in patients with the hereditary nevoid basal cell carcinoma syndrome (NBCCS or Gorlin syndrome).[39] Skin tumors in black patients are often scar-related, but these may be associated with sunlight as well.[36] Melanin-related effects result from less melanin in light skin,[40] less shielding by pheomelanin than eumelanin, and greater production of photosensitized reactive oxygen from pheomelanin.[41–43]

Molecular epidemiology has provided the most direct evidence for ultraviolet radiation (UVR) as the active component of sunlight: UVB signature mutations are present in human BCC, SCC, AK, and melanoma (see Section "Ultraviolet Radiation-Induced Mutations"). Mutant cells are associated with elastotic dermis, indicating chronic sun exposure.[44] UVB's effectiveness is due to its ability to partially penetrate the ozone layer and stratum corneum and then be absorbed by DNA.[45] The ozone layer absorbs all but 1 part per million of UVC (used in germicidal bulbs), which otherwise would be lethal; UVA penetrates well but is poorly absorbed by DNA.[45,46] Nevertheless, chronic UVA can induce tumors in mice[47] and malignantly transforms predisposed human cells.[48] The cumulative dose of sunlight required to cause BCC or SCC in adults is fairly large, approximately 10,000 and 70,000 hours of exposure, respectively.[16] Psoriasis patients who received long-term maintenance UVB phototherapy had a three- to eightfold higher risk of nonmelanoma skin cancer than people with an outdoor occupation, although the mean annual UVB dose received by psoriasis patients was 22 J/cm^2, lower than the solar UVB dose annually received by individuals with an outdoor occupation (134 J/cm^2).[49]

Some melanomas appear to be independent of sunlight: tumors of the mucosa, palms, soles, and nail beds are equally frequent in whites and blacks and have remained constant over time. In contrast, melanomas of the skin have increased manyfold in recent decades.[50] Ocular melanomas are more frequent in whites than blacks,[51] but have not increased in the last few decades.[52,53] Although the risk of external ocular melanoma (eyelid and conjunctival melanomas) decreases with higher latitude (less sun exposure), the risk of internal ocular melanoma (uveal melanoma), which is not exposed to sunlight, *increases* with higher latitude, as does the risk of other internal malignancies.[53,54]

THE SKIN CANCER EPIDEMIC

The incidence of melanoma and nonmelanoma skin cancers has doubled each decade since the 1960s.[10,23,25,55–57] AK, lentigo maligna, and lentigo maligna melanoma—typically lesions of the middle-aged and elderly—are now seen in young adults. The best evidence that recreational sun exposure is responsible for much of the increase in skin cancers is that intermittently sun-exposed sites, such as the trunk and limbs, account for most of the increase in skin cancers, with little change in melanomas of the head and neck.[10,23,25] Another suspect has been ozone depletion; because of a steep absorption curve in the UVB region, small changes in ozone concentration greatly affect UVB penetration (UVC is fortunately still blocked). Epidemiological data do not support a close relationship between ozone holes and skin cancer rates. The Antarctic ozone hole caused a 50% ozone reduction over southern Chile and Argentina in the last two decades, with UVB increasing up to 40-fold. Yet skin cancers in these areas are increasing at the same rate as elsewhere.[58,59] The Arctic ozone hole has been offset by screening from air pollutants, yet skin cancers in Scandinavia are rising.[60]

An iatrogenic source of increased skin cancer incidence is psoralen plus ultraviolet A (PUVA) therapy for psoriasis, which increases the risk of SCC eightfold; in some but not all patient cohorts it raises melanoma >14-fold (see Chapter 238).[61] Cancer is now increasing as a result of tanning beds. Individuals whose first sunbed exposure occurred as a young adult, or who had long durations or high frequencies of tanning bed exposure, already have a 70% higher risk of melanoma.[62]

CHARACTERISTICS OF ULTRAVIOLET RADIATION-INDUCED CANCERS AND PRECANCERS

In the United States, ~800,000 BCCs are diagnosed annually, as well as 200,000 SCCs and 70,000 melanomas.[11,12] Survival differs strikingly. Fewer than 1 in 10,000 BCCs will metastasize and threaten the patient (see Chapter 115). This number increases to 1 in 40 for SCC, with clinical experience indicating that SCCs on sun-exposed skin are less likely to metastasize than those arising in scars.[63] One in seven invasive melanomas is lethal (see Chapter 124). Merkel cell carcinoma (see Chapter 120) is a sun- and polyomavirus-induced cutaneous neuroendocrine cancer that will kill one in three patients diagnosed with it. Its reported incidence has tripled in the past 15 years to approximately 1,500 per year in the United States.[64,65]

The type of exposure preferentially leading to each malignancy differs. Cumulative lifetime sun exposure is strongly associated with SCC incidence.[16,20] BCC and AK instead seem to depend on reaching a certain threshold of UV exposure, often attained in youth, such that sensitive individuals develop BCC at a relatively early age, and the incidence does not increase with further exposure.[16,20,66] Case-control studies link melanoma with intense exposure early in life, with one or two blistering sunburns doubling the melanoma risk (see Chapter 124).[67]

Children are particularly sensitive to sunlight: moving from England to Australia before age 20 years confers the higher Australian incidence of AK, SCC, BCC, and melanoma, but the risk is much less when adults immigrate.[68,69] This is not simply due to children spending more time outdoors, as <25% of lifetime exposure occurs before age 18 years.[70] One explanation may be that mutant cells created in youth have more years in which to acquire the additional genetic requirements for cancer.

Precursor lesions for SCC (AK) and melanoma (nevi) are also usually related to sun exposure.[14,15,71–73] Accounting for roughly 3 million physician visits each year in the United States, AKs (see Chapter 113) are the fourth leading cause for a visit to a dermatologist.[74] They typically manifest as 1–3-mm scaly papules that involve erythema but often are easier felt than seen. They proceed to SCC in ~1% of cases if left untreated.[75] Actinic cheilitis is an analogous precancerous state on the sun-exposed lip. The importance of ongoing sun exposure is made apparent by clinical studies indicating that diminishing sun exposure can reduce the number of AKs over a span of months. In randomized sunscreen studies, statistically significant decreases in AKs were seen in the sunscreen group over brief periods.[76,77] Common nevi and especially clinically atypical nevi can be precursors of malignant melanoma, with abundant nevi conferring a tenfold risk for cancer.[22,78] Acquired melanocytic nevi begin to appear at age 1–5 years in proportion to sunlight exposure and are most frequent in individuals with freckles and red hair.[71,72,79] Acquired nevi typically carry the *BRAF* mutations seen in non-CSD melanomas, but congenital nevi instead have *NRAS* mutations.[80]

ULTRAVIOLET RADIATION-INDUCED GENETIC ALTERATIONS

ULTRAVIOLET RADIATION-INDUCED DNA DAMAGE AND REPAIR

DNA PHOTOPRODUCTS. The first molecular step in sunlight-induced carcinogenesis occurs when UVB photons induce DNA photoproducts (Fig. 112-1). UVB and UVC tend to be absorbed at the 5–6 double bond of pyrimidines (thymine and cytosine), allowing the bond to open.[81] If two adjacent pyrimidines are activated, their open bonds cross-react. This creates two single bonds (5–5 and 6–6) that result in a cyclobutane pyrimidine dimer (CPD; eFig. 112-1.1A in online edition). The most frequent is TT, but TC, CT, and CC cyclobutane dimers are also made. A single bond between the 6 position of one pyrimidine and the exocyclic group of the other instead creates a pyrimidine (6–4) pyrimidone photoproduct ((6–4)PP) (eFig. 112-1.1A in online edition).[82] The most frequent (6–4)PP is TC. Both photoproducts distort the DNA helix and are recognized by DNA repair enzymes. (6–4)PPs make the DNA helix more distorted, and thus are recognized and repaired much more rapidly than CPDs.[83,84] Half-lives of TT cyclobutane dimers and (6–4)PPs in human skin are 33 hours and 2 hours, respectively.[85] UVB induces 500 photolesions per 10^6 normal bases per J/cm^2 in human skin.[84]

Although there is 20-fold more UVA than UVB in sunlight, UVA requires up to 1,000-fold greater doses for some of its biological effects such as DNA damage.[45–47,86–88] Minimal erythemal doses (MEDs) at 300 nm (UVB) and at 360 nm (UVA) for skin type II are 25 mJ/cm^2 and 32,000 mJ/cm^2, respectively.[89] UVA induces T-containing cyclobutane dimers and lesser numbers of oxidized purines and pyrimidines and single-strand breaks.[84,90] UVA generates these lesions indirectly by photosensitization (see Chapter 90). UVA also efficiently photoisomerizes UVB-induced (6–4)PPs to their poorly repaired and highly mutagenic Dewar valence isomers[88,90] (eFig. 112-1.1A in online edition).

ULTRAVIOLET RADIATION-INDUCED MUTATIONS

UVR-damaged DNA contains characteristic "signature" mutations that are readily detected decades after sun exposure. These mutations have been used to answer many questions about the origin of cancer. A CPD can lead to a mutation in two ways (Fig. 112-2). When the lesion is copied during DNA replication, the DNA polymerase may read a damaged cytosine as a thymine and insert an adenine opposite it. At the next round of replication, the polymerase correctly inserts thymine across from adenine, with the result being a C→T substitution. Although the TT cylobutane dimer is the best known and most frequent photoproduct, the thymines are not mutagenic because the *XPV* gene encodes a specialized polymerase (pol eta) that adds adenines across from a T-containing cyclobutane dimer.[96,97] Alternatively, a mutation can arise because cyclobutane dimers accelerate spontaneous deamination of their cytosines to uracil (eFig. 112-1.1C in online edition), leading to a C→T substitution; no polymerase error is involved.[98] Deamination of cytosines to uracil within photolesions is increased at the transcribed strand, presumably mediated by persistent stalling of the transcription complex at the photolesion.[99] In either case, C→T mutations occur only where a cytosine lies next to a thymine or another cytosine, because the major UV photoproducts join adjacent pyrimidines. If two adjacent cytosines mutate, the result is CC→TT. This distinctive pattern of mutation, C→T where the C lies next to another pyrimidine, including CC→TT, is unique to UVR and is called the *UV signature mutation*.[100]

UV signature mutations (Table 112-1) provide a tool for deducing backward from mutations found in tumors to the original carcinogen. Nearly all experimentally created UVB or UVC mutations are located at adjacent pyrimidines, and about two-thirds are signature mutations.[100] The remaining third, typically G→T and T→C substitutions or one to two base insertions or deletions, are still caused by UV but probably arise

TABLE 112-1
Ultraviolet Radiation-Induced Mutation Patterns

Classical UVB signature mutations	C→T (CC→TT) at dipyrimidine sites
Oxidative mutations (could be induced by UVA)	G→T
UVA signature mutations	T→G
PUVA-type mutations	Mutations at the T of TA, TG, or TT sites

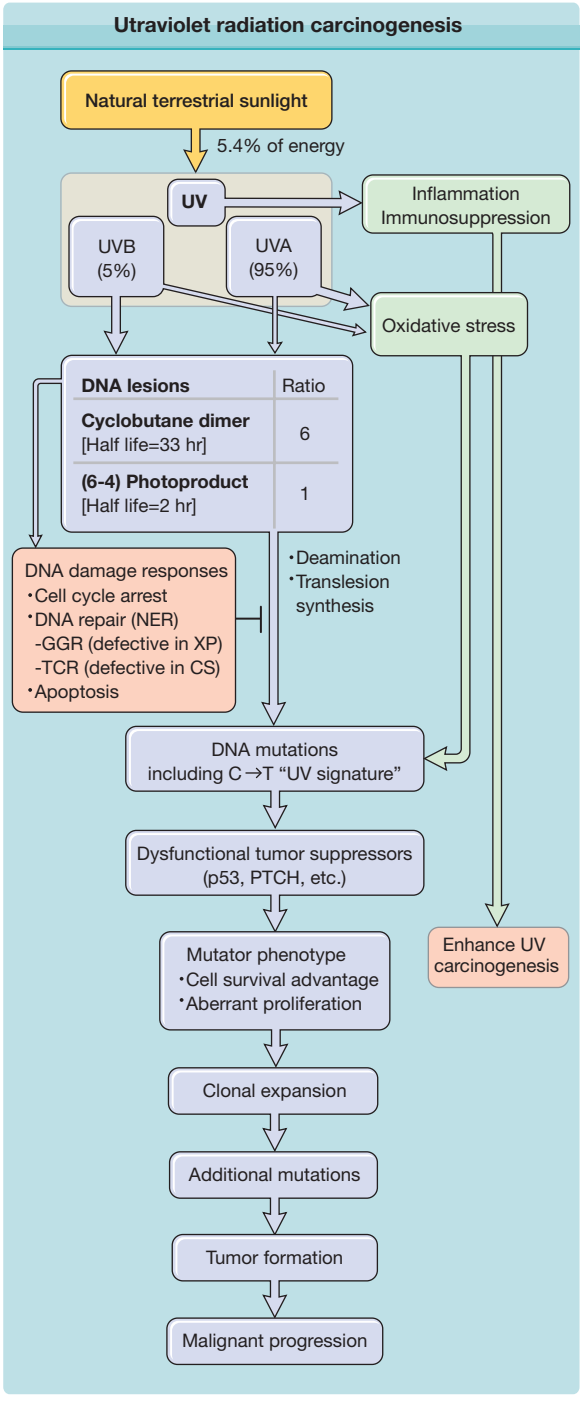

Figure 112-1 Ultraviolet radiation (UVR) carcinogenesis. UVR induces two major DNA lesions at dipyrimidine sites: cyclobutane pyrimidine dimers (CPDs) and pyrimidine (6–4) pyrimidone photoproducts [(6–4)PPs]. Ratio given [6 CPDs per 1 (6–4)PP] is that induced by simulated sunlight. UVB accounts for only 5% of UVR (~0.3% of all terrestrial sunlight energy), but produces the majority of UV-induced DNA lesions. Cells respond to UVR-induced DNA damage by activating DNA damage signaling pathways and inducing cell cycle arrest. Damaged DNA is repaired by nucleotide excision repair (NER), whose subpathways are global genome repair (GGR; defective in xeroderma pigmentosum, XP) and transcription-coupled repair (TCR; defective in Cockayne's syndrome, CS). Despite their DNA repair deficiency, individuals with CS exhibit no increased incidence of UV-induced skin cancer, likely due to enhanced intracellular accumulation of p53 and apoptosis. (6–4)PPs are rapidly repaired by NER. Unrepaired DNA lesions lead to genetic mutations through deamination or error-prone translesion synthesis. Unrepaired cytosine-containing CPDs contribute to UV signature mutation: C→T transition. Mutations in genes responsible for carcinogenesis confer mutator phenotype including resistance to apoptosis. Clonal expansion of mutant cells increases opportunities to receive additional mutations for tumor development.

indirectly by photosensitization-produced reactive oxygen species. G→T transversion can be caused by incorporation of adenine opposite 8-hydroxy-2′-deoxyguanosine (8-OHdG; also called 8-oxo-7,8-dihydro-2′-deoxyguanosine (8-oxo-dG)) (Fig. 112-2),[101,102] a common oxidative DNA lesion that remains at a high level in the epidermis even 7 days after UVR exposure.[103] Because this oxidative class of damage can be caused by many carcinogens, these mutations do not reveal whether their source was UVB, UVA, tobacco smoke, or intracellular oxidative phosphorylation. However, tumors carrying classic UV signature mutations must also contain UV-induced oxidative mutations. UVA, in contrast, only weakly induces UVB signature mutations by photosensitization but also generates oxidation-like mutations and T→G changes. The latter are rare with UVB or other carcinogens and have been proposed to be a UVA fingerprint,[104,105] although the mechanism of induction of T→G mutations remains unclear.

Although (6–4)PPs are rapidly repaired, they are mutagenic if they remain unrepaired. Error-prone DNA polymerases add a guanine opposite a thymine of (6–4)PP, resulting in a T→C mutation (Fig. 112-2).[106]

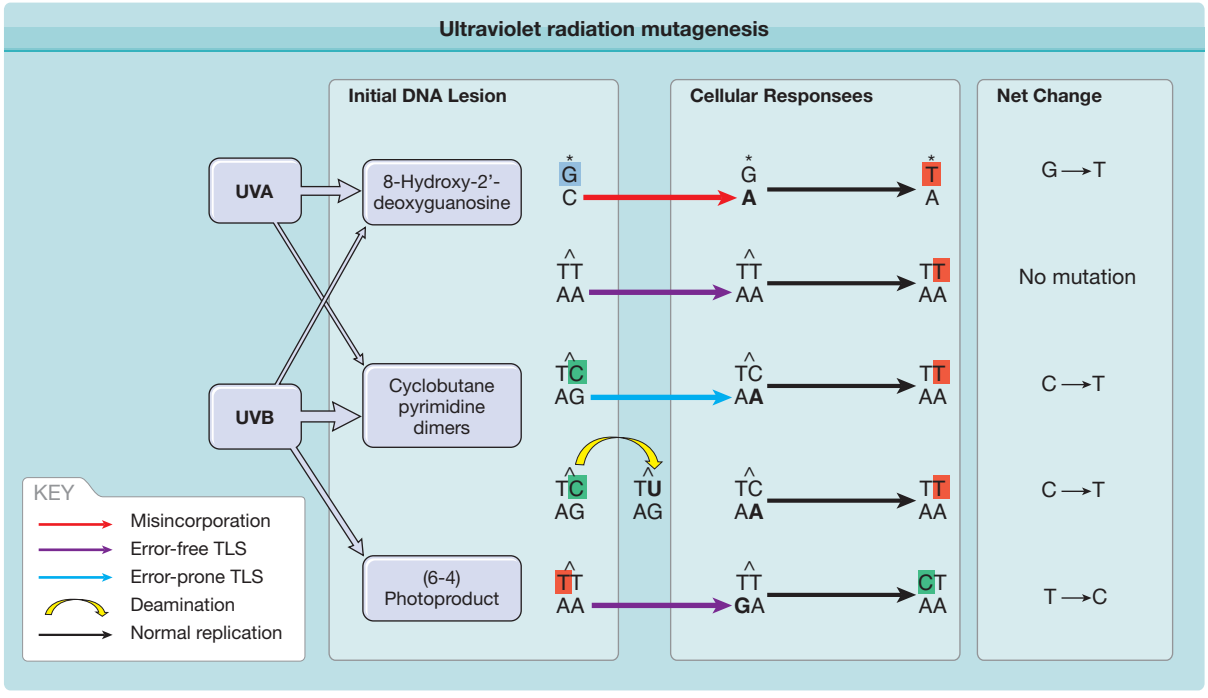

Figure 112-2 Ultraviolet radiation mutagenesis: how replication through unrepaired DNA lesions leads to DNA mutation. Cyclobutane pyrimidine dimers (CPDs) are the most relevant DNA lesions for UV mutagenesis and are primarily induced by UVB. Thymine cyclobutane dimers are most abundant but not mutagenic, because error-free translesion synthesis (TLS) correctly adds adenines opposite a thymine dimer. Cytosines within CPDs are mutagenic: error-prone TLS mistakenly adds adenine opposite cytosine, or deamination converts cytosine to uracil. This leads to the UV signature mutation, a C→T transition. The (6–4) photoproduct induced by UVB and 8-hydroxy-2′-deoxyguanosine induced by oxidative stress via UVA are also mutagenic but relatively rare.

p53

UV signature mutations identified *p53* as critical for preventing SCC and BCC but not melanoma.[100,107] The p53 protein is a transcription factor that controls genes involved in the cell cycle, apoptosis, and DNA repair; it also acts directly on apoptosis proteins.[7] The *p53* gene is mutated in about one-half of all human cancers and is termed a *tumor suppressor gene* because cancer arises from losing its normal function rather than gaining an abnormal function as for oncogenes. Over 90% of SCC in US patients contain these mutations, as well as three-fourths of AK.[108] Although nearly all BCCs overexpress p53 protein, only half carry *p53* mutations. Each mutation changes the amino acid, indicating that the mutation was selected for and contributed to tumor development, rather than being simply an indicator of sun exposure. These *p53* mutations are most frequent at nine mutation hot spots in important functional regions of the protein. Compared to internal cancers, some skin cancer hot spots are displaced several nucleotides to lie at a site of adjacent pyrimidines.[107] Some sites may be hot spots because repair is slower there.[109] Other skin hot spots, like internal cancer hot spots, lie at 5-methylCG sites where body temperature slowly deaminates 5-methylcytosine to thymine; UVR accelerates this process.

The *p53* mutations in AK indicate that these dysplasias are clonal; patients with multiple AKs have different mutations in discrete skin lesions.[108,110,111] The similarity of AK and SCC mutations supports the idea that AKs can progress to SCC. SCCs have more oxidative mutations than AKs, implying the involvement of oxidative stress in progression of AK toward SCC.[105] Aggressive skin tumors from patients exposed to both sun and chemicals contain multiple distinct *p53* mutation patterns, as if several tumors arose in an abnormal field and intermingled.[112] XP tumors contain very frequent CC→TT mutations, perhaps because slow repair allows more time for cytosine deamination.[113,114] Double-base mutations are also seen in conjunctival SCC, a tumor associated with human immunodeficiency virus (HIV) in sunny areas.[115] Sunscreens reduce the level of UV signature mutations.[116] In contrast, arsenic-induced BCC and SCC have non-UV *p53* mutations; *p53* mutations in BCCs from sun-shielded body sites resemble those seen with oxidative damage.[117,118] UV signature mutations in *p53* can also be seen in Merkel cell carcinoma.[119]

Sunlight mutates *p53* early.[108,120] Normal sun-exposed skin carries ~60,000 clones of p53-mutant keratinocytes, three to 3,000 cells in size.[121] By hematoxylin and eosin staining, the cells in these mutant clones appear completely normal.[44] The early appearance of *p53* mutations makes it possible to trace lineages in tumor development. Microdissecting lesions containing AK, carcinoma in situ, and SCC reveals that each stage contains the same *p53* mutation.[122] Although this result shows that each stage arose from

the same founder lesion, it does not show that the stages derived from each other. To show a lineage, it is necessary to find additional mutations that appear in succession. In microdissected BCCs, one *p53* mutation is present throughout the tumor, with various second mutations in different regions of the tumor.[123] Once both *p53* alleles are mutated, the cell is prone to aneuploidy,[124,125] increasing the likelihood of a mutator phenotype.

HEDGEHOG PATHWAY. Most sporadic BCCs have inactivating mutations in the *PTCH* tumor suppressor gene, a part of the hedgehog pathway (see Chapter 115); the remainder has activating mutations in its target, *SMO*. The hedgehog pathway appears to be a "gatekeeper" for basal cell carcinogenesis, needing to be mutated early in BCC: minute BCCs have *PTCH* mutations, as do all histological subtypes; no BCCs have loss on other chromosomes without involvement of *PTCH*; and a congenital lesion that can progress to BCC, the sebaceous nevus, has *PTCH* allelic loss in 40% of cases.[126–128]

In sporadic BCCs, about three-fourths of *PTCH* mutations are UVR-like (either UV signature mutations or the expected UVR-induced oxidative mutations) and a further 15% are 1- or 2-base insertions or deletions, often adjacent to a C→T at a dipyrimidine site.[129] BCCs from XP patients contain UVR-like *PTCH* and *SMO* mutations, with CC→TT mutations overrepresented.[130,131] About 20% of the mutations in sporadic BCCs are not UVR-like and resemble germline mutations seen in basal cell nevus syndrome patients—deletions or insertions larger than two base pairs. This finding may relate to the clinical observation that one-third of BCCs occur on parts of the body that are not chronically sun-exposed, as well as the correlation between truncal BCC and defects in the glutathione radical-scavenging system (see Section "Genetic Risk Factors for Ultraviolet Radiation Carcinogenesis"). *PTCH* mutations tend to code for stop codons or frameshifts that completely inactivate the protein. In hereditary BCCs, nearly all tumors arose after losing the normal allele. This allelic loss appears related to sunlight, as NBCCS tumors are most frequent on sun-exposed skin and are rare in blacks.[39] UVB rarely causes this type of large genetic rearrangement so, in analogy to X-ray sensitivity of NBCCS patients, UVA-photosensitized reactive oxygen may be important.

PSORALEN AND ULTRAVIOLET A LIGHT TUMORS. (See Chapter 238.) In psoralen-treated cells, UVA forms adducts at TA, TG, or TT sequences, as well as cross-links between the two DNA strands at these sites. In human PUVA-induced keratoses, SCCs, and BCCs, about one-fourth of mutations in *p53* or *HRAS* are psoralen-like mutations at the T of TA, TG, or TT; this proportion increases as the PUVA dose increases.[132,133] However, the majority of mutations are UV signature mutations. The UVR-like mutations could have arisen from the UVA in PUVA, UVB treatment for psoriasis, or environmental UVB.

MELANOMA MUTATIONS

(See Chapter 124.)

Despite the correlation between melanoma and sunlight and the fact that UVB signature mutations are present in melanoma,[134,135] genes with UV signature mutations for melanoma development are not prevalent. The *CDKN2A* locus is frequently mutated or deleted in familial and sporadic melanoma. Its two distinct tumor suppressor proteins, INK4A (also known as p16) and ARF, inhibit cell cycle progression via Rb and p53, respectively. INK4A inhibits CDK4/6's inactivation of the retinoblastoma protein, Rb. ARF inhibits MDM2-mediated degradation of p53. Germline mutations in *CDKN2A* are observed in ~25%–40% of familial melanomas.[136,137] In sporadic melanoma, allelic loss of *CDKN2A* is more common than the rare *INK4A* inactivating mutations[138–140] or inactivation of *INK4A* by promoter methylation.[141] The role of sunlight in these genetic events is unknown.

Oncogene mutations are found in the RAS-BRAF-MEK-ERK mitogen-activated protein kinase (MAPK) signaling pathway. This signaling cascade is normally activated on growth factor stimulation, and its sequential phosphorylation regulates cell proliferation and differentiation. Activating mutations in MAPK signaling remove the growth factor requirement. *RAS* mutations are present in 10%–20% of melanomas and have been correlated with UVR exposure.[142–144] The most prevalent *RAF* mutation in melanomas, the *BRAF* V600E point mutation, renders the kinase constitutively active and enhances ERK activation.[142] This mutation is present in ~80% of acquired melanocytic nevi, suggesting a potential early role of BRAF in melanoma development.[144] The V600E mutation is not UVR-like and is associated with intermittent sunlight exposure.[27,29]

ULTRAVIOLET RADIATION-INDUCED STEPS IN CANCER AND CANCER PREVENTION

Skin tumors arise on a background of sun-damaged skin. To prevent sun damage, the skin reacts to acute and chronic UVR exposure by multiple stress responses.

CELLULAR RESPONSES

APOPTOSIS. UV signaling generates sunburn cells—basal and suprabasal keratinocytes with dense, pyknotic nuclei and intensely eosinophilic cytoplasm.[175] This apoptotic morphology is accompanied by pathognomonic DNA double-strand breaks and cleaved caspase 3. UVR-induced apoptosis requires signals from both DNA damage and the cytoplasm: DNA photoproducts in active genes trigger p53 and its regulator MDM2,[108,176] but apoptosis also requires JNK and is partially blocked by antioxidants.[177,178] Although TNF-α is required, injecting TNF-α does not lead to sunburn cells, so UV-induced cytoplasmic signaling is not sufficient.[179,180] In fibroblasts, keratinocytes, or melanocytes

with normal p53 and irradiated with physiologic UVB or UVC doses, apoptosis proceeds through the intrinsic mitochondrial pathway rather than the death-receptor/caspase 8 pathway.[178,181]

Apoptosis then prevents cancer by removing UVR-damaged cells in a process termed "cellular proofreading".[182] Mice accumulate mutations at a rapid rate if they are defective in apoptosis due to a defect in *p53* or Fas ligand, or due to overexpressing the anti-apoptotic protein Survivin.[165,183,184] In Survivin's case, this increases SCC.[184] The epidermal hyperplasia that occurs several days after UVR exposure may replace cells lost by apoptosis or may remove additional damaged or mutant cells by desquamation. The signal for hyperplasia involves both DNA photoproducts and the epidermal growth factor receptor.[185] UVA inhibits UVB-induced apoptosis, suggesting that UVA may enhance UV carcinogenesis by disrupting elimination of UV-damaged cells.[186]

Dermal fibroblasts have a critical role in maintaining appropriate UVR responses of epidermal keratinocytes. The insulin-like growth factor 1 (IGF-1) secreted by normal human fibroblasts is required for appropriate induction of senescence of keratinocytes after UVR. UV-induced senescence protects keratinocytes from propagating UVR-induced mutations. In human geriatric skin, expression of IGF-1 is decreased in dermis and the aged keratinocytes proliferate in the presence of UV-damaged DNA, possibly leading to an increased carcinogenic potential in the skin of older individuals.[187]

STEM CELL POPULATIONS. In chronically UVB-exposed human skin, *p53*-mutant clones are found at both sites of epidermal stem cells (see Chapter 45): the hair follicle, whose bulge region contributes to follicle development and transiently to wound repair, and the interfollicular epidermis, which maintains epidermal homeostasis and can also generate follicles.[121,188,189] SCCs are thought to originate in interfollicular epidermis, whereas histologic evidence and the expression pattern of PTCH indicate that BCCs originate in the follicles.[190,191] Hedgehog signaling through PTCH is crucial for maintaining skin stem cell populations and for regulating hair follicle and sebaceous gland development.[192] Chronically UV-irradiated human or mouse skin contains scattered basal cells with unusually high levels of DNA photoproducts.[193] The tumor promoter TPA (12-*O*-tetradecanoylphorbol 13-acetate), which induces skin stem cells to proliferate,[194] causes these cells to disappear and be replaced by clusters of *p53*-mutant keratinocytes. This behavior resembles that of stem cells that are quiescent and poorly repaired, at least on the parental DNA strand, until triggered to divide.[195] The immortalization-promoting enzyme telomerase is normally present only in the epidermal basal layer, but is elevated in sun-exposed skin, skin precancers, and cancers.[196,197]

CLONAL EXPANSION OF MUTANT CELLS. A single mutant cell must clonally expand to reach a clinically discernible size. Less obviously, clonal expansion facilitates the multiple genetic hit mechanism of cancer. Physiologic UVR doses create mutations at a frequency of ~10^{-4}/gene per cell division.[198] The specific mutations needed to activate an oncogene are infrequent. Spontaneous mutations, which reflect errors by the replication machinery or DNA damage due to body temperature, are also rare, on the order of 10^{-5}/gene per cell division.[198] The probability of mutating five genes, such as an oncogene and both alleles of two particular tumor suppressor genes, is then at best 10^{-20}. Accounting for the 60% lifetime expectation of skin cancer in Australia solely in terms of simultaneous genetic hits in one cell is impossible. In contrast, clonal expansion increases by 1,000-fold the number of targets for the next mutation.

A stem cell's clonal expansion is normally limited to its stem cell compartment.[199] Sunlight is a key driver of clonal expansion beyond this point. The *p53*-mutant clones in human skin are larger in chronically sun-exposed skin.[121] In mice, *p53*-mutant clones stop growing and regress when UVB treatment ends, indicating that clone expansion is due to an ongoing UVR-induced physiologic event rather than an irreversible mutation.[199,200] One of these physiologic events is UVR-induced apoptosis.[184] Once a *p53* mutation arises, the cellular proofreading mechanism backfires: subsequent UVR exposures eliminate damaged normal cells but spare apoptosis-resistant mutants. An apoptosis-resistant mutant is no longer restrained within its stem cell compartment and escapes to colonize the adjacent apoptosis-sensitive compartment. Repeating this process further enhances clonal expansion. AKs also often regress once irradiation stops,[201,202] but SCCs do not, indicating that invasive tumors no longer need a promoter. Apoptosis thus has diverse effects on the stages of skin cancer progression: it prevents new *p53* mutations from initially arising, facilitates the expansion of *p53*-mutant clones and papillomas (via death of apoptosis-capable cells adjacent to mutant clones), and suppresses the mutations that convert a papilloma to SCC.[165,184]

CELL–CELL COMMUNICATION

Cell–cell interactions prevent abnormal cells from proliferating inappropriately. In human autotransplant experiments, BCCs transferred from their original site regressed—suggesting that an abnormal underlying dermis is required for the tumor to persist.[203] Dermal fibroblasts suppress transformed keratinocytes by secreting transforming growth factor-β that induces squamous differentiation.[204] Normal keratinocytes also suppress their transformed neighbors, and UVR interferes with these signals. Normal human keratinocytes eliminate adjacent transformed keratinocytes (mutated in *p53* and *HRAS*) by inducing cell cycle arrest and differentiation.[205] Physiologic doses of UVB cause apoptosis and differentiation in the normal cells, but not in the transformed keratinocytes, allowing the latter to clonally expand.[206] Other intercellular signals are mediated by integrins—membrane receptors for extracellular matrix proteins such as collagen ($\alpha_2\beta_1$ integrin), laminin ($\alpha_3\beta_1$), and fibronectin ($\alpha_5\beta_1$). In keratinocytes,

integrins bound to such ligand provide a "do not differentiate" signal through MAPK pathways, suppressing keratinocyte apoptosis, and allowing a stem cell pool to be maintained.[207,208] Integrin receptors are often dysregulated in tumors. UVB irradiation downregulates the β_1 integrin subunit. UVA downregulates the gap junction communication protein connexin 43, resembling the action of the tumor promoter TPA.[209,210]

Melanocyte proliferation is normally regulated by keratinocytes via cell–cell adhesion receptors such as E-cadherin, P-cadherin, and desmogleins; these receptors are lost in vertical growth phase melanomas.[211] UVR stimulates keratinocytes to secrete endothelin-1, which then downregulates melanocyte E-cadherin and upregulates N-cadherin.[212] This E- to N-cadherin switch diverts melanocyte interactions away from keratinocytes and toward fibroblasts and melanocytes.[211] Endothelin also downregulates the α_6 integrin subunit,[213] upregulates the $\alpha_v\beta_3$ and $\alpha_2\beta_1$ integrins that anchor melanocytes to dermal collagen and are associated with vertical growth phase melanoma, inhibits gap junction communication by phosphorylating connexin 43, and activates metalloproteinases associated with basement membrane invasion.

IMMUNE SURVEILLANCE

In humans, the primary evidence cited for immune surveillance in preventing UVR-induced skin cancer is the 10–20-fold increase in AK and SCC on previously sun-exposed skin in transplant patients receiving chronic immune suppression to prevent organ rejection. In one Australian study, 27% of deaths in a heart transplant cohort were due to skin cancer.[214] The increase begins months to a few years after immune suppression is initiated, and both the AKs and SCCs are unusually aggressive.[215–219] Melanomas are also increased.[220] Several lines of evidence complicate the data that support a role for immune surveillance. Cyclosporine promotes tumor growth in vitro and in immune-deficient mice in which there is no immune system to be suppressed.[221] Azathioprine, often a component of organ rejection therapy, is a mutagen when followed by UVA irradiation.[222] It may thus not only be working via immune suppression. HIV patients do have a modestly increased incidence of SCC, but these tumors at sun-shielded sites are associated with human papillomavirus (HPV).[223] Skin cancers are often said to develop in patients who are immunodeficient due to leukemia or lymphoma. Complicating interpretation, these patients have often received cyclophosphamide, a known mutagen. Most published reports lack controls or patient data, but an eightfold elevation in chronic lymphocytic leukemia seems valid.[224,225]

Merkel cell carcinoma, in part caused by a virus and by UV, appears to be truly sensitive to immune function. Its incidence increases tenfold not only in solid-organ transplant recipients but also in HIV patients (~13-fold) and in chronic lymphocytic leukemia (over 30-fold increase) (see Chapter 120). The chance of metastasis and mortality also increases in all types of immunosuppressed patients. Regardless of why immunosuppressed patients are at increased risk of skin cancer, it is critical that they be monitored closely because, when caught early, even tumors in immunosuppressed patients are curable.

GENETIC RISK FACTORS FOR ULTRAVIOLET RADIATION CARCINOGENESIS

PIGMENTATION AND INITIAL DAMAGE

Melanin has a large role in resistance to skin cancer. The Fitzpatrick skin phototypes are determined not only by baseline pigmentation but also by a person's response to UVR (always burns, tans easily, or rarely burns). This simple UVR skin response scale can account for up to a 100-fold difference in susceptibility to skin cancers.[263] Similarly, the many molecular etiologies of oculocutaneous albinism, which result in a deficiency of normal melanin, markedly increase the risk of skin cancer (see Chapter 73). Increased skin cancer among albinos is mostly nonmelanoma skin cancer, but melanomas seem elevated as well.[264] Another hereditary risk factor, red or blonde hair, is now understood at a molecular level as commonly caused by polymorphisms in the melanocortin 1 receptor (see Chapter 72).[265] This receptor is a G-protein coupled receptor that binds melanocyte-stimulating hormone and functions at a key point in melanogenesis. Certain mutations in this receptor render it insensitive to normal pigmentation signals, resulting in pheomelanin instead eumelanin. This is an important distinction in terms of skin cancer prevention. Red or yellow pheomelanin is a markedly less effective free radical scavenger; indeed, UVR-exposed pheomelanin is degraded with a net formation of superoxide.[42,266] Therefore, pheomelanin can act as a photosensitizer, even inducing apoptosis in nearby cells.[43] Decreased protection and increased damage from pheomelanin in the epidermis may partly underlie the markedly increased risk of skin cancer associated with red-haired individuals.

Reactive oxygen species are largely absorbed by radical scavengers, such as glutathione, before they cause significant membrane or DNA damage. Specific polymorphisms in the genes for glutathione *S*-transferase confer a twofold risk for truncal (minimally sun-exposed) AK, SCC, and BCC.[267] This genetic risk increases to sixfold in patients with high sun exposure and 12-fold in sun-exposed transplant patients.

DNA REPAIR AND APOPTOSIS

Xeroderma pigmentosum (XP; see Chapters 110 and 139) highlights the association between DNA repair capacity and skin cancer. Although defects in any of the XP genes result in some defect in NER, the severity of the XP disorder—number of skin tumors and life expectancy—correlates with DNA repair capacity.[95,268] The correlation between repair capacity and cancer incidence is also present in the general population.

Patients with AK have a 30%–50% reduced excision repair in their normal fibroblasts or lymphocytes.[269–271] Cells from BCC patients have reduced excision repair compared to cells from control individuals.[272] These data suggest that relatively subtle variability in DNA repair capacity contributes to an individual's risk of developing skin cancer.

VIRAL SENSITIVITY

In the rare inherited sensitivity to HPV infection termed *epidermodysplasia verruciformis* (see Chapter 196), roughly one-half of patients will develop SCC. These SCCs are typically on sun-exposed body sites and occur decades earlier than in the general population.[273] HPV may be important in UV carcinogenesis in immunosuppressed transplant patients, as it is detected twice as frequently in SCCs from these patients as in immunocompetent controls.[274]

PREVENTION

The potential of education and sunscreen to control skin cancer remains largely unproven due to the long latency between sun exposure and skin cancer appearance. In contrast, it is clear that adult sunscreen use can reduce AK by twofold.[76,77] Randomized studies of school children who aggressively applied sunscreen indicate that common nevi can be reduced.[275] A regimen of sun protection longer than the typical 2- to 4-year study would likely decrease nevi and subsequent melanoma risk more impressively. Encouraging data are emerging from Australia where education campaigns, covered sidewalks, and covered playgrounds at schools have led to a stabilization of the incidence of nonmelanoma skin cancers.[9] Excitingly, the efficacy of such campaigns is also highlighted by reduced melanoma rates in Australia, particularly in younger age groups.[276] Clearly, an effective campaign to reduce skin cancer needs to begin with school-age children. This is due to the combined factors that children younger than the age of 18 years spend a significant portion of their time in outdoor recreation, and sun damage sustained early in life has more time to contribute to UV carcinogenesis.

One could ask "how much sun is too much?" The answer will vary immensely depending on many factors such as pigmentation, whether sun exposure occurs in modest doses or large exposures, the immune status of the individual, and subtle differences in DNA repair capacity. Avoiding erythemal doses of UV may not be sufficient for preventing skin carcinogenesis, because much lower doses than 1 MED can induce genetic mutations, immunosuppression, and skin cancers.[277] Although highly controversial, there may be some benefit to sun exposure. Several studies have suggested twofold better survival after a diagnosis of invasive melanoma among patients with extensive sun exposure as compared to those with less exposure.[278] A potential explanation is greater vitamin D synthesis induced by UVR, because the antiproliferative and prodifferentiation effects of vitamin D have been demonstrated in melanoma cell lines *in vitro*. However, no association between vitamin D intake and melanoma risk was found in a recent human epidemiological study.[279]

NOVEL THERAPEUTIC APPROACHES

Despite the use of sunscreens and public awareness of the effects of long-term exposure to UVR, the incidence of both melanoma and nonmelanoma skin cancers continues to increase. This has led to investigation of novel chemopreventive agents that interfere with the development of cancer through diverse mechanisms. Perhaps the most important recent advance in this area is the use of imiquimod (see Chapter 221), an activator of the innate immune system through the TLR7 receptor. Imiquimod has recently been approved for treating AKs and superficial BCCs, and reports of imiquimod effects also exist for atypical melanocytic proliferations such as lentigo maligna.[280]

In terms of foods, coffee and tea appear to have chemopreventive activity. Orally administered green or black tea reduces UVR-induced skin cancers in mice to less than one-half of control levels.[281,282] Polyphenols and caffeine appear to be the major chemopreventive components. Oral administration of green tea polyphenols enhances IL-12 production, decreases UV-induced DNA lesions, and reduces subsequent inflammation and UV tumorigenesis.[283] Topical applications of caffeine or (–)-epigallocatechin gallate (EGCG), a major polyphenol in tea, were similarly effective in suppression of UV carcinogenesis in mice.[284] The protective effect of caffeine is attributed to its ability to augment apoptosis after UV irradiation via ATR-Chk1 pathway inhibition.[285,286] Precancerous, UV-damaged cells are more dependent on the ATR-Chk1 pathway, hence its inhibition by caffeine promotes elimination of these damaged cells. Moreover, caffeine and green tea polyphenols have a sunscreen effect that blocks UV-induced cyclobutane dimer formation when the compound is applied topically before UVR.[287,288] Human epidemiological studies showed that caffeine intake in coffee or tea decreases the risk of skin cancer development while de-caffeinated beverages had no such effect.[289–292] Each daily cup of caffeinated coffee was associated with a 5% reduction in nonmelanoma skin cancer among 93,676 Caucasian women.[291]

Topical application of sulforaphane-containing broccoli sprout extracts to mice showed a decreased incidence of UV-induced skin cancers. Sulforaphane possibly acted as an antioxidant.[293] Dietary feeding of proanthocyanidins extracted from grape seeds suppresses UV carcinogenesis in mice, associated with decreased tissue fat level.[294]

Low-fat diets have been well studied as an approach to preventing skin cancer. Animal studies have shown that high-fat diets shorten the time between UVR exposure and tumor formation and markedly increase the number of tumors per animal.[295] In human trials of patients with nonmelanoma skin cancer, restricting

calories from fat reduced the appearance of AKs by two-thirds and the development of new nonmelanoma skin cancers by one-half.[296,297] Although association of increasing total fat intake with overall risk of BCC and SCC is still controversial, a recent prospective study showed that high intakes of total fat increase the risk of developing SCC, but not BCC, among people who have a history of skin cancer.[298]

Retinoids inhibit UVR-induced AP-1 activation that contributes to human skin cancer progression, and they have been examined in several clinical trials for chemoprevention in individuals at high risk of developing nonmelanoma skin cancers.[299] One clinical trial demonstrated that daily supplementation of retinol lowered the incidence of SCC, but not BCC.[300]

Glycolic acid, derived from fruit and milk sugars, has been used as a cosmetic ingredient. It inhibits UV tumorigenesis in mice, by decreasing expression of the cell-cycle regulatory proteins.[301]

Chronic UVB exposure induces inflammatory responses that have been linked to tumor formation. Inflammation induces cyclooxygenase enzymes and prostaglandins. Because prostaglandins promote keratinocyte proliferation and block differentiation, inhibiting prostaglandin formation is expected to be chemoprotective. Topical application of a nonsteroidal anti-inflammatory drug (Diclofenac) is effective in treating AKs, with 50% of target lesions resolving after Diclofenac treatment versus 20% in placebo.[302] Celecoxib, a systemic inhibitor of cyclooxygenase 2, inhibits the development of UVR-induced skin tumors in mice by twofold.[303,304] Given the cardiovascular side effect profile of systemic cyclooxygenase 2 inhibitors, it is unlikely they will be developed for this indication.

An inducible repair process has been observed using DNA oligonucleotides that share sequence with the telomere.[305] In animal models and cell culture, these oligonucleotides can initiate multiple cellular responses, including melanin production and p53 activation, apparently in the absence of DNA damage. Topical application of these oligonucleotides to UV-irradiated mice diminished UVR-induced mutations and malignant lesions by fourfold.[306] If a therapeutically appropriate mechanism can be devised to activate this pathway, it may have utility in reversing DNA damage and preventing malignancies.

A recent development in the area of chemoprevention is the ability to augment normal DNA repair pathways. If one could increase DNA repair capacity, the mutations, chromosomal aberrations, and cell death known to be causal for skin tumors should be reduced. The most direct application of this concept is the use of a viral enzyme (T4 endonuclease V) capable of recognizing cyclobutane dimers and accelerating the initial incision step of the NER pathway. This enzyme has been formulated into a liposomal preparation, allowing penetration into the relevant layers of skin. Indeed, studies in XP patients have shown efficacy in decreasing the residual DNA damage as well as the number of AKs.[307] Also, cyclobutane dimers could be repaired by a photolyase that is absent in humans but found in certain animals and converts cyclobutane dimers to their original monomers by photoreactivation. Indeed, cyclobutane dimers were removed from UV-irradiated human skin by topical application of an encapsulated photolyase.[308] Transgenic mice that ubiquitously express the photolyase that can reverse CPDs showed marked inhibition of UV-induced skin cancers, suggesting that rapid removal of UV-induced CPDs is a powerful way to protect skin from UV carcinogenesis.[241] There are thus diverse emerging approaches by which chemopreventive therapies may increasingly serve as an adjunct to classical UVR protection with sunscreens and avoidance of UVR exposure to skin.

KEY REFERENCES

Full reference list available at www.DIGM8.com

DVD contains references and additional content

4. Leffell DJ, Brash DE: Sunlight and skin cancer. *Sci Am* **275**(1):52-53, 56-59, 1996
184. Zhang W et al: UV-induced apoptosis drives clonal expansion during skin tumor development. *Carcinogenesis* **26**:249-257, 2005
199. Zhang W et al: Escaping the stem cell compartment: Sustained UVB exposure allows p53-mutant keratinocytes to colonize adjacent epidermal proliferating units without incurring additional mutations. *Proc Natl Acad Sci U S A* **98**(24):13948-13953, 2001
275. Gallagher RP et al: Broad-spectrum sunscreen use and the development of new nevi in white children: A randomized controlled trial. *JAMA* **283**(22):2955-2960, 2000
291. Abel EL et al: Daily coffee consumption and prevalence of nonmelanoma skin cancer in Caucasian women. *Eur J Cancer Prev* **16**(5):446-452, 2007
296. Black HS et al: Effect of a low-fat diet on the incidence of actinic keratosis. *N Engl J Med* **330**(18):1272-1275, 1994

SECTION 21

Epidermal and Appendageal Tumors

Chapter 113 :: Epithelial Precancerous Lesions

:: Karynne O. Duncan, John K. Geisse, & David J. Leffell

A precancerous or premalignant lesion is one that has a strong likelihood of transforming into a malignancy. There is much debate about the validity of the concept of precancerous lesions, and the terminology has been confusing.[1–4] Lesions discussed in this chapter are those that have a clinically demonstrated potential to become invasive carcinomas and are characterized by histologic atypia confined to the epidermis. The focus is only on the precancerous keratinocyte lesions and not on those of other epithelial cells such as the melanocyte, Merkel, and appendageal cells. Discussion of malignancies and premalignancies associated with these cells can be found in (Chapters 119, 120, and 123) respectively.

A common feature of all premalignant keratinocyte tumors (Table 113-1) is that they have the potential to become invasive squamous cell carcinoma (SCC). These precancerous lesions and SCC are considered by many to represent a continuum of disease with dysplasia at one end of the spectrum and invasive carcinoma at the other.

ACTINIC KERATOSES AT A GLANCE

- Precancerous lesions on a spectrum from photodamaged skin to squamous cell carcinoma (SCC).
- Strongest predictors of subsequent development of nonmelanoma skin cancer and melanoma.
- Risk factors include individual susceptibility, cumulative ultraviolet (UV) radiation exposure, immunosuppression, prior history of skin cancers, genetic syndromes.
- Long-term and cumulative UV radiation exposure is the most important contributing factor for development of actinic keratoses (AKs).
- Risk of progression of AK to SCC varies from less than 1%–20%.
- AKs should be treated because their course is unpredictable, they are often symptomatic, and they can progress to SCC if untreated.
- Treatment methods include cryotherapy, curettage with or without electrosurgery, shave excision, topical agents, and photodynamic therapy.

ACTINIC KERATOSES

Actinic keratoses (AKs) or solar keratoses are cutaneous neoplasms consisting of proliferations of cytologically abnormal epidermal keratinocytes that develop in response to prolonged exposure to ultraviolet (UV) radiation. The concept of a precancerous keratosis was first presented by Dubreuilh in the late 1800s.[5] AKs were first identified and named *keratoma senilis* by Freudenthal in 1926.[6] In 1958, Pinkus further characterized these lesions and coined the term *actinic keratosis*.[7] These lesions have also been called *solar keratoses* and *senile keratoses*. *Actinic keratosis* literally means a condition (*-osis*) of excessive horny (*kerat-*) tissue induced by a ray of light (*aktis*), presumably UV light. AKs have historically been considered precancerous or premalignant lesions with a potential for developing into SCCs. However, in recent years there has been an effort to redefine AKs as malignant neoplasms, because these lesions are essentially intraepithelial SCCs in evolution. Although not all AKs become SCCs, AKs are the initial lesion in a disease continuum that may progress to SCC. This concept of a progression along a spectrum is analogous to that of cervical carcinoma, for which cervical intraepithelial neoplasia (CIN) is the initial, "precancerous" lesion.[8]

AKs are clinically important lesions, not only because of their potential to develop into SCC, but because they are one of the strongest predictors that an individual may subsequently develop melanoma or nonmelanoma skin cancer (NMSC).[9–11] With the increasing incidence and prevalence of melanomas

TABLE 113-1
Precancerous Keratinocytic Lesions

- Actinic keratoses (AKs)
- Arsenical keratoses (ArKs)
- Thermal keratoses (TKs)
- Hydrocarbon keratoses (HKs)
- Chronic radiation keratoses (CRKs)
- Reactional keratoses (RKs)
- PUVA keratoses
- Viral-associated precancerous keratinocytic lesions
  - Bowenoid papulosis (BP)
  - Epidermodysplasia verruciformis (EV)
- Bowen disease (BD) or squamous cell carcinoma (SCC) in situ
- Precancerous lesions of the lower anogenital tract
  - Vulvar intraepithelial neoplasia (VIN)
  - Anal (AIN) and perianal (PaIN) intraepithelial neoplasia
  - Penile intraepithelial neoplasia (PIN)
- Potentially malignant disorders of the oral cavity
  - Leukoplakia
  - Erythroplakia

PUVA = psoralen plus ultraviolet A radiation therapy.

and NMSCs (discussed in Chapters 114, 115, 123, and 124), persons with AKs are the perfect candidates for careful longitudinal observation for prevention of cutaneous malignancy and early intervention.

EPIDEMIOLOGY

A joint project of the American Academy of Dermatology Association (AAD) and the Society for Investigative Dermatology (SID) reported that in 2004 the prevalence of AKs in the United States was 39.5 million, the estimated annual costs were $1.04 million, and that AKs accounted for more than 10% of all dermatology visits.[12] AKs are second only to acne vulgaris as the most common reason for patients to visit a dermatologist and it is estimated that almost all persons over the age of 80 have AKs.[13]

Various risk factors have been identified for the expression of AKs. The two major ones are individual susceptibility and cumulative UV radiation exposure (Table 113-2). One of the most important susceptibility risk factors is age, because all the epidemiologic studies indicate that AKs increase in prevalence with increasing age, with rates ranging from less than 10% in white adults aged 20–29 years to 80% in white adults aged 60–69 years. Males appear to have more AKs than females in most epidemiologic studies, which presumably reflects greater cumulative sun exposure in males than in females.[14] This gender differential is more pronounced at younger ages. Other individual susceptibility risk factors include a phenotype of fair skin that easily burns and freckles, and rarely tans; blue or light-colored eyes; and red or blond hair.[14] Another individual risk factor is immunosuppression, because it is known that organ transplant recipients and patients receiving certain chemotherapy agents and possibly even biologic therapies are at increased risk of developing AKs and SCCs.[15–18] In addition, persons with certain genetic syndromes, namely, albinism and xeroderma pigmentosum, and possibly Rothmund–Thomson and Bloom syndromes, are at greater risk of developing AKs.

TABLE 113-2
Risk Factors for Development of Actinic Keratoses

- Individual susceptibility
  - Older age
  - Male gender
  - Fair skin that easily burns and freckles
  - Blond or red hair
  - Light-colored eyes
- Cumulative ultraviolet radiation exposure
- Immunosuppression
- Prior history of actinic keratoses or other skin cancers
- Genetic syndromes
  - Xeroderma pigmentosum
  - Bloom syndrome
  - Rothmund–Thomson syndrome

Cumulative exposure to UV radiation, including tanning beds, is the other major risk factor for developing AKs. Evidence that sun exposure plays a role in the development of AKs is the fact that over 80% of all AKs are distributed on habitually sun-exposed areas of the body, such as the scalp, head, neck, forearms, and dorsal hands.[14] Variables that affect a person's cumulative UV radiation exposure include age, gender, occupation, recreational activities, and place of residence. As previously stated, the older the individual, the greater the prevalence of AKs and, intuitively, the greater the cumulative exposure to UV radiation. The age at which a person received the greatest amount and intensity of exposure to UV radiation appears to be significant, with such exposure in childhood apparently posing the greatest risk. In migration studies in Australia, British immigrants who moved to Australia before the age of 20 had fewer AKs than the native white Australians early in life, but they had the same rate of AKs as the native Australians in later years. British immigrants who moved to Australia after the age of 20 years never showed the same rate of AKs as the native Australians or the British immigrants who arrived at a young age.[19]

ETIOLOGY AND PATHOGENESIS

Although genetic and environmental factors may play a role in the development of AKs and SCC, it has long been recognized that the most important contributing factor is habitual exposure to UV radiation, namely, sunlight exposure. UV radiation is responsible for the development of AKs, and eventually SCC, in two ways: first, it causes mutations in cellular DNA that, when not repaired, lead to unrestrained growth and tumor formation; and second, it acts as an immunosuppressant preventing tumor rejection[20] (see Chapters 109, 110, and 112).

UV radiation-induced mutations in the tumor suppressor gene *p53* play a pivotal role in the initiation of AKs and their development into SCC (Fig. 113-1; see Chapter 112). Multiple UV radiation-induced cellular insults to the skin result in a pathway to SCC that begins with photodamaged skin, progresses to the development

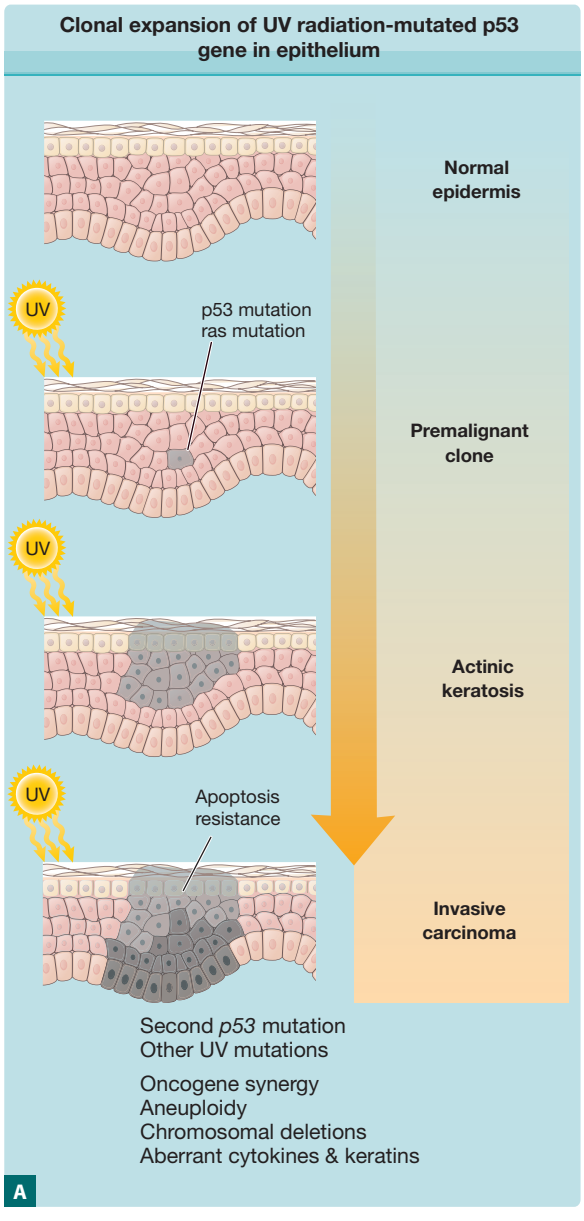

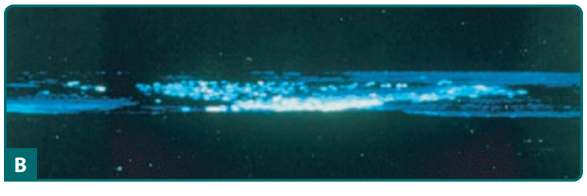

Figure 113-1 **A.** Development of clonal expansion of ultraviolet (UV) radiation-mutated *p53* gene in epithelium. In the multistage model of carcinogenesis, UV radiation-induced mutations provide selective growth advantage to neighboring cells, which leads to clonal expansion. (Adapted from Grossman D, Leffell DJ: The molecular basis of nonmelanoma skin cancer. *Arch Dermatol* **133**:1263, 1997.) **B.** Confocal microscopy revealing expansion of UV radiation-induced clone of abnormal keratinocytes in sun-damaged skin. (From Jonason et al: Frequent clones of *p53*-mutated keratinocytes in normal human skin. *Proc Natl Acad Sci U S A* **93**:1402, 1996, with permission.)

of AKs, and eventually leads to some SCCs. AKs on photodamaged skin clinically represent expanded clones of genetically mutated cells that have escaped apoptosis and immune surveillance and have gone on to proliferate into clinically evident premalignant lesions.

CLINICAL FINDINGS

The typical patient with AKs is an older, fair-skinned, light-eyed individual who has a history of significant sun exposure, who burns and freckles rather than tans, and who has significant solar elastosis on examination (Fig. 113-2). AKs can be seen in younger individuals if these individuals have sustained sufficient sun exposure over their lives. Eighty percent of AKs are found on habitually sun-exposed sites of the body, such as the head, neck, forearms, and dorsal hands. Common signs and symptoms include pruritus, burning or stinging pain, bleeding, and crusting. The typical AK lesion, sometimes called the *erythematous AK*, presents most commonly as a 2–6-mm erythematous, flat, rough, gritty or scaly papule. It is usually more easily felt than seen. AKs can vary in size and sometimes reach to several centimeters in diameter. They are most often found against a background of photodamaged skin or dermatoheliosis, with solar elastosis, dyspigmentation, yellow discoloration, ephelides and lentigos, telangiectases, and sagging skin notably prominent. At times, the number and confluence of AKs are so great that the patient appears to have a rash.

In addition to the typical erythematous AK, there are several other clinical subtypes (Table 113-3). The hypertrophic AK (HAK) presents as a thicker, scaly, rough papule or plaque that is skin-colored, gray–white, or erythematous (Fig. 113-3A). It can be found on any habitually sun-exposed site on the body but has a propensity for the dorsal hands, arms, and scalp. A

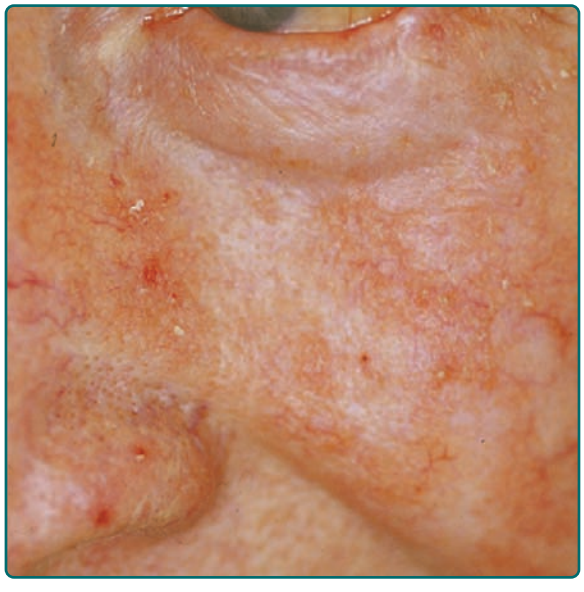

Figure 113-2 Severe solar damage of the face revealing telangiectases as well as actinic keratoses at different stages of development, including the flat, pink macules and hyperkeratotic papules.

TABLE 113-3
Clinical and Histopathologic Variants of Actinic Keratoses

Clinical Variants of Actinic Keratoses
- Erythematous actinic keratosis
- Inflamed actinic keratosis
- Hypertrophic actinic keratosis
- Cutaneous horn
- Actinic cheilitis
- Pigmented actinic keratosis
- Spreading pigmented actinic keratosis
- Proliferative actinic keratosis
- Conjunctival actinic keratosis

Histopathologic Variants of Actinic Keratoses
- Inflamed actinic keratosis
- Hypertrophic actinic keratosis
- Cutaneous horn
- Atrophic actinic keratosis
- Bowenoid actinic keratosis
- Pigmented actinic keratosis
- Proliferative actinic keratosis
- Lichenoid actinic keratosis
- Acantholytic actinic keratosis
- Clear cell actinic keratosis

typical erythematous AK can progress into an HAK. It can be difficult to distinguish an HAK from an SCC, clinically necessitating a biopsy. Biopsies must be taken to a level deep enough to ensure that the dermal extent of the keratinocytic proliferation can be evaluated in order to obtain an unequivocal histopathologic diagnosis. Induration or thickness, pain, and ulceration are the main clues to the transition of AK to SCC.

Cutaneous horn, also known as *cornu cutaneum*, refers to a reaction pattern and not a particular lesion (Fig. 113-4). In reference to AKs, a cutaneous horn is a type of HAK that presents with a conical hypertrophic protuberance emanating from a skin-colored to erythematous papular base. Classical definitions of a cutaneous horn maintain that the height is at least one-half of the largest diameter. Thirty-eight percent to 40% of all cutaneous horns represent AKs.[21] The pathology underlying a cutaneous horn can be a number of different lesions, such as AK, SCC, seborrheic keratosis, filiform verruca vulgaris, trichilemmoma, or keratoacanthoma. The most common underlying lesion in elderly, fair-skinned persons is an HAK.

Actinic cheilitis represents confluent AKs on the lips, most often the lower lip (Fig. 113-5). Persons with this condition have red, scaly, chapped lips, and at times erosions or fissures may be present. The vermillion border of the lip is often indistinct, and focal hyperkeratosis and leukoplakia may also be seen. Individuals with this condition often complain of persistent dryness and cracking of the lips, and the diagnosis of actinic cheilitis should always be suspected in photodamaged patients with such complaints. Persistent ulcerations or indurated areas on the lip require biopsy to ensure that SCC is not present.

PROGNOSIS AND CLINICAL COURSE

The prognosis of AK includes persistence, regression, or malignant transformation into invasive SCC. The relative risk of progression to SCC depends on factors related to the AK itself, such as the length of time an AK has been present and the number of baseline AKs that are on the skin. In addition, the risk for SCC increases with increased UV radiation exposure and with certain individual patient characteristics, such as suppressed immune status. Berhane et al observed that before an AK progresses to SCC it may become clinically tender and inflamed. Histopathologic examination of such clinically inflamed AKs revealed the actual presence of overt SCC in 50%.[31] Thus, pain and inflammation in an AK may be a marker of progression to SCC.

Several studies have attempted to determine the risk for the progression of AK to SCC, but most of them are inadequate in one respect or another. The risk for progression of AK to SCC reported in the literature varies from less than 1%[32] to 20%.[33] In a review of five clinical research studies carried out between 1988 and 1998, Glogau found that the published risk of progression of AK to SCC for individual lesions ranged from 0.025% to 16% per year.[34] Extrapolation from these clinical studies suggests a rate of risk of progression of AK to SCC of approximately 8%, computed as an average of the cited statistical rates.[34] A more recent study by Criscione et al found that the risk of progression of AK to primary SCC (invasive or in situ) was 0.60% at 1 year and 2.57% at 4 years.[35] The risk of

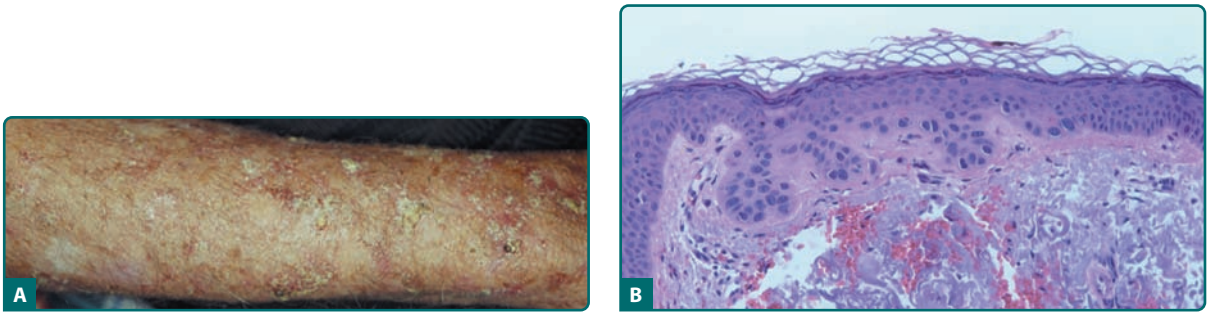

Figure 113-3 **A.** Severe solar damage of the dorsal arm demonstrating hypertrophic actinic keratoses (AKs) and AKs. **B.** Histopathologic preparation of actinic keratosis demonstrates atypical cells along the basal layer with sparing of adnexal epithelium.



Figure 113-4 **A.** Cutaneous horn of the ear. Only biopsy will confirm whether this is an actinic keratosis or a squamous cell carcinoma. **B.** Cutaneous horn of the cheek.

malignant transformation can also be assessed by evaluating the percentage of SCCs that arise from preexisting AKs. Several older studies have approached this issue by histopathologically examining invasive SCC specimens and determining the percentage of cases in which an associated or contiguous AK could be identified. An associated AK was identified at the periphery or within the SCC in 60%,[32] 82.4%,[36] 97%,[37] 97.2%,[38] and 100%[39] of reviewed cases in various studies. There has been one prospective study in which all SCCs treated by the authors in one calendar year were evaluated histopathologically to see if an AK was present in the specimen. They found a contiguous AK within a histopathologically confirmed SCC in 72% of cases.[40] The most recent 2009 VATTC trial by Criscione et al showed that the majority of primary SCCs (65%) and, interestingly, 36% of all primary BCCs arose within a previously clinically diagnosed AK.[35] Their findings that a sizeable number of initially clinically identified AKs were later determined to be BCCs at follow-up translated into a risk of progression of 0.48% at 1 year and 1.56% at 4 years. The authors commented that it was not clear if the initially identified AKs developed into BCCs, a phenomenon that has never before been reported, or if the BCCs were previously misidentified as AKs. We have to assume the latter, as BCCs originate from the follicular germ cells and are distinct from AK/SCC.[41]



Figure 113-5 Actinic cheilitis of the lower lip in a young man with a marine occupation. The patient is at risk for developing squamous cell carcinoma of the lip. Preventative treatment of the actinic cheilitis can include laser, cryosurgery, and topical treatment.

Their conclusion, however, was that there was an almost linear increased risk of clinically diagnosed AKs progressing to either SCC or BCC at 4 years, demonstrating that AKs have a significant role in the overall burden of keratinocyte carcinomas and are an important marker for the development of NMSC.[35]

Spontaneous regression of AKs has been reported, but it is impossible to predict for any particular AK lesion.[35,42,43] One study reported that up to 25% of AKs remitted over a 1-year period, especially if sun exposure was limited during that time.[44] Another study found that more AKs regressed in individuals who routinely wore sunscreen.[29] The 2009 VATTC study reported that 55% and 70% of AKs followed clinically were not present at 1-year and 5-year follow-up points, respectively.[35] However, the authors noted that most importantly the vast majority (87%) of AK lesions identified at the 1- and 5-year visits were not clinically identified during at least one of the 6-month intervals, suggesting that AKs come and go.[35]

The presence of AKs indicates long-term sun damage and identifies a group of people who are at high risk for developing SCC, BCC, and, to a lesser extent, melanoma.[9–11]

The estimated rates of metastases arising from actinically derived SCC have ranged from 1% to 2% to over 20% depending primarily on depth of invasion, location (with the lip, ear, and scalp representing the sites of highest risk), differentiation, and the presence of perineural invasion.[45]

TREATMENT

The inability to predict which AKs will persist, regress, or become SCCs makes treatment of these lesions equally confusing. Although some clinicians have argued that because of the low malignant transformation risk, treatment of AKs is unnecessary, most dermatologists advocate the treatment of AKs to avoid any chance of progression to invasive SCC.[46,47] The 2009 VATTC trial researchers concluded from their findings that despite the possibility of AK regression, new AKs and keratinocyte carcinomas can develop and that active treatment of AK lesions is warranted, especially given the overall contribution of AKs to SCC and BCC burden.[35] Treatment of this disease is also warranted to minimize symptoms, such as pain and pruritus, in affected patients.

In selection of the proper treatment, there are no absolute guidelines or algorithms because published studies vary considerably in their design, measured outcomes, and follow-up time (Fig. 113-6). The clinical diagnosis of AK even by expert dermatologists can be inconsistent.[27]

Treatment modalities for AKs can be broadly divided into lesion-targeted therapies and field therapies (Box 113-1).

LESION-TARGETED TREATMENTS FOR ACTINIC KERATOSIS. The majority of the lesion-targeted therapies for the treatment of AKs are destructive, i.e., they work by physically removing the AK. Such destructive treatments are currently the most common methods used to treat AKs.[48]

BOX 113-1 TREATMENT OF ACTINIC KERATOSES

LESION-TARGETED THERAPIES

- Liquid nitrogen cryotherapy
- Curettage with or without electrosurgery
- Shave excision

FIELD THERAPIES

- Topical
  - 5-fluorouracil cream and solution
  - imiquimod cream
  - 3% diclofenac gel
- Procedural
  - Cryopeeling
  - Dermabrasion
  - Medium-depth chemical peel
  - Deep chemical peel
  - Laser resurfacing
  - Photodynamic therapy

LIQUID NITROGEN CRYOSURGERY. Liquid nitrogen cryosurgery is the most common destructive procedure and is typically administered with a spray device or a cotton-tipped applicator (see Chapter 246). The first prospective study looking at efficacy rates of cryosurgery was performed in 2004.[49] The overall complete clearance rate when the patients were checked 3 months after treatment was 67.2%. A subgroup analysis of these data based on actual freeze times indicated that a complete response occurred in 39% of cases with freeze times of 5 seconds or less, in 69% with freeze times between 6 seconds and 20 seconds, and in 83% with freeze times longer than 20 seconds. Hypopigmentation was seen in 29% of sites from which AK was eradicated most probably those with longer freeze times as the melanocyte is particularly susceptible to cold injury. The investigators concluded that the ideal freeze time was somewhere between 10 seconds and 15 seconds.

The benefits of cryosurgery are its ease of administration in trained hands, the lack of need for anesthetic, and the lack of reliance on patient compliance other than in posttreatment care of treated lesions. Potential disadvantages of cryosurgery include pain and discomfort, the presence of unsightly blisters and crusted wounds for a week or longer, hypopigmentation, scarring, and possible alopecia in treated areas.[50] In rare cases, serious injury to underlying tendons and nerves may occur with deep or prolonged liquid nitrogen application to the hands. Most important, cryosurgery is best used to treat a limited number of clinically perceptible or symptomatic lesions.

CURETTAGE. Curettage, with or without electrosurgery (see Chapter 246), is another destructive lesion-targeted treatment for AKs. This procedure and cryosurgery together constitute approximately 80% of all treatments for AKs in the United States.[48] A curette is used to mechanically scrape away the atypical keratinocytes comprising the AK. Electrosurgery may or may not be used to further destroy atypical cells and to provide hemostasis. If electrosurgery is employed, minimal use is advised to enhance the final cosmetic result. A local anesthetic is needed for this procedure, and hemostatic agents such as aluminum chloride can be used to stop the bleeding if electrosurgery is not utilized. There are no controlled studies addressing cure rates with the use of this technique for the treatment of AKs, but experience says it is quite effective, at the expense of potential scarring. Patients can expect some discomfort with injection of the local anesthetic, and the treated area will take a few weeks to heal completely. This technique is most appropriate for patients with relatively few AKs. It is also beneficial for treatment of lesions after biopsy and for the treatment of HAKs. Potential side effects include infection, scarring, and dyspigmentation. If a biopsy is to be performed, procurement of a shaved specimen before curettage provides a much more acceptable histopathologic portrait

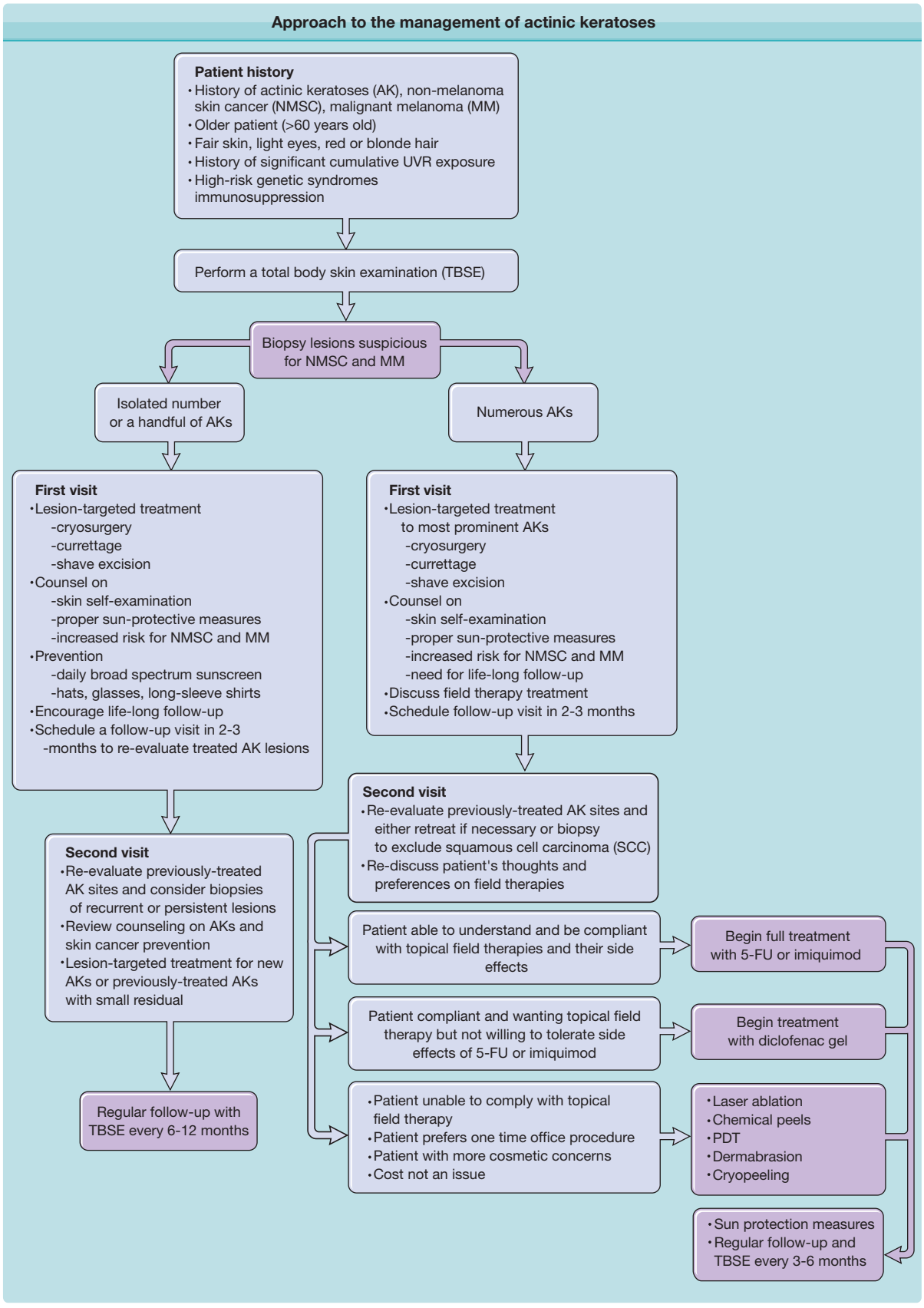

Figure 113-6 Approach to the management of actinic keratoses. 5-FU = 5-fluorouracil; PDT = photodynamic therapy; UVR = ultraviolet radiation.

and avoids overinterpretation or underinterpretation. Obtaining biopsy samples through curettage produces crushed and fragmented specimens that are difficult to interpret, which can lead to erroneous diagnoses.

SHAVE EXCISION. The third lesion-targeted destructive therapy for AKs is shave excision. This technique involves injection of a local anesthetic followed by tangential excision of the lesion with a surgical blade (see Chapter 243). Hemostatic agents must also be used to stop the bleeding. No data exist on the cure rate of this technique, but as with curettage, anecdotal experience says it is effective. Healing time may be 1–2 weeks, and potential complications include infection, scarring, and dyspigmentation. Use of this technique is most often indicated when a clinically apparent AK is suspicious for SCC or BCC and histopathologic examination is needed. Shave excision offers the patient an attempt at curative therapy simultaneous with a diagnostic procedure. Signs and symptoms that should arouse suspicion of SCC include marked erythema, pain, ulceration, bleeding, induration, or failure to respond to prior destructive therapies. Care must be taken to shave deeply enough to avoid transecting the AK at the deep margin, because this precludes unequivocal interpretation due to the proclivity for invasive SCC to develop at the deepest extensions of the atypical keratinocytes in AKs.

FIELD THERAPIES FOR ACTINIC KERATOSIS. Field therapies treat larger areas of photodamaged skin that contain both clinical and subclinical AK lesions. Field therapies can be further categorized into topical/medical and procedural field therapies. Such treatments are best used in patients with moderate to severely photodamaged skin and numerous AKs that would be too burdensome and painful to treat with the lesion-targeted therapies. Many patients with AKs, upon close inspection, are found to be extensively affected with early disease in sun-exposed areas, which may make field therapy a more rational approach to this difficult problem.

Topical Field Therapy. Several topical agents are available and approved by the US Food and Drug Administration (FDA) for the generalized treatment of AKs, including 5-fluorouracil (5-FU), 5% imiquimod cream, and 3% diclofenac gel (Box 113-2). A full discussion of these therapies can be found in the online edition.

PROCEDURAL FIELD THERAPY. The second category of field therapies for treating diffuse AKs is the procedural field therapies. These include cryopeeling (see Chapter 246), dermabrasion, medium and deep chemical peels (see Chapter 251), laser resurfacing (see Chapter 251), and photodynamic therapy (PDT) (see Chapter 238).

Cryopeeling consists of extensive liquid nitrogen cryosurgery to the areas of discrete AKs as well as to the surrounding actinically damaged skin.

Dermabrasion is an older technique that is quite effective in the treatment and prophylaxis of AKs but is now rarely used for this purpose. It causes physical destruction of the AKs with abrasion using either drywall sanding sheets or dermabrasion diamond fraises, which are powered or handheld (see Chapter 251).

Medium-depth chemical peels using Jessner's solution and 35% trichloroacetic acid (TCA) are moderately effective in treating diffuse AKs, especially when a series of such peels are administered over time[69,70] (see Chapter 251). A combined peel, in which 35% TCA is used, after applied to obtain uniform frosting after Jessner's solution degreasing and deepithelialization, has been shown to be equivalent in efficacy to 5-FU therapy.[71]

Deep chemical peeling using phenol or high concentrations of TCA is more effective in treating thick AKs or those with appendageal epithelial atypia but are rarely used because of the potential cardiac and renal toxicity of phenol, the greater risk of scarring and infection, and the dramatic hypopigmentation that may occur postoperatively.

Laser resurfacing for the treatment and prophylaxis of AKs is another procedural field therapy that has been utilized. The carbon dioxide (CO_2) laser and the erbium:yttrium-aluminum-garnet (er:YAG) laser are the two laser systems that have primarily been investigated for these purposes (see Chapter 252). Both of these devices ablate the epidermis at varying depths allowing reepithelialization with adnexal keratinocytes that are less actinically damaged.

In preliminary small series, both laser resurfacing systems have been reported to be effective in short-term clearing of multiple facial and scalp AKs[72–74] and in the long-term prevention of recurrences[75] and possibly the development of NSMC.[72] Laser resurfacing is probably best reserved for use by specially trained and experienced physicians and for patients with

BOX 113-2 TOPICAL FIELD THERAPIES OF ACTINIC KERATOSES*

MEDICATION	TOPICAL PREPARATION	DOSAGE
5-Fluorouracil	2% solution 5% solution 1% cream 5% cream	Twice daily for up to 4 weeks
	0.5% micronized cream	Once daily for 4 weeks
Imiquimod	5% cream	Twice per week for 16 wks
	3.75% cream	daily for 2 wks, then no treatment for 2 wks, then daily for 2 weeks
	2.5% cream	
Diclofenac	3% gel	Twice daily for 90 days

*FDA-approved regimens

more cosmetic concerns or with diffuse AKs for which topical field therapies and/or chemical peeling have failed. They are also excellent modalities for patients with severe actinic cheilitis and for those patients with multiple, thicker AKs.

PDT is another procedural therapy available for the treatment of multiple and diffuse AKs. The FDA has approved two PDT systems for the treatment of non-HAK lesions on the face and scalp (see Chapter 238). The first to receive approval was the combination of 5-aminolevulinic acid (ALA) with a blue light source in 1998. More recently, the FDA approved a system that has been widely available in Europe, combining a methyl ester of aminolevulinic acid (MAL) with a red light source. The topically applied ALA or MAL accumulates preferentially in the more rapidly dividing atypical cells and is converted sequentially to protoporphyrin IX, a heme precursor and photosensitizer. When the ALA or MAL-treated skin is then exposed to a light source of the appropriate wavelength several hours later, the accumulated protoporphyrin IX generates a phototoxic reaction that destroys the treated cells.[76–79]

Randomized, placebo-controlled studies have demonstrated the efficacy of both ALA and MAL PDT for the treatment of AKs.[79–82] A more recent, randomized, double-blind, prospective study comparing the safety and efficacy of ALA-PDT with MAL-PDT found both forms to have no significant difference in efficacy of decreasing AK lesion burden, but that ALA-PDT was associated with more painful and adverse effects and a longer duration of discomfort compared with MAL-PDT.[82] Patients can expect some discomfort with PDT, including erythema, edema, and burning or stinging during exposure to the light source. In a subgroup of patients with severe sun damage, PDT can create intolerable pain that sometimes results in premature discontinuation of treatment. Allergic reactions to ALA and MAL have also been reported. Severe phototoxic reactions can occur if patients do not follow the protocol and practice strict sun avoidance for the recommended period after ALA and MAL application. Cosmetic outcomes have been good to excellent in those who complete adequate treatment.

There is a paucity of comparative effectiveness research amongst these various field therapies for AKs. In general, topical 5-FU, 5% imiquimod cream, diclofenac gel, and PDT are all effective in decreasing the AK lesion burden. From the mostly small comparative studies that have been published, a few additional points can be made. Topical 5-FU and topical 5% imiquimod cream seem to create more inflammation, irritation, and patient discomfort compared with topical diclofenac gel. There is some data to suggest that topical 5% imiquimod cream may have lower, long-term recurrence rates of AKs, in part by creating longer term immune memory and antitumor response.[56,83] A pharmacoeconomic study of AK field treatment modalities (5% imiquimod vs. diclofenac gel vs. 5-FU vs. ALA-PDT) in combination with liquid nitrogen cryosurgery found that ALA-PDT was the least costly and that imiquimod was the most expensive.[84]

In summary, evidence supports the treatment of AKs to prevent the progression to malignancy. There are a number of effective lesion targeted and field treatments available to choose from to decrease the burden of AKs. Consideration of the individual's needs, the physician's skills, the mechanisms of action of the various treatments and their side effect profiles, plus the cost of treatment should all be considered when choosing a treatment strategy. To help physicians in choosing a treatment strategy for their patients, the American Academy of Dermatology and the European Dermatology Forum has proposed guidelines for the management of AKs, based upon available evidence at the time of their writings.[85,86] In addition, the authors of this chapter have proposed a treatment algorithm (Fig. 113-6).

PREVENTION

Given the potential of AKs to progress to malignant lesions, it is important to focus on the prevention of these precancerous lesions. Educational and preventive efforts should be directed toward children, targeted high-risk populations, and all patients. Avoidance of UV radiation is the single most effective means of decreasing the risk of AKs. A strategy designed to limit the amount and intensity of sun exposure, starting in childhood and continuing throughout the person's life, will likely decrease the number of AKs an individual will develop. Because complete avoidance of the sun is impractical, the next best preventive measures are to avoid exposure to intense midday sun; consistently apply and reapply broad-spectrum sunscreens; wear UV-protective clothing, hats, and sunglasses; install UV-protective windows where indicated; and make sure to take an oral vitamin D supplement if necessary to avoid vitamin D insufficiency or deficiency.[90]

Numerous randomized studies have shown that the use of sunscreen can decrease the incidence and prevalence of AKs, reduce the number of AK lesions, and increase their rate of regression.[29,91–94] There is also evidence that sunscreen use can prevent certain types of skin cancer, mostly SCC.[93,94] There is limited evidence that adhering to a diet low in fat may decrease the incidence of AKs[95,96] and NMSC.[97,98] In older studies, topical retinoids were shown to reduce the number of AKs after long-term consistent use,[99,100] and in another study, long-term treatment with topical retinoic acid was shown to reduce keratinocyte and melanocyte atypia in photoaged skin.[101] However, the more recent multicenter VATTC trial found that up to twice-daily application of 0.1% tretinoin cream over 1.5–5.5 years in mostly elderly (n = 1,131, mean age = 70 years) males (95%) at very high risk for NMSC was ineffective for preventing BCC and SCC.[102] This study was stopped 6 months prematurely because of excess mortality in the treatment group. However, the authors could not establish a cause and effect relationship.[103] They also concluded that retinoids may have very different clinical effects when administered topically as opposed to orally.[102]

Unlike the controversy with topical retinoids, there is strong evidence for the use of systemic retinoids in preventing NMSC and AKs, especially in high-risk populations, such as organ transplant recipients, patients with xeroderma pigmentosum, and other chronically immunosuppressed patients.[104–107] Unfortunately, the systemic retinoids are only effective while the patient is taking them and their use is also limited by the frequent occurrence of systemic toxicities, including hypercholesterolemia, hypertriglyceridemia, mucocutaneous xerosis, musculoskeletal abnormalities, and alteration in liver function. Thus, when considering the use of systemic retinoids in such high-risk patients, one must weigh these risks and benefits.

Topical imiquimod has also been safely used in the organ transplant population to prevent the development of cutaneous SCC.[65,108]

ARSENICAL KERATOSES

ARSENICAL KERATOSES AT A GLANCE

- Arsenical keratoses (ArKs) are precancerous lesions associated with chronic arsenicism.
- ArKs have the potential to become squamous cell carcinomas (SCCs).
- Chronic arsenicism has resulted from medicinal, occupational, and environmental exposures.
- Clinical appearance is of punctuate, keratotic, yellow papules overlying pressure points on palms and soles.
- Chronic arsenicism is associated with ArKs, Bowen disease, basal cell carcinoma, SCC, and internal malignancies, with latency periods of up to 40 years.
- No standard recommendations for treatment; most lesions are followed clinically or treated symptomatically.

Arsenical keratoses (ArKs) are precancerous lesions found in association with chronic arsenicism. These lesions have the potential to develop into invasive SCC. Arsenic is a ubiquitous element that has no color, taste, or odor. It has the potential to cause characteristic acute and chronic syndromes in persons exposed to it, and such exposures are typically obscure because medicinal, occupational, and environmental sources still exist. Detection of acute and chronic arsenicism is important, because the acute form can be fatal and the chronic form is associated with a variety of cutaneous and internal malignancies. ArKs are associated with chronic arsenicism.

PROGNOSIS AND CLINICAL COURSE

ArKs and arsenical-induced BD tend to persist for many years, and progression to invasive SCC is believed to be relatively rare. However, invasive SCCs that arise in ArKs are more locally aggressive and have a greater chance of metastasis than SCCs arising in AKs.[110] In lesions of arsenical-induced BD, locally invasive SCC has been seen histopathologically in up to 20% of cases. Once invasive SCC has occurred in BD, it is said that at least one-third will demonstrate evidence of metastasis unless adequate treatment is provided.[122]

TREATMENT

Management of patients with chronic arsenicism and ArKs should include regularly scheduled total-body skin examinations and general physical examinations, possibly every 6 months.[121] The exact incidence of internal malignancies associated with chronic arsenicism is unknown, so there is no standard protocol for the evaluation of potential internal malignancies. Exhaustive evaluations to detect such malignancies have not been recommended. Biannual detailed history taking and physical examination, yearly chest radiography, and selective testing when clinically indicated are probably reasonable recommendations.

Treatment of ArKs likewise is not standard and not mandatory, although treatment of these lesions is sometimes initiated to relieve the associated discomfort that some patients experience. Available treatment options include surgical excision, cryosurgery, curettage with or without electrosurgery, CO_2 laser treatment, and topical chemotherapy with 5-FU, although 5-FU therapy is less successful in treating ArKs than in treating AKs.[110] PDT has also been used to treat these lesions. Limited studies suggest that oral retinoids and keratolytics may be useful in treating ArKs.[123,124] One case report of effective treatment of ArKs, BD, and BCC lesions in one patient with chronic arsenicism with topical 5% imiquimod cream has been reported.[125]

THERMAL KERATOSES

THERMAL KERATOSES AT A GLANCE

- Precancerous lesions that result from long-term exposure to infrared radiation; can progress to squamous cell carcinoma (SCC).
- Sources of infrared radiation include open fires, railway engines, wood-burning stoves, heating pads and blankets, and laptop computers.
- Precursor lesion is erythema ab igne; biopsy should be performed on any hyperkeratotic papule or plaque within such a patch.
- Risk of progression of thermal keratosis to SCC is unknown.

HYDROCARBON KERATOSES

HYDROCARBON KERATOSES AT A GLANCE

- Hydrocarbon keratoses (HKs) are also known as *pitch keratoses*, *tar keratoses*, and *tar warts*.
- They occur in persons who are occupationally exposed to polycyclic aromatic hydrocarbons (PAHs).
- Occupations at risk include tar distiller, shale extractor, roofer, asphalt worker, road paver, highway maintenance worker, brick mason, diesel engineer, and chimney sweep.
- HK can progress to squamous cell carcinoma (SCC), but the rate of progression and risk are unknown.
- Latency periods between PAH exposure and development of HK or SCC range from 2.5 years to 45 years.
- Presence of atypical keratoses on the nostril rims, upper lip, and genitalia should prompt a search for occupational exposures to PAHs.
- Other skin findings include patchy hyperpigmentation, acne, and telangiectases.

CHRONIC RADIATION KERATOSES

CHRONIC RADIATION KERATOSES AT A GLANCE

- Chronic radiation keratoses (CRKs) are precancerous lesions that may arise at irradiated sites years after such exposure and may progress to squamous cell carcinoma (SCC).
- Ionizing radiation sources include X-rays, grenz rays, and contaminated gold rings.
- Common sites are the palms, soles, and mucosal surfaces.
- Clinically present as hyperkeratotic papules or plaques within areas of chronic radiation dermatitis and occasionally on clinically normal skin.
- Latency for the development of CRKs can be up to 56 years after exposure.
- Ionizing radiation-induced SCC can be extremely aggressive.
- Patients with ionizing radiation exposure and CRKs are also at risk for internal malignancies.

CHRONIC SCAR KERATOSES

CHRONIC SCAR KERATOSES AT A GLANCE

- Chronic scar keratoses (CSKs), or *cicatrix keratoses*, are precancerous lesions that arise in long-standing scars from various causes.
- *Marjolin's ulcer* describes malignant changes within a burn scar but can also refer to such changes in chronic ulcers or sinus tracts.
- Approximately 2% of burn scars will undergo malignant changes.
- Most burn scar carcinomas are squamous cell carcinomas (SCCs), but basal cell carcinomas (BCCs), melanomas, sarcomas, and malignant fibrous histiocytomas have also been described.
- Acute Marjolin's ulcer develops within 1 year of the time of injury; chronic Marjolin's ulcer develops more than 1 year after an injury, with an average latency period of 36 years.
- Sites of predilection are the extremities and overlying joints.
- Any persistent lesion, erosion, or ulceration within a scar requires biopsy.
- Prevention includes excellent wound care, early skin grafting, avoidance of contractures, and early excision of any tissue showing degenerative changes.

VIRAL-ASSOCIATED EPITHELIAL PRECANCEROUS LESIONS

Several types of precancerous epithelial lesions have a viral association (Box 113-3), including bowenoid papulosis (BP), epidermodysplasia verruciformis (EV), vulvar intraepithelial neoplasia (VIN), anal and perianal intraepithelial neoplasia (AIN and PaIN), and penile intraepithelial neoplasia (PIN). Extensive research has shown that certain oncogenic or high-risk HPV (hrHPV) types play a significant role in the p s of these precancerous lesions.[144] Over 100 types of HPV have been discovered, and the hrHPV subtypes that have been associated with these precancerous epithelial lesions are shown in Box 113-3. The role of the human papillomavirus (HPV) in the etiology and development of these precancerous lesions, as well as other malignant neoplasms, is further discussed in

VIRAL-ASSOCIATED PRECANCEROUS LESIONS AT A GLANCE

- Two viral-associated precancerous lesions are bowenoid papulosis (BP) and epidermodysplasia verruciformis (EV).
- BP is a precancerous condition of the genitalia caused by infection with human papillomavirus (HPV); oncogenic types 16, 18, and 33 are most commonly involved.
- BP may regress spontaneously, persist, or rarely transform into Bowen disease (BD) or squamous cell carcinoma (SCC).
- Treatment options include topical imiquimod, curettage, excision, and laser vaporization.
- Sexual partners of patients must be examined and followed closely for development of cervical, vulvar, or penile carcinoma.
- EV is a rare genodermatosis associated with mutations in the *EVER1* and *EVER2* genes.
- Affected individuals show a propensity toward infection with certain strains of HPV-5 and HPV-8.
- Clinical presentation is with widespread flat wart-like papules and plaques in childhood; risk of developing SCC later in life is high.
- Sun avoidance, sun-protective measures, regular dermatologic follow-up, and screening of family members for the disease are important.



Figure 113-7 Bowenoid papulosis of the penis. (Used with permission from James E. Fitzpatrick, MD.)

Chapter 196. The premalignant lesions of the lower anogenital tract (VIN, AIN, PaIN, PIN) are discussed later in this chapter.

BOWENOID PAPULOSIS

BP is characterized clinically by the presence of pigmented verrucous papules and plaques primarily on the genitalia of predisposed, usually younger, individuals, and histopathologically by the presence of SCC in situ-like changes (Fig. 113-7) (see also Chapters 77 and 78). Genital lesions that histopathologically resembled SCC in situ were first described by Lloyd in 1970 as multicentric pigmented BD of the groin.[145] In 1977, Kopf and Bart described multiple bowenoid papules of the penis.[146] In 1979, Wade et al coined the term *bowenoid papulosis of the genitalia*.[147] Other terms used for this condition include *pigmented penile papules with carcinoma in situ changes*, *genital keratinocytic dysplasia*, and *penile carcinoma in situ associated with HPV infection*.

BOX 113-3 VIRAL ASSOCIATED PREMALIGNANT NEOPLASMS

PREMALIGNANT LESION	ASSOCIATED VIRUS	
	Most Often Detected	***Less Often Detected***
Bowenoid papulosis (BP)	HPV-16,18	HPV-31–35,39,42,48,51–54
Epidermodysplasia verruciformis (EV)	HPV-5,8	HPV-9,12,14,15,17,19,25,26,38,47,50, etc.
Vulvar intraepithelial neoplasia (VIN)	HPV-16	HPV-18,31,33
Anal intraepithelial neoplasia (AIN)	HPV-16	HPV-18,31,33
Perianal intraepithelial neoplasia (PaIN)	HPV-16	HPV-18,31,33
Penile intraepithelial neoplasia (PIN)	HPV-16	
Digital or periungual Bowen disease	HPV-16	

BP is caused by infection with HPV, and numerous HPV types have been linked to BP, particularly hrHPV subtypes 16 and 18, but also including 31–35, 39, 42, 48, and 51–54 (see Chapter 196). Lesions are pink, reddish brown, or violaceous (see Fig. 113-7). Differential diagnosis includes early condylomata acuminata (see Chapters 77 and 78).

Histopathologically, the epidermis is usually hyperplastic with atypia, disordered maturation, scattered mitotic figures, and dyskeratotic keratinocytes.

The course of BP is variable, but mostly benign, ranging from spontaneous regression to persistence of lesions to rarely transformation into BD and invasive SCC. It has been estimated that the risk of malignant transformation is quite low, ranging from less than 1%–2.6 %.[144,148] BP is highly contagious and patients with BP and their sexual partners should be followed and examined periodically, because of the increased risk of developing SCC, cervical, and vulvar neoplasia.[149] Patients with persistent disease should probably undergo testing for altered immune status. Treatment of BP is recommended, and it typically responds well to local therapy, although recurrences are common. Therapeutic options include local destructive measures such as curettage with or without electrosurgery, CO_2 laser, neodymium:YAG laser, cryosurgery, and excision. Topical tretinoin, topical 5-FU, and topical cidofovir have been used in anecdotally reported cases with mixed results.[150] More recently, topical 5% imiquimod cream has shown promising results in a few case reports and would be the logical choice given its efficacy against HPV.[151–156]

EPIDERMODYSPLASIA VERRUCIFORMIS

(See Chapter 196)

EV is a rare inherited skin condition that arises when genetically susceptible individuals are infected with certain HPV subtypes, most notably HPV 5 and HPV 8, but also including HPV types 9, 12, 14, 15, 17, 19, 25, 36, 38, 47, and 50. EV individuals present in childhood with numerous thin, pink, flat papules and plaques that resemble verruca plana. They also have widespread scaly, erythematous, or hypopigmented macules and flat papules that appear similar to tinea versicolor. Approximately 30%–60% of persons with EV will develop cutaneous malignancies in these wart-like lesions, most often in the fourth to fifth decades of life and usually on sun-exposed areas of the skin. About 90% of these EV-related SCCs have been associated with HPV subtypes 5 and 8. A susceptibility for EV was localized to chromosome 17q25 in 1999,[157] and mutations in two novel genes from this same region (*EVER1* and *EVER2*) were identified and associated with EV more recently.[158] In addition to the host genetic background, these EV-HPVs are activated by UV exposure and immunosuppression.

EV histopathologically may mimic other skin conditions and therefore a combination of patient history, clinical and histopathologic findings, plus viral and genetic testing is crucial to making the diagnosis of EV. Lastly, as EV-like lesions have been observed in the setting of immunosuppression (acquired EV), patients suspected of having EV should also be tested for HIV and other etiologies for impaired cell-mediated immunity should be considered.[159] No specific or successful treatments exist for EV lesions. Mixed results have been seen with topical 5% imiquimod cream.[159]

SQUAMOUS CELL CARCINOMA IN SITU (BOWEN DISEASE)

SQUAMOUS CELL CARCINOMA IN SITU (BOWEN DISEASE) AT A GLANCE

- Bowen disease (BD) is squamous cell carcinoma (SCC) in situ, with the potential to progress to SCC.
- Etiologic factors include ultraviolet (UV) radiation exposure, chronic arsenicism, previous therapy with psoralen and UVA radiation, immunosuppression, exposure to ionizing radiation, and infection with human papillomavirus (HPV).
- Clinical variants are pigmented, intertriginous, periungual, and subungual BD.
- Histopathologic features include full-thickness epidermal atypia with adnexal involvement.
- Lesions progress to invasive carcinoma in 3%–5% of cases.
- Treatment methods include excision and Mohs micrographic surgery, which permit histopathologic evaluation to exclude invasive SCC.
- Curettage treatment of BD may miss appendageal involvement.
- Topical therapy may be used in areas that are difficult to treat with other methods with limited trials supporting their use.

Bowen disease (BD) is SCC in situ, originally described in 1912 by John T. Bowen, a Boston dermatologist.[160] It affects both skin and mucous membranes and has the potential to progress to invasive SCC.

EPIDEMIOLOGY

BD may occur at any age in adults, but it is rarely seen in individuals younger than 30 years. The

typical patient with BD is older than 60 years. The disease is said to occur with an equal incidence in men and women, although most studies report a slight preponderance in women.[161] BD can be found on any body site, including both sun-exposed and nonsun-exposed regions of the body, although it appears to have a predilection for sun-exposed surfaces such as the head and neck and for the lower legs of women, in particular. The exact incidence of BD in the United States is unknown, but in one population study in Hawaii, the incidence was estimated at 142 per 100,000 persons.[162] Lesions of BD are usually solitary but are multiple in up to 10%–20% of individuals.

ETIOLOGY AND PATHOGENESIS

A number of different factors have been implicated in the development of BD, including a history of significant sun exposure, arsenic exposure, ionizing radiation, immunosuppression, and certain types of HPV infection. Up to 30% of extragenital BD lesions have been found to harbor HPV DNA.[163,164] The age group and sites of predilection of BD suggest a strong association with sun exposure. BD is also rare in more heavily pigmented individuals, and it has been described with increased frequency in patients undergoing psoralen plus ultraviolet A (PUVA) therapy. The association with arsenic exposure has already been discussed. SCC in situ is seen commonly in organ transplant recipients after years of immunosuppressive drug therapy. Infection with HPV has been implicated in causing certain subtypes of BD. In particular, HPV-16 has been detected in many cases of anogenital BD and in some cases of finger and periungual BD.[165]

CLINICAL FINDINGS

BD typically presents as a discrete, slowly enlarging, pink to erythematous thin plaque with well-demarcated, irregular borders and overlying scale or crust (Fig. 113-8A) resembling a psoriatic plaque. Hyperkeratotic and verrucous surface changes may be seen, and a pigmented variant of BD has been reported in fewer



Figure 113-8 **A.** Large plaque of Bowen disease (BD) of the leg. **B.** BD of the nail unit. **C.** BD showing full-thickness atypia of epithelium.

than 2% of cases.[166] Individual lesions may measure up to several centimeters in diameter, and multiple lesions are not uncommon. As previously mentioned, sites of predilection include sun-exposed areas such as the head and neck and lower legs, although any body site may be affected.

A few clinical variants of BD deserve special mention. Intertriginous BD can present as an oozing, erythematous, dermatitic plaque or as a pigmented patch or plaque. BD involving the periungual region may appear as an erythematous, scaly, thin plaque around the cuticular margin, a crusted erosion, nail discoloration, erythronychia, onycholysis, a verrucous plaque, or destruction of the nail plate (Fig. 113-8B). BD of the mucosal surfaces can present as verrucous or polypoid papules and plaques, erythroplakia, or a velvety erythematous plaque. These last two entities are discussed below in the sections on precancerous lesions of the oral cavity and the lower anogenital tract, respectively.

HISTOPATHOLOGY

The epidermis displays full-thickness atypia, including in the intraepidermal portions of the adnexal structures (see Fig. 113-8C). Involvement reaches from the stratum corneum down through the basal cell layer, although the basement membrane remains intact. Characteristically, parakeratosis and hyperkeratosis are present, as is acanthosis, with complete disorganization of the epidermal architecture. At times, the hyperkeratosis and parakeratosis are so pronounced that a cutaneous horn is present. Throughout the epidermis are numerous atypical, pleomorphic, hyperchromatic keratinocytes. These cells are sometimes vacuolated and have a prominent pale-staining cytoplasm, reminiscent of the cells in Paget disease. These cells show loss of maturation and polarity, in addition to numerous mitotic figures. Individually, keratinized cells with large, rounded, eosinophilic cytoplasm, and hyperchromatic nuclei can be found in the epidermis, as can multinucleated cells. These atypical cells also are seen throughout the pilosebaceous units, within the acrotrichia, follicular infundibula, and sebaceous glands. The upper dermis is typically infiltrated by numerous chronic inflammatory cells, including lymphocytes, plasma cells, and histiocytes.

Several histopathologic subtypes of BD can be seen. Psoriasiform BD displays parakeratosis and marked acanthosis with broad, sometimes fused, epidermal rete ridges. Atrophic BD, like atrophic AK, demonstrates a thinned epidermis, but in addition there is full-thickness atypia and lack of maturation, as well as adnexal involvement. Acantholytic BD shows marked acantholysis in the epidermis. Epidermolytic BD has changes of incidental epidermolytic hyperkeratosis (EHK) present. The phenomenon of intraepidermal epithelioma of Borst-Jadassohn—namely, nesting of the atypical cells within the epidermis, or so-called *pagetoid BD*—can also be seen.

DIAGNOSIS AND DIFFERENTIAL DIAGNOSIS

Clinically, BD is most often mistaken for superficial BCC; patches of dermatitis, psoriasis, or lichen planus; AK; benign lichenoid keratosis (BLK) or lichen planus-like keratosis; irritated seborrheic keratosis; or amelanotic melanoma (Box 113-4). More

BOX 113-4 CLINICAL AND HISTOPATHOLOGIC DIFFERENTIAL DIAGNOSIS OF BOWEN DISEASE

CLINICAL DIFFERENTIAL DIAGNOSIS OF BOWEN DISEASE

- Erythematous Bowen disease
  - Superficial basal cell carcinoma
  - Dermatitis, eczema
  - Psoriasis
  - Seborrheic dermatitis
  - Lichen planus
  - Benign lichenoid keratosis
  - Irritated or inflamed seborrheic keratosis
  - Actinic keratosis
  - Squamous cell carcinoma
  - Amelanotic melanoma
- Hyperkeratotic Bowen disease
  - Verruca vulgaris
  - Seborrheic keratosis
  - Discoid lupus erythematosus
  - Hypertrophic lichen planus
  - Squamous cell carcinoma
- Pigmented Bowen disease
  - Melanoma
  - Bowenoid papulosis
- Intertriginous Bowen disease
  - Inverse psoriasis
  - Seborrheic dermatitis
  - Candidiasis
  - Paget disease
  - Hailey–Hailey disease
- Subungual or periungual Bowen disease
  - Nail dystrophy
  - Onychomycosis
  - Squamous cell carcinoma
  - Amelanotic melanoma

HISTOPATHOLOGIC DIFFERENTIAL DIAGNOSIS OF BOWEN DISEASE

- Paget disease
- Pagetoid melanoma in situ
- Intraepidermal eccrine carcinoma
- Intraepidermal Merkel cell carcinoma
- Intraepidermal sebaceous carcinoma
- Bowenoid papulosis
- Podophyllin-induced changes in a wart

hyperkeratotic or verrucous lesions of BD may be difficult to distinguish clinically from viral warts, seborrheic keratoses, and SCC, and pigmented BD lesions can be mistaken for melanoma. Superficial BCC can sometimes be distinguished by its raised, subtle, and translucent border. Histopathologically, BD must be differentiated from Paget's disease; pagetoid melanoma in situ; eccrine, Merkel, and sebaceous carcinomas; BP; and *podophyllin*-induced changes in a wart (see Box 113-4). Both Paget's disease and BD may have the findings of vacuolated cells, but in contrast with BD, Paget's disease shows no dyskeratosis. Also, the material present in Paget's cells is periodic acid-Schiff (*PAS*) positive and diastase-resistant, whereas the PAS-positive material sometimes present in BD cells (i.e., clear cell BD) is glycogen and therefore PAS labile. Finally, staining for carcinoembryonic antigen yields positive results in Paget's disease but negative results in BD. Pagetoid melanoma in situ can be difficult at times to distinguish histopathologically from BD. In BD, the intercellular desmosomal bridges should be identifiable between the atypical keratinocytes, and melanocyte specific immunoperoxidase staining gives positive results in melanoma cells but negative results in BD and Paget's disease cells. The other rare pagetoid neoplasms are usually recognizable, but erroneous diagnoses can be made by the unwary. BP may lack the full-thickness epidermal atypia present in BD, but the clinical setting is paramount. Podophyllin applied topically to skin lesions causes metaphase arrest with resultant bizarre keratinocyte formation and sometimes a pattern of pseudoepitheliomatous hyperplasia that can be mistaken for BD. These changes typically resolve after a few days to a week.[167]

PROGNOSIS AND CLINICAL COURSE

The risk that untreated BD will progress to invasive carcinoma has been estimated in one older study at approximately 3%–5%.[163] Estimates are that once invasive carcinoma occurs in BD [see thumbnail image in "Squamous Cell Carcinoma In Situ (Bowen Disease) At a Glance" box], approximately 13% of these carcinomas will metastasize, and of these cases, 10% will end in death from widespread dissemination.[168]

The presence of BD in any given individual is a marker for a high risk of developing a subsequent NMSC.[169] In studies addressing the association between the presence of BD and the risk of other NMSCs, approximately 30%–50% of BD patients had either previous or subsequent NMSC. Another study estimated the incidence ratio for subsequent NMSC to be 4.3.[169] Previous studies also claimed that the presence of BD is a marker for internal malignancy, although a significant number of other investigations have been unable to substantiate this association. Critical analysis and meta-analysis of these past studies do not support the need for routine investigation for internal malignancy in persons with BD. The one exception to this position is in cases of BD related to previous arsenic exposure, in which the possibility of internal malignancy is real, as previously discussed. Also, BD involving the vulvar region in females and the perianal region in males has been associated with an increased risk of uterine, cervical, vaginal, and anal cancer, possibly due to HPV infection, as discussed.[122,170]

TREATMENT

A number of different modalities are available for the treatment of BD. Such treatments can be divided into three main categories: surgical and destructive therapies, topical therapies, and nonsurgical ablative therapies (Box 113-5). Surgical and destructive therapies include excision, Mohs micrographic surgery, curettage with or without electrosurgery, chemoablation with TCA, and cryosurgery. Topical therapies include 5-FU and 5% imiquimod cream (see Chapter 221). Nonsurgical ablative therapies are laser ablation, radiotherapy, and PDT (see Chapter 238). Although some of these modalities have reported cure rates that are better than others, no one treatment is right for all forms of BD. Therapy must be guided by the size and location of the BD, in addition to individual patient characteristics, such as age and healing capability. BD warrants definitive surgical therapy if it has previously failed topical chemotherapy or ablative surgery, due to its propensity to eventually affect large surface areas and to become invasive.

BOX 113-5 TREATMENT OF BOWEN DISEASE

SURGICAL AND DESTRUCTIVE THERAPIES
- Excision
- Mohs micrographic surgery
- Curettage with or without electrosurgery
- Liquid nitrogen cryosurgery

TOPICAL THERAPIES
- 5-Fluorouracil (5% cream bid for 6–16 weeks)
- 5% imiquimod (daily for 16 weeks)

NONSURGICAL ABLATIVE THERAPIES
- Laser ablation
- Radiotherapy
- Photodynamic therapy

PRECANCEROUS LESIONS OF THE LOWER ANOGENITAL TRACT

ANAL (AIN) AND PERIANAL (PaIN) INTRAEPITHELIAL NEOPLASIA AT A GLANCE

- Anal intraepithelial neoplasia (AIN) is an human papillomavirus (HPV)-associated precursor lesion of anal squamous cell carcinoma (SCC) and has been previously called anal squamous intraepithelial neoplasia (ASIL) or anal dysplasia; it is embryonically and histopathologically analogous to cervical intraepithelial neoplasia (CIN).
- Perianal intraepithelial neoplasia (PaIN) is a precursor lesion of perianal, cutaneous SCC and has also been called genital Bowen disease (GBD), SCC in situ, and sometimes bowenoid papulosis (BP); it is less likely associated with HPV than AIN; and only 5% of such cases may progress to invasive SCC.
- AIN1 is a low-grade lesion and not a direct precursor of anal SCC.
- AIN2 and AIN3 are high-grade precursor lesions of anal SCC and histopathologically display moderate and severe dysplasia, respectively.
- The greatest risk factors for AIN are HPV infection, receptive anal intercourse, HIV infection, smoking, and a history of CIN in females.
- AIN is associated with oncogenic hrHPV types 16, 18, 31, and, less so, HPV-33.
- AIN may be asymptomatic or present with pruritus, pain, bleeding, tenesmus, or discharge.
- PaIN may present with a variety of clinical patterns, including well-demarcated erythematous, or variably pigmented plaques.
- Histopathology of PaIN is that of cutaneous SCC in situ and that of AIN is analogous to CIN.
- Dermatologists play a role in high-risk patients by examining the perianal skin and, if PaIN is diagnosed, initiating treatment for PaIN and then referring such patients to an expert in diagnosing and managing AIN and CIN for further evaluation.
- Treatment options for PaIN include wide local excision, Mohs micrographic surgery, and various topical agents.
- There is a high-risk of recurrence of AIN and an increased association with other anogenital intraepithelial neoplasias (Ins), necessitating referral and ongoing surveillance.
- HPV vaccination of males for prevention of AIN is undergoing investigation.

VULVAR INTRAEPITHELIAL NEOPLASIA (VIN)

VULVAR INTRAEPITHELIAL NEOPLASIA (VIN) AT A GLANCE

- Vulvar intraepithelial neoplasia (VIN) is a high-grade precancerous lesion of the vulva that may progress to vulvar squamous cell carcinoma (SCC).
- It is primarily a disease of younger females (75% of all cases) and its incidence is rising globally.
- There are three categories of VIN: (1) usual type, (2) differentiated type, and (3) unclassified type.
- VIN, usual type associated with hrHPV-16, 18, 31; occurs in younger premenopausal females; presents with multifocal and multicentric lesions; has 50% association with cervical intraepithelial neoplasia (CIN).
- VIN, differentiated type less common than usual type; usually not associated with HPV; affects postmenopausal females; is associated with lichen sclerosus; unifocal presentation.
- A diagnosis of VIN mandates referral to gynecologist to look for CIN.
- VIN has a varied clinical presentation and the differential diagnosis includes lichen sclerosus, lichen planus, condyloma acuminata, and cutaneous melanoma.
- No consensus on best treatment; consult with gynecologist.
- HPV vaccine in young females can prevent HPV-related VIN.

PENILE INTRAEPITHELIAL NEOPLASIA (PIN)

PENILE INTRAEPITHELIAL NEOPLASIA (PIN) AT A GLANCE

- Penile intraepithelial neoplasia (PIN) is a precursor lesion to penile squamous cell carcinoma (SCC); two clinical variants of PIN are the genital Bowen disease (GBD) and the erythroplasia of Queyrat (EQ) variants.
- PIN and penile cancer are rare in the Western world but increasing in incidence in developing countries.
- PIN and penile SCC are mainly diseases of older, uncircumcised males.
- Risk factors in uncircumcised males include poor hygiene, smegma retention, phimosis, chronic inflammatory and infectious conditions of the penis; and less so coinfection with oncogenic hrHPV (primarily 16, but also 18, 31, and 33), lichen sclerosus, HIV infection, immunosuppression, smoking, PUVA and UVR exposure of the genitalia.
- About 40%–45% of PIN and penile SCC are associated with HPV.
- There are two independent pathways in the development of PIN and penile SCC: an HPV-positive pathway and an HPV-negative pathway.
- The HPV-positive pathway is morphologically associated with the warty and basaloid subtypes of penile SCC and is thought to be more aggressive.
- The HPV-negative pathway is morphologically associated with the usual or differentiated type of penile SCC, which is the major type (~49%) of all of the penile SCCs.
- The EQ variant of PIN is the most common type of PIN and is always associated with HPV-8 and most often with concomitant HPV-16 coinfection; presents as a well-demarcated, glistening, erythematous, velvety plaque or plaques on the mucosal surfaces of the penis.
- The GBD variant of PIN is less common than the EQ variant; presents as a well-demarcated, erythematous to variably pigmented plaque on the shaft of the penis.
- Histopathology of both the GBD and EQ variants of PIN show SCC in situ changes, but EQ has more epithelial hypoplasia and plasma cells in the dermal infiltrate.
- EQ variant of PIN is more likely to progress to invasive SCC (~30%) vs. the GBD variant (3%–6%).
- No definitive treatment guidelines for PIN and treatment options are similar as those for other forms of SCC in situ; must be individualized to preserve anatomy and function as best as possible.
- Prevention is important and can be advocated with neonatal circumcision; in uncircumcised males, must advocate proper hygiene, stopping smoking, treating chronic inflammatory and infectious penile conditions, and avoiding genital PUVA and UVR exposure; HPV vaccine is investigational.

POTENTIALLY MALIGNANT DISORDERS OF THE ORAL CAVITY

In a World Health Organization (WHO) workshop held in 2005, the terminology, definitions, and classification of oral lesions with a predisposition to malignant transformation were discussed.[193] The term *potentially malignant* was preferred over *premalignant* or *precancerous*. In addition, it was recommended that the traditional distinction between potentially malignant *lesions* and potentially malignant *conditions* be abandoned and that the term *potentially malignant disorders* be used instead. In this chapter the focus will be on oral leukoplakia (OL) and erythroplakia.

LEUKOPLAKIA

Leukoplakia is a clinical term that refers to a predominantly white lesion of the oral mucosa that cannot be rubbed off or characterized by any other definable lesion or known disease.[194] Leukoplakia is the most common precancerous lesion of the oral mucosa, with

LEUKOPLAKIA AT A GLANCE

- Leukoplakia is a clinical diagnosis of exclusion for a fixed white lesion in the oral cavity that does not resolve spontaneously.
- Oral leukoplakia (OL) is the most common precancerous lesion of the oral mucosa, with the potential to become oral squamous cell carcinoma (OSCC).
- Prevalence is 0.2%–5.0%.
- Approximately 50% of OSCCs are associated with precancerous lesions.
- OL and oral erythroplakia (OE) are markers for increased risk for additional oral or upper aerodigestive tract malignancies.
- Risk factors for OL are the use of any tobacco product, concomitant alcohol use, history of previous OSCC or premalignant lesions, and infection with certain human papillomavirus (HPV) subtypes.
- No consensus exists on how best to treat OL.

the potential to become oral SCC (OSCC).[195] OL is in the same clinical spectrum of disease as oral erythroplakia (OE), but unlike OE it is a much more frequently diagnosed lesion with a much lower rate of malignant transformation.

EPIDEMIOLOGY

The reported prevalence of OL varies from 0.2% to 5%, although such rates vary significantly among different geographical areas and demographic groups.[196] In a worldwide systematic review of OL that included multiple studies involving more than 1,000 subjects, prevalence rates varied between 0.50% and 3.46%.[197] The pooled prevalence estimate of OL in this study was between 1.49% and 4.27%.[197] Leukoplakia is six times more common among smokers than among nonsmokers.[198] Alcohol is an independent risk factor, regardless of beverage type or drinking pattern.[199] There are conflicting results as to the possible role of HPV infection.[200–202]

In addition to potentially becoming a malignant growth, OL, and for that matter OE, have come to be viewed as risk factors or markers for other epithelial cancers of the oral cavity and upper aerodigestive tract. The concept of field cancerization applied to the oral mucosa implies that its entire surface can be affected by carcinogens. Indeed, approximately 20% of patients with SCC of the head and neck will develop another malignancy or precancerous lesion within 5 years of the first diagnosis.[203]

ETIOLOGY AND PATHOGENESIS

Given the current definition of leukoplakia, identification of an etiologic factor for a given white lesion would exclude this diagnosis. Two factors in this setting are tobacco use and candidiasis. Tobacco use is believed to be a strong risk factor for the development of OL. Tobacco-related white lesions of the oral mucosa have been identified and then subsequently found to disappear once the habit of tobacco use has been discontinued. By current definitions and standards, such tobacco-related white lesions are thought to be different entities than true OL, which would not disappear with cessation of tobacco use.

Likewise, there has been much debate as to whether or not *Candida* infection is a cause of leukoplakia or a superimposed infection within a preexisting OL lesion. If one adheres to the strict and accepted definition of leukoplakia, a white lesion that disappears upon treatment of *Candida* infection is not leukoplakia. Thus, it is probably best to make a preliminary diagnosis of leukoplakia and then treat any underlying candidal infection and have the patient discontinue use of any tobacco products to see if the white lesion resolves. If such a lesion then resolves, it is not true leukoplakia.

The development of OL has been associated most strongly with the use of tobacco products, including smoked tobacco (cigarettes, cigars, pipe tobacco), smokeless tobacco (snuff, chewing tobacco), pan masala, and betel nut quid, as well as alternative tobacco products like bidis and kreteks. Also, combined tobacco use and alcohol consumption are thought to be synergistic in the development of OL and OSCC. Persons with a previous malignancy or premalignancy of the upper aerodigestive tract are at increased risk for further such lesions and malignancies, as previously mentioned. Preliminary studies suggest that HPV infection is two to three times more prevalent in oral precancerous mucosa and four to five times more prevalent in OSCC than in normal epithelium.[204] In the same meta-analysis, hrHPV (16 and 18) were more frequently associated with OSCC than were low-risk HPV types.[204]

One study addressed the clinical risk factors for OL in a representative sample of the US population drawn from among the 15,811 participants in the US National Health and Nutrition Examination Survey III.[205] In this study, females were less likely than males to have OL. The strongest independent risk factor was tobacco smoking. Three other independent predictors of OL were diabetes, increasing age, and lower socioeconomic status. Alcohol consumption, race and ethnicity, years of education, and body mass index all showed no independent association with OL.[205] Investigators strongly urged further studies to confirm these findings (see Chapter 76).

CLINICAL FINDINGS

OL is clinically divided into two subtypes: homogeneous OL and nonhomogeneous OL. Homogeneous OL has been defined as a mostly white, flat, uniform lesion

that may have shallow cracks and a smooth, wrinkled, or corrugated surface that is consistent throughout.[206] Nonhomogeneous OL has been defined as a mostly white or white and red lesion (erythroleukoplakia) that may be irregular and flat, nodular (speckled), ulcerative, or verrucous. Nonhomogeneous OL purportedly has a risk of malignant transformation that is four to five times higher than that of homogeneous OL. Another clinical subtype of OL is proliferative verrucous leukoplakia, which is most often found in patients who do not use tobacco products. This subtype has a high rate of transformation to malignancy.[207]

HISTOPATHOLOGY

If the provisional diagnosis of OL is at all in doubt and/or a waiting period to assess for possible regression or disappearance of a white lesion after eliminating possible causative factors has not resulted in resolution of the lesion, the next advisable step in evaluating the oral white lesion is to obtain a biopsy specimen for histopathologic diagnosis. This is where the concepts of epithelial dysplasia and carcinoma in situ enter the picture.

In relation to the oral mucosa, epithelial dysplasia has been defined as a "precancerous lesion of stratified squamous epithelium characterized by cellular atypia and loss of normal maturation and stratification short of carcinoma in situ."[212] Carcinoma in situ of the oral cavity has been described as "a lesion in which the full thickness, or almost the full thickness, of squamous epithelium shows the cellular features of carcinoma without stromal invasion."[212] Criteria have been put forth for diagnosing these changes, and the more prominent and numerous the designated features are, the more severe the grade of dysplasia.[195,206]

On the basis of these subjective criteria, lesions are usually graded into mild-, moderate-, and severe epithelial dysplasia. A number of studies have shown significant intra- and interexaminer inconsistencies in assessing the presence or absence of oral epithelial dysplasia as well as its grade on histopathologic examination.[195] Other studies have shown great variability in the number of lesions that go on to develop into malignancies based on their degrees of dysplasia. Some studies have shown a positive correlation between the degree of dysplasia and the development of malignancy, and others have demonstrated no correlation whatsoever.[195]

On the basis of these inconsistencies, three major problems have been identified in attaching significance to the degree of epithelial dysplasia in OL lesions as predictors of their malignant potential. First, the diagnosis of epithelial dysplasia is largely subjective. Second, although a definite correlation between degree of dysplasia and malignant potential has been shown, not all dysplastic lesions will progress to malignancy, and some may even regress. Third, OSCC has been shown to develop from nondysplastic oral epithelial lesions.[195]

As imperfect as this histopathologic grading system is, epithelial dysplasia in its varying degrees is still one of the few indicators available of an increased risk for OSCC.

DIAGNOSIS AND DIFFERENTIAL DIAGNOSIS

A diagnosis of leukoplakia is made when a fixed white lesion of the oral mucosa is detected and cannot be identified as any other definable lesion or condition. Some suggest distinguishing between a provisional clinical diagnosis of OL and a definitive diagnosis of OL.[194] A provisional diagnosis of OL is made at the time of the initial examination when no other diagnosis for the white lesion is obvious. At this point, other possibilities to consider in the differential diagnosis are tobacco-associated lesions, *Candida*-associated lesions, lichen planus, leukoedema, lupus erythematosus, Epstein–Barr virus-associated oral hairy leukoplakia, oral white sponge nevus, mechanical or frictional irritation, contact lesions, cheek/lip/tongue biting, linea alba, aspirin burn, OSCC, and verrucous carcinoma (Box 113-6). If causative factors for the white lesion

BOX 113-6 CLINICAL DIFFERENTIAL DIAGNOSIS OF ORAL LEUKOPLAKIA AND ORAL ERYTHROPLAKIA

CLINICAL DIFFERENTIAL DIAGNOSIS OF ORAL LEUKOPLAKIA

- Tobacco-associated lesion
- *Candida*-associated lesion
- Leukoedema
- Lichen planus
- Lupus erythematosus
- Linea alba
- Habitual cheek biting
- Frictional lesion
- Aspirin burn
- Oral white sponge nevus
- Oral hairy leukoplakia
- Verrucous carcinoma
- Squamous cell carcinoma

CLINICAL DIFFERENTIAL DIAGNOSIS OF ORAL ERYTHROPLAKIA

- Erythematous candidiasis
- Atrophic lichen planus
- Lupus erythematosus
- Pemphigus
- Cicatricial pemphigoid
- Kaposi sarcoma
- Chronic contact or allergic contact dermatitis
- Chronic mechanical trauma
- Thermal or mechanical injury
- Squamous cell carcinoma
- Amelanotic melanoma

are suspected, it is recommended that these factors be eliminated for a period of 2–6 weeks to observe for regression of the white lesion. If upon reevaluation the white lesion persists, biopsy should be performed. If the lesion is clinically at high-risk for OSCC, biopsy should be performed before such a waiting period.

PROGNOSIS AND CLINICAL COURSE

Once a definitive diagnosis of OL has been made, the risk of transformation to OSCC needs to be evaluated. The rate of malignant transformation of OL into OSCC has been found to vary from almost 0% to 20% in 1–30 years.[213] A study based on European epidemiologic data investigated the natural limit of malignant transformation of OL to OSCC. This study concluded that the upper limit of the annual malignant transformation rate of OL is unlikely to exceed 1%.[196]

The commonly recognized variables that statistically carry an increased risk for malignant transformation into an SCC are listed in Box 113-7. Of these variables, the presence of dysplasia is the most important indicator. However, it should be recognized that not all dysplastic lesions progress to malignancy. Some remain clinically unchanged and others may spontaneously regress. Furthermore, malignant transformation may occur in nondysplastic leukoplakia.

In spite of great progress in the field of molecular biology, there is not yet one single marker or set of markers that reliably enables prediction of malignant transformation of leukoplakia in an individual with OL.[193]

TREATMENT AND PREVENTION

The goal of treatment is to prevent the malignant transformation of OL to OSCC and to relieve patient symptoms, although there is no evidence that treatment of OL can prevent the future development of OSCC. There is no consensus on the most appropriate treatment for OL. Some recommend the following approach: if no or mild epithelial dysplasia exists histopathologically, pursue treatment if the OL is in a high-risk location or is large; if moderate or severe dysplasia exists histopathologically, then active treatment to remove the entire lesion is recommended.[206] A systematic review of all the randomized, controlled trials of all therapies for OL ($n = 7$) concluded that there is no known nonsurgical therapy to prevent OL from developing in the first place or to prevent OL from transforming into OSCC.[213] The reviewers did find some evidence that treatment with *vitamin A*, retinoids, and β-carotene may completely resolve the oral lesions and that treatment with *retinoic acid* may prevent histopathologic worsening, but these findings were based on only a small number of patients.[213]

Postexcision recurrences are common and occur in 10%–20% of cases, and OSCC develops within excised areas in 3%–9% of instances.[210] In addition, surgical excision with histopathologically clear margins did not prevent OSCC or improve survival outcomes in the group of patients with aneuploid dysplastic OL, the most likely form of OL to progress to OSCC, in one study.[214]

CO_2 laser vaporization is another commonly employed treatment modality—again without substantial data to support its use. In one review of 200 patients with 282 OL lesions treated with CO_2 laser vaporization between 1976 and 2001, 89% (n = 251) had no recurrence during a mean follow-up time of 52 months; 9.9% (n = 28) had local recurrence between 5 months and 168 months after treatment; and 1.1% (n = 3) developed OSCC within the treated area at 7, 17, and 19 months after the CO_2 laser treatment.[215]

Because the recurrence of OL after treatment is common and the risk of OSCC is present with or without treatment, and because patients with OL are at increased risk for additional head and neck malignancies, these patients need to be followed at regular intervals with thorough examinations and potentially with additional biopsies. Follow-up intervals may vary from every 3 months in high-risk individuals to every 6 months in those at lower risk, for the rest of the patients' lives.

Despite all the controversies and inconsistencies surrounding OL, standard historical, clinical, and histopathologic findings are still the most important factors for predicting the possibility of malignant transformation of precancerous oral lesions. Treatment plans are guided mostly by findings from careful clinical and oral examinations, especially in individuals at high risk, and by histopathologic evaluation for the presence and degree of epithelial dysplasia (Fig. 113-9).

BOX 113-7 SIGNIFICANT RISK FACTORS FOR THE CONVERSION OF ORAL LEUKOPLAKIA (OL) INTO ORAL SQUAMOUS CELL CARCINOMA[a]

Most Important Risk Factor

- Presence of epithelial dysplasia

Other Risk Factors

- Female gender
- Long duration of oral leukoplakia (OL)
- OL in nonsmokers
- Location on the floor of the mouth or tongue
- Size >200 mm^3
- Nonhomogeneous type of OL

[a]Adapted from van der Waal I: Potentially malignant disorders of the oropharyngeal mucosa: Terminology, classification, and present concepts of management. *Oral Oncol* **45**:317, 2009.

ERYTHROPLAKIA (ERYTHROPLASIA)

Erythroplakia, or *erythroplasia*, is a clinical term used to describe a red macule or patch on a mucosal surface that cannot be categorized as any other known disease

ERYTHROPLAKIA (ERYTHROPLASIA) AT A GLANCE

- Erythroplakia is a clinical diagnosis of exclusion for a persistent fixed red patch in the oral cavity.
- It is the least common of all oral precancerous lesions but has the greatest potential to harbor or become oral squamous cell carcinoma (OSCC).
- Risk factors are use of tobacco products and alcohol use.
- Early and effective treatment is important.
- Treatment for severely dysplastic lesions or in situ carcinoma is complete excision or Mohs micrographic surgery.

Approach to the management of leukoplakia

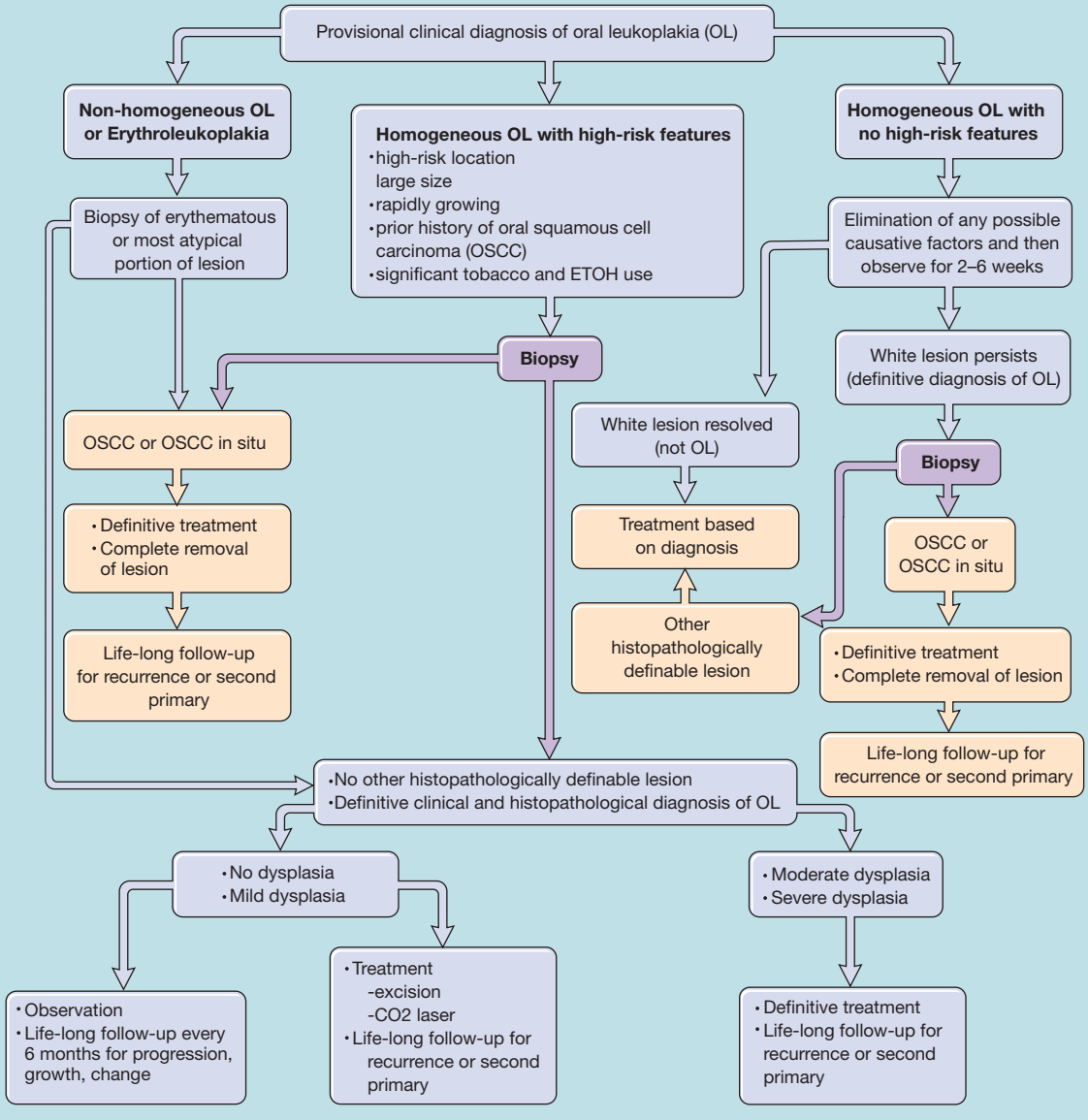

Figure 113-9 Approach to the management of oral leukoplakia. ETOH = ethanol.

entity caused by inflammatory, vascular, or traumatic factors. Histopathologically, it almost always displays either findings of SCC in situ or focal areas of invasive SCC, and thus is considered a precancerous lesion at best and always warrants treatment. Erythroplakia can involve any mucosal surface but most commonly occurs on the oral mucosa in more than half of all cases. Of all oral precancerous lesions, it is considered to be the most dangerous and carries the greatest risk of progressing to or harboring invasive carcinoma.

EPIDEMIOLOGY

Erythroplakia is an uncommon lesion in the oral cavity, and it is said to be one of the least commonly diagnosed lesions among the group of oral lesions that may or may not become malignant.[216] The prevalence, based on a small number of worldwide studies, is between 0.02% and 0.83%.[217] Both tobacco and alcohol are considered etiologic factors, and it mainly occurs in middle-aged individuals without a gender preference. It has been well described in the chutta smokers (reverse cigar smokers) of India.[217]

CLINICAL FINDINGS

OE is usually found either intraorally or on the vermillion surface of the lower lip. The most common areas in the oral cavity are the soft palate, the floor of the mouth, and the buccal mucosa. OE usually presents as a solitary, subtle, asymptomatic, erythematous macule or patch. Most often it is less than 1.5 cm in its widest diameter, but lesions up to 4 cm in diameter have been described.[217] Characteristically, it is sharply demarcated from the surrounding pink mucosa, and its surface is most often smooth and homogeneous in color. On occasion lesions of erythroplakia demonstrate a pebbled or stippled surface change and on palpation may have a soft and velvety feel. Induration indicates the presence of invasive carcinoma in many instances. Erythroplakia is commonly seen in association with leukoplakia, a condition termed *erythroleukoplakia*. It is the red patches of erythroleukoplakia that are most likely to contain or develop into a malignancy.

KEY REFERENCES

Full reference list available at www.DIGM8.com

DVD contains references and additional content

14. Salasche SJ: Epidemiology of actinic keratoses and squamous cell carcinoma. *J Am Acad Dermatol* **42**:S4, 2000
20. Grossman D, Leffell DJ: The molecular basis of nonmelanoma skin cancer. *Arch Dermatol* **133**:1263, 1997
29. Thompson SC et al: Reduction of solar keratoses by regular sunscreen use. *N Engl J Med* **329**:1147, 1993
46. Drake LA et al: Guidelines for the care of actinic keratoses. *J Am Acad Dermatol* **32**:95, 1995
58. Korman N et al: Dosing with 5% imiquimod cream three times per week for the treatment of actinic keratosis: Results of two phase 3, randomized, double-blind, parallel-group, vehicle-controlled trials. *Arch Dermatol* **141**:467, 2005
69. Lawrence N et al: A comparison of the efficacy and safety of Jessner's solution and 35% trichloroacetic acid vs 5% fluorouracil in the treatment of widespread facial actinic keratoses. *Arch Dermatol* **131**:176, 1995
79. Piacquadio DJ et al: Photodynamic therapy with ALA topical solution and visible blue light in the treatment of multiple actinic keratoses of the face and scalp: Investigator-blinded, phase 3, multicenter trials. *Arch Dermatol* **140**:41, 2004
110. Schwartz RA: Arsenic and the skin. *Int J Dermatol* **36**:241, 1997
143. Novick M et al: Burn scar carcinoma: A review and analysis of 46 cases. *J Trauma* **17**:809, 1977
164. Meyer T et al: Importance of human papillomaviruses for the development of skin cancer. *Cancer Detect Prev* **25**:533, 2001
195. Reibel J: Prognosis of oral premalignant lesions: Significance of clinical, histopathological and molecular biological characteristics. *Crit Rev Oral Biol Med* **14**:47, 2003

Chapter 114 :: Squamous Cell Carcinoma

:: Douglas Grossman & David J. Leffell

SQUAMOUS CELL CARCINOMA AT A GLANCE

- With basal cell carcinoma, most common human malignancy.
- Diagnosis is by biopsy.
- Caused by ultraviolet radiation in most cases.
- Precursor lesion is actinic keratosis.
- Treatment options are excision, Mohs micrographic surgery, and radiation.

Cutaneous squamous cell carcinomas (SCCs) are malignant neoplasms derived from suprabasal epidermal keratinocytes. These and basal cell cancers are the nonmelanoma skin cancers that represent the most common malignancies in humans. Whereas basal cell carcinoma (BCC) (see Chapter 115) is thought to arise de novo, SCC probably evolves in most cases from precursor lesions of actinic keratosis (AK) and Bowen disease (SCC in situ) (see Chapter 113). This chapter focuses on clinical aspects of invasive SCC. Cutaneous SCC represents a broad spectrum of disease ranging from easily managed, superficially invasive cancers to highly infiltrative, metastasizing tumors that can result in death. The clinical presentation can be variable despite the existence of easily identified typical

lesions. The cellular and molecular aspects of SCC carcinogenesis are discussed elsewhere (see Chapter 113).

HISTORICAL ASPECTS

EPIDEMIOLOGY

INCIDENCE. The precise incidence of BCC and SCC is unknown, because these cutaneous malignancies are not generally documented by the National Cancer Institute or most state cancer registries. However, it is generally accepted that well over 1 million cases are diagnosed in the United States each year, with approximately 200,000 representing SCC.[10] Although less common than BCC, SCC carries a risk of metastasis and thus accounts for the majority of the several thousand deaths attributable to nonmelanoma skin cancer each year. By comparison, cutaneous melanoma accounts for only 60,000 cases, but approximately 9,000 deaths, annually.[11] Similar trends for SCC have been noted in Australia[12] and the Caribbean.[13]

SCC is strongly associated with advanced age, and a sharp increase in incidence is seen after age 40 years.[14] Today, the lifetime risk of SCC among whites is approximately 15%, almost double that of two decades ago. Increased exposures to ultraviolet (UV) radiation (through greater use of tanning salons, increased time spent outdoors, changes in clothing styles, and ozone depletion) and greater longevity have been suggested as possible causes for the increase in disease. It is likely that this trend will continue as a result of further depletion of the ozone layer and the aging of the US population. The rising incidence of SCC over the past several decades has been paralleled by a 20% decrease in mortality, attributed largely to increased public awareness and aggressive treatment of high-risk lesions.[15] After a diagnosis of SCC, patients have a 44%–50% cumulative risk of developing another nonmelanoma skin cancer (18%–30% risk of SCC) in the subsequent 3–5 years.[16] In addition, these patients are at increased risk for extracutaneous–cancers.[17]

DEMOGRAPHICS

Squamous cell cancer is twice as common in men as in women, probably as a result of greater lifetime UV exposure in men. Similarly, longer hairstyles and use of lipstick may account for the lower frequency of SCC on the ears and lips of women. There is an inverse relationship between skin pigmentation and SCC incidence, largely because of the protective effect of eumelanin. Thus, persons with white skin, blue eyes, fair complexion, red hair, and Celtic ancestry who tan poorly are at greatest risk. Increased pigmentation is associated not only with a lower incidence of SCC, but also with an inversion in the BCC/SCC ratio. In comparison with whites, the incidence of SCC is decreased by 30-fold in American blacks and the BCC/SCC ratio falls to 0.8:1.[14] Tanzanian albinos all develop SCC by young adulthood, and the ratio of BCC to SCC is only 0.2:1. Asians and Polynesians, with intermediate skin pigmentation, have correspondingly intermediate levels of SCC. A gene (*MC1R*) involved in melanogenesis that encodes the melanocortin 1 receptor is a major determinant of skin pigmentation and hair color. The *MC1R* gene is highly polymorphic, with more than 20 variants described.[18] Several variant *MC1R* alleles are associated with increased risk of SCC that is independent of skin type and hair color.

ETIOLOGY AND PATHOGENESIS

PREDISPOSING FACTORS

There are a number of factors, including both acquired and genetic skin conditions that may predispose to SCC (Table 114-1). Patients often demonstrate a multiplicity of factors that together are sufficient to induce SCC development. For example, a given skin site may be exposed to both UV radiation and another environmental carcinogen.

PRECURSOR LESIONS. Most SCCs develop from precursor lesions such as AKs or Bowen disease (see Chapter 113).

ULTRAVIOLET RADIATION EXPOSURE. UV radiation is considered the predominant risk factor for SCC. Importantly, there is a linear correlation between the incidence of SCC and exposure to UV radiation. The incidence of SCC has been reported to double with each 8°–10° decline in geographic latitude and is highest at the equator.[19] World War II veterans stationed in the Pacific developed much higher rates of SCC than did their colleagues who served in Europe.[20] Similarly, SCC is more prevalent in Japanese people who emigrated to Hawaii than in those who remained in Japan.[21] Excessive UV radiation appears to be related more to the development of SCC than to the development of BCC. Rates of SCC rise more rapidly than those of BCC with increasing UV exposure,[22] and UV radiation-induced skin cancers in mice are almost exclusively SCCs rather than BCCs.[23] Moreover, in patients receiving long-term therapy with psoralen plus ultraviolet A (UVA) radiation for treatment of

TABLE 114-1
Predisposing Factors for Squamous Cell Carcinoma

- Precursor lesions (actinic keratosis, Bowen disease)
- Ultraviolet radiation exposure
- Ionizing radiation exposure
- Exposure to environmental carcinogens
- Immunosuppression
- Scars
- Burns or long-term heat exposure
- Chronic scarring or inflammatory dermatoses
- Human papillomavirus infection
- Genodermatoses (albinism, xeroderma pigmentosum, porokeratosis, epidermolysis bullosa)

psoriasis there is an associated 30-fold increase in nonmelanoma skin cancers, most of which are SCCs.[24]

IONIZING RADIATION. There is a strong association between SCC and exposure to ionizing radiation. In one survey of SCC patients, an association with radiation therapy was observed only in those whose skin was likely to sunburn (see Chapter 113).

ENVIRONMENTAL CARCINOGENS. Numerous occupational and environmental carcinogens, such as arsenic and aromatic hydrocarbons, predispose to the development of SCCs. With the exception of 3-methylcholanthrene and anthramine, chemical carcinogens generally produce SCCs rather than BCCs.[25] Exposures to insecticides and herbicides have also been associated with SCCs. In addition, smoking and alcohol use are strongly associated with SCCs of the oral cavity.

IMMUNOSUPPRESSION. Chronic immunosuppression may lead to an increase in SCCs, primarily on sun-exposed sites.[26] An 18-fold increase in SCC has been reported in renal transplant patients[27]; these tend to appear 3–7 years after the onset of long-term immunosuppressive therapy, with corticosteroids, azathioprine, and cyclosporine most frequently implicated. With the increase in the total number of organ transplant patients, management of SCCs in this population is becoming more important. In patients with leukemia and lymphoma, SCCs are both increased and more aggressive.[28] Although multiple SCCs have been described in patients infected with human immunodeficiency virus, advanced human immunodeficiency virus infection has generally not been associated with an increased incidence of SCC, possibly because many patients do not live long enough to develop them.

SCARS AND UNDERLYING DISEASES. Historically, SCC was associated with both burn scars and chronic ulcers as noted earlier, but such associations are seldom seen today. Also rare but reported is the development of SCCs in the context of chronic infections, particularly those associated with draining sinuses and scarring, such as perianal pyoderma, osteomyelitis, chromomycosis, hyalohyphomycosis, granuloma inguinale, lupus vulgaris, and leprosy. Chronic inflammatory processes, particularly those associated with scarring, such as venous ulcer, snakebite ulcer, discoid lupus erythematosus, oral lichen planus, morphea, lichen sclerosus, pilonidal cyst, acne conglobata, hidradenitis suppurativa, Hailey–Hailey disease, dissecting folliculitis of the scalp, and necrobiosis lipoidica, all can give rise to SCCs. An exception is vaccination scars, which are associated with BCCs rather than SCCs. SCCs have also been observed in transplanted skin, epidermal cyst, dental cyst, and dermoid cyst.

THERMAL FACTORS. Long-term heat exposure can lead to SCCs. The role of thermal radiation in the development of skin cancer has long been recognized in many cultures, where common practices include placing hot ashes under the clothes to keep warm in winter or smoking opium while lying on heated beds. The incidence of SCCs is increased in persons who habitually sit in front of heating stoves and at sites of erythema ab igne (see Chapter 113).

VIRAL INFECTION. A role for human papillomavirus (HPV) infection has been well established in some types of SCCs. Verrucous carcinoma appears to be associated with several HPV types, as noted later. Head and neck and periungual SCCs are frequently associated with HPV-16. Patients with epidermodysplasia verruciformis are chronically infected with HPV, most commonly type 5, and one-third of these patients ultimately develop SCCs (see Chapters 113 and 196). Recently, the MCPyV polyoma virus, originally discovered in Merkel cell carcinoma, was identified in approximately 15% of cutaneous SCCs from immunocompetent patients.[A] An etiological role for MCPyV in SCC remains to be demonstrated.

GENODERMATOSES. A variety of heritable diseases predispose to SCC development. Patients with oculocutaneous albinism develop predominantly SCCs (rather than BCCs) at an early age (see Chapter 73). Xeroderma pigmentosum (see Chapters 110 and 139), a disorder of DNA repair, is also characterized by early development of SCCs. SCCs have been reported to develop in the Mibelli, disseminated superficial actinic, and palmaris et plantaris disseminata forms of porokeratosis (see Chapter 52), and in oral lesions of dyskeratosis congenita. As noted in Section "Viral Infection," lesions of epidermodysplasia verruciformis can degenerate into SCCs (see Chapter 196). Finally, patients with the dystrophic form of epidermolysis bullosa are at increased risk for SCC (see Chapter 62).

MOLECULAR ASPECTS

As in most cancers, the development of SCC from normal keratinocytes begins with mutations in the cellular DNA and genomic instability. Alterations in gene expression lead to loss of growth controls, penetration of the basement membrane, and ultimately invasion into surrounding tissue. Along the pathway to SCC, keratinocytes become resistant to apoptosis (programed cell death) and immune attack.

GENETIC ALTERATIONS. Most analyses of genetic alterations in SCCs have been performed in cases of oral or head and neck SCCs. Chromosomal deletions (loss of heterozygosity) commonly involve chromosomes 3, 9, 11, and 17; the regions most commonly identified include 9p21 and 17p13 where the INK4A (p16/Arf) and *p53* tumor suppressors, respectively, are located.[29] Similar genetic lesions were found in a study of young patients (younger than 40 years of age).[30] It is unclear whether these genetic markers will serve as useful prognostic indicators.

***p53* IN THE DEFENSE AGAINST SKIN CANCER.** A role for *p53*, cyclin D1, human telomerase reverse transcriptase, p16, and thrombospondin 1 has

been identified in the multistep process of human skin carcinogenesis.[31]

Apoptosis of keratinocytes that have sustained UV radiation-induced DNA damage, termed *sunburn cells*, requires the *p53* tumor suppressor and represents a key protective mechanism against skin cancer by removing premalignant cells that have acquired mutations. In keratinocytes, UV radiation upregulates *p53*,[32] which delays cell cycle progression until DNA damage can be repaired or facilitates cell elimination by apoptosis.[33] Compromise of *p53* function could undermine this apoptosis-based defense mechanism, giving UV-damaged cells a selective advantage to survive additional cycles of UV exposure.[34] Further impairment of *p53* and other genes through additional UV radiation-induced mutations may then lead to even greater resistance to apoptosis, increased proliferation, and ultimately development of SCC. The increased susceptibility of *p53*-deficient mice to UV radiation-induced SCC[35] highlights this protective role of *p53*.

_p53_ MUTATIONS IN SQUAMOUS CELL CARCINOMA. Consistent with the scenario described in Section "*p53* in the Defense Against Skin Cancer," mutations in the *p53* gene are a common finding in SCC.[36] In most cases, these are C→T single base and CC→TT tandem transition mutations at dipyrimidine sequences, i.e., "UVB-signature" mutations.[37] Most SCCs exhibit loss of heterozygosity with respect to *p53* and isolated mutations on the remaining allele. In one study, the *p53*-apoptosis pathway was disrupted in 50% of oral SCCs. With respect to SCC precursors, *p53* mutations were found in up to 75% of AK and SCC in situ lesions.[38] Interestingly, although different *p53* mutations were found in separate AKs, all cells within a single precursor lesion had the same mutation.[31] Mutations in *p53* can also be detected in keratinocytes from clinically normal sun-exposed skin.[39] Keratinocytes with *p53* mutations occur in clonal patches that are larger and more frequently in sun-exposed skin.[40] These findings substantiate a clonal basis for UV radiation-induced SCC and suggest that *p53* mutation is an early event in the development of SCC.

In addition to undergoing mutation, *p53* can be compromised in keratinocytes infected with HPV. The E6 protein encoded by oncogenic HPV types binds *p53* and targets it for rapid degradation, which disables the *p53*-apoptosis pathway. This is a primary mechanism by which HPV infection predisposes to SCC (see Chapter 196).

OTHER APOPTOTIC REGULATORS IN SQUAMOUS CELL CARCINOMA. In addition to dysregulation of *p53*, dysregulation of other apoptotic regulatory proteins has been described in SCC. In a study of vulvar SCC, expression of the apoptotic inhibitor Bcl-2 correlated with metastasis.[41] Similarly, in esophageal SCC, expression of the apoptotic inhibitor Bcl-XL correlated with tumor invasion and metastasis.[42] In SCC of the tongue, low apoptotic index and decreased expression of the proapoptotic Bcl-2-associated X protein (Bax) correlated significantly with poor prognosis, whereas low Bcl-2 expression was associated with a favorable clinical outcome.[43] Expression of the antiapoptotic Bcl-2-associated athanogene 1 (BAG-1) was associated with nodal metastasis in oral SCC.[44] Consistent with these observations, transgenic mice expressing Bcl-2 and Bcl-XL in the skin exhibit increased susceptibility to chemical-induced tumorigenesis. In addition to these Bcl-2 family members, the inhibitor of apoptosis protein survivin is expressed in both SCC and precursor lesions,[45] and in one study its expression correlated with aggressive tumor phenotype.[46] Interestingly, survivin may be negatively regulated by the binding of *p53* to its promoter.[47] More recent studies in transgenic mice have yielded paradoxical results, which suggests that apoptosis may be required in the initial phase of UV radiation-induced clonal expansion.[48]

IMMUNE EVASION. Working with UV radiation-induced SCCs in mice, Kripke and colleagues first demonstrated the importance of immunosuppression in UV radiation-induced SCC in the 1970s (see Chapter 90). They found that although UV radiation-induced SCC was promptly rejected when transplanted into genetically identical recipient mice, the transplanted tumors grew rapidly, and rejection did not occur if recipient mice were first treated with a subcarcinogenic dose of UV radiation. These experiments suggested that UV radiation not only induced SCC but also impaired the ability of host animals to mount protective immune responses against foreign tumor antigens.

CLINICAL FINDINGS

In white men and women, the majority of SCCs arise on sun-exposed areas such as the head, neck, and dorsal hands. SCC of the legs is more common in women.[49] On the other hand, in blacks SCCs tend to be distributed equally on sun-protected and sun-exposed areas.[50] SCC typically presents in solitary fashion, arising from precursor lesions as noted earlier. An exception is in immunosuppressed patients, who may manifest eruptive SCCs.

DEVELOPMENT FROM PRECURSOR LESIONS

(See Chapter 113)

AKs often occur as a multiplicity of lesions, ranging in size from pinpoint to over 2 cm, and the borders are usually ill defined. A dry adherent scale gives them a rough, gritty texture. By contrast, lesions of Bowen disease are usually solitary, sharply demarcated, scaling papules or plaques, often initially mistaken for eczema, psoriasis, or lichen simplex. The latter disorders are often pruritic, whereas Bowen disease is usually not. In sun-protected sites, Bowen disease may have a noneczematous appearance. For example, it may appear verrucous in the anogenital area, nail bed, and eyelid, and as a dark patch or oozing erythematous plaque in intertriginous areas. These precursor lesions



Figure 114-1 Papular squamous cell carcinoma (SCC) of the ear. The differential diagnosis includes chondrodermatitis nodularis helicis, which, unlike SCC, is associated with pain.

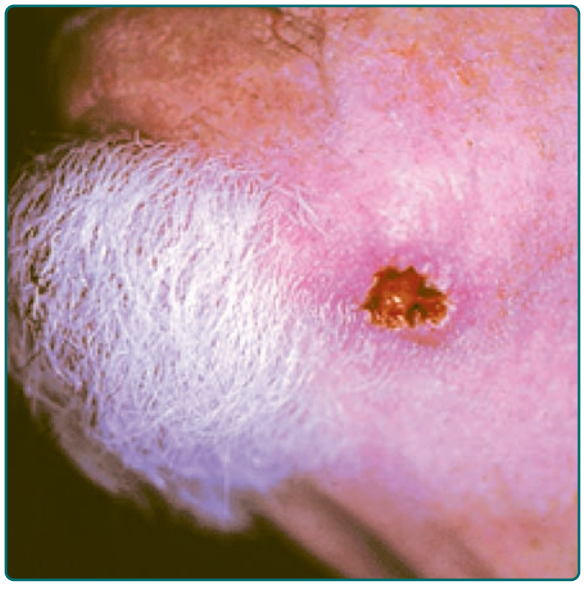

Figure 114-2 Ulcerative squamous cell carcinoma of the jaw. In this region, extension of the cancer can invade the marginal mandibular nerve.

are usually asymptomatic, and the development of tenderness, induration, erosion, increased scale, or enlarging diameter may herald evolution into SCC. Typically, a patient with multiple AKs may present with a single lesion that gradually becomes more prominent than the rest (Fig. 114-1), or with a solitary, persistent, nonpruritic, scaling patch that is unresponsive to treatment with topical steroids.

SQUAMOUS CELL CARCINOMA MORPHOLOGIES

A firm, flesh-colored or erythematous, keratotic papule or plaque is most common (see Fig. 114-1), but SCCs may also be pigmented. Other presentations include as an ulcer (Fig. 114-2), a smooth nodule (Fig. 114-3), or a thick cutaneous horn. SCC may also be verrucous or present as an abscess, particularly if in a periungual location (see Fig. 113-9 in Chapter 113). The margins may be indistinct. With enlargement, there is usually increased firmness and elevation. Progressive tumor invasion ultimately results in fixation to underlying tissues. Especially in the head and neck region, an enlarged lymph node nearby that is firm and nontender may indicate tumor metastasis (Fig. 114-4).

ORAL SQUAMOUS CELL CARCINOMA

SCC of the oral cavity usually occurs in patients with a long history of cigarette smoking, tobacco chewing, or alcohol use, but it has now been documented in younger adults without these traditional risk factors. There is a male predominance, and the palate and tongue are the most common sites. Oral SCC most commonly evolves from lesions of erythroplakia and is usually asymptomatic (see Chapter 113). Distinct patterns include a persistent rough red patch or granular velvety red plaque that ultimately becomes firm and nodular. Surprisingly, the risk of transformation to SCC does not appear to correlate with the degree of epithelial dysplasia.[51] The floor of the mouth, ventrolateral tongue, and soft palate are considered high-risk sites. It may also present as a peritonsillar abscess.

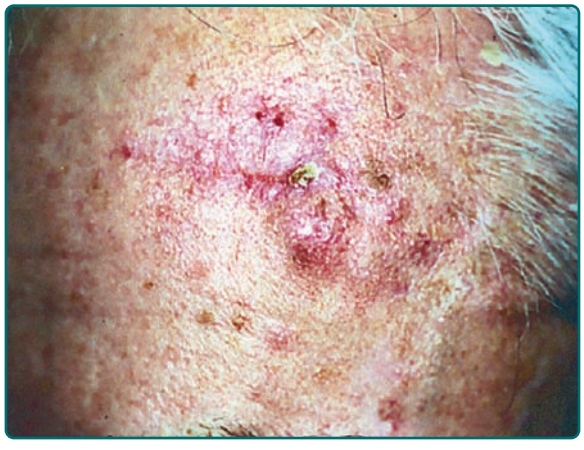

Figure 114-3 Nodular squamous cell carcinoma of the forehead. This lesion is recurrent and can be seen arising in the previous surgical scar. It should be considered high risk.



Figure 114-4 Preauricular mass resulting from metastasis of cutaneous squamous cell carcinoma (SCC). Involvement of the parotid gland can result from metastasis of SCC in the temple and ear region.

LOWER LIP SQUAMOUS CELL CARCINOMA

SCC of the lower lip begins as a roughened papule of actinic cheilitis or scaly leukoplakia, with slow progression to a tumor nodule (Fig. 114-5). Clinical clues associated with evolving SCC include persistent lip chapping with localized scale or crust, red and white blotchy atrophic vermilion zone of the lip, indistinct or "wandering" vermilion border, and small fissuring or ulceration within an area of indurated actinic cheilitis. Symptoms of underlying pain or altered sensation should be investigated as a potential sign of perineural invasion.



Figure 114-5 Squamous cell carcinoma of the lower lip that developed in the setting of habitual sun exposure and actinic cheilitis. There is a large but subtle nodule, better felt than seen, on the lower lip. There are areas of hyperkeratosis and ulceration. Metastasis to draining lymph nodes can occur.

GENITAL SQUAMOUS CELL CARCINOMA

SCC of the vulva most commonly occurs on the anterior labia majora, beginning as a small warty nodule or an erosive erythematosus plaque. These lesions may be asymptomatic but more often are associated with pruritus or bleeding. Lesions of lichen sclerosus are another common precursor of SCC of the vulva. SCC of the cervix is associated with HPV infection, most commonly with type 16. SCC of the scrotum begins as a small pruritic verrucous lesion that becomes friable with increasing size. SCC of the penis usually occurs in uncircumcised males (see eFig. 114-5.1 in online edition) and, although very uncommon in Western countries, may account for 10% of cancers in places where genital hygiene is poor. A distinct precursor of penile SCC is erythroplasia of Queyrat (see Chapter 113), characterized by a velvety red plaque. In addition to lack of circumcision, penile SCC has been associated with a history of condyloma and phimosis and lichen sclerosus et atrophicus (see Chapters 65 and 78). The genitalia were once thought to be a common location for SCC after long-term therapy with psoralen and UVA radiation, but this complication can be avoided by shielding the genitalia during treatment, and such an association is rarely seen today. Perianal SCC may also occur (Fig. 114-6).

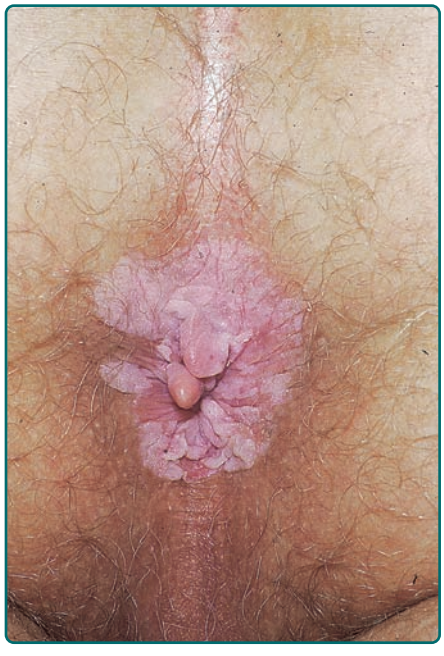

Figure 114-6 Perianal squamous cell carcinoma (SCC) in situ. Identification of these lesions requires thorough proctoscopic examination and monitoring for invasive SCC.

SCAR SQUAMOUS CELL CARCINOMA

SCCs arising in scars typically begin decades after injury, with skin breakdown and persistent erosion. Most commonly this occurs on the lower extremities at sites of chronic pyogenic or venous stasis ulcers. Gradually nodularity develops, although detection is often delayed because of concealment by surrounding indurated scar tissue. However, when SCC arises in chronic sinuses nodularity may not be present. The development of increased pain, drainage, or bleeding alone should raise concern and warrants further investigation.

KERATOACANTHOMA

(For Full Discussion, See Chapter 117)

The hallmark of keratoacanthoma is rapid growth, up to several centimeters in weeks, and then gradual involution over a period of months in most cases (see Chapter 117). The typical presentation is in an elderly patient on a sun-exposed site, particularly an extremity. Morphologically, keratoacanthoma is usually a large, smooth, dome-shaped, verrucous nodule with a central keratotic crater. Although historically viewed as a benign neoplasm because of its tendency toward spontaneous resolution, keratoacanthoma can be locally destructive and aggressive and must be viewed as a clinical subtype of SCC. This tumor may occur in association with sebaceous neoplasms and gastrointestinal malignancies in Muir–Torre syndrome.

VERRUCOUS CARCINOMA

Verrucous carcinoma is a form of SCC that encompasses several clinical entities, all characterized by slow-growing exophytic tumors with a cauliflower-like appearance that develop at sites of chronic irritation.[52] They may be clinically mistaken for giant warts. Four subtypes are recognized based on site of occurrence. Type I consists of oral tumors on the buccal mucosa of elderly male tobacco chewers and has been referred to as *oral florid papillomatosis* (Fig. 114-7). Representing 2%–12% of all oral cancers, these tumors are most commonly found on the buccal mucosa, tongue, gingiva, and floor of the mouth. Type II is the anogenital type, as described by Buschke and Loewenstein. It occurs on the glans penis of young uncircumcised males, on the scrotum, on the perianal region in both sexes, and, less commonly, on the female genitalia. Type III, also known as *epithelioma cuniculatum*, is a malodorous tumor often found on the plantar area in elderly men (Fig. 114-8) It usually involves the skin underlying the first metatarsal head and tends to form draining sinuses that are caniculated (like rabbit burrows) in appearance. Finally, type IV occurs at other sites, including the scalp, trunk, and extremities. Detection of sequences from HPV types 6, 11, 16, and 18 in epithelioma cuniculatum and type 11 sequences in oral verrucous carcinoma raises the possibility that these tumors evolve from verruca vulgaris.



Figure 114-7 Verrucous carcinoma presenting as a thick plaque arising on the buccal mucosa. This type of tumor was formerly called *oral florid papillomatosis*.

METASTATIC SQUAMOUS CELL CARCINOMA

Metastatic SCC in the skin can have a variety of presentations. It may be signaled by a palpable lymph node near the site of treatment of a previous SCC. On the other hand, it may present as large keratotic papules or nodules resembling the primary lesion (Fig. 114-9). Metastatic SCC on the skin may be the first sign of internal malignancy, initially presenting in the skin as clusters of firm pink or red papules that may be keratotic centrally.



Figure 114-8 Epithelioma cuniculatum, verrucous carcinoma of the foot.

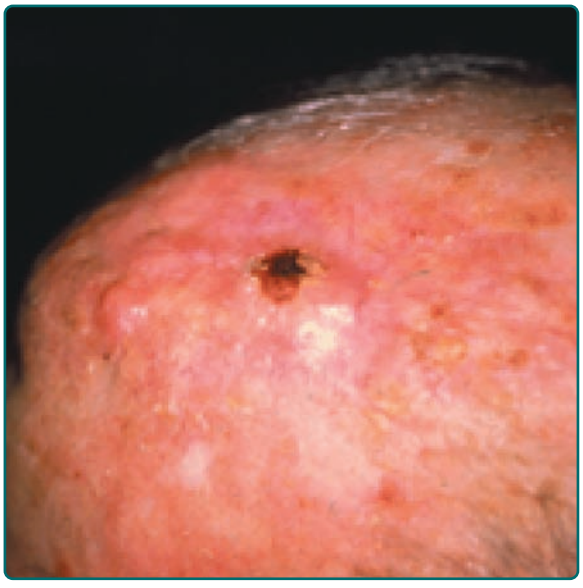

Figure 114-9 Squamous cell carcinoma metastatic to skin.

HISTOPATHOLOGY

GENERAL CONSIDERATIONS

The hallmark of invasive SCC is the extension of atypical keratinocytes beyond the basement membrane and into the dermis (Fig. 114-10). The absence of a connection between tumor cells and the epidermis should raise concern for metastatic SCC, although this may simply reflect undermining from adjacent tumor. In every case, it is important to note clues that may indicate a precursor lesion or particular etiology. For example, the presence of solar elastosis and keratinocyte atypia at the margins would suggest that the SCC is actinically derived. On the other hand, the presence of scar tissue may indicate recurrent disease or a sinister scar-associated SCC. These considerations have important implications for treatment and prognosis, as discussed in Section "Treatment."

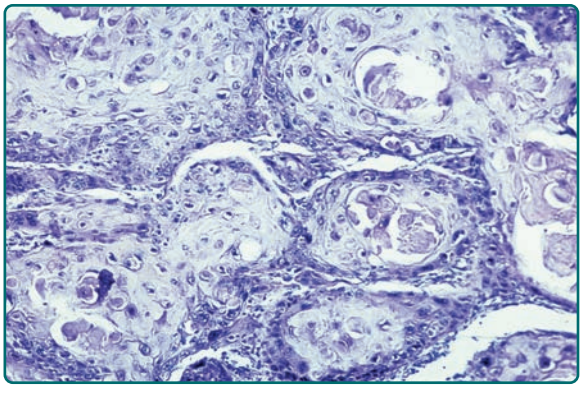

Figure 114-10 Squamous cell carcinoma demonstrating invasive cancer with atypical keratinocytes and foci of keratinization.

BASIC FEATURES

The tumor may appear as single cells, small groups or nests of cells, or a single mass. The inferior border may broadly impose on the dermis or be represented by individual foci of microinvasion. Invasive tumor is usually confined to the dermis and subcutaneous involvement is unusual. There are typically varying proportions of normal-appearing and atypical squamous cells, the latter characterized by increased mitoses, aberrant mitotic figures, nuclear hyperchromasia, and loss of intercellular bridges. Squamous differentiation is seen as foci of keratinization in concentric rings of squamous cells called *horn pearls*. Loss of differentiation is associated with decreased keratin production.

GRADING

Histologic grading of SCC is based on the degree of cellular differentiation. Low-grade tumors are comprised of uniform cells, resembling mature keratinocytes, with intracellular bridges and keratin production. By contrast, high-grade SCCs are characterized by atypical cells, loss of intracellular bridges, and minimal or absent keratin production. Another feature of higher grade tumors is a less distinct demarcation between malignant cells and adjacent normal stroma. In 1932, Broders[53] introduced a formal grading system based on keratinocyte differentiation that is still used today. Tumors are graded on a scale of 1–4 based on increasing percentages of undifferentiated cells (Table 114-2). In addition to grade, the depth of penetration, tumor thickness, and hair follicle involvement should also be reported.

HISTOLOGIC SUBTYPES

There are many histologic subtypes of SCC.[54] In the adenoid (or pseudoglandular) SCC, there is a tubular microscopic pattern and keratinocyte acantholysis. In clear cell SCC, the keratinocytes appear clear as a result of hydropic cytoplasmic swelling and accumulation of lipid vacuoles. Spindle cell SCC reveals spindle-shaped atypical cells. Signet-ring cell SCC is

TABLE 114-2
Broders' Grading System for Squamous Cell Carcinoma

Grade	% Undifferentiated Cells	Other Features
1	<25	Keratinization
2	<50	
3	<75	
4	>75	Atypia, loss of intracellular bridges

a rare variant characterized by concentric rings composed of keratin and large vacuoles corresponding to markedly dilated endoplasmic reticulum. In addition, a basaloid variant has been described. In verrucous carcinoma, the superficial component resembles verruca vulgaris with prominent acanthosis and papillomatosis, whereas the deeper component extends downward, displacing collagen bundles. Finally, keratoacanthoma reveals a symmetric keratin-filled crater, with the epidermis on each side extending over to form a distinct lip.

DIAGNOSIS AND DIFFERENTIAL DIAGNOSIS

DETERMINATION OF THE DIAGNOSIS

The diagnosis of SCC is always made by skin biopsy. Any persistent, enlarging, or nonhealing lesion, particularly if on a sun-exposed site, warrants biopsy evaluation. It is important that the biopsy be of sufficient depth so that invasive SCC can be distinguished from in situ disease. If a lesion is flat or minimally elevated (less than 1 mm), the superficial shaving technique can be used to minimize wound size and scarring and is usually adequate. For elevated lesions, the punch technique or a deep shave excision should be used to ensure that a specimen of adequate depth is taken. Because the diagnosis of keratoacanthoma depends largely on overall architecture, performing excisional biopsy or taking an incisional ellipse through the entire lesion is recommended. A tangential excision through the deep dermis also usually suffices.

DIFFERENTIAL DIAGNOSIS

Clinically, the differential diagnosis of SCC is long, but it can be narrowed based on lesion morphology. For verrucous or scaly lesions, benign conditions to consider include wart, seborrheic keratosis, AK, melanocytic nevus, pyogenic granuloma, eccrine poroma, and deep fungal infections such as chromomycosis. The entity "erosive pustular dermatosis of the scalp" is a benign condition that is often initially mistaken for SCC but responds to potent topical steroids.[55] Other malignant verrucous lesions include atypical fibroxanthoma, BCC, Bowen disease, verrucous melanoma, Merkel cell carcinoma, and, of course, metastatic SCC. Pigmented SCC in particular may mimic melanoma. For ulcerative lesions, additional diagnoses include trauma, BCC, and herpes virus infection (with either herpes simplex virus or varicella-zoster virus).

Histologically, the differential diagnosis of well-differentiated SCC includes verruca vulgaris and inverted follicular keratosis. In addition, reactive epidermal hyperplasia (pseudoepitheliomatous hyperplasia) secondary to mycosis, eruptions in response to halogenated drugs (bromoderma and iododerma), and even mechanical trauma can mimic SCC. However, in these hyperplasias the keratinocytes usually remain well differentiated; the margins of the proliferating epidermis are often pointed or irregular, rather than bulbous; there is leukocyte invasion with occasional keratinocyte disintegration; and granulomas or intraepidermal abscesses may be present.[56] Some adenoid SCCs may demonstrate a pseudovascular pattern, with erythrocytes in pseudovascular spaces, and may be confused with angiosarcoma; these tumors do not express factor VIII antigens or bind ulex agglutinin. Clear cell SCC may simulate adnexal tumors with sebaceous differentiation or sebaceous carcinoma. Distinguishing spindle cell SCC from atypical fibroxanthoma is difficult. The differential diagnosis of poorly differentiated SCC also includes fibrosarcoma, Merkel cell carcinoma, and melanoma. In most cases, SCC can be distinguished from these others by special stains for various cytokeratins, but in difficult cases electron microscopy may be needed to establish the diagnosis. In general, SCC does not stain for melanocyte (S100 protein, homatropine methylbromide) or smooth muscle (vimentin, actin) markers.

RECURRENCE AND METASTASIS

SCC, like BCC, may cause local tissue destruction, but it also has significant potential for metastasis. Metastases, when they occur, are generally to regional lymph nodes and are detected 1–3 years after initial diagnosis and treatment.[19] In many cases, metastasis is preceded by local recurrence at the site of the primary lesion. Historically, the reported rate of metastasis for SCC has ranged from 0.5% to 6%,[57] and metastasis tends to occur with tumors that are large, recurrent, and involve deep structures or cutaneous nerves (Fig. 114-11).

HIGH-RISK LESIONS

In a classic study, Rowe et al[58] reviewed all major series of SCC dating back to 1940 to determine risk factors associated with recurrence and metastasis. Table 114-3 summarizes the characteristics of "high-risk" lesions. With respect to size, tumors smaller than 2 cm in diameter are low risk, with an overall metastatic rate of roughly 1%. In one study,[59] the metastatic rate increased to 9.2% and 14.3% for tumors of 2–5 cm and larger than 5 cm, respectively. With respect to depth and invasion, tumors less than 4-mm deep and rated as Clark levels I–III have limited metastatic potential,

TABLE 114-3
High-Risk Squamous Cell Carcinoma

- Diameter >2 cm
- Depth >4 mm and Clark level IV or V
- Tumor involvement of bone, muscle, nerve
- Location on ear, lip
- Tumor arising in scar
- Broders grade 3 or 4
- Patient immunosuppression
- Absence of inflammatory infiltrate

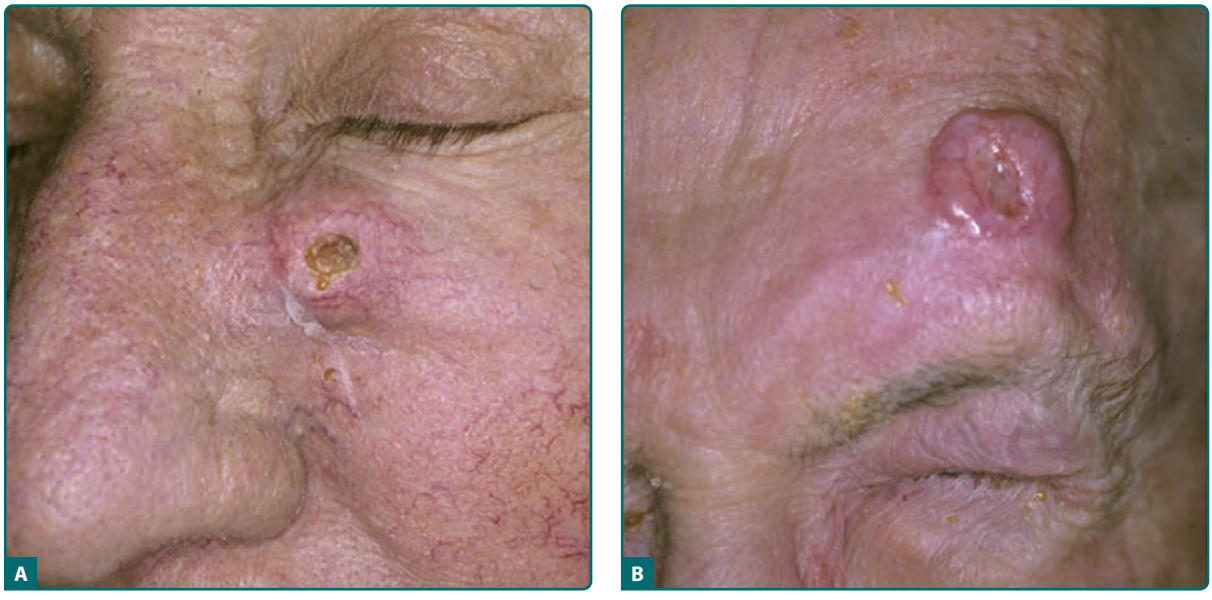

Figure 114-11 **A.** Infiltrative squamous cell carcinoma (SCC) demonstrating retraction of underlying tissue of the left cheek, where extension might involve infraorbital nerve. **B.** SCC of left side of forehead, where extension to bone with invasion or along the supraoptic nerves might lead to death.

whereas close to half of those deeper than 4 mm and at Clark levels IV or V were metastatic in some series. Tumor involvement of bone, nerve, or muscle tissue is strongly associated with metastasis. With respect to anatomic site, SCC of the ear has the highest rate of recurrence (18.7%), whereas lip SCC has the highest rate of metastasis (13.7%), with half of lip metastases present at the time of initial diagnosis. All SCCs arising in scars are high risk, with metastatic rates approaching 40% in some series.[60] By contrast, SCCs arising in actinically damaged skin are of considerably lower risk, with an average metastatic rate of 5.2%. Poorly differentiated SCCs (Broders grade 3 or 4) demonstrate a recurrence rate of 28.6% and a metastatic rate of 32.8%, compared with 13.6% and 9.2%, respectively, for well-differentiated tumors. The prognosis is particularly poor for spindle cell SCCs.[61] Immune status is another important consideration. One study[62] found that 23% of patients with metastatic SCC were immunosuppressed. A heavy inflammatory response appears to be a favorable prognostic sign, because absence of infiltrate has been correlated with higher rates of recurrence and metastasis.

TREATMENT

Box 114-1 summarizes the various modalities available for treatment of SCCs. Treatment selection is directed largely by assessment of tumor risk for recurrence and metastasis, as discussed in the previous section. Ablative techniques such as electrodesiccation and curettage, liquid nitrogen cryotherapy, carbon dioxide laser, intralesional chemotherapy, and photodynamic therapy are superficial, do not allow histologic margin control, and thus are generally inappropriate for treatment of invasive SCCs. Topical chemo/immuno therapy may be appropriate for SCC in situ, and topical 5-fluorouracil has been used for treatment of conjunctival SCCs.[63]

SURGICAL EXCISION

Conventional surgical excision is viewed by many as the treatment of choice for small primary SCCs. Recommended margins are 4 mm for low-risk lesions or SCCs with a depth of less than 2 mm; for lesions with a depth of more than 6 mm or a diameter larger than 1 cm, Mohs micrographic surgery is recommended.[64] Mohs micrographic surgery is also recommended in specific circumstances when the highest cure rate and minimal tissue destruction are desired (Table 114-4). Specifically, tumors involving the periocular or periauricular areas; recurrent or large tumors; lesions with poorly defined clinical margins; tumors at sites where tissue preservation is important (nasal tip, lip, eyelid, ear, genitalia); deeply infiltrative tumors; lesions

BOX 114-1 TREATMENT OF SQUAMOUS CELL CARCINOMA

- Nonexcisional ablative techniques (in situ disease only, or in special circumstances)
- Mohs micrographic surgery
- Conventional surgical excision
- Topical therapy (in situ disease only)
- Radiation therapy

TABLE 114-4
Indications for Mohs Micrographic Surgery

- Infiltrative squamous cell carcinoma (SCC)
- Poorly defined clinical margins
- Location on lip, ear, nail bed, nasal tip, eyelid, genitalia
- History of radiation at site
- Involvement of nerve, bone, muscle
- Immunosuppressed patient
- Recurrence of large SCC
- Verrucous carcinoma
- SCC arising from chronic scarring conditions

at sites that were previously irradiated; tumors with involvement of underlying structures (nerve, bone, muscle); tumors in immunosuppressed patients; and lesions at sites associated with high recurrence rates should strongly be considered for Mohs micrographic surgery.[65] Additional indications include verrucous carcinomas and high-risk SCCs such as those arising from chronic scarring conditions.

RADIATION

Radiation can be used to treat superficially invasive to moderate-risk lesions and serves as an important adjuvant to excisional surgery in treating residual microscopic disease and providing prophylaxis against metastatic disease. It has been shown to be particularly useful for SCCs of the external auditory canal,[66] although radiation therapy may lead to hearing loss.[67] Radiation therapy is not advised for verrucous carcinoma, in which there is an associated low rate of anaplastic transformation. Radiation may also be used as adjuvant therapy in cases in which perineural SCC was identified in surgical pathologic specimens but treatment failures occurred.

TOPICAL THERAPY

Both topical 5-fluorouracil and imiquimod have been used in patients with SCC in situ Practice varies, but most regimens consist of application either once or twice daily for 2–4 weeks (5-fluorouracil) or three to five times per week for 2–4 months (imiquimod). Recent evidence suggests that efficacy of imiquimod may be due to enhanced interferon-γ production and effector function of T cells infiltrating the tumor.[B] Topical therapy is not appropriate for invasive disease since there will be minimal penetration of drug into the dermis.

RECURRENCE RATES

Many risk factors for recurrence and metastasis have been identified.[9] In their review noted in Section "High-Risk Lesions," Rowe et al[58] also assessed responses to treatment. They reported increasing combined rates of recurrence for each of the following treatment modalities (for primary cancers): Mohs micrographic surgery (3.1%), electrodesiccation and curettage (3.7%), excisional surgery (8.1%), and radiation (10%). A review of the use of Mohs micrographic surgery to treat SCC with 4-year follow-up reported a cure rate of 92%.[68] The surprisingly low rate of recurrence for electrodesiccation and curettage likely reflects its judicious use for treatment of low-risk lesions. Similarly, the recurrence rates for both Mohs micrographic surgery and excisional surgery may be somewhat skewed by their use in treating high-risk lesions. A systematic review of studies using topical therapy for SCC in situ (with at least 6 months histologic follow-up) revealed clearance rates of 27%–85% with 5-fluorouracil and 73%–88% with imiquimod.[C] For lip SCC, the overall recurrence rate was 2.3% with Mohs micrographic surgery compared with 10.5% with other treatment modalities; for ear SCC, the recurrence rates were 5.3% and 18.7%, respectively. For all recurrent tumors, cure rates were 76.7% with excision, compared with 90% with Mohs micrographic surgery. For low-risk SCCs, overall recurrence rates were 1.9% with Mohs micrographic surgery versus 16.5% with all other modalities. Overall 5-year survival rate for patients with metastatic SCCs was 26.8%, with poorer outcomes among patients with lip lesions[69] and those treated with surgery alone (and no radiation).

TREATMENT OF HIGH-RISK LESIONS

Management of high-risk lesions is reviewed elsewhere.[70] Oral 5-fluorouracil has been used to treat aggressive lesions refractory to conventional therapies. Additional treatments, including β-carotene, interferon, and retinoids, have been employed with variable results. High-risk lesions may require formal staging. Computed tomography or magnetic resonance imaging may be useful in the detection of advanced perineural involvement of head and neck SCC.[71] Sentinel lymphadenectomy has been combined with Mohs micrographic surgery.[72] Involvement of lymph nodes may warrant radical lymph node dissection and radiation therapy. Elective cervical lymphadenectomy may be indicated for high-risk lesions of the lip.[73] When a clinical lymph node examination yields negative results, further intervention may still be indicated if the tumor is considered sufficiently high risk.

PATIENT FOLLOW-UP

After a diagnosis of SCC, all patients should be considered at high risk for developing additional lesions of SCC as well as BCC. They should be seen at regular intervals, ranging from 3 months to 12 months, depending on the degree of risk of prior lesions, status of precursor lesions, and individual patient compliance. A complete skin examination should be performed at each visit, including examination of the oral mucosa. In addition, sites of previous lesions and treatments should be assessed for signs of recurrence. Finally, a lymph node examination is indicated to monitor for metastatic disease.

PREVENTION

Those at risk for SCC—namely, persons with a prior history of nonmelanoma skin cancer or any of the predisposing conditions discussed earlier—should be monitored closely. They should receive complete skin examinations on a regular (annual or semiannual) basis.

SUN PROTECTION

The most effective preventive measure is protection from sun exposure. It is likely that adequate sun protection beginning in early childhood could prevent most SCCs.[74] This requires establishing patterns of behavior at an early age, such as applying sunscreen repeatedly, wearing hats and protective clothing, and avoiding the sun during the hours of peak intensity. However, the importance of sun exposure prevention in childhood should not be construed to mean that sun protection later in life will be of no benefit. There is evidence that aggressive sun protection throughout life can prevent the development of SCC precursor lesions and cancers themselves.

TREATMENT OF PRECURSOR LESIONS

Treatment of precursor lesions is expected to reduce the incidence of SCC. Several options are available for treatment of AK (see Chapter 113). Isolated lesions can often be effectively removed by liquid nitrogen cryotherapy. For patients with many AKs or areas of skin with a multitude or confluence of lesions, topical chemotherapy using 5-fluorouracil or imiquimod is a better option. Topical diclofenac has also been introduced as therapy for widespread AK. Photodynamic therapy using aminolevulinic acid is also an option for areas involving multiple lesions.

OTHER PREVENTIVE MEASURES

A number of additional preventive measures can be taken that may reduce the incidence of SCC in individual patients. For example, the use of condoms can prevent transmission of HPV and may thereby reduce the risk of genital SCC. Decreased alcohol consumption and smoking cessation is likely to reduce the risk of oral SCC. Several years ago there was great interest in the use of both retinoids and interferons as systemic chemopreventive agents. Low-dose etretinate (10 mg/day) has been used successfully in renal transplant patients.[75] A more recent recommendation is isotretinoin (Accutane; 10 mg every day or every other day) in addition to topically applied tretinoin.[76] The introduction of a vaccine for the prevention of infection with HPVs and of precancerous lesions of the cervix may one day translate into the prevention of all HPV-induced precancerous lesions of the skin.[78]

KEY REFERENCES

Full reference list available at www.DIGM8.com

DVD contains references and additional content

9. Alam M, Ratner D: Cutaneous squamous-cell carcinoma. *N Engl J Med* **344**:975, 2001
14. Miller DL, Weinstock MA: Nonmelanoma skin cancer in the United States: Incidence. *J Am Acad Dermatol* **30**:774, 1994
15. Weinstock MA: Nonmelanoma skin cancer mortality in the United States, 1969 through 1988. *Arch Dermatol* **129**:1286, 1993
19. Johnson TM et al: Squamous cell carcinoma of the skin (excluding lip and oral mucosa). *J Am Acad Dermatol* **26**:467, 1992
31. Burnworth B et al: The multi-step process of human skin carcinogenesis: A role for p53, cyclin D1, hTERT, p16, and TSP-1. *Eur J Cell Biol Jan* **86**(11-12):763-780, 2007
34. Leffell DJ, Brash DE: Sunlight and skin cancer. *Sci Am* **275**:52, 1996
36. Brash DE: Roles of the transcription factor p53 in keratinocyte carcinomas. *Br J Dermatol* **154**(Suppl 1):8, 2006
58. Rowe DE et al: Prognostic factors for local recurrence, metastasis, and survival rates in squamous cell carcinoma of the skin, ear, and lip. Implications for treatment modality selection. *J Am Acad Dermatol* **26**:976, 1992
64. Brodland DG, Zitelli JA: Surgical margins for excision of primary cutaneous squamous cell carcinoma. *J Am Acad Dermatol* **27**:241, 1992
78. Griffiths P: Anticipating full benefits from the new papillomavirus vaccines. *Rev Med Virol* **17**:1, 2007

Chapter 115 :: Basal Cell Carcinoma

:: John A. Carucci, David J. Leffell & Julia S. Pettersen

BASAL CELL CARCINOMA AT A GLANCE

- Most common cancer in humans.
- Caused by exposure to ultraviolet light; associated with *PTCH* gene mutation in many cases.
- Incidence increasing in younger populations.
- Locally destructive.
- Treated by surgical excision, electrodesiccation and curettage, Mohs micrographic surgery, and occasionally irradiation.

BCC EPIDEMIOLOGY

BCC is the most common cancer in humans. It is estimated that over 1 million new cases occur each year in the United States. The malignancy accounts for approximately 75% of all nonmelanoma skin cancers (NMSC) and almost 25% of all cancers diagnosed in the United States.[1] Epidemiological data indicate that the overall incidence is increasing worldwide significantly by 3%–10% per year.[2]

BCC is more common in elderly individuals but is becoming increasingly frequent in people younger than 50 years of age. Christenson et al noted a disproportionate increase in BCC in women under age 40.[3] Men are affected slightly more often than are women. Levi et al reported that the incidence of BCC rose steadily in the Swiss Canton of Vaud between 1976 and 1998 to levels of 75.1 in 100,000 in males and 66.1 in 100,000 in females.[4,5] Stang et al in Westphalia, Germany found that the incidence rate of BCC during a 5-year period (1998–2003) was 63.6 in men and 54.0 in women.[6] A study of NMSC in Aruba supported these findings.[7] In that study, BCC was the most common type of skin cancer diagnosed between 1980 and 1995. Tumors were more frequent in patients older than 60 years of age, and 57% were in men. The highest percentage of lesions occurred on the nose (20.9%), followed by other sites on the face (17.7%).[7] Incidence in Europe was examined by the recent study in Croatia. From 2003 to 2005, the crude incidence rate for the Croatian population of 100,000 was 54.9 for men and 53.9 for women. The vast majority of BCCs were located on the head and neck.[8]

BCC character develops on sun-exposed skin of lighter skinned individuals. Incidence rates of BCC in Asians living in Singapore increased from 1968 to 2006, especially among the older, more fairly complected Chinese patents. Skin cancer trends in Asians from 1968–2006 showed BCC rates increased the most among persons older than 60 years.[9]

BCC is rare in dark skin because of the inherent photoprotection of melanin and melanosomal dispersion. An estimated 1.8% of BCCs occur in blacks, and BCC is approximately 19 times more common in whites than blacks.[10]

Risk factors for BCC have been well characterized and include ultraviolet light (UVL) exposure, light hair and eye color, northern European ancestry, and inability to tan.[1] An Italian study indicated the important role of sunburns, and therefore intense sun exposure, rather than that of prolonged sun exposure to increase the risk of BCC.[11]

BCC ETIOLOGY AND PATHOGENESIS

The pathogenesis of BCC involves exposure to UVL, particularly the ultraviolet B spectrum (290–320 nm) that induces mutations in tumor suppressor genes.[12,13] UVB radiation damages DNA and affects the immune system resulting in a progressive genetic alterations and neoplasms. UV-induced mutations in the *p53* tumor suppressor gene have been found in about 50% of BCC cases.[14]

Currently, it is thought that the upregulation of the mammalian development signaling pathway, Hedgehog (HH), is the pivotal abnormality in all BCCs, and there is evidence that little more than this upregulation is required for BCC carcinogenesis.[15,16] The mutations that activate the aberrant HH signaling pathway are found in PTCH1 and Smoothened (SMO). Approximately 90% of sporadic BCCs have identifiable mutations in at least one allele of *PTCH1*, and an additional 10% have activating mutations in the downstream SMO protein.[17] The most frequently identified mutations in PTCH1 and SMO are of a type consistent with UV-induced damage.[18–20]

The contribution of high-intensity sunlight exposure to BCC development in the general population is well established.[11] A latency period of 20–50 years is typical between the time of UV damage and the clinical onset of BCC. Therefore, in most cases, BCC develops on sun-exposed skin in elderly people, most commonly in the area of head and neck.[21]

Some studies indicate that intermittent brief holiday exposures may place patients at higher risk than occupational exposure.[9,22] An Italian study confirmed the role of intermittent sun exposure as a strong risk factor for BCC.[11] Ramani and Bennett reported a significantly higher incidence of BCCs in World War II servicemen stationed in the Pacific theater than in those stationed in Europe. This suggests that several months or years of intense exposure to UVL may have deleterious long-term effects.[23] Truncal BCCs can result from acute intense exposures sufficient to cause sunburn on the skin of the trunk among people whose ability to tan makes the skin of their face generally less susceptible to the carcinogenic effects of UV radiation.[24]

Other factors that appear to be involved in the pathogenesis include mutations in regulatory genes,[17,25] exposure to ionizing radiation,[26,27] and alterations in immunosurveillance.[28–30]

The propensity to develop multiple BCCs may be inherited. Included among heritable conditions predisposing to the development of this epithelial cancer are nevoid basal call carcinoma syndrome or basal cell nevus syndrome (BCNS),[31] Bazex syndrome,[32] and Rombo syndrome.[33] Patients with BCNS may develop hundreds of BCCs and may exhibit a broad nasal root, borderline intelligence, jaw cysts, palmar pits, and multiple skeletal abnormalities. BCNS occurs due to mutations in the tumor suppressor *PTCH* gene.[34,35]

Bazex syndrome is transmitted in an X-linked dominant fashion.[32] Patients have multiple BCCs, follicular atrophoderma, dilated follicular ostia with ice pick scars, hypotrichosis, and hypohidrosis. In contrast, Rombo syndrome is transmitted in an autosomal dominant fashion.[33] Patients have vermiculate atrophoderma, milia, hypertrichosis, trichoepitheliomas, BCCs, and peripheral vasodilation. Hypohidrosis is not a feature of Rombo syndrome.

The role of the immune system in the pathogenesis of skin cancer is not completely understood. Immunosuppressed patients with lymphoma or leukemia[36,37] and

patients who have received an organ transplant have a marked increase in the incidence of squamous cell carcinoma but only a slight increase in the incidence of BCC.[28–30,38] Bastiaens et al found that transplant recipients developed more BCCs on the trunk and arms than did nonimmunosuppressed patients.[39] Harwood et al found that fewer BCCs occurred on the head and neck of renal transplant recipients, while more BCCs were found on the trunk and arms compared to the immune competent patients.[38] Patients with human immunodeficiency virus infection develop BCCs at the same rate as immunocompetent individuals, based on similar risk factors.[19,40,41] Immunosuppressed long-term alcoholics tend to develop infiltrative BCCs with increased frequency.[20,42] A potential link between UVL and decreased immunity has been suggested by Gutierrez-Steil et al, who demonstrated that UVL-induced BCCs express Fas ligand (CD95L).[43] They further showed that these cells were associated with CD95-bearing T cells undergoing apoptosis.[43,44] This represents a potential mechanism by which UVL might help tumor cells avoid being killed by cytotoxic T lymphocytes. Kaporis et al showed that immune suppressive regulatory T cells are surround BCC tumor nests thus providing another potential mechanism for BCC to evade host antitumor immunity.[45]

CLINICAL MANIFESTATIONS

PRESENTATION

The presence of any friable, nonhealing lesion should raise the suspicion of skin cancer. Frequently, BCC is diagnosed in patients who state that the lesion bled briefly then healed completely, only to recur. BCC usually develops on sun-exposed areas of the head and neck but can occur anywhere on the body. Features include translucency, ulceration, telangiectasias, and the presence of a rolled border. Characteristics may vary for different clinical subtypes, which include nodular, superficial, morphea-form, and pigmented BCCs and fibroepithelioma of Pinkus (FEP). The anatomic location of BCC may favor the development of a particular subtype.[46]

BASAL CELL CARCINOMA SUBTYPES

NODULAR BASAL CELL CARCINOMA. Nodular BCC is the most common clinical subtype of BCC (Fig. 115-1).[47,48] It occurs most commonly on the sun-exposed areas of the head and neck and appears as a translucent papule or nodule depending on duration. There are usually telangiectasias and often a rolled border. Larger lesions with central necrosis are referred to by the historical term *rodent ulcer* (Fig. 115-2). The differential diagnosis of nodular BCC includes traumatized dermal nevus and amelanotic melanoma.

PIGMENTED BASAL CELL CARCINOMA. Pigmented BCC is a subtype of nodular BCC that exhibits increased melanization. Pigmented BCC appears as a hyperpigmented, translucent papule, which may also be eroded (eFig. 115-2.1 in online edition). The differential diagnosis includes nodular melanoma.



Figure 115-1 Basal cell carcinoma (BCC), nodular type.

SUPERFICIAL BASAL CELL CARCINOMA. Superficial BCC occurs most commonly on the trunk and appears as an erythematous patch (often well demarcated) that resembles eczema (Fig. 115-3).[47] An isolated patch of "eczema" that does not respond to treatment should raise suspicion for superficial BCC.

MORPHEAFORM (SCLEROSING) BASAL CELL CARCINOMA. Morpheaform BCC is an aggressive growth variant of BCC with a distinct clinical and histologic appearance. Lesions of morpheaform BCC may have an ivory-white appearance and may resemble a scar or a small lesion of morphea (eFig. 115-3.1 in online edition). Thus, the appearance of scar tissue in the absence of trauma or previous surgical procedure



Figure 115-2 Basal cell carcinoma, rodent ulcer type.



Figure 115-3 Superficial basal cell carcinoma. The well-demarcated plaque with a rolled edge characteristically occurs on the trunk.

or the appearance of atypical-appearing scar tissue at the site of a previously treated skin lesion should alert the clinician to the possibility of morpheaform BCC and the need for biopsy.

FIBROEPITHELIOMA OF PINKUS. FEP classically presents as a pink papule, usually on the lower back.[25,50] It may be difficult to distinguish from an acrochordon or skin tag. Similar to basal cell carcinomas, fibroepitheliomas of Pinkus express androgen receptors, supporting its classification as a basal cell carcinoma.[51] The differential diagnoses of FEP includes acrochordon.[52]

BIOLOGIC BEHAVIOR

LOCAL INVASION

The greatest danger of BCC results from local invasion (Fig. 115-4). In general, BCC is a slow-growing tumor that invades locally rather than metastasizes.[26,27,53,54]



Figure 115-4 BCC, if untreated, can result in extensive local tissue damage.

The doubling time is estimated to be between 6 months and 1 year. If left untreated, the tumor will progress to invade subcutaneous tissue, muscle, and even bone. Anatomic fusion planes appear to provide a low-resistance path for tumor progression. Tumors along the nasofacial or retroauricular sulcus may be extensive. Metastases are rare and most are said to more closely correlate to the size and depth of tumor invasion and less so to the histologic subtype of the original tumor.[1]

Although metastases are rare, significant patient morbidity, such as local tissue destruction and disfigurement can occur. In one informative case, a patient documented the progression of his own tumor with photographs over a 27-year period.[28,55] The lesion, which encompassed an entire side of the face, including the maxillary sinus, apparently doubled over a 10-year period and grew rapidly in the 2 years before hospital admission. This scenario occurs in the context of physical or psychiatric disability that interferes with judgment or access to health care. In one of the first reports of giant BCC in India, a patient presented with a non-healing ulcer of the face, which had been present and increasing in size for over 20 years. On examination, the ulcer covered the entire left side of the face involving the preauricular, infraorbital, and bucco mandibular units of the cheek and the orbit and resulted in loss of vision.[56] In another case, a 35-cm BCC on the back of a 65-year-old man recurred after wide local excision and X-ray therapy (XRT), resulting in spinal cord compression.[57] Lethal extension to the central nervous system from aggressive scalp BCC has been reported.[58,59]

PERINEURAL INVASION

Perineural invasion (PNI) is uncommon in BCC and occurs most often in histologically aggressive or recurrent lesions.[54] The presence of PNI has been correlated with recurrent lesions, increased duration and size of lesions, and orbital invasion.[60] In one series, Niazi and Lamberty identified PNI in less than 0.2% of cases. In that series, perineural BCC was seen most often with recurrent tumors located in the preauricular and malar areas.[61] Brown and Perry found the incidence of PNI to be 3% in aggressive BCC cases. This incidence approaches that reported for cutaneous squamous cell carcinomas.[62] Leibovitch et al found an incidence rate of 2.74%.[63] Ratner et al found a higher incidence in their study (3.8%); however, this was a smaller study.[64] Leibovitch et al reported perineural spread in more than 50% of periocular BCCs eventuating in orbital invasion. These tumors required extensive surgery and in some cases exenteration (Fig. 115-5).[65] Perineural spread may manifest as pain, paresthesias, weakness, or paralysis. The presence of focal neurologic symptoms at the site of a previously treated skin cancer should raise concern about nerve involvement.

METASTASIS

Metastasis of BCC occurs only rarely, with rates varying from 0.0028% to 0.55%.[34–36,66–68] Involvement of regional lymph nodes and lungs is most



Figure 115-5 BCCs involving the canthus can invade the orbit.

common. Cases of pulmonary metastasis continue to be reported.[69] Metastasis to the bone and bone marrow has been reported.[70] Aggressive histologic characteristics, including morpheaform features, squamous metaplasia, and PNI, have been identified as risk factors for metastasis.[68] Von Domarus et al reported five cases of metastatic BCC in which perineural or intravascular invasion had been noted in three.[71] Squamous differentiation was not observed in the primary tumors in the cases they presented but was noted in two of five cases of metastatic cancer. Overall, squamous differentiation was present in 15% of the primary or metastatic tumors from the 170 cases reviewed in that series.

DIAGNOSIS

Diagnosis of BCC is accomplished by accurate interpretation of the skin biopsy results. The preferred biopsy methods are shave biopsy, which is often sufficient, and punch biopsy. A sterilized razor blade, which can be precisely manipulated by the operator to adjust the depth of the biopsy specimen, is often superior to a No. 15 scalpel for shave biopsies. A punch biopsy may be useful for flat lesions of morpheaform BCC or for recurrent BCC occurring in a scar. When biopsying a lesion, adequate tissue should be taken. Small, fragmented tissue samples may make diagnosis difficult; potentially compromising the ability to accurately assess BCC subtype and thickness, which can affect treatment choice.[72]

HISTOPATHOLOGY

Histopathologic features vary somewhat with subtype, but most BCCs share some common histologic characteristics. The malignant basal cells have large nuclei and relatively little cytoplasm. Although the nuclei are large, they may not appear atypical. Usually, mitotic figures are absent. Frequently, slit-like retraction of stroma from tumor islands is present, creating peritumoral lacunae that are helpful in histopathologic diagnosis.[73] The most common form of BCC is nodular, followed by superficial, then morpheaform. Also, nodular and morpheaform are most commonly found on the head and neck, while superficial is most often found on the trunk region.[74]

NODULAR BASAL CELL CARCINOMA

Nodular BCCs account for half of all BCCs and are characterized by nodules of large basophilic cells and stromal retraction (Fig. 115-6A). The term micronodular BCC is used to describe tumors with multiple microscopic nodules smaller than 15 µm (see Fig. 115-6B).[73] Clinically, this is the type of BCC that most commonly shows a translucent pearly papule or nodule with a rolled border and telangiectasia. The nodular form of BCC is characterized by discrete nests of basaloid cells in either the papillary or reticular dermis accompanied.[1]

PIGMENTED BASAL CELL CARCINOMA

Pigmented BCC shows histologic features similar to those of nodular BCC but with the addition of melanin.[38] Approximately 75% of BCCs contain melanocytes, but only 25% contain large amounts of melanin. The melanocytes are interspersed between tumor cells and contain numerous melanin granules in their cytoplasm and dendrites. Although the tumor cells contain little melanin, numerous melanophages populate the stroma surrounding the tumor.[73]

SUPERFICIAL BASAL CELL CARCINOMA

Superficial BCC is characterized microscopically by buds of malignant cells extending into the dermis from the basal layer of the epidermis.[38] The peripheral layer shows palisading cells. There may be epidermal atrophy, and dermal invasion is usually minimal. There may be a chronic inflammatory infiltrate in the upper dermis. This histologic subtype is encountered most often on the trunk and extremities, but may also appear on the head and neck.[73]

MORPHEAFORM BASAL CELL CARCINOMA

Morpheaform BCC, also called infiltrative or sclerosing BCC, consists of strands of tumor cells embedded within a dense fibrous stroma (see Fig. 115-6C).[73] Tumor cells are closely packed columns and, in some cases, only one to two cells thick enmeshed in a densely collagenized fibrous stroma. Strands of

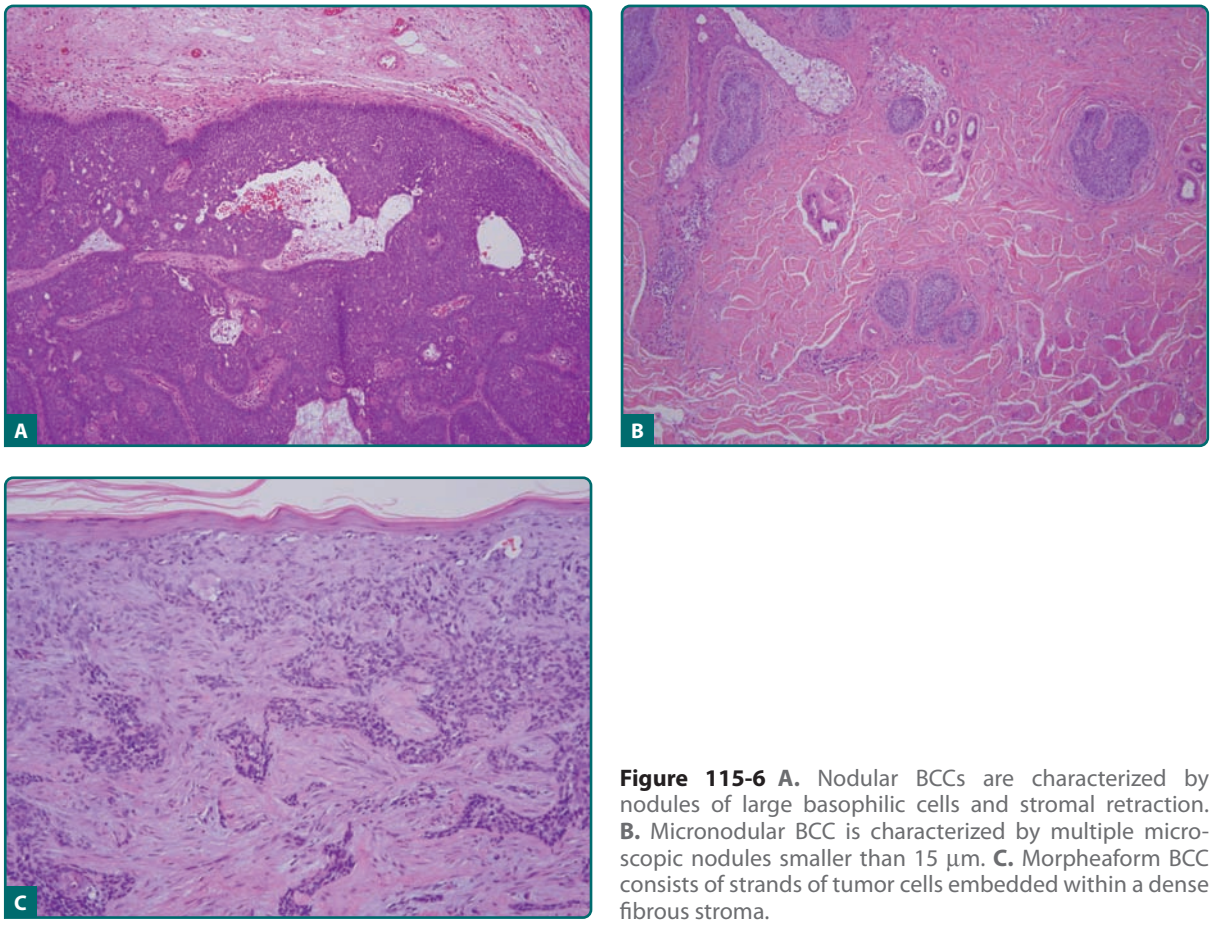

Figure 115-6 A. Nodular BCCs are characterized by nodules of large basophilic cells and stromal retraction. **B.** Micronodular BCC is characterized by multiple microscopic nodules smaller than 15 µm. **C.** Morpheaform BCC consists of strands of tumor cells embedded within a dense fibrous stroma.

tumor extend deeply into the dermis. The cancer is often larger than the clinical appearance indicates. Recurrent BCC may also demonstrate infiltrating bands and nests of cancer cells embedded within the dense fibrous stroma of scar.

FIBROEPITHELIOMA OF PINKUS

In FEP, long strands of interwoven basiloma cells are embedded in fibrous stroma with abundant collagen.[38] Histologically, FEP shows features of reticulated seborrheic keratoses and superficial BCC.[73]

BASOSQUAMOUS CARCINOMA

Basosquamous carcinoma is a form of aggressive growth BCC. It can be confused with squamous cell carcinoma and promotes controversy considering its precise histomorphologic classification as it shows both basal cell and squamous cell carcinoma differentiation in a continuous fashion.[1] Histologically, basosquamous carcinoma shows infiltrating jagged tongues of tumor cells admixed with other areas that show squamous intercellular bridge formation and cytoplasmic keratinization.

DIFFERENTIAL DIAGNOSIS

The differential diagnosis for BCC is summarized in Box 115-1.

BCC TREATMENT

Management of BCC is guided by anatomic location and histological features. Approaches include standard surgical excision, destruction by various modalities, Mohs micrographic surgery (MMS), and topical chemotherapy.[73] The best chance to achieve cure is through adequate treatment of primary BCC, because recurrent tumors are more likely to recur and cause further local destruction. An algorithmic approach to management is summarized in Fig. 115-7. While most trials have only evaluated BCCs in low-risk locations, surgery and radiotherapy appear to be the most effective treatments with surgery showing the lowest failure rates. Although cosmetic outcomes appear good with PDT, long-term follow-up data are needed. Other treatments might have some use but few have been compared to surgery. An ongoing study comparing imiquimod to surgery should clarify whether imiquimod is a useful option.[75] Overall, removal of the tumor with clear margins remains the gold standard for treating basal cell carcinoma.

BOX 115-1 DIFFERENTIAL DIAGNOSIS

NODULAR BCC
- Dermal nevus
- Squamous cell carcinoma
- Appendageal tumor
- Dermatofibroma

PIGMENTED BCC
- Nodular melanoma
- Superficial spreading melanoma
- Lentigo maligna melanoma
- Appendageal tumor
- Compound nevus
- Blue nevus

SUPERFICIAL BCC
- Bowen's disease
- Mammary or extramammary Paget's disease
- Superficial spreading melanoma
- Single plaque of psoriasis
- Single plaque of eczema

MORPHEAFORM BCC
- Scar
- Morphea
- Trichoepithelioma

FIBROEPITHELIOMA OF PINKUS
- Skin tag
- Fibroma
- Papillomatous dermal nevus

MOHS MICROGRAPHIC SURGERY

MMS offers superior histologic analysis of tumor margins while permitting maximal conservation of tissue compared with standard excisional surgery.[76,77] Rowe, Carroll, and Day report a recurrence rate of 1% for primary BCCs treated by MMS. This was superior to the rate for other modalities, including standard excision (10%), curettage and desiccation (C&D) (7.7%), XRT (8.7%), and cryotherapy (7.5%).[78] Recurrent BCCs treated by MMS reappeared at a rate of 5.6%, which was again superior to the rate for other modalities, including excision (17.6%), XRT (9.8%), and C&D (40%).[79] Leibovitch et al found that after 5 years BCC recurrence was diagnosed in 1.4% of primary and in 4% of recurrent tumors. This low 5-year recurrence rate of BCC with MMS emphasizes the importance of margin-controlled excision over other modalities.[80] MMS is the treatment of choice for morpheaform, poorly delineated, incompletely removed, and otherwise high-risk primary BCCs. It is the preferred treatment for recurrent BCC and for any BCC that occurs at a site where tissue conservation is desired. MMS is particularly useful in treating BCCs at high-risk anatomic sites, including the embryonic fusion planes represented by the nasofacial junction and retroauricular sulcus. Based on the fact that MMS provides the lowest recurrence rates, it is the treatment of first choice for primary facial BCCs with an aggressive histopathological subtype and for recurrent facial BCCs.[81] MMS has shown greater efficacy than surgical excision for the treatment of recurrent facial BCCs.[80] Mosterd et al also found that treatment with MMS leads to a significantly lower number of recurrences than treatment with surgical excision in recurrent facial BCCs.[77] From a patient perspective, one large prospective cohort study found that MMS was an independent factor for higher long-term patient satisfaction, when compared to standard excision or C&D.[82]

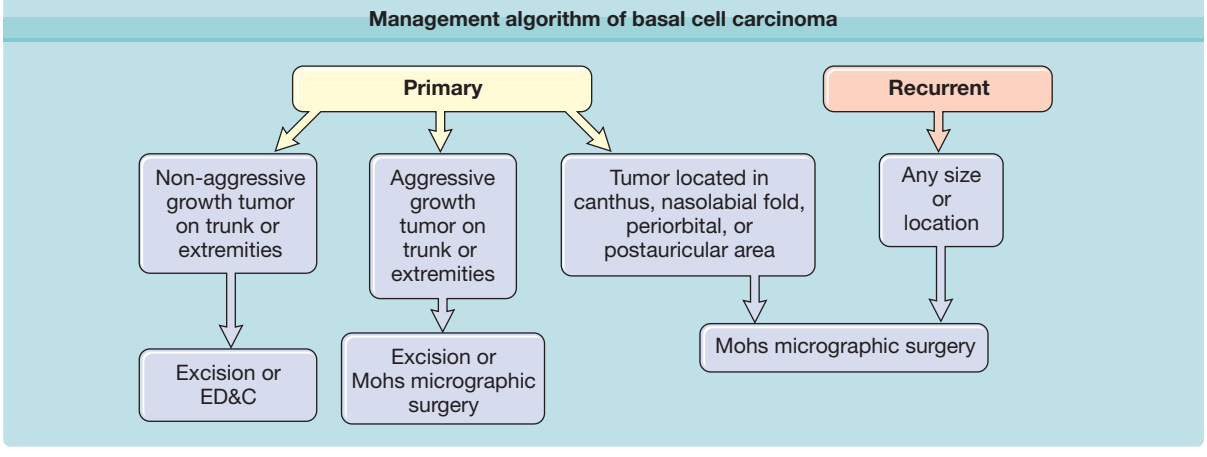

Figure 115-7 Algorithm for the management of basal cell cancer.

STANDARD EXCISION

Compared with nonexcisional techniques, standard surgical excision offers the advantage of histologic evaluation of the removed specimen; however, depending on the sectioning method used (e.g., bread-loafing), areas of margin involvement can be missed during routine histologic evaluation.[83] The authors of a recent Cochrane review concluded that, based on the available published work, surgery is the standard treatment of choice for BCC.[75] Although standard excision is appropriate for many BCCs, cure rates for standard excisional surgery are inferior to those for MMS in cases of primary morpheaform BCCs, recurrent BCCs, and tumors located in high-risk anatomic sites.[78,79] One disadvantage of standard surgical excision is the potential for incomplete margin control. The incidence of incomplete excision has varied, with reports ranging from 4.7% to 13.2% of treated patients.[84–88] Farhi et al found the pathologically reported incomplete excision rate was over 10% and was significantly associated with the location on the face, particularly on the nose and inner canthus, and with infiltrative and multifocal histologic types.[89] Wolf and Zitelli demonstrated that margins of 4 mm were adequate for 95% of nonmorpheaform BCCs smaller than 2 cm in diameter when treated by standard excision.[90] Huang and Boyce found that, for a 95% cure rate, BCCs <1 cm in diameter required a 0.5-cm margin, those between 1 cm and 2 cm in diameter required a 0.8-cm margin, and a 1.2-cm margin was required for those >2 cm in diameter.[91] Johnson, Tromovitch, and Swanson reported a 96.7% cure rate when the excision included a 2-mm margin beyond the area defined by curettage. Tumor was present in 64 of 403 curette margins and in 12 of 403 excision margins. The histologic subtype was aggressive in 11 of 12 cases with positive excision margins. Margins of 5 mm are necessary for primary morpheaform BCC or recurrent BCC.[92] Preoperative curettage decreases the frequency of positive margins in the management of BCC. Chiller et al found that curettage before excision decreased the surgical failure rate for BCC by 24% ($P = .03$).[93]

CURETTAGE AND DESICCATION

C&D is one of the most frequently used treatment modalities for BCC.[94] That C&D is operator-dependent was shown by Kopf et al, who identified a significant difference in cure rate between patients treated by private practitioners (94.3%) and those treated by residents (81.2%).[95] High 5-year cure rates of up to 98.8% have been obtained after C&D of primary, nonfibrosing BCCs of medium- and high-risk areas of the face when performed by a *skilled* operator.[96]

Spiller and Spiller reported a cure rate of 97% in 233 patients. Cure rate decreased as a function of primary lesion size: for lesions smaller than 1.0 cm, the cure rate was 98.8%; for lesions between 1.0 cm and 2.0 cm, 95.5%; and for lesions larger than 2.0 cm, 84%. Recurrences were noted most often on the forehead, temple, ears, nose, and shoulders. C&D is not recommended for large primary BCC, morpheaform BCC, or recurrent BCC.[97] For appropriately selected lesions and locations, C&D remains an efficacious and cost-effective treatment modality.[83]

CRYOSURGERY

Cryosurgery is another destructive modality that has been used in the treatment of BCC. Two freeze-thaw cycles with a tissue temperature of –50°C (–58°F) are required to destroy BCC. In addition, a margin of clinically normal tissue must be destroyed to eradicate subclinical extension.[83] A systematic review of recurrence rates published between 1970 and 1997 indicated that cryotherapy in the treatment of primary BCC resulted in a 5-year recurrence rate from 4% to 17%.[98] Cryosurgery lacks the benefit of histologic confirmation of tumor removal. Kuflik and Gage reported 99% cure rates in 628 patients followed for 5 years. Possible complications of cryosurgery include hypertrophic scarring and postinflammatory pigmentary changes.[99] In regards to cosmesis, patient satisfaction was found to be higher with surgical excision than with cryosurgery and should be taken into consideration when choosing a treatment option.[100] Another potential serious adverse outcome is the obscuring of tumor recurrence by fibrous scar tissue. Any recent change in a cryosurgery scar after normal healing is completed should raise the suspicion of recurrent BCC.

TOPICAL TREATMENT

IMIQUIMOD. Imiquimod (5% cream) has been used in the treatment of skin cancers.[101] Approved in 2004 by the FDA for the topical treatment of biopsy-confirmed, small (less than 2 cm), primary superficial BCC, imiquimod is a Toll-like receptor 7 agonist believed to induce interferon-α, tumor necrosis factor-α, and other cytokines to boost T helper 1 type immunity. In two double-blind, randomized, vehicle-controlled trials, clinical and histological clearance rates for dosing five and seven times per week were 75% and 73%, respectively, for superficial BCC.[102,103] In another study, 10 of 19 nodular BCCs (approximately 53%) cleared after treatment with imiquimod.[104] In general, adverse side effects are limited to local skin reactions; however, researchers have noted the significant correlation between the severity of the local skin reaction (erythema, erosion, and crusting) and the histological clearance rate.[102]

The safety and effectiveness of imiquimod for other types of BCC have not been established, and with up to 25% of treated patients failing therapy (or *with*

a one in four failure rate), this possible clinical consequence should be discussed and strongly considered when choosing the appropriate treatment. The cost of imiquimod can easily exceed the costs of destructive or surgical modalities as well.[105] A case series of 24 patients[105] highlights the clinical consequences of imiquimod failure rescued with MMS. The cost of imiquimod can easily exceed the costs of destructive or surgical modalities as well.

Imiquimod can be consideration as a monotherapy only for superficial BCCs limited to small tumors in low-risk locations in patients who will not or cannot undergo treatment with other better-established therapies.[106]

5-FLUOROURACIL. 5-Fluorouracil (5-FU), a topically applied chemotherapeutic agent used in the treatment of actinic keratoses, has also been used to treat BCCs. In one series, Epstein showed a 5-year recurrence rate of 21% after 5-FU treatment, which was reduced to 6% when curettage was performed initially.[107] Gross et al observed a 90% histologic clearance rate 3 weeks after 5-FU treatment, but with no follow-up. 5-FU was also found to be generally well tolerated with a good cosmetic outcome, with the majority of patients having no pain or scarring and only mild erythema.[108] 5-FU is metabolized by dihydropyrimidine dehydrogenase (DPD), and its use is contraindicated in patients deficient in that enzyme. A 2-(13)C-uracil breath test can identify DPD-deficient individuals.[109–111] The use of 5-FU to treat BCC should be considered carefully and should include an evaluation of the risk of recurrence and treatment failure. Topical therapies may be associated with adverse effects, produces lower clearance rates, may be more difficult to administer, and, in some instances, costs more than other well-established therapies for BCC.[106]

HEDGEHOG INHIBITORS. With strong evidence of HH activation in BCC, there has been significant recent development of HH inhibitors (HHI) for the treatment of metastatic or locally aggressive BCCs. The well-known HHI compound is the plant alkaloid, cyclopamine, which competitively inhibits SMO protein signaling and therefore the growth of malignant cells driven by HH activation.[112,113]

In a phase 1 trial, GDC-0449, an orally active small molecule derivative that targets the HH pathway via SMO, appears to have antitumor activity in locally advanced or metastatic BCC (ClinicalTrials.gov number, NCT00607724).[114] Further studies are needed to ascertain the full efficacy and adverse-effect profiles. Topical HH pathway inhibitors are also being developed for the treatment of BCC.

PHOTODYNAMIC THERAPY

Photodynamic therapy (PDT) involves the activation of a photosensitizing drug by visible light to produce activated oxygen species that destroy the constituent cancer cells. Exogenous δ-aminolevulinic acid increases intracellular production of the endogenous photosensitizer protoporphyrin type IX, which preferentially accumulates in tumor cells.[115] Morrison et al reported an 88% initial clearance of 40 large (>2 cm) BCCs after one to three treatments. The time of follow-up was between 12 months and 60 months.[116] Basset-Seguin et al reported complete response rates for superficial BCCs from 85% to 93% at 3 months and a response rate on par with cryosurgery at 60 months (75% vs. 74%).[117] Marmur et al reviewed PDT for nonmelanoma skin cancer and reported recurrence rates ranging from 0% to 31% for BCC.[118] A clinical study comparing methyl-aminolevulinate PDT (MAL-PDT) and surgery in small superficial BCC found that MAL-PDT offers similar high efficacy and a much better cosmetic outcome than standard excision surgery in the treatment of superficial BCC; however, at 12 months, 9.3% lesions recurred with MAL-PDT and none with surgery.[119] The long-term cure rates for superficial BCC with PDT remains around 75% and because of the appreciable nonresponse and recurrence rates, patients should be monitored closely during the first 2–3 years after PDT, which is when most lesion recurrences are seen.[120] The Cochrane collaboration found that cosmetic outcome for PDT was significantly better than surgery. However, there were also comparatively high failure rates associated with PDT when compared to surgery, radiotherapy and cryotherapy. PDT requires a number of hospital visits and this may not suit all people with BCC.[75] Reports of high recurrence rates suggest that this method may be best reserved for select situations in which better established methods are not feasible, particularly in situations where surgery may be problematic or where patients have multiple lesions.

RADIATION THERAPY

Radiation therapy (XRT) may be useful in cases of primary BCC or in cases in which postsurgical margins are positive for cancer. Advantages include minimal patient discomfort and avoidance of an invasive procedure for a patient unwilling or unable to undergo surgery. XRT may be a very useful modality as adjunct treatment for BCC when margins are positive after excision or for extensive perineural or large nerve involvement.[83] Potential disadvantages include lack of histologic verification of tumor removal, prolonged treatment course, cosmetic result that may worsen over time (cutaneous atrophy and telangiectasia), and predisposition to aggressive and extensive recurrences. Local control rates of 93%–97% have been reported; however, cosmesis has been rated inferior to results achieved surgically.[116,121]

The Cochrane Collaboration found surgery and radiotherapy to appear the most effective treatments for BCC, while the best overall results being obtained with surgery.[75]

SPECIAL MANAGEMENT ISSUES

INCOMPLETELY EXCISED BASAL CELL CARCINOMA. On the basis of data from the 1960s suggesting that 50%–70% of incompletely excised BCCs do not recur, some physicians adopted a "wait and see" approach.[122] In some cases, flap and graft repair may have been performed before confirmation of negative margins, so that the anatomy was distorted. This confounds identification of positive margins for definitive treatment. Incomplete resection was addressed by Robinson and Fisher,[61,123] who reported on 994 patients consecutively referred for treatment of incompletely excised BCCs with subsequent clinical recurrence. Of these, only 32 were referred for MMS for complete tumor removal at the time the original operating surgeon received the pathologic confirmation of positive excision margins. For the remaining 962 recurrent BCCs, the nose was the most common anatomic site (43%), and flap repair was the most common form of reconstruction (52%). The authors recommend MMS for the treatment of incompletely excised BCC. Ideally, patients should receive treatment at the time of diagnosis, because delay will likely result in increased local tissue damage (eFigs. 115-7.1A and 115-7.1B in online edition). Patients unable to undergo re-excision to achieve clear margins should be evaluated for XRT.

NEUROTROPIC BASAL CELL CARCINOMA. PNI by BCC is a rare event (<0.2% of cases). Defined as the observation of malignant cells in the perineural space of nerves,[124] when PNI is detected, every effort should be made to clear the tumor, preferably by MMS. Patients with gross PNI manifested by neurologic symptoms would benefit from preoperative magnetic resonance imaging to assess extent of tumor spread. Classic examples include brow paralysis due to involvement of the temporal branch of the facial nerve and midface paresthesias secondary to involvement of the trigeminal nerve.[64,65]

METASTATIC BASAL CELL CARCINOMA. Although it is exceedingly rare, the possibility of metastatic disease exists and may need to be addressed. If nodal disease is suspected on surgical examination, lymph node biopsy and imaging studies, as well as evaluation by medical and surgical oncologists, are indicated.[68] Platinum-based chemotherapy has been used with modest results in treatment of metastatic BCC; however, rapid clinical response was reported using a combination of cisplatin and paclitaxel.[125] Complete response to carboplatin and paclitaxel has been reported as well.[126]

COURSE AND PROGNOSIS

With appropriate treatment, the prognosis for most patients with BCC is excellent. Control rates as high as 99% have been achieved by MMS. Although tumor control rates for primary tumors are high, patients must be monitored for recurrence and development of new primary BCCs. The risk for development of a second primary BCC ranges from 36% to 50%.[127] Periodic full-body skin examinations and counseling about sun protection are recommended for any patient with a history of BCC. This is especially important because patients with a history of BCC are at increased risk for melanoma. The prognosis for patients with recurrent BCC is favorable, although recurrent tumors are more likely to appear again and to behave aggressively. Patients with a history of recurrent disease must be monitored more frequently for the development of further recurrences and new primary tumors. An estimated 40%–50% of patients with primary carcinoma will develop at least one or more further BCCs within 5 years.[128] For the rare patient with metastatic disease, prognosis is poor, with a mean survival of 8–10 months from the time of diagnosis.

KEY REFERENCES

Full reference list available at www.DIGM8.com

DVD contains references and additional content

1. Crowson AN: Basal cell carcinoma: Biology, morphology and clinical implications. *Mod Pathol* **19**(Suppl 2):S127-S147, 2006
15. Gailani MR et al: Relationship between sunlight exposure and a key genetic alteration in basal cell carcinoma. *J Natl Cancer Inst* **88**:349-354, 1996
19. Epstein EH: Basal cell carcinomas: Attack of the hedgehog. *Nat Rev Cancer* **8**:743-754, 2008
30. Berg D, Otley CC: Skin cancer in organ transplant recipients: Epidemiology, pathogenesis, and management. *J Am Acad Dermatol* **47**:1-17; quiz 8-20, 2002
36. Bale AE, Gailani MR, Leffell DJ: The Gorlin syndrome gene: A tumor suppressor active in basal cell carcinogenesis and embryonic development. *Proc Assoc Am Physicians* **107**:253-257, 1995
46. Kaporis HG et al: Human basal cell carcinoma is associated with Foxp3+ T cells in a Th2 dominant microenvironment. *J Invest Dermatol* **127**:2391-2398, 2007
63. Leibovitch I et al: Basal cell carcinoma treated with Mohs surgery in Australia III. Perineural invasion. *J Am Acad Dermatol* **53**:458-463, 2005
64. Ratner D et al: Perineural spread of basal cell carcinomas treated with Mohs micrographic surgery. *Cancer* **88**:1605-1613, 2000
80. Leibovitch I et al: Basal cell carcinoma treated with Mohs surgery in Australia II. Outcome at 5-year follow-up. *J Am Acad Dermatol* **53**:452-457, 2005
118. Marmur ES, Schmults CD, Goldberg DJ: A review of laser and photodynamic therapy for the treatment of nonmelanoma skin cancer. *Dermatol Surg* **30**:264-271, 2004

Chapter 116 :: Basal Cell Nevus Syndrome

:: Anthony E. Oro & Jean Y. Tang

BASAL CELL NEVUS SYNDROME AT A GLANCE

- A rare autosomal dominant disorder with phenotypic abnormalities that include developmental anomalies and postnatal tumors, especially basal cell carcinomas (BCCs).
- The three most characteristic abnormalities are tumors such as medulloblastomas or BCCs, pits of the palms and soles, and odontogenic cysts of the jaw.
- Related findings include calcification of the falx cerebri, enlarged body habitus, and skeletal abnormalities of the ribs and skull.
- Diagnosis is suspected in a patient with multiple BCCs arising at an unexpectedly early age with an average age of onset of 21 years.
- Histologic features of tumors in BCNS patients are similar to those of sporadic BCCs or medulloblastomas.
- Several new therapeutic agents, including SMO antagonists and celecoxib, have been shown to have efficacy in treating disease along with photodynamic therapy, imiquimod, and 5-fluorouracil.

Basal cell nevus syndrome (BCNS), also known as *nevoid basal cell carcinoma syndrome* and *Gorlin syndrome* [Online Mendelian Inheritance in Man (OMIM) #109400], is a rare autosomal dominant disorder associated with a panoply of phenotypic abnormalities that can be divided into developmental anomalies and postnatal tumors, especially basal cell carcinomas (BCCs).[1] Although individual aspects had been reported previously, their syndromic association was first appreciated widely in the late 1950s.[2,3]

EPIDEMIOLOGY

The prevalence of BCNS is variously estimated to be 1 in 60,000 and 1 in 120,000 persons.[4,5] The syndrome affects both sexes and occurs in a wide variety of cultural groups, and therefore does not have a predilection for a particular skin type. The condition appears to have complete penetrance but variable expressivity of traits, such that their clinical presentation within families is nonuniform. Further, as with many dominantly inherited conditions, new mutations are common. As a result, many patients may have no apparent affected ancestors or siblings.

ETIOLOGY AND PATHOGENESIS

GENETIC ABNORMALITY

Almost all known BCNS patients thus far carry mutations in the *PATCHED1* (*PTCH1*, UniGene Hs. 494538) gene residing on the long arm of chromosome 9.[6,7] PTCH1 plays a central role in the hedgehog signaling pathway that is essential for the establishment of normal body and limb patterning in metazoan organisms.[8] The *PTCH1* locus behaves like a classic tumor suppressor gene (Fig. 116-1). The appearance of BCCs in small numbers at an older age in sporadic cases and in larger numbers at a younger age in patients with BCNS is reminiscent of differences in sporadic and hereditary cases of retinoblastoma.[9] BCNS, like other tumor susceptibility syndromes, is inherited in an autosomal dominant manner, with inheritance of a loss-of-function allele followed by somatic loss of the remaining copy before tumor formation.

Identification of the gene mutation responsible for BCNS facilitated a molecular verification of the predicted PTCH1 tumor suppressor function.[6,7] BCNS patients inherit one defective *PTCH1* allele and their tumors contain an additional somatic mutation. As with other tumor suppressor genes, *PTCH1* mutations have also been found in older adults with sporadic BCCs and other sporadic tumors known to be overrepresented in BCNS patients (e.g., medulloblastomas and meningiomas), which supports the idea that two somatic "hits" are required in sporadic tumors.

In contrast, the two-hit genetic model proposed for PTCH1-dependent tumor development may not fully explain the developmental abnormalities seen in BCNS, which occur earlier. *PTCH1* heterozygote mice display many of the developmental abnormalities seen in BCNS patients despite a wild-type copy of the nonaffected allele.[10,11] This argues that certain tissues (skeleton, limb, neural tube) require higher levels of PTCH1 to regulate tissue development and that heterozygotes cannot compensate for loss of the other allele (haploinsufficiency). In addition, the *PTCH1* locus appears to be regulated in part by silencing. Recent observations indicate that methylation blockers can reactivate PTCH1 expression shut off during tumor formation, suggesting that silencing of PTCH1 expression may also play a role in normal development.[12]

Are *PTCH1* mutations the only cause of BCNS? Despite direct sequencing of *PTCH1* exons in patients, somatic mutations are found in fewer than half of BCCs and germ-line mutations in fewer than 100% of BCNS patients.[13,14] This suggests that mutations in

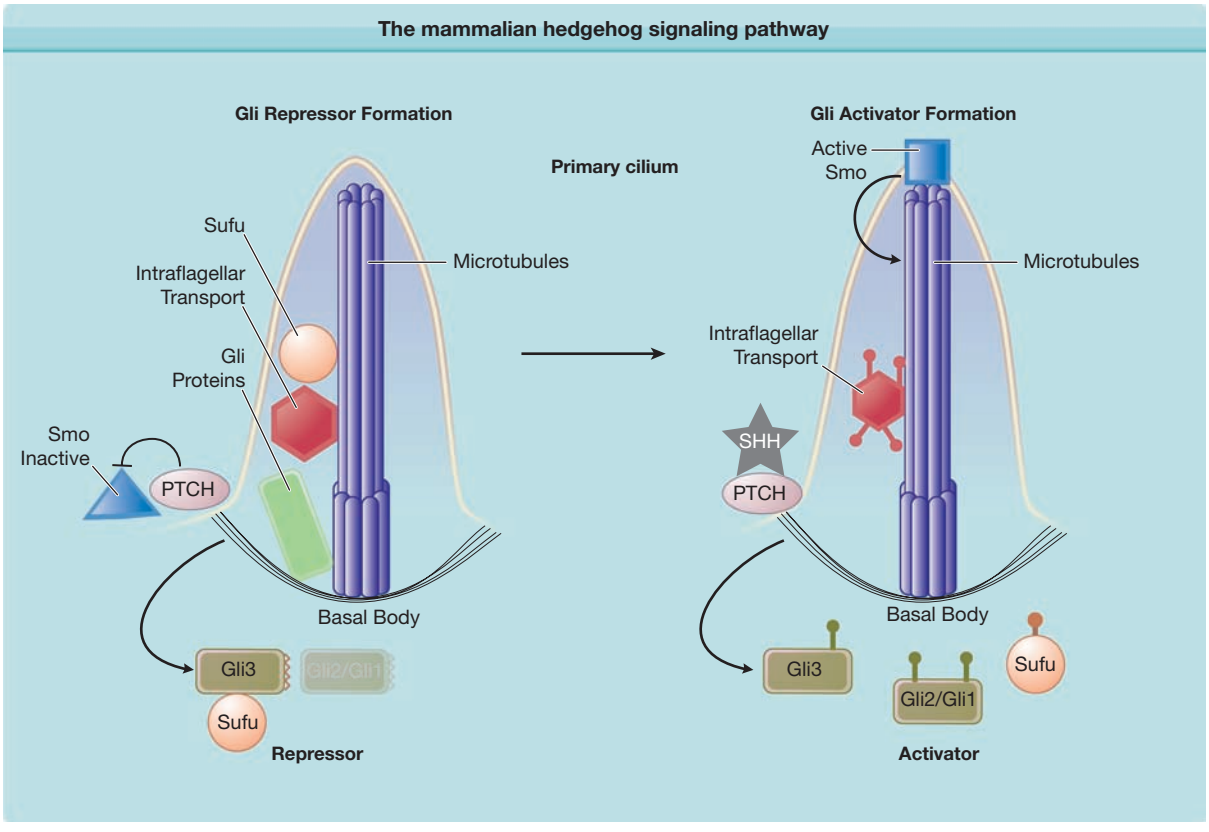

Figure 116-1 The mammalian hedgehog signaling pathway. PTCH1 is the receptor for the growth factor hedgehog and inhibits the function of smoothened (SMO) by sequestering it in an inactive state outside of the microtubule-based organelle, the primary cilum. Sonic hedgehog (SHH) inhibits PTCH1, allowing activation of SMO in the cilium. SMO inhibits Suppressor of Fused (SUFU), which in turn inhibits the GLI transcription factors GLI1, GLI2, GLI3. Intraflagellar transport proteins help mediate GLI processing.

other unidentified genes may underlie the disease. However, early linkage studies found a strong association with the *PTCH1* locus. Moreover, although mutations are not found in *PTCH1* exons in some patients, hedgehog signaling pathway abnormalities are still present in these tumors. Recently, one family with BCNS and atypical features (medulloblastoma, plantar pits, but no BCCs) was found to have germ-line mutations in Suppressor of Fused (SUFU)—a tumor suppressor gene and negative regulator of sonic hedgehog (SHH) signaling (Fig. 116-1).[15] This suggests mutations may be found in other members of the signaling pathway in rare cases.

PTCH1 FUNCTION

PTCH1 protein plays a critical role in the hedgehog-signaling pathway (Fig. 116-1). Genetic and biochemical studies in *Drosophila* and mammals indicate that PTCH1 protein inhibits this signaling pathway by inhibiting the function of the central G protein-coupled receptor smoothened (SMO), and that the extracellular ligand hedgehog abrogates this inhibition. Signaling by SMO results in the activation of the Glioma associated oncogene (GLI) family of zinc finger proteins that mediate all the transcriptional effects of hedgehog signaling. Three GLI proteins mediate activation and suppression of hedgehog target genes, with GLI1 and GLI2 acting as activators and GLI2 and GLI3 as suppressors. SMO signaling tips the balance toward activation and away from target gene suppression. In mammals, GLI activity is controlled by the novel cytoplasmic protein SUFU, which promotes the transcriptional repression and inhibits activation.[16] SMO inhibits SUFU activity, thus releasing GLI proteins to become transcriptional activators. When hedgehog binds to PTCH1, PTCH1 inhibition of SMO is relieved and the pathway is activated. Thus, loss of PTCH1 function allows unregulated SMO activity and initiates tumor formation.

How PTCH1 functions as a tumor suppressor is still under investigation. A significant function of PTCH1 is to inhibit SMO, although how PTCH1 accomplishes this is yet unknown. PTCH1 acts in an enzymatic manner as only a few molecules are necessary to inhibit SMO by several fold.[17] Moreover, PTCH1 and SMO are thought to exist in distinct endosomes and thought not to physically interact. Recent studies demonstrate that components of the hedgehog pathway are localized to a novel microtubule based organelle called the primary cilium (Fig. 116-1).[18] Mutations that affect the structure and function of the cilium, known collectively as the human ciliopathies, are also known to disrupt maximal hedgehog signaling and the patients

have some similarities to BCNS. SMO accumulates in the cilia via intraflagellar transport proteins and this accumulation is correlated with pathway activation. PTCH1 is localized at the base of the organelle and appears to prevent SMO entry. Loss of PTCH1 or mutations that allow SMO to move into the cilium result in increased pathway activity.[19] PTCH1 shares homology with sterol-sensing domain-containing proteins such as SREBP (sterol regulatory element-binding protein) and β-hydroxy-β-methylglutaryl–coenzyme A reductase.[20] It also shares significant structural identity with the resistance-nodulation-division (RND) permease family of small-molecule transporters, which suggests that PTCH1 may act as a molecular pump. This evokes the tantalizing hypothesis that PTCH1 regulates SMO entry and activation within the cilium by regulating the production or distribution of small-molecule second messengers in the cell.

MUTATIONS IN SONIC HEDGEHOG PATHWAY IN BCCs

The identification of mutations in members of the SHH pathway in both BCNS patients and in sporadic BCCs supports the central role of SHH target gene induction in BCC pathogenesis. PTCH1 mutations are by far the most common and are found in approximately 40% of tumors.[21] Epidemiologic evidence implicates ultraviolet light in the pathogenesis of sporadic BCCs. UV signature mutations have been found in PTCH1 and these provide additional evidence for a role of sunlight in cancer development.[22]

Mutations of SMO protein have been identified in approximately 10% of BCCs, and these mutations appear to render SMO protein resistant to PTCH1 inhibition.[23] Indeed, experimental transfection of cells with mutant SMO sequences can transform them to a malignant phenotype. This finding that BCCs may have upregulation of hedgehog target gene expression due to mutations in either *PTCH1* or *SMO* argues that it is the upregulation of hedgehog signaling rather than the specific mutation that is crucial to BCC formation. Consistent with this is the finding that mutations in the gene encoding SUFU have been reported to underlie formation of medulloblastomas and BCNS.[15,24]

The identification of these molecular abnormalities in BCCs for the first time has permitted the development of mouse models of this tumor. Previously, tumor-initiating insults to mouse skin (ultraviolet, ionizing radiation or chemical carcinogens) have produced papillomas and carcinomas of the squamous, but not the basal cell lineage. Mouse models that show spontaneous development of BCC-like tumors include those with epidermal overexpression of hedgehog,[25] of mutant SMO,[23] or of GLI1[26,27] or GLI2.[28,29] In addition, *ptc1*$^{+/-}$ mice, which, like BCNS patients, have one instead of two functioning alleles of *PTCH1*, not only develop BCCs and related tumors but also develop plantar pits, medulloblastomas, and rhabdomyosarcomas, as do BCNS patients. The mouse BCCs (mimicking human BCCs) occur spontaneously in low numbers and in small sizes, but in much higher numbers and of larger size in mice exposed to ultraviolet or ionizing radiation.[30]

CLINICAL FINDINGS

CUTANEOUS LESIONS

Hedgehog signaling plays a critical role in the expansion of progenitor cells in a wide variety of tissues in both invertebrate and vertebrate organisms. PTCH1 normally is expressed both during development and in the adult, which suggests an ongoing postnatal role. Studies involving experimental models inappropriately expressing components of the hedgehog signaling pathway have revealed significant developmental anomalies.[31] The resemblance of these anomalies to those characteristic of BCNS implies that aberrant activation of the hedgehog signaling pathway is a sufficient explanation for the developmental and tumorigenic anomalies of BCNS, even if the precise pathogenic mechanisms have yet to be elucidated.

Patients with BCNS show multiple abnormalities, none of which is unique to this syndrome (eTable 115-0.1 in online edition).[5,13,14] The three abnormalities considered to be most characteristic of the syndrome are tumors such as medulloblastomas or BCCs, pits of the palms and soles, and odontogenic cysts of the jaw.

Individual BCCs from patients with BCNS cannot be distinguished from those in sporadic cases (see Chapter 115), which is not surprising in view of the similar pathogenesis in familial and sporadic cases. What is distinguishing is their appearance in large numbers starting at an early age. They may be banal appearing and confused grossly with nevocytic nevi—hence the name *basal cell nevus*. They may also have a translucent, papulonodular appearance more characteristic of sporadic BCCs and may invade locally. In rare cases, they may even metastasize and cause death. Although the ratio of sun-protected to sun-exposed BCCs may be higher in BCNS than in sporadic cases, sunlight and ionizing radiation clearly accelerate BCC formation in BCNS patients, and darkly pigmented BCNS patients may have few to no BCCs (Figs. 116-2–116-4).

Palmoplantar pits are small defects in the stratum corneum and may be pink or, if dirt has accumulated, dark in color (Fig. 116-5). They appear early in life and can be a valuable aid in diagnosis in addition to jaw cysts or medulloblastoma. Their basis is poorly understood, but they are thought to be due to aborted attempts to generate hair follicles in the palms. They are also seen in mouse *PTCH1* heterozygotes.[31]

RELATED PHYSICAL FINDINGS

Tissue overgrowth, which is also a feature of hedgehog signaling pathway activation in *Drosophila*, often is manifested by an overall body size larger than that of other family members. Limbs may be particularly long, giving a marfanoid appearance (Fig. 116-6), and a large head circumference (at least in probands) and frontal bossing are often described.



Figure 116-2 Face of a man with severe scarring from growth and treatment of multiple basal cell carcinomas (BCCs). Note multiple outlined new BCCs despite extensive and frequent surgery.



Figure 116-4 Basal cell carcinoma (BCC) on the toe of a patient with basal cell nevus syndrome (BCNS), which illustrates that the whole skin surface of BCNS patients is susceptible to BCC formation.

Jaw cysts often are the first detectable abnormality (Fig. 116-7).[5,13,14] They may be asymptomatic and therefore diagnosed only radiologically. However, they also may erode enough bone to cause pain, swelling, and loss of teeth. They occur more often in the mandibular jaw than in the maxillary jaw.[32] These jaw cysts presumably form from inappropriate SHH induction of dental epithelium and can recur often and be the most debilitating aspect of the syndrome.[33]

eTable 116-0.1 in online edition lists the phenotypic abnormalities that have been reported often enough that they probably are true components of the syndrome.



Figure 116-3 Upper back of man with basal cell nevus syndrome with innumerable basal cell carcinomas, some of which are nodular and most of which are flat, erythematous patches.

These include tissue overgrowth seen in other epithelial organs such as the meninges or ovaries that give rise to meningiomas or ovarian fibromas. Variation in clinical severity is typical even within a single kindred, and this heterogeneity is likely due to both environmental differences (e.g., exposure to ultraviolet and ionizing radiation) and genetic background differences.

Of interest is the finding that SHH signaling plays a key role in up to 25% of all human cancers, including small cell lung cancer, pancreatic cancer, and prostate cancer.[30,34] This finding suggests a wider role for hedgehog signaling than that seen in BCNS patients. Although BCNS is a rare syndrome and exhaustive prospective studies have not been performed, no excess of these associated cancers has yet to be documented in BCNS patients. This might reflect a different mechanism of tumor development, because these visceral tumors demonstrate hedgehog ligand overexpression rather than the loss of PTCH1 as seen in BCCs. Alternatively, pathway induction in older adults may have different consequences than pathway activation in younger individuals.

DIAGNOSIS

Because the individual abnormalities are not unique to BCNS patients, it is possible to diagnose BCNS clinically only when multiple typical defects are present (Table 116-1). The severity of abnormalities may differ markedly among members of a single kindred, and diagnostic certainty may be difficult for specific individuals even if they belong to a kindred with known BCNS.[35] Generally, the diagnosis is suggested to the dermatologist when multiple BCCs arise in a patient at an unexpectedly early age and in unexpectedly large numbers, with the average age of onset in the early 20s.



Figure 116-5 **A.** Unusually florid palmar pits in a patient with basal cell nevus syndrome (BCNS). **B.** Larger magnification showing that these lesions in BCNS are really punched-out pits.

Further evaluation should include (1) questions about whether other family members have had abnormalities consistent with BCNS (although perhaps 30% of patients with BCNS have no affected ancestors) and whether the patient is taller and heavier than his or her relatives; (2) examination for palmoplantar pits and skin cysts and assessment of body and head size; and (3) radiologic evaluation for jaw cysts (which often appear around the start of the second decade), calcification of the falx (which occurs in nearly all adults with BCNS and may be present in early childhood in BCNS patients, thus suggesting the diagnosis of BCNS in those patients with early-onset medulloblastomas), and abnormalities of the ribs, spine, and phalanges (flame-shaped lucencies), each of which is present in one-third to one-half of BCNS patients.[5,13,14,36] Kimonis and colleagues proposed a set of major and minor criteria for presumptive diagnosis of BCNS, which has since been modified (see Table 116-1).[13] For cases in which the diagnosis is in doubt, or for genotyping of other family members, identification of *PTCH1* gene mutations is now available commercially through GeneDX (Gaithersburg, MD).

TABLE 116-1
Diagnostic Criteria for Basal Cell Nevus Syndrome (BCNS)

Major Criteria
1. Basal cell carcinoma before age 20 years
2. Odontogenic keratocysts before age 15 years
3. Three or more palmar and/or plantar pits
4. Bilamellar calcification of the falx cerebri (if younger than 20 years)
5. Fused, bifid, or markedly splayed ribs
6. First-degree relative with BCNS
7. *PTCH* gene mutation in normal tissue

Minor Criteria
1. Macrocephaly determined after adjustment for height
2. Congenital malformations: cleft lip or palate, frontal bossing, "coarse face," moderate or severe hypertelorism
3. Skeletal abnormalities: Sprengel deformity, marked pectus deformity, or marked syndactyly of the digits
4. Radiologic abnormalities: bridging of the sella turcica; rib anomalies such as bifid or splayed ribs; vertebral anomalies such as hemivertebrae, fusion, or elongation of the vertebral bodies; modeling defects of the hands and feet; or flame-shaped lucencies of the hands or feet
5. Ovarian fibroma
6. Medulloblastoma

Data from Kimonis VE et al: Clinical manifestations in 105 persons with nevoid basal cell carcinoma syndrome. *Am J Med Genet* **69**:299, 1997; and First BCCNS Colloquium, St. Louis, May 2005.

DIFFERENTIAL DIAGNOSIS

Other syndromes exist that are characterized by the development of multiple BCCs. These include Bazex syndrome (OMIM #301845),[37] Rombo syndrome (OMIM #180730),[38] and a syndrome observed in a family with BCCs, milia, and coarse, sparse hair.[39] Hair abnormalities are present in all three syndromes, which is a finding of interest in view of the often-repeated suggestion that BCCs arise from hair follicles rather than from interfollicular epidermis. The exact nosologic relationships among these three syndromes are uncertain, but patients with BCNS have normal hair, and all three syndromes seem quite different from BCNS.

Two other syndromes that have been described include multiple hereditary infundibulocystic BCC[40]



Figure 116-6 Skeletal and radiographic findings in basal cell nevus syndrome. **A.** Unusually large body habitus and extremities. **B.** Syndactyly in digits. **C.** Calcification of the falx cerebri. **D.** Rib development abnormalities, including rib fusion (*arrow*).

and generalized basaloid follicular hamartoma.[41] Both demonstrate histologic variants of BCCs, with more hamartomatous lesions, and are characterized by palmar pits and milia. The latter syndrome is acquired and associated with autoimmune disease, which suggests an immunologic stimulation of the hedgehog pathway. The former appears to be linked to the PTCH1 locus and thus may be due to a PTCH1 allele.

BCNS shares some developmental abnormalities with the group of human diseases known as the ciliopathies.[42] This likely occurs because the hedgehog pathway can be localized within the primary cilium and that defects in the functioning of this organelle can result in hedgehog signaling defects seen in BCNS patients such as polydactyly and craniofacial abnormalities. The ciliopathies do not manifest skin and cerebellar tumor predispositions. Furthermore, retinal degeneration, a hallmark of many ciliopathies, is not commonly seen in BCNS patients.

Patients with long-term arsenic ingestion may have multiple BCCs. Their dyschromia and lack of other phenotypic abnormalities differentiate them from BCNS patients (see Chapter 113). Patients with xeroderma pigmentosum develop multiple BCCs but are readily differentiated from BCNS patients by their severe photosensitivity and other phenotypic abnormalities (see Chapter 139).

The most challenging patients are those who have a marked propensity to develop multiple BCCs early in life, sometimes sporadically or in rare cases after

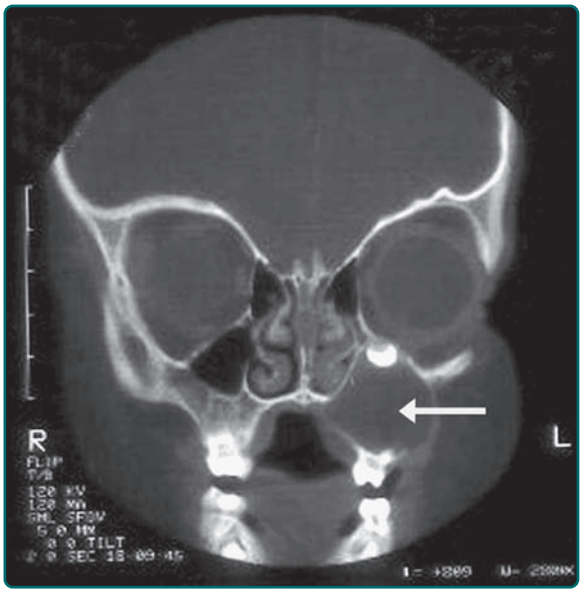

Figure 116-7 Radiographic findings of odontogenic keratocyst (*arrow*).

therapeutic irradiation (e.g., for Hodgkin disease) without showing any of the other signs of BCNS. These cases occasionally produce diagnostic confusion because, due to the variable expressivity of individual PTCH1 alleles, it is not known whether their defect is related to the hedgehog pathway, to DNA repair, to an unknown toxin, and/or to yet undescribed mechanisms. One insightful study argues against germ-line PTCH1 mutations as the cause of multiple BCCs, because PTCH1 mutations have not been found in individuals who do not have at least one other key manifestation of BCNS.[43]

COMPLICATIONS, PROGNOSIS, AND CLINICAL COURSE

Although disease pathogenesis involves abnormalities in SHH signaling, the wide variability in clinical course among families, and even between generations of the same family, make prediction of clinical course difficult. If BCNS is suspected or confirmed, physicians should also screen for the most frequent sequelae of the disease during childhood or adolescence (Fig. 116-8). No large-scale survival studies have been performed to determine whether BCNS patients die earlier because of their disease.[13,44] The major complications are developmental delay, physical impairment in children and the childhood tumors that arise, such as medulloblastoma. The latter often occur within the first 5 years of life and are frequently the initial sign of BCNS. Complications arising from medulloblastoma treatment (radiation, shunt placement) are relatively common, and multidisciplinary teams of physicians are required to optimally treat these patients.

In the skin, BCCs that arise are locally aggressive but very rarely metastasize.[45] No reports document an increased risk for metastatic BCCs, which suggests

Approach to a patient with known or suspected basal cell nevus syndrome (BCNS)

Pediatric patients

- Baseline MRI of brain, repeat yearly (if asymptomatic) until age 8
- Baseline dermatologic exam, repeat yearly until first BCC develops, then every 6 months or more frequently as needed) throughout life
- Digital panorex of jaw at age 3 or 4 years (or as soon as tolerated), then yearly until first jaw cyst develops. Repeat yearly (or more frequently as needed), until age 21
- Pelvic u/s in girls at menarche (or earlier if symptomatic)
- Molecular diagnosis, (if desired) for patients with family history and known mutation
- Baseline scoliosis assessment at year of age and then annually for progression if present
- Routine developmental screening and referral for all children who do not meet developmental milestones

Adult patients

- Baseline MRI of brain (if not done at age 8 or later)
- Dermatologic exam at 4 months (or more frequently if new lesions present at each exam)
- Digital panorex of jaw twice yearly until cyst free for two years, then yearly or less frequently (depending on patient's concern about radiation)
- Prenatal or preconception counseling if desired

Figure 116-8 Approach to the patient with known or suspected basal cell nevus syndrome (BCNS). BCC = basal cell carcinoma; MRI = magnetic resonance imaging; u/s = ultrasonography. (Data from Kimonis VE et al: Clinical manifestations in 105 persons with nevoid basal cell carcinoma syndrome. *Am J Med Genet* **69**:299, 1997; and First BCCNS Colloquium, St. Louis, May 2005.)

that the basic character of the tumor is similar to that seen in sporadic BCC cases. However, because of the high numbers and wide distribution of the tumor, even in the absence of sun exposure, involvement of key epithelial surfaces or membranes is likely and can be disfiguring for the patient.

TREATMENT

Therapy must be directed at the individual lesions as they arise, and the most important aspect of management is frequent examination, enthusiastic counseling about avoidance of sun exposure, and early treatment of small tumors. In animal models of BCNS, small clinically undetectable tumors arise throughout the skin. This suggests that many more tumors form than are detectable visibly by the clinician.[27,31] This has several therapeutic ramifications. One is that clinicians caring for BCNS patients should become confident in their clinical acumen so that they can diagnose and treat tiny BCCs without histopathologic confirmation. This would eliminate multiple scar-inducing biopsies in

addition to potentially disfiguring treatments. Another is that invasive treatments should be focused on those lesions that are potentially most harmful, such as those invading mucous membrane or adjacent structures. Repetitive surgical treatments run the risk of severe disfigurement for the patient. Finally, clear surgical margins may be difficult to achieve when using Mohs surgery, so aggressive pursuit of a clear margin needs to be balanced against other factors in treating these patients.

Nonsurgical approaches to BCC treatment should be used aggressively in BCNS patients when possible. Because the key is to convince the patient to accept frequent treatments, minimization of discomfort and scarring is a major goal. Approaches that may be of benefit are topical treatment with 5-fluorouracil (with or without occlusion, depending on the degree of inflammation produced),[46] the Toll-like receptor agonist imiquimod,[47] and photodynamic therapy.[48] Oral therapy with retinoids also may be of value, but often only at a dosage that causes severe side effects. There are several ongoing clinical trials for new agents for BCC prevention in BCNS patients based on positive results obtained from *ptc1*$^{+/-}$ mice. UV exposure induces inflammation and cyclooxygenase (COX) expression in tumor cells and stroma.[49] In addition, COX2 gene polymorphisms are thought to modify BCC risk.[50] Collectively, these data suggest a role for COX2 in BCC carcinogenesis: this is further supported by murine studies in which overexpression of COX2 in keratinocytes of *ptc*$^{+/-}$ mice resulted in a twofold increase in BCCs, while germ-line COX2 deletion resulted in a 75% reduction. A Phase 2 randomized, controlled trial of celecoxib (a COX2 inhibitor) was recently completed in 60 BCNS subjects. Overall, there was a trend of oral celecoxib decreasing BCC development by 30% and a significant reduction of 50% in the subset of patients with less severe disease.[51] Therefore, nonsteroidal anti-inflammatory drugs (NSAIDS) may have efficacy particularly in patients at lower risk. However, potential cardiovascular risks associated with celecoxib may preclude its use as a common chemoprevention strategy in patients with BCC.[52]

Studies have now identified a natural antagonist of the hedgehog pathway derived from the *Veratrum californicum* plant called *cyclopamine*.[12] This substance binds and antagonizes SMO and has been shown to be effective in animal models of BCCs. Other small-molecule hedgehog pathway antagonists with similar properties have been identified and are currently being tested for their clinical efficacy.[53] In a Phase 1 trial of the first of these specific hedgehog inhibitors, GDC-0449, 33 patients with locally advanced or metastatic BCCs were treated. The results were extremely promising in that there was significant shrinkage of metastatic and advanced cutaneous BCCs with relatively mild systemic toxicity.[54] Of the nine patients with advanced BCC, six partially responded, two had stable disease and one had disease progression. This early clinical data confirm that direct SHH pathway inhibition may be an effective therapy for those tumors driven by SHH pathway activation. Because of this initial success, GDC-0449 has now entered Phase 2 testing in patients with advanced BCC and BCNS, as well as for metastatic colorectal and ovarian cancer (NCT00959647). Unfortunately, as been the case with several other such molecularly targeted anti-cancer drugs, at least some of these advanced tumors driven by SHH signaling may eventually develop resistance to the targeted therapy.[55] The molecular mechanism(s) by which the tumors acquired resistance at least includes mutations in SMO.[56] Other SMO antagonists currently being developed for clinical application and that have entered Phase 1 clinical trials for treating BCCs include IPI-926,[57] XL-139 and LDE-225 (eTable 116-1.1 in online edition).



Figure 116-9 Basal cell nevus syndrome. Multiple large, fungating basal cell carcinomas (BCCs) arising in a portion of the lower back treated years earlier with superficial ionizing for BCCs.

The ionizing radiation treatment of BCCs has been advocated in otherwise normal patients who are not surgical candidates. However, excessive radiation should be avoided if possible, because enhanced radiation-induced carcinogenesis (e.g., in the skin of the portals of irradiation for childhood medulloblastomas) is characteristic of BCNS. Patients with BCNS who receive radiation have developed an unusually large number of basal cell tumors in the irradiated area a short time after exposure (Fig. 116-9). Radiosensitivity in PTCH heterozygotes has also been detected at the cellular level, although the mechanism is poorly understood.[58]

Genetic counseling is appropriate. With the availability of direct sequencing of the PTCH1 locus, genotyping for prenatal diagnosis is potentially achievable for interested families. Because PTCH1 is transmitted with complete penetrance, half of the children of affected individuals are expected to develop BCNS.

ACKNOWLEDGMENTS. The authors would like to thank Drs. Sheri Bale and Thierry Magnaldo for patient information.

KEY REFERENCES

Full reference list available at www.DIGM8.com

DVD contains references and additional content

2. Gorlin RJ, Goltz RW: Multiple nevoid basal-cell epithelioma, jaw cysts and bifid rib. A syndrome. *N Engl J Med* **262**:908-912, 1960
3. Howell JB, Caro MR: The basal-cell nevus: Its relationship to multiple cutaneous cancers and associated anomalies of development. *AMA Arch Derm* **79**(1):67-77; discussion 77-80, 1959
6. Hahn H et al: Mutations of the Human Homolog of Drosophila patched in the Nevoid Basal Cell Carcinoma Syndrome. *Cell* **85**:841-851, 1996
7. Johnson RL et al: Human homolog of *patched*, a candidate gene for the basal cell nevus syndrome. *Science* **272**(5268):1668-1671, 1996
9. Howell JB: Nevoid basal cell carcinoma syndrome. Profile of genetic and environmental factors in oncogenesis. *J Am Acad Dermatol* **11**(1):98-104, 1984
13. Kimonis VE et al: Clinical manifestations in 105 persons with nevoid basal cell carcinoma syndrome. *Am J Med Genet* **69**(3):299-308, 1997
14. Pruvost-Balland C et al: Etude clinique et recherche de mutations germinales du gene PTCH1 dans le syndrome des harmartomaes basocellulaires. *Ann Dermatol Venereol* **113**:117-123, 2006
18. Satir P, Christensen ST: Overview of structure and function of mammalian cilia. *Annu Rev Physiol* **69**:377-400, 2007
19. Rohatgi R, Milenkovic L, Scott MP: Patched1 regulates hedgehog signaling at the primary cilium. *Science* **317**(5836):372-376, 2007
25. Oro AE et al: Basal cell carcinomas in mice overexpressing Sonic Hedgehog. *Science* **276**:817-821, 1997
31. Aszterbaum M et al: Ultraviolet and ionizing radiation enhance the growth of BCCs and trichoblastomas in patched heterozygous knockout mice. *Nat Med* **5**(11):1285-1291, 1999
47. Stockfleth E et al: Successful treatment of basal cell carcinomas in a nevoid basal cell carcinoma syndrome with topical 5% imiquimod. *Eur J Dermatol* **12**(6):569-572, 2002
54. Von Hoff DD et al: Inhibition of the hedgehog pathway in advanced basal-cell carcinoma. *N Engl J Med* **361**(12):1164-1172, 2009
56. Yauch RL et al: Smoothened mutation confers resistance to a hedgehog pathway inhibitor in medulloblastoma. *Science* **326**(5952):572-574, 2009

Chapter 117 :: Keratoacanthoma

:: Lorenzo Cerroni & Helmut Kerl

KERATOACANTHOMA AT A GLANCE

- A common, rapidly growing epithelial tumor with histopathologic features similar to squamous cell carcinoma and a tendency to spontaneous regression.
- Considered by some a variant of squamous cell carcinoma because of potential of metastases and local tissue destruction if untreated. Considered by others a *pseudocancer*, but this issue is unresolved.
- Clinically, keratoacanthoma is mostly a rapidly growing, hyperkeratotic solitary tumor. Multiple keratoacanthomas occur.
- Predilection for sun-exposed areas.
- May be associated with Muir–Torre syndrome.
- Pathology reveals a central keratotic plug surrounded by an epithelial proliferation with atypical keratinocytes and mitoses; neurotropism may be observed.

Keratoacanthoma is a common epithelial tumor of the skin characterized by rapid growth, histopathologic features similar to those of cutaneous squamous cell carcinoma, and a certain tendency toward spontaneous regression. The exact nosology and classification of keratoacanthoma are still a matter of debate. Some authors regard keratoacanthoma as a benign cutaneous tumor that is the prototype of a "pseudomalignant" tumor of the skin, whereas others maintain that it is a malignant neoplasm and should be regarded as a variant of cutaneous squamous cell carcinoma.

EPIDEMIOLOGY

The exact incidence of keratoacanthoma is unknown. The tumor is more frequent in light-skinned persons, and rarer in dark-skinned and Japanese persons. The relative frequency in comparison with squamous cell carcinoma of the skin is controversial, but most studies show a lower incidence of keratoacanthoma than of squamous cell carcinoma. Discordant results may be explained, at least in part, by differences in classification of these lesions.

Studies on gender distribution reveal that both sexes are affected equally, possibly with a slight predilection for men. Keratoacanthoma occurs mostly in adult life, with a peak between the ages of 55 and 65 years; it has been observed rarely in younger patients. The

familial type of keratoacanthoma occurs often during adolescence, and a neonatal case has been reported.[8] Although the incidence was thought to remain stable after a peak in the sixth decade, a study conducted in a defined population in Hawaii revealed that keratoacanthoma increases with age, in a fashion similar to that observed for cutaneous basal and squamous cell carcinomas.[9]

RELATIONSHIP TO SQUAMOUS CELL CARCINOMA

The authors of earlier reports considered keratoacanthoma to be a form of epithelial cancer of the skin, and named it accordingly. However, since the introduction of the concept of keratoacanthoma as a benign, self-healing neoplasm distinct from squamous cell carcinoma, the relationship between these two epithelial tumors has been the subject of debate. In their paper published in 1950, Rook and Whimster wrote, "This disease is evidently not cancerous or precancerous."[2] On the other hand, Kwittken, in 1975, stated, "I have come to the firm conclusion that all of these lesions are malignancies and that the formerly accepted concept of a self-healing squamous cell carcinoma of the skin is a correct one,"[10] and in 1979, even Rook amended his initial concept by writing, "…transformation from keratoacanthoma to squamous cell carcinoma occurs frequently."[11] Cases of typical keratoacanthoma with metastases have been observed,[12] and four possible explanations for this phenomenon have been suggested: an initial misdiagnosis of keratoacanthoma; the presence of both keratoacanthoma and squamous cell carcinoma in the same lesion; the malignant transformation of keratoacanthoma into squamous cell carcinoma; and, finally, the possibility that keratoacanthoma may be a peculiar variant of squamous cell carcinoma.[13] The debate is not settled yet, and some authors still maintain that keratoacanthoma represents a benign epithelial tumor, distinct from squamous cell carcinoma,[14] whereas others hold that it is a variant of squamous cell carcinoma with tendency to spontaneous regression, but with the potential for giving rise to lethal distant metastases.[15] Two studies of large numbers of cases highlighted the impossibility of reliably differentiating keratoacanthoma from squamous cell carcinoma using histopathologic criteria alone.[16,17] A patient under infliximab therapy developed multiple squamous cell carcinomas as well as keratoacanthomas, suggesting a common pathogenetic pathway on immunosuppression.[18] In addition, multiple keratoacanthomas and multiple squamous cell carcinomas may be observed at the same skin site ("field cancerization") (Fig. 117-1). Keratoacanthomas have a higher proliferation rate than squamous cell carcinomas.[19] Other investigations pointed at similarities among squamous cell carcinoma and keratoacanthoma in the expression of oncogenetic and cell-cycle-regulating proteins as well as regarding the presence of trisomy 7 in a subset of tumors in both groups, thus suggesting a close relationship between these two entities.[20–25] On the other hand, studies on loss of heterozygosity, on expression



Figure 117-1 Multiple keratoacanthomas and invasive squamous cell carcinomas on the upper chest of a 90-year-old man.

of angiotensin type 1 receptor and of desmogleins 1 and 2, on adhesion molecules vascular cellular adhesion molecule and intercellular adhesion molecule, on telomerase activity, on apoptotic and cell adhesion markers, and on chromosomal aberrations assessed by comparative genomic hybridization showed differences among keratoacanthomas and squamous cell carcinomas.[26–33] Using different molecular techniques, both similarities and differences between keratoacanthoma and squamous cell carcinoma have been recently demonstrated.[34] In short, at present, and in spite of the great amount of clinical and experimental data collected over the decades, the exact nosology of keratoacanthoma is not clear, and the term *abortive malignancy* has been proposed.[35]

ETIOLOGY AND PATHOGENESIS

Different etiologic factors are probably involved in the development of keratoacanthomas in different patients, and it seems likely that these different factors act synergistically to induce the onset of a lesion in a given patient. The role of chronic ultraviolet (UV) light exposure in the etiology of keratoacanthoma is well documented by the frequent occurrence on sun-exposed areas, as well as by the presence of keratoacanthomas in patients with xeroderma pigmentosum and after prolonged psoralen and UVA light (PUVA) treatment. In patients with multiple keratoacanthomas, PUVA treatment accelerates the development of the tumors,[36] but the risk for keratoacanthoma after therapy with PUVA seems lower than that for squamous or basal cell carcinoma.[37] An etiologic link to UV light has been confirmed also by experimental studies in mice.

The relationship of keratoacanthoma to chemical carcinogens has been well documented in humans and in several animals.[38] In fact, the incidence of keratoacanthoma is higher in industrial towns, and among industrial workers coming in contact with pitch, mineral oils, and tar. Chemical carcinogens may act in conjunction with UV rays to induce the onset of keratoacanthomas. Smokers seem also to be more affected than nonsmokers.[38]

Keratoacanthomas have been reported at the site of injury. The association with trauma is also documented by the report of cases occurring after skin grafting, at both the donor and the recipient sites, and at the site of arterial puncture and vaccination.[39–41] A recent report described the onset of keratoacanthoma at the site of tattoo, particularly with red ink.[42] One of these patients had four keratoacanthomas arising within two separate tattoos. The role of human papillomavirus (HPV) remains controversial. Evidence of HPV infection has been documented by polymerase chain reaction technique,[43,44] but other studies failed to detect viral material within lesions of keratoacanthoma.[45] Some studies found an association with HPV-25, and HPV-19 and HPV-48 have been isolated in a lesion arising in a human immunodeficiency virus (HIV) patient.[46,47] Several other types of HPV have been linked to keratoacanthoma, including types 6, 9, 14, 16, 19, 35, 37, 58, and 61.

Genetic factors probably play a major role in the familial type of keratoacanthoma. In the other variants of keratoacanthoma, it seems likely that genetic aspects interplay with other etiologic factors (i.e., UV rays, trauma, infections) by providing the genetic predisposition for the development of the tumor. Keratoacanthomas are commonly observed in patients with Muir–Torre syndrome, suggesting that the genetic defect(s) of this syndrome also plays a role in the development of keratoacanthoma.[48–52] In addition, keratoacanthomas have been observed in patients affected by a variety of skin diseases including psoriasis, lupus erythematosus, lichen planus, atopic dermatitis, herpes zoster, acne conglobata, and pemphigus foliaceus, among others.[39]

Keratoacanthomas also have been observed in patients under immunosuppression as a result of bone marrow transplantation, cyclosporine treatment, or infection with HIV, thus suggesting that immunosuppression may play an etiologic role in some cases. In these patients, most lesions of keratoacanthoma tested for presence of HPV proved positive, suggesting that immunosuppression may contribute by decreasing the immune response against possible causative agents.[53] Similarly, UV light may act not only by direct carcinogenesis, but also by virtue of the local immunosuppression caused by sun exposure.

Little is known about the pathogenesis of keratoacanthoma, and about the exact mechanisms of regression in the absence of any treatment. Studies on p53 oncoprotein expression and *p53* gene mutations revealed expression of p53 oncoprotein in the great majority of tested cases, and association with a point mutation in the *p53* gene in slightly more than 10% of these cases, suggesting a possible role of *p53* gene in the development of some keratoacanthomas.[21,25]

Patients with incontinentia pigmenti may develop subungual keratoacanthomas. Incontinentia pigmenti is caused by genetic alterations of the NF-κB essential modifier (NEMO). There is evidence that loss of activity of NF-κB is related to development of skin cancer, but somatic mutations of NEMO have not been detected in keratoacanthomas not associated with incontinentia pigmenti.[54]

Multiple keratoacanthomas of the Ferguson–Smith type show a familial distribution and are transmitted in an autosomal dominant fashion. The gene responsible for this syndrome is localized to chromosome 9q. The majority of the cases have been described in some Scottish families, and in these patients, the syndrome is thought to be caused by a single genetic mutation that occurred before 1790.[55]

CLINICAL FINDINGS

Keratoacanthomas occur mostly on sun-exposed skin of the face, forearms, and dorsal aspects of the hands (Figs. 117-1 and 117-2). Actinic damage is commonly found in the surrounding skin. In most instances, they are located on hairy skin, but lesions with similar clinicopathologic aspects have been described in the oral cavity, the subungual region, the genital mucosa, and the conjunctiva.

The stereotypic example of keratoacanthoma is represented by a solitary lesion growing rapidly within a few weeks, and subsequently showing a slow involution over a period of a few months. Three clinical stages have been described: proliferative, mature, and resolving.[39] Lesions in the proliferative stage are rapidly enlarging erythematous papules that grow up to a dimension of 1–2 cm or more. In this stage, the lesions are symmetric and firm and show a smooth surface. In the mature stage there are symmetric, firm, erythematous or skin-colored nodules with a central keratotic core (Figs. 117-2 and 117-3). The central part can appear crateriform if the keratotic core is removed. Ghadially divided mature keratoacanthomas into three main morphologic types: type 1, or bud-shaped; type 2, or dome shaped; and type 3, or



Figure 117-2 Mature keratoacanthoma on the neck of an elderly man with prominent keratotic aspect.



Figure 117-3 Mature keratoacanthoma. Note central keratotic core giving a white–yellowish appearance to the superficial part of the lesion.

berry shaped.[40] Regressing lesions are characterized by a keratotic, partly necrotic nodule that becomes progressively flat upon elimination of the keratotic plug, eventually leaving a hypopigmented scar (Fig. 117-4; Box 117-1).

SYSTEMIC ASSOCIATIONS

Keratoacanthomas may be associated with multiple internal cancers in patients with Muir–Torre syndrome and the related hereditary nonpolyposis colorectal cancer syndrome. Patients with multiple keratoacanthomas should always be evaluated for the presence of typical traits of Muir–Torre syndrome, where cutaneous sebaceous tumors and low-grade visceral malignancies can be observed (most commonly carcinomas of the gastrointestinal tract, but also carcinomas of the lung and genitourinary system, and, occasionally, colonic polyps). It has been suggested that at least some of the patients with multiple keratoacanthomas of the Ferguson–Smith type may have an incomplete form of the Muir–Torre syndrome.



Figure 117-4 Regressing keratoacanthoma on the lower leg of a 59-year-old man. There is a whitish flattened plaque with superficial ulceration in the center.

BOX 117-1 CLINICAL DIFFERENTIAL DIAGNOSIS OF KERATOACANTHOMA

Most Likely

- Squamous cell carcinoma

Consider

- Well-developed tumors
  - Common warts
  - Molluscum contagiosum
  - Prurigo nodularis
  - Metastatic carcinoma
- Regressing tumors
  - Regressing lesions of lymphomatoid papulosis
  - Regressing lesions of anaplastic large cell lymphoma
  - Amelanotic melanoma

Keratoacanthomas may also occur in patients with xeroderma pigmentosum and, rarely, in patients with lymphomatoid papulosis. Subungual keratoacanthomas may be observed in patients with incontinentia pigmenti.

VARIANTS

Several variants of keratoacanthoma have been described, and different morphologic types of keratoacanthoma have been observed in a single patient.[56]

GIANT KERATOACANTHOMA

In some instances, keratoacanthomas may reach dimensions of several centimeters (Fig. 117-5), and even a tumor reaching 15 cm in its diameter has been observed. Giant keratoacanthomas show a predilection for the nose and the dorsum of the hands. In some



Figure 117-5 Giant keratoacanthoma on the cheeck of an elderly man.



Figure 117-6 Large keratoacanthoma on the tip of the nose of a 52-year-old man. Note the destructive appearance of the tumor.

cases, the growth of the tumor may be associated with destruction of underlying tissues (Fig. 117-6).

KERATOACANTHOMA CENTRIFUGUM MARGINATUM

Keratoacanthoma centrifugum marginatum is characterized by multiple tumors growing on a localized area, usually on the face, trunk, or extremities (Fig. 117-7).[57] Tumors are annular, polycyclic, or circular in morphology. The area affected may reach 20 cm in diameter, and resolution may be slower than in solitary keratoacanthoma.

MULTIPLE KERATOACANTHOMAS OF THE FERGUSON–SMITH TYPE

The Ferguson–Smith type is a familial form of keratoacanthoma that affects both sexes with approximately equal severity, which is characterized by the appearance of multiple, sometimes hundreds of keratoacanthomas, each with the clinicopathologic aspects of a solitary keratoacanthoma. The disorder is inherited in an autosomal-dominant manner, and the majority of the cases have been described in a few Scottish families. Patients develop keratoacanthomas during adolescence and early adulthood, but onset during childhood is not infrequent. It has been suggested that at least some of these patients may have an incomplete form of the Muir–Torre syndrome.



Figure 117-7 Multiple keratoacanthomas with an annular arrangement and central, keratin-filled craters on the back of the hand (keratoacanthoma centrifugum marginatum). This 42-year-old male patient also had lupus erythematosus.

GENERALIZED ERUPTIVE KERATOACANTHOMAS OF GRZYBOWSKI

Keratoacanthomas of Grzybowski is a variant characterized by the presence of hundreds to thousands of tiny follicular keratotic papules disseminated all over the body, with predominance on sun-exposed areas. Facial involvement is usually severe, and coalescence of lesions around the eyes may cause ectropion. The mucosal regions (oral, genital) may be affected, whereas palms and soles are usually not involved. The age of onset is similar to that of solitary keratoacanthoma, and clustering in families has not been observed.

SUBUNGUAL KERATOACANTHOMA

Subungual keratoacanthoma (Fig. 117-8) differs from the other types of keratoacanthoma by being persistent and often causing destruction of the underlying bone. The tumor originates in the distal nail bed, separating the nail plate from the nail bed, and can grow rapidly causing destruction of the entire phalanx.

KERATOACANTHOMA OF THE MUCOSAL REGIONS

Keratoacanthomas have been described in the oral mucosa, the conjunctiva, the nasal mucosa, and the genital mucosa. In fact, involvement of the oral and genital mucosa is common in the generalized eruptive keratoacanthomas of the Grzybowski type. Keratoacanthomas arising on mucosal regions, especially on the oral



Figure 117-8 Subungual keratoacanthoma in a 55-year-old woman.

mucosa, present clinically as slowly growing crateriform lesions that tend to persist for many months or years.

PATHOLOGY

The histopathologic diagnosis of keratoacanthoma rests mainly on the silhouette of the tumor as assessed at scanning magnification; inadequate specimens (i.e., punch biopsies, shave biopsies, curettage) do not allow a diagnosis and differentiation from squamous cell carcinoma. Two large studies on the histopathologic criteria for diagnosis of keratoacanthoma emphasized the overlapping features between this tumor and squamous cell carcinoma, which render differentiation very difficult or even impossible in given cases.[16,17]

The histopathologic features of keratoacanthoma depend on the stage of evolution of the tumor. In early, proliferative lesions, the epithelium is markedly hyperplastic, and the central keratotic plug is not as pronounced as in fully developed lesions. The lesion has an overall symmetric aspect (Fig. 117-9A). Although atypical cells do not represent the majority of the cells in typical keratoacanthoma, there may be atypical keratinocytes and mitoses, especially at the lower margin of the tumor. Nests of epithelial cells may detach from the main tumor mass and be found in the superficial reticular dermis. Fully developed, mature lesions are characterized by a large central core of keratin surrounded by a well-differentiated proliferation of squamous epithelium that in some cases may resemble squamous cell carcinoma (Fig. 117-9A). The epidermis at both sides of the central core extends over the keratotic area in a fashion that has been described as "lipping" or "buttressing," giving a distinct crateriform appearance to the lesion. Nests and strands of keratinocytes may be found apart from the main bulk of the tumor but usually do not extend lower than the level of sweat glands (Box 117-2). In regressing lesions the shape of a crater can still be recognized, but epithelial hyperplasia and atypical cells are no longer visible (Fig. 117-10); in the superficial dermis below the regressed lesion there is fibrosis with sparse inflammation.

Cytomorphologically, large keratinocytes with eosinophilic cytoplasm are commonly observed, together with atypical cells and mitoses (Fig. 117-9B). An inflammatory infiltrate containing lymphocytes, plasma cells, histiocytes, eosinophils, and neutrophils is a common feature, and in some instances may be conspicuous. Neurotropism and even vascular invasion can be observed in otherwise typical keratoacanthomas, but the prognosis does not seem to be affected by these histopathologically worrisome features (Fig. 117-9C).[14]

BOX 117-2 HISTOPATHOLOGIC DIFFERENTIAL DIAGNOSIS OF KERATOACANTHOMA

Most Likely

- Squamous cell carcinoma

Regressing Tumors: Consider

- Other regressing benign and malignant epithelial tumors
- Regressing lesions of lymphomatoid papulosis
- Regressing lesions of anaplastic large cell lymphoma

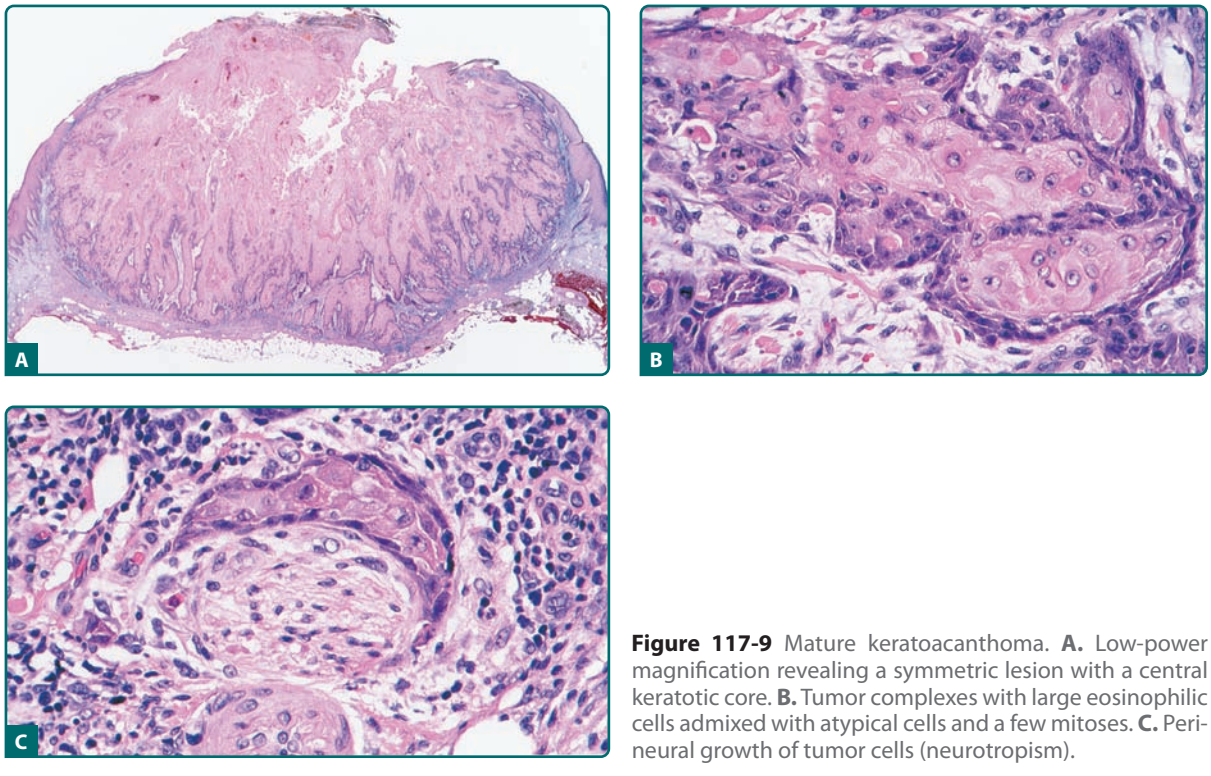

Figure 117-9 Mature keratoacanthoma. **A.** Low-power magnification revealing a symmetric lesion with a central keratotic core. **B.** Tumor complexes with large eosinophilic cells admixed with atypical cells and a few mitoses. **C.** Perineural growth of tumor cells (neurotropism).

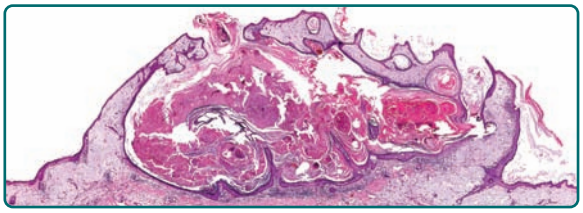

Figure 117-10 Regressing keratoacanthoma. Note exophytic collarette with keratotic core but lack of epithelial hyperplasia.

PROGNOSIS

Solitary keratoacanthoma behaves as a benign tumor in the majority of the cases, but lymph node and visceral metastases have been observed in a small number of patients. Central facial keratoacanthoma may behave aggressively. There are no clear-cut features to predict the biologic behavior of a given tumor, but persistent and recurrent lesions should be managed by complete surgical excision. Histopathologic features that are associated with a poor prognosis in common squamous cell carcinoma, such as neurotropism and vascular invasion do not seem to have prognostic implications in keratoacanthomas.[14] Ungual keratoacanthomas do not show a tendency to spontaneous regression and often are the cause of massive bone destruction.[58] However, in spite of aggressive local behavior, distant metastases have not been observed in ungual and mucosal types of keratoacanthoma.

TREATMENT

(See Box 117-3)

Keratoacanthomas show a tendency to spontaneous regression, and, in typical cases, an acceptable therapeutic option may be to adopt the so-called watchful waiting strategy. However, because of the uncertainty regarding the exact nosology of this tumor, as well as the difficulty in differentiating it clinically from squamous cell carcinoma, complete conservative excision is advised in most cases, especially in those of solitary keratoacanthoma and in keratoacanthoma of the face.[59] Removal by shave excision below the base to preserve architecture for diagnostic purposes followed by electrodesiccation and curettage are being increasingly performed for keratoacanthoma.[60] Punch biopsies never allow differentiation of keratoacanthoma from well-differentiated squamous cell carcinoma and should be avoided. For diagnostic purposes, a longitudinal biopsy that includes normal skin at both margins of the lesion as well as the underlying fat tissues is acceptable. Mohs micrographic surgery has been adopted for difficult cases such as recurrent lesions, lesions in the central facial area, giant lesions, or lesions of keratoacanthoma centrifugum marginatum that may cover a large area of the body.[61] Therapy by laser vaporization, electrodesiccation, and cryosurgery with liquid nitrogen has also been used, but does not allow the histopathologic verification of the clinical diagnosis.

BOX 117-3 TREATMENT FOR KERATOACANTHOMA

FIRST LINE

- Complete surgical excision

SECOND LINE

- Curettage followed by electrodesiccation
- Radiotherapy
- Intralesional chemotherapeutic agents, intralesional interferon
- Oral retinoids
- Photodynamic therapy
- Specific types of keratoacanthomas may require other treatment modalities (e.g., generalized eruptive keratoacanthomas of Grzybowski)

Keratoacanthomas have been treated by radiotherapy (electron beam, or the voltage radiation, superficial x-ray) with excellent results.[62] This type of treatment is particularly indicated for lesions that can be difficult to manage surgically. Intralesional instillation of chemotherapeutic agent (methotrexate, bleomycin, and 5-fluorouracil) has also proved therapeutically successful,[39,63] and 5-fluorouracil has been applied also topically.[64] Some keratoacanthomas have been treated by intralesional injection of interferon-α2a,[65,66] and others have been successfully treated with intralesional application of triamcinolone. Successful topical treatment has been performed with podophyllin, either alone or in combination with other treatment modalities. However, podophyllin is also capable of inducing keratoacanthomas. Multiple keratoacanthomas have been treated successfully with oral retinoids in several cases, but larger studies have not been performed.[67] Systemic treatments include chemotherapy with methotrexate, cyclophosphamide, or 5-fluorouracil.

Photodynamic therapy with δ-aminolevulinic acid is an additional treatment option for keratoacanthoma of both solitary and multiple types. The treatment is simple and has been shown to achieve good therapeutic and cosmetic results.[68,69] Topical imiquimod has been reported to induce regression of keratoacanthoma.[70] Recently, a case of aggressive keratoacanthoma centrifugum marginatum has been successfully managed with epidermal growth factor receptor inhibitor erlotinib.[71]

PREVENTION

Preventive measures against the development of keratoacanthomas are similar to those applied for basal and squamous cell carcinoma of the skin. In predisposed subjects (i.e., fair skin, history of multiple actinic keratoses, basal and/or squamous cell carcinomas, Muir–Torre syndrome), avoidance of direct sun exposure should be achieved, and skin protection creams applied.

KEY REFERENCES

Full reference list available at www.DIGM8.com

DVD contains references and additional content

11. Rook A, Whimster I: Keratoacanthoma: A thirty-year retrospect. *Br J Dermatol* **100**:41, 1979
17. Cribier B, Asch PH, Grosshans E: Differentiating squamous cell carcinoma from keratoacanthoma using histopathological criteria. Is it possible? A study of 296 cases. *Dermatology* **199**:208, 1999
30. Clausen OP et al: Are keratoacanthomas variants of squamous cell carcinomas? A comparison of chromosomal aberrations by comparative genomic hybridization. *Br J Dermatol* **126**:2308, 2006
39. Schwartz RA: Keratoacanthoma. *J Am Acad Dermatol* **30**:1, 1994
52. Stoebner PE et al: Solitary subungual keratoacanthoma arising in an MSH2 germline mutation carrier: Confirmation of a relationship by immunohistochemical analysis. *Dermatology* **219**:174, 2009
59. Karaa A, Khachemoune A: Keratoacanthoma: A tumor in search of a classification. *Int J Dermatol* **46**:671, 2007

Chapter 118 :: Benign Epithelial Tumors, Hamartomas, and Hyperplasias

:: Valencia D. Thomas, Nicholas R. Snavely, Ken K. Lee & Neil A. Swanson

Benign epithelial tumors, hamartomas, and hyperplasias comprise a large and disparate group of tumors and no single classification system unifies them, as their cells of origin and clinical presentation can vary substantially. In this chapter, the clinical entities are grouped by clinical or histologic features to better present them from a practical diagnostic and treatment perspective (Table 118-1).

SEBORRHEIC KERATOSIS

SEBORRHEIC KERATOSIS AT A GLANCE

- Seborrheic keratosis is the most common benign epidermal tumor.
- Usually begin as well-circumscribed, dull, flat, tan, or brown patches with pseudohorn cysts.
- Rapidly growing, symptomatic, or atypical lesions should be biopsied to rule out malignancy such as basal cell carcinoma, squamous cell carcinoma, or melanoma.
- Clinical and histopathologic variants include the common seborrheic keratosis, reticulated seborrheic keratosis, stucco keratosis, clonal seborrheic keratosis, irritated seborrheic keratosis, seborrheic keratosis with squamous atypia, melanoacanthoma, and dermatosis papulosa nigra.
- Hallmark histopathologic findings: acanthosis, papillomatosis, pseudohorn cysts, hyperkeratosis.
- Internal malignancy: individuals can develop multiple, eruptive seborrheic keratoses (Leser–Trélat sign). Adenocarcinoma of the stomach is most common associated malignancy.

EPIDEMIOLOGY AND CLINICAL FEATURES

Seborrheic keratoses (SKs) are the most common benign epidermal tumor of the skin and a frequent focus of patient concern because of their variable appearance. These lesions are common in middle-aged individuals and can arise as early as adolescence.[1] Although there are many clinical variants of the lesions, these lesions usually begin as well-circumscribed, dull, flat, tan, or brown patches. As they grow, they become more papular, taking on a waxy, verrucous, or stuck-on appearance (Figs. 118-1 and 118-2). Many lesions display distinctive pseudohorn cysts that likely represent plugged follicular orifices. SKs may arise on any nonmucosal surface, and multiple lesions may be distributed in a Christmas tree pattern along skin folds or



Figure 118-1 Seborrheic keratosis (basal cell papilloma) showing lackluster surface and stuck-on appearance.

TABLE 118-1
Overview

- Seborrheic keratosis
  - Common seborrheic keratosis
  - Reticulated seborrheic keratosis
  - Stucco keratosis
  - Melanoacanthoma (pigmented seborrheic keratosis)
  - Dermatosis papulosa nigra
  - Clonal seborrheic keratosis
  - Irritated seborrheic keratosis
  - Seborrheic keratosis with squamous atypia
  - Leser–Trélat sign
- Epidermal nevi
  - Linear verrucous epidermal nevus-localized, systematized
  - Nevus unius lateris
  - Ichthyosis hystrix
  - Inflammatory linear verrucous epidermal nevus
  - Nevus sebaceous of Jadassohn
  - Nevus comedonicus
  - Eccrine nevus
  - Apocrine nevus
  - Becker's nevus
  - White sponge nevus
  - Epidermal nevus syndrome
- Lichen striatus
- Clear cell acanthoma
- Warty dyskeratoma
- Acanthoma fissuratum
- Chondrodermatitis nodular helicis
- Cysts of epithelial origin
  - Epidermal cyst
  - Trichilemmal cyst
  - Milium
  - Steatocystoma multiplex
  - Dermoid cyst
  - Branchial cyst
  - Preauricular cyst and sinus



Figure 118-2 Multiple small seborrheic keratoses.

in Blaschko's lines.[2] The color of these lesions ranges from pale white to black. At times, distinguishing these lesions from a nevus or melanoma can be clinically challenging. Because melanoma, basal cell carcinoma, and other cutaneous malignancies have been reported to arise in SKs, care must be taken to critically evaluate rapidly growing, symptomatic, or unusual lesions.[3,4]

ETIOLOGY

The name seborrheic comes from the Greek word for sebum, and is a misnomer for these common growths. While the precise etiology of SKs is unknown, it is a tumor of keratinocytic origin. Genetics, sun exposure, and infection have all been implicated as possible factors. Many individuals with SKs have a positive family history for the condition. SKs demonstrate irregularities in the expression of the apoptosis markers p53 and Bcl-2, though no genetic locus or chromosomal imbalance has been detected to date.[5,6] The higher prevalence of SKs on sun-exposed skin implies a possible causative role.[7]

Viral infection has also been considered a possible cause of SKs based on occasional clinical similarities to warts. Although no human papillomavirus (HPV) DNA was detected in a study of 40 genital SK biopsies, nongenital skin yielded different results. Epidermodysplasia verruciformis-associated HPV DNA has been demonstrated in 42 of 55 (76%) nongenital SK biopsies compared to only 13 of 48 (27%) healthy controls ($p < 0.005$).[8] These findings indicate the possible role of viral infection in the development of SKs in nongenital skin.

Although the etiology of SKs remains unknown, the monoclonal nature of these neoplasms has been established in 2001.[9] By tracking polymorphisms in a human androgen receptor, researchers found that more than half of the 38 SKs sampled, regardless of subtype, were clonal in nature.[9] The development of SKs has also been associated with circulating epidermal growth factors and melanocyte-derived growth factors in addition to the local increased expression of tumor necrosis factor-α and endothelin-converting enzyme.[10] The latter two are associated with an increased expression of the keratinocyte melanogen, endothelin-1, resulting in hyperpigmentation within SKs.

CLINICOPATHOLOGIC VARIANTS

There are many clinicopathologic variants of SKs, and while distinction is usually unnecessary, the commonplace nature of SKs makes these variants relevant.

COMMON SEBORRHEIC KERATOSIS. A common SK is classically described as a stuck-on, verrucous plaque (Figs. 118-1 and 118-2) with pseudohorn cysts (Fig. 118-3). Hyperkeratosis, acanthosis, and papillomatosis are hallmark pathologic findings. An increased number of melanocytes may also be present, giving lesions a tan or dark brown color. SKs are



Figure 118-3 Seborrheic keratosis (basal cell papilloma) showing a papillomatous acanthotic epidermis consisting of basaloid cells.

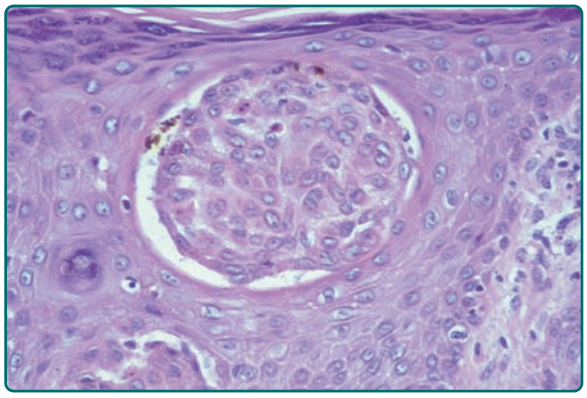

Figure 118-5 Clonal seborrheic keratosis showing round nests of keratinocytes and some melanocytes.

usually asymptomatic but may itch. Common SKs spare the palms, soles, and mucosa.

RETICULATED SEBORRHEIC KERATOSIS. Reticulated SKs are also known as *adenoid SKs*. Some believe a solar lentigo usually precedes this often pigmented patch or papule. Histologically, there are small horn cysts suspended among interwoven strands of basophilic cells (Fig. 118-4).[11]

STUCCO KERATOSIS. Stucco keratoses are also described as *verrucous*, *serrated*, *hyperkeratotic*, and *digitate*. These lesions are commonly 1- to 3-mm, flat-topped, white to tan papules that adhere tightly to the skin on the lower legs (eFig. 118-4.1 in online edition). Histologically, no keratinocytic vacuolar changes or viral cytopathic changes are observed, thus distinguishing them from verruca plana.

MELANOACANTHOMA. Melanoacanthoma is also known as *pigmented SK*. This benign, slow-growing SK resembles melanoma clinically, and is often located on the trunk, head, or neck of older individuals. The term *melanoacanthoma* was introduced in 1960 to describe a pigmented lesion composed of nested melanocytes and keratinocytes.[12]

Dermatosis Papulosa Nigra. Dermatosis papulosa nigra are small dark brown to black papules that are commonly found on the face of individuals of Fitzpatrick skin phototype IV or greater. They are histologically identical to SKs (Fig. 118-5).



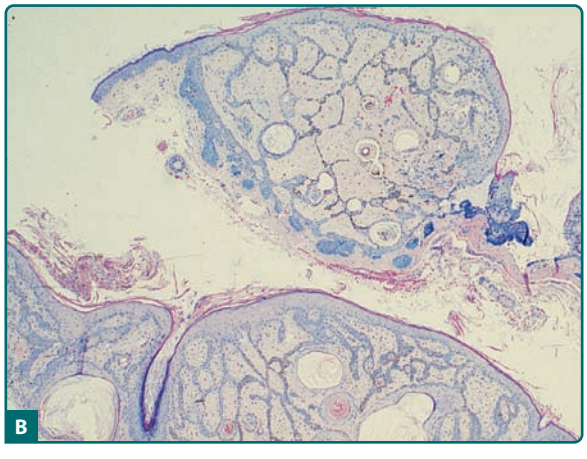

Figure 118-4 **A.** Multiple reticulated seborrheic keratoses. **B.** Reticulated seborrheic keratosis showing reticulated cords of basaloid cells descending from the base of the epidermis.

SKIN TAGS. While often felt to be a distinct entity, some skin tags share clinical and histologic overlap with some SKs. These rough, 1- to 2-mm pedunculated papules are commonly located in areas of friction. The axilla, inframammary area, and neck are common locations where these papules commonly appear. Spontaneous regression can occur.

HISTOLOGIC VARIANTS

CLONAL SEBORRHEIC KERATOSES. Clonal SK is a histologic term used to describe intraepithelial nests of basophilic keratinocytes of varying sizes with admixed melanocytes (Fig. 118-6). As previously stated, in one study, more than half of the 38 SKs sampled, regardless of subtype, were clonal in nature.[9]

IRRITATED SEBORRHEIC KERATOSIS. Irritated SKs represent SKs that have been mechanically or chemically irritated or are involved in immunologic responses. Although inciting trauma is occasionally associated with irritated SKs, spontaneous inflammation is common (Fig. 118-7). Histologically, the dermis underlying these lesions is filled with a dense inflammatory infiltrate predominantly of lymphocytes. This inflammation is occasionally lichenoid or neutrophil rich. Swirled collections of eosinophilic keratinocytes can be seen in the epidermis.[13] Eczematous changes in or around the lesion, also known as *Meyerson phenomenon*, can also be seen.[14]

Association with Skin Cancers. Varying degrees of squamous atypia can be seen in SKs. Bowenoid transformation of benign SKs into squamous cell carcinoma in situ has been documented but the development of basal or squamous cell carcinoma in a SK is rare.[15] Lesions demonstrating the histology of both SKs and malignancies have been reported.[16,17] Although it is likely that most of these lesions represent collision tumors, malignant transformation of SKs into basal cell carcinomas, squamous cell carcinomas, and melanomas can occur. In a retrospective study of 813 lesions histologically diagnosed as SKs, 5.3% were associated with nonmelanoma skin cancer. In this study, the most common malignancy was squamous cell carcinoma in situ, followed by basal cell carcinomas and invasive squamous cell carcinomas; no melanomas were observed.[17] Clinically atypical or rapidly growing SKs should be biopsied to rule out the possibility of malignancy.



Figure 118-6 Inflamed, irritated seborrheic keratoses occurring during cytarabine therapy. This is in the submammary region, and there are also pustules of *Candida* infection.



Figure 118-7 Dermatosis papulosa nigra.

LESER–TRÉLAT SIGN. In the context of internal malignancy, individuals can develop multiple, eruptive SKs also known as the *Leser–Trélat sign*. Adenocarcinoma of the stomach is the most commonly associated malignancy,[18,19] though adenocarcinoma of the lung and colon have also been linked. Other diseases reported to occur with eruptive SKs are leukemia, lymphoma, lepromatous leprosy, human immunodeficiency virus infection, erythrodermic eczema, and melanoma.[20–23] Inflammation of eruptive SKs during chemotherapy, especially cytarabine, is known to occur (Fig. 118-7).[24] The presentation of eruptive SKs with acanthosis nigricans led many to speculate a common reactive mechanism.[25] Abnormal immune responses may also play a role in the development of this clinical sign.

TREATMENT

Rapid growth, atypical morphologic features, unusual lesion location, or symptoms should all be considered when evaluating SKs, and care should be taken not to

destroy a lesion that begs further pathologic examination. For any lesion with a possibility of malignancy, removal must be performed in a fashion that yields tissue for evaluation.

For clearly benign, yet symptomatic or cosmetically undesirable lesions, destruction with cryotherapy, electrodesiccation followed by curettage, curettage followed by desiccation, or laser ablation have all been shown to be effective. Reports of giant SKs measuring many centimeters have been treated successfully with either dermabrasion or topical fluorouracil.[26,27] Surgical excision is also an accepted treatment approach, especially if the lesion is pedunculated and can be transected at its base. Common complications of these destructive measures include scarring, pigmentary alteration, incomplete removal, or recurrence. Recurrence of the lesions may occur, and it is not uncommon to require multiple treatments to ensure the complete destruction of the initial lesion. It is preferable to ensure that the method of removal minimizes the risk of scarring.

EPIDERMAL NEVUS

EPIDERMAL NEVUS AT A GLANCE

- Epidermal nevi are hamartomatous proliferations of the epithelium, including keratinocytes, sebocytes, pilosebaceous units, eccrine glands, or apocrine glands.
- Six different epidermal nevus syndromes: epidermal nevi present with developmental abnormalities of the nervous, cardiovascular, urogenital, or skeletal systems.
- Linear configurations common on limbs following Blaschko's lines or in relaxed skin tension lines. Tend to appear between birth and adolescence.
- Epidermal nevus presenting with pruritus, erythema, scaling is likely a variant known as *inflammatory linear verrucous epidermal nevus*.
- Differential diagnosis: lichen striatus, linear Darier disease, linear porokeratosis, linear lichen planus, linear psoriasis, and verrucous stage of incontinentia pigmenti.

Epidermal nevus is a generalized term for hamartomatous proliferations of epithelium. The subtypes of this tumor differ according to the distribution of the lesions or the predominant histologic cell type: keratinocyte (verrucous epidermal nevus), sebaceous gland (nevus sebaceous), pilosebaceous unit (nevus comedonicus), eccrine gland (eccrine nevus), or apocrine gland (apocrine nevus). eTable 118-1.1 in online edition provides a classification of one framework to discuss this large and diverse entity. Currently, there are six different epidermal nevus syndromes described: (1) Proteus, (2) congenital hemidysplasia with ichthyosiform nevus and limb defect syndrome, (3) phakomatosis pigmentokeratotica, (4) sebaceous nevus, (5) Becker's nevus, and (6) nevus comedonicus.[28]

EPIDEMIOLOGY

Epidermal nevi occur in 1 in 1,000 live births.[29] Eighty percent of lesions appear within the first year of life, with the majority of lesions appearing by age 14 years. There are rare reports of adult onset of epidermal nevi, with the oldest patient being a 60-year-old woman.[30] Such late-developing epidermal nevi probably represent lesions that have always been present subclinically, but recent growth resulted in clinical recognition.[31] There is an equal male–female prevalence, and most cases are sporadic. However, some familial cases have been documented.[32]

VERRUCOUS EPIDERMAL NEVUS

Verrucous epidermal nevus is also known as linear verrucous epidermal nevus or *linear epidermal nevus*.

CLINICAL FEATURES. Verrucous epidermal nevi are characterized by localized or diffuse, closely set, skin-colored, brown, or gray–brown verrucous papules, which may coalesce to form well-demarcated papillomatous plaques (Fig. 118-8). Linear configurations are common on the limbs as is distribution in Blaschko's lines or in relaxed skin tension lines (Fig. 118-9).

Extensive distribution of a verrucous epidermal nevus is termed *systemized epidermal nevus*. Variants of this type of nevus include nevus unius lateris (Fig. 118-10), epidermal nevi distributed on one-half of



Figure 118-8 Verrucous epidermal nevus.



Figure 118-9 Verrucous epidermal nevus showing linear configuration.

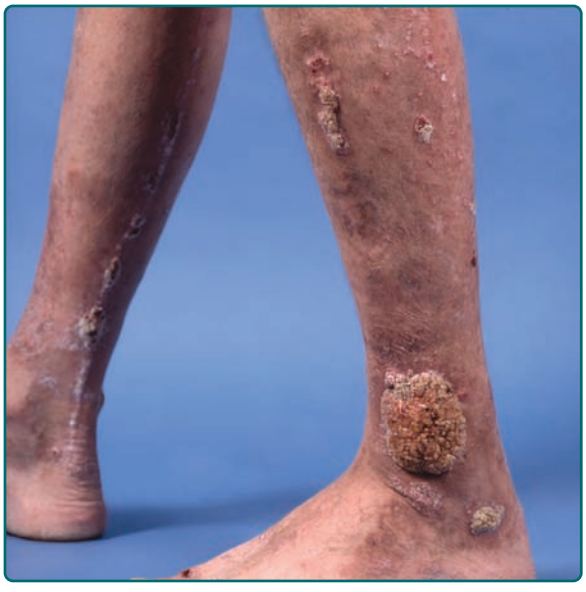

Figure 118-11 Inflammatory linear verrucous epidermal nevus showing psoriasiform erythema, scaling, and hyperkeratosis. The nodule on the left leg was a giant wart.

the body; and ichthyosis hystrix, epidermal nevi distributed bilaterally. Commonly, systematized nevi take on a transverse configuration on the trunk and linear configuration on the limbs.

An epidermal nevus presenting with pruritus, erythema, and scaling is likely a variant of the epidermal nevus termed an *inflammatory linear verrucous epidermal nevus* (ILVEN) (Fig. 118-11). These lesions are found most commonly on the buttocks and lower extremities.



Figure 118-10 Nevus unius lateris. Epidermal nevus affecting one-half of body.

COURSE AND COMPLICATIONS.

Linear epidermal nevi tend to appear between birth and adolescence. Although congenital lesions tend not to expand significantly, lesions that present after birth may expand during childhood, stabilizing in size at or around puberty.[33] Although intertriginous lesions may become macerated and secondarily infected, the majority of epidermal nevi remain quiescent after adolescence. Rare cases of basal cell carcinoma and squamous cell carcinoma arising within epidermal nevi have been reported. This malignant transformation is most common in middle-aged or elderly individuals, though the youngest reported case occurred in a 17-year-old woman.[34]

Epidermal nevi may present in conjunction with other epidermal lesions such as café-au-lait macules, congenital hypopigmented macules, and congenital nevocellular nevi and may be associated with abnormalities in other systems.[33] (See Section "Epidermal Nevus Syndrome").

Rarely, patients with epidermal nevi have offspring with epidermolytic hyperkeratosis (EHK), a condition resulting from a mutation in keratin 10 (K10). Paller et al[35] investigated three families with this occurrence. The analysis of skin samples of parents and offspring with EHK demonstrated a parental mutation in one of the two K10 alleles within the epidermal nevus; nonlesional skin showed no mutation. Offspring showed the same K10 mutation as their parents.[35] The presence of two genetically distinct cell lines in the parents, also known as *mosaicism*, is a result of postzygotic mutation during embryogenesis.[36] If histopathologic evaluation of an epidermal nevus reveals findings consistent with EHK, the patient is at risk of having a child with EHK. Prenatal counseling may be very important for these patients.

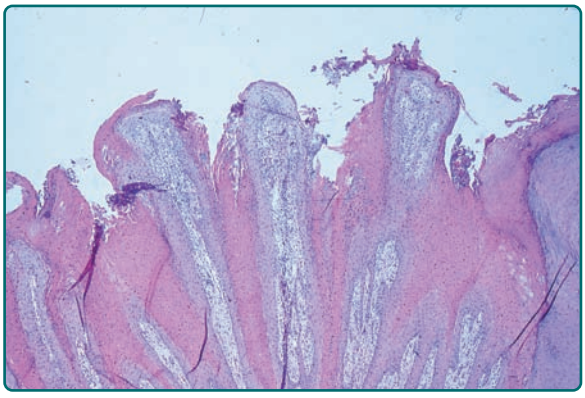

Figure 118-12 Epidermal nevus showing hyperkeratosis, acanthosis, papillomatosis, and elongation of rete ridges.

PATHOLOGY. There are ten histologic variants of the epidermal nevus, with over 60% of lesions displaying acanthosis, papillomatosis, and hyperkeratosis (Fig. 118-12).[37] Rare variants may have features similar to SKs, with thin, elongated rete ridges; or EHK, with compact orthokeratosis, vacuolization of the granular layer of the epidermis, and large keratohyalin granules within or outside cells.[38] Epidermal hyperkeratosis may be a more common finding in ichthyosis hystrix. ILVEN is a histologically distinct variant of the epidermal nevus that displays a chronic dermal inflammatory infiltrate, psoriasiform epidermal hyperplasia, and alternating bands of ortho- and parakeratosis. In this variant, the granular layer is absent underlying the areas of parakeratosis.[39]

DIFFERENTIAL DIAGNOSIS. (See Box 118-1). Lichen striatus, linear Darier disease, linear porokeratosis, linear lichen planus, linear psoriasis, and the verrucous stage of incontinentia pigmenti may all have similar clinical presentations as the linear verrucous epidermal nevus. Lichen striatus may mimic ILVEN clinically, but is self-limited as compared with epidermal nevi. Histology may be useful in differentiating these entities. Linear Darier disease and linear porokeratosis can be differentiated pathologically with linear Darier disease having the distinct pathologic findings of acantholytic dyskeratosis, and linear porokeratosis having coronoid lamellae. Although some consider linear lichen planus and linear psoriasis to be variants of the ILVEN, the genetics and the immunology has yet to be fully characterized.[40–42] Incontinentia pigmenti can be distinguished clinically based on the transient nature of this phase and the preceding verrucous phase. Histologically, this entity can be distinguished by its dyskeratosis, pigment incontinence, eosinophilic exocytosis, and basal layer vacuolization.

BOX 118-1 DIFFERENTIAL DIAGNOSIS OF LINEAR EPIDERMAL NEVUS

- Lichen striatus
- Linear Darier disease
- Linear porokeratosis
- Linear lichen planus
- Linear psoriasis
- Incontinentia pigmenti

TREATMENT. Complete excision of an epidermal nevus to the level of the deep dermis is necessary to prevent recurrences. However, based on the size and distribution of the lesion, excision may not be an appropriate treatment option. Multiple other surgical and medical treatments are available to treat or destroy these lesions. Laser ablation, electrofulguration, cryotherapy, and medium to full-depth chemical peels may offer partial or full destruction of lesions. Although topical retinoids and calcipotriene offer little relief, these medications can be used as an adjunctive therapy to increase the efficacy of the surgical intervention. Systemic retinoids and antipsoriatic agents may offer some clinical improvement. There are reports of successful treatment of ILVEN with etanercept.[43] If malignant transformation is confirmed within an epidermal nevus, the lesion should be completely excised.

NEVUS SEBACEOUS

NEVUS SEBACEOUS AT A GLANCE

- Linear, hairless, yellow, waxy, and verrucous plaque presenting from birth to adolescence.
- Benign tumor of sebaceous gland: immature sebaceous glands located high in the dermis and malformed pilosebaceous units are key features.
- Most common benign tumors arising within a nevus sebaceous: syringocystadenoma papilliferum, trichoblastoma.
- Differential diagnosis: epidermal nevi, aplasia cutis, congenital triangular alopecia.
- Rapidly growing papules or nodules: require pathologic evaluation to rule out malignancy but excision should be considered on a case-by-case basis.

Nevus sebaceous is also known as nevus sebaceous of Jadassohn and organoid nevus.

CLINICAL FEATURES. Nevus sebaceous presents as a linear, hairless, yellow, waxy, and verrucous plaque (Fig. 118-13). It can be flat at birth, becoming plaque-like under the hormonal influences of puberty. These nevi are common in the scalp, but there are reports of lesions on the face, chest, and in oral mucosa. Tumors can arise within nevus sebaceous. The most common benign tumors are syringocystadenoma papilliferum



Figure 118-13 Nevus sebaceous.

and trichoblastoma.[44] Other benign tumors reported to arise in a nevus sebaceous are the leiomyoma, syringoma, spiradenoma, hidradenoma, and keratoacanthoma.[45] It was once believed that individuals with this tumor were at increased risk of basal cell carcinomas, but a retrospective review of 596 cases by Cribier et al revealed that most lesions initially diagnosed as basal cell carcinoma were actually trichoblastomas.[46] A second retrospective study of 757 tumors confirmed this finding.[47] This does not exclude the possibility of the development of basal cell carcinoma in these lesions. Rarely, malignant tumors such as apocrine carcinoma, squamous cell carcinoma, and malignant eccrine poromas may arise within nevus sebaceous.[48]

Nevus sebaceous syndrome is the very rare association of an extensive, congenital nevus sebaceous with ocular abnormalities and cerebral defects such as mental retardation or seizures. This syndrome is also known as *Schimmelpenning-Feuerstein-Mims syndrome* or *organoid-nevus syndrome*.[49,50]

PATHOLOGY. Immature sebaceous glands located high in the dermis and malformed pilosebaceous units are features of nevus sebaceous (Fig. 118-14). Vellus hairs are more common than terminal hairs in these lesions. Epidermal acanthosis, hyperkeratosis, and pseudoepitheliomatous hyperplasia can also be seen.

DIFFERENTIAL DIAGNOSIS. Epidermal nevi and aplasia cutis may be clinically similar to nevus sebaceous but biopsy can easily distinguish between these entities.

TREATMENT. Excision of nevus sebaceous was common when these lesions were thought to carry an increased risk of basal cell carcinoma. Rapidly growing papules or nodules demand pathologic evaluation to evaluate for rare malignancies, but excision should be considered on a case-by-case manner.[48]



Figure 118-14 Nevus sebaceous showing epidermal hyperplasia and increased numbers of sebaceous glands and apocrine glands in the dermis.

NEVUS COMEDONICUS

NEVUS COMEDONICUS AT A GLANCE

- Presents as comedo-like dilated pores with keratinaceous plugs; linear, nevoid, bilateral, or zosteriform pattern.
- Nevus comedonicus syndrome: association of nevus comedonicus with noncutaneous findings such as skeletal defects, cerebral abnormalities, and cataracts.
- Hallmark findings: keratin-filled epidermal invaginations associated with atrophic sebaceous glands or follicles.
- Differential diagnosis: acne vulgaris, acne neonatorum, milia nevus sebaceous, linear Darier disease.
- Inflammatory variant can result in significant suppuration and pain, requiring medical or surgical intervention.

Nevus comedonicus is also known as *comedo nevus*, *nevus follicularis keratosis*, *nevus acneiformis unilateralis*, and *nevus zoniforme*.[51] Nevus comedonicus is a rare hamartoma of the pilosebaceous unit.[52,53] Clinically, comedo-like dilated pores with keratinaceous plugs present in a linear, nevoid, bilateral, or zosteriform pattern (Fig. 118-15).[52] An inflammatory variant also exists, with suppurative cysts and acne-like lesions. These lesions appear on the face, chest, or upper arms at birth or during childhood.[28] Nevus comedonicus syndrome is the association of nevus comedonicus with noncutaneous findings such as skeletal defects, cerebral abnormalities, and cataracts.[54]



Figure 118-15 Nevus comedonicus consisting of linear closely set comedones.

COURSE AND COMPLICATIONS. Nevus comedonicus lesions follow a noninflammatory or inflammatory course and do not resolve spontaneously. The inflammatory course may result in scarring. Nevus comedonicus syndrome results in developmental, cerebral, skeletal, or ocular defects that present by the age 15 years.[55]

PATHOLOGY. The hallmark findings in nevus comedonicus are keratin-filled epidermal invaginations associated with atrophic sebaceous glands or follicles. EHK may be seen.[56]

DIFFERENTIAL DIAGNOSIS. The differential diagnosis of this lesion includes acne vulgaris, milia, acne neonatorum, nevus sebaceous, and linear Darier disease.

TREATMENT. The noninflammatory variant of nevus comedonicus is usually asymptomatic, with treatment based on the cosmetic concerns of the patient. The inflammatory variant can result in significant suppuration and pain, requiring medical or surgical intervention. Inflammation may be controlled with tazarotene cream or other retinoids, tacrolimus ointment, calcipotriene cream, and intralesional steroids.[57] Keratolytics may be of some help. Systemic antibiotics may help to control infection or inflammation. Surgical interventions, such as extraction, excision, dermabrasion, or laser resurfacing, may result in good clinical results.[58,59]

ECCRINE NEVUS

An eccrine nevus, the simplest form of eccrine hamartoma, is characterized by an increase in the number or size of eccrine coils.[60–63] Fewer than 20 cases of eccrine nevi have been described in the literature. Distributed on the trunk, arms, or legs, these lesions occur equally in men and women. Although there seems to be a childhood predominance, the onset ranges from birth to the eighth decade.[64] The morphology of eccrine nevi may vary, appearing clinically as tan papules or normal skin.[65–66] These lesions do not always display hyperhidrosis, however, when they do, treatment is targeted at the control of that symptom. Agents such as aluminum chloride solution, anticholinergics, antidepressants with anticholinergic activity, botulinum toxin, iontophoresis, or sympathectomy have been reported to help control the hyperhidrosis. Surgical excision of the lesion is also an acceptable treatment.[67,68]

APOCRINE NEVUS

Apocrine nevi are hamartomatous proliferations of mature apocrine glands often found within a nevus sebaceous. Clinical presentation varies, but they can be found as soft nodules or papules in the axilla or on the upper chest. Histologically, the apocrine glands extend from the epidermis to the fat. These lesions can be surgically excised if desired.[69]

EPIDERMAL NEVUS SYNDROME[59]

EPIDERMAL NEVUS SYNDROME AT A GLANCE

- Epidermal nevus syndrome is the association of any type of epidermal nevus with various cutaneous, ocular, neurologic, skeletal, cardiovascular, or urogenital developmental abnormalities.
- Historically, six epidermal nevus syndromes described: Proteus syndrome, congenital hemidysplasia with ichthyosiform nevus and limb defects, phakomatosis pigmentokeratotica, sebaceous nevus, Becker's nevus, and nevus comedonicus.
- Affects men and women equally, and presents within the first 40 years of life.
- Patients with extensive epidermal nevi or those with epidermal nevi and systemic abnormalities should be suspected of having the epidermal nevus syndrome.
- Evaluation and management: require multidisciplinary team approach involving the dermatologist, pediatrician, ophthalmologist, neurologist, plastic surgeon, and orthopedic services.

Epidermal nevus syndrome is also known as *Schimmelpenning syndrome*, *Feuerstein–Mims syndrome*, and *Solomon syndrome*. Epidermal nevus syndrome is the association of any type of epidermal nevus with various cutaneous, ocular, neurologic, skeletal, cardiovascular, or urogenital developmental abnormalities. Historically, there have been six epidermal nevus syndromes described: (1) Proteus syndrome, (2) congenital hemidysplasia with ichthyosiform nevus and limb defects, (3) phakomatosis pigmentokeratotica, (4) sebaceous nevus, (5) Becker's nevus, and (6) nevus comedonicus. Some authors argue that epidermal nevus syndrome is a collection of many different distinct clinical syndromes.

Happle[70] proposed that the epidermal nevus syndrome is not a single entity but consists of at least six distinct diseases that differ in genetic origin and share the common feature of mosaicism. The entities include Schimmelpenning syndrome; nevus comedonicus syndrome; pigmented hairy epidermal nevus syndrome; Proteus syndrome; congenital hemidysplasia, ichthyosiform dermatitis, and limb defects syndrome; and phacomatosis pigmentokeratotica.

EPIDEMIOLOGY. Epidermal nevus syndrome affects men and women equally and presents within the first 40 years of life. Inheritance is sporadic, although anecdotal reports of familial transmission have been reported.[70] Although the exact incidence of epidermal nevus syndrome is unknown, a study of 119 cases of epidermal nevi showed that 33% of patients showed one or more extracutaneous abnormalities, 16% showed two or more abnormalities, 10% showed three or more abnormalities, and 5% showed five or more abnormalities.

CLINICAL FEATURES. Solomon and Esterly provided a detailed account of the spectrum of epidermal nevi seen in the epidermal nevus syndrome.[29] They described seven types of lesions. The majority of patients had nevus unius lateris; 20% of patients had ichthyosis hystrix; and another 20% had what the authors termed the *acanthotic form* of epidermal nevus. These lesions presented as large, unilateral, brown, slightly scaly patches. About 10% of patients had linear nevus sebaceous involving the scalp and face. Localized linear verrucous nevus and a velvety epidermal nevus in the axilla similar to acanthosis nigricans were seen in a minority of cases. Some patients had a mixture of several types of lesions.

Table 118-2 lists the mucocutaneous changes other than epidermal nevus that may be seen in patients with epidermal nevus syndrome.[71] Hemangiomas and pigmentary changes are found in 10%–20% of patients. Less common findings are hair abnormalities, dental abnormalities in association with mucosal epidermal nevi, and dermatomegaly. This last condition involves an increase in skin thickness, warmth, and hairiness. As discussed earlier, various cutaneous tumors may develop within the epidermal nevus.

TABLE 118-2
Cutaneous Findings in Epidermal Nevus Syndrome

- Epidermal nevus
- Hemangioma
- Pigmentary changes
  - Café-au-lait spots
  - Hypopigmentation
  - Melanocytic nevi
- Dermatomegaly
- Cutaneous malignancies
  - Keratoacanthoma
  - Basal cell carcinoma
  - Squamous cell carcinoma
  - Syringocystadenoma papilliferum
  - Other adnexal tumors

A wide range of skeletal abnormalities has been reported (eTable 118-2.1 in online edition).[70–72] The incidence of skeletal changes has ranged from 15% to 70%.

Neurologic abnormalities occur in 15%–50% of cases (eTable 118-2.2 in online edition).

From 9% to 30% of patients with epidermal nevus syndrome have ocular abnormalities (eTable 118-2.3 in online edition).[73]

As in isolated epidermal nevi, malignant transformation may occur within the epidermal nevi in patients with epidermal nevus syndrome. This occurrence is most common in those with nevus sebaceous. Perhaps less well known is the association of visceral malignancies with the epidermal nevus syndrome. The following tumors are reported to occur at a higher frequency and at an earlier age in patients with epidermal nevus syndrome: tumors of the genitourinary system (Wilms' tumor, nephroblastoma, metastatic transitional cell carcinoma of the bladder, and rhabdomyosarcoma of the bladder); tumors of the gastrointestinal tract (hepatic adenoma, salivary gland adenocarcinoma, and carcinoma of the esophagus and stomach); and tumors of the central nervous system (astrocytoma, mixed glioma, and meningioma). Breast carcinoma, mandibular ameloblastoma, chondroma, odontoma, and endometrioma are other tumors associated with epidermal nevus syndrome.[41] However, these associations have not been confirmed by case-controlled studies.

MANAGEMENT. Patients with extensive epidermal nevi or those with epidermal nevi and systemic abnormalities should be suspected of having the epidermal nevus syndrome. Evaluation and management of patients with epidermal nevus syndrome requires a multidisciplinary team approach involving the dermatologist, pediatrician, ophthalmologist, neurologist, plastic surgeon, and orthopedic services. These patients require a careful history

with particular attention given to developmental history, attainment of milestones, history of seizures, and abnormalities of the bones, eyes, and urinary tract. Thorough mucocutaneous, neurologic, ophthalmologic, and orthopedic examinations are necessary. Most cases of Proteus syndrome are caused by a mosaic activating mutation in *AKT1*. (*N Engl J Med* **365**:611-619, 2011). A regular follow-up program should be planned for the patient.

LICHEN STRIATUS

LICHEN STRIATUS AT A GLANCE

- Lichen striatus is a rare, idiopathic, linear, papular eruption that usually resolves in 1–2 years.
- Occurs most commonly on the limbs of females.
- Eruption is characterized by the sudden onset of flat-topped, 1–3 mm, pink, tan, or hypopigmented papules in a linear configuration or Blaschkoid distribution.
- Differential diagnosis: lichen planus, psoriasis, linear porokeratosis, lichen nitidus, Darier disease, and inflammatory linear verrucous epidermal nevus.

Lichen striatus is a rare, idiopathic, linear, papular eruption that usually resolves in 1–2 years.

ETIOLOGY AND EPIDEMIOLOGY

Lichen striatus, which is also known as *Blaschko linear acquired inflammatory skin eruption*, most commonly affects individuals from 4 months to 15 years of age.[74] The etiology is unknown. This self-limited dermatosis occurs most commonly on the limbs in females. However, distribution on the face and trunk has been reported.[75] Nail changes are uncommon.[76] Most cases are distributed in Blaschko's lines, though axial distributions have been reported. A retrospective analysis of 155 cases of children with lichen striatus revealed an association with atopic dermatitis in 70 of the cases.[77]

CLINICAL FEATURES[78]

Lichen striatus is an eruption characterized by the sudden onset of flat-topped, 1–3 mm, pink, tan, or hypopigmented papules in a linear configuration or Blaschkoid distribution (Fig. 118-16). Bilateral eruptions have been reported, though unilateral lesions are the norm. These flat-topped papules may have an associated scale. Longitudinal ridging and nail plate thinning can be seen. This eruption is usually self-limited, lasting from a few months to 2 years before spontaneously regressing.



Figure 118-16 Lichen striatus. Linear configuration of slightly scaling papules in Blaschkoid distribution on the leg.

PATHOLOGY

Lichen striatus is characterized by a lichenoid, lymphocytic infiltrate involving three to four adjacent dermal papillae with overlying epidermal acanthosis, dyskeratosis, hyperkeratosis, and occasional parakeratosis.[78,79] Intraepidermal vesicles containing Langerhans cells can be seen in half of the cases.[80]

DIFFERENTIAL DIAGNOSIS

Lichen planus, psoriasis, linear porokeratosis, lichen nitidus, Darier disease, and ILVEN can have similar morphology and distribution to lichen striatus. These clinical entities can usually be separated based on histopathology. ILVEN can be distinguished clinically because of its earlier onset and lack of spontaneous regression.[80]

TREATMENT

Symptomatic control of pruritus with topical steroids may be necessary. Otherwise, treatment is generally not necessary for this self-limited condition.

CLEAR CELL ACANTHOMA

CLEAR CELL ACANTHOMA AT A GLANCE

- Clear cell acanthoma is a tumor of epidermal origin.
- Solitary, shiny, erythematous or orange to brown, blanching, well-demarcated papule or nodule with collarette of scale.
- Composed of distinctive, glycogen-rich keratinocytes.
- Differential diagnosis: lichenoid keratosis, basal cell carcinoma.

EPIDEMIOLOGY

Clear cell acanthoma is most commonly found equally in men and women ages in the sixth to eighth decade.

ETIOLOGY

The etiology of clear cell acanthoma, also known as *Degos acanthoma* and *pale cell acanthoma*, is unknown. When initially described by Degos et al in 1962, the lesion was thought to be benign tumor of epithelial origin.[81] Although initially thought to be of follicular or sweat-gland origin, the expression of involucrin and epithelial membrane antigen by clear cell acanthomas indicates an epithelial origin.[82–84] The cytokeratin staining patterns, interestingly, reveal staining patterns commonly found in inflammatory dermatoses such as lichen planus, psoriasis, and discoid lupus.[85] The presence of clear cell acanthomas on psoriatic plaques has led many to question the role of inflammation in the development of these lesions.[86]

CLINICAL FEATURES

Clear cell acanthoma is commonly a solitary, shiny, erythematous to brown, well-demarcated papule or nodule that blanches almost fully with pressure (Fig. 118-17). Surrounding the lesion is a collarette of scale. These lesions range from 5 mm to 2 cm, although the giant clear cell acanthoma can measure greater than 5 cm.[87] The lesions are usually found on the legs but can be located on the trunk and face. Although commonly solitary, multiple lesions have been reported. The dermatoscopic findings of the clear cell acanthoma are similar to that seen in psoriasis, with vascular puncta prominent in the lesion.[88] These lesions bleed with trauma.

PATHOLOGY

Sharply demarcated, pale-staining keratinocytes within a background of epidermal psoriasiform hyperplasia is characteristic in a clear cell acanthoma (Fig. 118-17). The glycogen-rich keratinocytes in the epidermis stain distinctively with periodic acid-Schiff, which then can be washed out by diastase that digests the glycogen.[89] Other epidermal findings include suprapapillary plate thinning, neutrophils, and sparing of adnexal epidermis. A mixed inflammatory infiltrate,



Figure 118-17 **A.** Clear cell acanthoma presenting as a flat orange nodule on the sole. **B.** Histologically, it is a well-circumscribed epidermal tumor composed of clear (glycogen-rich) cells.

papillary dermal edema, and enlarged vessels can be seen in the dermis.

TREATMENT

Cryotherapy, curettage and electrodesiccation, laser ablation, or surgical excision, have been used to successfully treat this lesion.[90]

WARTY DYSKERATOMA (ISOLATED DYSKERATOSIS FOLLICULARIS)[91]

WARTY DYSKERATOMA AT A GLANCE

- Solitary focus of acantholytic dyskeratosis.
- Lesions: solitary, skin-colored, umbilicated papules located on the head or neck.
- Histology: cup-shaped epidermal invagination with acantholysis and dyskeratosis filled with keratinaceous material.
- Differential diagnosis: actinic keratosis, squamous cell carcinoma.
- Treatment: excision.

ACANTHOMA FISSURATUM

ACANTHOMA FISSURATUM AT A GLANCE

- Fissured or ulcerated, usually retroauricular nodule that appears in areas of friction, as with ill-fitting eyeglasses.
- Differential diagnosis: basal-cell carcinoma, squamous-cell carcinoma, chondrodermatitis nodularis helicis.
- Usually resolve after correction of ill-fitting appliance.

CHONDRODERMATITIS NODULARIS HELICIS

Also called clavus helicis, chondrodermatitis nodularis helicis (CNH) is a chronic, solitary, tender, ulcerated nodule on the helix of the ear, first described in 1915.[97]

CHONDRODERMATITIS NODULARIS HELICIS AT A GLANCE

- Chondrodermatitis nodularis helicis is a chronic, solitary, tender, nodule on the helix of the ear. Sometimes ulcerated.
- Thought to be a disease of degenerated collagen that undergoes transepithelial elimination.
- Often: History of a suddenly appearing, skin-colored to pink papule or nodule on the ear that grew rapidly and subsequently remained quiescent.
- Differential diagnosis: Basal cell carcinoma, keratoacanthoma, wart, rheumatoid nodules, squamous cell carcinoma, clavus, tophus.
- Treatment: conservative, includes pressure-relieving pillows with a doughnut, steroid injection. If needed: excision.

ETIOLOGY AND PATHOGENESIS

Many etiologic factors have been suggested for CNH. It is thought to be a disease of degenerated collagen that undergoes transepithelial elimination.[98] Vascular insufficiency, pressure, injury to the cartilage, sun-exposure, and low temperature have all been implicated in inciting cartilage damage. Recently, Magro et al described 24 patients with early-onset CNH who had concomitant microvascular disease, strengthening the argument for the role of ischemia in the development of this process.[99] Reports of CNH in association with the pressure from cell phone use has also been documented.[100] The finding of solar elastosis histologically at the periphery of many lesions along with the prevalence of CNH in lightly pigmented populations raise the possible link between sun-exposure and CNH.[101]

CLINICAL FEATURES

This disorder is found overwhelmingly in adult men over the age of 50, with the male–female prevalence being greater than 2:1.[102] Two cases of CNH in children have been reported.[103,104] Patients present with a history of a suddenly appearing, skin-colored to pink papule or nodule on the ear that grew rapidly and subsequently remained quiescent. These lesions tend to be on the right helix, measure less than 1 cm, and are associated with pain (Fig. 118-18). The pain can be paroxysmal or associated with changes in ambient temperature. The lesion may have a central ulceration with an adherent hemorrhagic or scale crust. Spontaneous resolution of CNH is unlikely. A possible subset

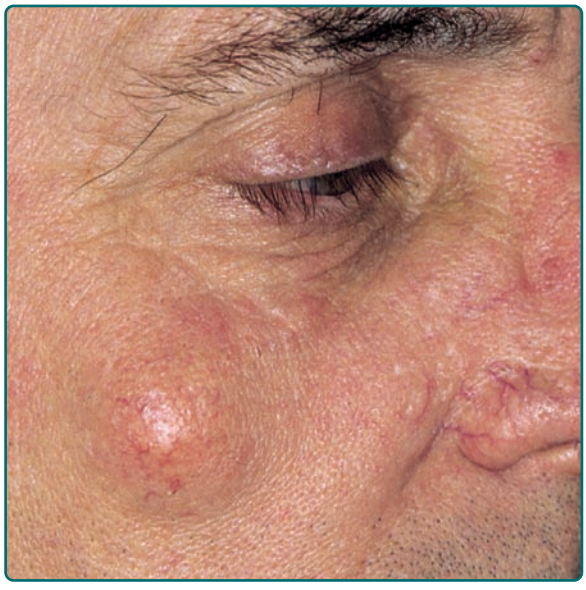

Figure 118-18 Epidermoid cyst presenting as a dome-shaped protuberance of the cheek.

of CNH may be seen in elderly women who have a history of prior trauma. For these women, spontaneous regression is not uncommon.

DIFFERENTIAL DIAGNOSIS

Basal cell carcinoma, keratoacanthoma, warts, rheumatoid nodules, squamous cell carcinoma, clavus, and tophus are all within the differential of CNH.

PATHOLOGY[105]

In the epidermis, there is commonly hyperkeratosis and parakeratosis; ulceration may be present. Occasionally, degenerated collagen is seen in the epidermis, indicating a transepidermal elimination process. A brisk, predominantly lymphocytic infiltrate is noted in the dermis with admixed histiocytes and few neutrophils. Telangiectasias and solar elastosis are often noted in the adjacent dermis. The perichondrium shows inflammation and fibrous thickening. The cartilage may show hyalinization, necrosis, and, at times, ossification.

TREATMENT

Conservative treatment includes pressure-relieving pillows with a doughnut shape that are commercially available. In a recent study examining the role of such pressure-relieving devices, 13 of 15 patients (87%) were healed at follow-up after 1 month of conservative treatment.[106] High-potency steroids, intralesional steroids, and laser ablation may also be used to induce symptom control or regression of the lesion.[107] Excision of CNH nodules using a shave or excisional technique through and around the affected cartilage is also an accepted treatment option, though recurrences may occur at the edge of the lesion.[108]

CYSTS OF EPIDERMAL ORIGIN

CYSTS OF EPIDERMAL ORIGIN AT A GLANCE

- Epidermoid cysts are keratin-filled epithelial-lined cysts.
- Result most commonly from a plugged pilosebaceous unit.
- Classically dermal or subcutaneous mobile nodules with a central punctum.
- Brisk, foreign-body giant cell reaction is possible if epidermoid cysts rupture into surrounding tissue.
- Trichilemmal cysts are keratin-filled, epithelial-lined cysts usually on the scalp arising from outer root sheath of the hair follicle. These pilar cysts are mobile, firm, well-circumscribed nodules. Pathology: cyst wall without a granular layer.
- Milia: Thought to be the result of pilosebaceous or eccrine sweat duct plugging.
- Pathology similar to epidermal cyst that is smaller in scale.
- Steatocystoma multiplex: numerous, epithelial-lined, sebum-filled dermal cysts with characteristic sebaceous glands in the cyst walls.
- Dermoid cysts: collections of epidermis located along embryologic fusion planes most commonly on the forehead, lateral eye, or neck.
- Branchial cysts: asymptomatic cysts caused by the occlusion of branchial cleft sinuses that are located along the angle of the mandible if arising from the first branchial cleft and the middle to lower third of the anterior border of the sternocleidomastoid in cases arising from the second branchial cleft.
- Preauricular cysts or sinuses: epithelial invaginations located in the preauricular area that arise from the incomplete fusion of the first and second branchial arches in the preauricular area.
- Rupture or secondary infections are the most common complications of epidermal cysts.
- Removal of the entire cyst wall is required to prevent cyst recurrence.

EPIDERMOID CYST

An epidermoid cyst, also known as a *follicular cyst-infundibular type*, *keratin cyst*, *epidermal cyst*, *epidermal inclusion cyst*, or an *epithelial cyst*, is a keratin-filled epithelial-lined cyst. The term *sebaceous cyst* is a misnomer and should be avoided, as these cysts do not involve sebaceous glands, nor do they contain sebum.

EPIDEMIOLOGY. Epidermoid cysts are found most commonly in adult men and women. Genetic disorders, such as Gorlin syndrome (nevoid basal cell carcinoma syndrome), pachyonychia congenita type 2 (Jackson–Lawler type), and Gardner syndrome, may predispose individuals to having this type of cyst.

ETIOLOGY AND PATHOGENESIS. Epidermal cysts are most commonly the result of plugged pilosebaceous units. These cysts express the same cytokeratin profile as the follicular infundibulum.[109] Epidermal cysts can also be caused by the traumatic implantation of epidermal cells into deeper tissues or by the proliferation of viable epidermal remnants along embryonic fusion planes.[110,111] Epidermoid cysts can be located anywhere on the body and are characterized by their distinctive pathology. Recently, HPV type 57 and 60 DNA has been detected in palmoplantar epidermoid cysts.[112,113]

CLINICAL PRESENTATION. Epidermoid cysts are classically dermal or subcutaneous mobile nodules with a central punctum (Fig. 118-19). Lesions not associated with trauma are commonly located on the upper chest, upper back, neck, or head. Traumatic lesions are more common on the palms, soles, or buttocks. The punctum, when present, represents the plugged pilosebaceous unit from which foul smelling cheesy debris may be expressed. These lesions can be skin-colored, yellow, or white. Cysts are usually slow growing and asymptomatic, though rupture is common.

COMPLICATIONS. A brisk, foreign-body giant cell reaction is possible if epidermoid cysts rupture into surrounding tissue. This foreign-body reaction may mimic that of secondary bacterial infection. However, polymicrobial infection of a cyst with aerobic or anaerobic organisms may occur. Common aerobes include *Staphylococcus aureus*, group A *Streptococcus*, and *Escherichia coli*, while common aerobes include *Peptostreptococcus* species and *Bacteroides* species. Polymicrobial infection is most common. Although the clinical course of epidermoid cysts is benign, basal cell carcinoma, squamous cell carcinoma, epithelioid carcinoma, and other malignancies have been reported to occur in conjunction with these cysts, though malignant transformation is rare.[114–116]

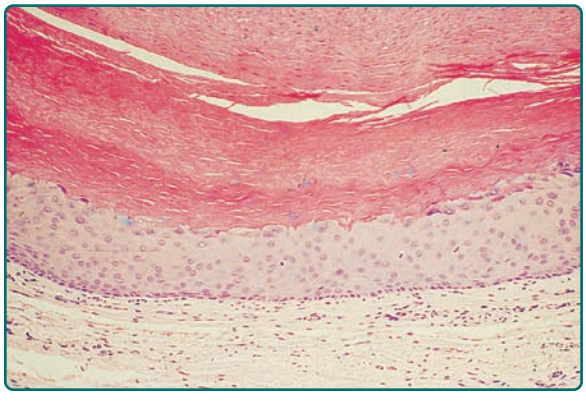

Figure 118-19 Epidermoid cyst lined by stratified epithelium with a granular layer. Within the cyst, the keratinous material is arranged in laminated layers.



Figure 118-20 A trichilemmal (pilar) cyst on the scalp.

PATHOLOGY. An epidermoid cyst has a stratified, squamous lining with an intact granular layer (Fig. 118-20). These cysts contain central, eosinophilic, keratinaceous debris that can incite a foreign-body reaction of multinucleated giant cells and histiocytes when released into the dermis and surrounding tissue.

DIFFERENTIAL DIAGNOSIS. Steatocystoma multiplex, pilar cysts, and lipomas can all mimic epidermoid cysts. However, clinically, steatocystoma multiplex usually express a liquid rather than a cheesy material, pilar cysts are most commonly on the scalp, and lipomas are softer, deeper, and without a punctum. Pathology also distinguishes between these lesions.

TREATMENT. Complete excision or destruction of the cyst lining is the definitive treatment, and is required to prevent cyst recurrence. Intralesional steroids at a concentration of 5 mg/mL can be used to control small, inflamed, symptomatic lesions. If the cyst becomes inflamed, painful, or purulent, infection must be considered. Incision and drainage with oral antibiotic therapy to treat *S. aureus* should be initiated. Wound cultures with directed therapy may be

indicated, based on the clinical presentation of the lesion. If the cyst has ruptured or has become infected, excision of the lesion should be deferred until the inflammation has decreased which will decrease the likelihood of wound dehiscence.

TRICHILEMMAL CYST (PILAR CYST)

Trichilemmal cysts are keratin-filled, epithelial-lined cysts usually on the scalp that arise from the outer root sheath of the hair follicle.

EPIDEMIOLOGY. Trichilemmal cysts can be found in 5%–10% of the population, most commonly in middle-aged women.

ETIOLOGY AND PATHOGENESIS. Pilar cysts arise from the epithelium located between the orifice of the sebaceous gland and the arrector pili muscle. This squamous epithelium undergoes rapid keratinization resulting in a cyst wall without a granular layer.

CLINICAL FEATURES. Pilar cysts are mobile, firm, well-circumscribed nodules located overwhelmingly in the scalp (Fig. 118-21). These lesions can also be found on the face, head, and neck. Most patients have more than one lesion, with 10% of people having more than 10 lesions. Rapid growth is abnormal and can be a sign of infection or malignant transformation.[117]

COMPLICATIONS. Although these lesions largely remain asymptomatic, rupture and infection can occur. Proliferating trichilemmal tumors are a variant of this benign lesion and are commonly found on the scalp of elderly women. This lesion can destroy adjacent lesions and ulcerate, mimicking skin cancer. Malignant degeneration of pilar cysts into malignant proliferating trichilemmal cysts can occasionally occur.

PATHOLOGY. The hallmark finding of these cysts is the absence of a granular layer within the cyst wall (Fig. 118-22). The cyst content is usually eosinophilic keratin, but basophilic areas of calcification may occur in the lumen of these lesions. If lobules of squamous epithelium are seen in the walls of the lesion, it is most likely a proliferating trichilemmal cyst. Invasion of the cyst lining into the surrounding tumor indicates malignancy.

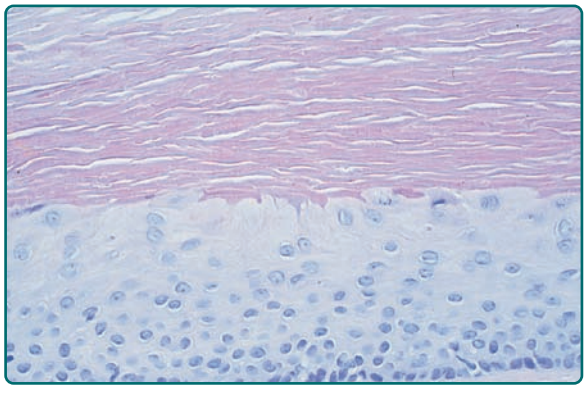

Figure 118-21 Trichilemmal cysts showing an epithelial lining that lacks a granular layer.



Figure 118-22 Primary milium. A 3-mm, hard, seed-like white papule.

DIFFERENTIAL DIAGNOSIS. See Section "Differential Diagnosis" under "Epidermoid Cyst."

TREATMENT. The treatment is the same as with epidermoid cysts. Because the cyst wall of these tumors is clinically more firm than that of epidermoid cysts, it is possible to extract the lesion through a small incision made with a dermal punch trephine.

MILIUM

Milia are minute epidermoid cysts, lined with epidermis and filled with keratin.

EPIDEMIOLOGY. Milia are common congenital and acquired lesions in both infants and adults. Men and women are affected equally.

ETIOLOGY AND PATHOGENESIS. Milia are thought to result from pilosebaceous or eccrine sweat duct plugging. These superficial lesions can be primary or secondary, with the latter resulting from injury to the basement membrane of the skin. Secondary lesions are common in subepidermal blistering diseases such as epidermolysis bullosa and porphyria cutanea tarda, burns, after dermabrasion or ablative laser resurfacing, or in conjunction with topical therapy such as glucocorticoid therapy or 5-fluorouracil treatment.[118–121]

CLINICAL FEATURES. Milia are 1- to 2-mm, white, domed papules commonly located on the cheeks and eyelids of adults (Fig. 118-23). In infants, milia are common on the face and the mucosa. Epstein's pearls are milia on the palate. Eruptive milia have been reported, though this is a rare occurrence.[121] *Milia en plaque* is a plaque-type, inflammatory variant of milia that is commonly located on the ear.[122] Acquired milia



Figure 118-23 Steatocystoma multiplex. Multiple skin-colored cystic lesions on the trunk.



Figure 118-24 Painful nodule of the ear: a typical lesion of chondrodermatitis nodularis helicis.

(eFig. 118-23.1 in online edition) can be located anywhere the predisposing trauma or other factors have occurred.

PATHOLOGY. The pathology of a milium is similar to that of an epidermoid cyst, but the small size and occasional connection to eccrine ducts or vellus hair follicles distinguish these two entities. Bacteria are not usually seen in milia.

TREATMENT. Congenital milia tend to spontaneously resolve. Acquired milia can resolve spontaneously as well, but can also be removed by disrupting the overlying epidermis with light electro-desiccation or incision, usually with an 11-blade and expressing the keratin contents.

STEATOCYSTOMA MULTIPLEX

Steatocystoma multiplex are numerous, epithelial-lined, sebum-filled dermal cysts with characteristic sebaceous glands in the cyst walls.

ETIOLOGY AND PATHOGENESIS. Steatocystoma multiplex, (sebocystomatosis, epidermal polycystic disease) can be a sporadic or autosomal-dominant disorder. These lesions can also be found in syndromes such as Alagille syndrome and pachyonychia congenita type II. In the latter, lesions are associated with mutations in K17. Sporadic solitary lesions are termed *steatocystoma simplex*.

CLINICAL FEATURES. These lesions present as asymptomatic, yellow or skin-colored dermal papules or cysts located most commonly on the trunk, upper arms, scrotum, or chest (Fig. 118-24). Oily material can be expressed from these lesions when incised. These lesions can become infected and suppurate, resulting in sinus formation and scarring.

PATHOLOGY. The cyst walls of steatocystoma multiplex are composed of stratified, squamous epithelium with an absent granular layer. Sebaceous glands are located in the cyst wall (eFig. 118-24.1 in online edition). There is an eosinophilic cuticle on the luminal side of this wall with keratin, oil, and hairs in the lumen.

DIFFERENTIAL DIAGNOSIS. Eruptive vellus hair cysts can mimic steatocystoma multiplex clinically. They may have a tuft of hairs protruding from the cyst centrally, with findings of vellus hairs in the lumen with follicles in the wall. Epidermal inclusion cysts also have to be excluded. The pathogenesis of steatocystoma, epidermal inclusion cysts, and eruptive vellus hair cysts may be similar.[123]

TREATMENT. At times, simple excision or drainage with manual removal of the cyst wall results in the clinical resolution of lesions.[124,125] Inflamed lesions have been reported to respond to intralesional steroids, carbon dioxide laser, oral retinoids, or cryotherapy.[126]

DERMOID CYST

Dermoid cysts are epithelial-lined cysts containing various appendageal structures resulting from retained epithelium along embryonic fusion planes. These cysts are either congenital or develop in childhood. The prevalence is equal in men and women.

CLINICAL FEATURES. Dermoid cysts are smooth, occur in the midline, and commonly possess a deep sinus tract that connects to the epidermis. They can measure between 1 cm and 4 cm, and are most commonly located on the forehead, lateral eye, or neck.[127,128] A superficial dermoid cyst located on the dorsal nose is referred to as *fistula of the dorsum of the nose* and is characterized by a central tuft of hair or communication intracranially. Dermoid cysts can be located deep in the subcutaneous tissue, intracranially, or intraorbitally.[129]

COMPLICATIONS. Infections, rupture, and abscess formation from the manipulation of these cysts are possible serious complications.

PATHOLOGY. Stratified squamous epithelium with a variety of adnexal structures may be present in the walls of dermoid cysts. Smooth muscle, pilosebaceous units, apocrine or eccrine glands, or goblet cells may also be present in the cyst walls. These cysts contain keratin and hairs.

DIFFERENTIAL DIAGNOSIS. The differential diagnosis of dermoid cysts includes gliomas, encephaloceles, hemangiomas, soft tissue sarcomas, and other epidermal cysts such as branchial cleft cysts and thyroglossal duct cysts.

TREATMENT. Imaging studies that help to characterize the extent of the tumor are necessary before excision is undertaken. Consultation with neurosurgery, otolaryngology, or plastic surgery may be indicated.

BRANCHIAL CYST (BRANCHIAL CLEFT CYST)

Sequestration of first or second branchial cleft membranes results in these cysts, sinuses, or tags.

EPIDEMIOLOGY. Branchial cleft cysts are largely sporadic, but autosomal dominant cases have been reported. There is no gender predominance. Ten percent of lesions are bilateral.

ETIOLOGY AND PATHOGENESIS. These cysts result from the occlusion of branchial cleft sinuses.

CLINICAL FEATURES. These asymptomatic lesions are often located along the angle of the mandible if arising from the first branchial cleft and the middle to lower third of the anterior border of the sternocleidomastoid in cases arising from the second branchial cleft. They may present after an upper respiratory infection as a painful mass. These lesions tend to drain internally, but communication with the epidermis can occur. Branchial cysts may become complicated by infection.

PATHOLOGY. Branchial cleft cysts are lined with epithelium containing lymphoid follicles, mucous glands, or smooth muscle. A dense lymphocytic infiltrate may also be seen. The cyst contents contain mucin.

TREATMENT. Excision is the treatment of choice. Infected cysts may require incision and drainage or antibiotic therapy.

PREAURICULAR CYST AND SINUS (CONGENITAL AURICULAR FISTULA, EAR PITS)

Preauricular cysts or sinuses are epithelial invaginations located in the preauricular area.

KEY REFERENCES

Full reference list available at www.DIGM8.com

DVD contains references and additional content

6. Hussein MR, Al-Badaiwy ZH, Guirguis MN: Analysis of p53 and bcl-2 protein expression in the non-tumorigenic, pretumorigenic, and tumorigenic keratinocytic hyperproliferative lesions. *J Cutan Pathol* **31**:643, 2004
7. Yeatman JM, Kilkenny M, Marks R: The prevalence of seborrhoeic keratoses in an Australian population: Does exposure to sunlight play a part in their frequency? *Br J Dermatol* **137**:411, 1997
9. Nakamura H et al: Clonal nature of seborrheic keratosis demonstrated by using the polymorphism of the human androgen receptor locus as a marker. *J Invest Dermatol* **116**:506, 2001
18. Schwartz RA: Sign of Leser-Trélat. *J Am Acad Dermatol* **35**:88, 1996
28. Vidaurri-de la Cruz H et al: Epidermal nevus syndromes: Clinical findings in 35 patients. *Pediatr Dermatol* **21**:432, 2004
29. Solomon LM, Esterly NB: Epidermal and other congenital organoid nevi. *Curr Probl Pediatr* **6**:1, 1975
33. Rogers M et al: Epidermal nevi and the epidermal nevus syndrome. A review of 131 cases. *J Acad Dermatol* **20**:476, 1989
37. Weedon D: Tumors of the epidermis. In: *Skin Pathology*, edited by D Weedon. New York, Churchill Livingstone, 2002, p. 754
43. Bogle MA: Successful treatment of a widespread inflammatory verrucous epidermal nevus with etanercept. *Arch Dermatol* **142**:401, 2006
46. Cribier B, Scrivener Y, Grosshans E: Tumors arising in nevus sebaceus: A study of 596 cases. *J Am Acad Dermatol* **42**:263, 2000
62. Vazquez MR et al: Eccrine naevus: Case report and literature review. *Acta Derm Venereol* **82**:154, 2002
70. Happle R: Epidermal nevus syndromes. *Semin Dermatol* **14**:111, 1995
99. Magro CM, Frambach GE, Crowson AN: Chondrodermatitis nodularis helicis as a marker of internal disease associated with microvascular injury. *J Cutan Pathol* **32**:329, 2005
106. Moncrieff M, Sassoon EM: Effective treatment of chondrodermatitis nodularis chronica helicis using a conservative approach. *Br J Dermatol* **150**:892, 2004
127. Pryor SG et al: Pediatric dermoid cysts of the head and neck. *Otolaryngol Head Neck Surg* **132**:938, 2005

Chapter 119 :: Appendage Tumors and Hamartomas of the Skin

:: Divya Srivastava & R. Stan Taylor

APPENDAGEAL TUMORS AT A GLANCE

- Tumors differentiate from cutaneous adnexal structures into sebaceous, apocrine, eccrine, and follicular neoplasms.
- Clinically, tumors are indistinct and typically present as papules and nodules, requiring histopathologic evaluation. Anatomic location, presence of single or multiple lesions, and knowledge of distribution of adnexal structures should be considered in development of a differential diagnosis.
- Appendageal tumors often serve as markers of underlying genetic syndromes.
- Risk of malignant degeneration varies with individual lesions, and is more common with sweat gland tumors than pilosebeceous tumors.

CLASSIFICATION AND PATHOGENESIS

Appendageal tumors of the skin comprise a wide spectrum of benign and malignant neoplasms that exhibit morphological differentiation toward one or more adnexal structures in normal skin. The classification and diagnosis of appendageal tumors is challenging due to the wide variety of tumor types, complicated nomenclature, and numerous classification systems that categorize these neoplasms.[1–8] Traditionally, cutaneous adnexal tumors are classified into four groups according to differentiation toward follicular, sebaceous, apocrine, and eccrine structures. These adnexal tumors can be further classified by a gradient of decreasing differentiation into three groups: hyperplasias and hamartomas, benign neoplasms, and malignant neoplasms (Table 119-1). This classification is similar to the approach of the World Health Organization International Histological Classification of tumor monographs.[4] The hyperplasias are characterized by an increased number of normal cells in a normal arrangement. Hamartomas are described as an abnormal arrangement of normal tissue. Benign neoplasms lack the potential to metastasize, whereas malignant tumors have the ability to cause local destruction and to metastasize to lymph nodes and viscera.

While adnexal tumors are classified based on differentiation, often a tumor is not easily classified into one group because the lesion exhibits histologic features of two or more adnexal cell lines. Since adnexal tumors originate from pluripotent stem cells in the epidermis and its appendages, neoplastic cells may aberrantly express one or more lines of appendageal differentiation. The ultimate histologic characteristics of a tumor are related to the activation of molecular pathways responsible for forming the normal mature adnexal structure, in conjunction with tumor genetics, local vascularity, and microenvironment.[4]

During embryogenesis, the eccrine apparatus develops separately from the folliculosebaceous-apocrine apparatus. Eccrine glands develop directly from the embryonic epidermis during the third to fifth months of fetal development. Hair follicles also arise directly from the epidermis during the third to fourth months of fetal life. Follicular development differs from eccrine development because mesenchymal cells, which serve as precursors of the follicular papilla, descend into the dermis with the developing epidermal elements. Sebaceous and apocrine glands and ducts begin as secondary structures from the bulges along the hair follicle. Clinically, as predicted by embryogenesis, follicular, sebaceous, and apocrine tumors coincide in the same individuals, whereas eccrine tumors are unrelated.[8]

Cytogenetics and molecular studies have further elucidated the pathogenesis of certain adnexal tumors. Mutations in p53 have been detected in some adnexal tumors, suggesting an etiologic role for ultraviolet light.[9] Germ-line mutations have been reported in various genodermatoses, suggesting a role for these genes in the pathogenesis of certain adnexal tumors. For instance, mutations in the patched (PTCH) genes have been demonstrated in follicular tumors in patients with the basal cell nevus syndrome.[10] Mutations in the tumor suppressor gene *PTEN* have been identified in patients with Cowden's syndrome.[11] Microsatellite instability and mutations in *MSH2*, *MLH1*, and *MSH6* mismatch repair genes have been detected in patients with Muir–Torre syndrome.[12] Technologies such as cDNA microarrays, microRNA microarrays, and proteomic studies may lead to the elucidation of additional molecular markers useful in classifying these neoplasms.

DIFFERENTIAL DIAGNOSIS

Clinically, appendageal tumors are indistinctive, and often present as flesh-colored papules or nodules. Lesions may be solitary or multiple. The anatomic distribution of these lesions corresponds to the normal location of the adnexal structure from which the

TABLE 119-1
Classification of Appendageal Tumors of the Skin

Sebaceous	Apocrine	Eccrine	Follicular
Hamartomas, Hyperplasias, and Cysts ■ Nevus sebaceus ■ Sebaceous hyperplasia	■ Apocrine hidrocystoma ■ Apocrine nevus	■ Eccrine hidrocystoma ■ Eccrine nevus	■ Hair follicle nevus ■ Basaloid follicular hamartoma
Benign Neoplasms ■ Sebaceous adenoma	■ Apocrine fibroadenoma ■ Erosive adenomatosis of the nipple ■ Hidradenoma papilliferum ■ Syringocystadenoma papilliferum ■ Cylindroma	■ Syringoma ■ Eccrine poroma ■ Eccrine syringofibroadenoma ■ Eccrine spiradenoma ■ Papillary eccrine adenoma ■ Nodular hidradenoma ■ Chondroid syringoma	■ Dilated pore of Winer ■ Pilar sheath acanthoma ■ Trichofolliculoma ■ Fibrofolliculoma ■ Trichodiscoma ■ Fibrous papule ■ Trichoblastoma ■ Trichoepithelioma ■ Desmoplastic trichoepithelioma ■ Trichoadenoma ■ Pilomatricoma ■ Trichilemmoma ■ Tumor of the follicular infundibulum ■ Proliferating trichilemmal cyst
Malignant Neoplasms ■ Sebaceous carcinoma	■ Apocrine adenocarcinoma ■ Hidradenocarcinoma papilliferum ■ Syringocystadenocarcinoma papilliferum ■ Cylindrocarcinoma	■ Aggressive digital papillary adenoma and adenocarcinoma ■ Mucinous eccrine carcinoma ■ Microcystic adnexal carcinoma ■ Porocarcinoma ■ Malignant eccrine spiradenoma ■ Malignant nodular hidradenoma ■ Malignant chondroid syringoma ■ Eccrine adenocarcinoma	■ Pilomatrical carcinoma ■ Malignant proliferating trichilemmal tumor ■ Trichilemmal carcinoma ■ Trichoblastic carcinoma

neoplasms originates. When patients present with multiple lesions, a characteristic anatomic distribution, autosomal dominant inheritance pattern, and association with visceral abnormalities may be observed. Often, appendageal tumors serve as a marker for genetic syndromes. While most lesions are benign, a malignant counterpart exists for most tumors, and it is often associated with a poor outcome.

The most important tool for diagnosing and classifying appendageal tumors is histopathology. The histopathology of the adnexal tumor can be interpreted by comparing its microscopic features to the histology of normal cutaneous appendages. Follicular tumors show a range of morphologic features that recapitulate specific portions of normal hair and the hair follicle such as the infundibulum, isthmus, stem, and bulb. The finding of matrical cells reflects differentiation toward follicular bulbs. Trichohyalin granules and blue–gray corneocytes indicate differentiation toward the inner root sheath. Differentiation toward the outer root sheath is manifested by the presence of either clear columnar cells aligned in a palisade at the bulb, subtly cornified cells with pink cytoplasm at the stem, or fully cornified cells with red cytoplasm, which corresponds to trichilemmal keratinization at the level of the isthmus. Sebaceous tumors reveal areas with sebocytes distinguished by a vacuolated cytoplasm, scalloped nuclei, and tubular structures. Ductal differentiation characterizes apocrine and eccrine tumors. Features of apocrine glands such as decapitation secretion are seen in ductal structures of apocrine neoplasms, whereas a flattened ductal epithelium distinguishes eccrine neoplasms.[4]

Immunohistochemical analysis has traditionally been of little value in definitively diagnosing adnexal tumors given the significant overlap of immunohistochemical features between apocrine tumors with ductal differentiation and certain visceral malignancies.

Determination of whether an appendageal neoplasm is benign or malignant requires assessment of architectural and cytomorphologic characteristics. Great care is necessary when applying traditional morphologic criteria of malignancy such as asymmetry, poor circumscription, and presence of epithelial aggregations with

prominent atypia and mitotic activity. Some malignant aggressive adnexal neoplasms have deceptively bland microscopic appearance. Furthermore, there are certain neoplasms whose malignant potential is not always predictable on histologic grounds alone.

TREATMENT

A diagnostic biopsy of a suspicious lesion yielding a correct diagnosis is the initial step in appropriate management of patients with appendageal skin tumors. A number of tumor-related and patient-related factors influence the choice of treatment. Tumor-related factors include the type, size, and anatomic location. Patient-related factors include life expectancy, comorbid conditions, and cosmetic concerns.

Specific treatment of benign appendageal tumors is sometimes unnecessary. In some cases, removal of the tumor is indicated for cosmetic reasons only. The treatment of choice for the majority of benign appendageal tumors is surgical excision. A variety of superficial ablative techniques such as electrodessication and curettage and cryotherapy have proven to be effective in selected patients. A number of other alternative treatment options, including the use of systemic retinoids, lasers, and photodynamic therapy have also been advocated for use in some cases; however, most do not have sufficient data for universal application.

Treatment of malignant appendageal tumors aims mainly at eradication of the cancer, preservation or restoration of normal function, and cosmesis. High-risk patients with tumors known to recur or metastasize most frequently require wide local excision, Mohs micrographic surgery, and/or radiotherapy. Notably, sentinel lymph node biopsy is sometimes valuable in staging of patients with eccrine and apocrine carcinomas.

SEBACEOUS NEOPLASMS

Sebaceous tumors consist of a wide spectrum of neoplasms from hamartomas, hyperplasias, and benign lesions to highly aggressive malignant tumors. Sebaceous neoplasms, with the exception of sebaceous hyperplasia, are relatively rare compared to the other appendageal tumors. Sebaceous lesions are associated with two systemic syndromes: Muir–Torre syndrome and the epidermal nevus syndrome.

Sebaceous glands develop from the hair sheath, and are located near hair follicles, apocrine ducts, and arrector pili muscles. Sebaceous glands are located in all hair bearing regions of the body, and are most abundant in the head and neck region.[13] Ectopic sebaceous glands are common and considered a normal variant. Fordyce spots are located on the vermilion border of the lip and labia minora, Tysons glands on the prepuce and mucosa of the penis, and Montgomery tubercles on the female areola.[14]

Terminology regarding sebaceous neoplasms remains controversial. The term sebaceous adenoma has been applied to superficial benign sebaceous neoplasms with predominantly mature sebocytes, whereas sebaceous epithelioma and sebaceoma have been used to describe lesions consisting of primarily germinative seboblasts. Others have used the term sebaceoma to describe benign sebaceous proliferations deep in the dermis as opposed to the more superficial sebaceous adenoma.[15] In this chapter, the term sebaceous adenoma is used to encompass superficial and deep sebaceous proliferations with varying degrees of sebocyte maturity.

HAMARTOMAS AND HYPERPLASIAS

NEVUS SEBACEUS OF JADASSOHN

Epidemiology. Nevus sebaceous of Jadassohn, described in 1895, is a benign hamartoma with epidermal, follicular, and apocrine elements.[16] It occurs in 3/1,000 neonates.[14]

Etiology and Pathogenesis. Nevus sebaceous is postulated to develop due to genetic mosaicism in stem cells that expand in the lines of Blaschko. The human papilloma virus (HPV) has been detected in nevus sebaceous tissue, with evidence of viral integration of HPV DNA into genomic DNA.[17] These results suggest that maternal transmission of HPV DNA to fetal ectodermal cells could result in epigenomic mosaicism and subsequent cutaneous changes. In familial cases, a paradominant mode of transmission has been suggested.[18] Loss of heterozygosity of the patched gene has also been demonstrated in some nevus sebaceous lesions.[19]

Clinical Findings. Nevus sebaceous presents as a well-demarcated, yellow–orange, alopecic, verrucous plaque that ranges in size from a few millimeters to several centimeters. It most commonly occurs on the scalp (59.3%), but can also occur on the face (32.6%), preauricular area (3.8%), and neck (3.2%).[20] It is usually solitary and linear or crescentic, and is distributed in the lines of Blaschko.[21]

Mehregan and Pinkus described three stages in the clinical and histological evolution of a nevus sebaceous.[22] The lesion is slightly raised and barely discernible at birth. The initial stage is characterized by papillomatous epithelial hyperplasia and underdeveloped hair follicles. The second stage commences at puberty and is associated with remarkable sebaceous gland development, epidermal verrucous hyperplasia, and the maturation of apocrine glands. Clinically, this correlates with progressive thickening and development of a pebbly verrucous surface. The final stage involves the development of benign and malignant neoplasms within the nevus sebaceous.

Several neoplasms have been described arising within a nevus sebaceous.[20,23] The most common benign neoplasm to occur in nevus sebaceous is trichoblastoma, followed by syringocystadenoma papilliferum. Trichoblastomas, seen in about 5% of nevus sebaceous, presents with new pigmented papules or nodules. The development of basal cell carcinoma is seen in less than 1% of lesions. Other tumors reported

to develop in nevus sebaceous include nodular hidradenoma, syringoma, trichilemmoma, proliferating trichilemmal cyst, squamous cell carcinoma, sebaceous carcinoma, apocrine carcinoma, and eccrine poroma.[24]

Histopathology. In early nevus sebaceous, the epidermis is acanthotic and papillomatous. The sebaceous gland is underdeveloped and decreased in number, leading to difficult diagnosis. The presence of immature hair follicles that resemble the embryonic stage of hair follicles can aid diagnosis in early lesions. At puberty, the epidermis is papillomatous, verrucous, and hyperplastic. Abundant sebaceous glands and vellus hairs are noted in the superficial dermis. Apocrine glands are seen in two-thirds of patients at puberty.[22,25]

Prognosis. The risk of malignancy in nevus sebaceous is quite low, with the incidence of basal cell carcinoma at 1%. The risk of malignancy increases with age with the majority of studies indicating that children are unlikely to develop malignant tumors.[23]

Nevus sebaceous is associated with the linear nevus sebaceous syndrome, a subset of the epidermal nevus syndrome. Also known as Schimmelpenning Syndrome, this syndrome is characterized by linear nevus sebaceous, mental retardation, seizures, ophthalmic, skeletal, cardiovascular, and urologic defects. Appropriate work-up in these patients includes electroencephalogram, cerebral computed tomography or magnetic resonance imaging, skeletal survey, analysis of renal and liver function, and calcium and phosphate levels.[26]

Treatment. Treatment is primarily cosmetic, and surgical excision to adipose or galea is the treatment of choice. Given the low risk of malignancy, many advocate that observation until adolescence is warranted as opposed to early excision. For facial lesions, consideration should be given to excision during childhood when scarring is minimal. Other treatment modalities including photodynamic therapy, carbon dioxide laser resurfacing, and dermabrasion have been advocated. However, since they fail to completely eradicate the lesion, there is a risk of recurrence or development of new tumors.[27–29]

SEBACEOUS HYPERPLASIA

Epidemiology. Sebaceous hyperplasia, a benign enlargement of the sebaceous lobule around a follicular infundibulum, is a common lesion especially in patients with significant sun exposure. The age of onset is 40, with males more commonly affected than females. Prevalence increases with time.[21]

Etiology and Pathogenesis. The cause of sebaceous hyperplasia is unknown. Although it is seen in individuals with extensive sun exposure, studies do not show an association with solar elastosis or skin type.[30] Sebaceous hyperplasia is associated with renal transplantation and chronic immunosuppression with cyclosporine.[31,32] Ten percent to 15% of patients on cyclosporine develop sebaceous hyperplasia, which can occur several years after starting the medication, and may affect ectopic locations such as the oral mucosa. Other associations include chronic renal failure, hemodialysis, corticosteroids, Muir–Torre syndrome, pachydermoperiostosis, and X-chromosomal ectodermal dysplasia.[33]

Clinical Findings. Sebaceous hyperplasia presents as solitary or multiple small ~3 mm yellow or flesh-colored telangiectatic papules with a central dell on the central face (Fig. 119-1A).[21] Nonfacial locations such as the neck, chest, areola, vulva, and penis have also been described.[34–36] Atypical presentations include giant or linear lesions, diffuse growths, and juxtaclavicular beaded lines.[21,36] Some reports have described sebaceous hyperplasia developing over neurofibromas, melanocytic nevi, verruca vulgaris, and acrochordons.[37] Premature or functional familial sebaceous hyperplasia occurs in adolescence and is typified by thick diffuse plaque-like lesions on the face, chest, and upper back.[38] Clinically, sebaceous hyperplasia can resemble basal cell carcinoma, and biopsy is performed to rule out malignancy. Dermoscopy can facilitate diagnosis of sebaceous hyperplasia, and reveals a yellow papule with telangiectasias and a central crater.[39]

Histopathology. Sebaceous hyperplasia reveals large mature sebaceous lobules clustered around discrete, often dilated, infundibula located in the upper dermis.

Prognosis and Clinical Course. The most common variant, the senile variant, is associated with an increased risk of nonmelanoma skin cancer in renal transplant patients.[31] Sebaceous hyperplasia may be associated with Muir–Torre syndrome, although it does not serve as a marker for the syndrome, given its high prevalence in the population.[40]

Treatment. Treatment of sebaceous hyperplasia is for cosmetic purposes. The following destructive modalities have been shown to be effective: excision, cryotherapy, electrodessication and curettage, electrocautery, photodynamic therapy with aminolevulinic acid, and laser therapy with the argon, carbon dioxide, pulse dye,

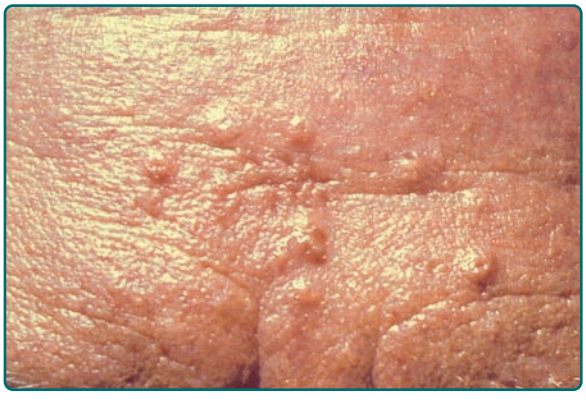

Figure 119-1 Sebaceous hyperplasia. One- to 3-mm smooth papules with central umbilication on the forehead.

and 1,450 nm diode lasers. These can be associated with scarring, hypopigmention, bleeding, and recurrence.[21,33] Isotretinoin has been shown to be effective, but lesions recur rapidly after the medication is continued.[33]

BENIGN NEOPLASMS

SEBACEOUS ADENOMA

Epidemiology. Sebaceous adenomas are rare benign tumors that typically present on the head and neck of elderly individuals.[41] These tumors serve as a marker for Muir–Torre syndrome.[40]

Etiology and Pathogenesis. As a marker of the Muir–Torre syndrome, these lesions demonstrate microsatellite instability and mutations in DNA mismatch repair genes *MSH2*, *MLH1*, and *MSH6*.[12]

Clinical Findings. A sebaceous adenoma usually presents as a smooth, well-circumscribed, slow-growing pink, flesh-colored, or yellow papule or nodule measuring less than 0.5 cm (Fig. 119-2A). The most common location is the head (70%), followed by the neck, trunk, and legs (30%). Lesions may bleed, ulcerate, and cause pain.[42]

Histopathology. Sebaceous adenomas reveal multiple well-circumscribed sebaceous lobules. Each lobule has two cell populations: peripheral basaloid germinative cells and mature lipid-filled vacuolated sebocytes in the center of the lobule. Usually, mature sebocytes outnumber the undifferentiated germinative cells (Fig. 119-2B). These lesions lack atypia, necrosis, and invasive growth, which differentiate them from sebaceous carcinoma. Mitoses can be seen in the germinative layers, and is not necessarily indicative of malignancy.[4]

Prognosis and Clinical Course. Sebaceous adenomas are the most common neoplasm associated with Muir–Torre syndrome, occurring in 68% of patients. In these patients, lesions tend to occur on the trunk. There are no reports of metastases from these neoplasms.[26]

Treatment. The treatment of choice is complete surgical excision. Persistence or recurrences are common. Mohs micrographic surgery may be beneficial for conservation of the nipple.[21] Cryosurgery may be useful in the treatment of some patients.

Excision. Work-up for Muir–Torre syndrome should be initiated in patients with a sebaceous adenoma.

MALIGNANT NEOPLASMS

SEBACEOUS CARCINOMA

Epidemiology. Sebaceous carcinoma is a rare aggressive neoplasm that typically presents on the eyelids of elderly individuals. It represents 1%–5.5% of all eyelid malignancies.[43] The mean age of onset is 63 years, although it has been reported in children.[44] While women and Asians were previously thought to have a higher incidence, an analysis of 1,349 cases in the National Cancer Institute's Surveillance, Epidemiology, and End Results (SEER) database revealed a slight male predisposition and no Asian predominance.[45] Other risk factors include previous irradiation, genetic predisposition for the Muir–Torre syndrome, and immunosuppression with renal transplantation or HIV.[45]

Etiology and Pathogenesis. Most sebaceous carcinomas develop de novo, although they can also originate from benign sebaceous neoplasms. These tumors are also associated with the Muir–Torre syndrome and may demonstrate microsatellite instability in DNA mismatch repair genes.[26]

Clinical Findings. The most common clinical presentation is a painless, slowly enlarging, subcutaneous

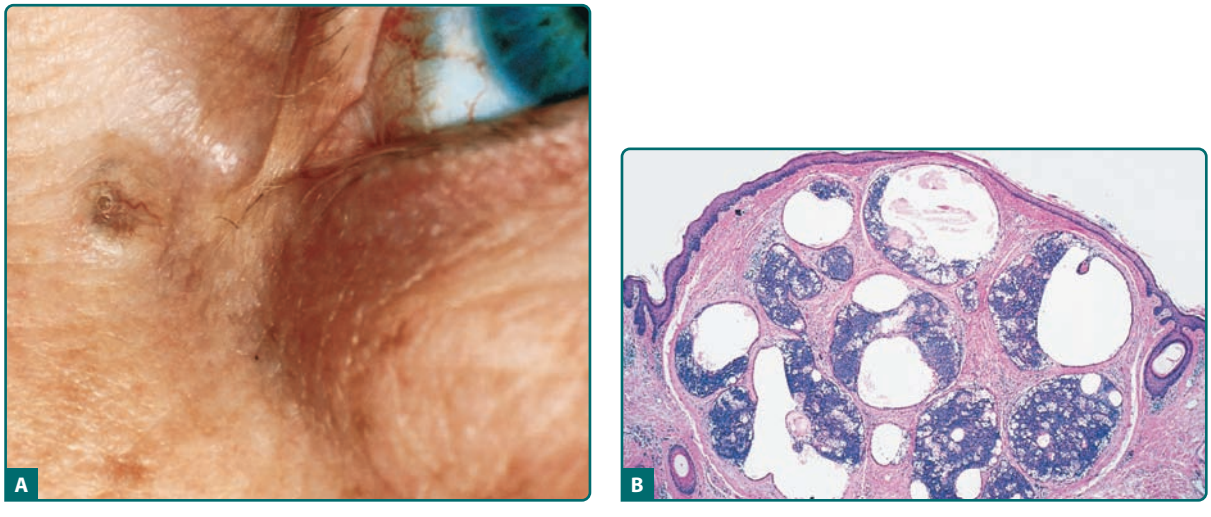

Figure 119-2 Sebaceous adenoma. **A.** Yellowish nodule near the inner canthus of the eye. **B.** Well-circumscribed tumor composed of basaloid aggregations admixed with sebocytes and ductal as well as cystic structures.

nodule.[45] Other clinical presentations mimic chalazion, blepharoconjunctivitis, and basal cell carcinoma, leading to delays in diagnosis.

The most common location is the eyelid, with upper eyelid involvement more frequent than lower eyelid involvement.[46] These tumors develop from the meibomian glands and glands of Zeis. Extraocular lesions present as firm, yellow, ulcerated, or bleeding nodules on the head and neck, and less commonly, on the trunk, feet, external genitals, and oral mucosa.

Histopathology. Sebaceous carcinoma is characterized by asymmetric, irregular sebaceous lobules centered in the dermis. Lesions are classified as well, moderately, or poorly differentiated, based on varying degrees of differentiation. Four patterns are recognized: lobular, comedocarcinoma, papillary, and mixed. Tumor cells show remarkable variation in nuclear shape and size, pleomorphism, hyperchromatism, and mitotic activity. Tumors may extend into the subcutaneous fat or muscle.[21]

Prognosis and Clinical Course. Sebaceous carcinoma is highly aggressive, with a potential for nodal and distant metastases. Recurrence after excision is common. Ocular lesions have a recurrence rate of 11%–30% with distant metastases occurring in up to 25% of patients. Extraocular sebaceous carcinoma is associated with a 29% recurrence rate, and 21% metastatic rate.[45] It was previously believed that ocular tumors were more aggressive than extraocular tumors, but this has been challenged, with many reports of metastatic extraocular disease.[47,48] The most common site of metastasis is regional lymph nodes, but there are reports of metastases extending to the liver, small bowel, urinary tract, lung, and brain.[49]

Mortality rates range from 9% to 50%.[21] Overall 5-year survival rates for ocular versus extraocular disease is 75.2% and 68%, respectively.[45] Negative prognostic signs include upper and lower lid involvement, lymphovascular invasion, multicentric disease, size larger than 1 cm, poorly differentiated tumors, and pagetoid spread.[45]

Treatment. The standard treatment has been wide local excision with 5–6 mm margins. However, this has been associated with high recurrence rates of 36% and a 5-year mortality rate of 18%.[21] Studies have shown that Mohs micrographic surgery may be more effective with recurrence rates of 12%.[46] Sentinel lymph node biopsy has been advocated by some authors, although there are minimal studies in this area.[23] Orbital exenteration is recommended for extensive orbital or bulbar conjunctival disease. Radiation has not been shown to be effective.

MUIR–TORRE SYNDROME

Epidemiology. In 1967, Muir and Torre independently described a syndrome of sebaceous cutaneous neoplasms, keratoacanthomas, and internal malignancy.[50,51] The occurrence of Muir–Torre syndrome in patients with an identified sebaceous neoplasm has been reported as high as 42%, and patients present with sebaceous neoplasm at a mean age of 63.[26]

Etiology and Pathogenesis. Muir–Torre syndrome is inherited in an autosomal dominant fashion. It occurs due to inactivating germ-line mutations in the DNA mismatch repair genes *MSH2*, *MLH1*, and *MSH6*, leading to microsatellite instability.[12] *MSH2* is the most commonly mutated gene.[52] Muir–Torre syndrome is considered a phenotypic variant of the Lynch Syndrome, or hereditary nonpolyposis coli cancer family syndrome, which is also associated with defects in the DNA mismatch repair system.

Clinical Findings. Muir–Torre syndrome is characterized by sebaceous neoplasms, keratoacanthomas, internal malignancies, and personal or family history of Muir–Torre syndrome. Internal malignancy usually precedes cutaneous lesions in 59% of patients. However, up to 32% of cases report the development of a sebaceous neoplasm occurring prior to visceral malignancy.[26] The sebaceous adenoma is the most specific marker for Muir–Torre syndrome, occurring in 68% of cases, but sebaceous hyperplasia, cystic sebaceous neoplasms, and sebaceous carcinoma can also be seen.[26] Extrafacial sites are more common in Muir–Torre syndrome than the typical central facial location for sebaceous neoplasms.[40]

The most common visceral malignancy is colon cancer, followed by genitourinary cancers, breast cancer, and hematologic disorders. *MSH2* mutations are associated with a higher risk of colon cancer, whereas *MSH6* mutations are associated with increased endometrial cancer.[53]

Histopathology. Histopathology is consistent with that of the sebaceous neoplasm present in the individual. Other diagnostic methods include immunohistochemical staining for mismatch repair genes, which has been supported as a sensitive, rapid, inexpensive, convenient method for screening patients with suspected Muir–Torre syndrome.[54] Gene sequencing confirms the diagnosis. Sebaceous neoplasms and keratoacanthomas in Muir–Torre syndrome are now included in the tumors to be tested for microsatellite instability via genotyping.[12]

Prognosis and Clinical Course. Visceral tumors tend to behave less aggressively in Muir–Torre syndrome than in sporadic tumors, with a longer median survival in patients with Muir–Torre syndrome for the same tumor types.[12] Aggressive cancer surveillance with colonoscopy and urinary cytology should be performed in these patients. Genetic counseling should also be provided.

Treatment. Surgical excision is the treatment of choice for cutaneous lesions. Clinically involved nodes should also be removed. Low dose isotretinoin has been effective.[26]

APOCRINE NEOPLASMS

Sweat gland neoplasms have traditionally been divided into apocrine tumors and eccrine tumors. However, the distinction between these can be

quite difficult due to numerous terms applied to the same histological entity, overlap between classic apocrine and pure eccrine features, and the coexistence of both tissue types in hamartomas or mixed tumors.

The anatomic distribution of apocrine tumors reflects that of the normal location of glands producing apocrine secretion. Therefore, these lesions are generally confined to the head and neck, axilla, genitals, and perianal skin. Additional sites include the umbilicus, eyelid (Moll's glands), areola, and external auditory meatus.[6]

Apocrine tumors are generally benign, although they possess the ability to degenerate into malignant lesions. An adnexal carcinoma developing from its benign counterpart generally has a history of explosive enlargement of a stable longstanding plaque or nodule. Adnexal carcinomas that develop de novo are more difficult to diagnose clinically, and require histopathologic evaluation. Features such as asymmetry, lack of circumscription, and infiltrative growth pattern support a malignant diagnosis. Histologically, these must be differentiated from cutaneous metastases from breast and gastrointestinal adenocarcinomas. Malignant adnexal tumors rarely metastasize, and treatment of choice is often Mohs micrographic surgery or local excision.

Histopathologically, apocrine lesions are characterized by cells with abundant eosinophilic cytoplasm, eccentric basally located nuclei, and decapitation secretion in the luminal cells. Cells contain periodic acid Schiff (PAS) positive diastase resistant granules. The luminal cells are also reactive to Carcino-embryonic antigen (CEA) and epithelial membrane antigen (EMA), while the secretory cells are positive for low molecular weight cytokeratin and gross cystic disease fluid protein-15 (GCDFP-15).[6]

HYPERPLASIAS AND HAMARTOMAS

APOCRINE HIDROCYSTOMA

Epidemiology. Apocrine hidrocystomas are relatively common cystic lesions that present in middle-aged or elderly individuals. There is a slight female predilection.[55,56]

Etiology and Pathogenesis. Apocrine hidrocystomas arise from a benign proliferation of apocrine glands.

Clinical Findings. The cystic lesions typically present as solitary, smooth, translucent, flesh-colored or bluish, 1–3 mm papules on the head or neck, particularly in the periorbital region (Fig. 119-3A). Rare presentations include multiple lesions, giant tumors, and childhood onset.[57] Apocrine hidrocystomas have been reported to appear within nevus sebaceus.[23,55]

Multiple lesions on the bilateral upper and lower eyelid margins are seen in Schopf–Schulz–Passarge syndrome, an ectodermal dysplasia characterized chiefly by multiple eyelid apocrine hidrocystomas, palmoplantar keratoderma, hypodontia, hypotrichosis, and nail dystrophy. While an autosomal recessive inheritance has been suggested, it can also be sporadic.[58,59]

Histopathology. On histologic examination, there is a unilocular or multilocular cyst located in the dermis. The epithelial lining consists of a single or double layer of cuboidal–columnar epithelium lying adjacent to an outer myoepithelial layer. Decapitation secretion is notable. Prominent papillations protruding into the lumen are seen in some cases (Fig. 119-3B).[55]

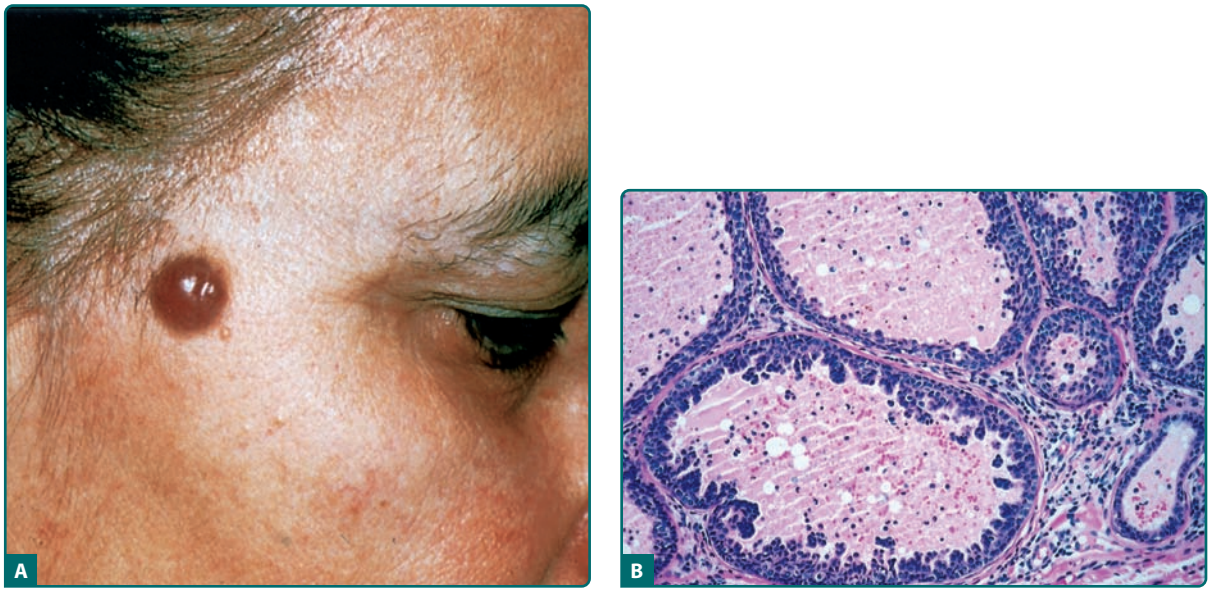

Figure 119-3 Apocrine hidrocystoma. **A.** Reddish-brown to bluish cystic nodule. **B.** Multilocular tumor with papillary projections ("apocrine secretion").

Prognosis and Clinical Course. Lesions tend to be asyptomatic, and enlarge until a certain size is attained.

Treatment. The treatment of choice for solitary lesions is surgical excision. Multiple lesions can be treated with electrodessication and curettage, carbon dioxide or pulsed dye lasers, local application of trichloroacetic acid, topical atropine, or botulinum toxin.[60–63]

APOCRINE NEVUS

Epidemiology. Apocrine nevus is a rare hamartoma consisting of a proliferation of normal appearing apocrine glands in the dermis.

Clinical Findings. There are two clinical variants of apocrine nevus. A pure apocrine nevus is quite rare, and presents as a unilateral or bilateral, soft, lobulated, dermal mass in the axilla or scalp.[1] A more common variant occurs as a part of a nevus sebaceus. Cases of apocrine nevus occurring as multiple papules on the chest have been reported.[64]

Histopathology. There are numerous, discrete, closely spaced tubular structures in the dermis and/or subcutaneous fat. The tubules are lined with typical apocrine glandular epithelium and contain a homogenous vacuolated pink secretion. An apocrine nevus that develops within a nevus sebaceous is usually deeper in the dermis and can coexist with syringocystadenoma papilliferum or trichoblastoma.[23]

Treatment. The treatment of choice is surgical excision.

APOCRINE FIBROADENOMA

Epidemiology. Apocrine fibroadenoma is a rare cutaneous apocrine neoplasm that occurs primarily in women younger than 25 years of age.[1,65]

Etiology and Pathogenesis. Apocrine fibroadenoma is considered analogous to fibroadenoma of the breast.[65] The etiology is unclear. Some feel that it most likely results from a proliferation of ectopic mammary tissue in response to excessive circulating estradiol over progesterone, whereas others believe it is derived from apocrine tissue.

Clinical Findings. Apocrine fibroadenoma typically presents as single or multiple firm, rubbery, smooth, mobile, painless nodules up to 2 cm in diameter. It most commonly occurs in the axilla, vulva, and perianal region.[65]

Histopathology. Histopathology reveals a variably hyalinized stroma surrounding a proliferation of ductal structures with decapitation secretion.

Treatment. The treatment of choice is complete surgical excision.

EROSIVE ADENOMATOSIS OF THE NIPPLE

Epidemiology. Erosive adenomatosis, also known as adenoma of the nipple or florid papillomatosis, is a rare benign neoplasm of breast lactiferous ducts. The peak incidence is in women in the fifth decade, although it has been reported in males and children.[66]

Etiology and Pathogenesis. The tumor derives from terminal lactiferous ducts and subareolar breast tissue.

Clinical Findings. The classic presentation of erosive adenomatosis is with a unilateral erythematous, eroded, crusted papule on the nipple of middle-aged females. Ulceration and serosanguinous discharge may also occur. The lesion is usually asymptomatic, but patients may complain of irritation, burning, pain, and pruritus. Secretion may vary during the menstrual cycle.[67] Clinically, the lesion is often indistinguishable from Paget's disease. Other entities in the differential diagnosis include allergic contact dermatitis, psoriasis, and infection.

Histopathology. Microscopically, erosive adenomatosis reveals a nonencapsulated endophytic proliferation of tubular structures in the dermis with a verrucous or ulcerated surface. Some of the tubular structures exhibit cystic dilations with discrete papillations. The tubules are lined by an inner apocrine secretory epithelium and an outer myoepithelial layer. Differentiating the histologic pattern from intraductal carcinoma of the breast is important. A lack of atypia and necrosis support the diagnosis of erosive adenomatosis.

Prognosis and Clinical Course. Studies have not supported a strong association with breast adenocarcinoma or fibrocystic disease of the breast.[66]

Treatment. Surgical excision and Mohs micrographic surgery are effective treatment choices. Traditionally, complete excision involved removal of the entire nipple and underlying tissue. However, this treatment is associated with recurrence and significant deformation of the cosmetically and functionally sensitive nipple requiring reconstruction.[68,69] More recently, Mohs micrographic surgery has been an effective treatment, with a lower recurrence rate, and minimal deformation. Unique reconstructive techniques, including closure with a purse-string suture, have been employed after Mohs micrographic surgery.[70]

HIDRADENOMA PAPILLIFERUM

Epidemiology. Hidradenoma papilliferum, also known as papillary hidradenoma, is a relatively uncommon benign neoplasm most commonly presenting in females between the ages of 30 and 49 years.[1,71]

Etiology and Pathogenesis. This benign neoplasm develops from the anogenital apocrine glands.

Clinical Findings. The lesion typically presents as a small, unilateral, asymptomatic, flesh-colored nodule on the female vulva. There are reports of ectopic or nonanogenital lesions on the head and neck, where it presents as a subcutaneous nodule, tumor, or cyst. Lesions have been reported on the eyelid, external auditory canal, lip, and nasal ala.[72] Hidradenoma papilliferum has also been reported to develop within a nevus sebaceous.[23]

Histopathology. On histopathology, there is a well-circumscribed dermal nodule that is partly solid or solid-cystic. It lacks an epidermal connection. The nodule consists of an anastomosing pattern of numerous glandular structures and papillary folds. The lumina are made of a double layer of cells: an inner layer of secretory cells demonstrating decapitation secretion, and an outer layer of cuboidal myoepithelial cells (Fig. 119-4). Hidradenocarcinoma papilliferum is notable for high cellularity and asymmetry.

Prognosis and Clinical Course. Hidradenoma papilliferum usually follows a benign course. Malignant transformation into hidradenocarcinoma papilliferum has been reported. It presents as a small, solitary, ulcerated nodule in the anogenital region, and rarely in the axilla. Patients may complain of slight pain or brown watery discharge. Fatal metastases, initially involving regional lymph nodes, have been described. Lesions have been seen in association with extramammary Paget's disease.[1,73]

A fatal metastasizing squamous cell carcinoma arising in a hidradenoma papilliferum has also been reported.[74] There are also rare cases of ductal carcinoma in situ arising in hidradenoma papilliferum.[75]

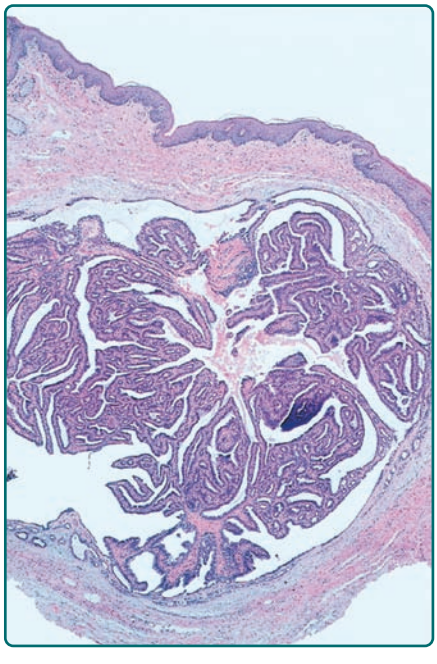

Figure 119-4 Hidradenoma papilliferum. Cystic tumor with papillary and glandular areas.

Treatment. The treatment of choice is surgical excision. In the case of perianal tumors, consultation with colorectal surgery is recommended to preserve anal sphincter function. Sentinel lymph node biopsy may be of value in patients with hidradenocarcinoma papilliferum.

SYRINGOCYSTADENOMA PAPILLIFERUM

Epidemiology. Syringocystadenoma papilliferum is a rare benign adnexal neoplasm that presents in young adults. Fifty percent are present at birth or early childhood, and an additional 15%–20% develop before puberty.[76,77]

Etiology and Pathogenesis. The derivation of syringocystadenoma papilliferum is unclear, with evidence supporting both apocrine and eccrine origin. Forty percent of lesions develop within a nevus sebaceous.[78] Some studies show that mutations in the tumor suppressors, PTCH and p16, may play a role in the evolution of syringocystadenoma papilliferum.[79]

Clinical Findings. Syringocystadenoma papilliferum presents as an asymptomatic, solitary, firm, pink papule or plaque measuring 1–3 cm. A small fistula draining clear, bloody, or malodorous fluid may develop (Fig. 119-5A). At puberty, the lesion often grows and becomes increasingly papillated and hyperkeratotic. The most common location is the scalp.[80] Rare presentations include unusual locations such as the trunk, arms, or vulva, and multiple or linearly arranged cutaneous nodules.

The lesion has been seen in conjunction with a wide variety of other adnexal tumors including nevus sebaceous, apocrine nevus, tubular apocrine adenoma, apocrine hidrocystoma, clear cell syringoma, eccrine nevus, verrucous carcinoma, and adenocarcinoma.[80] This tumor has also been noted in a patient with focal dermal hypoplasia due to a novel *PORCN* mutation. Additional apocrine neoplasms seen in this genetic condition include apocrine nevi and apocrine hidrocystomas.[81]

Histopathology. Syringocystadenoma papilliferum presents with papillomatous epidermal invaginations lined with a double layer epithelium composed of basilar cuboidal cells and an inner columnar layer of secretory cells (Fig. 119-5B). A plasma cell rich infiltrate is also characteristic. There is typically a connection between the epithelial invagination and adjacent glands in the dermis.

The malignant counterpart, syringocystadenocarcinoma papilliferum, is characterized by asymmetry, poor circumscription, extension to the deep subcutaneous tissue, and increases in cellularity, cellular atypia, and mitoses.

Prognosis and Clinical Course. Basal cell carcinoma has been reported to occur in as high as 9%

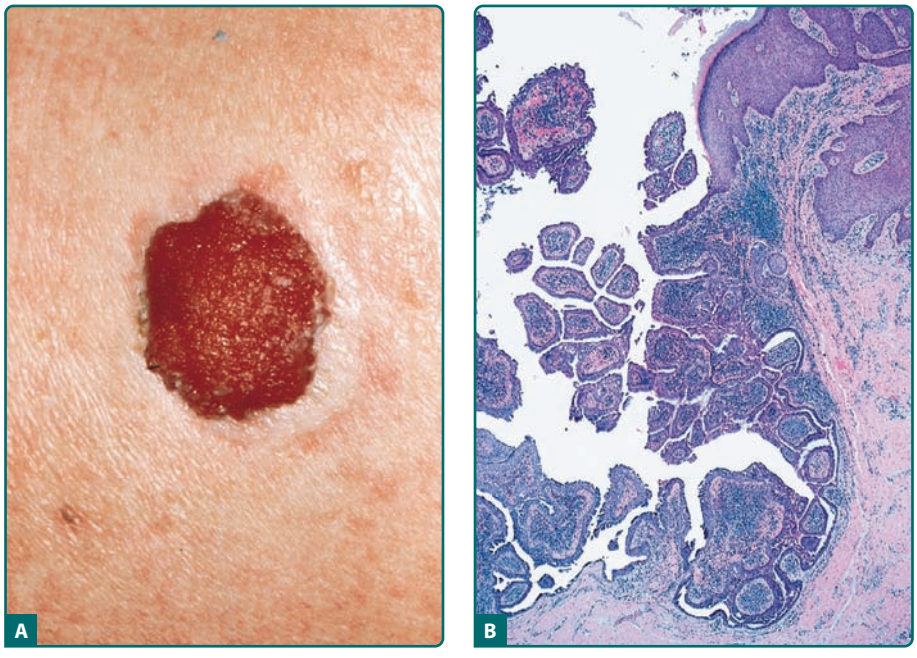

Figure 119-5 Syringocystadenoma papilliferum. **A.** Erosive nodule on the forehead. **B.** Epidermal invagination with papilliferous projections.

of cases, although this has not been corroborated by others.[76,78] Malignant degeneration into syringocystadenocarcinoma papilliferum has been reported, with signs of malignant behavior including rapid growth, ulceration, pain, and pruritus.[82,83] There is a low risk of regional lymph node metastases, while distant metastases have not been reported.

Treatment. Complete surgical excision is recommended given the malignant potential of syringocystadenoma papilliferum, although the benefit of prophylactic excision is unclear. In anatomic areas unfavorable for excision or grafting, carbon dioxide laser may be an alternative option.[84] For syringocystadenocarcinoma papilliferum, excision and Mohs micrographic surgery have been effective treatment options.[82]

CYLINDROMA

Epidemiology. Cylindromas are benign neoplasms that are more common in females and typically present in the third decade.[1,85]

Etiology and Pathogenesis. Cylindromas are thought to originate from apocrine glands although some support an eccrine or follicular origin.[86] Multiple cylindromas are seen in Brooke–Spiegler syndrome, an autosomal dominant condition with variable penetrance and expressivity, that presents with multiple cylindromas, eccrine spiradenomas, and trichoepitheliomas. Inactivating germ-line mutations or loss of heterozygosity in the tumor suppressor gene *CYLD* result in this disfiguring condition.[87] *CYLD* encodes a ubiquitin hydrolase implicated in the negative regulation of cell proliferation through the nuclear factor κB (NF-κB) pathway. Mutations in *CYLD* cause an increased expression of NF-κB, and lead to apoptotic resistance and development of tumors seen in Brooke–Spiegler syndrome.[88] Some also believe that ultraviolet radiation may play a role given that the most common presentation is on sun-exposed areas such as the face and scalp.

Clinical Findings. Cylindromas most commonly present as slow growing, pink, firm, smooth, alopecic, painful nodules ranging in size from 0.5 cm to 6 cm on the scalp. When multiple lesions coalesce on the scalp forming a confluent mass, the term "turban tumors" has been applied (Fig. 119-6A). While they can present as solitary lesions, the familial variant typically manifests with numerous tumors. Aside from pain, conductive deafness and sexual dysfunction have been reported in periauricular and pubic lesions.[86]

Patients with Brooke–Spiegler syndrome present with cylindromas, trichoepitheliomas, spiradenomas, sebaceous nevi, basal cell carcinoma and milia.[89] Incidental associations with cylindroma include polycystosis of the lungs and kidneys, cervical, breast, and parotid carcinomas, and multiple fibromas.[89]

Histopathology. Cylindromas are characterized by dermal aggregates of large epithelial cells with abundant cytoplasm in the center and small basaloid cells in the periphery. The nodules are lined by thick basement membrane-like material, and arranged in a classic jigsaw puzzle pattern (Fig. 119-6B).[90]

Prognosis and Clinical Course. Patients with Brooke–Spiegler syndrome are at risk for basal cell carcinomas, tumors of the salivary glands, and parotid adenomas.[91] Malignant degeneration of cylindromas into cylindrocarcinoma has been reported. Malignant transformation more commonly occurs in cases of multiple tumors, females, and in middle-aged to elderly

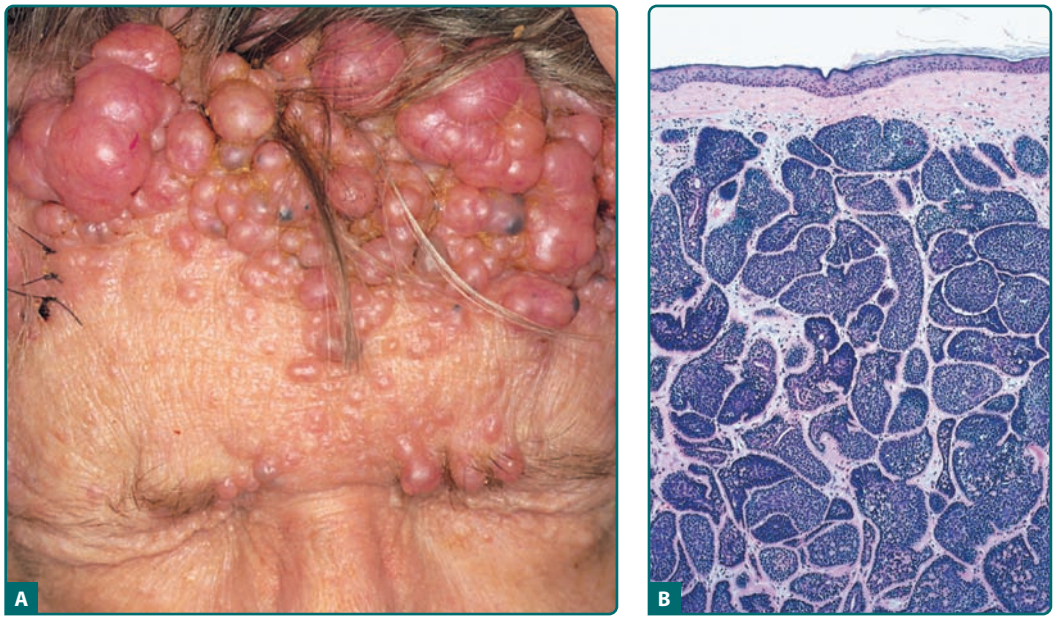

Figure 119-6 **A.** Cylindroma or turban tumor. **B.** Cylindroma with irregularly shaped aggregations of basaloid cells arranged in a "jigsaw puzzle" pattern.

patients.[92] Clinical signs include pink to blue discoloration, ulceration, rapid growth, and bleeding. These are highly aggressive tumors with potential for local destructive growth, metastases, and recurrence.[92,93] Metastases to the lymph nodes, stomach, thyroid, liver, lung, and bones have been reported.

Treatment. The treatment of choice for a cylindroma is surgical excision. In the case of multiple confluent tumors on the scalp, this can pose a challenge. Entire scalp excision carries the risk of significant blood loss requiring a blood transfusion and skin graft failure.[85] Alternative treatments include electrosurgery, dermabrasion, carbon dioxide laser, cryotherapy, and radiotherapy.[85,94] New insights into the role of *CYLD* in the NF-κB pathway has lead to the use of topical salicylic acid in cylindromatosis, with some reports showing complete remission after 6 months.[95]

MALIGNANT LESIONS

APOCRINE ADENOCARCINOMA

Epidemiology. Apocrine adenocarcinoma comprises a rare group of cutaneous adenocarcinomas that show apocrine differentiation. It most commonly presents in middle-aged to elderly males.[96]

Etiology and Pathogenesis. The lesion usually arises de novo; however, there are reports of it developing in association with apocrine adenoma, cylindroma, nevus sebaceus, extramammary Paget's disease, and accessory nipple.[96,97]

Clinical Findings. There is significant variation in the clinicopathologic presentation of apocrine adenocarcinoma. It generally presents as an indolent, slow-growing, rubbery, solid to cystic nodule or tumor ranging in size from 1.5 to 8 cm. The color varies from red to purple, and ulceration may be present.[98] There are rare presentations that can mimic cellulitis.[99] The most common location is the axilla followed by the anogenital skin, regions of high apocrine gland density.[98] Less frequent locations include the scalp, forehead, eyelid, upper lip, chest, nipple, and finger.[96] Patients may complain of pain, restricted range of motion, ulceration, and purulence.[96] Clinically, cutaneous metastases from breast and gastrointestinal cancers must be considered.

Histopathology. Histopathologically, apocrine adenocarcinoma presents with a dermal and/or subcutaneous non encapsulated tumor with infiltrative margins. The carcinoma is composed of large cells with eosinophilic cytoplasm, hyperchromatic nuclei, mitotic figures, and decapitation secretion. The epithelial component shows variable papillary, cribiform or trabecular, and solid patterns.[100–102] Signet ring cells and pagetoid spread have been reported.[100]

Prognosis and Clinical Course. Apocrine adenocarcinoma is a locally invasive neoplasm with potential for regional lymph node metastases. Despite its aggressive behavior, mortality is relatively low.[98,100] Local recurrence after wide local excision has been reported at 27.5%.[96] Over 40% of reported cases presented with nodal metastases at initial diagnosis. Distant metastases to the lungs, bones, brain, and parotid gland have been reported.[96]

Treatment. The treatment of choice is wide local excision with clear margins. Some believe that there is a role for sentinel lymph node biopsy and nodal dissection given the high rate of regional nodal metastases.[96] Adjunctive chemotherapy and radiation have

been used. In some cases, the presence of steroid receptors in the tumor has lead to the use of tamoxifen.[100]

ECCRINE TUMORS

Eccrine glands are widely distributed in the skin. Therefore, eccrine tumors have a wider anatomic distribution than apocrine tumors. Histologically, eccrine tumors comprise a large spectrum of lesions with differentiation toward various portions of the normal eccrine apparatus, including intraepidermal (acrosyringium), dermal, and secretory ducts. The distinguishing feature is the tendency to form lumina with flattened epithelium. Distinction from apocrine tumors is not always straightforward, as decapitation secretion can be observed in certain tumors traditionally classified as "eccrine." Similar to apocrine tumors, eccrine tumors are typically benign, but possess the ability to degenerate into malignant lesions.

HYPERPLASIAS AND HAMARTOMAS

ECCRINE HIDROCYSTOMA

Epidemiology. Eccrine hidrocystomas are common lesions found in middle-aged to elderly patients, predominantly in females.[103]

Etiology and Pathogenesis. Eccrine hidrocystoma is a benign proliferation of eccrine glands.

Clinical Findings. There are two clinical variants of eccrine hidrocystoma. Robinson first described multiple eccrine hidrocystomas in 1893.[104] The solitary type was first reported by Chernosky and Smith in 1973.[105] The lesions are typically translucent, skin-colored or blue, dome-shaped, cystic papules on the head and neck. Multiple lesions clustered in the periorbital region may be a sign of ectodermal dysplasia.[103] Multiple lesions have also been associated with warm climates, hyperhidrosis, and Graves disease.[106]

Histopathology. The cyst lining is a double layer of flattened epithelium lacking decapitation secretion. Eosinophilic contents may be seen.

Prognosis and Clinical Course. Eccrine hidrocystoma follows a benign course.

Treatment. Solitary lesions can be surgically excised. Destructive methods such as electrodessication, curettage, laser ablation, and pulsed dye laser therapy have been employed but are often associated with scarring. Botulinum toxin injections have been used with success.[103]

ECCRINE NEVUS

Epidemiology. Eccrine nevi, first described in 1976, encompass a variety of rare benign eccrine hamartomas that appear in childhood and adolescence.[107] Some lesions may be congenital, whereas others present at advanced ages.[108]

Etiology and Pathogenesis. Eccrine nevi originate from eccrine glands. Several distinct forms exist. The two main subtypes are the rare pure eccrine nevus and the common eccrine angiomatous hamartoma. Other presentations include the mucinous eccrine nevus and porokeratotic eccrine ostial and dermal duct nevus (PEODDN).[109]

Clinical Findings. The clinical presentation of eccrine hamartomas is variable depending on the subtype. Pure eccrine nevi classically present with a solitary, well-circumscribed, hyperhidrotic plaque with little to no epidermal change. Hyperhidrotic episodes are triggered by temperature, stress, and exercise. The most common location is the forearm (50%) followed by the back and trunk.[109,110] Rare presentations include hyperpigmented patches, linear lesions, centrally depressed plaques, and scaly borders.[110]

Eccrine angiomatous hamartomas (EAH) are more common and are often present at birth. They present with a solitary or multiple flesh-colored, red, or blue–brown nodules or plaques on the extremities, especially the legs. EAH can be painful.[109]

Mucinous eccrine nevi are extremely rare lesions that present with nodules or plaques with hyperhidrosis.[109,111] Porokeratotic eccrine ostial and dermal duct nevus (PEODDN) is a rare disorder of keratinization involving the intraepidermal eccrine duct or acrosyringium.[112] PEODDN presents with congenital punctuate keratoses on the hands and feet, and has been associated with deafness, developmental delay, seizures, scoliosis, anhidrosis, alopecia, onychodysplasia, and palmoplantar involvement.[113] Lesions are typically linear and follow the lines of Blaschko.

There are rare reports of coexistence with other cutaneous lesions such as clear cell syringoma and neurofibromatosis I.[114]

Histopathology. There is an increase in the number or size of normal eccrine glands. EAH also shows an increase in the number of capillaries. Mucinous eccrine nevi are characterized by large mucin deposits surrounding eccrine glands. PEODDN demonstrates parakeratotic coronoid lamellae over the eccrine ostia.[109]

Prognosis and Clinical Course. These lesions are benign. Indications for treatment include pain and excessive hyperhidrosis.

Treatment. The treatment of choice is surgical excision. Often, the lesions are quite large and surgery is not feasible. Alternative therapies include aluminum chloride, systemic and topical anticholinergic agents, clonazepam, antidepressants, and botulinum toxin injections.[108] PEODDN has been treated with the carbon dioxide laser and topical retinoids.[115]

SYRINGOMA

Epidemiology. Syringomas are common benign neoplasms most frequently seen in adult females. There is an increased frequency in Down's syndrome, with 18% of patients exhibiting this cutaneous sign.

An increased frequency has also been observed in Marfan's syndrome, Ehlers Danlos, and Nicolas balus syndrome. An eruptive form most commonly presents in adolescent females. The clear cell variant has been linked to diabetes.[116]

Etiology and Pathogenesis. Syringomas derive from the intradermal eccrine duct or acrosyringium. Local factors, including ductal obstruction by keratin plugs leading to ductal proliferation, may play a role in pathogenesis.[117,118] The etiology of eruptive syringomas is unclear. It has been hypothesized that these eruptive lesions demonstrate reactive eccrine gland proliferation following an inflammatory condition.[119]

Clinical Findings. Syringomas present with numerous, small, firm, smooth, flesh-colored or yellowish papules on the face, especially the lower eyelids, of adult females (Fig. 119-7A). Other sites, such as the scalp, axillae, abdomen, forehead, penis, and vulva can be affected. Four clinical variants have been described: a localized form, lesions associated with Down's syndrome, a generalized eruptive form, and a rare autosomal dominant familial form.[120,121]

The localized form traditionally occurs in the periorbital region, and can also present with scalp alopecia, a unilateral nevoid appearance, large lesions, and genital lesions.[122] Genital syringomas can be remarkably pruritic, and are often mistaken for genital warts.[123]

Eruptive syringomas, first described by Jacquet and Darier in 1987, present as a sudden onset of successive crops of numerous disseminated syringomas on the upper trunk, especially the anterior neck, chest, trunk, axilla, upper medial arms, and periumbilical region of adolescent females.[124]

Histopathology. Syringomas are well-circumscribed, symmetric collections of small tadpole-shaped tubular structures in the superficial dermis. These tubules are lined by a single or double layer of bland, monomorphic, cuboidal epithelial cells (Fig. 119-7B). Clear cell syringomas are notable for abundant cytoplasm. The tubular structures are surrounded by thickened collagen bundles. If the biopsy specimen is very superficial, microcystic adnexal carcinoma should be considered in the differential diagnosis.

Treatment. Numerous destructive methods have been described for the treatment of syringomas, including excision, dermabrasion, laser resurfacing, trichloroacetic acid, cryotherapy, and electrosurgery.[125,126] Unfortunately, these are often associated with significant scarring and recurrence. Topical and oral retinoids, and topical atropine have also been utilized with suboptimal results.[117] The Q-switched Nd:Yag laser has been used after temporary tattooing and shows promising results.[126]

POROMA

Epidemiology. Poromas were first reported by Pinkus in 1956, and represent 10% of all sweat gland tumors.[127,128] Poromas can occur in all age groups, but onset is usually over the age of 40.[129]

Etiology and Pathogenesis. Poromas represent a group of benign eccrine tumors composed of cuticular and poroid cells similar to those seen in the eccrine acrosyringium. Poromas are classified based on the location relative to the epidermis. Intraepidermal lesions are referred to as hidroacanthoma simplex. Poromas comprise lesions that span the epidermis and dermis, whereas dermal duct tumors exist entirely in the dermis. The etiology is unclear, but occurrence after trauma and radiation has been reported.[128–130]

Clinical Findings. Hidroacanthoma simplex presents as a solitary hyperkeratotic plaque on the extremities of middle-aged and elderly females. Eccrine poromas classically present as a solitary, slow growing, flesh-colored or bright red, pruritic, painful, pedunculated papule or nodule on the palms and soles of adults. There is a predilection for the sole and sides of the feet, followed by the hands, fingers, head, neck, and trunk.[131] A distinct feature is a cup-shaped shallow depression from which the tumor protrudes.[14] While poromas tend to be solitary, multiple lesions can exist. When hundreds of poromas are present, the condition is denoted "poromatosis" and is observed in patients with hidrotic ectodermal dysplasia.[132] Dermal duct tumors present with deep nodules on any part of the body.

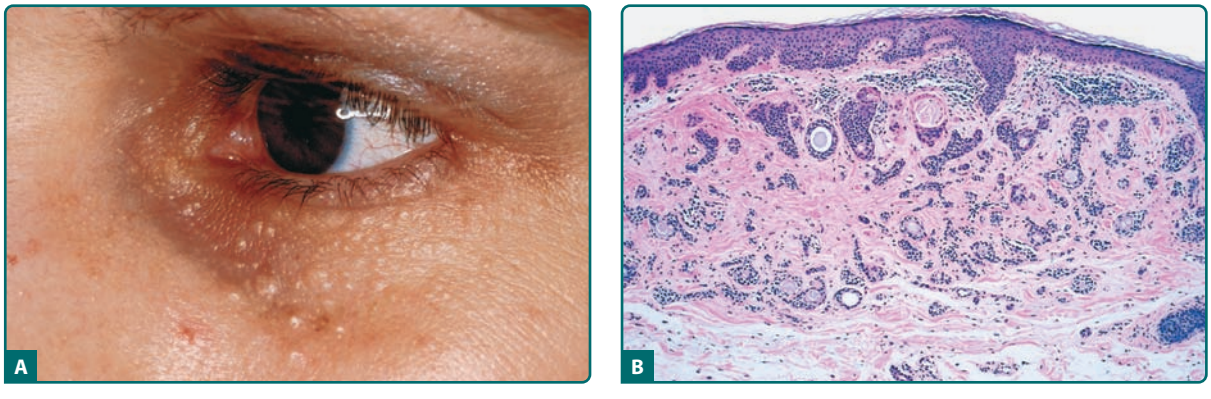

Figure 119-7 Syringoma. **A.** Multiple, small papules on the periorbital skin of a young woman. **B.** Solid, tubular, and cystic structures in the upper dermis. Note "tadpole"-like morphology of tumor lobules.

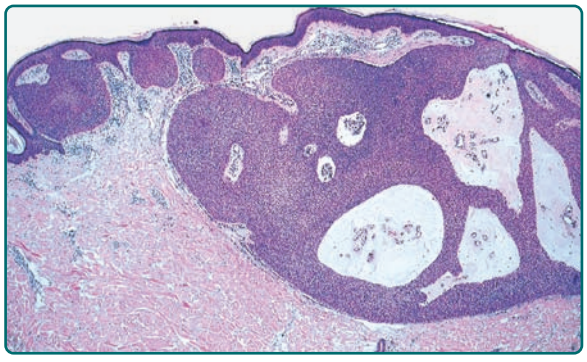

Figure 119-8 Eccrine poroma. Nodular aggregations of basaloid cells extend from the epidermis into the superficial dermis.

Histopathology. Hidroacanthoma simplex displays sharply demarcated aggregations of cuboidal to ovoid cells in the epidermis. Eccrine poromas reveal aggregations of uniform basaloid cells that radiate from the basal layer of the epidermis into the dermis (Fig. 119-8). Dermal duct tumors consist of several sharply circumscribed dermal nodules consisting of poroid cells with frequent ductal structures

Prognosis and Clinical Course. Eccrine poromas rarely progress to porocarcinoma, although porocarcinoma is the most common form of sweat gland carcinoma.[14] Clinically, porocarcinoma presents as a blue–black nodule or infiltrated plaque on the legs, feet, face, thighs, and arm. Interestingly, there is rare involvement of the palms and soles. The average age of onset is 75 years old, although there are reports as early as 12 years of age.[7] Porocarcinoma evolving from a poroma is characterized by rapid growth up to 10 cm, bleeding, and ulceration. There is a propensity to form multiple cutaneous metastases. Regional nodal metastases can occur in 20% of cases, but distant metastases are extremely rare. Porocarcinoma has a tendency to recur locally with a 20% recurrence rate after excision. Mortality is 65% if there are positive nodal metastases. Survival with distant metastases ranges from 5 to 24 months.[133]

Treatment. Mohs micrographic surgery is evolving as the treatment of choice for localized disease with a lower recurrence rate than local excision.[134,135]

ECCRINE SYRINGOFIBROADENOMA

Epidemiology. Eccrine syringofibroadenoma was first described by Mascaro in 1963.[136] It presents in older adults particularly in the seventh to eighth decades.[136–138]

Etiology and Pathogenesis. Eccrine syringofibroadenoma originates from or is differentiating toward the acrosyringium or eccrine dermal duct.[138] There is controversy as to whether the lesion is a hamartoma, reactive hyperplasia, or a true neoplasm. The lesion has been classified into five distinct subtypes: multiple lesions associated with an ectodermal dysplasia, multiple lesions with no additional cutaneous pathology, unilateral linear lesions, solitary lesions, and reactive lesions.[139] Reactive lesions have been reported in association with erosive lichen planus, trauma due to diabetic neuropathy, elephantiasis, bullous pemphigoid, burn scars, and peristomal skin.[138,140] Human papillomavirus 10 may also play a role in the development of eccrine syringofibroadenomas.[141]

Clinical Findings. The clinical presentation is nonspecific and variable. Eccrine syringofibroadenomas can range from solitary lesions to multiple papules, plaques, and nodules in a symmetrical and linear or nevoid pattern. The most common site is the limb.[137] Additional locations include the face, torso, buttocks, and nail.[138]

Eccrine syringofibroadenomas are observed in ectodermal dysplasia, and specifically, Clouston' syndrome. Clouston's syndrome is an autosomal dominant condition with progressive hyperkeratosis of the palms and soles, patchy alopecia, nail dystrophy, normal teeth, and normal sweating. It results from mutations in the *connexin 30* or *GJB6* gene.[141]

Histopathology. Unlike the variety of clinical presentations, the histologic picture is quite consistent. There are multiple anastomosing cords of benign epithelial cells surrounded by a loose fibrovascular stroma. The epithelial cords demonstrate ductal differentiation. Occasional luminal eccrine ducts are noted within the anastomosing cords.

Prognosis and Clinical Course. The course of eccrine syringofibroadenomas is typically benign, although malignant transformation into squamous cell carcinoma or eccrine syringofibroadenocarcinoma has been reported.[137,138] This occurrence is extremely rare and generally arises in elderly male patients. Signs of malignancy include ulceration, rapid growth, and crusting.

Treatment. Given the malignant potential, complete surgical excision is recommended. If the lesions are too numerous or large for excision, the pulse dye laser has shown promising results.[138]

ECCRINE SPIRADENOMA

Epidemiology. Eccrine spiradenoma is a benign adnexal tumor first described by Kersting and Helwig in 1956.[142] It is relatively common, and presents in young and middle-aged adults between age 15 and 35. Rare familial cases have been reported.[7]

Etiology and Pathogenesis. Eccrine spiradenoma derives from the intradermal straight eccrine duct.

Clinical Findings. Eccrine spiradenoma typically appears as a solitary, slow growing, 1–2 cm, red–brown deep-seated nodule (Fig. 119-9A). There may be a slightly bluish hue, and paroxysmal pain is a distinct trait. Rare atypical variants include large lesions, vascular lesions, and multiple lesions arranged in a linear or zosteriform configuration.[143–145] There is a predilection for the ventral



Figure 119-9 Spiradenoma. **A.** Reddish-brown tumor on the scalp. **B.** Tumor cells arranged in a trabecular pattern. Note hyaline material in the background.

upper trunk.[7] Eccrine spiradenoma has been observed growing within a nevus sebaceus.[146] These tumors are also seen in the setting of Brooke–Spiegler syndrome, an autosomal dominant condition with numerous cylindromas, eccrine spiradenomas, and trichoepitheliomas due to an inactivating mutation in the *CYLD* gene.

Histopathology. Biopsy reveals one or several well-circumscribed basophilic nodules in the dermis and/or subcutaneous tissue. Epithelial aggregates are arranged in sheets and cords or in a trabecular pattern. There are two distinct cell populations: small darkly staining basaloid cells rimming the periphery and larger cells with a pale nucleus in the center of the lesion. Tubular or cystic structures are noted within the epithelial aggregations. The basaloid cells are often arranged in rosettes. PAS-positive hyaline material is noted within the tumor (Fig. 119-9B).

Prognosis and Clinical Course. Malignant transformation to eccrine spiradenocarcinoma is extremely rare.[147] Long-standing lesions that rapidly enlarge, bleed, ulcerate, or change color should raise the suspicion of malignancy. The average age of presentation is 62. Lesions tend to present on the trunk and extremities and achieve an average size of 7.5 cm. Metastatic disease is most frequently seen in the regional lymph node basin, but can also be seen in the lung, liver, brain, spinal cord, bone, and parotid gland. Metastases can be fatal, and overall mortality has been reported between 20% and 40%.[148]

Treatment. The treatment of choice for eccrine spiradenoma is surgical excision with clear margins. There is no satisfactory treatment for pain. For spiradenocarcinoma, wide local excision is recommended. The role of sentinel lymph node biopsy, radiation, and tamoxifen for estrogen-receptor positive tumors is unclear.[149]

PAPILLARY ECCRINE ADENOMA

Epidemiology. Papillary eccrine adenoma is a rare benign adnexal tumor. While it can present from childhood to advanced age, the mean age is in the fifth decade. It is more common in women.[150] An African-American predilection has been noted.[151]

Etiology and Pathogenesis. Papillary eccrine adenomas exhibit eccrine differentiation. There are architectural similarities to the tubular apocrine adenoma.[4] Some classify these two entities under the heading of papillary tubular adenoma.[152]

Clinical Findings. It most commonly presents as a solitary, firm, flesh-colored nodule on the distal extremity. The size varies from 0.5 to 4 cm in diameter.[152]

Histopathology. Microscopic examination reveals a well-circumscribed, nonencapsulated dermal nodule comprised of numerous dilated tubules surrounded by a fibrous stroma. The tubules are lined with an outer layer of flattened epithelial cells and an inner layer of cuboidal or columnar cells with intraluminal papillary projections. The lack of atypia and mitoses differentiates this benign entity from aggressive digital papillary adenomas and adenocarcinomas.

Prognosis and Clinical Course. Papillary eccrine adenoma typically follows a benign clinical course with rare recurrence and no reports of metastatic disease.

Treatment. The treatment of choice is surgical excision with clear margins. Mohs micrographic surgery

is an effective therapeutic option, given the potential ability to preserve sensory and motor function of the hand.[152]

NODULAR HIDRADENOMA

Epidemiology. Nodular hidradenoma, also known as eccrine acrospiroma, is a benign adnexal tumor that presents most commonly in middle-aged and elderly females.[7,153]

Etiology and Pathogenesis. Nodular hidradenoma shows features of eccrine and apocrine differentiation, although it is typically classified as an eccrine tumor. It is also closely related to poroma, and both entities are often regarded together as acrospiromas.

Clinical Findings. Nodular hidradenoma usually presents as a slow-growing, solitary, firm, flesh-colored or red to blue, mobile, solid or cystic nodule that measures 1–2 cm in diameter. The most common locations are the scalp, face, and trunk (Fig. 119-10A).[7] Atypical presentations include childhood onset, large lesions, painful tumors, or rapidly growing lesions.

Histopathology. Nodular hidradenoma presents as a well-circumscribed, nonencapsulated nodular, solid, or solid-cystic lesion in the dermis and occasionally extends to the subcutaneous fat. Ductal differentiation is present. The closely packed tumor cells have a biphasic population with small dark polygonal cells and larger clear cells (Fig. 119-10B). Features such as poor circumscription, large size, solid sheet-like growth pattern, necrosis, and vascular and lymphatic invasion, pleomorphism, and high mitotic rate are suggestive of malignant nodular hidradenoma or hidradenocarcinoma.[154]



Figure 119-11 Hidradenocarcinoma. Large ulcerated tumor.

Prognosis and Clinical Course. Despite local excision, nodular hidradenoma has a recurrence rate of 12% if not fully excised.[6] Rarely, nodular hidradenoma can degenerate into hidradenocarcinoma (Fig. 119-11). Most hidradenocarcinomas arise de novo. The prognosis for hidradenocarcinoma is poor, with a 50% recurrence rate and a 60% metastatic rate. The prognosis for a 5-year disease free survival is only 30%. The most common site of metastases is the regional lymph nodes. Hematogenous spread to distant lymph nodes, bones, viscera, and pleura has been reported.[155]

Treatment. The treatment of choice for nodular hidradenoma is surgical excision with clear margins. Hidradenocarcinoma should be treated aggressively with wide local excision of 3–5 cm. Moh micrographic surgery has also been employed for margin control in irregular tumors.[156,157] Sentinel lymph node biopsy

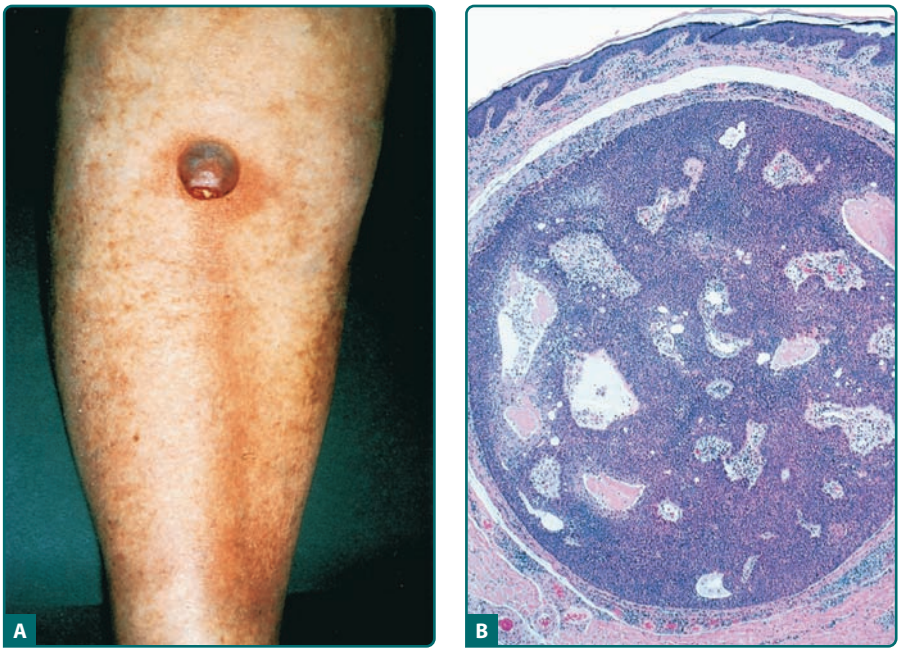

Figure 119-10 Hidradenoma. **A.** Dome-shaped nodule on the leg. **B.** Well-circumscribed, dermal nodule composed of two cell types.

has been advocated by some authors, but there is no known benefit.

CHONDROID SYRINGOMA

Epidemiology. Chondroid syringoma, or mixed tumor of the skin, is an uncommon benign appendageal tumor of mixed differentiation that was first described by Hirsch and Helwig in 1961.[158] It is generally observed in middle-aged and elderly males.[159]

Etiology and Pathogenesis. Chondroid syringoma comprises a group of adnexal neoplasms with ductal differentiation and a fibromyxochondroid stroma. The etiology of chondroid syringoma is unclear. It displays features of both folliculosebaceous-apocrine and eccrine differentiation. It is analogous to mixed tumor of the salivary gland.

Clinical Findings. Clinically, chondroid syringoma presents with slow-growing, painless, nonspecific, firm nodules on the head and neck, especially the nose, cheeks, and upper lip (Fig. 119-12A).[6] It can also be seen on the upper trunk, axilla, and genital regions. Lesions range in size from 5 to 30 mm, although lesions as large as 7 cm have been reported.[160]

Histopathology. Chondroid syringoma presents with a circumscribed dermal nodule with bland epithelial cells arranged in cords, ducts and tubules, embedded in a myxoid-cartilaginous stroma (Fig. 119-12B). Eccrine variants exhibit tubules with a small lumen lined with a single row of cuboidal cells. The apocrine variant is lined with two layers of epithelial cells and displays decapitation secretion.

Prognosis and Clinical Course. Chondroid syringomas very rarely transform into malignant chondroid syringomas. The malignant variant tends to present on the extremities and trunks of females, unlike its benign counterpart that predominates on the head and neck of males. The average age of onset is 48 years old. Malignant chondroid syringoma is associated with a nearly 50% metastatic rate to the lymph nodes, bone, and lung.[161]

Treatment. The treatment of choice for chondroid syringoma is complete surgical excision. Electrodessication, dermabrasion, and vaporization with argon or carbon dioxide laser have been tried with variable results.[162] Malignant chondroid syringoma requires a wide local excision with at least a 1 cm margin and possible adjuvant radiation.[162]

MALIGNANT NEOPLASMS

AGGRESSIVE DIGITAL PAPILLARY ADENOMA AND ADENOCARCINOMA

Epidemiology. Aggressive digital papillary adenoma (ADPA) and adenocarcinoma (ADPAca) are rare eccrine gland tumors that present primarily in Caucasian males in their fifties. There are three case reports of this condition occurring in children.[163]

Etiology and Pathogenesis. The origination of ADPA and ADPAca is controversial. While these entities have traditionally been classified as eccrine neoplasms, decapitation secretion and sebaceous differentiation have been noted in some cases of ADPAca. However, since most lesions present acrally, an anatomic site rich in eccrine units and devoid of apocrine glands, the most likely derivation is eccrine. ADPA and ADPAca exist on a spectrum, where ADPAca represents a more aggressive disease with metastatic potential, although ADPA can also behave in a destructive manner. This entity is not associated with the benign papillary eccrine adenoma.[163–165]

Clinical Findings. These tumors present as a solitary, firm, tan or pink, rubbery nodule on the acral extremities. Specifically, the most common location is the volar surface of the skin between the nail bed

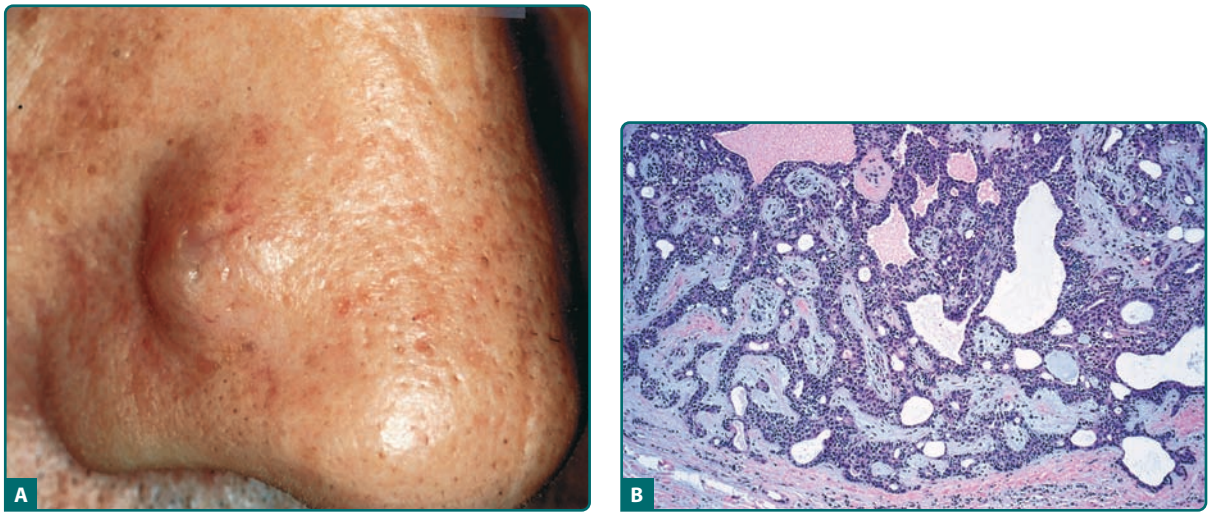

Figure 119-12 Chondroid syringoma. **A.** Chondroid syringoma on the nose. **B.** Solid cords and tubular structures in a background of a fibromyxoid stroma.

and distal interphalangeal joint.[164] While the lesions are generally asymptomatic, patients may experience pain, bleeding, ulceration, and rarely, limited range of motion.

Histopathology. Histologically, these lesions are multinodular dermal and/or subcutaneous proliferations of ductal and glandular structures with focal solid and cribriform zones. Ductal structures exhibit cystic dilatations, in which several papillary projections are present. A fibrocollagenous stroma surrounds the epithelial components. Atypia, necrosis, and invasion of bone and vasculature are signs of an aggressive tumor.

Prognosis and Clinical Course. ADPA and ADPAca are highly aggressive tumors with frequent local recurrence and metastases. The local recurrence rate is nearly 50% after surgical excision, with recurrence occurring as early as two months to 9 years.[163–165] Metastases occur in approximately 15% of cases, with the most common site being the lung.[164] Other sites of metastases include lymph nodes, brain, kidney, bone, or retroperitoneum.[165]

Treatment. ADPA and ADPAca should be treated aggressively with excision or digital amputation. Metastatic disease has been treated with chemotherapy with variable results. Annual monitoring for metastatic disease, including physical examination and chest X-ray, is recommended for 10 years after diagnosis.[165]

MUCINOUS ECCRINE CARCINOMA

Epidemiology. Mucinous eccrine carcinoma is a rare low-grade eccrine tumor that presents in elderly males. It is most commonly seen in Caucasian and African-American males.[6,166]

Etiology and Pathogenesis. Mucinous eccrine carcinoma originates from the deepest portion of the eccrine duct.[167] It is analogous to mucinous carcinoma of the breast, and may express estrogen and progesterone receptors.

Clinical Findings. Mucinous eccrine carcinoma typically presents with an asymptomatic, round, elevated, reddish, ulcerated mass. It most commonly occurs on the head and neck in 75% of cases, with 40% of cases on the eyelid. There is a propensity for sudden enlargement.[168] Metastatic mucinous gastrointestinal cancers must be excluded.

Histopathology. Histopathologically, mucinous eccrine carcinoma is a well-demarcated, lobular, dermal tumor with frequent extension into the subcutaneous tissue. It consists of PAS-positive, diastase-resistant multilocular pools of mucin, in which nests of bland polygonal cells are embedded. There are rare mitoses.

Prognosis and Clinical Course. This tumor has a favorable prognosis with low metastatic potential. While regional metastases are 15% and distant metastases are 7%, the local recurrence rate is much higher at 36%.[167,169]

Treatment. The treatment of choice is surgical excision. Wide local excision is associated with high recurrence rates, even with 1–2 cm margins.[169] Mohs micrographic surgery has been attempted with good results.[166,168,170]

MICROCYSTIC ADNEXAL CARCINOMA

Epidemiology. Microcystic adnexal carcinoma (MAC), also known as sclerosing sweat duct carcinoma or syringomatous carcinoma, is a rare adnexal tumor first described by Goldstein in 1982.[171] It is typically seen in middle-aged to elderly patients, with an average age in the seventh decade. Some reports reveal a slight female predilection.[172] While there is a Caucasian predominance, there are reports in African-American individuals.[173]

Etiology and Pathogenesis. MAC shows features of eccrine, apocrine, and follicular differentiation. Risk factors include immunosuppression and a prior history of therapeutic radiation.[6]

Clinical Findings. MAC presents as a slow-growing, firm, indurated plaque or nodule with indistinct borders on the face, especially the upper lip. The tumor is generally asymptomatic, but numbness, burning, anesthesia, and paresthesia have been noted.[7] The most common location is the head and neck with nearly 75% of lesions occurring in that region.[172] There is an increased prevalence on the left side versus the right side of the face.[174] The upper lip is nine times more common than the lower lip, unlike squamous cell carcinoma.[175] MAC has also been reported to occur on the nipple, axilla, vulva, external auditory canal, extremities, and perianal skin.[173,176] The average tumor size in 15 mm.

Histopathology. MAC is a poorly circumscribed dermal tumor embedded in a desmoplastic stroma that can extend into the subcutaneous tissue and muscle. Superficially, the tumor is composed of ducts, keratin horn cysts, and small cords of basaloid cells, resembling syringoma. The deeper component exhibits smaller strands and cystically dilated tubules and ductal structures. There is a lack of cytologic atypia. Perineural invasion is common and extensive. The histologic differential diagnosis includes syringoma, morpheaform basal cell carcinoma, and desmoplastic trichoepithelioma.

Prognosis and Clinical Course. MAC is a deeply infiltrative and locally aggressive tumor with significant morbidity. Local recurrence is common, with a recurrence rate in 50% of cases. Recurrence has been reported to occur several years after initial diagnosis. Local recurrence is attributed to the high rate of perineural invasion, seen in 17%–60% of cases. While recurrence is common, metastases are rare at a rate of 2.2%. Mortality is 0.4%.[177]

Treatment. The treatment of choice is Mohs micrographic surgery with a recurrence rate between 0% and 12%.[174,177–179] Wide local excision is associated with

recurrence rates of 50%. Radiation does not have an effect on survival, and may even lead to conversion into a more histologically and clinically aggressive tumor.[179]

FOLLICULAR NEOPLASMS

Follicular tumors demonstrate histopathologic features that resemble different portions of a normal hair follicle, including the hair germ, matrix, and outer root or trichilemmal sheath. Unlike apocrine and eccrine tumors that generally have a malignant counterpart, follicular tumors are generally benign with a rare chance of degeneration into a malignant lesion. Pilomatricoma and trichoblastoma have well-documented transformation into carcinomas. Malignant proliferating trichilemmal cysts and trichilemmal carcinoma are thought to be variants of squamous cell carcinoma, as opposed to true adnexal carcinomas.

HAMARTOMAS AND HYPERPLASIAS

HAIR FOLLICLE NEVUS

Epidemiology. The hair follicle nevus, also known as congenital vellus hamartoma, is a rare lesion present in all age groups. Often it is apparent at birth.[180]

Etiology and Pathogenesis. Some believe that the hair follicle nevus is a variant of trichofolliculoma or accessory tragus.[181]

Clinical Findings. Hair follicle nevus presents as a dome-shaped, skin-colored papule or nodule from which hair protrudes. It is most common on the hair-bearing surfaces, including the face and periauricular region.[180,182] Linear arrangement of multiple papules has been observed. Some authors also advocate that the faun tail, palmoplantar follicles, and Becker's nevus are variants of the hair follicle nevus.[183] Rare associations include ipsilateral alopecia, leptomeningeal angiomatosis, multiple epidermal nevi, and frontonasal dysplasia.[180]

Histopathology. Numerous closely packed mature vellus follicles confines to a focal well circumscribed area in the upper dermis. Follicles are surrounded by a prominent sheath of perifollicular connective tissue, which in turn are surrounded by clefts. Sebaceous lobules may be present.

Prognosis and Clinical Course. The relative size of the lesion decreases with time as the child grows. Therefore, excision may be deferred as it becomes a less prominent cosmetic issue over time.

Treatment. Treatment is not necessary. Surgical excision is effective for cosmetic purposes.

BASALOID FOLLICULAR HAMARTOMA

Epidemiology. Basaloid follicular hamartoma (BFH), also known as benign follicular hamartoma, is a rare follicular neoplasm that can be congenital or develop during adulthood.

Etiology and Pathogenesis. BFH may be related to dysregulation of the PTCH signaling pathway, similar to basal cell carcinomas.[184]

Clinical Findings. Clinically, there are five variants of BFH: a solitary 2–3 mm papule, a localized plaque with alopecia, linear or blaschkoid, generalized dominantly inherited familial type, and generalized papules associated with myasthenia gravis and diffuse alopecia.[184] The familial form presents early in childhood, and can also be associated with milia, comedones, hyperpigmented papules, hypotrichosis, hypohidrosis, and palmar pits. Other systemic associations include systemic lupus erythematosus and cystic fibrosis.[185,186] There are reports of circulating autoantibodies, namely antinuclear and antiacetylcholine receptor antibodies.

Histopathology. Histopathologically, there are anastomosing strands of basaloid cells with numerous epidermal connections. Central areas of epithelial aggregations occasionally reveal cells with a squamoid appearance. Features of follicular differentiation, including horn cysts, rudimentary germs, and follicular papillae, are variably present.

Prognosis and Clinical Course. BFH are benign lesions. Patients may have an increased risk of basal cell carcinoma, although it does not arise within the hamartoma. This association may be related to dysregulation of the patched (PTCH) signaling pathway.

Treatment. The treatment of choice is surgical excision.

BENIGN NEOPLASMS

DILATED PORE OF WINER AND PILAR SHEATH ACANTHOMA

Epidemiology. Dilated pore of Winer and pilar sheath acanthoma share the commonality of a central pore, and histologically, exhibit a large cystic space with squamous epithelium that is continuous with the surface epidermis, and filled with keratinaceous material. The dilated pore was described by Winer in 1954, and presents on the face of elderly males.[187] In 1978, the pilar sheath acanthoma was described as a separate entity observed on the upper lip of middle aged and elderly individuals.[188]

Etiology and Pathogenesis. There is a debate as to whether these entities are follicular cysts versus benign neoplasms.[3]

Clinical Findings. The dilated pore of Winer presents as a solitary, open comedo on the head and neck of elderly males.[189] It may arise in a background of cystic acne or actinic damage. It lacks palpable induration. The pilar sheath acanthoma is a solitary, open comedo filled with keratin on the upper lip.[188]

Histopathology. Histologically, the dilated pore reveals a single or several contiguous, markedly, dilated infundibula in upper dermis. The epithelial

lining reveals focal acanthosis and finger-like projections into the surrounding dermis. Dilated infundibula contain cornified cells arranged in basket-weave and laminated patterns. Heavy pigmentation of the epithelium can be observed. The pilar sheath acanthoma differs by exhibiting a larger more irregular branching cystic cavity. Rather than the thin projections seen in dilated pore, there are multiple lobulated masses of cells radiating from the central cavity into the dermis.

Prognosis and Clinical Course. These are benign entities.

Treatment. Treatment is not necessary. Surgical excision can be performed for cosmetic purposes.

TRICHOFOLLICULOMA

Epidemiology. Trichofolliculoma is a benign follicular neoplasm that presents at any age, but is most commonly seen in adults.

Etiology and Pathogenesis. Trichofolliculoma displays differentiation toward the hair follicle with intermediate differentiation between a hair follicle nevus and a trichoepithelioma.

Clinical Findings. Trichofolliculoma classically presents as a small dome-shaped nodule measuring 5 mm on the face, especially the nose or scalp. A fine tuft of hairs protrudes from a central pore (Fig. 119-13). Trichofolliculoma has been reported in association as a collision tumor with basal cell carcinoma.[190]

Histopathology. Trichofolliculoma has a characteristic histopathologic appearance with one or more central large dilated follicles with radiating secondary follicles. The secondary follicles display varying degrees of differentiation ranging from immature rudimentary matrix to well-formed follicles with papillae, matrix, trichohyalin granules, and fine hairs. If prominent sebaceous lobules are observed, the lesion is denoted a sebaceous trichofolliculoma.[191]



Figure 119-13 Trichofolliculoma. Papule on the forehead with a hair emanating from its central pore.

Prognosis and Clinical Course. Trichofolliculomas are benign. However, a single case of perineural invasion has been documented in the literature.[192]

Treatment. The treatment of choice is surgical excision.

FIBROFOLLICULOMA, TRICHODISCOMA, AND FIBROUS PAPULE

Epidemiology. Fibrofolliculoma, trichodiscoma, and fibrous papule or perifollicular fibroma are clinically indistinct from one another, and likely are on the same spectrum of follicular proliferations with differentiation toward the mantle. They also possess a specialized periadventitial dermis that surrounds the upper hair follicle.[3] These lesions are rare, appear in adulthood, and are seen in multiplicity together in the Birt–Hogg–Dube syndrome.

Etiology and Pathogenesis. These three lesions represent different stages of differentiation toward the follicular mantle.[193] The folliculin gene, a tumor suppressor, is mutated in Birt–Hogg–Dube syndrome and may play a role in the pathogenesis of these follicular tumors.

Clinical Findings. Fibrofolliculomas and trichodiscomas present as multiple small whitish papules measuring 2–4 mm on the head and neck, upper trunk, and arms. They are rarely solitary. Fibrous papules are solitary papules or multiple dome-shaped, skin-colored, pigmented or reddish lesions on the face, especially the perinasal area.[3] Multiple fibrous papules are seen in tuberous sclerosis, known as adenoma sebaceum, or Birt–Hogg–Dube syndrome.[194]

Multiple familial lesions are seen in Birt–Hogg–Dube syndrome, an autosomal dominant condition due to a mutation in folliculin. Although the function of folliculin is not entirely clear, it has been linked to the mammalian target of rapamycin (mTOR) pathway.[195] Cutaneous lesions include fibrofolliculomas, trichodiscomas, fibrous papules, and acrochordons. Patients have a predisposition to colonic polyposis, spontaneous pneumothorax, and renal cell carcinoma. Renal cancer risk is higher in males. The overall incidence of renal cell carcinoma, specifically renal oncocytomas and chromophobe renal carcinomas, is 12% in adults over the age of 40. Eighty percent of patients have pulmonary cysts, and nearly 25% are at risk of spontaneous pneumothorax, which typically presents at a younger age.[195]

Histopathology. Fibrofolliculomas present with a dome shaped lesion with a central relatively well-differentiated hair follicle displaying a single or several contiguous, dilated, keratin-filled infundibula. The infundibula are connected to several thin, focally anastomosing epithelial strands that extend in a radial fashion into the stroma. The infundibula are surrounded by a distinct fibrillary collagenous or mucinous stroma with scant elastic tissue.

Histologically, trichodiscomas reveal the fine fibrillary collagenous stroma containing ectatic blood vessels. A hair follicle may be found at the margin of the lesion, although the primary distinguishing characteristic of trichodiscoma is the stromal component.

Fibrous papule presents as a dome-shaped or polypoid lesion consisting of one or more poorly formed hair follicles surrounded by a cellular stroma with numerous proliferative small blood vessels in the dermis.

Prognosis and Clinical Course. While the cutaneous tumors themselves are benign, these patients should be screened for Birt–Hogg–Dube syndrome. In the case of multiple fibrous papules, a suspicion of tuberous sclerosis should be raised. Genetic counseling should be provided if a diagnosis is confirmed.

Treatment. Solitary lesions can be excised, although this is difficult for multiple lesions. Laser resurfacing with the erbium:Yag or carbon dioxide laser, electrodessication, cryotherapy, and dermabrasion have been tried with variable results.[195]

TRICHOBLASTOMA

Epidemiology. Trichoblastoma is a rare benign follicular neoplasm that presents in adults between the fourth and sixth decades. Childhood presentation outside the context of a nevus sebaceous is highly rare.[196]

Etiology and Pathogenesis. Trichoblastoma comprises a group of tumors with follicular germinative differentiation.

Clinical Findings. Trichoblastoma presents with a solitary, well-defined, slow-growing, brown or blue–black nodule on the head or neck, especially the scalp (Fig. 119-14A). It can reach up to 3 cm in diameter, although cases up to 10 cm have been reported.[197] Multiple lesions are seen in Brooke's disease, which is not associated with other anomalies. Trichoblastomas are the most common neoplasm to arise within a nevus sebaceous. They can also coexist with basal cell carcinoma.[23]

Histopathology. Histologically, there are several dermal and subcutaneous smooth-bordered collections of basaloid cells arranged in nodular, cribriform, retiform, and racemiform patterns.[198] The stroma is characteristically sclerotic or hyalinized. Peripheral palisading and rudimentary follicular papillae are also observed (Fig. 119-14B). Heavy melanin pigmentation and horn cysts can also be seen. The differential diagnosis includes trichoepithelioma and basal cell carcinoma. Cutaneous lymphadenoma is a variant with extensive infiltration of tumors nests with lymphocytes and histiocytes.

Prognosis and Clinical Course. Transformation to trichoblastic carcinoma or trichoblastic sarcoma is extremely rare. Trichoblastic carcinoma has been associated with fatal metastases.[199,200]

Treatment. Complete surgical excision is recommended given the potential for malignancy and difficult distinction from basal cell carcinoma.

TRICHOEPITHELIOMA

Epidemiology. The solitary trichoepithelioma presents in elderly patients. Multiple trichoepitheliomas, as seen in the autosomally dominant inherited Brooke–Spiegler syndrome, present in childhood or puberty.

Etiology and Pathogenesis. Trichoepithelioma shows follicular germinative differentiation. Some consider it a variant of trichoblastoma.

Clinical Findings. There are three clinical variants of trichoepithelioma: solitary, multiple, and desmoplastic. Solitary trichoepithelioma is a small 5–8 mm, skin-colored papule on the nose, upper lips, and cheeks.[3] It can also develop on the trunk, neck, or scalp. It is often mistaken for basal cell carcinoma. Occasionally, they can grow quite large to several centimeters. This giant solitary trichoepithelioma is most commonly seen on the thigh or perianal region of the elderly.[3]

Multiple trichoepitheliomas are seen in adolescents in the setting of Brooke–Spiegler syndrome, an

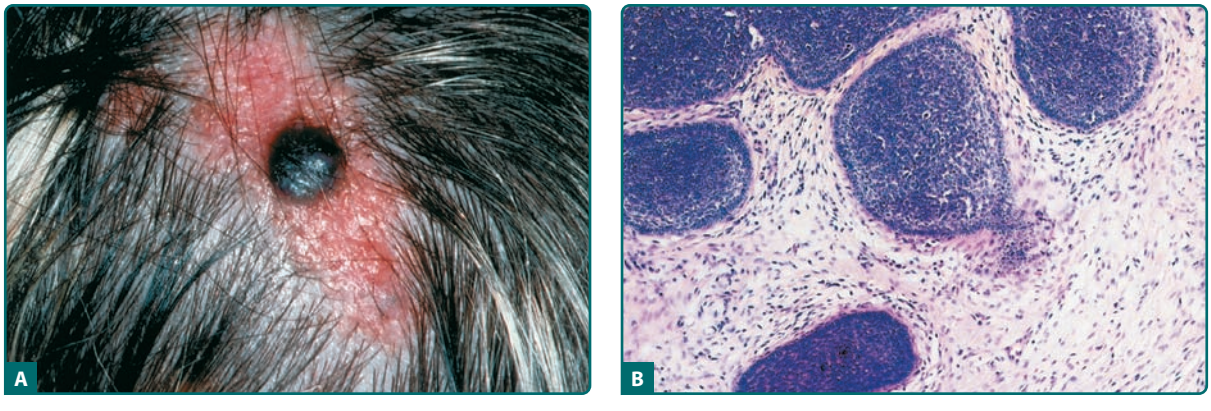

Figure 119-14 Trichoblastoma. **A.** Pigmented type arising in a nevus sebaceous. **B.** Nodular aggregations of basaloid cells surrounded by abundant fibrous stroma. Note prominent peripheral palisading of nuclei and a focus with a follicular germ and papilla.

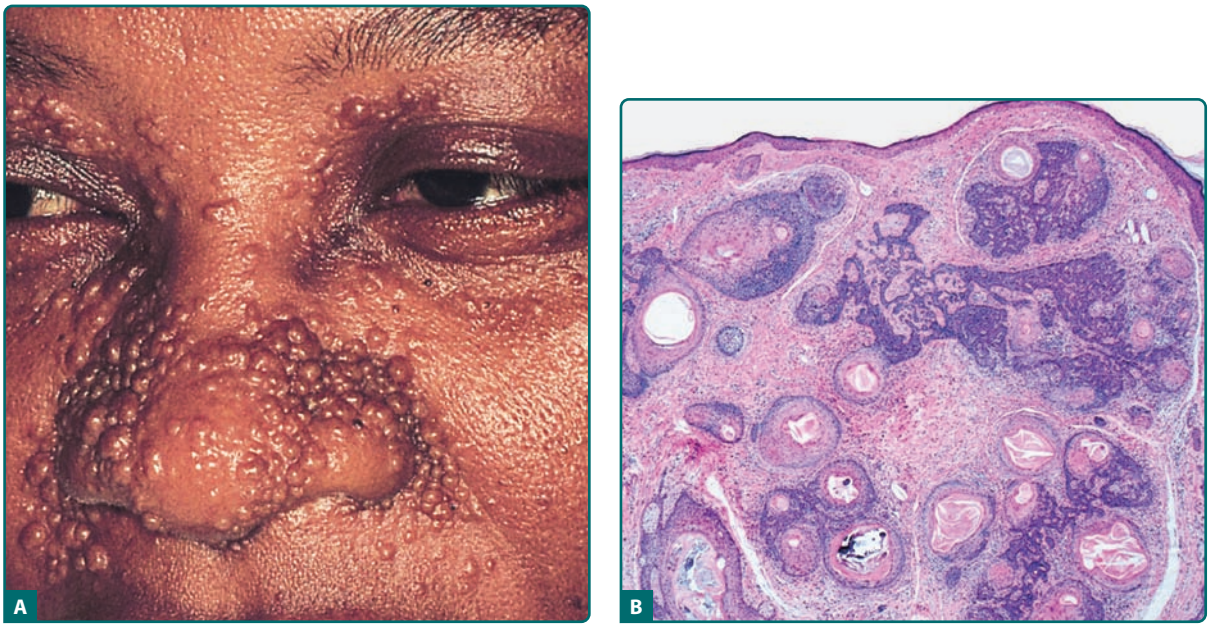

Figure 119-15 Trichoepithelioma. **A.** Multiple familial type. **B.** Well-circumscribed, multilobular dermal tumor consisting of solid and branching basaloid aggregations admixed with horn cysts surrounded by abundant fibrous stroma. Note a focal cribriform pattern.

autosomal, dominant condition characterized by multiple cylindromas, eccrine spiradenomas, and milia. It is due to germ-line mutations in the *CYLD* gene, which encodes an inhibitor of NF-κB.[201] Patients present with numerous small, shiny, firm papules on the face with a predilection for the upper lip, nasolabial folds, and eyelids (Fig. 119-15A).

Multiple trichoepitheliomas are also seen in Rombo syndrome, which is characterized by atrophoderma, milia, hypotrichosis, basal cell carcinomas, and peripheral vasodilatation.[202] Multiple trichoepitheliomas also have an association with systemic lupus erythematosus and myasthenia gravis.

Histopathology. Trichoepitheliomas present with sharply circumscribed, symmetric, dome shaped lesions composed of aggregates of relatively monomorphic basaloid cells in the upper dermis surrounded by abundant fibrous stroma with stromal–stromal retraction. The most common pattern is cribriform, but nodular, racemiform, and retiform patterns have also been observed (Fig. 119-15B). Trichoepitheliomas also exhibit peripheral palisading and papillary mesenchymal bodies.

Prognosis and Clinical Course. There are very few case reports that describe malignant degeneration into malignant trichoepithelioma or trichoblastic carcinoma.[203]

Treatment. The treatment of solitary trichoepithelioma is surgical excision. This is not feasible for multiple lesions. Cryotherapy, electrodessication, and carbon dioxide laser resurfacing can be employed as destructive methods.[201]

DESMOPLASTIC TRICHOEPITHELIOMA

Epidemiology. Desmoplastic trichoepithelioma, also known as sclerosing epithelial hamartoma, is a rare benign adnexal neoplasm initially described by Brownstein and Shapiro in 1977.[204] While it most frequently appears in young women, there are reports of congenital lesions.[205,206]

Etiology and Pathogenesis. Desmoplastic trichoepithelioma may be a variant of trichoblastoma or trichoepithelioma with extensive stromal sclerosis.

Clinical Findings. Desmoplastic trichoepithelioma presents as a solitary, firm, skin-colored to white–gray, sclerotic annular plaque with a central depression on the upper cheek or angle of the lip of a young female (Fig. 119-16). The lesion typically measures 1 cm and is asymptomatic. It is extremely rare to have multiple lesions. It is often mistaken for basal cell carcinoma.[205]



Figure 119-16 Desmoplastic trichoepithelioma located on the infraorbital region.

Histopathology. Histopathologically, there is a well-circumscribed lesion consisting of cords of basaloid cells that are 1–3 cells thick in the upper two-third of the dermis. There are small keratinous cysts and a characteristic desmoplastic stroma that exhibits stromal–stromal retraction. Histologic differential diagnosis includes morpheaform basal cell carcinoma and microcystic adnexal carcinoma.

Prognosis and Clinical Course. Desmoplastic trichoepithelioma behaves in a benign fashion. However, uncertainty regarding the histologic diagnosis often leads to excision.

Treatment. The treatment of choice is Mohs micrographic surgery or excision.[205,207] Alternatives include dermabrasion and laser surgery, although these are associated with a higher recurrence rate.

TRICHOADENOMA

Epidemiology. Trichoadenoma is a rare follicular tumor, described by Nikolowski in 1958, most commonly seen in adults.[208] It has also been reported in children, as well as in a congenital case.[209]

Etiology and Pathogenesis. Trichoadenoma is a follicular tumor with differentiation toward the infundibular portion of the folliculosebaceous canal. It lies on a differentiation spectrum between trichofolliculoma and trichoepithelioma.[3,210]

Clinical Findings. Trichoadenoma presents as a solitary slow-growing, grayish nodule measuring up to 1.5 cm. The most common location is the face, followed by the buttocks.[4,211] It can be vegetative or verrucous.

Histopathology. Microscopic examination reveals a dome-shaped, sharply defined nodule composed of numerous round infundibulocystic structures in the dermis. The infundibulocystic structures are lined by squamous epithelium. Conspicuous collagenous stroma surrounds the tumor nests.

Prognosis and Clinical Course. This is a benign tumor.

Treatment. While treatment is not necessary, excision can be performed for cosmetic purposes.

PILOMATRICOMA

Epidemiology. Pilomatricoma, also known as calcifying epithelioma of Malherbe and pilomatrixoma, is most frequently seen in children. However, a bimodal onset is observed with the majority occurring in the first and sixth decades. There is an increased prevalence in girls.[3]

Etiology and Pathogenesis. Pilomatricoma is derived from hair matrix cells.[212] It is associated with activating mutations in β-catenin, a mediator in the Wnt signaling pathway.

Clinical Findings. Pilomatricoma presents as a solitary, skin-colored or bluish, firm, cystic nodule on the head, neck, or proximal upper extremities (Fig. 119-17A). It displays a "tent-sign" with many angles and surfaces apparent on skin stretch. Overlying epidermal atrophy is common and designated "anetodermic" variant. Additional variants include multiple lesions, bullous, or giant tumors.[213] Giant pilomatricoma has been associated with hypercalcemia and elevated parathyroid hormone-related protein (PTH-rp).[214]

Multiple lesions are seen in Gardner's syndrome, myotonic dystrophy, Rubinstein–Taybi, and Turner syndrome.[215] More recent associations have been

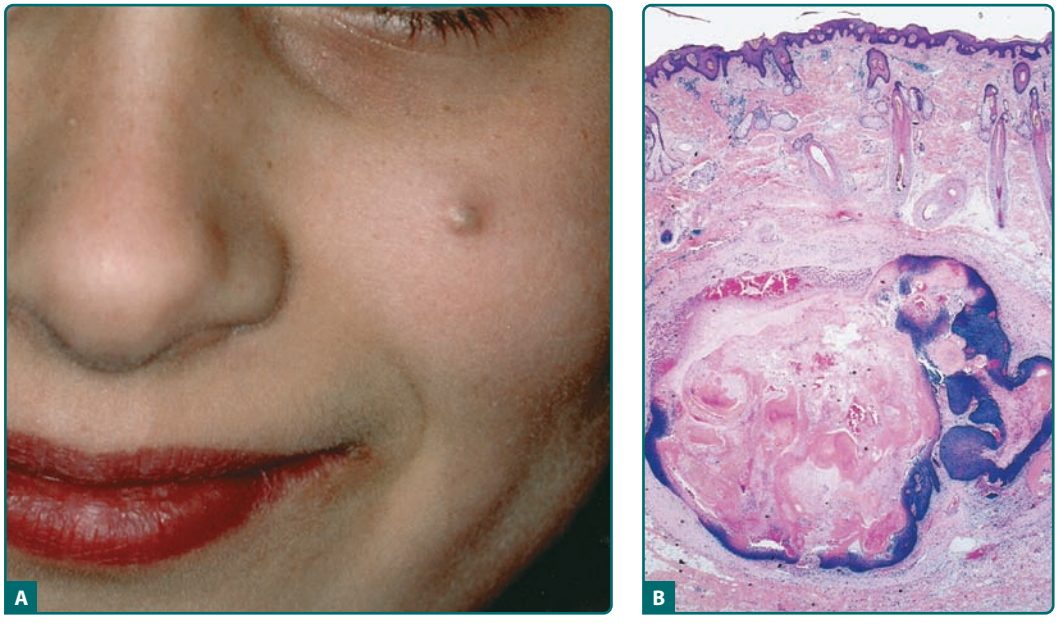

Figure 119-17 Pilomatricoma. **A.** A tumor in a young girl. **B.** Cystic lesion lined focally at the periphery by basaloid epithelium and filled with masses of eosinophilic, cornified material with shadow cells.

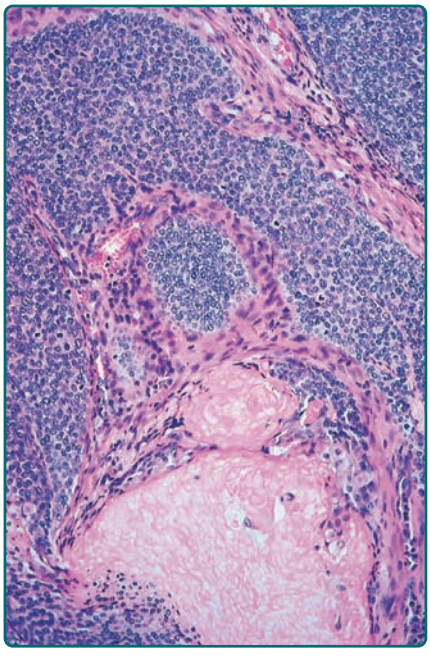

Figure 119-18 Pilomatrical carcinoma. Irregular aggregations of atypical basaloid cells continuous with an area of cornified material containing shadow cells.

made with trisomy 9, sarcoidosis, HIV, and Sotos syndrome.[215]

Histopathology. Pilomatricoma reveals a fairly characteristic encapsulated mass of basophilic cells with minimal cytoplasm that evolve into eosinophilic shadow or ghost cells toward the center of the lesion. Calcification can be prominent (Fig. 119-17B). Pilomatrical carcinoma demonstrates irregularly sized and variably sized islands of basaloid cells. Atypia, mitoses, and necrosis are notable (Fig. 119-18).

Prognosis and Clinical Course. Pilomatricomas rarely recur locally after excision. Rare malignant transformation to pilomatrical carcinoma has also been reported. Lesions tend to be on the head, neck, upper limbs, and buttocks. It tends to occur in older male patients with sun-damaged skin, as opposed to its benign counterpart pilomatricoma, which is more commonly seen in young females. Metastases to regional lymph nodes and distant sites can occur in 10% of patients.[216] Fifty percent of pilomatrical carcinoma recur with local excision. Pilomatrical carcinoma can rarely arise de novo.

Treatment. The treatment of choice for pilomatricoma is excision, and it is associated with a low recurrence rate. Pilomatrical carcinomas should be excised with a wide margin. Mohs micrographic surgery has been employed with good results.[216]

TRICHILEMMOMA

Epidemiology. Trichilemmoma is a benign follicular neoplasm first described by Headington and French in 1962.[217] It typically presents in adulthood.

Etiology and Pathogenesis. Trichilemmoma exhibits differentiation toward the outer root sheath or trichilemmal sheath at the level of the bulb. Some feel that trichilemmoma represents a viral wart, although DNA sequencing has not revealed papillomavirus in these lesions, making it less likely.[3]

Mutations in the *PTEN* gene have been implicated as multiple trichilemmomas have been observed in Cowden's syndrome, an autosomal dominant condition with germ-line mutations in the tumor suppressor *PTEN* gene. *PTEN* encodes phosphatase and tensin homolog, a phosphatase in the phosphoinositol-3-kinase (PI3K) pathway, which normally inactivates signals in the antiapoptotic PI3K/AKT kinase pathway. When *PTEN* is absent, decreased, or dysfunctional, there is uninhibited phosphorylation of AKT leading to the inability to undergo apoptosis.[218]

Clinical Findings. Trichilemmoma can present as a solitary, small 3–8 mm, flesh-colored, asymptomatic, keratotic papule on the face with a predilection for the nose and upper lip. It can be seen arising within a nevus sebaceous.[219]

Multiple lesions are a maker for Cowden's syndrome (multiple hamartoma syndrome), an autosomal dominant condition due to mutations in the tumor suppressor *PTEN* gene.[218] Additional cutaneous manifestations include oral papillomas and acral palmoplantar keratoses. There is an increased risk for breast, thyroid, and endometrial cancer. The most common cancer is breast cancer with a lifetime risk of 25%–50%, with two-thirds presenting in females between the age of 38 and 46. Trichilemmomas often precede the diagnosis of breast cancer, and therefore appropriate



Figure 119-19 Proliferating pilar tumor. Ulcerated giant nodule on the scalp.

dermatologic diagnosis is critical.[218,220] The second most common neoplasm is thyroid cancer, specifically follicular and papillary subtypes. Endometrial cancer is seen in 10% of cases.[218] Other manifestations include colonic polyps, breast adenomas, thyroid adenomas, fibrocystic breast disease, and Lhermite–Duclos disease or dysplastic gangliocytoma of the cerebellum.

Histopathology. On histologic examination, there is an exo-endophytic, lobular proliferation of polygonal, pale staining, glycogen containing squamoid cells extending from the epidermis. There is peripheral palisading of columnar cells, and a conspicuous PAS-positive basement membrane surrounding the lesion. The desmoplastic trichilemmoma variant displays tumor cells embedded in a sclerotic stroma.

Prognosis and Clinical Course. There are rare reports of trichilemmal carcinoma, although many feel that this is a variant of squamous cell carcinoma. There is a low metastatic potential associated with this entity.[221]

Treatment. The treatment of choice is excision. Mohs micrographic surgery has been used for desmoplastic trichilemmomas in cosmetically sensitive areas.[221] Alternatives for multiple lesions include cryotherapy, electrodessication and curettage, and laser ablation.

TUMOR OF THE FOLLICULAR INFUNDIBULUM

Epidemiology. Tumor of the follicular infundibulum (TFI), also known as isthmicoma, was first described by Mehregan and Butler in 1961.[222] It presents in middle-aged and elderly adults. It is unclear whether there is a male or female predominance as conflicting reports exist.[223,224]

Etiology and Pathogenesis. TFI is a neoplasm that demonstrates differentiation toward the follicular isthmus, not the infundibulum as the name would suggest.

Clinical Findings. TFI presents as a solitary, small, asymptomatic, thin, keratotic papule on the head or neck.[223] It is often misdiagnosed as a seborrheic keratosis or basal cell carcinoma. There are rare cases of numerous eruptive lesions, which typically appear as atrophic or hypopigmented macules and papules.[223,224] TFI has been shown to be associated with basal cell carcinoma and nevus sebaceous.[224]

Histopathology. Histopathologically, TFI reveals a horizontally oriented, plate-like tumor in the upper dermis with the epithelial component showing multiple connections to the epidermis or hair follicles. The epithelium exhibits a fenestrated pattern with interconnecting cords and columns. There is a surrounding collagenous stroma. Clear glycogenated cells, sebaceous differentiation, ductal structures, and papillary mesenchymal bodies are observed.

Prognosis and Clinical Course. TFI is generally considered a benign lesion. Two cases of degeneration to basal cell carcinoma have been reported.[225]

Treatment. Various destructive methods including excision, electrodessication, cryotherapy, and laser ablation have been attempted but are associated with potential scarring.[226] Topical corticosteroids, keratolytics, retinoic acid, and imiquimod have also been employed as less destructive treatments.[223,226]

PROLIFERATING TRICHILEMMAL CYST

Epidemiology. Proliferating trichilemmal cyst (PTC), also known as proliferating trichilemmal tumor or proliferating pilar tumor, presents on the scalp of elderly individuals. There is a female predominance.

Etiology and Pathogenesis. PTCs derive from the outer root or trichilemmal sheath.[227] It is felt that there is an evolution, histologically and clinically, from a pilar cyst to proliferating trichilemmal cyst to malignant proliferating trichilemmal cyst. PTC may evolve from a pilar cyst as a result of inflammation or trauma.[228] It is felt that PTC degenerates into malignant PTC with the loss of p53.[228,229]

Clinical Findings. PTC classically presents on the scalp or posterior neck of elderly patients. Other sites include the trunk, groin, vulva, and gluteal region.[227] PTC usually starts as a nodule and develops into a large, elevated, rubbery, lobulated mass that can enlarge to 10 cm (Fig. 119-19).[7] Lesions often ulcerate. PTC can be associated with nevus sebaceus and basaloid follicular hamartoma.

Histopathology. Histopathologic examination reveals a sharply circumscribed cystic neoplasm occupying the lower dermis and subcutaneous tissue. There is a proliferation of bland squamous cells lining nearly the whole lesion and extending within it in a radial fashion. A characteristic feature is the presence, in the center of lobules, of trichilemmal cornification, i.e., abrupt formation of compact eosinophilic keratin without granular layer interposition. Foci with keratohyaline granules, small horn pearls and squamous eddies, and calcification is noted.

Prognosis and Clinical Course. PTCs have a variable clinical course. While some lesions are well circumscribed, others recur locally, and still others display invasive growth patterns with infiltration into nerves and lymphovasculature.[230] Nearly 4% of PTCs recur after excision. There are thirty reported cases of degeneration of PTC into malignant PTC. The malignant tumor is associated with metastatic spread in 35% of cases. Many believe that malignant PTC is actually a variant of squamous cell carcinoma.[231]

Treatment. The treatment of choice is complete excision or Mohs micrographic surgery.[222] Malignant PTC should be treated like a squamous cell carcinoma with excision with clear margins.

KEY REFERENCES

Full reference list available at www.DIGM8.com

DVD contains references and additional content

5. Alsaad KO, Obaidat NA, Ghazarian D: Skin adnexal neoplasms—Part 1: An approach to tumors of the pilosebaceous unit. *J Clin Pathol* **60**:129-144, 2007
6. Obaidat NA, Alsaad KO, Ghazarian D: Skin adnexal neoplasms—Part 2: An approach to tumors of cutaneous sweat glands. *J Clin Pathol* **60**:145-159, 2007
7. Storm CA, Seykora JT: Cutaneous adnexal neoplasms. *Am J Clin Pathol* **118**(Suppl. 1):S33-S49, 2002
20. Jacqueti G, Requena L, Sanchex Yus E: Trichoblastoma is the most common neoplasm developed in nevus sebaceus of Jadassohn: A clinicopathologic study of a case series of 155 cases. *Am J Dermatopathol* **22**:108-118, 2000
21. Eisen DB, Michael DJ: Sebaceous lesions and their associated syndromes: Part I. *J Am Acad Dermatol* **61**(4):549-560
40. Abbas O, Mahalingam M: Cutaneous sebaceous neoplasms as markers of Muir-Torre syndrome: A diagnostic algorithm. *J Cutan Pathol* **36**:613-619, 2009
45. Dasgupta T, Wilson LD, Yu JB: A Retrospective review of 1349 cases of sebaceous carcinoma. *Cancer* **115**(1):158-165, 2009
85. Rajan N et al: Familial cylindromatosis and Brooke-Spiegler Syndrome: A review of current therapeutic approaches and the surgical challenges posed by two affected families. *Dermatol Surg* **35**:845-852, 2009
172. Yu J et al: Surveillance, epidemiology, and end results database analysis of microcystic adnexal carcinoma (sclerosing sweat duct carcinoma) of the skin. *Am J Clin Oncol* **XX**(X), 2009
220. Mangas C et al: Cowden disease in a family: A clinical and genetic diagnosis. *J Am Acad Dermatol* **53**(2):359-360, 2005
227. Satyaprakash AK, Sheehan DJ, Sangueze OP: Proliferating trichilemmal tumors: A review of the literature. *Dermatol Surg* **33**:1102-1108, 2007

Chapter 120 :: Merkel Cell Carcinoma

:: Andrew Tegeder, Olga Afanasiev, & Paul Nghiem

MERKEL CELL CARCINOMA AT A GLANCE

- Lower relative survival (54%) than melanoma (91%) at 5 years.
- Reported incidence quadrupled from 1986 to 2006.
- Affects elderly/whites/immunosuppressed and is associated with a newly discovered virus: Merkel cell polyomavirus (MCPyV).
- Consider in differential diagnosis of any rapidly growing, nontender nodule on a sun-exposed area.
- Sentinel lymph node biopsy, surgery, and radiation are indicated in many cases.
- Imaging (computed tomography/magnetic resonance/positron emission tomography): poor sensitivity and specificity at time of diagnosis and in early stages.
- Management is challenging as therapy is unique and controversial.
- Avoid overaggressive surgery: adjuvant radiation therapy highly effective.
- Adjuvant chemotherapy: high morbidity, no proven benefit.
- Optimal care: multidisciplinary coordination between dermatologists, surgeons, radiation, and medical oncologists referring to National Comprehensive Cancer Network Guidelines.

Merkel cell carcinoma (MCC) is an increasingly common neuroendocrine skin cancer that is associated with ultraviolet (UV)-light exposure, advanced age, immune suppression and a recently discovered polyomavirus. The reported incidence of MCC has more than tripled in the past 20 years[1] to approximately 1,500 US cases/year[2] and is expected to grow with the aging population. Although it is 40 times less common than malignant melanoma, it carries a markedly poorer prognosis, with disease-associated mortality at 5 years of 46%[3] as compared with 9% for invasive melanoma.[4] Management of MCC is challenging and optimal therapy is controversial, at least in part due to a lack of prospective or randomized data on which to base treatment decisions.

MCC is a relatively recently described entity, although the Merkel cell was identified more than 100 years ago. In 1875, human Merkel cells were first described by Friedrich S. Merkel (1845–1919). He named these cells *Tastzellen* (touch cells) assuming that they had a sensory touch function within the skin due to their association with nerves. In 2009, a series

of studies using elegant mouse models resolved several long-standing debates by conclusively establishing that (1) Merkel cells are essential for light touch responses,[5] (2) Merkel cells have an epidermal origin,[5,6] and (3) Merkel cells do not divide, but are renewed by a reservoir of epidermal progenitor cells.[6]

In terms of what we now call Merkel cell carcinoma, in 1972, Toker described five cases of "trabecular cell carcinoma of the skin." In 1978, Tang and Toker found that cells from these tumors contained dense core granules on electron microscopy that were typical of Merkel cells and other neuroendocrine cells. In 1980, the name Merkel cell carcinoma (MCC) was first applied to this tumor because of the characteristic ultrastructural features it shares with normal Merkel cells. In 1992, it was found that antibodies to cytokeratin-20 stain normal skin Merkel cells as well as the vast majority of MCC tumors. This critical finding allows specific and relatively easy diagnosis of MCC to be made through immunohistochemistry. Since that time, electron microscopy is no longer used to make this diagnosis.

EPIDEMIOLOGY

Over the 20-year period between 1986 and 2006, the reported incidence of MCC quadrupled from 0.15 per 100,000[1] to 0.6 per 100,000.[7] There are likely two factors that contribute to this increase in reported incidence that is more rapid than that of any other type of skin cancer. One factor is an increase in the accurate diagnosis of this malignancy through the routine use of cytokeratin-20 immunohistochemistry and the improved recognition of this malignancy by dermatopathologists. In the past, MCCs were often mischaracterized as lymphoma, melanoma, or undifferentiated carcinoma in the era before immunohistochemistry. A second likely reason is an increase in the number of people over age 65 years with extensive sun exposure history and people living with prolonged immune suppression. Each of these factors is a known risk factor for MCC and several are discussed in Section "Etiology and Pathogenesis."

As of 2008, there are approximately 1,500 MCC cases per year in the US.[2] This cancer is far more common in whites than in blacks, consistent with a known role for UV radiation in MCC pathogenesis. Specifically, the rates in whites have been reported as 0.23 per 100,000 as compared to 0.01 per 100,000 for blacks.[8] Although not specifically reported, rates in Hispanics and Asians are likely intermediate between those in blacks and whites. MCC tends to be more common in men than in women (2:1 in ratio).[9] Furthermore, men also tend to have a worse prognosis than women, with reported 10-year disease-associated survival rates of 51% for men and 65% for women.[7]

ETIOLOGY AND PATHOGENESIS

There are several known risk factors for MCC that will likely continue to lead to an increase in the incidence of this disease.

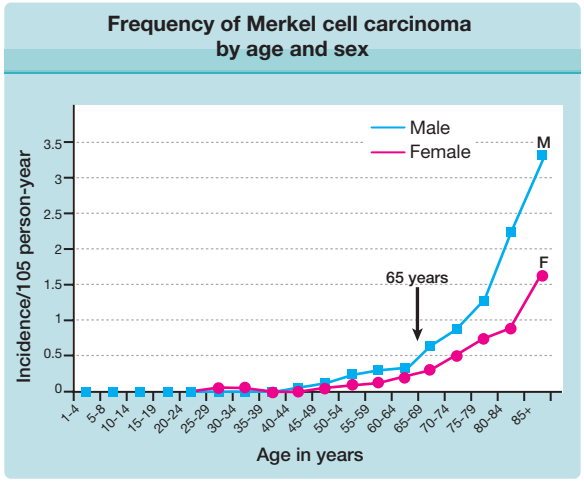

Figure 120-1 Frequency of Merkel cell carcinoma by age and sex. The most significant risk factor for Merkel cell carcinoma is age. M, male (■); F, female (●). (Reprinted from Agelli M, Clegg LX: Epidemiology of primary Merkel cell carcinoma in the United States. *J Am Acad Dermatol* **49**:832, 2003, with permission.)

AGE GREATER THAN 65 YEARS

The median age for diagnosis of MCC is 70 years, and there is a five- to tenfold increase in incidence after age 70 as compared with age less than 60 years, as shown in Fig. 120-1. Indeed, only about 10% of MCC cases present in patients under age 50 and it is extremely rare in childhood.[10]

SUN EXPOSURE

Sunlight, prolonged UV exposure, and photochemotherapy are all associated with an increased risk of MCC. As seen in Fig. 120-2, the vast majority (81%) of MCC tumors present on sun-exposed skin.[10] However, it is clear that sun is not required for MCC to develop. MCC cases can occur on sun-protected skin, including buttocks and vulva as well as portions of the scalp that are covered by hair.

IMMUNE SUPPRESSION

As compared to most cancers, MCC is strongly linked to immune suppression. Indeed, 7.8% of MCC patients are profoundly immune suppressed, a 16-fold overrepresentation compared with expected.[10] Multiple forms of immune suppression are associated with an increase in MCC risk. These include HIV/AIDS,[11] chronic lymphocytic leukemia,[10] and the immune suppressive regimens associated with solid organ transplant.[9] Additionally, there are 19 reported cases of complete spontaneous regression in the MCC literature, a far greater number than expected for its rarity, perhaps suggesting a sudden immune recognition and clearance of MCC.[8,12]

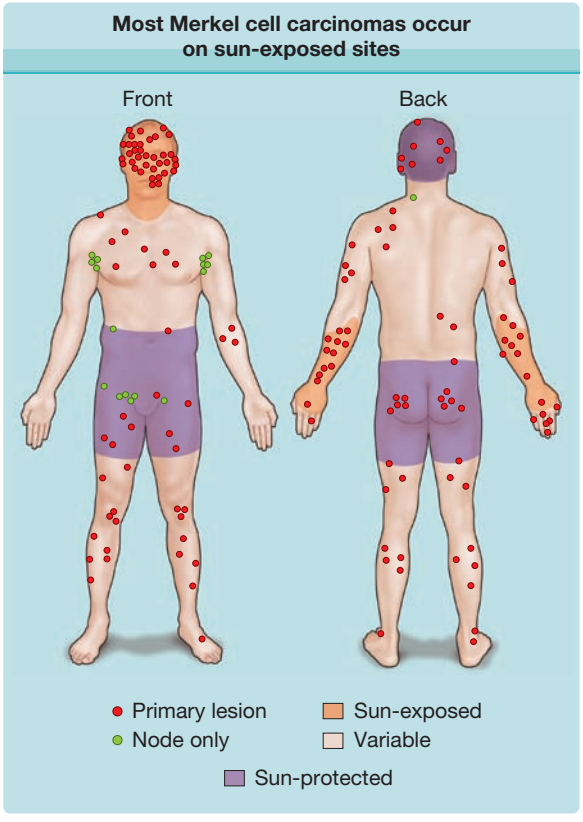

Figure 120-2 Most Merkel cell carcinomas (MCCs) occur on sun-exposed sites. This diagram shows the locations of tumor presentation for 195 MCC patients. For 168 patients, the site of the primary skin tumor is shown (**red** circles). The remaining 27 patients had no known primary and instead presented with nodal metastasis (**green** circles). The majority of patients (81%) presented with a primary tumor located on the heavily sun exposed face, neck, or dorsal forearm (**brown** shading). Five percent of patients presented with tumors in completely sun protected skin areas (**purple** shading), and 14% of patients presented with MCC in partially sun-protected skin (**skin tone**). (Adapted from Heath M et al: Clinical characteristics of Merkel cell carcinoma at diagnosis in 195 patients: The AEIOU features. *J Am Acad Dermatol* **58**:375-81, 2008.)

MERKEL CELL POLYOMAVIRUS

In 2008, a new polyomavirus, the Merkel cell polyomavirus (abbreviated MCV or MCPyV), was discovered by extensive sequencing of MCC tumor RNA. MCPyV was reported to be present in 80% of MCC tumors compared to only 7% of skin controls.[13] Numerous groups across several continents (over 25 literature citations) have verified the association between MCPyV and MCC, and all groups observed that the virus is strongly associated with MCC. MCPyV is a small, circular, double-stranded DNA virus related to other known polyomaviruses (SV40, BK, JC, KI, WU). MCPyV is unique among the human polyomaviruses as it is the only one proven to integrate into a human cancer. Monoclonal integration of MCPyV into MCC tumors suggests that the virus is present prior to or very early in tumorigenesis.

A large fraction of the population has been infected with MCPyV. By the age of 5, prevalence of antibodies is about 35%, but increases to 50% by the age of 15.[14] Interestingly, among MCC patients, the prevalence is significantly higher (88%) than age and sex-matched controls (53%).[15] Importantly, despite how common exposure is to this virus in the general population, the incidence of MCC is very low. Therefore, viral infection alone is clearly insufficient for the development of this cancer.

CLINICAL PRESENTATION OF MERKEL CELL CARCINOMA

A systematic analysis of 195 MCC patients characterized clinical features that may serve as clues in the diagnosis of MCC.[10] The most significant features can be summarized in an acronym: "AEIOU" (Table 120-1). This study found that 89% of 62 MCC cases exhibited at least three of the five features listed below. If a lesion exhibits at least three of these features, suspicion of MCC should increase and biopsy be considered. In particular, a lesion that is red or purple, rapidly growing, but nontender should be of concern. Strikingly, the clinician listed as clinical impression a benign diagnosis in over one half of cases. In particular, a cyst or acneiform lesion was the single most common of these (Box 120-1 and Figs. 120-3A and 120-3B) and nonmelanoma skin cancer was also relatively frequent as a presumptive diagnosis (Fig. 120-3C).

PATHOLOGY

As shown in Fig. 120-4A, the classic histologic features of MCC include sheets of small basophilic cells with scant cytoplasm, fine chromatin, and no nucleoli. There are numerous mitotic figures and occasional individual necrotic cells. Lymphovascular invasion is a very common feature and often can be found when it is specifically searched for even in a "negative" margin. This helps to explain the high local recurrence rate in MCC for narrow or even relatively wide margin excision when adjuvant radiation therapy is not given.

TABLE 120-1
Clinical Features of Merkel Cell Carcinoma

Asymptomatic (non-tender, firm, red, purple, or skin-colored papule or nodule; ulceration is rare; see Figs. 120-3A and 120-3B)
Expanding rapidly (significant growth noted within 1–3 months of diagnosis, but most lesions are <2 cm at time of diagnosis)
Immune suppression (e.g., HIV/AIDS, chronic lymphocytic leukemia, solid organ transplant)
Older than 50 years
Ultraviolet-exposed site on a person with fair skin (most likely presentation, but can also occur in sun-protected areas; Fig. 120-2)

BOX 120-1 DIFFERENTIAL DIAGNOSIS OF MERKEL CELL CARCINOMA

Most Likely

- Cyst
- Basal cell carcinoma
- Squamous cell carcinoma (see Fig. 120-3C)
- Amelanotic melanoma
- Cutaneous lymphoma
- Adnexal tumor

Consider

- Metastasis
- Dermatofibromasarcoma protuberans
- Keratoacanthoma
- Neuroblastoma

HEMATOXYLIN AND EOSIN STAIN

Three histologic patterns have been described up to now and none is clearly associated with a better or worse prognosis. The most common type is the "intermediate type." This has uniform small cells with minimal cytoplasm, pale nuclei, and a dispersed chromatin appearance. On hematoxylin and eosin staining, the differential diagnosis for this presentation is that of the small, blue-cell tumors including melanoma and lymphoma. The second most common pattern is the "small cell type." This takes its name from small cell lung carcinoma, which is the principal differential diagnosis for this pattern. It shows irregular, hyperchromatic cells with scant cytoplasm and malignant cells that are arranged in linear patterns infiltrating stromal structures. The least common but perhaps most histologically distinctive type is the "trabecular" type. This is the pattern originally described by Toker in 1972. It has a lattice-like, or network appearance, and the differential diagnosis includes metastatic carcinoid tumor.







Figure 120-3 Clinical appearance of Merkel cell carcinoma (MCC). **A.** MCC frequently has a "cyst-like" appearance. This is reflected in the differential diagnoses given by clinicians at the time of the biopsy, with cyst/acneiform lesion being the most common clinical impression. **B.** MCC on the knee of a 70-year-old woman with chronic lymphocytic leukemia. For 6 months this lesion was thought to be a "cyst"; consequently, diagnosis and treatment were delayed. Pen marks indicate palpable satellite metastases that developed several months after the primary lesion, presumably tracking via lymphatics. **C.** MCC on the ear of an 87-year-old woman. The lesion grew rapidly and was nontender. After approximately 3 months, it was biopsied by a clinician who listed squamous cell carcinoma as the presumptive diagnosis.

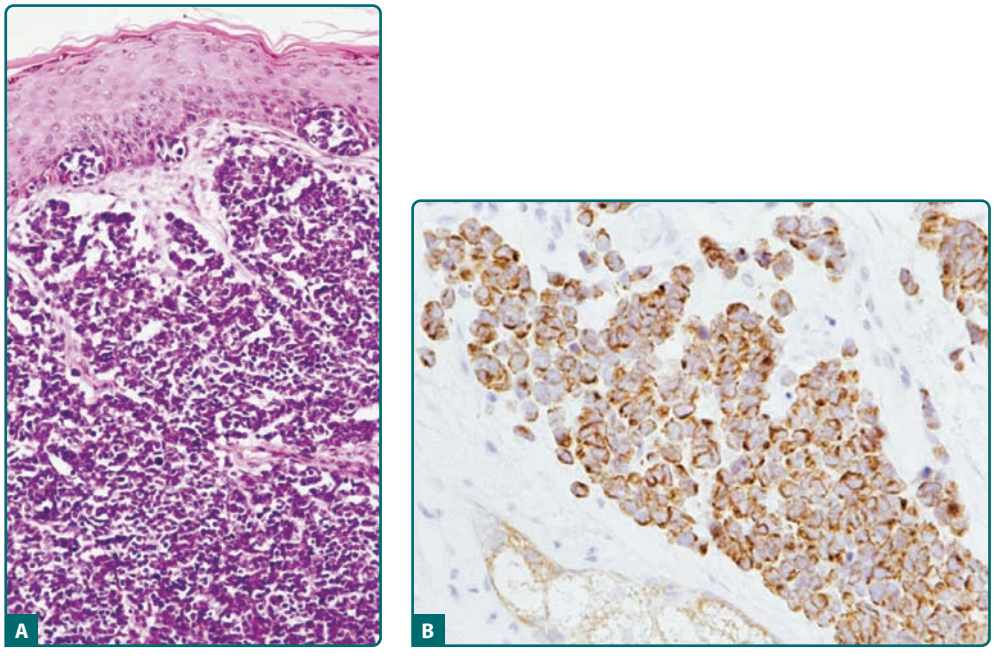

Figure 120-4 Merkel cell carcinoma pathology. **A.** Hematoxylin and eosin. There is diffuse dermal as well as intraepidermal involvement with Merkel cell carcinoma. This case was seen in consultation, with an initial diagnosis of cutaneous T-cell lymphoma. **B.** Cytokeratin-20. Showing the pathognomonic "perinuclear pattern" of cytokeratins (CAM5.2). [Reprinted from Nghiem P, Mckee P, Haynes H: Merkel cell (cutaneous neuroendocrine) carcinoma. In: *Skin Cancer, Atlas of Clinical Oncology*, edited by A Sober, F Haluska, American Cancer Society, 2001, with permission.]

IMMUNOHISTOCHEMICAL STAINS

The use of antibody-based stains has greatly facilitated the ease and specificity of MCC diagnosis (Table 120-2). The single most useful of these stains is cytokeratin-20.

CYTOKERATIN-20

Intermediate filament protein is expressed in MCC as well as in adenocarcinomas of the colon, stomach, and pancreas. However, within the skin the expression of cytokeratin-20 is limited to Merkel cells. A "perinuclear dot" pattern of cytokeratin is essentially pathognomonic for MCC (see Fig. 120-4B).

ANTIBODIES TO CAM5.2

CAM5.2, a cocktail of antibodies that detects multiple human cytokeratin epitopes, typically reacts with both MCC and small cell lung carcinoma. Although it is useful as an initial screening tool to detect tumors of squamous origin, its lack of selectivity relative to cytokeratin-20 means that it cannot be used to definitively diagnose MCC.

THYROID TRANSCRIPTION FACTOR-1

Thyroid transcription factor-1 is negative in MCC and positive in small cell lung cancer and thus useful for the differential diagnosis between these two tumors that can look identical by routine histology.

TABLE 120-2
Immunohistochemistry Panel

	Cytokeratin-20	Cytokeratin-7 and Thyroid Transcription Factor-1	Leukocyte Common Antigen	S-100
Merkel cell carcinoma	+	–	–	–
Small cell lung carcinoma	–	+	–	–
Lymphoma	–	–	+	–
Melanoma	–	–	–	+

TABLE 120-3
Description of MCC Staging and Associated Predicted Survival Percentages

	1-year Survival	3-year Survival	5-year Survival
Stage I: Local, Tumor Diameter ≤2 cm			
IA: Nodes microscopically negative and not clinically detectable	100%	86%	79%
IB: Nodes not clinically detectable (no pathologic evaluation of nodes done)	90%	70%	60%
Stage II: Local, Tumor Diameter >2 cm			
IIA: Nodes microscopically negative and not clinically detectable	90%	64%	58%
IIB: Nodes not clinically detectable (no pathologic evaluation of nodes done)	81%	58%	49%
IIC: Primary tumor is invading into bone/muscle/fascia/cartilage	72%	55%	47%
Stage III: Regional Nodal Disease			
IIIA: Micrometastasis	76%	50%	42%
IIIB: Macrometastasis (clinically detectable nodes)	70%	34%	26%
Stage IV: Distant Metastatic Disease	44%	20%	18%

CYTOKERATIN-7

Cytokeratin-7 has the same staining pattern as thyroid transcription factor-1, that is, typically negative in MCC and positive in small cell lung carcinoma; it is also expressed in epithelial cells of the lung, ovary, and breast.

STAGING AND PROGNOSIS

In 2010, the American Joint Committee on Cancer (AJCC) adopted a new staging system for MCC that replaced five existing—and conflicting—staging systems.[16] According to the new AJCC guidelines, there are four stages for MCC based on clinical and pathological features at the time of presentation. This new staging system is summarized in Fig. 120-5 and Table 120-3. Survival after a diagnosis of MCC is highly dependent on the stage at presentation. Patients with local disease have estimated 5-year relative survival between 60% and 79%. Survival decreases markedly with nodal involvement and metastatic disease (Fig. 120-5). Unlike malignant melanoma, if MCC recurs it tends to do so rapidly with ~80% of recurrences occurring within 2 years of diagnosis.[17]

Until 2009, MCC did not have its own specific International Classification of Diseases (ICD) code. Instead, MCC was often coded as "173.x: other malignant neoplasm of the skin." Specific ICD codes are important because they allow for more streamlined therapy, faster insurance approvals and improved tracking of patients and costs for clinical research purposes. As of 2010, MCC now has its own set of ICD codes (209.3x) to better facilitate treatment and tracking of patients with MCC.[18]

SENTINEL LYMPH NODE BIOPSY AND STAGING OF MERKEL CELL CARCINOMA

Over the past 20 years, sentinel lymph node biopsy (SLNB) has become quite common in staging malignant melanoma presenting with a depth of greater than 1 millimeter. More recently, several studies have indicated that SLNB is also a sensitive test for detecting MCC spread to the lymph nodes.[19–21] Interestingly, MCC is far more likely to have occult lymph node involvement (approximately 30% for the average 1.7 cm MCC) than melanoma (~1% for melanomas with the average Breslow thickness of 0.63 mm).[21,22] SLNB clearly has less morbidity than an elective lymph node dissection. Ideally, an SLNB should be performed at

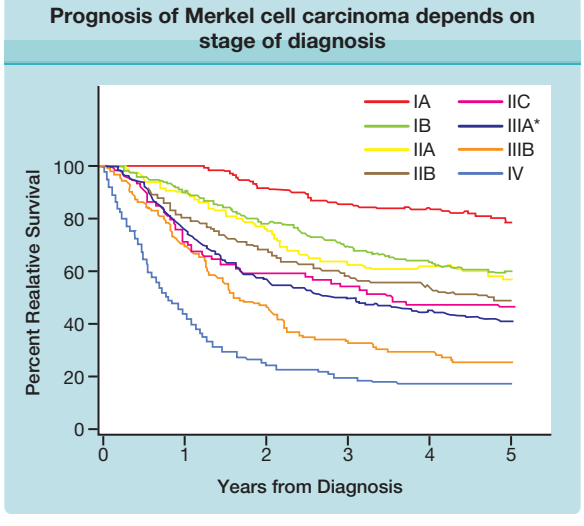

Figure 120-5 Prognosis of Merkel cell carcinoma depends on stage at diagnosis. This figure shows relative survival curves for 2,856 Merkel cell carcinoma patients by stage. Stage IIIA could not be directly derived from this dataset. The survival curve marked "IIIA*" represents pathologically node positive patients who had either clinically node-negative disease or clinically unknown node status. It is anticipated that true Stage IIIA patients (clinically node-negative disease) have better survival than the line marked with "IIIA*." (Reprinted from Merkel cell carcinoma. In: *AJCC Cancer Staging Manual*, 7th edition, edited by S Edge et al, Springer-Verlag, 2009, with permission.)

the time of the wide resection as opposed to after the wide excision when local lymphatics have been disturbed. The importance of performing an SLNB is that one-third of patients with local-only disease as determined by clinical palpation of lymph nodes, in fact, have microscopic disease in the lymph nodes that very much affects their subsequent survival (Fig. 120-5, Table 120-3).[21] Specifically, one-third of patients would be understaged by clinical exam only, and would shift to stage IIIA disease with microscopic examination. Identification of microscopic nodal disease also importantly alters therapy for the node bed, as discussed below.

RADIOLOGIC IMAGING STUDIES

Although many patients who present for management of MCC have not had an SLNB, the majority have had computed tomographic (CT) scans. We studied our own series of patients to determine the sensitivity and specificity of CT scans in patients presenting with MCC.[21] We found that scans were not sensitive (missing 90% of positive cases) in terms of detecting nodal involvement of MCC as compared with SLNB. Among patients who had low-risk disease (negative sentinel lymph nodes or very small primary tumors) all of the "positive" scan results were, in fact, false positives.[21] Therefore, we typically reserve CT or PET-CT scans for patients presenting with more advanced disease, such as positive nodal involvement or clinical evidence of metastatic disease.

PROGNOSTIC FINDINGS ON HISTOLOGY

A recently published retrospective study evaluated several histologic features of MCC and performed survival analyses on these features. This large study had over 4 years of average follow-up time and analyzed the primary tumor lesions from 156 patients with MCC. In addition to tumor stage, two new histologic features were of particular interest: (1) lymphovascular invasion (LVI) and (2) tumor growth pattern. LVI was defined as tumor emboli within vascular spaces. Persons with MCC tumors with detectable LVI had a worse overall survival as compared to those with tumors without LVI (hazard ratio, 3.84; $P = 0.007$).[23] Tumor growth pattern was described as nodular (well-circumscribed interface between tumor and surrounding tissue) or infiltrative (rows, trabeculae, or single cells that penetrate the dermis). Tumors that exhibited both features were considered infiltrative. An infiltrative tumor growth pattern was associated with poor outcomes as compared to MCC tumors with a nodular growth pattern (hazard ratio, 6.85; $P = 0.001$).[23]

TREATMENT

Optimal therapy for MCC is controversial and there is no broad consensus on how to manage this disease. The best summary of consensus treatment for MCC is available through the National Comprehensive Cancer Network (http://www.nccn.org) and is updated annually (these guidelines and other useful information can also be found at www.merkelcell.org/usefulinfo/index.php). The best outcome for MCC is clearly obtained when multidisciplinary management is carried out by an experienced team. Each major treatment modality is summarized below.

SURGERY AT PRIMARY SITE

The initial management in most cases of MCC is surgical excision of the tumor. When carried out without subsequent adjuvant radiation, surgery may have a relatively high recurrence rate depending on the margins chosen and the risk profile for the tumor. Surgery alone with 0.5 cm margins resulted in a 100% recurrence rate in 38 patients.[24] When wide local excision was carried out with 2.5 cm margins, the recurrence rate fell to 49%.[25] For Mohs surgical excision, the local recurrence rate was 16% for surgery alone and 0% in patients who also had adjuvant radiation therapy, although this difference was not statistically significant.[26] There are no data to suggest that extremely wide excision margins improve overall survival. Depending on the location of the tumor, significant morbidity can result when 2–3 cm margins are taken. Numerous studies show that if surgery is the sole treatment, recurrence rates are significantly higher than if radiation therapy is added to the regimen. Excision with narrow but clear margins (carried out at the time of SLNB) followed by adjuvant radiation therapy is a reasonable approach to management in many cases. Overly aggressive surgery, including amputation, or very wide margins in cosmetically sensitive areas, decreases quality of life, increases morbidity, delays time to initiation of adjuvant radiation, and does not appear to improve survival or local control rates.

SURGERY AT THE DRAINING NODE BED

Completion lymphadenectomy is typically carried out if there is gross involvement of the draining node bed detected clinically. However, the role of completion lymphadenectomy in MCC is controversial. For example, a 2010 study suggests that patients with nodal MCC disease who underwent complete lymphadenectomy had comparable outcomes with patients who only underwent radiation therapy to the nodal bed.[27] These two options have similar and excellent control rates for node-positive disease. Although either can be chosen, depending on the clinical situation, it is clear that for microscopic nodal disease, only one of these two modalities should be performed. This is because regional control rates were 100% for each modality and the combination of radiation and surgery to the lymph node bed greatly increases risk of chronic lymphedema.

RADIATION THERAPY

MCC is an unusually radiosensitive tumor.[25,28] Recently, there have been reports of successful treatment of MCC with radiation as monotherapy. One study of 43 patients with MCC for whom surgical excision was not possible demonstrated an excellent infield control rate (75%) after treatment with radiation therapy alone.[29] In a separate cohort, there were no recurrences among nine patients treated with radiation monotherapy.[28] One of our cases treated with radiation monotherapy is shown in Fig. 120-6. In most of these cases, the lesion was felt to be inoperable and radiation was given for palliation, but typically resulted in long-lasting local control.

The much more common use of radiation is as an adjuvant to surgery. Adjuvant radiation clearly is critical if surgical margins are positive or if microscopic margins are relatively narrow (<0.5 cm). A retrospective review of the literature indicates a statistically significant improved local and nodal rate of control in this cancer if radiation is added.[30] A cancer registry-based study also indicates improved survival in patients with adjuvant radiation therapy.[31] In this study, patients who received adjuvant radiation therapy had a median survival of 63 months compared to median survival of 45 months in patients who did not receive adjuvant radiation. The typical doses of radiation for MCC are 50–56 Gy for a primary site with negative excision margins. Detailed dosing regimens can be found in the National Comprehensive Cancer Network's MCC Guidelines. Radiation doses are typically given in 2-Gy fractions, five times/week over 4–6 weeks. Acute side effects from radiation therapy include erythema at the site and mild-to-moderate fatigue that peaks toward the end of radiation and usually resolves within 1–2 months of completing a 5-week course. Chronic radiation skin changes include temporary or permanent alopecia within the irradiated field, epidermal atrophy, loss of adnexal structures leading to skin or mucosal dryness, and risk of subsequent secondary skin cancers in the irradiated region in patients with a life expectancy of greater than 20 years after the radiation treatment. Perhaps the most significant potential side effect is lymphedema. This is more commonly an issue in lower extremities, when radiation therapy is given to the inguinal lymph nodes, especially after surgery has also been carried out in that region. Early referral to a physical therapist trained in lymphedema management is indicated to minimize the severity and incidence of this potential complication in higher risk cases.

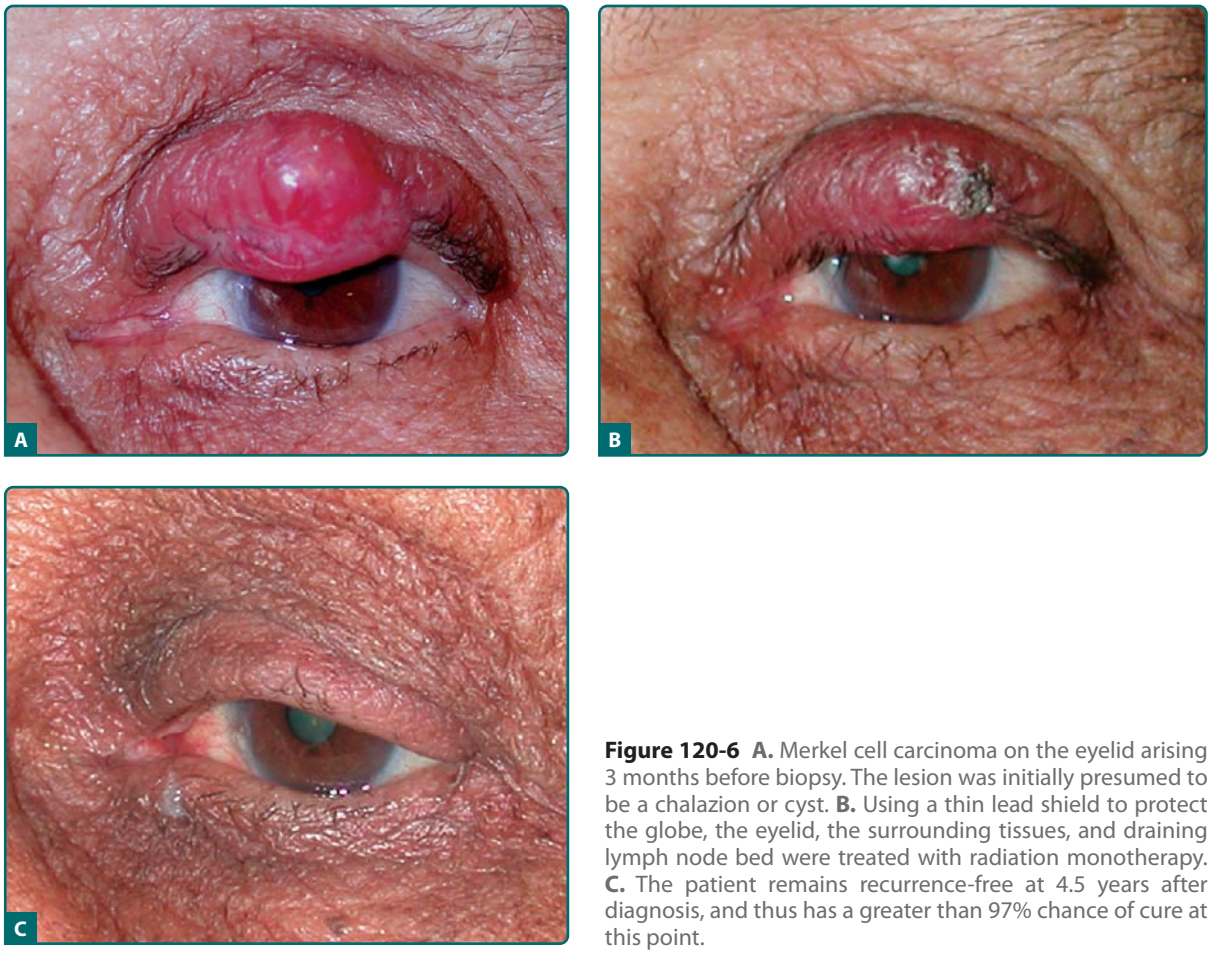

Figure 120-6 **A.** Merkel cell carcinoma on the eyelid arising 3 months before biopsy. The lesion was initially presumed to be a chalazion or cyst. **B.** Using a thin lead shield to protect the globe, the eyelid, the surrounding tissues, and draining lymph node bed were treated with radiation monotherapy. **C.** The patient remains recurrence-free at 4.5 years after diagnosis, and thus has a greater than 97% chance of cure at this point.

CHEMOTHERAPY

The most commonly used chemotherapeutic regimen for MCC is the combination of etoposide and either cisplatin (perhaps more clinically effective) or carboplatin (less nephrotoxic). Chemotherapy is often useful in palliation for symptomatic disease that is otherwise inoperable. MCC patients receiving chemotherapy for the first time usually have a significant response with shrinkage of the tumor. Unfortunately, in almost all cases, the tumor grows back and is resistant to chemotherapy even if entirely different agents are used on a subsequent round of chemotherapy. After careful analysis of the literature, we currently do not recommend adjuvant chemotherapy for patients whose MCC has been treated with surgery, radiation therapy, or both. There are six reasons why we currently do not recommend adjuvant chemotherapy:

1. *Mortality:* There is a 4%–7% acute death rate due to adjuvant chemotherapy in MCC partly due to the fact that these patients are often elderly.[32,33]
2. *Morbidity:* Neutropenia has been reported to occur in 60% of patients with fever, and sepsis in 40%.[34]
3. *Decreased quality of life:* This can be quite severe in this older population, including fatigue, hair loss, nausea, and vomiting.
4. *Resistance to chemotherapy:* MCC that recurs after chemotherapy is less responsive to later palliative chemotherapy.
5. *Immunity:* Chemotherapy suppresses immune function, and this is known in general to be very important in preventing and controlling MCC.
6. *Apparent poorer outcomes:* Among patients with nodal disease, there was a 60% survival if chemotherapy was not given among 53 patients. In contrast, survival was only 40% among node positive MCC patients who did receive adjuvant chemotherapy.[17] Although this is not a randomized trial and was not statistically significant, it certainly does not suggest a major survival benefit for administrating adjuvant chemotherapy.

OPTIMAL TREATMENT FOR MERKEL CELL CARCINOMA

In general, optimal treatment for MCC should involve obtaining pathologically clear margins by surgery, typically with 1- to 2-cm margins as possible, depending on the site. More narrow margins or even positive margins can often be effectively treated by local radiation, typically extending 3–5 cm beyond the tumor bed. We also recommend treating the draining lymph node bed, likely with radiation therapy, for patients with high-risk disease including a positive SLNB, immune suppression, or a tumor greater than 2 cm in diameter. Although still controversial, we currently do not recommend adjuvant radiation therapy for MCC patients with all of the following five good prognostic features: (1) primary tumor diameter ≤1 cm; (2) microscopic margins that are confidently negative following surgery; (3) no lymphovascular invasion noted in the tumor; (4) no profound immune suppression (HIV, chronic lymphocytic leukemia, etc.); and (5) SLNB that was negative with proper immunohistochemistry studies.

CLINICAL COURSE AND COMPLICATIONS

In more than 90% of cases, MCC is an unanticipated diagnosis at the time the pathology results become known. Most commonly, the lesion in question was thought to be a cyst or acneiform lesion. Although most patients and physicians are not familiar with this disease or its specific management, MCC can be lethal and there is a need to initiate therapy rapidly. In one Australian study, a high fraction of patients (45%) developed progressive disease while waiting for adjuvant radiation therapy to begin (median wait time 41 days).[35] Because of the rarity of this cancer, patients and physicians increasingly resort to the Internet for medical information. One Web site, http://www.merkelcell.org, is devoted to aiding patients and physicians by presenting current data and referral center availability.

Among patients who experience a recurrence of their MCC, ~80% of these happen within 2 years of diagnosis. The most common site of recurrence is the draining nodal basin or adjacent skin.[17] For those who have recurrences, the locations and frequencies are skin (28%), lymph nodes (27%), liver (13%), lung (10%), bone (10%), brain (6%), bone marrow (2%), pleura (2%), and other sites (4%).[33] Once MCC has spread to viscera, it is typically incurable.

Fortunately, for more than 50% of patients, a good outcome can be anticipated. Those who have had no recurrences for 3–5 years, unlike for melanoma, enjoy a greatly reduced risk of recurrence. The complications for those who do not experience a metastasis depend very much on the therapy they received. We believe that treatment with surgical excision and radiation therapy as outlined in this chapter has relatively minimal complication rates and the best possible chance of cure based on current literature. However, for those who receive very aggressive surgical excision, amputation or chemotherapy for low-risk disease, complication rates tend to be higher without improved outcomes.

KEY REFERENCES

Full reference list available at www.DIGM8.com

DVD contains references and additional content

3. Lemos BD et al: Pathologic nodal evaluation improves prognostic accuracy in Merkel cell carcinoma: Analysis of 5,823 cases as the basis of the first consensus staging system for this cancer. *J Am Acad Dermatol* **63**(5):751-761, 2010
10. Heath M et al: Clinical characteristics of Merkel cell carcinoma at diagnosis in 195 patients: The AEIOU features. *J Am Acad Dermatol* **58**:375-81, 2008

13. Feng H et al: Clonal integration of a polyomavirus in human Merkel cell carcinoma. *Science* **319**:1096-100, 2008
18. Iyer J, Koba S, Nghiem P: Toward better management of Merkel cell carcinoma using a consensus staging system, new diagnostic codes and a recently discovered virus. *Actas Dermo-Sifiliográficas* **100**:00-00, 2009
21. Gupta SG et al: Sentinel lymph node biopsy for evaluation and treatment of patients with Merkel cell carcinoma: The Dana-Farber experience and meta-analysis of the literature. *Arch Dermatol* **142**:685-690, 2006
29. Veness M et al: The role of radiotherapy alone in patients with merkel cell carcinoma: Reporting the Australian experience of 43 patients. *Int J Radiat Oncol Biol Phys* 1-13, 2009

Chapter 121 :: Mammary and Extramammary Paget's Disease

:: Sherrif F. Ibrahim, Roy C. Grekin, & Isaac M. Neuhaus

MAMMARY AND EXTRAMAMMARY PAGET'S DISEASE AT A GLANCE

- Rare intraepithelial adenocarcinoma occurring in apocrine gland-bearing skin in patients over 50.
- Erythematous, scaly, eczematous plaque frequently misdiagnosed as inflammatory or infectious dermatitis.
- Most commonly affected sites: unilateral nipple/areola complex [mammary Paget's disease (MPD)], vulva, perianal skin, scrotum, and penis [extramammary PD (EMPD)].
- Most cases are associated with underlying breast carcinoma (MPD); EMPD not usually associated with underlying neoplasm but may be present in minority (15%) of cases.

EPIDEMIOLOGY

Mammary Paget's disease (MPD) represents approximately 1% to 3% of breast neoplasms.[1] The peak incidence is between 50 and 60 years of age and almost all reported cases occur in women.

Extramammary Paget's disease (EMPD) is a rare neoplasm that affects apocrine gland-bearing skin such as the vulva, perianal region, scrotum, and penis. The majority of patients are in the sixth through eighth decades of life.[2–4] The genitals are the most commonly affected area, with EMPD representing 2% of all vulvar malignancies.[3]

ETIOLOGY AND PATHOGENESIS

MPD is almost always associated with underlying in-situ or invasive intraductal adenocarcinoma of the breast (up to 98% of cases in some studies).[5,6] Malignant cells directly extend from the underlying tumor into the epidermis via the lactiferous ducts. Rare cases are reported to have originated primarily in the epidermis of the nipple.[7]

Unlike MPD, in which almost all cases have a documented underlying neoplasm, EMPD does not have a consistent histogenesis. Primary EMPD occurs in the absence of underlying malignancy and accounts for the majority of patients with the disease. These cases represent a primary intraepithelial neoplasm of apocrine origin. The malignant cells are thought to originate from intraepidermal apocrine glands or from pluripotential cells of the epidermis. The neoplasm can then invade the dermis and metastasize via lymphatic spread. In contrast, cases of secondary EMPD are associated with an underlying apocrine carcinoma or internal malignancy. These cases are due to epidermotropic spread of malignant cells from the underlying tumor. Approximately 15% of cases are associated with an underlying internal carcinoma. The most common visceral malignancies associated with EMPD are carcinomas of the rectum, bladder, urethra, cervix, and prostate.[4,8,9]

CLINICAL FINDINGS

HISTORY

Both MPD and EMPD present with a long-standing history of pruritic, erythematous, scaly, or velvety patches on the breast or in apocrine-rich areas such as the groin, perineum, or axilla. Given the rather nondescript appearance, there is frequently a significant delay in diagnosis as initial treatment often involves topical steroids and/or antifungal agents for presumed inflammatory or infectious dermatitis. After continued recalcitrance to therapy, a diagnostic biopsy is performed and the correct diagnosis is made.

CUTANEOUS LESIONS

MPD frequently presents as a unilateral, erythematous, scaly plaque involving the nipple and/or the



Figure 121-1 Paget disease of the nipple. Sharply circumscribed erythematous and scaly plaque involving the nipple and areola.

areola (Fig. 121-1). Ulceration and weeping with an eczematous appearance is frequently present. Nipple erosion and discharge may occur. Retraction of the nipple can be seen. Pain, burning, and pruritus are frequently reported by patients. See Box 121-1 for differential diagnosis of MPD and EMPD.

Lesions of EMPD are clinically similar to MPD and often present as a well-defined, moist, erythematous, scaly, eczematous plaque. Hypo- and hyperpigmentation can occur. Burning and intense pruritus are commonly reported. Lesions typically involve apocrine gland-bearing skin (i.e., genitoperineal region and axilla). The most frequent site is the vulva, but perineal, scrotal (Fig. 121-2), perianal (Fig. 121-3), and penile skin are also common areas. Rarely, ectopic EMPD has been reported in areas that are relatively free of apocrine glands, such as the chest, abdomen, thigh, eyelids, face, and external auditory canal.[10–14]



Figure 121-2 Extramammary Paget disease. Moist, well-demarcated, eroded, oozing plaque on the scrotum of an older man.

Given the less established association with underlying carcinoma in EMPD as compared to MPD, a palpable mass or other malignant stigmata are much less frequently found on physical examination.

RELATED PHYSICAL FINDINGS

Up to one-half of all patients with MPD have a palpable underlying breast mass.[5,6,15,16] Of those patients with a palpable underlying tumor, half have axillary adenopathy due to lymph node metastasis.[5,6] Palpable lymph nodes are less frequently present in EMPD. Complete physical examination including thorough full body skin exam is required in all cases of MPD and EMPD. Patients may present with symptoms and physical findings reflective of an underlying carcinoma or metastatic disease.

LABORATORY TESTS

PATHOLOGY. The intraepidermal adenocarcinoma of EMPD and MPD has a similar histologic appearance.

BOX 121-1 DIFFERENTIAL DIAGNOSIS OF MAMMARY (MPD) AND EXTRAMAMMARY PAGET'S DISEASE (EMPD)

	MOST LIKELY	CONSIDER	ALWAYS RULE OUT
MPD	Nipple eczema Erosive adenomatosis Psoriasis Dermatophyte infection	Hailey–Hailey disease Pemphigus	Bowen disease Basal cell carcinoma Malignant melanoma
EMPD	Candidiasis Tinea cruris Psoriasis Seborrheic dermatitis Nummular dermatitis	Lichen sclerosus et atrophicus Pemphigus Lichen simplex chronicus Lichen planus Drug eruption	Bowen disease Erythroplasia of Queyrat Malignant melanoma



Figure 121-3 Perianal Paget disease presenting as moist, superficially eroded patch.

There are groups, clusters, or single cells within the epidermis that show nuclear enlargement with atypia, prominent nucleoli, and well-defined ample cytoplasm (Fig. 121-4).[15] Intercellular bridges are absent. The cells can be within all levels of the epidermis and can compress but preserve the basal layer without junctional nest formation. The cells can extend into the contiguous epithelium of hair follicles and sweat gland ducts. Acanthosis, hyperkeratosis, and parakeratosis are often present. These cells have a "pagetoid" appearance and simulate other intraepidermal malignancies, such as melanoma, pagetoid squamous cell carcinoma in situ, mycosis fungoides, cutaneous adnexal carcinomas (sebaceous carcinoma, porocarcinoma, and others), Merkel cell carcinoma, Langerhans cell histiocytosis, and other epidermotropic cutaneous metastases. The cells of MPD and EMPD can be pigmented, which does not necessarily indicate they are melanocytic.

Paget's cells have intracellular mucopolysaccharides, with EMPD having a greater amount of mucin as compared to MPD. As a result, cells frequently show positive staining for periodic acid-Schiff and diastase resistance, mucicarmine, Alcian blue at pH 2.5, and colloidal iron (see eFig. 121-4.1 in online edition). However, there are can be focal "skip areas" that are devoid of mucin, resulting in sections of negative staining.

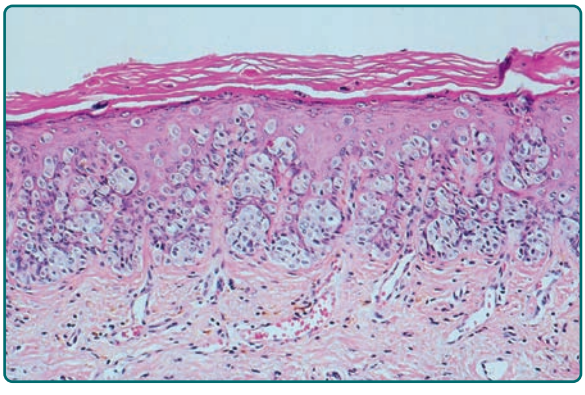

Figure 121-4 Paget disease, hematoxylin and eosin stain. Paget's cells have distinctive pale-staining cytoplasm and are usually randomly dispersed throughout the epidermis.

Immunohistochemistry is invaluable in making the correct diagnosis. Low-molecular-weight cytokeratin stains cytokeratin 7 (CK7) and anticytokeratin (CAM 5.2) are sensitive markers for both MPD and EMPD (see eFig. 121-4.2 in online edition). They are not completely specific, however, as both Toker and Merkel cells also exhibit CK7 positivity. The cells of MPD and EMPD may stain with carcinoembryonic antigen (CEA), epithelial membrane antigen (EMA), Ber-EP4, BRST-2, and HER-2/neu.[17–19] The most useful keratin markers for Paget's disease are CAM 5.2 and CK7, as they stain more than 90% of Paget's cells but do not react with epidermal or mucosal keratinocytes.[16,20] The cells of pagetoid squamous cell carcinoma in situ typically do not stain with CK7 and CAM 5.2. S100, Melan-A (MART-1), and HMB-45 are useful markers to exclude melanoma, and are typically negative in MPD and EMPD. CK20 positivity has been found more frequently in cases of secondary EMPD with underlying carcinoma as compared to those cases of primary intraepithelial EMPD ($CK7^+/CK20^-$).[21]

Gross cystic disease fluid protein-15 (GCDFP-15) is a marker for apocrine epithelium and is typically positive in primary EMPD (not associated with underlying neoplasm). In contrast, GCDFP-15 is frequently negative in those cases of secondary EMPD with an associated malignancy.[22]

Mucin core protein (MUC) expression is useful in the diagnosis of MPD and EMPD.[23] MUC1 positivity is noted in both MPD and EMPD. MUC2 expression is generally negative in primary EMPD, but may be expressed in those cases of secondary EMPD with an associated underlying gastrointestinal adenocarcinoma. MUC5AC is frequently positive in primary EMPD and less commonly noted in secondary EMPD or those cases of primary intraepithelial EMPD that becomes invasive. *CDX2* is a regulatory gene involved in intestinal proliferation and has been suggested as a useful maker in EMPD associated with underlying colorectal tumors.[19,24]

Recent studies investigating the role of androgen receptor and 5α-reductase suggest an elevated 5α-reductase level in invasive (81%) compared with noninvasive (45%) cases of EMPD.[25] For invasive cases, men had a significantly higher level of androgen receptor and 5α-reductase double positivity than women (70% vs. 17%), suggesting an autocrine synthesis of androgens in EMPD and gender-specific microenvironments that may contribute to invasiveness of the disease.

Expression of human telomerase reverse transcriptase (hTERT) has been shown to be significantly higher in patients with invasive lesions of EMPD as opposed to noninvasive cases.[26]

SPECIAL TESTS. Complete workup of MPD and EMPD should include a thorough search for underlying malignancy. Mammography is required in all cases of MPD, with immediate biopsy of any detectable breast mass.

In cases of EMPD, workup is directed toward the possibility of an underlying gastrointestinal or genitourinary neoplasm. Imaging of the abdomen and pelvis, colonoscopy, barium enema, cystoscopy, intravenous pyelogram, chest X-ray and mammogram (for the rare association of EMPD and MPD), and blood work are appropriate tests. In two recent studies, patients with significantly elevated carcinoembryonic antigen (CEA) had a greater risk of death from the disease compared with patients with normal serum CEA, and the level of CEA paralleled disease course.[4,8] Some reports have suggested that positron emission tomography (PET) scans may be useful for cases of invasive EMPD to evaluate for lymph node involvement and metastases.[8,27,28] The role of sentinel lymph node biopsy (SLNB) for patients with EMPD is discussed below.

COMPLICATIONS

Failure to identify and adequately treat cases of MPD can lead to metastatic disease with a poor prognosis. EMPD, if left untreated, can become invasive and metastatic disease can ensue with a less favorable outcome.

PROGNOSIS AND CLINICAL COURSE

Overall survival in patients with MPD is affected by lymph node status and the presence of an underlying breast mass. Patients with negative lymph nodes have been shown to have a 10-year survival rate of 75% to 95%, whereas those with positive lymph nodes have a survival rate of 20% to 45%.[5] Patients with a palpable breast mass have a 5-year survival probability of 35% to 51%, as compared to 75% to 82% in patients without a palpable mass.[6]

The prognosis for primary EMPD confined to the epidermis is excellent with appropriate treatment. Careful monitoring for early detection of local recurrence is critical given the multifocal pattern often present in EMPD. In contrast, invasive EMPD has a high rate of metastasis and carries a poor prognosis. The depth of invasion appears to be an important prognostic factor, with microscopic invasive disease (less than 1 mm) having a more favorable prognosis as compared to those with deeper invasion.[4,9,29,30] Lymphovascular invasion and regional lymph node metastases markedly reduce overall survival rate and indicate a very poor prognosis. Presence of clinically apparent nodules in the primary tumor and elevated CEA level have an association with decreased survival.[4] Clitoral EMPD has been shown to have a higher incidence of death from the disease as compared to other vulvar EMPD locations.[29] Gender and tumor size have not been shown to correlate significantly with survival.[4]

The most common sites of metastases are lymph nodes followed by bone and lung.[4,8] In a recent study of 44 patients with EMPD, those patients with metastatic involvement were younger and had elevated levels of CEA. Metastatic disease was present in all patients with elevated CEA; however, not all patients with metastases demonstrated increased serum CEA. Deeper invasion, lymphovascular involvement, and negative E-cadherin were important histologic prognostic factors for metastatic potential. The 2-year survival rate in patients with metastatic EMPD was 48%.[8]

In cases of secondary EMPD, the prognosis is related to the underlying carcinoma.

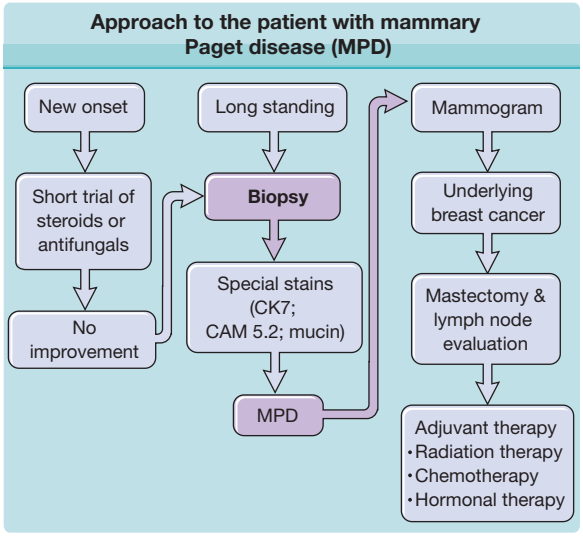

Figure 121-5 Approach to the patient with mammary Paget disease (MPD). CAM 5.2 = anticytokeratin stain; CK7 = cytokeratin 7 stain.

TREATMENT

MAMMARY PAGET'S DISEASE

(Fig. 121-5)

Treatment of MPD is surgical; however, optimal surgical management of MPD remains to be defined, and treatment choice is frequently based on the presence or absence of an underlying breast mass. Mastectomy remains the standard definitive treatment yet emerging evidence suggests that MPD treated with breast-conserving surgery results in local control and survival rates similar to those achieved with mastectomy.[31,32] Proper preoperative imaging is required to rule out multifocal disease that would make breast-conserving therapy less effective and favor mastectomy.[33] Lymph node evaluation via axillary dissection or SLNB must be considered in MPD. Adjuvant therapy with radiation, chemotherapy, or hormonal therapy is recommended based on lymph node status and specific features of the primary tumor.[5] All diagnoses of MPD require referral to a physician with expertise in the management of breast cancer.

EXTRAMAMMARY PAGET'S DISEASE

(Fig. 121-6)

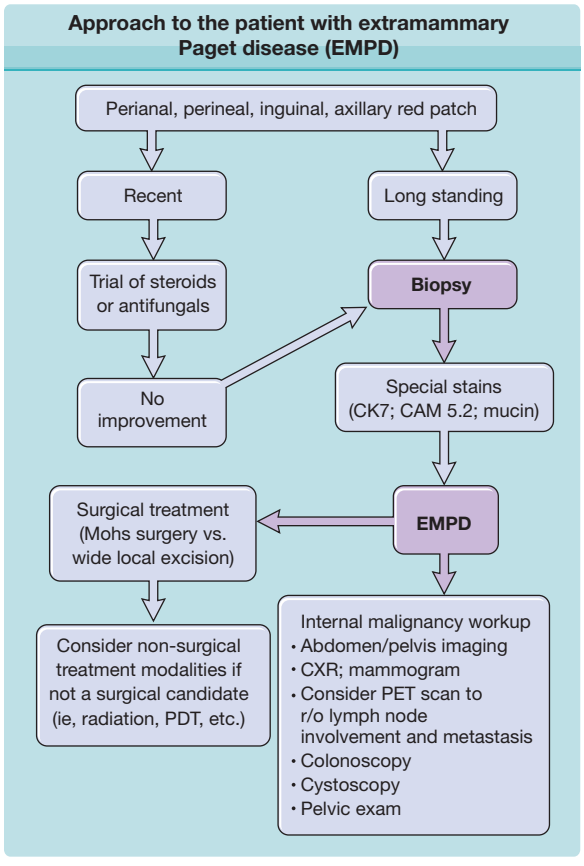

Figure 121-6 Approach to a patient with extramammary Paget disease (EMPD). CAM 5.2 = anticytokeratin stain; CK7 = cytokeratin 7 stain; CXR = chest X-ray; PDT = photodynamic therapy; PET = positron emission tomography; r/o = rule out.

EMPD has been treated with a variety of different modalities. Although surgical management of the disease is the most frequently used method, various other treatments have a role for poor surgical candidates and as adjuvant therapy.

SURGERY. Surgery remains the treatment of choice for EMPD in those patients that can tolerate the procedure. High local recurrence rates are seen after standard surgical excision, even when wide margins are used. This is most likely due to the ill-defined borders, multifocal nature of the condition, and subclinical involvement of apparently unaffected skin. Furthermore, because these tumors commonly occur in the genitoperineal region, wide excision may be technically difficult and disfiguring.

Several reviews have shown an overall recurrence rate of up to 44% with wide local excision.[2,34,35] The local recurrence rates are higher in cases of invasive disease as compared to those limited to intraepithelial involvement. In addition, more radical and extensive surgeries are associated with lower rates of local recurrence. Patients with primary vulvar EMPD treated with radical vulvectomy, radical hemivulvectomy, and wide local excision have reported recurrence rates of 15%, 20%, and 43%, respectively.[34]

In one study of 76 patients with EMPD, 66 patients underwent surgical excision, five developed local recurrence; however, recurrence rate did not differ between wide (>2 cm) and narrow (<2 cm) surgical margins, despite scouting biopsies.[4]

Multiple scouting biopsies to help delineate the extent of the disease before surgery can be a useful adjuvant technique.[36] Intraoperative staining with CK7 is the preferred immunostain for intraoperative tissue evaluation.[37] SLNB has been described in the treatment of EMPD.[38] Although this technique has been limited to a small number of reported patients and most cases of EMPD have in situ disease, SLNB may prove beneficial for those patients with increased risk of lymph node involvement and metastasis (i.e., dermal invasion of Paget's cells, elevated CEA).[39] Some advocate the use of SLNB and/or regional lymphadenectomy in all high-risk EMPD cases, despite negative findings on PET/CT, as micrometastases are undetectable with this form of imaging.[8] Due to the nature of inguinal lymphatic drainage, bilateral sentinel lymph nodes are not uncommon.

MOHS MICROGRAPHIC SURGICAL EXCISION. Given the high rates of local recurrence and the significant morbidity associated with radical and repeated surgeries, Mohs micrographic surgical excision (MMS) has been used to improve cure rates and for tissue sparing of critical genitourinary anatomic structures as compared to wide local excision.[2,35,37,40,41] The recurrence rate after treatment with MMS has been reported as 16% for primary EMPD and 50% for recurrent EMPD. Ninety-seven percent of the cases treated with MMS required margins of 5 cm from the clinical tumor margin. However, if surgical margins of only 2 cm were used, as may be the case because wider margins may not be feasible when operating on the genitalia, only 59% of the tumors would have been cleared. The 40% expected recurrence rate with 2 cm margins is consistent with what is seen in various reports of EMPD treated with standard wide excision. This further validates a potential benefit of frozen horizontal sectioning for complete peripheral and deep margin mapping and reduces the possibility of residual tumor. Immunohistochemical staining with CK7 during Mohs surgery has also been employed.[17]

RADIOTHERAPY. Although surgery remains the traditional treatment for EMPD, radiotherapy may be indicated in those patients who are poor surgical candidates or are concerned with the risk of compromising genitourinary function due to extensive surgery that is often required for curative treatment.[42–44] In addition, radiotherapy has been described as useful for local recurrence after surgery or as an adjuvant therapy in those patients with a high risk of recurrence.[43,45] No randomized controlled studies comparing surgery to radiotherapy have been performed to date.

TOPICAL CHEMOTHERAPY AND IMMUNOMODULATORS. Topical agents, including 5-fluorouracil (5-FU), bleomycin, and imiquimod, have been used to treat EMPD with varying degrees of success.

5-FU may be useful as a preoperative adjunctive treatment to highlight the subclinical extent of disease before

MMS or for early postoperative detection of recurrence.[46] However, topical 5-FU has not proven to be a reliably curative agent in the treatment of EMPD.[47] This is likely due to the limited penetration of the drug and the inability to reach the deeper epidermal layers and adnexal structures that are frequently involved in EMPD.

Imiquimod has been reported to result in clinical and histologic cure in several case reports.[48–52] Given the limited number of patients treated with this medication, further studies and long-term follow-up in a larger cohort is necessary.

SYSTEMIC CHEMOTHERAPY. Systemic chemotherapy has been used to treat patients with invasive and metastatic disease and may be considered in rare cases in which surgery and radiotherapy are contraindicated. Limited reports of systemic chemotherapy for the treatment of EMPD have been described, including a combination of low-dose 5-fluorouracil and cisplatin[53]; a combination of 5-FU, cisplatin, mitomycin C, epirubicin, and vincristine[54,55]; and docetaxel.[8,56,57]

PHOTODYNAMIC THERAPY. Given the patchy nature of EMPD and extension beyond clinically visible tumor, photodynamic therapy (PDT) is a potentially useful treatment modality. Although the limited number of studies and reports makes further investigation necessary, PDT may be considered in patients who are poor surgical candidates, are at risk for significant functional morbidity due to the anatomic location of the disease, or have recurrent postsurgical disease.[58–61] Limiting treatment to intraepithelial disease is prudent given the limitations of current PDT technology. PDT has been described as an adjuvant to surgical treatment to better define clinical margins and improve recurrence rates.[37]

PREVENTION

Both EMPD and MPD are not preventable diseases. Rather, early diagnosis is the key to a favorable prognosis, and any unilateral eczematous rash on the breast or in the groin that does not respond to an appropriate course of topical treatment warrants a biopsy. Routine mammography may allow early detection of underlying breast carcinoma in women of appropriate screening age.

KEY REFERENCES

Full reference list available at www.DIGM8.com

DVD contains references and additional content

2. Zollo JD, Zeitouni NC: The Roswell Park Cancer Institute experience with extramammary Paget's disease. *Br J Dermatol* **142**:59-65, 2000
3. Shepherd V, Davidson EJ, Davies-Humphreys J: Extramammary Paget's disease. *BJOG* **112**:273-279, 2005
4. Hatta N et al: Extramammary Paget's disease: Treatment, prognostic factors and outcome in 76 patients. *Br J Dermatol* **158**:313-318, 2008
5. Fu W, Mittel VK, Young SC: Paget disease of the breast: Analysis of 41 patients. *Am J Clin Oncol* **24**:397-400, 2001
6. Kollmorgen DR et al: Paget's disease of the breast: A 33-year experience. *J Am Coll Surg* **187**:171-177, 1998
8. Zhu Y et al: Clinicopathological characteristics, management and outcome of metastatic penoscrotal extramammary Paget's disease. *Br J Dermatol* **161**:577-582, 2009
9. Zhang N et al: Extramammary Paget's disease of scrotum-Report of 25 cases and literature review. *Urol Oncol* **28**:28-33, 2010
29. Parker LP et al: Paget's disease of the vulva: Pathology, pattern of involvement, and prognosis. *Gynecol Oncol* **77**:183-189, 2000
34. Fanning J et al: Paget's disease of the vulva: Prevalence of associated vulvar adenocarcinoma, invasive Paget's disease, and recurrence after surgical excision. *Am J Obstet Gynecol* **180**:24-27, 1999
35. Lee K et al: Comparison of Mohs micrographic surgery and wide excision for extramammary Paget's disease: Korean experience. *Dermatol Surg* **35**:34-40, 2009
37. O'Connor WJ et al: Comparison of Mohs micrographic surgery and wide excision for extramammary Paget's disease. *Dermatol Surg* **29**:723-727, 2003
43. Luk NM et al: Extramammary Paget's disease: Outcome of radiotherapy with curative intent. *Clin Exp. Dermatol* **28**:360-363, 2003

SECTION 22

Melanocytic Tumors

Chapter 122 :: Benign Neoplasias and Hyperplasias of Melanocytes

:: James M. Grichnik, Arthur R. Rhodes, & Arthur J. Sober

Benign melanocytic proliferative lesions form a spectrum of disorders ranging from a massive accumulation of cells in multiple tissue elements to epidermal foci with a simple increase in epidermal melanocyte number. Here these lesions are separated into *melanocytic neoplasias* and *melanocytic hyperplasias.* The term *melanocytic neoplasia* is used to describe the presence of melanocytic cells in epidermal nests [defined as three or more melanocytic cells in direct contact (also known as *thèque*)], within the dermis, or in other tissues. The melanocytic neoplasms are referred to as nevi (singular: nevus) and the melanocytic cells forming these nevi are referred to as *nevomelanocytes*. The term *melanocytic hyperplasia* is used to indicate increased melanocytes confined to the basal layer of the epidermis.

The specific molecular events causing melanocytic neoplasias and hyperplasias are beginning to be defined. Given the presence of immature (less melanized) cells in many melanocytic neoplasias, it seems likely that specific underlying mutations (such as *N-RAS*, *GNAQ*, and *B-RAF*) disrupt normal melanocytic development and result in accumulation of the nevomelanocytic cells that do not complete typical migration and differentiation. The melanocytic hyperplasias are comprised of epidermal melanocytes at an increased concentration and thus alterations of normal melanocytic homeostatic mechanisms appear to be operative. These alterations could be due to a primary melanocytic defect [such as an ultraviolet (UV)-induced mutation] or homeostatic signaling changes in the local environment (possibly driven by mutations within the local keratinocytes, fibroblasts, or other resident cells).

This heterogeneous group of disorders is currently loosely subcategorized based on clinical features and microscopic characteristics. The neoplasias described include congenital nevomelanocytic nevi (CNNs), nevus spilus, common acquired nevomelanocytic nevi (excluding atypical/dysplastic nevi covered in Chapter 123), blue nevi, pigmented spindle cell nevi (PSCN), Spitz nevi, and nodal nevi. Cutaneous melanoma is covered separately in Chapter 124. The benign melanocytic hyperplasias described in this chapter include lentigo simplex (including agminated lentigines) and solar lentigines.

CONGENITAL NEVOMELANOCYTIC NEVI

CONGENITAL NEVOMELANOCYTIC NEVUS AT A GLANCE

- Melanocytic neoplasm often exhibiting extensive nevomelanocytic infiltration of the dermis with potential involvement of the underlying adipose and muscular tissue.
- Lesions may be small or cover a substantial portion of the body surface. Nevi are generally darker than the surrounding skin, have a rugose or smooth elevated surface, and may demonstrate long, darker, thicker hairs.
- Present at birth (or shortly thereafter—tardive congenital nevomelanocytic nevus).
- Large lesions have a significant risk of melanoma development. Cranial or midline lesions and large congenital nevomelanocytic nevus lesions with satellite lesions have an increased risk of leptomeningeal involvement.
- Synonyms: garment nevus, nevus pigmentosus et pilosus, giant nevus, verrucous nevus, and giant pigmented nevus.

EPIDEMIOLOGY

The vast majority of CNNs noted at birth are small and singular, and no gender predilection has been



Figure 122-1 Familial aggregation of small congenital nevomelanocytic nevi. Note small congenital nevus on the thigh of a 3-year-old white boy and on the back of his 5-year-old male sibling.



Figure 122-2 Congenital divided nevomelanocytic nevus of the eyelid. The nevus is contiguous when the eyelids are closed, suggesting that the lesion was formed in the developing fetus before the eyelids split (i.e., before 24 weeks).

demonstrated. The most reliable prevalence rate for CNN in a homogeneous ethnic group was obtained by biopsying all pigmented lesions in 841 white infants examined within 72 hours of birth: of 21 infants with pigmented lesions, 7 babies (0.83% of 841) had a biopsy-confirmed nevomelanocytic nevus.[1] According to other studies, the prevalence of CNN appears to be slightly higher in nonwhites compared to whites. Many other series have yielded equivalent results. CNNs of 99 mm or more in diameter occur in only 1 of every 20,000 newborns, and CNNs with a garment distribution occur in only 1 of every 500,000 newborns.[2] Familial aggregation has been demonstrated for both large and small varieties of CNN (Fig. 122-1). Discordance for giant CNNs has been demonstrated for identical twins in at least three cases and for nonidentical twins in two cases.

ETIOLOGY AND PATHOGENESIS

CNNs represent a developmental abnormality of normal melanocytic development. This is presumably due to a mutation (often *NRAS*)[3] that occurs in a progenitor cell that results in the abnormal extensive accumulation of melanocytic cells along migration pathways during normal development. The events leading to the nevomelanocyte accumulation may also have effects on the surrounding tissue (i.e., increased length/darker hair) possibly due to changes in the local cytokine environment of the nevomelanocytic cells. Clinical findings such as a congenital divided nevus of the eyelid (Fig. 122-2) can give us insight into when these events occur.[4] The eyelids form at between 5 and 6 weeks in utero, begin to fuse at about 8 to 9 weeks, and reopen during the sixth uterine month.[5] Because of the contiguous nature of this lesion on the upper and lower eyelids, it may be presumed that the nevomelanocytes migrated into this location sometime during or after eyelid fusion but before the eyelids split.

CLINICAL FINDINGS

(Fig. 122-3)

HISTORY. Most CNNs are present at birth; however, there are also rare varieties of relatively large nevomelanocytic nevi (>1.5 cm) that appear for the first time between 1 month and 2 years of life, according to parental observations and corroborated by photographs (tardive congenital nevi). As a child grows, the CNN should grow relatively proportionally[6] and continue to "mature." History of disproportionate growth, especially after 6 months, or change in a nonuniform manner is of concern for possible melanoma. Both small and large varieties of CNNs have been associated with loss of pigmentation, halo depigmentation, and even regression.

CUTANEOUS LESIONS. Although CNNs are on average larger than acquired nevi, for lesions less than 1.5 cm in diameter there is no specific size limitation that can be used to predict reliably whether a given nevus is congenital or acquired. Lesions attaining a diameter of 1.5 cm or more are likely to be congenital, atypical melanocytic nevi, or melanoma.

There is no completely satisfactory way to categorize CNNs as small or large. Definitions have been based on ease of removal and termed *small* if they can be excised and the wound defect closed primarily without significant deformity. Arbitrary size criteria have also considered small (<1.5 cm; see eFig. 122-3.1 in online edition), medium (1.5–19.9 cm), and large (≥20 cm). Size, of

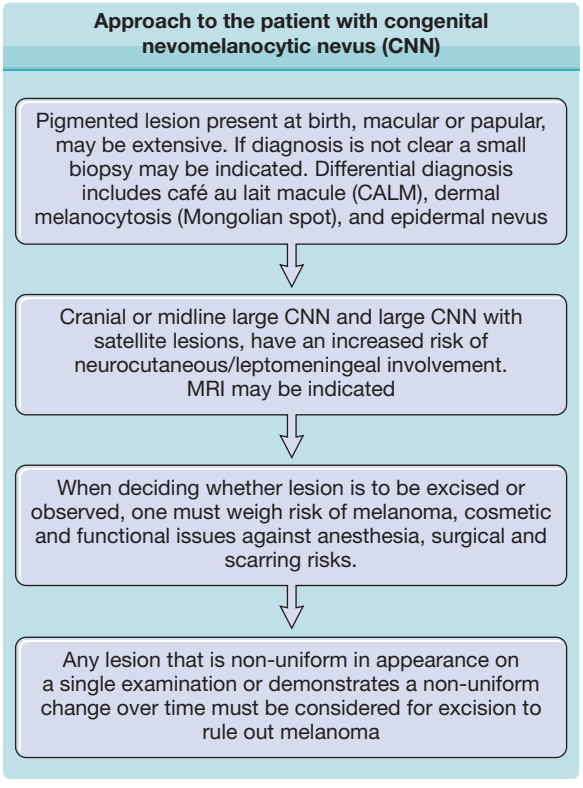

Figure 122-3 Approach to the patient with congenital nevomelanocytic nevus (CNN). MRI = magnetic resonance imaging.



Figure 122-4 Giant congenital pigmented nevus in the bathing trunk distribution. Note the satellite nevi.

course, is all relative to the affected anatomic location and the patient. *Giant* has been variously defined as a lesion as large as the patient's palm if it occurs on the head and neck (and twice that area for other anatomic sites), 30% of the body surface, or 900 cm^2 in adults (or smaller if it involves a major anatomic area) (see Fig. 122-4). Depending on the definition used, lesions that are regarded as small or medium in the newborn period may be designated medium or large, respectively, by late childhood or adulthood, given that CNNs appear to grow in proportion to the affected anatomic site.[6]

The contour of CNNs is usually smooth, regular, and sharply demarcated, and skin markings distort the skin surface at least slightly when assessed by oblique lighting. Some CNNs are relatively hairless. However, coarse, long, darkly pigmented hair may be present at birth, appear within the first year or two of life, or be delayed for several years. Lesions may have a smooth, pebbly, rugose, verrucous, cerebriform, or grossly lobular surface. CNNs with a cerebriform appearance may present as cutis verticis gyrata.

Dermoscopy may reveal a reticular pattern or globular/cobblestone pattern and may be useful in the identification of small foci of melanoma. In large congenital nevi, there can be significant variability in pigmentation and structure, and melanomas may develop in the deep components potentially reducing the utility of dermoscopy in these lesions.

Unique varieties of CNNs may have an atypical appearance and be striking for their haphazard, very dark-brown, black, or blue–black pigmentation or discontinuous pigmentation and poorly demarcated and/or irregular outlines, often associated with atypical histopathologic features. Very darkly pigmented CNNs are distinctly uncommon in whites and should suggest the possibility of atypical histopathologic features. In darkly pigmented infants, CNNs are usually darkly pigmented.

RELATED PHYSICAL FINDINGS. CNNs of the head, neck, or posterior midline, and/or the presence of multiple satellite lesions associated with large CNN may be complicated by underlying cranial and/or spinal leptomeningeal melanocytosis. This phenomenon may be asymptomatic or may give rise to communicating or noncommunicating hydrocephalus, seizures, focal neurologic deficits, mental retardation, or even melanoma. CNNs need not be giant to be associated with this underlying disorder.

There is a significant association between neurofibromatosis and giant CNNs. In a study by Crowe et al,[7] 3 of 223 patients with neurofibromatosis had extensive CNNs. In his monograph on neurofibromatosis, von Recklinghausen described 1 of 28 patients as having a giant CNN.[8] Tumors indistinguishable from neurofibroma in the absence of von Recklinghausen neurofibromatosis may develop in association with giant varieties of CNN.

Malignant degeneration of large CNNs may be associated with the relatively sudden appearance of a dermal or subcutaneous nodule, very dark pigmentation, itching, pain, bleeding, or ulceration. Often, CNN-associated melanomas appear to have evolved in nonepidermal locations.[9] Therefore, early detection of melanoma in association with a giant CNN may be difficult and not recognized until a dermal nodule or metastatic disease appears. The prognosis for patients who develop melanoma in association with giant CNNs is

usually grave.[9] Unlike melanoma in general, there is no ethnic predilection for melanoma developing in giant CNN. There have been multiple cases of lethal melanoma developing in association with small, medium, large, and giant CNNs in black children.

LABORATORY TESTS

HISTOPATHOLOGY. CNNs are characterized by the presence of nevomelanocytes in the epidermis as well-ordered thèques and/or nevomelanocytes in the dermis, which are present as sheets, nests, cords, and/or single cells. Although histopathologic features are cited as being useful in distinguishing nevi as congenital or acquired, there are no known features with absolute specificity and sensitivity. The histopathologic features of very large CNNs may be divided into nevomelanocytic, neuroid, epithelioid cell and/or spindle cell, blue, and mixed types.

In the nevomelanocytic type of large CNN, the histopathologic appearance may be identical to typical acquired nevi, with nevomelanocytes in the epidermis as well-defined thèques and/or nevomelanocytes in the papillary dermis as sheets, cords, or nests. CNNs are more likely than acquired nevi to have nevomelanocytes in the lower two-thirds of the reticular dermis and to be associated with appendageal and neurovascular structures (Fig. 122-5). There may be preferential involvement of one or more appendageal structures in CNN, such as eccrine ducts, and these structures may be abundant and malformed. Veins may be preferentially involved, with an "inflammatory" appearance showing nevomelanocytes within and around blood vessel walls. Subendothelial protrusion by nevomelanocytes in lymphatic vessels may be prominent. Arrector pili may be malformed, large, and infiltrated by nevomelanocytes. Hair follicles are often quite large and frequently associated with abundant melanin in the hair bulb. Nevomelanocytes in the deep reticular dermis may be distributed as single cells or as a single-file array insinuating among collagen bundles, sheets of cells, or combinations of patterns.

In the neuroid type of giant CNN, melanocytic elements take on the appearance of Wagner–Meissner corpuscles (lames foliacée), a palisaded arrangement of cells around a cellular mass of homogeneous material (Verocay body), and sheathing of nerves by neuroid tissue (neuroid tubes). The neuroid type of nevus may be responsible for lobulation and redundancy of tissue (pachydermatous or cerebriform appearance) due mainly to the production of connective tissue elements such as reticulin, collagen, and sometimes mucinous stroma. The neuroid type of giant CNN may take on the appearance of a pigmented neurofibroma and may be associated with congenital anomalies of bone (club foot, spina bifida, and atrophy) as well as with a "neurosarcomatous" morphologic variant of melanoma.

In the spindle cell and/or epithelioid cell type of giant CNN, the dermis may be infiltrated in whole or in part by nests or sheets of epithelioid cells and/or spindle cells. Unlike the usual variety of acquired epithelioid cell and/or spindle cell nevus, the epithelioid and spindle cell elements in CNN may involve deep reticular dermis, often intermixing with neuroid elements and ordinary nevomelanocytes. The epithelioid cell and/or spindle cell elements in giant CNN may have atypical cellular and architectural features, making differentiation from melanoma extremely difficult. In some cases, large epithelioid cells may comprise superficial papillary zones of the nevus, and smaller nevomelanocytes may appear in the same lesion in deeper zones of the reticular dermis, with a grenz zone separating the two elements.

In the blue (dermal melanocytic) type of giant CNN, the appearance may be that of a giant blue nevus, or the lesion may have elements of blue nevus (either common or cellular type) with heavily pigmented spindle-shaped melanocytic cells alone or intermixed

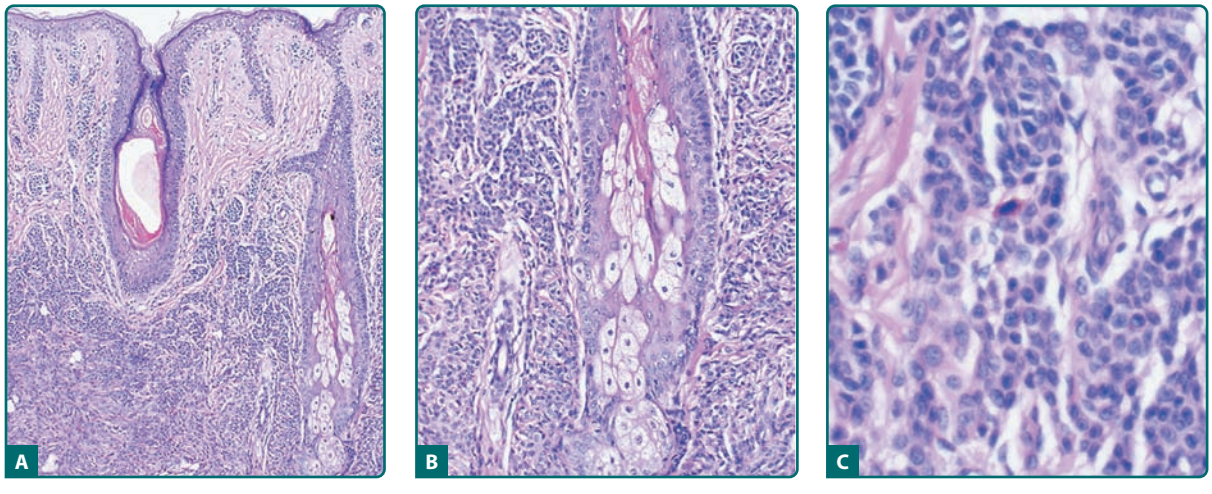

Figure 122-5 Histopathologic features of congenital nevomelanocytic nevus. Nevomelanocytes in the low-magnification image (**A**) reveal dense accumulation in the lower two-thirds of the dermis; at medium magnification (**B**), these cells encroach on dermal adnexal structures (follicular, sebaceous, and eccrine); and higher magnification (**C**) reveals dense collections of small nevomelanocytic cells.

with nevomelanocytes in the reticular dermis or deeper tissues. There may be some biologic overlap with nevus of Ito/Ota and Mongolian spot.

Unique to the very large CNN is the occasional presence of nevomelanocytes within the substance of muscle, bone, placenta, umbilical cord, cranium, and dura mater. Very extensive CNN may be intermixed with elements of vascular malformation, hemangiomas, increased numbers of mast cells, cartilage, calcification, and even bone. There may be sparse mononuclear cell infiltrates associated with some giant CNNs. In addition to melanoma, associated tumors developing in CNN include schwannoma, neuroid tumor, lipoma, rhabdomyosarcoma, neurofibroma, sebaceous nevus, hemangioma, lymphangioma, and mastocytoma. A possible explanation for these mixed neoplasms containing melanocytic, neuronal, and other elements is that the CNN precursor cell, at least in some cases, is a pluripotent stem cell that has the capacity to give rise to multiple cell types.

In giant CNNs, nevomelanocytes have been found in regional lymph nodes without further evidence of progressive metastatic disease. Whether this deposition occurred during the migration of the cells through the dermis or was secondary to migration from the skin after the neoplasm developed is unknown. The presence of nevomelanocytes in the nodal tissue from these lesions does not imply malignancy (see Section "Nodal Nevi").

CNNs may also give rise to proliferative nodules that may be difficult to differentiate from melanoma.[10]

SPECIAL TESTS. For patients with concern of possible leptomeningeal involvement, magnetic resonance imaging should be considered. For patients with concern of melanoma metastatic, positron emission tomography scan may be considered.

DIFFERENTIAL DIAGNOSIS

(Box 122-1)

BOX 122-1 DIFFERENTIAL DIAGNOSIS OF CONGENITAL NEVOMELANOCYTIC NEVUS

- Café-au-lait macule
- Nevus spilus
- Lentigo simplex
- Nevus of Ota/Ito
- Dermal melanocytosis (Mongolian spot)
- Becker's melanosis
- Arrector pili (smooth muscle) hamartoma
- Epidermal nevus
- Nevus sebaceous
- Solitary mastocytoma

COMPLICATIONS

The relationship between melanoma and large CNNs is well documented. The risk of melanoma development appears to be proportional to the size of the congenital nevus. The cumulative 5-year risk has been calculated to be 2.3%[11] and 5.7%[12] in patients with congenital nevi that involve over 5% of the body surface. The lifetime risk of melanoma for patients with very large CNNs has been estimated to be at least 6.3%, based on a questionnaire follow-up study of 151 persons with CNNs examined between 1915 and 1973 in Denmark.[13] Melanoma may develop in large CNNs at any time, but the diagnosis of melanoma was established in the first 3–5 years of life in approximately one-half of published cases in which patients ultimately developed melanoma in association with giant CNN.

A causal association between small CNNs and melanoma is more difficult to establish than for large CNNs. When histopathologic features were studied, 6% to 8% of primary melanomas were found to be in contiguity with nevi that had microscopic features characteristic of CNN.[14,15] These findings support the concept of melanoma risk even with small congenital nevi, given the expected chance association based on body surface area considerations.[16]

For cranial, midline, or CNN with multiple satellite lesions, there is a risk of leptomeningeal involvement. Symptomatic leptomeningeal melanocytosis carries a poor prognosis, even in the absence of malignant degeneration.

PROGNOSIS AND CLINICAL COURSE

CNNs have a dynamic evolution during body growth. CNNs at birth usually distort the skin surface at least slightly when assessed by oblique lighting and may become more elevated over time. Surface pigmentation also may change. Lightly pigmented CNNs may become more darkly pigmented, and darkly pigmented CNNs eventually may become less pigmented. CNNs may also develop a halo of depigmentation, potentially heralding spontaneous regression. Loss of pigmentation has been associated with regression of underlying nevomelanocytes and the replacement with sclerosis in some cases. Relatively hairless CNNs at birth may develop long, dark, coarse hair, or may maintain a relatively normal hair density. With few exceptions, CNNs generally expand in direct proportion to growth of a given anatomic zone, although disproportionately rapid area expansion of some congenital nevi may occur during early infancy.[6] Lesions in fully grown individuals should remain stable.

TREATMENT

The treatment of CNNs, large and small, depends on the perceived risk of melanoma plus cosmetic and functional considerations.

Melanoma may arise in very large CNNs even in the first several years of life. Therefore, excision of very

large CNNs should be considered as early as possible, but it is probably prudent to wait until after the first 6 months of life to reduce surgical and anesthetic risks. Management of patients with very large CNNs must be individualized. Extensive involvement of the body surface, with little or no normal skin available for graft sites, may necessitate abandoning efforts at prophylactic excision and accepting lifelong surveillance to detect the earliest signs of malignant change. It may be impossible to remove every nevomelanocyte in very large CNNs, particularly when there is involvement of vital structures or deep anatomic zones. The treatment goal is to remove as much of the nevus as possible while preserving function and improving cosmetic appearance. Other indications for surgical excision of very large CNNs include chronic pruritus, ulceration, and infection. Unlike surgical excision, dermabrasion and other modes of destructive therapy do not address the malignant potential of CNN; nevomelanocytes may still be left behind in the dermis, and the cosmetic results associated with destructive therapy are unpredictable. Melanoma has been reported after dermabrasion of large CNNs.[17] "Pseudomelanoma" has been described after laser treatment of a giant CNN.[18]

The approach to small CNNs needs to be considered carefully. It appears that the risk of melanoma development depends on CNN size, and therefore, smaller lesions appear to have less risk. However, due to the smaller size, complete excision of small congenital nevi may be relatively straightforward, resulting in excellent cosmetic results. Although atypical-appearing CNNs should be considered for immediate excision, careful surveillance without excision may be an option for clinically benign lesions depending on gross appearance, size, location, cosmetic and functional deficits (or improvement) resulting from excision, and general health issues. Given the risk of general anesthesia, for lesions perceived to be at low risk during the first decade of life it is appropriate to consider waiting until the child is old enough to tolerate local anesthesia. All CNNs should be documented at birth, preferably in the form of high-quality photographs that can be used to aid follow-up by parents and physicians. Follow-up is complicated by the natural evolutionary changes that take place in a nevus during body growth (i.e., surface, size, color, and hair), and periodic updates of photographs may be warranted. Suspicious changes in color, surface, or size require urgent evaluation.

PREVENTION

There is no known preventive approach to avoid the development of congenital nevi. UV radiation (UVR)-induced mutations clearly play no role in the initial development of the lesions already present at birth. There are no current data on parental exposure that may give rise to congenital nevus formation in their offspring. The role of subsequent UVR exposure for secondary development of melanoma is unclear. However, it seems prudent to protect lesions from unnecessary UVR exposure.

NEVUS SPILUS

NEVUS SPILUS AT A GLANCE

- Localized collection of melanocytic neoplasias forming in the background of a melanocytic hyperplasia. The neoplastic elements within the lesion tend to be histologically similar in appearance. In some lesions, the darker elements may only demonstrate increased hyperplasia compared to the background lesion.
- Clinically, the lesion appears as a hyperpigmented patch with scattered darker flat or raised elements clinically similar in appearance.
- Background lesion may be present at birth, but generally develops during infancy or early childhood. The neoplastic or hyperplastic elements may continue to develop within the lesion over time.
- Overall, risk is low but melanoma has been noted to develop in nevus spilus.
- Nevus spilus (derived from Greek *spilos*, meaning *spot*)—spotted nevus. Synonyms: speckled lentiginous nevus and zosteriform lentiginous nevus.
- Related variants with localized collection of nevomelanocytic neoplasias without the background of melanocytic hyperplasia are referred to as agminated nevomelanocytic nevi.
- Related variants with localized collection of melanocytic hyperplasias without the background of melanocytic hyperplasia are referred to as *agminated lentigines* (see Section "Lentigo Simplex").

EPIDEMIOLOGY

Nevus spilus occurs in less than 0.2% of newborns, 1% to 2% of white school children, and 2% of white adults.[19] There are no prevalence data in darkly pigmented persons. There does not appear to be a gender predilection.[19] When viewed as a risk marker for melanoma, nevus spilus shows a trend for being more common in melanoma cases than in controls. Kopf et al[19] detected nevus spilus in 5 (4.8%) of 105 white adults with melanoma compared with 14 (2.3%) of 601 dermatology outpatients.

Approach to the patient with nevus spilus

Background evenly hyperpigmented patch but also including scattered hyperpigmented foci. Wood's light maybe required to visualize background hyperpigmention.

↓

New hyperpigmented foci may develop over time. If one of the foci is unusual compared to the others, is non-uniform, and/or changing, it should be excised to exclude the possibility of melanoma.

Figure 122-6 Approach to the patient with nevus spilus.

ETIOLOGY AND PATHOGENESIS

Nevus spilus may be postulated to develop along similar pathways as a congenital nevus, but instead of the underlying mutation creating a massive accumulation of nevomelanocytic cells in the dermis, the genetic defect creates a field of cells that are susceptible to a secondary event leading to the development of focal individual melanocytic neoplasms within the localized melanocytic hyperplasia. The specific mutations, chromosomal aberrations (mosaicism), and/or dysregulated pathways involved in this process are unknown.

CLINICAL FINDINGS

(Fig. 122-6)

HISTORY. Rarely, nevus spilus may be present at birth. More commonly, the lesion becomes evident during infancy or early childhood. More darkly pigmented, flat, or raised elements are usually present when the lesion is first recognized, but new pigmented elements may appear over time.

CUTANEOUS LESIONS. Clinically, the lesion presents as a circumscribed macule/patch of tan pigmentation with features consistent with lentigo or café-au-lait macule including scattered, more darkly pigmented nevomelanocytic (or more hyperplastic) macular and/or papular elements. The tan macular background pigmentation ranges from less than 1 cm to greater than 10 cm in diameter (Fig. 122-7). Although nevus spilus may occur anywhere, lesions have been noted primarily on the torso and extremities. A divided nevus spilus of the eyelid has been reported.[20] Lesions may be localized or have a segmental distribution. Giant varieties of nevus spilus may occur.

RELATED PHYSICAL FINDINGS. Nevus spilus has been associated with other anomalies of vascular, central nervous system, or connective tissue origin. Multiple granular tumors and nevus flammeus have been associated with a giant nevus spilus. Large varieties of nevus spilus may be associated with muscle atrophy, other neurological disorders, and phacomatosis pigmentokeratotica.[21]

LABORATORY TESTS

HISTOPATHOLOGY. The tan background pigmentation usually consists of increased numbers of



Figure 122-7 Nevus spilus. **A.** Nevus spilus appearing first at age 3 years on the ankle and foot of a 25-year-old white woman. **B.** Congenital nevus spilus on the arm of a 10-year-old white male.

melanocytes in a lentiginous epidermal pattern. Routine and electron microscopic studies of nevus spilus may demonstrate melanin macroglobules in some cases. The flat, dark elements of nevus spilus may demonstrate foci of increased melanocytic hyperplasia or melanocytic dysplasia (architectural disorder and variable cellular atypia), whereas the raised elements usually contain collections of nevomelanocytes in the epidermis and/or dermis. The neoplastic elements of nevus spilus may also consist of epithelioid and/or spindle cell nevi, nevi with dysplastic features, or blue nevi.

SPECIAL TESTS. There are no identified molecular tests of value, at least currently.

DIFFERENTIAL DIAGNOSIS

(Box 122-2)

COMPLICATIONS

There are insufficient data to be certain of the natural history of nevus spilus or to comment specifically about its malignant potential; however, caution must be exercised in affected individuals. More than 20 cases of melanoma have been reported to develop in contiguity with nevus spilus, with some cases ending in metastatic disease and death.

PROGNOSIS AND CLINICAL COURSE

In general, nevus spilus is a benign lesion that may develop more spotted elements over time. Once developed, nevus spilus lesions are presumed to persist throughout life, although it is possible that some elements within the nevus spilus or even the entire nevus spilus itself could regress with time. There are no long-term follow-up studies of nevus spilus.

TREATMENT

No standard guidelines exist for the management of patients with nevus spilus. Clinical appearance (typical or atypical), history of stability or instability of pigmented elements, congenital or noncongenital onset, perceived risk of developing melanoma, and cosmetic concerns are considerations when determining whether to excise or recommend periodic clinical evaluation for life. Atypical-appearing new and/or unstable elements in nevus spilus should be evaluated by histopathologic examination to exclude melanoma. A nevus spilus with dysplastic or congenital features may have a greater risk of developing melanoma.[22,23]

BOX 122-2 DIFFERENTIAL DIAGNOSIS OF NEVUS SPILUS

- Agminated nevomelanocytic nevi
- Agminated lentigines
- Becker melanosis
- Congenital nevomelanocytic nevus with heterogeneous pigmentation
- Café-au-lait macule

PREVENTION

It is theoretically possible that increased UVR exposure results in the development of new nevomelanocytic proliferations or increased malignant potential of nevus spilus.

COMMON ACQUIRED NEVOMELANOCYTIC NEVUS

COMMON ACQUIRED NEVOMELANOCYTIC NEVUS AT A GLANCE

- A spectrum of nevomelanocytic neoplasias often subcategorized based on location of cells: cells in the epidermis (junctional), dermis (intradermal), or both areas (compound). Pathologically, the cells in the deeper dermis tend to be smaller in size and express melanocytic antigens at reduced levels. Melanocytes in the epidermis may be normal or increased in number compared to adjacent nonaffected skin.
- Clinically, the lesions tend to be uniform in appearance and relatively small in size.
- Primarily develop during childhood/young adulthood.
- Increased numbers of acquired nevi suggest an increased risk for melanoma development (also see Chapters 123 and 124).
- Synonyms: nevus cell nevus, nevocellular nevus, nevocytic nevus, soft nevus, neuronevus, pigmented nevus, pigmented mole, common mole, melanocytic nevus, hairy nevus, cellular nevus, and benign melanocytoma.

EPIDEMIOLOGY

Common (also called *typical*) acquired nevomelanocytic nevi develop after birth, slowly enlarge symmetrically, stabilize, and after a period of time may regress. The majority of common acquired nevi appear to develop during the second and third decades of life, although some lesions may appear in the first 3–6 months of life.

A number of studies have quantified the number of typical acquired nevi in different age groups. In 432 European whites between the ages of 4 days and 96 years, nevi that were 3 mm in diameter or larger were detected in females and males, respectively, at median numbers of 0 and 2 in the first decade, 10 and 16 in the second decade, 16 and 24 in the third decade, 10 and 19 in the fourth decade, 12 and 15 in the fifth decade, 4 and 12 in the sixth decade, and 2.0 and 3.5 in the seventh through the ninth decades.[24] In a series of Australian whites, the average number of nevi per person peaked at 43 for males and 27 for females during the second and third decades, respectively, and decreased to very few in the sixth and seventh decades.[25] A similar age-related prevalence rate for nevi has been documented in other countries. A difference in frequency distribution of nevi according to gender is not clear, although most series show a close to equal prevalence in males and females.

The prevalence of acquired nevi varies according to ethnicity. In African blacks, the overall prevalence of nevi (regardless of size) tends to be higher in those with lighter skin versus those with darker skin.[26] When prepubertal whites were examined for nevi, a significant association for excess nevi was documented for pale skin, blue or green eyes, blond or light-brown hair, and a tendency to sunburn, but not a tendency to freckle.[27] Other studies show variable relationships to these same parameters.

Environmental exposure to UVR appears to be a critical permissive or inciting factor for the development of nevomelanocytic nevi. In an Australian study, nevus density has been shown to increase with increasing sun intensity in the northern parts of the continent.[28] Furthermore, the use of UVR-blocking sunscreens has been shown to decrease the number of new nevi in children.[29]

Genetic factors appear to play a role in the development of nevomelanocytic nevi. The size, frequency, and distribution patterns of acquired nevi tend to aggregate in families. This observation is well documented for atypical nevi in the setting of familial cutaneous melanoma (see Chapter 123) and CNN.

Acquired nevi may be attacked by the patient's immune system, resulting in the development of a halo nevus (see Section "History"). Of 8,298 whites aged 12–16 years, there were 51 males (1.2%) and 22 females (0.5%) who had one or more halo nevi, for an overall prevalence rate of 0.9%.[30] In one large series of halo nevus,[31] individuals ranged in age from 3 to 42 years (mean age, 15 years), with the vast majority of cases occurring before age 20 years. The halo phenomenon has been associated with prominent numbers of common nevi, prominent numbers of atypical nevi, and CNN both small and large.

ETIOLOGY AND PATHOGENESIS

There has been an ongoing debate as to the origin of nevomelanocytic nevi. Although many theories have been proposed, and some supporting data are available, the critical events leading to nevus development remain a mystery. Although data suggest that nevomelanocytic nevi are clonal,[32–34] the *B-RAF*[35] mutation that is present in the majority of common acquired (including atypical) nevi appears to be polyclonal[36] suggesting that *B-RAF* mutation is either a secondary event or that nevomelanocytic nevi can incorporate multiple precursors. Melanocytic "precursor" cells have been shown to be present in adult human skin[37] and melanocytic stem cells have been identified in the mice.[39] It is assumed that these melanocytic stem cells accumulate mutations, and when needed to replenish melanocytes, they produce nevomelanocytes instead. Presumably, these nevomelanocytes then attempt to migrate along normal developmental pathways from the dermis into the epidermis. Dependent on the underlying mutation, some cells might also migrate aberrantly. The defect, timing, and local tissue influences could allow for the creation of a variety of different melanocytic neoplasias.[38]

The clinical phenomenon of eruptive nevi also further confounds the location of the cell of origin issue. In these patients, there is the abrupt appearance of numerous similar appearing nevi often in the setting of immunosuppression or chemotherapy. Although it is generally assumed that these lesions all directly originate in the skin, drawing a comparison with epidermotropic metastatic melanoma leaves open the possibility of a circulating nevomelanocytic precursor.

CLINICAL FINDINGS

(Fig. 122-8)

HISTORY. Acquired nevi primarily develop during childhood and early adulthood. Although nevi can clearly persist in a stable state for decades, many eventually regress. In a study following patients with dysplastic/atypical nevi, the highest rate of nevus development and nevus regression was present in patients younger than 30 years of age.[40] In later adult years, nevus counts are significantly less than those in young adulthood, and the rate of new or growing nevi declines, while melanoma incidence increases. Thus, a growing lesion in an older adult has a greater risk of being melanoma although new or changing moles still significantly outnumber melanomas.[40]

Spontaneous and concurrent development of scattered nevomelanocytic nevi often similar in appearance has been termed *eruptive nevi*. Often, these patients have experienced a blistering skin disease, immunosuppression, cytokine administration, or chemotherapy. Eruptive nevi may have a pattern consistent with common acquired nevi, but Spitz nevi and blue nevi have also been described.

Patients may also present with the history of spontaneous development of a zone of depigmentation around a preexisting nevus. This phenomenon has been called a *halo nevus*. The halo phenomenon may be associated with acquired and CNN as well as with melanoma and nonmelanocytic tumors. This phenomenon often, but not always, indicates the onset of involution and subsequent regression of the melanocytic nevus.

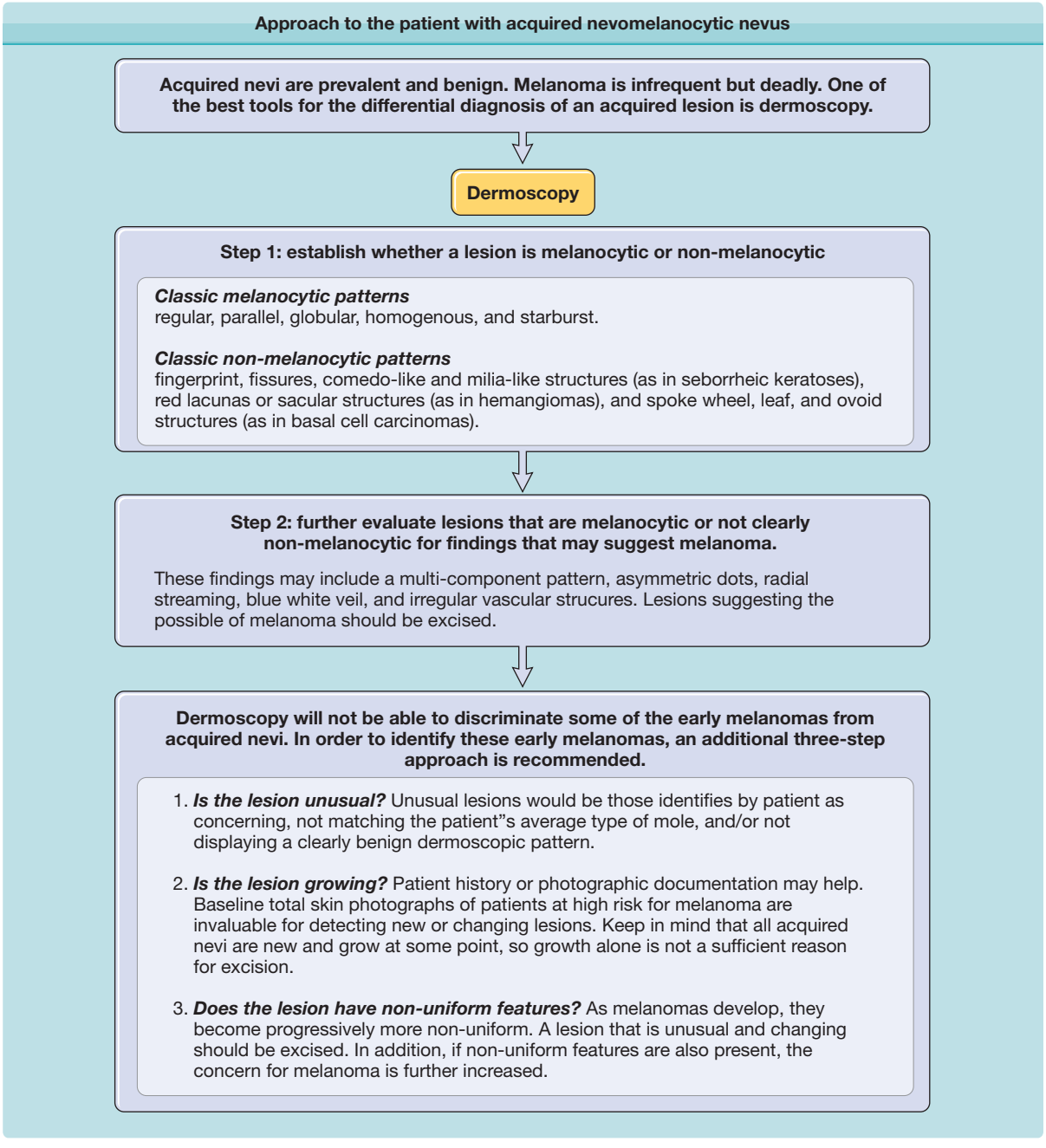

Figure 122-8 Approach to the patient with acquired nevomelanocytic nevus.

Other names for this phenomenon include *leukoderma acquisitum centrifugum*, *Sutton's nevus*, *leukopigmentary nevus*, *perinevoid vitiligo*, and *perinevoid leukoderma*. Time for full evolution to depigmentation of the halo is not known, but patients report the phenomenon occurring over days to weeks, with little change occurring in the halo thereafter. The central nevus may persist or eventually disappear. Disappearance may take months to years. Areas of depigmentation that remain after the central nevus disappears may remain stationary for many years or repigment after months to years. There are lesions in which the nevus does not involute, and repigmentation of the depigmented halo may occur. Halo may be associated with depigmentation at other sites, and the depigmentation may resolve when the CNN is excised (see Fig. 122-10).

CUTANEOUS LESIONS. Common acquired nevi vary considerably in their gross appearance. In general, appearance to the naked eye is orderly: the lesions have a homogeneous surface and coloration pattern, round or oval shape, regular outlines, and relatively sharp borders (Fig. 122-9). Common acquired nevi may be papillomatous, dome-shaped, pedunculated, or flat-topped and are usually skin-colored, pink, or brown. More elevated acquired nevi tend to be more



Figure 122-9 Typical acquired nevomelanocytic nevi. **A.** Junctional nevus. A uniformly dark brown macule, round in shape, with smooth, regular border. **B.** Two compound nevi. A uniformly pigmented papule and domed nodule. The upper lesion is flatter and tan with slight central elevation. The lower lesion is older and is uniformly elevated due to an increased intradermal component.

lightly pigmented, and flatter acquired nevi tend to be more darkly pigmented. More elevated and less pigmented lesions tend to have a prominent intradermal nevus component, whereas flatter and darker lesions have a more prominent junctional melanocytic or nevomelanocytic component and a less prominent dermal component. Very dark brown and black are unusual colors for common acquired nevi in lightly pigmented people. In contrast, dark pigmentation is usual for common acquired nevi in people who have darkly pigmented skin. Blue, gray, red, and white areas in a nevus are not typical features and ought to be viewed with suspicion. The surfaces of nevi may reveal hair that is less than, equal to, or greater than that of surrounding skin. Hair in nevi may be coarser, longer, and darker than that in surrounding skin (often these lesions reveal congenital features). Lesions on palms and soles are usually hairless. Size, shape, skin markings, and hair quality of nevi in darkly pigmented persons are similar to those in whites.

Dermoscopy reveals a number of diagnostic patterns in common acquired nevi. In general, these lesions reveal a reticular or globular pattern. On the palms or soles, a parallel-furrow, lattice, or fibrillar pattern may be present. Nonuniform patterns and parallel-ridge patterns are worrisome for melanoma.

Pigmented nevi of the nail apparatus may be a dark or light brown, extending from the nail matrix to the distal edge of the nail plate (see eFig. 122-9.1 in online edition); extension of the pigmentation onto the skin of the nail fold or beyond the distal nail groove should be considered suspicious for melanoma. Nevi on palms and soles, even compound nevi, may not distort the skin surface, perhaps because of a thickened stratum corneum in these sites.

The typical halo nevus has a pink or brown central nevomelanocytic nevus surrounded by a symmetric round or oval halo of depigmented skin. The central nevus may be small in typical acquired nevi, or large in acquired atypical or congenital nevi (Fig. 122-10). The halo of depigmentation is variable in size, usually a radial zone 0.5–5.0 cm around the central lesion. White hairs may be seen in hair-bearing depigmented areas. Alopecia areata surrounding a halo nevus has been reported. The number of halo nevi per person may be one or many, multiple lesions occurring in 25% to 50% of patients. For patients who have multiple lesions, only a few nevi are usually affected, but as many as 90 halo nevi have been reported in a single person. Any nevus in any anatomic site may be involved, but the posterior torso is involved most commonly. Lesions are usually asymptomatic. UVR may cause redness and even blistering in the perinevic halo. An atypical gross appearance of the central nevus or an asymmetric halo of depigmentation around a suspicious nevus, particularly in adults, should raise suspicion for melanocytic dysplasia or melanoma. The depigmented halo associated with melanoma tends to be irregular and surrounds the tumor asymmetrically, and the central lesion usually has an atypical appearance. Unfortunately, this appearance is not always the case and a high index of suspicion for melanoma must be maintained in patients who have prominent numbers of atypical nevi (with or without melanoma) and also have halo nevi.

A second process that may provide some insight into factors involved in melanocytic interactions with the



Figure 122-10 Halo nevomelanocytic nevus. **A.** Acquired halo nevus on the chest of a 16-year-old white boy whose maternal grandmother had melanoma. **B.** Acquired halo nevi on the back of a 6-year-old white boy who has dysplastic nevi in the hairy scalp and a history of melanoma in his maternal grandmother. Scale in millimeters. **C.** Halo congenital nevomelanocytic nevus on the neck of a 4-year-old female of a black African-American mother and white father. This child also had scattered areas of vitiligo-like depigmentation in other sites. A 3-year follow-up after excision of the nevus revealed almost total repigmentation of the widely scattered previously depigmented areas.

immune system is a process that results in the development of an eczematous dermatitis presenting as a red halo around nevi (halo dermatitis, Meyerson's nevus). Unlike halo nevi, regression of the nevus does not usually occur, and the eczematous changes clear over the course of several months.

RELATED PHYSICAL FINDINGS. For patients with multiple nevi, there is an increased risk for cutaneous melanoma (see Chapters 123 and 124). This risk is further increased in the setting of atypical nevi and/or a personal or family history of melanoma. For patients with eruptive nevi, there may be findings suggestive of a blistering disease or immunosuppression. For patients with halo nevi, the most common associated condition is vitiligo, occurring in 18% to 26% of patients. Halo nevus may be associated with poliosis, Vogt–Koyanagi–Harada syndrome, pernicious anemia, prominent numbers of nevi, atypical nevi, and a personal or family history of melanoma (including ocular melanoma). Relatively large and numerous nevi are common in Turner syndrome and Noonan syndrome.

LABORATORY TESTS

HISTOPATHOLOGY. Nevomelanocytes in the epidermis have a nuclear size similar to or larger than nuclei of epidermal melanocytes. Epidermal nevomelanocytes are arranged in nests surrounded by a smooth perimeter of epidermis, and the epidermis is separated from nevomelanocytes by a retraction artifact (Fig. 122-11). Nevomelanocytes have abundant pale-staining eosinophilic cytoplasm and may have pseudopodic or dendritic extensions that are more evident when enzymatic or immunohistochemical techniques are used for visualization. Nuclei of nevomelanocytes are pale-staining, characterized as vacuolated or reticulated; a nucleolus is usually visible.[41] Epidermal melanocytes between junctional thèques of nevomelanocytes in typical nevomelanocytic nevi are disposed as single typical cells, with overall numbers equal to or slightly greater than that in adjacent sun-exposed skin (see Fig. 122-11).[42] The overlying epidermis is often normal in appearance but may be thickened in a lentiginous pattern (elongated and club-shaped rete ridges), with an appearance similar to seborrheic keratosis complete with horn cysts or epidermal verrucous hyperplasia similar to epidermal nevus.

The dermal component of nevi has an orderly progression from top to bottom, with larger epithelioid cells above (epidermis and superficial papillary dermis) blending into a pattern of smaller cells in the deeper dermis.

Nevomelanocytes in the epidermis and upper papillary dermis frequently resemble epithelial cells, with an oval or cuboidal shape, a well-outlined cytoplasm that is homogeneous in character, a nucleus not much larger than nuclei of basal keratinocytes, and a visible nucleolus. In the epidermis and superficial dermis nevomelanocytes frequently contain small amounts of melanin. In the middle or deep dermis they are usually smaller than nevomelanocytes in the superficial dermis or epidermis and frequently resemble lymphoid cells. Nevomelanocytes in the deep dermis may be round or oval and often resemble Schwann cells or fibroblasts when they are singly disposed and may be difficult to differentiate from fibroblasts unless they are disposed in sheets, cords, or patchy aggregates (see Fig. 122-11).[43] Usually, dermal nevomelanocytes are interposed among collagen bundles, and there is no distinct rim of collagen or retraction artifact between surrounding collagen and cellular aggregates. Nevomelanocytes in the dermis of typical acquired nevi have a monotonous similarity one to another within the same anatomic level and an overall symmetry of architecture from top to bottom and side to side.

Some acquired lesions are found to have congenital features (reviewed in Section "Congenital Nevomelanocytic Nevi") suggesting that though these features may be present in congenital nevi, they are not limited to those present at birth. Other acquired nevi may be found to have atypical features (see Chapter 123).

Inflammatory cellular infiltrates in typical, stable acquired nevi are usually scanty[41] or absent.

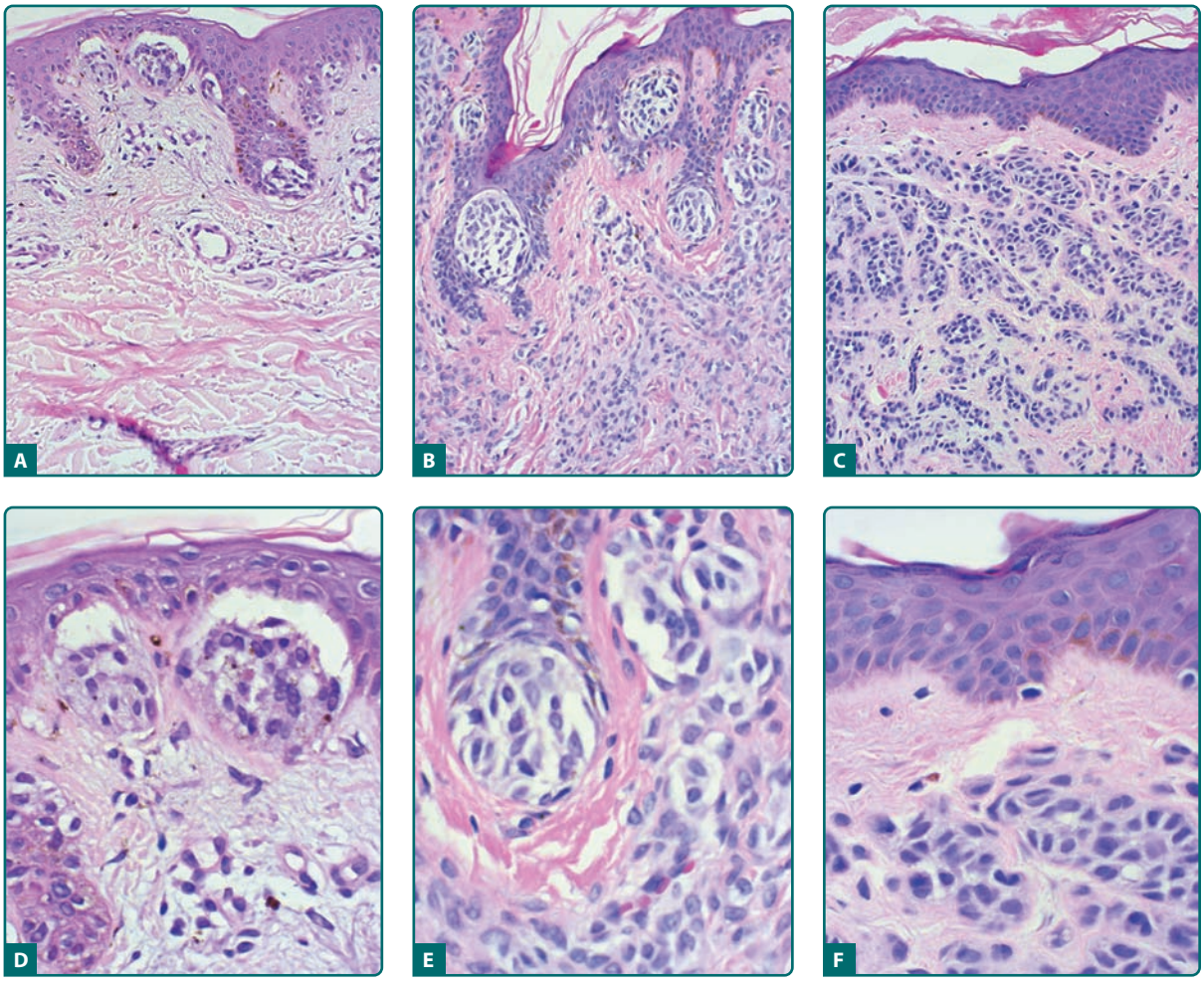

Figure 122-11 Histopathologic features of acquired nevi. Junctional nevus (**A**) and higher magnification (**D**). Compound nevus (**B**) and higher magnification (**E**). Intradermal nevus (**C**) and higher magnification (**F**). Well-formed nests of nevomelanocytes are present in the junctional and compound nevi. Sheets and cords of nevocytes are present in the dermis of the compound and intradermal nevi. A grenz zone free of nevomelanocytes is present just below the epidermis in the intradermal nevus (**C** and **F**).

Melanin-laden macrophages are usually apparent in the superficial papillary dermis of nevi, their number usually proportional to degree of melanin production.[41] Blood vessel proliferation, eosinophilic fibrosis, and lamellar fibroplasia (features frequently seen in atypical melanocytic nevi) are usually not prominent in typical acquired nevi. Langerhans cell density overlying typical acquired nevi and atypical nevi is increased compared with adjacent skin.[44]

Intradermal nevi that have few or no junctional nests frequently have a grenz zone relatively free of nevomelanocytes just below the epidermis (see Fig. 122-11).

Multinucleated nevomelanocytes occur occasionally and may be interpreted as a sign of benignity. Nevomelanocytes in the deep dermis may be disposed within a collagenous framework that is loose, pale, and wavy in formations called *neuroid tubes,* similar to a neurofibroma; they may be disposed in concentrically arranged whorls resembling Meissner's tactile corpuscles; and they may be spindle-shaped and embedded in loosely arranged connective tissue (neural nevi). Both neural nevi and neurofibromas show nonspecific cholinesterase activity. Myelin basic protein is detected in various neural tumors but not in melanocytic or nevomelanocytic tumors, and melanosomes are present in nevomelanocytes but not in neurofibromas or nerve tissue. Cutaneous neural lesions may be distinguished from melanocytic tumors by the presence of myelin basic protein and neurofilaments, and the absence of vimentin.

The *balloon cell nevus* is composed of peculiar foam cells comprising a portion or all of a given lesion. In addition to clear cells with single basophilic nuclei, multinucleated balloon cells and multinucleated giant cells are seen frequently. Electron microscopic studies suggest that vacuolization of nevomelanocytes in balloon cell nevi is due to enlargement and destruction of melanosomes. There appears to be no distinguishing gross features of balloon cell nevi.

The *combined nevus* refers to the incontiguity association of different types of melanocytic nevi. Most combined blue nevi are found in association with a benign compound nevus (acquired or congenital).

Recurrent melanocytic nevus (pseudomelanoma) is the name given to recurrent lesions after incomplete

removal of a benign nevomelanocytic nevus.[45] Recurrent nevi are relatively common after superficial destructive procedures (i.e., shave biopsy or dermabrasion). A markedly atypical clinical and histopathologic appearance may accompany this recurrence, making these lesions worrisome for possible melanoma. Clinically, the recurrent nevus is confined to the scar but may be markedly irregular. Histopathologically, recurrent lesions often demonstrate melanocytic hyperplasia in a lentiginous or junctional pattern (often to a greater extent than the original nevus). Moderate nuclear atypia may be present in 12% of recurrent nevi, mitotic figures in 8%, and pagetoid upward migration in 3%, raising concern about the potential biologic behavior of some recurrent lesions.[46] It is important to review the original histopathologic specimen when making re-excision and margin decisions.

No definitive and consistent histopathologic features have been described for eruptive nevi.

For halo nevi, the usual histopathologic findings are a central nevomelanocytic nevus associated with a dermal band-like lymphohistiocytic infiltrate and a depigmented zone totally or almost totally devoid of epidermal melanocytes. Immunohistochemical staining—melanoma antigen recognized by T cells (Mart-1), S100 protein, or other melanocytic markers—may help to identify residual epidermal melanocytes or the nevomelanocytes in the inflammatory infiltrate. Lymphocytes in halo nevi appear to be antigenically stimulated, and 80% are T lymphocytes, whereas B lymphocytes are scarce or absent. The T cells appear to belong to the $CD8^+$ phenotype.[47]

Other findings have been identified in nevi that may suggest modes of regression or elimination of melanocytic elements. Some of the findings include neuroid, fibrous, mucinous, and fatty degeneration.[48] Nevomelanocytes in the stratum corneum[49] represent transepidermal elimination. Psammoma bodies and amyloid bodies, present occasionally in nevi, also may be related to degeneration or regression. Fibrosis may occur as an age-related phenomenon, whereas true desmoplasia appears to be a reactive process or functional transformation by the nevomelanocytes. Follicular mucinosis has been reported in nevi in at least two cases. Spicules of bone are observed occasionally in nevi, possibly related to reactive metaplasia, trauma, or infection.

Histopathologic artifacts may occur in nevomelanocytic nevi. Shrinkage clefts may resemble lymphatics or vascular spaces, prominent in the midportion of nevi and particularly in areas with hemorrhage. Separation of sheets of nevomelanocytes into parallel rows may be caused by improper cutting. Local anesthesia injection directly into the nevus also may be associated with artifactual changes.

The state of the nevus at the time of excision may also influence the histopathologic appearance. Nevi acutely sunburned or traumatized may have features worrisome for melanoma, and these changes resolve over a short time period.[50] Nevi in a rapid growth phase also may have atypical features such as epithelioid cell appearance and pagetoid upward migration, but these observations require corroboration.

Worrisome features for possible melanoma include pagetoid upward migration of cells in the epidermis, atypical features of epidermal melanocytes [including irregularity of size and shape of cells, condensation of chromatin on nuclear membranes, a heterochromatin (clumping) pattern], failure of the cells to "mature" in the deeper dermis, persistence of pigment production in the deep dermis, lack of symmetry, frequent mitotic figures, focal areas of necrosis, and desmoplasia or fibrosis in the dermis.

SPECIAL TESTS. Special tests are not generally required in the gross and microscopic assessment of melanocytic or nevomelanocytic nevi. However, for patients who have eruptive nevi, given the association with immunosuppression, immunologic tests may be in order. Immunohistochemical profiles may be of value for difficult to diagnose lesions. Low Ki67 activity and loss of HMB45 in dermal (deeper) cells may help confirm a benign diagnosis. Compared to melanoma, common acquired nevi are genomically stable.[51] FISH (*f*luorescence *i*n *s*itu *h*ybridization) or CGH (*c*omparative *g*enomic *h*ybridization) analysis may ultimately be useful in discriminating benign lesions from lesions with a metastatic tendency.

DIFFERENTIAL DIAGNOSIS

(Box 122-3)

COMPLICATIONS

Multiple studies demonstrate that prominent numbers of nevi indicate an increased melanoma risk. Tucker et al[52] noted a 3.4 (95% confidence interval: 2.0 to 5.7) adjusted relative risk for patients with 100 nevi or more (>2 mm and <5 mm) compared with those with fewer than 25 nevi. The relative risk was increased to 12 (95% confidence interval: 4.4 to 31.0) for patients with ten or more atypical nevi compared with patients without atypical nevi. Absence of direct site specificity of nevi and melanoma suggests that nevus proneness per se indicates a general melanoma risk,[53] largely independent of hair and eye color and overall sun exposure.[54] Other traits, including skin color and freckles, may be multiplicative to the number of nevi in increasing melanoma risk.[55] The annual risk of a melanoma developing in a mole has been calculated to be approximately 1 in 200,000.[56] Furthermore, it has been reported that only 26% of melanomas are found in association with nevus elements.[57] Thus, it is likely that the majority of melanomas develop directly from normal skin (see Chapter 124). In patients with numerous nevi (and/or atypical nevi) these nevi are best viewed as risk markers, not precursors (or precancers) of melanoma.

PROGNOSIS AND CLINICAL COURSE

It is likely that acquired nevi evolve through a life cycle, first becoming apparent after infancy in the vast majority of cases, peaking in number during the second

BOX 122-3 DIFFERENTIAL DIAGNOSIS OF COMMON ACQUIRED NEVOMELANOCYTIC NEVUS

PIGMENTED LESIONS

- Solar lentigo
- Lentigo simplex
- Café-au-lait macule
- Blue nevus
- Pigmented fibrous histiocytoma (dermatofibroma)
- Kaposi sarcoma
- Pigmented basal cell carcinoma
- Pigmented actinic keratoses
- Mastocytoma
- Seborrheic keratoses
- Epidermal nevus
- Subungual hematoma
- Supernumerary nipple
- Pigmented spindle cell nevus
- Spitz nevus
- Sclerosing hemangioma
- Pyogenic granuloma
- Atypical (dysplastic) melanocytic nevus
- Cutaneous melanoma
- Nonpigmented/pink lesion
- Basal cell carcinoma
- Fibrous papule
- Verruca vulgaris
- Molluscum contagiosum
- Dermal mucinosis
- Spitz nevus (epithelioid cell nevus)
- Appendageal tumors
- Clear cell acanthoma
- Large cell acanthoma
- Other lesions with halo phenomenon
- Congenital nevomelanocytic nevus
- Atypical melanocytic nevus
- Melanoma
- Spitz nevus
- Histiocytoma
- Molluscum contagiosum
- Flat wart
- Acrochordon
- Basal cell epithelioma
- Neurofibroma
- Congenital dermal melanocytosis (mongolian spot)
- Blue nevus
- Lichen planus
- Sarcoidosis
- Psoriasis
- Angioma
- Angiokeratoma

and third decades of life, and then disappearing by the seventh to ninth decades.[24,25,48] Regression of nevi is believed to occur by neuroid, fibrous, mucinous, or fatty degeneration.[47] Transepidermal elimination of nevomelanocytes has also been noted.[49,58] Nevi also may involute during the course of inflammatory halo depigmentation (halo nevi). The pathogenesis of the halo phenomenon is poorly understood. Available evidence suggests that both humoral and cellular factors may be responsible for nevus destruction in halo nevi. Atypical nevi, melanoma, and vitiligo may occur more frequently in individuals with halo nevi.

Eruptive nevi occur as the spontaneous appearance of multiple nevomelanocytic or melanocytic nevi. These nevi are often similar in appearance to each other clinically and histopathologically. Reports generally link the initiating event to a blistering skin disease, systemic immunosuppression, chemotherapy, or treatment with "biologics."[59] The setting allowing for eruptive nevi may also predispose to melanoma development, as reported for some transplant patients. Patients who have eruptive nevi need to be monitored carefully.

There may be relatively sudden changes in nevi that are unrelated to malignant transformation. Any single nevus that is noted to suddenly change independently should be cause for concern. Causes of sudden changes in a nevus (color, surface, or size, with or without pain, itching, ulceration, or bleeding) over days or weeks include cystic dilatation of a hair follicle, epidermal cyst formation, folliculitis, abscess formation, trauma, hemorrhage, and, in the case of a pedunculated nevus, strangulation and thrombosis. These benign causes of sudden change may require close observation for several weeks until resolution occurs, or excision for histopathologic examination.

The vast majority of acquired nevi are harmless. New nevi may continue to appear and disappear throughout life, but most develop during childhood and early adulthood. New or growing nevi in older individuals are more worrisome. Melanoma risk appears to be related to the number and size of nevi; patients with numerous nevi, atypical nevi, and a personal or family history of melanoma should be considered for periodic surveillance examinations for life.

TREATMENT

The vast majority of acquired nevomelanocytic nevi require no treatment. Indications for removal of benign-appearing lesions may include cosmetic concerns or continual irritation. Lesions with worrisome clinical features need to be excised for histopathologic examination. These features are further addressed in Chapters 123 and 124. Dermoscopy may be used to differentiate benign from potentially malignant features. Photographic surveillance can play a critical role in identifying change, or lack of change, in suspicious nevi. All nevomelanocytic nevi have an initial growth phase. Thus, additional factors, such as unusual gross morphologic features, are required for decision-making for any particular lesion.[60]

Although a benign-appearing nevus associated with halo depigmentation does not require excision, it

is reasonable to recommend periodic examination of affected individuals for atypical melanocytic nevi, vitiligo, and melanoma. Atypical-appearing central nevi, presence of an asymmetric halo, eccentric placement of a melanocytic lesion in the halo, or the setting of atypical melanocytic nevi and/or melanoma (personal or family) suggest the need for histopathologic examination for melanoma. Cover-ups or sunscreens should be recommended for sun-exposed areas of depigmentation to prevent acute burn, chronic actinic damage, and UVR-induced carcinogenesis.

Complete removal of nevi is best accomplished by excision. Leaving a partially excised nevus, regardless of the initial pathology, is fraught with potentially concerning consequences of repigmentation and/or regrowth (pseudomelanoma).[45] Incisional biopsy, even for melanoma, is necessary at times, particularly for lesions that cannot be excised easily but require histopathologic diagnosis. Destructive modes of therapy (electrodesiccation, cryotherapy, dermabrasion, and laser) should be avoided. These destructive modes of therapy preclude histopathologic assessment of the treated nevi. They have the disadvantage of not providing tissue for histopathology. Although dermabrasion has been used to eliminate pigmentation of nevomelanocytic nevi, residual nevomelanocytes in the dermis are to be expected, cosmetic outcome is often unpredictable, and recurrence with worrisome clinical features may complicate future management. Laser treatment of melanocytic and nevomelanocytic lesions has the theoretic risk of malignant transformation, but a clear demonstration of this possibility is still wanting.

PREVENTION

There appears to be a direct relationship between the number of acquired nevi and sun exposure, and a decrease with sunscreen use. While there is no direct cause and effect relation between most cases of melanoma and UVR, patients at increased risk should be encouraged to minimize UVR overexposure without impeding day-to-day activities. Sensible UVR exposure includes confining outdoor activities to the early morning or late afternoon/evening, and avoiding the most intense UVR fluence occurring 2 hours either side of high noon. Cover-up clothing that blocks light transmission should be worn during intense UVR exposure. Clothing is often easier to put on than sunscreen and does not rapidly wear off with swimming or sweating. Effective sunscreens should be used as part of a comprehensive sun-protection program. Vitamin D supplementation should be recommended for patients who diligently practice UVR avoidance and protection.

BLUE NEVUS

EPIDEMIOLOGY

Blue nevi are present in fewer than 1 of 3,000 newborns, in approximately 1 of 1,000 children ≤5 years, in 1% to 2% of white school children, in 3% of Japanese adults, and in 0.5% to 4.0% of healthy white adults. The vast majority of blue nevi are single, small, deep-blue macules or papules approximately 1–3 mm in diameter.

Multiple blue nevi may be associated with lentigines, cardiac myxoma, and mucocutaneous myxomas [Carney complex/LAMB syndrome (*l*entigines, *a*trial myxomas, *m*ucocutaneous myxomas, and *b*lue nevi)]. Blue nevi have been associated with nodular mastocytosis, and a histogenic relationship has been claimed for melanocytes and mast cells.[61] Blue nevi have been reported to occur in oral mucosa, uterine cervix, vagina, spermatic cord, prostate, and lymph nodes.[62]

BLUE NEVUS AT A GLANCE

- Melanocytic neoplasia comprised of pigmented spindle and/or epithelioid melanocytes in the middermis. Includes common blue, cellular blue, combined blue, atypical, and large patch/plaque lesions.
- Lesions appear as blue, blue–gray, or blue–black papule, nodule, or plaques.
- Lesions are generally acquired but may be congenital.
- Cellular blue nevi may have an elevated risk for development of melanoma.
- Synonyms: benign mesenchymal melanoma, blue neuronevus, chromatophoroma, melanofibroma, Jadassohn–Tièche nevus, and dermal melanocytoma.
- Related lesions include nevus of Ota/Ito, Hori's nevus, and dermal melanocytosis.

ETIOLOGY AND PATHOGENESIS

The origin of common blue nevi and cellular blue nevi is unknown, but they may be derived from a mutant precursor cell resulting in the accumulation and differentiation of the melanocytic cells in the dermis instead of their normal location in the epidermis. Differentiation toward hair follicular melanocytes is possible. A specific mutation in the *GNAQ* gene has been identified in blue nevi.[63] Some varieties of cellular blue nevi stain for CD34,[64] suggesting a potential "stem cell" origin. Bednar's tumors (dermatofibrosarcoma protuberans including cells with melanocytic marker expression) also express $CD34^+$ suggesting a similar stem cell origin for these tumors with different differentiation pathways.[65] Nevus of Ito/Ota is related to common blue nevi but represents an extensive localized acquired proliferation. The extension of these neoplasms along specific neural pathways may provide insight into the etiology of these dermal proliferations, including the possible role of certain neural factors.

CLINICAL FINDINGS

(Fig. 122-12)

HISTORY. Common blue nevi are usually acquired, and once developed should remain stable. Nevus of Ota and Ito may share similar underlying defects to blue nevi and are also often acquired (in early childhood, often before age 1 year or around puberty) but are far more extensive, encompassing a portion of trigeminal (ophthalmic and maxillary) and brachial (posterior supraclavicular and lateral cutaneous) nerve distributions, respectively. Dermal melanocytosis (Mongolian spot) may also be related to blue nevi but is usually present at birth or within the first few weeks of life and centered over the lumbosacral area. Lesions of dermal melanocytosis usually regress in early childhood but may persist in approximately 10% of cases.

CUTANEOUS LESIONS. Common blue nevi are usually solitary, asymptomatic blue, blue–gray, or blue–black papules, usually less than 10 mm in diameter (Fig. 122-13). The blue–gray color of blue nevi is an optical effect of blue light backscatter from the skin over the dermal melanin (Tyndall effect). Hypopigmented, target or targetoid, and combined blue nevi (compound nevomelanocytic nevus and a blue nevus) also exist. Common blue nevi occur anywhere, but about half the reported cases present on the dorsa of hands and feet. Usually, the common blue nevus is singular, but rarely, lesions may be multiple and agminated or arranged in large plaques consisting of multiple solitary papules or nodules with intervening areas of blue discoloration. Common blue nevi also occasionally may have satellite lesions that may be mistaken for melanoma metastasis.[66] Rare giant varieties of congenital blue nevus occur, often with multiple satellite lesions.[9] The large plaque blue nevus (pilar neurocristic hamartoma) may occasionally be associated with a background of lentigo simplex.

The deep penetrating nevus may be considered a unique form of blue nevus, but some would include this lesion in the category of Spitz nevus. Deep penetrating nevi are darkly pigmented, blue–black papules or nodules, mostly on the head and neck or upper extremities, 2–9 mm in diameter, and occurring predominantly in the first four decades of life, including childhood.[67]

Cellular blue nevi are blue–gray or blue–brown nodules or plaques 1–3 cm in diameter, occasionally larger (see Fig. 122-13C). Their surface is usually smooth but may be irregular. Approximately one-half the cases are located on the buttocks or sacrum. Cellular blue nevi may develop in association with CNN, occasionally with target appearance. Cellular blue nevus differs from the common blue nevus in that it is usually larger, more elevated, more aggressive locally, and occasionally associated with lymph node "benign metastasis." Complicating the picture is the fact that melanoma may develop in a cellular blue nevus.

Malignant blue nevus (melanoma) may develop in contiguity with a cellular blue nevus, nevus of Ota, combined congenital blue nevus, or de novo. Malignant blue nevus presents as an expanding dermal nodule with or without ulceration. There is some dispute as to whether malignant blue nevus should be considered a separate entity from melanoma or simply referred to as a *melanoma developing in a blue nevus*.

RELATED PHYSICAL FINDINGS. The presence of epithelioid blue nevi may warrant consideration of Carney complex/myxoma syndrome/LAMB syndrome, with evaluation for related findings, including atrial myxomas and endocrine tumors.

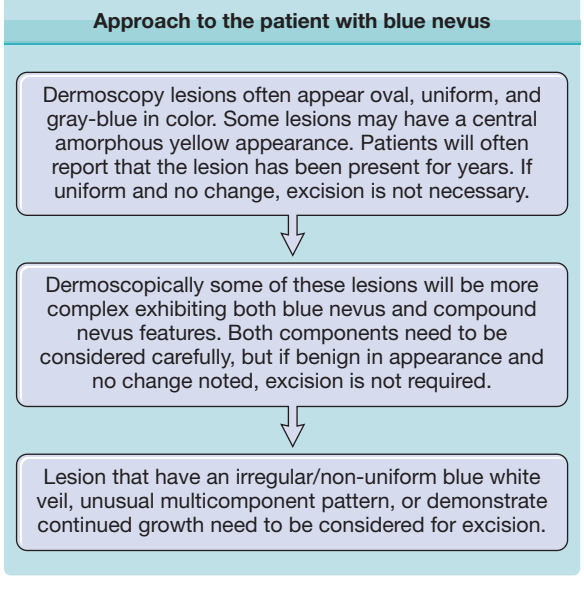

Figure 122-12 Approach to the patient with blue nevus.

LABORATORY TESTS

HISTOPATHOLOGY. In common blue nevi, dermal melanocytes appear as melanin-containing fibroblast-like cells grouped in irregular bundles admixed with melanin-containing macrophages, associated with excessive fibrous tissue in the middle or upper reticular dermis, occasionally extending downward to subcutaneous fat or upward to papillary dermis (Fig. 122-14). Elongated melanin-producing dermal melanocytes in common blue nevi usually lie with their long axis parallel to the epidermis. Except in the case of combined blue nevus (with a compound nevomelanocytic nevus component), the epidermis in common blue nevi appears normal. Combined blue nevi have been noted in 1% of melanocytic nevi excised for histopathologic examination.[68]

Pathology of the plaque-like blue nevus (pilar neurocristic hamartoma) reveals a peripilar grouped arrangement of mostly spindle cells containing varying amounts of melanin, patterns of a common blue nevus and dermal melanocytosis (Mongolian spot), and presence of abnormal (granular) melanosomes. There are other varieties of plaque-like blue nevi with subcutaneous cellular nodules with a range of histologic

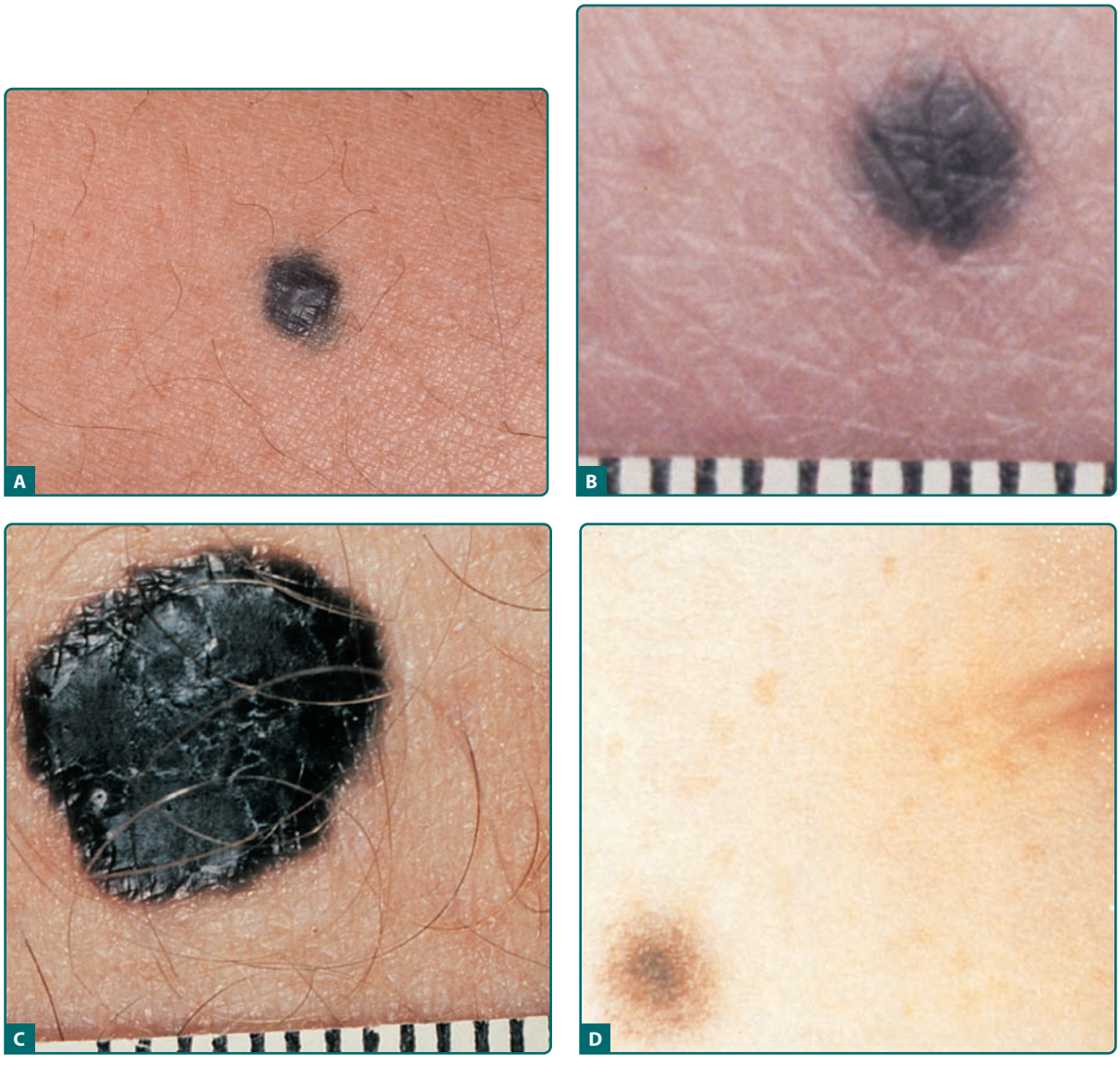

Figure 122-13 Blue nevus. **A.** Common blue nevus appearing as an acquired blue–gray papule on an adult male. Used with permission from Logical Images, Inc. Rochester NY. **B.** Common blue nevus appearing as an acquired blue–gray papule on the buttock of a 62-year-old white man. **C.** Cellular blue nevus appearing as a congenital blue papule on the low back of a 30-year-old white man. **D.** Combined common blue nevus–nevomelanocytic nevus appearing as a brown papule with a blue–gray center on the cheek of a 12-year-old white boy, beginning as a pinpoint dot at age 1 year and enlarging slowly over time. Scale in millimeters. (Part A used with permission from Logical Images, Inc., Rochester, NY.)

appearances from dermal melanocytosis to common blue and cellular blue nevi.[69]

Deep penetrating nevus—identical or similar to plexiform spindle-cell nevus—may have both spindle and epithelioid cell forms and demonstrates deep extension into the dermis or subcutis in a wedge-shaped structure potentially tracking with neurovascular or adnexal structures.[70] These lesions may be related to cellular blue nevi.

In cellular blue nevi, there is usually a component of a common blue nevus plus fascicles of spindle-shaped cells with ovoid nuclei and abundant pale cytoplasm with little or no melanin, and often epithelioid cells, present in the dermis and often in subcutaneous fat in nests, bundles, and neuroid forms with little or no intervening stroma (see Figs. 122-14C and 122-14D). Epithelioid cell and amelanotic varieties of the cellular blue nevus have been described. Epithelioid blue nevi have been reported in association with cardiac myxoma[71] or in isolation.[72] Histopathologic diagnosis may be difficult when the common blue nevus component and melanin production are sparse or inapparent. Differentiation of some cellular blue nevi from melanoma can be difficult. Occasionally, small groups of well-differentiated melanocytes are present in the marginal sinus or parenchyma of lymph nodes draining the anatomic site of the cellular blue nevus, making it difficult to differentiate malignant metastasis from benign "metastasis". It is likely that "inert" deposits of melanocytes in the capsules and peripheral sinuses of

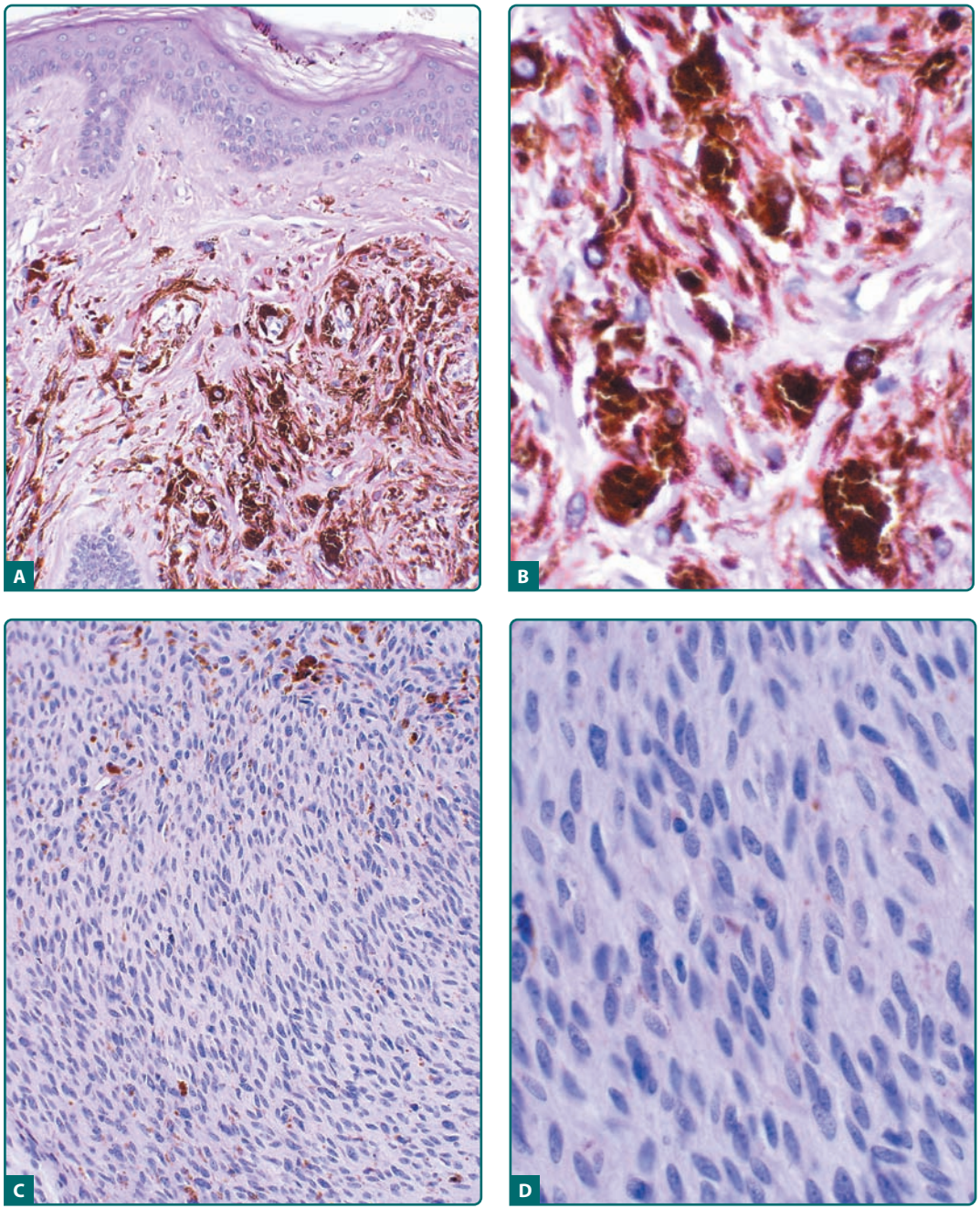

Figure 122-14 Histopathologic features of common and cellular blue nevi. Common blue nevus (**A**) and higher magnification of the dermal component (**B**) revealing heavily pigmented, elongated melanocytes. Cellular blue nevus (**C**) and higher magnification (**D**) revealing sheets of melanocytes with ovoid nuclei.

lymph nodes draining some varieties of cellular blue nevus are transported passively (see Section "Nodal Nevi").

The malignant blue nevus is a variant of melanoma, distinguished from cellular blue nevus by invasiveness, cellular atypia, pleomorphism, atypical mitoses, and areas of necrosis.

SPECIAL TESTS. Imaging tests of the heart may be required if there is concern for Carney complex/myxoma syndrome/LAMB syndrome.

DIFFERENTIAL DIAGNOSIS

(Box 122-4)

COMPLICATIONS

A major complication of blue nevi is the potential risk of melanoma. This risk appears to be highest for cellular blue nevi. Melanoma has been noted to evolve in large blue nevus patches or plaques and in associated with nevus of Ota and Ito.

BOX 122-4 DIFFERENTIAL DIAGNOSIS OF BLUE NEVUS

- Pigmented spindle cell nevus
- Tattoo (traumatic, radiation port marker)
- Primary or metastatic melanoma
- Glomus tumor
- Pyogenic granuloma
- Sclerosing hemangioma
- Dermatofibroma
- Ochronosis

PROGNOSIS AND CLINICAL COURSE

The natural evolution has not been studied for common blue nevi or cellular blue nevi. It is likely that once established, blue nevi remain unchanged or possibly regress over time. "Change" is worrisome for melanoma development.

TREATMENT

A common blue nevus that is stable for many years in an adult usually requires no therapy. Sudden appearance of a blue nodule, expansion of a preexisting blue nodule, a congenital blue nodule, or a relatively large blue nodule or plaque greater than 10 mm in diameter should be considered for histopathologic examination. Excision should include subcutaneous fat to ensure complete removal of deep dermal melanocytes, which are frequently present in the subcutaneous tissue of cellular blue nevus. The large plaque blue nevus (pilar neurocristic hamartoma) requires consideration for excision or periodic evaluation for suspicious change. Cellular blue nevus should be evaluated for excision because of its malignant potential.

PREVENTION

Sun exposure has been implicated as a causative factor in eruptive blue nevi.[73] Thus, as with other nevi, it is reasonable to minimize excessive UVR exposure.

PIGMENTED SPINDLE CELL NEVUS

PIGMENTED SPINDLE CELL NEVUS AT A GLANCE

- Acquired, benign melanocytic tumor comprised of heavily pigmented spindle-shaped melanocytes in nests confined primarily to the epidermis.
- The pigmented spindle cell nevus presents as a jet black lesion often with "starburst" appearance.
- These nevi are thought to develop quickly and then stabilize.
- Malignant degeneration is thought to be rare.
- Synonyms: Reed nevus and pigmented Spitz nevus.

EPIDEMIOLOGY

The mean age of presentation has been reported as 25.3 years, ranging from 2.5 to 56.0 years of age.[74] Similar age ranges have been reported in other studies.[75] The majority of cases occur in the third decade of life. Female patients outnumber male patients with reported ratios of 2:1,[74] 1.4:1.0,[75] and 1.3:1.0.[76] The majority of these lesions are found on the extremities with reported frequencies of 67.0%,[74] 69.6%,[76] and 75.0%.[75] There is a preference for the lower extremity, especially the thigh, with the back being the next most common site.[75]

ETIOLOGY AND PATHOGENESIS

It may be presumed that PSCN are derived from the same progenitor cells giving rise to epidermal melanocytes and nevomelanocytes. No known specific mutation has been identified.

CLINICAL FINDINGS

(Fig. 122-15)

HISTORY. PSCN was first described by Reed in 1975.[77] These lesions are generally detected as acquired lesions, often during the third decade of life. At presentation, patients often note that the lesion has increased in size.[75,76] It is not known how quickly these lesions

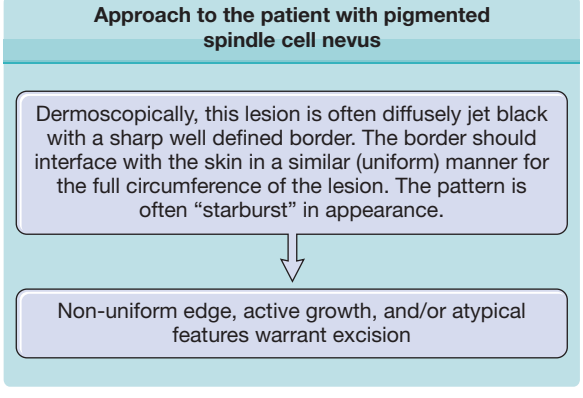

Figure 122-15 Approach to the patient with pigmented spindle cell nevus.

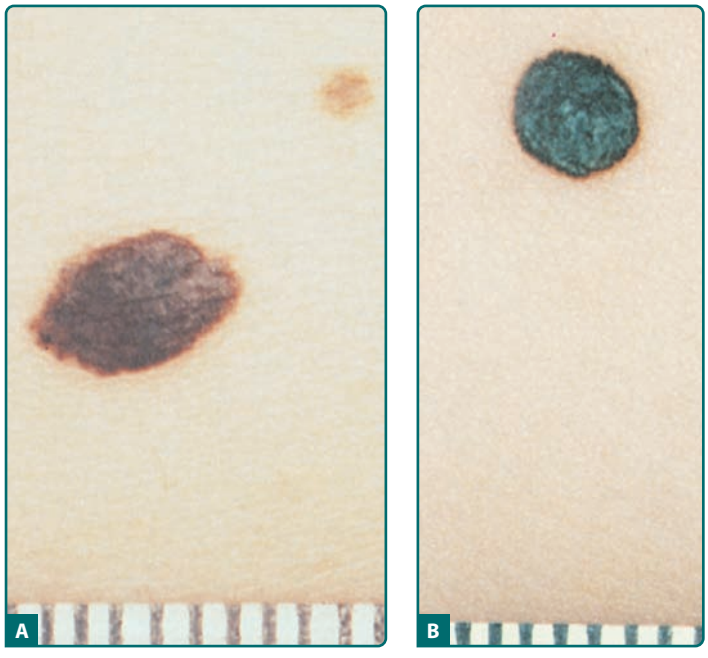

Figure 122-16 Pigmented spindle cell nevus. **A.** Very dark brown plaque appearing over several weeks on the posterior thigh of a 22-year-old white woman. **B.** Very dark-bluish plaque appearing de novo 3 months previously on the back of an 8-month-old white (Hispanic) boy. Scale in millimeters.

grow, but growth may be relatively rapid as one case report of a lesion on a 3-year-old child documented significant growth over a 3 to 6 month period.[78] Once fully developed, it is assumed that these lesions will remain stable, but the full natural history of these lesions is not well characterized.

CUTANEOUS LESIONS. The PSCN is usually a sharply circumscribed, uniformly darkly pigmented papule[74–76] (Fig. 122-16). Dermoscopically, most of the lesions are jet black but may be blue–gray or brown. In the initial growth phase, the lesions may have a globular appearance[78] but the vast majority of these lesions are uniformly dark, with a sharp interface with surrounding skin often exhibiting streaks/pseudopods and giving the lesion a starburst appearance.

RELATED PHYSICAL FINDINGS. No known association.

LABORATORY TESTS

HISTOPATHOLOGY. PSCN consists of vertically oriented fascicles of spindle-shaped, pigment-producing melanocytes (Fig. 122-17); some pagetoid upward migration may be present, but the lesion can be distinguished from melanoma by uniform nuclei, uniform cellular detail, and distinctive pattern of growth. Almost all cases of pigmented spindle cell nevus have a lymphohistiocytic host response. Spindle cells extend down eccrine ducts in 40% and involve hair follicles in 22% of lesions.[74] There is an overlap of these lesions with epithelioid cell and spindle cell nevi (Spitz tumor). In a review of 91 PSCN by Sagebiel et al,[74] cells were predominantly spindle in 74% and mixed spindle cell and epithelioid cell in 26% of patients. There are atypical variants of PSCN in which there are architectural alterations and striking cellular atypia.[76]

SPECIAL TESTS. Although BRAF mutations have been noted, these mutations are also present in other acquired nevi, and thus far there is no specific marker for PSCN.

DIFFERENTIAL DIAGNOSIS

(Box 122-5)

COMPLICATIONS

There are no reported complications, but misinterpretation of benign or malignant behavior of the lesion could result in unnecessary or insufficient treatment, respectively.

PROGNOSIS AND CLINICAL COURSE

The PSCN are thought to be benign. No local recurrence or distant spread was noted for 38 patients followed for an average of 14 months.[74] In another study, 57 patients were followed for an average of 6 years and again no local recurrence or metastasis was noted.[75]

BOX 122-5 DIFFERENTIAL DIAGNOSIS OF PIGMENTED SPINDLE CELL NEVUS

- Spitz tumor
- Blue nevus
- Hematoma
- Dysplastic junctional nevus
- Hypermelanotic nevomelanocytic nevus
- Combined nevomelanocytic/blue nevus
- Melanoma

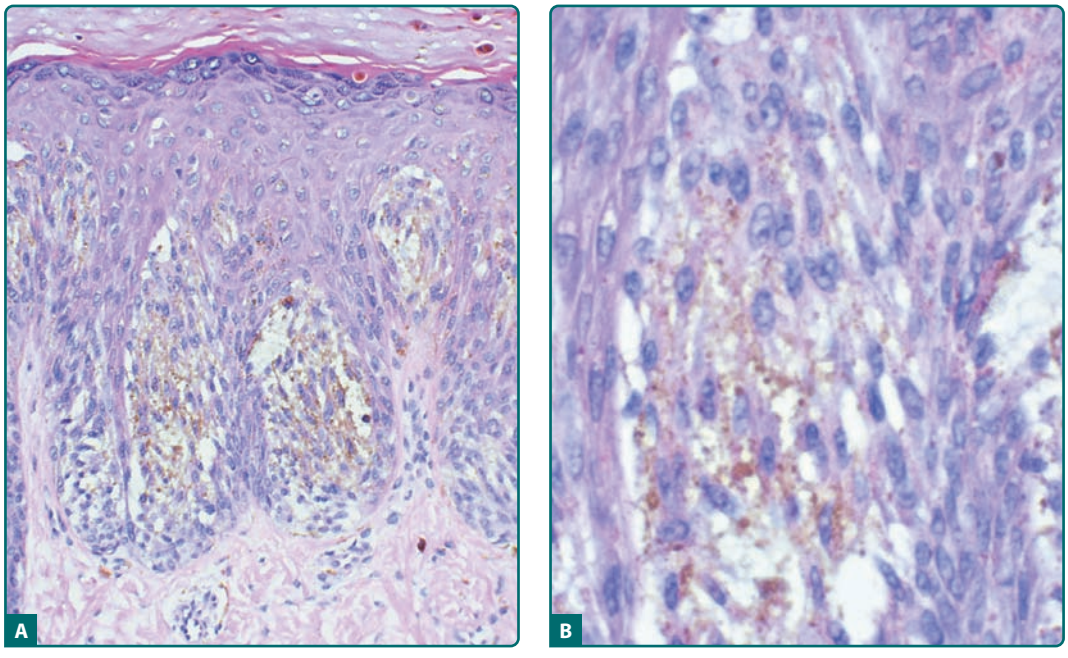

Figure 122-17 Histopathologic features of pigmented spindle cell nevus (**A**) and higher magnification of the intraepidermal component (**B**) revealing pigmented spindle-shaped cells.

TREATMENT

Given the frequent difficulties in the histopathological differentiation from melanoma, these lesions should be excised with 3–5 mm margins of normal skin.

PREVENTION

The role of UVR exposure in the development of PSCN is unknown.

SPITZ NEVUS

EPIDEMIOLOGY

An annual incidence rate of 1.4 cases of Spitz nevus per 100,000 individuals has been estimated in Australia, compared with 25.4 per 100,000 individuals for cutaneous melanoma during the same time interval.[79] Among melanocytic nevi excised in children, 1% to 8% of cases are interpreted as Spitz nevus.[80] In a case series of 308 patients with Spitz nevi reported by Allen,[81] 15% of lesions occurred in adolescents and adults, the oldest patient being 56 years of age. There appears to be no gender predilection for Spitz nevus. Published cases have been described primarily in whites.

ETIOLOGY AND PATHOGENESIS

It may be presumed that Spitz nevi are derived from the same progenitor cells that give rise to epidermal melanocytes and nevomelanocytes. Unlike common acquired nevi and congenital nevi, the *B-RAF* mutation does not appear to be involved. Amplifications of chromosome 11p and H-RAS and activating mutations of H-RAS have been noted in a subset of Spitz nevi.[82] Heritable genetic factors have not been investigated

SPITZ NEVUS AT A GLANCE

- Spitz nevi represent a spectrum of unique, usually acquired lesions, exhibiting epithelioid and often spindle-shaped melanocytic cells with abundant eosinophilic cytoplasm, large nuclei, and often prominent nucleoli. Often develop in the epidermis and dermis, or may be purely intradermal and even desmoplastic. Atypical variants exist.
- Clinically, pure epithelioid nevi are red, dome-shaped papules, while mixed epithelioid cell and spindle cell nevi may have varying degree of pigmentation.
- Spitz nevi are thought to develop quickly and then stabilize. Their clinical presentation and histopathology can cause diagnostic confusion for melanoma.
- Synonyms: Spitz tumor, nevus prominens et pigmentosus, pseudomelanoma, spindle and epithelioid cell nevus, nevus of large spindle and/or epithelioid cells, and compound melanocytoma. The previously used terms *Spitz's juvenile melanoma*, *benign juvenile melanoma*, and *prepubertal melanoma* should not be used to avoid confusion for melanoma.

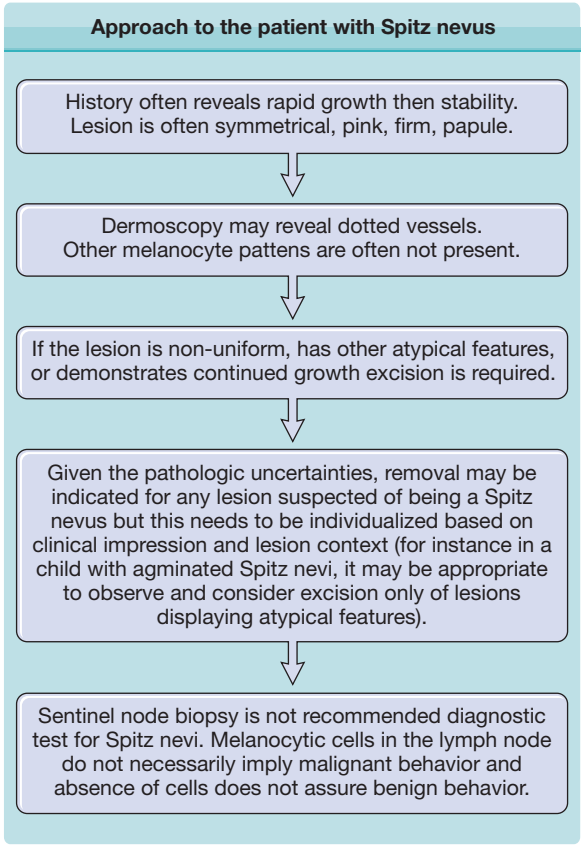

Figure 122-18 Approach to the patient with Spitz nevus.

systematically, but there is a single report of multiple nevi in identical twin boys.[80] The role of trauma in the histogenesis of Spitz nevi is speculative. One case has been reported at the site of Bacille Calmette-Guérin vaccination.[83]

CLINICAL FINDINGS

(Fig. 122-18)

HISTORY. The rate of growth, period of stabilization, and rate of regression of Spitz nevi are not known. The duration of solitary Spitz nevus before presentation is usually less than 9 months. Lesions usually show an increase in radial size over time, some gradual and others rapid.[84] Based on patients with eruptive Spitz nevi, regression has been reported to occur and may even occur in some lesions while new lesions are appearing.[85]

CUTANEOUS LESIONS. The most common variety of Spitz nevus is solitary, asymptomatic, pink or red, hairless, firm, and dome-shaped (Fig. 122-19). Some Spitz nevi may resemble a keloid. The surface is commonly smooth, and the borders may fade into surrounding skin. Verrucous, scaly, stippled, crusted, or (rarely) eroded lesions have been noted. Spitz nevi are usually asymptomatic, but pruritus, tenderness, and/or bleeding may occur.[80] A halo of depigmentation has been associated with several cases of Spitz nevus.[30,86] Spitz nevi are part of a spectrum in which some also include PSCN and deep penetrating nevi.

Spitz nevi can also present as widespread eruptive lesions or in a grouped manner as multiple agminated lesions consisting of red, red–brown, brown, or dark-brown papules or nodules, with a fine stippled surface (see Fig. 122-19C). Agminated Spitz nevi often occur in the early years of life within a background of congenital (sometimes acquired) macular pigmentation (nevus spilus) or occasionally within a hypopigmented plaque. Spitz nevi may also develop as single or multiple lesions in a large CNN.

The diameter of Spitz nevi ranges from several millimeters to several centimeters, the average being 8 mm in one series.[80] In 73% of patients in one series,[79] the nevus diameter was 6 mm or less, and in 94% of patients, the nevus diameter was less than 10 mm. Most cases are described as superficial papules or nodules, although subcutaneous involvement may occur.[85] In one series of 43 patients,[80] the anatomic location included the head or neck in 18, upper extremities in 9, torso in 9, and lower extremities in 7. Spitz nevi tend to spare palms, soles, and mucous membranes.

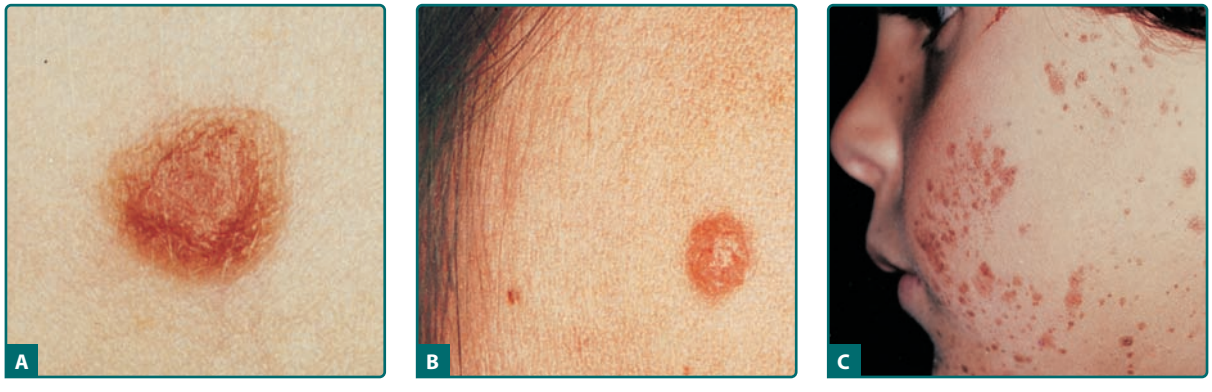

Figure 122-19 Spitz nevi. **A.** Pink plaque, which appeared de novo over an 8-week period, becoming more elevated with time, in the preauricular area of a 4-year-old white boy. **B.** Dome-shaped pink papule, which appeared de novo over a 2-week interval 4 months before, on the forehead of a 5-year-old white boy. **C.** Agminated Spitz tumors. Numerous grouped pink papules and plaques, appearing at age 6 months, on the face of a 4-year-old white boy.

RELATED PHYSICAL FINDINGS. There is no known association with other somatic abnormalities.

LABORATORY TESTS

HISTOPATHOLOGY. Unlike ordinary nevi and melanomas, melanocytic cells in Spitz nevi are large—often twice the size of epidermal basal keratinocytes,[84] with prominent mononuclear or multinucleated giant cells in the epidermis and/or dermis (Fig. 122-20). Mitoses, usually few in number, are detected in one-half the cases,[86] whereas atypical mitoses are uncommon in Spitz nevi. In contrast to melanoma, the melanocytic cells in Spitz nevi show progressive maturation with increasing depth, becoming smaller and more similar to ordinary nevomelanocytes,[84,86] with the overall distribution of cells in the dermis being wedge-shaped, with narrowing of the wedge toward the subcutaneous fat.

Coalescent eosinophilic globules (Kamino bodies), periodic acid-Schiff-positive and diastase-resistant (resembling colloid bodies), have been reported in 60% of Spitz nevi[87] (see Fig. 122-20). Similar globules may be detected in 2% of melanomas and 0.9% of typical acquired nevi, but the globules are smaller in size, more difficult to find, single rather than coalescent, and commonly periodic acid-Schiff-negative.[87]

Melanocytic elements are usually arranged in well-circumscribed nests, although there may be permeation of the epidermis by single cells or small groups of cells. In those cases with epidermal nests, artifactual clefts are usually seen above the nests in half the cases, a finding rarely observed in melanoma.[79] The epidermis is usually hyperplastic, with elongated and bulbous pegs and knobs extending into the dermis, although thinning and even ulceration may occur rarely. The dermal inflammatory cell infiltrate may be slight or marked, band-like, and mainly at the base or patchy around blood vessels and/or intermixing with nevus cells. Although melanin was observed in all 13 patients originally described by Spitz,[84] more recent studies have determined that melanin was moderate in 10% of cases and heavy in 5%.[86]

Although the bizarre histopathologic features and frequent occurrence of dermal inflammation may cause diagnostic confusion, Spitz nevus usually can be differentiated from melanoma. The histologic features of Spitz nevus in children and adults are similar.

SPECIAL TESTS. A subgroup of Spitz nevi have a gain of chromosome 11p and amplification or activation of H-RAS.[82] These markers are not routinely used in the clinical setting but may be helpful in the future for discriminating these nevi from other melanocytic neoplasias. Retention of p16 may also help discriminate Spitz nevi from Spizoid melanomas.[88]

DIFFERENTIAL DIAGNOSIS

(Box 122-6)

COMPLICATIONS

Misinterpretation of benign or malignant behavior of the lesion could result in unnecessary or insufficient treatment, respectively.

PROGNOSIS AND CLINICAL COURSE

The natural history of the Spitz nevus is largely unknown. Based on patients with eruptive Spitz nevi, it is clear that spontaneous regression can occur.[85]

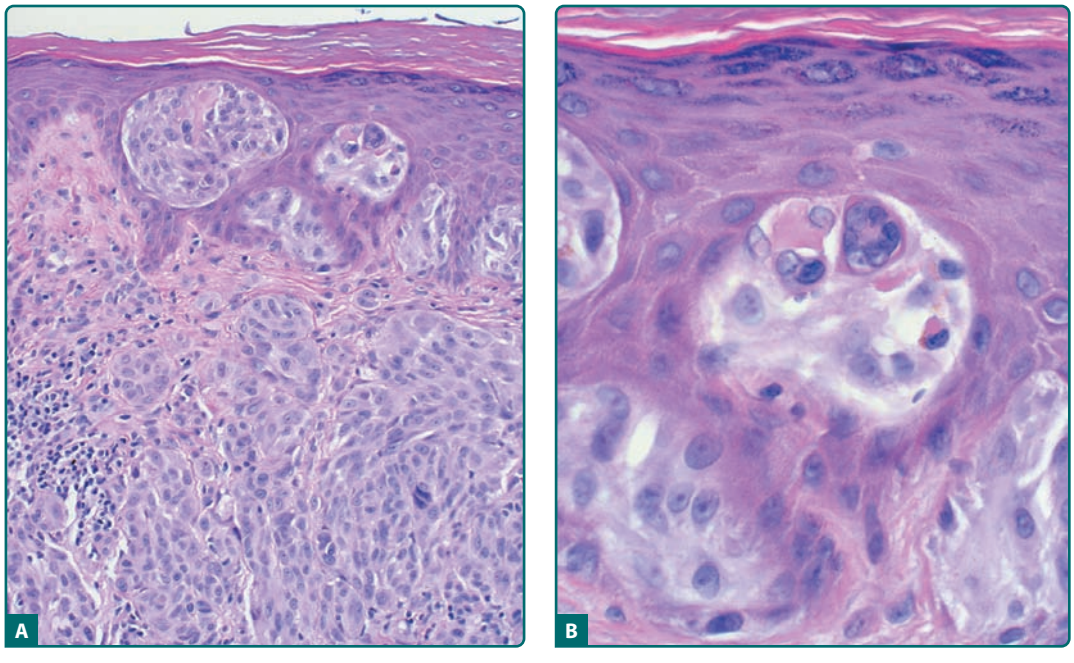

Figure 122-20 Histopathologic features of Spitz tumor (**A**) and higher magnification of the intraepidermal component revealing eosinophilic cytoplasmic changes (Kamino bodies) in several cells (**B**).

BOX 122-6 DIFFERENTIAL DIAGNOSIS OF SPITZ NEVI

NONPIGMENTED/RED

- Amelanotic melanoma
- Juvenile xanthogranuloma
- Hemangioma
- Pyogenic granuloma
- Molluscum contagiosum
- Intradermal nevus
- Solitary mastocytoma
- Granuloma
- Clear cell acanthoma
- Insect bite reaction
- Dermatofibroma
- Appendageal tumor
- Keloid

PIGMENTED

- Blue nevus
- Deep penetrating nevus
- Hypermelanotic intradermal nevus
- Melanoma
- Hematoma

WARTY VARIANTS

- Verruca vulgaris
- Seborrheic keratoses
- Epidermal nevus
- Epidermolytic acanthoma

A concern is that some lesions diagnosed as Spitz nevi may progress to melanoma or represent melanoma at the outset.[89]

TREATMENT

Complete excision with a 3–5 mm clear margin of normal skin is generally sufficient treatment for Spitz nevi. Given the difficulty of confidently excluding the possibility of melanoma in certain cases, an even wider margin of normal skin may be prudent for histopathologically worrisome lesions.[89] Incompletely excised lesions may recur in as many as 7% to 16% of patients.[80,90–92] Although some authors have advocated sentinel node biopsies in these lesions, this may only add to the confusion because Spitz nevus cells may be present in the regional lymph nodes but not necessarily indicate malignancy.[93] Management of patients who have numerous Spitz nevi requires individual judgment and periodic surveillance for new or unstable lesions.

PREVENTION

The role of UVR exposure in the development or progression of Spitz nevi is unknown.

NODAL NEVI

NODAL NEVI AT A GLANCE

- Benign melanocytic neoplasia present in a lymph node. Nevomelanocytes are often located in the capsule but may also be present in the nodal parenchyma.
- Generally asymptomatic and found incidentally as a result of lymph node removal.
- Cells may be deposited passively into the node from a cutaneous melanocytic lesion. It is also possible that abnormal migration pathways result in the nevomelanocytes taking up residence in the nodes during embryonic migration of melanocytes.
- The presence of melanocytic cells in nodal tissue creates difficulties for pathologists evaluating sentinel node biopsies in patients with cutaneous melanoma.

EPIDEMIOLOGY

Nevomelanocytes can be identified in lymph nodes with a frequency ranging from 0.3% to 7.3% in lymphadenectomies not related to melanoma and up to 22% in regional nodes removed because of melanoma.[94] When nevomelanocytes are evident in lymphadenectomies due to melanoma, it has been reported that 75% of the primary cutaneous melanomas had an associated nevomelanocytic nevus, often with congenital features.[95] A significant association has also been noted for the presence of cutaneous nevomelanocytic nevi in the zones of skin drained by lymph nodes that were found to include nevomelanocytes.[96] In most cases, the nevomelanocytes appear to be derived from common acquired nevomelanocytic nevi, but CNNs, blue nevi, cellular blue, and Spitz nevi have all also been reported to involve regional lymph nodes.[62]

ETIOLOGY AND PATHOGENESIS

There are two prevailing theories as to the mechanism by which nevomelanocytes appear in regional lymph nodes.

The first theory is that during development, nevomelanocytes get trapped in developing nodal tissues. Some support for this theory could be based on the fact that nodal nevi can be found in association with CNNs. This observation suggests that there is an opportunity for nevomelanocytes to be deposited during development. Further, blue nevus cells can be found in tissues such as prostate, cervix, vagina, spermatic cord, and seminal vesicles.[62] Thus, aberrant migration and differentiation of melanocytic cells does occur.

The second theory suggests that there may be passive transfer from the cutaneous lesion to the lymph node. Substances such as carbon, tattoo ink, and radioactive colloid are readily transferred to the draining lymph node. It is reasonable to assume that loosely adherent nevomelanocytes could also traverse the same path. In fact, nevomelanocytes have been noted in lymph channels.[62] Once in the lymph node, nevomelanocytes are generally identified in the capsule, but they can also be found in the parenchyma.[94] It is not known how nevomelanocytes get into the capsule, but it is reasonable to assume that these cells migrate from the parenchyma into the capsule. It is important to note that melanoma cells can also be found in the capsule,[97] so it is rational to assume that entry into the capsule is not limited to a developmental event. The fact that nevomelanocytes in regional lymph nodes are highly correlated with the presence of nevomelanocytic nevi in the skin supports the concept that these cells may arrive in lymph nodes via dissemination from benign cutaneous lesions.

CLINICAL FINDINGS

(Fig. 122-21)

HISTORY. Generally, nodal nevi are identified in lymph nodes that are removed because of melanoma, but these benign cells are also identified in nodes removed for other reasons. Generally, the patient does not note symptoms related to nodal nevi.

CUTANEOUS LESIONS. Common acquired nevomelanocytic nevi, CNNs, blue nevi, and Spitz nevi have been associated with nodal nevi.[62]

RELATED PHYSICAL FINDINGS. Due to concern for melanoma, patients should be evaluated for findings that might be worrisome for metastatic melanoma.

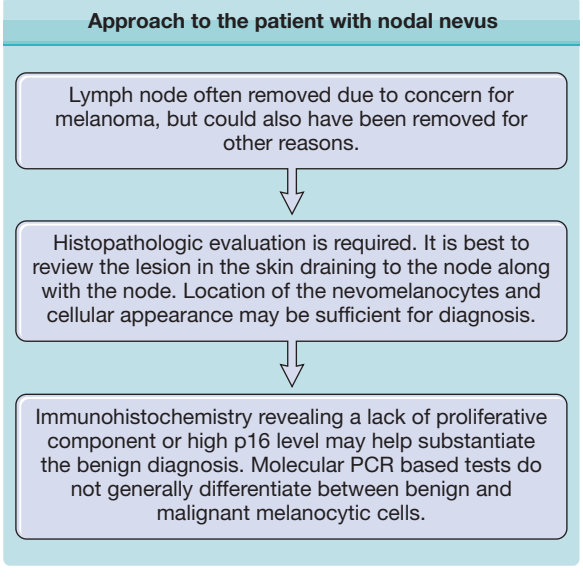

Figure 122-21 Approach to the patient with nodal nevus. PCR = polymerase chain reaction.

LABORATORY TESTS

HISTOPATHOLOGY. Pathology often reveals nevomelanocytes largely confined to the nodal capsule. However, cells may also be noted in the parenchyma. These cells should bear resemblance to the cells in the cutaneous lesion. Lack of proliferative markers (Ki67) and possibly high levels of p16 immunohistochemical markers support a benign diagnosis.[98]

SPECIAL TESTS. The use of standard immunohistochemical tests may help identify the location and cellular features of nevomelanocytes in lymph node tissue sections. Reverse transcriptase–polymerase chain reaction tests for tyrosinase mRNA in lymph nodes do not discriminate benign from malignant melanocytic nodal disease.

DIFFERENTIAL DIAGNOSIS

(Box 122-7)

COMPLICATIONS

Complications, such as scarring or lymphedema, may be the consequence of lymphadenectomy. Misinterpretation of benign nodal deposits as malignant could result in unnecessary regional lymph node dissection and treatment with systemic agents. Misinterpretation of malignant melanocytes as benign in lymph nodes may lead to undertreatment.

PROGNOSIS AND CLINICAL COURSE

If the lymph node deposits are determined to be benign, no further treatment is warranted.

TREATMENT

None required for benign nodal nevi.

LENTIGO SIMPLEX

EPIDEMIOLOGY

The frequency of lentigo simplex in children and adults has not been determined. There does not appear to be a racial or gender predilection. Lentigo simplex is the most common histopathologic pattern of darkly

BOX 122-7 DIFFERENTIAL DIAGNOSIS OF NODAL NEVI

- Melanoma
- Cells from another neoplastic source
- Foreign body deposit (tattoo ink, carbon)

LENTIGO SIMPLEX AT A GLANCE

- Includes a spectrum of melanocytic hyperplasias consisting of intraepidermal melanocytic hyperplasia and increased melanin formation. The extent of melanocytic hyperplasia can be quite variable, ranging from lesions in which the increased melanin content is notable but the increase in melanocyte number is marginal, to lesions in which accumulation of melanocytes is marked.
- Lesions consist of hyperpigmented macules and may be isolated, agminated (focal cluster), or multiple and present on skin, nails, and mucous membranes.
- May be congenital or acquired.
- Multiple lentigines may be associated with somatic abnormalities.
- Synonyms: simple lentigo, melanotic macule, lentiginosis. Other names for agminated lentigines include unilateral lentigines, partial unilateral lentiginosis, lentiginous mosaicism, and segmental lentiginosis.
- Other lesions in which epidermal melanocytic hyperplasia may be noted, and some overlap may exist with simple lentigines, include café-au-lait macules, melanoacanthoma, labial melanotic macule, melasma, and inflammatory/cytokine-induced proliferation.

pigmented lesions excised from acral sites of persons who have darkly pigmented skin.[29] Pigmented nail bands, noted in up to 20% of Japanese, may have histopathologic features of lentigo simplex.[99] For agminated lentigines, the population prevalence is unknown but believed to be rare.

ETIOLOGY AND PATHOGENESIS

The increased density of melanocytes in lentigines is presumably due to an underlying developmental or intrinsic defect in melanocyte homeostasis. In some lentigines, the presence of melanin macroglobules in melanocytes and keratinocytes suggests that defects affecting melanization pathways are also involved. The presence of lentigo simplex in association with somatic abnormalities in such diverse conditions as Peutz–Jeghers syndrome, LEOPARD syndrome (*l*entigines; *e*lectrocardiogram conduction defects; *o*cular hypertelorism; *p*ulmonary stenosis; *a*bnormalities of genitalia; *r*etardation of growth, and sensorineural *d*eafness), and LAMB/myxoma syndrome suggests that lentigo development may be influenced by a number of different developmental and genetic factors. For agminated lentigines, it is possible that chromosomal mosaicism plays a role in the development of the localized grouping of lentigines. The cause for delayed appearance of lentigines in the skin, mucosa, and nail matrix in Laugier–Hunziker pigmentation is unknown.

CLINICAL FINDINGS

(Fig. 122-22)

HISTORY. Unlike solar lentigines, lentigo simplex is by definition UVR independent. Lentigo simplex may appear as early as the first decade and may occur anywhere on skin or mucous membranes.

Generalized lentigines may occur as an isolated phenomenon without known familial aggregation and first appear at birth, during infancy, or during adulthood. Familial clustering in an autosomal dominant pattern has been noted. A number of syndromes are recognized (see Chapter 75).

In Moynahan (LEOPARD) syndrome, lentigines are present at birth or shortly thereafter and may increase in number during childhood. In Peutz–Jeghers syndrome, numerous lentigines may be present at birth or appear during early childhood. Oral pigmentation usually persists in Peutz–Jeghers syndrome, whereas cutaneous lentigines usually fade after puberty. In LAMB syndrome, the lentigines on the lips and genital sites appear in early childhood and tend to persist. In Laugier–Hunziker pigmentation, lentigines are acquired during

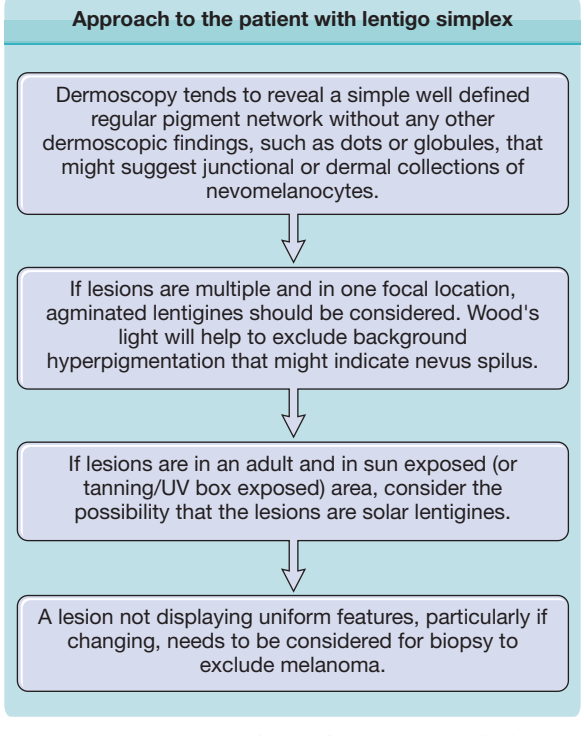

Figure 122-22 Approach to the patient with lentigo simplex. UV = ultraviolet.

adulthood and persist indefinitely, not associated with somatic abnormalities. Agminated lentigines first become manifest at birth or early childhood.

CUTANEOUS LESIONS. Lentigo simplex usually is a sharply circumscribed, light-brown to very dark-brown macule.

In Moynahan (LEOPARD) syndrome, lentigines occur on both sun-exposed and sun-protected sites, including genitalia, conjunctiva, oral mucosa, palms, and soles. In Peutz–Jeghers syndrome, lentigines are almost always present on the oral mucosa. Other common sites of involvement include lips, nose, eyelids, anus, nail bed, and dorsal and ventral surfaces of hands and feet.

Lentigines in the myxoma syndrome (LAMB) occur mainly on the face and genitalia as tan to black macules (Fig. 122-23). In centrofacial lentiginosis, the presence of pigmented macules is restricted to a horizontal band across the central face. Lentigines in Laugier–Hunziker pigmentation occur on the buccal and labial mucosa of the mouth, on fingertips and nail matrix, and occasionally in other sites of the skin and mucous membranes.

Agminated lentigines first become manifest at birth or early childhood as small, circumscribed, light-brown macules, 2–10 mm in diameter, confined to a localized area of the skin, often in a segmental distribution (Fig. 122-24) and frequently in a curvilinear or swirled pattern. Wood's lamp examination may be required to differentiate agminated lentigines from nevus spilus, because the macular background pigmentation is evident in the latter and absent in the former.

RELATED PHYSICAL FINDINGS. If there is concern that the lentigines are part of a syndrome, further evaluation is appropriate, and should be guided by the physical findings and syndrome under consideration.

LABORATORY TESTS

HISTOPATHOLOGY. Lentigo simplex consists of intraepidermal melanocytic hyperplasia in the basal layer of elongated epidermal rete ridges, without nest formation. At one end of the lentigo spectrum, lesions are more similar to café-au-lait lesions, in which the melanocyte number may only be minimally increased but pigmentary differences are marked; at the other end of the spectrum, the number of melanocytes is sufficiently increased to begin forming nests, appearing similar to a junctional nevus. Depending on the degree of keratinocytic hyperplasia, distinct separation from solar lentigo may not be possible based on histopathologic interpretation alone. Giant pigment granules (melanin macroglobules) may occur in lentigo simplex in isolation, and in association with multiple-lentigines (LEOPARD) syndrome.

In agminated lentigines and Laugier–Hunziker pigmentation, histopathologic studies reveal increased numbers of melanocytes in elongated epidermal rete ridges, similar to lentigo simplex, without nests of nevomelanocytes or cellular inflammation.

SPECIAL TESTS. Mart-1, Mel-5, and DOPA histochemistry may be useful to demonstrate increased number of melanocytes confined to the basal layer and lacking junctional nest formation. If a syndrome is under consideration, imaging studies may be required and genetic testing may be considered.

DIFFERENTIAL DIAGNOSIS

(Box 122-8)

COMPLICATIONS

There are no known complications from lentigo simplex. Complications arise from the associated syndromes.



Figure 122-23 Lentigo simplex. **A.** Acquired darkly pigmented lentigines on the vulva of a 13-year-old white girl who has *l*entigines, *a*trial myxomas, *m*ucocutaneous myxomas, and *b*lue nevi (LAMB, myxoma syndrome, Carney's complex). **B.** Multiple lentigines on the lips of the same patient. This patient died in her mid-20s of a malignant schwannoma.



Figure 122-24 Agminated lentigines. **A.** Grouping of small light brown macules, present since age 14 years, on the right side of the shaft and glans penis of a 17-year-old healthy white male. **B.** Grouping of small, light brown macules, present for at least 6 years, on the right cheek of a healthy 10-year-old African-American male. **C.** Grouping of small, light-brown macules, present since age 2 years, on the right neck and supraclavicular area of a 13-year-old healthy white female.

Atypical varieties of lentigo simplex (in any anatomic site) may be potential precursors or masqueraders of melanoma.

PROGNOSIS AND CLINICAL COURSE

The natural history of isolated lentigo simplex is not known. Once developed, lesions are presumed to be relatively stable. There is no convincing evidence that lentigo simplex evolves to a nevomelanocytic nevus. As with any process in which melanocytes are present (including normal skin), it is possible for melanoma to arise in a lentigo, but an elevated risk has not been demonstrated conclusively for lentigo simplex.

The long-term course and malignant potential of agminated lentigines and the lentigines in Laugier–Hunziker pigmentation are unknown.

BOX 122-8 DIFFERENTIAL DIAGNOSIS OF LENTIGO SIMPLEX

SOLITARY

- Solar lentigo/ephelis
- Junctional nevomelanocytic nevus
- Atypical (dysplastic) melanocytic nevus
- Café-au-lait macule
- Melanoma (lentigo maligna)

GROUPED

- Agminated nevomelanocytic nevi or lentigines
- Nevus spilus

TREATMENT

There is no need to treat benign-appearing lentigo simplex. Cosmetic removal may be achieved with cryotherapy or other destructive approaches such as Q-switched laser. There is a theoretical risk of malignant transformation of any variety of melanocytic hyperplasia or dysplasia using any type of laser. Caution must be exercised to ensure the lesion being treated using destructive therapy is benign. Lesions that are significantly unusual, irregular, asymmetric, or changing in shape should be examined histopathologically to exclude melanoma before destructive therapy is considered. Wood's lamp examination is useful in defining margins of lentigo simplex.

Until the long-term course of agminated lentigines and Laugier–Hunziker pigmentation is known, it may be prudent to recommend periodic examinations to detect the earliest signs of possible malignant evolution.

PREVENTION

UVR is clearly associated with the development of solar lentigines, but its role in the different types of simple lentigines is not known. However, it is rational to limit UVR overexposure.

SOLAR LENTIGO

EPIDEMIOLOGY

The prevalence of solar lentigines is correlated directly with increasing age, and they are present in 90% of white people over 60 years of age.[101] Solar lentigines are common in individuals who sunburn easily and do not tan, whereas they are uncommon among people who have darkly pigmented skin.[102]

Lentigines may be induced by photochemotherapy [psoralen and UVA light (PUVA) lentigo], occurring in 40% to 50% of patients an average of 5.7 years after starting therapy, their frequency and severity directly attributable to the total number of treatments (Fig. 122-25).[102] Darkly pigmented skin is associated with the lowest risk for PUVA-induced or solar-induced lentigines.[102] Lentigines have been associated with UVA tanning bed use.[103]

SOLAR LENTIGO AT A GLANCE

- Solar lentigo is distinguished from lentigo simplex histopathologically on the basis of shape and extent of epidermal hyperplasia. The epidermal hyperplasia is often more prominent in solar lentigines and may include "bud-like" structures at the base of rete ridges.
- Solar lentigines appear as circumscribed pigmented macules occurring singly or as multiple lesions and present on the skin surface exposed to natural or artificial sources of ultraviolet radiation. Distinct subtypes exist and include the ink spot lentigo.
- Solar lentigines occur in children and adults.[100] Children who have xeroderma pigmentosum develop solar lentigines even during the first 6 months of life, after minimal sun exposure.
- Solar lentigines are benign but caution must be taken to discriminate benign lesions from lentigo maligna.
- Synonyms: sun-induced freckle, liver spot (large cell acanthoma) lentigo senilis, and senile lentigo.

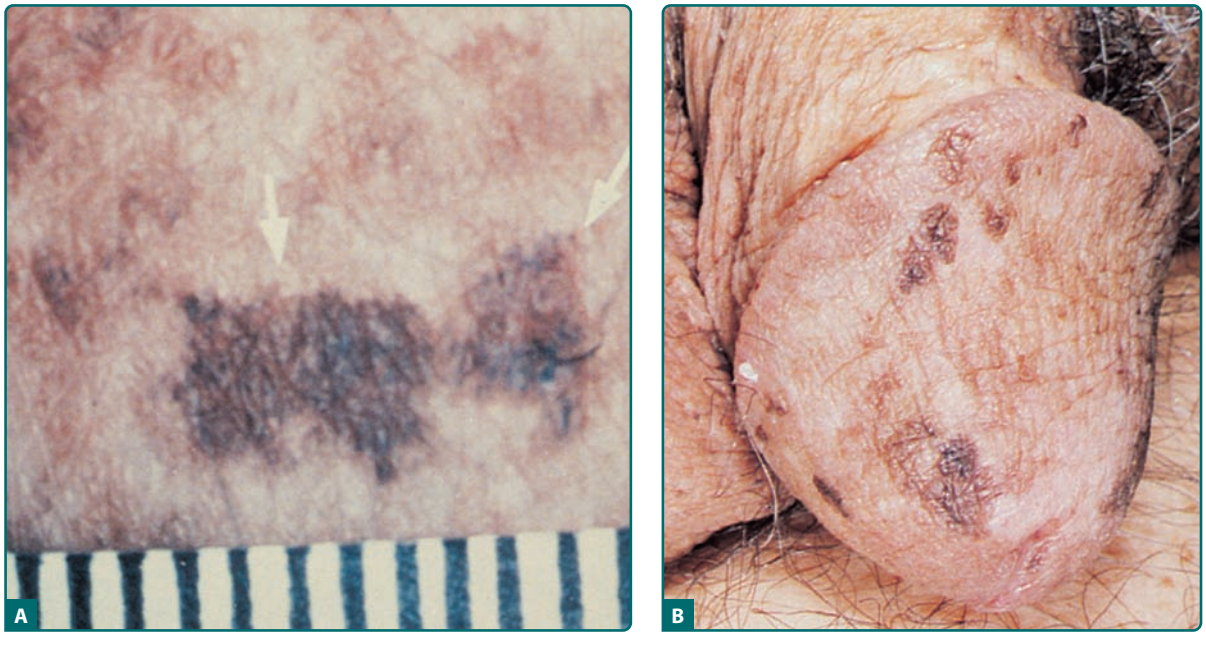

Figure 122-25 Photochemotherapy [psoralen and ultraviolet A light (PUVA)]-induced lentigines on the buttock (**A**) and penis (**B**) of a 57-year-old white man who had received PUVA for psoriasis several times per week for 5 years. The PUVA lentigines appeared between 1 and 2 years after PUVA therapy was begun. The current recommendation is to shield the male genitalia during PUVA therapy to prevent squamous cell carcinoma of the penis and scrotum.

Lesions similar in gross and microscopic appearance to solar lentigo, freckle (ephelis), may occur in children and young adults.[100] They may appear within the first 5 years of life, tend to aggregate in families, and are significantly associated with red hair; their location and density correlate with sun sensitivity and sun exposure. The presence of freckles has been associated with a 2.5-fold increase in the rate of sunburn susceptibility and poor tanning response and a threefold greater likelihood of a lower minimal erythema dose in people who mostly burn and tan minimally or not at all.[104] The presence of dense sun-induced freckling increases the estimated risk for melanoma by three- to fourfold.[105]

ETIOLOGY AND PATHOGENESIS

Solar lentigines are thought to represent a marker of intermittent high-intensity UVR, cumulative UVR, and/or a unique susceptibility to the proliferative, stimulatory, and/or mutagenic effects of UVR. Given the hyperplasia of both the keratinocytes and melanocytes, the primary defect in solar lentigines could be in either cell type eliciting a secondary proliferative response in the other.

There is a pronounced link between UVR exposure and the development of lentigines. Single exposures of experimental UVB radiation (320 mm) that is six to ten times the minimal erythema dose induces "freckling" in susceptible individuals.[106] Phototoxic doses of PUVA may lead to the development of lentigines 6–8 months later.[107] In addition to the total dose of UVR received during photochemotherapy, individual susceptibility factors to lentigo development include degree of skin pigmentation, ethnicity, age, and burning/tanning response to sunlight.[102]

Supportive of the underlying mutation being present in the melanocytes is the finding that epidermal melanocytic cellular atypia persists in lentigines developing in patients receiving chronic photochemotherapy for 1–2 years or longer after therapy is discontinued.[102] In xeroderma pigmentosum (XP), in which patients have an increased sensitivity to UVR, hyperpigmented macules develop on light-exposed skin within the first 5 years of life (see Chapter 139), and these lesions demonstrate hyperplasia of variably atypical epidermal melanocytes (i.e., atypical lentigines). In one series of XP patients from Japan,[108] lentigo maligna melanoma was the predominant melanoma type, suggesting an association between this tumor subtype, sensitivity to UVR, and the presence of UVR-induced atypical solar lentigines, and supportive of the underlying mutation being in the melanocytic lineage.

CLINICAL FINDINGS

(Fig. 122-26)

HISTORY. Solar lentigines appear as acquired lesions, generally in fair-skinned individuals, on sun-exposed skin surfaces. For the majority of solar lentigines, it is assumed that once present, they persist indefinitely.

CUTANEOUS LESIONS. Solar lentigo occurs as a pigmented macule on skin exposed to natural sunlight or artificial sources of UVR, usually in the presence of similar lesions in the same location (Fig. 122-27). Lesions may be tiny (<1 mm in diameter) or large (up to a few centimeters in diameter), with a tendency to confluence in severely sun-damaged skin and with smooth or irregular outlines. Lesions are usually light

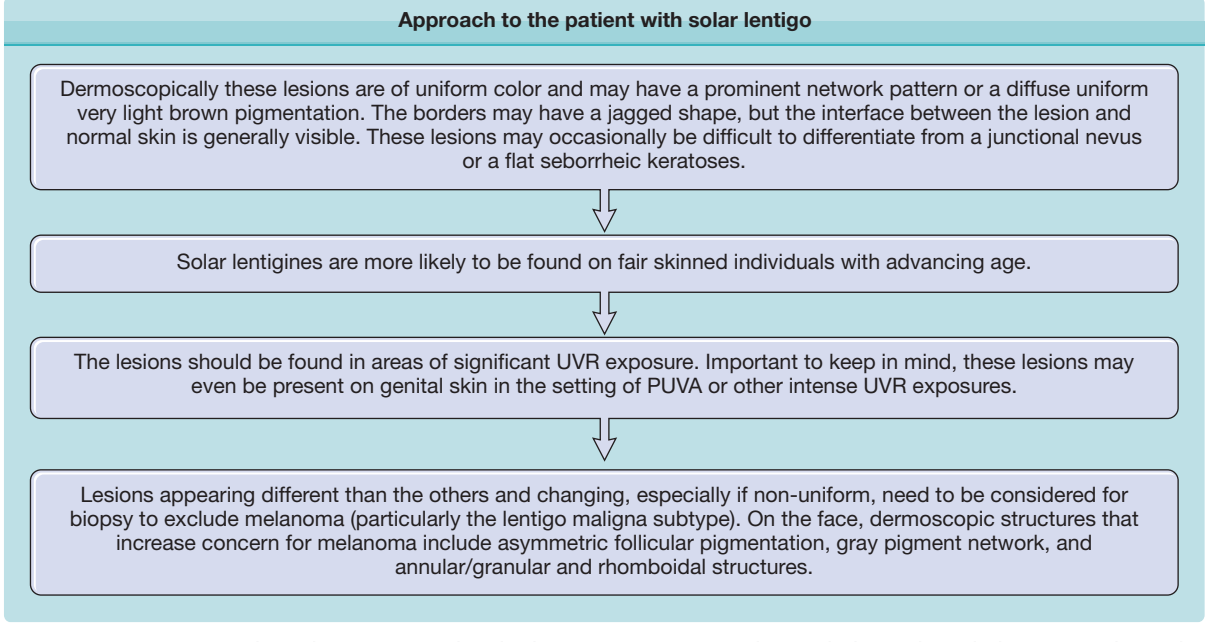

Figure 122-26 Approach to the patient with solar lentigo. PUVA = psoralen and ultraviolet A light; UVR = ultraviolet radiation.



Figure 122-27 Solar lentigo. **A.** Uncountable solar lentigines on the back of a 30-year-old white man, appearing initially during early childhood after multiple sunburns. **B.** High magnification of lentigines in (**A**) showing light-brown macules with markedly irregular outlines. **C.** Solar lentigines on sun-damaged dorsal hand skin (hypopigmentation, wrinkling, and telangiectasia) of an elderly white man.

brown, but varieties of solar lentigo are jet black, similar to an India ink stain (ink spot lentigo). Although solar lentigo usually occurs on sun-exposed skin, identical-appearing lesions may occur on sun-protected sites (including the penis and buttocks) that have been exposed to photochemotherapy (see Fig. 122-25). When examined by dermoscopy, solar lentigines reveal a uniform reticular network.[109] Lentigines in patients receiving PUVA and in individuals who have XP are often darkly and/or irregularly pigmented. Solar lentigines not apparent in visible light may be visualized using Wood's lamp illumination.

The oral–labial melanotic macule has gross morphologic characteristics similar to solar lentigo (Fig. 122-28), but its relation to a sun-sensitive phenotype or excessive sun exposure has not been well documented.

A clinical distinction has been made between a freckle (ephelis) and a solar lentigo. Freckles are common on the central face and often first noted in early childhood, presumably developing after significant sun exposure and are said to fade or even disappear when sun exposure is discontinued. Unfortunately, there are no longitudinal studies of ephelides or solar lentigines that document gross morphologic or time-course differences that would reliably allow a clinical distinction between ephelides and solar lentigines. According to L-3,4-dihydroxyphenylalanine (DOPA) studies on epidermal sheets, ephelides have been reported to show increased melanogenesis but decreased melanocyte number, which implies a different pathologic basis.[106,110] However, counting melanocytes in DOPA-incubated epidermal sheets is unreliable for pigmented lesions, and these early studies must be questioned. Studies in DOPA-incubated tissue vertical sections demonstrate that melanocytes are increased in "ephelides" in children and young adults, similar to solar lentigines.[42,109]



Figure 122-28 Labial melanotic macule, appearing 5 years earlier, on the lower lip of a 26-year-old white woman.

RELATED PHYSICAL FINDINGS. Patients with solar lentigines are more likely to be fair skinned, particularly those with red hair and or lighter eye color. Along with the lentigines, increased solar damage may be noted, and other lesions such as idiopathic guttate hypomelanosis, actinic keratoses, and seborrheic keratoses may be present. The presence of solar lentigines is a risk factor for melanoma, basal cell cancer, and squamous cell cancer.

LABORATORY TESTS

HISTOPATHOLOGY. Solar lentigines reveal elongated epidermal rete ridges with club-shaped or bud-like extensions, frequent branching and fusing of rete ridges, a thinned or atrophic epidermis between rete ridges, and increased numbers of epidermal melanocytes without nesting. The microscopic appearance suggests a concurrent proliferation of keratinocytes and melanocytes.[111] There is a scant to moderate perivascular mononuclear cell infiltrate in the dermis, usually associated with scattered melanin-laden macrophages.

Electron microscopic studies of solar lentigo reveal abundant melanosome complexes in keratinocytes, the complexes being generally larger than complexes in keratinocytes in adjacent skin.[111] Compared with melanocytes in sun-protected skin, melanocytes in solar lentigo reveal increased activity manifested by marked DOPA reactivity (suggesting increased tyrosinase activity), elongated dendrites, large numbers of normal-appearing melanosomes, enlarged perikarya with well-developed rough endoplasmic reticula, numerous mitochondria, and hypertrophic Golgi complexes.[112] Melanin macroglobules have also been noted.[100]

Pathologic features of PUVA-induced lentigo include increased numbers of melanocytes in elongated epidermal rete ridges, with large cell bodies and sometimes atypical cellular morphologic features, dendrites often extending high into the epidermis, and melanocytes frequently residing above the epidermal basal unit.[109] Melanocytes in PUVA lentigo occasionally manifest autophagocytosis, sharply invaginated nuclear contours, nuclear pseudoinclusions, double nuclei, striking melanosomal alterations, and melanin macroglobules; melanosomes in keratinocytes of PUVA lentigines are often large and single instead of small and compound as in solar lentigines.[112] Cosmetic UVA tanning also induces lentigines, and cellular atypia has been reported.

Histopathologic characteristics of the labial melanotic macule (labial lentigo) are similar to those of solar lentigo, showing melanocytic hyperplasia but without cellular atypia. The presence of melanocytic hyperplasia in labial melanotic macule is not a uniform finding in all studies.

SPECIAL TESTS. Mart-1 and DOPA histochemical studies may be useful to demonstrate increased number of melanocytes confined to the basal layer and a lack of junctional nest formation.

DIFFERENTIAL DIAGNOSIS

(Box 122-9)

COMPLICATIONS

A potential complication is the discovery that an atypical solar lentigo is actually melanoma (often of the lentigo maligna variety).

PROGNOSIS AND CLINICAL COURSE

Solar lentigines may appear at any time of life. A solar lentigo may enlarge, darken, and become stable over time, but longitudinal studies of solar lentigines are lacking. It is possible that once formed, solar lentigines may persist indefinitely or fade slightly with time if UVR is avoided. Solar lentigines may be a heterogeneous population that includes lesions that fade and lesions that do not fade after UVR avoidance. The presence of these lesions suggests an increased risk for melanoma and keratinocytic skin cancers.

It has been proposed that some varieties of lichenoid keratosis may be due to an acute inflammatory reaction

BOX 122-9 DIFFERENTIAL DIAGNOSIS OF SOLAR LENTIGO

- "Reticulated" seborrheic keratoses
- Lentigo simplex
- Ephelis
- Junctional nevomelanocytic nevus
- Pigmented actinic keratoses
- Large cell acanthoma
- Lentigo maligna

targeting the solar lentigo, and that resolution of lichenoid keratosis may cause regression of the associated lentigo.[113] This speculation has not been substantiated.

The long-term course of atypical varieties of PUVA lentigo is unknown, but it is clear that PUVA lentigines (see Fig. 122-25) may persist 1–2 years or longer after therapy is discontinued[102] and that cellular atypia of epidermal melanocytes in these lesions may persist as well. It is also clear that these patients may be at increased risk for melanoma[114] and should be followed periodically for life.

Lentigo maligna (see Chapter 124) may masquerade as a solar lentigo early in its development or, alternatively, may evolve from a preexisting solar lentigo. A solar lentigo not matching the patient's other lentigines and/or enlarging/darkening out of step should be examined histopathologically or followed closely.

TREATMENT

Solar lentigo usually requires no therapy, but importantly, its presence indicates sensitivity and/or excessive exposure to UVR. Bleaching creams containing hydroquinone are usually not effective. Cryotherapy or other superficial destructive techniques (such as Q-switched laser) may be an option if the lesion is clearly benign, but lesions may recur after therapy. There is a theoretical concern about intense light treatment (i.e., laser) of any melanocytic hyperplasia or dysplasia.

PREVENTION

It may be possible to prevent further UVR-induced lentigines by reducing or avoiding UVR exposure. Ideally, protection against overexposure to UVR should be initiated during early childhood and continued throughout life. Vitamin D supplementation needs to be considered for patients practicing UVR protection and avoidance.

KEY REFERENCES

Full reference list available at www.DIGM8.com

DVD contains references and additional content

3. Bauer et al: Congenital melanocytic nevi frequently harbor NRAS mutations but not BRAF mutations. *J Invest Dermatol* **127**:179, 2007
16. Rhodes AR et al: The malignant potential of small congenital nevocellular nevi: An estimate of association based on a histologic study of 234 primary cutaneous melanomas. *J Am Acad Dermatol* **6**:230, 1982
19. Kopf AW et al: Congenital nevus-like nevi, nevi spili, and cafe-au-lait spots in patients with malignant melanoma. *J Dermatol Surg Oncol* **11**:275, 1985
28. Kelly JW et al: Sunlight: a major factor associated with the development of melanocytic nevi in Australian schoolchildren. *J Am Acad Dermatol* **30**:40, 1994
32. Robinson WA et al: Human acquired naevi are clonal. *Melanoma Res* **8**:499, 1998
35. Gill MG, Celebi JT: B-RAF and melanocytic neoplasia. *J Am Acad Dermatol* **53**:108, 2005
36. Lin J et al: Polyclonality of BRAF mutations in acquired melanocytic nevi. *J Natl Cancer Inst* **101**:1423, 2009
37. Grichnik JM et al: KIT expression reveals a population of precursor melanocytes in human skin. *J Invest Dermatol* **106**:967, 1996
40. Banky JP et al: Incidence of new and changed nevi and melanomas detected using baseline images and dermoscopy in patients at high risk for melanoma. *Arch Dermatol* **141**:998, 2005
50. Pharis DB, Zitelli JA: Sunburn, trauma, and the timing of biopsies of melanocytic nevi. *Dermatol Surg* **27**:835, 2001
57. Bevona C et al: Cutaneous melanomas associated with nevi. *Arch Dermatol* **139**:1620, 2003
60. Lucas CR et al: Early melanoma detection: nonuniform dermoscopic features and growth. *J Am Acad Dermatol* **48**:663, 2003
62. Patterson JW: Nevus cell aggregates in lymph nodes. *Am J Clin Pathol* **121**:13, 2004
63. Van Raamsdonk CD et al: Frequent somatic mutations of GNAQ in uveal melanoma and blue nevi. *Nature* **457**:599, 2009
82. Bastian BC et al: Mutations and copy number increase of HRAS in Spitz nevi with distinctive histopathological features. *Am J Pathol* **157**:967, 2000

Chapter 123 :: Atypical (Dysplastic) Melanocytic Nevi

:: James M. Grichnik & Margaret A. Tucker

ATYPICAL/DYSPLASTIC NEVI AT A GLANCE

- Prevalence among Caucasian young adults roughly 10%; varies by population.
- Flat (totally or partially flat with central elevation), large (>5 mm) lesions with irregular shape, indistinct borders, and variable pigmentation.
- Risk markers for melanoma.
- Most frequent on sun-exposed areas, especially intermittently exposed, such as back.
- Associated with large numbers of common acquired nevi.
- Majority of lesions will involute and disappear over time.
- Histologic features include presence of immature, disordered growth pattern with a lymphocytic host response and random cytologic atypia in melanocytes.

Common atypical/dysplastic nevi were first recognized as distinct melanocytic neoplasias during the clinical assessment of melanoma-prone families.[1] The nomenclature associated with these lesions also includes B–K moles (recognizing the first two families described whose surnames began with B and K),[1] familial atypical multiple mole and melanoma syndrome,[2] atypical mole syndrome,[3] Clark's nevus,[4] atypical moles, and nevus with architectural disorder (with varying degrees of melanocytic atypia).[5] The nomenclature has been contentious. The term *dysplastic nevus* (DN) is frequently used both for clinical and histologic diagnoses,[6,7] and it is the term that will be used in this chapter. Although not covered in this chapter, it is also important to note that the terms *dysplastic* and *atypical* may also be occasionally used as a modifier for other melanocytic neoplasias (i.e., Spitz nevi) or hyperplasias to indicate a distinct histologic variant from a typical pattern or an increased concern for malignancy.

EPIDEMIOLOGY

DN are frequently found in melanoma-prone families in North America, Europe, and Australia.[8–16] One cross-sectional study in a New Zealand cohort (independent of melanoma) revealed DN in 9% of European descent adults.[17] A joint case-control study of nevi and melanoma in Australia and the United Kingdom demonstrated that DN were three times more frequent in the Australian controls (6%) than in the British controls (2%).[18] There are a few case reports of DN in Japanese, primarily in melanoma-prone families.[19]

ETIOLOGY AND PATHOGENESIS

DN occur in a familial pattern; limited segregation analyses suggest an autosomal dominant transmission of the trait.[20] However germ-line susceptibility genes have not yet been identified for DN. Germ-line mutation testing of candidate genes for melanoma (e.g., *PTEN*, *BRAF*, and *CDK4*) did not reveal an association with DN.[21] Germ-line polymorphisms in *BRAF* were also not related to nevi or freckles in another study.[22] Within families having *CDKN2A* germ-line mutations, DN appear to be an independent risk factor for melanoma.[11,23] Earlier, linkage analyses in twin studies found evidence of a gene for increased number of nevi in the region around *CDKN2A*[24,25] and recent genome wide association studies suggest that is close to *MTAP*[26,27]. Areas of modest interest have also been linked to areas on chromosomes 1, 6, and X.[25] Thus, it is likely that DN, like melanoma, is a complex, heterogeneous trait.

Genetic analysis of the cells in DN has revealed activating mutations of *BRAF*,[28,29] or *NRAS*,[30] as well as hemizygous deletions of p16 and p53.[31] However no consistent somatic mutation has been noted that defines the DN pattern.

Several lines of evidence suggest that sun or ultraviolet light (UV) exposure is important in the etiology of DN. First, the lesions occur most frequently in sun-exposed areas, particularly in those intermittently exposed, but DN may also occur in unexposed areas.[8,32–35] The most common area for DN is on the trunk, primarily the back (Fig. 123-1). There is relative sparing of the more sun-protected lateral thoracic regions and the inner aspect of the arms. Fewer DN



Figure 123-1 **A.** A back view showing the distribution of dysplastic nevus (DN) and lesion-to-lesion variability, with an increased number of common acquired nevi also. **B.** A closer view of a cluster of lesions marked as #2 on the back. The lesions are of different sizes, colors, and shapes, with differing amounts of asymmetry, and indistinct borders. Only the largest lesion meets all of the criteria for a clinical DN.

occur in doubly covered areas such as on the buttocks. In a comparison of Australian and British controls from a joint case-control study, the prevalence of DN was three times higher overall in the Australians, but the prevalence of nevi on non–sun-exposed areas was the same.[18] Second, several studies have also demonstrated, to varying degrees, that individuals with DN report more frequent sun exposure and sunburns, especially before age 20, than individuals without DN.[36–38] Individuals who tan well appear to develop fewer DN. Third, based on longitudinal studies of melanoma-prone families, individuals with DN who use sun-protective measures consistently develop fewer new nevi, and the dysplastic and common nevi they have are more likely to involute and disappear.[35] Sun-protected children in these high-risk families also develop fewer nevi.

CLINICAL FINDINGS

(See Fig. 123-2)

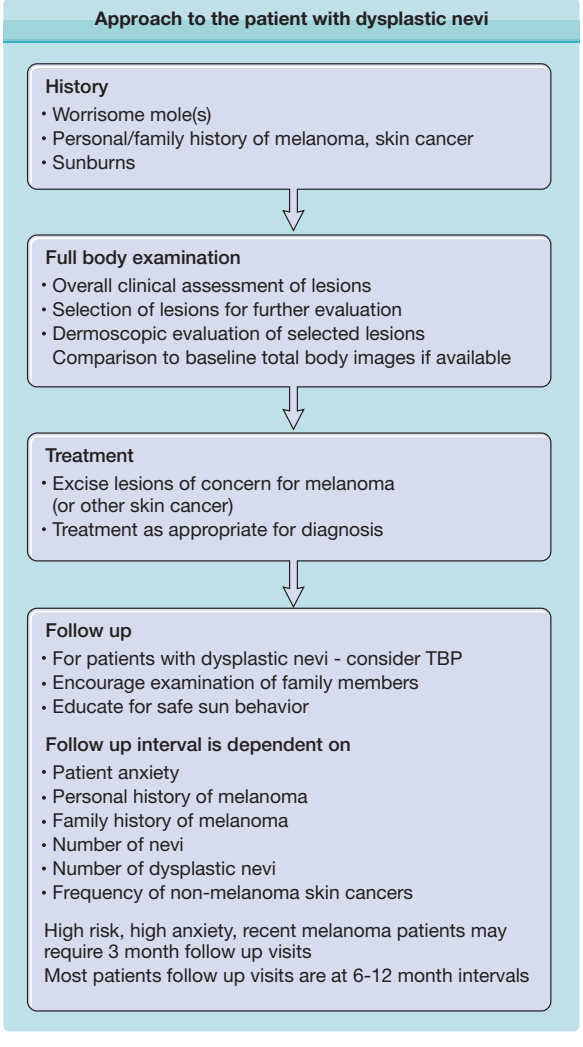

Figure 123-2 Approach to the patient with dysplastic nevi. TBP = total body photography.

CUTANEOUS LESIONS

The usual clinical criteria for the diagnosis of a DN are two obligate features: diameter in one dimension at least 5 mm and a prominent flat component, and two of three other features: irregular, asymmetric outline, indistinct borders, and variable pigmentation (Fig. 123-3).[44] The histologic features include the presence of an immature or disordered growth pattern with a lymphocytic host response and random cytologic atypia in melanocytes (Fig. 123-4).[45] Multiple studies have demonstrated that the clinical and histologic criteria are each reproducible across observers.[46–49]

Typically, DN are most frequent on intermittently exposed skin surfaces.[32–35] Epidemiologic studies have demonstrated that the most frequent site is the back (see Fig. 123-1A). DN can, however, occur in minimally sun-exposed areas such as the doubly covered buttocks, breasts, scalp, and pubic regions. Individuals with DN may also develop nevi, not necessarily atypical, on palmar and plantar surfaces and in web spaces of hands and feet. It is uncommon for individuals with DN to have nevi on mucosal surfaces, but they do occur.

Compared to common acquired nevomelanocytic nevi, DN tend to be larger, be entirely flat or have flat shoulders, with a degree of asymmetry and variable coloration (see Fig. 123-3). There may also be a degree of erythema caused by the inflammatory infiltrate in the DN. Within an individual, there is lesion-to-lesion variability, but there tends to be some consistency in the appearance (see Fig. 123-1B). Between individuals, even within the same family, there can be very broad differences in appearance of DN.[35] Any specific lesion needs to be assessed in the context of where it is in its natural life history.

RELATED PHYSICAL FINDINGS

Melanoma is the most important related physical finding in patients with DN. The majority of melanomas develop in normal skin, but may also occur in DN, or in common acquired nevi.[43,50] The challenge is to identify the melanomas as early as possible (see Chapter 124). Compared to DN, melanomas will be found to be (1) unusual (ugly duckling[51]), this is due to the rare combination of mutations giving rise to the melanoma and its growth pattern, they will be (2) growing (this due to defective growth control), and progressively more (3) nonuniform (asymmetry, border, color, dermoscopic structures, ABCDs) this is likely due to genomic instability. Nonuniform characteristics may not be present in early in situ melanomas.[50]

Patients with DN also have elevated numbers of common acquired nevomelanocytic nevi. Other physical findings that may increase melanoma risk in an individual with DN include extent of solar injury and cutaneous phenotype, both of which are independent risk factors for melanoma.[52] Evidence of chronic solar injury is also associated with an increased risk of melanoma in men with DN, especially in older men.[52] Individuals who are heavily freckled and have DN are at higher risk of developing melanoma than those with

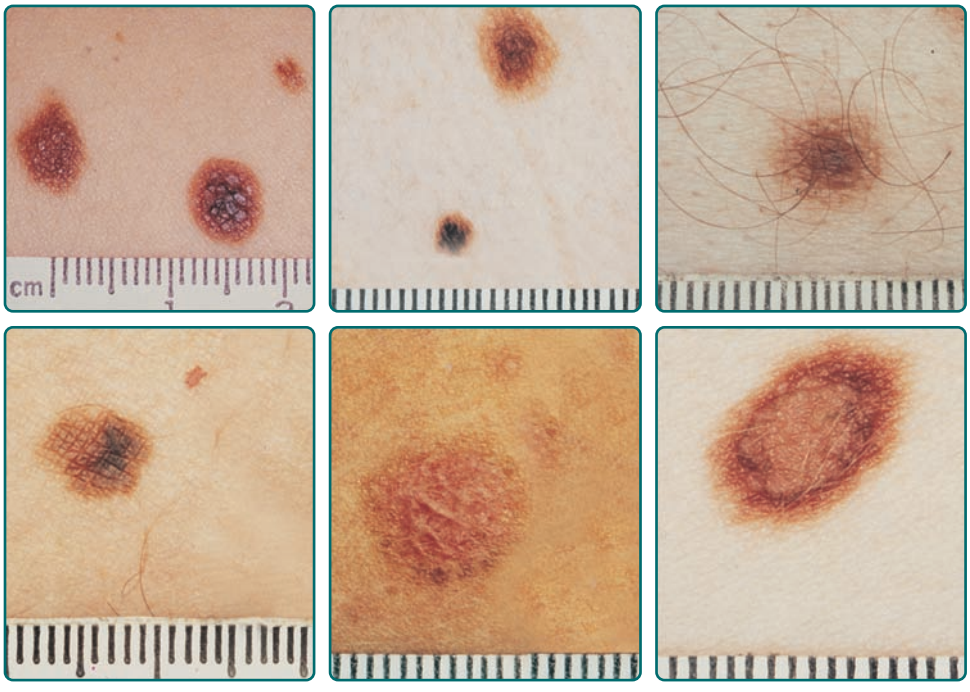

Figure 123-3 Atypical nevi have two obligate features: diameter in one dimension at least 5 mm and a prominent flat component, and two of three other features: irregular asymmetric outline, indistinct borders, and variable pigmentation.

DN who are not freckled.[44] DN and variations in *MC1R* both increase the risk of melanoma in *CDKN2A* mutation carriers.[53]

LABORATORY TESTS

HISTOPATHOLOGY. The histologic diagnosis of DN can be based on architectural and cytologic features.[54] Architectural features include a junctional component of scattered atypical melanocytes which may be most of the lesion, or an edge or shoulder extending several retia beyond a dermal component. Rete ridges are elongated, with the nests of melanocytes at the tips or along the side of the retia with occasional bridging of the nests across retia. There is fibroplasia in the dermis, often concentric eosinophilic fibroplasia or lamellar fibroplasia. Lymphocytes tend to be patchy and perivascular. The cytologic features include atypical melanocytes with abundant cytoplasm along the dermal-epidermal junction that are one-third to one-half larger than the melanocytes in the normal surrounding skin.[55] The nuclei may be slightly irregular or folded with hyperchromasia and clumping of chromatin. Some may have prominent nucleoli.

The dermatopathologist should also comment on whether the margins are clear. It is important to communicate with your dermatopathologist on lesions where the clinical and pathologic impressions differ. Marking of worrisome areas on the biopsy or review of dermoscopic images may help insure that particularly troublesome areas have been evaluated to insure that melanoma is not missed. Several groups have proposed criteria for grading histologic dysplasia.[48,56–58] These grading systems may help to define the risk of the lesion actually being a melanoma. Lesions with severe atypia may warrant re-excision or closer follow up after complete excision.

SPECIAL TESTS

Dermoscopy. Dermoscopy (dermatoscopy or epiluminescence microscopy) is also a useful adjunct for examining lesions. Several sets of criteria for differentiating nevi, including DN from melanoma, have been developed, including pattern analysis,[59] ABCD rule,[60] Menzie's method,[61] seven-point checklist,[62] and color, architecture, symmetry, and homogeneity (CASH).[63] The use of dermoscopy has been shown to increase the accuracy of melanoma detection.[64]

Dermoscopic imaging for follow up may also be considered when a lesion is of concern but not sufficiently worrisome to excise. Often these imaged lesions are then followed and excised only if changes are noted.[65,66] In one study with 90-day follow-up identified melanomas, all early, and avoided unnecessary biopsies.[66]

Total Body Photography. For clinical care of individuals with DN, total body photography (TBP, also known as mole mapping) is an essential tool.[35] The photographs serve as a medical record allowing determination to be made as to whether a lesion has changed. Change or lack thereof can then be integrated into the decision-making process as to whether a lesion needs to be excised. Patients with DN should be considered for TBP. Melanomas occurring in patients who are regularly followed using clinical photographs appear to be predominantly in situ or very thin invasive melanomas.[35,41,42,50,67–71] TBP not only allows for the detection of melanomas at earlier stages but it also

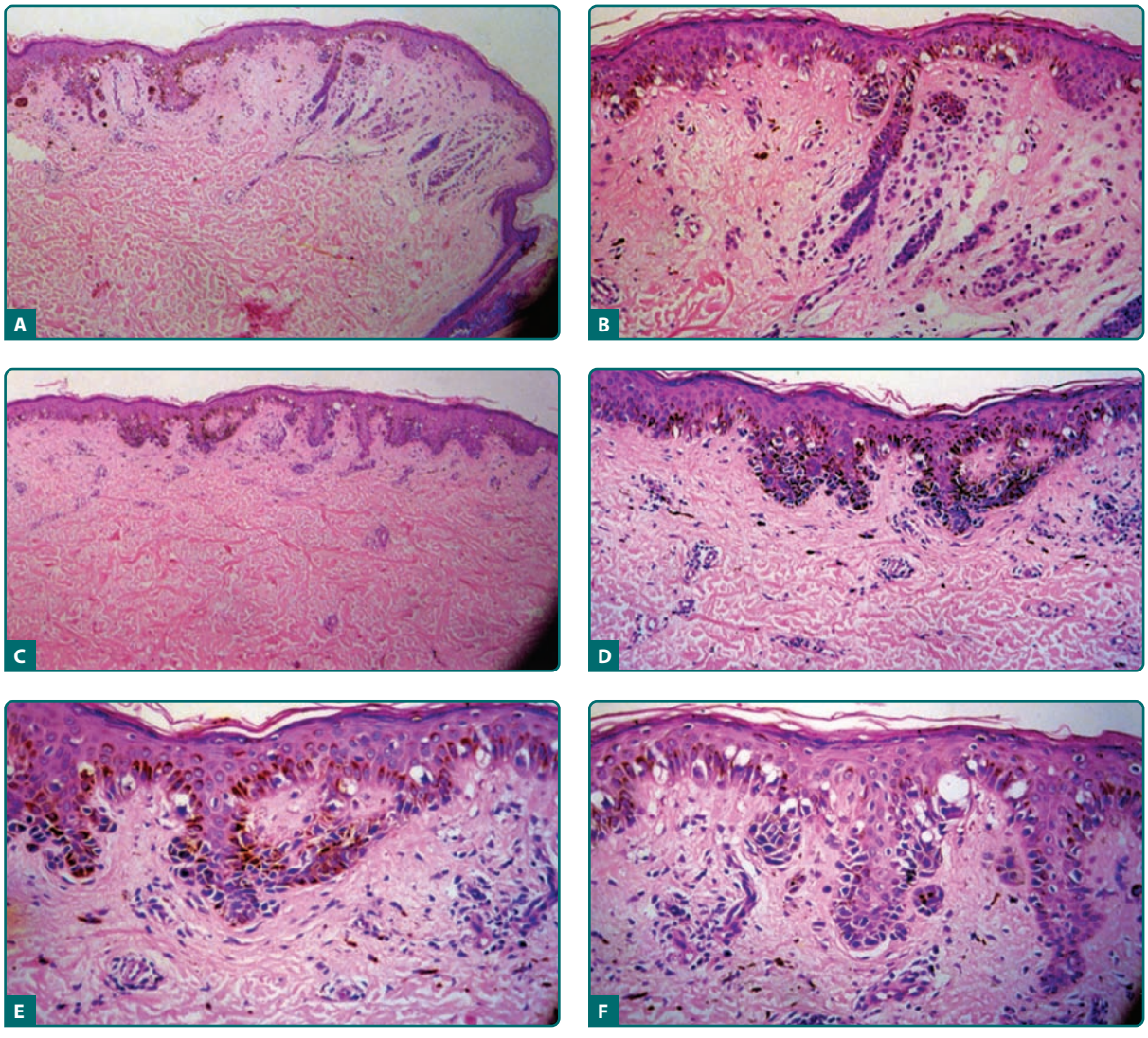

Figure 123-4 The histopathology of a dysplastic nevus (DN). **A.** The low-power view shows a dermal nevus with dysplasia. **B.** A closer view of the dysplasia at the shoulder of the dermal nevus. **C.** Another area of dysplasia. **D.** On closer view, there is an increased number of melanocytes without an apparent increase in keratinocytes, with the melanocytes clustered on the sides and the ends of the retia. The nuclei of the melanocytes are quite atypical. **E.** At higher power, the nuclei of the melanocytes are atypical and enlarged, characteristic of epithelioid melanocytic dysplasia. **F.** Another area of the lesion with melanocytes in linear array, characteristic of lentiginous melanocytic dysplasia. The melanocytes are not as enlarged as in the area of epithelioid dysplasia. With >30 atypical melanocytes and the level of disorganization of the architecture, the lesion is classified as severely dysplastic. (Photomicrographs used with permission from Wallace H. Clark, Jr.)

reduces unnecessary biopsies of benign lesions, and provides an overall cost savings.[43]

NEW IMAGING TECHNIQUES. New imaging techniques are being developed and include confocal microscopy,[72,73] multispectral imaging,[74] optical coherence tomography,[75] ultrasound,[76] Raman spectroscopy,[77] and melanin fluorescence[78] that may all play a role in enhancing our ability to discriminate benign DN from early melanoma.

DIFFERENTIAL DIAGNOSIS

(See Box 123-1)

COMPLICATIONS

The major complication for DN patients is melanoma. In most of the case-control studies evaluating risk of melanoma, melanoma risk increases with increasing DN.[44,79–81] Even one unequivocal DN, increases the risk of melanoma twofold. More than ten DN increased the risk 12-fold [95% confidence interval (CI): 4.4–31]. A meta-analysis of 47 studies revealed the risk of melanoma increased 10-fold (95% CU:5.0-20.3) if DN were present.[81]

The most frequent complication for patients with DN is scarring due to numerous biopsies. Although melanoma may develop within a preexisting nevus

BOX 123-1 DIFFERENTIAL DIAGNOSIS

Most Likely
- Common acquired nevus
- Congenital or congenital-type nevus
- Dermatofibroma
- Seborrheic keratosis

Consider
- Combined nevus
- Spitz nevus/Spitz variant
- Pigmented spindle cell nevus
- Blue nevus
- Pigmented actinic keratosis

Always Rule Out
- Melanoma in situ
- Superficial spreading melanoma
- Pigmented basal cell carcinoma
- Pigmented squamous cell carcinoma

on DN patients, it commonly appears to develop from normal appearing skin. Nevi need only be removed when clinically suspicious for melanoma.

PROGNOSIS AND CLINICAL COURSE

Many individuals with DN come to the attention of a clinician because they are worried about a changing mole or have personal or family history of melanoma/dysplastic nevi and are worried about their risk.

Despite the concern about melanoma in individuals with DN, most will never develop melanoma. Their overall melanoma risk is a composite of a number of factors. These individuals should be asked about their personal and family history of melanoma, nonmelanoma skin cancers, other cancers, nevi, and UV exposure. Individuals who have had one melanoma are at substantially increased risk of developing another primary melanoma (tenfold increased risk of melanoma during the first 5 years).[82] Members of melanoma-prone families with DN are at quite high risk of developing melanoma.[35] Having multiple nevi, especially DN, is one of the risk factors identifying those most likely to develop another primary melanoma.[83] A previous history of nonmelanoma skin cancer approximately doubles the risk for melanoma, especially in older men.[52] Other cancers in the patient or family such as pancreatic cancer in a member of a family where multiple individuals have had melanoma may warrant consideration of genetic testing if it changes clinical care. And finally, UV exposure (peeling sunburns, tanning bed use) have been associated with increased melanoma risk.[84]

Frequency of regular follow-up examinations is based on perceived risk (factors in paragraph above) and competence in self-examinations. While many melanomas appear to grow relatively slowly, some melanomas may grow very quickly and therefore is no defined "safe" period. For very high-risk patients 3-month follow-up may be warranted (especially after recent diagnosis of melanoma or other skin cancer). However, for most patients 6-month and eventually 12-month follow up examinations are appropriate (depending on patient ability and confidence in self examination). Most patients followed in pigmented clinics have their melanomas detected and removed at relatively early stages.[43,50]

Patients should receive copies of their TBP (if taken) and need to be instructed on monthly self-skin examination and the basics of early melanoma detection. Patients may wish to include a partner and the entire skin surface should be viewed. This may require the use of a full-size wall mirror and a hand-held mirror. Patients should look for a lesion that is unusual (not matching other nevi) and growing. This may represent an early melanoma. As these lesions enlarge the may also begin to also display nonuniform features (ABCDs). A lesion that is growing and unusual is worrisome for melanoma, if nonuniform features are also developing this lesion is very concerening for an early invasive melanoma.[50]

Family screening should be encouraged. Although the familiality of DN is not fully understood, it is reasonable to examine the first-degree relatives of individuals with multiple DN. If they are found to have DN, the same approach should be followed for their care.

The patient should be educated about appropriate sun-protection measures. The suggestions for sun protection should be the same as those for the prevention of melanoma: avoidance of midday sun exposure and tanning beds, shade seeking when out of doors, scheduling outdoor activity for early morning or late afternoon, use of protective clothing, and use of sunscreens. These same sun-protection measures behaviors should be encouraged for the patients family members especially their children.

It is also be reasonable to let the patients know that they may want to inform their ophthalmologist, gynecologist, dentist, and hairdresser/barber that they have dysplastic nevi and to be on the lookout for any unusual lesions.

TREATMENT

The treatment for DN is observation. It is not necessary to histologically verify that an individual has DN. Removal of DN does not substantially decrease a patient's risk of developing a melanoma. The challenge is to identify the melanomas as early as possible and excise them to reduce the risk of metastasis. It is important to pay attention to the mole the patient points out as worrisome. Melanomas tend to be growing, unusual, and progressively more nonuniform.

If a lesion is worrisome for melanoma, the entire lesion should be excised (if possible) with visibly clear margins. For DN shave biopsies are discouraged. Repigmentation and regrowth can occur. Histological evaluation of these recurrent lesions can be challenging.

All lesions worrisome for melanoma should be reviewed by a dermatopathologist trained in pigmented lesions and melanoma.

PREVENTION

The major preventive intervention for the development of dysplastic, as well as common acquired nevi, is decreased UV exposure. With the growing body of evidence that childhood sun exposure is important in the number of nevi that develop,[85] it is important to initiate sun-protective behaviors early.

KEY REFERENCES

Full reference list available at www.DIGM8.com

DVD contains references and additional content

1. Clark WH Jr et al: Origin of familial malignant melanoma from heritable melanocytic lesions. 'The B-K mole syndrome.' *Arch Dermatol* **114**:732, 1978
5. NIH Consensus Development Panel on Early Melanoma: Diagnosis and treatment of early melanoma. *JAMA* **268**: 1314, 1992
50. Lucas CR et al: Early melanoma detection: Non-uniform dermoscopic features and growth. *J Am Acad Dermatol* **48**:663, 2003

Chapter 124 :: Cutaneous Melanoma

:: Evans C. Bailey, Arthur J. Sober, Hensin Tsao, Martin C. Mihm Jr, & Timothy M. Johnson

MELANOMA AT A GLANCE

- Rising incidence worldwide; United States estimated lifetime risk of developing invasive melanoma is 1:1,500 if born in 1935, 1:600 if born in 1960, 1:62 if born in 2006, and 1:50 if born in 2010 (1:30 with inclusion of in situ melanoma).
- Risk factors include history of sunburns and/or heavy sun exposure, blue or green eyes, blonde or red hair, fair complexion, >100 typical nevi, any atypical nevi, prior personal or family history of melanoma, or *p16* mutation.
- Mean age of diagnosis is 52 years, 10–15 years younger than other more common cancers of the breast, lung, colon, and prostate.
- Most common location is the back for men, and lower extremities followed by trunk for women but can occur anywhere on the skin surface.
- Features used for melanoma recognition: A (*a*symmetry), B (irregular *b*orders), C (*c*olor variegation), D (*d*iameter >6 mm in most common use, but others have changed D to *d*ifference—"ugly duckling" sign or different with respect to change in size, shape, color, or persistent lesional pruritus), and E (*e*volving over time).
- Follows a highly variable course and represents a heterogeneous disorder; surgically curable if diagnosed and treated in early phase, but potentially lethal with increased risk when diagnosed and treated late.

EPIDEMIOLOGY

The incidence of melanoma has increased significantly worldwide over the last several decades. One in 50 born in the United States in 2010 is projected to develop invasive melanoma over their lifetime (1:39 men and 1:58 women), a 2,000% increase from 1930. With the inclusion of melanoma in situ, the lifetime risk increases to >1:30.[1] It is estimated that 121,840 men and women were diagnosed with melanoma of the skin in 2009, of which 68,720 were invasive melanomas and 53,120 were melanoma in situ.[2] Invasive melanoma of the skin is the fifth most frequent site for cancer to occur in men and the sixth most frequent site in women, representing approximately 5% of all newly diagnosed cancers.

Mortality rates for melanoma have recently stabilized for women, but continue to increase for men. The US surveillance, epidemiology, and end results (SEER) data estimates that in 2009, there were 8,650 deaths (5,550 men and 3,100 women) due to melanoma.[2] Melanoma accounts for 75% of all skin cancer deaths. Melanoma is one of the leading cancers in terms of average years of life lost per death from disease.

The mean age of diagnosis is relatively young at 52 years, which is 10–15 years earlier than the mean age of diagnosis in the more common tumors of the breast, lung, colon, and prostate. More than 35% of melanomas occur in persons less than 45 years of age.[1] Melanoma is the most common type of cancer in young adults in the US ages 25–29, second most common cancer in adolescents and young adults 15–29 years old. Incidence rises with age, especially in men. In the United States, women have a slightly higher incidence of melanoma than men before the age of 40 years. After age 40, men have a higher incidence, and the difference becomes remarkably large with increasing age.

Mortality data parallel incidence data, with older men having the highest mortality rates. Although mortality rates in older persons, especially men, are rising, melanoma mortality rates in younger persons and females have been steady or actually declined despite a rising incidence of melanoma in young women.[2–4] Lightly pigmented Caucasians have the highest incidence rates, much higher than Hispanics, Asians, and African-Americans.[1]

ETIOLOGY AND PATHOGENESIS

RISK FACTORS

(Table 124-1)

SUN EXPOSURE. Both genetic and environmental factors are related to melanoma pathogenesis and certainly not all melanomas are sun related. There is, however, clear convincing evidence that sun exposure, and more specifically ultraviolet (UV) exposure, is a major environmental cause of melanoma, especially in high-risk populations. Epidemiologic studies suggest that periodic, intense sun exposure (particularly during the critical time period of childhood and adolescence) rather than long, continued, heavy sun exposure is most important in melanoma causation, termed the *intermittent exposure* hypothesis. Sunburn history, notably blistering and peeling burns, serves as a surrogate measure of intermittent intense sun exposure. In one review of published literature, there was a significant positive association between sunburns during childhood and risk of melanoma development.[5] One blistering sunburn in childhood more than doubles a person's chances of developing melanoma later in life. Sunburns in adulthood have also been shown to contribute to melanoma risk.[6] Data from the behavior risk factor surveillance system of the Centers for Disease Control and Prevention show that nearly 32% of all adults aged ≥18 years, 58% between 18 and 29 years of age, and more than 40% of children report having had at least one annual sunburn defined as red skin for more than 12 hours.[7] Crude sunburn prevalence rates in white adults by state demonstrated higher sunburn rates among Caucasian adults living in the Midwest, possibly a reflection of a population that is more sun sensitive or less likely to practice sun-safe behaviors.

Migration studies generally indicate an increased melanoma risk in individuals who spent childhood in sunny geographic areas or emigrated to sunnier areas.[8] Younger migrants to sunny areas have an increased risk for melanoma as compared with adult immigrants. Lastly, there is an increased melanoma risk with longer duration of residence in the sunny locale.

Melanoma incidence and mortality among Caucasians correlate inversely with latitude of residence and dose of UV radiation, termed the *latitude gradient*. The highest rates are nearest the equator. In areas as geographically diverse as the United States, New Zealand, and Australia, the incidence of melanoma is greater in regions closer to the equator. However, this gradient may be confounded by other risk factors for melanoma. In Italy, for example, more darkly pigmented persons reside in the South whereas more lightly pigmented persons live in the North, so that the latitude gradient is actually reversed.[9] Even in the United States, SEER data from 1992 to 2001 demonstrate that the latitude gradient applies only to non-Hispanic whites; melanoma incidence was not associated with latitude and UV index in African-Americans, Hispanics, Asians, and Native Americans.[10]

The anatomic distribution of melanoma by body site demonstrates that intermittently exposed skin areas have the highest rates of developing melanoma. In men, the trunk, particularly the upper back, is the most common site for melanoma. In women, the lower legs, followed by the trunk, are the most common sites.[11] These intermittently exposed areas are the most common areas to develop melanoma in younger persons. In older persons, there is a greater incidence of melanomas located on chronically exposed areas with maximal cumulative sun exposure. The face is the most common location for melanoma in older persons, with the addition of the neck, scalp, and ears as well, in older men.[12,13]

Several forms of artificial light have been associated with the development of melanoma, particularly psoralen and UVA light (PUVA) and UVB, and tanning booths. The so-called *PUVA Follow-up Study* demonstrated increased rates of melanoma after PUVA exposure, with an incidence rate ratio of 9.3 approximately 20 years after PUVA therapy; these rates increased over time and were higher in patients exposed to high cumulative doses of PUVA.[12–14] However, the role of PUVA in the development of melanoma has been disputed on statistical grounds.[15] Furthermore, an increased incidence of melanoma was not seen in a large follow-up study of PUVA-treated patients in Sweden, although a difference in treatment regimens between the United States and Sweden represented a potential confounding variable. There is also rising concern over tanning beds and melanoma risk, especially as exposure

TABLE 124-1
Risk Factors for Cutaneous Melanoma

- Ultraviolet radiation exposure
  - Blistering sunburns at any time in life; intermittent or sporadic high levels of exposure
  - Excessive chronic exposure to sunlight
- Phenotypic characteristics
  - Fair skin, inability to tan, tendency to sunburn or freckle (SPT I and II)
  - Blue or green eyes
  - Red or blond hair
  - Numerous typical nevi and/or more than one atypical nevus
  - Large congenital nevus
- History of prior melanoma
- Family history of melanoma
- Mutation in p16, BRAF, or MC1R
- Xeroderma pigmentosum
- Immune suppression (debatable)

to the artificial UV radiation is intermittent in nature. Any exposure to artificial tanning devices modestly, but significantly, increases the risk of cutaneous melanoma (odds ratio, 1.25), and longer duration of bed use, younger age at first exposure, and higher frequency of use are associated with a significantly elevated risk (odds ratio, 1.69).[16] Exposure to tanning beds early in life, before age 35, may be the most harmful pattern of tanning bed use, with a summary relative risk of developing a melanoma of 1.75.[17] The evidence does not support a protective effect of tanning bed use before sun exposure.[17]

SKIN PHENOTYPE. Light skin pigmentation, blond or red hair, blue or green eyes, prominent freckling tendency, and tendency to sunburn with Fitzpatrick skin phototype I–II are phenotypic features associated with an increased risk of melanoma.[18–22] Melanoma occurs much less frequently in type V–VI skin, suggesting that skin pigment plays a protective role.

MELANOCYTIC NEVI. There is an increased risk of melanoma associated with nevi, both in a quantitative (i.e., number of nevi) and qualitative (i.e., typical vs. atypical nevi) manner.[23–26] Adults with more than 100 clinically typical-appearing nevi, children with more than 50 typical-appearing nevi, and any patient with atypical nevi are at risk. The presence of a solitary dysplastic nevus may double the risk of melanoma, while having ten or more atypical nevi may be associated with a 12-fold elevation of risk.[26] Nevi more often serve as a genetic marker of increased risk rather than a premalignant lesion, as most melanomas arise de novo. In a study of 1,606 patients with melanoma, only 26% of the melanomas were histologically associated with nevi (43% of these atypical nevi, 57% other nevi).[27]

On the other hand, large congenital nevi are recognized potential precursors of melanoma, although the degree of risk varies depending on the size of the lesion.[28] Many series define large congenital nevi as greater than 20 cm in diameter in adulthood, and lifetime risks for developing melanoma are generally accepted to be in the 5%–10% range. It is estimated that 70% of melanomas in large congenital nevi develop before the age of 10 years old and may occur deep within the nevus or even in the central nervous system, making detection of a thin lesion difficult. Patients with large congenital nevi located on the posterior axis (paraspinal, head, and neck regions) or in conjunction with multiple satellite lesions are at risk for neurocutaneous melanosis, with an increased risk of developing melanoma in the central nervous system. For small- to medium-sized congenital nevi, the melanoma risk is similar to any other area of skin; in this case, melanoma usually occurs later in life (after puberty), and arises at the dermal-epidermal junction, making early detection possible.[28] Thus, prophylactic excision of small- and medium-sized congenital nevi is usually unwarranted.

FAMILY HISTORY. Patients with familial melanoma are estimated to account for 10%–15% of all patients with melanoma. Having one first-degree relative with melanoma doubles the risk of melanoma, whereas having three or more first-degree relatives with melanoma increases the risk 35- to 70-fold.[29] Some of this risk may be attributed to shared risk factors such as skin phenotype, multiple nevi, and excessive sun exposure. The association between familial melanoma and multiple atypical nevi has historically been given various names, including *B-K mole syndrome, familial atypical multiple mole-melanoma syndrome*, and *dysplastic nevus syndrome*. Patients with familial melanoma typically have earlier onset melanoma and multiple primaries as well as atypical nevi. The molecular basis for some familial atypical multiple mole-melanoma syndrome kindreds are discussed under Section "Genetics."

PERSONAL HISTORY. A previous history of melanoma increases the risk for another primary melanoma, with 5%–15% of individuals developing multiple primary melanomas.[30,31] In patients with multiple primary melanomas, roughly one-half develop a second primary tumor in the same region of the body (i.e., trunk, extremity, head, and neck) and roughly one-half develop a second primary melanoma within the first year of initial diagnosis.[30] However, subsequent primary melanomas may develop decades after diagnosis of the initial lesion, stressing the need for long-term surveillance. Subsequent melanomas are thinner compared with the first melanoma in roughly 70%–75% of cases.[30]

An association with an increased incidence of melanoma with immunosuppression remains unclear; ranging from no increased risk to a modest 1.5- to fivefold increased incidence in few studies.[9,32] Several recent large reviews have revealed little to no increased risk of melanoma among HIV patients and no correlation of melanoma risk with declining CD4 count or the diagnosis of AIDS.[32,33] Several studies have provided some evidence for an increased risk of melanoma in patients with a history of non-Hodgkin's lymphoma (NHL), and possibly for melanoma patients having an increased risk of developing NHL, but these findings are not seen in all populations, and the clinical significance of these studies is not clear.[34–36] Outcomes in immunosuppressed transplant recipients are reported as similar to matched nonimmunosuppressed patients, albeit in relatively small series.

Finally, a history of actinic keratosis or nonmelanoma skin cancer also confers a small increased risk of developing melanoma.

GENETICS

CDKN2A-CDK4-TP53 Pathway. Germline mutations in the chromosome 9p21 tumor suppressor gene, cyclin-dependent kinase inhibitor 2A (*CDKN2A*), account for approximately 40% of hereditary melanoma cases (≥3 melanomas in one lineage) and confer a 76% chance of developing melanoma in the United States[37]; concordant with ambient rates, this risk is somewhat higher in Australia and lower in Europe. Individuals with germline *CDKN2A* mutations also exhibit a higher risk of pancreatic cancer; an estimated 15% of individuals with a mutant allele will develop pancreatic cancer in their lifetime.[38] Bonafide deleterious point mutations in *CDKN2A* are relatively uncommon in primary

melanoma tumors although homozygous deletions of this gene may obscure the true rate of somatic loss in melanoma. *CDKN2A* encodes two gene products: p16 (also known as *INK4a*, inhibitor of kinase 4a) and $p14^{ARF}$ (alternative reading frame). p16 is a cell-cycle regulator that binds and inhibits cyclin-dependent kinases Cdk4 or Cdk6, thereby inhibiting progression of cells through the G1 phase of the cell cycle. If p16 function is absent or inactivated by mutation, unrestrained Cdk4 activity phosphorylates the retinoblastoma protein thereby releasing the transcription factor E2-F and inducing S-phase entry. This sequence culminates in enhanced cellular proliferation, which, in the absence of checkpoint regulation, results in unrestrained growth and neoplasia.

The binding partner of the p16 protein is Cdk4. Only a handful of families worldwide thus far have been reported to carry hereditary mutations in *CDK4* while somatic mutations in this gene have also been detected in some melanoma cell lines. Functional studies suggest that mutations in Cdk4 render the cyclin-dependent protein kinase resistant to p16 inhibition, resulting in a phenotype identical to that from p16 loss.

The $p14^{ARF}$ protein from *CDKN2A* inhibits a cellular oncogene Hdm2, which in turn accelerates the destruction of the p53 tumor-suppressor gene.[39] Thus, complete loss of *CDKN2A* also leads to abrogation of $p14^{ARF}$ and loss of p53 function. Thus, this single locus can inactivate both the retinoblastoma protein and p53 pathways and probably explains the low rate of direct *TP53* mutagenesis in melanoma.

RAS Signaling Pathway. Davies et al. first reported in 2002 a somatic mutation in the *BRAF* gene in 66% of melanomas.[40] B-raf is a serine/threonine kinase, which is a major player in the Ras-Raf-Mek-Erk mitogen-activated protein kinase (MAPK) signaling transduction pathway that regulates cell growth, proliferation, and differentiation in response to various growth factors, cytokines, and hormones. The stimuli activate the G-protein Ras by inducing the exchange of guanosine 5′-diphosphate for guanosine 5′-triphosphate, which then binds and activates Raf. Raf phosphorylates and activates Mek, which in turn phosphorylates MAPK (i.e., Erks). This signaling cascade serves to intracellularly amplify the extracellular signals mediated by growth factors. There are three functional Raf proteins in humans, A-raf, B-raf, and C-raf. B-raf has a much higher basal kinase activity than either A-raf or C-raf, and somatic mutations in B-raf occur with moderate to higher frequency in melanoma and colorectal, ovarian, and papillary thyroid carcinomas, implicating activating oncogenic mutations of B-raf as critical promoters of malignancy.[41]

BRAF mutations are significantly more common in melanomas occurring on skin subject to intermittent sun exposure, with 81% of melanomas on skin without chronic sun damage having *BRAF* or *NRAS* mutations.[42] On the other hand, the majority of melanomas from acral sites (palms, soles, and subungual skin), mucosa, or chronically sun-damaged skin do not carry a mutation in either gene. There are also significant differences in the number of copies of genomic DNA in melanomas located in the various regions. Melanomas with wild-type *BRAF* or *RAS* frequently had increases in the number of copies of the genes for *CDK4* and *CCND1* (cyclin D1), two critical G1 cell-cycle proteins and two genes that are transcriptionally induced by activated MAPK signaling.[42]

Mutations in *PTEN/MMAC1* tumor suppressor gene also lead to enhanced Ras pathway signaling.[43] This protein/lipid phosphatase downregulates signaling through the Akt arm of the Ras circuitry. When PTEN is inactivated, there is dysregulated Akt activity along with increased cellular survival. There is both genetic[43] and animal data[44] to support cooperativity between PTEN loss and B-raf activation in driving melanoma formation.

OTHER GENES

Microphthalmia. Recently, somatic amplifications of the microphthalmia (*MITF*) gene in a subset of melanoma tumors were identified, and it was demonstrated that overexpression of *MITF*, in conjunction with ectopic expression of *BRAF*, resulted in melanocyte transformation.[45] The Mitf protein is a transcription factor that appears to be a master regulator of melanocyte differentiation, and amplification of this gene appears to contribute to a novel carcinogenic mechanism known as *lineage addiction*.

KIT. The *KIT* tyrosinse kinase receptor has also been shown to be mutated or amplified in a subset of melanomas predominantly from acral and mucosal sites.[46] These oncogenic lesions occur mostly in the juxtamembrane domain (*KIT* exons 11, 13, and 17)—a region that is frequently targeted in other cancers including gastrointestinal stromal tumors.[47] There is early evidence that imatinib, a tyrosine kinase inhibitor, may be useful in the treatment of c-Kit mutated melanomas.[48]

Melanocortin-1-Receptor. As mentioned above, red hair and sun sensitivity represent epidemiologically demonstrated risk factors for cutaneous melanoma. Recently, mutations in the melanocortin-1-receptor (*MC1R*) were shown to strongly contribute to the red hair/fair skin phenotype.[49] As such, germline mutations in the *MC1R* gene have also been shown to increase melanoma risk by approximately two- to fourfold in the general population[50]; it also confers risk for nonmelanoma skin cancer. Because the prevalence of *MC1R* mutations is quite high in the white population, its attributable risk to melanoma is higher than the rarer high-risk *CDKN2A* mutations.

Xeroderma Pigmentosum Genes. Xeroderma pigmentosum (XP) is a rare autosomal recessive genodermatosis comprised of at least seven complementation groups each defined by a separate gene. The XP genes are involved in excising DNA photoproducts in a reparative program termed *nucleotide excision repair*. Thus, heritable defects in these genes lead to increased mutagenesis and early carcinogenesis. Patients with XP harbor a 600- to 1,000-fold increased risk for skin cancer, including cutaneous melanoma.

Breast Cancer Susceptibility Gene. Carriers of the breast cancer susceptibility gene, *BRCA2*, appear to

harbor an increased risk for melanoma (2.58-fold).[51] Although an interaction between breast cancer and melanoma risk has been suggested on epidemiologic grounds, the genetic interaction between *BRCA2* and melanoma risk remains to be fully determined.

TUMORIGENESIS AND TUMOR PROGRESSION

Five stages of malignant transformation and tumor progression in melanocytes have been suggested, based on clinical, histopathologic, immunopathologic, cytogenetic, and in vitro properties: (1) benign melanocytic nevi; (2) atypical nevi; (3) primary malignant melanoma, radial growth phase; (4) primary malignant melanoma, vertical growth phase; and (5) metastatic malignant melanoma. It is believed that with each successive step of tumorigenesis, a new clone of cells emerges with growth advantages over the surrounding tissue, resulting in "clonal expansion." It has been postulated that a critical step in tumor progression of melanoma may be the transition from radial to vertical growth phases. The radial growth phase consists of primarily intraepidermal proliferation of melanoma cells, but also invasion of the papillary dermis by small numbers of cells that have gained a growth advantage. These cells are thought to have the capacity for autonomous proliferation in this location, but not for aggregative growth. Radial growth phase cells are characterized by the presence of E-cadherin, an adhesion molecule that interacts with keratinocytes and impedes migration of the cells from their intraepidermal location.[55] Melanomas in this phase are less capable of metastasis. The vertical growth phase is signaled by the property of aggregative growth, resulting in the formation of expansile nests or nodules of cells. Because the metastatic cascade comprises a complex range of numerous biochemical events, the vertical growth phase is likely an oversimplified correlate for the metastatic phenotype. Among other characteristics, vertical growth phase cells lose E-cadherin and express N-cadherin, a molecule that interacts with fibroblasts, macrophages, and endothelial cells. This latter interaction may facilitate intravasation of the malignant cells.[55]

A discussion of tumorigenesis of melanoma must take into account several important clinical observations: (1) the association between precursor nevi and melanoma in approximately 30% of cases (an apparent absence of precursor nevi in 70% of melanoma); (2) the role of UV light in the pathogenesis of melanoma; (3) pigmentary phenotype of patients in whom melanoma develops; and (4) family history of melanoma and other genetic factors. When the above observations are considered in light of the multistep process of tumor progression of melanoma, at least two major pathways of tumorigenesis can be envisioned.

In the first pathway, melanomas, particularly superficial spreading melanomas (SSMs), at least in some cases, develop in association with melanocytic nevi. Nevi may represent the first stage of tumor progression of melanoma or an initiated clonal proliferation. The most likely initiating agent would be UV exposure, perhaps at an early age. There is epidemiologic evidence that sun exposure earlier in life may result in larger numbers of nevi. The number of precursor nevi may be important as greater numbers of initiated cells would increase the target population for another mutational event. As UV is believed to be a complete carcinogen, sunlight exposure, perhaps of intermittent nature, could lead to this second mutational event, resulting in tumor progression. A second pathway of melanoma development is exemplified by lentigo maligna melanoma (LMM). This form of melanoma results from cumulative sun exposure and a corresponding cumulative insult to the DNA of melanocytes on sun-exposed skin. The age-incidence rates show a steady increase with age, consistent with continuous exposure (initiation) to a carcinogenic agent such as UV light.

Curtin et al. compared genome-wide alterations in the number of copies of DNA and mutational status of *BRAF* and *NRAS* in melanomas from variable groups in which the degree of exposure to UV light differed.[42] The genetic alterations identified in melanomas at different sites with different levels of sun exposure indicated that there are distinct genetic pathways in the development of melanoma. This supports the hypothesis that the clinical heterogeneity notable for melanoma may be explained by genetically distinct types of melanoma with different susceptibility to UV light.[42] Certainly, other as yet unknown pathways may exist that are independent of UV light.

CLINICAL FINDINGS

SUBTYPES OF MELANOMA

SUPERFICIAL SPREADING MELANOMA. SSM is the most common subtype, accounting for approximately 70% of all cutaneous melanomas. It is diagnosed most commonly on intermittently sun-exposed areas, most frequently the lower extremity of women, and the upper back of men. Its classic clinical appearance best fits into the ABCD criteria (see Section "Making a Diagnosis"), with irregular borders and irregular pigmentation, but it may present subtly as a discrete focal area of darkening within a preexisting nevus. The range of appearance of SSM is broad (Figs. 124-1 and 124-2). Although varying shades of brown typify most melanocytic lesions, striking aspects of dark brown to black, blue-gray, pink, red, and gray-white (which may represent regression) may be found in melanoma. SSM is the subtype of melanoma most commonly associated with preexisting nevi. The history of SSM is often of a lesion slowly changing over months to years. It may be mistaken for an atypical nevus or seborrheic keratosis.

DIFFERENTIAL DIAGNOSIS

(See Box 124-1)

NODULAR MELANOMA. Nodular melanoma (NM) is the second most common melanoma

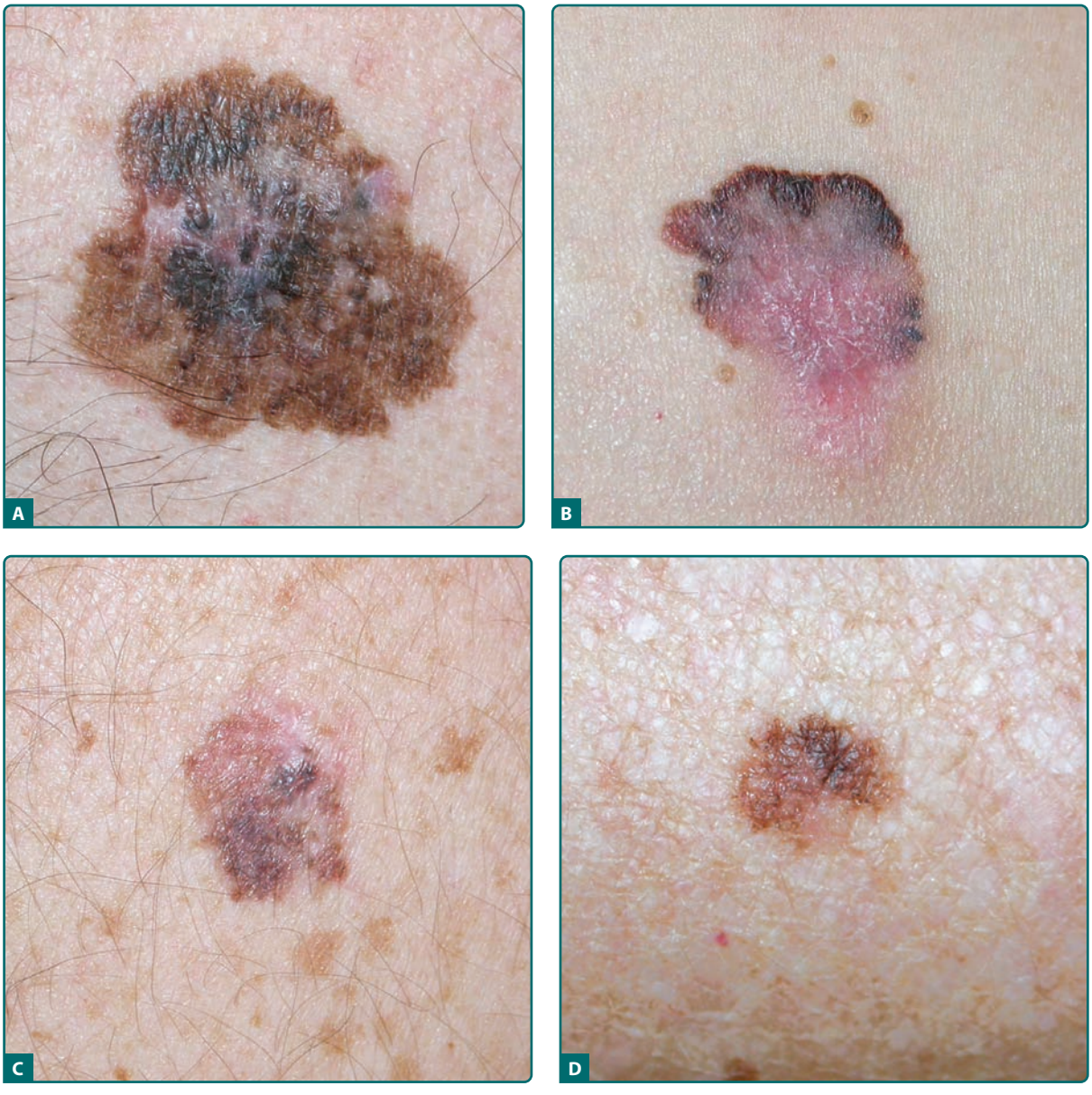

Figure 124-1 Superficial spreading melanoma (SSM). **A.** Classic clinical appearance with cardinal features of SSM: asymmetry, irregular scalloped borders, mottled variegate color, large diameter, and central elevation with surface distortion in a 45-year-old man, left chest, Breslow depth 1.25 mm. **B.** Another SSM with similar features but with pronounced areas of pink, shades of blue and white, with peripheral areas of black and brown in a 54-year-old woman, right lower abdomen, Breslow depth 3.5 mm, 26 mitoses/mm^2, ulceration focally present. **C.** Earlier detection in a 55-year-old man with many atypical nevi, patient unaware of the lesion, lesion noted by primary care physician during a routine physical examination, "different" than other nevi, right upper back, Breslow depth 0.50 mm. The pink/tan upper portion is an atypical nevus, the lower portion SSM arising in an atypical nevus. **D.** Still earlier detection with more subtle asymmetry, border, color, diameter/difference, elevation/evolving (ABCDs), forearm, Breslow depth 0.14 mm. The lesion was 0.8 cm in diameter with a history of a "brown spot," which grew in size, changed shape, and changed to a darker color over several months.

subtype and accounts for approximately 15%–30% of all melanomas. The trunk is the most common site. NM is remarkable for rapid evolution, often arising over several weeks to months. NM more often lacks an apparent radial growth phase. It is more common for NM to begin de novo than to arise in a preexisting nevus. NM typically appears as a uniformly dark blue-black or bluish-red raised lesion, but 5% are amelanotic (Fig. 124-3). A substantial proportion of thick melanomas are of the nodular type.[56] Early lesions often lack asymmetry, have regular borders, and are a uniform color. Amelanotic lesions may be mistaken for basal cell carcinoma, pyogenic granuloma, or hemangioma, whereas pigmented lesions may be mistaken for blue nevi or pigmented basal cell carcinomas.

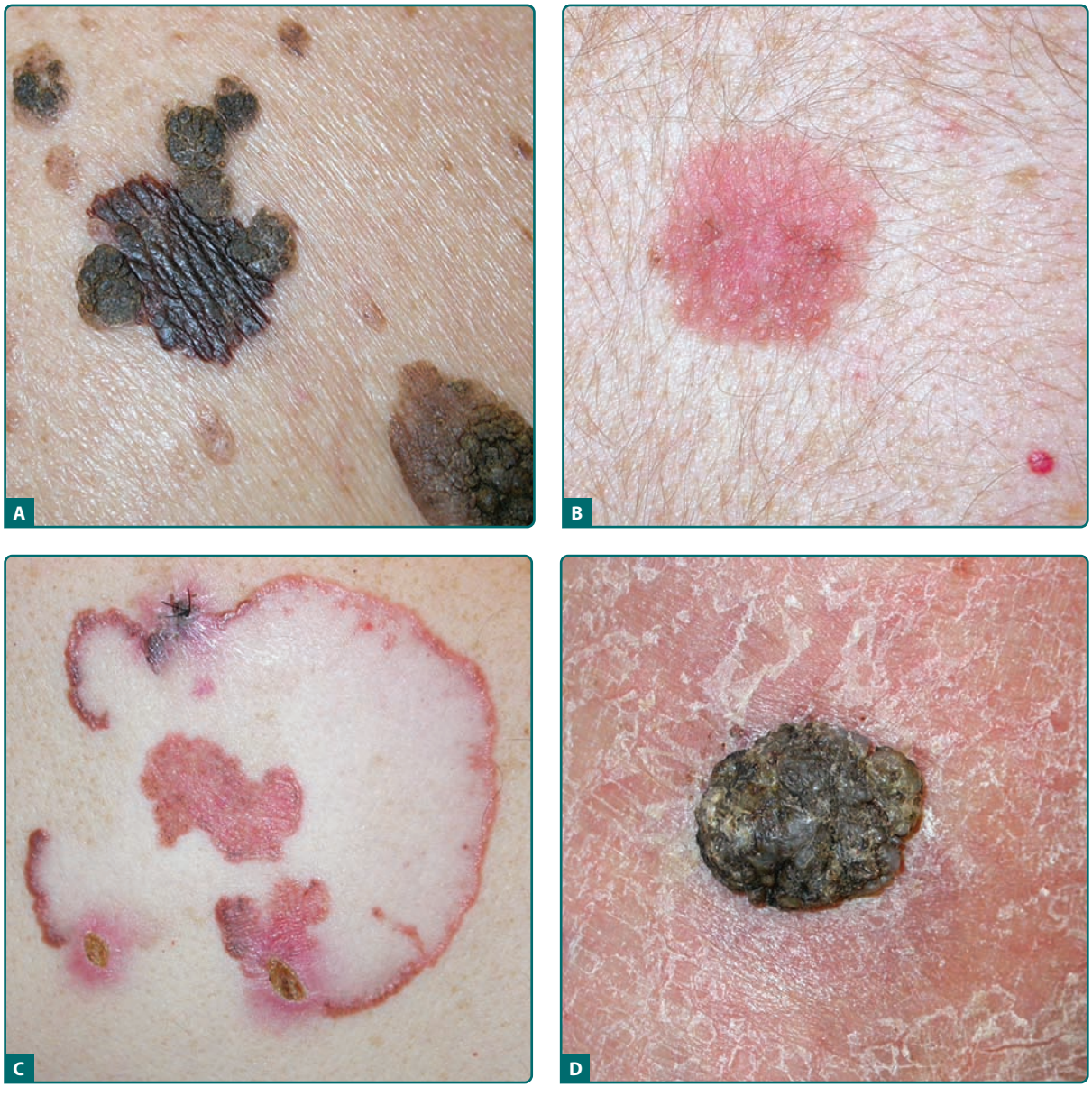

Figure 124-2 Superficial spreading melanoma (SSM) showing a broad range of appearance. **A.** Breslow depth 0.51 mm, central back within a "sea" of seborrheic keratosis but "different" than the surrounding seborrheic keratoses. **B.** Amelanotic SSM, upper back, Breslow depth 0.38 mm. **C.** Unusual presentation, left posterior shoulder, 60-year-old man, 11 cm × 9 cm SSM, slowly growing peripherally for over a decade, large areas of regression, pink amelanotic areas, and a small black component in the superior pole, Breslow depth 1.60 mm, 3 mitoses/mm^2. **D.** Unusual presentation of SSM with papillomatous features, right ankle, Breslow depth 6.3 mm, 3 mitoses/mm^2, vertical growth phase.

BOX 124-1 DIFFERENTIAL DIAGNOSIS OF SUPERFICIAL SPREADING MELANOMA

- Atypical nevus
- Common nevus
- Seborrheic keratosis
- Basal cell carcinoma

DIFFERENTIAL DIAGNOSIS

(See Box 124-2)

LENTIGO MALIGNA AND LENTIGO MALIGNA MELANOMA. LM is a subtype of melanoma in situ with a prolonged radial growth phase that may progress to invasive LMM with time. Invasive LMM constitutes 10%–15% of cutaneous melanomas. LM and LMM are diagnosed most commonly in

BOX 124-2 DIFFERENTIAL DIAGNOSIS OF NODULAR MELANOMA

PIGMENTED

- Common nevus
- Blue nevus
- Pigmented Spitz nevus
- Pigmented basal cell carcinoma

AMELANOTIC

- Basal cell carcinoma
- Hemangioma
- Pyogenic granuloma
- Merkel cell carcinoma

the seventh to eighth decades in an older population than other types of melanoma; uncommon before the age 40. The most common location is on the chronically sun-exposed face, on the cheeks and nose in particular; the neck, scalp, and ears in men. Its pathogenesis is thought to be related to cumulative sun exposure rather than intermittent exposure. LM is a flat, slowly enlarging, brown, freckle-like macule with irregular shape and differing shades of brown and tan, usually arising in a background of photodamage (Fig. 124-4). The lifetime risk of LMM developing from LM is estimated to be low but the invasive component is potentially

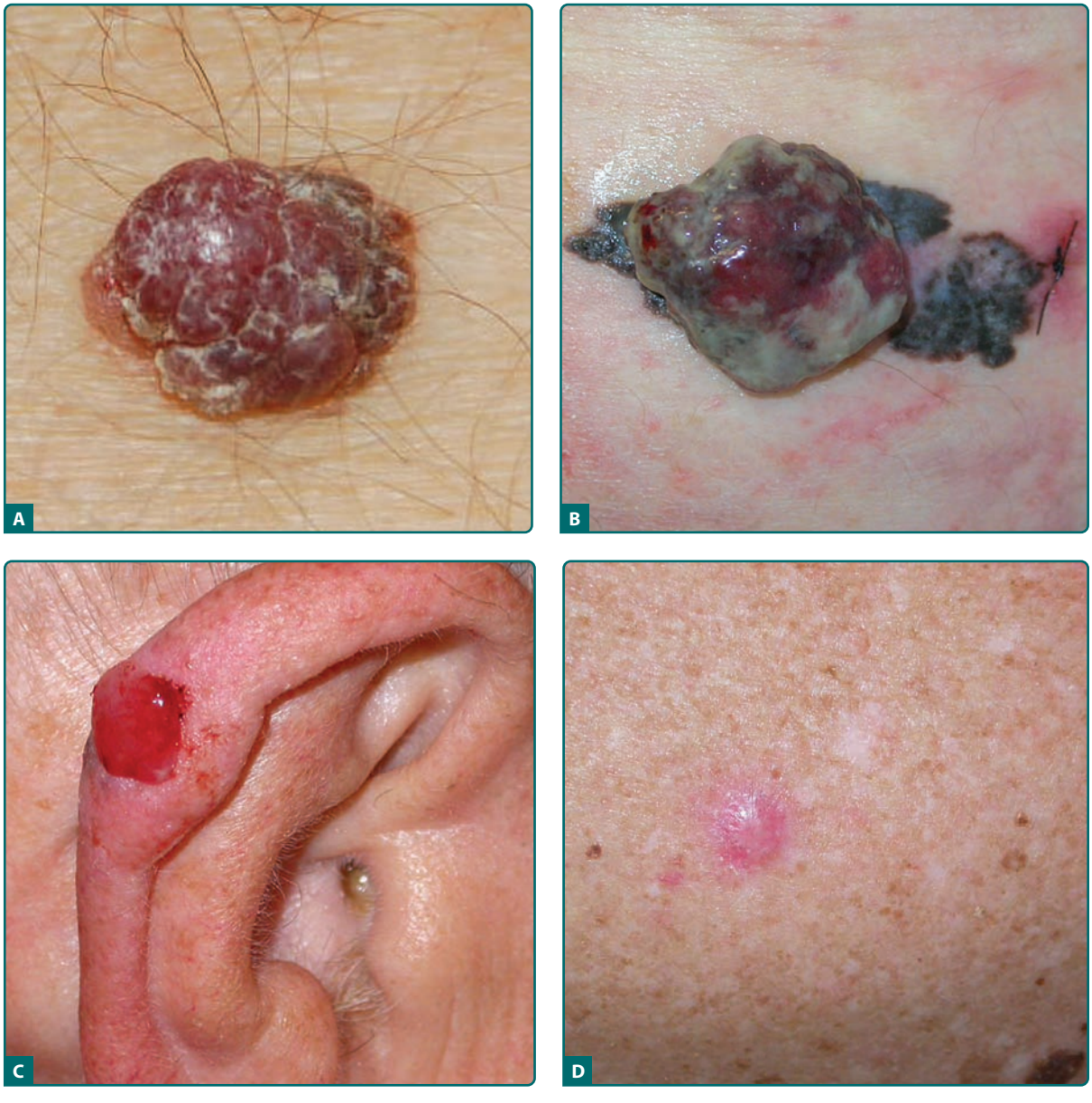

Figure 124-3 Nodular melanoma (NM). **A.** Classic NM, left lower back, Breslow depth 4.3 mm, angiolymphatic spread present. (Used with permission from Walter Barkey, MD.) **B.** Nodular polypoid melanoma, left flank, Breslow depth 16.0 mm, 38 mitoses/mm^2, ulceration and angiolymphatic spread present. **C.** Amelanotic NM, Breslow depth 2.37 mm, 32 mitoses/mm^2, vertical growth phase, ulceration present. **D.** Amelanotic NM with spindle cell features, noted approximately 1–2 months with elevation and bleeding, right posterior shoulder, Breslow depth 3.95 mm, 6 mitoses/mm^2.



Figure 124-4 Lentigo maligna and lentigo maligna melanoma (LMM). **A.** Lentigo maligna (in situ) displays prominent asymmetry, poorly defined irregular borders, and pigment variegation. **B.** Extensive LMM with large nodules. **C.** Amelanotic LMM with nodular component initially suspected to be a basal cell carcinoma, nose, Breslow depth 2.2 mm, 5 mitoses/mm^2, ulceration present. **D.** A pigmented patch of hair was noted after discontinuing practice of hair coloring. Over 6 weeks the area became pruritic and bled once. **E.** Inspection of the skin in the area of pigmented hair revealed the melanoma. Breslow depth 3.4 mm, ulceration present, 6 mitoses/mm^2, two foci of dermal melanoma satellite metastases.

lethal.[57] LMM is frequently larger than LM and may continue to be macular in early lesions, although a nodular portion is often seen within the macule later. Both LM and LMM often have clinically ill-defined borders, which may be obscured by background actinic damage consisting of lentigines, pigmented actinic keratoses, or ephelides. LM and LMM are associated with significantly higher rates of extensive subclinical lateral growth, resulting in higher recurrence rates with standard recommended margins and failure to completely excise the lesion. LM and LMM have the least common association with nevi, at 3% of cases, but the highest rate of association with desmoplastic melanoma (DM, see below).

DIFFERENTIAL DIAGNOSIS

(See Box 124-3)

ACRAL LENTIGINOUS MELANOMA. Acral lentiginous melanoma (ALM) is a subtype of melanoma with distinct differences in frequencies seen between ethnic groups. ALM constitutes only 2%–8% of melanomas in Caucasians but represents the most common form in darker-pigmented individuals (60%–72% African-Americans and 29%–46% Asians). Although the proportion of ALM seen in darker-pigmented individuals is higher, the incidence of ALM is similar for Caucasians and other ethnicities. ALM is diagnosed more often in an older population, with the median age of onset of 65. The most common site for ALM is the sole, with the palm and subungual locations following (Fig. 124-5). Not all palmar or plantar melanomas are ALMs; a minority are SSMs or NMs. The clinical appearance of ALM can be brown, black, tan, or red with variegations in color and irregular borders; however, the most common color is brown-black.



Figure 124-5 Acral lentiginous melanoma (ALM). **A.** Classic ALM demonstrating asymmetry, border, color, diameter/difference, elevation/evolving (ABCDs), left foot, Breslow depth 1.72 mm, ulceration present. **B.** Early detection of lesion followed by the patient, present for many decades, over several months began growing with irregular border and shape, changed in color from brown to black, in situ ALM arising in a dysplastic nevus. **C.** Amelanotic ALM, fourth toe of left foot, Breslow depth 5.0 mm.

BOX 124-3 DIFFERENTIAL DIAGNOSIS OF LENTIGO MALIGNA MELANOMA

- Solar lentigo
- Pigmented actinic keratosis
- Flat seborrheic keratosis
- Superficial pigmented basal cell carcinoma

There is often a delay in the diagnosis of ALM, often misdiagnosed as a plantar wart or hematoma, leading to a more advanced lesion upon diagnosis associated with poorer outcomes.[58] ALM is not thought to be associated with sun exposure.

Subungual melanoma, considered a variant of ALM, generally arises from the nail matrix, most commonly on the great toe or thumb (Fig. 124-6). It appears as a brown to black discoloration or growth in the nail bed. A widening, dark, or irregularly pigmented longitudinal



Figure 124-6 Subungual acral lentiginous melanoma (ALM). **A.** Extensive involvement of periungual skin (Hutchinson sign) with dystrophy and loss of the nail plate secondary to the tumor. **B.** ALM great toe, without notable Hutchinson sign, Breslow depth 3.4 mm, 6 mitoses/mm^2, two positive sentinel nodes identified, disease free at 2 years. **C.** Advanced subungual ALM with proximal periungual macular component and subungual and distal ulcerated nodular component. **D.** Subungual ALM, thumb nail bed streak, Breslow depth 0.5 mm. This was her fourth primary melanoma, other three located on the shoulder, cheek, and neck, the first 14 years prior.

nail streak (melanonychia striata) with or without nail dystrophy and nail plate elevation may be seen. Hutchinson sign, the finding of pigmentation on the proximal nail fold, may be noted with subungual melanoma. Benign lesions that mimic subungual melanoma include: benign longitudinal melanonychia, subungual hematoma, or pyogenic granuloma or even onychomycosis with pigmentation or hemorrhage.

DIFFERENTIAL DIAGNOSIS

(See Box 124-4)

OTHER VARIANTS

DESMOPLASTIC MELANOMA. DM most commonly develops in the sixth or seventh decade on sun-exposed head and neck regions. The lesions typically have a firm, sclerotic, or indurated quality, and one-half are amelanotic. Approximately half of the lesions arise in association with the LM histologic subtype. The DM pattern subtype may be associated with a higher rate of local recurrence due to a propensity to infiltrate perineurally with neurotropism and failure to appreciate occult growth, which may be deeply invasive at diagnosis. Although deeply invasive, DM is associated with lower nodal metastatic rates than other subtypes of melanoma when matched for depth of invasion. A recent study has shown that lesions with fusiform and/or epithelioid melanoma cells had a higher metastatic rate than those with pure DM with only fibrosing component.[59] Results from a small study that involved ten samples that investigated gene expression profiling demonstrated a molecular distinction between DM and nondesmoplastic melanoma.[60]

MUCOSAL MELANOMA. Melanoma can infrequently arise on mucosal surfaces on the head and neck (conjunctival, intranasal, sinus, and oral cavities), vulva, anorectal, or even urethral mucosa (Fig. 124-7). With the exception of the conjunctiva, patients present most often with delayed detection and a deeply pigmented, irregular lesion, but due to its location, may also present with bleeding or a mass lesion.[61] As most of these lesions present with a radial growth phase manifesting a macular pigmentation, any suspicious area in these sites should be biopsied. Lesions of the conjunctiva are visible and appear increased in patients with atypical nevi.[62,63]

NEVOID MELANOMA. Nevoid melanoma describes a heterogeneous group of rare lesions that histologically resemble benign nevi by their symmetry and apparent maturation with descent in the dermis, thus with greater potential for misdiagnosis. Clues to their histologic diagnosis include marked hyperchromasia of the nuclei of the tumor cells, the presence of mitoses, and an expansile growth of the dermal cells with effacement of the adventitia in affected areas. Clinically this may correspond to a tan papule or nodule, more often >1 cm in diameter on a young adult.[64]

SPITZOID MELANOMA. Spitzoid melanoma is a subtype of melanoma that clinically and histologically resembles a Spitz nevus, but tends to be larger and have asymmetry and irregular coloration. Distinction between the two is sometimes extremely difficult, and tumors with overlapping features of Spitz nevi and melanoma are classified as atypical Spitz tumors of uncertain biologic behavior (AST).[65] Features that favor the diagnosis of a Spitzoid melanoma over a benign Spitz nevus are large lesions, greater than 1 cm in diameter; lesions with a thick invasive component, well over 2 mm; lesions with numerous mitoses, many atypical, and lesions that have clinically concerning course such as rapid growth in size or satellitosis. Ambiguous lesions that are not clinically or histologically diagnostic for Spitzoid melanoma nor benign Spitz nevi, but with overlapping features of both, may be classified as AST.[65] Ongoing work with molecular profiling to identify genetic alterations in these tumors may provide markers to stratify AST into high- or low-risk lesions.

OTHER RARE TYPES. Several other rare and unusual types of melanoma are beyond the scope of this chapter, but previously reported in a comprehensive review, which include metaplastic melanoma, balloon cell melanoma, signet-ring cell melanoma, myxoid melanoma, rhabdoid melanoma, minimal-deviation melanoma, and animal-type melanoma, malignant blue nevus.[64,66]

BOX 124-4 DIFFERENTIAL DIAGNOSIS OF ACRAL LENTIGINOUS MELANOMA AND SUBUNGUAL ACRAL LENTIGINOUS MELANOMA

- Plantar wart
- Hematoma
- Palmoplantar nevus
- Longitudinal melanonychia
- Onychomycosis
- Pyogenic granuloma

MELANOMA AND PREGNANCY

Melanoma is the second most common cancer in women of child-bearing age, and thus constitutes one of the more common types of cancer diagnosed in pregnancy.[9,67] Historically, controversy existed regarding the effect of pregnancy on the clinical course of melanoma. The basis of potential hormonal effects included hyperpigmentation associated with pregnancy and the elevation of endogenous hormones, including estrogens and melanocyte-stimulating hormone. However, the literature demonstrates that pregnancy does not increase the risk of developing melanoma.[68] Furthermore, pregnancy before, during, or after a woman is

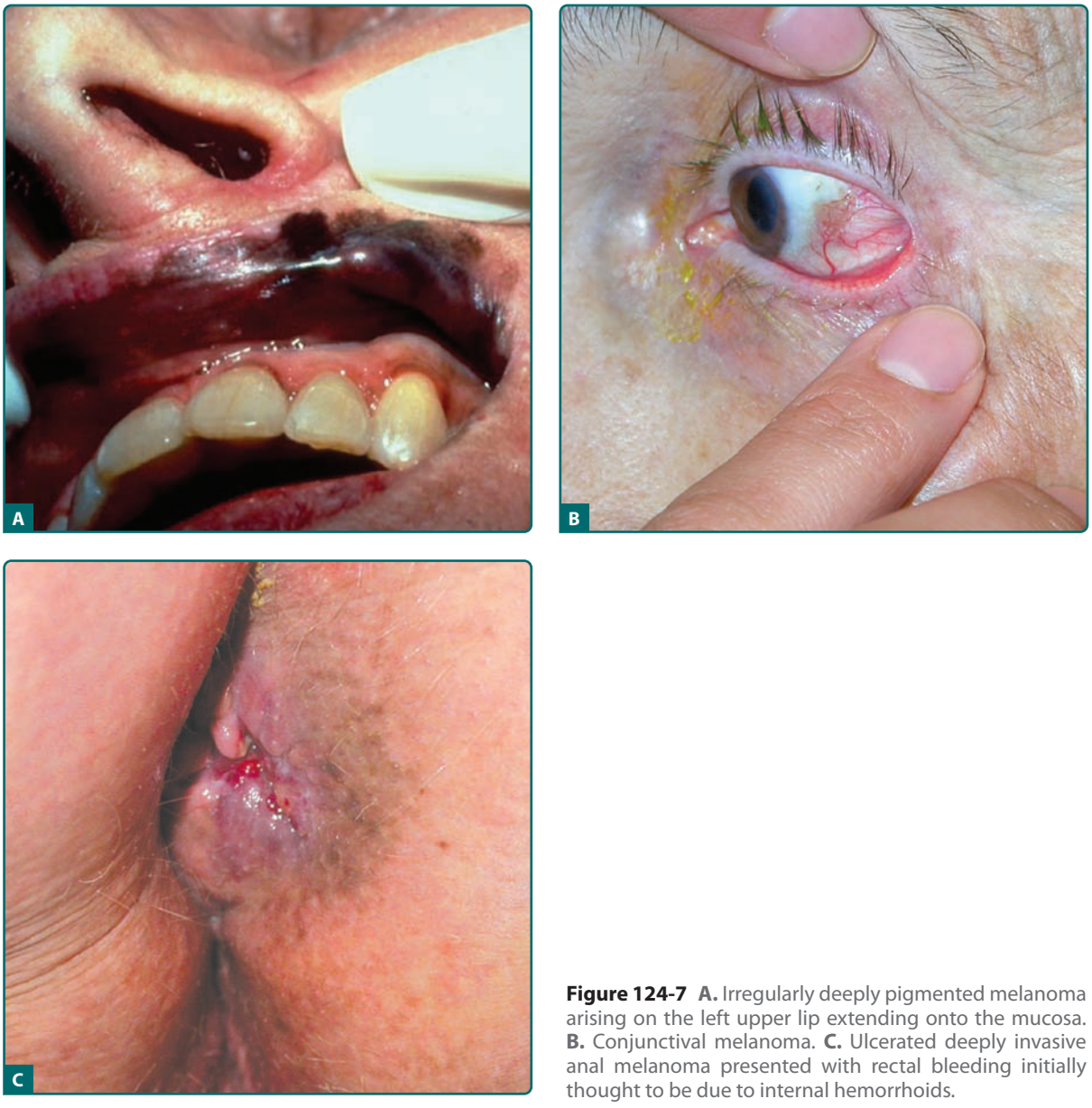

Figure 124-7 **A.** Irregularly deeply pigmented melanoma arising on the left upper lip extending onto the mucosa. **B.** Conjunctival melanoma. **C.** Ulcerated deeply invasive anal melanoma presented with rectal bleeding initially thought to be due to internal hemorrhoids.

diagnosed with melanoma does not appear to influence overall survival, although disease-free survival potentially may be shorted.[69,70,71] There is no reported difference in the distribution or stage of disease, tumor thickness, lymph node positivity, or overall survival for pregnancy-associated melanoma (i.e., melanoma diagnosed during or within 1 year).[72] Pregnant women with melanoma should be offered the same surgical treatments, including sentinel lymph node biopsy (SLNB) (usually with omission of blue dye) as nonpregnant patients; however, certain chemotherapeutic and immunologic regimens used in advanced melanoma may be contraindicated in pregnancy. After the initial diagnosis and treatment of melanoma, there are no standard, defined guidelines for patients who desire to become pregnant. Counseling recommendations should be comprehensive and individualized on a case-by-case basis, depending primarily on the risk of recurrence (related to the stage at diagnosis), patient age, and degree of personal desire to become pregnant relative to risk.

PEDIATRIC MELANOMA

Melanoma in childhood and adolescence is rare. Of all newly diagnosed melanomas, 1%–4% occur in patients younger than 20 years of age, and only 0.3%–0.4% occur in prepubertal children.[73] However, melanoma is being increasingly diagnosed in this age group and being reported to occur more commonly without the classic predisposing risk factors of familial melanoma, congenital nevi, dysplastic nevi, and xeroderma pigmentosum.[74] Based on SEER data of 1,255 melanoma patients less than 20 years of age, a 2.9% increase in the incidence of pediatric melanoma per year from 1973

to 2001 has been noted; the rate of increase was lower (1.4%) in young children less than 10 years.[75] Factors conferring risk of adult melanoma, including increasing age, UV exposure, and Caucasian background, were also found to be important in pediatric melanoma. The classic predisposing factors for adult melanoma are likely to be applicable to some proportion of children. In general, pediatric melanomas tend to have a greater proportion of thicker primaries, possibly related to delayed diagnosis compared with adults.

MAKING A DIAGNOSIS

Early detection is the key to improving prognosis in melanoma. Although melanoma may have a characteristic appearance, there is no single clinical feature that ensures or excludes a diagnosis of melanoma. Even among expert dermatologists, the clinical diagnosis of melanoma can be made in about 80%–90% of cases. The well-known ABCD acronym for melanoma detection continues to be a useful tool for the lay public and physicians.[76] A stands for asymmetry (one half is not identical to the other half); B for border (irregular, notched, scalloped, ragged, or poorly defined borders as opposed to smooth and straight edges); C for color (having varying shades from one area to another); and D for diameter (i.e., greater than 6 mm, approximately the size of a pencil eraser). Lesions having these characteristics may potentially represent melanoma. Studies have found the sensitivity of the ABCD checklist (Box 124-5) to be very high, but the specificity much lower.[77] Another diagnostic aid that is useful in detecting melanoma is the "ugly duckling" sign.[78] A pigmented lesion that is different from other pigmented lesions on a particular individual should be approached with a high index of suspicion. This is based on the premise that within an individual, nevi should globally share a common appearance or family resemblance. Even in an individual with multiple atypical nevi, the nevi should be morphologically similar.

History is very important in the evaluation of a lesion. The old ABCD rule is relatively static and does not account for a critical element of change. For this reason, some have added an E to the ABCD rule, where E stands for evolving.[79] Others have advocated for the D to stand for "difference" (i.e., a change in appearance or symptomatology over time or difference from the other lesions, similar to the "ugly duckling" sign). Change in color and increase in size (or a new lesion) are the two most common early characteristics noticed by patients that may be useful in discriminating between melanoma and other benign lesions.[80] In addition to change in color, size, or shape/elevation, persistent lesional itching is also an earlier (albeit nonspecific) symptom; ulceration, bleeding, and tenderness generally signify a more advanced primary lesion.[81] Therefore, it is important to ask patients if lesions have changed over time, and to pay particular attention to changing or symptomatic lesions. The development of a new pigmented lesion, especially in an individual beyond the age of 40–50 years old and on an anatomic site without similar lesions, is also worthy of suspicion.

BOX 124-5 ABCD CHECKLIST[a]

- A = Asymmetry
- B = Border
- C = Color
- D = Diameter/Difference
- E = Elevation/Evolving

[a]Does not apply to nodular melanoma.

PHYSICAL EXAMINATION

The skin examination should be conducted under optimal lighting and encompass the entire skin integument, including the scalp, external ocular/conjunctivae, oral mucosa, groin, buttocks, and palms/soles/web spaces. Melanomas in hidden anatomic sites are associated with thicker tumors at diagnosis, often due to later detection.[82] A global assessment of an individual's skin, including number of nevi, both typical- and atypical-appearing, and distribution of nevi should be noted. Other risk factors, such as a family or personal history of melanoma, skin type, UV history including tanning booths, or previously biopsied atypical nevi, should also be noted. Total body and lesional photography may be useful, especially in high-risk patients with numerous nevi.[83] The use of photography to document the appearance of skin lesions (or the absence of a skin lesion) can allow for better and earlier detection of a changing or new lesion. In high-risk patients, a proportion of melanomas are diagnosed with the aid of photographic surveillance rather than being noted by the patient or even the physician.[84] If a lesion suspicious for melanoma is found on skin examination, palpation of the regional lymph nodes should be performed to evaluate for lymphadenopathy.

DERMOSCOPY

Dermoscopy (also known as *epiluminescence microscopy, dermatoscopy, incident light microscopy*, and *surface microscopy*) is a noninvasive technique in which a handheld device is used to examine a lesion through a film of liquid, usually immersion oil, using nonpolarized light (contact dermoscopy), or the lesion is examined under polarized light without a contact medium (noncontact dermoscopy). In experienced hands, it may improve both the sensitivity and specificity for the clinical diagnosis of melanoma and other pigmented and nonpigmented lesions. Morphologic features that are otherwise not visible to the naked eye are observed using this technique.[85]

Different diagnostic algorithms using dermoscopic findings have been developed for melanoma, including the ABCD rule, the seven-point checklist, pattern analysis, Menzies method, modified ABC-point list, and CASH (color, architechture, symmetry, and homogeneity).[86–91] Several studies have compared these methods

to determine the most effective method for dermoscopic detection of melanoma.[92–94] Pattern analysis, which provides an overall impression of multiple dermoscopic patterns without rigid rules, based primarily on a subjective, simultaneous evaluation of a number of different criteria, is the most widely used method among experienced users of dermoscopy for evaluating pigmented lesions.[85] Lists of the important dermoscopy features with clinical pathologic correlations and significance have been widely published and are easily obtainable through courses, societies, and the Internet.

Digital dermoscopy or digital epiluminescent microscopy permits computerized digital dermoscopic images to be retrieved and examined at a later date so that comparisons can be made and changes detected over time. There are also a number of commercially available automated computer image analysis programs, devices that incorporate image analysis algorithms to digital dermoscopic images, providing objective measurement of changes over time. The use of automated instruments for the diagnosis of melanoma continues to evolve, but no system has demonstrated superior results to date in a clinically useful form. The use of body or lesional photography, professionally obtained or taken by the patient, is also useful to aid physicians and patients for following lesions, particularly in patients with many nevi. Finally, confocal scanning laser microscopy and multispectral digital dermatoscopy are among a number of new imaging techniques being evaluated for early detection of melanomas.[95,96]

HISTOPATHOLOGY

The gold standard for diagnosing melanoma is based on histopathologic evaluation of the biopsy specimen by a dermatopathologist or pathologist experienced with pigmented lesions.[97–99] The histologic diagnosis of melanoma is based on the assessment of a constellation of findings, including both architectural and cytologic features. No single feature is diagnostic. Cytologic atypia, referring to cellular enlargement, nuclear enlargement, nuclear pleomorphism, hyperchromasia of nuclei, nucleolar variability, and the presence of mitoses especially deep in the dermis, is considered necessary for a diagnosis of melanoma. The major architectural features of melanoma include asymmetry, poor circumscription (i.e., cells at the edge of the lesion tend to be small, single, and scattered), and large size (>5–6 mm). Nests of melanocytes in the lower epidermis and dermis tend to vary a good deal in size and shape, and to become confluent. There is a lack of maturation of nests with descent into the dermis. Pagetoid spread of large solitary epidermal melanocytes, usually considered diagnostic of melanoma, should be assessed cautiously in the context of other findings, as pagetoid spread may be seen in benign lesions including Spitz nevi, spindle cell nevi, vulvar nevi, and acral nevi.

The different subtypes of melanoma have histopathologic differences as well. SSM is characterized by a population of melanocytes appearing uniformly atypical (Figs. 124-8 and 124-9). LM and LMM are characterized by atypical melanocytes singly and in nests, predominantly confined to the basal layer of the epidermis, which become confluent without pagetoid spread, occurring in the background of photodamage

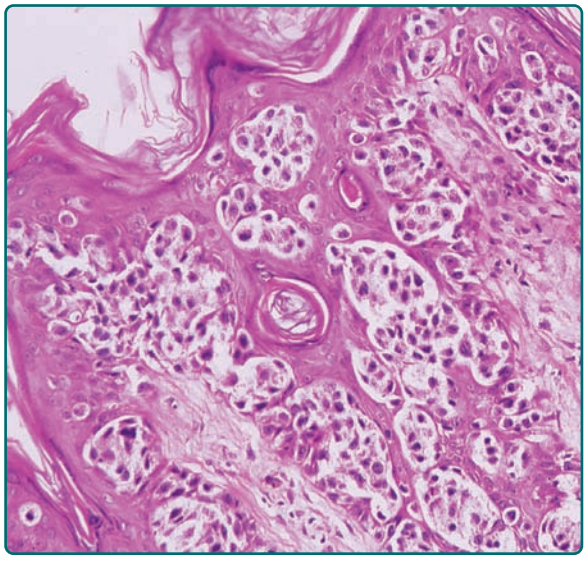

Figure 124-8 Superficial spreading melanoma. This tumor shows intraepidermal growth. In this photomicrograph, the pagetoid distribution is evident in the epidermis. The cells are relatively uniform and have an abundance of dusty, fine pigment. These relatively large melanoma cells are frequently referred to as epithelioid cell type.

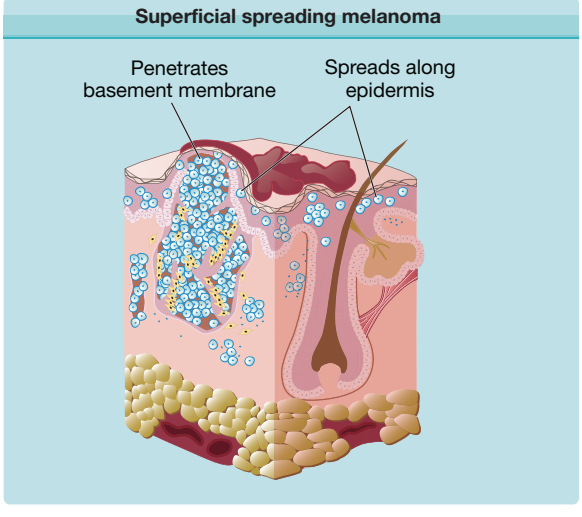

Figure 124-9 Superficial spreading melanoma. The border is irregular and the lesion is elevated throughout its entirety. Biopsy of the area surrounding the large nodule shows a "pagetoid" distribution of large melanocytes that are occurring singly or in nests, and uniformly atypical. On the left is a large nodule, and scattered throughout the surrounding portion of the nodule are smaller papular and nodular areas. The nodule on the left shows malignant melanocytes that are very large, have an abundance of cytoplasm, and often have regularly dispersed fine particles of melanin. The nodules may also show spindle cells or small malignant melanocytes as in lentigo maligna melanoma and nodular melanoma.

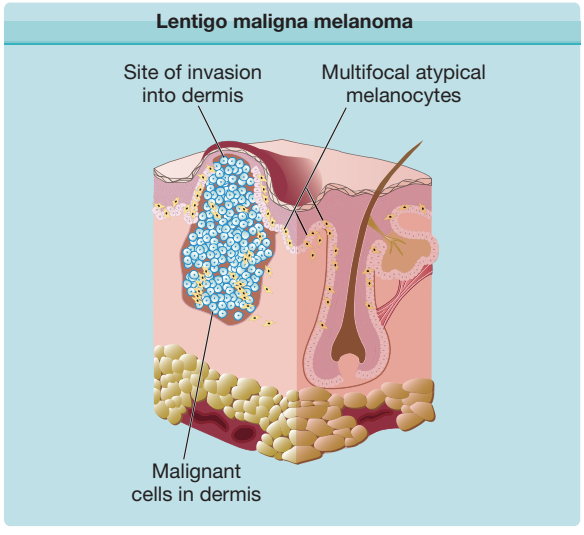

Figure 124-10 Lentigo maligna melanoma. Illustrated on the right is a large, variegated, freckle-like macule (not elevated above the plane of skin) with irregular borders; the tan areas show increased numbers of melanocytes, usually atypical and bizarre, and are distributed single file along the basal layer; at certain places in the dermis, malignant melanocytes have invaded and formed prominent nests. At the left is a large nodule that is composed of epithelioid cells in this illustration; the nodules of all four main subtypes of melanoma are indistinguishable from each other.

(Figs. 124-10–124-12). The cells may extend down hair follicles and appendageal structures. The epidermis is thin and atrophic, with loss of rete ridges. There is variable cytologic atypia. The "lentiginous" in ALM is derived from the characteristic lentiginous pattern of most cells being single and located near the dermal-epidermal junction (Fig. 124-13). ALM differs from LM in that there is irregular acanthosis, and the melanoma cells are uniformly malignant and often dendritic. In LM, the cells are highly pleomorphic in an atrophic

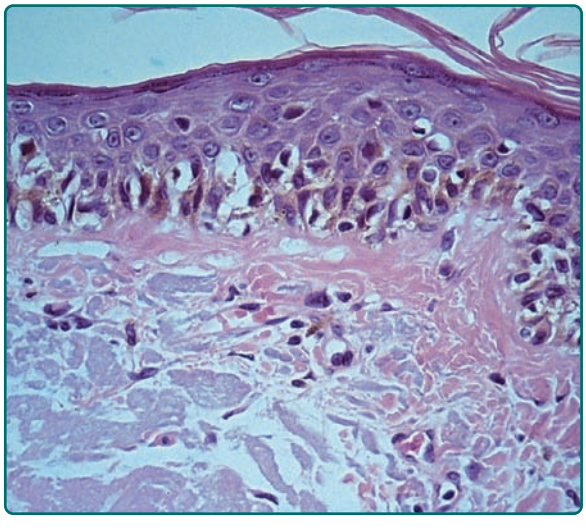

Figure 124-11 Lentigo maligna. This is a proliferation of pleomorphic melanocytes in the basal layer of an atrophic epidermis in sun-damaged skin.

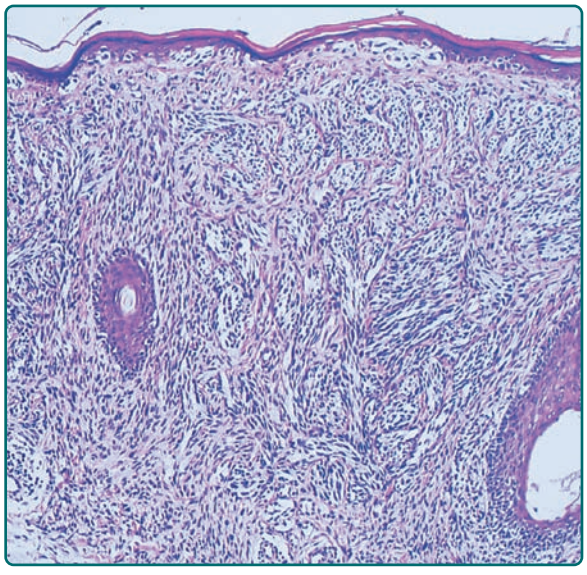

Figure 124-12 Lentigo maligna melanoma (LMM). Extending from the epidermis into the dermis are numerous elongated melanocytes. In LMM, these cells are frequently spindle shaped.

epidermis. NM demonstrates little tendency for intraepidermal growth; instead, there is a dermal mass of atypical melanocytes (Figs. 124-14 and 124-15). DM is composed of strands of elongated, spindle-shaped cells that often infiltrate deeply.

Current National Comprehensive Cancer Center Network (NCCN) guidelines endorse the use of a melanoma histologic profile established by the American Academy of Dermatology.[100] A typical 14-point comprehensive melanoma pathology report is shown in Box 124-6. Use of such a profile ensures that the appropriate histologic features of all melanomas are uniformly analyzed and reported to optimize treatment and future systematic study.

BOX 124-6 MELANOMA PATHOLOGY CHECKLIST

- Body site
- Histologic pattern subtype
- Breslow depth
- Clark level
- Mitotic rate
- Vertical vs. radial growth phase
- Ulceration
- Regression
- Satellitosis
- Angiolymphoid spread
- Neurotropism
- Tumor-infiltrating lymphocytes
- Coexisting nevus
- Margins

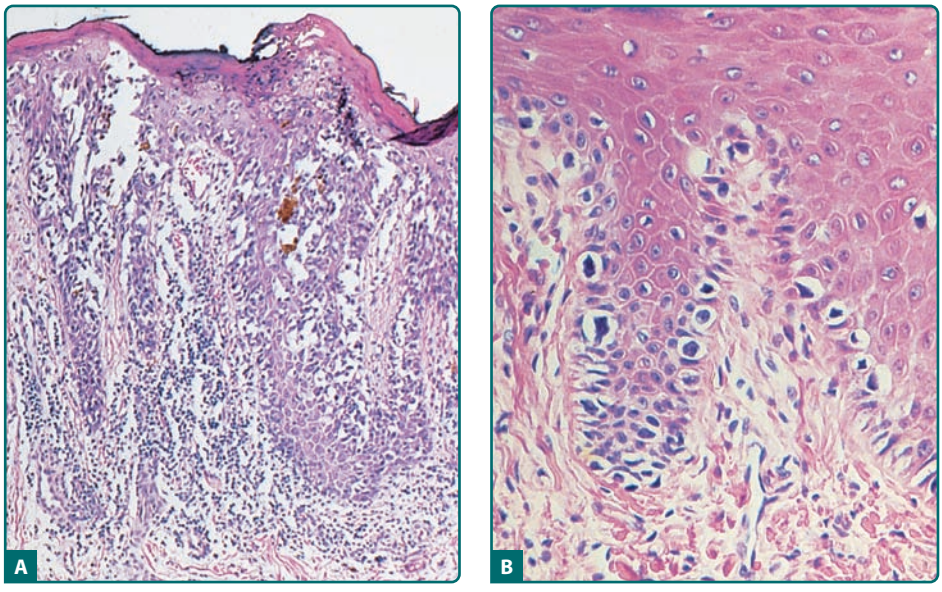

Figure 124-13 Acral lentiginous melanoma. **A.** Photomicrograph showing hyperkeratosis associated with plantar location of this melanoma. Fibrosis and patchy host response are noted in the dermis. **B.** High-powered photomicrograph showing lentiginous proliferation of abnormal melanocytes along the dermal-epidermal junction.

IMMUNOHISTOCHEMISTRY

Immunohistochemistry may be useful for the diagnosis of melanoma, especially in poorly differentiated neoplasms with little or no pigment (i.e., amelanotic melanomas), spindle cell tumors, or tumors with pagetoid spread that are not obviously melanoma. S100 protein is expressed by almost all melanomas; but also by melanocytic nevi, Langerhans cells, and cutaneous neural tumors. HMB-45 is a monoclonal antibody with high specificity for melanoma cells, although it is frequently negative in DM; DMs commonly exhibit vimentin and S100 positivity. Melan-A and MART-1 (melanoma antigen recognized by T cells) are the names given independently to the same gene encoding a melanocytic differentiation antigen expressed in skin and retina but not other normal tissues. Melan-A is broadly expressed in benign and malignant melanocytic lesions but not in most DMs. It is more sensitive than HMB-45 and more specific than S100 for melanoma. Search for the microphthalmia-associated transcription factor (Mitf) may be useful, especially in amelanotic melanomas, as it is a marker in the nucleus, whereas all other markers are intracytoplasmic.[101] It stains most melanomas except for DM where staining is usually negative but variable.

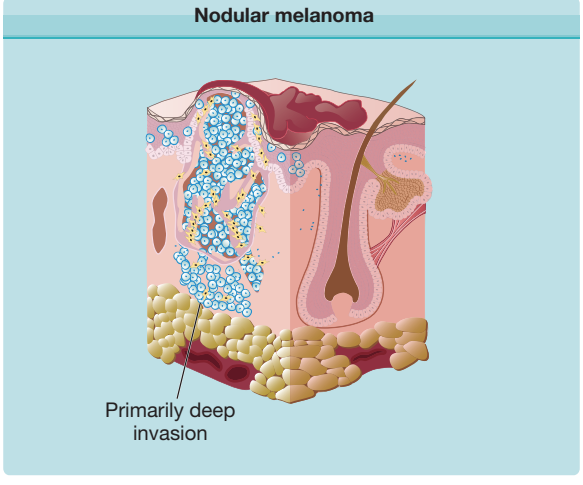

Figure 124-14 Nodular melanoma. This tumor arises at the dermal-epidermal junction and extends vertically into the dermis; intraepidermal growth is present only in a small group of tumor cells that conjointly are also invading the underlying dermis. The epidermis lateral to the areas of this invasion does not demonstrate atypical melanocytes. As with lentigo maligna melanoma and superficial spreading melanoma, the tumor may show large epithelioid cells, spindle cells, small malignant melanocytes, or mixtures of all three.

PROGNOSIS AND CLINICAL COURSE

STAGING AND PROGNOSTIC FACTORS

Accurate staging of melanoma is essential for determining optimal treatment and for assessing prognosis. Accurate staging forms the basis for prognosis and treatment, which is invaluable for the majority of patients in their informed decision-making process. The American Joint Committee on Cancer (AJCC) published a revised staging system for melanoma in 2009.[102,103] Whereas the previous melanoma staging system from 2002 was obtained from data from 17,600 melanoma patients primarily seen in the 1980s and early 90s, the 2009 melanoma staging system was obtained from a more contemporary dataset of 38,918 melanoma patients from 17 institutions/cooperative groups worldwide: 30,946 stage I, II, and III, 7,972 stage IV. This represents

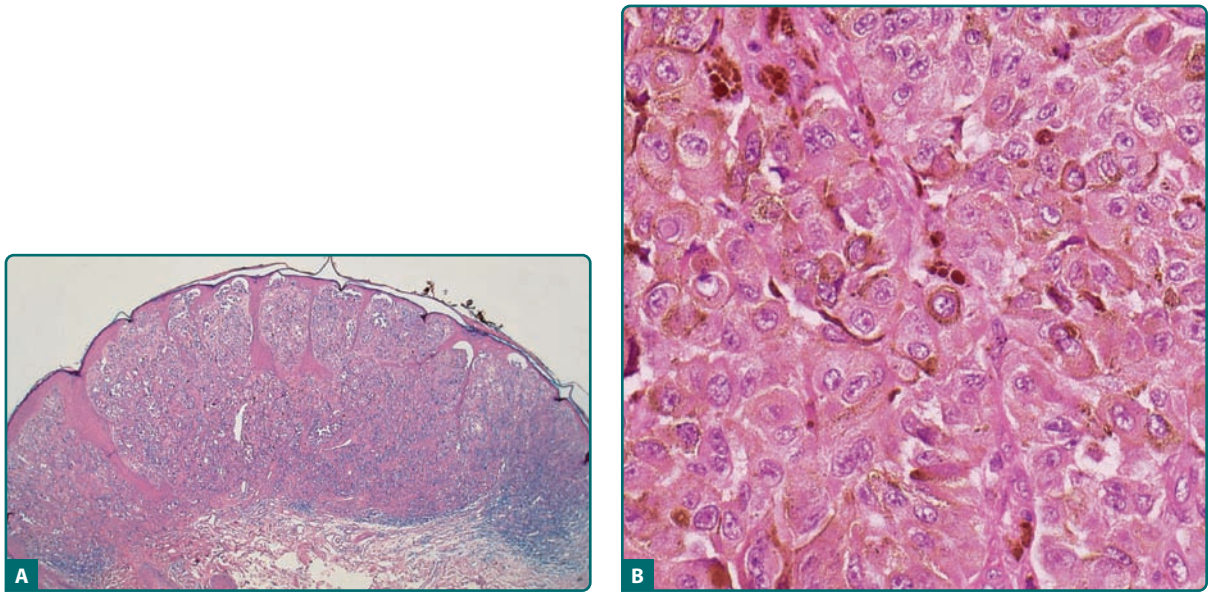

Figure 124-15 Nodular melanoma. **A.** Low-powered photomicrograph demonstrating a dome-shaped expansile tumor located in the upper dermis. **B.** High-powered photomicrograph reveals nests of anaplastic epithelioid cells in the tumor.

the largest body of AJCC melanoma data analyzed in an evidence-based approach and incorporates many patients more accurately staged using SLNB.[102,104,105] The 2009 AJCC melanoma staging system also incorporates mitotic rate, consistent with several previous studies demonstrating this to be an important, independent progonostic variable.[102,106–111] The *t*umor size, *n*ode status, *m*etastasis classification (TNM) system continues to be used, in which T describes the extent or thickness of the primary tumor, N the extent of lymph node metastases, and M the extent of distant metastases.[104] Table 124-2 presents the TNM categories, and Table 124-3 lists the stage groupings. There are five stages based on prognosis: stage 0 (in situ disease), stages I and II (localized disease), stage III (regional disease), and stage IV (distant metastatic disease). In general, prognosis and survival rates worsen with increasing stage (Table 124-4). At initial presentation, approximately 85% of patients have localized disease (stages I and II), 10% have regional metastatic disease, and 5% have distant metastatic disease.[104]

PROGNOSTIC FACTORS IN MICROSTAGING

TUMOR THICKNESS. The single most important prognostic factor for survival and clinical management in localized stage I and II cutaneous melanoma is tumor thickness.[102,105] As originally described by Breslow, thickness is measured from the top of the granular layer of the epidermis to the greatest depth of tumor invasion using an ocular micrometer measured in millimeters. Survival decreases with increasing Breslow depth. Clark level is an alternate, less accurate method of measuring tumor thickness by the anatomic level of invasion. Clark level of invasion is no longer used in routine staging of melanoma.[102]

ULCERATION. Ulceration is an independent prognostic factor for localized melanoma.[102,105] The presence of ulceration in the primary confers a higher risk of developing advanced disease and lower survival rate. The presence of ulceration upstages all patients with localized and regional disease [i.e., stages I to III (see Table 124-2)]. Ulceration correlates with tumor thickness; it occurs infrequently in thin melanomas (6% for melanomas <1 mm) and frequently in thick melanomas (63% for melanomas >4 mm).[105] One potential shortcoming of ulceration as a variable is that ulceration is not always a homogeneous phenomenon and may result from trauma, which is prognostically insignificant. For this reason, ulceration should be reported when there is evidence of host response at the site, including fibrin and nuclear debris. Their presence indicates a preoperative event not possibly associated with artifactual causes due to surgery or processing.

MITOTIC RATE. Several studies reported the importance of tumor mitotic rate as an independent predictor of survival, with an increasing mitotic rate correlating with a decreasing survival.[106–112] Among patients with clinically localized melanoma, a mitotic rate of 1/mm^2 or greater may be the second most powerful predictor of survival, after tumor thickness.[102] In the 2009 revised AJCC staging system, mitotic rate has replaced Clark level of invasion in defining T1b melanomas because. When ulceration, tumor thickness and mitotic rate are accounted for, Clark level is no longer an independent predictor of survival.[102,103] Clark level IV or V of invasion should only be used to define T1b melanoma in the rare cases of T1melanomas for which the mitotic rate cannot be determined. Mitotic rate, measured as the number of mitoses per square millimeter, is usually counted as the number of mitoses seen in four to five high-power (×40) microscope fields (the equivalent

TABLE 124-2
Melanoma TNM Classifications[a]

T Classification	Thickness (mm)	Ulceration Status
T1	≤1.0	a: without ulceration and mitosis <1/mm^2 b: with ulceration or mitosis ≥1/mm^2
T2	1.01–2.0	a: without ulceration b: with ulceration
T3	2.01–4.0	a: without ulceration b: with ulceration
T4	>4.0	a: without ulceration b: with ulceration
N Classification	**Number of Metastatic Nodes**	**Nodal Metastatic Mass**
N1	1	a: micrometastasis[b] b: macrometastasis[c]
N2	2–3	a: micrometastasis[b] b: macrometastasis[c]
N3	Four or more nodes, or matted nodes, or in-transit met(s)/satellite(s) with metastatic node(s)	c: in-transit met(s)/satellite(s) without metastatic nodes
M Classification	**Site**	**Serum Lactate Dehydrogenase**
M1a	Distant skin, subcutaneous, or nodal metastases	Normal
M1b	Lung metastases	Normal
M1c	All other visceral metastases	Normal
	Any distant metastasis	Elevated

TNM = tumor size, node status, metastasis classification.

[a]Four major changes are included in the 2009 version of American Joint Committee on Cancer melanoma staging system:

1. Anatomic level is no longer in the routine staging of thin tumors. Thickness and ulceration are primarily used to define the T category. For T1 melanomas, the anatomic level of invasion (Clark levels) has been replaced by mitotic rate as a prognostic feature for defining T1b melanomas. Clark level is only used for defining T1b melanomas if a mitotic rate cannot be determined for a nonulcerated T1 melanoma. Any mitosis rate ≥1 mitosis/mm^2 in a melanoma ≤1.0 mm in thickness upstages that tumor to T1b.
2. Mitotic rate has been included for categorizing T1 melanomas (see above).
3. The presence of nodal micrometastases can be determined using either hematoxylin and eosin (H&E) or immunohistochemical stains using melanoma specific markers.
4. Any amount of micrometastatic disease in a lymph node is considered to be positive and clinically significant.

[b]Micrometastases are diagnosed after sentinel or elective lymphadenectomy.

[c]Macrometastases are defined as clinically detectable nodal metastases confirmed by therapeutic lymphadenectomy or when nodal metastasis exhibits gross extracapsular extension.

From Chapter 31, Balch CM, et al:. Melanoma of the skin. In: *AJCC Cancer Staging Manual*, 7th edition, edited by SE Edge, DR Byrd, MA Carducci, CC Compton. New York, NY, Springer, 2010, with permission.

of a 1-mm^2 area), starting in the fields with the most mitoses. Patients with a mitotic rate of <1 mitoses/mm^2 have a significantly better survival than those with ≥1 mitosis/mm^2. Mitotic rate may also correlate with SLNB positivity, especially in younger patients.[111] There minimizevariability in reporting of mitotic rate, each microscopist is advised to seek technical assistance if necessary to determine the number of fields equal to 1 mm^2 in each microscope.

ANGIOLYMPHATIC INVASION. Vascular involvement denotes the invasion of tumor cells into the microvasculature in the dermis. Some reports note that vascular invasion significantly increases the risk of relapse, lymph node involvement, distant metastases, and death.[111–114]

MICROSCOPIC SATELLITES. The presence of microscopic satellitosis, in particular, has been consistently reported to correlate with a poorer outcome, and this has been retained in the current AJCC melanoma staging system.[102,104] Patients with any satellite metastases, including microsatellite metastases, are considered to have stage III disease even in the absence of nodal metastases (N2c, satellite metastases without nodal metastases).[102]

OTHER HISTOLOGIC FACTORS. Other factors have been variably reported as predictive of prognosis in melanoma including the presence of tumor-infiltrating lymphocytes, regression, tumor lymphangiogenesis (i.e., formation of new vessels), and radial versus vertical growth phase. None of these have been demonstrated to be strong independent predictors of melanoma outcome. Sentinel lymph node status, however, is a predictor of melanoma outcome, and the evaluation and histologic classification of nodal metastases in sentinel lymph node biopsies has been revised in the

TABLE 124-3
Stage Groupings for Cutaneous Melanoma

	Clinical Staging[a]			Pathologic Staging[b]		
	T	**N**	**M**	**T**	**N**	**M**
0	Tis	N0	M0	Tis	N0	M0
IA	T1a	N0	M0	T1a	N0	M0
IB	T1b T2a	N0 N0	M0 M0	T1b T2a	N0 N0	M0 M0
IIA	T2b T3a	N0 N0	M0 M0	T2b T3a	N0 N0	M0 M0
IIB	T3b T4a	N0 N0	M0 M0	T3b T4a	N0 N0	M0 M0
IIC	T4b	N0	M0	T4b	N0	M0
III[c]	Any T	N1 N2 N3	M0			
IIIA				T1–4a T1–4a	N1a N2a	M0 M0
IIIB				T1–4b T1–4b T1–4a T1–4a T1–4a/b	N1a N2a N1b N2b N2c	M0 M0 M0 M0 M0
IIIC				T1–4b T1–4b Any T	N1b N2b N3	M0 M0 M0
IV	Any T	Any N	Any M1	Any T	Any N	Any M1

T = tumor size; N = node status; and M = metastasis classification.
[a]Clinical staging includes microstaging of the primary melanoma and clinical/radiologic evaluation for metastases. By convention, it should be used after complete excision of the primary melanoma with clinical assessment for regional and distant metastases.
[b]Pathologic staging includes microstaging of the primary melanoma and pathologic information about the regional lymph nodes after partial or complete lymphadenectomy. Pathologic stage 0 or stage IA patients are the exception; they do not require pathologic evaluation of their lymph nodes.
[c]There are no stage III subgroups for clinical staging.
From Chapter 31, Balch CM, et al: Melanoma of the skin. In: *AJCC Cancer Staging Manual*, 7th edition, edited by SE Edge, DR Byrd, MA Carducci, CC Compton. New York, NY, Springer, 2010, with permission.

most recent AJCC staging system for melanoma (see Section "Sentinel Lymph Node Biopsy" under "Microscopic Metastases").

CLINICAL PROGNOSTIC FACTORS

Age. Many studies have reported that increasing patient age portends a worse prognosis with respect to overall survival rates. Males more than 60 years of age have the highest mortality rates from melanoma. Older patients have thicker primaries and a higher proportion of ulcerated melanomas, but even after adjusting for these factors, age appears to be an independent prognostic factor.[3,9,81,113] It has been postulated that age may serve as a surrogate for declining host immune defense mechanisms.

GENDER. A large number of studies have reported that women have better survival rates than men, even after adjustment for tumor thickness and anatomic site.

ANATOMIC SITE. The anatomic location of primary cutaneous melanomas has been variably reported to affect survival. In the 2002 AJCC study, melanomas located on the trunk and head and neck were correlated with worse prognosis than melanomas on the extremities, but the recorded locations were only (1) extremities or (2) trunk, head, or neck.[105] In another large study of 5,093 patients, melanomas on the back and thorax, upper neck, and scalp (BANS regions) were associated with significantly lower survival rates than melanomas on the lower trunk, thigh, lower leg, feet, lower arms, hands, and face.[115] Finally, review of 1,130 patients from a single institution showed a greater likelihood of SLNB positivity for melanomas located on the trunk and lower extremity.[111] Given the

TABLE 124-4
Survival Rates for Melanoma TNM Stage I–III[a]

Stage	Tumor	Node Status	Node Tumor Burden	5-Year Survival Rate (%)
IA	T1a	N0	—	97
IB	T1b	N0	—	94
IB	T2a	N0	—	91
IIA	T2b	N0	—	82
IIA	T3a	N0	—	79
IIB	T3b	N0	—	68
IIB	T4a	N0	—	71
IIC	T4b	N0	—	53
IIIA	T1-T4a	N1a/N2a	Microscopic	78
IIIB	T1-T4b	N1a/N2a	Microscopic	55
IIIB	T1-T4a	N1b/N2b	Macroscopic	48
IIIC	T1-T4b	N1b/N2b/N3	Macroscopic or 4+ any nodes	38
IIIC	T1-T4a	N3	4+ any nodes	47

[a]The complete dataset for the 2009 AJCC Melanoma Staging and Classification system is in preparation for publication.
From Chapter 31, Balch CM, et al: Melanoma of the skin. In: *AJCC Cancer Staging Manual*, 7th edition, edited by SE Edge, DR Byrd, MA Carducci, CC Compton. New York, NY, Springer, 2010, with permission.

conflicting data, it is likely that anatomic site is not a strong independent prognostic factor in melanoma.

PROGNOSTIC FACTORS IN REGIONAL METASTASIS

The status of the regional lymph nodes is the most powerful prognostic factor for survival in melanoma. The presence of regional lymph node metastasis portends a worse prognosis. The number of lymph nodes involved, independent of size, is the most significant risk factor in patients with stage III melanoma.[102,105] The second most important risk factor is tumor burden, stratified into micrometastatic disease as determined by SLNB, or macrometastatic disease (i.e., clinically palpable nodes). In clinically node-negative stage I or II patients, SLN status is the most significant prognostic factor with respect to disease-free and disease-specific survival.[116,117] As such, consideration of SLNB to search for micrometastatic disease has become the standard of care for most clinically node-negative patients with melanomas 1 mm and greater in thickness, and for a subset of T1b melanomas 0.76 mm and greater in thickness.[118] SNLB is a powerful tool for accurately staging clinically node-negative patients and as such, use of this technique continues play a central role in the AJCC staging classification system for melanoma.[102] SLNB is far more sensitive and accurate at detecting microscopic metastases than positron emission tomography (PET) scan, computed tomography (CT) scans, or ultrasound imaging combined with lymph node fine needle aspiration (reviewed in Sabel and Wong, 2009).[119] Ulceration of the primary lesion signifies a worse prognosis in regional stage III disease. Mitotic rate of the primary lesion strongly correlates with a worse prognosis for microscopic regional stage III disease. Satellite, both clinical and microscopic, metastases around a primary melanoma and in-transit metastases between the primary and its nodal basin represent intralymphatic metastases (N2c or N3) and portend the worst prognosis for regional metastases (stage IIIC disease) with a 5-year survival rate less than 50%.[102] Other changes in the AJCC melanoma staging system from the sixth Edition (2002) to the seventh Edition (2009) include: (1) the inclusion and use of immunohistochemistry markers for SLNB diagnosis and (2) no lower N+ size threshold, previously implied at 0.2 mm. Any tumor deposits, regardless of size, are now scored N+.

PROGNOSTIC FACTORS IN DISTANT METASTASIS

The presence of distant metastases portends the worst prognosis, with mean survival rates measured in months rather than years. Site of metastasis continues to be an important prognostic factor in the AJCC melanoma staging; with visceral metastases having a relatively poorer prognosis than nonvisceral (skin, subcutaneous tissue, and distant lymph nodes) sites.[102,105] Other variables of prognostic significance are the number of metastatic sites and surgical resectability. Solitary metastases resected after radiologic demonstration of stability over 3–6 months have been associated

with prolonged survival in some, but no strong evidence exists that asymptomatic detection is associated with significant overall survival to date.[120] Elevated serum lactate dehydrogenase (LDH) levels are associated with a worse prognosis, regardless of the site of metastatic disease. Patients with elevated LDH at the time of diagnosis of stage IV melanoma are assigned to M1c regardless of the location of the stage IV disease.[102]

CLINICAL COURSE

STAGES I AND II MELANOMA. In general, the 5–10-year survival for patients with localized thin primary melanoma <1 mm in Breslow depth is more than 90%. Melanoma typically recurs in a predictable fashion, first in a local and regional distribution, then to distant sites. It is also recognized that melanoma may bypass the regional nodes with direct hematogenous dissemination. The majority of recurrences manifest in the first 5 years after diagnosis and treatment, depending on tumor thickness and other prognostic features of the primary lesion (see Section "Prognostic Factors in Microstaging"). However, melanoma can recur at any time, and the incidence of late recurrence 10 or more years after initial diagnosis is approximately 1%–5%.[121] "Ultralate" recurrences more than 15 years after diagnosis are rare but do occur.[122]

STAGE III MELANOMA. Stage III melanoma represents a broad range of patients with a diverse clinical outcome, from patients with microscopic nodal disease (IIIA) to patients with bulky clinical nodes or in-transit metastases (IIIC) (Fig. 124-16). The general overall 5-year survival range of 38%–78% is wide, primarily related to several variables such as: the number of positive lymph nodes (most important), tumor burden within a lymph node (microscopic vs. macroscopic), age, and ulceration status, Breslow thickness, and mitotic rate of the primary melanoma (Table 124-4).[102]



Figure 124-16 Uncontrollable bulky metastatic melanoma to the regional lymph nodes.

There is a significant decline in survival in melanoma patients who present with clinically evident macroscopic nodal disease versus those with microscopic nodal disease identified via SLNB.[102,117] SLNB is a powerful staging technique (see Section "Sentinel Lymph Node Biopsy").

STAGE IV MELANOMA. Melanoma is known for its propensity to metastasize to virtually any organ and also for its highly variable clinical course. Melanoma metastasizes to nonvisceral sites: distant skin/subcutaneous tissue and distant lymph nodes in approximately half of the stage IV cases (42%–57%) (Fig. 124-17). The most common visceral sites are the lungs (18%–36%), liver (14%–20%), brain (12%–20%), bone (11%–17%), and gastrointestinal tract (1%–7%). Once metastases to distant sites have been detected, median survival is approximately 6–8 months, but rare longer term and even durable remissions do occur.[105]

METASTATIC MELANOMA OF UNKNOWN PRIMARY. Metastatic melanoma of unknown primary is defined as the presence of histologically confirmed melanoma in a lymph node, visceral site, or distant skin/subcutaneous tissues without a history or evidence of a primary cutaneous, mucosal, or ocular melanoma. This situation occurs in approximately 2%–5% of all cases of melanoma. Approximately 60% of these involve the lymph nodes, the remaining involve distant sites typically the skin/subcutaneous tissue, and less commonly lung, brain, or gastrointestinal tract.[122] Melanoma of unknown primary has similar survival rates compared to equivalently staged melanomas of known primary origin. In the largest study to date, melanoma of unknown primary metastatic to lymph nodes had 5- and 10-year survival rates of 46% and 41%, which is comparable to the equivalent stage III melanoma of known primary.[124] Melanoma of unknown primary metastatic to viscera had a median survival of 6 months.[125]

Although rare, a handful of cases have been reported in which a solitary melanoma of the skin confined to the dermis or subcutaneous tissue presumed to be metastatic melanoma of unknown primary has unexpectedly high survival rates.[126,127] *Primary dermal melanoma* is the term used to describe these solitary lesions with 5-year survival rates reported over 80%. It may represent a distinct subtype of primary melanoma actually originating in the dermal and/or subcutaneous tissue.

Evaluation of melanoma of unknown primary or dermal melanoma should involve a complete skin examination looking for a primary site. Wood's lamp may be used to identify subclinical hypopigmented areas, which may suggest a regressed primary lesion. In melanoma of unknown primary metastatic to a lymph node, particular attention should be focused on the skin areas that drain to the nodal basin involved. A complete history of previously excised skin lesions should be reviewed. The patient should be referred for proctoscopic, gynecologic, ocular, and nasal mucosal examinations, when warranted. Staging workup and treatment should be performed as for the equivalent clinical stage of known primary.



Figure 124-17 **A.** Zosteriform pattern metastases on the back. The primary melanoma was also on the back, Breslow depth 3.9 mm with ulceration and satellitosis. **B.** Epidermotropic and dermal metastatic melanoma on the scalp (also present on the face and neck) occurring 1 year following diagnosis of nodular primary mid-back melanoma, Breslow depth 3.75 mm, SLNB positive left and right axilla.

TREATMENT

STAGING WORKUP

(See Fig. 124-18)

BIOPSY. Patients with lesions clinically suspicious for melanoma should, whenever possible, undergo prompt excisional biopsy with narrow margins. A wider margin should be avoided to permit the most accurate subsequent SLNB if indicated. Most melanomas undergo initial biopsy in their clinical entirety, but if the lesion is large and/or located on anatomic areas such as the palm/sole, digit, face, or ear, an incisional full-thickness to adipose skin biopsy may be performed. Another common reason for incomplete incisional biopsy is lack of initial suspicion for rarer subtypes such as small amelanotic lesions that may resemble a small basal cell carcinoma or even eczema. An incisional biopsy should be obtained in the most elevated or darkest area of the lesion, with a strong appreciation that the clinically most suspicious area may not always correlate with the thickest portion of the lesion. There is no evidence that biopsy or incision of a primary melanoma leads to "seeding" of tissue and adversely affects survival. If subtotal incisional biopsy confirms melanoma <1-mm thickness, and significant residual clinical lesion remains, a narrow margin excisional biopsy should be considered first for accurate microstaging if the patient is a candidate for SLNB, or treatment would be altered with upstaging. Excisional biopsy performed after incisional biopsy of melanoma with ≥50% of the lesion remaining resulted in significant upstaging in 21% of patients, and change in SLNB consideration in 10% of patients in one large study.[128]

EVALUATION FOR REGIONAL METASTASIS

MACROSCOPIC METASTASES. The foundation of the initial workup following diagnosis of primary cutaneous melanoma is thorough history taking and physical examination. The findings on a good history and physical examination will, to a great extent, drive any further workup. Patients should be evaluated for regional spread by careful palpation of lymph nodes, particularly the primary echelon nodal basin(s). The concepts of aberrant lymphatic drainage pathways to unexpected nodal basins and interval nodes located between the primary site and the expected regional nodal basin have taught physicians to search for clinically detectable nodal disease in unexpected locations.[129,130] If a palpable lymph node or a dermal/subcutaneous nodule in the regional area of the primary is found, fine needle aspiration may be utilized to make a histological diagnosis.[118] An excisional biopsy of the lymph node should be performed if fine needle aspiration is inconclusive or not feasible.[131] Noninvasive imaging, most commonly with ultrasound or computerized or PET, is perhaps the most sensitive noninvasive method to detect small nodal metastases. However, the sensitivity and specificity of these tests are far inferior to tissue diagnosis obtained with SLNB, and not to be utilized for routine work up in the asymptomatic patient.[119,132–134]

MICROSCOPIC METASTASES

Sentinel Lymph Node Biopsy. SLNB is a powerful staging and prognostic tool used to detect occult micrometastases in regional lymph nodes for a subset of patients with melanoma.[135] SLNB represents

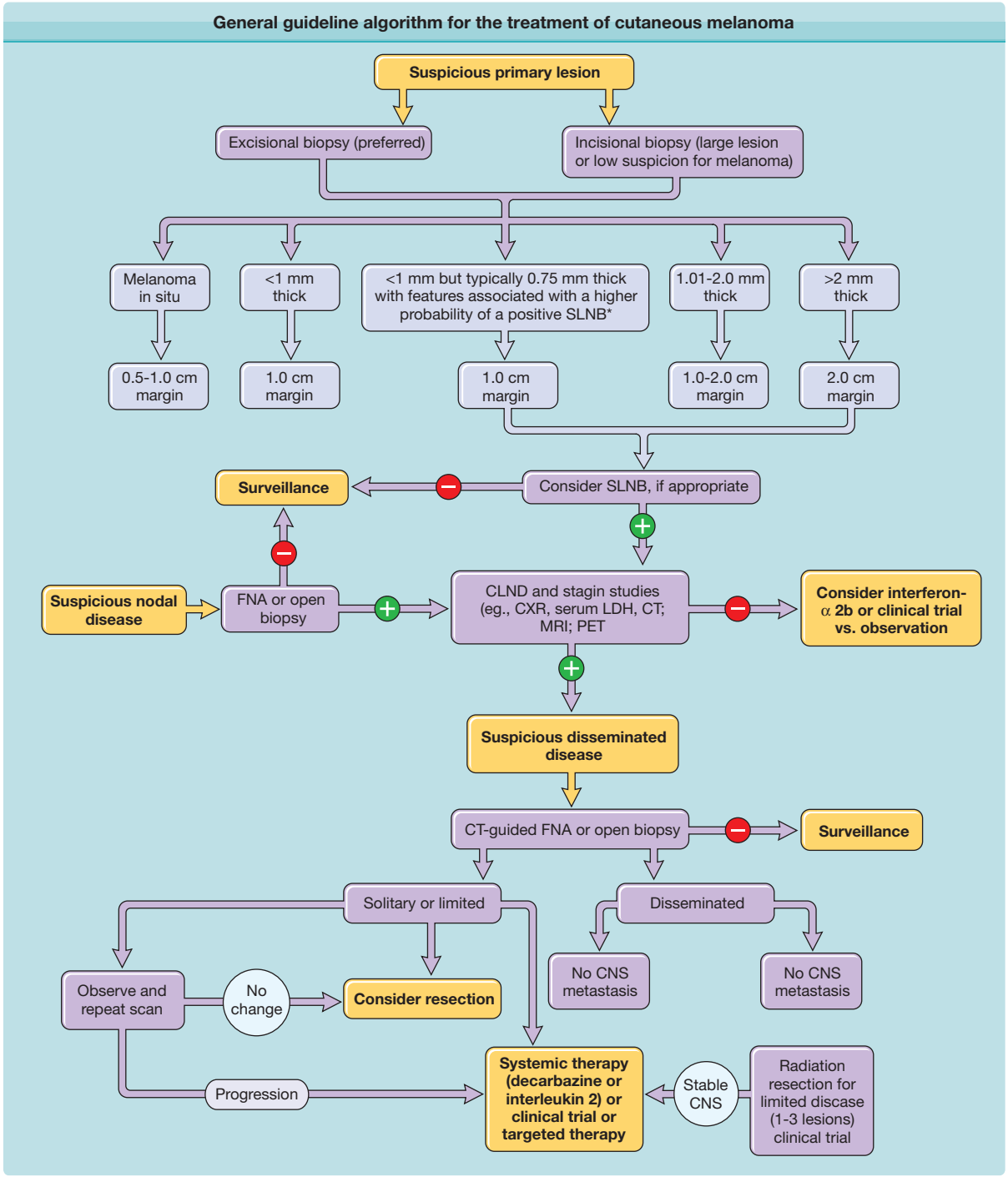

Figure 124-18 General guideline algorithm for the treatment of cutaneous melanoma. *Ulceration, extensive vertical regression to at least 1-mm thick, young patient age, high mitotic rate, especially in younger persons, shave biopsy with positive deep margin, presence of angiolymphatic invasion, and Clark level IV. CLND = completion lymph-node dissection; CNS = central nervous system; CT = computed tomography; CXR = chest X-ray; FNA = fine-needle aspiration; LDH = serum lactate dehydrogenase; MRI = magnetic resonance imaging; PET = positron emission tomography; and SLNB = sentinel-lymph-node biopsy. A minus sign indicates no evidence of disease, and a plus sign evidence of metastasis. Patients who are candidates for SLNB should be referred to a surgeon experienced in performing the procedure so that the benefits and complications can be fully discussed. (Used with permission from Tsao H, Atkins MB, Sober AJ: Management of cutaneous melanoma. *N Engl J Med* **351**:998, 2004)

the best baseline staging test for detection of occult nodal metastasis in the subset of melanoma patients where it is indicated, and is the only staging test with both relatively high sensitivity and specificity. There is a small likelihood of identifiable distant disease if the SLN is negative.[136] In the early 1990s, Morton et al initially reported the technique to selectively sample the first draining regional lymph node(s), or SLN(s) for melanoma; this SLN is most likely to contain any tumor cells that may have metastasized from the primary.[137,138] In current practice, technetium-99-labeled radio-colloid solution, often with vital blue dye, allows for detection of the SLN >95% of the time in skilled hands. Ideally, the procedure should be performed at the same time as wide local excision (WLE) of the primary melanoma for greatest accuracy. SLNB may not be accurate if performed after WLE in areas of ambiguous lymphatic drainage or following a local skin flap due to radiocolloid and dye injection location away from the true primary site. Once removed, the SLN(s) must be assessed with serial sectioning, using standard hematoxylin and eosin (H&E) techniques combined with immunohistochemical stains such as S100, HMB-45, and/or Melan-A if H&E is negative or inconclusive. This increases sensitivity for melanoma and has resulted in the upstaging of up to 10%–20% of patients.[139] The SLNB procedure requires the expertise and experience of three disciplines: surgery, nuclear medicine, and pathology.

In the new seventh edition of the AJCC melanoma staging system, an important revision concerns the definition of nodal positivity for sentinel lymph nodes. Previously, in the sixth edition of the AJCC melanoma staging system, metastatic melanoma foci in sentinel lymph nodes could only be identified by routine (H&E) stains. The seventh edition of the AJCC melanoma staging system now accepts as positive any sentinel lymph node containing metastatic foci that are clearly visualized by immunohistochemistry with melanoma markers, even if these metastatic deposits are not visible on H&E staining.

In 2006, Morton et al published the third interim analysis of the multicenter sentinel lymphadenectomy trial (MSLT)-I, the first prospective randomized controlled clinical trial of SLNB in melanoma.[117] In this analysis, 1,269 clinically node-negative patients with newly diagnosed melanoma 1.2–3.5 mm in depth were randomized to wide excision and nodal basin observation versus wide excision and SLNB. Patients with a positive SLN received an immediate node dissection, and patients in the observation arm also received node dissection if they developed regional lymph node metastasis. Sentinel lymph node status was demonstrated to be a powerful predictor of survival as those with a negative SLN had a 5-year survival of 90.2%, versus 72.3% 5-year survival for those with a positive SLN.

Current NCCN guidelines recommend consideration of SLNB for relatively healthy patients with primary localized melanoma ≥1 mm in Breslow depth (see Fig. 124-18).[118] The most important and consistently reported predictor of SLN positivity is Breslow depth. The likelihood of regional nodal involvement rises with increasing tumor thickness. For melanoma <1 mm Breslow depth, the probability of a positive SLN in general ranges from 5% to 10%; for 1–2 mm 15% to 20%; 2–4 mm, 25% to 35%; and >4 mm 40% to 50%.[116,135,140–143] Prognosis for thick melanoma >4 mm does correlate with SLNB status, while lesions <0.75-mm thick do not. However, SLNB may be considered for thinner lesions 0.76 to 0.99 mm in Breslow depth in the presence of certain adverse features that increase SLN positivity in thin lesions: ulceration, young patient age, mitotic rate ≥1 mm especially in younger persons, shave biopsy with positive deep margin, and the presence of angiolymphatic invasion.[110,116,141,142,144] Clark level IV is no longer used as an indication for consideration of SLNB for most melanomas, while extensive vertical regression to at least 1 mm is used in some centers.

EVALUATION FOR DISTANT METASTASIS

A thorough melanoma-focused review of systems constitutes the foundation of the evaluation for distant metastases with particular attention to the general/constitutional, neurologic, psychiatric, gastrointestinal, musculoskeletal, skin, lymphatic, endocrine, cardiovascular, and respiratory systems.[144] Routine imaging and hematologic tests in asymptomatic patients rarely identifies occult systemic disease that is associated with improved survival based on asymptomatic detection.[119,136] The presently available imaging modalities including CT, magnetic resonance imaging (MRI), PET, chest X-ray (CXR), and hematologic tests such as LDH lack both high sensitivity and specificity to make them routinely indicated. The reported true-positive rate of routine baseline CXR in asymptomatic patients is exceptionally low ranging from 0% to 0.5% [145]; with similar ranges for CT of the chest, abdomen, pelvis, and brain CT or MRI.[136] Specificity is also low, and false-positive rates with these modalities range from 8% to 15%[144]; which leads to additional cost of studies and possibly invasive procedures, as well as increased patient anxiety. Unfortunately, there are no data demonstrating improved survival rates if metastases are detected when clinically asymptomatic versus early symptomatic stage IV disease.[104,120,144] Current NCCN guidelines recommend no additional workup in Stage 0 and 1A, optional CXR in stage 1B and II, optional CXR and LDH for stage III, and CXR and/or chest CT plus LDH for stage IV.[118] Even for stage III and IV, further imaging with CT, MRI, or PET is recommended to be performed as clinically indicated, which emphasizes the importance of a thorough melanoma-focused review of systems and physical examination.

TREATMENT OF PRIMARY MELANOMA

SURGERY. A general guideline algorithm for the management of cutaneous melanoma in 2010 is noted in Fig. 124-18. The standard of therapy for primary cutaneous melanoma is WLE. The purpose of the wider excision is to prevent local recurrence due to persistent disease by complete excision with histopathologically



Figure 124-19 Potentially preventable deep local recurrence at both poles of previous local excision scar with satellite lesions, occurring approximately 4 years after narrow excision of a thin melanoma with 0.5-cm margins.

confirmed tumor-free margins. True local recurrence from inadequate excision is clinically significant in a small subset with the potential lethal consequence of preventable recurrence (Fig. 124-19). Current recommended clinical margins around the residual lesion or biopsy scar for melanoma in situ, non-LM pattern, is 0.5–1 cm, for melanoma <1 mm Breslow depth 1-cm margin, for melanoma 1–2-mm thick 1–2 cm as anatomically possible, and for melanoma >2-mm thick 2 cm (with pathologic confirmation of clear peripheral margins for all). Several large randomized controlled trials have failed to demonstrate a difference in survival rates or local recurrence rates between narrow (1–2 cm) versus wide (3–5 cm) margins.[146–152] Ultimately, each patient should be evaluated individually, taking into account current surgical guidelines as well as anatomic site (i.e., location near a vital structure), the possibility of primary closure versus need for skin graft, and the presence or lack of adverse prognostic factors from microstaging. Melanoma excision at special sites, such as the digits, soles, ears, vagina, or anus, also requires separate surgical and functional considerations. Still, the fundamental oncologic principle should always be: tumor clearance first, reconstruction second. A partial or complete amputation of the digit is still the preferred surgical treatment for subungual invasive melanoma.

LENTIGO MALIGNA AND LENTIGO MALIGNA MELANOMA. Histologic confirmation of negative margins is especially important for LM and LMM subtypes, which are characterized by a propensity for extensive subclinical peripheral extension. The risk of an invasive desmoplastic component is increased in the setting of LMM. Standard surgical recommendations of 0.5-cm margins for LM and 1-cm margin for LMM <1-mm thick are often insufficient. One study found the average margin required to clear LM was 0.8 cm, 1.5 cm needed to clear 96% of LM lesions. The mean margin to clear LMM was 1.1 cm, 2.6 cm to clear 95% of LMM lesions.[153] Another reported that 97% of melanomas <1.5 cm in diameter required 1.5-cm margin for complete excision with 95% of melanomas >3 cm in diameter required 2.5-cm margin for complete excision.[154] Another study of periocular LM/LMM melanoma revealed tumor-free margins were reached within a mean margin of 1.3 cm for LM melanoma in situ and of 1.6 cm for invasive LMM, associated with a 2% 8-year local recurrence rate.[155]

Recurrence rates for standard breadloaf processing following narrow excision of LM is unacceptably high, up to 20% or higher.[156] A variety of surgical techniques and methods of more comprehensive histologic evaluation have been advocated: standard excision with more comprehensive vertical sectioning (i.e., "breadloafing"); Mohs micrographic surgery with frozen horizontal sectioning with or without immunostains; Mohs micrographic surgery with permanent horizontal sectioning; and mapped (i.e., "slow Mohs"), and staged mapped excisions with vertical sectioning (i.e., "square" technique).[157] The Mohs technique is problematic with the use of frozen sections that are difficult to accurately interpret even with the use of immunostains. Despite debate, favorable studies with minimally acceptable methodological design and analyses are lacking. Formalin fixed permanent section histology remains the "gold standard" for histologic evaluation of surgical margin assessment of melanocytic lesions and are, in general, far superior to frozen sections.[158] Even with "slow Mohs," permanent processing and interpretation of horizontal sections is problematic in laboratories and for pathologists unaccustomed to this technique. Histologic margins require significant experience to evaluate, as there is a spectrum ranging from background benign junctional melanocytic hyperplasia to lesional trailing edge atypical junctional melanocytic hyperplasia.[159] One of the most frequently overdiagnosed proliferations are ones in which there are activated melanocytes. These cells are present in sun-damaged skin and exhibit a uniformity of appearance with either small round nuclei surrounded by a pale cytoplasm lying in the center of the "clear space" of a semilunar-shaped hyperchromatic nucleus with minimal cytoplasm lying along the basement membrane zone. This type of change can be found overlying most dermal nevi and angiofibromas in sun-exposed areas. The involvement of an experienced pathologist is crucial for all of the techniques described above and used today.

TREATMENT OF REGIONAL METASTASIS

MACROMETASTATIC NODAL DISEASE

Complete Lymph Node Dissection. The current standard of therapy for microscopic or macroscopic melanoma in lymph nodes is complete lymph node dissection (CLND) of the involved regional

basin. Uncontrolled nodal disease is a cause of melanoma-related morbidity with a significant high negative impact on quality of life (see Fig. 124-16). Current NCCN guidelines no longer specify the number of lymph nodes that constitute an adequate lymphadenectomy. Current guidelines state that the operative report from a completion dissection should fully describe the anatomic boundaries of the lymph node dissection.[118] CLND for regional metastatic melanoma is associated with long-term survival in a proportion of patients.[160]

MICROMETASTATIC NODAL DISEASE. Elective lymph node dissection (ELND) is the removal of regional lymph nodes draining the site of a primary cutaneous melanoma in the absence of any palpable or clinically evident metastatic disease. Historically, before the advent of SLNB, ELND was advocated for melanomas at higher risk of regional spread to eradicate occult micrometastases in a potentially curative manner. Multiple prospective randomized-controlled trials failed to demonstrate a significant benefit from ELND for melanoma.[161,162] Thus, there is no role for ELND today, especially in light of the development and availability of SLNB.[163]

As mentioned previously, the SLNB procedure is a powerful staging tool that identifies micrometastatic nodal disease E[164] SLNB cannot be classified as therapeutic to date based on interim data, and for the entire group, patients in the randomized MSLT-I trial who received a SLNB did not have an improved melanoma specific survival when compared to patients who did not receive a SLNB. This is not surprising since the study is underpowered to answer that question with approximately 80% of subjects not harboring nodal deposits. However, in the group of patients with melanoma metastatic to the lymph nodes, the 5-year survival was significantly higher among patients with a positive SLNB and immediate lymphadenectomy compared to patients in the observation followed by lymphadenectomy for clinical nodal disease arm (72% vs. 52%).[117] Critics accurately point to the fact that this trial component was not randomized and data is not mature. Still this data suggests a potential outcome benefit that needs mature data analysis.

After positive SLNB, up to 15%–20% of patients have evidence of non-SLN metastases found during CLND.[165] Therefore a positive SLNB should be followed by a CLND for both prognostic and therapeutic benefit. From a prognostic standpoint, among node-positive patients with melanoma, the presence of a positive non-SLN is a significant poor prognostic sign.[166] In addition, reports support improved regional control with less morbidity with patients undergoing a CLND for a positive SLN have a significantly lower risk of postoperative complication or lymphedema than patients undergoing CLND for clinically palpable disease.[167]

The MSLT-II is currently underway to determine if an identifiable subset of patients with a positive SLNB exist who may safely avoid CLND after a positive SLNB. In the absence of further data, patients with a positive SLNB should undergo completion lymph node dissection, or enroll in MSLT-II for several reasons above.

ADJUVANT THERAPY

Interferon-α 2b. Adjuvant therapy is additional treatment for patients surgically resected of clinical disease but at high risk for relapse such as thick primary melanoma >4 mm with ulceration or nodal disease. High-dose interferon-α 2b (IFN-α 2b) is the only adjuvant therapy approved by the U.S. Food and Drug Administration (FDA) that has been shown to improve disease-free survival for stage IIB–III melanoma.[168–170] Low-dose regimens failed to demonstrated an accepted benefit. The high-dose regimen consists of 20 million units per square meter of body surface area per day given intravenously 5 days a week for 4 weeks (induction phase), followed by 10 million units per square meter per day given subcutaneously three times a week for 48 weeks (maintenance phase). Interestingly, the appearance of autoantibodies or clinical manifestations of autoimmunity (vitiligo) during treatment with IFN may be associated with a significant improvement in relapse-free survival and overall survival in melanoma patients undergoing adjuvant IFN.[171,172]

There are significant toxicities associated with the high-dose IFN regimen, the most frequent being flu-like symptoms in almost all patients (i.e., fatigue, anorexia, weight loss, myalgias, fever, nausea, and headache). Other side effects include depression, hepatotoxicity (elevated transaminases), and myelosuppression. The toxicities may require dose modification and if the patient makes it through the first 3 months of therapy, most are able to complete at least 80% of the scheduled dosing and are able to finish treatment.[168] In addition, in this biased group, quality of life is improved and patients seem to prefer IFN therapy to no treatment.[173,174] Counseling and consideration of potential benefits and risks of toxicities is done on an individual basis.

Melanoma Vaccines. A number of autologous, allogeneic, and peptide vaccines have been studied in the management of melanoma but none are currently available as approved therapy. Vaccines are attractive, given antigen-directed approaches and low toxicities as they attempt to stimulate a specific immune response against melanoma-associated antigens. A number of promising approaches to developing melanoma vaccines are being explored.[175]

SATELLITE OR IN-TRANSIT METASTASES

Isolated Limb Perfusion. In general, regional in-transit or satellite disease should be surgically excised with clear margins whenever possible. However, if multiple lesions make surgery unreasonable, isolated limb perfusion (ILP) may be considered for locoregional disease control limited to an extremity. ILP is a form of regional chemotherapy that delivers higher doses of chemotherapeutic agents to the limb with less systemic toxicities. The technique involves perfusing an isolated extremity under hyperthermic conditions

with cytotoxic agents, conventionally melphalan. ILP with melphalan is an effective form of regional therapy in some cases with an associated considerable morbidity, producing partial or complete regional responses rate as high as 80%.[176] The benefit is aimed at locoregional control, not overall survival.

The ILP procedure may be associated with serious local morbidities, including significant tissue damage or compartment syndrome. Elderly age and serious medical comorbidities are generally considered exclusion criteria. Isolated limb infusion (ILI) is a, simpler, less-invasive technique. Early studies of ILI with melphalan and actinomycin D demonstrate comparable efficacy to ILP with melphalan.[177] ILI may be considered for patients ineligible for ILP.

TREATMENT OF DISTANT AND/OR DISSEMINATED METASTASIS

The treatment of stage IV melanoma must take into account that the average survival is 6–8 months and that no systemic therapies have been shown to significantly increase survival in randomized controlled trials.[135] Goals of treatment should be increasing length of survival and palliation of symptoms. The option of observation and conservative treatment is reasonable, especially in the asymptomatic, elderly, or those with serious comorbidities. Surgical excision of isolated visceral metastases (i.e., metastasectomy) demonstrated to be stable over a 3- to 6-month period may be performed with long-term disease free intervals in some. Surgical excision of skin/subcutis or distant lymph node metastases may result in improved locoregional control and decreased morbidity.[178] Surgery may also be palliative, for example, to relieve obstruction from gastrointestinal metastases. Melanoma is not known to be highly radiosensitive, but radiotherapy is an option and preferred used for brain metastases of more than three lesions, and following surgical removal with steriotactic radiosurgery or standard cold-knife surgery for focal disease. Palliative radiation may be indicated for spinal cord compression and painful bone metastases.

SYSTEMIC THERAPIES

Chemotherapy and Immunotherapies. The alkylating agent dacarbazine (DTIC) is the only FDA-approved chemotherapy for metastatic melanoma. Response rates are in the 10%–20% range, with median response duration 4 to 6 months.[179] There is no difference in terms of response rates and duration of response between the various dosing schedules used. The major side effects are nausea and vomiting. Temozolomide (TMZ) is an alkylating agent with the same active metabolite as DTIC, but it is able to cross the blood-brain barrier and can be absorbed orally. TMZ has been shown in a randomized phase III study to have efficacy equal to DTIC.[180] Other single agent regimens include paclitaxel or high-dose interleukin-2 (IL-2).[118] High-dose bolus IL-2 is the only FDA-approved immunologic treatment of metastatic melanoma that may produce rare but durable complete responses. It has been shown as a single agent to produce a 16% overall response rate but with a durable response in up to 5%–8% of patients, highest in those with lung, node, and/or skin metastases.[181] High-dose IL-2 is associated with significant toxicity and its use is limited to specialized programs with experienced clinicians and select patients.

Combination chemotherapies have been increasingly used for melanoma including regimens such as CVD (cisplatin, vinblastine and dacarbazine). The combination of CVD with interferon-α and IL-2 is known as biochemotherapy and may produce a higher response rate compared to CVD alone.[182] However, biochemotherapy is more toxic than CVD and may not improve overall survival.

Novel Therapies. B-raf mutations have been found in two-thirds of melanomas.[40] Sorafenib is an orally available RAF inhibitor that inhibits B-raf and C-raf but in a phase III trial this agent demonstrated little activity in patients with unresectable stage III or stage IV melanoma.[183] Recently, a phase I trial of a novel oral BRAF inhibitor, PLX4032 (also known as R05185426) demonstrated a 70% response rate in patients with metastatic melanoma.[185–186] This agent was approved in 2011 for targeted therapy in BRAF V600 positive tumors for stage IV disease.[187]

Melanomas from acral and mucosal sites are genetically distinct from other melanomas.[42] Most melanomas from acral and mucosal sites do not demonstrate mutations in *BRAF*, but a subset have activating mutations or amplification of the tyrosine kinase receptor *KIT*.[42,46] Early studies with the tyrosine kinase inhibitor imatinib have demonstrated significant responses in patients with metastatic melanoma harboring activating mutations in c-KIT.[48,188] Further studies are being conducted to evaluate approved and novel tyrosine kinase inhibitors in melanoma harboring mutations in c-KIT.

FOLLOW-UP

Patients with melanoma are at risk for local, regional, and distant recurrence, with the level of risk dependent on the stage at initial diagnosis and workup. Follow-up visits are an opportunity to review how to perform monthly self-skin and lymph node examinations, address any psychosocial emotional distress issues, obtain a melanoma-focused review of systems, and provide continuing patient education regarding early detection signs and symptoms and sun-protection/prevention strategies. Regular follow-up is indicated for all patients with melanoma. Current NCCN and national melanoma center guidelines call for at least annual follow-up visits for life, with follow-up intervals generally ranging from every 3 to 6 months for 1–3 years after diagnosis and annually thereafter, depending primarily on stage of disease.[118] Patients with other risk factors, such as a positive family history of melanoma, numerous nevi, a mutation in *p16* or *BRAF*, or difficulty with self-examination, may require more

frequent follow-up. A referral to a genetics counselor is warranted if there is a strong family history of melanoma, or a family history of pancreatic cancer.

The follow-up visit should consist of a thorough complete skin examination for additional primary lesions and cutaneous/subcutaneous metastases, particularly in the regional distribution of the primary, palpation of lymph nodes with particular attention to the regional nodal basin, and thorough history taking. The review of systems is the foundation for detecting symptomatology possibly attributable to melanoma, and directs additional testing or imaging. The yield and value of routine imaging to restage asymptomatic patients as part of standard melanoma follow-up are low and, thus, imaging and hematologic tests are based on any suspicious findings from a good history and physical examination.

PREVENTION

Public awareness and knowledge of melanoma and UV exposure is improving, but still a substantial gap exists between knowledge and behavior. Primary prevention strategy should focus on safe sun exposure, including limited UV exposure and sunburn prevention, especially in childhood and adolescence when the risk is greatest. Avoidance of peak sunlight hours and use of wide-brimmed hats, clothing, and sunscreen are recommended. In addition, early detection by regular self-skin examinations, skin awareness, and knowledge of the early signs and symptoms of melanomas should also be emphasized to patient, partners, and family members. The goal of secondary prevention is early diagnosis, which greatly reduces melanoma-related morbidity and mortality.

KEY REFERENCES

Full reference list available at www.DIGM8.com

DVD contains references and additional content

2. Jemal A et al: Cancer statistics, 2009. *CA Cancer J Clin* **59**(4):225-249, 2009
10. Eide MJ, Weinstock MA. Association of UV index, latitude, and melanoma incidence in nonwhite populations—US Surveillance, Epidemiology, and End Results (SEER) Program, 1992 to 2001. *Arch Dermatol* **141**(4):477-481, 2005
26. Tucker MA et al: Clinically recognized dysplastic nevi. A central risk factor for cutaneous melanoma. *JAMA* **277**(18):1439-1444, 1997
37. Bishop DT et al: Geographical variation in the penetrance of CDKN2A mutations for melanoma. *J Natl Cancer Inst* **94**(12):894-903, 2002
40. Davies H et al: Mutations of the BRAF gene in human cancer. *Nature* **417**(6892):949-954, 2002
42. Curtin JA et al: Distinct sets of genetic alterations in melanoma. *N Engl J Med* **353**(20):2135-2147, 2005
46. Curtin JA et al: Somatic activation of KIT in distinct subtypes of melanoma. *J Clin Oncol* **24**(26):4340-4346, 2006
48. Hodi FS et al: Major response to imatinib mesylate in KIT-mutated melanoma. *J Clin Oncol* **26**(12):2046-2051, 2008
102. Balch CM et al: Final version of 2009 AJCC melanoma staging and classification. *J Clin Oncol* **27**(36):6199-6206, 2009
104. Balch CM et al: Final version of the American Joint Committee on Cancer staging system for cutaneous melanoma. *J Clin Oncol* **19**(16):3635-3648, 2001
105. Balch CM et al: Prognostic factors analysis of 17,600 melanoma patients: Validation of the American Joint Committee on Cancer melanoma staging system. *J Clin Oncol* **19**(16):3622-3634, 2001
116. Morton DL et al: Sentinel-node biopsy or nodal observation in melanoma. *N Engl J Med* **355**(13):1307-1317, 2006
134. Tsao H, Atkins MB, Sober AJ: Management of cutaneous melanoma. *N Engl J Med* **351**(10):998-1012, 2004
183. Flaherty KT et al: Phase I study of PLX4032: Proof of concept for V600E BRAF mutation as a therapeutic target in human cancer. *J Clin Oncol* **24**, 2009.

SECTION 23

Tumors and Hyperplasias of the Dermis and Subcutaneous Fat

Chapter 125 :: Malignant Fibrous, Fibrohistiocytic, and Histiocytic Tumors of the Dermis

:: Jürgen C. Becker, Bernadette Liegl-Atzwanger, & Selma Ugurel

MALIGNANT FIBROUS DERMAL TUMORS AT A GLANCE

- A group of uncommon and rare cutaneous tumors with varying degrees of malignant potential.
- Includes dermatofibrosarcoma protuberans (DFSP), atypical fibroxanthoma (AFX), desmoids tumor, myxofibrosarcoma (MFS), undifferentiated pleomorphic sarcomas (UPS), and epithelioid sarcoma (ES).
- Diagnosis is made by biopsy.
- DFSP is a locally aggressive tumor with a high rate of local recurrence with rare metastases.
- AFX is an intermediate-grade neoplasm that usually arises on sun-damaged skin in the eighth decade.
- Desmoid tumors are slowly growing tumors arising from the muscular aponeurosis that have been associated with a history of trauma or an operation; thus, women undergoing cesarean sections are at greater risk.
- MFS represent a spectrum of malignant myxoid tumors of fibroblastic origin that exhibit a range of clinical and histopathologic features.
- UPS is almost never a cutaneous tumor.
- ES is a rare, highly aggressive tumor that classically presents on the hands and fingers of young males, which can mimic nonneoplastic inflammatory lesions.

Malignant fibrohistiocytic tumors are a heterogeneous group of mesenchymal neoplasms. These neoplasms occur in the dermis and subcutaneous tissue and may cause diagnostic difficulties. This is at least in part due to the fact that these tumors are relatively rare while at the same time there is a perplexing variety of morphological types and subtypes; thus, the individual physician usually has limited experience in these tumors. By light-microscopic examination cells constituting fibrohistiocytic tumors are characterized by morphologic similarities to fibroblasts and histiocytes. Notably, the term "fibrohistiocytic" only denotes this morphologic appearance, it does not necessarily account for the histogenesis of the respective neoplasm.

The initial descriptions of these tumors were based entirely on hematoxylin and eosin (H&E) morphology and the term "fibrohistiocytic" was chosen in an attempt to provide an organizing principle and nomenclature for this group of soft tissue tumors, composed of cells resembling fibroblasts and histiocytes.

Over the last decades all scientific attempts to demonstrate true histiocytic differentiation in these tumors failed. By means of electron microscopy, immunohistochemistry (IHC), and cytogenetics, it became increasingly obvious that the term "fibrohistiocytic" is a misnomer and falsely unite a heterogeneous group of tumors, many of them are probably unrelated. This notion has been also recently endorsed by the World Health Organization by the use of the terminology "**So-called Fibrohistiocytic Tumors**" indicating that this term is only used descriptively.[1]

The symptoms that call attention to a fibrohistiocytic tumor are usually those caused by its presence and growth at its site of origin. In most cases the patient may present with an asymptomatic mass. Thus, a biopsy (either open or large-gauge core needle) is needed to obtain adequate tissue for diagnosis. Care should be taken to ensure that the biopsy does not interfere with subsequent optimal definitive surgery. Moreover, it should be kept in mind that fibrohistiocytic tumors can be very heterogeneous: the smaller the biopsy sample, the more likely it is that only a temporary, working diagnosis becomes possible. This is of course particularly

true for a purely cytological examination, since this can only evaluate individual cells. Nevertheless, in the hands of an experienced investigator, the cytological findings in most cases provide enough information to plan the subsequent therapeutic strategy.

The diagnosis of fibrohistiocytic tumors is done principally on the basis of the H&E-stained section. Despite the enormous increase in additional methods available, the H&E section remains the gold standard of morphological diagnosis. When necessary, IHC can be employed; this can reveal cell-line differentiation or antigen expression patterns typical for a particular tumor entity. Likewise, methods of genetic analysis allow the detection of chromosomal translocations, as well as gene deletions or amplifications. These methods are usually exercised when no tumor classification is possible on the basis of the H&E section even in combination with IHC. Chromosomal translocations can be detected in formalin-fixed paraffin-embedded (FFPE) tissue by fluorescence in situ hybridization (FISH) or by reverse transcription polymerase chain reaction (RT-PCR) for the product generated by gene fusion (hybrid RNA). The latter has the advantage of demonstrating not only the translocation, but also the sites of the breakpoints in the genes. Unfortunately, chromosomal translocations are not always diagnostically unambiguous.

Malignant fibrohistiocytic tumors of the dermis represent the malignant end of a spectrum that begins with fibroplasias and benign fibrous tumors. Fibrous lesions are often composed predominantly of stroma, and only in certain high-grade sarcomas the neoplastic nature of the lesion is immediately obvious. However, it should be noted that the identification of defined chromosomal abnormalities in some fibrohistiocytic lesions traditionally regarded as reactive suggests their neoplastic status. Thus, the classification of fibrohistiocytic tumors, like that for other tumor entities, is not static. New aspects or interpretations have to be taken into account and incorporated into clinical practice, i.e., it becomes necessary to update the tumor classification, modify it, or even alter major parts of it.[1]

A prominent example for such an evolution is malignant fibrous histiocytoma (MFH). MFH as a tumor entity has already been a subject of debate for sometime. Tumors were originally classified as MFH based on the assumption that the histiocytic tumor cells possess the ability to modulate into facultative fibroblasts. Indeed, MFH was regarded as the most common soft-tissue tumor of advanced adulthood, with pleomorphic MFH being the prevalent subtype. Subsequently, however, it was demonstrated that the phenotype of pleomorphic MFH can be adopted by various soft tissue malignancies by loss of differentiation; thus, in the majority of cases there is no independent tumor entity and the cells of pleomorphic MFH are basically dedifferentiated or undifferentiated cells of different origin. By means of more advanced techniques it was possible to demonstrate markers of residual differentiation for the majority of these tumors and thereby to remove such defined soft-tissue tumors from the group of pleomorphic MFH. According to the recommendations of the WHO, the remaining tumors that cannot be further subtyped, i.e., pleomorphic MFH in the narrower sense, should be described as undifferentiated pleomorphic sarcomas (UPS); notably, these very rare tumors are almost never cutaneous lesions. The tumor cells of the second prominent MFH subtype—the myxoid variant—are now understood as fibroblastic cells; thus, the preferred designation today is myxofibrosarcoma (MFS).

With regard to the treatment of "so-called malignant fibrohistiocytic tumors" surgery is the primary treatment of choice. In cases where surgery is not feasible, i.e., large primary tumors or inoperable metastatic disease, beneath chemotherapy and radiation the search for suitable molecularly targeted agents is strongly pursued.[2] To achieve this goal, however, a pathogenetically essential molecular target is needed. This strategy up to now was successful in one tumor entity only, dermatofibrosarcoma protuberans (DFSP), which can be effectively treated with tyrosine kinase inhibitors (TKI) targeting the platelet-derived growth factor receptor (PDGFR), for example, imatinib. For all other entities of malignant fibrohistiocytic tumors, clinical studies investigating different targeted agents in an unselective manner did not show any promising results. Here, the key molecular pathways for pathogenesis and maintenance of the different tumor entities first have to be elucidated in more detail to subsequently serve as targets for a molecularly driven therapy.

DERMATOFIBROSARCOMA PROTUBERANS

EPIDEMIOLOGY

The incidence of DFSP ranges between 0.5 and 1:100,000, thus it is the most common cutaneous sarcoma. Although DFSP can present at birth or in children, most patients are middle-aged adults. There does not seem to be a gender or racial predilection for the tumor, however, the pigmented variant (Bednar's tumor) is more common in black patients.

ETIOLOGY AND PATHOGENESIS

The histogenesis of DFSP is uncertain: fibrohistiocytic, purely fibroblastic, and neural-related differentiation have all been hypothesized. At the molecular level, DFSP is characterized cytogenetically by a reciprocal translocation t(17;22) (q22;q13), or more frequently, a supernumerary ring chromosome composed of hybrid material derived from t(17;22).[2] The translocated chromosome and the supernumerary rings contain the same molecular genetic rearrangements. The t(17;22) translocation fuses the gene *PDGFB* on chromosome 22 with the strongly expressed collagen 1 alpha 1 (*COL1A1*) gene on chromosome 17. The *PDFGB* gene encodes the β chain of the PDGF, a ligand for the cell-surface receptor tyrosine kinase PDGFR (both PDGFRβ and PDFRα). PDGFβ is a growth factor that acts as a potent mitogen for a variety of connective tissue cells.

The formation of the *COL1A1-PFGFB* fusion gene results in constitutive production of COL1A1-PDGFβ protein. After translation the COL1A1-PDGFβ fusion undergoes posttranslational processing to form functional PDGFβ. Thus, the production of PDGFβ can lead to autocrine stimulation of the tumor's own PDGFR, promoting tumor growth and survival. These observations suggest that deregulated expression of PDGFβ, with concomitant autocrine stimulation of PDGFR, is the critical molecular event in the pathogenesis of DFSP. Notably, both fibrosarcomatous transformation of DFSP and some cases of superficial fibrosarcoma (which actually may represent fibrosarcomatous transformed DFSP) have been shown to harbor these fusion transcripts, suggesting a close affinity between DFSP and fibrosarcoma.

In some patients, there is a history of previous trauma; in this regard it should be noted that DFSP has also been described as arising in scars, including surgical, burn, and vaccination sites.

CLINICAL FINDINGS

DFSP is a slow-growing lesion that often presents on the trunk and proximal extremities, less frequently on the head and neck of patients. Due to its indolent onset, the patient may present rather late when the tumor is already several centimeters in size. The tumor is often misdiagnosed as a simple scar, keloid, or cyst (Box 125-1). Even when allowed to grow for many years, the tumor usually remains asymptomatic.

The clinical presentation of DFSP is variable. The most common presentation is a firm, indurated plaque, often skin-colored with red–brown exophytic nodules (Fig. 125-1A). Purely plaque-like DFSP never developing nodules or tumors consisting of only a single nodule are rare. Initially the tumor is freely moveable; subsequently, however, larger adherent tumors evolve. At this stage the overlying epidermis may be thinned and telangiectases appear. Bleeding and ulceration are uncommon. DFSP may less frequently present as a nonprotuberant, atrophic (Fig. 125-1B), violaceous lesion resembling morphea or a sclerosing basal cell carcinoma; this form is more common in childhood.

BOX 125-1 DIFFERENTIAL DIAGNOSES OF DFSP, AFX, AND ES

DERMATOFIBROSARCOMA PROTUBERANS

- Classic presentation
  - Keloid/hypertrophic scar
  - Dermatofibroma
  - Fibrous histiocytoma
  - Nodular melanoma (Bednar variant)
- Atrophic presentation
  - Morphea
  - Lichen sclerosis
  - Morpheaform basal cell carcinoma

ATYPICAL FIBROXANTHOMA

- Squamous cell carcinoma
- Basal cell carcinoma
- Amelanotic malignant melanoma

EPITHELIOID SARCOMA

- Granuloma annulare
- Rheumatoid nodule
- Dupuytren contracture
- Infectious ulcer

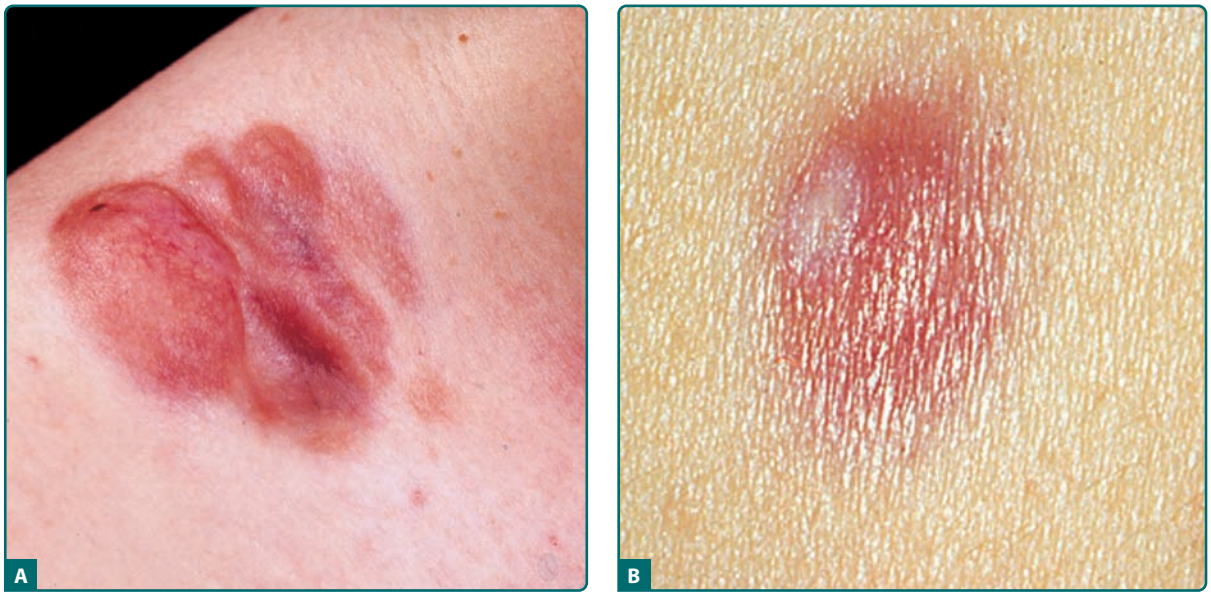

Figure 125-1 **A.** Dermatofibrosarcoma protuberans (DFSP) presenting as reddish brown confluent flat nodules. **B.** Atrophic variant of DFSP.

The pigmented variant of DFSP is termed **Bednar tumor**.

Giant cell fibroblastoma is considered a variant of DSFP, i.e., the juvenile variant of DFSP. Giant cell fibroblastoma typically presents as a dermal or subcutaneous mass, which most frequently involves the trunk, thigh, or inguinal region. It presents much earlier in life than the typical DFSP, often within the first decade, although occurrences in adults have been reported.

HISTOPATHOLOGY AND IMMUNOHISTOCHEMISTRY

DFSP is a dermal proliferation of monomorphous, slender, or slightly plump spindle cells with little pleomorphism arranged in a storiform pattern (Figs. 125-2A and 125-2B). The epidermis is usually uninvolved. The proliferation commonly infiltrates the subcutaneous fat along the fibrous septa, isolating adipocytes to form lucencies ("honeycomb" pattern). The periphery of the tumor is poorly defined, rendering histological control of the surgical margins difficult. In contrast to dermatofibroma, the tumor is much more cellular and usually does not have mature collagen interspersed between fascicles of spindle cells. Mitoses are present; a high mitotic rate may correlate with an impaired prognosis.

Variable histologic patterns described include myxoid, neuroid, fibrosarcomatous, and granular cell types. The tumor may be relatively monomorphous or may show combinations of various patterns within the original tumor or in the recurrences. The Bednar tumor is rich in melanocytes. Giant cell fibroblastoma is characterized by giant cells, irregular vascular-like space partially ligned by giant cells as well as myxoid to collagenous areas with elongated to stellated cells. Some lesions show overlap between giant cell fibroblastoma and DFSP. The fibrosarcomatous dedifferentiation appears histologically as cellular tumor zones with a fascicular growth pattern, cellular atypia, and numerous mitoses. These atypical cells are arranged in long fascicles in a herringbone (fibrosarcoma-like) pattern; this transformation appears to be related to mutations in the p53 pathway.

A very sensitive, although nonspecific, marker for DFSP is CD34.[3] DFSP cells label diffusely and strongly with antibodies to CD34 (Figs. 125-2C and 125-2D) and vimentin; however, CD34 positivity may be lost

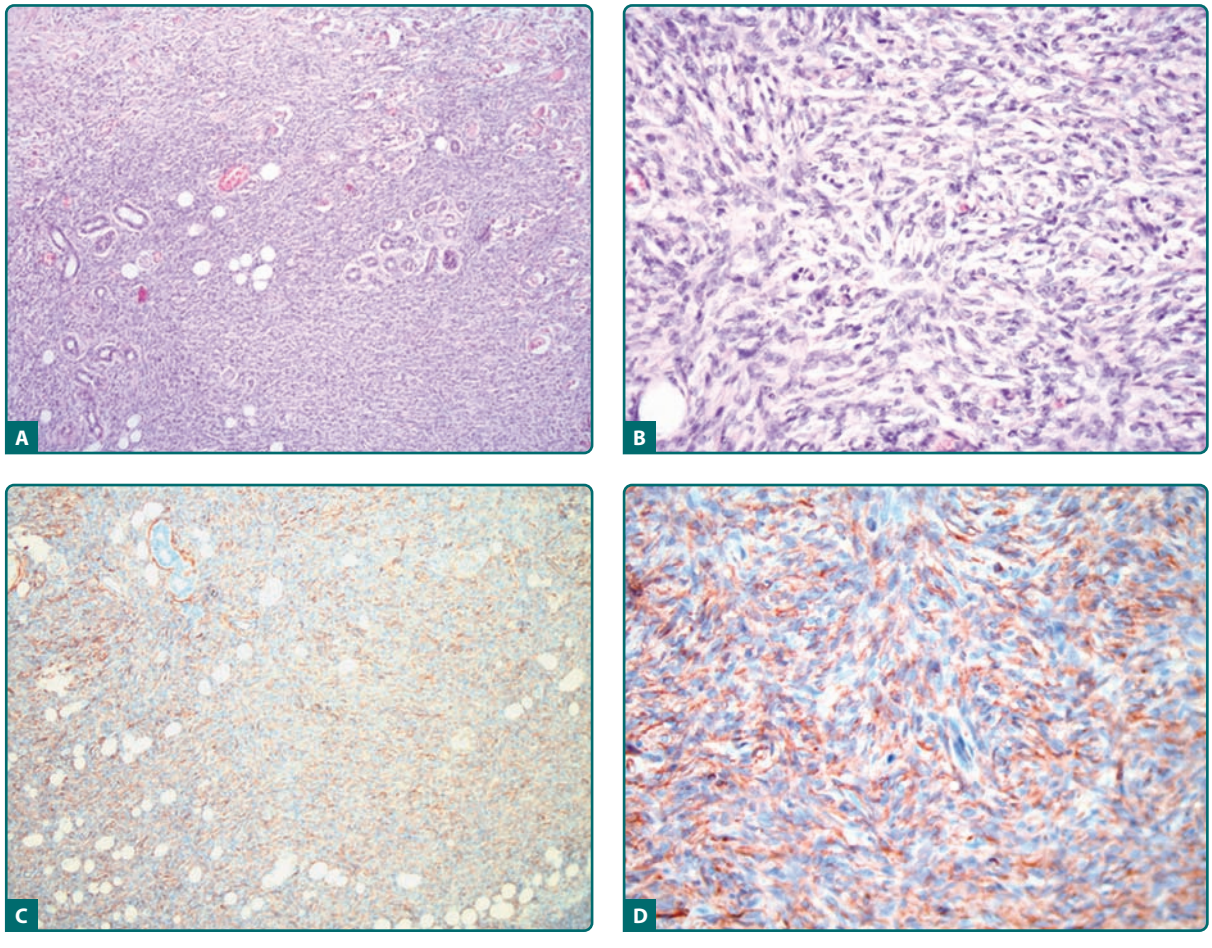

Figure 125-2 **A** and **B.** Dermatofibrosarcoma protuberans showing fibroblastic spindle cells that are arranged in interlacing fascicles. These intersect and bend at acute angles, producing a starburst (storiform) pattern. **C** and **D.** Strong expression of CD34 of the tumor cells. Magnification: **A** and **C,** 10×; **B** and **D,** 20×.

in nodular regions; particularly the fibrosarcomatous dedifferentiated cellular zones can be negative for CD34. The low-affinity nerve growth factor receptor p75 has been reported positive in DFSP cells. Scattered Factor XIIIa positive cells may be present. Tenascin is negative at the dermoepidermal zone in DFSP. DFSP cells are negative for S100 protein, smooth muscle actin (SMA), desmin, keratins, and epithelial membrane antigen (EMA). In contrast to dermatofibroma, stromelysin 3 is not expressed in DFSP.

CLINICAL COURSE, PROGNOSIS AND TREATMENT

DFSP is a low-grade malignant tumor, often infiltrating diffusely through the dermis and into the subcutaneous fat but seldom metastasizing. Increased age, high mitotic index, and increased cellularity are predictors of poor clinical outcome. Approximately 30%–50% of DFSPs recur locally after simple excision. Local recurrences even after wide excision with 1–3-cm margins to the fascia or periosteum are common. Best results can be achieved by means of micrographic controlled surgery (Mohs micrographic surgery) for tumor extirpation. However, it should be kept in mind that by use of frozen sections the histomorphology is not as good as by use of formalin-fixed paraffin embedded sections—in some cases impede correct diagnosis. Metastases of DFSP are extremely rare, usually occurring in the setting of multiply recurrent tumors and tumor progression to fibrosarcoma. Metastases to the lung are most common, with nodal disease the next most common site of spread. Metastatic disease portends a poor prognosis. It has been suggested that tumors with fibrosarcomatous change may have a higher risk of recurrence or metastases. It is estimated that there is a 5% transformation rate from DFSP to conventional fibrosarcoma. The true impact of fibrosarcomatous changes seen within a DFSP remains uncertain.

Standard management of localized disease is complete local surgical resection. With standard excision, margins of 1–3 cm may be necessary to achieve clear margins. However, local recurrence rates are high (13%–52%), especially in fibrosarcomatous DFSP. Risk of local recurrence decreases with increasing surgical margins. Pathologic examination of margins during surgery is helpful in delineating the extent of the tumor. Multiple case series have shown Mohs micrographic surgery to be an extremely effective method of resection of DFSP, with an extremely low rate of local recurrence. As a result, Mohs micrographic surgery represents the preferred surgical approach of many practitioners.

The role of radiotherapy remains unclear. Radiotherapy in the adjuvant setting following surgery is a treatment option particularly when margins are positive or close after maximal resection, if there is concern about the adequacy of negative margins, or if the achievement of wide margins would result in a functional or cosmetic defect.

Targeting the PDGF receptor signaling by receptor TKI, such imatinib or nilotinib, has demonstrated remarkable clinical success in the setting of advanced, unresectable primary tumors or metastatic disease.[4] These TKI are competitive antagonists of the adenosine triphosphate (ATP)-binding site, blocking the transfer of phosphate groups from ATP to tyrosine kinase residues of the substrates. This causes interruption of the downstream signaling process that leads to cell proliferation. The clinical activity of imatinib in patients with metastatic or locally advanced, unresectable DFSP was initially documented in case reports. The first published larger series of DFSP patients treated with imatinib confirmed the clinical activity with eight of eight patients with locally advanced disease obtained a clinical response. Four of these had a complete response; the other four patients were rendered free of disease after surgery following a partial response. Since 2007, imatinib has been approved in the United States and in the European Union for use in adult patients who have unresectable, recurrent, and/or metastatic DFSP and are no primary candidates for surgery. However, these observations raise the possibility of using PDGFR-specific TKI in the neoadjuvant setting in cases where surgery is associated with significant morbidity.[2] Clinical trials are needed to determine whether neoadjuvant use of such TKI to reduce tumor burden and facilitate resection, as well as adjuvant use following complete surgery, particularly in fibrosarcomatous DFSP, can improve patient outcome. Several studies in the United States and in Europe are ongoing in these clinical settings.

DESMOID TUMOR

EPIDEMIOLOGY

Desmoid tumors, or aggressive fibromatosis, are rare, with an estimated incidence rate of two to four cases per million per year. Desmoid tumors occur in a wide age range, between 16 and 79 years with a median age of 35, the majority being diagnosed before the age of 40.[5] Desmoids are slightly more common in women than men, but there are no apparent differences by race.

Desmoid tumors usually occur sporadically, but can be associated with familial adenomatous polyposis (FAP). Indeed, their incidence is 1,000-fold more frequently in patients with FAP; approximately 2% of desmoid cases occur in the setting of FAP. FAP, characterized by a mutation in the adenomatous polyposis coli (APC) tumor suppressor gene, has a clinical manifestation of hundreds, if not thousands, of adenomatous polyps in the colon and rectum. Although the association of desmoid tumor with FAP has been noted earlier, Gardner described a familial syndrome characterized by intestinal polyposis, fibromas, and sebaceous and epidermal cysts. Gardner syndrome is viewed as a variant of FAP. Notably, intra-abdominal and extremity desmoids tumors represent common extracolonic manifestations of disease in Gardner's syndrome.

ETIOLOGY AND PATHOGENESIS

The genetic predisposition to desmoid tumors in FAP patients prompted mutation analyses of the APC gene

to elucidate the pathogenesis of fibromatosis. However, current evidence demonstrates that there are likely undefined genetic or clinical factors independent of APC that are responsible for the pathogenesis of fibromatosis.[5]

Because APC and CTNNB1 are both part of the Wnt signaling pathway, mutations in either gene result in β-catenin protein stabilization and subsequent downstream activation of the T-cell factor/lymphoid enhancer factor (TCF/Lef) family of transcription factors. In a transgenic mouse model, induction of stabilized β-catenin leads to the development of desmoid tumors and hyperplastic cutaneous wounds, suggesting that β-catenin plays a role in these fibroproliferative disorders. Indeed, in a study of sporadic desmoid tumors, 3 of 12 cases had a mutation in β-catenin. In another study, 16 of 19 cases of desmoid tumors had a mutation of the Wnt pathway (APC or CTNNB1). The resulting activation of this pathway may be a potential target for future studies and the development of tailored therapies.

Recently the differential expression of estrogen receptors in desmoid tumors has been reported. There appears to be an increased estrogen receptor-β expression in 80% of desmoid specimens. Increased expression of PDGF receptors and their ligands in desmoid tumors have been reported.

CLINICAL FINDINGS

Desmoids are slowly growing tumors that may arise from the muscular aponeuroses at any site of the body, but are most commonly found on the trunk and extremities. In these locations, these solitary tumors tend to be located deep in the muscles or along fascial planes, such as at a point of muscular insertion. They may become quite large, displacing normal structures and hampering function. Patients will usually present with a greater than 5 cm, localized, firm mass with an indolent pattern of growth, which can be painless or minimally painful. The tumors of the abdominal wall occur along the anterior abdominal wall, most commonly in young women during or immediately after pregnancy. Desmoid tumors have been associated with a history of trauma or an operation. Thus, women undergoing cesarean sections are at higher risk.[5]

HISTOPATHOLOGY AND IMMUNOHISTOCHEMISTRY

Desmoid tumors are characterized by a monoclonal fibroblastic proliferation typically arising from muscular or aponeurotic structures. They may resemble low-grade fibrosarcoma, but their histologic appearance lacks nuclear and cytoplasmic features of malignancy. Desmoid tumors consist of spindle-shaped cells, separated by collagen fibers. The tumor cells have regular nuclei and show few mitoses. The tumor cells are arranged in long fascicles. Variable prominent elongated and compressed vessely can be seen. An infiltration of tumor cells into surrounding tissue frequently observed. By IHC, these spindle cells usually stain for vimentin and SMA, but are generally negative for desmin, cytokeratins, and S100. 70% of these tumors show a nuclear staining with antibodies against β-catenin.

CLINICAL COURSE, PROGNOSIS, AND TREATMENT

Desmoid tumors are notoriously infiltrative and persistent. Moreover, trauma, including surgery, can stimulate desmoid tumor growth. Thus, recurrence after surgery is common. Albeit to date no agreement has been reached on the optimal treatment of desmoid tumors, complete resection is generally considered the best choice of initial treatment and is potentially curative. Ability to accomplish complete resection at the first attempt defines likelihood of recurrence. Preoperative diagnosis with core needle biopsy may be helpful in planning a radical resection. Due to the locally aggressive nature of desmoid tumors and the therefore needed safety margins the localization of the tumor is important for treatment planning. Thus, clinical evaluation should include radiologic studies by MRI to determine proximity to adjacent structures.

There are no strong data to support the use of radiation therapy in the adjuvant setting following complete surgical resection. Thus, its use may be deferred until recurrence is seen and not amenable to repeat resection. Because palliative resection in most cases neither improves symptoms nor lengthens survival, there should be a consideration of radiation therapy in truncal or extremity desmoid tumors when a complete resection is not feasible.

Systemic therapy is indicated for patients with unresectable lesions. A number of treatment regimens have been reported in single case studies. Given the slow natural course of the disease, a low-toxicity regimen of chemotherapy is preferred; the combination of methotrexate and vinblastine is one of the most studied regimens. Chemotherapy, however, is met with scepticism since oncologic dogma dictates that cytotoxic treatments are not particularly effective in indolent tumors without metastatic potential.

Noncytotoxic agents that have been used for systemic treatment of desmoid tumors include antihormonal, nonsteroidal anti-inflammatory, and molecularly targeted agents. Because of clinical and experimental evidence linking hormonal surges to desmoid growth, antiestrogen agents (tamoxifen, toremifene, and raloxifene) have been commonly used over the years. Control of disease (either tumor shrinkage or stabilization) has been observed in up to 50% of patients; notably, responses are sometimes seen after the medication is discontinued. Recently, preliminary reports on the clinical activity of imatinib in desmoid tumors have generated some enthusiasm, though the mechanism of its action remains unclear. Nevertheless, several case reports have described meaningful responses to imatinib and in a series of 19 patients with desmoid tumors control of disease was achieved in almost 40% of the patients. The notion that the Wnt/β-catenin signaling pathway is involved in the pathogenesis of desmoid

tumors, opens new avenues for novel molecularly targeted agents.

ATYPICAL FIBROXANTHOMA

EPIDEMIOLOGY

AFX is a rare, rapidly growing neoplasm of intermediate malignant potential. It occurs mainly on sun-exposed skin (face, neck, and hands) of elderly individuals, mostly in the eighth decade of life, and shows male predominance.[6] However, in xeroderma pigmentosum (XP) patients, a rare, usually autosomal recessive disorder related to DNA repair defects, AFX does not only have a higher incidence but also occurs earlier in life, even in children.[7] Moreover, several lines of evidence indicate that the incidence of AFX is dramatically higher in transplant patients receiving immune suppression.

ETIOLOGY AND PATHOGENESIS

The nosologic nature of AFX has been the subject of much debate. Given its histologic appearance as well as its immunoperoxidase staining profile, AFX has traditionally been considered mesenchymal in origin. Because its histological appearance is similar to pleomorphic MFH, AFX is often regarded as a superficial version of this tumor. However, since the phenotype of "pleomorphic MFH" can be adopted by various soft-tissue tumors by loss of differentiation, AFX may also represent a tumor of dedifferentiated or undifferentiated cells of different origin. Thus, recently, some authors argue that AFX is an undifferentiated form of a spindle cell squamous cell carcinoma (SCC) or spindle cell melanoma. Indeed, one study has shown that depth-matched SCC and AFX behave similarly (Box 125-1).

Solar radiation probably represents a predisposing factor in the pathogenesis of AFX. This is supported by the common occurrence of the tumor on actinically damaged skin and its frequent association with other actinic-related lesions. The presence of cyclobutane pyrimidine dimers further supports a pathogenic role for ultraviolet radiation in the development of AFX.

Moreover, the majority of AFX cases are characterized by p53 immunoreactivity independent of acute stimuli for it expression; indeed, molecular analysis of the *p53* gene in a case series revealed that there were abnormal single strand conformational polymorphism patterns in all p53-immune reactive cases.[6] The increased incidence of AFX in XP patients also strongly suggests that UV-induced damage in the pathogenesis of the tumor.

CLINICAL FINDINGS

The patient may report a lesion on sun-damaged skin of relatively rapid onset. The predominant locations are ears, cheeks, nose, and scalp. The background skin is often sun damaged. The lesion usually presents as an asymptomatic, solitary, often dome-shaped nodule, which may be eroded or ulcerated (Fig. 125-3A). The size of presentation is usually less than 2 cm in diameter. AFX may resemble an SCC, basal cell carcinoma, or even a necrotic pyogenic granuloma.

HISTOPATHOLOGY AND IMMUNOHISTOCHEMISTRY

AFX is a poorly circumscribed hypercellular tumor that may extend deeply into the reticular dermis. It consists of an admixture of highly pleomorphic spindle, epithelioid (histiocyte-like), and multinucleated giant cells in the dermis (Figs. 125-3B and 125-3C). The proportion of individual cell types within individual lesions may vary, from predominantly spindle to predominantly epithelioid lesions. The neoplastic cells display pronounced atypia, with bizarre, large, round, or ovoid hyperchromatic nuclei with numerous mitotic figures (some of them atypical); large, prominent eosinophilic nucleoli; and abundant, occasionally vacuolated cytoplasm. An epidermal collarette at the periphery of the lesion is frequently observed and may extend along the base of the lesion. Skin adnexa are generally surrounded but not destroyed by the tumor. The deep margin is generally pushing rather than infiltrative. Surface ulceration precludes adequate evaluation of epidermal changes, for example, the presence of epidermal dysplasia or melanocytic proliferation.

At present, no single reliable immunohistochemical marker has been detected to confirm the diagnosis of AFX, which still remains a diagnosis of exclusion.[6] A panel of antibodies is therefore mandatory to exclude its potential mimics. Immunohistochemically, AFX has variable profiles, but cells usually express vimentin and histiocytic markers such as α_1-antitrypsin, α_1-antichymotrypsin, and CD68. Focal smooth muscle positivity can be detected in as many as 45% of AFXs. Although diffuse and strong CD10 and CD99 positivity has been described in AFXs, these markers are nonspecific and noncontributory in the diagnosis of AFX. MIB-1 and Ki-67 are useful markers in this highly proliferative tumor (Fig. 125-3D). CD74 expression has been suggested to represent a marker of more aggressive behavior in this tumor. By definition, AFXs are consistently negative for various low- and high-molecular-weight cytokeratins, S100 and desmin. Reactive S100+ dendritic cells are frequently seen dispersed among the lesional cells.

PROGNOSIS, CLINICAL COURSE, AND TREATMENT

The growth pattern of AFX has a propensity of local invasion beyond the obviously involved skin, there by inflicting the risk of local recurrence after surgical excision. In the literature, the recurrence rate of AFX is estimated to be 5%. Large case series from the 1960s and 1970s showed recurrence rates ranging from 2% to 21%, whereas more recently reported recurrence rates, particular if micrographic controlled surgery

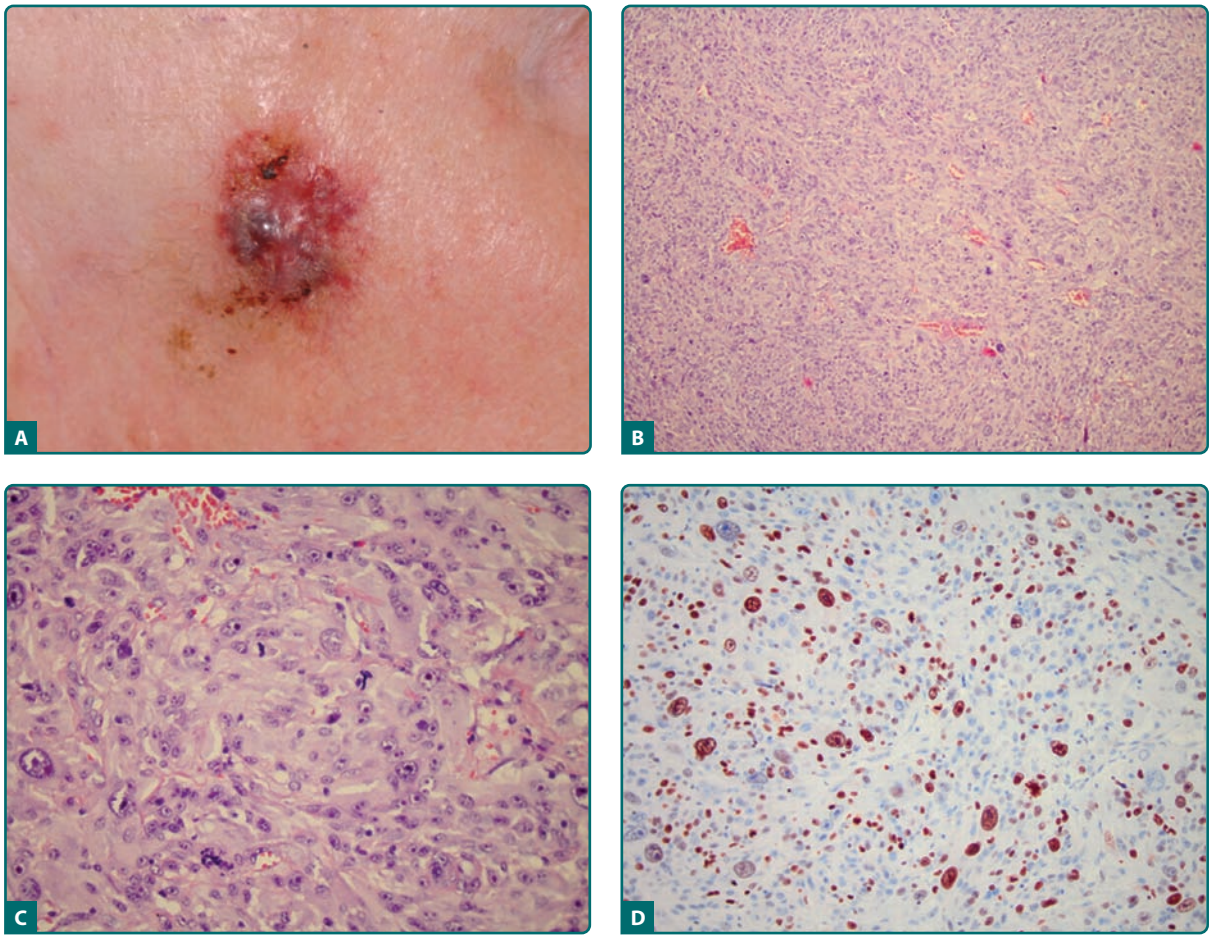

Figure 125-3 **A.** Atypical fibroxanthoma (AFX) presenting as a flat, ulcerated tumor on the temple of an elderly man. **B** and **C.** AFX showing atypical plump spindle cells and multinucleated giant cells. **D.** Tumor cells are characterized by a high proliferative rate revealed by MIB1 expression. Magnification: **B**, 10×; **C** and **D**, 20×.

(Mohs micrographic surgery) is used, are much lower. Thus, recurrent tumors may be better regarded as residual tumors.

AFX is a neoplasm with extremely low metastatic potential. In the largest case series reported to date by Ang et al, 3 out of 89 patients developed loco-regional or systemic metastases.[6] In 2005, Cooper et al described five cases of what they termed "metastasizing atypical fibroxanthoma"[8]; in their comprehensive review of the literature they identified additional 16 published cases of metastasized AFX since 1961. Thus, with respect to the management of patients, it is important to recognize that any tumor diagnosed as AFX has the potential for regional or even distant spread, whether it is an aggressive form of AFX or histologically misinterpreted as AFX instead of SCC. AFX is often found in the setting of diffuse actinic damage and other nonmelanoma skin cancer, so close follow-up after complete tumor exstirpation is prudent.

Treatment of AFX is surgical. Studies have suggested that Mohs micrographic surgery provides a lower rate of recurrence than wide local excision. Mohs micrographic surgery was found to be tissue sparing. Notably, even for larger tumors, the margins needed in Mohs micrographic surgery to clear the tumor effectively were smaller than that needed in wide local excision. In the series of 91 patients reported by Ang et al analysis of the Mohs micrographic surgery margins showed that in cases in which Mohs micrographic surgery cannot be employed a 2-cm margin is needed to ensure clearance of 96.6% of tumors by wide local excision. Excision should be to the level of the deep subcutaneous tissue.

In addition, follow-up examinations including inspection and palpation of the surgical site and the regional lymph nodes, should be performed for at least 2 years, because this is the time during which nearly all of recurrences reported in the literature occurred.

MYXOFIBROSARCOMA

EPIDEMIOLOGY

MFS represents a spectrum of malignant myxoid tumors of fibroblastic origin that exhibit a range of clinical and histopathologic features. For many years, this entity was generally known as myxoid MFH. However, several studies showed that MFS has reproducible cytoarchitectural features and consistent clinicopathologic characteristics and, therefore, these

tumors appear to constitute a defined entity and are better referred to as MFS.[1]

MFS is the most common malignant mesenchymal neoplasm of the extremities/limb girdles of older adults.[9] It shows marked predilection for subcutaneous tissue of the limbs and limb girdles; approximately more than two thirds of cases develop within the dermis or subcutis. MFS has no significant gender predilection and tend to affect patients in their sixth to eighth decades. However, the overall age range is wide, and cases in teenagers have been reported.

ETIOLOGY AND PATHOGENESIS

Cytogenetics demonstrated variable complex chromosomal abnormalities with translocations, for example, t(2;15)(p23;q21.2) or t(13;17)(q10;q10), or ring chromosomes as a consistent feature. To date, the constituents of these chromosomes remain unknown. Thus, there seems to be a number of different chromosomal alterations that contribute to the histogenesis of MFS.

CLINICAL FINDINGS

MFS is most frequently encountered on the extremities and limb girdles, but may also arise within the head and neck region, the trunk, hands, and feet. A gradually enlarging painless dermal or subcutaneous mass is the most frequent clinical presentation. The tumors are usually attached to a tendon or muscle but may also be superficially localized, presenting as multiple adherent cutaneous nodules, often with satellites. The most common clinical differential diagnosis is a benign dermal neoplasm such as lipoma, neurofibroma, or follicular cysts.

HISTOPATHOLOGY AND IMMUNOHISTOCHEMISTRY

MFS typically presents as a multinodular tumor characterized by variable amounts of hyaluronic acid-rich myxoid stroma, delicate blood vessels, and spindle-shaped or stellate fibroblasts. MFS exhibits a remarkably broad spectrum of histopathologic features ranging from banal to high grade. MFS grading is somewhat controversial and can be performed using a 3- or 4-tier grading system, which will grade these tumors in high, intermediate, and low-grade, or grades I to IV, respectively.[10] Both systems are based on the extent of the cellular components, nuclear pleomorphism, mitotic rate, and presence or absence of necrosis.

Low-grade MFS are hypocellular tumors comprised of relatively uniformly appearing spindle or stellate cells dispersed within a myxoid matrix; while nuclear pleomorphism and hyperchromasia may be present, mitotic figures and other overtly malignant features are absent. With increasing histological grade, MFS displays increasing cellularity, nuclear atypia, and mitotic activity. High-grade MFS is characterized by hypercellularity, marked nuclear atypia, hemorrhage and necrosis, and a high mitotic rate. It should be noted, however, that superficial portions of MFS tend to be morphologically low grade, regardless of the grade seen within the remainder of the tumor. Moreover, irrespective of the grade of MFS, the periphery is usually poorly defined, with finger-like extensions that account for satellites and a high recurrence rate.

At present, no single reliable IHC marker has been detected to confirm the diagnosis of MFS. The characteristic tumor cells in myxoid areas stain positively for vimentin, but are generally negative for CD68 or Factor XIIIa.

PROGNOSIS, CLINICAL COURSE, AND TREATMENT

The primary therapy for MFS is complete local surgical resection. Wide and deep local excision is required. The first excision offers the best chance for cure. Three-centimeter margins are usually suggested, but the deep extensions are hard to identify, even when one excises to the fascia; particularly as MFS is deceptively infiltrative, making clinical assessment of margins difficult. Thus, MFS has a high rate of local recurrence of almost 50%. The potential of MFS to recur and to spread seems to be related to the anatomic depth of the primary tumor and histologic grade; however, even histological bland lesions carry a significant risk of recurrence. Importantly, recurrent low-grade lesions may undergo progression to more malignant histopathology and this transition may be accompanied by increasing metastatic potential. Metastasis occurs in a significant number of high-grade tumors with an overall risk of approximately 20%–25%.[10] Lung and bone are the most common metastatic sites, but spread to regional lymph nodes may also occur. The overall 5-year survival rate is 60%–70%.

UNDIFFERENTIATED PLEOMORPHIC SARCOMA

EPIDEMIOLOGY

In the past, MFH has been considered to be the most common malignant soft-tissue tumor, with pleomorphic MFH being the prevalent subtype. However, the availability of more advanced techniques revealed markers of residual differentiation for the majority of these tumors; thus, MFH is not a distinct entity but rather a common histopathologic endpoint for several high-grade undifferentiated sarcomas and only such tumors that cannot be further subtyped, i.e., the pleomorphic MFH in the narrower sense, should be described as UPS[1]; notably, these very rare tumors are almost never cutaneous lesions.

ETIOLOGY AND PATHOGENESIS

The pathogenesis of soft-tissue sarcomas in general and UPS, in particular, has not been well defined. Depending

on the cells of origin, various genetic, physical, chemical, and viral etiologies have been suggested.

UPS may arise as a result of arrested maturation of tissue stem cells along the recently proposed differentiation spectrum from the fibroblastic mesenchymal stem-like cell to the fibroblast-myofibroblast-pericyte. It is possible that residual tumor stem cells that persist after treatment could have a role in progression or relapse, with implications for new therapeutic strategies.

CLINICAL FINDINGS

UPS is almost never a cutaneous tumor. The skin may be involved as a result of direct extension or metastasis. About 15% of UPS cases are found in the subcutaneous tissue, the remaining majority of cases arise from the deeper soft tissues.

HISTOPATHOLOGY AND IMMUNOHISTOCHEMISTRY

The most common appearance of tumor cells in UPS is that of spindle cells in a storiform pattern. The stroma may be finely fibrillary, myxoid, or densely collagenous. Bizarre epithelioid and giant cells may be present and may contain small amounts of lipid. Many mitotic figures, bizarre giant cells, and necroses are common. Ultrastructurally, the neoplastic cells have features consistent with fibroblastic, myofibroblastic, and histiocytic differentiation.

IHC using a broad antibody panel is required to rule out metastatic carcinoma, lymphoma, pleomorphic rhabdomyosarcoma, pleomorphic liposarcoma, high-grade leiomyosarcoma, defifferentiated liposarcoma, melanoma, and similar lesions. UPS is characterized by negative immunostains for EMA, cytokeratins, CD34, SMA, desmin, and HMB45. Among stem cell markers, CD117 and occasionally nestin may be expressed.

PROGNOSIS, CLINICAL COURSE, AND TREATMENT

Up to 50% of patients presenting with an UPS may have distant metastases (lung most likely). UPS should be treated in analogy to other poorly differentiated sarcomas. When the disease appears localized, treatment is based on the prognosis. In general, small low-grade tumors with wide pathologically negative margins can be treated with surgery alone. Large or high-grade lesions may benefit from radiotherapy with a reduction in the incidence of local recurrence but with no benefit in overall survival (OS). Chemotherapy may be used before surgery to try to shrink the lesion, and after surgery to try to prevent its recurrence.

Although with rare exceptions metastatic UPS is incurable, substantial benefit can be derived from the appropriate use of chemotherapy or local control measures including surgery, radiotherapy, and other interventional techniques.

EPITHELIOID SARCOMA

EPIDEMIOLOGY

ES is a relatively rare soft-tissue sarcoma of unknown histogenesis accounting for <1% of all soft-tissue sarcomas. ES is a slow-growing tumor with a seemingly benign pathomorphologic appearance due to which it is often misdiagnosed. The tumor may develop at any age with a peak in young adults and more frequently in males. A higher than usual proportion (i.e., one-fourth) of cases has been associated with prior trauma, including origin in scar tissue.

ETIOLOGY AND PATHOGENESIS

The etiology and histogenesis of ES is obscure; in the current World Health Organization classification, ES is categorized as a tumor of uncertain differentiation and described as being of unknown lineage. The reported histomorphology and immunophenotype, however, suggest a mesenchymal neoplasm with multidirectional differentiation, including epithelial, histiocytic, fibroblastic, myofibroblastic, endothelial, and perineural differentiation.

There are no consistent or specific cytogenetic findings in ES. Some tumors are diploid and others polyploid. Abnormalities involving 18q11 and 22q11 (including 22q deletions) have been observed. Furthermore, chromosomal rearrangements t(8;22)(q22;q11) in classic ES and t(10;22) in two cases of proximal ES have been described. Additionally, inactivation of a tumor-suppressor gene *Smarcb1*, located at band 22q11, has been found in a subgroup of ES, i.e., the proximal type. Inactivating mutations in the *Smarcb1* gene are a hallmark of rhabdoid tumors, i.e., especially lethal cancers that predominantly strike young children. SMARCB1 was the first member of an ATPase chromatin-remodeling complex to be implicated in the genesis of cancer. SMARCB1 loss causes cell-cycle progression in part via downregulation of $p16^{INK4a}$ and upregulation of E2F and Cyclin D. Heterozygous *Smarcb1* knockout mice are born at the expected frequency and appear normal, but are predisposed to cancer with approximately 20% developing sarcomas at a median age of 12 months.

CLINICAL FINDINGS

Clinically, ES usually presents as a painless, slow-growing, firm tumor. While most tumors are situated in the subcutaneous fat and fascia, some may arise in the dermis.[11] When the skin is involved, one or more slowly growing nodules are seen, often accompanied by superficial ulceration, hemorrhage, necrosis, and plaques. Ulcerating ES lesions have raised margins and are nonhealing (Fig. 125-4). Deeper ES lesions can extend along tendon sheaths or aponeuroses. In any case the tumor may grow to a large size, up to 20 cm in diameter. The usual presentation is with symptoms of an infiltrative mass. Often, there is a delay in diagnosis



Figure 125-4 Epithelioid sarcoma typically occurring over the wrist. Note ulceration and granuloma-like border.

due to the rare nature of this tumor and the resemblance to more common inflammatory skin lesions, such as granuloma anulare (Box 125-1).

ES can be differentiated by histology into two subtypes: classical and proximal ES (see below for details). Classic ES usually involves the extremities of young adults most often localized on the hands and fingers; whereas the proximal subtype occurs mainly in axial or proximal regions, including limb girdles, pelvis, perineum, or genitalia, mediastinum, and trunk. However, the classic and proximal types can each occur in either proximal or distal locations.

HISTOPATHOLOGY AND IMMUNOHISTOCHEMISTRY

The histopathological diagnosis of ES can be quite difficult, as a superficial biopsy may only show necrobiosis or granulomatous inflammation, thereby mimicking infectious processes or granuloma anulare.

The tumor forms nodules composed of relatively uniform polygonal cells, often with loss of cohesion, which merge in the periphery into spindle cells without demarcation. The cells have relatively abundant deeply eosinophilic cytoplasm; mitotic figures are rare and only minimal pleomorphism is evident. Stromal changes include desmoplasia with cords of bland spindle cells sometimes with storiform pattern. The nodules frequently have central necrosis; hemorrhage is frequently observed.[11]

The proximal variant is characterized by marked cytologic atypia, frequent mitosis, vascular invasion, and absence of a granulomatous appearance. The tumor cells are large epithelioid and may mimic a carcinoma, furthermore, cells with a rhabdoid morphology can be seen. Rarely, tumors have features of both the classic and proximal variants. Notably, both variants can each occur in either proximal or distal locations.

Although there are several reported immunohistochemical studies on ES, a specific tumor marker for the diagnosis of this tumor has not yet been established. Most cases coexpress cytokeratins (particularly CK8, 14, and 19), EMA, and vimentin, but a few cases are vimentin-negative. CD34 staining is positive in more than half of ES; other endothelial markers such as CD31, however, are usually negative. SMA and neurofilament are often positive, especially in the spindle cells. Most cases are negative for S100. Recently, loss of INI-1 expression has been proposed to be of diagnostic benefit.[12]

PROGNOSIS, CLINICAL COURSE, AND TREATMENT

Because the classic location of ES on distal extremities often discourages early deep biopsy, and because ES may closely mimic various nonneoplastic lesions histologically such as granuloma anulare, it often evades diagnosis at an early, localized stage.

ES is an aggressive neoplasm, and the rate of local recurrence is very high, often with successive lesions appearing more proximally; distant metastases of ES are frequent. In the large series of Chase and Enzinger assessing 202 cases with follow-up, 77% recurred, and 45% metastasized, predominantly to the lungs (51%), local lymph nodes (34%), skin, bone, brain, liver, and pleura. Metastases developed in 36% of patients without local recurrence.[11] The median OS of about 7 years for patients with localized disease, but only just months for patients with distant metastases. Adverse prognostic factors include proximal subtype, amount of necrosis and vascular invasion, and inadequate excision. Favorable factors are young age at first diagnosis, female sex, and small size of tumor.

Radical excision traditionally with clear margins has been the treatment of choice, but recurrences occur even with amputation. Conservative (limb-sparing) surgery combined with preoperative or postoperative radiation therapy has been tried, with results comparable with those reported for radical amputation.

For metastatic disease systemic chemotherapy is indicated. Of the chemotherapeutic agents that have been used to treat ES, the two currently most often used are doxorubicin and ifosfamide; the use of gemcitabine is also increasing. These drugs alone or in combinations were shown to elicit limited but distinct response rates ranging from <10% to >30%.

Chapter 126 :: Vascular Tumors

:: Erin F. Mathes & Ilona J. Frieden

Vascular anomalies are common birthmarks.[1] Their classification has often been problematic, with contradictory and confusing descriptive nomenclature. A classification system first proposed by Mulliken and Glowacki was revised in 1996 by the International Society for the Study of Vascular Anomalies based on clinical, radiologic, and hemodynamic characteristics, into vascular malformations and vascular tumors.[2] Vascular malformations (see Chapter 172) are errors of morphogenesis whereas hemangiomas and other vascular tumors grow by cellular proliferation.

There are several types of vascular tumors, many of which occur in childhood. These tumors have also had confusing nosology,[3] with descriptive but imprecise terminology such as *strawberry*, *capillary*, and *cavernous*. Several types of hemangiomas have been described (infantile, rapidly involuting congenital, lobular capillary, etc.), so whenever possible, *hemangioma* should not be used as a stand-alone noun but rather qualified by an adjective based on the specific condition.

INFANTILE HEMANGIOMAS

INFANTILE HEMANGIOMAS AT A GLANCE

- Infantile hemangiomas are the most common tumor of infancy.
- Hemangiomas in high-risk anatomic sites are likely to require further work-up and, often, intervention.
- Segmental hemangiomas have a greater risk for morbidity than localized hemangiomas.
- Kasabach-Merritt syndrome is not due to infantile hemangioma.

EPIDEMIOLOGY

Infantile hemangiomas (IH) are the most common benign tumors of childhood, occurring in approximately 4% of children by 1 year of age.[4,5] In contrast to other types of hemangiomas and vascular malformations, IH have a characteristic proliferative phase followed by a slower involution phase. They are more common in females (2–5:1 ratio) and in premature infants, especially those weighing less than 2,500 g.[6,7] Other risk factors are Caucasian race, multiple gestation pregnancy, and maternal age greater than 30 years. Preterm infants are more likely to have multiple tumors, and the sex ratio is less skewed toward females.[8] Contrary to prior observations, newer prospective studies do not support chorionic villus sampling as a risk factor.[7,8]

ETIOLOGY AND PATHOGENESIS

IH are primarily composed of endothelial cells but also contain fibroblasts, pericytes, interstitial cells, and mast cells. Although the precise pathophysiologic mechanisms of the growth and involution of endothelial cells remains unknown, several recent discoveries have advanced our understanding of IH.[9–13] The patterns found in segmental hemangiomas suggest at least some hemangiomas occur via developmental error as early as 4–6 weeks of gestation.[14] IH only occur in humans, and adequate animal or laboratory models have been difficult to develop.

The recognition that a glucose transporter protein, GLUT1, is expressed in all stages of hemangioma maturation spurred new hypotheses on the pathogenesis of IH.[15,16] GLUT1 expression in absent in the normal cutaneous vasculature but is found in placental blood vessels as well as in other so-called barrier tissues such as the blood–brain barrier. This, together with other immunohistochemical markers shared by IH and human placenta (FcγRII, merosin, and LeY), and the similar gene expression profiles found on DNA-based microarrays led to speculation that these tumors are of placental origin from either embolized placental cells or invading angioblasts that have differentiated toward a placental phenotype.[16,17] IH lack a villous architecture and do not express known placental trophoblastic markers suggesting that they are not placental emboli.[18] In addition, a recent study determined that hemangioma endothelial cells are of fetal, not maternal origin.[19] Further investigations into the cellular origin of hemangioma endothelial cells have demonstrated that these cells have features of immature mesenchymal cells. They have features similar to an early embryologic vessel, the cardinal vein[20] and express CD133, a primitive cell marker, during proliferation.[21,22] Implantation into immunodeficient mice of $CD133^+$ cells isolated from IH gives rise to $GLUT1^+$ vessels that later diminish and are replaced by adipocytes.[23] While not a perfect replica of IH growth, this model merits attention and additional study.

Additionally, while previous work suggested that IH arise because of aberrations in angiogenesis, recent investigations show that IH are *not* simply cutaneous capillaries with excessive growth, but more likely represent de novo vasculogenesis in the skin and other sites. Alterations in pathways that negatively control vascular endothelial growth factor receptor 2 (VEGFR2) signaling in vascular endothelial cells appear to play an important role in IH development and their rapid growth. In some patients germline mutations in VEGFR2 or tumor

endothelial marker 8 (TEM8) lead to these signaling abnormalities.[24,25] In vitro studies indicate that hypoxia and estrogen synergistically enhance hemangioma proliferation.[21] Some studies have demonstrated evidence of clonality in hemangiomas, but further research is needed to demonstrate whether these tumors, particularly when in segmental patterns, are truly clonal.[26,27]

CLINICAL FINDINGS

HISTORY. The clinical history is one of the most important keys to diagnosing an IH (Box 126-1).[28] Absence at birth or presence as a premonitory mark, usually an area of pallor, telangiectasias, or duskiness is characteristic, whereas a fully formed soft-tissue mass at the time of birth is most likely not an IH, but another vascular anomaly or other disease process.

BOX 126-1 HISTORY

- Birth history
  - Was the child premature?
  - Part of a multiple gestational birth?
  - Complications during the pregnancy or delivery?
- Overall health and past medical history
  - Is the child feeding well and gaining weight appropriately?
  - Have there been any hospitalizations or major illnesses?
- History of "birthmark"
  - Was it visible at the time of birth?
  - Has it changed since birth?
  - Growth: Is it growing proportionately or disproportionately with child's somatic growth? Is it still growing, stable, or shrinking in size? (Serial photographs are often helpful.)
  - Any complications such as pain, bleeding, or ulceration?
  - Any prior treatments?
- Family history
  - Is there a family history of hemangiomas or other vascular birthmarks?

CUTANEOUS LESIONS

Growth Characteristics. Though IH are not present at birth as fully formed tumors, superficial IH almost always become apparent within the first month of life. The period of most rapid growth typically occurs within the first 5 months of life, with 80% of growth being completed by 5 months of age.[29] Deep hemangiomas may be noted at a somewhat later age, on average 1 month later than superficial IH and uncommonly are not appreciated until a few months of life. Large, segmental, deep, and parotid gland hemangiomas may continue to enlarge slowly for months to years longer.[30] This growth phase is followed by a slower involution phase which is more variable in length, lasting for months to years (Fig. 126-1). Evidence of involution (change to a dull red, then gray or milky-white color, followed by flattening and softening) is usually apparent by 1 year of age.[29] Smaller hemangiomas typically involute sooner than very large ones, but there are exceptions. Most IH complete their course by the age of 7–10 years. Some children have normal skin after involution whereas the remainder has telangiectasias, atrophy, fibrofatty residuum, or scarring.



Figure 126-1 Natural history of segmental infantile hemangioma. Note the plaque-like, geographic configuration. **A.** Age 11 months, peak of proliferating phase. **B.** Age 2 years, involuting phase, apoptosis is maximal. **C.** Age 4 years, some further involution expected.



Figure 126-2 Localized infantile hemangioma, cheek of an infant.



Figure 126-3 Indeterminate infantile hemangioma, cheek, age 14 months.

Classification.[14] Hemangiomas which involve the upper dermis (so-called *superficial hemangiomas*) have a bright strawberry red color; whereas those with deep dermal and subcutaneous location are skin color to blue in color. Those involving both superficial and deeper skin structures, so-called *mixed* hemangiomas, have both features. In addition to this clinical appearance, IH can be classified as localized, segmental, or indeterminate.[31,32] Localized hemangiomas exhibit clear spatial containment as if arising from one central focus (Fig. 126-2). Segmental hemangiomas (similar to other segmental dermatologic disease such as vitiligo and neurofibromatosis) correspond to a portion of a developmental segment or broad anatomic territory (Fig. 126-3).[33] They are often plaque-like in nature with a linear or geographic configuration. Those hemangiomas not clearly identifiable as localized or segmental are termed *indeterminate* (see Fig. 126-3). The patterns of facial segmental IH have been found to correspond to neural-crest-derived facial prominences, and a new map for them has recently been proposed.[14] Multifocal hemangiomas are usually multiple localized hemangiomas. Though the exact number is somewhat arbitrary, the presence of more than five hemangiomas confers a risk of extracutaneous hemangiomas.

Classification of hemangiomas by subtype not only facilitates communication but also helps predict risk of complications and need for treatment. A prospective study of 1,058 children with IH showed that segmental hemangiomas are 11 times more likely to experience complications and eight times more likely to receive treatment than localized hemangiomas even when controlled for size.[34]

Atypical Presentations. Atypical presentations of IH include deep hemangiomas and those with minimal to no proliferation. Deep IH proliferate in the lower dermis and subcutaneous tissue without penetration of the papillary dermis (Fig. 126-4). They present as a localized, firm, rubbery subcutaneous mass that can be slightly raised with a bluish color or with telangiectasias involving the overlying skin, or they may be deep enough that the overlying skin is completely flat and of normal hue. If there is involvement of the papillary dermis, the cutaneous surface is often bright red and thus classified as a superficial and deep IH. IH with minimal to absent proliferation often have fine telangiectasias with a minimal to absent proliferative component thus resembling persistent premonitory IH (Fig. 126-5). They have recently been shown to be GLUT-1 positive indicating that they are indeed IH, but for unknown reasons, have not had a rapid proliferative phase. For unknown reasons, they are more common in the lower body.[35,36]

Medical and Extracutaneous Risks. Certain hemangiomas have known associated risks. Anatomic location is one of the most important factors affecting risk. Hemangiomas involving the central face (including the nose and perioral skin), periocular area, neck, mandibular region, and perineum should alert clinicians to possible increased risk of complications. In addition, the presence of multiple or segmental hemangiomas is associated with greater risk of extracutaneous disease.[28]

PHACE. Facial segmental IH are associated with PHACE (Online Mendelian Inheritance in Man #606519), a neurocutaneous syndrome that consists of the following features: posterior fossa brain malformations, segmental cervicofacial hemangioma, arterial anomalies, cardiac defects or coarctation of the aorta, eye anomalies, and sternal defects, such as sternal clefting or supraumbilical raphe.[37] A recent workshop reviewed knowledge about PHACE and consensus criteria for



Figure 126-4 Natural history of a deep infantile hemangioma, right cheek/parotid. **A.** Age 1 year, peak of proliferation. **B.** Age 3 years, involuting phase.

diagnosis have been proposed (see Table 126-1).[38,39] Up to one third of patients with large facial hemangiomas will be found to have PHACE when studied thoroughly.[38] While initial reports emphasized structural brain abnormalities, particularly Dandy–Walker malformation, recent reports have found that arterial anomalies of the head and neck are more common than structural brain abnormalities.[37–40] These intracranial arterial defects can lead to a Moyamoya phenomenon, ischemia, and stroke.[41,42] Other complications including seizure disorders and developmental delay are sometimes present in the setting of these CNS abnormalities.[40] The most common cardiac anomaly is coarctation of the aorta, most often involving the transverse aorta. Brain imaging [magnetic resonance imaging (MRI) and magnetic resonance angiography] should



Figure 126-5 Telangiectatic infantile hemangioma, left foot. This lesion could be confused with a port-wine stain. **A.** Reticulated stain and minor soft-tissue hypertrophy. **B.** Age 11 years, only fine telangiectasias remain (involuted phase).

TABLE 126-1
Diagnostic Criteria: PHACE Syndrome[38]

PHACE Syndrome		
Facial hemangioma >5 cm in diameter PLUS 1 major criterion OR 2 minor criteria		
Possible PHACE Syndrome		
Facial hemangioma >5 cm in diameter PLUS 1 minor criterion	Hemangioma of the neck or upper torso PLUS 1 major criterion OR 2 minor criteria	No hemangioma PLUS 2 major criteria
Organ System	**Major Criteria**	**Minor Criteria**
Cerebrovascular	Anomaly of major cerebral arteries Dysplasia[a] of the large cerebral arteries[b] Arterial stenosis or occlusion with or without moyamoya collaterals Absence or moderate to severe hypoplasia of the large cerebral arteries Aberrant origin or course of the large cerebral arteries[b] Persistent trigeminal artery Saccular aneurysms of any cerebral arteries	Persistent embryonic artery other than trigeminal artery Proatlantal intersegmental artery (types 1 and 2) Primitive hypoglossal artery Primitive otic artery
Structural brain	Posterior fossa anomaly Dandy-Walker complex or unilateral/bilateral cerebellar hypoplasia/dysplasia	Enhancing extra-axial lesion with features consistent with intracranial hemangioma Midline anomaly[c] Neuronal migration disorder[d]
Cardiovascular	Aortic arch anomaly Coarctation of aorta dysplasia[a] Aneurysm	Ventricular septal defect Right aortic arch (double aortic arch) Aberrant origin of the subclavian artery with or without a vascular ring
Ocular	Posterior segment abnormality Persistent fetal vasculature (persistent hyperplastic primary vitreous) Retinal vascular anomalies Morning glory disc anomaly optic nerve hypoplasia Peripapillary staphyloma Coloboma	Anterior segment abnormality Sclerocornea Cataract Coloboma Microphthalmia
Ventral or midline	Sternal defect Sternal cleft Supraumbilical raphe Sternal defects	Hypopituitarism Ectopic thyroid

[a]Includes kinking, looping, tortuosity, and/or dolichoectasia.
[b]Internal carotid artery, middle cerebral artery, anterior cerebral artery, posterior cerebral artery, or vertebrobasilar system.
[c]Callosal agenesis or dysgenesis, septum pellucidum agenesis, pituitary malformation, or pituitary ectopia.
[d]Polymicrogyria, cortical dysplasia, or gray matter heterotopia.

be considered in all infants with a large segmental hemangioma of the face.[43] In addition, formal ophthalmologic examination and echocardiogram may be performed, given the relative frequency of anomalies in these sites. Periodic developmental and neurologic assessments should be performed.

Periocular Hemangiomas. Infants with periocular hemangiomas are at risk for anisometropia and amblyopia, which if untreated, can lead to permanent visual loss (Fig. 126-6).[44,45] Direct pressure on the cornea can produce astigmatism or myopia, and the mass effect of the tumor itself can cause ptosis, proptosis, visual axis occlusion, or strabismus. Any patient with a hemangioma in the periocular area should have a prompt formal ophthalmologic evaluation with repeat visits during the proliferative phase (typically the first 3–4 months of life). Imaging studies may be needed to assess whether retrobulbar involvement is present.

"Beard Area" Hemangiomas. Segmental hemangiomas involving the preauricular, mandibular, chin, and neck skin (or so-called *beard area*) have a 60% risk of having symptomatic airway disease.[46] Airway hemangiomas often present with the insidious onset of

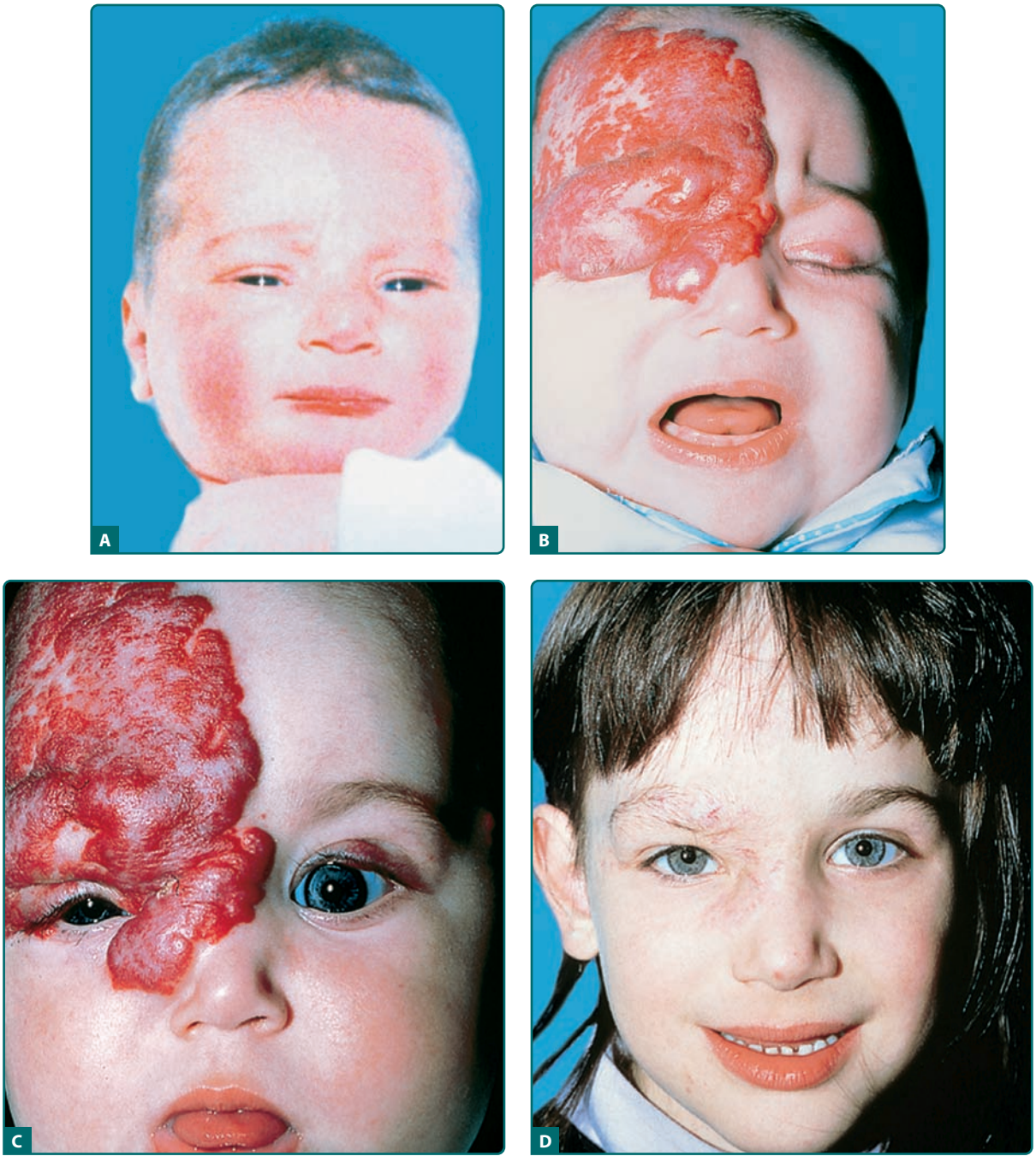

Figure 126-6 Vision-endangering segmental infantile hemangioma treated with systemic glucocorticoids. **A.** No premonitory signs of tumor seen on infant's photograph. **B.** By age 3 months, extensive infantile hemangioma infiltrating the upper lid and surrounding tissue, causing blocked vision. **C.** Eyelid opened within 2 weeks of glucocorticoid therapy. **D.** Involuted tumor, age 6 years.

biphasic stridor between weeks 4 and 12 of life and are often mistakenly diagnosed as tracheomalacia, upper respiratory infection, or croup. If the hemangioma continues to enlarge, respiratory distress can ensue and become life-threatening. Prompt evaluation by a pediatric otolaryngologist and treatment is essential.[47] Hemangiomas can also involve the parotid gland, and may require treatment due to massive growth, deformity of adjacent structures, and, in rare cases, high-output congestive heart failure.[48,49]

Lumbosacral and Perineal Hemangiomas. Segmental hemangiomas overlying the lumbosacral or perineal area can have associated spinal, bony, and genitourinary anomalies. Two acronyms have been proposed for this constellation of findings: PELVIS syndrome for perineal hemangioma, external genitalia malformations, lipomyelomeningocele, vesicorenal abnormalities, imperforate anus, and skin tag, and SACRAL syndrome, denoting spinal dysraphism, anogenital anomalies, cutaneous anomalies, renal and



Figure 126-7 Multifocal infantile hemangiomas in a 6-month-old infant. There are multiple, dome-shaped, erythematous papules on the left arm, flank, and back.

urologic anomalies, associated with angioma of lumbosacral localization.[50,51] Segmental hemangiomas overlying the lumbosacral spine have a significant risk of spinal dysraphism and tethered spinal cord. MRI is strongly recommended in this setting.[52] Other evaluations such as renal ultrasound should be based on clinical findings.

Multifocal Hemangiomas. Approximately 15% of infants will have more than one hemangioma, and premature infants have an even higher risk of multiple lesions (Fig. 126-7). In rare cases, infants can have hundreds of lesions. Until Glut-1 staining was recognized as a specific marker for IH, many infants with multifocal vascular tumors and extracutaneous disease were described as having *diffuse neonatal hemangiomatosis.* Many of these infants however actually have other vascular tumors. Infants with 5 or more IH are known to have an increased risk of having hepatic hemangiomas. Other sites of visceral involvement are exceeding rare in true IH. Visceral hemangiomas including those affecting the liver, gastrointestinal tract, and brain, have also been reported with solitary segmental hemangiomas.[53]

Hepatic Hemangiomas. The liver is the most common extracutaneous site of IH, Infants with >5 IH should be evaluated for the possibility of liver hemangiomas with liver ultrasound.[54] Even if present, hepatic hemangiomas are often asymptomatic, however a minority cause morbidity, and in rare cases are life threatening. A classification for liver hemangiomas has been proposed by Christison-Lagay et al including three types of hepatic hemangiomas, two of which are true IH.[55] The most common type (the presence of a few or multifocal liver hemangiomas) is often asymptomatic but can cause high-output congestive heart failure. A much rarer condition where the liver is virtually replaced by hemangiomas is termed "diffuse" disease. This life-threatening condition can result in abdominal compartment syndrome and a severe form of hypothyroidism due to tumor-related deiodination of thyroid hormone (see Section "Laboratory Tests"). A third type of hepatic hemangioma, wherein large solitary vascular tumors are typically present at birth is associated with arteriovenous shunting. In most cases these are not true infantile hemangioma but more likely analogous to rapidly involuting congenital hemangioma (RICH) occurring in the liver.

When cardiac compromise or severe hypothyroidism is a complication of hepatic hemangioma, systemic intervention is necessary. Embolization may be helpful if high-output congestive heart failure is present.[56,57] Aggressive thyroid hormone replacement is needed in cases with hypothyroidism.[58] In life-threatening cases liver transplant may be considered as a therapeutic option.

LABORATORY TESTS

Thyroid Function Tests. Hypothyroidism is a rare complication in infants with massive hemangiomas of the liver.[59,60] First reported by Huang et al, hemangioma tissue demonstrates high levels of type 3 iodothyronine deiodinase activity, which accelerates the degradation of thyroid hormone.[58,61] Infants with significant hepatic hemangiomas should have thyroid function evaluated, including T3 (the hormone consumed) and thyroid-stimulating hormone, because T4 levels may initially remain normal. Conversely, screening liver ultrasound looking for hemangiomas should be performed in infants with hypothyroidism of unknown etiology even in the absence of cutaneous hemangiomas. Hypothyroidism and other endocrine abnormalities have also been reported with PHACE syndrome. Infants with PHACE syndrome, large cutaneous hemangiomas, or extensive hepatic haemangiomas should have thyroid function [specifically thyroid-stimulating hormone, triiodothyronine (T3), and thyroxine (T4)] checked routinely.[62]

Platelet Studies. Platelet studies are not indicated in IH as the Kasabach-Merritt phenomenon (KMP) is not associated with IH but rather with kaposiform hemangioendothelioma (KHE) and tufted angioma (TA) (see Section "Pharmacologic Therapy").

Recommended tests and imaging studies are included in Section "Cutaneous Lesions" with discussion on specific IH and their related physical findings.

COMPLICATIONS

Ulceration is the most common complication of IH, occurring in approximately 15% of patients usually during the proliferative phase with a median age of onset of 4 months.[63] It occurs most frequently with segmental IH and at sites that are exposed to moisture and friction such as the perioral, perianal, and other intertriginous sites.[64] Secondary infection can occur but its frequency is debatable. Cultures usually show polymicrobial growth and are likely the result of colonization.[65] Localized infection will often improve with the use of topical mupirocin or metronidazole. However, if deeper or persistent infection is suspected, systemic antibiotics should be prescribed.

Local wound care, barrier protection, and pain control are essential for treatment. Bio-occlusive dressings may be helpful but those intended to stick to the skin may be limited by location because they do not adhere well near orifices.[66,67] In these areas, thick applications of petrolatum-based ointments can be helpful. Pain can be a major issue in management. It can be minimized with an occlusive dressing, oral acetaminophen with or without codeine, and the use of very small amounts of topical lidocaine ointment no more than a few times a day.[64] Ulcerations generally heal with scarring within 2–3 weeks with topical care. For refractory cases, other treatment modalities including pulsed dye laser (PDL) or Becaplermin 0.01% gel, a synthetic platelet-derived growth factor, have anecdotally been reported to be effective.[68,69] Therapies aimed at halting hemangioma growth, such as intralesional and systemic steroids or excision, may be useful in some cases.

Other serious complications such as hypothyroidism, internal organ involvement, or vital structure compromise due to the location of IH in certain anatomic sites have been discussed in Section "Cutaneous Lesions."

PROGNOSIS AND CLINICAL COURSE

The prognosis of most IH is excellent, with spontaneous involution and little to no sequelae, but a significant minority of IH result in permanent disfigurement or medical sequelae. Certain characteristics are associated with an increased risk of complications and need for treatment (Table 126-2).[29,70] Consideration of early treatment should be given to hemangiomas with these characteristics, depending on the specific clinical setting.

TREATMENT

The decision to initiate treatment is based on many factors, including size and location, psychosocial implications, and risks and benefits of the proposed therapy. For the majority of small hemangiomas, close observation and follow up is the most appropriate approach. This does not mean doing nothing. The infant should be seen frequently, especially during the first few months (corresponding to the proliferative phase). During these visits, education about the natural course of IH and discussions about the psychosocial impact on the child and/or the family should occur.[71] Photographs of the likely outcome for a similar lesion are often helpful. Many parents experience anxiety and may find themselves subject to comments from complete strangers about their child's hemangioma.[72] Most parents of young children do not think their child is deeply affected by these reactions, but facial hemangiomas, in particular, can cause psychological suffering once the child reaches school age.[73,74] Potential treatment options should be discussed well ahead of entrance to elementary school.

If it is decided that treatment is necessary, options include pharmacologic, laser, or surgical interventions (see Table 126-3). However, management remains controversial with few double-blind controlled studies and no Food and Drug Administration-approved labeled indications for medical treatments.

PHARMACOLOGIC THERAPY

Corticosteroids. Until recently systemic corticosteroids were the first-line treatment for deforming, endangering, or life-threatening IH (see Fig. 126-6).[75] They work best during the growth phase, causing slowing or cessation of growth in up to 90% of cases, with actual shrinkage in approximately one third. Although the mechanism of action is not well understood, recent studies suggest the upregulation of mitochondrial cytochrome b, clusterin/ApoJ (possible apoptotic markers), and/or interleukin-6 as markers of corticosteroid-induced cessation of hemangioma growth.[76–78] Prednisone or prednisolone is given at a dose of 2–3 mg/kg/day, typically for 4–8 weeks

TABLE 126-2
Features of IHs with Highest Risk for Morbidity According to Anatomic Location and/or Morphology of the Hemangioma

Anatomic Location/Morphology	Associated Risk
Facial, large segmental	PHACE syndrome (posterior fossa malformations, hemangiomas, arterial anomalies, cardiac defects, eye abnormalities, sternal clefting)
Nasal tip, ear, large facial (especially with prominent dermal component)	Permanent scarring, disfigurement
Periorbital and retrobulbar	Ocular axis occlusion, astigmatism, amblyopia, tear-duct occlusion
Segmental "beard area," central neck	Airway hemangioma
Perioral	Ulceration, disfigurement, feeding difficulties
Segmental overlying lumbosacral spine	Tethered spinal cord, genitourinary anomalies
Perineal, axilla, neck, perioral	Ulceration
Multiple hemangiomas	Visceral involvement (especially liver, gastrointestinal tract)

TABLE 126-3
Major Side Effects of Common Infantile Hemangioma Treatments

Treatment	Major Side Effects
Systemic corticosteroids	Diminished gain of height and weight, cushingoid facies, personality changes, gastric irritation, hypertension, immunosuppression
Intralesional corticosteroids	Arterial embolization/injection, atrophy, systemic absorption
Topical corticosteroids	Local atrophy, systemic absorption
Propranolol	Hypotension, symptomatic bradycardia, hypoglycemia, agitation, sleep alteration, sweating, cold hands, wheezing
Interferon-α	Spastic diplegia (neurotoxicity), fever, hepatotoxicity, neutropenia, anemia
Vincristine	Central line placement, neuropathy, abdominal pain, constipation
Laser	Pain, scarring, hypopigmentation, textural change, ulceration
Surgery	General anesthesia, scarring

followed by a tapering of varying length, depending on the age of the child and indication for treatment. A meta-analysis showed an 84% response rate with an average dose of 2.9 mg/kg for a mean of 1.8 months before tapering. Although 3 mg/kg/day is more effective (94% response) than 2 mg/kg/day (75% response), greater adverse events are found with the higher dose.[79]

Short-term complications of systemic corticosteroids include: cushingoid faces (71%), personality changes (29%), gastric irritation (21%), fungal infection (oral or perineal, 6%), and diminished gain of height (35%) and weight (42%) during treatment. More than 90% of children with diminished gain of height return to their pretreatment growth curve by 24 months of age (Table 126-3).[80,81] Other complications include hypertension, steroid-induced myopathy, immunosuppression, and transient adrenal insufficiency.[81,82] Blood pressure should be monitored with each visit to the dermatologist or pediatrician.[83] Children taking more than 2 mg/kg/day of prednisone for longer than 14 days are considered to have a deficit in cell-mediated immunity. Live viral vaccinations should be deferred in infants receiving high-dose corticosteroids. Rare cases of *Pneumocystis carinii* pneumonia have been reported in this setting, leading some physicians to use trimethoprim-sulfamethoxazole prophylaxis during treatment.[84,85]

Intralesional corticosteroids can be an effective treatment for relatively small localized hemangiomas located in high-risk sites such as the lip, nasal tip, cheek, and ear. Injections for periocular hemangiomas are usually performed by ophthalmologists, but reports of retinal artery embolization and blindness have resulted in a reduced use of this modality.[86–87] The largest published case series of intralesional steroids found that the majority showed greater than 50% reduction in volume with the best results occurring in relatively superficial hemangiomas. Adverse events occurred in 6.4% of patients and included cushingoid appearance, cutaneous atrophy, and anaphylactic shock (see Table 126-3).[88]

A few case series have reported on the efficacy of class 1 topical corticosteroids, especially for small, superficial hemangiomas.[89–91]

Propranolol. Recently, propranolol has been found to cause cessation of growth and shrinkage of IH and has replaced corticosteroids as the first line treatment for most deforming, endangering, or life-threatening IH.[91] In the 3 years since 2008 when the initial series of 11 infants reported by Leaute-Labreze and colleagues, more than 150 articles have been published, most of them enthusiastically attesting to the efficacy of this treatment modality. This includes a randomized controlled trial comparing placebo to propranolol and retrospective studies comparing the effects of corticosteroids and propranolol.[92,93] Most studies have used a dose range from 1.5 to 3 mg/kg/day given either 2 or 3 times per day. In most reports, patients are treated for at least 6 months with an acceptable side-effect profile. Unlike steroids which usually stabilize hemangioma growth, but do not cause involution, propranolol causes actual regression in the majority of cases. Rebound growth after cessation of therapy can occur, but usually responds well to retreatment.[92,93] Side effects of propranolol include asymptomatic transient decrease in blood pressure, agitation, sleep alteration, sweating, wheezing, and cold hands (See Table 125-4). However the most concerning side effect which has emerged is hypoglycemia, which while rare, can be potentially life-threatening. Anticipatory guidance to minimize hypoglycemia in young infants includes frequent feeding and stopping the medication if oral intake is poor.[94,95] Impressive results have been reported in other settings including fully proliferated cutaneous hemangiomas, airway, liver and orbital hemangiomas.[92,96–98] Patients with PHACE syndrome who have central nervous system vascular anomalies may be at risk for stroke or other sequellae due to impaired arterial blood flow related to a drop in blood pressure or heart rate. Uniformly accepted standard monitoring procedures for patients on propranolol for IH have not yet been established. The mechanism of action of propranolol for hemangiomas is unknown, but it has been postulated to its effects by three different molecular mechanisms: vasoconstriction, inhibition of angiogenesis and induction of apoptosis.[95,99]

Topical β Blockers. Preliminary reports have demonstrated good responses with timolol 0.5% administered twice a day for superficial hemangiomas. Timolol is much more potent than propranolol, and data regarding percutaneous absorption are lacking, so using only a small amount (i.e., 1 drop BID) is currently recommended. More studies are needed to assess the results of this modality to determine its place in therapy.[100,101,102]

Interferon-α. Interferon-α therapy is reserved for hemangiomas causing morbidity that are unresponsive to oral corticosteroids, or where such therapy is contraindicated. It is quite effective, but potential neurotoxicity, specifically spastic diplegia, has limited its use (see Table 126-3). A meta-analysis of 441 patients showed 11 developed irreversible spastic diplegia and 16 developed motor disturbances that were reversible on discontinuation of the drug.[103] All affected patients were younger than 1 year of age at initiation of therapy, suggesting that the drug may be safer after 1 year of age. Neurologic evaluations should also be performed monthly in treated children.

Chemotherapy. Vincristine is often used in the treatment of the KMP and its associated tumors, KHE and TA.[104–106] Given the potential neurotoxicity of interferon (see Section "Interferon-α"), vincristine is considered by some to be a second-line treatment for aggressive, complicated IH that do not respond to corticosteroids. However, further evaluation through prospective clinical trials is needed (see Table 126-3).

Cyclophosphamide has been reported in the pediatric hematology-oncology literature to be effective in the treatment of life-threatening diffuse neonatal hemangiomatosis.[78,107]

Imiquimod. A recent phase II open-label, uncontrolled study found that topical imiquimod 5% cream improved IH color, but not size, confirming that imiquimod's utility is limited superficial hemangiomas.[108] Crusting and ulceration are potential side effects.[109]

LASER THERAPY. The PDL, originally designed to treat portwine stains, has been used to treat IH with varying results.[110] Several reports have shown improvement in treating hemangioma ulceration,[111,112] and its use in diminishing residual telangiectasias and erythema after involution is well accepted. Its use in the treatment of proliferating hemangiomas is controversial.[113] Batta et al performed the only prospective, randomized, controlled study to date regarding the treatment of IH in 121 patients aged 1–14 weeks, using 585-nm PDL without cooling compared to observation alone.[110] Their results showed no difference between complete and nearly complete clearance with laser compared to observation alone at age 1 year, with a trend toward increased hypopigmentation and textural change in the laser-treated group. Other studies have shown good results with either the 585-nm PDL or 595-nm PDL, with varying fluences (total energy per unit area), but several have emphasized that treatments work best for more superficial hemangiomas and are unable to halt growth of deeper components.[114–117] Severe ulceration and scarring, particularly in treating segmental hemangiomas during the proliferative phase, have been reported (see Table 126-3).[118] A conservative approach is to reserve PDL primarily for treating ulceration and for hastening resolution of erythema in IH after the proliferative phase is completed.[119]

SURGICAL THERAPY. Surgical excision may be indicated at any time during the life cycle of an IH (Fig. 126-8).[1] In most instances, it is best to wait until regression is well under way and a more accurate assessment can be made regarding whether scarring and textural changes have occurred. Decisions regarding this can often be made at age 3–5 years, even if involution is not complete.[120] Certain anatomic locations such as the nasal tip and lip often require surgery.[121–126] Even earlier excision may be indicated in cases where clinical characteristics, such as pedunculated, very ulcerated, or extremely thick dermal involvement dictate that scarring will inevitably occur. A standard elliptical excision is often performed; however, circular excision followed by a purse-string closure may leave a smaller scar.[127]

OTHER VASCULAR TUMORS

OTHER VASCULAR TUMORS AT A GLANCE

- Congenital hemangiomas are fully formed at birth. Rapidly involuting congenital hemangiomas and noninvoluting congenital hemangiomas are recognized subtypes.
- Tufted angiomas represent subtle pink or dusky-red patches and may evolve into plaques or nodules and have a characteristic histology.
- Kaposiform hemangioendothelioma is morphologically similar to but etiologically distinct from Kaposi sarcoma and can be associated with Kasabach-Merritt phenomenon.
- Multifocal lymphangiomatosis with thrombocytopenia consists of cutaneous vascular papules and plaques associated with intermittent thrombocytopenia, often with gastrointestinal bleeding.
- Spindle cell hemangioendothelioma usually occurs in the extremities most often associated with Maffucci syndrome.
- Congenital eccrine angiomatous hamartoma is a rare ill-defined plaque associated with increased lanugo hair and sweating.
- Pyogenic granuloma is very common; a rapidly growing papule or nodule with a collarette of scale or eroded surface. Treatment is excision or electrocautery.



Figure 126-8 Surgical correction of involuting-phase infantile hemangioma. **A.** Age 3 years, infantile hemangioma on upper eyelid. **B.** Age 9 years, after staged surgical resection, including vertical shortening of eyelid, repair of blepharoptosis, and formation of tarsal crease.

Many other benign vascular neoplasms occur in both children and adults.[128] This chapter highlights selected important vascular tumors. More comprehensive reviews of this subject can be found elsewhere.[128–130]

CONGENITAL HEMANGIOMAS

Hemangiomas that are fully formed tumors at the time of birth and do not proliferate in postnatal life are referred to as *congenital hemangioma* or *congenital nonprogressive hemangioma*. There are two major subtypes recognized on the basis of their natural history: the RICH and noninvoluting congenital hemangioma (NICH).[131] Collectively, both are sometimes referred to as *congenital nonprogressive hemangioma*. The distinguishing pathologic features of these tumors are lobules of capillaries set within densely fibrotic stroma containing hemosiderin deposits, focal lobular thrombosis, and sclerosis.[132] They are GLUT-1 negative.[133] Both have similar anatomic sites of predilection, such as the extremities or postauricular skin, but they can occur elsewhere. RICH often appears as a raised, violaceous tumor with large, radiating veins or with overlying telangiectasia and a halo of pallor (Fig. 126-9). Central ulceration may be present. Most RICH involute spontaneously by age 14 months, often sooner, and usually leave residual atrophic inelastic skin in their wake.[134] In one report a presumed RICH was noted on prenatal ultrasound and involuted before birth, leaving



Figure 126-9 Rapidly involuting congenital hemangioma on left thigh. **A.** Note central ulceration, violaceous color, and pale periphery. Fast-flow vessels were detected on Doppler examination. **B.** Rapid regression at age 2 months.



Figure 126-10 Noninvoluting congenital hemangioma on right mandible. Note the overlying telangiectasias and rim of pallor.



Figure 126-11 Age 18 months. Tufted angioma (confirmed by biopsy) of the left leg, buttocks, lower abdomen. Laboratory evaluation revealed elevated D-dimers.

a scar tissue at the site of the lesion.[135] NICH are also present at birth, but usually flatter than RICH, presenting as a well-circumscribed round to oval, slightly indurated, or raised soft-tissue mass with overlying telangiectasias and a rim of pallor (Fig. 126-10).

Both NICH and RICH are high-flow vascular anomalies, often showing arteriovenous microfistulas on Doppler interrogation. Some cases of RICH involute only partially, and the residual tumor resembles NICH, supporting the concept that RICH and NICH may be variants of each other.

Indications for treatment of NICH or RICH are similar to those for IH, including impairment of visual function and congestive heart failure. Excision should definitely be considered for ulceration, which can lead to severe hemorrhage, and for postinvolutional skin changes if disfiguring. NICH do not go away but are often asymptomatic; decisions regarding their removal must weigh risks and benefits of the proposed treatment.

TUFTED ANGIOMA

ETIOLOGY. TA is a benign vascular tumor that has also been called *angioblastoma of Nakagawa*. Its etiology and pathogenesis are uncertain. Unlike IH, there are no known gender or gestational age correlates.

CLINICAL FINDINGS. Most cases are acquired early in childhood and have a protracted course. Rare congenital forms also exist. TAs display various clinical patterns. They may present as a subtle stain-like area that later thickens, as a large, plaque-like, infiltrated, red or dusky blue-purple lesion, or as an exophytic, firm, violaceous, cutaneous nodule (Fig. 126-11). TA are usually solitary, but multifocal cases have been reported.[136] TA must be differentiated from IH as well as other vascular tumors. They are often somewhat firmer and may be tender. Histologically, both acquired and congenital TAs demonstrate vascular tufts of tightly packed capillaries, randomly dispersed throughout the dermis in a typical "cannonball distribution" with crescentic spaces surrounding the vascular tufts, and lymphatic-like spaces within the tumor stroma.[137,138] Unlike IH, TA does not stain with GLUT1,[15] and D2–40, a lymphatic marker, is only partially positive in surrounding vessels, helping distinguish TA from KHE.[139]

COMPLICATIONS. KMP may develop in TA but this is more common with KHE (see Section "Kaposiform Hemangioendothelioma").

PROGNOSIS AND CLINICAL COURSE. TA may persist unchanged or regress completely within a few years.[140]

TREATMENT. No single treatment is effective. Interferon-α and PDL have anecdotally been reported to be effective.

KAPOSIFORM HEMANGIOENDOTHELIOMA

KHE is a rare vascular tumor that has usually been reported in association with KMP. It may be present at birth or develop in early childhood. Rare adult cases have been reported. It may present as a brown-red stain at birth which begins to thicken and become purpuric, or as a plaque or nodule similar to TA. Regional lymph node involvement may occur, but not distant metastases. Mediastinal or retroperitoneal disease may present with hemothorax and ascites.[141] Spontaneous involution is rare. Most reported cases have had associated KMP, but the KHE can occur in the absence of a coagulopathy.[142,143]

The histology of KHE is characterized by spindled cells with minimal atypia and infrequent mitoses lining slit-like or crescentic vessels containing hemosiderin. The tumor is GLUT-1 negative. The overlap of both clinical and histologic features has led some to suggest that TA and KHE are part of a spectrum of disease. Increased lymphatic spaces reactive with the lymphatic markers vascular endothelial growth factor receptor-3 and D2–40 suggest a lymphatic origin, similar to that of Kaposi sarcoma.[144,145]

The prognosis and management of KHE varies with extent and location of the tumor, in addition to the presence of KMP. Therapies for KMP are discussed below.

KASABACH-MERRITT PHENOMENON

The KMP refers to the presence of platelet trapping in the setting of vascular tumors (Fig. 126-12). It was long considered to be a complication of "hemangioma," but it is now recognized to be a complication of TA and KHE, not IH.[146,147]

KMP must be differentiated from the coagulopathy which can arise in association with venous and mixed venous-lymphatic malformations (sometimes erroneously called *KMP*) due to chronic clotting and consumption of clotting factors, but not primarily by platelet trapping.[148] The hallmark of KMP is a tender, expanding vascular tumor with thrombocytopenia, usually severe. Consumption of fibrinogen, elevated D-dimers, and decreased coagulation factors occurs to varying degrees. Most cases involve the skin and musculature, but deeper viscera including cervicothoracic, abdominal, and pelvic regions can be affected. Although the tumors causing KMP can persist, the coagulopathy usually abates by 1 year of age or sooner with treatment. KMP may resolve with atrophic or stain-like areas, infiltrated plaques and papules, or nodules. Residual fibrosis is not rare and can result in considerable morbidity.[149]

No one treatment is uniformly effective. Options include corticosteroids, vincristine, cyclophosphamide, actinomycin-D, methotrexate, interferon-α, ticlopidine plus aspirin, surgical excision, arterial embolization, and radiotherapy. Platelet transfusions should be avoided unless active bleeding occurs or before surgical procedures.[150–154]



Figure 126-12 Kasabach–Merritt phenomenon secondary to kaposiform hemangioendothelioma (KHE). An indurated, purpuric tumor appeared at age 3 months and is seen here at age 8 months. KHE confirmed by magnetic resonance imaging and biopsy. Platelet count <5,000/mm^3.

MULTIFOCAL LYMPHANGIOENDOTHELIOMATOSIS WITH THROMBOCYTOPENIA

Multifocal lymphangioendotheliomatosis with thrombocytopenia (MLT)—also known as *cutaneovisceral angiomatosis with thrombocytopenia*—is a rare condition, characterized by multiple cutaneous vascular papules and plaques that are usually present at birth with more developing over time. The use of GLUT1 as a specific histopathologic marker for IH has led to the recognition that these vascular growths are not a widespread variant of IH. The clinical spectrum of the disease is expanding. Some patients have prominent exophytic cutaneous vascular tumors, whereas others have subtle blueberry muffin-like papules.[155] Most affected infants have intermittent thrombocytopenia and lesions in the gastrointestinal tract, leading to gastrointestinal bleeding. Other reported sites of involvement include bones, synovium, lungs, liver, spleen, and brain. Undoubtedly, many patients previously diagnosed with "diffuse neonatal hemangiomatosis" actually had MLT. Skin biopsy specimens demonstrate thin-walled vessels, some hobnailed endothelial cells, and intraluminal papillary projections similar to Dabska tumor.[156,157] Some of the vessels stain with lymphatic markers such as LYVE-1 or D2–40.[155] No single treatment has been effective; patients have been treated with a variety of systemic medications including corticosteroids, interferon, vincristine, and most recently bevacizumab and thalidomide.[155,158] Prognosis varies based on extent of disease and bleeding complications.

SPINDLE CELL HEMANGIOENDOTHELIOMA

Spindle cell hemangioendothelioma is a rare vascular tumor most often seen with Maffucci syndrome. It can occur at any age and site but the extremities are the most commonly affected. The histology is of a nodular, dense, spindle cell proliferation in association with dilated dysplastic veins. Lesions can be locally aggressive and may recur even after excision.[159]

CONGENITAL ECCRINE ANGIOMATOUS HAMARTOMA (SUDORIPAROUS ANGIOMA)

Congenital eccrine angiomatous hamartoma is a rare condition characterized by ill-defined plaques with



Figure 126-13 Large pyogenic granuloma on chest, age 2 years.

increased lanugo hair and sweating at the site of the lesion. They are usually located on the extremities or abdomen. Diagnosis is established on the basis of characteristic histologic findings: closely packed eccrine sweat glands associated with dilated capillaries, a few dysplastic venous channels, and a dense collagenous matrix.[160]

PYOGENIC GRANULOMA (LOBULAR CAPILLARY HEMANGIOMA)

Pyogenic granuloma (PG) is also known by its correct histopathologic description *lobular capillary hemangioma.* It is one of the most common vascular tumors of infants and children and can also occur in adults, particularly in pregnant women. PG usually presents as a solitary, red, rapidly growing papule or nodule, often with a subtle collarette of scale (Fig. 126-13). Typical locations include the cheek or forehead but virtually any body site including the mucous membranes may be affected. They often develop an eroded surface, with subsequent bleeding which can be profuse, resulting in the moniker *the band-aid disease*. In very young infants, PG is often mistaken for an infantile hemangioma.[161]

PG does not involute spontaneously, but simple curettage with electrocautery is usually curative. Other options include excision, laser surgery (carbon dioxide or pulsed dye), and cryotherapy. Topical imiquimod has recently been shown to be an effective treatment.[162] Recurrence and even satellite lesions surrounding the original PG have been reported.[163,164]

OTHER VASCULAR TUMORS

Targetoid hemosiderotic hemangioma is a benign lesion presenting as a violaceous papule, often surrounded by a pale rim and peripheral ecchymotic halo, which fades with time. Lesions usually present on the trunk or extremities and histologically consist of dilated vascular channels within intraluminal papillary projections dissecting into collagen bundles in the subcutis. Extravasated erythrocytes and hemosiderin are present, hence the designation.

Endovascular papillary angioendothelioma (Dabska tumor) is a dermal nodule or a diffuse swelling on the head, neck, or extremities. Dabska tumor is a low-grade angiosarcoma. Epithelioid hemangioendothelioma and retiform hemangioendothelioma are other examples of low-grade angiosarcomas. These tumors, Kaposi sarcoma, and angiosarcoma are discussed in Chapter 128. Vascular malformations are discussed in Chapter 172.

KEY REFERENCES

Full reference list available at www.DIGM8.com

DVD contains references and additional content

1. Mulliken JB, Fishman SJ, Burrows PE: Vascular anomalies. *Curr Probl Surg* **37**:517, 2000
6. Haggstrom AN et al: Prospective study of infantile hemangiomas: Demographic, prenatal, and perinatal characteristics. *J Pediatr* **150**:291, 2007
29. Chang LC et al: Growth characteristics of infantile hemangiomas: Implications for management. *Pediatrics* **122**:360, 2008
34. Haggstrom AN et al: Prospective study of infantile hamangiomas: Clinical characteristics predicting complications and treatment. *Pediatrics* **118**:882, 2006
39. Metry D et al: Consensus statement on diagnostic criteria for PHACE syndrome. *Pediatrics* **124**:1447, 2009
92. Hogeling M, Adams S, Wargon O: A randomized controlled trial of propranolol for infantile hemangiomas. *Pediatrics* 128(2):e259-266, 2011

Chapter 127 :: Neoplasias and Hyperplasias of Muscular and Neural Origin

:: Lucile E. White, Ross M. Levy, & Murad Alam

TUMORS OF SMOOTH MUSCLE

The dermis contains smooth muscle fibers in the arrector pili muscles, in the walls of dermal blood vessels, and in the dartos muscle of the scrotum, vulva, nipple, and areola. There are three types of cutaneous smooth muscle lesions: (1) leiomyomas, (2) leiomyosarcomas, and (3) hamartomas. Smooth muscle is recognized histologically by spindle cell shape, eosinophilic, fibrillary cytoplasm, and blunt-ended, oval, "cigar-shaped" nuclei. On immunohistochemical staining, cells express smooth muscle actin and the muscle-specific intermediate filament desmin, but are negative for S100 protein and epithelial membrane antigen (EMA).

LEIOMYOMA

LEIOMYOMA AT A GLANCE

- Benign cutaneous neoplasm derived from arrector pili muscle (piloleiomyoma), mammillary, dartoic or labial/vulvar muscle (genital leiomyoma), or the walls of blood vessels (angioleiomyoma).
- Present as solitary or multiple flesh-colored, occasionally painful papules; rarely associated with uterine leiomyomas and renal cell cancer.
- Treatment: surgical; recurrence is common.

EPIDEMIOLOGY. The exact incidence of leiomyomas is unknown. In one study, the 10-year incidence was 0.04% with the majority of lesions occurring in women.[1] Although leiomyomas are thought to be relatively uncommon neoplasms, the actual incidence may be higher than previously believed due to failure to recognize and biopsy the lesion.

ETIOLOGY AND PATHOGENESIS. Cutaneous leiomyomas are divided into three subsets: (1) solitary or multiple piloleiomyomas originating from the arrector pili muscles; (2) genital leiomyomas originating from the mammillary, dartoic, or labial/vulvar muscles; and (3) angioleiomyomas, originating from vascular smooth muscle. Most leiomyomas are acquired; however, familial inheritance patterns have been described. Especially noteworthy are patients with multiple piloleiomyomas. Starting in early adulthood, these patients present with increasing numbers of tumors, developing as many as 100–1,000 lesions. Transmission appears to be autosomal dominant with variable penetrance.[2] Women with multiple piloleiomyomas may also develop uterine leiomyomas, an entity termed *multiple cutaneous and uterine leiomyomatosis* (also known as *familial leiomyomatosis cutis et uteri* or *Reed syndrome*).[2] In addition, some families with multiple cutaneous and uterine leiomyomatosis have been shown to cluster renal cell cancer, and this has been termed *hereditary leiomyomatosis and renal cell cancer*. Recently, a loss of function mutation in the gene encoding fumarate hydratase on chromosome 1q42.3–43 has been shown to predispose individuals to these conditions. Fumarate hydratase catalyses the conversion of fumarate to malate in the Krebs cycle but is also considered to be a tumor-suppressor gene.[3,4]

CLINICAL FINDINGS. The most common presentation is that of multiple piloleiomyomas.[5] Individual lesions range in size from several millimeters to 1 cm and are usually reddish-brown firm papulonodules that are fixed to the skin but freely moveable over underling deeper structures (Fig. 127-1). They can coalesce to form plaques or linear, grouped, or dermatomal patterns.[5] The extensor extremities, trunk, and sides of the face and neck are the most common locations. Patients with piloleiomyomas often have pain



Figure 127-1 Clinical photograph showing multiple leiomyomas involving the back.

that may be spontaneous or secondary to cold, pressure, or emotion.[2,5–7] Possible explanations for this phenomenon include pressure of the tumor on local nerve fibers and contraction of the smooth muscle fibers.[5] Genital leiomyomas are clinically similar to pilolеiomyomas except that they are usually asymptomatic.[5] They commonly present as solitary, deep papulonodules or occasionally, pedunculated papules on the scrotum, vulva, penis, or areolar region. Angioleiomyomas present most commonly as solitary, painful subcutaneous nodules on the legs in women that can grow to several centimeters in diameter.[8]

HISTOPATHOLOGY. Pilar leiomyomas are composed of a poorly circumscribed proliferation of haphazardly arranged, bland-appearing smooth muscle cells with characteristic eosinophilic cytoplasm, blunt-ended nuclei, and perinuclear halos in cross section. They are located in the dermis and can infiltrate the surrounding tissue with extension into the subcutis. Genital leiomyomas usually resemble pilar leiomyomas. Angioleiomyomas are well-circumscribed, richly vascularized dermal or subcutaneous nodules composed of well-differentiated smooth muscle fibers (Fig. 127-2). Occasionally, the vessel of origin can be identified. Leiomyomas stain positive with smooth-muscle actin and desmin.

DIFFERENTIAL DIAGNOSIS. Differential diagnosis of leiomyoma includes any flesh-colored or reddish-brown superficial or deep-seated papule or nodule: angiolipoma, glomus tumor, eccrine spiradenoma, neurofibroma, nevus, or lipoma.

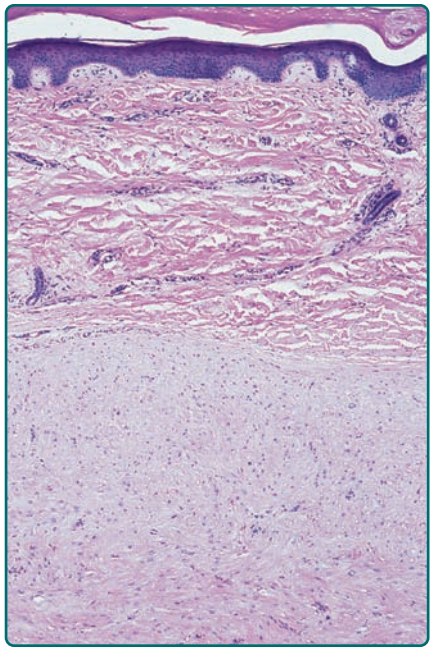

Figure 127-2 Histologic appearance of an angioleiomyoma. Compared with the pilar leiomyoma, this tumor is more sharply circumscribed (but not encapsulated). Furthermore, the smooth muscle fibers form a solid nodule with little, if any, intervening collagen. (Hematoxylin and eosin, ×40.)

PROGNOSIS AND CLINICAL COURSE. Cutaneous leiomyomas do not regress spontaneously, and there does not appear to be risk of malignant degeneration into leiomyosarcoma. A minority of patients may also develop uterine leiomyomas and, in some families, association with renal cell carcinoma has been described. Occasionally, leiomyomas are associated with polycythemia. This may be due to erythropoietin-like activity of leiomyomas, which has been demonstrated in tumor extracts.[9]

TREATMENT. Excision is the treatment of choice for leiomyomas that cause pain or cosmetic concern; however, recurrence is common. In patients with numerous lesions, this method is impractical. Carbon dioxide laser ablation was reported as an effective modality[10] whereas cryotherapy and electrosurgery have been used with disappointing results.[11] Pain may be a significant source of morbidity and, when surgical intervention is not possible, potential treatment options include nitroglycerin, phenoxybenzamine, nifedipine, gabapentin, intralesional botulinum toxin, or topical analgesics.[2,12–15]

LEIOMYOSARCOMA

LEIOMYOSARCOMA AT A GLANCE

- Rare malignant tumor of smooth muscle: cutaneous and subcutaneous types based on location of origin.
- Presentation: enlarging cutaneous or subcutaneous tumor most commonly on hair-bearing areas of the lower extremities.
- Recurrence rate: high, with significant risk of metastases in case of subcutaneous leiomyosarcoma.

EPIDEMIOLOGY. Exact incidence is unknown, but older studies suggest that leiomyosarcomas comprise approximately 3% of soft-tissue sarcomas.[16] Superficial leiomyosarcoma occurs in all age groups, and there appears to be no gender predilection.

ETIOLOGY AND PATHOGENESIS. Leiomyosarcoma is a rare, malignant mesenchymal tumor of smooth muscle origin usually found in the uterus, the retroperitoneum, gastrointestinal tract, or deep soft tissue. The term *superficial leiomyosarcomas* refers to those tumors whose primary site of origin is the skin. Those derived from arrector pili or genital smooth muscles are termed *cutaneous leiomyosarcomas*, and those derived from blood vessel smooth muscle are termed *subcutaneous leiomyosarcomas*. In some cases, tumors have arisen in sites of earlier radiotherapy or trauma.[5] Leiomyosarcomas typically arise de novo rather than from preexisting leiomyomas.

CLINICAL FINDINGS. Leiomyosarcomas present as solitary, enlarging lesions most commonly on the hair-bearing areas of lower extremities.[17] They can exhibit a variety of colors and may be painful, pruritic, or paresthetic. Cutaneous leiomyosarcoma usually presents as small (<2 cm), sometimes ulcerated nodules that are fixed to the epidermis. Subcutaneous leiomyosarcomas tend to be larger and are usually not associated with epidermal change. Some patients have multiple grouped lesions; in one series, four of seven such patients had a previous retroperitoneal leiomyosarcoma,[18] highlighting the importance of ruling out metastases in patients with numerous superficial leiomyosarcomas.

HISTOPATHOLOGY. Leiomyosarcomas are large tumors consisting of smooth muscle fibers arranged in irregular, intersecting bundles and fascicles in the dermis and subcutis, often with infiltrating borders. Tumor cells exhibit smooth muscle differentiation with atypical cytologic features such as nuclear hyperchromasia, prominent nucleoli, mitosis, and necrosis (Fig. 127-3). In less well-differentiated areas, highly pleomorphic and multinucleated cells may be found.[5] Granular cell, epithelioid cell, myxoid, and sclerosing (or desmoplastic) variants have been described.[19] Leiomyosarcomas must be histopathologically distinguished from other malignant cutaneous spindle cell tumors, such as spindle cell melanoma, spindle cell squamous cell carcinoma, or atypical fibroxanthoma. Leiomyosarcomas stain positive with smooth-muscle actin, desmin, and vimentin and occasionally with S100 and cytokeratin, which makes distinguishing them from melanoma and squamous cell carcinoma difficult in certain cases.[5,20,21]

DIFFERENTIAL DIAGNOSIS. Differential diagnosis of leiomyosarcoma includes any solitary, enlarging dermal or subcutaneous nodule: lipoma, dermatofibroma, dermatofibrosarcoma, neurofibroma, spindle cell melanoma, spindle cell squamous cell carcinoma, and atypical fibroxanthoma.

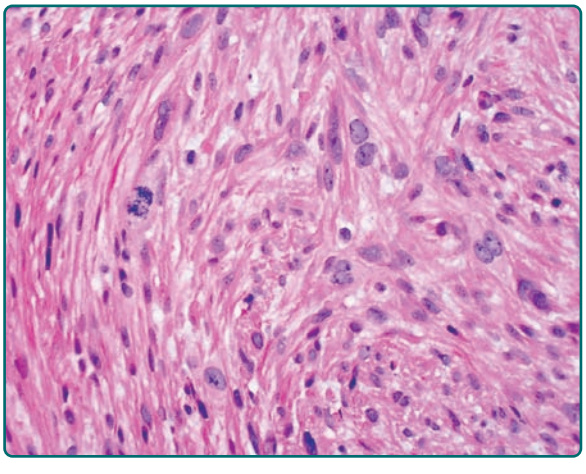

Figure 127-3 Histologic examination of a leiomyosarcoma. This tumor exhibits smooth muscle differentiation with atypical cytologic features such as nuclear hyperchromasia, prominent nucleoli, and mitoses. (Hematoxylin and eosin, ×400.)

PROGNOSIS AND CLINICAL COURSE. The most important prognostic factor depends on whether the leiomyosarcoma is of cutaneous or subcutaneous origin. Although both cutaneous and subcutaneous lesions may recur locally in up to one-third to one-half of cases, the risk of metastasis is 5%–10% for cutaneous leiomyosarcomas compared with 30%–60% for subcutaneous leiomyosarcomas.[5,9,16,17,22–25] The lung is the most common location of metastasis.

TREATMENT. Therapy for superficial leiomyosarcoma is wide local excision with 3- to 5-cm margins and re-excision for recurrent lesions.[17] On acral locations, complete excision may require amputation.[17] Patients with subcutaneous leiomyosarcomas should undergo a chest X-ray for metastases. Adjuvant radiation and/or chemotherapy have unclear benefit. Alternative local treatment modalities in selected patients include Mohs micrographic surgery, cryosurgery, and isolated limb perfusion with chemotherapeutic agents.[17,26]

SMOOTH MUSCLE HAMARTOMA

SMOOTH MUSCLE HAMARTOMA AT A GLANCE

- Benign hamartomatous proliferation of smooth muscle.
- Presenting as a solitary patch or plaque on the trunk.
- Associated with variable pigmentation, hypertrichosis, and follicular prominence.
- Clinical and histologic features similar to Becker's nevus.

EPIDEMIOLOGY. First described by Stokes in 1923,[27] smooth muscle hamartoma has become increasingly recognized during the last two decades. Most cases are congenital but some are acquired,[28,29] and prevalence estimates of up to 0.2% in children have been reported.[29]

ETIOLOGY AND PATHOGENESIS. Smooth muscle hamartoma is a benign proliferation of mature smooth muscle. The cause is unknown, and the majority of cases are present from birth.

CLINICAL FINDINGS. Smooth muscle hamartoma is usually found on the trunk or extremity (Fig. 127-4) and may take one of several forms: a single patch or plaque with or without follicular prominence, grouped solitary lesions (rarely with a linear distribution), and diffuse skin involvement as seen in the Michelin tire baby syndrome.[30,31] Lesions can exhibit variable hyperpigmentation and hypertrichosis. Vellus hairs may be prominent. Some can produce worm-like movements

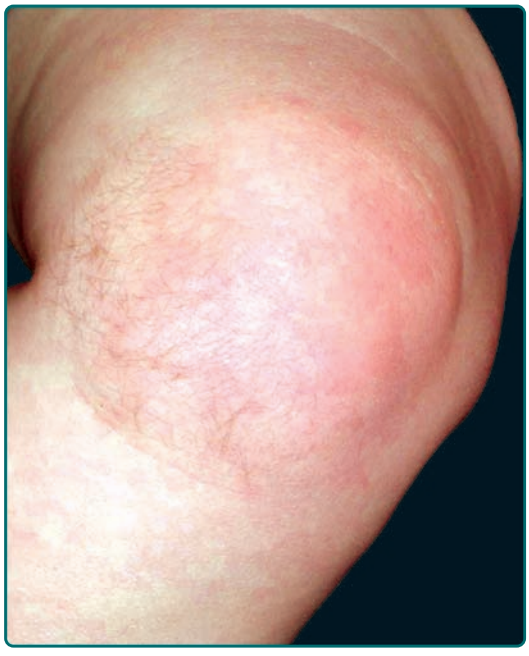

Figure 127-4 Smooth muscle hamartoma. This tumor presented with a focal area of hypertrichosis on the leg. (Photo from the collection of Dr. Amy Paller, MD, Children's Memorial Hospital, Chicago, IL.)

(vermiculation), and stroking may induce transient induration with piloerection (pseudo-Darier sign). Smooth muscle hamartoma shares some clinical and histologic features with Becker's nevus. Some authors consider these lesions a spectrum,[29] whereas others prefer to keep them separate.[28,32]

HISTOPATHOLOGY. There is a marked increase of sharply circumscribed bundles of smooth muscle fibers that are haphazardly arranged in the reticular dermis. These fibers are sometimes associated with follicular units. There may be basal layer hyperpigmentation, as well as acanthosis and papillomatosis of the overlying epidermis. Factors that help to distinguish smooth muscle hamartomas from pilar leiomyomas include the grouping of smooth muscle fibers into discrete bundles and the lack of intermingling of these bundles with dermal collagen fibers.

DIFFERENTIAL DIAGNOSIS. Differential diagnosis of hamartoma includes congenital nevus, Becker's nevus, café-au-lait macule, leiomyoma, neurofibroma, and solitary mastocytoma.

PROGNOSIS AND CLINICAL COURSE. Malignant degeneration has not been reported. Although the localized form is usually not associated with other congenital anomalies,[29] patients with the generalized form have been reported to have multiple associated congenital malformations[33] and psychomotor retardation.[33,34]

TREATMENT. No specific treatment is indicated. Surgical excision can be performed if the lesions are of cosmetic concern.

TUMORS OF STRIATED MUSCLE

Tumors of striated muscle include true neoplasms of striated muscle differentiation (rhabdomyomas and rhabdomyosarcomas) as well as non-neoplastic neuromuscular and rhabdomyomatous mesenchymal hamartomas (RMHs).

RHABDOMYOMA

RHABDOMYOMA AT A GLANCE

- Benign neoplasms of striated muscle.
- Most common on the head and neck of young males.
- Noncardiac rhabdomyomas usually asymptomatic.
- Surgical excision is treatment of choice.

EPIDEMIOLOGY. Extracardiac rhabdomyomas are extremely rare and comprise fewer than 2% of striated muscle neoplasms.[35] The adult and fetal types of rhabdomyomas occur predominantly in male patients. Cardiac rhabdomyomas occur in approximately 30%–50% of patients with tuberous sclerosis (TS; see Chapter 140).[36]

ETIOLOGY AND PATHOGENESIS. Rhabdomyomas are benign tumors of striated muscle. Extracardiac rhabdomyomas are not associated with TS, whereas significant portion of patients with cardiac rhabdomyomas are ultimately diagnosed with TS.

CLINICAL FINDINGS. Extracardiac rhabdomyomas are subdivided into three types: (1) adult, (2) fetal, and (3) genital.[35,37] The designation as *adult* or *fetal* refers to the tumor's resemblance to adult or fetal skeletal muscle, not to the age of the patient.[37] Adult and fetal types usually arise in the soft tissues or mucosal surfaces of the head and neck region soon after birth. They are usually asymptomatic. The fetal type has been repeatedly associated with basal cell nevus syndrome.[37] Genital rhabdomyomas usually occur as small polypoid vaginal or vulvar lesions in middle-aged women.[37]

HISTOPATHOLOGY. Rhabdomyomas are composed of fascicles of oval and polygonal-shaped cells with eosinophilic, often vacuolar cytoplasm and eccentrically placed nuclei.[35] Atypia, mitosis, and pleomorphism are absent.

DIFFERENTIAL DIAGNOSIS. Differential diagnosis of rhabdomyomas includes granular cell tumor (GCT), hibernoma, and reticulohistiocytoma.

PROGNOSIS AND CLINICAL COURSE. Extracardiac and cardiac rhabdomyomas have a very low

risk of malignant degeneration. Many cardiac rhabdomyomas regress spontaneously with age.

TREATMENT. The treatment of choice for symptomatic extracardiac rhabdomyomas is surgical excision.

RHABDOMYOSARCOMA

RHABDOMYOSARCOMA AT A GLANCE

- Malignant neoplasm of striated muscle.
- Most common soft-tissue sarcoma in children.
- Presentation: subcutaneous or ulcerated tumor on extremities or head and neck; rare cause of "blueberry muffin baby."
- Treatment: surgical excision, chemotherapy, and/or radiotherapy.
- Prognosis: poor.

EPIDEMIOLOGY. Rhabdomyosarcoma is the most frequent soft-tissue sarcoma of childhood with annual incidence of 4.3/million, accounting for approximately 50% of soft-tissue sarcomas in children younger than age 15 years and 5%–8% of all childhood cancers.[38–40] Only approximately 0.7% occur as primary skin lesions.[40] Males are more commonly affected than females.[38]

ETIOLOGY AND PATHOGENESIS. Rhabdomyosarcomas are malignant neoplasms derived from skeletal muscle precursors. Primary cutaneous disease is rare, and skin involvement is more commonly a result of either direct extension from underlying soft tissues or metastases.[41] Four subtypes have been described based on histologic appearance: (1) embryonal, (2) alveolar, (3) botryoid, and (4) pleomorphic. The embryonal type is most common, followed by alveolar. Alveolar rhabdomyosarcoma is characterized at the molecular level by novel fusion genes combining the forkhead (*FKHR*) gene with either the *PAX3* or the *PAX7* gene, producing a t(2;13)(q35;q14) or t(1;13)(p36;q14), respectively.[38]

CLINICAL FINDINGS. Cutaneous rhabdomyosarcoma typically presents as an enlarging subcutaneous or ulcerated tumor involving the head and neck, the genitourinary tract, or the extremities. A deep soft-tissue rhabdomyosarcoma can also extend into the overlying skin and present as a cutaneous nodule.[40] In neonates, congenital alveolar rhabdomyosarcoma is a very rare cause of "blueberry muffin baby" in which multiple cutaneous and subcutaneous metastases present as scattered blue nodules.

HISTOPATHOLOGY. Rhabdomyosarcoma is composed of sheets of pleomorphic, small blue cells infiltrating the dermis and subcutaneous tissue. High mitotic index is present, and focal areas of necrosis can often be identified.[41] The embryonic type is composed of interlocking bands of spindle cells and sheets of small round cells whereas the alveolar type exhibits loss of cellular cohesion leading to spaces resembling alveoli. Immunohistochemistry can be helpful in differentiating rhabdomyosarcoma from other "small blue cell tumors." Rhabdomyosarcomas express positivity for muscle-specific actin, desmin, myoD1, and myogenin. Reverse transcription polymerase chain reaction and fluorescence in situ hybridization analysis can used to detect the t(2;13)(q35;q14) and t(1;13)(p36;q14) chromosomal translocations.[38,41]

DIFFERENTIAL DIAGNOSIS. Differential diagnosis of rhabdomyosarcoma includes hemangioma, hematoma, neuroblastoma, and other soft-tissue sarcomas.

PROGNOSIS AND CLINICAL COURSE. Prognosis is poor, with many patients succumbing to their disease. Even with appropriate treatment, rhabdomyosarcomas can recur and metastasize to regional lymph nodes, lung, bone, and heart. Congenital alveolar rhabdomyosarcoma has an especially poor prognosis; there are no reports in the literature of survivors.[38]

TREATMENT. Treatment of rhabdomyosarcoma consists of a combination of surgical excision, chemotherapy, and radiotherapy.

BENIGN PROLIFERATIONS OF NERVES: NEUROMAS

NEUROMAS AT A GLANCE

- Nonneoplastic overgrowths of nerves; benign.
- Consist of both Schwann cells and axons.
- Presentation: flesh-colored papules or nodules.
- Treatment: excision.

TRAUMATIC (AMPUTATION) NEUROMA

EPIDEMIOLOGY. The exact incidence of traumatic neuromas is not known. Several small studies suggest that up to 30% of amputations result in neuromas.[44,45]

ETIOLOGY AND PATHOGENESIS. When a nerve is partially or completely severed, axons and Schwann cells can proliferate from the proximal stump and form a disorganized tangle of nerves and fibroblasts, called a *traumatic neuroma*. Within the bundle

of nerves and fibroblasts, the axons can begin to synapse and send pain signals. These signals occur spontaneously or after mechanical thresholds lower than in normal nerves. The nerve proliferation typical of accessory digits may also represent an example of traumatic neuroma.

CLINICAL FINDINGS. Traumatic neuromas are flesh-colored papules or nodules occurring at the sites of previous trauma or surgery. They often occur within suture lines and can be very painful.

HISTOPATHOLOGY. Histologically, a neuroma appears as a collection of nerve fascicles that are haphazardly arranged. A fibrous or collagen sheath may surround neuromas, but these neuromas are not encapsulated by perineurium. The neuromas stain for EMA. Staining of the neural lesions is reviewed in Table 127-1.

DIFFERENTIAL DIAGNOSIS. Differential diagnosis of neuromas includes hypertrophic scar, dermatofibroma, digital fibrokeratoma, and verruca vulgaris.

TREATMENT. Temporary pain relief can be achieved with a local anesthetic nerve block. For more permanent pain relief, surgical treatment aims either at isolating the nerve from injury or excising the neuroma.[46]

PALISADED ENCAPSULATED NEUROMA

EPIDEMIOLOGY. Palisaded encapsulated neuromas (PENs) present in adults, mostly in their third to fifth decade. There appears to be no gender predilection. PENs make up approximately one-fourth of benign cutaneous neural lesions.[47]

ETIOLOGY AND PATHOGENESIS. PENs consist of a hamartomatous overgrowth of Schwann cells.[48] The etiology is unknown.

CLINICAL FINDINGS. PENs often present as asymptomatic, flesh-colored papules or nodules that are smaller than 1 cm in diameter. PENs are located on the face in approximately 80% of cases.[47] PEN is almost never diagnosed clinically; the most common misdiagnoses are dermal melanocytic nevus, basal cell carcinoma, and adnexal tumor.

HISTOPATHOLOGY. PENs are well-demarcated dermal nodules composed of fascicles of Schwann cells (Fig. 127-5). Contrary to what the name implies, the capsule is rarely complete and the palisading typical of schwannomas is often indistinct. Special stains demonstrate variable numbers of axons within the lesion. The capsule often stains with EMA, suggesting

TABLE 127-1
Staining of Neural Hyperplasias and Neoplasms

Neural Proliferation	S100	Neurofilament	Epithelial Membrane Antigen (EMA)	Other
Traumatic neuroma	+	+	+	Neuron-specific enolase positive
Palisaded encapsulated neuroma	+	+	+ for the capsule	
Schwannoma	+	–	+ for the capsule only	Vimentin positive
Neurofibroma	+	Variable	–	
Plexiform neurofibroma	+	+		
Neurothekeoma	+/–	–	Variable	Vimentin variable; usually EMA negative
Cellular neurothekeoma	–		–	CD57 positive; Ki-Mip positive
Perineurioma	–	–	+	Vimentin positive; neuron-specific enolase negative
Malignant peripheral nerve sheath tumor	+	+	Variable	Vimentin variable; cytokeratin negative; neuron-specific enolase positive
Primitive neuroectodermal tumor	+ if differentiated			Neuron-specific enolase positive; CD99 positive
Granular cell tumor	+			Neuron-specific enolase positive

+ = positive; – = negative.

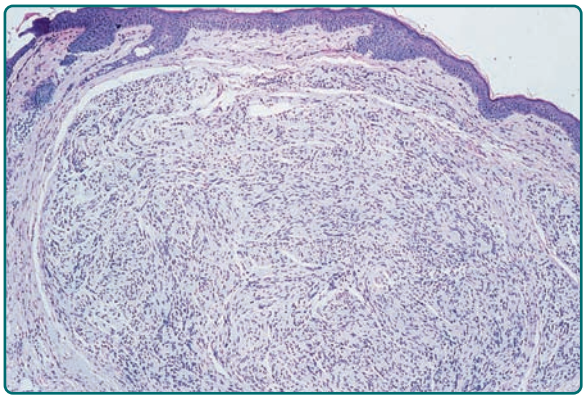

Figure 127-5 Histologic appearance of a typical palisaded encapsulated neuroma. The tumor is composed of fascicles of Schwann cells and surrounded by a delicate capsule best seen on the left. There is a suggestion of nuclear palisading, but this is not as pronounced as that seen in a schwannoma. (The axons that are normally also present cannot be seen on this stain; hematoxylin and eosin, ×40.)

a perineural origin, and the tumor body stains for S100, suggesting a Schwann cell origin (see Table 127-1).[49,50] Some PENs may actually be small dermal schwannomas that contain a few residual entrapped axons.[51]

DIFFERENTIAL DIAGNOSIS. Differential diagnosis of PEN includes dermal melanocytic nevus, basal cell carcinoma, adnexal tumor, and neurofibroma.

TREATMENT. Excision is the treatment of choice. There is no evidence of an association between PEN and neurofibromatosis (NF; see Chapter 141) or multiple endocrine neoplasia syndrome type 2B (MEN2B; see Section "Mucosal Neuromas and Multiple Endocrine Neoplasia Syndrome Type 2B").

MUCOSAL NEUROMAS AND MULTIPLE ENDOCRINE NEOPLASIA SYNDROME TYPE 2B

EPIDEMIOLOGY. Due to inconsistent nomenclature, the incidence of mucosal neuromas is not known.[52]

ETIOLOGY AND PATHOGENESIS. MEN2B is an autosomal dominant condition. MEN2B is caused by germ-line mutations of the *RET* proto-oncogene located on chromosome 10q11.2.[53] The mutation is a result of substituting a threonine for a methionine in the tyrosine kinase domain of the RET protein.[51]

CLINICAL FINDINGS. MEN2A is characterized by the triad of medullary carcinoma of the thyroid gland, pheochromocytoma, and parathyroid hyperplasia. The neoplastic spectrum of MEN2B is similar, but in addition, these patients have malformations (Marfanoid habitus, facial dysmorphism) and overgrowth of mucosal nerves leading to the mucosal neuromas.[54,55]

The neuromas appear by 2 years of age and thus serve as an important clinical marker for identifying affected individuals in MEN2B families.[53] The neuromas involve all mucosal surfaces (oral mucosa, lips, tongue, and conjunctivae) and appear as pink, pedunculated papules or nodules. The lips become enlarged and bulging, and the eyelids may be everted. Other cutaneous lesions include café-au-lait spots, facial lentigines, and hyperpigmentation of the hands and feet.

HISTOPATHOLOGY. Histologically, there is hypertrophy of the mucosal nerves; some lesions may resemble PENs.

DIFFERENTIAL DIAGNOSIS. Differential diagnosis of mucosal neuromas and MEN2B includes PEN and mucocele.

TREATMENT. The main threat to these patients is the development of related cancers. Virtually all patients have a medullary carcinoma of the thyroid by early adulthood, and approximately one-half develop pheochromocytomas. The thyroid carcinoma is highly aggressive. Early detection and prophylactic thyroidectomy by 5 years of age are essential.[53]

BENIGN NERVE SHEATH NEOPLASMS

BENIGN NERVE SHEATH NEOPLASMS AT A GLANCE

- Schwann cells and the endo- and perineurial fibroblasts make up the nerve sheath.
- Schwannomas: benign encapsulated tumors originating from the Schwann cells.
- Neurofibromas: benign nerve sheath tumors that are proliferations of all the nerve's elements.
- Presentation: usually isolated lesions, but multiple neurofibromas found in neurofibromatosis type 1 and bilateral vestibular schwannomas found in neurofibromatosis type 2.
- Treatment: if solitary, excision. Schwannomas can often be resected without sacrificing the nerve of origin, whereas resection of a neurofibroma usually requires transection of the nerve.

SCHWANNOMA

EPIDEMIOLOGY. The peak incidence of schwannomas is in the third to sixth decades. Men and women are affected similarly. Schwannomas occur sporadically or in association with neurofibromatosis type 2 (NF2), which is discussed in greater detail in Chapter 141).

ETIOLOGY AND PATHOGENESIS. Schwannomas are also called *neurinomas*, *neurolem(m)omas*, or *neurilem(m)omas*. Mutations in the NF2 gene are the

underlying cause of the schwannomas of both the sporadic type and NF2. They usually arise in cranial nerves, especially the vestibular nerve (the so-called *acoustic neuromas* are actually schwannomas of the vestibular division of the eighth cranial nerve); they also occur in other peripheral nerves and spinal roots.

CLINICAL FINDINGS

Cutaneous Lesions. The classic schwannomas often involve the head and neck. Most schwannomas are intracranial, intraspinal, or deep soft-tissue lesions. In the skin, schwannomas present as soft, asymptomatic, dermal, or subcutaneous papules or nodules. They are usually solitary.

Multiple Schwannomas. Neurilemmomatosis or schwannomatosis presents with multiple cutaneous, soft-tissue, or spinal schwannomas, but without vestibular schwannomas or other central nervous system tumors typical of NF2 (such as meningiomas or ependymomas). This entity is usually sporadic but can rarely be familial. Some of these patients may have unrecognized NF2, either because they have had insufficient cranial imaging or because they are still too young to exclude the eventual growth of the tumors.[58] Among those in whom vestibular schwannomas have been definitively excluded, a minority carry germ-line mutations of the NF2 gene.[58,59] Some patients are in fact somatic mosaics, which could explain the limited extent of their disease.[60] However, the majority of schwannomatosis patients (including those with the familial form) do not have germ-line mutations of NF2, even though their schwannomas do harbor the typical somatic mutations seen in NF2-associated schwannomas. It has been surmised that this type of schwannomatosis is due to an inheritable predisposition to somatic NF2 mutations.[60] Finally, a last group of patients has neither germ-line nor somatic NF2 mutations; in these individuals, an as yet unknown gene may be involved.[57]

HISTOPATHOLOGY. Because a schwannoma is a neoplastic proliferation composed only of Schwann cells and devoid of axons, it grows as an eccentric nodule, displacing its nerve of origin. This growth pattern and its cellular composition distinguish schwannoma from neurofibroma (Fig. 127-6).

Schwannomas are well encapsulated. The capsule is derived from the epineurium of the schwannoma's nerve of origin. The tumor cells are typically slender, spindled, elongated, and "wavy" in appearance. Areas of high cellularity (called *Antoni A*) alternate with areas of hypocellularity (*Antoni B*), which can have a myxoid quality. In the cellular Antoni A areas, adjacent cells have a tendency to align, creating stacks of nuclei known as *palisades*. These palisades are separated by an anuclear area made up of stacked cytoplasmic extensions; these stacks of nuclei and cell processes form the so-called *Verocay bodies* (see Fig. 127-6). Tumor blood vessels are characteristically thick and hyalinized.

By immunohistochemistry, schwannomas are strongly positive for S100 protein and negative for EMA and smooth muscle markers (desmin, α-actin),

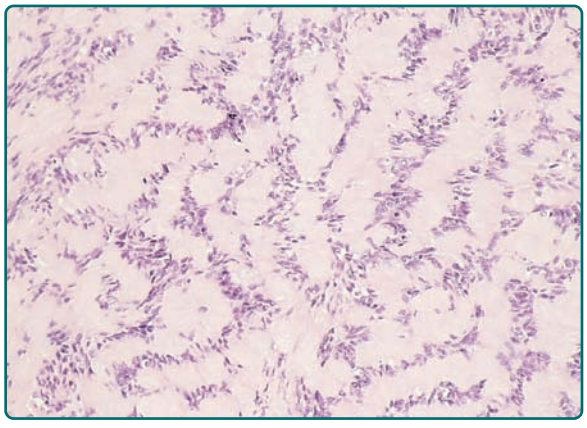

Figure 127-6 Photomicrograph of a schwannoma showing orderly arrangement of tumor cells into palisades and Verocay bodies. (Hematoxylin and eosin, ×100.)

which distinguishes them from perineuromas (S100 negative, EMA positive, desmin and α-actin negative) and leiomyomas (S100 and EMA negative, desmin and α-actin positive) (see Table 127-1).

Several histologic variants of schwannoma are recognized.[61] Some tumors have extensive degeneration with cyst formation, old hemorrhage, and marked hyalinization (ancient schwannoma). This may be accompanied by bizarre nuclear morphology that does not imply malignancy. Other schwannomas are cellular with few hypocellular areas and few palisades or Verocay bodies. These tumors have been called *cellular schwannomas*.[62] They may have significant mitotic activity but behave in a benign fashion. A rare and unusual variant is the melanotic schwannoma and contains concentrically lamellated microcalcifications called *psammoma bodies*. Although this psammomatous melanotic schwannoma only rarely involves the skin, it is noteworthy that roughly one-half the affected patients have Carney syndrome (myxomas, spotty hyperpigmentation, endocrine overactivities, and schwannomas)[52] and approximately 10% of cases metastasize.[63]

The plexiform schwannoma is a tumor that grows within a nerve, forming an agglomeration of small nodules and interconnected cords. Plexiform schwannomas have a distinct predilection for the dermis and subcutaneous tissue. The relationship between plexiform schwannoma and NF is somewhat ill defined, because of confusing nomenclature and because some authors do not distinguish between NF1 and NF2. Some solitary, and, especially, multiple plexiform schwannomas can be associated with NF2.[64,65]

DIFFERENTIAL DIAGNOSIS. Differential diagnosis of schwannomas includes lipoma, cyst, leiomyoma, and malignant peripheral nerve sheath tumor (MPNST).

TREATMENT. Malignant transformation of classic schwannomas is exceedingly rare but has been reported. Excision is the treatment of choice. Plexiform schwannomas may recur, but this probably reflects incomplete excision due to their multifocal nature rather than true recurrence. Pregnancy does not alter the natural history of schwannomas.[66]

NEUROFIBROMA

EPIDEMIOLOGY. Neurofibromas often occur as solitary lesions and are common in the general population. NF1 has a prevalence of 1 in 4,000.[67]

ETIOLOGY AND PATHOGENESIS. Neurofibromas are hyperplasias of all the nerves elements.[68] Neurofibromas can be seen as sporadic lesions or in the context of NF1, which is covered in detail in Chapter 141. The gene for NF1 is located on the long arm of chromosome 17 (17q11.2). At least one of the functions of the NF1 protein, neurofibromin, is regulation of the *ras* oncogene.[69–71] Although it has been shown that ablating NF1 in mice can lead to the development of neurofibromas,[72] the effects on the levels of *ras* are not consistent and, thus, other stromal or genetic effects must contribute to the development of neurofibromas.

CLINICAL FINDINGS. Cutaneous neurofibromas present as protuberant to pedunculated, flesh-colored, soft papules or nodules. They are usually asymptomatic, but they can be pruritic. Subcutaneous neurofibromas are usually larger than dermal lesions and consist of a fusiform swelling involving a larger nerve. In patients with NF1, the tumors start appearing in early childhood and may be quite variable in size. NF1 has a highly variable expressivity, even among patients from the same kindred who have identical germ-line mutations.[73] Another type of neurofibroma is the plexiform variant (Fig. 127-7), which involves an entire large nerve and its branches, forming a mass of tangled, rope-like structures that feel similar to a "bag of worms" on palpation and can be associated with massive soft-tissue overgrowth, leading to functional impairment.



Figure 127-7 Plexiform neurofibroma on the arm. The excoriations show the pruritus associated with these lesions. (Photo from the collection of Dr. Amy Paller, MD, Children's Memorial Hospital, Chicago, IL.)

HISTOPATHOLOGY. Histologically, a neurofibroma is composed of Schwann cells, fibroblasts, endothelial cells, perineurial fibroblasts, mast cells, and axons, all arranged haphazardly in a matrix that contains collagen and myxoid ground substance in various proportions. Dermal neurofibromas are circumscribed but unencapsulated nodules. A rare subtype of neurofibroma is the diffuse variant that involves the skin and subcutaneous tissue in a plaque-like fashion, surrounding rather than displacing preexisting structures such as skin appendages. Plexiform neurofibromas have the same histologic appearance as ordinary neurofibromas but involve an entire nerve and its branches; they also infiltrate the surrounding soft tissue. A variant with a very unusual histologic appearance has been described as *dendritic cell neurofibroma with pseudorosettes*.[74] Finally, some neurofibromas are melanotic.

DIFFERENTIAL DIAGNOSIS. Differential diagnosis of neurofibroma includes fibrolipoma, lipoma, and MPNST.

TREATMENT. Solitary dermal neurofibromas can be excised. Management of patients with NF1[75] is discussed in Chapter 141. Resection is currently the best treatment option for plexiform neurofibromas; however, the lesions frequently recur after resection. Recurrence is more commonly associated with a young patient age, incomplete tumor resection, or nonextremity tumor location.[76]

MALIGNANT TUMORS OF NERVE

MALIGNANT NERVE SHEATH TUMORS

MALIGNANT NERVE SHEATH TUMORS AT A GLANCE

- Malignant nerve sheath tumors are also known as neurofibrosarcoma, neurogenic sarcoma, neurosarcoma or malignant schwannoma.
- Two percent of nerve sheath tumors are malignant peripheral nerve sheath tumors (MPNSTs).
- Twenty percent to 70% of MPNSTs occur in neurofibromatosis type 1.
- Clinical presentation: nodules in the deep soft tissues.
- Treatment: surgical.
- Outcome: guarded, with 5-year survival rates of not more than 50%.

EPIDEMIOLOGY. Only 2% of nerve sheath tumors are MPNSTs.[91] Depending on the series, approximately 20%–70% of MPNSTs occur in patients with NF1.[71] Young and middle-aged adults are most commonly affected.

ETIOLOGY AND PATHOGENESIS. MPNST is also known as *neurofibrosarcoma*, *neurogenic sarcoma*, *neurosarcoma*, and *malignant schwannoma*, but because its histogenesis is uncertain, the noncommittal term *MPNST* is preferred. Plexiform neurofibromas and neurofibromas involving medium-sized to large nerves can undergo malignant degeneration into MPNSTs. Benign schwannomas and cutaneous neurofibromas, on the other hand, almost never undergo malignant transformation. There have been very few cases reported.[92]

CLINICAL FINDINGS. These neoplasms arise mostly in the deep, soft tissues as nodules. Primary cutaneous MPNSTs are rare.[93,94]

HISTOPATHOLOGY. MPNSTs often have a relatively nonspecific presentation of interlacing bundles of spindle cells. Most tumors consist of perineural or endoneural fibroblasts.[95] Often, the major reason for calling such a tumor MPNST is that it arises within a nerve or a neurofibroma and shows some immunoreactivity for S100 protein.[96] In addition to S100 staining, MPNSTs can also stain for neuron-specific enolase, neurofilament protein, and myelin basic protein, although staining can be very weak (see Table 127-1). Cytokeratin stains are negative. MPNSTs can contain heterologous components such as bone, cartilage, glandular or squamous epithelium, and skeletal muscle. An MPNST with a rhabdomyosarcomatous component is called a *malignant triton tumor* and stain positive for myoglobin. In some MPNSTs, the tumor cells have an epithelioid appearance, and this variant must be distinguished from melanoma.[97]

DIFFERENTIAL DIAGNOSIS. Differential diagnosis of MPNSTs includes neurofibroma, lipoma, and cyst.

TREATMENT. MPNSTs in patients with NF are aggressive tumors with a tendency to recur and metastasize. Treatment is surgical. Outcome is guarded with reported 5-year survival rates of no more than 50% in spite of aggressive therapy.[71] Primary cutaneous MPNSTs may have a better prognosis.[93,94]

MISCELLANEOUS TUMORS

GRANULAR CELL TUMOR

GRANULAR CELL TUMOR AT A GLANCE

- S100 positive; suspected to be of neural crest origin.
- Most common single anatomic site: tongue.
- Forty-four percent occur in skin.
- Treatment: excision.

EPIDEMIOLOGY. GCTs are rare. The age range at presentation is usually from the second through the sixth decades.[103]

ETIOLOGY AND PATHOGENESIS. GCTs may also be referred to as *Abrikossoff tumors*. GCTs are neoplasms of uncertain histogenesis, but due to the S100 staining, current opinion favors neural crest origin.[104] The etiology is unknown, but they have been attributed to chronic trauma.[103]

CLINICAL FINDINGS. GCTs have been reported in many anatomic sites but are most often seen in the tongue and skin. The tongue is the most common single anatomic site reported; however, 44% of GCTs occurred in skin or subcutaneous tissue. GCTs have also been reported in the breast, genitalia, esophagus, and larynx.[103] Multiple GCTs are seen in approximately 10%–25% of affected patients.[104] Most cutaneous GCTs are asymptomatic papules or nodules smaller than 3 cm in diameter.

HISTOPATHOLOGY. The classical histologic picture is that of an ill-defined, dermal, nonencapsulated nodule composed of large, polyhedral cells that grow in a sheet-like fashion. The cells have distinct cell borders, small, round, central nuclei, and abundant granular cytoplasm (Fig. 127-8). The cytoplasmic granules stain strongly with the periodic acid-Schiff stain and retain this characteristic after diastase digestion. By immunohistochemistry, the granular cells are strongly positive for S100 protein (see Table 127-1). When differentiating from melanoma, HMB-45 expression is 100% specific for the diagnosis of melanoma. Rare cases of GCT show focal Melan-A positivity, similar to melanoma.[105] Ultrastructurally, the granules consist of phagolysosomes containing granular and membranous debris.[104] An unusual plexiform variant has been described.[106] Cutaneous and mucosal lesions typically have pseudoepitheliomatous hyperplasia of the overlying epithelium.

Only 1%–2% of GCTs are malignant.[104] Clinical findings that should raise concern are a size larger than

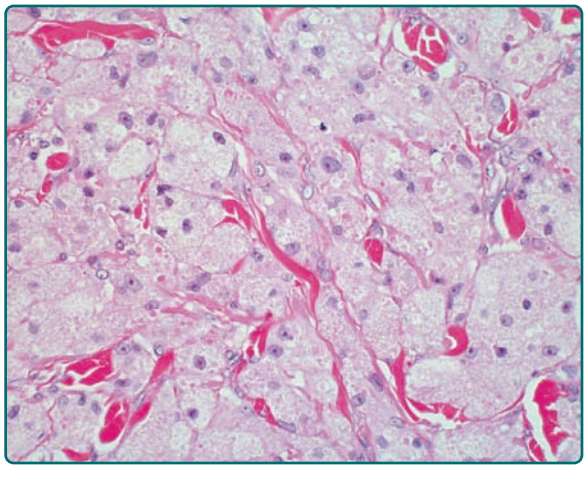

Figure 127-8 Histologic examination of granular cell tumor. The cells have distinct cell borders; small, round, central nuclei; and abundant granular cytoplasm. (Hematoxylin and eosin, ×400.)

4–5 cm, location in deep soft tissue, and recurrence. Histologic warning signs are the presence of increased cellularity, cytologic atypia, and especially mitotic figures and necrosis. However, some clinically malignant GCTs were small and/or histologically innocuous.[104] Therefore, the only definite proof of malignancy is metastasis. Other malignant cutaneous tumors that can contain a subpopulation of cells with granular cytoplasm, such as leiomyosarcoma, melanoma, or angiosarcoma have to be excluded pathologically.

DIFFERENTIAL DIAGNOSIS. Differential diagnosis of GCTs includes squamous cell carcinoma of the tongue, leiomyosarcoma, melanoma, and angiosarcoma.

TREATMENT. Excision is the treatment of choice.

NEUROGLIAL HETEROTOPIA

NEUROGLIAL HETEROTOPIA AT A GLANCE

- Rare congenital lesion commonly referred to as *nasal glioma*.
- Developmental anomaly consists of mature displaced neuroglial tissue; not a true neoplasm.
- Presentation: most commonly as round, firm papule on the nose.
- Rarely connected to intracranial cavity.

MENINGEAL HETEROTOPIA

MENINGEAL HETEROTOPIA AT A GLANCE

- Rare lesion characterized by meningothelial elements in skin.
- Occurs in children secondary to developmental defect; occurs in adults secondary to extension of intracranial meningioma.
- Can be connected to intracranial cavity.

CUTANEOUS GANGLIONEUROMA AND GANGLION CELL TUMOR

Ganglioneuromas are neoplasms composed of large mature neurons (ganglion cells) growing in a Schwann cell stroma. Pure ganglion cell tumors (or gangliocyto-mas) do not contain the Schwann cell component. Although they are usually seen as tumors of the autonomic nervous system, some very rare examples have been encountered in the skin or subcutis where they presented as small papules or nodules. Of the half dozen or so reported cases,[114,115] only one was congenital.[115] These lesions have to be distinguished from cutaneous metastases from a neuroblastoma, which can mature into ganglioneuroma. Furthermore, some plexiform neurofibromas in patients with NF arise in autonomic ganglia and can therefore contain residual, entrapped ganglion cells.[116]

KEY REFERENCES

Full reference list available at www.DIGM8.com

DVD contains references and additional content

3. Alam NA et al: Fumarate hydratase mutations and predisposition to cutaneous leiomyomas, uterine leiomyomas and renal cancer. *Br J Dermatol* **153**:11, 2005
4. Stewart L et al: Association of germline mutations in the fumarate hydratase gene and uterine fibroids in women with hereditary leiomyomatosis and renal cell cancer. *Arch Dermatol* **144**:1584-1592, 2008
5. Holst VA et al: Cutaneous smooth muscle neoplasms: Clinical features, histologic findings, and treatment options. *J Am Acad Dermatol* **46**:477, 2002
14. Alam M et al: Gabapentin treatment of multiple piloleiomyoma-related pain. *J Am Acad Dermatol* **46**:S27, 2002
15. Onder M, Adışen E: A new indication of botulinum toxin: Leiomyoma-related pain. *J Am Acad Dermatol* **60**:325-328, 2009
54. Marx SJ: Molecular genetics of multiple endocrine neoplasia types 1 and 2. *Nat Rev Cancer* **5**:367, 2005
55. Tsao H: Update on familial cancer syndromes and the skin. *J Am Acad Dermatol* **42**:939, 2000
104. Ordonez NG: Granular cell tumor: A review and update. *Adv Anat Pathol* **6**:186, 1999
105. Gleason BC, Nascimento AF: HMB-45 and Melan-A are useful in the differential diagnosis between granular cell tumor and malignant melanoma. *Am J Dermatopathol* **29**:22-27, 2007

Chapter 128 :: Kaposi's Sarcoma and Angiosarcoma

:: Erwin Tschachler

KAPOSI'S SARCOMA AT A GLANCE

- Multifocal tumor of endothelial cell origin with stage-dependent characteristic histopathology.
- Occurs in four clinical variants:
  1. Classical Kaposi's sarcoma (KS)—in old men; starts as localized form; progresses slowly.
  2. Endemic African KS—most frequent neoplasm in some Central African countries; also includes a rapidly progressive lymphadenopathic variant.
  3. KS associated with immunosuppressive therapy—most frequently in organ-transplant recipients.
  4. AIDS-related KS—rapidly progressive form in HIV-infected patients with early involvement of extracutaneous sites.
- KS development is invariably linked with human herpesvirus (HHV)-8 infection.
- Despite presumed viral pathogenesis, KS responds well to chemotherapy and radiation therapy.

GENERAL CONSIDERATIONS

In 1872, the Austro-Hungarian dermatologist Moriz Kaposi described five patients with multicentric cutaneous and extracutaneous neoplasm that primarily affected older individuals.[1] This disease, originally described as "idiopathic multiple pigment sarcoma," was later eponymously designated Kaposi's sarcoma (KS). Since then, different variants of this tumor have been described that have distinct epidemiologic features and run distinct clinical courses but show comparable histopathologies.

ETIOLOGY AND PATHOGENESIS

HHV-8 AND KAPOSI'S SARCOMA

Several decades of epidemiological data and electron microscopic studies have suggested an infectious agent as an etiologic factor in KS.[2,3] This suspicion was substantiated in 1994 when Chang and colleague discovered DNA of an unknown virus in KS lesions.[4] This finding led to cloning, isolation, and characterization of a novel human herpesvirus now referred to as KS-associated herpesvirus (KSHV) or alternatively, human herpesvirus (HHV)-8.[5,6]

HHV-8 is a member of the γ-Herpesviridae subfamily, genus Rhadinovirus.[5–9] Its 165-kb DNA genome has been entirely sequenced and shown to contain approximately 90 open reading frames.[5,7,8] Many of the HHV-8 regulatory genes are homologous to genes of other Rhadinoviruses, and several are homologous to human genes involved in the regulation of apoptosis, cell proliferation, and angiogenesis.[5,9,10] As with other herpesviruses, HHV-8 gene expression is tightly controlled and either associated with viral latency, such as LANA-1, V cyclin, and vFLIP, or lytic viral replication, such as vGPCR, vIL 6, and v-bcl-2.[5,10] Several HHV-8 gene products, both of the lytic and the latent viral life cycles, have been shown to transform cells in vitro as well as in animal models in vivo.[6,10–13] Therefore, it is generally accepted that this transforming capacity of HHV-8 plays a direct role in the development of KS.

The host range of HHV-8 in vivo and in vitro comprises vascular and lymphatic endothelial cells as well as different types of hemopoietic cells.[6] The widely expressed 12-transmembrane light chain of the human cystine/glutamate exchange transporter system xc and the C-type lectin DC-SIGN have recently been proposed as receptors of HHV-8.[14,15] The latter is of particular interest since in contrast to the former it is expressed by activated B cells, which are important host cells for HHV-8 in vivo.[6,15]

The routes of HHV-8 transmission are not yet completely known. The high incidence of KS in homosexual and bisexual patients and the association of tumor development with certain sexual practices originally suggested a role for the sexual transmission of the virus.[3] In later epidemiological studies, sexual activities were confirmed as a route for HHV-8 transmission, and it was demonstrated that the transmission risk increases with the number of sexual partners[16] and with certain practices such as oral/genital and oral/anal sex.[16] By contrast, in areas where the virus is widespread such as in Mediterranean countries and Africa, strong evidence exists that nonsexual transmission among family members[16,17] plays a major role. The oropharynx is the site of the most robust viral replication and high HHV-8 copy numbers are present in saliva.[18] On the basis of these findings, the nonsexual transmission via saliva is widely assumed to play the most important role in childhood transmission in endemic areas.[19] Vertical transmission from mother to child during pregnancy or birth seems not to play an important role for the spread of the virus.[16] For the medical profession, it is important to remember that HHV-8 may also be transmitted by blood and blood products as well as from donor organs in the course of transplantations.[16,20]

HHV-8 is present in all KS-variants,[21,22] and the evidence for a causal relationship between HHV-8 infection and KS tumor development is overwhelming. Amongst the most important arguments for the role of HHV-8 in KS pathogenesis are the findings that (1) the HHV-8 viral genome is detectable in KS lesions at all stages regardless of the clinical variant,[5,6,21,22] (2) within KS lesions HHV-8 is present in the latent form in virtually all tumor cells,[23,24] and (3) KS tumor cells show oligoclonal or monoclonal integration of viral DNA.[5,6] Furthermore, the prevalence of HHV-8 is largely congruent with that of KS: in areas of low incidence of KS, such as the United States and Northern Europe, HHV-8 infection is very rare (below 0.1%;[16,25] By contrast, in areas where high incidence of KS has been reported such as in southern Italy, HHV-8 prevalence is much higher and approaches 20%.[16,26] As expected the highest HHV-8 prevalence has been found in Central Africa in the regions known to be hot spots of African endemic KS. In this region, the seroprevalence in adults ranges from 22% to 71%.[16] Similarly, in HIV-1-infected patients in industrialized countries HHV-8 prevalence is highest in homosexual and bisexual men and reflects the incidence of KS in this risk group.[16,27]

The time span from infection with HHV-8 to development of KS depends on the clinical type. Immunosuppression/dysregulation plays an important aggravating role and leads to disease manifestation in organ-transplant recipients within 1–2 years and in HIV-1-infected patients 5–10 years after infection.[16] For classic KS, this time span is far longer and the contributions of either host-related or environmental factors are not yet established.[16]

In addition to KS, HHV-8 has been implicated in the pathogenesis of pleural effusion lymphoma, a rare B cell neoplasm seen primarily in AIDS patients, and multicentric Castleman's disease (MCD).[10,16,28,29] In the former HHV-8 is in variably present and diagnostic, in the latter it is found in the majority (>95%) of HIV-infected patients with MCD but only in about 40% of HIV-negative MCD patients.[10] Castleman's disease has been associated in the past also with classic KS.[30]

HISTOGENESIS

The histogenetic derivation of the KS tumor cells, i.e., the cells lining the irregular vascular-like spaces of early and angiomatous lesions and the cells composing the bundles and interlacing fascicles of solid tumors, has been the subject of intense research interest over the past two decades. The immunophenotype of these cells (i.e., vWF$^{+/-}$, PAL-E^{-}, CD31^{+}, CD34^{+}, VEGFR3^{+}) characterizes them as part of the lymphatic endothelial differentiation lineage.[31,32] The recent demonstration that HHV-8 replicates better in lymphatic than in blood vascular endothelial cells is a further argument for this assumption.[33] However, the finding that infection of blood vascular endothelial cells with HHV-8 leads to a phenotypic switch toward lymphatic endothelial cells[33,34] leaves the possibility open that an immature angioblast either resident in the skin or circulating and able to differentiate into both endothelial cell lineages is the initial precursor of KS tumor cells.[35]

Some discussion surrounds the question as to whether KS is a reactive proliferative disorder or a true malignant neoplasm. Analyses of the methylation pattern of the human androgen receptor gene by several investigators have shown that lesions with both clonal and polyclonal proliferations can be identified.[36,37] Similarly, studies of HHV-8 terminal repeat sequences have demonstrated both viral mono- and oligoclonality in KS lesions.[38,39] Taken together, these findings indicate that KS starts out as a polyclonal disease, i.e., as a reactive process, which with disease progression may develop into monoclonal tumors.

CLINICAL MANIFESTATIONS

CLASSIC KAPOSI'S SARCOMA

The typical patient with classic KS is a Caucasian male in his sixties with a Mediterranean or Jewish background. The tumors usually start on the skin as unilateral or bilateral bluish-red (hematoma-like) macules on the distal portions of the lower extremities. These lesions tend to progress only slowly both horizontally and vertically and develop into firm plaques (Fig. 128-1) and, subsequently, into nodules. During tumor progression, the color might change to brownish and the skin overlying the tumor becomes hyperkeratotic and, in particular on the lower extremities, might exulcerate. The tumor surroundings frequently show a pitting edema, which may evolve into fibrosis. Classic KS usually runs a rather prolonged benign course and patients may sometimes live with slowly progressive disease for decades.[40,41] After several years, progression (Fig. 128-2) and dissemination to other body sites



Figure 128-1 Classic variant. Plaques and papules localized on the dorsum of the foot, a site of predilection of classic KS.

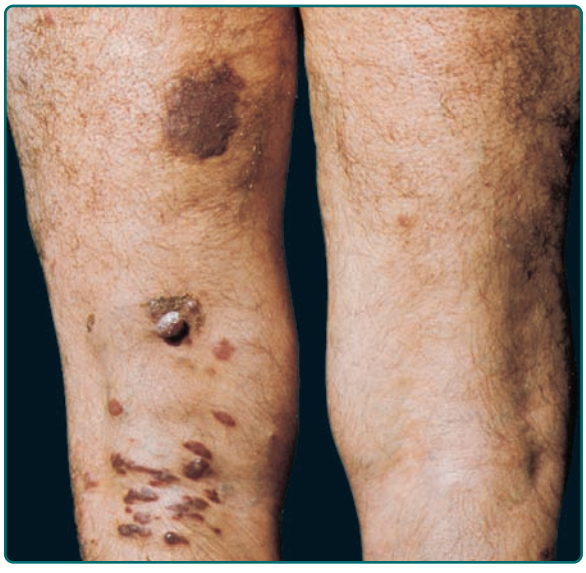

Figure 128-2 Tumor nodules of advanced classic KS with severe involvement of extremities.

are frequently seen, and tumors may become manifest in lymph nodes, on mucous membranes and in inner organs, in particular the gastrointestinal tract although it becomes rarely symptomatic.[40,41] Since mostly elderly patients are affected by KS, death from other causes may precede its full spread.

The annual incidence rates for classic KS vary greatly in different geographic regions and ranges from 0.14 per million inhabitants (for both women and men) in Great Britain to 10.5 per million in men and 2.7 per million in women in Italy.[40] A preponderance of male patients has persisted since the original description with a male:female ratio of about 3:1 noted in large surveys of most regions.[40,41] The higher KS incidence in countries surrounding the Mediterranean has led some authors to propose a Mediterranean KS variant as a distinct entity.[42] However, since the clinical course is comparable to the one of classical KS, Mediterranean KS will not be treated separately here.

AFRICAN ENDEMIC KAPOSI'S SARCOMA

An increased frequency of KS in black Africans in Central Africa was noted several decades before the outbreak of the AIDS pandemic.[43,44] In some countries of this region, KS accounts for up to 10% of all malignancies in men.[16,43,44] A prevalence of male patients, with ratios ranging from 3:1 in children and up to 18:1 in adults, is seen with endemic African KS.[40] The age at onset is lower than that in classical KS—around 35–39 years for males and 25–39 for females.[40]

According to clinical features, African endemic KS occurs as nodular-, florid-, infiltrative-, and lymphadenopathic-types.[45,46] The florid/vegetating and infiltrative variants are characterized by a more aggressive biologic behavior and lesions may extend deeply into the dermis, subcutis, muscle, and bone. Lymphadenopathic African KS predominantly affects children and young adults and may run fulminant courses with rapid progression[47]; skin and mucosa are affected to a lesser degree. The reasons for the different courses observed in African KS are not clear and potential cofactors have not unequivocally been identified.

KAPOSI'S SARCOMA IN THERAPEUTICALLY IMMUNOSUPPRESSED PATIENTS

During the 1970s, a high incidence of KS was described in organ-transplant recipients receiving immunosuppressive therapy with an up to 500-fold increase as compared to the control population.[48,49] Transplantation-associated KS is observed predominantly in kidney allograft recipients, while it occurs rarely in recipients of other solid organs and bone marrow allografts.[48–50] KS has also been reported in individual patients receiving immunosuppressive therapy for other reasons, most notably the treatment of autoimmune diseases.[51–53]

The clinical appearance and the course of KS in therapeutically immunosuppressed patients may be slowly progressive as with the classical variant. It can also rapidly disseminate as is the case with AIDS KS. KS can occur as early as 1 month and as late as more than 10 years after transplantation.[54] A very important risk factor for developing KS and determining its clinical course is the dose and type of the immunosuppressive drug.[40,50] For example, the risk associated with cyclosporine is higher than with other drugs such as glucocorticoids and azathioprine and the disease onset is earlier.[49,50] Regression of KS can be achieved by reduction or withdrawal of the immunosuppressive agent (see below). Similarly, rapid tumor progression can occur after increase of the dosage.[49,50] In transplantation-associated KS, a preponderance of male patients with a ratio of about 3:1 is observed,[50] and in geographic regions with a high incidence of classical KS as well as in ethnic groups with a higher risk of KS development, the risk for transplantation-associated KS is increased.[50] Skin involvement is most common in transplantation-associated KS. In a large series, skin involvement was found in more than 85% of the patients with transplantation-associated KS, whereas less than 15% had visceral (gastrointestinal, lungs, lymph nodes) disease without skin involvement.[50]

AIDS-ASSOCIATED KAPOSI'S SARCOMA

A major harbinger of the AIDS pandemic was clusters of young homosexual men suffering from KS identified in large US cities in 1981.[55] During the first decade of the AIDS pandemic, KS had been diagnosed as the AIDS defining disease in more than 20% of HIV-1-infected patients in Europe.[56] Despite a decline in recent years, KS is still the most frequent AIDS-associated tumor in homosexual patients. Other patient groups at risk for AIDS including intravenous drug users, hemophiliacs, blood-transfusion recipients, and children

born to HIV-positive mothers in industrialized countries are far less affected.[3,57] The situation is different in Africa where KS is the most frequent tumor arising in HIV-1-infected patients independently of their risk group and includes children suffering from AIDS.[58,59]

Clinically, AIDS KS differs from classical KS by its more rapid course and its rapid multifocal dissemination: early AIDS-KS lesions that appear as small oval violaceous macules develop rapidly into plaques and small nodules, which frequently are present at multiple locations at disease onset and have a tendency for rapid progression. In contrast to other variants of KS, the initial lesions in AIDS patients frequently develop on the face, especially on the nose, eyelids, ears, and on the trunk, where the lesions follow the relaxed skin tension lines (Fig. 128-3). If untreated, disseminated AIDS-KS lesions may coalesce to form large plaques involving large parts of the face, the trunk, or the extremities leading to functional impairment. The oral mucosa is frequently involved and represents the initial site of a 10%–15% of AIDS KS (Fig. 128-4). Involvement of the pharynx is not uncommon and may result in difficulty in eating, speaking, and breathing.[60]

The involvement of extracutaneous sites occurs more rapidly and more dramatically in patients with AIDS KS than those with classical KS. Besides the oral mucosa, KS lesions are most frequently found in the lymph nodes, the gastrointestinal tract, and the lungs.[61–63] Although gastrointestinal KS is usually found when cutaneous lesions are present, exclusive gastrointestinal involvement is possible as is noted in transplantation-associated KS. KS lesions have a predilection for the stomach and duodenum and can cause bleeding and ileus. Although visible by gastroscopy, such lesions are underdiagnosed histologically because they are located in the submucosa and may escape the biopsy forceps. Pulmonary KS can cause respiratory symptoms such as bronchospasm, coughing, and progressive respiratory insufficiency.[62] Bronchoscopy with transbronchial biopsy is most appropriate for the diagnosis of pulmonary KS.



Figure 128-3 AIDS-associated KS. Multiple lesions at all stages of development (macules, papules, nodules) are present on the trunk. Note that the lesions follow the skin relaxed tension lines.



Figure 128-4 KS lesions on the hard palate are typical manifestations of AIDS-associated KS.

The differential diagnosis of cutaneous KS depends on the clinical stage and hematoma, pseudo-Kaposi's sarcoma, melanoma, pyogenic granuloma, spindle cell hemangioendothelioma, arteriovenous malformations (pseudo-KS), severe statis dermatitis (pseudo-KS), bacillary angiomatosis, angiosarcoma, cavernous hemangioma, angiokeratoma, and nodal myofibromatoma. In the oral mucosal non-Hodgkin's lymphoma, squamous cell carcinoma, bacillary angiomatosis, and melanoma have to be considered (Table 128-1).

HISTOPATHOLOGY

The histopathology of KS is dependent on the stage of KS development[64–66]: early patch-like lesions exhibit rather discrete histopathologic changes, consisting mainly of a discrete increase in the number of dermal vessels, outlined by slightly irregular endothelial cells (Fig. 128-5). These vessels are parallel to the skin surface, which are frequently slightly irregular and may form bizarre slits and clefts mainly located on the superficial dermis. In the surrounding dermis, focal hemosiderin deposits and extravasated erythrocytes, as well as a moderate inflammatory infiltrate, can be found. Important differential diagnoses of this stage include lymphangioma and granulation tissue.

The pathology of KS plaques is more characteristic and reveals extensive vascular proliferation at all levels of the dermis with multiple dilated and angulated vascular spaces dissecting the collagen and leaving a spongy network of collagen tissue. A characteristic sign of KS papules is the presence of solid cords and

TABLE 128-1
Clinical Differential Diagnoses of Cutaneous and Mucosal Kaposi's Sarcoma

Most Likely
- Localized early disease
  - Hematoma
  - Bacillary angiomatosis
  - Well-differentiated angiosarcoma
- Advanced disease
  - Acroangiodermatitis (pseudo-Kaposi)
  - Bacillary angiomatosis
  - Pyogenic granuloma
- Oropharyngeal lesions
  - Non-Hodgkin's lymphoma
  - Squamous cell carcinoma
  - Bacillary angiomatosis

Consider
- Localized disease
  - Dermatofibroma
  - Melanoma
  - Dermatofibrosarcoma protuberans
  - Leiomyosarcoma
  - Kaposiform hemangioendothelioma (in children)
  - Blue rubber bleb nevus syndrome
- Advanced disease
  - Metastasing melanoma
  - Cutanous metastasis of internal malignancies and leukemias
  - Erythema elevatum et diutinum

Always Rule Out
- HIV-1 infection
- Non-HIV-1-related causes of immunosuppression

fascicles of spindle cells arranged between the jagged vascular channels. This biphasic angiomatous and solid tumor morphology changes to a clear-cut sarcomatous morphology with progression of the disease.

Nodular lesions consist predominantly of spindle cells arranged in bundles and interlacing fascicles and interspersed irregular slit-like vascular spaces without endothelial linings (Fig. 128-5). Advanced lesions may display pronounced pleomorphism, nuclear atypia, and mitotic figures. At the periphery of solid tumors, (lymph)angiomatous-like portions of KS with bizarre vascular lumina and intravascular and extravasated erythrocytes, as well as siderophages, may be preserved. Erythrocytes, which appear as eosinophilic globules, are trapped within the slits and clefts formed by the spindle cells, and occasionally erythrophagocytosis is observed. Like in all other stages of KS, a moderate inflammatory infiltrate consisting of lymphocytes, histiocytes, plasma cells, and, sporadically, neutrophils is regularly present.

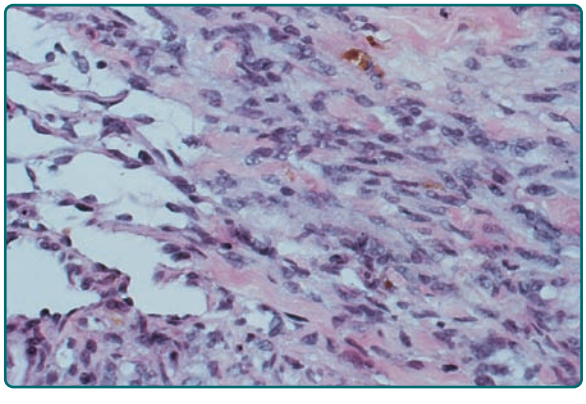

Figure 128-5 Histopathology of KS (biopsy taken from a nodular KS lesion). Angiomatous portions, reminiscent of a lymphangioma, as well as solid, sarcomatous fascicles are present.

TREATMENT

The treatment modalities for KS depend on the clinical type, the extent of the lesions, and on which organ system is involved (Table 128-2). Despite the overwhelming evidence that the infection with an oncogenic herpesvirus, i.e., HHV-8 plays a central role in KS pathogenesis, antiherpetic drugs so far have been only of experimental value.[67] Because in past decades the incidence of AIDS KS has been much higher than that of the other clinical variants and KS in AIDS patients quickly progresses into a life-threatening disease, studies on AIDS KS have brought about many of the recent insights and advances in the treatment of KS.[68,69]

TABLE 128-2
Treatment Options for Kaposi's Sarcoma

Localized Disease—Local Therapy
- Surgical excision
- Cryotherapy
- Topical 9-*cis*-retinoic acid
- Radiation therapy

Disseminated Disease/Internal Organ Involvement—Systemic Therapy
- For patients with AIDS: initiate highly active antiretroviral therapy (HAART)
- For patients on immunosuppressive therapy—reevaluate drug regimen
- For AIDS patients not responding to HAART alone—systemic cytotoxic chemotherapy
  - Liposomal anthracyclines (e.g., liposomal doxorubicin 20–40 mg/m^2 every 2–4 weeks)
  - Paclitaxel (100 mg/m^2 given every 2 weeks)
- For patients with classical KS
  - Liposomal anthracyclines (e.g., liposomal doxorubicin 20–40 mg/m^2 every 2–4 weeks)
  - Vinblastine (6 mg IV once a week)
  - Doxorubicin/bleomycin/vincristine (20–30 mg/m^2, or 10 mg/m^2, or 1–2 mg every 2–4 weeks)
  - Interferon-α (3–30 million units daily three times a week)
- Investigational treatments
  - Thalidomide
  - VEGF-antisense
  - COL-3 (MMP inhibitor)

LOCALIZED CUTANEOUS DISEASE

Regardless of the clinical variant, if a patient presents with only limited disease confined to the skin, local therapies aimed at eliminating individual lesions are frequently used as initial treatment.[68,69] Although recurrence rates are high, local therapies might be satisfactory for several years in slowly progressing classical KS. By contrast, in the other clinical variants it is imperative that local therapy is supported by additional measures such as change of the immune suppressive therapy in transplantation-associated KS and initiation of highly active antiretroviral therapy (HAART) in patients with AIDS KS.

Local therapies include surgical excision,[70] local destruction with liquid nitrogen, laser or photodynamic therapy,[71] and topical therapy with 9-*cis*-retinoic acid.[72] Radiation therapy[73] may be effective in localized disease at body sites that are otherwise difficult to reach, such as the oral mucosa and in more advanced KS in resource-poor settings.

PROGRESSIVE CUTANEOUS DISEASES AND INVOLVEMENT OF OTHER ORGANS

AIDS-ASSOCIATED KAPOSI'S SARCOMA. Until the advent of HAART, treatment of advanced AIDS KS has been mostly palliative with either combination chemotherapies or radiation therapy.[74] When HAART became available during the mid 1990s, it was possible for the first time to achieve sustained suppression of HIV-1 replication and immune recovery. Subsequent to the introduction of HAART, a decrease of AIDS KS incidence and frequent remission of early KS lesions were observed during therapy.[75] However, HAART alone is not sufficient to control advanced KS. Therefore, if widespread lesions and/or involvement of other organs develop despite successful HAART and the control of HIV-1 replication, addition of chemotherapy is required.[76] Amongst several chemotherapeutic regimens used in the past decades, liposomal anthracyclines have been shown to be more efficient and better tolerated than combination therapies such as bleomycin combined with vincristine or both combined also with doxorubicin.[77–79] A typical drug regimen consists of 20 mg/m^2 liposomal anthracyclines given intraveneously every 2–4 weeks.[80,81] An advantage of the use of liposomal anthracyclines is their continued therapeutic efficacy in patients who have been previously treated by other forms of chemotherapy. For patients with anthracycline-refractory AIDS KS paclitaxel is another treatment option.[82] Interferon-α, which has been a mainstay therapeutic approach for AIDS KS during the 1980s and early 1990s, still holds some promise for AIDS patients with early disseminated KS who simultaneously receive HAART.

KAPOSI'S SARCOMA IN PATIENTS WITH THERAPEUTIC IMMUNOSUPPRESSION. KS in transplant patients responds well to a reduction of immunosuppressive therapy.[49,50] Recently, replacement of calcineurin inhibitors by rapamycin has led to dramatic therapeutic effects with complete remission of advanced KS lesions.[83,84] This effect seems to be due to the modulation of the immune response by the change of therapy and to direct antitumor effects of the drug.[84] Therefore, rapamycin might potentially be of benefit for treating KS in nonimmunosuppressed persons.

CLASSIC KAPOSI'S SARCOMA. Chemotherapy, including doxorubicin, bleomycin, vincristine, etoposide, and dacarbazine, alone or in combination has been given to patients with rapidly progressive or widespread classic KS, in particular, when there is involvement of internal organs.[85] However, due to the low incidence of classic KS, large comparative, prospective studies are not available. As with AIDS KS, liposomal anthracyclines are efficient[86] and appears to be superior to low-dose interferon-α.[87]

In addition to the therapies mentioned above, there are several experimental therapies currently being evaluated in clinical trials ranging from vascular endothelial growth factor (VEGF) antisense to antiherpetic drugs.[67]

ANGIOSARCOMA

ANGIOSARCOMA AT A GLANCE

- Malignant tumor of endothelial cell origin.
- Occurs in three clinical variants:
  1. Primary angiosarcoma (mostly affects elderly with a predilection for head, neck, and face).
  2. Angiosarcoma in areas of chronic lymphedema (most frequently in patients after lymph node dissection due to mammary carcinoma—Stewart–Treves syndrome).
  3. Postirradiation angiosarcoma.
- Despite complete surgical excision and/or chemotherapies, the prognosis of angiosarcoma is poor.

EPIDEMIOLOGY AND PATHOGENESIS

Angiosarcoma is a highly malignant vascular tumor with an incidence of approximately 0.01/100,000/year affecting primarily adult patients.[88] It may occur in different organs, but in over 50% of the patients the cancer localizes to the skin of the head and neck region.[89,90] Besides primary tumors, which appear in previously normal skin, angiosarcoma has an increased incidence in skin with chronic lymphedema most frequently, but not exclusively, after mastectomy with lymph node

dissection. This variant is referred to as Stewart–Treves syndrome[91] and was formerly classified as lymphangiosarcoma. A further rare variation is postirradiation angiosarcoma, which may develop after radiation therapy for mammary carcinoma.[92]

Tumor cells of angiosarcoma express differentiation markers of both the lymphatic and vascular endothelial cell lineage to varying degrees.[93] Whether common precursor cells, i.e., angioblasts give rise to the tumor cells has not been determined. Therefore, the designation of angiosarcoma instead of either lymphangiosarcoma or hemangiosarcoma seems appropriate at this time. In contrast to KS, angiosarcoma is usually negative for HHV-8.

CLINICAL MANIFESTATIONS

Initially, primary angiosarcoma of the skin presents as singular or multifocal "bruise"-like patches on the skin, most frequently on the face (Fig. 128-6), the scalp, or the neck regions. Upon progression, the lesions become violaceous, ill-defined spongy nodular tumors that bleed easily. Horizontal spread can lead to the involvement of large skin areas (Fig. 128-7). Angiosarcoma that develops in chronic lymphedema (Fig. 128-8) as well as postirradiation angiosarcoma (Fig. 128-9) present as infiltrating hemorrhagic plaques or violaceous nodules.

DIFFERENTIAL DIAGNOSES

Early lesions can be confused with other skin lesions, which have vascular involvement including bruises, rosacea, and early KS. For advanced tumors, pyogenic granuloma, lymphoma, and cutaneous metastasis of internal malignancies have to be considered.

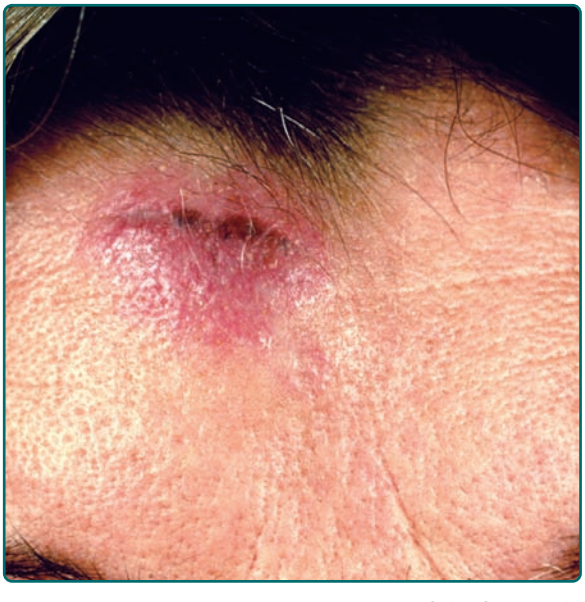

Figure 128-6 Cutaneous angiosarcoma of the face. Early bruise-like lesions on the forehead.



Figure 128-7 Cutaneous angiosarcoma of the head. Advanced lesion presenting as violaceous patch extending over the right forehead, ear, and scalp regions.

HISTOPATHOLOGY

The clinical variants are indistinguishable histologically and great variability with regard to differentiation of vascular elements can be seen even within individual lesions. Irregular, anastomosing vascular channels lined by endothelial cells with different degrees of atypia and mitotic activity may alternate with areas of closely packed cells with a high mitotic index and sometimes spindle-like morphology (Fig. 128-10). In the latter, less well-differentiated areas, little or no luminal differentiation is present. In particular, in these instances immunostaining for vascular markers, such as CD31 and CD34, is helpful for the establishment of the diagnosis.



Figure 128-8 Stewart–Treves syndrome on the right forearm and hand.



Figure 128-9 Postirradiation angiosarcoma of the breast.

TREATMENT

The overall estimated 5-year survival is 15%, reflecting the fact that the treatment of angiosarcoma[90,94] is currently not highly effective. Due to the rarity of angiosarcoma, comparative therapeutic trials are not available. The treatment of choice for small tumors is excision with wide margins.[94] When surgery is not an option, palliative radiotherapy or chemotherapy should be applied.[94–97] Both pegylated liposomal doxorubicin and paclitaxel were recently demonstrated to be of benefit for patients with widespread disease.[95–98] Recently, the tyrosine protein inhibitor sorafenib has also shown promise either alone[99] or together with paclitaxel[100]; however, larger clinical studies are necessary to confirm the benefit.

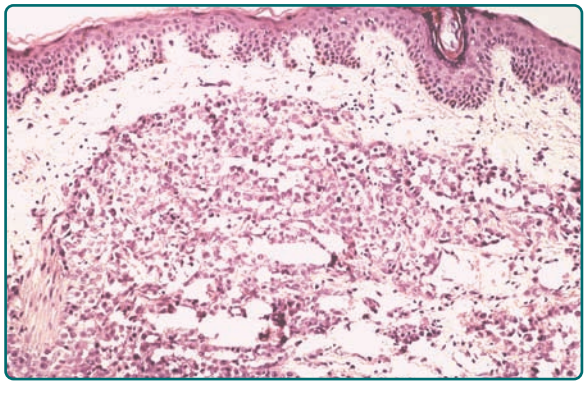

Figure 128-10 Histopathology of cutaneous angiosarcoma.

KEY REFERENCES

Full reference list available at www.DIGM8.com

DVD contains references and additional content

1. Kaposi M: Idiopathisches multiples Pigmentsarkom der Haut. *Arch Dermatol Syphil* **4**:265, 1872
4. Chang Y et al: Identification of herpesvirus-like DNA sequences in AIDS-associated Kaposi's sarcoma. *Science* **266**:1865, 1994
5. Dourmishev LA et al: Molecular genetics of Kaposi's sarcoma-associated herpesvirus (human herpesvirus-8) epidemiology and pathogenesis. *Microbiol Mol Biol Rev* **67**:175, 2003
6. Ganem D: KSHV and the pathogenesis of Kaposi sarcoma: Listening to human biology and medicine. *J Clin Invest* **120**:939, 2010
16. Dukers NH, Rezza G: Human herpesvirus 8 epidemiology: What we do and do not know. *AIDS* **17**:1717, 2003
31. Weninger W et al: Expression of vascular endothelial growth factor receptor-3 and podoplanin suggests a lymphatic endothelial cell origin of Kaposi's sarcoma tumor cells. *Lab Invest* **79**:243, 1999
40. Iscovich J et al: Classic Kaposi's sarcoma: Epidemiology and risk factors. *Cancer* **88**:500, 2000
44. Cook-Mozaffari P et al: The geographical distribution of Kaposi's sarcoma and of lymphomas in Africa before the AIDS epidemic. *Br J Cancer* **78**:1521, 1998
50. Penn I: Kaposi's sarcoma in organ transplant recipients. *Transplantation* **64**:669, 1997
66. Chor PJ, Santa Cruz DJ: Kaposi's sarcoma. A clinicopathologic review and differential diagnosis. *J Cutan Pathol* **19**:6, 1992
68. Aoki Y, Tosato G: Therapeutic options for human herpesvirus-8/Kaposi's sarcoma-associated herpesvirus-related disorders. *Expert Rev Anti Infect Ther* **2**:213, 2004
72. Walmsley S et al: Treatment of AIDS-related cutaneous Kaposi's sarcoma with topical alitretinoin (9-cis-retinoic acid) gel. Panretin Gel North American Study Group. *J Acquir Immune Defic Syndr* **22**:235, 1999
73. Housri N, Yarchoan R, Kaushal A: Radiotherapy for patients with the human immunodeficiency virus: Are special precautions necessary? *Cancer* **116**:273, 2010
80. Hengge UR et al: Long-term chemotherapy of HIV-associated Kaposi's sarcoma with liposomal doxorubicin. *Eur J Cancer* **37**:878, 2001
88. Beyeler M et al: The spectrum of mesenchymal skin neoplasms reflected by the new WHO classification. *Onkologie* **27**:401, 2004
90. Holden CA, Spittle MF, Jones EW: Angiosarcoma of the face and scalp, prognosis and treatment. *Cancer* **59**:1046, 1987
94. Budd GT: Management of angiosarcoma. *Curr Oncol Rep* **4**:515, 2002
97. Abraham JA et al: Treatment and outcome of 82 patients with angiosarcoma. *Ann Surg Oncol* **14**:1953, 2007

Chapter 129 :: Neoplasms of Subcutaneous Fat

:: Thomas Brenn

NEOPLASMS OF SUBCUTANEOUS FAT AT A GLANCE

- Adipocyte tumors are the most frequently encountered group of mesenchymal neoplasms. This is due to the high prevalence of lipoma and angiolipoma.
- Tumors range from entirely benign neoplasms (e.g., lipomas) to those of intermediate malignant potential with risk for local recurrence (e.g., atypical lipomatous tumor) to high-grade pleomorphic sarcomas (e.g., pleomorphic liposarcoma).
- Although liposarcoma is the single most frequently encountered sarcoma, the large majority of adipocyte tumors are benign.
- The clinical presentation of adipocyte tumors is generally nonspecific.
- Most adipocyte tumors show distinctive cytogenetic abnormalities that may be of diagnostic value.
- Treatment is surgical excision. Adjuvant radiation therapy and/or chemotherapy may be of benefit for treatment of malignant tumors that are not amenable to complete excision or in cases of advanced disease.

LIPOMA

LIPOMA AT A GLANCE

- Lipoma is the most common soft-tissue tumor.
- It is benign and presents in adulthood as a small circumscribed mass. The anatomic distribution is wide with relative sparing of the head, hands, and feet.
- Histologically, the tumors are circumscribed, encapsulated, and composed of mature white adipose tissue.

EPIDEMIOLOGY

Lipomas are the most common soft-tissue neoplasm. Although they affect individuals in a wide age range, they occur predominantly in adults between the ages of 40 and 60 years; presentation in childhood is rare. There is no gender predilection. Lipomas are multiple in approximately 5% of cases.[1]

ETIOLOGY AND PATHOGENESIS

The majority of lipomas (approximately 75%) show karyotypic abnormalities. The cytogenetic findings are heterogeneous, but rearrangements of 12q13–15 are most common.[2–4] Other affected loci are on chromosomes 6 and 13.[2–4] Numerical abnormalities are scarce, and most tumors are diploid.

CLINICAL FINDINGS

The most common presentation is as a painless, slowly enlarging mass involving the subcutaneous tissue of the trunk, neck, or proximal extremities. Involvement of the head, hands, and feet is uncommon. These superficial lipomas are typically small, measuring less than 5 cm.[1] Lipomas may be multiple and familial and show a predilection for the arms and thighs in familial multiple lipomatosis (Fig. 129-1).[5] The constellation of multiple lipomas, macrocephaly, lymphangiomas, and hemangiomas is known as *Bannayan (Bannayan–Zonana)* syndrome.[6,7] This autosomal dominant disease shares features with other independently described entities and is currently also referred to as *Bannayan–Riley–Ruvalcaba syndrome*.[8,9] Further clinical findings include intestinal polyposis, genital pigmented macules, and other hamartomas. The syndrome is caused by mutations in the *PTEN* gene and belongs to the larger family of PTEN hamartoma-tumor syndromes,



Figure 129-1 Familial multiple lipomatosis: multiple lipomas of variable size show a symmetric distribution involving the forearms of this middle-aged man.

including Cowden disease.[10–15] Lipomas may also be seen as a manifestation of Gardner's syndrome. Gardner's syndrome is part of the spectrum of familial adenomatous polyposis and includes extracolonic manifestations such as desmoid fibromatosis, osteomas, cysts, and lipomas.

Less frequently, lipomas may be deep-seated and grow to sizes larger than 5 cm. They can affect a variety of anatomic locations, including the surface of bone (parosteal lipoma) and skeletal muscle (intramuscular and intermuscular lipoma). Intramuscular lipoma arises within skeletal muscle and may be circumscribed or infiltrative. It presents in adulthood and only rarely affects children. The range of anatomic sites is wide, but there appears to be a predilection for the trunk.[16,17] In contrast, intermuscular lipoma develops between individual muscles and does not infiltrate skeletal muscle bundles. It is a rare lipomatous tumor with a predilection for the anterior abdominal wall.[16,17] Lipomas of the forehead are frequently deep-seated, presenting in a submuscular or subgaleal location. They show a predilection for male adults.[18,19] Lipoma arising in the orbit (orbital lipoma) is rare but may lead to exophthalmus and visual disturbances.[20–22]

HISTOLOGIC FEATURES

Conventional lipomas are circumscribed masses surrounded by a thin fibrous capsule. They are composed of lobules of mature white adipose tissue divided by delicate and inconspicuous fibrous septa containing thin-walled capillary-sized vessels (Fig. 129-2). The adipocytes are univacuolated and mature with eccentrically placed, compressed nuclei. There is only slight variation in adipocyte size, and nuclear atypia is not a feature. Morphologically, lipomas are indistinguishable from the surrounding adipose tissue and the identification of a distinct mass is necessary for the diagnosis. Lipomas may show changes of trauma with varying amounts of fat necrosis and inflammation. Extensive involvement of the dermis is known as *dermal lipoma*. These tumors are not encapsulated and

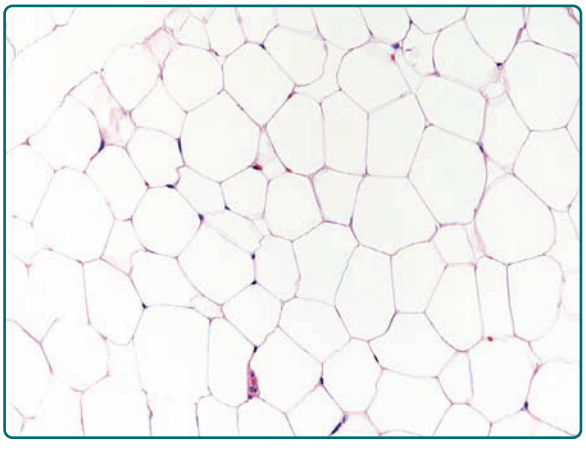

Figure 129-2 Lipoma: mature univacuolated adipocytes show only mild variation in size. Delicate intervening capillaries are present.

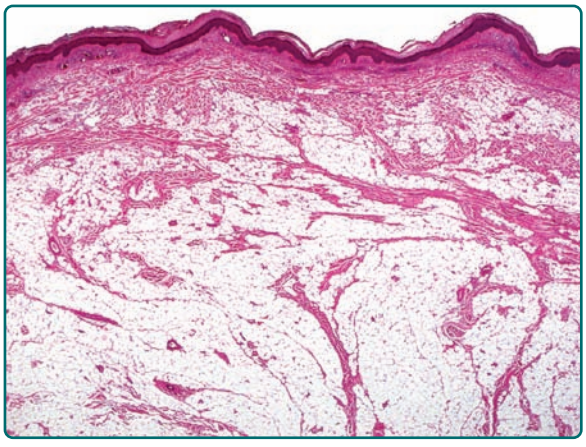

Figure 129-3 Intradermal lipoma: mature adipocytes diffusely infiltrate preexisting dermal collagen bundles. Note the sparing of the papillary dermis.

are frequently less circumscribed than other forms of superficial lipoma (Fig. 129-3). Lipomas with increased fibrous tissue are referred to as *fibrolipomas* (Fig. 129-4). In contrast to atypical lipomatous tumors, cellularity is low within the fibrous strands, and no nuclear atypia is present. *Myxolipomas* are characterized by the presence of conspicuous myxoid stroma. *Angiomyxolipoma* or vascular myxolipoma is characterized by a myxoid stromal background in addition to a proliferation of vessels of variable sizes.[23,24] A lipoma containing metaplastic bone or cartilage within the tumor is referred to as an *osteolipoma* or *chondrolipoma*, respectively. Cutaneous adenolipoma refers to the presence of intratumoral sweat ducts and sweat glands may be cystically dilated.[25,26]

Intramuscular lipoma can either present as a circumscribed intramuscular mass or show an infiltrative growth of adipocytes in between skeletal muscle fibers (Fig. 129-5).

CLINICAL COURSE, PROGNOSIS, AND TREATMENT

Lipomas are entirely benign tumors and, with the exception of intramuscular lipomas, local recurrence is rare. The infiltrative variant of intramuscular lipoma is associated with an approximately 19% chance of local recurrence, but metastasis does not occur.[16]

LIPOMATOSIS

LIPOMATOSIS AT A GLANCE

- Lipomatosis is characterized by diffuse overgrowth of adipose tissue infiltrating through preexisting structures.
- Different clinical presentations are recognized.

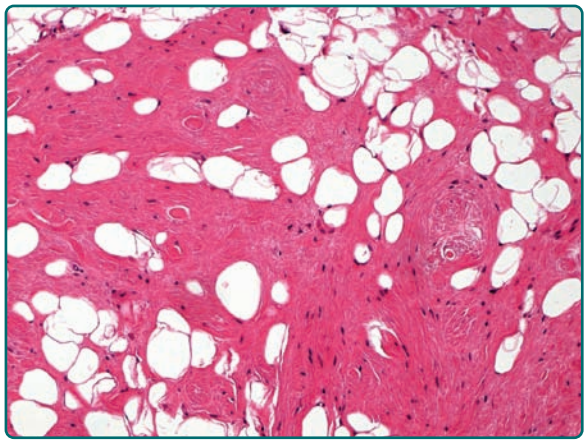

Figure 129-4 Fibrolipoma: this variant is characterized by the presence of increased fibrous tissue within a lipoma. The expanded fibrous bands contain bland appearing and uniform spindle cells. Cytological atypia is not a feature.

EPIDEMIOLOGY AND CLINICAL FINDINGS

Diffuse lipomatosis [27,28] is characterized by overgrowth of adipose tissue involving subcutaneous tissue and skeletal muscle of the trunk and extremities. Osseous involvement may also be a feature. Young children are predominantly affected, but presentation may become apparent in adulthood. Tumors can grow to a large size, causing disfigurement and loss of function of the affected limb. Due to the diffuse growth of these tumors, complete excision may not be possible and recurrences are frequent.

Benign symmetric lipomatosis (Madelung's disease, multiple symmetric lipomatosis)[29–36] is characterized by multiple symmetric masses composed of nonencapsulated adipose tissue with a predilection for the subcutaneous tissue and skeletal muscle of the neck, shoulder, and proximal upper limbs (Fig. 129-6). Presentation is in adulthood with a marked male predominance of 15:1. The estimated overall incidence is 1 in 25,000, with increased frequency in the Mediterranean region. The disease is associated with increased alcohol intake in the majority of cases. Two clinical variants are currently recognized. Type 1 disease is characterized by a symmetric distribution of adipose tissue, giving rise to a "pseudoathletic" appearance, whereas type 2 disease shows a more diffuse distribution, giving rise to a picture of more generalized obesity. An associated polyneuropathy affecting sensory, motor, and autonomic function is frequently present. The disease course is slowly progressive, and treatment is difficult due to infiltration of deep-seated structures and major nerves and vessels. There is significant disease-related mortality due to compression of vital structures as well as autonomic neuropathy with sudden cardiac death. Etiologically, the disease has been speculated to be a result of hypertrophy of brown fat due to a defect in adrenergic lipolysis.

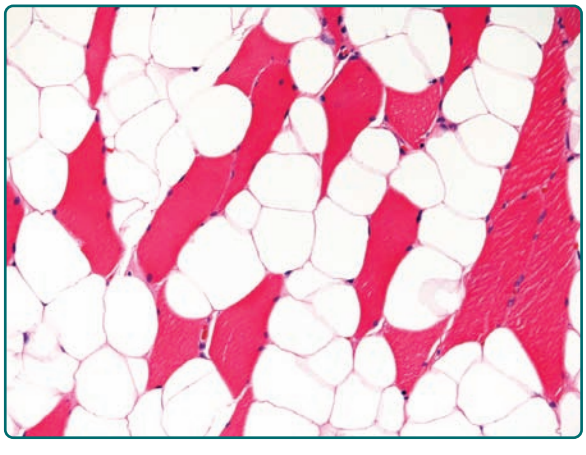

Figure 129-5 Intramuscular lipoma: mature adipocytes show an infiltrative growth pattern within skeletal muscle splaying apart individual muscle fibers.



Figure 129-6 Symmetric lipomatosis: there is diffuse and symmetric overgrowth of adipose tissue affecting predominantly the upper trunk, neck, and proximal arms.

Pelvic lipomatosis[37–40] is an unusual proliferation of adipose tissue involving the pelvis and retroperitoneal space. The disorder is most common among men in the third and fourth decades, and blacks account for about two-thirds of cases. Urinary symptoms are frequent presenting signs, and the disease is associated with cystitis in 75% of cases. Obstructive uropathy and renal failure may be complications of the disease.

Adiposis dolorosa (Dercum's disease)[41–48] is rare and typically affects middle-aged women, although men may occasionally also be affected. The disease is typically sporadic, and familial cases are exceptional. There is an increased incidence with obesity. Patients present with multiple painful subcutaneous lipomatous lesions frequently associated with other symptoms such as weakness, depression, confusion, lethargy, or dementia. The disease predominantly involves the arms and trunk but may be progressive to involve

large parts of the body. Treatment modalities include pain relief as well as surgical control with excision or liposuction. Weight reduction can be beneficial.

Human immunodeficiency virus lipodystrophy[49–53] occurs in the setting of protease inhibitor treatment or other forms of antiretroviral therapy in patients with acquired immunodeficiency syndrome (see Chapter 198). There is a predilection for cervical fat pads, the breast, and visceral fat. Other associations include hyperlipidemia, insulin resistance, type 2 diabetes, and fat wasting affecting the face and limbs.

HISTOLOGIC FEATURES

The histologic features of all forms of lipomatosis are similar and show unencapsulated adipose tissue diffusely infiltrating preexisting structures such as skeletal muscle.

LIPOMATOSIS OF NERVE (FIBROLIPOMATOUS HAMARTOMA OF NERVE)

LIPOMATOSIS OF NERVE (FIBROLIPOMATOUS HAMARTOMA OF NERVE) AT A GLANCE

- Lipomatosis of nerve is a rare tumor that affects infants and children and presents as a growing mass with a predilection for the hand.
- Pathology shows a proliferation of adipose and fibrous tissue within the epineurium and perineurium. The median nerve is predominantly affected.

NEVUS LIPOMATOSUS SUPERFICIALIS

NEVUS LIPOMATOSUS SUPERFICIALIS AT A GLANCE

- Nevus lipomatosus superficialis is a rare entity that affects children and young adults.
- Papules and plaques show a predilection for the buttocks, lumbar back, and posterior thighs.
- Bands of mature adipose tissue infiltrate dermal collagen.

ANGIOLIPOMA

ANGIOLIPOMA AT A GLANCE

- Angiolipoma is a relatively common lesion that presents as a small nodule with a predilection for the forearm.
- Young adults are affected, and lesions are frequently multiple and painful.
- Histologically, this circumscribed lesion shows an admixture of mature adipose tissue and a proliferation of capillary-sized vessels.

EPIDEMIOLOGY

Subcutaneous angiolipomas are relatively frequent and typically occur in young adults in their teens and 20s, with a strong male predilection.[72–74] They are rare in children and in the elderly.

ETIOLOGY AND PATHOGENESIS

Angiolipomas have traditionally been classified as adipocyte tumors. However, in contrast to most lipomas they appear to have a consistently normal karyotype, and it has been suggested that they may be reactive or hamartomatous rather than neoplastic.[74] The fact that angiolipomas can occasionally be almost exclusively composed of blood vessels (cellular angiolipoma) has led to the speculation that they may in fact be hemangiomas rather than lipomas.[74] There is an increased familial incidence, but no inheritance pattern has been elucidated as yet.[75]

CLINICAL FINDINGS

A wide range of sites can be affected, but there is a predilection for the forearm followed by the trunk, upper arm, and legs.[72–74] Angiolipomas are often multiple and present as subcutaneous nodules characteristically smaller than 2 cm. Tenderness and pain are frequently associated symptoms.

HISTOLOGIC FEATURES

Angiolipomas are circumscribed and encapsulated. They show an admixture of mature fat and capillary-sized small branching vessels in varying proportions (Fig. 129-7 and eFig. 129-7.1 in online edition). The vascular density is often increased at the periphery in a subcapsular distribution. Fibrin thrombi are typically encountered. The term *cellular angiolipoma* is applied to

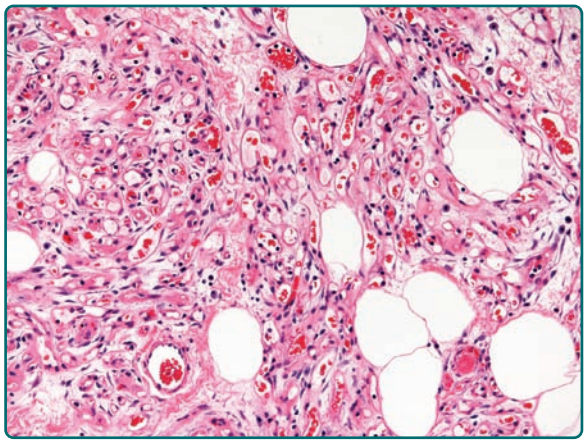

Figure 129-7 Angiolipoma: a proliferation of capillary-sized vessels is admixed with mature adipose tissue.

those lesions that are almost exclusively composed of vascular elements (eFig. 129-7.2 in online edition).[76–78]

DIFFERENTIAL DIAGNOSIS

The appearances of angiolipoma are quite characteristic. The differential diagnosis of cellular angiolipoma includes vascular tumors such as Kaposi sarcoma, spindle cell hemangioma, and angiosarcoma.

CLINICAL COURSE, PROGNOSIS, AND TREATMENT

The clinical behavior of angiolipomas is entirely benign. The tumors are frequently multiple as well as painful, however, and clinical management can be a challenge.

SPINDLE CELL AND PLEOMORPHIC LIPOMA

SPINDLE CELL AND PLEOMORPHIC LIPOMA AT A GLANCE

- Spindle cell lipoma and pleomorphic lipoma are currently considered to represent a morphologic continuum.
- They typically occur on the posterior neck, upper back, and shoulder of middle-aged men.
- Morphologically characteristic is the admixture of mature fat with bland and uniform spindle cells in a myxoid stroma containing ropey collagen bundles and mast cells. Multinucleate (floret-type) giant cells are present in pleomorphic lipoma.

HIBERNOMA

HIBERNOMA AT A GLANCE

- Hibernoma is a benign neoplasm that resembles brown fat and typically presents in adulthood.
- A wide range of anatomic locations may be affected.

EPIDEMIOLOGY

Hibernoma is a well recognized but rare benign adipocyte tumor that shows a wide age distribution. Young adults (mean age, 38 years) are predominantly affected, but presentation in the pediatric population as well as in the elderly is possible. Males appear to be affected only slightly more frequently than females.[107]

ETIOLOGY AND PATHOGENESIS

The etiology of this rare tumor is unclear. Karyotypes can be slightly more complex than those observed in other benign lipomatous tumors, but structural rearrangements involving chromosome band 11q13 appear to be reproducible.[108–111]

CLINICAL FINDINGS

Hibernoma is a painless, slowly enlarging tumor affecting a wide range of anatomic sites. There appears to be a predilection for areas in which brown fat can be found physiologically, and presentation on the trunk, especially the scapular area, the shoulder, and the head and neck is common. However, curiously the thigh appears to be the single most frequently affected site.[107] Hibernomas are typically located in subcutaneous tissue or skeletal muscle but may occasionally affect the abdominal cavity, retroperitoneum, or intrathoracic location.[112]

Presentation as multiple separate lesions is exceptional.[113] The average size is around 10 cm, but larger tumors up to 24 cm are not unusual.[107] Imaging studies reveal a well-demarcated lobulated and septated mass showing contrast enhancement and tissue attenuation intermediate between those of fat and skeletal muscle.[114–117]

HISTOLOGIC FEATURES

Hibernoma is a well-demarcated and lobulated neoplasm. The hallmark feature is its morphologic resemblance to brown fat. The tumors are composed of variable numbers of multivacuolated adipocytes with small, centrally placed nuclei and pale to eosinophilic and granular cytoplasm (eFig. 129-7.13 in online edition). On the basis of the appearance of these brown fat cells, the quality of

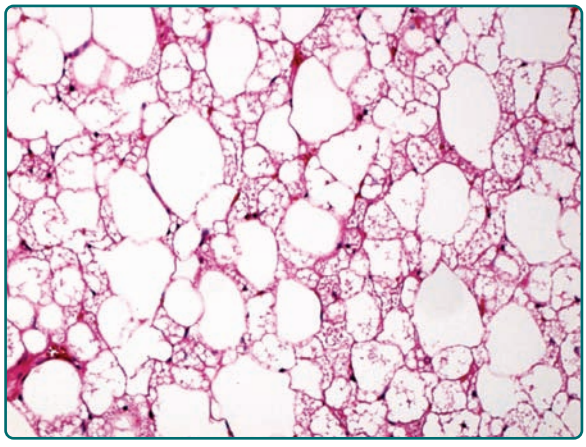

Figure 129-8 Hibernoma: brown fat is admixed with mature adipose tissue.

intervening stroma, and the presence of a spindle cell component, six histologic variants are recognized.[107]

The typical variant is the most frequently encountered form and is characterized by large numbers of brown fat cells admixed with mature white fat (Fig. 129-8). Those tumors composed almost exclusively of brown fat cells with palely staining cytoplasm are further subclassified as the *pale cell subtype*. Tumors are labeled *eosinophilic subtype* when at least 50% of brown fat cells contain a deeply eosinophilic and granular cytoplasm. The *mixed subtype* is intermediate between the two and shows a roughly equal distribution of eosinophilic and pale-staining brown fat cells. Myxoid, lipoma-like, and spindle cell variants exist.

Hibernomas showing acellular myxoid areas of the intervening stroma are recognized as the myxoid variant. This variant affects predominantly men and presents in the head and neck and shoulder area.

The lipoma-like variant shows large areas of white fat differentiation with only scattered hibernoma cells lying in between.

The least frequent is the spindle cell variant, showing overlapping features of spindle cell lipoma and hibernoma. Areas of brown fat are admixed with the short and bland spindle cells typical of spindle cell lipoma, and ropey collagen bundles, myxoid stroma, mast cells, and mature white fat are also present. As with spindle cell lipoma, this variant presents in the posterior neck and scalp.

By immunohistochemical analysis, hibernomas stain positively for S100. CD34 expression is seen in the spindle cells of the spindle cell variant of hibernoma.[107]

DIFFERENTIAL DIAGNOSIS

The differential diagnosis of hibernoma includes the following:

- Granular cell tumor
- Spindle cell lipoma
- Atypical lipomatous tumor/well-differentiated liposarcoma

CLINICAL COURSE, PROGNOSIS, AND TREATMENT

The behavior of hibernoma is entirely benign without recurrence after local excision.

LIPOBLASTOMA/ LIPOBLASTOMATOSIS

LIPOBLASTOMA/ LIPOBLASTOMATOSIS AT A GLANCE

- Morphologically, the benign adipocyte neoplasm lipoblastoma resembles fetal adipose tissue. It is most frequently found in individuals younger than 5 years of age.
- Lipoblastoma has a multilobular and circumscribed appearance, whereas lipoblastomatosis shows an infiltrative growth.

ATYPICAL LIPOMATOUS TUMOR/WELL-DIFFERENTIATED LIPOSARCOMA

ATYPICAL LIPOMATOUS TUMOR/WELL-DIFFERENTIATED LIPOSARCOMA AT A GLANCE

- Atypical lipomatous tumor/well-differentiated liposarcoma is a tumor of adulthood that presents as an enlarging mass with a predilection for the extremities, retroperitoneum, and paratesticular tissue.
- Best prognostic predictor is anatomic location:
  - Recurrence, risk of dedifferentiation, and mortality negligible if excised.
  - Retroperitoneum and paratesticular region, where complete excision is difficult, characterized by high long-term mortality.
  - When excision is curative, tumors are called atypical lipomatous tumors; when clear margins cannot be obtained should be regarded as *well-differentiated liposarcoma*.

EPIDEMIOLOGY

Atypical lipomatous tumor/well-differentiated liposarcoma is a neoplasm of adulthood with a peak incidence in the sixth decade.[145–153] It represents the largest subgroup of liposarcomas. There is no gender predilection.

ETIOLOGY AND PATHOGENESIS

Cytogenetically, atypical lipomatous tumors are characterized by supernumerary circular "ring" chromosomes as well as giant long marker chromosomes derived from the 12q13–15 region and resulting in consistent amplification of the *MDM2* gene along with adjacent genes such as *CDK4*.[154–160]

CLINICAL FINDINGS

Tumors typically present in deep soft tissue. The subcutaneous tissue may occasionally also be involved. The predominantly affected site is the musculature of extremities with a predilection for the thigh, followed by the retroperitoneum, groin, and paratesticular area as well as the mediastinum.[145–153] A wide range of other anatomic sites including the larynx, orbit, oral cavity, and vulva may be affected.[161–164] An enlarging painless mass is the typical presenting sign, and especially in a retroperitoneal location, tumors can grow to a very large size before becoming symptomatic.

HISTOLOGIC FEATURES

Atypical lipomatous tumors are large, multilobulated, and most often circumscribed. The most frequently observed adipocytic (lipoma-like) morphologic variant closely resembles a lipoma. It is composed of relatively mature-appearing adipocytes with marked variation in cell size (Fig. 129-9). Additional findings include focal adipocyte atypia (eFig. 129-9.1 in online edition) and the presence of hyperchromatic and often multinucleate bizarre stromal cells in cellular fibrous septa (eFigs. 129-9.2 and 129-9.3 in online edition).

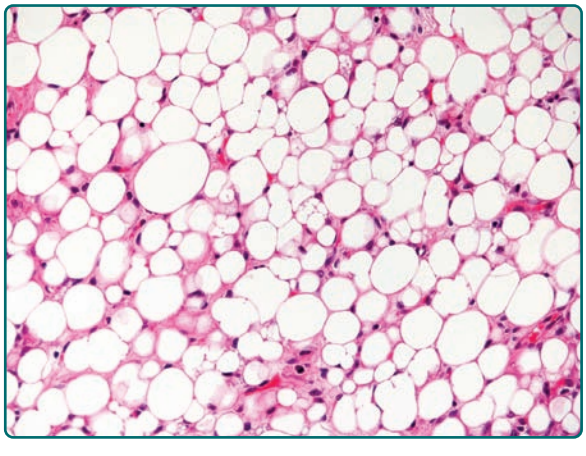

Figure 129-9 Atypical lipomatous tumor/well-differentiated liposarcoma: note the marked variation in adipocyte size.

Floret-type giant cells may also be a feature (eFig. 129-9.4 in online edition). Lipoblasts may be monovacuolated or multivacuolated and vary in number (eFig. 129-9.5 in online edition). They may be entirely absent and are not a prerequisite for the diagnosis. Sclerosing, inflammatory, and spindle cell variants exist.

The sclerosing variant occurs most commonly in a retroperitoneal or paratesticular location and is the second most frequently encountered histologic pattern (eFig. 129-9.6 in online edition). It is characterized by a paucicellular fibrillary collagenous matrix containing scattered hyperchromatic and bizarre-appearing stromal cells as well as rare multivacuolated lipoblasts (eFig. 129-9.7 in online edition). The adipocytic component may be inconspicuous, and often extensive sampling is required for the diagnosis.

Rarely, there is a marked chronic inflammatory infiltrate potentially obscuring the underlying adipocytic component. Such tumors have been designated as the *inflammatory* subtype. This variant occurs in the same distribution as the adipocytic subtype and is characterized by a heavy lymphoplasmacytic infiltrate arranged in a multinodular pattern and separated by variably cellular stroma. The lipogenic areas show features of the adipocytic variant. However, they comprise only a small fraction of the tumor.[165]

The spindle cell variant has only recently been recognized. It is rare and shows a predilection for the subcutaneous tissue of the shoulder girdle and upper limb. The characteristic finding is the presence of a proliferation of bland-appearing spindle cells arranged in fascicles and whorls and set in a myxoid matrix (eFig. 129-9.8 in online edition). This is accompanied by an atypical adipocytic component showing classic lipoblasts.[166]

Immunohistochemistry for *MDM2* and *CDK4* aided by fluorescence in situ hybridization to detect *MDM2-CDK4* amplification is a useful ancillary diagnostic tool to distinguish well-differentiated as well as dedifferentiated liposarcoma from benign adipocyte tumors as well as other nonlipogenic tumors.[160,167]

DIFFERENTIAL DIAGNOSIS

The differential diagnosis of atypical lipomatous tumor/well-differentiated liposarcoma includes the following:

- Lipoma
- Spindle cell/pleomorphic lipoma
- Dedifferentiated liposarcoma
- Angiomyolipoma
- Massive localized lymphedema

CLINICAL COURSE, PROGNOSIS, AND TREATMENT

The clinical behavior and prognosis are largely dependent on the anatomic site.[168] Surgery is curative at anatomic locations where complete surgical excision with clear margins can be achieved (e.g., somatic soft tissue such as the limbs). The estimated rate of progressing to dedifferentiated liposarcoma is less than 2% with a

mortality rate of virtually zero at these anatomic locations. In contrast, tumors arising at deep locations such as the retroperitoneum, mediastinum, or spermatic cord, where complete surgical clearance is not possible, are characterized by repeated local recurrence and ultimately may result in death from uncontrolled local disease or dedifferentiation with metastasis. The overall risk of development of dedifferentiated liposarcoma is estimated to be higher than 20% with an overall mortality rate of around 80% for tumors occurring in the retroperitoneum. The disease has a protracted course, and the median survival time ranges from 6 to 11 years.[149,152,169] The primary approach to treatment is surgical excision. Adjunct chemotherapy and radiation treatment are reserved for advanced disease.

DEDIFFERENTIATED LIPOSARCOMA

DEDIFFERENTIATED LIPOSARCOMA AT A GLANCE

- Tumors typically present as large masses in the retroperitoneum of adults.
- The disease course is protracted, with a high rate of local recurrence and a significant risk for metastasis and associated mortality.
- The morphologic characteristic is the presence of nonlipogenic areas adjacent to well-differentiated liposarcoma.

MYXOID/ROUND CELL LIPOSARCOMA

MYXOID/ROUND CELL LIPOSARCOMA AT A GLANCE

- Presentation is as a large mass involving the extremities and in particular the thigh of middle-aged adults.
- There is a significant rate of local recurrence as well as metastasis.
- Tumors are lobulated and circumscribed and are composed of a myxoid matrix containing primitive mesenchymal cells and lipoblasts in varying stages of differentiation. A prominent vascular pattern is a characteristic feature.
- Round cell liposarcoma is currently regarded to represent the high-grade end of the morphologic spectrum.

EPIDEMIOLOGY

Myxoid liposarcomas represent approximately 10% of all soft-tissue sarcomas. They comprise more than one-third of all liposarcomas and are the second most frequent variant of liposarcoma.[178] The tumor presents in young to middle-aged adults with a peak in the fourth to fifth decade and a slight male predominance.[178–180]

ETIOLOGY AND PATHOGENESIS

Cytogenetically, myxoid liposarcoma is characterized by the translocation t(12;16)(q13;p11), present in approximately 95% of cases. The translocation involves the *CHOP* (*DDIT3*) gene on chromosome band 12q13 and the *TLS* (also known as *FUS*) gene located on 16p11 resulting in the generation of the *TLS–CHOP* hybrid gene.[170,180–184] Rarely, the translocation t(12;22)(q13;q12), resulting in the *EWS–CHOP* hybrid gene, is observed.[185–187] CHOP belongs to the family of leucine zipper transcription factors and is implicated in adipocyte differentiation and growth arrest, whereas TLS, similar to EWS, is a potent activator of transcription. In turn, the *TLS–CHOP* hybrid gene is speculated to interfere with normal adipocyte development and proliferation by aberrant transcriptional activation.

CLINICAL FINDINGS

Presentation as a large, painless mass with a predilection for the extremities is characteristic. Tumors are located in deep soft tissue and involve the thigh in over two-thirds of cases.[178–180] Presentation in subcutis or retroperitoneum is rare. Not infrequently, patients are found to have multifocal disease at initial presentation, which is generally regarded to represent metastases.[185]

HISTOLOGIC FEATURES

Tumors are large, well circumscribed, and multinodular with a gelatinous cut surface on gross examination. The appearance becomes fleshier in areas with increased cellularity, but large areas of tumor necrosis are not typically seen.

Microscopically, myxoid liposarcoma is a lobulated tumor composed of a mixture of bland-appearing oval mesenchymal cells without evidence of adipocyte differentiation and small univacuolated or bivacuolated lipoblasts, often with a signet-ring cell appearance (eFig. 129-9.12 in online edition and Fig. 129-10). The cellularity is low but increased toward the periphery of the tumor lobules (eFig. 129-9.12 in online edition). The cells are placed in a myxoid matrix showing a characteristic pattern of delicate, branching capillary-sized vessels often referred to as *chicken wire* or *crow's feet* (eFig. 129-10.1 in online edition). In the central areas,

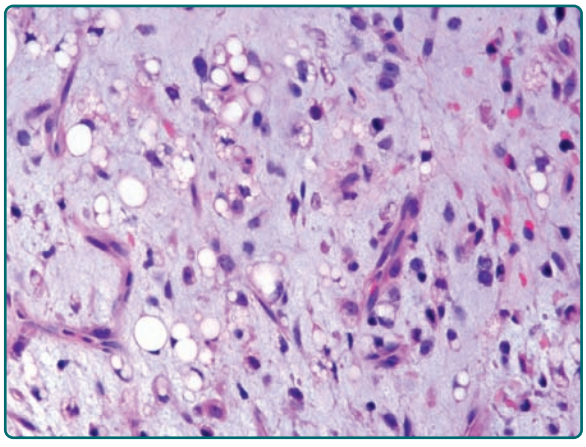

Figure 129-10 Myxoid liposarcoma: the presence of uni- to bivacuolated lipoblast and bland appearing oval shaped cells within a myxoid matrix is a characteristic feature.

the extracellular mucin may become confluent to form mucin pools, giving rise to a pulmonary edema-like appearance (eFig. 129-10.2 in online edition). In the well-differentiated areas, the tumors lack significant cytologic atypia, mitotic activity, or tumor necrosis. Poorly differentiated, high-grade tumors are characterized by increased cellularity with the formation of solid sheets of small-to-medium-sized round cells showing scant acidophilic cytoplasm (eFig. 129-10.3 in online edition). Mitotic figures are more easily identified, but nuclear pleomorphism is not a feature.

These cases have traditionally been classified as round cell liposarcoma and are associated with an adverse prognosis. However, the presence of classical myxoid and round cell areas within the same tumor with gradual transition from one to the other and the finding of identical cytogenetic alterations provide strong evidence that round cell liposarcoma represents the poorly differentiated, high-grade end of the spectrum of myxoid liposarcoma. Spindle cell differentiation may occasionally be seen in poorly differentiated tumors.

DIFFERENTIAL DIAGNOSIS

The differential diagnosis of myxoid liposarcoma includes the following:

- Lipoblastoma
- Myxofibrosarcoma
- Low-grade fibromyxoid sarcoma
- Chondroid lipoma
- Myxoid melanoma

CLINICAL COURSE, PROGNOSIS, AND TREATMENT

The clinical course of myxoid liposarcoma is characterized by local recurrence with a rate of distant metastasis of 30%–40%.[178–180] There is an unusually high incidence of soft-tissue and bone metastases in addition to metastases to the lung. Patients with multifocal disease at presentation have a poor prognosis, and adverse histologic features include the presence of round cell differentiation in more than 5% of the tumor, tumor necrosis, and p53 overexpression.[179,180,188,189]

PLEOMORPHIC LIPOSARCOMA

PLEOMORPHIC LIPOSARCOMA AT A GLANCE

- Pleomorphic liposarcoma is an aggressive sarcoma that shows a predilection for the extremities of adults and is associated with a high rate of metastasis and mortality.
- Histologic examination shows a pleomorphic high-grade sarcoma containing variable numbers of lipoblasts.

KEY REFERENCES

Full reference list available at www.DIGM8.com

DVD contains references and additional content

3. Willen H et al: Comparison of chromosomal patterns with clinical features in 165 lipomas: A report of the CHAMP study group. *Cancer Genet Cytogenet* **102**:46-49, 1998
74. Sciot R et al: Cytogenetic analysis of subcutaneous angiolipoma: Further evidence supporting its difference from ordinary pure lipomas: A report of the CHAMP Study Group. *Am J Surg Pathol* **21**:441-444, 1997
107. Furlong MA, Fanburg-Smith JC, Miettinen M: The morphologic spectrum of hibernoma: A clinicopathologic study of 170 cases. *Am J Surg Pathol* **25**:809-814, 2001
153. Rosai J et al: Combined morphologic and karyotypic study of 59 atypical lipomatous tumors. Evaluation of their relationship and differential diagnosis with other adipose tissue tumors (a report of the CHAMP Study Group). *Am J Surg Pathol* **20**:1182-1189, 1996
170. Nascimento AG: Dedifferentiated liposarcoma. *Semin Diagn Pathol* **18**:263-266, 2001
178. Tallini G et al: Combined morphologic and karyotypic study of 28 myxoid liposarcomas. Implications for a revised morphologic typing, (a report from the CHAMP Group). *Am J Surg Pathol* **20**:1047-1055, 1996
192. Hornick JL et al: Pleomorphic liposarcoma: Clinicopathologic analysis of 57 cases. *Am J Surg Pathol* **28**:1257-1267, 2004

This page intentionally left blank

PART 8 The Skin in Systemic Disease



Skin in Nutritional, Metabolic, and Heritable Disease

Chapter 130 :: Cutaneous Changes in Nutritional Disease

:: Melinda Jen & Albert C. Yan

PROTEIN ENERGY MALNUTRITION AT A GLANCE

- Marasmus: caused by chronic global nutrient deficiency and characterized by dry, loose, and wrinkled skin with a loss of subcutaneous fat.
- Kwashiorkor: caused by inadequate protein or fat in the context of ongoing carbohydrate intake and characterized by generalized edema with a "flaky paint" dermatosis.
- Rice milk intake during infancy has caused cases of kwashiorkor in the Western world.
- Particular attention should be taken to prevent refeeding syndrome, characterized by electrolyte abnormalities.

Nutrition is the complex series of events by which living organisms consume and assimilate foods and other nutrients in order to live, grow, and maintain homeostasis. Proper nutrition involves the consumption of key macronutrients in balanced tandem with essential micronutrients. Consisting of carbohydrates, proteins, and lipids, macronutrients are those that are needed in large quantities by an organism to both fuel metabolic processes and provide the substrate for building and maintaining cellular structure. By contrast, micronutrients signify vitamins and minerals, which while necessary to good health, are required in relatively minute quantities. Because humans are unable to synthesize these molecules, clinical disease results when disturbances occur in that equilibrium—most commonly from nutrient deficiencies, but also from an unbalanced ratio of consumed nutrients, or less commonly from nutrient excesses.

With an improved understanding of the role of diet in health and the advent of nutritional supplements, long-standing named scourges such as scurvy, beriberi, and pellagra have largely become diseases of historical interest. Even so, nutritional diseases remain problematic in developing countries and in settings of war, famine, and poverty. In industrialized countries, nutritional diseases may still arise among the disenfranchised: the homeless and those suffering from alcoholism or other forms of substance abuse. Individuals at risk also include those with derangements in their normal diets such as might be encountered with eating disorders or unusual dietary habits as well as with parenteral nutrition. Hypercatabolic states, exemplified by those with cancer, AIDS, hepatic or renal disease, and certain disease states such as carcinoid syndrome, may develop nutrient deficiencies even in the face of normal intake due to increased metabolic requirements. Excessive nutrient losses may occur as a result of decreased absorption arising from gastrointestinal diseases such as cystic fibrosis, inflammatory

bowel disease, celiac disease, or following gastrointestinal surgery. Those receiving chronic medications such as anticonvulsants or antibiotics may experience impaired utilization of their nutrients when their medications interfere with gastrointestinal absorption and normal metabolism. Impaired utilization may derive from underlying genetic metabolic defects, enzyme deficiencies, hepatic disease, or drug–nutrient interactions. By contrast, syndromes of nutrient excess generally stem from dietary surplus or iatrogenic therapeutic intake.

Because macronutrients and micronutrients are intrinsically involved in multiple biochemical pathways, disorders of nutrition may produce extracutaneous consequences. Moreover, those at risk for one nutrient deficiency may be suffering from other concomitant deficiencies as well. Appropriate evaluation of the patient with suspected nutritional disease should commence with a detailed history of dietary and medication intake, a review of past medical and family history, and careful inspection of the skin with special attention to the status of hair, nails, and mucous membranes. While some skin findings may be pathognomonic for certain nutritional disorders, physical findings are more oftentimes nondiagnostic. Laboratory analysis of blood and urine nutrient levels may be useful, but poor correlation with tissue levels limits their utility. Radiologic imaging studies may also offer corroboration for diseases such as scurvy, rickets, or beriberi. Clinical improvement following replacement therapy may represent the best or only means to confirm the clinical diagnosis of some nutritional deficiencies. This chapter reviews the important clinical features observed in nutritional disease states.

MACRONUTRIENTS

PROTEIN-ENERGY MALNUTRITION

EPIDEMIOLOGY. Malnutrition is a medical concern of global significance. The United Nations estimates that 1.02 billion individuals worldwide were malnourished in 2009.[1] The most recent approximation of child malnutrition estimates that 150 million children under the age of 5, or a quarter of children in this age group, suffered from malnutrition. Approximately 5 million children under the age of 5 die from malnutrition each year.[2]

In developing countries, malnutrition most commonly arises as a result of inadequate dietary intake, often compounded by disease. War, famine, and poverty states often aggravate the inadequate access to food, which may arise from political unrest, natural disasters, infectious diseases, seasonal and climactic factors, insufficient food production, lack of education, poor sanitation, regional and religious practices, and the limited availability of health care.[3] The availability of food in these settings may be limited to diets of corn, rice, and sometimes beans, which provide inadequate amounts of macronutrients, vitamins, and minerals. In Western industrialized countries such as the United States, less than 1% of children nationally suffer from protein–energy malnutrition (PEM). When it is encountered, chronic illness, malabsorption, presumed food allergies, food aversion, nutritional ignorance, and fad diets are more typical etiologies.

ETIOLOGY AND PATHOGENESIS. PEM refers to a spectrum of disorders describing varying degrees of protein and calorie deficiency. Several subtypes of PEM have been defined on the basis of relative deficiencies in protein and total calorie intake.

Children with marasmus are defined as those with severe wasting and stunting and are at less than 60% expected body weight for age. The term marasmus derives from the Greek *marasmos* meaning wasting. These changes are the result of chronic and global nutrient deficiencies, often because of a lack of available food. Children with kwashiorkor have body weights less than 60%–80% expected for age, generally as a result of being fed grain-derived foods without adequate accompanying protein or fat. This might occur in geographic areas where grains are more plentiful, but more expensive proteins and fats are not. In fact, the term kwashiorkor derives from the Ghanese term for "the one who is deposed," referring to the child who is weaned off of breastmilk onto a carbohydrate-rich but often protein-poor diet when the next child is born. The exclusive use of rice beverages, so-called "rice milk" products, as a substitute for baby formulas—either because of their lower cost or because of their perceived hypoallergenicity—has been linked to the development of kwashiorkor among infants in the United States and other Western countries.[4–6] A hybrid form of malnutrition in which stunting is associated with edema has been termed marasmic kwashiorkor.

The pathophysiology of these disorders can also be conceptualized as adapted and nonadapted forms of starvation. In adapted starvation (marasmus), decreased intake of all macronutrients, particularly carbohydrates, results in suppressed insulin production. As a result, catabolic hormones act unopposed and allow the appropriate conversion of glycogen into glucose. In the early stages of adapted starvation, muscle breakdown occurs within the first 24 hours, which permits gluconeogenesis to release glucose into the systemic circulation. Later, fat breakdown creates ketone bodies, which can also be utilized by the brain and central nervous system. This reduces the need for further muscle breakdown and therefore ammonia synthesis, so that lean body mass and some protein synthesis can be spared. In prolonged states of adapted starvation, wasting occurs and lean body mass is eventually utilized when all other sources are expended; in the absence of additional nutrient intake, the organism dies. In nonadapted starvation states (kwashiorkor), an imbalance results when intake of carbohydrate is increased relative to decreased intake of protein and fat. In this setting, insulin production is not appropriately suppressed. Without concomitant fat and protein intake, insulin inhibits protein synthesis. Hypoproteinemia, edema, and diarrhea develop, and without protein synthesis, affected individuals are unable to manufacture lipoproteins so fats accumulate resulting

in a fatty liver; more importantly, necessary immune proteins are not produced so patients become susceptible to opportunistic infection and septicemia, which represent major causes of mortality in these patients.

While the concepts of adapted and nonadapted starvation provide convenient explanations for why some children develop marasmus and others develop kwashiorkor, some controversy exists. For instance, aflatoxins have been detected with greater frequency in patients with kwashiorkor than in those with marasmus.[7] Also, the role of oxidative and nitrosative stress in kwashiorkor is supported by data showing that patients with edematous PEM have lower levels of erythrocyte glutathione and total plasma antioxidants than healthy controls.[8]

CLINICAL FINDINGS. Childhood is marked by periods of significant and rapid growth and development, and nutritional deprivation often manifests as alterations in these patterns of normal growth and development. Failure to thrive, a key finding in patients with PEM, may appear first as wasting in which patients have poor weight gain, and eventually, as decreased rates of linear growth (stunting). Various measurements have been recommended as markers for malnutrition, and include: body weight and length/height relative to age, body mass index, triceps or middle upper arm circumference, as well as skin and hair characteristics.[9,10] Suboptimal neurodevelopmental outcomes, heightened susceptibility to infection, and increased mortality may also be observed in chronically malnourished children.

Marasmus typically affects infants under 1 year of age. The physical findings of marasmus include dry, thin, loose, wrinkled skin resulting from loss of subcutaneous fat with an emaciated appearance (Box 130-1 and Fig. 130-1).[11] Hair growth slows and examination may reveal easy hair loss leading to thin, fine, brittle hair and alopecia. Increased lanugo hair may also be present. Nails may also show signs of fissuring with impaired growth.[12] As the body mobilizes all endogenous energy stores to survive, both subcutaneous fat and muscle mass are lost. The loss of buccal fat pads creates the aged or wizened appearance attributed to children with marasmus that has been referred to disparagingly as "monkey facies"(Fig. 130-2). Perianal fat loss can lead to rectal prolapse and abdominal muscle hypotonia may result in abdominal distention.[13] Constipation may alternate with periods of diarrhea that may or may not be associated with concomitant gastrointestinal infection. Angular cheilitis and mucous membrane changes have also been observed in patients with marasmus.[14] Patients often show both decreased resting body temperature and bradycardia.



Figure 130-1 Marasmus. General appearance with advanced disease.

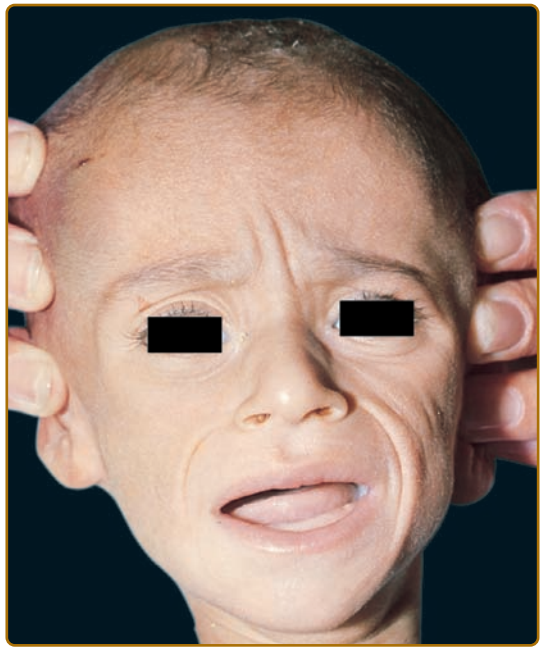

Figure 130-2 Marasmus. "Monkey facies" in an Arab infant, with wrinkled skin and loss of subcutaneous fat.

BOX 130-1 CLINICAL FEATURES OF MARASMUS

- Affects infants <1 year
- Failure to thrive
- Dry, thin, loose, wrinkled skin
- Hair loss; fine brittle hair; alopecia
- Fissuring and impaired growth of nails
- Loss of subcutaneous fat and muscle mass
- Loss of buccal fat (monkey facies)
- Rectal prolapse, abdominal distension
- Diarrhea, constipation
- Angular cheilitis

BOX 130-2 CLINICAL FEATURES OF KWASHIORKOR

- Affects children between 6 months and 5 years
- Failure to thrive, edema
- Irritability, lethargy, apathy
- Generalized dermatitis "flaking enamel paint," "cracked pavement"
- Increased pigmentation on arms and legs
- Hair color changes (red tint → gray–white; "flag sign")
- Distension of abdomen



Figure 130-3 The "flaky paint" or "crazy pavement" dermatitis of kwashiorkor.

The hallmark features of kwashiorkor—also known as edematous or "wet" PEM—include failure to thrive in association with edema and is primarily noted in children between 6 months and 5 years of age (see Box 130-2). Children are often irritable, but may become lethargic and apathetic. In contrast to marasmus, skin findings are common in kwashiorkor. The generalized dermatitis in edematous PEM has been likened to flaking enamel paint, with the pattern of skin fissuring suggesting cracked or "crazy" pavement (Fig. 130-3). Increased pigmentation of skin may be observed on extensor surfaces of the arms and legs. Hair often changes from its natural color, typically developing a red tint before further pigment dilution results in light, gray–white hair (Fig. 130-4B). If a child experiences intermittent periods of kwashiorkor and improved nutrition, alternate bands of light- and dark color within the hair shaft may be observed and has been referred to as the "flag sign" (Fig. 130-4A). Increased lanugo hair can also be noted in kwashiorkor. In addition to the peripheral edema, a direct consequence of hypoproteinemia, distention of the abdomen is noted as a result of fatty infiltration of the liver.

Adults may also be at risk for PEM, particularly those suffering from chronic illnesses, eating disorders such as anorexia nervosa, and the elderly. The prevalence of PEM in adult dialysis patients has been estimated at 25%–50% and is posited to occur as a result of semistarvation with inadequate caloric and protein intake, possibly complicated by the presence of a chronic systemic inflammatory response to dialysis.[15,16] Cases of macronutrient PEM have been reported as a complication of bariatric surgery.[17] The manifestations of PEM in adults may be less prominent, manifesting more as xerosis or acquired ichthyosis and may be the result of decreased sebaceous gland secretions or concurrent micronutrient deficiency.[18] Hyperpigmentation at characteristic sites may also be present, including the perioral, periocular, and malar areas. Diffuse telogen effluvium, lanugo, and thin, dry, dull hair has also been reported in adult PEM.[19]

LABORATORY TESTING. Initial laboratory testing in PEM recommended by the World Health Organization[20] includes screening for hypoglycemia, anemia, and an investigation into potential comorbid infectious diseases. Since patients with PEM are at



Figure 130-4 **A.** Flag sign in a Salvadoran child. **B.** Hypomelanization of the hair and skin.

significantly increased risk of serious infection, examination of urinalysis for bacterial infection, blood smear for malaria parasites, and feces for blood, ova, and parasites are essential. Skin testing for tuberculosis should be performed. Chest radiography may demonstrate concomitant signs of bacterial pneumonia, tuberculosis, heart failure, rickets, and fractures. Patients with kwashiorkor will also demonstrate hypoproteinemia, which may help guide treatment and prognosis. Evaluation of electrolyte levels before treatment should be interpreted with caution, as refeeding will likely alter mineral balances.

Elevated soluble CD14 levels have been associated with indicators of protein energy wasting, such as low body mass index and muscle atrophy, and increased mortality in hemodialysis patients. CD14 is a coreceptor that triggers immune activation in response to various ligands, including endotoxins and bacterial products. In patients with chronic renal failure on hemodialysis, increased soluble CD14 is associated with elevated markers of systemic inflammation, such as *C*-reactive protein, interleukin 6, fibrinogen, and plasma pentraxin 3. This suggests a possible link between chronic inflammation, PEM, and mortality in hemodialysis patients.[21]

Histologic evaluation is generally unnecessary since the clinical features in association with an appropriate history are diagnostic. However, histologic evaluation of the skin reveals increased thickness of the stratum corneum, atrophy of the granular layer, increased basal layer pigmentation, reduction of collagen fibers, and crowding of elastic fibers. Atrophy of the hair appendages with sparing of the sweat gland apparatus can also be noted.[22]

DIFFERENTIAL DIAGNOSIS. (See Box 130-3)

Treatment. Patients with severe PEM often require hospitalization due to the concurrent risks of hypoglycemia, hypothermia, dehydration, and sepsis. Individuals who are not awake and responsive may require intravenous hyperalimentation during the initial stages of therapy; care must be taken to avoid excessively rapid rehydration due to the risks of congestive heart failure. Oral refeeding is generally preferred using oral rehydration salts containing a mixture of essential electrolytes at least until diarrhea subsides or fortified formulas as soon as these can be tolerated. Since severely malnourished children are relatively immunocompromised, empiric antibiotic therapy may be considered on admission for suspected sepsis, and any identified infections should appropriately addressed.[20]

BOX 130-3 DIFFERENTIAL DIAGNOSIS

- Acrodermatitis enteropathica
- Atopic dermatitis
- Seborrheic dermatitis
- Langerhans cell histiocytosis

ESSENTIAL FATTY ACIDS

ESSENTIAL FATTY ACIDS AT A GLANCE

- Function: cell membrane fluidity, inflammatory mediators, and lamellar granule formation in the stratum corneum.
- Sources: fish oil and vegetable oil.

EPIDEMIOLOGY.

Naturally occurring essential fatty acids (EFA) deficiency states are uncommon in humans. Cases of deficiency arise instead from inadequate intake, malabsorption, or excessive loss. In the past, parenteral nutrition was a common cause of EFA deficiency, but with the introduction of lipid supplementation during parenteral nutrition in 1975, the incidence of EFA deficiency has decreased substantially. Patients at risk for EFA deficiency include those with poor dietary intake, including alcoholics and patients with anorexia nervosa, or those with malabsorptive conditions such as biliary disease, inflammatory bowel disease, postgastrointestinal surgery (e.g., bariatric surgery), and may represent one of the primary etiologies for the rash observed in cystic fibrosis patients.[23] Premature low birthweight infants are born with inadequate EFA stores and are also at risk.

ETIOLOGY AND PATHOGENESIS.

EFA represent a group of 18-, 20-, or 22-carbon polyunsaturated fatty acids that cannot be synthesized de novo by the human body. The ω-3 series of fatty acids is found in fish oils, and is derived from α-linoleic acid. The ω-6 series is found in vegetable oils, and is derived from linoleic acid.[11] Linoleic acid and α-linoleic acid are the two EFA– that serve as precursors for other EFA and therefore must be obtained from dietary intake. In cell membranes, EFAs increase lipoprotein unsaturation to modulate cell membrane fluidity. Arachidonic acid, a derivative of linoleic acid, is converted into prostaglandins, eicosanoids, and leukotrienes. In the epidermis, linoleic acid contributes to lamellar granule formation in the stratum corneum. Therefore, EFAs play a number of key roles in maintaining homeostasis.

CLINICAL FINDINGS.

Skin manifestations of EFA deficiency include: xerosis and scaly, diffuse erythema, and associated intertriginous erosions. Poor wound healing, traumatic purpura secondary to capillary fragility, brittle nails, and alopecia may be observed. Affected individuals may also demonstrate hyperpigmentation or hypopigmentation of the hair (Box 130-4). Extracutaneous findings include fatty liver infiltration, increased susceptibility to infection, a blunted immune response, anemia, thrombocytopenia, and growth retardation.

LABORATORY TESTING.

In EFA deficiency states, linoleic acid levels are low and the enzymes that normally

BOX 130-4 SKIN MANIFESTATIONS OF EFA DEFICIENCY

- Xerosis
- Scaly erythema, intertriginous erosions
- Traumatic purpura, poor wound healing
- Brittle nails, alopecia
- Hyper- and hypopigmentation of hair

convert linoleic acid to arachidonic acid use oleic acid to create an abnormal byproduct. Laboratory evaluation would therefore demonstrate decreased levels of linoleic and arachidonic acids, and elevated plasma levels of an abnormal intermediary, 5,8,11-eicosatrienoic acid. Measurements documenting an increased ratio (≥0.2) of this abnormal intermediary relative to arachidonic acid are diagnostic for EFA deficiency.

TREATMENT. While topical application of sunflower seed and safflower oils that contain linoleic acid may improve the clinical cutaneous findings of EFA deficiency,[24] topical absorption is unpredictable[25] and optimal treatment typically consists of oral or intravenous supplementation of EFA. In order to prevent EFA deficiency, EFA should represent 1%–2% of total daily calories.[26]

MICRONUTRIENTS

FAT-SOLUBLE VITAMINS

FAT-SOLUBLE VITAMINS AT A GLANCE

- Vitamin A, D, E, K.
- Vitamin A deficiency is the most common cause of preventable childhood blindness in the world.
- Carotenemia results from excess carotene not converted to vitamin A in the intestinal mucosa deposits in stratum corneum.
- Understanding of the full function of vitamin D is still evolving.
- Vitamin D supplementation is recommended for exclusively breast-fed infants, and others who have inadequate oral intake or sun exposure.
- Hemorrhagic disease of the newborn results from vitamin K deficiency and can present with a spectrum of bleeding, from ecchymoses to intracranial hemorrhage.

VITAMIN A (RETINOL)

Etiology and Pathogenesis. Vitamin A is a fat-soluble vitamin important in retinal photoreceptor function, epithelial proliferation, and keratinization. The two most clinically important metabolites of vitamin A are retinal, which is a key component of rhodopsin generation, and retinoic acid, which regulates cell differentiation.[27] Dietary intake of vitamin A derive from both plant and animal sources. Plant sources include dark, green, leafy vegetables, red palm oil, and brightly colored fruits such as papaya, mango, carrots, tomatoes, apricots, and cantaloupe. In plants, the vitamin A precursor β-carotene can be found as a two-molecule complex of the carotenoid known as retinal. The retinal can be later reduced to retinol in the intestinal villous cells. Animal sources of vitamin A include egg yolk, liver, fish, fortified milk, and other dairy products. In animal sources, vitamin A exists as retinyl esters, which are then hydrolyzed to retinol in the intestinal lumen and then absorbed into intestinal mucosal cells. All retinol vitamin A alcohol is esterified to retinyl esters within the intestinal mucosa, released into the bloodstream bound to chylomicrons, and then transported to the liver for storage. Here, retinol can be stored as retinyl esters in the liver; when needed, this storage form may be converted to retinol and bound to retinol binding protein and transthyretin and circulated throughout the body.

Vitamin A Deficiency

Epidemiology. Vitamin A deficiency (VAD) can result in cutaneous as well as ocular complications. It is, in fact, the most common cause of preventable blindness in children according to the World Health Organization. VAD has also been associated with defects in immune regulation.

Etiology and Pathogenesis. The primary causes of VAD continue to be inadequate intake, fat malabsorption states, and liver disease. In the United States, inadequate intake can be seen in individuals with eating disorders, restrictive diets, and chronic illness. Since vitamin A is fat-soluble, conditions associated with malabsorption of fat such as pancreatic or biliary tract disease, celiac disease, Crohn disease, Shwachman–Diamond syndrome, cystic fibrosis, cholestatic liver disease, chronic intestinal parasitic infection, and gastric bypass surgery can predispose to VAD.

Clinical Findings. (See Box 130-5). The earliest manifestations of VAD are ocular changes. Impaired dark adaptation (nyctalopia), is followed by xerophthalmia, and as corneal keratin desquamates and overgrowth of *Corynebacterium xerosis* on the sclera occurs, white patches known as Bitot spots develop. Severe deficiency may lead to corneal xerosis, ulceration, and keratomalacia, which may result in corneal perforation, prolapse of the iris, and blindness (Fig. 130-5).

The cutaneous findings of VAD are the result of abnormal keratinization. Mild deficiency may manifest as xerosis and scaling, while more severe deficiency may result in deep skin fissuring referred to as dermomalacia. Squamous metaplasia of the salivary glands as well as

BOX 130-5 MANIFESTATIONS OF VITAMIN A DEFICIENCY

- **Ocular**
  - Impaired dark adaption
  - Xerophthalmia
  - Corneal xerosis, ulceration, keratomalacia
  - Corneal perforation, blindness
- **Cutaneous, Mucocutaneous**
  - Xerosis
  - Skin fissuring (dermatomalacia)
  - Phrynoderma
- **Mucosa**
  - Xerostomia
  - Hypotonia
  - Hypogeusia

the nasal and oral mucosa may occur, leading to xerostomia, hyposmia, and hypogeusia. Laryngeal, bronchial, and vaginal mucosa can also become involved.

Phrynoderma, "toad skin," (Greek for toad + skin) is typically associated with VAD. These keratotic follicular papules often first develop on the anterolateral thighs and posterolateral upper arms, which then spread to extensory surfaces of the extremities, shoulders, abdomen, back, buttocks, face, and posterior neck (Fig. 130-6). Lucius Nicholas noted the association between this hyperkeratotic folliculitis or phrynoderma with VAD in 1933 when he observed these cutaneous findings among East African workers who developed night blindness and xerophthalmia.[28] While originally reported in association with VAD, phrynoderma is a nonspecific finding that can be observed with deficiencies in B-complex vitamins, vitamins C, E, as well as essential fatty acid deficiency, PEM, and general malnutrition states.[29]

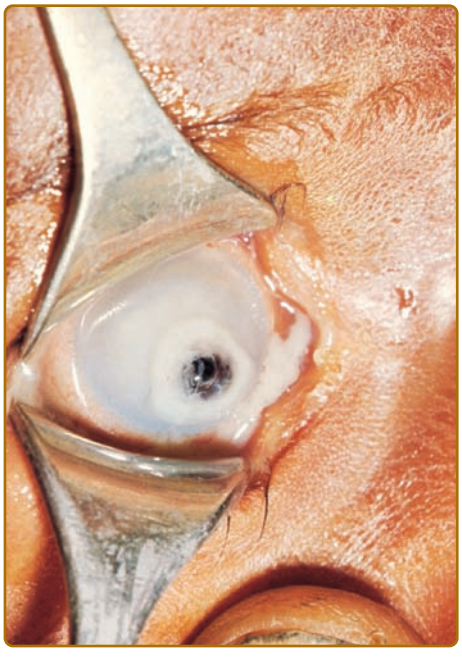

Figure 130-5 Vitamin A deficiency, advanced keratomalacia, in a 5-month-old Arab child. Note hyperkeratosis of facial skin. Serum vitamin A level was 2 µg/dL (normal, 20–50 µg/dL).



Figure 130-6 Vitamin A deficiency. Typical perifollicular hyperkeratosis of the chest in a Tanzanian adult male.

Laboratory Testing. Vitamin A levels can be measured from serum. Normal serum levels are between 20 and 50 µg/dL. Recently, assessment for the hydrolysis of retinoyl glucuronide to retinoic acid has shown promise as an adjunctive test for VAD. Retinoyl glucuronide is a water-soluble form of vitamin A that is not absorbed or hydrolyzed to retinoic acid in vitamin A-replete humans. The presence of serum retinoic acid for 4 hours after oral administration of retinoyl glucuronide was correlated with low serum retinol.[30]

Treatment. The recommended daily allowance (RDA) of vitamin A is between 1,000 and 5,000 IU, with younger individuals requiring a lower intake of vitamin A. Recommended treatment for VAD is 100,000–300,000 IU of oral vitamin A daily until symptoms resolve and serum levels normalize.

Vitamin A Toxicity. (See also Chapter 228)

Epidemiology. In 1856, Elisha Kent Kane published his two-volume *Arctic Explorations*, which included accounts of vitamin A toxicity that resulted after his team ingested polar bear liver during his expedition. The toxic substance in polar bear liver was later identified as vitamin A. Since that time, studies have shown that animal livers contain exceptionally high amounts of vitamin A.

Vitamin A toxicity is the result of excess intake of vitamin A and can occur on an acute or chronic basis. Acute toxicity occurs when excessive amounts of vitamin A are ingested over a period of several hours or days. Toxicity typically results when intake exceeds 20 times the RDA in a child or 100 times the RDA in an adult. Chronic toxicity results from daily ingestion of

greater than 25,000 IU for more than 6 years or greater than 100,000 IU for more than 6 months of preformed vitamin A. Children appear to be more sensitive to vitamin A intake than adults. Individuals most at risk for toxicity include patients taking systemic vitamin A derivatives for the treatment of dermatologic conditions such as acne, psoriasis, and ichthyosis. The other population at risk includes vitamin food faddists who consume large quantities of nonprescription vitamin A supplements.[31] Two notable episodes of vitamin A toxicity occurred in the 1950s when very high levels of vitamin A supplementation were added to infant formulas and the 1970s when high doses of vitamin A were used to treat a variety of dermatologic diseases.[32]

Recently, vitamin A derivatives have been studied in chemoprevention of keratinocytic carcinomas, such as squamous cell and basal cell carcinomas. A large, blinded randomized controlled study of elderly men with a history of two keratinocytic carcinomas in the 5 years prior to initiation of the study compared topical tretinoin 0.1% cream to placebo. Surprisingly, the study was terminated 6 months early because of a statistically significant increase in all-cause mortality in the tretinoin group compared to the placebo group.[33] Analysis of this increased risk was limited by its post hoc nature and suggests that further studies are needed to clarify this association.

Clinical Findings. (See Box 130-6). Individuals with acute vitamin A toxicity have dry, scaly skin, with large areas of desquamation and fissuring of the lips and angles of the mouth. Other signs and symptoms include headache, fatigue, anorexia, nausea, vomiting, blurred vision, pseudotumor cerebri, myalgias, and arthralgias. An early cutaneous sign of chronic vitamin A toxicity in adults is dryness of the lips, which may progress to diffuse, dry, pruritic, scaly skin with peeling of palms and soles, alopecia, follicular hyperkeratosis, and hyperpigmentation of the face and neck. Anorexia, fatigue, and weight loss may also occur. It is interesting to note that follicular hyperkeratosis may occur in the settings of both VAD and toxicity.

In children, chronic toxicity presents as coarse hair with diffuse alopecia, coarse skin with generalized exfoliation, hyperpigmentation, and exfoliative cheilitis. Associated pseudotumor cerebri with headaches and papilledema, and in infants may a bulging fontanelle may be present. Skeletal changes are common with vitamin A toxicity, and may present with growth retardation secondary to premature closure of the epiphyses and spontaneous bone fractures. Proposed mechanisms for the pathologic bone findings seen in vitamin A toxicity involves antagonism between vitamin A- and vitamin D-mediated intracellular signaling pathways and interactions with calcium-regulating hormones.[19,31]

Laboratory Testing. Laboratory findings in patients with hypervitaminosis A include elevated levels of calcium and alkaline phosphatase. This alteration in calcium homeostasis can lead to calcification of tendons, ligaments, and soft tissues. Deposition of excess vitamin A in adipose tissue and perisinusoidal fibrosis of the liver, which can lead to cirrhosis, are the most significant effect of long-term vitamin A toxicity.

Treatment. Almost all of the symptoms of vitamin A toxicity subside after the excess vitamin intake is discontinued, with the exception of liver cirrhosis and consequences of pseudotumor cerebri.

BOX 130-6 MANIFESTATIONS OF VITAMIN A TOXICITY

- Dry, scaly skin with desquamation
- Peeling of palms and soles, follicular hyperkeratosis
- Cheilitis, fissuring of lips and angles of mouth
- Alopecia
- Anorexia, nausea, vomiting
- Myalgias, arthralgias
- Blurred vision, pseudotumor cerebri
- Skeletal changes: premature closure of the epiphyses, spontaneous bone fractures

Carotenemia and Carotenoderma

Epidemiology. While hypervitaminosis A is a disease that causes a broad spectrum of clinical findings, excessive intake of carotene results in a benign disorder characterized by yellow–orange skin pigmentation. The condition was described as "carotenemia" in 1919 by Hess and Meyers who reported a connection between yellow skin pigmentation and increased serum carotene levels.[34] During World War I and World War II, carotenemia was more commonly seen because of the dietary shift from a meat-based diet to a more plant-based diet due to food shortages.

As antioxidants, carotenoids have also been studied in cancer prevention. Interestingly, β-carotene supplementation of 20–30 mg per day was associated with an increased risk of lung and gastric cancers.[35,36] β-Carotene supplementation is also associated with an increased risk of aggressive prostate cancer.[37] Animal studies suggest that excessive carotenoids may increase cyclic AMP signaling and cause deleterious effects on oxidative stress pathways, leading to the increased risk of malignancy.[38,39]

Etiology and Pathogenesis. Carotenes are not synthesized endogenously and are obtained through intake of carotene-rich foods. Plant carotenes are converted to vitamin A in the gastrointestinal tract, but approximately one-third of carotene is directly absorbed. Several factors can affect carotene absorption, including thyroid hormone, pancreatic lipase and bile acid concentrations, processing of foods, and dietary fat and fiber content. Hypothyroid patients notice an elevation of carotene levels as a result of decreased conversion to retinol. Pancreatic lipase and bile acids digest carotene so that a deficiency of these enzymes due to pancreatic or biliary or hepatic dysfunction could result in elevated carotene levels. Mashing, cooking, and pureeing fruits and vegetables increase

the availability of carotene because cell membranes are ruptured in the process. Dietary fiber decreases absorption. Because carotene is fat-soluble, a high-fat meal increases absorption. Patients with conditions that lead to hyperlipidemia, like diabetes mellitus, nephrotic syndrome, and hypothyroidism, also predispose patients to carotenemia because of a linear relationship between the amount of β-lipoprotein and carotene. Impaired conversion of carotene to vitamin A in patients with hypothyroidism and liver disease further contributes to carotenemia. Some patients with anorexia nervosa can present with carotenemia because of increased intake of vegetables. Other groups at risk for carotenemia are food faddists, those with excessive intake of nutritional supplements, dried seaweed (nori), carrots, and papayas, and infants ingesting a large amount of pureed vegetables.[40–42]

Clinical Findings. Excessive ingestion of carotenes does not result in hypervitaminosis A because the slow conversion of carotene to vitamin A in the intestinal mucosa is not rapid enough to produce toxic amounts of vitamin A.

Carotene deposits in the stratum corneum because of its high lipid content. The yellow discoloration of skin secondary to carotenemia is called carotenoderma. The carotene is excreted by sebaceous glands and in sweat, so the yellow pigmentation appears first on the face, predominantly in the nasolabial folds and forehead, and then progresses to manifest diffusely, especially on the palms and soles. The pigmentation is particularly noticeable in artificial light. Of note, carotenoderma, in contrast to jaundice, spares mucous membranes, like the sclera.

Laboratory Testing. Carotenemia does not occur until serum levels reach three to four times normal levels, greater than 250 µg/dL, and is detectable approximately 4–7 weeks following initiation of a carotenoid-rich diet.

Treatment. Treatment involves discontinuation of excessive carotene intake, and carotenoderma typically fades as the intake of carotene decreases.

VITAMIN D (CALCITRIOL)

Etiology and Pathogenesis. Vitamin D is essential for regulation of calcium and phosphorus metabolism. Vitamin D acts on the gastrointestinal tract to increase dietary calcium and phosphate absorption, stimulates increased bone resorption of calcium and phosphate, and stimulates the renal tubules to increase reabsorption of calcium and phosphate.

Humans obtain vitamin D from two sources: (1) dietary intake, and (2) synthesis in the skin from exposure to ultraviolet light. Common dietary sources of vitamin D include fortified milk, fish oil, and fishes such as salmon, sardines, herring, tuna, cod, and shrimp. Vitamin D can also be synthesized in the epidermis from the precursor molecule 7-dehydrocholesterol (provitamin D_3) by ultraviolet light in the 290–320 nm range. Previtamin D_3 then undergoes a spontaneous, temperature-dependent isomerization to vitamin D_3 (cholecalciferol), which enters the dermal capillaries. At this point, endogenous vitamin D_3 joins with exogenous D_2 (ergocalciferol) for hydroxylation in the liver to 25-hydroxyvitamin D. This molecule travels to the kidney where it is again hydroxylated to make mature vitamin D (1,25-hydroxyvitamin D, also known as calcitriol).

The most common disorder seen with vitamin D is vitamin D-deficient rickets related to decreased dietary intake of vitamin D. Several genetic causes of rickets also deserve mention. Two types of vitamin D-dependent rickets have been described. Type I represents an autosomal recessive defect in renal vitamin D-1α-hydroxylase, and is therefore treated with supplements of 1,25-hydroxyvitamin D. Type II, also referred to as hereditary vitamin-D resistant rickets, is associated with a rare autosomal recessive end-organ resistance to physiologic levels of 1,25-hydroxyvitamin D. Supplementation with high doses of 1,25-hydroxyvitamin D and calcium may overcome this resistance.

A surge in interest regarding the multisystem effect of vitamin D has spurred numerous studies. Evidence suggests that vitamin D deficiency is associated with increased systolic blood pressures,[43] fasting plasma glucose and insulin concentrations,[44] risk of cardiovascular disease,[45–47] risk of hip fractures in postmenopausal women,[48] and colon cancer mortality.[49] Vitamin D deficient individuals have an increased rate of all cause mortality when compared to those who are vitamin D replete.[47,50] Studies into the function of vitamin D in the immune system have indicated that vitamin D is involved in the innate immune response. Toll-like receptors (TLR) activation triggers expression of vitamin D receptor and vitamin D-1-hydroxylase, which promotes macrophage activation.[51] A low vitamin D level is associated with an increased risk of active *Mycobacterium tuberculosis* infection.[52]

Vitamin D-deficient rickets continues to occur in modern times. Groups at risk for vitamin D deficiency include those with inadequate diet, malabsorption, and decreased exposure to sunlight. This includes the elderly or debilitated who have decreased sun exposure or decreased vitamin intake; patients on anticonvulsant therapy; those with malabsorption from gastrointestinal surgery, celiac disease, or pancreatic or biliary disease; those with chronic renal failure; dark-skinned individuals living in areas with poor sun exposure; and breast-fed babies exclusively breastfed without vitamin supplementation.

A recent resurgence in vitamin D-deficient rickets has prompted further evaluation of those at risk. A review of 166 cases of rickets in the United States between 1986 and 2003 showed that most cases presented between 4 and 54 months of age. Eighty-three percent were African-American or black and 96% were breastfed.[55]

> *These results emphasized that exclusively breastfed infants, especially those with dark skin tones, may require vitamin supplementation. In response to the continued increase in cases of vitamin D-deficient rickets, the American Academy of Pediatrics in 2003*

outlined three populations who should be given supplemental vitamin D (200 IU): 1) all breastfed infants unless they take in 500 mL/day of fortified formula or milk; 2) all non-breastfed infants taking in less than 500 mL/day of fortified formula or milk; and 3) children and adolescents who do not obtain regular sun exposure, do not ingest at least 500 mL of fortified milk a day, or do not take a multivitamin with at least 200 IU vitamin D.[56]

Vitamin D-deficient rickets has been associated with congenital ichthyoses, such as lamellar ichthyosis,[57–59] nonbullous ichthyosiform erythroderma,[60] X-linked ichthyosis,[58] and epidermolytic hyperkeratosis.[61] Factors contributing to vitamin D deficiency include avoidance of sun exposure, excessive transepidermal calcium loss, defective vitamin D synthesis in affected skin, and decreased intestinal calcium absorption secondary to systemic retinoid therapy.

Given the movement to encourage sunscreen use, there has been concern regarding secondary vitamin D deficiency. Theoretically, regular use of the recommended amount of sunscreen can decrease 25-hydroxyvitamin D levels, but with real-life application of inadequate amounts of sunscreen and the tendency for increased sun exposure in individuals wearing sunscreen, there seems to be no significant impact on the incidence of vitamin D deficiency.[62]

At the same time, it appears that only limited sunlight exposure is necessary to produce adequate amounts of vitamin D3. For patients with Fitzpatrick skin type II, it has been calculated that only 5 minutes of summertime noon sun 2–3 times weekly provides adequate vitamin D production to satisfy physiologic requirements (see also Chapter 90).[63,64]

Clinical Findings. The classic manifestations of vitamin D-deficient rickets are skeletal (Box 130-7). Calcium and phosphorus deficiency leads to poor calcification of new bones, resulting in fraying and widening of the metaphysis. This can be seen at costochondral junctions of the anterior ribs, creating the well-known "rachitic rosary." Poor calcification of the skull bones results in craniotabes, a softening of the skull bones giving them a ping-pong ball feel. As the bones become weaker, they cannot support the weight of the child and progressive lateral bowing of the lower extremities occurs. Other findings can include frontal bossing, widening of the wrists, scoliosis, hypotonia, fractures, dental defects, and rarely hypocalcemic seizures or tetany. Early radiographic signs of rickets include widening of the epiphyseal plate and blurring of the epiphyseal and metaphyseal junction. If the disease progresses, deformities at the growth plate develop, including cupping, splaying, formation of cortical spurs, and stippling. The bone cortices appear thinner and generalized osteopenia is noted.

A potentially fatal manifestation of vitamin D deficiency is a dilated cardiomyopathy. In a report of 16 British cases, three infants died and six additional infants were successfully resuscitated from cardiopulmonary arrest.[65] Importantly, the cardiomyopathy is responsive to vitamin D supplementation and can result in complete resolution.[65–67]

Vitamin D-dependent rickets type II has also been associated with cutaneous features that are clinically indistinguishable from the syndrome of generalized atrichia associated with mutations in the hairless gene.[68,69] Affected patients in both conditions are born with hair. However, within a few months after birth, scalp and body hair are lost with the exception of eyebrows and eyelashes. Small papules and cysts representing abnormal, rudimentary hair structures characteristically develop on the face and scalp. These cysts typically show disintegration of the lower two-thirds of the follicular unit. While the cutaneous features—notably the alopecia and cysts—are phenotypically and histologically identical, these are distinct clinical entities (Table 130-1).

Laboratory Testing. In addition to the clinical and radiological signs of rickets, laboratory examination may be helpful. Elevated alkaline phosphatase levels and low serum 25-hydroxyvitamin D levels are often useful laboratory indicators of vitamin D deficiency. In the early stages of rickets, parathyroid hormone levels increase to compensate, but this compensatory mechanism becomes inadequate if the deficiency continues.

Treatment. The recommended daily value of vitamin D is 5–10 µg. Treatment includes oral vitamin D

BOX 130-7 CLINICAL MANIFESTATIONS OF RICKETS

- Rachitic rosary
- Craniotabes, frontal bossing
- Lateral bowing of lower extremities
- Widening of wrists, scoliosis, fractures
- Dental defects
- Rarely hypocalcemic seizures

TABLE 130-1
Comparison of Vitamin D-Resistant Rickets and Generalized Atrichia

Vitamin D-Resistant Rickets Type I	Generalized Atrichia
Chromosome 12q14	Chromosome 8p12
Mutations in vitamin D receptor (Zn finger)	Mutations in human hairless gene (Zn finger)
End-organ unresponsiveness to Vitamin D	Defect in catagen remodeling
Atrichia with papules and milia; + eyebrows/eyelashes	Atrichia with papules and milia; + eyebrows/eyelashes
Alopecia by 1–3 months of age	Alopecia by 40 days to 4 months

repletion with dihydroxyvitamin D in addition to a calcium-rich diet. Supplementation with 200–400 μg vitamin D per day until resolution of symptoms, about 2–3 months, is usually adequate.[176] Additional therapy can include judicious sun exposure.

Two additional therapies can be used in cases of hepatic rickets, which is unresponsive to oral vitamin D supplementation because of decreased intraluminal bile salts. D-α-tocopheryl polyethylene glycol-1,000 succinate (TPGS), a water-soluble vitamin E that forms micelles at low concentrations, enhances vitamin D absorption and successfully treated eight pediatric cases of hepatic rickets. These patients maintained adequate levels of vitamin D while on continued TPGS and vitamin D supplementation, without elevation of vitamin E levels.[70] Promoting cutaneous synthesis of vitamin D through ultraviolet radiation successfully treated two cases of hepatic rickets secondary to chronic cytomegalovirus hepatitis and to Alagille's syndrome.[71] Ultraviolet light therapy has also treated an Asian male with poor dietary intake of vitamin D.[72]

VITAMIN E (TOCOPHEROL).

Vitamin E is rarely associated with deficiency or excess states of disease. Found in oils and shortenings, as well as various fortified grains, dark-green leafy vegetables, legumes, nuts, avocado, and small fishes such as herring and sardines.[73] Because it is a fat-soluble vitamin, excessive intake may augment the effects of anticoagulant medications leading to purpura and propensity for hemorrhage.[74] Deficiency states are rare. However, ataxia with isolated vitamin E deficiency (AVED) is a rare and severe spinocerebellar neurodegenerative disorder with autosomal recessive inheritance. Patients with mutations in the α-tocopherol transfer protein are unable to properly transfer α-tocopherol from lysosomes into lipoproteins that results in a predisposition to oxidative stress in affected cells.[75–77]

VITAMIN K (PHYTONADIONE)

Etiology and Pathogenesis. Vitamin K is a necessary cofactor in the carboxylation of glutamate residues on coagulation factors II, VII, IX, X, and proteins C and S. Dietary vitamin K, phylloquinone, is found in green, leafy vegetables, certain legumes, soybeans, cereals, and beef liver. Phylloquinone is actively transported in the distal small bowel. Approximately half of the body's vitamin K is obtained though these dietary sources, and the other half is synthesized by gastrointestinal flora as menaquinones, which are passively absorbed in the distal small bowel and colon.

Vitamin K is derived from the German word "*Koagulationsvitamin*," which literally translates to mean "clotting vitamin." In the early-1900s, Henrik Dam of Denmark discovered an "antihemorrhagic factor" that reversed diet-induced bleeding disorders in chicks. In 1943, Edward Doisy and Henrik Dam were awarded the Nobel Prize in Physiology and Medicine for their separate work on isolating vitamin K.

Clinical Findings. Vitamin K deficiency leads to impaired coagulation and hemorrhage, which in neonates is referred to as hemorrhagic disease of the newborn (HDN). Neonates are particularly prone to vitamin K deficiency because of poor transplacental transfer, low dietary intake, and a sterile bowel. HDN is divided into early presentation and late presentation. The incidence of early HDN is 0.25%–1.7% and causes unexpected bleeding in the first week of life in an otherwise healthy neonate. It can present as ecchymoses, cephalohematomas or nasal, subgaleal, umbilical, intestinal, or intracranial hemorrhages. Late HDN is defined by the American Academy of Pediatrics as unexpected bleeding from severe vitamin K deficiency in 2–12 week old infants who are primarily breastfed and who received no or inadequate neonatal vitamin K prophylaxis.[78] Vitamin K deficiency beyond the newborn period is rare, but may result from malabsorption, liver disease, inadequate dietary intake, or medications. Fat malabsorption occurs in conditions such as regional ileitis, topical sprue, celiac disease, cystic fibrosis, pancreatic insufficiency, and biliary obstruction. Antibiotic use can result in vitamin K deficiency by altering the populations of normal bowel flora. Coumarin interferes with vitamin K epoxide reductase, an enzyme important in the recycling of inactive vitamin K into its active form. Other medications that can interfere with vitamin K metabolism include anticonvulsants (phenytoin), rifampin, isoniazid, high-dose salicylates, cholestyramine, and cephalosporins.[11,79] Vitamin K deficiency in older children and adults can present as purpura, ecchymoses, gingival bleeding, and gastrointestinal, genitourinary, and retroperitoneal hemorrhage.

Laboratory Testing. Because vitamin K is a key cofactor in the coagulation pathway, deficiency of vitamin K typically manifests as elevations in both prothrombin time and activated partial thromboplastin time (PT and PTT). Serum levels of vitamin K can also be measured.

While des-γ-carboxyprothrombin (DCP), also known as the abnormal "protein induced by vitamin K absence" (PIVKA), can be a sensitive indicator for vitamin K deficiency, its presence has also been strongly linked to certain malignancies, in particular, hepatocellular carcinoma. It appears that hepatocellular carcinoma cells produce DCP directly rather than as a byproduct of low vitamin K levels, which may be normal in patients with hepatocellular carcinoma.[80]

Treatment. Neonatal prophylaxis is traditionally with a single intramuscular dose of 0.5–1.0 mg vitamin K. There have been some studies regarding the use of oral vitamin K prophylaxis, but there is no definitive data on efficacy, safety, or bioavailability.[78]

Acute treatment is with fresh frozen plasma to replace deficient coagulation factors. Vitamin deficiency can also be treated with parenteral or intramuscular 5–10 mg vitamin K per day to correct severe deficiency.

WATER-SOLUBLE VITAMINS AT A GLANCE

- B complex vitamins, vitamin C, biotin.
- Niacin supplementation should be given with isoniazid therapy to prevent pellagra, characterized by a photosensitive dermatitis, diarrhea, dementia, and death.
- Vitamin C is an essential cofactor in multiple biologic reactions, including collagen synthesis. Deficiency causes scurvy, which presents with follicular hyperkeratosis, curled corkscrew hairs, and a bleeding diathesis.

VITAMIN B_1 (THIAMINE)

Etiology and Pathogenesis. Disorders of thiamine may have broad-ranging implications because thiamine is an essential coenzyme for three separate enzymes involved in NADPH synthesis, carbohydrate metabolism, and deoxyribose and ribose synthesis. Thiamine is used as a coenzyme for transketolase in the pentose phosphate pathway to produce NADPH. Thiamine pyrophosphate acts as a coenzyme in pyruvate dehydrogenase and α-ketoglutarate dehydrogenase, which are involved in oxidative decarboxylation reactions in the metabolism of carbohydrates and branched-chain amino acids.

Epidemiology. Thiamine is obtained from whole grains, enriched bread products, dried peas and beans, potatoes, and fish. Polished rice eliminates the thiamine-containing husk and predisposes to thiamine deficiency.

Disorders of thiamine excess are extremely rare. Most arise as a result of intravenous administration for suspected thiamine deficiency in the context of chronic alcoholism. Local irritation at the site of intravenous administration, generalized pruritus, and anaphylactic or anaphylactoid reactions have been described.[81] Neurotoxicity can occur in experimental settings when thiamine is administered directly into the central nervous system.[82] In general, thiamine excess states are extremely rare in humans.

Beriberi refers to a thiamine deficiency state. The word is derived from Sinhalese meaning "extreme weakness." The symptoms of beriberi have been recognized in East Asian countries for thousands of years because polished white rice is a dietary staple. The Japanese navy observed in the 1890s that beriberi could be eradicated by adding meat, fish, and vegetables to the diet.[83] Beriberi became an epidemic in the Dutch East Indies in the late 1800s. Christiaan Eijkman was part of the medical team stationed in the Dutch East Indies to study beriberi. In 1929, Eijkman was awarded the Nobel Prize in Physiology and Medicine for his work starting in 1886 studying the effect of polished rice and unpolished rice on the incidence of beriberi in chickens. Through a series of detailed experiments on populations of chickens fed various diets and injected with various bacteria, he concluded that there was a direct correlation between diet and beriberi, but like many, had initially misattributed the cause to a nonexistent infectious agent in polished rice. In 1926, Barend Coenraad Petrus Jansen and William Frederick Donath successfully isolated thiamine from rice polishings, and Robert Williams was able to synthesize thiamine in the 1930s.[84]

Clinical Findings. Thiamine deficiency in the United States is now rare. Predisposing factors for pediatric thiamine deficiency include unsupplemented parenteral nutrition, breastfed infants of thiamine-deficient mothers, congestive heart failure,[85] and severe malnutrition. Early signs include irritability, apathy, restlessness, and vomiting. As the disease progresses, neurologic signs of Wernicke's encephalopathy may develop, such as ophthalmoplegia, ataxia, nystagmus, and characteristic laryngeal nerve paralysis resulting in aphonia, which is a classic manifestation of infantile beriberi. Other symptoms include congestive heart failure, tachycardia, dyspnea, and cyanosis. In 2003, a series of infants presenting with ophthalmoplegia as a manifestation of Wernicke's encephalopathy was reported in Israel as a result of a thiamine-deficient infant soy formula. In all these cases, a prodromal illness was observed. Early symptoms included vomiting, anorexia, diarrhea, lethargy, irritability, and developmental delay. Upbeat nystagmus and ophthalmoplegia were the primary neurological signs. Following treatment, those with early disease had complete recovery, but those with severe disease had residual neurological complications.[86]

Adult beriberi has been categorized into dry and wet forms. Dry beriberi describes a symmetric distal peripheral neuropathy involving both sensory and motor systems. Wet beriberi includes neuropathy and signs of cardiac involvement, including cardiomegaly, cardiomyopathy, congestive heart failure, peripheral edema, and tachycardia. Rarely, wet beriberi can be associated with pulmonary hypertension that is reversible after thiamine supplementation.[87] A red, burning tongue and peripheral edema have also been observed with wet beriberi.

Laboratory Testing. Diagnosis of thiamine deficiency is made by measurement of erythrocyte thiamine transketolase or blood thiamine concentration. The more reliable measure is erythrocyte thiamine transketolase before and after thiamine pyrophosphate stimulation, represented as a percentage of thiamine pyrophosphate effect (TPPE). Normal values are up to 15%.

Treatment. Because thiamine is a cofactor in a variety of metabolic pathways, daily thiamine requirements are calculated from an individual's ideal total caloric intake, with current recommendations indicating 0.5 mg per 1,000 kcal.

Treatment of thiamine deficiency can be via intravenous, intramuscular, or oral routes of administration. Usually, treatment for beriberi is initiated with intravenous or intramuscular thiamine of 50–100 mg per day for 7–14 days, then oral supplementation is provided until full recovery is documented.

VITAMIN B_2 (RIBOFLAVIN)

Etiology and Pathogenesis. Riboflavin was discovered in 1879 as a fluorescent yellow–green substance found in milk. Its chemical structure was later determined in 1933. Riboflavin is used in two coenzymes, (1) flavin mononucleotide (FMN) and (2) flavin-adenine dinucleotide (FAD), both of which are involved in oxidation-reduction reactions in cellular respiration and oxidative phosphorylation. These two enzymes are also involved in pyridoxine (vitamin B_6) metabolism. Recent studies have suggested that riboflavin deficiency may contribute to increase plasma homocysteine levels, impaired handling of iron, and night blindness.[88]

Riboflavin is typically obtained through dairy products, nuts, meat, eggs, whole grain and enriched bread products, fatty fish, and green leafy vegetables. A small amount of dietary riboflavin is present as free riboflavin; most are found as FAD or FMN. Dietary FAD and FMN are hydrolyzed to riboflavin by brush border membranes or enterocytes. Free riboflavin in the intestinal lumen is then taken up by active transport in the proximal small bowel.

Deficiency states can be caused by decreased intake, inadequate absorption, and phototherapy. Alcoholics, elderly, and adolescents are groups at risk for riboflavin deficiency secondary to poor nutritional intake. Malabsorption after gastric bypass surgery can also predispose individuals to riboflavin deficiency.[89] In areas of India, China, and Iran, riboflavin deficiency is endemic because of their dependence on an unenriched cereal diet. Infants of riboflavin-deficient mothers are also at risk of deficiency because breast milk concentrations of the vitamin are proportional to maternal concentrations. Once weaned from the breast, these infants are at additional risk if they are not transitioned to milk. When confounded by PEM, riboflavin deficiency may be worsened because the usual renal compensatory mechanism of increased riboflavin absorption is impaired in this setting. Visible light phototherapy for jaundiced neonates causes photodecomposition of riboflavin.[90] Certain drugs also affect riboflavin levels through effects on absorption or metabolic inhibition. Chlorpromazine and other tricyclic drugs inhibit transport of riboflavin in the gastrointestinal tract predisposing to deficiency states.[91] Borate displaces riboflavin from binding sites, increases urinary riboflavin excretion, and inhibits riboflavin-dependent enzymes contributing to riboflavin deficiency.[92]

Clinical Findings. Signs of acute riboflavin deficiency include a deep red erythema, epidermal necrolysis, and mucositis. The severity of symptoms depends on the severity of deficiency[93] (Box 130-8).

Clinical signs of chronic riboflavin deficiency or ariboflavinosis begin 3–5 months after initiation of an inadequate diet. Skin and mucous membrane findings predominate. Initially, angular stomatitis manifests as small papules at the corners of the mouth that enlarge and ulcerate before developing into macerated fissures that extend laterally and often bleed (Fig. 130-7). Pronounced cheilosis with erythema, xerosis, and vertical fissuring of lips can occur. Early glossitis appears as prominent lingual papillae, but after these papillae are lost, the tongue becomes smooth, swollen, and magenta in color. The dermatitis of riboflavin deficiency resembles seborrheic dermatitis in that it involves the nasolabial folds, nostrils, nasal bridge, forehead, cheeks, and posterior auricular regions. Flexural areas of the limbs may also be affected. Plugging of the sebaceous glands (dyssebacia) may be observed around the nose. The dermatitis can affect the genitalia, more often to a greater extent in males than in females. A red, confluent, crusty, or lichenified dermatitis of the scrotum often spreads to involve the inner thighs. In general, the dermatitis is worse in areas of chafing or trauma. Infants frequently manifest the dermatitis in the

BOX 130-8 CLINICAL SIGNS OF RIBOFLAVIN DEFICIENCY

Acute

- Erythema
- Epidermal necrolysis
- Mucositis

Chronic

- Angular stomatitis
- Cheilosis with erythema, xerosis, and fissuring
- Glossitis
- Seborrheic dermatitis-like dermatitis affecting typical sites and flexural areas of limbs and genitalia
- Photophobia and conjunctivitis



Figure 130-7 Riboflavin deficiency. Angular stomatitis with maceration in an Arab child. Riboflavin excretion in the urine was diminished.

inguinal areas. In older individuals, the dermatitis is often more pronounced in facial creases and wrinkles, and if incontinent, can involve the perianal and buttock areas. Cutaneous findings are not aggravated by light exposure, but are exacerbated by heavy physical activity. Ocular findings are also a prominent feature of this disorder with photophobia and conjunctivitis being most notable. Oculo-orogenital syndrome is the term used to describe this constellation of symptoms.

Laboratory Testing. A normochromic, normocytic anemia may be observed. Erythrocyte glutathione reductase activity can be used as a screening test, but a trial of riboflavin supplementation is often the most optimal method to confirm a riboflavin deficiency.

Treatment. The recommended daily value of riboflavin is 0.6 mg per 1,000 kcal. Treatment for deficient infants and children are 1–3 mg per day, and 10–20 mg in adults.

VITAMIN B_3 (NIACIN)

Etiology and Pathogenesis. Niacin is a vitamin cofactor that can be obtained for the diet or synthesized endogenously from the essential amino acid tryptophan. Niacin is found in whole grains and enriched bread products, nuts, dairy products, liver, animal meat, mushrooms, and dried beans. Dietary niacin exists primarily in the form of nicotinamide-adenine dinucleotide (NAD) and nicotinamide-adenine dinucleotide phosphate (NADP). NAD and NADP are hydrolyzed in the intestinal lumen to form nicotinamide. Nicotinamide can be converted to nicotinic acid by intestinal bacteria or be absorbed into plasma. Nicotinamide and nicotinic acid then travel to the liver, kidney, enterocytes, where they are converted back to NAD and NADP. These two agents act as hydrogen donors and acceptors in oxidation-reduction reactions involved in the synthesis and metabolism of carbohydrates, fatty acids, and proteins.

Deficiency of niacin or vitamin B_3 results in pellagra.

Historical Background. (See online edition)

Pellagra remains endemic in parts of the world, including South Africa, China, and India, where corn and maize continue to be a dietary mainstay. Corn and maize contain bound niacin, so without alkaline hydrolysis to release the niacin, it is unavailable for absorption. Jowar, a type of millet found in parts of India, contains adequate levels of niacin, but large quantities of leucine interfere with the conversion of tryptophan to niacin.[96] Although Mexicans have a predominantly maize-based diet, pellagra is relatively uncommon because preparation of the maize includes washing it in lime water, which releases the complexed niacin.

Because niacin is absorbed from the gastrointestinal tract, gastrointestinal disorders can predispose to pellagra. Impaired absorption of tryptophan and niacin occurs in patients with jejunoileitis, gastroenterostomy, prolonged diarrhea, chronic colitis, ulcerative colitis, cirrhosis, Crohn disease, and subtotal gastrectomy.[97] Patients with Hartnup disease, a rare autosomal recessive disorder, develop pellagra-like symptoms in childhood. This is caused by a defect in the neutral brush border system, resulting in malabsorption of amino acids, including tryptophan. Alcoholics develop pellagra from a combination of poor diet and malabsorption. Overly restrictive diets from eating disorders such as anorexia nervosa, presumed food allergies, or food faddism can also cause pellagra.

Patients with increased metabolic needs as seen in carcinoid syndrome can develop pellagra. Normally, about 1% of tryptophan is metabolized to serotonin, but in carcinoid syndrome, an excessive amount, about 60%, of tryptophan is converted to serotonin. Because of this diversion of tryptophan to serotonin production, less tryptophan is available to make niacin.

Medications can also induce pellagra symptoms. Isoniazid is a competitive inhibitor of NAD because of their similar structures, and also impairs pyridoxine functioning, which is essential for niacin synthesis from tryptophan. 5-fluorouracil inhibits conversion of tryptophan to niacin, and 6-mercaptopurine inhibits NAD phosphorylase, which inhibits NAD production. Other implicated medications include phenytoin, chloramphenicol, azathioprine, sulfonamides, and antidepressants.[98]

Clinical Findings. Pellagra is classically described with the four Ds of (1) dermatitis, (2) diarrhea, (3) dementia, and (4) death. The characteristic dermatitis begins as painful, erythematous, pruritic patches in photodistributed areas. The skin becomes progressively more edematous, and several days later may develop vesicles and bullae, which can rupture, leaving crusted erosions, or develop into brown scales. Over time, the skin thickens into sharply demarcated, keratotic, hyperpigmented plaques. Painful fissures can develop in the palms and soles, resembling goose skin. The dorsum of the hands is the most commonly affected sites, and when the rash extends proximally, more on the radial than ulnar side, it forms the "gauntlet" of pellagra (Fig. 130-8A). A butterfly distribution may be apparent on the face when it extends from the nose to the cheeks, chins, and lips. When the dermatitis affects the upper central portion of the chest and neck, it is referred to as "Casal's necklace" (Fig. 130-8B). It can sometimes extend down over the sternum to create a "cravat." Mucous membrane involvement may manifest as cheilitis, angular stomatitis, a red tongue, and ulceration of the buccal mucosa and vulva. Half and half nails may also be present[99] (Box 130-9).

Gastrointestinal symptoms may represent the earliest signs of pellagra. Diarrhea, nausea, vomiting, abdominal pain, and anorexia have been reported. Neurologic symptoms, such as insomnia, fatigue, nervousness, apathy, impaired memory, and depression, can progress to psychosis and dementia in later stages. Without treatment, pellagra leads to death from multiorgan failure.

Laboratory Testing. Diagnosis is primarily made on clinical grounds and through a rapid response to vitamin supplementation. However, measurement of urinary metabolites of niacin—*N*-methylnicontinamide and pyridone—may be used to aid in the diagnosis.



Figure 130-8 Pellagra. Acute dermatosis. **A.** "Glove" or "gauntlet" exudative and crusted lesions on the hands. **B.** "Casal's necklace" on the neck with facial involvement.

Treatment. The recommended daily value of niacin is 15–20 mg of niacin, or about 60 mg of exogenous tryptophan. Treatment with 500 mg per day of nicotinamide or nicotinic acid is given over several weeks. Nicotinamide is preferred over nicotinic acid because nicotinic acid is frequently associated with headache and flushing. Neuropsychiatric symptoms may remit after 24–48 hours of treatment, but skin lesions often take 3–4 weeks to clear.[100]

VITAMIN B_6 (PYRIDOXINE)

Etiology and Pathogenesis. Pyridoxine deficiency was elucidated by Albert Szent-Gyorgi in 1934 while studying pellagra in rats. Esmond Snell identified the two other forms of vitamin B_6 and worked extensively to clarify the biochemical properties of these molecules in the mid 1900s.

Vitamin B_6 describes three interchangeable molecules: (1) pyridoxine, (2) pyridoxamine, and (3) pyridoxal. Humans are unable to synthesize any of these molecules, but fortunately they are widely available in both plant and animal products. Meats, whole grains, vegetables, and nuts are the best sources for vitamin B_6. Processing of these foods can decrease the amount of vitamin available. They are absorbed through passive diffusion in the jejunum and undergo phosphorylation to become components of active coenzymes. The most common form existing is pyridoxal-5-phosphate. Vitamin B_6 is employed in multiple pathways including the decarboxylation and transamination of amino acids, gluconeogenesis, and conversion of tryptophan to niacin, sphingolipid synthesis, prostaglandin synthesis, and neurotransmitter synthesis. As such, clinical features of pyridoxine deficiency may overlap with those of niacin deficiency.

Due to the availability of dietary vitamin B_6, deficiency is seldom caused by inadequate intake, but can occur in alcoholics due to poor diet. More commonly, malabsorption and medication-induced deficiency is etiologic. Small bowel disorders, such as Crohn disease and celiac disease, can interfere with absorption and produce deficiency. Medications that have been implicated in causing deficiency include isoniazid, hydralazine, penicillamine, and oral contraceptives. Isoniazid, hydralazine, and penicillamine bind to pyridoxal-5-phosphate to increase excretion or decrease activity of the coenzyme.

Clinical Findings. Vitamin B_6 toxicity from excessive intake does not typically produce skin findings, although it can be associated with peripheral neuropathy.

BOX 130-9 CLINICAL MANIFESTATIONS OF PELLAGRA

- Painful pruritic dermatitis in photo-exposed areas
- May be vesicular, crusted, and develops into scaly, keratotic plaques
- Dorsum of hands ("gauntlet"), neck (Casal's necklace), dorsa of feet ("gaiter" of pellagra); butterfly distribution in face.
- Angular stomatitis, cheilitis, glossitis
- Diarrhea, nausea, vomiting, abdominal pain, anorexia
- Insomnia, fatigue, nervousness, apathy, impaired memory, depression, psychosis, dementia

Vitamin B_6 deficiency classically presents as a seborrheic-like dermatitis of the face, scalp, neck, shoulders, buttocks, and perineum. Clinical features overlap those of niacin deficiency including features of photodermatitis, glossitis, and cheilitis. Glossitis appears as redness, burning, and ulceration of the tongue, leading to flattening of the filiform papillae. Other areas of oral mucosa also become red and ulcerated, resulting in angular stomatitis, cheilosis, and conjunctivitis. This condition produces an oculo-orogenital syndrome quite similar to that seen with riboflavin deficiency.[101] Neurological signs such as somnolence, peripheral neuropathy, paresthesias, weakness, and confusion. Other signs and symptoms are nonspecific, and include nausea, vomiting, depression, anorexia, and anemia. The clinical manifestations of vitamin B_6 deficiency often resemble pellagra because vitamin B_6 is needed for the conversion of tryptophan to niacin.

Laboratory Testing. Vitamin B_6 can be evaluated by mean measurement of plasma pyridoxal-5-phosphate. Low levels of plasma pyridoxal-5-phosphate indicate deficiency.

Treatment. Recommended daily values of pyridoxine depend on age and gender. Adult males require at least 2 mg per day; adult females require at least 1.6 mg per day; and infants require about 0.3 mg per day. Treatment involves discontinuation of inciting medication and initiating replacement therapy of 100 mg of pyridoxine per day. Oral lesions resolve in days, skin, and hematologic changes resolve in weeks and neurologic symptoms over several months.[11]

VITAMIN B_9 (FOLATE)

Etiology and Pathogenesis. Folate can be found in almost all foods, particularly in liver, wheat bran and other grains, leafy green vegetables, and dried beans. Tetrahydrofolate, the coenzyme form of folate, is used for single-carbon transfers in amino acid, purine, and pyrimidine metabolism. The poor diets of alcoholics, malabsorption, and medications can produce folate deficiency. Malabsorptive states (such as celiac disease, chronic diarrhea, status post total gastrectomy) and antifolate medications (such as methotrexate, trimethoprim, oral contraceptives and pyrimethamine) have been implicated in producing folate deficiency. The antiepileptics phenobarbital and phenytoin can also lead to folate deficiency states through induction of microsomal hepatic enzymes by antiepileptics, which deplete folate stores.[102] In children, folate deficiency can be also be associated with excessive boiling of milk, or a goat's milk diet. Human milk has greater bioavailability of folate when compared with goat's milk.[103,104]

Clinical Findings. As with vitamin B_{12} deficiency, the primary manifestation is hematologic: hypersegmented neutrophils, followed by macrocytosis and megaloblastic anemia. Neutropenia, thrombocytopenia, diarrhea, and irritability may also be observed. In contradistinction to vitamin B_{12} deficiency, folate deficiency is not associated with neurologic symptomatology.

Mucocutaneous findings include glossitis with atrophy of the filiform papillae, angular cheilitis, mucosal ulceration, perirectal ulcerations, perineal seborrheic dermatitis, and diffuse brown hyperpigmentation concentrated in the palmar creases and flexures.[105,106]

Laboratory Testing. Macrocytic and megaloblastic anemia with hypersegmentation of neutrophils is suggestive. Diagnostic confirmation can be accomplished through measurement of serum folic acid levels.

Treatment. Folic acid supplementation is typically curative. Discontinuation of antifolate agents is recommended if involved. Ruling-out concurrent vitamin B_{12} deficiency is crucial before initiating treatment for folate deficiency. If vitamin B_{12} deficiency is present but not treated, the hematologic symptoms may be respond to folate, but the neurologic symptoms will progress. Treatment involves 1–5 mg of folic acid per day.

VITAMIN B_{12} (COBALAMIN)

Historical Background. (See online edition)

Etiology and Pathogenesis. Vitamin B_{12} is an important coenzyme for two biochemical pathways in humans. The first enzyme uses methylcobalamin as a coenzyme for methyltransferase to methylate homocysteine to methionine, which is used in DNA, protein, and lipid metabolism. The second requires 5′-adenosylcobalamin to catalyze the reaction by methylmalonyl CoA mutase to convert methylmalonic acid to succinyl-CoA, which is used in fat and carbohydrate metabolism.

Vitamin B_{12} is found primarily in animal products, with liver, eggs, milk, beef, and organ meats being excellent sources. Gastric acid separates vitamin B_{12} from food proteins so it can bind to intrinsic factor in the duodenum. This complex is taken up by specific ileal receptors in the terminal ileum. In the enterocyte, vitamin B_{12} dissociates from intrinsic factor and enters the portal circulation bound to transcobalamin II for transport to tissues. Between 1% and 5% of free cobalamin is absorbed along the intestinal wall by passive diffusion. The body is able to store large amounts of vitamin B_{12}, so symptoms of deficiency often take 3–6 years to develop.

Epidemiology. Causes of vitamin B_{12} deficiency can be divided into three groups: inadequate intake, malabsorption, and other. Elderly individuals and psychiatric patients with poor diets, and strict vegetarians and their breastfed infants are most likely to become deficient from inadequate intake. Cases related to malabsorption can be further divided into four groups: (1) decreased gastric acid states leaving more B_{12} food-bound (chronic proton pump inhibitors and histamine H_2 receptor blockers), (2) decreased intrinsic factor (pernicious anemia, atrophic gastritis, postgastrectomy), (3) microbial competition in the gut (bacterial overgrowth, *Diphyllobothrium latum* infection), and (4) impaired absorption (Crohn disease, Whipple

disease, Zollinger–Ellison syndrome, celiac disease, short bowel syndrome). The other causes of cobalamin deficiency relate to inborn errors of transport or metabolism.[110]

Clinical Findings. Vitamin B_{12} deficiency manifests primarily in four systems. As with cases of folate deficiency, mucocutaneous manifestations include glossitis, angular cheilitis, hair depigmentation, and cutaneous hyperpigmentation. Glossitis is characterized by an atrophic, red, and painful tongue with atrophy of the filiform papillae, which is referred to as Hunter's glossitis. Early vitamin B_{12} deficiency can manifest as a linear glossitis.[111] Hair depigmentation may be localized or diffuse. Hyperpigmentation can be diffuse and symmetric or few scattered macules. The greatest concentration is usually observed on the hands, nails, and face, with the most commonly affected areas being the palmar creases, flexural regions, and pressure points. This hyperpigmentation often resembles Addison's disease, but patients show no evidence of adrenal insufficiency.[112–115]

Three proposed hypotheses exist regarding the pathophysiology of the hyperpigmentation. Vitamin B_{12} maintains glutathione in reduced form, which is used to regulate tyrosinase, an enzyme necessary in melanogenesis. In B_{12} deficiency, increased tyrosinase activity results in hypermelanosis. Another proposed hypothesis involves defective melanin transport between melanocytes and keratinocytes. Finally, megaloblastic changes in keratinocytes from B_{12} deficiency may affect melanin distribution.[11,19,114,115]

The importance of cobalamin deficiency lies in its association with the classically described neurologic manifestations of subacute combined degeneration of the dorsal and lateral spinal column. Generalized weakness with paresthesias progresses to ataxia and symmetric loss of vibration and proprioception, worse in the lower extremities, eventuating in severe weakness, spasticity, paraplegia, and incontinence. Other neurological findings include apathy, somnolence irritability, memory loss, dementia, and psychosis. Early neurologic findings may present before hematologic signs.

Laboratory Testing. The hematologic findings are similar to those found in folate deficiency, namely macrocytic anemia and hypersegmented neutrophils. Bone marrow biopsy reveals a hypercellular marrow secondary to disordered maturation.

Deficiency is diagnosed by measuring serum cobalamin levels, with levels less than 200 pg/mL indicating definite B_{12} deficiency and 200–300 pg/mL being borderline low.

Treatment. Treatment depends on treating the cause of deficiency and supplementing with vitamin B_{12}. Oral and parenteral supplementations have both been used. Oral supplementation can even be used in patients with pernicious anemia, but require much larger doses of enteral B_{12} than when parental since absorption has to be through the intrinsic-factor-independent mechanism. Supplementation with cyanocobalamin of some form is 1 mg per week for 1 month. If symptoms persist, or if deficiency is to be a long-term problem, as in pernicious anemia, then addition supplementation is with 1 mg of cyanocobalamin every month.

VITAMIN C (ASCORBIC ACID)

Etiology and Pathogenesis. Vitamin C is an antioxidant and essential cofactor in several biological reactions, including collagen biosynthesis, prostaglandin metabolism, fatty acid transport, and norepinephrine synthesis. Humans are unable to synthesize ascorbic acid because they lack gulonolactone oxidase, an enzyme most other animals possess use to convert glucose to ascorbic acid. Other organisms that require ascorbic acid include: the guinea pig, the fruit bat, and certain fish and bird species.

The majority of Western dietary vitamin C is obtained from fruits and vegetables, like potatoes, tomatoes, berries, citrus fruits, and green vegetables. Vitamin C is absorbed in the distal small bowel. Most dietary vitamin C is completely absorbed, but there is a decrease in absorption as dietary intake increases. Vitamin C is found in greatest concentration in the pituitary, adrenal glands, liver, leukocytes, and eyes. Depletion of body stores occurs after 1–3 months of a deficient diet.

As a water-soluble vitamin, ascorbic acid excess states are not typically associated with significant clinical disease. However, vitamin C deficiency is a disease of both great clinical importance and one of great historical significance. Vitamin C deficiency results in scurvy.

Historical Background. (See online edition)

Etiology and Pathogenesis. Causes of scurvy include insufficient vitamin C intake, increased vitamin requirement, and increased loss. Inadequate intake is the most common cause. Elderly individuals living alone may have limited diets as a result of poverty, immobility, poor dentition, poor access to groceries, or dementia.[121,122] Alcoholics, food faddists, individuals with presumed food allergies, and cancer patients may have decreased overall dietary intake or may simply avoid fruit and vegetables.[123] Iatrogenic scurvy occurs when physicians recommend dietary restrictions for certain conditions, such as in ulcerative colitis, Whipple disease, peptic ulcers, and gastroesophageal reflux, or with inadequate vitamin supplementation with parenteral nutrition. Increased vitamin C requirements are encountered with certain drugs, including aspirin, indomethacin, tetracycline, oral contraceptives, corticosteroids, and tobacco smoking. Scurvy has been reported as a complication of interleukin-2 treatment of metastatic renal cell carcinoma.[124] Peritoneal dialysis and hemodialysis can induce scurvy because the water-soluble vitamin is removed during the dialyzing process.[125] Scurvy has also been reported among patients receiving liver transplants.[126]

Impaired collagen synthesis is the basis for many cutaneous manifestation of scurvy. Ascorbic acid is required for the hydroxylation of proline residues on procollagen, allowing the formation of hydrogen–hydrogen bonding in the triple helix of mature collagen. Without ascorbic acid, the polypeptides are

BOX 130-10 CLINICAL MANIFESTATIONS OF SCURVY

Skin	Follicular keratotic plugging Corkscrew hairs Perifollicular purpura Lower extremity edema with ecchymosis Poor wound healing and dehiscence
Mucosa	Swelling, ecchymoses, and bleeding of gingiva Hemorrhagic gingivitis, necrosis, loss of teeth
Other Organs	Hemorrhagic intraarticular, subperiosteal, intramuscular, disruption of growth plates, bowing of bones, depressed sternum Epistaxis, hematuria, gastrointestinal, and cerebral hemorrhage

unstable and unable to form stable triple helices. This results in decreased collagen secretion from fibroblasts, increased collagen solubility, and unstable collage fibrils. This abnormal collagen creates pathology in skin, mucous membranes, blood vessels, and bone, leading to the four Hs of scurvy: (1) hemorrhagic signs, (2) hyperkeratosis of hair follicles, (3) hypochondriasis, and (4) hematologic abnormalities (Box 130-10).

Clinical Manifestations. (See Box 130-10). The earliest cutaneous sign of scurvy is phrynoderma—enlargement and keratosis of hair follicles, especially on the posterolateral aspect of the arms, resembling keratosis pilaris. The keratotic plugging generalizes, extending to the back, buttocks, posterior thighs, calves, and shins. The hairs within these plugged follicles become curled, resulting in corkscrew hairs. The corkscrew hair results from impaired keratin cross-links by disulfide bonds. As the disease progresses, the follicles red from congestion and proliferation of surrounding blood vessels, then turn purple, and finally red and hemorrhagic (Fig. 130-9). This palpable perifollicular purpura is characteristically found on the legs. Lower extremity edema is often referred to as "woody edema," associated with pain and ecchymosis. Other nonspecific cutaneous findings include xerosis and acne. Poor wound healing and even dehiscence of old wounds involving skin and bone can occur because vitamin C is necessary for wound healing and maintenance of healed wounds. Hemorrhage in the nail bed is noted as subungual linear (splinter) hemorrhages.

Oral manifestations are common. Gingival disease manifests as swelling, ecchymoses, bleeding, and loosening of teeth. Interdental and marginal gingivae become red, smooth, swollen, and shiny before becoming purple, black, and necrotic. This hemorrhagic gingivitis is secondary to poor osteodentin formation, which produces softer teeth that are prone to infection. Existing gingivitis and poor dentition predispose to more severe disease, but those without teeth do not develop hemorrhagic gingivitis.



Figure 130-9 Vitamin C deficiency in an 18-year-old girl after gastrointestinal surgery. Note the "corkscrew" or "swan-neck" hairs associated with perifollicular purpura.

Hemorrhage can occur in areas other than the skin, mouth, and nails. Bone disease is a frequent manifestation in children. Hemorrhage can be intra-articular, intramuscular, and subperiosteal. All of the above can lead to pain and disruption of the growth plates. Bowing of the long bones and a depressed sternum with and outward projection of the end of the ribs are noted on musculoskeletal examination. Metaphyseal spurs with marginal fractures (Pelkan sign), a ring of increased density surrounding the epiphysis (Wimberger sign), widening of the zone of provisional calcification (white line of Frankl), and a transverse band of radiolucency in the metaphysis (scurvy line or Trummerfeld zone) are seen on radiographs of extremities. Periosteal bleeding may occur. Epistaxis, hematuria, intracerebral hemorrhage, subconjunctival hemorrhage, and gastrointestinal hemorrhage have been reported. Weakness, fatigue, emotional lability, hypochondriasis, weight loss, arthralgias, hypotension, anorexia, and diarrhea are nonspecific findings associated with vitamin C deficiency.

The causes of a normochromic, normocytic anemia are multifactorial, including blood loss from hemorrhage, intravascular hemolysis, intracellular iron depletion, and decreased folate levels.

Laboratory Testing. Scurvy is a clinical diagnosis, but when unsure of the diagnosis, measurement of leukocyte ascorbate level can be helpful. Levels less than 75 mg/L indicate a deficient state.

Treatment. Recommended daily intake of vitamin C is 40–60 mg of ascorbic acid. With vitamin C supplementation, clinical symptoms rapidly improve within several days following initiation of supplementation. Therapeutic doses of 100–300 mg of ascorbic acid are administered daily until symptoms completely resolve.

BIOTIN

Etiology and Pathogenesis. Biotin is an essential cofactor for four carboxylating enzymes: (1) acetyl-CoA

carboxylase in fatty acid synthesis and lipogenesis, (2) pyruvate carboxylase in gluconeogenesis, and (3) propionyl-CoA carboxylase (4) 3-methylcrotonyl-CoA carboxylase—both involved in amino acid catabolism.

Eggs, liver, milk, peanuts, mushrooms, chocolates, and hazelnuts are common sources of biotin. Release of protein-bound dietary biotin depends on pancreatic biotinidase. Free biotin diffuses across the gut to bind to plasma proteins. Since biotin is found in many dietary sources and can be synthesized by enteric bacteria, deficiency is uncommon. In 1941, Paul Gyorgy described that avidin in egg white bound and inactivated biotin. Virgil Sydenstricker took this observation and induced biotin deficiency by feeding normal volunteers raw egg white rich diets. Avidin, a protein found in egg whites, binds free biotin in the bowel, therefore preventing absorption of both dietary and synthesized biotin. Although an uncommon cause of biotin deficiency, individuals following fad diets high in raw egg whites can be at risk for deficiency.[127] Biotin deficiency may arise from long-term parenteral nutrition without biotin supplementation.[128] Individuals on unsupplemented parenteral nutrition and on long-term antibiotics are particularly at risk because the antibiotics eradicate biotin-producing enteric flora.[129] Anticonvulsants, such as valproic acid, carbamazepine, and phenytoin, can increase biotin catabolism or impair liver function, leading to biotin deficiency.[130–132] A series of biotin deficiency cases were reported in Japan secondary to an elemental infant formula without supplemental biotin.[133,134]

Clinical Findings. Symptoms can develop 3–6 months after initiation of unsupplemented parenteral nutrition or raw egg white rich diet, but appear earlier in infants because of the greater biotin requirement for growth. The cutaneous manifestations are similar to those of acrodermatitis enteropathica (AE) (see below) and essential fatty acid deficiency (see above) (Box 130-11). An erythematous, scaling, and crusting dermatitis usually begins around the eyes, nose, and mouth and continues to involve multiple periorificial areas, including the perianal region. Alopecia, conjunctivitis, and glossitis have also been associated. Neurological findings include irritability, lethargy, paresthesias, hypotonia, developmental delay, and myalgias. Nausea and anorexia have also been described.

Two inborn errors of metabolism, both autosomal recessive multiple carboxylase deficiencies, also alter normal biotin metabolism. The neonatal (early onset) form is associated with a defect in holocarboxylase synthetase. This enzyme is used to catalyze the formation of the amide bond linking biotin to several carboxylase enzymes. Symptoms develop during the first 6 weeks of life and the condition is typically fatal. Patients present with a bright red scaling dermatosis that starts on the scalp, eyebrows, and eyelashes, which can spread to involve the perioral, perinasal, and intertriginous regions. Hair thinning can progress to patchy or total alopecia. Holocarboxylase synthetase deficiency can also present as a collodion membrane and subsequent ichthyosis.[135] Neurological findings are common and manifest as difficulty feeding and breathing, hypotonia, ataxia, seizures, lethargy, and global developmental delay. Associated metabolic derangements are metabolic acidosis, mild-to-moderate hyperammonemia, lactic acidosis, ketoacidosis, and organic aciduria, all of which can be exacerbated by intercurrent illness.[136]

The juvenile (infantile or late-onset) form presents after 3 months of age and is caused by biotinidase deficiency. Biotinidase is found in pancreatic secretions to recycle endogenous biotin and release protein-bound dietary biotin. Since symptoms derive from a relative biotin deficiency, large supplemental doses of biotin are used to treat this disorder. In biotinidase deficiency, children present with a scaly, erythematous periorificial dermatitis. Severe cases develop lichenification, crusting, and eroded lesions, which can become infected by *Candida*. Keratoconjunctivitis, total alopecia including eyebrows and eyelashes, and glossitis are associated mucocutaneous findings. Ataxia, developmental delay, hypotonia, seizures, optic nerve atrophy, hearing loss, and myoclonic spasms are common neurological findings. Hypertonia does not rule out this deficiency.[137] Sensorineural hearing loss is preventable with early diagnosis of biotinidase deficiency, but once present, is irreversible.[138] In contrast, the metabolic encephalopathy is reversible once appropriate therapy is initiated.[139] Like holocarboxylase synthetase deficiency, metabolic acidosis, lactic acidosis, and organic aciduria are found. Humoral and cellular immunodeficiencies can predispose to cutaneous and systemic infections.

Laboratory Testing. If dietary history is not explanatory, consultation to evaluate for inborn errors of metabolism is recommended in children who present with findings suggestive of a biotin deficiency. Biotinidase levels, serum amino acids, urine organic acids, carnitine studies, and ammonia may be helpful in differentiating this disorder from other metabolic diseases.

Treatment. The recommended daily value increases from 30 µg in neonates to 100–200 µg in adults. Acquired deficiency is treated with 150 µg of biotin per day until resolution of symptoms. Although holocarboxylase synthetase deficiency can be treated with 10–40 mg of biotin per day to reverse cutaneous symptoms, neurological deficits may persist. Patients with biotinidase deficiency are treated with 5–10 mg of

BOX 130-11 CLINICAL MANIFESTATIONS OF BIOTIN DEFICIENCY AND MULTIPLE CARBOXYLASE DEFICIENCY

- Erythematous, crusting, scaly dermatitis around eyes, nose, mouth, and other periorificial areas
- Alopecia, glossitis, conjunctivitis
- Irritability, lethargy, paresthesias, hypotonia, developmental delay

biotin and have better clinical outcomes than that seen with holocarboxylase synthetase deficiency.

MINERALS

MINERALS AT A GLANCE

- Cutaneous changes associated with iron deficiency include koilonychia, spoon-shaped nails; brittle, lusterless hair; aphthous stomatitis; and angular stomatitis.
- Acrodermatitis enteropathica is an inherited defect in the intestinal zinc transporter ZIP4.
- Zinc deficiency presents with a periorificial and acral eczematous and erosive dermatitis.
- Zinc status can be measured by serum zinc or alkaline phosphatase, a zinc-dependent enzyme.
- Menkes disease is an X-linked disorder of intestinal copper transport, and results in characteristic kinking of the hair and neurologic deficits.

COPPER

Etiology and Pathogenesis. Copper is an essential component of several metalloenzymes, including tyrosinase and lysyl oxidase. Tyrosinase is involved in melanin biosynthesis, and lysyl oxidase deaminates lysine and hydroxylysine in the first step in collagen cross-linking. Other copper enzymes are involved in catecholamine production, free radical detoxification, and oxidation-reduction reactions.

Epidemiology. Copper is found in fish, oysters, whole grains, beef and pork liver, chocolate, eggs, and raisins. Copper deficiency is uncommon, but can result from malnutrition, malabsorptive states, chronic unsupplemented parenteral nutrition, infants with a strictly cow's milk diet, and excessive intake of antacids, zinc, iron, or vitamin C, that can interfere with absorption. Celiac disease, cystic fibrosis, gastric bypass surgery, and short bowel syndrome lead to malabsorption of dietary copper.

Clinical Findings. Clinical manifestations in these cases include hypopigmentation of hair and skin and bony abnormalities (osteoporosis, fractures, periosteal reaction, and flaring of anterior ribs). Copper deficiency myeloneuropathy presents as a progressive and symmetric sensory loss and motor weakness of both upper and lower extremities.[140–142] All sensory modalities are affected. If untreated, optic nerve involvement may occur, with permanent vision loss.[142] Copper supplementation prevents further neurologic deterioration, but recovery of function is not guaranteed.

Laboratory Testing. Microcytic anemia, neutropenia, hypocupremia, and hypoceruloplasminemia can be observed. Neutropenia is the earliest and most common sign of copper deficiency and is a sensitive measure of treatment adequacy.

Treatment. Treatment is with supplemental copper in the diet.

Copper and Menkes Disease

Epidemiology. Menkes disease, also known as kinky hair disease, was described by John Menkes in 1962 as a multifocal degenerative disease of gray matter. The connection between copper deficiency and demyelinating disease was first suggested in the 1930s by Australian veterinarians after observing ataxia in lambs born to mothers grazing in copper-deficient pastures. Menkes described five male infants born into an English-Irish family who showed an X-linked syndrome of neurologic degeneration, particular hair, and failure to thrive. The incidence of Menkes' disease ranges from 1 in 100,000 to 1 in 250,000 live births.

Etiology and Pathogenesis. The Menkes gene, MNK, was identified on chromosome Xq13 in 1993. The protein product is a copper-transporting *P*-type ATPase, which is expressed in almost all tissues, except the liver. Mutations in MNK lead to decreased concentrations of copper because of impaired intestinal absorption and consequent decreased activity of cuproenzymes.

Clinical Findings. Classically, signs of Menkes disease begin at 2–3 months of age, although neonatal indicators include preterm labor, large cephalohematomas, hypothermia, hypoglycemia, and jaundice. The characteristic facies of Menkes disease is a cherubic appearance with a depressed nasal bridge, ptosis, and reduced facial movements. At 2–3 months of age, there is loss of developmental milestones, hypotonia, seizures, and failure to thrive. Structural changes in the hair are seen, with the general appearance of short, sparse, lusterless, tangled, and depigmented hair. The eyebrows have the same steel wool appearance as scalp hair. On light microscopy, pili torti is classically seen. Monilethrix, segmental shaft narrowing, and trichorrhexis nodosa, small beaded swelling of the hair shaft with fractures at regular intervals, may also be observed. Other cutaneous findings include follicular hyperkeratosis and soft, inelastic, depigmented skin especially at the nape of the neck, axillae, and trunk. A high arched palate and delayed tooth eruption may be noted on oral examination (Box 130-12).

Neurologic deficits represent the major morbidity in this disorder. Profound truncal hypotonia with poor head control is typical, while appendicular tone may be increased. Deep tendon reflexes are hyperactive. Suck and cry remain strong. Optic disks are pale with impaired visual fixation and tracking. Hearing remains normal. Developmental arrest occurs at occasional smiling and babbling. Bony changes most often involve the extremities and the skull, and less often the thorax, vertebrae, and pelvis. They include osteoporosis, metaphyseal widening and lateral spur formation,

BOX 130-12 CLINICAL FEATURES OF MENKES DISEASE

- Depressed nasal bridge, ptosis, and reduced facial movements
- Loss of developmental milestones, hypotonia, seizures, hypothermia, and failure of thrive
- Steel wool appearance of hair: short, sparse lusterless, tangled, and depigmented. Microscopically: pili torti, trichorrhexis nodosa
- Follicular hyperkeratosis, inelastic depigmented skin at nape of neck, axillae, and trunk
- Arched plate, delayed tooth eruption
- Severe neurologic deficits
- Bony and renal changes

ossification of sutures, a diaphyseal periosteal reaction, and scalloping of the posterior aspects of the vertebral bodies, and subperiosteal new bone formation. Renal involvement as hydronephrosis, hydroureter, and diverticula of the bladder can occur. Elongation and tortuosity of many large vessels lead to severe arterial disease, a frequent cause of death by age of 3–4 years.

Laboratory Testing. Diagnosis is through the clinical history, physical examination, and reduced levels of serum ceruloplasmin and copper.

Treatment. Early treatment with copper histidinate has resulted in good outcomes, including normal neurodevelopmental milestones, in some patients. Initiation of therapy in older patients may be helpful in alleviation of symptoms like irritability and insomnia.[143,144]

SELENIUM

Etiology and Pathogenesis. Selenium is an essential component of glutathione peroxidase, an antioxidant. Selenium is found in seafood, red meat, egg yolks, grain products, and chicken. The amount of selenium available in cereal grains depends on the selenium content of the soil where it was grown. An area with low soil selenium is Keshan, China, where selenium deficiency in humans is endemic. Selenium-deficient soil is seen in the context of heavy erosion of the surface soil, resulting in trace mineral depletion.[145,146]

Selenium Deficiency

Epidemiology. Selenium deficiency is primarily seen in geographic areas where low soil selenium exists, but can also occur in the context of restricted protein diets, unsupplemented parenteral nutrition, malabsorption states, and increased losses.[147,148]

Clinical Findings. Two disorders have been attributed to selenium deficiency: (1) Keshan disease and (2) Kaschin–Beck disease. These diseases have only been reported in endemic areas of Asia.

Keshan disease is a multifocal myocarditis leading to fatal cardiomyopathy that is seen primarily in women and young children in endemic areas. Acute or chronic insufficiency of cardiac function, cardiomegaly, arrhythmias, and electrocardiographic abnormalities have been noted. Muscle pain and weakness with hepatic congestion, mesenteric lymphadenosis, erythrocyte macrocytosis without anemia, and pancreatic exocrine dysfunction have also been seen. Cutaneous findings in these patients have included white nail beds, similar to those of Terry's nails in hepatic cirrhosis, and hypopigmentation of skin and hair (pseudoalbinism). These findings resolve with selenium supplementation.

Kaschin-Beck disease is an osteoarthropathy that affects the epiphyseal and articular cartilage and the epiphyseal growth plates, resulting in enlarged joints, and shortened fingers and toes.

Laboratory Testing. Diagnosis of selenium deficiency is through measurement of plasma selenium levels and glutathione peroxidase activity.

Treatment. Selenium supplementation is used for both acute correction and long-term maintenance.

Selenium Excess

Epidemiology. Selenium toxicity can be acutely fatal. Cases of toxicity have been associated with increased soil selenium. Marco Polo described findings consistent with selenium poisoning in Western China during his explorations in 1,295. In the 1960s, reports of selenium toxicity came out of Enshi County in Hubei, China. The cause of this endemic toxicity arose from coal contaminated with selenium that was then used to fertilize the soil.[149] Sporadic cases of selenium intoxication secondary to excess supplement ingestion have been reported.[150] Additional cases of acute selenium toxicity have been documented after ingestion of glass blue (used in stained glass manufacturing),[151] selenite broth (enriched culture media used to isolate *Salmonella bacilli*), and gun bluing agent (a finishing product for firearms).[152]

Clinical Findings. Hair becomes dry and brittle in association with an exfoliative dermatitis on the scalp, often resulting in broken hairs and alopecia. Nails also become brittle with white horizontal streaking on the surface. Breaks in the wall of then nail eventually leads to nail loss. The new nail is fragile and thickened with a rough surface. Nails, hair, and teeth can all develop a reddish hue. Skin on the extremities and neck can become red, swollen, blistered, and occasionally ulcerate that heal slowly. Neurologic complaints of peripheral anesthesia, hyperreflexia, numbness, convulsions, and paralysis have been reported. Nausea, vomiting, diarrhea, garlic or sour-milk breath odor, and hypersalivation can occur. Severe corrosive hemorrhagic gastritis can progress into a deep gastric ulcer after acute intoxication. Acute tubular necrosis of the kidneys with the potential for acute renal failure requiring dialysis may also complicate selenium toxicity.[153]

Laboratory Testing. Screening of plasma can be used to document elevation selenium levels.

Treatment. Treatment involves removal of the source of excess selenium and supportive care for complications.

MANGANESE

Etiology and Pathogenesis. Manganese activates glycosyltransferases used in the synthesis of glycosaminoglycans and glycoproteins and is used in two metalloenzymes [(1) pyruvate carboxylase and (2) superoxide dismutase]. Manganese is also found in high concentrations in melanocytes. Reported cases of manganese deficiency are rare. Manganese deficiency was reported during a study of vitamin K requirements, when a study subject was accidentally placed on a manganese-deficient diet. He developed a mild dermatitis, reddening of his black hair, slowed hair and nail growth, and occasional nausea and vomiting with moderate weight loss. A subsequent study of manganese-deficient states showed no hair changes, but miliaria crystallina developed in half the subjects, and disappeared after repletion. Long-term parenteral nutrition without adequate supplementation can induce manganese-deficient states.[154] Likewise, in cases where manganese is supplemented in parenteral nutrition, hypermagnesemia can occur and has been associated with neurologic sequelae.[155]

IRON.

Iron is used in several biological pathways including heme synthesis, oxidation-reduction reactions, collagen synthesis, and as a cofactor for enzymes such as succinic dehydrogenase, monoamine oxidase, and glycerophosphate oxidase. Iron is found in red meats, egg yolks, dried beans, nuts, dried fruits, green leafy vegetables, and enriched grain products.

Iron Deficiency. Iron deficiency continues to be an international problem that crosses socioeconomic and ethnic divides. Deficiency states result from inadequate intake or chronic blood loss. Groups at high risk include infants, menstruating females, and individuals with chronic gastrointestinal bleeds. Infants on an iron-fortified formula are at risk for deficiency 3–6 months after transitioning to cow's formula because of the lower iron content of cow's milk.[156]

Skin changes have been seen in iron deficiency involve the skin, mucous membranes, hair, and nails (Box 130-13). Moderate iron deficiency causes fragile, longitudinally ridged, lamellated, or brittle nails. As deficiency progresses, the nail plate shows thinning, flattening, and a spoon-shaped convexity known as koilonychia. The index and third fingernails are usually the most severely involved. Even after iron replacement therapy begins, koilonychia resolves slowly.

Hair changes include a lusterless, brittle, dry, and focally narrow or split hair shafts, likely caused by impaired keratin production. Heterochromia of black scalp hair with alternating segments of dark brow, white, and liver bands have been described. Cunningham noted in 1932 that hair loss occurred in iron deficiency, but Hard was the first to show an etiologic connection between iron deficiency anemia and diffuse scalp hair loss.[157,158] However, the role of iron deficiency in hair loss continues to be a controversial topic.[159,160]

BOX 130-13 CUTANEOUS FEATURES OF IRON DEFICIENCY

- **Nails:** Fragile, longitudinally ridged Lamellated brittle nails → thinning, flattening of nail plate, koilonychia
- **Hair:** Lusterless, dry, focally narrow and split hair shafts, heterochromia of black hair. Hair loss.
- **Mucous Membranes:** Aphthous stomatitis, angular stomatitis, glossodynia, atrophied tongue papillae
- **Blue sclerae**
- **Pruritus**

Mucous membrane manifestations include aphthous stomatitis, angular stomatitis, glossodynia, and absent or atrophied tongue papillae. Blue sclerae that persists after iron replacement is likely secondary to impaired collagen synthesis. Generalized pruritus of variable severity has been reported in some individuals with iron deficiency, and sometimes associated with dermatitis herpetiformis. Plummer–Vinson syndrome is an iron deficiency associated syndrome encountered predominantly in middle-aged women with microcytic anemia, dysphagia, glossitis, koilonychia, and angular stomatitis. This is considered to be a precancerous phenomenon, associated with carcinoma of the mouth or upper respiratory tract.

Iron deficiency in a microcytic anemia is diagnosed by measurement of serum iron levels, ferritin, total iron binding capacity, transferrin saturation, as well as free or zinc protoporphyrin levels. Treatment involves appropriate iron supplementation.

Iron Excess. Chronic iron overload, hemosiderosis, can be associated with tissue injury, which is called hemochromatosis. Hyperpigmentation and ichthyosis-like changes of the skin are seen. Associated findings are cirrhosis of the liver, diabetes mellitus, and cardiomyopathy.

ZINC.

Zinc is an important micronutrient that is an essential component of many metalloenzymes involved in a variety of metabolic pathways and cellular functions, and is particularly important in protein and nucleic acid synthesis. Adequate zinc levels are also important for wound healing and for T-cell, neutrophil, and natural killer cell function. Zinc homeostasis depends on adequate zinc absorption and maintenance of appropriate intracellular and extracellular zinc levels as well as its regulated transport across luminal surfaces. Dietary sources of zinc include meat,

fish, shellfish, eggs, dairy products, and legumes, with the highest and most bioavailable forms of zinc found in meats, fish, and shellfish. Other vegetables, fruits, and refined carbohydrates contain very little zinc. Phytates (found in cereal grains, legumes, and nuts) and fiber interfere with intestinal zinc absorption. Human breast milk contains very high levels of zinc during the first 1–2 months of lactation, averaging 3 mg/L; subsequently, zinc levels decrease. Human breast milk also contains a zinc-binding ligand that increases the bioavailability of breast milk zinc. Although cow's milk formula contains higher levels of zinc, the bioavailability is significantly less than that in human breast milk.

Enteral zinc absorption occurs in the small intestine. Zinc excretion occurs primarily via the gastrointestinal tract via pancreatic and intestinal secretions, with lesser amounts excreted in the urine complexed to free amino acids. Two important families of zinc transporter proteins, including *9 ZnT* (zinc transporter) genes and 15 Zip (Zrt- and Irt-like proteins) transporters, have been identified in humans.

Although total body zinc is stored primarily in the bones, muscles, prostate, and skin, there is no free exchange of stored zinc, and metabolic needs must be met by a continued supply of dietary zinc. In plasma, approximately 50% of the total zinc is complexed with albumin, while the remainder is bound to other serum proteins, including transferrin and α_2-macroglobulin, or bound to free amino acids. Plasma levels may decrease transiently in response to intercurrent illness, surgery, or other stressors. Excess plasma zinc levels inhibit copper absorption, possibly through competitive inhibition of a common divalent cationic transporter. Zinc deficiency also results in impaired mobilization of hepatic retinol stores and is associated with impaired night vision (nyctalopia). Conversely, excessive calcium intake can interfere with normal zinc absorption, likely also a result of competitive inhibition.

Zinc Deficiency

Epidemiology. Zinc deficiency occurs worldwide. Populations at special risk include patients with intestinal malabsorption syndromes liver disease, anorexia nervosa or food faddism, extensive cutaneous burns, and nephritic syndrome. Iatrogenic zinc deficiency may result from prolonged parenteral or enteral nutrition that contains inadequate zinc levels to meet the metabolic demands. Certain rural populations with diets high in phytates, as have been reported in certain parts of Iran, Turkey, and the former Yugoslavia, are also at risk for acquired zinc deficiency (AZD).

Etiology and Pathogenesis. Zinc deficiency may be either inherited, a form commonly referred to as AE, or acquired, and therefore referred to as AZD.

Acquired Zinc Deficiency. AZD may result from states associated with inadequate intake, impaired absorption, or increased excretion, including pregnancy, lactation, extensive cutaneous burns, generalized exfoliative dermatoses, food faddism, parenteral nutrition, anorexia nervosa, and even excessive sweating. Intestinal malabsorption syndromes, such as inflammatory bowel disease and cystic fibrosis, result in impaired intestinal absorption of zinc, whereas alcoholism and nephrotic syndrome result in increased renal zinc losses. Penicillamine has been reported to cause zinc deficiency in a patient with Wilson disease. Ornithine transcarbamylase deficiency has also been associated with zinc deficiency.

Acrodermatitis Enteropathica. The inherited form of zinc deficiency, AE, is a rare autosomal recessive disorder of zinc absorption. These infants have a defect in an intestinal zinc transporter, the human ZIP4 protein encoded on the *SLC39A4* gene. Mutations in this gene prevents appropriate enteral zinc absorption.[161–163]

AE classically presents during infancy on weaning from breast milk to formula or cereal, which have lower zinc bioavailability than breast milk. There is a form of AZD that may also present during infancy but, in contrast to AE, these infants become symptomatic while breast-feeding and improve after weaning to formula or table foods. Many of these reported infants have been premature, but cases have also been reported in full-term infants. The mothers of these infants have a presumed defect in mammary excretion of zinc into their breast milk, resulting in inadequate zinc intake in their infants.[164,165] In a case we evaluated, breast milk zinc deficiency occurred as a result of excessive maternal intake of calcium that the mother was taking in the belief that calcium supplements might mitigate postpartum depression. Measured breast milk zinc levels were significantly decreased and rebounded to normal levels upon discontinuation of maternal calcium supplementation. Measurement of breast milk zinc levels is a useful tool and is diagnostic when less than 70 µg/dL.

AE presents soon after weaning in affected infants or during the fourth to tenth week of life in infants who are not breast-fed. The classic features of AE include alopecia, diarrhea, lethargy, and an acute eczematous and erosive dermatitis favoring periorificial (perioral, periocular, anogenital) and acral areas (hands and feet) (Box 130-14). The cutaneous findings are highly characteristic and often present initially as a nonspecific, acrally distributed, symmetric, eczematous dermatitis.

BOX 130-14 CLINICAL FEATURES OF ACRODERMATITIS ENTEROPATHICA

- Eczematous and erosive dermatitis
- Preferentially localized to periorificial and acral areas
- Alopecia
- Diarrhea
- Lethargy, irritability
- Whining and crying
- Superinfection with *Candida albicans* and *Staphylococcus aureus*



Figure 130-10 **A.** Patient with acrodermatitis enteropathica. These clinical findings resolved within 2 weeks of initiating zinc supplementation. **B.** This crusted and scaly, erosive, and sharply demarcated eruption appeared shortly after weaning. The child was highly irritable, whining and crying, and had diarrhea.

Over time, bullae and erosions with a characteristic peripheral crusted border develop (Fig. 130-10). Vitiligo-like depigmented patches have been described.[167] In addition to dry and brittle hair, alternating dark and light bands with polarized light can be seen.[168] Patients also appear to be predisposed to systemic infections as a result of impaired cell-mediated immunity, and superinfection with *Candida albicans* and bacteria, usually *Staphylococcus aureus*, is common. Delayed wound healing, acute paronychia, conjunctivitis, blepharitis, and photophobia may also be observed. Diarrhea may be prominent but is not seen in all cases. If untreated, the disease is fatal.

Acquired Zinc Deficiency. Acute AZD secondary to impaired absorption of zinc, inadequate intake, or excessive renal or intestinal losses may result in a clinical picture that resembles AE (see above) and occurs also in adults (Fig. 130-11).

A chronic or subacute form of zinc deficiency is also recognized. These patients often have zinc levels in the mildly deficient range (40–60 µg/dL). Clinical manifestations include growth retardation in children and adolescents, hypogonadism in males, dysgeusia, poor appetite, poor wound healing, abnormal dark adaptation, and impaired mentation. Cutaneous manifestations, when present, are usually less striking and present predominantly as a psoriasiform dermatitis involving the hands and feet and, occasionally, the knees.

Laboratory Testing. A low plasma zinc level is the gold standard for diagnosing zinc deficiency. Use of contaminated needles, catheters, and sample tubes may



Figure 130-11 Zinc deficiency. **A.** There are plaques of dry, scaly, eczematous skin around the buttocks. The lesions often become secondarily infected with *Candida albicans*. **B.** Hands. The fingers are enlarged, and there are paronychia and bright erythema on the terminal phalanges.

lead to erroneously high measured zinc levels. Contact with collection tubes with rubber stoppers should be avoided as they may contain high levels of zinc. Normal plasma zinc levels range from 70 to 250 µg/dL. Measurement of serum alkaline phosphatase—a zinc-dependent enzyme—is another useful and rapid indicator of zinc status, as alkaline phosphatase may be low-normal; serum alkaline phosphatase will increase with zinc supplementation, thus confirming the diagnosis.

In cases in which the plasma zinc level is equivocal and the diagnosis is uncertain, skin biopsy for routine histology may be helpful. The characteristic features are variable psoriasiform hyperplasia with confluent parakeratosis, spongiosis and pallor of the upper epidermis, focal dyskeratosis, and variable epidermal atrophy. However, these findings are not specific; and may be seen in a number of other nutritional deficiencies.

Treatment. Zinc supplementation with either an enteral or parenteral formulation is appropriate. Clinical response is usually rapid, with initial improvement noted within several days. Irritability and whining disappear first, followed by improvement of skin lesions. Although several zinc formulations are available, the most commonly used enteral formulation is zinc sulfate. Zinc chloride is recommended for parenteral supplementation.

In children, 0.5–1.0 mg/kg of elemental zinc given as one to two daily doses is recommended for mild-to-moderate zinc deficiency. Higher doses may be required in cases of AZD due to intestinal malabsorption. In adults, 15–30 mg of elemental zinc per day is usually sufficient in cases of AZD. Serum zinc levels should be monitored during therapy. Patients with AE require lifelong treatment. Patients with AZD may need variable levels of supplementation, depending on their underlying disease. Of note, excess zinc levels may interfere with copper metabolism.

Zinc Toxicity. Zinc toxicity has been reported with exposure to zinc-containing fumes, intravenous poisoning, and ingestion of large amounts of zinc. There are no cutaneous manifestations, but patients may present with severe vomiting, nausea, lethargy, dizziness, neuropathy, and dehydration. Hypocupremia may result.

NOMA

NOMA AT A GLANCE

- Devastating gangrene of the soft and hard tissue of the face found in developing countries.
- Malnutrition, vitamin deficiencies, and immune dysregulation create an environment for this rapidly progressive destructive polymicrobial infection.

BOX 130-15 CLINICAL PRESENTATION OF NOMA

- Rapid progression of soreness of mouth, halitosis, purulent oral discharge, tenderness of lips and cheeks
- Necrotizing stomatitis starting at alveolar margin and extending to mucosal surface of cheek
- Swelling and blue–black discoloration of cheek → cone-shaped black necrosis, tissue destruction, and ulceration

EPIDEMIOLOGY

Noma (necrotizing ulcerative stomatitis, stomatitis gangrenosa, or cancrum oris) is a devastating gangrenous condition that destroys soft and hard tissue of the face that predominantly affects children between the ages of 1 and 4. "Noma" originates from the Greek word *νομη*, which means to graze or to devour, which reflects the rapid progression of this condition.

In 1848, Tourdes was the first to define noma as

> *a gangrenous disease affecting the mouth and face of children living in poor hygiene conditions and suffering from debilitating diseases, especially eruptive fevers. Beginning with an ulcer on the oral mucosa rapidly spreading outside and destroying the soft and hard tissues of the face—and almost always fatal*[169]

As public health initiatives improved sanitation in developed countries, the global epidemiology of noma likewise improved. In general, noma has become a rare occurrence in developed countries and is predominantly encountered now only in parts of Africa, Latin America, and Asia. Intermittent epidemics of noma have been noted during World War I, the malaria epidemic in 1938, and World War II in the Belsen and Auschwitz concentration camps.[170] In response to reports from humanitarian organizations, the World Health Organization declared noma a health priority in 1994. The WHO estimates the worldwide incidence of noma to be 500,000 cases per year with a 79% mortality rate. An estimated 25,000 children are affected in the developing countries bordering the Sahara every year.[171] Unfortunately, the data on the incidence of noma are likely an underestimation of the true incidence since less than 10% of affected individuals actually seek medical care.[53] The high mortality rate and rapid progression of disease means that many patients die before reaching medical attention. Moreover, many cultures perceive noma as a curse on the family, so affected children are often ignored or hidden. Finally, the nomadic lifestyles of many patients make them difficult to register and follow.

An increase in noma has been observed in developed countries over the last two decades, mostly in association with immunosuppressive therapy, HIV/AIDS, and severe combined immunodeficiency.[54]

Noma neonatorum is thought to be a related but separate entity from noma. The original description

by Ghosal in 1978 described 35 premature and low birthweight infants in India who developed gangrenous lesions on their noses, eyelids, oral cavities, anal regions, and genitalia. These infants had *Pseudomonas aeruginosa* isolated from their skin lesions and many of their blood cultures. This condition is almost uniformly fatal. Since Ghosal's description, clinical experience has shown that preterm and low birthweight newborns, especially those with severe intrauterine growth retardation, are at highest risk. The causative organism is usually *Pseudomonas*, but *Escherichia coli*, *Klebsiella*, and *Staphylococci* have occasionally been isolated. Since most cases of noma neonatorum are caused by *Pseudomonas*, some have wondered if it is really ecthyma gangrenosum.[55] Almost all reported cases have been from India, China, Lebanon, or Israel, but there was one reported case in the United States in 2002.

ETIOLOGY AND PATHOGENESIS

The pathogenesis of noma is a complex, and yet undefined, interaction between infection, impaired host defense, and malnutrition. The one known risk factor for noma is poverty. There have been no reported cases of noma in well-nourished African children. An epidemiological study in a Nigerian hospital in 2002 revealed that 98% of affected children lived in very poor homes with an average of seven children per family.[56]

Malnutrition and associated vitamin deficiencies contribute to the pathogenesis of noma. Deficiencies in vitamin A, B_6, C, and E, and the trace elements iron, zinc, and amino acids cysteine, methionine, serine, and glycine have been identified as possible contributing factors to immune dysfunction in the malnourished. Adrenal hyperfunction in PEM has also been implicated in depression of cell-mediated immunity, and decrease in mucosal resilience. Early malnutrition and chronic infections due to early weaning from breast milk may also represent predisposing factors.[172]

In the early 1940s, Albert Eckstein proposed that acute necrotizing gingivitis (ANG), a painful inflammation and necrosis of the interdental papillae, was the precursor to noma. He hypothesized that progression to necrotic stomatitis and noma occurred if appropriate dental hygiene and antibiotics were not initiated. ANG is associated with poor oral hygiene, stress, and malnutrition. However, any oral mucosal ulceration or trauma, including tooth eruption and viral ulcers, can develop into noma.[173]

Patients with noma frequently have a recent history of debilitating infections, with measles and malaria being the most frequent. Unfortunately, the causative link between these preceding infections and noma remain unclear. Studies in Nigeria show that the frequencies of malaria in northern and southern regions are equal, but the prevalence of noma in the north is higher than in the south. The link between measles and noma appears stronger, but still elusive. The ulcerative oral lesions in patients with measles are one proposed site of initiation of noma.[174]

Noma is a polymicrobial infection, with *Prevotella intermedia* and *Fusobacterium necrophorum* being the two most frequently isolated organisms.[175] Other frequently identified organisms are *Tannerella forsynthesis*, *Peptostreptococcus micros*, *Campylobacter*, *Streptococci*, and enteric Gram-negative rods. Although organisms are isolated from noma lesions, there is a low likelihood of transmissibility. There are no reports of outbreaks in families or villages after one child develops noma. Groupings of noma seem to be more associated with common risk factors rather than true transmission.

CLINICAL FINDINGS

The prodrome of noma is not well documented because of late presentation to medical care and rapid progression. Parents often describe fever and apathy. Early acute noma often presents with soreness of the mouth, halitosis, tenderness of the lip or cheek, cervical lymphadenopathy, and purulent oral discharge. The intraoral lesion is a necrotizing stomatitis generally starting on the alveolar margin and extending to the mucosal surface of the cheek. This evolution is rapid, taking 24–48 hours. Swelling and blue–black discoloration of the skin overlying the intraoral lesion develops and rapidly becomes necrotic with well-defined borders. As it becomes black, this necrotic zone expands and forms a classic cone shape, cone gangreneux, with internal destruction greater than external involvement (Fig. 130-12). Laboratory investigation often shows severe anemia, a high white blood cell count, and hypoalbuminemia (see Box 130-15).

Healing noma lesions are also difficult to manage because of the extensive fibrous scars. These scars can lead to strictures of the mouth, severe dental malposition, defective speech, and even complete closure of the mouth from contractures.

TREATMENT. Management of acute noma is geared toward minimizing damage, but invasive intraoral



Figure 130-12 Cancrum oris (noma). Massive destruction of the face in a Tanzanian child.

procedures are contraindicated. Key goals of acute management are:

1. Correction of dehydration and electrolyte imbalances
2. Treatment of predisposing disease, i.e., malaria, measles, HIV, TB
3. Antibiotics: some researchers recommend broad-spectrum antibiotics, while others believe that metronidazole is adequate since anaerobic organisms predominate.
4. Oral hygiene with chlorhexidine digluconate rinses
5. Nutritional rehabilitation: oral, enteral, or parenteral
6. Local wound care
7. Physiotherapy: to reduce strictures from fibrous scarring

Surgical intervention should not occur until the acute phase has ended, and is aimed at restoring function and improving appearance to allow patients to reintegrate into society.

CONCLUSION

Nutritional disorders arise most commonly as a result of nutrient deficiencies, but may also derive from imbalances in nutrients or at times from nutrient excess. Because macronutrients and micronutrients play roles in multiple biochemical pathways, these disorders often present with clinical features in a variety of organ systems. The key to diagnosis is in having a familiarity with the range of clinical presentations associated with these disorders and maintaining an appropriate index of suspicion for these disorders when evaluating dermatologic patients with skin findings or a history that might suggest a nutritional etiology.

ACKNOWLEDGMENTS

The authors thank Kara N. Shah, MD, PhD, FAAP, for her contributions to this chapter in previous editions.

KEY REFERENCES

Full reference list available at www.DIGM8.com

DVD contains references and additional content

9. Barness L: *Nutrition and Nutritional Disorders*, 14th edition. Philadelphia, WB Saunders, 1992
11. Miller S: Nutritional deficiency and the skin. *J Am Acad Dermatol* **21**:1-30, 1989
12. Prendiville J, Manfredi L: Skin signs of nutritional disorders. *Semin Dermatol* **11**:88-97, 1992
14. Ruiz-Maldonado R, Orozco-Ovarrubias L: *Skin Manifestations of Nutritional Disorders*. Malden, MA, Blackwell Publishing Ltd., 2006
18. Strumia R: Dermatologic signs in patients with eating disorders. *Am J Clin Dermatol* **6**:165-173, 2005
19. Ryan A, Goldsmith L: Nutrition and the skin. *Clin Dermatol* **14**:389-406, 1996
33. Weinstock M et al: Topical tretinoin therapy and all-cause mortality. *Arch Dermatol* **145**:18-24, 2009
62. Norval M, Wulf H: Does chronic sunscreen use reduce vitamin D production to insufficient levels? *Br J Dermatol* **161**:732-736, 2009
64. Lim H et al: Sunlight, tanning booths, and vitamin D. *J Am Acad Dermatol* **52**:868-876, 2005
97. MacDonald A, Forsyth A: Nutritional deficiencies and the skin. *Clin Exp Dermatol* **30**:388-390, 2005
176. Gartner LM, Greer FR: American Academy of Pediatrics, Section on Breastfeeding and Committee on Nutrition. Prevention of rickets and vitamin D deficiency: new guidelines for vitamin D intake. *Pediatrics* **111**(4):908-910, 2003

Chapter 131 :: Cutaneous Changes in Errors of Amino Acid Metabolism

:: Peter H. Itin

Inborn errors of amino acid metabolism are inherited defects of enzymes that result in important disturbance in amino acid biology.[1] Most of them are autosomal recessive disorders. Amino acids are the molecular units that make up proteins, and all proteins are various combinations of 20 specific naturally occurring amino acids.

Diseases of amino acid metabolism may lead to multiorgan disorders with signs and symptoms of mental retardation and dysfunction in numerous additional organs, including skin and hair.[2] With more sophisticated diagnostic techniques, metabolic diseases have gained increasing importance, and numerous rare entities have been identified, including hyperphenylalaninemias, hypertyrosinemias, disorders of histidine metabolism, disorders of proline and hydroxyproline metabolism, hyperornithinemias, dysfunctions of urea cycle enzymes, disorders of lysine metabolism, disorders of branched-chain amino acid and keto acid metabolism, disorders of transsulfuration with homocystinuria and homocystinemia, sarcosinemia, and nonketotic hyperglycinemia.[3]

Several diseases have important cutaneous manifestations that might be a clue to diagnosis (Table 131-1). An example of such a key manifestation representing errors of amino acid metabolism is acrodermatitis

TABLE 131-1
Inherited Disorders of Amino Acid and Organic Acid Metabolism with Skin Manifestations

Disease	Skin Manifestations	Deficient Enzyme/ Pathophysiology (Mode of Inheritance)
Alkaptonuria	Ochronosis Black cerumen, eccrine, and apocrine secretions	Homogentisic acid oxidase (AR)
Argininosuccinic aciduria	Trichorrhexis nodosa Rough skin	Argininosuccinase (AR)
Aspartylglycosaminuria	Thick skin Coarsening of face Sagging skinfolds Increased acne Photosensitivity	Aspartylglycosamidase (AR)
Biotinidase deficiency	Erythematous rash Alopecia Oral candidiasis Seborrheic dermatitis Glossitis	Biotinidase (AR)
Citrullinemia	Light, short hair with interrupted cuticle	Argininosuccinate synthetase (AR)
Hartnup disease	Pellagra-like lesions Photosensitivity	Defect of neutral amino acid transport in renal and intestinal brush border (AR); increases excretion of tryptophan metabolites
Histidinemia	Light-colored hair and eyes	Histidase (AR)
Holocarboxylase synthetase deficiency	Seborrheic dermatitis Alopecia	Holocarboxylase synthetase (AR)
Homocystinuria	Fine, sparse, friable hair Thin skin Livedo reticularis Malar flush Vascular occlusions Marfanoid habitus	Cystathionine β-synthetase (AR)
Hydroxykynureninuria	Chronic stomatitis Ulcerated gums, gingivitis Photosensitivity	Kynureninase (AR)
Hyperprolinemia	Ichthyosis	Proline oxidase (AR)
Iminodipeptiduria (prolidase deficiency)	Chronic skin ulcers Recurrent infections	Prolidase (AR)
Isovaleric acidemia	Odor of sweaty feet, alopecia	Isovaleryl-coenzyme A dehydrogenase (AR)
Methionine malabsorption syndrome	White hair Dried celery or oasthouse odor Edema	Defective methionine transport
Phenylketonuria	Hypopigmentation Atopic dermatitis Scleroderma	Phenylalanine hydroxylase (AR) Dihydropterine reductase Defective dihydropterine synthesis
Tyrosinemia II	Painful, acral erosions Hyperkeratosis Corneal/conjunctival plaques and erosions	Tyrosine aminotransferase (AR)
Xanthurenic aciduria	Urticaria	Kynureninase (AD)

AD = autosomal dominant; AR = autosomal recessive.

acidemica. These patients have characteristic cutaneous lesions that are similar to those in acrodermatitis enteropathica (see Chapter 130). Psoriasiform dermatitis on the trunk and extremities may occur together with diffuse alopecia and brittle hair.[4] In general, acral dermatitis with perioral erythema and desquamation is associated with poor feeding, lethargy, hypotonia, vomiting, and dehydration. Patients often have progressive neurologic symptoms. Patients with branched-chain aminoacidopathies may have methylmalonic acidemia, propionic acidemia, glutaric acidemia, biotinidase deficiency, multiple carboxylase deficiency, or maple syrup urine disease, all of which are sometimes accompanied by cutaneous problems.

In general, all patients with acrodermatitis acidemica have absolute missing enzyme activity of their autosomal recessive mutated gene. Diagnosis is confirmed by documentation of increased amounts of amino acids in the urine. Exact diagnosis is the first step for adequate treatment of these diseases.

Hartnup disease results from a deficiency of neutral amino acid transport within the kidneys and small intestine and leads to pellagra-like features in a photodistribution (see Chapter 130). Neurologic deficiencies and reduced mental skills are often associated. The treatment of choice is nicotinamide.

TYROSINEMIAS

TYROSINEMIA AT A GLANCE

- Approximately 100 cases are reported worldwide.
- Tyrosinemia is an autosomal recessive disease induced by a deficiency of cytoplasmic tyrosine aminotransferase related to a defect on chromosome bands 16q22.1–22.3 (OMIM #276600).
- Dermatologic manifestations include focal/diffuse palmoplantar keratosis with erosions, bullae or erythema, hyperhidrosis, and painful corneal erosions with photophobia; 50% of patients have mental retardation.
- Diet restriction of phenylalanine and tyrosine leads to amelioration of cutaneous symptoms and eye lesions.
- Differential diagnosis includes other forms of palmoplantar keratodermas and herpetic keratitis.
- Prenatal diagnosis is possible by amniocentesis with tyrosine aminotransferase assay and DNA analysis.

The genetic tyrosinemias are characterized by the accumulation of tyrosine in body fluids and tissue.[5,6] Tyrosine is a semiessential amino acid, derived from the liberation of tyrosine from hydrolysis of dietary or tissue protein, or from the hydroxylation of the essential amino acid phenylalanine, and is the starting point for the synthesis of catecholamines, thyroid hormones, and melanogenesis. There are three types of tyrosinemia. The skin is not involved in tyrosinemia types I and III, but it is involved in tyrosinemia II, which is also called the *oculocutaneous tyrosinemia* and *Richner–Hanhart syndrome* [Online Mendelian Inheritance in Man (OMIM) #276600]. Tyrosinemia II is a rare distinctive clinical symptom complex involving the eyes, skin, and central nervous system and is potentially treatable. Tyrosine levels are elevated because of a deficiency of hepatic tyrosine aminotransferase (TAT).

CLINICAL FEATURES

Approximately 100 patients with this clinical syndrome have been reported. Goldsmith and Reed were the first to correlate the oculocutaneous syndrome with an underlying tyrosinemia.[7] All patients had tyrosinemia, phenolic aciduria, and inflammatory skin and eye lesions. The sexes are affected equally, and the disease is worldwide in distribution. Transmission of tyrosinemia II is autosomal recessive. Consanguinity has been documented, and occurrence in several siblings within a family is well known (pseudodominant pattern). Heterozygotes are unaffected clinically and demonstrate no biochemical alterations of tyrosine or its metabolites in blood or urine.

DERMATOLOGIC FEATURES. Patients have hyperkeratotic yellowish skin lesions limited to the palms and soles, which in 80% of cases occur on the peripheral pressure-bearing areas.[5,7] Lesions usually begin during the first year of life. The skin lesions are painful, nonpruritic, and frequently associated with hyperhidrosis (Fig. 131-1). Diffuse plantar keratoderma and self-mutilation have been observed in individuals with tyrosinemia II.[8] Leukokeratosis of the tongue has been reported. Bullous lesions may occur and progress rapidly to erosions; these then become crusted and hyperkeratotic.[9] The fingertips and hypothenar eminences are commonly involved. Rare patients have hyperpigmentation and/or hyperkeratotic subungual lesions, and in older persons hyperkeratosis in the elbows, knees, and ankles may appear.[2]

OPHTHALMOLOGIC FEATURES. The most important manifestations of oculocutaneous tyrosinemia are those involving the eye, because they can lead to permanent visual impairment.[10] Eye lesions occur weeks to months before the skin lesions. Ophthalmologic symptoms start as early as the first day of life and as late as 38 years of age. Tearing, redness, pain, and photophobia are early signs and symptoms; late findings include corneal clouding and central or paracentral opacities, which are initially intraepithelial and can progress to superficial or deep pseudodendritic



Figure 131-1 Hyperkeratotic (**A**) and erosive (**B**) lesions in a patient with tyrosinemia II.

keratitis (Fig. 131-2). Slit-lamp examination may reveal some degree of corneal ulceration, and occasionally birefringent crystals of tyrosine may be observed. Neovascularization is prominent. The eye disease occurs in 75% of affected patients and may lead to scarring, nystagmus, and exodeviation. Ocular symptoms may show spontaneous remission and recurrences and may occur independently of other manifestations. Topical therapy is ineffective, and herpes simplex virus and bacterial cultures consistently yield negative results.



Figure 131-2 Corneal changes in tyrosinemia II. **A.** Cornea before treatment (left eye); corneal opacity and neovascularization are prominent. **B.** The right eye has even more extensive involvement. **C.** After 6 weeks of therapy, there is marked clearing of the lesions.

NEUROLOGIC FEATURES. Mental retardation of varying degrees is reported in half the cases, as is normal mental development. Hyperactivity has been observed in several affected children, as has abnormal language development. Untreated tyrosinemia II during pregnancy may be associated with mental retardation or seizures in the children resulting from that pregnancy.[11]

LABORATORY FINDINGS

AMINO ACID ABNORMALITIES. In establishing the diagnosis in a child with tyrosinemia II, laboratory verification of plasma amino acid and urine organic acid levels is mandatory. The blood and urine tyrosine levels of affected patients are markedly elevated. Levels of other amino acids are not increased. Urinary tyrosine metabolite levels are elevated; these include *p*-hydroxyphenylpyruvic acid, *p*-hydroxyphenyllactic acid, *p*-hydroxyphenylacetic acid, and *N*-acetyltyrosine (Fig. 131-3). All these metabolic effects are consequences of the deficiency of hepatic TAT. A fluorometric procedure exists as well as a tandem mass spectrometry, which is used for neonatal screening. Recently, an asymptomatic newborn was detected to have Richner–Hanhart syndrome on the third day of life as a result of the newborn screening. Interestingly the 8-year-old brother with persistent plantar hyperkeratotic plaques of the soles of yet unknown origin was subsequently identified to be also affected tyrosinemia type II.[12]

TAT is a pyridoxal phosphate-dependent cytoplasmic enzyme that transaminates tyrosine, forming *p*-hydroxyphenylpyruvate (PHPPA). The human *TAT* gene contains 12 exons and transcribes a 2.75-kb messenger RNA (mRNA) that codes for a 454-amino acid protein.[5] The liver is the richest source of TAT; this specific TAT is not present in skin. In tyrosinemia II, the liver biopsy specimen shows little or no soluble TAT, although there is normal or slightly increased mitochondrial tyrosine (aspartate) transaminase activity.[12,13] Mitochondrial aspartate aminotransferase using tyrosine as a substrate produces increased amounts of PHPPA from the increased amounts of tyrosine available in tyrosinemia II. Because mitochondria do not have PHPPA oxidase activity, PHPPA and its metabolic products increase and appear in the urine, which creates the unusual situation in which metabolites are increased both proximally and distally to the defective enzyme.

HISTOPATHOLOGY. Routine histopathologic analysis of the skin is not diagnostic; it shows hyperkeratosis, parakeratosis, and acanthosis.[9] In some cases, electron microscopy studies have shown lipid droplets in the cornified layer, increases in tonofibrils and keratohyalin, very tightly packed microtubular and microfibrillar masses, and minute tyrosine crystals in keratinocytes and Merkel cells.[14]

GENETICS. Mutations occur in the human *TAT* gene, which results in high levels of tyrosine. *TAT* maps to the q22-q24 region of chromosome 16 and has been sequenced.[5] Multiple point mutations scattered throughout the *TAT* gene have been associated with tyrosinemia II.[15]

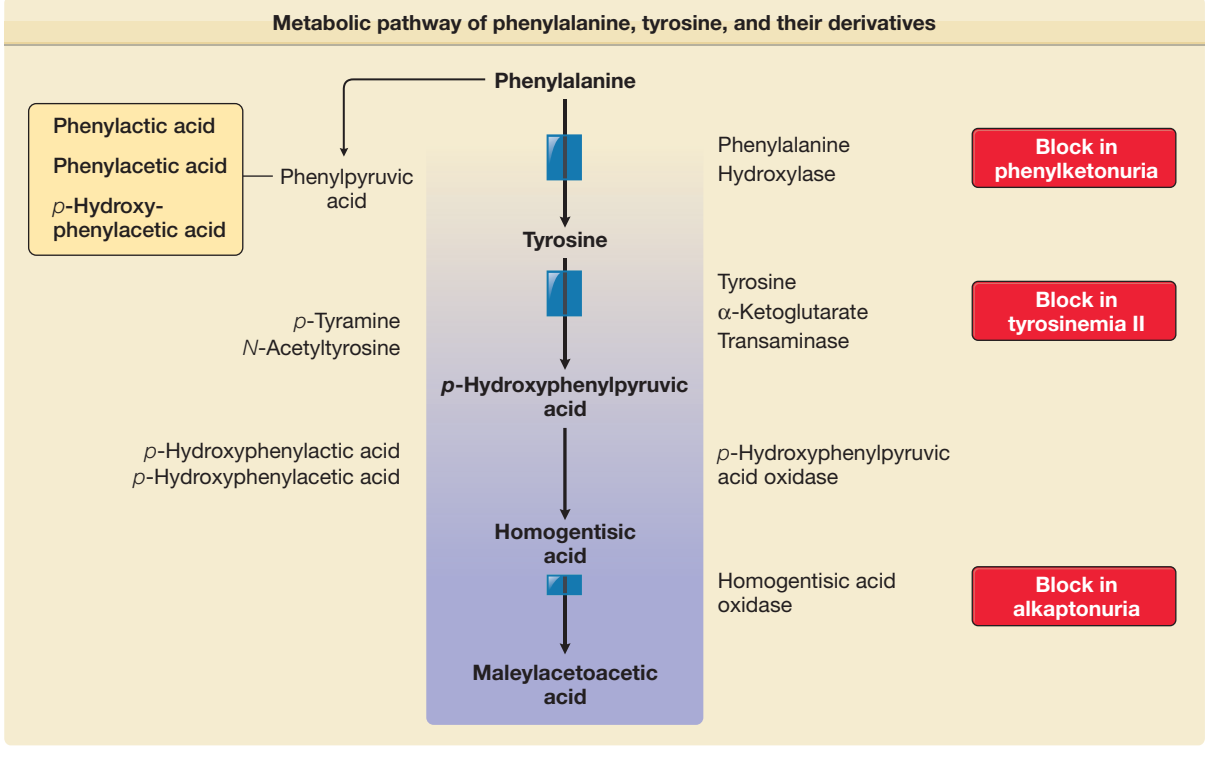

Figure 131-3 Metabolic pathway of phenylalanine, tyrosine, and their derivatives.

BOX 131-1 DIFFERENTIAL DIAGNOSIS OF TYROSINEMIA

Main Features

- Eyes
  - Herpetiform corneal ulcers
- Skin
  - Punctate, painful palmoplantar keratoderma on weight-bearing areas
- Neurologic features
  - Mental retardation
  - Hyperactivity

Consider

- Palmoplantar keratoderma with associated features
  - Corneodermatoosseous syndrome

Always Rule Out

- Eyes
  - Viral and bacterial infection
- Skin
  - Other forms of keratodermas, acquired or genetic

BOX 131-2 TREATMENT OF TYROSINEMIA

- Low-tyrosine, low-phenylalanine diet
- Etretinate systemically

DIFFERENTIAL DIAGNOSIS. (See Box 131-1). Corneodermatoosseous syndrome (OMIM #122440), an autosomal dominant symptom complex of volar keratosis and keratitis that is clinically similar to tyrosinemia II, has been described in one family.[20] The lesions were more extensive than those in the classic Richner–Hanhart syndrome. In addition, brachydactyly with short distal phalanges, short stature, and soft teeth may occur.

TREATMENT

With consumption of a low-tyrosine, low-phenylalanine diet (Mead Johnson, Tyromex-Ross), there is a rapid decrease in tyrosine to normal levels (30–90 μM). Skin and eye lesions cleared within days and weeks in all individuals treated with the diet[7,12] (see Fig. 131-2C; Fig. 131-4; Box 131-2).

Some patients have responded objectively to etretinate, although plasma tyrosine levels remained unchanged.[21] In none of the patients studied has there been a response to cortisone acetate, ascorbic acid, pyridoxine, or folic acid, which are cofactors or known inducers of TAT and PHPPA oxidase. Surgical treatment is recommended for palmar lesions but not for the plantar form.

Because the consequences of tyrosinemia II are serious and a safe treatment is available, a patient presenting with any atypical bullous or hyperkeratotic disease on the palms and soles in the first months of life should be screened for tyrosine and its metabolites; screening tests are available in most hospital laboratories.[22] Amino acid analysis is necessary to confirm the diagnosis and follow the response to diet therapy. Dietary control in pregnancy should be recommended. A patient with tyrosinemia II was reported who had undergone two untreated pregnancies. During the pregnancies, plasma tyrosine level was raised, and the infants were retarded. On the other hand, several normal children of mothers with the disease have been observed.[23]

PHENYLKETONURIA

Phenylketonuria (phenylpyruvic oligophrenia, PKU) is an autosomal recessive disorder of aromatic amino acid metabolism (OMIM #261600) in which phenylalanine cannot be converted to tyrosine. Its discovery over 70 years ago has established the link between metabolic disease and intellectual impairment, and led to the development of neonatal screening programs across the globe. In addition, it demonstrated how effective treatment could lead to a near normal outcome for affected individuals. PKU is caused by a deficiency of hepatic



Figure 131-4 **A.** Diffuse plantar hyperkeratosis in an adult with tyrosinemia. **B.** The hyperkeratosis cleared on a low-tyrosine, low-phenylalanine diet without topical treatment.

PHENYLKETONURIA AT A GLANCE

- Autosomal recessive disorder induced by phenylalanine hydroxylase deficiency (OMIM #261600). Gene on chromosome bands 12q22–24.1; incidence of 1 in 10,000 live births among Europeans.
- Clinical features include mental retardation, generalized hypopigmentation, blond hair, blue eyes, eczematous rash, vomiting in infancy, hyperactivity and seizures, mousy odor.
- Diagnosis is confirmed by a positive result on urinary ferric chloride test.
- Treatment consists of restricting phenylalanine in the diet.
- Differential diagnosis includes albinism, Chédiak–Higashi syndrome, and scleroderma.
- Prenatal diagnosis is possible by chorionic villus sampling/amniocentesis, measurement of metabolite levels, and DNA analysis.

phenylalanine hydroxylase or cofactors for phenylalanine hydroxylase. PAH deficiency seems to be a protein-misfolding disease in which global conformational changes hinder molecular motions essential for physiological enzyme function.[24] There are additional causes that may lead to hyperphenylalaninemias, and eight subtypes have been described. Maternal PKU may lead to hyperphenylalaninemia. Unless the mother follows a special diet, the child is at risk to develop the typical signs and symptoms of PKU. Defects of biopterin metabolism, prematurity, liver disease, use of medications such as methotrexate, and high-protein diets may produce findings similar to those in PKU. Genotype-based prediction and classification of the biochemical phenotype is now possible in the majority of newborns with hyperphenylalaninemia.[24]

EPIDEMIOLOGY

The prevalence of PKU varies markedly in various countries. The highest incidence of PKU is found in Ireland and Scotland (1 in 4,000), whereas in Finland only 1 in 40,000 births are affected. The overall frequency among northern Europeans was calculated to be approximately 1 in 10,000 and in the United States classic PKU was estimated to occur in approximately 1 in 11,000 births in the white population. Among blacks the frequency was estimated to be only approximately 1 in 50,000.[25]

CLINICAL FEATURES

The clinical hallmarks of PKU are mental retardation, diffuse hypopigmentation, seizures, eczematous dermatitis, and photosensitivity.[26] Newborns appear to be normal and develop manifestations of psychomotor alterations between 4 and 24 months of age. Early symptoms include heavy vomiting. The most important defects are marked mental retardation with irritability, hyperactivity, self-destructive behavior, hypertonicity, and seizures. Peculiar gait and increased deep tendon reflexes are noted. Microcephaly, brain calcification, and cataracts are observed quite commonly. Typically, a mousy odor induced by phenylacetic acid is noted in urine and sweat.

Early infantile eczema, indistinguishable from atopic dermatitis, or seborrheic dermatitis may be one of the first signs of PKU and occurs in 20%–50% of affected infants during the first year of life. Later on, the incidence may be even higher. Dramatic clearing of eczematous skin lesions with a low-phenylalanine diet has been reported in some patients, and a potential role for altered biotin recycling is suggested.[27] A further skin clue in PKU is pigment dilution, with impressive pale pigmentation, blond hair, and blue eyes seen in 90% of patients. The pigment dilution and hair loss is reversible with phenylalanine restriction.[28] The color changes may be especially striking in the rare black or Japanese patient with PKU, whose eye or hair color may be very different from that of other members of the ethnic group. The increased levels of phenylalanine and its oxidation products (phenylpyruvic acid, *o*-hydroxyphenylacetic acid, phenylacetic acid) inhibit the enzyme tyrosinase and therefore reduce melanization.[28]

Patients develop moderate photosensitivity. Edematous scleroderma-like induration of the skin of the extremities, which spares the hands and feet, is characteristic.[29] Plaque, guttate or generalized morphea, and atrophoderma of Pasini and Pierini (see Chapter 64) as well as lichen sclerosus et atrophicus (see Chapter 65) have been observed in PKU.[30]

DIAGNOSIS

Diagnosis of PKU is made by documenting elevated levels of phenylalanine in the serum (20 mg/dL or higher, 10–50 times the normal level). Plasma tyrosine levels may be normal or elevated. In addition, elevated urinary phenylpyruvic acid levels can be documented. Additional laboratory abnormalities include phenylalanine hydroxylase deficiency, phenylpyruvic acidemia, and increased urinary levels of *o*-hydroxyphenylacetic acid and phenylacetylglutamine. Increased urinary levels of phenylpyruvic acid can be detected by a typical green coloration of urine after addition of 10% ferric chloride. In numerous countries, PKU screening is performed in the neonatal screening program either by the semiquantitative bacterial inhibition assay method in which several drops of capillary blood may show an elevated level of phenylalanine in a microbiologic procedure (Guthrie test) or by a quantitative chemical

reaction method (Quantase test).[31] In affected babies, serum phenylalanine levels begin to rise on the third or fourth day of life. Prenatal diagnosis is possible by performing amniocentesis or chorionic villus sampling with identification of the gene. In addition, preimplantation genetic diagnosis for PKU made possible the birth of PKU-free children.[32]

PATHOPHYSIOLOGY AND HISTOLOGY

The classic type of PKU is induced by a deficiency of phenylalanine hydroxylase or its cofactor tetrahydrobiopterin and a consequent accumulation of the precursor phenylalanine. The normal phenylalanine–tyrosine ratio is 1:1, whereas in PKU it is more than 3:1. It is widely believed that the pigment dilution is a result of the inhibitory effect of phenylalanine on tyrosinase. Biopsy specimens show increased fibroblasts and histiocytes and atrophy of skin appendages. The elastic fibers are scanty and fragmented and are thus different from those found in true scleroderma. Histologic examination shows a normal number of melanocytes but a decrease in mature melanosomes.

DIFFERENTIAL DIAGNOSIS

Atopic dermatitis and scleroderma as primary disorders must be distinguished from PKU (Box 131-3). Premature infants and individuals with liver disease may also show elevated plasma levels of phenylalanine.

TREATMENT

With a low-phenylalanine diet, which should probably be followed for life, the skin color, photosensitivity, odor, and eczema are reversible. In addition, early diet can dramatically reduce mental retardation, and if the blood phenylalanine levels are maintained at reasonable levels in early childhood, normal to low-normal intelligence can be expected[33] (Box 131-4). However, rigorous control of diet can lead to protein deficiency and an eczematous dermatitis. Recently, sapropterin has been shown to increase phenylalanine tolerance while maintaining blood phenylalanine control.[34–37]

BOX 131-3 DIFFERENTIAL DIAGNOSIS OF PHENYLKETONURIA

Main Features

- Skin
  - Pale pigmentation, dry skin and eczema, scleroderma-like lesions, fair hair
- Eyes
  - Blue eyes
- Neurologic features
  - Mental retardation
  - Seizures
  - Irritability and increased deep tendon reflexes

Consider

- Other disorders of amino acid metabolism with neurocutaneous features

Always Rule Out

- Atopic dermatitis
- Scleroderma

BOX 131-4 TREATMENT OF PHENYLKETONURIA

- Low-phenylalanine diet
- Fish oil supplementation, which seems to improve visual evoked potentials
- Tyrosine supplementation (?)
- New phenylalanine-free formulas
- Reduction of phenylalanine uptake with purified phenylalanine ammonia-lyase
- Recombinant or pegylated phenylalanine ammonia-lyase
- Tetrahydrobiopterin supplementation to increase phenylalanine hydroxylase activity
- Large neutral amino acids supplementation to compete for blood-brain barrier carriers

ARGININOSUCCINIC ACIDURIA

DEFINITION AND CLINICAL FEATURES

Argininosuccinic aciduria (ASA; OMIM #207900) is an autosomal recessive disorder of the urea cycle. Its incidence is estimated to be 1 in 70,000. ASA is characterized by hepatomegaly, mental retardation, seizures, episodic lethargy and ataxia, and friable, brittle hair with the morphology of trichorrhexis nodosa (see Chapter 88). The deficiency of an essential cytosolic enzyme in the urea cycle, argininosuccinase (argininosuccinate lyase), causes citrullinemia and an increase in blood ammonia. Argininosuccinate is increased in the blood and spinal fluid and is excreted in large amounts (2–9 g/day) in the urine.

The detailed clinical and biochemical features of the disease and the principles of therapy are reviewed by Nyhan, Barshop, and Ozand.[2] The hair abnormality is more characteristic of the late-onset disease, but in the early cases this peculiar type of alopecia brought the first patients to clinical attention.[38] Weaning and a change to a diet with a higher protein content can be precipitating factors in clinical disease. Essential to current therapeutic regimens are diets providing adequate energy, protein, and arginine.

The molecular pathology of the nucleic acids in this disease has been clarified, but the detailed pathophysiology of the hair defect remains to be determined.[39–41]

HAIR DEFECTS

CLINICAL AND MORPHOLOGIC FEATURES.[42]

About half the reported patients have had abnormally friable hair with visible trichorrhexis nodosa (see Chapter 88); the other half have had grossly normal hair. Brushing and combing accentuate breaking (i.e., brittle hair). No definite correlation can be made between liver argininosuccinase level, argininosuccinic acid levels, arginine levels, and the degree of hair abnormalities; some patients with severe ASA have had seemingly normal hair. Some patients' hair has improved with diet or without specific therapy. Hair shafts may show pseudotrichothiodystrophy under polarizing microscopy with the typical dark and light banding.[45] Diet reverses grooving and abnormal polarization of hair shafts in argininosuccinase deficiency.[44] Eyelashes, eyebrows, and general body hair, as well as the nails, may be involved.

MOLECULAR NATURE OF HAIR DEFECTS.

The basic nature of the hair defects is not known.[45,46]

Increasing arginine in the diet aids hair growth and structure in this disease, which suggests that the decrease in arginine may be related to the defective hair. Because the urea cycle is depressed in ASA, the arginine required for protein synthesis would come predominantly from dietary sources. Hair protein is rich in arginine (up to 10% of the amino acid residues are arginine); furthermore, the citrulline present in certain specialized proteins in the medulla and internal root sheath is derived from arginine.

OTHER DISORDERS OF THE UREA CYCLE[30]

In citrullinemia (OMIM #215700), a rare recessive disease caused by the absence of argininosuccinic acid synthetase, there is somatic and mental retardation and increased levels of citrulline in blood, urine, and cerebral spinal fluid; low to normal values of plasma arginine; and increased blood ammonia levels.[48] Hair in such patients may be brittle, breaking easily. Microscopically, plucked hairs may be flattened, may be twisted through 180° on their own axes, and may show breakage at the point of twisting.[47] Irregular areas of dystrophy and interruption of the cuticle were observed.

Deficiency of the cytosolic enzyme argininosuccinic acid synthetase is associated with trichorrhexis nodosa (see Chapter 88). Its overall clinical presentation is almost identical to that of ASA, although the plasma citrulline levels are usually higher (more than 1 mM) in the former disease. Enzymatic and genetic analyses confirm the diagnosis.

DIAGNOSIS

Retardation, ammonia intolerance, and abnormal hair will suggest these syndromes. The diagnosis is confirmed by high-voltage electrophoresis or ion-exchange chromatography of the urine, blood, or spinal fluid.[48] Only a tiny percentage of the cases of trichorrhexis nodosa and brittle hair are due to ASA. Prenatal diagnosis is possible after chorionic villus sampling or amniocentesis to ensure the birth of unaffected infants.[40]

ALKAPTONURIA

ALKAPTONURIA AT A GLANCE

- Autosomal recessive metabolic disease in which homogentisic acid, an intermediate product in the metabolism of phenylalanine and tyrosine, cannot be further metabolized (OMIM #203500). The cause is a mutation in the homogentisate 1,2-dioxygenase acid oxidase gene on chromosome bands 3q21-q23.
- Clinical features are blue–black or gray discoloration of sclerae, face, pinnae, cartilage, and nails; dark sweat; arthritis; and homogentisic aciduria. Urine is dark after standing in alkaline pH.
- It is suggested that high tissue concentrations of ascorbic acid might delay and possibly reduce the degree of pathologic changes in the connective tissue.
- Differential diagnosis includes argyria, chrysiasis, and pigmentation after treatment with amiodarone and other medications.
- Prenatal diagnosis is possible through DNA analysis.

Alkaptonuria (OMIM #203500), or homogentisic acid oxidase (HGO) deficiency, is a rare metabolic disorder. Excessive homogentisic acid (HGA) is excreted in the urine, which often turns dark, and HGA accumulates in connective tissues, including the dermis[49] (ochronosis).

EPIDEMIOLOGY

Alkaptonuria is inherited as an autosomal recessive trait. Pedigrees suggestive of a dominant mode of transmission contain a high degree of consanguinity and, when subjected to careful scrutiny, are actually found to show pseudodominance. In general populations, alkaptonuria is rare (1 in 250,000), but clusters of high incidence are found in certain groups with inbreeding (e.g., in Slovakia and Santo Domingo). Among Slovakian newborns the incidence is 1 in 19,000. Disease distribution is worldwide, and there is an approximately equal incidence in both sexes.[50]

ETIOLOGY AND PATHOGENESIS

The *HGO* gene maps to the q21-q23.60 region of chromosome 3. Multiple mutations have been found and the mutation spectrum was reviewed recently.[50,51–53] The mutations change residues, which are conserved evolutionarily between *Aspergillus* HGO and human HGO, which suggests that they are fundamental to the activity of HGO. Both compound heterozygotes and homozygotes have been detected.[54]

The biochemical pathway by which phenylalanine and tyrosine normally undergo oxidative degradation to acetoacetic acid is shown in Fig. 131-3. HGA (2,5-dihydroxyphenylacetic acid), the last molecule in the sequence to contain an intact aromatic ring, is cleaved to maleylacetoacetic acid (Fig. 131-5). The enzyme catalyzing ring cleavage, HGO, is normally present in the soluble fraction of liver and kidney cells. It is highly specific for HGA. HGO mRNA is found in liver, kidney, and prostate.[54] Atmospheric oxygen, ferrous ion, and sulfhydryl groups are required for enzymatic function. Quinones inhibit the enzyme. HGO activity is totally absent in both liver and kidney tissue from alkaptonuric subjects. In patients with alkaptonuria, HGA undergoes renal excretion or is transformed to ochronotic pigment within connective tissue. HGA may not be present in the first days of life due to the absence of enzymatic activity of other enzymes in the pathway of tyrosine catabolism.

The renal clearance of HGA is extremely high (up to 400–500 mL/minute) in both normal and alkaptonuric subjects, which indicates active tubular secretion of HGA. This explains how with relatively low fasting plasma concentrations of HGA (in the range of 3 mg/dL) excretion may be up to 4–8 g/day in HGO deficiency. Compounds inhibiting this secretion may be an important factor in ochronosis. Once excreted, HGA (which is itself colorless in solution) gradually oxidizes to dark products. Oxidation occurs by degrees when the urine is exposed to air, but it can be hastened markedly by alkalinization. Urinary pH is the major variable causing the darkening of the urine, and some patients with acidic urine may never have spontaneously black urine. A diet high in protein or tyrosine increases the amount of HGA excreted in disease.

The precise manner by which HGA accumulation in tissues leads to ochronosis is only partially understood. A presumed HGA polymer has never been characterized.[55]

Alkaptonuric mice (*aku*) do not have black urine or deposition of pigment, which is possibly related to the mouse's ability to synthesize ascorbic acid.[56]

Experimental ochronosis induced by prolonged feeding of high-tyrosine diets to rats may delineate the precise interaction between HGA and its products and connective tissue.[57] HGO also has been produced in experimental animals by L-phenylalanine feeding and diets deficient in sulfur amino acids or tryptophan and the iron chelator α,α′-dipyridyl.

HGA inhibits lysyl hydroxylase, an enzyme crucial for collagen cross-linking, in chick embryo calvaria, which suggests that a reduction in the structural integrity of collagen consequent to deficient hydroxylysine-derived cross-linkages may be responsible for cartilaginous degeneration in alkaptonuria.[58]

Metabolic pathway of phenylalanine and tyrosine degradation with homogentisic acid metabolites

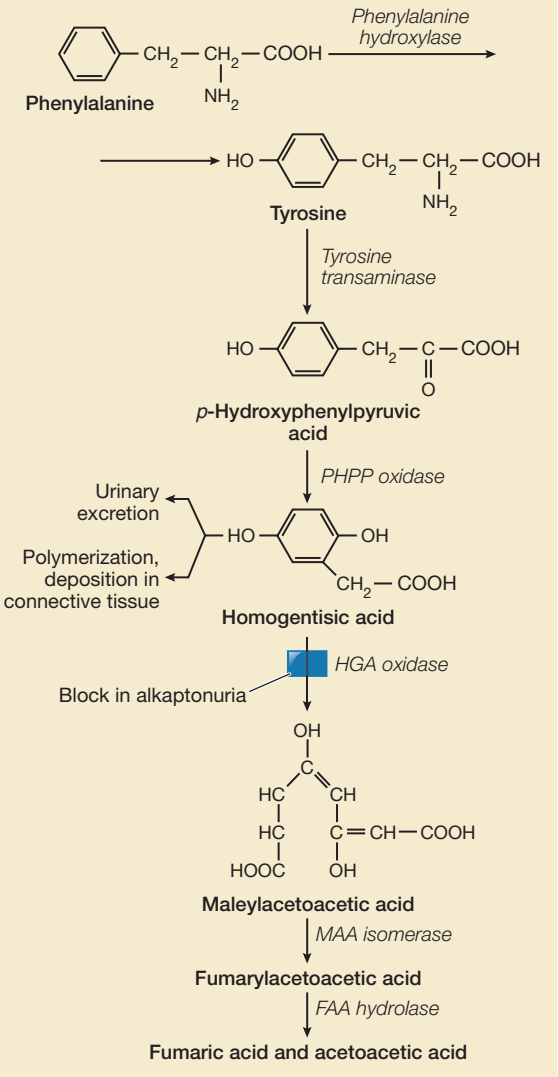

Figure 131-5 Metabolic pathway of phenylalanine and tyrosine degradation with homogentisic acid metabolites. FAA = fumarylacetoacetic acid; HGA = homogentisic acid; MAA = maleylacetoacetic acid; PHPP = *p*-hydroxyphenylpyruvic.

CLINICAL FEATURES

Dark urine is not always the initial manifestation of HGO deficiency. The urine is most apt to discolor rapidly when pH is above 7.0 and when reducing substances, such as ascorbic acid, which normally protect HGA from oxidation, are not present in sufficient quantity. An early diagnosis of HGO deficiency is frequently made when (1) it is specifically sought because of family history, (2) discoloration of diapers occurs after cleansing in (alkaline) soap, (3) the urinary pH favors the oxidation of HGA, or (4) testing for urinary glucose with

Benedict's solution yields an orange precipitate (which indicates a reducing substance) accompanied by a dark supernatant. A positive finding for Benedict's reaction and a negative result on glucose analysis with a glucose oxidase test reagent strongly suggests the diagnosis.

Although the diagnosis of alkaptonuria may be made during childhood, in rare cases the disorder is not detected until the individual develops pathologically significant changes in connective tissue in the third or fourth decade.[59] If coincidental renal disease prevents effective HGA excretion, the development of ochronosis may be accelerated, and diffuse hyperpigmentation may result.

Dark brown or black cerumen may be present in the first decade, even in those younger than 5 years of age. Axillary skin pigmentation (greenish blue, blue, greenish yellow, or brown) in the pattern of glandular orifices may be present late in the first decade. This may be accompanied by staining of underwear ("sweat that stains"). A patient with pigmentary changes confined to sun-exposed areas has been described.[60] Caviar-like ochronotic papules have been reported recently in a patient with ochronosis.[51]

A grayish blue tinge overlying ear cartilage is common in adulthood but is rarely seen before 20 years of age.[61] Ochronotic discoloration is rarely seen in childhood but is common in adulthood and can affect the sclera, cornea, conjunctiva, tarsus, and eyelid skin. Scleral involvement is noted in most patients[62,63] (Fig. 131-6). Scleral discoloration generally is restricted to that portion of the globe exposed by the palpebral fissure. The scleral pigmentation is usually triangular, with the base of the triangle facing the cornea. Tiny "oil droplets" of ochronotic pigment appear at the inner and outer poles of the corneas in advanced ochronosis. Later in the disease, structural changes result in loss of transillumination, stiffening, irregular contours, and eventually, in the third decade, calcification of the pinnae. The tympanic membrane may be blue. Tinnitus and variable degrees of deafness have been ascribed to ochronotic degeneration of the tympanic membrane and underlying ossicles. Laryngeal and tracheal cartilage becomes heavily pigmented but is asymptomatic.

The visible changes that occur with the passage of time are primarily due to the formation of ochronotic pigment granules in the dermis and sweat follicles and, most important, to the transmission of ochronotic discoloration through thin areas of skin overlying pigmented cartilage and tendon. The latter pigmentation, which is fairly uniform in ochronosis, is most apparent at the nose tip, ear (Fig. 131-7), costochondral junctions, and extensor tendons of the hands. Pigmented colloid milium on the dorsa of the hands have been reported.[64] Pigmentation of the skin is less prominent but may occur in a butterfly pattern on the nose and cheeks and even the palms as a presenting sign.[65] Rarely, bluish gray fingernails and intensely dark nevi have been reported.[66] Insidious progression of ochronotic arthropathy, which generally begins in the third and fourth decades in men and approximately 10 years later in women, is the most disabling manifestation of alkaptonuria.[67] The disease is more severe in males. Bouts of acute inflammation may occur. Hip, knee, and shoulder limitation is an early sign. Lumbar pain, lordosis, kyphosis, and sciatica are common. Radiographs

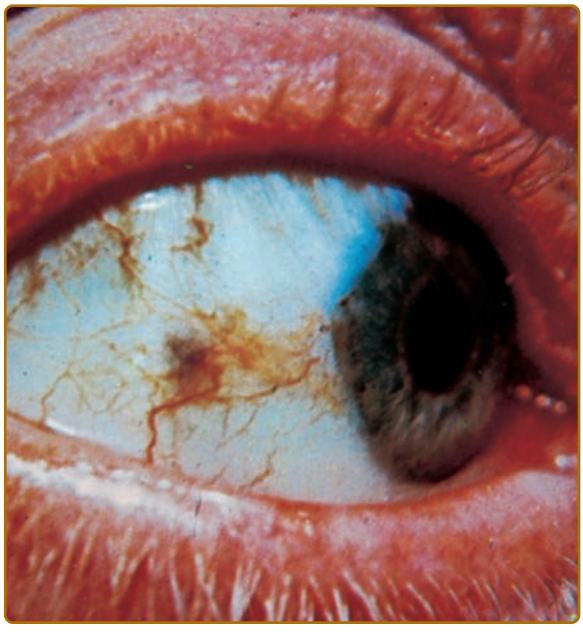

Figure 131-6 Ochronosis (alkaptonuria) has pathognomonic ocular signs. The first to appear is grayish black scleral pigmentation anterior to the tendon insertions of the horizontal recti muscles. At times, pigmentation of the elastic tissue in pinguecula may stain a dark brown or black, and it usually has the configuration of small, dark rings. In advanced cases of ochronosis, Bowman's membrane, adjacent to the limbus, may have areas of black pigmentation.



Figure 131-7 Ochronotic discoloration seen through the thin area of skin overlying the pigmented cartilage of the ear.

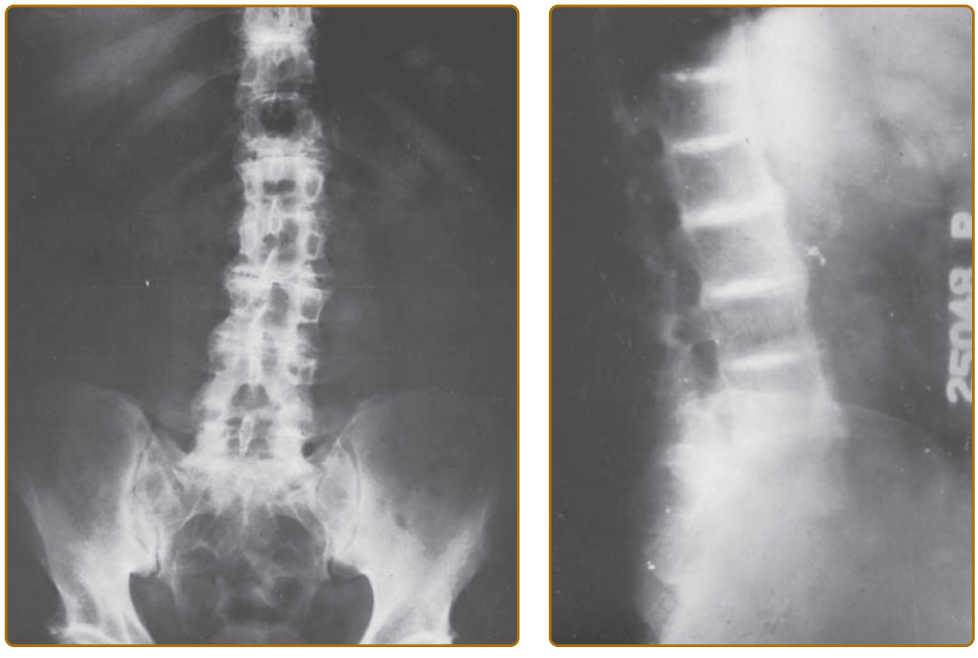

Figure 131-8 Roentgenographic findings in ochronosis. Marked intervertebral disk calcification is present.

show a characteristic appearance of early calcification of the intervertebral disk and later narrowing of the intervertebral spaces, with eventual disk collapse and progressive loss of height (Fig. 131-8). The hands and feet generally are spared. Pseudogout may coexist with ochronosis. It is of note that exogenous ochronosis and striae atrophicae may follow the use of bleaching creams in individuals who do not have alkaptonuria.[66]

There is some suggestion of an increased incidence of cardiovascular disease in patients with ochronosis, but accelerated arteriosclerosis has not been clearly documented. At postmortem examination, pigmentation is commonly observed in the heart valves and annuli and in arteriosclerotic plaques.[68] Prostatic symptoms in older men frequently are due to the formation of soft pigmented calculi in the alkaline secretions of the ducts and sinuses of that gland. Porous black renal stones containing calcium, phosphate, and oxalate also have been reported. The prostate has high levels of HGO mRNA, which may explain the black prostate calculi that are occasionally present in the disease.[41]

LABORATORY FINDINGS

Aside from the excretion of HGA, alkaptonuric patients show no abnormalities on routine clinical laboratory tests. Normal individuals do not excrete HGA; therefore, darkening of the urine on the addition of sodium hydroxide is presumptive evidence of alkaptonuria.

Other tests based on the reducing properties of HGA include the black reaction after treatment with $FeCl_3$ and blackening of photographic emulsion paper on application of a drop of alkaptonuric urine followed by a drop of sodium hydroxide. Specific identification and quantification of urinary (as well as blood) HGA can be achieved by the use of a direct spectrophotometric method using HGO or with high-performance liquid chromatography or stable isotopes.[54]

With the development of ochronotic arthropathy, radiographs of the spine show characteristic disk calcification, which occurs rarely in other forms of spondylitis (see Fig. 131-8). Periostitis, ligament calcification, and sacroiliac sclerosis are not features of ochronotic spondylitis.

PATHOLOGY. Yellow to light-brown (ochre) pigment granules, which led to the original designation of *ochronosis*, are present as free bodies in dermal macrophages.[69] Irregular masses may be over 100 µm in diameter. The pigment, in contrast to melanin, is not bleached by 10% H_2O_2 after 72 hours.[69] Routine special stains for melanin react with the ochronotic pigment.

Electron microscopic studies show smaller-sized homogeneous bodies fusing to form larger nonmembrane-bound structures.[69] Although the original pigment is brown, Tyndall scattering of light makes involved skin appear blue.

The tendency of connective tissue, cartilage in particular, to darken gradually over the years constitutes the cardinal pathologic finding in alkaptonuria. Intervertebral disks are pigmented (jet black) and darken when examined. Articular cartilage, when heavily pigmented, displays the degenerative changes of fibrillation, fissuring, fragmentation, and erosion to bare bone. Phagocytosis of collagen fibrils is found in synovial macrophages.[70]

DIAGNOSIS AND DIFFERENTIAL DIAGNOSIS

The diagnosis of alkaptonuria may be made on the basis of typical urinary discoloration or may await

the onset of ochronosis in adulthood. Inasmuch as the disease behaves in a quite stereotypical manner with few confusing variants in its mode of presentation, it has been concluded that the diagnosis need only be thought of to be made. Other causes of dark urine—melaninuria, porphyria, myoglobinuria, bilirubinuria, and hematuria—should not to be confused with alkaptonuria. An ochronosis-like pigmentation of skin and cartilage has been produced iatrogenically by quinacrine administration over a period of months and at the site of quinine injections.[63] Pigmentation due to antimalarial treatment is usually much more pronounced on mucosal surfaces and will fluoresce with a Wood's lamp. A slate gray to blue pigmentation in sun-exposed sites occurs after amiodarone treatment, and similar discoloration also involving the mucous membranes is seen in argyria and chrysiasis (Box 131-5).

It is possible that the reversible ochronotic pigmentation caused by prolonged carbolic acid treatment is due to polymerization of the carbolic acid by HGA polyphenol oxidase to an HGA polymer-like substance that differs from the polymer found in the genetic disease by the reversibility of the polymerization.

Exogenous ochronosis and pigmented colloid milia have been reported in a number of South Africans who used hydroquinone bleaching creams at strengths greater than 2% for a prolonged period.[66,71,74] Forty-two percent of women and 15% of men who used hydroquinones developed exogenous ochronosis.[72] A similar condition has been seen in American blacks.[73–75]

BOX 131-5 DIFFERENTIAL DIAGNOSIS OF ALKAPTONURIA

Main Features

- Skin
  - Black–gray skin on ear cartilage
- Eyes
  - Brown to black pigmentation of the sclera
- Rheumatologic features
  - Skeletal pathologies, including spinal degeneration with kyphosis
  - Ochronotic arthritis and arthropathy
  - Thickened Achilles tendon
- Miscellaneous
  - Urolithiasis
  - Ochronotic prostate stones
  - Aortic and mitral valve calcification

Consider

- Exogenous ochronosis
- Argyria
- Chrysiasis
- Treatment-induced pigmentation (amiodarone, quinacrine, quinine)

BOX 131-6 TREATMENT OF ALKAPTONURIA

- Avoidance of high-protein diet
- Avoidance of high-phenylalanine diet
- Avoidance of high-tyrosine diet
- Large amounts of dietary vitamin C
- 2(-2-nitro-4-trifluoromethylbenzoyl)-1,3-cyclohexanedione
- Nitisinone in investigative stage

TREATMENT

The course of alkaptonuria is generally slow but irreversible. Treatment is primarily supportive, with close observation for the development of arthropathy, cardiac disease, and urinary tract disease (Box 131-6). Appropriate management includes genetic counseling, pain management with nonsteroidal anti-inflammatory agents, physical therapy to increase range of motion, and regular follow-up visits.[20] Avoidance of high-protein, high-phenylalanine, and high-tyrosine diets has been reported to be important. A well-balanced normal diet seems the best approach during childhood.[76–78] It has been postulated that large amounts of dietary vitamin C may be helpful, because vitamin C protects HGA against oxidation and thus may prevent the deposition of ochronotic pigment; however, no long-term clinical studies have been undertaken to verify the effectiveness of this approach.[76] In recent years nitisinone has been used in ochronotic patients in an investigational basis and excretion of homogentisic acid could be decreased.[49,78]

It is disappointing that despite advances in our biochemical understanding of alkaptonuria and the disposition of accumulated HGA to form ochronotic pigment in connective tissue, this information has yet to be translated into a successful therapeutic program for managing the disease. Exogenous cutaneous ochronosis induced by hydroquinone has been treated with the carbon dioxide laser.[79]

COURSE AND PROGNOSIS

The ultimate course in adults with alkaptonuria is that of increasing pigmentation and skeletal incapacity. Little can be done to interrupt this progression; however, the disease is not incompatible with a normal life span, and the oldest patient on record lived to 99 years of age.

OTHER ABNORMALITIES OF AMINO ACID METABOLISM

Table 131-1 lists some of the abnormalities of amino and organic acid metabolism and their associated skin manifestations.

KEY REFERENCES

Full reference list available at www.DIGM8.com

DVD contains references and additional content

2. Nyhan WL, Barshop BA, Ozand PT: *Atlas of Metabolic Diseases*, 2nd edition. London, Hodder Arnold, 2005
5. Scott CR: The genetic tyrosinemias. *Am J Med Genet C Semin Med Genet* **142**:121, 2006
7. Goldsmith LA, Reed J: Tyrosine-induced eye and skin lesions: A treatable genetic disease. *JAMA* **236**:382, 1976
8. Madan V, Gupta U: Tyrosinaemia type II with diffuse plantar keratoderma and self-mutilation. *Clin Exp Dermatol* **31**:54, 2006
9. Viglizzo GM et al: Richner-Hanhart syndrome (tyrosinemia II): Early diagnosis of an incomplete presentation with unusual findings. *Pediatr Dermatol* **23**:259, 2006
10. Macsai MS et al: Tyrosinemia type II: Nine cases of ocular signs and symptoms. *Am J Ophthalmol* **132**:522, 2001
12. Meissner T et al: Richner–Hanhart syndrome detected by expanded newborn screening. *Pediatr Dermatol* **25**:378, 2008
14. Minami-Hori M et al: Richner-Hanhart syndrome: Report of a case with a novel mutation of tyrosine aminotransferase. *J Dermatol Sci* **41**:82, 2006
15. Charfeddine C et al: Clinical and mutational investigations of tyrosinemia type II in Northern Tunisia: Identification and structural characterization of two novel TAT mutations. *Mol Genet Metabol* **88**:184, 2006
16. Leib SR, McGuire TC, Prieur DJ: Comparison of the tyrosine aminotransferase cDNA and genomic DNA sequences of normal mink and mink affected with tyrosinemia type II. *J Hered* **96**:302, 2005
16. Pasternack SM et al: Identification of two new mutations in the TAT gene in a Danish family with tyrosinaemia type II. *Br J Dermatol* **160**:704, 2009
19. Jackson JK et al: The involvement of phosphatidylinositol 3-kinase in crystal induced human neutrophil activation. *J Rheumatol* **24**:341, 1997
23. Cerone R et al: Pregnancy and tyrosinaemia type II. *J Inherit Metab Dis* **25**:317, 2002
24. National Institutes of Health Consensus Development Panel: National Institutes of Health consensus conference statement: Phenylketonuria: Screening and management. *Pediatrics* **108**:972, 2001
24. Gersting SW et al: Loss of function in phenylketonuria is caused by impaired molecular motions and conformational instability. *Am J Hum Genet* **83**:5, 2008
25. Hanley WB: Adult phenylketonuria. *Am J Med* **117**:590, 2004
27. Schulpis KH et al: Biotin recycling impairment in phenylketonuric children with seborrheic dermatitis. *Int J Dermatol* **37**:918, 1998
28. Donati A et al: Acute hair loss in phenylketonuria. *J Eur Acad Dermatol Venereol* **23**:570, 2009
30. Belloso LM, Lowitt MH: Cutaneous findings in a 51-year-old man with phenylketonuria. *J Am Acad Dermatol* **49**:S190, 2003
31. Abadie V et al: Neonatal screening and long-term follow-up of phenylketonuria: The French database. *Early Hum Dev* **65**:149, 2002
34. Trefz FK et al: Efficacy of Sapropterin Dihydrochloride in increasing phenylalanine tolerance in children with phenylketonuria: A phase III, randomized, double-blind, placebo-controlled study. *J Pediatr* **154**:700, 2009
40. Kleijer WJ et al: Prenatal diagnosis of citrullinemia and argininosuccinic aciduria: Evidence for a transmission ratio distortion in citrullinemia. *Prenat Diagn* **26**:242, 2006
41. Reid Sutton V et al: A mouse model of argininosuccinic aciduria: Biochemical characterization. *Mol Genet Metabol* **78**:11, 2006
49. Phornphutkul C et al: Natural history of alkaptonuria. *N Engl J Med* **347**:2111, 2002
50. Itin P et al: Hereditary metabolic disorders. In: *Pediatric Dermatology*, 3rd edition, edited by LA Schachner, RC Hansen. Edinburgh, Mosby, 2003, p. 350
50. Vilboux T et al: Mutation Spectrum of Homogentisic Acid Oxidase (HGD) in Alkaptonuria. *Hum Mutat* **30**:1611, 2009
61. Turgay et al: Endogenous ochronosis. *Clin Exp Dermatol* **34**:865-868, 2009
66. Bongiorno MR, Arico M: Exogenous ochronosis and striae atrophicae following the use of bleaching creams. *Int J Dermatol* **44**:112, 2005
68. Butany JW et al: Ochronosis and aortic valve stenosis. *J Card Surg* **21**:182, 2006

Chapter 132 :: The Porphyrias

:: David R. Bickers & Jorge Frank

The porphyrias are among the most intriguing human diseases. Widely variable, even bizarre in their clinical manifestations, these disorders of porphyrin or porphyrin-precursor metabolism result from aberrations in the control of the heme biosynthetic pathway. Heme is essential for oxygen binding and transport (as in hemoglobin and myoglobin), for electron transport (as in cytochromes), and for monooxygenases such as cytochrome P_{450}. Chlorophyll, a magnesium-chelated porphyrin, is another important tetrapyrrole that is critical for photosynthesis, the specialized energy-storing system found in plants in which the conversion of light energy into stabilized chemical energy is achieved with a sequence of oxidation-reduction reactions. The corrin ring, a cobalt-chelated tetrapyrrole, is a major constituent of vitamin B_{12}, the lack of which results in pernicious anemia. Therefore, porphyrins are ubiquitous and essential biochemical constituents of living beings. The biologic importance of the porphyrins and their iron complexes lies in their capacity to facilitate metabolic reactions, either as oxidative components in the metabolism of steroids, drugs, and environmental chemicals or by enhancing gas exchange, such as oxygen and carbon dioxide, between the environment and the tissues of the body.

Daily synthesis of porphyrins and heme in humans occurs in amounts sufficient to provide for the body's metabolic requirements. The control of heme synthesis is so precise that, under normal circumstances, only microgram quantities or less of pathway intermediates are present in plasma, red blood cells (RBC), urine, and stool (Table 132-1).

The porphyrias are a clinically and genetically heterogeneous group of metabolic diseases, which result from an either inherited or acquired dysfunction of enzymes crucial for heme biosynthesis (Fig. 132-1). Heme synthesis is controlled by eight enzymes along the heme biosynthetic

TABLE 132-1
Normal Values of Porphyrins and Porphyrin Precursors in Humans

Porphyrins or Precursors	Urine (μg/24 h)	Red Blood Cells (μg/100 mL Packed Cells)	Plasma (μg/100 mL)	Feces (μg/g Dry Weight)
δ-Aminolevulinic acid (ALA)	<4,000	—	15–23	—
Porphobilinogen (PBG)	<1,500	—	—	—
Uroporphyrin (URO)	<40	0–2.0	0–2	10–50
Coproporphyrin (COPRO)	<280	0–2.0	0–1	10–50
Protoporphyrin (PROTO)	Absent	<90	0–2	0–20
X-porphyrin	Absent	Absent	Absent	Trace
Isocoproporphyrin (ISOCOPRO)	Absent	Absent	Absent	—
	(nmolL/Day)	**(nmol/dL)**	**(nmol/dL)**	**(nmol/g Dry Weight)**
ALA	8.8×10^3	—	$1.1–1.8 \times 10^2$	—
PBG	4.6×10^4	—	—	—
URO	<40	—	24	—
COPRO	<280	—	46	—
PROTO	0	285	0.5	134

pathway. Deficient activity of seven of these eight enzymes can give rise to a specific type of porphyria (Fig. 132-1).[1–3] A gain of function of the first enzyme in the pathway, δ-aminolevulinic acid synthase (ALAS) is responsible for X-linked dominant protoporphyria (XLDPP), a recently recognized type of porphyria.[4] Each of these enzymes will be discussed separately below, in the context of the corresponding type of porphyria.

Biochemically, the different porphyrias are characterized by particular patterns of accumulation and excretion of porphyrins and/or their precursors. In general, the porphyrins excreted in a specific type of porphyria are the irreversibly oxidized substrate(s) of the deficient enzyme (Table 132-2). These intermediates, when present in excess amounts, exert toxic effects that are responsible for the cutaneous and neurological signs and symptoms of clinically overt porphyria. The porphyrias are of particular dermatologic interest because several types exhibit cutaneous manifestations that may permit diagnosis from clinical signs alone.

PORPHYRIN-HEME BIOSYNTHESIS

The major sites of heme synthesis in the body are the bone marrow and the liver. Heme is the prosthetic group for a number of proteins, including among others hemoglobin, myoglobin, mitochondrial cytochromes, microsomal cytochromes (including cytochrome P_{450}), catalase, peroxidase, tryptophanpyrrolase, prostaglandin endoperoxide synthase, and the soluble form of guanylate cyclase. Approximately 85% of heme synthesis occurs in the bone marrow where it is utilized for the production of hemoglobin; the majority of the rest occurs in the liver for making cytochrome P_{450}, catalase, and various mitochondrial cytochromes. Heme is a critical cellular constituent essential for a variety of metabolic processes, primarily because of its unique ability to take up and release oxygen and to facilitate electron transport. Heme synthesis is regulated by the interplay of a number of factors and is directly dependent upon its concentration within cells and upon the requirements of the cell for production of the various hemoproteins described above. Many of these have rapid turnover times (minutes to hours), thereby necessitating continuously high rates of hepatic heme synthesis. For example, cytochrome P_{450}, an important membrane-bound enzyme in the liver involved in the detoxification and metabolism of drugs, has a half-life of 90–180 minutes.

REGULATION OF HEME BIOSYNTHESIS

Heme synthesis begins in the mitochondrion of the cell where succinate and glycine (single molecules of glycine and succinyl CoA) are conjugated by ALAS to form a five-carbon aminoketone, δ-aminolevulinic acid (ALA). This reaction requires pyridoxal 5′-phosphate as a cofactor. The regulation of heme biosynthesis (and indeed the ability to synthesize heme at all) is dependent upon the serial interaction of eight intracellular enzymes (Figs. 132-1 and 132-2). The first, as well as the last three enzymes involved, coproporphyrinogen oxidase (CPOX), protoporphyrinogen oxidase (PPOX),

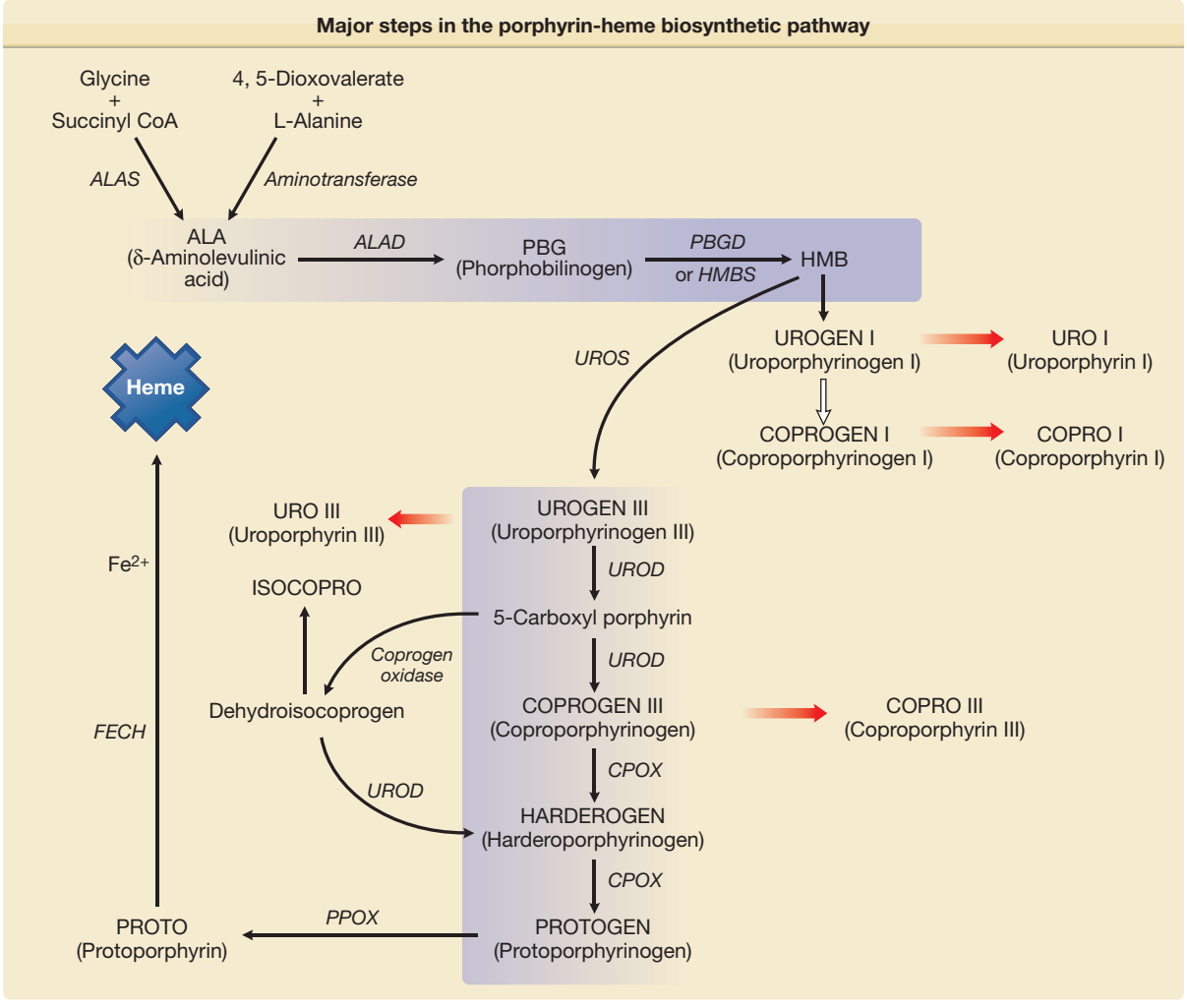

Figure 132-1 Major steps in the porphyrin-heme biosynthetic pathway. δ-Aminolevulinic acid (ALA) can be formed from glycine and succinyl coenzyme A (SCoA), which is the primary source in mammalian systems and is catalyzed by the mitochondrial enzyme ALA synthase (ALAS). Two molecules of ALA form the monopyrrole porphobilinogen (PBG) in a reaction catalyzed by the enzyme ALA dehydratase (ALAD). Four molecules of PBG are converted by PBG deaminase (PBGD) also known as hydroxymethylbilane synthetase (HMBS) to a linear tetrapyrrole, hydroxymethylbilane (HMB), which can cyclize spontaneously to form uroporphyrinogen (UROGEN) I. The four acetyl groups of UROGEN I are sequentially decarboxylated by UROPORPHYRINOGEN decarboxylase (UROD) to form coproporphyrinogen (COPROGEN) I. HMB can also be converted to UROGEN III by the enzyme UROPORPHYRINOGEN III synthase (UROS). In this reaction, one of the monopyrrole rings is "flipped over," which alters the sequence of the side chains. The acetyl groups of UROGEN III are sequentially decarboxylated by UROD to form COPROGEN III. COPROGEN III is converted to protoporphyrinogen (PROTOGEN) IX by the enzyme COPROPORPHYRINOGEN oxidase (CPOX), which oxidatively decarboxylates each of the propionyl groups. PROTOGEN IX is converted to protoporphyrin (PROTO) IX by PROTOPORPHYRINOGEN oxidase (PPOX). PROTO IX is converted to heme by ferrochelatase (FECH), which catalyzes the insertion of ferrous iron into the molecule.

and ferrochelatase (FECH) are mitochondrial, whereas the remaining enzymes including δ-aminolevulinic acid dehyratase (ALAD), porphobilinogen deaminase (PBGD), uroporphyrinogen synthase (UROS), and uroporphyrinogen decarboxylase (UROD) are localized in the cytosol. The degradation of heme is catalyzed by the microsomal enzymes NADPH-cytochrome C reductase, heme oxygenase 1 and 2. Heme oxygenase 1 is a -signature of oxidative tissue injury and is a potent antioxidant. Heme oxygenase 2 is an oxygen sensor. The metabolic by-products of these enzymes are the linear tetrapyrrole biliverdin IXα and carbon monoxide and also possess antioxidant properties. cDNAs for each of the eight enzymes involved in heme biosynthesis as well as the enzymes responsible for heme catabolism have been cloned in mammalian cells.[1–3] Abnormal regulation of heme synthesis may result from defects in enzymes of the synthetic pathway, and this may occur as the result of inherited and/or environmental factors leading to the accumulation in the body of one or more heme pathway intermediates, such as the porphyrins or their precursors. Although a diagnosis of porphyria can often be made from a careful medical history (including the family history) and physical examination, the definitive diagnosis requires measurement of: (1) porphyrins and/or porphyrin precursors in urine, stool, plasma, or RBCs, or (2) the residual activity of specific enzymes in the heme pathway, or (3) the identification

TABLE 132-2
Pattern of Enzyme Activities in Various Porphyrias

Enzyme	Tissue	Enzymatic Defect in Porphyria
δ-Aminolevulinic acid synthase 1 (ALAS1) δ-Aminolevulinic acid synthase 2 (ALAS2)	Liver, kidney, fibroblasts, and lymphocytes Erythrocytes	Increased in AIP, HCP, VP Increased in XLDPP
ALA dehydratase (ALAD)	Erythrocytes, liver, and kidney	Decreased in lead intoxication Decreased in ALA dehydratase deficiency porphyria
Porphobilinogen deaminase (PBGD)	Erythrocytes, liver, fibroblasts, lymphocytes, and amnion cells	Decreased in AIP
Uroporphyrinogen III synthase (UROS)	Erythrocytes and fibroblasts	Decreased in CEP
Uroporphyrinogen decarboxylase (UROD)	Erythrocytes and liver	Decreased in all tissues in hereditary or familial PCT and HEP Only decreased in the liver in acquired or sporadic PCT
Coproporphyrinogen oxidase (CPOX)	Fibroblasts, lymphocytes, and liver	Decreased in HCP
Protoporphyrinogen oxidase (PPOX)	Liver and fibroblasts	Decreased in VP
Ferrochelatase (FECH)	Bone marrow and fibroblasts	Decreased in EPP and lead poisoning

AIP = acute intermittent porphyria; CEP = congenital erythropoietic porphyria; EPP = erythropoietic protoporphyria; HCP = hereditary coproporphyria; HEP = hepatoerythropoietic porphyria; PCT = porphyria cutanea tarda; VP = variegate porphyria; XLDPP = X-linked dominant EPP.

of mutations in the genes encoding these enzymes (Fig. 132-1). Modern molecular biological techniques have helped to clarify the mechanistic basis of the porphyrias.[3–8] The steps involved in the biosynthesis of porphyrins and heme and their regulatory control are summarized in Figs. 132-1–132-4.

δ-AMINOLEVULINIC ACID SYNTHASE

THE PORPHYRIAS AT A GLANCE

- The porphyrias result from a dysfunction of specific enzymes involved in heme biosynthesis.
- At least eight different types of porphyria are known, classified as nonacute and acute.
- Cutaneous features manifest predominantly on sun-exposed body areas.
- Life-threatening acute neurologic attacks can occur.
- Diagnosis is often difficult due to overlapping clinical and biochemical findings.
- All genes encoding the enzymes involved in heme synthesis are well characterized, which allows for accurate molecular diagnosis and genetic counseling.

CLASSIFICATION OF THE PORPHYRIAS

Traditionally, most classifications of the porphyrias are based on the primary site of expression of the specific enzymatic defect, thereby distinguishing erythropoietic and hepatic types. From a dermatologic perspective, the porphyrias might also be classified into cutaneous and noncutaneous forms. However, from a general clinical perspective, we have chosen to classify the porphyrias into two subtypes: (1) nonacute and (2) acute thereby distinguishing patients in whom dermatologic findings predominate from those susceptible to potentially life-threatening acute neurovisceral attacks (Tables 132-3 and 132-4). We will employ this classification throughout this chapter. It should be pointed out that two of the acute porphyrias, variegate porphyria (VP) and hereditary coproporphyria (HCP), are also referred to as neurocutaneous porphyrias since patients with these diseases may have both neurovisceral and cutaneous manifestations.

An acute porphyric attack can present a constellation of symptoms and signs, among them, intense abdominal pain, vomiting, electrolyte dysregulation (hyponatremia), constipation, tachycardia, hypertension, muscle pain and weakness, seizures, paresis of the upper and lower extremities, paralysis, and a variety of other neurological and psychiatric symptoms.[11] These myriad clinical manifestations inevitably mimic other diseases, thereby challenging the diagnostic acumen of even the most experienced clinicians particularly since the porphyrias are rare disorders.[12] It is known that acute porphyric attacks can be precipitated by a variety of external factors, in particular porphyrinogenic drugs, ethanol, hormonal fluctuations, and

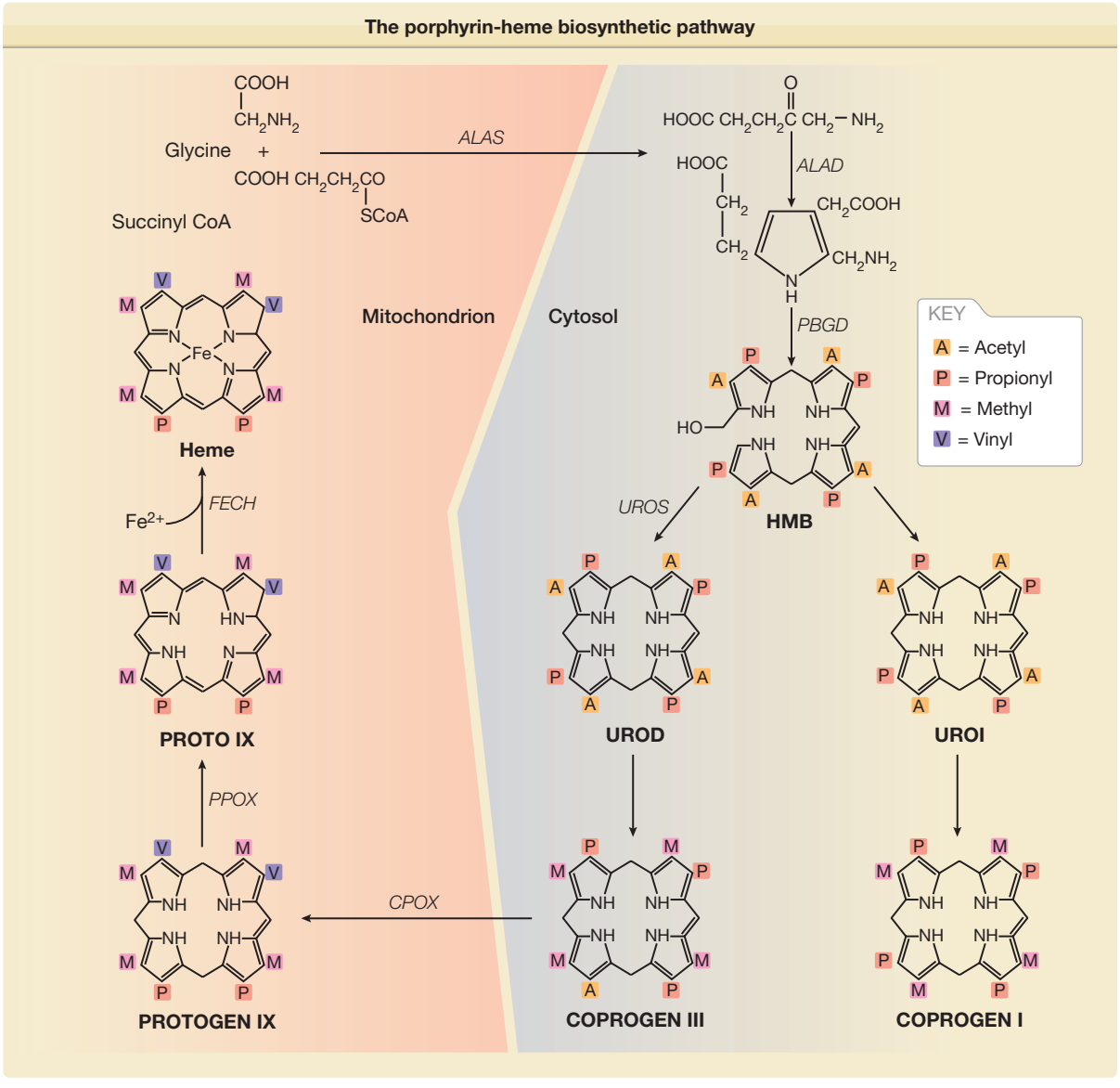

Figure 132-2 The porphyrin-heme biosynthetic pathway (with structural components). (See also Figure 132-1.)

diminished caloric intake from dieting or fasting.[11,13] Yet in practice, it is often impossible to identify the immediate cause of an acute attack in an individual patient. Timely diagnosis of an acute porphyric attack can be lifesaving because several complications may have fatal consequences if not recognized and treated. It is crucial to keep in mind that many drugs are capable of inducing heme synthesis in the liver.[11,13] Thus, in a patient an acute porphyria with episodic abdominal pain, treatment with certain analgesics may prolong or aggravate the attack. Diffuse abdominal pain can mimic acute appendicitis, diverticulitis, intestinal obstruction, or other painful gastroenterological disorders that may necessitate urgent surgical intervention.[14,15] After administration of certain drugs (e.g., barbiturates) or during general anesthesia, acute attacks may ensue.[1] A particularly problematic complication is muscle weakness. This can range from mild paralysis of small muscle groups to flaccid paralysis of multiple muscle groups resulting in paraplegia and respiratory compromise. These findings may be accompanied by severe sensory loss and amyotrophy.[16] In some cases, paralysis may progress rapidly and can affect cranial nerves or develop into a Guillain–Barré-like syndrome.[17]

NONACUTE AND ACUTE PORPHYRIAS

(See Tables 132-3 and 132-4)

Patients with all forms of nonacute porphyria manifest cutaneous findings predominantly on sun-exposed body areas. The nonacute porphyrias include porphyria cutanea tarda (PCT), the most prevalent

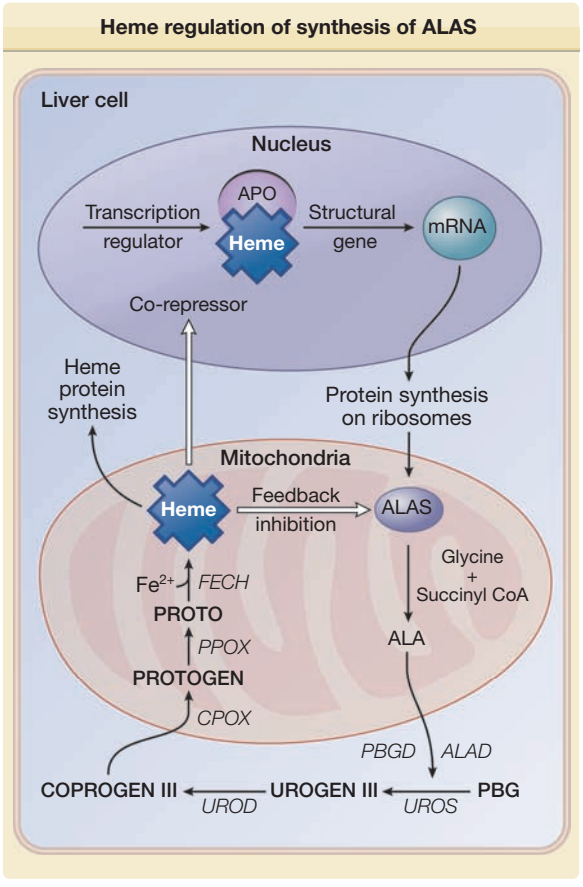

Figure 132-3 Heme is capable of regulating its synthesis by either directly inhibiting or repressing the synthesis of its rate-limiting enzyme ALAS. The repression may result from the binding of heme, as a corepressor, to an aporepressor protein (APO), which, when combined with heme, becomes a functional unit that blocks transcription of ALAS messenger RNA (mRNA). Heme may also block transport of the holoenzyme into the mitochondrion. ALA = δ-aminolevulinic acid; ALAD = δ-aminolevulinic acid dehydratase; CoA = coenzyme A; COPROGEN = coproporphyrinogen; PBGD = porphobilinogen deaminase; PROTO = protoporphyrin; PROTOGEN = protoporphyrinogen; UROGEN = uroporphyrinogen.

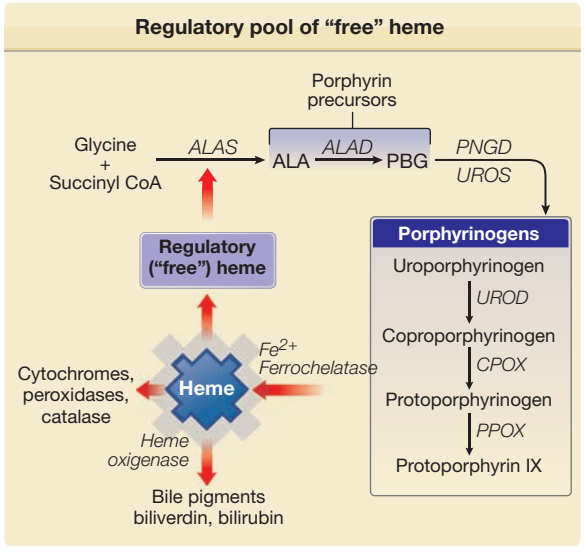

Figure 132-4 A regulatory pool of "free" heme unbound to apoproteins may be the critical determinant for regulation of synthesis of ALAS activity. ALA = δ-aminolevulinic acid; ALAD = δ-aminolevulinic acid dehydratase; CoA = coenzyme A; PBG = porphobilinogen; PBGD = porphobilinogen deaminase; COPROGEN = coproporphyrinogen; PROTOGEN = protoporphyrinogen; UROGEN = uroporphyrinogen.

type of porphyria overall, hepatoerythropoietic porphyria (HEP), the homozygous variant of PCT, erythropoietic protoporphyria (EPP), XLDPP, the most recently recognized type of porphyria, and congenital erythropoietic porphyria (CEP) (Table 132-3). The nonacute porphyrias can present with variable cutaneous features, including mild-to-severe photosensitivity, increased skin fragility, vesicles and bullae, scarring with milia formation, burning and stinging, edema, pruritus, hypertrichosis, hyperpigmentation, and mild-to-severe scleroderma-like changes with tissue calcification.[4]

The acute porphyrias include acute intermittent porphyria (AIP), VP, HCP, and δ-aminolevulinic acid dehydratase (ALAD) deficiency porphyria (also known as plumboporphyria) (Table 132-4). Whereas AIP is the most prevalent form of acute porphyria worldwide, in some countries other acute forms may predominate, as is the case for VP in South Africa.[1,2,18,19] Besides neurovisceral symptoms, individuals suffering from VP or HCP can also present with cutaneous findings, including increased photosensitivity, abnormal skin fragility, and bullous skin lesions on sun-exposed areas, erosions, chronic scarring, and postinflammatory pigmentary change. Thus, VP and HCP are also referred to as neurocutaneous porphyrias, to distinguish them from AIP and ALAD deficiency porphyria in which there are no cutaneous abnormalities.[4,20]

It is of interest that ethanol and estrogens, which can trigger acute porphyric attacks in AIP, VP, and HCP, can also exacerbate PCT, although acute attacks do not occur in this disease and the mechanisms likely differ.[21]

PATHOPHYSIOLOGY OF CUTANEOUS SIGNS AND SYMPTOMS IN THE NONACUTE PORPHYRIAS

The most common cutaneous manifestation of the nonacute porphyrias is photosensitivity; it is observed in patients with several of these disorders (PCT, HEP, EPP, XLDPP, CEP) as well as in patients with VP and HCP who have both cutaneous and neurovisceral findings. The sine qua non of photosensitivity in porphyria is increased plasma and tissue porphyrins. Patients with AIP, in whom only nonphotosensitizing porphyrin precursors (ALA, PBG) are formed in substantially increased amounts, do not have photosensitivity nor do any patients with ALAD deficiency porphyria.

TABLE 132-3
Overview and Summary of the Features of the Nonacute Porphyrias

	Porphyria Cutanea Tarda	Erythropoietic Protoporphyria	Congenital Erythropoietic Porphyria	Hepatoerythropoietic Porphyria
Synonym(s)	Symptomatic porphyria, acquired hepatic porphyria, chemical porphyria	Erythropoietic porphyria, protoporphyria	Günther disease, congenital hematoporphyria, erythropoietic uroporphyria	Hepatoerythrocytic porphyria
Inheritance	Autosomal dominant in approximately 20% of patients; otherwise acquired	Autosomal dominant with hypomorphic IVS3–48C allele; X-linked dominant; Autosomal recessive	Autosomal recessive	Autosomal recessive
Age of onset	Usually in third or fourth decade; rare before puberty	Early childhood (1–4 years); late onset extremely rare	Usually infancy or first decade	Early infancy, before age 2 years
Incidence	Most common porphyria worldwide	Second most common of the cutaneous porphyrias	Very rare (fewer than 250 cases)	Extremely rare (fewer than 40 cases)
Photosensitivity	Moderate-to-severe with high interindividual variation; indistinguishable from variegate porphyria	Mild-to-severe; onset immediate (in minutes); interindividual variation	Severe to very severe	Severe
Skin reactions (on sun-exposed areas)	Vesicles and bullae, erosions, crusts, milia, scarring, hypertrichosis; indistinguishable from variegate porphyria	Edema, erythema, urticarial plaques; very rarely bullae, skin thickening, waxy scars	Vesicles and bullae, erosions, hypertrichosis, hypermelanosis, mutilation	Vesicles and bullae, erosions, crusts, milia, scarring, hypertrichosis, mutilation

TABLE 132-4
Overview and Summary of the Features of the Acute Porphyrias

	Acute Intermittent Porphyria	Variegate Porphyria	Hereditary Coproporphyria	ALA Dehydratase Deficiency Porphyria
Synonym(s)	Swedish porphyria	Mixed porphyria, South African genetic porphyria, protocoproporphyria hereditaria, PCT hereditaria	Idiopathic coproporphyria	Plumboporphyria
Inheritance	Autosomal dominant	Autosomal dominant	Autosomal dominant	Autosomal recessive
Age of onset	10–40 years; extremely rare before puberty	Usually between ages 15 and 30 years	Any age	Early and late clinical onset has been described
Incidence	1.5 in 100,000; more common in Scandinavia and Lapland	Common in South Africa (3 in 1,000); relatively rare elsewhere	Rare (fewer than 50 cases reported)	None reported
Photosensitivity	Absent	Moderate to severe with high interindividual variation; similar to that in PCT	Very rare	Absent
Skin reactions (on sun-exposed areas)	None	Vesicles and bullae, erosions, crusts, milia, scarring, hypertrichosis; similar to those in PCT	Usually blistering	None

ALA = δ-aminolevulinic acid; PCT = porphyria cutanea tarda.

TABLE 132-5
Fluorescence Characteristics of Porphyrin-Containing Plasma Diluted with 1:10 Phosphate Buffered Solution

Type	Peak Excitation (nm)	Peak Emission (nm)	Fluorescent Porphyrins
Congenital erythropoietic porphyria	398	619	URO I, COPRO I
Erythropoietic protoporphyria X-linked dominant Erythropoietic protoporphyria	409	634	FREE PROTO FREE and ZINC PROTO
Porphyria cutanea tarda	398	619	URO I, III; COPRO III
Variegate porphyria	405	626	COPRO III, PROTO
Acute intermittent porphyria	398	619	URO III
Hereditary coproporphyria	398	619	COPRO III
Hepatoerythropoietic porphyria	398	619	URO I

COPRO = coproporphyrin; PROTO = protoporphyrin; URO = uroporphyrin.
Modified from Poh-Fitzpatrick MB, Lamola AA: Direct spectrofluorometry of diluted erythrocytes and plasma: A rapid diagnostic method in primary and secondary pophyrinemias. *J Lab Clin Med* **87**(2):362, 1976.

Patients with the erythropoietic porphyrias frequently complain of a painful and intense burning sensation and pruritus during or following sun exposure. A "priming" effect of sun exposure on cutaneous photosensitivity in EPP has been described in which a threshold exposure on one day that evokes virtually no reaction seems to augment the response to subsequent exposure on the following day.[22] The cause of this is unknown, but the phenomenon suggests that repair of damage to skin by photosensitized porphyrins may be prolonged. These acute symptoms are notably absent in patients with the chronic hepatic porphyrias such as PCT and VP. Although there is some information about the pathophysiology of photosensitivity and sclerodermoid skin changes in the chronic hepatic porphyrias, the causes of the pigmentary alterations and hypertrichosis seen in these patients remain to be elucidated.

Porphyrins have certain unique photobiologic and spectroscopic properties that make them potent photosensitizers. Importantly, metal-chelated porphyrins (e.g., heme or FePROTO) show no fluorescence and are not photosensitizers. Porphyrins that are chelated to other paramagnetic metals, such as Mn^{2+}, Co^{2+}, or Zn^{2+} (e.g., chlorophyll, ZnPROTO), also do not fluoresce. For this reason patients with lead intoxication, in which ZnPROTO is elevated, do not have photosensitivity.[23,24] However, metal-free porphyrins including, Uroporphyrin (URO), Coproporphyrin (COPRO), and Protoporphyrin (PROTO) in acidic solutions show a major absorption peak in the 400- to 410-nm region (Soret band); they also exhibit four additional absorption bands with decreasing intensity between 500 and 700 nm. Exposure of porphyrins to the Soret band spectra results in fluorescence emission peaks between 550 and 680 nm (Table 132-5). Although there is no single clearly defined pathway that can currently explain the photosensitization evoked by porphyrins and light, there are a number of potential cellular and soluble factors that are likely to be involved. Among them, reactive oxygen species (ROS) and their effect upon certain cells (erythrocytes, mast cells, polymorphonuclear cells, and fibroblasts), and soluble mediators (the complement system and matrix metalloproteinases) are discussed (Table 132-6). It is likely that a combination of these factors will prove to be responsible for the pathogenesis of the cutaneous lesions in the porphyrias.

Of note, porphyrin abnormalities can also occur in lead poisoning, sideroblastic, hemolytic and iron deficiency anemia, renal failure, cholestasis, liver disease, and gastrointestinal hemorrhage. Of these, however, cutaneous photosensitivity has only been documented in rare cases of sideroblastic anemia.

TABLE 132-6
Factors Contributing to the Development of Cutaneous Lesions in Porphyrias

- Sunlight, especially blue and red light (380–760 nm)
- Reactive oxygen species ($^1O_2$, $O_2^{\cdot-}$, H_2O_2, $\cdot OH$).
- Cells
- Erythrocytes
- Mast cells
- Polymorphonuclear leukocytes
- Fibroblasts
- Soluble mediators
- The complement system
- Factor XIII–dependent pathways
- The eicosanoids
- Matrix metalloproteinases

PATHOPHYSIOLOGY OF NEUROVISCERAL SIGNS AND SYMPTOMS IN THE ACUTE PORPHYRIAS

Two acute porphyrias, AIP and ALAD deficiency porphyria, do not manifest cutaneous symptoms. In these diseases, the dysfunctional enzymes function early in heme biosynthesis and their substrates are nonphototoxic porphyrin precursors. However, patients with both AIP and ALAD deficiency porphyria as well as VP and HCP can manifest life-threatening acute neurovisceral attacks. Although the exact pathogenesis of these attacks is not well understood, it is known that the porphyrin precursors ALA and PBG are massively excreted from the liver during an acute attack and in particular ALA is known to be have neurotoxic properties. Furthermore, as a result of porphyria-related enzyme defects the net result may be heme deficiency in nerve tissue. Thus, the autonomic and peripheral nervous systems are particularly susceptible to porphyrin precursor induced neuropathy.[25]

CELLULAR AND SOLUBLE FACTORS CONTRIBUTING TO PHOTOSENSITIVITY

(See Table 132-6)

REACTIVE OXYGEN SPECIES. Porphyrins such as URO, COPRO, and PROTO absorb light intensely around 400 nm and in the longer visible spectrum between 580 and 650 nm. Absorption results in the generation of "excited" state porphyrin molecules (Fig. 132-5). The initial excited state porphyrin generated has an extremely short half-life of less than 0.01 µs. Singlet excited state porphyrins may spontaneously convert to a triplet, another excited state that has a lower energy level but a longer half-life (in the order of microseconds to milliseconds). Because of their longer half-life, triplet-state porphyrins have a higher probability of reacting with biologic substrates and are likely candidates to mediate most porphyrin-associated photobiological reactions. Excited state porphyrin molecules ultimately must return to their normal ground states by releasing their absorbed energy in the form of light (fluorescence is emitted by singlet state molecules and phosphorescence by triplet states), heat, or by transferring energy to cell constituents (cell membranes, organelles, proteins, DNA) (Figs. 132-5 and 132-6).

Excited porphyrins in their singlet and triplet states can also transfer their absorbed energy to oxygen molecules thereby creating reactive "excited" oxygen states.[26] Cellular and tissue damage induced by photoactivated porphyrins is believed to occur primarily as a result of the formation of reactive singlet oxygen ($^1O_2$), as illustrated in Figs. 132-5 and 132-6.[27,28] In some cases, the sensitized porphyrin may further react with oxygen to yield hydrogen peroxide (H_2O_2) or with water to form hydroxyl radicals ($^{\bullet}OH$). Those processes in which activated oxygen species play a role in photosensitization are referred to as photodynamic reactions.[29] Most of the porphyrin-mediated cutaneous photosensitization reactions are essentially photodynamic (oxygen-dependent) and can be minimized or prevented if ROS are eliminated by inactivation processes known as quenching or scavenging.

Although these concepts regarding excited porphyrins and ROS are valid in simple systems and several hypotheses have been advanced regarding the mechanism of porphyrin-induced photosensitivity, their applicability to complex tissues such as the skin remains to be established.

Photoexcited porphyrins

	$PP_0 + h\nu \longrightarrow {}^1PP$		(Singlet state)
1	$^1PP \longrightarrow$ a)	$PP_0 + h\nu$	(Fluorescence)
2	$\longrightarrow$ b)	PP_0	(Non-radiative decay)
3	$\longrightarrow$ c)	^3PP	(Triplet-state transition)
4	$^3PP \longrightarrow$	$PP_0 + h\nu$	(Phosphorescence)
5	$^3PP + {}^3O_2 \longrightarrow$	$PP_0 + {}^1O_2$	(Singlet state oxygen)
6	$^1O_2 + A \longrightarrow$	A (ox)	(Substrate oxidation, lipid peroxidation, and cell membrane damage)

Figure 132-5 Photoexcited porphyrins release energy in a variety of ways when returning to their ground state, and these may contribute to damaging reactions in biologic systems. A = acceptor; A (ox) = oxidized acceptor; hν = radiant energy; PP = photoexcited porphyrin.

ERYTHROCYTES. Photoexcited PROTO elicits peroxidation of cholesterol groups in erythrocyte membranes, whereas URO or COPRO has no such effect. This difference is also true of mast cells, polymorphonuclear leukocytes (PML), and fibroblasts, and most likely relates to variations in lipid-water partitioning of the different porphyrins, which may in turn relate to their polarity. Lipophilic PROTO, a 2-carboxyl porphyrin, is more damaging to lipid-rich membranes as compared to the more hydrophilic COPRO and URO.[30]

MAST CELLS. Phototoxic damage to mast cells is associated with elevated serum histamine levels and dermal mast cell degranulation,[31] and the phototoxic response can be suppressed by pretreatment with antihistamines (H_1 blockers) or by intradermal injection of a mast cell secretagogue (compound 48/80).[32]

Mast cell degranulation occurs in the exposed skin of patients with EPP.[33] Irradiation of PROTO-treated mast cells in vitro induces release of mast cell-derived mediators, although exposure to lower doses of PROTO and radiation results in inhibition of secretagogue-induced

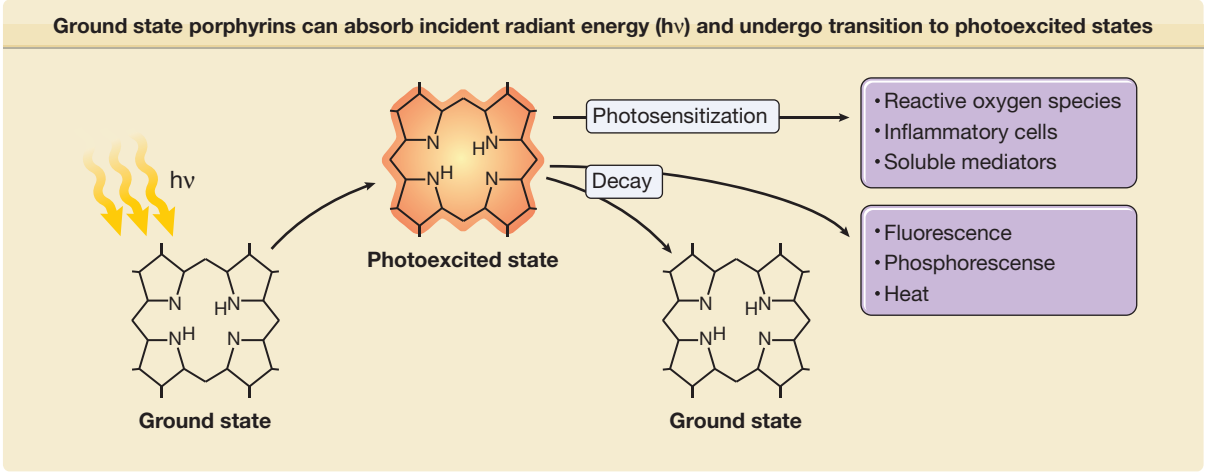

Figure 132-6 Ground state porphyrins can absorb incident radiant energy (hν), and undergo transition to photoexcited states. The photoexcited porphyrins generate reactive oxygen species, which damage cells by release of proinflammatory mediators; in turn, these may contribute to damaging reactions in biologic systems such as skin.

histamine release from these cells.[34] In contrast, no mediator release is detectable when cells are radiated in the presence of URO. These findings may help to explain the differences in the clinical presentation of patients with EPP and PCT. The elevated PROTO in patients with EPP may induce the release of mast cell mediators in vivo following sun exposure, resulting in painful, pruritic erythema and edema. The absence of these changes in patients with PCT may be explained by the apparent inability of photoexcited URO to damage cutaneous mast cells.

POLYMORPHONUCLEAR CELLS. Exposure of human PML to PROTO and radiation in vitro results in membrane damage, whereas photoexcited URO induces no such alterations.[35] These results are strikingly similar to those obtained in studies with mast cells (see above). In an animal model, porphyrin-induced phototoxicity was associated with a dermal PML infiltrate[31,36] and the response was markedly suppressed in leukopenic animals.[32] These results appear to suggest that PML may be necessary but not sufficient to induce porphyrin-induced phototoxicity.

FIBROBLASTS. Differential phototoxic effects of various porphyrins have also been verified in studies using dermal fibroblasts. An increase in collagen biosynthesis is observed following incubation of fibroblasts with URO.[37] This effect is independent of irradiation and may partly explain the sclerodermoid changes observed in patients with PCT, which can occur in sun-exposed and in sun-protected areas. In contrast, PROTO induces photolysis of fibroblasts in vitro.[38,39]

MATRIX METALLOPROTEINASES. Photoexcited URO has been shown to coordinately induce interstitial collagenase (MMP-1), 72-kDa type IV collagenase (MMP-2) and stromelysin-1 (MMP-3) in human dermal fibroblasts in vitro.[40] The induction of the MMPs by porphyrin photosensitization suggests that activation/release of these enzymes could contribute to the blistering process.

COMPLEMENT SYSTEM. The complement system is activated by photoexcited porphyrins such as URO and PROTO. In vitro exposure to Soret band radiation activates the complement cascade and releases anaphylatoxins.[41,42] Exposure of the skin of patients with EPP and PCT to Soret band energy in vivo also generates anaphylatoxins.[43] Granular and homogeneous deposits of the complement membrane attack complex C5b9 have been observed in skin biopsies obtained from the skin of patients with PCT.[44] It is of interest that target tissue heme pathway enzymes may be a crucial determinant of skin susceptibility to porphyrin photosensitization. Using a mouse model of EPP it has been shown that in transplanting bone marrow from EPP animals to wild-type mice the skin of the recipients was resistant to photosensitivity despite very high levels of plasma porphyrins suggesting that the normal FECH levels in the recipients somehow protected them against phototoxicity.[45]

In summary, cutaneous phototoxicity in the porphyrias is directly related to the interaction of porphyrins with light of the Soret and other bands in the solar spectrum, resulting in the generation of ROS. This in turn can induce lipid peroxidation and cell membrane alterations. Release of mediators and enzymes from cells such as mast cells and PML contributes to the inflammatory response. Variations in solubility influenced by the lipid–water partitioning of porphyrins may account for the striking patterns of the skin findings observed in various types of porphyria. It is important to emphasize that porphyrinogens (reduced porphyrins) are the true intermediates in heme synthesis. The irreversibly oxidized porphyrins, with the exception of PROTO, do not function as substrates for the enzymes of the pathway. Thus, porphyrins are actually heme pathway by-products, which are of special interest to dermatologists because of their unique photosensitizing properties.

THE NONACUTE PORPHYRIAS

(See Table 132-3)

PORPHYRIA CUTANEA TARDA (PCT)

PORPHYRIA CUTANEA TARDA AT A GLANCE

- Most frequently occurring type of porphyria worldwide.
- Sporadic and inherited (autosomal dominant) forms of the disease arise due to deficiency of UROD.
- Age of onset is usually in the third to fourth decade of life; the disorder is unusual before puberty.
- Characterized by moderate-to-severe photosensitivity; cutaneous signs include vesicles and bullae, erosions, crusts, milia, sclerodermoid changes and scarring, hyperpigmentation, and hypertrichosis.
- Cutaneous features overlap with those of variegate porphyria and hereditary coproporphyria.

EPIDEMIOLOGY. PCT occurs throughout the world and is the most common of all the porphyrias.[46] The prevalence is estimated at 1:10,000.[47] The disease most often begins in middle-aged individuals but can develop earlier. Prior to the widespread use of oral contraceptives, PCT developed predominantly in males.[48,49] In contrast, others have emphasized that the sex incidence is approximately equal.[50] The rising incidence of PCT in females is probably due to the widespread ingestion of estrogens in oral contraceptives or in hormone supplements. It should be noted that males treated with estrogens, for example, as adjunctive therapy for carcinoma of the prostate, have also developed PCT.

ETIOLOGY AND PATHOGENESIS

PCT is due to either an inherited or acquired deficiency of UROD, the fifth enzyme in the heme pathway (Figs. 132-1 and 132-2) and it has a molecular mass of about 42 kDa.[51] UROGEN I and III each contain eight carboxyl groups as side chains, four of which are acetate ($-CH_2COOH$) and four of which are propionate ($-CH_2-CH_2-COOH$) moieties (Fig. 132-2). The soluble cytosolic enzyme UROD catalyzes the sequential oxidative decarboxylation of the four carboxyl groups of the acetate side chains to methyl groups to form COPROGEN (Fig. 132-2). Decarboxylation first occurs on ring D, after which the enzyme turns around to decarboxylate rings A, B, and C in a clockwise fashion. This converts the original 8-carboxyl porphyrinogen (UROGEN I or III) first to 7-carboxyl, then to 6-carboxyl, and 5-carboxyl porphyrinogen. The 5-carboxyl porphyrinogen can then undergo decarboxylation of its last acetyl group to form the 4-carboxyl porphyrinogen that is known as coproporphyrinogen (COPROGEN I or III) (Fig. 132-2). These intermediates are also referred to as hepta-, hexa-, penta-, and tetracarboxylate porphyrinogens. COPROGEN I cannot be further metabolized to heme.

Human UROD is encoded by a single copy of the gene of the same name that is located on chromosome 1p34 spreads over a genomic distance of 3 kb, and contains ten exons.[51] The human UROD cDNA has been isolated, and the deduced sequence was found to be equivalent to 367 amino acids, consistent with the molecular mass and the amino acid composition of the purified protein.

Most classifications of PCT separate the disorder into at least two broad categories, both associated with decreased UROD activity: (1) acquired PCT, also referred to as sporadic or type I PCT; and (2) hereditary PCT, also referred to as familial or type II PCT.

In acquired (type I) PCT, the enzyme is deficient only in the liver and no mutations have been detected in the coding or promoter sequences of the *UROD* gene (Table 132-2).[46,52] Some of the precipitating substances (e.g., alcohol and estrogen) may provoke PCT only in selected individuals and others [e.g., hexachlorobenzene (HCB)] in practically all exposed individuals (Table 132-7).

Hereditary (type II) PCT is an autosomal dominant disorder and the residual UROD activity is decreased approximately 50% in all tissues, including RBC and cultured skin fibroblasts.[53–56] Decreased enzyme concentration appears to follow a bimodal distribution, suggesting two overlapping groups of patients: a large group (>80%) with normal UROD concentration and a small group (<20%) in who the amount of detectable enzyme is about half normal. Some patients with type II PCT were found to have UROD activity at the lower end of the normal range. The clinical penetrance of type II PCT is relatively low (approximately 20%), so that the majority of individuals with the inherited enzyme defect do not manifest the disease, suggesting that additional genetic or nongenetic factors are needed for

TABLE 132-7
Drugs and Chemicals Associated with the Clinical Expression of Porphyria Cutanea Tarda

- Ethyl alcohol
- Estrogenic hormones
- Hexachlorobenzene (HCB)
- Chlorinated phenols
- Iron
- 2,3,7,8-Tetrachlorodibenzo-*p*-dioxin (TCDD)
- Polychlorinated biphenyls (PCB)
- Herbicides 2,4-dichloro- and trichlorophenoxyacetic acid

disease expression. To date, more than 50 mutations in the *UROD* gene have been identified in type II PCT, mostly in exons 5–10, which encode 75% of the protein that either decrease the stability of the enzyme or produce defective pre-mRNA splicing.[3,46,47,51,56–59]

It is important to emphasize that not all patients with a positive family history of PCT will have type II disease. In support of this notion, several patients have been described with one or more relatives with type I PCT but with normal RBC UROD activities.[60] This latter category of PCT has been designated as type III by some investigators.[54] These patients could either have inherited some form of UROD that is immunochemically indistinguishable from the normal enzyme but which is uniquely susceptible to inhibition in the liver, or they may have a second inherited enzyme deficiency unrelated to UROD. These possibilities require further investigation.

It is likely that some patients who were initially reported as having hereditary PCT actually had VP, another dominantly inherited porphyria. PCT and VP may occur in different members of the same family, in the so-called dual porphyrias.[61–63] Another form of dual porphyria in which PCT and AIP coexist has also been described.[64]

Numerous agents are known to contribute to the development of PCT (type I, acquired, or sporadic) including alcohol, estrogens, iron, viral infections (hepatitis C and HIV), polychlorinated hydrocarbons, particularly HCB and TCDD, and hemodialysis in patients with renal failure (Table 132-7). Each of these precipitating factors is discussed briefly below.

Alcohol. Alcohol ingestion has long been recognized to exacerbate PCT. Ethanol has been shown to induce hepatic ALAS1 in patients with PCT.[65] Erythrocyte UROD activity is diminished in healthy subjects following acute ethanol ingestion and in chronic alcoholics.[66] Ethanol can also inhibit the activity of other enzymes in the heme pathway, including FECH and ALAD. Chronic alcoholism leads to suppression of erythropoiesis[67] and increased absorption of dietary iron, perhaps linked to inherited mutations associated with hemochromatosis (see below). The fact that ALAS1 is increased in patients with hepatic cirrhosis without porphyria raises questions concerning the relevance of alcohol effects on ALAS1 in the clinical expression of PCT.[68]

Estrogens. The widespread use of estrogens as contraceptive agents or as hormone supplements for postmenopausal replacement therapy in females and as adjunctive hormonal therapy in males with prostatic carcinoma has been associated with PCT.[50] The mechanism of the estrogen effect on the expression of PCT has not been elucidated. Although diethylstilbestrol, an estrogen, induces hepatic ALAS1,[69] this would not explain the distinctive porphyrin excretion pattern found in PCT. The vast majority of patients receiving estrogens do not manifest the biochemical abnormalities associated with PCT.

Hexachlorobenzene. This fungicide caused an "epidemic" of a PCT-like syndrome in Southeastern Turkey in the 1950s.[70] It was added as a preservative to wheat intended for planting, but, because of a famine, several thousand individuals of diverse ethnic origin, mostly children, ingested the seed wheat and subsequently developed typical PCT. Over 4,000 cases of this syndrome were reported from 1956 to 1961. The porphyrin excretion pattern and the cutaneous findings in these patients were quite similar to those seen in PCT evoked by ethanol or estrogens. The outbreak of PCT in Turkey caused by ingestion of HCB indicated that the disease could occur in nongenetically predisposed individuals.

Twenty-five years later, the most common clinical findings in these HCB-poisoned individuals were those of chronic porphyria, including sclerodermoid scarring (84%), hyperpigmentation (78%), hirsutism (49%), thyromegaly, and increased skin fragility (38%).[71] A painless arthritis was seen in two-thirds of affected individuals, and a variety of neurologic signs and symptoms occurred in the majority. Stool and urine porphyrins remained elevated in many patients.

Studies have shown that the chronic administration of HCB to experimental animals produces excessive porphyrin accumulation in the liver in a pattern quite similar to that seen in PCT in humans.[72] These data are consistent with the hypothesis that chlorinated hydrocarbons, such as HCB, or their metabolites inhibit hepatic UROD, leading to excessive hepatic storage of URO and other acetate-substituted porphyrins.[73,74] Experimental studies have also shown that HCB can inactivate UROD, thereby abolishing catalytic activity without changing the amount of immunoreactive enzyme protein.[75] Chemical porphyria, similar to PCT, is caused by other chlorinated hydrocarbons such as the polychlorinated biphenyls (PCBs) and 2,3,7,8-tetrachlorodibenzo-*p*-dioxin (TCDD), a by-product in the synthesis of the herbicide 2,4,5-trichlorophenoxyacetic acid.[76] Additional studies of the porphyrinogenic effects of chlorinated hydrocarbons suggest that metabolic activation of the compounds mediated by cytochrome $P_{450\ 1A2}$ and involving iron-generated ROS is associated with an attack on the catalytic site of UROD.[56,77]

Tetrachlorodibenzo-*p*-Dioxin. TCDD is a toxic environmental pollutant chemical. Among its numerous effects are chloracne, liver damage, and hepatic porphyria in experimental animals and perhaps also in humans.[78] It has been shown that the hepatic porphyrinogenic effect of TCDD can be abolished in mice by first depleting them of iron.[79] Furthermore, it is known that highly inbred mouse strains vary in their susceptibility to induction of hepatic porphyria by TCDD, indicating that the porphyrogenic effect of this hydrocarbon is modulated by as yet undefined genetic factors.[80]

Iron. Serum iron and ferritin concentrations are often elevated or in the upper range of normal in PCT, confirming the important role of iron in the pathogenesis of the disease.[81] Hepcidin is a 25-amino acid peptide that is encoded in humans by the HAMP gene and it is secreted by the liver and inhibits iron transport

by binding to the iron channel ferroportin located on the surface of gastrointestinal enterocytes and the plasma membrane of reticulo-endothelial cells. The net result is that iron is trapped in these cells and cannot be absorbed. Ajioka et al showed that hepatic HAMP expression is decreased in patients with PCT suggesting that the hepatic siderosis associated with PCT likely results from dysregulated HAMP.[82] Hepatic iron overload accompanies clinical PCT in practically all cases, and elevation of plasma iron is found in one-third to one-half of patients.[50] In PCT, the quantity of iron that can be mobilized by phlebotomy indicates that total body iron stores are approximately twice normal. Ferrokinetic studies in patients with PCT are said to be normal. The long remissions that follow repeated phlebotomy and the apparent ineffectiveness of this treatment if supplemental iron is administered concomitantly suggest that iron plays a role in the excessive hepatic porphyrin production of PCT.[83] PCT is particularly common where alcoholism and iron overload occur together.

The role of iron in the pathogenesis of PCT is complex, and several hypotheses have been proposed to explain it. Iron may directly inhibit UROD. However, studies with purified UROD prepared from human erythrocytes show that the purified enzyme is not inhibited by Fe^{2+} or Fe^{3+}.[84] Chronic iron overload can produce peroxidative damage to lipid-rich mitochondrial and microsomal membranes in the liver of experimental animals, but the relationship of this toxic effect to changes in hepatic heme synthesis has not been clearly defined.[85] An increased frequency of the hemochromatosis (*HFE*) gene *C282Y* mutation has been found in British patients with sporadic PCT.[86,87] This mutation is responsible for much of the iron overload in populations of European descent. A second mutation in the *HFE* gene, *H63D*, may also be associated with PCT in some populations.[88] PCT is rare in heterozygotes for each of these mutations but 20% of British patients with PCT are *C282Y* homozygotes. *C282Y* homozygosity is an important susceptibility factor for both type I and type II PCT.[57] However, iron stores are increased in many patients with PCT without mutations in the *HFE* gene.[46]

Iron may have a permissive effect on the inhibition of UROD by halogenated hydrocarbons, and it can also enhance the induction response of hepatic ALAS1 to drugs.[89,90] Although such an iron-augmented increase in ALAS1 activity could lead to enhanced porphyrinogenesis, this alone would not explain the porphyrin excretion pattern seen in PCT. It is known that addition of ferrous iron to liver in vitro causes a marked increase in porphyrin synthesis and inhibits UROS activity, providing an explanation for the URO isomer I excess characteristic of PCT.[91] A mouse model of type II PCT has been described in which one allele of UROD is disrupted and the animals bred to mice null for HFE thereby creating a PCT-like phenotype.[92]

Viral Infections. There is an association between PCT and hepatitis C virus (HCV) infections and combined HCV and HIV infections.[56,93,94] The role of these viruses in the pathogenesis of PCT is unclear, although some connection with the *HFE* gene mutation *H63D* has been suggested. It is also possible that the connection is fortuitous and secondary to nonspecific hepatotoxic effects of these viruses.

From these known effects of alcohol, estrogens, chlorinated hydrocarbons, iron, and viral infections on the heme pathway, it is clear that each of these could contribute to the excessive hepatic porphyrinogenesis characteristic of PCT.[56] There is growing evidence that hepatic siderosis is the critical pathologic endpoint in PCT and that the other agents somehow intensify the ability of iron to attack the catalytic site of UROD. The clinical expression of PCT is therefore dependent upon the interaction of a number of factors, both genetic and environmental. However, it is important to note that the ingestion of drugs that have been associated with inducing acute neurovisceral attacks in the acute porphyrias is not known to exacerbate similar neurological crises in PCT.

Vesicles and bullae followed by erosions and crusting occur predominantly in areas subject to repeated trauma (Figs. 132-7 and 132-8). There is increased skin fragility, usually on the dorsa of the hands (Fig. 132-8). The traumatized skin becomes crusted and, as the lesions resolve, areas of scarring may ensue. Numerous small milia can develop, particularly on the fingers and hands. These pearly white to yellow papules occur in each of the hepatic porphyrias with cutaneous photosensitivity (PCT, VP, and HCP) (Fig. 132-7). Although the cutaneous lesions are primarily seen on the light-exposed areas, patients are often unaware that sunlight plays a role in producing their lesions because the acute painful and burning photosensitivity, so

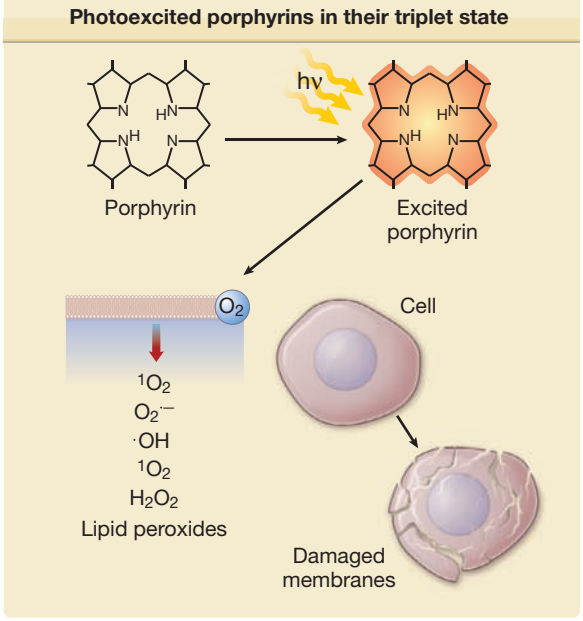

Figure 132-7 Photoexcited porphyrins in their triplet state transfer the absorbed hν to oxygen (O_2) molecules, thereby producing reactive oxygen species ($^1O_2$, $O_2^{\bullet-}$, $^\bullet OH$, and lipid peroxides). These reactive oxygen species interact with cell membranes to cause tissue damage.



Figure 132-8 Porphyria cutanea tarda. This shows bullae filled with clear fluid. Elsewhere are remnants of blisters and over the second metacarpophalangeal joint are small milia.

characteristic of the erythropoietic porphyrias, is rare in PCT. However, most patients do recognize that their skin condition worsens in the spring and summer and seems to improve in the fall and winter.

Other skin changes seen in PCT include hyperpigmentation and hypopigmentation that may be mottled, resembling chloasma. There may be an associated purplish-red ("heliotrope") suffusion of the central part of the face, particularly involving the periorbital areas, which may bear a striking resemblance to the plethora seen in polycythemia rubra vera (Fig. 132-9). This is not seen in the porphyrias of bone marrow origin.

Hypertrichosis (nonvirilizing) is a useful diagnostic sign that often brings the female patient to the dermatologist (Fig. 132-10). Facial hypertrichosis develops gradually and occurs in both males and females. The hair may vary in texture between fine and coarse and in color between light and dark. These hairs are particularly prominent along the temples and the cheeks, but may occasionally involve the trunk and extremities in severe cases. Such hair may continue to grow, darken, and thicken, particularly on the cheeks, the forehead between the eyes, and at the hairline of the scalp. Males may complain that shaving is more difficult and that the growth pattern of their beard has changed. A particularly severe form of hypertrichosis may occur in younger children with PCT and HEP. In the reports of HCB poisoning in Turkey, some of the children were described as "monkey-like" because of marked hypertrichosis.[95] The mechanism of this phenomenon is unknown; androgen levels are reported to be normal. It is possible that surface receptors or growth factors for hair bulb keratinocytes are activated by the dual action of light and porphyrins. The hypertrichosis of PCT usually improves slowly following depletion of excessive hepatic iron stores.

Sclerodermoid plaques can occur in PCT and in HEP and typically develop on both light-exposed and light-protected body areas (Figs. 132-11A and 11B). These are usually scattered, waxy yellow to white, indurated plaques that closely resemble, both clinically and histopathologically, morphea or scleroderma. There is some evidence to indicate that PCT may occur concomitantly with true scleroderma but this seems to be quite rare. As discussed earlier, URO I stimulates collagen synthesis in human skin fibroblasts.[37] In some patients,

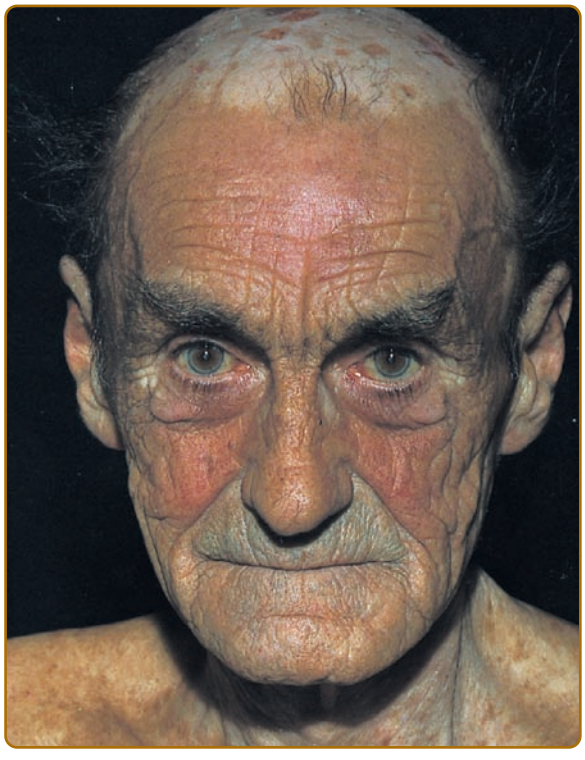

Figure 132-9 Porphyria cutanea tarda. Purple–red suffusion ("heliotrope") of central facial skin is most pronounced in the periorbital and frontal areas. Note also sclerodermoid plaque on scalp.

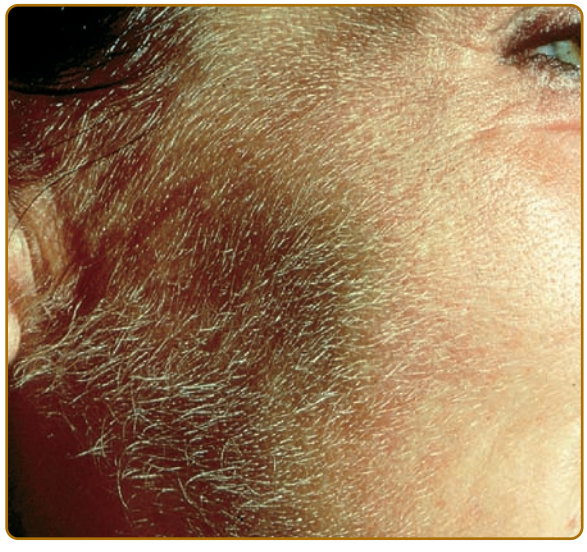

Figure 132-10 Porphyria cutanea tarda. Hypertrichosis occurring in a female with that is most pronounced on the zygomatic and malar skin.



Figure 132-11 Porphyria cutanea tarda. Indurated sclerodermoid plaques occurring on the chest of a patient with this disease.

calcification has developed in these sclerodermoid plaques, necessitating surgical excision and grafting.

PCT-like syndromes are occasionally seen in association with hepatic tumors and lupus erythematosus.[96,97] Subepidermal bullous dermatoses mimicking PCT clinically and histologically have been described (see Section "Pseudoporphyria"). A number of cases of true PCT have occurred in patients with renal failure undergoing hemodialysis.[98] Confirmation of the diagnosis rests on detection of markedly elevated plasma porphyrins (usually 5–100-fold) and increased ISOCOPRO in the feces.

LABORATORY TESTS. Patients with PCT excrete increased amounts of porphyrins in the urine, which rarely may exhibit characteristic pink–red fluorescence when examined with a Wood's lamp. The porphyrin excretion pattern of PCT has three main features: (1) increased urinary excretion of URO and of other acetate-substituted porphyrins; (2) a distinctive pattern of excretion of isomer series I and III porphyrins; and (3) increased excretion of fecal ISOCOPRO.[56,99,100] PCT patients excrete greatly increased amounts of urinary 8-carboxyl URO and also porphyrins with 7-, 6-, and 5-carboxyl groups; 4-carboxyl porphyrin (COPRO) is also increased but to a lesser extent than URO and rarely surpasses 600 µg per 24 hours (Table 132-8). In PCT, the hepatic UROD deficiency results in the accumulation of 5-carboxylporphyrinogen III (Figs. 132-1 and 132-2). This can be utilized as a substrate by the enzyme CPOX and thereby forming dehydroisocoproporphyrinogen, which in turn is oxidized to ISOCOPRO, resulting in the characteristic elevation of this compound in the feces of these patients.

The 8-carboxyl URO and 7-carboxyl porphyrins are the predominant urinary porphyrins in PCT (>90% of total porphyrins). The urinary porphyrin excretion pattern is a mixture of type I and type III isomers. URO is about 60% type I isomer and 40% type III; the 7- and 6-carboxyl porphyrins are >90% type III and <10% type I isomer; the 5- and 4-carboxyl porphyrins are about 50% each isomer. This distinctive isomer pattern is found consistently in patients with PCT.

In general, only trace amounts of URO are present in the stools of normal individuals. The porphyrin content of stool is increased in PCT and consists primarily of ISOCOPRO (type III), 7-carboxyl porphyrin, and lesser amounts of URO and COPRO. The total daily 24-hour fecal porphyrin excretion may exceed total urinary porphyrin excretion.

The ratio of URO to COPRO in the urine is often helpful in differentiating PCT and VP. Thus, in PCT, the URO:COPRO ratio usually exceeds >3:1, whereas in VP the ratio is typically less than 1:1. Occasionally, 24-hour urine porphyrins will be normal or only slightly increased in a patient with the cutaneous findings of PCT. This should alert the physician to suspect the diagnosis of VP and thus to evaluate stool porphyrins, as these are almost always elevated in patients with VP (see Section "Variegate Porphyria").

It should be emphasized that in patients with clinical signs of PCT a fluorescent screening test for urinary porphyrins is often negative. In such patients, it is absolutely essential to measure plasma porphyrin levels and perform quantitative 24-hour urine URO and COPRO determinations and quantitative stool PROTO and COPRO determinations preferably using high-performance liquid chromatography, which often permit differentiation of PCT from VP. Rarely, some patients with VP will have normal fecal porphyrin excretion, and bile porphyrin measurements may be helpful in evaluating such patients.[101]

Virtually all patients with PCT have excessive total body iron stores manifested as increased serum iron, ferritin, and/or hepatocellular iron.[46,56] Occasionally, there is mild erythrocytosis. An abnormal glucose tolerance test occurs in a minority of patients.

Biochemical tests for liver function often reveal elevated serum transaminases and γ-glutamyltranspeptidase levels. Serum iron and ferritin concentrations may be elevated. The measurement of erythrocyte UROD is useful for the detection of patients with type II PCT. Mutational analysis is an essential part of evaluating these patients (see below).

HISTOPATHOLOGY. The characteristic histopathologic finding in PCT is a subepidermal blister (Fig. 132-12). Bullae characteristically show a corrugated, undulating base that has been termed *festooned*.[102] There is little or no inflammatory infiltrate. PAS stain reveals a mild degree of thickening of the papillary vessel wall, not nearly so marked as that seen in patients with EPP. Reticulin staining demonstrates slight proliferation of fibers along

TABLE 132-8
Biochemical Features of the Porphyrias

	Blood				Stool			Urine				
Type of Porphyria	**RBC URO**	**RBC COPRO**	**RBC PROTO**	**Plasma**	**URO**	**COPRO**	**PROTO**	**Color**	**ALA**	**PBG**	**URO**	**COPRO**
Nonacute												
Porphyria cutanea tarda	N	N	N	↑URO	++	+ ISOCOPRO	+++	Pink to red	N	N	++++	++
Hepatoerythropoietic porphyria	N	±	++++	↑URO	N	ISOCOPRO	N	Pink to red			+++	ISOCOPRO
Erythropoietic protoporphyria	N	N to +	++++	↑PROTO	N	++	++ to ++++	N	N	N	N	N
X-linked dominant protoporphyria	N	N to +	++++ predominantly zinc-chelated	↑PROTO	N	++	++ to ++++	N	N	N	N	N
Congenital erythropoietic porphyria	++++	++++	+++	↑URO & COPRO	+	+++	+	Pink to red	N	N	++++[a]	++[a]
Acute												
Acute intermittent porphyria												
Latent	N	N	N	N	N to +	N to +	N to +	Red to purple	+ to +++	+ to +++	N	N to +
Acute	N	N	N	N	N to +	N to +	N to +	Red to purple	++ to ++++	++ to ++++	++++	++
Variegate porphyria												
Latent	N	N	N	?N	N	+++	++++	N	N	N	N	N
Acute	N	N	N	?N	++	++	+++	Pink to red	++ to +++	++ to ++++	+++	+++
Hereditary coproporphyria												
Latent	N	N	N	?N	++	++++	N to +	N	N to +	N to +	N	N
Acute	N	N	N	?N	+	+++	N to +	Red	++ to N	++ to N	++	+++
ALA dehydratase deficiency porphyria	N	N	++	↑ALA ↑COPRO ↑PROTO	N	+	+	?	+++	N	+	++

+ = above normal; ++ = moderately increased; +++ and ++++ = greatly increased; ↑ = increased; ALA = δ-aminolevulinic acid; COPRO = coproporphyrin; ISOCOPRO = isocoproporphyrin; N = normal; PBG = porphobilinogen; PROTO = protoporphyrin; RBC = red blood cell; URO = uroporphyrin.
[a]Type I isomers.
Findings of major diagnostic importance are boxed.

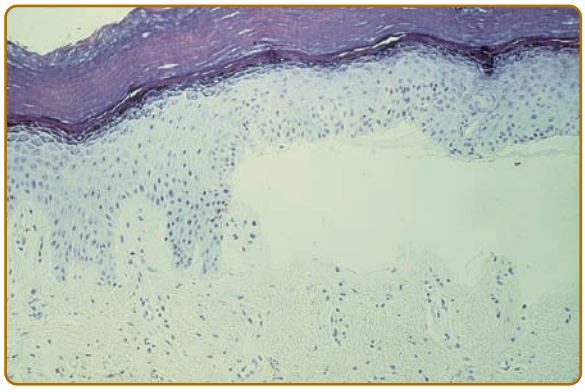

Figure 132-12 Porphyria cutanea tarda. Subepidermal blistering shows virtually no inflammatory infiltrate with partial preservation of dermal papillae.

the basement membrane. Direct immunofluorescence studies reveal deposition of C3, C5b-9, and IgG in a granular pattern at the dermal–epidermal junction and in and around vessel walls in affected individuals.[44,103] These changes are most apparent in sun-exposed areas of patients with active disease and high urinary porphyrin excretion, and they decrease substantially in patients after appropriate treatment. It is possible that the deposition of immunoglobulins and complement is a nonspecific result of injury to the cutaneous tissue. Damage of the upper dermal vessels and at the dermal–epidermal junction suggests that structural changes evoked by porphyrin photosensitivity may be responsible for the unique skin fragility seen in PCT.

Regardless of these findings, it should be emphasized that histopathologic examination does not substantially contribute to confirming the diagnosis of PCT. This is also true for the other cutaneous porphyrias and, consequently, it is not essential to obtain a skin biopsy if one of the cutaneous porphyrias is suspected, mainly for two reasons. First, simple noninvasive biochemical laboratory techniques (see above) can usually permit presumptive diagnosis of porphyria and, second, external trauma (such as a biopsy or excision) inevitably constitutes an avoidable risk for delayed and/or dysfunctional wound healing that is a characteristic feature of all cutaneous porphyrias.

DIFFERENTIAL DIAGNOSIS. Other dermatoses that can be confused with PCT include VP, HCP, mild forms of HEP and/or CEP, pseudoporphyria, scleroderma, and epidermolysis bullosa acquisita (EBA). Each of these can be differentiated by appropriate porphyrin studies. Careful evaluation of urine, stool, and plasma porphyrins will almost always permit confirmation of the diagnosis of PCT. Nonsteroidal anti-inflammatory drugs such as naproxen and antibiotics such as the tetracyclines and nalidixic acid as well as a variety of other agents may rarely produce bullous lesions closely resembling PCT but in contrast show no evidence of abnormal porphyrins (see Section "Pseudoporphyria").

TREATMENT. (See Box 132-1). Initially, a careful history should be taken in an effort to identify an environmental toxin, for example, alcohol, estrogen, or chlorinated hydrocarbon, which may have triggered the disease.[46,56] If HCV or HIV infection is present these should be managed appropriately. Elimination of toxin exposure alone may result in gradual improvement. However, in most patients with PCT, more aggressive treatment is usually appropriate to accelerate therapeutic benefit and this currently consists of either repeated phlebotomy[56,104,105] or orally administered antimalarial drugs, either chloroquine or hydroxychloroquine[106,107] or a combination of both.[108] Other forms of treatment that have been described include administration of iron chelators[109,110] and the oral administration of cholestyramine.[111]

Phlebotomy. Phlebotomy is still the treatment of choice for PCT. Numerous reports have confirmed the safety and efficacy of this form of therapy[112] which was introduced by Ippen.[104] Phlebotomy is effective because it depletes the excessive hepatic iron stores characteristic of PCT. Biochemical remission of PCT has occurred in patients treated with phlebotomy with iron overload as well as in patients with quantitatively normal iron stores. Replenishment of iron following phlebotomy-induced remission of PCT has resulted in biochemical and clinical exacerbation of the disease. Abstinence from the environmental triggers alone, especially alcohol, may induce a clinical and biochemical remission, although this may take months to years.[112]

The efficacy of phlebotomy may relate to several effects:

1. *Iron effect on ALAS1*. Iron can enhance the induction response of ALAS1 to drugs and the hepatic porphyrinogenic response to HCB in experimental animals, and its depletion could render ALAS1 less inducible and thereby diminish hepatic porphyrinogenesis.
2. *Iron depletion effects on other heme pathway enzymes*. Ferrous iron inhibits UROD and increases the rate of hepatic porphyrin synthesis from ALA or PBG, suggesting that removal of iron can allow UROD activity to return to normal and/or reduce excessive porphyrinogenesis.[81,91] This concept has been verified by the creation of genetically engineered mice in which iron overload inhibits the enzyme.
3. *Iron effects on hepatic lipid peroxidation secondary to ROS*. Iron depletion could reverse this response of the liver to iron overload.[85]
4. *Iron effects on oxidation of URO*. Removal of iron could result in a diminished capacity of the ferrous metal to irreversibly oxidize the UROGEN substrate to nonmetabolizable porphyrins.[113] The first product in the oxidation of UROGEN to URO is uroporphomethene in which one methane bridge is oxidized.[46] This metabolite is an inhibitor of UROD.

Phlebotomy is carried out as an ambulatory procedure. The total amount of blood removed varies widely, usually ranging from 1,500 to 12,000 mL. It is most convenient to use plastic blood-drawing bags

BOX 132-1 TREATMENT OF THE NONACUTE PORPHYRIAS

TYPE	MANAGEMENT
Porphyria cutanea tarda	▪ Photoprotection (e.g., with broad-band sunscreens and/or protective clothing) ▪ Avoidance of sun exposure and trauma ▪ Discontinuation of alcohol ingestion and estrogen therapy ▪ Phlebotomy (venesection): 400–500 mL every 2 weeks over 3–6 months ▪ Low-dose chloroquine treatment: 125 mg twice weekly for 6–12 months until porphyrin excretion is within normal range ▪ Measurement of urinary porphyrin excretion and plasma porphyrins quarterly to monitor progress
Erythropoietic protoporphyrias	▪ Photoprotection (e.g., with broad-band sunscreens and/or protective clothing) ▪ Avoidance of sunlight exposure (common window glass does not provide protection) ▪ Oral β-carotene: 30–90 mg/day in children; 60–180 mg/day in adults; desirable maximum plasma level is 600–800 µg/dL
Congenital erythropoietic porphyria	▪ Photoprotection (e.g., with broad-band sunscreens and/or protective clothing) ▪ Strict avoidance of sunlight exposure ▪ Change of day-night rhythm ▪ Splenectomy if hemolytic anemia is severe ▪ Bone marrow transplantation
Hepatoerythropoietic porphyria	▪ Photoprotection (e.g., with broad-band sunscreens and/or protective clothing) ▪ Strict avoidance of sunlight exposure and trauma ▪ Change in day-night rhythm ▪ *Caution:* Therapeutic approaches used in porphyria cutanea tarda (phlebotomy, antimalarials) are ineffective.

available in any blood bank. Approximately 500 mL of blood is removed at weekly or biweekly intervals until the hemoglobin decreases to approximately 10 g/dL or until the serum iron drops to 50–60 µg/dL. Some believe that phlebotomies should be continued until serum ferritin falls to the lower range of normal. Patients are strongly encouraged to discontinue or decrease exposure to porphyrinogenic agents as this usually hastens clinical and biochemical remission.

It is particularly important to reassure the patient that clinical improvement may not become apparent for variable intervals after beginning the phlebotomies. Porphyrin excretion continues to fall long after phlebotomies are discontinued. Urinary URO excretion reaches normal levels (<100 µg per 24 hours) after 5–12 months in more than 90% of patients treated with regular phlebotomy. Blistering is the first sign to disappear, followed by improvement in skin fragility and in hypertrichosis over a period of 3–18 months. Even sclerodermoid changes can resolve slowly, although this may take several years. There are few published data on long-term follow-up of treatment, but most relapsed patients have again responded to repeated courses of phlebotomies.[105] The length of remission induced by phlebotomy varies widely and ranges from 6 months to more than 10 years. At least 10%–20% of patients will relapse within 1 year.

Phlebotomy is a safe, effective, and relatively simple form of therapy with minimal associated morbidity. A few patients may complain of mild-to-moderate fatigue and weakness during the treatment period, but this usually resolves as the hemoglobin returns to normal. Phlebotomy remains the treatment of choice for uncomplicated PCT. The availability of more effective oral iron chelators such as deferiprone and deferasirox suggest that these agents may prove to be a useful alternative to phlebotomy in managing the iron overload of PCT.[114]

Antimalarials. In some patients, phlebotomy is not recommended or is contraindicated owing to the presence of anemia or cardiopulmonary disorders or HIV infection. In such cases low-dose antimalarial therapy is a useful alternative. The antimalarial aminoquinolines, chloroquine, and hydroxychloroquine, are used.[106,107] The cutaneous signs of the disease cleared within 1 year in one patient who received 500 mg daily for several months. However, such doses may trigger severe hepatotoxicity in many PCT patients and this is no longer considered an acceptable approach.

Instead, low-dose chloroquine therapy at a dose of 125 mg twice weekly is effective in treating PCT and obviates the hepatotoxic effects of high-dose therapy.[115] Beside the successful therapeutic outcome in single patients and small cohorts,[116] low-dose chloroquine (125 mg twice weekly for 8–18 months) was employed successfully in more than 100 patients with PCT.[117] Liver function tests and urinary porphyrins are

monitored quarterly, and the medication continued until urinary URO is <100 µg per 24 hours. This usually requires 6–12 months of treatment. Studies comparing the therapeutic efficacy of phlebotomy with that of low-dose chloroquine suggest that they are equally efficacious and, likewise, the clinical and biochemical remission of PCT obtained with chloroquine appears to be identical in all respects to that evoked by phlebotomy. However, it has been reported that rapid relapse occurred in several patients treated with hydroxychloroquine[118] and, therefore, chloroquine may be preferable. The mechanism of action of chloroquine may relate to formation of water-soluble drug-porphyrin complexes that are then excreted from the liver.[119] However, Taljaard et al feel that chloroquine chelates iron in the hepatocyte and that the bound iron is then eliminated.[116]

The combination of phlebotomy and chloroquine treatment may reduce the severity of the hepatotoxic response to chloroquine and also accelerate remission of the disease.[108] Patients are treated with a series of one to four phlebotomies prior to starting chloroquine (250 mg daily for 7 days). The procedure is repeated when signs of biochemical or clinical relapse develop, which may occur in 1–2 years. It should be emphasized that despite the tendency of the antimalarials to evoke hepatotoxic responses in patients with PCT, there is no evidence to suggest that the changes in hepatocellular pathology characteristic of PCT worsen as a result of treatment with these drugs.[120] The antimalarials may cause retinopathy, and the low-dose regimen helps to minimize the risk of this complication. Pretreatment and semiannual ophthalmologic examinations should be obtained on patients treated with these drugs. In patients with PCT and chronic renal failure standard phlebotomy and antimalarial therapy are not feasible. The combination of high-dose recombinant erythropoietin and small volume phlebotomy has been successful in selected patients.[121]

HEPATOERYTHROPOIETIC PORPHYRIA

HEPATOERYTHROPOIETIC PORPHYRIA AT A GLANCE

- Extremely rare (approximately 40 cases reported).
- Autosomal recessive disorder due to homozygous deficiency of UROD.
- Patients have been reported in the United States and Europe.
- Age of onset in early childhood (1–4 years).
- Characterized by severe photosensitivity, including vesicles and bullae, erosions, excoriations, crusts, and milia; mutilating scarring; and hypertrichosis.

HEP is the homozygous/compound heterozygous variant of PCT and results from a profound deficiency of UROD due primarily to a *G281E* mutation (GGG → GAG, codon 281). Measurement of the enzyme in hemolyzed whole blood or skin fibroblasts from three unrelated patients with the disease showed that it was reduced to less than 5% of normal levels. There is no evidence as yet to show that clinical expression of HEP is related to exposure to environmental drugs or chemicals, as is true for PCT. In one family clinical, biochemical, and enzymatic studies of three generations in which a second-generation 31-year-old male was shown to have HEP revealed that both of the proband's parents and each of his three children had a moderate deficiency of UROD.[122] Additional cases of HEP with *UROD* gene mutations other than *G281E* have been reported in which there is 30% residual UROD activity associated with a milder phenotype.

EPIDEMIOLOGY. Patients with HEP have been reported in Europe (predominantly in Spain), America, and Japan.

CLINICAL MANIFESTATIONS. The disease typically manifests in early childhood and dark-red urine is often the first sign. Severe cutaneous photosensitivity with blistering and pruritus then ensues. The photosensitivity may diminish with age and is followed by hypertrichosis, hyperpigmentation, and scleroderma-like scarring similar to that seen in CEP (Günther's disease) (Fig. 132-13). Ocular manifestations include ectropion associated with cutaneous sclerosis and scleromalacia perforans. Splenomegaly has occurred in a small percentage of affected individuals, particularly



Figure 132-13 Hepatoerythropoietic porphyria. Sclerodermoid thickening and scarring of facial and scalp skin with ulcerations occurring in a patient with this disease. The sclerodermoid changes are particularly pronounced.

after the age of 10, and hemolytic anemia has been documented as well. In some patients, liver function tests have been abnormal, but serum iron and iron binding are normal. In summary, the clinical manifestations of HEP resemble a combination of PCT and CEP.

LABORATORY FINDINGS. The urinary porphyrin pattern is similar to that found in PCT (see Table 132-8). However, elevated RBC PROTO in HEP helps to distinguish it from PCT. Elevated urinary URO I and III (URO:COPRO ratio>5~1) and 7-carboxyl porphyrins (>90% isomer III), elevated fecal COPRO and ISO-COPRO, and elevated RBC PROTO (zinc-chelated) have been observed in all patients. These findings suggest that there is abnormal porphyrin synthesis in both the liver and the bone marrow. In contrast to PCT patients, serum iron concentrations are usually normal in HEP.

HISTOPATHOLOGY. Skin biopsies of blistering lesions show subepidermal bullae resembling those of PCT and PAS-positive material is seen in and around dermal capillaries. However, skin biopsy is not essential for making the diagnosis of HEP.

DIFFERENTIAL DIAGNOSIS. These include childhood porphyrias (e.g., the rare homozygous or compound heterozygous variants of VP and HCP), clinically severe forms of PCT, and CEP. In contrast to HEP, CEP manifests erythrodontia and mutilating scarring.

TREATMENT. There is no known treatment aside from careful photoprotection, including protection from visible light.

PSEUDOPORPHYRIA

This term is used to describe patients who clinically exhibit cutaneous manifestations resembling PCT without the characteristic abnormal porphyrin profile. This disorder may develop in association with ingestion of certain drugs such as furosemide,[123] nalidixic acid.[124] tetracycline,[125] naproxen,[126] pyridoxine,[127] and isotretinoin.[128]

In the drug-induced type of pseudoporphyria, the blistering process is subepidermal with little or no dermal inflammation. Staining with PAS reveals little or no positive deposition around upper dermal blood vessels and capillary walls. Indirect immunofluorescence studies conducted on split skin reveal no dermal deposition of fluorescent material in pseudoporphyria. Direct immunofluorescence studies have shown patchy granular deposition of IgG and C3 at the basement membrane zone in pseudoporphyria, PCT, and in epidermolysis bullosa acquisita.

A bullous dermatosis that is morphologically and histologically indistinguishable from PCT has also been observed in patients with chronic renal failure treated with long-term hemodialysis. Such patients have moderately elevated plasma porphyrins (two- to fourfold) secondary to impaired renal clearance as well as diminished clearance through dialysis filters.

ERYTHROPOIETIC PROTOPORPHYRIA

ERYTHROPOIETIC PROTOPORPHYRIA AT A GLANCE

- Second most common of the cutaneous porphyrias.
- Autosomal dominant or autosomal recessive disorder involving a deficiency of ferrochelatase or X-linked dominant disorder involving gain of function of δ-ALAS2.
- Age of onset in early childhood (1–4 years); rarely late onset can occur.
- Cutaneous findings include erythema, edema, purpura, skin thickening, and waxy scars; blistering is rare.
- Symptoms include acute burning and stinging of the skin that may be severe.
- In approximately 5% of patients, potentially fatal hepatic failure develops.

EPIDEMIOLOGY

Although the exact incidence of EPP is unknown, it has been reported with increasing frequency since its initial recognition in 1961, indicating that it is likely the second most common type of cutaneous porphyria after PCT. The disease occurs globally with a prevalence estimated between 1:75,000 and 1:200,000.[129] A recent review of the demographic, clinical, biochemical and genotypic features of EPP in Sweden showed that the prevalence was 1: 180,000 and the most commonly reported age of onset of symptoms was the first year of life and the mean age at diagnosis was 22 years.[130]

ETIOLOGY

The specific defective enzyme in EPP is FECH, which is decreased in various tissues of affected patients, including RBC, mitogen-stimulated lymphocytes, and cultured skin fibroblasts of patients and unaffected carriers.[131–134] FECH is located at the matrix face of the inner mitochondrial membrane and catalyzes the final step in the formation of heme, the incorporation of ferrous iron (Fe^{2+}) into PROTO (Figs. 132-1 and 132-2). This lysine-rich enzyme has a molecular mass of 63 kDa, a pH optimum of 7.8, and is also referred to as heme synthase or proto-heme-ferro-lyase. Unlike other enzymes in the heme biosynthesis pathway, that require reduced forms of the porphyrins (porphyrinogens) as substrates, FECH, utilizes PROTO, the oxidized isomer of PROTOGEN. The endproduct

of the pathway, ferrous-PROTO (FePROTO) or heme, diffuses out of the mitochondrion into the cytoplasm, where it is available to function as a prosthetic group by combining with appropriate apoproteins (Figs. 132-1, 132-3, and 132-4). Through rate of consumption of heme in the cytoplasm, heme thus controls its own synthesis based upon the needs of the cell.

The cDNA for human FECH has been cloned, sequenced, and shown to have 88% homology to the mouse enzyme. Human FECH mRNA is encoded by a single nuclear gene of the same name, *ferrochelatase* (*FECH*), that is located on chromosome 18q21.3 and spans about 45 kb of genomic DNA.[134] The gene consists of eleven exons and ten introns. Molecular genetic studies have been conducted in patients with EPP and revealed more than 110 different mutations of various types with deletions and insertions being the most common. The molecular epidemiology of EPP involves three patterns of inheritance.[135] In the majority, the disease is inherited in a pseudodominant manner such that disease expression only occurs in the setting of a *FECH* mutation that is inherited *trans* to a hypomorphic allele (*FECH* IVS3–48C, c.315–48C). This additional nucleotide alteration *in trans* leads to modulation of splicing and the use of a constitutively aberrant acceptor splice site. The aberrantly spliced mRNA is degraded by a nonsense-mediated decay mechanism, producing a decreased steady-state level of mRNA. This results in an additional in vivo decrease in residual FECH activity of about 15%–40% that diminishes catalytic activity to the point where the EPP phenotype is expressed.[136] The second pattern of inheritance of EPP (approximately 5%) is autosomal recessive in which a *FECH* mutation occurs on both alleles and the third pattern is due to *C*-terminal deletions in the *ALAS2* gene resulting in gain of function that causes EPP without anemia or iron overload. This is inherited in an X-linked dominant manner (see below).[5]

CLINICAL MANIFESTATIONS

Skin. Typically, the disease begins early in life and is characterized by acute episodes of cutaneous photosensitivity including burning, stinging (smarting), and pruritus affecting light-exposed skin, particularly the nose, cheeks, and dorsal aspects of the hands. These are followed by erythema, edema (Fig. 132-14), urticarial lesions, and less commonly purpura. Symptoms may occur within minutes of sun exposure; it is often seasonal, starting early in the spring, continuing through the summer, and diminishing in the winter. The skin lesions often resolve slowly, leaving small, atrophic, waxy, or pitted scars (Fig. 132-15). There may be some pursing of perioral skin (pseudorhagades). The skin of the knuckles and fingers, particularly over the metacarpophalangeal and interphalangeal joints, often appears thickened, wrinkled, and waxy, resembling the features of aging (so-called old knuckles, in a child). This subtle change is pathognomonic. Superficial scarring over the bridge of the nose and small annular shallow scars occur on the face. Vesicular or bullous lesions are rare in temperate climates, although they have been reported in patients exposed to tropical sunlight. In most affected individuals cutaneous involvement persists throughout life, although some patients seem to become less symptomatic over time.

Liver. Severe life-threatening hepatotoxicity occurs in approximately 5% of patients with EPP. PROTO is a lipophilic molecule that is cleared by the liver and



Figure 132-14 Erythropoietic protoporphyria **A.** One hour after exposure to sunlight, the face of this 35-year-old woman is edematous and erythematous, and there is purpura on the forehead, cheeks, and nose. The patient experiences severe burning pain in the affected areas. **B.** Swelling and purpura on the dorsa of the hands resulting from exposure to solar radiation.



Figure 132-15 Erythropoietic protoporphyria. A 15-year-old patient with severe photosensitivity. The nose, lower lip, and chin show erythematous, eroded, and crusted lesions. Nose and cheeks show erythematous lesions, a few small slightly depressed scars, and characteristic waxy thickening of skin. Linear scars are seen in the infranasal area and on the cheeks and face.

these patients are at increased risk for cholelithiasis and obstructive hepatic disease that ultimately compromises liver function. This may be aggravated by hemolysis of PROTO-laden RBCs creating a vicious cycle of increased erythropoiesis and increased PROTO loading of the liver. The net result of these alterations is terminal hepatic failure in about 5% of EPP patients.[137] Affected individuals become severely jaundiced, develop hepatic cirrhosis, and may go into hepatic coma and die. Some EPP patients with end-stage liver disease may develop axonal neuropathy resembling that in the acute hepatic porphyrias despite normal serum ALA and PBG.[138] Risk factors for EPP-associated hepatic failure remain unknown but parenchymal crystallization of incompletely cleared hepatic PROTO is a likely explanation. Mitoferrin1 (Mfrn1) is 1 of 2 homologous mitochondrial **iron** transporters and is required for mitochondrial **iron** delivery in developing erythroid cells. Deletion of Mfrn1 in hepatocytes has no phenotype or biochemical effect under normal conditions but in the presence of increased porphyrin synthesis, Mfrn1 deletion in hepatocytes results in decreased ability to convert protoporphyrin IX into heme, leading to protoporphyria, cholestasis, and bridging cirrhosis. Altered heme synthesis can cause hepatotoxicity.[139] Experimental studies have shown that perfusion of rat liver with PROTO induces a dose-dependent cholestasis that could contribute to the hepatotoxicity of PROTO.[140] Liver failure has also occurred in two siblings who inherited EPP in an autosomal recessive pattern as compound heterozygotes, suggesting that this genotype may somehow augment the risk of this complication.[141] This is debatable since some compound heterozygotes maintain normal liver function while others develop liver failure.[142]

The cutaneous and hepatic symptoms described above are the major findings in EPP. There is no hypertrichosis, milia, sclerodermoid change, or hyperpigmentation as in PCT and no erythrodontia as in CEP. Hemolytic anemia is decidedly uncommon, although about 11% of patients with EPP have a mild anemia of unknown cause.[129] Gallstones have been reported in some patients with EPP at a relatively early age; in one series, 12% of patients had cholelithiasis, of whom three underwent cholecystectomy.[143]

LABORATORY FINDINGS.

The diagnosis of EPP is based on the detection of elevated free PROTO in the RBC and/or feces (Table 132-8). Controversy exists concerning the tissue origin of the excessive PROTO. Some have shown that RBC PROTO levels alone are sufficient to explain the increased levels of PROTO,[24,144] whereas others have suggested that hepatic PROTO production contributes to the excessively high levels of circulating PROTO.[145] In addition, there may be increased plasma PROTO, increased fecal COPRO, and occasionally slightly increased RBC COPRO. In patients with deteriorating hepatic function, the fecal excretion of PROTO may decrease as plasma levels and cutaneous photosensitivity increase.[146]

Examination of a blood smear under a fluorescent microscope reveals red-fluorescing RBC (5%–30%) (Fig. 132-16). Since the fluorescence is often transient and quite light sensitive the procedure should be carried out in subdued light or preferably in the dark. However, this is not a reliable diagnostic test, since RBCs from patients with chronic lead intoxication also show fluorescence.

A rapid quantitative microfluorometric assay for free erythrocyte and plasma PROTO may be used to screen for suspected EPP.[147] In one series of 32 patients with EPP, the RBC PROTO levels ranged from 131 to 1617 μg/dL of RBC (normal <90 μg/dL of RBC).[148] It has been shown that erythrocyte accumulation of PROTO in EPP patients influences hematologic and iron status. Patients with EPP had a mild anemia and thrombocytopenia that positively correlated with the amount of erythrocyte PROTO. Iron and transferrin saturation saturation negatively correlated with erythrocyte PROTO.

HISTOPATHOLOGY

Skin. Immediately following irradiation, endothelial cell damage, mast cell degranulation, and polymorphonuclear cells are seen in the dermis.[33] In sun-exposed areas, there is often marked eosinophilic homogenization and thickening of vessels in the papillary dermis due to the accumulation of an amorphous, homogeneous, slightly basophilic (hyaline-like) substance in and around the vessel walls.[129] The perivascular deposits of concentric eosinophilic layers of hyaline-like material stain strongly

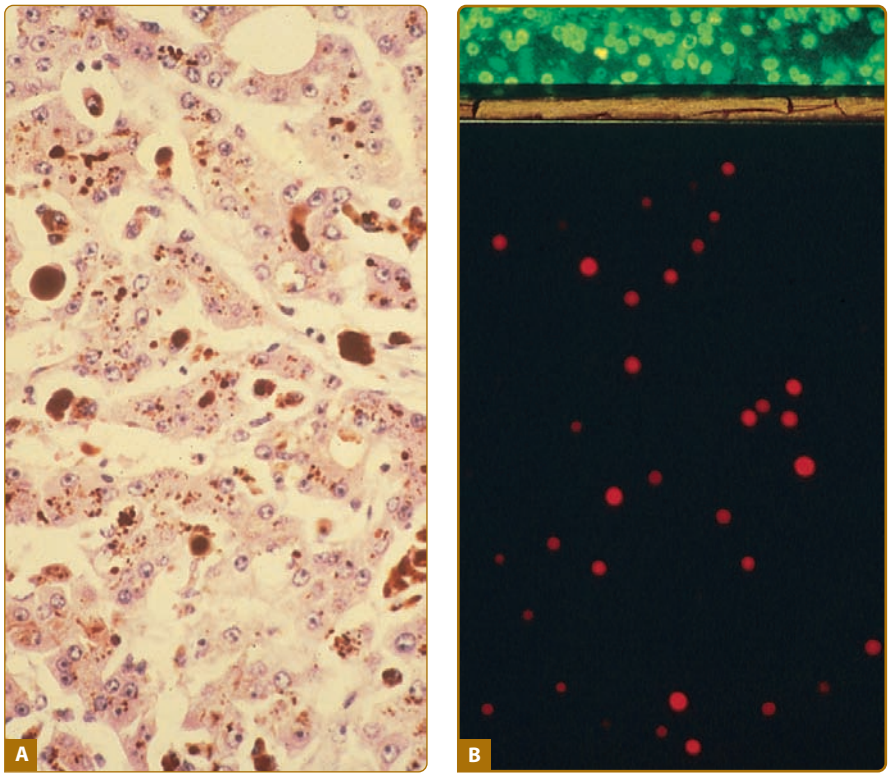

Figure 132-16 Erythropoietic protoporphyria. **A.** Brown pigment deposits in the liver are present in bile canaliculi, hepatocytes, and Kupffer cells. **B.** Bright red fluorescence in red blood cells (RBCs) of a fresh smear from a patient with this disease. Whereas almost all RBCs on the slide show green fluorescence only (*top*), a few RBCs contain increased amounts of protoporphyrin and the characteristic red–pink fluorescence of porphyrins (*bottom*).

positive with periodic acid-Schiff (PAS) and are diastase positive (Fig. 132-17). Histochemical studies suggest that this material may be a neutral glycoprotein with smaller amounts of acid mucopolysaccharide and lipids.[149] The histologic findings are similar to those of lipoid proteinosis (hyalinosis cutis et mucosae).[150] Electron microscopic studies in EPP show that the amorphous material consists of a multilayered partially fragmented basement membrane and finely fibrillar material of moderate density that permeates and surrounds the vessel walls.[151] Other studies have shown that type IV collagen and laminin as well as amyloid P and fibronectin are deposited in the walls of dermal blood vessels.[152]

Liver. Light microscopy of liver biopsies has revealed slight portal and periportal fibrosis and deposition of brown pigment, which may occlude bile canaliculi and ducts; it is also present in hepatocytes, in Kupffer cells, and in periportal macrophages. The pigment is birefringent on polarization microscopy.[153] Hepatocytes may also contain cytoplasmic or mitochondrial inclusions, which at the ultrastructural level appear as needle-like crystals (Maltese crosses), probably due to precipitated PROTO (Fig. 132-16).[154] Biliary excretion of PROTO is coupled to secretion of phospholipid, translocated from the inner to outer canalicular membrane leaflet by the mdr2P glycoprotein.[135] PROTO excretion from the liver requires bile acids and excessive amounts of the porphyrin inhibit its transport out of the hepatocyte.

DIFFERENTIAL DIAGNOSIS.

EPP must be differentiated from other photosensitivity diseases, primarily, polymorphous light eruption, drug-induced phototoxicity, actinic prurigo, hydroa vacciniforme, idiopathic solar urticaria, and other types of porphyria, in particular the newly identified variant XLDPP. Photoallergic and phototoxic contact dermatitis and angioedema should also be considered.

In polymorphous light eruption (PMLE), the lesions are characteristically papules, plaques, and papulovesicles. A family history of photosensitivity is less common. Burning and stinging of the skin during or soon after sun exposure is unusual in PMLE, whereas it is a common feature of EPP. If doubts persist, RBC PROTO measurement or plasma porphyrin determination will differentiate the two. The same is true for idiopathic solar urticaria. Airborne contact dermatitis may involve nonlight-exposed areas such as the skin folds and the submental areas. Patch testing with suspected allergens and negative porphyrin values help to differentiate this condition. The lesions of angioedema may occur anywhere on the body, including the mucous membranes. Because the discomfort described by patients with EPP is often disproportionate to visible lesions, the disease can be confused with psychoneurosis or even malingering. Porphyrin determinations will clarify this issue.

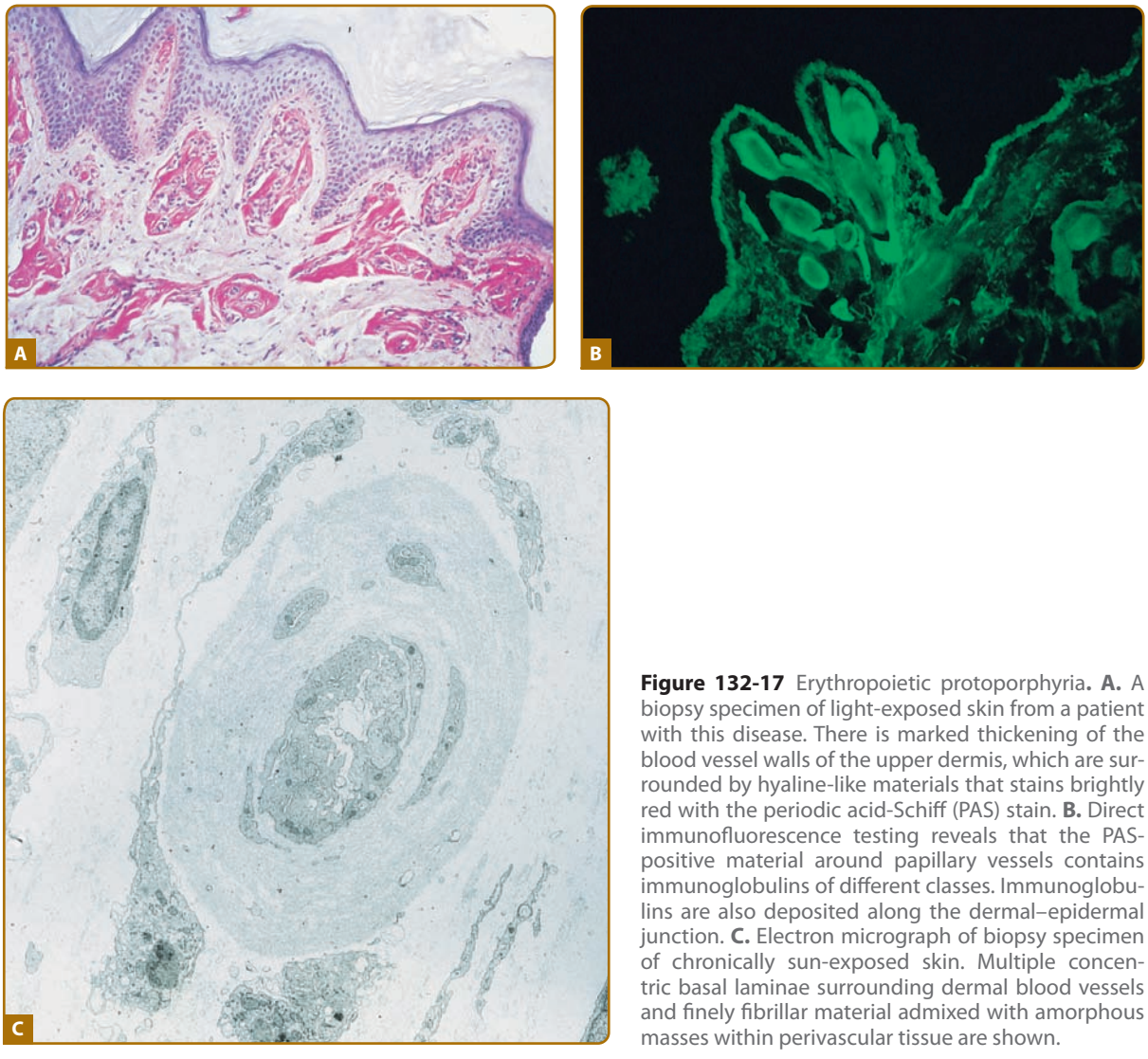

Figure 132-17 Erythropoietic protoporphyria**. A.** A biopsy specimen of light-exposed skin from a patient with this disease. There is marked thickening of the blood vessel walls of the upper dermis, which are surrounded by hyaline-like materials that stains brightly red with the periodic acid-Schiff (PAS) stain. **B.** Direct immunofluorescence testing reveals that the PAS-positive material around papillary vessels contains immunoglobulins of different classes. Immunoglobulins are also deposited along the dermal–epidermal junction. **C.** Electron micrograph of biopsy specimen of chronically sun-exposed skin. Multiple concentric basal laminae surrounding dermal blood vessels and finely fibrillar material admixed with amorphous masses within perivascular tissue are shown.

TREATMENT. (See Box 132-2). Photoprotection is absolutely essential although the use of topical sunscreens, such as products containing mexoryl, titanium, or zinc oxides are at best only marginally helpful because absorption and reflection of visible light is modest. Other agents such as orally administered antimalarial drugs, cholestyramine, and vitamins E and C have all been suggested but are of unproven benefit.

Although not confirmed by double-blind placebo-controlled trials, tolerance to sunlight in some patients with EPP may improve with the use of orally administered β-carotene.[155] Many patients claimed to triple their tolerance to sunlight after a course of β-carotene exceeding 2 months. However, these results are based on limited controlled laboratory testing and uncontrolled clinical impressions. Indeed, a recent review concluded that the available data are insufficient to prove the efficacy of any treatments for dermal photosensitivity in EPP.[156,157] The mechanism of the putative photoprotective effect of β-carotene is not precisely known. Recent studies in cultured keratinocytes showed that β-carotene can suppress induction of matrix metalloproteinases (MMPs) including MMP-1, MMP-3, and MMP-10, and that these effects are mediated by quenching singlet oxygen-mediated induction of MMPs.[158] In further studies using microarrays it was shown that β-carotene inhibited UVA-induced extracellular matrix degradation.[159]

The amino acid cysteine has been shown to improve photosensitivity.[160] Hematin infusions may decrease the production of heme temporarily and are associated with a decrease in fecal and plasma PROTO in some patients.[144] The use of RBC exchange with autologous washed cells has also been explored for its ability to induce clinical and biochemical remission of EPP. In one patient with EPP, such therapy resulted in a marked decrease in photosensitivity associated with a decline in free erythrocyte PROTO levels.[161] In summary, the currently available treatments for EPP are minimally effective and do not address the underlying molecular pathogenesis of the disease.

BOX 132-2 TREATMENT OF THE ACUTE PORPHYRIAS

A. TREATMENT OF THE ACUTE PORPHYRIAS

Type	*Management*
Acute intermittent porphyria, variegate porphyria, hereditary coproporphyria, δ-aminolevulinic acid dehydratase deficiency porphyria	▪ Acute attacks ▪ Identification and elimination of precipitating factors (porphyrinogenic drugs, alcohol, hormones) ▪ Monitoring in intensive care unit and/or contacting of specialized porphyria center (centers are available worldwide) ▪ Provision of appropriate analgesia (e.g., with pethidine or other opiate derivatives) ▪ Management of nausea and vomiting (e.g., with promazine, chlorpromazine, or triflupromazine) ▪ Intravenous administration of either heme arginate (Normosang, Europe) in a dose of 3 mg/kg body weight once daily over four consecutive days or hematin (Panhematin, USA; see http://www.blooddiagnostics.com/Product%20Inserts/Ovation/panhematin_pi.pdf) ▪ If necessary, intravenous glucose loading ▪ Measurement of excretion of urinary porphyrin precursors (δ-aminolevulinic acid and porphobilinogen) during the acute attack (daily, if possible)
Variegate porphyria, hereditary coproporphyria	▪ Cutaneous manifestations ▪ Photoprotection (e.g., with broadband sunscreens and/or protective clothing) ▪ Avoidance of sunlight exposure and trauma

B. TREATMENT OF SPECIFIC SIGNS AND SYMPTOMS

Symptom/Sign	*Treatment*
Abdominal pain	Acetylsalicylic acid; morphine chlorpromazine; promethazine
Vomiting	
Hypertension and tachycardia	Propranolol
Hyponatremia	Electrolyte balance; saline infusions
Convulsions	Gabapentin
Constipation	Neostigmine

Liver Disease. Management of EPP-associated hepatic failure is particularly challenging. Orally administered bile salts may diminish the enterohepatic recirculation of the excessive PROTO and thereby enhance the clearance capacity of the liver.[162] Orally administered iron was attempted in one patient who manifested incipient hepatic failure as well as elevated erythrocyte and plasma PROTO levels with concomitant iron deficiency anemia but proved ineffective.[163] In another patient oral iron therapy exacerbated the disease.[164] Liver transplantation, bone marrow transplantation, and a combination of both have been used successfully in EPP, but in the case of liver transplantation recurrence of EPP hepatic disease is a significant risk.[165–167] Future therapy could include recombinant enzyme replacement of defective FECH. The feasibility of obtaining detectable levels of the enzyme in fibroblasts from EPP patients by adding the cDNA for normal FECH employing a retroviral vector has been demonstrated. Gene replacement has been achieved in a mouse model of EPP in which ex vivo preselection of hematopoietic stem cells transduced with a polycistronic retrovirus expressing human FECH resulted in complete correction of skin photosensitivity.[168]

X-LINKED DOMINANT PROTOPORPHYRIA

ALAS is the mitochondrial enzyme that catalyzes the formation of ALA and is a homodimer of two identical catalytically active subunits of molecular mass 55 kDa, linked to catalytically inactive substrates of higher molecular mass.[3,8,9]

X-LINKED DOMINANT PROTOPORPHYRIA AT A GLANCE

- Most recent type of porphyria to be recognized.
- Very rare; prevalence data not yet available.
- X-linked dominant disorder due to gain-of-function mutation of erythroid ALAS2.
- Age of onset, skin symptoms and complications similar to EPP.
- Prevalence of liver disease may exceed that of EPP.

The major significance of this enzyme is its role in controlling the rate of heme synthesis in the liver via a negative feedback mechanism. Heme acts at multiple sites to regulate hepatic ALAS. Currently, two differentially expressed isoforms of ALAS are known, one with ubiquitous expression, including the liver ALAS1, and the other with exclusive expression in erythroid tissues, ALAS2. It is thought that two pools, one cytosolic and one nuclear, regulate the respective isozymes. Two genes encoding different, tissue-specific ALAS mRNAs have been found. The human housekeeping gene is located on chromosome 3p21 and the erythroid gene has been assigned to a distal subregion of chromosome Xp21-Xq21. The erythroid preprotein reveals more than 75% homology with the hepatic protein. Immunochemical differences exist between the hepatic and erythroid enzyme in various animal species.[9,10] In contrast to deficiencies of the second to eighth enzyme in the heme biosynthetic pathway, a reduction in residual ALAS activity is not associated with a specific type of porphyria.

Mutations in the *ALAS2* gene were previously associated with X-linked sideroblastic anemia (see below.). However, eight families have been described with *ALAS2* deletions resulting in frameshifts that cause replacement or deletion of the 19–20 terminal residues of the enzyme that in turn creates gain-of-function of the enzyme and markedly increases its catalytic activity.[5] A characteristic biochemical feature in these patients is elevation of both free and zinc-chelated PROTO in the erythrocytes. The clinical manifestations of XLDPP closely resemble those of EPP (see above).

CONGENITAL ERYTHROPOIETIC PORPHYRIA

EPIDEMIOLOGY. CEP occurs globally; fewer than 500 cases have been reported. The disease nearly always begins in childhood, although apparent adult onset has occurred in 13 cases.[169] CEP also occurs in animals, including swine, cattle, and cats, and these animal models have greatly aided research in this disease.

CONGENITAL ERYTHROPOIETIC PORPHYRIA AT A GLANCE

- Very rare (approximately 250 patients reported).
- Autosomal recessive disorder involving a deficiency of UROS.
- Age of onset in infancy or first decade of life.
- Cutaneous manifestations include vesicles and bullae, erosions, crusting, milia, mutilating scarring, hyperpigmentation, and hypertrichosis.
- Systemic findings include hemolytic anemia and hepatosplenomegaly.
- Porphyrin deposition occurs in bones and teeth (erythrodontia).

ETIOLOGY. CEP is an autosomal recessive disorder that results from a variable but profound deficiency of UROS, the fourth enzyme in the heme synthetic pathway, which catalyzes the formation of uroporphyrinogen III from hydroxymethylbilane (HMB) or from PBG if PBGD is also present. The only difference between the porphyrinogen isomers I and III is the reversal of the side chains on the "D" ring of this tetrapyrrole. By simple inversion of one PBG molecule during synthesis of UROGEN I, the III isomer is formed (Fig. 132-2). This apparently minor structural alteration is of considerable biologic importance as only III isomers can form heme. The formation of UROGEN III is catalyzed by the cytoplasmic enzyme UROS, closely linked to PBGD. This enzyme has been purified from human erythrocytes, is monomeric, and has a molecular mass of approximately 29.5 kDa; it is thermolabile and exhibits maximum catalytic activity at pH 7.4.[170] In most tissues, UROGEN III synthase is present in considerable excess as compared to PBGD, thus assuring efficient conversion to the III isomer. The hepatic and erythroid forms of the enzyme are identical.

Human UROS is a cytosolic protein encoded by a single copy gene of the same name, *UROS*, which consists of ten exons, and is located on chromosome 10q25.2-q26.3 Human UROS cDNA has been cloned and sequenced and encodes a protein of 265 amino acids.[171] To date, approximately 30–40 mutations in the *UROS* gene have been identified including several in the erythroid-specific promoter. UROS deficiency results in the accumulation of HMB that mostly converts spontaneously to URO-1. CEP has also been reported in association with thalassemia secondary to

a novel germ line mutation in the X-linked erythroid-specific transcription factor GATA binding protein 1 (GATA-1).[172]

CLINICAL MANIFESTATIONS. The disease usually develops during the first few months of life with moderate-to-severe cutaneous photosensitivity associated with pink to red urine.[173] The patients have excessive URO I and COPRO I in RBC, plasma, and skin.

Cutaneous manifestations include increased skin fragility, vesicles and bullae, which may contain pink fluorescent fluid. Secondary infection, delayed healing, and scarring is common. This may lead to loss of acral tissue, such as the tips of the ears, the nose, and fingers (Figs. 132-18A and 132-18B), and facial mutilation. CEP is the most mutilating of the cutaneous porphyrias. Hirsutism, with long, dark, lanugo-like hair, may occur and is particularly evident in light-exposed areas such as the face, neck, and extremities. The scalp may develop a cicatrizing alopecia. Other chronic findings include eye changes (photophobia, keratoconjunctivitis, ectropion, symblepharon, and even loss of vision) and irregular hyper- and hypopigmentation of the skin. Erythrodontia (red-stained teeth) is a common finding in both deciduous and permanent teeth and is virtually pathognomonic of CEP. The urine may also fluoresce reddish pink.

Associated, noncutaneous findings include splenomegaly, porphyrin-rich cholelithiasis, and fluorescent bone marrow normoblasts. Hemolytic anemia associated with shortened erythrocyte life span and hypersplenism (36 vs. 120 days) occurs. Whether the hemolytic anemia is due to "photohemolysis" of circulating porphyrin-laden erythrocytes or to an associated intracorpuscular red cell defect is unresolved.[174]

LABORATORY FINDINGS. The primary defect in CEP is decreased UROS activity resulting in accumulation of predominantly type I porphyrins in the tissues. The pink to burgundy red color of the urine from excess URO I is often visible on inspection. Marrow normoblasts exhibit relatively stable fluorescence



Figure 132-18 Congenital Erythropoietic (Günther's) porphyria. **A** and **B.** Severe scarring of nasal cartilage, hair loss, and discolored teeth (erythrodontia). (Used with permission from A. Wiskemann, MD, and J. Kimmig, MD.) **C.** Skin fragility, blisters, erosions, and contractures due to severe scarring of the hands.

and contain markedly elevated URO I, COPRO I, and PROTO. Urinary excretion of ALA and PBG is normal. COPRO I may be present in large amounts in the feces. The typical biochemical findings of CEP are summarized in Table 132-8.

HISTOPATHOLOGY. The bullous lesion of CEP is subepidermal with minimal inflammation. Thickening of collagen bundles may be seen in areas of scarring. Perivascular deposits of porphyrin can be found when the unstained sections of skin or liver are viewed with a fluorescence microscope.

DIFFERENTIAL DIAGNOSIS. The diagnosis of CEP can usually be made from the early onset of severe cutaneous photosensitivity associated with reddish-pink fluorescent urine and erythrodontia. Distinguishing CEP from other congenital photodermatoses is important. Cutaneous findings in patients with xeroderma pigmentosum, epidermolysis bullosa, hydroa vacciniforme, and bullous pemphigoid may mimic those of patients with CEP, but porphyrin analysis will distinguish them.

Patients with chronic hepatic porphyrias such as PCT and VP have normal RBC PROTO. The cutaneous manifestations of HEP may be strikingly similar to those of CEP and measurement of RBC UROS (decreased in CEP) and UROD (decreased in HEP) will distinguish the two. The dual occurrence of HCP and CEP in a single patient who inherited the HCP trait from her mother and the CEP trait from both of her parents has been reported.[175]

TREATMENT. The treatment of CEP is essentially preventive and symptomatic and includes avoidance of sun exposure, surveillance of the anemia, and treatment of recurrent skin infections. Absolute protection from sunlight using photoprotective clothing may be of substantial benefit. Topical sunscreens have no proven efficacy. Orally administered β-carotene is not effective. Splenectomy performed to relieve intractable hemolytic anemia has occasionally resulted in marked improvement of both the anemia and cutaneous photosensitivity. Suppression of erythropoiesis by transfusion of packed erythrocytes can diminish porphyrin production and excretion[176]; however, secondary iron overload is of concern. Oral administration of activated charcoal to a single patient (60 g three times a day) for 9 months decreased porphyrin levels in plasma and skin with complete remission of photosensitivity during the treatment period.[177] Charcoal is thought to interfere with the enterohepatic recirculation of the porphyrin. However, this beneficial effect has been disputed.[178] Allogeneic bone marrow transplantation has been curative for a small number of patients and, thus, seems to be the current first-line treatment.[179,180]

THE ACUTE PORPHYRIAS

(See Table 132-4)

ACUTE INTERMITTENT PORPHYRIA

ACUTE INTERMITTENT PORPHYRIA AT A GLANCE

- Most common of the acute porphyrias.
- Autosomal dominant disorder involving deficiency of PBGD also known as hydroxymethylbilane synthetase (HMBS).
- Frequency as high as 1–2 in 100,000.
- Age of onset in second to fourth decade of life; rare before puberty.
- Acute neurologic attacks but no photosensitivity or cutaneous findings.

EPIDEMIOLOGY. This form of porphyria occurs globally and the incidence in the human population is approximately 1.5:100,000, although it is much higher in Scandinavia, particularly Lapland (1:1,000).[181] AIP rarely, if ever, manifests before puberty. Most published series emphasize the female predominance of affected patients, ranging from ratios of 1.5–2.0:1.[7]

ETIOLOGY. AIP is due to a deficiency of PBGD also known as hydroxymethylbilane synthetase (HMBS), the third enzyme in the heme biosynthetic pathway (Figs. 132-1 and 132-2). This enzyme combines four molecules of the monopyrrole PBG to form the linear tetrapyrrole HMB, which cyclizes spontaneously to form the initial porphyrinogen, or tetrapyrrole, known as uroporphyrinogen I (UROGEN I) (Fig. 132-2). Depending on the manner in which the PBG molecules are arranged, several different isomers of the tetrapyrroles are possible. The sole difference between type I and type III porphyrinogens is that one of the four pyrrole rings is "flipped over." Only two of them (labeled I and III) are known to occur in the mammalian heme synthetic pathway. PBGD was purified from human RBC and shown to have a molecular mass of approximately 37 kDa and a pH optimum of 8.2.[182] In AIP patients, PBGD activity is approximately 50% of that in unaffected normal individuals, consistent with an autosomal dominant mode of inheritance. Diminished PBGD partially blocks heme synthesis, which in turn decreases the regulatory heme pool and leads to derepression of ALAS mRNA synthesis.

The *PBGD* gene has been cloned and characterized.[183] Two isoforms, one ubiquitous, and one erythroid-specific, are encoded by a single gene localized to chromosome 11q23→11qter.[3] It comprises 15 exons spread over 10 kb of DNA. The two isoforms of the enzyme are encoded by two distinct mRNAs that arise from two overlapping transcription units, the first of which (upstream) is active in all tissues and

its promoter has some features of a housekeeping promoter, whereas the second, located 3 kb downstream, is active only in erythroid cells and displays structural homology with β globin gene promoters. Differential splicing gives rise to two isozymes of slightly different molecular size.[8] To date, more than 200 mutations have been reported at the *PBGD* locus, including deletions, insertions, missense, nonsense, and splicing mutations.[2,184]

PBGD is present in the second lowest concentration of any enzyme in the heme pathway; ALAS is the lowest. This suggests that additional factors (genetic or acquired) that influence PBGD activity may have important regulatory influences on the rate of heme synthesis. Consequently, if excessive PBG is formed because of increased ALAS activity, as is often seen in the acute hepatic porphyrias, there may be only partial conversion of this monopyrrole to UROGEN I. These factors account for the elevated urinary PBG characteristic of attacks of the acute hepatic porphyrias. PBGD activity is known to be reduced by about 50% in the tissues of patients with AIP and is currently thought to be the primary enzymatic abnormality in this autosomal dominant disorder. There is a variant form of AIP (perhaps 10% of cases) in which the PBGD defect is restricted to nonerythropoietic tissues due to mutations in exon 1 that is absent from the erythroid mRNA.

CLINICAL MANIFESTATIONS.

(See Table 132-4). Less than 10% of latent carriers of the PBGD defect ever express the clinical phenotype. Hence, the gene defect alone seems to be inconsequential unless the individual is exposed to additional triggering factors, of which certain drugs that induce hepatic cytochromes (CYPs), are particularly important (Table 132-9).[185,186] The clinical signs and symptoms of AIP may also relate to the effects of excessive porphyrin precursors or to heme depletion in the autonomic nervous system.[5]

The acute porphyric attack is characterized by abdominal pain (in 80%–90% of AIP patients) and neurologic and psychiatric symptoms that can mimic numerous disorders. The pain may be vague or localized and is often intermittent and spastic. Vomiting and constipation are frequently associated. Mild fever and leukocytosis may occur, making differential diagnosis extremely difficult. This is one reason many patients with AIP may have undergone multiple exploratory laparotomies prior to establishing the correct diagnosis. Between attacks patients are often remarkably symptom free. Attacks are often precipitated by ingestion of drugs such as those listed in Table 132-9. Acute attacks of AIP may be accompanied by seizures, especially in patients with hyponatremia resulting from vomiting and inappropriate fluid therapy. Peripheral neuropathy is a major part of the clinical syndrome in many patients varying from sensory (localized pain) to motor (weakness progressing to generalized flaccid paralysis).[12,187] Patients may die during an attack, usually due to respiratory failure, or may improve slowly, although residual muscle weakness may be permanent.

TABLE 132-9
Examples of Drugs Potentially Hazardous in Patients with the Acute Hepatic Porphyrias

Amidopyrine	Hydralazine
Aminoglutethimide	Isopropylmeprobamate
Aminopyrine	Mephenytoin
Amphetamines	Meprobamate
Antipyrine	Methyldopa
Barbiturates	Methyprylon
Bemegride	*N*-butylscopolammonium bromide
Carbamazepine	Nalidixic acid
Carbromal	Nikethamide
Chloromethazone	Nitrazepam
Chlorpropamide	Nortriptyline
Chloroquine	Novobiocin
Danazol	Pargyline
Dapsone	Pentazocine
Diclofenac	Pentylenetetrazole
Diethylpropion	Phenoxybenzamine
Diphenylhydantoin	Phenylbutazone
Dramamine	Primidone
Enflurane	Pyrazinamide
Ergot preparation	Rifampin
Erythromycin	Sedormid
Ethchlorvynol	Succinimides
Ethinamate	Sulfonamides
Ethosuximide	Sulfonethylmethane
Ethyl alcohol	Sulfonylureas
Fentanyl	Synthetic estrogens, progestins
Furosemide	Theophylline
Furoxone	Tolazamide
Glutethimide	Tolbutamide
Griseofulvin	Trimethadione
Halothane	Sodium Valproate
Heavy metals	

Cutaneous photosensitivity does not occur in AIP. This is logical as the abnormal excretion pattern of the disease consists mostly of the nonphotosensitizing porphyrin precursors ALA and PBG.

LABORATORY FINDINGS.

The primary gene defect in AIP results in PBGD deficiency, which causes excessive urinary excretion of ALA and PBG. Urinary porphyrins may also be slightly elevated (Table 132-8). Urinary excretion of ALA and PBG may be as high as 100 mg/24 hours in an acute attack. During remission urinary excretion of ALA and PBG decreases but usually remains above normal values. This is in contrast to patients with VP and HCP who often exhibit normal urinary excretion of ALA and PBG between acute attacks.

Two rapid screening tests are available to test freshly voided urine for increased PBG. The first is simply to expose the urine to bright sunlight for several hours. Darkening to a deep-red color suggests but does not prove that excessive PBG is present since porphobilin, another dark pigment, can also be photocatalytically formed in urine from AIP patients. The second rapid screening procedure, known as the Hoesch test is more definitive and involves a simple

assay for detecting excessive urinary PBG.[188] Two drops of fresh urine are added to 2 mL of Ehrlich's reagent (3 g of *p*-dimethylaminobenzaldehyde dissolved in 125 mL of acetic acid and 24 mL of perchloric acid). A uniform cherry-red color of the sample indicates a positive reaction. This test is based upon the formation of a chromogen by PBG and Ehrlich's aldehyde reagent that produces a red pigment with strong absorbance at 552 nm. The classic Watson–Schwartz test is based on this same principle. These qualitative tests while potentially useful for screening must be confirmed by quantitative 24-hour measurement of urinary ALA and PBG using ion-exchange chromatography or high-performance liquid chromatography.[189]

HISTOPATHOLOGY. AIP does not manifest cutaneous symptoms.

DIFFERENTIAL DIAGNOSIS. The clinical manifestations of AIP are protean and resemble so many different diseases that Waldenström has used the term *little imitator* to describe it.[12,181] Several excellent reviews have summarized the differential diagnosis of AIP and because this disorder has no cutaneous findings it will not be discussed further here.[3,184,190]

TABLE 132-10
Drugs Considered to be Safe (or Probably Safe) in Patients with the Acute Hepatic Porphyrias

Acetaminophen	Indomethacin
Adrenaline	Insulin
Amitriptyline	Labetalol
Aspirin	Lithium
Atropine	Mandelate
Bromide	Methenamine
Cephalosporins	Naproxen
Chloral hydrates	Narcotic analgesics
Chloramphenicol	Neostigmine
Chlordiazepoxide Clonazepam	Nitrofurantoin
Colchicine	Nitrous oxide
Digoxin	Oxazepam
Diphenhydramine	Penicillin and derivatives
Ethylenediaminetetraacetic acid (EDTA)	Phenothiazines
	Propranolol
Ether	Prostigmin
Glucocorticoids	Rauwolfia alkaloids
Guanethidine	Streptomycin
Heparin	Succinylcholine
Hyocine	Tetracycline
Hypocine	Thiouracil
Ibuprofen	Thyroxine

TREATMENT. There is no cure for AIP. A major component of managing patients with the acute hepatic porphyrias including AIP is focused on prevention of the acute attacks. This is accomplished by minimizing exposure to porphyrinogenic drugs and chemicals.[11] Management of the acute attack utilizes multiple approaches including glucose loading (2 liters of 20% glucose over 24 hours in divided doses of 500 mL through a central venous line).[120,190,191] Administration of a gonadotropin-releasing hormone analogue has also been recommended.[192] Intravenous infusion of hematin in the form of heme arginate (Normosang®, Orphan Europe, Paris, or Panhematin®, Ovation Pharmaceuticals, Deerfield, Il) is effective in shortening attacks.[190] Precipitating factors such as drugs (Table 132-9), sex steroid hormones, starvation, etc, should be avoided.[11] AIP patients should wear medical warning bracelets and be given lists of drugs to avoid. Drugs thought to be safe for AIP patients are listed in (Table 132-10).

Currently, recommended therapeutic regimens for the treatment of an acute porphyric attack and associated prophylactic/preventive measures are described below in detail. These procedures are applicable for all patients with acute porphyrias presenting with neurovisceral manifestations.

Treatment of the Neurovisceral Attacks in the Acute Porphyrias. (See Box 132-2). Most patients with acute porphyria experiencing an attack can now be treated successfully and life-threatening complications like muscle paralysis, respiratory failure, and coma can be avoided if appropriate aggressive treatment is implemented immediately. Untreated or inappropriately treated patients suffering an acute porphyric attack may have a 10%–15% risk of mortality.[11] Today with mechanism-based therapeutic intervention the mortality rate of the acute attack has decreased to approximately 2%. There are four major steps in treating an acute porphyria attack.

First, all potentially porphyrinogenic drugs should be stopped immediately and the patient should be monitored carefully and admitted to an intensive care unit if possible. Several sources are available that categorize drugs as relatively "safe" or "unsafe" in patients with acute porphyria.[13] Additional information is available on the Internet at the Web site of the European Porphyria Initiative (EPI) at: http://www.porphyria-europe.com/. See also Tables 132-9 and 132-10.

Second, symptomatic treatment of neurovisceral manifestations like abdominal pain, vomiting, tachycardia, and seizures should be initiated promptly. These recommendations originate from different sources including recently published guidelines from the EPI and a consortium of North American porphyria specialists.

Third, intravenous infusion of high doses of carbohydrates, preferably 400–500 g of glucose/24 hours using 5% or 10% glucose solutions. Simultaneously, diuresis should be induced by administration of furosemide with careful monitoring of serum electrolytes. Patients experiencing an acute attack are often unable to eat or drink because of severe nausea and recurrent vomiting. The rationale for high doses of glucose is based on experimental evidence showing that carbohydrates suppress the induction of ALAS, the first and rate-limiting enzyme of the heme biosynthetic pathway. Recent studies have shown that ALAS is regulated by the peroxisome proliferator-activated receptor γ coactivator 1α (PGC-1α).[193] Elevation of PGC-1α in

mice increases the levels of heme precursors in vivo as observed in acute porphyric attacks, whereas the induction of ALAS by fasting is lost in liver-specific PGC-1α knockout animals, as is the ability of porphyrogenic drugs to dysregulate heme biosynthesis. These data show that PGC-1α links nutritional status to heme biosynthesis and acute hepatic porphyria and provides a rationale for high-dose glucose infusions. Unfortunately, in many patients this regimen is only partially helpful and, thus, glucose infusions are considered to be adjuvant therapy until hematin preparations are available.

Fourth, intravenous administration of heme arginate (Normosang®), currently non-FDA approved, is the most efficient method to suppress heme synthesis. The rationale for this approach is based on intravenous administration of high doses of the end-product heme to repress the synthesis of ALAS.[194] Initially the available hematin preparations were quite unstable and were prothrombotic.[120,195] One derivative that is now available, heme arginate, consists of human hemin and L-arginine as an additive to increase the solubility and stability of the product. This preparation does not affect coagulation and fibrinolysis and the frequency of thrombophlebitis is markedly reduced.[196] Heme arginate exerts its specific action by correcting the underlying heme deficiency and restoring the negative feedback control of heme on ALAS, thereby decreasing the excessive hepatic production of porphyrins and porphyrin precursors. Heme arginate should be administered intravenously as a short infusion at a dose of 3 mg/kg body weight/day over a period of 4 days. Further, administration can be continued if the attack is not aborted; however, use of heme arginate for more than 7 days is not recommended. In the United States, an alternative form of heme known as hemin (Panhematin®) can be administered for the treatment of an acute attack. It is currently recommended that Panhematin should be considered only after an appropriate period of alternate therapy (i.e., 400 g glucose/day for 1–2 days).

Prevention of Attacks. Patients should be advised to avoid crash dieting, to abstain from alcohol, and to be fully conversant with porphyrinogenic drugs, such as barbiturates, sulfonamides, and estrogens to name several.[11,13,189] Lists of safe and unsafe drugs are available on the Web site of the America Porphyria Foundation: http://www.porphyriafoundation.com/about_por/drugs/drugs02.html and, in ten different languages, on the Web site of the EPI (see above).

Using appropriate screening procedures, asymptomatic family members of individuals with known acute porphyria should be screened for enzymatic deficiency/mutations to help define inheritance patterns and to identify individuals at risk.

VARIEGATE PORPHYRIA

(See Table 132-9)

VARIEGATE PORPHYRIA AT A GLANCE

- Incidence of approximately 1 in 300 in South Africa; relatively rare elsewhere, with the exception of Chile.
- Autosomal dominant disorder involving deficiency of PPOX.
- Age of onset in second to third decade of life; rare before puberty.
- Skin manifestations are indistinguishable from those of porphyria cutanea tarda; acute attacks similar to those in acute intermittent porphyria can occur (neurocutaneous porphyria).
- Founder mutations have been identified in South Africa and Chile.

EPIDEMIOLOGY

The disease occurs worldwide but is most prevalent in South Africa and Chile, mainly due to founder effects in both countries.[5,18,197–199] Within South Africa, this form of porphyria is quite common among the Caucasian and so-called Cape-Colored South Africans. A high proportion of the present Caucasian population in South Africa is descended from a pair of early Dutch settlers who emigrated from the Netherlands in 1688. The incidence of VP in South Africa is the highest in the world, with approximately 1:300 individuals in the white population.

ETIOLOGY

VP results from decreased PPOX activity and is an autosomal dominant disorder.[200–202] PPOX is an integral protein of the inner mitochondrial membrane and catalyzes the oxidation of PROTOGEN IX to PROTO thereby removing six hydrogens from PROTOGEN IX (Figs. 132-1, and 132-2). This reaction can also occur nonenzymatically, but the enzyme appears to be necessary for normal heme synthesis. The enzyme acts specifically on PROTOGEN IX, the penultimate step in heme synthesis. COPROGEN I or III or UROGEN I or III are not substrates for this enzyme. PPOX isolated from rat liver mitochondria has been shown to have a molecular mass of 51 kDa and requires molecular oxygen to catalyze the oxidation of PROTOGEN to PROTO.

Human PPOX is encoded by a single copy gene of the same name, *PPOX*, which has been mapped to chromosome 1q22–23, spans 8 kb, and consists of 13 exons. Northern blot analyses from a variety of tissues indicate that there is a single transcript of 1.8 kb encoding a protein of 477 amino acids.[203] Multiple mutations have been identified, including founder mutations in South Africa (R59W) and Chile (1239delTACAC).[19,204]

CLINICAL MANIFESTATIONS

The clinical manifestations of VP encompass those of both PCT and the other acute hepatic porphyrias, which can occur simultaneously or separately in the same individual. The major difference between VP and PCT is that skin signs and symptoms usually develop at an earlier age in VP (second and third decades) as compared to PCT (fourth and fifth decades). The major difference between VP and the other acute hepatic porphyrias (AIP and HCP) is that acute attacks are much less common in VP. In South Africa, excessive intake of home-brewed spirits (Kaffir beer) and dietary iron overload from cooking vessels have been considered to be important factors in the development of clinically overt disease. Thus, VP occurring in the descendants of the Dutch immigrants of South Africa is quite distinct from the PCT seen in the native black population. As pointed out by Dean in a group he designated as Cape-Colored, (descendants of white European and Indian immigrants who intermarried with black natives), VP and PCT may cosegregate in the same family.[205]

Skin. The cutaneous lesions of VP are indistinguishable from those of PCT and HCP. These include bullae and erosions on light-exposed skin (Figs. 132-19 and 132-20). Hyperpigmentation, milia, hypertrichosis, and increased skin fragility are also seen. They appear to be more common in the hot climate of South Africa and are less frequently seen in affected individuals in colder climates. Blisters often contain blood, heal slowly, and result in scarring and milia formation. Occasionally, the patient gives a history of acute sun sensitivity occurring during or soon after a period of exposure; this may include burning, erythema, and edema. In its chronic state, the skin changes may include thickening and scarring. Some believe that melanin pigmentation may reduce the severity of the photocutaneous findings. The skin manifestations do not correlate with the acute attacks in most patients and, in general, males are more likely to have the PCT-like skin findings, whereas females are more prone to AIP-like acute attacks.



Figure 132-19 Variegate porphyria. Large bullae on the dorsum of foot and toes of a patient with this disease. Note that these patients also develop pigmentary changes and milia identical to the findings in porphyria cutanea tarda.

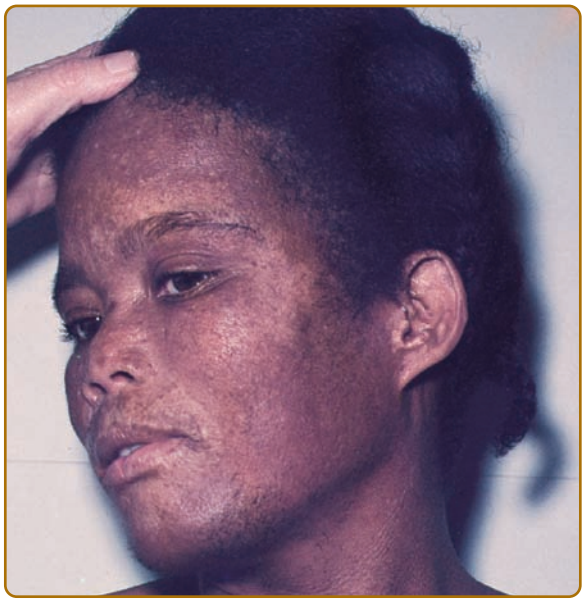

Figure 132-20 Variegate porphyria. South African patient showing facial pigmentary changes similar to that in porphyria cutanea tarda.

Neurovisceral Symptoms. These are identical to those occurring in AIP and HCP consisting of attacks of abdominal pain, constipation, vomiting, muscle weakness, and neuropsychiatric manifestations of stupor and coma. Factors that trigger attacks of AIP and HCP also appear to induce VP (various drugs, starvation, etc.). All patients with the skin findings of PCT should be screened for VP because of the life-threatening potential of the acute neurovisceral attacks.

These clinical features rarely develop before puberty, except in the rare homozygous patients who may develop cutaneous signs and symptoms at or shortly after birth. Beside the early onset of skin symptoms, these patients frequently manifest short stature and small hands with shortening of the digits.[206–208]

LABORATORY FINDINGS. Urinary ALA and PBG are elevated during acute attacks of VP (when the Watson–Schwartz test may be positive) but characteristically fall to normal levels between attacks (Table 132-8), whereas in AIP patients, the urinary

ALA and PBG are elevated, both during and between attacks. Another distinguishing feature of the two disorders is stool porphyrin excretion. Asymptomatic patients with VP commonly have marked elevations of stool PROTO and COPRO between attacks.[209] These may fluctuate somewhat during acute attacks and PROTO typically exceeds COPRO. In AIP, fecal porphyrins are not elevated between attacks and usually increase only slightly during attacks. It is said that certain patterns of fecal and urinary porphyrin excretion may help in distinguishing VP from PCT.[210] URO in the urine is only moderately elevated in VP and urinary COPRO typically exceeds URO. This is in marked contrast to active PCT where the reverse is seen, i.e., urinary URO is usually several-fold higher than COPRO. Again in VP, fecal porphyrins usually exceed 500 µg/g dry weight in >90% of patients, whereas in PCT this amount of stool porphyrin is excreted by only 1% of patients. Furthermore, the ratio of stool PROTO to COPRO in VP usually exceeds 1.5:1, whereas in PCT the ratio is almost always <1:1 due to the increased ISOCOPRO content characteristic of the latter disease. Stool porphyrin excretion patterns consistent with both VP and PCT have been found in different members of single families.[61,62] These types of findings have led to the suggestion that measurement of bile porphyrins may be decisive in confirming a diagnosis of VP when excretory porphyrin patterns are ambiguous.[101] Saline-diluted plasma specimens from patients with VP have characteristic fluorescence emission spectra (626-nm emission peak) that can be used to differentiate this disease from other forms of acute porphyria, PCT, EPP, and lead poisoning (Table 132-6).[211]

HISTOPATHOLOGY. The histopathologic alterations in VP are indistinguishable from those of PCT.

DIFFERENTIAL DIAGNOSIS. The differential diagnosis of VP should be considered from two perspectives. The skin lesions of VP are identical to those of PCT and HCP, and, as such, the differential diagnosis includes the bullous diseases as well as other photosensitivity disorders. HEP must also be considered, but this usually begins in early childhood and is characterized by markedly deficient erythrocyte UROGEN decarboxylase activity and elevated erythrocyte PROTO as well as increased stool ISOCOPRO. HCP is characterized by increased excretion of COPRO III in urine and feces. Markedly elevated (usually 10–100-fold) fecal COPRO, more than 90% of which is the III isomer, is present at all times in these patients. The presence of skin lesions rules out AIP. The determination of urinary ALA and PBG concentrations may help to rule out PCT and HEP. Screening of family members by measuring fecal porphyrins may also be helpful in differentiating VP from PCT and HCP.

Acute attacks of abdominal pain and neurologic signs and symptoms are identical to those described for AIP. Fecal and biliary PROTO and COPRO determinations and plasma fluorescence spectra are decisive in making the diagnosis. In HCP, there may be identical acute attacks, but markedly elevated fecal COPRO III is diagnostic for this disease.

TREATMENT. Preventive and symptomatic treatment of the acute attacks in VP is identical to that described in AIP, including avoidance of inducing drugs (Table 132-4) and glucose loading as well as hematin infusions. In contrast to PCT, there is no evidence of iron overload in VP and therefore phlebotomy and the antimalarials are ineffective.[212]

HEREDITARY COPROPORPHYRIA

(See Table 132-9)

HEREDITARY COPROPORPHYRIA AT A GLANCE

- Very rare (fewer than 50 cases reported).
- Autosomal dominant disorder involving a deficiency of CPOX.
- Age of onset in second to third decade of life; rare before puberty.
- Skin findings that are indistinguishable from those of porphyria cutanea tarda occur in fewer than 10% of patients; acute attacks similar to those of acute intermittent porphyria are the most common feature (neurocutaneous porphyria).

EPIDEMIOLOGY. Although apparently rare, the disease occurs worldwide and, like AIP and VP, has a female preponderance. To date, fewer than 75 patients have been reported. Beside classical HCP, an extremely rare form of porphyria, designated as harderoporphyria, has been described. This disease is a homozygous variant of HCP in which CPOX activity is very low (10% of control values).[213–215]

ETIOLOGY. HCP is an autosomal dominant disorder resulting from a decrease in the residual catalytic activity of CPOX (Figs. 132-1 and 132-2).[216,217] The enzyme is localized in the mitochondrial intermembrane space, has a molecular mass of 74 kDa and catalyzes the conversion of COPROGEN III to PROTOGEN. COPROGEN III has four carboxyl groups, each of which is part of a propionate side chain. COPROGEN oxidase catalyzes the sequential oxidative removal of the carboxyl group from two of the propionate groups, forming first the 3-carboxyl porphyrinogen known as, harderoporphyrinogen (HARDEROGEN), and next the 2-carboxylporphyrinogen, known as PROTOGEN (Fig. 132-2).

CPOX is encoded by a single copy gene of the same name, *CPOX*, as suggested by Southern blot analysis of human restriction fragments. The *CPOX* gene is located on chromosome 3q12, spans a genomic distance of 14 kb, and consists of seven exons and six

introns.[218] Multiple mutations have been found in patients with heterozygous and homozygous HCP. These include point mutations resulting in base substitutions or exon skipping. This results in increased excretion of COPRO in the urine and stool suggesting the presence of a single gene.[218]

CLINICAL MANIFESTATIONS. As in VP, the spectrum of clinical symptoms includes both cutaneous manifestations and potentially life-threatening acute neurological attacks. Cutaneous symptoms apparently occur in less than 10% of the patients and are clinically indistinguishable from those seen in PCT and VP.[189] (Fig. 132-21).

The acute attacks are similar to those of AIP, and neurovisceral symptomatology predominates in HCP. This includes abdominal pain, vomiting, constipation, neuropathy, and psychiatric symptoms. The oral hypoglycemic agent glipizide has been reported to exacerbate a coproporphyria-like syndrome that was reversible following discontinuation of the drug.[219]

LABORATORY FINDINGS. HCP is characterized by increased excretion of COPRO III in urine and feces. Markedly elevated (usually 10–100-fold) fecal COPRO, more than 90% of which is the III isomer, is present at all times in these patients. In addition, the feces may also contain increased amounts of hepta-, hexa-, and pentacarboxylic porphyrins. Urinary COPRO III is also raised, as are the precursors ALA and PBG, during attacks. The latter may be normal between attacks (Table 132-8).

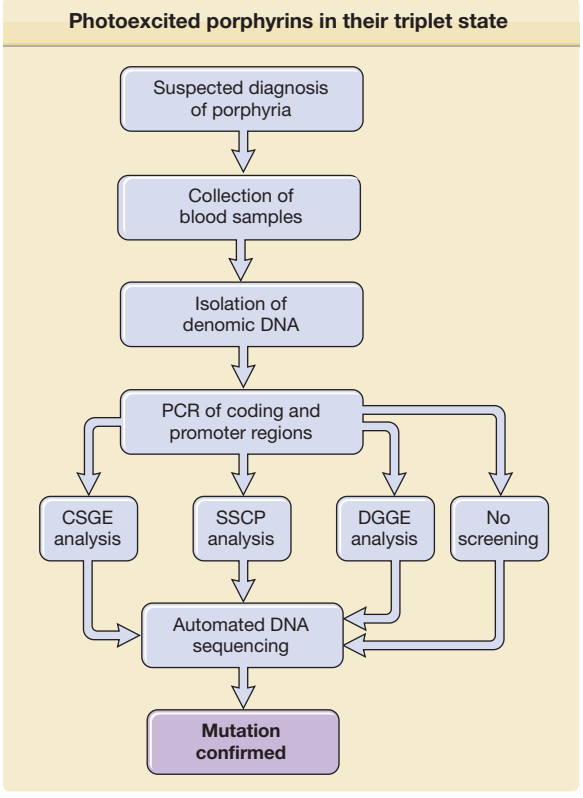

Figure 132-21 Algorithm for detecting gene mutations in patients with human porphyria. CSGE = conformation sensitive gel electrophoresis; DGGE = denaturing gradient gel electrophoresis; PCR = polymerase chain reaction; SSCP = single strand conformational polymorphis.

HISTOPATHOLOGY. None

DIFFERENTIAL DIAGNOSIS. In HCP, cutaneous signs are uncommon and if they do occur are most often seen in homozygous patients with onset in childhood and the skin manifestations resemble those seen in PCT and VP (Fig. 132-21). Fecal predominance of COPRO III is more suggestive of HCP than VP, in which PROTO and COPRO are usually increased.

Acute attacks are similar to those of AIP. The differential diagnosis rests on stool porphyrin determinations and measurement of CPOX in fibroblasts or leukocytes. DNA analysis for mutations in the *CPOX* gene can also be performed.

TREATMENT. (See Table 132-4). Same as for AIP and VP described above and in Table 132-4.

ALA DEHYDRATASE DEFICIENCY PORPHYRIA

(See Table 132-9)

δ-AMINOLEVULINIC ACID DEHYDRATASE DEFICIENCY PORPHYRIA AT A GLANCE

- Extremely rare (fewer than ten cases reported).
- Early and late clinical onset has been described.
- Neurologic symptoms similar to those in other acute hepatic porphyrias can occur; no photosensitivity or cutaneous symptoms.

This is a very rare autosomal recessively inherited type of acute hepatic porphyria, and not more than ten patients have been reported.[220–223] Clinically, these patients have symptoms similar to AIP. Alcohol ingestion is reported to precipitate attacks.

The disease results from a profound deficiency of ALAD, the second enzyme in heme biosynthesis, i.e., <5% of normal. ALAD is a cytosolic enzyme and catalyzes the formation of PBG from two molecules of ALA.

The enzyme is encoded by the *ALAD* gene that is located on chromosome 9q34 and the mutations described to date are very heterogeneous. Although it has been suggested that ALAD deficiency porphyria may represent a homozygous *ALAD* defect, cloning of a mutant ALAD cDNA in a patient showed that the

patient was compound heterozygous for two independent mutant alleles of the enzyme.[221]

In the few patients studied, the urinary porphyrin excretion shows elevated ALA, COPRO, and, to a lesser extent, URO. Fecal porphyrins revealed mildly elevated COPRO and PROTO in one patient, elevated COPRO in another, and a normal profile in two others. Erythrocyte PROTO was elevated in all patients. Increases of plasma ALA, COPRO, and PROTO have been reported.[224] The porphyrin excretion pattern in these patients is unexplained.

MANAGING SUSPECTED CASES OF PORPHYRIA

Disease management consists of a combination of obtaining a thorough medical history (particularly a complete family history), clinical examination, and biochemical determination of porphyrins and porphyrin precursors in urine, feces, and blood. In specialized laboratories, these diagnostic procedures can be extended to the measurement of specific enzymatic activities in erythrocytes, lymphocytes, or fibroblasts of affected patients and family members. Molecular techniques now provide the most precise diagnostic information based on DNA isolation from peripheral blood followed by polymerase chain reaction (PCR) and automated DNA sequencing (Fig. 132-22B). Furthermore, these methodologies permit detailed analyses of genes and their function and provide affected individuals and their family members with genetic counseling.

But even with the use of these sophisticated diagnostic tools, there are times when the results may remain inconclusive. This is particularly true for the so-called dual porphyrias.

DUAL PORPHYRIAS

In the dual porphyrias, laboratory tests may point to the simultaneous deficiency of two enzymes in the heme biosynthetic pathway either in one individual or within one family. To date, approximately 15 patients and families with this constellation of findings have been reported, indicating that these porphyria variants are very rare.

The majority of the so-called dual porphyrias encompass combined deficiency of UROD, with PBGD, CPOX, or PPOX, respectively, and this is not surprising since the prevalence of PCT exceeds that of any other type of human porphyria. In three families, the simultaneous deficiency of CPOX and either PBGD, UROS, or ALAD was detected. In one patient with CEP, the UROS defect was accompanied by a deficiency of UROD.

Until recently, the diagnosis of dual porphyria in all patients and families was established based on biochemical measurement of porphyrins and/or porphyrin precursors in urine and feces and enzymatic assays.

Porphyria patients have been described in whom DNA analysis unequivocally confirmed the presence of mutations in two different genes encoding distinct enzymes in the heme synthetic pathway. Harraway et al described a young female patient who developed skin symptoms on the sun-exposed areas of the body and had increased urinary PBG excretion.[225] The initial diagnosis of VP, however, could not be confirmed and biochemical analysis of urine, feces, and plasma suggested a combined deficiency of PBGD and UROD. Subsequent automated sequencing of the *PBGD* and *UROD* genes revealed mutations in both confirming the diagnosis of dual porphyria. Akagi et al studied a patient who suffered from acute porphyric attacks accompanied by increased urinary excretion of ALA, PBG, and COPRO.[226] Although these findings were suggestive of HCP, the authors observed marked elevation of ALA and increased erythrocyte zinc PROTO, suggesting ALAD deficiency. Subsequent automated sequencing of both the *CPOX* and *ALAD* genes led to the detection of disease-causing mutations in each gene. Both genetic defects were confirmed by in vitro expression experiments, establishing the molecular basis of dual porphyria in a single individual consisting of simultaneous CPOX and ALAD deficiencies.

These reports emphasize that in patients with biochemical and enzymatic studies indicating coexistent deficiency of two enzymes in the heme biosynthetic pathway, molecular genetic analysis of the corresponding genes should be carried out to identify the disease-causing mutations underlying a particular variant of dual porphyria.

ABNORMAL PORPHYRIN PROFILE AND SIDEROBLASTIC ANEMIA

Some cases of sideroblastic anemia may be associated with abnormal porphyrin profiles.[227–229] These patients may have cutaneous photosensitivity closely resembling that of EPP and they subsequently develop sideroblastic anemia; in some cases, the two conditions may develop within a few months of each other. All patients have elevated PROTO in RBC and/or plasma; many also have elevated stool PROTO levels. Urinary COPRO and URO are also elevated. The activities of FECH and, less frequently, of ALAS may be decreased. Chromosomal abnormalities, which include deletions in chromosomes 18 and 20, have been described.

MOLECULAR GENETIC STRATEGIES FOR THE PORPHYRIAS

In the various types of porphyrias, discrepancies between clinical findings and the results of biochemical tests or enzyme assays often lead to doubtful or incorrect diagnoses. In the case of the acute porphyrias, this can have fatal consequences for the patient if an accurate diagnosis is not established in a timely manner.

Once a mutation is identified in a patient with porphyria, the detection of asymptomatic gene carriers

within the patient's family is easily accomplished using standard molecular biological techniques. In the acute porphyrias, the identification of these "silent" carriers is the first and most important step in the prevention of life-threatening acute attacks. Genetic analysis provides an effective way to make an early diagnosis thereby enhancing the likelihood of providing patients and asymptomatic gene carriers in their family with advice regarding the avoidance of precipitating factors.

ANIMAL MODELS AND FUTURE OPTIONS FOR GENE THERAPY

Animal models for EPP and PCT have been described.[92,168,230] These models afford unique opportunities to explore the pathogenesis of these types of porphyria using in vivo models, and to study the feasibility of achieving phenotypic reversion by gene therapy. Retrovirus-mediated gene transfer of human FECH cDNA into deficient fibroblasts from an EPP patient has been achieved.[167] In transduced cells, FECH catalytic activity increased from 7% to 550% of the normal value, and partial metabolic correction of the phenotype was demonstrated. In CEP, correction of the underlying enzymatic defect in cultured cells was also accomplished by retrovirus-mediated gene transfer leading to partial normalization.[231] Excessive porphyrin levels in the transduced cells were reduced to normal. These investigations demonstrate the potential utility of somatic stem cell gene therapy for the treatment of different types of human porphyria.

CONCLUSIONS AND FUTURE PROSPECTS

Human porphyrias often present with overlapping clinical and laboratory findings making precise diagnosis a challenging proposition, especially in the acute porphyrias. The clinical signs and symptoms are highly variable in different patients and even in the same patient at different times. Biochemical analyses of urinary and/or fecal porphyrins/precursors often display overlapping values. These methods, as well as the measurement of enzymatic activities in fibroblasts or lymphocytes, are somewhat imprecise, and it is not uncommon to find values that do not distinguish between clinically unaffected gene carriers (so called "silent" carriers), and normal controls. Once a DNA-based diagnosis is made, patients and their families can be provided with genetic counseling and with advice regarding the avoidance of precipitating factors. In case of a life-threatening acute attack, a prior genetic diagnosis permits the attending physician to begin appropriate treatment immediately.[189]

KEY REFERENCES

Full reference list available at www.DIGM8.com

DVD contains references and additional content

1. Puy H, Gouya L, Deybach JC: Porphyrias. *Lancet* **375**:924, 2010
2. Whatley SD et al: Diagnostic strategies for autosomal dominant acute porphyrias: Retrospective analysis of 467 unrelated patients referred for mutational analysis of the *HMBS*, *CPOX*, or *PPOX* gene. *Clin Chem* **55**:1, 2009
5. Whatley SD et al: C-terminal deletions in the ALAS2 gene lead to gain of function and cause X-linked dominant protoporphyria without anemia or iron overload. *Am J Hum Genet* **83**:408, 2008
11. Thunell S, Pomp E, Brun A: Guide to drug porphyrogenicity prediction and drug prescription in the acute porphyrias. *Br J Clin Pharmacol* **64**:668, 2007
25. Kauppinen R: Porphyrias. *Lancet* **365**:241, 2005
45. Pawliuk R et al: Prevention of murine erythropoietic protoporphyria-associated skin photosensitivity and liver disease by dermal and hepatic ferrochelatase. *J Invest Dermatol* **124**:256, 2005
46. Smith AG, Elder GH: Complex gene-chemical interactions: Hepatic uroporphyria as a paradigm. *Chem Res Toxicol* **23**:712, 2010
54. Held JL et al: Erythrocyte uroporphyrinogen decarboxylase activity in porphyria cutanea tarda: A study of 40 consecutive patients. *J Invest Dermatol* **93**:332, 1989
56. Jalil S et al: Associations among behavior-related susceptibility factors in porphyria cutanea tarda. *Clin Gastroenterol Hepatol* **8**:297, 2010
87. Roberts AG et al: Increased frequency of the haemochromatosis Cys282Tyr mutation in sporadic porphyria cutanea tarda. *Lancet* **349**:321, 1997
129. Lecha M, Puy H, Deybach JC: Erythropoeitic Protoporphyria. *Orphanet J Rare Dis* **4**:19, 2009
135. Whatley SD et al: Molecular epidemiology of erythropoietic protoporphyria in the U.K. *Br J Dermatol* **162**:642, 2010
136. Gouya L et al: The penetrance of dominant erythropoietic protoporphyria is modulated by expression of wild-type FECH. *Nat Genet* **30**:27, 2002
167. Rand EB et al: Sequential liver and bone marrow transplantation for treatment of erythropoietic protoporphyria. *Pediatrics* **118**:1896, 2006
168. Pawliuk R et al: Long-term cure of the photosensitivity of murine erythropoietic protoporphyria by preselective gene therapy. *Nat Med* **5**:768, 1999
180. Thomas C et al: Correction of congenital erythropoietic porphyria by bone marrow transplantation. *J Pediatr* **129**:453, 1996
220. Doss M et al: New type of hepatic porphyria with porphobilinogen synthase defect and intermittent acute clinical manifestation. *Klin Wochenschr* **57**:1123, 1979
225. Harraway JR et al: Dual porphyria with mutations in both the UROD and HMBS genes. *Ann Clin Biochem* **43**:80, 2006
230. Fontanellas A et al: Successful therapeutic effect in a mouse model of erythropoietic protoporphyria by partial genetic correction and fluorescence-based selection of hematopoietic cells. *Gene Ther* **8**:618, 2001

Chapter 133 :: Amyloidosis of the Skin

:: Helen J. Lachmann & Philip N. Hawkins

AMYLOIDOSIS AND THE SKIN AT A GLANCE

- In amyloidosis normally soluble plasma proteins are deposited in the extracellular space in an abnormal insoluble fibrillar form.
- Amyloid deposition is remarkably diverse and can be localized or systemic, rapidly lethal or incidental.
- Diagnosis of amyloidosis relies on the demonstration of pathognomonic red–green birefringence when biopsies stained with Congo red are viewed under cross-polarized light.
- Management relies on determining the type (defined by the precursor protein) and discriminating systemic from localized forms.
- Treatment of systemic disease centers on reducing the production of the fibril precursor protein and management of localized disease is usually surgical or symptomatic.

EPIDEMIOLOGY

Amyloidosis is a rare condition and the exact incidence remains unclear. The overall sex and age adjusted rate per million person years was reported as 6.1 from 1950 to 1969 and 10.5 from 1970 to 1989 in the United States of America, and localized amyloidosis accounts for less than 10% of all diagnoses. Both localized and systemic forms of the disease become more frequent with age, and presentation before the age of 30 years is extremely unusual. No known racial, occupational, geographic, or other environmental factors have been implicated in the genesis of systemic amyloidosis, although there is evidence for a slight male preponderance.

ETIOPATHOLOGY AND PATHOGENESIS

Amyloidosis is caused by extracellular deposition of insoluble abnormal fibrils, derived from the aggregation of misfolded protein.[1,2] At least 26 unrelated proteins are known to form human amyloid fibrils in vivo.[3] The ultrastructural morphology and histochemical properties of all amyloid fibrils, regardless of the precursor protein type, are remarkably similar and fibril diffraction studies have confirmed that they all share a common core structure consisting of a cross β core and polypeptide chains lying perpendicular to the long axis of the fibril. This extremely abnormal, highly ordered conformation underlies the distinctive physicochemical properties of amyloid fibrils, including their relative stability and resistance to proteolysis. Amyloid deposits universally contain the normal plasma glycoprotein, serum amyloid P component (SAP), and heparan sulfate and dermatan sulfate proteoglycans and glycosaminoglycan chains as nonfibrillar constituents Other plasma proteins, such as apolipoprotein E, are sometimes detectable in amyloid deposits, but without the universality and abundance of SAP.

Amyloid formation in vivo occurs with both normal wild-type proteins and with genetically variant proteins. The fibrils may contain the intact amyloidogenic protein or proteolytic cleavage fragments. There is always a lag period, often of many years, between first appearance of the potentially amyloidogenic protein and the deposition of clinically significant amyloid. There are many ways of classifying amyloidosis of which the most useful is according to the deposited protein (Table 133-1). In addition, it is vital to determine whether the amyloid deposits are localized, distributed in only one tissue or organ, or deposited more widely.

SYSTEMIC AL AMYLOIDOSIS

This is the commonest type of systemic amyloidosis, accounting for more than 60% of cases. AL amyloidosis may occur in association with any monoclonal B cell dyscrasia.[4] AL fibrils are derived from monoclonal immunoglobulin light chains and consist of the whole or part of the variable (V_L) domain.[5] A degree of amyloid deposition is seen in up to 15% of patients with myeloma, but the vast majority, more than 80%, of patients who present with clinically significant AL amyloidosis have very low grade and otherwise "benign" monoclonal gammopathies.

SYSTEMIC AA AMYLOIDOSIS

Reactive systemic, AA, amyloidosis is a potential complication of any disorder associated with a sustained acute phase response and the list of chronic inflammatory, infective, or neoplastic disorders that can underlie it is almost without limit.[6] Although 60% of patients have inflammatory arthritis, some of the underlying diseases have cutaneous features that may facilitate diagnosis. These include: psoriatic arthritis, epidermolysis bullosa, basal cell carcinoma,

TABLE 133-1
Classification of Systemic Amyloidosis

Type	Fibril Protein Precursor	Clinical Syndrome
AA	Serum amyloid A protein	Reactive systemic amyloidosis associated with chronic inflammatory diseases
AL	Monoclonal immunoglobulin light chains	Systemic amyloidosis associated with monoclonal plasma cell dyscrasias
$A\beta_2M$	β_2-microglobulin	Periarticular and, occasionally, systemic amyloidosis associated with long-term dialysis
ATTR	Normal plasma transthyretin	Senile systemic amyloidosis with prominent cardiac involvement
ATTR	Genetically variant transthyretin	Autosomal dominant systemic amyloidosis Familial amyloid polyneuropathy
ACys	Genetically variant cystatin C	Hereditary cerebral hemorrhage with cerebral and systemic amyloidosis
AGel	Genetically variant gelsolin	Autosomal dominant systemic amyloidosis Predominant cranial nerve involvement with lattice corneal dystrophy
ALECT2	Leukocyte cell-derived chemotaxin-2 (LECT2)	Systemic amyloidosis with predominant renal involvement
ALys	Genetically variant lysozyme	Autosomal dominant systemic amyloidosis Non-neuropathic with prominent liver and renal involvement
AApoAI	Genetically variant apolipoprotein AI	Autosomal dominant systemic amyloidosis May be neuropathic, prominent liver and renal involvement
AApoAII	Genetically variant apolipoprotein AII	Autosomal dominant systemic amyloidosis Non-neuropathic with prominent renal involvement
AFib	Genetically variant fibrinogen A α chain	Autosomal dominant systemic amyloidosis Non-neuropathic with prominent renal involvement

chronic cutaneous ulcers, and hereditary periodic fever syndromes, particularly cryopyrin-associated periodic syndrome (CAPS) and TNF receptor associated periodic syndrome (TRAPS).[7] Biopsy and postmortem series suggest that the prevalence of AA amyloid deposition in patients with chronic inflammatory diseases is between 3.6% and 5.8%, though a smaller proportion of patients have clinically significant amyloidosis. The amyloid fibrils are derived from the circulating acute phase reactant, serum amyloid A protein (SAA). SAA is an apolipoprotein of high-density lipoprotein (HDL)[8] which, like C-reactive protein (CRP), is synthesized by hepatocytes under the transcriptional regulation of cytokines. A sustained high plasma level of SAA is a prerequisite for the development of AA amyloidosis, but why amyloidosis develops in only a small proportion of cases remains unclear.

HEREDITARY AMYLOIDOSIS

These are very rare autosomal dominantly inherited conditions. The most common cause of hereditary amyloidosis is mutations in the gene for transthyretin (TTR), which affects around 10,000 individuals worldwide, and causes familial amyloid polyneuropathy (FAP). The other hereditary systemic amyloidoses are derived from apolipoproteins AI and AII, fibrinogen A α chain, gelsolin, and lysozyme.[9]

LOCALIZED AMYLOIDOSIS

Localized amyloid deposition is not uncommon, although often undiagnosed, and reportedly accounts for 9.3% of all amyloidosis.[10] It results either from local production of fibril precursors or from properties inherent to the particular microenvironment, which favor fibril formation of a widely distributed precursor protein. The vast majority of deposits are AL in type, and symptomatic deposits occur most frequently in the eye, skin, gastrointestinal, respiratory, or urogenital tracts.[8] They are often associated with extremely subtle focal monoclonal B cell proliferation confined to the affected site and surgical resection of these localized "amyloidomas" can sometimes be curative. Symptomatic apparently localized amyloid deposits can rarely be manifestations of systemic disease and patients should always be fully investigated to exclude more generalized amyloid deposition.[11] Progression from localized to systemic amyloidosis is very rare. In lichen and macular amyloidosis, the fibrils are derived from proteins released from apoptotic keratinocytes. The etiology is not entirely clear but the association with other pruritic conditions suggests that mechanical factors associated

with chronic scratching and skin friction are probably crucial.[12]

CLINICAL FINDINGS

APPROACH TO PATIENT ALGORITHM

(See Fig. 133-1)

HISTORY. In the majority of patients with systemic amyloidosis the presentation is nonspecific, and as a result amyloid is often an unexpected finding on biopsy of an affected organ.

AL AMYLOIDOSIS. AL amyloid usually presents in patients over the age of 50 years, although it can present in very young adults.[4] In the majority of cases, the underlying plasma call clone is not detected prior to presentation with amyloid-related organ dysfunction. Clinical manifestations are extremely variable since almost any organ other than the brain can be directly involved.[13] Although certain clinical features such as macroglossia and periorbital ecchymoses are very strongly suggestive of AL amyloidosis (Table 133-2), and multiple vital organ dysfunction is common, many patients present with nonspecific symptoms such as malaise and weight loss.

AA AMYLOIDOSIS. AA amyloidosis can present anytime between childhood and old age with a median age at presentation of 48 years in the United Kingdom. Almost 95% of patients have a clinically overt previously diagnosed chronic inflammatory disease such as rheumatoid or one of the other inflammatory arthritides,

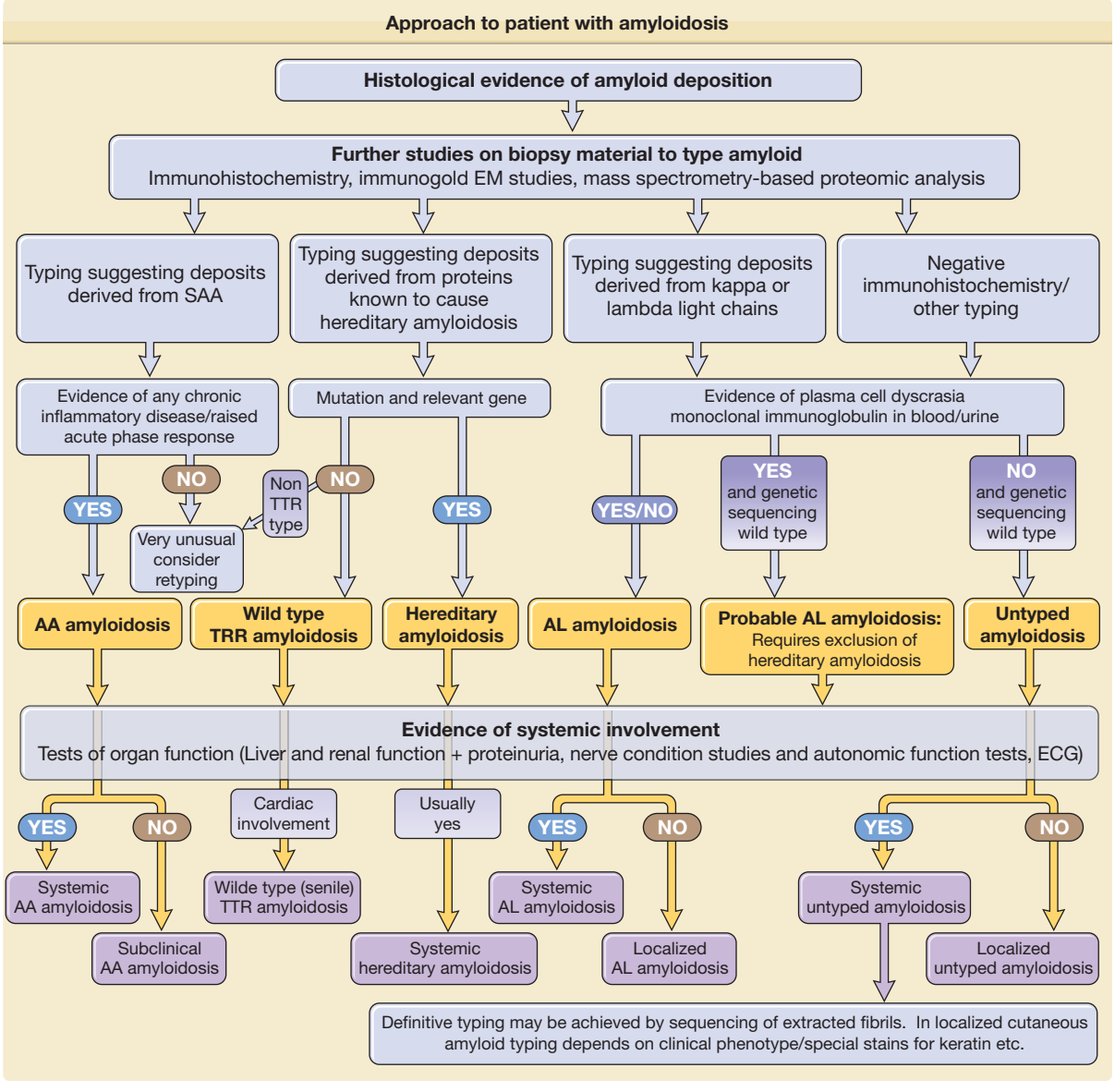

Figure 133-1 Approach to patient algorithm. Management of amyloidosis depends entirely on correct typing. This is both highly specialized and complex. Definitive typing requires a number of special tests and is best done in experienced centers.

TABLE 133-2
Clinical Features that may be Seen in Association with Systemic AL Amyloidosis

Visible tissue infiltration	Bruising (particularly periorbital) Macroglossia Muscle or joint pseudohypertrophy
Renal	Proteinuria Hypertension Chronic renal failure
Cardiac	Restrictive cardiomyopathy Arrhythmias Congestive cardiac failure
Hepatic	Hepatomegaly Liver failure (very rare)
Peripheral nervous system	Carpal tunnel syndrome Symmetrical sensorimotor neuropathy
Autonomic nervous system	Orthostatic hypotension Impotence Disturbed bowel motility Impaired bladder emptying
Gastrointestinal	Weight loss GI blood loss Disturbed bowel motility
Lymphoretiicular	Splenomegaly Lymphadenopathy
Adrenal axis	Hypoadrenalism

chronic sepsis usually bronchiectasis, complications of paraplegic conditions, or drug abuse. It is slightly more common in men. Although the disease can develop very rapidly, the median latency between presentation with a chronic inflammatory disorder and clinically significant amyloidosis is almost two decades. It usually presents with proteinuria and subsequently progressive renal dysfunction, often accompanied by nephrotic syndrome.[6]

Hereditary Amyloidosis. The presentation of hereditary amyloidosis varies depending on the variant protein, mutation, and even within kindreds.[14,15] Severe progressive peripheral and/or autonomic neuropathy is the major feature of hereditary TTR amyloidosis (FAP), but cardiac involvement is also common. ApoAI amyloidosis sometimes causes neuropathy, but this is not a feature of the other hereditary types, which typically involve the viscera. All the amyloidogenic mutations are dominant, but they are variably penetrant and therefore a family history may be absent.

CUTANEOUS LESIONS

Systemic AL Amyloidosis. Cutaneous manifestations are common in systemic amyloidosis, particularly the AL type, and are reported in up to 40% of patients.[4] The lesions usually reflect capillary infiltration and fragility with petechiae and purpura, particularly affecting the eyelids, beard area, and upper chest (Fig. 133-2A).[16] Xanthomatous papules or plaques are also frequently observed and amyloidotic hyperpigmented keratotic lesions have been reported occasionally. Other rare cutaneous lesions include scleroderma-like changes (Fig. 133-2B), alopecia, and







Figure 133-2 Cutaneous manifestations of systemic AL amyloidosis. **A.** Purpura due to capillary fragility. **B.** Scleroderma-like skin changes affecting the hands. **C.** Nail dystrophy.



Figure 133-3 Purpuric rash in hereditary lysozyme amyloidosis.

nail dystrophy (Fig. 133-2C). Bullous amyloidosis affecting the skin and mucosa has been described.[17] The bullae can be intradermal or subepidermal and present as tense, often hemorrhagic blisters. Generalized infiltration of cutaneous tissues can frequently cause the appearance of skin thickening with loss of facial wrinkles and can limit mouth opening.

Hereditary Amyloidosis. Lysozyme amyloidosis frequently causes petechial eruptions (Fig. 133-3) and apolipoprotein AI amyloidosis can also manifest as yellowish infiltrated plaques and acanthosis nigricans-type lesions.[15,18] Cutaneous lesions in FAP seem to be largely due to the peripheral neuropathy. They manifest as xerosis in 82%, seborrheic dermatitis in 22%, trauma or burn lesions in 20%, neuropathic ulcers in 14%, and onychomycosis in 10.5% of patients.[19]

Localized Cutaneous AL Amyloidosis. As in systemic AL amyloidosis, the fibrils are derived from *N*-terminal cleavage fragments of monoclonal immunoglobulin light chains. The lesions are those seen in systemic AL amyloidosis and present as single or more frequently multiple lesions anywhere on the skin.[20] In our series of 20 patients; 35% had indolent papular, nodular, or xanthomatous lesions (Fig. 133-4), 20% purpuric rash, 20% pruritus, 15% local bleeding, and 10% localized swelling. In only 15% of cases were the lesions painful.[21]

Macular Amyloidosis and Lichen Amyloidosis. Macular and lichen amyloidosis are variants of a single pathology in which the amyloid fibrils are derived from galectin-7 following epidermal damage and keratinocyte apoptosis.[22] They are usually idiopathic or friction related, but have been reported in association with connective tissue diseases (primary biliary cirrhosis, systemic lupus erythematosus and Sjögren's syndrome)[23] and in a few kindreds with pachyonychia congenita[24] or multiple endocrine neoplasia type 2a.[25]

Macular amyloidosis usually affects the upper back and limbs and can persist for many years. The rash is pruritic in the great majority of cases and consists of small brownish macules distributed in a rippled pattern. There may be a female preponderance,[26] and it is more common among Central and South Americans, Middle Easterners, and non-Chinese Asians. Amyloid deposits usually are confined to the papillary dermis and do not involve blood vessels or adnexal structures. Early lesions contain small, multifaceted, amorphous globules within the papillae, and these are missed easily without the use of special stains. Later lesions show globules that coalesce, expand the papillae, and displace the rete ridges laterally. Lichen amyloidosis is the commonest type of cutaneous amyloidosis in Chinese individuals and usually affects adults.[12,27] It is clinically characterized by an intensely pruritic eruption of multiple discrete hyperkeratotic papules that may coalesce to form gray–brown plaques that are distributed on the extensor surfaces of the lower extremities. There may be spread to the extensor aspects of the arms and the trunk. Histologically, the deposits are very similar to macular amyloid but slightly larger and are accompanied by irregular acanthosis and hyperkeratosis of the overlying epidermis.

Other Localized Cutaneous Amyloidosis. Deposition of insignificant microscopic amounts of amyloid in relation to a variety of cutaneous lesions is well recognized. Reported predisposing conditions include intradermal nevi, sweat gland tumors, pilomatrixoma, dermatofibroma, seborrheic keratosis, solar elastosis, photosensitive annular elastolytic giant cell granuloma, actinic keratosis, porokeratosis of Mibelli,[28] Bowen's disease, and basal cell carcinoma and following PUVA therapy.

Anosacral Cutaneous Amyloidosis. This is a rare syndrome described in Japanese and Chinese males in which pigmented macules and glossy hyperkeratotic lesions radiate out from the anus.[29]

Insulin-Derived Amyloidosis. A rare complication of long-term insulin use in diabetics is formation of insulin-derived amyloidomas at sites of repeated insulin injection. These can be confused with tumors.[30]

Familial Primary Localized Cutaneous Amyloidosis. This very rare autosomal dominant disorder is characterized by chronic pruritus from childhood or early teenage-years and hyperkeratotic papules and/or hyperpigmented macules on the limbs or trunk. It is relatively common in Southeast Asia and the amyloid appears to be confined to the skin. It is associated with mutations in the *OSMR* and *IL31RA* genes, related genes which are members of the interleukin-6 cytokine receptor family.[31]

RELATED PHYSICAL FINDINGS

SYSTEMIC AL AMYLOIDOSIS. Systemic AL amyloidosis is protean in its manifestations (Table 133-2,

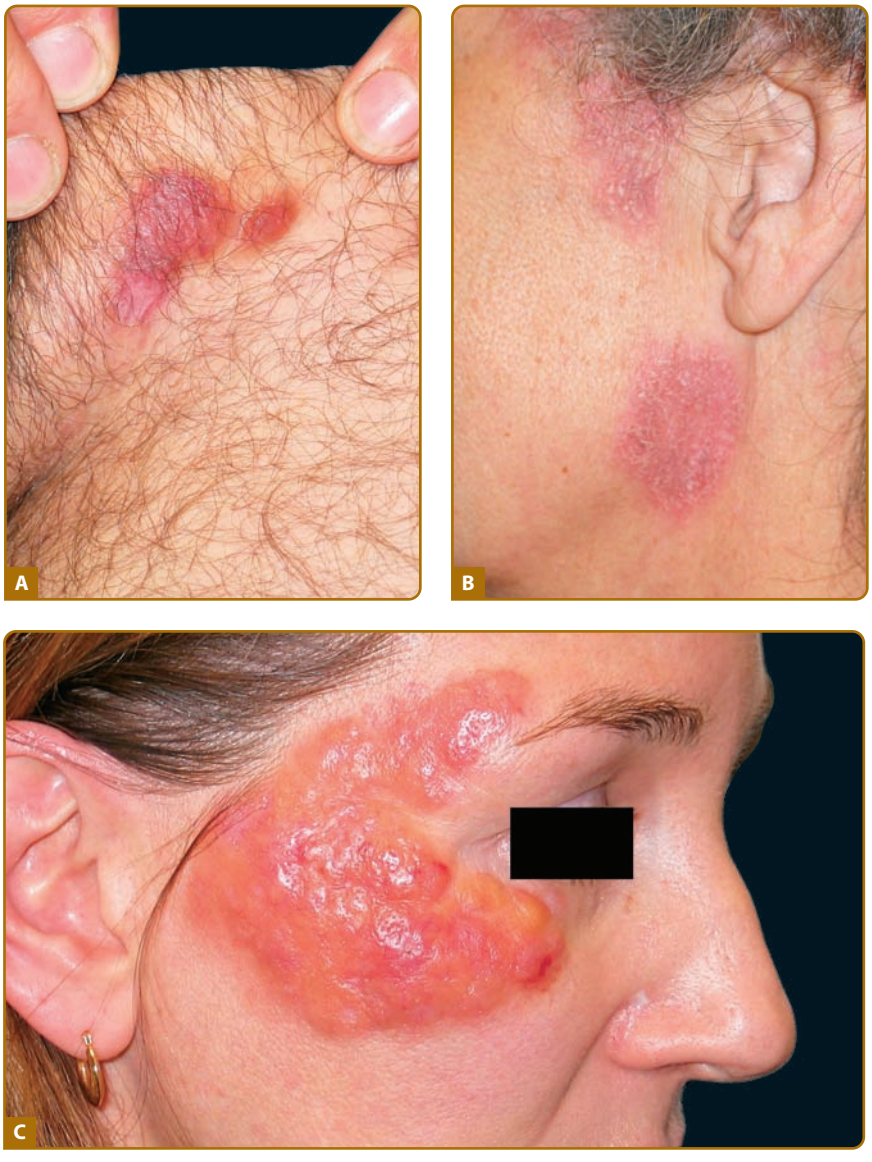

Figure 133-4 **A–C.** Localized AL amyloidosis resulting in slowly progressive papular lesions.

Fig. 133-5) and can cause signs in any organ system except the brain.

SYSTEMIC AA AMYLOIDOSIS. This presents with nephrotic syndrome in just under half of patients. Clinically, splenomegaly is frequent and hepatomegaly is detected in 10% of cases. Cardiac involvement and peripheral or autonomic neuropathy are very rare.

HEREDITARY AMYLOIDOSIS. The physical findings depend on the variant protein and specific mutations and may vary even within individual families.

LABORATORY TESTS

All patients should have comprehensive assessment of renal and liver function, including blood tests, and quantification of creatinine clearance and proteinuria.[32] A search should be made for evidence of an underlying plasma cell dyscrasia by serum and urine electrophoresis and immunofixation.[33] In suspected amyloid of AL type, a bone marrow aspirate and trephine are usually mandatory. Where available serum assays of potential fibril precursor proteins; free immunoglobulin light chains in AL type and SAA in AA amyloidosis are very valuable.[34]

SPECIAL TESTS

HISTOLOGY

The identification of amyloid depends on the pathognomonic red-green dichroism observed when tissue stained with the aniline dye Congo red is viewed under cross-polarized light (Fig. 133-6).[35] This optical effect



Figure 133-5 Visible tissue infiltration in systemic AL amyloidosis causing: **A.** Lymphadenopathy. **B.** Macroglossia. **C.** Muscle pseudohypertrophy. **D.** Periorbital purpura.

is produced by alignment of the dye molecules along the fibrils. Binding of thioflavin T usually corresponds with Congo red birefringence but is less specific. Congo red staining for amyloid is not a very sensitive test and requires the presence of an adequate amount of amyloid, use of sufficiently thick tissue sections, technically correct staining and visualization procedures, and adequate observer experience. In negatively stained electron microscopy amyloid fibrils are usually about 10 nm in diameter, straight, rigid, nonbranching, of indeterminate length, and composed of twisted protofibrils.

Positive histology for amyloid must be followed up by immunohistochemistry to determine the fibril protein type.[11] Suitable antibodies are widely available but, although immunohistochemistry usually yields

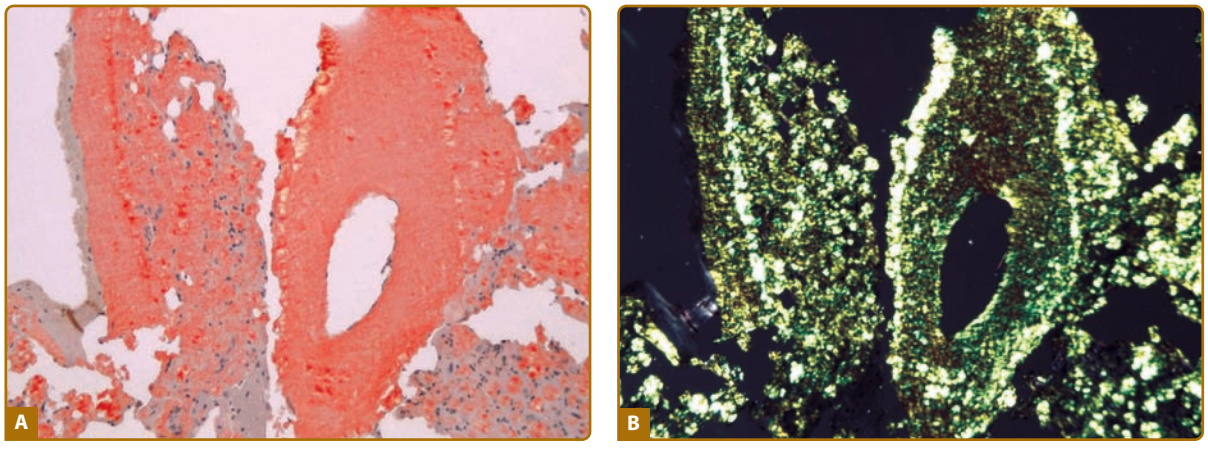

Figure 133-6 Typical appearances of amyloid deposits. **A.** Congo Red staining. **B.** Same section viewed under cross-polarized light with red–green birefringence.

definitive results in AA amyloidosis, it is frequently not diagnostic with AL deposits. Expertise in the immunohistochemical typing of hereditary amyloid is restricted, and definitive immunohistochemical typing of amyloid deposits cannot always be achieved.[36] Direct sequencing of extracted fibrils permits identification of the amyloid type as does laser microdissection and mass spectrometry[37] however, these techniques are generally only available in a research setting.

GENETIC SEQUENCING

Amyloidogenic mutations should be sought in all patients in whom the amyloid type remains undetermined as hereditary amyloidosis accounts for a substantial number of these cases.[38]

IMAGING AMYLOID IN VIVO

SAP SCINTIGRAPHY. SAP is a highly conserved, invariant plasma glycoprotein of the pentraxin family that becomes specifically and highly concentrated in amyloid deposits of all types as a result of its calcium-dependent binding to amyloid fibrils. Radiolabeled SAP scintigraphy can be used for diagnosis and quantitative monitoring of amyloid deposits.[39] This safe noninvasive method provides information on the presence, distribution and extent of visceral amyloid deposits, and serial scans monitor progress and response to therapy (Fig. 133-7). Unfortunately, the method is not informative about amyloid deposition in the moving heart and is not commercially available.

CARDIAC IMAGING. Cardiac amyloidosis is best evaluated by a combination of echocardiography and ECG.[40] Two-dimensional Doppler echocardiography classically reveals concentric biventricular wall thickening with a restrictive filling pattern. Amyloid causes diastolic dysfunction with well-preserved contractility until a very late stage. The ECG may be normal in patients with substantial cardiac amyloidosis, but in advanced disease commonly shows small voltages, pathological "Q" waves (pseudoinfarct pattern). Recent developments in magnetic resonance imaging can also contribute to assessment of the severity of cardiac amyloidosis,[41] as can serum assays of the cardiac biomarkers, *N*-terminal-pro-BNP[42] and troponin T.[43]

DIFFERENTIAL DIAGNOSIS

(See Box 133-1)



Figure 133-7 Anterior whole body I^{123}-labeled SAP scintigraphy demonstrating amyloid deposition in the liver and spleen.

BOX 133-1 DIFFERENTIAL DIAGNOSIS OF CUTANEOUS AMYLOIDOSIS

Most Likely

- Atopic dermatitis
- Lichen sclerosus
- Prurigo nodularis
- Poikiloderma of Civatte
- Postinflammatory hyperpigmentation
- Sebaceous hyperplasia
- Xanthoma

Consider

- Dermatomyositis
- Scleroderma
- Mastocytosis
- Pseudoxanthoma elasticum
- Colloid milium
- Pretibial myxedema
- Nodular pseudolymphomas

Always Rule Out

- Systemic amyloidosis

COMPLICATIONS

AL AMYLOIDOSIS

Restrictive cardiomyopathy is the presenting feature in up to one-third of patients and ultimately the cause of death in one-half.[44] Renal involvement is frequent and presents with proteinuria and progressive renal impairment.[45] Gut involvement can cause motility disturbances (often secondary to autonomic neuropathy), malabsorption, perforation, hemorrhage, or obstruction.[46] Peripheral neuropathy occurs in one-fifth of cases and typically presents with a painful sensory polyneuropathy followed later by motor deficits.[47] Autonomic neuropathy causing orthostatic hypotension, impotence, and gastrointestinal disturbances may occur in isolation or with a peripheral neuropathy.

AA AMYLOIDOSIS

Progressive renal failure and nephrotic syndrome are the usual complications in AA amyloidosis. Although splenic amyloid deposits are almost universally present in AA type, they are usually asymptomatic. Hepatic involvement and autonomic neuropathy are well recognized, but usually occur very late in the disease. Cardiac amyloidosis occurs in less than 2% of cases.[6]

HEREDITARY AMYLOIDOSIS

Familial polyneuropathy causes progressive peripheral and/or autonomic neuropathy and cardiomyopathy and in some cases visual loss due to vitreous amyloid deposits.[14] Apolipoprotein AI amyloidosis can cause peripheral neuropathy but, in common with Apolipoprotein AII, lysozyme, and fibrinogen A α chain types renal or hepatic amyloidosis is typical.[8] Gelsolin-related amyloidosis causes a characteristic clinical picture of corneal lattice dystrophy and cranial neuropathy.

LOCALIZED CUTANEOUS AMYLOIDOSIS

This only produces local complications usually in the form of pruritus or bleeding and is rarely painful.

PROGNOSIS/CLINICAL COURSE

Although recent advances have greatly extended median survival, the prognosis of systemic amyloidosis remains grave.

AL AMYLOIDOSIS

Prognosis is particularly poor in AL disease as the diagnosis is often made late, when patients already have substantial visceral and/or neural involvement. Indeed, a 5-year survival of approximately 10% and a 10-year survival of less than 5% have been reported for the AL type,[4] although more recent series suggest a median survival of 40 months.[48] Most affected individuals eventually die of heart failure, uremia, or autonomic failure.

AA AMYLOIDOSIS

The prognosis of AA amyloidosis depends on the degree of renal dysfunction at presentation and whether the underlying chronic inflammatory disease can be effectively suppressed, so that the plasma SAA is maintained within the normal healthy range. In our cohort of 374 patients, median survival was just over 11 years and a third of patients developed end-stage renal failure, which was the major cause of death.[6]

HEREDITARY AMYLOIDOSIS

In FAP median survival is 10–15 years without liver transplantation.[49] Death is from progressive neuropathy and or cardiomyopathy. In the other hereditary amyloidosis, organ failure either renal or hepatic is the major cause of mortality, but the time to reach end-stage organ failure is very variable.

LOCALIZED CUTANEOUS AMYLOIDOSIS

These skin-limited conditions are not usually associated with any increase in mortality.

TREATMENT

Treatment of all types of amyloidosis is focused on measures that can reduce the supply of the respective amyloid fibril precursor protein, while supporting or replacing compromised organ function. Under favorable circumstances, this results in regression of existing amyloid deposits, preservation or recovery of the function of amyloidotic organs, and much improved patient survival. Such treatment requires precise identification of the amyloid fibril type through immunochemistry, DNA sequencing and direct fibril sequencing. Monitoring of therapeutic efficacy and rational decisions about further treatment options are enhanced by the recent availability of routine assays for circulating free immunoglobulin light chains in AL amyloidosis and SAA in AA type.

AL AMYLOIDOSIS

Treatment in AL amyloidosis aims to suppress the proliferation of the underlying B-cell clone and, therefore, production of the amyloidogenic monoclonal immunoglobulin. This is not without problems[50]: chemotherapy regimens are based on those used in multiple myeloma, but the majority of plasma cell dyscrasias in AL patients are low grade and may be less chemosensitive. Diagnosis can be delayed, and many patients have advanced multisystem disease, which limits their options for chemotherapy. Regression of amyloid is a gradual process that may not lead to measurable clinical improvement or recovery of organ function for many months, or even years after successful suppression of the causative plasma cell dyscrasia.[48] Mobilization of amyloid from the heart is much slower than from the liver or kidneys, and many patients with cardiac or multisystem dysfunction do not live long enough to benefit from chemotherapy, even when it has suppressed their clonal disease. Nonetheless, many patients with AL amyloidosis do benefit substantially from chemotherapy. Prolonged low-intensity cytotoxic regimes such as oral melphalan and prednisolone are beneficial in about 20% of patients. Although there have been few comparative clinical trials,[51] chemotherapy regimens containing melphalan and dexamethasone, cyclophosphamide, thalidomide and dexamethasone,[52] or velcade,[53] and autologous peripheral blood stem-cell transplantation are almost certainly much more effective.[54] Very rigorous patient selection for high-dose chemotherapy is essential because the procedure-related mortality is extremely high in individuals with multiple organ involvement.[55]

AA AMYLOIDOSIS

Treatment of the primary inflammatory conditions responsible for AA amyloidosis reduces amyloid levels, dramatically improves survival, and is associated with arrest of amyloid deposition and frequently regression of deposits. The new biological drugs targeting key cytokine mediators of inflammation potently suppress the acute phase response in many patients with inflammatory arthritis, Crohn's disease, and some hereditary periodic fevers.[56] Colchicine is the treatment of choice to prevent AA amyloidosis in familial Mediterranean fever.

HEREDITARY AMYLOIDOSIS

At present, apart from transplantation to replace failed organs and liver transplantation to reduce production of amyloidogenic proteins that are synthesized by the liver, only symptomatic treatment is available for hereditary systemic amyloidosis. The liver is the source of plasma TTR, and over 1,000 liver transplants have been performed for treatment of hereditary TTR amyloidosis since this "surgical gene therapy" approach was introduced in 1991.[49] In younger patients carrying the common *Val30Met* mutation, the outcome is generally good, with arrest of neuropathy and regression of visceral amyloid, but the outcome in patients with other mutations has been less successful.[57]

NOVEL TREATMENTS FOR SYSTEMIC AMYLOIDOSIS

Better understanding of the mechanisms underlying amyloid formation has led to the development of novel treatment strategies aimed at inhibiting fibrillogenesis or destabilizing existing amyloid deposits.[58,59] Preliminary work in mice has demonstrated that antiamyloid antibodies were effective in clearing cutaneous amyloid deposits without the necessity of an immune response.[60]

LOCALIZED CUTANEOUS AL AMYLOIDOSIS

Small localized amyloid deposits can be removed surgically or by laser if they are cosmetically disfiguring or bleeding, but there is a very high rate of local recurrence. The possibility that systemic chemotherapy may be of any benefit in localized AL amyloidosis has not been systematically tested.

MACULAR AND LICHEN AMYLOIDOSIS

Chronic friction is a major etiological factor in these and treatment modalities should be directed toward the relief of pruritus in these conditions. Sedating antihistamines have been found to be moderately effective and intralesional steroids are beneficial if combined with other modalities. Topical dimethyl sulfoxide (DMSO), a solvent, has been used with modest success at best[61] but is often unacceptable to patients due to the smell. Treatment with ultraviolet B (UVB) light can provide symptomatic relief.[62] There is one report of improvement following treatment with 0.1% topical tacrolimus ointment.[63] Systemic cyclosporine or retinoids may also be beneficial.[64]

KEY REFERENCES

Full reference list available at www.DIGM8.com

DVD contains references and additional content

1. Pepys MB, Hawkins PN: Amyloidosis. In: *Oxford Text Book of Medicine*, 5th edition, edited by DA Warrell, TM Cox, JD Firth. Oxford University Press, 2010, pp. 1766-1779
2. Merlini G, Bellotti V: Molecular mechanisms of amyloidosis. *N Engl J Med* **349**:583-596, 2003
13. Gertz MA et al: Amyloidosis. *Best Pract Res Clin Haematol* **18**:709-727, 2005
14. Benson MD, Kincaid JC: The molecular biology and clinical features of amyloid neuropathy. *Muscle Nerve* **36**:411-423, 2007
16. Schremi S et al: Cutaneous amyloidoses and systemic amyloidoses with cutaneous involvement. *Eur J Dermatol* **20**(2):152-160, 2010
38. Lachmann HJ et al: Misdiagnosis of hereditary amyloidosis as AL (primary) amyloidosis. *N Engl J Med* **346**:1786-1791, 2002
48. Wechalekar AD, Hawkins PN, Gillmore JD: Perspectives in treatment of AL amyloidosis. *Br J Haematol* **140**:365-377, 2008
58. Dember LM: Emerging treatment approaches for the systemic amyloidoses. *Kidney Int* **68**:1377-1390, 2005

Chapter 134 :: Systemic Autoinflammatory Diseases

:: Chyi-Chia Richard Lee & Raphaela Goldbach-Mansky

SYSTEMIC AUTOINFLAMMATORY DISEASES AT A GLANCE

- Autoinflammatory diseases are disorders of the innate immune system. Excessive, innate immune responses lead to uncontrolled systemic and organ inflammation.
- Although these syndromes can mimic infections clinically, the inflammatory lesions in autoinflammatory disorders are aseptic. Fever typically accompanies some autoinflammatory diseases but is not present in all disorders.
- A number of pediatric autoinflammatory syndromes are caused by single gene mutations that have been crucial in pointing to key proinflammatory pathways, in particular the regulation of the cytokine interleukin-1 (IL-1).
- Most monogenic autoinflammatory syndromes typically present in childhood and can be differentiated on the basis of their clinical features.
- These disorders present with evidence of systemic inflammation often accompanied by generalized lymphadenopathy. Organ-specific inflammation can affect the skin, the joints/bones, serosal surfaces, the eyes, cochlea, meninges, but are often specific for one of the syndromes.
- Autosomal recessive autoinflammatory syndromes include: familial Mediterranean fever (FMF) and hyperimmunoglobulinemia D with periodic fever syndrome (HIDS), Majeed syndrome, *d*eficiency of the *I*L-1 *r*eceptor *a*ntagonist (DIRA), and deficiency of the IL-10 receptor.
- Autosomal dominant autoinflammatory syndromes include: i) tumor necrosis factor receptor-associated periodic syndrome (TRAPS) and the spectrum of the cryopyrinopathies or cryopyrin-associated periodic syndromes (CAPS)—familial cold autoinflammatory syndrome (FCAS), Muckle-Wells syndrome (MWS), and neonatal-onset multisystem inflammatory disease (NOMID); ii) pyogenic arthritis, pyoderma gangrenosum, and acne (PAPA) syndrome; and iii) pediatric granulomatous arthritis (PGA).
- Characteristic skin eruptions are associated with a number of these disorders and include, neutrophilic urticaria, skin erythema, macular papular eruptions, and pustulosis.
- Colchicine effectively prevents the inflammatory attacks and the development of amyloidosis in FMF.
- Anti-IL-1 therapy is the standard of care in treating the cryopyrinopathies (CAPS), and DIRA. Anti-IL-1 therapy is also used to treat syndromes with more variable responses to IL-1 blockade such as resistant patients with HIDS, TRAPS, FMF, PAPA, and PGA.
- Mutations for these disorders are available in an online database called Infevers: available at http://fmf.igh.cnrs.fr/ISSAID/infevers/).

OVERVIEW OF AUTOINFLAMMATORY DISEASES

This chapter focuses on the clinical and immunologic description of the currently known monogenic autoinflammatory syndromes. Most of these syndromes present with predominantly neutrophilic skin eruptions and either fever or systemic inflammation, with elevation of acute-phase reactants during the attacks. Disease-specific organ inflammation often involves the skin, serosal surfaces, the eyes, the inner ear the meninges, the bones, the gastrointestinal tract, lymphadenopathy and more rarely, the vasculature. The characteristic clinical pattern of organ-specific inflammation in the various syndromes can, in most cases, be used to make a clinical diagnosis, which is then confirmed by genetic testing. The syndromes are summarized here and are detailed in the online edition of this chapter.

CRYOPYRINOPATHIES (FCAS, MWS, NOMID)

EPIDEMIOLOGY AND ETIOLOGY

The spectrum of cryopyrinopathies includes (1) the familial cold autoinflammatory syndrome (FCAS; OMIM #120100),[29] (2) Muckle–Wells syndrome (MWS; OMIM #191900),[30] and (3) the noninherited sporadic disease neonatal-onset multisystem inflammatory disease (NOMID) also called *c*hronic *i*nfantile *n*eurologic, *c*utaneous and *a*rthritis (CINCA) syndrome (OMIM #607115).[31] These three clinical disorders were initially described as distinct disorders, but the discovery that the familial disorders FCAS and MWS and the sporadic disease NOMID/CINCA are all caused by autosomal dominant gain of function mutations in *NLRP3*, which is also called *NALP3*, *CIAS1* or *PYPAF1*[10–12] led to the recognition that these disorders form a disease spectrum with FCAS on the mild and NOMID on the most severe end of the spectrum.

The prevalence of CAPS is estimated to be between 1 and 2 patients per 1,000,000 people in Europe and the United States based on known cases in centers studying these patients, but actual epidemiologic studies to assess incidence and prevalence have thus far not been conducted.

PATHOGENESIS

NLRP3/CIAS1 encodes the protein, cryopyrin, which belongs to a family of intracellular sensor molecules, the NLRs (NOD-like receptors). Cryopyrin can associate with adaptor proteins to form a multimolecular complex called the NLRP3 inflammasome that activates caspase-1, an enzyme that cleaves pro-IL-1β into its 17-kDa active IL-1 fragment.[32] Mutations in cryopyrin result in an "overactive" inflammasome that leads to higher production of active IL-1.[12,33–35] The inflammasome can be activated by a number of different triggers including bacterial triggers and molecules released during cell injury or stress [such as adenosine triphosphate (ATP) and uric acid], which leads to formation and activation of the NLRP3 inflammasome and activation of caspase-1, an enzyme that cleaves the proinflammatory cytokine IL-1β into its active form.

CRYOPYRINOPATHIES AT A GLANCE

- Rare autosomal dominant disorders.
- Disease spectrum includes familial cold autoinflammatory syndrome (FCAS; OMIM #120100), Muckle–Wells syndrome (MWS; OMIM #191900), and neonatal-onset multisystem inflammatory disease (NOMID/CINCA; OMIM #607115).
- Most cases of NOMID caused by sporadic, de novo mutations.
- Mutations in *NLRP3,* (also referred to as *NALP3* or *CIAS1*) on chromosome 1q11, encode an intracellular danger receptor that activates the proinflammatory cytokine IL-1. 50% of NOMID patients and small percentages of patients with FCAS or MWS have no detectable mutation in *CIAS1*.
- Features include urticaria-like eruption, fever, conjunctivitis, arthralgia (FCAS, MWS, NOMID); progressive hearing loss, progressive vision loss (MWS, NOMID); mental retardation, hydrocephalus, bony overgrowth (NOMID).
- Histopathological evaluation of lesional skin shows papillary dermal edema and telangiectasis of the superficial dermal capillaries. A predominantly perivascular and perieccrine neutrophilic inflammatory infiltrate is present in the superficial dermis and middermis, but leukocytoclasis and vasculitis are absent.
- Anti-IL-1 therapy is very effective and the standard of care in treating cryopyrinopathies (CAPS).
- Information for patients and professionals at http://www.nomidalliance.net/.

CLINICAL FINDINGS

All CAPS patients present with episodes of fever, urticaria-like eruption, conjunctivitis (Fig. 134-1H), arthralgia, and elevations in acute-phase reactants, but differ in the spectrum of multiorgan disease manifestations and in long-term morbidity and mortality.

TABLE 134-1
"Monogenic" Autoinflammatory Syndromes

Inflammatory Pathogenesis	Disease	Gene	Protein	Inheritance Pattern	Disease Onset	Flare/Fever Pattern	Specific Organ Inflammation	Treatment
IL-1-mediated	CAPS:							
	FCAS	*CIAS1* (1q44)	Cryopyrin	Autosomal dominant	First 6 months of life, cold induced	<24 hours	Skin, eyes, joints	IL-1 blockade
	MWS	*CIAS1* (1q44)	Cryopyrin	Autosomal dominant	Infancy to adolescence	24–48 hours	Skin, eyes, joints, inner ears, meninges (mild)	IL-1 blockade
	NOMID	*CIAS1* (1q44)	Cryopyrin	Autosomal dominant/de novo	Neonatal or early infancy	Continuous with flares	Skin, eyes, joints, inner ears, meninges, bony epiphyseal hyperplasia	IL-1 blockade
	DIRA	*IL1RN* (2q14)	IL-1 receptor antagonist	Autosomal recessive	Neonatal or early infancy	Continuous with flares	Skin, bones, lungs (rare), vasculitis (rare)	Anakinra
Partially IL-1-mediated	FMF	*MEFV* (16p13)	Pyrin	Autosomal recessive	80% of the cases occur before the age of 20	1–3 days	Skin, joints, peritoneum, pleura	Colchicine, rarely IL-1 and TNF blockade or thalidomide if colchicine-resistant
	HIDS	*MVK* (12q24)	Mevalonate kinase	Autosomal recessive	Median age at onset 6 months	3–7 days	Skin, eyes, joints, prominent lymph nodes	NSAIDS, corticosteroids, TNF and IL-1 blockade
	Mevalonic aciduria	*MVK* (12q24)	Mevalonate kinase	Autosomal recessive	Neonatal or early infancy	Continuous with flares	Lymph nodes, hepatosplenomegaly, eyes microcephaly, cerebellum, GI tract	TNF and IL-1 blockade? Allogeneic bone marrow transplant
	PAPA	*CD2BP1* (15q24)	PSTPIP1	Autosomal dominant	Early childhood	Common	Skin, joints	Local and systemic corticosteroids, TNF or IL-1 blockade
Other pathways/ effector pathway not yet known	TRAPS	*TNFRSF1A* (12p13)	TNF receptor 1	Autosomal dominant	Median age at onset 3 years	1–4 weeks	Skin, eyes, joints, peritoneum, pleura	TNF blockade, steroids, IL-1 blockade, colchicine is ineffective
	PGA[a]	*NOD2* (16q12)	Nod2	Autosomal dominant/de novo	Early childhood	Uncommon	Skin, eyes, joints	NSAIDS, corticosteroids, methotrexate, cyclosporine, TNF or IL-1 blockade
	Majeed's syndrome	*LPIN2* (18p11)	Lipin-2	Autosomal recessive	Early infancy (1–19 months)	Weeks–months	Bones, periosteum, anemia	NSAIDS, corticosteroids, interferon-α
	Early-onset inflammatory bowel disease (IBD)	*IL10RA* (11q23) *IL10RB* (21q22)	IL-10 receptor, *IL10RB* also forms IL-22, -26, -28, -29 receptors	Autosomal recessive	Neonatal or early infancy	Continuous with flares	Colitis with fistula formation, folliculitis in patients with *IL10RB* mutations	Bone marrow transplantation in severe cases

[a]Including Blau syndrome (OMIM #186580) and early-onset sarcoidosis (OMIM #609464).
CAPS = cryopyrin-associated periodic syndromes; DIRA = deficiency of the IL-1-receptor antagonist; FCAS = familial cold autoinflammatory syndrome; FMF = familial Mediterranean fever; HIDS = hyperimmunoglobulin D syndrome; OMIM = Online Mendelian Inheritance in Man number; MWS = Muckle–Wells syndrome; NOMID = neonatal-onset multisystem inflammatory disease; PAPA = pyogenic arthritis, pyoderma gangrenosum, and acne syndrome; PGA = pediatric granulomatous arthritis; TRAPS = tumor necrosis factor receptor-associated periodic syndrome.

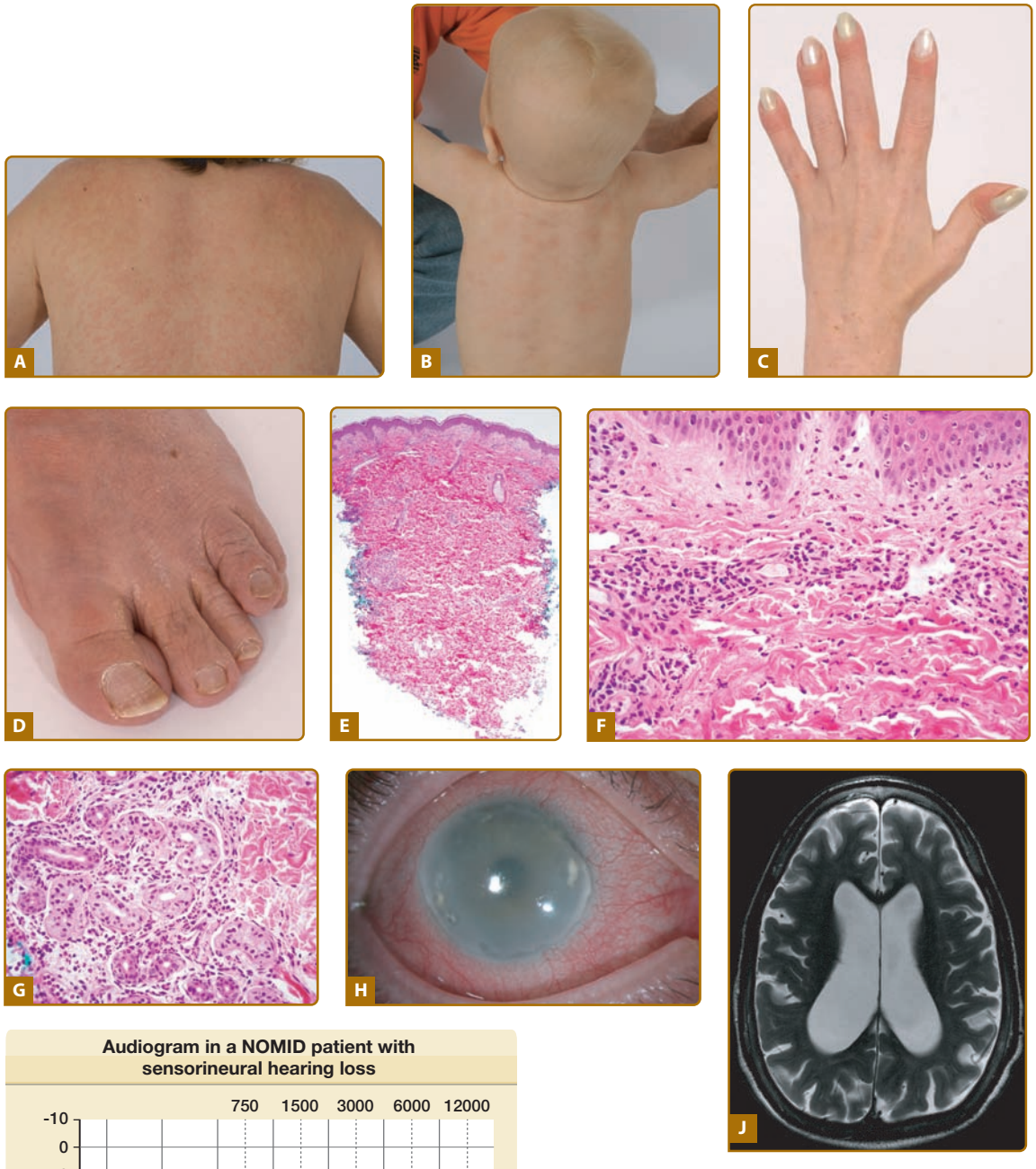

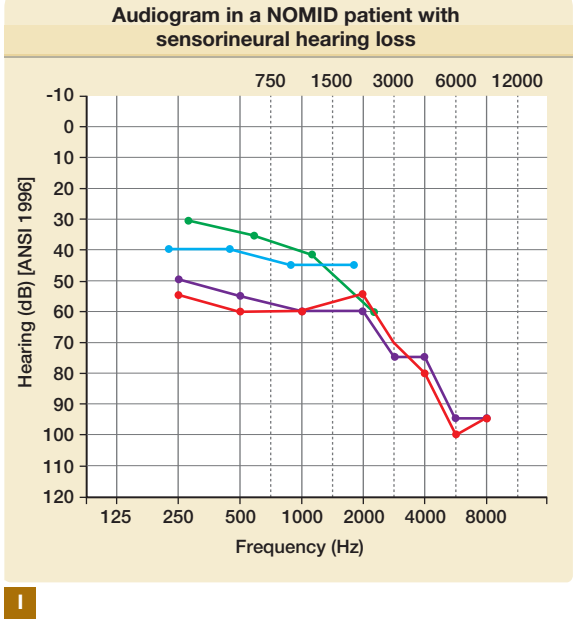

Figure 134-1 CAPS/NOMID. **A.** Urticaria-like skin eruption in a patient with NOMID/MWS. **B.** Urticaria-like skin eruption in an infant with NOMID/MWS. **C.** Clubbing fingers. **D.** Wrinkled, excess skin around the toenails and toes. **E.** At scanning magnification, there is a perivascular and periadnexal inflammatory infiltrate, extending from the superficial dermis to middermis. The epidermal changes are unremarkable. **F.** The superficial dermal capillaries are dilated and are surrounded by neutrophils. Changes of frank leukocytoclastic vasculitis are absent. **G.** The eccrine glands are also surrounded and infiltrated by neutrophils. **H.** Conjunctivitis and corneal clouding due to subcorneal inflammatory infiltrates. **I.** Sensorineural hearing loss most pronounced at high frequencies. **J.** Ventriculomegaly and brain atrophy.

In patients with FCAS the episodes are triggered by exposure to cold temperatures or air drafts and present with fevers, eruption, joint pain, conjunctivitis, and headaches. Typical episodes last for 12–48 hours and then resolve. The disease typically starts in early childhood.

Patients with MWS or NOMID typically present with urticaria-like eruptions at birth or within hours of birth; however, in some patients the first symptoms can present later. Patients with MWS have similar symptoms of fevers, urticaria-like eruption, joint pain, conjunctivitis, and headaches; however, in contrast to patients with FCAS, these symptoms can be continuous and are not typically precipitated by cold exposure. Episcleritis and optic disc edema are exceedingly uncommon in FCAS but are seen in some Muckle Wells patients; sensorineural hearing loss typically develops in the second to third decade of life in MWS patients.[33] Patients with NOMID/CINCA present with the most severe phenotype. Often their initial presentation is thought to be neonatal sepsis as they present with fevers, urticaria-like eruption, leukocytosis, and high elevation of the acute-phase reactants around birth. Joint swelling and conjunctivitis can develop at birth but usually within the first months of life. CNS inflammation with aseptic leptomeningitis and neutrophilic pleocytosis in the cerebrospinal fluid are common. Severely affected children develop hydrocephalus (Fig. 134-1J), brain atrophy, and cognitive impairment. Patients typically develop sensorineural hearing loss within the first year of life (Fig. 134-1I), and on magnetic resonance imaging (MRI) cochlear enhancement is seen and suggests cochlear inflammation as the cause of hearing loss.[35] Conjunctivitis, anterior and posterior uveitis, and subcorneal infiltrates can lead to retinal scarring, corneal clouding, and blindness. Arthralgia is common, true arthritis in most cases is very mild; however, between 50% and 70% of patients with NOMID develop characteristic bony overgrowth of the epiphyses of the long bones.[38] Most commonly involved is the epiphyses of the distal femur and proximal tibia of the knee, which frequently leads to joint deformities and contractures. Other features include elevated inflammatory markers, short stature, and leukocytosis.

CUTANEOUS LESIONS. All CAPS patients present with an urticaria-like skin eruption (Figs. 134-1A and 134-1B). In most cases, the eruption is nonpruritic and is not associated with any particular sensation, but some patients describe the eruption as burning or stinging. The skin eruption is often the first noticeable disease manifestation particularly in the less severe cases and is typically considered to be allergic. The eruption is often present at birth or develops within hours of birth but in FCAS patients can also be discovered later in childhood. The eruption is migratory and nonscarring and can vary in severity from day to day and from patient to patient. A persistent livedoid or cutis marmorata pattern, in addition to the urticarial lesions that come and go, is often seen in older patients with long-standing disease. Other cutaneous manifestations can include soft, doughy palms, soles, fingers and toes (Fig. 134-1D) and clubbing of the finger (Fig. 134-1C) and toenails, without any evidence of pulmonary disease. In contrast to true familial and acquired cold urticaria, the ice cube test is negative in CAPS patients.[39,40]

DERMATOPATHOLOGY

The histological features in FCAS, MWS, and NOMID are very similar and are discussed together. Histologically, the epidermis in CAPS is usually unaffected. There may be mild edema of the papillary dermis. The superficial dermal capillaries are dilated. A predominantly perivascular neutrophilic inflammatory infiltrate is present in the superficial dermis and middermis (Fig. 134-1E and 134-1F); however, there is no evidence of vascular destruction or true vasculitis and the number and appearance of mast cells is within normal limits.[40–43] The eccrine glands are also surrounded and infiltrated by neutrophils (Fig. 134-1G). The histological finding of neutrophilic urticaria contrasts with the lymphocytic and eosinophilic infiltrate seen in classical urticaria and is an important clue to the diagnosis of CAPS.[44]

LABORATORY TESTS AND SPECIAL TESTS (INCLUDING IMAGING STUDIES)

Evidence of systemic inflammation is present with marked leukocytosis, thrombocytosis, and mild anemia of chronic disease. Elevated levels of acute-phase reactants, *C*-reactive protein, erythrocyte sedimentation rate and serum amyloid A (SAA) levels are typically seen. Eosinophilia can be present and is variable. Careful assessment of central nervous system disease in NOMID/CINCA is indicated. Lumbar punctures are performed in patients with NOMID to diagnose leptomeningitis and to monitor intracranial pressures and leukocytosis, which predominantly consists of neutrophils, and the elevation of protein in the cerebrospinal fluid when patients are on treatment. High-resolution gadolinium-enhanced MRI can show leptomeningeal and cochlear enhancement at various degrees in patients with NOMID. X-rays of the long bones indicate the location of epiphyseal lesions and are used to follow the bony overgrowth in patients with NOMID and MRIs of an individual lesion can be helpful to rule out bone tumors and to distinguish the presence of synovial inflammation which is usually fairly nonimpressive compared to the bony abnormalities in NOMID patients.[38]

Genetic testing for *NLRP3/CIAS1* mutations confirms the diagnosis. Although almost all patients with FCAS and MWS are mutation positive, only 50%–60% of patients with NOMID have germ-line mutations that can be detected on genetic testing; therefore, a negative genetic test does not exclude the diagnosis of CAPS.

DIFFERENTIAL DIAGNOSIS

In the neonate the differential diagnosis includes benign newborn eruptions, NOMID patients can present more dramatically, mimicking neonatal sepsis or congenital

"TORCH" infections. Still's disease, systemic-onset juvenile idiopathic arthritis (SoJIA), and adult-onset Still's disease (AOSD) need to be considered in the differential diagnosis; although they typically do not present at birth. Patients with FCAS are often diagnosed with allergies or acquired cold urticaria. The bony lesions in NOMID patients can be painful and can initially resemble other benign or malignant bone tumors.

COMPLICATIONS AND PROGNOSIS/ CLINICAL COURSE

As treatment with IL-1 blocking agents has radically changed the outcome of these disorders, the prognosis in untreated and treated patients with CAPS differs significantly. In addition, the prognosis of the spectrum of CAPS depends on the disease phenotype. Untreated patients with FCAS usually have a good prognosis without hearing loss and the development of amyloidosis is rare. However, in a few families with cold-induced urticaria, the development of hearing loss and amyloidosis have been reported.[45,46] The most severe complications of untreated MWS are hearing loss and the development of amyloidosis in up to 30% in European cohorts. Untreated NOMID/CINCA patients present with early-onset hearing loss usually in the first decade of life, develop mental retardation, progressive vision loss due to progressive optic nerve atrophy, hydrocephalus, cerebral atrophy, and children with severe bony overgrowth and the development of joint contractures can develop limb length discrepancies and severe physical disabilities.[47]

TREATMENT AND PREVENTION

Despite clinical heterogeneity, all patients with FCAS, MWS, and NOMID respond dramatically and invariably to IL-1 blockade. Studies have shown efficacy of anakinra (Kineret®, recombinant IL-1 receptor antagonist) and the long-acting drugs rilonacept (Arcalyst®, IL-1 Trap, a fusion protein of the IL-1 receptor and the Fc portion of IgG) and canakinumab (Ilaris®, IL-1β-blocking antibody) for the treatment of CAPS. All patients show rapid improvement in clinical and laboratory parameters with treatment.[58–63]

The drugs are generally well tolerated and these medications have now become the standard of care in the treatment of these conditions. Although anakinra has been used longer in the treatment of CAPS, rilonacept and canakinumab have undergone a development program for orphan diseases and are now FDA approved for the treatment of FCAS and MWS.[48,49,64] Consistent with the clinical observations of the varied disease severity in FCAS, MWS, and NOMID/CINCA, increasing doses of IL-1-blocking agents such as anakinra are necessary to control more severe disease. Typically, subcutaneous injections of anakinra at 0.5–1.5 mg/kg/day is sufficient to suppress disease activity in FCAS patients. However, in NOMID patients doses up to 6 mg/kg/day or even 10 mg/kg/day[50] have been administered to control disease.

The resolution of symptoms and the achievement of inflammatory remission not only in the blood but also in the specific organs with treatment by IL-1 inhibitors are an important proof of concept that the systemic and organ-specific inflammation seen in these disorders is dependent on IL-1β. Notably, only bony overgrowth changes progress on treatment with IL-1-blocking agents which suggests that the continuation of lesional bone growth is likely independent of IL-1.[65]

DEFICIENCY OF THE IL-1 RECEPTOR ANTAGONIST

DEFICIENCY OF IL-1 RECEPTOR ANTAGONIST (DIRA) AT A GLANCE

- Rare autosomal recessive disorders (DIRA; OMIM #612852).
- Autosomal recessive inheritance.
- Mutations in *IL1RN* on chromosome 2q14 encodes the IL-1 receptor antagonist, a negative regulator of the IL-1 type 1 receptor.
- Cutaneous features include pustular eruption/folliculitis, onychomadesis.
- Extracutaneous features include aseptic osteomyelitis of long bones and vertebra and ribs and periosteitis of long bones.
- Dermatopathology is characterized by intraepidermal neutrophils and neutrophilic pustules, marked papillary dermal edema with subepidermal vesiculation, and an intense neutrophilic inflammatory infiltrate throughout the dermis and superficial subcutis; changes of frank vasculitis are absent in most patients.
- Anti-IL-1 therapy with the recombinant IL-1 receptor antagonist anakinra is very effective and can be lifesaving.

FAMILIAL MEDITERRANEAN FEVER

EPIDEMIOLOGY AND ETIOLOGY

Familial Mediterranean fever (FMF; OMIM #249100) is an autosomal recessive disease caused by mutations in *MEFV* (MEditerranean FeVer), the gene encoding the protein pyrin.[2,3] FMF is the most common monogenic autoinflammatory disease. FMF is most common among populations around the Mediterranean Sea. Clinical symptoms of FMF present in most patients before the age of 20 and therefore the diagnosis is mainly made by pediatricians.

FAMILIAL MEDITERRANEAN FEVER (FMF) AT A GLANCE

- Most common monogenic autoinflammatory disorder (FMF; OMIM #249100).
- Autosomal recessive inheritance first genetically characterized autoinflammatory disease.
- Mutations in *MEFV* on chromosome 16p13 and encoding pyrin/marenostrin.
- Cutaneous features erysipeloid erythema.
- Extracutaneous features include 1–3-day episodic attacks of fever, abdominal pain, pleuritis.
- Histopathologic evaluation of erysipeloid lesions shows a perivascular and interstitial neutrophilic infiltrate, with prominent edema of the papillary dermis and dilatation of superficial dermal capillaries.
- Colchicine is effective in most patients and prevents the development of amyloidosis
- Information for patients and professionals at http://ghr.nlm.nih.gov/condition=familialmediterraneanfever.

CLINICAL FINDINGS

FMF typically presents with 1–3-day episodes of fever with serositis, which typically consists of sterile peritonitis, but pleuritis, arthritis, and eruption can also be present. The arthritis attacks can last up to 1 week. The frequency of the attacks can vary from once weekly to once every few years. Physical exertion and emotional stress can induce these attacks, but in many instances there are no obvious triggers associated with the onset of attacks. In infants, particularly children under the age of 2, fever alone can be the initially presenting feature which typically progresses to more classic features within 3 years,[84] which may be complicated by the development of amyloidosis.[22] Abdominal pain is the second most common clinical finding in FMF presenting at some time in over 90% of patients. The peritonitis can be severe and mimic a surgical abdomen with a rigid abdominal wall, rebound tenderness, and absent bowl sounds. Not uncommonly, FMF patients have a history of a nondiagnostic exploratory laparoscopy and/or laparotomy. Small peritoneal effusions can be seen on abdominal CT and likely present an inflammatory exudate. Pleurisy is also common and is usually unilateral. A sharp chest pain, worse on inspiration and coughing, can give a clue to the diagnosis.

Symptomatic pericarditis during the attacks occur but are rare,[85,86] but on echocardiogram small, nonclinically significant effusions can be present during attacks.

Other rare clinical features of FMF include, protracted febrile myalgia, which presents with up to 6-week episodes of debilitating muscle pain, fever and elevation of acute-phase reactants but normal CK levels.[87] Inflammation of the tunica vaginalis, an embryological remnant of the peritoneal membrane,[88] can lead to severe scrotal pain and ischemic testicular necrosis and rarely aseptic meningitis have been seen.[89]

CUTANEOUS LESIONS. Erysipeloid erythema is the most characteristic eruption of FMF, but it is rarely present in isolation.[90] These lesions appear on the lower limbs, usually below the knee. They tend to affect the dorsum of the foot and ankle and lower extremity. They consist of warm, tender, swollen erythematous plaques, 10–15 cm in diameter, with well-defined borders (Fig. 134-2A). The lesions may be bilateral, may be initiated by prolonged walking, and subside within 24–48 hours. Other cutaneous manifestations described in FMF include a localized edema affecting the upper or lower limbs, face, or neck, and subcutaneous nodules.[91] In children, episodic scattered nonspecific purpuric papular lesions that affect the face, trunk, or extremities are more frequently observed.[92] A higher incidence of vasculitic purpura, including Henoch–Schönlein purpura, has also been described in FMF patients in some case series.[69]

DERMATOPATHOLOGY

Biopsies of erysipeloid skin eruptions are rarely reported; on biopsies, a perivascular and interstitial inflammatory infiltrate composed of predominantly neutrophils and lymphocytes in the dermis, with prominent edema of the papillary dermis and dilatation of superficial dermal capillaries, can be seen. The epidermal changes may include mild hyperkeratosis and acanthosis[90,91] (Fig. 134-2B). In one series, direct immunofluorescence studies show deposition of complement C3 in the vessel wall of the small superficial dermal vessels in all cases and deposition of fibrinogen and IgM in some case.

LABORATORY TESTS AND SPECIAL TESTS

During the inflammatory attacks nonspecific markers of inflammation, the acute-phase reactants, ESR, CRP, and SAA levels are typically elevated.[93] Mild hypergammaglobulinemia including elevation of IgD, mostly in patients who are homozygous for the *M694V* mutations, can be seen during as well as in between attacks.[94] In between the febrile attacks, elevation of the acute-phase reactants can persist—a finding that has also been observed in heterozygous carriers for the mutation.[95,96] Similar to many other autoinflammatory diseases, autoantibodies to ANA, RF, and

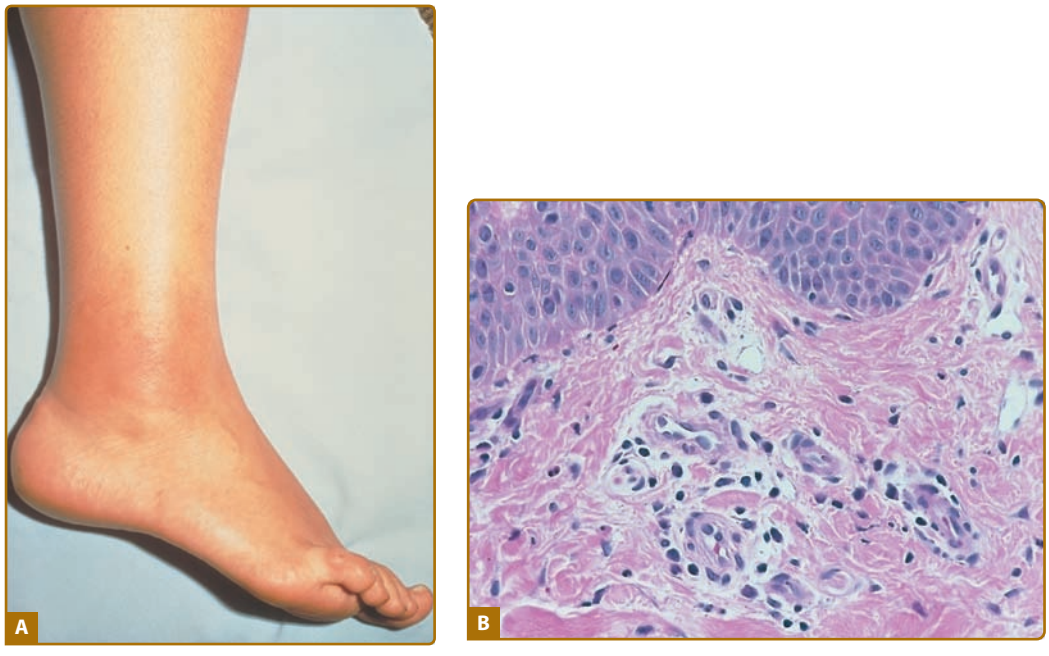

Figure 134-2 FMF. **A.** Erysipelas-like eruption on right ankle showing sharply demarcated, swollen, bright erythematous skin. (From Azizi E et al: Cutaneous manifestations of Familial Mediterranean Fever. *Arch Dermatol* **112**:364–366, 1976, with permission. © 1976 by the American Medical Society.) **B.** Histology of erysipeloid eruption showing a perivascular inflammatory infiltrate in the superficial dermis. (Used with permission from Dan Kastner.)

ANCA are typically not found, which initially led to the hypothesis that these disorders are caused by an innate immune defect.

DIFFERENTIAL DIAGNOSIS

In patients with peritonitis, acute appendicitis may be suspected; however, spontaneous resolution of fever is a clue to the diagnosis of FMF. Hereditary angioedema may present with abdominal pain but usually does not cause fever. Hypertension and a pattern of dominant inheritance help to differentiate porphyria from FMF in patients with abdominal pain and fever. In children, systemic-onset juvenile idiopathic arthritis (SOJIA) is a consideration; however, an evanescent eruption, quotidian fever pattern, lymphadenopathy, and polyarthritis and the absence of abdominal pain are suggestive of SoJIA. FMF needs to be distinguished from the other familial fever disorders.

COMPLICATIONS AND PROGNOSIS/ CLINICAL COURSE

The most common and severe complication of FMF is the development of AA amyloidosis.[22] Before the use of colchicine, renal failure secondary to amyloidosis was the most common cause of death in patients with FMF. Acquired amyloidosis in patients with inflammatory conditions, including FMF, is caused by deposition of a degradation product of SAA, which is an acute-phase reactant that is released during inflammation by the liver. Although AA amyloid is deposited in kidneys, the GI tract, lungs, testes, thyroid, and adrenal glands can also be affected, but the renal involvement usually dominates the clinical course.[97] Amyloidosis usually presents in patients with a long-standing history of febrile attacks, it rarely can be a first manifestation of FMF.[98–100]

All patients with FMF should be monitored for the development of amyloidosis by following the development of proteinuria in between the febrile attacks. Renal failure typically develops 3–5 years after the onset of proteinuria. SAA levels are a sensitive measure for predicting progression of renal dysfunction in patients with amyloidosis and the therapeutic goal should be normalizing SAA levels or decreasing them at least below 10 mg per liter[97] (see Chapter 133).

Risk factors for the development of amyloidosis were evaluated in a survey that collected data from 14 countries on genetically confirmed cases of FMF. The prevalence of renal amyloidosis in these patients was 11.4%. The country of recruitment—Armenia, Turkey, and Arab countries—conferred the highest risk of amyloidosis followed by homozygosity for *M694V*. The infant mortality rate, which can be used as a sensitive proxy indicator of population health and hygiene,[101] correlated with the risk for amyloidosis suggesting an environmental impact on the development of amyloidosis. These data were strengthened by the fact that one-third of the patients currently living in countries with the lower risk of renal amyloidosis (Israel and "other" including the US) were Arabs, Turks, or Armenians, who were from ethnic groups originating from high-risk countries.[102] Another factor associated with the risk of developing AA amyloidosis is an allelic variant in the *SAA1* gene encoding for SAA.[103,104] Deterioration of amyloid deposits was seen in patients with

a median of 28 mg per liter and regression of amyloid deposits was seen in 60% of patients with a median SAA concentration of less than 10 mg per liter.

TREATMENT AND PREVENTION

Antipyretics are typically administered during the acute febrile attacks to lower the fever and prevent the development of febrile seizures. Colchicine is first-line treatment and is very effective in the treatment of most patients in preventing amyloidosis.[105] Daily use of colchicine results in near complete remission in three-fourths of patients, with 95% noting a marked improvement. Recently, the similarity between symptomatic patients who present with two versus one mutation has been noted. Patients with only one mutation but typical disease require and respond to treatment with colchicine.[106] Daily oral colchicine doses of 1.2–1.8 mg are often required for clinical effect in most adults and children over 5 years[107] and younger children can be treated with lower doses. Commonly, colchicine causes diarrhea, but gradual uptitration of the dose helps to overcome this problem. Bloating and abdominal pain can also be caused by lactose intolerance that may develop in patients on colchicine. Elderly patients or those with renal impairment treated with colchicine may develop a myopathy or neuropathy.[108] In patients with persistent disease, IL-1- and TNF-blocking therapies are used to treat the disease.

HYPERIMMUNOGLOBULINEMIA D WITH PERIODIC FEVER SYNDROME AND MEVALONATE ACIDURIA

HYPERIMMUNOGLOBULINEMIA D WITH PERIODIC FEVER SYNDROME (HIDS) AND MEVALONIC ACIDURIA (MA) AT A GLANCE

- Rare autosomal recessive autoinflammatory disorders, mainly in patients with Dutch ancestry HIDS (milder, OMIM #260920) and MA (most severe, OMIM #610377).
- Mutations in *MVK* on chromosome 12q24, which encodes mevalonic kinase.
- Cutaneous features include erythematous macules and papules with attacks.
- Extracutaneous features include 1–3-day episodic attacks of fever, lymphadenopathy, and eruption abdominal pain.
- NSAIDs, anti-TNF and anti-IL-1 therapy.
- Information for patients and professionals at http://www.hids.net.

EPIDEMIOLOGY AND ETIOLOGY

Hyperimmunoglobulinemia D with periodic fever syndrome (HIDS) (OMIM #260920) and mevalonic aciduria (OMIM #610377) are autosomal recessive disorders caused by mutations in *MVK*, the gene which encodes mevalonate kinase an enzyme involved in the cholesterol and isoprenoid biosynthesis pathway.[5,109] The discovery that HIDS is caused by mutations in the mevalonate kinase gene led to the recognition that MA, a "classic" metabolic disorder that had previously been associated with autosomal-recessive mutations in *MVK*, are indeed similar disorders along a severity spectrum with HIDS on the milder and MA on the most severe side of the disease spectrum.[110,111] Most patients with HIDS are of Western European (particularly Dutch and French) ancestry, suggesting a founder gene effect in these populations.[109]

HIDS mutations are evenly distributed along the coding region of the *MVK* gene, in contrast to mutations causing MA, which cluster between amino acids 243 and 334.[112] Most patients carry two missense mutations and *V377I* which is the most common mutation in patients with HIDS, followed by mutations in *I268T*; these two mutations accounted for 65%–80% of the cases in two case series,[112,113] including a recent cohort of 103 genetically defined patients.[113] The male–female ratio was 1.5:1 and the prevalence of the disease is not known. In the recent case study, patients were contributed from 13 countries and three continents but the majority came from the Netherlands.[113] The carrier frequency for the common mutation *V377I* mutation is 0.6% in the Dutch population and the marked underrepresentation of homozygotes for this mutation suggests that homozygotes may have a milder clinical phenotype or no clinical phenotype.[114,115]

PATHOGENESIS

The activity of mevalonate kinase, the enzyme that catalyzes the first step in mevalonate metabolism, can be examined in the patient's fibroblasts, lymphocytes, and lymphoblasts. Residual enzyme function is associated with the severity of the clinical phenotype. In most patients with MA, the enzyme activity is below the level of detection, while patients with the HIDS phenotype still have residual mevalonate kinase enzyme activity between 1% and 8% of the activities measured in normal controls.[116] The metabolite mevalonic acid accumulates at higher levels in plasma, urine, and tissues in patients with the MA phenotype and no enzyme function and to low-to-moderately increased levels in patients with the HIDS presentation and residual enzyme activity. During febrile attacks, the MVK activity in peripheral blood mononuclear cells of HIDS patients drops two- to eightfold, which suggests that minor elevations in body temperature can trigger a chain of events, leading to a temporary deficiency of products which cannot be produced because of the enzyme block.[117] Mevalonate kinase is the rate-limiting step in the conversion from mevalonate to mevalonate

phosphate and end products of this pathway include cholesterol and a number of isoprenoids, molecules that participate in cellular processes related to cell growth and differentiation, cytoskeletal function, and vesicle trafficking.[118] In peripheral blood, mononuclear cells from patients with HIDS, but not from normal controls, and the shortage of isoprenoid end products, but not the excess of mevalonate, contribute to increased IL-1β production.[119] IL-1 secretion can be lowered by the addition of geranylgeranyl, suggesting that isoprenoids have an anti-inflammatory role and their lack of production during an attack further aggravates the disease.[120]

CLINICAL FINDINGS

The median disease onset ranges from the first week of life to 10 years. Episodes may occur once or twice per month and typically last 3–7 days. Prodromal symptoms such as malaise, headache, and chills are found in two-thirds of patients. A rapid rise in temperature, often over 40°C, typically follows. In 63% of cases, childhood vaccinations induce the first attack; other nonspecific triggers are physical and emotional stress. Painful lymphadenopathy accompanies the fever in 90% of patients. Axillary and inguinal lymphadenopathies are less frequent and splenomegaly occurs in one-third of patients. Gastrointestinal symptoms, including abdominal pain, vomiting, and/or diarrhea, are present in over 90% of patients, and the severity may prompt exploratory surgery, leading to the discovery of residual adhesions from past episodes of aseptic peritonitis.[113] Articular symptoms are seen in over 80% of patients, and predominantly affect the large joints and metacarpophalangeal and proximal interphalangeal joints of the hands.[113] Similar to HIDS, patients with MA present with febrile episodes and systemic inflammation, but other features include severe failure to thrive, lymphadenopathy, developmental delay, anemia, hepatosplenomegaly, central cataracts, and dysmorphic facies (microcephaly), cerebellar ataxia, as well as diarrhea and malabsorption.

CUTANEOUS LESIONS. Two-thirds of patients with HIDS have an eruption with the fevers. Erythematous macules, papules, and nodules ranging from 0.5 to 2.0 cm in diameter, which may be confluent or solitary in distribution, are frequently observed during attacks[121] (Fig. 134-3). Petechiae and purpura are also seen during attacks.[122] Oral aphthous ulcers with or without genital lesions occur in 48.5% of patients and may mimic Behçet's disease.[113] MA is much more severe then HIDS, but the cutaneous manifestations are similar.[122]

DERMATOPATHOLOGY

Biopsies of lesional skin reportedly show a perivascular neutrophilic and lymphocytic inflammatory infiltrate with slight leukocytoclasis and fibrinoid changes of vessel walls, consistent with leukocytoclastic vasculitis. Perivascular deposits of IgD and C3 in a granular staining pattern can be detected on direct immunofluorescence studies of skin biopsies from some of the patients.[123] Sweet syndrome-like or cellulitis-like findings and deep vasculitis have also been reported. Erythema elevatum diutinum have been reported in association with HIDS.[124,125]



Figure 134-3 HIDS. Erythematous macules and papules distributed over both palms, arms, legs, and trunk (not shown) during an attack of hyperimmunoglobulinemia D with periodic fever syndrome (HIDS). (From Takada K et al: Favorable preliminary experience with etanercept in two patients with the hyperimmunoglobulinemia D and periodic fever syndrome. *Arthritis Rheum* **48**:2645, 2003. Copyright © 2003 by the American College of Rheumatology. Reprinted with permission of Wiley-Liss, Inc., a subsidiary of John Wiley & Sons, Inc.)

LABORATORY TESTS AND SPECIAL TESTS

The diagnosis of HIDS is usually suspected clinically, but the definitive diagnosis is made by genetic testing. During the attacks, patients usually have elevated acute-phase reactants. Most patients have a persistently elevated serum IgD level (>100 U/mL), and in 82% of cases the serum IgA was likewise elevated[121] with median concentrations for IgD being 400 U/mL.[113] Between attacks some patients continue to have elevations of the acute-phase reactants. Although the elevation of IgD is not specific for HIDS and can be normal in genetically proven cases, it is often a helpful clue in considering the diagnosis.

DIFFERENTIAL DIAGNOSIS

The diagnosis of HIDS is often delayed by a median of 9.9 years after onset of symptoms. The differential diagnoses include other forms of hereditary fever syndromes including FMF. However, FMF does not present with lymphadenopathy or oral ulcers, and HIDS attacks do not respond to colchicine. In patients with prominent oral and genital ulcers, the disease can mimic Behçet's disease. Other erroneous diagnoses

include adult-onset Still's disease, juvenile idiopathic arthritis, rheumatic fever, and chronic infection.[113] MVK deficiency can mimic congenital infections, myelodysplastic syndromes, or chronic leukemia, and emphasizes the importance of considering a broad differential in patients with hematologic abnormalities.[126]

COMPLICATIONS AND PROGNOSIS/ CLINICAL COURSE

Long-term consequences of inadequately treated disease included amyloidosis in less than 3%, joint contractures, abdominal adhesions in ~10%. School children with HIDS miss more school days and adults have higher rates of discharges from their jobs and a higher rate of unemployment in comparison to the control population.[113]

TREATMENT AND PREVENTION

NSAIDs are administered for fever and arthralgia. Short courses of corticosteroids may be effective in some patients, but colchicine is ineffective. Based on the assumption that mevalonate accumulation is pathogenic, simvastatin, an HMG-CoA reductase inhibitor, was given to six patients, of whom five had a nonstatistically significant decrease in the number of febrile days.[127] In 80% of patients in whom anticytokine therapy with either anti-IL-1 or anti-TNF agents was offered, benefit was observed. One patient with severe MA was treated with an allogeneic bone marrow transplant and achieved complete inflammatory remission.[128]

PYOGENIC ARTHRITIS, PYODERMA GANGERENOSUM, AND ACNE SYNDROME

EPIDEMIOLOGY AND ETIOLOGY

Pyogenic arthritis, pyoderma gangrenosum and cystic acne (PAPA) syndrome (OMIM #604416) is a very rare autosomal dominant disorder characterized by pyogenic arthritis, pyoderma gangrenosum and cystic acne, and is caused by mutation in *CD2BP1*, a gene on chromosome 15q24.[129]

PATHOGENESIS

PAPA syndrome is caused by mutations in *CD2BP1* that encodes proline-serine-threonine-phosphatase-interacting protein 1 (PSTPIP1). PSTPIP1 undergoes phosphorylation by PTP-PEST, a protein tyrosine phosphatase. In its phosphorylated form, PSTPIP1 cannot bind to pyrin. Mutations in PSTPIP1 prevent its phosphorylation and lead to a prolonged binding to pyrin. It is hypothesized that mutations in the *CD2BP1* gene result in production of a hyperphosphorylated protein that binds excessively to pyrin, and that the PSTPIP1/pyrin complex prevents the inhibitory function of pyrin on the NLRP3 inflammasome, which would lead to increased IL-1β production and inflammation.[9,82,130,131]

PYOGENIC ARTHRITIS, PYODERMA GANGRENOSUM AND CYSTIC ACNE (PAPA) AT A GLANCE

- Very rare autosomal dominant autoinflammatory disorder PAPA (OMIM #604416).
- Mutations in *CD2BP1*, on chromosome 15q24, which encodes PSTPIP1.
- Pyoderma gangrenosum, cystic acne, pyogenic arthritis.
- Dermatopathology: biopsies of pyoderma gangrenosum show a predominantly neutrophilic inflammatory infiltrate in the dermis and superficial ulceration. Acne conglobata shows burrowing and interconnecting abscesses and scars.
- Corticosteroids, and anti-TNF and anti-IL-1 therapies.
- Information for patients and professionals at http://dermnetnz.org/systemic/papa.html.

CLINICAL FINDINGS

The clinical manifestations of this disorder include pyoderma gangrenosum, cystic acne, and pyogenic sterile arthritis.[9] Arthritis first begins in the first decade of life and may be triggered by episodes of mild trauma; the arthritis can be progressively destructive. Pyoderma gangrenosum lesions often occur at sites of injury. Nodulocystic acne can cause scarring if untreated. The recurrent sterile arthritis usually occurs after minor trauma, but may also occur spontaneously. PAPA attacks can be self-limiting or chronic, which can then lead to joint destruction and joint deformities.[129]

CUTANEOUS LESIONS. Dermatologic manifestations include pyoderma gangrenosum (Fig. 134-4A) and acne conglobata (nodulocystic acne of the face and trunk) (Fig. 134-4B). The acne begins in childhood or adolescence and persists into adulthood.[131] The pyoderma gangrenosum lesions start as violaceous nodules, usually on the legs, resulting in poorly healing ulcers with undermined rolled edges.



Figure 134-4 PAPA. **A.** Forearm of a patient with pyogenic arthritis with pyoderma gangrenosum and acne syndrome (PAPA) showing a large ulcerated lesion with granulation tissue and purulent exudate at the base and with erythematous, slightly elevated borders, typical of pyoderma gangrenosum. (From Shoham NG et al: Pyrin binds the PSTPIP1/CD2BP1 protein, defining familial Mediterranean fever and PAPA syndrome as disorders in the same pathway. *Proc Natl Acad Sci USA* **100**:3501, 2003, with permission. © 2003 by the National Academy of Sciences of the USA.) **B.** Severe cystic acnes with scarring in a patient with PAPA syndrome. (Used with permission from Daniel Kastner.)

DERMATOPATHOLOGY

Biopsies of lesional skin of pyoderma gangrenosum show a predominance of neutrophilic inflammatory infiltrate in the dermis and superficial ulceration. Biopsies of acne conglobata are characterized by burrowing and interconnecting abscesses and scars.

LABORATORY TESTS AND SPECIAL TESTS

Elevations of acute-phase reactants are seen during the acute attacks and can be persistently elevated in patients with more chronic lesions. The diagnosis is established by genetic testing. Cultures of the skin and joint lesions from these patients are sterile.

DIFFERENTIAL DIAGNOSIS

Pyoderma gangrenosum is primarily a clinical diagnosis, after excluding other causes of ulcers such as infection. The histologic differential for pyogenic granuloma may include infectious causes of abscesses and other diseases with neutrophils in the dermis such as Sweet syndrome.

TREATMENT AND PREVENTION

Treatment of pyoderma gangrenosum is challenging since it is not responsive to antibiotics and only responds partially to systemic glucocorticosteroids and immunosuppressive therapies. Treatment with infliximab[132,133] or anakinra[134] has been effective in treating the skin and joint findings in these patients.

TNF RECEPTOR-ASSOCIATED PERIODIC SYNDROME

TNF RECEPTOR-ASSOCIATED PERIODIC SYNDROME (TRAPS) AT A GLANCE

- Rare autosomal dominant autoinflammatory disorder, TRAPS or tumor necrosis factor receptor-associated periodic syndrome (OMIM #191190).
- Mutations in *TNFRSF1A*, on chromosome 12p13, encoding TNF receptor 1.
- Cutaneous features include centrifugal migratory, erythematous patches.
- Extracutaneous features include fever, myalgia, serositis, periorbital edema, conjunctivitis, and arthritis.
- Histopathology is relatively nonspecific.
- NSAIDs, corticosteroids, anti-TNF and anti-IL-1 therapies for treatment.

EPIDEMIOLOGY AND ETIOLOGY

TNF receptor-associated periodic syndrome (TRAPS) (OMIM #191190) is an autosomal dominantly inherited disease caused by mutations in *TNFRSF1A*, the gene located on chromosome 12p13 that encodes the 55-kDa TNF receptor 1.[4] The reported incidence is 5.6 per 10,000,000 person-years.[136] Male to female ratio is 1.5:1.[135]

PATHOGENESIS

More than 50 mutations in *TNFRS1A* have been described in patients with clinical disease. Most are missense mutations, leading to cysteine substitutions in the extracellular domain of the TNF receptor.[137–139] Mutations resulting in loss of a cysteine residue correlate with clinically more severe disease and a higher risk of amyloidosis.[141]

Most of the mutations are single nucleotide missense mutations occurring within exons 2, 3, and 4. The TNF type 1 receptor or p55 receptor is expressed on leukocytes and endothelial cells. The extracellular domain of the receptor is composed of four cysteine-rich domains (CRD), each containing six cysteine residues that form three intradomain disulfide bridges in each CRD.[140] Nearly all TRAPS mutations are found in the first two CDRs at the *N*-terminal region of the receptor. The interpretation of noncysteine substitutions in TNFRSF1A has been more difficult, as some substitutions such as the P46L variant occur in up to 20% of clinically asymptomatic individuals in a West African population, which suggests that this variant in this population represents a polymorphism rather than a disease-causing mutation. The presence of another TNFRSF1A variant, R92Q, did not correlate with the TRAPS phenotype, although it was associated with heterogeneous clinical inflammatory symptoms suggesting a reduced penetrance variant that may play a role in a wider clinical spectrum of inflammatory disorders.[142,143] Despite the known genetic defect, the mechanism of disease pathogenesis remains incompletely understood. In some patients, delayed TNF receptor cleavage from cells may account for an increased signaling through the TNF receptor; however, the majority of patients do not have receptor shedding defects,[143,144] which led to the search for other pathways. Interestingly, most mutations in the TNF receptor affect receptor folding and trafficking, resulting in the retention of misfolded TNF receptor complexes in the endoplasmic reticulum and the presence of only the wild-type receptor on the cell surface.[145,146] This phenomenon was examined in a mouse knockin model confirming that the mutant TNFR1 receptor can no longer oligomerize with wild-type receptor molecules but rather forms disulfide-linked homooligomers that can bind TNF with high affinity but not on the cell surface. Mutant receptors accumulate in the endoplasmic reticulum within the cells and LPS stimulation of these cells leads to enhanced activation of mitogen-activated protein kinases (MAPKs) and secretion of proinflammatory cytokines upon stimulation with the bacterial cell wall component, lipopolysaccharide (LPS).[147] The presence of an intact TNF receptor on the cell surface is necessary in this model to from an autocrine loop between mutated TNFR1 signaling in the endoplasmic reticulum and wild-type TNF receptor on the cell surface receiving a TNF signal.[147] These findings provide a rationale as to why the disease is inherited in an autosomal dominant manner and also offer an explanation regarding the partial response to TNF blockade.[148] In one report, NF-κB activation may in fact be decreased in response to TNF stimulation of leucocytes from patients with TRAPS.[151] This was not seen in response to LPS or IFN-γ suggesting that there may be an alternative stimulus other than TNF that is responsible for the previously observed activation of NF-κB.

Cytokines other than TNF have also been implicated in the disease. Patients with TRAPS have increased NF-κB activation, the major signaling molecule involved in the secretion of proinflammatory cytokines; they also have higher than expected levels of functional TNFR1 at the cell surface.[149] Interestingly, some TRAPS patients have an exaggerated inflammatory response to treatment with infliximab.[150]

CLINICAL FINDINGS

The median age of onset is 3 years with initial presentation ranging from 2 weeks to 53 years of age.[135] TRAPS attacks present with fever, disabling myalgia, skin eruption, serositis (pleuritic and abdominal pain), arthritis, and eye involvement. Attacks last on average 21 days per month and occur every 5–6 weeks; however, there is considerable variability in the length and the time between attacks. An early sign of an impending attack often is a "deep" muscle cramping that increases in severity over 1–3 days and then remains severe for more than 3 days before the symptoms gradually resolve. A minority of patients present with daily symptoms that vary in severity. Although the actual trigger for an attack is often unknown, physical and emotional trauma and menstruation can be associated with attacks. Pregnancy may be associated with amelioration. Fevers of between 38°C and 41°C for more than 3 days usually precede other inflammatory symptoms. Fever is invariably seen in pediatric patients but may be absent during some attacks in adults.

The involved areas often move centrally and the tissues over the involved muscles are warm, tender to palpation, and erythematous. Other findings include arthralgia and frank synovitis. The arthritis is nonerosive, asymmetric, and monoarticular, and affects primarily large joints including the hips, knees, or ankles. Tenosynovitis of flexor and extensors also occurs and is not confined to febrile episodes.

Abdominal pain is present in more than 90% of patients. Often, fever and abdominal pain are the only manifestations of a clinical attack of TRAPS. Patients can present with vomiting and constipation, suggestive of bowel obstruction, and the abdominal findings can present as an acute abdomen leading to laparotomy and appendectomy without histologic evidence of inflammation. The presence of intra-abdominal adhesion on laparotomy and a mononuclear infiltrate on tissue biopsies from resected bowel suggest peritonitis and some mucosal inflammation.

More than 80% of patients present with conjunctivitis and/or periorbital edema. Lymphadenopathy, if observed, is usually limited to a single anatomical location. Severe uveitis and iritis may be seen. Chest

pain may be either musculoskeletal or pleuritic and was present in 57% in one large cohort.[135]

CUTANEOUS LESIONS. Over 80% of patients present with skin eruptions during the attacks. Patients often present with periorbital edema (Fig. 134-5A). The most characteristic cutaneous manifestation is a centrifugal migratory, erythematous patch (Figs. 134-5B and 134-5C), which typically migrates from the periphery to the center of the body. The tissue

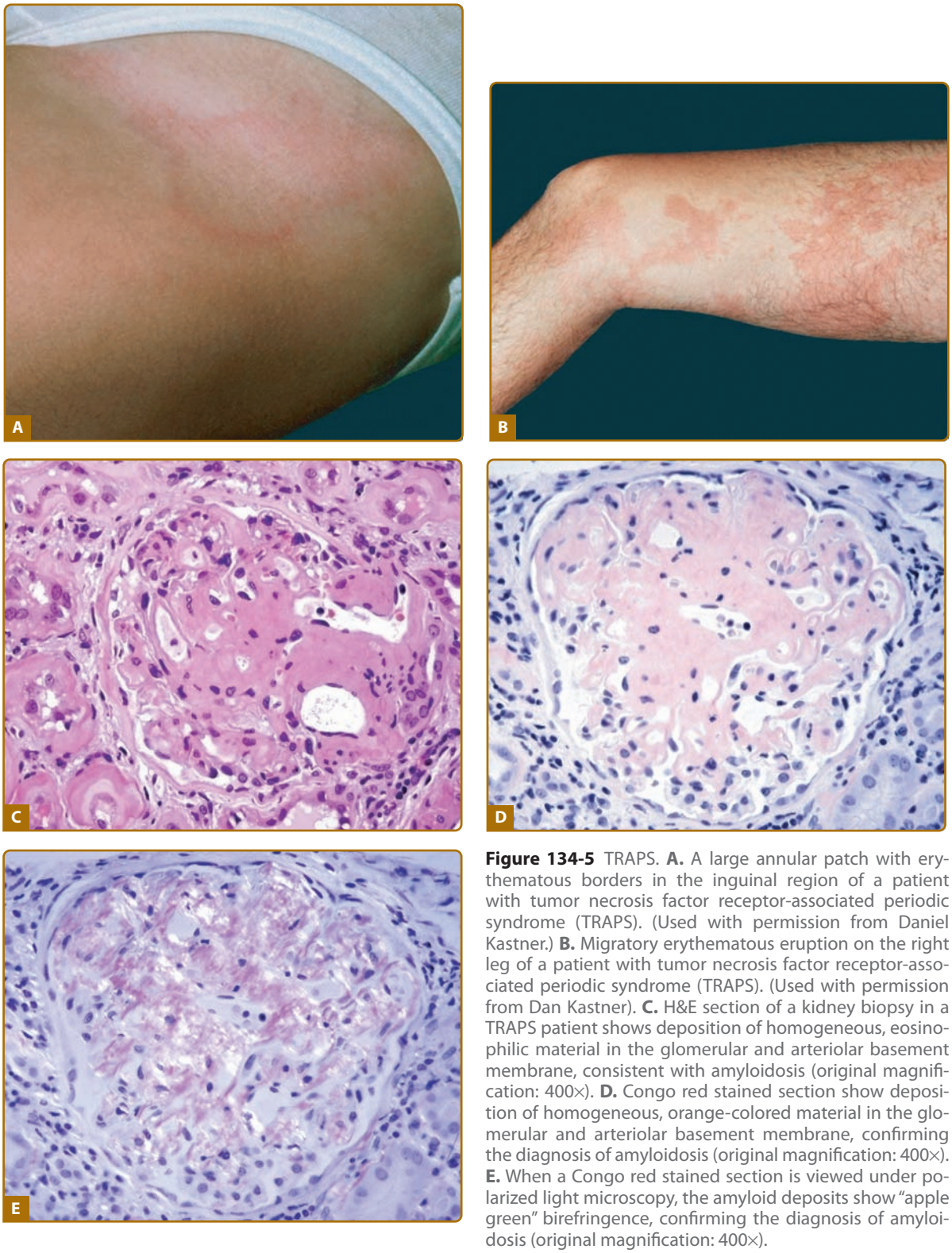

Figure 134-5 TRAPS. **A.** A large annular patch with erythematous borders in the inguinal region of a patient with tumor necrosis factor receptor-associated periodic syndrome (TRAPS). (Used with permission from Daniel Kastner.) **B.** Migratory erythematous eruption on the right leg of a patient with tumor necrosis factor receptor-associated periodic syndrome (TRAPS). (Used with permission from Dan Kastner). **C.** H&E section of a kidney biopsy in a TRAPS patient shows deposition of homogeneous, eosinophilic material in the glomerular and arteriolar basement membrane, consistent with amyloidosis (original magnification: 400×). **D.** Congo red stained section show deposition of homogeneous, orange-colored material in the glomerular and arteriolar basement membrane, confirming the diagnosis of amyloidosis (original magnification: 400×). **E.** When a Congo red stained section is viewed under polarized light microscopy, the amyloid deposits show "apple green" birefringence, confirming the diagnosis of amyloidosis (original magnification: 400×).

overlying the local area of myalgia is often tender to palpation, warm and erythematous and blanchable.[152] Some patients present with diffuse erythema of cheeks and confluent salmon-pink-colored macules and papules or mottled erythema of the chest, abdomen, and extremities.[153]

DERMATOPATHOLOGY/ HISTOPATHOLOGY

Microscopic evaluation of lesional skin shows a mild perivascular lymphocytic inflammatory infiltrate in the dermis and edema of the upper dermis, and may reveal slight C3 and C4 deposition around the small vessels in the dermis.[153] A fascia/muscle biopsy shows normal myofibril architecture without evidence of inflammation, but extensive acute and chronic inflammation of the surrounding connective tissue, including panniculitis, fasciitis, and perivascular chronic inflammation.[154]

LABORATORY TESTS AND SPECIAL TESTS

Elevations of acute-phase reactants are seen during the acute attack, including elevation of erythrocyte sedimentation rate, C-reactive protein, haptoglobin, fibrinogen, and ferritin. A large percentage of patients also demonstrate an elevated acute-phase response between clinically symptomatic attacks. Anemia of chronic disease is seen in patients with long-standing elevation of acute-phase reactants and most patients demonstrate a polyclonal gammopathy. MRI of affected muscle groups reveals focal areas of edema in discrete muscular compartments and intramuscular septa myalgia.[154] As seen with the other diseases, autoantibodies, including antinuclear antibodies and rheumatoid factor, are typically negative.

DIFFERENTIAL DIAGNOSIS

TRAPS can mimic other autoinflammatory disorders and the diagnosis needs to be made by genetic testing. TRAPS can also mimic SoJIA or AOSD, but the characteristic migratory, erythematous eruption with underlying myalgia and periorbital edema seen in TRAPS are not seen in SoJIA or AOSD. The quotidian fever pattern observed in SoJIA/AOSD has also not been seen in TRAPS.

COMPLICATIONS AND PROGNOSIS/ CLINICAL COURSE

Similar to descriptions in the FMF section, systemic AA amyloidosis and the development of renal failure is the most severe complication of TRAPS (Figs. 134-5D–134-5F). As in FMF, all patients, particularly those with cysteine mutations, need to be closely monitored for the development of proteinuria. The majority of patients with kidney involvement develop nephritic syndrome and ultimately renal failure.

Amyloidosis is common among families with the *C30R*, *C52F*, and *C88R* mutations and is uncommon in patients from families with the *C33Y*, *T50M*, and *C88R* mutations.[135,143]

TREATMENT AND PREVENTION

Nonsteroidal anti-inflammatory drugs may be sufficient to treat mild attacks. Corticosteroids suppress the attacks, but the steroid requirement may increase over time and is associated with considerable side effects. Colchicine is not effective in treating TRAPS symptoms nor in the prevention of amyloidosis. Etanercept, the p75 TNF receptor fusion protein, suggests a favorable clinical response.[135,155–158] In patients at risk of amyloidosis, tailoring the dose of anticytokine therapy to lower SAA levels in an attempt to prevent the development of amyloidosis is indicated. Anakinra has been reported to be successfully used in some therapy-resistant cases and is often considered before using anti-TNF agents.[159,160]

PEDIATRIC GRANULOMATOUS ARTHRITIS

PEDIATRIC GRANULOMATOUS ARTHRITIS (PGA) AT A GLANCE

- Very rare autosomal dominant autoinflammatory disorders, PGA includes the familial disorder Blau syndrome (OMIM #186580) and the sporadic form caused by de novo mutations early onset sarcoidosis (OMIM #360464).
- Mutations in *NOD2*, on chromosome 16q12, encoding a protein belonging to the family of NACHT-leucine-rich repeat (LRR) receptors.
- Cutaneous features: early-onset cutaneous "sarcoidosis" with generalized skin eruption.
- Extracutaneous features include arthritis and recurrent uveitis.
- Dermatopathology is characterized by nonnecrotizing well-demarcated dermal granulomas.
- Treatment includes methotrexate, NSAIDs, and anti-TNF and anti-IL-1 therapies.

MAJEED SYNDROME

MAJEED SYNDROME AT A GLANCE

- Very rare autosomal recessive autoinflammatory disorders, Majeed syndrome (OMIM #609628).
- Mutations in *LPIN2*, on chromosome 18p, encoding the protein lipin-2.
- Cutaneous features include a neutrophilic dermatosis seen in Sweet syndrome.
- Extracutaneous features include early-onset chronic recurrent multifocal osteomyelitis (CRMO) and congenital dyserythropoietic anemia (CDA).
- Dermatopathology: neutrophilic infiltrate in the dermis and no histologic evidence of vasculitis.
- NSAIDs or corticosteroids for the treatment of CRMO; red blood cell transfusion for the treatment of CDA if clinically indicated.

EARLY-ONSET INFLAMMATORY BOWEL DISEASE (IBD)

EARLY-ONSET INFLAMMATORY BOWEL DISEASE (IBD) AT A GLANCE

- Very rare autosomal recessive disorder, early onset IBD (OMIM #613148).
- Mutations in *IL10RA*, on chromosome 11q23 or on IL10RB, on chromosome 21q22, encoding the IL-10 receptor
- Cutaneous features can include early onset folliculitis, enterocutaneous fistulae, perianal abscess and anocutaneous fistulas.
- Extracutaneous features are dominated by the early onset, before the age of 1 year of early onset enterocolitis.
- Corticosteroids, NSAIDs, azathioprine, anti-TNF agents, and in severe cases bone marrow transplantation.

KEY REFERENCES

Full reference list available at www.DIGM8.com

DVD contains references and additional content

13. Goldbach-Mansky R: Blocking interleukin-1 in rheumatic diseases. *Ann N Y Acad Sci* **1182**:111-123, 2009
14. Aksentijevich I et al: An autoinflammatory disease with deficiency of the interleukin-1-receptor antagonist. *N Engl J Med* **360**(23):2426-2437, 2009
17. Ferguson PJ, El-Shanti HI: Autoinflammatory bone disorders. *Curr Opin Rheumatol* **19**(5):492-498, 2007
21. Schroder K, Tschopp J: The inflammasomes. *Cell* **140**(6): 821-832, 2010
22. Masters SL et al: Horror autoinflammaticus: The molecular pathophysiology of autoinflammatory disease (*). *Annu Rev Immunol* **27**:621-668, 2009
35. Goldbach-Mansky R et al: Neonatal-onset multisystem inflammatory disease responsive to interleukin-1beta inhibition. *N Engl J Med* **355**(6):581-592, 2006

Chapter 135 :: Xanthomatoses and Lipoprotein Disorders

:: Ernst J. Schaefer & Raul D. Santos

XANTHOMATOSES AND LIPOPROTEIN DISORDERS AT A GLANCE

- Several lipoprotein disorders manifest as xanthomas, which contain cholesterol and triglycerides in macrophages.
- Tendinous xanthomas with thickening of the Achilles tendons and disposition in tendons on the hands, elbows, and knees are observed in familial hypercholesterolemia (FH), phytosterolemia, or cerebrotendinous xanthomatosis (CTX).
- Familial Hypercholesterolemia is diagnosed by finding a markedly elevated low-density lipoprotein (LDL) cholesterol level (usually >300 mg/dL), which can be treated with statins, ezetimibe, anion exchange resins and, if necessary, LDL apheresis.
- Xanthelasma on the eyelids are common and can be associated with elevated LDL cholesterol, but more often are seen in patients with normal lipids and treated cosmetically.
- Phytosterolemia, associated with moderately elevated LDL cholesterol levels and markedly elevated plasma β-sitosterol and campesterol, is best treated with ezetimibe.
- Cerebrotendinous xanthomatosis is due to markedly elevated plasma levels of cholestanol and therapy consists of oral chenodeoxycholate to prevent progression of xanthomas and neurologic disease.
- Tubo-eruptive, planar, and palmar xanthomas can be observed with combined hyperlipidemia as well as occasionally with marked high-density lipoprotein deficiency, and can be treated with dietary modification, statins, fibrates, and niacin.
- Eruptive xanthomas are usually due to severe hypertriglyceridemia (fasting level >1,000 mg/dL, with chylomicrons present), and are often transient.
- Patients with severe hypertriglyceridemia are at increased risk of pancreatitis and need to restrict dietary fat and sugars, control diabetes if present, and use fibrates and fish oil.
- Xanthomas are occasionally observed in patients with monoclonal gammopathies or multiple myeloma.

XANTHOMAS

Xanthomas are plaques or nodules consisting of abnormal lipid deposition and foam cells in skin or in tendons. They do not represent a disease but rather are signs of a variety of lipoprotein disorders. Xanthomas are occasionally seen without an underlying metabolic effect. Xanthomas are thought to develop through several mechanisms. Through scavenger receptors for enhanced low-density lipoprotein (LDL) uptake, macrophages (converted from monocytes) incorporate lipid that has been transported through the capillary walls, thus becoming foam cells. Foam cells can also develop as a result of in situ lipid synthesis by the macrophage. Further, lipid that has been extravasated by the capillaries can also recruit additional foam cells into an already established xanthoma. Extravasated and oxidized LDL recruits foam cells by inducing vascular cellular adhesion molecule and E-selectin.[1,2] Local factors such as heat, movement, and friction may increase LDL capillary leakage, and, hence, result in the development of xanthomata.[3] These local factors help explain the location of tuberous xanthomas, tendinous xanthomas, and xanthelasmata.

CLINICAL FINDINGS

CUTANEOUS LESIONS. Clinically, xanthomas can be classified as eruptive, tubo-eruptive or tuberous, tendinous, or planar.[4] Planar xanthomas include xanthelasma palpebrarum/xanthelasma, xanthoma striatum palmare, and intertriginous xanthomas. There are characteristic clinical phenotypes associated with specific metabolic defects (Tables 135-1 and 135-2 showing older Frederickson classification).

Eruptive xanthomata are multiple, reddish-yellow papules that appear suddenly and are arranged in crops on the extensor surface of the extremities and the buttocks (Figs. 135-1 and 135-2). Tuberous xanthomata are nodules that are frequently localized to the extensor surfaces of the elbows, knees, knuckles, and buttocks (Fig. 135-3). Tendinous xanthomata are

TABLE 135-1
Clinical Presentations of Xanthomas

Type of Xanthoma	Genetic Disorders	Secondary Disorders
Eruptive	Familial lipoprotein lipase deficiency ApoC-II deficiency ApoA-I and apoA-I/C-III deficiency Familial hypertriglyceridemia Familial hypertriglyceridemia with chylomicronemia	Obesity Cholestasis Diabetes Medications: retinoids, estrogen therapy, protease inhibitors
Tuberous	Familial hypercholesterolemia Familial dysbetalipoproteinemia Phytosterolemia	Monoclonal gammopathies Multiple myeloma Leukemia
Tendinous	Familial hypercholesterolemia Familial defective apoB Familial dysbetalipoproteinemia Phytosterolemia Cerebrotendinous xanthomatosis	
Planar		
Palmar	Familial dysbetalipoproteinemia Homozygous apoA-I deficiency	
Intertriginous	Familial homozygous hypercholesterolemia	Cholestasis
Diffuse	Familial hypercholesterolemia	Monoclonal gammopathies, cholestasis
Xanthelasma	Familial dysbetalipoproteinemia	Monoclonal gammopathies
Other		
Corneal arcus	Familial hypercholesterolemia	
Tonsillar	Tangier disease	

apo = apolipoprotein.

TABLE 135-2
Frederickson Classification of Familial Hyperlipidemias (Only Occasionally Used)

Frederickson Classification	Condition	Defect	Lipoprotein Increase	Type of Xanthoma
Type I	Familial chylomicronemia	Decreased lipoprotein lipase or altered apoC-II	Chylomicrons (and VLDL)	Eruptive xanthomata
Type IIa	Familial hypercholesterolemia Heterozygous Homozygous	LDL receptor or apoB deficiency	LDL	Tendon, tuberous, plane xanthomas (xanthelasma and intertriginous) 15% with xanthoma by second decade Xanthomata by age 6 years
Type IIb[a]	Familial combined hypercholesterolemia	Decreased LDL receptor and increased apoB	LDL and VLDL	Usually absent, but can have xanthomas as in type IIa
Type III	Familial dysbetalipoproteinemia	Defective apoE-2 synthesis	IDL	Palmar, tuberous, tubo-eruptive xanthoma, xanthelasma
Type IV[b]	Familial hypertriglyceridemia (pure)	Increased VLDL production and decreased elimination	VLDL	Rare eruptive xanthomas
Type V	Mixed hyperlipidemia	Increased VLDL production and decreased LPL	VLDL and chylomicrons	Eruptive xanthomas

Most familial hyperlipidemias associated with xanthomas are rare.
[a]~10% of population.
[b]~16% of population.



Figure 135-1 Eruptive skin xanthomata characteristic of severe chylomicronemia.



Figure 135-2 Eruptive skin xanthomata in an African-American woman characteristic of severe chylomicronemia.

firm subcutaneous nodules found in fascia, ligaments, Achilles tendons, or extensor tendons of the hands, knees, and elbows (Fig. 135-4). Planar xanthomata are yellow macules, soft papules, or plaques found commonly on the upper eyelids (xanthelasma palpebrarum), the wrists and palms (xanthoma striatum palmare) (Fig. 135-5), and in intertriginous areas. Xanthelasmas (eFig. 135-5.1 in online edition) can be found in patients with elevated LDL cholesterol levels, but most often occur in patients with relatively normal lipid levels and the occurrence of these lesions on the eyelids usually not associated with coronary heart disease (CHD). If xanthelasmas cause cosmetic concern, treatment options include surgical excision,[42] ablative laser therapy, trichloroacetic acid, or cryotherapy.[40]

HISTOPATHOLOGY. Foam cells are macrophages that contain lipid. These cells characterize xanthomata.



Figure 135-3 Tubo-eruptive and tuberous xanthomata typical of familial dysbetalipoproteinemia. **A.** Knee. **B.** Palm.



Figure 135-4 Tendon xanthomata typical of heterozygous familial hypercholesterolemia. Similar xanthomata occur in patients with familial defective apolipoprotein B-100, cerebrotendinous xanthomatosis, and sitosterolemia.

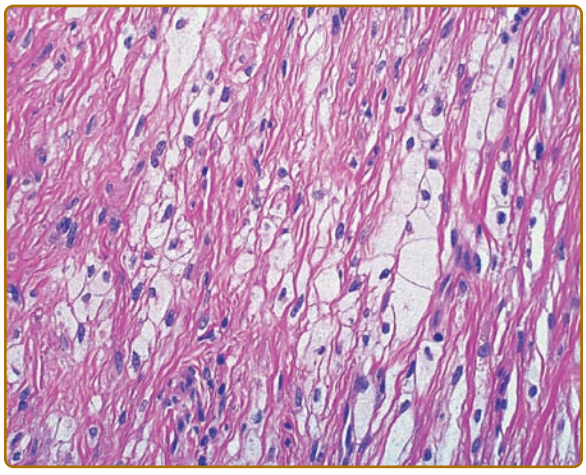

Figure 135-6 Histopathologic evaluation of skin from a tuberous xanthoma reveals foam cells.

Along with foam cells, eruptive xanthomata often consist of lymphoid cells, histiocytes, neutrophils, and, frequently, free lipid in the dermis. Tuberous xanthomata reveal foam cells and cholesterol clefts (Fig. 135-6). Cholesterol is doubly refractile whereas other types of lipid are not. Tendon xanthomata are histopathologically similar to tuberous xanthomata; however, xanthelasmata



Figure 135-5 Signs of dysbetalipoproteinemia due to apolipoprotein E deficiency. Tubo-eruptive xanthomas are seen on the ears (**A**), elbows (**C**), and hands (**D**), while palmar xanthomas in the creases of the hands are also observed (**B**).

BOX 135-1 DIFFERENTIAL DIAGNOSIS OF XANTHOMAS

- Eruptive xanthomas
  - Sarcoid
  - Interstitial granuloma annulare
  - Xanthoma disseminatum
  - Juvenile xanthogranulomas
- Tuberous or tendinous xanthomas
  - Cyst
  - Lipoma
  - Neurofibroma
- Plane xanthomas
  - Pseudoxanthoma elasticum
  - Amyloidosis
  - Sarcoidosis
- Xanthelasma
  - Syringoma
  - Sebaceous hyperplasia
  - Adnexal neoplasms

can be differentiated by their superficial location. Along with the foam cells, xanthelasmata may reveal striated muscle, vellus hair, and/or a thinned epidermis, indicative of the superficial location.[5]

DIFFERENTIAL DIAGNOSIS

See Box 135-1.

TREATMENT

The treatment for xanthomas depends on the underlying etiology (see below).

LIPID AND LIPOPROTEIN METABOLISM

See Fig. 135-7.

CHOLESTEROL

Cholesterol is a waxy substance of molecular weight 387 Da, and is by far the most abundant sterol in plasma. Cholesterol is synthesized in cells in the body, and this source accounts for about 75% of the cholesterol in the bloodstream. Cholesterol serves as a precursor for the bile acids—cholic acid and chenodeoxycholic acid, and steroid hormones including estrogen, testosterone, and cortisol. Cholesterol is also an important constituent of cell membranes. Precursors of cholesterol include lathosterol and desmosterol, which can be measured in plasma or serum and high values indicate increased cholesterol production. Subjects who overproduce cholesterol have elevated absolute levels of these constituents as well as increased values normalized to blood cholesterol levels. Cholesterol production is increased in patients with obesity and metabolic syndrome. There are also patients who have defects in producing the bile acid chenodeoxycholate from cholesterol, leading to cerebrotendinous xanthomatosis.

There are many steps in the cholesterol synthesis pathway from acetate to cholesterol. The rate-limiting enzyme in cholesterol synthesis is 3-hydroxy-3-methylglutaryl CoA reductase or HMG-CoA reductase. Statins competitively inhibit this enzyme, thereby lowering cholesterol production in the body, and decreasing cellular cholesterol synthesis by up to 80%. The cells in the body respond by increasing the level and activity of LDL receptors on their surface, enhancing the clearance of LDL particles from the bloodstream, and lowering LDL cholesterol levels in plasma.[3] However, in intestinal cells statins can also increase the amount of cholesterol absorption. Statins are especially effective in subjects who have elevated markers of cholesterol production, and are least effective in patients with elevated plasma markers of absorption.[31]

Cholesterol is also absorbed in the intestine. About 25% of the cholesterol found in the bloodstream is from dietary sources. The cholesterol found in the intestine is derived from the diet and also made by the liver, secreted into the bile, and reabsorbed. Major dietary sources include eggs, butter, whole milk, and animal fats as found in meat.[3] The equivalent substances to cholesterol in plant cells are known as plant sterols (β-sitosterol and campesterol). Almost all of dietary cholesterol and plant sterols are transported into the intestine via the Niemann-Pick C-like protein 1 (NPC1L1) transporter.[32–35] This process is blocked about 50% by ezetimibe, a specific inhibitor of NPC1L1.[34] Cholesterol in the intestinal cell is either placed onto chylomicrons or high-density lipoproteins (HDL) for entry into the bloodstream, stored in the intestine as either free cholesterol or cholesteryl ester (cholesterol with a fatty acid attached), or transported back out into the intestinal lumen via the action of the two transporters—ATP-binding cassette transporters G5 and G8 (ABCG5 and ABCG8). About 50% of the intestinal cholesterol and more than 95% of the intestinal β-sitosterol and campesterol are transported back out into the intestinal lumen via these ABC transporters. Patients who have defects in ABCG5 and ABCG8 have elevated plasma levels of β-sitosterol as in phytosterolemia, and often develop tendinous xanthomas.[5]

PLASMA LIPOPROTEINS

Cholesterol and triglyceride along with phospholipids are carried in plasma or serum on lipoproteins. Lipoproteins have a surface layer of phospholipids (each phospholipid has two fatty acids attached to it) with the fatty acids directed toward the core of the particle, as well as proteins known as apolipoproteins, and free cholesterol. The hydrophobic components of

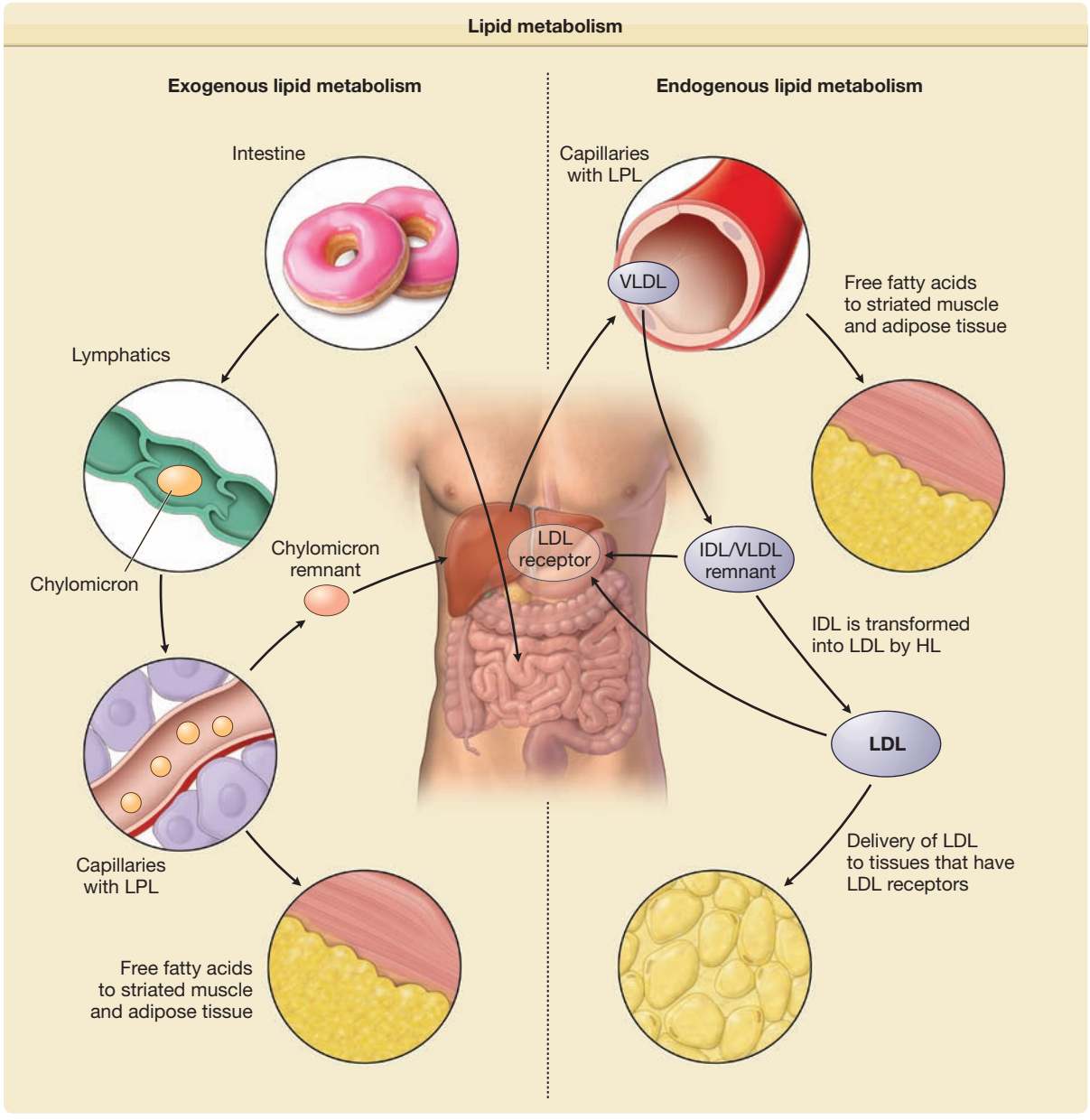

Figure 135-7 Lipid metabolism. The exogenous pathway of lipid metabolism involves eating foods that contain fat and delivering the fatty acids to tissues. The triglycerides in the intestines are packaged into chylomicrons in the intestinal enterocytes. Capillary lipoprotein lipase (LPL), which requires apolipoprotein IIC (apoC) as a cofactor, hydrolyzes the triglycerides and releases fatty acids to the peripheral tissues. The remaining chylomicron particle is called a *chylomicron remnant* and is recycled by the liver in a process that requires apoE as a ligand for the LDL receptors in the liver. The endogenous pathway of lipid metabolism involves the hepatic production of very low-density lipoprotein (VLDL) and the delivery of free fatty acids to peripheral tissues. VLDL particles have apoB-100 apoB-100 instead of apoB-48 on the chylomicron. LPL, which requires apoC as a cofactor, hydrolyzes the triglycerides and releases fatty acids to the peripheral tissues. This remnant is called an *intermediate-density lipoprotein* (IDL). The LDL receptor of the liver removes these remnants by binding to apoE on the remnant. IDL can also be transformed into LDL by hepatic lipase (HL) in the liver. The new particles of LDL can bind to the LDL receptor through apoB-100.

lipoproteins, namely, cholesteryl ester and triglyceride, are carried within the core of generally spherical lipoprotein particles. Plasma lipoproteins exist in a variety of sizes and densities, ranging from very large triglyceride-rich lipoproteins of density <0.94 g/mL made in the intestine (chylomicrons) to small HDL of density up to 1.21 g/mL.

A model of a spherical lipoprotein particle with proteins (*yellow*), phospholipids with two fatty acids attached (*blue*), and free cholesterol (*green*) on the particle surface, and triglyceride with three fatty acids attached (*purple*) and cholesteryl ester with one fatty acid attached (*green*) in the core of the particle is shown in eFig. 135-7.1 in online edition.

CHYLOMICRONS

Lipoproteins known as chylomicrons are made in the intestine and vary greatly in molecular weight (50–1,000 × 10^6 Da) and size (diameter 75–1,200 nm), have a plasma density of <0.93 g/mL, and migrate at the origin on lipoprotein electrophoresis. These particles are very rich in triglyceride (about 85% by weight in the core of the particle) and contain about 3% cholesteryl ester. These particles can also carry significant amounts of fat-soluble vitamins in their core, namely, vitamin A as retinyl palmitate, carotenoids, vitamin D, vitamin E as α- or γ-tocopherol, and vitamin K. On their surface these particles contain about 2% protein, 2% free cholesterol, and 7% phospholipids. The major protein of these particles is known as apolipoprotein (apo) B-48. After chylomicrons are released into the lymph, they pick up apoA-I, apoA-IV and the C apolipoproteins (C-I, C-II, and C-III) on their large surface. The average daily production of apoB-48 in humans is about 2 mg/kg/day.[3]

Once chylomicrons enter the bloodstream, much of the triglyceride is rapidly removed via the action of lipoprotein lipase (LPL). LPL cleaves the free fatty acids off the glycerol backbone of triglycerides. The apoC-II acts as a cofactor for LPL in this reaction and apoA-V promotes LPL-mediated triglyceride lipolysis. The free fatty acids are taken up by adjacent myocytes and adipocytes. Some free fatty acids bind to albumin and are taken up by fat tissue or transported to a variety of other tissues in the body, including the liver. In the fat the free fatty acids are converted back into triglyceride for long-term energy storage. ApoC-III inhibits this process of lipolysis. When much of the chylomicron triglyceride has been removed, the particles pick up cholesteryl ester from HDL in exchange for triglyceride via the action of cholesteryl ester transfer protein (CETP). They then are much smaller particles and are called chylomicron remnants. In this process of being metabolized to remnants, chylomicrons have lost virtually all of their surface apoA-I, apoA-IV, apoA-V, and C apolipoproteins to HDL, but have retained all of their apoB-48, and have picked apoE from HDL. While the plasma residence time of chylomicron triglyceride is about 5–10 minutes that of chylomicron apoB-48 is about 5 hours.[3] Chylomicron remnants are taken up by the liver, a process that is mediated by the binding of apoE to the LDL receptor.[3]

VERY LOW-DENSITY LIPOPROTEINS

Very low-density lipoproteins (VLDLs) are made in the liver. They vary in molecular weight (10–80 × 10^6 Da) and in size (diameter 30–80 nm), have a plasma density of 0.93–1.006 g/mL, and migrate in the prebeta region on lipoprotein electrophoresis. These particles are rich in triglyceride (about 60% by weight in the core of the particle) and contain about 10% cholesteryl ester. On their surface these particles contain about 8% protein, 7% free cholesterol, and 15% phospholipids. Although they resemble chylomicrons, the major protein of these particles is apoB-100, compared to apoB-48 in chylomicrons. Other surface proteins include apoC-I, apoC-II, and apoC-III. In the fed state, the average daily production of VLDL apoB-100 in humans is about 20 mg/kg/day.[3] When VLDLs enter the bloodstream, the particles pick up apoE and other apolipoproteins from HDL. Most of the triglycerides in VLDLs are rapidly removed via the action of LPL, similar to intestinal chylomicron particles. In the fat, the free fatty acids are converted back into triglyceride for long-term energy storage. As with chylomicrons, apoC-III inhibits this process of lipolysis. Once VLDL dissociates from LPL, they become intermediate-density lipoproteins (IDLs), which have approximately the same amount of cholesterol and triglyceride. The liver takes up IDL by binding apoE to the LDL receptor and subsequent endocytosis of the IDL. The rest is converted to LDL by hepatic lipase (HL). This conversion process takes about 4–5 hours.[3]

LOW-DENSITY LIPOPROTEINS

Low-density lipoproteins (LDLs) are the end product of VLDL catabolism and are mainly produced from the conversion of VLDL to IDL and then to LDL. They are the major cholesterol-transporting lipoproteins in the plasma. LDL have a molecular weight of about 2 × 10^6 Da, a diameter of 18–25 nm, a plasma density of 1.019–1.063 g/mL, and migrate in the beta region on lipoprotein electrophoresis. These particles are rich in cholesteryl ester (about 40% by weight in the core of the particle) and contain about 5% triglyceride. On their surface, these particles contain about 25% protein, 10% free cholesterol, and 20% phospholipids. The predominant protein of LDL is apoB-100. Occasionally, LDL can contain trace amounts of other surface proteins, namely, apoC-I, apoC-II, apoC-III, and apoE. In the fed state, the average daily conversion of VLDL apoB-100 to LDL apoB-100 in humans takes about 4–5 hours, and is about 12 mg/kg/day. In normal plasma, LDL contains about 60%–70% of the total cholesterol and about 80%–90% of the total apoB. LDL apoB-100 has a plasma residence of about 3.5 days, and is taken by various tissues through the action of the LDL receptor. LDL has been divided into large LDL (density 1.019–1.044 g/mL) and small dense LDL (density 1.044–1.063 g/mL). Small dense LDL is reported to be more atherogenic than large LDL, and its apoB-100 has also has a significantly longer residence time than that of apoB-100 in large LDL.[3]

Another lipoprotein particle similar to LDL is lipoprotein (a) or Lp(a). This particle is often a small dense LDL particle, with a protein known as apo(a) attached to apoB-100. The apo(a) protein has multiple and variable copies of kringle 4-like domains and one copy of a kringle 5-like domain. These kringles have a high degree of homology with the kringle domains of plasminogen, important for clot lysis. High levels of Lp(a) (>30 mg/dL) are associated with an increased risk of CHD.[36,37] Lp(a) is atherogenic because it not only is directly deposited in the artery wall, but also because it may prevent clot lysis by plasminogen. Moreover,

Lp(a) serves as an acceptor of oxidized phospholipid from LDL.

HIGH-DENSITY LIPOPROTEINS

High-density lipoproteins (HDLs) (density 1.063–1.21 g/mL) contain about 50% protein, 30% phospholipid, 20% triglyceride, and 5% triglyceride by weight. HDLs show alpha mobility on lipoprotein electrophoresis and have a diameter of about 5.5–12 nm. The major proteins of HDL are apoA-I and apoA-II, and HDL apoA-I has a residence time of about 4.5. HDL participate in reverse cholesterol transport, in which HDL pick up cholesterol from cells from peripheral tissues, and then deliver them to the liver for excretion or transfer it to triglyceride-rich lipoproteins in exchange for triglyceride. In HDL, the enzyme lecithin–cholesterol acyltransferase (LCAT) catalyzes the formation of the cholesterol ester, which are later transferred to lipoproteins via CETP. Decreased HDL cholesterol <40 mg/dL is a significant CHD risk factor.[1]

Xanthomas are caused by excess deposition of lipid in skin or in tendons, with resultant monocyte migration and uptake of lipid by scavenger receptor on the surface of macrophages (converted from monocytes). Clinically, patients who develop accumulations of chylomicrons and VLDL, remnant lipoproteins, LDL, Lp(a), synthesize excess cholestanol, overabsorb plant sterols, have marked decreases in HDL, or have monoclonal gammopathies or multiple myeloma can develop xanthomas.[4–60]

Patients that have defects in the catabolism of triglycerides on chylomicrons and VLDL can develop severe hypertriglyceridemia, which can lead to eruptive xanthomas. Patients that have defects in the clearance of chylomicron and VLDL remnant particles can develop combined hyperlipidemia and tubo-eruptive xanthomas. Such xanthomas can also be observed in marked HDL deficiency due to lack of HDL apoA-I production. Patients that have defects in the clearance of LDL can develop very high LDL cholesterol levels and may develop tendinous xanthomas. Such xanthomas can also be seen in patients who synthesize excess cholestanol or overabsorb pant sterols. Both cholestanol and plant sterols (β-sitosterol and campesterol) are then carried in excess on LDL particles.

Xanthomas are uncommonly seen in common familial lipoprotein disorders associated with premature CHD.

Common genetic lipoprotein disorders associated with premature coronary heart disease include familial Lp(a) excess (Lp(a) >30 mg/dL), seen in about 20% of families with premature CHD, familial combined hyperlipidemia (LDL cholesterol >160 mg/dL and triglyceride >150 mg/dL) (15% of families) and familial dyslipidemia (triglycerides >150 mg/dL and HDL cholesterol <40 mg/dL) (15% of families), and familial hypoalphalipoproteinemia (isolated low HDL cholesterol <40 mg/dL) (5% of families).[38] Patients with markedly elevated Lp(a) levels or with markedly elevated levels of LDL cholesterol and triglycerides due to familial combined hyperlipidemia occasionally develop tendinous or tubo-eruptive xanthomas. In addition, patients with elevated levels of triglycerides (>400 mg/dL) and low HDL cholesterol (<40 mg/dL) or marked HDL deficiency alone may occasionally develop tubo-eruptive xanthomas. Tangier disease is a rare, autosomal-recessive condition that often leads to CHD, but is not typically associated with xanthomas.

FAMILIAL DISORDERS IN WHICH XANTHOMAS ARE MORE LIKELY TO OCCUR

In contrast to the previously mentioned disorders where any form of xanthoma is rare, the disorders listed below, are commonly associated with xanthomas.

DISORDERS ASSOCIATED WITH TENDINOUS XANTHOMAS

Tendinous xanthomas are usually associated with markedly elevated levels of either LDL cholesterol (>300 mg/dL), or plant sterols (β-sitosterol and campesterol) or cholestanol within LDL.[4–30]

FAMILIAL HYPERCHOLESTEROLEMIA

FAMILIAL HYPERCHOLESTEROLEMIA AT A GLANCE

- Homozygous familial hypercholesterolemia, heterozygous familial hypercholesterolemia, or defective apoliprotein-B100 causes this type of hyperlipidemia.
- Severe hypercholesterolemia can present with tendinous or tuberous xanthomas.
- Usually treated by statins.
- Significant risk of coronary atherosclerosis.

About 1 in 500 subjects in the general population, and about 1% of families with premature CHD (age <60 years) have heterozygous familial hypercholesterolemia (type II hyperlipoproteinemia), due to delayed clearance of LDL associated with defects in the LDL receptor or apoB genes.[4–21] These patients can develop arcus senilis (eFig. 135-7.2 in online edition, tendinous xanthomas in the Achilles tendons (Fig. 135-4 and eFig. 135-7.3 in online edition) and on the hands, as well as xanthelasma (eFig. 135-5.1 in online edition), due to cholesterol deposition. Homozygous patients are also at risk for the development of tubo-eruptive xanthomatous plaques (over the extremities, buttocks, and hands) (Fig. 135-8 and eFig. 135-8.1 in online edition). Intertriginous xanthomas are rare but usually associated with this



Figure 135-8 Tubo-eruptive xanthomas. This 10-year-old boy with homozygous familial hypercholesterolemia shows tubo-eruptive xanthomas on his hands (**A**), elbows (**B**), and knees (**C**); the same locations demonstrate marked regression of xanthomas 1 year after he started every 2 weeks LDL apheresis (**D**, **E** and **F**).

condition. The rate of xanthoma deposition and growth is associated with the duration and severity of the LDL elevation, and can regress significantly with weekly LDL apheresis over time (Fig. 135-8). Heterozygotes with this disorder usually have LDL cholesterol levels in excess of 300 mg/dL, while homozygotes often have value over 600 mg/dL.[4–21] Triglyceride and HDL levels are typically normal. Homozygotes are at high risk of developing CHD and aortic stenosis prior to age 20 years, unless treated.[4] Optimal therapy in homozygotes includes LDL apheresis, as well as ezetimibe and high-dose statin therapy. Heterozygotes can usually be effectively treated with the combination of a statin and ezetimibe. Effective control of LDL cholesterol levels below 130 mg/dL will prevent the development of xanthomas in these patients, or promote their regression.[4–21] It should be noted now that many FH patients never develop xanthomas because of the availability of effective statin therapy.

PHYTOSTEROLEMIA. Patients with rare defects in the ABCG5 and ABCG8 transporters have markedly elevated plasma levels of plant sterols or phytosterols (specifically β-sitosterol and campesterol)

and develop tendinous and tuberous xanthomas and premature CHD.[22–26] Normally, these sterols are excreted very efficiently back into the intestinal lumen by the intestinal ABCG5 and ABCG8 transporters. However, these patients have defects in these transporters resulting in the retention of these sterols in the intestinal cell and their secretion on chylomicrons into the plasma space. The definitive diagnosis in these patients is made by the measurement of plasma sterols by gas chromatography, with markedly elevated levels of β-sitosterol and campesterol. Such subjects are at increased risk for developing CHD, and the most effective treatment for them is ezetimibe, which lowers their levels of plant sterols by 50% and stabilizes xanthomas.[22–26]

CEREBROTENDINOUS XANTHOMATOSIS. There are a rare group of patients with cerebrotendinous xanthomatosis who develop cholestanol deposits in their tendons and brain tissue, despite have only modest elevations in plasma cholesterol levels. They are at increased risk of developing severe neurologic disease including cerebellar ataxia and dementia. They cannot convert cholesterol to chenodeoxycholate, one of the major bile acids, due to defects in the sterol 27-hydoxylase gene.[27–30] Instead, they produce excess amounts of cholestanol, a physiologic sterol found in lower concentrations than cholesterol. The diagnosis is established by the finding of markedly elevated plasma cholestanol levels as measured by gas chromatography. The treatment of choice is 250 mg orally three times daily of chenodeoxycholate, which prevents them from getting severe neurologic disease, and also prevents the progression of their xanthomas.

TUBO-ERUPTIVE, PALMAR, AND PLANAR XANTHOMAS. Tubo-eruptive and palmar xanthomas are observed in patients with significant combined elevations of both plasma or serum cholesterol and triglycerides, due to increases in intestinal and liver remnant lipoprotein particles (dysbetalipoproteinemia). Very rarely, tubo-eruptive, planar, and palmar xanthomas are observed in severe HDL deficiency (HDL cholesterol levels <10 mg/dL) or in patients with monoclonal gammopathies or multiple myeloma.

DYSBETALIPOPROTEINEMIA AT A GLANCE

- Defined by accumulation of chylomicron remnants and very low-density lipoprotein remnants.
- Xanthoma striatum palmare is the characteristic cutaneous feature.
- Tuberous xanthomas can also be seen.
- Treatment: fibrates, nicotinic acid, or statin therapy.

DYSBETALIPOPROTEINEMIA

Patients with dysbetalipoproteinemia (also called type II hypolipoproteinemia or Frederickson type III hyperlipidemia) have elevations in total plasma cholesterol and triglyceride that are both in the range of 250–500 mg/dL. Their non HDL cholesterol (total cholesterol—HDL cholesterol) and remnant lipoprotein cholesterol levels are markedly elevated (>200 and >100 mg/dL, respectively), their direct LDL cholesterol levels are usually decreased, and their HDL cholesterol levels are usually relatively normal. These patients usually present in adulthood with tubo-eruptive xanthomas on their elbows, hands, and even ears, and palmar xanthomas. They also develop premature CHD, other vascular disease, gout, and diabetes. They usually have the apoE2/2 genotype, but may occasionally have apoE deficiency (undetectable plasma apoE) or hepatic lipase deficiency. Deficiency in apoE can lead to very defective clearance of both chylomicron and VLDL remnants from plasma. With deficiency of apoE, HDL cholesterol levels may be elevated.[43–46] Tubo-eruptive and palmar xanthomas in a homozygous patient with dysbetalipoproteinemia or type III hyperlipoproteinemia due to familial apoE deficiency with undetectable plasma apoE levels is shown in Fig. 135-5.[44] The patient pictured died at age 59 years of a stroke. The diagnosis in these patients is established by the measurement of apoE in plasma or serum and/or apoE genotyping of their DNA.[43,44] When apoE is present and the genotype is normal (i.e., apoE3/3), the patient may have familial hepatic lipase deficiency diagnosed by the measurement of hepatic lipase activity in postheparin plasma (obtained 10 minutes after the injection of 100 units/kg body weight of heparin). The plasma must be promptly isolated and frozen at –80°.[45,46] Treatment of these patients consists of a diet low in cholesterol, saturated fat, and sugar, as well as niacin 2 g/day, micronized fenofibrate 200 mg/day, and/or a statin. Treatment often can lead to complete regression of their xanthomas. These patients are also at increased risk of developing diabetes, gout, and premature CHD.

MARKED HDL DEFICIENCY. Undetectable plasma levels of apoA-I can be observed in various familial forms of homozygous HDL deficiency (HDL cholesterol <10 mg/dL) such as apoA-I/C-III/A-IV deficiency, apoA-I/C-III deficiency, or apoA-I deficiency.[47–54] These patients generally have normal LDL cholesterol and normal or decreased triglyceride levels, and often develop strikingly premature CHD in their 30s. The defect in these patients is an inability to produce apoA-I, the major protein of HDL. Planar xanthomas have been observed in homozygous apoA-I/C-III deficiency, and marked tubo-eruptive and planar xanthomas filled with lipid-laden macrophages have been noted in homozygous apoA-I deficiency, along with palmar and planar xanthomas (Fig. 135-9).[49–54] These patients also often have corneal opacification were their eyes are examined by slit lamp examination. Therapy in these patients consists of optimizing all other CHD risk factors (LDL cholesterol <70 mg/dL, triglycerides <150 mg/dL, no smoking, systolic blood pressure <130 mmHg, and glycosylated hemoglobin <7.0%), because it is not

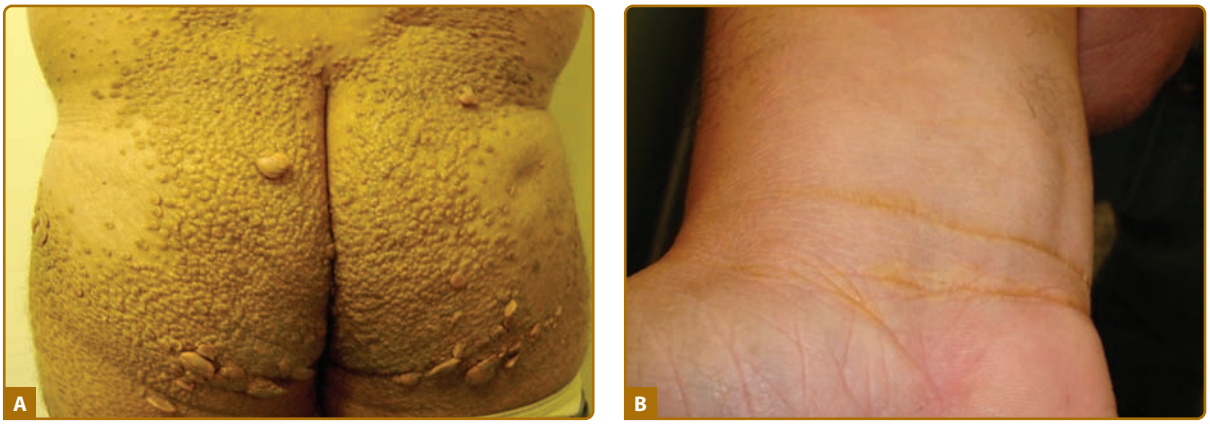

Figure 135-9 Marked HDL deficiency. This 39-year-old man with apoA-I deficiency shows tubo-eruptive xanthomas on the buttocks and lower back (**A**) and yellow creases on the palms of the hands and wrists (**B**).

feasible to raise their HDL cholesterol levels without gene therapy, which is still unavailable.

XANTHOMAS AND SYSTEMIC DISEASE

Various types of xanthomas, including tubo-eruptive and planar xanthomas, have been observed in patients with monoclonal gammopathies, multiple myeloma, lymphoma (Fig. 135-10) and various forms of leukemia.[55–58] It is known that immunoglobulins can bind to plasma lipoprotein particles and in some cases, can markedly delay the clearance of chylomicron remnants or VLDL remnants, resulting in combined hyperlipidemia or dysbetalipoproteinemia, and the potential for lipid deposition in many tissues, including the skin.



Figure 135-10 Diffuse plane xanthoma in a patient with lymphoma.

The treatment consists of management of the underlying disorder, as well as fenofibrate therapy.

Prolonged obstruction of the biliary tree leads to accumulation of cholesterol in the serum. Causes include primary biliary cirrhosis and secondary biliary obstruction. Serum cholesterol is high in unesterified cholesterol. Long-term hypercholesterolemia can lead to plane xanthomas (beige–orange plaques on hands, feet, and trunk), xanthelasma, and occasionally, tuberous xanthomas. Patients with prolonged biliary obstruction can also manifest jaundice, pruritus, and hyperpigmentation of the skin. Treatment involves relieving the underlying cause of obstruction. The underlying treatment is the use an anion exchange resin to prevent pruritus, and liver transplantation for stage 4 disease.

ERUPTIVE XANTHOMAS

Eruptive xanthomas may rapidly emerge and then disappear as rapidly. They are associated with severe hypertriglyceridemia, or moderate hypertriglyceridemia aggravated by uncontrolled diabetes or oral estrogen therapy. Eruptive xanthomas can also be a result of secondary causes, and it is important to rule out obesity, excessive alcohol intake, diabetes (type 2), and drugs as a cause of these lesions. Drugs that can cause eruptive xanthomas include retinoids, estrogen therapy, and protease inhibitors.

SEVERE HYPERTRIGLYCERIDEMIA (SOMETIMES CALLED FREDERICKSON TYPE I HYPERLIPIDEMIA)

Patients with this disorder generally present in childhood or young adulthood with plasma triglyceride values over 1000 mg/dL. They usually have defects in lipoprotein lipase, but may also have apoC-II deficiency, or mutations in the *ApoA-V* gene.[59,60] Plasma cholesterol levels are usually around about one-fifth to one-tenth of the triglyceride levels, with remnant lipoprotein cholesterol levels that are about twofold increased, direct LDL cholesterol levels that are less than 50 mg/dL,

FAMILIAL CHYLOMICRONEMIA SYNDROME AT A GLANCE

- Chylomicronemia and hypertriglyceridemia often presents with eruptive xanthomas.
- Chylomicronemia is due to lipoprotein lipase deficiency or apolipoprotein-C2 deficiency.
- Secondary causes of elevated chylomicrons include obesity, diabetes, alcohol abuse, or medications.
- Medications that can cause elevated triglycerides, and thus eruptive xanthomas, include oral retinoids, estrogen therapy, and protease inhibitors.
- There is very little risk of coronary atherosclerosis.
- Treatment is most commonly through dietary modification.

with HDL cholesterol levels that are usually around 20 mg/dL. These patients have marked elevations of chylomicrons and VLDL in plasma or serum, and its color is usually white. When lipoprotein lipase activity is measured in postheparin plasma (plasma obtained 10 minutes after injecting 100 units of heparin/kg of body weight, and promptly separated and frozen at –80°), it is usually very low or absent. However, some patients may have a deficiency of the activator protein of lipoprotein lipase, namely, apoC-II or abnormalities of apoA-V that modulates lipoprotein lipase activity. Patients with severe hypertriglyceridemia can present with recurrent episodes of severe abdominal pain and develop recurrent pancreatitis and enlarged livers because of triglyceride deposition in these organs. They can also develop transient eruptive xanthomas. Lipemia retinalis (milky plasma which can be visualized in retinal veins) is associated, but patients are generally are not at increased risk for CHD.

In general, the treatment of choice is dietary fat restriction to less than 15% of calories from fat, but to ensure some intake of essential fatty acids by using vegetable oil and fish oil capsules (1–2/day). Fenofibrate may help those that have decreased LPL activity, since fibrates are known to increase LPL gene expression and activity. In children the dose of generic micronized fenofibrate is 67 mg/day, while in adults the dose is 200 mg/day. When such patients present in adulthood, they are usually heterozygous for LPL deficiency or apoC-II deficiency, and are often obese, and diabetic. Sometimes, in women their disease has been exacerbated by oral estrogen therapy for the treatment of perimenopausal symptoms. Treatment with a low calorie, low saturated fat, and low refined carbohydrate diet is indicated in such patients. Weight loss is important if indicated, along with exercise, and tight control of blood glucose levels in diabetic patients. If after treatment for triglyceride elevation, with triglycerides below 300 mg/dL, their LDL cholesterol may become elevated, and at that point a statin may need to be added to control their LDL cholesterol levels.

XANTHOMAS IN CHILDREN

Xanthomas in children are uncommon and must always be investigated. The differential for xanthomas in children includes homozygous FH, phytosterolemia/sitosterolemia, cerebrotendinous xanthomatosis (CTX), and Alagille syndrome. If laboratory investigation reveals a childhood hyperlipidemia, treatment algorithms are available.[36]

In children, Alagille syndrome is an inherited syndrome of biliary hypoplasia leading to elevated serum cholesterol. Children with Alagille syndrome have a characteristic facies with a prominent forehead, hypertelorism, pointed chin, and nasal dystrophy. In Alagille syndrome, serum cholesterol is elevated when patients are young but can decrease over time. Cirrhosis develops in approximately 12% of patients with Alagille syndrome. Treatment for Alagille syndrome is medical management or, if cirrhosis develops, liver transplantation. Xanthomas have been found to resolve after liver transplantation.[35]

VERRUCIFORM XANTHOMA

Verruciform xanthomas commonly occur in the oral cavity and are discussed in Chapter 76. Histologically, it shows foamy histiocytes within elongated dermal papillae. Nonmucosal verruciform xanthoma is the characteristic lesion in *c*ongenital *h*emidysplasia with *i*chthyosiform erythroderma and *l*imb *d*efects (CHILD) syndrome (see Chapter 49), and mutations in the 3β-hydroxysteroid dehydrogenase gene (the gene that is mutated in CHILD syndrome) have been shown to underlie two cases of sporadic verruciform xanthoma. Verruciform xanthomas have also been described in a variety of other skin disorders, among them in epidermolysis bullosa.

TESTING LIPID LEVELS

For dermatologists seeking to evaluate the causes of xanthomas or xanthelasmas, the standard approach is to order a serum or plasma lipid profile, performed after the patient fasts overnight. This test provides a measurement of the concentration of total cholesterol, triglyceride, HDL cholesterol, and calculated LDL cholesterol. A total cholesterol of >240 mg/dL and associated LDL cholesterol value of >160 mg/dL have been classified as elevated and are associated with an increased CHD risk.[1] A total cholesterol value of <200 mg/dL and an LDL cholesterol value of <100 mg/dL have been classified as optimal.[1] A triglyceride value of >150 mg/dL

has been classified as increased, while an HDL cholesterol of <40 mg/dL has been classified as decreased, and both of these abnormalities have been associated with an increased CHD risk.[1]

Occasionally, patients will have elevated total cholesterol levels due to increased levels of β-sitosterol (>225 μmoles/mmol of total cholesterol) and campesterol (>270 μmoles/mmol of total cholesterol), as in phytosterolemia, or elevated cholestanol, as in cerebrotendinous xanthomatosis.[22–30] These abnormalities can only be detected by measuring plasma sterols using gas chromatography. A triglyceride level of >1,000 mg/dL has been classified as markedly elevated and is associated with an increased risk of pancreatitis, as well as eruptive xanthomas.[55,56] A full evaluation of patients with xanthomas includes complete metabolic profile with a serum creatinine and a hepatic panel, fasting glucose, thyroid function tests, urine protein, a fasting lipid profile, lipoprotein(a), apoE genotyping and, as appropriate, measurement of β-sitosterol, campesterol, and cholestanol. These studies permit consideration of secondary causes of lipid abnormalities, particularly if the patient has elevations of LDL cholesterol (>160 mg/dL) or triglycerides (>150 mg/dL), or decreased levels of HDL cholesterol (<40 mg/dL). Diabetes and renal disorders, notably nephrotic syndrome, are both associated with elevated triglycerides and decreased HDL cholesterol. Hypothyroidism and obstructive liver disease (with elevated levels of alkaline phosphatase) are both often associated with elevated LDL cholesterol. Hepatocellular disease with elevated transaminases is often observed in patients with hypertriglyceridemia. Oral estrogens and alcohol intake can significantly raise triglyceride levels and raise HDL, while anabolic steroids usually markedly lower HDL cholesterol levels. If no secondary causes are present then a familial disorder may be present, and measuring lipids in first-degree relatives is warranted, especially when premature CHD and/or xanthomas runs in the family.[1]

TREATMENT OF HYPERLIPIDEMIAS

LIFESTYLE THERAPY

Lifestyle represents the cornerstone of therapy for lipid disorders. Increased physical activity (at least 30 min/day of walking, riding on an exercycle, or some other activity) as well as weight control are very important for preventing diabetes, lowering triglycerides, and raising HDL cholesterol levels.[1,3] In patients with elevated LDL cholesterol and high-risk patients, referral to a nutritionist for dietary restriction is appropriate.

Dietary management involves restriction of dietary saturated fat to <7% of calories, minimization of trans fats, restriction of dietary cholesterol to <200 mg/day, replacement of animal fats by vegetable oils, and increasing fish intake.[1] This is best accomplished by: (1) replacing butter with soft no trans fats margarine (including high plant sterol margarines) and vegetable oils (especially soybean and canola oils); (2) replacing whole milk, and cream with 1% low-fat or skim milk; (3) replacing red meat with chicken, turkey (white meat) or fish; and (4) replacing high-fat/high-sugar desserts, with fruits, vegetables, and whole grains. Replacing animal fat with vegetable oil has been shown to be an extremely powerful modality to reduce CHD risk, and polyunsaturated oils lower LDL cholesterol and increase reverse cholesterol transport.[1,3]

PHARMACOLOGIC AGENTS

Statins are the best available agents for lowering LDL cholesterol, followed by ezetimibe, and then resins. Fibrates, such as fenofibrate, are the best available agents for triglyceride lowering, followed by fish oil and niacin therapy. Niacin is the best available agent for raising HDL and lowering Lp(a).

ACKNOWLEDGMENT

The authors acknowledge Lucile E. White, MD, for her authorship of this chapter in the previous edition, and Kavitha Menon, MD for her editorial review.

KEY REFERENCES

Full reference list available at www.DIGM8.com

DVD contains references and additional content

11. Neil HA et al: Simon Broome Familial Hyperlipidaemia Register Group and Scientific Steering Committee. Comparison of the risk of fatal coronary heart disease in treated xanthomatous and non-xanthomatous heterozygous familial hypercholesterolaemia: A prospective registry study. *Atherosclerosis* **170**(1):73-78, 2003
19. Oosterveer DM et al: Differences in characteristics and risk of cardiovascular disease in familial hypercholesterolemia patients with and without tendon xanthomas: A systematic review and meta-analysis. *Atherosclerosis* **207**(2):311-317, 2009
22. Kidambi S, Patel SB: Sitosterolemia, pathophysiology, clinical presentation, and laboratory diagnosis. *J Clin Pathol* **61**(5):588-594, 2008
25. Keren Z, Falik-Zaccel TC: Cerebrotendinous xanthomatosis (CTX), a treatable lipid storage disorder. *Pediatr Endocrinol Rev* **7**:6-11, 2009
40. Ghosh YK, Pradhan E, Ahluwalia HS: Excision of xanthelasmata—Clamp, shave, and suture. *Int J Dermatol* **48**(2):181-183, 2009

Chapter 136 :: Fabry Disease

:: Atul B. Mehta & Catherine H. Orteu

FABRY DISEASE AT A GLANCE

- Incidence estimated at 1:3,200 to 1:170,000 in all ethnicities.
- X-linked lysosomal storage disorder.
- Highly penetrant in males; female heterozygotes have variable expressivity.
- Partial or complete deficiency of α-galactosidase A with deposition of glycosphingolipids (mostly globotriaosylceramide).
- Classical variants affect predominantly skin, kidneys, heart, eyes, and brain.
- Life expectancy shortened by 20 years in males and 15 years in females.
- Later onset variants: milder, predominantly single organ involvement, for example, renal or cardiac.
- Dermatologic manifestations: angiokeratomas, telangiectasias, "pseudoacromegalic" facies, hypo- and hyperhidrosis, lymphedema, and Raynaud's phenomenon.
- Light microscopy: ectatic upper dermal vessels, peripheral epidermal acanthosis, variable hyperkeratosis.
- Electron microscopy: intracytoplasmic electron dense vacuolar "Zebra bodies."
- Treatment: symptomatic, enzyme replacement.

EPIDEMIOLOGY

Fabry disease (α-galactosidase A, GLA, deficiency) is generally considered the second most prevalent lysosomal storage disorder, after Gaucher disease[1,2] with an estimated incidence ranging between 1:40,000 to 1:170,000 persons. All ethnic groups are affected. Milder variants of the disease are associated with significant residual enzyme activity and may occur with much higher frequency (e.g., 1:3,200), as suggested by a recent survey of neonates in Northern Italy.[3] These variants often have predominant involvement of a single organ (e.g., heart or kidney) and have onset in adult life.

ETIOLOGY AND PATHOGENESIS

Fabry disease (OMIM #301500) is caused by the partial or complete deficiency of a lysosomal enzyme, α-galactosidase A (Fig. 136-1). As a result of this enzyme deficiency, neutral sphingolipids with terminal α-galactosyl residues [predominantly globotriaosylceramide (Gb3)] accumulate in the lysosomes of different tissues and fluids (epithelial cells of glomeruli and tubules of the kidneys; cardiac myocytes; ganglion cells of the autonomic system; cornea; endothelial, perithelial, and smooth muscle cells of blood vessels; and histiocytic and reticular cells of connective tissue). Clinical onset is variable (Fig. 136-2). Although the condition is X linked, heterozygous females are frequently affected and may be as severely affected as hemizygous males.[4] Clinical symptoms typically occur a decade or so later in females than in males and organ damage is usually less severe. Variable expression in females is attributed to the Lyon hypothesis, whereby one X chromosome is inactivated on a random basis in the female, while the other provides the genetic information.

The *GLA* gene for α-galactosidase A is located at the Xq22.1 region. More than 400 mutations have been identified in the *GLA* gene,[5,6] including missense, nonsense mutations, and single amino acid deletions and insertions. Most of these mutations are "private," having been identified only in individual families. Some (e.g., the *p.N215S* mutation) have been associated with single organ or late onset variants and patients have normal levels of urinary Gb3, despite having clinical evidence of Fabry disease.

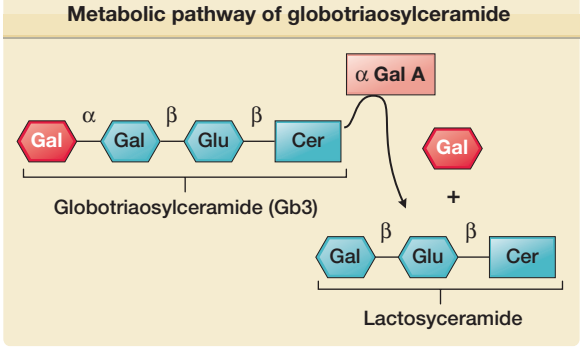

Figure 136-1 Metabolic pathway: α-galactosidase A (α-Gal A) metabolizes globotriaosylceramide to galactose (Gal) and lactosylceramide. Cer = ceramide; Glu = glucose.

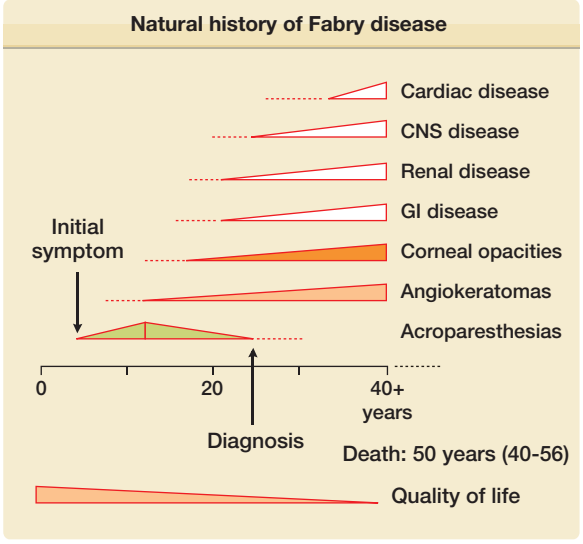

Figure 136-2 Natural history of Fabry disease: acroparesthesias, angiokeratomas, corneal opacities, and gastrointestinal symptoms are often the first manifestations. Diagnosis is usually delayed and occurs around the second decade. CNS = central nervous system; GI = gastrointestinal.

HISTORICAL ASPECTS

CUTANEOUS MANIFESTATIONS

CUTANEOUS VASCULAR LESIONS

ANGIOKERATOMA. Angiokeratoma (AK), the cutaneous hallmark of Fabry disease,[7,8] are present in 70% of males and 39% of females.[9,10] They are pinpoint to 4-mm diameter, dark-red to blue–black, macular, and papular lesions, which do not blanch on pressure (Fig. 136-3). Overlying hyperkeratosis is variable and frequently absent at sites other than the genitalia and umbilicus.[9,11] AKs appear between the ages of 5 and 15 years in males and 3–10 years later in females.[12–15] They were a presenting feature in 14.2% of 352 pediatric patients,[15] 31.7% of adult males (n = 359), and 11.2% of adult females (n = 118).[4] They may be widespread or grouped. In males, lesions are typically within the "bathing trunk" area (genitals, buttocks, lower abdomen, umbilicus, groins, inner thighs, and sacrum). AK are also often seen on the proximal limbs, particularly their medial aspects, the elbows and knees, the palms and soles, and over the distal phalanges of the digits (Fig. 136-4). Lesions may occur on the lips, particularly along the vermilion border, and occasionally on the mucosal surfaces (Fig. 136-5). They rarely occur elsewhere on the face. In females, AK are usually sparsely distributed (Fig. 136-6) and may occasionally occur in a dermatomal distribution.[9,16] The commonest sites are the trunk and proximal limbs.[9] Female genital lesions are relatively infrequent.

HISTOPATHOLOGY. Histologic evaluation of lesional skin typically shows dilated, ectatic capillaries in the papillary dermis, a variably thinned epidermis centrally, with epidermal acanthosis at the edges of the lesion, and variable degrees of overlying focal compact orthohyperkeratosis (eFig. 136-6.1A in online edition). Endothelial, perithelial, perineural, eccrine, smooth muscle cells, and fibroblasts are filled with cytoplasmic vacuoles containing glycosphingolipid that can be visualized with toluidine blue stains. Characteristic, electron dense, lamellated intracytoplasmic vacuolar inclusions (zebra bodies) are typically seen on electron microscopy[17] (eFig. 136-6.1B in online edition; Fig. 136-7; eFig. 136-7.1 in online edition; and Figs. 136-8A and 136-8B). They exhibit a pattern of alternating light and dark 4–6-nm bands. These inclusions may be present in biopsies from AK or from normal skin. They may be absent in the skin of heterozygous females.[17] Electron microscopy and immunoelectron microscopy using anti-Gb3 antibodies are useful tools when other diagnostic tests are not conclusive.[18]

ANGIOMAS AND TELANGIECTASIAS. Up to a third of Fabry males and two-thirds of females do not have AKs.[9,10,13,14] A proportion have no cutaneous vascular lesions (CVL),[9] and others have bright red macular angiomatous lesions, which could represent

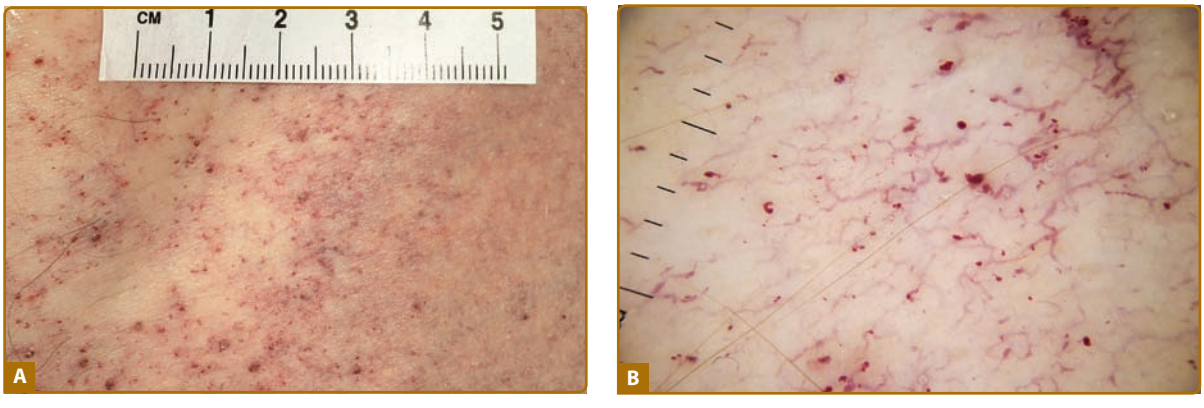

Figure 136-3 **A.** Angiokeratomas and telangiectatic vessels on the flank in a patient with angiokeratoma corporis diffusum. **B.** Dermatoscopic view showing angiokeratomas and upper dermal vessel tortuosity.

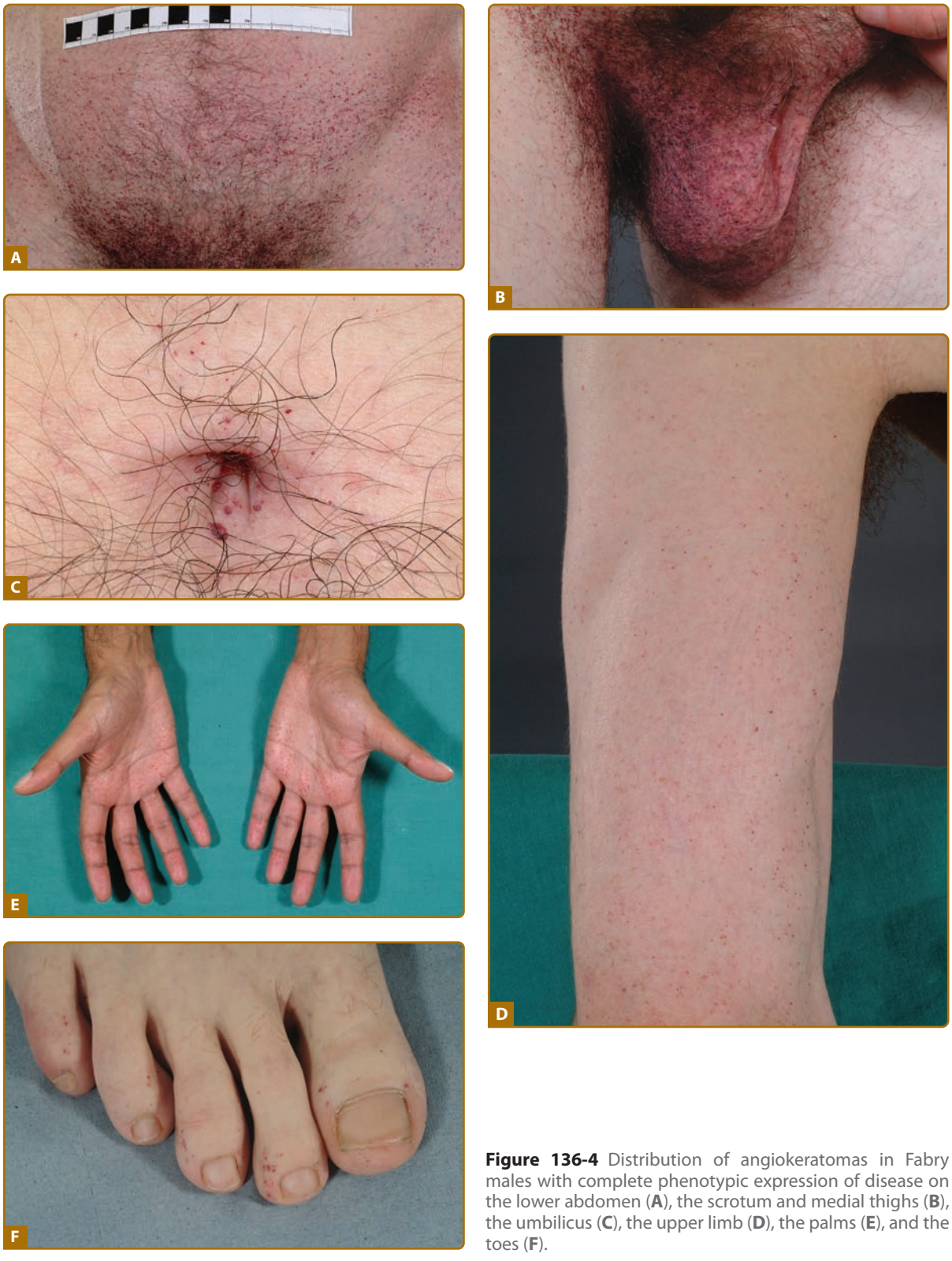

Figure 136-4 Distribution of angiokeratomas in Fabry males with complete phenotypic expression of disease on the lower abdomen (**A**), the scrotum and medial thighs (**B**), the umbilicus (**C**), the upper limb (**D**), the palms (**E**), and the toes (**F**).

early AKs or macular angiomas clinically.[11] Patients with widespread papular angiomas clinically and histologically in keeping with cherry angiomas are also recognized. In one series, patients with a predominantly cardiac phenotype (*N215S* mutation) rarely had classical AK, but a third of males in this group had widespread (>100) cherry angiomas.[19] Since the prevalence of such lesions in the general population may be as high as 50%, their significance in patients with Fabry disease is not clear. Telangiectasias are also common,[9] and may be distinguished from AKs and macular and cherry angiomas by the presence of blanching

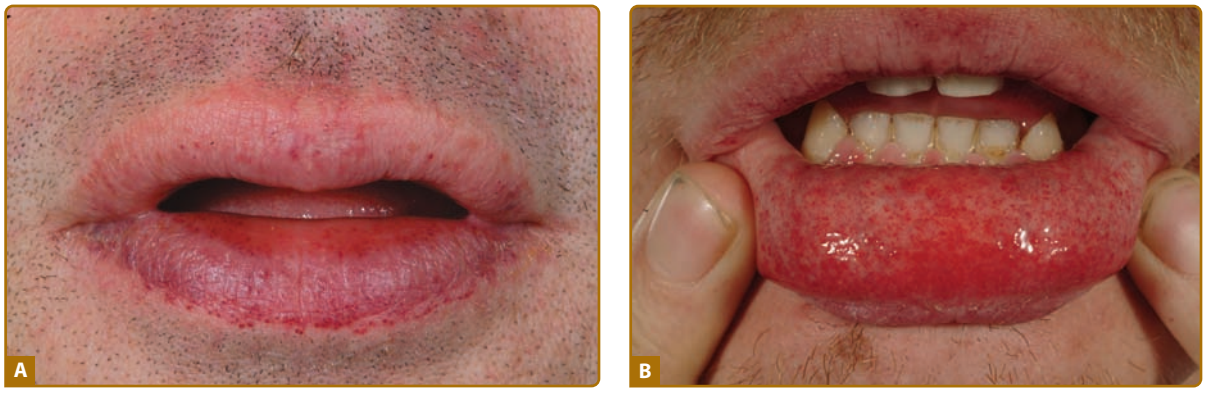

Figure 136-5 Angiomatous lesions on the lips concentrated along the vermilion border (**A**) and on the mucosal surface of the lower lip (**B**).

on diascopic pressure. Registry data show that they are more common in males (23%) than in females (9%).[9,10] Although based on patient recall, data suggest that they appear later than AK, with a mean age at onset of 26 years in males (range 3–70) and 42 years in females (range 5–73).[9] In a majority of cases, telangiectasias occur at sun-exposed sites, such as the face and V of the neck, often in patients with skin type I or II. Occasionally, telangiectasias may be seen at unusual sites such as the flanks, groins, elbow, and knee flexures. Dermoscopy of these areas reveals dilated, tortuous upper dermal vessels (Fig. 136-3 and eFig. 136-8.1 in online edition). This tends to occur in patients with widespread AK and full phenotypic expression of disease.

RELATIONSHIP TO DISEASE SEVERITY. In both sexes, the presence of CVL, namely telangiectasias and/or AK, has been associated with higher disease severity scores and a higher prevalence of major organ involvement.[9,10] Thus, cerebrovascular involvement (stroke and transient ischemic attacks) was present in 38% females and 32% males with CVL, but only in 12% females and 9% males without CVL. Cardiac involvement occurred in 80% females and 73% males with CVL versus 38% females and 49% males without; renal involvement in 62% females and 72% males with CVL versus 29% females and 42% males without. Similar differences are observed for hypertension, eye, ear, gastrointestinal (GI), and other neurological involvement.[10] These findings demonstrate the importance of dermatological assessment and its possible predictive value in terms of systemic morbidity.

FACIAL FEATURES

A "pseudoacromegalic" facial appearance has been described in some families with Fabry disease (Fig. 136-9 and eFig. 136-9.1 in online edition). This feature is



Figure 136-6 Sparsely distributed pinpoint dark-red macular and papular lesions on the trunk of a Fabry female.

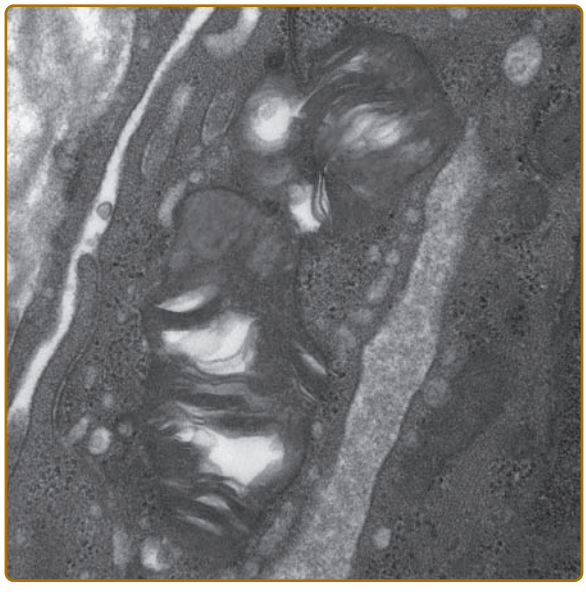

Figure 136-7 Histopathologic features of angiokeratoma. At high power electron microscopy a lamellar or "zebra" body is seen (×63,000 magnification).

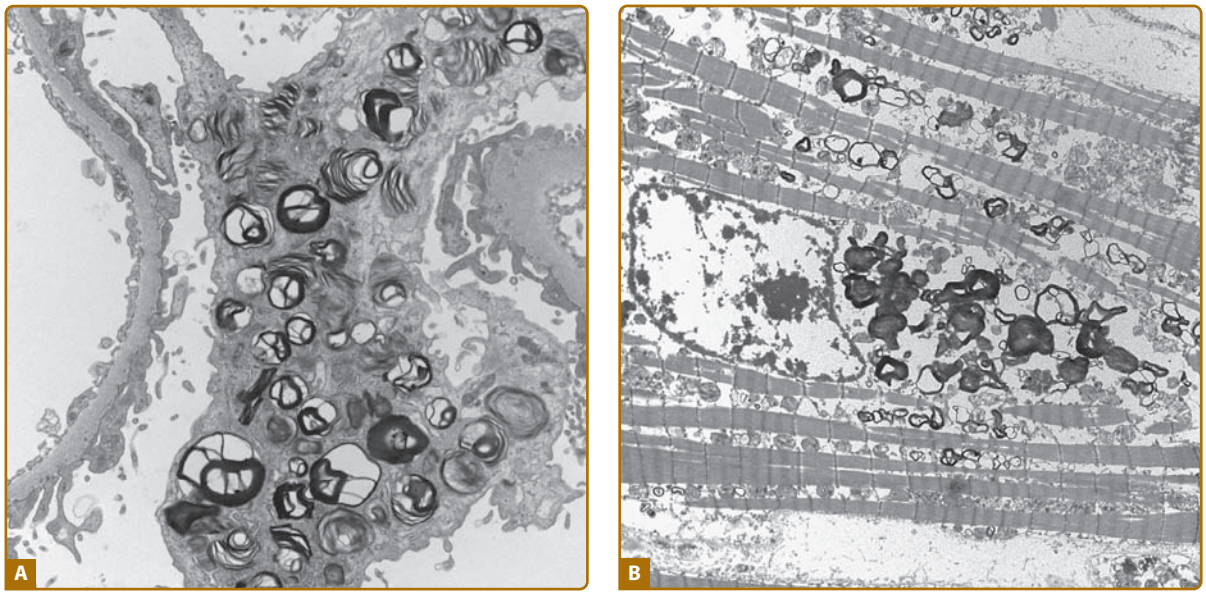

Figure 136-8 Electron microscopy: multiple electron dense inclusions in the kidney (**A**) and cardiac muscle in Fabry disease (**B**).

documented in two larger studies. An assessment of 38 patients by a panel of three clinical geneticists, based on standardized medical photography[20] identified (in order of decreasing frequency): periorbital fullness, prominent ear lobes, bushy eyebrows, recessed forehead, pronounced nasal angle, generous nose/bulbous nasal tip, prominent supraorbital ridges, shallow midface, full lips, prominent nasal bridge, broad alar base, coarse features, posteriorly rotated ears, and prognathism. A second study, in which facial dysmorphism was objectively assessed by three-dimensional (3D) dense surface modeling and anthropometric analysis using a 3D photogrammetric camera, compared facial features in 20 males and 22 females with Fabry disease with controls.[21] This study confirmed, in males and less prominently in females, the presence of the facial features noted above. The presence of these facial features should prompt appropriate investigations for Fabry disease.



Figure 136-9 Typical facial features: bushy eyebrows, prominent supraorbital ridges, periorbital fullness, large bitemporal width, broad nasal base, full lips, and prominent chin.

The Fabry face appears commoner in patients with widespread AKs and classical disease at the more severe end of the spectrum. Moderate or marked facial changes were present in 63% of 41 males with a classical disease phenotype, 61% of whom had AK corporis diffusum. In contrast, facial features were present to a very mild degree (periorbital puffiness only) in only 10.5% of 19 males with a predominantly cardiac phenotype of disease.[10]

LOWER LIMB EDEMA AND LYMPHEDEMA

Edema and lymphedema, particularly affecting the lower limbs, is frequently observed in Fabry patients (Fig. 136-10). Lymphedema was cited in the original description of Fabry Disease (FD) and is recognized in other lysosomal storage disorders (LSDs) such as α-*N*-acetylgalactosaminidase deficiency.[22] Case reports document it as an unusual presenting feature of the condition[23] and some suggest that familial lymphedema and Fabry disease might be linked.[24] Registry data from the Fabry Outcome Survey (FOS) on more than 700 patients confirm that reversible peripheral edema of the lower limbs was present in 25% of Fabry males and 17% of females; lymphedema was present in 16% of males and 7% of females. The mean age of onset was 37 years for males (range 13–70) and a



Figure 136-10 Bilateral lower limb lymphedema in a 43-year-old Fabry male.

decade or so later for females.[9] This is significantly more than the documented UK community prevalence of 1.33/1,000.[25] In the community it is five times commoner in women. The mechanism underlying the changes is unclear; their presence does not correlate with renal or cardiac involvement. Contributory factors may include glycosphingolipid accumulation,[26] recurrent edema, and primary abnormality of the lymphatics.[27,28] Using the technique of fluorescence microlymphography and measurement of lymph capillary pressure, Amann-Vesti et al demonstrated fragmentation of the microlymphatic network in 5/5 hemizygous males and 5/5 heterozygous females but in none of 12 healthy controls.[28] Severe structural and functional changes in the initial lymphatics of the skin were present, even when lymphedema was not manifest.[28] The possibility that abnormalities in expression or function of recently identified mediators of lymphangiogenesis (VEGF-C/-D and VEGF-Rs)[29] may be involved in the development of lymphedema in Fabry disease remains to be investigated.

ABNORMALITIES OF SWEATING

Reduced sweating is a classical feature of Fabry disease and thought largely to be a consequence of autonomic neuropathy, though substrate accumulation within sweat glands may play a role.[30,31] Hypohidrosis was reported by 53% of males and 28% of females, with earlier onset in males (23 years vs. 26 years). Anhidrosis was described by 25% of males, but only by 4% of females.[9] Heat intolerance is a commonly associated and disabling symptom, resulting in reduced exercise tolerance, nausea, dyspnea, light-headedness and headache, or complete collapse with loss of consciousness. Previous studies[31,32] have demonstrated an improvement in sweating in Fabry patients undergoing enzyme replacement therapy (ERT). Hyperhidrosis may also occur, more commonly in females (11.9%) than in males (6.4%).[33] This is higher than the estimated prevalence of 1%–2.8% of the general population in the United States.[34] In a majority of Fabry patients, it affects palms and soles and is not generalized.[33]

RAYNAUD PHENOMENON

"Cold intolerance" and the development of pain in the extremities in cold environments is a frequent complaint amongst Fabry patients. More recently, Raynaud phenomenon has been documented in 8% of 710 females and 11% of 644 males (data from FOS). This reversal of the sex ratio and high prevalence in males suggest a possible causal link to the underlying Fabry disease. A recent fluoroscopic nail fold capillaroscopy study[35] examined 25 Fabry patients (17 males) and showed significantly more bushy capillaries and clusters in cases (72%) than controls (10%). Morphological and functional abnormalities of nail fold capillaries were present. This abnormal vasoreactivity of digital vessels could be related to autonomic dysfunction. Abnormalities of nitric oxide synthetase and increased oxidative stress in vascular endothelium and smooth muscle might also be important triggers.[36]

NONCUTANEOUS FINDINGS

(Table 136-1, see Fig. 136-2)

The noncutaneous findings in Fabry disease are illustrated in Fig. 136-2 and listed in Table 136-1 in relation to their typical age of onset. Fabry disease is a progressive, multisystem disorder, which typically results in a global reduction in quality of life of affected individuals. Symptoms in childhood typically relate to lethargy, tiredness, pain, cutaneous abnormalities, changes to sensory organs, and often GI disturbances. In early adulthood, patients may suffer extension of any of the above symptoms and often develop lymphedema, proteinuria, and the first signs of renal, cardiac, or central nervous system (CNS)/cerebrovascular disease. In later adulthood (age >30 years), symptoms include worsening of the above and more severe organ dysfunction (cardiac disease, renal disease, and cerebrovascular disease).

NEUROLOGIC FINDINGS

Acroparesthesias occur in 80%–90% of affected individuals and typically occur in the first decade.[37] Patients describe the sensation as pain, feeling like pins and needles in hands and feet, often radiating proximally. Triggers include increased body temperature, exercise, or stress. Pain typically declines over time and this may be due to damage to nerve fibers as a result of inflammation and substrate accumulation.

TABLE 136-1
Typical Signs and Symptoms of Fabry Disease According to Age

Typical Time at Onset	Signs and Symptoms
Childhood and adolescence (≤16 years)	▪ Pain (acroparesthesia) particularly in the extremities ▪ Angiokeratomas ▪ Ophthalmological abnormalities (cornea verticillata and tortuous retinal blood vessels) ▪ Hearing impairment ▪ Dyshidrosis (hypohidrosis and hyperhidrosis) ▪ Hypersensitivity to heat and cold ▪ Gastrointestinal disturbances and abdominal pain ▪ Lethargy and tiredness ▪ Onset of renal and cardiac signs, e.g., proteinuria, arrhythmia
Early adulthood (17–30 years)	▪ Extension of any of the above ▪ Proteinuria and progressive renal failure
Later adulthood (age >30 years)	▪ Worsening of any of the above ▪ Heart disease (e.g., left ventricular hypertrophy, angina, arrhythmia, and dyspnea) ▪ Stroke and transient ischemic attacks ▪ Osteopenia and osteoporosis

SENSORY ORGAN ABNORMALITIES

The commonest ocular finding is cornea verticillata (opacities in the cornea characterized by one or more lines radiating from the near the center of the cornea), which occurs in over 90% of males and 70% of females. Other changes include increased tortuosity of retinal vessels, optic atrophy, cataracts, and lenticular changes. The extent of ocular abnormalities correlates with the overall extent of the disease.[38] Tinnitus and high frequency sensorineural hearing loss are also common manifestations, occurring in over 50% of subjects. Sudden deafness and dizziness due to vestibular pathology can also occur.

GASTROINTESTINAL CHANGES

Cramping abdominal pain, nausea, diarrhea, and occasionally constipation are frequent and are often the presenting symptom.[39] The pathogenesis is probably related to neurologic abnormalities.

ORGAN DAMAGE IN FABRY DISEASE

Renal manifestations are seen in over 90% of males.[37] Microalbuminuria and hyperfiltration are early features, proteinuria is typically seen in the third and fourth decades, and progressive decline in renal filtering capacity occurs. Females frequently show proteinuria, although progression to end-stage renal failure is less common. A renal variant of Fabry disease has been described in patients with decreased,[1] but not absent, α-galactosidase A activity; these patients lack other characteristic manifestations.

Cardiac manifestations are a constant feature and increasingly recognized as the major cause of death in both male and female patients.[40] Substrate deposition can be demonstrated throughout the myocardium, valves, and conduction system and is often accompanied by an inflammatory cell infiltrate. A common presentation is with left ventricular hypertrophy, but mitral valve prolapse, arrhythmia, and coronary artery disease can all be present. A cardiac variant[1] has been described in patients with reduced, but not absent, α-galactosidase A activity and presents later in life (often above 40 years) with predominant cardiac symptomatology.

Cerebrovascular manifestations include ischemic or hemorrhagic strokes occurring early in life, transient ischemic attack and strokes affecting the posterior circulation. Stroke is often reported as the presenting feature of Fabry disease, and Fabry disease should be considered in the differential diagnosis of young patients with cryptogenic stroke.[41]

Other manifestations: Global manifestations of Fabry disease include lethargy, tiredness, failure to thrive in children, and anemia. Depression is frequent and often underdiagnosed, affecting up to 50% of Fabry males and females.[42] Sexual activity is often affected by the presence of AKs in the genital region, which can lead to decreased self-esteem and libido. Autonomic dysfunction is underrecognized and can lead to hyperhidrosis, abnormal tear and saliva formation, abnormal cardiac reactivity, GI dysmotility, altered pain, and temperature perception. Endocrine abnormalities are uncommon but osteopenia and hypothyroidism[43] are well described. Pulmonary abnormalities are underrecognized; Fabry disease can lead to an obstructive airways pattern[44] in some patients, but asthma is the presenting feature in other patients. In contrast to other lysosomal storage disorders, cognitive impairment is not generally seen; however, older patients (above 50 years) are increasingly seen with memory loss, global intellectual deterioration, and personality change.

DIAGNOSIS

The definitive diagnosis of Fabry disease is usually delayed, with a mean time between the onset of symptoms and diagnosis of 15 years.[45] The diagnosis must be confirmed by the demonstration of deficient α-galactosidase A activity in plasma, serum, or leukocytes and the identification of a pathogenic mutation. Female patients have variable and, occasionally, even normal levels of enzyme activity and DNA confirmation of the diagnosis is essential.

Biopsy of tissues, such as skin and kidney, demonstrates the presence of lipid deposition and multilamellated intracytoplasmic electron dense bodies in electron micrographs (see eFig. 136-6.1 in online edition; Fig. 136-7; and eFig. 136-7.1 in online edition). As Gb3 deposition starts in utero, prenatal

diagnosis can be performed from chorionic villi or culture of amniotic cells, where low α-galactosidase A activity can be demonstrated.[1]

DIFFERENTIAL DIAGNOSIS

(Box 136-1, Tables 136-2 and 136-3)

The pain associated with acroparesthesia is often misdiagnosed as rheumatoid arthritis, rheumatic fever, erythromelalgia, Raynaud disease, or simply as "growing pains."[37]

The clinical diagnosis of AKs in Fabry disease may be difficult. Careful inspection of the skin may be required to distinguish AKs from purpura, petechiae, and angioma serpiginosum. AKs should also be distinguished from the solitary and localized forms of AK, which occur in the absence of underlying systemic disease[46] (Box 136-1 and Table 136-2).

Widespread AKs occur in other lysosomal storage disorders, which should be considered in the differential diagnosis. They include fucosidosis, in which more than 50% of patients have the changes, α-*N*-galactosaminidase deficiency, and galactosialidosis[47–50] (Box 136-1 and Table 136-3). In addition to the distinct enzyme deficiency in each of these storage diseases and other clinical features, AKs from

BOX 136-1 DIFFERENTIAL DIAGNOSIS OF ANGIOKERATOMAS

LOCALIZED FORMS	ANGIOKERATOMA CORPORIS DIFFUSUM
Angiokeratoma of Fordyce	Fucosidosis
Angiokeratoma of the vulva	Aspartylglucosaminuria
Angiokeratoma of Mibelli	Galactosialidosis
Solitary papular angiokeratoma	Schindler/Kanzaki disease
Angiokeratoma circumscriptum	β-Mannosidosis
	GM1-gangliosidosis/ β-galactosidosis
	Sialidosis
	Idiopathic

TABLE 136-2
Clinical Features of Different Types of Angiokeratoma

Type	Age at Onset (Yr)	Sex	Clinical Aspect	Body Site	Inherited	Association
Fabry	5–12	Both, males > females	Multiple, clustered dark-red to blue–black macules and papules Larger lesions warty (1–4 mm)	Any part of the body, especially bathing trunk area, umbilicus, lips	Yes, X-linked	Acroparesthesias, heart and renal failure, stroke, cornea verticillata, deafness, etc.
Mibelli	10–15	Both, female > males	Grouped, warty, dark-red papules (1–5 mm)	Lateral aspect and dorsa of fingers and toes, hands, and feet	Yes, autosomal dominant	Acrocyanosis and chilblains
Fordyce	>60	Male	Multiple warty, blue–black papules (1–4 mm)	Genitals—mainly scrotum	No	Local venous hypertension
Vulva	>60	Female	Grouped, warty, blue–black papules (1–4 mm)	Vulva	No	Local venous hypertension
Solitary papular	10–40	Both	Single dark-red to black keratotic papules (2–10 mm) often bleed/ thrombose	Any part of the body, especially in lower extremities	No	—
Circumscriptum	Usually early onset or at birth	Both	Unilateral plaque keratotic dark-red papules, may bleed	Lower legs or foot may be zosteriform[53]	No	Cobb syndrome Vascular malformations

TABLE 136-3
Differential Diagnosis of Angiokeratoma Corporis Diffusum

Group	Name	Enzyme Deficiency	Gene	Electron Microscopy Findings[55]	Clinical Findings	Dermatologic Findings
Sphingolipidoses	Fabry (OMIM #301500)	α-Galactosidase A	*Xq22*	Electron-dense lysosomal deposits	Acroparesthesias, heart and renal failure, stroke, cornea verticillata	Angiokeratoma (AK) corporis diffusum, telangiectasias, hypo/anhidrosis, lymphedema
	GM1 gangliosidosis (OMIM #230500)	β-Galactosidase	*3p21–3pter*	Electron-lucent lysosomal dilation	Facial dysmorphism, hematologic signs, mental retardation, organomegaly	AK corporis diffusum
Glycoproteinoses	Aspartylglucosaminuria (OMIM #208400)	Aspartylglycosaminidase	*4q32–33*	Electron-lucent lysosomal dilation	Coarse facies, macroglossia, organomegaly, ocular findings, cardiac valve involvement	AK corporis diffusum, facial angiofibromas, oral fibromatosis and leukokeratosis
	Fucosidosis (OMIM #230000)	α-Fucosidase	*1p34*	Electron-lucent lysosomal dilation	Mental retardation, coarse facies, growth retardation, recurrent respiratory infections, dysostosis multiplex, visceromegaly	AK corporis diffusum, widespread telangiectasias, acrocyanosis, purple transverse distal nail bands, increased vasculature in hands and feet, sweating abnormalities
	β-Mannosidosis (OMIM #248510)	β-Mannosidase	*4q22-q25*	Electron-lucent lysosomal dilation	Mental retardation, neuropathy, hearing loss, recurrent infections	AK corporis diffusum in bathing trunk area
	Sialidosis II (OMIM #256550)	Neuraminidase	*6p21.3*	Electron-lucent lysosomal dilation	Mental retardation, dysostosis multiplex, vacuolated lymphocytes, subtle coarse facial features	AK corporis diffusum
Multiple enzyme deficiency	Galactosialidosis (OMIM #256540)	β-Galactosidase and neuraminidase	*20q13.1*	Electron-lucent lysosomal dilation	Dwarfism, gargoyle facies, mental retardation, seizures, corneal clouding, dysostosis multiplex, and hearing loss	AK corporis diffusum scattered along entire body, especially knees, elbows, and bathing trunk area
	Kanzaki (OMIM #104170)	α-N-acetylgalactosaminidase (α-Nacetylgalactosaminidase)	*22q11*	Electron-lucent lysosomal dilation	Mental retardation, coarse facial features, ocular signs, hearing loss, neuropathy	AK corporis diffusum of entire body, more dense on the bathing trunk area, axillae, and breasts Telangiectasias on lips and oral mucosa

OMIM = Online Mendelian Inheritance in Man.

Fabry disease can be differentiated by electron microscopic examination by the characteristic electron-dense, lamellar (zebra-like) inclusions within endothelial and other cell types.[51] Chloroquine therapy may result in storage of biochemically and ultrastructurally similar inclusions in many of the same cells as Fabry disease and may result in similar clinical manifestations, including the development of AK.[52] Widespread AKs have also been described in association with tuberous sclerosis,[53] juvenile dermatomyositis,[54] and without an associated metabolic disorder.[55]

PROGNOSIS AND CLINICAL COURSE

Earlier studies suggested that males with Fabry disease typically die in the fourth or fifth decade, and females live perhaps 15 years longer. More recently, the life expectancy for males has been estimated as 58.2 years (compared to 74.7 in the general US population) and 75.4 years for females (compared to 80 years).[56] There is also evidence that, whereas renal failure was previously the commonest cause of death, cardiac and cerebrovascular diseases are increasingly common. Some of these changes may be due to the impact of ERT.[56,57]

TREATMENT

(Box 136-2)

Fabry disease is a multisystem disorder and patients should be assessed within a multidisciplinary setting. The advent of ERT has meant that patients and families are increasingly assessed in a specialty center, where they will have access to a primary care physician, dermatologist, and possibly cardiologist/nephrologist/neurologist. Access to audiologists, ophthalmologists, gastroenterologists, and psychiatrists/counselors, as well as to genetic counselors and nurses, is desirable and available at larger centers.

SYMPTOMATIC THERAPIES

Individual end-organ manifestations of disease are treated symptomatically (Box 136-2).

SKIN-DIRECTED THERAPIES. Clearance of Gb3 from the skin following ERT[58,59] does not necessarily translate into clearance of AKs. The variety of vascular lesions seen in Fabry disease can, however, be treated effectively with quasicontinuous wave and pulsed lasers, and intense pulsed light systems.[60,61] Newer lasers, which combine a high-powered pulsed-dye laser and a 1064-nm long-pulse Nd:YAG laser penetrate deeper and seem to work particularly well for the larger genital AKs.[62,63]

Prophylactic therapy with grade II graduated below knee compression hosiery can prevent the development of lymphedema in patients whose edema is still fully reversible. Once lymphedema is established, control can be maintained by regular skin care, exercise, manual lymphatic draining and/or self-massage, and the use of appropriate specialist bandaging and hosiery.[25,64]

There is some evidence that hypohidrosis improves with ERT.

For those patients with hyperhidrosis, treatment options include the use of topical aluminium chloride hexahydrate, tap water iontophoresis and local botulinum toxin injections, oral glycopyrrolate sodium up to 2 mg three times daily (a well-tolerated anticholinergic with minimal side effects, provided there are no

BOX 136-2 TREATMENT: A MULTIDISCIPLINARY APPROACH IS ALWAYS ADVISABLE

SYMPTOMATIC

Angiokeratomas
Liquid nitrogen, electrocoagulation, surgical excision, laser (pulsed-dye 585-nm, neodymium YAG 1,064 nm, combined pulsed-dye and Nd:YAG) and intense pulsed light (IPL)

Lymphedema
Manual lymphatic drainage massage and compression

Hyperhidrosis
Aluminium chloride hexahydrate, electrophoresis, botulinum toxin, glycopyrrolate sodium

Raynaud Phenomenon
Avoid smoking, cold and vasoconstrictor therapies; losartan, diltiazem, fluoxetine, sildenafil

Pain
Avoid triggers; carbamazepine, gabapentin

Stroke
Antiplatelet, Anticoagulant

Hearing
Hearing aid devices, avoid noise trauma

Lungs
Avoid smoking; bronchodilators

Gastrointestinal
Pancrelipase, metoclopramide

Cardiovascular
Antihypertensive drugs, antiarrhythmic drugs, Artificial pacemakers, implantable defibrillators, coronary bypass

Chronic Renal Failure
Angiotensin converting enzyme inhibitors
Hemodialysis, allograft transplant

SPECIFIC
Enzyme replacement
α-Galactosidase B (Fabrazyme), α-galactosidase A (Replagal)

cardiac contraindications), and chemical or endoscopic sympathectomy.[65,66]

For patients with cold extremities, standard measures such as stopping smoking, avoiding vasoconstricting medications such as β-blockers, and maintaining warm hands and feet with suitable clothing during winter months are generally recommended. Drug therapies with proven efficacy for Raynaud phenomenon in other patient groups include angiotensin II receptor antagonists, calcium channel blockers, fluoxetine, and sildenafil.[67,68] Possible cardiac and renal contraindications should be taken into account before prescribing these drugs in Fabry patients.

THERAPIES DIRECTED AT OTHER ORGAN SYSTEMS. Pain is the most disturbing and early symptom, and can sometimes be partially managed with diphenylhydantoin, carbamazepine, or gabapentin. Patients should be encouraged to identify and try to avoid their personal precipitating factors. For the primary or secondary prevention of stroke and other vascular pathologies, such as retinal artery occlusion, antiplatelet, and anticoagulant therapy might be needed.

Metoclopramide and pancrelipase are used to reduce GI symptoms. Hypertension must be controlled, as it significantly affects three of the most affected organs, the kidney, brain, and heart. Angiotensin receptor blockade should be undertaken at the first sign of proteinuria and is an important adjunct to ERT in slowing the decline in renal function. Fabry patients are good candidates for kidney transplant in the event of end-stage renal failure and the role of ERT in this situation is to preserve the function of other organs. Ancillary care from a cardiac perspective includes consideration of antiarrhythmics, artificial pacemakers, and surgery, including septal ablation or even cardiac transplant.

SPECIFIC THERAPEUTICS: ENZYME REPLACEMENT THERAPY

Two formulations of ERT have been developed, agalsidase β (Genzyme, Massachusets, USA) and agalsidase α (Replagal, Shire HGT). Only agalsidase β is licensed in the United States, whereas both formulations are available in most other parts of the world. Agalsidase β is administered at a dose of 1.0 mg/kg biweekly and is manufactured using a recombinant technology in a Chinese hamster ovary (CHO) cell line. Agalsidase α is given at a dose of 0.2 mg/kg biweekly and is manufactured using a gene activation methodology in a human fibroblast cell line. The efficacy of both ERT formulations has been demonstrated in randomized controlled trials[69,70,71] and both improve biochemical (e.g., levels of Gb3 in plasma, urine, and tissue biopsy) and clinical parameters. The main clinical parameters chosen for study are renal function, pain, cardiac size and function, and quality of life. Longer term trials have been reported for both preparations. Long-term effectiveness has been demonstrated in Registry studies of agalsidase α. Both preparations are considered safe and well tolerated. The main side effects are infusion related (fever, temperature) and both preparations can induce antibody formation. However, the impact of antibodies on clinical effectiveness has not been demonstrated. The two ERT formulations are generally considered to be of equivalent effectiveness. The optimum time for commencement of treatment has not been established. ERT is recommended for all symptomatic males and at the first sign of organ dysfunction in females. Patients receiving ERT should be regularly monitored with serial measurements of pain, quality of life, and renal and cardiac function. Their data should be entered onto Registries wherever possible.[72] ERT has been shown to improve hearing and GI symptoms. Direct beneficial effects of ERT on CNS abnormalities have not been demonstrated and enzyme cannot cross the blood brain barrier.

NEW TREATMENTS[73]

Chaperone-based enzyme enhancement therapy (phase III clinical trial by Amicus/Glaxo Smith Klein) consists of small molecules that rescue misfolded/mistrafficked enzymes from the lysosomes and transport them to the endoplasmic reticulum. Chaperone-based therapy can be administered orally but is useful only for patients with residual enzyme activity. Substrate deprivation (inhibition of an early step in the synthesis of glycosphingolipids) and the infusion of galactose are other therapeutic options that are still in the research state. Gene therapy and hematopoietic cell transplantation are still being developed.

GENETIC COUNSELING

All families that have a member with Fabry disease should have an opportunity to receive genetic counseling. Given the X-linked nature of Fabry disease, female patients have a 50% chance of transmitting the gene both to their sons and daughters, while male patients will have no affected sons and 100% of daughters are affected. The genotype–phenotype variability should also be stressed especially among patients with subtle manifestations.

KEY REFERENCES

Full reference list available at www.DIGM8.com

DVD contains references and additional content

1. Mehta A, Hughes DA: (updated March 2011) Fabry Disease in: GeneReviews at GeneTests: Medical Genetics Information Resource [database online]. Copyright, University of Washington, Seattle. 1997–2008. Available at http://www.genetests.org
9. Orteu CH et al: Fabry disease and the skin: data from FOS the Fabry outcome survey. *Br J Dermatol* **157**:331, 2007
17. Navarro C et al: Fabry disease: an ultrastructural comparative study of skin in hemizygous and heterozygous patients. *Acta Neuropathol (Berl)* **7**:1, 2006
21. Cox-Brinkman J et al: Three-dimensional face shape in Fabry disease. *Eur J Hum Genet* **15**:535, 2007
28. Amann-Vesti BR et al: Severe Lymphatic micrangiopathy in fabry disease. *Lymphat res Biol* **1**:185, 2003
31. Hilz MJ et al: Enzyme replacement therapy improves function of C-adelta-, and Abeta-nerve fibers in Fabry neuropathy. *Neurology* **62**:1066, 2004

33. Lidove O et al: Hyperhidrosis: a new and often early symptom in Fabry disease. International experience and data from the fabry outcome survey. *Int J Clin Pract* **60**:1053, 2006
37. Mehta A et al: Fabry disease defined: Baseline clinical manifestations of 366 patients in the Fabry Outcome Survey. *Eur J Clin Invest* **34**:236, 2004
56. Waldek S et al: Life expectancy and cause of death in males and females with Fabry disease: Findings from the Fabry Registry. *Genetics in Medicine* **11**(11):790-796, 2009
72. Mehta AB et al: Evidence of benefit of 5 years of enzyme replacement therapy with agalsidase alfa in patients with Fabry disease – a report from the Fabry Outcome Survey (FOS). *Lancet* **374**:1986, 2009

Chapter 137 :: Lipoid Proteinosis and Heritable Disorders of Connective Tissue

:: Jonathan A. Dyer

Inherited connective tissue disorders are clinically and genetically diverse conditions affecting the skin, joints, and a variety of extracutaneous tissues, including the cardiovascular (CV) system. The nature and severity of the skin phenotype is dependent on the type of mutation as well as the role of the affected protein on dermal structure and function (see Chapter 63). The diagnosis of many inherited connective tissue disorders is clinical, although CLIA-approved genetic testing is increasingly available. A listing of research laboratories that may offer testing can be found at http://www.genetests.org.

EHLERS–DANLOS SYNDROME

EHLERS–DANLOS SYNDROMES AT A GLANCE

- Combined incidence of almost 1 in 5,000 persons.
- Seven subtypes.
- Most commonly autosomal dominant (classical and hypermobile types).
- The gene encoding collagen V is most often affected.
- Cutaneous features include soft, velvety skin that bruises easily and wounds that heal as thin, atrophic, gaping scars.
- Extracutaneous manifestations include hypermobile joints with frequent dislocations, problems with pregnancy and delivery, and, less commonly, cardiovascular manifestations, particularly aortic root dilatation.
- Information for patients and professionals at http://www.ehlers-danlos.org and http://www.ednf.org.

A variety of genetically and clinically heterogeneous inherited conditions characterized by varying degrees of skin fragility and hyperextensibility, joint hypermobility, and easy bruising, have been collected under the rubric of the Ehlers–Danlos syndromes (EDS). A new classification system was proposed in 1997[1] to consolidate and simplify existing subgroups (Table 137-1). Despite these revisions, many patients defy clear-cut classification due to overlapping features. The spectrum of EDS disease severity ranges from nearly imperceptible findings to severe, debilitating disease. As such, it is difficult to estimate EDS prevalence, but if milder forms are included it may be as high as 1:5,000 individuals. The kyphoscoliosis, arthrochalasia, and dermatosparaxis types are considerably less common than the classical, hypermobility, and vascular types. Confusion over the diagnosis of the hypermobility type and its overlap with joint hypermobility syndrome interferes with prevalence estimates. If inclusive definitions are used, it may be the most common subtype. Generalized joint hypermobility is the consistent and unifying finding in all forms of EDS.[3] EDS types other than the common classic type and the life-threatening vascular type are discussed in the online edition of the book.

CLASSICAL TYPE

EPIDEMIOLOGY. Classical EDS occurs in 1 in 10,000–20,000 newborns.[4]

ETIOLOGY AND PATHOGENESIS. Approximately half of classical EDS cases are caused by autosomal dominant (AD) defects in the α1 or α2 chain of type V collagen (COL5A1 and COL5A2). Type V collagen is a minor fibrillar collagen that regulates collagen fibril diameter. These mutations may result in dominant negative or haploinsufficient states and approximately one-third of cases are due to haploinsufficiency of the *COL5A1* gene.[5] Recently, mutations in the signal peptide region of COL5A1, which disrupt type V collagen secretion, have also been identified in patients with classical EDS.[6] An additional locus may exist, as several families do not exhibit linkage to *COL5A1* or *COL5A2*.[7,8]

TABLE 137-1
The Ehlers–Danlos Syndromes: Clinical Subtypes and Associated Defects

Villefranche Type/ (OMIM)	Clinical Features	Inheritance	Protein/(Gene Defect)
Classical/(130000 and 130010)	Hyperextensible skin; easy bruising; wide, atrophic scars; hypermobile joints	AD	Collagen type V/(*COL5A1*, *COL5A2*)
Hypermobility/(130020)	Smooth, velvety skin; joint hypermobility	AD/AR	Unclear for most; collagen type III; tenascin XB/(*COL3A1*; *TNXB*)[a]
Vascular/(130050)	Thin, translucent skin with easy bruising; arterial and visceral rupture; typical facies	AD	Collagen type III/(*COL3A1*)
Kyphoscoliosis/(225400 and 229200)	Atrophic scars, easy bruising; neonatal hypotonia; scoliosis; ocular rupture; marfanoid habitus	AR	Lysyl hydroxylase/(*PLOD1*)
Arthrochalasia/(130060)	Hyperextensible and fragile skin; severe joint hypermobility; congenital hip dislocation	AD	Collagen type I/(*COL1A1*; *COL1A2*)
Dermatosparaxis/(225410)	Severely fragile, sagging, redundant skin; hernias and premature rupture of fetal membranes	AR	Procollagen I *N*-peptidase/(*ADAMTS2*)
Other types[a]	Wrinkled, loose facial skin; curly fine hair; scanty eyebrows and eyelashes	AR	Due to mutations in galactosyltransferase
Progeroid variant[2]/(130070)			

AD = autosomal dominant; AR = autosomal recessive; OMIM = Online Mendelian Inheritance in Man.
[a]Few reported cases.

Patients with features of classic EDS exhibiting defective type I collagen due to AD *COL1A1* mutations have also been described.[9] These patients have nonglycine substitutions in the type I collagen triple helical domain and, during adulthood, some have developed vascular complications, including spontaneous arterial rupture, similar to the complications of the vascular EDS subtype.[10] An autosomal recessive (AR) "cardiac valvular subtype of EDS" exhibits clinical findings of classic EDS as well as the onset of severe cardiac valve problems later in life and results from total loss of the proa2(I) chains of type I collagen due to homozygous or compound heterozygous mutations in COL1A2.[11] An AR form of EDS resembling a mild version of classic EDS can result from homozygous tenascin-X (TNX) deficiency. Heterozygotes (especially females) for these mutations may exhibit hypermobility EDS.[12]

Electron microscopy of the skin in EDS reveals thickened collagen fibrils, highlighting the role of type V collagen in regulating their size. It is proposed that the amino terminus of α1(V) carries a negative charge, conferred by abundant tyrosine residues, and appears to limit fibril growth. Less than 5% of fibrils may exhibit "collagen cauliflowers," which are rare composite fibrils.[13–15]

CLINICAL FINDINGS.

Patients with classic EDS typically exhibit some degree of skin and joint hyperextensibility, tissue fragility, and bruising. In the past, patients exhibiting very mild features were termed "mitis." Typical patients have hyperextensible skin (Fig. 137-1) that recoils easily to its normal position after stretching, in contrast to the skin in cutis laxa (CL). Skin hyperextensibility should be assessed by pulling until resistance is met at a site not subjected to mechanical forces or scarring, such as the volar surface of the forearm. The normal upper limit of extensibility

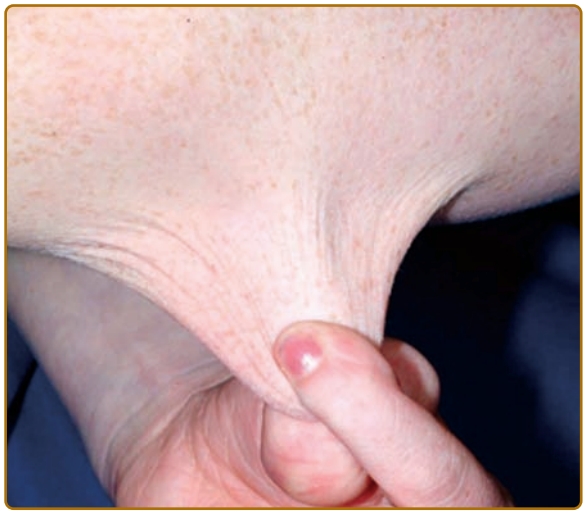

Figure 137-1 Classical Ehlers–Danlos syndrome. Dermal elasticity is demonstrated. Unlike cutis laxa, the skin returns to original shape after stretching.



Figure 137-2 Classical Ehlers–Danlos syndrome. Chronic discolored scars on the shin and ankle after repeated trauma. This is often associated with firm subcutaneous nodules that can be confused with subcutaneous granuloma annulare. Note the widened scar at the knee area.

at the volar forearm is 1–1.5 cm. Skin overlying extensor joints tends to be redundant and should not be used to assess extensibility.

The skin is velvety, thin, and bruises easily. Fetuses with classical EDS may exhibit growth retardation, hernias, and joint dislocations. Bruising manifests early in childhood and is often persistent in areas prone to trauma in young children, especially the shins (Fig. 137-2) Tissue fragility can be striking, with seemingly innocuous trauma resulting in disproportionately large skin tears that are relatively painless without excessive bleeding. Wounds often gape.

Even with surgical repair, wounds in EDS often exhibit slow healing and frequent infection. Postoperative wound dehiscence is common if wounds are not adequately secured, often necessitating repeated repairs or secondary intention healing (Fig. 137-3). Even with surgical repair, dehiscence upon suture removal may occur. Healed wounds result in atrophic, often widened cigarette paper-like (or "fish mouth") scars, especially on pressure points (knees, elbows, forehead, chin) (Figs. 137-2 and 137-3). Hematoma formation, especially at pressure points, often results in persistent hyperpigmentation. Calcification and fibrosis of hematomas produce subcutaneous, nodular molluscoid pseudotumors, most frequently around the elbow and knee. These are often associated with scars. Spheroids are small subcutaneous spherical hard nodules, usually on the forearms



Figure 137-3 Classical Ehlers–Danlos syndrome. After suturing for a laceration, the wound dehisced with secondary infection and marked widening. Note the evidence of former sutures at the lower border, now 3 weeks after the injury and treatment with antibiotics. Scars tend to stretch further in the 6 months after closure.

and shins that may become calcified and thus detectable radiographically. Additionally, subcutaneous fat herniation on the medial or lateral aspects of the heels or wrists with pressure (piezogenic pedal papules) may be seen. Acrocyanosis and chilblains have also been described in affected individuals.

Joint hypermobility is frequent (Fig. 137-4), and often greatest at the fingers and/or wrists. In suspected patients, including older children and adolescents, it is assessed using the Beighton scale Table 137-2).[1,3] Sprains, dislocations or subluxations, scoliosis, and pes planus are common complications and patients frequently describe chronic joint and limb pain, although skeletal radiographs may be normal.[16] Patients are



Figure 137-4 Classical Ehlers–Danlos syndrome. Hyperextensibility of digits is demonstrated.

TABLE 137-2
Beighton Criteria for Joint Hypermobility

1. Passive dorsiflexion of the fifth finger >90°
2. Passive apposition of the thumbs to the flexor aspect of the forearm (Beighton sign)
3. Hyperextension of the elbow >10°
4. Hyperextension of the knees >10°
5. Ability of the palms to completely touch the floor during forward flexion of the trunk with knees fully extended

Numbers 1–4 are scored for each side, so that a maximal score of two is possible if both left and right sides show criteria; number 5 is scored as 1. A score of ≥5/9 is hypermobile.

typically "double-jointed" and often able to perform various "tricks" with their joints as a result. Such chronic and excessive joint hypermobility frequently leads to early-onset osteoarthritis. Osteoporosis is more common when compared to age-matched controls. Muscle hypotonia and delayed gross motor development are also described. EDS may carry a diagnosis of chronic fatigue syndrome or fibromyalgia due to persistent fatigue and chronic pain.

Most patients with classic or hypermobile EDS are able to extend the tongue to touch the tip of the nose (Gorlin's sign) (Fig. 137-5), although this sign can be displayed by ~10% of individuals without inherited disorders of connective tissue. Lack of lingual and labial frenulae has recently been noted to be a minor feature of EDS, and is particularly common in patients with the vascular type[17] Hypermobility and absence of the frenulae allow some EDS patients to "swallow" their own tongue (eFig. 137-5.1 in online edition). Hiatal and postoperative hernias as well as anal prolapse have been noted as manifestations of the tissue hyperextensibility and fragility.[18] Sexual dysfunction, including dyspareunia is reported, and functional bowel disorders occur in up to half of patients.[19]



Figure 137-5 Classical Ehlers–Danlos syndrome (EDS). Gorlin's sign is the ability to touch the tip of the nose with the tongue and is described in approximately 50% of patients with Ehlers–Danlos, in contrast to 10% of individuals who do not have EDS.

Approximately 40%–50% of affected individuals (in addition to ~20% of infants born to affected mothers) are born prematurely (32–37 weeks), either due to premature rupture of fetal membranes or chorioamnionitis.[20,21] Monitoring during pregnancy and the postpartum period is recommended, because of the risk of premature labor during the third trimester, the increased risk for skin tears, postpartum hemorrhage, and uterine/bladder prolapse.[19] The fragility of the already abnormal connective tissue may be worsened by the effect of pregnancy-related hormones that soften connective tissue, such as relaxin.

Patients with classical EDS occasionally exhibit structural heart malformations. Mitral valve prolapse (MVP), and less often tricuspid valve prolapse, may occur and recent reports suggest that aortic root dilatation may occur more frequently than past studies indicated.[22] Arterial rupture, intracranial aneurysms, and arteriovenous fistulae have been described in classic EDS, typically in patients exhibiting severe clinical phenotypes, but are much less common than in Marfan syndrome. Baseline echocardiography with measurement of aortic diameter is recommended,[19,22] with CT or MRI exams if needed.[16] Longitudinal data on progression of aortic dilatation in classic EDS do not exist. The current recommendation is yearly echocardiogram if cardiac abnormalities (aortic dilatation, MVP) are present. If no abnormalities are noted, subsequent studies are only recommended as dictated by symptoms. β-blocker therapy has been successful anecdotally.

VASCULAR TYPE

EPIDEMIOLOGY. This is the most clinically significant EDS subtype due to the risk of arterial or major organ rupture. Inherited in an AD fashion, the incidence is approximately 1 in 100,000–200,000 individuals.[4]

ETIOLOGY AND PATHOGENESIS. Vascular EDS is associated with dominant negative mutations in the type III collagen gene (*COL3A1*), resulting in reduced amounts of type III collagen in the dermis, vessels, and viscera, as well as decreased production and secretion of type III collagen by cultured fibroblasts.[35] More than 320 different mutations have been reported (exon-skipping or missense) and typically lead to disruption of the triple-helical structure of type III collagen. As type III collagen is a homotrimer, mutant proα1(III) chains affect most fibrils, interfering with secretion, and leading to intracellular accumulation. Type III collagen plays an important role in the integrity of both blood vessel walls and the upper dermis. Analysis of type III procollagen and collagen chains and direct genetic testing of *COL3A1* have been utilized to test for vascular EDS.

CLINICAL FINDINGS. The classic quadrad of vascular type of EDS includes a characteristic facial appearance (which may be subtle), thin, translucent



Figure 137-6 Vascular Ehlers–Danlos syndrome. The venous pattern is apparent in a fair-skinned individual. (In order to enhance visibility of the venous network, the image was colorized.)

skin with a prominent venous pattern (Fig. 137-6), extensive bruising or hematomas, and vascular or visceral rupture (or both).[18] Joint hypermobility is usually minimal and limited to the digits. The facial features include a thin nose and upper lip, small earlobes, and sunken, pigmented periocular regions. Subcutaneous fat is decreased, especially of the face and limbs. Widened, thin (papyraceous) scars may be noted on bony prominences. Hematomas, which may be frequent and/or quite large, may develop after minimal to no trauma, such as sphygmomanometer inflation.

Spontaneous rupture of arteries, particularly mid-sized arteries, may occur during childhood, although its peak age of incidence is the third or fourth decade of life. Mesenchymal abdominal, splenic, and renal arteries are often involved, as is the descending aorta. Aortic rupture/dissection is typically not preceded by detectable aortic dilatation,[22] occurs distal to the mid-aortic arch, and exhibits distal extension. Arterial or intestinal rupture often presents as acute abdominal or flank pain; arterial rupture is the most common cause of death. Stroke is also reported in vascular EDS. Pregnancies may be complicated by pre- and postpartum arterial bleeding, and by intrapartum uterine rupture. Pregnancies carry a 12%–25% fatality rate[20,36] Vaginal and perineal tears from delivery heal poorly and caesarean wounds often dehisce.[4]

LABORATORY FINDINGS. Routine histopathologic examination of the skin from EDS patients is typically normal. Electron microscopy demonstrates abnormalities in the appearance of collagen fibrils as noted above. Despite the bruising and increased bleeding, tests of platelet function and coagulation are usually normal, further highlighting the underlying defects in skin and blood vessel structural integrity. As noted above for specific subtypes, while genetic diagnosis is possible, especially as a research tool, a variety of biochemical tests are available as well.

DIFFERENTIAL DIAGNOSIS. EDS must be distinguished clinically and histologically from CL. In CL, the hyperelastic skin does not return to its normal position after stretching. The kyphoscoliotic and hypermobility forms of EDS must be distinguished from Marfan syndrome, which additionally is characterized by ectopia lentis and characteristic skeletal abnormalities. Molluscoid pseudotumors of the lower legs may mimic subcutaneous granuloma annulare. The easy bruisability and poor wound healing of EDS patients has led to concerns of child abuse.

Vascular EDS exhibits significant clinical similarities to Loeys–Dietz syndrome type 2, an aortic aneurysm syndrome caused by mutations in transforming growth factor (TGF)-β receptor 1 and 2 (*TGFBR1* and *TGFBR2*) genes. These patients also exhibit skin findings including velvety translucent skin, easy bruising, and widened, atrophic scars.[60] Prior to detection of arterial anomalies Loeys–Dietz syndrome patients may be misdiagnosed as classic or hypermobility EDS.

TREATMENT AND PREVENTION

A multidisciplinary preventative strategy is the most productive approach to the management of EDS patients. Early identification of affected patients with appropriate intervention (pain management, physical therapy, surgery) and education is important.[68–70] Nonweight-bearing exercise (swimming) can promote muscle development. Exercise regimens are typically designed to strengthen muscles to stabilize joints and relieve stress. Physical therapy focused on shoulder girdle strengthening, has decreased the frequency of shoulder dislocations in patients with a history of chronic or recurrent dislocation. Some patients use orthopedic devices such as orthotics and braces with benefit.

Avoiding and preventing injuries is of great importance. Assessment of the home environment with modifications to make homes "EDS safe," such as avoiding hard, sharp edges on furniture and arrangement to prevent or minimize falls, can be helpful. Patients with significant skin fragility or bruising may require protective padding or bandaging and should avoid contact sports and heavy exercise.

When cutaneous wounds do occur, they should be sutured using both subcuticular and cuticular sutures, which are tightly spaced and left in place for a prolonged duration (at least twice as long as standard). Adhesive tapes, bolsters, or pressure bandages are necessary to aid healing, diminish scarring, and lower the risk of hematoma and pseudotumor formation. Close monitoring for postoperative infection is critical and preventative antibiotic therapy is often employed. Pseudotumors of the elbows or knees are typically more easily surgically removed than those on the heels.

Ongoing rheumatologic and orthopedic care may be required to prevent progressive joint disease in certain patients. Low-impact sports are preferable to contact sports and weight training in patients with hypermobility EDS. Ascorbate therapy (~2 gm/day in adults with proportional decreases in pediatric patients) may improve bruising (but not other findings) in classic EDS.

Anti-inflammatory drugs may improve the musculoskeletal pain associated with EDS, but those interfering with platelet function (especially aspirin) should be avoided in patients with significant bruising. Patients with valvular heart disease should be followed by cardiologists, and a baseline echocardiogram with measurement of aortic diameter is recommended before 10 years of age.[25]

Joint dislocation (with the exception of congenital dislocation of the hip) in EDS typically spontaneously resolves or can be remedied with closed reduction. Patients with hypermobility EDS may benefit from a variety of physical therapy interventions, such as myofascial release therapies and low-resistance exercises for muscle toning. Exercise progression should involve increasing the number of repetitions, frequency, or duration of exercise, rather than increasing resistance and should progress slowly. Pain from writing utensils can be lessened by altering the grip to rest the shaft of writing utensils on the thenar web and holding the tip between the index and ring fingers. Transvaginal pelvic physical therapy has been successfully utilized for abdominal and back pain as well as radicular pain of the lower extremities and dyspareunia. Braces are commonly used to stabilize joints. Intervention is typically multidisciplinary and should involve rheumatology, orthopedic surgery, physical and occupational therapy, and pain management specialists as appropriate. Pain in hypermobility EDS is often undertreated. While reparative or corrective surgeries are often delayed as long as possible, the perioperative complication rate in patients with hypermobility EDS is not increased. Gastrointestinal (GI) symptoms may be quite troublesome and require aggressive therapy with proton pump inhibitors, H2-blockers, and other agents. Calcium and vitamin D supplementation is typically encouraged.[31]

Patients with vascular EDS should refrain from contact sports or isometric exercise and avoid medications, which impair platelet function. The traditional recommendation has been that invasive vascular procedures should be avoided, unless absolutely necessary (such as with arterial rupture), due to the extremely high risk of vascular rupture. When performed, tissues must be handled with extreme caution due to pronounced intraoperative tissue fragility. A recent series suggested early intervention by skilled surgeons and provided suggestions for management.[71] Studies examining the use of β-blockers in vascular EDS are in progress.

Fatigue is a common finding in EDS of most types, present in over three-fourth of patients. It appears most common in hypermobility EDS, but is seen in other forms as well. Contributing factors include disruptions of sleep, impaired self-efficacy, and pain.[72] A variety of neuromuscular findings, including reduction in vibration sense and mild-to-moderate muscle weakness, were commonly found in a small group of multiple types of EDS. These symptomatic findings correlated with myopathic features on needle electromyography (EMG) (a mixed neurogenic–myopathic pattern in 60%) as well as muscle ultrasound showing increased echo-intensity and atrophy. The subset of patients with hypermobility EDS resulting from TNX-B haploinsufficiency seem to have fewer neuromuscular issues, although TNX levels correlate inversely with neuromuscular symptoms.[73]

Pregnancy in the EDS patient should be considered high-risk. The effects of hormonally mediated connective tissue softening on the abnormal connective tissue of EDS have not been studied, but may account for the increased skin fragility, as well as other EDS sequelae, that occur during pregnancy and the immediate postpartum period. Prenatal diagnosis is possible by genetic and biochemical analyses. Unless children are severely affected by their disorder, they generally adjust well to the skin findings and joint hypermobility. The Ehlers–Danlos Foundation is a national support group (www.ednf.org).[70]

MARFAN SYNDROME

MARFAN SYNDROME AT A GLANCE

- Incidence: 1 in 5,000–10,000 (OMIM #154700).
- Autosomal dominant inheritance with mutations in fibrillin 1 (*FBN1*; chromosome 15q21.1).
- Cutaneous features include striae distensae (two-thirds of patients), inguinal or incisional hernias, and, rarely, elastosis perforans serpiginosa.
- Extracutaneous manifestations include hyperextensible joints, upward lens displacement, skeletal abnormalities, and cardiac aberrations, such as aortic aneurysm and rupture.
- Information for patients and professionals at http://www.marfan.org.

EPIDEMIOLOGY

Marfan syndrome is an AD disorder primarily affecting the skeletal, ocular, and CV systems.[74] About 25% of cases occur sporadically, particularly in patients born of older fathers. Parental germline mosaicism has been described.[75] The overall prevalence of Marfan syndrome is estimated at approximately 1:5,000–10,000 persons with no racial, gender, or geographic predilection.[76] The prognosis for patients with Marfan syndrome has improved over the past three decades due to better medical and surgical treatments.[77]

ETIOLOGY/PATHOGENESIS

While standard histopathology of affected skin appears normal, with electron microscopy dermal collagen in Marfan syndrome exhibits abnormal thickness, array,

and shape, including fibrils of variable thickness, disarray, twisted fibrils, and fibrils with a flower-like appearance and ragged margins, similar to those found in EDS. The content ratio of collagen I to collagen III is also decreased.[32] Recently, defects in the architecture of the collagen microfibrils of large vessels, rather than collagen content or cross-linking, have been described.[78] The resultant architecture is similar to that seen in abdominal aortic aneurysms and is proposed to explain the weakened aneurysmal vessels in Marfan syndrome.

Marfan syndrome results from heterozygous mutations[79] in the profibrillin 1 gene on chromosome 15q21.1.[80] The spectrum of clinical phenotypes resulting from *FBN1* defects extends beyond classic Marfan syndrome and these disparate conditions have been termed *fibrillopathies/fibrillinopathies*[81] These range from the severe neonatal Marfan phenotype to isolated aortic root dilatation or marfanoid skeletal features without typical CV pathology or ectopia lentis. Fibrillin is a 350-kDa glycoprotein that is a major component of extracellular matrix (ECM) microfibrils, which are structural components of the zonular fibers of the suspensory ligament of the lens and associated with elastic fibers in the aorta and skin. Virtually every family's mutation is different and over 500 mutations have been reported occurring in any of the 65 exons of the gene. No hot spots have been identified, except in cases of neonatal Marfan syndrome. Interestingly, mutations creating premature termination codons appear to lead to milder disease, while those in exons 24–31 are associated with neonatal Marfan syndrome and more severe disease.[76,82] Marfan syndrome type II is caused by mutations at the *TGFBR2* gene locus.

Fibrillin interacts with latent TGF-β binding protein, sequestering it, and controlling TGF-β availability. Deficiency of fibrillin increases TGF-β availability and fibrillin-1 mutation leads to constitutive activation of latent TGF-β with signaling through both "classic" and noncanonical TGF-β pathways. In vascular tissues, TGF-β is believed to be a critical mediator of both the structure and the function of the vascular ECM, via both matrix deposition and degradation. Increased TGF-β signaling enhances ECM degradation, leading to aneurysm development and progression. Stimulation of either TGF-β pathway can also lead to phosphorylation of Smad, which triggers a profibrotic signaling response. Angiotensin II signals through two receptor types, type 1 (AT1) and type 2 (AT2), which exhibit opposite signaling effects. Angiotensin II signaling through AT1 also increases expression of TGF-β ligands and receptors and stimulates vessel wall fibrosis. In addition to the action of activated TGF-β, macroaggregates of fibrillin monomers form the basic scaffold on which mature elastin fibers are assembled; as a result, abnormal fibrillin creates a disordered microfibril matrix that may further lead to disordered and weak elastic fiber formation and disruption of the microfibril network that connects elastic lamellae to neighboring interstitial cells.[83]

Research into the impact of these pathways and their potential therapeutic implications for Marfan syndrome is ongoing. Losartan, a blocker of angiotensin II type 1 receptor, has already shown promise in slowing the aortic root dilatation in individuals with Marfan syndrome. Losartan not only blocks TGF-β but appears to decrease phosphorylation of Smad2 independent of its TGF-β effects. Thus, AT1 blockade may interrupt several pathways, which affect vascular remodeling and disease progression.[84]

CLINICAL FINDINGS

Marfan syndrome is a generalized connective tissue disorder exhibiting abnormalities of three primary organ systems: ocular (typically lens dislocation); skeletal (excessive extremity length, loose joints, anterior chest deformities, and kyphoscoliosis); and most importantly, CV (classically aortic aneurysm and mitral valve redundancy).[81] Many of the typical physical features of Marfan syndrome are age-dependent, making diagnosis in childhood more difficult. No single clinical sign is pathognomonic.[85]

The "Marfanoid habitus" is characteristically dolichostenomelic (tall and thin), with a lower body segment (pubic symphysis to floor) that is longer than the upper segment (height minus lower segment) (Fig. 137-7). Characteristically, the arm span exceeds the person's height by several centimeters. The distal bones are excessively long (arachnodactyly). Skeletal features of Marfan syndrome are characterized by bone overgrowth and joint laxity. Kyphoscoliosis may be severe and increases with the adolescent growth spurt.[86]



Figure 137-7 Marfan syndrome. Frontal view of teenage girl with Marfan syndrome. Note the tall stature, arachnodactyly, abnormally low ratio of the upper segment to lower segment, and long arms.

Thoracic cage abnormalities, such as pectus excavatum (sternal depression) or carinatum (sternal projection), both result from excessive rib overgrowth and are common. The combination of kyphoscoliosis and pectus excavatum rarely compromises cardiopulmonary function. Joint laxity from capsular, ligamentous, and tendinous involvement may cause flat feet, knee or elbow hyperextensibility (genu recurvatum), and occasional joint dislocation. Patellar dislocation is not uncommon; dislocation of the hip, often detected during the newborn period, may be the first sign of Marfan syndrome. Screening tests for joint hypermobility are the thumb (or Steinberg) sign, in which the thumb extends well beyond the ulnar border of the hand when overlapped by the fingers, and the wrist (or Walker–Murdoch) sign, in which the thumb overlaps the fifth finger as they grasp the opposite wrist.[86] The underlying joint hyperextensibility and long extremities of Marfan patients often enable them to reach around their back and touch their umbilicus from the opposite side.

Most patients with Marfan syndrome exhibit myopia due to flattening of the corneas and an abnormally long anterior–posterior orbital axis.[87] An estimated 50%–70% of patients have ectopia lentis, typically with upward lens displacement. Subluxation and complete dislocation of the lens often lead to secondary ocular abnormalities, including ametropia, myopia, acute glaucoma, and increased risk of retinal detachment.[75] As mild displacements may be missed with standard ocular exams, referral to ophthalmology for a dilated slit lamp exam is necessary if a diagnosis of Marfan syndrome is suspected.

CV abnormalities are responsible for the majority of the morbidity and mortality in Marfan patients. CV abnormalities are detected in ~40% of patients with Marfan syndrome by cardiac examination and almost 100% of patients by autopsy examination. Medial necrosis of the aorta is the most common defect and diffuse dilatation of the proximal segment of the ascending aorta with aortic regurgitation often occurs. Such dilatation is progressive, and may even be detected in utero. The progression of dilatation is not always continuous and this unpredictability mandates frequent monitoring.[88] Death in Marfan patients usually occurs in adulthood as a result of CV sequelae, most commonly secondary to dilatation of the aortic root,[89,90] leading to aortic dissection or rupture and pericardial tamponade. MVP results from dilation of the mitral valve annulus, with stretching of the chordae and MV leaflet redundancy. It occurs in ~25% of affected children and adolescents, and in 86% with associated pectus excavatum.[91] MVP increases with age, and eventually occurs in ~75% of patients.[92] MVP may lead to abnormal findings on electrocardiogram, mitral valvular regurgitation, and even cardiac arrhythmias leading to sudden death.[74]

Lack of subcutaneous fat and the presence of striae, most prominent on the upper chest, arms, thighs, and abdomen, are the most common cutaneous manifestations of Marfan syndrome. These cutaneous features are found in up to two-third of patients. Elastosis perforans serpiginosa (see Chapter 69) is more common in individuals with Marfan syndrome, and inguinal or incisional hernias may occur. Skin findings are considered minor diagnostic features in the revised diagnostic criteria.[93]

Dural ectasia (stretching of the dural sac in the lumbosacral region) often develops in patients with Marfan syndrome. Emphysema has been described, and lung bullae increase the risk of pneumothorax, particularly involving the upper lobes. Oral findings may include a high-arched palate and crowding of anterior teeth.

NEONATAL MARFAN SYNDROME

Infants with the neonatal form of Marfan syndrome have the body disproportion of Marfan syndrome in addition to lax skin, emphysema, ocular abnormalities, joint contractures, kyphoscoliosis, adducted thumbs, crumpled ears, micrognathia, muscle hypoplasia, and deficient subcutaneous fat over joints.[94,95] Severe cardiac valve insufficiency and aortic dilatation result in death during the first 2 years of life.

MARFAN SYNDROME IN PEDIATRIC PATIENTS

A recent large retrospective study highlighted clinical features of children in a cohort of more than 1,000 patients with *FBN1* mutations. The median age of diagnosis was 6.5 years, and only 30% had a positive family history. Patients with neonatal Marfan syndrome represented 14% of the cohort. Of the affected children, 19% were noted to be severely affected, 32% to have classic Marfan, and 35% of the patients to have probable Marfan syndrome. In the pediatric population, 71% already exhibited dilatation of the ascending aorta. Ectopia lentis was present in approximately half and typical marfanoid skeletal findings in 28%. Aortic arch dilatation was more common in neonatal cases; however, aortic complications were rare in childhood. In uncertain cases the identification of *FBN1* mutations often aided diagnosis. While neonatal Marfan syndrome represents a severe de novo early-onset form with associated high mortality, patients diagnosed after adolescence typically resembled adult patients in phenotype. Milder cases were more often had a positive family history, likely because milder cases are more commonly survived to reproductive age. Importantly, pediatric patients often did not meet international criteria for the diagnosis of Marfan syndrome at the time of first examination. As the features of the syndrome increase with age, follow-up examination is critical in suspected pediatric cases to identify affected patients.[76]

LABORATORY INVESTIGATION

The diagnosis of Marfan syndrome is based on a constellation of clinical findings. There is no diagnostic laboratory test or histologic abnormality. Increased urinary hydroxyproline and desmosine are not consistent findings. Ophthalmologic examination by an experienced ophthalmologist with interventions as necessary should be performed as early as possible. Orthopedic

BOX 137-1 DIFFERENTIAL DIAGNOSES FOR MARFAN SYNDROME

DISORDER	CLINICAL SIMILARITIES TO MARFAN	CLINICAL DIFFERENCES FROM MARFAN	DEFECT
Homocystinuria	Dolichostenomelia Orthopedic abnormalities Ectopia lentis (downward displacement)	Elevated fasting homocysteine levels AR	Cystathionine β synthetase deficiency causes abnormal methionine metabolism and increased levels of urinary homocysteine
MASS (*M*itral valve prolapse; *A*ortic root diameter; *S*tretch marks; *S*keletal features) syndrome	Mitral valve prolapse Myopia Skin—striae Skeletal findings AD	Borderline aortic enlargement is not progressive	Heterozygous fibrillin 1 mutations
Mitral valve prolapse (MVP) syndrome	Mitral valve prolapse Skeletal findings AD	Lack of other features	Fibrillin 1
Familial ectopia lentis	Ectopia lentis Skeletal changes	Questionable risk of eventual aortic enlargement: Current recommendations are for periodic imaging	Heterozygous fibrillin 1 mutations
Shprintzen–Goldberg syndrome	Dolichostenomelia Arachnodactyly Scoliosis Pectus Highly arched palate Occasional aortic root enlargement	Craniosynostosis Developmental delay Hypertelorism Proptosis Rib anomalies Chiari malformation Equinovarus deformity	Fibrillin mutations not present in most cases
Loeys–Dietz syndrome (LDS)	Generalized arterial tortuosity with aneurysms and dissection occurring throughout Aneurysms more labile than Marfan syndrome Early dissections and ruptures even in childhood AD	No ectopia lentis Dolichostenomelia less frequent/obvious Hypertelorism Cleft palate with broad/bifid uvula Learning disabilities Chiari I malformation Hydrocephalus Blue sclerae Craniosynostosis Talipes Exotropia Soft, velvety, translucent, easily bruised skin	Mutations in *TGFBR1* and *TGFBR2* have been detected
Familial thoracic aortic aneurysms and aortic dissection (FTAAD) syndrome	Vascular disease AD	No other typical clinical features	*TGFBR2* mutations and other loci
Ehlers–Danlos syndrome (see above)	Kyphoscoliotic form EDS may exhibit increased risk for rupture of medium-sized arteries Vascular EDS has joint laxity (often only small joints), translucent skin, characteristic facies, organ rupture, and tendency for aneurysm or dissection of medium to large muscular arteries AD	Vascular pathology not limited to the aortic root, although this may be involved	
Weil–Marchesani syndrome	Ectopia lentis	Orthopedic features differ Short stature Brachydactyly Spherophakia Stiff joints	
Congenital contractural arachnodactyly (CCA; Beals syndrome)	Congenital contractures (elbows, knees, hips, and fingers)—improve with time Ocular (keratoconus) and/or cardiovascular (aortic root dilatation, mitral valve prolapse, and septal defects) findings rare Arachnodactyly, progressive severe kyphoscoliosis High, arched palate Muscular hypoplasia/weakness	Characteristic folded upper helix—"crumpled" appearance of ear—improves with time	Defects in second fibrillin gene (*FBN2*- typically in the "neonatal region" of exons 23–34)[96] Likely locus heterogeneity[97,98]

evaluation as needed and echocardiographic monitoring of aortic root size and valvular function is paramount with cardiology involvement depending on the findings.

DIFFERENTIAL DIAGNOSIS

Marfan syndrome is rarely confused with disorders other than homocystinuria (see online edition of this book). However, a variety of conditions exhibit partial phenotypic overlap with Marfan syndrome, including some also caused by fibrillin-1 mutations. These are summarized in Box 137-1.

TREATMENT

Management of Marfan syndrome has focused on prevention of the disabling and life-threatening potential complications. Early and regular ophthalmologic examinations are required to detect correctable amblyopia and retinal detachment. Ectopia lentis and even complete subluxation may be tolerated for decades. Lens extraction may be required to treat diplopia, glaucoma, cataracts, or retinal detachment. Lasix surgery is contraindicated.

Repair of pectus excavatum is appropriate if cardiopulmonary compromise develops, but is delayed until skeletal maturation is nearly complete to prevent recurrence and should utilize internal stabilization.[99] Scoliosis may be lessened in adolescent girls by estrogen therapy, but this may produce an overall decrease in height. Bracing, physical therapy, and vertebral fusion may all be required to prevent severe scoliosis.

A family history of early aortic dissection mandates aggressive monitoring. At a minimum, patients with Marfan syndrome should undergo yearly monitoring. Aortic complications have not been reported in patients with an aortic diameter normal for age or less than 40 mm in diameter (in adults)[74] Long-term propranolol therapy has been administered to prevent aortic dilatation by decreasing myocardial contractility,[100] but may not affect survival.[101] In a small number of children with Marfan syndrome who were recalcitrant to β-blockers, angiotensin II type 1 receptor blockers (losartan and irbesartan) led to a significant decrease in aortic root diameter and dilation of the sinotubular junction. Larger randomized trials examining the effect of these agents are underway.[102] Aneurysmal and valvular heart defects may require prosthetic replacement, but this should be delayed for as long as possible to avoid recurrent prosthesis replacement, particularly in growing children. Replacement of the aortic root has led to increased life expectancy and is indicated once the maximal measurement is greater than 5 cm in adults and older children, the rate of size increase is ~1 cm/year, or progressive aortic regurgitation develops. Patients with known aortic dilatation should avoid caffeine, stressful circumstances, and vigorous exercise. Patients with pulmonary involvement should avoid situations with rapid changes in air pressure, such as scuba diving or flying and, of course, should not smoke.[103]

Doxycycline inhibits matrix metalloproteinase and has been shown to improve aortic wall architecture and delay aortic dissection in mouse models. Future studies may focus on synergy between doxycycline and losartan, as matrix metalloproteinases can activate TGF-β.[77]

Children should be excused from participation in physical education in order to avoid potentially harmful exertion, contact sports, and isometric exercises, which might lead to aortic rupture or congenital heart failure. Unfortunately, this can add to the isolation of a child who may already be concerned about an unusual body image or is socially ostracized because of looking "different" or being excessively tall. Importantly, not all patients with Marfan syndrome exhibit striking "classic" phenotypes. When the diagnosis in a patient with an atypical presentation is suspected, one must make certain that appropriate studies are performed, so that potentially lethal internal manifestations are not neglected. The Web site for the National Marfan Foundation is www.marfan.org.

HOMOCYSTINURIA

HOMOCYSTINURIA AT A GLANCE

- Incidence: 1 in 65,000 to 344,000 (OMIM #236200).
- Autosomal recessive inheritance, mutations in cystathionine β-synthase, chromosome 21q22.3.
- Cutaneous features include malar flush, fair and thin skin and hair, and livedo reticularis.
- Extracutaneous manifestations include downward lens displacement, osteoporosis, mental retardation, thromboembolism, and severe hyperhomocysteinemia.
- Information for patients and professionals at http://www.pku-allieddisorders.org and http://www.hcusupport.com.

PSEUDOXANTHOMA ELASTICUM

EPIDEMIOLOGY

Also known as *Grönblad–Strandberg syndrome*, this rare entity is a multisystem disorder exhibiting progressive calcification of elastic tissue. It occurs in ~1:70,000–160,000 individuals but is likely underdiagnosed. Now classified as an AR disorder, occasional pseudodominance is reported and heterozygous carriers may exhibit a phenotype closely resembling pseudoxanthoma elasticum (PXE)[123] PXE appears to be more severe in female patients.[124] The average age of

PSEUDOXANTHOMA ELASTICUM AT A GLANCE

- Incidence: 1 in 25,000 to 100,000 (OMIM #177850 and #264800).
- Autosomal recessive inheritance, occasional pseudodominant.
- Mutations in multidrug resistance associated protein (MRP6), encoded by (*ABCC6*) on chromosome 16q13.1.
- Cutaneous features include yellow, flat papules in the neck, flexures, and per umbilical areas. Less frequent skin lesions include acneiform lesions, elastosis perforans serpiginosa, reticulate pigmentation, and granulomatous nodules.
- Extracutaneous manifestations include angioid streaks, visual impairment, *peau d'orange* retinal hyperpigmentation, cardiovascular disease, and bleeding.
- Histopathology shows swollen, clumped, fragmented elastic fibers and calcium deposits in the mid and deep reticular dermis. Alterations easily visualized with calcium (i.e., von Kossa) and elastic (i.e., Verhoeff–van Gieson or orcein) stains.
- Information for patients and professionals at http://www.pxe.org and http://www.napxe.org.

diagnosis in patients with a positive family history is 8–12 years.[125]

ETIOLOGY AND PATHOGENESIS

The mutated gene in typical PXE is *ABCC6*, a member of the ATP-binding cassette (ABC) transmembrane transporter family (subfamily C member 6). It encodes multidrug resistance protein 6 (MRP6) and is located on chromosome 16p13.1.[126] Most mutations are unique, although two occur more frequently: (1) *R1141X*, found predominantly in Europe (28.4% of European patients and 18.8% overall) and (2) *ABCC6del23–29*, which occurs at an overall frequency of 12.9% and is most prevalent in US patients (28.4%).[127] MRP6 is expressed primarily in the liver and kidney, two sites not affected by PXE, and little to none is expressed in tissues affected by PXE. Evidence supports the concept that PXE is a "metabolic" disease, with deficiency of hepatic ABCC6 leading to the deficiency of circulating factors necessary to prevent tissue mineralization. This hypothesis is supported by: (1) the progressive nature of the disease; (2) the delayed clinical onset; (3) the inability of serum from PXE patients and Abcc6 null mice to prevent calcium/phosphate precipitation in human smooth muscle cell cultures; and (4) the development of typical calcification in wild-type skin grafted onto a Abcc6 null mouse, but not in Abcc6 null skin grafted onto a wild-type mouse[125]; and (5) the rescue of PXE mice from developing typical PXE changes by parabiotic pairing with normal mice.[128] The great phenotypic heterogeneity exhibited by PXE patients suggests that additional genes or environmental factors contribute to and modify the development of clinical findings. Certain polymorphisms in the promoter of the *SPP1* gene (osteopontin) are more frequent in PXE patients than controls, and one is associated with a significantly reduced PXE risk.

Mutations in *GGCX*, which encodes an enzyme necessary for γ-glutamyl carboxylation of gla proteins, have been described in patients with PXE associated with multiple coagulation factor deficiency.[126] In patients with *GGCX* mutations, PXE, and in *ABCC6* null mice, matrix gla protein (MGP), which prevents tissue mineralization when fully carboxylated, is undercarboxylated. It is thought that a factor, such as vitamin K conjugated with glutathione, is potentially transported by ABCC6 from the hepatocyte to the extracellular space, and necessary for MGP carboxylation. ABCC6 deficiency disrupts this transport, leading to defective MGP carboxylation and inability to prevent peripheral tissue mineralization.[126] In support of this hypothesis, a recent report described significantly lower levels of vitamin K in the serum of patients with PXE.[129]

CLINICAL FINDINGS

Patients with PXE show marked clinical heterogeneity, with some patients displaying lesions of the skin, eye, and systemic vasculature (e.g., GI and coronary vessels),[130] while others in the same family (presumably with the same gene mutations) show only involvement of one system. Typically, the skin in PXE demonstrates yellowish, flat-topped, discrete, and confluent papules in the skin creases of the sides and nape of the neck (Fig. 137-8), perineum, axillae, umbilicus, and flexural folds with skin redundancy that increases with advancing age. These changes are often termed "plucked chicken skin." Calcification of affected skin is common. Multiple comedones have been described in association with the typical skin changes, likely related to elastic fiber degeneration similar to solar elastosis. Perforating periumbilical PXE has also been described.[131] Infiltrative oral, anal, and vaginal mucosal lesions may also occur. The dermatologic features generally begin in the second decade but are often subtle and overlooked. Rarely, progression may lead to diffuse skin involvement and/or CL-like laxity in the flexures. Some authors suggest that prominence of the horizontal and oblique mental creases (which separate the lower lip from the chin) prior to 30 years of age is highly specific for PXE. Skin biopsy can be quite helpful, as the typical histologic findings may be found even with minimal or absent skin lesions.[132] A differential

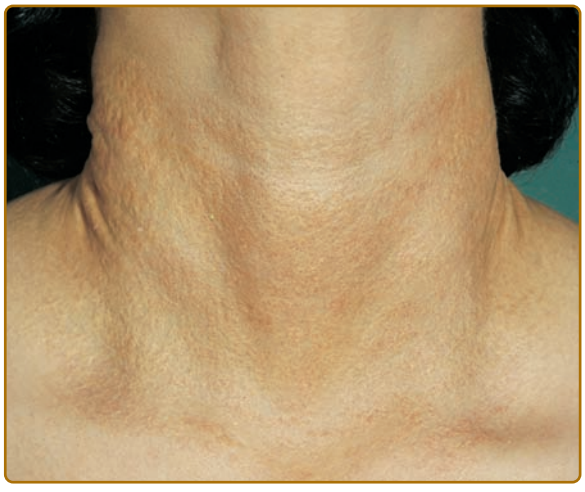

Figure 137-8 Pseudoxanthoma elasticum papules on the neck. There is a distinct yellowish hue. Loose, thickened skin with a pebbled appearance on the neck.

diagnosis for the characteristic skin lesions of PXE is provided in Box 137-2.

Elastosis perforans serpiginosa is reported in patients with PXE (see Chapter 69).[138] Hyperpigmented, reticulated macules, lip telangiectasias, and acneiform and granulomatous lesions have also been described.[138,139] While cosmetic concerns over cutaneous lesions may prompt some patients to seek medical input, it is more commonly a visual or vascular complication, such as a GI tract hemorrhage, which prompts patients to seek medical attention.

The most common ophthalmologic finding is angioid streaks (87% of patients). These are radial curvilinear extensions of gray, brown, or reddish coloration from the optic disc, caused by visualization of the choroid through tears in the elastic-rich Bruch's membrane. Calcification of its outer layer, the lamina elastica, leads to fragility and fissuring. Angioid streaks often develop during the third or fourth decade of life, although the youngest patient described was 10 years of age.[140,141] Angioid streaks rarely interfere with visual acuity and may progress or remain stationary. Trauma is likely a precipitating factor in the development of neovascularization and hemorrhagic complications. Characteristic irregular retinal epithelial mottling ("peau d'orange") is commonly seen resulting from degenerated elastic tissue. Peau d'orange retinal changes precede angioid streaks and are the more common ocular finding in children with PXE. Drusen of the optic nerve have also been described, and drusen-like lesions of the posterior pole have been reported in a 12-year-old boy with PXE.[140] Additional changes reported in PXE include healing subretinal hemorrhages ("salmon patches"); small scars or white foci that represent residua of past hemorrhage ("pearls"); or pigmented foci from previous hemorrhage ("black dots").

Loss of vision in PXE tends to occur later in life and is due to scarring and fibrosis from choroidal neovascularization and retinal hemorrhage. It can lead to a disc-shaped degeneration of the central visual area causing central visual loss, although peripheral vision often remains intact.

Calcification of degenerated elastic tissue of the internal lamina of blood vessels with subsequent hemorrhage and/or intimal proliferation is a common and potentially serious complication of PXE. The GI tract and renal vasculature are sites of early manifestations of this degenerative damage, which often presents as acute-onset hemorrhage in the second to fourth decade. It is estimated that 10%–15% of PXE patients will have at least one GI hemorrhagic event. Both hypertension from renal artery stenosis and GI bleeding (especially gastric) may occur as early as adolescence.[128] Late vascular sequelae in PXE include cerebrovascular accidents (subarachnoid hemorrhage has been a significant cause of mortality in PXE), intermittent claudication (most common) and myocardial infarction. Severe coronary artery disease has been noted, even in adolescents with PXE; coronary artery bypass surgery may be ameliorative.[142] Physical signs may include diminished peripheral pulses, hypertension (three times more common in PXE than the general population), murmurs related to MVP and/or congestive heart failure, and peripheral gangrene. Rectovesical prolapse may also occur.[143] Pulmonary and pulmonary vascular involvement is described, but not common. Pregnancy is not contraindicated, but miscarriage rates may be higher in the first trimester, and multiple pregnancies may accelerate the pace of the disease.[143]

LABORATORY INVESTIGATION

The histologic changes on biopsy of lesional skin from patients with PXE are diagnostic, showing distinctive broken curls of basophilic elastic fibers with routine hematoxylin and eosin or Verhoeff–van Gieson staining (Fig. 137-9). Calcium deposition on elastic fibers can be easily detected with von Kossa stain. Similar dystrophic fibers have been noted histologically as an incidental finding in inflammatory skin diseases in patients who do not have PXE.[144] Electron microscopy shows calcification in a centripetal pattern within

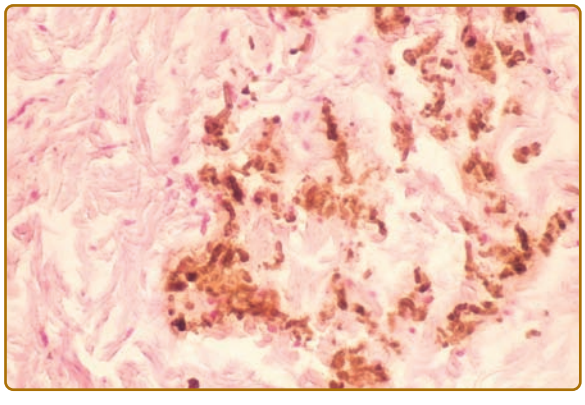

Figure 137-9 Pseudoxanthoma elasticum, elastic tissue stain. The elastic fibers show marked degeneration: They are swollen, tortuous, and irregularly clumped.

BOX 137-2 DIFFERENTIAL DIAGNOSIS OF THE SKIN LESIONS OF PSEUDOXANTHOMA ELASTICUM (PXE)

DISORDER	MORPHOLOGY	DISTRIBUTION	ASSOCIATIONS	DIFFERENTIATION
Dermatofibroma lenticularis[133]	Asymptomatic, flat-topped yellowish papules and nodules, which, when grouped, form large plaques several centimeters in diameter	Often proximal extremities, truncal; symmetric; may be more widespread	Osteopoikilosis, fractures in Buschke–Ollendorff syndrome—due to *LEMD3* (*MAN1*) mutations[133]	Clinical; biopsy shows increased elastic tissue
Localized acquired cutaneous PXE[134]	Asymptomatic, coalescing yellow macules and papules, occasional reticulate or checkered pattern; lax, redundant areas	Neck, axillae, groin, flexural surfaces, areas exposed to saltpeter fertilizer (calcium-ammonium-nitrate)	Older age, exposure to saltpeter fertilizer in Norwegian farmers, uremia	Histology shows fragmented, thickened, mineralized elastic fibers in mid- and deep-reticular dermis
Perforating periumbilical PXE[135]	Asymptomatic or pruritic, erythematous lesions that progress to hyperpigmented plaques, with central atrophy, a red, scaly border, and peripheral hyperkeratotic papules, sometimes expressing elastotic debris	Periumbilical or breast area	Multiparity, ascites, abdominal surgery; uremia, and hyperphosphatemia in chronic renal failure	Histopathology shows elimination of basophilic, elastotic debris through channels in addition to thickened and mineralized elastic fibers in mid- and deep-reticular dermis
Long-term penicillamine therapy[136]	Varied presentations; may resemble pseudoxanthoma elasticum, elastosis perforans serpiginosa, cutis laxa, and anetoderma	Similar to those seen in idiopathic forms of disease (i.e., neck and flexures for PXE, flexures in elastosis perforans serpiginosa)	Use of D-penicillamine	Histopathology shows thickened elastic bundles with prominent lateral protrusions ("bramble-bush"), granulomatous dermal inflammation, infrequent calcification, and transepidermal elimination of elastic fibers
Actinic damage to neck[137]	Numerous small, asymptomatic, discrete, white papules	Neck	Middle aged to elderly individuals	Histology shows elastolysis and fibrosis in papillary and midreticular dermis
Papular elastorrhexis[137]	Asymptomatic, firm, nonfollicular 1- to 5-mm whitish papules on trunk and upper extremities	Chest, abdomen, shoulders, back, proximal extremities	Rarely familial occurrence	Loss of elastic tissue in reticular dermis (relative increase in fibrillar component) and fragmentation, with occasional perivascular mixed infiltrate

TABLE 137-3
Monitoring Studies for Patients with Pseudoxanthoma Elasticum

Study	Reason
Complete blood cell count	Occult blood loss; iron-deficiency anemia
Calcium, phosphate	Rare reports of hypercalcemia and hyperphosphatemia
Fasting lipids	Hyperlipidemia aggravates risk of cardiovascular disease
Urinalysis	Hemorrhage from urinary tract
Fecal test for blood	Occult blood loss from GI hemorrhage
Eye examination	To detect angioid streaks, retinal hemorrhage, early retinopathy
Endoscopy	If evidence of GI bleeding
Echocardiography	If murmur, angina, or personal or family history of coronary artery disease
Doppler blood pressure (ankle, brachial)	To investigate claudication or if decreases peripheral pulses
Computed tomography of head	If focal neurologic problems or evidence of cerebral hemorrhage
Radiographs	If seeking calcifications

GI = gastrointestinal.

elastic fibers.[145] Soft tissue radiographs of the upper and lower extremities may reveal vessel wall calcification. Dental radiographs may demonstrate early vascular calcification. Ultrasonography shows a characteristic pattern of dotted increased echogenicity of renal arteries.[146] Similar patterns have been described on ultrasound of affected pancreas and spleen. The recommended testing for patients with PXE is summarized in Table 137-3.

DIFFERENTIAL DIAGNOSIS

(Box 137-2)

The pebbly pattern and yellow discoloration of flexural skin of classical PXE is quite distinctive. The later development of redundancy may be confused with the sagging skin of CL. Ten percent of patients with β-thalassemia have both angioid streaks and the skin manifestations of PXE, while 16% have only the skin lesions that are clinically and histopathologically typical of PXE.[147] D-Penicillamine may induce an acquired form of PXE, but elastic fibers do not become calcified.[136,148] PXE-like changes have also been noted both clinically and histologically in long-standing nephrogenic systemic fibrosis.[149] (See eFig. 137-9.1 in online edition.)

Angioid streaks have been described in a variety of disorders, among them EDS, Marfan syndrome, lead poisoning, sickle cell anemia, thalassemia,[150] Paget disease of bone, acromegaly and other pituitary disorders, and familial hyperphosphatemia.[151]

PREVENTION AND TREATMENT

There is no cure for PXE and a multidisciplinary approach is required to address the myriad manifestations of the disease. Plastic surgery may improve the appearance of sagging skin, although extrusion of calcium particles through the surgical wound may result in delayed healing and unsightly scars.[152] Fillers or autologous fat injections have been used to soften the prominent facial creases. GI bleeding can usually be managed conservatively with iced saline lavage and transfusion and rarely requires balloon embolization or surgery for control.[153] Anticoagulants [nonsteroidal anti-inflammatory drugs (NSAIDs)/aspirin] are typically avoided in PXE patients. All patients should be followed by a retina specialist and instructed in the use of an Amsler grid to detect early symptoms of retinal hemorrhage. There is no ideal treatment for the ophthalmologic complications, although laser photocoagulation (such as verteporfin photodynamic therapy every 3 months)[154] may ameliorate the choroidal neovascularization. Recently, intravitreal injections of bevacizumab have been employed for the choroidal neovascularization of PXE with promising results if initiated early.[155]

Although low calcium (60–1,200 mg/day)[156] and low-lipid diets have been advocated, their value has not been clinically tested. A report describing the use of aluminum hydroxide as an oral phosphate binder noted improvement in PXE skin lesions in three of six patients treated.[157] Oral ascorbic acid and tocopherol were administered to a single patient with apparent positive response after several years.[158] Most recently, a diet with fivefold the standard of magnesium to ABCC6 null mice prevented the development of connective tissue mineralization.[159,160] Dietary supplementation with magnesium carbonate, which is used as an antacid and commonly added to table salt to prevent caking, is a simple and attractive therapeutic intervention and studies are ongoing in PXE patients to determine its effectiveness at preventing or ameliorating the progression of the disease.

Regular evaluation and follow-up with a cardiologist should be encouraged. Patients should be advised to protect their eyes from even mild trauma, and about the potential for future visual loss. Because of the potential risk to eyes and calcified vessels when traumatized, contact sports and high-intensity CV exercise should be prohibited for persons with PXE. This can be quite life altering for the child or adolescent, who may not fully understand the consequences of the seemingly minor skin changes. Avoidance of high-cholesterol foods and smoking, control of blood pressure, and safe aerobic exercises may be recommended by the physician. Two support groups are available: (1) the National Association for Pseudoxanthoma Elasticum (www.napxe.org), and (2) PXE International, Inc. (www.pxe.org).

CUTIS LAXA (GENERALIZED ELASTOLYSIS)

CONGENITAL CUTIS LAXA AT A GLANCE

- Inheritance may be autosomal dominant (OMIM #123700), autosomal recessive (OMIM #219100 or #219200), or X-linked recessive (also known as *occipital horn syndrome* (OMIM #304150).
- Mutations in elastin (*ELN*) or fibulin-5 (*FBLN5*) in autosomal dominant; in fibulin-5 (*FBLN5*, *EVEC*, *DANCE*) or fibulin-4 (*FBLN4*) in autosomal recessive; a copper transport adenosine triphosphatase (*ATP7A*) in the X-linked type.
- Cutaneous features include pendulous, inelastic skin, with an aged facies.
- Extracutaneous manifestations may include pulmonary emphysema, aortic aneurysm, pulmonary artery and valve stenosis, hernias, gastrointestinal diverticula, joint laxity, low serum ceruloplasmin, and bilateral exostoses of the occiput (or occipital horn syndrome).
- Histopathology shows sparse and fragmented elastic fibers, better visualized with stains (i.e., Verhoeff–van Gieson or orcein).
- Information for patients and professionals at http://www.orpha.net/nestasso/cutislax/.

EPIDEMIOLOGY

CL is a heterogeneous group of disorders (Table 137-4) that results from abnormalities in elastic tissue. It is characterized by widespread laxity of skin and, in some cases, involvement of other organs. AD, AR, and X-linked forms exist, with recessive forms the most common. Review of the world literature suggests only ~200 cases and, importantly, only a striking minority of these patients have a known underlying molecular cause. It is estimated that the success for detecting mutations in patients with AR form of CL (ARCL) type I is only ~10%.[167]

ETIOLOGY AND PATHOGENESIS

The skin contains a variety of fibers, which contain increasing amounts of elastin as they progress deeper into the skin. Abnormalities in elastic fiber synthesis, stabilization, or degradation may all lead to the clinical phenotype of CL. Elastic fibers are composed of an amorphous elastin component (90% of fibril) surrounded by a microfibrillar sheath based on fibrillin. Elastic fibers do not spontaneously assemble; their construction requires a carefully orchestrated sequence of reactions.[161,166] Elastin is synthesized from individual tropoelastin molecules aligned on a network of elastic fibers and the alignment is stabilized via the formation of intermolecular cross-links mediated by copper-dependent lysyl oxidase. Skin elasticity (reversible deformability), as well as that of other tissues such as lung or larger arterial vessels, results from a network composed of elastin fibers. Mutations in the elastin gene (45 kb in length and mapped to 7q11.2.) lead to abnormal elastic fibers (in some due to decreased mRNA stability) and many cases of AD form of CL (ADCL; OMIM #123700).[166]

Superficial oxytalan fibers extend from the dermoepidermal junction and are composed primarily of microfibril bundles. These extend through elaunin fibers, which run perpendicularly in the papillary dermis and contain a small amount of elastin. Deeper, in the reticular dermis, thick horizontal elastic fibers contain higher amounts of elastin.[166] Mutations in genes whose protein products form part of the elastic fiber interface such as fibulin 4 (OMIM #604633) and fibulin 5 (*FBLN5*, *EVEC*, or *DANCE*, OMIM #604580) have been associated with the frequently fatal ARCL type I (OMIM #219100) in humans. Fibulin 5 binds cell surface integrin receptors and key components of elastic fibers, suggesting a role in cell-directed elastic fiber assembly. ARCL type I fibulin 5 mutations lead to abnormal protein folding, decreased secretion, and decreased interaction with elastin and fibrillin-1.[169] One patient with ADCL and a duplication in the fibulin 5 gene has been reported.[165] Missense mutations in fibulin 4 (EGF-containing fibulin-like ECM protein 2 (OMIM #604633)) have been noted in several patients with unusually severe ARCL type I. Elastic fibers in these patients are severely underdeveloped.[170]

ARCL type II (Debre type) patients exhibit loss of function mutations in *ATP6V0A2*, which encodes a subunit of the V-type H^+ ATPase. Defects in *ATP6V0A2* result in a congenital disorder of glycosylation (CDG-II), due to defective serum protein *N*- and *O*-linked glycosylation. Fibroblasts from affected patients demonstrate impaired Golgi trafficking, likely due to abnormal pH regulation in the Golgi compartments. Increased cellular apoptosis also occurs. The exact mechanism by which this leads to the connective tissue defects seen in this syndrome is unclear, although impaired intracellular trafficking may lead to suppressed transport of tropoelastin from the cell.[173] Analysis of apolipoprotein C-III isoelectric focusing is diagnostic in all cases.[172]

Recently, mutations in pyrroline-5-carboxylate synthase (PYCR1), a mitochondrial proline metabolic enzyme, were reported in a group of patients that had previously been diagnosed with a variety of disorders, including wrinkly skin syndrome, De Barsy syndrome, and gerodermia osteodysplastica (GO). This new subgroup has been designated ARCL type II with progeroid features. The resulting abnormal proline metabolism

TABLE 137-4
Cutis Laxa Syndromes: Clinical Subtypes and Associated Defects

Subtype/(OMIM)	Clinical Features	Inheritance	Protein (Gene Defect/ OMIM)	Cellular Defect
Autosomal dominant (ADCL)/(123700)[161,162]	Later onset Primarily cutaneous Hernias Rare vascular complications Normal life expectancy[163,164] Some clinical variability	AD	Elastin (ELN/130160) Fibulin 5 (FBLN5/604580)[165]	Abnormal elastic fibers[166]
X-linked recessive/ (304150)[167]	Congenital Skin laxity—often distal Characteristic facies Hoarse cry—vocal cord redundancy Brittle hair Joint laxity—mild Occipital exostosis—develop after several years of age Skeletal abnormalities Failure to thrive Diarrhea GU diverticulae	XLR	α polypeptide of Cu^{2+} transporting ATPase (ATP7A/300011)	Defective copper metabolism[168]
ARCL I (219100)[163,167]	Congenital Severe Loose hanging redundant skin Early lethality Emphysema Cor pulmonale Hernias (various including diaphragmatic) Mucosal prolapsed No mental retardation Cardiovascular abnormalities rare No hip dislocation	AR	Fibulin 5 (FBLN5/604580)	Abnormal protein folding Decreased secretion Decreased interaction with fibrillin-1 and elastin May have role in cell-directed elastic fiber assembly[169]
	Arachnodactyly Vascular anomalies Increased dissection risk Diaphragmatic abnormalities GI and GU diverticulae	AR	Fibulin 4 (FBLN4/604633)	Severely underdeveloped elastic fibers[170]
ARCL II (Debre type)/ (219200)[171]	Clinical variability Microcephaly Developmental delay Hypotonia Congenital hip dislocation Mental retardation Delayed fontanel closure Progressive neurologic abnormalities CL improves—especially after puberty[163,167] Dental caries common Apolipoprotein C-III isoelectric focusing is diagnostic[172]	AR	α2 subunit of V-type H^+–ATPase (ATP6V0A2/611716)	Congenital disorder of glycosylation (CDG-II) Abnormal pH regulation of Golgi compartments Leads to impaired Golgi trafficking[173] Increased cellular apoptosis ?Impaired transport of tropoelastin from cell Increased vascularization of dermis; reduced collagen Bundle size; underdeveloped elastic fibers distinguish from WSS
ARCL with Progeroid features/(612940)[171]	Progeroid appearance Osteopenia Variable connective tissue weakness Wrinkly, lax skin—especially over hands Finger contractures Triangular facies with mandibular hypoplasia causing prognathism Variable MR Agenesis of corpus callosum Overlap with WSS/GO/DBS Cataracts and dystonia in more severe cases similar to De Barsy syndrome No glycosylation defects	AR	Pyrroline-5-carboxylate reductase 1(PYCR1/179035)	Abnormal mitochondrial proline metabolism Increased cellular apoptosis Mitochondrial defects Elastic fiber abnormalities similar to other ARCL[171]

(continued)

TABLE 137-4
Cutis Laxa Syndromes: Clinical Subtypes and Associated Defects (Continued)

Subtype/(OMIM)	Clinical Features	Inheritance	Protein (Gene Defect/ OMIM)	Cellular Defect
Gerodermia osteodysplastica (GO)/ (231070)[167]	Progeroid features Malar/mandibular hypoplasia Joint laxity Short stature dwarfism Normal mental development Osteoporosis Frequent fractures—especially vertebral Progressive No glycosylation defects	AR	SCYL1-binding protein 1 (GORAB (formerly SCYL1BP1)/607983)	Soluble protein present in both skin and osteoblasts Interacts with Rab6, which interacts with conserved oligomeric Golgi complex (COG complex) Disrupted Golgi trafficking[174]
De Barsy syndrome (DBS)/(219150)[175]	Cutis laxa Significant MR Eye anomalies Dystonia Progeroid features Progressive	AR	?	Frayed elastic fibers
Cantu syndrome/ (114620)	Cardiac anomalies Osteochondrodysplasia	AR	?	
Wrinkly skin syndrome (WSS)/(278250)[176]	Mild Cutis laxa—hands/feet/abdomen—more prominent while sitting Hypotonia Prominent venous pattern on chest Microcephaly and mental retardation Variable May not represent true entity	AR	Pyrroline-5-carboxylate reductase 1(PYCR1/179035)[a] α2 subunit of V-type H^+-ATPase (ATP6V0A2/611716)[a]	
Additional syndromes				
Latent transforming growth factor binding protein 4 (LTBP4) deficiency[177]	Cutis laxa GI and GU abnormalities Respiratory dysfunction Early lethality Prematurely aged appearance Distinctive facies Normal mental development Mild cardiovascular lesions Growth delay	AR	Latent transforming growth factor binding protein 4 (LTBP4)	Increased TGFβ activity Impaired elastic fiber assembly ?Role for angiotensin II type I receptor blockers
Transaldolase deficiency[178]	Congenital cutis laxa Hydrops fetalis Dysmorphic features Hypertrichosis Variable multiorgan involvement Hepatomegaly Cirrhosis Liver failure Hemolytic anemia GU malformation Renal Splenomegaly with thrombocytopenia Many exhibit gradual improvement including skin—except for liver and renal	AR	Transaldolase	Inborn error in pentose phosphate metabolic pathway
Accumulation of sugar-phosphate intermediates				

AD = autosomal dominant; AR = autosomal recessive; XLR = X-linked recessive; OMIM = Online Mendelian Inheritance in Man.
Table adapted from Morava et al.[167]
[a]Patients with mutations in these genes have been reported as wrinkly skin syndrome prior to identification of their underlying mutation.

leads to mitochondrial defects and increased cellular apoptosis.[171]

GO (OMIM #231070) results from mutations in GORAB (*SCYL1BP1*), a soluble protein highly expressed both in skin and osteoblasts. It interacts with Rab6, which interacts with the conserved oligomeric Golgi complex (COG complex) and is important in Golgi trafficking.[174] In contrast to ARCL of the Debre type, no glycosylation defects are present in GO.

The etiology of ARCL type III/De Barsy syndrome remains unknown, however, there is significant clinical overlap with ARCL type II with progeroid features. Molecular analysis of patients carrying the clinical diagnosis of De Barsy syndrome, including mutation screening of PYCR1, should clarify its position as a distinct clinical entity.

Mutations in the *ATP7A* gene, which encodes a protein member of the *P*-type adenosine triphosphatase family responsible for copper transport, cause X-linked CL, which is allelic to Menkes syndrome.[168] *ATP7A* mediates copper transport from the GI tract, efflux of excess copper from cells, and delivery of intracellular stores of copper to cuproenzymes.

Acquired forms of CL present after skin inflammation and structural damage of elastic fibers. Increased neutrophil elastase present in affected skin is presumed to disrupt elastic fiber integrity.[179] Abnormalities in the genes in which mutations lead to hereditary CL may also play a role in acquired forms of CL. For example, a patient with compound heterozygous elastin mutations showed partial rescue of elastic fiber synthesis by a heterozygous missense mutation in fibulin 5. The resultant elastic fiber system functioned normally, until challenged by *Toxocara canis* parasite infestation during adolescence, leading to acquired CL.[180]

CLINICAL MANIFESTATIONS

The skin in CL is inelastic and appears pendulous. At birth the infant may appear to have unusually soft and loose skin. The skin is hyperextensible, but does not resume its normal shape after stretching (see eFig. 137-9.2 in online edition). Persons with CL are often described as having a bloodhound-like facial appearance (Fig. 137-10) and loose skin of the face, neck, shoulders, and thighs often first attracts attention. Young affected children appear aged. Signs of skin fragility are typically absent in contrast to EDS. Both AR and X-linked forms of CL can exhibit congenital onset. Internal organ involvement may be seen with both inherited and acquired CL. The clinical features of described CL subtypes are summarized in Table 137-4.

The ADCL (OMIM #123700) primarily affects the skin. It may present in infancy or adulthood and tends to be relatively benign with a normal life expectancy.[163,164]

X-linked CL (OMIM #304150) includes patients with the *occipital horn syndrome* and Menkes disease. Patients with X-linked CL demonstrate distinct congenital findings, including skin laxity, often distal, a thin face with long philtrum and short columella, inverted lower eyelids, a high forehead, and a hooked/beaked nose, as well as large fontanels and brittle hair.



Figure 137-10 Cutis laxa due to fibulin-4 mutation. The facial skin hangs in loose folds, giving the appearance of premature aging. Note the prominent periorbital vessels. The tracheostomy was placed for diaphragmatic eventration and respiratory difficulty.

Clinical findings in the ARCL syndromes are quite heterogeneous in both severity and organ involvement. ARCL type I (OMIM #219100) exhibits a severe phenotype with hernias, visceral involvement, and early lethality resulting from profound elastic tissue defects in several organs. The cutaneous findings are pronounced, with loose, hanging, pendulous skin. Children with ARCL type II have distinct clinical findings and can be divided into two groups based on the presence or absence of *N*- and *O*-linked glycosylation defects (CDG type II). To date, obvious clinical differences between these groups are not evident. Additional syndromes considered subtypes of CL are summarized in Table 137-4.

LABORATORY INVESTIGATION

Special stains for elastic tissue (Verhoeff–van Gieson stain) of skin biopsy specimens demonstrate significantly decreased or absent dermal elastic fibers (in both AD and AR forms of CL).[166] Remaining fibers are often clumped, short, granular, and fragmented. Increased elastin-associated microfibrils are noted on electron microscopy. Calcification is not typically seen. Electron microscopy is considered diagnostic for most cases of ARCL, revealing moth-eaten elastic fibers, with abnormal elastin fiber branching and reduced elastin synthesis creating loose microfibrils. Increased vascularization of the dermis, reduced collagen bundle size, and underdeveloped elastic fibers reputedly distinguish ARCL type II from wrinkly skin syndrome

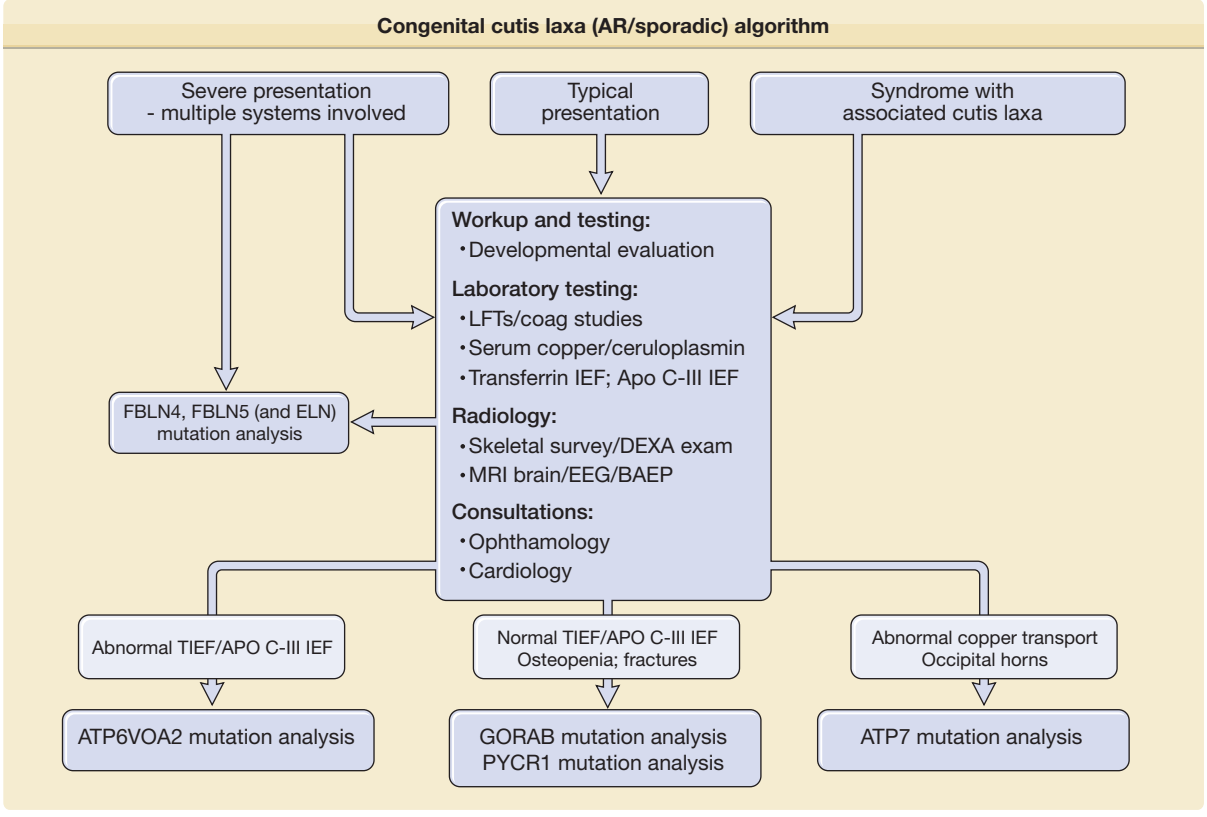

Figure 137-11 Congenital cutis laxa (AR/sporadic) algorithm.

(WSS).[167] Importantly, in both AD and ARCL some patients have exhibited relatively normal electron microscopy and thus the presence or absence of histologic or electron microscopic findings is not necessary for the diagnosis of CL in the clinical setting of loose, hanging skin with decreased elasticity.[167] In acquired cases a mononuclear or mixed inflammatory infiltrate containing neutrophils may be present.

An algorithm for evaluation of a new patient with suspected CL has been proposed (Fig. 137-11). Transferrin immunoelectric focusing studies (TIEF) and ApoC-III IEF should be considered in all patients with AR or sporadic CL (especially those with typical facies, late fontanel closure, and developmental delay or central nervous system involvement). It is important to note that CDG may be missed by the TIEF method in young children. However, the ApoC-III IEF pattern is typically abnormal, even in very young patients. Both studies should likely be repeated after 6 months of age.[167]

DIFFERENTIAL DIAGNOSIS

Patients with EDS have skin that regains a normal appearance when released after stretching. Other features of EDS, including joint laxity, increased bruising, and poor wound healing, are not seen with CL. Older patients with PXE may have laxity of skin, especially in flexural areas, but the skin shows a pebbly yellow appearance.[181] Histologic examination of lesional skin further distinguishes these entities. A disorder with features of both PXE and CL, as well as deficiency in multiple coagulation factors, results from mutations in the γ-glutamyl carboxylase (*GGCX*) gene. These patients exhibit mineralized elastic fibers with positive dermal von Kossa staining, and mild retinopathy similar to PXE but with the pronounced skin folds more typical of CL. Patients also exhibit an abnormal bleeding tendency from deficiency of vitamin K-dependent clotting factors (factors II, VII, IX, and X), atherosclerosis, and possibly cerebral aneurysms.[182] As in PXE, CL-like changes are also reported in long-standing nephrogenic systemic fibrosis.[183]

ACQUIRED CUTIS LAXA

Acquired forms of generalized and localized CL occasionally occur.[137] In type I-acquired CL, ill-defined areas of loose skin appear insidiously but progressively with elastolysis occurring beyond inflammatory areas in many cases. Type I skin lesions involve the head and neck and progress in a cephalocaudal direction. The development of CL is preceded by an inflammatory eruption (urticaria, erythema multiforme, eczematous eruption) in ~50% of cases. Although type I acquired CL usually begins in adulthood, children have been described with this condition. Pulmonary involvement presents as emphysema and is the most frequent cause of death in acquired cases.[137] Severe tracheobronchomegaly is described. Aortic aneurysms with subsequent rupture, and GI and genitourinary diverticulae

have also lead to mortality in these patients. Most affected children have not had evidence of systemic elastolysis.

Type II-acquired CL (Marshall syndrome) is a postinflammatory elastolysis characterized by more localized, well-demarcated, nonpruritic erythematous plaques that extend peripherally and have a hypopigmented center. These appear in crops over a period of days to weeks, often in association with fever, malaise, and peripheral eosinophilia. Localized, or less commonly generalized, areas of CL gradually occur at sites of previous inflammation.[184] While systemic involvement is rare, fatal aortitis has been reported.[185]

Acquired CL may develop after drug exposure to penicillin, D-penicillamine,[186] or isoniazid. It has been associated with α-1 antitrypsin deficiency, complement deficiency (C3, C4), sarcoidosis, syphilis, systemic lupus erythematosus, systemic amyloidosis, cutaneous mastocytosis,[187] and multiple myeloma.

Acquired CL is one of the primary presenting features of hereditary gelsolin amyloidosis (AGel amyloidosis), an AD condition resulting from mutations in gelsolin, an actin modulating protein. Cleavage of the mutant protein creates amyloidogenic protein fragments, which accumulate into amyloid fibrils and are deposited in most tissues. While normal at birth, CL develops with age, initially involving eyelid and scalp skin but eventually becoming more widespread. Patients also note dry skin, pruritus, and fissuring as well as loss of hair. Petechiae and ecchymoses are also common. Noncutaneous findings include corneal lattice dystrophy, as well as cranial and peripheral polyneuropathy. Skin biopsy reveals elastic fiber diminution and fragmentation as well as widespread deposition of AGel amyloid including around elastic fibers. How this leads to destruction of the elastic fibers over time is unknown.[188]

A transient form of neonatal CL with generalized skin laxity and inguinal hernias has been described in infants born to mothers administered D-penicillamine during pregnancy.[189,190] In these cases, the loose skin resolved during the first year of life.

TREATMENT

While some forms of CL improve with time, others worsen with age. It is important for the clinician to recognize that patients with CL often sustain significant psychological trauma due to their appearance. Intervention as appropriate or desired by the patient, addressing not only the physical aspects of the disease, but the psychological and emotional aspects as well, is critical.

Plastic surgery has been somewhat successful in improving the physical appearance of some patients temporarily and is a reasonable consideration as vasculature and wound healing capability are normal.[191] Numerous procedures may be necessary. Herniations are typically repaired when clinically indicated. In cases where cardiopulmonary failure occurs, appropriate drug and ventilatory support is managed by the appropriate specialties. Acquired CL is often recalcitrant to treatment. Dapsone is reported to control acute swelling, which may support a role for neutrophil elastase.[192] Botulinum toxin has been used to improve facial cosmesis.[193] Recently rescue of elastin insufficiency in mice via introduction of the human elastin gene was described, suggesting a potential avenue for future molecular therapies.[194]

OSTEOGENESIS IMPERFECTA

OSTEOGENESIS IMPERFECTA AT A GLANCE

- Combined incidence of 1 in 12,000 people (OMIM #166200 and #166240 type I; #166210 type II; #259420 type III; #166220 type IV; #166220 type V).
- Seven subtypes (ranging from mild, nondeforming (type I) to severe perinatal lethal (type II).
- Most commonly autosomal dominant inheritance.
- The gene encoding procollagen I is most often affected.
- Cutaneous features include hyperextensible skin and blue sclerae.
- Extracutaneous manifestations include increased fractures, dentinogenesis imperfecta, ligament laxity, triangular facies, short stature, hearing impairment, and wormian bones.
- Information for patients and professionals at http://www.oif.org.

BUSCHKE–OLLENDORFF SYNDROME

Buschke and Ollendorff originally reported the association of connective tissue nevi and osteopoikilosis.[207] The disorder is inherited in an AD manner with variable expressivity, but usually complete penetrance. The estimated incidence is 1:20,000.[208] It results from loss of function mutations in the *LEMD3* gene (also called *MAN1*).[133] *LEMD3* appears to antagonize both bone morphogenetic protein (BMP) and TGF-β signaling pathways in human cell lines and, consequently, loss of *LEMD3* leads to enhanced TGF-β signaling. Defects in *LEMD3* have also been detected in cases of both isolated osteopoikilosis and osteopoikilosis with melorheostosis ("flowing" hyperostosis over the cortex of tubular bones),[133] but not in cases of sporadic isolated melorheostosis.[209]

The connective tissue nevi appear as collections of skin-colored to yellow papules or plaques (dermatofibrosis lenticularis disseminata) that are most commonly located on the buttocks, proximal trunk, and limbs. Many patients begin to develop lesions in early childhood, although later onset and emergence of new lesions while others disappear have also been reported. Histopathologic examination of lesional skin may show increased amounts of elastic tissue (elastoma), although decreased or normal amounts of elastic tissue and abnormalities of collagen have also been described. The bony lesions most frequently appear after 15 years of age. They are discrete spherical areas of increased radiodensity, most frequently noted in the epiphyses and metaphyses of long bone, pelvis, scapulae, carpal, and tarsal bones. The radiographic appearance of the lesions may raise concerns for neoplasia. Although the osteopoikilosis is typically asymptomatic, functional limitation due to decreased mobility of an affected cutaneous area has been reported. Other skeletal abnormalities, including short stature, otosclerosis, and supernumerary vertebrae and ribs have been described. Cataracts and peptic ulcer disease have rarely been reported in patients with Buschke–Ollendorff syndrome. Connective tissue nevi without associated bony changes, morphea, and PXE are the most frequent disorders considered in the differential diagnosis. No therapy is available or necessary.

LIPOID PROTEINOSIS

EPIDEMIOLOGY

Lipoid proteinosis (LP) is also known as *hyalinosis cutis et mucosae* (OMIM #247100). Only about 300 cases have been reported in the literature. However, it is relatively common in the Namaqualand area of Northern Cape Province in South Africa (frequency of 1 in 300 population). To date, all South African LP patients studied have carried the same mutation (*Q276X*), likely contributed by a German settler who arrived in 1652 (founder effect).[210]

ETIOLOGY AND PATHOGENESIS

LP is inherited in an AR fashion and is caused by mutations in the gene encoding ECM protein-1 (ECM-1). Although given this name because of its discovery among various connective tissue proteins in a murine stromal cell line, ECM-1 likely has broader functions. ECM-1 is known to inhibit bone mineralization, contribute to epidermal differentiation, and stimulate angiogenesis.[211]

The *ECM1* gene is located next to the epidermal differentiation complex on chromosome band 1q21. ECM-1 is present both in the epidermis and as a secreted protein in the dermis. There are four splice variants: ECM-1a is encoded by the full gene, *ECM-1b* lacks exon 7, *ECM-1c* contains an additional exon 5a, and a fourth form shows truncation of 57 amino acids.[212] ECM-1a is widely expressed, whereas ECM-1b is expressed only in tonsils, keratinocytes, and the upper respiratory tract. ECM-1c is also expressed in the skin.

ECM-1 appears to have several functions. In the skin, it interacts with several ECM proteins, including perlecan (a heparin sulfate proteoglycan present in basement membranes), fibulin 1C/D, fibulin 3, matrix metalloproteinase 9, fibronectin, the β 3 chain

LIPOID PROTEINOSIS AT A GLANCE

- Rare worldwide occurrence, with the greatest incidence (1 in 300) in the Namaqualand region of South Africa.
- Autosomal recessive disorder with variable phenotype, even within families.
- Caused by defects in extracellular matrix protein-1.
- Hoarseness is the most frequent finding.
- Skin fragility and blistering occur in some affected children; blisters heal as infiltrated lesions with scar-like appearance.
- Progressive development of infiltrated papules and plaques is seen, especially on the elbows and extensor aspects of the arms and lower legs.
- Beaded papules on the eyelid margin (moniliform blepharosis) are a classic finding in adolescents and adults, but are not always present.
- Calcification of the temporal lobes and amygdala may lead to neurologic and/or psychiatric symptoms.
- Some patients have airway compromise from upper airway infiltration.
- Periodic acid-Schiff-positive, diastase-resistant thickening is seen at the dermal–epidermal junction, perivascularly, and along adnexal epithelia with hyaline material in the dermis.
- Electron microscopy reveals deposited dermal material and excess basement membrane material around blood vessels with irregular duplication of the lamina densa at the dermal–epidermal junction.
- No effective treatment exists. Laser ablation/dermabrasion of papules is helpful in some cases.

of laminin 332, and collagen type IV. ECM1 may well serve as a "binding core" for cutaneous extracellular and basement membrane proteins.[212] The second tandem repeat of ECM1, encoded by exon 7, binds fibulin-1, an extracellular component of most basement membranes. Thus, ECM-1a binds to fibulin, whereas ECM-1b, lacking exon 7, does not.[212,213] While ECM-1a is expressed in basal keratinocytes ECM-1b is only expressed in terminally differentiated keratinocytes. Given the differential expression of ECM-1 isoforms in skin, the ability to bind fibulin-1 may be important in keratinocyte differentiation. A report describing ultrastructural evidence of desmosomal detachment in cultured keratinocytes from a pediatric patient with the vesicular lesions of LP suggests a role in normal differentiation as well.[214] A recent report in mice found no epidermal alteration in association with over- or underexpression of ECM1, arguing against a role in epidermal differentiation in murine systems, but the relevance for human skin is unclear.[215] Both ECM-1a and ECM-1b may stimulate blood vessel endothelial cell proliferation and promote angiogenesis in chicken embryo.[216] Abnormalities of the cutaneous vasculature are described in LP.[217]

Mutations in ECM1 in LP lead to loss of function of ECM-1. The majority of mutations occur in exon 7, with frameshift mutations leading to ablation of the ECM-1a transcript but not that of ECM-1b, which typically lacks exon 7. Mutations outside of exon 7 typically occur in exon 6 and are nonsense or frameshift mutations. Patients with exon 7 mutations may have a slightly milder phenotype than those with nonexon 7 mutations with regard to respiratory and skin (but not neurologic) manifestations.

Antibodies to ECM-1 have been detected in patients with lichen sclerosus (see Chapter 65), which suggests that this disorder represents an acquired form caused by antibody-induced ECM-1 loss.[218]

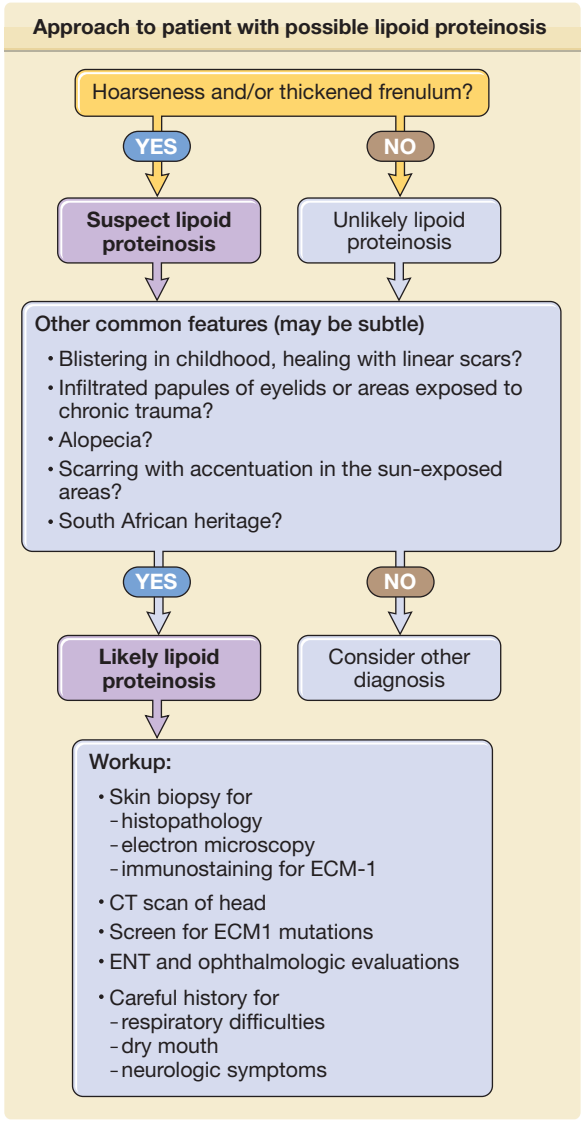

Figure 137-12 Approach to the patient with possible lipoid proteinosis. CT = computed tomography; ECM-1 = extracellular matrix protein-1; ENT = ear, nose, and throat.

CLINICAL FINDINGS

The most reliable clinical signs for diagnosing LP are a hoarse voice and thickened sublingual frenulum, which prevents patients from protruding the tongue. Secondary features include beaded eyelid papules, infiltration of warty papules of the skin around the elbows and extensor forearms, and mild alopecia. Increased scarring and photoaging of sun-exposed skin may be seen. Scars or scar-like lesions are present in areas of minor trauma but are not increased at sites of surgery or vaccination.[210] An algorithm outlining an approach to the patient with suspected LP is shown in Fig. 137-12.

CUTANEOUS LESIONS

The phenotypic features of LP are quite variable, even within families. This is well demonstrated in studies of South African patients, all of whom share the same mutation yet exhibit highly variable phenotypes. The variable expressivity can lead to difficulty in diagnosis of affected patients. The earliest finding in LP is hoarseness from vocal cord infiltration, which occurs at birth or in the first few years of life. Initially, this may be noted as a faint or weak cry and is one of the most striking and consistent features. Hoarseness may progress during the lifetime of a patient. Dysphagia may occur from involvement of the upper aerodigestive tract and esophagus.[210,219] Skin lesions usually develop in the first years of life, although the timing of their onset is variable. Importantly, two stages of skin lesions may be noted. A long-neglected and underappreciated clinical feature of LP is the erosions that can develop during childhood.

Blistering can be extensive enough to mimic epidermolysis bullosa. The associated vesicles (and rarely bullae) are typically noninflammatory and heal slowly

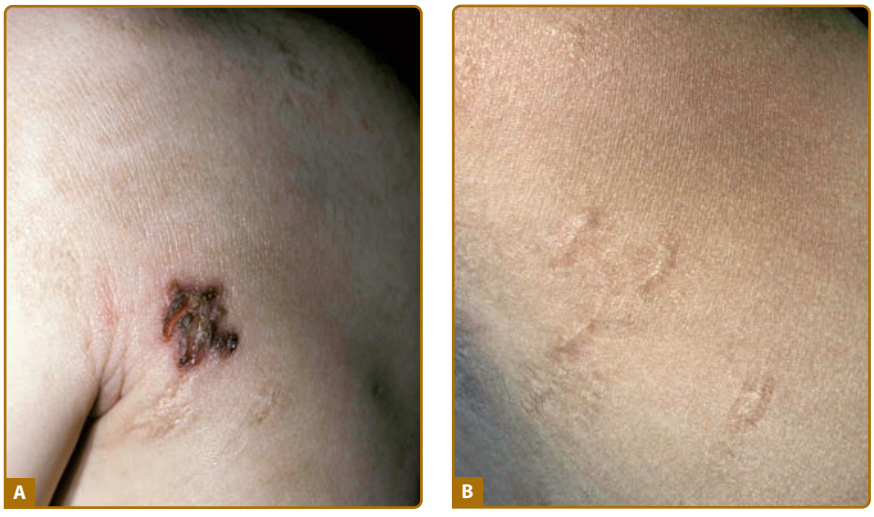

Figure 137-13 Lipoid proteinosis. **A.** Early bullous lesion with typical hemorrhagic crust, **B.** healing with scarring. (From Dyer JA, Yu QC, Paller AS: "Free-floating" desmosomes in lipoid proteinosis: An inherent defect in keratinocyte adhesion? *Pediatr Dermatol* **23**:1, 2006, with permission.)

with hemorrhagic crusting and resultant scarring (Fig. 137-13). Scars may be linear and resemble pseudoporphyria on the face. In some patients, blistering is worse during warmer weather. Skin fragility and easy wounding with minor trauma or friction are noted. Spontaneous development of extrafacial pustular lesions has also been noted. Shedding of sheets of skin, which leaves red oozing areas, has also been described.

The skin lesions of the second stage are better recognized. Although beaded papules along the eyelid margins (moniliform blepharosis) (Fig. 137-14) are considered a classic clinical finding, they are variable and may be subtle. Other cutaneous stigmata include generalized skin thickening with a waxy, yellow appearance as well as areas of distinct papules and nodules. Areas subject to repeated friction or trauma, such as the elbows, halluces, and extensor aspects of the arms and lower legs, may develop overlying hyperkeratosis, which may be quite striking and verrucous (eFig. 137.14.1 in online edition). The scarring usually begins during childhood and is often worst on the face. It may follow trauma or occur spontaneously, yet no tendency to excessive scarring is noted after surgery or vaccination. Pock-like or acneiform scarring is well described in LP, especially on the face and extremities. Some areas may resemble solar elastosis. Flexural lichenification may also be seen, and patients with LP have been misdiagnosed as having atopic dermatitis. Some patients report increased photosensitivity, and, in some patients, sun-exposed areas exhibit the greatest amount of scarring. Significant pruritus, alterations in the ability to sweat, and abnormal pain sensation have been noted. Alopecia may occur, although it is variable in severity. Nails are normal.[219]



Figure 137-14 Lipoid proteinosis. Beaded papules along margin of the eyelids (moniliform blepharosis). Note increased severity of yellowish, waxy lesions in sun-exposed areas. (Used with permission from O. Braun-Falco, Munich.)

RELATED PHYSICAL FINDINGS

The mucosae of patients with LP exhibit infiltration and thickening. Early in life, oral erosions may be noted and these may persist.[220] Thickening of the lingual frenulum leads to inability to protrude the tongue (Fig. 137-15). The pharynx, tongue, soft palate, tonsils, and lips are typically involved. Laryngeal and pharyngeal involvement may be severe enough to trigger respiratory difficulty, and tracheostomy has been required in rare cases. Shortness of breath or worsening of respiratory difficulties, as well as swelling of the salivary glands (submandibular and parotid), may be triggered by upper respiratory tract infections. Xerostomia and dental caries may be seen.[221] Dental abnormalities (absent permanent upper lateral incisors) have also been described. Parotitis from infiltration of Stenson's duct and subsequent blockage can occur.

Central nervous system involvement is a well-recognized, but variable, feature of LP. Amygdala



Figure 137-15 Restricted mobility of the tongue due to infiltration of the frenulum is seen in most patients with lipoid proteinosis. Note discoloration of the lips as well. (Used with permission from O. Braun-Falco, Munich.)

dysfunction has been described, which leads to abnormal perception and appraisal of fear. More recent studies have demonstrated subtle differences between LP patients and normal controls in the judgment of facial expression and emotion, in memory for negative and positive pictures, and in odor-figure association tests. Because of the frequent bilateral amygdala damage, LP has been used as a model disorder for investigation of the function of the amygdala. Neurologic and psychiatric findings include seizures, memory deficits, social and behavioral changes, paranoid symptoms, mental retardation, and aggressiveness. Severe generalized dystonia has also been reported.[222]

The ocular examination may reveal drusen-like fundal lesions.[168] Eyelid infiltration may induce corneal ulcers due to abnormal eyelash positioning, and alopecia of the eyebrows and eyelashes can occur. The abnormal deposition of hyaline material has been detected histopathologically in many internal organs, although this is typically asymptomatic.

LABORATORY TESTS

Light microscopic evaluation of lesional sections reveals deposition of amorphous eosinophilic material at the dermoepidermal junction, perivascularly, and along adnexal epithelia. There is deposition of hyaline material in the dermis, often perpendicular to the basement membrane (Fig. 137-16). The hyaline material is periodic acid-Schiff positive and diastase resistant, with a composition similar to that of basement membrane. Often arranged in concentric, "onion-skin" layers around vessels, these layers include type III and type IV collagen as well as laminin. Electron microscopy reveals irregular duplication of the lamina densa at the dermal–epidermal junction. Cytoplasmic vacuoles are noted in dermal fibroblasts.[223] The presence of lipids varies and is considered a secondary phenomenon due to lipid adherence to glycoproteins present in the hyaline material rather than a primary defect of LP.

The histologic features of the early bullous lesions of LP have only recently been described. Acantholysis of keratinocytes apparently is the cause.[224] Electron microscopy suggests an abnormality of desmosomal attachment, with "free-floating" desmosomes noted in bullous lesions. These preliminary findings require confirmation; but are intriguing given the pattern of expression of ECM-1 in the epidermis.[214]

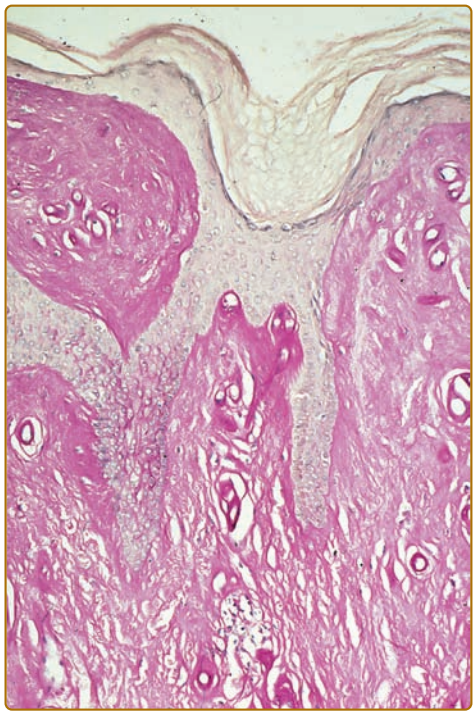

Figure 137-16 Extensive deposition of periodic acid-Schiff-positive, diastase-resistant hyaline material in the dermis of a scar-like lesion of lipoid proteinosis.

Three-dimensional analysis of the cutaneous vasculature in LP shows enlarged vessels in the mid- and deep dermis with an orientation parallel to the dermal–epidermal junction. The dermal papillary plexus also lacks capillary loops. As in lichen sclerosus, the subcutaneous plexus and transverse connecting vessels are atretic or poorly formed.[217] Such vascular abnormalities may reflect a disturbance of ECM-1 function during angiogenesis.

SPECIAL TESTS

Computed tomographic scans of the brain reveal bilateral anterior medial temporal lobe calcifications, often bean-shaped, and especially within the amygdala, in 50%–75% of LP patients.[222]

Histopathologic evaluation of these lesions shows amorphous masses of calcium and bone along with multiple haphazardly arranged small blood vessels with wall calcification and gliotic adjacent tissue. The cortex and white matter show isolated blood vessels occluded by fibrin, parietal calcification, small perivascular infarctions, and demyelination.[225] Immunohistochemical staining of skin biopsy specimens may show absence or attenuation of ECM-1. This may prove to

BOX 137-3 DIFFERENTIAL DIAGNOSIS OF LIPOID PROTEINOSIS

CLINICAL

Most Likely

- Erythropoietic protoporphyria (EPP) or pseudoporphyria (clinically and histologically)—in EPP most changes are in sun-exposed areas, whereas in lipoid proteinosis they are present in nonsun-exposed sites as well; EPP has no beading of the eyelids.
- Variegate porphyria—especially in South Africa
- Epidermolysis bullosa—hoarseness with blistering (infancy)
- Impetigo—childhood blisters and erosions

Consider

- Scarring from acne
- Scleromyxedema
- Amyloidosis
- Residual lichenification from atopic dermatitis

HISTOPATHOLOGIC

- Erythropoietic protoporphyria
- Diabetic microangiopathy
- Amyloidosis
- Lichen sclerosus

be a valid diagnostic test, not only to aid in diagnosis in mild cases but also potentially to direct molecular investigations.[226]

DIFFERENTIAL DIAGNOSIS

(Box 137-3)

PROGNOSIS AND CLINICAL COURSE. The prognosis of LP is variable. Often, there is progressive worsening of cutaneous features, with clearance during childhood of blistering lesions and progressive development of infiltrative lesions. The hoarseness and mucosal lesions also may progress with time. Although some patients have experienced respiratory complications from upper respiratory tract infiltration that have, in rare cases, led to early mortality, most patients have a normal life span. It is important to recognize the impact of LP on the quality of life of affected patients. The disfiguring nature of the skin lesions, along with the abnormal voice, significantly impacts the interactions of LP patients with others. Patients have increased difficulty in holding jobs.[210]

TREATMENT

Many agents, including topical and systemic corticosteroids, oral dimethyl sulfoxide,[227] and intralesional heparin, have been investigated and used in the treatment of LP. None of these agents has demonstrated any sustained benefits. A recent report describes the use of acitretin in one patient, with improvement in hoarseness but not skin lesions.[228] Given the apparent photoexacerbation of lesions in a subset of LP patients, photoprotection seems reasonable, although there are no data confirming any benefit. Additionally, avoidance of friction or trauma may be helpful given the prominence of lesions on frequently traumatized sites. Early intervention for developmental problems is important, and management of other stigmata by the appropriate specialists is warranted. Various surgical modalities such as dermabrasion and CO_2 laser procedures have been used to treat cutaneous lesions. CO_2 laser surgery for vocal cord lesions and eyelid papules has been helpful.[229,230]

PREVENTION

Prenatal genetic testing in families at risk is theoretically possible using DNA-based analysis.

KEY REFERENCES

Full reference list available at www.DIGM8.com

DVD contains references and additional content

25. Callewaert B et al: Ehlers-Danlos syndromes and Marfan syndrome. *Best Pract Res Clin Rheumatol* **22**(1):165-189, 2008
83. Goumans MJ, Liu Z, ten DP: TGF-beta signaling in vascular biology and dysfunction. *Cell Res* **19**(1):116-127, 2009
101. Gray JR et al: Life expectancy in British Marfan syndrome populations. *Clin Genet* **54**(2):124-128, 1998
105. Naughten ER, Yap S, Mayne PD: Newborn screening for homocystinuria: Irish and world experience. *Eur J Pediatr* **157**(Suppl. 2):S84-S87, 1998
124. Uitto J, Jiang Q: Pseudoxanthoma elasticum-like phenotypes: More diseases than one. *J Invest Dermatol* **127**(3):507-510, 2007
160. LaRusso J et al: Elevated dietary magnesium prevents connective tissue mineralization in a mouse model of pseudoxanthoma elasticum (Abcc6(-/-)). *J Invest Dermatol* **129**(6):1388-1394, 2009
173. Kornak U et al: Impaired glycosylation and cutis laxa caused by mutations in the vesicular H+-ATPase subunit ATP6V0A2. *Nat Genet* **40**(1):32-34, 2008
200. Barnes AM et al: Lack of cyclophilin B in osteogenesis imperfecta with normal collagen folding. *N Engl J Med* **362**(6):521-528, 2010
209. Hellemans J et al: Germline LEMD3 mutations are rare in sporadic patients with isolated melorheostosis. *Hum Mutat* **27**(3):290, 2006

Chapter 138 :: Cutaneous Mineralization and Ossification

:: Janet A. Fairley

CUTANEOUS MINERALIZATION AT A GLANCE

- Results from the deposition of calcium salts in the dermis, subcutaneous tissue, or vascular endothelium when the local calcium concentration exceeds its solubility in the tissue.
- Clinically, may be categorized as dystrophic, metastatic, idiopathic, or iatrogenic.
- Pathology shows aggregates of calcium that stain with Alizarin red S or von Kossa stains.

CALCIUM

Calcium is involved in many physiologic processes. It is key to skeletal muscle and myocardial contraction, neurotransmission, and blood coagulation. In addition, it is the primary mineral in the bony skeleton. On the cellular level, its diverse functions include transmission of information into and between cells, regulation of plasma membrane potential, and exocytosis. Only over the last 20 years has its effect on skin been fully appreciated. Calcium regulates major functions in the epidermal keratinocytes including proliferation, differentiation, and cell–cell adhesion.[1–6]

REGULATORY HORMONES

At least three regulatory hormones control the ionic calcium concentration in serum: (1) parathyroid hormone (PTH), (2) calcitonin, and (3) 1,25-dihydroxyvitamin D_3 ($1,25(OH)_2D_3$).

PTH is an 84-amino acid, single-chain polypeptide that is synthesized in the parathyroid glands. Under normal conditions, a decrease in the serum concentration of ionized calcium results in an increase in PTH production, whereas an increase in the serum concentration of ionized calcium results in a decrease in PTH production. In the kidney, PTH increases renal tubular reabsorption of calcium and increases renal clearance of phosphate. PTH also acts directly on the bone to increase the plasma calcium concentration. It does this acutely by mobilizing calcium from bone into the extracellular fluid. Osteocytes and osteoblasts are the presumed target cells for this effect. PTH also stimulates osteoclastic bone resorption, possibly by stimulating osteoblasts to release factors that activate osteoclasts. PTH together with a decreased plasma phosphate concentration stimulates 1α-hydroxylase activity in the kidney, causing an increase in the plasma concentration of $1,25(OH)_2D_3$. $1,25(OH)_2D_3$ increases intestinal absorption of calcium.

Calcitonin is a 32-amino acid polypeptide that is produced by parafollicular or C cells of the thyroid gland. Calcium is the primary stimulant for calcitonin secretion. Calcitonin lowers the serum calcium concentration, primarily through osteoclast inhibition, but whether it plays a major role in serum calcium metabolism outside of the neonatal period in vivo is unclear.

Vitamin D_3, or cholecalciferol, is a secosteroid (steroid with a "broken" ring) formed by the opening of the β ring of 7-dehydrocholesterol. In humans, this formation occurs in the basal layer of the epidermis. First, there is an ultraviolet B-mediated conversion of 7-dehydrocholesterol to previtamin D_3. Previtamin D_3 then undergoes thermal isomerization to form vitamin D_3. To become biologically active, vitamin D_3 must first be hydroxylated at carbon position 25 in the liver and then at carbon position 1α by the enzyme 1α-hydroxylase in the kidney. 1α-hydroxylase is tightly regulated. PTH and calcitonin increase its activity, whereas calcium, phosphate, and $1,25(OH)_2D_3$ inhibit it.[7]

$1,25(OH)_2D_3$, similar to PTH, increases the concentration of plasma calcium. Its primary action is to stimulate the active transport of calcium across the intestine. $1,25(OH)_2D_3$ also increases the plasma calcium concentration by mobilizing calcium from bone.[8] The simultaneous presence of PTH appears to be necessary for this effect.

$1,25(OH)_2D_3$ also plays a major role in the growth and differentiation of tissues, including skin.[9] $1,25(OH)_2D_3$ acts through its nuclear receptor (vitamin D receptor, VDR), which is a member of the superfamily of steroid/thyroid/retinoid nuclear receptors. In the skin, receptors for $1,25(OH)_2D_3$ are present on epidermal keratinocytes, pilosebaceous structures, and in the dermis.[10–13] In human keratinocyte cultures, $1,25(OH)_2D_3$ causes a dose-dependent decrease in proliferation, an increase in morphologic differentiation, and an increase in terminal differentiation markers.[14] Cultured human keratinocytes can also convert $25(OH)D_3$ to $1,25(OH)_2D_3$, suggesting that the epidermis may regulate its own growth and differentiation by endogenously produced $1,25(OH)_2D_3$.[14] The mechanism by which $1,25(OH)_2D_3$ may induce differentiation of epidermal cells may be through calcium, because calcium is required for terminal differentiation of keratinocytes. $1,25(OH)_2D_3$ may facilitate calcium entry into cells and, through induction of calcium-binding proteins, facilitate the ability of calcium to regulate various cellular processes.

ABERRANT CALCIFICATION AND OSSIFICATION

Despite the careful regulation of serum calcium, calcification and ossification of cutaneous and subcutaneous tissues may occur.[15] Calcification is the deposition of insoluble calcium salts; when it occurs in cutaneous tissues it is known as *calcinosis cutis*. Ossification is the formation of true bony tissue by the deposition of calcium and phosphorus in a proteinaceous matrix as hydroxyapatite crystals. Cutaneous calcification may be divided into four major categories: (1) dystrophic, (2) metastatic, (3) idiopathic, and (4) iatrogenic. Dystrophic calcification is the most common type of calcinosis cutis and occurs as a result of local tissue injury. Although calcium and phosphate metabolism and serum levels are normal, local tissue abnormalities, such as alterations in collagen, elastin, or subcutaneous fat may trigger calcification. The internal organs usually remain unaffected. Metastatic calcification is the precipitation of calcium salts in normal tissue secondary to an underlying defect in calcium and/or phosphate metabolism. The calcification may be widespread and, in addition to the skin, affects predominantly blood vessels, kidneys, lungs, and gastric mucosa. All patients presenting with signs of metastatic calcification should receive a calcium and phosphate metabolic evaluation. Idiopathic calcification occurs without identifiable underlying tissue abnormalities, abnormal calcium, and/or phosphate metabolism. Cutaneous calcification also may be iatrogenic. Cutaneous ossification most commonly occurs secondary to local tissue alteration or preexisting calcification. Any calcifying disorder of the skin may ossify secondarily. On rare occasions, primary cutaneous ossification may occur without underlying tissue abnormalities or preexisting calcification.

DYSTROPHIC CALCIFICATION

CONNECTIVE TISSUE DISEASES

Dystrophic calcification frequently occurs in connective tissue diseases.[16] Scleroderma and CREST syndrome (*c*alcinosis cutis, *R*aynaud phenomenon, *e*sophageal dysfunction, *s*clerodactyly, *t*elangiectasia) are notable examples that are frequently associated with calcinosis cutis (Fig. 138-1; see Chapter 157). In these disorders, nodules and plaques of calcium deposits may occur in the skin, subcutaneous tissue, muscle, or tendons. The calcium deposits most commonly occur on the upper extremities, especially on the fingers and wrists, but may occur in any area subject to trauma or motion. As the calcifications enlarge, they may ulcerate and exude a chalky material.

Dystrophic calcification also occurs in dermatomyositis (see Chapter 156). It is more commonly associated with juvenile rather than adult-onset dermatomyositis (formerly in about 44% of children as opposed to 20% of adults); nevertheless, the more aggressive early



Figure 138-1 Dystrophic calcification in CREST syndrome (*c*alcinosis cutis, *R*aynaud phenomenon, *e*sophageal dysfunction, *s*clerodactyly, *t*elangiectasia).

treatment of juvenile dermatomyositis has been associated with a decrease in the occurrence of dystrophic calcification.[17] The calcification tends to occur 2–3 years after disease onset and most frequently appears on the elbows, knees, shoulders, and buttocks.[18] The calcium deposits may be painful and can ulcerate. They also may exude a chalky material, form sinuses, and become chronically infected. Calcium salt deposition may become quite extensive, progressing along fascial planes of skin and muscle, forming an "exoskeleton," and leading to significant morbidity and mortality. Calcinosis cutis in dermatomyositis is difficult to treat; however, if the patient survives long enough, the calcified nodules may improve spontaneously. Although uncommon, calcinosis cutis has been described in all clinical subsets of lupus erythematosus.[19–22]

There is no standard treatment for dystrophic calcification. A diet low in calcium and phosphate along with aluminum hydroxide has been reported to arrest or facilitate regression of the calcified nodules.[23] Disodium etidronate has also been used with some success.[24] Several series report long-term treatment with diltiazem improves the calcinosis in some patients.[25,26] Other reported treatments include warfarin, colchicine, probenecid, and bisphosphonates.[16,27] Occasionally, calcium deposits must be removed surgically to clear sinus tracts, ulcers, or chronic infections.

PANNICULITIS

Pancreatic enzyme panniculitis (see Chapter 70) is a lobular panniculitis that commonly demonstrates dystrophic calcification. It occurs in patients with pancreatitis or pancreatic adenocarcinoma and is presumably caused by the action of liberated pancreatic enzymes on subcutaneous fat. The fatty acids formed by lipolysis may combine with calcium and form calcium soap.

In subcutaneous fat necrosis of the newborn, erythematous, well-defined nodules and plaques occur during the first few weeks of life over the cheeks, back, buttocks, and extremities.[28,29] The affected infants are generally otherwise healthy, and the nodules and plaques usually clear spontaneously. Occasionally, the lesions calcify, and in a small subset of

patients symptomatic hypercalcemia may develop, sometimes several months after birth.

INHERITED DISORDERS

Dystrophic calcification occurs in patients with pseudoxanthoma elasticum (PXE; see Chapter 137). PXE is a hereditary disorder of elastic tissue characterized by progressive calcification of elastin fibers, primarily within the skin, Bruch's membrane of the retina, and the cardiovascular system. The cause of PXE was recently identified as a mutation in the *ABCC6* gene.[30] This gene is thought to play a critical role in transmembrane transport. Most patients with PXE have normal calcium phosphate metabolism, but a few have been identified who have abnormal calcium, phosphate, and/or vitamin D metabolism. Patients in this subset may develop metastatic calcification in the form of calcified or ossified tumors, calcification of the falx cerebri, and arterial calcification.[31–33]

Ehlers–Danlos syndrome (EDS; see Chapter 137) is a group of inherited disorders of fibrillar collagen metabolism. Mutations in the collagen genes or enzymes that regulate collagen biosynthesis have been determined to underlie a number of EDS subtypes.[34–36] The skin characteristically shows hyperelasticity and fragility with formation of pseudotumors and large gaping scars. Subcutaneous calcified nodules, termed *spheroids* may appear, and are thought to represent calcified ischemic fat lobules.[37,38] Calcification of healing surgical incisions has also been reported in patients with EDS.[39]

Dystrophic calcification has been observed in patients with porphyria cutanea tarda (see Chapter 132).[40,41] Sclerodermoid plaques with dystrophic calcification have occurred on the preauricular area, scalp, neck, and dorsa of the hands. Ulceration with transepidermal elimination of sheets of calcium is also rarely reported. Other genetic disorders in which calcification may occur include Werner syndrome and Rothmund–Thomson syndrome (see Chapter 139).[42,43]

CUTANEOUS NEOPLASMS

Dystrophic calcification occurs in association with a variety of benign and malignant cutaneous neoplasms. Often the neoplasms also show ossification in the surrounding stroma.

Pilomatricomas (see Chapter 119) are the most common cutaneous neoplasms that manifest calcification and ossification. Approximately 75% of pilomatricomas show calcification and 15% to 20% show ossification.[44,45] Ossification usually occurs within the connective tissue adjacent to the shadow cells, probably through metaplasia of fibroblasts into osteoblasts. Activating mutations in the adherens junction protein β-catenin have been identified in some pilomatricomas.[46]

A large number of other neoplasms may be associated with calcification and ossification, including: pilar cyst, basal cell carcinoma, intradermal nevi (probably as a result of inflammation or folliculitis), desmoplastic malignant melanoma, atypical fibroxanthoma, pyogenic granuloma, hemangioma, neurilemmoma, trichoepithelioma, and seborrheic keratoses.[47–51] Mixed tumors (chondroid syringomas) may also show calcification and ossification. However, unlike other neoplasms, the ossification occurs within the tumor via ossification of the chondroid cells, much like endochondral bone formation occurring in the epiphyses of bones.

INFECTIONS

Infectious agents may produce enough cutaneous damage to cause dystrophic calcification. Parasitic infections that may result in calcinosis cutis include onchocerciasis (*Onchocerca volvulus*) and cysticercosis (*Taenia solium*).[52,53] Calcinosis cutis has also been reported as a complication of intrauterine herpes simplex infection.[54]

OTHER

Dystrophic calcification has been reported in a variety of settings where local tissue injury occurs, such as in scarring caused by burns, trauma, neonatal heel sticks (subepidermal calcified nodule), surgery, and keloids.[55–59]

METASTATIC CALCIFICATION

CHRONIC RENAL FAILURE

Metastatic calcification most commonly occurs in chronic renal failure and takes the form of either benign nodular calcification or calciphylaxis. In chronic renal failure, decreased clearance of phosphate results in hyperphosphatemia. In addition, the impaired production of $1,25(OH)_2D_3$ results in a decrease in calcium absorption from the intestine and decreased serum calcium levels. The hypocalcemia results in increased PTH production and secondary hyperparathyroidism. Elevated levels of PTH cause bone resorption and mobilization of calcium and phosphate into the serum, leading to normalization of the serum calcium concentration but marked hyperphosphatemia. If the solubility product of calcium and phosphate is exceeded, metastatic calcification may occur. In benign nodular calcification, the calcifications typically occur at periarticular sites, and their size and number tend to correlate with the degree of hyperphosphatemia. The lesions disappear with normalization of calcium and phosphate levels.

Calciphylaxis is a life-threatening disorder characterized by progressive vascular calcification, soft tissue necrosis, and ischemic necrosis of the skin (see Chapter 151).[60] Clinically, it presents as firm, extremely painful, well-demarcated, violaceous plaques associated with soft tissue necrosis and ulceration (Fig. 138-2). The



Figure 138-2 Calciphylaxis. The lesions develop as violaceous plaques that may progress to necrotic ulcers, as shown in this patient.

lesions may occur anywhere, but the lower extremities are most frequently involved. The mortality rate is estimated to be approximately 80%. Histopathologically, there is medial calcification of small and medium-sized arteries with intimal hyperplasia, primarily in dermal and subcutaneous tissues. Calciphylaxis occurs almost exclusively in patients with a history of chronic renal failure and prolonged secondary hyperparathyroidism. However, there exist rare reports of the occurrence of calciphylaxis in the absence of renal failure.[61] Most of the patients reported are female, and there may be an association with obesity and poor nutritional status.[62,63]

The pathogenesis of calciphylaxis remains controversial. Experiments in a rat model suggested that calciphylaxis may be triggered by exposure to a sensitizing agent (PTH, dihydrotachysterol, or vitamin D) followed by a challenging agent (metal salts, albumin, or corticosteroids).[64] However, the clinical description and histopathology of the animal lesions differ from the human disease. Protein C dysfunction has also been described in a subset of patients with calciphylaxis, but this more likely is a mark for a coagulation defect that predisposes this group to calciphylaxis.[65] More recently, it has been proposed that conversion of vascular smooth muscle cells into osteoblast-like cells is a critical step in the development of progressive vascular calcification as is seen in calciphylaxis. This conversion may be stimulated by phosphates, substances that stimulate inflammation in the vascular wall and bone morphogenic protein (BMP)-2. Other proteins that are currently under study as potential effectors, both positive and negative, are BMP-7, osteoprotegerin, matrix Gla protein, fetuin-A, and phosphatonins.[66]

The current therapy of calciphylaxis involves a multifaceted approach. The calcium-phosphate product should be normalized by methods including: low calcium dialysis, use of phosphate binders that combine calcium acetate and magnesium carbonate, sodium thiosulfate, and parathyroidectomy in those instances where medical management fails.[67] Aggressive management of wound infections and judicious use of debridement may help lower the incidence of sepsis and death in these patients.

HYPERVITAMINOSIS D

Chronic ingestion of vitamin D in supraphysiologic doses (50,000–100,000 units/day) may produce hypervitaminosis D.[68] The initial signs and symptoms of hypervitaminosis D are attributable to hypercalcemia and hypercalciuria, and include weakness, lethargy, headache, nausea, and polyuria. Metastatic calcification may also occur.

MILK–ALKALI SYNDROME

Milk–alkali syndrome is characterized by excessive ingestion of calcium-containing foods or antacids, leading to hypercalcemia.[69] Complications other than the acute manifestations of hypercalcemia include irreversible renal failure, nephrocalcinosis, and subcutaneous calcification, occurring predominantly in periarticular tissues.

TUMORAL CALCINOSIS

Tumoral calcinosis (TC) is a disorder characterized by the deposition of calcific masses around major joints, such as hips, shoulders, elbows, and knees. The masses are intramuscular or subcutaneous and may enlarge to sizes causing significant impairment of joint function. Usually, the overlying skin is normal, but associated ulceration and calcinosis cutis may occur. It generally occurs in otherwise healthy adolescents. Tumoral calcinosis may be either sporadic or familial. The familial type may be associated with hyperphosphatemia or normophosphatemia. Inactivating mutations in either the *GALNT3* or *FGF23* genes may lead to hyperphosphatemic TC.[70–72] *GALNT3* encodes a glycosyltransferase (*N*-acetylgalactosaminyltransferase 3 or ppGalNAc-T3) that initiates mucin-type *O*-glycosylation. It is hypothesized that FGF23, an important regulator of phosphate homeostasis, must be glycosylated by ppGalNAc-T3 to function properly. Normophosphatemic familial TC has been associated with mutations resulting in the absence of SMAD9, an anti-inflammatory protein that has also been suggested to be a tumor suppressor. Surgical excision is the treatment of choice, but phosphate deprivation via dietary restriction and antacids that impair phosphate absorption has met with some success.[73]

OTHER DISORDERS

Other systemic disorders associated with hypercalcemia and/or hyperphosphatemia are reported to cause metastatic calcification. These include neoplasms associated with bony destruction, such as lymphoma, leukemia, multiple myeloma, and metastatic carcinoma.[74–76] Sarcoidosis may also be associated with metastatic calcification.[77]

IDIOPATHIC CALCIFICATION

Calcified nodules characterize idiopathic calcification of the scrotum. The lesions usually appear in otherwise

healthy males and tend to increase in size and number with time.[76] Eventually, they may break down and exude a chalky material. Controversy exists over the etiology of this disorder.[78–81] The largest series of patients to date with calcified nodules of the scrotum ($n = 100$) exhibit a spectrum of histologic findings from clear cut calcification of an epidermal cyst, to inflamed cyst with partial loss of the epithelia lining, to calcium deposits, suggesting that these nodules form from dystrophic calcification of cysts and obliteration of the cyst wall.[82] Excision of the lesions is the treatment of choice, although patients may continue to develop nodules at other sites. Idiopathic calcification of the penis, vulva, and breast has also been reported.[83,84]

Subepidermal calcified nodules appear on the exposed areas of the head and the extremities.[85] They may be congenital or acquired and typically appear as hard, 3- to 10-mm solitary lesions, although multiple lesions may occur. Some investigators believe the lesions represent calcified sweat gland hamartomas.[86]

Reports have described the appearance of milia-like idiopathic calcinosis cutis on the dorsa of hands and forearms of patients with Down syndrome.[87–89] Some of the calcifications are associated with syringomas.

IATROGENIC CALCIFICATION

Cutaneous calcification may be iatrogenic. Calcinosis cutis is a complication of intravenous calcium chloride and calcium gluconate therapy.[90] Calcified nodules may appear at sites of extravasation, probably as a result of an elevated tissue concentration of calcium and tissue damage. Minor trauma and prolonged contact with calcium salts can lead to calcinosis cutis in a variety of settings.[91,92] It has occurred in patients undergoing electroencephalography with saturated calcium chloride electrode paste.[93] Cutaneous calcification of skin graft donor sites after the application of calcium alginate dressings has also been reported.[94] Transient deposits of calcium in the skin and other soft tissues have also been reported after liver transplantation.[95] It is hypothesized that these transient deposits are caused by the large amounts of calcium- and cit-rate-containing blood products used during surgery, combined with metabolic abnormalities in the perioperative period.

PRIMARY OSSIFICATION

Primary ossification of cutaneous and subcutaneous tissues rarely occurs without any underlying tissue abnormality or preexisting calcification. In addition to miliary osteoma of the face, there are three well-described ossifying syndromes[96]: fibrodysplasia ossificans progressiva (FOP), and two GNAS-associated disorders, Albright hereditary osteodystrophy (AHO), and progressive osseous heteroplasia (POH). Other primary ossification disorders reported in the literature, such as plate-like osteoma cutis, isolated osteoma or widespread osteoma, probably are variants of the described ossifying syndromes or represent a group of poorly described primary ossification disorders.

FIBRODYSPLASIA OSSIFICANS PROGRESSIVA

FOP is an autosomal-dominant syndrome characterized by the progressive ossification of deep connective tissues leading to significant morbidity and mortality.[97] Ossification is of the endochondral type, and involvement of the skin occurs as a result of direct extension from underlying tissues. Dysmorphic great toes are a characteristic feature of FOP. Other features include abnormal phalanges of the hands, deafness, baldness, and mental retardation. Point mutations in the activin (*ACVR1*) gene have been identified as the cause of FOP. Most cases represent spontaneous mutations but in a few families parental germ-line mosaicism has been identified.[98] ACVR1 (also known as activin-like kinase 2; ALK2) is a bone morphogenic protein type I receptor and its mutation leads to overactive BMP signaling, leading to ectopic bone formation.

ALBRIGHT HEREDITARY OSTEODYSTROPHY, PROGRESSIVE OSSEOUS HETEROPLASIA, AND PLATE-LIKE OSTEOMA CUTIS

AHO, and POH, are closely related syndromes that are characterized by intramembranous bone formation in skin. Mutations in the gene encoding for the α-subunit of the stimulatory G protein of adenyl cyclase (GNAS1), a negative regulator of bone formation, have been identified in both of these disorders.[96,99–101] In addition, some patients have been described in which features of both disorders are present.[102] Several families have demonstrated an "imprinting" effect; inheritance of an inactivating mutation in GNAS1 from the mother results in pseudohypoparathyroidism type Ia, whereas paternal inheritance leads to POH.[103,104] In addition, different splice variants are expressed solely by maternal or paternal alleles. AHO more commonly arises from maternally inherited mutations but no clear genotype–phenotype correlation has yet been established between these disorders. Those patients described as plate-like osteoma cutis appear to be form frustes of AHO or POH.

AHO is an autosomal dominantly inherited syndrome characterized by the ossification of cutaneous and subcutaneous tissues in childhood. AHO generally follows a limited course, and significant deformity and physical impairment are rare. Patients typically have brachydactyly dimpling over the metacarpophalangeal joints (Albright's sign), obesity, round or moon facies, short stature, and mental retardation. Most patients have a deficient end-organ response to PTH or "pseudohypoparathyroidism" with hypocalcemia, hyperphosphatemia, and elevated levels of PTH. Other patients have "pseudopseudohypoparathyroidism" with normal serum levels of calcium and phosphorus.[93]

POH is characterized by progressive ossification of skin and deep tissues during infancy or childhood.[105,106] Most reported patients are female, although



Figure 138-3 Progressive osseous heteroplasia. The appearance of the skin in progressive osseous heteroplasia can be subtle, but the lesions have a distinctive textural change that feels like rice grains in the skin.

a small number of male patients have also been described. Ossification usually begins in the dermis and progresses to involve deeper tissues, such as muscle, as well as overlying skin. Skin involvement has been described as a papular eruption resembling "rice grains" and having a "gritty" consistency (Fig. 138-3). Unlike AHO or FOP, there are no associated dysmorphic features. Secondary orthopedic problems, such as limb-length discrepancy or ankylosis of the joint, arise if the cutaneous ossification is severe enough to limit motion.

Miliary osteoma cutis of the face most commonly occurs as multiple small, firm nodules on the faces of young women with a history of acne vulgaris. However, there are reports of multiple miliary osteoma cutis in older patients without acne vulgaris or other underlying skin disease.[104]

ACKNOWLEDGMENT

The author thanks John S. Walsh, MD, for his work on this chapter in previous editions.

KEY REFERENCES

Full reference list available at www.DIGM8.com

DVD contains references and additional content

9. Bikle DD: Vitamin D regulated keratinocyte differentiation. *J Cellular Biochem* **92**:436, 2004
15. Walsh JS, Fairley JA: Calcifying disorders of the skin. *J Am Acad Dermatol* **33**:693, 1995
16. Boulman N et al: Calcinosis in rheumatic d. *Semin Arthritis Rheum* **34**:805, 2005
60. Weenig RH et al: Calciphylaxis: Natural history, risk factor analysis and outcome. *J Am Acad Dermatol* **56**:569, 2007
73. Sprecher E: Familial tumoral calcinosis: From characterization of a rare phenotype to the pathogenesis of ectopic calcification. *J Invest Dermatol* **130**:652, 2010
96. Adegbite NS et al: Diagnosis and mutational spectrum of progressive osseous heteroplasia (POH) and other forms of GNAS-based heterotopic ossification. *Am J Med Genetics* **146A**:1788, 2008

Chapter 139 :: Hereditary Disorders of Genome Instability and DNA Repair

:: Thomas M. Rünger, John J. DiGiovanna, & Kenneth H. Kraemer

HEREDITARY DISORDERS OF GENOME INSTABILITY AND DNA REPAIR AT A GLANCE

- Genome instability characterizes a large group of inherited disorders with prominent cutaneous abnormalities; many have an increased cancer risk.
- Genome instability is caused by impaired repair and/or maintenance of DNA.
- Xeroderma pigmentosum is a prototype with impaired repair of environmentally induced DNA damage and a greatly increased frequency of sunlight-induced cancer.
- Although these disorders are rare, heterozygotic carriers of affected genes, which may comprise several percent of the general population, may carry an increased cancer risk as well.

Because the genome exerts control for cellular function, maintaining genome stability is important for the continued function of cells, tissues, and organisms. DNA is the carrier of genetic information. Its structure is regularly threatened by damaging agents that include oxidative stress, ultraviolet (UV) and X-radiation, and chemical agents. Although much damage is repaired, failure to maintain genomic integrity may lead to abnormal cell function or cell death. If the cell divides, progeny may accumulate additional damage and this progressive accumulation of damage can lead to malignancy (see Chapter 110).

This chapter describes the relevant skin disorders with genome instability and the underlying defective mechanisms of DNA repair or DNA maintenance (Tables 139-1 and 139-2). All of these exhibit prominent cutaneous abnormalities that involve dermatologists in their diagnosis and management. Most, but not all, are also characterized by an increased risk of malignancies. This demonstrates that the maintenance of genome integrity is of utmost importance for the prevention of malignant transformation. Malignant transformation requires the accumulation of several mutations in specific genes of a single cell. Thus a mutator phenotype is often regarded a prerequisite for carcinogenesis, because without genome instability it would be exceedingly unlikely that all of those mutations occur in a single cell.[1–4] The same genes that are affected in the hereditary genome instability disorders can also confer genome instability to individual cells when impaired through acquired mutations, thereby playing an important role early in spontaneous carcinogenesis.

In addition, although these heritable diseases are rare (of the order of 10^{-5} or 10^{-6}), carriers of the affected genes may comprise several percent of the general population. These individuals are usually free of clinical symptoms, as most of these disorders are characterized by autosomal recessive inheritance. However, epidemiologic studies suggest that heterozygotic carriers may have an increased risk of neoplasia as well.[5,6]

Spontaneous genome instability is present in Bloom syndrome (BS), ataxia telangiectasia, and Fanconi anemia (FA) as manifested by increased chromosome breakage in primary blood or skin cells. On the other hand, genome instability is present in cells from patients with xeroderma pigmentosum (XP) only after exposure to DNA-damaging agents such as UV radiation or other carcinogens such as benzo[*a*]pyrene, which is present in cigarette smoke. In XP, many of the severe disease manifestations such as cancer and corneal scarring leading to blindness are the result of the interplay between genetic risk and environmental exposure. For example, XP patients who avoid UV radiation dramatically reduce or eliminate the probability of developing skin cancer and blindness.

In some of the disorders discussed here, genome instability is caused by an impaired ability to repair damage to DNA introduced by certain physical or chemical agents. Cells are equipped with different DNA repair pathways (reviewed in Chapter 110) that repair different types of DNA damage. The nucleotide excision repair (NER) pathway, which processes bulky DNA lesions, including UV-induced DNA photoproducts, is impaired in XP, Cockayne syndrome (CS), and trichothiodystrophy (TTD). Cells from patients with these conditions are characterized by increased killing and mutation formation following exposure to UV radiation. However, only XP patients have increased cancer risk. The reason for this difference in cancer risk is not known.

Proteins encoded by some of the affected genes in these three disorders are not only involved in DNA repair, but also in transcription and cellular DNA damage responses. Thus, mutations affecting different functions of the same gene (such as nervous system development or immune competence) appear to play a role in various phenotypes that are not directly linked to DNA repair functions and underlie several overlap syndromes between those three conditions (Table 139-3). Multiple clinical phenotypes of DNA repair diseases have been recognized. Defects in many genes have been associated with these clinical phenotypes. Mutations in different DNA repair genes can be associated with the same clinical phenotype. On the other hand, different mutations in one DNA repair gene can be associated with different clinical phenotypes. For example, mutations in the XPD(ERCC2) gene have been associated with the following clinical phenotypes: XP, XP with neurologic abnormalities, the XP-Cockayne syndrome complex (XP/CS), XP/TTD, COFS (cerebro-oculofacio-skeletal syndrome), or CS/TTD. XP variant, which is clinically indistinguishable from XP, is a disorder of DNA damage tolerance. Although normal cells can bypass DNA damage during replication (translesional DNA synthesis), cells from XP-variant patients have a defect in this process. The DNA mismatch repair pathway (see Chapter 110) is affected in hereditary nonpolyposis colon cancer (Lynch syndrome) and its subform, Muir–Torre syndrome. Muir-Torre syndrome has cutaneous features including sebaceous gland tumors. These are reviewed in Chapter 153.

Helicases are proteins that unwind DNA and are required for a multitude of metabolic processes involving DNA, such as transcription, replication, repair, and more. Two genes involved in NER are helicases that are also part of the basal transcription factor, TFIIH. The XPB (ERCC3) gene product unwinds DNA in the 3′ to 5′ direction whereas the XPD (ERCC2) gene product unwinds DNA in the opposite direction. The RecQ family of DNA helicases is highly conserved in evolution from bacteria to humans.[7,8] Of the five known human RecQ family members, three [(1) BLM, (2) WRN, and (3) RECQL4, which cause BS, Werner syndrome (WS), and Rothmund–Thomson syndrome (RTS), respectively] are mutated in distinct clinical disorders associated with chromosomal instability, cancer predisposition, and/or premature aging.[9]

Genetic instability can also result from abnormal telomere maintenance. Telomeres are long nucleotide $(TTAGGG)_n$ repeats that are important for the maintenance of chromosomal integrity.[10] Some telomeric repeats are lost at each cell division and shortened telomere lengths are a feature of aged cells. Accelerated telomere shortening is a hallmark of cells from patients

TABLE 139-1
Clinical Features of Hereditary Disorders of Genome Instability and DNA Repair

	Clinical Features			
Disorder	**Cutaneous**	**Neoplasia**	**Other**	**Inheritance**
Disorders of Genome Instability with Defective DNA Repair				
Xeroderma pigmentosum (XP)	Photosensitivity (blistering on minimal sun exposure in some patients), freckle-like (lentiginous) macules, poikiloderma (hyper- and hypopigmentation, atrophy, telangiectasia), skin cancer	BCC, SCC, melanoma, central nervous system tumors	Sensorineural deafness, progressive neurologic degeneration, primary loss of neurons (some patients)	Autosomal recessive
Cockayne syndrome (CS)	Photosensitivity (burning on sun exposure)	No increased incidence	Typical facial features (deep set eyes, loss of subcutaneous fat), pigmentary retinal degeneration, postnatal growth failure, sensorineural deafness, progressive neurologic degeneration, primary dysmyelination, brain calcifications	Autosomal recessive
Xeroderma pigmentosum/Cockayne syndrome complex (XP/CS)	Photosensitivity (burning on sun exposure), freckle-like (lentiginous) macules, poikiloderma (hyper- and hypopigmentation, atrophy, telangiectasia), skin cancer	BCC, SCC	Neurologic changes of CS	Autosomal recessive
Trichothiodystrophy` (TTD)	Brittle hair, photosensitivity (burning on sun exposure), ichthyosis, collodion membrane, "tiger tail banding" of hair with polarized microscopy	No increased incidence	Congenital cataracts, short stature developmental delay, microcephaly, primary dysmyelination, recurrent infections	Autosomal recessive
Xeroderma pigmentosum/ trichothiodystrophy (XP/TTD)	Clinical features of both TTD and XP including skin cancer	BCC, SCC, melanoma	Clinical features of both TTD and XP	Autosomal recessive
Hereditary nonpolyposis colon cancer (HNPCC)/MUIR–TORRE Syndrome (MTS)	Sebaceous tumors (benign and malignant), keratoacanthomas	Low-grade cancer of the colon, endometrium, stomach, small intestine, hepatobiliary system, upper urethral tract, larynx and ovary; sebaceous carcinoma, BCC with sebaceous differentiation		Autosomal dominant

Other Disorders of Genome Instability				
Bloom syndrome (BS)	Photosensitivity (burning on sun exposure), malar erythema, café-au-lait macules	Most cancer types; in particular leukemia, lymphomas, carcinomas of the breast and gastrointestinal tract	Immune deficiency, growth retardation, unusual facies, male infertility and female subfertility, type II diabetes	Autosomal recessive
Werner syndrome (WS)	Graying of hair, skin atrophy, leg ulcers, melanomas	Sarcomas, thyroid cancer, meningiomas, melanomas (acral lentiginous, and mucous membrane melanomas)	Premature aging (atherosclerosis, diabetes mellitus, osteoporosis, cataracts)	Autosomal recessive
Rothmund–Thomson syndrome (RTS)	Photosensitivity (burning on sun exposure), poikiloderma, alopecia	Osteosarcomas, cutaneous SCC and others	Skeletal abnormalities, growth deficiency, juvenile cataracts, osteoporosis	Autosomal recessive
Fanconi anemia (FA)	Café-au-lait macules	Myeloid leukemia, SCC of head and neck	Aplastic anemia, pancytopenia, growth retardation, thumb and other bone abnormalities	Autosomal recessive
Dyskeratosis congenita	Lacy, reticular pigmentation of neck and upper chest; nail dystrophy; premature gray hair, hyperhidrosis, skin cancer	Mucosal leukoplakia leading to cancer of anus or mouth, Hodgkin disease, pancreatic adenocarcinoma	Stenosis of lacrimal duct, anemia, pancytopenia, immunodeficiency, learning difficulties, deafness, brain calcifications, cerebellar hypoplasia, testicular atrophy, short stature, intrauterine growth retardation, retinopathy	X-linked recessive, autosomal dominant, autosomal recessive
Ataxia telangiectasia (AT)	Telangiectasias	T-cell leukemia, lymphomas	Progressive cerebellar ataxia, immune defects, hypogonadism, increased acute toxicity of therapeutic X-ray	Autosomal recessive
AT-like disorder (ATLD)	Similar to AT	Similar to AT	Similar to AT, but no ocular telangiectasias	Autosomal recessive
Nijmegen breakage syndrome (NBS)	Café-au-lait macule, vitiligo	B- and T-cell lymphomas, rhabdomyosarcoma, neuroblastoma	Immune defects, growth retardation, microcephaly, mental retardation, characteristic facies	Autosomal recessive
Seckel syndrome	Café-au-lait macules	Leukemia	Proportionate dwarfism, microcephaly, mental retardation, characteristic facies (receding forehead, narrow face, large beaked nose, micrognathia), immune deficiency, pancytopenia	Autosomal recessive

TABLE 139-2
Mechanisms of Hereditary Disorders of Genome Instability and DNA Repair

Disorder	Mechanisms		
	Cellular Abnormalities	Affected Gene(s)	Impaired Function
Disorders of Genome Instability with Defective DNA Repair			
Xeroderma pigmentosum (XP)	Increased UV-induced cell killing and mutagenesis	*XPA*, *XPB*, *XPC*, *XPD*, *XPE*, *XPF*, *XPG*, or DNA polymerase η	Nucleotide excision repair: global genome and transcription-coupled DNA repair; translesional DNA synthesis (XP-variant)
Cockayne syndrome (CS)	Increased cell killing and mutagenesis after exposure to UV and ionizing radiation	*CSA* or *CSB*	Nucleotide excision repair: transcription-coupled DNA repair only
Xeroderma pigmentosum/ Cockayne syndrome complex (XP/CS)	Increased UV-induced cell killing and mutagenesis	*XPB*, *XPD*, or *XPG*	Nucleotide excision repair: global genome and transcription-coupled DNA repair
Trichothiodystrophy (TTD)	Increased UV-induced cell killing	*XPB*, *XPD*, *TTD-A*, or *TTDN1*	Nucleotide excision repair: transcription-coupled pathway of nucleotide excision repair
Xeroderma pigmentosum/ trichothiodystrophy (XP/TTD)	Same as XP	*XPD*	Nucleotide excision repair: global genome and transcription-coupled DNA repair
Hereditary nonpolyposis colon cancer (HNPCC)/MUIR–TORRE SYNDROME (MTS)	High level of microsatellite instability in tumors	*hMSH2* (MTS, HNPCC1), *hMLH1* (MTS, HNPCC2), *PMS1* (HNPCC3), *hPMS2* (HNPCC4), *hMSH6* (HNPCC5), *TGFBR2* (HNPCC6), or *hMLH3* (HNPCC7)	Mismatch repair
Other Disorders of Genome Instability			
Bloom syndrome (BS)	Spontaneous chromosome breakage and rearrangements, increased sister chromatid exchanges, quadriradial chromosomes	*BLM*	A RecQ DNA helicase, recombination, replication
Werner syndrome (WS)	Chromosomal instability, accelerated telomere shortening	*WRN*	A RecQ DNA helicase, transcription, DNA repair (DSBR, SSBR, recombination), DNA replication, telomere maintenance
Rothmund–Thomson syndrome (RTS)	Chromosomal instability in response to ionizing radiation	RECQL4 (some patients)	A RecQ DNA helicase
Fanconi anemia (FA)	Increased sensitivity to DNA cross-linking agents	*FANCA*, *FANCB*, *FANCC*, *FANCD1/ BRCA2*, *FANCD2*, *FANCE*, *FANCF*, *FANCG/XRCC9*, *FANCI*, *FANCJ/BACH1/ BRIP1*, *FANCL*, *FANCM*, *FANCN/PALB2*	DNA damage signaling, recombination repair
Dyskeratosis congenita	Shortened telomeres	*DKC1* X-linked; *TERC*, *TERT*, *TINF2*, autosomal dominant; *TERT*, *NOLA3*, *NOLA2* autosomal recessive	Abnormal telomere biology
Ataxia telangiectasia (AT)	Increased spontaneous and X-ray-induced chromosome breakage, increased sensitivity to killing by ionizing radiation, impaired cell cycle arrest and/or apoptosis in response to DNA damage	*ATM*	DNA damage signaling (control of cell cycle, apoptosis), repair of DNA double strand breaks
AT-like disorder (ATLD)	Increased spontaneous and X-ray-induced chromosome breakage, increased sensitivity to killing by ionizing radiation, impaired DNA strand break repair	*LIG4*	DNA ligase 4, strand break repair
Nijmegen breakage syndrome (NBS)	Increased spontaneous and X-ray-induced chromosome breakage, increased sensitivity to killing by ionizing radiation	*NBS1*	Nibrin (p95), which is part of the MRE11–RAD50–NBS1 complex, DNA damage signaling, recombination, DNA double strand break repair, cell cycle checkpoint
Seckel syndrome	Spontaneous and mitomycin C-induced chromosome instability, sensitivity to killing by UV and DNA cross-linking agents	*ATR*	Ataxia telangiectatica- and RAD3-related protein, DNA damage response, cell cycle checkpoints

TABLE 139-3
DNA Repair Disorders and Molecular Defects

Clinical Disorders	Molecular Defects
Xeroderma pigmentosum	XP-C, XP variant, XP-D, XP-A, XP-F, XP-G, XP-E
Xeroderma pigmentosum with neurological Abnormalities	XP-A, XP-D, XP-B
Trichothiodystrophy	XP-D, TTD-A, XP-B, TTDN1
Cockayne syndrome	CS-B, CS-A
Xeroderma pigmentosum/ Cockayne syndrome complex	XP-B, XP-G, XP-D
Xeroderma pigmentosum/ Trichothiodystrophy complex	XP-D
Cerebro-ocular-facial skeletal (COFS) syndrome	CS-B, XP-D

with the cancer-prone disorder dyskeratosis congenita. In about half of dyskeratosis congenita patients, mutations have been found in one out of six genes involved in telomere maintenance.[11]

BASC (*B*RCA1-*a*ssociated genome *s*urveillance *c*omplex) is a multienzyme complex centered around the BRCA1 protein in the nucleus.[12] It contains important DNA damage response proteins including ATM, ATR, the MRE11-RAD50-NBS1 complex, BRCA1, BLM, FANCD2, and MLH1. These proteins physically interact with each other. Genome instability may result from a defect in any of those and cause the genome instability disorders ataxia-telangiectasia (reviewed in Chapter 143), Seckel syndrome, Nijmegen breakage syndrome, hereditary breast cancer, BS, FA, or hereditary colon cancer. BS and FA are reviewed here.

DISORDERS OF DNA REPAIR

XERODERMA PIGMENTOSUM

XP serves as the prototype heritable disease with increased sensitivity to cellular injury.[12–14] XP is an autosomal recessive disease with sun sensitivity, photophobia, early onset of lentigines and freckling, and subsequent neoplastic changes on sun-exposed surfaces. There is cellular hypersensitivity to UV radiation and to certain chemicals in association with abnormal DNA repair. Some of the patients have progressive neurologic degeneration.

FREQUENCY. XP occurs with a frequency of about 1 in 1 million persons in Europe and the United States[15,16] It is relatively more common in areas such as the Middle East where marriage of close relatives is practiced. Patients have been reported worldwide in all races, including whites, Asians, blacks, and Native Americans.

CLINICAL FEATURES

Skin. Approximately one-half the patients with XP have a history of acute sunburn reaction on minimal UV exposure. The other patients tan normally without excessive burning. In all patients, numerous freckle-like hyperpigmented macules (lentigines) appear predominately on sun-exposed skin (Fig. 139-1). The median age of onset of the cutaneous symptoms in XP is between 1 and 2 years (Fig. 139-2).[14] These generally spare sun-protected sites such as the buttocks (see Fig. 139-1D). However, some severely sun-exposed patients may show pigmentary abnormalities in the axillae. Continued sun exposure causes the patient's skin to become dry and parchment-like, with increased pigmentation, hence the name *xeroderma pigmentosum* ("dry pigmented skin"; see Fig. 139-1A). Premalignant actinic keratoses develop at an early age (see Fig. 139-1B). The appearance of sun-exposed skin in children with XP is similar to that occurring in farmers and sailors after many years of extreme sun exposure.

Cancer. Patients with XP younger than 20 years of age have a greater than 10,000-fold increased risk of cutaneous basal cell carcinoma, squamous cell carcinoma, or melanoma.[12,13,16,17] The median age of onset of nonmelanoma skin cancer reported in patients with XP is 8 years. This 50-year reduction in comparison with the general population is an indication of the importance of DNA repair in protection from skin cancer in unaffected individuals (see Fig. 139-2).

Review of the world's literature on XP has revealed a substantial number of cases of oral cavity neoplasms, particularly squamous cell carcinoma of the tip of the tongue, a presumed sun-exposed location. Brain (sarcoma and medulloblastoma), central nervous system (astrocytoma of the spinal cord), lung, uterine, breast, pancreatic, gastric, renal, and testicular tumors and leukemia have been reported in a few patients with XP.[11,12,15,16] Overall, these reports suggest an approximate 10- to 20-fold increase in internal neoplasms in XP.

Eyes. Ocular abnormalities are almost as common as the cutaneous abnormalities and are an important feature of XP (see Fig. 139-1C).[14,18,19] The posterior portion of the eye (retina) is shielded from UV radiation by the anterior portion (lids, cornea, and conjunctiva). Clinical findings are strikingly limited to these anterior, UV-exposed structures. Photophobia is often present and may be associated with prominent conjunctival injection. Schirmer's testing frequently reveals reduced tearing leading to dry eyes. Continued UV exposure of the eye may result in severe keratitis, leading to corneal opacification and vascularization. The lids develop increased pigmentation and loss of lashes. Atrophy of the skin of the lids results in ectropion, entropion, or, in severe cases, complete loss of the lids. Benign conjunctival inflammatory masses or papillomas of the lids may be present. Epithelioma, squamous cell carcinoma, and melanoma of UV-exposed portions of the eye are common. The ocular manifestations may be more severe in black patients.[20]



Figure 139-1 Xeroderma pigmentosum. **A.** Pigmentary changes, atrophy, dryness, and cheilitis in a 16-year-old patient. **B.** Cheek of a 14-year-old patient with pigmented macules of varying size and intensity, actinic keratosis, basal cell carcinoma, and a surgical scar. **C.** Corneal clouding, prominent conjunctival blood vasculature, and loss of lashes. **D.** Myriads of pigmented macules of varying size and intensity and scattered achromic areas on the back, with marked sparing of sun-protected buttocks of a 14-year-old patient.

Neurologic System. Neurologic abnormalities have been reported in approximately 30% of the patients.[13,21] The onset may be early in infancy or, in some patients, delayed until the second decade. The neurologic abnormalities may be mild (e.g., isolated hyporeflexia) or severe, with progressive mental retardation, sensorineural deafness (beginning with high-frequency hearing loss), spasticity, or seizures. The most severe form, known as the *De Sanctis–Cacchione syndrome,* involves the cutaneous and ocular manifestations of classic XP plus additional neurologic and somatic abnormalities, including microcephaly, progressive mental deterioration, low intelligence, hyporeflexia or areflexia, choreoathetosis, ataxia, spasticity, Achilles tendon shortening leading to eventual quadriparesis, dwarfism, and immature sexual development. The complete De Sanctis–Cacchione syndrome has been recognized in very few patients; however, many patients with XP have one or more of its neurologic features. In clinical practice, deep tendon reflex testing and routine audiometry usually can serve as a screen for the presence of XP-associated neurologic abnormalities. In cases where there is clinical evidence of early neurologic abnormalities, a brain magnetic resonance imaging (MRI) may show enlarged ventricles.

The predominant neuropathologic abnormality found at autopsy in patients with neurologic symptoms was loss (or absence) of neurons, particularly in the cerebrum and cerebellum. There is evidence for a primary axonal degeneration in these patients.[20] In a long term follow-up study of 106 XP patients those with neurodegeneration had a younger age at death (29 years) than those without neurodegeneration (37 years).

LABORATORY ABNORMALITIES

Cellular Hypersensitivity. Cultured cells from patients with XP generally grow normally when not exposed to damaging agents. However, the population growth rate or single-cell colony-forming ability is reduced to a greater extent than normal cells after exposure to UV radiation. A range of post-UV colony-forming abilities has been found with fibroblasts from patients, some having extremely low post-UV colony-forming ability and others having nearly normal survival (see Chapter 110).[12,14]

XP fibroblasts are deficient in their ability to repair some UV-damaged viruses or plasmids to a functionally active state.[12,14,20] These host cell reactivation assays have detected an abnormality in every form of XP tested.

UV-irradiated XP fibroblasts are hypermutable compared to normal fibroblasts. This post-UV hypermutability is believed to be the basis of the increased frequency of sunlight-induced somatic mutations that lead to cancer in XP patients.[22]

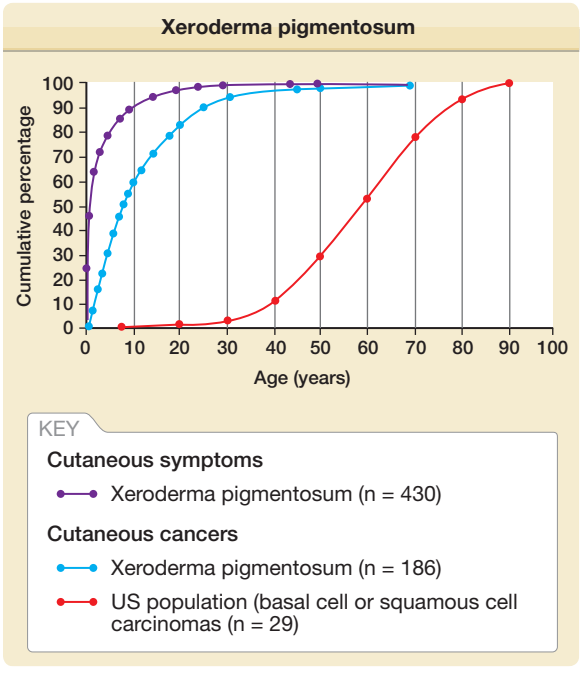

Figure 139-2 Xeroderma pigmentosum. Age at onset of clinical symptoms and skin cancer. Age at onset of cutaneous symptoms (generally sun sensitivity or pigmentation) was reported for 430 patients. Age at first skin cancer was reported for 186 patients and is compared with the age distribution for 29,757 patients with basal cell carcinoma or squamous cell carcinoma in the US general population. There is a 50-year reduction in age of onset of skin cancer in the XP patients compared with the US general population. (From Kraemer KH, Lee MM, Scotto J: Xeroderma pigmentosum. Cutaneous, ocular, and neurologic abnormalities in 830 published cases. *Arch Dermatol* **123**:241, 1987, with permission.)

Chromosome Abnormalities. XP cells generally are found to have a normal karyotype without excessive chromosome breakage or increased sister chromatid exchanges (as seen in BS). However, after exposure to UV radiation, abnormally large increases in chromosome breakage and in sister chromatid exchanges have been observed.[23] The extent of this induced abnormality varies in different patients.

DNA Repair. In 1968, hypersensitivity of cultured XP cells to UV damage was reported by Cleaver[24] to be the result of defective DNA repair. He found defective UV-induced repair replication, indicating a defect in the NER pathway. Most XP cells have a normal response to treatment with X-rays, indicating the specificity of the DNA repair defect.[25] The defective genes for the seven NER-defective forms of XP and the XP variant have been cloned[26] and their functions are being investigated (see Chapter 110).

Complementation Groups. Genetic heterogeneity among the XP DNA repair defects was found by fusing cultured fibroblasts from different patients and defining complementation groups (see Chapter 110). Up to 2011, seven such DNA excision repair-deficient complementation groups have been identified (named XP-A to XP-G) and the corresponding genes have been identified (see Table 139-3).[26] Additional patients with clinical XP but normal NER have been called *XP variants*. Studies of cellular hypersensitivity revealed a slightly increased sensitivity to UV-induced inhibition of cell growth that was potentiated by caffeine. Cells from XP-variant patients have a defect in an error-prone DNA polymerase (pol η) that bypasses unrepaired DNA damage.[27,28]

Prenatal Diagnosis. Prenatal diagnosis has been reported by measuring UV-induced unscheduled DNA synthesis in cultured amniotic fluid cells[29] and by use of DNA diagnosis of trophoblast cells obtained early in pregnancy.[30,31] DNA-based prenatal diagnosis may also be possible in selected cases.[32]

Drug and Chemical Hypersensitivity. A number of DNA-damaging agents other than UV radiation have been found to yield hypersensitive responses with XP cells. These agents include drugs (psoralens, chlorpromazine), cancer chemotherapeutic agents (cisplatin,[33] carmustine), and chemical carcinogens (benzo[*a*]pyrene derivatives). Presumably, these agents induce DNA damage whose repair involves portions of the DNA repair pathways that are defective in XP.[33]

TREATMENT

Management of patients with XP is based on early diagnosis, lifelong protection from UV radiation exposure, and early detection and treatment of neoplasms. Diagnosis rests on recognition of the characteristic clinical features and is confirmed by laboratory tests of cellular hypersensitivity to UV and defective DNA repair (see Chapter 110). Molecular determination of some of the XP disease-causing mutations is offered in a laboratory that is certified for clinical testing (see http://genetests.org for the most recent listing).

Sun Protection. Patients should be educated to protect all body surfaces from UV radiation by wearing protective clothing and UV-absorbing glasses and long hair styles. They should adopt a lifestyle to minimize UV exposure and use sunscreens with high sun protective factor (SPF) ratings (minimum SPF 30) daily. Patients should be examined frequently by a family member who has been instructed in recognition of cutaneous neoplasms. A set of color photographs of the entire skin surface with close-ups of lesions (including a ruler) is often extremely useful to both the patient and the physician in detecting new lesions. A physician should examine patients at frequent intervals (approximately every 3–6 months depending on severity of skin disease). Premalignant lesions such as actinic keratoses may be treated by freezing with liquid nitrogen, or with topical 5-fluorouracil or imiquimod. Photodynamic therapy, using, for example, the topical photosensitizer 5-aminolevulinic acid followed by exposure to blue light, is an effective treatment modality for normal patients with multiple actinic keratoses. There are no data on the safety or efficacy of this treatment in XP patients. *Caution is recommended because an abnormal response to photodynamic therapy or*

other light- or laser-based therapies cannot be excluded in XP cells. Larger areas have been treated with therapeutic dermatome shaving or dermabrasion to remove the more damaged superficial epidermal layers.[34–37] This procedure permits repopulation by relatively UV-shielded cells from the follicles and glands.[38]

Because cells from patients with XP are also hypersensitive to environmental mutagens such as benzo[*a*]pyrene found in cigarette smoke, prudence dictates that patients should be protected against these agents. One of our patients who smoked cigarettes for more than 10 years died of bronchogenic carcinoma of the lungs at age 35 years and another patient who smoked has developed a lung cancer at age 48 years.[39] Thus, we recommend that XP patients refrain from smoking cigarettes and that parents should protect children with XP from being exposed to secondhand smoke.

Cancer. Cutaneous neoplasms are treated in the same manner as in patients who do not have XP. This involves electrodesiccation and curettage, surgical excision, or Mohs micrographic surgery (see Chapters 115 and 244). Because multiple surgical procedures are often necessary, removal of undamaged skin should be minimized. Extremely severe cases have been treated by excision of large portions of the facial surface and grafting with uninvolved skin.[35]

Most patients with XP are not abnormally sensitive to therapeutic X-rays, and XP patients have responded normally to full doses of therapeutic X-radiation for treatment of inoperable neoplasms such as an astrocytoma of the spinal cord,[40] a frontal lobe astrocytoma, or recurrent squamous cell carcinoma in the orbit. However, cultured cells from two XP patients were found to be hypersensitive to X-rays,[41,42] so when X-ray therapy is indicated, an initial small dose is advisable to test for clinical hypersensitivity.

Oral isotretinoin has been shown in a controlled study to be effective in preventing new neoplasms in patients with multiple skin cancers.[43] Because of its toxicity (hepatic, hyperlipidemic, teratogenic, calcification of ligaments and tendons, premature closure of the epiphyses), oral isotretinoin should be reserved for patients with XP who are actively developing large numbers of new skin cancers. We found that the effective dose varies among patients and some patients may respond to doses of oral isotretinoin as low as 0.5 mg/kg/day.

A bacterial DNA repair enzyme, denV T4 endonuclease, in a topical liposome-containing preparation, has been reported to reduce the frequency of new actinic keratoses and basal cell carcinomas in XP patients in one research study.[44] As of 2010, this treatment has not been approved by the U.S. Food and Drug Administration.

A study treating multiple melanoma in-situ lesions with intralesional interferon-α in one XP patient showed localized clearing only of lesions injected with the intralesional interferon-α but not with the control diluent.[45] There are several case reports of XP patients responding to topical treatment with the immune modulator imiquimod (see Chapter 221).[46–49] However, none of these reported long-term follow-up.

Eyes. The eyes should be protected by wearing UV-absorbing glasses with side shields. Methylcellulose eye drops can be used to keep the cornea moist. Corneal transplantation has restored vision in patients with corneal opacity from severe keratitis. However, some of these suffered graft rejection due to neovascularization. Neoplasms of the lids, conjunctiva, and cornea are usually treated surgically.[50–52] We are examining the possibility of using a swab to obtain cytologic specimens from the surface of the eye to determine if early neoplasms can be detected or excluded without the need for performing biopsies.

CLINICAL-LABORATORY CORRELATIONS.

Patients with XP are hypersensitive to UV radiation, as are their cultured cells. Cutaneous and ocular abnormalities are strikingly limited to UV-exposed areas and usually spare such UV-shielded locations as the axillae, buttocks, and retina. The fact that black patients with XP have an increased frequency of skin cancer suggests that a normally functioning DNA repair system provides greater protection against skin cancer than does the natural pigmentation of black skin.

Complementation Groups. At least eight different molecular defects are associated with the clinical abnormalities recognized as XP, as indicated by the existence of seven DNA excision repair-deficient complementation groups (A to G) and the variant form. A discussion of the cloned XP genes and their function can be found in Chapter 110. A Web site listing disease-causing mutations in XP and CS genes has been established at http://xpmutations.org/. There is a complex relationship among the DNA repair genes and clinical disease (see Table 139-3 and see http://genetests.org for review of xeroderma pigmentosum). Multiple NER genes are associated with at least a spectrum of different clinical phenotypes. A clinical phenotype can be associated with defects in each of several genes. Conversely, mutations in one gene can be associated with several different clinical phenotypes. These complex relationships and the roles of DNA repair genes in regulation of transcription and in immune functions are under intense investigation.

Complementation Group A. Complementation group A (see Table 139-3) contains patients with the most severe neurologic and somatic abnormalities (the De Sanctis–Cacchione syndrome) as well as patients with minimal or no neurologic abnormalities.[13] Long-term follow-up of these patients has revealed a relationship between the genotype and the phenotype. Patients with the most severe disease appear to have truncating mutations in both alleles of the *XPA* gene leading to no detectible normal protein. In contrast, patients with minimal neurologic abnormalities have splice-site mutations that permit a small amount of normal messenger RNA (mRNA) to be made. This form is seen in the United States, Europe, and the Middle East. It is the most common form of XP in Japan. Approximately 90% of Japanese XP-A patients have the same single-base-substitution founder mutation.[53] This finding has served as the basis for development of a rapid diagnostic



Figure 139-3 Xeroderma pigmentosum (XP/CS) complex. **A.** 28-year-old patient (XP11BE) in XP complementation group B with cutaneous changes of XP, including pigmentary changes and atrophy. She has a beak-like nose and loss of subcutaneous tissue typical of Cockayne syndrome. **B.** The patient is of short stature (less than 4 ft. tall). Her mother, an obligate heterozygote, is clinically normal.

assay for Japanese XP-A patients (including prenatal diagnosis) using polymerase chain reaction analysis of a small sample of DNA.[37] Heterozygous carriers of this disease-causing mutation who have one mutated allele and one normal allele have been estimated to comprise approximately 1% of the Japanese population.[16]

Complementation Group B. Complementation group B (Fig. 139-3) is composed of five patients in four kindreds who had the cutaneous abnormalities characteristic of XP (including neoplasms) in conjunction with neurologic and ocular abnormalities typical of CS.[13,54] Another family had two adult sisters with XP without CS who had ocular melanomas and were parents of normal children. Surprisingly, a patient with TTD also was found to have a defect in the *XPB* gene.

Complementation Group C. Patients in complementation group C, with rare exceptions, have XP with skin and ocular involvement but without neurologic abnormalities.[13,55–61] This is the most common group in the United States, Europe, and Egypt, but has been found rarely in Japan. Most patients have truncating mutations in both alleles leading to undetectable levels of *XPC* mRNA (due to nonsense-mediated message decay). However, a splice lariat branchpoint mutation resulting in as little as 3% to 5% of normal mRNA resulted in milder clinical symptoms in one family in Turkey.[58] XP-C patients typically do not give a history of severe blistering sunburns on minimal sun exposure and at times are first diagnosed with the appearance of skin cancer in a child. One XP-C patient was reported to be hypersensitive to ionizing radiation[42]; however, correction of the *XPC* gene defect did not correct the cellular ionizing radiation hypersensitivity, suggesting that more than one gene was defective in this patient.

Complementation Group D. Patients in complementation group D have been described with several different clinical phenotypes. They may have cutaneous XP with late onset of neurologic abnormalities in their second decade of life or XP with no neurologic abnormalities.[13,62] Two XP-D patients have been reported with clinical symptoms of both XP and CS. Cells from patients with a photosensitive form of TTD (without XP) also were assigned to the XP complementation group D. Two patients were reported with combined symptoms of both TTD and XP (one patient had a skin cancer and another died of metastatic melanoma) and mutations in the *XPD* gene.[63] Finally, a patient with cerebro-oculo-facio-skeletal (COFS) syndrome had a mutation in the *XPD* gene.[64]

Complementation Group E. Complementation group E was found in one kindred in Europe and several in Japan.[13,65] We have studied adult patients with multiple skin cancer in 3 kindreds in the US and Germany. These patients had no neurologic involvement.[66]

Complementation Group F. Complementation group F patients have been found mainly in Japan.[67,68] Most of these patients have mild clinical symptoms without neurologic abnormalities or skin cancer. However, we recently found two families with adult onset of severe neurodegeneration with mutations in the *XPF* gene. The residual rate of DNA repair is very low (only 10% to 20% of normal).

Complementation Group G. Thirteen patients in XP complementation group G have been identified in the United States, Europe, and Japan (Fig. 139-4).[69] There is a large variation in clinical features among these patients. Several patients with mutations in the



Figure 139-4 Severe and mild xeroderma pigmentosum XP-G patients. **A** and **B.** XP82DC. **C–F.** XP65BE. **A.** Patient XP82DC at 3 years of age has deep-set eyes characteristic of Cockayne syndrome (CS) and irregular lentiginous pigmentation on her face characteristic of XP, indicating XP/CS complex. **B.** Patient XP82DC at 3 years of age has characteristic XP-pigmented lesions on her forearms and dorsa of hands along with thin, translucent skin with readily visible veins. The small size of her hands is apparent in comparison with the hands of her mother. **C.** Patient XP65BE at age 6 months experienced severe sunburn on her face with minimal sun exposure. Erythema and swelling are seen on skin of forehead, cheeks, and periorbital area. **D.** Patient XP65BE at age 9 months shows erythema and peeling of skin of malar area of face after sun exposure. **E.** Patient XP65BE at age 4.5 years shows pigmentary changes on her nose, malar area, and other portions of her face. **F.** Patient XP65BE at 4.5 years shows blistering sunburn on her upper thigh. Note spared area above knee where sunscreen was applied **G.** Patient XP65BE shows minimal pigmentary changes on face and sparing of neck and hand. She used measures to protect her skin from sun exposure. (From Emmert S et al: Relationship of neurologic degeneration to genotype in three xeroderma pigmentosum group G patients. *J Invest Dermatol* **118**:972, 2002, with permission.)

XPG gene had clinical features of both XP and severe CS with cachexia and death in the first decade (see Fig. 139-3). Other patients with different mutations in the same gene had no neurologic abnormalities.

Xeroderma Pigmentosum Variant. XP-variant cells have normal DNA NER and thus do not fall into any of the complementation groups of cells with defective DNA excision repair.[14] However, there is a defect in an error-prone, translesional DNA damage bypass polymerase, pol η (see Chapter 110).[25,27,70] Most XP-variant patients have clinical XP with no neurologic abnormalities.[71] The cutaneous and ocular abnormalities have been severe in some patients and mild in others.

Heterozygotes. XP heterozygotes (parents and some other relatives) are carriers of the gene for XP but are clinically normal. There is limited epidemiologic evidence to indicate that such persons have an increased risk of developing skin cancer.[72] Most tests of cell function or DNA repair yield normal responses with cells from XP heterozygotes.

PATIENT SUPPORT GROUPS

The Xeroderma Pigmentosum Society is an educational, advocacy, and support organization for XP patients and their families: Xeroderma Pigmentosum Society, Inc., Box 4759, Poughkeepsie, NY 12602–4759;

Web site: http://www.xps.org; e-mail: xps@xps.org; telephone: toll-free (877) XPS-CURE (877-977-2873). Another support group is the XP Family Support Group, 8375 Folsom Blvd Suite 201, Sacramento Ca, 95826. Their Web site is http://www.xpfamilysupport.org/. A Web site listing disease-causing mutations in XP and CS genes has been established at http://xpmutations.org/.

COCKAYNE SYNDROME (INCLUDING XERODERMA PIGMENTOSUM–COCKAYNE SYNDROME OVERLAP)

CS is a very rare, autosomal recessive degenerative disease with cutaneous, ocular, neurologic, and somatic abnormalities (see Table 139-1).[73,74] A review published in 1992 described 140 cases reported in the literature.[75]

CLINICAL FEATURES

In 1936, E. A. Cockayne described a syndrome characterized by cachectic dwarfism, deafness, and pigmentary retinal degeneration with a characteristic "salt and pepper" appearance of the retina.[76] The skin had photosensitivity without the excessive pigmentary abnormalities seen in XP. There was marked loss of subcutaneous fat, resulting in a "wizened" appearance with typical "bird-headed" facies and prominent "Mickey Mouse" ears. Other ocular findings included cataracts and optic atrophy.[77] Neurologic abnormalities, in addition to deafness, include peripheral neuropathy, normal pressure hydrocephalus, and microcephaly. Birth weight and early development are usually normal. The disease onset is usually in the second year of life with slowly progressive neurologic degeneration. Intellectual deterioration may be nonuniform, with some functions preserved better than others. A severe infantile form has been described[78,79] as well as a milder form with late onset. COFS syndrome[64,80,81] with microcephaly and severe mental retardation and CAMFAK syndrome of congenital *ca*taracts, *m*icrocephaly, *fa*ilure to thrive, and *k*yphoscoliosis[82] have some similar features. CS is not associated with an increased incidence of neoplasia.

LABORATORY ABNORMALITIES

Clinical laboratory testing often shows sensorineural deafness, neuropathic electromyogram, and slow motor nerve conduction velocity.[13,20,69,75,78,83] The electroencephalogram may be abnormal, and X-ray examination may show thickened skull and microcephaly. Computed tomography may be diagnostically useful in the detection of normal-pressure hydrocephalus and showing calcification of the basal ganglia and other structures (see eFig. 139-4.1 in online edition). MRI of the brain shows atrophy and dysmyelination of the cerebrum and cerebellum. Bone age is usually normal. Height and weight are usually well below the third percentile for the age.

Cellular Hypersensitivity. As with XP, cultured cells (fibroblasts or lymphocytes) from patients with CS are hypersensitive to UV-induced inhibition of growth and colony-forming ability.[13,84] Host cell reactivation of UV-damaged adenovirus or plasmids is reduced, although generally to a lesser extent than in XP. There are two complementation groups (A and B) in CS (see Table 139-3). Patients with defects in CSA or CSB have similar features.[75] A recent report from Europe identified CSA (*ERCC8*) and CSB (*ERCC6*) mutations in 84 kindreds. 62% (52) had mutations in the CSB gene.[85] A patient with COFS syndrome was reported with a defect in CSB[82] and another with a defect in *XPD* (Table 139-3).[57] Molecular determination of some of the CS disease-causing mutations is offered in a laboratory that is certified for clinical testing (see http://genetests.org for the most recent listing).

Prenatal Diagnosis. Prenatal diagnosis of CS has been performed[86] based on the delay in recovery of post-UV RNA synthesis and the increased cell killing by UV radiation.

CLINICAL-LABORATORY CORRELATION.

Patients with defects in CSA or CSB have similar clinical features.[75]

PATIENT SUPPORT GROUP

The Share and Care Cockayne syndrome network (http://cockaynesyndrome.net or http://www.cockayne-syndrome.org) is an educational, advocacy, and support organization for CS patients and their families (Box 570618, Dallas, TX 75357).

XERODERMA PIGMENTOSUM–COCKAYNE SYNDROME COMPLEX

Approximately one dozen patients with CS have been found to have, in addition, clinical features of XP.[19,48,61] These features include freckle-like pigmentation on sun-exposed skin and cutaneous neoplasms (see Fig. 139-4). Cells from these XP/CS patients have reduced DNA excision repair characteristic of XP. Clinically, these patients may be distinguished from XP patients with neurologic abnormalities by the presence of the CS features of pigmentary retinal degeneration, calcification of the basal ganglia, normal-pressure hydrocephalus, and hyperreflexia. Cells from patients with this complex have been found to have mutations in three different XP genes: *XPB*, *XPD*, and *XPG*,[54,59,84] demonstrating that several different genes are implicated in this disorder (see Table 139-3).

TRICHOTHIODYSTROPHY

TTD is a rare autosomal recessive disorder that is characterized by sulfur deficient, brittle hair and includes a broad spectrum of clinical abnormalities that may include photosensitivity, ichthyosis, intellectual impairment, short stature, microcephaly, characteristic facial features (protruding ears, micrognathia), recurrent infections, bilateral cataracts, dystrophic nails, and other features (Fig. 139-5).[85–94] Bone abnormalities include osteosclerosis of the axial skeleton with osteopenia of

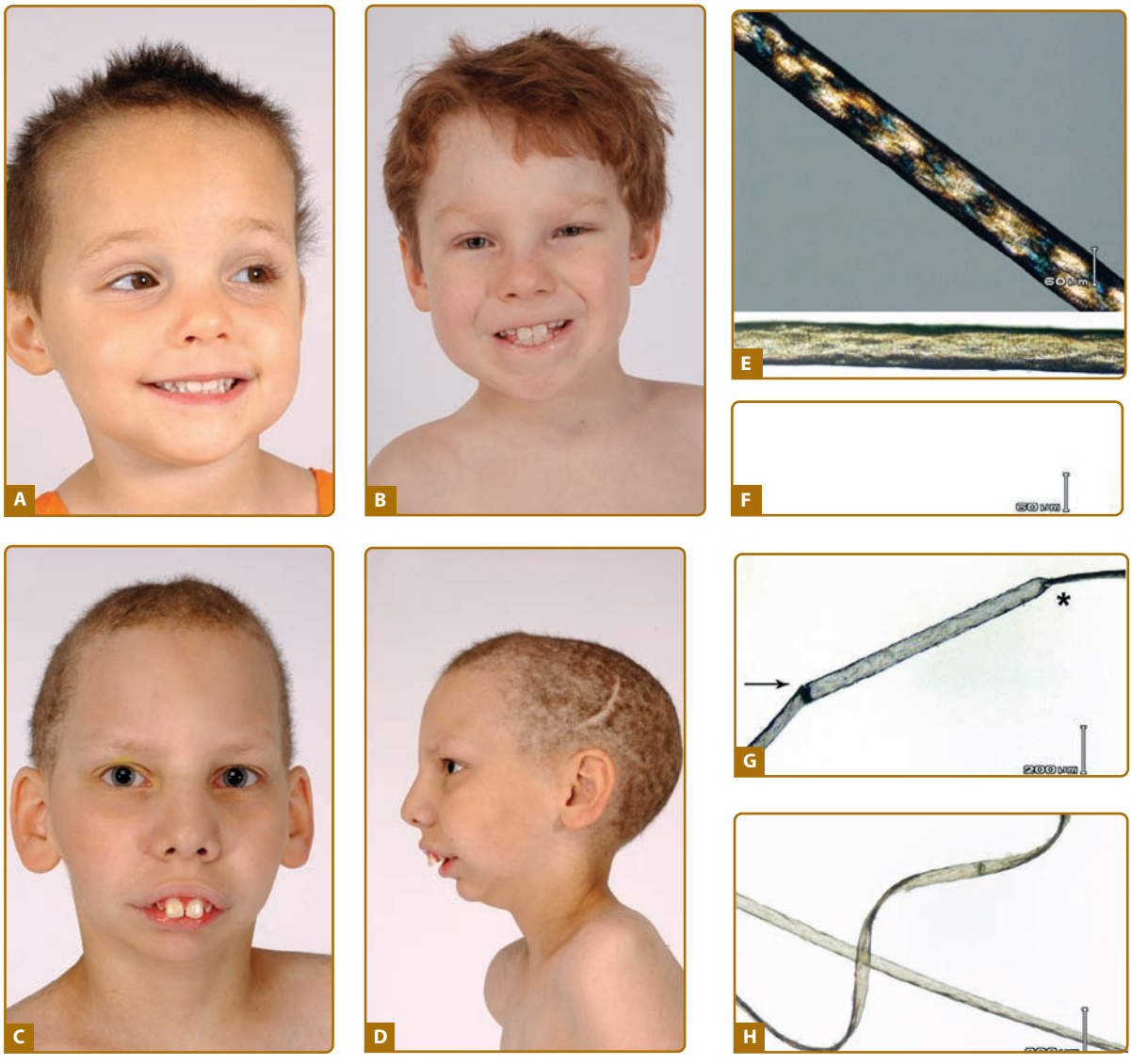

Figure 139-5 Trichothiodystrophy (TTD): clinical and microscopic hair findings. **A.** Three-year-old girl with TTD having short brittle hair that is sparse and broken off at different lengths. She rarely has haircuts except to trim uneven hairs. She has developmental delay. **B.** Seven-year-old boy with TTD with sun sensitivity, congenital cataracts, multiple infections, and developmental delay. In contrast to the patient in **A**, he has long hair. He has a happy engaging personality. **C** and **D.** Severe clinical phenotype: 14-year-old boy with short brittle hair and dysmorphic facies with protruding ears, micrognathia, deep set eyes, head elongation in fronto-occipital plane. He also has ichthyosis, intellectual impairment, short stature, photosensitivity, osteosclerosis, neurologic abnormalities, and recurrent infections. Light microscopy findings: **E.** TTD hairs displaying alternating light and dark "tiger tail" bands using polarizing microscopy. **F.** Irregular, undulating hair shaft with light microscopy **G.** Trichoschisis (*arrow*): clean, transverse cleavage fracture; marked narrowing of shaft diameter (*asterisk*). **H.** Ribboning. (Modified from Liang C et al: Characterization of tiger tail banding and hair shaft abnormalities in trichothiodystrophy. *J Am Acad Dermatol* **52**:224, 2005.)

the limbs. Decreased red blood cell mean corpuscular volume and increased hemoglobin A2 levels mimic β-thalassemia trait. eTable 139-3.1 in online edition lists the clinical findings in one TTD patient, as an example of the diverse findings.[85] Developmental delay may be associated with dysmyelination,[96] a feature similar to CS; however, patients do not have retinal changes of CS. The spectrum of clinical involvement is broad ranging from only hair to severe multisystem abnormalities (Fig. 139-5). TTD encompasses patients who have been described as *Tay syndrome*, *Amish brittle hair syndrome*, *Sabinas brittle hair syndrome*, or *Pollitt syndrome*.

In 1980, Price proposed the term *trichothiodystrophy* [derived from Greek *tricho*: hair; *thio*: sulfur; *dys*: faulty; *trophe*: nourishment] recognizing the hair shaft sulfur deficiency as a marker for this symptom complex.[90] While most TTD patients have short, broken hair (Figs. 139-5A, 139-5C, and 139-5D), some patients have long hair (Fig. 139-5B). Under light microscopy with polarization, TTD hair shafts have a characteristic dark and light banding pattern that gives a "tiger tail" appearance (Fig. 139-5E). In addition, they usually have hair shaft abnormalities including trichoschisis (a clean transverse break through the hair) (Fig. 139-5G),

trichorrhexis nodosa-like defects, and ribboning (Fig. 139-5H).[79,80] Hair shafts are brittle because of a reduction of high-sulfur matrix proteins, and amino acid analysis of the hair demonstrates reduced levels of cysteine and cystine in hair shaft proteins.[97] This is associated with a decrease in the ratio of strong to weak disulfide bonds within the hair shafts.[91] Approximately 50% of TTD patients have clinical photosensitivity that ranges from subtle to severe. However, in contrast to the typical clinical features of XP, patients with TTD do not develop poikilodermatous changes (hyper- and hypopigmentation, telangiectasias, and atrophy) or skin cancer. Rarely, patients may have an overlap syndrome with features of both TTD and XP, with typical hair features of TTD and the pigmentary and skin cancer characteristic of XP (see Table 139-3).[63]

The majority of TTD patients have a defect in *XPD* (*ERCC2*). A few have mutations in *XPB* (*ERCC3*) or *TTDA* (*TFB5*) genes, which are components of the transcription factor TFIIH that regulates both DNA repair and transcription. Some TTD patients have mutations in *TTDN1*, a gene of unknown function.[98] It is believed that mutations that affect the repair function of the NER genes are associated with features of XP, whereas mutations affecting the transcription-related function results in features of TTD.[99]

The diagnosis of TTD is based on examination of hair shafts (Fig. 139-5E–H). TTD hair shafts display tiger tail banding under polarizing microscopy. In addition, they show a spectrum of typical hair shaft abnormalities, including trichoschisis, trichorrhexis nodosa-like fractures, surface irregularities, and ribboning.[88,89] Amino acid analysis of hair shafts can confirm reduced levels of cysteine and cystine (see Chapter 88).

A recent review of the literature identified 112 patients, whose clinical features are detailed in eTable 139-3.2 in online edition. Patients with TTD show a wide spectrum of clinical findings, including abnormal characteristics at birth, pregnancy complications in mothers carrying an affected fetus, ocular abnormalities and infections (eTable 139-3.1 in online edition).[100,101] Clinical features of *p*hotosensitivity, *i*chthyosis, *b*rittle hair, *i*ntellectual impairment, *d*ecreased fertility and *s*hort stature have been used to describe patients with the acronyms *PIBIDS*, *IBIDS*, and *BIDS*. While patients can be found who fit having these features, all of these individuals have additional clinical findings, making these acronyms poor descriptors of the actual disease features. Moreover, more than a third of patients do not fit these acronyms. Because they are misleading they should be abandoned.

Management includes sun protection and varies with the individual clinical features. Patients with developmental delay and intellectual impairment may have dysmyelination as seen on MRI of the brain and may benefit from neurologic and developmental assessment and rehabilitation medicine consultation. Ophthalmologic involvement can include cataracts (which may be congenital), nystagmus, and errors of refraction.[102] A review of the literature identified a high mortality (>20%) in children below the age of 10, with most deaths due to infection. In some patients, recurrent infections have been managed with prophylactic antibiotics or intravenous immunoglobulin. Patients with skeletal abnormalities may benefit from rehabilitation medicine evaluation and support. In addition, a high frequency of complications occur during pregnancies, including intrauterine growth restriction, preeclampsia, preterm delivery, hemolysis-elevated liver enzymes-low platelets (HELLP) syndrome, and abnormal levels of maternal serum screening markers, highlighting the role of DNA repair in normal development.[103] Several our TTD patients in their first or second decade of life have experienced progressive inability to walk over a few year interval resulting from bilateral aseptic necrosis of their hips.

DISORDERS OF GENOME INSTABILITY

BLOOM SYNDROME

BS is a rare, autosomal recessive disorder characterized by growth deficiency, unusual facies, sun-sensitive telangiectatic erythema, immunodeficiency, and predisposition to a variety of different cancers.[7,104] It is most frequent among Ashkenazi Jews.[105] Approximately 250 patients have been recognized.

CLINICAL FEATURES

Facial erythema and telangiectasia superficially resembling lupus erythematosus (Fig. 139-6) are often present within the first few weeks after birth in the malar

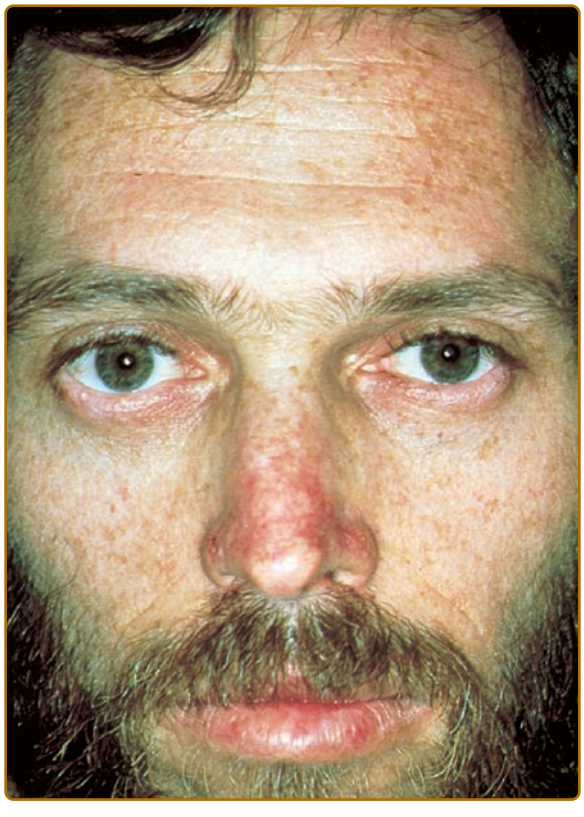

Figure 139-6 Bloom syndrome. Prominent telangiectasia in malar distribution.

area, on the nose, and around the ears.[104] Sun exposure accentuates these abnormalities and may induce bullae, bleeding, and crusting of the lips and eyelids. Café-au-lait spots are common, at times accompanied by adjacent depigmented areas. Patients are well proportioned but small. Adult height is usually under 150 cm. Patients have a long, narrow head with a characteristic facies consisting of a narrow, prominent nose, relatively hypoplastic malar areas, and a receding chin.

Patients with BS are predisposed to multiple infections, as there is immune dysfunction. Fertility is decreased and diabetes mellitus is common. Approximately 20% of patients with BS develop malignancies, comprising a normal spectrum of cancer types, of which one-half occur before age 20 years.[104] Patients usually die before the age of 30 years from either cancer or infection.

GENE DEFECT, PATHOGENESIS, AND LABORATORY ABNORMALITIES

BS is caused by mutations in *BLM*, which encodes a RecQ helicase.[7,9,105,106,107] BS cells are characterized by an increase in the frequency of spontaneous sister chromatid exchanges (see Chapter 110) and in exchanges between homologous chromosomes. The latter is often visualized by quadriradial chromosomes. These are four-armed chromosomes most likely formed by recombination between two chromosomes (and almost never found in unaffected individuals). These observations demonstrate that BS cells are characterized by hyperrecombination. Although the exact mechanisms of how mutations in the BLM helicase lead to hyperrecombination are still not completely understood, it has been suggested that they are related to defective DNA replication or defective resolution of stalled replication forks. Hyperrecombination may result in an increased frequency of loss of heterozygosity and through that mechanism, in conjunction with increased spontaneous mutation frequency, an increased frequency of malignant transformation. The immune deficiency, characterized by diminished immunoglobulin levels, reduced cellular proliferative response to mitogens, and decreased proliferation in the mixed leukocyte reaction, probably further contributes to the increased cancer risk.

TESTING

The observation of quadriradial chromosomes (observed in 0.5% to 14% of lymphocytes of BS patients) and the approximately tenfold increased frequency of spontaneous sister chromatid exchanges are used to diagnose BS.[108] A founder deletion/insertion mutation in the *BLM* gene was identified in Ashkenazi Jews at a frequency of approximately 1% (BLM^{Ash})[105,109] and can be used for DNA diagnosis of BS patients and carriers among Ashkenazi Jews.[57] Diagnostic testing for BS is offered in a number of laboratories that are certified for clinical testing (see http://genetests.org for the most recent listing).

WERNER SYNDROME (ADULT PROGERIA)

WS is a rare, autosomal recessive disorder, characterized by several features of premature aging and an increased cancer risk. More than 800 patients have been reported.[110] Most of the WS patients are Japanese.

CLINICAL FEATURES

Patients with WS are clinically normal until adolescence, when they do not show the usual growth spurt and start to prematurely develop features and diseases of aging, including graying and thinning of hair, loss of subcutaneous fat, wrinkling of skin, type 2 diabetes, osteoporosis, and cardiovascular disease secondary to atherosclerosis.[111] Often, ophthalmologists are first to make the diagnosis of WS as cataracts develop early.[112] Other features that are not part of the normal aging process are scleroderma-like changes with subcutaneous atrophy, leg ulcers, soft tissue calcifications, and bird-like facies. Although an increased incidence and early onset of cancer is related to aging, the 10:1 ratio between epithelial to mesenchymal cancer seen in a normal aging population is shifted to 1:1 in WS patients, with, for example, sarcomas and melanomas being more frequent.[113] As in the Japanese general population, most of the melanomas are of the acral-lentiginous type or arise from mucous membranes and are therefore not considered to be related to UV-exposure. Thyroid cancer occurs at a younger age in WS patients than in the Japanese general population. Death usually occurs before the age of 50 years due to either myocardial infarction or cancer.

GENE DEFECT, PATHOGENESIS, AND LABORATORY ABNORMALITIES

WS is caused by a mutation in *WRN*, which encodes a RecQ helicase.[7,114,115] Most mutations of *WRN* result in truncation of the protein, sometimes by only a small amount, with loss of the nuclear targeting sequence. WRN is involved in many metabolic processes of DNA metabolism and *WRN* mutations cause various defects in DNA replication, recombination, base excision repair of oxidative DNA damage, repair of DNA strand breaks, DNA damage signaling, and transcription. Cells from WS patients have a reduced replicative lifespan in culture[116] and show altered telomere structure and length. Genome instability in WS cells is shown by an increased frequency of nonhomologous chromosome exchanges and of large chromosomal deletions.

ROTHMUND–THOMSON SYNDROME

CLINICAL FEATURES

The hallmark of RTS, a rare, autosomal recessive disorder, is poikiloderma with variegated cutaneous pigmentation, atrophy, and telangiectasias beginning in infancy.[117,118] RTS patients are photosensitive and develop prominent erythema and facial swelling on sun exposure early in life, which may be accompanied by blister formation. They often have sparse scalp hair, eyebrows, and eyelashes. Other clinical features include juvenile cataracts, stunted growth, skeletal abnormalities including radial bone defects, and a predisposition for cancer, in particular for osteosarcomas (32% of patients). Five percent of RTS patients also develop nonmelanoma skin cancer.

GENE DEFECT, PATHOGENESIS, AND LABORATORY ABNORMALITIES

Mutations in the helicase RecQL4 have been identified in a majority of patients with RTS.[119] Cells from RTS patients are characterized by chromosomal instability with trisomy, aneuploidy, and chromosomal rearrangements, suggesting a role of RECQL4 in maintaining chromosome stability.[120,121] RTS cells have also been reported with an increased sensitivity to ionizing radiation with increased formation of chromosome gaps and breaks.[120,121] However, this was not confirmed in other patients, possibly reflecting heterogeneity in this disease.[122] The exact function of the RECQL4 helicase remains unclear.[115,123] Cells from one patient had reduced DNA repair after exposure to UVC.[124] One RTS patient had increased acute toxicity after high-dose radiotherapy after surgery and subsequent palliative chemotherapy. However, another RTS patient was reported to have a normal acute response to radiation therapy for a squamous cell carcinoma of his tongue.[125] He died 2 years later with extensive squamous cell carcinoma in the thorax, but no tumor in the oral cavity.

FANCONI ANEMIA

FA is an autosomal recessive disease characterized by progressive pancytopenia, growth retardation, various congenital abnormalities of the heart, kidney, and limbs, and a predisposition to cancer.[126,127] More than 1,200 patients have been reported to the International Fanconi Anemia Registry.

CLINICAL FEATURES

Cutaneous abnormalities are present in almost 80% of patients (Figs. 139-7A–139-7D).[126,128,129] Hyperpigmentation is present from birth or early childhood and is diffuse and accentuated over the neck, joints, and trunk. Café-au-lait spots and achromic lesions are also present.

Hematopoietic manifestations usually have their onset before age 10 years and most commonly lead pediatricians to make the diagnosis of FA. These consist of a hypocellular bone marrow with progressive decrease in the number of circulating platelets, granulocytes, and erythrocytes. Skeletal malformations are common and often include aplasia or hypoplasia of the thumb, metacarpals, or radius.[130,131] Short stature, renal deformities, strabismus, microphthalmia, hypogonadism, and central nervous system abnormalities, including hyperreflexia and mild mental retardation, are also observed. The frequency of acute myelogenous leukemia has been reported to be elevated 500-fold.[132–135] If patients survive aplastic anemia and/or leukemia (e.g., as a result of bone marrow transplantation), they often develop solid tumors by the fifth decade of life, mostly squamous cell carcinomas of the head and neck and the anogenital area.

GENE DEFECT, PATHOGENESIS, AND LABORATORY ABNORMALITIES

FA is genetically heterogeneous with 13 complementation groups (FANCA to FANCN). All 13 genes have been identified and all of the FA proteins have been shown to act in a common DNA damage response signaling pathway, which also involves *BRCA1* and *BRCA2* (these genes are mutated in hereditary breast cancer; see Chapter 110) and multiple other proteins involved in cellular DNA damage responses.[136–147] Activation of this FA/BRCA pathway is thought to mediate DNA recombination to repair DNA strand breaks and DNA cross-links, generated, for example, by ionizing radiation or DNA cross-linking agents and to facilitate resolution of stalled replication forks.

TESTING

Increased chromosome breakage after exposure to DNA cross-linking agents such as mitomycin C or diepoxybutane is a feature of FA. Central to the FA/BRCA pathway is the monoubiquitination of the FANCD2 protein. The inability of FA cells to ubiquitinate the FANCD2 protein, as shown in Western blots after, for example, exposure to DNA cross-linking agents, is currently used as a screening tool to confirm the diagnosis of FA. Diagnostic testing for FA is offered in a number of laboratories that are certified for clinical testing (see http://genetests.org for the most recent listing).

RESOURCES: THE FANCONI ANEMIA RESEARCH FUND

Patients, physicians, and researchers may obtain information from the Fanconi Anemia Research Fund, Inc. (http://www.fanconi.org) or from Fanconi Canada (http://www.fanconicanada.org).

DYSKERATOSIS CONGENITA

Dyskeratosis congenita, the Zinsser–Cole–Engman syndrome, is an X-linked multisystem disease with cutaneous, mucosal, ocular, gastrointestinal, and hematologic abnormalities and an increased incidence of cancer (see Table 139-1). There are also autosomal dominant and autosomal recessive forms. A Registry at Hammersmith Hospital in London recruited 228 families having 354 affected patients from 40 countries.[148] More than 500 patients have been reported in the literature.[149] Affected females may have either the autosomal dominant or autosomal recessive form.

CLINICAL FEATURES

The most common features are a triad of reticulated hyperpigmentation, dystrophic nails, and mucosal leukoplakia (see Figs. 139-7E–139-7H).[150–152] During the first decade of life, patients develop reticulated poikiloderma of sun-exposed areas, with hyperpigmentation and, occasionally, bullae. Nail dystrophy is present in virtually all patients beginning at approximately age 2–5 years. The nails initially split easily, then develop longitudinal ridging with irregular free edges. Eventually, the nails become smaller, resulting in rudiments remaining. The fingernails are usually involved before the toenails. Other skin abnormalities include atrophic, wrinkled skin over the dorsum of hands and feet and hyperhidrosis and hyperkeratosis of palms and soles with disappearance of dermal ridges (absence of fingerprints).

Leukoplakia may be present in any mucosal site. The oral mucosa is the most frequent, but leukoplakia is also



Figure 139-7 Skin and oral mucous membrane findings in Fanconi anemia (**A–D**) and dyskeratosis congenita (**E–H**). **A–D.** Fanconi anemia. **A.** Congenital absence of thumb. The second finger has been surgically altered to function as a thumb. Keratotic papules are present on the palm. **B.** Oral leukoplakia on right buccal mucosa (*arrow*). **C** and **D.** Dyspigmentation of Fanconi anemia. **C.** Hyperpigmentation of left axilla with discrete hyperpigmented and hypopigmented macules. **D.** Several irregular café-au-lait macules, smaller fine tanned hyperpigmented macules, and dozens of guttate hypopigmented macules in the lower back. **E–H.** Dyskeratosis congenita. **E.** Oral leukoplakia involving the tongue. **F.** Severe atrophy of all fingernails and thickening of the palm. **G.** Longitudinal ridging and dystrophy of several fingernails with dyspigmentation and thickening of the palm. **H.** Poikiloderma showing reticular hypo- and hyperpigmentation of the skin of the neck and chest. (**A–D** modified from Braun M et al: Thrombocytopenia, multiple mucosal squamous cell carcinomas, and dyspigmentation. *J Am Acad Dermatol* **54**:1056, 2006; **E–H** used with permission from Dr. Blanche Alter, NCI, Bethesda, MD.)

found in the urethra, glans penis, vagina, and rectum. Lingual hyperkeratosis may be present. Mucosal surfaces such as the esophagus, urethra, and lacrimal duct may become constricted and stenotic, resulting in dysphagia, dysuria, and epiphora. Multiple dental caries and early loss of teeth are common. Progressive pulmonary disease, including infections and fibrosis (and cirrhosis in some patients) was reported in 19% of affected males.[151] Approximately 20% of the patients had learning difficulties or mental retardation.[151] There have been several reports of intracranial calcifications, especially of the basal ganglia.[153,154] These are also seen in CS.

There is an increased incidence of neoplasia, particularly squamous cell carcinoma of the mouth, rectum, cervix, vagina, esophagus, and skin. A large British kindred had Hodgkin disease and adenocarcinoma of the pancreas.[155] Similar to FA, although hypoplasia is the main abnormality seen in bone marrow, there is a predisposition to both myelodysplasia and acute myeloid leukemia.[151]

The majority (93%) of patients developed bone marrow failure which was the main cause (71%) of early death.[151] Approximately one-half of the patients (21 of 41) developed pancytopenia under the age of 10 years with a hematologic picture similar to FA. Patients have been treated with bone marrow transplantation.[156]

LABORATORY STUDIES

A gene for dyskeratosis congenita (*DKC1*) has been cloned,[148,157,158] which is located on the q28 region of the X

chromosome. The protein, dyskerin, has a nucleolar function, and a role in telomere maintenance and aging.[159–163] Mutations in the *DKC1* gene have been detected in affected patients.[148,164–166] There is also evidence for an autosomal form with affected females[148,151,167,168] having mutations in the *TERC* gene, which is also involved in telomere function. Approximately half of the DC patients have a mutation in a gene in the telomere biology pathway: *DKC1*, *TERC*, *TERT*, *TINF2*, *NOLA2*, and *NOLA3*. Many DC patients have very short telomeres.

TESTING. Diagnostic testing for DC is offered in a number of laboratories that are certified for clinical testing (see http://genetests.org for the most recent listing).

KEY REFERENCES

Full reference list available at www.DIGM8.com

DVD contains references and additional content

4. Loeb LA: Cancer cells exhibit a mutator phenotype. *Adv Cancer Res* **72**:25, 1998
13. Bootsma D et al: Nucleotide excision repair syndromes: Xeroderma pigmentosum, Cockayne syndrome, and trichothiodystrophy. In: *The Genetic Basis of Human Cancer*, 2nd edition, edited by B Vogelstein, KW Kinzler. New York: McGraw-Hill, 2002, p. 211
14. Kraemer KH, Lee MM, Scotto J: Xeroderma pigmentosum. Cutaneous, ocular, and neurologic abnormalities in 830 published cases. *Arch Dermatol* **123**:241, 1987
75. Nance MA, Berry SA: Cockayne syndrome: Review of 140 cases. *Am J Med Genet* **42**:68, 1992
87. Itin PH, Sarasin A, Pittelkow MR: Trichothiodystrophy: Update on the sulfur-deficient brittle hair syndromes. *J Am Acad Dermatol* **44**:891, 2001
105. German J: Bloom's syndrome. 20. The first 100 cancers. *Cancer Genet Cytogenet* **93**:100, 1997
111. Epstein CE et al: Werner syndrome. A Review of its symptomatology, natural history, pathologic features, genetics and relationship to the natural aging process. *Medicine* **45**:177, 1966
117. Wang LL et al: Clinical manifestations in a cohort of 41 Rothmund-Thomson syndrome patients. *Am J Med Genet* **102**:11, 2001
126. Auerbach AD: Fanconi anemia. *Dermatol Clin* **13**:41, 1995
152. Dokal I: Dyskeratosis congenita in all its forms. *Br J Haematol* **110**:768, 2000

Chapter 140 :: Tuberous Sclerosis Complex

:: Thomas N. Darling

TUBEROUS SCLEROSIS COMPLEX AT A GLANCE

- Autosomal dominant syndrome with variable expressivity.
- Manifested by hamartomatous tumors in multiple organs, including brain (causing seizures), eyes, heart, kidneys, lungs, and skin.
- Skin lesions occur in nearly all individuals and are important for diagnosis.
- Skin lesions include hypomelanotic macules, "confetti" lesions, facial angiofibromas, fibrous facial plaque, shagreen patch, and ungual fibromas.
- Hypomelanotic macules appear at birth or shortly thereafter and are most useful in early diagnosis.
- Although the skin lesions are benign, they may require treatment due to symptoms or disfigurement.

EPIDEMIOLOGY

The incidence of tuberous sclerosis complex (TSC) is as high as 1 in 6,000 live births.[1,2] It occurs with equal frequency in males and females and in different races and ethnicities. Hereditary transmission is evident in approximately one-third of patients. Sporadic disease occurs in about two-thirds of patients, and this is attributed to de novo mutations.[3]

ETIOLOGY AND PATHOGENESIS

TSC is caused by mutations in a tumor suppressor gene, either *TSC1* or *TSC2*.[3] Mutations in *TSC2* are observed in about three-fourths of patients, and even more commonly in de novo cases.[4,5] Patients with mutations in *TSC2* tend to exhibit a more severe phenotype.[4–7]

TSC1 maps to chromosome band 9q34. The 8.6-kb full-length transcript encodes a protein called *hamartin* or TSC1.[8] *TSC2* maps to chromosome band 16p13.3. The 5.5-kb transcript encodes a protein called *tuberin* or TSC2.[9] Immediately adjacent to *TSC2* on chromosome 16 is *PKD1*, the gene mutated in polycystic kidney disease. Some patients with TSC have severe, early-onset renal cystic disease, and most of these patients have a contiguous deletion of *TSC2* and *PKD1*.[10]

Typical of mutations in tumor suppressor genes, the mutations observed in patients with TSC are inactivating mutations located anywhere along the sequence of *TSC1* or *TSC2*. Consistent with Knudson's two-hit hypothesis, most TSC tumors show a second somatic mutation that inactivates the wild-type allele.[11,12] TSC1 and TSC2 form a complex that inhibits signaling through the mammalian target of rapamycin (mTOR) pathway (Fig. 140-1). Loss of TSC1/TSC2 function leads to increased mTOR signaling and increased cell growth. Rapamycin is a drug that inhibits mTOR and may be useful for the treatment of internal tumors in TSC.[13]

CLINICAL FINDINGS

CLINICAL CRITERIA

The diagnosis of TSC is based on clinical criteria categorized as major or minor features (Table 140-1).[14,15] Cutaneous and oral lesions comprise 4 of 11 major features and 3 of 9 minor features. Major features are thought to have a high degree of specificity for TSC, whereas minor features are less specific or substantiated. No single feature is present in all patients, and no feature is specific for TSC. Genetic testing can be

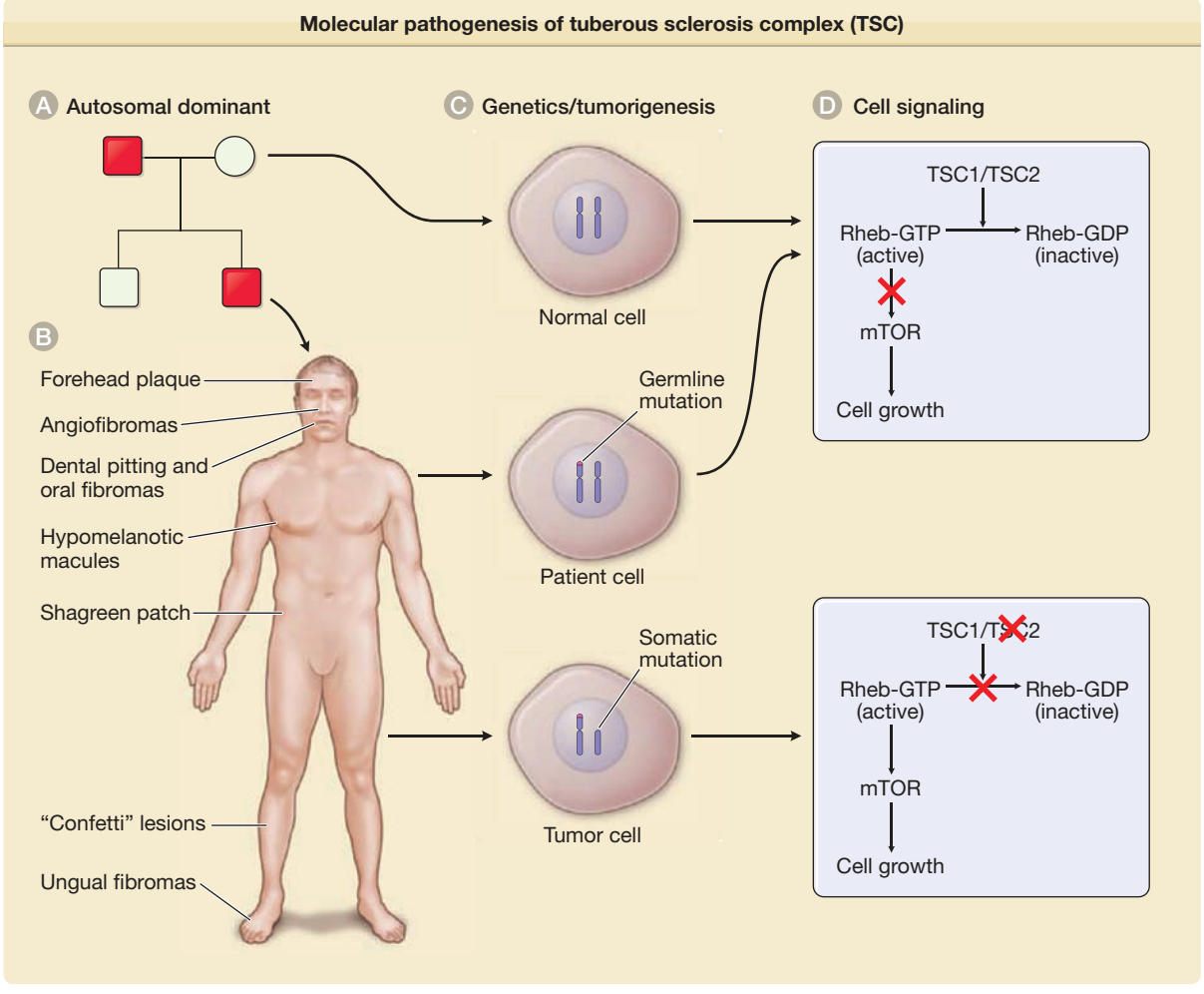

Figure 140-1 Molecular pathogenesis of tuberous sclerosis complex (TSC). **A.** An example is shown in which a mutation in *TSC2* is passed from the father (*red square*) to the son (*red square*), whereas the mother (*white circle*) and another son (*white square*) are unaffected. **B.** Skin lesions are observed in the son at the indicated locations. **C.** A cell from the mother shows two normal alleles for *TSC2 on* chromosome band 16p13.3. A cell from the son shows the *TSC2* mutation inherited from his father. A tumor from the son has this germ-line mutation and a "second-hit" mutation, detectable as loss of heterozygosity at this locus, that inactivates the other allele. **D.** TSC2, in a complex with TSC1, is a guanosine triphosphatase-activating protein, converting active Ras-homolog enriched in brain (Rheb) guanosine triphosphate (GTP) to inactive Rheb guanosine diphosphate (GDP). Rheb GTP activates mammalian target of rapamycin (mTOR), a kinase that increases protein translation and cell growth, so TSC2 normally acts to inhibit cell growth. Loss of TSC2 function in tumors results in increased levels of Rheb GTP, activation of mTOR, and increased cell growth.

TABLE 140-1
Diagnostic Criteria for Tuberous Sclerosis Complex (TSC)

Major Features
- **Facial angiofibromas or forehead plaque**
- **Nontraumatic ungual or periungual fibromas**
- **Hypomelanotic macules (three or more)**
- **Shagreen patch (connective tissue nevus)**
- Multiple retinal nodular hamartomas
- Cortical tuber[a]
- Subependymal nodule
- Subependymal giant cell astrocytomas
- Cardiac rhabdomyoma, single or multiple
- Lymphangiomyomatosis[b]
- Renal angiomyolipomas[b]

Minor Features
- **Multiple randomly distributed pits in dental enamel**
- Hamartomatous rectal polyps[c]
- Bone cysts
- Cerebral white matter migration lines[a,d,e]
- **Gingival fibromas**
- Nonrenal hamartoma[c]
- Retinal achromic patch
- **Confetti skin lesions**
- Multiple renal cysts[c]

[a]When cerebral cortical dysplasia and cerebral white matter migration tracts occur together, they should be counted as one rather than two features of TSC.
[b]When both lymphangiomyomatosis and renal angiomyolipomas are present, other features of TSC should be present before a definitive diagnosis is assigned.
[c]Histologic confirmation is suggested.
[d]Radiographic confirmation is sufficient.
[e]One panel member recommended that three or more radial migration lines constitute a major feature.
Note: Cutaneous and oral lesions are in bold.
Definite TSC: Presence of either two major features or one major feature and two minor features.
Probable TSC: Presence of one major feature and one minor feature.
Possible TSC: Presence of either one major feature or two or more minor features.
Adapted from Roach ES, Gomez MR, Northrup H: Tuberous sclerosis complex consensus conference: Revised clinical diagnostic criteria. *J Child Neurol* **13**:624, 1998.

offered and may be important in particular situations (see Section "Molecular Diagnosis").[15]

HISTORY

The medical and family history taking should include questions about seizures, learning disability, behavioral disorders, visual problems, and tumors of the brain, heart, kidneys, lungs, and skin. Determining the ages of onset of skin lesions and their subsequent changes may assist in discriminating TSC skin lesions from similar-appearing non-TSC skin lesions. Many TSC skin lesions are not present at birth, but appear later at ages typical for the lesion.[16] For example, infants show multiple hypomelanotic macules but not angiofibromas or ungual fibromas. Adults may have multiple angiofibromas and ungual fibromas, but hypomelanotic macules may have faded or disappeared.

CUTANEOUS AND ORAL LESIONS

HYPOMELANOTIC MACULES. Hypomelanotic macules (Fig. 140-2) are observed in over 90% of children with TSC.[4,17–21] They are often present at birth or appear within the first few years of life and may fade or disappear in adulthood. The ultraviolet light of a Wood's lamp is used to improve detection, especially in lightly pigmented individuals[22] (Fig. 140-3).

Hypomelanotic macules typically measure 0.5–3.0 cm in diameter. They are off-white and not completely depigmented as in vitiligo.[23] Some are oval at one end and taper to a point at the other. Such lesions are called *ash-leaf spots* because of their resemblance to the leaf of the European mountain ash.[24] They number from 1 to over 20. They can be located anywhere on the body but tend to occur most often on the trunk and buttocks. When located on the scalp, they cause poliosis.[17]

Three or more hypopigmented macules constitutes a major feature for the diagnosis of tuberous sclerosis. One or two, and in rare individuals up to three, hypomelanotic macules occur in 4.7% of the general population.[25] A less common type of hypopigmentation is the "confetti" skin lesion (Fig. 140-4), which is considered a minor feature for diagnosis. It typically occurs on the legs below the knees or on the forearms,



Figure 140-2 Hypomelanotic ash-leaf macules on the lower leg of a child with tuberous sclerosis complex.

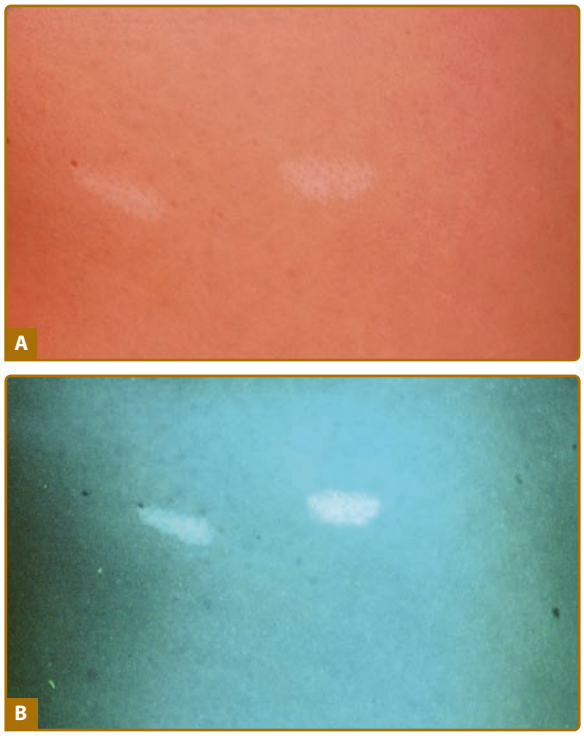

Figure 140-3 **A.** Hypomelanotic macules on the lateral chest of an adult with tuberous sclerosis complex. The macules may be easily overlooked. **B.** Wood's lamp accentuates the macules.

and consists of multiple hypopigmented macules 2–3 mm in diameter.[17,24]

FACIAL ANGIOFIBROMAS. Angiofibromas appear at 2–5 years of age and eventually affect 75% to 90% of patients.[4,17,20,21] These 1–3 mm in diameter pink to red papules have a smooth surface (Fig. 140-5). They may be hyperpigmented, especially in individuals with darker pigmentation. They occur on the central face and are often concentrated in the alar grooves (see eFig. 140-5.1 in online edition), extending symmetrically onto the cheeks and to the nose, nasal opening, and chin, with relative sparing of the upper lip and lateral face. Sometimes lesions occur on the forehead, scalp, or eyelids. They may number from 1 to over 100. Lesions may coalesce to form large nodules, especially in the alar grooves.[17,20,22] Angiofibromas are unilateral in rare cases and may indicate a segmental or mosaic defect.[26–29]



Figure 140-4 Confetti-like hypopigmented macules on the lower leg of an adult with tuberous sclerosis complex.



Figure 140-5 Multiple facial angiofibromas on the nose, cheeks, and chin, with relative sparing of the upper lip as commonly observed in tuberous sclerosis complex.

The development of papules may be preceded by mild erythema that is intensified by emotion or heat. During puberty, angiofibromas may grow in size and number. During adulthood they tend to be stable in size, but redness may gradually diminish.[22]

Angiofibromas must be multiple to be counted as a major feature. A solitary angiofibroma is clinically and histologically indistinguishable from the fibrous papule that occurs sporadically as a single lesion in the general population.[30] Multiple angiofibromas are also observed in multiple endocrine neoplasia type 1,[31–33] and as an unusual finding in Birt–Hogg–Dubé syndrome.[34]

FIBROUS FACIAL PLAQUE. The forehead plaque may be congenital or show gradual development over years.[17,35] It is present in 20% to 40% of patients.[4,17,20] It is an irregular, soft to firm, connective tissue nevus with the color of the normal surrounding skin, red, or hyperpigmented in darkly pigmented individuals



Figure 140-6 The forehead fibrous plaque in tuberous sclerosis complex is often pink-red and has a bumpy surface and irregular outline.

(Fig. 140-6). The plaque can also be found on the scalp, cheeks, and elsewhere on the face and is therefore sometimes referred to as a fibrous facial plaque. The forehead plaque is grouped together with angiofibromas as a major feature for diagnosis.[14]

SHAGREEN PATCH. The shagreen patch is observed in approximately 50% of patients.[4,17,20,21] It may be present in infancy but usually becomes apparent later. It is a firm or rubbery irregular plaque ranging in size from 1 to 10 cm (Fig. 140-7). The surface may appear bumpy with coalescing papules and nodules, or the patch may have the surface appearance of an orange peel. The color may be that of the surrounding skin, or it may be slightly pink or brown. There may be scattered smaller oval papules with or without a larger plaque (see eFig. 140-7.1 in online edition). The most common locations are on the lower back and buttocks; the patch is found less commonly on the thighs.[22]

UNGUAL FIBROMAS. Ungual fibromas, also known as *Koenen's tumors*, usually appear after the first decade and eventually affect up to 88% of adults with TSC.[20] They are more common on the toes than on the fingers.[36]

Ungual fibromas measure 1 mm to 1 cm in diameter. They arise from under the proximal nail fold (periungual fibromas) and under the nail plate (subungual fibromas). Periungual fibromas are red papules and nodules that are firm, pointed, and hyperkeratotic, or soft and rounded (Fig. 140-8). They press on the nail matrix and cause a longitudinal groove, and sometimes a groove forms without an evident papule[20,36] (see eFig. 140-8.1 in online edition). Subungual fibromas can be seen through the nail plate as red or white oval lesions or as red papules emerging from the distal nail plate, causing distal subungual onycholysis (see eFig. 140-8.2 in online edition). In addition to ungual



Figure 140-7 The shagreen patch in tuberous sclerosis complex is a firm, bumpy plaque that is usually located on the lower back.

fibromas, TSC patients may develop "red comets" (subungual red streaks), splinter hemorrhages, and longitudinal leukonychia.[36]

Presence of a nontraumatic ungual fibroma is a major feature for diagnosis of TSC.[14] Solitary lesions (also termed *acral* or *acquired digital fibrokeratomas*) are also observed in the general population, especially after nail trauma.[37] Multiple acral fibromas with a myxoid stroma were reported in one patient with familial retinoblastoma.[38]

OTHER SKIN LESIONS. Molluscum fibrosum pendulum (skin tags) is the name given to multiple fibroepithelial polyps in TSC. These range from soft pedunculated papules to larger firm pedunculated nodules located on the neck, axillae, trunk, and flexures (see eFig. 140-8.3 in online edition). They can be skin colored or hyperpigmented.[17] Skin tags are common in the general population, so these are not useful for diagnosis. Miliary fibromas are patches of multiple minute papules, usually on the neck or trunk that appear like "gooseflesh."[22] Pachydermodactyly



Figure 140-8 Multiple periungual and subungual fibromas on the toes in a patient with tuberous sclerosis complex.

is a benign thickening of the proximal fingers that has been observed in a few patients with TSC.[36,39,40]

DENTAL PITTING. Multiple pits of the dental enamel are observed in up to 100% of TSC patients.[41–44] These pits can be tiny pinpoint lesions or larger crater-like lesions (see eFig. 140-8.4 in online edition). They occur on both deciduous and permanent teeth. The identification of these lesions is enhanced by using a dental plaque stain. Dental pits can also be seen in the general population, albeit with lower prevalence and at lower numbers than in TSC.[41] The presence of multiple dental pits is a minor feature for diagnosis.[14]

ORAL FIBROMAS. Approximately 50% of TSC patients have oral fibromas[20] (see eFig. 140-8.5 in online edition). These sometimes occur in the first decade but are more common in adulthood.[45] They are most common on the gingivae, but also occur on the buccal and labial mucosa, hard palate, and tongue.[45] Some patients have diffuse gingival overgrowth. Gingival overgrowth is a common side effect of anticonvulsants, especially phenytoin and cyclosporine, but gingival overgrowth can be observed in TSC even in patients not treated with anticonvulsants or immunosuppressive agents.[45,46] Gingival fibromas are a minor feature for diagnosis.[14] Oral fibromas in the general population are typically single and form at sites of trauma, usually on the tongue or buccal mucosa.[47]

RELATED PHYSICAL FINDINGS

Tuberous sclerosis can affect almost any organ. Only one-third of patients have the classic triad of seizures, mental retardation, and angiofibromas.

BRAIN. Cerebral lesions include cortical tubers, subependymal nodules, and subependymal giant cell astrocytomas. Cerebral lesions may manifest as seizures, cognitive disability, and behavioral disorders. Seizures occur in approximately 80% of patients, with onset common in the first 2 months and usual by the first 2 years of life. Seizures are most likely infantile spasms but can be all types except pure absence (classic petit mal).[48] Seizures are controlled with antiepileptic drugs. A ketogenic diet can decrease seizures and mTOR inhibitors may also prove to be useful in reducing seizures.[49,50] Epilepsy surgery may be required for seizures intractable to anticonvulsant therapy.[51,52]

Learning disability tends to occur in patients with seizures, but many children with seizures have no obvious neurologic impairment. The extent of mental disability ranges from mild to profound. Individuals with normal intelligence may have specific deficits in attention, executive control, and memory.[53] Behavioral disorders include autism, attention deficit disorder, hyperactivity, aggressive behavior, impulsivity, anxiety, and sleep disorders.[7,53,54]

Subependymal giant cell astrocytomas occur in 6% to 14% of individuals with TSC. They may increase intracranial pressure and cause headache, vomiting, and bilateral papilledema.[55]

HEART. Cardiac rhabdomyomas are observed in 50% to 70% of infants with TSC.[56] These neoplasms are often asymptomatic and spontaneously regress, but they may cause fetal hydrops and stillbirth or heart failure shortly after birth.[57,58] Cardiac rhabdomyomas may cause dysrhythmias, commonly Wolff–Parkinson–White syndrome, noticed in utero or in the first year of life in TSC patients.[57–59]

KIDNEYS. Angiomyolipomas (AMLs) are observed in approximately 75% TSC patients over 10 years of age.[56,60] Additional renal lesions include renal cysts and rarely renal cell carcinoma.[61] Polycystic kidney disease is present in 2% to 3% of patients.[56] Renal lesions can cause renal insufficiency, hypertension, and potentially fatal retroperitoneal hemorrhage. Patients may require selective embolization or partial nephrectomy.[62–65]

LUNGS. Lung involvement in TSC includes lymphangioleiomyomatosis (LAM), multifocal micronodular pneumocyte hyperplasia, and clear cell tumors of the lung. LAM develops in females with TSC during the third or fourth decade of life. Radiographic evidence of LAM was observed in 26% to 40% of adult females with TSC, most of whom had subclinical disease.[66] It may cause spontaneous pneumothorax, chylothorax, dyspnea, cough, and hemoptysis.[67]

EYES. Retinal astrocytic hamartomas are observed in 44% to 87% of patients.[68] The most common type is a slightly raised, smooth, translucent, gray, noncalcified circular or oval lesion with indistinct boundaries. Also common are elevated and opaque multinodular "mulberry" lesions that have calcified, glistening nodules. Retinal astrocytic hamartomas can be similar to retinal lesions in neurofibromatosis type 1 and may appear similar to retinoblastomas. Some patients have vision loss, but blindness is rare.[69] In exceptional cases, enucleation has been required for enlarging retinal astocytomas.[70] TSC patients may also have "punched out" depigmented retinal lesions, which were observed in 39 of 100 patients compared to 6 of 100 controls.[68] Additional eye findings include angiofibromas of the eyelids, colobomas, strabismus, and sector iris depigmentation. Retinal astrocytic hamartomas are a major feature for the diagnosis of TSC.

GASTROINTESTINAL TRACT. Rectal polyps, usually asymptomatic, have been observed in 14 of 18 adults (78%) with TSC.[71] Histologically, they are hamartomas and rarely adenomas. Polyps have also been observed in the upper gastrointestinal tract and colon of TSC patients.[72,73] The presence of hamartomatous rectal polyps is a minor feature for TSC. Hepatic AMLs occur in TSC, typically in association with renal AMLs.[74] They are more common in females than in males with TSC.

OTHER ORGANS

Benign tumors have been found in the spleen, thymus, and thyroid. TSC may also be associated with

pituitary, parathyroid, and islet cell tumors.[75] Arterial stenotic-occlusive disease and arterial aneurysms including aortic and intracranial aneurysms have been observed,[76] Bone lesions in TSC are usually asymptomatic and may be sclerotic (calvaria, pelvis, vertebrae, ribs, and long bones)[77] or cystic (phalanges).[78] In unusual cases, there is localized overgrowth of a digit.[36]

LABORATORY TESTS

SKIN HISTOPATHOLOGIC FINDINGS

Hypomelanotic macules have normal numbers of melanocytes, in contrast to the lesions of vitiligo, in which melanocytes are absent. The melanocytes in hypomelanotic macules have poorly developed dendritic processes, and melanosomes are decreased in numbers, size, and melanization.[23] Angiofibromas contain plump, spindle-shaped, or stellate fibroblastic cells in the dermis among increased numbers of dilated vessels (see eFig. 140-8.6 in online edition). Collagen fibers are oriented in an onionskin pattern around follicles and vessels. The epidermis shows melanocytic hyperplasia and flattening of rete ridges. Periungual fibromas are similar, but with more extensive hyperkeratosis and a variable increase in vascularity (see eFig. 140-8.7 in online edition). The shagreen patch has sclerotic bundles of collagen in the reticular dermis (see eFig. 140-8.8 in online edition). Elastic fibers are typically reduced in amount.

SPECIAL TESTS (INCLUDING IMAGING STUDIES)

Besides dermatologic and ophthalmologic examination, the initial evaluation of a patient suspected to have TSC includes the following: (1) cranial computed tomography (CT) or cranial magnetic resonance imaging (MRI), (2) renal ultrasonography (or MRI or CT), and (3) electrocardiography.[60] In addition, the following tests are recommended for subsets of patients. Electroencephalography is valuable if seizures are suspected and subsequently for seizure management. In children, standardized cognitive and behavioral assessments are indicated at the time of diagnosis, in response to changes in behavior or worsening performance, and at regular intervals tailored to the individual.[53] In adult women, high-resolution chest CT is used to detect LAM. Echocardiography is indicated if the patient exhibits cardiac symptoms.[60]

After diagnosis, the patient should have periodic surveillance for the development of new lesions or changes in existing lesions. Cranial CT or MRI is recommended every 1–3 years in children. This may reveal the presence of a subependymal giant cell astrocytoma, which allows removal before it becomes locally invasive or causes symptoms. Similarly renal ultrasonography is recommended every 1–3 years, depending on clinical suspicion and results of previous examinations. If large or numerous renal tumors are present, renal CT or MRI should be performed. Echocardiography and chest CT are indicated for cardiac and pulmonary symptoms, respectively[60]

Screening of first-degree relatives of a TSC patient begins with examination of the skin, oral mucosa, teeth, and retina. Most affected family members will show TSC lesions with this approach, but additional imaging studies are recommended even in their absence.[60] When results of the physical examination are negative, cranial CT is recommended over MRI because of its lower cost and the lower likelihood of detecting lesions unrelated to TSC. Renal ultrasonography is also recommended. Molecular diagnosis may be useful for individuals in families with a known genetic change.[60]

MOLECULAR DIAGNOSIS

Genetic testing may be useful to confirm diagnosis in individuals not meeting criteria for definite TSC.[60] It can provide additional information for genetic counseling, and it can be used in prenatal diagnosis.[15] Genetic testing may yield false-negative or inconclusive results. Extensive analysis of *TSC1* and *TSC2* fails to identify a mutation in approximately 15% of TSC patients.[4,5] *TSC1* and *TSC2* are large genes, and mutations may occur anywhere along the sequence. Also, sequence analysis does not identify large deletions and must be supplemented by other methods of analysis.[4,5,79] Mutation detection may also be hampered by somatic mosaicism.

DIFFERENTIAL DIAGNOSIS

Differential diagnoses for several major features of TSC are summarized in Boxes 140-1, 140-2, 140-3, and 140-4.

COMPLICATIONS

None of the skin lesions in TSC is prone to malignant degeneration, but the lesions can be a major cosmetic concern for the patient, causing social isolation and difficulties with self-esteem.[80] Angiofibromas, facial plaques, and ungual fibromas can be painful or bleed spontaneously or in response to minor trauma. Ungual fibromas can cause nail dystrophy and eventual loss of the nail. Large facial lesions may obstruct vision or occlude the nasal passages.[81]

PROGNOSIS AND CLINICAL COURSE

Individuals with tuberous sclerosis exhibit decreased overall survival compared with the general population. The causes of premature death include renal failure, intractable seizures, obstructive hydrocephalus, cardiac outflow obstruction, arrhythmia, respiratory failure, pneumothorax, and hemorrhage from an aneurysm or a tumor, especially AMLs.[82,83] Fatal events may

BOX 140-1 DIFFERENTIAL DIAGNOSIS OF HYPOMELANOTIC MACULES

- Polygonal or ash leaf
  - Nevus depigmentosus
  - Piebaldism
  - Vitiligo
  - MEN1 hypomelanotic macules
  - Nevus anemicus
- Confetti
  - Idiopathic guttate hypomelanosis (adults)
  - MEN1 confetti lesions
  - Pityriasis alba
  - Pityriasis lichenoides chronica
- Poliosis
  - Waardenburg syndrome
  - Piebaldism
  - Vitiligo
  - Vogt–Koyanagi–Harada syndrome
  - MEN1 hypomelanotic macules
  - Nevus anemicus
  - Segmental pigment mosaicism

MEN1 = multiple endocrine neoplasia type 1.

occur at any age. Brain and heart tumors may cause death in infancy, whereas lung and kidney tumors are more likely to cause premature death in adulthood. The prognosis for the individual patient depends on disease expressivity. Some individuals have a normal life span with few medical complications.

TREATMENT

When an infant is newly diagnosed with TSC, a major aspect of care is answering questions and addressing the concerns of the family. Unfortunately, many parents report negative experiences because of physician insensitivity and the provision of inaccurate information and inadequate support.[84] Patients should be promptly referred to other specialists and social services as needed, and genetic counseling should be offered. Families should be informed about organizations dedicated to TSC, such as the Tuberous Sclerosis Alliance (http://www.tsalliance.org).

Current treatments for TSC skin tumors are mostly surgical. Angiofibromas have been treated by excision, curettage, chemical peel, cryosurgery, dermabrasion,

BOX 140-2 DIFFERENTIAL DIAGNOSIS OF ANGIOFIBROMAS

- Fibrous papules
- Multiple endocrine neoplasia type 1 angiofibromas
- Birt–Hogg–Dubé angiofibromas
- Trichoepitheliomas
- Fibrofolliculomas/trichodiscomas
- Tricholemmomas
- Syringomas
- Dermal melanocytic nevi
- Acne vulgaris
- Rosacea

BOX 140-3 DIFFERENTIAL DIAGNOSIS OF UNGUAL FIBROMA

Most Likely

- Periungual
  - Acral fibrokeratoma
  - Superficial acral fibromyxoma
  - Epidermoid cyst
  - Pseudomyxoid cyst
  - Wart
  - Pyogenic granuloma
  - Juvenile xanthogranuloma
- Subungual
  - Acral fibrokeratoma
  - Superficial acral fibromyxoma
  - Wart
  - Subungual exostosis
  - Subungual horn
  - Familial retinoblastoma
  - Pyogenic granuloma
  - Onychomycosis
  - Psoriasis

Always Rule Out

- Subungual
  - Squamous cell carcinoma
  - Bowen disease
  - Amelanotic melanoma

BOX 140-4 DIFFERENTIAL DIAGNOSIS OF SHAGREEN PATCH

Most Likely

- Familial cutaneous collagenoma
- Eruptive collagenomas
- Dermatofibrosis lenticularis disseminata (in Buschke–Ollendorf syndrome)

Consider

- Multiple endocrine neoplasia type 1 collagenomas
- Sclerotic fibroma (Cowden syndrome)
- Isolated connective tissue nevus
- Juvenile elastoma
- Nevus elasticus
- Nevus mucinosis (Hunter syndrome)

electrosurgery, and different types of laser procedure.[81,85–89] Multiple sessions using several approaches may be required for optimal results. Potential complications of surgical treatments include infection, hypertrophic scarring, postinflammatory hyperpigmentation, and hypopigmentation. Treated angiofibromas tend to recur over a couple of years, and new lesions may form.[81] Ungual fibromas are usually treated by excision, but these lesions also have a high recurrence rate. Hypomelanotic macules may be temporarily concealed using self-tanning lotions or makeup matched to the person's skin color. The shagreen patch is usually left untreated, but it can be excised. For further details regarding surgical approaches to TSC skin lesions, as well as preoperative and postoperative issues, consult reference nos. 22 and 81.

Clinical trials are in progress to test potential medical therapies for TSC tumors. Oral rapamycin caused regression of subependymal giant cell astrocytomas, decreased the size of renal AMLs, and improved pulmonary function in patients with LAM.[13,90] Several patients showed improvement in angiofibromas while on oral rapamycin,[91,92] but the potential for serious side effects is likely to limit systemic use of rapamycin for these benign skin lesions, especially in children. Application of a topical form of rapamycin has recently been shown in a single case to diminish the size and numbers of angiofibromas while reducing the risks of systemic administration[93] and maintaining efficacy against TSC skin lesions, but surgical approaches continue to be the mainstay of treatment until appropriate studies are done.

GENETIC COUNSELING ISSUES

It is not unusual for a child with TSC to be born to parents who do not carry the diagnosis of TSC. This may represent a de novo mutation, parental mosaicism, or it may indicate that one parent has a very mild form of TSC that has escaped detection. Both parents should be carefully screened as described earlier. If one parent has TSC, there is a 50% chance that subsequent children will inherit the mutation.

If neither parent has TSC, it is possible that there is alternate paternity or undisclosed adoption. Another possibility is that one parent is mosaic for a mutation in TSC1 or TSC2.[94,95] This has profound implications for genetic counseling. Whereas it would be extremely unlikely for parents of a child with a de novo mutation to have another affected child, germ-line mosaicism in one parent greatly increases the risk of having another child with TSC. An estimate of the overall risk that apparently unaffected parents will have a second child with TSC is approximately 2%.[15]

Prenatal testing can be performed on cells obtained by chorionic villus sampling or amniocentesis.[15,96,97] It is also possible to use high-resolution ultrasonography and ultrafast MRI to examine for TSC tumors in the fetus, but the sensitivity of these tests is unknown.[15,98–101] It should be emphasized that TSC is highly variable, even within a family, and that genetic testing does not predict disease severity in offspring. Also, this brief summary does not detail many issues surrounding genetic testing that require utmost thought and sensitivity and consultation with genetics professionals.

KEY REFERENCES

Full reference list available at www.DIGM8.com

DVD contains references and additional content

13. Sampson JR: Therapeutic targeting of mTOR in tuberous sclerosis. *Biochem Soc Trans* **37**(Pt 1):259-264, 2009
15. Roach ES, Sparagana SP: Diagnosis of tuberous sclerosis complex. *J Child Neurol* **19**:643, 2004
17. Jozwiak S et al: Skin lesions in children with tuberous sclerosis complex: Their prevalence, natural course, and diagnostic significance. *Int J Dermatol* **37**:911, 1998
20. Webb DW et al: The cutaneous features of tuberous sclerosis: A population study. *Br J Dermatol* **135**:1, 1996
22. Darling TN, Moss J, Mausner M: Dermatologic Manifestations of TSC. In: *Tuberous Sclerosis Complex: Genes, Clinical Features, and Therapeutics*, edited by D Kwiatkowski, E Thiele, V Whittemore. New Jersey, Wiley-VCH, 2010; in press
56. Crino PB, Nathanson KL, Henske EP: The tuberous sclerosis complex. *N Engl J Med* **355**:1345-1356, 2006
60. Roach ES et al: Tuberous Sclerosis Consensus Conference: Recommendations for diagnostic evaluation. National Tuberous Sclerosis Association. *J Child Neurol* **14**:401, 1999

Chapter 141 :: The Neurofibromatoses

:: Robert Listernick & Joel Charrow

NEUROFIBROMATOSIS TYPE 1 AT A GLANCE

- Autosomal dominant condition with incidence of 1 in 3,000 live births.
- Diagnosed clinically if two major features are present (see Table 141-1).
- Cutaneous neurofibromas:
  - Softer than the surrounding connective tissue and protrude just above the skin surface or lie just under the skin with an overlying violaceous hue.
- Subcutaneous neurofibromas:
  - Arise from peripheral nerves, both under the skin and deep in the viscera.
  - Generally much harder.
- Plexiform neurofibromas:
  - Generally present at birth or apparent during the first several years of life.
  - May lead to disfigurement, blindness (secondary to amblyopia, glaucoma, or proptosis), loss of limb function, or organ dysfunction by compression of vital structures.
- Segmental neurofibromatosis type 1 (NF-1):
  - Manifestations of NF-1, usually limited to one area of the body.
  - Occurs as result of a postconceptional mutation in the NF-1 gene, leading to somatic mosaicism.

EPIDEMIOLOGY

The "modern age" of neurofibromatosis began in 1981, with Riccardi's detailed clinical descriptions of the features and natural history of von Recklinghausen disease and the subsequent description of "central neurofibromatosis with bilateral acoustic neuroma." With the availability of gene-based diagnosis, several distinct clinical syndromes have been identified: (1) neurofibromatosis type 1 (NF-1), also known as von Recklinghausen disease; (2) neurofibromatosis type 2 (NF-2), whose cardinal feature is the development of bilateral vestibular schwannomas; (3) segmental or mosaic NF-1; (4) Legius syndrome (*SPRED1* mutation) leading to autosomal dominant transmission of café-au-lait spots, intertriginous freckling and macrocephaly; and (5) schwannomatosis. Both NF-1 and NF-2 occur equally in all ethnic groups. NF-1 occurs at an incidence of 1 in 3,000 live births, whereas NF-2 is much less common with an estimated incidence of 1 in 40,000 live births.

ETIOLOGY AND PATHOGENESIS

GENETICS

NF-1 is inherited in an autosomal dominant fashion. Although the expressivity of NF-1 varies considerably, even among individuals in the same family who are genotypically identical, the disorder is considered to be 100% penetrant. Thus, apparent skipping of NF-1 between generations may be the result of misdiagnosis, nonpaternity, or the occurrence of a new mutation in the grandchild. Although a large number of *NF1* mutations have been described, only two genotype-phenotype correlations have been noted. Individuals who have deletions of the entire NF1 gene have an increased risk of facial dysmorphism, mental retardation, early appearance of neurofibromas, and the presence of plexiform neurofibromas.[1] In addition, individuals who have a specific 3 base pair in-frame deletion in exon 17 of the *NF1* gene may have café-au-lait spots, intertriginous freckling and Lisch nodules, but do not develop cutaneous, subcutaneous or plexiform neurofibromas. neurofibromas. There is evidence that NF-1 is more severe when inherited from the mother rather than from the father.

The gene *NF1* is located on the long arm of chromosome 17, and encodes a protein called neurofibromin. Homozygosity for mutant *NF1* alleles has not been reported, probably because it is a lethal condition.

TABLE 141-1

Diagnostic Criteria for NF-1 (Two or More Required for Diagnosis)

1. Six or more café-au-lait macules over 5 mm in greatest diameter in prepubertal individuals, and over 15 mm in postpubertal individuals
2. Two or more neurofibromas of any type *or* one plexiform neurofibroma
3. Freckling in the axillary or inguinal regions
4. Optic glioma
5. Two or more iris Lisch nodules
6. A distinctive osseous lesion such as sphenoid dysplasia or thinning of long bone cortex with or without pseudarthrosis
7. A first-degree relative (parent, sibling, or offspring) with NF-1 by the above criteria

NF1 has an unusually high mutation rate, estimated at 2.4×10^{-5} to 10×10^{-5} gametes per generation, one of the highest of known inherited disorders.[2] This may reflect the large size of the gene, which spans 350 kb of genomic DNA, and contains 59 exons which encode a peptide containing over 2,800 amino acids. An alternative hypothesis is that there is some structural property of the gene that renders it particularly susceptible to mutation. New mutations account for approximately 50% of cases, and are usually on the paternally inherited allele. In contrast to many other dominant disorders, the frequency of new mutations does not appear to increase with advancing paternal age.

MOLECULAR BIOLOGY

Most *NF1* mutations result in reduced intracellular levels of the *NF1* gene product, neurofibromin; this appears to be sufficient to cause many of the clinical manifestations of the disease. Tumorigenesis, including the development of benign dermal neurofibromas, appears to be dependent on inactivation of the normal *NF1* allele in somatic cells, a process referred to as loss of heterozygosity.[3] Loss of heterozygosity is a critical step in tumorigenesis in many inherited cancer predisposition syndromes (e.g., retinoblastoma, Li-Fraumeni syndrome), and the genes involved are called "tumor suppressor genes." Tumorigenesis is initiated when both copies of the gene cease functioning normally—the first as a result of an inherited mutation, and the second as the result of a second somatic "hit" interfering with the function of the previously normal allele.

Neurofibromin is found in a variety of cell types, including neurons, oligodendrocytes, and nonmyelinating Schwann cells. Considerable evidence has been developed for the role of neurofibromin as a negative regulator of RAS.[4,5] The RAS gene family encodes membrane-associated, guanine nucleotide-binding proteins that are involved in the regulation of cellular proliferation, differentiation, and learning. RAS exists in an active (RAS-GTP) and inactive (RAS-GDP) state. By favoring conversion of RAS from its active state to its inactive state, neurofibromin downregulates the downstream effects of RAS, which include promoting learning, memory, synaptic plasticity, and cell growth and proliferation.[4,6] Mediators of the downstream effects of RAS include mitogen-activated protein kinase (MAPK), phosphatidylinositol 3-kinase (PI3K), protein kinase B (PKB), and mammalian target of rapamycin (mTOR) kinase. Spred1 also inhibits activation of the MAPK pathway.

Four different forms of neurofibromin exist, resulting from alternate splicing. The type II variant includes a 21 amino acid sequence encoded by exon 23a, while type I does not. This sequence appears to be critical for RAS regulation and learning. In the brain, there are three major isoforms of RAS; K-RAS has been shown to be the primary target of neurofibromin activity.[5] Activation of RAS by neurofibromin stimulates G-protein activity, resulting in activation of adenylyl cyclase. Cyclic AMP and other downstream intermediates appear to play a role in cell growth, learning, and memory. Neurofibromin also associates with microtubules and plays a role in regulating GABA-ergic inhibitory neuronal activity in the hippocampus.[7]

RAS is a membrane-bound protein, and requires farnesylation (addition of a C15 isoprenoid to a cysteine residue near the *C*-terminus) for activity, a process that is catalyzed by farnesyltransferase. Agents that inhibit farnesyltransferase cause general inhibition of the RAS pathway, much as neurofibromin does. Farnesyltransferase inhibitors reverse the proliferative phenotype in *Nf1*-deficient mouse cells, and can reverse spatial learning impairments in a mouse model of *NF1*, by decreasing RAS levels.[6] These observations have prompted investigations into the use of farnesyltransferase inhibitors for the treatment of NF-1-related complications, such as rapidly growing plexiform neurofibromas.

Loss of heterozygosity of the *NF1* gene in Schwann cells has been shown to be the necessary event for the development of discrete neurofibromas.[8] Furthermore, neurofibromin-deficient Schwann cells secrete a substance which stimulates mast cell migration which, in turn, stimulates production of extracellular matrix and angiogenesis.[9] Astrocytes lacking *NF1* expression cannot form optic nerve gliomas on their own; a brain environment heterozygous for *NF1* is necessary for the development of these tumors.[10]

CLINICAL FINDINGS

A consensus development conference was held by the National Institutes of Health in 1987 in order to establish diagnostic criteria to promote better clinical research and care of patients with NF-1.[11] The seven diagnostic features recognized at this conference (Table 141-1), and the recommendation that two or more of these seven features be present before a diagnosis of NF-1 is established, have proven extremely useful and continue to be used without modification 20 years later. Perhaps the one caveat is the identification of a separate autosomal dominant syndrome caused by an inactivating mutation of the gene encoding sprouty-related EVH1 domain-containing protein 1 (*SPRED1*) which leads to the development of café-au-lait spots, intertriginous freckling, and macrocephaly, but none of the other manifestations of NF-1 (Legius syndrome).[12]

CAFÉ-AU-LAIT SPOTS

Café-au-lait spots, which are flat, pigmented macules, are often the first manifestation of NF-1 to appear (Fig. 141-1). Frequently present at birth, they become more numerous as the infant grows; new ones may continue to appear throughout the first decade of life. Once noticed, they tend to grow in size in proportion to the overall growth of the child. Although infrequently found on the face, they may be noted anywhere on the body. The size, shape and contour of café-au-lait spots are of no diagnostic significance, and the oft-quoted adage about smooth-edged café-au-lait spots being more typical of NF-1 rather than McCune–Albright syndrome is incorrect



Figure 141-1 Café-au-lait spots.

(see Section "Differential Diagnosis" and Box 141-1). When café-au-lait spots overlap each other, the area of overlap may be darker than either individual spot. When found within Mongolian spots, they are typically surrounded by a more lightly pigmented halo. Individuals with large numbers of café-au-lait spots do not have "more severe" NF-1, and the location of the macules in no way predicts the location of subsequent neurofibromas.[13]

Café-au-lait spots represent collections of heavily pigmented melanocytes of neural crest origin in the epidermis. Although the cells may contain increased numbers of "giant" melanosomes, or melanin macroglobules, these are not unique to NF-1, and their presence or absence in biopsies is not helpful diagnostically.

The diagnostic criterion for NF-1 is six or more café-au-lait spots greater than 5 mm in diameter in prepubertal individuals or 1.5 cm in adults. Of all children ultimately diagnosed with NF-1, 53% will have six or more café-au-lait spots by age 3 years and 97% by age 6 years.[14]

BOX 141-1 DIFFERENTIAL DIAGNOSIS OF SYNDROMES ASSOCIATED WITH MULTIPLE CAFÉ-AU-LAIT SPOTS

Most Likely

- Neurofibromatosis type-1
- Neurofibromatosis type-2
- Familial café-au-lait spots (consider Legius syndrome)
- LEOPARD syndrome (multiple lentingines syndrome)

Less Likely

- Tuberous sclerosis
- Fanconi anemia
- Multiple endocrine neoplasia type 2B
- Bannayan–Riley–Ruvalcaba syndrome
- McCune–Albright syndrome (polyostotic fibrous dysplasia)
- Bloom syndrome
- Ataxia-telangiectasia

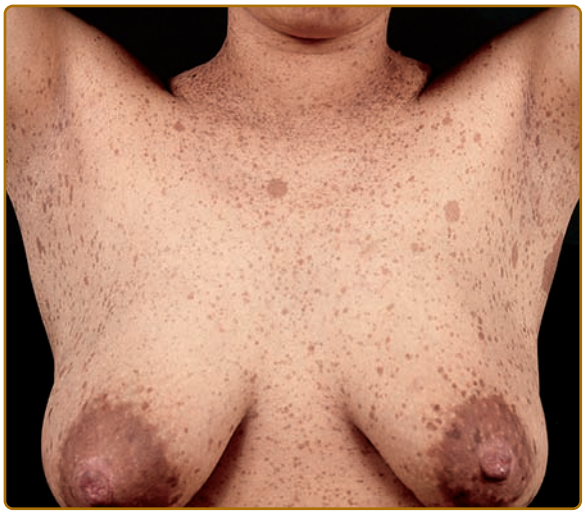

Figure 141-2 Axillary freckling.

INTERTRIGINOUS FRECKLING

Café-au-lait spots smaller than 5 mm are referred to as freckles, and are commonly present in the axillae, inguinal region, and under the breasts (Fig. 141-2). Unlike ordinary freckles in these locations, these lesions are not related to sun exposure, and are considered virtually pathognomonic of NF-1 (Crowe's sign). Of all children ultimately diagnosed with NF-1, 81% will have intertriginous freckling by age 6 years.[14]

DISCRETE NEUROFIBROMAS

Neurofibromas, which consist of Schwann cells, mast cells, fibroblasts, and perineural cells, are benign nerve sheath tumors that appear as discrete masses arising from peripheral nerves.[15] Cutaneous neurofibromas protrude just above the skin surface or lie just under the skin with an overlying violaceous hue (Fig. 141-3). They are softer than the surrounding connective tissue, often creating a "buttonholing" sensation when a finger is rubbed gently over the surface (Fig. 141-4). Subcutaneous neurofibromas that arise from peripheral nerves, both under the skin and deep in the viscera, are generally much harder (Fig. 141-5). If they arise from the dorsal root ganglia, they may grow through neural foramina, compressing the spinal cord, creating a "dumbbell" appearance. Subcutaneous neurofibromas in the neck may feel like a "beaded necklace," often being confused with lymph nodes. While less than 20% of children under 10 years of age have cutaneous



Figure 141-3 Cutaneous neurofibromas with overlying hyperpigmentation.



Figure 141-5 Subcutaneous neurofibroma.

neurofibromas,[14] they generally start appearing after puberty and increase in number as the patient grows older. Women who have NF-1 often comment on the appearance of cutaneous neurofibromas during pregnancy. The majority of adult patients with NF-1 probably have numerous asymptomatic deep neurofibromas involving the dorsal roots and other larger nerves. On occasion, neurofibroma-associated pruritus may be severe enough to require treatment with antihistamines.

PLEXIFORM NEUROFIBROMAS

Plexiform neurofibromas, histologically similar to discrete neurofibromas, are benign peripheral nerve sheath tumors which involve single or multiple nerve fascicles, often arising from branches of major nerves.[16] They may elicit a "wormy" sensation on palpation, as one feels multiple thickened nerve fascicles. Often there is overlying hyperpigmentation ("giant café-au-lait spot") or hypertrichosis (Fig. 141-6). Most plexiform neurofibromas are present at birth or become apparent during the first several years of life. Externally visible plexiform neurofibromas are easily identified and may lead to disfigurement, blindness (secondary to amblyopia, glaucoma, or proptosis), or loss of limb function (eFig. 141-6.1 in online edition, Fig. 141-7, Fig. 141-8). In contrast, thoracic or abdominal plexiform neurofibromas may have no external manifestations but may have equally devastating consequences due to invasion or compression of vital structures (e.g., ureters, bowel, spinal cord, etc.).

The growth rate of plexiform neurofibromas is highly variable. Periods of rapid growth alternating with long periods of quiescence are common. Malignant peripheral nerve sheath tumors, which generally arise from plexiform neurofibromas, may develop silently in deep plexiform neurofibromas and not give rise to symptoms until distant metastases have occurred. While loss of heterozygosity at the NF-1 locus may lead to the formation of benign neurofibromas, the generation of malignant transformation of a benign plexiform



Figure 141-4 Multiple cutaneous neurofibromas.



Figure 141-6 Plexiform neurofibroma with overlying hyperpigmentation and hypertrichosis.



Figure 141-7 Plexiform neurofibroma of left first toe leading to isolated macrodactyly.

neurofibroma may be due to cell cycle regulators beyond the *ras* oncogene. For example, mice which have null mutations in both the Nf-1 and *p53* genes uniformly develop malignant tumors.[17,18] Physicians caring for individuals with NF-1 should be alert to development of a malignancy; plexiform neurofibromas should be biopsied if they exhibit rapid growth or cause significant pain or focal neurologic dysfunction.

OPTIC PATHWAY TUMORS

Approximately 15% of children with NF-1 will develop optic pathway tumors (OPT); however, only half of these patients will ever develop symptoms, giving an overall incidence of *symptomatic* OPT of 7%.[19,20] Recent series of NF-1-associated OPT have identified an approximately 2:1 female predominance of patients, as well as a lower incidence in African-American children. These observations suggest the possibility that either hormonal factors or modifying genes may influence the development of OPT.

The period of greatest risk for the development of symptomatic OPT in NF-1 is during the first 6 years of life. In addition, the development of a symptomatic tumor after age 6 years is extremely unusual.[19,20] Thus, physicians caring for children with NF-1 should be sensitive to the signs and symptoms of OPT in this young age group. Approximately 30% of children with symptomatic OPT will present with the rapid onset of proptosis, with moderate to severe visual loss in the affected eye (eFig. 141-8.1 in online edition). Another 30% of children will have abnormal ophthalmologic examinations, without any visual symptoms, leading to discovery of the tumors. As young children rarely complain of visual loss, even when severe, thorough annual eye examinations are imperative in all young children with NF-1. When present, ophthalmologic signs may include an afferent papillary defect, optic nerve atrophy, papilledema, strabismus, or defects in color vision. Finally, as many as 40% of children who have chiasmal tumors develop precocious puberty. Accelerated linear growth will be the first sign of precocious puberty, underscoring the need for all children with NF-1 to have annual assessments of growth using standard growth charts. Children with chiasmal tumors often have no ophthalmologic symptoms or signs. Early detection of precocious puberty is important as both the accelerated linear growth and the development of secondary sexual characteristics can be can be aborted with the use of a long-acting luteinizing hormone releasing hormone agonist.[21]



Figure 141-8 Plexiform neurofibroma of left lower extremity leading to leg length discrepancy.

LISCH NODULES

Lisch nodules are slightly raised, well-circumscribed melanocytic hamartomas of the iris thought to be virtually pathognomonic of NF-1 (Fig. 141-9). They

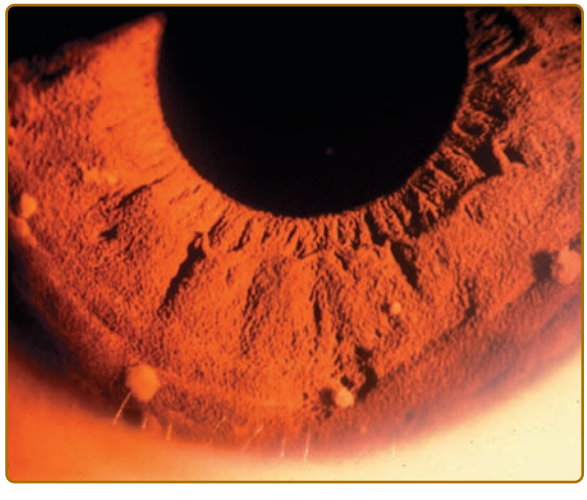

Figure 141-9 Lisch nodules.

are best seen using a slit lamp, which is necessary to distinguish them from the more commonly seen flat iris nevi, which are not associated with NF-1. They do not cause any functional impairment of vision. The frequency with which they are found increases with age; although Lisch nodules are found in over 90% of adults with NF-1, only 30% of children with NF-1 under 6 years of age have them.[14]

DISTINCTIVE OSSEOUS LESIONS

There are two bony lesions distinctive enough to be included in the diagnostic criteria for NF-1. The first, dysplasia of the wing of the sphenoid bone, results in poor formation of the wall and/or floor of the orbit (eFig. 141-9.1 in online edition). This congenital mesodermal dysplasia may be, but is not always, clinically apparent leading to proptosis (from herniation of meninges or brain into the orbit) or enophthalmos.

Dysplasia of a long bone, characterized by congenital thinning and bowing, affects approximately 2% of children with NF-1 (eFig. 141-9.2 in online edition). Although the tibia is most commonly affected, the femur, humerus and other long bones may also be involved. Even when the bone is intact, thinning and bowing produce a visible deformity, and the weakened mechanical properties of the bone predispose to fracture, particularly in the weight bearing bones. Failure of primary union following a fracture results in a "false joint," or pseudarthrosis.[22]

LABORATORY TESTS

Despite the identification of the NF-1 gene and its complete sequencing, the diagnosis of NF-1 remains primarily a clinical one. Although laboratory confirmation of the diagnosis is extremely useful in specific circumstances, in most cases it is unnecessary. Since no common mutations have been identified, molecular diagnosis can only be based on strategies that screen the entire gene for mutations. Several laboratories now offer sequencing of some or all exons and/or mutation scanning with a resulting sensitivity of as high as 95%. This testing is available for both presymptomatic individuals and can be applied to prenatal diagnosis of NF-1 when a mutation has been identified in an affected parent.

Inexperienced clinicians often biopsy cutaneous masses in an effort to confirm the diagnosis of NF-1 in an individual with multiple café-au-lait spots or other stigmata of NF-1. Such procedures are invariably unnecessary as the clinical diagnosis of NF-1 is usually quite straightforward. Biopsy of a plexiform neurofibroma should be reserved for those situations in which the physician wishes to exclude the possibility of a malignancy.

RADIOGRAPHIC EVALUATION

There has been considerable debate regarding the role of screening neuroimaging in the care of asymptomatic children with NF-1. Routine "screening" would be important if it led to early detection of OPT and early initiation of therapy which prevented visual deterioration. A longitudinal study of children with NF-1 failed to identify any tumors in which early detection altered the patient's clinical course.[19] Moreover, targeted screening of very young children with NF-1, the high-risk group for the development of OPT, failed as three children developed symptomatic tumors shortly after having had normal MRI scans. Brainstem tumors in both children and adults with NF-1 are generally more indolent than their counterparts in non-NF-1 individuals, suggesting that routine screening would not be beneficial.[23] Thus, the National Neurofibromatosis Foundation Optic Pathway Task Force has recommended against routine screening neuroimaging of all children with NF-1.[24]). Although there are no comparable longitudinal data for adults regarding the performance of "routine" MRI scans of the head and spinal cord, it seems reasonable to perform such testing only in individuals who have symptoms or signs suggestive of CNS pathology.

Similarly, there is debate as to whether patients with NF-1 should be "screened" for the presence of hidden, internal plexiform neurofibromas; most studies have demonstrated an approximately 30% incidence.[25,26] Newer techniques utilizing whole body MRI scans have been shown to reliably assess the entire tumor burden of individuals with NF-1.[27] As such a strategy incurs great cost without offering any proven benefit in preventing morbidity from plexiform neurofibromas, it is not recommended.[28] However, if current chemotherapeutic trials prove successful in the treatment of rapidly growing tumors, their identification at an early age may become more important.

COMPLICATIONS OF NF-1

SKELETAL COMPLICATIONS

All children with NF-1 should be regularly screened for scoliosis, beginning in early childhood. Scoliosis is the most common skeletal manifestation of NF-1, affecting 10%–30% of patients. Scoliosis is divided into dystrophic and nondystrophic types. Dystrophic scoliosis is the result of primary bone dysplasia, and may present very early in childhood, typically resulting in a sharply angulated curve spanning relatively few vertebral bodies (eFig. 141-9.3 in online edition). It is often accompanied by extreme rotation, scalloping of the posterior margins of the vertebral bodies, vertebral wedging, defective pedicles, and enlargement of the neural foramina and spinal canal.[22] The curvature may progress rapidly, necessitating surgery which may be particularly complicated because of the complex, multiplanar curves, poor quality of bone, potential for nerve root and spinal cord injury, and the presence of intraspinal and extraspinal neurofibromas. The nondystrophic type of scoliosis is more common, and is similar to idiopathic scoliosis in adolescents. Many children can be managed expectantly or with bracing.

Localized regions of bony overgrowth may also occur in children with NF-1 and are often in areas free of neurofibromas. The overgrowth may affect only a single digit or a larger region such as a hand or an extremity, but true hemihypertrophy is unusual. Bony overgrowth may also occur in a region affected by a plexiform neurofibroma.

CANCER

There is little doubt that NF-1 predisposes one to an increased risk for certain cancers. In a Swedish cohort of 212 probands and their affected relatives followed for more than 40 years, malignant neoplasms or central nervous system tumors occurred in 45% of the probands, for a relative risk of 4 compared with that in the general population. However, when the affected relatives of the probands were examined, only the female relatives with NF-1 had an increased risk of neoplasms.[29] This illustrates the tremendous bias inherent in data obtained through hospital records and disease-specific clinics. In reviewing the records of Japan's Children's Cancer Registry, the incidence of NF-1 was 6.45 times the expected estimated rate.[30]

Malignant peripheral nerve sheath tumors almost exclusively arise from preexisting plexiform neurofibromas. Estimates of the lifetime risk for the development of this tumor vary but may be as high as 13%.[31,32] As the outcome of therapy is poor, physicians should be diligently aware of the early symptoms referable to these tumors including a rapidly growing mass or unexplained pain or dysfunction. Although conventional imaging cannot identify malignant tissue within a benign plexiform neurofibroma, newer modalities such as 18-fluorodeoxyglucose positron emission tomography may be useful.[33]

Pheochromocytoma clearly is associated with NF-1 with an incidence potentially as high as 1.4%. In a recent review, the mean age at presentation was 42 years; 84% had solitary adrenal tumors, 9.6% had bilateral adrenal tumors, and 6% had ectopic tumors in the abdominal sympathetic chain, organ of Zuckerkandl, and the bladder.[34] Catecholamine-associated symptoms and hypertension each were present in 61% of the patients; 22% of the patients had neither of these findings. Malignant pheochromocytomas were found in 11.5% of patients, often with distant metastases at presentation. Loss of heterozygosity of the NF-1 gene has been demonstrated both in NF-1-associated and sporadic pheochromocytomas.[35,36]

There is an increased risk of chronic myelomonocytic leukemia and acute lymphoblastic leukemia in children with NF-1. In contrast to the fourfold predominance of lymphocytic leukemia generally seen in childhood, there is a clear excess of cases of myelogenous leukemia in children with NF-1.[37] Homozygous inactivation of the NF-1 gene in the bone marrow cells children with NF-1 and malignant myeloid disorders have been identified, suggesting that the NF-1 gene plays a role in downregulating the growth of immature myeloid cells.[38] Some children with NF-1 also develop juvenile xanthogranulomas, yellowish papules less than 1 cm in diameter that are usually found on the head or trunk (Fig. 141-10) and may be multiple.



Figure 141-10 Multiple juvenile xanthogranulomas on the forehead.

An unusual association between juvenile xanthogranulomas, NF-1, and the development of myeloid leukemias has been reported.[39,40] Although the pathogenesis is obscure, this association also has been observed independent of NF-1. Juvenile xanthogranulomas are yellowish papules less than 1 cm in diameter usually found on the head or trunk (Figure 142-15). Some authors have recommended "screening" blood counts for individuals who have juvenile xanthogranulomas and NF-1. Given that the magnitude of the risk is unknown but certainly extremely small, this recommendation only serves to increase parental anxiety without providing any useful information and is not endorsed by the authors. Rhabdomyosarcoma also occurs more frequently in individuals with NF-1.[41,42] Although a relationship between both neuroblastoma and Wilms tumor and NF-1 has been suggested, there are no strong epidemiologic data linking these tumors with NF-1. Other tumors that appear to occur in excess frequency in adults with NF-1 are somatostatinomas of the duodenum and the ampulla of Vater, and gastrointestinal stromal tumors (GIST). Compared to those tumors seen in non-NF-1 individuals, somatostatinomas in NF-1 rarely arise in the pancreas, are smaller, and generally are not associated with hormonal symptoms (i.e., diabetes, steatorrhea, and gallbladder disease).[43]

VASCULOPATHY

Patients with NF-1 may have a vasculopathy affecting essentially any arterial vessel. Clinical manifestations may include renal artery stenosis with hypertension, cerebral infarcts, bleeding aneurysms, and intermittent claudication of an extremity. This vasculopathy is a developmental problem not related to compression of an arteriole by a neurofibroma, and appears to be acquired after birth, as the appearance of new lesions and the progression of preexisting ones have been described. Characteristic pathologic changes have been described in all layers of the vascular wall which ultimately leads to narrowing of the arterial lumen.[44,45]

The most commonly identified vascular lesion in patients with NF-1 is in the renal artery, leading to renovascular hypertension.[46] Renal artery vasculopathy should be considered in any adult NF-1 patient with hypertension that is not easily controlled with a single antihypertensive medication; all NF-1 children should be evaluated for this complication. Aortography with selective angiography of the renal arteries should be used to confirm the diagnosis. If the blood pressure is uncontrollable using oral antihypertensives, percutaneous transluminal angioplasty can be performed and repeated if initially unsuccessful.

UNIDENTIFIED BRIGHT OBJECTS

Brain magnetic resonance imaging of children with NF-1 frequently demonstrates regions of increased signal intensity on T2-weighted images, referred to as "unidentified bright objects" or UBOs (eFig. 141-10.1 in online edition). UBOs may be found in the internal capsule, basal ganglia, cortex, cerebellar hemispheres, optic tract, or brainstem. They do not enhance and are not associated with compression of surrounding tissue, which distinguish them from neoplasms. UBOs are present in approximately 60% of children with NF-1, but disappear with age, and are uncommon in adults. They are not associated with focal neurologic signs, and are of uncertain significance. Histopathologic studies have shown that the UBOs corresponded to areas of myelin vacuolization with increased water content.[47] Recent studies have found that NF-1 children with UBOs have significantly lower IQ and language scores, significantly impaired visual-motor integration and motor coordination, and are at much greater risk for impaired academic achievement, when compared with NF-1 subjects without UBOs.[48]

INTELLIGENCE AND LEARNING DISABILITIES

Contrary to gross misstatements in the older literature, the mean IQ of patients with NF-1 is only 5–10 points lower than the general population and unaffected siblings.[49] However, learning disabilities, defined as discrepancies between ability (intellect) and performance, are quite common with an estimated prevalence of 30%–60%.[50,51] Although earlier reports suggested there might be a specific "cognitive phenotype" in NF-1 characterized by an excess of visual/perceptual disabilities, more recent studies have demonstrated that verbal deficits (e.g., reading) are at least as common as nonverbal disabilities in individuals with NF-1. These learning disabilities are lifelong and can affect adult functioning. Many children with NF-1 also have poor attention and impulse control, and may be diagnosed with attention deficit hyperactivity disorder, significantly interfering with school performance and learning. Stimulant medications may have a profound beneficial effect on these individuals' ability to succeed academically and professionally.

TREATMENT OF NF-1

Individuals with NF-1 are best cared for within a multidisciplinary clinic, which has access to a wide range of subspecialists. The exact physician composition of the clinic is less important than the ability to obtain expeditious subspecialty consultation. All first-degree relatives should be examined for the cutaneous manifestations of NF-1 and should undergo slit-lamp examination at the first visit to ascertain the presence of Lisch nodules. Yearly visits allow the physician to identify NF-1 complications early while providing counseling and dissemination of information regarding NF-1.[13] Individuals and families can obtain further information from the Web sites of the two national support groups: (1) the Children's Tumor Foundation (www.ctf.org) and (2) Neurofibromatosis, Inc. (www.nfinc.org).

All children with NF-1 who are 6-years-old and younger should have yearly complete ophthalmologic examinations looking for signs of an optic pathway tumor. These should include assessment of visual acuity, color vision, visual fields, fundoscopy, and slit-lamp examination. As almost all optic pathway tumors arise in children in this age group, the frequency of ophthalmologic examinations can be reduced in children over 10 years of age. Yearly measurements of weight and height should be plotted on standardized growth charts, as the earliest indication of precocious puberty may be accelerated linear growth. Blood pressure measurements should be obtained at each visit to look for signs of renovascular hypertension. In addition, the spine should be examined each year for early signs of scoliosis.[13]

CAFÉ-AU-LAIT SPOTS

Café-au-lait spots on the face are unusual in individuals with NF-1. On occasion, they do occur and affected individuals may seek to improve cosmesis. Attempts at removing café-au-lait spots with laser therapy have provided very mixed results. Although total disappearance of the lesion may occur, some studies cite a recurrence rate as high as 67%. While results with use of the Q-switched ruby laser (694 nm) have been mixed, favorable reports in a limited number of cases using either the continuous mode copper vapor laser (511 nm) or the erbium:YAG laser (2,940 nm) have been published.[52,53] Multiple treatments of a single lesion may be more effective.

CUTANEOUS NEUROFIBROMAS

Discrete cutaneous neurofibromas may be removed surgically to improve cosmesis or to prevent local irritation, for example, in the hairline while brushing or on the foot rubbing against the shoe. Deeper neurofibromas may require surgical removal when pushing on vital structures, such as a dorsal root neurofibroma that infiltrates the neural foramen and compresses the spinal cord. Complications of surgery include regrowth of the original tumor and nerve damage. In individuals who have severe pruritus from a large burden of

cutaneous neurofibromas, antihistamines may provide symptomatic relief. Uncontrolled anecdotal case reports have suggested that ketotifen, an antihistamine and mast cell stabilizer, has provided relief from pruritus and pain and prevented the rapid growth of new neurofibromas.[54] Use of the CO_2 laser under general anesthesia to remove hundreds of cutaneous neurofibromas has resulted in markedly increased patients' quality of life and decreased pain and pruritus.[55] The residua of a flat smooth depigmented scar was not felt to be an impediment to such surgery by most patients.

PLEXIFORM NEUROFIBROMAS

Until recently, the treatment of plexiform neurofibromas was limited to surgical debulking either to improve cosmesis or to prevent loss of function (e.g., upper airway obstruction, blindness). Such surgery was highly limited in its efficacy; complete resection was impossible given the highly infiltrative nature of these tumors and tumor regrowth was common. Thus, there has been considerable interest in the development of nontraditional chemotherapy for use against these tumors. Not surprisingly, the design of studies to test the efficacy of such agents is fraught with complications. Plexiform neurofibromas are quite different biologically from more conventional solid neoplasms. Lack of growth following treatment may be part of the natural history of the tumor rather than a true therapeutic response. In addition, tumor burden may be difficult to quantify radiographically; plexiform neurofibromas may "spread" along nerve roots sending out multiple finger-like projections, quite different than a single, solid tumor mass.

Despite the above difficulties, several Phase I and II chemotherapeutic trials are in progress. Preliminary studies utilizing pirfenidone, an antifibrotic agent that decreases proliferation of fibroblasts and collagen matrix synthesis, and a farnesyltransferase inhibitor which downregulates the *ras* oncogene, did not yield promising results. In a recently described case and based on studies of the important role of mast cell c-kit receptor signaling, administration of imatinib to a 3-year-old with an unresectable airway plexiform neurofibroma led to 70% diminution in size during 3 months of therapy.[56] Other newer agents are also currently being studied. These include: (1) AZD2171, which is a potent inhibitor of vascular endothelial growth factor receptor tyrosine kinases; (2) sirolimus, an mTOR pathway inhibitor; (3) PEG interferon-α-2b; and (4) photodynamic therapy. If any of these studies demonstrate potential efficacy, the role of screening imaging to detect "hidden" plexiform neurofibromas would need to be readdressed.

OPTIC PATHWAY TUMORS

Once identified, OPT should be followed by serial MRI and ophthalmologic examinations. Treatment should be initiated only after demonstration of clear radiographic progression or deterioration of vision. The goal of treatment should be preservation of vision while minimizing the side effects of therapy. Chemotherapy with carboplatin and vincristine has proven effective in the management of these tumors.[57] Radiation therapy, while a mainstay of treatment of progressive CNS neoplasms not associated with NF-1, is not appropriate for *NF1*-associated OPTs because of the risk of vasculopathy, second malignancies, and detrimental neurocognitive and endocrinologic side effects in very young children.

RELATED CONDITIONS

NEUROFIBROMATOSIS-2 (NF-2)

NEUROFIBROMATOSIS TYPE 2 AT A GLANCE

- Autosomal dominant disorder with incidence of 1 in 40,000 live births.
- Hallmark is the presence of bilateral vestibular schwannomas.
- At risk for development of multiple meningiomas, schwannomas, gliomas, and neurofibromas throughout neural axis.

NF-2 is an autosomal dominantly inherited condition characterized by bilateral vestibular schwannomas, meningiomas (intracranial, intraspinal, and optic nerve sheath), schwannomas (dorsal roots of the spinal cord, peripheral nerves, and cranial nerves), ependymomas and gliomas of the central nervous system, and juvenile posterior subcapsular cataracts.[58] The estimated birth incidence is 1 in 40,000 live births. While much less common than NF-1, its morbidity is much greater, with patients frequently becoming paralyzed and deaf. The most recent clinical diagnostic criteria have led to increased sensitivity in establishing the diagnosis, particularly in those cases without a positive family history (Table 141-2). Approximately 60% of patients present in adulthood with hearing loss, tinnitus, or loss of balance. The younger the age at presentation, the greater the ultimate severity of the disease. Children are more apt to present with a noneighth nerve tumor such as an optic nerve sheath meningioma. Ophthalmologic findings include juvenile posterior subcapsular cataracts (60%–80% of patients), retinal hamartomas, and optic nerve sheath meningiomas.[58]

Individuals with NF-2 may have several café-au-lait spots, but rarely have more than six; intertriginous freckling is not seen. The characteristic cutaneous lesion of NF-2 is the cutaneous schwannoma (Fig. 141-11). It is a plaque-like, slightly raised lesion with a faint violaceous hue, occasionally with hair. Less commonly,

TABLE 141-2
Manchester Clinical Diagnostic Criteria for NF-2

A patient has the clinical diagnosis of NF-2 if one of the following criteria is present:

A. Bilateral vestibular schwannomas
B. First degree family relative with NF-2 and unilateral vestibular schwannomas or any two[a]: meningioma, schwannoma, glioma, neurofibroma, or posterior subcapsular lenticular opacities
C. Unilateral vestibular schwannoma and any two[a]: meningioma, schwannoma, glioma, neurofibroma, or posterior subcapsular lenticular opacities
D. Multiple meningiomas (two or more) and unilateral vestibular schwannoma and any two[a]: schwannoma, glioma, neurofibroma, cataract

[a]"Any two" refers to two individual tumors or cataract.
From Evans DGR et al: Management of the patient and family with neurofibromatosis 2: A consensus conference statement. *Br J Neurosurg* **19**:5-12, 2005.

cutaneous neurofibromas, indistinguishable from those seen in NF-1, may be found.

NF-2 is caused by mutations in a gene on chromosome 22, which encodes the membrane-related protein merlin, also known as schwannomin. As in NF-1, the *NF-2* gene is a tumor suppressor gene which downregulates cellular growth. The exact cellular pathways by which this control is exerted have yet to be delineated.

SEGMENTAL NF-1

The term "segmental neurofibromatosis" refers to individuals who have manifestations of NF-1, usually café-au-lait macules and neurofibromas, limited to one area of the body.[59] Ruggieri and Huson have proposed use of the term "mosaic localized NF-1" for these individuals, as an acknowledgement that the pathogenesis of this condition is a postconceptional mutation in the NF-1 gene leading to somatic mosaicism.[60] This has been confirmed in a patient in whom the mutant NF-1 allele was present in a mosaic pattern in cultured fibroblasts from a café-au-lait macule and absent in fibroblasts from normal skin.[61]



Figure 141-11 Cutaneous schwannoma.

The vast majority of patients with segmental NF-1 have café-au-lait macules or intertriginous freckling limited to one area of the body (Fig. 141-12). These individuals are at risk for developing complications of NF-1 in the affected area, most commonly neurofibromas. Localized manifestations of NF-1 other than café-au-lait macules, freckling, or cutaneous neurofibromas may also represent examples of somatic mosaicism. There have been numerous reports of isolated plexiform neurofibromas, including one case in which loss of heterozygosity of the NF-1 gene in Schwann cells from the tumor was demonstrated. Since only 50% of cases of tibial pseudarthrosis occur in the context of NF-1, the others may actually represent cases of segmental NF-1. Other examples of segmental NF-1 include a child who had a unilateral optic pathway glioma that acted that acted biologically like an NF-1-associated tumor and individuals with isolated sphenoid bone dysplasia.

Genetic counseling of patients with segmental NF-1 is problematic. Many of these patients are misdiagnosed as having NF-1, leading to unnecessary anxiety and inappropriate genetic counseling. In addition, gonadal mosaicism for NF-1 has been demonstrated; patients with segmental NF-1 have had offspring with complete NF-1.

NF1–NOONAN SYNDROME

It has been recognized that there are individuals who meet the diagnostic criteria for NF-1, yet have many features of Noonan syndrome, which is characterized by hypertelorism, ptosis, downsloping palpebral fissures, low set, posteriorly rotated ears, webbed neck, pectus deformities, and short stature. Over 50% of children with Noonan syndrome have cardiovascular disease, most commonly pulmonary valve stenosis. Noonan's syndrome is caused by mutations in the gene *PTPN11* in 50% of cases. Mutations in several other genes (*KRAS*, *SOS1*, *BRAF*, *MEK1*, *MEK2*, *HRAS* and *RAF1*) have also been associated with this phenotype. Genetic testing has shown that most individuals with LEOPARD syndrome also have mutations in *PTPN11*. A recent study documented mutations in the NF-1 gene in 16 of 17 unrelated subjects who clinically had the NF-1–Noonan phenotype; no mutations in *PTPN11* were found.[62] Thus, it appears that the vast majority of cases of NF-1–Noonan syndrome are due to mutations in NF-1.

LEGIUS SYNDROME

Families recently have been identified who have autosomal dominant transmission of café-au-lait spots, intertriginous freckling, and macrocephaly without any other manifestations of NF-1, including neurofibromas, in whom no NF-1 mutation was detected. Further genetic studies of these individuals revealed

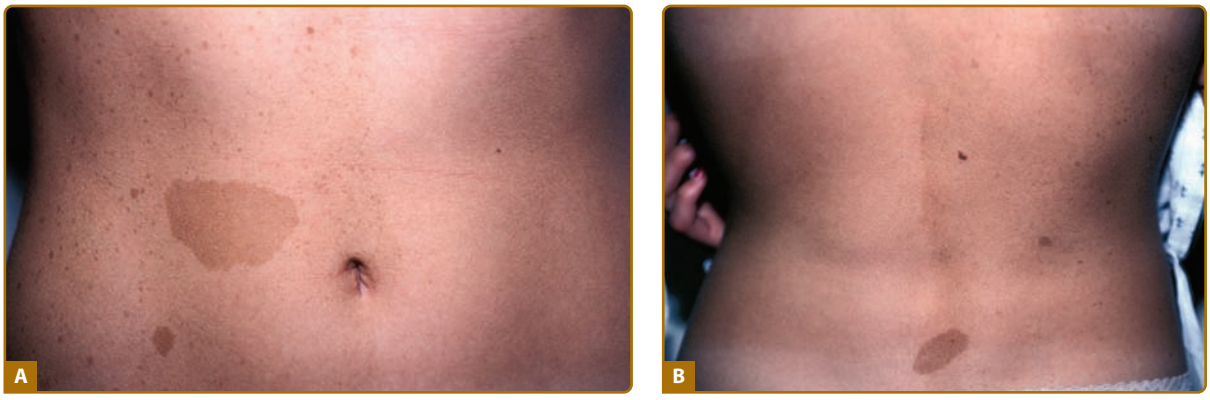

Figure 141-12 **A** and **B.** Segmental NF-1. Note café-au-lait spots and freckling limited to one side of body.

mutations in *SPRED1*, a gene that negatively regulates the mitogen-activated protein kinase (MAPK) pathway. None of these individuals has discrete neurofibromas, plexiform neurofibromas, Lisch nodules, optic pathway tumors, or NF-1-specific bony abnormalities.[12] The frequency of cognitive deficits in these individuals is, as yet, unknown. Genetic testing for *SPRED1* mutations is available in individuals suspected of having Legius syndrome in whom NF-1 gene testing has failed to detect a mutation.

SCHWANNOMATOSIS

It had been noted for some time that there are patients who develop multiple schwannomas but who fail to develop other manifestations of NF-2, particularly vestibular schwannomas.[63,64] Patients with this condition, now called schwannomatosis, develop multiple painful schwannomas within peripheral nerves and paraspinal nerve roots. The tumors most often start appearing during the second and third decades of life. Surgery of individual lesions is often necessary to treat intractable pain. In contrast to NF-2, individuals with schwannomatosis have a normal life span. Before making a diagnosis of schwannomatosis, it is extremely important to exclude the possibility of NF-2 by both genetic testing and performing an MRI scan to look for vestibular schwannomas. Germ-line mutations in *SMARCB1/INI1*, another tumor-suppressor gene previously implicated in the development of rhabdoid tumors in infants and young children, have been identified as the cause of a large number of the familial cases of schwannomatosis.[65]

KEY REFERENCES

Full reference list available at www.DIGM8.com

DVD contains references and additional content

12. Messian L et al: Clinical and mutational spectrum of neurofibromatosis type-1 like syndrome. *JAMA* **302**:2111-2118, 2009
13. Listernick R, Charrow J: Neurofibromatosis-1 in childhood. *Adv Dermatol* **20**:75-115, 2004
51. Hyman SL, Shores A, North KN: The nature and frequency of cognitive deficits in children with neurofibromatosis type 1. *Neurology* **65**(7):1037-1044, 2005
56. Yang FC et al: Nf1-dependent tumors require a microenvironment containing Nf1+/- and c-kit-dependent bone marrow. *Cell* **135**:437-448, 2008
58. Evans DG et al: Management of the patient and family with neurofibromatosis 2: A consensus conference statement. *Br J Neurosurg* **19**(1):5-12, 2005
59. Listernick R, Mancini AJ, Charrow J: Segmental neurofibromatosis in childhood. *Am J Med Genet* **121**(2):132-135, 2003
64. MacCollin M et al: Diagnostic criteria for schwannomatosis. *Neurology* **64**(11):1838-1845, 2005

Chapter 142 :: Ectodermal Dysplasias

:: Alanna F. Bree, Nnenna Agim, & Virginia P. Sybert

ECTODERMAL DYSPLASIAS AT A GLANCE

- A group of inherited disorders characterized by developmental abnormalities in two or more ectodermal structures.
- These include hair, teeth, nails, and sebaceous and sweat glands.
- There may be abnormalities in nonectodermal structures and functions.
- Distinction is based on clinical features, mode of inheritance, and molecular findings.
- Clinically distinct disorders may be due to different mutations in the same gene (allelic heterogeneity), and clinically similar conditions may be due to mutations in different genes (locus heterogeneity).

The ectodermal dysplasias (EDs) are a group of inherited disorders that share in common developmental defects involving at least two of the major structures classically held to derive from the embryonic ectoderm—hair, teeth, nails, and sweat glands. Freire-Maia and Pinheiro[1] published an exhaustive review and classification system for these disorders using a numeric system of 1 (hair), 2 (teeth), 3 (nail), and 4 (sweat glands) for characterization. This system has little use in practice, although it did allow for a rational approach to a previously chaotic field. Freire-Maia and Pinheiro laid claim to more than 150 ectodermal disorders in their most recent compilation.[2] Several other classification schemes have been suggested. Each has limited clinical application but can help in ordering thinking about these disorders.[3,4] In an attempt to move to a more useful and unified system, an international classification conference was convened in 2008 to initiate this process which is still ongoing.[5]

This chapter covers only the more common of these conditions and those in which ectodermal defects are likely to bring them to a dermatologist for diagnosis and medical attention. Fig. 142-1 is an algorithm showing the approach to the diagnosis of EDs. The first step in the algorithm for making a specific diagnosis of an ED is to determine the presence of sweating (hidrotic) or absence of sweating (hypohidrotic/anhidrotic). The involvement of other ectodermal structures and of nonectodermally derived tissues provides further branching points in a diagnostic hierarchy. Mode of inheritance may differ within a seemingly uniform diagnostic group, and care must be taken in evaluating family members before providing recurrence risks.

Within the last few years, causal genes have been identified for many of the EDs. Given continuing discoveries, the reader is directed to the following resources: http://www3.ncbi.nlm.nih.gov/Omim (Online Catalog of Mendelian Inheritance in Humans) and http://www.ncbi.nlm.nih.gov/sites/GeneTests (an up-to-date listing of laboratories offering molecular testing). The National Foundation for Ectodermal Dysplasias (http://www.nfed.org) is a lay support group that has numerous informative pamphlets for families and physicians, as well as a strong advocacy program for dental care, insurance coverage, and research.

HYPOHIDROTIC ECTODERMAL DYSPLASIA [ANHIDROTIC ECTODERMAL DYSPLASIA, CHRIST–SIEMENS–TOURAINE SYNDROME; OMIM #305100]

HISTORICAL ASPECTS

One of the earliest descriptions of hypohidrotic ectodermal dysplasia involving male first cousins and their grandmother with sparse hair, missing teeth and dry skin was described in 1848 by Thurnam.[6] Darwin described this condition in his writings from 1875.

EPIDEMIOLOGY

X-linked hypohidrotic ED (XLHED) occurs in all racial groups and is thought to have an incidence at birth of anywhere from 1 in 5,000–17,000 births.[7] Accurate prevalence and incidence data are not available.

ETIOLOGY, PATHOGENESIS, AND GENETICS

XLHED results from alterations in the gene *ectodysplasin* (*EDA*, *EDA1*, *HED*) located at Xq12-13.[8] It codes for a transmembrane protein, ectodysplasin, which is composed of 391 amino acids and has alternative splicing forms, the significance of which is not known. A multitude of mutations in this gene causing XLHED have been identified. There does not appear to be a correlation between the nature of the mutation and the clinical features[9] (i.e., to date, there have been no phenotype–genotype correlations). Interfamilial and intrafamilial variation occurs to a mild degree.

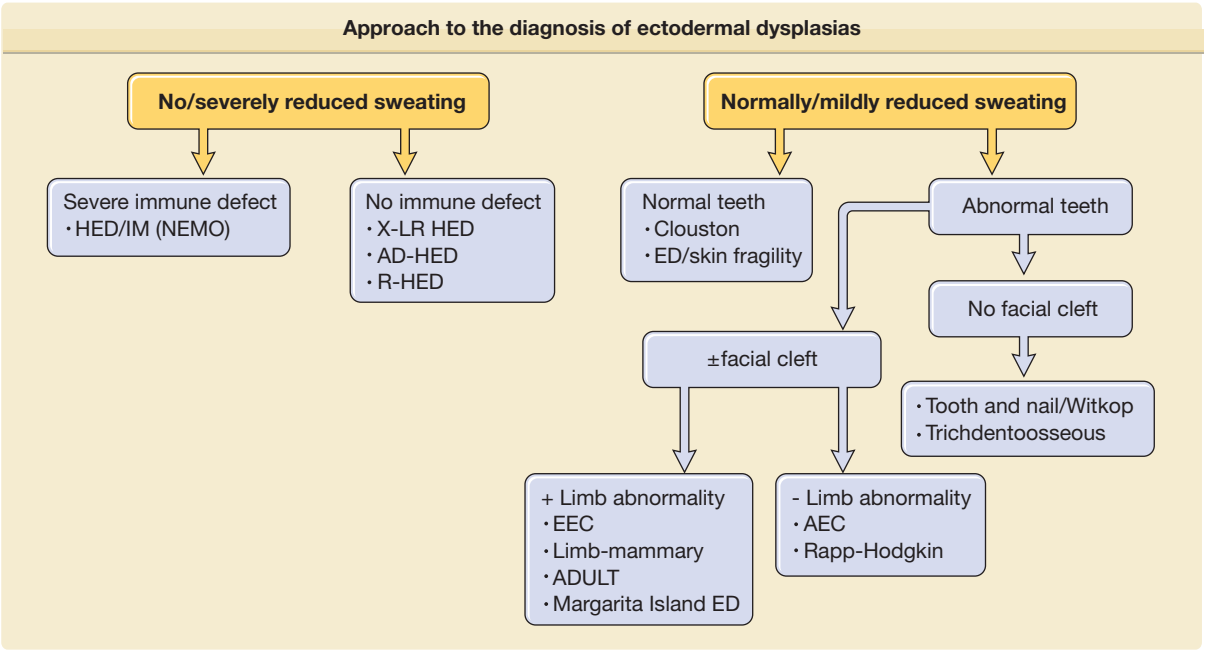

Figure 142-1 Approach to the diagnosis of ectodermal dysplasias. AD = autosomal dominant; ADULT = *a*cro-*d*ermato-*u*n-gual-/acrimal-*t*ooth syndrome; AEC = *a*nkyloblepharon filiforme adnatum–*e*ctodermal dysplasia–*c*left palate syndrome; AR = autosomal recessive; ED = ectodermal dysplasia; EEC = ectrodactyly–ED–cleft lip/palate syndrome; HED = hypohidrotic ectodermal dysplasia; IM = immune defects; X-LR = X-linked recessive.

Ectodysplasin belongs to the tumor necrosis factor family and plays a role in regulation of the formation of ectodermal structures. It forms trimers and is expressed in keratinocytes, the outer root sheath of hair follicles, and sweat glands. It localizes to the lateral and apical surfaces of cells.

As is typical of X-linked recessive disorders, expression is full blown in affected males, and carrier females may express none, some, or all of the features of the disorder, often in a patchy distribution. Between 60% and 80% of carrier females express some clinical signs of the disorder; the most frequent are patchy hypotrichosis and hypodontia. The disorder can be inherited from a carrier mother or occur in an affected individual as the result of a de novo mutation. Approximately 70% of affected males inherited the mutation from a carrier mother.

Mutations in an autosomal gene, *EDAR*, mapped to 2q11-q13, have been implicated in an autosomal dominant form of hypohidrotic ectodermal dysplasia (HED; OMIM #129490) and in an autosomal recessive form (OMIM #224900)[10] that are clinically similar to XLHED. Both these entities are much rarer. EDAR acts as a receptor for ectodysplasin. Mutations in yet another gene, *EDARADD*, have been identified recently in autosomal recessive HED and autosomal dominant HED.[11,12] EDARADD is an intracellular adaptor protein that assists in transmitting the signal from the activated EDA receptor to the nucleus of the cell. Individuals with autosomal dominant HED appear to have a milder defect in the ability to sweat.

Certain mutations in the X-linked *NEMO* gene, which causes incontinentia pigmenti (IP) in females, have been shown to result in HED and immune defects in males (see Chapter 143).[13,14]

CLINICAL MANIFESTATIONS

DERMATOLOGIC. Affected males may present at birth with a collodion membrane or with marked scaling of the skin,[15] similar to congenital ichthyosis. Scalp hair is usually sparse, fine, and blonde. It may thicken and darken at puberty, and secondary sexual hair is typically normal. Other body hair is usually sparse or absent.

The ability to sweat is significantly compromised, and most affected males have marked heat intolerance. Sweat pores are usually undetectable on physical examination, and fingerprint ridges are effaced. The inability to sweat adequately in response to environmental heat results in an elevation of core temperature and bouts of unexplained high fevers, usually leading to an extensive workup for infectious disease, malignancy, or autoimmune disease before the correct diagnosis is recognized. In an older series of patients, mental retardation was reported as a feature of XLHED. Currently, this is believed to have been due to damage from prolonged high fevers and seizures and not to be an intrinsic feature of the disorder.[16]

The nails are usually normal; reports of thin, fragile nails are not convincing.[17] Periorbital wrinkling and hyperpigmentation are typical and often present at birth (Figs. 142-2A–142-2C). Eczema affects more than two-thirds of affected males and is often difficult to manage. Hyperplasia of sebaceous glands,



Figure 142-2 Hypohidrotic ectodermal dysplasia. **A.** Newborn with periorbital wrinkling, beaked nose. Diagnosis would not be suspected unless there were a positive family history. **B.** Peg-shaped teeth; fine periorbital wrinkling can be appreciated. **C.** Two unrelated males with X-linked hypohidrotic ectodermal dysplasia; adult is wearing dentures; periorbital wrinkling and hyperpigmentation are evident. (Used with permission from the National Foundation for Ectodermal Dysplasias.)

particularly on the face, can develop over time and appear as small, pearly, flesh-colored to white papules that may resemble milia.

SYSTEMIC ASSOCIATIONS. Hypodontia, oligodontia, or anodontia are invariable features of XLHED in affected males. Hypoplastic gum ridges in an affected infant can be an early clue to the diagnosis of the disorder. Teeth that do erupt are usually peg-shaped and small (see Fig. 142-2B). The facies of the disorder are characterized by frontal bossing and a depressed midface with a saddle nose and full, everted lips. Otolaryngologic manifestations include thick nasal secretions and impaction, ozena, sinusitis, recurrent upper respiratory tract infections and pneumonias, decreased saliva production, hoarse voice, and an increased frequency of asthma. The increased frequency of respiratory tract infections has been attributed to hypoplastic or absent mucus secreting glands in the bronchial tree.[18] Gastroesophageal reflux and feeding difficulties may be a problem in infancy. The basis for this is unknown. Preliminary studies suggest that there may be failure to thrive in infancy and early childhood in as many as 20% to 40% of affected boys, with catch-up growth seen later.[19] Although several reviews have suggested that infant mortality may be increased, unbiased confirmatory data are lacking.

Female carriers for XLHED may be affected as severely as males or show few, if any, signs of the disorder (Fig. 142-3). Heat intolerance, if present, is usually mild; adult carrier women comment that they do not sweat much or that they do not like very warm weather, but it is unusual for a female to experience fever due to inability to sweat. Typically, a few teeth



Figure 142-3 Hypohidrotic ectodermal dysplasia. **A.** Female carrier of X-linked hypohidrotic ectodermal dysplasia with her affected son. **B.** Two sisters with X-linked hypohidrotic ectodermal dysplasia manifesting to different degrees. Note periorbital hyperpigmentation, full everted lips, and sculpted noses. (From Sybert VP *Genetic Skin Disorders.* New York, Oxford University Press, 1997.)

may be peg-shaped or missing and scalp hair may be patchy or thin. Careful examination of the skin of carrier females often reveals a diminution in or patchy distribution of sweat pores. This sometimes can be appreciated readily just by magnification of fingertip pads or may require more sophisticated sweat testing.

VARIANTS. As noted in Section "Etiology, Pathogenesis, and Genetics," the autosomal dominant and autosomal recessive forms of HED are similar, although the autosomal dominant form may be milder. The X-linked form is by far the most common and always should be the diagnosis of default in a sporadic case.

HISTOPATHOLOGY

The epidermis is thinned and flattened. There is a reduction in the number of sebaceous glands and hair follicles. Eccrine glands are absent or incompletely developed. Histologic evaluation of the skin is usually not necessary.

DIAGNOSIS AND DIFFERENTIAL DIAGNOSIS

(Box 142-1)

The scaling skin at birth may result in a misdiagnosis of congenital ichthyosis. Repeated bouts of fever may be thought to have an infectious source. The diagnosis of HED is recognized readily when expected, such as when an at-risk male is born into a family in which the disorder is known to segregate. Examination for sweat pores and a Panorex view of the jaw leads quickly to the correct diagnosis. Absence of eccrine structures in skin biopsies of the scalp and/or palmar region may help confirm a diagnosis,[20] but are rarely necessary. In an isolated, fully expressing female, the autosomal dominant and recessive forms of HED need to be considered. Family history is mandatory, and mothers

BOX 142-1 DIFFERENTIAL DIAGNOSIS OF SOME DIAGNOSTIC FEATURES OF ECTODERMAL DYSPLASIAS

- Collodion membrane
  - Lamellar exfoliation of the newborn
  - Neutral lipid storage disease
  - Autosomal recessive congenital ichthyosis
    - Nonbullous congenital ichthyosiform erythroderma
    - Lamellar ichthyosis
  - Trichothiodystrophy
  - Storage diseases (e.g., Gaucher)
  - Chondrodysplasia punctata
- Ankyloblepharon filiforme adnatum (AFA)
  - Lethal popliteal pterygium syndrome
  - Popliteal pterygium syndrome
  - Isolated AFA
  - AFA and cleft palate
- Hypodontia
  - Isolated hypodontia
  - Incontinentia pigmenti
- Skin fragility/erosions
  - Epidermolysis bullosa disorders
  - Incontinentia pigmenti
  - Acrodermatitis enteropathica
  - Plakophilin/ectodermal dysplasia
  - Congenital erythropoietic porphyria
  - LOGIC (*l*aryngeal and *o*cular *g*ranulation tissue *i*n children from the Indian subcontinent)
- Atrophic streaks
  - Incontinentia pigmenti—stage 4
  - MIDAS (*mi*crophthalmia, *d*ermal *a*plasia, and *s*clerocornea)
  - Focal dermal hypoplasia

always should be examined fully to detect mild manifestations of the X-linked form. Molecular testing may be helpful but is not indicated for clinical diagnosis in most instances. Referral to a pediatric dermatologist may be helpful if the diagnosis is in question.

TREATMENT

Maintenance of cool ambient temperatures is vital to prevent hyperpyrexia. Most children do well with simple measures, such as wet T-shirts, air conditioning in home and school, wet headbands, etc. Occasionally, cooling vests allow a broader range of participation in sports and vigorous physical activity in warm climates.

Dental restoration is of primary importance, and early implementation of dentures and ultimate use of dental implants are mainstays of treatment.

Management of otolaryngologic complications, asthma, and recurrent infections needs to be individualized. The eczema may be quite refractory to care.

> The National Foundation for Ectodermal Dysplasias (http://www.nfed.org) has several pamphlets for individuals and professionals dealing with diagnosis and treatment.

Although infancy and childhood are complicated by many problems, most individuals with HED lead adult lives that allow them to function successfully in society. Heat intolerance seems to decrease due to the development of some ability to sweat in adolescence or to the development of common sense and adaptation of lifestyle, or both.

Recombinant ectodysplasin protein injections of pregnant affected (*Tabby*) mice led to permanent rescue of the phenotypic features in the offspring.[21] Further, early postnatal injections were also shown to ameliorate the developmental defects. Similar results have been seen in affected canine models who were infused with recombinant ectodysplasin protein in the postnatal period, with resultant normalization of teeth, lacrimation and sweating ability, as well as decreased eye and respiratory infections.[22,23] These developments in animal models have been encouraging and human trials are planned. An international patient registry has been established by the NFED to facilitate these clinical trials.

HIDROTIC ECTODERMAL DYSPLASIA (CLOUSTON SYNDROME; OMIM #129500)

EPIDEMIOLOGY

Hidrotic ED was first described in a French–Canadian kindred.[24] It has been reported in other ethnic groups, but the majority of affected individuals can trace their ancestry back to an original French–Canadian settler.

ETIOLOGY, PATHOGENESIS, AND GENETICS

Hidrotic ED is autosomal dominant with variable expression (the degree of severity can vary within and between families). Males and females are affected in equal numbers and to equal degree. The gene maps to the centromeric region of the long arm of chromosome 13.

The disorder is caused by mutations in a connexin gene, *GJB6* or *connexin-30*.[25] Different mutations in the same gene are responsible for a form of nonsyndromic autosomal dominant deafness and at least one patient with *k*eratitis-*i*chthyosis-*d*eafness (KID syndrome) (see Chapter 49). Other connexin genes show similar variability in mutation: disease correlations [e.g., mutations in *connexin-31* (*GJB3*)] can cause either erythrokeratodermia variabilis (see Chapter 49) or late-onset autosomal deafness.

CLINICAL MANIFESTATIONS

The scalp hair is wiry, brittle, and pale, and there is often patchy alopecia (Fig. 142-4A). This progresses in adult life and may lead to total alopecia. Body and facial hair are affected. The nails may be milky white in infancy and early childhood, gradually thickening and becoming dystrophic. The nail plates in adults are thick, short, and slow growing. They separate distally from the nail bed (see Fig. 142-4C), and may cause pain. Anonychia has been reported. Not all the nails are necessarily affected to the same degree. Progressive palmar/plantar hyperkeratosis is common (see Fig. 142-4B). In contrast to HED, sweating is normal, as are the teeth. Oral leukoplakia has been reported. Conjunctivitis and blepharitis, possibly due to poor function of sparse eyelashes, are common.

HISTOPATHOLOGY

The thickened palms and soles show orthohyperkeratosis with a normal granular layer. On electron microscopy, an increase in the number of desmosomes in the cells of the stratum corneum is found. The hair shows nonspecific changes.

DIAGNOSIS AND DIFFERENTIAL DIAGNOSIS

(See Box 142-1)

The diagnosis is straightforward. The involvement of nails and hair and palmar/plantar thickening, in the absence of other signs of ED, are reasonably specific. Other palmar/plantar hyperkeratoses do not have similar hair changes. Orofacial clefting differentiates other forms of autosomal dominant hidrotic ED, such as ankyloblepharon–ED–cleft palate (AEC) syndrome or Rapp–Hodgkin syndrome. Although the nail changes are similar to those of pachyonychia congenita, the hair changes are distinctive.



Figure 142-4 Hidrotic ectodermal dysplasia (Clouston syndrome). **A.** Patchy alopecia in adult. Coarseness of hair can be appreciated. **B.** Palmar hyperkeratosis. **C.** Nail dystrophy.

TREATMENT

Occasionally, ablation of the nail matrix is necessary for relief of pain. Wigs may provide cosmetic benefit. Treatment of the thickened palms and soles is not specific and minimally successful.

ANKYLOBLEPHARON FILIFORME ADNATUM–ECTODERMAL DYSPLASIA–CLEFT PALATE SYNDROME (HAY–WELLS SYNDROME; OMIM #106260) (INCLUDES RAPP–HODGKIN SYNDROME; OMIM #129400)

EPIDEMIOLOGY

Described first in 1976,[26] Hay–Wells syndrome has been found in ethnically and geographically disparate families. Described in 1968, Rapp–Hodgkin syndrome, with many clinical similarities to Hay–Wells syndrome, was once thought to be a distinct clinical entity. More recently, it has become evident that Rapp–Hodgkin syndrome is allelic to Hay–Wells syndrome.[27–30] Although there are some clinical differences, the genotype–phenotype correlations are limited at best and it is reasonable to consider these disorders to be the same.

ETIOLOGY, PATHOGENESIS, AND GENETICS

The disorder is caused by mutations in the tumor-suppressor gene *p63*, a gene that has been implicated in the pathogenesis of ectrodactyly–ED–cleft lip/palate (EEC) syndrome, limb–mammary syndrome, *a*cro-*d*ermato-*u*ngual-*l*acrimal-*t*ooth (ADULT) syndrome, and other autosomal dominant forms of ED. Mutations that cause EEC and AEC cluster in different regions of the gene.[31,32] AEC syndrome is an autosomal dominant disorder with complete penetrance and variable expression.

CLINICAL FEATURES

DERMATOLOGIC. Eighty percent to 90% of affected infants present at birth with shiny red, cracking, peeling skin, and superficial erosions, similar to the appearance of a collodion membrane (Fig. 142-5A).[17] This sheds within a few weeks, and the skin underneath is dry and thin. The scalp is almost invariably affected by recurrent erosions, and many individuals are plagued by a chronic erosive dermatitis with abnormal granulation tissue on the scalp (see Figs. 142-5B and 142-5C).[33] Recurrent bacterial infection of the scalp is common. Patchy alopecia is the rule, and the scalp hair that is present is often wiry, coarse, and light in color with an uncombable hair appearance. Sparseness to absence of body hair is typical. Dyspigmentation, both hypo- and hyperpigmentation, can be quite striking and is seen universally in affected patients.[34,35] Ankyloblepharon



Figure 142-5 Ankyloblepharon filiforme adnatum–ectodermal dysplasia–cleft palate (Hay–Wells) syndrome. **A.** Newborn with peeling collodion membrane. **B.** Scalp erosions. **C.** Mild ankyloblepharon, blepharitis, midfacial hypoplasia, repair cleft lip, and abnormal granulation tissue on scalp. **D.** Fine strands of tissue (ankyloblepharon filiforme adnatum) between eyelids.

filiforme adnatum (AFA)—strands of skin between the eyelids—is seen in approximately 70% of affected infants (see Fig. 142-5D). These may tear spontaneously prior to birth, minimally involve the lateral eyelids or require surgical lysis. Lacrimal duct atresia or obstruction is common. The nails may be normal, hyperconvex and thickened, absent, or partially dystrophic, and all changes can be found in a single individual. Effaced dermatoglyphics and palmoplantar erosive changes are also quite common. Sweating may be normal, although most affected individuals describe subjective heat intolerance. Supernumerary nipples and ectopic breast tissue are seen occasionally, as is mild cutaneous syndactyly of toes two and three. More prominent limb defects, including ectrodactyly, have recently been observed.[36,37]

In Rapp–Hodgkin, hypohidrosis usually without episodes of frank hyperpyrexia, abnormal hair with pili torti or pili trianguli et canaliculi and progressive balding, along with nail dystrophy, similar to Hay–Wells, are seen.[38,39] The face in Rapp–Hodgkin syndrome is striking, with a short nasal columella and maxillary hypoplasia, thin upper lip, and full lower lip (Figs. 142-6A and 142-6B). The nails are thick and short, worsening with age (see Fig. 142-6C). The teeth may be conical and prone to caries (see Fig. 142-6D). The lacrimal puncta are aplastic in almost one-third of affected individuals. Scalp involvement with breakdown and granulation tissue formation appears to be far less common in patients with Rapp–Hodgkin than in AEC syndrome, and AFA is rare.

SYSTEMIC ASSOCIATIONS. Cleft palate, with or without cleft lip, occurs in 80% to 100% of reported cases, with some cases displaying submucosal clefts alone.[40] There is typically hypodontia with missing or misshapen teeth, and maxillary hypoplasia is also common.[41] Malformed auricles have been described in some. Recurrent otitis media and secondary conductive hearing loss are common and may be consequence of the cleft palate. Hypospadias has been described in several affected males with AEC syndrome. In Rapp–Hodgkin, hypospadias has been reported in two-fifths of affected males; labial hypoplasia and absence of the opening of the vagina have been reported in a single female. These features are also reminiscent of the EEC syndrome.



Figure 142-6 Rapp–Hodgkin syndrome. **A.** Affected infant at 5 months. **B.** Fine, blond, sparse hair; beginnings of nail changes on middle finger of right hand. (Used with permission from the National Foundation for Ectodermal Dysplasias.) **C.** Abnormal nails in same patient as (**A**), at age four-and-half years with thickened and friable nail plates. (From Sybert VP: *Genetic Skin Disorders*. New York, Oxford University Press, 1997.) **D.** Abnormal dentition, missing teeth, and peg teeth.

HISTOPATHOLOGY

Consistent histopathologic changes include mild epidermal atrophy, focal orthokeratosis, prominent superficial vascular plexus, and pigment incontinence with melanophages.[42] Electron microscopy of hairs shows a defective cuticular structure, atrophy and loss of melanin, along with structural abnormalities including pili torti and pili trianguli et canaliculi. There is a decrease in the keratins of the basal and suprabasal layers of the epidermis and disorganized keratin filaments in the stratum corneum.

DIAGNOSIS AND DIFFERENTIAL DIAGNOSIS

(See Box 142-1)

Among the autosomal dominant EDs associated with clefting, EEC syndrome is characterized by bony hand and foot abnormalities not typically seen in AEC and also lacks the ankyloblepharon. The peeling, eroded skin of the newborn can lead to misdiagnosis of epidermolysis bullosa or congenital ichthyosis. AFA can occur in the absence of syndromic associations, and strands of tissue between the eyelids have been seen in several forms of arthrogryposis, in association with chromosomal aneuploidy, and in CHANDS (*c*urly *h*air, *a*nkyloblepharon, and *n*ail *d*ysplasia *s*yndrome), an autosomal recessive form of ED.

TREATMENT AND PROGNOSIS

Light emollients should be used until the collodion membrane sheds. Ankyloblepharon may require surgical lysis. Ongoing ocular hygiene is important. Vigorous and meticulous but gentle scalp care with prompt treatment of infection is extremely important. Grafting of skin to the scalp has not proven successful in most instances. Clefting requires a team approach for repair and follow-up for secondary issues, such as feeding difficulties, speech defects, orthodontia, and ear infections.

ECTRODACTYLY ECTODERMAL DYSPLASIA–CLEFT LIP/PALATE (EEC) SYNDROME; SPLIT HAND–SPLIT FOOT–ECTODERMAL DYSPLASIA–CLEFT LIP/PALATE SYNDROME (OMIM #604292)

HISTORICAL ASPECTS AND EPIDEMIOLOGY

EEC syndrome is an ED classified as a multiple congenital anomaly syndrome because it has major involvement of structures other than those derived ectodermally. EEC syndrome has occurred in all racial groups worldwide.

ETIOLOGY, PATHOGENESIS, AND GENETICS

Mutations in *p63*, a tumor-suppressor gene mapped to 3q27, have been found in most, but not all, individuals with EEC syndrome.[43] The gene is expressed widely, including in the basal cells of proliferating epithelial tissues. Mutations in the same gene cause some cases of isolated split hand–split foot disease, limb–mammary syndrome, the ADULT (OMIM #103285) syndrome, and Hay–Wells/Rapp–Hodgkin syndrome. There appear to be some genotype–phenotype correlations.[44] The majority of alterations identified thus far in Hay–Wells syndrome have been missense mutations in the sterile α motif domain of p63; in EEC syndrome, the majority of mutations result in single-amino-acid substitutions in the DNA-binding domain of p63.[19] Similar mutations in the DNA-binding domain are also found in the split hand–split foot malformation.[45] Frameshift mutations in *p63* cause limb–mammary syndrome, in which ectodermal structures other than the mammary gland often, but not always, appear normal. Among three unrelated families with ADULT syndrome, all shared the same point mutation in *p63*.[46]

EEC syndrome is an autosomal dominant disorder with variable expression and reduced penetrance. Intrafamilial and interfamilial differences in severity are common.

CLINICAL MANIFESTATIONS

DERMATOLOGIC. The ED may be quite mild. The hair is usually blond, coarse, and dry. It may be sparse and slow growing. Axillary and pubic hair also may be affected. The nails are dystrophic in approximately four-fifths of individuals with transverse ridging, pitting, and slow growth. Dry skin and thickening of the palms and soles can occur. Sweating is usually normal.

SYSTEMIC ASSOCIATIONS. The major distinguishing feature of EEC syndrome is ectrodactyly—abnormal development of the median rays of the hands and feet (Figs. 142-7A–142-7C). The feet are involved more frequently than the hands, and there may be asymmetry of involvement (see Figs. 142-7A–142-7C).

Cleft palate, with or without cleft lip, occurs in 70% to 100% depending on the series.[47,48] Hypodontia and premature loss of secondary teeth and the dental abnormalities associated with clefting are found in most affected individuals. Lacrimal gland abnormalities are common. Secondary conductive hearing loss is frequent. Genitourinary abnormalities that include hydronephrosis, and structural renal or genital malformations affect one-third or more of persons with EEC syndrome. Although mental retardation has been reported, it is not believed to be an inherent feature of the disorder.

DIAGNOSIS AND DIFFERENTIAL DIAGNOSIS

Among disorders with limb defects that need to be considered in the differential diagnosis of EEC syndrome are the odontotrichomelic syndrome (OMIM #273400), in which there are severe absence deformities of the limbs, and aplasia cutis congenita with limb defects (Adams–Oliver syndrome, OMIM #100300), which does not have clefting or ectodermal defects other than absence of skin. Cutis marmorata telangiectatica congenita (see Chapter 107) has been described in some individuals with Adams–Oliver syndrome. Other EDs with clefting include Hay–Wells syndrome, and limb–mammary syndrome, all of which, in at least some families, appear to be allelic to EEC syndrome. Ectrodactyly with cleft palate without ED (OMIM #129830) also may be a distinct entity. There appear to be some families with EEC in whom linkage studies have suggested other causal genes located at different chromosomal loci. These genes have not yet been identified, but Dlx protein regulation by *p63* may play an important role in the development of limb abnormalities. Prenatal diagnosis by ultrasound for detection of limb abnormalities is unreliable; molecular testing may prove useful in some families.

TREATMENT

As for other EDs with orofacial clefting and ophthalmologic involvement, management requires a team approach. Similarly, treatment for the limb defects must be individualized. Renal ultrasound and a high index of suspicion for urinary tract problems are appropriate and warranted.

TOOTH AND NAIL SYNDROME (WITKOP SYNDROME; HYPODONTIA WITH NAIL DYSGENESIS; OMIM #189500)

HISTORICAL ASPECTS AND EPIDEMIOLOGY

The earliest case was reported by Witkop in 1965 when he described a pedigree demonstrating autosomal



Figure 142-7 Ectrodactyly–ectodermal dysplasia–clefting syndrome. **A.** Hands of an affected adult. **B.** Hands and feet of affected infant. **C** and **D.** Feet and hands of parent of infant in (**B**) demonstrating variability of expression both among limbs and between family members. Note the nail dystrophy in the mildly affected mother, especially evident on the thumbs.

dominant inheritance.[49] Along with Hudson, he later went on to describe 23 cases in six families in 1975. All demonstrated hypoplastic nails and hypodontia; the latter manifested as failure of permanent teeth to erupt.[50]

ETIOLOGY, PATHOGENESIS, AND GENETICS

A nonsense mutation in *MSX1*, a gene expressed in the developing teeth and nail beds in mice, has been found in one family with Witkop syndrome.[51,52] Other mutations in *MSX1* have been associated with isolated tooth agenesis or tooth agenesis with cleft palate. Tooth and nail syndrome is autosomal dominant, with variable expression and intrafamilial variability.

CLINICAL MANIFESTATIONS

DERMATOLOGIC. The nails are thin, small, and friable and may show koilonychia at birth. Toenails are usually more severely involved than fingernails (Fig. 142-8B). Nail changes improve with age and may

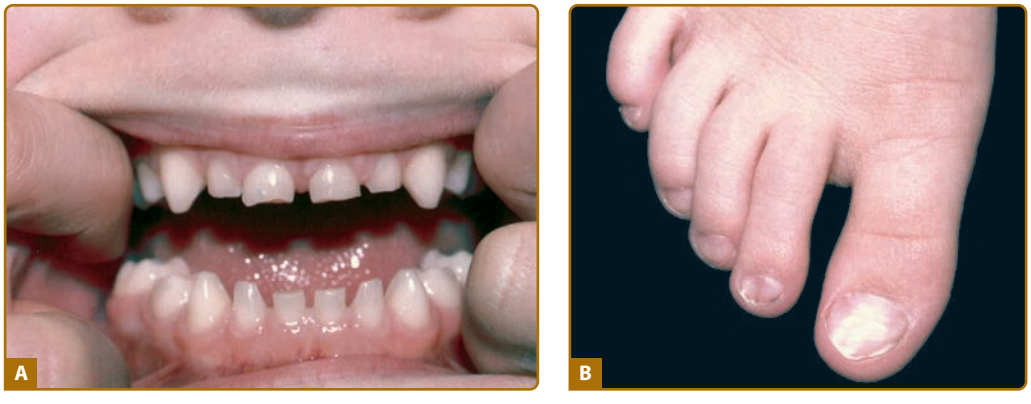

Figure 142-8 Tooth–nail syndrome. **A.** Primary teeth still in place; failure of adult teeth to erupt. **B.** Dystrophic toenails with flattening of nail plates.

be unappreciated in affected adults. A few individuals have reported thin, fine hair.

SYSTEMIC ASSOCIATIONS. The primary teeth usually are unaffected, although they may be small. The secondary teeth may fail to erupt, and there can be partial or total absence (see Fig. 142-8A). The mandibular incisors, second molars, and maxillary canines are missing most often. No other ectodermal structures are affected.

DIAGNOSIS AND DIFFERENTIAL DIAGNOSIS

This is an easy condition to miss. The nail changes may be subtle. The tooth abnormalities may be mild enough to escape detection by a physician. The lack of associated features, either dermatologic or systemic, readily distinguish Witkop syndrome from other EDs. There is a presumed autosomal recessive disorder characterized by taurodontia (teeth with an elongated body and pulp chamber and short roots), absent teeth, sparse hair, and hypoplastic nails that appears similar.

TREATMENT AND PROGNOSIS

The nails usually require no treatment. Restorative dentistry is important.

FOCAL DERMAL HYPOPLASIA OF GOLTZ (OMIM #305600)

EPIDEMIOLOGY

Focal dermal hypoplasia of Goltz (FDH), first described in 1934, received its name from a report by Goltz and coauthors[53] of three patients. Subsequently, there have been over 200 case reports published.

ETIOLOGY, PATHOGENESIS, AND GENETICS

Focal dermal hypoplasia is an X-linked dominant disorder, usually lethal in males. Case reports of males with the condition are believed to be due to mosaicism for postzygotic mutations (as is true for incontinentia pigmenti); the presence of some normal cells allows survival in the male. The mutated gene is *PORCN*, the human homolog of the porcupine gene in *Drosophila*. *PORCN* is thought to be important for palmitoylation and secretion of Wnt protein, a key regulator of the development of skin and bone.[54,55]

CLINICAL MANIFESTATIONS

DERMATOLOGIC. The skin changes of FDH are the primary diagnostic features with considerable phenotypic variability. There is linear, punctate, streaky cribriform atrophy (Fig. 142-9) with telangiectasia. The cribriform atrophy is marked by tiny ice pick-like depressions in the skin. These are distributed along the lines of Blaschko. Areas of thinned to absent dermis are irregularly distributed and the resultant herniations of fat appear as yellow–pink excrescences on the skin surface (see Fig. 142-9C). These are easily depressed. Papillomas that may be fleshy or vascular develop throughout life and favor the perigenital, perioral, intertriginous, and mucosal surfaces. Other dermatologic features include patchy alopecia, brittle or sparse hair, and palmar and plantar hyperkeratoses. Some individuals have had hyperhidrosis and some have had aplasia cutis congenita.

SYSTEMIC ASSOCIATIONS. The other organ systems most frequently involved in FDH are the skeletal, central nervous system, teeth, and eyes. Microphthalmia and coloboma are common and the diagnosis of FDH should prompt a full ophthalmologic evaluation. Oligodontia, tooth dysplasia, and enamel defects are common. The skeletal abnormalities are too numerous to list; the more common are vertical banding of the bones (osteopathia striata), syndactyly (both cutaneous and bony), asymmetry, and short stature. Mental retardation has been reported in approximately 15% of cases. Defects in other organ systems have been described in a minority of cases, including cardiac defects, abdominal wall defects, and renal malformations. It is not certain that these are inherent features of FDH.

DIAGNOSIS AND DIFFERENTIAL DIAGNOSIS

(See Box 142-1)

The diagnosis of FDH is relatively straightforward. Cribriform atrophy has been described in X-linked dominant Conradi–Hünermann syndrome (chondrodysplasia punctata), but ichthyosis is not a feature of FDH, and fat herniation is not part of Conradi–Hünermann. The streaky distribution of the atrophic lesions of IP is similar, as are the other system malformations, but the blistering, hyperkeratosis, and hyperpigmentation of IP are not found in FDH. In microphthalmia and linear skin defects/microphthalmia, dermal aplasia, sclerocornea, the skin defects are limited to the head and neck; there is atrophy and scarring of the skin more similar to aplasia cutis congenita and not dermal atrophy alone. The disorders do share similar ocular abnormalities.

TREATMENT AND PROGNOSIS

There is no specific treatment for the dermatologic and systemic features of FDH. Papillomas can be excised if they interfere with function. Use of vascular lasers to decrease the erythema of telangiectatic areas may have cosmetic benefit. As with most X-linked dominant disorders, clinical involvement varies considerably, and the range in severity is marked. This makes prognostic counseling difficult early in infancy, and usually it is wiser to counsel patience and reassurance until the



Figure 142-9 Focal dermal hypoplasia of Goltz. **A.** Streaky and patchy involvement in the newborn. Note similarity to the distribution of lesions in incontinentia pigmenti. **B** and **C.** Same girl at age 2 showing atrophy and fat herniation. **D.** Now a young adult, erythema and atrophy, with dryness and scale, predominate. (From Sybert VP: *Genetic Skin Disorders.* New York, Oxford University Press, 1997.)

extent to which there is systemic involvement becomes clear. It is important to inquire about the family history of lost pregnancies (a distorted male–female ratio in offspring and increased pregnancy loss are clues to the mother being a carrier). Both mothers and fathers should be examined carefully; fathers may have subtle features, and, presumably, represent individuals with postzygotic mutations for the *FDH* gene.

ECTODERMAL DYSPLASIA WITH SKIN FRAGILITY

(See Chapter 62)

KINDLER SYNDROME

(See Chapter 62)

KEY REFERENCES

Full reference list available at www.DIGM8.com

DVD contains references and additional content

1. Freire-Maia N, Pinheiro M: *Ectodermal dysplasias: a clinical and genetic study*. New York: Alan R. Liss, p. 251, 1984
3. Lamartine J: Towards a new classification of ectodermal dysplasias. *Clin Exp Dermatol* **28**:351, 2003

9. Vincent MC et al: Mutational spectrum of the ED1 gene in X-linked hypohidrotic ectodermal dysplasia. *Eur J Hum Genet* **9**:355, 2001
14. Berlin AL, Paller AS, Chan LS: Incontinentia pigmenti: A review and update on the molecular basis of pathophysiology. *J Am Acad Dermatol* **47**:169, 2002
16. Clarke A et al: Clinical aspects of X-linked hypohidrotic ectodermal dysplasia. *Arch Dis Child* **62**:989, 1987
19. Motil KJ et al: Growth characteristics of children with ectodermal dysplasia syndromes. *Pediatrics* **116**:e229, 2005
25. Lamartine J et al: Mutations in GJB6 cause hidrotic ectodermal dysplasia. *Nature Genet* **26**:142, 2000
32. van Bokhoven H, McKeon F: Mutations in the p53 homolog p63: Allele-specific developmental syndromes in humans. *Trends Mol Med* **8**:133, 2002
52. Jumlongras D et al: A nonsense mutation in MSX1 causes Witkop syndrome. *Am J Hum Genet* **69**:67, 2001
53. Goltz RW: Focal dermal hypoplasia syndrome. An update. *Arch Dermatol* **128**:1108, 1992

Chapter 143 :: Genetic Immunodeficiency Diseases

:: Ramsay L. Fuleihan & Amy S. Paller

GENETIC IMMUNODEFICIENCY DISEASES

Primary immunodeficiency diseases are inherited disorders of the immune system that result in an increased susceptibility to infection and an increased morbidity and mortality. Many of these genetic immunodeficiency diseases may be associated with a variety of cutaneous abnormalities, and recognition of these clinical features may allow an early diagnosis of primary immunodeficiency. Cutaneous abnormalities may include cutaneous infections, atopic- or seborrheic-like dermatitis, macular erythemas, alopecia, poor wound healing, purpura, petechiae, telangiectasias, pigmentary dilution, cutaneous granulomas, extensive warts, angioedema, and lupus-like changes (Table 143-1). Other clinical features often include failure to thrive, visceral infection, autoimmune disorders, connective tissue/rheumatologic diseases, allergic reactions, and neoplasias.

CLINICAL FINDINGS

Immunodeficiency should be suspected when patients have recurrent infections of increased duration or severity, particularly with unusual organisms. Incomplete clearing of infections, unexpected or severe complications of infection, or poor response to antibiotics may be associated.[1] Affected infants often grow poorly (failure to thrive). The most common noncutaneous abnormalities are infections, diarrhea, vomiting, hepatosplenomegaly, arthritis, adenopathy or paucity of lymph nodes/tonsils, and hematologic abnormalities.

The classification of genetic immunodeficiency disorders includes (1) antibody deficiencies, (2) cellular deficiencies, (3) combined antibody and cellular deficiencies, (4) disorders of phagocytosis and cell killing, and (5) complement defects. The characteristic clinical signs of each group suggest that proper classification and laboratory tests may be used to confirm the diagnosis. The laboratory testing and clinical patterns of illness associated with each group of immunodeficiency disorders that allow their differential diagnosis are outlined in Table 143-2 and Fig. 143-1. The most important disorder in the differential diagnosis of all genetic immunodeficiency disorders is human immunodeficiency virus (HIV) infection. In addition to the lack of HIV antigen as detected by polymerase chain reaction in patients with genetic immunodeficiency, other features help to differentiate the disorders. Patients with HIV infection tend to show an inverted CD4/CD8 ratio and hypergammaglobulinemia, in contrast to the hypogammaglobulinemia of many patients with genetic immunodeficiency.

ANTIBODY DEFICIENCY DISORDERS

AGAMMAGLOBULINEMIA

X-LINKED AGAMMAGLOBULINEMIA AT A GLANCE

- Synonym: Bruton disease.
- Early-onset, recurrent bacterial infections.
- Absent or barely detectable tonsillar and cervical lymph node tissue.
- Profound hypogammaglobulinemia and decreased or absent peripheral B cells.

EPIDEMIOLOGY. Agammaglobulinemia results from gene defects that prevent the assembly of a full B cell antigen receptor. X-linked agammaglobulinemia (XLA) is the most common cause of agammaglobulinemia and results from defects in a cytoplasmic tyrosine

TABLE 143-1
Manifestations of Genetic Immunodeficiencies

Cutaneous Manifestations	Associated Immunodeficiency	Cutaneous Manifestations	Associated Immunodeficiency
■ Angioedema	Hereditary angioedema	■ Mucocutaneous telangiectasias	Ataxia-telangiectasia
■ Atopic-like dermatitis	IgA deficiency/IgM deficiency Chronic granulomatous disease Common variable immunodeficiency Elevated IgM with hypogammaglobulinemia Ectodermal dysplasia with immunodeficiency Hyperimmunoglobulinemia E syndrome Severe combined immunodeficiency Wiskott–Aldrich syndrome X-linked agammaglobulinemia	■ Petechiae and/or purpura	Chédiak–Higashi syndrome Griscelli syndrome Wiskott–Aldrich syndrome
		■ Pigmentary dilution/silvery hair	Chédiak–Higashi syndrome Griscelli syndrome IgA deficiency
		■ Pyoderma gangrenosum-like ulcerations	Chédiak–Higashi syndrome Chronic granulomatous disease Hyperimmunoglobulinemia E syndrome Leukocyte adhesion deficiency
■ Cutaneous abscesses	Chronic granulomatous disease Hyperimmunoglobulinemia E syndrome Leukocyte adhesion deficiency	■ Seborrheic-like or exfoliative dermatitis	X-linked hypogammaglobulinemia Ataxia-telangiectasia "Leiner" phenotype: complement deficiency or dysfunction Severe combined immunodeficiency X-linked agammaglobulinemia
■ Cutaneous granulomas	Ataxia-telangiectasia Chronic granulomatous disease Chronic mucocutaneous candidiasis Common variable immunodeficiency Severe combined immunodeficiency, especially TAP2 deficiency X-linked hypogammaglobulinemia	■ Warts, extensive	Common variable immunodeficiency Elevated IgM with hypogammaglobulinemia Epidermodysplasia verruciformis (see Chapter 196) IgM deficiency Severe combined immunodeficiency after transplantation (mutations in *IL2RG* or *JAK3*) WHIM syndrome
■ Cutaneous candidal infection	Chronic mucocutaneous candidiasis DiGeorge syndrome Hyperimmunoglobulinemia E syndrome Severe combined immunodeficiency especially TAP2 deficiency		
■ Eosinophilic folliculitis, infantile	Hyperimmunoglobulinemia E syndrome		
■ Graft-versus-host disease	DiGeorge syndrome Severe combined immunodeficiency		
■ Lupus-like cutaneous change	IgA deficiency Chronic granulomatous disease, autosomal recessive Chronic granulomatous disease, X-linked carrier Common variable immunodeficiency Complement deficiency, early components Elevated IgM with hypogammaglobulinemia		

Ig = immunoglobulin; TAP = transporter associated with antigen processing or transporter, ATP-binding cassette; WHIM = warts, hypogammaglobulinemia, infections, myelokathexis.

kinase, Bruton's tyrosine kinase (BTK). XLA is inherited in an X-linked fashion, and approximately 50% of affected boys have a family history of the disorder.[2] Autosomal recessive agammaglobulinemia affects males and females equally and results from defects in the genes that encode for components of the pre-B cell and B cell receptors or in BLNK, a scaffold protein that assembles signaling molecules associated with the pre-B cell and B cell receptor.[23]

CLINICAL FINDINGS. Agammaglobulinemia is characterized by recurrent pyogenic infections that often begin between 3 and 18 months after birth, concurrent with the waning of maternal immunoglobulins (Ig). These patients have absent or barely detectable tonsils and cervical lymph nodes.[5] Skin infections, especially furunculosis and impetigo, occur in 28% of patients and often surround body orifices. An atopic-like eczematous eruption that fails to improve with Ig therapy has

TABLE 143-2
Patterns Associated with Primary Immune Deficiency

Disorder	Infection	Other
Antibody	Sinopulmonary (pyogenic bacteria) Gastrointestinal (enterovirus, *Giardia*) Normal handling of fungal and viral infections (exception is enterovirus)	Autoimmune disease (autoantibodies, inflammatory bowel disease) Minimal growth retardation Paucity of lymphoid tissue
Cellular	Low-grade or opportunistic infections Pneumonia (pyogenic bacteria, *Pneumocystis*, viruses) Gastrointestinal (viruses) Skin, mucous membranes (fungi)	Growth retardation Graft-versus-host disease Fatal infections from live vaccines Malignancy
Phagocytosis and cell killing	Skin, reticuloendothelial system (*Staphylococcus*, enteric bacteria, *Aspergillus*, *Mycobacteria*)	Ulcerative stomatitis
Complement	Alternative, late components Sepsis/blood-borne (*Streptococci*, *Pneumococci*, *Neisseria*)	Early components Autoimmune disease (systemic lupus erythematosus, glomerulonephritis) C1 esterase inhibitor deficiency Angioedema

been described in many affected children. Pyoderma gangrenosum and noninfectious cutaneous granulomas have been reported. Childhood exanthematous disorders are handled appropriately, but the infections may recur, owing to a failure to develop specific antibodies.

Recurrent otitis, sinusitis, bronchitis, and pneumonia are the earliest infectious manifestations and usually are caused by *Pneumococci*, *Staphylococci*, or *Haemophilus*. Untreated pulmonary infections may lead to progressive bronchiectasis and chronic pulmonary disease, seen in 45% of XLA patients over the age of 10.[6] Patients can also suffer from chronic enteroviral infections and hearing loss from repeated otitis and sinusitis infections. Other common bacterial infections include conjunctivitis, osteomyelitis, septic arthritis, and meningitis. Protracted diarrhea may be due to infection, particularly with *Giardia*, *Salmonella*, *Campylobacter*, or *Cryptosporidium* spp. Three virus groups cause problems: (1) enterovirus, (2) hepatitis B virus, and (3) rotavirus. Patients have developed paralysis after administration of the live polio vaccine. A rheumatoid-like arthritis, characterized by chronic inflammation and swelling of the large joints, may develop in as many as one-third to one-half of boys with XLA and is often due to mycoplasmal infection (*Ureaplasma urealyticum*). Disseminated echovirus infection has caused meningoencephalitis and a dermatomyositis-like disorder with brawny edema, induration of the muscles with accompanying weakness, muscle contractures, and poikiloderma.

The diagnosis of agammaglobulinemia is made by serum concentrations of IgG, IgA, and IgM that are far below the 95% confidence limits for appropriate controls (usually less than 100 mg/dL total Ig) and by the virtual absence of B cells in the peripheral circulation (<1% of normal). Identification of a defect in one of the known genetic causes of agammaglobulinemia confirms the diagnosis and allows for genetic counseling and prenatal diagnosis.

TREATMENT, PROGNOSIS, AND CLINICAL COURSE. Early Ig replacement, intravenously (IVIG) or subcutaneously, and antibiotic use markedly reduces the risk of infections, although it may not be helpful in diminishing the risk and morbidity of chronic lung disease or chronic enterovirus infection.

COMMON VARIABLE IMMUNODEFICIENCY

COMMON VARIABLE IMMUNODEFICIENCY AT A GLANCE

- Heterogeneous group of disorders in which both antibody deficiency and abnormalities of T cells may be found.
- Most common underlying gene defect in transmembrane activator, calcium modulator, and cyclophilin ligand interactor, which also can lead to IgA deficiency.
- May manifest during childhood, but average of onset is almost at 30 years of age.
- Variable severity of autoimmune and infectious complications.

CLINICAL FINDINGS. CVI commonly presents in young adults, but 25% of cases are diagnosed before the age of 21 years.[9] Patients have infections similar to those in patients with XLA, particularly sinopulmonary infections, but are less susceptible to enteroviral infections and more susceptible to *Giardia* infections.

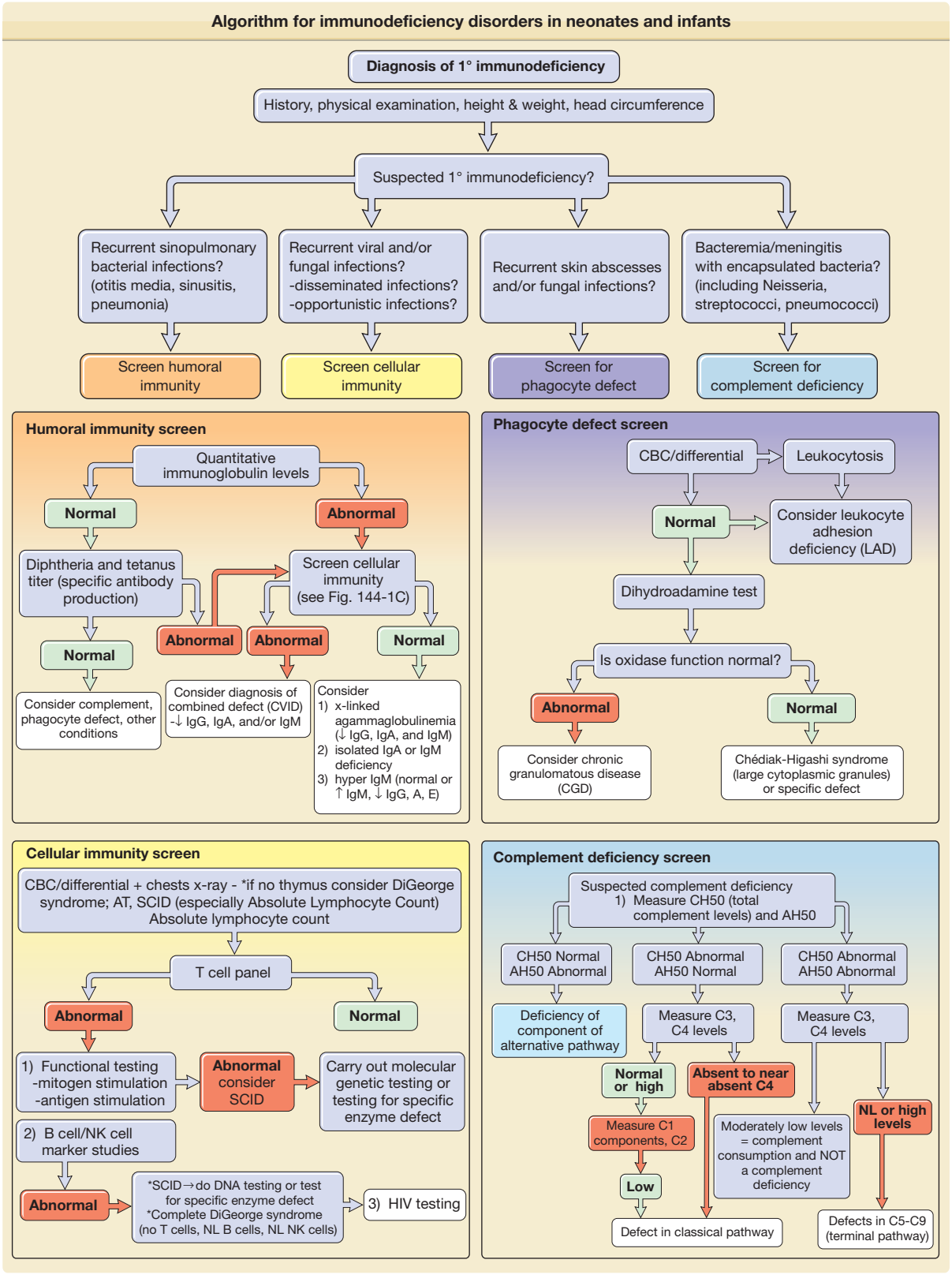

Figure 143-1 A–C. Algorithm for immunodeficiency disorders in neonates and infants. If the clinical presentation is concerning for severe combined immunodeficiency (SCID), this is a medical emergency and patient needs immediate referral to an immunologist. AT = ataxia-telangiectasia; CBC = complete blood cell count; CVID = common variable immunodeficiency; HIV = human immunodeficiency virus; Ig = immunoglobulin; NK cell = natural killer cell; NL = normal; ↓ = decreased; ↑ = increased.



Figure 143-2 Noncaseating granulomas on the legs of a child with common variable immunodeficiency. Cultures and special stains showed no organisms.

Many patients with CVI have liver disease and gastrointestinal (GI) disease, causing malabsorption syndromes. Noncaseating granulomas of skin (Fig. 143-2), lungs, liver, and spleen have been reported. Caseating granulomas of the skin and viscera, although rare, have also been described.[11,12] Extensive warts can be a major problem in individuals with CVI (Fig. 143-3). Lymphoid tissues often are enlarged, and splenomegaly with hypersplenism is found in 25% of patients. Autoimmune disorders are especially frequent (11% to 22%),[9,13] particularly autoimmune thrombocytopenia, autoimmune hemolytic anemia, rheumatoid arthritis, sicca syndrome, and pernicious anemia. Alopecia areata and lupus also have been described. In 10% to 20% of patients, at least one family member is also immunodeficient, particularly with CVI or IgA deficiency.[14] The incidence of lymphoreticular malignancy and gastric carcinoma are markedly increased, particularly in the fifth and sixth decades of life.[15]



Figure 143-3 The dorsal aspect of the hands were covered with recalcitrant verrucae vulgaris in this girl with common variable immunodeficiency.

SELECTIVE IMMUNOGLOBULIN DISORDERS

SELECTIVE IMMUNOGLOBULIN A DEFICIENCY AT A GLANCE

- IgA deficiency is usually asymptomatic; only 10% to 15% of affected individuals demonstrate clinical manifestations, especially bacterial sinopulmonary infections and autoimmune disorders.

CELLULAR DEFICIENCIES

CHRONIC MUCOCUTANEOUS CANDIDIASIS

CHRONIC MUCOCUTANEOUS CANDIDIASIS AT A GLANCE

- A heterogeneous group of disorders with altered immune responses selective to *Candida*.
- Recurrent, progressive candidal infections of the skin, nails, and mucous membranes.
- May be associated with the later development of endocrinopathy [APECED, *a*utoimmune *p*oly*e*ndocrinopathy-*c*andidiasis-*e*ctodermal *d*ystrophy].

EPIDEMIOLOGY. Several clinical subtypes of chronic mucocutaneous candidiasis (CMC) have been defined (Table 143-3). They have varied clinical manifestations, variable immunodeficiency, and different forms of genetic inheritance. Patients with CMC may have childhood or mature onset, familial, or sporadic occurrence, and CMC may be present with or without endocrinopathy. Patients with *a*utoimmune *p*oly*e*ndocrinopathy-*c*andidiasis-*e*ctodermal *d*ystrophy (APECED or autoimmune polyendocrine syndrome or APS, type 1) often have affected siblings. APECED and other familial forms of CMC are autosomal recessive. Autosomal dominant inheritance is seen in patients with associated keratitis.

CLINICAL FINDINGS. Patients with CMC have recurrent, progressive infections of the skin, nails, and

TABLE 143-3
Classification of Patients with Chronic Mucocutaneous Candidiasis[a]

CMC Type	Inheritance/ Gene Defect	Onset	Clinical Features	Associated Disorders	NonCandidal Infections
Chronic oral candidiasis	No known genetic defect	Middle-aged or elderly women	Candidiasis of tongue and buccal mucosa No esophageal, skin, or nail involvement	Fe^{2+} deficiency	No
Familial chronic mucocutaneous candidiasis	Autosomal recessive and autosomal dominant Males and females are equally affected	Early childhood, often before age 2 years	Oral candidiasis Limited skin and nail involvement	No endocrinopathies	Yes
Autoimmune polyendocrinopathy–candidiasis–ectodermal dystrophy syndrome	Autosomal recessive Mutations in the *AIRE* (autoimmune regulator) gene on 21q22.3 More common in the Finnish population, Iranian Jews, and Sardinians Rarely, dominant form with *AIRE* mutations or mapped to chromosome 2p	Candidal infections before age 5 years Endocrine abnormalities between 10 and 15 years of age	Oral and diaper area candidiasis more often than skin and nail involvement Endocrinopathies and autoimmune disorders	*Most common endocrinopathies*: Hypoparathyroidism Hypoadrenalism *Other associated disorders*: Thyroid disease Primary hypogonadism Hepatitis Malabsorption Pernicious anemia Alopecia areata Vitiligo *Ectodermal manifestations:* Dental enamel hypoplasia Pitted nail dystrophy Keratoconjunctivitis Myasthenia gravis Hypogammaglobulinemia	Yes
CMC with thymoma	No known genetic basis	Adult onset	Mucous membrane and cutaneous candidiasis	Malignant/benign thymomas Aplastic anemia Myasthenia gravis Hypogammaglobulinemia	No
Chronic localized candidiasis (candida granuloma)	No known genetic basis Males and females are equally affected	Early childhood, often before age 5 years	Thick, adherent candidal crusts on the scalp and face Oral candidiasis	None	Yes
CMC with keratitis	Autosomal dominant	Early childhood	Candidiasis of the oral cavity, diaper area	Keratoconjunctivitis Alopecia Endocrine abnormalities	Yes

CMC = chronic mucocutaneous candidiasis.
[a]Chronic candidal infections have been described in patients with DiGeorge, hyperimmunoglobulinemia E, severe combined immunodeficiency, ectrodactyly-ectodermal dysplasia-clefting, and keratitis-ichthyosis-deafness syndromes; multiple carboxylase deficiency; and acrodermatitis enteropathica.

mucous membranes most commonly due to *Candida albicans*.[33,37] Depending on the subtype, the clinical presentation ranges from recurrent, recalcitrant thrush (Fig. 143-4) to mild erythematous scaling plaques (see eFig. 143-4.1 in online edition) with a few dystrophic nails to severe generalized, crusted granulomatous plaques (Fig. 143-5). The cutaneous plaques occur most commonly in intertriginous areas, periorificial sites, and the scalp, but they may be generalized. The nails are thickened, brittle, and discolored, and the paronychial areas are often erythematous, swollen, and tender. Scalp infections may lead to scarring and alopecia. Although the oral mucosa is the most frequent site of mucosal alteration, esophageal, genital, and laryngeal mucosae may be affected. Strictures may be formed by candidal infection at these mucosal sites. Scrapings and cultures from cutaneous or mucosal lesions demonstrate candidal organisms.

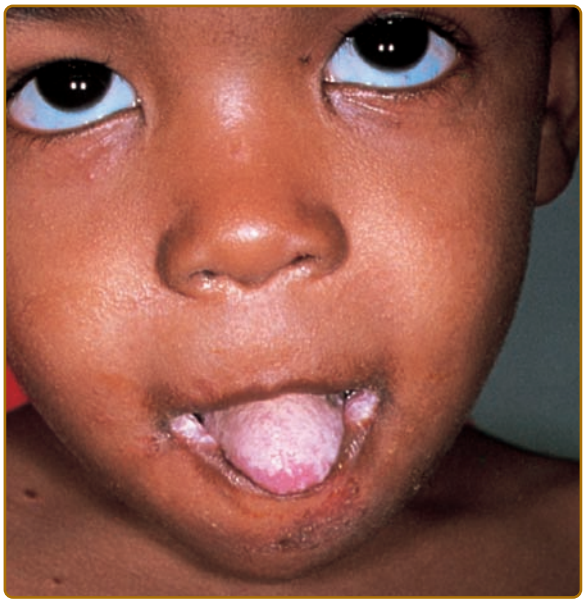

Figure 143-4 Recurrent thrush and candidal cheilitis in a boy with mucocutaneous candidiasis.

Patients with CMC rarely develop systemic candidiasis, but 50% may develop recurrent or severe infections due to other organisms. In one study, 81% of patients with early-onset CMC also had infections with bacteria, fungi, and parasites, including bacterial septicemia.[33] Concomitant dermatophyte infections may occur.

In patients with APECED, the candidal infections tend to begin by 5 years of age, although the endocrinologic dysfunction may not be apparent until 12–13 years of age (see Fig. 143-5). The most commonly associated endocrinopathies are hypoparathyroidism (88%) and hypoadrenocorticism (60%). One-third of patients have candidiasis, hypoparathyroidism, and defective adrenal function. Other associated endocrinopathies or autoimmune disorders include gonadal insufficiency (45%), alopecia areata (20%), pernicious anemia (16%), thyroid abnormalities (12%), chronic active hepatitis or juvenile cirrhosis (9%), vitiligo, diabetes mellitus, and hypopituitarism. Chronic diarrhea and malabsorption have been reported in 25% of patients and usually are associated with hypoparathyroidism. Some affected patients also have pulmonary fibrosis, dental enamel hypoplasia, and keratoconjunctivitis. The "ectodermal dysplasia" features are likely to be secondary to the candidal infections or autoimmunity.[37] Patients with APECED often have autoimmune antibodies, including antithyroglobulin, antimicrosomal, antiadrenal, and antimelanocyte antibodies, and rheumatoid factor. Autoantibodies also have been found in patients with CMC who do not have clinical endocrinologic disease.



Figure 143-5 This 3-year-old child with hypothyroidism had oral thrush, intertriginous candidiasis, verrucous crusting on the scalp and face, and candidal onychomycosis. The warty growths shown in the photograph consisted of dried pus and serum, and grew only *Candida albicans*.

PROGNOSIS, CLINICAL COURSE, AND TREATMENT. Candidal lesions in patients with CMC generally respond to systemically administered azole antifungal agents (itraconazole, fluconazole) or terbinafine.[38] Ketoconazole is no longer used because of the risk of hepatitis. Patients who are resistant usually respond to amphotericin B with or without flucytosine. Cutaneous granulomas often are less responsive despite clearance of infection. Recurrences are common, and the antifungal agents must be used intermittently. The drugs have no effect on the abnormal cell-mediated immunity. All patients with CMC should have an annual endocrine evaluation and patients with documented endocrinopathy or a family history of APECED should be monitored more closely. Patients who have a history of infections other than candidal should have further evaluation of their immune status.

CARTILAGE–HAIR HYPOPLASIA SYNDROME

CARTILAGE–HAIR HYPOPLASIA SYNDROME AT A GLANCE

- Synonym: metaphyseal chondrodysplasia McKusick type.
- Autosomal recessive disorder, common in Amish and Finnish populations.
- Mutations in the RNA component of a ribonucleoprotein endoribonuclease, leading to defective cell-mediated and humoral immunity.
- Characterized by fine, sparse hypopigmented hair, short-limbed dwarfism.
- Supportive treatment with appropriate antibiotic use, bone marrow transplant corrects immune deficiency but not dermis or cartilage.

COMBINED ANTIBODY AND T-CELL DEFICIENCY

HYPERIMMUNOGLOBULIN M SYNDROME

HYPERIMMUNOGLOBULIN M SYNDROME AT A GLANCE

- Most cases of hyperimmunoglobulin M syndrome have the X-linked recessive form with deficiency of CD40 ligand; common clinical features are recurrent sinopulmonary and gastrointestinal infections, oral ulcerations, and verrucae.
- Autosomal recessive hyperimmunoglobulin M syndrome, except CD40 deficiency, does not have a susceptibility to opportunistic infections and have lymphoid hyperplasia.

WISKOTT–ALDRICH SYNDROME

WISKOTT–ALDRICH SYNDROME AT A GLANCE

- X-linked recessive.
- Mutations in Wiskott–Aldrich syndrome protein gene.
- Recalcitrant dermatitis.
- Recurrent pyogenic infections.
- Hemorrhage due to thrombocytopenia and platelet dysfunction.
- Therapy: bone marrow stem cell transplantation.

EPIDEMIOLOGY. Wiskott–Aldrich syndrome (WAS) is an X-linked recessive disorder with an incidence of approximately 4 per million male births.[75]

PATHOGENESIS. The defective gene is *WASP,* mapped to Xp11.22–11.23, which encodes WASp, a hematopoietic specific cytoplasmic protein that functions in signaling and cytoskeletal organization. WASp couples signals arising at the cell membrane with reorganization of the cellular cytoskeleton, resulting in cellular activation and promotion of cell motility. Mutations in WASp affect organization of the immunologic synapse and T-cell activation, T and B lymphocyte migration, and initiation of the primary antibody response.[76] There is a strong phenotype–genotype correlation; classic WAS occurs when WASp is absent or truncated, while X-linked thrombocytopenia occurs when mutated WASp is expressed.[77] The atopic dermatitis is likely associated with the observed skewing of $CD4^+$ T cell differentiation towards Th2 cells with suppression of Th1 and regulatory T cells (Treg) differentiation.[78] Given the expression of WASp on epidermal Langerhans cells, abnormal interactions of Langerhans cells with T cells and ability of Langerhans cells to move to the lymph node after antigen stimulation may be involved as well.

WAS patients have decreased function and number of both T- and B-lymphocytes, beginning in the first years of life.[79] The lymphocytes of patients with WAS lack microvilli formed by actin bundles, resulting in defective chemotaxis and, in some patients, there is decreased expression of sialoglycoproteins (e.g., CD43 and others) on lymphocytes and platelets. Defects in humoral immunity include abnormal serum Ig and decreased antibody response to polysaccharide antigens. WAS patients also have defects in NK cell cytotoxicity, dendritic cell migration, and activation, and impaired macrophage chemotaxis.[76]

CLINICAL FINDINGS. The classic triad of WAS is (1) hemorrhage due to thrombocytopenia and platelet dysfunction, (2) recurrent pyogenic infections, and (3) recalcitrant dermatitis, but this triad appears in only 25% of patients.[80] The bleeding diathesis is the most common manifestation of mutations in WAS, present in 84% of patients[79] and often manifests initially during the first weeks or months of life with bloody diarrhea. Epistaxis, hematemesis, hematuria, mucocutaneous petechiae, and intracranial hemorrhage also may occur. Recurrent bacterial infections begin in infancy as levels of placentally transmitted maternal antibodies diminish. These infections include furunculosis, conjunctivitis, otitis media and otitis externa, pansinusitis, pneumonia, meningitis, and septicemia. Infections with encapsulated bacteria such as *Pneumococcus*, *Haemophilus influenzae*, and *Neisseria meningitidis* predominate. Patients are also susceptible to infections due to herpes and other viruses and to *Pneumocystis jiroveci*.

The atopic dermatitis associated with WAS, which occurs in approximately 80% of patients,[75] usually develops during the first few months of life and may be quite severe. The face, scalp, and flexural areas are the most severely involved, although patients commonly have widespread involvement with progressive lichenification. The eruption may be more exfoliative than that of atopic dermatitis in individuals without WAS, and excoriated areas frequently have serosanguineous crusts (Fig. 143-6). Secondary bacterial infection of eczematous lesions is common, as are eczema herpeticum (see eFig. 143-6.1 in online edition) and molluscum contagiosum. IgE-mediated allergic problems, such as urticaria, food allergies, and asthma, are seen in addition to the atopic dermatitis.

As many as 40% of patients with WAS develop an autoimmune disorder.[81] The most common are vasculitis (particularly involving the skin, GI tract, brain, and heart) in 20% of patients, autoimmune



Figure 143-6 Severe atopic dermatitis in a boy with Wiskott–Aldrich syndrome. Note the serosanguineous crusting.

hemolytic anemia in 14%, and IgA nephropathy in up to 10% of patients.[82] Other immune-mediated cutaneous manifestations are angioedema, dermatomyositis, pyoderma gangrenosum, and erythema nodosum.[81] Hepatosplenomegaly is common, and lymphadenopathy, transient arthritis, and joint effusions are present occasionally.

The thrombocytopenia of WAS is persistent, and platelet counts may range from 1,000 to 80,000 platelets per µL. A platelet count of <70,000 is required for formal diagnostic criteria. The platelets are small, and platelet aggregation is defective. Levels of IgM and sometimes, IgG, are low, and isohemagglutinins are absent. IgA, IgE, and IgD levels usually are elevated. Eosinophilia, leukopenia, and lymphopenia are also seen. Delayed hypersensitivity skin-test reactivity is diminished, and patients fail to respond to polysaccharide antigens. WASp can be detected by flow cytometry using intracellular staining with an antibody to WASp and sequencing of the *WASP* gene can confirm the diagnosis of WAS or X-linked thrombocytopenia, which results also from mutations in the *WASP* gene that do not affect immune function.[76] Mutation analysis allows for prenatal diagnosis.[83]

PROGNOSIS, CLINICAL COURSE, AND TREATMENT. Therapeutic interventions allow some patients with WAS to survive into adulthood; however, a significant proportion die before the age of 10 years due to infections secondary to hemorrhage, malignancies, or the complications of transplantation.[75,84,85] Thirteen percent of patients with WAS develop lymphoreticular malignancies,[80] especially non-Hodgkin lymphoma, with a predominance of extranodal and brain involvement. Development of autoimmune hemolytic anemia is a poor prognostic factor and associated with the development of lymphoid malignancies; overall 25% of patients with autoimmunity develop a malignancy.[82] Ten percent of patients die from these malignancies, usually as adolescents or young adults.

Appropriate antibiotics, immunizations, and transfusions of platelets and plasma decrease the risk of fatal infections and hemorrhage. Ig replacement therapy is useful in some patients. Splenectomy has been advocated to ameliorate the bleeding abnormality in patients with recurrent severe hemorrhage, but this procedure increases the risk of infection from encapsulated bacterial organisms. Bone marrow or stem cell transplantation is the treatment of choice for patients with recurrent problems, especially significant autoimmunity. Full engraftment results in normal platelet number and function, normal immunologic status, and clearance of the dermatitis (T lymphocyte engraftment). The 5-year survival rate with HLA-matched sibling donors is 87%.[80] Topical glucocorticoid preparations and Ig replacement may improve the dermatitis, and chronic administration of oral acyclovir is appropriate for patients with recurrent eczema herpeticum.

SEVERE COMBINED IMMUNODEFICIENCY

SEVERE COMBINED IMMUNODEFICIENCY AT A GLANCE

- Heterogeneous group of X-linked and autosomal recessive disorders with deficient cell-mediated and humoral immunity.
- Failure to thrive in early infancy; diarrhea; recurrent mucocutaneous candidiasis, bacterial and viral infections; risk of graft-versus-host disease.
- Transplantation may prevent death during infancy.

CLINICAL FINDINGS. Infants with SCID usually fail to gain weight by 3–6 months of age, following the onset of recurrent sinopulmonary and skin infections. Persistent mucocutaneous candidiasis is often present at the time of diagnosis, and systemic candidal infections occur occasionally. Patients with SCID also may have chronic diarrhea and malabsorption caused by viral infections. *P. jiroveci* pneumonia (PCP) is often a presenting feature. Although bacterial infections usually respond to systemic antibiotics, viral infections tend to be fatal. Infants with SCID lack palpable lymphoid tissue despite recurrent infections.

In addition to cutaneous bacterial and candidal infections, the most common cutaneous eruptions are morbilliform or resemble seborrheic dermatitis. In some infants with SCID, biopsy sections show GVHD (see Chapter 28). GVHD may result from in utero exposure to maternal lymphocytes, from transfusion with nonirradiated blood products, or may follow

TABLE 143-4
Subtypes of Severe Combined Immunodeficiency

Lymphocyte Profile	Disorder	Gene	Gene Product Function
T–/B–/NK–	ADA deficiency[a,b] PNP deficiency	*ADA* *PNP*	Enzyme necessary for detoxification of metabolic products of the purine salvage pathway that cause lymphocytes to undergo apoptosis Enzyme necessary for detoxification of metabolic products of the purine salvage pathway that cause lymphocytes to undergo apoptosis: located downstream from ADA
T–/B–/NK+	RAG 1 or 2[c] Artemis deficiency[d,e] LIG4 syndrome[e,93]	*RAG1/RAG2* *Artemis* *LIG4*	Required for somatic V, D, and J rearrangements during Band T-cell development Required for DNA repair during somatic V, D, and J rearrangements during B- and T-cell development Ligase required for ATP-dependent repair of double-stranded DNA
T–/B+/NK–	X-linked severe combined immunodeficiency[a,f] Janus protein kinase deficiency[f]	*IL2RG* *JAK3*	Common γ chain of IL-2, -4, -7,-9,-15, and -21 Tyrosine kinase; primary signal transducer from common γ chain
T–/B+/NK+	IL-7 receptor (IL-7R) deficiency T-cell receptor/CD3 complex deficiency CD45 deficiency[92] Winged helix nude deficiency	*IL7R* *CD3δ* and *CD3ε* *PTPRC* *WHN*	α Chain of IL-7 receptor Facilitates expression of T-cell receptor/CD3 complex; block at pre-T-cell receptor stage of development Phosphatase that regulates immune cell signaling Defect in thymic development. Human homolog of nude mouse with total alopecia and onychodystrophy; critical transcription factor for thymic development
Other Defects in T Cell Development			
$CD4^+$ $CD8^-$ /B+/NK+	CD8 deficiency[94] ZAP-70 deficiency MHC class I deficiency/ TAP deficiency (bare lymphocyte syndrome I)	*CD8A* *ZAP-70* *TAP1* *TAP2*	Promotes survival and differentiation of activated T cells to memory $CD8^+$ T cells Signaling tyrosine kinase Transporter associated with antigen processing, transports peptides to assemble the class I molecule, dysregulated NK cells
$CD4^{low}$ $CD8^+$ /B+/NK+	MHC class II deficiency (bare lymphocyte syndrome II)	*CIITA* *RFXB* *RFX5* *RFXAP*	Defects in the transactivating factors of MHC II molecules, nonfunctional CD4 T cells if present
T+/B+/NK+	T-cell receptor/CD3 complex deficiency	*CD3γ*	Chain facilitates expression of T-cell receptor/CD3 complex

ADA = adenosine deaminase; ATP = adenosine triphosphate; IL = interleukin; MHC = major histocompatibility complex; NK = natural killer cell; PNP = purine nucleoside phosphorylase; RAG = recombination activating gene; TAP = transporter associated with antigen processing.
[a]Most common severe combined immunodeficiency defects. X-linked severe combined immunodeficiency accounts for approximately 50% of patients. Adenosine deaminase deficiency accounts for approximately 20% of patients.
[b]Eighty-five percent to 90% of patients present in infancy with severe immunodeficiency; one-half have skeletal deformities, neurologic symptoms, behavior problems, and decreased IQ.
[c]Deletions/frameshift mutations of *RAG1 /RAG2* genes result in severe combined immunodeficiency phenotype. Less severe mutations result in Omenn syndrome, clinically distinct from other forms of severe combined immunodeficiency. Mutations in other genes may lead to the Omenn phenotype and immunodeficiency.
[d]Common genetic defect seen in Athabascan-speaking Native Americans, the defect is called *SCIDA* in this population. Gene frequency may be as high as 2%. These patients have a higher incidence of oral/genital ulcers.
[e]Both *Artemis* and *LIG4* mutations lead to hypersensitivity to irradiation.
[f]Highest risk of human papillomavirus infections after transplantation may reflect a persistent abnormality in expression on keratinocytes despite transplantation.[195]

transplantation. Patients with GVHD most commonly present acutely with morbilliform erythema, papular dermatitis, or diffuse erythroderma. The face, neck, palms, and soles are usually affected initially, before the eruption becomes generalized. Severe cases are complicated by diffuse bullae or toxic epidermal necrolysis. The clinical presentation of GVHD from maternal engraftment (without transplantation) is indistinguishable from the clinical presentation of GVHD from transplantation, but histopathologic features differ.[98] Biopsy sections from GVHD secondary to maternal engraftment show psoriasiform hyperplasia with parakeratosis and variable spongiosis in contrast to the vacuolar interface pattern observed in conventional

GVHD.[98] Overall, 83% of SCID patients with maternal engraftment develop skin manifestations.[98] Oral and genital ulcerations are also seen in SCID, particularly in Athabascan-speaking American Indian children with a defect in the *Artemis* gene.[99] Patients with Omenn syndrome show erythroderma, hepatosplenomegaly and lymphadenopathy with eosinophilia and increased IgE production. B cells tend to be undetectable, and T cells, although often increased in number, are nonfunctional. Recently, Omenn syndrome has been shown to be a phenotype with several underlying genetic bases. Most patients have RAG1/RAG2 mutations, but the phenotype of Omenn syndrome has been described in patients with mutations in Artemis and IL7R.[100–102] Two individuals with CHH and another with complete DGS also showed features of Omenn syndrome.[103–104]

ECTODERMAL DYSPLASIA WITH IMMUNODEFICIENCY

ECTODERMAL DYSPLASIA WITH IMMUNODEFICIENCY AT A GLANCE

- Mutations in nuclear factor κB essential modulator, leading to abnormal nuclear factor κB signaling.
- Characteristic facies of hypohidrotic ectodermal dysplasia.
- Often severe immunodeficiency; bacterial, atypical mycobacterial, and viral infections are common.
- Therapy: transplantation.

EPIDEMIOLOGY. X-linked recessive transmission is most common with an estimated incidence of 1:250,000 live male births.[108] An autosomal dominant form of ectodermal dysplasia with immunodeficiency has also been described.[109]

ETIOLOGY AND PATHOGENESIS. Several genetic disorders result from gene mutations in NEMO and lead to abnormal nuclear factor κB (NF-κB) signaling (see Section "Hypohidrotic Ectodermal Dysplasia" in Chapter 142, and Section "Incontinentia Pigmenti" in Chapter 73). One of these, hypohidrotic ectodermal dysplasia with immunodeficiency, results from hypomorphic mutations in the *NEMO* gene [also called *ectodermal dysplasia, anhidrotic, with immunodeficiency* (EDA-ID), or *hyperimmunoglobulinemia M, immunodeficiency, X-linked with ectodermal dysplasia*]. NF-κB is recognized as a DNA-binding factor,[110] and its ability to transcribe genes is regulated by a cytoplasmic inhibitor, IKB. NF-κB signaling affects inflammation, apoptosis, development, and immunity.[111,112] NF-κB activation requires phosphorylation of IKB by IKB kinase (IKK). IKK is composed of two catalytic components (IKKα and IKKβ) and a regulatory subunit, IKKγ or NEMO. NEMO has no catalytic function, but is the structural scaffold that supports the IKK complex.[111] When NEMO is absent or defective, no functional IKK complex is formed and, as a result, NF-κB cannot translocate to the nucleus and activate gene transcription.

The hypomorphic mutations that cause EDA-ID allow early survival in males, in contrast to the large deletions in *NEMO* (usually of exons 4 to 10) that lead to incontinentia pigmenti in carrier females and fetal death in affected males (see Chapter 73). Female carriers of hypomorphic *NEMO* mutations often show mild features of incontinentia pigmenti, but may also express an incontinentia pigmenti phenotype with transient immunodeficiency.[113] In boys with hypomorphic mutations of *NEMO*, the ectodermal dysplasia phenotype results from impaired NF-κB signaling.[114] Immunodeficiency results from impaired NF-κB activation in response to Toll-like receptor (TRL), interleukin-1 receptor and tumor necrosis factor (TNF) α receptor signaling.[115] Gain of function mutations in IκBα, the component of the inhibitor of NF-κB that is phosphorylated by IKK, lead to an autosomal dominant form of ectodermal dysplasia with a distinct immunologic phenotype,[114] characterized by a profound T-cell deficiency,[109] but normal natural killer (NK) cytotoxicity and responses to *Mycobacteria*. Mutations in *NEMO* have also been reported that cause immunodeficiency without the ectodermal dysplasia phenotype.[116]

CLINICAL FINDINGS. Affected patients present with classic characteristics of hypohidrotic ectodermal dysplasia (Fig. 143-7). These include the characteristic



Figure 143-7 Ectodermal dysplasia with immunodeficiency gene mutation. This boy with a hypomorphic mutation in *NEMO* showed failure to thrive, slightly exfoliative dermatitis, and the typical facial features of hypohidrotic ectodermal dysplasia. Note the small chin, the "pouty" lower lip, thin upper lip, small pinched nose with malar hypoplasia. His mother had a pigmented streak following a line of Blaschko, typical of that seen in incontinentia pigmenti. (Used with permission from Dr. Anthony Mancini.)

facies, hypotrichosis or atrichia, hypohidrosis (leading to heat intolerance), hypodontia or anodontia with conical incisors, and associated dermatitis (see Chapter 142).[66,108,116–118] A subset of patients has associated osteopetrosis and lymphedema in association with severe immunodeficiency. Boys with immunodeficiency from *NEMO* mutations without the features of hypohidrotic ectodermal dysplasia have also been described.[119] In a recent analysis of 72 patients with *NEMO* mutations, only 77% had ectodermal dysplasia.[120] Bacterial infections early in infancy are common, particularly sepsis, pneumonia, otitis, sinusitis, and lymphadenitis. Recurrent pneumonias may lead to bronchiectasis. Common pathogens include *Streptococcus pneumoniae*, *H. influenzae*, *Klebsiella*, *Salmonella*, and *Pseudomonas.* Infections with atypical *Mycobacteria* and viruses, including cytomegalovirus (systemic and GI involvement), herpes simplex virus, molluscum contagiosum, human papillomavirus, and *Pneumocystis carinii,* are also reported.[66,108,117]

The immunodeficiency is often severe, but its characteristics are variable with an apparent genotype–phenotype correlation that can be further identified by in vitro reconstitution of the mutations.[119] Immune dysfunction includes impaired B-cell class switching with hypogammaglobulinemia (and often increased levels of IgM and/or IgA), impaired specific antibody production (particularly to polysaccharide antigens), deficient NK cell cytotoxicity, poor cytokine production in response to CD40 signaling and autoinflammation, especially of the gut.[108,118,120] Biopsy of skin may show evidence of keratinocyte apoptosis, reflecting the dysfunction in NF-κB signaling, and must be differentiated from GVHD.

TREATMENT AND PROGNOSIS. There is an increased mortality with 36% of patients dying at a mean age of 6.4 years.[120] Therapy is guided by the patient's clinical and immunologic phenotype. Ectodermal dysplasia is treated supportively (see Chapter 142). Patients with impaired antibody production may benefit from Ig replacement. All infections (bacterial and viral) should be treated aggressively with the appropriate antibiotics/antivirals. Prophylaxis for both *P. jiroveci* and *Mycobacterium avium-intracellulare* should be considered.[108] Stem cell transplantation may lead to immune reconstitution.[121] The mothers and sisters of these patients should be offered genetic testing for the *NEMO* mutation and counseling.

ATAXIA-TELANGIECTASIA

EPIDEMIOLOGY. Ataxia-telangiectasia [AT; Online Mendelian Inheritance in Man (OMIM) #208900], also called *Louis–Bar syndrome*, is an autosomal recessive disorder with an incidence of approximately 1:40,000 and a carrier rate of up to 1%. Carriers have an increased risk of breast cancer, hematologic malignancies,[122] and ischemic heart disease, with a reduced life expectancy of approximately 8 years.[123] These heterozygotes show an increased risk of chromosomal breaks after exposure to irradiation in vitro, suggesting that mammograms in known carriers of AT are contraindicated.

ATAXIA-TELANGIECTASIA AT A GLANCE

- Autosomal recessive disorder with mutations in *ataxia-telangiectasia mutated (ATM).*
- Early onset of ataxia with progressive neurologic deterioration; conjunctival. telangiectasia first appears in preschool years in most patients.
- Sinopulmonary infections, lymphoreticular neoplasia.
- Deficiency of IgA, IgE, IgG_2, IgG_4; variable manifestations of T-cell deficiency; high levels α-fetoprotein; chromosomal breaks; sensitive to irradiation.

CLINICAL FINDINGS. Characteristic oculocutaneous telangiectasias begin near the ocular canthi and progress across the bulbar conjunctivae (Fig. 143-8). These telangiectasias usually appear when patients are 3–6 years of age; rarely have they been described at earlier ages. Cutaneous telangiectasias subsequently may develop on the malar prominences, ears, eyelids, anterior chest, and popliteal and antecubital fossae, and the dorsal aspects of the hands and feet (Fig. 143-9). The telangiectasias may be subtle and resemble fine petechiae, especially in the flexural areas. The development of telangiectasias may be related to sun exposure, because ocular, but not cutaneous, telangiectasias develop in affected dark-skinned children. The development of telangiectasias may relate, at least in part, to the sensitivity of some AT strains to ultraviolet (UV) light.[127]

Progeric changes of the skin, including xerosis and gray hair, occur in 90% of patients.[128] During adolescence, the facial skin may become progressively more atrophic and sclerotic, causing a mask-like appearance. Occasionally, the ears, arms, and hands also become sclerodermatous. The hair may be diffusely gray by

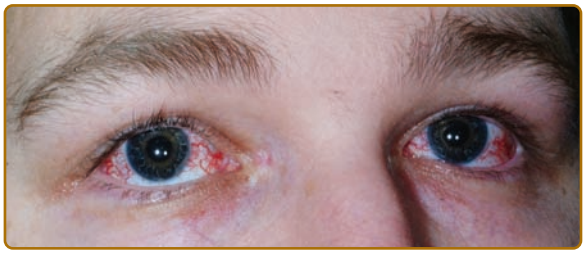

Figure 143-8 Bulbar conjunctival telangiectasias in a patient with ataxia-telangiectasia.



Figure 143-9 Ataxia-telangiectasia. Telangiectasias inside and on the helix.



Figure 143-10 Noninfectious granulomatous dermatitis of a patient with ataxia-telangiectasia. These persistent lesions tend to ulcerate, but often respond to injections of triamcinolone acetonide.

adolescence, and subcutaneous fat is generally lost in childhood. Recurrent severe impetigo often develops. Seborrheic dermatitis occurs in many patients, and the associated blepharitis may lead to a diagnosis of blepharoconjunctivitis rather than ocular telangiectasia. Mottled hyper- and hypopigmentation commonly occur and, together with the telangiectasias and atrophy, can resemble the poikiloderma of radiodermatitis, actinic damage, or scleroderma. Other pigmentary changes include café-au-lait spots that may be found in a dermatomal distribution,[129] multiple ephelides, and vitiligo. Hypertrichosis of the arms and legs, alopecia areata, multiple warts, atopic dermatitis, keratosis pilaris, nummular eczema, and acanthosis nigricans have also been described in association with AT. Among the most common cutaneous manifestations are noninfectious cutaneous granulomas (Fig. 143-10).[129] These persistent, atrophic, and often ulcerative lesions are often mistaken for other granulomatous processes, including sarcoidosis, necrobiosis lipoidica diabeticorum, granuloma annulare, and granulomatous dermatitis.

Usually, the progressive cerebellar ataxia first becomes apparent during infancy (median age, 1.2-years-old) with swaying of the head and trunk and apraxia of eye movements, often years before skin or conjunctival abnormalities develop. In childhood, dysarthric speech, drooling, choreoathetosis, and myoclonic jerks become prominent. The diagnosis of AT is usually made at a median age of 7 years, after appearance of the mucocutaneous telangiectasia. Patients usually require a wheelchair by their teenage years.

Recurrent bacterial and viral sinopulmonary infections occur in up to 80% of patients; these are the most common cause of death, which is usually from bronchiectasis and respiratory failure. Approximately 75% of patients with AT may have growth retardation and endocrine disorders, especially ovarian agenesis or testicular hypoplasia and insulin-resistant diabetes.

Neoplasia occurs in 40% of surviving adolescents or young adults, although lymphoid malignancy has been described as the presenting sign during infancy. Most common are lymphomas (especially B cell; 200-fold increased risk) and leukemia (especially T-cell chronic lymphocytic; 70-fold increased risk).[130,131] Basal cell carcinomas have been reported in young adults.

Patients with AT tend to have both humoral and cellular immunologic abnormalities. Serum IgA and IgE are absent or deficient in 70 and up to 80% of patients, respectively. Circulating anti-IgA antibodies are common in AT patients with IgA deficiency. Approximately 60% of patients have selective IgG_2 and IgG_4 deficiencies. Defective cell-mediated immunity is found in 70% of patients, particularly lymphopenia and deficient in vitro responses to antigens and mitogens[132]; T cells bearing γ/δ receptors are increased in number, while $CD4^+$ T cells tend to be reduced.

Virtually all patients have elevated levels of α-fetoprotein (which is particularly significant after 2 years of age), and many have detectable carcinoembryonic antigen. Patients with AT often have elevated hepatic transaminases (40% to 50%), and glucose intolerance. DNA is exquisitely sensitive to X-irradiation, and patients also show an increased rate of telomere shortening. Spontaneous chromosomal abnormalities (fragments, breaks, gaps, and translocations) occur 2–18 times more frequently in patients with AT than in

normal individuals and mainly involve chromosomes 2, 7, and 14. Rearrangements of chromosomes 7 and 14, and especially 14:14 translocations, seem to predict the development of lymphoreticular malignancy including leukemia. The thymus is absent or hypoplastic, and the spleen may be reduced in size.

Among techniques to confirm diagnosis are an elevated serum α-fetoprotein level in children older than 8 months of age, analysis of radio-resistant DNA synthesis (which demonstrates an abnormal S phase checkpoint), radiosensitivity testing with the colony survival assay, immunoblotting for the ATM protein, assessment of ATM kinase activity, and molecular genetic testing.

PROGNOSIS, CLINICAL COURSE, AND TREATMENT. Therapy for AT is supportive and includes administration of antibiotics for infection, physiotherapy for pulmonary bronchiectasis, physical therapy to prevent contractures in patients with neurologic dysfunction, and sunscreens and sun avoidance to diminish actinic-like changes. Patients should be aggressively screened for malignancy, especially after the first decade of life. Intralesional injections of triamcinolone have helped to promote healing of the painful associated ulcerations, although the lesions do not clear completely with treatment. Autopsy findings indicate that approximately 50% of the patients die from pulmonary disease, the most common cause of death. Lymphoreticular malignancies, including lymphoid leukemia, are the second most common cause of death (15% of patients with AT). The remaining patients tend to die of both pulmonary disease and malignancy. Therapeutic radiation and radiomimetic chemotherapeutic agents, especially bleomycin, may lead to extensive tissue necrosis. The administration of small doses of other chemotherapeutic drugs and low-dose, fractionated radiation is the least harmful means of managing these malignancies. In a small subset of patients with milder AT, treatment with aminoglycosides increased ATM gene function.[133] Death usually occurs by late childhood or early adolescence; the oldest surviving patient died at the age of 50 years. Prenatal diagnosis is currently best achieved by DNA analysis.

DISORDERS OF PHAGOCYTOSIS AND CELL KILLING

Patients with defects in phagocyte function or cell killing typically present during infancy or childhood with recurrent, unusual, and/or difficult to clear bacterial infections. Infections commonly seen include those of skin or mucosa, lung, lymph nodes, deep tissue abscesses, or childhood periodontitis. The most distinctive disorders of phagocytosis and cell killing are chronic granulomatous disease (CGD), leukocyte adhesion deficiencies, hyperimmunoglobulinemia E syndrome (HIES), and the silvery hair syndromes with immunodeficiency.[134] However, several disorders with neutropenia, neutrophil dysfunction, or cytokine dysfunction also lead to a decreased ability to engulf and/or kill organisms. These are reviewed in Table 143-5.

CHRONIC GRANULOMATOUS DISEASE

CHRONIC GRANULOMATOUS DISEASE AT A GLANCE

- Group of disorders in which defective production of reactive oxygen intermediates impairs intracellular killing of microorganisms.
- X-linked or autosomal recessive.
- Mutations in genes that encode components of nicotinamide adenine dinucleotide phosphate oxidase system.
- Pneumonias, lymphadenopathy, hepatosplenomegaly, and skin infections.
- Granulomas, most commonly of lungs and liver.

EPIDEMIOLOGY. CGD is a heterogeneous group of X-linked and autosomal recessive disorders. Ninety percent of patients with the disorder are male, and the overall incidence is 1 in 200,000 to 250,000 persons. X-linked disease with deficiency of $gp91^{phox}$ occurs in 70% of affected individuals with signs and symptoms manifesting in the first year of life. Individuals with autosomal recessive disease (30%) present later in life with milder signs and symptoms; 56% of these patients have a deficiency of $p47^{phox}$ and deficiencies in $p22^{phox}$ and $p67^{phox}$ account for the remaining cases.[135]

PATHOGENESIS. CGD is caused by defects in the reduced nicotinamide adenine dinucleotide phosphate (NADPH) oxidase, the enzyme complex responsible for the generation of superoxide.[136] Normal bactericidal activity after phagocytosis requires the NADPH oxidase system, which consists of NADPH, an unusual phagocyte cytochrome b (b_{558}), and cytosolic proteins. In patients with CGD, this membrane-associated NADPH oxidase system fails to produce superoxide and other toxic oxygen metabolites. Until recently, it was thought that the oxidative metabolites themselves were solely responsible for killing intracellular organisms. A new paradigm for NADPH oxidase-mediated microbial killing suggests that the oxidative molecules act as intracellular signaling molecules, activating the release of primary granule proteins neutrophil elastase and cathepsin G inside the phagocytic vacuole that in turn are necessary to kill microbes.[137] Evidence supports a dual role for NADPH oxidase, as oxidative metabolites have direct microbicidal effects.[138] and activate other microbicidal pathways.

TABLE 143-5
Other Disorders of Phagocytosis or Cell Killing

Disorder	Genetics	Gene	Functional Consequence	Clinical Findings
Neutropenia				
Cyclic neutropenia	AD	*ELA2*	Defects in neutrophil elastase	Cycles of neutropenia and monocytopenia, about every 3 week. Oral ulcers and fever when low.
Severe congenital neutropenia	AD AD	*ELA1* *GF11*	Defects in neutrophil elastase lead to abnormal neutrophil trafficking Repressor of elastase transcription leads to accumulation of elastase	Neutropenia, myelodysplastic syndrome, and acute myelogenous leukemia. Neutropenia and lymphopenia. Myeloid progenitors in circulation.
Shwachman–Diamond syndrome (SBDS)	AR	*SBDS*	SBDS protein participates in metabolism of ribosomal RNA	Pancytopenia with myelodysplastic syndrome and acute myelogenous leukemia. Pancreatic insufficiency. Chondrodysplasia.
WHIM[160]	AD	*CXCR4*	Receptor regulates development and migration of neutrophils; affects viral entry into cells	Chronic cutaneous and cervical warts, antibiotic-responsive bacterial sinopulmonary infections; often low Ig levels, peripheral neutropenia in the face of bone marrow hypercellularity (myelokathexis), and distinctive neutrophil morphology.
Cytokine Defects				
	AR	*IL12B*	Absence of component of IL-12 and IL-23 that stimulates IFN-γ production	Severe mycobacterial infections. Disseminated Bacille Calmette-Guérin after vaccination. Severe *Salmonella* infections.
	AR	*IL12RB1*	β1 chain of IL-12 and IL-23 receptors	
	AR, AD	*IFNGR1*	Affects ligand binding to IFN-γ receptor	
	AR	*IFNR2*	Affects IFN-γ receptor signaling	
	AR, AD	*STAT1*	Affects transcription in IFN receptor signaling	Also severe viral infections.
	AR	*STAT5B*	As in Stat1, but also growth hormone receptor signaling	Also growth hormone insensitivity.
Defects of Killing				
Myeloperoxidase deficiency	AR	*MPO*	Myeloperoxidase required for bacterial killing	Especially *Staphylococcus aureus* and candidal infections. May be asymptomatic.
Specific granule deficiency	AR	*C/EBPE*	C/EBPε transcription factor required for granulocyte differentiation	Recurrent bacterial infections. Neutrophils with two lobes.

AD = autosomal dominant; AR = autosomal recessive; IFN = interferon; IL = interleukin; WHIM = warts, hypoimmunoglobulinemia, infections, myelokathexis.

In X-linked kindreds the *CYBB* gene encoding the gp91^{phox} (phagocyte oxidase) subunit of cytochrome b_{558} is mutated. Patients with autosomal recessive CGD are deficient in NADPH oxidase cytosolic factors (p47^{phox} or p67^{phox}); occasionally, the p22^{phox} (γ subunit of cytochrome b_{558}), which contains a docking site for p47^{phox}, is deficient. It is thought that cytochrome b_{558} is the membrane attachment site for these cytosolic factors that translocate from the cytosol to the plasma membrane, assembling oxidase components to allow activation of the NADPH oxidase.

The types of microbial organisms that cause infections in patients with CGD require intracellular killing and are usually catalase-positive. Only five organisms are responsible for the overwhelming majority of infections in CGD in North America and Europe: (1) *Staphylococcus aureus*, (2) *Serratia marcescens*, (3) *Burkholderia cepacia*, (4) *Nocardia* spp., and (5) *Aspergillus* spp.[136] The intense humoral and granulomatous responses of CGD are thought to be compensatory in the robust but ineffectual response to organisms.

CLINICAL FINDINGS. Pyodermas with associated regional lymphadenopathy and dermatitis, especially around the nares and ears, usually occur during infancy and sometimes even in affected neonates. Staphylococcal abscesses are found in 40% of patients, particularly of the perianal area. Purulent inflammatory reactions may develop at sites of lymph node drainage or minor cutaneous trauma and heal slowly with scarring. Patients with CGD often develop chronic inflammatory granulomas, most commonly of the lungs and liver. Cutaneous granulomas are nodular and often necrotic. Granulomas can occlude vital structures, especially of

the GI and genitourinary systems. Intraoral ulcerations resembling aphthous stomatitis, chronic gingivitis, perioral ulcers, scalp folliculitis, and seborrheic dermatitis have also been described in many patients. Female carriers for X-linked CGD do not have the increased risk of infections but may have cutaneous lesions of discoid or systemic lupus erythematosus (SLE), Jessner lymphocytic infiltration of the skin, aphthous stomatitis, granulomatous cheilitis, photosensitivity, and/or Raynaud phenomenon.[139]

The lymph nodes, lungs, liver, spleen, and GI tract are the most frequent areas of noncutaneous involvement. Suppurative lymphadenitis with abscess and fistula formation usually affects cervical nodes. Pneumonia occurs in almost all affected children and may lead to abscess formation, cavitation, and empyema. Hepatosplenomegaly has been reported in 80% to 90% of patients; more than 30% of patients develop hepatic abscesses, and staphylococcal liver abscesses are almost pathognomonic to CGD.

Patients with bacterial and *Nocardia* spp. infections tend to be symptomatic and frequently have leukocytosis, anemia, and elevated sedimentation rate. In contrast, lack of fever, normal erythrocyte sedimentation rate, and few symptoms are more common in *Aspergillus* spp. infections. Thus, laboratory values within normal limits do not rule out infection in a CGD patient. Patients show an increased erythrocyte sedimentation rate, hypergammaglobulinemia, leukocytosis, and mild anemia; other immune function tests are otherwise usually normal.

The diagnosis of CGD is made on the basis of assays that rely on superoxide production. The dihydrorhodamine flow cytometry-based test is currently favored and can readily identify patients or carriers of X-linked disease[140]; the ferricytochrome c reduction assay is another quantitative measure of the respiratory burst. The screening test for CGD is the nitroblue tetrazolium (NBT) reduction assay, in which the yellow NBT becomes insoluble, oxidized form (blue formazan) when precipitated with normal oxidative metabolism. Quantitative NBT tests and chemiluminescence assays also may be performed. Immunoblot analysis confirms the absence of the glycoprotein 91^{phox} ($gp91^{phox}$) component; because deficiency of one component of cytochrome b_{558} leads to absence of the other, sequencing of the *gp91*^{phox} or *p22*^{phox} gene is necessary if absence is noted by immunoblot analysis. Immunoblots that show the absence of $p47^{phox}$ or $p67^{phox}$ can be diagnostic.

Biopsy of cutaneous granulomas shows histiocytic infiltrates associated with foreign body giant cells and accumulation of neutrophils with necrosis. Although the histopathologic features of lupus erythematosus-like skin lesions in CGD patients and carriers may resemble those of lupus patients, immunofluorescence examination of lesional skin is usually negative.

PROGNOSIS, CLINICAL COURSE, AND TREATMENT.

Patients with X-linked CGD, $p22^{phox}$ CGD and $p67^{phox}$ CGD tend to have a more severe clinical course compared to patients with $p47^{phox}$ CGD. The mean age of diagnosis of X-linked CGD is 3 years of age, and of autosomal recessive forms 8 years of age. More than 90% of patients with non-$p47^{phox}$ CGD have undetectable levels of superoxide production.[136] Some patients will develop severe infections as early as infancy while others will unexpectedly develop a serious infection typical of CGD later during childhood.

Small foci of localized inflammation may not be associated with fever and may be difficult to detect without vigorous investigation of the lungs, liver, and bones by routine screening radiographs, scans, or ultrasound. Cultures should be performed to identify the infectious agent, and invasive procedures may be necessary to obtain adequate tissue samples. Patients with evidence of infection should be treated empirically with broadspectrum parenteral antibiotics that cover *S. aureus* as well as Gram-negative organisms. Intravenous therapy should be continued for at least 10–14 days, followed by a several-week course of oral antibiotics. Surgical interventions (drainage, debridement) may be required for deeper infections (Table 143-6 Trimethoprim/sulfamethoxazole therapy

TABLE 143-6
Treatment of Chronic Granulomatous Disease

Treatment	Indication	Dose
Trimethoprim-sulfamethoxazole[a] (dicloxacillin if allergic)	Bacterial infections	5 mg/kg/day divided bid
Itraconazole[a]	Fungal infections	100 mg/day if <50 kg; 200 mg/day if >50 kg
Interferon-γ[a]	Infections	50 μg/m^2 subcutaneous 3×/week
Leukocyte transfusion	Life-threatening infections	
Bone marrow transplantation	Life-threatening infections	
Systemic glucocorticoids	Granulomas, particularly if obstructive	
Debridement/drainage/surgical intervention	Abscesses (particularly liver)	

[a]Regardless of genetic subgroup, the current recommendation is to use prophylaxis with trimethoprim-sulfamethoxazole, itraconazole, and interferon-γ.[136]

decreases the incidence of bacterial infection without increasing the incidence of fungal infection. Itraconazole is an effective agent for prophylaxis for fungal infections.[141] Prophylactic IFN-γ has been shown to decrease the number and severity of infections without increasing the incidence of chronic inflammatory complications in both X-linked and autosomal recessive CGD.[142] Use of IFN-γ is not accompanied by any measurable improvement in NADPH oxidase activity; its clinical benefit is related to enhanced phagocyte function and killing by nonoxidative mechanisms.[143] Leukocyte transfusions have been used for rapidly progressive, life-threatening infections. A recent study shows a survival rate of 90% after stem cell transplantation[144] and, therefore, this procedure should be considered for patient with matched related or unrelated donors and for those that have severe, life-threatening infections despite appropriate medical care. Systemic glucocorticoids have been helpful for patients with obstructive visceral granulomas. Prenatal diagnosis has been performed by the NBT slide test and now can be based on molecular analysis.

The prophylactic administration of antibiotics and IFN-γ has reduced the mortality of CGD to about 2% per patient-year for autosomal CGD and 5% for X-linked CGD.[135] The most common causes of death are pneumonia and/or sepsis due to *Aspergillus* or *B. cepacia*.

LEUKOCYTE ADHESION DEFICIENCIES

LEUKOCYTE ADHESION DEFICIENCY AT A GLANCE

- Group of three autosomal recessive and one autosomal dominant disorders.
- Gingivitis and periodontitis.
- Poor wound healing; delayed separation of the umbilical stump and development of pyoderma gangrenosum-like necrotic ulcerations after wounding.
- Life-threatening bacterial and fungal infections.

HYPERIMMUNOGLOBULINEMIA E SYNDROME

EPIDEMIOLOGY. HIES is rare (incidence 1 in 10^6).[148] It is found equally in males and females. Most cases are sporadic or consistent with an autosomal dominant inheritance. Autosomal recessive inheritance has also been described, but patients show different associated features.

HYPERIMMUNOGLOBULINEMIA E SYNDROME AT A GLANCE

- Synonyms: Job syndrome, Buckley syndrome, hyperimmunoglobulin E recurrent infection syndrome.
- Most cases are sporadic or show autosomal dominant inheritance with variable penetrance.
- Classic triad: (1) recurrent staphylococcal skin abscesses, (2) pneumonia with pneumatocele formation, and (3) high serum levels of IgE.
- Other common features are the atopic dermatitis, scoliosis, fractures, and dental abnormalities.
- Sporadic and autosomal dominant cases suffer from a multisystem disorder, affecting the skin, soft tissues, skeletal system, and dentition. Autosomal recessive cases have severe viral infections, lack skeletal and dental involvement, and develop severe neurologic complications.

ETIOLOGY AND PATHOGENESIS. Three different gene defects have been identified in HIES. The most common is a dominant negative mutation in signal transducer and activator of transcription 3 (STAT3)[149,150] and is associated with a severe reduction of Th17 cells.[151] STAT3 signals downstream of IL-6, which together with TGF-β is important for the development of Th17 cells. Autosomal recessive HIES has been shown to result from mutation in *TYK2* in a single patient[152] and with defects in the dedicator of cytokinesis 8 (*DOCK8*), which encodes for a protein that is implicated in the regulation of the actin cytoskeleton.[153,154] In all three types of HIES, there is an absence of Th17 cells, demonstrating the role of this T cell differentiation pathway in immunity to bacterial and fungal organisms. The pathogenesis of other features of HIES is not well known, but probably related to the lack of response or absence of Th17 cells and the resultant cytokine abnormalities.

CLINICAL FINDINGS. The clinical presentation of individual patients with HIES may vary greatly. The neonatal or infantile rash of HIES is often a papulopustular eruption with prominent crusting distributed on the scalp, face, neck, axillae, and diaper area. The most consistent finding on skin biopsy is an eosinophilic spongiotic dermatitis, sometimes centered in the dermal follicles.[155] In other infants, early candidal infections of the skin, mucosae, and nails and/or infantile atopic dermatitis are alternative presentations; in patients with the eosinophilic papulopustules, the



Figure 143-11 Coarse facial features, atopic dermatitis furuncles, and a cold abscess at the glabella in a boy with hyperimmunoglobulinemia E syndrome.

atopic dermatitis commonly follows later in infancy. Superinfection of the dermatitis with *S. aureus* is very common,[156] and patients show high levels of anti-staphylococcal IgE antibodies. Staphylococcal skin infections include impetigo, furunculosis, paronychia, cellulitis, and characteristic "cold" abscesses (see Fig. 143-11) that do not demonstrate the anticipated degree of erythema, warmth, and purulence. The abscesses occur most commonly on the head and neck and in intertriginous areas.

Pulmonary bacterial pneumonia, abscesses, and empyema are the most frequent systemic infections and may result in pneumatoceles that serve as the nidus for bacterial or fungal superinfection. The most common infecting organisms are *S. aureus* and *H. influenzae*. Other than pneumonias, deep-seated infections, bacteremia, and sepsis are rare.[148]

Facial and skeletal abnormalities are common. Patients develop progressive coarsening of facial features (see Fig. 143-11), probably reflecting the skeletal defects, but the recurrent facial pustulation and lichenification from dermatitis may contribute. Distinctive facial features, including prominent forehead, a broad nasal bridge, and wide nasal tip are universally present by the age of 16 years. Dental anomalies include retention of primary teeth and lack of eruption of secondary teeth. Osteopenia is common, and 57% of patients have had at least three pathologic fractures, especially of the long bones, ribs, and pelvis. Scoliosis occurs in 63% of adult patients and hyperextensibility of joints in 68% of patients.[148]

By definition, serum IgE levels must be elevated, but normal levels of IgE increase markedly during childhood. Levels of >2,000 IU/mL are seen in adolescents and adults; considerably lower levels during infancy are seen, given that the upper limit of normal in infants <1-year-old is 12.7 IU/mL and by 5 years of age is 47.1 IU/mL; an IgE level tenfold above the 95th percentile for age is required for diagnosis. Eosinophilia of at least two standard deviations above normal (usually above 700 cells/μL) is also a clinical manifestation. The total white blood cell count is typically normal and often fails to elevate in the setting of acute infection. The most common clinical features and laboratory values of patients with sporadic or autosomal dominant HIES are summarized in Table 143-7.

TABLE 143-7
Characteristics of Hyperimmunoglobulinemia E Syndrome[131]

	Incidence (%)
Immune System	
■ Dermatitis	100
■ Skin abscesses	87
■ Recurrent pneumonia (three or more, proved by X-ray)	87
■ Pneumatoceles	77
■ Mucocutaneous candidiasis	83
Skeletal System	
■ Characteristic fades	83
■ Wide nose	65
■ Failure of dental exfoliation (>three teeth)	72
■ Hyperextensibility	68
■ Recurrent pathologic fractures	57
■ Scoliosis (>10°)	63
Laboratory Values	
■ IgE >2,000 IU/mL or >10 times the age-specific norm	97
■ Eosinophilia (>two standard deviations above the norm)	93

Autosomal recessive disease is characterized by recurrent bacterial and viral infections, autoimmunity and devastating neurologic complications that are often fatal in childhood (see Fig. 143-12). Patients with autosomal recessive HIES show no tendency to form pneumatoceles and have no skeletal or dental abnormalities.[157] Eosinophilia tends to be more severe (e.g., 17,500/μL).[148] These patients have a global defect in T cell activation, which may explain their susceptibility to viral infections (including herpes and molluscum) in addition to bacterial and fungal infections.[154]

PROGNOSIS, CLINICAL COURSE, AND TREATMENT. Given the lack of correlation between serum levels of IgE, eosinophilia, and the susceptibility to severe infections, the clinical course is difficult to predict. Patients with autosomal recessive HIES have a more severe course related to the neurologic complications.[157]

Antistaphylococcal antibiotics are effective for most cutaneous infections in patients with HIE, and oral triazole antifungals treat the mucocutaneous candidiasis. The prophylactic use of antistaphylococcal antibiotics markedly reduces the incidence of skin



Figure 143-12 This boy with autosomal recessive HIES due to a *DOCK8* mutation shows extensive molluscum contagiosum infection on the neck. (Used with permission form Dr. I. Barlan.)

abscesses and pneumonia. The cutaneous and pulmonary abscesses often require incision and drainage and may require partial lung resections. IVIG therapy has been used successfully. IVIG may influence IgE levels due to an increased Ig catabolism or neutralization of the IgE.[148] Ascorbic acid and cimetidine have decreased the number of infections and the chemotactic defect in some patients. Isotretinoin has been reported to eliminate the recurrent staphylococcal abscesses in an isolated patient without any change in immunologic status. Cyclosporine A has also been used with good clinical and laboratory response.[158,159] IFN-γ has shown inconsistent effects on IgE levels and infection susceptibility. Bone marrow transplant has been attempted in typical autosomal dominant HIES with limited success.

WHIM SYNDROME

WHIM (*w*arts, *h*ypogammaglobulinemia, *i*nfections, *m*yelokathexis) syndrome is an immunodeficiency that is characterized by neutropenia, hypogammaglobulinemia, and a susceptibility to infection by human papilloma virus. The disorder results from defects in the chemokine receptor gene *CXCR4*,[160] and thus mature neutrophils are not able to exit the bone marrow (myelokathexis). The susceptibility to human papilloma virus infections suggests an important role for CXCR4 in immunity to this virus.

SILVERY HAIR SYNDROMES: CHÉDIAK–HIGASHI AND GRISCELLI SYNDROMES

The silvery hair syndromes comprise a group of autosomal recessive disorders in which a peculiar metallic sheen to hair and often skin is noted (see also Chapter 73). Of these, Chédiak–Higashi and Griscelli (type 2) syndromes have associated immunodeficiency (Table 143-8). Another syndrome with silvery hair, Elejalde syndrome, does not have associated immunodeficiency and may be allelic with the myosin 5a-deficient form of Griscelli syndrome (GS), with severe associated CNS dysfunction.

CHÉDIAK–HIGASHI SYNDROME

CHÉDIAK–HIGASHI SYNDROME AT A GLANCE

- Autosomal recessive disorder of vesicle trafficking that results in giant organelles, including melanosomes, leukocyte granules, and platelet-dense granules.
- Mutations in *LYST*.
- Silvery hair, often hyperpigmentation on nose and ears, and a variable degree of photophobia and nystagmus.
- Recurrent pyogenic infections and a mild bleeding diathesis.
- An "accelerated phase" with pancytopenia and organomegaly due to lymphohistiocytic infiltration (fatal without hematopoietic stem cell transplantation).
- Progressive neurologic deterioration.
- Therapy: transplantation.

Epidemiology. Chédiak–Higashi syndrome (CHS) is a rare autosomal recessive disorder. Parental consanguinity is often reported, and there are approximately 300 reported cases worldwide.

Etiology and Pathogenesis. CHS is caused by mutations in the *LYST* gene, located on chromosome lq42, which encodes a protein required for the final steps of vesicle trafficking and secretion.[161,162] The *LYST* gene is expressed in lysosomes and other secretory organelles (melanosomes, cytolytic granules, and platelet dense granules). Characteristic giant granules are thought to result from altered granule maturation and fusion.[163] Enlarged melanosomes are unable to be transferred to keratinocytes. NK cells and cytotoxic T lymphocytes do not release proteolytic enzymes necessary for target cell killing. Cytotoxic T lymphocyte-associated antigen is trapped in abnormally large vesicles rather than on the cell surface and thus may be unable to regulate T-cell activation, increasing the risk of lymphoproliferative disease.[164] Platelet dense granules are delayed in secretion of storage pools required for normal coagulation. Diminished chemotaxis of neutrophils and monocytes and delayed intracellular microorganism killing are often associated.

Clinical Findings. Patients usually first show manifestations during infancy or early childhood. Pigment abnormalities occur in 75% of patients, particularly the

TABLE 143-8
Characteristics of Griscelli and Chédiak–Higashi Syndromes

	Griscelli (GS1)	Griscelli (GS2)	Griscelli (GS3)	Chédiak–Higashi
Gene defect/protein	*MYO5A*/myosin5a.	*RAB27A*/Rab27a.	a. *Slac2-a/mlph.* b. *MYO5A* F-exon deletion.	LYST/lysosomal transport protein.
Functional consequence	Intracellular organelle transport and neurotransmitter secretion; interacts with Slac2-a/mlph.	GTPase for organelle movement and transfer. Essential for T and NK lymphocyte cytotoxic granule release and target cell death. Interacts with Slac2-a/mlph.	Interacts with both myosin 5a and Rab27 to form a protein complex essential for melanosome movement to melanocytes.	Protein required for final steps of membrane fusion and vesicle trafficking.
Tissue expression	Brain. Not in cytotoxic cells.	Cytotoxic cells. Not in brain.	Slac2-a/mlph is not in cytotoxic cells.	
Clinical features	Silvery metallic hair. Mild skin pigment dilution. Onset of neurologic disorder in infancy.	Silvery metallic hair. Mild skin pigment dilution. Severe immune disorder with hemophagocytic syndrome. Neurologic symptoms are associated with hemophagocytic syndrome and central nervous system infiltration.	Silvery metallic hair.	Silvery metallic hair and skin. Recurrent infections. Bleeding tendencies. Progressive neurologic defects. Immune disorder with hemophagocytic syndrome.
Immune defects	None	T and NK cell function; hypogammaglobulinemia.	None	T and NK cell function, diminished neutrophil chemotaxis and bactericidal activity.
Hair mount	Large, uneven clusters of pigment.	Same as GS1.	Same as GS1.	Granular, evenly distributed pigment.
Skin light microscopy	Pigmentary dilution in keratinocytes, accumulation of melanosomes in melanocytes.	Same as GS1.	Same as GS1.	Pigmentary dilution in both keratinocytes and melanocytes.
Skin electron microscopy	Mature melanosomes filling epidermal melanocytes.	Same as GS1.	Same as GS1.	Reduced numbers of giant melanosomes.
Leukocyte granules	None	None	None	Large, cytoplasmic.

GTPase = guanosine triphosphatase; mlph = melanophilin; NK = natural killer.

silver sheen to the hair (Fig. 143-13A). Ocular hypopigmentation may cause photophobia, and strabismus and nystagmus are common. Visual acuity does not tend to be reduced. The skin is typically fair, but dark slate-colored areas of pigmentation and diffuse speckled hypopigmentation may be seen in the sun-exposed skin of dark-skinned individuals.[165]

Infections can be observed in the newborn period and continue through the lifetime of the patient. Infections most commonly involve the skin, lungs, and respiratory tract where microbes such as *S. aureus*, *Streptococcus pyogenes*, and *Pneumococcus* are prevalent. Deep ulcerations resembling pyoderma gangrenosum have been described.

Neurologic manifestations include muscle weakness, cranial and peripheral neuropathy and progressive neurologic deterioration. CHS patients have also been observed to exhibit a mild coagulation defect. Patients bruise easily, manifest petechiae, and have some mucosal bleeding, although platelet numbers remain normal.

The finding of large cytoplasmic granules in blood leukocytes is highly diagnostic. Hair shafts have evenly distributed small pigment granules (see Fig. 143-13B), in contrast to the irregular, large pigmentary clumping of GS (see Fig. 143-13C). Skin biopsy shows pigmentary dilution in both melanocytes and keratinocytes and electron microscopy reveals giant melanosomes.

Prognosis, Clinical Course, and Treatment.

Hemophagocytic syndrome, an accelerated phase of the disease that resembles lymphoma, occurs by late childhood. Hemophagocytic syndrome is characterized by widespread visceral infiltration by atypical lymphoid and histiocytic cells. This lymphoma-like stage is precipitated by viruses, particularly by EBV

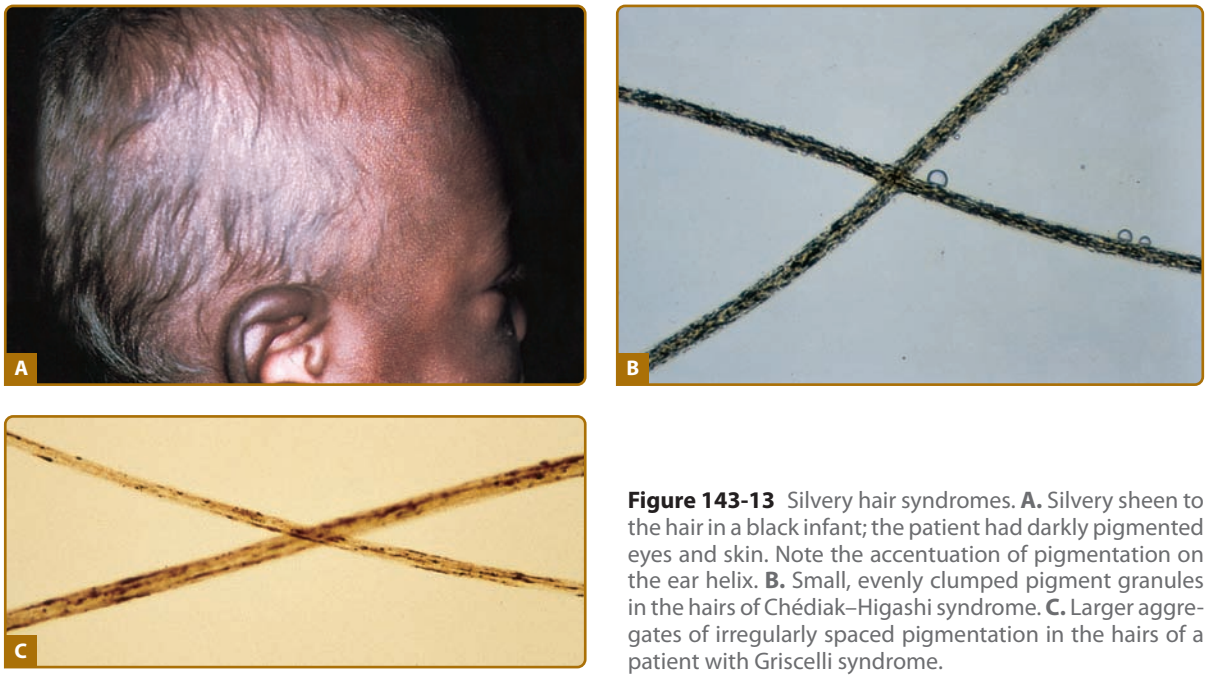

Figure 143-13 Silvery hair syndromes. **A.** Silvery sheen to the hair in a black infant; the patient had darkly pigmented eyes and skin. Note the accentuation of pigmentation on the ear helix. **B.** Small, evenly clumped pigment granules in the hairs of Chédiak–Higashi syndrome. **C.** Larger aggregates of irregularly spaced pigmentation in the hairs of a patient with Griscelli syndrome.

infection. Hepatosplenomegaly lymphadenopathy pancytopenia, jaundice, fever, a leukemia-like gingivitis, and pseudomembranous sloughing of the buccal mucosa are common features.

The hemophagocytic syndrome associated with lymphohistiocytic proliferation of silvery hair syndromes needs to be distinguished from massive lymphoproliferation in other immunodeficiency disorders, particularly X-linked lymphoproliferative disorder (see Section "Antibody Deficiency Disorders"), familial hemophagocytic lymphohistiocytosis, autoimmune lymphoproliferative syndrome, and immunodeficiency due to mutations in the IL-2R. *Familial hemophagocytic lymphohistiocytosis* is a group of autosomal recessive disorders with hemophagocytosis and absence of NK cell cytotoxicity that tends to be fatal without early stem cell transplantation.[166] The condition can result either from mutations in the gene that encodes perforin, which is a critical intracellular granule protein of NK cells and cytotoxic T lymphocytes, or in *UNC13D*, which encodes Munc 13–4, a protein that allows secretion of cytolytic granules. Mutations in several genes can lead to autosomal recessive or dominant autoimmune lymphoproliferative syndrome, also known as Canale–Smith syndrome.[102,167] These include the genes that encode Fas or CD95 (*TNFRSF6*), the cell surface apoptosis receptor, and its ligand (*TNFSF6*), and the caspase proteins 8 and 10, proteases in the cascade leading to apoptosis. This group of disorders features autoimmune disorders (cytopenias, leukocytoclastic vasculitis, lupus erythematosus) and an increased risk of lymphoma, and is associated with increased numbers of circulating $CD4^-$/$CD8^-$ α/β T cells. Immunodeficiency with extensive lymphocytic infiltration of viscera is also a manifestation of autosomal recessive mutations in the α chain of the interleukin-2 receptor.[168] Patients demonstrate bacterial, viral, and fungal infections because of early apoptosis of the developing thymic T lymphocytes.

The mean age of death for patients with Chédiak–Higashi syndrome is 6 years, usually from overwhelming infection or hemorrhage during the lymphoma-like accelerated phase. Prenatal diagnosis has been achieved by examination of hair from fetal scalp biopsies and of leukocytes from fetal blood samples.

The treatment of choice for patients with Chédiak–Higashi syndrome is early transplantation, which corrects the immunologic status but does not affect the pigment abnormality nor inhibit the development of neurologic disorders that grow increasingly worse with age. Acyclovir, high-dose intravenous γ-globulin, vincristine, cyclosporine, and prednisone have been used to control the accelerated phase, but it is usually fatal. Ascorbic acid corrects the microtubular defects in vitro but has no clinical ameliorative effects.[169] Interferon has been demonstrated by some authors to partially restore NK cell function.[170]

GRISCELLI SYNDROME

GRISCELLI SYNDROME AT A GLANCE

- Autosomal recessive group of disorders.
- Mutations in *MYO5A* (more neurologic), *RAB27A* (hemophagocytosis), or *Slac-2a*.
- Silvery hair is a hallmark.
- Hemophagocytosis often precipitated by Epstein–Barr virus infection.
- Treatment: transplantation.

Epidemiology. The majority of affected patients with this autosomal recessive disorder are of Mediterranean or Middle Eastern origin and born into consanguineous families.

Etiology and Pathogenesis. Mutations in three genes may underlie GS. GS1 is caused by a mutation in the *MYO5A* gene that encodes myosin 5a, a motor protein responsible for intracellular organelle transport. *MYO5A* is abundantly expressed in brain tissue and is important for neurotransmitter secretion. It is not expressed in cytotoxic cells. GS2 is caused by a mutation in the *RAB27A* gene, which encodes Rab27a, a guanosine triphosphatase protein involved in the function of the intracellular-regulated secretory pathway. It is essential for T and NK lymphocyte cytotoxic granule release and cell death. This defective cytotoxic activity most likely leads to the uncontrolled activation of lymphocytes and macrophages in the hemophagocytic syndrome. Both *MYO5A* and *RAB27A* have been mapped to chromosome 15q21.1.[171] A third type of Griscelli syndrome (GS3) is the result of a homozygous missense mutation in *Slac2-a/mlph* (melanophilin, mlph) or a deletion of the *MYO5A* F-exon. Melanophilin (also not expressed in cytotoxic cells) encodes a member of the Rab effector family and interacts with both myosin 5a (through the F-exon) and *RAB27A* to form a triprotein complex essential for the capture and local transport of melanosomes to the melanocytes (Fig. 143-14).[171,172] All three genetic subtypes share the inability to construct this complex for melanosome transport, thus leading to the characteristic pigmentary abnormality of GS.

Clinical Findings. The pigmentary dilution of GS is often limited to the hair, characterized by a silver-gray sheen with a few cases of skin involvement. The hair shaft shows large uneven clusters of pigment (see Fig. 143-13C) and the skin shows pigmentary dilution in keratinocytes but accumulation of melanosomes in melanocytes. Electron microscopy reveals numerous stage IV melanosomes in epidermal melanocytes. In contrast to Chédiak–Higashi syndrome, smears of leukocytes do not show giant granules. The additional clinical features present in each subtype are dependent on the function and tissue expression of the defective protein. Patients with GS1 have a primary neurologic disorder that presents in infancy with hypotonia and developmental delay. Severe immune disorder characterized by hemophagocytic syndrome or an "accelerated phase of the disease" is seen in GS2. Hemophagocytic syndrome is characterized by infiltration of various organ systems by activated lymphocytes and macrophages. It develops at mean age of 36 months, and often is precipitated by a virus, particularly EBV. Patients have fever, hepatosplenomegaly, neurologic impairment, coagulopathy, and pancytopenia.[173] Patients with GS3 present solely with the pigmentary abnormalities.

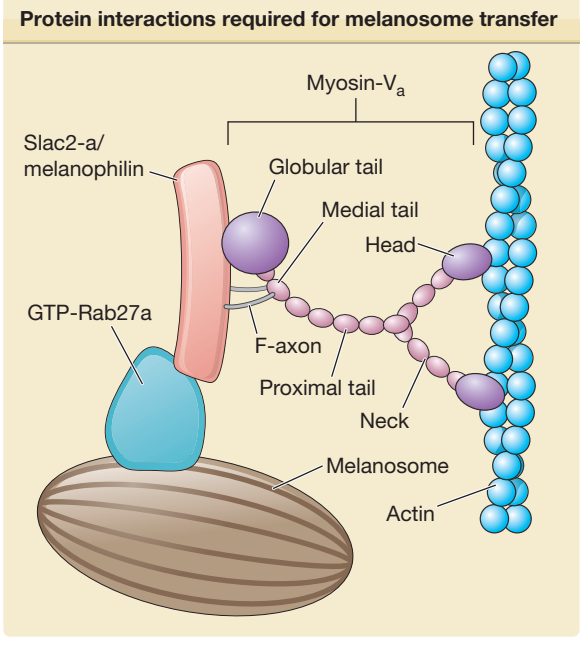

Figure 143-14 Protein interactions required for melanosome transfer. GTP = guanosine triphosphate. [Adapted from Menasche G et al: Griscelli syndrome restricted to hypopigmentation results from a melanophilin defect (GS3) or a MYO5A F-exon deletion (GS1). *J Clin Invest* **112**:450, 2003.]

Prognosis, Clinical Course, and Treatment. GS has been uniformly fatal but now can be reversed by successful hematopoietic stem cell transplantation. Eighty-five percent of patients with GS2 have mutations in the *RAB27A* gene that lead to early protein truncation. They have the most severe form of the disease with early development of hemophagocytic syndrome and rapid progression. The median survival from the onset of the accelerated phase to death in these patients is 5 months. Most patients die by 5 years of age secondary to progressive CNS disease or recurrent infections.[173] Missense mutations in the *RAB27A* gene show a milder phenotype with later age of hemophagocytic syndrome onset and a good response to chemotherapy treatment.[174] Patients with GS1 do not develop hemophagocytic syndrome. Prenatal diagnosis has been achieved by examination of hair from fetal scalp biopsies and DNA from leukocytes of fetal blood samples.[175]

COMPLEMENT DEFICIENCY DISORDERS

COMPLEMENT DEFICIENCY DISORDERS AT A GLANCE

- Deficiency or dysfunction of early complement components is associated with autoimmune disorders, particularly systemic lupus erythematosus.
- Deficiency or dysfunction of early complement components leads to risk of infections caused by encapsulated bacteria.
- Deficiency of late complement components markedly increases susceptibility to neisserial infections.

TABLE 143-9
Clinical Manifestations of Hereditary Deficiency or Dysfunction of Complement Components

Manifestation	Component	Pathway	Associations
Infection	C1q, C1r, C1s, C4, C2	Classical	Autoimmune disorders, especially SLE Increased encapsulated bacterial infections
	Mannan-binding lectin	Lectin	Pyogenic infections in neonates and children (SLE)
	Factors H, I	Inhibitors, alternative	Recurrent pyogenic infections (C3 depletion)
	Properdin	Stabilizer, alternative	Fulminant neisserial infections
	CR3	Receptor for iC3b	Leukocyte adhesion defect (see LAD type 1)
	C5–C9	Terminal (membrane attack complex)	Recurrent neisserial infections; milder with C9 deficiency
Autoimmune disorders	C1, C4, C2	Classical	Autoimmune disorders, especially SLE Increased encapsulated bacterial infections
	Mannan-binding lectin	Lectin	Pyogenic infections in neonates and children SLE
Exfoliative erythroderma	C3, C5	Shared, terminal	Failure to thrive, diarrhea, infections
Angioedema	C1 esterase inhibitor	Inhibitor, classical	Angioedema
Renal disease and/or hemolysis	Factor H	Inhibitor, alternative	Glomerulonephritis, atypical hemolytic uremic syndrome
	Decay accelerating factor (CD59)	Inhibitor, alternative	Hemolysis, thrombosis
	Membrane cofactor protein (CD46)	Inhibitor, alternative	Atypical hemolytic uremic syndrome
	C3	Shared	Membranoproliferative glomerulonephritis, severe bacterial infections

LAD = leukocyte adhesion deficiency; SLE = systemic lupus erythematosus.

HEREDITARY ANGIOEDEMA

HAE is almost always inherited in an autosomal dominant fashion with a spontaneous mutation rate of 25% (for clinical features and management, see Chapter 38).[190] It occurs in 1 in 150,000 persons and has no racial or ethnic predilection. Seventy-five percent of patients report a positive family history. There are three types of HAE. Type I is characterized by low antigenic levels of C1 INH and affects 85% of patients, whereas the remainder of patients have Type II, with low functional levels but normal/high antigenic levels of C1 INH.[191] A third type of HAE does not show a deficiency of C1 INH.[192] This type of HAE was previously thought to only affect women, although recently a family was described in which three male family members were affected.[193] One family has been identified in which the disease is transmitted as an autosomal recessive trait due to a mutation in the promoter region of the gene.[194]

KEY REFERENCES

Full reference list available at www.DIGM8.com

DVD contains references and additional content

3. Conley ME, Dobbs AK, Farmer DM: Primary B cell immunodeficiencies: Comparisons and contrasts. *Annu Rev Immunol* **27**:199, 2009
8. Chapel H, Cunningham-Rundles C: Update in understanding common variable immunodeficiency disorders (CVIDs) and the management of patients with these conditions. *Br J Haematol* **145**:709, 2009
10. Notarangelo LD et al: International Union of Immunological Societies Expert Committee on Primary Immunodeficiencies: Primary immunodeficiencies: 2009 update. *J Allergy Clin Immunol* **124**:1161, 2009
27. Bassiri H et al: X-linked lymphoproliferative disease (XLP): a model of impaired anti-viral, anti-tumor and humoral immune responses. *Immunol Res* **42**:145, 2008
31. Puel A et al: Autoantibodies against IL-17A, IL-17F, and IL-22 in patients with chronic mucocutaneous candidiasis and autoimmune polyendocrine syndrome type I. *J Exp Med* **207**:291, 2009
63. Notarangelo LD et al: Defects of class-switch recombination. *J Allergy Clin Immunol* **117**:855, 2006
78. Bosticardo M et al: Recent advances in understanding the pathophysiology of Wiskott-Aldrich syndrome. *Blood* **113**:6288, 2009
107. Aiuti A et al: Gene therapy for immunodeficiency due to adenosine deaminase deficiency. *N Engl J Med* **360**:447, 2009
120. Hanson EP et al: Hypomorphic NEMO mutation database and reconstitution system identifies phenotypic and immunologic diversity. *J Allergy Clin Immunol* **122**:1169, 2008
145. Etzioni A: Genetic etiologies of leukocyte adhesion defects. *Curr Opin Immunol* **21**:481, 2009
150. Minegishi Y et al: Dominant-negative mutations in the DNA-binding domain of STAT3 cause hyper-IgE syndrome. *Nature* **448**:1058, 2007

SECTION 25

Skin Manifestations of Bone Marrow or Blood Chemistry Disorders

Chapter 144 :: Hematologic Diseases

:: Warren W. Piette

HEMATOLOGIC DISEASES AT A GLANCE

- Mucocutaneous changes (i.e., pallor, jaundice, flushing, erythema, and cyanosis) often predict underlying hematologic pathology.
- Anemia is best differentiated by mean corpuscular volume value.
- Megaloblastic anemia of vitamin B_{12} deficiency is distinguished from folate deficiency by lack of neurologic signs in folate deficiency.
- Carcinoid tumor results in flushing, typically for 10 minutes or less; in comparison, flushing from mastocytosis lasts 30 minutes or more.
- Polycythemia vera presents with acrocyanosis, aquagenic pruritus, urticaria, Sweet syndrome, and purpura.
- The morphologic diagnosis of purpura begins with three Ps: (1) is the lesion *p*urpuric, (2) is it *p*rimary, and (3) is it *p*alpable?
- Leukemia cutis is a localized or disseminated skin infiltration by leukemic cells. It is a sign of dissemination or systemic disease or relapsing leukemia.

Hematology includes the study of blood and blood-forming tissues. Given the number and variety of hematologic disorders, it is not surprising that mucocutaneous manifestations of hematologic disorders are common. Many hematologic malignancies and pseudomalignancies can involve the skin through atypical cell infiltration (specific lesions), and some of these may present preferentially in the skin. These conditions, such as leukemias and lymphomas, plasma cell dyscrasias including myeloma, and Langerhans and non-Langerhans histiocytoses, are discussed in other chapters. Likewise, complications of chemotherapy, radiotherapy, cytokine use, or marrow transplantation are discussed elsewhere.

The first section of this chapter is directed toward the differential diagnosis of purpura with an emphasis on those subsets of purpura with important underlying hematologic abnormalities. The second major section of this chapter is directed toward nonspecific (nontumor-containing) findings that may be associated with hematologic disorders. Although the ready availability of laboratory testing has made early recognition of such conditions as anemia and polycythemia much less dependent on physical findings, cutaneous associations still may aid in the diagnosis of a hematologic condition or complicate its management. A comprehensive listing of these associations is presented in Table 144-1.

Selected associations are covered in more detail in the text.

HEMOSTASIS AND THE DIFFERENTIAL DIAGNOSIS OF PURPURA

HEMOSTASIS

Hemostasis can be defined as the arrest of bleeding, and has two phases, primary and secondary, though research findings are blurring the compartmentalization of this process.[65] Primary hemostasis depends both on the vasoconstriction of the injured vessel and on formation of a platelet plug at the injury site. It is usually sufficient for focal microcirculatory injury repair. Larger defects or injury in larger cutaneous vessels require secondary hemostasis to reinforce the platelet plug.

Primary hemostasis is characterized by vascular contraction, platelet adhesion and activation, and subsequent development of a plug at the site of vessel injury. Vascular contraction leads to slowing of the blood flow, so the platelets can adhere to the injured site and diminish blood loss.[66] Secondary hemostasis promotes vascular integrity when primary hemostasis is insufficient and when larger vessels are involved. This phase maintains vasoconstriction through the secretion of prostaglandins, thromboxane, and serotonin. It also solidifies

TABLE 144-1
Cutaneous Findings with Hematologic Associations[1,2]

Pigmentary Changes

- Generalized hyperpigmentation
  - POEMS syndrome (*p*olyneuropathy, *o*rganomegaly, *e*ndocrinopathy, *M*-protein, *s*kin lesions)[3,4]
    - Hyperpigmentation, 93%–98%; apparent skin thickening, 77%–85%; hypertrichosis, 78%–81%; peripheral edema, ~90%; digital clubbing, 56%; white fingernails; verrucous angiomata, telangiectasia
  - Hemochromatosis may have bronze or grayish pigmentation of the skin
  - Megaloblastic anemia of vitamin B_{12} or folate deficiency
  - Fanconi anemia[5,6]
    - Begins age 4–10 years with skin or hematologic presentation
    - Generalized hyperpigmentation, especially lower trunk, flexures, neck, 85%
    - Scattered darker and lighter macules within hyperpigmented areas
    - Progressive hypoplastic anemia with pancytopenia
    - Death from leukemia, other neoplasms, or infections 2–5 years after onset
- Dyskeratosis congenita[7]
  - Nail dystrophy, beginning 5–13 years of age
  - Fine reticulate gray-brown hyperpigmentation, especially neck, thighs, and trunk
  - Atrophic skin with telangiectasis
  - Oral leukoplakia
  - Mucocutaneous carcinomas, occasional pancreatic carcinoma, Hodgkin disease
  - Frequent blood dyscrasias, aplasias, refractory anemias, pancytopenias
- Localized hyperpigmentation
  - Hypermelanosis and hemosiderosis may develop on the lower legs in hemolytic anemia, may develop focally in vitamin B_{12} or folate deficiency
  - Porphyria cutanea tarda, variegate porphyria, erythropoietic porphyria, occasionally hereditary coproporphyria cause hyperpigmentation, primarily in sun-exposed areas (see Chapter 132)
  - Adult Gaucher disease[8]
  - Brown chloasma-like macules on face, neck, and hands
  - Symmetric hyperpigmentation of lower legs
- Niemann–Pick disease[9,10]
  - Indurated discolored patches, especially on checks, café-au-lait spots
  - Mongolian on skin and oral mucosa
- Generalized hypopigmentation
  - Chédiak–Higashi (see "Recurrent cutaneous infections")[11,12]
  - Hermansky–Pudlak[11]
    - White, red, or brown hair; cream-gray to light normal skin
    - Blue–gray to brown iris
    - Platelet bleeding diathesis
    - Ceroid-like deposits in reticuloendothelial system, gastrointestinal tract, lung, and kidney that lead to pulmonary interstitial fibrosis, nephritis, granulomatous colitis
- Localized hypopigmentation
  - POEMS syndrome (see "Generalized hyperpigmentation")
  - Pernicious anemia with vitiligo
  - Vitamin B_{12} deficiency associated with poikilodermatous hypopigmentation
  - Anemia of autoimmune hypothyroidism may be associated with vitiligo
  - Porphyria cutanea tarda, variegate porphyria, erythropoietic porphyria, usually in areas of scarring

Recurrent Cutaneous Infections

- Neutropenia
  - Severe neutropenia (counts of 500/μL usually associated with fever, erythema without pus, painful ulcers). Causes include congenital and cyclic neutropenia; leukemia, lymphoma; marrow toxicity, failure, infiltration; and immune and autoimmune neutropenias.
- Functional leukocyte defects (counts may be low, normal, or elevated; defects identified in adherence, chemotactic response, phagocytosis, and killing)[85,86]
  - Chédiak–Higashi syndrome
    - Autosomal recessive
    - Defect in cytoplasmic granule function
    - Fair skin, light blond or silvery hair, and pale retina; translucent irises due to abnormal melanosomes
    - Large neutrophil inclusion on Wright-stained blood smear
    - Usually die in childhood

(continued)

TABLE 144-1
Cutaneous Findings with Hematologic Associations (Continued)

Recurrent Cutaneous Infections (Continued)

- Griscelli syndrome[13] (see Chapter 143)
  - Pigmentary dilution with silvery-gray hair
  - Autosomal recessive
  - Hypogammaglobulinemia, defective cell-mediated immunity
  - Neutropenia, thrombocytopenia, lymphohistiocytosis, hepatosplenomegaly
  - Neurologic deterioration
- Chronic granulomatous disease of childhood (see Chapter 143)
  - Leukocytes ingest bacteria normally but fail to kill them because of defects in H_2O_2 and oxygen radical production
  - Multiple types, most X-linked; overall sex ration, male-female 6:1
  - Skin lesions eczematous and purulent initially, transition to chronic cutaneous granulomas
  - Catalase-positive microbes (e.g., *Staphylococcus aureus*, *Salmonella*, *Aspergillus*) can multiply intracellularly, whereas catalase-negative microbes (e.g., pneumococci or streptococci) that generate their own H_2O_2 are killed
  - Nitroblue tetrazolium dye helpful in diagnosis
  - X-linked carriers may develop lupus-like skin lesions, aphthous stomatitis, or granulomatous cheilitis
- Myeloperoxidase deficiency
  - Autosomal recessive affecting neutrophils but not eosinophils
  - Functional impairment not severe
  - Occasional difficulty with pyogenic infections, persistent fungal infection more common
- Membrane and cytoskeletal defects (see Chapter 143)
  - Leukocyte adherence disorders due to congenital lack of defect or some component of CD11/CD18 surface glycoproteins (Chapter 143)
    - Neutrophils unable to adhere firmly to surfaces or complement-opsonized microorganisms
    - Possible persistent leukocytosis
    - Failure to develop much neutrophil response at inflammatory or infectious sites
  - Cytoskeletal defect in polymerizable actin[14]
    - Similar presentation to leukocyte adherence defects, but with normal CD11/CD8 but impaired motility
  - Complement abnormalities
    - C3 deficiency, C3b inactivator deficiency
    - Hyperimmunoglobulin E (IgE) syndrome
    - Job and Buckley syndromes are subsets
    - Elevated IgE, defective neutrophil chemotaxis
    - No clear relationship between IgE levels and neutrophil motility defect
    - Cold abscesses
  - Leiner disease
    - Severe seborrheic dermatitis
    - Diarrhea, failure to thrive
    - Gram-negative bacterial and candidal infection during infancy
  - Wiskott–Aldrich syndrome[15]
    - X-linked defect in WAS gene, WAS protein (WASp), less severe defect leads to chronic/intermittent X-linked thrombocytopenia or X-linked neutropenia
    - Thrombocytopenia, small but dysfunctional platelets, hemorrhage
    - Eczema
    - Recurrent infections: initially bacteria such as *Pneumococcus*, *Haemophilus influenzae*, *Neisseria meningitidis*; over time, T-cell function deteriorates and patient becomes susceptible to opportunistic viral, bacterial, and fungal infections
    - Immunologic abnormalities and lymphoreticular malignancies
    - CD43, a ligand for intercellular adhesion molecule-1, is defective; however, probably not primary defect because CD43 gene is on chromosome 16, not X
  - Persistent or extensive herpes simplex or recurrent or disseminated herpes zoster suggest underlying immune defect or hematologic malignancy

Neutrophilic Cutaneous Reactions

- Acute febrile neutrophilic dermatosis (Sweet syndrome): less than 10% of reported patients have heme association, usually acute myelogenous leukemia, myeloproliferative disorder, myelodysplastic syndrome, multiple myeloma, or monoclonal gammopathy
- Pyoderma gangrenosum: often atypical or bullous–hematologic association similar to those in Sweet syndrome
- Antineutrophil cytoplasmic autoantibody (ANCA)-positive neutrophilic dermatosis
- Polymorphic disease with monoclonal IgA ANCA[16]
- Erythema elevatum diutinum (see "Vascular disorders and coagulopathies")
- Leukocytoclastic vasculitis (see "Vascular disorders and coagulopathies")

TABLE 144-1
Cutaneous Findings with Hematologic Associations (Continued)

Vesiculobullous Disease

- Pemphigus vulgaris: lymphoproliferative diseases[2,17]
- Paraneoplastic pemphigus: lymphoproliferative diseases, thymoma[18]
- Acquired immunobullous disease with skin fragility: Waldenström macroglobulinemia[19]
- Linear IgA dermatosis: associations include Hodgkin lymphoma, non-Hodgkin lymphoma, polycythemia vera, chronic lymphocytic leukemia, plasmacytoma[20]
- IgA pemphigus: occasional monoclonal gammopathy or myeloma, most often IgA
- Subcorneal pustular dermatosis: IgG or IgA monoclonal gammopathy or myeloma[3,4]
- Dermatitis herpetiformis: frequent polyclonal IgA gammopathy, occasional myeloma, lymphomas, angioimmunoblastic lymphadenopathy
- Porphyria cutanea tarda, variegate porphyria, hereditary coproporphyria, and erythropoietic porphyria (see "Pruritus, prurigo, and burning," and "Generalized hyperpigmentation")
- Bullous mastocytoma, bullous urticaria pigmentosa of infancy[21]
- Hypereosinophilic syndrome can induce vesiculobullous lesions[22]
- Skin cancers
- Basal cell and squamous cell carcinoma increased in non-Hodgkin lymphoma and chronic lymphocytic leukemia (CLL)[23]
- Kaposi sarcoma increased in lymphoma, CLL, some immune deficiencies

Vascular Disorders and Coagulopathies

- Vasculitis
  - Usually cutaneous leukocytoclastic vasculitis (including urticarial vasculitis) and polyarteritis nodosa; ~5% of patients with vasculitis have an underlying malignancy[24]; lymphoproliferative disease most common, especially hairy cell leukemia, other hematologic associations include cryoglobulinemia, Hodgkin disease, non-Hodgkin lymphoma, myelodysplastic syndrome, chronic myelogenous leukemia, and multiple myeloma[2,25]
  - Erythema elevatum diutinum: gammopathy or myeloma, frequently IgA[3,4]
  - Urticaria and angioedema
    - Lymphoproliferative disease, sometimes with decreased C1-esterase inhibitor function[3,4]
    - Cryoglobulinemia; can also cause cold-induced urticaria[3,4]
    - Lymphocytic vasculitis: angioblastic lymphadenopathy, non-Hodgkin lymphoma, CLL[26]
    - Vasculitis panniculitis: children, non-Hodgkin lymphoma[27]
    - Hypereosinophilic syndrome[22]
- Vasculopathies and altered vascular reactivity
  - Flushing, erythroderma
  - Plethora, ruddy cyanosis
  - Erythema annulare centrifugum: lymphoma, "malignant histiocytosis," hypereosinophilic syndrome[28]
  - Erythralgia/erythromelalgia[29,30]
    - Polycythemia vera, essential thrombocytopenia; less commonly myelofibrosis, chronic myelogenous leukemia, cryoglobulinemia
  - Raynaud phenomenon
    - Waldenström macroglobulinemia[4]
    - Cryoglobulinemia[4]
  - Livedo reticularis[31,32]
    - Plasma cell dyscrasias with hyperviscosity, cryoglobulinemia, or cold agglutinin disease, macroglobulinemia[33]
    - Hyperleukocytosis
    - Polycythemia vera, thrombocythemia[34] (for the following, see also Tables 144-3–144-5)
    - Antiphospholipid antibody, lupus anticoagulant[35,36]
    - Hereditary protein C deficiency[37]
    - Antithrombin III deficiency[37]
    - Heparin-associated thrombocytopenia[38]
  - Acral cyanosis
    - Coumadin or other anticoagulant-enhanced tendency for cholesterol embolization: blue toe syndrome
    - Polycythemia vera, thrombocythemia, rarely with myeloblast leukostasis syndrome of chronic myelogenous leukemia[39]
    - Cryoglobulinemia[4,40]
    - Cold agglutinins[4,33]
    - Crystal globulin vasculopathy: multiple meloma[41,42]
- Vascular changes
  - POEMS syndrome: telangiectasias or angiomas
- AESOP syndrome: adenopathy with extensive skin patch (telangiectasia) overlying an osseous plasmacytoma; may have POEMS at curable stage[43]
  - Langerhans cell histiocytosis: telangiectasias, petechial hemorrhage
  - Telangiectasia macularis eruptive perstans variant of urticaria pigmentosa[44]

(continued)

TABLE 144-1
Cutaneous Findings with Hematologic Associations (Continued)

Vascular Disorders and Coagulopathies (Continued)
- Bleeding or coagulopathy secondary to dysproteinemia[4,45]
  - Mucocutaneous hemorrhage
    - Hyperviscosity syndrome, usually Waldenström macroglobulinemia, occasionally myeloma, cryoglobulinemia
    - Abnormal platelet function from dysproteinemias
    - Clotting factor deficiencies or inhibitors: factor V or VIII with IgM or IgA[36]; factor VII with IgG[46]; factor X adsorptive depletion in amyloidosis[42]
    - Low-grade disseminated intravascular coagulation with protein C dysfunction secondary to IgG gammopathy

Cutaneous Deposition/Induration/Altered Texture[3,4]
- AL (light-chain related) systemic amyloidosis: papules, plaques, nodules, bullae, sclerotic plaques, urticaria-pigmentosa-like lesions, alopecia, macroglossia; occurs with idiopathic or disease-associated monoclonal gammopathies
- Nodular cutaneous amyloidosis: local monoclonal plasma cell infiltrate; atrophic outpouchings of abdominal skin[47]
- Storage papule disease (translucent, often crusted or purpuric centers, buttocks and lower extremities): Waldenström macroglobulinemia[48]
- Cutaneous swelling associated with crystalline protein deposition: myeloma[49]
- Follicular spicules of the nose: multiple myeloma, cryglobulinemia[50]
- Scleromyxedema variant of lichen myxedematosus: usually IgGγ gammopathy[51]
- Scleroderma: usually IgG monoclonal gammopathy, occasionally myeloma
- Niemann-Pick: waxy induration with transient xanthomas overlying enlarged lymph nodes[9,52]
- Thickened, doughy, skin of diffuse cutaneous mastocytosis[53]
- Anetoderma: cutaneous plasmacytoma, benign lymphoid hyperplasia[54]

Xanthomas[3,4]
- Necrobiotic xanthogranuloma with paraproteinemia
  - Usually periorbital xanthoma, typically ulcerative
  - Leukopenia
  - Monoclonal gammopathy or multiple myeloma
- Xanthoma disseminatum—occasional association with monoclonal gammopathy, multiple myeloma, Waldenström macroglobulinemia
- Generalized plane xanthomatosis
  - Multiple myeloma, monoclonal gammopathies, leukemias
  - Xanthomas and café-au-lait spots: juvenile chronic granulocytic leukemia
  - Eruptive or tuberous xanthomas rarely reports with dysproteinemias

Cutaneous Sarcoidal or Histiocytic Tissue Reactions
- Cutaneous sarcoidal reactions: lymphoma {Warkentin, 1906 #72}
- Multicentric reticulohistiocytosis: lymphoproliferative disorders[55]

Epidermal Changes
- Acquired ichthyosis: lymphoproliferative malignancies, primarily Hodgkin disease[56]
- Sign of Lesser-Trélat: lymphomas comprise one-fifth of cases[57]

Hypertrichosis
- Porphyria cutanea tarda, erythropoietic porphyria

Pruritus, Prurigo, and Burning
- Severe itching occurs in 1%–11% of patients with Hodgkin disease even in the absence of any visible skin lesions; occasional complication of non-Hodgkin lymphoma and leukemia[2]
- Mycosis fungoides, Sézary syndrome, or other lymphomas with skin involvement may also present as itching
- Eosinophilic folliculitis after marrow transplant or chemotherapy for heme malignancies[58]
- Aquagenic pruritus: polycythemia vera, hypereosinophilic syndrome, myelodysplastic syndrome, juvenile xanthogranuloma[59]
- Hypereosinophilic syndrome: pruritic, erythematous papules or nodules, and angioedematous or urticarial plaques common[22]
- Mastocytosis: pruritic and usually pigmented papules or diffuse pruritius[60]
- Erythropoietic protoporphyria: pruritus and burning within minutes of sun exposure; may develop urticaria, edema, erythema, purpura
- Angioimmunoblastic lymphadenopathy/lymphoma: macular and popular eruptions, petechial, purpuric, nodular, ulcerative, and erythrodermic eruptions described[61,62]

Ulcerations
- Nonmalignant red blood cell disorders and leg ulcers
  - α or β thalassemias
  - Hemoglobin (Hb) SS, Hb-S-β thal Hb SC
  - Hereditary spherocytosis and elliptocytosis
  - Paroxysmal nocturnal hemoglobinuria

TABLE 144-1
Cutaneous Findings with Hematologic Associations (Continued)

Ulcerations (Continued)
- Cutaneous lesions of leukemia, lymphoma, and some histiocytoses may ulcerate
- Lymphomatoid papulosis
- Polycythemia vera and essential thrombocytopenia
- Kaposi sarcoma
- Reactive hemophagocytic syndrome
- Angioimmunoblastic lymphadenopathy
- Necrobiotic xanthogranuloma with paraproteinemia, xanthoma disseminatum
- Sweet syndrome
- Cryoglobulinemia
- Hypereosinophilic syndrome, especially mucosal ulcerations and erosions[63]
- Protein C deficiency, inherited and acquired (including Coumadin necrosis, some disseminated intravascular coagulation)
- Heparin necrosis
- Antiphospholipid antibody syndrome
- Neutropenic and immune deficiency-related infections
- Chédiak–Higashi: pyoderma gangrenosum or pyoderma gangrenosum-like ulcers[64]
- Leukocyte adhesion deficiency
- Chronic granulomatous disease
- Hyperimmunoglobulinemia E
- Felty syndrome
- Acute myelogenous leukemia

the platelet plug formed during primary hemostasis, through a series of clotting cascade pathways.

Because of the rich and highly visible nature of the skin microcirculation, and because of the very dynamic alterations of cutaneous blood flow (e.g., increasing to promote heat exchange, decreasing dramatically in shock states) as well as hydrostatic pressure variations by anatomic site and body position, the skin can be a very early and sensitive locale for signs of hemostatic alterations and coagulopathy. In nondisease states, the blood participates in an ongoing homeostatic balance between site-specific hemostasis or clot formation, clot extension inhibition, and clot lysis at the appropriate stage of injury repair. The platelet and coagulation cascade participate in clot formation, the antithrombin III and thrombomodulin/protein C/protein S systems in clot inhibition, and the plasminogen/plasmin system in clot lysis.

DIFFERENTIAL DIAGNOSIS OF PURPURA

The bedside dissection of the likely differential diagnosis of purpura can be summarized by five Ps: are lesions **p**urpuric, **p**rimary, **p**alpable, and what is their **p**attern and **p**lacement? For a lesion to qualify as purpuric, it must have a color that is compatible with hemorrhage—usually some shade of red, blue, or purple, but sometimes yellow–brown, green, or black—and at least some of this color must persist on compression of the skin. If the vessels are compressible, and if the color is due to mobile red cells within the vessels, then the skin color should completely blanch on compression, and no hemorrhage is clinically evident. False-positive results occur if the lesions contain tortuous vessels that kink on compression, or if compression is incomplete. Extravasated cells are not free to move, and therefore color persists on compression. It is important not only to determine the persistence of some color on compression, but also to assess in early lesions the proportion of erythema to hemorrhage. Complete blanching is a nonpurpuric lesion, but may be the physical presentation of mild urticarial vasculitis with clinically nonevident hemorrhage. Significant partial blanching of early lesions suggests an inflammatory etiology of the purpuric process. No detectable color change suggests no inflammatory component, and is characteristic of simple hemorrhage and most microvascular occlusive lesions.

Purpura may be primary or secondary in etiology. Hemorrhage may occur in inflammatory syndromes such as cellulitis, psoriasis, stasis dermatitis, or eczema, and these should be considered secondary purpura syndromes. In these and similar settings, the hemorrhage is generally secondary to nonvessel-directed inflammation increasing vascular permeability, and usually hydrostatic pressure increasing the likelihood of incidental red cell extravasation in areas of dependency.

Palpability rarely reflects the amount of cutaneous hemorrhage except for very large and deep focal cutaneous hemorrhage, resulting in a hematoma typically localizing in or below the fat layer of skin. Upward movement of the hemorrhage may occasionally result in an overlying ecchymosis. Most simple hemorrhage in the skin is nonpalpable. Instead, palpability typically results from protein-rich edema secondary to inflammation or microvascular ischemia with vascular and tissue injury. While the presence of palpability should exclude simple hemorrhage as a pathogenesis, the absence of palpability does not exclude inflammatory or occlusive hemorrhagic etiologies.

Many approaches to the differential diagnosis of purpura begin with pathophysiologic mechanisms.

TABLE 144-2
Purpura Number and Distribution Patterns and Their Clinical Relevance

Distribution/ Number Pattern	Distribution	Number of Lesions	Most Common Etiologies
Dependent	Gravity-dependent increasing density of lesions	Few to few 100s	Platelet-dependent hemostatic failure Immune-complex vasculitis
Minor Trauma-Prone areas	Extensor surface of arms, lateral thighs, anterior lower legs	One to a dozen	Extensor arm only suggests actinic purpura; multiple areas suggest minor trauma ecchymosis differential in Table 144-3
Multigeneralized			
Multigeneralized with round lesions	Generalized eruption	Many 100s	Usually drug or viral eruptions
Multigeneralized with retiform lesions	Widespread eruption	Few to Fifty	Sepsis-related microvascular occlusion/ purpura fulminans
Pauci-random	Random localization	Few	Nonimmune complex vasculitis, especially ANCA +; Systemic microvascular occlusive disease
Acral			
Acral: erythema multiforme type	Involves hands and feet, with or without a more generalized distribution	Few on hands/ feet, may have many more if accompanied by a generalized eruption	Usually drug or viral eruption, especially recurrent HSV eruptions
Acral: cold-localized type	Hands, feet, nasal tip, ears	Few	Cold-occlusion phenomena
Acral: hypotensive,	Digital gangrene, or retiform purpura on hands and/or feet	Few	Shock, usually in association with vasoconstrictor administration and sepsis-related coagulopathy
Acral: feet with livedo reticularis extending proximally	Livedo reticularis of legs often prominent early, expect few distal retiform purpura lesions[3]	Few purpura lesions	Cholesterol embolus, can be mimicked by antiphospholipid antibody syndrome
Acral: wedge-shaped	Distal, usually one limb or digit	One wedge-shaped lesion	Arterial occlusion

However, pathophysiology is usually what the physician is attempting to ascertain, and the diagnostic process begins with clinical clues. Some of the most important clinical information available from the bedside examination is lesional number, distribution, and morphology. Exploration of the differential diagnosis can begin with helpful patterns of lesional number and distribution are listed in Table 144-2.

The initial diagnostic considerations based on these patterns should then be combined with information gleaned from the lesional morphologic differential diagnosis (Tables 144-3, 144-4, and 144-5; Fig. 144-1).

The goal of the history and examination is to develop a narrow differential diagnosis or testable clinical hypothesis as to the etiology of purpura in a particular patient, and to order or review the appropriate laboratory studies that may prove or disprove suspected pathophysiologies. While the differential diagnosis of purpura could easily include hundreds of possible etiologies, the diagnostic process can be powerfully refined if one is able to determine clinically whether the early primary purpuric lesions is likely due to simple hemorrhage, inflammatory hemorrhage, or ischemia/occlusion.[67,68,73] In concert with the number and distribution, lesional morphology is critical in facilitating this determination. Simple hemorrhage not severe enough to produce hematoma presents as nonpalpable (macular), nonblanchable purpura, and usually is either primarily petechial or ecchymotic, each pattern having its own differential composition (Tables 144-3, Figs. 144-2 and 144-3). Partially blanchable purpura, often palpable, is the expected clinical manifestation of inflammatory hemorrhage, including but not limited to necrotizing vasculitis (Table 143-4). If early lesions are both partially blanchable and retiform, the differential diagnosis is further narrowed (Fig. 144-4). Finally, if early lesions are retiform with minimal to no blanchable component, microvascular occlusion becomes the likely differential category, always with the caveat that some occlusive syndromes may be accompanied by inflammation when lesions are large and deep, and two vasculitides in particular [granulomatosis with polyangiitis (Wegener's) and microscopic polyangiitis] may present with purpura lesions which show no clinical evidence of inflammation.

TABLE 144-3
Partial Differential Diagnosis of Nonpalpable, Nonretiform Purpura by Size of Lesion[67–70]

- Petechiae: ≤4 mm
- Platelets <50,000/μL, usually <10,000/uL
  - Immune thrombocytopenia
  - Thrombotic thrombocytopenic purpura
  - Disseminated intravascular coagulation
  - Acquired thrombocytopenia (including drug-related)
    - Peripheral destruction (especially quinine)
    - Marrow failure
    - Marrow infiltration, fibrosis, failure
  - Abnormal platelet function
    - Congenital/hereditary platelet function defects
    - Acquired platelet function defects
      - Aspirin, nonsteroidal anti-inflammatory drugs
      - Renal or hepatic insufficiency
      - Gammopathy
      - Myeloproliferative thrombocytosis
- Nonplatelet etiologies
  - Minimally inflammatory conditions
    - Chronic pigmented purpura
    - Waldenström hypergammaglobulinemic purpura
  - Intravascular pressure increase
    - Valsalva-like spikes (nondependent); repetitive vomiting, coughing, childbirth
    - Relatively fixed increased pressure: ligature, strangulation, stasis
    - Trauma: usually linear arrangement
- Midsize macules: 5–10 mm (indeterminate hemorrhage)
  - Waldenström hypergammaglobulinemic purpura
  - Immunocompromised patients with sepsis
- Ecchymoses: ≥1 cm
  - Procoagulant defect and minor trauma
    - Anticoagulant use
    - Vitamin K deficiency
    - Disseminated intravascular coagulation
    - Hepatic diagnosis, poor factor synthesis
    - Platelet abnormality and minor trauma
      - Thrombocytopenia (always <50K, usually <10K)
      - Inherited platelet dysfunction, esp von Willebrand disease
      - Acquired platelet dysfunction (aspirin, uremis, liver disease, gammopathies)
  - Poor dermal vessel support and minor trauma
    - Actinic (senile) purpura
    - Glucocorticoid treatment, topical/systemic
    - Vitamin C deficiency—scurvy
    - Systemic amyloidosis (mostly light chain-related amyloidosis)
    - Ehlers–Danlos syndrome (some types)
    - Pseudoxanthoma elasticum
    - Other pathophysiology
    - Major trauma
    - Waldenström hypergammaglobulinemic purpura

The differential diagnosis of minimal inflammatory retiform purpura, with these caveats, is listed in Table 143-5.

NONPALPABLE, NONBLANCHABLE PETECHIAE (<4 mm)

Palpable or partially blanching petechiae do not fit in this category; such lesions should instead prompt consideration of the differential diagnosis of classical palpable purpura. Nonpalpable petechial hemorrhage is typically the dominant type of hemorrhage resulting from problems in platelet number, always below 50,000/mm, and almost always below 10,000/mm (Table 144-3). In patients with immune thrombocytopenia, either idiopathic or alloimmune, the marrow is healthy, and platelet production is increased, leading to larger and more effective platelets. In such instances, spontaneous formation of petechiae is often minimal, even when platelet numbers are below 5,000. However, when thrombocytopenia is due to marrow failure (medications, especially chemotherapy, radiation exposure, marrow infiltration from leukemia, lymphoma, or other neoplasms), the platelets in circulation are often small, old, and poorly functional, and

TABLE 144-4

Partial Differential Diagnosis of Palpable or Retiform Purpura with Prominent Early Erythema by Lesion, Shape, and Degree of Erythema[67,68,71,72]

Classical Palpable Purpura (Round, Port-Wine Color, Partially Blanchable Early)

Morphology of early lesion: prominent erythema with palpable purpura suggests inflammatory hemorrhage

- Leukocytoclastic vasculitis and immune complex disease (lesions usually cluster in dependent areas)
  - Small vessels only
    - Idiopathic, infection-, drug, or malignancy-associated immunoglobulin G (IgG) or IgM complexes
    - Idiopathic IgA complexes (Henoch-Schönlein purpura, or IgA idiopathic with drugs, infection, or malignancy
    - Subacute bacterial endocarditis—hands
    - Waldenström hypergammaglobulinemia
    - Urticarial vasculitis—often random localization
    - Pustular vasculitis—often random localization
  - Small and medium-size cutaneous vessels may be involved
    - Mixed cryoglobulinemia
    - Rheumatic vasculitis (lupus erythematosus, dermatomyositis, rheumatoid arthritis)
- Leukocytoclastic vasculitis and pauci-immune vasculitis (lesions usually localize randomly)
  - Antineutrophil cytoplasmic antibodies (ANCA)-associated
    - Granulomatosis with polyangiitis (Wegener's)
    - Microscopic polyangiitis
    - Churg-Strauss rarely
  - Other
    - Erythema elevatum diutinum—hands/feet/elbows/buttocks
    - Sweet syndrome (rarely vasculitic)
- Not leukocytoclastic (lesions usually localize randomly)
  - Small vessels only
    - Erythema multiforme—acral early
    - Pityriasis lichenoides et varioliformis acuta (PLEVA)
    - Chronic pigmented purpura—often legs
    - Waldenström hypergammaglobulinemia—usually dependent
    - Urticarial lymphocytic "vasculitis"
- Classic target lesion
  - Usually erythema multiforme—expect acral and mucosal involvement, as well as elsewhere

Inflammatory Retiform Purpura

Morphology of early lesion: prominent erythema with retiform purpura suggests subset of inflammatory hemorrhage (and, rarely, ischemic syndromes)

- Leukocytoclastic vasculitis and immune complex disease (lesions usually cluster in dependent areas)
  - Small vessels only
    - IgA (Henoch-Schönlein purpura) vasculitis
  - Small and medium-sized cutaneous vessels may be involved
    - Mixed cryoglobulinemia
    - Rheumatic vasculitides
- Leukocytoclastic vasculitis, dermal and subcutaneous vessels, pauci-immune
  - ANCA-associated—random location
    - Granulomatosis with polyangiitis (Wegener's)
    - Microscopic polyangiitis
    - Churg-Strauss
  - ANCA-negative syndromes
    - Benign cutaneous polyarteritis nodosa, often legs
- Nonvasculitic
  - Usually lower leg
    - Livedoid vasculitis
  - Usually fingers/toes
    - Chilblains (pernio)
- Usually random location
  - Pyoderma gangrenosum
  - Sweet syndrome/atypical pyoderma gangrenosum

TABLE 144-5

Differential Diagnosis of Palpable or Retiform Purpura with Minimal Early Erythema by Lesion, Shape, and Degree of Erythema[68,73]

Morphology of early lesion: minimal erythema with retiform purpura or with necrosis suggests occlusion with ischemic hemorrhage or infarction.

- Platelet plugs
  - Heparin necrosis (distant or injection sites)
  - Myeloproliferative thrombosis
  - Paroxysmal nocturnal hemoglobinuria
  - Thrombotic thrombocytopenic purpura (plugs mainly visceral vessels, skin lesions usually simple hemorrhage)
- Cold-related gelling or agglutination (lesions localize to acral, cold-exposed areas)
  - Cryoglobulinemia, usually monoclonal
  - Cryofibrinogenemia (often incidental finding in ill patients)
  - Cold agglutinins (rarely occlusive, usually hemolytic)
- Embolization or crystal deposition (lesions localize to dependent or acral areas)
  - Cholesterol emboli
  - Oxalate crystal deposition
  - Both usually have extensive livedo
  - Hypereosinophilic syndrome
- Embolus from atrial myxoma, septic, or marantic endocarditis
  - Crystal globulin vasculopathy
- Systemic changes in coagulation control
  - Coumarin necrosis (altered protein C function)
  - Disseminated intravascular coagulation with severe protein C deficiency or dysfunction: sepsis-related purpura fulminans
- Postinfectious purpura fulminans (usually children, following varicella and/or streptococcal infection, due to antibody inhibition of protein S)
  - Homozygous protein C or S deficiency: neonatal purpura fulminans
  - Antiphospholipid antibody/lupus coagulant
- Local changes in coagulation control
  - Idiopathic livedo reticularis with CVA (Sneddon syndrome): may show only livedo without purpura
  - Livedoid vasculitis atrophie blanche: rarely retiform
  - Malignant atrophic papulosis: never retiform, in skin limited syndromes should suspect antiphospholipid antibody syndrome
- Occlusion caused by organisms growing in vessel and vessel walls (usually immunocompromised host)
  - Vessel-invasive fungus (*Mucor*, *Aspergillus*, *Cephalosporium*, *Rhizopus*, etc.)
  - Ecthyma gangrenosum (*Pseudomonas*)
  - Disseminated strongyloidiasis
  - Lucio phenomenon in leprosy
- Cell occlusion syndromes: typically ulcerative but nonretiform
  - Hemoglobinopathy occlusion (sickle cell, severe thalassemia): probably role for sticky reticulocyte syndrome; Hg S-related disease adds complication of sickling, rigid membrane abnormalities.
  - Typically ulcerative but usually non-retiform
  - Intravascular lymphomas
- Uncertain pathophysiology
  - Cutaneous calciphylaxis
  - Reperfusion necrosis
  - Interferon injection
  - *Loxosceles* spider bite

hemorrhage may occur despite platelet counts many thousands higher than in the immune thrombocytopenias. Drug-related thrombocytopenia can be due to several different mechanisms, including immune, destructive, and cytotoxic.[69]

IMMUNE THROMBOCYTOPENIAS. Idiopathic thrombocytopenic purpura (ITP) is a common bleeding disorder in children caused by autoantibodies against platelet surface antigens, especially glycoproteins IIb/IIIa and Ib. It presents with increased immunoglobulin (Ig) M, IgG, and IgA autoantibodies with decreased platelet surface antigens (CD41, CD61, and CD42b).[74,75] Patients are usually asymptomatic with mostly petechiae and a few ecchymoses found on their physical examination. Oral blood blisters with gastrointestinal or mucocutaneous bleeding can also occur and are referred to as *wet purpura*. As in ITP, immunothrombocytopenic purpura can be associated with recent viral illness and vaccination.[76] Alloimmune thrombocytopenic purpura occurs when alloantibodies against human platelets form during blood or platelet transfusion, or maternal–fetal blood exchange, leading to posttransfusion purpura and fetal and neonatal alloimmune thrombocytopenia, respectively.[46] CD109 is a protein expressed on platelets, T lymphocytes, and endothelial cells. Antibodies against HPA-1, HPA-5, and HPA-15 on $CD109^+$ cells should be sought.

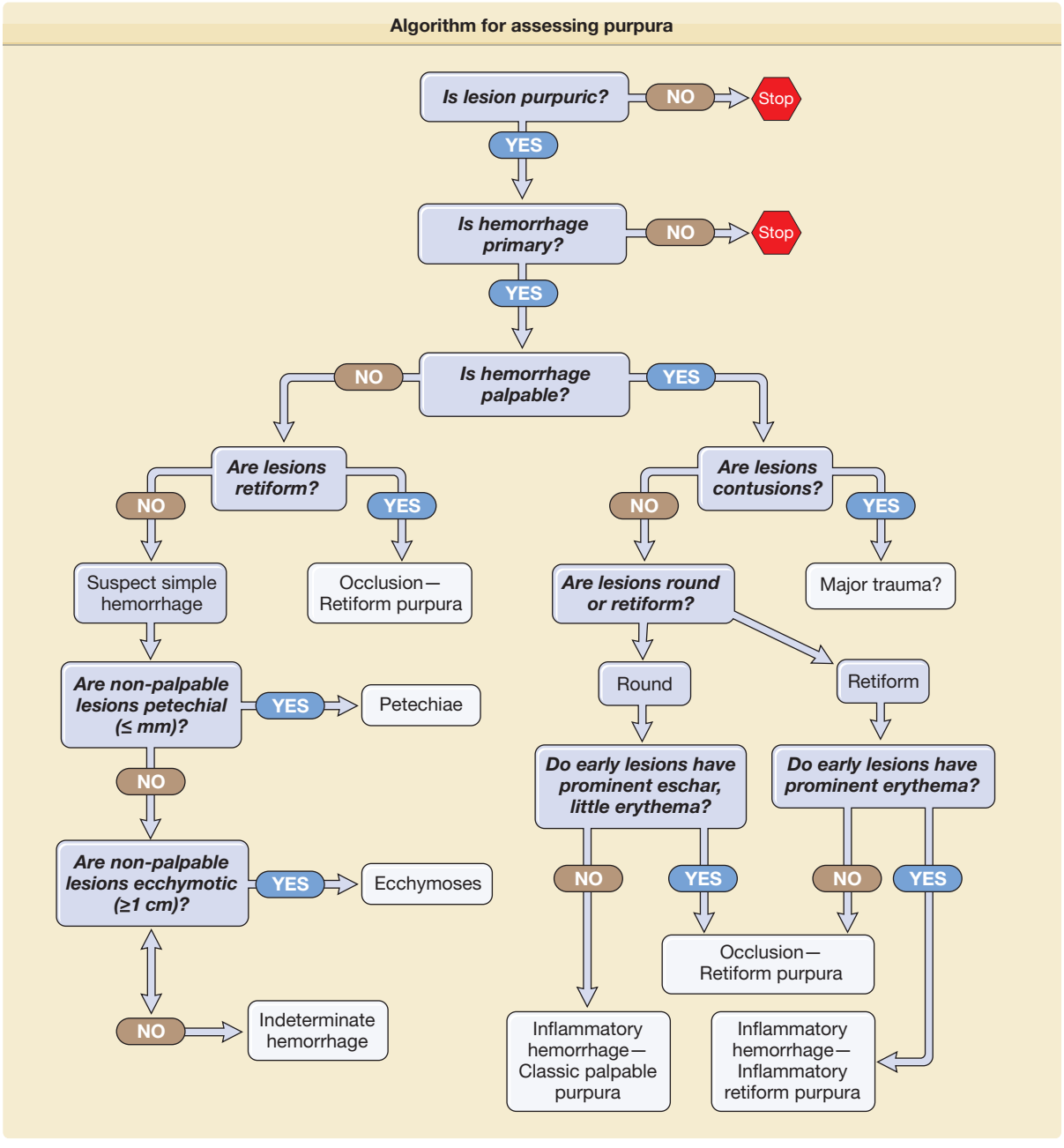

Figure 144-1 Algorithm for assessing purpura.

Unique localization of petechial hemorrhage may result from intravascular pressure spikes. For example, vigorous Valsalva maneuver-like actions from crying in children, vigorous retching, or bearing down during childbirth may result in petechial hemorrhage above the clavicles. A ligature, blood pressure cuff, or attempted strangulation may result in hemorrhage in the affected venous drainage area.

Chronic pigmented purpuras, especially Schamberg type, may mimic simple petechial hemorrhage in the legs, despite histologic evidence of mild nonvasculitic hemorrhage such lesions. Clinically, the inflammation may not be evident, but clues to this diagnosis consist of a tendency of pigmented purpura and petechiae to cluster, leaving an orange–brown pigmentation in affected areas. The pigmented purpuric dermatoses are discussed in detail in Chapter 168.

THROMBOTIC THROMBOCYTOPENIC PURPURA/THROMBOTIC MICROANGIOPATHIES.

Thrombotic thrombocytopenic purpura (TTP) is most commonly seen in adults, whereas hemolytic-uremic syndrome (HUS) is more frequent in children.[77] TTP can result from pregnancy, cancer, drugs (chemotherapeutic-bevacizumab, and immunosuppressives—cyclosporine/tacrolimus, oral contraceptives, ticlopidine, and quinine), bone marrow transplantation, and autoimmune diseases. The most common pathogenesis



Figure 144-2 Nonpalpable ecchymoses in a patient on chronic oral glucocorticoid therapy. Note the rectangular and linear lesions that suggest the minor trauma component; the distal lesion shows that the ecchymosis surrounds a linear traumatic injury. (From Piette W: Myeloma, paraproteinemias, and the skin. *Med Clin North Am* **70**:155, 1986, with permission.)

is from antibodies, which interfere with the function of ADAMTS13. The result is improper cleavage of von Willebrand factor (VWF) and platelet-fibrin thrombotic microangiopathy.[78,79] Patients have increased levels of LDH with associated schistocytes, helmet cells, and megakaryocytes; clinical signs include fever, renal (especially in HUS), and central nervous system (headache, seizures, hemiparesis, disorientation) abnormalities. Despite clear evidence of visceral vessel occlusion from platelet plugging, the mechanism of petechial hemorrhage in TTP is far from clear. Occlusive disease was reported in a small series of mucous membrane lesions, but biopsies of cutaneous lesions are not reported, and the morphology of these lesions is more in keeping with simple hemorrhage. Deficiency of ADAMTS13 has been shown in familial TTP (congenital TTP, Upshaw–Schulman syndrome). The treatment of choice is fresh frozen plasma/plasmapheresis. Acquired functional deficiency of ADAMTS13 is known to occur in several other settings, most commonly with lupus and other



Figure 144-3 Classic palpable purpura on the leg of a patient with immunoglobulin A vasculitis. Partial blanching of an early lesion on compression supports the clinical impression of inflammatory hemorrhage.

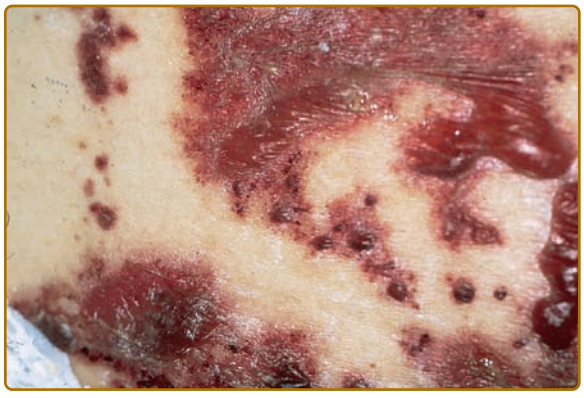

Figure 144-4 Inflammatory retiform palpable purpura in a patient with immunoglobulin A vasculitis. The initial erythematous phase is still present but fading in these lesions, and bullae have formed.

autoimmune diseases.[80] HUS is commonly caused by Shiga toxin, producing Gram-negative bacilli, especially *Escherichia coli* O157:H7 infection. It presents with bloody diarrhea and hemorrhagic colitis, and usually causes oliguric or anuric renal failure. Cutaneous lesions are not seen. Diarrhea-negative or atypical HUS is not associated with Shiga toxin-producing organisms, and occurs without an obvious predisposing condition. Preeclampsia-HELLP (hemolysis, elevated liver enzymes, low platelets) is another thrombotic microangiopathy that can mimic TTP/HUS syndromes.

TTP typically presents as round nonpalpable petechial hemorrhage, in contrast to the typical cutaneous presentation of heparin-induced thrombocytopenia (HIT), in which the retiform morphology of purpura is consistent with platelet-related occlusion of the cutaneous microvasculature. The platelet aggregation is triggered by an antibody, which recognizes antigenic sites on both heparin and platelet factor 4 on the platelet surface. Treatment of heparin necrosis typically involved anticoagulation with coumarin, but this treatment may worsen the vascular occlusion, leading to limb necrosis.[81] Worldwide, three accepted drugs are used in the treatment of patients with HIT: (1) danaparoid (not available in the United States), (2) recombinant hirudin (lepirudin), and (3) argatroban.[79]

NONPALPABLE, NONBLANCHABLE ECCHYMOSES (>1 cm)

The cutaneous lesions associated with scurvy are characterized by purpura that surrounds corkscrew hairs on the lower extremities (see Chapter 130), but nonspecific hemorrhage is more typical. True senile purpura is uncommon, and is usually the misdiagnosis for solar damage in poorly pigmented, often elderly individuals. Solar purpura usually occurs on the extensor surfaces of the forearms and results from the photoinduced loss of cutaneous elasticity and weakened dermal capillary support. Erythrocyte (RBC) extravasation occurs with minor trauma to the hands and other sites (see Chapter 109). Ecchymotic hemorrhage

after minor trauma generally results from procoagulant defects, poor dermal vessel support, or Waldenstrom hypergammaglobulinemic purpura (on the legs) (Table 144-3, Fig. 144-2).

PARTIALLY BLANCHING ROUND PURPURA (CLASSICAL PALPABLE PURPURA) AND PARTIALLY BLANCHING RETIFORM PURPURA

Lesions of inflammatory hemorrhage are round, partially blanching, and palpable, and most commonly represent leukocytoclastic or necrotizing vasculitis. The differential diagnosis of this morphologic presentation is listed in Table 144-4 (Fig. 144-3).

When purpura is *retiform* in configuration, but also associated with prominent early partial blanching, the potential causes of the inflammatory hemorrhage are more limited (Table 144-4, Figs. 144-4 and 144-5, inflammatory retiform purpura). Given the lesional number and distribution, a highly probable clinical hypothesis can be formulated. However, four occlusive syndromes may occasionally present with a few, large, indurated plaques of early inflammation of the dermis and subcutaneous tissue surrounding retiform purpura or eschar. These include: (1) antiphospholipid antibody syndrome; (2) warfarin necrosis; (3) heparin necrosis; and (4) cutaneous calciphylaxis. Among inflammatory causes of hemorrhage/vasculitis, only benign cutaneous polyarteritis nodosa is likely to cause such large necrotic thick plaques with early inflammation.

NONBLANCHING RETIFORM PURPURA

The differential diagnosis of cutaneous microvascular occlusion is extensive, and differs considerably from the usual list of causes of venous thrombosis and pulmonary emboli. Underlying causes can be organized by pathophysiology into eight categories, as shown in Table 144-5 (Figs. 144-6–144-8, nonblanching retiform purpura). Of note, although early lesions of cutaneous vasculitis typically blanch partially, occasionally patients with granulomatosis with polyangiitis (Wegener's) and microscopic polyangiitis may present with necrotic or retiform lesions without discernible erythema. Discussion of all occlusive syndromes is beyond the space limitations of this chapter, but two syndromes merit discussion because of frequent confusion in their use and definition: (1) disseminated intravascular coagulation (DIC) and (2) purpura fulminans. A newly recognized vasculopathy thought secondary to levamisole used to cut illicit cocaine typically presents with nonblanching retiform purpura and necrosis, typically involving ears and trunk or extremities (Fig. 144-8).[82,83] Though associated with both antineutrophil cytoplasmic antibodies



Figure 144-6 Disseminated intravascular coagulation and sepsis, with presumed sepsis-associated protein C depletion leading to purpura fulminans. Extensive geographic areas of cutaneous infarction with hemorrhage involving the face, breast, and extremities; although the patient looked alert, she died within several days. This catastrophic event followed sepsis after abdominal surgery.



Figure 144-5 Noninflammatory retiform palpable purpura on the thigh in a patient with disseminated intravascular coagulation secondary to sepsis, and sepsis-associated protein C depletion leading to purpura fulminans None of the lesional color faded on compression. The biopsy showed multiple dermal vessels occluded by clot without inflammation.



Figure 144-7 Cocaine/levamisole associated noninflammatory retiform purpura. This syndrome associated with cocaine use is most consistent with a levamisole-induced antiphospholipid antibody-related vascular occlusion syndrome, and on biopsy of early lesions in this case showed noninflammatory occlusion.



Figure 144-8 Leukemia cutis. Hundreds of tan-pink papules and a nodule on the trunk of a female with acute myelogenous leukemia arose during a 1-week interval. Per se, these lesions are "nonspecific" and do not represent a diagnosis; but when such an eruption is seen, one should perform a peripheral blood count and a biopsy.

and antiphospholipid antibodies, and both vasculitic and thrombotic histologic findings are reported, early lesional findings seem most consistent with thrombotic vasculopathy, with secondary vasculitic changes (personal observation, author).

DISSEMINATED INTRAVASCULAR COAGULATION.

DIC is not a disease, but rather always secondary to an underlying disorder. The disorders most commonly associated with DIC are listed in Table 144-6.

DIC is characterized by systemic activation of coagulation, insufficiently controlled by natural anticoagulant mechanisms, in concert with clot lysis, leading to the intravascular deposition of fibrin in the (micro) vasculature and the simultaneous consumption of coagulation factors and platelets.[84] In addition to evidence of clot formation, DIC is also defined by prolonged prothrombin and partial thromboplastin times (PT and PTT) as well as depleted fibrinogen. Elevated fibrin degradation products or d-dimers typically provide evidence of active clot lysis, although increased plasma soluble fibrin may be more specific. This combination can result in three clinical scenarios: (1) no clinical evidence of thrombosis or hemorrhage; (2) clinically evident thrombosis; or (3) simple bleeding into skin or tissues, including at from puncture sites. The pathogenetic pathways that play a role in the development of thrombosis include tissue factor-dependent activation of coagulation, defective physiologic anticoagulant pathways (such as the antithrombin system and the protein C system), and impaired fibrinolysis, caused by elevated levels of plasminogen activator inhibitor type 1.[85] Therapeutic strategies are based on the pathogenesis of DIC (trauma, burns, postsurgical, sepsis). These include administration of anticoagulants and strategies to restore physiologic anticoagulant pathways (such as activated protein C concentrate or antithrombin III.[84])

PURPURA FULMINANS.

Purpura fulminans is a severe skin disorder typically associated with DIC that was first reported in children and infants.[86] This term has been used by some to describe widespread cutaneous hemorrhage of any type in seriously ill patients. However, use of the term is best limited to neonatal, sepsis-related, and postinfectious syndromes associated with histologic evidence of small vessel thrombi, typically with clinical lesions of nonblanching retiform purpura or eschar.[68,73]

TABLE 144-6
Clinical Conditions Associated with Disseminated Intravascular Coagulation

- Sepsis/severe infection (any microorganism)
- Trauma (e.g., polytrauma, neurotrauma, fat embolism)
- Organ destruction (e.g., severe pancreatitis)
- Malignancy
  - Solid tumors
  - Myeloproliferative/lymphoproliferative malignancies
- Obstetric calamities
  - Amniotic fluid embolism
  - Abruptio placentae
- Vascular abnormalities
  - Kasabach–Merritt syndrome
  - Large vascular aneurysms
- Severe hepatic failure
- Severe toxic or immunologic reactions
  - Snake bites
  - Recreational drugs
  - Transfusion reactions
  - Transplant rejection

Purpura fulminans occurs in three clinical settings: (1) in relation to acute sepsis, (2) after infection, and (3) in neonates. Catastrophic antiphospholipid antibody syndrome is a mimic. In acute sepsis-associated or secondary purpura fulminans, the related overwhelming infection is most commonly meningococcal (see Chapter 181), but may be caused by many other Gram-positive and Gram-negative organisms. Patients are hypotensive with reduced peripheral perfusion, contributing to the skin necrosis on distal extremities and elsewhere (Fig. 144-6). Sometimes, skin necrosis occurs in a patchy distribution. Postinfectious purpura fulminans can manifest within 10 days of an antecedent illness, most commonly following streptococcal and/or varicella infections in children. Neonatal purpura fulminans is most often seen in association with homozygous protein C deficiency, in which massive intravascular thrombosis and abdominal wall gangrene can also develop.[87]

OTHER CUTANEOUS SIGNS AND SYMPTOMS ASSOCIATED WITH HEMATOLOGIC DISEASES

PALLOR

Pallor of the mucocutaneous tissue is observed most readily in the palms, nail beds, face, and conjunctivae. In these areas, the microvascular bed is visible through the skin. Pallor is the result of lowered hemoglobin content. Among the multiple causes for pallor are acute and chronic hemorrhage, emotion, drugs (i.e., vasopressors), cold, shock, and pathophysiologic adjustments that lead to anemia. Cutaneous edema can also produce pallor. Successful treatment of the underlying etiology corrects the pallor as well.

ANEMIA. The definition of anemia depends on the patient's age and sex. The palmar creases are a good indicator of the severity of anemia. Unless the hemoglobin level drops below 7 g/dL, palmar creases appear pink.[88] Constitutional signs and symptoms of anemia include malaise, fatigue, dizziness, postural hypotension, dyspnea on exertion, and tachycardia.

Anemias may be classified based on RBC volume as microcytic, normocytic, and macrocytic.[89] Review of the blood smear may also reveal distinctive morphologic red cell changes, such as targeting, spherocytosis, red cell fragmentation, or poikilocytosis, which narrow the diagnostic possibilities. Laboratory evaluation should be based on the suspicion of the underlying cause of anemia. In addition to complete blood count with white blood cell differential and red cell morphology, iron studies (iron, total iron blood count, percent saturation of iron), ferritin, B_{12}, lactate dehydrogenase (LDH), haptoglobin, folate levels, platelet and reticulocyte counts may be warranted based on initial laboratory evaluation.

MICROCYTIC ANEMIAS. Microcytic anemias are most often due to (1) iron deficiency, (2) anemia of chronic disease, (3) autoimmune hemolytic anemias, or (4) thalassemias. Of these, the first two are by far the most common.

IRON DEFICIENCY. Sixty percent to 70% of the body stores of iron are in the RBCs in the form of hemoglobin.[90] Heme-containing proteins are essential for metabolic processes in virtually all cells.[91] Hemoglobin, myoglobin, and the cytochromes are heme-containing proteins and enzymes. The average life of an erythrocyte is 120 days, after which it is phagocytized by macrophages of the liver, spleen, and bone marrow. The iron is then stored in the form of ferritin to be recycled.

Iron deficiency anemia can result from increased iron demand in the setting of inadequate iron stores. This is most commonly seen during pregnancy, because increased blood volume is necessary for fetal growth and development.

Symptoms of iron deficiency include fatigue, headache, tinnitus, irritability, paresthesias, burning sensations of the tongue, akathisia (restless leg syndrome), and pica (the craving to eat substances such as dirt, clay, ice, laundry starch, salt, or cardboard).[90] The physical findings of anemia in their approximate order of frequency include: pallor, glossitis (smooth red tongue), stomatitis, and angular cheilitis.[68] Skin dryness and coarsening, brittle nails, and fine, dry hair may also occur. Blue sclerae and koilonychias (spooning of nails) are rare. Retinal hemorrhages or exudates may develop with severe anemia (hemoglobin <5 g/dL), and iron deficiency may accelerate proliferative retinopathy in diabetics. Generalized fatigue often disrupts the patient's ability to focus on daily activities at work, home, and school, resulting in poor performance.[92]

Anemia of chronic disease is a common finding in chronically ill patients. Associated laboratory features somewhat mimic those of iron deficiency anemia with mild microcytosis and low serum iron, but with normal (i.e., not elevated) serum iron-binding capacity and transferrin. In some cases, bone marrow biopsy to stain for iron stores may be required to assess iron status.[91] This form of anemia appears to result from altered recycling of iron in chronic diseases states, and is not repaired by iron replacement. Appropriate diagnosis is important before beginning iron supplementation for microcytic anemia, since iron supplementation may worsen iron storage overload in patients with thalassemia.

Treatment of iron deficiency anemia requires replacing lost iron and maintaining the daily iron dietary requirement. The recommended daily dose for treatment of iron deficiency is between 150 to 200 mg/day of elemental iron (325 mg ferrous sulfate = 65 mg of elemental iron), usually continued until the hemoglobin reaches a normal value.[52]

MACROCYTIC ANEMIA. Megaloblastic anemia is classified as a macrocytic anemia characterized by enlarged erythroid precursor cells. There are numerous etiologies for macrocytic anemia; folate and cobalamin (vitamin B_{12}) deficiency are the most common. Folate and vitamin B_{12} deficiencies are distinguishable by their noncutaneous clinical presentations (see below),

but not by hematologic findings. Their deficiency leads to impaired purine and pyrimidine synthesis, preventing normal DNA replication. The macrocytic cells are a result of nuclear-cytoplasmic asynchronization.

Vitamin B_{12} is found only in meat and dairy products, making vegetarians prone to deficiency.[93] In nonvegetarian populations (especially of Scandinavia, Turkey, and Israel), vitamin B_{12} deficiency is caused by a rare genetic disorder of malabsorption, the Imerslund–Grasbeck syndrome. Pernicious anemia (PA) is the most common cause of vitamin B_{12} deficiency. It is an autoimmune disorder that attacks intrinsic factor in the ileum, which is essential to absorb vitamin B_{12}. The second cause of PA, chronic atrophic gastritis, results in autoantibodies against gastric parietal cells, which produce intrinsic factor.

Folate is found in animal products and in green leafy vegetables. Its deficiency is usually attributed to dietary inadequacy, alcohol abuse, malabsorption, and drugs that interfere with folate metabolism, i.e., methotrexate, phenytoin, trimethoprim. The demand for folate by the placenta and fetus usually doubles. Therefore, it is now standard care to give prophylactic folic acid supplements to all pregnant women to reduce the risk of neural tube defects in newborns.[94] Exfoliative skin disease and hemolysis can also lead to folate deficiency due to increased demand. Hereditary folate malabsorption results in impaired folate transport in the gastrointestinal tract and the blood–brain barrier.

Clinical findings of megaloblastic anemia develop slowly and vary, depending on the level of hemoglobin concentration and the etiology. The commonly shared signs and symptoms are malaise, fatigue, palpitation, glossitis, shortness of breath, and light-headedness. Mild jaundice can also be seen when ineffective erythropoiesis leads to hyperbilirubinemia and this, combined with anemic pallor, may lead to a characteristic lemon-yellow skin color. Hyperpigmentation is common in vitamin B_{12}- and folate-deficient patients, especially skin types III–VI. Patients with PA may also develop vitiligo or Hashimoto thyroiditis.[95] Hyperpigmentation is a common cutaneous manifestation of vitamin B_{12} deficiency.[96] The hyperpigmentation is usually prominent on the knuckles of the hands and feet, especially in darkly pigmented individuals.[97]

Neurologic findings in vitamin B_{12} deficiency, but not folate deficiency, help to clinically distinguish between the two causes of megaloblastic anemia.[93,94] Memory loss, dementia, tremor, Lhermitte's sign, irritability, atrophic glossitis, and neuropathy may occur. Specifically, patients with vitamin B_{12} deficiency develop subacute combined degeneration of the dorsal and lateral spinal columns—paresthesia (initial presentation), loss of vibration and position sense, shuffling gait, ataxia, spasticity, and paraplegia. The signs are symmetric in presentation and affect the lower extremities more than the upper extremities.

Typically, patients with folate deficiency are malnourished and often have diarrhea. Patients with alcoholism are prone to folate deficiency. Another distinguishing marker is that vitamin B_{12} deficiency takes many years to occur, given the large liver stores. Folate deficiency, on the other hand, can occur in a few months.

Correcting the underlying etiology usually resolves the anemia and reverses the signs and symptoms. Vitamin B_{12} is best administered parenterally. Prophylactic folic acid supplementation of 400 µg/day is recommended for all women of childbearing age. In folate-deficient patients, 1–5 mg/day of oral folic acid is recommended with subsequent maintenance therapy.

ANEMIA OF ENDOCRINE DISORDERS. Panhypopituitarism, hypothyroidism, and Addison disease are the most common endocrine disorders in association with anemia, although anemia may occur in hyperthyroidism and gonadal disease as well (see Chapter 151).

FLUSHING

DIFFERENTIAL DIAGNOSIS. Flushing occurs as a result of cutaneous vasodilation, and when associated with sweating is mediated through the sympathetic cholinergic fibers (Box 144-1; see Chapter 151).

POLYCYTHEMIA VERA

The hallmark cutaneous finding of polycythemia vera (PV) is ruddy cyanosis and plethora. Other skin findings are aquagenic pruritus, neutrophilic dermatosis, pyoderma gangrenosum, and purpura. Acrocyanosis is seen in conditions with elevated hemoglobin levels, but deoxygenated blood through the dilated vessels in the skin. Increased red cell mass is either a direct result of compensation for hypoxia or from primary disorders such as PV. These changes lead to an increase in

BOX 144-1 DIFFERENTIAL DIAGNOSIS OF FLUSHING

- Toxins: scombroid poisoning, drugs—ethanol, calcium channel blockers
- Rosacea
- Malignant carcinoid
- Mastocytosis
- Frey syndrome
- Fever
- Benign cutaneous flushing (blushing, exercise, temperature changes, spicy foods)
- Climacteric flushing (hot flashes)
- Chromaffin tumor
- Anaphylaxis
- Renal cell cancer
- Vasoactive intestinal polypeptide tumor
- Medullary carcinoma of thyroid
- Polyneuropathy, organomegaly, endocrinopathy, M protein, and skin changes
- Neurologic diseases (brain tumors, migraine headache, orthostatic hypotension, Parkinson)

POLYCYTHEMIA VERA AT A GLANCE

- Myeloproliferative disorder that involves all cell lines, with dominant erythropoietin proliferation and, subsequently, increased plasma volume and hematocrit.
- Presents with acrocyanosis, aquagenic pruritus, urticaria, and Sweet syndrome.
- Diagnostic criteria are (1) elevated red cell mass, (2) normal arterial O_2, and (3) splenomegaly.
- Treatment: concomitant therapy of aspirin and phlebotomy, cytoreductive therapy with hydroxyurea; narrowband ultraviolet B phototherapy for pruritus.

blood viscosity and vascular volume, resulting in a hypercoagulable state, especially when associated with thrombocytosis, and occasionally paradoxical hemorrhage from platelet dysfunction.[98]

Other symptoms are headache, paresthesia, and erythromelalgia. Erythromelalgia is a syndrome of altered acral responses, resulting in erythema and burning pain, especially when triggered by touching a warm object.[99] In myeloproliferative diseases, this syndrome is most probably secondary to platelet abnormalities, and may result in microvascular occlusion and necrotic lesions in affected areas. The catastrophic symptoms include large vessel arterial cerebrovascular (stroke) or cardiovascular (myocardial infarction) events, and peripheral arterial occlusion. PV has an unusually high incidence of portal and hepatic vein thrombosis (Budd–Chiari syndrome), lower extremity deep venous thrombosis, leg ulcers, Raynaud phenomenon, and pulmonary emboli. Bleeding manifestation is assumed to be a direct cause of dysfunctional platelets or von Willebrand disease. Defective primary hemostasis manifests with ecchymosis, menorrhagia, epistaxis, gingival hemorrhage, and, less frequently, gastrointestinal hemorrhage. Risk factors for PV are age (more than 60 years of age), history of thrombosis, cardiovascular risk factors (hypertension, smoking, hypercholesterolemia, diabetes), hereditary and acquired thrombophilic states (congenital deficiency of anticoagulants: antithrombin III, protein C and S; genetic mutation in factor V Leiden, prothrombin G20210A, or methylenetetrahydrofolate reductase), and acquired conditions (anticardiolipin antibodies and/or lupus anticoagulants).[98]

Diagnosis of PV has been greatly simplified in most cases by the ability to test for the *JAK2617F* mutation present in 95% of all patients.[100]

There is no specific therapy for PV. Treatment is directed toward preventing thrombohemorrhagic episodes and progression to myelofibrosis or leukemia. Aspirin may be of minor help in preventing thrombosis. Those not benefiting symptomatically from aspirin usually require platelet cytoreduction, (hydroxyurea, busulfan, radioactive phosphorus, chlorambucil, interferon) or anagrelide to inhibit platelet function. Phlebotomy is useful in controlling red cell mass, but may exacerbate thrombocytosis or leukocytosis.[100]

CYANOSIS

Cyanosis refers to discoloration of the mucocutaneous tissue that results in a blue or purple tinge, particularly in the peripheral tissues such as lips, ears, and nail beds. *Central cyanosis* refers specifically to the lingual and sublingual regions, and is more reflective of reduced hemoglobin in the blood; in peripheral cyanosis (skin, hands, feet, earlobes, etc.), the cause is often vasoconstriction. Cyanosis may be difficult to detect and is often missed on physical examination. Many factors, including natural skin pigment, thickness of the skin, and blood flowing through the cutaneous capillaries, determine the degree of cyanosis.

Cyanosis is detectable when at least 5 g of deoxygenated hemoglobin are circulating in the capillary blood, which correlates with an arterial concentration of deoxygenated hemoglobin of 3.4 g/dL. A patient with severe anemia of less than 7 g/dL Hg may never manifest cyanosis because they may become fatally hypoxic long before they reach 5 g/dL of desaturated hemoglobin, whereas a patient with PV frequently manifests ruddy cyanosis because the total increased hemoglobin content of their blood allows adequate oxygenation of tissue despite reaching the 5g/dL level at which the cyanosis becomes clinically evident (Box 144-2). Fluorescent light is best for detecting cyanosis. The diagnostic workup for a complete assessment of cyanosis includes complete blood cell count, arterial blood gas, pulse oximetry, partial arterial pressure of oxygen (PaO_2) level, and arterial oxygen saturation. If cyanosis is positional, an intracardiac mass must be considered.[24]

BOX 144-2 DIFFERENTIAL DIAGNOSIS OF CYANOSIS

- Deoxyhemoglobin
  - Acquired and inherited methemoglobinemia
  - Sulfhemoglobinemia
  - Low oxygen-affinity hemoglobin
- Abnormal hemoglobin
  - Congenital heart defects
  - Transposition of the great vessels
  - Tetralogy of Fallot
  - Ebstein's anomaly
- Arteriovenous fistulae, e.g., in Osler–Weber–Rendu syndrome or dyskeratosis congenital.
- Disorders of the central nervous system, respiratory system, musculoskeletal and circulatory systems can disrupt the oxygen supply to the tissues.

The causes of cyanosis are broad, but best if characterized into two groups: (1) disorders involving deoxygenated hemoglobin and (2) disorders of abnormal hemoglobin.[101,102] The latter includes acquired and inherited methemoglobinemia, sulfhemoglobinemia, and low oxygen-affinity hemoglobin. Methemoglobinemia causes clinically discernible cyanosis when the absolute level of methemoglobin exceeds 1.5 g/dL; this correlates with approximately 10%–15% methemoglobin. Offending agents are nitrates (found in drinking water, drugs, and food), topical anesthetic agents (lidocaine, benzocaine, and prilocaine), drugs (i.e., dapsone, phenazopyridine, sulfamethoxazole), and aniline dyes. Congenital methemoglobinemia is caused by deficiency in nicotinamide adenine dinucleotide (reduced form)–cytochrome b_5 reductase.[103] Treatment of choice for methemoglobinemia is intravenous methylene blue. Methylene blue should not be administered to patients with glucose-6-phosphate dehydrogenase deficiency. [104] If methylene blue is contraindicated, ascorbic acid can be given. RBC exchange transfusion has also been reported to be an effective treatment in symptomatic methemoglobinemic patients with coexistent glucose-6-phosphate dehydrogenase deficiency (see Chapter 225).

Sulfhemoglobin in concentrations greater than 0.5 g/dL in capillary blood also causes cyanosis, and cannot be reversed. Medications (especially sulfonamides, phenacetin, acetanilide, and phenazopyridine are the usual causes, but this condition has occurred independent of drug use in association with chronic constipation and purging. Offending agents in cases of acquired methemoglobinemia should be discontinued. No other therapy may be required. But if the patient is symptomatic, methylene blue, 1–2 mg/kg over 5 minutes, provides an artificial electron acceptor for the reduction of methemoglobin via the NADPH-dependent pathway. Response is usually rapid; the dose can be repeated in 1 hour, but frequently this is unnecessary. Caution should be exercised to avoid an overdose because large (more than 7 mg/kg) cumulative doses have been reported to cause dyspnea, chest pain, and hemolysis. Because co-oximetry detects methylene blue as methemoglobin, it cannot be used to monitor methemoglobin levels after treatment with methylene blue; however, the specific Evelyn-Malloy method allows for the discrimination of methemoglobin from methylene blue. Sulfhemoglobinemia occurs as sulfur binds to hemoglobin, resulting in irreversible deoxyhemogobinemia. It produces cyanosis at levels of only 0.5-g/dL capillary blood. Etiologies are drugs (sulfonamides, phenacetin, acetanilide, and phenazopyridine), constipation, and purging.

Low oxygen hemoglobin affinity occurs at altitude of 5,000 m (16,000 ft) or higher and can cause hypoxemia severe enough to result in cyanosis. Emotion, cold exposure, Raynaud phenomenon, and cryoglobulins (cold agglutinins) are some nonhematologic causes of peripheral cyanosis.

Disorders involving deoxygenated hemoglobin include congenital heart defects in the newborn (i.e., transposition of the great vessels, tetralogy of Fallot, and Ebstein's anomaly). X-linked dyskeratosis congenita presents with abnormal pigmentation, telangiectasias, nail dystrophy, leukoplakia; rarely, arteriovenous fistulas with central cyanosis occur. Arteriovenous fistulas are a feature of Osler–Weber–Rendu syndrome as well. Other disorders of the central nervous system, respiratory tract, and musculoskeletal and circulatory systems can also disrupt the oxygen supply to the tissues.

JAUNDICE

JAUNDICE AND EXTRAMEDULLARY HEMATOPOIESIS AT A GLANCE

- Jaundice is detectable when bilirubin levels are approximately 51 M (3.0 mg/dL) under nonfluorescent lighting, especially in the sclerae and sublingual region
- Differential diagnosis of jaundice: carotenemia causes yellow pigment in palms, soles, forehead, and nasolabial folds; quinacrine leads to yellowing of skin, but not sclera.
- Extramedullary hematopoiesis: cutaneous lesions include nodules ulcers, erythematous papules, violaceous plaques, and diffusely erythematous induration; biopsy confirms diagnosis but underlying cause needs to be determined.

Jaundice (icterus) refers to the yellowish discoloration of the skin, caused by elevated bilirubin levels. The discoloration is a direct result of the bile pigment that stains the skin, suggesting an abnormality in bilirubin clearance or increased production due to hepatobiliary disease (see Chapter 150) or a hemolytic disorder. Kernicterus or permanent damage to the neonatal brain associated with hyperbilirubinemia is a serious risk.

INFILTRATIVE LESIONS

EXTRAMEDULLARY HEMATOPOIESIS. Synthesis of blood elements outside the bone marrow usually takes place in the spleen and liver but can also affect the skin. The dermis is a normal site of hematopoiesis during early fetal development. Cutaneous lesions of extramedullary hematopoiesis include nodules (can be sclerosing), ulcers, erythematous papules, violaceous plaques, and diffusely erythematous induration. Neonates with dermal hematopoiesis present as blueberry muffin babies with dark blue-colored to violaceous nodules. In neonates, the causes are erythroblastosis fetalis, chromosomal abnormalities, infections, congenital hemolytic anemia, thalassemia, and twin-to-twin transfusion.[105] Older individuals may show dermal hematopoiesis from hemolytic anemias, myeloproliferative syndromes such as chronic idiopathic myelofibrosis and

PV, thalassemia, and osteoporosis. The histologic findings are intradermal proliferation of immature granulocytes, megakaryocytes, and erythroid and myeloid precursor cells.

LEUKEMIA CUTIS. Leukemia cutis (LC) is a localized or disseminated skin infiltration by leukemic cells. It is usually a sign of dissemination of systemic disease or relapse of existing leukemia. Reported incidence varies from less than 5%–40%, depending on the type of leukemia, both acute and chronic, including the leukemic phase of non-Hodgkin lymphoma and hairy cell leukemias. It most commonly occurs with acute monocytic leukemia (AML-M5) and acute myelomonocytic leukemia (AML-M4).

Pattern of presentation of skin lesions in LC is variable and may have features that overlap with other (inflammatory) eruptions. Most common lesions are small (2–5 mm) papules (Figs. 144-9 and 144-10), nodules (Fig. 144-11), or plaques. LC lesions are usually somewhat more pink, violaceous, or darker than normal skin, always palpable, indurated, firm, or guttate psoriasiform or lymphomatoid papulosis-like lesions, but usually not tender. They are localized or disseminated; usually on trunk (Fig. 144-9), extremities, and face (Fig. 144-10), but may occur at any site. They may be hemorrhagic when associated with thrombocytopenia or may ulcerate. Erythroderma may (rarely) occur. Leukemic gingival infiltration (hypertrophy) occurs with acute monocytic leukemia. Similar lesion morphologies occur with different types of leukemia or specific types of leukemia may present with a variety of morphologies.

Inflammatory disorders occurring in patients with leukemia are modified by the participation of leukemic cells in the infiltrate, resulting in unusual presentations of such disorders (e.g., psoriasis with hemorrhage or erosions/ulcerations). Also, there are a number of cutaneous inflammatory diseases that may be associated with leukemia: Sweet syndrome (see Chapter 32), bullous pyoderma gangrenosum (see Chapter 33), urticaria (see Chapter 38), and necrotizing vasculitis (see Chapter 163).



Figure 144-9 Leukemia cutis. Multiple skin-colored and erythematous papules in a 38-year-old febrile woman that had erupted approximately 1 week before this picture was taken. The patient had acute myelogenous leukemia.



Figure 144-10 Leukemia cutis: chloroma. Large, ulcerated, green-hued tumors (chloromas) in the inguinal and perineal regions of a female with acute myelogenous leukemia; similar lesions were also present in the axillae and on the tongue.

Systemic symptoms are those associated with hematologic malignancy. Not infrequently, cutaneous manifestation may be the initial presenting symptom and may contribute importantly to the diagnosis.

The diagnosis is made by suspicion and verified by skin biopsy, immunophenotyping, and B- or T-cell receptor rearrangement studies. Hematologic studies with complete analysis of bone marrow aspirate and peripheral blood smear are then needed to make the diagnosis. If cutaneous findings precede any systemic disease, careful assessment of peripheral blood smears and bone marrow biopsies must be made.

The prognosis of LC is directly related to the prognosis for systemic disease. Therapy is usually directed at the leukemia itself.

KEY REFERENCES

Full reference list available at www.DIGM8.com

DVD contains references and additional content

67. Piette WW: The differential diagnosis of purpura from a morphologic perspective. *Advances Dermatology* **9**:1994
69. George JN, Aster RH: Drug-induced thrombocytopenia: Pathogenesis, evaluation, and management. *Hematology Am Soc Hematol Educ Program 2009* 153–158,2009
70. Piette WW: Cutaneous manifestations of leukemias, myelodysplastic and myeloproliferative syndromes, and systemic leukemias. In: *Dermatological Signs of Internal Disease*, edited by JP Callen et al. Saunders. 2009, pp. 125–134

73. Robson JK, Piette WW: The presentation and differential diagnosis of cutaneous vascular occlusion. *Advances Dermatology* **15**, 1999
77. Sadler JE, Mortimer P: Antibody-mediated thrombotic disorders: Thrombotic thrombocytopenic purpura and heparin-induced thrombocytopenia. In: *Williams Hematology*, edited by K Kaushanshky, et al. New York, McGraw-Hill, 2010, pp. 2163-2183
78. Zhou Z, N.T. C, D.J. F: Von Willebrand factor, ADAMTS-13, and thrombotic thrombocytopenic purpura. *Sem Thromb & Hemostasis* **36**(1):71–81, 2010
79. Moake J: Thrombotic thrombocytopenia purpura (TTP) and other thrombotic microangiopathies. *Best Pract Res Clin Haematol* **22**(4):567–576, 2009
88. Weiss G, Goodnough LT: Anemia of chronic disease. *N Engl J Med* 352:1011, 2005

Chapter 145 :: Cutaneous Lymphoma

:: Marc Beyer & Wolfram Sterry

CUTANEOUS LYMPHOMA AT A GLANCE

- Second most common group of extranodal lymphomas; estimated annual incidence is 1 in 100,000.
- Clonal proliferations of neoplastic T or B lymphocytes, and rarely of natural killer cells or plasmacytoid dendritic cells, arising in mid and late adulthood.
- Clinical behavior and prognosis are completely different from those of histologically similar systemic lymphomas.
- Most common form of cutaneous lymphoma is mycosis fungoides (MF), a cutaneous T-cell lymphoma, which is categorized as patch, plaque, or tumor stage. Related features include severe pruritus, alopecia, palmoplantar hyperkeratosis, and bacterial superinfection
- Histologically the patch/plaque stage of MF is characterized by an epidermotropic band-like infiltrate of neoplastic T lymphocytes with hyperconvoluted cerebriform nuclei involving the upper dermis variably with exocytosis and formation of intraepidermal Pautrier's microabscesses. The tumor stage consists of a dermal nodular infiltrate sparing the epidermis.

INTRODUCTION

Cutaneous lymphomas (CLs) represent clonal proliferations of neoplastic T or B lymphocytes and rarely of natural killer (NK) cells or—for historical reasons—plasmacytoid dendritic cells. CLs have been recognized as a heterogeneous group with distinct variability in clinical presentation, histopathology, immunophenotyping, and prognosis.

Primary CLs often show a completely different clinical behavior and prognosis than do histologically similar systemic lymphomas, which may involve the skin secondarily. Therefore, primary CLs require different approaches to treatment. For this reason, a consensus classification has been created based on both the European Organisation for Research and Treatment of Cancer (EORTC) classification for primary CLs and the World Health Organization (WHO) classification for tumors of hematopoietic and lymphoid tissues. This first common classification (WHO-EORTC)[1] categorizes the entities according to lineage and then according to a combination of morphology, immunophenotype, genetic features, and clinical syndromes (Box 145-1) and constituted the basis for the classification of CLs in the new WHO classification 2008.[2] This chapter discusses the most frequent cutaneous T-cell lymphomas (CTCLs)—mycosis fungoides (MF), Sézary syndrome (SS), primary cutaneous anaplastic large-cell lymphoma (cALCL), and lymphomatoid papulosis (LyP)—and the most frequent cutaneous B-cell lymphomas (CBCLs)—primary cutaneous follicle center lymphoma (PCFCL), primary cutaneous marginal zone lymphoma (PCMZL), and primary cutaneous diffuse large B-cell lymphoma (PCLBCL), leg type. These seven types of cutaneous lymphoma represent nearly 90% of all CLs.[3] Rare entities occurring primarily in the skin are also described.

EPIDEMIOLOGY

CLs represent the second most common group of extranodal lymphomas after the primary gastrointestinal lymphomas.[4] The annual incidence is estimated to be 1 per 100,000.[5]

PRIMARY CUTANEOUS T-CELL LYMPHOMAS

CTCLs are non-Hodgkin lymphomas characterized by a dominant skin-homing T-cell clone. They represent

BOX 145-1 WHO-EORTC CLASSIFICATION OF PRIMARY CUTANEOUS LYMPHOMAS

CUTANEOUS T-CELL AND NK-CELL LYMPHOMAS

- Mycosis fungoides
- Mycosis fungoides variants and subtypes
  - Folliculotropic mycosis fungoides
  - Pagetoid reticulosis
  - Granulomatous slack skin
- Sézary syndrome
- Adult T-cell leukemia/lymphoma
- Primary cutaneous CD30-positive lymphoproliferative disorders
  - Primary cutaneous anaplastic large-cell lymphoma
  - Lymphomatoid papulosis
- Subcutaneous panniculitis-like T-cell lymphoma
- Extra-nodal NK/T-cell lymphoma, nasal type
- Primary cutaneous peripheral T-cell lymphoma, unspecified
  - Primary cutaneous aggressive epidermotropic $CD8^+$ T-cell lymphoma (provisional)
  - Cutaneous γ/δ T-cell lymphoma (provisional)
  - Primary cutaneous $CD4^+$ small or medium-sized pleomorphic T-cell lymphoma (provisional)

CUTANEOUS B-CELL LYMPHOMAS

- Primary cutaneous marginal zone B-cell lymphoma
- Primary cutaneous follicle center lymphoma
- Primary cutaneous diffuse large B-cell lymphoma, leg type
- Primary cutaneous diffuse large B-cell lymphoma, other
  - Intravascular large B-cell lymphoma (provisional)
- Precursor hematologic neoplasm
- $CD4^+/CD56^+$ hematodermic neoplasm (blastic NK-cell lymphoma)

NK = natural killer; WHO-EORTC = World Health Organization and European Organisation for Research and Treatment of Cancer.

approximately 80% of all CLs. The most common forms (approximately 65% of CTCL) are MF and SS, with an annual incidence of five new cases per million people. After MF and SS, the primary cutaneous $CD30^+$ lymphoproliferative disorders comprising LyP and cALCL represent the second most common group of CTCLs (approximately 27%).

ETIOLOGY

For many years, CTCLs were thought of as a disease of long-term antigen stimulation in which an initial inflammatory response in the epidermis leads to T-cell proliferation and, finally, to the emergence of a malignant clone.[6] Despite much effort to identify such an antigen, the etiology remains unknown.

ENDOGENOUS FACTORS

Due to the above-mentioned hypothesis of antigen stimulation several studies have analyzed the HLA background of affected individuals. Two independent studies showed an association of distinct HLA class II molecules and MF or SS, i.e., the alleles HLA-DRB1*11 and DQB1*03 are significantly overrepresented in these patients.[7,8]

EXOGENOUS FACTORS

A viral etiology for CTCLs was an attractive hypothesis given the cutaneous similarities to adult T-cell lymphoma/leukemia, which is associated with human T-cell lymphotrophic virus type 1 (HTLV-1) infection (see Chapter 197). The results of studies to determine an association between CTCL and HTLV-1 are contradictory. Although few studies reported detection of HTLV-1 or -2 sequences by polymerase chain reaction (PCR) analysis in peripheral blood mononuclear cells (PBMCs) or skin biopsies of CTCL patients,[9,10] most reports of American and European populations repeatedly failed to demonstrate an association of MF with HTLV-1 infection by PCR, Southern blot, and reverse transcriptase assays.[11–13] These data suggest that HTLV-1 does not play an important role in the etiology of CTCLs, and that the only reason to screen patients for antibodies is suspicion that the diagnosis is adult T-cell lymphoma/leukemia rather than MF. Epstein-Barr virus (EBV) has also been proposed as a causative pathogen.[14] Given its association with other lymphoproliferative disorders and lymphomas, such as Burkitt lymphoma, this seemed logical. Several studies have shown that EBV is detectable only in a minor percentage of CTCL lesions. In these studies, EBV detection was related to a poor prognosis and its presence is more likely related to immunosuppression caused by either the disease or the therapy, than to etiology of CTCL.[15] However, a strong association of EBV and a rare cutaneous lymphoproliferative disease with a hydroa vacciniforme-like appearance, which occurs mostly in people of Asian origin has been observed.[16]

Bacterial infections have also been implicated in the etiology of CTCLs.[17] Of special interest has been the hypothesis that superantigens from *Staphylococcus aureus* may be responsible for chronic antigenic stimulation.[18] In several studies, *S. aureus* has been detected in a high percentage on the skin of CTCL patients with a high tumor burden, while patients in early stage disease did not show significant differences to control groups.[19,20] Though these studies conclusively demonstrated the involvement of *S. aureus* in disease exacerbation and clinical improvement following antibiotic treatment, the missing difference in *S. aureus* colonization of early stages of CTCL and control groups questions the involvement of *S. aureus* or superantigens produced by these bacteria in initiation of CTCLs.

Besides infectious pathogens, it has also been suggested that environmental and occupational risk factors play a causative role in CTCL, because an indolent dermatitis often precedes the diagnosis. Exposure to carcinogens in the work environment could provide the suspected long-term antigenic stimulation for the initiation of the clonal expansion. In epidemiologic studies,[21,22] several occupations like glass formers, potters, or paper and wood industry workers have been associated with a higher risk for development of MF. However, neither are the results of the different studies consistent nor could a common denominator like exposure to known carcinogens be identified. With regard to chronic antigenic stimulation by occupational contact allergens it has to be taken into account that MF arises typically on body areas like the lateral trunk, which are protected by clothing during working time. Also other environmental risk factors, like consumption of alcohol, smoking, or exposure to ultraviolet (UV) radiation, were not consistently observed in association with an increased risk for CTCLs.

PATHOGENESIS

The clinical entities encompassed by the term *cutaneous T-cell lymphoma*s share several components: the epidermal and/or dermal microenvironment, a clonal T-cell population, and a modulated antitumor response.[23,24] It has to be kept in mind that due to the rare occurrence of CTCLs in general and of the less prevalent subtypes in particular, nearly all of the knowledge on pathogenetic events has arisen from studies on specimens from MF and SS patients.

The basis for CTCLs as a malignancy confined to the skin, at least in the initial stages of the disease, is the expression of skin-specific homing receptors on the malignant T-cell clone. Skin-homing T cells can be distinguished from other T cells by a unique cell surface receptor called *cutaneous lymphocyte-associated antigen* (CLA). CLA is an inducible posttranslational carbohydrate modification of the ubiquitously expressed T-cell surface protein, P-selectin glycoprotein ligand 1 by α(1,3)-fucosyltransferase and is expressed on 30% of memory T cells in the peripheral blood.[25] It has been shown that induction of CLA expression on T cells occurs during the transition from naive to memory T cells and is mediated by dendritic cells isolated from peripheral skin draining lymph nodes.[26] CLA-positive cells have the ability to home to the skin by binding to E-selectin, which is expressed on endothelial cells of dermal postcapillary venules and is superinduced during cutaneous inflammation. As T cells in CTCLs express CLA and CD45RO, a memory T-cell marker, it is though that CTCLs arise from skin homing memory T cells. However, as CLA expression is strongly detectable in skin biopsies from both MF and inflammatory dermatoses, it cannot be used for the distinction of malignant and reactive T cells or malignant from inflammatory skin conditions.[27] In addition to CLA, expression of the chemokine receptors CCR4 and CXCR3 has been implicated in homing of the malignant cells to the epidermis and dermis. Furthermore, the respective ligands, i.e., the chemokines CCL17 and CCL22 have been found in skin lesions of CTCLs.[28] Interestingly, diminished expression of these skin homing receptors seems to be associated with more aggressive disease, i.e., large cell transformation, tumor formation. and dissemination of tumor cells into the blood or lymph nodes.[29,30]

Besides chemokines that attract the T cells into the skin, cytokines play an important role in the pathogenesis of CTCLs. Because of the memory phenotype of the tumor cells the cytokines interleukin 7 (IL-7) and IL-15, which are necessary for long-term survival and basal homeostatic proliferation of CD4 memory T cells, are of special interest.[31] In vitro studies and immunohistochemical analyses on skin biopsy specimens from lesions of MF demonstrate the presence of IL-15 and IL-7 and their capacity to prolong survival of a cell line derived from a SS patient in vitro, probably by an upregulation of the antiapoptotic protein bcl-2. As source of these cytokines both keratinocytes and the tumor cells themselves have been discussed.[32,33]

Direct genetic analysis of the clonal T cells and the identification of pathogenetically relevant genes in CTCLs have been hampered by the difficult differentiation of malignant and reactive lymphocytes in skin specimens on the one hand and by a large variety of reported genetic alterations on the other. The basis for the latter phenomenon is a chromosomal instability in tumor cells of patients with CTCLs, which has been described repeatedly.[34] In the last years, the application of large-scale genome analysis by comparative genomic hybridization and array technologies has elucidated the genetic basis for established pathogenetic factors and disclosed several new pathways, which are of central importance in the pathogenesis of CTCLs. These studies were conducted on samples with high tumor load from MF (skin biopsy specimens from tumors) and SS (PBMCs) patients, and also demonstrated considerable differences of these two entities in regard to genetic abnormalities.[35] The most consistent results were obtained for chromosomal and transcriptional gains affecting the proto oncogene *MYC* and loss of the tumor suppressor gene *TP53*, a combination for which it is shown to induce genetic instability by disrupting cell cycle control and apoptosis.[36] Furthermore, gains of genes important for the generation of survival signals, for example, the cytokine IL-7, the IL-2 receptor or transcription factors like STAT3/5, as well as alterations in members of the NFκB pathway, have been described.[37] In addition to gains, losses of well-known tumor suppressor genes, for example, *CDKN2A* (p16), were detected.[38]

Loss of Fas expression on tumor cells is of special importance as the Fas receptor/Fas ligand (FasL) pathway is involved in activation induced cell death of physiologically activated T cells. Loss of Fas has been linked to escape from the antitumoral immune response in diverse cancer entities.[39] Fas receptor and FasL are transmembrane proteins of the tumor necrosis factor family and are expressed on cells of lymphoid and myeloid lineage. On binding of the Fas ligand to Fas, a cascade of events is initiated that finally leads to apoptosis.

Aberrations of the Fas/FasL pathway have been studied in CTCLs. Immunohistochemical studies of Fas

expression in skin biopsy specimens from MF lesions demonstrated loss of Fas expression the in tumor stage, while expression was clearly detectable in early patch and plaques stage.[40] In addition to the loss of Fas expression on the cell surface, upregulation of intracellular proteins like cFLIP, which inhibit Fas-initiated apoptosis has been shown in CTCL cells.[41] Thus, downregulation or loss of Fas expression as well as disturbance of intracellular pathways activated by death receptors may counteract proapoptotic signals given to the tumor cells by antitumoral immune cells, finally resulting in immune escape of the tumor cells in CTCLs.

In conclusion, specific mechanisms for all features that have been proposed to be necessary for the evolution of tumor cells,[42] like evasion of apoptosis, generation of growth or survival signals and insensitivity to antigrowth signals, mechanism of tissue homing and metastasis have nowadays been demonstrated in CTCL cells.

Finally CTCLs exhibit a modulated antitumor response. It is well established that patients with CTCLs have variable production and response to T helper 1 and 2 (Th1, Th2) cytokines. Early studies that measured the messenger RNA (mRNA) levels of Th1 and Th2 cytokines showed that, at any stage of disease, mRNA of the Th2 cytokines interleukin 4 and 5 (IL-4, IL-5), could be found, with the persistence of Th2 cytokine mRNA in skin more frequent in the tumor stage. Correlation of the amount of the Th2 cytokine IL-10, which has immunosuppressive functions, and disease stage in CTCLs has been described.[43] The decline in interferon (IFN)-γ and predominance in Th2 cytokines, which is accompanied by a decreasing number of circulating dendritic cells in the blood, might be responsible for the loss of immunosurveillance, which allows CTCL to progress. Lesions of CTCLs often have a $CD8^+$ T-cell component. Although they were once thought to be innocent bystanders in the epidermis, data have now defined the responsibility of $CD8^+$ T cells in the antitumor response. The first insight into defects in the integrity of normal T-cell function in patients with advanced stages of CTCLs came from the observation of patients who had been treated with extracorporeal photochemotherapy (ECP).[44] Responding patients had significantly lower CD4/CD8 T-cell ratios and higher absolute numbers of $CD8^+$ T cells in their peripheral blood at the outset of treatment than did nonresponders. In general, skin biopsy specimens of MF lesions in early stages (T1 and T2) harbor a higher proportion of $CD8^+$ cells than lesions in advanced stages. Improved long-term prognosis was correlated with the presence of these $CD8^+$ tumor-infiltrating lymphocytes (TIL) in MF.[45] It is now believed that these $CD8^+$ cytotoxic T cells play an important part in the pathogenesis of CTCLs, mainly in mediating an antitumor response.

An interesting hypothesis pursued during the recent years, proposes that the malignant T cells themselves exhibit properties of regulatory T cells (T regs) and thereby are able to modulate the antitumoral immune response.[46] However, the results of studies enumerating T regs in CTCL biopsy specimens were inconsistent. These conflicting results may be due to the fact that both a decrease of T regs as well as an increase of CD25-negative T regs, which then are phenotypically identical with the malignant clone, can be observed in SS.[47]

MYCOSIS FUNGOIDES

DEFINITION. MF is the most frequent disease among CTCLs, usually arising in mid-to-late adulthood (median age at diagnosis, 55–60 years) with a male predominance of 2:1.

CLINICAL FINDINGS

Skin Signs. Clinically, MF is categorized as being in the patch, plaque, or tumor stage, but patients may simultaneously have more than one type of lesion. In early patch-stage MF (Figs. 145-1 and 145-2), there are single or multiple erythematous, scaly macules and patches that vary in size and are usually well defined. The color of the lesions may vary from orange to a dusky violet–red. The distribution classically favors nonsun-exposed sites, with the "bathing trunk" and intertriginous areas predominant early in the course of the disease. The eruption may be intensely pruritic or asymptomatic and occasionally may be transitory, disappearing spontaneously without scarring. Diagnosis at this stage may be difficult. Often a patient will recall a preceding "chronic dermatitis" for 10–20 years that may have been considered to be therapeutically resistant contact dermatitis, atopic dermatitis, psoriasis, or eczema. In any patient with a dermatosis that is refractory to the usual modalities of treatment, multiple biopsy specimens should be taken to pursue a diagnosis.

Patches may last for months or years before progressing to the plaque stage (Fig. 145-3), or plaques may arise de novo. Plaques appear as sharply demarcated, scaly,



Figure 145-1 Patch lesions of mycosis fungoides in typical locations on the lateral trunk.



Figure 145-2 Large patch lesions of mycosis fungoides surrounding areas of uninvolved skin.



Figure 145-4 Multiple patches and plaques of mycosis fungoides on the lateral trunk. In this patient the plaques developed rapidly and partially show central necrosis.

elevated lesions that are dusky red to violaceous and variably indurated (Figs. 145-3 and 145-4). Lesions in this stage may regress spontaneously or may coalesce to form large plaques with annular, arcuate, or serpiginous borders, and may clear centrally with disease activity remaining at the periphery of the lesion. There may be purpuric hyperpigmentation or hypopigmentation and poikiloderma.

Tumors may occur anywhere on the body, but have a predilection for the face (Figs. 145-5 and 145-6) and body folds: axillae, groin, antecubital fossae, and, in women, the inframammary area. These may occur in preexisting plaques or patches of MF, which coincides with an extension of these lesions in the vertical dimension (Fig. 145-3). At this point, the neoplastic cells behave in a biologically more aggressive manner, with pronounced tumor cell accumulation that leads to the clinical appearance of an expanding dermal nodule (see Fig. 145-6). De novo occurrence suggests metastatic spread by cells of a malignant T-cell clone. The nodules are reddish brown or purplish red and smooth surfaced, but they often ulcerate and may become secondarily infected. Growth rate is variable.



Figure 145-3 Polymorphic nature of mycosis fungoides. Patches and a plaques with a developing nodule on the left buttock.



Figure 145-5 Leonine facies characterized by infiltrated plaques and tumors of cutaneous T-cell lymphoma.



Figure 145-6 Tumor lesions of mycosis fungoides on the right arm, which are partially eroded and ulcerated.

Patients with tumors tend to have a more aggressive form of the disease than patients with patch and plaque disease.

Erythroderma (Fig. 145-7A) may start de novo or develop in MF. The nomenclature for erythrodermic phases of CTCL varies. It has been proposed that erythroderma be defined as the involvement of 80% of body surface area with lesions of ill-defined borders and that patients with a history of preexisting MF be defined as having a separate syndrome of "erythrodermic MF."

The skin is diffusely bright red with readily apparent scaling, but there may be characteristic islands of uninvolved skin, termed *nappes claires* (Fig. 145-2). There may be sparing of the areas of skin that are frequently folded, such as the abdomen and antecubital and axillary areas. This sparing produces a finding often called the *deck chair* or *folded luggage* sign. Some patients with the erythrodermic form of CTCL develop tumors.

Other Symptoms. Patients may complain of fever, chills, weight loss, malaise, insomnia secondary to the overwhelming pruritus, and poor body temperature homeostasis. There may be hyperkeratosis, scaling and fissuring of the palms and soles, alopecia, ectropion, nail dystrophy, and ankle edema, with the integument being shiny and hidebound. These changes result in pain on walking and extreme difficulty with tasks requiring manual dexterity. Such patients experience severe restrictions by the extent and localization of their skin manifestations. Pruritus is often intense, which results in excoriation, exudation, and secondary infection that may dominate the clinical picture.

DIFFERENTIAL DIAGNOSIS.

The differential diagnosis of MF is summarized in Box 145-2.

HISTOPATHOLOGY.

In the patch, plaque, and also in the erythrodermic stage, there is a band-like infiltrate in the upper dermis composed of reactive T cells and neoplastic T lymphocytes, which are characterized by hyperconvoluted cerebriform nuclei. The neoplastic T cells show an epidermotropism with formation of intraepidermal Pautrier's microabscesses (Figs. 145-8 and 145-9). In the tumor stage, a nodular infiltrate in the dermis is found, and the epidermal component is much less pronounced (Fig. 145-10). Immunohistologically, the malignant cells express a mature peripheral T-cell ($CD4^+$) phenotype. Partial loss of pan-T-cell antigens



Figure 145-7 Sézary syndrome patient with erythroderma (**A**), palmar fissuring (**B**), and plantar hyperkeratosis (**C**).

BOX 145-2 DIFFERENTIAL DIAGNOSIS OF MYCOSIS FUNGOIDES

PATCH/PLAQUE STAGE

- "Chronic dermatitis"
- Psoriasis
- Contact dermatitis
- Eczema
- Tinea corporis

TUMOR STAGE

- B-cell lymphoma
- Carcinoma cutis
- Sarcoidosis
- Deep fungal infection
- Atypical mycobacterial infection
- Leprosy
- Leishmaniasis

ERYTHRODERMA

- Pityriasis rubra pilaris
- Psoriasis
- Atopic dermatitis
- Drug eruption
- Seborrheic dermatitis

such as CD7 and CD3 may be a feature of MF but is not pathognomonic of the disease. Analysis of T-cell receptor genes (TCR) typically shows a clonal rearrangement as demonstrated by PCR or Southern blot techniques.

TREATMENT AND PROGNOSIS. Treatment should be stage-adapted and alleviate symptoms (see Sections "Staging of Cutaneous T-Cell Lymphomas" and "Principles of Treatment of Cutaneous T-Cell Lymphoma"). The prognosis depends on the type and extent of skin involvement (plaques, tumors, or erythroderma), the presence of lymph node involvement, and the presence of visceral disease. Overall, patients

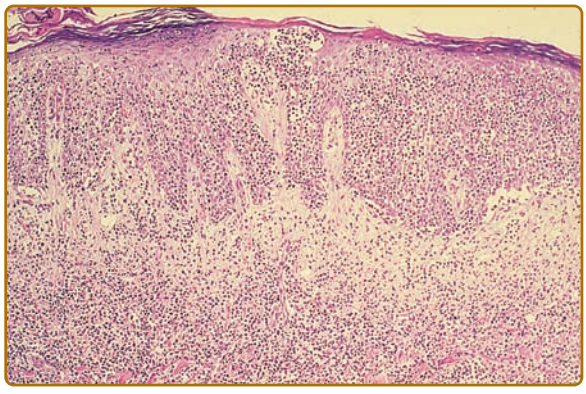

Figure 145-8 Dense mononuclear cell infiltrate extending from the papillary dermis into the epidermis. The epidermis is completely permeated by these cells, which form a Pautrier's abscess.

with MF limited to the skin have a 5-year survival rate of 80%–100%. In contrast, patients with lymph node involvement show a 5-year survival rate of 40%.

MYCOSIS FUNGOIDES VARIANTS

FOLLICULOTROPIC MYCOSIS FUNGOIDES. Folliculotropic MF represents a distinct variant of MF characterized by preferential involvement of the head and neck by folliculotropic T-cell infiltrates, with or without mucinous degeneration of the hair follicles (Fig. 145-11B). Previously, this variant was called *follicular mucinosis* or *alopecia mucinosa*. Folliculotropic MF affects mostly adults and is rarely observed in children and adolescents. Patients may have grouped follicular papules (see Fig. 145-11A), acneiform lesions, indurated plaques, and sometimes tumors, which usually involve the head and neck region. The occurrence of hair loss within the lesions, most conspicuous on the eyebrows, an intense pruritus, and secondary bacterial infections is common.

HYPOPIGMENTED MYCOSIS FUNGOIDES. Patients with dark skin develop hypopigmented MF,

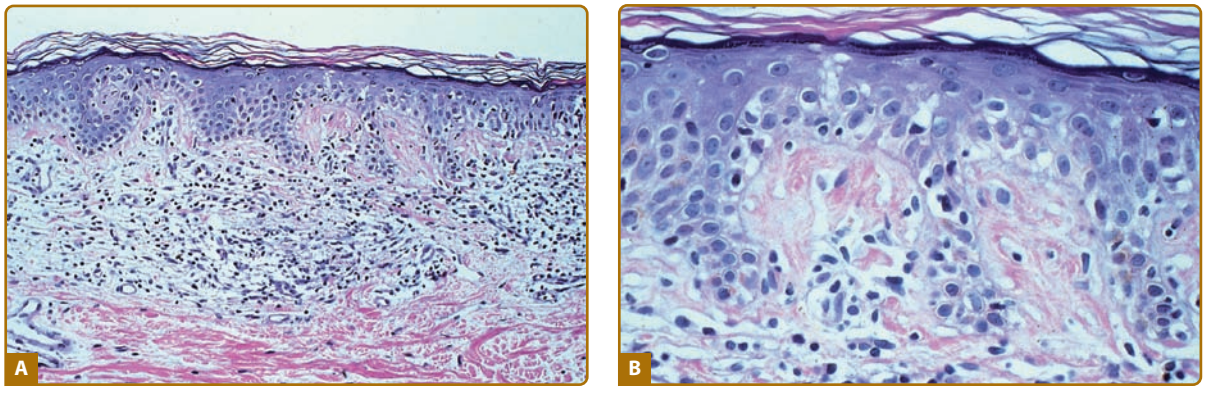

Figure 145-9 Patch stage of mycosis fungoides. **A.** Single atypical mononuclear cells in epidermis with sparse superficial perivascular infiltrate in the papillary dermis. (Hematoxylin and eosin-stained section.) **B.** High-power view of atypical cells in epidermis of same section.

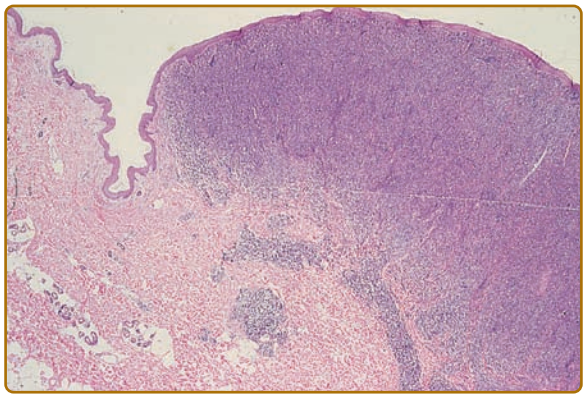

Figure 145-10 Low-power view of a mycosis fungoides tumor. The dense infiltrate extends deep into the dermis.

a variant of patch MF. In darker skinned individuals, this may be the most common presentation of the disease. Patients respond to therapy by repigmentation, and the reappearance of hypopigmented lesions often indicates a relapse.

PAGETOID RETICULOSIS. Pagetoid reticulosis (Woringer–Kolopp disease) is a distinct variant of MF that is characterized by the presence of localized patches or plaques with an intraepidermal proliferation of neoplastic cells. Patients present with a solitary psoriasiform or hyperkeratotic patch or plaque, which is usually localized on the extremities (Fig. 145-12) and is slowly progressive. Unlike in classic MF, extracutaneous dissemination has not been observed.

In the past, the term pagetoid reticulosis also included a disseminated form (called Ketron–Goodman type). As this type usually shows a more aggressive behavior, it is now classified as an aggressive primary cutaneous epidermotropic $CD8^+$ T-cell lymphoma (see Section "Primary Cutaneous Aggressive Epidermotropic $CD8^+$ T-Cell Lymphoma").

GRANULOMATOUS SLACK SKIN. Granulomatous slack skin is a rare subtype of MF characterized by localized areas of bulky folding of the skin, with a predilection for the axillae and groins (Fig. 145-13).



Figure 145-12 Pagetoid reticulosis. Hyperkeratotic plaque localized on the lower leg of a male patient.

Light microscopy reveals a dense granulomatous infiltrate in the entire dermis. In addition to small atypical cells with cerebriform nuclei, macrophages and multinucleated giant cells occur and loss of elastic fibers is observed. The neoplastic cells express a $CD3^+$ $CD4^+$ $CD8^-$ phenotype.[48]

SÉZARY SYNDROME

DEFINITION. SS is characterized by the triad of diffuse erythroderma, generalized lymphadenopathy, and circulating malignant T cells with cerebriform nuclei, the so-called *Sézary cells*.

CLINICAL FINDINGS. The erythroderma is often accompanied by severe scaling or fissuring of the palms and soles (see Fig. 145-7A–C), alopecia, and



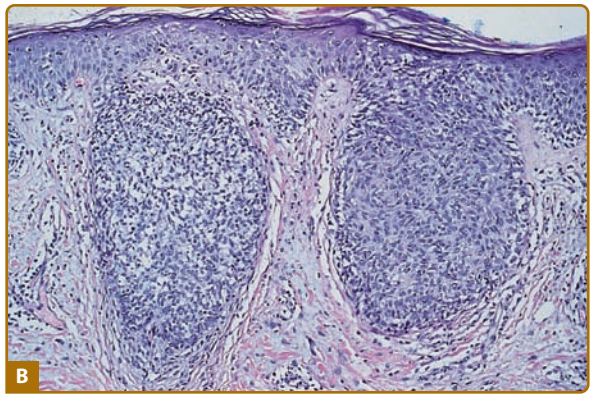

Figure 145-11 **A.** Folliculotropic mycosis fungoides. Note follicular localization and resulting hair loss. **B.** Outer root sheath of hair follicle is disrupted by T cells and mucin deposition, which leads to small cystic spaces.



Figure 145-13 Granulomatous slack skin. Note skinfolds due to secondary elastolysis.

onychodystrophy and may be associated with marked exfoliation, edema, and lichenification and an intense pruritus.

LABORATORY FINDINGS. SS demonstrates histologic features similar to those of MF, but repeated biopsies may be necessary as specimens often show nondiagnostic findings. Therefore, several diagnostic criteria for the blood involvement proposed by the International Society for Cutaneous Lymphoma—including an absolute Sézary cell count in the peripheral blood of at least 1,000 cells/mm^3 detected by light microscopic examination of a blood smear, or an increased CD4/CD8 ratio of more than 10 measured by fluorescence-activated cell-sorting analysis, or evidence of a circulating T-cell clone detected by cytogenetic methods—were included in the WHO–EORTC classification.[1] Patients lacking the atypia on the peripheral blood smear or the corroborating evidence are considered to have erythrodermic CTCL.[49]

TREATMENT AND PROGNOSIS. Compared with patients with patch- or plaque-stage MF, patients with SS have a markedly decreased 5-year survival rate of 24%. By the time the SS appears, there is very little normal immunity left. Indeed, SS patients often die because of infectious complications.[50]

PRIMARY CUTANEOUS CD30$^+$ LYMPHOPROLIFERATIVE DISORDERS

Primary cutaneous CD30$^+$ lymphoproliferative disorders consist of LyP and cALCL. Both entities are now recognized to form the ends of a spectrum, which includes borderline cases that, on histomorphologic grounds alone, cannot be clearly assigned to LyP or cALCL.

LYMPHOMATOID PAPULOSIS

Definition. LyP was first described by Macaulay in 1968. It is an uncommon chronic disorder (incidence of 1.2–1.9 cases in 1,000,000) characterized by recurrent self-healing crops of papules and papulonodules.

Clinical Findings. Disseminated recurrent self-healing papules and papulonodules occur that may become necrotic in the center (Fig. 145-14) and often erupt over a period of months or several years. The lesions typically involve the trunk and extremities, and lesions in various stages of evolution may be present concurrently.

Histopathology. LyP shows a highly variable histologic picture that closely mimics that of malignant lymphoma. Three major histologic types, designated as *A*, *B*, and *C*, have been recognized.[51] Types A and C are characterized by the presence of large atypical blasts, including mononucleated and binucleated or multinucleated cells resembling Reed–Sternberg cells characteristic of Hodgkin lymphoma. The atypical blasts express one or more T-cell antigens as well as the lymphoid activation antigen CD30 (Fig. 145-15). Although in type A these cells are embedded in a dense inflammatory background consisting of histiocytes, small lymphocytes, neutrophils, and/or eosinophils, in type C they form large sheets closely simulating cALCL. LyP type B is composed of small-to-medium-sized CD30-negative T cells showing epidermotropism and thus closely resembles classic MF. Importantly, different histologic types of LyP can be present in one patient, because the histologic picture also correlates with the age of the individual lesion.

Treatment and Prognosis. Because a curative therapy is not available and none of the available treatment modalities affects the natural course of the disease, the short-term benefits of active treatment should be balanced carefully against the potential side effects. Low-dose methotrexate (5–20 mg/week) is the most effective therapy to suppress the development of new skin lesions. Treatment with psoralen plus ultraviolet A light (PUVA) has been reported to yield beneficial effects but duration of response is often short-lived after discontinuation of treatment. Therefore, in patients with few, nonscarring lesions, long-term follow-up without active treatment should be considered.[52]

In general, LyP shows a benign clinical course and a favorable 10-year survival rate of nearly 100%. However, in a proportion of patients, estimated at 10%–20% of cases, LyP can precede, coexist with, or follow malignant lymphoma, especially MF, Hodgkin lymphoma, or nodal anaplastic large cell lymphoma. In many of these cases, the same clonal TCR rearrangements have been found in the LyP as well as in the associated lymphoma. In the majority of LyP cases, despite the sometimes extremely long course of the disease, there is no evolution of a secondary lymphoma.

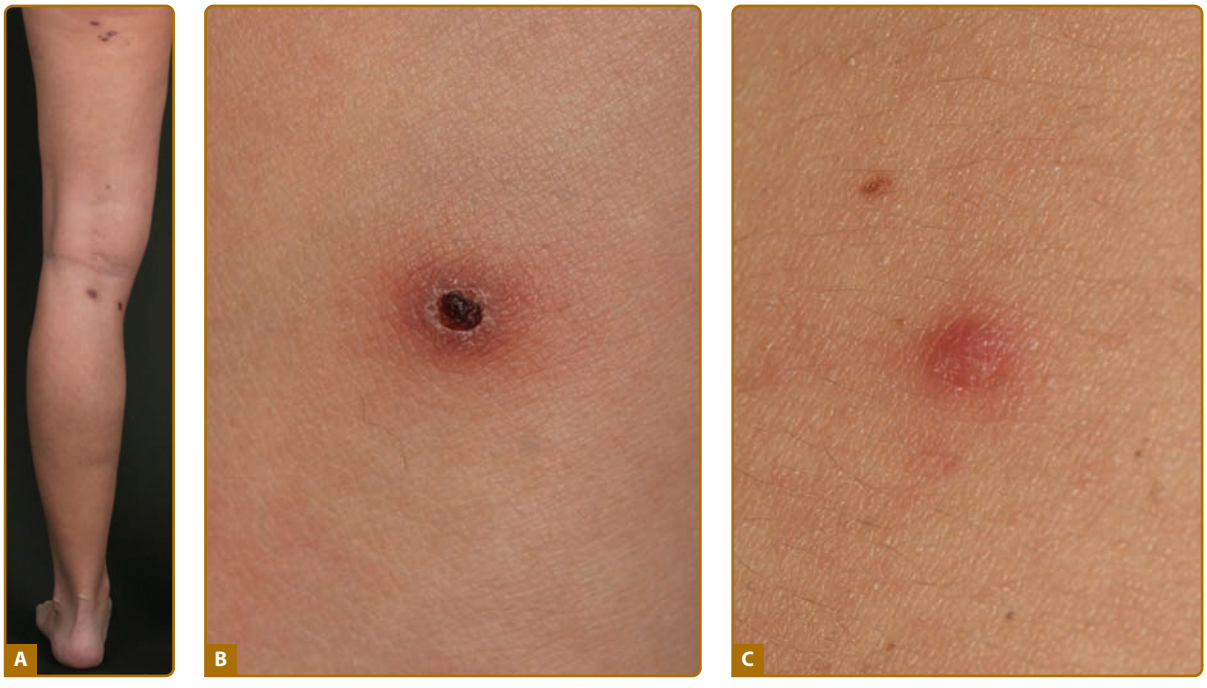

Figure 145-14 Lymphomatoid papulosis. **A.** Papular skin lesions on the right leg. The lesions may appear disseminated and grouped. **B.** Lymphomatoid papulosis papulonecrotic lesion. **C.** Lymphomatoid papulosis erythematous papulonodule.

CUTANEOUS ANAPLASTIC LARGE CELL LYMPHOMA

Definition. The cutaneous lymphoma cALCL is characterized by large tumor cells, of which the majority express the CD30 antigen, with no evidence or history of MF or another type of primary CTCL. Regardless of the morphology of the tumor cells (anaplastic, immunoblastic, or pleomorphic large cells), the clinical presentation and behavior are identical.

Clinical Findings. $CD30^+$ cutaneous large-cell lymphomas occur in adults and rarely in children and adolescents, with a male–female ratio of 1.5:1. The clinical picture is characterized by the solitary or locoregional occurrence of reddish to brownish nodules and tumors, which frequently ulcerate (Fig. 145-16A). Although secondary involvement of the regional lymph nodes is observed in roughly 10% of the patients, it is not necessarily associated with an unfavorable prognosis.

Histopathology. A nodular or diffuse nonepidermotropic infiltrate of large cells is seen in the dermis (see Fig. 145-16B). In the majority of cases, the neoplastic cells show an anaplastic morphology with oval or irregularly shaped nuclei, prominent nucleoli, and an abundant cytoplasm. Less commonly, a pleomorphic or immunoblastic appearance is observed. Atypical mitotic figures are frequent. In the periphery of the lesions, inflammatory cells (lymphocytes, eosinophils, and neutrophils) are present, sometimes imitating the histologic picture seen in LyP.

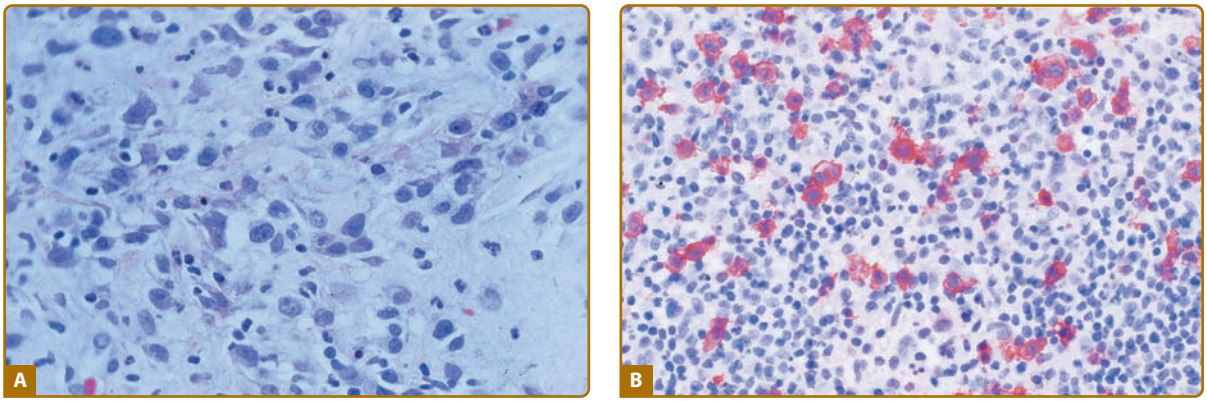

Figure 145-15 **A.** Lymphomatoid papulosis. Dermal infiltrate contains several large lymphoid cells with nuclei showing evenly dispersed chromatin and variably prominent nucleoli (so-called *type A cells*). **B.** Type A with large $CD30^+$ T cells (*red*) among admixed inflammatory cells.

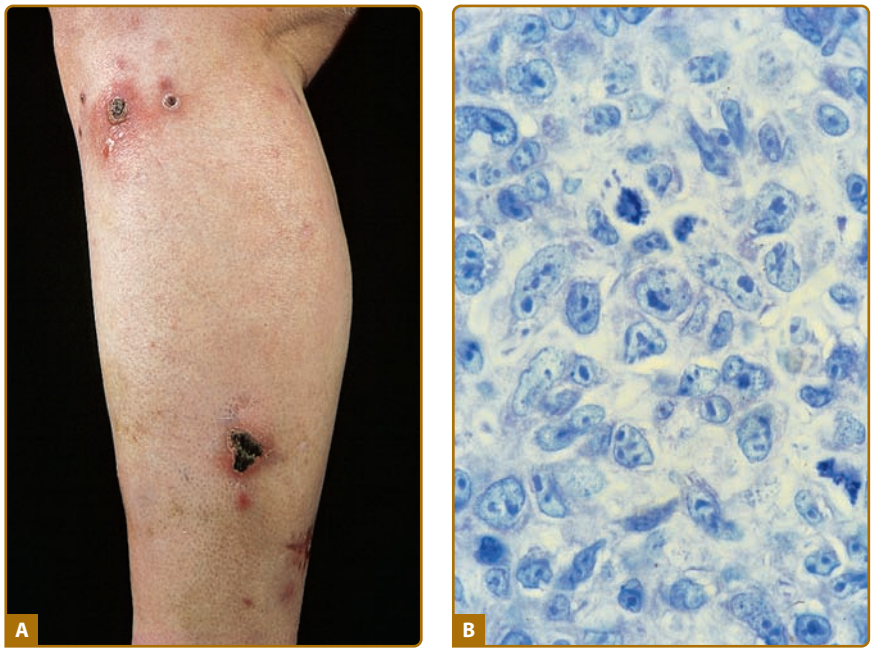

Figure 145-16 Primary cutaneous anaplastic large-cell lymphoma. **A.** Localized nodules, some with ulcerations. **B.** Pleomorphic large-cell lymphoma T-cell infiltrate.

By definition, at least 75% of the large cells are CD30$^+$. In addition, they express a CD4$^+$ phenotype with variable loss of pan-T-cell antigens such as CD2, CD3, and CD5. Cases with CD8$^+$ neoplastic cells occur rarely. Unlike nodal CD30$^+$ lymphomas, CD30$^+$ large-cell lymphomas of the skin test negative for CD15 and epithelial membrane antigen, and expression of the anaplastic lymphoma kinase ALK is also absent in most cases of cALCL. Clonal TCR rearrangements are detected in most cases.[53]

For diagnosis clinicopathologic correlation is crucial. The histologic picture may suggest LyP, but lesions of CD30$^+$ cutaneous large cell lymphoma are clinically larger and localized, and they usually do not tend to disappear spontaneously.

Treatment and Prognosis. In cases of solitary or localized skin lesions, excision or radiotherapy is the treatment of choice. Successful treatment with PUVA in combination with IFN-α has been reported. If skin lesions are generalized systemic therapy with methotrexate (20 mg/week) is preferred and in the case of extracutaneous dissemination multiagent chemotherapy should be considered. A chimeric monoclonal anti-CD30-antibody has shwon promising results in phase II study in CD30$^+$ CTCL.[54] In contrast to extracutaneous large-cell lymphomas, CD30$^+$ cutaneous large-cell lymphomas of the skin have a favorable prognosis, with a disease-related 5-year survival rate of 90%.

SUBCUTANEOUS PANNICULITIS-LIKE T-CELL LYMPHOMA

DEFINITION. Subcutaneous panniculitis-like T-cell lymphoma (SPTL) is defined as a cytotoxic T-cell lymphoma characterized by the presence of primarily subcutaneous infiltrates of small, medium-sized, or large pleomorphic αβ T cells and many macrophages, predominantly affecting the legs and occasionally complicated by a hemophagocytic syndrome. Subcutaneous lymphomas with a γ/δ phenotype of the TCR show a more aggressive course and are nowadays classified within the cutaneous γδ T-cell lymphomas.

CLINICAL FINDINGS. SPTL is characterized by subcutaneous nodules and plaques, which usually involve the extremities and the trunk, less commonly the face. Patients may present with B symptoms, i.e., weight loss, fever, and fatigue.

HISTOPATHOLOGY. Histologic examination shows subcutaneous infiltrates simulating a lobular panniculitis. Infiltrates contain a mixture of neoplastic pleomorphic cells of various sizes and macrophages. Rimming of individual fat cells by neoplastic T cells is a helpful diagnostic feature. Immunophenotyping shows that the neoplastic cells express CD3, CD8, CD45RO, T cell-restricted intracellular antigen 1 (TIA-1), perforin, granzyme B, and the TCR α/β. The neoplastic T cells show a clonal TCR gene rearrangement.

TREATMENT AND PROGNOSIS. The optimal therapy has not been defined so far and patients have been treated with immunosuppressive agents like prednisone or multiagent chemotherapy. However, the prognosis of the SPTL with a TCRα/β-phenotype seems to be favorable with a 5-year survival rate of 85% and therefore justifies an initial treatment approach with corticosteroids alone.[55]

EXTRANODAL NATURAL KILLER/ T-CELL LYMPHOMA, NASAL TYPE

DEFINITION. Extranodal NK/T-cell lymphoma, nasal type, is a lymphoma that is nearly always EBV-positive. The tumor cells are small, medium, or large, and usually have an NK-cell or, more rarely, a cytotoxic T-cell phenotype. The skin is the second most common site of presentation after the nasal cavity.[1]

CLINICAL FINDINGS. Extranodal NK/T-cell lymphoma either affects the naso-oropharynx, which leads to destruction of the nasal region (formerly described as *lethal midline granuloma*) or manifests in skin, subcutis, lungs, viscera, and testes. Skin lesions enclose subcutaneous tumors, erythematous plaques, ulcers, or an exanthematous eruption with macules and papules. The clinical course is often aggravated by a hemophagocytic syndrome with pancytopenia.

HISTOPATHOLOGY. This type of lymphoma shows dense infiltrates involving the dermis and, often, the subcutis. Epidermotropism may be present. Prominent angiocentricity and angiodestruction are often accompanied by extensive necrosis. Immunophenotypically, the neoplastic cells express CD56, and cytotoxic proteins (TIA-1, granzyme B, perforin) and are characteristically positive for EBV. While they show positivity for CD3ε in the cytoplasm, they lack CD3 on the surface.

TREATMENT AND PROGNOSIS. Even with aggressive chemotherapy, the disease is often lethal within months.[56] A study of the EORTC cutaneous lymphoma group suggested that bone marrow transplantation may be the treatment of choice.[57]

PROVISIONAL ENTITIES OF CUTANEOUS T-CELL LYMPHOMA

In addition to the diseases discussed in the preceding sections, a number of provisional entities are included in the WHO-EORTC classification system. These primary CTCLs display characteristic histologic features, but no distinct clinical presentation and/or outcome has been defined so far.

PLEOMORPHIC SMALL- OR MEDIUM-SIZED CUTANEOUS T-CELL LYMPHOMA

Definition. A neoplastic proliferation of pleomorphic, small- or medium-sized T cells in the skin without any clinical signs of classic MF defines the pleomorphic, small- or medium-sized CTCL.

Clinical Findings. Patients have one or several red-purplish papules or nodules with a predilection for the head and neck area.[58] Because histologic differentiation from MF and MF-associated follicular mucinosis can raise problems, the absence of patches and plaques in pleomorphic small- or medium-sized CTCL is the decisive criterion.

Histopathology. Histologically, a dense, diffuse or nodular infiltrate containing small- to medium-sized pleomorphic cells is observed within the dermis and, sometimes, the subcutis. Epidermotropism may be present. The neoplastic cells express a T-helper cell phenotype with frequent loss of pan-T-cell markers. Demonstration of an aberrant phenotype and of T-cell clonality, as well as predominance of pleomorphic T cells in the infiltrate, serve as useful criteria for the exclusion of pseudolymphomas, which often show an identical histologic pattern. MF is excluded by the absence of a dominant cerebriform tumor cell population.[59] In cases of CD8 expression these tumors show a more aggressive clinical course and are grouped within the primary cutaneous aggressive epidermotropic $CD8^+$ T-cell lymphoma.

Therapy and Prognosis. Solitary lesions are often excised for diagnostic purposes. If excision is not possible or lesions are localized, radiotherapy is the preferred mode of treatment. PUVA therapy, possibly in combination with IFN-α, is useful in cases with disseminated lesions.

A 5-year survival rate of between 60% and 90% is reported for this type of lymphoma.

PRIMARY CUTANEOUS AGGRESSIVE EPIDERMOTROPIC $CD8^+$ T-CELL LYMPHOMA

Definition. Primary cutaneous aggressive epidermotropic $CD8^+$ T-cell lymphoma is a CTCL characterized by a proliferation of $CD8^+$ cytotoxic T cells that exhibit a strong epidermotropism and an aggressive clinical behavior. Differentiation from other types of CTCL expressing a $CD8^+$ cytotoxic T-cell phenotype, as observed in pagetoid reticulosis and rare cases of MF, LyP, and cALCL, is based on the clinical presentation and clinical behavior.

Clinical Findings. Primary cutaneous aggressive epidermotropic $CD8^+$ T-cell lymphoma presents with hyperkeratotic patches and plaques, or by papules and tumors. A metastatic spread to unusual sites such as the lung, testis, central nervous system, and oral cavity, but not to the lymph nodes is often observed.

Histopathology. Histologically, band-like infiltrates consisting of pleomorphic lymphocytes or immunoblasts are observed, displaying a diffuse infiltration of the epidermis with variable degrees of spongiosis, intraepidermal blistering, and necrosis. The neoplastic cells express the Ki67 antigen at a high frequency and are positive for CD3, CD8, CD45RA, and TIA, whereas CD2 and CD5 are frequently lost. Expression of TIA identifies these lymphomas derived from a cytotoxic T-cell subset.

Treatment and Prognosis. Even with multiagent chemotherapy the disease shows an aggressive course, and median survival is 32 months.

CUTANEOUS γ/δ T-CELL LYMPHOMA

Definition. Cutaneous γ/δ T-cell lymphoma encompasses the peripheral T-cell lymphomas with a clonal

proliferation of mature, activated γ/δ T cells with a cytotoxic phenotype. This group includes cases previously termed *subcutaneous panniculitis-like T-cell lymphoma with a γ/δ phenotype*.[1]

Clinical Findings. Patients have disseminated ulceronecrotic nodules or tumors, particularly on the extremities, but other sites may be affected as well. Involvement of mucosal and other extranodal sites is frequent, but involvement of lymph nodes, spleen, or bone marrow is uncommon. A hemophagocytic syndrome may occur.

Histopathology. Histologically, three major patterns of involvement can be present in the skin: epidermotropic, dermal, and subcutaneous. The neoplastic cells are generally medium-to-large with coarsely clumped chromatin. Large blastic cells with vesicular nuclei and prominent nucleoli are infrequent. Apoptosis and necrosis are common, often with vessel invasion. Immunohistologically the tumor cells have a $\beta F1^-$, $CD3^+$, $CD2^+$, $CD5^-$, $CD7^{+/-}$, $CD56^+$ phenotype with strong expression of cytotoxic proteins. Most cases lack both CD4 and CD8, although CD8 may be expressed in some cases. In frozen sections, the cells are strongly positive for TCR δ (antibody testing is not available for paraffin sections). If only paraffin sections are available, the absence of βF1 may be used to conclude a γ/δ origin.

Treatment and Prognosis. Most patients have aggressive disease resistant to multiagent chemotherapy and/or radiation therapy. Median survival is 15 months.

PRIMARY CUTANEOUS PERIPHERAL T-CELL LYMPHOMA, UNSPECIFIED

Definition. PTL, unspecified, is a diagnosis of exclusion of any of the above-characterized subtypes of CTCL.

Clinical Features. Usually adult patients, present with solitary, localized, or generalized nodules or tumors without predilection for specific locations.

Histopathology. The infiltrate is nodular or diffuse and shows varying numbers of medium-sized and at least 30% large-sized pleomorphic or immunoblast-like T cells. Epidermotropism is unusual. Immunohistologically, the cells are in general CD4-positive but otherwise demonstrate a variable loss of pan-T-cell antigens.

Treatment and Prognosis. The 5-year survival rate is less than 20% and therefore multiagent chemotherapy is the treatment of choice.

STAGING OF CUTANEOUS T-CELL LYMPHOMAS

After the diagnosis of a cutaneous T-cell lymphoma has been established, appropriate staging investigations are obligatory to exclude secondary involvement of the skin by an extracutaneous lymphoma and to determine the extent of disease. The first classification and staging system of CTCLs has been published in 1979 by the MF cooperative group. In the meantime, it has been recognized that this staging system does not apply to

TABLE 145-1
Staging System for Mycosis Fungoides and Sézary Syndrome

Stage	T (Tumor)	N (Lymph Node)	M (Metastases)	B (Blood)
IA	T1	N0	M0	B0 or B1
IB	T2	N0	M0	B0 or B1
IIA	T1 or T2	N1 or N2	M0	B0 or B1
IIB	T3	N0-2	M0	B0 or B1
III	T4	N0-2	M0	B0 or B1
IIIA	T4	N0-2	M0	B0
IIIB	T4	N0-2	M0	B1
IVA1	T1–T4	N0-2	M0	B2
IVA2	T1–T4	N3	M0	B0–2
IVB	T1–T4	N0–N3	M1	B0–2

T1 = patch/plaque ≤10% of body surface; T2 = patch/plaque ≥10% of body surface; T3 = skin tumor(s); T4= erythroderma; N0 = normal nodes; N1 = palpable nodes without clear histologic evidence of lymphoma [for N1 and N2, "a" or "b" may be added for either no (a) or detection (b) of a T cell clone by Southern blot or PCR analysis]; N2 = palpable nodes, histologic evidence of lymphoma, node architecture preserved; N3 = palpable nodes with histologic evidence of lymphoma, effacement of node architecture; M0 = no visceral involvement; M1 = histologically confirmed visceral involvement. B0 = ≤5% Sézary cells (for B0 and B1, "a" or "b" may be added for either no (a) or detection (b) of a T cell clone by Southern blot or PCR analysis); B1 = >5% Sézary cells but either less than 1.0 K/microL absolute Sézary cells or absence of a clonal rearrangement of the TCR or both; clonal rearrangement of the TCR in the blood and either 1.0 K/microL or more Sézary cells or one of the following two: (1) increased $CD4^+$ or $CD3^+$ cells with CD4/CD8 of ten or more or (2) increase in $CD4^+$ cells with an abnormal phenotype (>40% $CD4^+/CD7^-$ or >30% $CD4^+/CD26^-$).

all entities of CTCLs listed in the current WHO classification. Furthermore, the Ann Arbor system, commonly used for staging of nodal non-Hodgkin lymphomas, is not suitable for all entities of CTCLs. Because of these facts and new data on prognostic factors, both revisions of the staging and classification for MF and SS and a TNM classification system for CLs other than MF and SS have been proposed by the EORTC and the International Society for CLs in the recent years.[60,61] It has to be mentioned that staging according to the TNM system has been proven to be useful to choose an appropriate therapy for patients with MF and SS, but data correlating results of the TNM staging and prognosis are missing for some entities of CTCLs. Staging examination for all entities of CTCLs include examination of the entire skin, chest radiography, and ultrasonography of abdominal organs and peripheral lymph nodes (cervical, axillary, and inguinal). Blood investigations should include complete blood cell count, clinical chemistry with liver enyzmes, kidney function tests and lactate dehydrogenase level, as well as T-cell clonality. Staging may be completed by computed tomographic scan and/or histologic and molecular (TCR rearrangement) investigations of suspicious lymph nodes and/or visceral organs. Staging examination should be repeated at relapse or progression of disease. A bone marrow examination is only recommended at a B2 blood rating (Table 145-1) or unexplained hematological abnormalities. However, this procedure is not of direct clinical relevance, as detection of atypical cells in the bone marrow has not been shown to be an independent prognostic factor.

The aforementioned investigations allow for classification according to the tumor, lymph node, metastases (TNM) system (Table 145-1 and Box 145-3). Although the prognostic value and applicability of TNM staging for different CTCLs is controversial, the TNM scheme directs the decision-making process toward an appropriate therapeutic regimen for most CTCLs.

PRINCIPLES OF TREATMENT OF CUTANEOUS T-CELL LYMPHOMA

Every successful strategy in managing CTCL with generalized skin lesions begins with goals, tumor-burden assessments, questionnaires, and a timetable. The primary goals of therapy are to achieve a remission, improve the quality of life, to prolong life, and if possible to cure. The chronic disease course of the most prevalent CTCL subtypes MF and SS, makes surrogate markers necessary, and tumor burden is still the best surrogate marker for survival. Additionally, measures of symptoms like pruritus or quality of life assessments are commonly used. Currently, skin scores provide a measure of objective responses to therapy, and questionnaires guide the assessment of subjective responses to therapy. It has not been shown that reducing disease in a patient from T3 to T1 is accompanied by any benefit in survival, yet it is also recognized that cure is unattainable unless the patient is first in remission with a skin score of 0 by whatever skin scoring system is used. Thus, remission is the first step toward achieving a cure.

BOX 145-3 STAGING SYSTEM FOR CUTANEOUS LYMPHOMAS OTHER THAN MYCOSIS FUNGOIDES AND SÉZARY SYNDROME

T (TUMOR)

- T1: solitary skin involvement
  - T1a: a solitary lesion <5-cm diameter
  - T1b: a solitary lesion >5-cm diameter
- T2: regional skin involvement: multiple lesions limited to one body region or two contiguous body regions[a]
  - T2a: all-disease-encompassing in a <15-cm diameter circular area
  - T2b: all-disease-encompassing in a >15- and <30-cm diameter circular area
  - T2c: all-disease-encompassing in a >30-cm diameter circular area
- T3: generalized skin involvement
  - T3a: multiple lesions involving 2 noncontiguous body regions
  - T3b: multiple lesions involving ≥3 body regions

N (LYMPH NODE)

- N0: No clinical or pathologic lymph node involvement
- N1: Involvement of one peripheral lymph node region[b] that drains an area of current or prior skin involvement
- N2: Involvement of two or more peripheral lymph node regions[b] or involvement of any lymph node region that does not drain an area of current or prior skin involvement
- N3: Involvement of central lymph nodes

M (METASTASES)

- M0: No evidence of extracutaneous nonlymph node disease
- M1: Extracutaneous nonlymph node disease present

[a]Definition of body regions.[61]
[b]Definition of lymph node regions is consistent with the Ann Arbor system: Peripheral sites: antecubital, cervical, supraclavicular, axillary, inguinal-femoral, and popliteal. Central sites: mediastinal, pulmonary hilar, paraortic, iliac.

A few principles help guide therapy strategies.[62] Excellent long-term results have been reported with the localized treatment of localized disease. More widespread disease requires total skin or systemic therapy. However, it is not known at what percentage of skin surface involvement it becomes imperative to treat the entire skin. Once remission is achieved, maintenance therapy has a role in preventing relapse. Because many patients will undergo treatments that span decades, it is also important to minimize exposure to therapies

that have cumulative toxicities on keratinocytes (i.e., mutagens) or the bone marrow.

With these principles in mind, one can approach the treatment of a given patient based on the patient's individual presentation. The clinical presentation of the patient can be matched up with a successful therapy modality for both the remission-induction phase of therapy and the maintenance phase. For patients with several types of lesions, priority is given to those further down in Table 145-1. For example, a patient with both patches and tumors would be approached as a patient with tumors until those lesions are cleared.

The therapies used to treat a patient with CTCL can best be categorized into skin-directed therapies, biologic response modifiers (BRMs), cytotoxic therapies, and combination therapies. Within each category, the individual modalities have unique properties that are discussed in the following sections in the context of how these modalities are used.

UNILESIONAL/LOCALIZED CUTANEOUS T-CELL LYMPHOMAS: SKIN-DIRECTED THERAPY.

The modalities considered for inducing a remission of unilesional/localized disease depend on the type and localization of the lesion as well as on the specific entity.

Distinct demarcated nodules as they are commonly seen in small- or medium-sized CTCL and $CD30^+$ lymphoproliferations are best treated by excision or spot X-ray therapy. Patches and plaques can be approached with spot X-ray therapy, but also with topical chemotherapy with carmustine (BCNU), and topical retinoid therapy with bexarotene due to their superficial flat appearance.

Spot radiotherapy is the most reliable and rapid method of inducing a remission of solitary or localized lesions. Radiotherapy is widely available, and most lesions, no matter where they occur on the body (e.g., eyelid, buttock crease, ear), can be treated with this modality. There are no compliance problems, with each treatment session conducted by a professional radiotherapist. The immediate toxicity is minimal, but the long-term toxic effects of radiation dermatitis and cutaneous malignancy encourage conservative use of this modality.

The limitations of topical BCNU therapy are the systemic toxicity from absorption of the chemotherapeutic agent and local irritation. As a result, topical BCNU is used primarily for a limited body surface area. The initial protocols for BCNU administration called for an alcohol-based solution kept in the refrigerator. However, ointment-based protocols are now more common. BCNU can be easily made up in 10-mg/100 g or 20-mg/100 g ointments with a petrolatum base. Patients typically apply BCNU ointment at night and wash it off in the morning. Locally, a dose-related irritation and/or hyperpigmentation may appear over the 8–20 weeks needed to clear lesions. Monitoring includes performing complete blood cell counts every 2 weeks to check for marrow suppression. The cumulative toxicity of BCNU is primarily structural damage with skin thinning and telangiectasias. The patient must be reliable and adherent to the regimen for this therapy to succeed.[63]

The limitations of topical bexarotene gel are also due primarily to dose-related irritant effects. Hence, bexarotene gel is typically used for lesions on less than 15% of body surface area, as was the case in most of the patients in the pivotal trial that led to its approval.[64] The gel is commercially available in a 1-% formulation, so that dose intensity is varied by changing the frequency of application. Patients typically initiate therapy with nightly lesional applications of bexarotene gel. After a week, the frequency is increased to twice daily, and the patient has to be made aware of the possibility of an irritant dermatitis at the site of the lesions. Complete clearance of lesions will usually occur after 12–16 weeks of therapy. Irritant responses can be managed by decreasing the frequency of application.[65] Successful topical bexarotene therapy also requires a patient who adheres to the treatment regimen and is willing to put up with the irritant properties of this synthetical retinoid.

DISSEMINATED SKIN-LIMITED DISEASE.

Cutaneous T-cells recirculate through the vascular system and are capable of patrolling the entire skin. When CTCL lesions are scattered, the most successful treatment strategies are those that treat the entire skin so as to extend the antilymphoma effect to the entire range of the cutaneous T cell. Recirculating CTCL cells are detectable even in limited disease, and such recirculating cells are capable to induce disease recurrences. These cells provide some of the rationale for the use of maintenance therapy after a complete response has been achieved in the management of patients with disseminated patch/plaque disease. Due to the variation in biological behavior, the therapy of disseminated disease differs markedly in CTCLs. The total skin treatment modalities most commonly used as first-line therapy against disseminated patch/plaque disease of MF are phototherapies, topical chemotherapy, and total skin electron-beam radiotherapy. However, $CD8^+$ epidermotropic CTCL or blastic plasmacytoid dendritic cell neoplasm (BPDCN), also presenting with plaque disease show a much more aggressive course and polychemotherapy is the treatment of choice. Furthermore widespread disease of $CD30^+$ lymphoproliferations responds well to low-dose methotrexate therapy in most instances.

Phototherapies. PUVA (see Chapter 238) can produce a definite clinical response and complete remissions of long duration in patients with patch/plaque CTCL. PUVA therapy requires regular treatments, initially three to four times a week, for up to 3 months or until remission occurs. The follow-up of a patient receiving PUVA for CTCL includes an assessment to be sure there is some mild degree of phototoxicity. Otherwise, dosing of either the psoralen or the UVA light may be insufficient. Risks of the treatment include possible induction of cutaneous epithelial neoplasms and cataract formation. Therefore, all patients should be observed closely and checked regularly for the development of skin cancer. In addition, patients are advised to protect their eyes for 12 hours after PUVA therapy and to have annual ophthalmologic examinations. These precautions should be enforced early, because PUVA is

a therapy that may continue for years as a maintenance treatment. Even after poor responses to conventional therapy, patients have experienced complete clearing of the skin with PUVA.[66] However, maintenance therapy may be needed, as shown by the prolongation of clinical remission with continued PUVA.[67] For this reason, a gradual taper of therapy from thrice weekly to one session every 2–4 weeks after the patient has achieved a stable remission is typical. Combination of PUVA with IFN-α reduces the total UV dose necessary to induce a remission and prolongs the duration of remission.

UVB and narrow-band UVB light are both effective in treating CTCL. These phototherapies are more convenient for patients, although their efficacy, especially for plaque disease, may not be as great as that of PUVA. Patch-stage MF can often be completely cleared with UVB or narrowband UVB light. A complete response can typically be induced with three to five treatment sessions per week for a duration of 2–3 months. After a complete response has occurred, phototherapy can be continued on a maintenance schedule, initially once a week. The immediate adverse effects are primarily phototoxicity; the long-term toxicity is an increased risk for cutaneous malignancy.

Total Skin Topical Chemotherapy. Total skin topical chemotherapy consists of nitrogen mustard (mechlorethamine hydrochloride) applied as either an ointment or a freshly prepared aqueous solution. As an initial dose, 10 mg of the drug is dissolved in approximately 50 mL of tap water. The entire amount is then applied to the whole body surface by the patient. The patient should wear protective plastic gloves while applying the solution. A delayed hypersensitivity reaction may complicate treatment, and it is possible to desensitize patients, although their confidence in the therapy may be compromised. Ointment-based mechlorethamine, typically 10 mg/100 g strength, may be less sensitizing and is shelf stable for a long period. Other side effects from mechlorethamine hydrochloride therapy, besides hypersensitivity reactions and primary irritant reactions, include the development of second cutaneous malignancies and hypo- as well as hyperpigmentation. This therapy is relatively easy for the patient to use at home, but daily whole-body application is required for maintenance therapy once remission is induced.

Total Skin Radiation Therapy. The radiosensitivity of CLs has been therapeutically exploited by the administration of total skin electron-beam radiation. Because electrons penetrate only to the upper dermis, electron-beam therapy may be used without systemic effect. The limited penetration of the electrons is advantageous because it spares the mucous membranes, bone marrow, gastrointestinal tract, and other vital internal organs. Only those portions of the skin that are directly exposed to the beam are irradiated. Therefore, the palms, soles, scalp, axillae, and perineum may need separate exposures to ensure total body treatment. The eyelids are routinely covered with lead eye shields to protect the cornea and lens from the effects of radiation. If the eyelids are involved, 5-mm-thick contact lenses are worn between the lid and cornea within the conjunctival sac. Nail shields may also be used to prevent anonychia.

Whole body electron-beam irradiation brings about complete remission in 80%–95% of patients. The relapse rate is highest in the later stages of CTCL, i.e., in those patients with tumors, lymphadenopathy, and visceral involvement. Patients with limited plaque disease were found to have the highest relapse-free rate (42% at 10 years). Most relapses occurred within the first year after completion of therapy, and relapses were very rare 3 years or more after completion of therapy. The median disease-free interval was longer than 3 years in the limited plaque group, approximately 1 year for patients with generalized plaque or erythrodermic disease, and less than 6 months for patients with cutaneous tumors. The total dose of radiation is important. A dose of 30 cGy (3,000 rad) or more gives higher complete remission rates and disease-free survival than do lower doses. The major disadvantages are that this type of therapy must be provided at a specialized center and up to 3 months are required for complete treatment.

Local side effects include alopecia, atrophy of sweat glands and skin generally, radiodermatitis, and edema. When the total dose is highly fractionated, these complications are minimized and often avoided. The question is, what is the maximum radiation tolerance of the skin? When the highly fractionated approach is used, patients can receive a second course of electron-beam therapy of 36 cGy (3,600 rad) to reinduce a remission. As the total radiation dose increases, so does the risk of squamous cell carcinoma and radiodermatitis. Small-field or spot orthovoltage radiotherapy using soft X-rays (60–100 kV with half-value layers of 1–1.5 mm Al) fractionated to doses of 0.75–5 cGy (75–500 rad) and total doses of 8–15 cGy (800–1,500 rad) will adequately eliminate most lesions.

In many patients, a second or even third complete course of total skin electron-beam radiation can be safely given. The strategy of administering electron-beam radiation for repeat courses requires the use of a highly fractionated dose of 1 Gy per dose.

Maintenance Therapy and Topical Steroid Therapy. The concept of treating normal skin evolved from the clinical experiences with skin-directed therapies. There are two components to this approach: the treatment of normal skin during remission-induction skin-directed therapy and the treatment of normal skin during the remission–maintenance phase. Topical chemotherapy, PUVA, and total skin electron-beam radiation all involve the exposure of normal skin as an integral component of their success in achieving remission. This success reflects the ability of the therapy to interrupt the critical skin-based phase of the life cycle of a recirculating CTCL cell. Once a remission has been achieved, normal skin can be maintained with lower doses and frequencies of the therapies used to clear it. Maintenance therapies have been described with PUVA, total skin application of nitrogen mustard, ECP, and IFN. The most commonly used maintenance therapy is PUVA (see Chapter 238)

or UVB irradiation (see Chapter 237). As a maintenance therapy, PUVA is initially administered at once-weekly intervals until 1 year has passed. At this point, the schedule is changed to every other week for another year, to every third week for the following year, and finally to every fourth week for 2 years. At this point, the patient should have been in remission for 5 years. Consideration should be given to stopping therapy at this point. A cure is defined as freedom from disease for 8 years off all therapy. This definition arose from the experience with nitrogen mustard treatment and total skin electron-beam radiotherapy showing that after a patient achieves a remission-off therapy of 5–8 years, late relapse is extremely rare. This would imply that malignant cutaneous T cells recirculate without causing lesions for up to 5 years. With 5 years of intermittent PUVA, it is less likely that one of these cells will survive, but it is still possible. After therapy has been discontinued, patients should not be considered cured unless they remain clear of disease for 8 years.

The management of suspected relapse often includes the use of topical glucocorticoids and reflects the critical role this modality can play in the treatment of suspicious lesions. Early in the course of CTCL and in a recurrence of the disease in a patient in remission, the T-cell activation process can be blunted by the aggressive use of topical glucocorticoids. Indeed, most patients have a history of using these agents before a firm diagnosis is made. A regimen for treating early lesions of MF is twice-daily applications of a class I topical glucocorticoid for 8 weeks. This regimen is one of the first-line modalities for suspected relapse, and it can help identify which patients need to undergo a 4-week "wash-out" before repeat biopsies are performed.

ERYTHRODERMA. In erythrodermic CTCLs, immune dysfunctions and inflammatory processes initiated by the malignant cells result in total skin redness, scaling, and discomfort. It is not surprising that immune-based therapies take the forefront in the management of these disorders. The three major BRMs used in the treatment of erythrodermic CTCLs are (1) oral retinoids, (2) ECP via an intravenous route, and (3) subcutaneous injections of IFN-α. In the clinical trials of these agents, patients have undergone monotherapy for what has usually been heavily pretreated refractory disease. In practice, these treatments are often used as first-line monotherapy in erythroderma, and other agents are incorporated for combination therapies if the response is incomplete. With these agents, partial responses are more common than complete responses. Thus, if the goal is remission, combination therapy is used more commonly than monotherapy. If the goal is palliation, monotherapy with a BRM is often sufficient. The BRMs differ in terms of their administration, side effects, interactions with other therapy modalities, and availability.

Retinoid Therapy. The first-generation retinoids such as isotretinoin have an effect on CTCL. The synthetic retinoid bexarotene binds the retinoid X receptor with high selectivity, whereas the other available retinoids have less specific binding patterns. In the monotherapy trials, bexarotene was dosed at 300 mg/m^2. Responses were seen in patients in all stages of the disease: plaques, erythroderma, and tumors. Responses paralleled the secondary end points: decreases in overall body surface area involved and in overall tumor aggregate area, and improvement in pruritus. Erythrodermic patients may experience increased desquamation during the first few weeks of oral bexarotene therapy. Improvement typically starts by week 12 of therapy.[68]

Although there appeared to be a dose-response relationship with respect to efficacy, the higher dosages were also associated with a higher rate of adverse events and dose-limiting toxicities, of these hyperlipidemia/hypercholesterolemia and neutropenia were most common. Elevations in lipid levels occurred rapidly, within 2–4 weeks, and were associated with serious, but reversible, pancreatitis. Monitoring of lipids and the use of lipid-lowering drugs were helpful in controlling the lipid levels.[69] Dosage reduction of bexarotene capsules was also required in some patients. Drug interactions of oral bexarotene with gemfibrozil and warfarin have been observed.

Patients started on bexarotene therapy develop central hypothyroidism with low levels of thyroid-stimulating hormone and free thyroxine within weeks of starting the medication. Symptoms of hypothyroidism may be subtle and include feeling fatigued and feeling cold, which may wrongly be attributed to the disease itself. Supplementation with levothyroxine while patients are taking bexarotene alleviates the symptoms and improves tolerance of treatment. The condition is reversible within weeks of stopping therapy. There is no immunosuppression with bexarotene therapy. Patients taking bexarotene typically have monthly monitoring visits to follow lipid, liver, and thyroid parameters.

Extracorporeal Photochemotherapy. (See Chapter 238). ECP involves the treatment of a portion of a patient's lymphocyte compartment with 8-methoxypsoralen in the presence of UVA light, followed by reinfusion of these cells. The treatment is performed via an intravenous line that feeds into an UVA-radiation device, and the procedure typically requires the patient to remain recumbent for 3 hours. Treatments are conducted on two consecutive days every 4 weeks. Erythrodermic CTCLs can be managed with ECP monotherapy, but treatment of other disease stages with monotherapy has not been rigorously studied. In a multicenter study involving erythrodermic CTCL patients, approximately one-fourth had a complete response, one-fourth had no response, and the remainder had partial responses. However, it is clear that even a partial response can improve the quality of life of these patients. Improvement sometimes began as early as 6 weeks into therapy, but some patients did not show complete lesion clearance until 12 months after starting therapy. There were occasional temporary responses immediately after a 2-day cycle of therapy. On average, after 4–6 months there was typically a gradual and permanent decrease in erythema, scaling, and pruritus. Patients often notice more subtle changes, such as the return of body hair,

loss of rigors, and a return of the ability to sweat. Partial responses may also decrease the morbidity these patients experience in terms of infectious complications. More heavily involved and inflamed skin is more readily colonized, providing both a reservoir and access point for microbes to invade the host. Thus, cutaneous improvement can also minimize complications of CTCLs.

The clinical experiences with ECP for erythrodermic MF and SS suggest that the therapeutic response may well be based in the immune system. One feature is that when less than 5% of the malignant lymphocyte pool is photoinactivated with 8-methoxypsoralen and UVA light, clinical responses can be seen, with more than 95% of the malignant lymphocytes disappearing over time. It also appears that most immunocompetent patients respond. Patients who were heavily pretreated, with longer disease durations, were less responsive. Also, patients with normal or only slightly decreased $CD8^+$ lymphocyte levels were responsive to ECP. In one study, total skin electron-beam radiotherapy was combined with ECP in patients with T3 and T4 disease. Comparison of patients receiving skin-directed radiotherapy plus BRM with historic controls who underwent electron-beam radiotherapy at the same institution demonstrated the impact of ECP, because patients in the skin-directed therapy plus BRM group showed significantly longer survival.[70]

Interferon-α Therapy. The most-studied IFN has been IFN-α, but clinical trials have also been done with IFN-β and IFN-γ in the treatment of CTCLs. The initial studies using IFN-α as monotherapy showed rates of complete responses that varied from 10%–27% with treatment durations of less than 6 months.[71] Again, the heterogeneity of the disease and the pretreatments patients undergo affect outcomes and make comparisons with other modalities impossible. IFN-α is typically started at 3 million units (MU), three times a week, and can be increased to a maximally tolerated dose, typically in the range of 9 MU/day. As with the other BRMs, the response to IFN is gradual, and 3–6 months are needed to determine the maximal response. After patients achieve a maximal response, IFN dosage can be lowered to a maintenance level of 1 MU daily.[72]

All IFNs have similar toxicities. Initially IFN therapy is complicated by a flu-like illness that is characterized by fever, headache, myalgia, and fatigue. As this wears off, patients are often left with a slight feeling of chronic fatigue. The long-term toxicity that causes most concern is neurologic: depression, neuropathy, dementia, and myelopathy. Autoimmune phenomena, such as thyreoiditis, may occur. Furthermore, toxic effects of the liver and bone marrow may occur. Monitoring of IFN therapy includes blood counts and urinanalysis along with questionnaires assessing the impact on the patient's quality of life.

Other BRMs. *$DAB_{389}IL$-2* (Denileukin Difititox, Ontak®) is a recombinant cytotoxic fusion protein composed of the receptor binding domain of IL-2 and a mutated diphtheria toxin (DT) molecule. After binding to the IL-2-receptor, which is expressed on activated lymphocytes and monocytes as well as CTCL cells, and after internalization of DAB_{389}IL-2, the DT fragment becomes active and inhibits the protein synthesis leading to cell death. DAB_{389}IL-2 is administered intravenously and has shown efficacy in a phase III trial in CTCL patients with an overall clinical response rate of 30%. Side effects are generally mild, but few patients suffered from allergic reactions or a capillary-leak syndrome.[73]

Alemtuzumab is a humanized monoclonal IgG antibody binding to CD52, which is expressed on monocytes, granulocytes, and normal and malignant lymphocytes. In a phase II trial efficiency, including complete remissions, but also fatal infectious complications were seen in patients with therapy refractory advanced MF/SS.[74] Efficiency has also been shown with lower doses and s.c. application resulting in less administration-related and infectious complications.[75] Because of the side effects, alemtuzumab should be reserved for patients with advanced MF/SS disease who did not respond to previous systemic therapies.

Vorinostat: The first histone deacetylase inhibitor (HDACI) approved by the FDA was vorinostat for the treatment of therapy refractory CTCL. The increased histone acetylation by HDACI favors transcription of genes involved in cell differentiation, cell cycle arrest, and apoptosis. In a phase II trial, mostly partial remissions and a decrease in pruritus were seen in CTCL patients refractive to previous therapies. Common adverse events of HDACI were fatigue, nausea, and thrombocytopenia.[76]

PRIMARY CUTANEOUS B-CELL LYMPHOMAS

Primary CBCLs are B lymphocyte-derived malignancies that develop in the skin without extracutaneous involvement at the time of diagnosis. CBCLs comprise approximately 20% of all CLs. The primary cutaneous marginal zone B-cell lymphoma (PCMZL) and the PCFCL are indolent subtypes, whereas the diffuse large B-cell lymphoma, leg type (PCLBCL, leg type) has an intermediate to aggressive clinical behavior. These three entities [i.e., (1) PCMZL, (2) PCFCL, and (3) PCLBCL] together comprise 97% of the CBCL.

ETIOLOGY

As for CTCL an infectious trigger has been hypothesized to be involved in the etiology of CBCL. A strong association of gastric extranodal marginal zone lymphomas (MZL) and Helicobacter pylori infection is well known. In a minority of PCMZL from European patients but not in American or Asian patients *Borrelia burgdorferi* has been detected. It has recently been hypothesized that two different types of PCMZL exist: one that is phenotypically related to gastric MZL, triggered by *B. burgdorferi* infection, while the majority of PCMZL is not. A viral agent, in particular Hepatitis C virus, has also been suspected to be of relevance in the etiology of CBCL, but the results of the studies were contradictory.

PATHOGENESIS

Because of the rarity of the CBCL subtypes, studies investigating pathogenetic events in CBCL have been mainly conducted on small series of cases. However, in the recent years considerable progress has been made.

A phenomenon called aberrant somatic hypermutation (SHM) that has been previously reported in nodal B cell lymphomas has been detected in all three main types of CBCL.[77,78] This term describes the activity of the enzyme activation induced deaminase, which contributes to the process of affinity maturation of immunoglobulins (Ig) by SHM, in regions of the genome that do not encode Ig genes. If this process occurs in oncogene-containing gene loci, in association with the loss of the physiologically high-fidelity DNA repair mechanisms, tumorigenic mutations may occur and contribute to lymphomagenesis.[79]

Furthermore, genetic investigations demonstrated distinct differences of CBCL subtypes. A genetic basis for differentiation of histological akin PCFCL with a diffuse growth pattern of large cells and PCLBCL, leg type, was shown. The gene expression profiles, of these entities were consistent either with germinal center B cells for PCFCL or with activated B cells for PCLBCL, leg type.[80] Alike results were found in a study focusing on pro- and antiapoptotic genes. While PCLBCL, leg type with a poor prognosis had a genetic profile called *activate apoptosis cascade*, PCFCL and cases of PCLBCL, leg type with a favorable prognosis had a high expression level for genes that are associated with an antitumoral cytotoxic immune response.[81] These findings also give an explanation the more favorable prognosis of PCFCL compared to PCLBCL, leg type.

Furthermore, PCMZL were found to arise in a different pathogenetic background than extranodal MZL. The main differences were the high percentage of CXCR3-negative PCMZL, which also, in contrast to other extranodal MZL, exhibited an Ig class switch and a Th2 cytokine milieu.[82] How this relates to the presence of plasmacytoid DCs in PCMZL, which were also found in cutaneous pseudolymphomas, but not in DLBCL and only rarely in PCFCL, has to be investigated in the future.[83]

PRIMARY CUTANEOUS FOLLICLE-CENTER LYMPHOMA

DEFINITION. PCFCL can be defined as a neoplasm of clonal centrocytes (small and large cleaved follicle center cells) and centroblasts (large follicle center cells with prominent nucleoli) with or without formation of follicles.

CLINICAL FINDINGS. Patients with PCFCL present with nonscaling solitary or grouped papules, plaques or tumors. Patients with PCFCL have a median age of 58 years at diagnosis and men are nearly two times more often affected than women.[84] Occasionally, an annular erythema can be observed in the surrounding area (Fig. 145-17A). A typical finding is the occurrence of lesions in a circumscribed area of the head and neck region or the trunk but rarely on the legs.

HISTOPATHOLOGY. The typical histologic finding in PCFCL is a nodular or diffuse infiltrate with sparing of the epidermis. In the initial lesion a mixture of centrocytes, few centroblasts, and many reactive T cells is present that creates a follicular growth pattern or remnants of follicles with a network of $CD21^+$ follicular dendritic cells (fDC). In parallel with progression of the tumor, the number and size of neoplastic B lymphocytes increases and the infiltrate is more diffuse with scattered fDC. In persisting lesions large follicle center cells (centrocytes and centroblasts) dominate (see Fig. 145-17B). The abnormal follicles show a reduced or even absent mantle zone, lack tingible body macrophages, and contain malignant $bcl\text{-}6^+$ follicle center cells. The typical immunophenotype of the neoplastic cells is $CD20^+$

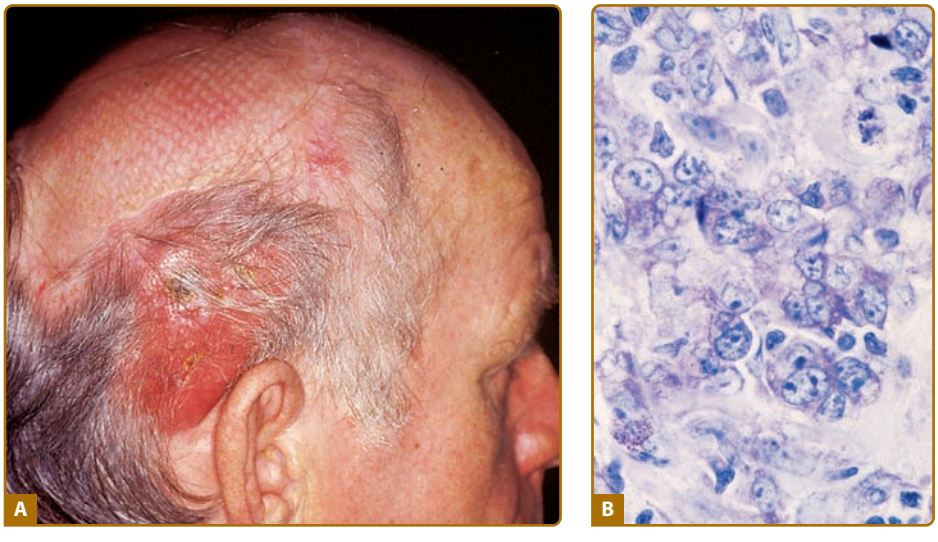

Figure 145-17 Primary cutaneous follicle center lymphoma. **A.** Tumor in the head area surrounded by erythema. **B.** The cellular infiltrate consists of a mixture of centrocytes, a number of centroblasts, and reactive T cells.

CD79a$^+$. Expression of CD10 is found only in infiltrates with a follicular pattern. Unlike in nodular follicular lymphomas, the t(14;18) translocation is not present. Bcl-2 protein may be detectable in few cases but only in a minority of tumor cells and in a weak-staining intensity. Therefore, detection of bcl-2 in the majority of tumor cells is indicative of a secondary cutaneous involvement of a systemic lymphoma. A clonal rearrangement of the variable part of the immunoglobulin heavy chain gene is detected in 60%–80% of cases.[85]

TREATMENT AND PROGNOSIS. Radiotherapy is the preferred mode of treatment; solitary lesions may also be excised. Immune therapies such as administration of IFN-α or monoclonal antibodies against CD20 may be beneficial in cases with disseminated lesions. Chemotherapy should be considered only in rare cases where more generalized skin lesions are present. With an estimated 5-year survival rate of 97%, the follicle center cell lymphoma is classified as an indolent type of primary CBCL. In untreated patients, the skin lesions increase in size over the years, but extracutaneous dissemination is uncommon.

PRIMARY CUTANEOUS MARGINAL-ZONE B-CELL LYMPHOMA

DEFINITION. PCMZL is an indolent B cell lymphoma composed of small B-lymphocytes, marginal zone cells, lymphoplasmacytoid cells, and plasma cells, which are initially localized in the marginal zone of a follicular center. In the current WHO classification, it is classified within the extranodal marginal zone lymphoma of Mucosa-associated lymphatic tissue. In a subgroup of PCMZL, *B. burgdorferi* is thought to have an etiologic role.

CLINICAL FINDINGS. PCMZLs are seen most commonly on the upper extremities or the trunk and occur at a median age of 55 years; they predominate in females. Patients have small red to violaceous papules, plaques, or nodules that, in contrast to the lesions of PCFCL, frequently occur in multiple locations. PCMZL accounts for 25% of primary CBCLs.

HISTOPATHOLOGY. Histologic analysis of well-developed lesions shows dense nodular or diffuse infiltrates with sparing of the epidermis. The infiltrate is composed of marginal zone cells, small to medium-sized cells with indented nuclei, lymphoplasmacytoid cells and plasma cells. The marginal zone cells are found in the periphery of reactive germinal centers, the atypical plasma cells in the periphery of the infiltrate. Monotypic expression of immunoglobulin light chains can be observed in approximately 75%–85% of cases. Importantly, the number of neoplastic cells within the infiltrate is variable and may be very low and is often accompanied by a substantial number of reactive T cells.

The typical immunophenotype is CD20$^+$ CD79a$^+$ CD5$^-$ CD10$^-$ and bcl-2$^+$, bcl-6$^-$. An immunoglobulin light chain restriction can frequently be found. Monoclonal immunoglobulin gene rearrangement can be demonstrated by molecular genetic methods such as PCR or Southern blotting.

TREATMENT AND PROGNOSIS. In case of detection of *B. burgdorferi*, a systemic antibiotic treatment should be given first. Otherwise radiotherapy or excision is the treatment of choice for solitary tumors. However, in most cases PCMZL present with multifocal lesions and systemic therapy is mandatory. Chlorambucil and rituximab have been used with success and a good safety profile.[86,87] For relapsing disease immune agents such as IFN-α may be administered subcutaneously or intralesionally. In the absence of symptoms a watch and wait strategy can be followed. The disease has an indolent course with an excellent prognosis, and the 5-year survival rate is nearly 100%. However, local recurrences are frequently observed. Extracutaneous involvement is extremely rare.

PRIMARY CUTANEOUS DIFFUSE LARGE B-CELL LYMPHOMA, LEG TYPE

DEFINITION. PCLBCL, leg type has been identified as a distinct clinical entity because of its perceived poor outcome compared with the indolent subtypes described above. This entity shows an intermediate and in some patients aggressive clinical course and is defined by tumors composed of large B cells that presents in the overwhelming majority of cases on the legs, but can also arise at other locations. It has been shown that the majority of patients with PCLBCL, leg type have aberrations on chromosome 9p21 and that loss of this region, which contains the *CDKN2A* gene is associated with a worse prognosis.[88]

CLINICAL FINDINGS. PCLBCL, leg type affects elderly patients (over 65 years), with a predominance in females. Typically, patients have solitary or clustered bluish erythematous plaques and tumors located on one or, sometimes, both legs (Fig. 145-18A). Ulceration is common and sometimes leads to the misdiagnosis of an ulcer due to chronic venous insufficiency.

HISTOPATHOLOGY. The diffuse infiltrate spares the epidermis and often extends into the subcutaneous tissue. Monotonous populations or confluent sheets of centroblasts and immunoblasts with a high mitotic rate are admixed with few reactive T cells (see Fig. 145-18B). The neoplastic B-lymphocytes express CD20, CD79a, multiple myeloma-1/IFN regulatory factor-4 (MUM-1/IRF4), and the bcl-2 molecule. Staining for bcl-6 gives positive results in most cases, whereas results for CD10 are negative. A clonal immunoglobulin rearrangement is detected in most cases.

TREATMENT AND PROGNOSIS. This tumor belongs to the intermediate aggressive group of CBCLs. Patients develop rapidly growing painless lesions, which initially disseminate along the lymph vessels. The tumor can involve the regional lymph nodes and progress to extracutaneous involvement. In cases of solitary or localized skin lesions, radiotherapy may be

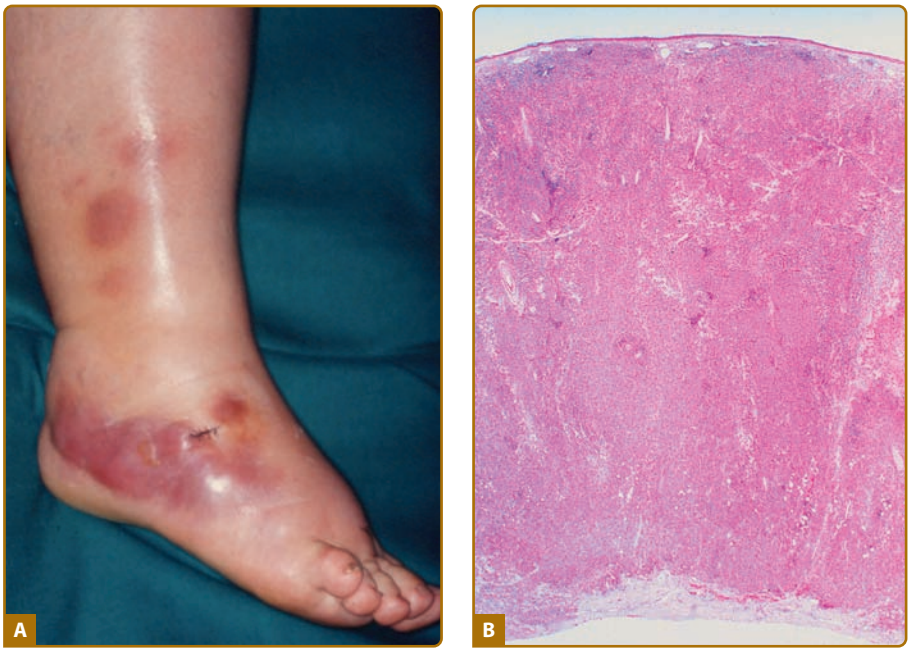

Figure 145-18 Primary cutaneous diffuse large B-cell lymphoma, leg type. **A.** Nodules and tumors on the right leg. **B.** Histology shows a diffuse infiltrate of large B cells with centroblasts, large centrocytes, and numerous immunoblasts.

undertaken; in all other cases and when progression is observed, multiagent chemotherapy in combination with an immunotherapy agent {e.g., CHOP [*c*yclophosphamide, *h*ydroxydaunomycin, *O*ncovin (vincristine), *p*rednisone] plus anti-CD20 antibody treatment} should be administered. An unfavorable prognosis is reported, with a 5-year-survival rate of 55%.

PRIMARY CUTANEOUS DIFFUSE LARGE B CELL LYMPHOMA, OTHER

This term covers diffuse large cell B cell lymphomas, which do not belong to PCLBCL, leg type, or PCFCL. These cases may represent a skin manifestation of systemic lymphomas. T cell/histocyte rich B-cell lymphomas with skin lesions only are also included; these cases show, in contrast to their nodal counterparts, an excellent prognosis.

INTRAVASCULAR CUTANEOUS B-CELL LYMPHOMA. Intravascular cutaneous B-cell lymphoma is characterized by clusters of large neoplastic B cells within dermal and subcutaneous blood vessels. Occasionally, slight extravascular infiltrates of atypical cells are observed. Clinically, red to bluish, indurated plaques occur on the legs or trunk. Sometimes, a panniculitis-like pattern can be seen. Multiagent chemotherapy is the preferred mode of treatment.

STAGING OF CUTANEOUS B-CELL LYMPHOMA

Staging of cutaneous B-cell lymphoma includes examination of the entire integument, a complete blood cell count, blood chemistry including lactate dehydrogenase level, and if indicated a serum electrophoresis to exclude a monoclonal gammopathy and/or flow cytometry on peripheral blood. In endemic regions, *Borrelia* serologic testing and PCR of skin biopsy specimens should be performed. Imaging studies include a contrast-enhanced CT scan with or without positron emission tomography, for chest, abdomen, and pelvis, and if lesions arose on the head and neck area, of the neck. Staging is completed by a bone marrow biopsy.[89] Although the necessity of a bone marrow biopsy has been questioned for MZL appearing in the skin, a definite diagnosis of PCMZL can not be made without a complete staging procedure.[90] With the results of the staging examinations patients can be classified according to a proposal of the ISCL/EORTC. While the T stage is not of prognostic significance for PCMZL and PCFCL, for PCLBCL, leg type an increasing T stage seems to be prognostically relevant.[91]

PRINCIPLES OF TREATMENT OF CUTANEOUS B-CELL LYMPHOMA

Treatment of primary CBCLs should be adapted to the favorable prognosis of these entities, in particular of PCFCL and PCMZL. Because no curative regimen has been defined so far, therapy depends on the entity and the dissemination of the cutaneous lesions. In the case of solitary lesions, complete excision of the tumor is the treatment of choice. Alternatively or in the case of few localized lesions local irradiation (single dose of 3–4 Gy; total dose of 30–40 Gy) by X-ray or electron beam is effective. When this regimen is used, long-lasting remissions can be achieved.

Systemic treatment is recommended for disseminated PCMZL or PCFCL with chlorambucil or anti-CD20 antibodies, respectively. For recurrence of indolent CBCLs with disseminated lesions a wait and see-strategy in conjunction with treatment of symptomatic lesions may be followed.

Systemic treatment regimens are recommended in cases of PCLBCL, leg type, and in PCFCL with localization on the legs, as these PCFCL have a worse prognosis or when secondary extracutaneous manifestations are present. Polychemotherapy (six cycles of CHOP, COP), in combination with an anti-CD20 antibody is recommended. In patients, that would not tolerate such an aggressive treatment local radiotherapy or rituximab monotherapy may be considered.

PRECURSOR NEOPLASMS

BLASTIC PLASMACYTOID DENDRITIC CELL NEOPLASM

DEFINITION. In the WHO-EORTC classification $CD4^+/CD56^+$ hematodermic neoplasm was included for the first time as a clinically aggressive neoplasm with a high incidence of cutaneous involvement and risk of leukemic dissemination. The blastic cytologic appearance and CD56 expression initially suggested an NK precursor origin. More recent studies suggested derivation from a plasmacytoid dendritic cell precursor and therefore this entity is classified as BPDCN.

CLINICAL FINDINGS. BPDCN commonly presents in the skin as solitary or multiple nodules or tumors (Fig. 145-19) with or without concurrent extracutaneous manifestations. Approximately 50% of patients have nodal or bone marrow involvement at presentation. Most patients who have only skin lesions when they first come for treatment rapidly develop involvement of bone marrow, peripheral blood, lymph nodes, and extranodal sites.

HISTOPATHOLOGY. The typical findings are diffuse monomorphous infiltrates of medium-sized cells separated by a grenz zone from the epidermis. Perivascular patchy infiltrates and an Indian file pattern are observed occasionally. Angiotropism is uncommon. The neoplastic cells express CD4, CD43, and CD56, as well as TCL1. Tests for the lineage markers CD20, CD3, or other markers like CD30, TIA1, granzyme B give negative results. The cells further express CD123 and blood dendritic cell antigen 2, both of which support a relationship to plasmacytoid dendritic cells. *TCR* genes are in germline configuration. Tumor cells test negative for EBV.

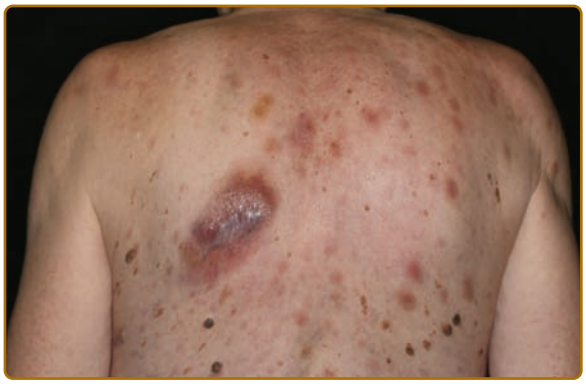

Figure 145-19 Blastic plasmacytoid dendritic cell neoplasm. Multiple lesions on the back. The large tumor was the initial site of manifestation (centrally located is the scar of a biopsy), the multiple small lesions developed in a short period of time.

TREATMENT AND PROGNOSIS. BPDCN is associated with a highly aggressive clinical course and thus a poor prognosis (median survival of 14 months). Although systemic chemotherapy is the first choice for treatment of this disease, the results are often disappointing. Studies suggest that patients can best be treated with regimens used to treat acute myeloid leukemias, including bone marrow transplantation.

PREVENTION. Not applicable.

KEY REFERENCES

Full reference list available at www.DIGM8.com

DVD contains references and additional content

3. Assaf C et al: Classification of primary cutaneous lymphomas. *Front Radiat Ther Oncol* **39**:25, 2006
10. Zendri E et al: The HTLV tax-like sequences in cutaneous T-cell lymphoma patients. *J Invest Dermatol* **128**:489, 2008
20. Talpur R, Bassett R, Duvic M: Prevalence and treatment of Staphylococcus aureus colonization in patients with mycosis fungoides and Sézary syndrome. *Br J Dermatol* **159**:105, 2008
35. van Doorn R et al: Oncogenomic analysis of mycosis fungoides reveals major differences with Sezary syndrome. *Blood* **113**:127, 2009
60. Olsen E et al: Revisions to the staging and classification of mycosis fungoides and Sezary syndrome: A proposal of the International Society for Cutaneous Lymphomas (ISCL) and the cutaneous lymphoma task force of the European Organization of Research and Treatment of Cancer (EORTC). *Blood* **110**:1713, 2007
90. Senff NJ, Kluin-Nelemans HC, Willemze R: Results of bone marrow examination in 275 patients with histological features that suggest an indolent type of cutaneous B-cell lymphoma. *Br J Haematol* **142**:52, 2008

Chapter 146 :: Inflammatory Diseases That Simulate Lymphomas: Cutaneous Pseudolymphomas

:: Gary S. Wood

CUTANEOUS PSEUDOLYMPHOMAS AT A GLANCE

- A diverse group of skin disorders characterized by dense lymphoid infiltrates mimicking various types of cutaneous lymphomas.
- Two major immunologic categories: (1) mixed B and T cell (cutaneous lymphoid hyperplasia, Kimura disease, angiolymphoid hyperplasia with eosinophilia, Castleman disease) and (2) T cell (pseudomycosis fungoides, lymphomatoid contact dermatitis, Jessner's lymphocytic infiltration of the skin).
- Most are idiopathic but some are reactions to foreign antigens introduced locally or systemically.
- Usually present as violaceous, solitary, or localized papules, plaques, or nodules.
- Some cases harbor occult dominant lymphoid clones; occasional cases progress to overt cutaneous lymphomas.

Cutaneous pseudolymphoma is a term used to describe skin lesions that bear a clinical and/or histopathologic resemblance to lymphoma. Over the years, a wide variety of designations have been included in this category. Some of these represent outdated synonyms, some refer to variants of the same entity, and some are misnomers for diseases now recognized to be true lymphomas. The relevant entities that are discussed in this and other chapters can be organized into several distinct disorders based on their lymphoid subset composition, pattern of cutaneous infiltration, and associated clinical findings (Table 146-1).

CUTANEOUS LYMPHOID HYPERPLASIA

EPIDEMIOLOGY

Cutaneous lymphoid hyperplasia (CLH) has a worldwide distribution and affects all races and ethnic groups. It occurs in both adults and children. Females are more commonly affected than males.

ETIOLOGY AND PATHOGENESIS

CLH is characterized by a relatively dense lymphoid infiltrate, centered in the reticular dermis, which is usually B-cell rich and may resemble lymphoma clinically and/or histopathologically. Many terms are used to refer to this type of pseudolymphoma, including *Spiegler–Fendt sarcoid*, *lymphocytoma cutis*, *lymphadenosis benigna cutis*, and *cutaneous lymphoplasia*. *Cutaneous lymphoid hyperplasia* is the preferred term because it accurately describes the underlying pathophysiology of the lesion and is unlikely to be confused with terms used to describe various forms of cutaneous lymphoma.[1–6]

In most cases, CLH is idiopathic; however, some lesions are associated with exposure to foreign antigens from arthropods (bites, stings, infestations), infections (herpes zoster, *Borrelia burgdorferi*, *Helicobacter pylori*), tattoos, acupuncture, trauma, gold jewelry, vaccinations, hyposensitization injections, or medications (Figs. 146-1–146-4).[1–9] Medications that may induce CLH include phenytoin, carbamazepine, phenobarbital, β blockers, calcium channel blockers, angiotensin-converting enzyme inhibitors, allopurinol, d-penicillamine, penicillin, mexiletine chloride, cyclosporine, and agents that inhibit binding of histamine to H_1, H_2, or H_{1c} receptors. These drugs include conventional H_1 and H_2 antagonists, as well as tricyclic and nontricyclic antidepressants and phenothiazines.[10] It has been proposed



Figure 146-1 Cutaneous lymphoid hyperplasia. Solitary infiltrated nodule with a smooth surface in a classic location. (Lymphocytoma cutis in Lyme borreliosis.)

TABLE 146-1
Classification of Cutaneous Pseudolymphomas

Clinicopathologic Subtype	Predominant Lymphoid Subset(s)	Predominant Localization	Major Associated Findings
Cutaneous lymphoid hyperplasia	B and T cell	Reticular dermis	—
Kimura disease	B and T cell	Subcutis	Lymphadenopathy
Angiolymphoid hyperplasia with eosinophilia	B and T cell	Reticular dermis	Eosinophilia
Castleman disease	B and T cell	Subcutis	Lymphadenopathy, POEMS syndrome
Pseudomycosis fungoides	T cell	Papillary dermis and epidermis	—
Lymphomatoid contact dermatitis	T cell	Papillary dermis and epidermis	Contact allergen
Lymphocytic infiltration of the skin (Jessner's)	T cell	Perivascular and periadnexal dermis	—

POEMS = polyneuropathy, organomegaly, endocrinopathy, M protein, and skin changes.

that, rather than being the target of an immune response themselves, these latter agents may alter lymphocyte reactivity in a way that promotes a CLH response to other antigens in some individuals.[11,12]

CLINICAL FINDINGS

APPROACH TO THE PATIENT. Although the details of the workup for individual patients will vary with the specific type of pseudolymphoma being considered, certain data are generally important for establishing the correct diagnosis, identifying potential causative factors, and ruling out an underlying lymphoma. The clinical history taking should elicit information about the duration and symptomatology of lesions; the nature and pace of clinical progression; past treatment; local or systemic exposure to foreign antigens, including medications; and personal or family history of other lymphoproliferative disorders. It should also include a review of systems focusing on so-called *lymphoma B symptoms*, such as fever of unknown origin, unexplained weight loss, night sweats, fatigue, and malaise. A general physical examination is important, with special attention to the type and distribution of skin lesions and to the status of peripheral lymph nodes, liver, and spleen. A complete blood count with differential review, general chemistry panel, and a chest radiograph are screening tests that help to exclude



Figure 146-2 Cutaneous lymphoid hyperplasia. Involvement of the breast in a patient with elevated titers of antibodies against *Borrelia burgdorferi spirochetes.*



Figure 146-3 Cutaneous lymphoid hyperplasia. Multiple lesions of nodular scabies involving the genitalia.



Figure 146-4 Cutaneous lymphoid hyperplasia. Lymphomatoid drug reaction manifest as a generalized papulonodular eruption in a patient who was taking various neuroleptics.

extracutaneous involvement. Lesional skin biopsy is an essential part of the diagnostic evaluation. The use of topical and systemic glucocorticoids should be discontinued approximately 4 weeks before biopsy if possible, because these agents can attenuate lymphoid infiltrates and thereby confound their interpretation. Skin specimens should be large enough and deep enough to ensure representative sampling and to provide adequate tissue for routine histopathologic, immunohistologic, and molecular biologic studies. As with squamoproliferative skin lesions, the most diagnostic areas within cutaneous lymphoid infiltrates are often their deepest portions (Fig. 146-5). For cost-effectiveness, one can often perform these biopsy studies in a sequential fashion, proceeding to the next test only if a firm diagnosis cannot be made based on the results of preceding analyses. However, rigorous characterization of a pseudolymphomatous infiltrate requires the full complement of these assays. If there is only a solitary lesion, it is generally best to obtain all biopsy material at one time, because inflammatory changes induced by the initial biopsy may interfere with the interpretation of subsequent specimens from the same locale.

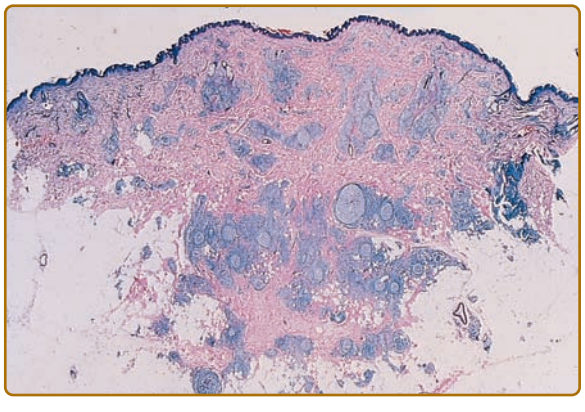

Figure 146-5 Cutaneous lymphoid hyperplasia. Infiltrate is wedge shaped and tapers out in its deeper portions. Note reactive lymphoid follicles containing pale germinal centers.

In the event that there is still uncertainty as to whether the lymphoid infiltrate represents a pseudolymphoma or a lymphoma, additional workup can be helpful. This includes computed tomographic scans of the chest, abdomen, and pelvis, as well as bone marrow aspiration and biopsy. Biopsy can be performed on abnormally enlarged lymph nodes identified by physical examination or radiography and the specimens evaluated as described in the preceding paragraph for skin lesions. It is possible for patients with atypical cutaneous B-cell infiltrates manifesting as only one or a few skin lesions to have an otherwise unremarkable workup until radiographic scans of deep lymph nodes or bone marrow sampling demonstrates advanced-stage B-cell lymphoma with minor skin involvement.

HISTORY. There may be a history of contact with an etiologically relevant foreign antigen; however, the majority of CLH cases are idiopathic. Lesions may be pruritic or asymptomatic. Occasionally, they may be slightly tender.[13]

CUTANEOUS LESIONS. CLH presents most commonly as a solitary nodule, but it can also appear as a localized array of nodules, plaques, or papules. Generalized forms occur rarely. The head, neck, extremities, breasts, and genitalia are common sites (see Figs. 146-1–146-4). Lesions have a doughy to firm consistency and range from red–brown to violaceous in color. Lesions secondary to arthropod bites can be pruritic, ulcerated, or crusted. Occasionally, reactive lymphadenopathy may be present in the area of regional lymphatic drainage.[13,14]

Hydantoin-associated pseudolymphoma syndrome is caused by anticonvulsant drugs such as phenytoin. This syndrome is characterized by fever, lymphadenopathy, hepatosplenomegaly, arthralgia, eosinophilia, and generalized cutaneous macules and papules or, rarely, nodules.[4,6] Nodules may contain aggregates of large lymphoid cells that raise concern for lymphoma; however, both B and T cells are polyclonal. Subcutaneous lymph nodes may exhibit reactive follicular hyperplasia or atypical features suggestive of lymphoma. The macular and papular lesions of this syndrome share histopathologic features with those of hypersensitivity reactions to other drugs.

Acral pseudolymphomatous angiokeratoma of children presents as a unilateral eruption of angiomatous papules on the extremities.[15] There is a dense lymphoid infiltrate associated with histiocytes, plasma cells, and prominent, thickened capillaries.[16] This disorder is probably a variant of CLH secondary to arthropod bites.

Large cell lymphocytoma, originally reported as a cutaneous pseudolymphoma, most likely represents a mixed cell or large cell form of primary cutaneous B-cell lymphoma (CBCL).[5]

LABORATORY TESTS

HISTOPATHOLOGY. Histopathologic examination of CLH lesions reveals a dense, nodular or diffuse lymphoid infiltrate that is concentrated in the reticular



Figure 146-6 Cutaneous lymphoid hyperplasia. Nodular scabies. Patchy dense infiltrate composed of small lymphocytes, histiocytes, eosinophils, and plasma cells.

dermis (see Figs. 146-5 and 146-6). It tends to be top heavy and to taper out in the lower dermis, although more widespread dermal infiltration with extension into the subcutis can sometimes be seen. In most cases, the epidermis is normal and separated from the underlying infiltrate by a narrow grenz zone of uninvolved papillary dermis. Occasionally, the epidermis may exhibit variable degrees of hyperkeratosis, parakeratosis, acanthosis, dyskeratosis, spongiosis, and basal vacuolar degeneration. Arthropod-induced reactions may show prominent epidermal hyperplasia or ulceration. Rarely, retained mouth parts may be seen associated with foreign-body granulomatous reactions. The dermal infiltrate is composed primarily of small mature lymphocytes, with a minor component of large lymphoid cells containing large, pale vesicular nuclei with small nucleoli (Fig. 146-7). Fewer than half of cases exhibit well-defined reactive lymphoid follicles discernible in routinely stained sections (see Figs. 146-5 and 146-8). These B-cell follicles may be either primary or secondary. The former are composed of homogeneous small lymphocytes, whereas the latter are compartmentalized into a peripheral mantle zone of small lymphocytes surrounding a germinal center composed of a heterogeneous mixture of small and large lymphoid cells with cleaved and noncleaved nuclei known as *centrocytes* and *centroblasts.* Germinal centers contain $CD4^+$ T-follicular helper cells characterized by expression of PD-1, Bcl-6, and CXCL13.[17] Also present in germinal centers are tingible-body macrophages, so named because they contain phagocytized debris from apoptotic lymphoid

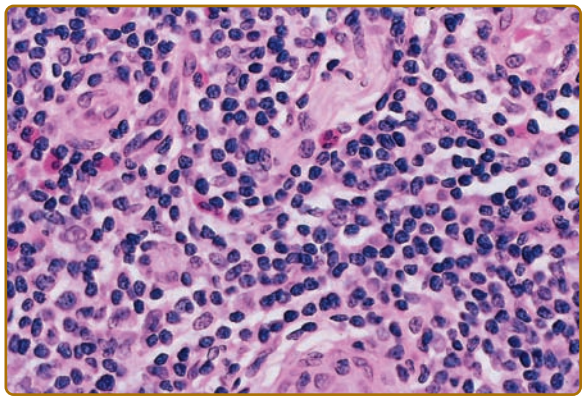

Figure 146-7 Cutaneous lymphoid hyperplasia. Infiltrate consists predominantly of small lymphocytes with an admixture of large lymphoid cells, histiocytes, and eosinophils.

cells. Mitotic figures may be numerous within germinal centers but are usually uncommon elsewhere in the infiltrate. Various types of histiocytes, including macrophages, dermal dendritic cells, and Langerhans cells, are scattered throughout the infiltrate in variable proportions. Capillary hyperplasia and endothelial swelling are often present. Other cells are sometimes admixed, including plasma cells, eosinophils, mast cells, neutrophils, and histiocytic giant cells. The first two are particularly common in arthropod-induced reactions such as nodular scabies (see Fig. 146-6).[13,14]

In the less common T-cell CLH, there are only rare B cells.[4–6,18–20] Lesions may be idiopathic or secondary to drugs or arthropod bites. Sparse to moderate epidermotropism by atypical lymphoid cells may be seen. The dermal infiltrate has a nodular or diffuse pattern and may contain cerebriform cells, immunoblasts, and histiocytes mixed with a preponderance of small mature lymphocytes. The histiocytes are sometimes numerous enough to impart a vaguely granulomatous appearance.[18] The author has seen one such case presenting as multiple nodules on the trunk and extremities that was associated with rheumatoid arthritis and eventuated in T-cell lymphoma.

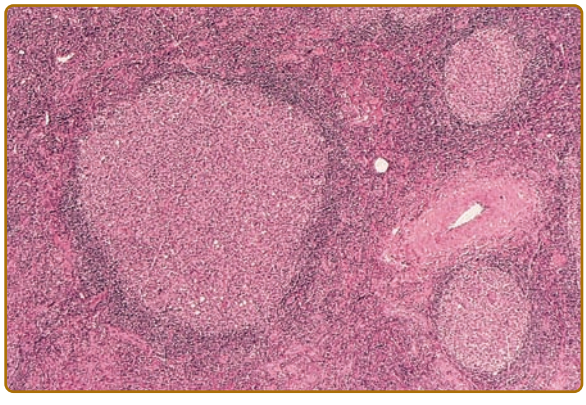

Figure 146-8 Cutaneous lymphoid hyperplasia. Lymphoid follicles in the dermis contain pale germinal centers surrounded by darker mantle zones.

SPECIAL TESTS. CLH is just one special case of extranodal lymphoid hyperplasia that may occur in a variety of organ systems. In their most well-developed form, these extranodal reactions recreate the immunoarchitectural features of reactive follicular lymphoid hyperplasia occurring in lymphoid tissues. CLH is generally a mixed B-cell/T-cell disorder. B cells may be organized into primary or secondary lymphoid follicles, simple clusters devoid of the follicular dendritic cell network seen in B-cell follicles, or may be randomly scattered throughout the infiltrate (Fig. 146-9). A defining immunophenotypic feature of CLH is that the small, nongerminal center B cells and plasma cells are polytypic; i.e., instead of restriction to only one type of immunoglobulin light chain, there is a mixture of κ-positive and λ-positive cells.[21–23] The follicular dendritic cell networks in lymphoid follicles coexpress both immunoglobulin light chains because of the polytypic nature of the immunoglobulins bound to these networks (Fig. 146-10). The larger germinal center B cells are also polytypic but generally have very low levels of immunoglobulin expression, which is obscured by the more intense staining of the follicular dendritic cell networks in which they are enmeshed.[24] Consistent with their role as a site of antigen selection and apoptosis, reactive germinal centers test negative for the bcl-2 oncoprotein.[5]

Some researchers classify CLH into follicular and diffuse variants based on the identification of lymphoid follicles in routinely stained sections. This distinction is probably not relevant biologically, because most of the apparently diffuse cases also exhibit B-cell follicles when examined immunohistologically. T cells are also present in all cases of CLH. They are found in small numbers within lymphoid follicles, for example, T follicular helper cells, but are concentrated mainly between follicles, constituting an interfollicular T-cell domain. This imparts an overall compartmentalization of B and T cells in CLH lesions. The $CD4^+$ T-cell subset

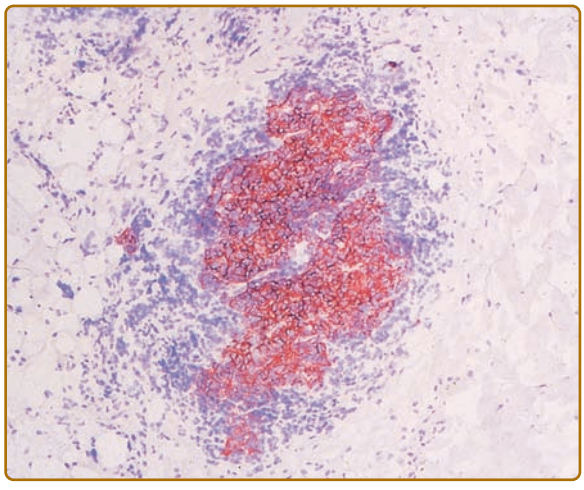

Figure 146-9 Cutaneous lymphoid hyperplasia. Reactive lymphoid follicle contains B cells (*blue*) enmeshed in a network of follicular dendritic cells (*red*). Frozen section immunoperoxidase-stained using the antidendritic reticulum cell monoclonal antibody.

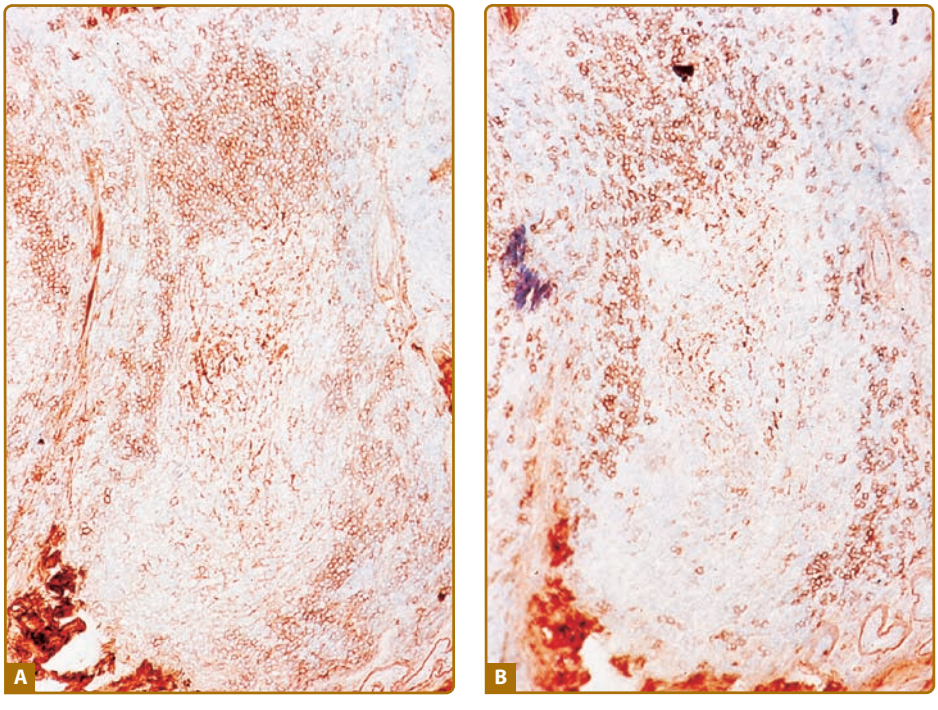

Figure 146-10 Cutaneous lymphoid hyperplasia. Reactive lymphoid follicle contains a germinal center surrounded by a mantle zone composed of a mixture of B cells that express either κ-immunoglobulin light chain (**A**) or λ-immunoglobulin light chain (**B**). Note that the central follicular dendritic cell network stains positive for both light chains because polytypic immunoglobulins are bound to its surface.

predominates over the CD8$^+$ subset. There is a normal pattern of T-cell antigen expression except that CD7 may be moderately deficient at times, being expressed by only 20% to 40% of T cells. Germinal center B cells, mantle zone B cells, interfollicular B cells, and plasma cells also express the same complement of cell surface differentiation antigens expressed by their counterparts in reactive lymphoid tissues.

Unlike in most nodal follicular B-cell lymphomas (Chapter 145), the t(14;18) translocation, which results in inappropriate expression of the bcl-2 oncoprotein, is absent in CLH.[5,25–27] Molecular biologic studies show that 5% to 33% of CLH cases defined by clinicopathologic and immunohistologic criteria contain occult dominant immunoglobulin gene rearrangements, which indicate the presence of a dominant B-cell clone.[5,28–32] These cases, known as *clonal CLH*, have progressed in some cases to overt B-cell lymphoma exhibiting the same dominant B-cell clone. These findings support the view that CLH, clonal CLH, and primary CBCL exist as points along a continuum of cutaneous B-cell lymphoproliferative disorders. Progression across this spectrum of disease clearly occurs in some cases, most likely as the result of serial mutations within the dominant B-cell clone. This implies that patients with persistent CLH require regular monitoring for the development of lymphoma.[22] Clonal T-cell receptor gene rearrangements have also been detected in up to one-third of CLH cases.[28,33] This may represent an expanded reactive T-cell clone within the CLH infiltrate. Evidence for this has been observed in CLH related to human immunodeficiency virus infection.[34] Other possibilities include a low-grade T-cell lymphoma such as the CD4$^+$ small/medium pleomorphic type[17,35] or an evolving B-cell lymphoma bearing T-cell receptor gene rearrangements.

DIFFERENTIAL DIAGNOSIS

The differential diagnosis of CLH includes all of the conditions listed in Box 146-1. Many of these entities, such as granuloma faciale, Merkel cell tumor, histiocytomas, granulomas, and metastatic carcinoma, are readily distinguished from CLH by their histopathologic features.

A principal challenge in the differential diagnosis of CLH is its distinction from CBCL of either the diffuse or follicular types (see Chapter 145).[4–6,27,36] The most common variant of CBCL is diffuse large cell lymphoma, which is readily distinguished from follicular CLH on the basis of its diffuse architecture and monomorphous large cell composition. Differentiating follicular CLH from follicular CBCL can be difficult. Follicular CBCL tends to be more bottom heavy with adnexal infiltration and lymphoid follicles lacking the cellular heterogeneity, zonation, and macrophages typical of reactive follicles. Immunophenotyping shows that neoplastic B-cell follicles are either monotypic or immunoglobulin negative.[18–20] Cases involving cutaneous lymphoid infiltrates that are hard to classify or that contain a dominant lymphoid clone often benefit from a staging workup as described in Section "Approach to the Patient." In those instances representing lymphoma, workup will sometimes reveal extracutaneous involvement, and biopsy specimens from these lesions may be easier to diagnose as lymphoma. Staging also provides useful prognostic data and is essential for appropriate management of patients with overt lymphoma.

CLH must also be distinguished from other disorders with prominent lymphocytic infiltrates such as chronic lymphocytic leukemia, deep figurate erythemas, polymorphous light eruption, discoid lupus erythematosus, and Jessner's lymphocytic infiltration of the skin. All of these disorders tend to produce perivascular, and sometimes periadnexal, infiltrates whose density is far lower than that of the nodular or diffuse infiltrates typical of CLH. With the exception of chronic lymphocytic leukemia, these are all T-cell disorders. Chronic lymphocytic leukemia is a B-cell disorder that exhibits monotypic immunoglobulin and CD5 expression and involves the blood and bone marrow. CLH lesions rich in plasma cells must be distinguished from the lesions of secondary syphilis, plasmacytoma, myeloma, and immunocytoma. The infiltrate in secondary syphilis is generally richer in plasma cells or histiocytes than in small lymphocytes and is associated with epidermal hyperplasia, an interface inflammatory component, and positive results on serologic tests. The plasma cells in plasmacytoma and myeloma are monotypic and tend to exhibit mitotic figures, atypia, immaturity, and multinucleated forms. Monotypic immunoglobulin is also present in the tumor cells of primary cutaneous immunocytoma. This B-cell neoplasm is also known as *marginal zone lymphoma*, *mucosa-associated lymphoid tissue (MALT)-type lymphoma*, and *low-grade skin-associated lymphoid tissue (SALT) B-cell lymphoma*.[5,27,37]

BOX 146-1 DIFFERENTIAL DIAGNOSIS OF CUTANEOUS LYMPHOID HYPERPLASIA

Most Likely
- Chronic cutaneous lupus erythematosus
- Jessner's lymphocytic infiltration of the skin
- Granuloma faciale

Consider
- Polymorphous light eruption
- Drug eruption
- Angiolymphoid hyperplasia with eosinophilia
- Deep figurate erythemas
- Metastatic carcinoma
- Merkel cell carcinoma
- Secondary syphilis
- Histiocytomas
- Infectious and inflammatory granulomas

Always Rule Out
- Cutaneous B-cell lymphoma
- Cutaneous CD4$^+$ small/medium pleomorphic T-cell lymphoma
- Leukemia cutis

It is composed of varying proportions of small lymphocytes, plasmacytoid lymphocytes, plasma cells, and marginal zone-like B cells. The latter have monocytoid features with a halo of cytoplasm visible around their nuclei. These cells often surround clusters of small lymphocytes, imparting a "reverse reactive follicle" appearance with smaller cells centrally and the larger monocytoid cells peripherally.

Other disorders that can contain dense cutaneous infiltrates of both T cells and B cells include (1) lymphomatoid keratosis,[38] (2) pseudolymphomatous folliculitis,[39] (3) systemic immunoglobulin IgG4-related plasmacytic syndrome (SIPS),[40,41] and (4) $CD4^+$ small/medium pleomorphic T-cell lymphoma.[17,35] The first three are readily distinguished from classic CLH on clinicopathological grounds. Although it can mimic CLH clinically and contain abundant B cells and plasma cells, $CD4^+$ small/medium pleomorphic T-cell lymphoma is recognized by its predominance of $CD4^+$ atypical lymphoid cells, frequent dominant T-cell clonality, paucity of reactive lymphoid follicles, and T-follicular helper cell phenotype.

It should be noted that typical reactive lymphoid follicles with germinal centers are not specific for CLH. They can be seen in some lymphomas (e.g., marginal zone lymphoma), Kimura disease, angiolymphoid hyperplasia with eosinophilia, Castleman disease, inflammatory pseudotumor of the skin, and morphea and as part of the host response to tumors such as basal cell carcinoma. The broad histopathologic differential diagnosis of CLH also includes histiocytoses, especially Rosai–Dorfman disease (sinus histiocytosis with massive lymphadenopathy; see Chapter 148), as well as so-called *small round cell tumors* such as Merkel cell carcinoma (see Chapter 120), oat cell carcinoma, neuroblastoma, and Ewing sarcoma.

Differentiation between T-cell CLH and T-cell lymphomas relies on the fact that most cases of mycosis fungoides exhibit marked epidermotropism, and most nonmycosis fungoides cutaneous T-cell lymphomas are diffuse large cell types, although a pleomorphic small/medium cell type occurs rarely as discussed above. Many T-cell lymphomas show loss of one or more T-cell antigens, and most have monoclonal T-cell receptor gene rearrangements. Progression to T-cell lymphoma has been reported in occasional patients with T-cell CLH.[19,20]

COMPLICATIONS

One of the most challenging issues concerning cutaneous pseudolymphomas has been the nature of their relationship to true lymphomas. Many patients with CBCL have a history of prior diagnosis of biopsy specimens as CLH or atypical CLH. Patients with disorders such as lymphomatoid papulosis, lymphomatoid granulomatosis, and angioimmunoblastic lymphadenopathy with dysproteinemia have an increased risk of developing various forms of overt lymphoma.[5,6,27,37] The advent of molecular biologic methods for determining B-cell or T-cell clonality by analyzing immunoglobulin or T-cell receptor gene rearrangements, respectively, has provided important insights into the relationship between pseudolymphomas and lymphomas.[5,6,27] It appears that many forms of cutaneous pseudolymphoma represent the benign end of a lymphoproliferative continuum eventuating in true lymphoma at its malignant extreme. In between lies a spectrum of intermediate disorders that are often difficult to classify unless one conceptualizes the disorders along such a continuum. In some cases, such as the CLH–CBCL spectrum, lesions range from polyclonal CLH at the benign extreme, through an intermediate form known as clonal CLH, to overt CBCL at the malignant extreme. In other instances, such as the lymphomatoid papulosis–$CD30^+$ lymphoma spectrum, dominant clonality is already present in most cases at the clinically benign end of the spectrum. The most compelling evidence for the validity of this concept of a continuum is that case studies verify that the same dominant lymphoid clone is involved in the clonal pseudolymphomatous precursor and the subsequent overt lymphoma when they arise in the same individual. This relationship between overt neoplasia and clonal precursor lesions is not unique to cutaneous pseudolymphomas. It is also seen in the connection between other forms of extranodal lymphoid hyperplasia and overt lymphoma and in the relationship between monoclonal gammopathy of uncertain significance (formerly termed *benign monoclonal gammopathy*) and subsequent B-cell malignancies.

The concept of a spectrum for cutaneous pseudolymphomas and associated lymphomas has several important implications for the diagnosis, management, and pathogenesis of these disorders. First, because some cases will exhibit lesions at an intermediate point along the lymphoproliferative continuum, they may be difficult to classify neatly into a specific disease entity. It is probably more important to recognize that they belong to a particular disease spectrum, because it is the spectrum that is often the most relevant factor for determining optimal therapy as well as the magnitude and nature of the subsequent lymphoma risk. Second, because many patients with cutaneous pseudolymphomas are at increased risk for a clonally related lymphoma, they should have regular clinical follow-up, and all reasonable attempts should be made to eradicate or suppress their disease. Third, patients with pseudolymphomas probably have underlying abnormalities in the regulation of lymphoid proliferation and/or clearance (e.g., via apoptosis). Clonal evolution and concomitant clinical disease progression are likely to occur through a sequence of somatic mutations that act through these mechanisms to confer progressively increasing autonomy to the dominant lymphoid clone. Elucidating these pathogenetic mechanisms will be important not only for developing novel therapies for cutaneous pseudolymphomas but also for improving the treatment of analogous lymphoproliferative disorders occurring in other organ systems.

PROGNOSIS AND CLINICAL COURSE

CLH lesions may resolve spontaneously or persist indefinitely. Nodular scabies (see Figs. 146-3 and 146-6)

is a well-recognized form of persistent CLH. Solitary lesions sometimes regress after biopsy or may be eradicated by excision. Those lesions that are secondary to drug use usually regress when the offending agent is withdrawn.

TREATMENT

CLH related to infection with *Borrelia burgdorferi* (lymphocytoma cutis; see Chapter 187) responds to antibiotic therapy with cephalosporins, as do some cases of idiopathic CLH. Glucocorticoids (topical, intralesional, systemic), cryotherapy, antimalarials, minocycline, and radiation therapy have all been used with variable success (Box 146-2). The latter is particularly effective but is usually regarded as a treatment of last resort. Laser therapy and photodynamic therapy have also been beneficial in some cases.[43,44] Local or distant recurrence can arise after any of these treatments. Cases of atypical CLH that cannot be distinguished from lymphoma are usually treated as localized lymphoma after staging rules out extracutaneous disease. Treatment typically involves local radiation therapy, which may be preceded by excision of the lesion.

PREVENTION

The principal preventive strategy is to avoid contact with, or ingestion of, agents known to induce CLH in those patients with a relevant clinical history. Examples include anticonvulsant medications, arthropods, gold jewelry, and hair dyes.[45–49]

BOX 146-2 TREATMENT OF CUTANEOUS LYMPHOID HYPERPLASIA

FIRST LINE

- Excision
- Topical corticosteroids (mid-to-high potency twice daily)
- Intralesional corticosteroids (5–40 mg/mL, 1 mL monthly)
- Systemic antibiotics (e.g., minocycline 50–100 mg PO twice daily; cephalexin 500 mg PO twice daily)
- Topical tacrolimus[42]

SECOND LINE

- Cryotherapy
- δ-Aminolevulinic acid photodynamic therapy
- Laser therapy (e.g., pulsed dye laser)
- Hydroxychloroquine (200 mg PO twice daily)
- Systemic corticosteroids (60/40/20 mg PO taper, 5 days each)
- Local radiation therapy

KIMURA DISEASE AND ANGIOLYMPHOID HYPERPLASIA WITH EOSINOPHILIA

EPIDEMIOLOGY

The skin lesions of Kimura disease and angiolymphoid hyperplasia with eosinophilia (AHLE) most commonly affect young to middle-aged adults. Kimura disease is more common in Asian men, whereas AHLE is more common in women.[50–53]

ETIOLOGY AND PATHOGENESIS

It is possible that Kimura disease represents a florid, subcutaneously deep-seated form of the same basic pathogenetic process that gives rise to classic dermal CLH. Most favor the concept that Kimura disease and AHLE are distinct clinicopathologic entities despite some clinicopathologic overlap.[54–56] The terms *epithelioid hemangioma* and *pseudopyogenic granuloma* have been used as synonyms for AHLE. Some regard AHLE essentially as a malformation of blood vessels caused by an underlying arteriovenous shunt. They consider the CLH-like aspects of the lesional infiltrate to be a secondary feature. There is also evidence of lymphatic vessel proliferation in AHLE.[52] Compared with the lesions of Kimura disease, AHLE lesions tend to be smaller (Fig. 146-11) and more superficial (centered in the dermis rather than the subcutis) and exhibit a more prominent vascular hyperplasia, characterized by small blood vessels lined by plump endothelial cells with abundant cytoplasm and sometimes atypical nuclei (see Fig. 146-11). In addition, there is often evidence of arteriovenous anastomoses, the lymphoid infiltrate is less extensive, secondary lymphoid follicles are present in only a minority of cases, and lymphadenopathy is usually absent. Patients with both AHLE and Kimura disease have been shown to harbor dominant clonal T-cell populations in some cases.

CLINICAL FINDINGS

Kimura disease presents as solitary or multiple nodules up to 10 cm in diameter centered in the subcutis, most commonly involving the head and neck.[54–56] Peripheral eosinophilia and regional lymphadenopathy are characteristic. AHLE tends to present with multiple smaller, more superficial intradermal papulonodules that are typically unilateral. Salivary glands, lymph nodes, and other cutaneous sites can also be affected in either disorder, although such locations are more typical of Kimura disease.

Histopathologically, the dermis and/or subcutis exhibit hyperplasia of small blood vessels lined by plump endothelial cells similar to those present in the high endothelial venules of lymphoid tissues. These venules are a major point of lymphocyte trafficking between the blood and the paracortical T-cell domain

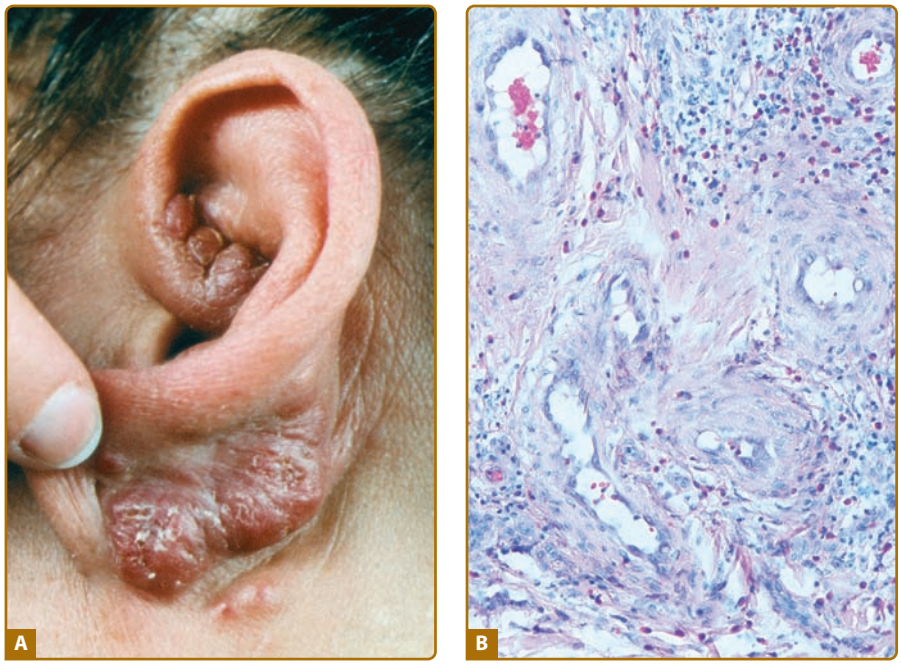

Figure 146-11 Angiolymphoid hyperplasia with eosinophilia. **A.** Clinically, there are soft, confluent papular lesions typically located in the auricular region. **B.** Histologically, blood vessels are lined by plump endothelial cells protruding into the lumen; there is vascular hyperplasia with thickened vascular walls lymphocytic infiltrates, and prominent eosinophilia.

of lymph nodes. Surrounding these hyperplastic vessels is a dense infiltrate composed of small lymphocytes, plasma cells, histiocytes, and eosinophils. The latter are typically prominent but may be absent in some cases. There are usually multiple secondary lymphoid follicles with prominent germinal centers, particularly in the subcutaneous lesions. In general, lesions are more superficial and the vascular features are more prominent in AHLE, whereas lesions are deeper and the lymphoid features are more prominent in Kimura disease.[50,51,57]

DIFFERENTIAL DIAGNOSIS

Kimura disease, which generally forms deeper, larger lesions, needs to be distinguished from CBCL, sinus histiocytosis with massive lymphadenopathy, soft tissue tumors, and subcutaneous deposits of metastatic carcinoma (Box 146-3). AHLE, which has smaller, more superficial lesions, should be differentiated from CLH, CBCL, hemangioma, angiosarcoma, pyogenic granuloma, nodular Kaposi sarcoma, bacillary angiomatosis, and bartonellosis. Many of these entities have distinctive histopathologic features. The distinguishing features of CLH and CBCL have been discussed earlier (see Section "Differential Diagnosis" under "Cutaneous Lymphoid Hyperplasia").

COMPLICATIONS

Kimura disease has been associated with lichen amyloidosis and renal disorders such as nephrotic syndrome.[58]

PROGNOSIS AND CLINICAL COURSE

Some cases, such as those associated with dominant T-cell clonality, have exhibited a chronic clinical course marked by multiple recurrences and resistance to treatment.

BOX 146-3 DIFFERENTIAL DIAGNOSIS OF KIMURA DISEASE AND ANGIOLYMPHOID HYPERPLASIA (AHLE)

Most Likely
- Cutaneous lymphoid hyperplasia (both)
- Sinus histiocytosis with massive lymphadenopathy (both)
- Pyogenic granuloma (AHLE)
- Hemangioma (AHLE)

Consider
- Soft tissue tumors (both)
- Angiosarcoma (AHLE)
- Kaposi sarcoma (AHLE)
- Bacillary angiomatosis (AHLE)
- Bartonellosis (AHLE)

Always Rule Out
- Cutaneous B-cell lymphoma and other lymphomas (both)
- Metastatic carcinoma (both)

BOX 146-4 TREATMENT OF KIMURA DISEASE AND ANGIOLYMPHOID HYPERPLASIA (AHLE)

FIRST LINE

- Excision
- Topical corticosteroids (high potency twice daily)
- Intralesional corticosteroids (5–40 mg/mL, 1 mL monthly)

SECOND LINE

- Topical tacrolimus ointment (twice daily)
- Systemic corticosteroids (60/40/20 mg PO taper, 5 days each)
- Cyclosporine [microemulsion (Neoral) 2.5–4 mg/kg/day total dose divided into twice daily PO doses; use the minimum]
- Local radiation therapy
- Vinblastine (15 mg/week IV; one report of extensive AHLE lesions treated successfully)
- Photodynamic therapy (AHLE)
- Ultralong pulse dye laser (AHLE)
- Radiofrequency ablation and sclerotherapy (AHLE)
- Isotretinoin (0.5 mg/kg/day) (AHLE)
- Rituximab (375 mg/m^2/week × 4 weeks) (Kimura disease)

TREATMENT

The treatment of Kimura disease and AHLE is not well established because of the rarity of the disorders. Many approaches have been tried in only a limited number of cases. The most common and distinctive therapies are listed in Box 146-4. Topical treatments are used mainly for AHLE. Local radiation therapy has been reported to be superior to surgery and corticosteroids for treatment of Kimura disease.[51,58–60]

CASTLEMAN DISEASE

EPIDEMIOLOGY

Castleman disease is also known as *angiofollicular lymphoid hyperplasia* or *giant lymph node hyperplasia*.[61–64] Four subtypes are recognized: (1) hyaline-vascular, (2) plasma cell, (3) HHV-8-associated, and (4) multicentric, not otherwise specified.[65] The hyaline vascular variant is more common in younger patients, the HHV-8 variant occurs among the immunosuppressed and the other variants tend to occur in older individuals.

ETIOLOGY AND PATHOGENESIS

Castleman disease is a polyclonal lymphoproliferative disorder of undetermined etiology. The hyaline-vascular type might involve abnormalities of follicular dendritic cells or vascular endothelial growth factor (VEGF). Epstein–Barr virus (EBV) has been detected in 20/20 cases in Taiwan.[66] Studies of multicentric Castleman disease demonstrate increased levels of lesional and circulating interleukins 1β and 6, which suggests that cytokine abnormalities may be pathogenic and mediate the systemic manifestations of POEMS syndrome (*p*olyneuropathy, *o*rganomegaly, *e*ndocrinopathy, *M* protein, and *s*kin changes).[67,68] Castleman disease occurring in the setting of human immunodeficiency virus infection or other immunosuppression is associated with human herpesvirus type 8,[69,70] which has also been detected in Kaposi sarcoma (see Chapter 128) and primary effusion lymphomas.

CLINICAL FINDINGS

CUTANEOUS LESIONS. Castleman disease most often presents as an isolated mediastinal mass, although a multicentric form of the disease also exists. Lesions can be nodal and/or extranodal. Rarely, it may present as solitary or multiple, subcutaneous or cutaneous tumors in various locations.

RELATED PHYSICAL FINDINGS. The plasma cell variant can be associated with polyneuropathy, organomegaly, endocrinopathy, the presence of M protein, hyperpigmentation, and hypertrichosis (POEMS syndrome).[68,71]

LABORATORY TESTS

Three histopathologic variants of Castleman disease exist. The more common hyaline vascular variant exhibits small, concentrically whorled, lymphoid follicles surrounded by small lymphocytes arranged in a concentric, onionskin pattern. An extensive proliferation of capillaries is present between follicles. The rarer plasma cell variant exhibits large, hyperplastic secondary lymphoid follicles associated with a highly vascular interfollicular zone rich in plasma cells. An intermediate form has also been reported.

DIFFERENTIAL DIAGNOSIS

The differential diagnosis of cutaneous and subcutaneous Castleman disease includes eosinophil-poor AHLE, Kimura disease, plasmacytoma, myeloma, sinus histiocytosis with massive lymphadenopathy, CLH, angioimmunoblastic T-cell lymphoma, and follicular types of CBCL (Box 146-5). All of these diseases lack the characteristic features of the lymphoid follicles seen in the two histopathologic variants of Castleman disease. These disorders also lack prominent vascular hyperplasia except for AHLE and Kimura disease, whose characteristic endothelial cells aid in their recognition, and angioimmunoblastic T-cell lymphoma, which contains large clonal atypical T cells. Plasmacytoma and

BOX 146-5 DIFFERENTIAL DIAGNOSIS OF CASTLEMAN DISEASE

Most Likely
- Cutaneous lymphoid hyperplasia

Consider
- Angiolymphoid hyperplasia with eosinophilia
- Kimura disease
- Plasmacytoma
- Sinus histiocytosis with massive lymphadenopathy

Always Rule Out
- Cutaneous B-cell lymphoma
- Myeloma
- Nonmycosis fungoides cutaneous T-cell lymphoma

myeloma contain dense sheets of atypical plasma cells and differ in their associated clinical findings. CLH is usually centered in the dermis rather than the subcutis. Most cutaneous lymphomas have a diffuse, monomorphous appearance. The rare follicular types of CBCL have distinctive features, as summarized earlier in Section "Differential Diagnosis" under "Cutaneous Lymphoid Hyperplasia." Sinus histiocytosis with massive lymphadenopathy is rich in $S100^+$ histiocytes that exhibit emperipolesis (intact lymphocytes within their cytoplasm).

COMPLICATIONS

Castleman disease has been associated with paraneoplastic pemphigus, plane xanthomas, vasculitis, and peliosis hepatis.[72,73] Lymphomas and follicular dendritic cell sarcomas can develop in the setting of Castleman disease.

PROGNOSIS AND CLINICAL COURSE

The clinical course is usually favorable for patients with localized and extranodal lesions.

TREATMENT

Surgical excision is effective therapy for localized Castleman disease. Radiation therapy, chemotherapy, and immunotherapy have been used to treat multicentric variants (Box 146-6).[74,75]

BOX 146-6 TREATMENT OF CASTLEMAN DISEASE

FIRST LINE
- Excision

SECOND LINE
- Radiation therapy
- Chemotherapy
- Rituximab +/– chemotherapy or thalidomide
- Anti-IL6 or anti-IL6R antibody
- Bortezomib

PSEUDOMYCOSIS FUNGOIDES

EPIDEMIOLOGY

Eruptions mimicking mycosis fungoides occur typically in adults. Both genders can be affected.

ETIOLOGY AND PATHOGENESIS

Pseudo-T-cell lymphomas with a band-like or mycosis fungoides-like histopathologic pattern may arise spontaneously or may occur as a T-cell infiltrate coexisting with B-cell chronic lymphocytic leukemia, as a rare variant of the eruption of lymphocyte recovery (which occurs in the setting of leukocyte reconstitution after iatrogenic marrow aplasia), or in association with ingestion of various drugs, including hydantoins, carbamazepine, propyl valerate, imatinib mesylate, and dexchlorpheniramine maleate and other antihistamines.[4–6,10,12,56,76]

CLINICAL FINDINGS

HISTORY. There may be a history of an associated disease or medication. Lesions may be pruritic or asymptomatic.

CUTANEOUS LESIONS. The lesions present clinically as one or a few plaques on the trunk or extremities. Occasionally, several plaques or a Sézary-like syndrome develops.

LABORATORY TESTS

Histopathologically, there is a papillary dermal, band-like infiltrate containing mostly small and medium-sized atypical lymphocytes with clefted and cerebriform nuclei. Moderate numbers of histiocytes are admixed, but eosinophils and plasma cells are rare. The dermal–epidermal junction is obscured, and there is no grenz zone. The overlying epidermis may be hyperplastic and/or may contain a sparse to moderate atypical lymphoid infiltrate; however, compared with mycosis fungoides, epidermotropism is typically far less prominent and Pautrier's microabscess-like cell aggregates are rare. Most cases contain polyclonal T cells, although occasional cases exhibit dominant T-cell clonality.[10,77]

DIFFERENTIAL DIAGNOSIS

The differentiation of these pseudolymphomas from mycosis fungoides is aided by their tendency toward

minimal epidermotropism in many cases, the small number of lesions, their tendency to be polyclonal, and their resolution after discontinuation of an inducing drug and/or local therapy.

Lichenoid drug eruptions caused by agents such as gold, thiazides, and antimalarials may also bear a histopathologic resemblance to atrophic forms of large plaque parapsoriasis and overt mycosis fungoides when they result in a band-like dermal lymphoid infiltrate that involves an atrophic epidermis. As in mycosis fungoides, eosinophils and plasma cells may also be present. However, these lesions lack lymphoid atypia, exhibit the clinical features of typical lichenoid drug rashes, and regress eventually after discontinuation of the causative agent. Poikilodermatous skin lesions of collagen vascular diseases and genodermatoses are distinguished from mycosis fungoides by their associated clinical and laboratory findings; by sparser infiltrates lacking atypia; and, for collagen vascular diseases, by dermal mucin, thickened epidermal basement membranes, and characteristic epidermal alterations. Lymphomatoid keratosis is a solitary keratotic lesion that contains a mixture of T cells and B cells, both of which can be epidermotropic. Chronic radiodermatitis may resemble poikilodermatous mycosis fungoides clinically but is distinguished by clinical history, sparse infiltrate, keratinocyte atypia, dermal fibrosis, and loss of adnexa. Some cases of secondary syphilis may also mimic mycosis fungoides, showing a dense, band-like, upper dermal infiltrate that obscures the dermal–epidermal junction and invades a nonspongiotic epidermis. However, the infiltrate contains more plasma cells and fewer lymphocytes than expected in mycosis fungoides; there is no lymphoid atypia; there may be neutrophils in the epidermis; and there is a deep perivascular extension of the infiltrate that is unusual in mycosis fungoides except in the tumor phase. Furthermore, the patient's history, the clinical appearance of the lesions, serologic testing, and response to antibiotic therapy will facilitate the correct diagnosis (Box 146-7).

Three other disorders that may mimic mycosis fungoides/Sézary syndrome clinically and/or pathologically are (1) follicular mucinosis, (2) lymphomatoid contact dermatitis, and (3) actinic reticuloid. Because of their distinctive features, each is discussed separately in this text.

COMPLICATIONS

Severe pseudomycosis fungoides eruptions such as erythrodermas may be associated with serious complications common to other forms of generalized exfoliative dermatitis, including local skin infection, sepsis, disrupted barrier function, and cardiovascular imbalance.

PROGNOSIS AND CLINICAL COURSE

Prognosis depends heavily on the clinical context and the ability to remedy the underlying cause of the pseudomycosis fungoides lesions. If this can be accomplished, then the lesions generally regress, although lichenoid infiltrates may require many months to resolve.

BOX 146-7 DIFFERENTIAL DIAGNOSIS OF PSEUDOMYCOSIS FUNGOIDES

Most Likely
- Lichenoid drug eruption
- Psoriasis
- Tinea corporis

Consider
- Dermatomyositis
- Subacute cutaneous lupus erythematosus
- Pityriasis rubra pilaris
- Secondary syphilis
- Chronic radiodermatitis
- Genodermatoses with poikiloderma
- Alopecia mucinosa
- Actinic reticuloid
- Noncutaneous T-cell lymphoma erythrodermas

Always Rule Out
- Mycosis fungoides
- Large plaque parapsoriasis
- Associated drug ingestion
- Associated iatrogenic marrow aplasia
- Associated B-cell chronic lymphocytic leukemia

TREATMENT

When the disorder is drug induced, identification and withdrawal of the offending agent is the principal therapy (Box 146-8). Corticosteroids (topical or systemic) and various forms of phototherapy may also be beneficial in hastening the resolution of skin lesions. Excision can be effective for isolated or sparse lesions. When pseudomycosis fungoides is associated with a

BOX 146-8 TREATMENT OF PSEUDOMYCOSIS FUNGOIDES

FIRST LINE
- Drug discontinuation (when drug induced)
- Treatment of underlying disorder (when associated with a specific disease)
- Topical corticosteroids
- UVB and narrowband UVB phototherapy
- Psoralen plus UVA phototherapy

SECOND LINE
- Systemic corticosteroids (60/40/20 mg PO taper, 5 days each)

specific disease, treatment should be directed at that underlying disorder.

PREVENTION

Strategies for prevention are similar to those described for treatment.

LYMPHOMATOID CONTACT DERMATITIS

EPIDEMIOLOGY

Lymphomatoid contact dermatitis has been observed in adults of both genders.

ETIOLOGY AND PATHOGENESIS

Lymphomatoid contact dermatitis was described originally in four patients with persistent allergic contact dermatitis proven by patch testing.[78] Responsible allergens include phosphorus sesquisulfide, *para*-tertiary butyl phenol formaldehyde resin, ethylenediamine dihydrochloride, *N*-isopropyl-*N*′-phenyl-p-phenylenediamine (IPPD), benzydamine hydrochloride, teak wood, cobalt naphthenate, gold, nickel, and *para*-phenylenediamine.[79–86] The clinical and histopathologic changes in the lesions are said to resemble those of mycosis fungoides.

CLINICAL FINDINGS

HISTORY. Skin lesions are generally pruritic. Patients may be aware of the offending contact allergen.

CUTANEOUS LESIONS. Clinically, lymphomatoid contact dermatitis is characterized by generalized red, scaly papules and plaques that may become confluent (Fig. 146-12) with resultant exfoliative erythroderma.



Figure 146-12 Lymphomatoid contact dermatitis. Erythematous papules and plaques on the forehead. Patch test with local anesthetics gave positive results.

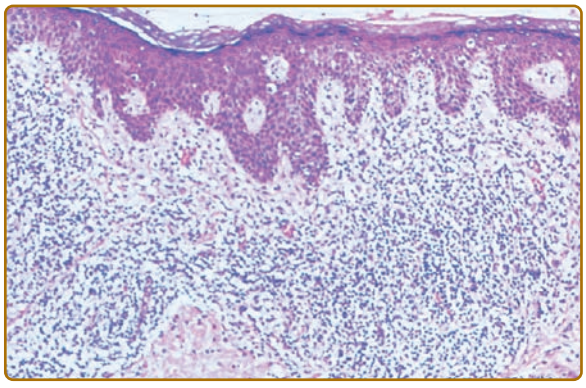

Figure 146-13 Lymphomatoid contact dermatitis. Dense band-like infiltrate in the upper part of the dermis and spongiotic foci in the epidermis ("spongiotic simulator" of mycosis fungoides).

LABORATORY TESTS

Results of patch tests for a variety of common allergens, such as ethylenediamine dihydrochloride, may be positive.

Histopathologically, lymphomatoid contact dermatitis exhibits a superficial lymphocytic dermatitis that contains foci of spongiosis simulating the appearance of cutaneous T-cell lymphomas. It must be differentiated from mycosis fungoides (Fig. 146-13), usually on the basis of changes within the epidermis; specifically, in mycosis fungoides more atypical lymphocytes have a tendency to form Pautrier's microabscesses. Frequently, there is edema in the papillary dermis in lymphomatoid contact dermatitis, a finding that is usually absent in mycosis fungoides. Immunohistopathologic investigations indicate that lymphomatoid contact dermatitis represents a T-cell pseudolymphoma. Examination of the cells in the infiltrate by electron microscopy reveals many atypical lymphocytes with cerebriform nuclei like those in mycosis fungoides.

DIFFERENTIAL DIAGNOSIS

Concern for mycosis fungoides is based mainly on the histopathologic features of the lesions. Recognition of the contact allergen is central to the correct diagnosis, aided by the microscopic distinctions noted in the preceding section. Other causes of spongiotic dermatitis and, in severe cases, erythroderma should also be considered (Box 146-9).

COMPLICATIONS

Although in rare cases lymphomatoid contact dermatitis has been reported to evolve into lymphoma, it is possible that those patients had lymphoma from the outset.

BOX 146-9 DIFFERENTIAL DIAGNOSIS OF LYMPHOMATOID CONTACT DERMATITIS

Most Likely
- Conventional allergic contact dermatitis
- Irritant contact dermatitis

Consider
- Drug eruption
- Psoriasis
- Tinea corporis
- Noncutaneous T-cell lymphoma erythrodermas (when extensive)

Always Rule Out
- Mycosis fungoides and Sézary syndrome
- Large plaque parapsoriasis

PROGNOSIS AND CLINICAL COURSE

Avoidance of the responsible allergens leads to eventual resolution of the condition in most cases.

TREATMENT

A thorough search for the offending antigen by way of patch testing is necessary if the process of lymphomatoid contact dermatitis is to be interrupted. Topical application of glucocorticoids is beneficial (Box 146-10).

PREVENTION

The only relevant preventive measure for lymphomatoid contact dermatitis is avoidance of known causes.[78–80,86–91]

LYMPHOCYTIC INFILTRATION OF THE SKIN

EPIDEMIOLOGY

The vast majority of cases of lymphocytic infiltration of the skin (LIS) occur in middle-aged adults, with a roughly equal gender ratio. Children have been affected rarely. There is also a rare familial variant.[92]

BOX 146-10 TREATMENT OF LYMPHOMATOID CONTACT DERMATITIS

FIRST LINE
- Elimination of responsible allergen
- Topical corticosteroids

SECOND LINE
- Topical tacrolimus or pimecrolimus

ETIOLOGY AND PATHOGENESIS

The etiology of LIS is unknown. Some regard it as a distinct disease, whereas retrospective studies have allowed some authors to reclassify many cases as dermal variants of lupus erythematosus or, less commonly, CLH, polymorphous light eruption or other dermatoses.[93,94] Some of the CLH-like cases have been associated with *B. burgdorferi* in Europe. One case appeared due to hydroquinone, suggesting that dermal delayed-type hypersensitivity reactions can be an etiology.[95] Photoexacerbation occurs in a minority of patients according to some observers. Immunologic investigations have shown decreased natural killer cell function as well as elevation in circulating immune complexes, the levels of which were reported to parallel disease activity.[96] Skin lesions known as *arcuate dermal erythema* may arise in female carriers of chronic granulomatous disease. These lesions resemble LIS clinically and microscopically.

CLINICAL FINDINGS

HISTORY. Skin lesions are typically asymptomatic.

CUTANEOUS LESIONS. LIS, which was first described by Jessner and Kanof,[97] presents as one or more erythematous plaques or nodules, generally localized to only one or a few sites on the face, neck, upper trunk, or arms.[98,99] Pustules, pruritus, and epidermal alterations are absent. In contrast to discoid lupus lesions, LIS lesions show no epidermal atrophy or follicular plugging.

LABORATORY TESTS

Histopathologic examination reveals a superficial and deep, perivascular and variably periadnexal infiltrate of small mature lymphocytes, often with a minor admixture of histiocytes, plasmacytoid monocytes, and plasma cells. Lymphoid follicles and eosinophils are absent. The epidermis is unremarkable. Results of direct immunofluorescence studies are negative or nonspecific. Immunohistologic studies have demonstrated a predominantly HLA-DR$^-$ Leu-8$^+$ T-cell infiltrate with some B cells and histiocytes admixed. In contrast, most of the T cells in discoid lupus are HLA-DR$^+$ Leu-8$^-$.[100–102] Immunopathologic studies have shown a predominance of CD8$^+$ T cells within lesional infiltrates. Initial studies indicate that the infiltrate lacks dominant clonality.[5,103,104]

DIFFERENTIAL DIAGNOSIS

The differential diagnosis of LIS includes chronic cutaneous lupus erythematosus, polymorphous light eruption, CLH, lymphocytic lymphoma and leukemia, deep figurate erythemas such as erythema chronicum migrans, granuloma faciale, and reticular erythematous

BOX 146-11 DIFFERENTIAL DIAGNOSIS OF LYMPHOCYTIC INFILTRATION OF THE SKIN

Most Likely

- Chronic cutaneous lupus erythematosus
- Cutaneous lymphoid hyperplasia
- Polymorphous light eruption

Consider

- Granuloma faciale
- Infectious and inflammatory granulomas
- Erythema chronicum migrans
- Other deep figurate erythemas
- Reticular erythematous mucinosis

Always Rule Out

- Cutaneous B-cell lymphoma
- Leukemia cutis (especially B-cell chronic lymphocytic leukemia)

BOX 146-12 TREATMENT OF LYMPHOCYTIC INFILTRATION OF THE SKIN

FIRST LINE

- Topical corticosteroids
- Topical tacrolimus and pimecrolimus
- Photoprotection (if historically relevant)
- Intralesional corticosteroids (5–40 mg/mL, 1 mL monthly)

SECOND LINE

- Hydroxychloroquine (100–200 mg PO twice daily)
- Systemic corticosteroids (60/40/20 mg PO daily taper, 5 days each; if effective, then as needed)
- Auranofin (3 mg PO twice daily)
- Acitretin (25–50 mg PO daily)
- Thalidomide (100 mg PO daily)
- Pulsed-dye laser (595 nm)

mucinosis (Box 146-11). In considering differential diagnostic features, keep in mind that some authors regard both LIS and reticular erythematous mucinosis to be misdiagnosed lupus erythematosus, CLH, or other miscellaneous disorders.[93,94] Discoid lupus generally exhibits epidermal changes, an interface inflammatory component, and a lupus band on direct immunofluorescence. The tumid variant of discoid lupus is typified by abundant dermal mucin and subtle alterations at the dermal–epidermal interface. These changes are not seen in LIS. Antinuclear antibody (ANA) panel results and erythrocyte sedimentation rate are also normal in most cases; however, positive ANAs have been reported in some patients leading to reclassification of their disease as lupus. Polymorphous light eruption exhibits papillary dermal edema, which is absent in LIS. CLH contains nodular or diffuse, dermal lymphoid infiltrates that are much denser than the predominantly perivascular infiltrate of LIS. Furthermore, LIS lacks reactive B-cell follicles. Well-differentiated or small lymphocytic lymphoma/leukemia is usually a monoclonal B-cell process, and there is a peripheral lymphocytosis in the leukemic form of the disease. These findings are absent in LIS. In erythema chronicum migrans and some cases of CLH, there is serologic evidence of active infection with *B. burgdorferi*, whereas this is rarely seen in LIS except when there has been suspicion of misdiagnosis of CLH as LIS.[94] Granuloma faciale is rich in neutrophils and eosinophils that are not features of LIS. Reticular erythematous mucinosis has a reticulated clinical appearance, favors the trunk rather than the head and neck, and shows bipolar fibroblasts. These are not features of LIS.

COMPLICATIONS

Postinflammatory pigmentary alterations and corticosteroid-associated skin atrophy may complicate the clinical course of LIS, especially in cosmetically sensitive locations.

PROGNOSIS AND CLINICAL COURSE

LIS has a chronic course and may show periods of spontaneous remission and eventual resolution. Lesions may recur at their original sites or elsewhere. Some patients have subsequently developed features typical of lupus erythematosus.[93,94]

TREATMENT

LIS may respond favorably to topical or intralesional glucocorticoids, calcineurin inhibitors, antimalarials, pulsed-dye laser or thalidomide; however, a persistent, indurated variant has been described that may require systemic glucocorticoid therapy to achieve remission[105] (Box 146-12).

PREVENTION

Photoprotection may be helpful in those cases with a history of photoexacerbation.

KEY REFERENCES

Full reference list available at www.DIGM8.com

DVD contains references and additional content

3. Albrecht J, Fine LA, Piette W: Drug-associated lymphoma and pseudolymphoma: Recognition and management. *Dermatol Clin* **25**(2):233-244, vii, 2007
6. Gilliam AC, Wood GS: Cutaneous lymphoid hyperplasias. *Semin Cutan Med Surg* **19**(2):133-141, 2000
12. Magro CM, Crowson AN: Drugs with antihistaminic properties as a cause of atypical cutaneous lymphoid hyperplasia. *J Am Acad Dermatol* **32**(3):419-428, 1995

28. Nihal M et al: Cutaneous lymphoid hyperplasia: A lymphoproliferative continuum with lymphomatous potential. *Hum Pathol* **34**(6):617-622, 2003
52. Miteva M et al: D2–40 highlights lymphatic vessel proliferation of angiolymphoid hyperplasia with eosinophilia. *J Cutan Pathol* **36**(12):1316-1322, 2009
53. Sun QF et al: Kimura disease: Review of the literature. *Intern Med J* **38**(8):668-672, 2008
65. Cronin DM, Warnke RA: Castleman disease: An update on classification and the spectrum of associated lesions. *Adv Anat Pathol* **16**(4):236-246, 2009
86. Martinez-Moran C et al: Lymphomatoid contact dermatitis. *Contact Dermatitis* **60**(1):53-55, 2009
93. Lipsker D et al: Could Jessner's lymphocytic infiltrate of the skin be a dermal variant of lupus erythematosus? An analysis of 210 cases. *Dermatology* **213**(1):15-22, 2006
94. Ziemer M et al: Lymphocytic infiltration of the skin (Jessner-Kanof) but not reticular erythematous mucinosis occasionally represents clinical manifestations of Borrelia-associated pseudolymphoma. *Br J Dermatol* **161**(3):583-590, 2009

Chapter 147 :: Cutaneous Langerhans Cell Histiocytosis

:: Carlo Gelmetti

LANGERHANS CELL HISTIOCYTOSIS AT A GLANCE

- A group of rare disorders that are considered reactive but have a broad spectrum of severity.
- The reactive vs. neoplastic nature of the disease is debated. A clonal origin for the cells of Langerhans cell histiocytosis (LCH) in genetically predisposed patients is the most probable hypothesis.
- Histopathologic features consist of a dense infiltrate of histiocytes with a strong epidermotropism. The unifying element is the typical "LCH cell"—a histiocyte with an irregular vesiculated, often reniform nucleus and an abundant, slightly eosinophilic cytoplasm. These cells test are positive for S100 protein, CD1a, and CD207, and contain cytoplasmic Langerhans granules.
- Cutaneous lesions vary from papules to vesicles, pustules, nodules, and ulcers.
- The course of LCH ranges from localized self-healing forms to generalized and fatal cases.
- The most common sites of involvement are the head, trunk, and skin folds.
- Mucosal lesions are usually ulcerated nodules involving mainly gingival and genital regions.
- Associated manifestations include diabetes insipidus and exophthalmos.
- Systemic lesions may affect bones, lungs, bone marrow, liver, spleen, and lymph nodes.
- Aggressive forms may be treated successfully with vinblastine and other drugs.

INTRODUCTION

The term "histiocytoses" identifies a group of diseases that have in common the proliferation of cells of the mononuclear phagocyte system, including dendritic cells.

Histiocytes, formally connective tissue macrophages, and dendritic cells constitute two of the major types of nonlymphoid mononuclear cells and are involved in immune and nonimmune inflammatory responses. Both cells arise in the bone marrow from pluripotential stem cells, but follow different paths of differentiation (Fig. 147-1). The macrophage, detectable by CD68, is a monocyte in the peripheral blood and a macrophage in tissue. It may differentiate into a number of different giant cells, including foreign body, epithelioid, Touton, and Langhans types.

Dendritic cells are antigen-presenting cells that interact with T cells. The prototype of dendritic cell in the skin is the Langerhans cell (LC). First described by Paul Langerhans in 1868 as a neuronal cell, the LC was first linked to antigen presentation during the 1940s. Precursor cells to the LCs migrate from the dermis into the epidermis where they complete differentiation. LCs have long cytoplasmic projections and a large almost kidney-shaped nucleus. Electron microscopy reveals the characteristic cytoplasmic organelle, the Langerhans or Birbeck granule, a tennis racket-shaped structure that is involved in pinocytosis and receptor-mediated endocytosis. Langerin (CD207), a receptor that permits internalization of antigen into Birbeck granules and presentation of antigen at the cell surface, is the most specific marker for LCs. LCs are also S100- and CD1a-positive. Once LCs have contacted antigen, they move via the lymphatics to the T-cell zones of the regional lymph nodes where they are designated interdigitating reticulum cells. There LCs present antigen to naive T-cells, activating them to proliferate if the antigen is recognized. Indeterminate cells are most likely immature Langerhans cells that lack Birbeck granules. Dermal dendritic cells are perivascular cells that are also capable of antigen uptake and presentation. Dermal macrophages can be identified in the normal dermis but their number increases during inflammation.

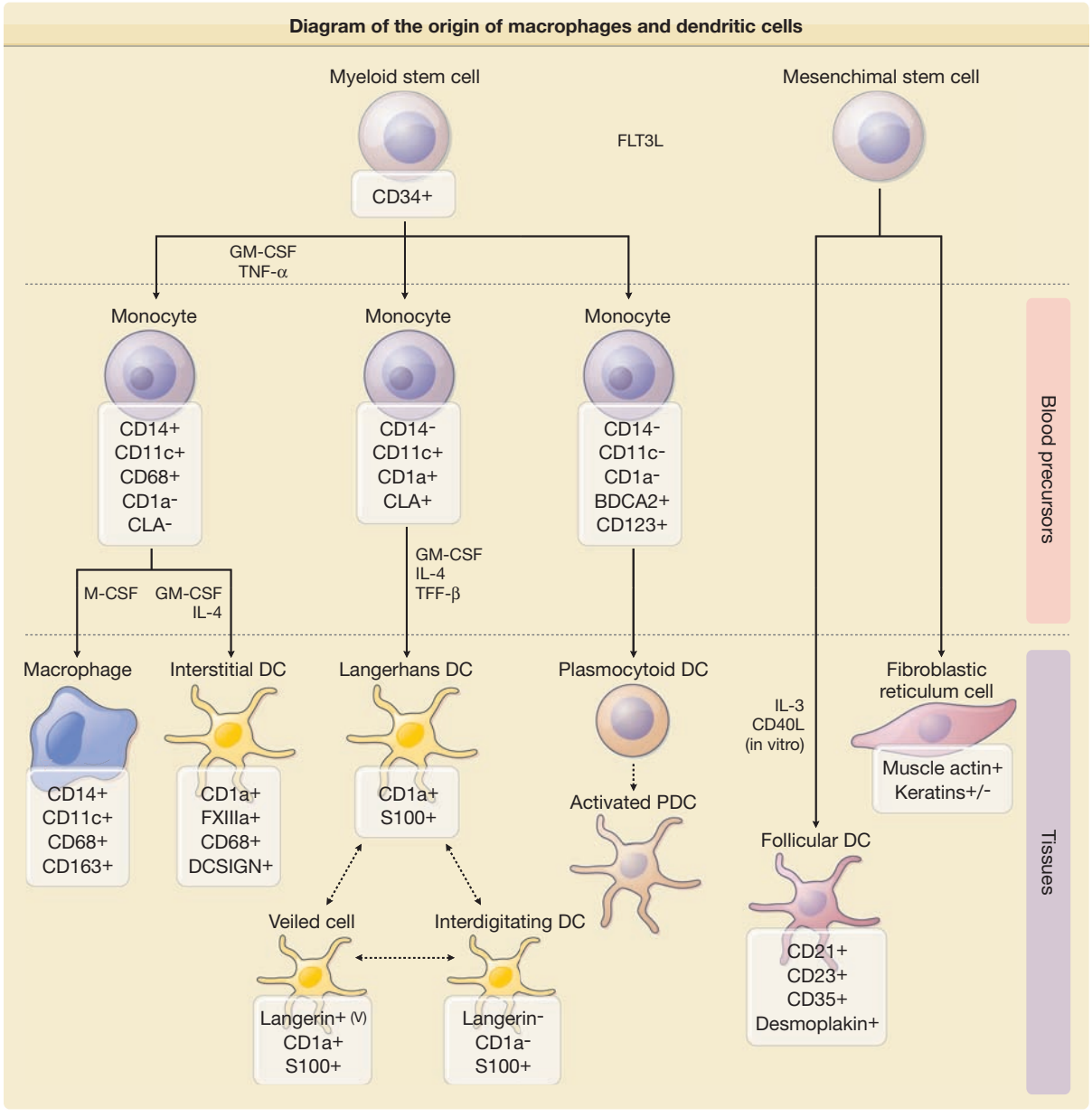

Figure 147-1 Schematic diagram of the origin of macrophages and dendritic cells. Both macrophages and dendritic cells (antigen presenting cells) are derived from a common bone marrow precursor. In contrast, follicular dendritic cells are thought to be of nonhematopoietic origin. +, most, if not all, cells positive; –, all cells negative, +/–, a minority of cells positive; v, variable intensity. (Adapted from Jaffe R et al: Histiocytic and dendritic cell neoplasms, introduction. In: *WHO Classification of Tumors of Haematopoietic and Lympoid Tissues*, edited by SH Swerdlow et al. Geneva, Lyon, WHO Press, 2008.)

Dermal macrophages, dermal dendritic cells, and Langerhans cells have a common bone marrow precursor, explaining why there are so many overlapping functions and markers.[1]

LANGERHANS CELL HISTIOCYTOSIS

Langerhans cell histiocytosis (LCH) is characterized by aberrant proliferation of the LCs. Lichtenstein grouped Letterer–Siwe disease, Hand–Schüller–Christian disease, and eosinophilic granuloma of bone as "histiocytosis X" in 1953, based on finding abnormal histiocytes in these three related disorders. During the ensuing decade, Basset and Nezelof investigated novel intracellular granules in the lesional histiocytes and recognized them to be identical to those described in normal LCs. The term *Langerhans cell histiocytosis (LCH)* is now preferred to "histiocytosis X".[2]

EPIDEMIOLOGY

The prevalence of LCH is internationally estimated to be from 4.0 to 5.4 per million population, but these

numbers may be low because of failure to recognize the organ and skin involvement in many patients. In children, the annual incidence is estimated at 0.5 per 100,000 children in the United States and at 4 per million worldwide.[3] The male–female ratio is 2:1. The disease can occur in individuals of any age and can also be congenital, but is most common in children aged 1–3 years.

ETIOLOGY AND PATHOGENESIS

Histiocytoses are caused by a dysregulated proliferation or activation of dendritic cells or macrophages, both belonging to the mononuclear phagocyte system. Despite the improved knowledge of the classification of histiocytic disorders and the establishment of guidelines for diagnosis, treatment, and follow-up provided by the Histiocyte Society, the etiology and pathogenesis of most of these diseases are poorly understood, partially because of the lack of reliable animal models.[4]

The pathogenesis of LCH remains a mystery despite numerous investigative efforts. In addition to genetic factors, infectious agents (especially viruses), and cellular and immune system dysfunction, including abnormalities of lymphocytes and cytokines (interleukin 1α, interleukin 10), cellular adhesion molecules, and a combination of these, have been implicated. The role of genetics is not well defined. Although LCH has been reported in both monozygotic and dizygotic twins, the relative rarity of the familial occurrence does not favor a significant hereditary influence.

The reactive versus neoplastic nature of LCH cells is also debated. Although clonality has been demonstrated in all forms of LCH, this does not mean that the process is histologically and biologically malignant. The following features substantiate the reactive hypothesis: (1) LCH cells are highly differentiated, (2) histologically the granulomatous lesions resemble those seen in infections or foreign-body reactions, and (3) lesions may spontaneously regress. These pathogenic steps have been suggested: (1) viruses induce activation of histiocytes, (2) immunologic mechanisms produce the pathologic Langerhans cell phenotype, and (3) a cytokine-mediated storm results in LCH lesions. Many viruses (human herpesvirus 6, cytomegalovirus, adenovirus, and parvovirus) are suspected to play an etiologic role, but none has been proven to be responsible for the disease.

In contrast, the following observations support a clonal neoplastic origin of LCH: (1) bone marrow derivation and clonality of LCH cells, (2) the existence of familial cases of LCH, (3) findings of chromosomal instability with an abnormality on chromosome 7 and of p53 protein in LCH, and (4) cooccurrence of LCH and a myelodysplastic marrow. Two possible explanations have been proposed for the association between LCH and myelodysplasia. The first is that the marrow dysplastic features are secondary to the infiltration of the marrow by LCH cells induced by cytokines and do not represent elements of a true myelodysplastic syndrome. A second possibility is that the abnormal marrow cells are related to the clonal LCH cells and are part of the disease process, for example, myelodysplastic cells could be arising from the same clonal cell, an anomalous pluripotent dendritic (stem) cell line. This possibility raises the issue of whether LCH could be considered a "myeloid dendritic stem cell disorder." These findings also suggest a genetic predisposition in LCH and stimulate the search for potential candidate genes in LCH. Figure 147-1 illustrates the histiocyte developmental pathway according to Jaffe et al.[5]

CLINICAL FINDINGS

CLASSIFICATION

LCH is a disorder with a broad spectrum of forms: it can be local, asymptomatic with an indolent course, limited to an isolated bone lesion, or systemic and aggressive involving multiple organs and producing significant symptoms. Thus, the clinical manifestations depend on the site of the lesions and the systems involved. Historically, LCH has been described under various names: Letterer–Siwe disease is the prototype of the acute, disseminated, multisystemic form that usually appears in infants or newborns. Its course, if the disease is untreated, is fatal; Hand–Schüller–Christian disease is the chronic, progressive, multifocal form, commonly beginning in childhood; eosinophilic granuloma is the localized, benign form; and Hashimoto–Pritzker disease represents the benign, self-healing variant of LCH, usually present at birth or during the first few days of life. In 1997, experts of the Reclassification Working Group of the Histiocyte Society advocated the disuse of the eponyms. They recommended the use of the term *Langerhans cell histiocytosis* only and the stratification of patients based on the extent of disease. The classification system for histiocytosis defined by the Histiocyte Society is shown in Table 147-1. At present, it seems realistic to describe LCH as a continuum as in Fig. 147-2, because every patient is unique with regard to the type, number, and location of lesions.

Although the historical terminology can be maintained for didactic purposes, it is more important to distinguish the forms with systemic involvement that require systemic management (multisystemic LCH) from those with localized lesions and the best prognosis that can be treated with a topical medication or observational approach (single-system LCH) or that are "self-healing" (Fig. 147-3).

The Writing Group of the Histiocyte Society proposed a guideline identifying confidence levels for the diagnosis of class I histiocytosis (LCH). These criteria were as follows: (1) presumptive diagnosis—light morphologic characteristics; (2) designated diagnosis—light morphologic features plus two or more supplemental positive results to stains for adenosine triphosphatase, S100 protein, α-D-mannosidase, and peanut lectin; (3) definitive diagnosis—light morphologic characteristics plus Birbeck granules in the lesional cell visible with electron microscopy and/or positive results on staining for CD1a antigen on the lesional cell.

Current immunostaining techniques allow the definitive diagnosis of LCH from just paraffin-embed-

TABLE 147-1
Classification of Langerhans-Cell Histiocytosis (LCH)[6,7]

Single-system Disease	
Localized (single site)	Monostotic bone involvement[a] Isolated skin involvement Solitary lymph node involvement
Multiple site	Polyostotic bone involvement[a] Multifocal bone disease (two or more different bones) Multiple lymph node involvement
Multisystem Disease	
Low-risk group	Disseminated disease with involvement of low-risk organs (skin, bone, lymph node, pituitary)
High-risk group	Disseminated disease with involvement of one or more of the high-risk organs (hematopoietic system, lungs, liver, and spleen)

[a]CNS-risk lesions: involvement of facial bones, sinuses, the maxilla, or anterior or middle cranial fossa (temporal, mastoid, sphenoidal, ethmoidal, zygomatic, orbital bones) with intracranial tumor extension. Not included are vault lesions.

ded tissue, which avoids the need for sophisticated and expensive methods such as electron microscopy. Because the location and diffusion of the lesions have a significant influence on the course of the disease and its prognosis, various classification schemes assign scores for each organ and system involved. The former classification of LCH into three or four disease categories is no longer used. The present system attempts to evaluate the extent of involvement and its relationship to prognosis. The former classification of LCH into three or four disease categories is no longer used. The present system attempts to evaluate the extent of involvement and its relationship to prognosis.

CUTANEOUS LESIONS

Cutaneous manifestations are very common in LCH and may represent the earliest sign of the disease. The typical lesion is a small translucent papule, 1–2 mm in diameter, slightly raised, rose-yellow (Figs. 147-4A and 147-4B), and usually located on the trunk (see Figs. 147-4A and 147-4B) and scalp. The lesions frequently show scaling (see Fig. 147-4A) and may become crusted and ulcerated (see Figs. 147-4B and 147-4C). Vesicles and pustules may occur, simulating eczema, miliaria, scabies, and varicella. This is an especially common presentation during the neonatal period (first month of life). The presence of purpura is a poor prognostic sign. Hashimoto–Pritzker disease has traditionally been characterized by the eruption of multiple or solitary elevated, firm, red–brown nodules (Fig. 147-5A) or flesh-red lesions similar to infantile angiomas; late papulonodular lesions may show elevated borders and ulcerate easily. These lesions can grow in size and number in the first few weeks of life, and some may become quite large. They then form brown crusts, which are shed and occasionally leave whitish atrophic scars after spontaneous resolution. Since the original description of the papulonodular lesions, it is clear that small reddish-brown crusted papules that may resemble chickenpox are also a common manifestation of

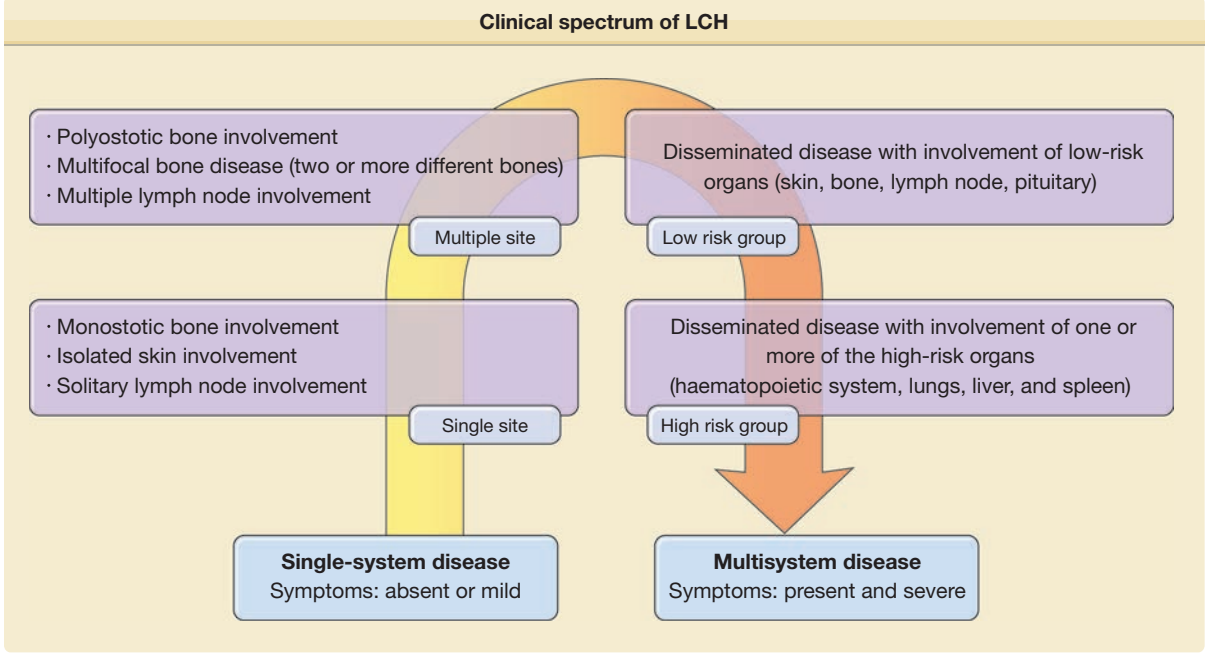

Figure 147-2 Clinical spectrum of LCH. Any single patient affected by LCH can be situated in a given point of the arrow.

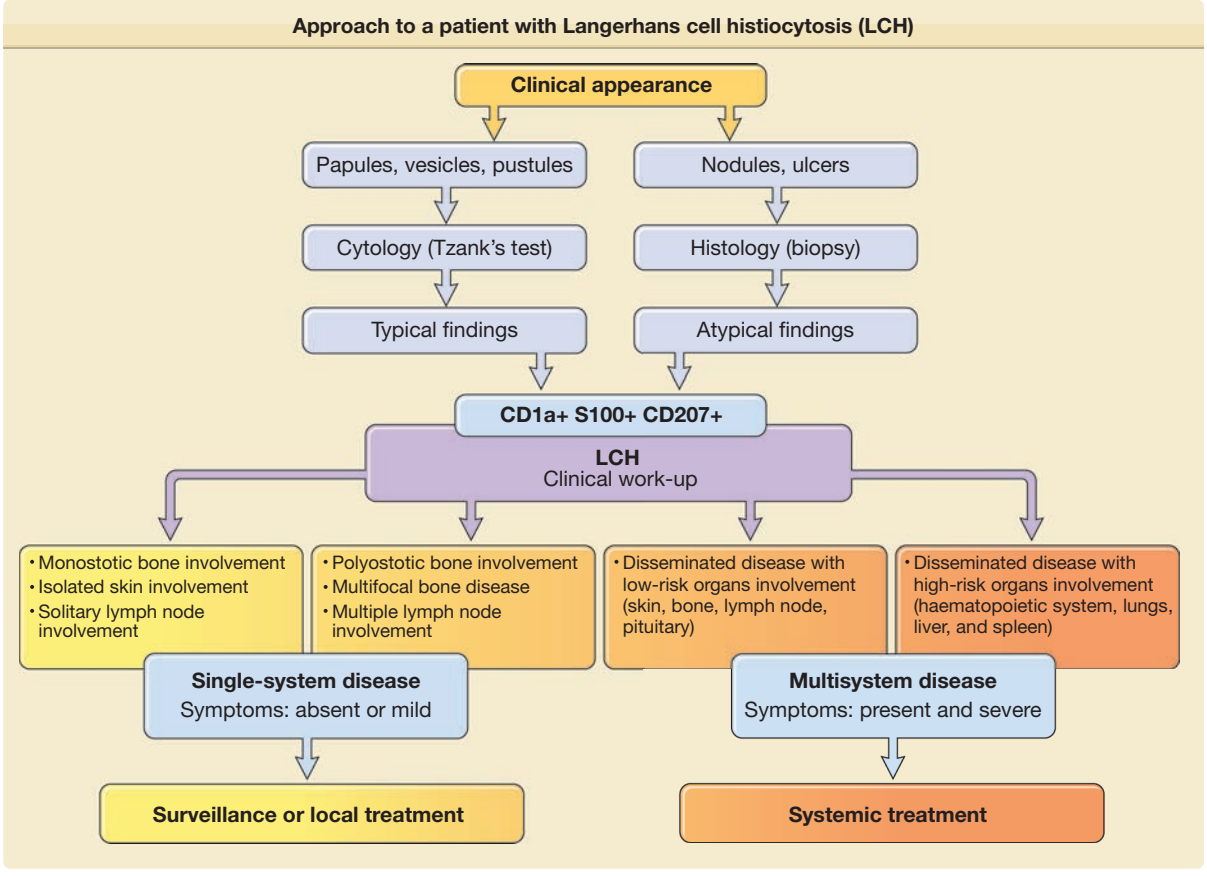

Figure 147-3 Approach to the patient with Langerhans cells histiocytosis.

"self-healing Langerhans cell histocytosis," with spontaneous clearance by 2–3 months of age (see Fig. 147-5B). Presentation with extensive, erosive, superficial lesions suggestive of congenital bullous epidermolysis has also been described.[8]

Cutaneous lesions may appear rapidly in successive crops. The lesions tend to merge on the scalp, mimicking seborrheic dermatitis or folliculitis, and leading to alopecia, and on the folds (retroauricular, axillary, and genital), mimicking intertrigo. Occasionally, the lesions merge into plaques on the medial aspect of the chest (Fig. 147-6), the midback, and temporoparietal regions, and may become xanthomatous.

Mucous membrane lesions are commonly noduloulcerative and mainly involve the perioral area and gingiva (Fig. 147-7) and the perigenital or perianal regions (Fig. 147-8). Oral manifestations may be the first sign of LCH: nonspecific pain, aphthae, gingival bleeding, candidiasis, ulceration with loosening of the teeth, and premature eruption of the teeth can be observed.

Nail changes include fragile lamina, paronychia, subungual pustules, nail fold destruction, onycholysis, subungual hyperkeratosis, longitudinal grooving, and pigmented and purpuric striae of the nail bed (Fig. 147-9). These features are considered to be unfavorable prognostic signs. Cutaneous manifestations in elderly patients (Fig. 147-10) are similar to those seen in children.

RELATED PHYSICAL FINDINGS

Malaise, weight loss, failure to thrive, nausea, myalgia, arthralgia, and fever are frequently present in aggressive forms. Bone lesions are the most frequent manifestations of LCH (80% of cases), and bone involvement alone is seen in 50% to 60% of cases. The bones that are most commonly involved by LCH are the skull, femur, mandible, pelvis, and spine. Cervical LCH lesions often extend to paravertebral soft tissue, epidural space, pedicles, and even to the endplate and lamina.[9] The lesions of the skull most often involve the temporoparietal region, in which infiltrates lead to limited osteolytic foci that merge to form typical "map" lesions (Fig. 147-11). Because osteolysis of the lower maxillary bones is also frequent, the teeth appear to be floating in the mouth in X-rays. Mastoid involvement is common and often symptomatic. Bone involvement can be shown by computed tomography (CT) or gadolinium-enhanced magnetic resonance imaging (MRI) and can lead to organ dysfunction such as diabetes insipidus and growth retardation. Retro-ocular bone involvement is responsible for exophthalmos. In addition, flat bones, vertebral bones, and long bones



Figure 147-4 Extensive Langerhans cell histiocytosis. **A.** Abdominal area of infant with multiple yellowish erythematous papules covered by scale or crust. **B.** Infant with multiple ulcerated skin lesions on the trunk. **C.** Severe disease with confluent erosive and crusted lesions forming ulcers; distension of the abdomen reflects hepatosplenomegaly.

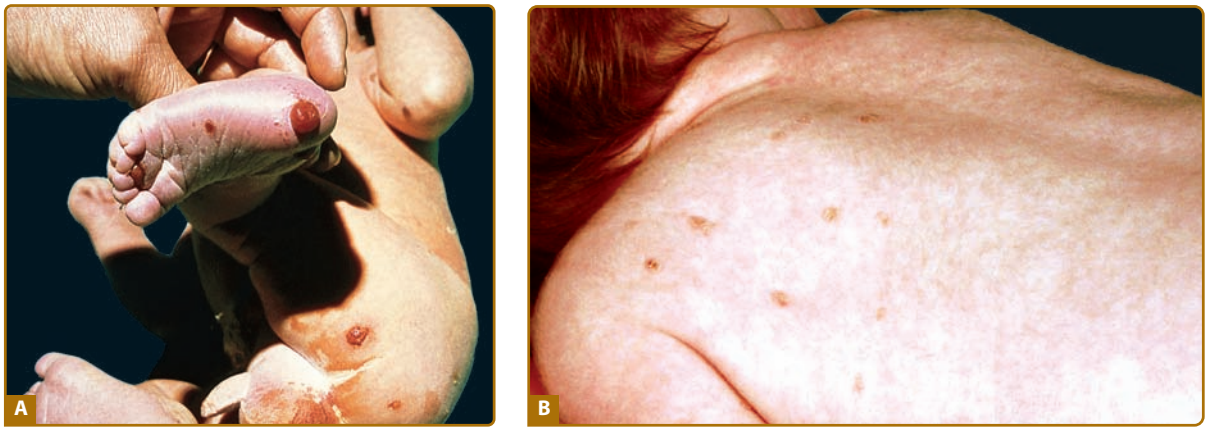

Figure 147-5 **A.** Congenital "self-healing" reticulohistiocytosis (also called self-regressive cutaneous LCH and formerly Hashimoto–Pritzker disease). Multiple disseminated, elevated, firm red–brown or dark red nodules (multiple form) present at birth. (From Bonifazi L et al: Congenital self-healing histiocytosis. *Arch Dermatol* **118**:267, 1982, with permission.) **B.** Resolving crusted reddish brown papules of congenital self-healing Langerhans cell histiocytosis with chickenpox-like lesions.



Figure 147-6 Extensive Langerhans cell histiocytosis. The papuloscaling and papulocrusted lesions show a typical distribution on the trunk and the scalp. The involvement of the face in this patient is unusual.

can be involved. Osteolytic lesions, either asymptomatic or accompanied by pain and functional impairment, are generally multiple and appear gradually. At times, lesions may cause a significant periosteal reaction. Extension to the adjacent tissues (e.g., muscles) can produce symptoms, which may be unrelated to the bone involvement. The onset can be insidious, and the osseous lesion can be single and may go undetected until spontaneous fracture or destruction of an organ occurs. When the lesions become symptomatic, there is localized pain, tenderness, soft tissue swelling, deformation, fracture or medullar compression (vertebra plana), or premature teeth loss.

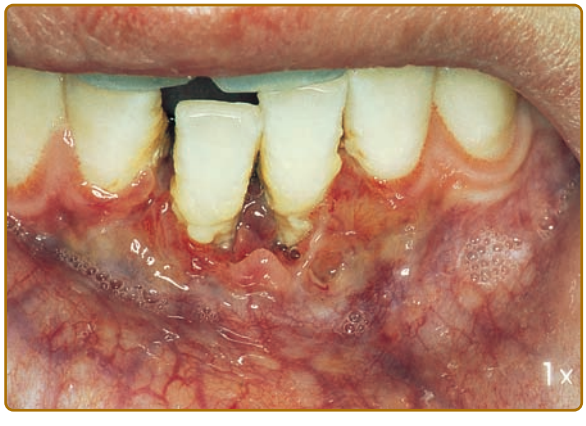

Figure 147-7 Extensive Langerhans cell histiocytosis. Infiltrating lesions of the gingival tissue which frequently leads to loss of teeth.



Figure 147-8 Restricted Langerhans cell histiocytosis. Noduloulcerative lesions in the vulva and on the perianal area. These lesions, although rare, are as unique as the bone lesions.

Bone marrow involvement, which is rare and generally occurs late in aggressive forms of LCH, is characterized by the presence of numerous histiocytic cells. When thrombocytopenia, leukopenia, and anemia occur, death is almost certain.

Conventional radiography and MRI can both be used in the diagnosis of bone LCH lesions, but MRI has an advantage in the detection of muscle involvement. In addition, isotopic bone scanning can be used for multiple lesions, and scintigraphy and fluorodeoxyglucose positron emission tomography can identify active osseous lesions. Isolated bone lesions, typically with bevelled margins and without sclerosis, have the best prognosis, whereas bone lesions with multisystem involvement predict a more problematic course.



Figure 147-9 Extensive Langerhans cell histiocytosis. All nails, save one, show purpuric linear lesions of the nail bed. Nail changes are considered an unfavorable prognostic sign.



Figure 147-10 Extensive Langerhans cell histiocytosis in an 81-year-old woman. The diffuse papuloscaling and papulocrusted lesions on the trunk are similar to those seen in early childhood. Systemic involvement consists of hepatosplenomegaly and pulmonary lesions. (From Caputo R et al: Mucocutaneous expressions of Langerhans cell histiocytosis in adults. *Eur J Dermatol* **13**:481, 1994, with permission.)

Pulmonary involvement may be asymptomatic but can also cause death. Pulmonary lesions are more often problematic in elderly patients and are quite frequent (12% to 23% of patients). Functional signs consist of dyspnea, tachypnea with rib retraction, cough, cyanosis, and thoracic pain. Other signs include mediastinal compression and pneumothorax caused by bulla

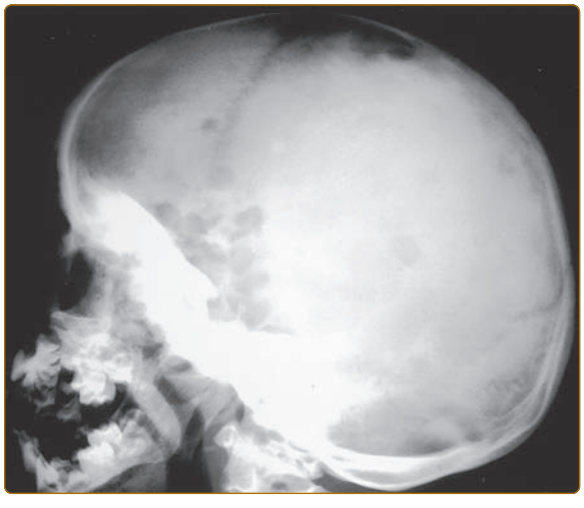

Figure 147-11 Extensive Langerhans cell histiocytosis. Radiograph of the skull shows well-circumscribed osteolytic areas with a typical "map" appearance.

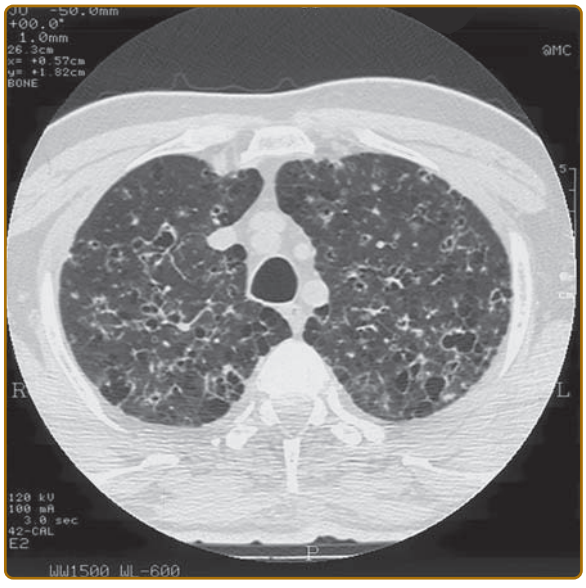

Figure 147-12 Extensive Langerhans cell histiocytosis. Bilateral involvement of the lungs characterized by multiple cystic cavities (honeycomb appearance). (Used with permission from E. De Juli, MD.)

formation. In chest radiographs, the lungs may show a classic "honeycomb" appearance (Fig. 147-12) or a micronodular pattern. Pulmonary function tests may reveal restrictive lung disease with decreased pulmonary volume. The diagnosis of LCH can be made if more than 5% of the cells in specimens obtained by bronchoalveolar lavage are Langerhans cells as indicated by immunostaining or electron microscopic examination. Involvement of the liver and spleen is quite frequent (15% to 50% of patients). Hepatic lesions may evolve to severe fibrosis, biliary cirrhosis, and liver failure. Hepatosplenomegaly, often due to portal infiltration by Langerhans cells or Kupffer cell hyperplasia, is never the initial sign of the disease but is a frequent complication and is a prognostically unfavorable sign, particularly when accompanied by jaundice and ascites. Splenomegaly may increase the severity of thrombocytopenia.

LCH may manifest orally with single or multiple lesions of the alveolar or basal bone, ulcerated mucosal lesions accompanied by adenopathy and/or periodontal lesions. The latter show gingival inflammation, bleeding, recession, necrosis, odontalgia, dental hypermobility, and premature loss of teeth. The principal differential diagnoses include advanced periodontal disease or a periapical process of dental or periodontal origin.[10] Gastrointestinal tract involvement in LCH is rare (~1%–2% of the patients) but, when present, tends to manifest at a very young age. Symptoms are nonspecific and are due to mucosal infiltration.[11] LCH may manifest as hematochezia, constipation, or diarrhea leading to protein-losing enteropathy and can range in severity from mild to life threatening.[12] The gastrointestinal symptoms can be preceded by or associated with the characteristic cutaneous lesions in the majority of the patients.

Although conventional radiographs may show either dilated or stenotic segments, the specific diagnosis can be made by only endoscopic biopsy. Since most of gut biopsies demonstrated histologic evidence of LCH, even in patients who were not experiencing gastrointestinal symptoms, endoscopic assessment of both the upper (gastroduodenal) and lower (distal colon) gastrointestinal tract should be considered with multiple mucosal biopsies in the initial LCH-staging studies in patients with no other evidence of systemic disease. Since patients with gastrointestinal tract involvement of LCH have poor outcome, they should be treated as a multisystemic disease irrespective of the patient's clinical status.

Lymphadenopathy is rarely prominent but has been noted in 25% to 75% of fatal cases. Cervical lymph nodes are the most often affected. The nodes are only rarely symptomatic, but if massive, they may damage the surrounding structures. For example, enlargement of the nodes surrounding the respiratory tract may provoke cough, dyspnea, or cyanosis. Suppuration and chronic drainage can also occur.

Diabetes insipidus is present in more than 50% of cases and occurs more often in patients with involvement of the skull and the orbits. It should be evaluated by water deprivation testing and measurement of urinary levels of arginine vasopressin. Diabetes insipidus is easily controlled by vasopressin therapy. Although diabetes insipidus is an obvious marker of skull invasion, it is not considered a prognostically unfavorable symptom. Growth retardation in children can be due to anterior pituitary involvement leading to growth hormone deficiency; however, it is more commonly caused by chemotherapy, systemic steroids, malabsorption, and general malaise. Other endocrine organs, such as the pancreas, thymus, and gonads can also be affected.

Exophthalmos is present in only 10% to 30% of cases. It may be unilateral or bilateral and is due to retroocular bone infiltration by Langerhans cells. Mastoid involvement mimics an infectious mastoiditis and leads to chronic otitis media, otorrhea, and also deafness caused by the extension of the disease to the middle ear.

CNS involvement by LCH is probably not as uncommon as believed in the past. Moreover, the clinical picture is very heterogeneous and may develop years after the initial diagnosis of LCH with mild symptoms as subtle behavioral disturbances or learning difficulties.[13] Besides growth retardation (in children), signs may include cranial nerve deficit, blurred vision, tremors, dysarthria, ataxia, reflex abnormalities, spastic paraplegia or tetraplegia, progressive intellectual deficit, headaches, psychosis, and hydrocephalus. Other signs, such as seizures and those related to increased intracranial pressure, are rare and depend on the site and size of the lesion. Cerebellar manifestations may appear as a first sign, followed by signs of involvement of the paraventricular cerebral white matter. CT or MRI may reveal tumor lesions as a sign of primary invasion or secondary atrophic or demyelinating lesions. Yet other patients are free of neurologic symptoms despite typical MRI changes.

TABLE 147-2
Laboratory Investigations for Langerhans Cell Histiocytosis

Complete blood count[a]
Coagulation profile[a]
Serum protein electrophoresis
Erythrocyte sedimentation rate
C-reactive protein level
Serum glucose level
Liver function tests[a]
Electrolyte levels
T- and B-cell counts and T-cell subset analysis for immunologic evaluation
Urinalysis including urine osmolality testing[a]

[a]Every 6 months, or every month if indicator for currently involved system.

Hypogonadotropic hypogonadism,[14] chronic erosive oligoarthritis of large joints,[15] and a high incidence of hearing loss[16] have also been reported. An association between LCH and acute myeloid leukemia has been recorded in a few series.[17]

LABORATORY TESTS

The recommended laboratory evaluations for a patient with LCH are shown in Table 147-2. Other investigations that should be carried out in LCH are listed in Table 147-3.

IMAGING STUDIES

Diagnostic imaging, from plain films to axial high-resolution CT and gadolinium-enhanced MRI, plays a major role in the diagnosis and management of LCH. The most common intracranial manifestation in LCH is hypothalamic pituitary region infiltration in 10% to 15% of patients with LCH and is associated with diabetes insipidus or anterior pituitary hormone deficiency. The second-most common CNS finding is neurodegenerative LCH, characterized by bilateral symmetric lesions in the dentate nucleus of the cerebellum or basal ganglia of variable signal intensity on MRI. By conventional MRI, using T1- and T2-weighted sequences, the classical pattern of neurodegeneration in LCH is represented by bilateral T2-hyperintense and T1-hypointense, noncontrast-enhancing signal alterations and discrete T1-hyperintense calcifications.[18] Susceptibility-weighted imaging (SWI), a newly developed MRI sequence, is more sensitive for intraparenchymal calcifications and hemorrhages. SWI may reveal areas of tissue injury, for example, certain gray matter structures, like the substantia nigra, that go undetected on conventional MRI.[19]

As already noted, bone involvement can be investigated using isotopic bone scans to reveal multiple lesions and fluorodeoxyglucose positron emission tomography

TABLE 147-3
Procedural Investigations for Langerhans Cell Histiocytosis

Specific Investigation	Indication
Skin biopsy or cytology	Mandatory to determine diagnosis
Weight and height	To determine general health
Chest radiography[a]	To determine respiratory system involvement
Abdominal ultrasonography[a]	To determine gastrointestinal involvement
Endoscopy and biopsy	To investigate malabsorption
Bone marrow biopsy	To evaluate cause of anemia, leukopenia, thrombocytopenia
Liver biopsy	To determine specific infiltration and involvement
Pulmonary function tests	To investigate tachypnea; to assess before chemotherapy
Bronchoalveolar lavage	To determine specific infiltration
Lung biopsy	To exclude opportunistic infection
Brain magnetic resonance imaging	To evaluate neurologic, visual, endocrine anomalies
Endocrine evaluation	
Growth hormone level	To determine cause of short stature, hypothalamic syndrome
Thyroid-stimulating hormone level	To investigate galactorrhea, precocious puberty
Otorhinolaryngologic evaluation, audiogram	To evaluate auricular discharge, deafness
Bone scans, skeletal survey, or fluorodeoxyglucose positron emission tomography	To assess bone involvement
Urine osmolality after water deprivation	To investigate diabetes insipidus

[a]Every 6 months, or every month if indicator for currently involved system.
Adapted from Cambazard F, Stephan JL: The histiocytoses, Langerhans cell and non-Langerhans cell histiocytosis. In: *Textbook of Pediatric Dermatology*, edited by J Harper, A Oranje, N Prose. Oxford, Blackwell Publishing, 2006, p. 1699.

to identify active osseous lesions. These techniques may allow the precise visualization of lesions in potentially dangerous bony locations such as the skull and the spine. In the thorax, reticulonodular shadowing and honeycombing of the lung with preserved lung volume is typically revealed.

HISTOPATHOLOGIC, IMMUNOHISTOCHEMICAL, AND ULTRASTRUCTURAL EVALUATION

The pathologic features of LCH provide the unifying aspect for the entire continuum of LCH disorders. The common histologic element of the different lesions is the typical "LCH cell," a cell easily identified and differentiated from the nonspecific elements of the infiltrate by its size and configuration. This cell is approximately four to five times larger than small lymphocytes, has an irregular and vesiculated nucleus, is often reniform (kidney shaped), and has abundant, slightly eosinophilic cytoplasm (Figs. 147-13–147-15). The histologic patterns observed in LCH are of three types: (1) proliferative, (2) granulomatous, and (3) xanthomatous. A proliferative reaction is seen in early papules. It consists of an extensive epidermotropic, lichenoid infiltration of LCH cells in the upper dermis. The epidermis soon becomes compressed, thinned, invaded, and even destroyed (see Fig. 147-13). In the upper dermis, LCH cells are typically separated by edema, whereas in the lower dermis their cell membranes coalesce. In the deep dermis, the infiltrate is often localized around vessels and may invade the hypodermis. A few mitotic figures are occasionally found. Cytologic examination of LCH cells is easily accomplished by scraping early papules. The granulomatous reaction (see Fig. 147-14) consists of an aggregation of LCH cells with some multinucleated histiocytes and a varying number of eosinophils, generally in clusters. Neutrophils, lymphocytes, and plasma cells may also be present in the infiltrate. This type of reaction is seen in the chronic stages of the disease. The xanthomatous reaction is encountered mainly in what was formerly called HSC and consists of numerous foam cells intermingled with LCH cells and eosinophils (see Fig. 147-15). Multinucleated giant cells are frequently seen. They are mainly of the foreign-body type but occasionally may have the appearance of Touton giant cells. Lipid accumulation is considered to be a late secondary phenomenon. These different types of histologic reactions may be

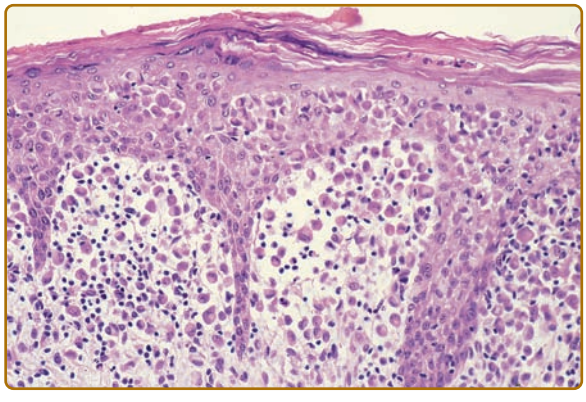

Figure 147-13 Langerhans cell histiocytosis (LCH). Proliferative reaction. A pure LCH cell infiltrate invades and destroys the epidermis.

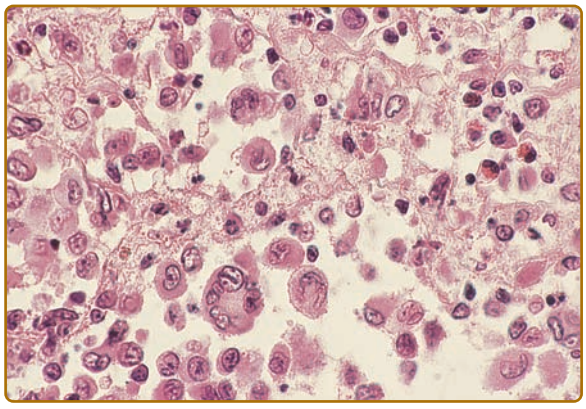

Figure 147-14 Langerhans cell histiocytosis (LCH). The granulomatous reaction consists of an aggregation of LCH cells with some multinucleated histiocytes and varying numbers of eosinophils, neutrophils, lymphocytes, and plasma cells. This type of reaction is seen in the chronic stage of the disease.

found simultaneously in the same patient, and the visceral lesions present in LCH show the same three types of reactions observed in the skin.

In historical, nodular Hashimoto–Pritzker disease, the infiltrate appears to consist mostly of large multinucleated giant cells intermingled with typical LCH cells. The cytoplasm of the giant cells is either acidophilic or has a "ground glass" appearance. It is usually localized in the middermis and deep dermis; occasionally, the epidermis may be infiltrated and ulcerated. The LCH cells show the immunophenotype of normal Langerhans cells, expressing high levels of major histocompatibility complex class II molecules, CD1a complex, CD4, CD207 molecules, and S100 protein. Electron microscopic studies show that approximately 50% of the histiocytes of LCH contain Langerhans granules (see eFig. 147-15.1 in online edition).

E-cadherin expression on LCs in lesional skin may be an indicator of a good prognosis and limited disease.

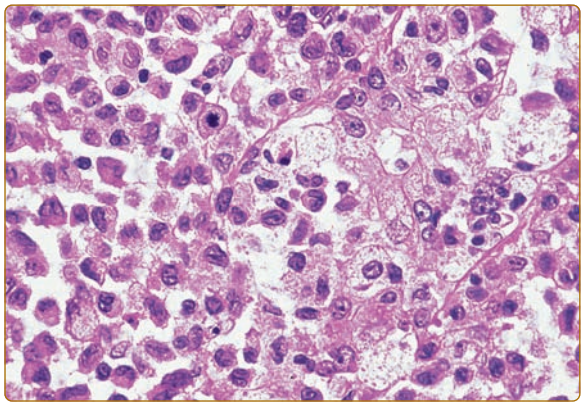

Figure 147-15 Langerhans cell histiocytosis (LCH). The xanthomatous reaction consists of numerous foam cells intermingled with LCH cells and is encountered mainly in the subtype of LCH formerly called Hand–Schüller–Christian disease. Mitotic figures are occasionally seen.

Some authors suggest testing E-cadherin expression on frozen tissue samples because of a lack of sensitivity in the use of paraffin-embedded tissue. Regulator T (Treg) cells have been shown to be numerous in skin lesions of LCH and may be involved in its pathogenesis, but their density does not predict disease evolution.[20]

DIFFERENTIAL DIAGNOSIS

The differential diagnosis for LCH is summarized in Boxes 147-1 and 147-2.

COMPLICATIONS

Intercurrent infections, mainly candidiasis and sometimes dermatophytosis, are frequently observed in LCH, especially in LSD. The development of severe pyogenic abscesses has been reported in elderly patients. The results of the progressive destruction of the surrounding tissue by invading histiocytes can therefore be highly variable and multifocal. The association of LCH with malignant neoplasms, particularly solid tumors (lung tumors, celiomesenteric neuroblastoma), malignant lymphomas, or acute leukemia is not unusual. In some of these cases, LCH may be considered as a reactive process associated with malignancy. Neoplasms may also be related to chemotherapy or radiotherapy for LCH. The synchronous occurrence of LCH with leukemia may be interpreted as additional clinical evidence in favor of a common origin of monocytes and Langerhans cells.

PROGNOSIS AND CLINICAL COURSE

Although the presence of numerous lesions, either in the skin or in other tissues, generally indicates an unfavorable course, the evolution of LCH is unpredictable. The prognosis is based on clinical features and is related to the age at onset, the rate of disease progression, and the number of organ systems involved. It is not related to the histopathologic features. In short, an early-onset (under the age of 2 years), extensive disease, and the presence of organ failure are the three main negative prognostic indicators.

Single-system LCH is usually associated with a good prognosis, whereas multisystem LCH may be fatal. However, some patients with multiple lesions have been reported to recover spontaneously. The appearance of xanthomatous lesions in the course of LCH is considered by some authors to be an expression of a shift from a disseminated aggressive form into a progressive chronic form; others believe that these lesions may represent a distinct clinical entity independent of the primary disease. Organ dysfunction (liver, bone marrow, and lung), which occurs in approximately 15% of patients with LCH, is the most important predictor of poor outcome; however, diabetes insipidus is not a poor prognostic indicator. In infants with organ

BOX 147-1 DIFFERENTIAL DIAGNOSIS OF LANGERHANS CELL HISTIOCYTOSIS (LESION SPECIFIC)

	TYPE OF LESION			
	Papular	**Vesicopustular**	**Xanthomatous**	**Noduloulcerative**
Most Likely	Seborrheic dermatitis Lichen nitidus Generalized eruptive histiocytosis Benign cephalic histiocytosis Darier disease Lichen planus	Scabies Miliaria Varicella Intertrigo Candidiasis Rosacea Folliculitis decalvans	Papular xanthoma Xanthoma disseminatum Juvenile xanthogranuloma Urticaria pigmentosa	Juvenile xanthogranuloma Urticaria pigmentosa Diffuse neonatal hemangiomatosis Blueberry muffin baby Hidradenitis Tuberculosis
Consider	Leukemia Pityriasis lichenoides chronica Hidradenitis suppurativa Psoriasis, guttate Tinea corporis, tinea capitis	Dermatitis Pityriasis lichenoides et varioliformis acuta Granuloma faciale Perioral dermatitis Lupus miliaris faciei	Hyperlipidemic xanthomatosis Granuloma annulare disseminatum	Leukemia Pyoderma gangrenosum Cherry angioma

dysfunction, the mortality rate may be as high as 50% to 65%. The most frequent causes of death are pulmonary and bone marrow dysfunction and intercurrent infections.

It is impossible to attribute significance to any single sign, but jaundice, thrombocytopenia, anemia, hepatic failure, and nail involvement are considered unfavorable prognostic indicators. A favorable prognosis is associated with a small number of lesions, nodular lesions, prompt resolution of lesions, and the involvement of only one organ system (skin or bones). Multisystem LCH carries a better prognosis in adults than in children.

Liver dysfunction is considered present if there is hypoproteinemia not due to protein-losing enteropathy (less than 5.5 mg/dL total protein and/or less than 2.5 g/dL of albumin), edema, ascites, and/or hyperbilirubinemia (total serum bilirubin of more than 1.5 mg/dL). Lung dysfunction is considered present if there is cough, dyspnea or tachypnea, cyanosis, radiologically evident interstitial disease, restrictive lung disease, pneumothorax, or pleural effusion attributable to the disease rather than to infection.[22] The presence of dense areas on radiography alone is not interpreted as evidence of dysfunction. Hematopoietic dysfunction is considered present if there is anemia (less than 10 g/dL hemoglobin) not due to infection or iron deficiency, leukopenia (white blood count of fewer than 4,000/μL), or thrombocytopenia (fewer than 100,000 platelets/μL). The presence of excessive numbers of histiocytes in the marrow aspirate per se is not considered as evidence of dysfunction. Hypercalcemia is also associated with a poor prognosis and is sometimes caused by bone resorption or excess prostaglandin production. Finally, the rapidity and intensity of the clinical response to initial treatment is a good indicator of prognosis.

Hashimoto–Pritzker disease is classically characterized by congenital or neonatal isolated cutaneous involvement (nodules in the historical cases, papules and vesicopustules in other cases) without systemic involvement. Lesions regress spontaneously in weeks to months, with an excellent prognosis. As such, Hashimoto–Pritzker disease is the prototype of self-regressive cutaneous LCH (SR-LCH; also called "self-healing" LCH). However, in the same age group, cutaneous involvement is also the most common presentation of nonself-regressive cutaneous LCH (NSR-LCH). Unfortunately, there are no absolute criteria that can reliably distinguish SR-LCH from NSR-LCH in the neonatal and early infancy periods other than continued follow-up for signs of resolution.

In the recent past, it has been postulated that a higher degree of necrosis and ulceration on physical examination and a denser infiltrate of eosinophils on histopathology would suggest a self-healing process as opposed to a multisystem disease. Despite these differences, patients who were initially diagnosed with single-system LCH (cutaneous involvement only) eventually developed progression of the disease and required systemic treatment.[21]

A recent retrospective survey has reviewed a cohort of 31 patients with a diagnosis of cutaneous LCH in the first 3 months of life and no previous visceral LCH in an attempt to define predictors of disease evolution. While no single item can be a reliable indicator of a good prognosis, a solitary lesion or the tendency to involve the extremities were more common in SR-LCH. Given the marked overlapping features of SR-LCH and NSR-LCH, the term Hashimoto–Pritzker disease should be

BOX 147-2 DIFFERENTIAL DIAGNOSIS OF LANGERHANS CELL HISTIOCYTOSIS (SITE SPECIFIC)

Most Likely

- Scalp
  - Seborrheic dermatitis
  - Folliculitis decalvans
  - Tinea capitis
- Face
  - Seborrheic dermatitis
  - Rosacea
- Intertriginous areas
  - Intertrigo
  - Candidiasis
  - Hidradenitis suppurativa
  - Darier disease
- Trunk
  - Lichen nitidus
  - Lichen planus
  - Miliaria
  - Non-Langerhans cell histiocytosis
  - Scabies
  - Urticaria pigmentosa
  - Varicella (especially neonatal)

Consider

- Scalp
  - Psoriasis
- Face
  - Granuloma faciale
  - Perioral dermatitis
  - Lupus miliaris faciei
- Trunk
  - Pityriasis lichenoides et varioliformis acuta
  - Psoriasis guttate
  - Dermatitis

avoided. Spontaneous regression of the lesions, the lack of multiorgan involvement, and close long-term follow-up to monitor for progression of the disease are the only ways to definitively diagnose SR-LCH.[22]

TREATMENT

Treatment strategies for LCH are chosen on the basis of the age of the patient, the extent of disease, and the location of lesions (see Fig. 147-3 and the treatment algorithm in eFig. 147-15.2 in online edition).

In single-system disease involving skin or bone, management is nonaggressive. In children with skin involvement only, observation is the best option. Topical drugs, including corticosteroids (also intralesional injections),[23] tacrolimus, and imiquimod,[24] can be used for localized lesions. In adults with skin involvement only, topical treatment with nitrogen mustard may be effective. In one patient with localized LCH, complete clearance was achieved after 12 sessions of narrowband UVB with a cumulative dose 970 mJ/cm^2.[25] Significant improvement has been obtained with conventional psoralen plus UVA light treatment in a considerable number of cases. CO_2 laser therapy has been suggested to treat periorificial eosinophilic granuloma. Systemic glucocorticoids or antimitotic drugs are indicated for limited disease only in resistant cases. The use of thalidomide at a dosage of 100 mg/day for 1 month and then 50 mg/day for 1 or 2 months may induce a remission of skin lesions. Usually, the disease recurs after treatment is stopped. The effect of thalidomide seems to be a result of its immunomodulatory and anti-inflammatory properties. In one case, a complete remission of skin lesions was obtained after oral isotretinoin therapy. The patient was treated with 1.5 mg/kg daily for 8 months and remained free of recurrence and visceral involvement for 5 years. For patients with bone involvement only, surgery (excision or curettage) is the treatment of choice if the lesions are accessible (see eFig. 147-15.3 in online edition). In children, glucocorticoid injections into selected sites may prevent surgical trauma to developing teeth or the growth plate of long bones. In adults, radiotherapy is indicated for involvement of vertebrae, the sella turcica, and weight-bearing bones with risk of spontaneous fracture. In children, radiotherapy must be reserved for cases that fail to respond to other measures to avoid the risk of long-term effects. Recent data indicate that indomethacin at a daily dose of 1–2.5 mg/kg administered for an average of 7.7 months (range, 5–12 months) may effectively treat isolated LCH of bone in children.[26] In the case of multiple bone lesions, monochemotherapy is suggested as with multiorgan involvement.

The management of patients with multisystem disease has several options. Currently, monochemotherapy with vinblastine with or without glucocorticoids is probably the most suitable treatment.[27] Vinblastine is given intravenously at doses of 0.1–0.2 mg/kg (6.5 mg/m^2) once weekly for 1–3 months. Readministration of the alkaloid should be instituted only when new lesions appear. In the event of relapse, retreatment with the same type of monochemotherapy results in complete clearing in 60% of cases. Finally, methylprednisolone (30 mg/kg intravenously on 3 consecutive days) may be the initial therapeutic choice.

Multiagent regimens including vincristine, cyclophosphamide, doxorubicin, and chlorambucil may be considered for patients for whom monochemotherapy is not effective. In refractory and advanced cases of LCH, cyclosporine and interferon-α2, and 2-chlorodeoxyadenosine (2-CdA, cladribine) have been used. cladribine has excellent activity in patients with LCH, even though response is not uniform across all risk groups. Recent literature have shown cladribine as monotherapy has significant activity in patients with disease in nonrisk organs such as bone, but limited activity in refractory risk organ disease. In a large prospective study, the only other factors predictive of response to cladribine were age at cladribine therapy and the time from diagnosis to cladribine therapy. The response to the drug and survival were significantly

better in patients greater than 2 years of age, while the time from diagnosis to cladribine therapy was also significantly different in the responding patients compared to those who failed to respond. The potential serious side effects of cladribine (transient neutropenia, absolute monocytopenia, T-cell suppression, autoimmune hemolytic anemia, and severe skin rashes) call for a careful risk-benefit evaluation in each case. High-risk patients who fail to respond to cladribine have a high-risk of mortality.[27]

A current open pilot study of the Histiocyte Society for patients with refractory LCH is investigating whether the response rate can be improved by the addition of cytosine arabinoside (Ara-C) to cladribine. Allogenic bone marrow transplantation or autotransplantation with CD1a-depleted bone marrow has been successful in some patients. Other approaches, including stem cell transplantation with myeloablative and nonmyeloablative preparative regimes, are also being tested (eFig. 147-15.2 in online edition).

KEY REFERENCES

Full reference list available at www.DIGM8.com

DVD contains references and additional content

5. Jaffe R et al: Histiocytic and dendritic cell neoplasms, introduction. In: *WHO Classification of Tumors of Haematopoietic and Lympoid Tissues*, edited by SH Swerdlow et al. Geneva, Lyon, WHO Press, 2008
6. Favara BE et al: WHO Committee on Histiocytic/Reticulum Cell Proliferations, Reclassification Working Group of the Histiocyte Society. Contemporary classification of histiocytic disorders. *Med Pediatr Oncol* **29**(3):157-166, 1997
7. Satter EK, High WA: Langerhans cell histiocytosis: A review of the current recommendations of the Histiocyte Society. *Pediatr Dermatol* **25**(3):291-295, 2008
8. Le Bidre E et al: Extensive, erosive congenital self-healing cell histiocytosis. *J Eur Acad Dermatol Venereol* **23**:835-862, 2009
10. Madrigal-Martínez-Pereda C et al: Langerhans cell histiocytosis: Literature review and descriptive analysis of oral manifestations. *Med Oral Patol Oral Cir Bucal* **14**(5):E222-E228, 2009
12. Shima H, Takahashi T, Shimada H: Protein-losing enteropathy caused by gastrointestinal tract-involved Langerhans cell histiocytosis. *Pediatrics* **125**(2):e426-e432, 2010
13. Allen CA, Flores R, Rauch R: Neurodegenerative central nervous system langerhans cell histiocytosis and coincident hydrocephalus treated with vincristine/cytosine arabinoside. *Pediatr Blood Cancer* **54**:416-423, 2010
19. Ertan G, Huisman TA: Susceptibility-weighted imaging in neurodegeneration in Langerhans cell histiocytosis. *J Pediatr* **156**(6):1032, 2010
20. Battistella M et al: Neonatal and early infantile cutaneous langerhans cell histiocytosis: Comparison of self-regressive and non-self-regressive forms. *Arch Dermatol* **146**(2):149-156, 2010
27. Weitzman S et al: 2′-Chlorodeoxyadenosine (2-CdA) as salvage therapy for Langerhans cell histiocytosis (LCH). Results of the LCH-S-98 protocol of the Histiocyte Society. *Pediatr Blood Cancer* **53**(7):1271-1276, 2009

Chapter 148 :: Non-Langerhans Cell Histiocytosis

:: Carlo Gelmetti

NONLANGERHANS CELL HISTIOCYTOSIS AT A GLANCE

- A broad group of disorders characterized by the proliferation of histiocytes involving cells other than Langerhans cells.
- Not rare. Most cases are in infants and run a benign, self-healing course lasting a few years.
- The primary histopathologic feature is a dense, diffuse infiltrate that is less epidermotropic than in Langerhans cell histiocytosis (LCH) and composed of occasionally foamy macrophages intermingled with lymphocytes, plasma cells, eosinophils, and sometimes Touton giant cells.
- In typical cases, histiocytes are $CD68^+$ but $CD1a^-$ and $CD207^-$.
- Most common sites of involvement are the head, trunk, and skin folds, with mucosal lesions rare.
- Systemic manifestations such as ocular involvement, diabetes insipidus, and joint and visceral impairment are rare in juvenile xanthogranuloma, the most common type of non-Langerhans cell histiocytosis (NLCH), but are common in the rarer forms of NLCH.

TABLE 148-1
Disorders Categorized as Non-Langerhans Cell Histiocytosis (with Abbreviations)

Juvenile xanthogranuloma (JXG)
- Papular xanthoma (PX)

Generalized eruptive histiocytosis (GEH)
- Benign cephalic histiocytosis (BCH)

Xanthoma disseminatum (XD)
- Erdheim–Chester disease (ECD)

Multicentric reticulohistiocytosis (MRH)
- Solitary cutaneous reticulohistiocytosis (SRH)
- Diffuse cutaneous reticulohistiocytosis (DRH)

Progressive nodular histiocytosis (PNH)
Necrobiotic xanthogranuloma (NXG)
Sinus histiocytosis with massive lymphadenopathy (SHML)

Note: Major disorders are in bold. The other forms are considered variants of these diseases.

Non-Langerhans cell histiocytosis (NLCH), or class II histiocytosis, represents a broad group of different disorders characterized by the proliferation of histiocytes other than Langerhans cell (LC) (Table 148-1).

In some textbooks, these diseases are gathered under the term: macrophage/dermal dendritic cell disorders. In 2001, Zelger et al suggested a unifying approach to understand this disease group. They identified different types of macrophages in the prototype lesion, juvenile xanthogranuloma, and then used this morphology to subcategorize the diseases.

Clinicopathologic overlap makes it difficult to place some patients exactly into one defined entity, indicating a close relationship between these disorders. While many of these disorders may feature foamy cells, affected patients are normolipemic. In all instances, the etiology and pathogenesis are unknown.[1]

Most of these cells share the same immunophenotypes, but the resulting disorders differ in clinical presentation and course. Although all NLCH disorders are considered reactive with no clinical evidence of malignancy, some forms, as with class I histiocytosis (Langerhans cell histiocytosis or LCH), can be invasive and therefore they are not necessarily biologically benign. Patients have been described who have developed both LCH and an NLCH, particularly, juvenile xanthogranuloma (JXG).

These cases seem to demonstrate a relationship between LCH and NLCH.[2] According to some authors the dendritic cell is the presumed cell of origin of both LCH and NLCH, leading to the shared categorization of these diseases as dendritic cell-related disorders and separated from macrophage-related proliferations such as sinus histiocytosis with massive lymphadenopathy (SHML), also known as Rosai–Dorfman disease. However, the coexistence of LCH and cutaneous SHML has also been reported, further complicating the complex relationships among histiocytic disorders. See Table 147-2 for a list of the recommended laboratory evaluations for a patient with LCH and Table 147-3 for a list of other investigations that should be carried out in LCH.

Several attempts have been made to classify NLCH, but none has been universally accepted.

Although impossible to perfectly correlate histologic features and immunophenotype with either clinical presentation or course of a single disease, one practical classification is infantile versus adult disease. Infantile forms with individual papulonodular lesions tend to be almost all cutaneous and self-healing [e.g., JXG, generalized eruptive histiocytosis (GEH), benign cephalic histiocytosis (BCH)], whereas the adult forms with coalescing plaque-like lesions tend often to be systemic and progressive/aggressive [e.g., Erdheim–Chester disease (ECD); necrobiotic xanthogranuloma (NXG); SHML]. Other rare forms including hereditary progressive mucinous histiocytosis are not discussed. An approach to the patient with NLCH is outlined in Fig. 148-1.

This chapter discusses only disorders of significance to the general dermatologist. Forms that are very rare (e.g., indeterminate cell histiocytosis) or that have been described in a single patient (e.g., fat-storing hamartoma of dermal dendrocytes) are not considered.

EPIDEMIOLOGY

JXG accounts for 80%–90% of cases of NLCH. All of the other NLCHs are rare. The author has encountered almost 300 cases in the past 35 years. There is no sexual or racial predilection. JXG appears within the first year of life in approximately 80% of cases; in 20%–35% of cases, it is congenital. Approximately, 30 adult cases are reported in the literature. There is a slight male predominance among individuals with solitary JXG lesions and a strong male predominance among those with multiple cutaneous lesions. Papular xanthoma (PX), considered a variant of JXG, is a rare disorder; fewer than 20 cases have been described. The onset of PX in children is usually during the first year of life. The disease seems to be more frequent in males. GEH is rare, with approximately 40 cases described, of which 10 were in children. It may start at any age, with reports of onset ranging from 3 months to 58 years. BCH is also rare. Over the past 3 decades, approximately 30 cases have been described, with the same incidence in boys and girls. The age of onset is 5–34 months (mean, 13.5 months). Progressive nodular histiocytosis (PNH) is an exceptional form described in a few children and adults. Xanthoma disseminatum (XD) is rare (approximately 100 published cases) and affects males more frequently than females. The random nature of the disorder does not permit an exact evaluation of either familial involvement or morbidity. In approximately 60% of patients, onset is before age 25 years. ECD is also rare, and only about 60 cases have been described in 70 years. Multicentric reticulohistiocytosis (MRH) is an uncommon disorder but has been observed in more than 100 individuals reported up to

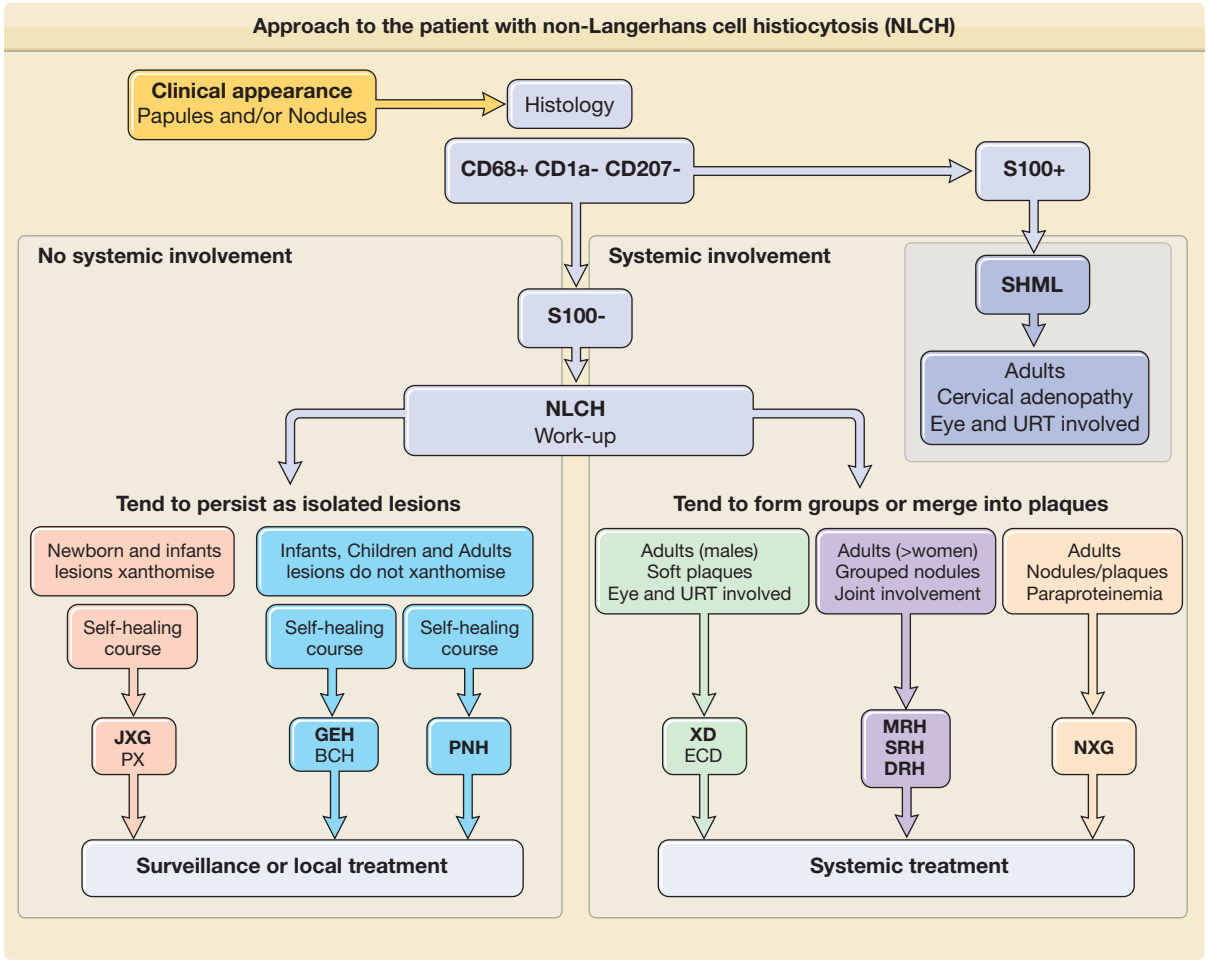

Figure 148-1 Approach to the patient with non-Langerhans cell histiocytosis (NLCH). BCH = benign cephalic histiocytosis; DRH = diffuse cutaneous reticulohistiocytosis; ECD = Erdheim–Chester disease; GEH = generalized eruptive histiocytosis; JXG = juvenile xanthogranuloma; MRH = multicentric reticulohistiocytosis; NXG = necrobiotic xanthogranuloma; PNH = progressive nodular histiocytosis; PX = papular xanthoma; SRH = solitary cutaneous reticulohistiocytosis; SHML = sinus histiocytosis with massive lymphadenopathy; URT = upper respiratory tract; XD = xanthoma disseminatum.

1990, with the purely cutaneous forms seen in more than 50 patients. Caucasians are affected in more than 85% of cases, and women are more frequently affected than men (female–male ratio of 3:1). In general, MRH affects adults 40 years of age, but the disease may appear during adolescence and rarely in childhood (pure cutaneous forms). NXG has been described in approximately 60 cases. The age of onset of NXG ranges from 17 to 85 years, and the disease shows no gender predilection. SHML is also a relatively rare disease; approximately 365 cases have been studied. The disease has a worldwide distribution with increased incidence in blacks from Africa and the West Indies. There is no gender predilection. Any age group may be affected, but 80% of cases occur in the first or second decade of life.

ETIOLOGY AND PATHOGENESIS

The pathogenesis of NLCH is unknown. Virus-induced local immune alternation in the transformation of the NLCH has been postulated since previous studies have suggested that the proliferation of histiocytes is a physiologically appropriate response to viral infection.[3]

MRH may represent an abnormal histiocytic reaction to different stimuli. In forms with solitary lesions, local trauma may play a role, whereas in diffuse forms, the association with internal malignancies and autoimmune diseases suggests an immunologic basis for the initiation of the reaction.

PNH is a progressive disease with no tendency to involute spontaneously. It is thought to entail proliferation of mature spindle-shaped cells and may represent an evolution of another form of NLCH. MRH may evolve from a less developed form of NLCH, such as GEH or adult JXG. It has also been suggested that urokinase released by the activated histiocytes may play a role in the extracellular matrix degradation leading to erosion of cartilage and adjacent bone. The origin and function of the pleomorphic cytoplasmic inclusions that are frequently present in the histiocytes forming the infiltrate in this disease are still debated. They may result from a peculiar kind of endocytosis or from

the expression of an exocytosis phenomenon. These unique granules have already been described in several cases of reticulohistiocytosis, and if their presence is confirmed by subsequent observations, they could represent the ultrastructural marker.

The cause of NXG and its link to paraproteinemia are uncertain. It has been suggested that serum immunoglobulins complexed with lipid become deposited in the skin, eliciting a giant cell foreign-body reaction. Another hypothesis is that the paraproteinemia is the primary phenomenon, and a secondary proliferation of macrophages with receptors for the Fc portion of immunoglobulin G occurs. It has also been proposed that the paraprotein in NXG has functional features of a lipoprotein that may bind to lipoprotein receptors of histiocytes and induce granuloma formation. Mutations in *SLC29A3*, encoding an equilibrative nucleoside transporter (ENT3), have recently been shown to cause both familial histiocytosis syndrome (Faisalabad histiocytosis) and familial SHML.[4]

JUVENILE XANTHOGRANULOMA

CLINICAL FINDINGS

CUTANEOUS LESIONS. JXG is a benign, self-healing disorder that is characterized by asymptomatic yellowish papulonodular lesions of the skin and other organs in the absence of a metabolic disorder. Lesions consist of an infiltrate of histiocytes with a progressively greater degree of lipidation. Two main clinical forms can be distinguished, a papular and a nodular form. In both the lesions are initially orange–red or red–brown but quickly turn yellowish. The papular form (Fig. 148-2) is characterized by numerous (up to 100) firm hemispheric lesions 2–5 mm in diameter. These lesions are irregularly scattered throughout the skin but are located mainly on the upper part of the body. PX is considered to be a form of JXG in which the lesions rapidly become xanthomatous. PX lesions range from 2 to 12 mm and show a generalized distribution with no tendency to merge into plaques. The nodular form (Fig. 148-3) is less frequent and occurs as one or a few lesions. Such nodules are generally round, 10–20 mm in diameter, and translucent, and might show telangiectases on their surface. The term *giant juvenile xanthogranuloma* is applied to lesions larger than 2 cm. Unusual clinical variants have been also reported. The mixed form is characterized by the simultaneous presence of both small and large nodules. The term *juvenile xanthogranuloma en plaque* defines a group of JXG lesions with a tendency to coalesce into a plaque as the only expression of the disease. In one study, 67% of 174 cases involved solitary papular lesions, and an additional 16% showed solitary nodular lesions. Multiple cutaneous lesions were noted in 7% of affected individuals, a solitary extracutaneous lesion in 5%, and multiple cutaneous and visceral-systemic lesions in an additional 5%.

Recently, two new variants have been described. The first was a case with skin lesions consisting of bluish papules and nodules (mimicking a "blueberry muffin baby") located on the head, trunk, and proximal extremities. The second, "multiple lichenoid JXG," was characterized by hundreds of discrete papules.[5]



Figure 148-2 Juvenile xanthogranuloma. Papular form.



Figure 148-3 Juvenile xanthogranuloma. Nodular form.

RELATED PHYSICAL FINDINGS. Ocular involvement is the most typical extracutaneous manifestation. It may precede or follow the cutaneous lesions. Approximately 0.4% of cases exhibit ocular manifestations, usually unilateral.[6] Lesions may affect the orbit, iris, ciliary body, cornea, and episclera, and can result in spontaneous hyphema, glaucoma, and blindness. JXG of the uvea is a rare disease that usually responds to systemic steroids or low-dose radiotherapy; aggressive cases can be treated with chlorambucil.[7] Therefore, the importance of ocular screening in patients with JXG, especially those with periocular lesions, should be emphasized. However, it is important to realize that the absence of skin lesions should not rule out JXG because skin lesions can often regress spontaneously.

An extremely rare extracutaneous manifestation of the papular variant is central nervous system (CNS) involvement. The nodular form of JXG may occasionally be related to systemic lesions of the lungs, bones, kidneys,[8] pericardium, colon, ovaries, and testes. Juvenile chronic myelogenous leukemia (JMML) has been observed in association with this variant of JXG.

Café-au-lait macules and JXGs occur together in 20% of individuals with papular JXGs and can be considered an excellent marker of neurofibromatosis type 1 (NF-1) (see Chapter 141) during the first years of life, even in the absence at that age of other reliable markers of NF-1. The occurrence of the triad of NF1, JXG, and JMML was first reported case in 1958, but is rare (approximately 20 cases in the literature). However, children with NF1 and JXG have a 20–30-fold higher risk for JMML than patients with NF1 without JXG.[9]

LABORATORY TESTS

No abnormalities in laboratory test results are usually found in JXG except in the very rare cases in which juvenile chronic myeloid leukemia is associated with JXG.

HISTOPATHOLOGIC AND ULTRAMICROSCOPIC FINDINGS

Biopsy sections of JXG lesions show a feature that is common to many NLCHs, i.e., a nonepidermotropic histiocytic infiltrate lacking Langerhans granules. Early lesions of JXG are characterized by a monomorphous, nonlipid-containing histiocytic infiltrate that occupies at least the upper half, and sometimes the entire thickness, of the dermis. Mature lesions (Fig. 148-4) contain foam cells, foreign-body giant cells, and Touton giant cells, mainly distributed in the superficial dermis and on the border of the infiltrate. Lymphocytes, eosinophils, and neutrophils are variably associated. Older lesions may show fibrosis. In mature lesions, fat stains yield positive results. The majority of JXG lesional biopsy sections stain positive for CD68/Ki-M1P and factor XIIIa but negative for CD1a and S100 protein. Recently, a 9-month-old boy was clinicopathologically diagnosed as S100-positive JXG. Longitudinal observation revealed that strong S100 reactivity disappeared in parallel with maturation of the lesions within 2 years after the initial diagnosis.[10]

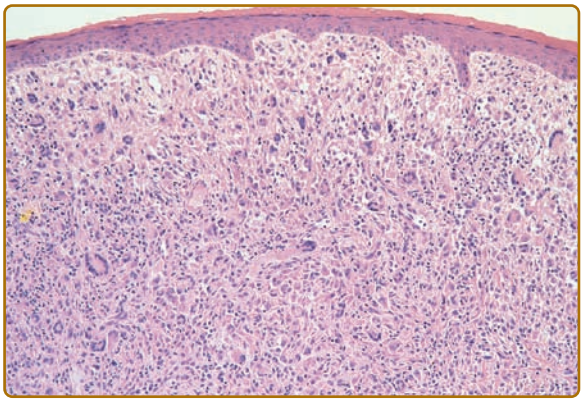

Figure 148-4 Juvenile xanthogranuloma. Histopathologic features. A mature lesion containing foam cells, foreign-body giant cells, and Touton giant cells.

Under the electron microscope, the histiocytes that characterize the early stage of the disease exhibit pleomorphic nuclei, are rich in pseudopods, and contain many elongated and irregular dense bodies. Clusters of comma-shaped bodies can occasionally be observed. In older lesions, there is a predominance of foam cells, the cytoplasm of which is completely filled with lipid vacuoles, cholesterol clefts, and myeloid bodies. Touton giant cells are extremely large and sometimes contain more than ten nuclei. Lipid material fills the periphery, whereas mitochondria and lysosomes predominate at the center.

The lesions of PX are composed almost entirely of foam cells and Touton giant cells. There is no evidence of a primitive histiocytic phase, and inflammatory cells are scarce or absent. Ultrastructurally, the cytoplasm is completely filled with lipid vacuoles without a limiting membrane, myeloid bodies, and lysosomal inclusions. Comma-shaped bodies are not found in these histiocytes.

DIFFERENTIAL DIAGNOSIS

The differential diagnosis of JXG is summarized in Box 148-1.

COMPLICATIONS

Eye involvement of a JXG lesion can cause severe secondary glaucoma. Lesions compatible with JXG have

BOX 148-1 DIFFERENTIAL DIAGNOSIS OF JUVENILE XANTHOGRANULOMA

PAPULAR

Most Likely

- Papular xanthoma
- Xanthoma disseminatum
- Tuberous xanthoma (hyperlipemic)
- Sarcoidosis (lichenoid form)
- Papular mastocytosis

Consider

- Benign cephalic histiocytosis
- Generalized eruptive histiocytosis
- Diffuse cutaneous reticulohistiocytosis
- Eruptive Spitz nevi
- Molluscum contagiosum
- Leukemia

NODULAR

Most Likely

- Hashimoto-Pritzker LCH
- Nodular mastocytoma
- Spitz nevus

Consider

- Dermatofibroma
- Solitary cutaneous reticulohistiocytosis
- Giant molluscum contagiosum

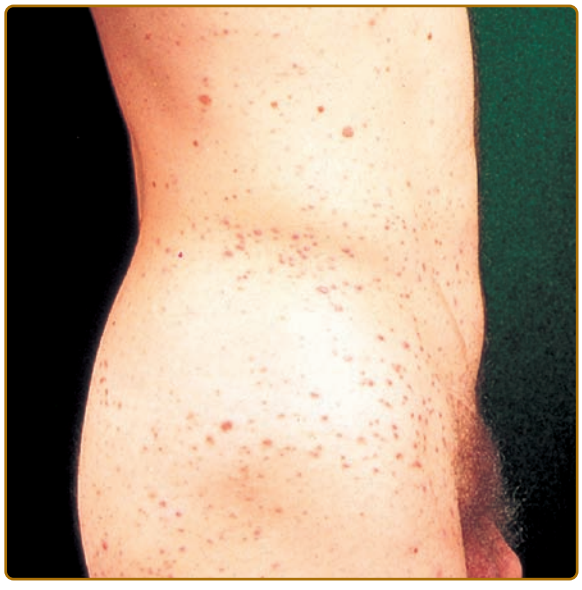

Figure 148-5 Generalized eruptive histiocytosis in an adult.

been described in many other organs as well, including oropharynx, lungs, spleen, liver, testes, heart, pericardium, gut, kidney, pancreas, lymph nodes, bone marrow, and even the CNS, and in rare cases can lead to death.[11] Severe multisystemic JXG in infants is a life-threatening disorder, and thus treatment is often required.[12] Patients may respond to multiagent chemotherapeutic regimens used to treat LCH.

PROGNOSIS AND CLINICAL COURSE

The cutaneous lesions of JXG tend to flatten with time. Each lesion evolves separately; thus, lesions at different stages of development may be seen in the same patient. Both cutaneous and visceral lesions disappear spontaneously, usually within 3–6 years. The patient's general health is not impaired, and physical and mental development is normal. Metabolic disturbances have not been identified. In the absence of associated conditions, prognosis is good. However, it is important to recognize that JXG may herald hematopoietic disorders in children and adults.[13]

GENERALIZED ERUPTIVE HISTIOCYTOSIS

CLINICAL FINDINGS

The skin lesions of GEH consist of an asymptomatic eruption of round or oval papules that are firm, pink or dark red, and range in size from 3 to 10 mm (Fig. 148-5). These lesions appear in successive crops and are usually numerous (in the hundreds). In adults, the lesions are symmetrically distributed and may involve the mucous membranes, whereas in children the lesions are irregularly scattered over the entire body and the mucous membranes are spared.

BCH may evolve into GEH and therefore is now considered a limited form of the latter. BCH manifests as asymptomatic, slightly raised, round or oval, orange–red or red–brown lesions, 2–8 mm in diameter, that are initially localized on the upper part of the face, mainly around the eyelids, forehead, and cheeks (Fig. 148-6). Other lesions subsequently appear over the entire head, the auricles (particularly on the posterior side), the occipital region, and the neck. A few lesions may appear on the shoulders and arms. The number of early lesions varies considerably, from 2 to more than 100, and new ones continue to appear



Figure 148-6 Benign cephalic histiocytosis. Note the distribution on the face (**A**) and also on the neck (**B**).

for many months. GEH and BCH do not, in general, show other features and do not lead to abnormalities in laboratory test results, or have known complications. However, diabetes insipidus has been reported in association with BCH from infiltration of the pituitary stalk, as has been described more commonly in LCH (see Chapter 147) and XD (see Section "Xanthoma Disseminatum").

HISTOPATHOLOGIC AND ULTRAMICROSCOPIC FINDINGS

The lesions of GEH (Fig. 148-7) show a dense, monomorphous, nonxanthomatous histiocytic infiltrate in the papillary and midportion of the dermis, with a few lymphocytes. The histiocytes contain a nucleus with scanty chromatin and an abundant light, poorly limited cytoplasm. These cells are often arranged in nests around vessels. Older lesions in children may contain rare foam cells and few multinucleated giant cells with peripheral nuclei. By conventional microscopy, lesions of BCH cannot be distinguished from GEH lesions. In GEH, electron microscopy shows the tumor cells to contain a large number of dense and regularly laminated bodies, often clustered together. Occasionally, worm-like bodies are found. In BCH, many coated vesicles with a diameter ranging from 500–1500 nm are seen in all the histiocytes. Clusters of comma-shaped bodies are present in nearly one-fourth of the histiocytes. The comma-shaped bodies are formed by two electron-dense membranes of approximately 6 nm, separated by a light space of approximately 8 nm. Where the infiltrate is denser, desmosome-like junctions may be observed among the histiocytes.

DIFFERENTIAL DIAGNOSIS

The disorders from which GEH should be differentiated are listed in Box 148-2.

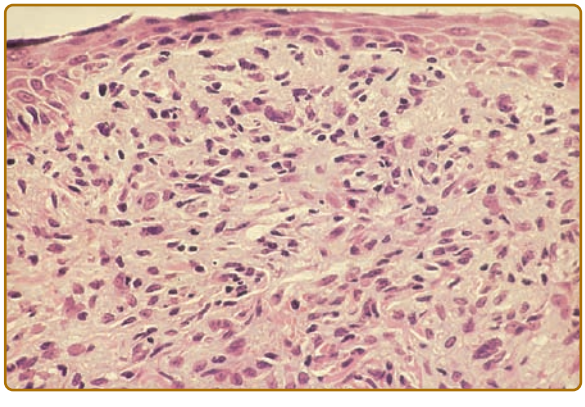

Figure 148-7 Generalized eruptive histiocytosis. Histopathologic features. Dense monomorphous histiocytic infiltrate in the papillary and mid-dermis, intermingled with a few lymphocytes.

BOX 148-2 DIFFERENTIAL DIAGNOSIS OF GENERALIZED ERUPTIVE HISTIOCYTOSIS

Most Likely

- Papular xanthoma
- Xanthoma disseminatum
- Multicentric reticulohistiocytosis
- Indeterminate cell histiocytosis
- Sarcoidosis (lichenoid form)
- Juvenile xanthogranuloma[a]
- Papular mastocytosis[a]

Consider

- Granuloma annulare disseminatum

[a]Children.

PROGNOSIS AND CLINICAL COURSE

In GEH, new crops of lesions may continue to appear for years. Slowly the disease subsides spontaneously without a trace or leaving anetoderma-like macules. Spontaneous regression of lesions occurs months to years after the onset of BCH. Regression of lesions starts characteristically where papules first appeared. The papules begin to flatten, and then, after a short period of hyperpigmentation, the lesions disappear without leaving scars.

PROGRESSIVE NODULAR HISTIOCYTOSIS

CLINICAL FINDINGS

PNH is a histiocytic disorder of skin and mucous membranes with a progressively deforming course. Cutaneous lesions consist of the eruption of hundreds of lesions of two different types: (1) superficial papules and (2) deep nodules. The most common lesions are yellow to orange papules, 2–10 mm in diameter that are randomly scattered over the body without localization in the flexural areas. These lesions may be present in the oral, laryngeal, and conjunctival mucosae. The deep lesions are dermal nodules ranging from 1 to 5 cm, with overlying telangiectasia, mainly located on the trunk. Café-au-lait spots, arthritis, and diabetes insipidus are absent. PNH has been described in a child with a hypothalamic tumor, probably histiocytic. Other patients with PNH have had hepatosplenomegaly, hypothyroidism, hypocholesterolemia, hyperuricemia, and chronic myeloid leukemia, or extensive involvement of pharynx and supraglottic larynx; the link between PNH and these other features is not clear.[14]

HISTOPATHOLOGIC AND ULTRAMICROSCOPIC FINDINGS

The histopathologic features of PNH are those of a xanthogranuloma with a predominance of storiform, spindle-shaped histiocytes that are positive for macrophage/dendritic cell line markers (CD68), and negative for CD1a and S100. Electron microscopic examination reveals histiocytes with a large indented nucleus.

DIFFERENTIAL DIAGNOSIS

The differential diagnosis for PNH is summarized in Box 148-3.

PROGNOSIS AND CLINICAL COURSE

In PNH, new lesions continue to develop during successive years with no sign of spontaneous involution. Despite the progressive nature of the lesions, patients remain in good health.

XANTHOMA DISSEMINATUM

CLINICAL FINDINGS

CUTANEOUS LESIONS. XD is a rare, benign, normolipemic form of NLCH affecting the skin and mucous membranes. It is frequently associated with diabetes insipidus. The cutaneous manifestations consist of hundreds of papules that are red–brown at first and then become yellowish. They symmetrically involve the eyelids, trunk, face, and proximal extremities and, in flexures and folds, tend quickly to merge, forming soft plaques (Fig. 148-8). ECD is considered a variant of XD that has visceral manifestations and is progressive.

RELATED PHYSICAL FINDINGS. In approximately 50% of cases of XD, xanthomatous lesions may also be observed on the mouth, pharynx, larynx, conjunctiva, and cornea. Symptoms of dyspnea and dysphagia are not uncommon. Vasopressin-sensitive transitory diabetes insipidus may be present, but polyuria and polydipsia are generally mild. Osteolytic lesions have been reported in only a few patients. XD may be associated with multiple myeloma, Waldenström macroglobulinemia, and monoclonal gammopathy. In ECD, the most common sign is chronic bone pain, usually mild and localized in the lower limbs. Extraosseous involvement can affect almost every organ, including the lungs, liver, kidney, heart, and CNS.



Figure 148-8 Xanthoma disseminatum.

BOX 148-3 DIFFERENTIAL DIAGNOSIS OF PROGRESSIVE NODULAR HISTIOCYTOSIS

Most Likely
- Multicentric reticulohistiocytosis
- Papular xanthoma
- Xanthoma disseminatum
- Generalized eruptive histiocytosis
- Sarcoidosis
- Lepromatous leprosy

Consider
- Nodular mastocytoma

LABORATORY TESTS

A normal lipid profile is present in this disease, but slightly elevated levels of serum cholesterol or triglycerides have been found in a few cases. In some cases, multiple myeloma, Waldenström macroglobulinemia, and monoclonal gammopathy have been detected. When lesions affect the CNS, magnetic resonance imaging may show foci of abnormally high signal intensity. In ECD, radiographs show symmetric sclerosis typically affecting the long bones of the lower limbs with involvement of the diaphyseal and metaphyseal regions.

HISTOPATHOLOGIC AND ULTRAMICROSCOPIC FINDINGS

In the early stage of XD, biopsy specimens show a mixture of histiocytes, foam cells, and inflammatory cells; later, foam cells predominate and Touton giant cells are frequently present (Fig. 148-9). Siderosis is often observed. The proliferating cells resemble those of JXG

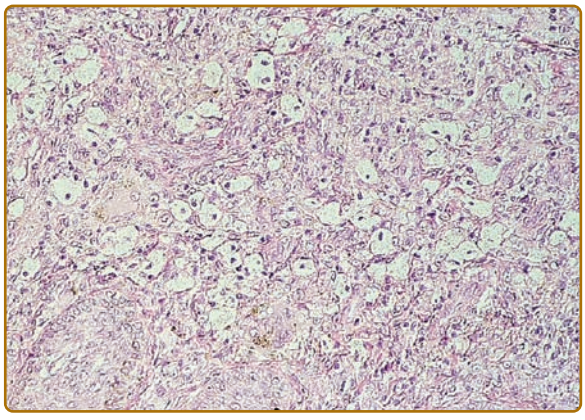

Figure 148-9 Xanthoma disseminatum. Histopathologic features. The lesions are characterized by a mixture of histiocytes, inflammatory cells, and foam cells. Touton giant cells are present.

ultrastructurally, but the plasma membranes of foam cells show many microvilli. Lesional skin sections in ECD show an infiltrate of lipid-laden histiocytes intermingled with Touton giant cells and eosinophils, surrounded by fibrosis.

DIFFERENTIAL DIAGNOSIS

The disorders from which XD should be differentiated are listed in Box 148-4.

COMPLICATIONS

In XD, organ involvement may lead to a variety of complications, particularly conjunctival inflammation and respiratory obstruction. Seizures, diabetes insipidus, and growth retardation have also been described. Chronic bone pain is the hallmark of ECD.

PROGNOSIS AND CLINICAL COURSE

Based on the evolution and prognosis of reported cases, three clinical variants of XD have been distinguished: (1) a self-healing form, (2) a persistent form, and (3) a progressive form (ECD). The persistent form is the most frequent one. Prognosis is usually good, but respiratory tract involvement may lead to dyspnea and dysphagia. Tracheotomy has been required in a few cases. In ECD, the prognosis is poor because of the high risk of visceral involvement, particularly pulmonary fibrosis.

BOX 148-4 DIFFERENTIAL DIAGNOSIS OF XANTHOMA DISSEMINATUM

Most Likely

- Chronic disseminated Langerhans cell histiocytosis
- Tuberous xanthoma (hyperlipemic)
- Papular xanthoma

Consider

- Juvenile xanthogranuloma
- Generalized eruptive histiocytosis
- Multicentric cutaneous reticulohistiocytosis
- Progressive nodular histiocytosis

MULTICENTRIC RETICULOHISTIOCYTOSIS

CLINICAL FINDINGS

CUTANEOUS LESIONS. MRH is characterized by the association of a cutaneous and mucosal eruption with severe arthropathy and other visceral symptoms. The papulonodular lesions range in diameter from a few millimeters to 2 cm and are round, translucent, and yellow-rose or yellow-brown (Figs. 148-10 and 148-11). Grouping of lesions into plaques can give a cobblestone appearance, but lesions are generally scattered and isolated. They do not tend to ulcerate and are pruritic in about one-third of cases. These lesions preferentially affect the fingers (see Fig. 148-10), the palms and backs of the hands, the juxta-articular regions of the limbs, and the head (see Fig. 148-11). Small, scattered lesions may be found on the trunk. Periungual papules (see Fig. 148-10), arranged around the nail folds, resemble "coral beads" and have been noted in approximately 40% of cases. Severe involvement of the face may lead to a leonine facies. Xanthomatous lesions are found in 30% of cases. Periarticular nodules, resembling rheumatoid nodules, may occasionally be seen. Erythematous, photodistributed macules and papules have been observed in approximately 15% of cases and may be confused with dermatomyositis. Nail changes, including brittleness, longitudinal ridging, and atrophy, may occur. Almost 50% of affected patients have specific nodular lesions of the oral, nasal, and pharyngeal mucosae.

Two different subtypes without joint or visceral manifestations have been described: (1) solitary cutaneous



Figure 148-10 Hands of a patient with active skin lesions of multicentric reticulohistiocytosis. Note the periungual array of some of the nodules, resembling "coral beads."



Figure 148-11 Mucocutaneous nodular infiltrate on the perioral and perinasal areas, as well as the oral and nasal mucosae in a patient with multicentric reticulohistiocytosis.

reticulohistiocytosis (or reticulohistiocytoma cutis) and (2) diffuse cutaneous reticulohistiocytosis. Solitary cutaneous reticulohistiocytosis is characterized by a single firm, rapidly growing nodule varying in color from yellow-brown to dark red (Fig. 148-12). Its most common location is the head, but it may be found in almost any cutaneous site. It occurs without evidence of systemic involvement, and its onset may be preceded by trauma. Diffuse cutaneous reticulohistiocytosis is a purely cutaneous form characterized by the eruption of firm, smooth, asymptomatic papulonodular lesions, 3–10 mm in diameter, scattered diffusely over the skin.



Figure 148-12 Solitary cutaneous reticulohistiocytosis.

The color of early lesions is pinkish yellow, whereas older lesions show a red–brown color.

RELATED PHYSICAL FINDINGS. In MRH, severe chronic diffuse polyarthritis with arthralgias is the initial sign of the disease in up to two-thirds of cases. The lesions symmetrically involve the hands (80% of cases), knees (70%), wrists (65%), and less frequently the shoulders, ankles, elbows, hips, feet, and spine. The osteoarticular lesions show a progressive destructive course for 6–8 years and then become stable. Involvement of the muscles (myositis, myotonia, and myoatrophy), cardiopulmonary system (pericarditis, cardiac insufficiency, pleuritis, pulmonary infiltration), eyes (exophthalmos, conjunctival infiltration), gastrointestinal system (gastric ulcer), thyroid gland (thyroid nodules), and submandibular salivary glands have occasionally been reported, but histologic documentation of involvement at these sites is rare. Fever, weight loss, and weakness can be present. The term *familial histiocytic dermatoarthritis* is used to indicate a particular form of MRH characterized by familial occurrence and typical ocular involvement (glaucoma, uveitis, and cataracts). Internal malignancy may be associated in 15%–27% of cases. Solid tumors such as bronchial, breast, gastric, and cervical carcinomas are most common. Lymphomas and myelodysplastic syndromes have been found less frequently, and malignant melanoma has been reported in three cases. Whether MRH can be interpreted as a true paraneoplastic disease is not clear. Whatever the nature of the association, the incidence of internal neoplasia is such that patients who come for treatment of MRH should be investigated for concomitant internal neoplasm. MRH has been described in association with autoimmune diseases, systemic vasculitis, tuberous sclerosis, sclerosing lesions of the leg, and tuberculosis.

LABORATORY TESTS

In MRH, elevated erythrocyte sedimentation rate and anemia have been observed in about half of patients and hypercholesterolemia in one-third of cases. An increase in immunoglobulin G and the presence of cryoglobulinemia and cold agglutinins have occasionally been reported. Rheumatoid factor is usually not detected. Radiographically, the joint lesions of MRH are characterized by bilateral, symmetrical, sharply circumscribed, and rapidly progressive erosions that spread from the margins to the joint surfaces, often with concomitant separation of the bone ends but without subchondral sclerosis.

HISTOPATHOLOGY AND ULTRAMICROSCOPIC FINDINGS

The histologic findings in MRH and its subtypes are identical. Histologically, the early lesions may be composed of histiocytes and lymphocytes, and therefore may be confused with other cutaneous histiocytoses. Older lesions show the presence of numerous large,

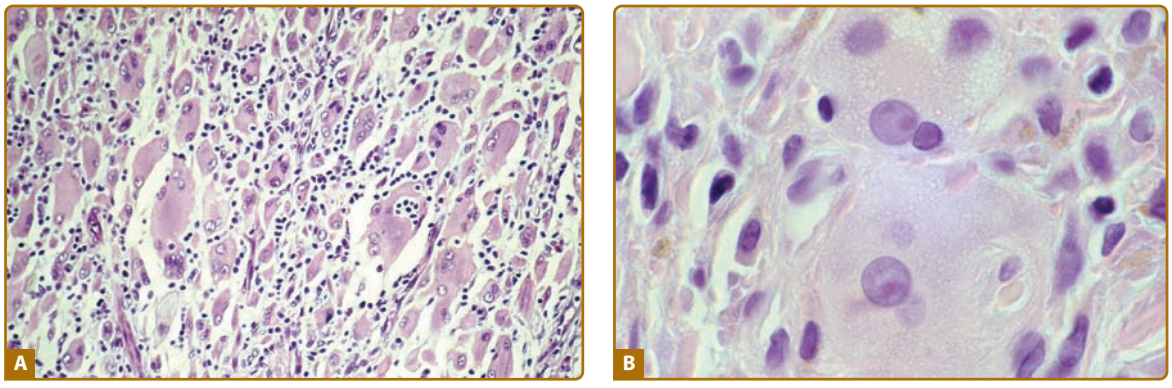

Figure 148-13 Photomicrographs of a lesion of multicentric reticulohistiocytosis. Note the histiocytic infiltrate (**A**) and multinucleated giant cells with aggregated nuclei and ground-glass cytoplasm (**B**).

mononucleated or multinucleated histiocytes with an abundance of eosinophilic, homogeneous cytoplasm containing fine granules that has a ground-glass appearance (Fig. 148-13). The number of giant cells may vary, and the diameter of these cells may reach 100 nm. The nuclei of the multinucleated cells may be arranged haphazardly or they may align along the periphery or cluster in the center. Plasma cells and eosinophils are sometimes present. Fragmentation and clumping of collagen and elastic fibers have been reported. At times, connective tissue and cell phagocytosis may be seen. Histochemically, the granular material in histiocytes and giant cells stains with periodic acid-Schiff after diastase digestion, Sudan black, and scarlet red, which indicates the presence of glycolipids and/or glycoproteins and neutral fat. Dermal proliferation of histiocytes with diffuse cytoplasmic granular cell changes has recently been described.[15]

DIFFERENTIAL DIAGNOSIS

The differential diagnosis for MRH is summarized in Box 148-5.

BOX 148-5 DIFFERENTIAL DIAGNOSIS OF MULTICENTRIC RETICULOHISTIOCYTOSIS

Most Likely

- Rheumatoid arthritis
- Dermochondrocorneal dystrophy
- Familial histiocytic dermatoarthrosis
- Lipodermoarthrosis
- Progressive nodular histiocytosis

Consider

- Farber lipogranulomatosis
- Xanthoma disseminatum
- Lipoid proteinosis
- Lepromatous leprosy
- Sarcoidosis
- Self-healing cutaneous mucinosis
- Fibroblastic rheumatism

COMPLICATIONS

Complications occurring in MRH are mainly due to visceral involvement of the disease. Lesions in the upper airway may lead to dysphonia and/or dysphagia. Cardiopulmonary manifestations are more frequently reported and may also be fatal. In addition, bones and all the visceral organs may be affected, which leads to weight loss and pyrexia that complicate the potentially mutilating inflammatory polyarthritis.

PROGNOSIS AND CLINICAL COURSE

The purely cutaneous forms of reticulohistiocytosis may involute spontaneously. It is possible that the diffuse, purely cutaneous form is an early stage of MRH before the appearance of joint and visceral lesions. In MRH, the mucocutaneous course does not parallel the articular course. The mucocutaneous lesions have an unpredictable course and may remit spontaneously. In half of the patients, the osteoarticular manifestations become stable, whereas in the other half, they cause progressive destruction. The prognosis is favorable for cutaneous forms. The prognosis for MRH is related to the severity of the osteoarticular manifestations, the presence of visceral involvement, and underlying neoplasms if present.

To date, no treatment of MRH has been shown to be universally successful; the tendency to use multiple therapies as well as the natural relapsing and remitting nature of the condition makes interpretation of therapeutic response difficult. Recently, leflunomide was successful in one patient and therefore it can be considered a therapeutic option.[16]

NECROBIOTIC XANTHOGRANULOMA

CLINICAL FINDINGS

CUTANEOUS LESIONS. In NXG, early cutaneous lesions consist of indurated papulonodules varying in color from red–orange to violaceous or yellow and involving the dermis and subcutaneous tissue. These



Figure 148-14 Necrobiotic xanthogranuloma on the calf. Note "granulomatous" periphery of the lesion, with central ulceration and necrotic material at the base.

lesions slowly enlarge into plaques with well-demarcated edges, ranging in diameter from a few to 25 cm. There is central atrophy with telangiectasias or areas of ulceration (Fig. 148-14). Most cases are asymptomatic, but pain or a burning sensation may be noted. The lesions are usually multiple and involve, in order of frequency, the face, trunk, and extremities. The periorbital area is the site of predilection and is involved in 85% of cases. The oral mucosa is occasionally involved. Hepatosplenomegaly has been observed in approximately 20% of patients.

RELATED PHYSICAL FINDINGS. NXG may be associated with myeloma, arthropathy, hypertension, neuropathy, neoplastic syndrome, primary biliary cirrhosis, and Graves disease.

LABORATORY TESTS

Ninety percent of patients with NXG have paraproteinemia (immunoglobulin G κ or λ light chains), especially in cases with associated myeloma. Cryoglobulinemia has been found in approximately 40% of cases. Other abnormal laboratory test results may include an elevated sedimentation rate, neutropenia, leukopenia, anemia, and decreased levels of CH50.

HISTOPATHOLOGIC AND ULTRAMICROSCOPIC FINDINGS

The histopathologic picture of NXG is characteristic and consists of a granulomatous infiltrate involving the whole dermis and subcutis composed of a mixture of lymphocytes, epithelioid cells, foam cells, and Touton giant cells. Areas of severe, clearly defined necrosis are sharply delineated from the surrounding granuloma. Typically, cholesterol crystals are located within the necrobiotic areas. Numerous, atypical, very large, bizarrely angulated, multinucleated giant cells may be seen adjacent to the areas of necrosis. Dense, well-defined lymphoid nodules, occasionally containing a germinal center, may be present in the dermis or subcutis. Touton cell panniculitis may involve the entire fat lobules. Occasionally, a granulomatous infiltrate may surround some vessels. Ultrastructurally, cells are rich in lipid droplets, cholesterol clefts, and myeloid bodies and are similar to those observed in JXG.

BOX 148-6 DIFFERENTIAL DIAGNOSIS OF NECROBIOTIC XANTHOGRANULOMA

Most Likely

- Granuloma annulare
- Necrobiosis lipoidica
- Xanthoma disseminatum
- Multicentric reticulohistiocytosis

Consider

- Juvenile xanthogranuloma
- Hyperlipemic xanthoma

DIFFERENTIAL DIAGNOSIS

The disorders from which NXG should be differentiated are listed in Box 148-6.

COMPLICATIONS

In NXG, the periorbital involvement may lead to ocular complications such as lagophthalmos, conjunctivitis, keratitis, scleritis, uveitis, corneal ulceration, and even loss of ocular function. Nausea, vomiting, epistaxis, back pain, and Raynaud phenomenon have also been recorded.

PROGNOSIS AND CLINICAL COURSE

NXG has a chronic, often progressive course that is characterized by the appearance of new lesions and ulcerations. The prognosis in given cases is difficult to predict and depends on extracutaneous involvement and the presence of visceral tumors such as multiple myeloma.

SINUS HISTIOCYTOSIS WITH MASSIVE LYMPHADENOPATHY (ROSAI–DORFMAN DISEASE)

CLINICAL FINDINGS

CUTANEOUS LESIONS. SHML is a benign, generally self-limited disease confined mainly to cervical



Figure 148-15 Sinus histiocytosis with massive lymphadenopathy.

lymph nodes. Cutaneous manifestations are observed in approximately 10% of patients and are polymorphic (Fig. 148-15). They may occur as yellowish macules and patches, reddish-brown papules, and plaques and nodules that may become eroded or ulcerated. In one patient, firm purple nodules and tumors as large as 10 cm in diameter were noted, but in most instances the lesions are much smaller, multiple, widespread, and asymptomatic. Periocular involvement of SHML can result in lobulated induration of the eyelids. Cutaneous lesions may be the initial manifestation and sole presenting feature of the disease. Massive bilateral cervical lymphadenopathy, usually painless, is the hallmark of the condition. Less commonly, axillary, mediastinal, inguinal, and preauricular lymph nodes may be affected.

RELATED PHYSICAL FINDINGS. SHML is usually accompanied by fever. Extranodal disease occurs in approximately 25% of patients and may be the initial manifestation of the disorder. The extranodal noncutaneous sites most commonly affected are the eye, upper respiratory tract, liver, spleen, testes, skeleton, and nervous system. Involvement of the gastrointestinal tract is rare. An elderly woman with hematochezia was found to have SMLH of the rectum presenting as a rectal mass.

LABORATORY TESTS

SHML is usually accompanied by an elevated erythrocyte sedimentation rate, leukocytosis with neutrophilia, and polyclonal hypergammaglobulinemia. Less frequent findings include moderate anemia (60%), lymphopenia, elevated titers of Epstein–Barr virus, and, in one case, elevated *Klebsiella* antibody titers. Axial postcontrast computed tomography can highlight the lymphadenopathy.

HISTOPATHOLOGIC AND ULTRAMICROSCOPIC FINDINGS

Histopathologically, the skin lesions of SHML are characterized by a diffuse dermal infiltrate composed predominantly of histiocytes with large vesicular nuclei and abundant pale cytoplasm. Some histiocytes are foamy, multinucleated, or both. Histiocytes are sometimes aggregated in clusters resembling lymph node sinuses. Lymphocytes, plasma cells, and polymorphonuclear leukocytes, typically eosinophils, may be intermixed in the infiltrate. Emperipolesis (phagocytosis of leukocytes, especially lymphocytes) is a constant feature. In electron microscopic views, most of the histiocytes are rich in phagosomes and may contain clusters of comma-shaped bodies.

DIFFERENTIAL DIAGNOSIS

The differential diagnosis for SHML is summarized in Box 148-7.

COMPLICATIONS

The organs affected by primary extranodal SHML include: skin, soft tissue, nasal cavity and paranasal sinuses, eye (bilateral anterior granulomatous uveitis) and orbit, bone (leading to chronic ankle arthritis), CNS (mimicking neurofibromatosis, meningioma, pachymeningitis), and salivary glands. The digestive system is one of the least common sites of involvement by SHML, and only three pathologically confirmed cases of primary pancreatic SHML have been reported to date.[17] Infections such as HIV and cytomegalovirus (CMV) can act synergistically in a myelosuppressive manner and provide the antigenic and inflammatory context for the development of fatal histiocytic complications.[18]

BOX 148-7 DIFFERENTIAL DIAGNOSIS OF SINUS HISTIOCYTOSIS WITH MASSIVE LYMPHADENOPATHY

Most Likely
- Abscesses
- Hodgkin disease
- Tuberculosis

Consider
- Sarcoidosis
- Leukemia
- Acquired immunodeficiency syndrome

PROGNOSIS AND CLINICAL COURSE

In most patients, SHML has a benign course with spontaneous regression over a period of months to years. Usually the extranodal lesions regress first, whereas adenopathy may persist for years. A worse prognosis results mainly from the associated immunologic abnormalities.

TREATMENT

Most forms of NLCH, such as JXG, do not require treatment because the disease is asymptomatic and self-healing. When treatment is necessary, as in XD, ECD, MRH, NXG, or SHML, therapy options are few and treatment is often unsuccessful.

Treatment of XD is usually not helpful. Vasopressin is necessary for the associated diabetes insipidus. Radiotherapy, cryotherapy, corticosteroids, and antiblastic chemotherapy have been attempted with palliative results in the more disfiguring forms.

Therapy for MRH has frequently been disappointing. Anti-inflammatory agents such as aspirin, indomethacin, and pyrazolones have shown little effect. Systemic corticosteroids may be effective on articular lesions, but only for a short period of time. Dexamethasone pulse therapy led to a dramatic response in one case. Azathioprine is of no benefit alone but in association with prednisolone may have a beneficial effect on both skin and joint lesions. Antimitotic agents (mainly cyclophosphamide and chlorambucil) have been reported to induce regression of lesions in only a few patients. Oral methotrexate seems to be the most effective. Etanercept has been used successfully to treat both cutaneous and articular symptoms. Generally, solitary cutaneous lesions are surgically excised.

In NXG, intermittent glucocorticoid treatment can induce a partial response. Low dosages of alkylating agents, such as chlorambucil or melphalan, may lead to remission of the paraproteinemia and skin lesions but do not prevent the evolution to multiple myeloma. Temporary remission of skin lesions has been obtained with radiation therapy and with plasmapheresis.

As a rule, because the vast majority of lesions of SHML heal spontaneously, no treatment is necessary. In rare instances, a space-occupying lesion will interfere with the function of an organ, and then treatment with systemic glucocorticoids or with various chemotherapeutic regimens might be useful.

PREVENTION

At present, because the causes of all of the forms of NCLH are unknown, the possibility of preventing such diseases does not exist. As in LCH, future directions include complete genome hybridization and derivation of a gene expression profile.

KEY REFERENCES

Full reference list available at www.DIGM8.com

DVD contains references and additional content

1. Zelger BW, Cerio R: Xanthogranuloma is the archetype of non-Langerhans cell histiocytosis. *Br J Dermatol* **145**:369-371, 2001
2. Yu H et al: A child with coexistent juvenile xanthogranuloma and Langerhans cell histiocytosis. *J Am Acad Dermatol* **62**(2):329-332, 2010
9. Raygada M et al: Juvenile xanthogranuloma in a child with previously unsuspected neurofibromatosis type 1 and juvenile myelomonocytic leukemia. *Pediatr Blood Cancer* **54**(1):173-175, 2010
16. Lonsdale-Eccles AA et al: Successful treatment of multicentric reticulohistiocytosis with leflunomide. *Br J Dermatol* **161**(2):470-472, 2009
18. Nastouli E et al: Fatal histiocytic proliferative disorders in paediatric HIV infection with cytomegalovirus end-organ disease. *Br J Haematol* **146**(5):580-582, 2009

Chapter 149 :: Mastocytosis

:: Michael D. Tharp

MASTOCYTOSIS AT A GLANCE

- The hallmark of mastocytosis is a pathologic accumulation of mast cells in tissues.
- Mastocytosis occurs at any age.
- The skin is the most commonly involved organ system.
- Cutaneous findings consist of hyperpigmented macules, papules or nodules, or a diffuse infiltration of the dermis.
- Generally benign in children.
- In adults, most commonly associated with a somatic activating mutation of *c-kit* (codons 816 and 560).
- Cutaneous manifestations may occur alone or in association with systemic disease.
- Related features may be flushing, pruritus, hypotension, nausea, dyspepsia, and diarrhea.
- Most common extracutaneous tissues involved are the bone marrow, liver, spleen, and lymph nodes.
- May be associated with myeloproliferative and myelodysplastic disorders.
- Classification of mastocytosis is critical for prognosis and treatment.

MAST CELLS AT A GLANCE

- Mast cells are derived from pluripotent stem cells.
- Stem cell factor is required for proliferation and survival.
- Mast cells release both pre-formed and generated mediators when activated.

EPIDEMIOLOGY

Mastocytosis represents a group of disorders characterized by an abnormal accumulation of mast cells in one or more organs. While the true incidence of this disease is unknown, most cases are in children, with 60%–80% presenting within the first year of life. Congenital mastocytosis is less common, representing approximately 18%–31% of childhood cases.[1,2] Adult-onset mastocytosis also occurs and is being more commonly recognized with newly established World Health Organization (WHO) criteria for this disease[3] (Tables 149-1 and 149-2). This disorder has no gender preference, and it has been reported in all races.[4] While most patients with mastocytosis have no family history, there are reports of familial cases, including monozygotic twins, some of which were discordant for this disease.[4–6]

PATHOGENESIS

Mast cells arise from the bone marrow as agranular, undifferentiated, $CD34^+$, KIT^+ (CD117) pluripotent progenitor cells. After migrating into tissues, immature mast cells assume their typical granular morphology.[7] KIT is a type III tyrosine kinase receptor product of the proto-oncogene c-*kit* located on chromosome 4q12. This enzyme is expressed on mast cells, as well as melanocytes, primitive hematopoietic stem cells, primordial germ cells, and interstitial cells of Cajal. Cross-linking KIT by its ligand, stem cell factor (SCF), is essential for precursor cells to differentiate into mast cells. The gene for SCF is located on chromosome 12, and encodes a protein that localizes to the cell membrane.[7,8] Membrane-bound and a soluble forms of SCF exist, both of which are capable of inducing KIT activation. Soluble KIT is thought to arise from chymase-induced cleavage of the membrane bound form.[9] SCF is produced by bone marrow stromal cells, fibroblasts, keratinocytes, endothelial cells, as well as reproductive Sertoli and granulosa cells. Mature mast cells require SCF for survival.[8,9] Other cytokines that appear important in regulating mast cell growth and differentiation include interleukin-3 (IL-3), IL-4, IL-6, and IL-9 and IFN-γ. IL-3 shares a number of signal transduction pathways with SCF, but has minimal direct effects on human mast cell proliferation except in early cultures. IL-4 enhances mast cell function when added to mature cultures. IL-6 has been shown to increase mast cell mediator concentration,[10] and IL-9 appears to increase the number of mast cells in culture.[11] In developing mast cells, IFN-γ inhibits mast cell proliferation and influences mast cell phenotype and function.[10]

Mutations in *c-kit* appear to play a central role in some forms of mastocytosis. Somatic mutations in codon 816 of c-*kit*, leading to amino acid substitutions (D816V, D816Y, D816F, and D816H), cause constitutive activation of KIT and continued mast cell growth and development.[12] Mutations in this codon are most common in adults with mastocytosis.[3] An activating mutation in codon 560 (V560G) also has been characterized in some adult patients with mastocytosis, but appears to be much less common.[6,13] Activating mutations in

TABLE 149-1
World Health Organization Classification of Mastocytosis[a]

Variant Term	Abbreviation	Subvariants	Examples
Cutaneous mastocytosis	CM	Telangiectasia macularis eruptiva perstans (TMEP)	Urticaria pigmentosa Diffuse CM Mastocytoma of skin
Indolent systemic mastocytosis	ISM	Smoldering SM Isolated bone marrow mastocytosis	SM-acute myelogenous leukemia SM-myelodysplastic syndrome SM-myeloproliferative disease SM-chronic myelomonocytic leukemia SM-non-Hodgkin lymphoma
Systemic mastocytosis with an associated clonal hematologic nonmast cell lineage disease	SM-AHNMD		
Aggressive systemic mastocytosis Mast cell leukemia Mast cell sarcoma	ASM MCL MCS		
Extra-cutaneous mastocytoma	ECM		

[a]For details of the WHO classification of mastocytosis, see Valent P et al: *World Health Organization Classification of Tumours: Pathology and Genetics of Tumours of the Haematopoietic and Lymphoid Tissues*, edited by Jaffe ES et al. Lyon, IARC Press, 2001.

c-kit have been reported in children with mastocytosis as well. Among 50 children with this disorder, 42% had detectable mutations of codon 816 (exon 17), while another 42% had demonstrable activating mutations in the extracellular and transmembrane regions of KIT (exons 8–11). The remaining eight children reported in the study had no detectable *c-kit* mutations.[14] There was no clear correlation between the extent of disease and the presence or absence of *c-kit* mutations among these patients. In another report of 22 children and adults with mastocytosis, 11 adult patients and 4 children had 816 activating mutations. Four other pediatric patients with typical lesions of urticaria pigmentosa (UP) lacked changes in this codon, and in three other children, an inactivating *c-kit* mutation (codon E839K) was detected.[12]

A transgenic mouse model of mastocytosis also has been reported using the human activating D816V *c-kit* mutation.[15] The clinical expression of this disorder ranged from indolent mast cell hyperplasia to invasive mast cell tumors, despite the fact that genetically identical animals expressed the same D816V mutation. It appears from these clinical and investigative observations that *c-kit* activating mutations of codon 816 play an important role in the development of mastocytosis. However, the finding of a varied clinical expression of mastocytosis in an animal model along with that fact that some children with mastocytosis have no *c-kit* mutations or have inactivating *c-kit* mutations strongly suggests that other, yet to be defined, factors influence the full clinical expression of this disease.

TABLE 149-2
Diagnostic Criteria for Systemic Mastocytosis (Major and One Minor or Three Minor Criteria Are Needed)[a]

Major
- Multifocal dense infiltrates of mast cells in bone marrow and/or other extracutaneous organs

Minor
- More than 25% of the mast cells in bone marrow aspirate smears or tissue biopsy sections are spindle shaped or display atypical morphology.
- Detection of a codon 816 c-kit point mutation in blood, bone marrow, or lesional tissue.
- Mast cells in bone marrow, blood, or other lesional tissue expressing CD25 or CD2.
- Baseline total tryptase level greater than 20 ng/mL.

[a]For details of the WHO classification of mastocytosis, see Valent P et al: *World Health Organization Classification of Tumours: Pathology and Genetics of Tumours of the Haematopoietic and Lymphoid Tissues*, edited by Jaffe ES et al. Lyon IARC Press, 2001.

CLINICAL FINDINGS

CLASSIFICATION

Mastocytosis represents a disease spectrum characterized by a diverse phenotypic expression, along with pathologic and genetic findings that affect prognosis. Table 149-1 represents the WHO classification of mastocytosis.[3] Cutaneous mastocytosis (CM) and indolent SM (ISM) represent the majority of patients with this disease. Most children have CM, which is manifested as UP (Fig. 149-1) or less commonly as mastocytomas (Fig. 149-2) or diffuse CM (Fig. 149-3). SM occurs



Figure 149-1 Urticaria pigmentosa in a child.

mostly in adults, and ISM is the most common form. Criteria for SM are listed in Table 149-2. Systemic mastocytosis with an associated clonal hematologic, nonmast cell lineage disease (SM-AHNMD) appears unique to adults. In this group, examination of the bone marrow and peripheral blood reveals a hematologic abnormality. Hematologic disorders associated with SM-AHNMD include myeloproliferative and myelodysplastic disorders such as polycythemia rubra vera, chronic myeloid leukemia, chronic myelomonocytic leukemia, idiopathic myelofibrosis, chronic eosinophilic leukemia and the hypereosinophilic syndrome, acute and chronic lymphocytic leukemia, and non-Hodgkin and Hodgkin lymphoma. Patients with aggressive SM (ASM)[16] frequently have evidence of impaired liver function, hypersplenism, and/or malabsorption, but they do not have a distinctive hematologic disorder or mast cell leukemia (MCL). Patients with ASM have rapidly increasing mast cell numbers and are difficult to manage medically. MCL is characterized by multiorgan failure, and in bone marrow smears mast cells represent greater than 20% of the nucleated cell population. Mast cells also account for 10% or more of peripheral blood nucleated cells.[17,18] Mast cell sarcomas are rare; they have localized destructive growth, and distant spread is possible. Mast cells in these tumors are highly atypical and immature. Extracutaneous mastocytomas are extremely rare, usually localized to the lung, and consist of mature mast cells.[3,19]



Figure 149-2 Mastocytoma on the sole of a child.



Figure 149- 3 Diffuse cutaneous mastocytosis in a child.

CUTANEOUS LESIONS

UP is the most common skin manifestation of CM; however, the morphology of UP lesions differs significantly between children and adults. UP lesions in children appear as tan to brown papules and less commonly as macules, ranging in size from 1.0 to 2.5 cm in diameter (Fig. 149-1). These lesions may be present at birth or arise during infancy. They frequently appear on the trunk and often spare the central face, scalp, palms, and soles. UP lesions in adults, on the other hand, are reddish-brown macules and papules, usually 0.5 cm or less in diameter (Fig. 149-4). On close lesion inspection, variable hyperpigmentation and fine telangiectasias are detectable. Adult UP lesions are most numerous on the trunk and proximal extremities and appear less frequently on the face, distal extremities, or palms and soles. While adult UP lesions appear and resolve over months in individual patients, their number usually increases over years.[20] UP lesions are seen in most adults with ISM, but are much less common in patients with SM-AHNMD, ASM, or MCL.[3,19,20]

Solitary mastocytomas are tan-brown nodules that occur in approximately 10%–35% of children and frequently appear on the distal extremities (Fig. 149-2).[11] Their onset is generally before 6 months of age.[2]

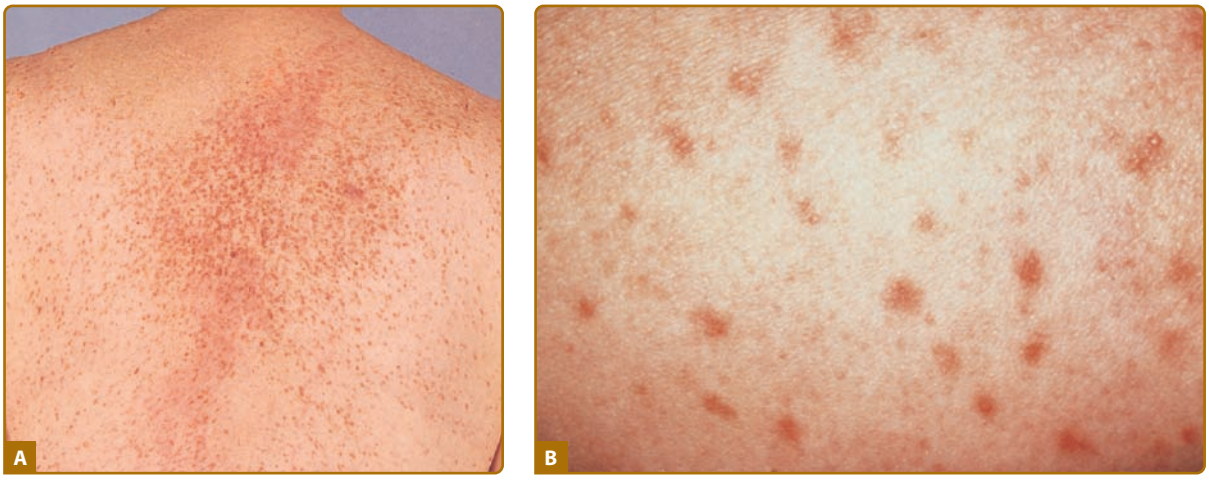

Figure 149-4 Urticaria pigmentosa in an adult with indolent systemic mastocytosis. **A.** Hundreds of lentigo-like macules are seen on the back of this adult. If vigorously rubbed, these lesions will show urtication and become erythematous, raised, and pruritic. **B.** Close-up.

Trauma to mastocytomas has been associated with systemic symptoms such as flushing and hypotension (Fig. 149-1).[2,20]

Scratching or rubbing lesions of CM leads to urtication and erythema known as *Darier's sign*. This reaction is readily demonstrated in childhood UP lesions and mastocytomas, but often is less apparent in adult UP lesions.[20] This likely explanation is that mast cell concentrations in mastocytomas and childhood UP have been reported to be 150-fold and 40-fold greater than normal skin, respectively, whereas the mast cell content of lesional skin in adult mastocytosis patients was only eightfold greater than normal controls.[21]

Diffuse CM (DCM) is seen almost exclusively in infants (Fig. 149-3), although it may persist into adult life. The skin may be thickened with a peau d'orange appearance and yellowish brown discoloration without discrete lesions. Dermographism with formation of hemorrhagic blisters frequently occurs in the first few years of life in patients with DCM, but these blisters often resolve within several years, even though the DCM may persist (Fig. 149-5).[2,20] Telangiectasia macularis eruptiva perstans is rare, and is seen almost exclusively in adults. It appears as telangiectatic macules with irregular borders (Fig. 149-6). Darier's sign and pruritus is variable.[20] Recently, nodular mastocytosis has been described in an adult patient with red–purple lesions infiltrating the axillae and inguinal areas. Mast cells in this rare variant of mastocytosis expressed the V560G *c-kit* mutation.[22]

RELATED CLINICAL FINDINGS

Most children with CM and adults with ISM have few, if any, symptoms. When symptoms do occur, they are due to the release of mast cell mediators, such as histamine, eicosanoids, and cytokines (Table 149-3). Symptoms and signs of mastocytosis may range from pruritus and flushing to abdominal pain, nausea, vomiting and diarrhea, palpitations, dizziness, and syncope. Of interest is the relative absence of pulmonary symptoms in mastocytosis patients. Complaints of fever, night sweats, malaise, weight loss, bone pain, epigastric



Figure 149-5 Bullous eruption on the back of a child with diffuse cutaneous mastocytosis.



Figure 149-6 Telangiectasia macularis eruptive perstans (TMEP).

TABLE 149-3
Selected Mast Cell Mediators

Mediators	Biologic Effects	Possible Consequences
Preformed		
Histamine	Vasodilation, increased vascular permeability, gastric hypersecretion, bronchoconstriction	Hypotension, flushing, urticaria, abdominal pain; (peptic, colic), nausea, vomiting, diarrhea, malabsorption
Heparin	Anticoagulant, inhibition of platelet aggregation	Prolonged bleeding time
Tryptase	Endothelial cell activation, fibrinogen cleavage, mitogenic for smooth muscle cells	Osteoporosis/osteopenia, disruption of cascade systems (clotting, etc.)
Chymase	Converts angiotensin I to II, lipoprotein degradation	Hypertension
	Cleaves membrane bound stem cell factor	Hyperpigmentation, Skin mast cell accumulation (?)
Newly Synthesized		
Leukotrienes	Increased vascular permeability, bronchoconstriction, vasoconstriction	Bronchospasm, hypotension
Prostaglandins	Vasodilatation, bronchoconstriction	Flushing, urticaria, hypotension
Cytokines		
Stem cell factor	Growth and survival of mast cells, chemotaxis of KIT^+ cells, melanogensis	Mast cell hyperplasia, focal aggregates
Tumor necrosis factor-α	Activation of vascular endothelial cells, cachexia, fatigue	Weight loss, fever, fatigue
Transforming growth factor-β	Enhanced production of connective tissue components	Fibrosis
IL-5	Eosinophil growth factor	Eosinophilia
IL-6	Growth and survival of mast cells	Fever, bone pain, osteoporosis/osteopenia
GM-CSF	Granulocyte and monocyte growth and activation	Eosinophilia

IL = interleukin. GM-CSF = granulocyte/monocyte colony stimulating factor.

distress, and problems with mentation (cognitive disorganization) often signal the presence of SM. Symptoms of mastocytosis can be exacerbated by exercise, heat, or local trauma to skin lesions (childhood UP and mastocytomas). In addition, alcohol, narcotics, salicylates, nonsteroidal anti-inflammatory drugs (NSAIDs), polymyxin B, anticholinergics, and some systemic anesthetic agents may induce mast cell mediator release.[19,20,23] Deaths associated with extensive mast cell mediator release are rare.

Noncutaneous disease is extremely uncommon in children, although gastrointestinal (GI) symptoms are the most frequent noncutaneous feature. Gastric hypersecretion due to elevated plasma histamine may cause gastritis and peptic ulcer disease, and present as abdominal pain in both children and adults.[24] Malabsorption with associated diarrhea is limited to a subset of patients with usually more advanced disease. While hepatic disease in adults and children with ISM is rare, hepatic and splenic involvement, including portal hypertension and ascites associated with liver fibrosis, is more common in patients who have SM-AHNMD or ASM.[3,25] Splenomegaly, detected either clinically or by CT scan, has been reported in 50%–60% of adult SM patients.[20,26] However, in two other studies, each with over 140 adult mastocytosis patients, splenomegaly was observed in only 8%–9% of cases.[27,28] Increased numbers of mast cells and eosinophils are frequently observed in the spleen, as are various degrees of fibrosis and hematopoiesis. Lymph node enlargement is uncommon in most mastocytosis patients, but occurs in patients with more advanced systemic disease. Among 58 SM patients, 26% had peripheral lymphadenopathy, whereas 19% had central nodal disease.[29] Anemia, leukopenia, thrombocytopenia, and eosinophilia also may occur in association with systemic disease and suggest SM-AHNMD or ASM.[3,19]

Musculoskeletal pain affects 19%–28% of mastocytosis patients. Skeletal lesions occur more frequently in patients with SM, but are rare in children with this disorder.[2,20] In one large study of 142 adults with mastocytosis, 40% had skeletal involvement.[27] Bony lesions may appear as radio-opacities, radiolucencies, or a mixture of the two. The skull, spine, and pelvis are most commonly involved. In one large study of 58 adult systemic mastocytosis patients, 57% had diffuse bone involvement, whereas only 2% had focal lesions.[30] In patients with severe or advanced disease, pathologic fractures may occur.[19,30]

Neuropsychiatric abnormalities have been reported, and include decreased attention span, memory impairment, headache, and irritability.[31,32] Depression as a consequence of chronic disease or possibly mediated by mast cell mediators may occur.

LABORATORY TESTS

The diagnosis of mastocytosis is established by demonstrating increased numbers of mast cells in one or more organs. For patients with CM, mast cell infiltrates can be detected in a biopsy of lesional skin using special stains, such as toluidine (Fig. 149-7) or Giemsa, or monoclonal antibodies that recognize mast cell tryptase or CD117 (KIT).[20,33] Biopsy specimens of normal-appearing skin from patients with mastocytosis have normal concentrations of mast cells as determined by morphometrics, and thus are not helpful in establishing the diagnosis.[21]

Detection of circulating mast cell mediators and/or their metabolites can offer indirect evidence of mastocytosis, and their measurement may be useful in patients without cutaneous lesions. Two forms (α and β) of mast cell tryptase have been identified.[34] α-tryptase is elevated in patients with SM, with or without acute symptoms, whereas increased levels of β-tryptase can be detected both in mastocytosis patients and in allergic patients experiencing anaphylactic reactions. Total (α and β) serum tryptase levels have been correlated with the extent of mast cell disease. Fifty percent of patients with total serum tryptase levels between 20 and 75 ng/mL had evidence of SM, whereas all patients with levels >75 ng/mL had proven systemic involvement. Total serum tryptase levels of >20 ng/mL are currently considered abnormal and represent one of the minor criteria for SM[3] (Table 149-2). Total serum tryptase levels can provide an estimate of a patient's overall mast cell burden, and thus serial measurements in adults every 6 to 12 months may prove useful in following disease activity.

Determinations of urinary histamine metabolite levels may be worthwhile as a diagnostic test in patients without cutaneous lesions. The major urinary metabolite of histamine, 1,4-methylimidazole acetic acid (MeImAA) is often persistently elevated in SM patients and has been correlated with the extent of mast cell disease.[35] Methylhistamine is next most common urinary histamine metabolite, and can be measured if MeImAA levels are not available in commercial laboratories. Certain foods high in histamine content, such as spinach, eggplant, cheeses (Parmesan, Roquefort, and blue), and red wines, can artificially elevate the levels of urinary histamine and its metabolites, and thus should be avoided during the collection process.

Mast cells can induce bone changes that cause radiographically detectable lesions. Skeletal lesions occur more frequently in adult patients with SM, and are rare in children with this disorder.[2] In one large study of 142 adults with mastocytosis, 40% had skeletal involvement.[27] The proximal long bones, skull, spine, ribs, and pelvis are most commonly affected. Skeletal scintigraphy (bone scan) is more sensitive, but less specific, than routine X-rays for detecting and locating active lesions. Thus, X-rays of the skull, spine, and pelvis serve as a reasonable preliminary test for detecting bone involvement in mastocytosis patients.[19,20]

The bone marrow is often involved in patients with SM, and bone marrow biopsies are indicated for patients suspected of having more advanced (SM-AHNMD, ASM, MCL) disease.[3] In a report of 71 adults with mastocytosis, 90% had increased numbers of spindle-shaped, bone marrow mast cells (BMMCs) with focal perivascular, peritrabecular and/or intertrabecular accumulations.[20] WHO criteria for SM have been defined (Table 149-2), which include the BM findings of multifocal dense mast cell aggregates, atypical mast cell morphology, and the expression of CD2 and/or CD25 by BMMCs. A bone marrow biopsy in childhood-onset disease is not recommended unless there is evidence of systemic involvement as demonstrated by hepatosplenomegaly, lymphadenopathy, and/or unexplained peripheral blood abnormalities. Mast cells in BM biopsies are best identified by immunostaining with antitryptase (Fig. 149-8) or CD117 monoclonal antibodies since decalcification interferes with the effectiveness of metachromatic stains.[3]

Roentgenographic abnormalities of the GI tract fall into three major categories: (1) peptic ulcers;

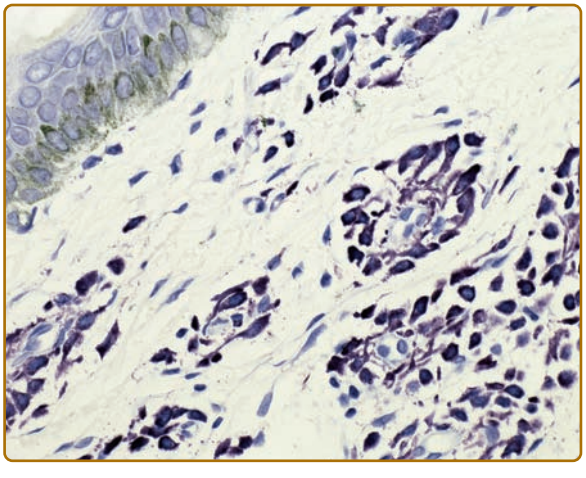

Figure 149-7 Histopathology of urticaria pigmentosa, toluidine blue.

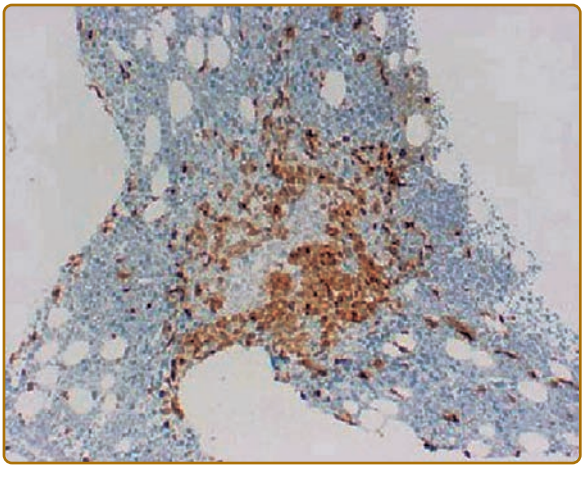

Figure 149-8 Classic mastocytosis bone marrow lesion (100×), tryptase stain.

(2) abnormal mucosal patterns such as mucosal edema, multiple nodular lesions, coarsened mucosal folds, or multiple polyps; and (3) motility disturbances. A biopsy of the GI tract may be indicated for patients in whom the diagnosis of SM is suspected, but who lack skin lesions. Histologic sections of jejunal biopsies show moderate blunting of the villi and may show increased mast cell numbers in association with variable numbers of eosinophils.[19,20]

Despite the infrequency of significant hepatic disease, liver function tests are abnormal in approximately one-half of all patients with extracutaneous disease. Other surrogate markers of mastocytosis are elevated serum IL-6 levels, soluble SCF receptor (CD117), and IL-2 receptor (CD25) levels.[36] The levels of the latter receptors are highly correlated with the severity of bone marrow pathology.[37]

The initial evaluation of a prepubertal child with mastocytosis generally does not require extensive evaluation if the history and physical examination do not indicate the presence of SM. In contrast, the presence of noncutaneous signs and symptoms or disease onset in adolescents or adults necessitates a CBC with differential, liver function test, total serum tryptase level, and skeletal X-rays (see Fig. 149-9 and Table 149-3). Because the presence and type of *c-kit* mutation may predict disease longevity as well as a patient's response to treatment (see Section "Treatment"), determination of *c-kit* mutations in the skin or blood of mastocytosis patients with systemic disease should be considered.

DIFFERENTIAL DIAGNOSIS

Cutaneous lesions of childhood and adult mastocytosis are very characteristic, and thus are rarely confused with other skin disorders. Since UP lesions may urticate, they could initially be mistaken for urticaria. However, individual urticaria lesions last only a few hours and lack the associated hyperpigmentation seen

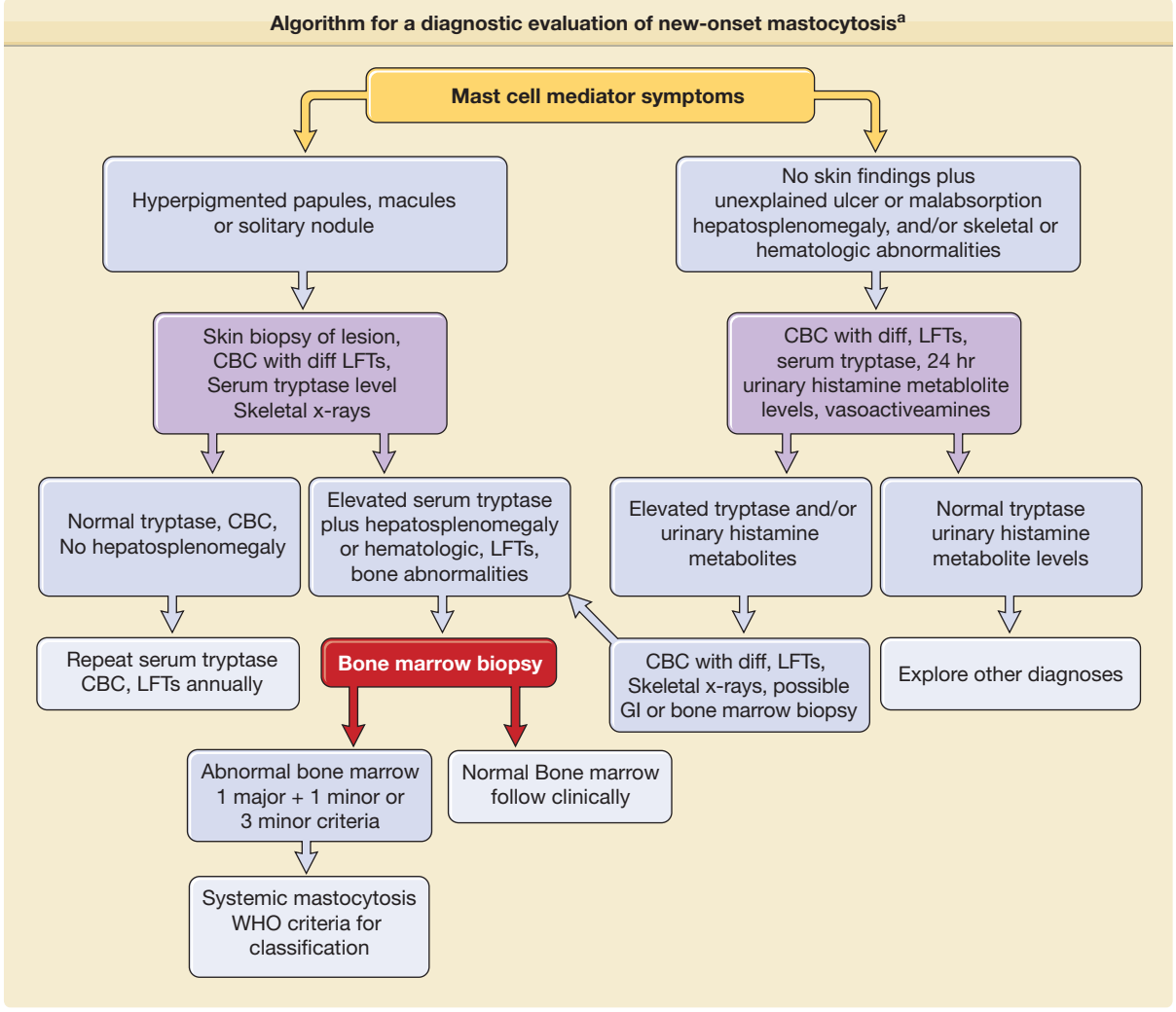

Figure 149-9 Algorithm for a diagnostic evaluation of new-onset mastocytosis (especially in adolescents and adults). CBC = complete blood cell count; Tc = technetium; WHO = World Health Organization. [a]For details of the WHO classification of mastocytosis, see Valent P et al: *World Health Organization Classification of Tumours: Pathology and Genetics of Tumours of the Haematopoietic and Lymphoid Tissues,* edited by Jaffe ES et al. Lyon, IARC Press, 2001.

in UP. Some childhood mastocytosis patients may develop bullae. Therefore, the differential diagnosis for blisters in infants such as bullous impetigo, bullous arthropod bites, linear IgA bullous dermatosis, bullous pemphigoid, epidermolysis bullosa, toxic epidermal necrolysis, and incontinentia pigmenti should be considered. Rarely, nodular scabies lesions have been confused with UP (see Box 149-1). The differential diagnosis of mastocytomas in children includes juvenile xanthogranulomas, Spitz nevi, pseudolymphomas or rarely in resolving lesions, a café au lait macule. Adult UP lesions might initially appear as lentigines or atypical melanocytic nevi; however, they usually have an associated erythema (telangiectasia) not seen in these melanocytic lesions.

Mastocytosis should be suspected in patients without skin lesions if they have symptoms suggesting mast cell mediator release and one or more of the following: peptic ulcer disease or malabsorption, radiographic or ^{99}technetium bone scan abnormalities, hepatomegaly, splenomegaly, lymphadenopathy, and/or peripheral blood abnormalities (Box 149-2). In adults suspected of having SM without cutaneous lesions, the diagnosis of a carcinoid tumor or pheochromocytoma should be considered. Patients with mastocytosis do not excrete increased amounts of 5-hydroxyindoleacetic acid, and patients with carcinoid tumor or pheochromocytoma do not have histologic evidence of mast cell proliferation or elevated serum tryptase levels.[38]

BOX 149-1 DIFFERENTIAL DIAGNOSIS OF CUTANEOUS MAST CELL DISEASE

Most Likely

- Diffuse or localized hyperpigmented papules/macules
  - Urticaria
  - Multiple nevi
  - Langerhans cell histiocytosis
  - Juvenile xanthogranulomas
  - Nodular scabies
  - Café-au-lait spots
  - Multiple cutaneous lentiginosis
  - Postinflammatory hyperpigmentation
- Bullous lesions
  - Linear immunoglobulin A dermatosis
  - Bullous impetigo
  - Epidermolysis bullosa
  - Arthropod bite reaction
  - Toxic epidermal necrolysis
  - Incontinentia pigmenti
- Solitary papule or nodule
  - Congenital nevus
  - Juvenile xanthogranuloma
  - Pseudolymphoma

BOX 149-2 DIFFERENTIAL DIAGNOSIS OF SYSTEMIC MASTOCYTOSIS WITHOUT SKIN LESIONS[a]

- Gastrointestinal
  - Peptic ulcer disease
  - Ulcerative colitis
  - Gluten-sensitive enteropathy
  - Hepatitis
  - Parasitic disease
- Cardiovascular
  - Allergy
  - Idiopathic anaphylaxis
  - Cardiac disease
- Endocrine
  - Adrenal tumor
  - Vasoactive intestinal polypeptide tumor
  - Carcinoid syndrome
  - Medullary thyroid carcinoma
  - Gastrinoma
  - Diabetes mellitus
- Neoplastic/oncologic
  - Hypereosinophilic syndrome
  - Lymphoma
  - Myeloma
  - Histiocytosis
  - Bone tumor metastases

[a]Some forms of mast cell disease may not show cutaneous manifestations. These include aggressive systemic mastocytosis, mast cell leukemia, systemic mastocytosis with an associated clonal hematologic nonmast cell lineage disease, and isolated bone marrow mastocytosis.

PROGNOSIS

Pediatric-onset cutaneous disease has a favorable prognosis with at least 50% of cases of childhood UP resolving by adulthood.[1,16] Furthermore, children born of mothers with ISM reportedly are free of disease.[17] It has been postulated that children with activating *c-kit* mutations may represent the 10%–15% of those whose disease persists into adulthood[2,12]; however, with the recent report of detectable activating *c-kit* mutations in 84% of children with mastocytosis, the prognostic significance of this abnormality is unclear.

Most adults with UP have only CM or ISM and rarely develop more advanced disease. Patients with ISM appear to have a good prognosis with limited potential to progression to more severe forms of SM.[3,19] Older patients with UP who experience fading of their lesions continue to exhibit bone marrow lesions typical of their diagnosis, whether ISM or SM-AHNMD.[18] Patients with SM-AHNMD have a variable course, which is dependent on the prognosis of their hematologic disorder. In patients with ASM, the mean survival is 2–4 years, but the prognosis may improve with

TABLE 149-4
Treatment for Cutaneous Mastocytosis

	Topical	Physical	Systemic
First line	Emollients		$H_1 \pm H_2$ antihistamines
Second line	Topical glucocorticoids Calcineurin inhibitors	Psoralen and ultraviolet A light (adults only) Pulsed dye laser for telangiectasia macularis eruptiva perstans	Leukotriene antagonists Oral cromolyn sodium
Third line		Intralesional corticosteroids or Surgical excision (mastocytoma)	Glucocorticoids

Note: Avoidance of triggering factors such as heat, friction, or drugs.

aggressive symptomatic management. The prognosis for MCL is poor with a mean survival of less than 6 months.[19,28]

TREATMENT

The management of patients with mastocytosis includes counseling patients and care providers as to the features of the disease, avoidance of factors that provoke mast cell mediator release, and management of symptoms associated with these released mediators (Tables 149-4 and 149-5). Mastocytosis patients should be cautioned to avoid potential mast cell degranulating agents such as ingested alcohol, anticholinergic preparations, aspirin and other NSAIDs, narcotics, and polymyxin B sulfate. In addition, heat and friction can induce local or systemic symptoms and should be avoided whenever possible. A number of systemic anesthetic agents, including systemic lidocaine, d-tubocurarine, metocurine, etomidate, thiopental, succinylcholine hydrochloride (suxamethonium chloride), enflurane, and isoflurane, have been directly or indirectly implicated in precipitating symptoms of mastocytosis. Recent reports indicate that fentanyl, sufentanil, remifentanil, paracetamol, midazolam, propofol, ketamine, desflurane, sevoflurane, *cis*-atracurium, pancuronium, and vecuronium bromide, are safe alternative systemic anesthetics for mastocytosis patients. It has been recommended that mastocytosis patients undergoing general anesthesia be monitored postoperatively for 24 hours since delayed anaphylaxis can occur hours after surgery. In contrast to systemic anesthetics, local injections of lidocaine can be used safely in these patients.[23]

There is currently no generally recognized safe and effective mast cell ablative therapy, nor are there effective mast cell stabilizing drugs. Thus, treatment of milder forms of mastocytosis is focused, in great part, on symptomatic relief. In children with asymptomatic mastocytomas or UP lesions, no therapy is needed. Chronic administration of H_1 antihistamines (hydroxyzine, cetirizine, and fexofenadine) is often helpful in reducing pruritus and flushing associated with histamine release.[19] Both ketotifen and azelastine, antihistamines with mast cell-stabilizing properties may help relieve the pruritus and whealing associated with mastocytosis, but neither drug offers a significant advantage over a standard antihistamines.[39] H_2 antihistamines (cimetidine or ranitidine) are most useful in the management of excess gastric acid secretion, but may assist in controlling pruritus, flushing, and wheal formation when administered with an H_1 blocker. If GI symptoms persist with the use of H_2 antihistamines, then proton pump inhibitors may be effective, secondary treatments.[19,20]

TABLE 149-5
Treatment of Noncutaneous Mastocytosis Symptoms

	Gastrointestinal	Cardiovascular	Musculoskeletal	Hematologic
First line	H_2 antihistamines, oral cromolyn (children)	H_1 and H_2 antihistamines Subcutaneous epinephrine (anaphylaxis)	Calcium supplement ± vitamin D supplement	Systemic chemotherapy appropriate for hematologic disorder
Second line	Proton pump inhibitors Leukotriene antagonist Anticholinergics	Glucocorticoids (prophylaxis)	Bisphosphonates Nonsteroidal anti-inflammatory drugs with caution	
Third line	Glucocorticoids		Local radiation to bony lesions	

Note: Cytoreductive therapy is restricted to patients with aggressive variants of mastocytosis (systemic mastocytosis with an associated clonal hematologic nonmast cell lineage disease, aggressive systemic mastocytosis, and mast cell leukemia).

Disodium cromoglycate (cromolyn sodium) inhibits degranulation of mast cells and may have some efficacy in the treatment of mastocytosis, particularly in relieving GI complaints in children.[40] Cromolyn sodium, however, does not lower plasma or urinary histamine levels in patients with mastocytosis. Low-dose aspirin has been used in some patients to reduce flushing, tachycardia, and syncope. However, aspirin must be used with extreme caution, as it may cause vascular collapse in some patients with mastocytosis and exacerbate peptic ulcer disease. Antileukotrienes have proven effective in controlling symptoms of flushing, diarrhea, and abdominal cramping in some mastocytosis patients.[19,20]

Potent topical glucocorticoids under occlusion for 8 h/day for 8–12 weeks reduces the number of UP lesions. However, these lesions eventually recur after discontinuation of therapy within the year.[41,42] Oral glucocorticoids have some efficacy in patients with malabsorption and ascites. After control is achieved, glucocorticoid therapy should be tapered to the lowest effective dose.[17,19] Osteoporosis should be treated with calcium and vitamin D supplementation and, when appropriate, the addition of estrogen replacement or bisphosphonates as determined by monitoring bone density.

Epinephrine should be used to treat episodes of anaphylaxis. Patients with such episodes should carry epinephrine, be prepared to self-administer this drug, and have a plan for emergency management. If subcutaneous epinephrine is insufficient, intensive therapy for vascular collapse should be instituted. Patients with recurrent episodes of anaphylaxis should receive continuous H_1 and H_2 antihistamines to lessen the severity of attacks. Episodes of vascular collapse in mastocytosis patients may be spontaneous, but have also occurred after insect stings or after administration of iodinated contrast media. In the latter case, premedication with corticosteroids and antihistamines is recommended before such procedures.

Methoxypsoralen with ultraviolet A (PUVA) light can relieve pruritus and whealing after 1–2 months of treatment.[43,44] However, pruritus usually recurs within 3–6 months after PUVA is stopped. Pigmentation induced by PUVA also may camouflage lesions of UP in some adult patients; however, this benefit must be weighed against the increased risk of skin cancers associated with long-term treatment.

Cytoreductive therapy should be considered in patients with SM-AHNMD, ASM, or MCL. The risk-benefit must be carefully considered due to the dose-limiting toxicities of the various drugs. IFN-α may be considered for ASM with and without associated hematologic malignancy. In a prospective study, IFN-α was most efficacious in ameliorating the signs and symptoms mast cell disease; however, improvement was only transitory.[45] 2-Chlorodeoxyadenosine has been shown to be efficacious in reducing ascites, mediator-associated symptoms, and BMMC burden in patients with more advance mastocytosis, and appears to be the treatment of choice in this patient group. However, its use is restricted by the associated myelosuppression.[46,47]

Tyrosine kinase inhibitors, such as imatinib mesylate, inhibit growth of neoplastic cells through receptors such as KIT, ABL, and PDGFR tyrosine kinases and have been successful in the treatment of a patient with a transmembrane mutation of KIT at the F522C position.[48,49] Imatinib, however, does not inhibit the growth of mast cells expressing *D816* mutation, and thus is ineffective in the treatment of mastocytosis patients with this KIT abnormality.[50] Disatinib has been demonstrated to inhibit the in vitro growth of mast cell lines expressing D816V; however, this agent has not been effective in reducing the signs or symptoms of mast cell disease in SM patients with this *c-kit* mutation.[51]

Splenectomy may improve survival in patients with ASM that has a poor prognosis.[52] Radiotherapy has been used to treat refractory bone pain in advanced disease.[53] Nonmyeloablative bone marrow transplantation may be considered for gravely ill patients, although a recent report using this therapy in three patients with advanced SM showed no sustained improvement despite inducing a graft-versus-mast cell state.[54]

KEY REFERENCES

Full reference list available at www.DIGM8.com

DVD contains references and additional content

2. Heide R, Tank B, Oranje AP: Mastocytosis in childhood. *Ped Dermatol* **19**:375, 2002
12. Longley BJ et al: Activating and dominant inactivating *c-kit* catalytic domain mutations in distinct clinical forms of human mastocytosis. *Proc Natl Acad Sci U S A* **96**:1609, 1999
14. Bodemer C et al: Pediatric mastocytosis is a clonal disease associated with $D^{816}V$ *c-KIT* mutations. *J Invest Dermatol* **130**:804, 2010
19. Valent P et al: Mastocytosis: Pathology, genetics and current options for therapy. *Leukemia Lymphoma* **46**:35, 2005
23. Konrad FM, Schroeder TH: Anaesthesia in patients with mastocytosis. *Acta Anaesthesiol Scand* **53**;207, 2009
28. Escribano L et al: Prognosis in adult indolent systemic mastocytosis: a long-term study of the Spanish newtwork on mastocytosis in a series of 145 patients. *J Allergy Clin Immunol* **124**:514, 2009
47. Pardanani A et al. Treatment of systemic mast cell disease with 2-chlorodeoxyadenosine. *Leuk Res* **28**:127-131, 2004
50. Vega-Ruiz A et al: Phase II study of imatinib mesylate as therapy for patients with systemic mastocytosis. *Leuk Res* **33**;1481, 2009

SECTION 26

Skin Manifestations of Internal Organ Disorders

Chapter 150 :: The Skin and Disorders of the Alimentary Tract, the Hepatobiliary System, the Kidney, and the Cardiopulmonary System

:: Graham A. Johnston & Robin A.C. Graham-Brown

DISORDERS OF THE ALIMENTARY TRACT, THE HEPATOBILIARY SYSTEM, THE KIDNEY AND THE CARDIOPULMONARY SYSTEM AT A GLANCE

- A full physical examination should be part of a full dermatologic assessment.
- It is important to examine the skin in a patient presenting with a systemic problem.
- Look for generalized changes in skin quality first.
- Then examine specific organ systems systematically.
- The majority of causes of jaundice can be found on clinical history and examination.
- In both abdominal pain and gastrointestinal bleeding there can be cutaneous findings that suggest the underlying cause.
- Some cardiopulmonary syndromes have specific dermatologic clues.
- Remember dermatologic drugs as a cause of systemic symptoms.

Diseases of the skin frequently indicate, or associate with, diseases of the alimentary tract, the hepatobiliary system, the kidneys, and the cardiopulmonary system. Just as a full physical examination should be part of a full dermatologic assessment, it is important to examine the skin in a patient presenting with a systemic problem. This chapter is presented in the same order that a physician performing a full physical examination might approach the patient. The cutaneous manifestations that indicate internal disease are discussed for each step of the examination.

GENERAL SKIN CHANGES

ALTERATIONS IN SKIN QUALITY

The presence of pallid, dry, rough, and scaly skin that is usually itchy in patients with malabsorption, chronic renal disease, or chronic hepatic disease is nonspecific. Asteatotic eczema may develop. Some patients itch without any visible abnormality of their skin.

CARDIAC DISEASE

EHLERS–DANLOS SYNDROME. Hyperelastic velvety skin that rebounds to the original position after being stretched, "cigarette-paper" scars, and hyperextensible joints are characteristic of the Ehlers–Danlos syndrome. Mitral and tricuspid prolapse, dilatation of the aorta and pulmonary artery, arterial rupture, myocardial infarction, and emphysema may accompany this syndrome (see Chapter 137).[1]

CUTIS LAXA. Progressive looseness of the skin with pendulous folds and droopy eyelids may be associated with generalized hyperelastosis leading to aortic

dilatation and rupture, congestive heart failure, or cor pulmonale with pulmonary artery stenosis and progressive emphysema (see Chapter 137).

PSEUDOXANTHOMA ELASTICUM. The skin of patients with pseudoxanthoma elasticum (PXE) is thick, lax, and yellowish, especially over the axillae, antecubital area, and neck. Yellow patches may occur on mucous membranes, especially the labia. The alterations in the *ABCC6* gene responsible for PXE may also lead to arteries becoming calcified, the aortic and mitral valves thickened, and cardiovascular symptoms, such as angina pectoris and claudication are frequent symptoms (see Chapter 137).[2]

PROGERIA. In Hutchinson–Gilford syndrome (progeria) and progeroid states such as Werner's syndrome, the skin appears atrophic and tight from a very early age. There is marked loss of subcutaneous tissue, with leg ulceration. Coronary atherosclerosis frequently leads to premature death by myocardial infarction (see Chapter 139).

LIVER DISEASE

Skin changes are very common in chronic liver disease.[3] Hormone-induced changes of the skin include loss of forearm, axillary, and pubic hair in both sexes. Men may experience a decreased rate of growth of facial hair, pectoral alopecia, and a female pubic hair distribution, as well as loss of libido, testicular atrophy, and oligospermia. Striae distensae occur in both men and women (Fig. 150-1). Gynecomastia, together with Dupuytren contracture and swelling of the parotid gland, is associated with cirrhosis.

Many of these changes occur more commonly in those where alcohol is the underlying cause. Patients with chronic alcoholism also develop a "pseudo-Cushing syndrome," even in the absence of liver disease; signs include facial mooning, truncal obesity, and proximal muscle wasting. These changes may regress if the patient discontinues alcohol.

Patients with chronic liver disease often have telangiectatic changes, mainly on light-exposed skin. Numerous tiny telangiectases sometimes give the impression of a diffuse, almost exanthematic redness. They are known as "dollar paper markings" after the small threads visible in paper money held up against the light. They fade on pressure with a glass slide and rarely pulsate.



Figure 150-1 Widespread striae in a 16-year-old boy with chronic active hepatitis.

RENAL DISEASE

The skin of patients with chronic renal failure (CRF) is frequently dry, often with ichthyosis-like scaling,[4] possibly resulting in part from altered vitamin A metabolism.[5] The fluid volume shifts of dialysis may exaggerate this.

COLOR CHANGES

Skin color is altered in CRF. The skin is pale due to anemia and often exhibits a distinctive muddy hue, due to accumulation of carotenoid and nitrogenous pigments (urochromes) in the dermis, although its etiology is complicated and may depend in part on treatment modalities used.[6]

CYANOSIS

An increase in the absolute amount of desaturated (reduced) hemoglobin results in a purple–blue discoloration of the skin. Cyanosis is classified into "central" and "peripheral" types: the terms referring to the level of arterial oxygen saturation rather than the anatomic source of cyanosis. Thus, central cyanosis occurs in states that produce low arterial oxygen saturation, such as congenital heart disease with intracardiac or intrapulmonary right-to-left shunting, or severe lung disease. Peripheral cyanosis develops when there is normal arterial oxygen saturation but reduced blood flow, such as low-output cardiac failure and local vasoconstriction. Pulmonary embolism may result in a combination of central cyanosis and peripheral cyanosis.

Central cyanosis is usually visible on warm areas of the skin like the tongue, oral mucosae, and conjunctivae. Peripheral cyanosis is seen on cooler areas such as the nose, lips, earlobes, and fingertips. In the anemic patient, detection of cyanosis may be impossible because the absolute amount of reduced hemoglobin is not increased. Cyanosis fades when pressure is applied because the coloration is within the blood vessels.

ERYTHEMA

Redness of the skin is caused by an increase in the amount of saturated hemoglobin, an increase in the diameter or actual number of skin capillaries, or a combination of these factors. Edema of the face, arms, and

hands associated with redness and/or cyanosis may indicate obstruction of the superior vena cava due to mediastinal disease.

Primary polycythemia may produce a characteristic "ruddy" complexion but, in secondary disease especially, may also cause a peculiar ruddy cyanosis. This is most pronounced on the tongue, lips, nose, earlobes, conjunctivae, and fingertips. It is due to increased amounts of saturated hemoglobin producing erythema with increased amounts of desaturated hemoglobin producing cyanosis because of the inability of the body to fully oxygenate the increased absolute amounts of hemoglobin. The absence of nail clubbing in polycythemia vera may help differentiate patients with from those patients with cardiopulmonary disease who develop secondary polycythemia. In addition, the hypervolemic state of polycythemia vera is associated with increased stroke volume and may lead to high-output cardiac failure. Pulmonary emboli may result from venous thrombosis secondary to hyperviscosity.

FLUSHING

Paroxysmal intense flushing of the face, neck, chest, and abdomen, often with telangiectases of the face and neck, may occur in patients with carcinoid tumors, systemic mastocytosis, and pheochromocytoma, alone or in Sipple syndrome.

PIGMENTARY CHANGES

In addition to jaundice (see below), both diffuse and circumscribed pigmentary changes may occur in chronic liver disease. A diffuse muddy gray color in patients with long-standing cirrhosis is due to basal cell melanin.

CIRRHOSIS. Melanosis is common in primary biliary cirrhosis (PBC) and may be an early presenting sign. It initially involves exposed areas, but gradually becomes generalized. Blotchy, circumscribed areas of dirty brown pigmentation are also occasionally evident. Accentuation of normal freckling and areolar pigmentation can occur. Localized linear pigmentation may appear in the creases of the fingers and palms. Pigmentation resembling chloasma may localize to the perioral and periorbital areas. Guttate hypomelanosis, a condition in which small white macules, sometimes with a central spider, appear on the skin of the buttocks, back, thighs, and forearms, may occur in cirrhosis and, rarely, in PBC.[7] The yellow and orange lesions of dermal, subcutaneous, and tendon xanthomas and also xanthelasma are common in PBC and can be extensive (see Chapter 135).

HEMOCHROMATOSIS. The generalized metallic gray or bronze-brown color of the skin in hemochromatosis can be striking. There is accentuation in sun-exposed and traumatized skin, and occasionally there is buccal and conjunctival pigmentation.[8]

The etiology and pathogenesis of hyperpigmentation in chronic liver disease remains obscure and varies from disease to disease. The pigmentation in PBC is due predominantly to excess melanin with no stainable iron, while in hemochromatosis, pigmentation results both from the presence of hemosiderin in the skin and excess melanin. After phlebotomy, histologic siderosis and pigmentation decrease, even though melanosis remains histologically.

VITAMIN DEFICIENCY. Pellagra gives rises to lichenified, and often deeply pigmented skin in sun-exposed sites and can develop in patients with alcoholic liver disease. Vitamin B_{12} deficiency causes pigmentation of the distal extremities in a glove and stocking distribution. Diffuse hyperpigmentation occurs in folate deficiency. Kwashiorkor produces generalized depigmentation (see Chapter 130).

JAUNDICE

(Box 150-1)

In jaundice, raised plasma bilirubin produces a generalized coloration of the skin, mucous membranes, and other body tissues varying in hue from faint golden to dark green–yellow. Both jaundice and pigmentation are most prominent in extrahepatic biliary obstruction and in PBC.

Jaundice results from increased cellular or connective tissue binding of bilirubin and its metabolites in the skin. Bilirubin has an affinity for elastin, but circulates almost exclusively as a tightly bound complex with albumin. Eighty-five percent of bilirubin comes from the degradation of heme, the remainder from other heme-containing proteins, such as myoglobin and cytochromes. Jaundice results from an imbalance between tissue production and hepatic clearance of bilirubin.

Tissue-serum equilibration is slow, and so the intensity of clinical jaundice often fails to reflect the concurrent serum bilirubin level. Hyperbilirubinemia may, therefore, antedate the onset of detectable jaundice, and jaundice may persist despite falling or normal serum bilirubin levels. The correlation between skin color and serum pigment levels is especially poor in newborns. The intensity of jaundice and levels of serum bilirubin in patients with biliary atresia, acquired bile duct obstruction, or defective bilirubin conjugation tend to stabilize despite continued pigment production. Congestive cardiac failure may cause hyperbilirubinemia and jaundice secondary to raised intrahepatic pressure.

CLINICAL FEATURES. Clinically detectable jaundice appears when sufficient amounts of bilirubin become tissue bound. Involvement of the sclerae differentiates jaundice from other causes of skin pigmentation, including carotenemia, the yellow skin pigmentation produced by quinacrine and busulfan, and lycopenemia due to the ingestion of tomato juice.

The urine becomes dark yellow and even brown in color as conjugated serum bilirubin rises. Because

BOX 150-1 A FUNCTIONAL CLASSIFICATION OF JAUNDICE

- Unconjugated hyperbilirubinemia
- New and infant
- "Physiologic"—functional hepatic immaturity
- Hemolysis—Rh, ABO, sepsis, drug factors
- Prematurity
- Transient familial hyperbilirubinemia—maternal steroid inhibitors
- Crigler–Najjar syndrome—glucuronyl transferase deficiency (hereditary)
- Adult
- Excess bilirubin production
  - Hemolysis
  - Congenital
  - Acquired
  - Dyserythropoietic—"shunt" hyperbilirubinemia
- Deficient conjugation
- Familial
  - Constitutional hepatic dysfunction (Gilbert syndrome)
  - Crigler–Najjar syndrome type II
- Acquired
  - Posthepatic
  - Associated disease—cardiac, enteric, metabolic
  - Drug-induced
- Diagnostic features
- Serum-conjugated bilirubin less than 15% of total
- Absence of bilirubinuria
- Low to normal urine urobilinogen
- Absence of other liver function disturbances
- Normal morphologic features of liver
- Conjugated hyperbilirubinemia
- Hepatic cell damage
- Acute—viral, toxic, anoxic, metabolic
- Chronic—cirrhosis, metabolic
- Impaired bile excretion
- Extrahepatic obstruction
- Intrahepatic cholestasis—atresia, viral, drugs, hormones, pregnancy, benign recurrent cholestasis
- Familial (defect confined to bilirubin excretion)
- Dubin–Johnson syndrome—excretory defect and cell pigment
- Rotor's syndrome—excretory defect and no pigment
- Diagnostic features
- Serum-conjugated bilirubin more than 15% of total
- Bilirubinuria common
- Urine urobilinogen often elevated
- Other liver functions often abnormal in hepatic cell damage and impaired bile excretion
- Characteristic morphologic abnormalities of liver

most of the brown color of normal feces is due to urobilins derived from degradation of bilirubin in the intestine, the jaundice of impaired bilirubin excretion or bile obstruction is associated with "clay-colored" stools. Ultraviolet radiation enhances degradation of bilirubin; this is the rationale for phototherapy to prevent kernicterus in severe neonatal jaundice.

The jaundice of biliary obstruction resolves after the obstruction is relieved. Jaundice in patients with acute hepatitis resolves spontaneously. The jaundice of chronic liver disease may improve after transplantation. Jaundice in chronic active hepatitis can decrease after glucocorticoid therapy. Neonatal jaundice may respond to phototherapy (see Chapter 237).

PRURITUS

CHOLESTATIC PRURITUS

PATHOGENESIS OF CHOLESTATIC PRURITUS.

One of the most common and distressing symptoms of hepatobiliary disease is pruritus. Although retained cutaneous bile acids have been implicated, there is a poor correlation between the plasma bilirubin and the severity of pruritus. However, the partial relief of itching by bile salt-chelating resins and the disappearance of pruritus when liver cells fail strongly indicates that the liver must manufacture at least one of the contributing agents.

Opiate agonists, such as morphine, induce pruritus. Animal studies show that the intracerebral presence of morphine induces pruritus that is reversed by the opiate antagonist nalaxone,[9] demonstrating that opiate agonists induce itching centrally. In addition, the administration of the opioid antagonist nalmefene to patients with PBC produces a reaction similar to that of opiate withdrawal, and the injection of plasma from patients with PBC into monkeys produces pruritus. Taken together, these studies suggest that opioidergic tone increases in cholestasis.[9] These studies do not, of course, tell us which agent(s) cause the pruritus of cholestasis, nor whether it originates peripherally (e.g., in the liver) or centrally.[10]

CLINICAL FEATURES. Pruritus more commonly occurs in conditions causing cholestasis and ranges from mild and transient to severe and prolonged. Pruritus may be debilitating in patients with PBC, mechanical biliary obstruction, or intrahepatic obstruction. Drugs, especially erythromycin, oral contraceptives, phenothiazines, chlorpropamide, *para*-aminosalicylic acid, and nitrofurantoin, induce cholestasis accompanied by pruritus. Pruritus is the presenting symptom in more than 50% of cases of PBC and may precede jaundice by months or even years. However, in viral hepatitis, itching is frequently missed as an early sign of the disease until it occurs in the later, icteric phase.

Pruritus is usually most marked on the extremities and only rarely involves the neck and face, and genitalia. There is little correlation between the severity of cholestasis and the severity of perceived pruritus: a spontaneous decrease in the intensity of pruritus may signal the development of hepatocellular failure rather

than improvement. Scratching gives only very temporary relief in the pruritus of cholestasis. There may be no visible skin changes except excoriations, although lichenified plaques, nodular prurigo or peforating collagenoses may be seen (see Chapter 69).

MANAGEMENT. Pruritus rapidly decreases when cholestasis secondary to mechanical bile duct obstruction is relieved. Drugs to relieve cholestasis such as ursodeoxycholic acid do not consistently relieve pruritus, nor do the anion exchange resins cholestyramine and cholestipol, which are thought to bind intestinal pruritogens and prevent them making their way to the skin. Neurotransmitter receptor antagonists such as oral nalmefene have been advocated for the pruritus of cholestasis[11] Intravenous naloxone has short-term efficacy[12] as has oral naltrexone.[13] However, while these, together with sedating antihistamines or ultraviolet light can help, long-term results with any approach, including plasmapheresis, charcoal hemoperfusion, and hepatic enzyme inducers (such as rifampicin) have been disappointing.[14]

RENAL PRURITUS

Renal pruritus is a major problem[4] and reported to be as high as 90% in patients undergoing hemodialysis.[15–17]

PATHOGENESIS OF RENAL PRURITUS. Renal pruritus has been thought to be caused by a combination of increased serum histamine, vitamin A, and parathyroid hormone (PTH); mast cell hyperplasia; peripheral polyneuropathy; xerosis.[16,18]; and inflammatory factors.[19] Clinically, the skin may appear normal or demonstrate a variety of lichenified or hyperkeratotic lesions.[20]

MANAGEMENT. Topical moisturizers alleviate pruritus associated with xerotic skin. Topical glucocorticoids and ultraviolet phototherapy[21,22] are often used to suppress inflammation in treated areas. Topical capsaicin depletes substance P from nerve endings, thereby suppressing itch sensation.[23] Gabapentin and the κ-opioid-receptor-agonist nalfurafine have also been found useful.[19] Improving the efficacy of dialysis and/or changing the dialysate concentration may help to alleviate pruritus.[24] Some patients have responded to treatments with intravenous lidocaine, heparin, and cholestyramine.[22] Surgical options include subtotal parathyroidectomy, electric needle stimulation, and renal transplantation. Erythropoietin lowers plasma histamine concentrations with subsequent improvement in pruritus.[25] There are reports of success with oral evening primrose oil,[26] and endocannibinnoids.[27] Thalidomide, pentoxiphylline, and topical tacrolimus ointment may help some patients.[19,28]

ALTERATIONS IN SWEATING

Sweating may be prominent in a number of cardiopulmonary states such as acute myocardial infarction, cardiogenic shock, left ventricular failure, massive pulmonary emboli, and pulmonary edema. Pallor and clamminess/coldness of the extremities and exposed surfaces are also often found. Excessive sweating may suggest pheochromocytoma when associated with hypertension.

The sodium and chloride content of sweat is increased in patients with cystic fibrosis and may lead to an increase in skin wrinkling after immersion, as when bathing.[29]

SKIN CHANGES IN MALIGNANCY

(See also Chapter 153)

Many skin changes occur in association with malignancies.

Dry skin (acquired ichthyosis) with asteatotic dermatitis as well as hyperpigmentation is not uncommon.

DERMATOMYOSITIS

(See Chapter 156)

Adult onset dermatomyositis is associated with underlying malignant disease in a significant minority of cases.[30] Blind CT scans may help uncover occult malignancy in these patients.[31] Pancreatic, gastric, and colorectal cancers are the third most common after bronchogenic and ovarian cancers in Europe and North America. In China, nasopharyngeal carcinoma is common. The rash and myopathy can regress after removal of the tumor.

Interstitial lung disease occurs[32] with bronchiolitis obliterans, subcutaneous emphysema, and spontaneous pneumothorax. Upper pharyngeal weakness can lead to chronic aspiration an, exertional dyspnea can occur because of weakness of the respiratory muscles. Lung disease is associated with anti-Jo-1 antibodies.

ACANTHOSIS NIGRICANS

(See Chapter 151 and 153)

In two-thirds of patients with acanthosis nigricans and cancer, the tumor is gastric. The changes may regress if the tumor, usually an adenocarcinoma of the stomach or bowel, is removed.

HYPERTRICHOSIS LANUGINOSA

Excessive growth of lanugo hair is a rare complication of gastrointestinal cancer.

OTHER SKIN CHANGES IN MALIGNANCY

Diverse cutaneous paraneoplastic syndromes may arise from underlying tumors.[33] They may precede, coincide with, or follow the diagnosis of cancer and usually indicate a poor prognosis. They include



Figure 150-2 Patient with "tripe hands" due to adenocarcinoma of the jejunum.

reactive erythemas, such as erythema gyratum repens and necrolytic migratory erythema; the vascular dermatoses (trousseau syndrome); and papulosquamous disorders, including tripe palms (Fig. 150-2), palmar hyperkeratosis, acquired ichthyosis, pityriasis rotunda, Bazex syndrome, florid cutaneous papillomatosis, the sign of Leser–Trélat, and extramammary Paget disease. Migratory superficial thrombophlebitis occurs in association with neoplasia, particularly carcinoma of the pancreas. Glucagonoma, one of the amine precursor uptake and decarboxylation (APUD) cell tumors, usually arises in the islet cells of the pancreas, and occurs in association with a distinctive necrolytic migratory erythema (see Chapter 153).

Any tumor may metastasize to the skin. The scalp is a common site. Metastases at the umbilicus (Sister Joseph nodules) occur particularly with carcinoma of the stomach, colon, or ovary (Fig. 150-3).

ERYTHRODERMA

(See Chapter 23)

The systemic effects of erythroderma can be considerable. Patients can develop hypothermia, hypoalbuminemia, hypovolemia, secondary sepsis, the initial stages of renal failure, and high-output cardiac failure with secondary effects on hepatic function. Death from sepsis, cardiac failure, adult respiratory distress syndrome, and capillary leak syndrome occur.[34]

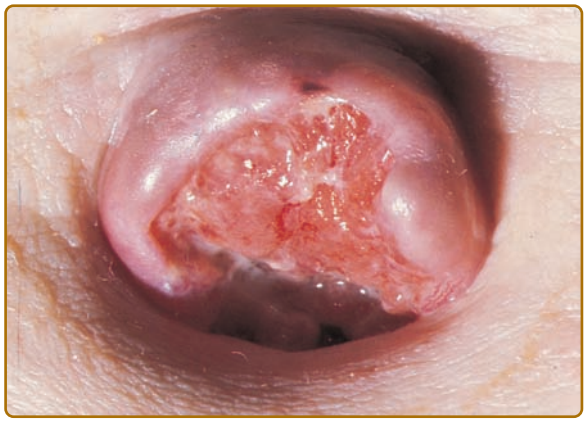

Figure 150-3 Umbilical metastasis (Sister Joseph nodule) from intraabdominal adenocarcinoma.

SPECIFIC ORGAN AND SYSTEM CHANGES

NAILS

(See Chapter 89)

Lindsey, or half-and-half, nails are normal in their distal 50% and white in the proximal 50% and found in CRF.

In malabsorption or malnutrition, nails grow more slowly, become brittle, and may develop fissures.[35,36] Multiple pigmented bands can appear. Koilonychia usually indicates iron deficiency, even without anemia (see below). White nails, thought to be due to selenium deficiency, have occurred with total parenteral nutrition.

Flushing of the nail beds that is synchronous with the heartbeat is a sign of aortic regurgitation called Quincke pulsation.

NAIL CHANGES IN LIVER DISEASE

Nail abnormalities are a less constant physical sign than spider nevi or liver palms. In cirrhosis, however, a number of changes may occur: clubbing, curved nails, thickened nails, longitudinally ridged nails, white nails, watch-glass deformity, flattened nails, white bands, striations, and brittleness.[36]

White nails may occasionally be seen in healthy individuals or in association with systemic disease, including congestive heart failure, diabetes, cryoglobulinemia, Raynaud syndrome, and systemic sclerosis. Intensely white nails (Terry nails) are characteristic of cirrhosis (Fig. 150-4).[37] Thumbs and forefingers are often most affected. The whiteness does not alter with nail growth or with compression of digital vessels and is thought to be due to the opacity of the nail plate itself. The so-called watch-glass deformity may accompany white nails (see Fig. 150-5).

Azure lunulae, a bluish color of the lunular portion of nails, occurs in hepatolenticular degeneration (Wilson disease). Azure lunulae and corneal changes resembling Kayser–Fleischer rings may also be evident in patients with argyria or following treatment with busulfan or antimalarials.[36]

The characteristic nail changes of lichen planus, including longitudinal ridging, pterygium formation, and permanent nail loss, occur both with and without skin changes in PBC (see Section "Cutaneous Manifestations of Primary Biliary Cirrhosis").

Splinter hemorrhages also occur in cirrhosis. Flat or spoon nails are less common in patients with liver disease. The nails are flat or concave, pale in color, and frequently show longitudinal ridging. In hemochromatosis, koilonychia is probably the most common of the nail abnormalities, but it is not related to anemia.[36]

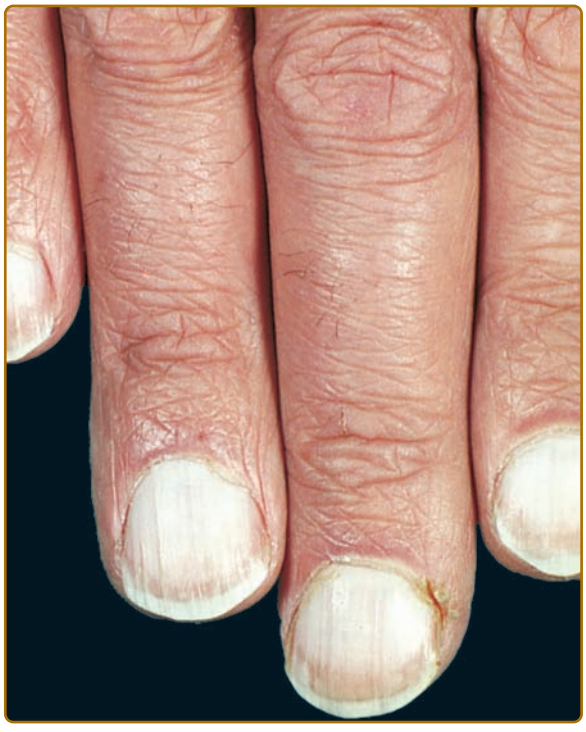

Figure 150-4 Terry's white nails in a patient with cirrhosis.

NAIL CLUBBING

Nail clubbing most commonly occurs in patients with bronchogenic carcinoma, suppurative lung disease, endocarditis, and congenital heart disease, but it may be idiopathic or familial (Fig. 150-6). Clubbing is quite common in all forms of cirrhosis, especially PBC and chronic active hepatitis. Signs include beaking or distal curvature of the nail. There may be loss of the angle between the nail and cuticle. Sponginess or "floating" of the nail when pressure is applied is also characteristic and the size of the terminal tuft may increase.

Anatomically, there is an increased thickness of the nail bed. This is due to edematous infiltration of the soft parts of the terminal segment followed by hyperplasia of the dermal fibrovascular tissue with increased vascularity.[36]



Figure 150-5 Flat white nails with slight convex watchglass deformity, showing a distal pink band in a patient with liver disease.



Figure 150-6 Clubbing of fingernails.

YELLOW NAIL SYNDROME

This is the triad of yellow nails, primary lymphedema, and pleural effusion(s). The characteristics of the nails include thickening, transverse ridging, diminished growth, increased curvature with a "hump," and onycholysis. The lunulae and cuticles may be absent. The color may vary from pale yellow to green (Fig. 150-7). The nail changes are secondary to congenitally hypoplastic lymphatics,[38] leading to lymphedema, which is characteristically slowly progressive and somewhat



Figure 150-7 Yellow nail syndrome. There is thickening, increased curvature, and yellowish discoloration of all fingernails. This patient had lymphedema of the extremities and bronchiectasis with multiple recurrent respiratory infections.

asymmetric, with induration and hyperkeratosis extending to the thighs. Periodic lymphangitis is frequent and may contribute to the swelling.

Respiratory findings include sinusitis, bronchiectasis, and pleural effusions. Patients may have frequent upper respiratory infections, and pneumonia. The appearance of pulmonary features and lymphedema may be late and lymphoma or sarcoma have been reported.

FINGERS

ERYTHROMELALGIA

(See also Chapter 173)

Erythromelalgia (labile hyperthermia) is a chronic clinical syndrome that is characterized by recurrent attacks of burning pain in the hands and/or feet with redness and warmth.[39] There may be swelling that extends to the elbows and knees. Erythromelalgia may be primary or secondary to a disorder such as atherosclerosis, hypertension, and polycythemia. Symptoms are thought to be caused by vascular dysfunction including arteriovenous shunting and reduced capillary perfusion with subsequent tissue hypoxemia.[40] Management includes analgesia, controlling secondary and underlying factors, and use of drugs such as aspirin and calcium channel blockers.[41] A possible role for high-dose oral magnesium has been proposed[42] and the use of a combination gel of 1% amitriptyline and 0.5% ketamine used to treat refractory erythromelalgia pain.[43]

HANDS

HYPERTROPHIC OSTEOARTHROPATHY. Clubbing is often a feature of hypertrophic osteoarthropathy (HOA) but there is also associated arthralgia and/or arthritis of the fingers, wrists, knees, and ankles. There is a painful periostitis with subperiosteal new bone formation on X-ray. There may be pitting edema, shiny skin, increased sweating, and paronychial thickening. HOA is most often secondary to malignant tumors of the chest.

Pachydermoperiostosis, a primary form of HOA, is frequently familial with an onset around puberty, and has a number of cutaneous manifestations. Distinctive thickening and furrowing of the skin of the scalp, forehead, and cheeks may create leonine facies. Other features include excessive sweating and dermatitis, especially of the hands and feet, severe seborrhea of the scalp and face. Familial clubbing alone may also be found and may represent a partial expression of this syndrome. Thyroid acropachy (Chapter 151) may mimic osteoarthropathy but is most often painless.

REFLEX SYMPATHETIC DYSTROPHY

The shoulder–hand syndrome is a painful periarthritis or adhesive capsulitis of the shoulder ("frozen shoulder"), usually on the left side, associated with erythema, increased sweating, shiny induration, edema, tenderness, pain, and immobility of the ipsilateral hand. Reduction of finger flexion, loss of movement, temperature changes, sensory disturbances, and, hair/nail growth changes have been reported.[44] Neurotrophic ulcerations of the fingers and thickening of the palmar aponeurosis with nodules and/or Dupuytren contracture may be late sequelae.[45] Predisposing conditions include arterial embolization, cerebrovascular accidents, and protective disuse of the arms for any reason.[46]

PALMS

PALMAR ERYTHEMA. There are two clinical forms of palmar erythema. In the first (Fig. 150-8), there is an exaggeration of normal mottling; the hands are warm and bright red, especially on the palm, the dorsae of the hands, the fingers, and the nail bases. In the second, there is well-demarcated redness of the hypothenar eminence that gradually spreads to the fingertips and then to other areas of the palm. The soles of the feet may show similar changes. The mottling blanches on pressure and flushes synchronously with the pulse rate under a glass slide. Patients may complain of throbbing or tingling. Often termed "liver palms" these changes also occur in pregnancy and thyrotoxicosis. In cirrhosis, though, atrophy of the muscles of the thenar and hypothenar eminence may coexist. This is of myogenic rather than neurogenic origin.[47]



Figure 150-8 Palmar erythema showing the characteristic blotchy redness.

FACE

SPIDER NEVUS. The spider nevus, or spider angioma, is the most representative and classic vascular lesion of chronic liver disease. Clinically, it has a central arteriole from which numerous small, twisted vessels radiate (Fig. 150-9). Spider nevi range in size from a pinhead to 2 cm. Larger lesions can be seen to pulsate when pressed with a glass slide. Pressure over the central arteriole causes blanching of the whole lesion. Spider nevi are characterized by the abnormal permanent dilatation of end vessels. Histologically, spider nevi consist of a central ascending arteriole ending in a thin-walled ampulla beneath the epidermis from which small arterial branches radiate outward into the papillary dermis.[3]

Spider nevi are most common on the face, neck, and upper part of the chest (i.e., over the region drained by the superior vena cava; see Fig. 150-9). They may be seen in 15% of healthy adults and not infrequently in children, where they tend to affect the hands and fingers. They may appear in large numbers during pregnancy, but usually disappear after parturition. They may also be seen in thyrotoxicosis or due to oral contraceptives.

In liver disease, spider nevi usually persist but can regress with improvement of the underlying condition. Spider nevi are more common in patients with alcoholic cirrhosis than in those with viral or idiopathic cirrhosis. In alcoholic cirrhosis, they are associated with the presence of esophageal varicosities, and their presence may be a useful predictive marker for the future risk of esophageal bleeds.[48]

Vascular spider nevi and palmar erythema (see above) are generally attributed to estrogen excess, particularly because they also occur during pregnancy and because estrogens have an enlarging, dilating effect on the spiral arterioles of the endometrium. This would also explain spider nevi in men receiving estrogen therapy for prostatic cancer. However, in addition to higher plasma estradiol:testosterone ratios, patients with nonalcoholic cirrhosis have been shown to have higher substance P levels than healthy controls.[49] Vascular endothelial growth factor (VEGF) may also have an etiopathogenic role.[50] In alcoholic cirrhosis, the presence of alcoholism and elevated serum bilirubin are both important predictors of the presence of spider nevi.[51]



Figure 150-9 Spider nevi in a patient with cirrhosis.

EYES

Corkscrew scleral vessels (tortuous small arteries that traverse the margins of the ocular sclerae) can develop in patients with chronic liver disease.

MOUTH AND ESOPHAGUS

DYSPHAGIA. When dermatologic diseases extend into the pharynx and esophagus, dysphagia may occur. Cutaneous and oral infections are discussed elsewhere. Symptoms resulting from infections of the esophagus occur in patients taking oral or inhaled glucocorticoids or in those who have an immunodeficiency. *Candida albicans* is the most frequent pathogen, although opportunistic bacteria and viruses can also be responsible.

Extensive esophageal involvement with blisters, erosions, and strictures can occur in hereditary epidermolysis bullosa particularly in the recessive dystrophic and junctional forms (see Chapter 62).[52] The acquired immunobullous disorders can affect mucosae. Dysphagia is most troublesome in cicatricial pemphigoid where half of patients have pharyngeal involvement and up to 13% esophageal involvement (see Chapter 57).[53]

Esophageal lichen planus has been reported only in women, typically middle-aged with oral involvement (see Chapter 26). Therapeutic dilatation can lead to a Koebner-like exacerbation of the stricture.[54] Esophageal involvement also occurs in Darier disease, sometimes in association with esophageal carcinoma (see Chapter 51),[55] and in acanthosis nigricans. The mucosae may be extensively involved in Stevens–Johnson syndrome and toxic epidermal necrolysis (see Chapters 39 and 40).

In Behçet syndrome (see Chapter 166), which should always be considered in a patient with three episodes of oral ulceration in a 12-month period, isolated mucosal ulcers can occur at any point along the gastrointestinal tract.[56] A typical site is the ileocecal region. Oral ulceration can sometimes be difficult to distinguish from the mouth ulceration associated with Crohn disease.

In Plummer–Vinson (Paterson–Kelly) syndrome, a postcricoid web is associated with koilonychia, angular stomatitis, a sore tongue, and, usually, iron deficiency. Up to 10% of patients with a postcricoid web develop carcinoma at the site. The form of tylosis in which 95% of patients develop esophageal cancer is exceedingly rare.[57]

Up to 90% of patients with systemic sclerosis have gastrointestinal involvement, but this is subclinical in one-third (see Chapter 157). Dyspepsia due to gastroparesis is common; decreased peristalsis, esophageal dilation, and stricture formation occur. Gastric antral vascular ectasia is a rare manifestation that may cause significant bleeding.[58] In dermatomyositis and polymyositis, decreased esophageal motility and difficulty swallowing are indications for urgent systemic treatment with high-dose glucocorticoids and immunosuppressive drugs (see Chapter 156). Vasculitic ulcers in the mouth and pharynx may occur in systemic lupus erythematosus (see Chapter 155).

EARS

EARLOBE CREASE. The presence of a diagonally positioned skin crease along the earlobe, either unilateral or bilateral, suggests an increased risk for coronary artery disease (CAD) in men under 60 years of age.[59]

RELAPSING POLYCHONDRITIS

(See Chapter 159)

Relapsing polychondritis is characterized by inflammation and destruction of cartilage and connective tissues, including those of the cardiopulmonary system. It is idiopathic but frequently associated with other immunologic disorders such as systemic lupus erytematosus (SLE). Auricular chondritis with pain, swelling, and redness of the pinna but complete sparing of the lobes is characteristic. Respiratory tract involvement may begin with hoarseness or tenderness of the anterior trachea. Degeneration of the laryngeal, tracheal, and/or bronchial rings may lead to progressive insufficiency or to sudden collapse. Cardiac involvement includes degeneration of the aortic ring with valvular insufficiency and aneurysmal dilatation. "Floppy" mitral valve syndrome also occurs. Pericardial and myocardial abnormalities have been reported.

HAIR

(See Chapter 88)

Malnutrition causes hair to grow more slowly, fall out more easily, and become gray. The hair root diameter and the proportion of anagen hairs decrease. Lanugo hair may develop. Kwashiorkor, a form of protein–energy malnutrition, causes hair to become hypopigmented, varying from red–yellow to white, and curly. There may be alternating bands of pale and dark hair.[35] Total parenteral nutrition has been associated with hair loss and pigmentation of remaining hair. Type 2 vitamin D-dependent rickets is associated with alopecia totalis.

MALE BALDING

Frontoparietal male pattern baldness is more prevalent in men admitted with nonfatal myocardial infarction.[59] Vertex hair loss may be more strongly associated with cardiovascular risk factors, such as hypertension and hypercholesterolemia.[60]

THE CARDIOVASCULAR SYSTEM

(Box 150-2)

Cardiac output frequently increases in patients with cirrhosis, and total peripheral resistance may decrease.

BOX 150-2 DISEASES WITH BOTH CUTANEOUS AND CARDIAC INVOLVEMENT

- Joint and connective tissue diseases
- Rheumatoid arthritis
- Systemic lupus erythematosus
- Reactive arthritis
- Behçet disease
- Systemic scleroderma
- Dermatomyositis
- Rheumatic fever
- Ehlers–Danlos syndrome
- Cutis laxa
- Marfan syndrome
- Periarteritis nodosa
- Multicentric reticulohistiocytosis
- Metabolic diseases
- Hemochromatosis
- Amyloidosis
- Fabry disease
- Carcinoid tumors
- Myxedema
- Hyperlipidemias
- Hyperthyroidism
- Nevoid or genetic disorders
- Progressive lentigines (Moynahan syndrome)
- Watson syndrome
- Neurofibromatosis
- Tuberous sclerosis
- LEOPARD syndrome
- NAME/LAMB/Carney complex
- Danoff syndrome
- Infectious diseases
- Varicella
- Gonococcemia
- Subacute and acute bacterial endocarditis
- Chagas disease
- Diphtheria
- Miscellaneous (protozoal, viral, rickettsial, and bacterial infections)
- Diseases of uncertain etiology
- Sarcoidosis
- Whipple disease
- Kawasaki disease
- Degos disease

CORONARY HEART DISEASE

FAMILIAL HYPERLIPIDEMIA. The familial hyperlipidemias comprise a group of metabolic disorders with elevated plasma cholesterol and/or triglycerides, associated with a high incidence of CAD. Xanthelasmata and cutaneous xanthomata are important clinical features (see Chapter 135).

CARDIOMYOPATHY

NAXOS DISEASE. This is an autosomal recessive mutation in desmoplakin, a desmosomal protein important in cell adhesion.[61] Generalized striate keratodermas are seen, particularly on the palmoplantar epidermis, with woolly hair and dilated left ventricular cardiomyopathy leading to arrhythmias, heart failure, and early sudden death (see Chapter 50).

ATRIAL MYXOMA

Atrial myxomas, the most common primary tumors of the heart, are benign hamartomatous intracardiac tumors. The cardiopulmonary findings include, in order of frequency, congestive heart failure, mitral murmur, chest pain, pulmonary edema, and pulmonary emboli. Additionally, valvular insufficiency, constrictive pericarditis, conduction blocks, and arrhythmias may occur. Variable murmurs can be an important clue. Other systemic findings include fever, cachexia, arthralgia, clubbing, hypergammaglobulinemia, and leukocytosis.

The cutaneous manifestations of atrial myxomas may be dramatic. In addition to biphasic digital color changes on cold exposure, skin lesions may simulate collagen vascular disease or vasculitis with tender, violaceous, nonblanching, annular, and serpiginous lesions of the digital pads, as well as splinter hemorrhages presenting as a systemic vasculitis or infective endocarditis. Characteristic pruritic, erythematous papules as well as cyanosis and ecchymosis of the extremities may also occur. Histologically myxomatous emboli with large pale cytoplasm and stellate nuclei may be found among occluded blood vessels. Mucocutaneous pigmented lesions, including lentigines (Fig. 150-10), melanocytic nevi, and dermal myxomatous nodules, have been described (NAME/LAMB/Carney Complex).[62]

LEOPARD SYNDROME

Multiple lentigines syndrome is an autosomal dominant disorder comprising lentigines; electrocardiogram conduction defects; ocular hypertelorism; pulmonary stenosis; abnormalities of genitalia; retardation of growth and sensorineural deafness. Electrocardiographic features include axis deviation; prolonged P–R interval, bundle branch block, and complete heart block. Hypertrophic cardiomyopathy appears to be the most common anatomic abnormality. Subaortic stenosis is the most common valvular lesion.



Figure 150-10 Lentiginous lesions in the atrial myxoma syndrome complex. This child has the LAMB syndrome.

SUBACUTE BACTERIAL ENDOCARDITIS

(See also Chapter 181)

The cutaneous manifestations of bacterial endocarditis include Osler nodes, Janeway lesions, subungual splinter hemorrhages, cutaneous purpura and petechiae, and conjunctival petechiae (Roth spots).

Petechiae are the commonest manifestation with small, red, or violaceous nonblanching macules especially on the heels, shoulders, and legs.

Osler nodes and Janeway lesions may both present as erythematous or hemorrhagic macules, papules, or nodules (Fig. 150-11). However, while Osler nodes are exquisitely painful, tender, and located distally on the digital tufts, Janeway lesions are nontender and located proximally on the palms and soles. Histologically, Osler nodes are a perivasculitis or necrotizing



Figure 150-11 Osler nodes (*arrows*).

vasculitis *without* microabscess formation or other evidence of infection or emboli whereas Janeway lesions have been described as a vasculitis *with* microabscess formation. Both are found in patients with other conditions, particularly systemic lupus erythematosus, gonococcemia, hemolytic anemia, and typhoid fever.

COLLAGEN VASCULAR DISEASE AND THE HEART

SYSTEMIC LUPUS ERYTEMATOSUS. (See Chapter 155). Pericarditis may be more common in patients with drug-induced lupus or photosensitive discoid lesions. Myocarditis is often undiagnosed and may be associated with prolonged P–R intervals, heart block, and arrhythmias. Valvular heart disease in patients with SLE, most often of the Libman–Sacks type, is frequently associated with antiphospholipid antibodies.[63] Diastolic murmurs may occur with mitral stenosis or aortic insufficiency but the onset of a new diastolic murmur should provoke a search for subacute infective endocarditis. Splinter hemorrhages, Osler nodes, Janeway lesions, and Roth spots may occur in SLE per se without infection. SLE is associated with complete heart block in newborns because of placental transfer of maternal antibodies, especially the anti-Ro antibody.[64] The newborn infants of patients with SLE or of clinically normal but Ro-antibody-positive mothers may also have distinctive evanescent eruptions, including prominent telangiectasia and periorbital erythema.[65]

SYSTEMIC SCLEROSIS. (See Chapter 157). Acute or chronic pericarditis is an important feature of systemic sclerosis. Pericardial effusions may be occult, and constrictive pericarditis and tamponade may occur. Additionally, small-vessel involvement of the myocardium may lead to fibrosis.[66] Fibrosis of the conduction system may cause arrhythmias and sudden death.

THE RESPIRATORY SYSTEM

PULMONARY ARTERIOVENOUS FISTULAS

Pulmonary arteriovenous fistulas are congenital abnormalities of capillary development that may not become clinically apparent until late adolescence. Osler–Weber–Rendu disease[67] is an autosomal dominant trait, characterized clinically by punctate, linear, or spider-like telangiectasias of the skin, especially on the upper body, oral and nasal mucous membranes, and nail beds (Fig. 150-12). Radiating arms about an elevated punctum are the most characteristic feature, especially on the lips and tongue. They are distinguished from spider nevi in that they do not pulsate. Recurrent epistaxis, often beginning in childhood or adolescence, is the most frequent presenting symptom. The liver, gastrointestinal, and central nervous system can be involved (see below) and recurrent hemorrhage



Figure 150-12 Osler–Rendu–Weber disease. Note the punctate and splinter-like telangiectasia on the lips and tongue.

may result. Bleeding may be enhanced by associated disorders such as von Willebrand disease. In those with an arteriovenous fistula of the lungs pulmonary bruits accentuated by inspiration can be heard.

In cirrhosis, arteriovenous shunting may occur within the lungs (the hepatopulmonary syndrome),[68] liver, and extremities. These arteriovenous malformations, including spider nevi, may regress after transplantation.[69]

LARVA MIGRANS

(See Chapter 207)

Cutaneous larva migrans, may cause mild respiratory symptoms and be associated with transient pulmonary infiltrates and a peripheral eosinophilia (Löffler syndrome). Visceral larva migrans, or toxocariasis, may lead to granulomatous involvement of the liver, lungs, heart, muscle, brain, and eyes. Marked eosinophilia, hyperglobulinemia, pneumonitis with wheezing, recurrent bronchitis, fever, and tender hepatomegaly frequently occur. Skin lesions may present as patchy urticaria or erythematous papular eruptions.

FAT EMBOLISM SYNDROME

Petechiae, respiratory insufficiency, and cerebral dysfunction after long bone fracture are termed the *fat embolism syndrome*. Petechiae alone after fractures should suggest this diagnosis. The petechiae are most common on the neck, axillae, shoulders, chest, and conjunctivae. They often appear before other manifestations on the second or third day after injury, and appear in crops. When widespread, they herald more significant cerebral and pulmonary dysfunction. Histologically, fat globules are present within dermal and pulmonary vessels. Respiratory involvement includes

cyanosis, hemoptysis and pulmonary edema. Jaundice and thrombocytopenia may occur.[70]

LIPOID PROTEINOSIS (HYALINOSIS CUTIS ET MUCOSAE)

(See Chapter 137)

Skin changes include confluent, waxy papules, plaques, and scarring, particularly on the face. The tongue is enlarged. Oropharyngeal and laryngeal mucous membranes are usually affected early in the course of the disease, during infancy or childhood. Laryngeal infiltration may present early on as hoarseness, and may progress to obstruction and respiratory insufficiency. The trachea and main stem bronchus may be thickened and studded with warty projections.

MULTICENTRIC RETICULOHISTIOCYTOSIS

(See Chapter 148)

Multicentric reticulohistiocytosis is an uncommon disorder presenting with characteristic mucocutaneous lesions consisting of deeply set, firm, small papules in association with a deforming arthritis, fever, malaise, weight loss, and myopathy. Neurofibroma-like, soft, sessile, larger lesions have been reported, as has an association with malignancy.[71] Cardiopulmonary complications include pleural effusions, pulmonary infarctions, pericarditis, angina pectoris, myocardial infarction, and congestive heart failure.

SARCOIDOSIS

(See Chapter 152)

Cardiac involvement in sarcoidosis may be occult and results from myocardial or conduction system granulomata. Ventricular arrhythmias and conduction disturbances present as palpitations and syncope. Congestive heart failure and chest pain occur as do cardiomyopathy or cor pulmonale. The prognosis for patients with cardiac involvement is unfavorable. Sarcoidosis affecting the pulmonary system is relatively common in association with lupus pernio: involvement of the hilar nodes, bronchi, and/or alveoli may result in obstructive and/or restrictive dysfunction and respiratory failure.[72] Indwelling vascular catheters can, rarely, disintegrate and embolise into small pulmonary vessels and lymphatics, causing granulomatous changes and dyspnoeic symptoms. These lesions have also been reported in the skin.[73]

AMYLOIDOSIS

(See Chapter 133)

Systemic amyloidosis may cause waxy induration of the skin, with hemorrhagic skin changes on stroking (pinch purpura). Amyloid deposition within the vessels is found in clinically normal skin in up to 50% of patients.

Cutaneous involvement occurs most often in the primary and myeloma-associated types, and therefore serves as a marker for cardiopulmonary involvement. Congestive heart failure with cardiomegaly or a restrictive cardiomyopathy occurs. Pathologically, there is infiltration of the endocardium, myocardium, pericardium, valves, and coronary vessels.[74] Senile amyloidosis may also affect the heart but is often asymptomatic.

Respiratory tract involvement is also commonest in primary and myeloma-associated types. Macroglossia may impede respiration, the larynx and trachea may become infiltrated, causing stridor and bronchial and parenchymal involvement cause asthma-like symptoms.

LYMPHOMATOID GRANULOMATOSIS

(See Chapter 145)

Lymphomatoid granulomatosis is a rare angiocentric and angiodestructive, Epstein–Barr virus-associated B cell lymphoproliferative disorder, varying from an indolent process to an aggressive large cell lymphoma. The skin is the extrapulmonary organ most commonly involved. The disease also affects the lungs,[75] heart, central nervous system, and kidneys. Although many patients remain asymptomatic, cough, dyspnea, and chest pain may occur. Chest X-rays show transient infiltrates which may progress to nodules that cavitate and cause profuse hemoptysis.

COLLAGEN VASCULAR DISEASE AND THE LUNGS

The pulmonary complications of the various collagen vascular diseases may sometimes be associated with a specific cutaneous sign or constellation of features.

RHEUMATOID ARTHRITIS. (See Chapter 160). Extra-articular manifestations of rheumatoid arthritis, especially in the lungs, appear to correlate with subcutaneous nodules and vasculitic skin lesions. Skin lesions are also associated with high-titer rheumatoid factor, hypocomplementemia, cryoimmunoglobulinemia, and hypereosinophilia. These occur more commonly in men with long-standing disease, but may not correlate with current arthritis activity. The pulmonary symptoms include cough and hemoptysis.

SYSTEMIC LUPUS ERYTHEMATOSUS. (See Chapter 155). Pleuritis may be present half of patients with SLE and pleural effusions also occur. Parenchymal lung involvement in SLE is usually a result of secondary factors such as infections or pulmonary emboli. Primary lung involvement in SLE may be classified as (1) diffuse interstitial pneumonitis, (2) acute pneumonitis, (3) intrapulmonary hemorrhage, (4) diaphragm dysfunction with decreased lung volume, (5) pulmonary hypertension with cor pulmonale, and (6) fibrosing alveolitis.[76]

SYSTEMIC SCLEROSIS. (See Chapter 157). Raynaud phenomenon, telangiectases, and dilated and distorted

capillary loops of the nails are cutaneous clues. Exertional dyspnea chronic, nonproductive cough, and pleuritic chest pain indicate lung involvement.[77] Pulmonary hypertension with cor pulmonale and congestive heart failure may develop independently of parenchymal disease. Esophageal dysmotility causing aspiration pneumonia is associated with a higher incidence of interstitial lung disease.[64]

THE GASTROINTESTINAL SYSTEM

On examining the abdomen in patients with cirrhosis portal-systemic collateral vessels may be seen and are a clue to the existence of portal hypertension. Often, the umbilical vein is dilated and visible in the epigastrium, an occurrence more common than the well recognized, but rare, caput medusae.

GASTROINTESTINAL BLEEDING

Hematemesis, melena, or passing of fresh blood in the stools are signs of gastrointestinal bleeding (Box 150-3). The characteristic picture of hereditary hemorrhagic telangiectasia is of a familial pattern of epistaxis with telangiectases on mucosal surfaces (see Fig. 150-12) and arteriovenous malformations in multiple organs.[67] Hemorrhage from the gut, usually from the stomach or duodenum, occurs in up to 40% of patients and at an average age of 55 years.

Most cases of blue rubber bleb nevus syndrome are sporadic, but there are some autosomal dominant pedigrees. The gastrointestinal venous malformations look and feel as their name suggests and project into the gut lumen, particularly the small intestine. In contrast to cutaneous lesions, they bleed easily, causing chronic anemia and, less commonly, acute hemorrhage (see Chapter 172).[78]

In the autosomal dominant vascular type of the Ehlers–Danlos syndrome rupture of the bowel, often involving the sigmoid colon, accounts for one-quarter of all complications and 8% of all deaths.[1] Diverticula, and hernias, may also occur (see Chapter 137).

Gastrointestinal bleeding, usually from the stomach, is an important complication of PXE.[2] This may be the first clinical manifestation of the disease (see Chapter 137).

The gut, particularly the small intestine, is a common site for Kaposi sarcoma. While involvement is commonly asymptomatic, severe bleeding may occur (see Chapter 128).

Gastrointestinal bleeding in a patient with a dermatologic disease may also be due to drug therapy. The systemic administration of glucocorticoids commonly causes dyspepsia but may, more significantly, result in gastric erosions, ulceration, and hemorrhage. Methotrexate may cause enteritis, gastrointestinal ulceration, and hemorrhage.

BOX 150-3 SKIN ABNORMALITIES IN PATIENTS WITH GASTROINTESTINAL BLEEDING

- Congenital malformations of blood vessels
- Hereditary hemorrhagic telangiectasia
- Blue rubber bleb nevi
- Inherited defects of connective tissue
- Ehlers–Danlos syndrome
- Pseudoxanthoma elasticum
- Kaposi sarcoma
- Vasculitis
- Polyposis
- Ulcerative colitis and Crohn's disease
- Gastrointestinal tumors
- Drugs used to treat skin disease

ABDOMINAL PAIN

(Box 150-4)

Involvement of the sensory roots of the vertebrae T6–L1 in herpes zoster may produce abdominal pain even before skin lesions appear. Occasionally, herpes zoster in the distribution of S2, S3, and S4 is associated with perineal pain and disturbances of urination and defecation.

Acute attacks of urticaria or angioedema may present as abdominal pain. Edema of the bowel wall and mucosal thickening, often in association with free peritoneal fluid, is evident ultrasonographically—an aid to

BOX 150-4 SKIN ABNORMALITIES IN PATIENTS WITH ABDOMINAL PAIN

- Herpes zoster
- Angioedema
- Porphyria
- Fabry disease
- Vasculitis
- Henoch–Schönlein purpura
- Collagen vascular diseases
- Malignant atrophic papulosis
- Polyposis
- Gardner's syndrome
- Peutz–Jeghers syndrome
- Cronkhite-Canada syndrome
- Neurofibromatosis
- Ulcerative colitis
- Inflammatory bowel disease: ulcerative colitis and Crohn's disease
- Pancreatitis
- Gastrointestinal tumors
- Metastases
- Dermatomyositis
- Acanthosis nigricans
- Hypertrichosis lanuginosa

avoiding unnecessary surgery.[79] This is especially true in hereditary angioedema where colicky abdominal pain and life-threatening laryngeal edema occur and require treatment with injection of purified C1 inhibitor concentrate.[80]

It is only in the rare variegate porphyria that skin involvement and attacks of abdominal pain coexist (see Chapter 132). The skin shows changes identical to those in porphyria cutanea tarda (PCT). Pregnancy or drugs such as estrogen and griseofulvin may precipitate acute attacks. Although the detection of urinary uroporphyrin and fecal protoporphyrin indicates the diagnosis, plasma fluorescence with emission maxima at 626 nm is faster, easier and more sensitive it revealing the condition even in patients who are in remission.[81]

One-third of patients with systemic mastocytosis have gastrointestinal involvement. Symptoms include vomiting, abdominal pain, malabsorption, diarrhea, peptic ulceration, and gastrointestinal bleeding. Patients with more aggressive disease may develop hepatosplenomegaly with ascites and lymphadenopathy.[82–85]

ANGIOKERATOMA CORPORIS DIFFUSUM AND ANDERSON–FABRY DISEASE. Angiokeratoma corporis diffusum is the cutaneous marker for several inherited lysosomal disorders, due to deficiency of a number of enzymes, notably α-galactosidase A (the cause in Anderson–Fabry disease) (see Chapter 136). Signs include severe, painful neuropathy; progressive renal, cardiovascular, and cerebrovascular dysfunction. Gastrointestinal symptoms include abdominal pain and diarrhea. The diagnosis may be missed without the skin signs. Angiokeratomas may not appear until adolescence and, even then, can be subtle. Assay of α-galactosidase A is possible not only in established cases, but also before birth, and female carriers often identifiable. Treatment with intravenous infusions of α-galactosidase A is safe and efficacious.[86]

VASCULITIS. (See Chapter 163). Henoch–Schönlein purpura is palpable, especially on the legs and buttocks, and may occur in conjunction with joint swelling. Up to 76% of patients have gastrointestinal involvement, ranging from colicky abdominal pain, nausea, and vomiting to bloody diarrhea, intussusception, and pancreatitis. Renal involvement is common, especially in patients with bloody stools.[87] Upper gastrointestinal endoscopy reveals multiple raised erythematous lesions or ulceration that resolves after systemic treatment with glucocorticoids.[88]

Malignant atrophic papulosis is an idiopathic, systemic, obliterative vasculopathy (see Chapter 171). The characteristic skin lesions are recurrent crops of porcelain-white atrophic papules with an elevated erythematous border. These may have been present for years with no other apparent disease although gut vessels are involved in half of the cases.[89] Clinically bleeding, abdominal pain, diarrhea, malabsorption, and bowel perforation with peritonitis occur.

POLYPOSIS. True polyps are rare except in the colon and rectum. Polyp-like lesions that are hamartomatous or inflammatory occur in all parts of the gut. The term *hamartoma* implies a nonneoplastic tumor composed of tissue elements normally present in that organ. The hamartomatous polyposis syndromes (e.g., Peutz–Jeghers, Cronkhite-Canada) should be distinguished from the adenomatous polyposis syndromes (e.g., Gardner). In many of these syndromes, hamartomatous polyps of the gastrointestinal tract coexist with adenomas, and adenomas may develop within hamartomatous polyps contributing to the frequent occurrence of adenocarcinoma in most of these syndromes.[90]

Gardner syndrome is an autosomal dominant disorder characterized by cutaneous cysts and premalignant adenomatous polyps, particularly in the colorectum. Duodenal and hepatic carcinoma can also occur. The cutaneous lesions frequently predate the gastrointestinal lesions and include solitary or multiple epidermoid cysts, fibromas, lipomas, pilomatricomas, facial osteomas, and distinctive ocular lesions.[91]

Peutz–Jeghers syndrome is autosomal dominant and characterized by small darkly pigmented macules around the mouth, on the lips, buccal mucosa, and digits. A histologically unique type of hamartomatous polyp occurs, mainly in the small intestine, which predisposes to recurrent intussusception. Bleeding is relatively rare, but up to 2% of patients develop adenocarcinoma of the stomach, duodenum, and colon.[90] There is also an increased risk of malignancy in general.[92]

In *Cronkhite-Canada syndrome*, there is patchy alopecia and characteristic, nail changes.[90] Inflammatory polyps are present in the stomach and bowel, and abdominal pains with a severe protein-losing enteropathy are common.

Both ulcerative colitis and Crohn disease present with abdominal pain, gastrointestinal bleeding, or diarrhea. *Ulcerative colitis* predisposes to carcinoma of the colon. The skin complications of the two diseases are similar, although some occur with different frequencies. Up to one-half of patients with pyoderma gangrenosum may have inflammatory bowel disease, although only 12% of patients with ulcerative colitis and 2% of patients with Crohn disease will develop the condition (see Chapter 33).[93] The severity and extent of ulceration in pyoderma gangrenosum may be linked to the activity of the underlying disease, and pyoderma gangrenosum can heal with effective treatment of the underlying bowel disease. Erythema nodosum is well recognized.

Oral granulomatous nodules are common in *Crohn disease*, where they may coalesce to give a "cobblestone" appearance. Crohn disease is one cause of granulomatous cheilitis, which may predate bowel disease by several years. Granulomas may also occur in the perineum, at colostomy and ileostomy sites, and in association with scars, sinuses, and fistulas. Very rarely, granulomas occur at sites not contiguous with the bowel, such as the trunk and limbs: the so-called "metastatic" cutaneous Crohn disease.[94] Aphthous ulcers may be a presenting feature. Bruising of

the skin around the umbilicus (Cullen sign) or in the flanks (Grey Turner sign) are well-known features of acute pancreatitis, but occur in less than 3% of cases.[95] Chronic pancreatitis may cause tender, subcutaneous nodular areas of fat necrosis that may ulcerate (see Chapter 70).

DIARRHEA AND MALABSORPTION

(Box 150-5)

Gastric bypass surgery or reduction with jejunoileal and jejunocolic anastomoses is used to treat morbid obesity. Dryness of the skin, hair loss, recurrent fever, arthralgia, and inflammatory and vasculitic skin lesions have been reported post operatively. "Bowel bypass syndrome without bowel bypass" is recognized as the same constellation of symptoms, but with other gastrointestinal disorders.[96]

CUTANEOUS EFFECTS OF MALABSORPTION OF SPECIFIC NUTRIENTS. Vitamin deficiency can follow intestinal surgery, pancreatic disease, malabsorption syndromes, and malnutrition, including that associated with alcoholism (see Chapter 130).[35]

- Vitamin A deficiency causes xerotic wrinkled skin covered with fine scales, occasionally accompanied by deep erosions (dermomalacia).
- Deficiency of vitamin B_3 causes pellagra with its triad of diarrhea, dermatitis, and dementia.
- Vitamin B_{12} (cyanocobalamin) deficiency is common in ileal malabsorption syndromes such as pancreatic disease. There is a symmetric "glove and stocking" hyperpigmentation, but a lemon yellow pallor to the skin elsewhere.
- Vitamin C deficiency classically causes follicular keratoses, hemorrhage, and corkscrew hairs.
- Malabsorption of vitamin K occurs in obstructive jaundice and leads to impaired coagulation, resulting in cutaneous hemorrhage with ecchymoses and purpura.
- A diffuse hyperpigmentation, cheilitis, and perineal ulceration or dermatitis can occur in folic acid deficiency states. Theoretically, drugs used for dermatologic diseases such as methotrexate, a folate antagonist, can exacerbate folic acid deficiency.
- Iron deficiency presents with angular stomatitis, smooth painful tongue, and fragile/brittle nails, which have longitudinal ridging and lamellation. In marked iron deficiency anemia koilonychia, a spoonlike convexity of the nails, develops. Hair changes include diffuse scalp alopecia with brittle, split hairs. All take a long time to resolve on replacement therapy.
- Zinc deficiency can result from acrodermatitis enteropathica, malabsorption, or a lack of zinc in long-term parenteral nutrition. Acrodermatitis enteropathica usually presents at weaning or in very early infancy with dermatitic or vesicobullous lesions of the hands, on the feet, and around the mouth and anus, together with progressive alopecia and "failure to thrive."

BOX 150-5 MALABSORPTION AND SKIN DISEASE

- Skin changes due to malabsorption
- Nonspecific
- Acquired ichthyosis and pruritus
- Hair and nail changes
- Hyperpigmentation
- Skin texture and elasticity
- Eczematous and psoriatic rashes
- Jejunoileal and jejunocolic anastomoses
- Specific nutrients
- Zinc
- Essential fatty acids
- Vitamins
- Malabsorption due to skin disease
- Dermatogenic enteropathy
- Collagen vascular disease
- Dermatitis herpetiformis and celiac disease

MALABSORPTION DUE TO SKIN DISEASE

Malabsorption can result from poor intestinal peristalsis in systemic sclerosis or chronic obliteration of mesenteric vessels in polyarteritis and other forms of vasculitis. In systemic sclerosis, 8% of patients develop malabsorption or recurrent intestinal pseudo-obstruction, usually within 3 years of disease onset.[66,97] Vasculopathy interferes with peristalsis and leads to malabsorption by allowing bacterial colonization higher up the bowel than is usual.

Small bowel tumors produce a variety of hormones and vasoactive amines of which the best characterized is serotonin. The most common tumors are in the appendix, rectum, and ileum, where they are usually multiple. Episodic flushing, wheezing, or diarrhea does not occur until the vasoactive amines reach the systemic circulation. Therefore, flushing usually indicates metastasis to the lymph nodes or liver or a primary tumor at a different site (e.g., lung or ovary).[98,99]

THE HEPATOBILIARY SYSTEM

Skin lesions occurring in association with liver disease are usually not specific to a particular disease. The most florid cutaneous lesions appear in patients with chronic active hepatitis or alcoholic liver disease, but may also occur in physiologic states such as spider nevi in pregnant women. There may be no visible skin changes in patients with severe liver disease and, conversely, dramatic cutaneous manifestations may develop in those with minimal hepatic dysfunction.

HEPATITIS AND THE SKIN

Cutaneous striae may appear in patients with chronic hepatitis, whatever the underlying cause and even before glucocorticoid therapy (see Fig. 150-1). Pyoderma gangrenosum, urticaria, vasculitis, acne, scleroderma, and splinter nail hemorrhages occur, depending on the underlying cause of the hepatitis.

The clinical features of infection with the different hepatotrophic viruses that cause *acute* viral hepatitis are similar. In the preicteric phase, malaise, lethargy, nausea, and abdominal pain occur. A discrete, transient, maculopapular, urticarial, or petechial rash may develop, together with arthritis or arthralgia. These symptoms may worsen with the appearance of jaundice, dark urine, and pale stools. Malaise and fatigue may persist for some time after resolution of the disease.

HEPATITIS A. Transmission of hepatitis A virus takes place via the fecal–oral route. Although relapses occur, hepatitis A does not progress to chronic hepatitis.

HEPATITIS B. Hepatitis B virus (HBV) is transmitted by percutaneous and permucosal routes. It is endemic in many countries, and health care professionals are at risk. A recombinant DNA vaccine is available, but has been associated with cutaneous side effects.[100–102] Five percent of HBV-infected subjects become carriers, and 90% of infants born of infected mothers develop chronic infection.

There are four main cutaneous associations of hepatitis B: (1) a serum sickness-like syndrome, (2) cryoglobulinemia, (3) polyarteritis nodosa, and (4) papular acrodermatitis of childhood. The serum sickness-like syndrome occurs in approximately 10% of patients in the preicteric phase of acute hepatitis B infection. Urticaria may be the predominant or sole feature, but is usually accompanied by a low-grade fever, arthralgia of the peripheral joints, proteinuria, and hematuria. There may be vasculitis.

Both HBV and hepatitis C virus (HCV) infection are associated with cryoglobulinemia although HCV infection is more common. Mixed cryoglobulinemia in HCV infection is usually of type III,[103] and the cryoglobulinemia may indicate the presence of active viral replication.[104] Patients develop recurrent purpura, acrocyanosis, arthralgia, lymphadenopathy, peripheral neuropathy, and hepatosplenomegaly. Renal involvement is common. Histopathologically, there is a necrotizing vasculitis (see Chapter 169).[104]

Polyarteritis nodosa can occur in the acute phase of HBV infection, or it may not present for several years. Circulating immune complexes containing hepatitis B surface antigen (HBsAg) and immunoglobulin occur. Leukocytoclastic vasculitis may develop.

Papular acrodermatitis (Gianotti–Crosti syndrome) (see Chapter 192) usually affects children. The appearance of monomorphic, flat-topped, erythematous papules on the face and limbs is characteristic. This eruption is self-limiting and asymptomatic in most, but may be accompanied by lymphadenopathy.[105] Other infectious agents and immunizations have been implicated in papular acrodermatitis.[106] Sweet syndrome has recently been reported with both acute[107] and chronic HBV infection.

HEPATITIS C. The majority of cases of posttransfusion hepatitis have been due to HCV infection, but screening has reduced the number of new cases dramatically. Cutaneous manifestations of acute and chronic HCV infection include leukocytoclastic vasculitis, usually due to cryoglobulinemia (see above); cutaneous necrosis[104] pruritus[108]; acquired angioedema[109] PCT; erythema nodosum; urticaria; erythema multiforme; and polyarteritis nodosa.[110]

Lichen planus occurs more commonly in patients infected with HCV,[111] although studies disagree on the incidence.[112] There is an increased frequency of the HLA-DR6 allele in Italian patients with HCV-associated oral lichen planus,[113,114] suggesting that host factors may play a part in this association.

Treating psoriasis in patients with hepatits C poses particular problems, partly because systemic therapies for psoriasis may be more hazardous but also because interferon α, which is frequently used in such patients, may exacerbate psoriasis.[115]

DISORDERS OF BOTH SKIN AND LIVER

(Box 150-6)

BOX 150-6 DISEASES WITH BOTH CUTANEOUS AND HEPATIC INVOLVEMENT

- Argininosuccinic aciduria
- Dermatomyositis
- Drug reactions
- Eruptive neonatal angiomatosis
- Graft-versus-host disease
- Hereditary hemorrhagic telangiectasia (Osler–Weber–Rendu disease)
- Histiocytoses
- Immunodeficiency states
- Mastocytosis
- Mucocutaneous lymph node syndrome (Kawasaki disease)
- Porphyrias
- Porphyria cutanea tarda
- Variegate porphyria
- Erythropoietic (erythrohepatic) porphyria
- Hereditary coproporphyria
- Sarcoidosis
- Syphilis
- Systemic lupus erythematosus
- Tuberous sclerosis
- Vinyl chloride disease

Argininosuccinic aciduria is a rare autosomal recessive disorder characterized by ataxia, seizures, severe mental retardation, hepatomegaly with liver dysfunction, and brittle hair. Dermatomyositis may be the presenting sign of a primary[116] or secondary hepatic tumour. In eruptive neonatal angiomatosis, multiple angiomas may occur anywhere on the skin surface; in addition, vascular lesions may occur in internal organs, including the liver. Both acute and chronic phases of graft-versus-host reactions may have prominent effects on both skin and liver, most commonly in patients receiving bone marrow transplants. In hereditary hemorrhagic telangiectasia, arteriovenous fistulas can cause shunting, and "cirrhosis" (i.e., multiple small telangiectatic hepatic vessels) occurs.[67] Several of the histiocytoses, including Langerhans cell histiocytosis and malignant histiocytosis, may involve both skin and liver. Immunodeficiency states may result in multiple infections of skin and liver. Examples include congenital disorders (e.g., ataxia telangiectasia, Chediak–Higashi syndrome, chronic granulomatous disease) and acquired disorders (e.g., AIDS).

Hepatomegaly occurs in systemic mastocytosis.[82–85] In Kawasaki disease, children may develop upper abdominal pain associated with hepatobiliary changes, nonspecific elevation of liver enzyme levels due to vasculitic changes, or bile duct inflammation.[117] Sarcoidal infiltration of the liver may accompany the cutaneous signs of sarcoidosis. Hepatic granulomas may also occur in tuberculosis, glandular fever, and syphilis, or as a side effect of drugs such as phenylbutazone, allopurinol, and the sulfonamides. True syphilitic hepatitis is rare but may present with pruritus and cholestatic jaundice.

Patients with systemic lupus erythematosus can have abnormal liver tests.[118] The most common cause is drug-induced hepatitis. Thrombotic conditions, including Budd–Chiari syndrome and veno-occlusive disease, occur with or without lupus anticoagulant. Rare abnormalities include nodular regenerative hyperplasia, perihepatitis, and hepatic or splenic rupture. Autoimmune hepatitis, PBC,[119] granulomatous hepatitis, cryptococcal infection, porphyria, or idiopathic portal hypertension[120] may also occur.

Cholestatic hepatitis occurs as a rare complication of Stevens–Johnson syndrome and has been reported to precede the skin signs.[121]

Angiomyolipomas are frequently seen on ultrasound examination of the livers of patients with tuberous sclerosis but are usually asymptomatic. Liver function abnormalities are common in patients with vinyl chloride disease and may be associated with hepatosplenomegaly, cirrhosis, and, rarely, angiosarcoma.

CUTANEOUS MANIFESTATIONS OF PRIMARY BILIARY CIRRHOSIS. The basis for a diagnosis of PBC is a clinical picture of a middle-aged female with jaundice and pruritus, cholestatic liver function tests, antimitochondrial antibodies, and histologic changes in the liver of inflammatory duct destruction with fibrosis and cirrhosis. Severe itching may antedate other features of biliary cirrhosis by months or years.

The combination of the CREST syndrome (calcinosis cutis, Raynaud phenomenon, esophageal dysfunction, sclerodactyly, and telangiectasia) and PBC occurs more often than would be expected by chance and has been termed Raynold syndrome. Patients have a higher incidence of anticentromere antibodies (especially the antiprotein C isotype) and Sjögren syndrome.[122]

Lichen planus has a well-recognized association with PBC and may occur in either the presence or the absence of penicillamine treatment for PBC,[123] and isolated nail involvement has been described.[124] The skin lesions can resolve following liver transplantation.[125] Cutaneous xanthomas also occur with PBC. Rarely, both lichenoid and xanthomatous changes appear in the same lesion.[126]

EFFECTS OF SKIN DISEASE ON THE LIVER

Several systemic complications occur as a consequence of skin disease, and some of them reflect abnormalities of hepatic function.

EXTENSIVE LOSS OF SKIN. Patients may lose large areas of skin because of thermal burns, immunobullous disease, or toxic epidermal necrolysis. In experimental animal models, extensive thermal injury results in a halving of the hepatic arterial blood flow.[127] Postburn sepsis amplifies this injury and induces portal hypertension.[128] This may in turn account for a gut barrier dysfunction (the so-called "dermatogenic enteropathy"), but research has not convincingly demonstrated this relationship in humans with extensive skin disease.

PSORIASIS. The high incidence of abnormalities of the liver architecture in patients with psoriasis has been attributed to alcohol misuse. Psoriasis is more common than expected in alcoholic cirrhosis than in cirrhosis due to other causes.[8,129] Those who misuse alcohol are said to have a unique, acral, distribution of psoriasis.[8] Alcohol appears not only to trigger psoriasis, especially in men, but also to influence the course of the disease, as heavy drinkers have more severe, extensive, inflamed disease. Patients who decrease alcohol consumption may decrease the extent of their disease and increase their response to treatment.[129]

DERMATITIS HERPETIFORMIS. Results of liver function tests are sometimes abnormal in patients with dermatitis herpetiformis[130] and can also occur secondary to treatment or as a result of associated conditions.[131]

SKIN CANCER. Primary cutaneous neoplasms, including melanoma, squamous cell carcinoma, Merkel cell tumor, and Kaposi sarcoma, occasionally metastasize to the liver.

TABLE 150-1
Hepatotoxic Drugs Used in the Treatment of Skin Diseases

Drug	Indication	Side Effect
Azathioprine	Bullous disorders, dermatomyositis	Raised liver enzymes
Cyclosporin	Psoriasis, dermatitis	Raised liver enzymes
Cyproterone acetate	Hirsutism and virilization	May worsen preexisting dysfunction
Danazol	Hereditary angioedema	May worsen preexisting dysfunction and porphyria
Dapsone	Dermatitis herpetiformis, erythema elevatum diutinum, granuloma faciale, and others	May cause dapsone syndrome (rash, eosinophilia fever hepatitis). Avoid in porphyria
Griseofulvin	Fungal infections	May worsen preexisting liver disease
Ketoconazole	Fungal infections	Raised liver enzymes and hepatitis
Methotrexate	Psoriasis, sarcoidosis	Cirrhosis
Minocycline	Acne	Hepatitis
Retinoids	Acne, psoriasis, disorders of keratinization	Elevated liver enzymes, increases hepatotoxicity of methotrexate
Stanozolol	Hereditary angioedema	May worsen preexisting dysfunction and porphyria
Terbinafine	Fungal infections	Hepatitis

HEPATOTOXIC EFFECTS OF DRUGS USED IN THE TREATMENT OF SKIN DISEASE

Several drugs used in managing patients with skin disease are hepatotoxic (Table 150-1). Many others, such as antimalarials or terbinafine, warrant caution in patients with hepatic impairment.

Patients who have psoriasis and who are undergoing long-term treatment with methotrexate are at risk of liver fibrosis and cirrhosis, especially if their total doses exceed 1.5 g, and/or if there is a history of alcohol misuse, impaired renal function, diabetes, and obesity. The definitive diagnosis of fibrosis is histologic but the morbidity of liver biopsy can be as high as 10%, and the mortality up to 0.1%.[133] Reducing the risk factors and careful monitoring probably reduces the need for invasive investigation considerably,[132] especially if more sophisticated screening methods are used. In hepatic fibrosis, the synthesis of predominantly type III collagen is increased, and the amino-terminal propeptide of type III procollagen (PIIINP) is cleaved off and released into the circulation.[134,135] Because it is now possible to measure serum PIIINP levels accurately, this test has become a valuable noninvasive marker of active hepatic fibrogenesis during methotrexate treatment of psoriasis.[136] Thus, the number of liver biopsies taken in patients with normal serial serum PIIINP levels can be reduced to a minimum.[137] Another technique that may prove useful is transient elastography, which has already been used for monitoring patients with Crohn disease.[138] Some preliminary work in methotrexate-treated psoriatics has been reported,[139] but further studies are required.[140]

THE RENAL SYSTEM

The cutaneous manifestations of renal disease are primarily encountered in patients with CRF. In contrast, only two skin changes—edema and uremic frost—occur in acute renal failure (ARF). Edema is a particular feature of ARF with nephrotic syndrome. Uremic frost results from eccrine deposition of urea crystals on the skin surface of individuals with severe uremia. It is now rare because of the wide availability of acute hemodialysis.

CALCIFICATION

Metastatic calcification of the skin in CRF results from secondary or tertiary hyperparathyroidism. Abnormally elevated levels of PTH may trigger deposition of crystalline calcium pyrophosphate in the dermis, subcutaneous fat, or arterial walls.[141] Vascular calcification is common in patients with long-term CRF, and is seldom symptomatic. Occasionally, however, calcified vessels may thrombose acutely, resulting in a syndrome that has been called *calciphylaxis*. This acute thrombosis produces livedoid areas that are excruciatingly painful due to ischemia, and quickly become hemorrhagic and ulcerate (Fig. 150-13). Calciphylaxis is associated with a high mortality, particularly when the skin of the trunk is involved.[141] PTH is usually markedly elevated. The serum calcium and



Figure 150-13 Calciphylaxis. (Used with permission from Suzanne N. Granados, MD.)

phosphate levels, and the calcium-phosphate product, are frequently only minimally elevated and may be normal. Treatment of calciphylaxis includes analgesia debridement of gangrenous tissue, and parathyroidectomy.[141,142]

In addition to vascular calcification and calciphylaxis, nodular calcification may occur in the skin and fat of patients with CRF. These calcium deposits are identical to calcinosis cutis in other disorders, such as tumoral calcinosis or CREST syndrome. The involved skin may ulcerate, but this process occurs in a subacute fashion, without livedo or ischemic pain.

BULLOUS DISEASE OF HEMODIALYSIS

PCT has been described in patients with CRF undergoing hemodialysis.[143] Although the etiology of this phenomenon is still unclear, inadequate clearance of plasma-bound porphyria precursors by urine excretion or hemodialysis[144] may lead to porphyrin deposition in the skin manifested clinically as photosensitivity and subepidermal bullae.[143–147] Patients undergoing hemodialysis may also produce or be exposed to compounds that alter normal heme synthesis.

Bullous dermatosis of dialysis or pseudoporphyria may occur in up to a fifth of patients undergoing hemodialysis.[143,145,147] This condition is often clinically indistinguishable from PCT with marked skin fragility and blister formation on sun-exposed skin (see Chapter 132). However, hypertrichosis is less common, and plasma porphyrin levels are typically normal.[143,145] Pseudoporphyria may also occur in some patients taking tetracycline, nabumetone, nalidixic acid, furosemide, and phenytoin.[143]

When treating PCT or pseudoporphyria, phlebotomy can reduce iron levels in the liver, allowing new hepatic uroporphyrinogen decarboxylase to be formed.[148] However, patients with end-stage renal disease often have significant anemia and cannot tolerate phlebotomy. Intravenous erythropoietin[147] may both lower total body iron stores and support phlebotomy as needed.[146,148] Chloroquine effectively clears porphyrins from the liver. In patients with CRF, however, porphyrins may not be effectively cleared by hemodialysis or excreted in the urine.[147] Deferoxamine may lower serum porphyrin levels in some patients.[146] Others may require renal transplantation to obtain complete resolution of symptoms.[146]

ACQUIRED PERFORATING DERMATOSES

Acquired perforating dermatosis can occur in association with CRF and diabetes mellitus (see Chapter 69)[149] This condition occurs in up to 10% of patients undergoing hemodialysis[150,151] and appears to be distinct from the four primary perforating disorders elastosis perforans serpiginosa, Kyrle disease, perforating folliculitis, and reactive perforating collagenosis.[152] Clinically, patients develop hyperkeratotic papules with a central crust-filled crater on the trunk and extensor surfaces, often in a linear distribution.[150] Simultaneous transepidermal elimination of both collagen and elastic fibers has been detected.[151]

Proposed mechanisms for the etiology of this process include diabetic microangiopathy, dysregulation of vitamin A or vitamin D metabolism, abnormality of collagen or elastic fibers, or inflammation and connective tissue degradation caused by dermal deposition of substances such as uric acid and calcium pyrophosphate.[153] Many authorities regard this entity as a response to trauma caused by scratching in chronic renal pruritus. Successful treatment depends on addressing the underlying etiology of pruritus. Topical and intralesional glucocorticoids, topical and systemic retinoids, cryotherapy, and ultraviolet light may be useful.[150,151]

NEPHROGENIC FIBROSING DERMOPATHY

Nephrogenic fibrosing dermopathy (NFD),[154] resembling scleromyxedema in some of its aspects,[155] largely occured in patients with end stage renal disease, most of whom were on hemodialysis. NFD also has been described in a few patients with ARF. Clinically, patients progressively develop erythematous, sclerotic dermal plaques on the arms and legs, with sparing of the head and neck. Pruritus is a common feature. The histopathology of NFD similarly resembles that of scleromyxedema, with proliferation of fibroblasts in the dermis and subcutaneous septae, accompanied by increased dermal and septal collagen and mucin.[156] It is now clear that NFD is closely linked to the use of gadolinium contrast in magnetic resonance procedures.[157]

LOWER LIMBS

In acquired clotting defects, such as thrombocytopenia and vascular fragility, purpuric lesions, ranging from pinpoint-sized spots to large ecchymoses, occur. They may be transient and recurrent, and they are sometimes accompanied by follicular hyperkeratosis.[3]

CHOLESTEROL EMBOLI

In patients with advanced atherosclerosis of the abdominal aorta, cholesterol crystals may microembolize to the lower extremities, particularly after invasive vascular procedures or surgery (see Chapter 173). The pulses may remain normal. Patients complain of pain in the legs, buttocks, and low back, as well as myalgia, restless legs, and abdominal symptoms. Livedo reticularis may affect the lower abdomen and back, buttocks, and legs. Ulcers on the legs and feet, surrounded by an erythematous or violaceous halo and a small scab, may be present. Digital cyanosis and gangrene may simulate necrotizing vasculitis (Fig. 150-14). Indurated plaques and nodules are firm, violaceous, painful, and necrotic in the center. Deep skin biopsy of areas of livedo reticularis or adjacent to nodules or ulceration reveal occlusions of arterioles by multinucleated foreign-body giant cells and fibrosis surrounding biconvex, needle-shaped clefts corresponding to the cholesterol crystal microemboli.[158]

POSTBYPASS SKIN CHANGES

Coronary artery bypass surgery is commonly performed using the superficial veins of the legs as donor-graft sites. Dermatitis has been reported to occur along the saphenous vein graft scars on the medial aspect of the legs 2–6 months after surgery. Patients have no history of venous stasis, thrombophlebitis, ankle edema, or skin disease. Examination reveals a reddish-brown, scaling and fissured dermatitis along the distal part of a well-healed saphenous vein graft scar. The dermatitis responds to topical steroids but recurrence is usual and most patients require continued treatment. The cause may be due to postoperative thrombophlebitis and stasis dermatitis.

Recurrent cellulitis may develop in the healed vein graft many months after surgery. Erythema may extend along the entire vein graft site, accompanied by pain and tenderness. Swelling may be significant. Beta-hemolytic streptococcus has been isolated. The presence of tinea pedis has been reported and patients should be assessed and treated prior to surgery.



Figure 150-14 Cholesterol emboli: blue toe and infarctions.

KEY REFERENCES

Full reference list available at www.DIGM8.com

DVD contains references and additional content

3. Koulaouzidis A, Bhat S, Moschos J: Skin manifestations of liver diseases *Ann Hepatol* **6**(3):181-184, 2007
8. Smith KE, Fenske NA: Cutaneous manifestations of alcohol abuse. *J Am Acad Dermatol* **43**(1 Pt 1):1-16; quiz 16-8, 2000
14. Zein CO, Lindor KD: Latest and emerging therapies for primary biliary cirrhosis and sclerosing cholangitis. *Curr Gastroenterol Rep* **12**(1):13-22, 2010
19. Mettang M, Weisshaar E. Pruritus: control of itch in patients undergoing dialysis. *Skin Therapy Lett* **15**(2):1-5, 2010
30. Hill CL, Zhang Y, Sigurgeirsson B et al: Frequency of specific cancer types in dermatomyositis and polymyositis: a population-based study. *Lancet* **357**(9250):96-100, 2001
33. Kurzrock R, Cohen PR: Cutaneous paraneoplastic syndromes in solid tumors. *Am J Med* **99**(6):662-671, 1995
64. Marie I, Dominique S, Levesque H et al: Esophageal involvement and pulmonary manifestations in systemic sclerosis. *Arthritis Rheum* **45**(4):346-354, 2001
75. Keane MP, Lynch JP, 3rd: Pleuropulmonary manifestations of systemic lupus erythematosus. *Thorax* **55**(2):159-166, 2000
91. Tsao H: Update on familial cancer syndromes and the skin. *J Am Acad Dermatol* **42**(6):939-969, quiz 970-972, 2000
92. Doxey BW, Kuwada SK, Burt RW. Inherited polyposis syndromes: molecular mechanisms, clinicopathology, and genetic testing. *Clin Gastroenterol Hepatol*, **3**(7):633-641, 2005
97. Steen V. Targeted therapy for systemic sclerosis. *Autoimmun Rev*, **5**(2):122-124, 2006
115. Frankel AJ, Van Voorhees AS, Hsu S et al. Treatment of psoriasis in patients with hepatitis C: From the Medical Board of the National Psoriasis Foundation. *J Am Acad Dermatol* **61**:1044-1055, 2009
132. Kolbe RE, Strober B, Weinstein G, Lebwohl M. Methotrexate and psoriasis: 2009 National Psoriasis Foundation Consensus Conference. *J Am Acad Dermatol*. **60**(5):824-837, 2009
135. Zachariae H. Have methotrexate-induced liver fibrosis and cirrhosis become rare? A matter for reappraisal of routine liver biopsies. *Dermatology*, **211**(4):307-308, 2005
157. Weinreb JC, Abu-Alfa AK. Gadolinium-based contrast agents and nephrogenic systemic fibrosis: why did it happen and what have we learned? Gadolinium-based contrast agents and nephrogenic systemic fibrosis: why did it happen and what have we learned? *J Magn Reson Imaging*. 2009 Dec;**30**(6):1236-1239, 2009

Chapter 151 :: Diabetes Mellitus and Other Endocrine Diseases

:: Andrea A. Kalus, Andy J. Chien, & John E. Olerud

DIABETES MELLITUS

DIABETES MELLITUS AT A GLANCE

- The incidence of diabetes in America is increasing steadily with the epidemic of obesity.
- Eleven percent of health care expenditures in America are diabetes related.
- Metabolic abnormalities in glucose and insulin relate directly to diabetic thick skin, limited joint mobility, eruptive xanthomas, and acanthosis nigricans.
- Neuropathy, vasculopathy, and immune dysfunction associated with diabetes contribute directly to lower extremity ulcers and certain cutaneous infections.
- Diabetes-associated skin conditions without a known pathogenesis include: necrobiosis lipoidica, granuloma annulare, diabetic dermopathy, acquired perforating dermatosis, and bullosis diabeticorum.

EPIDEMIOLOGY

Diabetes mellitus (DM) is a major cause of morbidity and mortality in the United States. More than 24 million Americans have the disease[1], and approximately 11% ($92 billion) of all health care expenditures in the United States were directly attributable to the medical care of diabetes in 2002.[2] Men and women diagnosed with diabetes at age 40 years are expected to lose 12 and 14 life-years, respectively.[3] Major studies have shown that tight glycemic control decreases microvascular disease, i.e., retinopathy, neuropathy, nephropathy, however, coronary vascular disease, the major contributor to morbidity and mortality in patients with diabetes, showed no benefit from intensive glycemic control for patients with a known 10-year duration of diabetes. In one large randomized controlled trial with about a third of patients with known coronary artery disease, intensive glycemic control was, in fact, associated with an increase in mortality. Newly diagnosed type 2 diabetes appears to have long-term benefit from similar degrees of tight control.[4] New guidelines for glycemic control (HbA1c <7%) attempt to balance this body of evidence. The data and guidelines have been recently reviewed.[5] Tight glycemic control may have a beneficial effect on a subset of skin-related, diabetes-associated disorders, but evidence is generally lacking.

Diabetes is characterized by a state of relative or complete insulin deficiency, leading to gross defects in glucose, fat, and protein metabolism. In type 1 diabetes (formerly insulin-dependent DM), an insufficiency of insulin occurs through a gradual, immune mediated destruction of β islet cells in the pancreas, marked by autoantibodies. In type 2 diabetes (formerly noninsulin-dependent DM), chronic hyperglycemia occurs mainly through end-organ insulin resistance followed by a progressive decrease in pancreatic insulin release associated with aging. A fasting blood glucose level of ≥126 mg/dL or a random value of ≥200 mg/dL on two separate occasions confirms the diagnosis of diabetes. Diabetes may also now be diagnosed with an HbA1c level ≥6.5%. A genetic predisposition and a strong association with obesity exist in type 2 diabetes. In both types of diabetes, abnormalities of insulin and elevated blood glucose levels lead to metabolic, vascular, neuropathic, and immunologic abnormalities. Affected organs include the cardiovascular, renal, and nervous systems, the eyes, and the skin.

ETIOLOGY AND PATHOGENESIS

Nearly all patients with diabetes have cutaneous findings related to their condition, including those listed in Box 151-1. Some diabetes-associated skin conditions are a direct result of the related metabolic changes such as hyperglycemia and hyperlipidemia. Progressive damage to the vascular, neurologic, or immune systems also contributes significantly to skin manifestations. The mechanisms for other diabetes-associated skin conditions remain unknown.

Hyperglycemia leads to nonenzymatic glycosylation (NEG) of various structural and regulatory proteins, including collagen. Although NEG occurs normally with aging, the process is greatly accelerated in diabetes.[6,7] NEG leads to the formation of advanced glycation end products (AGEs) that are responsible for decreases in both acid solubility and enzymatic digestion of cutaneous collagen. Disorders such as diabetic thick skin and limited joint mobility (LJM) are thought to result directly from accumulation of AGEs.[8] Studies show that the degree of cutaneous AGEs correlates strongly with retinopathy, nephropathy, and other microvascular complications of diabetes.[9]

Derangements of immunoregulatory mechanisms also occur in diabetes. Hyperglycemia and ketoacidosis diminish chemotaxis, phagocytosis, and

BOX 151-1 APPROACH TO PATIENT WITH DIABETES

CUTANEOUS FINDINGS IN DIABETES

- Acanthosis nigricans
- Limited joint mobility and scleroderma-like syndrome
- Scleredema diabeticorum
- Eruptive xanthomas
- Bacterial infections (streptococcal, malignant external otitis, necrotizing fasciitis)
- Fungal infections (candidal, onychomycosis, mucormycosis)
- Foot ulcers
- Necrobiosis lipoidica
- Granuloma annulare
- Diabetic dermopathy
- Acquired perforating disorders
- Bullosis diabeticorum

RELATED FEATURES IN DIABETES

- Retinopathy
- Nephropathy
- Neuropathy
- Cardiovascular disease
- Peripheral vascular disease
- Hyperlipidemia
- Hypertension

DIAGNOSIS

- In the absence of symptoms, the diagnosis must be confirmed by two separate abnormal tests, fasting blood glucose of ≥126 mg/dL or random value of ≥200 mg/dL.
- Hemoglobin A1C is increasingly being used in conjunction with fasting plasma glucose for the diagnosis of diabetes mellitus.

MANAGEMENT

- Diet and exercise.
- Referral to primary care provider or endocrinologist for medical management with either oral hypoglycemic agents or insulin.
- Always perform a foot examination.
- Address modifiable risk factors.

bactericidal ability of white blood cells.[10] Historically, infections were a major cause of death in the diabetic patient. This has changed dramatically with improved glucose control and antibiotic use. Despite these improvements, certain infections, such as malignant external otitis, necrotizing soft tissue infections, and the devastating disease of mucormycosis, occur more frequently in patients with diabetes.[11]

Metabolic abnormalities, including hyperinsulinemia, as is seen in early insulin-resistant type 2 diabetes, can contribute to cutaneous manifestations as well. The action of insulin on the insulin-like growth factor-1 (IGF1) receptor appears to mediate the abnormal epidermal proliferation and resulting phenotype of acanthosis nigricans.[12] Dysregulated lipid metabolism occurs with diabetes-associated insulin deficiency. The activity of lipoprotein lipase (LPL) is directly dependent on insulin,[13] making insulin central to the processing of triglyceride-rich chylomicrons and very-low-density lipoproteins. In insulin-deficient diabetic patients, defective lipid processing can lead to massive hypertriglyceridemia, manifesting in the skin as eruptive xanthomas. Naturally, disorders of lipid processing also play an integral role in the vasculopathies of diabetes.

Macro- and microangiopathy contribute significantly to the cutaneous complications of diabetes. In patients with diabetes, there is increased "leakiness" or vessel wall permeability, decreased vascular responsiveness to sympathetic innervation, and less ability to respond to thermal and hypoxemic stress.[10] In combination with arteriosclerosis of large vessels, these microvascular abnormalities contribute to the formation of diabetic ulcers. In addition, a loss of cutaneous sensory innervation occurs with diabetes, predisposing patients to infection and injury. The loss of neuroinflammatory cell signaling plays a causal role in nonhealing, lower extremity ulcers.[14] Patients with diabetes who lack lower extremity vibratory perception have a 15.5-fold increased probability of leg amputation.[15]

The cutaneous disorders associated with DM are characterized in the following section by disorders with evidence for metabolic, vascular, neurologic, or immunologic pathogenesis induced by glucose and insulin abnormalities and by disorders associated with diabetes, but without a clear pathogenesis (see below).

CUTANEOUS DISORDERS OF DIABETES MELLITUS ASSOCIATED WITH METABOLIC, VASCULAR, NEUROLOGIC, OR IMMUNOLOGIC ABNORMALITIES

ACANTHOSIS NIGRICANS

EPIDEMIOLOGY. Acanthosis nigricans is probably the most readily recognized skin manifestation of diabetes. Acanthosis nigricans is common in the general population, and most cases are linked to obesity and insulin resistance. In some cases, increased androgen production is also identified.[16,17] Drug-related and idiopathic acanthosis nigricans or familial acanthosis nigricans have been reported.[18] In general, though, acanthosis nigricans should be considered a prognostic indicator for developing type 2 diabetes.[19] The prevalence of acanthosis nigricans varies among different ethnic groups. In one study, despite similar obesity rates, the prevalence was lower in whites (0.5%)

and Hispanics (5%) than in African-American children (13%).[17] This finding suggests a possible genetic predisposition or increased sensitivity of the skin to hyperinsulinemia among certain populations.[19] Although historical data have emphasized the relationship between acanthosis nigricans and malignancy, a true association is rare. Only when the onset is particularly rapid, the clinical findings are florid, or in the nonobese or nondiabetic adult with acanthosis nigricans is an evaluation for malignancy beyond routine age appropriate screening warranted. In one author's experience with seeing more than 12,000 patients with cancer, only two developed acanthosis nigricans.[20]

ETIOLOGY AND PATHOGENESIS. Advances are taking place in understanding the pathogenesis of acanthosis nigricans. Insulin clearly plays a central role in the presentation of acanthosis nigricans. In a subset of women with hyperandrogenism and insulin resistance with acanthosis nigricans, loss of function mutations in the insulin receptor or anti-insulin receptor antibodies can be found (type A and type B syndrome).[21] It is postulated that excess growth factor stimulation in the skin causes the aberrant proliferation of keratinocytes and fibroblasts that results in the phenotype of acanthosis nigricans.[16] In states of insulin resistance and hyperinsulinemia, acanthosis nigricans may result from excess insulin binding to IGF1 receptors on keratinocytes and fibroblasts.[12] IGF1 receptors are expressed on basal keratinocytes and are upregulated in proliferative conditions.[22] Studies show that high concentrations of insulin stimulate fibroblast proliferation through IGF1 receptors in vitro.[23] Other members of the tyrosine kinase receptor family, including the epidermal growth factor receptor and the fibroblast growth factor receptor, have been implicated in acanthosis nigricans. Several genetic syndromes [Crouzon and SADDAN (severe achondroplasia with developmental delay and acanthosis nigricans)] with mutations in fibroblast growth factor receptor 3 result in acanthosis nigricans in the absence of hyperinsulinemia or obesity, implicating this growth factor receptor in the pathogenesis of acanthosis nigricans.[22] In several reports of acanthosis nigricans associated with malignancy, evidence suggests that transforming growth factor-β released from the tumor cells may stimulate keratinocyte proliferation via the epidermal growth factor receptors.[24,25] Support for the role of different growth factors in the pathogenesis of acanthosis nigricans continues to accrue.

In addition to the direct effects of hyperinsulinemia on keratinocytes, insulin also appears to augment androgen levels in women. High insulin levels stimulate the production of ovarian androgens and ovarian hypertrophy with cystic changes.[21] Although associated with elevated androgen levels, the acanthosis nigricans in women with polycystic ovarian syndrome (PCOS) does not respond reliably to antiandrogen therapy, implicating the relative importance of hyperinsulinemia over hyperandrogenism in acanthosis nigricans. Several drugs have also been reported to cause acanthosis nigricans, including systemic glucocorticoids, nicotinic acid, and estrogens such as diethylstilbestrol.[16]



Figure 151-1 Acanthosis nigricans involving the neck.

CLINICAL FINDINGS: CUTANEOUS LESIONS. Clinically, acanthosis nigricans presents as brown to gray-black papillomatous cutaneous thickening in the flexural areas, including the posterolateral neck, axillae, groin, and abdominal folds. The distribution is usually symmetric. The affected skin has a dirty, velvety texture. In some cases, oral, esophageal, pharyngeal, laryngeal, conjunctival, and anogenital mucosal surfaces may be involved. In general, however, the back of the neck is the most consistently and severely affected area[19] (Fig. 151-1). The development of superimposed acrochordons in involved areas is well described (Fig. 151-2). In particularly florid cases, involvement on the back of the hands over the knuckles and even on the palms can be seen. When the palms are involved, the rugated appearance of the palmar surface has been called *tripe palms* and is usually associated with acanthosis nigricans seen in the



Figure 151-2 Acanthosis nigricans involving the axilla with numerous acrochordons.

setting of malignancy. In the majority of cases, the most important factor in diagnosing acanthosis nigricans is recognizing the usually associated hyperinsulinemia, which is a known risk factor for type 2 diabetes and the metabolic syndrome.

The histopathology of clinical lesions demonstrates papillomatosis and hyperkeratosis but minimal acanthosis. Hyperpigmentation of the basal layer has been variably demonstrated and the brown color of the lesions is attributed to the hyperkeratosis by most.[26,27]

TREATMENT. Treatment of acanthosis nigricans is generally ineffective. Topical treatment with calcipotriol,[28] salicylic acid, urea, systemic, and topical retinoids have all been used with anecdotal success.[29] When identifiable, treatment of the underlying cause may be beneficial. Improvement or resolution does occur with weight loss in some obese patients.[12,16] Medications that improve insulin sensitivity, such as metformin, have a theoretic benefit. Removal of an offending medication generally results in clearance of the skin.[30] In patients with acanthosis nigricans in association with malignancy, there is usually improvement following treatment of the underlying malignancy. The skin finding may present before or after the diagnosis of malignancy is made. When it is associated with malignancy, a tumor of intraabdominal origin, usually gastric, is seen in the majority of cases.[31] It has been repeatedly described that patients' skin improves with chemotherapy and remits with recurrences.

DIABETIC THICK SKIN

Several specific syndromes are associated with localized thickening of the skin in diabetes. The common underlying pathogenesis involves biochemical alterations in dermal collagen and mucopolysaccharides. The clinical syndromes are a result of increased deposition and improper degradation of these constituents, likely related to the formation of AGEs.

LIMITED JOINT MOBILITY AND SCLERODERMA-LIKE SYNDROME

Diabetic LJM, or cheiroarthropathy, presents as tightness and thickening of the skin and periarticular connective tissue of the fingers, resulting in a painless loss of joint mobility. Initial involvement of the distal interphalangeal joints of the fifth digit usually progresses proximally to involve all fingers. Larger joints of the elbow, knee, and foot may be affected. The actual joint space, however, remains uninvolved, so that LJM is not a true arthropathy. This disorder is characterized by the "prayer sign," which is an inability to approximate the palmar surfaces and interphalangeal joint spaces with the hands pressed together and fingers separated (Fig. 151-3). In addition to joint contractures, the skin may appear thickened, waxy, and smooth with apparent loss of adnexa, resembling skin changes in scleroderma.

Thirty to fifty percent of adult patients with type 1 diabetes have LJM, and it is common in type 2 diabetes as well. LJM is associated with increased duration of diabetes and poor glucose control.[32,33] One longitudinal prospective study showed a 2.5-fold increase in the risk of LJM for every unit increase in the glycosylated hemoglobin.[33] In addition, it appears that LJM may be correlated with the presence of microvascular disease.[34]



Figure 151-3 Limited joint mobility in a 31-year-old male patient with type 1 diabetes mellitus. The patient is unable to approximate the palmar surface of the proximal and distal interphalangeal joints with palms pressed together (known as the *"prayer sign"*). **A.** Ulnar view; only fingertips are approximated. **B.** Radial view; straining to press palms together.

Most important, the evidence indicates that intensive insulin therapy is central in prevention and, possibly, treatment of LJM and scleroderma-like syndrome. Long-term tight glycemic control leads to decreased skin AGEs,[9] and tight glycemic control is associated with delayed onset and severity of LJM.[33] On the basis of improvements in diabetes management, a fourfold reduction in the frequency of LJM over the last 20 years was reported.[35] Treatment for LJM is difficult and should focus on tight control of blood sugar as well as physical therapy to preserve active range of motion.

Although the scleroderma-like skin changes can occur independently, they often occur together with LJM in patients with diabetes. The scleroderma-like syndrome is not associated with systemic sclerosis but does correlate with the duration of diabetes, the severity of joint contractures, and retinopathy.[36] It seems likely that the historical description of "diabetic hand syndrome" represents a combination of LJM and the scleroderma-like syndrome.

SCLEREDEMA DIABETICORUM

(See Chapter 158)

Recognized in 1970 as a syndrome,[37,38] scleredema of diabetes (scleredema diabeticorum) presents with the insidious onset of painless, symmetric induration and thickening of the skin on the upper back and neck. Spreading to the face, shoulders, and anterior torso may occur. The skin retains a nonpitting, woody, *peau d'orange* quality. Identical changes occur with postinfectious scleredema, usually associated with streptococcal pharyngitis. In scleredema associated with infection, however, the onset is often sudden, and the symptoms usually remit over time. Scleredema diabeticorum affects 2.5%–14% of patients with diabetes.[39,40] Scleredema diabeticorum is a disease of long-standing diabetes associated with obesity. Most patients have type 2 diabetes. This disorder has not been reported in children.

The pathogenesis of scleredema diabeticorum is postulated to be unregulated production of extracellular matrix molecules by fibroblasts, leading to thickened collagen bundles and increased deposition of glycosaminoglycans (GAGs, mainly hyaluronic acid). Studies using in vitro fibroblast analysis from involved skin have variably demonstrated increased synthesis of GAGs and type I collagen.[41] However, most of these reports involved nondiabetic patients with paraproteinemia and are based on small numbers of cases.

Patients with scleredema diabeticorum may experience decreased sensation to pain and light touch over the affected areas and difficulties with upper extremity and neck range of motion. Extreme cases may result in full loss of range of motion. Unlike in LJM and scleroderma-like syndrome, the presence of scleredema does not correlate with retinopathy, nephropathy, neuropathy, or principal vascular disease.[39] However, no large-scale prospective studies have been done. Most patients with scleredema diabeticorum become insulin dependent are difficult to treat, and have multiple complications of diabetes.[41] Treatment for scleredema diabeticorum is usually unsuccessful. Case reports describe treatment with radiotherapy, low-dose methotrexate, bath psoralen and ultraviolet A light (PUVA), extracorporeal photopheresis, factor XIII, and prostaglandin E_1.[38,42,43] Weight reduction and physical therapy to preserve range of motion may be useful.

ERUPTIVE XANTHOMAS

(See Chapter 135)

Eruptive xanthomas present clinically as 1- to 4-mm, reddish-yellow papules on the buttocks and extensor surfaces of the extremities (Fig. 151-4). The lesions occur in crops and may coalesce into plaques over time. Although eruptive xanthomas are generally asymptomatic, there is often underlying severe hypertriglyceridemia (>1,000 mg/dL) and potentially undiagnosed diabetes. Histologic and biochemical studies show that lipoproteins (mainly chylomicrons) in the blood permeate cutaneous vessel walls and accumulate in macrophages in the dermis.[44] Initially, triglycerides predominate in the skin lesions but, because triglycerides are mobilized more easily than cholesterol, the lesions contain progressively more cholesterol as they resolve.[44] Whether this mechanism plays a role in the atherosclerosis of large arteries is unknown.

Insulin is an important regulator of LPL activity. The degree of enzymatic dysfunction and subsequent clearing of serum triglycerides is proportionate to the amount of insulin deficiency and hyperglycemia.[13] Clearance of plasma lipoproteins depends on adequate insulin.[45] In uncontrolled diabetes, this inability to metabolize and clear triglyceride-rich chylomicrons and very-low-density lipoproteins can lead to plasma triglyceride levels in the thousands. Uncontrolled diabetes is a common cause of massive hypertriglyceridemia.

In addition to eruptive xanthomas, triglyceride levels above 4,000 may cause lipemia retinalis. On funduscopic examination, lipemia retinalis appears as pale pink to white retinal arterioles and venules.



Figure 151-4 Eruptive xanthomas appear as yellow–orange papules and plaques on a male patient with type 2 diabetes mellitus. (Used with permission from Greg Raugi, MD.)

The fundus may have a milky hue. Untreated, severe hypertriglyceridemia may also present clinically with abdominal pain, hepatosplenomegaly, pancreatitis, or dyspnea from decreased pulmonary diffusing capacity and abnormal hemoglobin oxygen affinity.[46] Treatment of hypertriglyceridemia involves strict dietary fat restrictions and control of the underlying diabetes. LPL activity returns to normal after treatment with long-term insulin or oral glucose-lowering agents.[13] The eruptive xanthomas respond rapidly and usually resolve completely in 6–8 weeks.[47]

CUTANEOUS INFECTIONS

In diabetic patients, there is not strong evidence for an increased susceptibility to infections in general, but several skin infections do occur more commonly, with greater severity, or with a greater risk for complications in patients with DM. Joshi et al have reviewed this subject.[11]

There is extensive research on the pathogenesis of immune dysfunction in diabetes. Although some studies could not detect defects at the cellular level,[48] other studies show that leukocyte chemotaxis, adherence, and phagocytosis are impaired in patients with diabetes, especially during hyperglycemia and diabetic acidosis.[49] Further studies show that cutaneous T-cell function and response to antigen challenge are also decreased in diabetes.[11] Some of the skin infections which occur more commonly or more severely in diabetic patients are shown in Table 151-1.

DIABETIC ULCERS

EPIDEMIOLOGY. Foot ulcers are a significant problem for patients with diabetes, occurring in 15%–25% of diabetic patients.[50] Patients with diabetes have an estimated increased risk of lower extremity amputation that is 10–30 times greater than the general population. Lower extremity ulcers were the proximal cause of amputation in 67 of 80 patients (84%) in a study by Pecoraro et al.[51] In diabetic patients with foot ulcers, 14%–24% will eventually undergo amputation.[52] The attributable cost of treating a diabetic foot ulcer, excluding the cost of amputation, was estimated to be $28,000 in a 1999 US study.[53]

ETIOLOGY AND PATHOGENESIS. Many of the factors previously described in this chapter contribute to the pathogenesis of diabetic ulcers. Peripheral neuropathy, pressure, and trauma are felt to play prominent roles in the development of diabetic ulcers. Neuropathy (associated with uncontrolled hyperglycemia) is one of the major predictors of diabetic ulcers.[15] Patients with diabetes also suffer the loss of cutaneous sensory nerves.[54] The subsequent diminished neuroinflammatory signaling via neuropeptides to keratinocytes, fibroblasts, endothelial cells, and inflammatory cells may adversely affect wound healing.[55] Excessive plantar pressure develops from foot deformities (Charcot arthropathy), as a result of LJM related to NEG, and from callus formation. Ill-fitting shoes and socks were the most common reasons for foot ulcers in a study of 314 diabetic patients with ulcers.[56] By wearing running shoes, patients with diabetes had a measurable reduction of calluses in one study.[57] Callus formation is a sign of excess friction and often precedes foot ulcers. Once an ulcer develops, peripheral vascular disease and intrinsic wound healing disturbances contribute to adverse outcomes. Known factors associated with foot ulceration in the setting of diabetes include previous foot ulceration, prior lower extremity amputation, long duration of diabetes (>10 years), impaired visual acuity, onychomycosis, and poor glycemic control. Boyko and colleagues have recently published a prediction model for foot ulceration based on the relative contributions of these factors.[58]

CLINICAL FINDINGS. Callus formation precedes necrosis and breakdown of tissue over bony prominences of feet, usually on great toe and sole, over first and/or second metacarpophalangeal joints. Ulcers are surrounded by a ring of callus and may extend to underlying joint and bone (Fig. 151-5). Complications are soft tissue infection and osteomyelitis.

TABLE 151-1
Infections More Common or Severe in Diabetes

Bacteria	Fungal and Yeast
▪ Invasive Group B Strep	▪ Candida
▪ Invasive Group A Strep	▪ Dermatophyte
▪ Malignant external otitis	▪ Rhinocerebral Mucormycosis
▪ Necrotizing fasciitis	



Figure 151-5 "Diabetic foot." Two larger ulcers overlying the first right and second left metacarpophalangeal joints in a 56-year-old man with diabetes of 20 years' duration. There is significant sensory neuropathy and peripheral vascular disease.

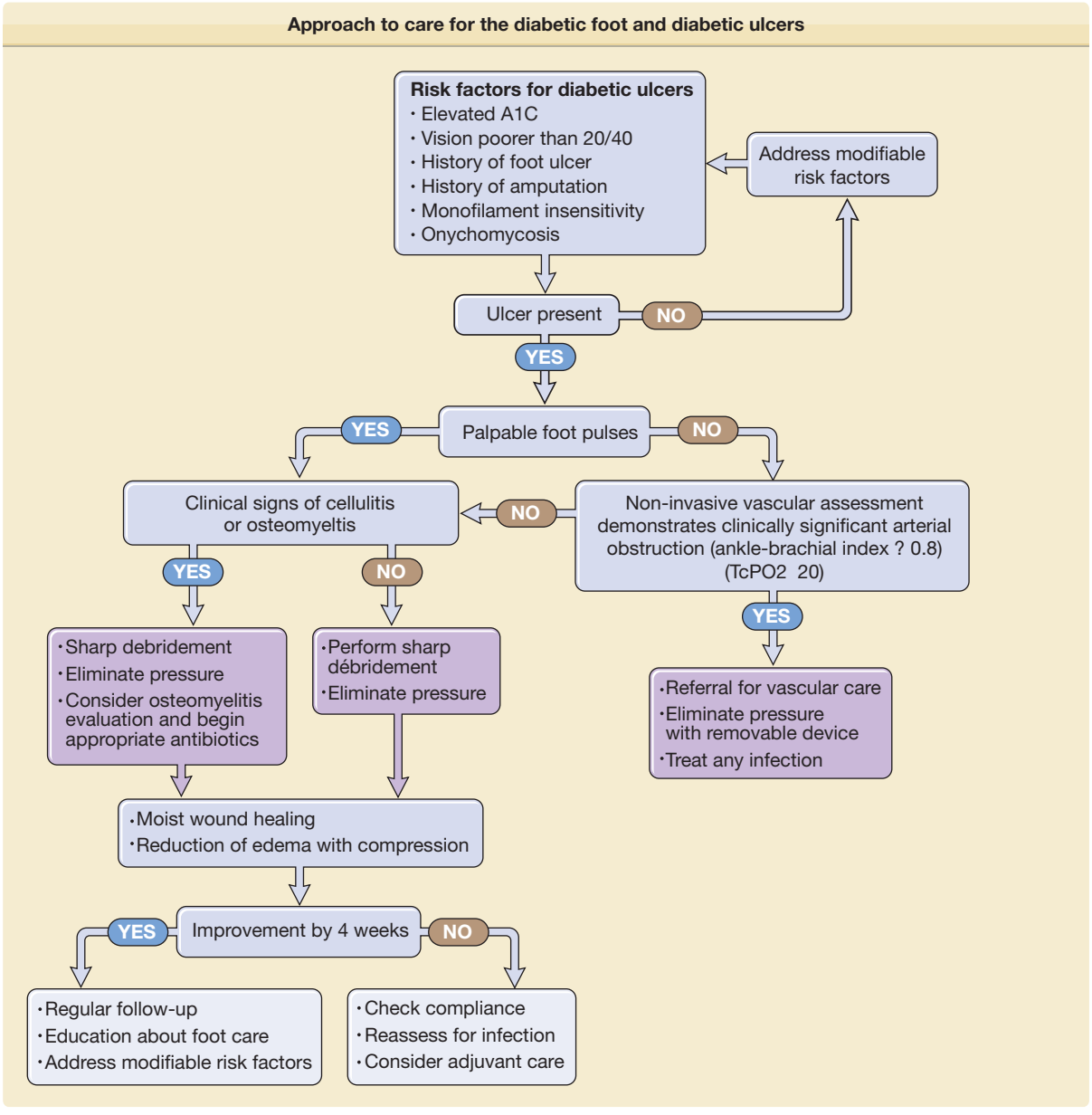

Figure 151-6 Approach to the care of the diabetic foot and diabetic ulcers. A1C = hemoglobin A1C; $TcPO_2$ = transcutaneous oxygen tension.[178]

TREATMENT. Treatment of diabetic ulcers requires modification of factors that contribute to ulcer formation, for example, stasis dermatitis, leg edema, and skin infection. Standard therapy for neuropathic diabetic ulcers includes debridement, off-loading (often nonweight bearing), moist wound care, and protective dressings (Fig. 151-6).

There has been substantial interest in developing adjunctive therapies for diabetic ulcers, including growth factors and skin-replacement products, but data have not supported their use as a replacement for standard wound care. Recombinant platelet-derived growth factor for the topical treatment of diabetic foot ulcers demonstrates a modest benefit if used with adequate off-loading, debridement, and control of infection.[59] A large multicenter, clinical trial of a bilayered living skin equivalent[60] showed 56% healing at 12 weeks as compared with 38% healing for standard care. The most favorable published results for a monolayered living skin equivalent and platelet-derived growth factor show roughly comparable improvement in healing to that reported for bilayered living skin equivalents when each is compared with standard care or placebo.[60] These technologies await definitive analysis of cost effectiveness compared with standard older approaches. While studies available do not support the routine use of these biologic approaches they may have a role in the treatment of large ulcers (>2 cm) or ulcers poorly responsive to standard therapy. A recent meta-analysis makes the points that typically a higher percentage of ulcers heal during a 12-week study period with biologic products, but analysis of cost effectiveness is made difficult by

differences in study designs, short duration of studies, different cost structures, the absence of quality of life measures and pharmaceutical funding of the primary studies and analysis.[61]

PREVENTION. Ulcer prevention is the most important intervention physicians and other health care professionals can provide for diabetic patients. An excellent review of ulcer prevention was published by Singh et al.[50] Optimizing glycemic control is well supported to prevent the neuropathy that is so intimately associated with foot ulceration. In a recent study, the risk of a foot ulcer increased in nearly direct proportion to every 1% increase in hemoglobin A1C.[58] Foot examination should be part of every patient visit if diabetes is on the problem list. Failure to perceive touch by a Semmes-Weinstein 10-g monofilament means a patient lacks protective sensation in the foot tested. If tinea pedis is present, it should be treated to prevent the associated skin barrier disruption. Smoking cessation should be encouraged. Patients should be counseled about the importance of daily foot care (Box 151-2).

Specialized ulcer care teams have published impressive results on the prevention and healing of ulcers.[62] This multidisciplinary team approach is becoming more important in the treatment of diabetic ulcers in large population centers. Patients with a history of ulceration are at high risk for reulceration (34% at 1 year, 61% at 3 years, and 70% at 5 years).[56] Intensifying education (formal foot care classes) and prevention efforts in this group along with lifelong surveillance is required.

BOX 151-2 GENERAL FOOT CARE GUIDELINES FOR PATIENTS WITH DIABETES

- Examine feet every day, including areas between the toes.
- Regular washing of feet with careful drying, especially between the toes.
- Water temperature should always be less than 37°C (98.6°F) and checked first with the hand rather than the foot.
- Barefoot walking in- or outdoors and wearing of shoes without socks is discouraged.
- Daily inspection and palpation of the inside of the shoes for irregular surfaces or foreign objects.
- If vision is impaired, patients should not try to treat their feet (e.g., nails) by themselves.
- Emollients should be used for dry skin but not between the toes.
- Change stockings daily.
- Wearing of stockings with seams inside out or preferably without any seams at all.
- Nails should be cut straight across.
- Corns and calluses should not be cut by patients but by a health care provider.
- The patient must ensure that the feet are examined regularly by a health care provider.
- The patient should seek early health care attention for any blister, cut, scratch, sore, ingrown toenail, or dermatitis.

DISORDERS ASSOCIATED WITH DIABETES MELLITUS BUT OF UNKNOWN PATHOGENESIS

NECROBIOSIS LIPOIDICA

EPIDEMIOLOGY AND PATHOGENESIS. Coined by Urbach in 1932 as *necrobiosis lipoidica diabeticorum*, this disorder was named after characteristic histologic findings and was first described in patients with diabetes. Because not all patients have concurrent diabetes, the shortened term, *necrobiosis lipoidica* (NL) is preferred. Epidemiologic data show that the mean age of onset is around 30 years, with women representing three times more cases than men.[63] The most often quoted statistics concerning the association of NL with diabetes are from a 1966 retrospective study at the Mayo Clinic. Of 171 patients with NL, two-thirds had diabetes at diagnosis, and another 5%–10% had glucose tolerance abnormalities.[63] However, in a 1999 study of 65 patients with NL, only 11% had diabetes after 15 years of follow-up.[64] Conversely, the prevalence of NL has been found to be only 0.3%–3.0% in patients with diabetes.[63] Although lacking full concordance, NL definitely has a strong association with diabetes and remains a valid marker of the disease. The pathogenesis of this skin disease is unclear. Many etiologic mechanisms have been proposed and reviewed.[65] Evidence suggests that the degree of hyperglycemia and diabetic control does not correlate with the presence of NL.[66]

CLINICAL FINDINGS: CUTANEOUS LESIONS. Classically, NL presents with one to several sharply demarcated yellow–brown plaques on the anterior pretibial region (Fig. 151-7). The lesions have a violaceous, irregular border that may be raised and indurated. Initially, NL often presents as red–brown papules and nodules that may mimic sarcoid or granuloma annulare (GA). Over time, the lesions flatten, and a central yellow or orange area becomes atrophic, and commonly telangiectasias are visible, taking on the characteristic "glazed-porcelain" sheen. Aside from the shins, other sites of predilection include ankles, calves, thighs, and feet. Fifteen percent of patients develop lesions on the upper extremities and trunk that tend to be more papulonodular. Although pain and pruritus have been reported, most lesions are asymptomatic. Anesthesia of the plaques does occur.[67]

The clinical course is often indolent, with spontaneous remission in less than 20% of cases.[10] Over time, the plaques tend to stabilize, and formation of

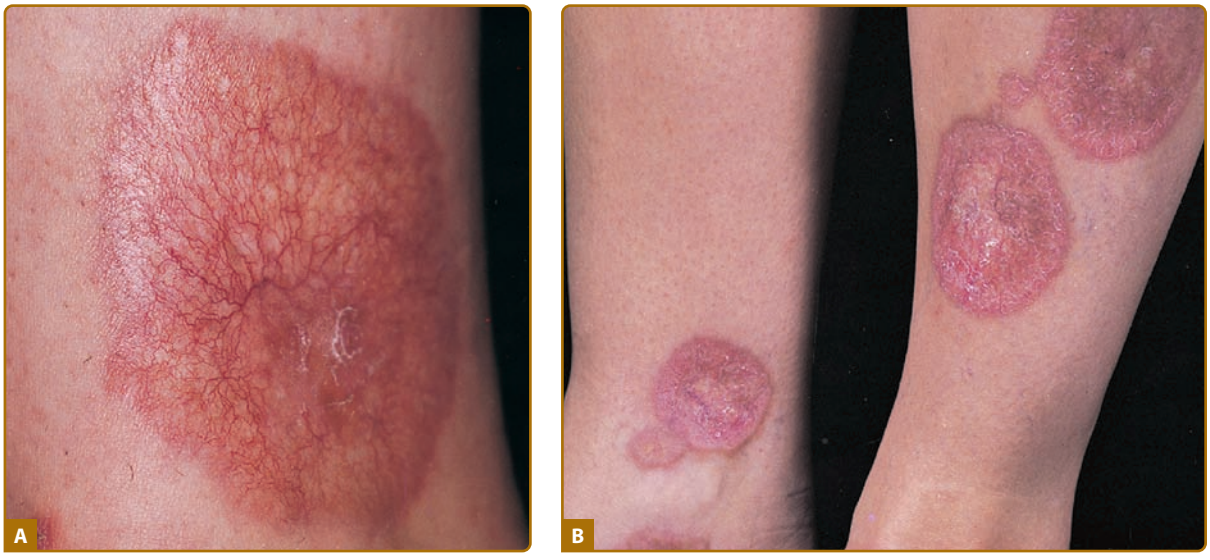

Figure 151-7 Necrobiosis lipoidica. **A.** A single orange plaque with atrophy of the overlying epidermis and arborizing telangiectasias is seen on the lower leg of a juvenile with diabetes mellitus; the crust marks an area of early ulceration. **B.** Older lesions with striking central atrophy involving both the dermis and epidermis.

new lesions tapers off. However, the possibility of ulceration, a poor spontaneous remission rate, and cosmetic concerns lead patients to seek treatment. Ulceration, the most serious complication, occurs in approximately 13%–35% of cases on the legs.[63,65] A few cases of squamous cell carcinoma arising in chronic ulcerative lesions of NL have been reported.[68] Multiple reports document the association of NL with GA and sarcoidosis.[69]

TREATMENT. Treatment for NL is disappointing. At this time, only case reports and small, uncontrolled trials provide the basis for treatment decisions. Early application of potent topical glucocorticoids might slow progression.[65] Although some authors[63] report improvement with intralesional injection of glucocorticoids to the active border, the risk of ulceration with this treatment modality should be considered. A few case reports and one series of six patients[70] showed benefit with short-term systemic glucocorticoids. Aspirin and dipyridamole have produced variable results.[65] Anecdotal reports exist that support the use of topical retinoids and topical PUVA. Treatment with fumaric acid esters in 18 patients was reported to improve lesions clinically and histologically.[71]

Given the generally benign nature of the lesions, physicians should consider the adage "do no harm." Focus should be on prevention of ulcers. When ulceration occurs in patients with NL, the same wound care principles apply as for all diabetic ulcers. Healing of ulcerated lesions with cyclosporine has been demonstrated in several patients.[72] Surgical excision down to fascia and split-thickness skin grafting remain as the last resort for very recalcitrant ulcers in NL.[73]

GRANULOMA ANNULARE

(See Chapter 44)

EPIDEMIOLOGY AND PATHOGENESIS. The association of GA with diabetes is weaker than that of NL. Although most patients with GA are in good health, without underlying systemic illness, an association with diabetes is supported in the literature. Dabski and Winkelmann[74] found diabetes in 10% of 1,353 patients with localized GA and 21% of 100 patients with generalized GA. An additional small retrospective case-control study showed an increased prevalence of diabetes among patients with GA (18%) as compared with the prevalence in age-matched controls (8%).[75] Furthermore, there is an impression that diabetes is found more frequently in patients with adult onset GA and in those with generalized or perforating GA, and that these patients tend to experience a more chronic, relapsing course of GA. The pathogenesis is unclear.

CLINICAL FINDINGS AND TREATMENT. Clinical findings and treatment of GA are discussed in Chapter 44.

DIABETIC DERMOPATHY

ETIOLOGY AND PATHOGENESIS. Atrophic skin lesions of the lower extremity, or shin spots, were first characterized and proposed as a cutaneous marker for diabetes in 1964.[76] Shortly after, Binkley coined the term *diabetic "dermopathy"* to correlate the pathologic changes with those of retinopathy, nephropathy, and neuropathy[77] Since that time, controversy has existed about the disorder's etiology, specificity for diabetes, and association with other microangiopathic complications of diabetes.

The prevalence of shin spots in ambulatory patients with diabetes varies. In a population-based study from Sweden, diabetic dermopathy was found in 33% of patients with type 1 diabetes and in 39% of patients with type 2 diabetes, compared with 2% of controls.[78]

In other studies, the prevalence rate for individuals without diabetes ranges from 1.5% for healthy medical students to 20% for a group of nondiabetic endocrine patients.[79] Diabetic dermopathy occurs more often in patients with an increased duration of diabetes and is more frequent in men.[79]

It is likely that the lesions are related to antecedent trauma. Lithner[80] induced diabetic dermopathy on the legs of diabetic patients with heat and cold injury, whereas nondiabetic control subjects healed without residual change. When questioned, most patients think that the changes are caused by injury, but they are often unable to detail preceding trauma.

CLINICAL FINDINGS, DIAGNOSIS, AND TREATMENT. Diabetic dermopathy presents as small (<1 cm), atrophic, pink to brown, scar-like macules on the pretibial areas (Fig. 151-8). The lesions are asymptomatic and clear within 1–2 years with slight residual atrophy or hypopigmentation.[77] The appearance of new lesions gives the sense that the pigmentation and atrophy are persistent.

An association seems to exist between diabetic dermopathy and the more serious complications of diabetes. In a study of 173 patients with diabetes, the incidence of shin spots correlated with the duration of diabetes and the presence of retinopathy, nephropathy, and neuropathy.[81] Diabetic dermopathy does not, however, correlate with obesity or hypertension in patients with diabetes.[79] No treatment is necessary for the individual atrophic tibial lesions. They are asymptomatic and are not directly associated with an increase in morbidity.

ACQUIRED PERFORATING DISORDERS

(See Chapter 69)

The acquired perforating disorders comprise an overlapping group of disorders characterized by transepidermal elimination or "spitting" of altered dermal constituents. Included in this group are Kyrle disease, reactive perforating collagenosis, perforating folliculitis, and elastosis perforans serpiginosa.[82] These disorders and their treatment[83] are fully described in Chapter 69.



Figure 151-8 Diabetic dermopathy with hyperpigmented macules on the anterior lower legs.

Clinically, these lesions appear as pruritic, keratotic papules mainly on the extensor surfaces of the extremities. Papules and nodules with a perforating component may also occur on the trunk and face. Many are follicular and contain a prominent central keratotic plug. The papules may be grouped, or coalesce to form verrucous plaques. Treatment for the perforating disorders is usually unsuccessful. Retinoic acid, topical glucocorticoids, and PUVA are partially successful.[83]

BULLOSIS DIABETICORUM

ETIOLOGY AND PATHOGENESIS. The abrupt, spontaneous development of blisters on the lower extremities without other demonstrable cause is a rare characteristic skin manifestation of diabetes. The pathogenesis of diabetic bullae is unknown. Patients with bullosis diabeticorum (BD) do not have a history of antecedent trauma or infection. One study found a decreased threshold to suction-induced blister formation in patients with diabetes.[84] Reduced suction blister time is also observed with increasing age in nondiabetic subjects.[85] Although a history of antecedent trauma is not elicited, this finding suggests a role of increased skin fragility in diabetic bullae. Perhaps the formation of AGEs leads to increased fragility.

CLINICAL FINDINGS, DIAGNOSIS, AND TREATMENT. BD is characterized by the abrupt onset of bullae on the lower extremities, usually the toes, feet, and shins, arising in normal skin. Occasionally, the distal upper extremities are involved. The blisters are usually painless and not pruritic. Healing occurs within 2–5 weeks and rarely leaves scarring. The condition may recur as successive crops of bullae over many years. Studies of affected individuals excluded other blistering skin disorders, and revealed no abnormalities of porphyrin metabolism.[84] Histopathologic examination of the bullae shows an inconsistent level of separation varying from intraepidermal to subepidermal.[85] No immunopathologic features are consistently observed (Box 151-3).

BOX 151-3 DIFFERENTIAL DIAGNOSIS AND EVALUATION OF BULLOSIS DIABETICORUM

DIFFERENTIAL DIAGNOSIS

- Bullous impetigo
- Bullous pemphigoid
- Epidermolysis bullosa acquisita
- Porphyria cutanea tarda
- Bullous erythema multiforme
- Insect bite reaction

LABORATORY TESTS

- Skin biopsy for histology and immunofluorescence
- Bacterial cultures
- Screening for porphyrins

BD runs a benign course without involvement of large body surface areas. The only serious complication is that of secondary infection, which should be managed with culture and appropriate antibiotics if suspected. Otherwise, therapy is supportive. The real importance of this disorder is that of correct diagnosis because several of the blistering skin diseases have a high rate of morbidity and require potentially toxic systemic treatments. Even a negative workup is important. The patient should be educated, reassured, and good wound care implemented.

OBESITY AND THE METABOLIC SYNDROME

EPIDEMIOLOGY. Obesity is characterized by excess fat mass and defined according to the body mass index (BMI, kg/m^2), a calculation based on weight and height [BMI = body weight (in kg) ÷ square of stature (height in meters)]. BMI is correlated with body fat and the WHO defines overweight as a BMI of >25 and obesity as >30 kg/m^2. For Americans the risk of becoming overweight or obese in adulthood is high. As part of the National Health and Nutrition Examination Survey (NHANES) in 2003–2004, 17.1% of children and adolescents were overweight and 32.2% of adults were obese. Approximately 30% of nonhispanic white adults were obese as were 45.0% of nonhispanic black adults and 36.8% of Mexican American. It was also noted that obesity increased in the adult population with age.[86]

ETIOLOGY AND PATHOGENESIS. Contributing factors to obesity are nutritional choices, activity and exercise, medications, and rarely one of several endocrine disorders. In the setting of nutrient excess and weight gain, numerous comorbid factors occur that may contribute to further weight gain by increasing energy intake or decreasing energy expenditure. These include, inflammation and insulin resistance, depression and emotional eating, degenerative joint disease, obstructive sleep apnea, gonadal dysfunction, vitamin D deficiency, among others. Familial studies suggest a strong genetic basis for human obesity. The genetics of obesity are complex, though most human obesity is likely polygenic, multiple single genes have been identified as key regulators of body adiposity. Three of these genes [(1) leptin, (2) pro-opiomelanocortin (*POMC*), and (3) agouti-related protein (*AGRP*)] with dermatologic relevance are discussed in detail below.

The hormone leptin is secreted by adipose tissue in proportion to total body fat. Leptin regulates energy homeostasis, neuroendocrine function, and metabolism.[87] Rare cases in humans have shown that leptin deficiency causes extreme obesity, hyperphagia, diabetes, neuroendocrine abnormalities, and infertility, all of which can be reversed by administration of exogenous leptin. However, most obese humans are leptin resistant, have high circulating levels of leptin and pharmacological leptin administration has not proven to be a successful weight-loss strategy. Leptin resistance appears to be at the hypothalamic leptin receptor or downstream.[87] Congenital and acquired forms of lipoatrophy (HIV or HAART associated) are characterized by low leptin levels and metabolic abnormalities including insulin resistance, hyperlipidemia, and fatty liver. Leptin treatment in these patients can improve insulin resistance, lipid abnormalities, and fat distribution.[88,89]

Leptin stimulates the hypothalamic melanocortin pathway including hypothalamic neurons expressing POMC. Cleavage of POMC results in peptide agonists for all five homologous melanocortin receptors. The melanocortin 1 receptor (MC1R) is expressed on melanocytes and mutations in MC1R are known to cause red hair and fair skin.[90] Inactivating mutations in MC4R and to a lesser degree MC3R are associated with obesity. Studies estimate that inactivating mutations in MCR4 account for up to 6% of all severe cases of early onset obesity. Further emphasizing the importance of the POMC pathway is the finding that homozygous loss of function of POMC (complete POMC deficiency) produces obesity, pale skin, and red hair.[91]

AGRP is an endogenous hypothalamic melanocortin receptor antagonist, which causes obesity when overexpressed. Though studies have found high serum AGRP levels in obese men,[92] the role of AGRP in common obesity is unclear. The gene is closely related to *agouti*, a skin pigmentation gene, which causes yellow coat color and obesity when overexpressed in mice.

The hormonal regulation of obesity is similarly complex and several gut hormones are likely involved in the regulation of food intake. The gastric derived, appetite stimulating hormone ghrelin impacts obesity and diabetes by modulating body weight, insulin secretion, and gastric motility.[93] Serum ghrelin levels rise before meals and are thought to promote food intake. Sharp rises are seen in states of starvation and after weight loss in obesity. This likely contributes to weight regain. Interestingly, postgastric bypass surgery patients have altered ghrelin secretion and this may be one of the reasons for the long-term success of this surgical treatment for obesity.[94] Ghrelin receptors are located in the pituitary and hypothalamus and stimulate growth hormone (GH1) release and regulate energy expenditure[93] (see Fig. 151-15). Several ghrelin antagonists are in development for the treatment of obesity, metabolic syndrome, and diabetes.

CLINICAL FINDINGS. Physiologic changes in the skin related to obesity include alterations in epidermal barrier function,[95,96] increased sweating along with larger skin folds, increased skin surface pH in intertriginous areas,[97] poor lymphatic drainage (eFig. 151-8.1 in online edition), impaired wound healing in animal models,[98] and impaired responsiveness of the microvasculature.[99] Several reviews regarding obesity and dermatology have been published.[100,101] The cutaneous disorders seen in obesity are listed in Box 151-4. Detailed discussion of findings and treatments for these disorders are found in the appropriate sections of the text.

It is now well recognized that the presence of abdominal—central rather than subcutaneous—obesity (more than just increased BMI) is associated with insulin resistance, hyperlipidemia, hypertension, and vascular inflammation (Box 151-5). The coexistence of

BOX 151-4 CUTANEOUS DISORDERS ASSOCIATED WITH OBESITY

METABOLIC
- Acanthosis nigricans
- Acrochordons
- Keratosis Pilaris
- Hyperandrogenism
- Hirsutism
- Tophaceous gout

INFECTIOUS
- Candidiasis
- Dermatophytosis
- Intertrigo
- Cellulitis
- Erysipelas
- Necrotizing fasciitis

MECHANICAL
- Plantar hyperkeratosis
- Striae distensae
- Lymphedema
- Elephantiasis nostras verrucosa
- Venous stasis
- Cellulite

MISCELLANEOUS
- Hidradenitis supprativa
- Adiposis dolorosa
- Psoriasis

these disorders increases the risk for diabetes and cardiovascular disease and has been called the metabolic syndrome. It is not clear that the metabolic syndrome confers risk beyond that of the individual components but because the traits co-occur, those with one trait are likely to have others. The most important therapy is weight reduction and exercise along with adequate control of cardiac risk factors.

The cornerstones of treatment for overweight and obesity are dietary changes, increased physical activity, and behavioral modification. In high-risk patients with comorbid conditions, pharmacologic therapy (sibutramine or orlistat) can be considered as an additional intervention. In clinically severe obesity, surgical therapies may be appropriate. All successful patients will require long-term nutritional adjustments that reduce caloric intake. The role of liposuction in weight loss has been studied and despite the removal of a large volume of subcutaneous adipose tissue there was no improvement seen in the metabolic risk factors associated with obesity.[102,103]

BOX 151-5 DEFINITION OF THE METABOLIC SYNDROME (ANY THREE OF FIVE TRAITS)

1. Abdominal Obesity
2. Serum triglycerides ≥150 mg/dl (or drug treatment for elevated triglycerides)
3. Serum HDL cholesterol <40 mg/dl in men and <50 mg/dl in women (or drug treatment for low HDL-C)
4. Blood pressure ≥130/85 (or drug treatment for elevated blood pressure)
5. Fasting plasma glucose ≥100 mg/dl (or drug treatment for elevated blood glucose)

THYROID DISEASE

THYROID DISEASE AT A GLANCE

- The most common cause of hyperthyroidism is Graves disease, characterized by the triad of autoimmune thyroid disease, eye disease, and thyroid dermopathy (pretibial myxedema).
- Toxic multinodular goiter is another cause of hyperthyroidism that should be considered, particularly in elderly individuals.
- Serious signs of thyrotoxicosis include atrial fibrillation and fever.
- Hashimoto thyroiditis and thyroid ablation for treatment of hyperthyroidism are the two most common causes of hypothyroidism.
- The best screening test for thyroid disease is thyrotropin (TSH), which is elevated in hypothyroidism and depressed or absent in hyperthyroidism.

EPIDEMIOLOGY. Worldwide estimates of the prevalence of goiter (enlargement of the thyroid gland) range from 200 to 800 million affected people. The majority of these worldwide cases are secondary to iodine deficiency. However, in industrialized countries where salt is routinely iodized, the main causes of goiter are autoimmune thyroiditis and nodular thyroid disease. The overall incidence of hyperthyroidism in the US population is estimated at approximately 1%, but may be four to five times higher in older women.[104] Graves disease accounts for 60%–80% of all cases of hyperthyroidism and was first described by Caleb Parry in 1825 (and later by Robert Graves in 1835) as an association between goiter, palpitations, and exophthalmos.[105] Although the incidence of Graves disease is similar between whites and Asians, it appears to be

lower in blacks.[105] *Toxic adenoma* and *toxic multinodular goiter* refer to the hyperplastic growth of thyroid tissue that is functioning independent of TSH regulation, resulting in increased levels of thyroid hormone. Toxic multinodular goiter has been reported to be more common in areas of low iodine intake, particularly in patients older than the age of 50 years.[106] Population-based screening with laboratory testing found hypothyroidism in 4.6% of the US population, although >90% of individuals with tests consistent with hypothyroidism were normal clinically.[104]

The majority of thyroid disease is acquired, but thyroid disease can also be congenital. Congenital hypothyroidism is the most common treatable cause of mental retardation, and occurs in up to 1 in 3,000 neonates worldwide due to either an absent or anatomically defective gland, inborn errors of thyroid metabolism, or iodine deficiency.[107] Congenital hyperthyroidism is much less common, and although 0.2% of pregnant women have Graves disease, only about 1% of the resultant neonates will have hyperthyroidism, with most cases resulting from the transfer of maternal thyroid-activating autoantibodies.[108]

ETIOLOGY AND PATHOGENESIS.

The metabolic regulation of every cell in the body relies on thyroid hormones, which is synthesized primarily in the thyroid gland. Hyperthyroidism (also known as *thyrotoxicosis*) results from the excess levels of thyroid hormones with resultant hypermetabolism, whereas hypothyroidism (or myxedema) is characterized by hypometabolism secondary to diminished levels of thyroid hormone. Thyroid hormones act on target tissues by activating cytoplasmic receptors that subsequently translocate to the nucleus and activate specific thyroid-responsive genes.[109] Thyroid hormone synthesis is heavily dependent on iodine and, consequently, changes in iodine intake can result in both hyperthyroidism and hypothyroidism.

Synthesis of thyroid hormone is regulated by the pituitary via release of TSH in response to hypothalamic release of thyrotropin-releasing hormone (TRH). TSH acts on the thyroid gland by binding a G-protein-coupled receptor (TSHR) to trigger thyroid hormone synthesis and release. Aberrant activation of TSHR is thought to underlie the hyperthyroidism seen in Graves disease, where almost all patients have long-acting thyroid-stimulator autoantibodies that bind and activate TSHR.[110] Release of TSH is, in turn, stimulated by TRH, which also acts via a G-protein-coupled receptor. Administration of recombinant TRH followed by measurement of the response in TSH levels provides a useful test for distinguishing whether hypothyroid disease results from dysfunction of the hypothalamic–pituitary axis or the thyroid gland. Levels of TSH and TRH are both tightly controlled by circulating levels of thyroxine (T_4) and triiodothyronine (T_3), which provide feedback regulation (eFig. 151-8.2 in online edition). Persistent stimulation of the thyroid leads to the hypertrophy of the gland, known as *goiter*.

The great majority of thyroid hormone in the blood is bound by plasma proteins, including thyroid-binding globulin, which is the major determinant of protein binding, and to a lesser extent transthyretin (formerly called *prealbumin*) and albumin. A variety of medical conditions (Box 151-6) and medications can alter levels of thyroid hormone-binding proteins or peripheral conversion of T_4 to T_3 (which is responsible for most of thyroid hormone's effects), and subsequently alter the tissue availability of thyroid hormone independent of changes in thyroid hormone synthesis. Thyroid hormone levels can be affected by a variety of medications, including several that are prescribed by dermatologists (Box 151-7).[111]

BOX 151-6 MEDICAL CONDITIONS THAT CAN AFFECT THYROID HORMONE LEVELS

Increased thyroid-binding globulin
- Pregnancy
- Infectious/chronic active hepatitis
- Biliary cirrhosis
- Acute intermittent porphyria

Decreased thyroid-binding globulin
- Chronic liver disease
- Severe systemic illness
- Active acromegaly
- Nephrosis

Decreased peripheral conversion of thyroxine to triiodothyronine
- Fasting/malnutrition
- Systemic illness
- Physical trauma
- Postoperative state

Hyperthyroidism can be broadly classified into two categories: (1) high radioiodine (radioactive iodine) uptake and (2) low radioiodine uptake. The presence of high radioiodine uptake indicates increased synthesis of thyroid hormone, while diminished or absent radioiodine uptake suggests either an extrathyroidal source of thyroid hormone or the destruction of thyroid tissue with concomitant release of preformed thyroid hormone into the circulation. Evidence suggests that genetic predisposition as well as environmental factors, including infection, may play a role in the pathogenesis of autoimmune thyroid disease.[112] In the case of toxic adenoma, molecular studies have identified a high prevalence of TSHR mutations, resulting in a receptor that triggers thyroid hormone synthesis in the absence of bound TSH.[113]

Although some of the cutaneous findings seen in hyperthyroidism are indirect consequences of thyroid hormone's actions on other tissues, most of the skin manifestations of thyroid disease result from the direct effects of thyroid hormones on the keratinized epithelium of the epidermis, hair, and nails as well as effects on stromal cells in the dermis. Thyroid hormones are essential for optimal epidermal proliferation both in vitro and in vivo.[114] Thyroid hormones regulate genes

BOX 151-7 MEDICATIONS AFFECTING THYROID HORMONE LEVELS

Drugs that affect thyroid hormone secretion
- Lithium (decreases secretion)
- Iodide (can increase or decrease secretion)
- Amiodarone (can increase or decrease secretion)

Drugs that increase serum thyroid-binding globulin concentrations
- Estrogens/tamoxifen
- Heroin/methadone
- Fluorouracil

Drugs that decrease serum thyroid-binding globulin concentrations
- Androgens
- Anabolic steroids
- Slow-release nicotinic acid
- Glucocorticoids

Drugs that increase hepatic metabolism of thyroid hormone
- Phenobarbital
- Rifampin
- Phenytoin
- Carbamazepine

Drugs that decrease deiodination of thyroxine to triiodothyronine
- Propylthiouracil (used to treat hyperthyroidism)
- Amiodarone
- β Blockers
- Glucocorticoids
- Certain radiographic contrast dyes

Drugs that decrease thyrotropin
- Bexarotene

Adapted from Surks MI, Sievert R: Drugs and thyroid function. *N Engl J Med* **333**:1688, 1995.

involved in keratinocyte proliferation and also stimulate the expression of certain keratins.[114]

Approximately 95% of cases of hypothyroidism are thought to arise from defects in the thyroid gland itself, whereas the remaining cases result from defects in the hypothalamic–pituitary axis. Ironically, the most common cause of hypothyroidism without a goiter is the surgical or radioiodine-induced ablation of the thyroid gland for the treatment of Graves thyrotoxicosis. Cretinism occurs with untreated congenital hypothyroidism and does not have a goiter. The most common cause of hypothyroidism with a goiter in North America is Hashimoto thyroiditis. Less common causes of hypothyroidism include inherited defects in hormone synthesis or the ingestion of drugs that inhibit hormone synthesis, such as lithium or aspirin. Bexarotene, a retinoid-X-receptor agonist (see Chapter 228) used to treat cutaneous T-cell lymphoma, causes a central hypothyroidism with a decrease in TSH, followed by low levels of T_3 and T_4.[115] In rare cases, hypothyroidism can occur from decreased secretion of TSH, such as with pituitary failure, a tumor of the pituitary region, or postpartum pituitary necrosis (Sheehan syndrome). Inadequate secretion of TRH by the hypothalamus is another very rare cause of hypothyroidism.

CLINICAL FINDINGS

CUTANEOUS MANIFESTATIONS OF HYPERTHYROIDISM

(Box 151-8) Signs and symptoms of hyperthyroidism and hypothyroidism are variably present and summarized in Table 151-2. The skin changes of hyperthyroidism have been likened to infant's skin and described as soft, warm, and velvety in texture. Pruritus can be a manifestation of thyroid disease, and laboratory screening for thyroid disease is often included in working up patients experiencing diffuse pruritus with no obvious rash. Scalp hair in hyperthyroid patients is described as soft and fine, and in certain

BOX 151-8 APPROACH TO PATIENT WITH HYPERTHYROIDISM

CUTANEOUS FINDINGS IN HYPERTHYROIDISM
- Soft, velvety, infant-like skin
- Thyroid dermopathy
- Soft, fine with diffuse nonscarring alopecia
- Facial flushing
- Palmar erythema
- Hyperpigmentation
- Plummer's nails
- Thyroid acropachy
- Hyperpigmentation

RELATED FEATURES
- Hyperhidrosis
- Atrial fibrillation
- Ophthalmopathy
- Goiter
- High-output cardiac failure
- "Thyroid storm"

DIAGNOSIS
- Best initial test is serum thyrotropin
- Other tests include serum free triiodothyronine, thyroxine, and antithyroid antibodies
- Radioactive iodine uptake and imaging

MANAGEMENT
- Appropriate surgical and endocrine consultation
- Propanolol for symptomatic treatment
- Propylthiouracil to inhibit thyroid hormone metabolism
- Methimazole to inhibit thyroid hormone synthesis
- Radioiodine ablation of the thyroid gland

TABLE 151-2
Symptoms, Clinical Findings, and Complications of Thyroid Disease

Symptoms, Clinical Findings, and Complications of Hyperthyroidism	Symptoms, Clinical Findings, and Complications of Hypothyroidism
Symptoms ■ Unintentional weight loss ■ Heat intolerance/sweating ■ Palpitations ■ Agitation/emotional lability ■ Multiple daily loose stools ■ Pruritus ■ Weakness ■ Oligomenorrhea in women Clinical Findings and Complications ■ Goiter ■ Tachycardia ■ Atrial fibrillation ■ High-output cardiac failure ■ Fine tremor ■ Hot sweaty extremities ■ Ophthalmopathy ■ Agitation/confusion ■ Muscle weakness/wasting ■ "Thyroid storm" with fever, confusion, dehydration, and eventual death, if untreated	Symptoms ■ Unexplained weight gain ■ Fatigue ■ Cold intolerance ■ Constipation ■ Dry skin ■ Muscle weakness ■ Carpal tunnel syndrome ■ Hoarseness ■ Decreased body temperature ■ Facial swelling ■ Menorrhagia in women Clinical Findings and Complications ■ Goiter ■ Cold, doughy skin ■ Bradycardia ■ Facial and finger swelling ■ Slowed relaxation of deep tendon reflexes ■ Hair loss/lateral eyebrow loss ■ Pericardial effusion ■ Myocardial infarction or congestive heart failure with aggressive thyroid hormone replacement ■ Coma and death without treatment

cases may be accompanied by a diffuse nonscarring alopecia analogous to telogen effluvium. Patients with hyperthyroidism frequently have nail changes that are commonly described as soft, shiny, and brittle nails with an increased rate of growth. A small percentage of patients with hyperthyroidism will have Plummer's nails, which exhibit a concave shape with distal onycholysis (see Chapter 89). Plummer's nails can also be found in a variety of other conditions and are not pathognomonic for hyperthyroidism. Vitiligo appears to be overrepresented in patients with Graves disease, but not in patients with other forms of hyperthyroidism. Vitiligo may often predate the diagnosis of thyroid disease and does not improve with the treatment of the hyperthyroidism (see Chapter 74).

Thyroid dermopathy is most commonly seen with Graves disease but has been reported in hypothyroid patients as well. Pretibial thyroid dermopathy (in the past referred to as *pretibial myxedema*) is a classic manifestation of hyperthyroidism and Graves disease (Fig. 151-11). The term *thyroid dermopathy* is used in this chapter because the lesions can occur at any site on the body, are not limited to the pretibial region, and the name does not suggest myxedema as a cause.[116] Although there are reports of hyperthyroid patients who have presented with thyroid dermopathy as their initial finding, thyroid dermopathy is usually a later manifestation of thyroid disease. Almost all patients with thyroid dermopathy also have thyroid ophthalmopathy, another late manifestation of hyperthyroidism.[117] The clinical appearance of thyroid dermopathy can be quite varied. Classically, thyroid dermopathy occurs bilaterally as painless nonpitting nodules and plaques with variable coloring and a waxy, indurated texture (Fig. 151-9). The distribution can range from very circumscribed to diffuse, but by far the most common location is on the extensor surfaces of the legs.[117] Some cases can exhibit a peau d'orange appearance as well. An extreme form of diffuse thyroid dermopathy has been termed the *elephantiasic* variant, which occurs in less than 1% of patients with Graves disease and is characterized by progressive thickening and gray-black hyperpigmentation of the pretibial skin accompanied by a woody, firm edema with nodule formation. The exact pathophysiology underlying thyroid dermopathy is still unclear.[116] Biopsies of thyroid dermopathy reveal a thickened dermis with splayed collagen fibrils and abundant mucin, usually hyaluronic acid, in the interstitial space.

The increased amounts of hyaluronic acid in the dermis and the subcutis have led the hypothesis that fibroblasts or other cells in the dermis may be



Figure 151-9 Hyperthyroidism with thyroid dermopathy in a classic location on the anterior shins. Note that infiltrated plaques extend to the calf and are partially hyperkeratotic. An isolated nodule is also present on the dorsum of the foot.

synthesizing increased levels of GAGs secondary to stimulation by activating autoantibodies. However, antibodies that bind TSHR on fibroblasts can be seen in patients with and without thyroid dermopathy, indicating that other determinants are likely involved. The presence of dependent edema in the lower extremities may also contribute somehow to either the fibroblast stimulation or hyaluronic acid accumulation, and thus account for the tendency of thyroid dermopathy to occur in this anatomic site.

Thyroid acropachy refers to digital clubbing, soft-tissue swelling of the hands and feet, and the presence of characteristic periosteal reactions.[116] This very rare clinical finding is also associated with thyroid dermopathy and exophthalmos, and almost always presents after the diagnosis and treatment of hyperthyroidism (eFig. 151-9.1 in online edition). Like thyroid dermopathy, thyroid acropachy has also been reported in hypothyroid conditions. Clubbing occurs most frequently on the first, second, and fifth metacarpals, the proximal phalanges of the hand, and the first metatarsal and proximal phalanges of the feet.[116] The radiologic findings are characterized by a lamellar periosteal reaction of the hands or wrists, with long bones only rarely involved. Because increased osteoblastic activity has been observed in the diaphyseal parts of small bones, the use of bone scan has been suggested as a sensitive way to aid in diagnosis.[118] The mechanisms underlying thyroid acropachy remain unknown, although interestingly, a large case series identified a disproportionately high percentage of smokers (80%) in patients with thyroid acropachy.[119]

The effects of thyroid hormone excess on other organ systems can also result in cutaneous findings. Hyperpigmentation similar to Addison disease has been seen with hyperthyroid disease, with resultant pigment in the palmar creases, gingiva, and buccal mucosa that is usually more prominent in individuals with darker skin. It has been postulated that the hyperpigmentation may be the result of increased corticotropin (ACTH) resulting from accelerated cortisol metabolism.[116] The cardiovascular effects of thyroid hormone excess include atrial fibrillation, increased cardiac output, and decreased peripheral vascular resistance, resulting in increased blood flow to the skin along with facial flushing and palmar erythema. The overall increased metabolism, along with changes in peripheral blood flow and temperature dysregulation, can also result in a generalized hyperhidrosis as well as high-output cardiac failure similar to that seen with Paget disease of bone.

There is extensive literature regarding the association between thyroid disease and urticaria[120] (see Chapter 38). Several studies have found a much higher incidence of thyroid disease in patients with chronic urticaria compared with control populations, although the mechanism behind this association remains unclear. Other dermatologic conditions have been reported in association with Graves disease, including dermatitis herpetiformis, Sweet syndrome, pemphigoid gestationis, vitiligo, pemphigus vulgaris, anetoderma, and middermal elastolysis.[116]

BOX 151-9 APPROACH TO THE PATIENT WITH HYPOTHYROIDISM

CUTANEOUS FINDINGS
- Myxedema
- Cool temperature
- Doughy, dry skin with fine wrinkling
- Yellow–orange carotenemia
- Dry, brittle hair
- Slow growth of hair and nails

RELATED FEATURES
- Macroglossia
- Broadened nose, thickened lips, puffy eyelids
- Impaired wound healing
- Cretinism with congenital cases
- "Myxedema coma"

DIAGNOSIS
- Best initial test is serum TSH
- Other tests include serum free T3 and T4

MANAGEMENT
- Appropriate endocrine consultation
- Oral thyroxine (usually in the range of 75–150 µg/day)
- Careful follow-up for heart, lung, and adrenal disease

CUTANEOUS MANIFESTATIONS OF HYPOTHYROIDISM.

(Box 151-9). In hypothyroidism, decreased core temperature and increased peripheral vasoconstriction cause the skin to be cool and pale. The skin is also xerotic, and the stratum corneum is poorly hydrated. Histologically, the epidermis is thin, and there is hyperkeratosis with follicular plugging. The generalized distribution of these findings can help distinguish these changes from those of atopic dermatitis and keratosis pilaris, which tend to be more prominent on the extremities. A fine wrinkling can also be seen. A yellow–orange discoloration of the skin can be seen secondary to the accumulation of β-carotene in the stratum corneum, possibly secondary to increased circulating carotene from diminished hepatic conversion of β-carotene to vitamin A.

Myxedema is the most classic finding associated with hypothyroidism and is distinct from the thyroid dermopathy seen with Graves disease. Myxedema occurs as a result of dermal accumulation of mucopolysaccharides, namely, hyaluronic acid and chondroitin sulfate, and tends to resolve with treatment of the hypothyroidism. The myxedema tends to be generalized but can appear more striking in the extremities. Characteristic facial changes can be seen, including a broadened nose, thickened lips, puffy eyelids, and macroglossia with a smooth and clumsy tongue (eFig. 151-9.2 in online edition). The skin can be doughy, swollen, and waxy, but without pitting. Wound healing is impaired in hypothyroidism.

The hair in hypothyroidism is coarse, dry, and brittle with slowed growth. Hair loss in the scalp can be either diffuse or patchy. Hypothyroidism can result in increased numbers of hair follicles in telogen, as well as telogen effluvium when the onset of hypothyroidism is abrupt. There can be loss of eyebrow hair in a characteristic pattern involving the outer third (see eFig. 151-9.2 in online edition). Although body hair can be diminished, hypothyroidism can also result in increased lanugo hair on the back, shoulders, and extremities. The nails in hypothyroidism grow slowly and can be thickened and brittle with longitudinal and transverse striations. In patients with a goiter, hoarseness can result secondary to compression of the recurrent laryngeal nerve. With large goiters, tracheal or esophageal displacement can be seen. In extreme cases, large retrosternal goiters can cause Pemberton's sign, characterized by facial plethora suggestive of compression when patients raise their arms above their head.

Hashimoto thyroiditis has been associated with several other dermatologic disorders, including alopecia areata, connective tissue disease (including lupus and dermatomyositis), bullous pemphigoid, dermatitis herpetiformis, and chronic mucocutaneous candidiasis (CMC).[121–125]

LABORATORY TESTS. The diagnosis of thyroid-related cutaneous disease is often suspected clinically, although in certain instances a skin biopsy may prove helpful in confirming the diagnosis. The clinical diagnosis of thyroid disease is confirmed by thyroid function tests. Serum levels of TSH are recommended as an initial screen, and any abnormalities in TSH should be followed up with measurements of serum T_4 and free T_3 to confirm whether the abnormal TSH truly reflects a thyroid disorder. Other tests that can be useful include in vitro T_3 resin uptake and measurements of antithyroid antibodies. This combination of tests will diagnose the vast majority of patients with suspected thyroid disease.

TREATMENT. The mainstay of treatment for the cutaneous findings of thyroid disease is normalization of thyroid function, either through replacement of thyroid hormone for hypothyroidism or through ablation of thyroid function for hyperthyroidism. Thyroid dermopathy and thyroid acropachy can be a chronic problem even in patients who are treated effectively for their thyroid disease, and the current treatment options can be classified as either experimental or palliative at best. Complete or partial remission of cutaneous findings can be seen even in the absence of any localized topical treatment.[126] Reported treatments of thyroid dermopathy include topical corticosteroids, systemic corticosteroids, intralesional corticosteroids, intralesional octreotide, intravenous (IV) immunoglobulin, plasmapheresis, compression therapy, and even surgical excision.[126,127] The success of these therapies is still controversial and based on small uncontrolled case series or anecdotal reports.

PARATHYROID DISEASE

PARATHYROID DISEASE AT A GLANCE

- The most common cause of hypercalcemia in outpatients is hyperparathyroidism, while the most common cause of hypercalcemia in hospitalized patients is malignancy.
- The most common causes of hypocalcemia are vitamin D deficiency and surgically induced hypoparathyroidism.
- Calciphylaxis is most commonly seen in the setting of secondary hyperparathyroidism of renal failure.

EPIDEMIOLOGY. The annual incidence of primary hyperparathyroidism has decreased in the past two decades to about 20 cases per 100,000, potentially reflecting a decrease in the use of ionizing radiation to the neck, which is a known risk factor for developing primary hyperparathyroidism.[128] The majority of cases occur in individuals older than 45 years of age, with an approximate 2:1 female–male predominance. In the outpatient setting, parathyroid disease accounts for almost all cases of hypercalcemia. In hospitalized patients, parathyroid disease accounts for approximately one-third of all cases of hyperparathyroidism, while the majority of other cases are accounted for by malignancy. Together, hyperparathyroidism and malignancy account for greater than 90% of all cases of hypercalcemia.

ETIOLOGY AND PATHOGENESIS. Parathyroid hormone (PTH) is secreted by the parathyroid gland in response to low levels of serum calcium and acts as one of the main regulators of calcium levels in the body. Elevations of PTH (hyperparathyroidism) are associated with hypercalcemia, whereas decreased levels of PTH (hypoparathyroidism) are associated with hypocalcemia. PTH acts through varying mechanisms that include the stimulation of vitamin D production, stimulation of calcium absorption in the gastrointestinal tract, regulation of renal absorption of calcium and phosphate, and direct regulation of calcium mobilization from bone. Circulating free calcium acts on the parathyroids via a G-protein-coupled receptor to control the release of PTH. Released PTH then acts in target tissues by binding another G-protein-coupled receptor, the PTH receptor, resulting in changes in calcium metabolism. Because problems with PTH result primarily in alterations of circulating calcium, it is not surprising that the skin manifestations of parathyroid disease are primarily changes resulting from calcium dysregulation. The skin is likely a site of PTH action, although the exact effects of PTH on skin are

not understood. Keratinocytes express a PTH-related peptide (PTHLH) that has been implicated in regulating keratinocyte growth and differentiation and utilizes the same receptors as PTH.[129–132] Although PTHLH has been associated with normal wound healing, elevated PTHLH can also be seen in the setting of certain squamous cell carcinomas.[131,133,134] The elevated PTHLH with squamous cell carcinoma can result in malignancy-related hypercalcemia in these patients.

Primary hyperparathyroidism results from abnormal function of the parathyroid gland, resulting in increased levels of PTH. In 80% of diagnosed cases, the cause of hyperparathyroidism is a result of either parathyroid hyperplasia, parathyroid carcinoma, or parathyroid adenoma. Pseudohyperparathyroidism occurs when PTH or a PTH-like molecule (for instance, PTHLH) is secreted from a nonparathyroid tissue such as occurs in malignancy.

Secondary hyperparathyroidism occurs most commonly in the setting of renal disease. Resistance of end organs to PTH results in hypersecretion of PTH and consequent hypocalcemia and hyperphosphatemia. Secondary hyperparathyroidism is found in almost all patients with chronic renal failure requiring dialysis. Secondary hyperparathyroidism can also be associated with idiopathic hypercalciuria as well as with certain medications, including oral contraceptives and long-term furosemide therapy. In renal patients with long-term secondary hyperparathyroidism, hyperplastic parathyroid tissue can become autoactivated, resulting in tertiary hyperparathyroidism. This condition is characterized by persistent hypersecretion of PTH and resultant osteomalacia despite hypercalcemia.

Primary hypoparathyroidism occurs primarily from iatrogenic causes such as the removal of the parathyroid glands during a thyroidectomy. There are also several genetic and nongenetic congenital causes of primary hypoparathyroidism, although these are much less common. Secondary hypoparathyroidism refers to decreased PTH secretion secondary to a primary process that causes hypercalcemia.

CLINICAL FINDINGS. Parathyroid disease most often presents in the setting of altered calcium metabolism. The physical findings and symptoms associated with hyper- and hypocalcemia are shown in Box 151-10. As for hypercalcemia and hyperparathyroidism, skin manifestations are rarely seen but can be impressive and dramatic. An approach to a patient with suspected hyperparathyroidism is outlined in Box 151-11. Cutaneous calcinosis (sometimes referred to as *calcinosis cutis* or *metastatic calcinosis*) is thought to be related to elevated calcium and phosphate[135] (see Chapter 138). Subcutaneous calcifications can be found in a symmetric distribution, often overlying large joints or in linear arrayed papules and plaques that are normally of skin color and hard on palpation (Fig. 151-10). These lesions can be pruritic. Chronic urticaria has been associated with hyperparathyroidism as well.[136] Signs of hyperparathyroidism in association with cutaneous skin tumors, such as angiofibromas, collagenomas, and lipomas, should engender a workup for multiple

BOX 151-10 PHYSICAL FINDINGS ASSOCIATED WITH HYPERCALCEMIA AND HYPOCALCEMIA

HYPERCALCEMIA

- Anorexia
- Nausea and vomiting
- Constipation
- Hypotonia
- Lethargy and coma

HYPOCALCEMIA

- Increased neuromuscular irritability and tetany
- Chvostek's sign: induced tetany of the facial muscles induced by tapping on the zygoma
- Trousseau sign of hypocalcemia: carpal spasm with inflation of blood pressure cuff above systolic value
- Peripheral and perioral paresthesias
- Seizures
- Bronchospasm/laryngospasm
- Lengthening of QT interval on electrocardiogram

BOX 151-11 APPROACH TO THE PATIENT WITH SUSPECTED HYPERPARATHYROIDISM

CUTANEOUS FINDINGS

- Cutaneous (metastatic) calcinosis
- Calciphylaxis

RELATED DISORDERS

- Renal disease
- Multiple endocrine neoplasia type 1 with angiofibromas, collagenomas, and lipomas
- History of head/neck irradiation

DIAGNOSIS

- Serum calcium and serum parathyroid hormone
- With suspected malignancy, serum parathyroid hormone-related peptide

MANAGEMENT

- Identify underlying cause of hyperparathyroidism.
- Appropriate endocrine, surgery, and nephrology consultation.
- Hospitalization for acute cases with hypercalcemia.
- Aggressive fluid management to treat hypercalcemia, with forced diuresis.
- Phosphate replacement as warranted.
- Dialysis for acute renal failure.
- Calciphylaxis warrants aggressive management of wounds and infection.
- Surgical parathyroidectomy.



Figure 151-10 Papules of cutaneous calcinosis are arranged in a linear array in the skin overlying the mandible.

endocrine neoplasia type 1 (MEN1), which is caused by mutations in the *MEN1* gene and characterized by tumors of the anterior pituitary, the pancreas, and the parathyroid. The finding of somatic (nongermline) mutations and loss of heterozygosity of the *MEN1* gene in 20%–30% of spontaneous parathyroid tumors further supports a role for this gene in parathyroid oncogenesis.[137] The differential diagnosis is of hypercalcemia is shown in Box 151-12.

Calciphylaxis (also called calcific uremic arteriolopathy or CUA) is a rare but life-threatening cutaneous condition associated with hyperparathyroidism. Calciphylaxis occurs most often in the setting of chronic renal failure and secondary hyperparathyroidism, although there are reports of calciphylaxis associated with primary hyperparathyroidism and normal renal function. Although the name may falsely imply an immune etiology, calciphylaxis actually results from calcium deposition in the walls of small- to medium-sized vessels, resulting in vascular occlusion and skin necrosis. Clinically, patients present initially with violaceous patches that may exhibit a mottled or reticular pattern. Subsequently, involved areas can become indurated and painful, with eventual ulceration and eschar formation that proceeds to tissue gangrene (Fig. 151-11). Both the trunk and extremities can be involved. A calcium-phosphate product (serum calcium × serum phosphate) of greater than 70 mg/dL has often been cited as a predisposing risk factor. The histologic finding of calcium deposits in vessel walls coupled with compatible clinical findings is diagnostic. Calciphylaxis has a very poor prognosis, with reported mortality rates up to 80%, usually from infection. Parathyroidectomy and aggressive management of wounds and infections has been successful in treating some cases. There is not compelling evidence to support the use of hyperbaric oxygen, but there are small case series reporting successful treatment of calciphylaxis using hyperbaric oxygen, suggesting use for this often life-threatening condition.[138,139] An accumulating number of case reports using the calcium-sequestering compound sodium thiosulfate have demonstrated considerable efficacy, particularly in patients with renal disease.[140] While large clinical trials are lacking, the lack of any serious short-term side effects reported

BOX 151-12 DIFFERENTIAL DIAGNOSIS OF HYPERCALCEMIA

- Increased parathyroid hormone
  - Solitary adenoma
  - Multiple adenomas (i.e., multiple endocrine neoplasia type 1)
  - Tertiary hyperparathyroidism with renal failure
- Increased parathyroid hormone-related peptide
  - Squamous cell carcinoma
  - Renal carcinoma
  - Bladder carcinoma
  - Human T-cell leukemia virus type 1
  - Breast cancer
  - Lymphoma
- Increased 1,25-vitamin D
  - Sarcoidosis
  - Excess ingestion
- Increased bone resorption of calcium
  - Myeloma
  - Lymphoma
  - Breast cancer
- Renal failure
  - Secondary hyperparathyroidism
  - Tertiary hyperparathyroidism
  - Vitamin D intoxication
- Milk-alkali syndrome (susceptibility to hypercalcemia with ingestion of calcium-based antacids and milk)

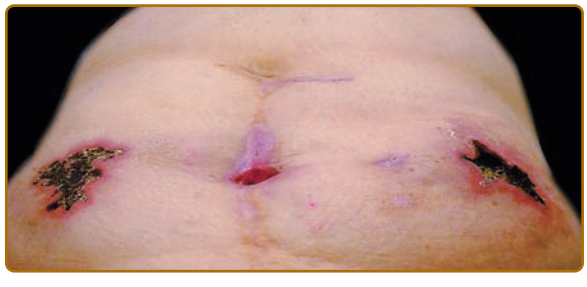

Figure 151-11 Calciphylaxis in a patient with chronic renal failure. Note the stellate-shaped necrotic plaques on the abdomen and the scars from peritoneal dialysis. Often the thighs and buttocks are also involved. A deep biopsy that includes subcutaneous fat can help make the diagnosis if it demonstrates the characteristic findings of calcification in the media of small- and medium-sized vessels. Histologically, subcutaneous calcium deposits and fat necrosis can also be seen.

BOX 151-13 APPROACH TO THE PATIENT WITH SUSPECTED HYPOPARATHYROIDISM

CUTANEOUS FINDINGS
- Scaly, hyperkeratotic, puffy skin
- Patchy alopecia with hair thinning
- Brittle nails with transverse ridging

RELATED FINDINGS
- Paresthesias
- Neuromuscular irritability
- Bronchospasm or laryngospasm
- Electrocardiogram changes

DIAGNOSIS
- Serum calcium and serum parathyroid hormone
- Serum magnesium levels to rule out hypomagnesemia
- Electrocardiogram to rule out QT elongation

MANAGEMENT
- Vitamin D or vitamin D metabolites (i.e., calcitriol at 0.2–1.0 µg/day)
- Calcium supplementation at 2–3 g of elemental calcium per day
- Magnesium supplementation when appropriate

with sodium thiosulfate suggests serious consideration of this therapy for patients with calciphylaxis.

Hypoparathyroidism is associated with scaly, hyperkeratotic, and edematous puffy skin (Box 151-13). Paresthesias secondary to hypocalcemia can be seen. Patchy alopecia and generalized thinning of the hair have been reported. Nails can be brittle with transverse ridging. Hypoparathyroidism has been associated with psoriatic flares, which is interesting in light of the response of psoriasis to calcipotriene.[141] These skin abnormalities often resolve with normalization of serum calcium levels, suggesting that they are due to changes in calcium homeostasis rather than deficiency of PTH.

Hypoparathyroidism in the setting of familial autoimmune polyglandular syndrome type 1 has been associated with CMC and adrenal failure.[142] The CMC can precede the diagnosis of hypoparathyroidism, although the CMC does not improve significantly with treatment of the hypoparathyroidism with calcium and vitamin D. Other findings in these patients include dental enamel hypoplasia, vitiligo, and the cutaneous manifestations of adrenal failure (see under Section "Addison Disease").

Hypoparathyroidism in the setting of elevated serum PTH is known as *pseudohypoparathyroidism* or *PTH-resistant hypoparathyroidism*. Although several variants of pseudohypoparathyroidism have been described, perhaps the best characterized is Albright's hereditary osteodystrophy.[143] These patients present with a constellation of findings that include short stature, obesity, rounded facies, dental hypoplasia, and shortened bones of the hands and feet. Characteristic shortening of the fourth metacarpal leads to a dimpling of the fourth knuckle, known as *Albright's sign*. These patients can also have subcutaneous ossifications and calcifications.

LABORATORY TESTS. The diagnosis of parathyroid disease can be made with measurements of serum calcium levels and serum levels of PTH. In the case of hypercalcemia related to malignancy, measurement of PTHLH may also be useful in the workup.

TREATMENT. The main treatment for hyperparathyroidism is partial or total parathyroidectomy (see Box 151-11). For hypoparathyroidism, treatment focuses on correction of serum calcium and phosphate (see Box 151-13). In the setting of acute hypercalcemia, aggressive fluid and electrolyte management are essential, because cardiorespiratory failure may result from dehydration.

DISORDERS OF THE ADRENAL GLANDS

ADRENAL GLANDS AND THE SKIN AT A GLANCE

- Excessive production of cortisol manifests as Cushing syndrome and results from pituitary oversecretion of corticotropin or excess production of cortisol by the adrenal cortex.
- Destruction of the adrenal gland with loss of glucocorticoids, mineralocorticoids, and adrenal androgens is known as Addison disease.
- Although many etiologies of Addison disease are described, the most common cause is autoimmune destruction with detectable circulating autoantibodies.

CUSHING SYNDROME

Excessive production of endogenous cortisol manifests clinically as Cushing syndrome. Similar findings are seen from chronic exogenous administration of glucocorticoids (see Chapter 224). In the normal physiology of the hypothalamic–pituitary–adrenal axis, corticotropin-releasing hormone is secreted from the hypothalamus and stimulates the production of corticotropin, also known as ACTH, by the anterior pituitary. ACTH is synthesized as part of a larger precursor molecule,

POMC. This relationship of POMC to ACTH is important in diseases of the adrenal gland and the resulting skin manifestations. POMC is processed into several peptides, including melanocyte-stimulating hormone (MSH) and ACTH, which stimulates the production of cortisol from the adrenal cortex. In a classic negative feedback manner, cortisol inhibits corticotropin-releasing hormone and ACTH production.

EPIDEMIOLOGY, ETIOLOGY, AND PATHOGENESIS. The overall incidence of Cushing syndrome is about 10 persons per million per year, with a female predominance.[144] Cushing syndrome is divided into two categories. The first is caused by inappropriately high secretion of ACTH, usually from a pituitary microadenoma. It is given the unique name of *Cushing disease*. The excess ACTH drives glucocorticoid production in the adrenals. Rarely ectopic, or nonpituitary, production of ACTH results in Cushing syndrome. This clinical presentation is most often associated with a pulmonary carcinoid tumor, although numerous other tumor types have been reported.[145] The second category of Cushing syndrome results from excess cortisol produced by the adrenal cortex independent of regulation by the pituitary or hypothalamus. This is usually due to an adrenal adenoma, which may be benign or malignant, or is the result of generalized hyperplasia of the adrenal gland. Cushing syndrome can be seen in the McCune–Albright syndrome[146] and in association with primary pigmented nodular adrenocortical disease in the Carney complex.[147]

CLINICAL FINDINGS. The clinical presentation of Cushing syndrome may be subtle (Box 151-14). Skin findings may be present, and if careful attention is paid to the relationship of skin findings and systemic complaints, one may consider the diagnosis early in the clinical course. Common skin complaints are easy bruisability and skin thinning. Mild hypertrichosis often of the lanugo type and acne may occur. Frank hirsutism and severe acne raise the possibility of a concurrent androgen-secreting tumor. The development of multiple violaceous striae wider than 1 cm on the abdomen or proximal extremities is highly suggestive of Cushing syndrome (eFig. 151-11.1 in online edition). The width and color of these striae differentiate them from the commonly seen striae in pregnancy or with weight gain. Relatively dramatic changes in fat distribution often occur along with a generalized gain in weight. There is an increase in central obesity and concurrent thinning of the arms and legs with loss of muscle mass. Increased facial fat results in a rounded appearance of the face, often with increased redness and telangiectasias. This appearance has been referred to as a moon facies. In addition to truncal obesity, there is an increase in the size of the dorsocervical fat pad, known as a *buffalo hump* and increased fat in the supraclavicular fossae. Men may experience gynecomastia.

Although unusual, hyperpigmentation can occur in cases of Cushing syndrome caused by massive increased ACTH production either from the pituitary or, more commonly, an ectopic source.[148] ACTH itself, in addition to MSH derived from POMC, contributes to increased melanin synthesis. This is similar to the hyperpigmentation more commonly associated with Addison disease. Acanthosis nigricans may be seen because Cushing syndrome contributes to insulin resistance, and, often, patients develop diabetes. The immunosuppressive effects of glucocorticoids result in increased dermatophyte and candidal nail and skin infections. Women may experience irregular menses or amenorrhea. Additional extracutaneous signs and symptoms of Cushing syndrome include hypertension, osteoporosis, and decreased muscle mass and strength.[149]

LABORATORY TESTS. Diagnostic confirmation of Cushing syndrome requires demonstration of excess cortisol production. Cortisol production varies throughout the day and, as a rule, should be examined in the early morning when it is usually at its highest value. The average daily cortisol level can be measured using a 24-hour urine collection. Any abnormal test should be repeated two or three times for confirmation. If the urine or serum levels are elevated, failure to suppress the 8:00 a.m. serum cortisol level or 24-hour urine cortisol with a low-dose dexamethasone suppression test is confirmatory. Additional testing, including a high-dose dexamethasone suppression test, can be useful to determine if the source

BOX 151-14 APPROACH TO THE PATIENT WITH CUSHING SYNDROME

CUTANEOUS FINDINGS IN CUSHING SYNDROME

- Increased central adiposity (moon facies and buffalo hump) with thinning of the extremities
- Skin thinning and easy bruisability
- Violaceous striae
- Acanthosis nigricans
- Increased dermatophyte and candidal skin and nail infections
- Rarely, hyperpigmentation

RELATED FEATURES

- Diabetes
- Hypertension
- Osteoporosis
- Irregular menses

DIAGNOSIS

- Measurement of cortisol in serum and urine
- Failure to suppress cortisol production with dexamethasone suppression tests

MANAGEMENT

- Appropriate endocrine and surgical consultation
- Surgical removal of pituitary or adrenal adenoma
- Adrenal enzyme inhibitors
- Radiation therapy

of the excess cortisol production is from the pituitary or elsewhere. Hypercortisolism may be present in patients without true Cushing syndrome. This is known as *pseudo-Cushing syndrome* and can be caused by obesity, major depressive disorders, and chronic alcohol abuse. With further testing, these patients can usually be identified.

TREATMENT. The primary treatment of Cushing disease is surgical removal of the ectopic focus of ACTH production or adenoma in the pituitary or adrenal gland. Cure is achieved in the majority of patients, but resistant disease requires radiation in the case of pituitary disease or medical therapy with adrenal enzyme inhibitors.[148] Historically, Cushing syndrome was treated with bilateral adrenalectomy. This frequently resulted in Nelson syndrome, which is characterized by unchecked ACTH production from an enlarging pituitary adenoma with resulting hyperpigmentation. Pituitary radiation can be helpful in these cases.[150]

ADDISON DISEASE

EPIDEMIOLOGY, ETIOLOGY, AND PATHOGENESIS. Destruction of the adrenal glands and the resulting life-threatening deficiency of glucocorticoids, mineralocorticoids, and adrenal androgens is known as *Addison disease*. It occurs at an estimated prevalence rate of 120 per million in Western countries.[151] It is suspected that many more cases remain undiagnosed. Historically, the most common cause was tuberculosis infection, but now autoimmune destruction as part of the autoimmune polyglandular syndromes 1 and 2 is the most common etiology. In autoimmune cases, enzymes of the adrenal cortex, including 21-hydroxylase and 17-hydroxylase, are target autoantigens, and circulating autoantibodies can be detected. Subsequent lymphocytic infiltration of the adrenal gland with damage and scarring results.

Infectious causes of adrenal insufficiency remain the next most common etiology. Tuberculosis is still a major problem in many areas of the world. Atypical mycobacterial infection can also cause adrenal insufficiency. This is seen more commonly in immunosuppressed patients. Addison disease is increasingly recognized in patients with acquired immunodeficiency syndrome and, in these patients, infection with cytomegalovirus is the most recognized cause. Fungal infections have also been associated with Addison disease, including histoplasmosis, blastomycosis, paracoccidioidomycosis, coccidioidomycosis, and cryptococcosis. In the setting of an acute bacterial infection, bilateral adrenal infarction due to adrenal hemorrhage is known as the *Waterhouse–Friderichsen syndrome*. Classically this is due to meningococcal infection, although other infections have been reported (see Chapters 180 and 181).[152] Other rare causes of Addison disease include drugs, congenital adrenal hypoplasia, and infiltrative disorders, including amyloidosis, sarcoidosis, and metastatic carcinomas. The surgical treatment of Cushing syndrome can be an additional cause of adrenal insufficiency.

BOX 151-15 APPROACH TO THE PATIENT WITH ADDISON DISEASE

CUTANEOUS FINDINGS IN ADDISON DISEASE
- Hyperpigmentation of skin and mucous membranes
- Longitudinal pigmented bands in the nails
- Vitiligo
- Decreased axillary and pubic hair in women
- Calcification of auricular cartilages in men

RELATED FEATURES
- Abdominal pain
- Electrolyte abnormalities (hyponatremia and hyperkalemia)
- Postural hypotension
- Anorexia and weight loss
- Shock, coma, and death, if untreated

DIAGNOSIS
- Failure to respond adequately to corticotropin stimulation test

MANAGEMENT
- Lifelong replacement therapy of glucocorticoids and mineralocorticoids

CLINICAL FINDINGS. (Box 151-15). The clinical and cutaneous manifestations of adrenal insufficiency are not usually present until 90% of the gland function is destroyed.[151] The most recognized cutaneous manifestation is the hyperpigmentation of skin and mucous membranes. This occurs after long-standing adrenal insufficiency and would not be present in an acute presentation of adrenal crisis unless it is superimposed on a history of chronic adrenal insufficiency. The skin pigmentation is accentuated in sun-exposed areas, flexural folds, and skin creases, including the creases on the palms (Fig. 151-12). Pigment may develop in scars and longitudinal pigmented bands may appear in the nails. These pigment changes are a consequence of low cortisol levels and the resulting loss of negative regulatory feedback on the hypothalamus and pituitary. This results in unchecked production of POMC, ACTH, and MSH, which increase melanogenesis. In contrast, vitiligo can be seen in 10%–20% of patients.[153] Axillary and pubic hair may be sparse in women, due to the loss of adrenal androgens. This does not occur in men because adequate androgen levels are maintained by the testes. Unique to men is the reported calcification of the auricular cartilages.[154] Extracutaneous symptoms include weakness, anorexia, weight loss, abdominal pain, and postural hypotension due to electrolyte abnormalities.

LABORATORY TESTS. Acute adrenal crisis can occur in the setting of chronic adrenal insufficiency and can be life threatening. The primary treatment is glucocorticoid replacement and, in an acute crisis, a blood sample should be obtained for measurement of



Figure 151-12 **A.** This patient with Addison disease demonstrates the characteristic hyperpigmentation of the skin with accentuation in sun-exposed areas. **B.** Palmar creases are also hyperpigmented compared to a normal hand.

cortisol, but therapy with 100 mg IV hydrocortisone should be instituted immediately. In chronic adrenal insufficiency, the diagnosis is confirmed using the cosyntropin stimulation test. This involves the IV administration of synthetic corticotropin (ACTH) and the measurement of stimulated cortisol in the blood 30 minutes later. Inability to produce adequate cortisol is diagnostic. Chronic replacement therapy is necessary and may require adjustments for illness or severe stress. With treatment, there is a gradual improvement in the skin changes.

ESTROGEN AND PROGESTERONE

ESTROGEN AND SKIN AT A GLANCE

- Exogenous estrogen, either through oral contraceptives or hormone replacement, is the most common cause of estrogen excess.
- Wrinkling, xerosis, and atrophy are signs of estrogen deficiency.
- Triple-ingredient preparations are firstline therapy for treating melasma if patients are not content with covering cosmetics.

EPIDEMIOLOGY. The most commonly encountered cause of estrogen excess is the pharmacologic use of estrogens for birth control, treatment of dysfunctional uterine bleeding, and as postmenopausal hormone replacement. Up to one-third of child-bearing age women in the United States use oral contraceptives.[155] Ovarian, testicular, or hypothalamic tumors can also cause estrogen excess. Estrogen deficiency occurs most commonly as a result of menopause, which occurs on average at about 50 years of age. Other less common causes of estrogen deficiency include pituitary or gonadal failure. Exercise-induced amenorrhea is also associated with a concomitant estrogen deficiency.

ETIOLOGY AND PATHOGENESIS. Estrogen receptors are found throughout the skin, including on keratinocytes, sebaceous glands, eccrine and apocrine glands, in hair follicles, in dermal fibroblasts, and in melanocytes. In women of reproductive age, reported variations in dermatological responses seen throughout the menstrual cycle suggest that estrogens and progesterones have important effects on the clinical presentation of numerous disease states and allergic conditions of the skin.[156] Estrogens bind to cytosolic receptors that subsequently translocate to the nucleus and activate gene transcription. Estrogen receptors are found in greater numbers in women compared with men. The main observations regarding the effects of estrogen on skin come from studies of postmenopausal women, in whom estrogen deprivation leads to skin wrinkling, xerosis, and atrophy. Increased epidermal and dermal thickness, increased water-holding capacity, changes in lipid composition of the stratum corneum, and improvement in skin laxity all occur with estrogen replacement, highlighting the important effects of this hormone throughout the skin.[157] Estrogen deprivation has also been reported to hinder wound healing, which subsequently improves with estrogen replacement. Estrogens have also been reported to suppress sebaceous gland function and also tend to inhibit hair growth.

The most potent naturally occurring estrogen is estradiol, which is the principal estrogen secreted by the ovary. Estrone, another estrogen secreted by the ovaries, is synthesized primarily in peripheral tissues from the conversion of androstenedione. In the menstrual cycle, estradiol levels peak at midcycle immediately preceding ovulation, and then again near the end of the cycle around day 24 before falling to baseline before menses. During pregnancy, the main estrogen is estriol, which is synthesized by the placenta. Progesterone is the main hormone secreted by the corpus luteum, and peak levels are seen after ovulation, remaining elevated until just before menses. Gonadal hormones are not entirely specific, and progesterone is able to crossreact by binding to androgen receptors to exert androgenic or antiandrogenic effects.

CLINICAL FINDINGS AND DIAGNOSIS: CUTANEOUS MANIFESTATIONS OF ESTROGEN EXCESS AND DEFICIENCY. Estrogen can have both beneficial and undesired effects. Estrogen replacement therapy in postmenopausal women can reverse epidermal atrophy and restore cutaneous collagen. The inhibitory actions of estrogen on sebum production can lead to improvement of acne with oral contraceptive therapy, particularly with the use of estrogen-dominant preparations. Despite circulating estriol during pregnancy, the relative androgen excess due to elevated progesterone can actually exacerbate acne in some patients. Telogen effluvium characterized by diffuse loss of scalp or body hair can occur after delivery or discontinuation of oral contraceptives. Both pregnant women and patients taking synthetic estrogen can be more prone to certain side effects of estrogen, including telangiectasias, palmar erythema, spider angiomas, and pigmentary changes.

Melanocytic lesions, including preexisting nevi and malignant melanoma, can darken during pregnancy. Hyperpigmentation of the nipples, linea nigra, and genitalia can be seen. Melasma, sometimes referred to as the *mask of pregnancy*, presents as irregularly shaped, hyperpigmented patches on the forehead, cheeks, nose, upper lip, chin, and neck (Fig. 151-13). Although melasma may improve after delivery, it can persist or reoccur with subsequent pregnancies. When caused by oral contraceptives, melasma can still persist even after discontinuation of the medication. In the very rare cases of men with melasma, the suspected etiology is thought to be sun exposure or familial susceptibility rather than estrogen excess, but the clinicopathological features are similar to that seen in female patients.[158]

Acanthosis nigricans can be associated with estrogen excess. In clinical states characterized by elevated estrogen levels, including pregnancy and the use of oral contraceptives, increased hair growth over the face, breasts, and extremities can be seen. This phenomenon may be a result of the complex interplay of estrogens and androgenic hormones rather than a direct effect of increased estrogen levels on the hair follicles themselves. Estrogen and progesterone dermatitis has been described in the literature and is characterized by a polymorphous eruption marked by cyclical premenstrual flares that may include pruritus.



Figure 151-13 Melasma is demonstrated in a symmetric pattern on the face of a young woman. The upper lip is also a common site of involvement.

The diagnosis may be made by separate subcutaneous injection of both estrogen and progesterone in the skin of the forearm, checking within 15–60 minutes for reactions ranging from erythema to a wheal.[159] Oral contraceptives have been implicated as a cause of erythema nodosum.

Estrogen deficiency from either menopause or pituitary failure can result in hot flashes, epithelial atrophy of the genitalia, and decreased breast size. Certain medications, such as danazol, leuprolide, and clomiphene citrate, can induce a pharmacologic menopause that presents with flushing. Flushing episodes accompanied by uncomfortable heat lasting several minutes can occur in younger women immediately before or during their period when estrogen levels are at their lowest.

TREATMENT. The Pigmentary Disorders Academy generated a consensus statement on the treatment of melasma and recommended the use of fixed "triple-ingredient" combinations as first-line therapy.[160] Topical retinoids, corticosteroids, azelaic acid, and hydroquinone-based bleaching creams have been used in various combinations to treat melasma. Kligman's formula, first developed in 1975, is the classic triple-ingredient melasma preparation consisting of 5% hydroquinone, 0.1% tretinoin, and 0.1% dexamethasone in a hydrophilic ointment. Dual ingredient combinations or single agents are reasonable alternatives. For refractory cases, chemical peels (i.e., glycolic acid or trichloroacetic acid) in combination with topical therapy can be tried. Lasers can also be considered but seem to be of limited usefulness. Given the exacerbation of hyperpigmentation with sun exposure, the consistent use of broad-spectrum sunscreens is also important for melasma treatment.

Although estrogen therapy can reverse some of the epithelial atrophy seen during menopause, the risks

and benefits of hormone replacement therapy must be weighed on an individual basis. Low-dose clonidine has been reported as an effective treatment for menopause-related flushing. There has been controversy regarding the use of estrogen therapies in patients with systemic lupus erythematosus, although two recent, well-designed trials suggest that these therapies can be used safely in most patients with systemic lupus erythematosus whose disease is stable.[161,162]

ANDROGENIC HORMONES

ANDROGENS AND SKIN AT A GLANCE

- The peripheral conversion of testosterone to 5 α-dihydrotestosterone is important for the pathophysiology of androgenic alopecia.
- Hirsutism secondary to androgen excess has a characteristic distribution that includes the beard area, chest, back, and suprapubic region.

EPIDEMIOLOGY. In males, cutaneous manifestations of androgen excess occur most commonly with either the onset of sexual maturation or with androgen replacement therapy. Androgen-secreting tumors are a less common cause of androgen excess. In women, androgen excess can occur due to congenital adrenal hyperplasia (CAH) secondary to deficiency of enzymes in adrenal enzymes such as 21-hydroxylase (encoded by the gene *CYP21A2*), which accounts for almost 90 percent of CAH in the United States.[163] Deficiency of CYP21 is inherited as an autosomal recessive trait and results in accumulation of 17-hydroxyprogesterone. Although progestins in oral contraceptives are listed as potential causes of hirsutism due to their chemical similarity to testosterone, they likely do not cause androgenic effects at clinically used doses based on data from animal studies. Polycystic ovary syndrome (PCOS) occurs in about 5% of premenopausal women in the United States and is characterized by insulin resistance, polycystic ovaries, and the presence of androgenic cutaneous findings, including acne, hirsutism, and androgenic alopecia. PCOS is also associated with the metabolic syndrome, which is characterized by lipid abnormalities, diabetic predisposition, and heart disease. Androgenic alopecia affects approximately one-half of men older than age 40 years, and potentially as many women as well, with most patients showing signs of alopecia by age 30 (see Chapter 88).

ETIOLOGY AND PATHOGENESIS. Like estrogen receptors, androgen receptors are also present throughout the skin. In men, androgens are synthesized in the testis and adrenals, whereas in women androgens are secreted by the ovaries and adrenals. In addition to testosterone, progesterone, dehydroepiandrosterone (DHEA), and DHEA sulfate (DHEA-S) are all natural androgens that can lead to cutaneous findings when they are present in excess.[164] Testosterone is subsequently converted in peripheral target tissues to the active metabolite 5 α-dihydrotestosterone (5α-DHT) by the enzyme 5α-reductase. Unlike testosterone, which can be aromatized to form estrogen, 5α-DHT cannot be aromatized and thus retains purely androgenic properties. In addition, 5α-DHT binds the androgen receptor with greater affinity than testosterone.

Androgens are significant regulators of hair growth and sebaceous gland function. Androgens have also been implicated in wound healing, epidermal differentiation, and the regulation of dermal fibroblasts. Androgen receptors have a trophic distribution throughout the body that is most evident with the appearance of "male pattern" hair growth on the face, chest, and back, as well as areas of hair loss on the scalp. Both estrogens and androgens can be bound by sex hormone-binding globulin (SHBG). SHBG levels are decreased by synthetic progestins found in oral contraceptives (i.e., norgestrel, norethindrone, norgestimate, and desogestrel), as well as in obesity, acromegaly, hypothyroidism, and hyperinsulinemia. The decreased SHBG results in higher levels of circulating androgens and accounts, in part, for why androgenic findings can be associated with these conditions.

CLINICAL FINDINGS AND DIAGNOSIS: CUTANEOUS MANIFESTATIONS OF ANDROGEN EXCESS. Androgen-related skin conditions are commonly seen in dermatology practice. Although our knowledge regarding acne pathogenesis is still incomplete, at least part of acne's pathophysiology involves the response of sebaceous glands to androgens. In most males and females, acne tends to subside after adolescence (see Chapter 80). Cases of persistent acne should elicit a differential diagnosis that includes causes of persistent androgen excess, including CAH, PCOS in women, or an androgen-secreting tumor (Fig. 151-14), in addition to rosacea and chemically induced acne. In the appropriate clinical setting, laboratory studies may be helpful in determining the source of androgen excess (Box 151-16). Performance-enhancing anabolic steroids are derivatives of testosterone, and the resulting androgen excess can manifest as acne.

There is some genetic variation underlying the response of hair follicles to androgens as evidenced by the varying degrees of hirsutism seen among women with different ethnic backgrounds but similar serum androgen levels. Hirsutism secondary to androgen excess occurs in a characteristic distribution involving the beard region of the face, the chest, the upper back, and the suprapubic area.

Ironically, although androgens can cause hair excess, they are also responsible for male-pattern alopecia as well. Scalp hairs are eventually converted first to indeterminate hairs and then to vellus hairs. Clinically, scalp hairs become thinner until they are replaced by nonpigmented vellus hairs. In men, the pattern is characteristic and consists of symmetric recession of the hairline and the temples along with hair loss on the



Figure 151-14 Hyperandrogenism manifests clinically in this woman with an androgen-secreting adrenal tumor. Note the characteristic facial hair, the receding hairline, and the acneiform eruption on the chest.

BOX 151-16 APPROACH TO THE FEMALE PATIENT WITH SUSPECTED HYPERANDROGENISM

History and physical findings concerning for hyperandrogenism

- Sudden onset of acne
- Severe acne refractory to conventional treatments
- Irregular menstrual periods
- Hirsutism

Laboratory evaluation (most accurate when patient is off oral contraceptives for 4–6 weeks and if tests are drawn before menses)

- Dehydroepiandrosterone sulfate: screens for adrenal androgen source
  - >8,000 ng/mL may suggest adrenal tumor
  - 4,000–8,000 ng/mL may suggest congenital adrenal hyperplasia
- Testosterone: screens for ovarian source
  - 150–200 ng/dL can occur in polycystic ovarian syndrome
  - Some adrenal tumors can also secrete testosterone
- Luteinizing hormone–follicle stimulating hormone ratio
  - >2–3 can be consistent with polycystic ovarian syndrome

Adapted from Thiboutot D: Acne: Hormonal concepts and therapy. *Clin Dermatol* **22**:419, 2004.

vertex. In women, the frontal hairline is usually preserved, and the pattern is mostly diffuse thinning without an area of frank baldness. Although androgenetic alopecia can be acquired in patients with androgen excess, it is most commonly an incompletely characterized genetic disorder that appears to be inherited in an autosomal dominant manner (see Chapter 88).

TREATMENT. In women whose acne appears to be hormonally related, the use of antiandrogens, including the diuretic spironolactone or the oral contraceptive drospirenone, may prove more effective than conventional topical and oral acne medications. These drugs act as competitive inhibitors of DHT binding to androgen receptors. Specific 5α-reductase inhibitors, such as finasteride, can be used to treat androgenetic alopecia, although this medication is contraindicated in women of child-bearing age due to possible effects on development of genitalia and gonads in the male fetus. The use of finasteride has been linked to an increased risk of high-grade prostate cancer but without an increase in the absolute risk of prostate cancer in men with benign prostatic hypertrophy, although similar data on men using finasteride for hair loss has not been reported.[165] In postmenopausal women finasteride treatment has not demonstrated significant benefit in a large placebo-controlled trial.[166]

When patients have an excess of adrenal androgens such as DHEA-S, the use of low-dose glucocorticosteroids (such as prednisone, 2.5–5.0 mg/day) can be used for suppressive therapy, and the efficacy of therapy can be monitored by measuring serum DHEA-S levels. Cyproterone acetate is an antiandrogen that is not available in the United States, although it has shown promise in the treatment of acne when used in other countries in oral contraceptive preparations. Flutamide is a nonsteroidal androgen receptor antagonist that is rarely used due to the risk of fatal hepatitis as well as concerns about effects on fetal development in women of child-bearing age.[167]

DISORDERS OF GROWTH HORMONE

GROWTH HORMONE AT A GLANCE

- Growth hormone plays a central role in longitudinal growth.
- In children, deficiency manifests as short stature while gigantism occurs from oversecretion of growth hormone before puberty, when the growth plates in long bones are still open.
- The disease acromegaly occurs in adults after the growth plates have closed.
- Acromegaly results from oversecretion of growth hormone, usually due to a pituitary adenoma.

ACROMEGALY

GH is secreted by the pituitary in a pulsatile fashion and reaches its maximum rate during puberty and then declines over time. The pulsatile pattern of secretion is equally important to the amount of hormone for normal function. Secretion of GH is primarily regulated by GH-releasing hormone (GHRH) and somatostatin.[168] The natural GH secretagogue ghrelin, produced in the stomach, has been discovered to have potent GH-releasing properties and may be involved in a separate pathway of GH regulation.[168,169] GHRH stimulates the release of GH, whereas somatostatin has an inhibitory effect. The target of these regulatory factors is the GHRH receptor in the pituitary. The peripheral effects of GH are largely indirectly mediated through production of IGF1 in the liver and stimulation of the IGF1 receptor. GH contributes significantly to linear growth in children, increases protein synthesis, mobilizes stored triglycerides, and antagonizes the action of insulin (Fig. 151-15).

ETIOLOGY AND PATHOGENESIS. Excessive production of GH is almost always due to a pituitary adenoma. In children, this results in pituitary gigantism, whereas in adults, excessive GH manifests as the clinical syndrome acromegaly. This syndrome is diagnosed in about 3 to 4 people per million every year.[170] Very rarely, acromegaly is caused by a GH-producing tumor in the hypothalamus or by an ectopic nonendocrine tumor such as small cell lung cancer or carcinoid tumor.[171] GH-producing adenomas are present in 8% of patients with Carney complex, an inherited disorder with multiple lentigines and multiple endocrine abnormalities.[172]

CLINICAL FINDINGS. (Box 151-17). The clinical manifestations of acromegaly include the overgrowth of bone and connective tissue, metabolic effects, and localized tumor mass effects. The onset is insidious, and the average age at the time of diagnosis is 40–45 years, but often the condition has been present for many years before the diagnosis.[173] The metabolic effects include diabetes, hypertension, and hyperlipidemia. There is a gradual coarsening of the features and increased head, hand, and foot size. This acral pattern of overgrowth may be noticed as increasing shoe, ring, glove, or hat size (Fig. 151-16A). Macroglossia can be seen. The skin becomes thickened, almost doughy, with deep grooves prominent on the forehead and around the nasolabial folds (Fig. 151-16B). On the scalp, cutis verticis gyrata may develop. Heel pads and the pads of the digits become thickened. Nails are thickened and brittle, and some patients develop hirsutism. Hyperhidrosis and malodor are common complaints. Many patients develop acanthosis nigricans and multiple acrochordons with or without frank diabetes. Retinal angioid streaks can be seen in acromegaly (as well as in osteogenesis imperfecta and pseudoxanthoma elasticum) (see Chapter 137). Histologically, there is a dense deposition of GAGs in the papillary and superficial reticular dermis. Often, coarse collagen bundles with normal elastin and increased numbers of fibroblasts are seen in the dermis.

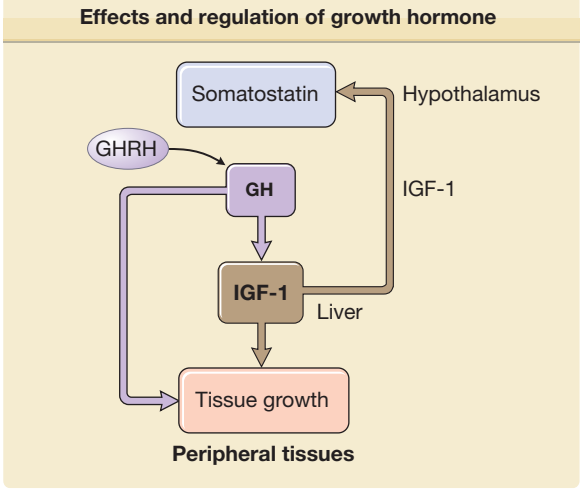

Figure 151-15 Effects and regulation of growth hormone (GH). GHRH = growth hormone releasing hormone; IGF-1 = insulin-like growth factor-1.

BOX 151-17 APPROACH TO THE PATIENT WITH ACROMEGALY

CUTANEOUS FINDINGS IN ACROMEGALY
- Enlargement of hands and feet with a doughy texture
- Increased ring, glove, shoe, and hat size
- Jaw enlargement with separation of teeth (prognathism)
- Macroglossia
- Cutis vertices gyri
- Acanthosis nigricans
- Hirsutism
- Hyperhidrosis
- Brittle thick nails

RELATED FEATURES
- Diabetes
- Hypertension
- Hyperlipidemia

DIAGNOSIS
- Elevated serum insulin-like growth factor-1 levels
- Failure to suppress growth hormone levels by oral glucose-tolerance test

MANAGEMENT
- Appropriate endocrine and surgical consultation
- Surgical removal of adenoma by transphenoidal resection
- Somatostatin analogues or growth hormone receptor antagonists for residual disease
- Radiation therapy is an option for resistant cases



Figure 151-16 **A.** Acral enlargement is a prominent feature of acromegaly and is easily demonstrated in comparison with a normal hand. **B.** Patients develop deep grooves on the forehead and around the nasolabial folds. When jaw enlargement is present, spaces between the teeth can be seen. (Reprinted from Braverman I: *Skin Signs of Systemic Disease,* 3rd edition. Saunders, 1997, with permission.)

LABORATORY TESTS. Measurement of the serum GH level is highly variable and unreliable diagnostically because of the pulsatile pattern of secretion. Plasma IGF1 levels are very much dependent on GH and fairly stable during any 24-hour period. Serum IGF1 can be used as a surrogate measurement of GH. As a screening test for acromegaly, IGF1 levels will be elevated. Further workup with assistance from a consulting endocrinologist may include an oral glucose tolerance test. In the proper clinical setting failure to suppress the GH level to <1 ng/mL within 1–2 hours after 75–100 g of oral glucose is diagnostic for acromegaly.[174]

TREATMENT. Because most cases of GH excess are due to a pituitary adenoma, surgical removal is the primary therapy. This is most commonly accomplished through a selective transsphenoidal resection.[175] Residual disease after surgery is more common in larger adenomas and may be higher than 30% for tumors larger than 1 cm. The inhibitory effect of somatostatin on GH secretion is harnessed for therapy. Somatostatin analogues, including octreotide, are used for the medical treatment of residual disease after surgery and are increasingly being considered as potential primary therapy. The somatostatin analogues alone have demonstrated the ability to reduce the size of tumors and to control IGF1 levels in select patients. In resistant cases, radiation therapy can be considered.

GROWTH HORMONE DEFICIENCY AND PANHYPOPITUITARISM

GH deficiency can occur in children or adults and be inherited or acquired. The primary clinical manifestation of this deficiency occurs in children as abnormal short stature. This can be corrected by the administration of GH. The clinical presentation of GH deficiency in adults includes decreased lean body mass, decreased strength and exercise capacity in part due to decreased sweating, and a loss of general vitality. Replacement therapy in adults is a complex discussion and beyond the scope of this chapter. Recently, practice guidelines have been established by the Endocrine Society for the assessment and treatment of GH deficiency in adults.[176] In the setting of panhypopituitarism, there is total loss of all pituitary function, including GH (Box 151-18). These patients usually present with a combination of symptoms either due to a space-occupying lesion in the

BOX 151-18 CAUSES OF HYPOPITUITARISM

- Mass lesions: nonfunctioning pituitary adenoma, cyst, craniopharyngioma, metastasis
- Infectious causes: tuberculosis, histoplasmosis
- Pituitary infarction: known as Sheehan syndrome when occurs with childbirth
- Pituitary apoplexy: sudden hemorrhage into the pituitary
- Lymphocytic hypophysitis
- Infiltrative disorders: hemochromatosis, sarcoidosis, Langerhans cell histiocytosis
- Head trauma
- Surgery or radiation



Figure 151-17 In this patient with panhypopituitarism, fine wrinkling and pale skin can be seen as well as other features suggestive of hypothyroidism. Her decreased pigmentation is contrasted by that of her nurse on the right. Patients with panhypopituitarism often present with findings of multiple endocrine disorders.

pituitary or to hormone dysregulation. These symptoms may be a manifestation of any number of endocrine systems that are regulated at the level of the pituitary including features of hypothyroidism. Skin findings that have been described in these patients include fine wrinkling of the skin, decreased pigmentation, and decreased to absent pubic and axillary hair (Fig. 151-17).

KEY REFERENCES

Full reference list available at www.DIGM8.com

DVD contains references and additional content

3. Narayan KM et al: Lifetime risk for diabetes mellitus in the United States. *JAMA* **290**:1884, 2003
5. Skyler JS et al: Intensive glycemic control and the prevention of cardiovascular events: Implications of the ACCORD, ADVANCE, and VA diabetes trials: A position statement of the American Diabetes Association and a scientific statement of the American College of Cardiology Foundation and the American Heart Association. *Diabetes Care* **32**:187, 2009
11. Joshi N et al: Infections in patients with diabetes mellitus. *N Engl J Med* **341**:1906, 1999
15. Reiber GE, Pecoraro RE, Koepsell TD: Risk factors for amputation in patients with diabetes mellitus. A case-control study. *Ann Intern Med* **117**:97, 1992
16. Schwartz RA: Acanthosis nigricans. *J Am Acad Dermatol* **31**:1, 1994
24. Ellis DL et al: Melanoma, growth factors, acanthosis nigricans, the sign of Leser-Trelat, and multiple acrochordons. A possible role for alpha-transforming growth factor in cutaneous paraneoplastic syndromes. *N Engl J Med* **317**:1582, 1987
34. Rosenbloom AL et al: Limited joint mobility in childhood diabetes mellitus indicates increased risk for microvascular disease. *N Engl J Med* **305**:191, 1981
39. Cole GW, Headley J, Skowsky R: Scleredema diabeticorum: A common and distinct cutaneous manifestation of diabetes mellitus. *Diabetes Care* **6**:189, 1983
45. Bagdade JD, Porte D Jr, Bierman EL: Diabetic lipemia. A form of acquired fat-induced lipemia. *N Engl J Med* **276**:427, 1967
50. Singh N, Armstrong DG, Lipsky BA: Preventing foot ulcers in patients with diabetes. *Jama* **293**:217, 2005
58. Boyko EJ et al: Prediction of diabetic foot ulcer occurrence using commonly available clinical information: The Seattle Diabetic Foot Study. *Diabetes Care* **29**:1202, 2006
60. Edmonds M et al: New treatments in ulcer healing and wound infection. *Diabetes Metab Res Rev* **16**(Suppl 1):S51, 2000
63. Muller SA, Winkelmann RK: Necrobiosis lipoidica diabeticorum. A clinical and pathological investigation of 171 cases. *Arch Dermatol* **93**:272, 1966
65. Lowitt MH, Dover JS: Necrobiosis lipoidica. *J Am Acad Dermatol* **25**:735, 1991
74. Dabski K, Winkelmann RK: Generalized granuloma annulare: Clinical and laboratory findings in 100 patients. *J Am Acad Dermatol* **20**:39, 1989
77. Binkley GW: Dermopathy in diabetes mellitus. *Arch Dermatol* **92**:106, 1965
85. Toonstra J: Bullosis diabeticorum. Report of a case with a review of the literature. *J Am Acad Dermatol* **13**:799, 1985
86. Ogden CL et al: Prevalence of overweight and obesity in the United States, 1999–2004. *Jama* **295**:1549, 2006
87. Kelesidis T et al: Narrative review: The role of leptin in human physiology: Emerging clinical applications. *Ann Intern Med* **152**:93, 2010
93. Sonnett TE et al: Diabetes mellitus, inflammation, obesity: Proposed treatment pathways for current and future therapies. *Ann Pharmacother* **44**:701, 2010
100. Yosipovitch G, DeVore A, Dawn A: Obesity and the skin: Skin physiology and skin manifestations of obesity. *J Am Acad Dermatol* **56**:901, 2007
105. Weetman AP: Graves' disease. *N Engl J Med* **343**:1236, 2000
109. Brent GA: The molecular basis of thyroid hormone action. *N Engl J Med* **331**:847, 1994
111. Surks MI, Sievert R: Drugs and thyroid function. *N Engl J Med* **333**:1688, 1995
116. Ai J, Leonhardt JM, Heymann WR: Autoimmune thyroid diseases: Etiology, pathogenesis, and dermatologic manifestations. *J Am Acad Dermatol* **48**:641, 2003

119. Fatourechi V, Ahmed DD, Schwartz KM: Thyroid acropachy: Report of 40 patients treated at a single institution in a 26-year period. *J Clin Endocrinol Metab* **87**:5435, 2002
135. Walsh JS, Fairley JA: Calcifying disorders of the skin. *J Am Acad Dermatol* **33**:693, 1995
140. Schlieper G et al: Sodium thiosulfate in the treatment of calcific uremic arteriolopathy. *Nat Rev Nephrol* **5**:539, 2009
148. Orth DN: Cushing's syndrome. *N Engl J Med* **332**:791, 1995
151. Ten S, New M, Maclaren N: Clinical review 130: Addison's disease 2001. *J Clin Endocrinol Metab* **86**:2909, 2001
157. Hall G, Phillips TJ: Estrogen and skin: the effects of estrogen, menopause, and hormone replacement therapy on the skin. *J Am Acad Dermatol* **53**:555, 2005
160. Rendon M et al: Treatment of melasma. *J Am Acad Dermatol* **54**:S272, 2006
161. Petri M et al: Combined oral contraceptives in women with systemic lupus erythematosus. *N Engl J Med* **353**:2550, 2005
166. Price VH et al: Lack of efficacy of finasteride in postmenopausal women with androgenetic alopecia. *J Am Acad Dermatol* **43**:768, 2000
174. Melmed S: Medical progress: Acromegaly. *N Engl J Med* **355**:2558, 2006

Chapter 152 :: Sarcoidosis

:: Richard M. Marchell, Bruce Thiers, & Marc A. Judson

SARCOIDOSIS AT A GLANCE

- Sarcoidosis is a systemic granulomatous disease of unknown cause that primarily affects the lungs, but often involves the skin.
- The highest prevalence of sarcoidosis is in Denmark and Sweden; in the United States, it is higher in persons of African descent.
- The most common sites of cutaneous sarcoidosis are the head and neck. Scar tissue at all sites can be affected.
- The most common cutaneous form of sarcoidosis, the papular form, is characterized by translucent yellow-red papules with an "apple jelly" appearance on diascopy.
- Noncaseating, "naked" granulomas on biopsy are quite suggestive, but not specific for the diagnosis.
- Erythema nodosum is the main nonspecific cutaneous manifestation of sarcoidosis, and heralds a good prognosis.

Sarcoidosis is a multisystem granulomatous disease of unknown cause. The lung is the most commonly affected organ, but the skin is frequently involved.[1] The first descriptions of sarcoidosis in the late 1800s were limited to its skin manifestations.[1] The term *sarcoidosis* is derived from Caesar Boeck's 1899 report of what he described as "multiple benign sarkoid of the skin," because he believed the lesions resembled sarcomas but were benign.[2]

EPIDEMIOLOGY

Sarcoidosis occurs worldwide and affects all ages and races. Disease onset is most often in the third decade of life, although a smaller second peak occurs in people older than 50 years.[1] The prevalence rate is slightly higher in women.[1] Sarcoidosis is more frequent away from the equator. The highest prevalence of sarcoidosis is found in Caucasians in Denmark, Sweden, and, in the United States, in persons of African descent.[1] In the United States, the lifetime risk of sarcoidosis is 2.4% in African-Americans and 0.85% in Caucasians.[3] The age-adjusted annual incidence rate of sarcoidosis in the United States is 35.5 per 100,000 for African-Americans and 10.9 per 100,000 for Caucasians.[3] The frequency and severity of the disease also vary between different ethnicities and races. African-Americans tend to have more severe disease, whereas Caucasians are more likely to present with asymptomatic disease.[4,5] African-Americans are also more likely to have extrapulmonary disease,[6] require treatment,[7] develop new organ involvement,[8] and have a lower rate of clinical recovery than Caucasians.[5,8] The disease is more common in life-long nonsmokers.[9]

ETIOLOGY AND PATHOGENESIS

The current understanding is that the development of sarcoidosis requires at least three major events: (1) exposure to antigen(s), (2) acquired cellular immunity directed against the antigen and mediated through antigen-presenting cells and antigen-specific T lymphocytes, and (3) the appearance of immune effector cells that promote a nonspecific inflammatory response.[10] The identity of the putative antigen(s) of sarcoidosis is unknown.

Presumably, antigen-presenting cells such as macrophages recognize, process, and present the processed antigen to $CD4^+$ T cells of the T helper 1 type

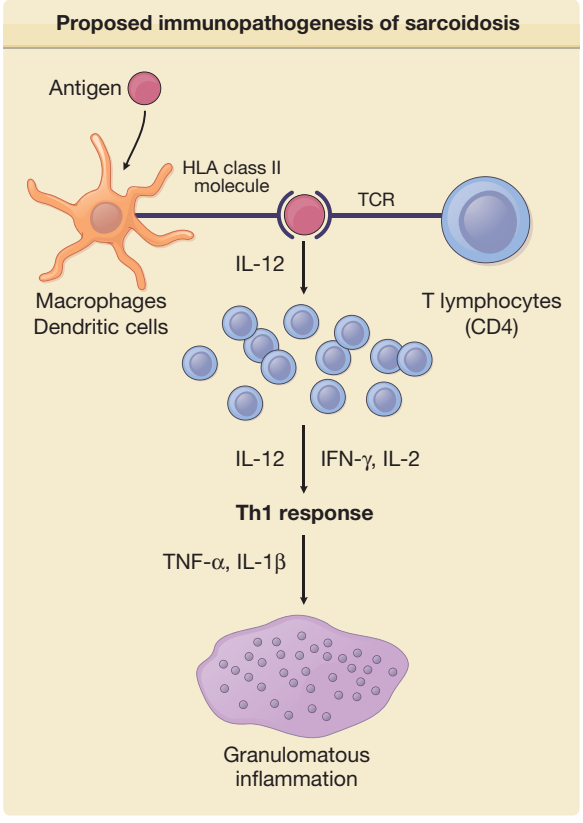

Figure 152-1 Proposed immunopathogenesis of sarcoidosis. An antigen, presently unknown, is engulfed and processed by an antigen-presenting cell (macrophage or dendritic cell). The processed antigen is presented to a T-cell receptor (TCR) of a T lymphocyte via an HLA class II molecule. Once the HLA receptor and TCR have bound the processed antigen, numerous lymphokines and cytokines of the T helper 1 (Th1) class are released that lead to T-cell proliferation, recruitment of monocytes, and eventual granuloma formation. A few of these lymphokines and cytokines are shown, with those released by the antigen-presenting cells on the left and those released by lymphocytes on the right. IFN = interferon; IL = interleukin; TNF = tumor necrosis factor.

(Fig. 152-1). The processed antigen is presented to these lymphocytes via HLA class II molecules on the antigen-presenting cells that have undergone enhanced expression from exposure to the sarcoidosis antigen and possibly interferon-γ (IFN-γ).[10,11] These activated macrophages produce interleukin (IL)-12, which induces lymphocytes to shift toward a T helper 1 profile and causes T lymphocytes to secrete IFN-γ. These activated T cells release IL-2 and chemotactic factors that recruit monocytes and macrophages to the site of disease activity. IL-2 and other cytokines also expand various T-cell clones. IFN-γ further activates macrophages and transforms them into giant cells.[11] Tumor necrosis factor (TNF), IL-2, and other cytokines may also be important in stimulating macrophages.[12] Figure 152-1 displays the major features of the presumed immunopathogenesis of sarcoidosis.

A variety of candidate antigens have been suggested as provocative agents for the cascade of immunologic events that eventuate in sarcoidosis. Infectious agents such as mycobacteria,[13] *Propioni-bacterium acnes*,[14] and *Chlamydia*[15] have been associated with sarcoidosis. Mineral dusts, such as silica, iron,[16] and titanium,[17] also have been associated with sarcoidosis as have combustible wood products because the disease has been found more commonly in individuals who use wood stoves.[18] Interestingly, firefighters have been found to be at greater risk of developing sarcoidosis.[19]

Genetics play a major role in determining susceptibility to sarcoidosis, as it is more common in relatives of an affected person than in individuals in the general population.[20] Genes coding for HLA class II antigens are thought to be prime candidates for a role in the development of the disease because these molecules present exogenous peptides to $CD4^+$ T-cell receptors. Numerous studies in various ethnic groups have shown a relationship of HLA antigens to the development of disease, protection from disease, good prognosis, poor prognosis, acute disease, chronic disease, and various phenotypic expressions of sarcoidosis.[21]

The interplay of antigenic and genetic factors suggests that there may be multiple causes of sarcoidosis. Patients may have to experience a specific interaction between one or several exposures and be genetically programmed to one or several abnormal immunologic responses. Each putative antigen may be associated with a specific HLA class II molecule and T-cell receptor.

CLINICAL FINDINGS

HISTORY

The diagnosis of sarcoidosis is often delayed for months to years because symptoms are nonspecific and can relate to involvement of any organ.[22]

Thirty to sixty percent of patients with pulmonary sarcoidosis are asymptomatic.[23] Other than the lung, the skin, eye, liver, and peripheral lymph nodes are commonly involved. Consequently, sarcoidosis should be considered in a patient with skin lesions and concomitant pulmonary symptoms, eye complaints, right upper quadrant abdominal pain, or peripheral lymphadenopathy. In addition, the cytokines associated with the granulomatous inflammation of sarcoidosis may cause constitutional symptoms such as fever, night sweats, malaise, and weight loss.

Cutaneous lesions of sarcoidosis may occur before, coincident with, or after systemic involvement. Specific cutaneous lesions are usually asymptomatic. Pruritus and pain are rare. Cosmetic disfigurement is the most common complaint. Erythema nodosum associated with sarcoidosis is indistinguishable from erythema nodosum unassociated with sarcoidosis (see Chapter 70).

CUTANEOUS LESIONS

Classically, lesions are divided into two categories: (1) specific and (2) nonspecific. Specific lesions have



Figure 152-2 Cutaneous sarcoidosis of the face. Micropapular form.

granulomas on biopsy. Nonspecific skin findings are reactive and do not exhibit sarcoidal granulomas.

SPECIFIC LESIONS SKIN. Specific sarcoidal lesions most often are found on the head and neck (Figs. 152-2–152-4) but may occur symmetrically or asymmetrically on any part of the skin and mucosa. Almost all morphologies have been reported, including macules, papules, patches, plaques, and nodules. Alopecia occurs with scalp involvement, and nail changes also occur. Specific lesions of sarcoidosis may be scaly, telangiectatic, or atrophic. Despite the diversity in appearance, there are several clinical presentations that are classically associated with cutaneous sarcoidosis.

The most common presentation is the papular form (see Figs. 152-2–152-4). These firm, 2–5-mm papules often have a translucent red-brown or yellow-brown appearance. The yellow-brown color has been likened to "apple jelly" and is accentuated with diascopy (Fig. 152-5). In addition to the color change, the underlying granulomas have a nodular quality that can also be appreciated with diascopy. The apple jelly appearance and nodules are not pathognomonic for



Figure 152-3 Cutaneous sarcoidosis of the face. Papular form. Some of the papules have enlarged to small plaques.



Figure 152-4 Cutaneous sarcoidosis of the face. Symmetric papules on cheeks.

sarcoidosis, as other granulatomous skin conditions, such as lupus vulgaris (see Chapter 184), may exhibit similar diascopic properties. Epidermal changes may or may not be present, but often the lesions have a waxy appearance, which reflects mild epidermal atrophy. Papular lesions occur most commonly on the face and neck, with a predilection for periorbital skin (see eFig. 152-5.1 in online edition). Annular plaques (Fig. 152-6), nonannular plaques (Fig. 152-7 and see eFig. 152-7.1 in online edition), and nodules (Fig. 152-8) may develop from these papular lesions and may or may not retain the classic translucent quality of the papules.

Lupus pernio describes the relatively symmetric, violaceous, indurated plaques and nodules



Figure 152-5 Diascopy highlights the "apple jelly" coloration of cutaneous sarcoidosis.

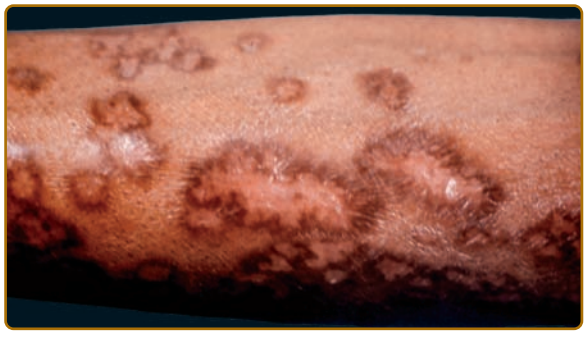

Figure 152-6 Cutaneous sarcoidosis with an annular configuration.

that occur on the nose, earlobes, cheeks, and digits (Figs. 152-9–152-11). This clinical variant of sarcoidosis is distinctive and has been associated with systemic involvement. Lupus pernio is associated with a higher prevalence of upper respiratory tract disease.[24] Lupus pernio lesions may directly extend into the nasal sinus, leading to epistaxis, nasal crusting, and sinus bone involvement.

Angiolupoid lesions are pink papules and plaques with prominent telangiectasias that usually occur on the face (see eFig. 152-11.1 in online edition) and may be a variant of lupus pernio, as both lesions usually appear on the face and can be violaceous.[25,26] However, angiolupoid lesions tend to be less numerous than the papular and lupus pernio forms.[26]

Rarely, sarcoidosis can present as persistent subcutaneous nodules (Darier-Roussy sarcoid).[27] The nodules may be tender or painless and preferentially occur on the extremities.



Figure 152-7 Plaques of cutaneous sarcoidosis on the neck and upper back.



Figure 152-8 Nodular sarcoidosis in the face. In Caucasians, lesions of sarcoidosis are often red or purple.

SCARS. Cutaneous sarcoidosis occurs preferentially within scar tissue, at traumatized skin sites, and around embedded foreign material such as silica. Scars become inflamed and infiltrated with sarcoidal granulomas (Fig. 152-12). Inflammation of old scars (see eFig. 152-12.1 in online edition) may parallel or precede systemic disease activity. Infiltrated scars may be tender or pruritic. Scar sarcoidosis may be the only cutaneous finding in a patient with systemic sarcoidosis; therefore, it is important to closely examine scar tissue in patients suspected of having the disease. The presence of sarcoidal granulomas surrounding foreign material does not establish the diagnosis of sarcoidosis, nor does foreign material in the presence of granulomas exclude the diagnosis.[28] Other signs of systemic

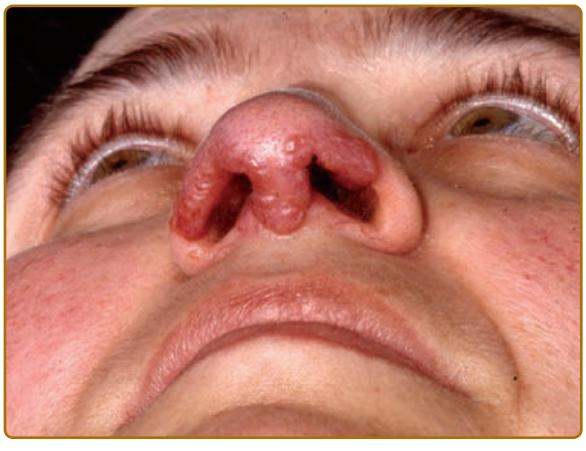

Figure 152-9 Lupus pernio along the nasal rim. This patient also had sarcoidosis of the upper respiratory tract (SURT) (see Section "Other Organs").



Figure 152-10 Violaceous lupus pernio lesions on cheek and nose.

or cutaneous involvement are required to confirm the diagnosis.

SCALP. Alopecia occurs with involvement of the scalp and may be scarring or nonscarring (see eFig. 152-12.2 in online edition).[29–32] Biopsy shows noncaseating granulomas. Its reversibility is dependent on the degree of destruction of hair follicles.

NAILS. Sarcoidosis may cause nail plate deformation and discoloration, but the incidence is very low.[33] There may be clubbing, (Fig. 152-11) subungual hyperkeratosis, and even nail plate destruction. Nail manifestations may result from granulomas in the nail matrix or from involvement of adjacent bone.



Figure 152-11 Violaceous lupus pernio on distal fingers.



Figure 152-12 Sarcoidosis arising in old facial scars sustained after car accident.

MUCOUS MEMBRANES. Sarcoidal granulomas may cause papules and plaques of the mucosal surfaces and tongue. Sarcoidosis is one cause of Mikulicz syndrome, the bilateral enlargement of the lacrimal (see eFig. 152-12.3 in online edition), parotid, sublingual, and submandibular glands.

ADDITIONAL PRESENTATIONS. A myriad of additional clinical presentations have also been reported. These include ichthyosis,[34] erythroderma,[29] ulcerations (see eFigs. 152-12.4 and 152-12.5 in online edition),[35] morphea-form plaques,[36] lichen niditus-like papules,[37] folliculitis-like lesions,[38] psoriasiform plaques,[39] hypopigmented areas,[40] gyrate erythema,[41] verrucous lesions,[38] faint erythema, penile (see eFig. 152-12.6 in online edition) and vulvar lesions,[42,43] palmar erythema,[44] discoid lupus-like plaques,[45] lower extremity edema,[46] lesions mimicking tuberculoid leprosy (see eFig. 152-12.7) polymorphous light eruption,[38] and pustular lesions.[38]

NONSPECIFIC LESIONS. Erythema nodosum (see Chapter 70) is the main nonspecific cutaneous manifestation of sarcoidosis (prevalence of approximately 17%). Erythema nodosum with bilateral hilar adenopathy, arthralgias, and fever is frequently the initial manifestation of sarcoidosis and is called *Löfgren syndrome*. These patients tend to have an acute form of sarcoidosis with eventual resolution.

Other nonspecific cutaneous manifestations of sarcoidosis are much less common. The neutrophilic dermatoses, Sweet disease and pyoderma gangrenosum, have been reported as nonspecific cutaneous sarcoid lesions. Most of the sarcoid patients with Sweet disease lesions or pyoderma gangrenosum have concomitant erythema nodosum.[47] Nonspecific erythematous

eruptions resembling viral exanthems or drug reactions without histologic evidence of granulomatous inflammation occur rarely with acute sarcoidosis. Additionally, patients with sarcoidosis may have pruritus without granulomatous infiltration, leading to prurigo nodules.[25] Erythema multiforme had been regularly cited as a nonspecific cutaneous manifestation of sarcoidosis,[38] but reports of histologically proven erythema multiforme with interface dermatitis associated with sarcoidosis are virtually nonexistent in the literature,[25,38,48,49] and any association is probably coincidental. Erythroderma and lower extremity swelling have been described as both specific and nonspecific lesions of sarcoidosis.[25,46,50,51]

RELATED CLINICAL FINDINGS

LUNGS. The lung is the most common organ involved with sarcoidosis. Findings on pulmonary examination are usually absent. Patients with pulmonary sarcoidosis are often asymptomatic, with the disease detected on a screening chest radiograph. Common symptoms include dyspnea, cough, chest pain, and wheezing. The chest radiograph is abnormal in more than 90% of patients with sarcoidosis. Bilateral hilar adenopathy is noted in 50%–85% of cases (see eFig. 152-12.8 in online edition). Pulmonary parenchymal infiltrates are seen in 25%–60% of cases.

Chest computed tomography (CT) reveals more thoracic disease than can be appreciated on the chest radiograph. CT is superior to the chest radiograph in detecting thoracic involvement with sarcoidosis, but there is insufficient evidence that CT has a clinical role in the management of pulmonary sarcoidosis.[52]

In sarcoidosis patients with normal lung parenchyma on chest radiograph, pulmonary function tests are abnormal in 20%–40% of cases. When the chest radiograph is abnormal, pulmonary function tests are abnormal in 50%–70% of cases.

EYES. The eyes are involved in one-fourth to three-fourths of sarcoidosis patients.[53] Eye involvement with sarcoidosis is potentially vision threatening, and the patient may be asymptomatic. For this reason, every patient diagnosed with sarcoidosis requires an ophthalmologic examination.[53] Redness, burning, itching, or dryness are the most common ocular symptoms when present. Any portion of the eye may be involved, and eye involvement may be the first manifestation of the disease.[53] Uveitis is the most common ocular manifestation and can lead to cataracts and glaucoma. Other ocular manifestations include conjunctivitis, lacrimal gland involvement causing kerato-conjunctivitis sicca (dry eyes), and optic neuritis, which may rapidly lead to loss of vision. Heerfordt syndrome includes fever, parotid gland enlargement, facial palsy, and anterior uveitis.[1]

LIVER. Hepatic involvement is common at disease onset but usually does not cause signs or symptoms.[54] Although histologic evidence of hepatic sarcoidosis is present in more than one-half of sarcoidosis patients,[55] signs of organ dysfunction due to hepatic sarcoidosis are far less common.[54] Hepatomegaly, abdominal pain, and pruritus are present in only 15%–25% of patients with hepatic sarcoidosis. An increased serum alkaline phosphatase level occurs in approximately one-third of patients,[56] but it is rarely associated with permanent hepatic dysfunction and therefore does not mandate treatment.[54,56] Treatment is required in the rare patient with significant symptoms, evidence of synthetic dysfunction, or hyperbilirubinemia. Rarely, hepatic sarcoidosis may lead to a primary biliary cirrhosis-type picture, and portal hypertension may develop.[57]

HEART. Clinical evidence of cardiac involvement is found in only 5% of sarcoidosis patients,[58] although myocardial granulomas have been found in approximately 25% of patients at autopsy.[59] Most clinical problems are related to cardiac arrhythmias or left ventricular dysfunction.[60,61] Sudden death may occur. Congestive heart failure may result when the myocardium is massively infiltrated with granulomas. Because of the potential lethal nature of heart involvement with sarcoidosis, an electrocardiogram is recommended for every patient diagnosed with the disease.[1]

NERVOUS SYSTEM. Any portion of the central nervous system or peripheral nervous system may be affected by sarcoidosis. Neurosarcoidosis has a predilection for the base of the brain, and cranial neuropathies are the most common manifestation.[62] The facial nerve is the cranial nerve most frequently involved.[62] In fact, it is common for Bell palsy to be the first manifestation of sarcoidosis and resolve completely before other manifestations of the disease occur. Mass lesions may develop in the brain or spinal cord. Aseptic meningitis and peripheral neuropathy are other neurologic manifestations of sarcoidosis.[63]

OTHER ORGANS. The sinuses and upper airway are commonly involved with sarcoidosis, a condition known as *SURT*: *s*arcoidosis of the *u*pper *r*espiratory *t*ract.[64] Nasal SURT is often associated with lupus pernio skin lesions (see Fig. 152-9) and may cause epistaxis and severe nasal crusting. Sarcoidosis of the spleen is not rare.[65] Sarcoidosis may also cause a disorder in calcium metabolism that results from activated sarcoidal macrophages demonstrating an increase in 1-α hydroxylase activity. This enzyme converts 25-hydroxyvitamin D to 1,25-dihydroxyvitamin D, the active form of the vitamin, an increase of which may result in hypercalcemia, hypercalciuria, and nephrolithiasis.[66] Sarcoidosis may be associated with a reduction in any blood cell line. Leukopenia may result from bone marrow involvement or from splenic sequestration. Thrombocytopenia may result from bone marrow involvement, splenic sequestration, or from an idiopathic thrombocytopenic purpura-like syndrome related to the hypergammaglobulinemia often seen in patients with sarcoidosis.[67]

BOX 152-1 RECOMMENDED INITIAL EVALUATION OF PATIENTS WITH SARCOIDOSIS

- History (occupational and environmental exposure, symptoms)
- Physical examination
- Posteroanterior chest X-ray
- Pulmonary function tests: spirometry, DL_{CO} and KL_{CO}
- Peripheral blood counts: white blood cells, red blood cells, platelets
- Serum chemistries: calcium, liver enzymes (alanine aminotransferase, aspartate aminotransferase, alkaline phosphatase), creatinine, and blood urea nitrogen
- Urine analysis
- Electrocardiogram
- Routine ophthalmologic examination
- Tuberculin skin test

DL_{CO} = diffusing capacity of lung for carbon monoxide; KL_{CO} = diffusing capacity per liter alveolar volume.
Adapted from American Thoracic Society/European Respiratory Society: Statement on sarcoidosis. Joint Statement of the American Thoracic Society (ATS), the European Respiratory Society (RS) and the World Association of Sarcoidosis and Other Granulomatous Diseases (WASOG) adopted by the ATS Board of Directors and the ERS Executive Committee, February 1999. *Am J Respir Crit Care Med* **160**:736, 1999, with permission.

LABORATORY TESTS

Box 152-1 lists clinical, imaging, and laboratory tests recommended when a diagnosis of sarcoidosis is entertained. These tests screen for involvement of various organs. A careful history and physical examination should be performed to detect signs and symptoms of organ involvement as well as to obtain a history suggesting another granulomatous disease (e.g., exposure to tuberculosis, endemic fungi, beryllium exposure).

Additional laboratory tests that assess disease activity are listed in the following sections. Although controversial, these tests are not routinely recommended because active granulomatous inflammation in sarcoidosis may remit spontaneously and therefore does not mandate treatment.

ANGIOTENSIN-CONVERTING ENZYME

The epithelioid cell of the sarcoidal granuloma secretes angiotensin-converting enzyme[68]; therefore, serum angiotensin-converting enzyme (SACE) levels reflect the total granuloma burden in sarcoidosis. Clinical data concerning SACE in sarcoidosis suggest that an elevated SACE level is insufficiently specific for the diagnosis of sarcoidosis to rest on it alone and insufficiently sensitive to exclude the diagnosis.[69] However, SACE may be useful as an adjunct in the diagnosis of the disease. Because SACE reflects the total body granuloma burden, SACE levels may be useful to monitor the course of sarcoidosis. Initial SACE levels are not different between patients who deteriorate and those who improve[70]; thus, SACE levels should not be used as a basis for treatment decisions.

GALLIUM, NUCLEAR MAGNETIC, AND POSITRON EMISSION SCANS

The mechanism of gallium-67 uptake in sarcoidosis is not completely understood. It is thought that inflammatory processes cause hyperemia and increased capillary permeability of gallium. Gallium also accumulates in macrophages and, to a lesser extent, in T lymphocytes, which are major participants in the granulomatous inflammation of sarcoidosis. Sarcoidosis may cause gallium uptake in thoracic and extrathoracic sites, although typically not in areas of skin involvement. Gallium scanning has not been found to be useful for monitoring the clinical course of sarcoidosis, but it may have a role in identifying organs with sarcoid involvement (see Section "Panda and Lambda Sign on Gallium-67 Scan"). Recently, organ activity from sarcoidosis has been detected by gadolinium enhancement on nuclear magnetic imaging (MRI) and by fluorodeoxyglucose positron emission tomography (PET) scanning.[71] These latter scanning techniques may be more sensitive than gallium-67 scanning in revealing granulomatous inflammation from sarcoidosis. In addition, they are less cumbersome tests in that the patient does not have to return 48–72 hours later for rescanning.

PATHOLOGY

The epithelioid granuloma of sarcoidosis usually contains a compact collection of mononuclear phagocytes. The granulomas typically are surrounded by a paucity of lymphocytes ("naked granulomas"), but varying degrees of lymphocytic inflammation may be present (Fig. 152-13 and see eFig.152-13.1 in online edition).[68]

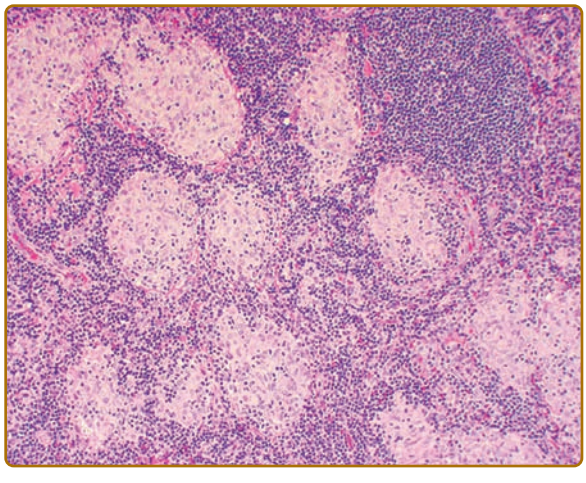

Figure 152-13 Histologic specimen of sarcoidosis demonstrating noncaseating granulomatous inflammation with multinucleated giant cells and a surrounding zone of lymphocytes.

BOX 152-2 MAJOR PATHOLOGIC DIFFERENTIAL DIAGNOSIS OF SARCOIDOSIS ON SKIN BIOPSY

- Tuberculosis
- Atypical mycobacteriosis
- Fungal infection
- Reaction to foreign bodies: beryllium, zirconium, tattooing, paraffin, etc.
- Rheumatoid nodules

Adapted from American Thoracic Society/European Respiratory Society: Statement on sarcoidosis. Joint Statement of the American Thoracic Society (ATS), the European Respiratory Society (RS) and the World Association of Sarcoidosis and Other Granulomatous Diseases (WASOG) adopted by the ATS Board of Directors and the ERS Executive Committee, February 1999. *Am J Respir Crit Care Med* **160**:736, 1999, with permission.

Epithelioid cells, which are themselves transformed monocytes, are commonly present within the sarcoidal granuloma. Multinucleated giant cells of the Langhans type result from the fusion of epithelioid cells. Although central fibrinoid necrosis is not uncommon, gross necrosis is not a characteristic feature of sarcoid granulomas and suggests an alternative diagnosis, such as tuberculosis, fungal infection, or vasculitis.[68] Mycobacterial and fungal diseases must always be considered as alternative diagnoses; therefore, stains and cultures for mycobacteria and fungi should be routinely performed on biopsy specimens. Box 152-2 lists the major pathologic differential diagnoses of sarcoidosis on skin biopsy.

A clinically important aspect of the pathology of sarcoidosis involves the development of fibrosis. Dense bands of fibroblasts may encase the ball-like granulomas. This fibrotic response can produce tissue destruction and organ dysfunction that is often irreversible.[10] Currently available chemotherapeutic agents for sarcoidosis can effectively treat the granulomatous inflammatory response but not the fibrotic reaction.

DIAGNOSIS

The diagnosis of sarcoidosis requires a compatible clinical picture, histologic demonstration of noncaseating granulomas, and exclusion of other diseases capable of producing similar histology or clinical features.[1] Because sarcoidosis is a diagnosis of exclusion, the diagnosis can never be confirmed with 100% certainty.[72]

Normally, the diagnosis of sarcoidosis requires a compatible clinical picture, histologic demonstration of noncaseating granulomas, and exclusion of other diseases capable of producing similar histology or clinical features (Fig. 152-14). Alternatively, the diagnosis can be assumed without biopsy when the clinical presentation is typical for the disease and is not explained by an alternative cause.

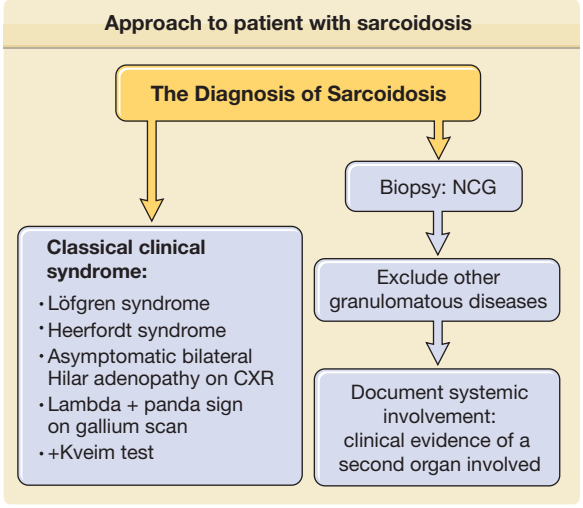

Figure 152-14 Approach to patient with sarcoidosis. Diagnostic algorithm. Usually the diagnosis is made by following the pathway on the right: A tissue biopsy demonstrates noncaseating granulomatous inflammation with a compatible clinical picture, alternative causes of granulomatous inflammation are excluded (including tuberculosis), and there is clinical evidence of systemic (multiorgan) granulomatous inflammation. On occasion, the diagnosis can be assumed without biopsy confirmation if the clinical presentation is very specific for sarcoidosis. These clinical presentations are listed on the left side of the pathway. CXR = chest X-ray; NCG = noncaseating granulomas.

The presence of noncaseating granulomas in a single organ does not conclusively establish the diagnosis of sarcoidosis because sarcoidosis is, by definition, a systemic disease that should involve multiple organs.[73] Isolated skin granulomas should not be assumed to represent sarcoidosis, and efforts must be made to exclude alternative diagnoses (see Box 152-2). Although a confirmed diagnosis of sarcoidosis requires proof of granulomatous involvement in at least two separate organs, histologic confirmation is usually not required in the second organ.[74]

Certain disease presentations are so specific for the diagnosis of sarcoidosis (e.g., Löfgren syndrome,[75] Heerfordt syndrome, and asymptomatic bilateral hilar adenopathy) that the diagnosis may be accepted without a tissue biopsy.

ASYMPTOMATIC BILATERAL HILAR ADENOPATHY

Asymptomatic hilar adenopathy on chest radiograph almost always represents sarcoidosis.[76] It has been suggested that histologic confirmation of sarcoidosis may not be required in asymptomatic patients with bilateral hilar adenopathy, provided the physical examination, complete blood cell count, and routine blood tests are all normal and there is no prior history of malignancy.[23] In such cases, chest radiographs should be monitored at 3- to 6-month intervals, and a biopsy should be performed if there is significant change in the chest radiograph.[23]

PANDA AND LAMBDA SIGN ON GALLIUM-67 SCAN

The presence of panda sign (bilateral lacrimal and parotid gland uptake) and lambda sign (bilateral hilar and right paratracheal uptake) on gallium-67 scanning is highly specific for sarcoidosis and may obviate the need for invasive diagnostic procedures. However, these signs are both positive in only a small percentage of sarcoidosis patients.

NATURAL HISTORY AND PROGNOSIS

The granulomatous inflammation of sarcoidosis can remit spontaneously or with therapy. Therefore, the general prognosis of sarcoidosis is good.[73] Pulmonary sarcoidosis resolves, improves, or stabilizes in 60% 90% of patients even without treatment.[77] Remissions often occur within the first 6 months after diagnosis, although it may take 2–5 years.[78] The prognosis is generally favorable for liver and peripheral lymph node sarcoidosis as well. The skin lesions may resolve with or without scarring or pigmentary changes.

Almost all severe impairment from sarcoidosis is the result of the development of fibrosis. As mentioned previously, this is probably the result of hyalinization of granulomatous inflammation. Presently it is unclear if this is the result of inadequate treatment or a host propensity for a brisk fibrotic response. Such cutaneous fibrosis may result in permanent scarring and disfigurement. Rarely, cutaneous lesions may ulcerate or destroy nearby bone or cartilage; this most commonly occurs in patients with lupus pernio.

Because sarcoidosis is a systemic disease, the prognosis is not solely related to pulmonary involvement. In the United States, three-fourths of sarcoidosis deaths result from pulmonary involvement. Sarcoidosis of the heart and central nervous system accounts for most of the remaining deaths.[79]

There is no current laboratory or radiologic test that can predict the outcome of sarcoidosis. Skin lesions are not a reliable indicator of prognosis, but several useful associations have been documented. Patients with cutaneous lesions are more likely to have chronic systemic sarcoidosis than sarcoidosis patients without skin involvement.[80] Erythema nodosum with fever and arthralgias portends a good prognosis.[81] Patients with Löfgren syndrome have a more than 80% rate of spontaneous remission, generally within 4–6 weeks.[1] Lupus pernio indicates chronic disease and is associated with upper respiratory tract involvement, pulmonary fibrosis, and bony cysts.[1] Table 152-1 reviews various clinical features that are associated with the prognosis of sarcoidosis.

TABLE 152-1
Prognosis for Sarcoidosis

	Good	Poor
Erythema nodosum	+	
African descent		+
Extrathoracic disease		+
Stage I vs. II–III CXR	+	
Age >40 years		+
Splenic involvement		+
Lupus pernio		+
Disease duration >2 years		+
FVC <1.5 L		+
Stage IV CXR/aspergilloma		+

CXR = chest X-ray; FVC = forced vital capacity.
Adapted from Judson MA et al: Sarcoidosis. In: *Diffuse Lung Disease, A Practical Approach*, edited by Baughman RP, DuBois RM, Lynch JP. London, Arnold Publishers, 2004, p. 109, with permission.

TREATMENT

Because sarcoidosis often spontaneously remits and therapy may be associated with significant side effects, it is not mandatory to treat the disease.[82] Treatment is indicated when there is evidence of progressive organ damage.[82] Table 152-2 shows suggested indications for treatment of various organs with sarcoidosis involvement. Tests of disease activity that are discussed in preceding sections are rarely used to determine the need for therapy. This is because the presence of active granulomatous inflammation from sarcoidosis does not imply that the disease will be progressive or lead to significant fibrosis and permanent organ damage.

TOPICAL/INTRALESIONAL THERAPY

Cutaneous sarcoidosis, including lupus pernio, may be improved with prolonged application (longer than 8 weeks) of class I topical steroids, but intralesional injections of triamcinolone are generally more effective. Topical tacrolimus reportedly has been effective for skin disease in several cases as well.[83–85]

SYSTEMIC CORTICOSTEROIDS

In general, corticosteroids are the drug of choice for the treatment of sarcoidosis. The recommended initial dose for pulmonary sarcoidosis is 20–40 mg of prednisone equivalent/day.[1,82] Cardiac and neurologic sarcoidosis may require higher initial doses, up to 60–80 mg of prednisone equivalent/day.[1] The corticosteroid dose can often be tapered to 0.1–0.2 mg/kg of prednisone equivalent/day over a few months.[1,82] It is unusual for patients with pulmonary sarcoidosis to require a maintenance corticosteroid dose of more than 15 mg of prednisone equivalent/day, although more may be required for sarcoidosis of the skin, heart, or nervous system. An attempt should be made to taper the corticosteroid dose

TABLE 152-2
Indications for Treatment by Organ

	No Treatment	Treatment
Lung		
No symptoms	X	
Normal pulmonary function	X	
Worsening pulmonary symptoms/function		X
Severe pulmonary symptoms/function		X
Skin		
Asymptomatic	X	
Scarring or infiltrative (e.g., lupus pernio)		X
Cosmetically unacceptable to patient		X
Neurologic		
Other than facial nerve (Bell palsy)		X
Cardiac		
Symptomatic		X
Liver		
Asymptomatic, elevated alkaline phosphase	X	
Synthetic dysfunction (international normalized ratio increased, albumin decreased)		X
Cholestatic symptoms		X
Spleen		
Hypersplenism		X
Eye		
Anterior uveitis		Topical (eyedrops)
Other manifestations		X

within 9–12 months of the initiation of therapy.[82] Cardiac sarcoidosis may be an exception to this rule if the patient has had previous life-threatening manifestations of cardiac involvement. If life-threatening arrhythmias have occurred, placement of an internal defibrillator is indicated.[60,86,87]

IMMUNOSUPPRESSIVE MEDICATIONS

If the patient cannot be successfully weaned from corticosteroids, adjunctive immunosuppressive medications can be used.[82] Most of these are inadequate as monotherapy but are effective as corticosteroid-sparing agents. The appropriate doses for sarcoidosis are listed in Table 152-3 and discussed in the following sections.

METHOTREXATE. After corticosteroids, methotrexate is the next most studied agent for sarcoidosis. It is usually corticosteroid sparing, and corticosteroids can be discontinued in one-fourth of cases.[88] The drug requires careful monitoring of liver function tests and blood cell counts. Folic acid may be given in conjunction with methotrexate. Approximately 10% of sarcoidosis patients taking methotrexate develop cirrhosis, even if their liver function tests are normal.[89] Therefore routine liver biopsies should be considered after 2 g of total therapy (usually after 2 years).[89] Low-dose methotrexate, 10–25 mg a week, is used for the treatment of cutaneous sarcoidosis.[90] Cutaneous improvement may be noted within 1 month, but maximal therapeutic benefit often does not occur until at least 6 months after the initiation of treatment.

HYDROXYCHLOROQUINE/CHLOROQUINE. Antimalarial drugs are useful for skin and joint sarcoidosis, and hypercalcemia.[91,92] Antimalarial agents are not highly effective for pulmonary disease, often take several months to be effective, and cannot be used in patients with glucose-6 phosphodiesterase deficiency. Either drug, especially chloroquine, can cause retinal damage.[93] Patients taking antimalarial agents must therefore have regular ophthalmologic examinations.

CYCLOPHOSPHAMIDE. Cyclophosphamide is effective for many forms of sarcoidosis. However, because of its significant side-effect profile, including its carcinogenic potential, it is usually only used for severe or potentially life-threatening disease.

TETRACYCLINE DERIVATIVES. Minocycline and doxycycline have been reported to improve skin sarcoidosis in case series. These drugs may take more than 2 years to be effective.[94] Although the efficacy of

TABLE 152-3
Sarcoidosis Chemotherapy

Agent	Dose/Comment
Corticosteroids Topical	Localized skin lesions: ultrapotent topical steroids or intralesional injections. Anterior uveitis: eyedrops.
Prednisone equivalent	20–40 mg/day, then taper. Consider higher dose for cardiac, neurologic involvement.
Methotrexate	10–25 mg/week. Monitor LFTs, CBC. Consider adjunctive folate.
Hydroxychloroquine	200–400 mg/day. Check glucose-6 phosphodiesterase. Monitor ophthalmology examinations.
Chloroquine	250–1,000 mg/day. Check glucose-6 phosphodiesterase. Monitor ophthalmology examinations.
Tetracyclines	Minocycline: 200 mg/day. Doxycycline: 200 mg/day. Primarily for nonlupus pernio skin disease.
Pentoxifylline	400 mg tid.
Thalidomide	50–200 mg/day. Very sedating; give qhs. Peripheral neuropathy common.
Leflunomide	100 mg/day for 3 days loading, then 10 mg/day. Can increase to 20 mg/day. Monitor CBC and LFTs.
Infliximab	5 mg/kg IV q6 week. Need pretreatment purified protein derivative skin test and close monitoring for tuberculosis.
Cyclophosphamide	500–1,000 mg IV q3–4 week. Monitor CBC and urinalysis. Stop if hematuria develops. Patients must be informed of carcinogenicity. Only for severe life-threatening disease (e.g., neurosarcoidosis).

CBC = complete blood cell count; LFTs = liver function tests.

these drugs suggests that sarcoidosis may be caused by an infectious agent, the tetracyclines also modify the immune response by suppressing activity of macrophages and T lymphocytes.[95]

TUMOR NECROSIS FACTOR ANTAGONISTS. TNF is a cytokine that is secreted in macrophages associated with sarcoidal granulomas.[9] Antagonists of TNF have been shown to be useful for the treatment of sarcoidosis. Pentoxifylline,[96] thalidomide,[97] and infliximab[98] have been the most studied. Infliximab appears to be particularly useful for the treatment of lupus pernio,[99] and it may be superior to other TNF antagonists, as a study of etanercept failed to show benefit for sarcoidal uveitis.[100] A tuberculin skin test is required before the use of TNF antagonists, and patients taking the drugs must be monitored closely for the development of tuberculosis. Adalimumab has also been reported to treat sarcoidosis effectively.[101]

OTHER AGENTS. Azathioprine,[102] mycophenolate mofetil,[103] leflunomide,[104] and cyclosporine[105] have been reported to be useful for the treatment of systemic sarcoidosis in case reports or small case series. Allopurinol,[106] isotretinoin,[107] and fumaric acid esters[108] have been reported to be effective for sarcoidal skin disease. Resolution of sarcoidal skin manifestations after phototherapy and photodynamic therapy has also been described.[109]

SURGICAL TREATMENT

Electrodesiccation, pulse dye laser therapy, carbon dioxide laser therapy, and reconstructive surgical procedures have all been used successfully to improve the cosmetic disfigurement of cutaneous sarcoidosis, but these interventions do not have any effect on disease progression.

PREVENTION

As the cause of sarcoidosis remains unknown, prevention is currently impossible.

ACKNOWLEDGMENTS

Several clinical photographs were contributed by Lawrence Lieblich, M.D.

KEY REFERENCES

Full reference list available at www.DIGM8.com

DVD contains references and additional content

1. American Thoracic Society/European Respiratory Society: Statement on sarcoidosis. Joint Statement of the American Thoracic Society (ATS), the European Respiratory Society (RS) and the World Association of Sarcoidosis and Other Granulomatous Diseases (WASOG) adopted by the ATS Board of Directors and the ERS Executive Committee, February 1999. *Am J Respir Crit Care Med* **160**:736, 1999
6. Baughman RP et al: Clinical characteristics of patients in a case control study of sarcoidosis. *Am J Respir Crit Care Med* **164**:1885, 2001
10. Newman LS et al: Sarcoidosis. *N Engl J Med* **336**:1224, 1997
21. Martinetti M et al: HLA and sarcoidosis: New pathogenic insights. *Sarcoidosis Vasc Diff Lung Dis* **19**:83, 2002
23. Lynch JP et al: Pulmonary sarcoidosis. *Clin Chest Med* **18**:755, 1997
28. Callen JP: The presence of foreign bodies does not exclude the diagnosis of sarcoidosis. *Arch Dermatol* **137**:485, 2001
73. Judson MA et al: Sarcoidosis. In: *Diffuse Lung Disease, A Practical Approach*, edited by Baughman RP, DuBois RM, Lynch JP. London, Arnold Publishers, 2004, p. 109

Chapter 153 :: Cutaneous Manifestations of Internal Malignant Disease: Cutaneous Paraneoplastic Syndromes

:: Christine A. DeWitt, Lucinda S. Buescher, & Stephen P. Stone

PARANEOPLASTIC DERMATOSES

PARANEOPLASTIC DERMATOSES AT A GLANCE

- Skin can be a marker for internal malignancy.
  - Epi-phenomenon.
  - Familial cancer syndromes.
  - Direct tumor extension.
- Paraneoplastic dermatoses follow a parallel course with the malignancy and allow early diagnosis and monitoring.
- Dermatoses with high associations with internal malignancy include tripe palms, Bazex syndrome, paraneoplastic pemphigus, erythema gyratum repens, necrolytic migratory erythema, and hypertrichosis lanuginose acquisita.
- Weakly associated with internal malignancy are acanthosis nigricans, acquired ichthyosis, and multiple seborrheic keratoses.
- Management of the dermatosis is the treatment of the malignancy.

Cutaneous manifestations of cancer can present with a variety of clinical findings that may reflect direct involvement of malignant cells, an epiphenomenon of a distant malignancy, or in the context of a familial cancer syndrome. The term "paraneoplastic dermatoses" refers to dermatoses (often unique) secondary to a distant cancer. There are two essential criteria: (1) the dermatosis must develop only after the development of the malignant tumor, even though some tumors may be asymptomatic and occult and (2) both the dermatosis and the malignant tumor follow a parallel course in that complete removal of the cancer results in clearing of the dermatosis and recurrence of the cancer causes relapse of the dermatosis. A suggested classification of clinicopathologic categories is shown in Table 153-1.

EPIDEMIOLOGY

Changes of the skin can be markers of an internal malignancy, but the exact prevalence is unknown. This is in part due to the complexity of disease variation in some cases and the rarity of occurrence in others. Age, sex, and risk factors for developing a paraneoplastic dermatosis correlate with the overall risk for the respective internal malignancy.

The specific relationship of the cancer with the marker can be variable. For instance, hypertrichosis lanuginosa acquisita can be a marker for many different malignant neoplasms, whereas necrolytic migratory erythema (NME) is nearly specific for a glucagon-producing tumor of the pancreas. The specific correlations with internal malignancies for each paraneoplastic dermatosis are listed in Table 153-1.

TABLE 153-1
Classic Paraneoplastic Dermatoses

Paraneoplastic Dermatosis	Major Internal Malignancy	Percent with Cancer	Approach to the Patient	Unique Features
Hyperkeratotic Diseases				
Acanthosis nigricans[a]	Adenocarcinomas: intra-abdominal; gastric (50%–60%)	Unknown	CBC, CMP, fasting blood glucose; upper endoscopy or CT scan of abdomen if history supports	Older age, rapid course, and oral involvement more common in malignancy associations. Usually with insulin resistance.
Acquired ichthyosis[a]	Hodgkin's lymphoma (70%–80%)	Unknown	CBC, CXR; consider CT of abdomen to rule out lymphoma	Spares flexures, palms, soles; up to 30% of cases may occur in patients with AIDS
Pityriasis rotunda	Hepatocellular, gastric carcinoma	5%–30%	CMP, RPR, HIV	Type I: African/Asian; <30 lesions, high rate malignancy Type II: Caucasians, familial; >30 lesions, cancer rare
Tripe palms	Lung CA most common; gastric CA second	>90%	CBC, CMP, CT of chest and abdomen	Coexists with acanthosis nigricans in 75%
Leser-Trelat sign	Adenocarcinomas: GI (47%); lymphoproliferative (20%)	Unknown	CBC, imaging of GI tract	Early onset, eruptive nature, and pruritus are paraneoplastic features; coexists with acanthosis nigricans in 20%
Bazex syndrome[a]	SCC of upper aerodigestive tract	Nearly 100%	ENT exam; CXR; thoracoabdominal CT	Acral papulosquamous lesions (ears, nose), paronychia, onychodystrophy
Collagen-vascular Diseases				
Dermatomyositis[a]	Women: ovarian and breast CA Men: GI and respiratory tract CA	25%–30%	CBC, CMP, CXR; up to date cancer screenings, bimanual exam in women; CA-125, CT chest, abdomen, pelvis in select cases	Patients older than in idiopathic form; males predominate; refractory or flaring of previously well controlled disease may signal malignancy
Progressive systemic sclerosis	Lung; SCC of the tongue (25× increased risk)	3%	Annual oral exam; pulmonary function test	Decreased pulmonary CO diffusion (<70%) risk factor for lung CA
Reactive Erythemas				
Erythema gyratum repens[a]	Bronchial CA (32%)	82%	CXR, upper GI evaluation, mammogram	"Wood-grain"-patterned erythema
Necrolytic migratory erythema	Pancreatic α-cell tumor	Nearly 100%	Abdominal CT, somatostatin receptor scintigraphy	Not parallel to malignancy
Neutrophilic Dermatoses				
Sweet's syndrome[a]	AML and lymphoma (85%)	20%	CBC with different-bone marrow biopsies if multiple abnormalities seen; skin biopsy for histology and culture	Neutrophilia and fever may not be present in patients with hematologic malignancy; presentation often more severe in this form
Pyoderma gangrenosum	AML most frequent; multiple myeloma second	7%	Same as Sweet's syndrome; SPEP/UPEP	Atypical presentation more common with malignancy; may be on a continuum with Sweet's syndrome; IgA paraproteinemia 10%–18%
Dermal Proliferative Diseases				
Multicentric reticulohistiocytosis	No specific cancer type or location	28%	CBC, CMP, CXR	Not parallel to malignancy
Necrobiotic xanthogranuloma	IgG paraproteinemia with 10% progressing to multiple myeloma	80% (gammopathy)	CBC, CMP, SPEP/UPEP	Periorbital involvement especially with necrosis

(continued)

TABLE 153-1
Classic Paraneoplastic Dermatoses (Continued)

Paraneoplastic Dermatosis	Major Internal Malignancy	Percent with Cancer	Approach to the Patient	Unique Features
Disorders of Dermal Deposition				
Scleromyxedema	Monoclonal gammopathy of undetermined significance; rare multiple myeloma	80% (gammopathy)	CBC, CMP, ECG, CXR; thyroid studies; SPEP/UPEP	Most have IgG-λ monoclonal gammopathy; only rarely convert to multiple myeloma but poor prognosis if it occurs
Systemic amyloidosis	Multiple myeloma, thyroid or multiple endocrine neoplasia	13%–26% (multiple myeloma)	Bx of clinically involved skin, rectal or abdominal fat tissue; SPEP/UPEP	Macroglossia, pinch purpura, carpal tunnel clue to systemic amyloidosis; 1-year mean survival in patients with multiple myeloma
Bullous Disorders				
Paraneoplastic pemphigus	Lymphoproliferative (75%): non-Hodgkin (42%), CLL (29%)	Nearly 100%	CBC, CMP, CXR, CT abdomen	Parallels benign, but not malignant tumors
Dermatitis herpetiformis	Gastrointestinal (78%) and non-Hodgkin lymphoma	4%	Colonoscopy with mucosal biopsy	Occurs significantly more in patients who do not follow a gluten-free diet
Other Changes				
Hypertrichosis lanuginosa acquisita	Men: lung, colorectal Women: colorectal, lung or breast	Nearly 100%	CXR, colonoscopy, mammogram	Excessive downy hair initially concentrated on face, spreading caudally
Trousseau's syndrome (migratory thrombophlebitis)	Lung and pancreatic carcinoma	50%	CBC, CXR, CT of abdomen	Responds best to low molecular weight heparin

[a]Dermatoses established to closely parallel course of malignancy.

ETIOLOGY AND PATHOGENESIS

Paraneoplastic syndromes are often grouped by their major clinical presentations, and several classification systems exist. Unfortunately, our lack of knowledge prevents a more pathophysiologic approach.

Proven association of the cutaneous eruption with a tumor can be more easily made when the supposed manifestation is very rare and the tumor is also very uncommon. It becomes a major problem, however, when the manifestation is very common, such as the seborrheic keratoses in the sign of Leser-Trélat, and the presumed association is with a wide spectrum of commonly occurring neoplasms. In this situation, anecdotal reports abound.

HYPERKERATOTIC DERMATOSES

ACANTHOSIS NIGRICANS

(See also Chapter 151)

ACANTHOSIS NIGRICANS AT A GLANCE

- Acanthosis nigricans is a cutaneous marker, most commonly of insulin resistance and less frequently of genetic disorders and malignancy.
- Characterized by symmetric hyperpigmented, hyperkeratotic, verrucous plaques that bestow a velvety texture on intertriginous skin and occasionally mucocutaneous areas.
- Darker skin pigmentation, insulin resistance, and obesity are more commonly associated with benign acanthosis nigricans.
- Malignant acanthosis nigricans often appears rapidly in older individuals and can involve atypical areas such as mucosal surfaces.

The term *acanthosis nigricans* was originally proposed by Unna, although the first cases were malignancy associated and described independently by Pollitzer and by Janovsky in 1890. Curth clinically classified acanthosis nigricans into malignant, benign, syndromic acanthosis nigricans or pseudoacanthosis nigricans (obesity related). Today acanthosis nigricans is classified into two broad categories: (1) benign (familial, obesity related, hyperinsulinemic states, autoimmune disease associated) and (2) malignant. Malignant acanthosis nigricans typically occurs in older patients and frequently coexists with other paraneoplastic dermatoses such as tripe palms and the sign of Leser-Trélat.

EPIDEMIOLOGY.

The majority (80%) of acanthosis nigricans occurs idiopathically or in benign conditions such as endocrinopathies and/or heritable diseases.[1] Malignancy-associated acanthosis nigricans is rare. It was present in 1 of 35 patients with intrathoracic or intraabdominal malignancies,[2] and in 2 of 12,000 cancer patients. Although reported in all age groups, at least 80% of malignancy related acanthosis nigricans occurs in individuals over the age of 40.[1]

ETIOLOGY AND PATHOGENESIS.

Although the precise etiology of benign acanthosis nigricans remains unclear, there is evidence that insulin plays a significant role (see Chapter 151). The pathogenesis of malignancy-associated acanthosis nigricans is even less clear. A humoral factor produced by the tumor is likely, given cases in which the skin disorder improved or resolved following treatment of the malignancy. Elevated urinary transforming growth factor (TGF)-α and increased expression of epidermal growth factor (EGF) receptors in lesional skin were noted in a patient with acanthosis nigricans, acrochordons, Leser-Trélat sign, and melanoma. The enhanced expression of this cytokine and its receptor normalized after removal of the melanoma, and the acanthosis nigricans, acrochordons, and seborrheic keratoses improved postoperatively.[3] A separate case, with gastric cancer, was also shown to express TGF-α and EGF receptors.[4]

More recently, a pathogenic role has been proposed for a tyrosine kinase receptor expressed on the basal cells of the epidermis. In several inherited human skeletal dysplasias associated with acanthosis nigricans, such as craniosynostoses and dwarfing chondrodysplasias, activating mutations in the fibroblast growth factor receptor 3 (FGFR3) can be observed, whereby FGFR3 has an inhibitory affect on bone formation.[5] In other studies, FGFR3 has oncogenic affects in such malignancies as multiple myeloma, bladder, and cervical carcinoma. With respect to the role of FGFR3 on the epidermis, animal models with activating mutations develop benign epidermal tumors resembling acanthosis nigricans and seborrheic keratoses.[6]

CLINICAL FINDINGS.

(See also Chapter 151). The clinical hallmark of acanthosis nigricans is development of gray-brown, velvety plaques that may start as a dirty appearance. The hyperpigmentation is later accompanied by hypertrophy, increased skin markings, and papillomatosis. Pruritus can be a problem in some patients. The most commonly involved locations are the axillae, neck, external genitalia, groin, face, inner thighs, antecubital and popliteal fossae, umbilicus, and perianal area. Acrochordons may develop, superimposed on the acanthosis nigricans or on other locations (Fig. 153-1).



Figure 153-1 Acanthosis nigricans involving the axilla with numerous acrochordons.

Several inherited syndromes have acanthosis nigricans described as a feature of the disease. Those that have been reported are listed in Box 153-1 in online edition.

The lesions of malignant and benign acanthosis nigricans are indistinguishable. However, there are subtle differences regarding the age of onset, distribution, and speed of onset that may assist in recognizing the paraneoplastic form. The benign form typically presents at a younger age and has a gradual progression of flexural surfaces. Concerns for malignancy-associated acanthosis nigricans should arise when a rapid appearance of the lesions in an older individual along with atypical sites such as the oral mucosa is involved (Fig. 153-2). For the clinical differential diagnosis of acanthosis nigricans, see eBox 153-1.1 in online edition.

Many consider tripe palms (see below) and the sign of Leser-Trélat (see below) to be along a spectrum of malignant acanthosis nigricans given the high degree of co-occurrence and histologic similarities. *Florid cutaneous papillomatosis* is also a part of this same spectrum. It presents as a rapid appearance of verrucous papillomas that are identical in appearance to typical viral warts. This phenomenon occurs with malignant acanthosis nigricans and in a large series had a 100% correlation with an internal malignancy, most commonly gastric adenocarcinoma.[7]

Many types of malignancies have been reported in association with malignant acanthosis nigricans. A review of the literature has shown up to 90% of patients have an associated intra-abdominal adenocarcinoma, of which approximately 60% are gastric.[8]

BOX 153-1 SYNDROMES ASSOCIATED WITH ACANTHOSIS NIGRICANS

- Acromegaly
- Addison disease
- Alström syndrome[a]
- Ataxia-telangiectasia
- Bartter syndrome
- Beare-Stevenson syndrome
- Benign encephalopathy
- Bloom syndrome
- Capozucca syndrome
- Chondrodystrophy with dwarfism
- Costello syndrome
- Crouzon syndrome
- Cushing syndrome
- Dermatomyositis
- Diabetes insipidus
- Donohue syndrome (leprechaunism)[a]
- Down syndrome
- Edwards syndrome[a]
- Gigantism
- HAIR-AN syndrome (hyperandrogenism, insulin resistance, and acanthosis nigricans)[a]
- Hashimoto thyroiditis
- Hepatic cirrhosis
- Hirschowitz syndrome
- Hypothyroidism
- Laurence-Moon-Bardet-Biedl syndrome
- Lawrence-Seip syndrome (congenital lipodystrophy)[a]
- Lipoatrophic diabetes[a]
- Lupoid hepatitis
- Lupus erythematosus
- MORFAN syndrome (mental retardation, overgrowth, remarkable facies, and acanthosis nigricans)
- Phenylketonuria
- Pituitary hypogonadism
- Pituitary tumors
- Prader-Willi syndrome
- Pseudoacromegaly[a]
- Pyramidal tract degeneration
- Rabson-Mendenhall syndrome[a]
- Rud syndrome[a]
- Scleroderma
- Stein-Leventhal syndrome (polycystic ovarian disease)[a]
- Streak gonads
- Type A syndrome of insulin resistance[a]
- Type B syndrome of insulin resistance[a]
- Werner syndrome
- Wilson disease (hepatolenticular degeneration)

[a]Associated with insulin resistance.

Histopathology of acanthosis nigricans classically shows hyperkeratosis and epidermal papillomatosis. There is only slight acanthosis and in some places, atrophy can be seen. Other features that can be observed include pseudocyst formation and increased melanin pigmentation. The dermis is usually devoid of inflammatory cells with the exception of mucosal acanthosis nigricans, which may have a mixed infiltrate of lymphocytes, plasma cells, and occasional neutrophils. The pathologic differential diagnosis includes confluent and reticulated papillomatosis of Gougerot and Carteaud, seborrheic keratosis, and epidermal nevus.

COMPLICATIONS. The cutaneous complications of acanthosis nigricans are most often of cosmetic concern. With time, severe papillomatosis and acrochordon formation can lead to frictional irritation and can be quite problematic. Of most concern with these patients, however, is an undiagnosed endocrinopathy or malignancy.

PROGNOSIS AND CLINICAL COURSE. The malignant form may also parallel the course of the underlying malignancy. Unfortunately, most associated malignancies present at an advanced stage, and thus the median survival rate for those with malignant acanthosis nigricans has been reported to be from 10–24 months.[9]

TREATMENT. Management of any co-occurring disease or malignancy often improves and may even resolve acanthosis nigricans. Topical keratolytics, including the retinoids, and oral retinoids can reduce the appearance of acanthosis nigricans. Other oral medications reported to show improvement include dietary fish oil, metformin, and cyproheptadine, possibly by inhibition of tumor secreted growth factors in the case of the latter.[10]

PREVENTION. Unfortunately for those with acanthosis nigricans associated with inherited conditions and malignancy, there is no effective prevention.

ACQUIRED ICHTHYOSIS

(See also Chapter 49)

The sudden onset of ichthyosis in an adult may indicate an occult malignant tumor, most often Hodgkin's lymphoma. However, patients with AIDS can represent up to 30% of patients with acquired ichthyosis.[11] The ichthyosiform variant of mycosis fungoides should also be considered as it can rarely be the sole manifestation.[12] Diffuse rhomboidal scaling is observed on extensor surfaces and typically spares skin folds, palms, and soles. Erythema is often present in the ichthyotic fissures. Although the ichthyosis usually occurs as a late manifestation of a lymphoma, it may precede the diagnosis by several years and typically parallels the course of the malignancy.

Pityriasis rotunda may be considered a variant that presents as strikingly discrete circular patches with ichthyosiform scale. Individual lesions are usually less

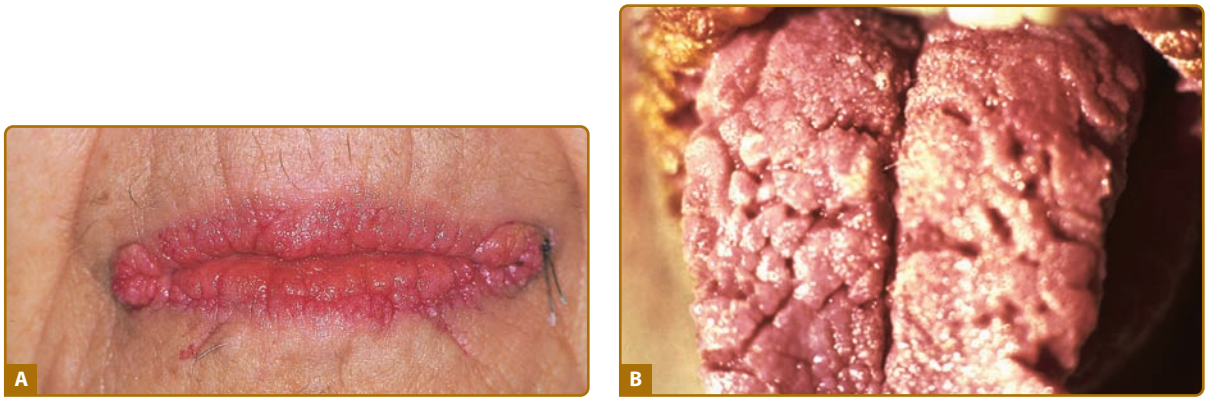

Figure 153-2 Acanthosis nigricans. **A.** Verrucous and papillomatous growths of the vermillion border of the lip. **B.** Velvety thickening of the tongue. (**A** and **B** are not the same patient.) (**A** and **B:** From Wolff K, Johnson RA: *Fitzpatrick's Color Atlas and Synopsis of Clinical Dermatology*, 6th edition. New York, McGraw-Hill, 2009)

than 3 cm but may become confluent and most often involve the trunk and proximal extremities. Paraneoplastic pityriasis rotunda is most commonly associated with hepatocellular and gastric carcinoma. There also exists a familial variant that is not reported to be associated with malignancy.[13,14] The pathogenesis is felt to be related to malabsorption resulting in a hypovitaminosis A and a possible contribution by tumor-secreted EGFs. Treatment is with emollients, retinoids, and α-hydroxy acids.

TRIPE PALMS

EPIDEMIOLOGY. Tripe palms are a rare paraneoplastic dermatosis with approximately 100 cases reported in the literature. The association with malignancy is high with a greater than 90% occurrence.

ETIOLOGY AND PATHOGENESIS. Specific mechanisms of development have not been fully elucidated. Similar to acanthosis nigricans, there is limited evidence for the role of TGF-α inducing cellular proliferation in the pathogenesis of tripe palms, and that normalization of this cytokine results in clinical improvement.[15]

Other investigations have shown melanocortin-1 and EGFs to be upregulated in malignancy-associated tripe palm.[16,17] However, these are not uniformly present.[18]

CLINICAL FINDINGS. The name originated from the description in the first reported case in 1963 whereby the patient suggested his hands looked similar to the rugose surface of the bovine stomach (Fig. 153-3).[19] Based on clinical similarities and frequency of co-occurrence, many consider this to be a form of palmar acanthosis nigricans. Indeed, tripe palms have also been called "*acanthosis nigricans of the palms*" and "*acanthosis palmaris*." The honeycombed and corrugated thickening of the palms may be associated with periungual tenderness. Normal dermatoglyphic ridges are accentuated. As a clinical differential diagnosis, the palmar morphology can be similar in keratitis–ichthyosis–deafness (KID) syndrome (see Chapter 49).

Histopathology of tripe palms includes hyperkeratosis, acanthosis, and papillomatosis. These features closely resemble those pathologic findings observed in acanthosis nigricans and seborrheic keratoses. Additional findings can include dermal mucin and mast cells in approximately 20% of specimens.

The majority (75%) of patients will have concomitant acanthosis nigricans. In patients with only tripe palms, pulmonary carcinoma (53%) is the most frequent malignancy, especially squamous cell type. In patients with both tripe palms and acanthosis nigricans, gastric carcinoma (35%) is the most common followed by lung carcinoma (11%).[20]

COMPLICATIONS. This is often a complication itself of underlying malignancy.



Figure 153-3 Tripe palm. The palmar ridges show maximal accentuation, thus mimicking the mucosa of the stomach of a ruminant.

PROGNOSIS AND CLINICAL COURSE. A complete malignancy work up should be performed in patients with tripe palms due to the high association and because the appearance precedes the diagnosis of malignancy in approximately 40% of cases.[20]

TREATMENT. There is no specific therapy for tripe palms. Similar to acanthosis nigricans, there are anecdotal reports of improvement with oral retinoids alone and in combination with metformin.[21] Approximately 30% will resolve with treatment of the underlying tumor.[22] However, there are many cases whereby a remission of the cancer has had no effect.

PREVENTION. There is no way to prevent the development of tripe palms. Patients should be up-to-date with standard cancer screenings. An expanded cancer investigation is warranted if no coexistence of malignancy is noted at the time of diagnosis.

LESER-TRÉLAT SIGN

LESER-TRÉLAT SIGN AT A GLANCE

- Rapid and eruptive increase in numbers and size of seborrheic keratoses.
- Pruritus common.
- Often with malignant acanthosis nigricans.
- Adenocarcinomas of the gastrointestinal tract are most common malignancy followed by lymphoproliferative malignancies.
- Differential diagnosis includes "regular" seborrheic keratoses, verrucae vulgares, dermatosis papulosa nigra, melanocytic nevi, and warty dyskeratomas.

EPIDEMIOLOGY. The sign of Leser-Trélat is a rare paraneoplastic dermatosis that occurs with equal frequency between men and women and among different races. Similar to the occurrence of malignancy, this sign is more common in older individuals.

Controversy has surrounded this as a true diagnosis due to the extremely common nature of benign seborrheic keratoses and furthermore, occurring in the age group most susceptible to malignancy. In a large population based study of 1,752 consecutive cases of seborrheic keratoses, there was no statistical evidence of an increased incidence of internal malignancy compared to the general population. Subanalysis of those presenting with eruptive seborrheic keratoses also failed to demonstrate an increased risk of internal malignancy.[23] In other large studies of patients with seborrheic keratoses and a recent solid tumor, a comparison with age- and sex-matched controls have not demonstrated a difference in either the clinical features or numbers of seborrheic keratoses.[24,25] As such, large epidemiologic studies have not provided the evidence needed to conclusively define this sign as a true paraneoplastic dermatosis.

Although large studies have not shown a statistical difference, there exists evidence to demonstrate that this sign may signify an internal malignancy. First, there are cases of eruptive seborrheic keratoses in patients in their 20s, an age group that rarely exhibits these lesions. Further workup in both cases led to a diagnosis of an internal malignancy.[26,27] Clinically, Leser-Trélat sign often coexists with malignant acanthosis nigricans, a more established paraneoplastic phenomenon. Additionally, alterations in growth factor expression differ from control patients. Together, this provides evidence that the Leser-Trélat sign is a legitimate but extremely uncommon paraneoplastic dermatosis.

ETIOLOGY AND PATHOGENESIS. An exact pathogenesis has yet to be elucidated. However, similar to acanthosis nigricans and tripe palms, evidence also exists with the Leser-Trélat sign that an alteration in growth factor homeostasis is contributory. In several instances, a state of increased growth factor expression has been observed with increased urinary levels of the growth factors EGF and TGF-α detected in patients with an underlying malignancy and eruptive seborrheic keratoses. Subsequently, growth factor levels decreased following primary tumor resection.[28]

It is not known if the tumors are the primary source or are inducing a secondary secretion of such growth factors as TGF-α and EGF. In an analysis of a patient with pancreatic carcinoma and the Leser-Trélat sign, the tumor cells expressed low levels of EGF while the hyperkeratotic lesions of seborrheic keratoses expressed increased EGF.[29] In a comparison of Leser-Trélat lesional skin and that of control seborrheic keratoses, increased levels of the growth factor homologs EGF and HER-2/neu were detected in the downward branching epithelial strands.[30] In addition to increased levels of growth factor expression, lesional skin in paraneoplastic acanthosis nigricans and seborrheic keratoses has alterations in the extracellular matrix.[31] It is unknown what the direct impact of growth factor signaling has on the skin. Proposed ideas include either inducing a hyperproliferative state primarily or by altering the surrounding environment such as via the extracellular matrix. These similar mechanisms further support the idea of a continuum between acanthosis nigricans and the Leser-Trélat sign.

CLINICAL FINDINGS. Clinical features signifying a paraneoplastic phenomenon include patients with widespread eruptive seborrheic keratoses. Pruritus is a significant feature occurring in 43%.[1] Co-occurrence with other hyperkeratotic paraneoplastic dermatoses is common with 20% having acanthosis nigricans. There are several reports of Leser-Trélat sign and tripe palms coexisting in the same patient.[8,32–34] The rapid occurrence of pruritic eruptive seborrheic keratoses, especially in a setting of acanthosis nigricans should

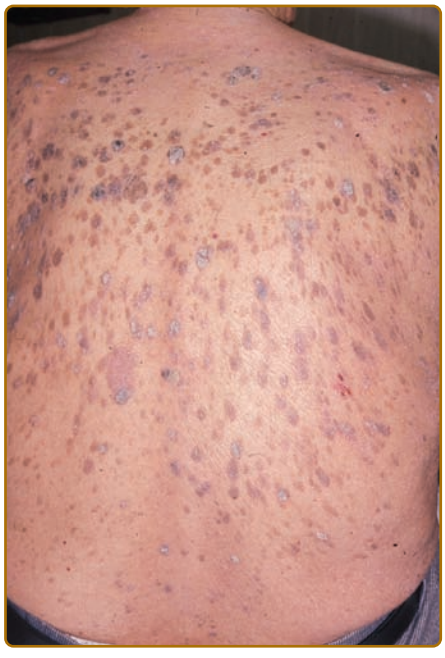

Figure 153-4 Leser-Trélat sign consisting of multiple pruritic eruptive seborrheic keratoses.

alert the clinician to a potential internal malignancy (Fig. 153-4). For the differential diagnosis, see Box 153-2.

Adenocarcinomas account for the majority of malignancies described with the sign of Leser-Trélat. Of 130 malignancies reported with this sign, 47.7% involve the gastrointestinal tract.[29] The second most common malignancy is lymphoproliferative disorders, and includes leukemias, lymphomas, Sézary syndrome and mycosis fungoides. Involvement of other organs such as the pancreas, kidneys, ovaries, and lungs has been reported in several cases as well. In a series of 44 patients with lung cancer, the sign of Leser-Trélat was observed in 2.27%.[35]

Typically defined by a concurrent malignancy, the sign of Leser-Trélat has also been reported in non-neoplastic tumors, HIV, conditions of erythroderma and in association with the chemotherapeutic drug cytaribine.[36–39] The term "pseudosign of Leser-Trélat" has been used to designate nonmalignancy associated eruptive seborrheic keratoses that presents identically to its paraneoplastic counterpart. Unfortunately, these examples do not help to further define an already confusing and controversial clinical entity.

BOX 153-2 DIFFERENTIAL DIAGNOSIS OF THE SIGN OF LESER TRELAT

Most Likely
- Seborrheic keratoses
- Verruca vulgaris
- Dermatosis papulosa nigra
- Melanocytic nevi
- Warty dyskeratoma

Consider
- Confluent and reticulate
- Cytaribine-induced irritation of seborrheic keratoses
- Cowden's syndrome
- Tuberous sclerosis
- Gorlin's syndrome

Always Rule Out
- Internal malignancy
- Erythroderma-induced irritation of seborrheic keratoses
- Pregnancy
- HIV

COMPLICATIONS. As with many paraneoplastic dermatoses, sudden reappearance may herald tumor recurrence, although this particular sign only occasionally parallels the malignancy.

PROGNOSIS AND CLINICAL COURSE. This sign can develop from 5 months prior to 9.8 months after the diagnosis of malignancy and once diagnosed, the prognosis is poor with an average survival time of 10.6 months.[40] This eruption parallels the course of the underlying malignancy in some cases, but not as a general rule.

TREATMENT. Treatment should be directed toward the underlying tumor. If the lesions are symptomatic or cosmetically concerning to the patient, other options for treatment include standard therapies for seborrheic keratoses such as α-hydroxy acids, retinoids, trichloracetic acid, cryosurgery with or without curettage, dermabrasion, laser, and shave excision.

PREVENTION. There is no effective prevention other than keeping up with age-appropriate cancer screenings.

ACROKERATOSIS PARANEOPLASTICA OF BAZEX

ACROKERATOSIS PARANEOPLASTICA OF BAZEX AT A GLANCE

- Distribution of cutaneous lesions is symmetrical and characteristically involves the helices, nose, cheeks, digits, and nails.
- Lesions evolve from nonspecific dermatitis and paronychia to inflammatory plaques, acral keratoderma, and nail plate changes.
- Skin lesions often predate detection of internal malignancy.
- Upper aerodigestive tract malignancy most common.

EPIDEMIOLOGY. Bazex established an association between this uniquely distributed papulosquamous eruption and underlying malignancy.[41] There have been over 100 cases reported in the medical literature. Patients are typically men over the age of 40. Acrokeratosis paraneoplastica is unrelated to Bazex-Dupre-Christol which is a genodermatosis characterized by congenital hypotrichosis, follicular atrophoderma, and basal cell carcinomas arising at an early age.

ETIOLOGY AND PATHOGENESIS. The mechanism by which this characteristic eruption occurs is still speculative. One theory proposes that antibodies mounted against the tumor cross react with keratinocyte or basement membrane antigens (similar to those found in paraneoplastic bullous pemphigoid).[41] Other theories include a T-cell-mediated immune response to tumor-like antigens in the epidermis or by excessive expression of autocrine growth factors from the tumor resulting in epidermal hyperplasia.[42–44] Other hypotheses include low serum levels of vitamin A and zinc.

CLINICAL FINDINGS. The name, acrokeratosis paraneoplastica, is aptly descriptive because characteristic lesions are located acrally and exhibit hyperkeratosis. The plaques are usually erythematous to violaceous with overlying scale. Almost all patients have lesions affecting the ears and nails during the disease. Nearly two-thirds will demonstrate involvement of the nose and fingers, and over half have lesions on the hands and feet, especially volar surfaces.[45] Other clinical findings include hyperpigmentation and bullae. Bullae, when present, are most common on the hands and feet.

Three stages of skin lesions parallel the growth and dissemination of the underlying tumor. In the first stage, the helices, nose, fingers, and toes are usually affected in a symmetrical fashion. Early lesions are macular and not clearly demarcated, simulating a nonspecific dermatitis. They may exhibit crust in addition to scale. The eruption is classically asymptomatic, but pruritus may be a problem. Paronychia is the first sign of nail involvement (Fig. 153-5). In most cases, the responsible tumor is occult at this stage and remains so for an average of 11 months.[45]



Figure 153-5 Distal edema of toes, painful generalized paronychia, and distal subungual hyperkeratosis in early acrokeratosis paraneoplastica.



Figure 153-6 Keratoderma characteristically spares central aspects of plantar (and palmar) surfaces in acrokeratosis paraneoplastica.

During the second stage the tumor exhibits symptoms, due to local extension or metastatic spread, and the skin eruption becomes more extensive. The cheeks display the typical red to purple scaly or crusted plaques. The palms and soles develop a keratoderma that often spares the central volar surfaces but may lead to painful fissures (Fig. 153-6). Nail plate changes include yellowing, thickening, onycholysis and ridging, both horizontal and vertical.

The final stage is observed when the tumor goes untreated or fails to respond to treatment. All of the above signs and symptoms persist while the papulosquamous lesions begin to appear on the trunk, elbows, knees, and dorsal hands and feet. Rarely, vesicles and bullae may be present, most commonly on the fingers, hands, and feet. Nail changes can be quite variable, ranging from the typical thickening to nail atrophy and loss.

The main differentiation to be made in diagnosis is psoriasis, especially acral variants. The distinguishing clinical feature, which is nearly always present in acrokeratosis paraneoplastica, is involvement of the helices of the ears (Fig. 153-7) and the tip of the nose. Knees and elbows may develop plaques but it occurs late in the disease. Typically, Bazex is treatment resistant unlike other diseases considered in the differential (see Box 153-3).

Mucosal squamous cell carcinoma of the head and neck is the most frequently associated malignancy in acrokeratosis paraneoplastica and is markedly overrepresented when compared to the cancer statistics in the general population. Tumors in the oropharynx or larynx and cervical squamous cell lymph node metastases of an occult primary malignancy make up more than 60% of cancers associated with Bazex



Figure 153-7 Characteristic helical inflammation with scale in acrokeratosis paraneoplastica.[45]

syndrome but only 7% of cancer patients without Bazex. The lung[46] and esophagus were the next most frequent site of tumors (15% and 10%, respectively), though not always squamous cell carcinomas.[45] If the classically associated malignancies are excluded on workup, other less common locations such as genitourinary or lower gastrointestinal tract, should be considered.

Histologically, some psoriasiform features are present including hyperkeratosis, parakeratosis and a superficial lymphohistiocytic infiltrate, but other nonpsoriasiform changes also exist. These include vacuolar degeneration with melanin-containing macrophages in the dermis and dyskeratotic keratinocytes.

BOX 153-3 DIFFERENTIAL DIAGNOSIS OF ACROKERATOSIS PARANEOPLASTICA

Most Likely
- Psoriasis
- Dermatitis (seborrheic, eczematous, or contact)
- Dermatophytosis/Onychomycosis

Consider
- Mycosis fungoides
- Drug eruption
- Cutaneous lupus erythematosus
- Keratoderma blenorrhagicum
- Arsenical keratoses

Always Rule Out
- Internal malignancy
- Dermatophyte infection

COMPLICATIONS. The keratoderma affecting volar surfaces may develop fissures. On the feet, this can lead to painful ambulation. Secondary infection occurs. Paronychia is usually painful and may be debilitating.

PROGNOSIS AND CLINICAL COURSE. The skin eruption is expected to resolve with treatment of the underlying malignancy and can reappear with tumor recurrence. For some patients, the cutaneous lesions, but more commonly the nail dystrophy (ridging and subungual hyperkeratosis), may persist despite (presumed) successful tumor eradication.

TREATMENT. Adequate treatment of the underlying malignancy usually results in improvement of acrokeratosis paraneoplastica and recurrence of the eruption heralds tumor recurrence. The skin lesions are typically resistant to standard therapies for hyperkeratotic conditions and few treatments specific for the cutaneous component of acrokeratosis paraneoplastica have been reported. Retinoids have been used with variable success. Isolated reports suggest benefit from oral psoralen and ultraviolet A phototherapy, topical salicylic acid, and corticosteroids.[47]

PREVENTION. There is no effective prevention other than keeping up with age-appropriate cancer screenings.

COLLAGEN-VASCULAR DISEASE

DERMATOMYOSITIS

(See Chapter 156)

Dermatomyositis can be a marker for internal neoplasia, and the development of the dermatomyositis can predate the diagnosis of the cancer. The clinical manifestations of dermatomyositis appear to be the same with and without a malignant tumor, although Basset-Sequin et al[48] noted that cutaneous necrosis and an elevated erythrocyte sedimentation rate appeared to be markers for those with cancer and a reduced survival. Up to 30% of adults with a new diagnosis may have an associated malignancy with men over the age of 50 having the greatest risk of malignancy. The most common cancers are ovarian, lung, pancreatic, stomach, colorectal, and lymphoma.[49] While dermatomyositis in an adult is strongly associated with concurrent cancer, polymyositis alone is much less strongly associated.[50]

The cancers are usually identifiable by history and physical examination. Adults with dermatomyositis should be examined thoroughly for evidence of an associated malignant tumor including all recommended cancer screenings. The diagnosis of malignancy is usually made within a year, but can be several years later. In children, dermatomyositis is not statistically linked to malignancy.

PROGRESSIVE SYSTEMIC SCLEROSIS

(See Chapter 157)

Systemic scleroderma is not commonly associated with internal malignancy. In a Japanese review of 8,327 patients with systemic sclerosis, the frequency of malignancy was 5.4% in men and 2.8% in women (overall 3.1%).[51] Several population based studies have been performed to determine the incidence of malignancy with mixed results. Some have detected no increase in overall malignancy incidence as compared to the general population, while others have detected a small, but statistically significant increased risk.[52] In a nested cohort comparing patients diagnosed with systemic sclerosis before the age of 60 and after the age of 75, not surprisingly there was an increased frequency of all malignancies in the older age, but especially esophageal and oropharyngeal cancer.[53,54]

Lung cancer has been the most often associated malignancy, but there is also a nearly 25-fold increased risk of squamous cell carcinoma of the tongue.[55] Almost all patients with associated lung tumors have very advanced systemic scleroderma, particularly older patients with advanced interstitial lung disease. Evidence suggests the association is most likely one of a lung tumor developing secondary to the chronic pulmonary fibrosis.

REACTIVE ERYTHEMAS

ERYTHEMA GYRATUM REPENS

(See Chapter 43)

This particular annular ("gyratum" is Latin for circle) erythema is nearly always indicative of internal malignancy and is one of the most dramatic skin diseases in both its appearance and evolution. Affected individuals are often Caucasian men (2:1) in their 60s. Numerous serpiginous bands are arranged in a parallel configuration of concentric red swirls over most of the body. This presentation is occasionally referred to as a "wood-grained" appearance (Fig. 153-8). Even more striking is the relatively rapid rate at which lesions migrate ("repens" is Latin for creeping), estimated at one centimeter per day.[56] A slight scale may be found along the trailing edge of erythema (Fig 153-9). The hands, feet, and face are commonly spared, except for occasional volar hyperkeratosis. Ichthyosis is present in many cases. Pruritus is universal and may be severe.

An underlying malignancy is associated with erythema gyratum repens over 80% of the time. This distinctive migratory eruption appears 4–9 months before the diagnosis of malignancy in approximately 80% of cases. Approximately one-third of patients will manifest a lung cancer, whereas 8% have esophageal cancer and 6% have breast cancer. Individual case reports of many other types of associated tumors are published, as well as 6% of cases with an unknown primary. In those individuals with erythema gyratum repens who did not have a detectible underlying malignancy; concurrent conditions included tuberculosis, pregnancy, and bullous dermatoses, among others.[56]



Figure 153-8 Erythema gyratum repens. Serpiginous parallel bands on axilla and arm. (Used with permission from Michael Adler.)

The exact etiology of erythema gyratum repens is unknown, but it has been suggested that the tumor may induce a chemical alteration of the normal components of the surrounding tissue. Molecular mimicry ensues as the inflammatory response directed against the tumor cross reacts with benign cutaneous proteins. This theory is supported by documentation of IgG and C3 deposition at the basement membrane of affected skin and bronchial basement membrane in one case associated with lung cancer.[56] Migration characterizes all of the figurate erythemas, but is notably rapid in erythema gyratum repens and the mechanism for this is not clear, although recent studies have focused on fibroblast activity. Inflammatory cells and/or fibroblasts may mediate ground substance alterations which may localize the inflammation that orchestrates the movement of the infiltrate in a patterned mode.[57,58]



Figure 153-9 Erythema gyratum repens. Characteristic "wood-grained" pattern of erythema and slight scale in a woman with breast cancer. (Used with permission from Jill McKenzie, MD.)

The treatment for erythema gyratum repens is to locate and treat the primary malignancy. With adequate control of the cancer the rash usually abates, but this may not be possible in cases that are widely metastatic at the time of diagnosis. Otherwise, the eruption is often treatment resistant, although variable results occur with systemic steroids.[59] Topical steroids, vitamin A, and azathioprine have not been beneficial.[60–62] The eruption has been known to resolve immediately before death, possibly due to generalized ante mortem immunosuppression.

NECROLYTIC MIGRATORY ERYTHEMA

NECROLYTIC MIGRATORY ERYTHEMA AT A GLANCE

- Painful, eroded, crusted intertriginous, and facial skin eruption.
- Highly suggestive of pancreatic malignancy (glucagonoma).
- Half of tumors are metastatic at the time of diagnosis.
- Pseudoglucagonoma syndrome occurs in absence of glucagonoma.
- Skin improves with treatment of underlying nutritional aberrations.

EPIDEMIOLOGY. NME is virtually pathognomonic for pancreatic glucagonoma and is present in more than two thirds of patients at the time of tumor diagnosis.[63] When the characteristic eruption occurs without underlying pancreatic malignancy the condition is referred to as pseudoglucagonoma syndrome. Glucagonomas are rare, with an estimated 400 cases cited in the literature. There is no sexual predilection and it most commonly affects people in their sixth decade.

ETIOLOGY AND PATHOGENESIS. Most of the signs and symptoms can be attributed to the metabolic effects of excess glucagon. Amino acid levels are depressed due to glucagon stimulating consumption of amino acid substrates for gluconeogenesis and increasing amino acid oxidation.[64] With insufficient amino acids epidermal protein deficiency and necrolysis ensues. Reduced amino acid levels (histidine and tryptophan) can cause painful, erythematous eroded skin, especially in intertriginous areas in several nutritional disorders. Glucagon also increases cutaneous levels of arachadonic acid, which likely increases downstream inflammatory mediators (prostaglandins and leukotrienes).

CLINICAL FINDINGS. The skin lesions of NME are polymorphous, but erosions and crusts are usually apparent. Primary lesions are erythematous patches that eventuate into plaques that develop central bullae. The blisters erode rapidly, form crust and eventually resolve. The erythematous and eroded annular patches and plaques coalesce into large geographic areas. The eruption disappears and reappears spontaneously over the course of weeks. Pruritus and pain are common symptoms. The distribution of NME is characteristic and includes intertriginous areas (groin, perineum, buttocks, and lower abdomen), the central face (especially perioral), and distal extremities (Fig. 153-10). Mucosal involvement manifests as angular cheilitis, atrophic glossitis, and stomatitis. Dystrophic nails may accompany the syndrome. For the differential diagnosis, see Box 153-4.

The features of glucagonoma syndrome are weight loss, sore mouth, diarrhea, weakness, mental status changes, and diabetes mellitus. Weight loss is the most common presenting sign. Laboratory abnormalities include a dramatically elevated



Figure 153-10 The glucagonoma syndrome, necrolytic migratory erythema. Flaccid and papulovesicular lesions (**A**) with erosions, crusting, and fissures around the orifices, and (**B**) appearing as geographic, circinate "necrolytic migratory erythema" in the groin. (**A** and **B** are not the same patient.)

BOX 153-4 DIFFERENTIAL DIAGNOSIS OF NECROLYTIC MIGRATORY ERYTHEMA

Most Likely
- Dermatitis (seborrheic, eczematous, or contact)
- Drug eruption

Consider
- Pemphigus (foliaceus, erythematosus)
- Acrodermatitis enteropathica
- Essential fatty acid deficiency
- Vitamin deficiency (especially B2, B3, B6)
- Amino acid deficiency (histidine, tryptophan)
- Cutaneous lupus erythematosus

Always Rule Out
- Glucagonoma (abdominal CT)
- Liver disease
- Pancreatitis
- Nutritional deficiencies (zinc, vitamin, amino and fatty acids)
- Malabsorption
- Inflammatory bowel disease

serum glucagon, usually well over 1,000 pg/mL (normal range 50–150 pg/mL). Most patients have hyperglycemia and a normochromic normocytic anemia. Abnormal liver function is present and serum levels of amino acids, total protein, albumin, and cholesterol are low. Occasionally, zinc levels are deficient. For individuals suspected of having an underlying glucagonoma, somatostatin receptor scintigraphy is positive in approximately 95% of patients.[65]

Pseudoglucagonoma syndrome presents identically, but the α-cell pancreatic tumor is not present, which may explain why the serum glucagon levels are not elevated. Underlying diseases identified in patients with the pseudosyndrome are: liver disease, pancreatitis, celiac sprue, inflammatory bowel disease, acrodermatitis enteropathica, pellagra, and nonpancreatic malignancies.

The histology of NME is characteristic. Acute lesions demonstrate a striking degree of epidermal necrosis in the upper layers of the stratum spinosum. Neutrophils may be abundant in the necrotic layer and frank separation from the underlying intact epidermis may occur. Chronic lesions also show a psoriasiform dermatitis with parakeratosis and loss of the granular layer. The constellation of hyperkeratosis, architectural disorder and scattered degenerating keratinocytes may be seen in other nutritional deficiencies, graft-versus-host disease, connective tissue disorders, and phototoxic drug eruptions.[66]

COMPLICATIONS. Nearly all patients suffer from weight loss, malaise, and anemia as a result of the catabolic effects of glucagon. Gastrointestinal symptoms such as abdominal pain, diarrhea, and anorexia may be debilitating. Neuropsychiatric features occur in approximately 20% of patients and may present as depression, dementia, psychosis, agitation, ataxia, and decreased cognitive function.[67] Venous thrombosis occurs in up to 30% of patients with glucagonoma.[68]

PROGNOSIS AND CLINICAL COURSE. If the glucagonoma is not metastatic and can be completely resected at the time of diagnosis, symptoms of the syndrome will resolve. Unfortunately, by the time of diagnosis, tumors are frequently large and metastatic in most cases. Fortunately, the tumors are slow growing and patients may experience symptom improvement with surgically decreasing the tumor burden, although survival may not be affected by the procedure. Chemotherapy has been disappointingly ineffective.

TREATMENT. The underlying cause for hyperglucagonemia must be addressed to eradicate the painful skin disease. For patients with glucagonoma, resection of the tumor is important for symptom relief. Measures to correct nutritional deficiencies and glucagon levels have provided relief for many patients. Given the high incidence of venous thromboses, deep vein thrombosis prophylaxis should be instituted. Intravenous somatostatin (a glucagon antagonist) has been shown to improve the cutaneous symptoms of the syndrome, however this does not affect the growth of the underlying tumor.[69] Supplementation to correct zinc, amino acid or fatty acid deficiencies has been shown to be beneficial in some cases when a deficiency is observed.

PREVENTION. None known.

NEUTROPHILIC DERMATOSES

SWEET SYNDROME

(See Chapter 32)

Many authors have suggested that the neutrophilic dermatoses Sweet syndrome and pyoderma gangrenosum represent a continuum when associated with an underlying malignancy. In approximately 40% of patients with malignancy-associated Sweet's syndrome, a diagnosis of cancer is made within one month of the dermatoses.[70] Two-thirds of the time cutaneous manifestations occur prior to the diagnosis of malignancy and is seen most commonly with acute myelocytic leukemia but also may be associated with other leukemias, myelodysplastic syndrome, multiple myeloma, and lymphoma.[71] Of note, patients with an underlying hematologic malignancy may have a normal neutrophil count but is in actuality a relative neutrophilia.

Much less commonly, associations have also been reported with solid tumors such as cancers of the genitourinary tract, embryonal carcinoma of the testes, ovarian carcinoma, gastric carcinoma, and adenocarcinoma of the breast, prostate, and rectum.[72] Unlike

many of the other paraneoplastic dermatoses, the neutrophilic dermatoses respond to systemic corticosteroids and other standard treatments regardless of the course of the underlying malignancy.

PYODERMA GANGRENOSUM

(See Chapter 33)

Overall, there is a low incidence of malignancy in patients with pyoderma gangrenosum but the incidence increases up to 27% in those presenting with atypical features such as hemorrhagic bullae, superficial and/or rapid appearance, involvement of the upper extremities/hands, and scaring. Similar to Sweet syndrome, the most common underlying malignancy is hematologic with acute myelogenous leukemia the most common followed by multiple myeloma.[73]

Another unexplained co-occurrence in patients with pyoderma gangrenosum is an IgA paraproteinemia, occurring in 10%–18% of patients. By itself, this is not a malignancy. However, studies of individuals with monoclonal gammopathy of undetermined significance show an increased risk of malignant transformation occurring at a rate of approximately 1%, and can be as high as 40% at 25 years. Those with IgA gammopathies have a higher probability of malignant transformation.[74,75] Therefore, careful monitoring is warranted in these patients as well. A parallel course to the underlying malignancy has not been well established with this paraneoplastic dermatosis.

DERMAL PROLIFERATIVE DISORDERS

MULTICENTRIC RETICULOHISTIOCYTOSIS

(See Chapter 148)

Though malignancy has been diagnosed in many patients with multicentric reticulohistiocytosis, no one malignancy predominates. Neoplasms that have been reported most commonly include melanoma, hematologic malignancies and carcinomas of the breast, colon, ovaries, cervix, and stomach.[11] The natural course of the disease is generally one of spontaneous remission after several years of activity that resides with permanent joint destruction. While active though, treatment options for multicentric reticulohistiocytosis have only been partially effective and the course of the disease does not consistently parallel the activity of the underlying malignancy.

NECROBIOTIC XANTHOGRANULOMA

(See Chapter 148)

This non-Langerhans cell histiocytosis is a rare disease that has a high association with hematologic abnormalities. In the majority (80%) of patients with necrobiotic xanthogranuloma, an IgG paraproteinemia can be detected with an approximate 10% conversion to multiple myeloma. Periorbital involvement is seen in 85% of patients and ulceration is more common in this particular xanthoma.[76] Other malignant associations include chronic lymphocytic leukemia, Hodgkin disease, and non-Hodgkins lymphoma.[1]

DERMAL DEPOSITION

SCLEROMYXEDEMA

(See Chapter 158)

Scleromyxedema is the generalized form of papular mucinosis (lichen myxedematosus) and has a particular predilection for face, arm, and hand involvement. Systemic organ involvement is common, and the majority (80%) of patients with scleromyxedema has an IgG-λ light chain monoclonal gammopathy of undetermined significance. Serum protein electrophoresis should be performed in conjunction with thyroid studies to rule out thyroid dysfunction and myxedema. Fortunately, the paraproteinemia only rarely converts to multiple myeloma, but when it occurs portends a poor prognosis. Other rare malignancies to co-occur include *Waldenstrom* macroglobulinemia, leukemia, or Hodgkin or non-Hodgkin lymphoma.[1] It is uncertain if treatment of scleromyxedema with agents such as melphalan triggers malignant transformation.[77] The course of the disease is usually progressive with major cardiac and pulmonary involvement and there is no established marker for those most likely to progress to malignancy.

SYSTEMIC AMYLOIDOSIS

(See Chapter 133)

Systemic amyloidosis can be classified as primary, secondary to inflammation and/or infection, familial, or idiopathic. It is important to differentiate skin lesions of primary systemic amyloidosis from the far more commonly seen purely cutaneous variants. With primary systemic amyloidosis, the integumentary system (cardiac, renal, carpal tunnel syndrome, macroglossia, etc.) is more commonly involved. The amyloid subtype in primary systemic amyloidosis most commonly associated with internal malignancy is the amyloid light chain (amyloid AL).

Multiple myeloma is the most common malignancy, seen in 13%–26% of patients, and once diagnosed has an extremely poor prognosis with a mean survival of 1 year. Other malignancies reported include Hodgkin disease and gastric, breast, and renal cell carcinoma.[11,78,79] Familial cutaneous lichenoid amyloidosis has been reported in association with multiple endocrine neoplasia (MEN) type 2A.[80] All patients with skin lesions of systemic amyloidosis should have a serum and urine electrophoresis performed.

BULLOUS DISORDERS

PARANEOPLASTIC PEMPHIGUS

(See Chapter 55)

The signature clinical finding is the early onset of severe refractory oral mucosal involvement. Other sites of involvement can include the ocular, respiratory, and gastrointestinal epithelium. Because nearly every patient with paraneoplastic pemphigus has an associated malignancy, if there is no diagnosed malignancy at the time of presentation, an extensive workup is required. There are occasional instances whereby the association is with a benign tumor. The most common malignancy associated is non-Hodgkin lymphoma. The next most common malignancies in frequency are chronic lymphocytic leukemia, Castleman disease, and thymoma.

DERMATITIS HERPETIFORMIS

(See Chapter 61)

Dermatitis herpetiformis and celiac disease are independent risk factors for gastrointestinal lymphoma. There is no indication that there is a greater than expected number of patients with dermatitis herpetiformis developing tumors other than intestinal lymphoma.[81] The incidence of lymphoma has been reported as between 1%–4% developing 2–31 years after the diagnosis.[82,83] Interestingly, the increased risk is observed only in adults and the incidence ratio decreases with every calendar year after diagnosis, ultimately reaching null.[84]

The most commonly associated malignancy is enteropathy-associated T-cell lymphoma of the gastrointestinal tract but patients are also at risk to develop B-cell lymphoma both in and out of the gastrointestinal tract and non-Hodgkin lymphoma.[82,85] The relative risk of non-Hodgkin lymphoma associated with dermatitis herpetiformis is 5.4 (95%, CI 2.2–11.1) in males, less in females.[85] It is often observed that affected patients with lymphoma are less compliant with a gluten free diet as compared to those without malignancy.

BULLOUS PEMPHIGOID

(See Chapter 56)

Case-control studies have failed to show a significant increased risk of a malignant tumor in patients with bullous pemphigoid, other than that associated with the age of the patient.[86] However, a Japanese cohort of patients with bullous pemphigoid had a 5.8% prevalence of neoplasia versus 0.61% of controls.[87] In younger patients, bullous pemphigoid under the age of 60 was observed in 9.5% of patients in a retrospective review of 74 patients and there are anecdotal reports of patients clearing when the concomitant tumor is treated.[88]

MISCELLANEOUS

HYPERTRICHOSIS LANUGINOSA ACQUISITA

Acquired hypertrichosis lanuginosa (described by Fretzin[89] as *malignant down*) is a rare condition characterized by the relatively sudden appearance of long, fine, nonpigmented lanugo (Latin for "down") hairs. The lanugo most frequently appears on the face and ears early in the course (Fig. 153-10). The hairs may grow to an extraordinary length; eyebrows and eyelashes may grow to inches long. The long fine hairs may also be seen on the trunk and limbs including the axillae. Epithelial proliferation of the oral mucosa may cause glossodynia, hypertrophy of the papillae of the tongue, mucosal pigmentation, and disturbances of taste or smell.[90,91] Symptoms in the mouth are similar to those seen in various vitamin deficiencies and one case has been reported with decreased vitamins A and B_1 and niacinamide levels.[92]

This condition is frequently paraneoplastic and nearly always predates the diagnosis of malignancy. The most commonly associated malignancies are located in the lung and colon. Breast and uterine adenocarcinomas, lymphoma and urinary bladder transitional carcinomas have also been found in patients with acquired hypertrichosis lanuginosa as have other malignancies.[90,91] Unfortunately, tumors are usually widespread by the time hypertrichosis manifests and thus this paraneoplastic condition portends a poor prognosis.

Hypertrichosis lanuginosa may also be seen in other disorders. These include acquired immunodeficiency syndrome (most characteristically hypertrichosis and trichomegaly of the eyelashes),[93] anorexia nervosa, thyrotoxicosis, porphyria cutanea tarda (see Chapter 132). The condition may be a consequence of medications such as cyclosporin, phenytoin, penicillin, spironolactone, corticosteroids, or minoxidil.

TROUSSEAU SYNDROME

In general, malignancy predisposes to alterations in the clotting cascade resulting in a combined state of hemorrhage and hypercoagubility. Approximately 11% of all cancer patients will develop migratory thrombophlebitis during the course of their disease and up to 23% will have evidence at autopsy.[94,95] Trousseau syndrome is an acquired coagulopathy presenting as migratory thrombophlebitis often in a setting of underlying malignancy. Both the arterial and venous vasculature can be affected and can lead to devastating complications such as pulmonary embolism, stroke, limb necrosis, and organ ischemia.

The human oncogene MET induces increased production of plasminogen activator inhibitor type 1 (PAI-1) and cyclooxygenase-2 (COX-2) in some models and may be part of the mechanism linking the hypercoagulable and hemorrhagic state with malignancy.[96]

The most common malignancy reported with Trousseau syndrome is lung carcinoma. However, this most likely reflects the frequency with which it occurs in the general population. The less common pancreatic cancer has a more striking association with 42% having evidence of pulmonary embolism. Furthermore, certain characteristics of tumors have been shown to correlate with an increased risk for the development of Trousseau syndrome. These features include adenocarcinoma, metastatic progression, and involvement of the gall bladder, gastrointestinal, and/or pulmonary systems.[95]

Treatment is best achieved with eradication of the underlying malignancy. To manage the embolic sequelae in Trousseau syndrome, anticoagulation can be achieved with the use of heparin. Low-molecular weight heparin is the treatment of choice, as unfractionated heparin exhibits strong neutralization in the presence of tumor cells.[97]

FAMILIAL CANCER SYNDROMES

It is important for clinicians to recognize cutaneous features of genetic conditions that predispose to internal malignancy. In several cases, cutaneous features predate the development of malignancy and increased surveillance may improve the survivability in these patients.

For malignancies associated with a genodermatosis, there may be an increased risk for family members to develop cancer. Appropriate genetic testing may elicit the carrier state of each relative in question, and can assist with genetic counseling of the patient and the patient's family.

The characteristic cutaneous findings and the major associated internal malignancy for the genodermatoses with cancer susceptibility are listed in Table 153-2.[98–104]

DIRECT TUMOR INVOLVEMENT OF THE SKIN

CUTANEOUS METASTASES

Direct involvement of the skin by metastatic spread from a distant primary tumor is perhaps the most unquestioned sign of internal malignancy. The overall incidence of cutaneous involvement is approximately 5%.[105] In a review of over 100,000 cancer patients, skin involvement was the first sign of internal malignancy in 7.8%.[106] The most common malignancies to metastases to the skin in women are breast, colon, and melanoma. In men, the most common are lungs, colon, and melanoma.



Figure 153-11 Hypertrichosis lanuginosa acquisita in a 19-year-old woman with pancreatic carcinoma.

Several clinical and pathologic features can aid in determining the source of the metastasis. Metastatic breast cancer can present as an erysipelas-like eruption known as *carcinoma erysipelatodes* (Fig. 153-12A). Usually asymptomatic, this type of breast cancer can be painful. Another clinical variant is the leather-like skin change of sclerosing metastatic breast cancer known as *carcinoma en cuirasse,* which may later present as nodules and ulceration (Fig. 153-12B and C). Carcinoma en cuirasse can be progressive for many years, even decades, in the absence of any apparent systemic involvement.

Metastases from malignant melanoma are usually pigmented (Fig. 153-13). Often there is a bluish tint to



Figure 153-12 **A.** Carcinoma erysipelatoides. Intralymphatic spread of mammary carcinoma that manifests as erysipelas-like erythema. **B.** Bilateral cutaneous metastases from underlying breast carcinoma. **C.** Carcinoma en cuirasse involving both breasts and thoracic wall.

TABLE 153-2
Genetic Syndromes Involving Skin and/or Mucous Membranes and Associated with Malignancy

Syndrome	Gene/Protein Defect	Cutaneous Findings	Other Characteristic Features	Major Associated Internal Malignancy	Minor Associated Internal Malignancy
Autosomal Dominant					
Birt-Hogg-Dube syndrome[99]	BHD (folliculin)	Fibrofolliculomas, trichodiscomas, acrochordons	Lung cysts, emphysema, recurrent spontaneous pneumothoraces	**Renal carcinoma** (12%)	
Carney complex[107]	PRKAR1-α (regulatory subunit type 1A protein kinase A)	Mucocutaneous myxomas, nevi, ephelides, blue nevi	Primary pigmented nodular adrenocortical disease (26%-benign, causes Cushing's syndrome)	**Myxomas** (cardiac- 53%, skin-33%) **Sertoli cell testicular cancer** (33% of males)	Other testicular cancers, breast and thyroid tumors, pituitary adenoma, and melanotic schwannomas
Cowden disease[98]	PTEN (tyrosine phosphatase)	Trichilemmomas, acral papules and keratoses, oral papillomas, sclerotic fibromas	Ovarian cysts, adenoid facies	**Breast cancer** (22%) **Hamartomatous intestinal polyps** (60%) **Thyroid abnormalities** (62%, includes follicular thyroid carcinoma, goiter, and adenoma)	Transitional cell and renal cell carcinomas, glioblastoma multiforme, liposarcoma, lung, hepatocellular, pancreatic, uterine, and ovarian cancer
Gardner disease[98]	APC (regulator of β-catenin)	Epidermoid cysts, fibromas, pilomatricomas	Congenital hypertrophy of retinal pigment epithelium (CHRPE), supernumerary teeth, osteomas	**Intestinal polyposis and colorectal adenocarcinoma** (near 100%)	Thyroid cancer, adrenal adenomas and adenocarcinomas, hepatoblastoma; bone and CNS tumors
Gorlin syndrome[98]	PTCH1 (patched 1)	Multiple BCCs, epidermoid cysts, milia, palmar and plantar pits	Calcified falx cerebri, bifid ribs, odontogenic cysts, kyphoscoliosis	**Medulloblastoma** (10%), **meningiomas** (5%)	Ovarian fibromas, fibrosarcomas, cardiac fibromas, ovarian desmoids
Howel-Evans syndrome[101]	TOC (tylosis and esophageal cancer gene)	Palmoplantar keratoderma (nontransgrediens)	Oral leukoplakia	**Esophageal carcinoma** (up to 90%)	
MEN I syndrome[98,100]	MEN1 (menin)	Angiofibromas, collagenomas, CALMs, lipomas, hypopigmented macules, gingival papules; necrolytic migratory erythema	Various endocrine sequelae based on underlying tumor	**Parathyroid adenomas** (90%) **Pancreatic islet cell tumors** (80%) **Gastrinomas** (54%, includes Zollinger-Ellison syndrome) **Anterior pituitary tumors** (10%–30%)	Foregut and thymic carcinoids, pheochromocytoma, thyroid adenomas
MEN IIa syndrome[98,100]	RET (tyrosine kinase receptor)	Scapular macular or lichen amyloidosis	No mucosal neuromas or marfanoid habitus	**Medullary thyroid carcinoma** (90%) **Pheochromocytomas** (50%) **Parathyroid tumors** (20%–30%)	

MEN IIb/III syndrome[98,100]	RET (tyrosine kinase receptor)	Mucosal neuromas, CALMs, thickened eyelids and lips	Marfanoid habitus, no parathyroid tumors	**Medullary thyroid carcinoma** (90%) **Pheochromocytoma** (50%)	Conjunctival neuromas, intestinal ganglioneuromas
Muir-Torre syndrome[98]	MSH1/2 (DNA mismatch repair)	Sebaceous tumors (epitheliomas, hyperplasias, and adenomas), keratoacanthomas		**Colorectal carcinomas** (51%) **Genitourinary cancers** (25%)	Breast, head and neck, and small intestine carcinomas, hematologic malignancies
Neurofibromatosis I[98]	NF1 (neurofibromin)	CALMs, NF, plexiform NF, axillary freckling	Lisch nodules, glaucoma, sphenoid wing dysplasia, pseudoarthrosis of tibia, learning disability	**Optic gliomas** (66%) **Neurofibrosarcoma** (3.5%) **Chronic myelomonocytic leukemia** (if associated with juvenile xanthogranuloma-increased risk)	Astrocytomas, ependymoma, meningioma, non-Hodgkins lymphoma, acute lymphoblastic leukemia, pheochromocytoma
Neurofibromatosis II[98]	NF2 (schwannomin/merlin)	Schwannomas, NF, CALMs, plexiform NF	Juvenile posterior subcapsular cataract, deafness	**Bilateral vestibular schwannomas** (near 100%) **Spinal tumors** (90%, usually schwannomas) **Meningiomas** (50%)	Gliomas, astrocytomas, intramedullary ependymomas
Peutz-Jeghers syndrome[98]	STK11 (serine/threonine kinase 11)	Perioral and mucosal lentigenes	Intussusception, bowel obstruction	**Polyps** (near 100%) **Gastrointestinal carcinoma** (13%)	Pancreatic, esophageal, breast, and ovarian carcinoma
Reed syndrome[102] (hereditary leiomyomatosis and renal cell carcinoma)	FH (fumarate hydratase)	Cutaneous leiomyomas		**Uterine leiomyoma** (98%) **Renal carcinoma*** (type II papillary renal cell)	
Tuberous sclerosis	TSC1 (hamartin) TSC2 (tuberin)	Ash leaf macules, shagreen patches, CALMs, facial angiofibromas, periungual fibromas	Tonic-clonic seizures, paraventricular calcification, subependymal nodules, retinal hamartomas	**Intracranial cortical/subcortical tubers** (near 100%) **Cardiac rhabdomyomas** (50%) **Renal angiomyolipomas** (49%) **Lung lymphangiomyomatosis**	Wilms tumor, pancreatic carcinoma, parathyroid adenoma
Autosomal Recessive Ataxia-Telangiectasia	ATM (DNA repair)	Telangiectasias (skin and conjunctiva), masklike progeric facies, CALMs, poikiloderma	Ataxia, nystagmus, choreathetosis, recurrent respiratory infections, radiosensitive	**Leukemia/lymphomas** (38%) **Breast cancer** (increased risk in heterozygotes)	Various solids tumors
Bloom syndrome[98,103]	RecQL3 (helicase)	Cheilitis, CALMs, malar poikiloderma	Immunodeficiency, short stature, hypogonadism, high-pitched voice	**Acute leukemia*** **Lymphoma*** **GI adenocarcinoma***	Wilms tumor, medulloblastoma, osteogenic sarcoma
Chediak-Higashi syndrome[103]	LYST (lysosomal trafficking)	Silver hair, slate-gray skin, ecchymoses	Immunodeficiency, pyogenic infections (staph), photophobia, cytopenia, neurodegeneration	**Lymphoma-like accelerated phase** (85%)	
Fanconi anemia[104]	FANC (multiple proteins that form a nuclear complex)	Short stature, CALMs microcephaly, thumb, and/or radial ray anomalies	Short stature, multiple birth anomalies, pancytopenia, infection, radial anomalies	**Acute myeloid leukemia** (9%) **Liver tumors** (5%) **Mucosal SCC** (5%)	Myelodysplastic syndrome, gynecologic, head/neck, and esophageal malignancies

(continued)

TABLE 153-2
Genetic Syndromes Involving Skin and/or Mucous Membranes and Associated with Malignancy (Continued)

Syndrome	Gene/Protein Defect	Cutaneous Findings	Other Characteristic Features	Major Associated Internal Malignancy	Minor Associated Internal Malignancy
Griscelli syndrome	RAB27A (GTP-binding protein) MYO5A (myosin)	Silver hair, partial albinism	Immunodeficiency, pancytopenia, neurodegeneration (MYO5A), hemophagocytic syndrome (RAB27A)	**Lymphoma-like accelerated phase** (in the majority)*	
Rothmund-Thomson syndrome[98]	RecQL4 (helicase)	Poikiloderma nail dystrophy, acral keratoses, photosensitivity, hypotrichosis	Short stature, radial anomalies, juvenile cataracts, hypogonadism	**Osteogenic sarcomas***	Fibrosarcoma, gastric carcinoma, SCCs
Werner syndrome[98,103]	RecQL2 (helicase)	Premature aging, birdlike facies, sclerodermoid changes, ulcers	Short stature, cataracts, diabetes, osteoporosis, high-pitched voice, hypogonadism	**Sarcomas** (10%, soft tissue, bone) **Thyroid cancer***	Mengiomas, adenocarcinomas; acrolentiginous melanoma in Japan
Xeroderma pigmentosum[98]	XP (multiple proteins that form DNA repair complex)	Photosensitivity, actinic keratoses, lentigenes, poikiloderma	Photophobia, multiple ocular complications, neurodegeneration (XPA, XPD)	**Ocular cancers** **Lung and gastric carcinomas** (10–20× incr. risk) **Cutaneous cancers** (BCC, SCC, and melanoma 100%)	Sarcomas, leukemia
X-linked Recessive					
Dyskeratosis congenita	DKC1 (XLR; dyskerin-telomerase component) TERT/TERD (AD; telomerase component) NOP10 (AR; telomerase component)	Leukoplakia, nail dystrophy, reticulate pigmentation, alopecia, palmoplantar hyperkeratosis, adermatoglyphia, hyperhidrosis	Pancytopenia, various ocular complications, mental retardation, pulmonary complications	**Cutaneous and mucosal squamous cell carcinoma***	Hodgkins lymphoma, gastrointestinal carcinoma
Wiskott-Aldrich syndrome	WASP (actin assembly in hematopoietic cells)	Eczema, petechiae/purpura	Immunodeficiency (decreased IgM), recurrent infections, thrombocytopenia	**Lymphoreticular malignancy** (20%, non-Hodgkins disease)	
X-linked ichthyosis[103]	STS (steroid sulfatase)	Adherent brown scales that spares face, palms, soles and flexural creases	Failure of maternal labor, comma-shaped corneal opacities	**Testicular cancer** (from associated cryptoorchidism)	
Sporadic					
Beckwith-Wiedemann syndrome	P57 (cyclin-dependent kinase inhibitor)	Capillary malformation, macroglossia, earlobe creases, helical pits	Omphalocele, hypoglycemia, mental retardation, hemihypertrophy	**Wilms tumor**[a] **Hepatoblastoma**[a]	Adrenocortical tumors, rhabdomyosarcoma
Epidermal nevus syndrome	Unknown, may be related to FGF-23	Epidermal nevi, hemangiomas, CALMs, capillary malformation	Mental retardation, neurologic deficits, ocular complications, rickets (Vit D resistant)	**Wilms' tumor** **Cutaneous cancers** (BCC, SCC, keratoacanthoma, syringocystadenoma papilleferum)	Astrocytoma, rhabdomyosarcoma
Famililial melanoma (dysplastic nevus syndrome)[98]	CDKN2A (cyclin-dependent kinase)	Multiple dysplastic nevi, melanomas		**Pancreatic cancer** (22× incr. risk)	Lung, laryngeal, and breast carcinomas
Mafucci syndrome	Unknown	Venous malformations	Encondromas, secondary fractures	**Chondrosarcoma** (20%)	Angio- and lymphangio-sarcoma, fibrosarcoma, osteosarcoma

[a]Frequency unable to be reported due to rarity of the genodermatosis and/or a specific malignancy.



Figure 153-13 Deeply pigmented cutaneous metastases from melanoma.

the lesion, even if it is deep in the skin. However, even if the primary tumor was pigmented, the metastases can be amelanotic. The reverse is also true.

Other tumors that commonly metastasize to skin include tumors of the lung (Fig. 153-14), stomach, kidney, and ovary. The scalp, is quite commonly involved by metastases from lung, kidney, and breast tumors. Alopecia may result. The face and neck may be involved by metastases from oropharyngeal carcinomas. Metastases from renal and thyroid carcinoma may be pulsatile and may have a bruit.



Figure 153-14 Metastatic lung cancer presenting as a forehead nodules.

A proposed diagnostic truncated immunohistochemical battery includes CK-7, CK-20, and S-100. When administered to a cohort of patients with lung, colorectal, bladder, renal cell carcinoma, and melanoma, there was an overall diagnostic accuracy of 83.3%. Other useful markers include antithyroid transcription factor (lung), HMB-45 (melanoma), PSA (prostate), estrogen/progesterone receptors (breast), and mucicarmine (salivary gland).[106]

Generally, though, cutaneous metastases herald a poor prognosis because evidence of systemic spread to other sites is usually quickly apparent. The average survival time of patients with cutaneous metastases is approximately 7.5 months.[106]

LEUKEMIA/LYMPHOMA CUTIS

(See Chapters 144 and 145)

Involvement of the skin with lymphoma cells is quite common, particularly in the case of a T-cell lymphoma. T-cell leukemias frequently have skin involvement, and this involvement may manifest itself as a diffuse erythroderma, as is seen in Sézary syndrome.

B-cell lymphomas also can involve the skin, with Hodgkin disease being the most common. B-cell lymphoma involvement of the skin is usually manifested by the development of one or more papules or nodules that may be ulcerated and form arcuate lesions. Alopecia also can be caused by lymphoma. Alopecia mucinosa is involvement of the hair follicles by lymphoma, with associated mucin deposition.

Aside from the erythroderma seen in T-cell leukemia, other lymphocytic, myeloid, and myelomonocytic leukemias can have cutaneous manifestations. The most common of these are the infiltrations of the skin produced by monocytic or myelomonocytic leukemia, which can produce a leonine facies in addition to other infiltrative plaques. Involvement of the skin can be a presenting feature in myelomonocytic leukemia, although it generally occurs late in the course of the disease.

When assessing a solitary nodule that is histologically lymphoma but in the absence of any definable systemic disease, it is important to consider benign cutaneous lymphoid infiltrates in the differential diagnosis.

PAGET AND EXTRAMAMMARY PAGET DISEASE

(See Chapter 121)

Paget disease of the nipple is an erythematous scaling eruption indicating ductal carcinoma of the underlying breast. Extramammary Paget disease, which can occur in the anogenital skin, similarly may be associated with an underlying adenocarcinoma. The underlying carcinoma may be of apocrine or

eccrine sweat gland origin, or can be from the rectum or urethra.

KEY REFERENCES

Full reference list available at www.DIGM8.com

DVD contains references and additional content

1. Chung VQ et al: Clinical and pathologic findings of paraneoplastic dermatoses. *J Am Acad Dermatol* **54**:745, 2006
5. Torley D, Bellus GA, Munro CS: Genes, growth factors and acanthosis nigricans. *Br J Dermatol* **147**:1096, 2002
11. Cohen PR, Kurzrock R: Mucocutaneous paraneoplastic syndromes. *Semin Oncol* **24**:334, 1997
45. Bolognia JL, Brewer YP, Cooper DL: Bazex syndrome (acrokeratosis paraneoplastica) an analytic review. *Medicine* **70**(4):269-280, 1991
56. Eubanks LE, McBurney E, Reed R: Erythema gyratum repens. *Am J Med Sci* **321**(5):302-305, 2001
91. Hovenden AL: Hypertrichosis lanuginosa acquisita associated with malignancy. *Clin Dermatol* **11**:99-106, 1993
98. Tsao H: Update on familial cancer syndromes and the skin. *J Am Acad Dermatol* **42**:939, 2000
106. Saeed S, Keehn CA, Morgan MB: Cutaneous metastasis: A clinical, pathological, and immunohistochemical appraisal. *J Cutan Pathol* **419**, 2004

SECTION 27

The Skin in Vascular and Connective Tissue and Other Autoimmune Disorders

Chapter 154 :: Mechanisms of Autoimmune Disease

:: Insoo Kang & Joseph Craft

MECHANISMS FOR AUTOIMMUNE DISEASES AT A GLANCE

- Autoimmune diseases are relatively common disorders and can be divided into organ-specific and systemic autoimmune diseases based on the autoantigens targeted by immune cells.
- Although the underlying etiologies of these illnesses are still elusive, they arise in the context of a break in the immune tolerance to self.
- The mechanisms for abrogation of immune self-tolerance appear to be multifactorial, including genetic and environmental, that lead to unregulated immune activation against self-antigens and subsequent tissue destruction.
- B cells and T cells recognize self-antigens and dominate the phenotype of the patient with autoimmunity, although other immune components including antigen-presenting cells and complement are involved in various steps from initiation of the autoimmune response to tissue destruction.

INTRODUCTION

Autoimmune diseases including rheumatoid arthritis (RA) and systemic lupus erythematosus (SLE) are relatively common disorders.[1] Although the underlying etiologies of these illnesses are still elusive, they arise in the context of a break in the immune tolerance to self.[2,3] The mechanisms for abrogation of immune self-tolerance appear to be multifactorial, including genetic and environmental, that work in concert to initiate the eventual hallmarks of disease: unregulated immune activation against self-antigens and subsequent tissue destruction. Immune activation against self-antigens is clinically manifest by the presence of autoantibodies and autoreactive T cells.[1,2] Based upon their autoantigenic targets, autoimmune diseases can be classified into organ-specific and systemic autoimmune processes. For example, Grave's disease, with its autoantibodies against the thyroid-stimulating hormone (TSH) receptor, is a typical example of organ-specific autoimmune disease, as is type I diabetes mellitus (DM) with its autoantibodies and autoreactive T cells directed against components of pancreatic β cells, whereas SLE with its characteristic autoantibodies against ubiquitous nuclear antigens is a good example of a systemic autoimmune disease. Although adaptive immune cells such as B cells and T cells recognize self-antigens and hence dominate the phenotype of the patient with autoimmunity, other immune components including antigen-presenting cells (APC) and complement are involved in various steps from initiation of the autoimmune response to tissue destruction.[4–6] In this chapter, the contributions of these components to the development of autoimmune diseases will be discussed, focusing on the latest discoveries.

GENETICS

AUTOIMMUNE DISEASES ARE POLYGENIC

Autoimmune diseases are polygenic, involving both major histocompatibility complex (MHC) and non-MHC genes.[7,8] Yet, the concordance rate of autoimmune diseases in monozygotic twins is not 100%, ranging from 10% to 50%, including in RA and SLE,[7,9] indicating a significant role for nongenetic factors in the development of these disorders. Nevertheless, genetic influences are strong. For instance, the contribution of alleles of MHC to the development of autoimmunity has been known for more than 30 years. An increased frequency of HLA (human leukocyte antigen)-DR4 has been observed in some patients with RA.[8] Using more sophisticated molecular techniques, the sequence of genetic alleles encoding HLA loci have been typed, with the resultant demonstration that the *HLA-DRB1* gene is highly polymorphic and such polymorphisms can affect the binding of peptides to HLA molecules and the contacts between the T-cell receptor (TCR) and

the HLA molecule.[8] Thus, the associations between autoimmune diseases and particular HLA molecules can be explained by a model where disease susceptibility is determined by differences in the ability of different HLA alleles to present autoantigenic peptides to autoreactive T cells.[2,8] However, the genetic effect of MHC on disease propensity is broader. As an example, a recent study genotyped a panel of 1,472 single nucleotide polymorphisms (SNPs) across the 3.44 megabase (Mb) classic MHC region in 10,576 DNA samples from patients with autoimmune diseases including SLE, RA, and multiple sclerosis, and from appropriate controls.[10] The results of this study showed multiple risk alleles across MHC class I, II, and III in these autoimmune diseases, indicating complex, multilocus effects that span the entire region.

NON-MHC ASSOCIATIONS WITH AUTOIMMUNE DISEASES

The association of non-MHC genes with autoimmune diseases is now well established,[1,7,11] with the recent advent of genome-wide association (GWA) scans that are powerful tools for identifying new genes in autoimmunity.[11] These genes include those involved in antigen clearance, apoptosis, cell signaling, and cytokine production as well as in the expression of costimulatory molecules and cytokine receptors.[1,2,7,11] For instance, complement components are required for proper clearance of immune complexes, and an increased incidence of homozygous C4 deficiency is found in patients with SLE who have immune complex deposits in damaged organs such as the kidneys.[9]

AUTOIMMUNE REGULATOR

Recently, a gene called *autoimmune regulator* (*AIRE*) gene has been identified as a candidate gene responsible for the development of autoimmune diseases.[12,13] AIRE is a transcription factor that regulates the ectopic expression of proteins, normally expressed in peripheral tissues, in the thymus, allowing for thymic expression of the latter and subsequent negative selection of self-reactive thymocytes before they migrate as mature T cells to the secondary lymphoid organs such as the spleen and lymph nodes. An alteration in thymic expression of *AIRE* can lead to increased generation of autoreactive T cells due to their impaired negative selection.[14] Indeed, patients with mutations of the *AIRE* gene develop a syndrome called autoimmune polyendocrinopathy candidiasis ectodermal dystrophy (APECED) or autoimmune polyglandular syndrome 1 (APS-1) that is characterized by chronic mucocutaneous candidiasis, hypoparathyroidism, and Addison's disease.[15] In addition, patients with this condition often have other organ-specific autoimmune diseases including type 1 DM, autoimmune thyroid diseases, gonadal failure, vitiligo, alopecia, dystrophy of dental enamel and nails, and pernicious anemia.[15]

CYTOTOXIC T-LYMPHOCYTE ANTIGEN-4

An increased incidence of autoimmune diseases has been reported in individuals with a particular variant of genes that affect T-cell activation. These include the cytotoxic T-lymphocyte antigen-4 (*CTLA-4*) gene and the protein tyrosine phosphatase 22 gene (*PTPN22*)[1,11,16] (see below). CTLA-4 is a key immunoregulatory molecule that restrains T-cell activation. It is expressed on T cells upon TCR stimulation by antigen on APC and competes with CD28, a positive costimulatory molecule also on T cells, for binding to CD80 and CD86 expressed on APC.[17] By contrast to CD28 engagement by CD80 and CD86, binding of CTLA-4 to the latter molecules inhibits T-cell activation. The association of SLE and RA with SNPs in the *CTLA-4* promoter and coding region has been reported. These polymorphic sites include –1722 position of the *CTLA-4* promoter and +49 position of exon-1,[18,19] although the functional consequence of such gene polymorphisms is not clear yet. CTLA-4 polymorphisms also have been linked to autoimmune endocrinopathies; for example, a decrease in the alternate splice product of *CTLA-4* that is the soluble form of CTLA-4 is found in individuals with CTLA-4 SNP CT60 G/G which is linked with increased susceptibility to Grave's disease, autoimmune hypothyroidism, and type 1 DM.[20] This finding suggests a possible functional role for CTLA-4 polymorphisms in autoimmune diseases.

PROGRAMMED CELL DEATH 1

In a manner analogous to CTLA-4, a protein called programmed cell death 1 (PD-1) is expressed on T cells providing an inhibitory signal upon their activation. This molecule is also expressed on other immune cells including B cells and myeloid cells.[1,21] PD-1 is encoded by the *PDCD1* gene, with a SNP in its fourth intron associated with autoimmunity, including SLE and RA.[22–24] Of interest, this disease-associated SNP impairs the binding of the hematopoietic runt-related transcription factor 1 (RUNX1), leading to aberrant expression of *PDCD1* gene and subsequently uncontrolled T-cell activation.[22] The association of genetic polymorphisms of CTLA-4 and PD-1, molecules involved in regulating T-cell activation, with autoimmune diseases supports the notion that regulation of T-cell activation by these costimulatory molecules is a critical checkpoint for the development of autoimmunity.

PROTEIN TYROSINE PHOSPHATASE 22

The protein tyrosine phosphatase 22 (*PTPN22*) gene is another recently identified gene that is associated with autoimmune diseases.[1] A variant of the *PTPN22* gene, which encodes a tryptophan at codon 620 (620W) instead of an arginine (wild-type), has been found to be associated with an increased risk of RA, SLE, type 1 DM, and Grave's disease.[1] Such a mutation appears to have functional consequences, since the *PTPN22* gene encodes lymphoid tyrosine phosphatase (LYP) that modulates the activation of Lck and other kinases

involved in TCR signaling.[25] Indeed, the *PTPN22* 620W allele appears to potentially increase the inhibition of TCR activation by downregulating Lck activation.[25] Thus, it still needs to be clarified how this allele promotes the development of autoimmunity.

TUMOR NECROSIS FACTOR RECEPTOR SIGNALING PATHWAY

Recently, multiple genes encoding molecules involved in tumor necrosis factor (TNF) receptor signaling have been found to be associated with autoimmunity.[11] The best known is *TNFAIP3* that encodes TNF inducible protein A20 that is a negative regulator of TNF-induced NF-*k*B signaling pathways. SNP markers in the gene region near the *TNFAIP3* locus have been associated with RA, psoriasis, and SLE.[26–28] The gene encoding *TNFAIP3*-interacting protein 1 (*TNIP1*) that interacts with TNFAIP3 is associated with psoriasis and SLE,[27,29] with an association of the *TRAF1* (TNF receptor-associated factor 1) gene with RA also reported.[30]

CYTOKINE RECEPTORS

Polymorphisms in several cytokine receptors are associated with autoimmunity.[11] The IL-23 receptor complex consists of IL-23R and IL-12Rβ1 subunits, with the latter shared with the IL-12 receptor complex that is composed of IL-12Rβ1 and IL-12Rβ2 subunits. The *IL23R* receptor gene is associated with inflammatory bowel disease and psoriasis.[31,32] This is an intriguing point since IL-23 is involved in regulating the development of T helper 17 (Th17) cells that produce the potent proinflammatory cytokine IL-17. In fact, IL-17 is found in psoriatic skin lesions.[33] Likewise, the *IL12B* gene that encodes IL-12β (the p40 subunit of IL-12) has been found to associated with psoriasis.[34]

RECEPTORS FOR IMMUNOGLOBULIN G Fc PORTION (FcγR)

In addition to genes expressed by T cells, those involved in humoral immune responses also appear to be associated with autoimmunity. The receptors for immunoglobulin G (IgG) Fc portion (FcγR) are expressed on B cells, macrophages, monocytes, granulocytes, and dendritic cells (DCs). There are eight genes identified for the human FcγR: *FCGRIA, FCGRIB, FCGRIC, FCGRIIA, FCGRIIB, FCGRIIC, FCGRIIIA,* and *FCGRIIIB*.[35] The binding of FcγRs to IgG, except for that to FcγRIIb, results in a broad spectrum of activating cellular responses including phagocytosis, cytolysis, cytokine production, and degranulation that lead to inflammation. By contrast, FcγRIIb physiologically serves as an inhibitory receptor that downregulates the effector function of cells.[35] An increased frequency of some variants of *FCGR* genes has been reported in humans with autoimmune diseases including SLE and RA.[35–39] FcγRIIa with an arginine at position 131 has greater signaling in response to IgG1 engagement than FcγRIIa with a histidine at the same position, suggesting that FcγRIIa gene polymorphisms have physiologic relevance.[39] Of interest, FcγRIIa with an arginine has been reported as a susceptibility factor for SLE in some ethnic groups.[35,40] Similarly, a variant of FcγRIIIa with a phenylalanine at position 158 may be a susceptibility factor for SLE and RA.[36,38] In addition, genetic polymorphisms of the inhibitory FcγRIIb have been reported in patients with SLE.[37,41,42] The best known such polymorphism is a substitution of an isoleucine at position 232 (187 by counting from the *N*-terminus of the mature protein) with a threonine.[37,41,42] The latter genotype is more commonly reported in patients with SLE. While the biologic implication of such an alteration on the development of SLE is as yet unclear, functioning inhibitory FcR are necessary for dampening autoimmunity in murine lupus.[43]

Overall, genetic studies on MHC genes and non-MHC genes support the notion that some patients with autoimmune diseases have an increased genetic risk for the development of autoimmune diseases secondary to genetic alterations affecting immune cell function. However, such alterations are not always observed in patients with autoimmune diseases and ethnic differences in genetic susceptibility are not uncommon. These findings support the idea that autoimmune diseases are polygenic and that environment factors are also involved in their development (Fig. 154-1).

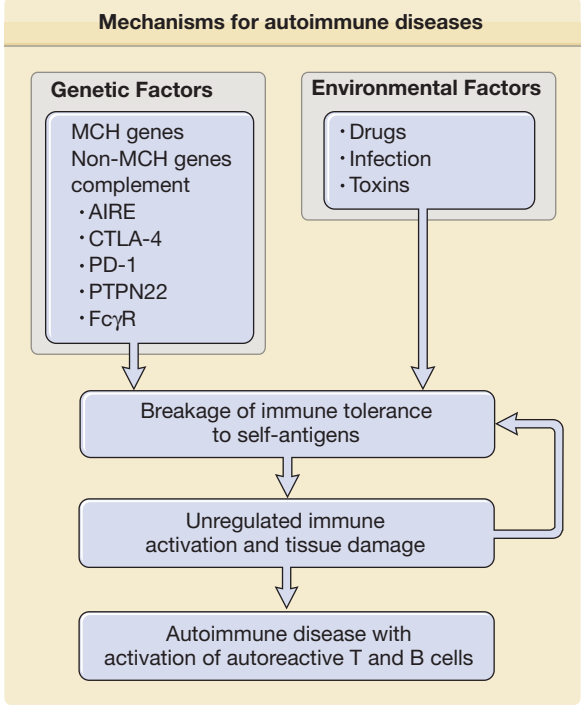

Figure 154-1 Mechanisms for autoimmune diseases. The figure shows potential mechanisms for initiation of autoimmune diseases including genetic and environmental factors that work in concert to initiate breakage of immune tolerance to self-antigens. Subsequently, unregulated immune activation and tissue damage arise, leading to the development of autoimmune disease with activation of autoreactive T cells and B cells with autoantibody production. Abbreviations: AIRE (autoimmune regulator), CTLA-4 (cytotoxic T-lymphocyte antigen-4), PD-1 (programmed cell death 1), PTPN22 (protein tyrosine phosphatase 22), and FcγR (receptor for immunoglobulin G (IgG) Fc portion). See details in text.

TOLERANCE AND AUTOIMMUNITY

CENTRAL TOLERANCE

Intact mechanisms of self-tolerance are necessary to prevent the development of autoimmune diseases.[2] Self-tolerance is generated and maintained through the capacity of the immune system to distinguish self-reactive B and T cells from nonself-reactive cells. These processes begin during the development of lymphocytes in the bone marrow and thymus, respectively.[3] Such selective processes are controlled by the binding affinity of antigen receptors to self-antigens during lymphocyte development. B and T cells expressing antigen receptors with affinity for self-antigens are altered, either becoming nonreactive to antigenic stimuli (through a process called anergy induction) or changing their antigen receptors so that they no longer bind self-antigens (a process called receptor editing, operative in self-reactive B cells), or if they bind too strongly to self, they are simply killed via apoptosis. These interventions lead to central tolerance to self-antigens.[3] A defect in central tolerance can cause autoimmune diseases as evidenced by the development of APS-1 in humans with an alteration in the *AIRE* gene (see Section "Genetics") that is involved in negatively selecting autoreactive T cells.[44,45]

PERIPHERAL TOLERANCE

Despite removing or modifying autoreactive lymphocytes in the thymus and bone marrow by selective processes, some lymphocytes reactive to self-antigens still mature and enter the peripheral immune system; i.e., negative selection is not perfect, probably because if it were, potentially beneficial T and B cells would never make it past central selection in the thymus and bone marrow, respectively. The autoreactive T and B cells that escape central selection can potentially be activated upon recognition of self-antigens; thus, peripheral tolerance mechanisms need to be available to avoid the development of autoimmunity. Such mechanisms are several, and involve minimizing contacts of autoreactive cells with self-antigens (ignorance of the self-reactive lymphocyte), not providing appropriate signals for their activation, terminating activated autoreactive cells by regulatory molecules such as PD-1 or CTLA4, and/or actively suppressing autoimmune responses by other T cells.[2] In critical organs like the brain, eyes, and gonads, immunological ignorance is a principal mechanism for avoidance of autoreactivity via the provision of anatomical barriers separating the tissue and lymphocytes. Activation of the latter can be further prevented by the relative paucity of APCs in these organs and the minimal expression of MHC molecules in these tissues.[46,47] These sites are termed immunologically privileged since even tissue grafts do not elicit immune responses therein. Immunologically privileged sites have additional mechanisms that prevent immune activation, including production of TGF-β, which can suppress immune responses such as in the anterior chamber of the eyes, and constitutive expression of Fas ligand that induces apoptosis of infiltrating activated lymphocytes.[46,47]

Nevertheless, since autoantigens are expressed on some tissues and autoreactive T (and B) lymphocytes are present in the circulation, there is still a reasonable chance for the latter to recognize autoantigens expressed by MHC molecules on APC. However, such an autoantigenic signal through potentially self-reactive antigen receptors is not enough to activate lymphocytes, as additional signals (second signals) provided by APCs, such as CD80 and CD86, to CD28 on T cells are required for proper activation.[17,48] When proper costimulation is not provided by antigen presenting cells, autoreactive T cells that are only signaled through the TCR undergo apoptosis or become anergized. As CD80 and CD86 upregulation on APCs requires an inflammatory stimulus provided to the APC such as that provided by a pathogen during infection, presentation of self-antigens in the absence of inflammation does not lead to autoreactive T cell activation. By contrast, peptides of pathogens lead to cellular activation as they are presented to the immune system in the appropriate inflammatory context. Of course, this regulatory control on autoimmunity may be bypassed if in a similar manner self-antigens are presented at a site of inflammation. Fortunately, this appears to be a relatively unusual event, and autoimmunity invoked by this mechanism is typically avoided.

Autoreactive lymphocytes that manage to get activated in the periphery can be also deleted by apoptosis (programmed cell death) and/or their activation terminated by inhibitory molecules expressed on autoreactive lymphocytes. Fas ligand, or Fas, expressed on T cells is largely responsible for the former.[49,50] The latter process can be achieved through CTLA-4 and PD-1 expressed on activated T cells that inhibit and downregulate T cell activation.[17,21] The potential roles for CTLA-4 and PD-1 in controlling autoimmunity have been demonstrated by mouse studies where these genes have been genetically eliminated, for example, with resultant autoimmunity.[51,52] In addition, genetic polymorphisms in these molecules have been reported to be associated with autoimmune diseases including SLE and RA (see Section "Genetics"). More importantly, there have been attempts to treat autoimmune diseases by modulating CTLA-4 and PD-1 inhibitory pathways.[53,54] Indeed, abatacept, a recombinant fusion protein comprising the extracellular domain of human CTLA4 and a fragment of the Fc domain of human IgG1, is available for the treatment of RA.[53] This drug, like CTLA4, competes with CD28 for CD80 and CD86 binding; however, in contrast to CTLA4 engagement that leads to downregulation of T cell activation, it blocks T cell activation and thus selectively modulates T cell activation.

The activation of autoreactive lymphocytes is also actively suppressed through other mechanisms. The most appealing such mechanism is immune suppression through subsets of T cells called regulatory T cells (Tregs), discussed below.

REGULATORY T CELLS

The concept that certain T cells can regulate immune responses dates back to early 1970s. These cells, that Gershon initially called "suppressor cells,"[55] remained largely undefined and their mechanism of suppression not identified. After their original discovery, they remained out of vogue until over a decade later when others including Sakaguchi reported modulation of immune responses by $CD4^+$ T cells expressing CD25 (IL-2 receptor alpha chain)[56] as well as by T cells producing TGF-β and IL-10.[57–59] Cells with immune regulatory functions are now called regulatory T cells (Tregs). Several subsets of Tregs have been identified thus far, including: (1) naturally occurring $CD4^+$ $CD25^+$ Tregs expressing the transcription factor protein forkhead box P3 (Foxp3); (2) $CD4^+$ T cells producing IL-10 called type 1 regulatory T cells (Tr1); (3) $CD4^+$ T cells producing TGF-β named T helper 3 cells (Th3); and (4) $CD8^+$ T cells producing IL-10 or TGF-β.[60,61]

CD4+ CD25+ REGULATORY T CELLS

Among the best characterized Tregs are naturally occurring $CD4^+$ $CD25^+$ $Foxp3^+$ cells ($FOXP3^+$ Treg) that are produced in the thymus. The potential role for these Tregs in controlling the development of autoimmunity was initially demonstrated by studies where mouse T cell suspensions were transferred into congenic athymic nude mice. If the latter animals received such suspensions depleted of $CD4^+$ $CD25^+$ T cells, they developed an autoimmune syndrome including thyroiditis, gastritis, insulitis, sialoadenitis, adrenalitis, oophoritis, glomerulonephritis, and polyarthritis.[56] By contrast, athymic nude mice that received whole T-cell suspensions did not develop autoimmunity, indicating a role for $CD4^+$ $CD25^+$ T cells in preventing autoimmune diseases.[56] Subsequently, the inhibitory effects of $CD4^+$ $CD25^+$ Tregs in different types of animal models of autoimmune diseases including collagen-induced arthritis (CIA) and autoimmune diabetes were documented.[62,63] Yet, not all $CD4^+$ $CD25^+$ T cells have immunoregulatory functions as CD25 is upregulated upon T-cell activation. Thus, the search for other markers that specifically identify these cells has been extensive, and has led to the identification of CD39, CD103, CTLA-4, glucocorticoid-induced TNF receptor (GITR), lymphocyte activation gene 3 (LAG-3), interleukin 7 receptor, and Foxp3[64,65] as potential markers. The most promising of this group is Foxp3. Disruption of its gene in mice results in autoimmune diseases,[66,67] whereas overexpression of Foxp3 in T cells induces expansion of $CD4^+$ T cells with immunosuppressive function.[66–68] Furthermore, $CD4^+$ $CD25^-$ T cells transfected with FoxP3 acquire immunosuppressive function.[66,67] Although it was originally thought that $FoxP^+$ Tregs develop only in the thymus, studies indicate that $CD25^-$ $CD4^+$ T cells in the periphery can become $FoxP3^+$ Treg-like cells with immune regulatory function in the presence of T-cell receptor triggering, IL-2, and TGF-β.[69] The latter cells are now called adaptive or inducible $FoxP3^+$ Treg ($FOXP3^+$ iTreg) whereas the former cells are called naturally occurring FoxP3 Treg (nTreg).[69]

Although the exact mechanism(s) by which naturally occurring $FoxP3^+$ Tregs suppress autoreactive T cells is not fully understood, cell-to-cell contact is necessary and CTLA-4 appears to be required.[70,71] CTLA-4 expressed on Tregs interacts with CD80 and CD86 expressed on APC as well as on the target T cells[72,73]; while CD80 and CD86, ligands for CTLA-4, are conventionally expressed on APC as noted above, they have also been found on activated $CD4^+$ T cells.[72,73] These molecules likely interact with CTLA-4 expressed on $FoxP3^+$ Treg, providing "outside-in" signaling leading to immune suppression. IL-2 appears to be involved in inducing and maintaining these cells.[71] IL-2 can upregulate FoxP3 expression through activating STAT5.[74,75] Of interest, CD25, the IL-2 receptor α chain, could be involved as a suppressive mechanism of $FoxP3^+$ Tregs by absorbing IL-2 and subsequently reducing the availability of this cytokine to other T cells.[76] These Tregs also express CD39 (ectonucleoside triphosphate diphosphohydrolase 1) and CD73 (ecto-5-nucleotidase). These molecules generate pericellular adenosine with immunosuppressive activity by catalyzing extracellular nucleotides.[77] $FoxP3^+$ Tregs can suppress T cell function by inducing the production of the enzyme indoleamine 2,3-dioxygenase (IDO) from DCs. IDO catabolizes conversion of the essential amino acid tryptophan to kynurenine that is harmful to T cells.[71,78] Overall, FoxP3 Tregs likely employ multiple mechanisms in suppressing other T cell function.

By contrast to animal studies, the data on $CD4^+$ $CD25^+$ Tregs in human autoimmune diseases is relatively minimal. In patients with type 1 DM, a typical example of an organ-specific autoimmune disease, the frequency of $CD4^+$ $CD25^+$ Tregs has been shown to be significantly lower than in healthy controls and patients with type 2 DM, suggesting a role for these cells in disease development.[79] However, in separate studies, no difference in the frequency of $CD4^+$ $CD25^+$ Tregs and *FOXP3* gene allelic variation has been reported in patients with type 1 DM compared to healthy controls,[80,81] although the inhibitory function of such cells was impaired.[81] Similarly, there was no difference in the frequency of $CD4^+$ $CD25^+$ T cells and their functional markers including Foxp3 among patients with APS-II characterized by Addison's disease, type I diabetes and autoimmune thyroid disease as well as control patients with single autoimmune endocrinopathies and normal healthy donors.[82] However, $CD4^+$ $CD25^+$ Tregs from APS-II patients were defective in their suppressive capacity.[82] These findings suggest that patients with autoimmune endocrinopathies including type 1 DM and APS-II may have an alteration in the suppressive function of $CD4^+$ $CD25^+$ Tregs.

A role for $CD4^+$ $CD25^+$ Tregs in the development of SLE and RA, typical systemic autoimmune diseases, has also been explored. Most studies on $CD4^+$ $CD25^+$ Tregs in human lupus reported a decreased frequency of this cell subset,[83] suggesting their potential role in

the development of SLE. In RA, $CD4^+$ $CD25^+$ Tregs from both peripheral blood and synovial fluid have been studied.[84–86] The frequency of $CD25^+$ $CD4^+$ Tregs in the latter fluid was higher than that in peripheral blood,[85,86] although there was no significant difference in the numbers of $CD4^+$ $CD25^+$ Tregs in peripheral blood between patients and controls.[85,86] Of interest, compromised function of $CD4^+$ $CD25^+$ Treg cells in suppressing inflammatory cytokines from $CD4^+$ $CD25^-$ T cells was reported in RA.[87] Furthermore, such impairment was reversed after treating patients with anti-TNF-α therapy. These findings suggest that patients with RA have a functional, but not a numerical, defect in $CD4^+$ $CD25^+$ Tregs.

OTHER REGULATORY T CELLS

In contrast to $CD4^+$ $CD25^+$ Tregs that naturally occur, other regulatory T cells can be induced in vivo and in vitro.[61] These cells include Tr1, Th3 ($CD4^+$ T cells producing large amounts of TGF-β) and $CD8^+$ $CD28^-$ T cells that develop in the setting of immune stimulation such as that initiated by chronic infections. For instance, humans chronically infected with hepatitis C or Epstein Barr viruses, or with *M. tuberculosis* or the nematode *Onchocerca volvulus,* may develop pathogen-specific Tr1 cells that produce large amounts of IL-10 that can suppress antigen-specific or nonspecific T-cell responses.[88–91] These cells can also be generated after ingestion of a foreign antigen via the oral route.[57] The immunosuppressive mechanisms employed by Tr1 and Th3 cells are dependent on IL-10 and TGF-β production rather than direct cell-to-cell contact as in natural Tregs.[61]

$CD8^+$ T cells may also have immunosuppressive activity.[60] Mice deficient in $CD8^+$ T cells develop experimental autoimmune encephalomyelitis (EAE), an animal model of multiple sclerosis.[92] However, EAE in the same animals was milder when they received adoptive transfers of $CD8^+$ $CD28^-$ T cells. Moreover, $CD8^+$ $CD28^-$, but not $CD8^+$ $CD28^+$, T cells suppressed in vitro IFN-γ production by $CD4^+$ T cells specific for myelin oligodendrocyte glycoprotein, an autoantigen in EAE. Such suppression required cell-to-cell contact and was mediated by inhibition of upregulation of costimulatory molecules on APCs that led to decreased costimulation of $CD4^+$ T cells. Of interest, a recent study suggested a potential role for $CD8^+$ T cells with suppressor activity in improving lupus-like disease in mice.[93] Decreased levels of pathogenic anti-dsDNA antibodies with a resultant increase in survival were found in lupus-prone (NZB × NZW)F_1 mice when injected with an artificial peptide called pConsensus (pCons) that was developed based on T cell stimulatory V_H sequences found in (NZB × NZW)F_1 anti-DNA antibodies. This protection depended in part on the generation of peripheral $TGF\beta^-$ and Foxp3-expressing inhibitory $CD8^+$ T cells, and suggested that $CD8^+$ T cells with regulatory activity could be a potential way to modulate autoimmune diseases.

T HELPER 17 (Th17) CELLS

IL-17 (IL-17A), a potent pro-inflammatory cytokine, has an important role in defending the mammalian host against challenge with extracellular bacteria and fungi. IL-17 is made primarily by a unique $CD4^+$ T cell subset called T helper 17 (Th17) cells, although it is also produced by $CD8^+$ and γδ T cells[94–96] as well as by $CD3^+CD4^-CD8^-$ (double negative or DN) T cells and NK cells.[97,98] Cytokines including IL-1β, IL-6, TGF-β, IL-21, and IL-23 are critical for the development and expansion of Th17 cells.[99–102] In fact, studies reported that $CD4^+$ T cells expressing IL-1 receptor I or IL-23 receptor had the strong capacity to produce IL-17.[103,104] The development of Th17 cells is regulated by the transcription factors RORγt (retinoic-acid related orphan receptor) (the human ortholog is RORC), RORα,[105] and IRF4.[106] In addition to IL-17, Th17 cells produce IL-17F, IL-22, and IL-26 as well as chemokine CCL20.[104,107,108] Th17 cells characteristically express CD161, a c-type lectin receptor associated with natural killer cells, as well as chemokine receptors CCR4 and CCR6.[109] These molecules have been used to purify Th17 cells.

IL-17 induces cytokines (IL-6, IL-8, GM-CSF, and G-CSF), chemokines (CXCL1 and CXCL10), and metalloproteinases from target cells including epithelial cells and fibroblasts.[110] IL-17 potently recruits and activates neutrophils through inducing GM-CSF and IL-8 production,[110] leading to neutrophil-mediated inflammatory responses. A potential role for IL-17 in autoimmunity has been demonstrated through mouse studies of EAE and CIA, models for multiple sclerosis and RA, respectively,[111–113] as well as murine lupus models.[114,115] Increased levels of IL-17 in blood and tissues as well as an increased frequency of peripheral Th17 cells were reported in patients with psoriasis, inflammatory bowel disease, and SLE,[97,116–121] suggesting a pathogenic role in human inflammatory diseases. A recent study reported that IL-17 could promote the survival and proliferation of human B cells in conjunction with B-cell activating factor (BAFF).[122] This can be an additional mechanism of how IL-17 promotes inflammatory autoimmune diseases like lupus and MS where autoantibodies have a pathogenic role.

INNATE IMMUNITY AND AUTOIMMUNITY

DENDRITIC CELLS AND TOLL-LIKE RECEPTORS

Various cells of the innate immune system appear to be involved in the regulation of autoimmunity, including DCs, natural killer cells, γδ T cells, natural killer T cells, and even mast cells.[123–128] Among the best characterized are DCs, or professional APCs.[129] DCs present antigens to T cells for their activation, but their requirement to provide costimulation via CD80

and CD86 limits autoreactive T-cell activation in the absence of inflammatory signals. Interaction of CD80 on DCs and CD28 on T cells polarizes TCR-triggered naive T cells into T helper 1 cells producing IFN-γ. In addition, activated DCs produce multiple cytokines including IL-12, TNF-α, and IL-6 that can promote inflammation. DCs express Toll-like receptors (TLRs), or pattern recognition receptors that recognize various pathogen-associated molecular structures including lipopolysaccharide, dsRNA, ssRNA, and hypomethylated cytosine and guanosine sequence (CpG) DNA.[130] Thus, microorganisms can potentially promote autoimmunity and inflammation through these receptors by activating DCs.[129] Activated DC can also affect $CD4^+$ $CD25^+$ Treg function. Microbial activation of TLRs blocks the suppressive effect of $CD4^+$ $CD25^+$ Treg cells, allowing activation of pathogen-specific adaptive immune responses.[131] This block of suppressor activity is dependent in part on interleukin-6, which was induced by TLRs upon recognition of microbial products.

DCs and TLRs are also likely involved in the development of SLE. Rönnblom and Alm have demonstrated that immune complexes in lupus serum containing autoantibodies associated with apoptotic fragments of cells including DNA or RNA can stimulate plasmacytoid DCs (pDCs) to produce interferon-α (IFN-α) with resultant autoimmune inflammation.[5,132] Such events can be mediated by TLRs.[133,134] pDCs express TLR9 that recognize CpG DNA[130]; thus, immune complexes in lupus serum containing CpG DNA and anti-DNA antibodies can stimulate pDC to produce IFN-α, which promotes autoimmunity (see below). This notion is supported by two studies showing that engagement of B cell receptors binding self-Ig (rheumatoid factor) complexes with DNA or DNA per se with their cognate ligand activates B cells by subsequent delivery of the nucleic acid TLR9 in endosomes.[135,136] A similar concept has been raised by recent studies demonstrating the role of TLR7 and TLR8 in cellular responses to ssRNA[137,138] since antibodies against small nuclear RNA and protein complexes are often found in lupus patients.[133,134]

ENVIRONMENTAL FACTORS AND AUTOIMMUNITY

DRUGS AND AUTOIMMUNITY

Certain drugs can induce autoimmune diseases, with potentially protean clinical manifestations.[139] Among the best-known inducers of autoimmunity are procainamide and hydralazine that can lead to drug-induced lupus in a minority of patients who take these agents. Although the exact mechanisms that promote procainamide- and hydralazine-induced lupus are not fully understood, recent studies suggest that alterations in DNA methylation, a process critically involved in gene regulation, by these drugs could be responsible for the development of lupus.[140,141] Procainamide and hydralazine can decrease DNA methylation in T cells, resulting in increased expression of genes such as lymphocyte function-associated antigen (LFA-1) which can potentially promote autoimmunity.[142,143] Evidence from mice also suggests that procainamide may alter central (thymic) tolerance in T-cell selection, leading to escape of autoreactive T cells into the periphery.[144]

INTERFERON-α AND AUTOIMMUNITY

Ironically drugs that modulate the immune system, for example IFN-α, can also induce autoimmunity. In patients treated with IFN-α for hepatitis C or for malignancies, drug-induced lupus with nephritis and antineutrophil cytoplasmic antibodies (c-ANCA)-associated vasculitis have been reported.[133,134,139] In fact, the potential role of IFN-α in the pathogenesis of lupus was suggested in late 1970s by a study reporting increased serum levels of IFN-α in lupus patients.[145] This notion has been recently revived by several groups that have demonstrated increased expression of interferon-induced genes in peripheral blood cells from lupus patients, using microarray analyses.[146,147]

IFN-α can affect innate and adaptive immune cell function. While it has antiproliferative effects on T cells,[148] at the same time it enhances immunoglobulin isotype switching by stimulating DCs.[149] IFN-α also induces maturation of DCs and drives monocytes to become more effective in stimulating T cells, including those that are potentially autoreactive.[150–152] The results of studies in mice also provide evidence for a role of this cytokine in the development of lupus. Administration of poly(inosine-cytosine), a synthetic dsRNA and strong IFN-α inducer, accelerated development of disease in lupus-prone $(NZB \times NZW)F_1$ mice.[153] Lupus-prone mice lacking receptors for type I IFN including IFN-α had reduced anti-dsDNA antibodies and disease activity.[154]

TOXINS AND AUTOIMMUNITY

Environmental chemicals and toxins also have been reported as a potential cause for autoimmune diseases.[155] Probably the best-known chemical is crystalline silica that has been reported to be associated with the development of systemic sclerosis.[155] In addition to this condition, there are patients with SLE and RA who were exposed to crystalline silica,[155] although such epidemiologic data is difficult to provide evidence for causation. On the other hand, lupus-prone $(NZB \times NZW)F_1$ mice exposed to silica have increased levels of antinuclear antibodies, with decreased survival compared to mice not exposed to this chemical.[156] Although the exact mechanism for the development of autoimmune diseases after crystalline silica exposure is unknown, this chemical could serve as an adjuvant promoting immune responses with an increase in the production of proinflammatory cytokines such as

TNF-α.[157] Although there are case reports of autoimmune diseases associated with the exposure to toxic chemicals as well as animals with autoimmune diseases aggravated by such chemicals, additional studies are needed to define the causal relationship between chemical exposure and autoimmunity.

INFECTIONS AND AUTOIMMUNITY

Infection has been suggested as a possible causative factor for autoimmunity. Postulated mechanisms include: (1) release of inflammatory cytokines such as IFN-α by APC that can modulate immune responses; (2) production of cross-reactive antibodies or T cells that can recognize both autoantigens and foreign antigens (molecular mimicry); and (3) polyclonal activation of autoreactive T cells by superantigens.[2] However, these possible mechanisms are not yet proven. Nevertheless, a variety of infectious organisms including virus and bacteria have been linked to autoimmune diseases,[158] including Epstein Barr virus (EBV) as a trigger for SLE. The prevalence of EBV infection as determined by measuring anti-EBV antibodies is higher in patients with SLE compared to healthy controls,[159,160] and patients with SLE have increased EBV viral loads in peripheral blood and altered T-cell immune responses to EBV compared to healthy controls.[161] These findings suggest that the immune control of EBV is altered in SLE although it is not clear whether such an alteration is the cause or the consequence of SLE. Of interest, a recent study showed that EBV-encoded small RNA (EBER) and EBV double-stranded DNA (dsDNA) could induce IFN-α production from human plasmacytoid DC via binding to TLR7 and 9, respectively, suggesting a potential pathologic role for increased viral loads of EBV in human lupus.[162] An intriguing question is why only a small fraction of individuals develop autoimmunity even though infections that may be associated with autoimmunity such as EBV are very common in the population. One likely answer is diversity in the genetic background among individuals, which can lead to different immune responses to the same infectious organisms and possible development of autoimmune diseases.

PATHOGENESIS OF TISSUE DAMAGE IN AUTOIMMUNITY

The mechanisms involved in tissue damages in autoimmune diseases are similar to those that are used in eradicating invading foreign organisms. Autoantibodies can directly bind to autoantigens that are expressed on cells, which results in destruction of cells (type II antibody-mediated hypersensitivity reaction).[2] Autoimmune hemolytic anemia and autoimmune thrombocytopenia, which can be seen in SLE, are good examples of cell destruction by this mechanism.[9] Some autoantibodies can bind autoantigens and activate the complement cascade, which leads to the recruitment of inflammatory cells and subsequent tissue damage (type III immune complex-mediated hypersensitivity reaction).[163] For instance, autoantibodies against chromatin and ribonucleoproteins appear to have a pathogenic role in lupus.[164] The deposition of immune complexes of these autoantibodies with their respective autoantigens in target organs, such as in the kidney, leads to activation of complement and Fc receptor binding with subsequent tissue injury.[165,166] Although autoreactive T cells are required for the development of autoimmune diseases and autoantibodies,[167,168] it is still unclear whether autoreactive T cells are directly involved in damaging tissues in systemic autoimmune syndromes such as SLE, whereas their role in directly promoting tissue injury in organ-specific autoimmune syndromes, such as type 1 DM and multiple sclerosis, are much better established.

KEY REFERENCES

Full reference list available at www.DIGM8.com

DVD contains references and additional content

3. Goodnow CC et al: Cellular and genetic mechanisms of self tolerance and autoimmunity. *Nature* **435**(7042):590-597, 2005
4. Ronnblom L, Alm GV: An etiopathogenic role for the type I IFN system in SLE. *Trends Immunol* **22**(8):427-431, 2001
11. Gregersen PK, Olsson LM: Recent advances in the genetics of autoimmune disease. *Annu Rev Immunol* **27**:363-391, 2009
64. Lan RY et al: Regulatory T cells: Development, function and role in autoimmunity. *Autoimmun Rev* **4**(6):351-363, 2005
71. Sakaguchi S et al: Regulatory T cells: How do they suppress immune responses? *Int Immunol* **21**(10):1105-1111, 2009
102. Chen Z, O'Shea JJ: Th17 cells: A new fate for differentiating helper T cells. *Immunol Res* 41:87-102, 2008
130. Iwasaki A, Medzhitov R: Toll-like receptor control of the adaptive immune responses. *Nat Immunol* **5**(10):987-995, 2004

Chapter 155 :: Lupus Erythematosus

:: Melissa I. Costner &
Richard D. Sontheimer

LUPUS AT A GLANCE

- A group of heterogeneous illnesses that have in common the development of immunity to self-nucleic acids and their associated proteins, with skin-only disease at one end of the spectrum and severe visceral involvement at the other.
- Skin lesions may be specific to lupus or nonspecific and are seen in other conditions as well.
- Acute cutaneous lupus erythematosus (malar rash) is almost always associated with underlying visceral involvement, subacute cutaneous lupus patients meet systemic lupus erythematosus criteria about 50% of the time (but typically express only mild systemic clinical manifestations), and chronic cutaneous lupus (discoid lupus erythematosus, lupus panniculitis, chilblain lupus, and tumid lupus erythematosus) patients most often have skin-only or skin-predominant disease.
- Discoid lupus erythematosus causes scarring and can be permanently disfiguring. Subacute cutaneous lupus and acute cutaneous lupus erythematosus are highly photosensitive and are characteristically nonscarring.
- Lupus erythematosus-nonspecific skin lesions include nonscarring alopecia, mouth ulcers, photosensitivity, Raynaud's phenomenon, and vasculitis/vasculopathy, among others. They often herald a systemic lupus erythematosus flare.
- Treatment consists of sunscreens, local and systemic (short-term) glucocorticoids, antimalarials, retinoids, immunosuppressives, thalidomide, and biologic therapies.
- Lupus erythematosus occurs much more commonly in women (9:1 female-male ratio).
- Both systemic lupus erythematosus and cutaneous lupus erythematosus are associated with upregulation of class I interferon signaling.

LUPUS ERYTHEMATOSUS: A CHALLENGE TO DEFINE, CLASSIFY, AND TREAT

Lupus erythematosus (LE) is the root designation for a diverse array of illnesses that are linked together by the development of autoimmunity directed predominantly at the molecular constituents of nucleosomes and ribonucleoproteins. Some patients present with life-threatening manifestations of systemic LE (SLE); whereas others, who are affected with what likely represents the same basic underlying disease process, express little more than discoid LE (DLE) skin lesions throughout their illness. It is convenient to conceptualize LE as a clinical spectrum ranging from mildly affected patients with only localized DLE skin lesions to those at risk of dying from the systemic manifestations of LE such as nephritis, central nervous system disease, or vasculitis. The pattern of skin involvement expressed by an individual patient with LE can provide insight about the position on the spectrum where the patient's illness might best be placed.

The nomenclature and classification system originally devised by James N. Gilliam divides the cutaneous manifestations of LE into those lesions that show characteristic histologic changes of LE (LE-specific skin disease) and those that are not histopathologically distinct for LE and/or may be seen as a feature of another disease process (LE-nonspecific skin disease). Within this context, the term "LE-specific" relates to those lesions displaying an interface dermatitis. The term *cutaneous LE* (CLE) is often used synonymously with "LE-specific skin disease" as an umbrella designation for the three major categories of LE-specific skin disease: acute cutaneous LE (ACLE), subacute cutaneous LE (SCLE), and chronic cutaneous LE (CCLE). This will be the framework used in our discussion of the extraordinarily diverse set of cutaneous lesions that occur in patients with LE (Table 155-1).

The essence of LE is in its heterogeneity, and the challenge for those who treat it is to recognize clinically useful patterns within the mosaic of features that constitute this protean illness. An overview of the systemic manifestations of LE can be seen in the American College of Rheumatology's (ACR) classification criteria for SLE,[1] which are presented in Table 155-2, and from the outline of the systemic manifestations of SLE presented in Table 155-3.

EPIDEMIOLOGY

The epidemiology and socioeconomic impact of LE in general,[2] and CLE specifically,[3] have been reviewed.

TABLE 155-1
The Gilliam Classification of Skin Lesions Associated with Lupus Erythematosus

LE-Specific Skin Disease [Cutaneous LE (CLE)]	LE-Nonspecific Skin Disease
A. Acute cutaneous LE (ACLE) 1. Localized ACLE (malar rash; butterfly rash) 2. Generalized ACLE (lupus maculopapular lupus rash, SLE rash, rash, photosensitive lupus dermatitis) B. Subacute cutaneous LE (SCLE) 1. Annular SCLE (syn. lupus marginatus, symmetric erythema centrifugum, autoimmune annular erythema, lupus erythematosus gyratus repens) 2. Papulosquamous SCLE (syn. disseminated DLE, subacute disseminated LE, superficial disseminated LE, psoriasiform LE, pityriasiform LE, and maculopapular photosensitive LE) C. Chronic cutaneous LE (CCLE) 1. Classic discoid LE (DLE) a. Localized DLE b. Generalized DLE 2. Hypertrophic/verrucous DLE 3. Lupus profundus/lupus panniculitis 4. Mucosal DLE a. Oral DLE b. Conjunctival DLE 5. Lupus tumidus (urticarial plaque of LE) 6. Chilblain LE (chilblain lupus) 7. Lichenoid DLE (LE/lichen planus overlap, lupus planus)	A. Cutaneous vascular disease 1. Vasculitis a. Leukocytoclastic (1) Palpable purpura (2) Urticarial vasculitis b. Periarteritis nodosa-like cutaneous lesions 2. Vasculopathy a. Degos disease-like lesions b. Secondary atrophie blanche (syn. livedoid vasculitis, livedo vasculitis) 3. Periungual telangiectasia 4. Livedo reticularis 5. Thrombophlebitis 6. Raynaud phenomenon 7. Erythromelalgia (erythermalgia) B. Nonscarring alopecia 1. "Lupus hair" 2. Telogen effluvium 3. Alopecia areata C. Sclerodactyly D. Rheumatoid nodules E. Calcinosis cutis F. LE-nonspecific bullous lesions G. Urticaria H. Papulonodular mucinosis I. Cutis laxa/anetoderma J. Acanthosis nigricans (type B insulin resistance) K. Erythema multiforme L. Leg ulcers M. Lichen planus

LE, lupus erythematosus; SLE, systemic lupus erythematosus.
From Sontheimer RD: The lexicon of cutaneous lupus erythematosus—A review and personal perspective on the nomenclature and classification of the cutaneous manifestations of lupus erythematosus. *Lupus* **6**:84, 1997, with permission from Stockton Journals, Macmillan Press, Ltd.

Skin disease is the second most frequent clinical manifestation of LE after joint inflammation. As many as 45% of patients with CLE experience some degree of vocational handicap. A recent quality of life study suggested that the impact of skin manifestations in patients with SLE was preceded only by pain and fatigue related to their disease.[4] The Dermatology Life Quality Index and SF-36 have been used to measure quality of life in patients with CLE. Both questionnaires showed that patients with active skin lesions had lower quality of life and that patients with associated alopecia were particularly impacted.[5]

Malar, or butterfly rash (localized ACLE), has been reported in 20%–60% of large cohorts of patients with LE. Limited data suggest that the maculopapular or SLE rash of generalized ACLE is present in about 35%–60% of patients with SLE. ACLE, like SLE in general, is much more common in women than men (8:1). All races are affected; however, the early clinical manifestations of ACLE can be overlooked in a dark-skinned individual.

Patients presenting with SCLE lesions constitute 7%–27% of LE patient populations. SCLE is primarily a disease of white females, with the mean age of onset in the fifth decade. Drug-induced SCLE patients are somewhat older at disease onset, perhaps reflecting greater exposure to drugs for age-related medical problems (hypertension, cardiovascular disease).

The most common form of CCLE, a classic DLE skin lesion, is present in 15%–30% of SLE populations selected in various ways. Approximately 5% of patients presenting with isolated localized DLE subsequently develop SLE. Rheumatologists have estimated that SLE patients are sevenfold more common than isolated cutaneous LE patients. However, dermatologists have estimated that isolated cutaneous LE patients may be 2-3 times more common that SLE patients. Recently published population-based data have argued strongly that the incidence and prevalence of isolated forms of cutaneous LE are equivalent to those of SLE.[6] Although DLE can occur in infants and the elderly, it is most common in individuals between 20 and 40 years of age. DLE has a female-male ratio of 3:2 to 3:1, which is much lower than that of SLE. All races are affected, but investigations suggest that DLE might be more prevalent in blacks.

TABLE 155-2
The 1982 Revised Criteria for Classification of Systemic Lupus Erythematosus[a]

Criterion	Definition
1. Malar rash	Fixed erythema, flat or raised, over the malar eminences, tending the spare the nasolabial folds
2. Discoid rash	Erythematous raised patches with adherent keratotic scaling and follicular plugging; atrophic scarring may occur in older lesions
3. Photosensitivity	Skin rash as a result of unusual reaction to sunlight, by patient history or physician observation
4. Oral ulcers	Oral or nasopharyngeal ulceration, usually painless, observed by a physician
5. Arthritis	Nonerosive arthritis involving two or more peripheral joints, characterized by tenderness, swelling, or effusion
6. Serositis	a. Pleuritis—convincing history of pleuritic pain or rub heard by a physician or evidence of pleural effusion *Or* b. Pericarditis—documented by electrocardiogram or rub or evidence of pericardial effusion
7. Renal disorder	a. Persistent proteinuria— >0.5 g/day or greater than 3+ if quantitation not performed *Or* b. Cellular casts—may be red cell, hemoglobin, granular, tubular, or mixed
8. Neurologic disorder	a. Seizures—in the absence of offending drugs or known metabolic derangements (e.g., uremia, ketoacidosis, or electrolyte imbalance) *Or* b. Psychosis—in the absence of offending drugs or known metabolic derangements (e.g., uremia, ketoacidosis, or electrolyte imbalance)
9. Hematologic disorder	a. Hemolytic anemia—with reticulocytosis *Or* b. Leukopenia— <4,000 µL total on two or more occasions *Or* c. Lymphopenia— <1,500/µL on two or more occasions *Or* d. Thrombocytopenia— <100,000 µL in the absence of offending drugs
10. Immunologic disorder	a. Anti-DNA—antibody to native DNA in abnormal titer *Or* b. Anti-Sm—presence of antibody to Sm nuclear antigen *Or* c. Positive finding of antiphospholipid antibodies based on (1) an abnormal serum level of immunoglobulin G or immunoglobulin M anticardiolipin antibodies, (2) a positive test result for lupus anticoagulant using a standard method, or (3) a false-positive serologic test for syphilis known to be positive for at least 6 months and confirmed by *Treponema pallidum* immobilization or fluorescent treponemal antibody absorption test
11. Antinuclear antibody	An abnormal titer of antinuclear antibody by immunofluorescence of an equivalent assay at any point in time and in the absence of drugs known to be associated with "drug-induced lupus" syndrome

[a]The proposed classification is based on 11 criteria. For the purpose of identifying patients in clinical studies, a person shall be said to have systemic lupus erythematosus if any 4 or more of the 11 criteria are present, serially or simultaneously, during any interval or observation.
From Tan EM et al: The 1982 revised criteria for the classification of systemic lupus erythematosus. *Arthritis Rheum* **25**:1271, 1982, copyright 1982, with permission of the American College of Rheumatology.

ETIOLOGY AND PATHOGENESIS

The cause(s) of and pathogenetic mechanisms responsible for LE-specific skin disease are not fully understood, although recent work has provided many new insights. The pathogenesis of LE-specific skin disease is inextricably intertwined with SLE pathogenesis. Simply put, SLE is a disorder in which the interplay between host factors (susceptibility genes, hormonal milieu, etc.) and environmental factors [ultraviolet (UV) radiation, viruses, and drugs] leads to loss of self-tolerance, and induction of autoimmunity. This is followed by activation and expansion of the immune system, and eventuates in immunologic injury to end organs and clinical expression of disease[7] (eFig. 155-0.1 in online edition). Recent work has highlighted the important role of interferon-α signaling in the pathogenesis of both SLE and LE-specific skin disease.

ENVIRONMENTAL FACTORS

Genetic predisposition for a lupus diathesis does not, in itself, produce disease. Rather, it appears that induction of autoimmunity in such patients is triggered by some inciting event, likely an environmental exposure. Drugs, viruses, UV light, and, possibly, tobacco, have been shown to induce development of SLE.

Ultraviolet radiation (UVR) is probably the most important environmental factor in the induction phase of SLE and especially of LE-specific skin disease. UV

TABLE 155-3
Overview of the Extracutaneous Manifestations of Systemic Lupus Erythematosus

- General
  - Fever, fatigue, malaise, weight loss
- Musculoskeletal
  - Symmetric small joint arthralgia, arthritis, (nondeforming and deforming), morning stiffness
  - Myalgia, myositis
  - Tendinitis
  - Avascular (aseptic) bone necrosis
- Hematologic
  - Anemia
    - Normocytic, normochromic
    - Hemolytic
  - Leukopenia
    - Lymphopenia
    - Granulocytopenia
  - Thrombocytopenia
- Cardiopulmonary
  - Pleurisy, pleural effusions, aseptic pneumonitis, pulmonary, hemorrhage
  - Pericarditis, tachycardia, cardiomegaly, congestive heart failure, arrhythmias, conduction defects, coronary arteritis, Libman-Sacks endocarditis
- Renal
  - Mesangial glomerulitis (WHO class II)
    - Mild proteinuria
  - Focal proliferative glomerulonephritis (WHO class III)
    - Proteinuria, hematuria, occasionally nephrotic syndrome, hypertension
  - Diffuse proliferative glomerulonephritis (WHO class IV)
    - Proteinuria, hematuria, red cell casts, renal insufficiency, nephrotic syndrome, hypertension
  - Membranous glomerulonephritis (WHO class V)
    - Severe proteinuria, nephrotic syndrome
- Neuropsychiatric
  - Peripheral neuropathy, transverse myelitis, Guillain-Barré syndrome
  - Chorea, choreoathetosis
  - Seizures
  - Headaches (severe, migraine-like)
  - Brain infarcts secondary to cerebral arteritis
  - Organic brain syndrome
    - Psychosis due to diffuse cerebritis
  - Psychological
    - Depression
- Gastrointestinal
  - Anorexia, nausea, vomiting, abdominal pain
  - Bowel infarction/perforation secondary to mesenteric vasculitis
  - Pancreatitis
  - Peritonitis, ascites
  - Hepatomegaly, chronic active hepatitis
- Ocular
  - Conjunctivitis, episcleritis
  - Blindness secondary to central retinal artery occlusion
  - Cytoid bodies
  - Keratoconjunctivitis sicca
- Lymphatic system
  - Lymphadenopathy
  - Splenomegaly

WHO = World Health Organization.

light likely leads to self-immunity and loss of tolerance because it causes apoptosis of keratinocytes, which in turn, makes previously cryptic peptides available for immunosurveillance. UVB radiation has been shown to displace autoantigens such as Ro/SS-A and related autoantigens, La/SS-B, and calreticulin, from their normal locations inside epidermal keratinocytes to the cell surface.[13] UVB irradiation induces the release of CCL27 (cutaneous T cell-attracting chemokine), which upregulates the expression of chemokines that activate autoreactive T cells and interferon-α (IFN-α), producing dendritic cells (DCs), which likely play a central role in lupus pathogenesis.[14,15]

A recent, large, case-control study reported that smokers are at a greater risk of developing SLE than are nonsmokers and former smokers. A cross-sectional analysis of a collaborative Web-based database established by Werth and colleagues documented that patients with treatment resistant CLE were much more likely to smoke.[16] Several authors have shown that patients with LE-specific skin disease who smoke are less responsive to antimalarial treatment.[17–19]

Numerous drugs have been implicated in inducing various features of SLE (Table 155-3). The drugs that induce CLE can be linked by their photosensitizing properties. It has been suggested that these drugs cause an increase in keratinocyte apoptosis, exposure of previously intracellular peptides on epidermal cell surfaces, and enhance proinflammatory cytokines such as TNF-α and IFN-α.[20,21]

There has been much speculation about the role of infectious agents, particularly viruses, in the induction of SLE and CLE. Seroconversion to Epstein-Barr virus (EBV) among patients with SLE is nearly universal, and recent data have demonstrated that patients with SLE have defective control of latent EBV infection that probably stems from altered T-cell responses against EBV.

CLINICAL FINDINGS

(eFig. 155-0.2 in online edition)

CUTANEOUS LESIONS

eTable 155-3.1 in online edition compares the key clinical, histopathologic, and laboratory features of patients presenting with ACLE, SCLE, and CCLE (classic DLE)



Figure 155-1 Localized acute cutaneous lupus erythematosus. Erythematous, slightly edematous, sharply demarcated erythema is seen on the malar areas in a "butterfly" distribution.

skin lesions. It is important to distinguish among the subtypes of LE-specific skin disease, because the type of skin involvement in LE can reflect the underlying pattern of SLE activity. In fact, the designations acute, subacute, and chronic, in regard to CLE, refer to the pace and severity of any associated SLE and are not necessarily related to how long individual lesions have been present. For example, ACLE almost always occurs in the setting of acutely flaring SLE, whereas CCLE often occurs in the absence of SLE or in the presence of mild smoldering SLE. SCLE occupies an intermediate position in this clinical spectrum. Subclassification, although important for assigning risk, is sometimes difficult, as it is not uncommon to see more than one subtype of LE-specific skin disease in the same patient, especially in patients with SLE.

ACUTE CUTANEOUS LUPUS ERYTHEMATOSUS. Although ACLE localized to the face is the usual pattern of presentation, ACLE can assume a generalized distribution. Localized ACLE has commonly been referred to as the *classic butterfly rash* or *malar rash of SLE* (Fig. 155-1). In localized ACLE, confluent symmetric erythema and edema are centered over the malar eminences and bridges over the nose (unilateral involvement with ACLE has been described). The nasolabial folds are characteristically spared. The forehead, chin, and V area of the neck can be involved, and severe facial swelling may occur. Occasionally, ACLE begins as small macules and/or papules on the face that later may become confluent and hyperkeratotic. Generalized ACLE presents as a widespread morbilliform or exanthematous eruption often focused over the extensor aspects of the arms and hands and characteristically sparing the knuckles (Fig. 155-2A). Although perivascular nail fold erythema and telangiectasia can occur (see Fig. 155-2B), they are considerably more common and occur in more exaggerated forms in dermatomyositis (see Fig. 157-5). Generalized ACLE has been indiscriminately referred to as the *maculopapular rash of SLE*, *photosensitive lupus dermatitis*, and *SLE rash*. An extremely acute form of ACLE is rarely seen that can simulate toxic epidermal necrolysis (TEN). This form of LE-specific vesiculobullous disease results from widespread apoptosis of epidermal keratinocytes, and eventuates in areas of full-thickness epidermal skin necrosis, which is subsequently denuded. It can be differentiated between true TEN because it



Figure 155-2 Generalized acute cutaneous lupus erythematosus. **A.** Well-demarcated patches of erythema with fine overlying scale on the dorsal aspect of the hands, fingers, and periungual areas. Note the characteristic sparing of the knuckles, which are preferentially involved in dermatomyositis. **B.** Closeup view of periungual erythema and grossly visible telangiectasia. Although these lesions can be seen in lupus erythematosus, they are more typical of dermatomyositis.



Figure 155-3 Subacute cutaneous lupus erythematosus (SCLE). **A.** Annular SCLE on the upper back of a 38-year-old woman. Note the central areas of hypopigmentation in which no dermal atrophy is present. **B.** Papulosquamous SCLE over the extensor aspect of the forearm of a 26-year-old woman.

occurs on predominantly sun-exposed skin and has a more insidious onset.[30] The mucosa may or may not be involved, as in TEN.

ACLE is typically precipitated or exacerbated by exposure to UV light. This form of CLE can be quite ephemeral, lasting only hours, days, or weeks; however, some patients experience more prolonged periods of activity. Postinflammatory pigmentary change is most prominent in patients with heavily pigmented skin. Scarring does not occur in ACLE unless the process is complicated by secondary bacterial infection.

SUBACUTE CUTANEOUS LUPUS ERYTHEMATOSUS. A disease presentation dominated by SCLE lesions marks the presence of a distinct subset of LE having characteristic clinical, serologic, and genetic features. Although a finding of circulating autoantibodies to the Ro/SS-A ribonucleoprotein particle strongly supports a diagnosis of SCLE, the presence of this autoantibody specificity is not required to make a diagnosis of SCLE.

SCLE initially presents as erythematous macules and/or papules that evolve into hyperkeratotic papulosquamous or annular/polycyclic plaques (Fig. 155-3). Whereas most patients have either annular or papulosquamous SCLE, a few develop elements of both morphologic varieties. SCLE lesions are characteristically photosensitive and occur in predominantly sun-exposed areas (i.e., upper back, shoulders, extensor aspects of the arms, V area of the neck, and, less commonly, the face). SCLE lesions typically heal without scarring but can resolve with long-lasting, if not permanent, vitiligo-like leukoderma, and telangiectasias.

Several variants of SCLE have been described. On occasion, SCLE lesions present initially with an appearance of erythema multiforme. Such cases are similar to Rowell syndrome (erythema multiforme-like lesions occurring in patients with SLE in the presence of La/SS-B autoantibodies). As a result of intense injury to epidermal basal cells, the active edge of an annular SCLE lesion occasionally undergoes a vesiculobullous change that can subsequently produce a strikingly crusted appearance. Such lesions can mimic Stevens-Johnson syndrome/TEN. Pathogenesis is similar to that described above for TEN-like ACLE. Rarely, SCLE presents with exfoliative erythroderma or displays a curious acral distribution of annular lesions. Pityriasiform and exanthematous variants of SCLE have been reported. The skin lesions of neonatal LE (transient, photosensitive, nonscarring LE-specific skin lesions in neonates who have received IgG anti-Ro/SS-A, and, occasionally, other autoantibody specificities transplacentally) share many features with SCLE.

Unlike ACLE skin lesions, SCLE lesions tend to be less transient than ACLE lesions and heal with more pigmentary change. They are also less edematous and more hyperkeratotic than ACLE lesions. SCLE more commonly involves the neck, shoulders, upper extremities, and trunk, whereas ACLE more commonly affects the malar areas of the face. When the face is involved with SCLE, it is most often the lateral face, with sparing of the central, malar regions. In comparison to SCLE lesions, DLE lesions are generally associated with a greater degree of hyper- and hypopigmentation, atrophic dermal scarring, follicular plugging, and adherent scale. A consistent clinical difference is that DLE lesions are characteristically indurated, whereas SCLE lesions are not; this difference reflects the greater depth of inflammation seen histopathologically in DLE lesions.

Approximately one-half of patients with SCLE meet the ACR's revised criteria for the classification of SLE. However, manifestations of severe SLE, such as nephritis, central nervous system disease, and systemic vasculitis, develop in only 10%–15% of patients with SCLE. It has been suggested that the papulosquamous type of SCLE, leu-kopenia, high titer of antinuclear antibody (ANA) (>1:640), and anti-dsDNA antibodies are risk factors for the development of SLE in a patient presenting with SCLE lesions.

SCLE can overlap with other autoimmune diseases, including Sjögren's syndrome, rheumatoid arthritis, and Hashimoto's thyroiditis. Other disorders that have been anecdotally related to SCLE are Sweet syndrome, porphyria cutanea tarda, gluten-sensitive enteropathy, and Crohn's disease. There has also been the suggestion that SCLE can be associated with internal malignancy (breast, lung, gastric, uterine, hepatocellular, and laryngeal carcinomas as well as with Hodgkin lymphoma).[31]

CHRONIC CUTANEOUS LUPUS ERYTHEMATOSUS

Classic DLE. Classic DLE lesions, the most common form of CCLE, begin as red-purple macules, papules, or small plaques and rapidly develop a hyperkeratotic surface. Early classic DLE lesions typically evolve into sharply demarcated, coin-shaped (i.e., discoid) erythematous plaques covered by a prominent, adherent scale that extends into the orifices of dilated hair follicles (Fig. 155-4).

DLE lesions typically expand with erythema and hyperpigmentation at the periphery, leaving hallmark atrophic central scarring, telangiectasia, and hypopigmentation (Fig. 155-5). DLE lesions at this stage can merge to form large, confluent, disfiguring plaques. DLE in persons of certain ethnic backgrounds, such as Asian Indians, can present clinically as isolated areas of macular hyperpigmentation. When present on hair-bearing skin (scalp, eyelid margins, and eyebrows), DLE causes scarring alopecia, which can lead to disfigurement and markedly impact quality of life. Follicular involvement in DLE is a prominent feature. Keratotic plugs accumulate in dilated follicles that soon become devoid of hair. When the adherent scale is lifted from more advanced lesions, keratotic spikes similar in appearance to carpet tacks can be seen to project from the undersurface of the scale (i.e., the "carpet tack" sign). DLE lesions can be difficult to diagnose in Caucasian patients because the characteristic peripheral hyperpigmentation is often absent. Such lesions are often confused with actinic keratoses, squamous cell carcinoma, or acne.

DLE lesions are most frequently encountered on the face, scalp, ears, V area of the neck, and extensor aspects of the arms. Any area of the face, including the eyebrows, eyelids, nose, and lips, can be affected. A symmetric, hyperkeratotic, butterfly-shaped DLE plaque is occasionally found over the malar areas of the face and bridge of the nose. Such lesions should not be confused with the more transient, edematous, minimally scaling ACLE erythema reactions that occur in the same areas. Facial DLE, like ACLE and SCLE, usually spares the nasolabial folds. It may be difficult to distinguish early lesions of malar DLE from ACLE, but induration and recalcitrance to topical steroids/calcineurin inhibitors favors the former diagnosis. When DLE lesions occur periorally, they resolve with a striking acneiform pattern of pitted scarring. DLE characteristically affects the external ear, including the outer portion of the external auditory canal (Fig. 155-6A). Such lesions often present



Figure 155-4 Classic discoid lupus erythematosus. Typical early erythematous plaque on the forehead demonstrating hyperkeratosis and accentuation of follicle orifices in a 60-year-old man with a 25-year history of cutaneous lupus erythematosus. The lesion had been present for 3 months; no dermal atrophy was present at this stage.



Figure 155-5 Classic discoid lupus erythematosus. Sharply demarcated, round-to-ovoid slightly indurated, erythematous plaques on the neck and face. Most plaques show a mild degree of hyperkeratosis, and some show dermal atrophy. Noninflamed areas of hypopigmentation and scarring mark the sites of prior lesions that have resolved.

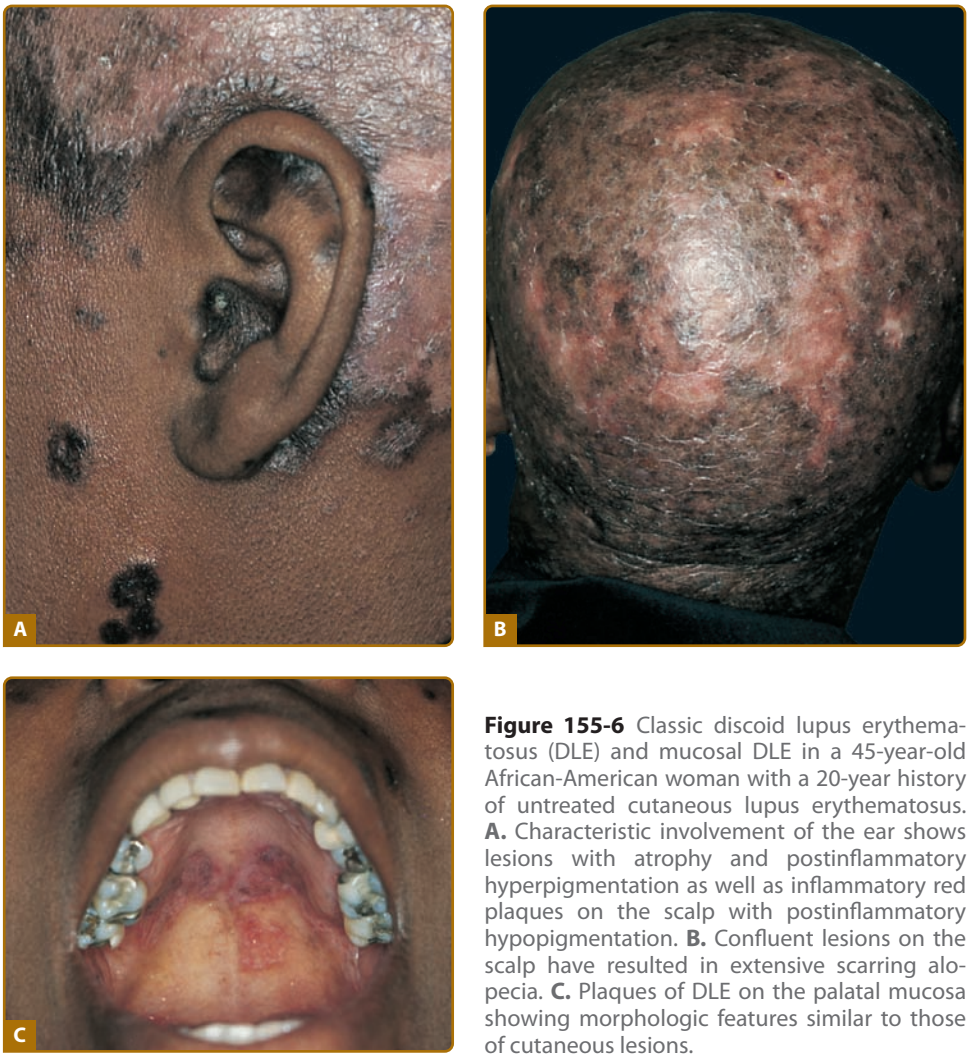

Figure 155-6 Classic discoid lupus erythematosus (DLE) and mucosal DLE in a 45-year-old African-American woman with a 20-year history of untreated cutaneous lupus erythematosus. **A.** Characteristic involvement of the ear shows lesions with atrophy and postinflammatory hyperpigmentation as well as inflammatory red plaques on the scalp with postinflammatory hypopigmentation. **B.** Confluent lesions on the scalp have resulted in extensive scarring alopecia. **C.** Plaques of DLE on the palatal mucosa showing morphologic features similar to those of cutaneous lesions.

initially as dilated, hyperpigmented follicles. The scalp is involved in 60% of patients with DLE; irreversible, scarring alopecia resulting from such involvement has been reported in one-third of patients (see Fig. 155-6B). The irreversible, scarring alopecia resulting from DLE differs from the reversible, nonscarring alopecia that patients with SLE often develop during periods of systemic disease activity. This type of hair loss, so-called *lupus hair*, may be telogen effluvium occurring as the result of flaring systemic disease.

Localized DLE lesions occur only on the head or neck, whereas *generalized DLE* lesions occur both above and below the neck. Generalized DLE is more commonly associated with underlying SLE and is often more recalcitrant to standard therapy, frequently requiring layering of antimalarial and immunosuppressive medications. DLE lesions below the neck most commonly occur on the extensor aspects of the arms, forearms, and hands, although they can occur at virtually any site on the body. The palms and soles can be the sites of painful, and at times disabling, erosive DLE lesions. On occasion, small DLE lesions occurring only around follicular orifices appear at the elbow and elsewhere (follicular DLE). We have observed that elbow/extensor arm lesions seem to cooccur with acral finger lesions of DLE, and that patients with this combination of findings more frequently have active systemic disease. DLE activity can localize to the nail unit. The nail can be impacted by other forms of CLE as well as SLE, producing nail fold erythema and telangiectasia, red lunulae, clubbing, paronychia, pitting, leukonychia striata, and onycholysis.

DLE lesions can be potentiated by sunlight exposure but to a lesser extent than ACLE and SCLE lesions. DLE, as well as other forms of LE skin disease activity, can be precipitated by any form of cutaneous trauma (i.e., the Koebner phenomenon or isomorphic effect).

The relationship between classic DLE and SLE has been the subject of much debate.[32] The following summary points can be made: (1) 5% of patients presenting with classic DLE lesions subsequently develop unequivocal evidence of SLE and (2) patients with generalized DLE (i.e., lesions both above and below the neck) have somewhat higher rates of immunologic abnormalities, a higher risk for progressing to SLE, and a higher risk for developing more severe manifestations of SLE than patients with localized DLE.

Roughly one-fourth of patients with SLE develop DLE lesions at some point in the course of their

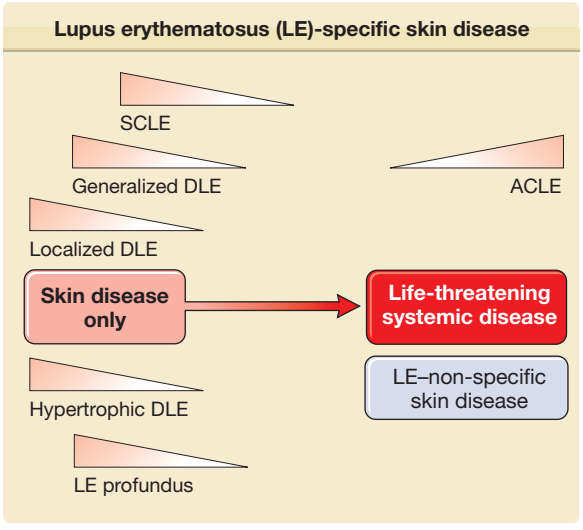

Figure 155-7 Relative risk for coexistence of or progression to systemic lupus erythematosus in patients presenting with various forms of lupus erythematosus (LE)-specific skin disease. The spectrum of LE is depicted as a disease continuum ranging from skin disease alone to life-threatening systemic disease. ACLE = acute cutaneous lupus erythematosus; DLE = discoid lupus erythematosus; SCLE = subacute cutaneous lupus erythematosus.

disease, and such patients tend to have less severe forms of SLE. Figure 155-7 illustrates the relative risks for systemic disease activity that are associated with the clinical varieties of LE-specific skin disease.

Aside from Classic DLE, there are several other less common variants of CCLE, which are subclasssified as such because of their overlapping histologies and tendency to occur in a low frequency in association with underlying SLE.

Hypertrophic DLE. Hypertrophic DLE, also referred to as *hyperkeratotic* or *verrucous DLE,* is a rare variant of CCLE in which the hyperkeratosis normally found in classic DLE lesions is greatly exaggerated. The extensor aspects of the arms, the upper back, and the face are the areas most frequently affected. Overlapping features of hypertrophic LE and lichen planus have been described under the rubric *lupus planus.* The entity *lupus erythematosus hypertrophicus et profundus* appears to represent a rare form of hypertrophic DLE, affecting the face with the additional features of violaceous/dull red, indurated, rolled borders and striking central, crateriform atrophy. The name for this clinical entity is ambiguous because LE panniculitis is not characteristic of its histopathology. Patients with hypertrophic DLE probably do not have a greater risk for developing SLE than do patients with classic DLE lesions.

Mucosal DLE. Mucosal DLE occurs in approximately 25% of patients with CCLE. The oral mucosa is most frequently affected; however, nasal, conjunctival, and genital mucosal surfaces can be targeted. In the mouth, the buccal mucosal surfaces are most commonly involved, with the palate (see Fig. 155-6C), alveolar processes, and tongue being sites of less frequent involvement. Lesions begin as painless, erythematous patches that evolve to chronic plaques that can be confused with lichen planus. Chronic buccal mucosal plaques are sharply marginated and have irregularly scalloped, white borders with radiating white striae and telangiectasia. The surfaces of these plaques overlying the palatal mucosa often have a honeycomb appearance. Central depression often occurs in older lesions, and painful ulceration can develop. Rarely, oral mucosal DLE lesions can degenerate into squamous cell carcinoma, similar to longstanding cutaneous DLE lesions. Any degree of nodular asymmetry within a mucosal DLE lesion should be evaluated for the possibility of malignant degeneration. Chronic DLE plaques also appear on the vermilion border of the lips. At times, DLE involvement of the lips can present as a diffuse cheilitis, especially on the more sun-exposed lower lip.

DLE lesions may present on the nasal, conjunctival, and anogenital mucosa. Perforation of the nasal septum is more often associated with SLE than DLE. Conjunctival DLE lesions affect the lower lid more often than the upper lid. Lesions begin as focal areas of nondescript inflammation most commonly affecting the palpebral conjunctivae or the lid margin. Scarring becomes evident as lesions mature, and the permanent loss of eyelashes and ectropion can develop, producing considerable disability.

LE Profundus/LE Panniculitis. LE profundus/LE panniculitis (Kaposi-Irgang disease) is a rare form of CCLE typified by inflammatory lesions in the lower dermis and subcutaneous tissue. Approximately 70% of patients with this type of CCLE also have typical DLE lesions, often overlying the panniculitis lesions. Some have used the term *LE profundus* to designate those patients who have both LE panniculitis and DLE lesions, and *LE panniculitis* to refer to those having only subcutaneous involvement. Typical subcutaneous lesions present as firm nodules, 1–3 cm in diameter. The overlying skin often becomes attached to the subcutaneous nodules and is drawn inward to produce deep, saucerized depressions (Fig. 155-8). The head,



Figure 155-8 Lupus erythematosus panniculitis. Lupus panniculitis has resulted in large, sunken areas of overlying skin; erythema and atrophy of the skin are present.

proximal upper arms, chest, back, breasts, buttocks, and thighs are the sites frequently affected. LE panniculitis, in the absence of overlying DLE, may produce breast nodules that can mimic carcinoma clinically and radiologically (lupus mastitis). Confluent facial involvement can simulate the appearance of lipoatrophy. Dystrophic calcification frequently occurs in older lesions of LE profundus/LE panniculitis, and pain associated with such calcification can, at times, be the dominant clinical problem. Roughly 50% of patients with LE profundus/panniculitis have evidence of SLE. However, the systemic features of patients with LE panniculitis/profundus tend to be less severe, similar to those of patients with SLE who have DLE skin lesions.

Chilblain LE. Chilblain LE lesions initially develop as purple-red patches, papules, and plaques on the toes, fingers, and face, which are precipitated by cold, damp climates and are clinically and histologically similar to idiopathic chilblains (pernio) (see Chapter 94). As they evolve, these lesions usually assume the appearance of scarred atrophic plaques with associated telangiectases. They may resemble old lesions of DLE or may mimic acral lesions of small vessel vasculitis. Histologic findings include a superficial and deep lymphocytic vascular reaction in addition to fibrin deposition in reticular, dermal-based blood vessels. Patients with chilblain LE often have typical DLE lesions on the face and head. It is possible that chilblain LE begins as a classic acral, cold-induced lesion that then koebnerizes DLE lesions, thus explaining the spectrum of clinico-histologic findings, which seem to vary based on when, in the course of the lesion, the biopsy sample is taken.

Chilblain LE appears to be associated with anti-Ro/SS-A antibodies,[33] and is linked to Raynaud's phenomenon in many cases.[34] Persistence of lesions beyond the cold months, a positive ANA, or presence of one of the other ACR criteria for SLE at the time of diagnosis of chilblain lesions helps to distinguish chilblain LE from idiopathic chilblains.[35] Approximately 20% of patients presenting with chilblain LE later develop SLE. Chilblain LE is an underrecognized entity, yet it is likely that it is one of the most common causes of digital lesions in patients with LE. It is sometimes misdiagnosed as vasculitis and may overlap with acral DLE as mentioned above. An autosomal dominant, familial form of Chilbalin LE has recently been described, and is caused by a missense mutation in the *TREX 1* (endonuclease repair) gene.[36]

Lupus Erythematosus Tumidus. Lupus erythematosus tumidus (LET; tumid LE) is a variant of CCLE in which the dermal findings of DLE, namely, excessive mucin deposition and superficial perivascular and periadnexal inflammation, are found on histologic evaluation. The characteristic epidermal histologic changes of LE-specific skin disease are only minimally expressed, if at all. This results in succulent, edematous, urticaria-like plaques with little surface change (Fig. 155-9). Annular urticaria-like plaques can also be seen. The paucity of epidermal change often produces confusion concerning the diagnosis of LET as a form of CCLE.[37,38]



Figure 155-9 Lupus erythematosus tumidus. Note succulent, indurated plaques.

There have been several recent reports that support this subclassification and further characterize this subtype of CCLE.[39–44] Although described to occur in some patients with SLE, most patients with LET have a negative ANA and a benign disease course. LET appears to be the most photosensitive subtype of cutaneous lupus, and typically demonstrates a good response to antimalarials. Additionaly, LET lesions tend to resolve completely without either scarring or atrophy.

There continues to be debate about the validity of LET as an authentic form of LE-skin disease. Some argue that LET lesions may in fact not be a form of CLE[45] while others feel that LET deserves to be recognized as a distinct type of CLE (intermittent cutaneous LE) equivalent in importance to acute cutaneous LE, subacute cutaneous LE, and chronic cutaneous LE.[46]

Other Variants. Other rare forms of chronic cutaneous LE have been described. These include LE hypertrophicus et profundus, lichenoid DLE, LE vermiculatus, LE telangiectaticus, linear CLE, and LE edematous (probably a historical designation for urticaria-like plaque DLE. Further information on these clinical entities has recently been presented.[47]

LABORATORY TESTS

eTable 155-3.1 in online edition summarizes the major laboratory findings associated with the varieties of LE-specific skin disease, and Table 155-5 presents the autoantibody associations of SLE. Because of the strong association between ACLE and SLE, the laboratory features of ACLE are those associated with SLE (high-titer ANA, anti-dsDNA, anti-Sm, and hypocomplementemia).

The laboratory markers for SCLE are the presence of anti-Ro/SS-A (70%–90%) and, less commonly, anti-La/SS-B (30%–50%) autoantibodies. ANA are present in 60%–80% of patients with SCLE, and rheumatoid factor is present in approximately one-third. Other autoantibodies in patients with SCLE include false-positive serologic tests for syphilis (VDRL rapid plasma reagin) (7%–33%), anticardiolipin (10%–16%),

TABLE 155-4
Causes of Drug-Induced Lupus

Drug-induced SCLE
ACE inhibitors
Phenytoin
Hydroxychloroquine
Griseofulvin
Terbinafine
Tetracycline
Beta blockers
Calcium Channel Blockers
Tamoxifen
Docetaxel
Paclitaxel
Anastrozole
NSAIDS
Thiazide diuretics
Buproprion
Leflunomide
Proton Pump inhibitors
Anti-TNF biologics
Interferon-α
Drug-induced SLE (typically without skin involvement)
Hydralazine
Isoniazid
Antihyperlipidemic agents
Minocycline
Procainamide
Anti-TNF biologics

antithyroid (18%–44%), anti-Sm (10%), anti-ds-DNA (10%), and anti-U1 ribonucleoprotein (10%). Patients with SCLE, particularly those with systemic involvement, may have a number of laboratory abnormalities, including anemia, leukopenia, thrombocytopenia, elevated erythrocyte sedimentation rate, hypergammaglobulinemia, proteinuria, hematuria, urine casts, elevated serum creatine and blood urea nitrogen, and depressed complement levels (resulting from genetic deficiency or increased complement consumption).

ANA are present in low titer in 30%–40% of patients with DLE; however, fewer than 5% have the higher ANA levels that are characteristic of patients with overt SLE (>1:320). Antibodies to single-stranded DNA are not uncommon in DLE, but antibodies to dsDNA are distinctly uncommon. Precipitating antibodies to U1RNP are sometimes found in patients whose disease course is dominated by DLE lesions; however, such patients usually have only mild manifestations of SLE or overlapping connective tissue disorders such as mixed connective tissue disease. Precipitating Ro/SS-A and La/SS-B autoantibodies are rare in patients with DLE; low levels of anti-Ro/SS-A antibody detected by enzyme-linked immunoassay are more common. A small percentage of patients with DLE have low-grade anemia, biologic false-positive serologic tests for syphilis (VDRL rapid plasma reagent), positive rheumatoid factor tests, slight depressions in serum complement levels, modest elevations in γ globulin, and modest leukopenia. It has been suggested that such findings

TABLE 155-5
Autoantibodies Associated with Unselected Systemic Lupus Erythematosus

	Autoantibody Frequency (%)			
Antigen	**ID**	**SPA/RIA**	**Molecular Specificity**	**Clinical Association**
High disease specificity for SLE				
dsDNA		60	Native DNA	LE nephritis
Sm	25		Ribonucleoprotein	—
rRNP	10		Ribosomal P protein	CNS LE
PCNA	3		Cyclin	—
Low disease specificity for SLE				
ssDNA		60	Denatured DNA	Risk for SLE in patients with DLE
Histones		50	Histones	Drug-induced SLE
U1RNP	25		Ribonucleoprotein	Overlap CTD (MCTD)
Ro/SS-A	25	50	Ribonucleoprotein	SLCE, SSj, neonatal LE
La/SS-B	10	20	Ribonucleoprotein	SSj, SCLE
Ku	10		Transcription factor	Overlap CTD

CNS = central nervous system; CTD = connective tissue disease; DLE = discoid lupus erythematosus; dsDNA = doubled-stranded DNA; ID = immunodiffusion; MCTD = mixed CTD; PCNA = proliferating cell nuclear antigen; RIA = radioimmunoassay; RNP = ribonucleoprotein; SCLE = subacute cutaneous lupus erythematosus; SLE = systemic lupus erythematosus; SPA = solid phase immunoassay (i.e., enzyme-linked immunoassay); ssDNA = single-stranded DNA; SSj = Sjögren syndrome.

Reprinted from Sontheimer RD, Provost TT: Lupus erythematosus. In: *Cutaneous Manifestations of Rheumatic Diseases*, edited by Sontheimer RD, Provost TT. Baltimore, Lippincott Williams & Wilkins, 1996, with permission from Lippincott Williams & Wilkins Publishers.

are risk factors for the development of SLE. ANA are present in 70%–75% of patients with LE profundus/panniculitis, but anti-dsDNA antibodies are rare.

The laboratory findings associated with SLE, as well as with CLE, in both adults and newborns, have been reviewed.[71,72]

HISTOPATHOLOGY

The LE-specific skin disease histopathology is a distinctive constellation of hyperkeratosis, epidermal atrophy, vacuolar basal cell degeneration, dermal-epidermal junction basement membrane thickening, dermal edema, dermal mucin deposition, and mononuclear cell infiltration of the dermal-epidermal junction and dermis, focused in a perivascular and periappendageal distribution (eFig. 155-9.1 in online edition). Variable degrees of these features are encountered in the different forms of LE-specific skin disease (see Chapter 6). Differences of opinion exist as to whether ACLE, SCLE, and DLE lesions can be distinguished reliably on the basis of their histopathologic appearances alone.[72–74]

ACUTE CUTANEOUS LUPUS ERYTHEMATOSUS

The histopathologic changes in ACLE lesions are generally less impressive than those in SCLE and DLE lesions, and are mainly those of a cell-poor interface dermatitis. The lymphohistiocytic cellular infiltrate is relatively sparse. Some authors have noted an increase in the number of neutrophils in the infiltrate. A mild degree of focal vacuolar alteration of basal keratinocytes can be seen, in addition to telangiectases and extravasation of erythrocytes. One may see individually necrotic keratinocytes, and in its most severe form, ACLE can display extensive epidermal necrosis similar to TEN. The upper dermis usually shows pronounced mucinosis and may be very helpful in distinguishing ACLE from other causes of a cell-poor interface dermatitis. It is uncommon to see basement membrane zone thickening, follicular plugging, or alteration of epidermal thickness in ACLE, although epidermal atrophy is sometimes present.[73,74]

SUBACUTE CUTANEOUS LUPUS ERYTHEMATOSUS

SCLE also frequently presents as an interface dermatitis, with foci of vacuolar alteration of basal keratinocytes alternating with areas of lichenoid dermatitis. Pronounced epidermal atrophy is often present. SCLE is in the differential diagnosis of atrophic lichenoid dermatitis, along with atrophic lichen planus and lichenoid drug eruptions. Dermal changes include edema, prominent mucin deposition, and sparse mononuclear cell infiltration usually limited to areas around blood vessels and periadnexal structures in the upper one-third of the dermis. Lesser degrees of hyperkeratosis, follicular plugging, mononuclear cell infiltration of adnexal structures, and dermal melanophages might help distinguish SCLE lesions from DLE lesions. It has not been possible to differentiate papulosquamous from annular SCLE by histopathologic criteria alone.[72]

CHRONIC CUTANEOUS LUPUS ERYTHEMATOSUS

In classic DLE lesions, epidermal changes include hyperkeratosis, variable atrophy, and interface changes similar to those described for SCLE. The epidermal basement membrane is markedly thickened. Dermal changes include a dense mononuclear cell infiltrate composed primarily of CD4 T lymphocytes and macrophages predominantly in the periappendageal and perivascular areas, melanophages, and dermal mucin deposition. The infiltrate is often quite dense and typically extends well into the deeper reticular dermis and/or subcutis, which may help to distinguish it from ACLE or SCLE. In chronic scarring DLE lesions, the dense inflammatory cell infiltrate subsides and is replaced by dermal fibroplasia. A folliculotropic variant of DLE, in which the inflammatory infiltrate is predominantly around hair follicles, has been described, as have lymphomatoid variants, in which there are extremely dense infiltrates that may contain atypical lymphoid cells.[73]

IMMUNOHISTOLOGY

Immunohistology is often helpful in confirming a diagnosis of LE-specific skin disease and has been shown to boost the sensitivity and specificity of diagnosis.[73] Because it is not uncommon to see negative immunofluorescence studies in patients with acute, subacute, and chronic LE, and false-positive studies in healthy individuals, immunohistology must be interpreted in the context of clinical and histologic findings in a given patient.

IgG, IgA, IgM, and complement components (C3, C4, Clq, properdin, factor B, and the membrane attack complex C5b-C9) deposited in a continuous granular or linear band-like array at the dermal-epidermal junction have been observed in the lesional and nonlesional skin of patients with LE since the early 1960s (Fig. 155-10). However, debate about terminology in this area continues to cloud the field. Some restrict the use of the term *lupus band test* to refer to the examination of nonlesional skin biopsies for the presence of this band-like array of immunoreactants at the dermal-epidermal junction. Others qualify the LBT as being either "lesional" or "nonlesional." Less confusion might exist if the terms *lesional LBT* (lesional lupus band) and *nonlesional LBT* (nonlesional lupus band) were uniformly adopted.

ACUTE CUTANEOUS LUPUS ERYTHEMATOSUS

The sparse data that exist suggest that 60%–100% of ACLE lesions display a lesional lupus band. However,

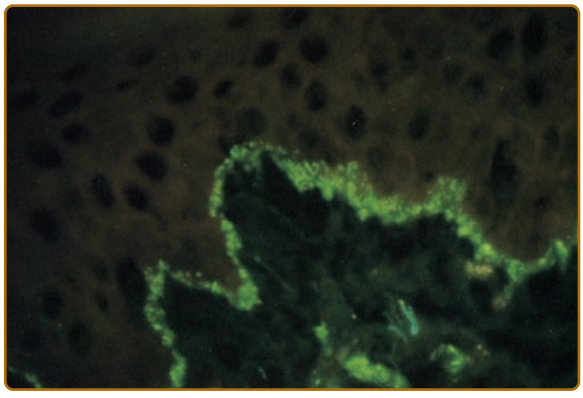

Figure 155-10 Immunopathology of lupus erythematosus-specific skin disease. Direct immunofluorescence examination of a discoid lupus erythematosus lesional skin biopsy showing a continuous band of granular fluorescence at the dermal-epidermal junction as a result of staining with fluorescein isothiocyanate-conjugated goat anti-immunoglobulin G.

the realization that sun-damaged skin from otherwise healthy individuals can display similar immunopathology has diluted the clinical value of this finding.

SUBACUTE CUTANEOUS LUPUS ERYTHEMATOSUS

Initial studies indicated that approximately 60% of patients with SCLE had lesional lupus bands. A "dust-like particle" pattern of IgG deposition focused around epidermal basal keratinocytes has been suggested to be more specific for SCLE by reflecting the presence of *in vivo* bound Ro/SS-A autoantibody.

CHRONIC CUTANEOUS LUPUS ERYTHEMATOSUS

Early reports suggested that more than 90% of classic DLE lesions had lesional immunoreactants at the dermal-epidermal junction, often extending along the basement membrane of the hair follicle, but subsequent studies report somewhat lower rates. Lesions on the head, neck, and arms are positive more frequently (80%) than those on the trunk (20%). The lesional lupus band also appears to be a function of the age of the lesion being examined, with older lesions (>3 months) being positive more often than younger ones. Ultrastructural localization of immunoglobulin at the dermal-epidermal junction confirms that these proteins are deposited on the upper dermal collagen fibers and along the lamina densa of the epidermal basement membrane zone.

In LE profundus, immunoglobulin and complement deposits are usually found in blood vessel walls of the deep dermis and subcutis. Immunoglobulin deposits at the dermal-epidermal junction may or may not be present, depending on the site biopsied, the presence or absence of accompanying SLE, and the presence or absence of overlying changes of DLE at the dermal-epidermal junction.

NONLESIONAL LUPUS BAND TEST

There has been much debate over the past three decades regarding the diagnostic and prognostic significance of an immunoglobulin/complement band at the dermal-epidermal junction of nonlesional skin taken from patients with LE.[72] When totally sun-protected nonlesional skin (e.g., buttocks) is sampled, the diagnostic specificity for SLE appears to be very high when three or more immunoreactants are present at the dermal-epidermal junction. Prospectively ascertained follow-up data also suggest that the presence of a nonlesional LBT correlates positively with risk for developing LE nephritis. However, the nonlesional LBT has fallen out of favor as a clinical tool largely because the information gained has not been proven to be of significantly greater value than the results of more readily available serologic assays such as antibody to dsDNA.

DIFFERENTIAL DIAGNOSIS

The differential diagnosis of CLE is outlined in Box 155-1 and eBox 155-1.1 in online edition. In addition, reticulated erythematosus mucinosis (REM) has been suggested by some to be a form of photosensitive cutaneous LE perhaps related to LE tumidus. REM presents as a reticulated array of macules and/or papules on the upper chest and back.

PROGNOSIS AND CLINICAL COURSE

ACUTE CUTANEOUS LUPUS ERYTHEMATOSUS

Both localized and generalized forms of ACLE lesions flare and abate in parallel with underlying SLE disease activity. Therefore, the prognosis for any given patient with ACLE is dictated by the pattern of the underlying SLE. Both 5-year (80%–95%) and 10-year (70%–90%) survival rates for SLE have progressively improved over the past four decades as a result of earlier diagnosis made possible by more sensitive laboratory testing and improved immunosuppressive treatment regimens. Ominous prognostic signs in SLE are hypertension, nephritis, systemic vasculitis, and central nervous system disease.

SUBACUTE CUTANEOUS LUPUS ERYTHEMATOSUS

Because SCLE has been recognized as a separate disease entity for only two decades, the long-term outcome associated with SCLE lesions has yet to be determined. It is the authors' experience that most patients with SCLE have intermittent recurrences

BOX 155-1 DIFFERENTIAL DIAGNOSIS OF LUPUS ERYTHEMATOSUS

MOST LIKELY

- ACLE
  - Localized
    - Acne rosacea
    - Dermatomyositis
  - Generalized
    - Drug hypersensitivity reaction
    - Photoallergic/phototoxic drug reactions
    - Viral exanthems
- SCLE
  - Papulosquamous
    - Photosensitive psoriasis
  - Annular
    - Erythema annulare centrifugum
    - Granuloma annulare
- DLE
  - Early DLE/LET
    - Polymorphous light eruption
    - Acne
  - Fully Evolved DLE/Hypertrophic DLE
    - Squamous cell carcinoma
    - Actinic keratosis
    - Keratoacanthoma
  - Lupus panniculitis
    - Morphea profundus

CONSIDER

- ACLE
  - Localized
    - Seborrheic dermatitis
    - Polymorphous light eruption
    - Photoallergic contact dermatitis
  - Generalized
    - Dermatomyositis
- SCLE
  - Papulosquamous
    - Photoallergic/photo lichenoid drug eruption
  - Annular
    - Erythema gyratum repens
- DLE
  - Early DLE/LET
    - Granuloma faciale
    - Sarcoidosis
    - Jessner benign lymphocytic infiltration of the skin
    - Pseudolymphoma
    - Lymphoma cutis
    - Lupus vulgaris
    - Urticaria
    - Urticarial vasculitis
  - Fully evolved/hypertrophic DLE
    - Prurigo nodularis
    - Hypertrophic lichen planus
    - Lupus panniculitis
    - Subcutaneous sarcoidosis
    - Traumatic panniculitis
    - Eosinophilic fasciitis

ALWAYS RULE OUT

- ACLE
  - Generalized
    - Toxic epidermal necrolysis
- DLE
  - Tinea incognito
  - Cutaneous T-cell lymphoma
  - Lupus panniculitis
  - Infectious panniculitis (deep fungal/atypical mycobacterial organisms)
  - Calciphylaxis

ACLE, acute cutaneous lupus erythematosus; DLE, discoid lupus erythematosus; LET, lupus erythematosus tumidus; SCLE, subacute cutaneous lupus erythematosus.

of skin disease activity over long periods of time without significant progression of systemic involvement (we are aware of only one death directly attributable to SLE in approximately 150 patients with SCLE). Other patients enjoy long-term if not permanent remissions of their skin disease activity. A few patients have experienced unremitting cutaneous disease activity.

It has also been the authors' experience that approximately 15% of the patients with SCLE develop active SLE, including lupus nephritis. This subgroup of patients is marked by the presence of papulosquamous SCLE, localized ACLE, high-titer ANA, leukopenia, and/or antibodies to dsDNA. Long-term follow-up studies of SCLE are required to determine the true risk of severe systemic disease progression in patients presenting with SCLE skin lesions. CCLE lesions, typically classic DLE, have also arisen in patients initially presenting with SCLE.

Evidence suggests that overlap occurs between SCLE and Sjögren's syndrome. Patients with SCLE who develop Sjögren's syndrome are at risk for developing the extraglandular systemic complications associated with Sjögren's syndrome, including vasculitis, peripheral neuropathy, autoimmune thyroiditis, renal tubular acidosis, myositis, chronic hepatitis, primary biliary cirrhosis, psychosis, lymphadenopathy, splenomegaly, and B-cell lymphoma.

CHRONIC CUTANEOUS LUPUS ERYTHEMATOSUS

Most patients with untreated classic DLE lesions suffer indolent progression to large areas of cutaneous dystrophy and scarring alopecia that can be psychosocially devastating and occupationally disabling. However, with treatment, skin disease can be largely controlled. Spontaneous remission occurs occasionally, and the disease activity can recrudesce at the sites of older, inactive lesions. Rebound after discontinuation of treatment is typical, and slower taper of medications during periods of inactivity is recommended. Squamous cell carcinoma occasionally develops in chronic smoldering DLE lesions.

Death from SLE is distinctly uncommon in patients who present initially with localized DLE. As discussed in Section "Epidemiology," patients presenting with localized DLE have only a 5% chance of subsequently developing clinically significant SLE disease activity. Generalized DLE and persistent, low-grade laboratory abnormalities appear to be risk factors for such disease progression. Unrecognized squamous-cell carcinoma developing within a longstanding DLE skin lesion could be a cause of morbidity and mortality.

OUTCOMES MEASURES

The recent development of a validated instrument to measure activity of CLE, the Cutaneous Lupus Erythematosus Area and Severity Index (CLASI), has made it possible to objectively follow patients' disease course and response to therapy. The instrument has separate scores for damage (scarring) and activity which is important, because one would not expect a "burned-out" scarred area to normalize with drugs that were meant to abate LE activity.[76] It has been validated as a useful tool to measure clinical response.[77]

TREATMENT

The initial management of patients with any form of CLE should include an evaluation to rule out underlying SLE disease activity at the time of diagnosis. All patients with CLE should receive instruction about protection from sunlight and artificial sources of UVR and should be advised to avoid the use of potentially photosensitizing drugs such as hydrochlorothiazide, tetracycline, griseofulvin, and piroxicam. With regard to specific medical therapy, local measures should be maximized and systemic agents used if significant local disease activity persists or systemic activity is superimposed.

ACLE lesions usually respond to the systemic immunosuppressive measures required to treat the underlying SLE disease activity that so frequently accompanies this form of CLE (e.g., systemic glucocorticoids, azathioprine, and cyclophosphamide). Increasing evidence suggests that aminoquinoline antimalarial agents such as hydroxychloroquine can have a steroid-sparing effect on SLE, and these drugs can be of value in ACLE. The local measures discussed in Local Therapy below can also be of value in treating ACLE. Because the lesions of SCLE and CCLE are often found in patients who have little or no evidence of underlying systemic disease activity, unlike the lesions of ACLE, nonimmunosuppressive treatment modalities are preferred for SCLE and CCLE (Table 155-6). For the most part, SCLE and CCLE lesions respond equally to such agents.

LOCAL THERAPY

SUN PROTECTION. Advise patients to avoid direct sun exposure, wear tightly woven clothing and broad-brimmed hats, and regularly use broad-spectrum, water-resistant sunscreens [SPF ≥30 with an efficient UVA blocking agent such as a photostabilized form of avobenzone (Parsol 1789), micronized titanium dioxide, micronized zinc oxide, or Mexoryl SX]. UV-blocking films should be applied to home and automobile windows, and acrylic diffusion shields should be placed over fluorescent lighting. Corrective camouflage cosmetics such as Dermablend® and Covermark® offer the dual benefit of being highly effective physical sunscreens as well as aesthetically pleasing cosmetic masking agents. An in-depth discussion of practical and theoretical photoprotection and local therapy for autoimmune connective tissue skin disease has been discussed in detail (see Chapter 223).[78]

LOCAL GLUCOCORTICOIDS. Although some prefer intermediate-strength preparations, such as triamcinolone acetonide 0.1%, for sensitive areas such as the face, superpotent topical class I agents, such as clobetasol propionate 0.05% or betamethasone dipropionate 0.05%, produce the greatest benefit in CLE. Twice-daily application of the superpotent preparations to lesional skin for 2 weeks followed by a 2-week rest period can minimize the risk of local complications such as steroid atrophy and telangiectasia. Alternatively, a topical calcineurin inhibitor can be used daily during the 2-week rest period from topical corticosteroids. Ointments are more effective than creams for more hyperkeratotic lesions such as hypertrophic DLE. Occlusive therapy with glucocorticoid-impregnated tape (e.g., flurandrenolide) or glucocorticoids with plastic food wrap (e.g., Saran or Glad Press-N-Seal) can potentiate the beneficial effects of topical glucocorticoids but also carries a higher risk of local side effects. Class I or class II topical glucocorticoid solutions and gels are best for treating the scalp. Unfortunately, even the most aggressive regimen of topical glucocorticoids by itself does not provide adequate improvement for most patients with SCLE and CCLE.

TOPICAL CALCINEURIN INHIBITORS. Pimecrolimus 1% cream and tacrolimus 0.1% ointment have demonstrated efficacy in the treatment of ACLE, DLE, and SCLE.[79–81] A double blind, placebo controlled pilot study showed that pimecrolimus 1% cream had equal efficacy with betamethasone valerate 0.1% cream in treating facial DLE,[82] and a different study demonstrated

TABLE 155-6
Therapeutic Options for Lupus Erythematosus-Specific Skin Disease

	Drug	Dose
First line	Topical glucocorticoids Topical calcineurin inhibitor Intralesional triamcinolone acetonide	Class I steroid qd–bid for 2 weeks alternating with pimecrolimus 1% or tacrolimus 0.1% bid for 2 weeks; 2.5–10.0 mg/cc
Second line (low threshold for use if scarring, widespread lesions, systemic symptoms)	Hydroxychloroquine Chloroquine Quinacrine (if monotherapy fails, add quinacrine to either hydroxychloroquine or chloroquine)	6.5 mg/kg/day ideal body weight 3.0–3.5 mg/kg/day ideal body weight 100 mg daily (available at compounding pharmacies)
Short courses only (2–16 weeks) (must have patient on concomitant alternative agent to prevent rebound on discontinuation)	Prednisone Thalidomide	5–60 mg/day 50 mg qd–200 mg/day; taper to 50 mg qod on response
Third line (safer immunosuppressives)	Azathioprine Mycophenolate mofetil Methotrexate	1.5–2.5 mg/kg/day PO 2.5–3.5 g/day PO 7.5–25 mg PO or SQ/wk
Worth consideration	Dapsone Accutane Acitretin Gold	50–200 mg/day 0.5–2 mg/kg/day 10–50 mg/day Work up to 50 mg weekly, taper after 1 g
Fourth line (limited by side effects)	Cyclophosphamide Clofazimine	1.5–2.0 PO mg/kg/day
Investigational (some currently available)	Efalizumab (Raptiva) Leflunomide (Arava) Antitumor necrosis factor agents Rituximab (Rituxan) Abatacept Epratuzumab Anti-interferon-α agents	

the efficacy of topical tacrolimus 0.3% compound in clobetasol propionate 0.05% for recalcitrant CLE.[83]

INTRALESIONAL GLUCOCORTICOIDS. Intralesional glucocorticoids (e.g., triamcinolone acetonide suspension, 2.5–5.0 mg/mL for the face with higher concentrations allowable in less sensitive sites) are more useful in the management of DLE than SCLE. Intralesional glucocorticoids themselves can produce cutaneous and subcutaneous atrophy (deep injections into the subcutaneous tissue enhances this risk). A 30-gauge needle is preferred because it produces only mild discomfort on penetration, especially when injected perpendicularly to the skin. The active borders of lesions should be thoroughly infiltrated. Intralesional therapy is indicated for particularly hyperkeratotic lesions or lesions that are unresponsive to topical glucocorticoids, but most patients with CLE have too many lesions to be managed exclusively by intralesional glucocorticoid injections.

SYSTEMIC THERAPY

ANTIMALARIALS. One or a combination of the aminoquinoline antimalarials can be effective for approximately 75% of patients with CLE who have failed to benefit adequately from the local measures described in Section "Local Therapy."[84] The risks of retinal toxicity should be discussed with the patient, and a pretreatment ophthalmologic examination should be performed. However, the risk of antimalarial retinopathy is extremely rare, particularly in the first 10 years of therapy, if recommended daily dose maximum levels of these agents are not exceeded (hydroxychloroquine, 6.5 mg/kg/day based on ideal body weight; chloroquine, 3 mg/kg/day). Patients should have follow-up ophthalmologic evaluations every 6–12 months while on therapy.

Hydroxychloroquine sulfate (Plaquenil), 6–6.5 mg/kg, should be given daily, either once daily or in two divided doses to prevent GI side effects. Patients should be informed about 2–3 month delayed onset of therapeutic benefit. If no response is seen after 8–12 weeks, quinacrine hydrochloride, 100 mg/day (currently available in the United States only through compounding pharmacies), can be added to the hydroxychloroquine without enhancing the risk of retinopathy (quinacrine does not cause retinopathy). If, after 4–6 weeks, adequate clinical control has not been achieved, consideration should be given to replacing the hydroxychloroquine with chloroquine diphosphate (Aralen), 3 mg/kg to prevent retinopathy. Doses may need to be adjusted for patients with decreased renal or hepatic function. In Europe, chloroquine is generally felt to be more efficacious than hydroxychloroquine in treating CLE, perhaps due to the earlier therapeutic

responses that might occur as a result of the shorter time period required to reach steady state blood levels with chloroquine as compared to hydroxychloroquine. Hydroxychloroquine and chloroquine should not be used simultaneously because of enhanced risk for retinal toxicity. There is some evidence that chloroquine may be more retinotoxic than hydroxychloroquine.

Multiple side effects other than retinal toxicity are associated with the use of antimalarials. Quinacrine is associated with a higher incidence of side effects, such as headache, gastrointestinal intolerance, hematologic toxicity, pruritus, lichenoid drug eruptions, and mucosal or cutaneous pigmentary deposition, than is either hydroxychloroquine or chloroquine. Quinacrine commonly produces a yellow discoloration of the entire skin and sclera in fair-skinned individuals, which is completely reversible when the drug is discontinued. Quinacrine can produce significant hemolysis in patients with glucose-6-phosphate dehydrogenase deficiency (this adverse effect has also been reported to occur rarely with hydroxychloroquine and chloroquine). Each of the aminoquinoline antimalarials can produce bone marrow suppression, including aplastic anemia, although this effect is exceedingly rare with the current dosage regimens. Toxic psychosis, grand mal seizures, neuromyopathy, and cardiac arrhythmias occurred with the use of high doses of these drugs in the past; these reactions are uncommon with the lower daily dose regimens used today.

Before therapy with hydroxychloroquine and chloroquine is begun, complete blood cell counts, as well as liver and renal function tests, should be performed; these tests should be repeated 4–6 weeks after therapy has been initiated, and every 4–6 months thereafter. A screen for hematologic toxicity when quinacrine is used is recommended more often. Patients with overt or subclinical porphyria cutanea tarda are at particularly high risk for developing acute hepatotoxicity, which often simulates an acute surgical abdomen, when treated with therapeutic doses of antimalarials for CLE. It is also recommended to check urine levels of β-human chorionic gonadotropin initially in women with childbearing potential, although recent evidence indicates that the risk to pregnant women of currently recommended dose regimens of antimalarials is minimal.

NONIMMUNOSUPPRESSIVE OPTIONS FOR ANTIMALARIAL-REFRACTORY DISEASE.

Some patients with refractory CLE (SCLE more than DLE) respond to diaminodiphenylsulfone (dapsone).[85] An initial dose of 25 mg by mouth twice daily can be increased up to 200–400 mg/day, if necessary. Significant dose-related hemolysis and/or methemoglobinemia can result from the use of dapsone, especially in individuals deficient in glucose-6-phosphate dehydrogenase activity, and, therefore, complete blood counts and liver function tests should be performed regularly. Isotretinoin, 0.5–2.0 mg/kg/day, and acitretin, 10–50 mg/day, have also been used in this setting, but their efficacy is limited by their side effects (teratogenicity, mucocutaneous dryness, and hyperlipidemia). In addition, breakthrough of CLE activity has been a problem with the long-term use of retinoids.

Thalidomide (see Chapter 235) (50–200 mg/day) is strikingly effective for CLE that is refractory to other medications. Numerous studies have cited response rates between 85% and 100%, with many patients experiencing complete remission.[86] However, strict prescribing regulations put in place in the United States in 1998 because of severe teratogenicity, make thalidomide challenging to dispense to women of childbearing potential. Sensory neuropathy is another toxicity associated with thalidomide, and 25%–75% of patients with CLE develop peripheral neuropathy while taking the drug. Most cases are reversible when therapy is stopped. Neuropathy seems to correlate with total treatment times so that short courses are preferred. Relapses after the drug is stopped are common. Excess somnolence as well as constipation and other minor side effects sometimes limit its use, although these effects usually abate with lower daily doses.[87] Thromboembolism is a serious adverse event that may occur in patients with a preexisting hypercoagulable state (e.g., presence of antiphospholipid antibodies). Oncologists who use thalidomide for multiple myeloma frequently initiate concomitant anticoagulation therapy to prevent this side effect. Lenalidomide (Revlamid, Celgene) is a thalidomide analog that is more efficacious but has similar rates of teratogenicity, peripheral neuropathy, thromboembolism, and also has the additional potential side effect of profound leukopenia.[88]

Other drugs reported to be of value in the treatment of refractory CLE are gold and clofazimine; however, the benefit varies from case to case and both of these agents are associated with the risk of significant side effects. Vitamin E, phenytoin, sulfasalazine, danazol, DHEA, and phototherapy (UVAI phototherapy, photopheresis) have also been reported in uncontrolled trials to be of value in CLE.

SYSTEMIC GLUCOCORTICOIDS.

Every effort should be made to avoid the use of systemic glucocorticoids in patients with LE limited to the skin. However, in occasional patients who have especially severe and symptomatic skin disease, intravenous pulse methylprednisolone has been used. In less acute cases, moderate daily doses of oral glucocorticoids (prednisone, 20–40 mg/day, given as a single morning dose) can be used as supplemental therapy during the loading phase of therapy with an antimalarial agent. The dose should be reduced at the earliest possible time because of the complications of long-term glucocorticoid therapy, especially avascular (aseptic) bone necrosis, a side effect to which patients with LE are particularly susceptible.

Because steroid-induced bone loss occurs most rapidly in the first 6 months of use, all patients who do not have contraindications should begin agents to prevent osteoporosis with the initiation of steroid therapy. An excellent review describing current recommendations for prevention of bone loss and other side effects of systemic glucocorticoids has been published.[89] When the disease activity is controlled, the daily dosage should be reduced by 5- to 10-mg decrements until activity flares again or until a daily dosage of 20 mg/day is achieved. The daily dose should then be lowered by 2.5-mg decrements (some physicians prefer to use 1-mg

dose decrements below 10 mg/day). Alternate-day glucocorticoid therapy has not been successful in suppressing disease activity in most patients with CLE or SLE. Prednisolone rather than prednisone should be used in patients who have significant underlying liver disease, because prednisone requires hydroxylation in the liver to become biologically active. Any amount of prednisone given as a single oral dose in the morning has less adrenal-suppressing activity than the same amount given in divided doses throughout the day. However, any given amount of this drug, taken in divided doses, has a greater LE-suppressing activity than does the same amount of drug given as a single morning dose.

PREVENTION

Predicting and preventing the initial clinical manifestation of LE, whether it is skin disease or systemic, is not feasible at this time. However, as many LE patients exhibit worsening of their skin disease activity with UV light exposure, physical protection from sunlight and artificial sources of UV light as well as the regular use of broad-spectrum sunscreens having a SPF of 30 or greater should be encouraged.

KEY REFERENCES

Full reference list available at www.DIGM8.com

DVD contains references and additional content

1. Tan EM et al: The 1982 revised criteria for the classification of systemic lupus erythematosus. *Arthritis Rheum* **25**(11):1271-1277, 1982
2. Watanabe T, Tsuchida T: Classification of lupus erythematosus based upon cutaneous manifestations. Dermatological, systemic and laboratory findings in 191 patients. *Dermatology* **190**(4):277-283, 1995
6. Lin JH et al: Pathophysiology of cutaneous lupus erythematosus. *Clin Rev Allergy Immunol* **33**(1-2):85-106, 2007
22. Pascual V, Banchereau J, Palucka AK: The central role of dendritic cells and interferon-alpha in SLE. *Curr Opin Rheumatol* **15**(5):548-556, 2003
47. Zecevic RD et al: Skin lesions–an indicator of disease activity in systemic lupus erythematosus? *Lupus* **10**(5):364-367, 2001
79. Costner MI, Sontheimer RD, Provost TT: Lupus Erythematosus. In: *Cutaneous Manifestations of Rheumatic Diseases*, 2nd edition, edited by RD Sontheimer, TT Provost. Philadephia: Lippincott Williams & Wilkins, 2004, pp. 15-64

Chapter 156 :: Dermatomyositis

:: Richard D. Sontheimer, Christopher B. Hansen & Melissa I. Costner

DERMATOMYOSITIS AT A GLANCE

- Dermatomyositis (DM) is thought to evolve through multiple sequential phases: (1) a genetically determined susceptibility phase, (2) an induction phase triggered by an environmental stimulus (e.g., ultraviolet light, infection) involving loss of tolerance to self-antigens in skin and skeletal muscle, (3) an autoimmune expansion phase, and (4) an injury phase involving multiple immunologic effector mechanisms.
- All clinical types of the idiopathic inflammatory dermatomyositis are rare orphan diseases.
- Some clinical subphenotypes of DM such as clinically amyopathic DM have been underdiagnosed in the past, often being confused with isolated forms of cutaneous lupus erythematosus.
- Clinical features are a function of age of onset (e.g., juvenile-onset classic DM: vasculopathy, dystrophic calcification; adult-onset classic DM: associated occult malignancy, interstitial lung disease).
- The sine qua non of DM is a hallmark constellation of inflammatory skin changes presenting as patchy or confluent, macular, violaceous erythema that assumes a highly characteristic anatomic distribution and is often photoaccentuated. With time, additional diagnostic skin changes appear, including Gottron papules, prominent periungual nail fold microvascular changes, and poikiloderma atrophicans vasculare.
- Joint disease (arthritis/arthralgia), pulmonary disease (interstitial lung disease, aspiration pneumonia), esophageal disease (dysphagia), vasculopathic injury of multiple organ systems (gastrointestinal system, central nervous system, eye), and cardiac disease (conduction defects, cardiomyopathy) may be related features.
- Pathologic features include the following: in skin—a cell-poor interface dermatitis with dermal mucin accumulation; in muscles—a characteristic pattern of myositis.

The idiopathic inflammatory myopathies (IIDMs) are a heterogeneous group of genetically determined autoimmune disorders that predominately target the skeletal musculature and/or skin and typically result in symptomatic skeletal muscle weakness and/or cutaneous inflammatory disease. Some physicians continue to refer to this group of clinical disorders by an earlier designation, idiopathic inflammatory myopathies. Among the IIDM, dermatomyositis (DM) is of special interest to the dermatologist due the universal presence of a hallmark pattern of cutaneous inflammation. DM is the only idiopathic inflammatory myopathy (IIM) that expresses a characteristic pattern of primary cutaneous inflammation.

In this chapter, the term *classic DM* is used to refer to DM as traditionally defined (i.e., the concurrence of myositis resulting in clinically significant proximal muscle weakness and a set of hallmark inflammatory skin lesions occurring in a specific anatomical distribution). Also of interest to the dermatologist is the subgroup of patients who express the hallmark cutaneous manifestations of DM for prolonged periods (6 months or longer) without developing clinically evident muscle weakness. This pattern of DM expression is referred to as *clinically amyopathic DM* (CADM); this term is synonymous with the historical designation, *dermatomyositis sine myositis*.

On occasion, other organ systems, such as the lungs (interstitial lung disease), joints (arthritis), and heart (cardiomyopathy, conduction defects), are targeted by inflammatory injury in IIM patients. In addition, differences exist between classic DM presenting in adults and that presenting in children. For example, juvenile-onset classic DM is associated with higher rates of vasculopathy/vasculitis resulting in the complication of dystrophic calcification, whereas adult-onset classic DM is associated with a significantly increased risk of internal malignancy and interstitial lung disease.

The diagnostic criteria for DM under the current consensus IIM classification system have not allowed for the inclusion of cutaneous-only or cutaneous-predominant subsets of DM, such as amyopathic DM and hypomyopathic DM, which together are referred to here as CADM (see eTable 156-0.1 in online edition). A more inclusive disease category designation, "idiopathic inflammatory dermatomyositis, " has been proposed by one of the authors (Richard D. Sontheimer) as an alternative to the "IIM" designation because it allows for the inclusion of these cutaneous subsets of DM[1–16] (eTable 156-0.2 in online edition). Other rheumatologic disorders such as lupus erythematous (LE) and scleroderma are broadly recognized to include skin-only subsets (e.g., discoid LE, morphea). However, the group designation "idiopathic inflammatory dermatomyopathies" has yet to be broadly embraced.

Thus, IIDM represents a heterogeneous group of clinical disorders that can be conveniently conceptualized as a continuum of illness with subgroups of patients who share common clinical and immunologic features at distinct positions along this spectrum (Fig. 156-1).

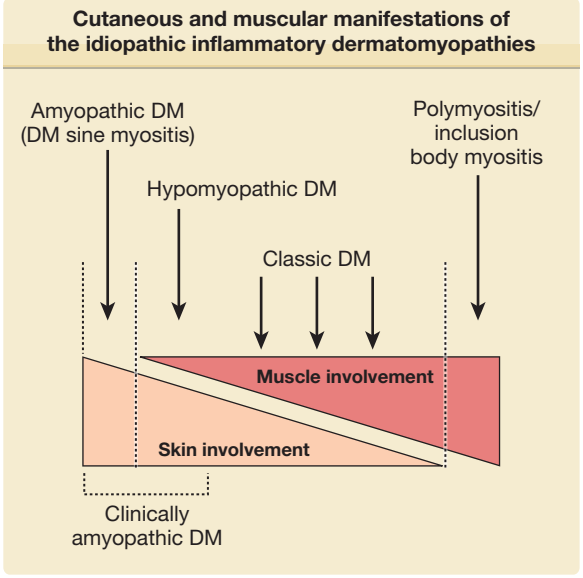

Figure 156-1 Graphic representation of the relationships between the cutaneous and muscular manifestations of the idiopathic inflammatory dermatomyositis, including the nosologic entities within this spectrum of illness. DM = dermatomyositis.

EPIDEMIOLOGY

CLASSIC DERMATOMYOSITIS

Cutaneous involvement occurs in 30% to 40% of adults and in 95% of children with IIDM. By definition, skin disease is absent in patients with PM and present in 100% of patients with classic DM and CADM. Skin disease activity can precede muscle disease activity in classic DM by weeks to several months.

Classic DM can occur from infancy to adulthood and most frequently presents in the fifth and sixth decades (PM is extremely rare in children). The incidence of classic IIDM between 1963 and 1982 was estimated to be 5.5 cases per million. The incidence probably is higher, inasmuch as this study[17] was based only on hospital inpatient-ascertained diagnoses and did not include cases of CADM. Familial concordance occurs rarely, and concordant disease expression has been reported in identical twins.

The epidemiology of juvenile-onset classic DM in the United States has been reviewed.[18] For children 2–17 years of age, the estimated annual incidence rates from 1995 to 1998 in the United States ranged from 2.5 to 4.1 cases per million children, and the 4-year average annual rate was 3.2 per million children. Estimated annual incidence rates by race were 3.4 for white non-Hispanics, 3.3 for African American non-Hispanics, and 2.7 for Hispanics. Girls were affected more than boys (ratio of 2.3:1). Cutaneous ulceration occurring as a result of infarctive vasculopathy and subsequent calcification is more common in the childhood form of the disease.

Environmental factors have been implicated as disease triggers. Seasonality has been noted in both juvenile-onset and adult-onset DM, which suggests the possibility of an infectious etiology. DM- and PM-like syndromes have been reported in patients infected with coxsackievirus, parvovirus B19, Epstein–Barr virus, human immunodeficiency virus, and human T-cell leukemia virus type 1.

CLINICALLY AMYOPATHIC DERMATOMYOSITIS

A population-based study in Olmsted County, Minnesota identified 29 patients over a 30-year period with dermatomyositis of which 21% had the clinically amyopathic subtype. The incidence of CADM in the study was 2.08 per million persons.[19–24] In Europe, a similar incidence has been observed,[25] whereas in Asia, CADM appears to be relatively more common. A retrospective analysis of 28 patients with DM at the National Skin Center in Singapore between 1996 and 1998 revealed that 13 (46%) had CADM.[26] In another cohort of 143 Taiwanese patients with IIDM treated in a veterans hospital system, CADM was the second most commonly encountered type of IIDM (14%) after classic adult-onset DM (64%). CADM was somewhat more common than juvenile-onset IIDM (13%) and PM (10%) in this study.[27] In Asian patients, adult-onset CADM appears to be more common in males.[27] One of the authors (Richard D. Sontheimer) has personally observed an unreported familial constellation of CADM in a father and his only children—two adult daughters. Indirect evidence suggests that CADM has human leukocyte antigen (HLA) associations similar to those found in patients with classic DM (i.e., HLA-DQA1).[28]

DRUG-INDUCED DERMATOMYOSITIS

An increasing number of cases of DM are reported to be caused or exacerbated by systemic medications. A number of different drug classes have been implicated including statin-type cholesterol-lowering agents.[31,32] The average incubation time is approximately 2 months. The majority of these cases present with both myositis and pathognomonic cutaneous findings and resolve with discontinuation of the medication. Pulmonary involvement appears to be uncommon in drug-induced DM.[33] Long-term hydroxyurea therapy for chronic myelogenous leukemia can produce a DM-like cutaneous eruption that is clinically and histopathologically similar to that of idiopathic DM-specific skin disease.[21] This subtype of drug-induced DM is unique in that muscle weakness and other systemic symptoms are absent. Painful leg ulcers are often seen in association, as are xerosis and cutaneous atrophy. This symptom complex usually occurs only after the patient has been treated with hydroxyurea for long periods (2–10 years). The presence of concurrent therapy with hydroxyurea has been proposed as the exclusion criterion for CADM.[1]

ETIOLOGY AND PATHOGENESIS

The inflammatory nature of the muscle and skin manifestations coupled with the characteristic humoral autoimmune abnormalities has led to the hypothesis that DM results from a genetically determined, aberrant autoimmune response to environmental agents. Figure 156-2 presents a summary overview of current thought in this area. Like other systemic autoimmune diseases involving autoantibody production such as systemic lupus erythematosus (SLE), DM is thought to evolve through multiple sequential phases: the susceptibility phase, the induction phase, the expansion phase, and the injury phase.

The susceptibility phase of DM is thought to result largely from a genetic predisposition. DM is one of the human autoimmune diseases that is linked to the 8.1 ancestral haplotype (HLA-A1, C7, B8, C4AQ0, C4B1, DR3, DQ2).[22] PM and DM have been specifically associated with HLA-B8, DR3, and DRw52, especially in white patients. This association is likely a result of linkage disequilibrium with HLA-DQA1*0501. The production of antisynthetase antibodies such as Jo-1 is strongly linked to HLA-DR3 and even more strongly linked to its supertypic specificity HLA-DRw52.

A single nucleotide polymorphism in the tumor necrosis factor-α promoter (TNF-α-308A), which is also a component of the 8.1 ancestral haplotype, has been associated with disease chronicity, calcinosis, and high levels of TNF-α in a cohort of white patients with juvenile-onset classic DM.[23] This same TNF-α promoter polymorphism has been associated with photosensitive subacute cutaneous LE.[34] This same TNF-α promoter polymorphism has been associated with photosensitive subacute cutaneous LE.[24,35] Several gene polymorphisms associated with low production of mannose-binding protein, a molecule involved in the physiologic clearance of apoptotic cells, have been associated with adult DM.[24] There has also been a single case report of adult-onset CADM that evolved to classic DM in a young Japanese woman who was shown to be genetically deficient in the fifth component of complement.[36]

The cutaneous manifestations of DM are precipitated or exacerbated by natural and artificial sources of ultraviolet (UV) light.[37] Approximately 50% of patients with DM experience photosensitivity. The action spectrum appears to include both UVB and UVA light. UV radiation intensity has been shown to associate with the proportional incidence of DM compared to other IIMs and correlate with the detection of anti-Mi-2 antibodies in women.[38] Environmental stimuli, including UV radiation and infection, could represent inductive factors in DM leading to loss of self-tolerance. Various types of infections have been circumstantially implicated as causative factors in DM. These include infection with RNA viruses such as coxsackievirus, echovirus, and human retroviruses (i.e., human T-cell leukemia/lymphoma virus type 1 and human immunodeficiency virus). Nonviral pathogens such as *Toxoplasma gondii* have also been implicated. However,

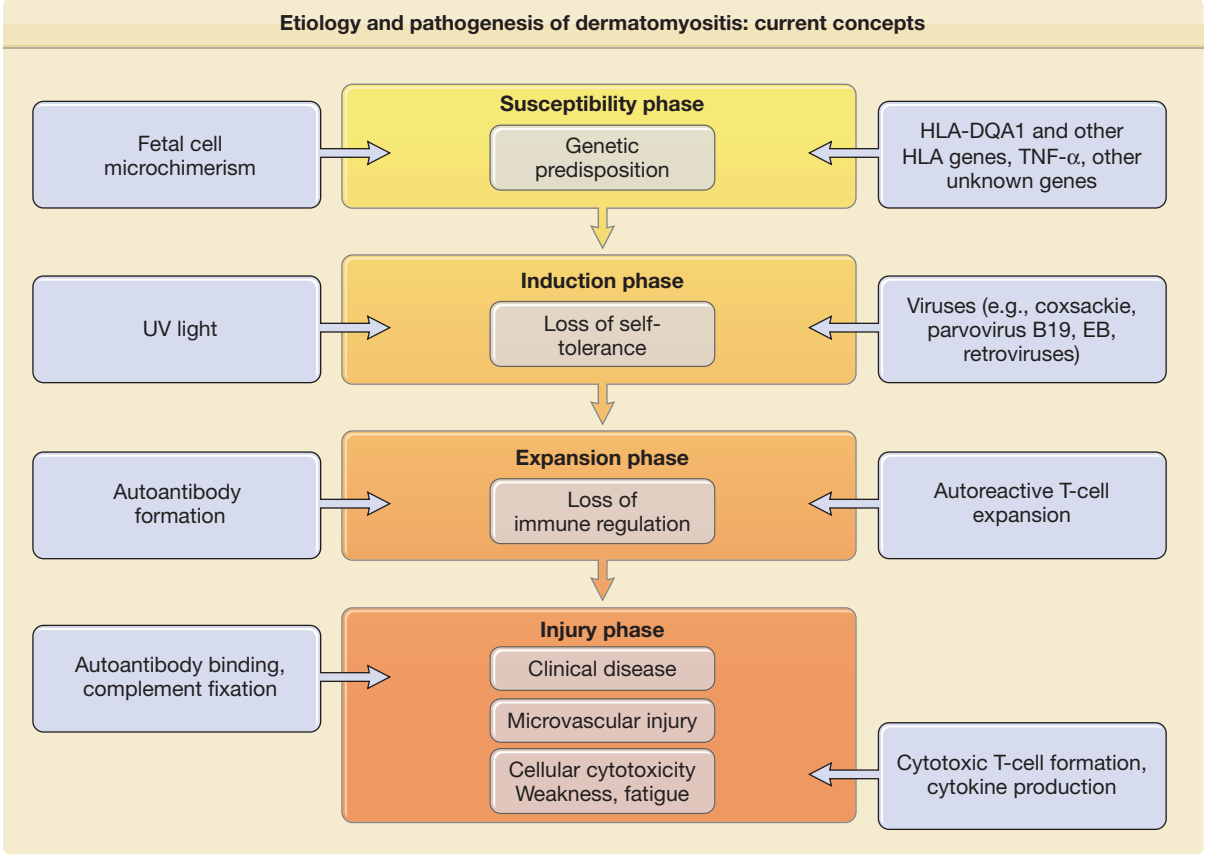

Figure 156-2 Etiology and pathogenesis of dermatomyositis: current concepts. See text for discussion. EB = Epstein–Barr; TNF-α = tumor necrosis factor-α; UV = ultraviolet.

repeated attempts to confirm persistent myotropic infection by viruses or other pathogens have not been successful.

The expansion phase of DM is marked by autoantibody production signaling the loss of normal immune regulation. DM is associated with the production of a number of specific autoantibodies that probably predates by some period the first evidence of clinical disease activity (Table 156-1). Whether these autoantibodies are truly pathogenetic or represent only a by-product of muscle injury is unknown. It has been suggested that CADM might be associated with a specific autoantibody profile (antibodies to 140-kDa, 155-kDa, and Se antigens).[39,40]

It is thought that autoantibodies, immune complexes, and/or autoreactive T cells play a major role in the tissue injury phase of DM. Cell-mediated immune activity against muscle autoantigens is thought to be primarily responsible for the muscle injury that occurs in PM. Both myocytotoxic $CD3^+$ T-cell clones and non-HLA-restricted myocytotoxic cells of other lineages have been identified in the peripheral blood of patients with inflammatory myopathies.[41] Little has been done in the past experimentally to date to probe for T-cell-mediated cytotoxic epidermal or dermal cell injury in DM skin lesions.

Predominantly humoral autoimmune mechanisms targeting the microvasculature have been implicated in the pathogenesis of muscle injury in DM. Microvascular ischemia is an early feature of DM muscle involvement. Components of the C5 to C9 membrane attack complex are regularly found in the walls of microvessels in muscle biopsy specimens from DM patients.

There is not always good agreement between the degree of muscle weakness or fatigue experienced by patients with classic DM and the degree of inflammation noted in muscle biopsy specimens and the elevation of serum muscle enzyme levels. This observation has led to the idea that inflammatory cytokines might be capable of mediating metabolic disturbances within muscle that can exacerbate muscle weakness and fatigue.[42] As with other rheumatic diseases such as systemic sclerosis, maternal microchimerism has been observed in children with juvenile classic DM.[43] The pathogenetic significance of the presence of alloreactive maternal lymphoid cells in the circulation, muscle, and skin of patients with juvenile DM is unknown.

The pathogenesis of cutaneous inflammation in classic DM and CADM and has received little attention, owing in part to the lack of an experimental animal model of this pattern of cutaneous inflammation. Histopathologic analysis of cutaneous DM reveals three general abnormalities: (1) a cell-poor interface dermatitis, (2) a vasculopathy of dermal microvessels, and (3) prominent dermal mucin deposition. These histopathologic elements can be precipitated or exacerbated by exposure to UV radiation.

TABLE 156-1
Autoantibodies in the Idiopathic Inflammatory Dermatomyositis

Autoantibody	Median Prevalence[a]	Molecular Specificity	Clinical Association
High Specificity for DM/PM			
155 kDa and/or Se	20%–80%	transcriptional intermediary factor-1γ	Classic DM, clinically amyopathic DM with increased risk of internal malignancy
140 kDa	53%	helicase C domain protein 1 (IFIH1)/melanoma differentiation-associated gene 5 (*MDA-5*)	Clinically amyopathic DM with increased risk for interstitial lung disease
Jo-1	20%	Histidyl-tRNA synthetase	PM, antisynthetase syndrome
Mi-2	15%	Helicase nuclear proteins	Shawl sign, cuticular overgrowth
SRP	5%	Signal-recognition particle	Fulminant DM/PM, cardiac involvement
PL-7	3%	Threonyl-tRNA synthetase	Antisynthetase syndrome
PL-12	3%	Alanyl-tRNA synthetase	Antisynthetase syndrome
OJ	Rare	Isoleucyl-tRNA synthetase	Antisynthetase syndrome
EJ	Rare	Glycyl-tRNA synthetase	Antisynthetase syndrome, possibly increased frequency of skin changes
Fer	Rare	Elongation factor 1α	—
Mas	Rare	Small RNA	—
KJ	Rare	Translation factor	—
Low Specificity for DM/PM			
ANA (most common nuclear immunofluorescence patterns—specked and nucleolar)	40%		Clinically amyopathic DM (80%)
SsDNA	40%		SLE, SSc
PM-Scl (PM-1)	40%	Ribosomal RNA processing enzyme	Overlap with scleroderma
Ro (52-kDa Ro)	15%	RNP	Overlap with SSJ, SCLE, neonatal LE/CHB, SLE
U1RNP	10%	U1RNP	Overlap connective tissue disease
Ku	3%	DNA end-binding repair protein complex	Overlap with scleroderma
U2RNP	1%	U2RNP	Overlap with scleroderma

ANA = antinuclear antibody; CHB = chronic hepatitis B; DM = dermatomyositis; LE = lupus erythematosus; PM = polymyositis; ssDNA = single-stranded DNA; SLE = systemic lupus erythematosus; SRP = signal recognition particle; SSc = systemic sclerosis; SSJ = Sjögren syndrome; tRNA = transfer RNA.
[a]Using current assay techniques.

CLINICAL FINDINGS

APPROACH TO THE PATIENT

The approach to a new patient with cutaneous DM is presented in eFig. 156-2.1 in online edition.

HISTORY

In 60% of patients with classic DM, the cutaneous lesions and muscle weakness present simultaneously. In 30% of patients, the cutaneous findings appear before the onset of muscle weakness. In 10%, muscle weakness precedes the appearance of skin lesions. The onset of cutaneous disease is typically accompanied by pruritus and/or a burning skin sensation. Sensitivity to sunlight or artificial sources of UV light is often present. Muscle weakness initially affects the shoulder and hip girdle musculature, presenting clinically as difficulty raising the arms above the head and arising from a sitting position. Weakness can be accompanied by muscle pain and tenderness.

CUTANEOUS LESIONS

HALLMARK SKIN LESIONS. eTable 156-1.1 in online edition presents the hallmark cutaneous manifestations of DM (to date, no recognizable differences in the clinical, histopathologic, and immunopathologic manifestations of classic DM and CADM have been reported). Some of these lesions, such as Gottron sign of DM (Fig. 156-3) and Gottron papules (see Fig. 156-4; Fig. 156-5), are pathognomonic of this disease, whereas others, such as periorbital, confluent, macular, violaceous (heliotrope) erythema/edema and grossly visible periungual telangiectasia associated with dystrophic cuticles, are highly characteristic.



Figure 156-3 Hand of a 30-year-old woman with a 15-year history of amyopathic dermatomyositis (DM). Note the confluent macular violaceous erythema, most pronounced over the metacarpophalangeal/interphalangeal joints, extending in a linear array overlying the extensor tendons of the hand and fingers. These changes, referred to as *Gottron sign,* are a hallmark cutaneous feature of DM. Early Gottron papules, an extension of Gottron sign, can be seen over the distal interphalangeal joints along with periungual erythema and dystrophic cuticles. In DM, the violaceous erythema is centered over the metacarpophalangeal/interphalangeal joints, whereas in lupus erythematosus these areas are relatively spared.

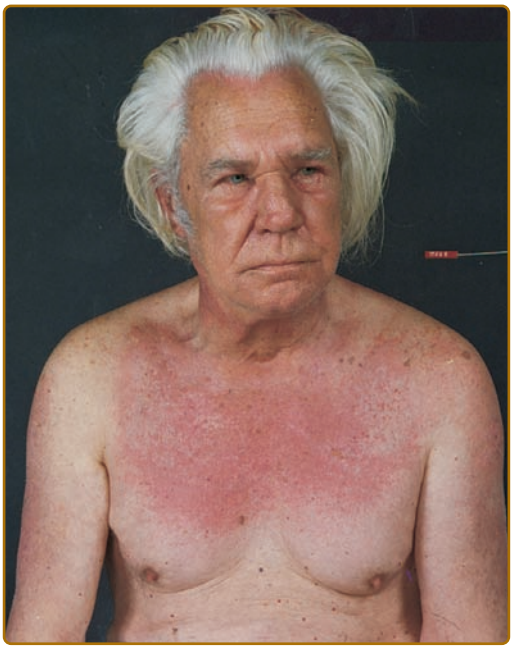

Figure 156-5 The confluent, macular, violaceous erythema of the V area of the upper chest and neck (V sign), when persistent over time, can evolve into poikilodermatous skin changes. Less evident in this photograph are periorbital edema and confluent, macular, violaceous (heliotrope) erythema of the upper eyelids. Note the absence of involvement of the malar areas, which are often involved in lupus erythematosus.

The primary skin change of DM is a highly characteristic, often pruritic, symmetric, confluent, macular violaceous erythema variably affecting the skin overlying the extensor aspect of the fingers, hands, and forearms; the arms, deltoid areas, posterior shoulders, and neck (the shawl sign); the V area of the anterior neck and upper chest; and the central aspect of the face, periorbital areas, forehead, and scalp (Fig. 156-6). Central facial involvement can occasionally simulate the appearance of seborrheic dermatitis with nasolabial fold involvement. The lateral aspects of the hips and thighs (holster sign) are also frequently involved.[50] Lesions such as poikiloderma atrophicans vasculare (poikilodermatomyositis) and calcinosis cutis are often present in patients with DM but may also appear in patients with cutaneous T-cell lymphoma (poikiloderma atrophicans vasculare) and scleroderma (SCL; calcinosis cutis). In addition, overlapping features of



Figure 156-4 Fingers of an elderly woman with classic dermatomyositis (DM). Note the fully formed Gottron papules over the distal interphalangeal joints, a hallmark cutaneous feature of DM. Prominent grossly visible nailfold telangiectasias are also present, along with dystrophic cuticles. The combination of Gottron papules and nail fold changes such as these is pathognomonic for DM. Such changes are seen to an equal degree in classic DM and amyopathic DM.

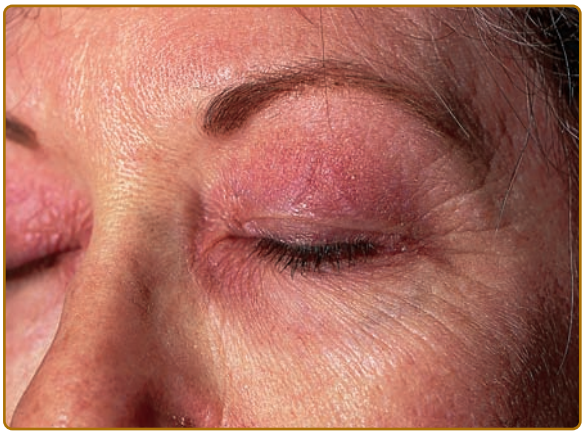

Figure 156-6 Periorbital confluent, macular, violaceous (heliotrope) erythema most prominent on the upper eyelids. Like Gottron papules and Gottron sign, this is a hallmark cutaneous feature of dermatomyositis.

cutaneous DM and cutaneous SCL (see Chapter 155) can occur in the same individual (sclerodermatomyositis).

Several other types of skin lesions have been suggested to be characteristic of IIDM; however, there is not yet enough published experience to determine their true disease specificity or prevalence. The mechanic's hand lesion consists of a nonpruritic, hyperkeratotic eruption accompanied by scaling, fissuring, and hyperpigmentation, which give the false appearance of the callused hands of a laborer. These changes are bilaterally symmetric and distributed along the medial aspect of the thumb and lateral aspect of the index and middle fingers. These hyperkeratotic changes can extend onto the palmar surface. A strong association between this skin lesion and the presence of active myositis and antisynthetase antibodies such as Jo-1 was originally suggested. However, subsequent observations indicate that this same skin change occurs in classic DM without all the elements of the antisynthetase syndrome, as well as in CADM.[51–53]

Table 156-2 presents the characteristic anatomic distribution of the hallmark cutaneous manifestations of DM. There is very little published information on the prevalence of involvement in these different anatomic locations. In some series reported by dermatologists, Gottron papules have been more commonly seen than periorbital heliotrope erythema, which by many outside of dermatology is felt to be the hallmark cutaneous manifestation of DM.

The violaceous hue of the cutaneous inflammation in lightly pigmented individuals is a striking clinical finding that usually is evident from the outset of disease activity. This hue helps to distinguish cutaneous DM from cutaneous LE, in which it is a late finding when present. It has been suggested that edema associated with the DM skin disease indirectly produces the violaceous hue by displacing the hyperemic cutaneous vasculature more deeply into the dermis. One might also speculate that this could result from the deoxygenation of blood flowing through an abnormal dermal microvascular bed. In this regard, it is interesting to note that cutaneous DM often presents in the skin over joints that is frequently stretched and thus often made to become transiently ischemic under normal physiologic conditions.

A striking clinical feature that helps to distinguish cutaneous DM from cutaneous LE is pruritus, which can be so severe in DM as to be disabling, even in the absence of systemic involvement. In addition to pruritus, DM patients often described severe burning, painful sensations associated with the DM skin inflammation. Some work has suggested that severe DM skin disease can have a greater impact on quality of life than other skin diseases such as psoriasis and atopic dermatitis for which aggressive systemic immunomodulatory therapies are often used.[54]

A number of other skin changes can be encountered in patients with DM. Hyperkeratosis may follow the onset of the confluent, macular, violaceous erythema;

TABLE 156-2
Anatomic Distribution of Hallmark Cutaneous Manifestations of Dermatomyositis

Anatomic Location	Lesions
Scalp	CMVE; nonscarring diffuse alopecia
Face	
Periorbital region	CMVE (usually most intense on the upper eyelids), edema
Malar eminences	CMVE sparing or involving the nasolabial fold[114]
Forehead, chin	CMVE
Neck and shoulders	
Anterior	CMVE evolving to poikiloderma
Posterior	CMVE (shawl sign)
Upper extremities	
Arms, forearms	CMVE on the extensor aspects
Elbows	CMVE usually most intense in this location (Gottron sign of dermatomyositis)
Hands, fingers	
Dorsal aspect	CMVE usually most intense over the extensor tendons and metacarpophalangeal/interphalangeal joints (Gottron sign), Gottron papules overlying the dorsal–lateral aspect of the metacarpophalangeal/interphalangeal joints, relative sparing of the dorsal aspects of the phalanges, periungual nail fold telangiectasia (often grossly visible), cuticular microvascular hemorrhage, dystrophic/ragged cuticles
Palmar aspect	Mechanic's hand lesion, mucinous plaques centered over the flexural creases
Trunk	CMVE evolving to large unilateral areas of poikiloderma (poikiloderma atrophicans vasculare) commonly seen over the flanks and lower back
Lower extremities	
Thighs	CMVE (holster sign)
Knees	CMVE (Gottron sign)
Lower legs, feet	CMVE, often focal, centered over the medial malleoli; Gottron sign overlying the medial malleoli

however, the scale in DM skin lesions is usually less prominent than that in subacute cutaneous LE and discoid LE. Secondary skin changes in DM skin lesions include excoriation with secondary infection and ulceration. Subepidermal vesicles and/or bullae occasionally occur in areas of particularly intense cutaneous inflammation. Postinflammatory pigmentary changes, both hyperpigmentation and hypopigmentation, occur. Older lesions may have white lacy markings somewhat similar to those of Wickham's striae in lichen planus. Another similarity between cutaneous DM and lichen planus is the characteristic violaceous hue. Mucinous infiltration, a common histologic finding in the dermis of DM skin lesions, can be clinically prominent, producing an infiltrated, glistening appearance. Superficial erosions and ulcers can subsequently develop over the face and eyelids as well as in other areas affected by intense and protracted inflammation. Deep, irregular, retiform ulcers can also develop in areas of poikiloderma in both adults and children. It has been suggested that the penetrating ulcers reflecting vasculopathy can be a bad prognostic sign in both juvenile-onset and adult-onset DM.

Clinical experience suggests that, as with cutaneous LE/SLE, the activity of IIDM can be precipitated or exacerbated by emotional and physical stress, although there is scant published evidence. Strenuous physical exertion can be detrimental to patients who have active myositis.

Magnetic resonance imaging (MRI) may identify edema/inflammation in skin, subcutaneous tissue, and fascia resulting from vasculopathy and vasculitis in patients with classic juvenile DM.[55] In approximately 80% of the 26 children studied, MRI abnormalities indicating skin, subcutaneous, and/or fascial edema were observed. Clinical skin disease activity scores correlated positively with MRI skin edema scores. Five children developed soft tissue calcification in areas previously found to be edematous by MRI after 4–9-month follow-up intervals. These observations suggest that the assessment of soft tissue by MRI could be of value in predicting risk for developing calcification and in monitoring treatment to prevent or minimize it.

DM can develop as a component of an overlap connective tissue disorder. Most common are overlaps with SLE (see Chapter 155) and systemic sclerosis (see Chapter 157). Raynaud phenomenon, sclerodactyly, sclerosis of the skin, and the characteristic hyperpigmentation can all be present in the latter setting. The term *sclerodermatomyositis* describes the disorder in patients who present with DM and who develop striking features of SCL 6 months to 3 years later. In addition, myositis occurs in approximately 5% of patients who test positive for anti-Ro/SSA autoantibody (most of whom have Sjögren's syndrome (see Chapter 161). The cutaneous manifestations of DM are not usually found in this setting.

The highly pruritic/burning scaling scalp involvement in patients with adult-onset classic DM and CADM that can be associated with nonscarring alopecia[56] has also been found to occur in approximately 25% of patients with juvenile-onset DM.[30] Localized scalp involvement can at times be the presenting manifestation of DM.

SYSTEMIC FEATURES

Table 156-3 outlines the systemic manifestations and associations of classic IIDM. Most of the extramuscular systemic features associated with classic DM have not been reported in CADM except for arthritis and interstitial lung disease.

MUSCLE DISEASE. Muscle involvement typically presents as symmetric weakness of the proximal muscles of the extremities. Lower-extremity weakness manifested as difficulty in performing routine activities of daily living, such as rising from a chair or bathtub and climbing stairs, is often the initial clinical finding. Weakness of the upper extremities soon follows, often manifested by difficulty in raising the arms above the head to perform routine activities such as combing the hair. Pain or tenderness in the affected muscle groups commonly occurs. Some patients experience a fulminant disease course that results in disabling weakness within a few weeks. Weakness involving the upper one-third of the esophagus and/or the laryngopharyngeal muscles may present as dysphagia or a hoarse voice (dysphonia), respectively.

Confirmation that proximal muscle weakness is caused by the inflammatory myositis of IIDM can be difficult, because so many other clinical disorders produce proximal muscle weakness (eTable 156-3.1 in online edition). The diagnosis can be supported by demonstration of characteristic elevations in serum levels of muscle enzymes (CK, aldolase) as well as identification of

TABLE 156-3
Systemic Manifestations/Associations of Dermatomyositis/Polymyositis

- Musculoskeletal
  - Myositis with proximal weakness
  - Muscle atrophy and contracture[a]
  - Muscular calcification[a]
- Cardiac
  - Cardiomyopathy
  - Conduction defects
- Respiratory
  - Dysphonia
  - Diffuse interstitial pneumonitis/fibrosis
  - Aspiration pneumonia
  - Respiratory failure from muscle weakness
- Gastrointestinal
  - Proximal dysphasia
  - Large bowel infarction/perforation secondary to vasculopathy[a]
- Ophthalmologic
  - Retinopathy[a]
  - Internal malignancy[b]

[a]Usually limited to juvenile dermatomyositis.
[b]Not significantly increased in juvenile dermatomyositis.

diagnostic changes in electromyography (EMG) results, muscle imaging, and muscle biopsy specimens. Some patients with CADM have low-grade, subclinical muscle disease (i.e., hypomyopathic DM). However, in some patients who express the hallmark cutaneous manifestations of DM, no symptoms of muscular weakness have developed for up to 28 years (unpublished personal observation, Richard D. Sontheimer).

Inclusion-body myositis is a pathologically distinctive type of steroid-resistant myositis that more commonly affects the distal muscle groups of men in an asymmetric pattern. Cutaneous involvement is not seen with this disorder or with classic PM.

A retrospective analysis encompassing all patients with DM seen at the Mayo Clinic between 1976 and 1994 revealed that 32 (4%) of 746 patients conformed to the definition of CADM[63]; 27 had amyopathic DM and 5 had what can be classified as hypomyopathic DM. Follow-up information was available on 16 of the patients with amyopathic DM. Ten had no muscle weakness after 2–10 years, four had no weakness at 1 year, and two developed weakness within 5 years after diagnosis. None of the three patients classified as having hypomyopathic DM showed evidence of muscle weakness 8–17 years after diagnosis. Thus, of these 19 patients with CADM, only 2 developed clinical evidence of myositis after prolonged periods of time. Therefore, the presence of subclinical muscle abnormalities at the time of diagnosis of CADM does not necessarily portend the subsequent development of clinically significant muscle disease.

Although fatigue and/or myalgia without objective evidence of muscle inflammation have been described in a number of CADM case reports, a single case report of documented fibromyalgia occurring in amyopathic DM has now appeared.[64] The symptoms of fatigue, muscle pain, and muscle tenderness associated with fibromyalgia could falsely imply the development of myositis in a patient with CADM. There continues to be debate concerning the risk that patients with juvenile-onset CADM will ultimately develop clinically significant myositis. Some groups see a relatively low risk,[65] whereas others see a relatively high risk.[66] For the definition of CADM to be fulfilled, clinical evidence of muscle weakness should not be present. Muscle strength testing is graded on a scale of 1–5, where 0 = no muscle action; 1 = trace contraction; 2 = visible contraction but with inability to overcome gravity; 3 = fair contraction with ability to overcome gravity; 4 = contraction with ability to offer some resistance; 5 = muscle contraction that cannot be overcome by the evaluator. The examination should focus on the proximal muscle groups that control the neck, shoulders, and hips. Manual muscle testing is reproducible; variables such as pain, contractures, voluntary effort, and motivation may influence the ability of an individual to exert maximal muscle effort.

PULMONARY DISEASE. Among the most feared nonmuscular systemic manifestations of IIDM is pulmonary disease. Lung function can be compromised in a number of ways in patients with classic DM: by a restrictive lung defect resulting from respiratory muscle weakness; by aspiration pneumonia secondary to gastrointestinal reflux and impaired esophageal muscle function; by opportunistic infections; or by interstitial pneumonitis related to the underlying autoimmune disease process. In addition, some systemic drugs used to treat DM can produce pulmonary complications (e.g., methotrexate hypersensitivity pneumonitis).

Interstitial pneumonitis resulting from both classic DM and CADM has been reviewed.[67,68] Between 5% and 40% of patients with classic DM develop interstitial lung disease [high-resolution chest computed tomographic (CT) scan can identify lung involvement earlier than can routine chest radiography]. This complication presents clinically with symptoms of nonproductive cough and exertional dyspnea that are accompanied by bibasilar fine crackling rales. Pulmonary function test results show a restrictive pattern with reduced diffusion capacity. Several clinical patterns of interstitial lung disease have been described: usual interstitial pneumonia, nonspecific interstitial pneumonia, diffuse alveolar damage, and bronchiolitis obliterans with organizing pneumonia.

Interstitial lung disease can present clinically as an acute/subacute type or a chronic type. In the acute/subacute type, patients experience severe, rapidly progressive dyspnea and progressive hypoxemia within a month of the onset of lung involvement. In such cases, the lung disease is often resistant to treatment, and patients are at risk for death. In the chronic type, patients experience a much slower pace of progressive dyspnea. Interstitial lung disease can also be identified by chest CT and/or pulmonary function tests in the complete absence of symptoms. It has been suggested that interstitial lung disease associated with the myositis-specific autoantibodies (antisynthetases) can occasionally occur in the absence of skin and muscle disease.[69] In some individuals, interstitial lung disease occurs before the clinical appearance of myositis. Patients with classic DM who have the antisynthetase syndrome (the presence of Jo-1, PL-7, PL-12, or other synthetase autoantibodies; arthritis; Raynaud phenomenon) have increased risk of developing interstitial lung disease. The antisynthetase syndrome and interstitial pneumonitis occur also in children with classic DM. Interstitial pneumonitis and air leakage were observed in one child with classic juvenile DM.[70]

Interstitial pneumonitis of various subtypes is increasingly being recognized as a potential complication of CADM.[29,71] Published data indicate that the prevalence of interstitial pneumonitis in CADM is approximately 13%.[29] A disproportionately high percentage of patients with CADM and interstitial lung disease has been reported in Japan related to the fact that interstitial pneumonitis appears to be an especially common complication of classic DM in the Japanese. Curiously, the acute/subacute pattern of disease presentation with rapidly progressive dyspnea, progressive hypoxemia, treatment resistance, and fatal outcome has been observed in CADM patients who develop interstitial pneumonitis and is less common in classic DM patients.[72] A recent study from Japan

demonstrated a 45% mortality rate in patients with CADM and interstitial lung disease vs. 6% in classic DM with interstitial lung disease.[73] However, this difference in mortality has not yet been demonstrated in other patient populations.[72]

In most cases, interstitial pneumonitis has occurred in patients with CADM in the absence of antisynthetase autoantibodies such as Jo-1, which are considered to be markers for interstitial lung disease risk in patients with classic DM and the antisynthetase syndrome. However, it has been suggested that newly observed autoantibodies to 140-kDa and 155-kDa autoantigens that appear to be highly specific for classic DM and CADM might serve as a marker for interstitial lung disease in Japanese CADM patients.[40]

The appearance of symptoms of interstitial pneumonitis, especially the acute/subacute type, in a patient with any form of DM should be considered a medical emergency, and the assistance of a pulmonary medicine specialist should be obtained as soon as possible to ensure proper diagnosis and therapy. Aggressive multidrug systemic immunosuppressive therapy is typically required in such cases, and the patient is often admitted to a pulmonary intensive care unit.[74]

ARTHRITIS. Arthritis occurs in 20% to 65% of patients with juvenile-onset classic DM.[75] Typically, this is a nonerosive arthritis involving knees, wrists, elbows, and fingers. It is seen early in the course of the disease. For some patients, arthritis can be a major symptomatic problem. Arthritis also occurs in some patients with juvenile-onset CADM. In one study, three of five patients with juvenile CADM followed over an average of 4.9 years were reported to have arthritis, whereas 49 of 80 children with classic DM had arthritis.[75]

LABORATORY TESTS

CLASSIC DERMATOMYOSITIS

MUSCLE ENZYMES. An elevation in the serum level of CK is the most sensitive and specific laboratory indicator of muscle disease activity in IIDM. Ninety percent of patients with classic IIDM have elevated levels of CK at some point. The elevated CK activity is caused primarily by the CK-MM isoenzyme (muscle form of CK); however, elevations caused by the CK-MB isoenzyme (muscle and brain form of CK) are also seen. Elevated levels of CK can be associated with some of the disorders listed in eTable 156-3.1 in online edition (e.g., other myopathies, hypothyroidism, and ingestion of certain drugs), as well as with strenuous physical exertion and needle trauma (intramuscular injection, EMG needle insertion). Enzymatic detection of CK activity can at times be inhibited by serum factors. Levels of CK may become elevated before the development of weakness and can normalize several weeks before the return of normal strength during treatment. Patients with IIDM who have normal CK levels may have a worse prognosis with respect to pulmonary disease and associated malignancy. Levels of CK are usually normal in patients with glucocorticoid-induced myopathy.

Serum aldolase level is a somewhat less sensitive indicator than CK for active myositis in IIDM. However, aldolase level is occasionally elevated in the presence of a normal CK level, especially in juvenile DM. Levels of transaminases (aspartate aminotransferase, alanine aminotransferase) and lactic dehydrogenase can also be elevated in active myositis, but these values are less useful clinically because of their low degree of specificity. Elevations of transaminase levels during treatment with methotrexate may reflect the activity of myositis as well as drug-induced hepatotoxicity. Urinary creatine excretion can also be used to monitor the status of myositis. However, the specificity is low because urinary creatine excretion can also be elevated in steroid myopathy. Serum myoglobin levels can also be elevated in severe IIDM.

AUTOANTIBODIES. Elevated antinuclear antibody (ANA) levels with human tumor cell substrates are found in 60% to 80% of patients with both classic DM and CADM.[29] Autoantibodies of known molecular specificity in DM are now categorized into two groups: (1) myositis-specific autoantibodies and (2) myositis-associated autoantibodies.[77,78] Myositis-specific autoantibodies include the antisynthetases [Jo-1, PL-7, PL-12, OJ, Mi-2, and signal-recognition particle (SRP)]. PM/Scl, Ro/SSA (Ro52, Ro60), and U1RNP represent the major myositis-associated autoantibodies. Table 156-1 lists the molecular specificities and clinical correlations of these autoantibodies. The fact that none of the myositis-specific autoantibodies occurs with a prevalence greater than one in five patients with DM makes routine testing for these autoantibodies of little clinical use.

Among the most frequently encountered myositis-specific autoantibodies are those that target the various aminoacyl-transfer RNA synthetases. Of these antisynthetase autoantibodies, autoantibodies to Jo-1 (histidyl-transfer RNA synthetase) are the most common and are found in 20% of patients with classic IIDM overall and 30% to 40% of adult patients with PM. Fever, interstitial lung disease, polyarthritis, Raynaud phenomenon, and incomplete response to therapy occur more often in patients who produce these antibodies (antisynthetase syndrome), as does the mechanic's hand skin lesion. Patients who produce Jo-1 antibodies less frequently display the classic cutaneous manifestations of DM.

SRP antibodies occur in 5% of patients with PM and are more common in those who exhibit acute-onset, severe, treatment-resistant forms of classic IIDM with cardiac involvement. Such patients rarely have any type of skin involvement. Autoantibodies to Mi-2, a nuclear protein complex containing histone deacetylase and nucleosome remodeling activities, are seen almost exclusively in patients with classic DM. Mi-2 antibody is found in 5% to 10% of patients with classic IIDM overall and in 15% to 20% of patients with classic DM. This autoantibody is associated with more treatment-responsive forms of classic DM as well as with the shawl sign and prominent cuticular changes.

The clinical correlations of the myositis-specific autoantibodies found in adults (e.g., Jo-1) also occur in children with classic IIDM. IIDM autoantibodies that currently have less clinical significance are also listed in Table 156-1. An autoantibody to a 155-kDa nuclear antigen (transcriptional intermediary factor-1γ)[7] has recently been reported to be highly specific for classic DM and CADM. In classic DM patients, this antibody has been suggested to be associated with an increased risk for internal malignancy.[79]

SPECIAL TESTS (INCLUDING IMAGING STUDIES)

ELECTROMYOGRAPHY. The EMG changes of myositis include a myopathic pattern of the motor unit action potential, a myopathic recruitment pattern, increased insertional activity, and increased spontaneous activity. EMG changes of myositis can be erratically distributed. EMG recordings from the paraspinous muscles can be abnormal when those from the limb girdle musculature are normal. As many as 10% of patients with biopsy-documented myositis have normal EMG findings.

MUSCLE BIOPSY. Muscle fiber degeneration/regeneration, perifascicular atrophy, and capillary injury are frequently present in the muscle biopsy specimens of patients with IIDM. A perivascular infiltrate of T lymphocytes and histiocytes and, occasionally, of B lymphocytes, plasma cells, and eosinophils is also seen. Biopsy specimens from patients with DM often show CD4 T cells and B cells in the perivascular areas, whereas CD8 T cells preferentially associate with damaged muscle fibers in patients with PM. The capillary density in muscle specimens from patients with DM is decreased. Inflammation may be absent in up to 25% of biopsy specimens from patients with otherwise typical muscle disease by clinical, EMG, or biochemical criteria.

An occlusive vasculopathy is a striking aspect of the pathology of juvenile-onset classic DM. Phlebitis and arteritis leading to intimal hyperplasia, fibrinous occlusion of vessels, and infarction of the involved tissues can be seen. The muscles, gastrointestinal tract, and nerves are particularly affected. This vasculopathy in muscles is noninflammatory and occurs predominately in the capillaries. There is a spectrum of endothelial changes from swelling to obliteration to necrosis. In muscles this occlusive vasculopathy is most commonly seen in small vessels, resulting in microvascular ischemia. The local production of interferon-induced angiostatic ELR-negative CXC chemokines has been implicated as a pathogenetic factor in the vasculopathy of juvenile-onset DM.[85]

MUSCLE IMAGING. Myositic inflammation can be highly focal. A number of noninvasive techniques are currently being examined for their ability to localize affected muscle groups. MRI is the method of choice for diagnostic imaging of muscle abnormalities in patients with myositis.[86] However, the MRI signal associated with myositis is not specific for IIDM muscle involvement. The possibility that MRI-guided needle biopsy could obviate the need for the more costly and invasive open muscle biopsy is being explored. In addition, MRI and phosphorus-31 magnetic resonance spectroscopy are also useful in assessing the status of muscle disease activity during treatment with systemic glucocorticoids and other immunosuppressive drugs. These procedures are expensive and cannot be used in some individuals with metallic implants. Less costly approaches to monitoring muscle disease activity, such as power Doppler and grayscale ultrasonography and ultrasonography with contrast material are being examined.[87]

Functional metabolic changes in muscles identified by magnetic resonance spectroscopy have been especially evident on exercise in some patients with amyopathic DM (such patients would better be

BOX 156-1 DIFFERENTIAL DIAGNOSIS OF DERMATOMYOSITIS (DM)

CLASSIC DM

Most Likely

- Few illnesses can be confused with the fully expressed combination of hallmark skin changes and proximal weakness seen in classic DM. However, treatment with certain drugs, such as statin lipid-lowering agents, has been reported to be capable of triggering the appearance of both the cutaneous and muscle manifestations of DM.

Consider

- There are a number of causes of proximal muscle weakness other than myositis (see eTable 156-3.1 in online edition). It is possible that co-occurrence of one of these other causes of proximal muscle weakness with a common dermatologic condition mimicking the early manifestations of cutaneous DM could be confused with classic DM.

CLINICALLY AMYOPATHIC DM

Most Likely

- Cutaneous lupus erythematosus (acute cutaneous lupus erythematosus or subacute cutaneous lupus erythematosus, but not discoid lupus erythematosus)

Consider

- Seborrheic dermatitis
- Contact dermatitis
- Lichen planus
- Psoriasis
- Polymorphic light eruption
- Atopic dermatitis
- Overlap connective tissue disease
- DM-like skin changes induced by drugs (e.g., hydroxyurea, statins)

classified as having hypomyopathic DM). Artificial neural networks have been proposed as an effective way to analyze the multichannel functional data that result from phosphorus-31 magnetic resonance spectroscopy examination.[88] A central issue in this area is whether the subtle muscular abnormalities that can be identified with these sensitive imaging systems have true prognostic value.

DIFFERENTIAL DIAGNOSIS

(Box 156-1)

In the earlier stages, cutaneous DM might be confused with contact dermatitis, seborrheic dermatitis, lichen planus, psoriasis, polymorphic light eruption, and atopic dermatitis. In the later stages, when the more typical cutaneous manifestations of DM have evolved, the greatest challenge can be to distinguish the skin involvement of DM from that of cutaneous LE, especially acute cutaneous LE and subacute cutaneous LE (Table 156-4).

Periorbital heliotrope erythema and edema can occasionally be observed in SLE, but fully formed Gottron papules are never seen as a cutaneous manifestation of LE. It has been the authors' experience that, excluding the rare occurrence of hydroxyurea- or statin-induced DM-like skin changes, the concurrent presence of Gottron papules and grossly visible periungual nail fold telangiectasia is pathognomonic of DM skin disease. Pruritus or related dysesthetic symptoms such as burning pain are typical of DM skin inflammation, whereas the various forms of LE-specific skin disease are characteristically not pruritic.

TABLE 156-4
Comparative Features of Skin Involvement on Dermatomyositis and Lupus Erythematosus

	Dermatomyositis	Lupus Erythematosus
Distribution		
Face		
Malar eminences	+	++
Eyelids, periorbital areas	++	+
Scalp	++	++
Oral mucosa	+	++
Extensor arms, forearms	++	++
Hands		
Dorsal aspect	++	++
Palmar aspect	+	+
Dorsal fingers	+	++
Knuckles	++	+
Periungual telangiectasia	++	+
Color of skin lesions		
Violaceous	++	+
Red, pink	+	++
Alopecia	+	++
Hyperkeratosis	+	++
Gottron papules	++	0
Pruritus	++	+
Pathology		
Dermal mucinosis	++	++
Intense mononuclear cell infiltrate	+	++
Immunopathology		
Dermal–epidermal junction immunoglobulin, complement band	+	++
Dermal microvessel C5 to C9 deposits	++	+
Laboratory findings		
Antinuclear antibodies	++	++
Anti-Ro/SSA	+	++
Antinative DNA	0	++
Anti-Sm	0	++
Elevated erythrocyte sedimentation rate	+	++
Malignancy association	++	0

++ = frequently seen; + = occasionally seen; 0 = absent.

From Euwer RL, Sontheimer RD: Dermatomyositis. In: *Cutaneous Manifestations of Rheumatic Disease,* edited by Sontheimer RD, Provost TT Baltimore, Lippincott Williams & Wilkins, 1996, p. 73, with the permission of Lippincott Williams & Wilkins.

The pattern of involvement over the hands also differs; in LE the skin over the dorsal interphalangeal and metacarpophalangeal joints is spared, and the hair-bearing skin between these joints is preferentially involved. The opposite is true for DM: the skin overlying the dorsal interphalangeal and metacarpophalangeal joints is preferentially affected (see Fig. 156-4). However, when extensive, the linear streaking of violaceous erythema that tracks over the extensor tendons of the hands and fingers can sometimes obscure this point of differential diagnosis.

Poikiloderma commonly occurs in DM patients. Various forms of "poikilodermatous" cutaneous LE have also been reported. However, it has been the authors' personal experience that most of the patients with "poikilodermatous LE" that have been referred to them have turned out to have CADM. For most physicians outside of dermatology, the absence of clinically evident muscle weakness reflexively prevents further consideration of cutaneous DM, no matter how typical the skin features might be. This confusion is exacerbated by the fact that the majority of CADM patients test positive for ANA.

In addition, multicentric reticulohistiocytosis (see Chapter 148) has been reported to masquerade as DM. However, the "string of pearls" papules that occur in the periungual areas in multicentric reticulohistiocytosis can be clearly distinguished from the periungual inflammatory changes of DM by clinical and pathologic examination. Many conditions other than IIDM can be associated with proximal muscle weakness.[89] eTable 156-3.1 in online edition outlines these disorders.

As previously noted (see Section "Epidemiology"), drugs such as hydroxyurea, penicillamine, niflumic acid/diclofenac, phenytoin, tryptophan, and practolol have been reported in rare cases to produce an eruption with clinical similarities to the hallmark cutaneous features of DM. In addition, statin-type lipid-lowering drugs (atorvastatin, fluvastatin, lovastatin, pravastatin, rosuvastatin, simvastatin) and other classes of lipid-lowering drugs (fenofibrate, gemfibrozil) are well known to produce a drug-induced myositis and/or rhabdomyolysis that can simulate the myositis seen in DM. However, considering the high rate of usage of these drugs, confirmed reports of statins and other lipid-lowering drugs triggering the hallmark cutaneous manifestations of DM are quite rare. To prove that a case of classic DM or CADM is drug induced would require a rechallenge with the suspected drug once the cutaneous and/or muscle manifestations of DM have remitted. Few patients or physicians would be willing to do this, and the ethics of such an attempt could be questioned.

COMPLICATIONS

CUTANEOUS ULCERATION

Cutaneous ulcers are more common in juvenile than in adult classic DM and appear to be quite rare in both juvenile and adult CADM. The skin can ulcerate in DM as a result of a number of different mechanisms. Superficial erosion/ulceration can develop from vesiculobullous changes occurring within intensely inflamed DM skin lesions. Retiform ulcers can result from skin breakdown in poikilodermal areas. Deep penetrating ulcers can result from cutaneous infarction secondary to vasculopathy. The skin can ulcerate as a result of pressure from underlying calcium deposits. In addition, leg ulcers are a component of the clinical constellation of hydroxyurea-induced DM skin changes. Because of their frequent association with vasculopathy, deeply penetrating cutaneous ulcers have traditionally been thought to be a poor prognostic sign. One of the authors (Melissa I. Costner) has noted that deeply penetrating ulcers may correlate with pulmonary involvement in DM.

SYSTEMIC VASCULOPATHY

Clinical manifestations of systemic vasculopathy are seen most often in patients with juvenile-onset classic DM. This can result in perforation of the gastrointestinal tract, ocular damage, and central nervous system damage.

CALCINOSIS

Extraosseous calcification is also more common in children than in adults with classic DM. As with cutaneous ulceration and systemic vasculopathy, calcinosis is seen less commonly in both children and adults with CADM. The higher rate of vasculopathy that occurs in juvenile DM is thought to be a forerunner of dystrophic calcification. Approximately 25% of children with classic DM have dystrophic calcification at the time of diagnosis, and 40% to 50% develop calcinosis sometime during the course of their illness.

DM patients experience several different patterns of calcinosis. In adults, cutaneous calcification often presents as firm dermal and/or subcutaneous papules or nodules that are often most prominent around the elbows and hands. Large subcutaneous tumoral deposits can also occur over the trunk of adults. Such lesions can be filled with a liquid suspension of calcium crystals (i.e., "milk of calcium"). Four types of calcification have been described in children with DM: (1) a superficial pattern consisting of small, firm nodules and plaques in the skin; (2) periarticular subcutaneous nodules (calcinosis circumscripta); (3) deposition along fascial planes in muscles (calcinosis universalis); and (4) a severe "exoskeleton" pattern of deposition in the subcutaneous tissue. Calcinosis cutis or calcium deposition in muscles and tendons is more common in the late phases of the disease in children. The TNF-α-308A promoter polymorphism might represent a risk factor for developing calcinosis.[8] The complications of calcinosis, such as ulceration and sepsis, are a significant cause of both morbidity and mortality in patients with juvenile classic DM.

INTERNAL MALIGNANCY

Population-based studies document that adult-onset classic DM is associated with a higher than expected risk for internal malignancy.[90–94] Relative risks for malignancy range from 2.4 in males with DM to 3.4 in females with DM. The risk for malignancies was negligible in patients with PM. During the 5-year period after the diagnosis of DM, the risk of a woman developing ovarian cancer in these studies was 16.7-fold higher than the risk for women without DM. In a more recent study, the standardized incidence ratio for malignancy in adult patients with DM was 6.5.[91] In the first year after diagnosis, the relative risk for malignancy in patients with DM was 26.0. Females with DM in this study had a 32-fold higher risk of developing ovarian carcinoma. This study also found that PM was not associated with an increased risk of cancer and that the treatment of DM with cytotoxic drugs did not increase the risk of malignancy. Because of the risk of ovarian cancer in females with DM, it has been suggested that all women with DM (classic DM and CADM) undergo an initial comprehensive gynecologic examination and repeat examinations at 6–12-month intervals for at least the first 2 years after the diagnosis. Determination of serum levels of cancer antigen-125 and transvaginal ultrasonography have been recommended for females with DM who have intact ovaries. However, it is an unfortunate fact that there is no foolproof way to screen for early ovarian cancer.

Tumors other than ovarian carcinoma have been reported with DM, including melanoma, mycosis fungoides, and Kaposi sarcoma. Carcinomas are more frequent than sarcomas, and lymphoproliferative malignancies are uncommon. Except for ovarian cancer in women, no preponderance of specific types of cancer is seen in whites with IIDM. Asian males most frequently develop nasopharyngeal carcinoma.[90,91]

The diagnosis of cancer is most often made by history, review of systems, physical examination, and routine laboratory and radiologic testing. Debate exists about the routine use of surveillance imaging techniques, such as chest, abdominal, and pelvic CT and/or MRI in this setting. Age appears to be a factor in malignancy risk. There is not a significant risk of occult malignancy in patients with juvenile-onset classic DM,[95] whereas individuals 50 years of age or older at the time of onset of classic DM appear to have a definite increased risk of malignancy (20% to 30%). The leading cause of death in patients with IIDM who have malignancy is metastatic spread of the malignancy rather than complications directly related to myositis. In patients with malignancy, the myositis and cutaneous manifestations are less responsive to systemic glucocorticoid therapy. In a few well-documented cases, definitive therapy for the malignancy resulted in resolution of the DM disease activity, and a recurrence of the cancer was associated with the reappearance of DM activity.

Older age, greater extent and severity of skin disease [i.e., intense generalized erythema ("malignancy suffusion"), blistering, ulceration], and elevated CK levels appear to enhance the risk of malignancy in adults with classic DM. It has been suggested that other systemic manifestations of DM, such as interstitial lung disease, are negatively correlated with risk for internal malignancy.[27] All routine age- and sex-directed malignancy surveillance guidelines should be followed.

OPPORTUNISTIC INFECTIONS AND LYMPHOMA

Early initiation of aggressive systemic immunosuppression is required for both juvenile-onset and adult-onset classic DM. Because DM frequently pursues a chronic and/or recurring course, such patients frequently are exposed to the consequences of long-term use of specific immunosuppressive regimens, including a panoply of opportunistic systemic infections (bacterial, mycobacterial, viral, fungal) and opportunistic infection-induced lymphoma (Epstein–Barr virus infection).[96,97]

PROGNOSIS AND CLINICAL COURSE

CLASSIC DERMATOMYOSITIS

GENERAL CONSIDERATIONS. Reported mortality rates vary from 25% to 80%, depending on the case mix and the medical era in which the cases were collected.[98,99] The 5- and 8-year survival rates for 76 patients with IIDM studied in the 1980s were 80% and 73%, respectively. Global survival rates for the IIDMs have been more reported to be 95%, 92%, and 89% for 1, 5, and 10 years, respectively. Pulmonary and cardiac complications were the most frequent causes of death. Cancer-associated myositis had the worst prognosis, whereas juvenile-onset and overlap myositis had the best. Five- and 10-year survival rates were 94.2% and 89.4% for patients with primary PM and 90.1% and 86.4% for those with primary DM.[100] Individuals who receive early systemic treatment for their disease have a better prognosis. The early, aggressive use of glucocorticoids has reduced the mortality rate in children to less than 10%.

CLINICALLY AMYOPATHIC DERMATOMYOSITIS

Data are not available to allow adequate discussion of mortality in either adult-onset or juvenile-onset CADM. Individual reports of death from occult malignancy and interstitial lung disease in adult-onset CADM have appeared.[29]

Insufficient long-term follow-up data are available to assess prognosis and clinical course in adults or children with CADM. All six patients in one cohort with adult-onset disease who initially had only skin disease and who were treated conservatively ultimately

developed muscle disease.[101] In another cohort, none of the five adults with CADM treated aggressively with high-dose systemic glucocorticoids developed clinical evidence of myositis.[102] Both of these small case series could have suffered from case selection/publication bias.

A systematic review of adult-onset CADM identified 291 cases among which there was a 13% incidence of interstitial lung disease and 14% incidence of associated internal malignancy.[29] However, this compilation of individual case reports and small case series is likely to have also been affected by reporter bias. Population-based studies of the epidemiology and management of CADM are greatly needed to address this and other clinical issues relating to this subtype of DM.

One study has suggested that patients with juvenile-onset DM who have only the cutaneous manifestations are usually not treated aggressively and may frequently develop pathologic calcifications.[66] This report is contrary to the findings of other studies of CADM in both children[65] and adults,[25,63] which have indicated that this mode of presentation is usually not associated with a high rate of subsequent dystrophic calcification. One study, indicating that both rheumatologists and dermatologists tend to be conservative in treating patients with CADM,[65] also reported that a high percentage of patients with juvenile-onset CADM enjoy spontaneous remission without systemic immunosuppressive treatment.

TREATMENT

The following discussion of the clinical management of DM skin disease is the product of published anecdotal observation by others, expert opinion by others, and the personal clinical experience of the authors. The goals of treatment of DM are to arrest inflammation in the skin and muscles and obtain a clinical remission. Improvement of both the clinical and laboratory features of the disease should be objectively monitored incrementally over time during treatment. The Cutaneous Dermatomyositis Disease Area and Severity Index (CDASI) appears to be a reproducible assessment tool to measure change in the cutaneous features of DM during treatment.[103]

The treatment of CADM patients differs from that of classic DM patients only in the absence of the need to treat symptomatic inflammatory myositis. The cutaneous manifestations of classic DM and CADM respond similarly to aggressive systemic immunosuppressive therapy; however, this therapy is difficult to justify in some cases of CADM when nonimmunosuppressive topical and systemic measures might be of benefit.

LOCAL TREATMENT

Patients with either classic DM or CADM should avoid excessive sun exposure and use effective broad-spectrum sunscreens. An in-depth discussion of practical and theoretical photoprotection and local therapy for autoimmune connective tissue skin disease such as DM has been presented elsewhere.[104] However, efforts should be made to insure that vitamin D deficiency does not occur.

Topical glucocorticoids (classes I and II) can dampen cutaneous inflammation and pruritus, and such agents can be used safely for prolonged periods of time when administered cyclically (2 weeks of daily treatment followed by 2 weeks off treatment). However, these agents alone usually cannot fully suppress DM skin disease activity. Daily use of a medicated shampoo followed by application of a topical class I and II glucocorticoid solution, gel, spray, or foam to the affected areas can provide relief for scalp pruritus. Xerosis is often present, especially in the elderly, and effective moisturization regimens can be of value in managing the pruritus often experienced by patients with DM. Topical antipruritic agents such as combinations of menthol/phenol/camphor, pramoxine, and doxepin can provide short-term relief.

Pulsed dye laser therapy has been advocated for the cosmetic treatment of the residual poikilodermatous skin changes that can follow in the wake of active cutaneous DM.[105]

SYSTEMIC TREATMENT

When nonimmunosuppressive systemic therapy is possible, its use should be maximized. Nonsedating or sedating antihistamines can be used during the day as appropriate. Doxepin, a tricyclic antidepressant, is a potent H_1 and H_2 receptor-blocking antihistamine. When given at bedtime in doses of 10–50 mg titrated to the degree of somnolence the next morning, this long-acting antihistamine can ameliorate the pruritus and excoriation that often occur during sleep. The addition of cimetidine 200–400 mg four times daily for its histamine H_2 receptor-blocking ability can also be helpful. With the appropriate precautions, oral naltrexone and mirtazapine may be used to treat the intractable pruritus and burning sensations that can be seen in this setting.

ANTIMALARIALS. Hydroxychloroquine sulfate (6 mg/kg given as two divided doses per day) has been used to treat DM skin disease. Hypersensitivity reactions to hydroxychloroquine may occur at higher frequencies in DM patients than in other patient groups.[106]

Some DM patients will respond better to a combination of hydroxychloroquine and quinacrine, 100 mg/day, or to chloroquine (3.5 mg/kg/day) and quinacrine (100 mg/day)[107] than to hydroxychloroquine alone (see Fig. 156-3). However, even combination antimalarial therapy will not adequately control the cutaneous symptoms of many DM patients. Precautions should be taken to minimize the risk of retinal toxicity with hydroxychloroquine or chloroquine and of hematologic toxicity with quinacrine. If extrapolation from the experience gained from patients with cutaneous LE is valid, patients with DM who smoke cigarettes may be less responsive to antimalarial therapy than those

who do not smoke. On rare occasion, antimalarials can contribute to muscular weakness by causing a toxic vacuolar myopathy. Other nonimmunosuppressive systemic therapies may benefit in cutaneous DM include dapsone[108,109] and antiestrogen therapy.[110]

SYSTEMIC GLUCOCORTICOIDS. Systemic glucocorticoids remain the traditional first-line therapy for classic DM. Early intervention with systemic glucocorticoids is associated with a better overall prognosis. In adults, prednisone (prednisolone for those with decreased liver function) is given orally in divided doses of 1.0–1.5 mg/kg/day, whereas in children the dosage is 1–2 mg/kg/day. Significant improvement of muscle strength, normalization of muscle enzyme levels, and improvement in cutaneous inflammation are the endpoints of therapy. Most patients require 1–3 months of full-dose treatment with prednisone. When symptoms improve, the dose can be consolidated from a divided dose to a single daily dose given in the morning to reduce the risk of adrenal suppression and other glucocorticoid side effects. The glucocorticoid dosage can then be progressively decreased. Treatment should be continued for 12 to 24 consecutive months to minimize the chance for recurrence. Attention should be paid from the outset to managing the side effects of long-term systemic glucocorticoid use such as osteoporosis. Calcium loss from bones starts within the first 3 months after initiation of systemic corticosteroid therapy.

In acutely ill patients, intravenous pulse therapy with methylprednisolone can be used. This approach has become increasingly popular in the management of juvenile DM. Alternate-day glucocorticoid administration usually does not provide adequate relief during active phases of the disease. The cutaneous lesions of DM can be refractory to high-dose, long-term glucocorticoid therapy in some patients. Other patients have recrudescent disease activity only in the skin after complete suppression of muscle disease with systemic immunosuppressive therapy.

Systemic glucocorticoids and other systemic immunosuppressives can be used to treat disabling skin disease activity in patients with CADM. However, it remains to be determined whether early aggressive immunosuppressive treatment of CADM might prevent the subsequent development of clinically significant myositis in the minority of CADM patients in whom this occurs.

Approximately 25% of patients with classic DM do not respond adequately to systemic glucocorticoids within the first 2 months of treatment. Azathioprine (2–3 mg/kg/day), cyclophosphamide (1–2 mg/kg/day), methotrexate (7.5–50 mg/week), chlorambucil (2–6 mg/day), cyclosporine (3–5 mg/kg/day), and mycophenolate (1–3 g/day) have been used in this setting in patients who cannot tolerate the side effects of prolonged high-dose glucocorticoid therapy.

METHOTREXATE, CYCLOSPORINE, MYCOPHENOLATE MOFETEL, AND CYCLOPHOSPHAMIDE. Methotrexate (7.5–25.0 mg) given once weekly by mouth has been successful in the treatment of patients with classic DM and some patients affected primarily by the cutaneous manifestations of DM. Higher dosages can be given subcutaneously or intravenously; administration by the intramuscular route may cause spurious elevation of muscle enzyme levels. Cyclosporine and cyclophosphamide have each been reported to be of benefit in treating severe complications of interstitial lung disease in patients with CADM, especially when started before frank respiratory failure has developed.[111,112] In children, oral cyclophosphamide (2–4 mg/kg/day) has traditionally been used in cases that could not be managed satisfactorily with systemic glucocorticoids. Mycophenolate mofetil has been tried with some effectiveness in recalcitrant DM.[113] There are also early indications that it may be beneficial in the setting of interstitial lung disease.[114] High-dose intravenous γ globulin therapy has been used in both children and adults in this setting and has the advantage of low toxicity. Plasmapheresis and leukapheresis appear to have little additional value in the management of IIDM.

ANTITUMOR NECROSIS FACTOR-α AND OTHER IMMUNOBIOLOGIC AGENTS. Based on experimental evidence indicating a role for TNF-α in the pathogenesis of the muscle inflammation in classic DM, anti-TNF-α therapy has been used anecdotally to treat both the muscular and cutaneous manifestations of DM. A small number of cases of severe, therapy-resistant DM have been successfully treated with etanercept (Enbrel) or infliximab (Remicade).[115] More systematic study is needed to define the value of this treatment. Such therapy would have to be used with caution because of the possibility of its uncovering other patterns of systemic autoimmunity (e.g., SLE). In addition, anecdotal reports have appeared suggesting benefit from the use of rituximab, a depletor of memory B cells, in patients with therapeutically refractory DM.[116,117]

B cells have also been implicated in the pathophysiology of DM. Studies of therapy with rituximab (a CD20 B cell-depleting antibody) have provided encouraging results in patients whose disease responded poorly to other treatments.[117,118]

TREATMENT OF CLINICALLY AMYOPATHIC DERMATOMYOSITIS

Current approaches to the treatment of adults and children with CADM are based on anecdotal observations of individual cases or a relatively small case series. One approach has been to treat patients with CADM aggressively from the outset with systemic glucocorticoids in the hope that progression to systemic involvement might be delayed or prevented.[102] This approach is supported by studies of patients with both juvenile- and adult-onset classic DM, which indicate that early systemic immunosuppressive treatment can lessen long-term disability from muscle dysfunction and complications such as calcification. However, in the large majority of published reports to date, a more

conservative approach has been taken to the treatment of CADM.[20,29,124] This approach is validated by reports of patients with CADM who go 10 to 28 years and longer without any sign of disease activity or damage other than in the skin.[1,63,64,125]

Until it is confirmed that adult patients with CADM do not have a significantly increased risk of internal malignancy, they should be evaluated for this potential complication in a manner similar to for patients with classic DM. Because internal malignancy has not been reported to be associated with juvenile-onset classic DM or CADM, it can be assumed that routine evaluation for internal malignancy is not indicated in this population.

KEY REFERENCES

Full reference list available at www.DIGM8.com

DVD contains references and additional content

5. Sontheimer RD et al: Dermatomyositis. In: *Cutaneous Manifestations of Rheumatic Diseases*, 2nd edition, edited by RD Sontheimer, TT Provost. Baltimore, Williams & Wilkins, 2004, p. 65
23. Pachman LM et al: TNFalpha-308A allele in juvenile dermatomyositis: Association with increased production of tumor necrosis factor alpha, disease duration, and pathologic calcifications. *Arthritis Rheum* **43**:2368, 2000
29. Gerami P et al: A systematic review of adult-onset clinically-amyopathic dermatomyositis: A missing link in the spectrum of the idiopathic inflammatory myopathies. *J Am Acad Dermatol* **54**:597, 2006
30. Peloro TM et al: Juvenile dermatomyositis: A retrospective review of a 30-year experience. *J Am Acad Dermatol* **45**:28, 2001
40. Sato S et al: Autoantibodies to a 140-kd polypeptide, CADM-140, in Japanese patients with clinically amyopathic dermatomyositis. *Arthritis Rheum* **52**:1571, 2005
48. Wenzel J et al: Type I interferon-associated skin recruitment of CXCR3+ lymphocytes in dermatomyositis. *Clin Exp Dermatol* **31**:576, 2006
54. Hundley JL et al: Cutaneous symptoms of dermatomyositis significantly impact patients' quality of life. *J Am Acad Dermatol* **54**:217, 2006
85. Fall N et al: Association between lack of angiogenic response in muscle tissue and high expression of angiostatic ELR-negative CXC chemokines in patients with juvenile dermatomyositis: Possible link to vasculopathy. *Arthritis Rheum* **52**:3175, 2005
90. Sigurgeirsson B et al: Risk of cancer in patients with dermatomyositis or polymyositis. A population-based study. *N Engl J Med*. **326**:363, 1992
117. Levine TD: Rituximab in the treatment of dermatomyositis: An open-label pilot study. *Arthritis Rheum* **52**:601, 2005
118. Noss EH, Hausner-Sypek DL, Weinblatt ME: Rituximab as therapy for refractory polymyositis and dermatomyositism. *J Rheumatol* **33**:1021, 2006
124. Plamondon S, Dent PB: Juvenile amyopathic dermatomyositis: Results of a case finding descriptive survey. *J Rheumatol* **27**:2031, 2000

Chapter 157 :: Scleroderma

:: P. Moinzadeh, Christopher P. Denton, T. Krieg, & Carol M. Black

SYNOPSIS AT A GLANCE

- Systemic sclerosis (SSc) is a multisystemic disease, characterized by excessive fibrosis, inflammation, and vasculopathy.
- The pathogenesis of this autoimmune process remains unclear.
- Differential diagnosis of SSc includes severe forms of localized scleroderma as well as many other scleroderma-like conditions.
- Patients with SSc are classified into two major subtypes depending on the extent of skin sclerosis [diffuse systemic sclerosis (dSSc) and limited systemic sclerosis (lSSc)]. Patients with an overlap syndrome, are characterized by additional clinical features of other rheumatic diseases.
- Raynaud phenomenon (RP) and skin sclerosis are almost always present.
- SSc is defined by sclerotic/fibrotic alterations of the skin and internal organs (digestive tract, lung, kidney, and heart), which can lead to severe dysfunction of almost any visceral organ.
- The heterogeneity and clinical course of SSc requires the urgent need of interdisciplinary collaborations and regular, at least yearly, follow-up visits.
- Although the disease is still not curable, there have been substantial advances in therapy for organ-based complications of SSc.

DEFINITION AND EPIDEMIOLOGY

Systemic sclerosis (SSc) is a rare, multisystem disease, based on autoimmunological processes, vascular endothelial cell injury and an extensive activation of fibroblasts. It is characterized by a large individual variability in the extent of skin and organ involvement, as well as in disease progression and prognosis. The skin, esophagus, lung, heart and kidneys are the most frequently affected organs.

Women are more frequently affected by SSc, with a female-to-male ratio between 3:1 up to 14:1.[1–4] The age of disease onset ranges between 30 and 50 years.[4] However, male patients have earlier onset than female patients. Blacks with SSc are frequently younger than whites. Published data about incidence rates increased from 0.6 to 16 patients per million inhabitants, which is also true for the prevalence rates, which rose from 2 to 233 patients per million inhabitants per year,[1–3,5] depending on methodological differences in case definition and ascertainment as well as the investigated time period.

SSc has the highest case-specific mortality of any of the autoimmune rheumatic diseases, but it varies individually depending on racial or ethnic differences, presence and severity of organ involvement, SSc subsets, age at diagnosis and gender differences. Although not curable, there have been substantial advances in treatment options for organ-based complications of SSc.

ETIOLOGY AND PATHOGENESIS

The pathogenesis of this complex disease involves multiple cell types (endothelial cells, epithelial cells, fibroblasts, and lymphocytic cells) interacting through a variety of mechanisms that are dependent on their microenvironment and key mediators.

Major facets of the disease include inflammation, vasculature, and connective tissue-producing cells. The clinical heterogeneity of SSc makes it likely that distinct pathogenetic mechanisms predominate in particular patients or subsets of disease. Similarly, it is likely that the mechanisms are not the same at different stages of SSc. Although a genetic component to etiopathogenesis is likely and evidence supports genetic factors in severity and susceptibility, there is also strong evidence supporting environmental and chemical factors as triggers for the disease.

GENETIC FACTORS

The best evidence for a genetic contribution to SSc comes from studies that report familial clustering and from the limited twin studies that have been undertaken. Although the absolute risk for familial occurring SSc is relative low, the relative risk for first-degree relatives is 13-fold higher compared to the normal population.[6] Several studies suggest that a positive family history for SSc is the strongest risk factor, but ethnicity also contributes.[6] Assassi et al suggest that members of SSc-affected families tend to show concordant scleroderma-specific autoantibodies.[7] Studies of the whole-genome microarray expression studies of skin biopsies and circulating blood cells support the involvement of multiple and complex pathways in the development of SSc.[6] Further support is provided from genetic association studies with candidate gene approaches. Most success has been observed in genetic analysis of individual components of the disease such as autoantibody profiles. These appear to have a strong genetic determinant, and this may underlie the apparent mutual exclusivity of the SSc hallmark reactivities. It has been demonstrated that the ability to mount an immune response to a particular SSc-associated antigen is restricted by major histocompatibility complex haplotype. Several studies suggest an association of HLA-DRB1*1302, DQB1*0604/0605 haplotypes with antifibrillarin positive patients,[8] while HLA SRB1*0301 occurs in patients with anti-Pm-Scl antibodies.[9] Observation from a large number of studies examining genetic markers has identified a number of candidate genes (AIF-1, CD19, CD22, CD86, CTLA-4, CCL-2, CCl-5, CXCL-8, CXCR-2, IL-1α, IL-1β, IL-2, IL-10, IL-13, MIF, PTPN22, TNF-α).[6,10] However, as with other complex diseases, in very many instances, it has not always possible to replicate initially promising data. Studies of genetically homogeneous populations have been especially informative, including those of the Choctaw nation of Native Americans. However, it is of interest that some of the associations are very plausible in terms of molecular pathogenesis. It is likely that epistasis and the effect of multiple modifier genes confound simple genetic association studies in SSc, just as in other complex diseases.[11]

IMMUNE EVENTS

There is substantial evidence of inflammatory changes in the skin and lung of patients with SSc. One example is the presence of highly specific hallmark autoantibodies, which are summarized in Table 157-1. The first inflammatory infiltrates in lesional skin are predominantly cells of the monocyte lineage[13] (T cells, macrophages, B cells, and mast cells). Later, T lymphocytes predominate and are detectable in both the circulation and affected organs. These T cells are predominantly $CD4^+$, bear markers of activation, exhibit oligoclonal expansion, suggesting an antigen-driven proliferation, and show a predominant Th2-helper phenotype.[14,15] Consequently, increased serum levels of Th2 cell-derived cytokines, i.e., IL-2, IL-4, IL-10, IL-13, and IL-17, have been observed in scleroderma patients.[16,17] Besides T cells, B cells are also found in involved skin. Several studies suggest that B cells are able to induce extracellular matrix (ECM) production through secretion of IL-6 and transforming growth factor-β (TGF-β) and are involved in the production of autoantibodies.

Several of these autoantibodies are associated with defined subsets of the disease and are important diagnostic markers (see Table 157-1). The potential role of autoantibodies in pathogenesis is a fascinating and

TABLE 157-1
Clinical Association of Hallmark Autoantibodies in Systemic Sclerosis (SSc)[12]

Reactivity	Target Antigen	Frequency in SSc (%)	HLA Association	Clinical Association
Centromere	CENP proteins speckled pattern	20–30	HLA-DRB1 HLA-DQB1	Limited skin sclerosis, severe gut disease, isolated PAH, calcinosis
Scl-70	Topoisomerase-1 speckled pattern	15–20	HLA-DRB1 HLA-DQB1 HLA-DPB1	Diffuse skin sclerosis, pulmonary fibrosis and secondary PAH, increased SSc-related mortality rate
RNAP III	RNA polymerase III speckled pattern	20	HLA-DQB1	Diffuse skin sclerosis, hypertensive renal crisis, correlated with a higher mortality rate
nRNP	U1-RNP speckled pattern	15	HLA-DR2, -DR4 HLA-DQw5, -DQw8	Overlap features of SLE, arthritis
PM-Scl	Polymyositis/Scl nuclear staining pattern	3	HLA-DQA1 HLA-DRB1	Limited skin sclerosis, myositis–sclerosis overlap, calcinosis
Fibrillarin	U3-RNP nuclear staining pattern	4	HLA-DQB1	Diffuse skin sclerosis, myositis, PAH, renal disease
Th/To	7–2RNP nuclear staining pattern	2–5	HLA-DRB1	Limited skin sclerosis, pulmonary fibrosis

exciting area. The majority of SSc cases have circulating antibodies. These include a number of hallmark reactivities, as well as autoantibodies, that occur in other autoimmune rheumatic diseases (e.g., anticyclic citrullinated peptide, rheumatoid factor) but also antibodies that may have functional significance, since they are directed against cell surface antigens [antiendothelial cell antibodies (AECA), antifibrillin antibodies, anti-PDGF receptor antibodies, etc.]. However, functional impact of these antibodies remains an area of investigation. The best evidence of functional significance is for antiendothelial cell autoantibodies and for antifibroblast-reacting antibodies. Recent reports suggest the presence of antifibrillin autoantibodies and stimulatory autoantibodies reacting with platelet-derived growth factor (PDGF) receptors, although this observation requires further confirmation.

Microchimerism and graft-versus-host disease mechanisms have been suggested in some cases, although the relatively high frequency of microchimerism in healthy individuals or other disease states suggests that this may be contributory rather than causal if it has a role in SSc.

VASCULOPATHY

Vasculopathy in SSc is based on inappropriate vascular remodeling and repair processes. It involves the microcirculation and arterioles and is very likely a primary event in the pathogenetic processes of the disease and precedes fibrosis. Vascular abnormalities are characterized by vasoconstriction, adventitial and intimal proliferation, inflammation, and thrombosis.[18] The earliest signs of vascular dysfunction are represented by enhanced vascular permeability with an imbalance between vasodilatory (NO, prostacyclin, calcitonin gene-related peptide) and vasoconstrictive mediators [endothelin 1 (ET 1), angiotensin II, α2-adrenoreceptors]. Consequently, the impaired blood-flow leads to tissue hypoxia, which induces strong expression of vascular endothelial growth factor (VEGF) and its receptors, associated with a defect of vasculogenesis. However, inflammatory cytokines like TNF-α may stimulate or inhibit angiogenesis depending on the duration of the stimulus.[19]

In addition to these functional abnormalities, intravascular and structural changes contribute to overt Raynaud phenomenon (RP), and in the course of time to progressive reduction of vessels and blood flow. These vasculopathies clinically manifest in all vessels of virtually all organs. Early lesions in the microcirculation because of structural damage are initially seen in the nail fold capillaries and as vasospastic responses in RP. Furthermore, vascular changes, i.e., overgrowth of the endothelium and deposition of scar tissue produce some of the major complications of SSc, including pulmonary arterial hypertension (PAH), scleroderma renal crisis (SRC), and digital vasculopathy.

FIBROSIS

SSc is a multisystem fibrotic disease. The initial inflammation and hypoxia in fibroblasts induces the production of several proteins that are involved in ECM remodeling as, for example, thrombospondin 1, fibronectin 1, lysylhydroxylase-2, TGF-β-induced proteins.[20] Deposition of excessive ECM in specialized organs is responsible for much of the morbidity and mortality of the disease. Fibrous connective tissue is deposited by activated fibroblasts and myofibroblasts. From an early stage in the disease, an autonomous population of fibroblasts appears to be established

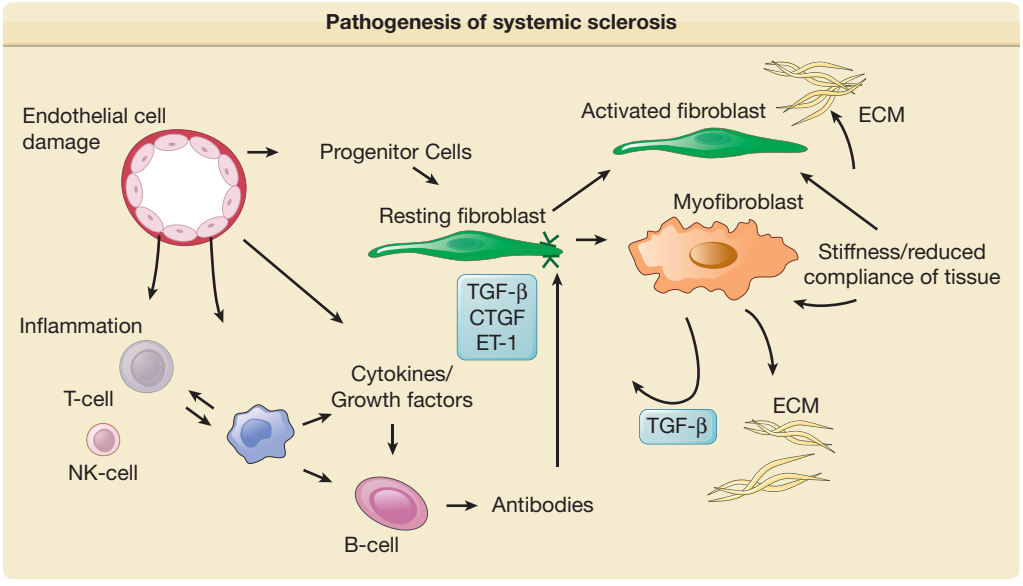

Figure 157-1 Pathogenesis of systemic sclerosis. The schematic shows how the development of systemic sclerosis results from a complex interplay between cells within the immune system, including adaptive and innate compartments, the vasculature, and the connective tissue. Cell–matrix interactions are important regulators of cellular functions. Early vascular events lead to later development of an autonomous population of activated fibroblasts and myofibroblasts that contract soft tissue and deposit excessive ECM. These cells may develop from resident connective tissue fibroblasts; transdifferentiation from other cell types, including activated microvascular pericytes; and recruitment of circulating progenitor cells (fibrocytes). The contribution of each lineage to the fibrotic lesion is still unclear. Many growth factors and cytokines are implicated as mediators of this process, and complex reciprocal networks may lead to a profibrotic microenvironment. Potential disease-modifying therapies could target individual mediators alone or in combination [e.g., tumor growth factor-β (TGF-β), endothelin (ET-1), connective tissue growth factor (CTGF), platelet-derived growth factor (PDGF)] or modulate immune cells (e.g., cyclophosphamide) or the endothelial cell (e.g., prostacyclin analogues). The extracellular matrix is an important repository for mediators that are later released and play a key role in pathogenesis. CCL = CC chemokine ligand; Ig = immunoglobulin; IL = interleukin.

that are responsible for the excessive production and accumulation of ECM. The initiators of this process include a number of key cytokines and growth factors that may represent logical therapeutic targets. The key factor seems to be a disturbed balance between synthetic and degradative mechanisms. Quiescent fibroblasts may be activated by TGF-β, connective tissue growth factor (CTGF), PDGF, or ET-1.[21–24] There is increasing evidence that fibroblasts are induced to differentiate into myofibroblasts, which are characterized by a high contractility, ECM production, and cytokine release. Together with altered biophysical properties of the resulting connective tissue this leads to persistent activation of fibroblasts leading to the excessive deposition of ECM components.

A schematic summarizing pathogenetic mechanisms is shown in Fig. 157-1.

ENVIRONMENTAL FACTORS

Scleroderma-like syndromes have been reported in association with numerous environmental toxins and drugs. These agents include solvents (vinyl chloride, benzene, toluene, epoxy resins), drugs (bleomycin, cardiopa, pentazocine, cocaine, docetaxel, metaphenylenediamine), and miscellaneous substances.[25]

SSc was reported to occur in underground coal and gold miners. In male patients with silicosis who were older than 40 years of age, the likelihood of developing SSc was approximately 190 times greater than in males not exposed to silica, and 50 times greater than in males without silicosis but exposed to silica dust.[26] The role of silicone gel implants and other silicone products in the development of scleroderma has been questioned.[27] However, most epidemiologic studies have failed to show a significant association. An unusual form of scleroderma characterized by RP, morphea-like skin changes, capillary abnormalities of the nail fold (similar to those in SSc), osteolysis of the distal phalanges, and hepatic and pulmonary fibrosis (PF) may occur in workers exposed to polyvinyl chloride. Bleomycin also produces PF, RP, and cutaneous changes indistinguishable from those of SSc.[27] The development of these changes appears to be dose-dependent and is reversible on discontinuation of the drug. Collectively, chemical exposures account for a small fraction of scleroderma-like diseases. Large epidemiologic studies have not yet revealed a significant role for toxins and drugs in scleroderma.

CLINICAL FEATURES OF SYSTEMIC SCLEROSIS

The clinical manifestations of SSc depend to a large extent on the subset and stage of disease. The clinical features of established SSc are diverse, include severe fibrosis of the skin with all additional cutaneous manifestations and reflect the multiple patterns of internal organ involvement and the consequences of progression of the underlying pathologic processes of vasculopathy, inflammation, and fibrosis. Particular consideration must be given to the hallmark complications of hypertensive SRC, PAH, PF, and gastrointestinal (GI) dysmotility.

CLASSIFICATION AND DEFINITION OF DIFFERENT SSC SUBSETS

The heterogeneity of SSc arises from the range of disease manifestations that vary in extent and severity of organ involvement between patients. However, some clinical features that are almost always present are RP and skin sclerosis. The extent of skin sclerosis defines each major disease subset. Each subset has particular features, although there are common features to each.

The American College of Rheumatology (ACR) published in 1980 preliminary classification criteria for SSc to classify patients with established disease,[28] showing 97% sensitivity and 98% specificity for SSc. The diagnosis is proven, if either one major criterion or at least two or more minor criteria are found. As major criterion are chosen scleroderma proximal to the metacarpophalangeal or metatarsophalangeal joints, and the minor criteria included sclerodactyly, digital ulcerations and/or pitting digital scars, and bibasilar PF.

Furthermore, in 1988 a descriptive subclassification of limited versus diffuse SSc by LeRoy,[29] which was primarily associated with the extent of cutaneous involvement, has been widely accepted and used in clinical practice. In 2001, LeRoy and Medsger[30] published amended criteria, with the additional presence of autoantibodies and nail fold capillaroscopic alterations. Furthermore, these criteria include a separate group of patients with early onset of SSc, with minimal skin thickening. It was mandatory that patients with early (limited) SSc have evidence of RP plus scleroderma-specific autoantibodies and/or nail fold capillaroscopic manifestations.[31,32] However, there are several other classifications published, for example, by Nadashkevich O et al, Maricq and Valter, etc.[32,33]

Diffuse cutaneous SSc (dcSSc) is defined as a progressive form with an early onset of RP, usually within 1 year of onset of skin thickening. This subset is characterized by rapid skin involvement of trunk, face, upper arms, and thighs, showing very frequently, anti-Scl 70 (antitopoisomerase-I) or anti-RNAPIII antibodies.[29] Furthermore, there is a higher propensity to develop PF, cardiac involvement, and SRC.

Limited cutaneous SSc is characterized by a long preexisting history of RP and skin changes of the extremities distal to the knee and elbow joints, including facial skin.[29] This variant of SSc-subset often (50%–70%) presents with anticentromere-antibodies (ACA) and is frequently associated with isolated PAH. The traditional acronym CREST (calcinosis, RP, esophageal dysmotility, sclerodactyly, and telangiectasias) is nowadays obsolete and assigned to the limited form of SSc.

Patients with features of scleroderma together with those of another autoimmune rheumatic disease are combined; are designated overlap syndromes. This is defined as a disease occurring with clinical aspects of SSc (according to the ACR-criteria) or main symptoms of SSc simultaneously with those of other connective tissue diseases or other autoimmune diseases such as dermatomyositis, Sjögren's syndrome, systemic lupus erythematosus, vasculitis, or polyarthritis. These patients present mostly high titers of anti-U1-RNP-, anti-nRNP-, antifibrillarin-, or anti-PmScl-antibodies.[34]

Patients suffering from early SSc, also known as undifferentiated SSc, are defined by positive RP and at least one further feature of SSc (positive nail fold capillary alterations, puffy fingers, pulmonary hypertension) and/or detectable scleroderma-associated autoantibodies without fulfilling the ACR-criteria.[35]

A very small proportion of cases (1.5%) develop vascular (RP and/or PAH), immunologic (most commonly anticentromere antibodies), and organ-based fibrotic features of SSc but do not show skin sclerosis.[36] Patients suffering from this subset are classified as SSc sine scleroderma.

In addition, the frequency and timing of different visceral manifestations of SSc differs between major subsets. However, there is some overlap between subsets in terms of organ-based disease and the extent and severity of skin sclerosis. In all patients, the extent and severity of skin sclerosis can be assessed by the modified Rodnan skin score (mRSS). Skin score at baseline correlates with disease severity and outcome in dcSSc. Thickening and fibrosis of the skin as one of the first recognized phenomenon in SSc still forms the basis of most classification criteria and proposed subsets of the disease.

Autoantibody-based classification of SSc has been proposed, and there is evidence from association studies that this may be clinically meaningful, as indicated in Table 157-1. Moreover, genetic association analysis using a candidate gene approach has demonstrated an association between serologically based subsets of SSc that are stronger than with SSc overall. The significance of this is uncertain, and it should be noted that a genetic basis for autoantibody reactivity has been well described, leading to the suggestion that the serologic subsets may be more genetically homogeneous than unselected SSc cases or clinically defined subsets of SSc.

ORGAN MANIFESTATION

VASCULOPATHY. Distinctive for this disease is the initial onset of RP, which appears in more than 90% of SSc-patients. It is defined by recurrent attacks of vasospasm of small digital arterioles/arteries at fingers and toes, usually caused by cold and/or other stimuli, for example, emotional stress. RP clinically appears suddenly and is clearly restricted and is accompanied by painful pallor/ischemia of single or several digits/toes, followed by reactive hyperemia after reheating at



Figure 157-2 Clinical feature of patients with early disease. **A.** Raynaud phenomenon with typical discoloration (white–blue pallor), localized mostly at fingers and/or toes as the result of vasospasm. Coldness and emotional stress are the most frequently triggers for these attacks. **B.** Limited disease with puffy fingers.

the end of a RP attack, in severe cases cyanosis (tricolore phenomenon) also ensues (see Fig. 157-2).

Patients presenting only with RP should be studied for capillary alterations as well as autoantibody-status. To identify and visualize vascular-cutaneous alterations due to SSc, nail fold capillaroscopy is a noninvasive, simple, and one of the most useful diagnostic and prognostic methods (see Table 157-2). Furthermore, it is

TABLE 157-2
Recommended Diagnostic Procedures in SSc[48]

Organ Involvement	Clinical Feature	Diagnostic Procedures
Vascular system	Raynaud phenomenon	■ Coldness provocation ■ Nail fold capillaroscopy ■ Antinuclear antibody levels
Skin	Scleroderma Calcinosis cutis	■ Clinical assessment regarding puffy fingers, telangiectasias, mechanic hands, hypo-/hyperpigmentations, digital ulcerations, dermatogenous contractures ■ Modified Rodnan skin score ■ 20-MHz ultrasound ■ Radiography (X-ray, MRI, CT)
Musculoskeletal system	Arthralgia/Synovitis Muscle weakness	■ Clinical assessment regarding fist closure-deficiency, joint contractures, tendon friction rub, muscle weakness ■ Laboratory parameters: erythrocyte sedimentation rate, rheumatoid factor, antinuclear autoantibodies ■ Creatine kinase (>threefold?) ■ MRI, electromyography ■ Muscle biopsy
Gastrointestinal tract	Reflux Dysphagia Diarrhoea, obstipation	■ Gastro-/Esophageal-endoscopy ■ Oesophageal-szintigraphy ■ Oesophagus-manometry ■ Coloscopy
Respiratory system	Dyspnoea	■ Lung function test (TLCOc SB, TLC, FVC) ■ Radiography (X-ray or HR-CT) ■ Bronchioalveolar Lavage (BAL) (optional)
Cardiac system	Dyspnoea, arrhythmia	■ Electrocardiography (conduction blocks?) ■ Echocardiography (mPAP, diastolic dysfunction?, ventricular ejection fraction) ■ (Spiro-)Ergometry ■ 24-hour blood pressure controls ■ Right-heart catheterization
Kidney	Renal function failure	■ Regular blood pressure controls (>140/90 mm Hg) ■ Ultrasound ■ Serum levels of creatinine, urine-analyses (protein-, albuminuria, microelectrophoresis)



Figure 157-3 Extensive skin involvement in patients with dSSc. **A.** Sclerodactyly with dermatogenous contractures (restricted mobility of digital joints) as well as salt-and-pepper typical hyper- and hypopigmentations. **B.** Microstomia (radial furrowing around the mouth) with the typical frenulum sclerosis. **C.** Skin hardening/thickening proximal of the metacarpophalangeal-joints. **D.** Scleroderma-typical facial physiognomy with hypermimia, microstomia, telangiectasias and a beaked nose.

a useful tool to categorize capillary changes into early, active, and late patterns. Furthermore, laser Doppler perfusion imaging (LDPI) is also a noninvasive microvascular imaging technique able to provide maps of the cutaneous blood flow.[37]

SKIN INVOLVEMENT

Skin involvement is a cardinal feature of SSc and usually appears first in the fingers and hands. Within time, patients develop nonpitting oedema of the fingers (puffy fingers) (see Fig. 157-2), hands, and extremities, whereupon an increasing induration and skin thickening appear (sclerodactyly). Depending on the localization of skin thickening, restricted mobility of joints (dermatogenous contractures), and/or restricted breath-excursion may be present. Typical facial features include telangiectasias, a beak-shaped nose as well as reduced mouth-aperture (microstomy). The typical physiognomy of FSSc patients is characterized by a radial furrowing around the mouth, no expression, a stiff and mask-like facial appearance, and sclerosis of the frenulum. Besides cosmetic/aesthetic problems, skin sclerosis causes considerable difficulties regarding eating and oral hygiene (summarized in Fig. 157-3).

The abnormal deposition of cutaneous and/or subcutaneous calcium (calcinosis cutis), usually occurs over pressure points (acral, joints) (see Fig. 157-4). Calcinosis cutis next to joints is designated as Thieberge–Weissenbach syndrome. Further skin manifestations include hypo- and hyperpigmented skin (salt and pepper) (see Fig. 157-3), loss of hair follicles and sweat glands (hypo-/anhydrosis).



Figure 157-4 Digital alterations with complications. **A.** Digital ulcerations at the fingertips. **B.** Digital ulcerations and necrosis of the fingertips. **C.** Severe calcifications with deposition of subcutaneous masses. **D.** Multiple ulcerations at bone protuberantes with inflammation in the surrounding sclerotic skin.

Skin involvement/scleroderma should be evaluated using mRSS. Usually, 17 sites are assessed and skin thickness is categorized to grade 1, 2, or 3, corresponding to mild, medium, and severe, according to palpation of the skin by a trained examiner (see Fig. 157-5). Furthermore, new techniques for calculating skin thickening have been evaluated. Besides mRSS[38] also 20-MHz ultrasound,[39] MRI,[40] and Plicometer[41] are useful methods to assess skin thickening (recommended diagnostic procedures are listed in Table 157-2). Further physical procedures to monitor skin fibrosis are Durometer,[42] Cutometer,[43] and Elastometer.[44] Besides all these non-invasive methods, a further appropriate but invasive method includes skin biopsy with histological evaluation of the dermal skin thickness. This also allows the characterization of the inflammatory infiltrates.

Approximately 50% of patients with SSc are affected by digital ulceration associated with vasculopathy at some point in their disease. This is the major external feature of structural vessel disease, probably due to thickened intima and lumen-occluded vessels. Tender and painful pitting scars are very frequent and, on occasion, progress to ulcers. These occur on the finger- or toe-tips, over the extensor surfaces of the joints due to microtrauma or in association with the above-mentioned calcinosis cutis. Digital ulcers are associated with strong, local pain and a major impact on quality of life regarding all-day functions, i.e., dressing, eating, etc. Other complications include critical digital ischaemia, paronychia, infections, gangrene, osteomyelitis, and finger pulp loss or amputation.

CARDIOPULMONARY MANIFESTATIONS

There are different ways that the cardiopulmonary system may be involved, most often appearing as fibrosis and PAH. The differentiation between these manifestations is often clinically difficult because of similar, overlapping clinical features, such as dyspnea, non-productive cough, disturbed diffusion-capacity, and cyanoses. PAH is currently the most common cause of disease-related death in SSc. It occurs in both limited and diffuse cutaneous subsets, although the most typical cases are those of limited SSc (lSSc) associated with isolated PAH. This condition has substantial similarities to idiopathic PAH. Thus, two patterns of disease occur in SSc. Most cases have PAH, but there are some patients with late-stage extensive interstitial lung fibrosis in SSc that develop a true secondary PH. Besides the right-heart worsening due to PAH, the heart could also be involved because of diffuse interstitial myocardio-fibrosis. This could lead to a diastolic dysfunction as well as a restricted contractibility of the myocardium. These patients clinically present cardiac arrhythmia, paroxysmal tachycardia, incomplete or complete right-heart blocks, and heart insufficiency.

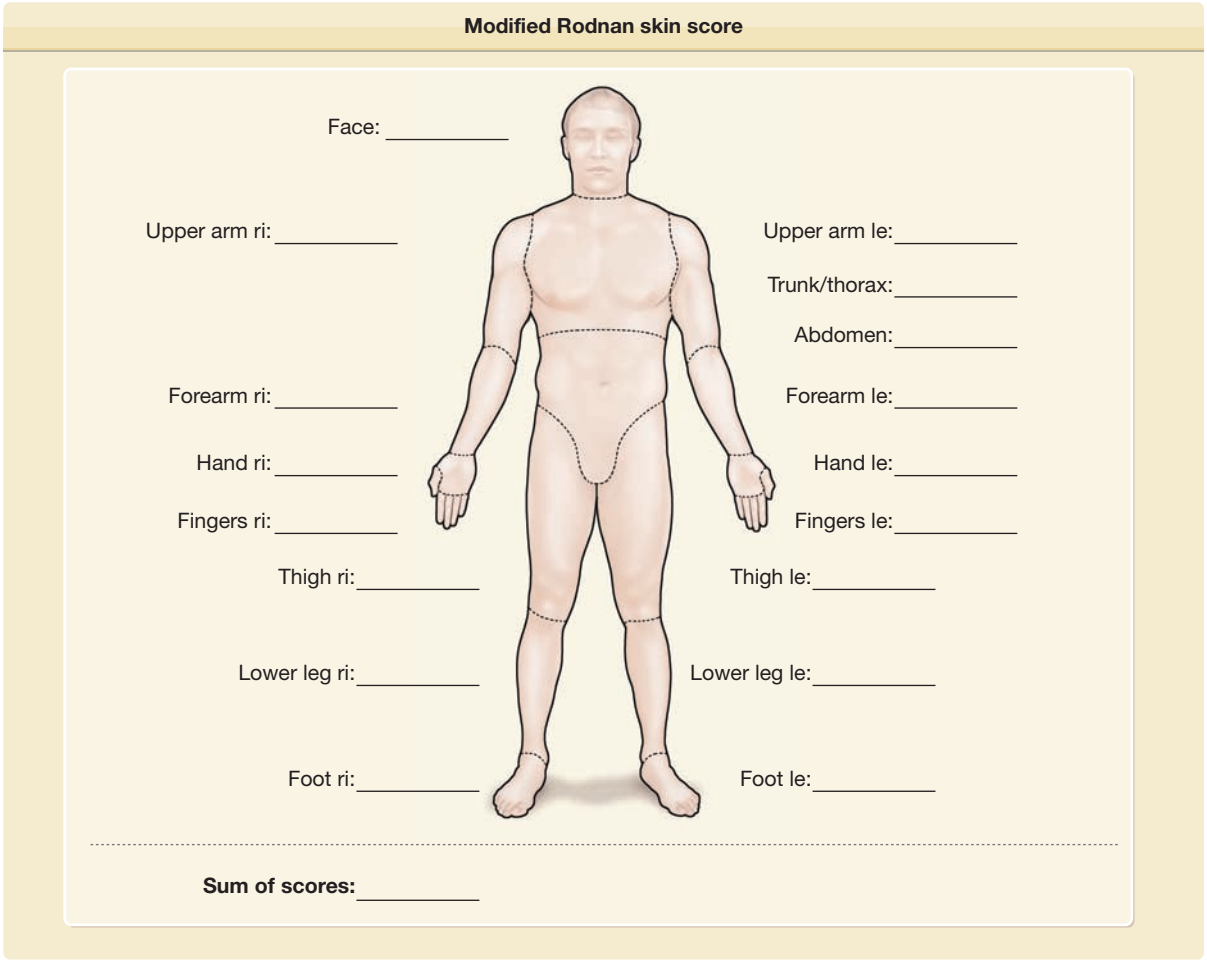

Figure 157-5 Modified Rodnan skin score (mRSS). Skin hardening will be evaluated with the modified mRSS that is usually performed by assessing the skin thickness at 17 different areas. The skin sclerosis is categorized by palpation to grade 1, corresponding to mild, 2, moderate, and 3, corresponding to severe ri = right, le = left.

Individuals with SSc should be followed up at least annually using pulmonary function tests, echocardiography, a 6-minutes walk test, and high-resolution computer tomography (HRCT). Pulmonary function tests are the most important techniques to determine possible cardiopulmonary involvement, because of impaired diffusion capacity (DLCO ≤75%) being an early marker of both lung fibrosis and PAH.

To determine the presence of interstitial lung involvement, i.e., subpleural localized line opacities, ground-glass opacities, and subpleural cysts with honeycomb formations, HRCT and/or thoracic X-ray should be used.

Follow-up should also include transthoracal-executed Doppler echocardiography, a noninvasive procedure, which can indicate a hypertrophy with or without enlargement of the right ventricle, paradoxical motion of the interventricular septum, tricuspid valve insufficiency, and pericardial effusion. Right-heart catheterization is indeed the gold standard, but an invasive diagnostic procedure for certain determination of PAH. Pulmonary arterial hypertension (PAH) is defined as a mean pulmonary pressure (mPAP) of >25 mm Hg at rest together with a pulmonary capillary wedge pressure of <15 mm Hg as determined by right-heart catheterization.[45,46]

Cardiac magnetic resonance imaging is also a further potential strategy for assessing myocardiac involvement in SSc. Besides imaging procedures, there is also some promise for the use of *N*-terminal brain natriuretic peptide (NTproBNP) to detect right ventricular impairment (see Table 157-2).

GASTROINTESTINAL INVOLVEMENT

GI involvement is the most common internal organ involvement in patients suffering from both, limited and diffuse SSc (>60%).[4] Many parts of the GI-tract may be impaired, affecting motility, digestion, absorption, and excretion.[47]

Esophageal involvement includes symptoms like dysphagia, heartburn due to reflux, nausea, and/or vomiting. A weakened lower esophageal sphincter and impaired peristalsis increase the risk for esophagitis. If untreated, this could lead to peptic esophagitis,

gastric/esophageal ulcerations, peptic stricture formations, and fistulae. Chronic gastroesophageal reflux can be complicated after a time by a higher risk of Barrett's esophagus, which may progress into an adenocarcinoma.

Possible gastric manifestations include atrophy of the mucous membrane associated with anacidity, ulcerations, and delayed gastric emptying.

SSc can also affect the intestine, and includes atonic dilatation, constrictions, malabsorption, pseudoobstructions, diarrhea, fecal incontinence, and severe malnutrition.

The presence of esophagitis can be determined by upper GI endoscopy with histological evaluations. Impaired motility of the esophagus can usually be diagnosed by scintigraphic evaluation following a radiolabeled meal or 24 hours ph-manometry (see Table 157-2).

KIDNEY INVOLVEMENT

SRC appears in 5%–10% of SSc patients, and may cause an abrupt onset of significant systemic hypertension (>150/85 mm Hg), proteinuria (>200 mg/g urine-creatinine), followed by an acute renal failure (≥30% reduction in estimated glomerular filtration rate). Studies suggest that a chronic vasculopathy with reduced glomerular filtration rate is frequent. In addition, there is evidence of an increase in fibrillar collagen deposition within the renal interstitium in SSc. Many cases occur within the first 12 months of disease, and in up to one-fourth of patients with SRC the diagnosis of SSc is made at the time of the renal presentation. End-organ damage can result in encephalopathy with generalized seizures or flash pulmonary edema. Microangiopathic anemia is common, and sometimes disseminated, intravascular coagulation develops. Nephrotoxic drugs and high-dose prednisolone (>7.5 mg/day) should be avoided in patients suffering from SSc. Early diagnosis is the key role in improving the outcome of SRC using regular blood pressure monitoring, urine-analyses microelectrophoresis, and determination of creatinine clearance (see Table 157-2).

HISTOPATHOLOGY

The histopathology of SSc shows fibrosis of the lower two-thirds of the dermis and the subcutaneous fibrous trabeculae, because of excessive deposition of ECM proteins, most notably collagen type I and III (Fig. 157-6).

Panniculitis and mucoid edema may also be prominent features in the early stages, whereby subcutaneous fat is replaced by a fibrous connective tissue. It is possible to differentiate histologically an early cellular stage on the one hand and a later fibrotic stage on the other hand. In the early stages, the dermis presents pathologically collagen bundles within the reticular dermis, and appear pale, homogenous, running parallel to the skin surface, and swollen, and there is often a perivascular lymphocytic infiltrate. These inflammatory cell infiltrates are localized between the collagen bundles but mainly around the vessels, and can also spread into subcutaneous fat tissue. The infiltrate can also entrap sweat glands. The epidermis often becomes atrophic in the overlying areas. Vessels of all sizes may be involved in SSc. In the early stages, there may only be dilatation of capillaries, then endothelial proliferation and complete occlusion of vessels occur. With the progression of scleroderma, the involved skin becomes more avascular and inflammation decreases. In later stages, pilosebaceous units and eccrine glands disappear, collagen bundles appear to be packed closely, and there may be an effacement of the rete ridges.

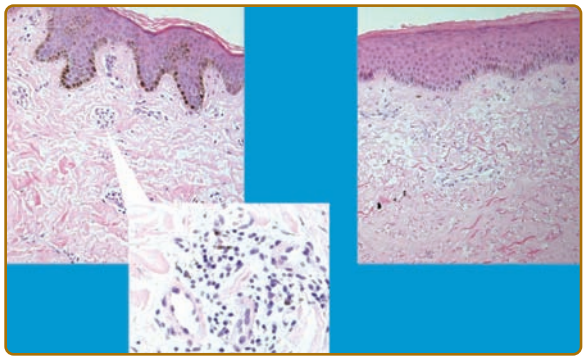

Figure 157-6 Histologic appearance of skin in early and late-stage diffuse cutaneous systemic sclerosis (dcSSc). In SSc, there is perivascular mononuclear cell infiltrate at the early stages of disease. This precedes the development of skin sclerosis. Perivascular changes are shown at high power in the left panel. Later stage disease is accompanied by skin sclerosis, a low density of blood vessels, and absence of inflammatory cells. At this stage, there may be associated epidermal changes with thickening and loss of secondary skin structures, including hair follicles and sweat glands. Absence of the rete ridges is also characteristic at the later stages of dcSSc. Similar changes are predicted in localized cutaneous SSc, but this is rarely biopsied due to limited skin sclerosis and concerns about healing.

DIFFERENTIAL DIAGNOSIS

The diagnosis of SSc is clinical. Although there are classification criteria that were developed to facilitate the distinction of SSc from other connective tissue diseases, no formal diagnostic criteria have been developed. The main differential diagnosis is with other conditions within the scleroderma spectrum and with the scleroderma overlap syndromes. There are several differential diagnoses, which imitate scleroderma, i.e., circumscript (localized) scleroderma, eosinophilic fasciitis, sclerodermiform genodermatoses, acrodermatitis chronica atrophicans, scleroderma-like syndromes induced by environmental factors, scleroderma adultorum Buschke, scleroderma diabeticorum, sclero-myxoedema, nephrogenic fibrosing dermopathy, porphyria cutanea tarda, graft-versus-host disease, and scleroderma-like lesions in malignancies. More details are summarized in Table 157-3).

TABLE 157-3
Differential Diagnosis of Systemic Sclerosis (SSc)

Differential Diagnosis
- Other disorders within the scleroderma spectrum
- Circumscript (localized) scleroderma (morphea)
- Eosinophilic fasciitis
- Lichen sclerosus et atrophicans
- Acral Vasospasm
  - Raynaud phenomenon (primary versus secondary)
  - Other autoimmune rheumatic diseases
    - Systemic lupus erythematodes
    - Rheumatic diseases
    - Dermato-/polymyositis
  - Other vascular diseases
    - Hematologic
      - Cryoglobulinemia
      - Cold agglutinin disease
      - Hyperviscosity syndrome
- Systemic vasculitis
- Buerger disease (thromboangiitis obliterans)
- Macrovascular disease
- Other Causes For Skin Sclerosis
  - Sclerodermiform genodermatoses (e.g., progeria, acrogeria)
  - Sclerodermiform acrodermatitis chronica atrophicans
  - Scleroderma adultorum Buschke
  - Scleroderma diabeticorum
  - Scleroderma amyloidosum
  - Scleromyxedema
  - Nephrogenic fibrosing dermopathy
  - Porphyria cutanea tarda
  - Sclerodermiform chronic graft-versus-host disease
  - Eosinophilia–Myalgia syndrome

DISEASE-MODIFYING TREATMENT

Three facets of SSc are potentially amenable to therapeutic modulation, and this raises the possibility of true disease-modifying treatment. At present, vascular therapies and immunomodulation have the widest range of candidate therapies. These approaches are summarized in Tables 157-4 and 157-5. Antifibrotic treatment remains much more of a challenge. Some encouragement is provided by recent clinical trials of idiopathic PF. However, at present there is no proven antifibrotic agent. Further details about possible treatment approaches are provided in Table 157-6. A simplified schematic for integrating putative disease-modifying therapy with programs of screening and surveillance that permit timely intervention in SSc is shown in Figure 157-7 with organ-based strategies that currently form the basis of the majority of SSc therapeutics. Possibilities for targeted disease modifying therapy depend on the availability of therapeutic agents and a clear understanding of their role in pathogenesis.

There has been much more success in the field of organ-based therapeutics in SSc.

DIGITAL VASCULOPATHY AND ITS COMPLICATIONS

Simple but important recommendations include the reduction of vasoconstriction by avoiding precipitating factors like nicotine, sympathomimetics, emotional

TABLE 157-4
Immunomodulatory Strategies for Treatment of Systemic Sclerosis

Agent	Clinical Trial Data
Cyclosporin A (CyA)	■ Open study, 10 patients. Improvement in skin score.[49] ■ RCT, combination of low-dose CyA with iloprost; 20 patients. Improvement of skin, microvascular, and esophageal parameters.[50]
Methotrexate (MTX)	■ RCT, placebo-controlled trial, 29 patients; Significant improvement in skin score ($p = 0.06$).[51] ■ RCT, placebo-controlled trial, 73 patients; improvement of mRSS.[52] ■ Placebo-controlled, 18 patients; clinical improvement in the MTX group.[53]
Cyclophosphamide (CyC)	■ Minor effect on lung function tests but significant benefit for skin and disability in Scleroderma Lung Study of oral cyclophosphamide for 12 month.[54] ■ Randomized, unblended trial, 30 patients; significant improvement in mRSS, attack frequency of RP and erythrocyte sedimentation rate.[55] ■ Scleroderma lung study, 153 patients; one year of treatment leads to an improvement in health-related quality of life.[56]
Immunoablation/stem cell transplantation	■ Ongoing studies in United States and Europe.[57]
Extracorporeal photopheresis	■ Multicenter, RCT, placebo-controlled and double-blind; 64 patients. Significant improvement of skin and joint manifestation.[58]
Antithymocyte globulin oral tolerization to type I collagen	■ Pilot study of 13 patients; combination with mycophenolate mofetil in dSSc; improvement of skin score.[59] ■ Open pilot study, ten patients with early SSc no improvement in skin and pulmonary features.[60]
Mycophenolat mofetil (MMF)	■ Retrospective chart review of 17 patients, show stable pulmonary function.[61] ■ Retrospective analysis of 109 patients, well tolerated and seems to be at least as effective as other current treatment options.[62]
Rapamycin	■ Single-blind pilot study, 18 patients with dSSc; mRSS improved significantly as well as the patient's global assessment.[63]

TABLE 157-5
Therapies for Raynaud Phenomenon and Digital Ischemia in Systemic Sclerosis

Intervention	Evidence
Calcium channel blockers (nifedipine) Diltiazem	■ Several studies confirm benefit of this class of drug for Raynaud phenomenon.[64,65] ■ Two RCTs gave contradictory results.[64,66]
Angiotensin-converting enzyme inhibitors	■ Anecdotal support for benefit in Raynaud phenomenon and proven efficacy in scleroderma renal crisis.[67]
Angiotensin receptor blockers	■ Study suggests superiority over nifedipine in small trial.[68]
Antioxidant agents	■ Study suggests benefit for probucol, a synthetic antioxidant, in Raynaud phenomenon. Antioxidant vitamins not helpful in clinical trials.[69,70]
Prostacyclin analogues	■ RCT, placebo-controlled trials, intravenous iloprost effective for Raynaud phenomenon ■ RCT, placebo-controlled trial; oral iloprost not effective at low dose, and side effects limit higher dose treatment.[71] ■ RCT, placebo-controlled trial; intravenous iloprost significantly effective for healing digital ulcers.[72]
α-Adrenergic blockers	■ Preliminary studies suggest benefit compared with placebo.[73]
Endothelin receptor blockade	■ Two large placebo-controlled studies show reduction in new digital ulcer formation on bosentan. No effect on healing of established ulcers.[74]
Anticoagulants	■ One study suggests benefit for low-molecular-weight heparin.[74]
Serotonin reuptake inhibitors	■ Small study suggested benefit over nifedipine and favorable side-effect profile.[75]
Phosphodiesterase type 5 inhibitors	■ Uncontrolled studies of sildenafil and tadalafil suggest benefit for Raynaud phenomenon.[76]
Nitrate formulations	■ Uncontrolled trials suggest benefit for Raynaud phenomenon. Vasodilator side effects may limit usefulness.[84]

TABLE 157-6
Recommended Therapeutic Strategies for Internal Organ Involvement in SSc

Organ Involvement	Clinical Feature	Therapeutic Options
Vasculopathy	RP DU	Consistent warm keeping, Paraffin-bath Calcium channel blockers (nifedipine, creeping) p.o. Iloprost i.v. Bosentan p.o. Sildenafil p.o. (off-label) Wound dressing (hydrocolloid membrane, mepilex)
Musculoskeletal system	Synovitis/myositis	Methotrexate (p.o., i.m.)
Gastrointestinal tract	Reflux Dysphagia Diarrhea, obstipation	PPI, procinetica H_2-receptor-antagonists Change habit of eating Antibiotics (Erythromycin)
Respiratory system	Dyspnoea Alveolitis/lung fibrosis	Oxygen Cyclophosphamide p.o. or i.v. Azathioprine p.o. Glukokortikoide (short dated)
Cardiac system	PAH	Oxygen Diuretics Bosentan p.o. Sildenafil p.o. Epoprostenol p.o.
Kidney	SRC	ACE-Hemmer (high-dosed)

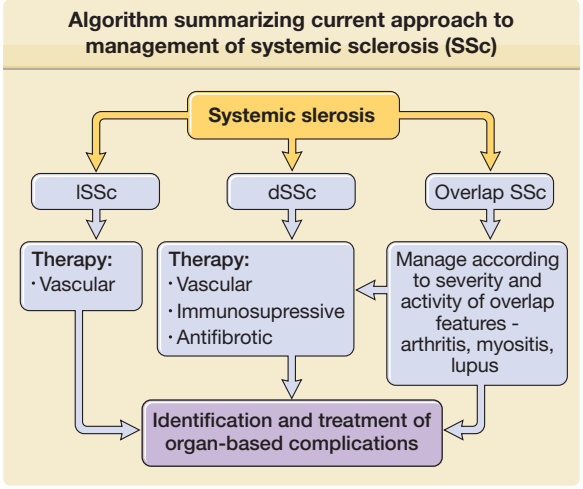

Figure 157-7 Algorithm summarizing current approach to management of systemic sclerosis (SSc). The principles of therapy for SSc include accurate diagnosis and treatment according to the disease subset, the presence of overlap features, and the likely predominant pathologic process according to the stage of disease. In all cases, screening for and treatment of organ-based complications has a major role in successful management. Education of patients and a multidisciplinary team, including specialist nurses, physiotherapists, occupational therapists and many subspecialty physicians, and surgeons, are central to providing appropriate care for severe cases of SSc. dSSc = diffuse systemic sclerosis; lSSc = limited systemic sclerosis.

stress and coldness, and instead to pay attention to have a heated home, thick and airtight clothes, heatable gloves, soles, or infrared hyperthermy, regular paraffin bath treatments, and minimal trauma.

Current local management of digital ulcers includes a combination of nonpharmacological care, antibiotics (in case of infection), analgesia, and individually applied wound dressings, if necessary.

Potential pharmacological treatment requires optimal therapy for RP, including agents that may have the potential for vascular remodeling and/or dilatation, such as calcium channel blockers, i.e., nifedipine, that should be considered as first-line therapy, while experience with other treatment options such as diltiazem, ACE-inhibitors, etc, have given contractory results.[64,65,66,67,77]

Parenteral prostacyclin derivatives, in particular iloprost, are widely used, and help to heal digital ulcers and may prevent recurrent lesions. Prostacyclin derivatives by intravenous infusion are the mainstay of therapy for critical digital ischaemia.[71,72] Antiplatelet agents such as aspirin or clopidogrel are used especially in critical digital ischaemia.

More recently, there has been enthusiasm about therapies that are effective for PAH in digital vasculopathy. Thus, Bosentan, an oral dual specificity endothelin receptor antagonist, has been demonstrated in two large controlled trials to significantly reduce the number of new digital ulcers, compared with placebo.[78] No positive effect on healing of established ulcers has been demonstrated. Other agents, such as phosphodiesterase type 5 inhibitors sildenafil and tadalafil, have also been used for treatment of RP and digital ulcers, but prospective clinical trial data are not available.[76] Surgical treatments include digital microarteriolysis, which can benefit single fingers with refractory ulcers. Whenever possible, surgical amputation of digits is avoided, and prolonged treatment with parenteral prostacyclin and potent analgesia may help with this. Lumbar sympathectomy may be helpful for lower limb RP or ulceration. Generally, a temporary procedure is performed initially to determine the likely benefit from a definitive sympathectomy. In cases of critical digital ischemia, antiplatelet therapies are often given, with anecdotal reports of the benefit of clopidogrel in preventing digital infarction (see Table 157-5 and 157-6).

SKIN INVOLVEMENT

A key element in the management of skin manifestations of SSc physical therapy and regular exercise to maintain circulation, joint mobility, and muscle strength to improve the quality of life of SSc patients. Skin affected by scleroderma tends to be very dry, taut, and susceptible for trauma.

Skin hardening may be improved by physical therapy and exercise, lymphatic drainage, topical treatment with steroids, calcineurin inhibitors, and moisturizing crèmes. Systemic therapies include immunosuppressive drugs, systemic steroids (for just a short time), and phototherapy (UVA1 or PUVA). UVA1-irradiation appears to inhibit fibrotic and inflammatory processes and reduce the amount of sclerotic skin.

Dry and itching skin should be treated topically with steroids, cannabinoid agonists, capsaicin, emollients, and phototherapy (see above). Local steroid injections and laser or surgical therapies could also be tried for the treatment of calcinosis cutis.

Laser therapies or noninvasive methods like camouflage have been used for telangiectases. Bleaching agents, salicylic acids, and chemical peels as well as camouflage, retinoids, or corticosteroids may have the potential to improve hyper- or hypopigmentations[79] (see Table 157-7).

Two randomized clinical trials have shown that methotrexate improves the skin score in early diffuse SSc, while positive effects on other organ manifestations have not been established.[51–53] On the other hand, cyclophosphamide has been shown to improve skin sclerosis in two randomized clinical trial.[54,55] All other systemic treatment options have not demonstrated success (see Table 157-4). Protein kinase-inhibitors (e.g., imatinib) have recently been used but controlled clinical trials have not yet been reported.

CARDIOPULMONARY MANIFESTATIONS

It is increasingly appreciated that a group of patients with some lung fibrosis have predominantly PAH and that this group may respond to standard PAH therapies. There have been substantial advances in the treatment of PAH over the past decade. Most cases are treated with oral agents: either an endothelin receptor antagonists (e.g., bosentan, ambrisentan) or a phosphodiesterase

TABLE 157-7
Therapeutic options for Skin Involvement in SSc[79]

Clinical Feature	Therapeutic Options
Skin hardening	■ Lymphatic drainage ■ Physiotherapy ■ Topical treatment with steroids or calcineurin inhibitors ■ Systemic treatment with steroids (short dated) and/or immunosuppressants ■ Phototherapy (PUVA, UVA1, ECP)
Dryness and itching	■ Topical treatment with steroids, capsaicin ■ Cannabinoid agonists ■ Emollients ■ Phototherapy (PUVA, UVA1) ■ Systemic treatment with antihistamines or gabapentin
Digital ulcerations	■ Intravenous iloprost ■ Bosentan p.o. ■ Hydrocolloid dressings ■ Skin substitutes ■ Physical therapy
Calcifications	■ Bisphosphonate p.o. ■ Local corticosteroid injection ■ Laser therapy ■ Surgery
Telangiectases	■ Laser therapy ■ Camouflage
Hyper- and hypopigmentation	■ Bleaching agents, camouflage, sunscreens ■ Salicylic acid and chemical peelings ■ Hydroquinone, retinoids, corticosteroids

5 inhibitor (e.g., sildenafil, tadalafil) once they are significantly functionally limited (New York Heart Association class III). Later, if progression takes place, combination of oral treatment or introduction of parenteral prostacyclin is used, by either the intravenous or subcutaneous route. Inhaled delivery systems for iloprost are available.

Although PAH is probably responsible for more deaths than lung fibrosis in SSc, lung fibrosis remains an important complication. Treatment of SSc-PF remains challenging.[80] Adding to a substantial body of uncontrolled or retrospective data suggesting benefit for cyclophosphamide in SSc-PF, the results of two randomized double-blind placebo-controlled trials have recently been reported. Both show a modest placebo-subtracted benefit for cyclophosphamide.[56,81,82] For change in forced vital capacity (percent predicted), this was statistically significant for the Scleroderma Lung Study comparing oral cyclophosphamide with placebo, showing a strong trend ($p = 0.06$) in the trial of intravenous cyclophosphamide followed by oral azathioprine. At present, most centers use cyclophosphamide as treatment for severe or progressive SSc-PF, defining the extent and severity by pulmonary function tests and HRCT. The extent of disease by HRCT and a history of progressive restrictive abnormality on pulmonary function tests is the best predictor of future decline in lung function and is generally used to make decisions about therapy. Other therapies that are in use include carbocysteine and low-dose corticosteroids. The place of other immunosuppressive strategies remains uncertain and requires evaluation in prospective multicenter clinical trials. It is noteworthy that despite strong theoretic rationale as a treatment for lung fibrosis, the endothelin receptor antagonist bosentan was not superior to placebo in a recent large multicenter study of SSc-PF cases.

Cardiac involvement from SSc is also an important contributor to mortality but remains one of the least

TABLE 157-8
Frequency of Organ Involvement in Two Networks for Systemic Sclerosis (Germany and United Kingdom)

	Diffuse SSc		Limited SSc	
Clinical Features	**Germany ($n = 780$)**	**United Kingdom ($n = 741$)**	**Germany ($n = 1190$)**	**United Kingdom ($n = 1505$)**
Raynaud phenomenon	95.3%	97.0%	96.3%	99.0%
Skin Hardening	95.9%	100.0%	90.0%	90.0%
Digital ulcerations	36.0%	28.0%	24.3%	13.0%
PAH	20.2%	12.0%	14.0%	15.0%
Lung fibrosis	62.9%	38.0%	26.7%	16.0%
GIT involvement	65.2%	90.0%	60.7%	90.0%
Heart involvement	20.0%	3.0%	9.9%	1.0%
Kidney involvement	15.9%	19.0%	9.7%	3.0%
Musculoskeletal inv.	48.8%	45.0%	38.8%	35.0%

well understood and poorly recognized of the internal organ complications of SSc. A large number of studies confirm that radionuclide imaging, electrophysiologic, and functional abnormalities are frequent in SSc, but the significance of these findings is uncertain. Hemodynamically significant cardiac involvement occurs in up to 10% of cases of dcSSc. An inflammatory component of myocarditis may respond to immunosuppression, and so an operational approach to management of cardiac scleroderma is indicated in Fig. 157-7. This is not based on data but could form the basis for prospective evaluation of the significance of impaired left ventricular ejection fraction and elevated circulating troponin levels in SSc.

There have been many advances in SSc, including a better appreciation of the diversity of the condition, improved understanding of the underlying pathologic mechanisms, and major progress in treating organ-based complications. This includes the accumulation of robust clinical trial data that demonstrate effectiveness or lack of benefit of individual therapies and in validation of measures of disease assessment.[83]

GASTROINTESTINAL INVOLVEMENT

Involvement of the GI tract is very frequent in SSc. Esophageal symptoms can respond very well to proton pump inhibitors and agents that increase lower esophageal sphincter tone such as domperidone. Midgut involvement takes many forms. Pseudo-obstruction requires conservative management initially but may require parenteral nutritional supplementation. Small intestinal bacterial overgrowth can be treated using broad-spectrum antibiotics, and pancreatic insufficiency may require enzyme supplements. Large bowel involvement is a major challenge. Anorectal incontinence sometimes responds well to an implanted sacral nerve stimulator or to less elaborate approaches such as bioplastic injection to increase the internal anal sphincter bulk. Associated rectal prolapse may require additional surgical intervention. Chronic constipation, sometimes with overflow diarrhea, is a common problem. An adjustment to diet and judicious use of stimulating, softening, or bulking aperients is recommended, but an individualized approach with substantial patient involvement is generally the most successful approach. On occasion, defunctioning colostomy is needed, but this is only appropriate in a very limited number of cases.

SCLERODERMA RENAL CRISIS

Overall, approximately two-thirds of cases of SRC presenting to a specialist center require renal replacement therapy. Of these, approximately one-half of cases eventually recover sufficiently to discontinue dialysis. This can occur over 24 months after the crisis, and so decisions about renal transplantation should be postponed until that time. The possibility of late recovery distinguishes SRC from other causes of end-stage renal failure. These outcomes are possible through the use of angiotensin-converting enzyme inhibition as routine therapy for SRC. Before their availability, the mortality from established SRC was more than 90% at 12 months. The most critical aspect of management of SRC is prompt identification and treatment of significant hypertension in the context of scleroderma, with initiation of ACEi. This is a medical emergency and any features of renal impairment or end-organ damage should prompt hospitalization.

The frequency of organ involvement in two networks for SSc (Germany and United Kingdom) are seen in Table 157-8.

KEY REFERENCES

Full reference list available at www.DIGM8.com

DVD contains references and additional content

2. Silman AJ: Epidemiology of scleroderma. *Curr Opin Rheumatol* **3**:967-972, 1991
6. Agarwal S et al: Genetics and Genomic Studies in Scleroderma (Systemic Sclerosis). *Rheum Dis Clin N Am* **34**:17-40, 2008
21. Gabrielli A et al: Scleroderma. *N Engl J Med* **360**:1989-2003, 2009
22. Kawakami T et al: Increased expression of TGF-beta receptors by scleroderma fibroblasts: Evidence for contribution of autocrine TGF-beta signaling to scleroderma phenotype. *J Invest Dermatol* **110**:47-51,1998
23. Baroni SS et al: Stimulatory autoantibodies to the PDGF receptor in systemic sclerosis. *N Engl J Med* **354**:2667-2676, 2006
25. Nietert PJ, Silver RM: Systemic sclerosis: Environmental and occuptional risk factors. *Curr Opin Rheumatol* **12**:540, 2000
28. Subcommittee for scleroderma criteria of the American Rheumatism Association Diagnostic and Therapeutic Criteria Committee. Preliminary Criteria for the classification of systemic sclerosis (scleroderma). *Arthritis Rheum* **23**:581-590, 1980
29. LeRoy EC et al: Scleroderma (systemic sclerosis): Classification, subsets and pathogenesis. *J Rheumatol* **15**:202-205, 1988
30. Le Roy EC, Medsger TA Jr.: Criteria for the classification of early systemic sclerosis. *J Rheumatol* **28**:1573-1576, 2001
36. Poormoghim H et al: Systemic sclerosis sine scleroderma: Demographic, clinical, and serologic features and survival in forty-eight patients. *Arthritis Rheum* **43**:444-451, 2000
43. Balbir-Gurmann A et al: Non-invasive measurements of biochemical skin properties in systemic sclerosis. *Ann Rheum Dis* **61**:237-241, 2002
46. Wells AU et al: Pulmonary complications: One oft he most challenging complications of systemic sclerosis. *Rheumatology* **48**:iii40-iii44, 2009
51. Van den Hoogen FH et al: Comparison of methotrexate with placebo in the treatment of systemic sclerosis: A 24 week randomized double-blind trial, followed by a 24 week observational trial. *Br J Rheumatol* **35**:364-372, 1996
52. Pope JE et al: A randomized, controlled trial of methotrexate versus placebo in early diffuse scleroderma. *Arthritis Rheum* **44**:1351-1358, 2001
54. Tashkin DP et al: Scleroderma Lung Study Research Group. Cyclophosphamide versus placebo in scleroderma lung disease. *N Engl J Med* **354**:2655, 2006
69. Denton CP, Black CM: Novel therapeutic strategies in scleroderma. *Curr Rheumatol Rep* **1**:22-27, 1999
77. Kowal-Bielecka O et al: EULAR recommendations for the treatment of systemic sclerosis: A report from the EULAR Scleroderma Trials and Research group (EUSTAR). *Ann Rheum Dis* **68**:620-628, 2009
78. Korn JH et al: Digital ulcers in systemic sclerosis: Prevention by treatment with bosentan, an oral endothelin receptor antagonist. *Arthritis Rheum* **50**:3985-3993, 2004

Chapter 158 :: Scleredema and Scleromyxedema

:: Roger H. Weenig & Mark R. Pittelkow

Disorders characterized by excessive mucin deposition, increased collagen production, or fibrocyte hyperplasia are historically categorized as mucinoses, sclerosing disorders, and fibrosing disorders, respectively. The fibroblast is central in each of these conditions. Thus, shifting our focus from the fibroblast product (mucin, collagen, and fibrosis) to the cell of origin, the fibroblast and the mechanisms that stimulate specific fibroblast activities will provide better understanding of the histopathogenesis of these diseases and also lays a foundation for the development of more effective treatments for these incapacitating conditions. In some disorders, a singular fibroblast activity predominates, such as excessive mucin or collagen production [pretibial myxedema (see Chapter 151) and sclerodermoid disorders respectively (see Chapter 157)]. In others, a combination of excessive mucin and collagen production is observed (scleredema) or excessive mucin production and fibroblast hyperplasia occurs [scleromyxedema and nephrogenic systemic fibrosis (see Chapter 150)].

Fibroblasts are derived from CD34-positive hematopoietic precursors that originate in the bone marrow and populate the skin during development and wound repair. The chief role of the skin fibroblast is to deposit collagen, elastin, and ground substance, the major constituents of the dermis and pannicular septae and the substrate to which the epidermis and skin appendages attach (see Chapter 63).

The stimuli that cause fibroblasts to overproduce mucin or collagen or to proliferate or aberrantly immigrate into skin are varied. Infectious triggers, inflammatory states, diabetes mellitus, drugs, genetic mutations, and toxins as well as specific mediators such as eicosanoids, growth factors, cytokines, immunoglobulin-paraproteins, and other circulating factors have been implicated, but the precise mechanisms that result in fibroblast pathology (fibropathy) are poorly characterized. Some of these stimuli may recruit bone-marrow-derived fibroblast precursors to the skin; others may act directly on fibroblasts already residing in the skin.

This chapter will discuss scleredema and scleromyxedema. Other diseases relevant to cutaneous fibroblasts are discussed elsewhere in this textbook and listed in Table 158-1.

SCLEREDEMA

HISTORICAL ASPECTS

Scleredema was described by Buschke in 1902[1] and is also designated as scleredema of Buschke and scleredema adultorum, although the latter is a misleading term because children or adolescents can develop the condition.

SCLEREDEMA AT A GLANCE

- Acute skin induration characterized by dermal mucinosis and mild sclerosis
- Disease associations:
  - Postinfectious scleredema of youth
  - Diabetes mellitus-associated scleredema of adulthood
  - Paraproteinemia-associated scleredema
  - Rare associations: hyperparathyroidism, connective tissue disease, human immunodeficiency virus infection
- Histopathology: pandermal thickening with broad collagen bundles separated by mucin deposits, chiefly hyaluronate.
- Clinical course:
  - Postinfectious: usually resolves in 1–2 years
  - Diabetes mellitus-associated: may improve with better control of diabetes, but a prolonged course is expected
  - Paraprotein associated: often more chronic although remissions observed with specific treatments
  - Treatment: treat underlying disease; UVA-1; psoralen plus ultraviolet A light

EPIDEMIOLOGY

Scleredema is rare, although the precise incidence and prevalence are unknown. Men and women are affected with equal frequency. More than half of cases of scleredema occur in childhood or adolescence, most commonly after an upper respiratory tract infection.[2] Streptococcal infection is most commonly identified, but other infectious agents have also been implicated. Disease development in adulthood in association with adult-onset diabetes mellitus is the second most common presentation of scleredema. Uncommonly, scleredema occurs in association with paraproteinemia or multiple myeloma, and this association possibly is becoming more common as other causes diminish in frequency with better treatment and management of underlying disease.

TABLE 158-1
Selected Fibroblast Disorders

Excessive Collagen Production by Fibroblasts—*Sclerosing Disorders*	**Chapter**
■ Scleroderma	157
■ Morphea	64
■ Sclerodermoid graft-versus-host disease	28
■ Sclerodermoid porphyria cutanea tarda	132
■ Eosinophilic fasciitis	36, 157
■ Sclerodermoid drug reactions (bleomycin, epoxy resin, pentazocine)	157
■ Lipodermatosclerosis (sclerosing panniculitis)	70, 174
■ Collagenoma	66, 140
Fibroblast Hyperplasia—*Fibrosing Disorders*	
■ Fibromatosis (Dupuytren contracture, Peyronie disease)	66
Excessive Collagen and Mucin Production by Fibroblasts—*Scleromucinoses*	
■ Scleredema	158
Fibroblast Hyperplasia and Excessive Mucin Production by Fibroblasts—*Fibromucinoses*	
■ Lichen myxedematosus and scleromyxedema	158
■ Nephrogenic systemic fibrosis / nephrogenic fibrosing dermopathy	150
■ Toxic oil syndrome	64
■ Eosinophilia–Myalgia syndrome	36
Fibroblast hyperplasia and Excessive Collagen Production by Fibroblasts—*Fibrosclerosing Disorders*	
■ Juvenile hyaline fibromatosis	66
■ Gingival fibromatosis	66
Excessive Mucin Production by Fibroblasts—*Mucinoses*	
■ Pretibial myxedema	151
■ Generalized myxedema	151
■ Localized myxedema	151
■ Reticular erythematous mucinosis and plaque-like mucinosis	156
■ Connective tissue disease	155, 156, 157, 159, 160, 161
■ Degos disease	171

PATHOGENESIS

Type 1 collagen and hyaluronate appear to be the major fibroblast products that are increased in scleredema-affected skin.[3–5] The precise mechanism(s) for increased collagen and glycosaminoglycan production in scleredema is not known. Stimulation of fibroblasts by serum factors or immunoglobulin may be related to the pathogenesis of scleredema, particularly cases associated with infectious agents or a paraproteinemia. Serum from a patient with scleredema associated with paraproteinemia was able to increase collagen production by cultured fibroblasts in vitro.[6] However, the factor(s) involved has not been elucidated. Other soluble circulating cytokines and small molecule mediators likely also play critical roles.



Figure 158-1 Scleredema. Waxy, nonpitting induration of back skin.

CLINICAL FINDINGS

The clinical findings of scleredema are distinctive. An acute onset of nonpitting induration of neck, shoulders, and upper back skin may be followed by involvement of the face and arms. Characteristically, the affected skin appears smooth and waxy, with tense dermal induration and prominent follicular ostia, at times imparting a "peau d'orange" appearance (Fig. 158-1). In general, however, skin changes are better felt on palpation than seen. The skin of the upper trunk (especially the back) is a favored site for scleredema, but more widespread involvement may be observed. The affected and unaffected skin blend imperceptibly. Scleredema involving the esophagus, bone marrow, nerve, liver, or salivary glands has been described rarely.[7,8] However, investigations to identify internal organ involvement by scleredema are infrequently pursued. Patients may report symptoms of restricted motion of joints, the tongue, or eyes, as well as weak or tender muscles.

HISTOPATHOLOGY

Punch biopsies of affected skin reveal a nontapered (square) appearance on low power. The proportion of dermis in dramatically increased in comparison to adjacent nonaffected skin (Fig. 158-2A). A decreased number or higher placement of eccrine units may be appreciated. Fibroblasts are normal in number and morphology. The collagen bundles are slightly thickened and separated from each other by subtle deposits of mucin. Stains for mucin (alcian blue, colloidal iron) are often used to identify the mucin deposits (Fig. 158-2B).

PROGNOSIS AND CLINICAL COURSE

Postinfectious scleredema usually abates in 1–2 years. Scleredema associated with adult-onset diabetes tends

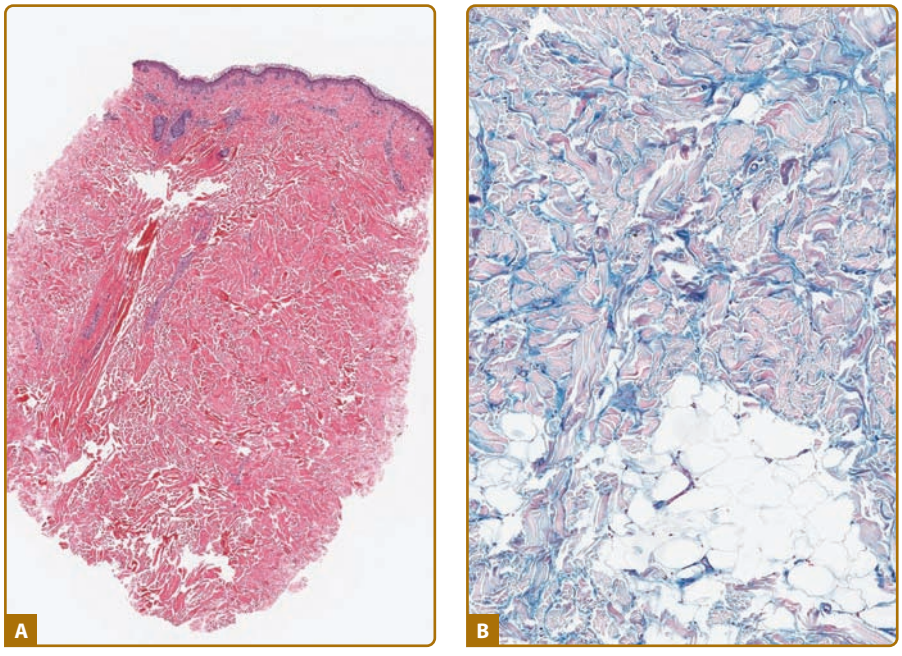

Figure 158-2 **A.** Scleredema. Thickened dermis characterized by enlarged collagen bundles separated by clear spaces (15 × original magnification). **B.** Scleredema. Mucin deposition identified in clear spaces by acid mucopolysaccharide stain (80 × original magnification).

to be protracted, although some patients appear to improve with better glucose control. Gammopathy-associated scleredema is more chronic and can be resistant to many therapies.

TREATMENT

Antibiotics do not appear to affect the course of postinfectious scleredema. Treatment of the associated disease (e.g., improved glucose control or treatment of paraproteinemia) may lead to improvement. Ultraviolet A1 phototherapy has been reported effective in a few adult patients,[9,10] as has psoralen plus ultraviolet A phototherapy.[11] Treatment with methotrexate did not provide benefit in a series of cases of scleredema. Scleredema has responded to local radiotherapy or electron-beam irradiation. Scleredema associated with monoclonal gammopathy has responded to extracorporeal photopheresis.

SCLEROMYXEDEMA

SCLEROMYXEDEMA AT A GLANCE

- Chronic, progressive condition characterized by dermal fibrosis and mucinosis and normal thyroid function
- Usually associated with paraproteinemia
- Clinical variants
  - Generalized, confluent lichenoid eruption (scleromyxedema)
  - Discrete papular (rarely nodular) eruption on the trunk or extremities (lichen myxedematosus)
    - Papular mucinosis of infancy
    - Papular mucinosis of adulthood
    - Self-healing papular mucinosis
    - Acral persistent papular mucinosis
    - Nodular variant
  - Localized or generalized lichenoid plaques (but distinct from plaque-like mucinosis/reticulated erythematous mucinosis)
  - Urticarial plaques
- Histopathology: superficial to mid-dermal fibroplasia and mucin deposition
- Clinical course: chronic progressive course and poor outcome in generalized cases; localized and self-healing forms have a better prognosis
- Treatment: correct paraproteinemia: through melphalan therapy, intravenous immune globulin, autologous stem-cell transplant

EPIDEMIOLOGY

Lichen myxedematosus/scleromyxedema is a rare disease afflicting men and women with equal frequency and symptom onset in mid to later life.

PATHOGENESIS

The pathogenesis of scleromyxedema is unknown. Most patients with scleromyxedema have a monoclonal paraproteinemia, typically designated as monoclonal gammopathy of undetermined significance (MGUS). Rare patients meet criteria for multiple myeloma. Excessive hyaluronate production and fibroblast proliferation are observed, but support for a direct effect of the monoclonal protein on fibroblasts is lacking.[15,16] Indirect mechanisms appear to include circulating cytokines, inflammatory mediators, and fibroblast precursor cell lineages that migrate from the blood, take up residence in the dermis and, in more extensive cases, in other tissues, and synthesize mucin.

CLINICAL FINDINGS

Several distinct clinical presentations, and hence nosologic designations have been recognized. Although there is considerable clinical overlap and patients may show progression from limited to widespread involvement, it is useful to distinguish localized from generalized disease as well as patients that present with discrete papules from those with confluent plaques. The generalized lichenoid eruption consists of numerous minute (1–3 mm) papules scattered on the extremities and the trunk. Scleromyxedema presents with confluent lichenoid plaques. Individual lesions and plaques may exhibit marked erythema or hyperpigmentation. The face is involved in most cases, resulting in significant deformity, "bovine facies" (Fig. 158-3). The trunk and extremities are usually affected (Fig. 158-4A) and often results in decreased flexibility and range of motion in the involved areas (Fig. 158-4B).



Figure 158-3 Scleromyxedema. Marked, nodular induration of facial skin with accentuation of skin folds.

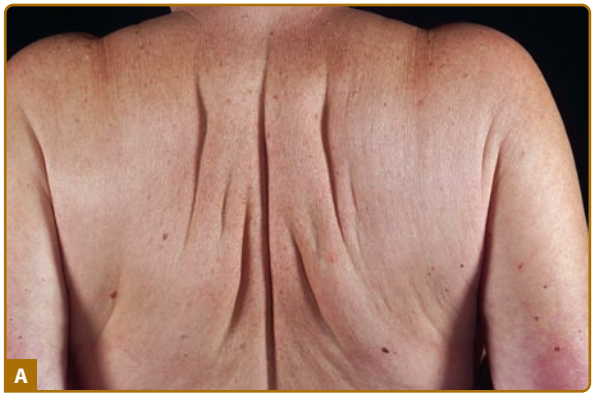



Figure 158-4 **A.** Scleromyxedema. Thickened bound-down skin of the back. **B.** Scleromyxedema. Confluent lichenoid papules and indurated skin of the hand and wrist.

A monoclonal paraproteinemia of undetermined significance, usually immunoglobulin-γ-κ type is identified in most patients. Paraproteinemia is less common in localized variants. Progression to multiple myeloma occurs rarely.

Muscle weakness, contractures, restrictive lung disease, upper airway involvement, pulmonary hypertension, esophageal dysmotility, and neurologic disorders (seizures, motor impairment, carpal tunnel syndrome, depression, memory loss, aphasia, peripheral neuropathy, and psychosis) have been reported in association with scleromyxedema. Thyroid function is normal by definition.

HISTOPATHOLOGY

Regardless of the clinical presentation, the histopathologic findings of scleromyxedema are identical and demonstrate superficial to mid-dermal mucin deposition with admixed fibroblast proliferation (Fig. 158-5). Moreover, scleromyxedema is histologically distinct from other mucinoses as well as sclerosing and fibrosing conditions. Nephrogenic systemic fibrosis [(NSF), formerly nephrogenic fibrosing dermopathy] shows close histologic resemblance to scleromyxedema. However, the pannicular septae are the focus for histologic distinction: they are always involved in NSF and never involved in scleromyxedema. Moreover, scleromyxedema tends to be restricted to the upper half of the dermis and nephrogenic fibrosing dermopathy becomes more prominent in the lower dermis and then extends to pannicular septae. Although occasional multinucleated histiocytes with or without elastophagocytosis may be identified in biopsies of scleromyxedema, there is typically minimal associated inflammation. A highly unusual histologic presentation with a marked dermal granulomatous infiltrate was observed in association with fibromucinous deposition in a 56-year-old male with scleromyxedema.[17] This unique case emphasizes the importance of correlating clinical and pathologic findings and raises the question if this patient may have had a second superimposed granulomatous disorder such as sarcoidosis in addition to scleromyxedema.

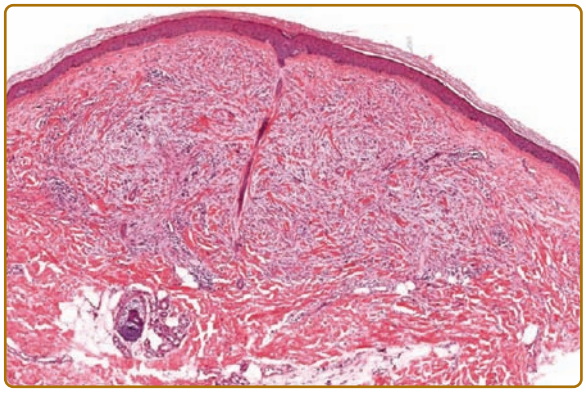

Figure 158-5 Scleromyxedema. Superficial to mid-dermal fibroplasia and increased mucin (40 × original magnification).

PROGNOSIS AND CLINICAL COURSE

Localized, "self-healing" variants are usually confined to the skin and self-limiting. However, prospective follow-up and caution is advised as some cases fitting criteria for localized disease have been associated with internal organ involvement or progression to more generalized disease (so called "atypical papular mucinosis"). Scleromyxedema usually follows a chronic and progressive clinical course and a poor outcome is expected. Respiratory failure, cerebral disease, and infection usually lead to a gradual decline and death.

TREATMENT

Melphalan had been used for decades to treat scleromyxedema with variable efficacy.[18–20] Other therapies directed towards quantitatively reducing or ameliorating the effects of the paraproteinemia have shown variable results. Agents or therapies with reported efficacy include: glucocorticoids,[21] intravenous immune globulin (IVIg),[22] thalidomide,[23] extracorporeal photophoresis,[24] interferon alpha,[25] combination chemotherapy,[26] and PUVA.[27] Partial to complete remission was achieved in 8 of 10 patients treated with IVIg.[28] Autologous peripheral blood stem cell transplantation has resulted in dramatic remission of scleromyxedema in a number of patients with severe disease.[29,30]

KEY REFERENCES

Full reference list available at www.DIGM8.com.

DVD contains references and additional content

3. Oikarinen A et al: Scleredema and paraproteinemia. Enhanced collagen production and elevated type I procollagen messenger RNA level in fibroblasts grown from cultures from the fibrotic skin of a patient. *Arch Dermatol* **123**:226, 1987
8. Basarab T et al: Systemic involvement in scleredema of Buschke associated with IgG-kappa paraproteinaemia. *Br J Dermatol* **136**:939, 1997
10. Eberlein-Konig B et al: Successful UVA1 phototherapy in a patient with scleredema adultorum. *J Eur Acad Dermatol Venereol* **19**:203, 2005
12. Montgomery H, Underwood LJ: Lichen myxedematosus; differentiation from cutaneous myxedemas or mucoid states. *J Invest Dermatol* **20**:213, 1953
20. Dinneen AM, Dicken CH: Scleromyxedema. *J Am Acad Dermatol* **33**:37-43, 1995
28. Blum M et al: Scleromyxedema: A case series highlighting long-term outcomes of treatment with intravenous immunoglobulin (IVIG). *Medicine* **87**:10, 2008
29. Lacy MQ et al: Successful treatment of scleromyxedema with autologous peripheral blood stem cell transplantation. *Arch Dermatol* **141**:1277, 2005

Chapter 159 :: Relapsing Polychondritis

:: Camille Francès

RELAPSING POLYCHONDRITIS AT A GLANCE

- Relapsing polychondritis is a rare multisystem autoimmune disease with both autoantibodies and cellular immune reactions to different cartilage proteins.
- More than 30% of patients have an associated autoimmune or hematologic disorder.
- Recurrent episodes of chondritis lead to progressive destruction of cartilaginous structures in joints, ears, and the nose.
- Other proteoglycan-rich structures such as eyes, blood vessels or inner ear are also affected.
- Dermatologic manifestations including nodules that may ulcerate; purpura and aphthae occur frequently.

EPIDEMIOLOGY

The incidence of RP has been estimated to be 3.5/million in Rochester, Minnesota.[1] The peak age for disease onset is the fifth decade; however, development of the disease may occur in young children and in the elderly.[2] The male to female ratio has been estimated from 1.1 to 1.3.[3] Although most cases have been reported in Caucasians, there is no evidence supporting the role of ethnic or geographical factors.

ETIOLOGY AND PATHOGENESIS

Several lines of evidence have been accumulated that suggest the role of autoimmunity in RP. More than 30% of patients have an associated disease, mainly of autoimmune origin.

The role of the humoral immune response was based on the presence of antibodies to collagen type II in the acute phase of RP. Antibody titers seemed to correlate with the severity of symptoms. Other antibodies were secondarily detected in patients with RP: antibodies to collagen type IX and type XI, minor collagens which represent 5–10% of cartilage collagens, antibodies to matrilin-1, an extracellular matrix protein, predominantly expressed in upper respiratory tract cartilage, and antibodies to cartilage oligomeric matrix protein, other cartilage proteins expressed in auricular, tracheal and nasal cartilage. Several animal models have been published in which immunization with these various cartilage proteins induced a variety of chondritis manifestations that mimic those seen in patients.[4] A role for immune complexes and subsequent activation of the complement system is suggested by examination of tissue lesions that usually show the presence of granular deposits of immunglobulins and the C3 component of complement associated with $CD4^+$ lymphocytes and plasma cells. The influence of T cells in RP pathogenesis, although less investigated, has also been demonstrated in patients and in animal models with specificity against the same cartilage proteins. T-cell clones isolated from an RP patient were found to be specific for a peptide corresponding to residues 261–273 of the type II collagen and were restricted to either the DRBI*0101 or the DRBI*0401 allele.[5] A significant near two fold increase in DR4 antigen frequency was found in RP patients as compared to that in healthy controls, but the genotyping of DR-4 positive patients and controls did not show a predominance of any DR4 subtype. Genetic susceptibility was also confirmed by animal models.[6]

CLINICAL FINDINGS

Disease onset is usually sudden with characteristic chondritis, and/or less frequently arthritis or ocular inflammation. Nonspecific initial symptoms such as fever or weight loss are rare.

Attacks of chondritis usually occur in a relapsing and remitting pattern. Inflammatory episodes generally last a few days or weeks and may subside spontaneously or after treatment is initiated; recurrences after weeks or months occur and result subsequently in cartilage destruction. Auricular chondritis is the most frequent (85%), causing pain, redness, and swelling of the cartilaginous portion of the pinna, sparing the noncartilaginous lobe (Fig. 159-1). Biopsy of the auricular cartilage is not usually necessary to



Figure 159-1 Relapsing polychondritis. Painful inflammation of the cartilaginous portion of ear.



Figure 159-2 Relapsing polychondritis. Soft and sloppy ear with a "cauliflower" aspect.

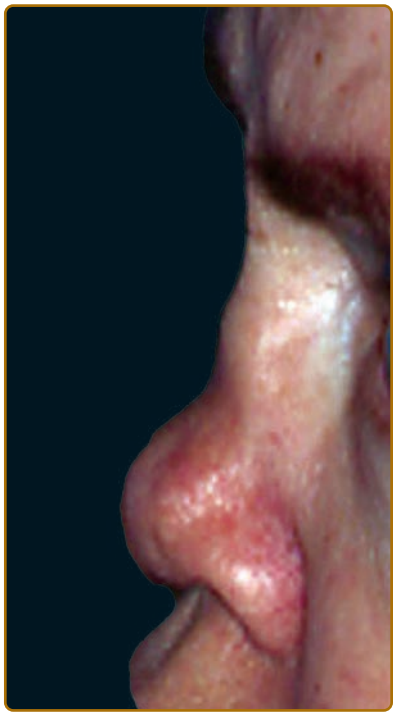

Figure 159-3 Relapsing polychondritis. Saddle nose deformity.

make a diagnosis. The histology shows perichondrial inflammation and the loss of the normal cartilaginous basophilia. After several attacks, the pinna may become soft and floppy with a cauliflower appearance (Fig. 159-2); sometimes it is stiff due to calcifications. Nasal chondritis (65%) is less inflammatory, presenting with nasal pain, stuffiness, rhinorrhea, and sometimes epistaxis. The characteristic saddle-nose deformity (Fig. 159-3) may appear secondarily or without previous inflammatory episodes. Respiratory tract chondritis, though uncommon at presentation, occurs in up to 50% of patients, and may be lethal. This results in complaints of hoarseness, nonproductive persistent cough, dyspnea, wheezing. Complications include upper airway collapse, obstructive respiratory insufficiency and secondary infections. Costochondritis (35%) induces parietal pains, which may also compromise respiration.

Joint pain is a common presenting feature (30%). Large and small joints of the peripheral or axial skeleton may all be affected (>70%). Arthritis is intermittent, migratory, asymmetric, seronegative, and usually nonerosive.

Nearly 60% of patients develop ocular inflammation. Episcleritis and scleritis (see eFig. 159-3.1 in online edition) are the most common manifestations, followed by keratoconjunctivitis sicca, iritis, retinopathy, keratitis. Rarely corneal perforation, retinal vasculitis, and optic neuritis lead to blindness.

Conductive hearing loss is secondary to stenosis of the external auditory canal, Eustachian tube chondritis or serous otitis media while perception hearing loss may occur as a consequence of sensorineural involvement. Symptoms of vestibular dysfunction such as dizziness, ataxia, nausea, and vomiting are usually acute and improve with time.

The spectrum of cardiovascular manifestations is wide including different cardiac tissues (aortic and/or mitral regurgitation, impairment of the conduction system, pericarditis) and all types of vessels (thoracic and abdominal aortitis leading to aneurysms, Takayasu-like aortic arch syndrome, medium and large vessels vasculitis, leukocytoclastic vasculitis, thrombophlebitis). Lesions are inflammatory and/or thrombotic. Some but not all thrombotic manifestations have been linked to antiphospholipid syndrome. Large vessel vasculitis tends to occur after several years of smoldering and often occult disease, despite immunosuppressive therapy.

Dermatologic manifestations are sometimes the presenting feature of RP (12%), and become apparent in more than one-third of patients of a large series.[7] They are nonspecific including nodules on the limbs (see eFig. 159-3.2 in online edition), annular eruptions, purpura (see eFig. 159-3.3 in online edition), oral or complex aphthosis (see eFig. 159-3.4 in online edition), papules, sterile pustules (see eFig. 159-3.5 in online edition), superficial phlebitis, livedo reticularis, ulcerations on the limbs, distal necrosis (see eFig. 159-3.6 in online edition). They appear concomitantly or independent of attacks of chondritis. Pathological features include inflammatory or thrombotic vascular lesions, neutrophil infiltrates as in neutrophilic dermatoses, and inflammation of the dermis or subcutis. Patients with and without dermatologic manifestations have similar clinical manifestations of RP. However, the frequency of dermatologic manifestations (>90%), age at first chondritis and male/female ratio seems higher

BOX 159-1 EMPIRICAL DIAGNOSTIC CRITERIA

1. Bilateral auricular chondritis
2. Nonerosive seronegative inflammatory polyarthritis
3. Nasal chondritis
4. Ocular inflammation
5. Respiratory chondritis
6. Audiovestibular damage

For the diagnosis of RP, patients must have one of the following:

(a) At least three of the above clinical criteria
(b) One or more of the above clinical criteria + biopsy confirmation of cartilage inflammation
(c) Chondritis at two or more separate anatomic locations with response to steroids and/or dapsone

when RP is associated with myelodysplasia[7]; so, their presence in an old man warrants repeated blood counts to detect a smoldering myelodysplasia.

Laboratory findings in RP are nonspecific, consistent with acute or chronic inflammation. Urinalysis may be abnormal in the presence of renal involvement (mesangial expansion, IgA nephropathy, tubulointerstitial nephritis, or necrotizing glomerulonephritis).

Pulmonary function tests, including inspiratory and expiratory flow volume curves, should be performed systematically to detect occult pulmonary involvement, which may be confirmed by computed tomography of the respiratory tract. Three-dimensional or spiral magnetic resonance imaging may provide better resolution. Although not routinely available, autoantibodies to collagen type II, IX, XI and to matrilin I can be found in patients with RP. Urinary type II collagen neoepitope measurement may be a useful tool to follow evolution of disease.[8]

DIAGNOSIS

(Box 159-1)

DIFFERENTIAL DIAGNOSIS

(Box 159-2)

PROGNOSIS AND CLINICAL COURSE

The clinical course of RP is progressive with intermittent flares. The number of different organ manifestations, their severity, and the response to treatment are unpredictable. Common causes of death are respiratory or cardiovascular complications and secondary infections. Patients have an increased risk of developing lethal myelodysplastic malignancies.

BOX 159-2 DIFFERENTIAL DIAGNOSIS

AURICULAR CHONDRITIS

- Bacterial cellulitis
- Leishmaniasis
- Leprosy
- Traumatisms (rugbyman, boxer)

NASAL CHONDRITIS

- Sinusitis
- Infectious perichondritis
- Granulomatosis with polyangiitis (Wegener's)
- Congenital syphilis

MAIN DISEASES ASSOCIATED WITH RELAPSING POLYCHONDRITIS AND/OR WITH CLINICALLY SIMILAR MANIFESTATIONS

- Autoimmune diseases
  - Rheumatoid arthritis
  - Systemic lupus erythematosus
  - Sjögren syndrome
  - Mixed connective tissue disease
  - Thyroid autoimmune disease
  - Diabetes mellitus
- Hematologic disorders
  - Myelodysplastic syndromes
  - Immunoglobulin A myeloma
  - Others
- Skin diseases
  - Vitiligo
  - Psoriasis
  - Alopecia areata
  - Lichen planus
- Vasculitides
  - Leukocytoclastic
  - Granulomatosis with polyangiitis (Wegener's)
  - Polyarteritis nodosa
  - Microscopic polyangiitis
  - Churg–Strauss syndrome
  - Behçet's disease
  - MAGIC syndrome
  - Takayasu arteritis
- Intestinal diseases
  - Crohn disease
  - Ulcerative colitis
- Others
  - Ankylosing spondylitis
  - Reiter syndrome

MAGIC = mouth and genital ulcers with inflamed cartilage.

TREATMENT

Because of the highly variable course of relapsing polychondritis, individualized therapy is the key to optimum management. General therapeutic guidelines are based on retrospective analyses of series of patients or isolated case reports. Nonsteroidal anti-inflammatory drugs, colchicine or dapsone may be useful for patients with mild auricular or nasal chondritis, arthralgia or mild arthritis. More serious manifestations require oral corticosteroids in a dose of 0.3–1 mg/kg of body weight according to severity. Pulse intravenous steroids are prescribed for acute airway obstruction, sudden hearing loss and/or before surgical intervention (tracheostomy, aortic aneurysm repair, cardiac valve replacement). Long-term corticosteroids decrease the frequency and severity of recurrences although it has no preventive effect of vital organ involvement. Many kinds of immunosuppressants have been used with some success as disease-modifying and steroid-sparing agents. Methotrexate, azathioprine, cyclophosphamide, and cyclosporine A are the more commonly

used. The beneficial effects of new biological therapies such as antitumor necrosis factor agents, anti-interleukin-1 or -6 receptor, and of autologous stem cell transplantation have been reported in isolated cases.

KEY REFERENCES

Full reference list available at www.DIGM8.com

DVD contains references and additional content

1. Kent PD et al: Relapsing polychondritis. *Curr Opin Rheumatol* **16**:56, 2004
2. Gergely P et al: Relapsing polychondritis. *Best Pract Res Clin Rheumatol* **18**:723, 2004
3. Letko E et al: Relapsing polychondritis: A clinical review. *Semin Arthritis Rheum* **31**:384, 2002
4. Hansson AS et al: Cartilage-specific autoimmunity in animal models and clinical aspects in patients-focus on relapsing polychondritis. *Arthritis Res* **4**:296, 2002
5. Buckner JH et al: Identification of type II collagen peptide 261–273-specific T-cell clones in a patient with relapsing polychondritis. *Arthritis Rheum* **46**:238, 2002
6. Lamoureux JL et al: Mice expressing HLA-DQ6α8β transgenes develop polychondritis spontaneously. *Arthritis Res Ther* **8**: R134, 2006
7. Frances C et al: Dermatologic manifestations of relapsing polychondritis. *Medicine (Baltimore)* **80**:173, 2001
8. Kraus VB et al: Urinary type II collagen neoepitope as an outcome measure for relapsing polychondritis. *Arthritis Rheum* **48**:2942, 2003

Chapter 160 :: Rheumatoid Arthritis, Rheumatic Fever, and Gout

:: Warren W. Piette

RHEUMATOID ARTHRITIS AT A GLANCE

- Affects roughly 1% of the world population.
- Chronic disfiguring inflammatory condition.
- Genetics and environment play a role in etiology.
- Symmetric arthritis of the proximal interphalangeal and metacarpophalangeal joints.
- Skin findings include granulomatous dermatitis, vasculitis, rheumatoid nodules, pyoderma gangrenosum, and Bywater lesions.
- Treatment based on severity of disease.

This chapter discusses common rheumatologic diseases that have predominantly musculoskeletal presentations; however, all of these conditions have cutaneous manifestations.

RHEUMATOID ARTHRITIS

Rheumatoid arthritis (RA) is a systemic inflammatory autoimmune disease that is characterized by a debilitating chronic, symmetric polyarthritis with significant extra-articular manifestations, which include rheumatoid nodules, pyoderma gangrenosum, granulomatous dermatitis, vasculitis, and internal organ involvement. The disease process is often progressive, resulting in limitation of joint function. Ultimately, there may be a resultant decline in functional status, possibly leading to premature death. Permanent remission is unusual.

EPIDEMIOLOGY

Rheumatoid arthritis has an annual incidence of approximately 0.4 per 1,000 in females and 0.2 per 1,000 in males, with a prevalence of approximately 0.4% to 1% of the adult population in diverse populations worldwide.[1–3] Approximately 70% of patients follow a chronic disease course with exacerbations and remissions; 25% have intermittent disease with brief attacks of inflammation followed by remissions; approximately, 5% have an aggressive, malignant form with multiple extra-articular manifestations.[4] RA has a peak onset at 50 years of age.[1,2]

ETIOLOGY AND PATHOGENESIS

The exact etiology of RA remains unknown. Genetics plays at least some role in the development, severity, and outcome of the disease in certain patients.[5] Furthermore, an association between extra-articular disease and *HLA-DR1* and *-DR4* genes has been noted in some populations.[6]

Mechanical stress on joints may initiate an inflammatory response creating an imbalance between the rapid response to trauma and the need to protect self from damage. Patients with seropositive RA (positive rheumatoid factor) have circulating and tissue-bound immune complexes. B cells produce autoantibodies in

some RA patients. After binding to antigen, these autoantibodies result in complement fixation and recruitment of polymorphonuclear leukocytes, which result in joint destruction. Possible antigens in RA include heat shock proteins, collagen, and cyclic citrullinated peptides.[7] Indeed, antibodies to several citrullinated peptides are enriched in the joints of patients with RA.[8]

Patients with negative rheumatoid factor (seronegative RA) may not create autoantibodies, but other immune mechanisms are involved. This theory led to the recognition that T cells are important players in the etiology of this disease. In the SKG mouse model, autoreactive T cells are preferentially selected, leading to inflammatory arthritis similar to RA. T cells also activate other cells via cytokines, including osteoclasts, which play a major role in the bone resorption seen in RA. Effector cytokines of the T cell include interferon-γ, interleukin 1, interleukin 17, and tumor necrosis factor-α (TNF-α), many of which have been, or are being, used as therapeutic targets to treat RA.[4,7]

Lastly, joints have unique anatomic and physiologic qualities that render them targets for immune and inflammatory assault. Cartilage is subject to repetitive mechanical stress, retains antigens and proinflammatory cytokines, and has a limited capacity for regeneration. Only two groups of enzymes found in the joint are capable of degrading native type I and II collagen fibrils: (1) cysteine cathepsins and (2) matrix metalloproteinases.[9]

CLINICAL FEATURES

RA often begins with general constitutional symptoms such as fatigue, anorexia, vague musculoskeletal complaints, and generalized weakness. It may be weeks or months before the characteristic synovitis presents. It is in these early stages that definite diagnosis is most difficult, despite a thorough patient evaluation. However, early diagnosis and treatment are essential because most of joint damage is thought to occur early in the disease process. The American College of Rheumatology has guidelines for the diagnosis of RA (Table 160-1).[10] For a patient to be diagnosed with RA, four of the seven criteria must be present, and the first four criteria listed must be present for at least 6 weeks. Extra-articular manifestations may help to delineate the disease process early and may signify a more serious disease process requiring the initiation of aggressive therapy.[11,12] Several conditions can mimic RA, and must be considered in the differential diagnosis of early disease: viral syndromes (especially parvovirus B19, rubella, hepatitis B and C), polymyalgia rheumatica, remitting seronegative symmetric synovitis with pitting edema (RSSSPE), palindromic rheumatism, adult Still's disease, systemic lupus erythematosus, and multicentric reticulohistiocytosis.[13]

ARTICULAR MANIFESTATIONS. The articular manifestations of RA relate to an inflammatory synovitis that can affect the synovial lining of joints, tendons, and bursae. Synovial inflammation usually results in warmth but not erythema of the affected area. There is significant pain in association with stretching of the joint capsule. Hand and foot involvement forms the basis of the disease in most patients. Although the initial manifestations in the hand may be asymmetric, the clinical course subsequently takes on a symmetric and diffuse pattern. There is a characteristic involvement

TABLE 160-1
1987 American College of Rheumatology Revised Criteria for the Classification of Rheumatoid Arthritis (Modified)

Criterion	Definition
Morning stiffness	Morning stiffness in and around the joints, lasting at least 1 hour before maximal improvement
Arthritis of three or more joint areas	At least three joint areas simultaneously afflicted with soft-tissue swelling or joint fluid observed by a physician. The possible areas are (right or left): PIP, MCP, wrist, elbow, knee, ankle, and MTP joints
Arthritis of hand joints	At least one area swollen in a wrist, MCP, or PIP joint
Symmetric arthritis	Simultaneous involvement of the same joint areas on both sides of the body (bilateral involvement of PIP, MCP, or MTP acceptable without perfect symmetry)
Rheumatoid nodules	Subcutaneous nodules over bony prominences or extensor surfaces or in juxta-articular regions (observed by a physician)
Serum rheumatoid factor	Abnormal amount of serum rheumatoid factor by any method while the result has been positive in 5% of control subjects
Radiographic changes	Erosions or unequivocal bony decalcification localized in or most marked adjacent to the involved joints

MCP = metacarpophalangeal; MTP = metatarsophalangeal; PIP = proximal interphalangeal.
From Arnett FC et al: The American Rheumatism Association 1987 revised criteria for the classification of rheumatoid arthritis. *Arthritis Rheum* **31**:315, 1988.

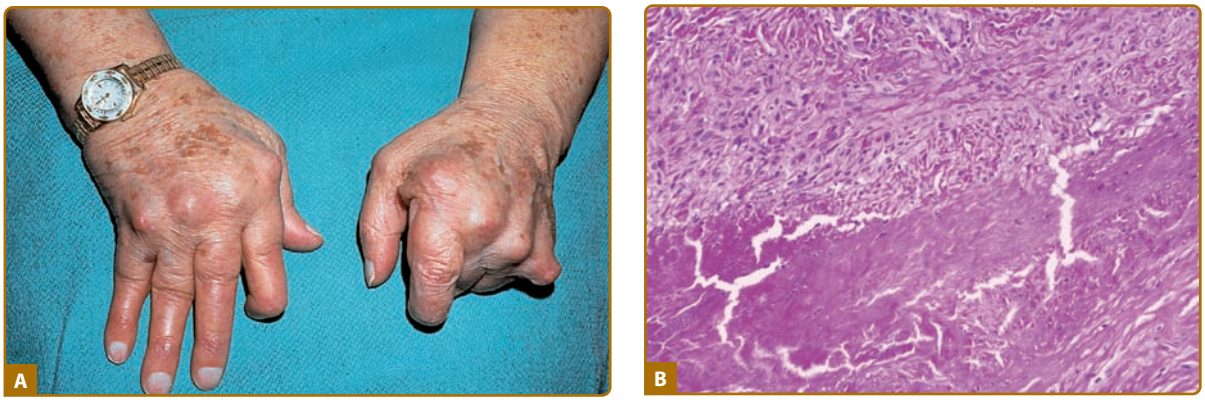

Figure 160-1 Rheumatoid nodules. **A.** Severely affected joints of a patient with rheumatoid arthritis with overlying rheumatoid nodules. **B.** Histopathologically, rheumatoid nodules are palisaded granulomas in the deep reticular dermis surrounding degenerated collagen.

of the proximal interphalangeal (PIP) and metacarpophalangeal joints with sparing of the distal interphalangeal (DIP) joints. The pattern of joint involvement is highly suggestive of the diagnosis.

Chronic inflammation may result in irreversible structural damage of the joint, including cartilage destruction and bony erosion. Late structural deformities may result from soft-tissue contractures or from bony ankylosis. Characteristic deformities include radial deviation of the hand with ulnar deviation of the digits, the "swan neck" deformity from hyperextension of the PIP joint and compensatory flexion of the DIP joint, and the boutonnière deformity from flexion contracture of the PIP joint and extension of the DIP joint. Similar structural deformities can occur in the feet, and all can be debilitating. Involvement of the thoracic and lumbar spine in RA is exceptional. Although the shoulder joint is often affected, it is soft-tissue structures, which include the rotator cuff tendons and muscles and the subacromial bursa that are usually involved in the patient's symptomatology.

DERMATOLOGIC MANIFESTATIONS. Extra-articular manifestations occur in more aggressive or extensive forms of RA.[11,12] The most common dermatologic finding in RA is the rheumatoid nodule. The classic rheumatoid nodule is a subcutaneous nodule that occurs in approximately one-fourth of patients with RA (Fig. 160-1A). More than 90% of patients with rheumatoid nodules have seropositive RA. The usual location is over pressure points such as the olecranon, the extensor surface of the forearms, and the Achilles tendon; but they have been described in almost every location, including viscera.[12] The main histologic findings (see Fig. 160-1B) are palisaded granulomas in the deep dermis or subcutaneous tissues with fibrinoid degeneration of collagen, a multitude of neutrophils, and neutrophilic dust, with surrounding fibrosis and proliferation of vessels. The main differential diagnoses histopathologically include subcutaneous granuloma annulare, necrobiosis lipoidica, foreign body or infectious granulomatous reaction, and epithelioid sarcoid.[14]

Though rheumatoid nodules are benign, they can lead to complications, including ulceration, infection, joint effusion (rheumatoid chyliform bursitis), and fistulas (fistulous rheumatism). All conditions may lead to the need for surgical excision.[12]

Rheumatoid vasculitis has an estimated annual incidence of less than 1%, most often affects patients with seropositive disease, and is believed to affect 1 in 8 males with RA, versus 1 in 38 females.[15] A study of 30-year cumulative incidence of extra-articular manifestations, major cutaneous vasculitis occurred in 5.1% of the study population.[16] Small- to medium-sized vessels are primarily affected, often with associated peripheral neuropathy (including motor), digital gangrene, nail fold infarcts, and palpable purpura (see Chapter 163 and 164).[12,17] Some patients may have nail fold telangiectasias, with minute digital ulcerations or petechiae and digital pulp papules (Bywaters lesions) (Fig. 160-2). These papules are a manifestation of mild vasculitis and typically occur without systemic signs of vasculitis. Histopathology of skin biopsy specimens usually shows leukocytoclastic vasculitis with neutrophilic infiltration of the vessel wall, fibrinoid necrosis, and hemorrhage without palisaded granulomatous



Figure 160-2 Bywaters lesions. Note the purpuric papule on the dorsal finger.



Figure 160-3 Felty syndrome. A refractory ulcer on the foot of a patient with rheumatoid arthritis and hypersplenism.

reaction.[14] Cutaneous small-vessel vasculitis mostly involves postcapillary venules and may affect arterioles and larger vessels of the viscera, heart, and central nervous system. The spectrum of clinical lesions reported in rheumatoid vasculitis is wide and varies with the size and location of the vessels involved and with the extent of the disease (see Chapters 163 and 164). Unfortunately, the presence of vasculitis, especially at the onset of the disease, portends a poor outcome.[18] Vasculitis, along with certain other extra-articular manifestations of RA (pericarditis, pleuritis, amyloidosis, and Felty syndrome), are associated with a diminished lifespan.[16] Rheumatoid vasculitis can present as lower-extremity ulcers; however, pyoderma gangrenosum (see Chapter 33) should be suspected if deep liquefying ulcers with a characteristic purple, undermined border occur in patients with RA. The ulcers may occur at any site but are most common on the lower extremities and abdomen. Pyoderma gangrenosum occurs more frequently and more severely in females and may take years to heal. Leg ulcers may also appear in patients with Felty syndrome, a combination of chronic RA, hypersplenism, and leukopenia (Fig. 160-3).[12] In some instances, the ulcers of Felty syndrome exhibit the same morphologic characteristics and behavior of pyoderma gangrensoum ulcers, suggesting that these ulcers are not necessarily a manifestation of rheumatoid vasculitis.

Rheumatoid neutrophilic dermatosis is a very rare cutaneous manifestation in patients with severe RA. First described by Ackerman in 1978, these lesions are usually chronic, erythematous, and urticaria-like plaques and papules that are sharply marginated (Fig. 160-4A). Histopathologically, these lesions have a dense infiltrate of neutrophils without leukocytoclasia, in the setting of a mixed infiltrate and papillary edema (see Fig. 160-4B).[14] It may be difficult to differentiate rheumatoid neutrophilic dermatosis from acute febrile neutrophilic dermatosis (Sweet syndrome) (see Chapter 32). Some authors accept palisaded neutrophilic granulomatous dermatitis as a histologic finding consistent with rheumatoid neutrophilic dermatitis.[19] However, in the absence of granuloma formation, it seems reasonable to separate rheumatoid neutrophilic dermatitis from multiple named entities, which would seem to be now included under the term interstitial granulomatous dermatitis.

Other vasculitis syndromes, such as erythema elevatum diutinum (see Chapter 165) and livedo vasculitis (segmental hyalinizing vasculitis), have also been described in patients with RA. Skin manifestations such as palmar erythema, erythromelalgia, autoimmune bullous diseases such as epidermolysis bullosa acquisita (see Chapter 60), yellow nail syndrome (see Chapter 89), erythema multiforme (see Chapter 39), erythema nodosum (see Chapter 70), and urticaria (see Chapter 38) also have been reported in patients with RA.[20]

Low-dose methotrexate, often used for the treatment of rheumatoid arthritis, may precipitate erythema and enlargement of preexisting rheumatoid nodules, known as accelerated nodulosis.[21] Regression of these changes is expected when the methotrexate dose is decreased or discontinued. A second reaction to methotrexate has also been reported as a syndrome of clustered, erythematous, indurated papules arising most commonly on the proximal extremities and buttocks. This has been reported not only in patients

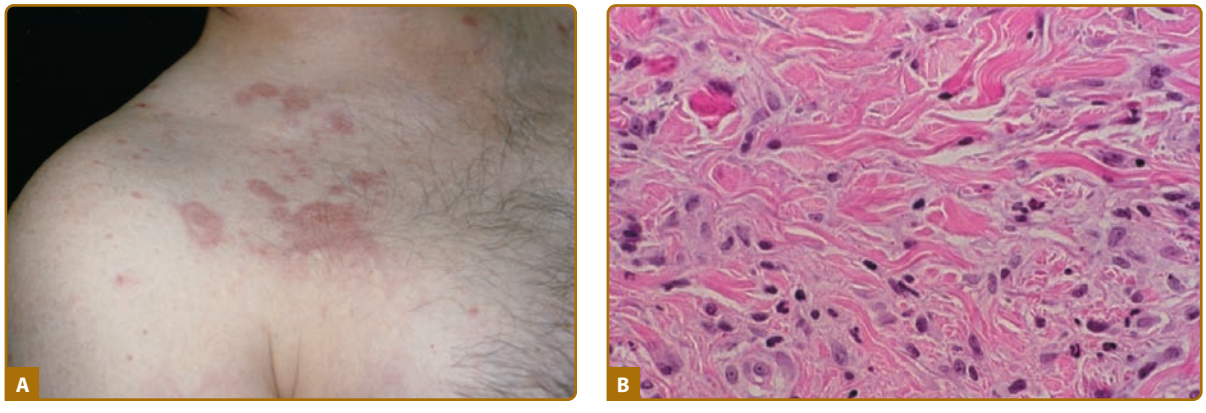

Figure 160-4 Rheumatoid neutrophilic dermatosis. **A.** Lesions are erythematous urticarial papules often coalescing into plaques in a patient with rheumatoid arthritis. **B.** Histopathologically, there is an interstitial mixed dermal infiltrate predominated by neutrophils without leukocytoclasis. This is often accompanied by papillary edema.

with rheumatoid arthritis, but also in association with other diseases as well, especially collagen vascular diseases.[22,23] In rare instances, some lesions may develop erosions or surrounding livedo. The histologic pattern seen in the popular eruption is that of a mostly histiocytic infiltrate arranged interstitially between collagen bundles in the dermis, intermixed with a few neutrophils. Small rosettes of histiocytes may surround thick collagen bundles in the reticular dermis. Yet another possible cutaneous complication of methotrexate therapy in rheumatoid arthritis is the development of Epstein–Barr virus-associated multifocal cutaneous lymphoproliferative disease, which may regress on discontinuation of therapy.[24]

A histologically related eruption of interstitial granulomatous dermatitis has been described in association with a number of disorders, including rheumatoid arthritis.[23] Cutaneous lesions consist of linear slightly red or skin-colored cords, most often extending from the upper back to the axillae.[23,25] Histopathologic findings include a dense, diffuse infiltrate of histiocytes arranged in a band-like configuration in middle or deep reticular dermis. There may be foci of basophilic collagen surrounded by palisaded histiocytes. These cells may also exhibit large and pleomorphic nuclei, and scattered mitotic figures are readily seen. Neutrophils and eosinophils are present, most notably in areas of degenerated collagen.

Indurated erythema, livedo-like erythema, and papules over the elbows have been reported as clinical findings of intravascular or intralymphatic histiocytosis in rheumatoid arthritis.[25]

NONDERMATOLOGIC EXTRA-ARTICULAR MANIFESTATIONS. In addition to systemic vasculitis, which can affect numerous organ systems, there are multiple nondermatologic extra-articular manifestations of RA. Table 160-2 lists the more common ones.

TABLE 160-2
Nondermatologic Extra-Articular Manifestations of Rheumatoid Arthritis

Type	Manifestations
Ocular	Keratoconjunctivitis sicca, scleritis, episcleritis, scleromalacia
Renal	Amyloidosis and vasculitis
Hematologic	Anemia, thrombocytosis, lymphadenopathy, Felty syndrome
Neurologic	Entrapment neuropathy, cervical myelopathy, mononeuritis multiplex (vasculitis), peripheral neuropathy
Lung	Pleural effusions, pulmonary fibrosis, bronchiolitis obliterans, rheumatoid nodules, vasculitis
Cardiac	Pericarditis, premature atherosclerosis, vasculitis, nodules, aortic root dilatation

DIFFERENTIAL DIAGNOSIS OF RHEUMATOID NODULES

(Box 160-1)

LABORATORY FINDINGS

There is no one specific histologic, radiographic, or laboratory test that conclusively permits the diagnosis of RA. Rheumatoid factor, an autoantibody that reacts with the Fc portion of immunoglobulin G (IgG), is found in sera of 85% of patients with RA. Rheumatoid factor should not be used as a definitive screening tool because it can be found in other disease processes (sarcoidosis, liver diseases, pulmonary fibrotic processes, and cryoglobulinemia). It is also found in approximately 5% of the unaffected population.[17] A false-positive rheumatoid factor can be caused by many factors, including chronic bacterial infections such as infective endocarditis, tuberculosis, and Lyme disease, as well as by viral diseases such as rubella and infectious mononucleosis.[26] Anticitrullinated protein antibodies have been shown to be a more specific marker than rheumatoid factor, particularly in early disease where specificity ranges from 94% to 100%, compared to 23% to 94% for rheumatoid factor, with roughly equivalent sensitivities.[3]

TREATMENT

Because the exact cause of RA is unknown, treatment has been directed against various components of the inflammatory process. No single therapy is the treatment of choice. In the past, most patients with early disease were started on nonsteroidal anti-inflammatory drugs until joint erosions were evident.

These medications are useful to alleviate symptoms. They do not alter disease progression.

Furthermore, new understanding of disease mechanism and the chronic disabling nature of RA have resulted in a shift to earlier use of disease-modifying

BOX 160-1 DIFFERENTIAL DIAGNOSIS OF RHEUMATOID NODULES

Consider
- Subcutaneous granuloma annulare
- Foreign body granuloma
- Infectious granuloma
- Sarcoid granuloma
- Myxoid cyst
- Traumatic epidermal cyst
- Xanthoma

Rule Out
- Epithelioid sarcoma
- Fibromatous nodules in Lyme borreliosis

TABLE 160-3
Disease-Modifying Antirheumatic Drugs

- Methotrexate
- Hydroxychloroquine
- Gold salts
- Sulfasalazine
- Azathioprine
- Cyclosporine
- Cyclophosphamide
- Leflunomide
- D-penicillamine

antirheumatic drugs (DMARDs). New guidelines released by the American College of Rheumatology in 2002[18] advocate this switch.[27] DMARDs decrease inflammation (confirmed by a reduction in acute-phase reactants), reduce or prevent joint damage, and modify the disease process. The use of DMARDs is now recommended early in the disease course, when joint damage has already occurred or is imminent. Multiple medications fall into this category (Table 160-3). They may be used alone or in combination, but their use may be limited by loss of efficacy or systemic toxicity. Medications are often used in combination, but the decision about which drug to use is often individualized and determined by the clinical severity and loss of function and resultant disability, along with concerns about the safety profile of each given patient.

Systemic glucocorticoids are potent anti-inflammatory agents but have a serious side-effect profile when used in large doses over long periods of time. They are not a good option alone for RA, but are sometimes used in a low dose with other DMARDs. Methotrexate has been used as a very effective DMARD for many years, and is often the standard of care for initial DMARD therapy of RA.[28,29] Other nonbiologic DMARDs include hydroxychloroquine sulfate, sulfasalazine, leflunomide, gold salts, azathioprine, cyclosporine, and minocycline.

The newest additions to the antirheumatic armamentarium are the biologic response modifiers, which act to inhibit the proinflammatory cytokines that play a role in RA. The best known commercially available members of this category are the anti-TNF-α agents. TNF-α is a proinflammatory agent released by macrophages and T cells contributing to synovitis and joint destruction.

There are five anti-TNF-α drugs currently approved by the US Food and Drug Administration, which have been used in the treatment of RA: (1) etanercept, (2) infliximab, (3) adalimumab, (4) golimumab, (each approved for use in RA), and (5) certolizumab (approved for use in Crohn disease).[28] Etanercept is a recombinant human TNF dimeric receptor fusion protein consisting of the ligand-binding portion of the human 75-kDa TNF receptor linked to the Fc portion of human IgG1. This treatment is given as a subcutaneous injection twice per week. Infliximab is a chimeric (mouse/human) *IgG1* monoclonal antibody to TNF-α. It is given intravenously every 6 to 8 weeks. Adalimumab is a human IgG1 monoclonal antibody that binds membrane bound and soluble TNF-α. Adalimumab, like other TNF inhibitors, commonly induces autoantibodies, but only rarely induces autoimmune diseases, such as lupus.[30] Golimumab, a human monoclonal antibody, is the newest TNF inhibitor approved for use in rheumatoid arthritis, administered as a once monthly subcutaneous injection.[31] Certolizumab is a humanized, pegylated, Fc-free anti-TNF monoclonal antibody, which has been used alone or in combination with methotrexate in rheumatoid arthritis. These agents render TNF-α biologically inactive, thereby significantly decreasing the synovitis and retarding the progression of joint destruction.[32] Cutaneous vasculitis presumed secondary to RA has been reported in three patients treated with anti-TNF agents.[33] An apparent rare class effect of TNF inhibitors is the development of sarcoidosis in patients with psoriatic or rheumatoid arthritis.[34]

Other biologic DMARDs include rituximab (CD20 monoclonal antibody), abatacept (T-cell activation inhibitor, anakinra (IL-1 receptor antagonist), and tocilizumab (an IL-6 receptor antagonist).[28] Rituximab is commonly given with methotrexate or another nonbiologic DMARD, and is administered as two 1,000-mg intravenous infusions given 2 weeks apart.[28] Rituximab has been helpful in patients refractory to TNF blockade.[35] Pretreatment with methylprednisolone 50–100 mg infused 30 minutes beforehand may mitigate infusion reactions. Cutaneous vasculitis has been reported as a rare association with rituximab therapy.[36] Ofatumumab is also an anti-CD20 monoclonal antibody approved for use in chronic lymphocytic leukemia, which has been used in some patients with DMARD-resistant rheumatoid arthritis.[37] Abatacept is a fusion protein that interferes with T-cell activation, given as an initial IV dose, then at week 2 and 4, then monthly thereafter. Infusion reactions may occur within an hour after infusion. Increase in pneumonia, pyelonephritis, cellulitis, and diverticulosis is suspected, but increase in tuberculosis is not documented.[28,38] Anakinra competitively inhibits the interleukin-1 effects, but is currently felt to be the least effective biologic DMARD for RA.[28] Tocilizumab may achieve clinical improvement within a few weeks. Adverse effects include hypertension, neutropenia, elevated transaminases, dyslipidemia, and rarely GI perforation, serious infection, or anaphylaxis.

There are a number of limitations to the use of biologic response modifiers. They are expensive, ranging between 18,000 to 30,000 dollars per year, and both etanercept and adalimumab require the patient to self-administer injections. Not all patients are willing to do this. Injection site reactions are common with etanercept and adalimumab. Infliximab, on the other hand, is an infusion, which inherently requires that the patient has more time from work/home and lends itself to the possibility of infusion reactions, including fever, urticaria, dyspnea, and hypotension. In addition, there needs to be an infusion center nearby where the patient can receive therapy. Most patients receiving TNF-α-blocking agents have failed therapy with one or a combination of the previously mentioned DMARDs.

Inhibiting the normal host immune response has led to concern about reactivation of tuberculosis, increased susceptibility to other infections, and predisposition to the development of malignancy. The true risk of malignancy is difficult to establish because patients with RA are thought to have a higher incidence of lymphoid malignancy than the normal population, and some have shown that the incidence of lymphomas may in fact be increased in patients taking anti-TNF-α drugs.[39] As with all medications, knowing your patient's medical history is the key to proper use of these medications. They should not be used in patients with concurrent serious infection or in those predisposed to serious infections (patients with poorly controlled diabetes). Extreme caution and consultation with the hematologist-oncologist should be used before prescribing these medications to patients with a recent history of malignancy.

In conclusion, the dermatologist and rheumatologist must function as a cohesive team in the treatment of patients with cutaneous manifestations of RA, which often present during phases of intense disease activity. Patients need their underlying rheumatic disease to be treated aggressively, but proven treatments for these associated dermatologic processes, such as pyoderma gangrenosum, cryoglobulins, vasculitis, and others, should not be forgotten. These specific treatment regimens are beyond the scope of this chapter.

JUVENILE IDIOPATHIC ARTHRITIS, STILL'S DISEASE, ADULT-ONSET STILL'S DISEASE

In 1995, the International League of Associations for Rheumatology (ILAR) Task Force on the Classification of Childhood Arthritis proposed juvenile idiopathic arthritis (JIA) for all chronic childhood arthritides of unknown cause, beginning before age 16 and persisting for at least 6 weeks, and encompassing previous terms including juvenile rheumatoid arthritis and Still's disease.[40] Using their criteria, JIA can be diagnosed as early 6 weeks after the onset of symptoms, while the assignment to a specific JIA category requires a disease duration of up to 6 months These categories include systemic arthritis, oligoarthritis, RF-negative polyarthritis, RF-positive polyarthritis, psoriatic arthritis, enthesitis-related arthritis, and others.[40] The expression adult-onset Still's disease (AOSD) was introduced by Bywaters in 1971 to characterize 14 women with seronegative polyarthritis, rash, fever, and raised erythrocyte sedimentation rate.[41] This syndrome most often affects younger adults, and females more often in Eastern than in Western countries. The classical adult presentation includes high spiking fever, an evanescent salmon pink rash, and arthritis, often accompanied by sore throat, myalgias, lymphadenopathies, splenomegaly, and neutrophilic leukocytosis.[42] High fever of unknown origin (FUO) exceeding 39°C is the presenting sign of AOSD in 95% of patients, but only 5% of all persons with FUO have AOSD.[41] Classically, patients present with one to two daily fever spikes above 39°C occurring in the afternoon or evening and receding within hours. Musculoskeletal pain is often present, including myalgia (20%–90%), arthralgia (27%–100%), and arthritis (18%–82%).[41] Multiple arthritis patterns may occur, but polyarticular and symmetric involvement affecting knees, wrists, fingers, and ankles is most common.

A rash may be seen in 25% to 100% of patients.[41,42] It is seen more often in the febrile presentation than in the solely arthritic form of disease. It most characteristically occurs on the chest, abdomen, and extensor surfaces of the arms, and tends to peak with the fever in the late afternoon, and then disappears, only to recur with fever the following day.[41,43] The rash consists of discrete pink to red macules or slightly edematous papules ranging in size from 5 to 10 mm. The lesions tend to be relatively fixed in shape and site during their daily eruption and seldom itch. Koebner phenomena may be seen. Histologic findings include dermal edema, a mild mostly lymphocytic perivascular infiltrate that may include a few neutrophils. In some patients, the lesions may demonstrate prominent perivascular neutrophilic infiltrates, sometimes involving dermis but without the edema typical of Sweet lesions, with leukocytoclasia but without vasculitis. This finding has been reported as neutrophilic urticarial dermatosis, and found in association with autoinfammatory diseases, Schnitzler syndrome, hepatitis C, asthma, and adult-onset Still's disease.[44]

Two unusual syndromes appear to be associated with AOSD: (1) thrombotic thrombocytopenic purpura and (2) reactive hemophagocytic syndrome.[45,46] Both are rare, and the reason for association unclear, but each syndrome has multiple reports supporting these as a complication of AOSD.

Laboratory findings include an increased sedimentation rate, leukocytosis with neutrophilia, hypoalbuminemia elevated hepatic enzymes, anemia (<10 g/dL), and thrombocytosis, in decreasing order of frequency. Antinuclear antibody and rheumatoid factor are negative in most patients. More recently, a very elevated serum ferritin with a lowered concentration of glycosylated ferritin, has been seen as strongly suggestive of, but not specific for, this diagnosis.[41,42] Very high levels of serum ferritin between 3,000 and 30,000 ng/mL (normal range 40–200 ng/mL) are not uncommon, and levels above 250,000 ng/mL have been reported.[42] A threshold level of 1,000 ng/mL appears to offer an 80% to 82% sensitivity and 41% to 46% specificity for a diagnosis of AOSD. Perhaps more specific is the fraction of glycosylated ferritin. In healthy individuals, 50% to 80% of serum ferritin is glycosylated, but this drops to 20% to 50% in patients with inflammatory diseases.[42]

Acute disease is often treated with nonsteroidal anti-inflammatory agents, particularly enteric-coated aspirin, while some begin with corticosteroid and most would use corticosteroids if NSAID therapy is ineffective. A variety of second-line drugs has been used: intramuscular gold, D-penicillamine, sulfasalazine, hydroxychloroquine, methotrexate, thalidomide, azathioprine, cyclosporine, cyclophosphamide, intravenous immunoglobulins, anti-TNF agents, anakinra,

rituximab, and tocilizumab (an IL-6 receptor inhibitor) are reported as sometimes effective.[41,42,47]

RHEUMATIC FEVER

Acute rheumatic fever (ARF) is a delayed sequel to group A β-hemolytic streptococcal (GAS) infection of the oropharynx. It is an inflammatory disease that can affect the heart, joints, central nervous system, skin, and subcutaneous tissues. There are no specific diagnostic tests, rather it is a clinical diagnosis made on the basis of certain criteria. Treatment of the underlying infection leads to prevention of rheumatic fever.

EPIDEMIOLOGY

ARF is rare and most commonly occurs in children 5 to 15 years of age after clinically severe tonsillopharyngeal infections. However, it has been reported in patients of all ages and in those with asymptomatic disease. The incidence of rheumatic fever has decreased since the beginning of the twentieth century, and dropped precipitously since the 1950s with widespread recognition of disease and treatment with penicillin. It has been nearly eradicated from the developed world but remains a serious health problem in developing countries. Currently, the average incidence in most developed communities is less than 5/100,000 population.[48,49] Rates of 72 to 150/100,000 have been reported in countries with sizable less affluent populations, where overcrowding and poorer public hygiene may play a role. The World Health Organization estimates that 15.6 million people worldwide are affected by rheumatic heart disease, and that 233,000 people die annually either from rheumatic heart disease or acute renal failure as a result of complicated GAS infection.[48,49]

PATHOGENESIS

The exact mechanism by which ARF results from an infection with group A streptococcal bacteria is unclear, but it is thought to be an exaggerated immune response to infection. Some strains of streptococcus are more likely to cause ARF than others. For instance, pharyngeal strains are much more likely to cause ARF than extrapharyngeal strains responsible for impetigo or cellulitis.[48] Molecular mimicry has also been implicated in the etiology of ARF. M protein has structural similarity to cardiac myosin. Studies have demonstrated that rats immunized with streptococcal M protein develop myocarditis. Oddly, however, the morbidity and mortality of rheumatic fever results from valvular disease rather than acute carditis.[49] Familial clustering of disease, and the linkage of HLA-DR4 and -DR2 to ARF in Caucasian and African-American patients demonstrates that host properties also affect the susceptibility of individual patients in the development of disease.[48]

CLINICAL FEATURES

The clinical features of ARF vary widely and are largely outlined in the Jones criteria used to aid in diagnosis of the disease. The Jones criteria, updated in 1992,[50] emphasize five characteristic major manifestations: (1) polyarthritis, (2) carditis, (3) chorea, (4) subcutaneous nodules, and (5) erythema marginatum (Box 160-2). Nonspecific signs of systemic inflammation are considered minor criteria and include arthralgia, fever, elevated acute-phase reactants, and a prolonged P–R interval by echocardiogram.

Diagnosis is based on the presence of two major criteria and one minor criteria plus evidence of preceding infection with group A *Streptococcus*. If, however, chorea and carditis are present then demonstration of antecedent strep infection is not required to make the diagnosis.[50] There is some evidence that a revision of the Jones criteria should be considered, particularly in endemic areas.[51] These might include monoarthritis, subclinical carditis, and a low-grade fever, (≥37.5), in order to avoid an important subset of patients who develop cardiac complications but do not meet standard Jones criteria.

Rheumatic carditis usually involves the endocardium, myocardium, and pericardium and almost always is associated with a murmur, either mitral or aortic regurgitation.[49] Carditis, if present, usually presents in the first 3 weeks of the illness. There has been much debate about the use of echocardiography to aid in diagnosis of rheumatic heart disease without clinical evidence of a murmur; however, thus far its routine use has not been advocated. Its use has been accepted in patients with polyarthritis where other diagnostic criteria have not yet been met and in indistinguishable heart murmurs.[49]

BOX 160-2 THE JONES CRITERIA FOR RHEUMATIC FEVER, UPDATED 1992

Major Criteria

- Carditis
- Migratory polyarthritis
- Sydenham chorea
- Subcutaneous nodules
- Erythema marginatum

Minor Criteria

- Clinical
  - Fever
  - Arthralgia
- Laboratory
  - Elevated acute-phase reactants
  - Prolonged P–R interval

plus

Supportive evidence of a recent group A streptococcal infection (e.g., positive throat culture or rapid antigen detection test, and/or elevated or increasing streptococcal antibody test)

From Guidelines for the diagnosis of rheumatic fever. Jones Criteria, 1992 update. Special Writing Group of the Committee on Rheumatic Fever, Endocarditis, and Kawasaki Disease of the Council on Cardiovascular Disease in the Young of the American Heart Association. *JAMA* **268**:2069, 1992.



Figure 160-5 Erythema marginatum of rheumatic fever. Enlarging and shifting transient annular and polycyclic lesions.

Migratory polyarthritis can affect any joint but most often involves the large joints. Early administration of anti-inflammatory medications does mitigate the arthritis and may therefore mask it. In addition, post-streptococcal reactive arthritis exists and can confound the picture.[49] The diagnosis of chorea is based entirely on clinical signs, which include fleeting local muscular weakness, emotional lability, personality changes, and erratic, jerky, purposeless movements. Chorea does not occur in adult men.

The dermatologic manifestations of ARF are characteristic but rare. Subcutaneous nodules are small, painless, and localized over bony prominences and in tendon sheaths. They are usually smaller, more discrete, and less persistent than rheumatoid nodules, and are usually seen in children with prolonged active carditis, rather than in the early stages of rheumatic fever.[48] These resemble histologically the Aschoff nodules seen in the heart.[48] Typically, they last for 1 to 2 weeks and spontaneously resolve. Erythema marginatum begins as an erythematous macule or papule extending outward while the central skin returns to normal. The border is pink and serpiginous, is not indurated, and blanches with pressure (Fig. 160-5). Patients are often unaware of its presence. Histopathologically, there is a sparse superficial perivascular infiltrate of lymphocytes and neutrophils.[14,48]

TREATMENT

Treatment is directed at eradication of GAS from the oropharynx. Penicillin is the antibiotic of choice, is inexpensive, and can be administered orally or intramuscularly. Oral therapy should be continued for at least 10 days.[48] Penicillin-allergic patients can be treated with cephalosporins or macrolide antibiotics.[21] Due to the high rate of recurrence in previously affected people, antibiotic prophylaxis is recommended, especially in endemic areas.

The acute inflammatory process is largely treated symptomatically, including bed rest during the early phase of the syndrome.[48] Anti-inflammatory medications including salicylates and nonsteroidal agents are effective for the arthritis, fever, and arthralgia. However, salicylates alone have not been shown to be effective in decreasing the incidence of rheumatic heart disease after ARF. Corticosteroids are believed to be beneficial in the treatment of carditis; though this has never been shown in a randomized controlled trial. Lastly, intravenous Ig has also been tested but has not shown any benefit.[19] Approximately 80% of patients who fulfill the criteria for this disorder recover spontaneously.

GOUT

Gout is a clinical syndrome caused by a group of heterogeneous diseases characterized by deposition of monosodium urate crystals in synovial fluid and joints with or without hyperuricemia, renal disease, or nephrolithiasis.[52,53] It tends to occur in both acute and chronic forms. Classically, the acute presentation is that of an acute lower extremity peripheral joint inflammatory synovitis. The most commonly affected sites are the first metatarsophalangeal joint and the ankle. In the chronic form, aggregates of crystals are deposited in tissue, especially in skin and around joints. While skin disease is often asymptomatic, periarticular and osseous deposition may lead to bone destruction.

EPIDEMIOLOGY

Gout affects approximately 5 million Americans and has historically been described as a disease that affects men; however, it also affects women. Recent epidemiologic studies demonstrate that on average, women develop gout a decade later than men, and that female patients with gout are more likely to have renal insufficiency or to be taking diuretics.[22] Obesity has been linked to gout, and both diseases have increased in incidence over the past two decades. Alcohol has long been recognized as a risk factor for gout, but only recently consumption of purine rich foods such as meat and seafood has been shown to correlate positively with serum urate levels and gout. It has also been shown that eating low-fat dairy products may be protective.[23] Gouty attacks in children are so uncommon that this diagnosis should prompt an evaluation for a malignant or genetic cause.

PATHOGENESIS

Hyperuricemia is a risk factor for gout, but acute gouty arthritis can occur in patients with normal serum uric acid levels. Patients with serum uric acid levels greater than 7 mg/dL have a 22% chance of developing gout

TABLE 160-4
Classification of Hyperuricemia

- Overproduction of uric acid
  - Primary hyperuricemia
    - Idiopathic
    - Hypoxanthine-guanine phosphoribosyltransferase deficiency
    - Phosphoribosylpyrophosphate synthetase superactivity
  - Secondary hyperuricemia
    - Excessive dietary purine intake
    - Increased nucleotide turnover (e.g., myeloproliferative and lymphoproliferative disorders, hemolytic disease, psoriasis)
- Diminished excretion of uric acid
  - Primary hyperuricemia
    - Idiopathic
  - Secondary hyperuricemia
    - Diminished renal function
    - Inhibition of tubular urate secretion by competitive anions (e.g., keto- and lactic acidosis)
  - Enhanced tubular urate reabsorption
    - Dehydration, diuretics
  - Miscellaneous
    - Hypertension
    - Hyperparathyroidism
    - Certain drugs (e.g., cyclosporine, pyrazinamide, ethambutol, low-dose salicylates)
    - Lead nephropathy

over a 5-year period, demonstrating that many patients with elevated serum uric acid levels may never have gouty arthritis.[6]

Uric acid is the end product of purine catabolism. In most fish, amphibians, and nonprimate mammals, purine-generated uric acid is degraded through a uricase (a uric acid oxidase).[53] In primate mammals and humans, the *uricase* gene is silenced by two mutations. This absence of uricase, along with extensive reabsorption of filtered urate, results in plasma urate levels that are 10 times that of most other mammals.[53] Hyperuricemia results from either overproduction or underexcretion of uric acid. Ninety percent of affected patients are underexcreters.[6]

Table 160-4 presents a classification of hyperuricemia. Less than 10% of patients with hyperuricemia or gout excrete excessive quantities of uric acid in a 24-hour urine collection. It is usually in this group that identifiable and inherited derangements in mechanisms regulating protein nucleotide synthesis, specifically a deficiency of hypoxanthine-guanine phosphoribosyltransferase, glucose-6-phosphatase, or fructose-1-phosphatase, either partial or complete, can be found. These are genetically inherited by X-linked and autosomal recessive means (in the latter two); therefore, family history or early presentation may be a clue. The Lesch–Nyhan syndrome, well described but very rare, is an extremely severe form of hypoxanthine-guanine phosphoribosyltransferase deficiency associated with mental retardation, gout, and self-mutilation.[26]

Uric acid underexcretion is idiopathic in patients with hyperuricemia. The anatomic appearance and physiologic function of the kidney appear normal; however, alteration of renal tubular function in these patients by many drugs can precipitate gouty attacks. These pharmacologic agents include loop diuretics, low-dose cyclosporine, and salicylates.

Precipitating causes of an acute gouty attack are not well understood. Studies have shown the presence of intracellular monosodium urate crystals in synovial fluid of asymptomatic patients, suggesting that inflammation in gout is chronic. There must be an unidentified trigger in the acute attack that incites a more robust inflammatory response. Monocytes are present and secrete cytokines, including TNF-α, interleukin 1, interleukin 6, and interleukin 8. Neutrophils are then attracted to the site as well; they ingest the crystals, and release multiple inflammatory mediators, initiating further inflammation and tissue damage.[53]

CLINICAL MANIFESTATIONS

It is felt that gout occurs in four stages: (1) asymptomatic hyperuricemia, (2) acute gouty arthritis, (3) intercritical gout (between gouty attacks), and (4) chronic tophaceous gout.[26]

Patients are often asymptomatic for years, requiring no therapeutic intervention in the absence of other evidence of disease (e.g., nephrolithiasis or renal insufficiency).

Acute gouty arthritis usually occurs in middle age and primarily affects a single joint in the lower extremities, the first metatarsophalangeal being the most common site of initial involvement (podagra).[26,52] Clinically, the affected joint is erythematous and exquisitely tender to palpation. This may be confused with a sprain, a septic joint, or cellulites. Cytokine release can lead to fever and systemic symptoms, confounding the picture further. Further differential diagnoses include other forms of arthritis (psoriatic, reactive arthritis osteoarthritis, or RA) and pseudogout (chondrocalcinosis).[26]

Intercritical gout describes the interval that occurs between attacks of gout, an interval of between 6 months to 2 years. As attacks continue, they tend to be polyarticular, more severe, and of longer duration. Chronic tophaceous gout describes gout where patients rarely have asymptomatic periods. Urate crystals may be found in the soft tissues, cartilage, and tendons (Fig. 160-6A).[26] They have been reported in a variety of unusual places as well, including the nasal dorsum.[24] They may be confused with rheumatoid nodules, and aspiration or biopsy may prove useful.

LABORATORY PRESENTATION AND PATHOLOGY

Laboratory analysis may reveal elevated uric acid levels, but this finding is not necessary for the diagnosis. Leukocytosis and elevated sedimentation rate are often seen during acute arthritic attacks. Accurate diagnosis rests on the demonstration of intracellular,

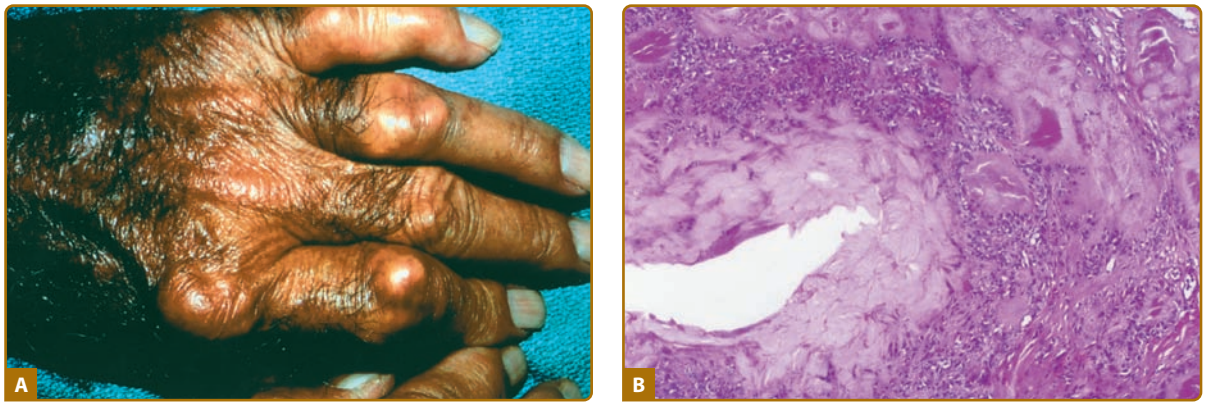

Figure 160-6 Gouty tophi. **A.** Tender nodules overlying joints and tendons, which may drain chalky white material. **B.** Histopathology shows granulomatous "fluffy" appearing infiltrate surrounding radially arranged needle-like spaces.

negatively birefringent, needle-shaped crystals by polarized microscopy. Histopathologic examination of a gouty tophus reveals granulomatous inflammation surrounding yellow–brown urate crystals or needle-like spaces in a radial arrangement, representing crystals dissolved during processing (see Figs. 160-6B and 160-7).[14]

TREATMENT

The goal of therapy in acute gouty attacks is analgesia and reduction in inflammation. The main options to choose from are the nonsteroidal anti-inflammatory drugs, colchicine, and corticosteroids. Indomethacin has been shown in randomized controlled trials to decrease pain, as has colchicine; however, the adverse gastrointestinal side effect of colchicine is often a deterrent for its use. However, a newer regimen for colchicine use in acute attacks appears to greatly reduce the incidence of gastrointestinal symptoms.[54] This regimen of 1.2 mg of colchicine followed in 1 hour by 0.6 mg, also is likely to reduce drug–drug interactions mediated by colchicine inhibition of *P*-glycoprotein and cytochrome 3A4 pathways. Severe adverse reaction and deaths have been reported when colchicine is combined with other strong inhibitors of one or both pathways (e.g., clarithromycin, erythromycin, and cyclosporine).[54] Indomethacin can precipitate acute renal failure in patients with underlying renal disease. Corticosteroids, both oral and intra-articular, are also believed to be effective. Because patients with gout are older and often have many comorbidities, therapy should be individualized. Treatment should continue for 7 to 10 days after the acute attack, and prophylactic therapy may be continued for 3 to 6 months.[26,52]



Figure 160-7 Gouty tophi on helix.

In patients with only one gouty attack, a conservative management approach can be used. This includes avoidance of drugs that decrease the excretion of uric acid such as thiazide or loop diuretics, aspirin, pyrazinamide, or niacin. Patients should maintain adequate hydration, lose weight, control hypertension and hyperlipidemia, and make diet adjustments by decreasing purine intake. Effectiveness of limiting cholesterol, fat, meat, and alcohol has never been studied, but should be advocated to avoid the need for lifelong oral therapy.[26,53]

Uric acid-lowering therapy is probably necessary in patients in whom the diagnosis of gout has been established, and who have had more than one gouty attack or are suffering from chronic tophaceous gout. It is also indicated in patients with history of gout and renal calculi, extremely high values of serum uric acid, high serum uric acid levels in the setting of a known familial history of gout (e.g., where there is a known deficiency of one of the relevant enzymes previously described), and prophylaxis for patients receiving acute courses of chemotherapy.

The goal of urate-lowering drugs is to maintain the serum urate level consistently at less than 6 mg/dL. Uricosuric therapy is ideal in younger patients

(age less than 60 years) with normal kidneys who are underexcreters of uric acid. Uricosurics include probenecid, sulfinpyrazone, and benzbromarone.[55,56] The major risks associated with these medicines include hypersensitivity reactions and increased risk of uric acid nephrolithiasis (avoided by alkalinizing the urine). Unfortunately, most patients with gout do not fit this "ideal" situation. Benzbromarone is not commercially available in the United States and many other countries; though potent, it is potentially hepatotoxic.[56]

For all other patients, the xanthine oxidase inhibitors are used. Allopurinol is the first-line drug for serum urate lowering.[55] It decreases production of uric acid, and is indicated for patients with nephrolithiasis, renal impairment, those who failed uricosuric agents, with myeloproliferative disorders on chemotherapy, and patients with hyperuricemia due to enzyme abnormalities. Dosages must be reduced in patients with renal failure. Twenty percent of patients taking allopurinol report side effects, and 5% discontinue medication as a result. Side effects include dyspepsia, headache, diarrhea, a pruritic papular eruption, thrombocytopenia, and hepatic function abnormalities. Allopurinol hypersensitivity syndrome is rare and includes fever, urticaria, leukocytosis, eosinophilia, interstitial nephritis, acute renal failure, granulomatous hepatitis, and toxic epidermal necrolysis. A second xanthine oxidase inhibitor is febuxostat, labeled for use at 40 mg once daily.[55,56] It appears to be roughly equivalent to allopurinol. However, it does show higher efficacy in the setting of renal impairment, when allopurinol, but not febuxostate, must be reduced.[56]

Uricases are an additional class of therapeutic agents used in treating urate disorders. The nonpegylated recombinant fungal enzyme rasburicase is Food and Drug Administration (FDA) approved for short-course therapy to prevent tumor lysis syndrome.[55] It is highly immunogenic, and its plasma half-life is less than 24 hours. Pegylation of uricases with production of PEG multimers has decreased the immunogenicity and increased the serum half-life to days or weeks. Infusion reactions may be seen, and include flushing, urticaria, hypotension, and anaphylaxis. All uricase therapies may induce oxidative stress, which can lead to methemoglobinemia or anemia, occurring more often but not confined to glucose-6-phosphate dehydrogenase-deficient (G6PD-deficient) individuals.[55] The role of pegylated uricases in treating urate disease remains to be determined.

KEY REFERENCES

Full reference list available at www.DIGM8.com

DVD contains references and additional content

1. Alamanos Y, Drosos AA: Epidemiology of adult rheumatoid arthritis. *Autoimmun Rev* 50, 2004
5. Gorman J et al: Impact of shared epitope genotype and ethnicity on erosive disease: A meta-analysis of 3240 rheumatoid arthritis patients. *Arth Rheum* **50**:400, 2004
6. Agrawal S et al: Compound heterozygosity of HLA-DR4 and DR1 anigens in Asian Indians increases the risk of extra-articular features in rheumatoid arthritis. *Br J Rheumatol* **34**:41, 1995
10. Arnett F et al: The American Rheumatism Association 1987 revised criteria for the classification of rheumatoid arthritis. *Arthritis Rheum* **31**:315, 1988
11. Jorrizo JL, Daniels JC: Dermatologic conditions reported in patients with rheumatoid arthritis. *J Am Acad Dermatol* **8**:439, 1983
19. Sangueza OP et al: Palisaded neutrophilic granulomatous dermatitis in rheumatoid arthritis. *J Am Acad Dermatol* **47**:251-257, 2002
25. Yamamoto T: Cutaneous manifestations associated with rheumatoid arthritis. *Rheumatol Int* **29**:979-988, 2009

Chapter 161 :: Sjögren's Syndrome

:: Gabor Illei & Stamatina Danielides

SJÖGREN'S SYNDROME AT A GLANCE

- Chronic autoimmune disease characterized by chronic inflammation involving the exocrine glands.
- Salivary and lachrymal glands are predominantly affected leading to dry mouth and dry eyes.
- May occur alone (primary Sjögren's syndrome), or may coexist with other systemic connective tissue disorders (secondary Sjögren's syndrome).
- Systemic manifestations, such as fatigue, arthritis, vasculitis, interstitial pulmonary disease, peripheral or central neuropathy, and autonomic nervous dysfunction may accompany glandular involvement.
- Patients with systemic manifestations are at higher risk of lymphoma.
- Treatment of sicca symptoms is mainly symptomatic, whereas management of extraglandular manifestations is similar to other autoimmune diseases.

EPIDEMIOLOGY

Sjögren's syndrome (SS) is one of the most common rheumatic autoimmune diseases. SS affects predominantly women with a female to male ratio of 9:1. Women are most commonly diagnosed in their fifth or sixth decade, but it can affect individuals of any age and sex.

SS has a worldwide distribution. In most studies done mainly in Caucasian populations the estimated prevalence rate in the adult general population is between 0.1% and 0.8%. However, one study in the United Kingdom showed a prevalence rate of 3.3%, whereas another study in Japan showed only a 0.02% prevalence rate. The estimated annual incidence rate was consistently approximately 0.005% in several studies.[1]

PATHOGENESIS

The pathogenesis of SS is still largely unknown. In a genetically predisposed individual, various environmental factors, such as viral infections, may lead to epithelial-cell activation and a protracted inflammatory response with features of autoimmunity. Autoreactive lymphocytes and autoantibodies are considered important in this process, although the pathogenic role of any particular autoantibody is still undefined. Abnormal apoptosis may be important in several ways. First, increased apoptosis of epithelial cells may lead to functional defects and provide autoantigens, whereas the prolonged survival of B and T cells through upregulation of antiapoptotic signals may be involved in sustaining a self-perpetuating autoimmune process. Decreased apoptosis of lymphocytes may also contribute to the increased frequency of lymphoma in SS patients.

IMMUNOGENETIC FACTORS

The role of genetic factors in SS was recognized in family studies where first-degree relatives of patients had an increased prevalence of SS.[2] Such family clustering was further observed among first-degree relatives of individuals with anti-Ro/SSA antibodies regardless of their clinical diagnoses (SS or systemic lupus erythematosus or even healthy controls).[3]

There is a well-established association between SS or anti-Ro/SSA and anti-La/SSB antibodies with HLA class II genes.[4] Genes other than those of the HLA loci may also be associated with an increased risk of disease. Associations with a number of cytokine gene polymorphisms, such as interleukin (IL) 6, IL-10, tumor necrosis factor-α (TNF-α) and the IL-1 receptor antagonist, have been reported, but none of these have been confirmed to date.[4] Several genetic polymorphisms previously linked to systemic lupus erythematosus and other autoimmune diseases are also associated with SS. From these, two transcription factors, (1) signal transducer and activator of transcription 4 (STAT4)[5] and (2) interferon regulatory factor 5 (IRF 5),[6] which were both independently associated with SS showed an additive effect in increasing the risk of Sjögren's syndrome from around 1.6–1.9 for one risk allele to 6.7 when both risk alleles were present.[7]

ENVIRONMENTAL FACTORS

The inciting event in the pathogenesis of SS is not known, and it may not be a single event. The strong predominance of females suggests gender-specific predisposing factors. Although sex hormones are obvious targets, there is no conclusive proof yet that the difference in the pathogenesis between males and females is due to sex hormones alone.[8,9] Viral infections have also been proposed as inciting events. This theory is strongly supported by the fact that chronic inflammation of the salivary glands has been observed with chronic hepatitis C and human immunodeficiency virus infections, and such infections cause a disease with a clinical spectrum very similar to SS. The fact that some viruses, such as Epstein–Barr virus (EBV), are known to replicate in oropharyngeal and lachrymal glands led to the hypothesis that these viruses may be involved in Sjögren's pathogenesis. In fact, genetic material from EBV was detected by DNA hybridization in SS salivary tissue, but it was also found in normal individuals. Further experiments have identified an unusual strain of EBV containing a deletion in the genome in salivary gland specimens from Chinese SS patients.[10] Similarly, in a Japanese cohort, defective human T-lymphotropic virus-I genome was isolated from salivary gland tissue.[11] Other viruses, such as coxsackievirus[12] or endogenous retroviruses have also been proposed as causative agents. However, there is no proof, to date, that any of these viruses play a pathogenic role in SS.

EPITHELIAL-CELL ACTIVATION AND CHRONIC INFLAMMATION

Sections of salivary and lachrymal glands in SS are characterized by periductal mononuclear infiltrates. The majority of the infiltrating cells are $CD4^+$ T lymphocytes, whereas $CD8^+$ cytotoxic T cells are found in smaller numbers. Activated B lymphocytes are also present, including immunoglobulin-secreting cells.

Inflammation seems to target glandular epithelial cells, and recent research has demonstrated the central role of epithelial-cell activation in initiating the recruitment of the inflammatory infiltrate.[13] In animal models, changes in epithelial cells occur before the appearance of lymphocytes in the salivary glands. Initial events include the expression of HLA class II molecules and various activation markers, such as the costimulatory molecules CD80 and CD86, on the surface of acinar and ductal[14] salivary epithelial cells. These molecules are crucial in regulating the interaction between antigen-presenting cells and lymphocytes. Their expression in acinar and ductal[15,16] epithelial cells suggests that epithelial cells in SS act as antigen-presenting

cells and actively participate in lymphocyte activation. Another important step is the upregulation of adhesion molecules and chemokines, all of which contribute to the recruitment of inflammatory cells, such as T and B lymphocytes, macrophages, and dendritic cells. The activation of lymphocytes leads to abnormal cytokine and chemokine expression,[17] perpetuating the chronic inflammatory process characterized by a complex interaction between activated epithelial cells, the innate and acquired immune system. Extraglandular manifestations occur as a result of similar lymphocytic infiltrations at other organs. This is described by some as *autoimmune epithelitis* to better reflect the systemic nature of the disease. Some epithelial cells express Fas and Fas ligand[18] and, as a consequence, undergo apoptosis; others may be destroyed by perforin, granzymes, and other cytotoxins produced by lymphocytes. However, in most patients, only partial destruction of the glands is noted. Local production of cytokines, autoantibodies, metalloproteinases, and other inflammatory mediators may contribute to the dysfunction of the remaining epithelial cells by various mechanisms. For example, it has been shown that TNF interferes with the intracellular trafficking of aquaporin-5, one of the water channels required for saliva production. Enhanced activity of the type-1 interferon system has been linked to multiple autoimmune diseases, including Sjögren's syndrome. Increased expression of interferon-regulated genes was described both in the salivary glands and peripheral blood.[19–21] One of the cytokines upregulated by interferon-α is B-cell activating factor (BAFF), which promotes B-cell survival and has also been found at higher levels in Sjögren's patients.[22,23] Interestingly, both of these cytokines can be upregulated by viruses.[24]

AUTOANTIBODIES

Autoantibodies are the hallmarks of systemic autoimmune diseases, including SS. The best-defined autoantibodies in SS are the anti-Ro/SSA and anti-La/SSB antibodies.[25] Both are targeted against ribonucleoprotein antigens. Anti-Ro/SSA recognizes two RNA-binding proteins (the 52-kDa or the 60-kDa protein), whereas anti-La/SSB antibodies recognize RNA polymerase III. Anti-Ro/SSA antibodies are found in over 70% of patients with SS, but are not specific for SS and are frequently found in SLE and other autoimmune diseases even when there are no symptoms or signs of oral or ocular dryness. Anti-La/SSB is more specific; it is present in 50% of patients with primary SS or SS/SLE but is rarely seen in other diseases. The pathogenic role of these antibodies is not yet defined, but, because Ro and La are expressed on the surface of apoptotic epithelial cells, it is possible that an immune response against these antigens contributes to inflammation in the gland. The most compelling in-vivo evidence for a pathogenic role of these autoantibodies comes from newborns with fetal heart block born to women with anti-Ro/SSA and/or anti-La/SSB antibodies. These antibodies can cross the placenta and bind to Ro and La antigens located on the cell surface of fetal myocardial tissue, leading to fetal heart block. Other autoantibodies, such as antinuclear antibodies and rheumatoid factor, are frequently present in patients with both primary and secondary SS. Although they lack specificity, they are markers of a systemic autoimmune response and thus can help distinguish SS from other causes of salivary or lachrymal gland dysfunction.

In recent years, research has focused on identifying antibodies more specific for SS, such as anti-α-fodrin and antimuscarinic acetylcholine receptor antibodies, but the results have been controversial. The major stimulus for saliva production is the binding of acetylcholine to muscarinic acetylcholine receptors. The hypothesis that oral and ocular dryness could result from antibodies antagonizing the muscarinic acetylcholine receptor-3 is intriguing. These antibodies have been demonstrated to play an essential role in eliciting glandular dysfunction in the nonobese diabetic (NOD) mouse model of SS, possibly through an inhibitory effect on the receptor.[26] In humans, however, results are still contradictory as multiple attempts to detect these antibodies with conventional immunologic methods have been fruitless.[27,28]

CLINICAL MANIFESTATIONS

EXOCRINE GLAND INVOLVEMENT

The dominating feature of SS is exocrine gland dysfunction, leading to the classic sicca symptoms of xerostomia (oral dryness) and xerophthalmia or keratoconjunctivitis sicca (dry eyes).

XEROSTOMIA. Oral dryness is the principal symptom of SS, caused by decreased saliva secretion, which is persistent and continuous throughout the day and night and can significantly compromise quality of life. Reduced salivation causes difficulty in chewing and swallowing dry foods. Dryness of the tongue and oral mucosa leads to an altered sense of taste and, at times, produces a burning discomfort, especially when eating acidic or spicy foods. Physical examination may reveal a red and fissured tongue with a characteristic atrophy of the filiform papillae or angular cheilitis. Ulcerations can be found, particularly in SS patients with dentures, usually in proximity to the mucosal surface that makes contact with the denture.

Saliva has antimicrobial properties, so lack of saliva can predispose to infections. Oral thrush is common and can be manifested as pseudomembranous or erythematous mucosal lesions. Furthermore, patients with SS have an increased incidence of caries. A characteristic feature of caries in SS is its primary location at the cervical and incisal regions of the teeth.

Bilateral salivary gland enlargement usually occurs in the parotid glands of SS patients. It is frequently nontender, and it can be recurrent or chronic (Box 161-1). Painful, unilateral parotid enlargement should raise the suspicion of an infection (Fig. 161-1) or a salivary gland stone. In cases of persistent unilateral



Figure 161-1 Acute infectious parotitis. Note the asymmetric swelling of the left parotid gland.

BOX 161-1 DIFFERENTIAL DIAGNOSIS OF PAROTID GLAND SWELLING

BILATERAL	**VIRAL INFECTIONS**	**MUMPS**
		Epstein's–Barr, cytomegalovirus, coxsackie
		Human immunodeficiency virus, human T-lymphotropic virus-I
		Hepatitis C
	Immune mediated	Sjögren's syndrome
		Sarcoidosis
		Amyloidosis
	Endocrine/metabolic	Diabetes mellitus
		Hyperlipoproteinemia
		Chronic pancreatitis
		Acromegaly
	Other	Alcohol
		Recurrent parotitis of the childhood
Unilateral	Bacterial infections	
	Neoplasms	Mainly lymphomas
	Sialolithiasis	

parotid gland enlargement, the presence of lymphoma should be excluded (see Box 161-1).

Medical causes of oral dryness, such as dehydration, diabetes, viral infections, or drug treatment, should be considered when evaluating a patient for Sjögren's syndrome.

KERATOCONJUNCTIVITIS SICCA. Ocular dryness is the other dominant feature of SS. A burning and itching sensation in the eyes, commonly exacerbated by smoke, is caused by lack of tear production. Patients frequently complain of intolerance to contact lenses. Paradoxically, the quantity of tears produced during crying may not be affected. Physical evaluation shows corneal injection and mucous discharge in the lower fornix. Enlarged lachrymal glands have been described in Sjögren's patients, but occur less commonly than enlarged salivary glands. The constellation of symptoms and signs indicating dry eyes constitutes keratoconjunctivitis sicca.

OTHER SICCA MANIFESTATIONS. *Cutaneous xerosis*, a term used to describe dryness of the skin, is very common in SS, with a frequency varying between 23% to 68%. The most common symptoms of xerosis are nonspecific pruritus, burning sensation and a pinprick-like feeling. Physical examination reveals roughness, fine scaling, and loss of elasticity of the skin. The pathogenesis of xerosis is unknown. Impairment of the sweat glands is considered an important factor because decreased sweating has been reported in SS patients. A recent study has indicated that xerosis may be related to increased epidermal proliferation with disturbed epidermal differentiation.[29]

Dryness of the upper respiratory tract can cause epistaxis, hoarseness, and bronchial hyper-responsiveness. Another common complaint in women with SS is vaginal dryness, which may lead to an increased incidence of vaginal infections and dyspareunia.

NONEXOCRINE GLAND INVOLVEMENT

SKIN INVOLVEMENT. Cutaneous manifestations are common extraglandular features of SS (Table 161-1).[30] They are generally considered either vasculitic or nonvasculitic lesions.

Vascular Lesions. Raynaud's phenomenon is probably the most common abnormality. It can be seen in 15% to 35% of patients and can precede sicca symptoms by many years. Raynaud's phenomenon in Sjögren's syndrome is not accompanied by telangectasias as seen in systemic sclerosis. Calcifications have been described, but are uncommon. Although Raynaud's is usually mild in SS, it is a marker of a subgroup with increased risk of extraglandular manifestations.[31]

Hypergammaglobulinemic Purpura. Purpuric macules are very common in Sjögren's. Flat, nonpalpable, blanching purpura has been associated with an entity called benign hyperglobulinemic purpura, characterized by polyclonal hypergammaglobulinemia and a positive rheumatoid factor. The skin biopsies reveal ruptured blood vessels with complement deposition.[32]

TABLE 161-1
Cutaneous Manifestations of Sjögren's Syndrome

Vascular	■ Raynaud's phenomenon ■ Cutaneous vasculitis ■ Nonpalpable purpura ■ Palpable purpura ■ Urticarial vasculitis ■ Necrotizing vasculitis ■ Annular erythema ■ Erythema multiforme ■ Erythema perstans ■ Erythema nodosum
Nonvascular	■ Oral ■ Dry mucous membranes ■ Papillary atrophy of the tongue ■ Candidiasis ■ Angular cheilosis ■ Eyelid dermatitis ■ Alopecia ■ Vitiligo



Figure 161-2 Cutaneous vasculitis in primary Sjögren's syndrome. Biopsy showed leukocytoclastic vasculitis.

Cutaneous vasculitis (CV) can present as palpable purpura or urticarial vasculitis.

Palpable purpura, which does not blanch when pressure is applied to the skin is due to dermal vasculitis with extravasation of red blood cells, and typically involves the lower extremities and buttocks (see Chapter 164). It represents an important marker of more severe disease, and is associated with an increased risk of lymphoma development and mortality. Histopathologically, palpable purpurae can be divided into two groups. Neutrophilic inflammatory vascular disease is characterized by a predominantly neutrophilic infiltrate, fibrinoid necrosis, occlusion of the lumen, and extravasation of red blood cells, and is indistinguishable from the classical leukocytoclastic vasculitis (Fig. 161-2) (see Chapter 163). On the other hand, mononuclear inflammatory vascular disease is characterized by a mononuclear inflammatory infiltrate with invasion of the blood vessel walls. Fibrinoid necrosis is present but less prominent. The clinical presentation of these two forms are indistinguishable, but neutrophilic inflammatory vascular disease is associated more strongly with markers of systemic autoimmunity, such as antinuclear antibodies and anti-Ro/SSA and anti-La/SSB antibodies, hypergammaglobulinemia, rheumatoid factor, and hypocomplementemia. Cryoglobulinemic vasculitis can also be seen among Sjögren's patients and has the same cutaneous manifestations (see Chapter 169).

Urticarial vasculitis is the second most frequent form of CV in SS and presents as pruritic wheals with erythema (see Chapter 38). In contrast to true urticaria, individual lesions last for more than 24 hours and often resolve with hyperpigmentation. Biopsy of the skin lesions demonstrates a perivascular neutrophilic infiltrate accompanied by leukocytoclasia. Necrotizing vasculitis is not commonly seen in Sjögren's syndrome. It can present as palpable purpuric lesions of the lower extremities, which may ulcerate, finally resolving within 1–4 weeks. They heal with atrophy or scar tissue formation. This form of vasculitis has been observed more frequently among patients with more active disease; it has been associated with arthritis, Raynaud's phenomenon, peripheral neuropathy, fever, and pulmonary or glomerular involvement. Antineutrophil cytoplasmic antibodies with perinuclear fluorescence can be found, but are uncommon in Sjögren's syndrome.

Annular erythema is found primarily among Asian patients who have anti-Ro/SSA antibodies. Characteristic lesions are annular erythematous plaques with elevated borders and central clearing. They are localized on the face, arms, back, trunk, and proximal thighs. Lesions are similar to subacute cutaneous lupus but seem to represent a distinct clinical and histopathologic entity.

A painful nodular eruption of the anterior surface of the lower extremities, suggesting erythema nodosum (see Chapter 70) may occur in patients with sicca manifestations. Because erythema nodosum in SS patients is rare, its presence should raise suspicion for sarcoidosis. Erythema multiforme-like lesions and superficial ill-defined patches (erythema perstans) have also been described in SS.

Nonvascular Cutaneous Manifestations. Xerostomia predisposes to angular cheilitis, which presents as recurrent, symmetric, itching fissures. Eyelid dermatitis is defined by the presence of erythematous, infiltrated and lichenificated lesions of the eyelids associated with itching and foreign body sensation. Alopecia and vitiligo can also be seen in SS, albeit infrequently. Despite multiple case reports describing

cutaneous B- and T-cell lymphomas in SS patients, they are, in fact, rare.

NONCUTANEOUS EXTRAGLANDULAR MANIFESTATIONS

Musculoskeletal Manifestations. A symmetric nonerosive polyarthritis can frequently be seen in primary SS. The distinction from rheumatoid arthritis may be difficult; the absence of rheumatoid factor and anti-CCP antibodies and the absence of erosions on X-rays would favor SS over RA. Arthralgias and myalgias are common complaints but true myositis is rare in primary SS.

Visceral Manifestations. Dry cough due to dryness of the tracheal mucosa is common (tracheobronchitis sicca). Rarely, patients can develop interstitial pneumonitis. Patients may also develop mucosa-associated lymphoid tissue (MALT) lymphoma in the lungs.

Genitourinary manifestations include interstitial cystitis, renal tubular acidosis, interstitial nephritis, and, rarely, glomerulonephritis.

Dysphagia due to xerostomia and esophageal dysmotility is common. *Helicobacter pylori* is associated with an increased risk of MALT lymphomas, therefore, SS patient with gastritis should be checked for *H. pylori* and treated if found positive. An asymptomatic, chemical pancreatitis with high-serum amylase concentrations has been reported in 25% of patients.

SS is associated with various other diseases, such as celiac disease, primary biliary cirrhosis, and hypothyroidism. Because of these associations, a high index of diagnostic suspicion is warranted to identify and treat these conditions.

Neurologic Manifestations. Neurologic manifestations can be divided into those that involve the central nervous system, and those that involve the peripheral nervous system and autonomic dysfunction.

The peripheral nervous system is involved in approximately 20% of patients with SS.[33] The most common manifestations are peripheral axonal polyneuropathies, which are mostly sensory. Another entity that has been described is a ganglionopathy involving the sensory ganglia of the posterior column. This starts with unilateral peripheral paresthesias evolving over months to years to deep sensory impairment, positive Romberg sign, generalized areflexia, and ataxia.[34] Cranial neuropathies are also frequent among SS patients. The most common form is unilateral trigeminal neuropathy; it usually spares the ophthalmic division, thus preserving the corneal reflex. Other cranial neuropathies may lead to Bell's palsy (facial nerve), neural deafness and vestibular dysfunction (vestibulecochlear), and diplopia (oculomotor, trochlear, abducent nerve).

The central nervous system can be involved, although the prevalence and the spectrum of manifestations are still controversial. Manifestations similar to multiple sclerosis as well as transverse myelitis have been described. The latter is frequently associated with antiaquaporin-4 autoantibodies.

Lymphoproliferative Disease. The incidence of lymphoma in Sjögren's patients is increased 15- to 44-fold, according to various studies,[35] and 4% to 8% of SS patients develop lymphoma. Most of these are indolent, extranodal, marginal-zone B-cell lymphomas of MALT, but higher grade lymphomas are also seen.

A variety of clinical and laboratory features have been correlated to an increased risk of lymphoma development. Recurrent or persistent salivary gland swelling, palpable purpura, low complement levels, low CD4 counts, and persistently elevated inflammatory markers indicate an increased disease activity and increased risk for lymphoma development.[36,37]

Pregnancy. In Sjögren's syndrome, pregnancy outcomes are similar to those in healthy women. Carriers of the SSA antibody, however, can transmit it through the placental circulation to the fetus. These antibodies can cause congenital heart block or neonatal lupus, characterized by an annular rash with central scarring in the scalp and around the eyes, as well as, liver inflammation and transaminitis. This syndrome develops around the sixth week postpartum. Although the rash spontaneously resolves around the sixth to eighth months of age, the heart block is permanent and requires placement of a pacemaker. Expectant mothers with anti-SSA antibodies should be counseled about this risk and their fetuses should be followed closely for the development of fetal heart block.

DIAGNOSIS

The diagnosis of SS in a patient with complaints of oral and ocular dryness requires evaluation by a dentist or salivary gland specialist (such as a otorhinolaryngologist) and an ophthalmologist for specialized tests to quantify mucosal dryness, as well as laboratory evidence of autoantibodies and salivary gland biopsy for evidence of inflammation within the gland itself.

Several sets of diagnostic criteria were developed, and used by various groups over time, creating some confusion about how to define SS. Recently, an international consensus group agreed on a set of criteria, and this revised American–European classification system has been widely accepted (Table 161-2).[38] Six features are taken into consideration: subjective complaints and objective evidence of dry eyes or dry mouth, objective evidence of salivary gland inflammation, and the presence of specific autoantibodies in the serum. For the diagnosis of primary SS, at least four criteria should be present, and at least one of them should be either evidence of lymphocytic infiltration or the presence of autoantibodies. Patients with a coexisting connective tissue disease are labeled secondary SS. Exclusions include other diseases and medications that may cause sicca symptoms.

To establish subjective symptoms of dry eyes and dry mouth, a validated uniform questionnaire is used. A variety of noninvasive methods can be used to diagnose reduced salivary flow in clinical practice.

TABLE 161-2
Revised International Classification Criteria for Sjögren's Syndrome

I. **Ocular symptoms:** A positive response to at least one of the following questions:
   1. Have you had daily, persistent, troublesome dry eyes for more than 3 months?
   2. Do you have a recurrent sensation of sand or gravel in the eyes?
   3. Do you use tear substitutes more than three times a day?

II. **Oral symptoms:** A positive response to at least one of the following questions:
   1. Have you had a daily feeling of dry mouth for more than 3 months?
   2. Have you had recurrently or persistently swollen salivary glands as an adult?
   3. Do you frequently drink liquids to aid in swallowing dry food?

III. **Ocular signs:** Objective evidence of ocular involvement defined as a positive result for at least one of the following two tests:
   1. Schirmer's test, performed without anesthesia (≤ 5 mm in 5 minutes)
   2. Rose Bengal score or other ocular dye score (≥ 4 according to van Bijsterveld's scoring system)

IV. **Histopathology:** In minor salivary glands (obtained through normal appearing mucosa) focal lymphocytic sialoadenitis, evaluated by an expert histopathologist, with a focus score ≥ 1, defined as a number of lymphocytic foci (which are adjacent to normal appearing mucous acini and contain more than 50 lymphocytes) per 4 mm^3 per glandular tissue

V. **Salivary gland involvement:** Objective evidence of salivary gland involvement defined as a positive result for at least one of the following diagnostic tests:
   1. Unstimulated whole salivary flow (<1.5 mL/15 min)
   2. Parotid sialography showing the presence of diffuse sialectasias (punctuate, cavitary or destructive pattern), without evidence of obstruction in the major ducts
   3. Salivary scintigraphy showing delayed uptake, reduced concentration and/or reduced excretion of tracer

VI. **Autoantibodies:** Presence in the serum of the following autoantibodies: antibodies to Ro/SSA, La/SSB or both

Modified from Vitali C et al: Classification criteria for Sjögren's syndrome: A revised version of the European criteria proposed by the American-European Consensus Group. *Ann Rheum Dis* **61**:554, 2002.

ORAL DRYNESS

SIALOMETRY. Sialometry involves measurement of the total saliva produced from all salivary glands in a time period of 15 minutes. The whole unstimulated salivary flow is considered suggestive of SS if it is less than 1.5 mL in 15 minutes. A "stimulated" salivary flow can be measured after administration of lemon juice or citric acid, and low values are also suggestive of SS.

SALIVARY GLAND SCINTIGRAPHY. Salivary gland scintigraphy is a functional study to assess saliva production by measuring the secretion of a radioisotope (^{99m}technetium-sodium pertechnetate) into the oral cavity. Salivary gland scintigraphy (SGS) provides functional information about individual salivary glands and can potentially distinguish between decreased production and/or decreased excretion of saliva. The past decade has seen a shift towards the quantitative evaluation of SGS based on various parameters generated from time–activity curves.[39] Given the high cost and the exposure to radiation, their routine use may not yet be justified but it is a useful diagnostic tool in selected cases. Sialography is an imaging method based on retrograde injection of contrast media into the parotid duct. Dilatations of salivary ducts and sialolithiases are the most common findings.

OCULAR DRYNESS

The diagnosis of keratoconjuctivitis sicca is based on the demonstration of decreased tear production, corneal damage, or both. Tear production is measured by Schirmer's test. This is performed by placing a standardized paper strip in the inferior fornix of each eye and measuring the length of filter paper that becomes wet after 5 minutes. The American–European classification system uses a cut-off value of 5 mm in 5 minutes, below which the diagnosis of dry eyes is made. An alternative method is staining with a dye (rose Bengal or lissamine green) that preferentially stains the devitalized cornea and conjunctiva. This staining is evaluated through the van Bijsterveld scoring system; a score of 4 or more indicates keratoconjunctivitis sicca. These tests have a high sensitivity but low specificity; they identify ocular dryness, but cannot attribute abnormal findings to SS.

LABORATORY TESTS. High inflammatory markers, such as high sedimentation rates and signs of chronic inflammation (anemia, hypoalbuminemia) are common in SS patients.

Serologies can demonstrate hyperglobulinemia, in as high as 80% of primary SS patients. Autoantibodies include Ro (SSA) and La (SSB) antibodies, as well as rheumatoid factors and ANA.

PATHOLOGY

None of the above diagnostic procedures is specific for SS. The most reliable objective diagnostic feature is seen on biopsy of the minor salivary gland. A small incision is made on the inner surface of the lip, and a minor salivary gland tissue sample is collected. Evidence of a focal, periductal infiltrate composed of T and B lymphocytes and few plasma cells is the histologic hallmark of SS (Fig. 161-3). The degree of lymphocytic infiltration is evaluated semiquantitatively by means of a focus

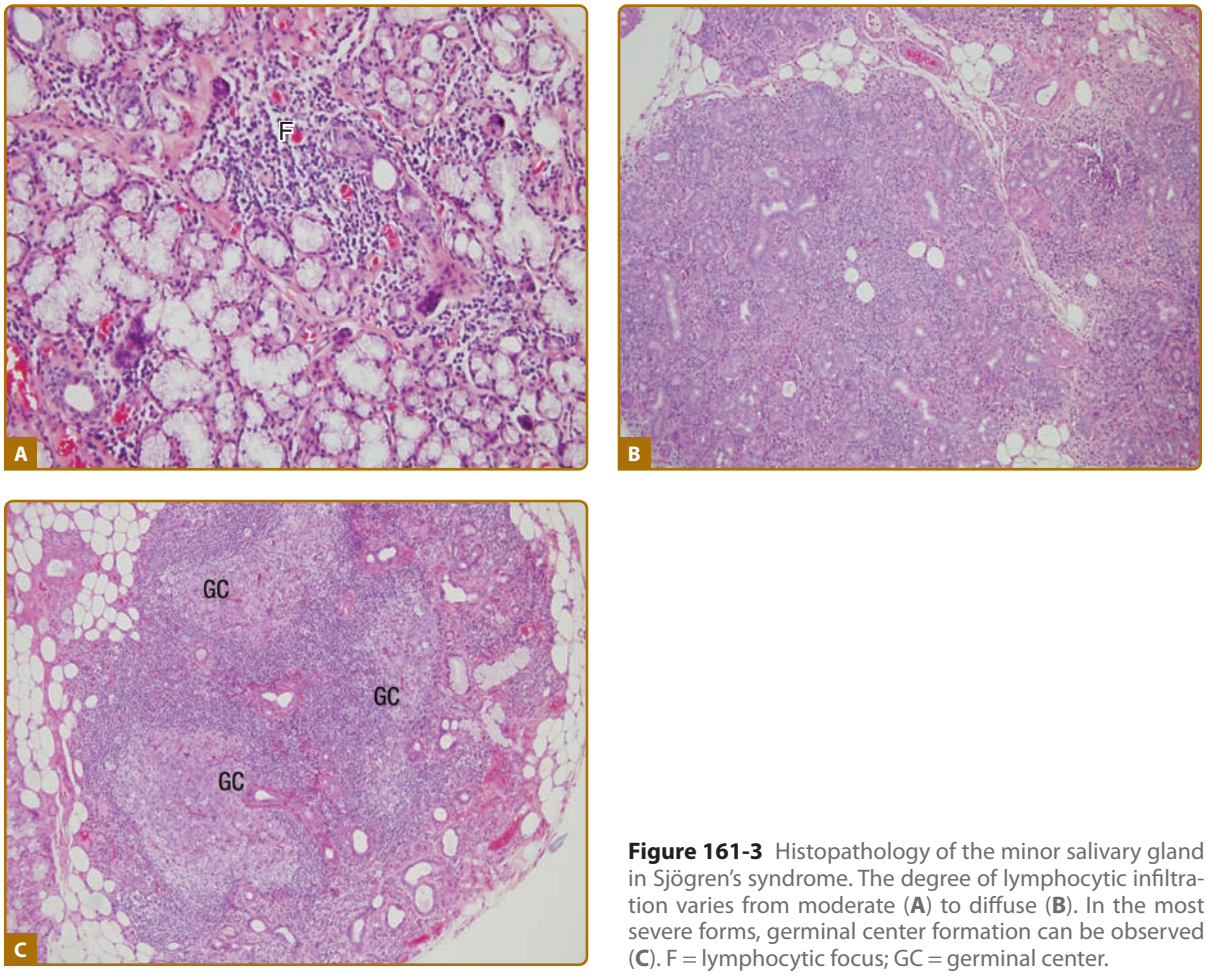

Figure 161-3 Histopathology of the minor salivary gland in Sjögren's syndrome. The degree of lymphocytic infiltration varies from moderate (**A**) to diffuse (**B**). In the most severe forms, germinal center formation can be observed (**C**). F = lymphocytic focus; GC = germinal center.

scoring system. Evidence of one or more focus is considered indicative of SS, and a focus is considered a conglomeration of at least 50 lymphocytes per 4 mm^2 of glandular tissue. Atrophy and fat tissue are other findings that may be present in SS patients, but are also present among healthy, elderly individuals. Although salivary gland biopsy provides important clues that may lead to definitive diagnosis, some controversy still exists regarding its sensitivity and specificity. Some patients with primary SS diagnosed on the basis of reduced salivary flow and evidence of anti-SSA and anti-SSB antibodies have no lymphocytic infiltration in biopsy specimens of minor salivary glands. In addition, some healthy individuals may demonstrate lymphocytic foci in their salivary glands.

PROGNOSIS

There are two patterns of primary SS that define two distinct disease categories with very different clinical risks. Patients with low complement C4 levels and/or palpable purpura early in their disease course may be classified as a high-risk disease syndrome (type I). This group comprises approximately 20% of the primary SS diagnoses and carries a significantly increased risk of lymphoproliferative disease and also has an increased mortality rate. Most severe extraglandular manifestations also occur in this group. Patients without these two predictors (80% of all primary SS diagnoses) may be reassured that they have a low-risk (type II) form of primary SS that carries no increased risk of death and in general has a more benign course dominated by sicca symptoms.[37]

TREATMENT

TREATMENT OF DRY MOUTH

(Table 161-3)

The treatment of oral dryness is largely symptomatic.[40]

Nonpharmacologic strategies are the mainstay of treatment.

Adequate hydration, and reduction of irritants like coffee, alcohol and nicotine as well as substitution of drugs that can lead to dry mouth when possible (diuretics, tricyclics, antihistamines, β-blockers) is essential.

Frequent sips of water are recommended initially to maintain moisture. Patients should also be encouraged to use sugar-free candies and chewing gums to

TABLE 161-3
Management of Sicca Symptoms in Sjögren's Syndrome

Xerostomia	■ Frequent water ■ Mechanical stimulation of saliva secretion (sugar-free gum and candies) ■ Artificial saliva ■ Meticulous oral hygiene ■ Caries prevention with fluoride-containing toothpaste and rinses ■ Aggressive treatment of candidiasis with topical and systemic antifungals ■ Sialogogues: pilocarpine (5 mg orally three times/day) or cevimeline (30 mg orally three times/day)
Xerophthalmia	■ Frequent use of preservative-free artificial tears ■ Nighttime use of moisturizing ointments ■ Topical cyclosporine A ophthalmic solution (0.05%, one drop every 12 hours) ■ Surgical: punctal plug placement ■ Sialogogues

increase saliva production. Saliva substitutes are available in the form of gels, oils or sprays, but the need for frequent application is inconvenient for many patients.

Sugar-containing foods should be avoided because they contribute to the increased risk of dental caries and oral candidiasis. Meticulous dental hygiene is essential for SS patients to prevent or treat dental caries.

Caries prevention with fluoride applications including prescription-strength toothpaste, fluoride gels, and oral rinses is further recommended.

Oral candidiasis is treated with oral and systemic antifungal therapy. To prevent candidiasis, patients should not wear dentures at night, and the dentures should be soaked in 2% chlorhexidine. Nystatin or clotrimazole cream can be used to treat angular cheilitis.

If dry mouth is not adequately controlled with replacement methods, pharmacologic therapy with secretagogue drugs is an option. Two drugs are approved for this indication: (1) pilocarpine (5 mg four times a day)[41] and (2) cevimeline (30 three times/day).[42] Both act on muscarinic receptors and increase exocrine gland secretion. They are contraindicated in narrow-angle glaucoma and uncontrolled asthma. Cholinergic side effects, such as excessive sweating, urinary frequency, flushing, and headaches, are common for both agents. Tolerability can be increased if treatment is started at a lower dose, which is then gradually increased (see Table 161-3).

TREATMENT OF DRY EYES

(See Table 161-3)

Non pharmacologic measures are very important therapeutic interventions; avoidance of dry, smoky and windy environments, avoiding contact lenses or opting for those higher in water content, and minimizing medications that inhibit tear production (diuretics, β-blockers, tricyclic antidepressants, antihistamines) are first-line measures.

Many tear substitutes are available and are commonly used by patients to alleviate ocular dryness. Preservative-free preparations are preferred, especially if used more than four times a day. Methylcellulose-containing ointments may provide longer relief, but their use is limited to nighttime use by the risk for blurred vision.

A frequently used surgical option is the occlusion of the puncta to block tear drainage and consequently increase moisture. The occlusion can be transient by the insertion of collagen or silicone plugs, or permanent by electrocautery.

Cyclosporine A 0.05% ophthalmic solution has been approved by the FDA for the treatment of keratoconjunctivitis sicca.[43] Topical corticosteroids are rarely needed and should probably only be prescribed after ophthalmic examination. Infections may present with aggravation of symptoms or increased mucus secretion, and should be promptly treated with topical antibiotics.

Pilocarpine and cevimeline can be effective for dry eyes, too, especially in patients with the most severe dryness.[42]

TREATMENT OF EXTRAGLANDULAR MANIFESTATIONS

The treatment of musculoskeletal manifestations of SS is similar to those of other systemic rheumatologic diseases.[44] Because of reduced saliva production and esophageal dysmotility, these patients have reduced tolerance to nonsteroidal anti-inflammatory drugs. Antimalarial drugs, such as hydroxychloroquine, are effective for arthralgia/arthritis, myalgia, and fatigue.[45] Dryness of eyes and mouth may also improve slightly in some cases.[46] Visceral manifestations such as vasculitis, pneumonitis, glomerulonephritis, and neurologic manifestations are treated with corticosteroids and immunosuppressive drugs, in doses similar to those used in systemic lupus erythematosus.

Treatment of lymphoma in SS is the same as in the general population. Most SS-associated lymphomas are low-grade B-cell lymphomas localized to the exocrine glands. For these, watchful waiting may be the most appropriate approach. Higher grade lymphomas require more aggressive treatment with a rituximab, cytotoxic regimen, and/or radiation therapy.

TARGETED THERAPY

Several randomized case-control studies have focused on therapy for SS using biologic agents, such as the TNF-blocking agents infliximab[47] and etanercept,[48] but none of the studies showed clinical benefit. There is increasing interest in therapies targeting B cells, such

as monoclonal antibodies against CD20 (rituximab) or CD22 (epratuzumab). A recent randomized placebo-controlled study demonstrated efficacy of rituximab over placebo in patients with active primary SS.[49] Rituximab improved stimulated salivary flows, laboratory parameters of inflammation and subjective symptoms. This clinical efficacy was supported by reduced glandular infiltration and morphologic improvements of epithelial cells on salivary gland biopsies.[50] Other potential targets for biologic therapy include cytokines such as IL-6 and BlyS (BAFF), interferons, adhesion molecules, and chemokines. However, even if effective, systemic immunomodulatory therapy may be associated with unwanted side effects and may not be justified in patients with primary SS whose disease is limited to exocrine glands. An alternative approach is to develop a localized form of immunotherapy by using gene therapy restricted to the salivary and lachrymal glands. This approach would most likely alter the abnormal immune response locally but may avoid the systemic side effects.[51]

KEY REFERENCES

Full reference list available at www.DIGM8.com

DVD contains references and additional content

1. Alamanos Y et al: Epidemiology of primary Sjogren's syndrome in north-west Greece, 1982–2003. *Rheumatology (Oxford)* **45**(2):187-191, 2006; [Epub 2005]
4. Cobb BL et al: Genes and Sjogren's syndrome. *Rheum Dis Clin North Am* **34**(4):847-868, vii, 2008
13. Fox RI. Sjogren's syndrome. *Lancet* **366**(9482):321-331, 2005
30. Roguedas AM et al: Cutaneous manifestations of primary Sjogren's syndrome are underestimated. *Clin Exp Rheumatol* **22**(5):632-636, 2004
38. Vitali C et al: Classification criteria for Sjogren's syndrome: a revised version of the European criteria proposed by the American-European Consensus Group. *Ann Rheum Dis* **61**(6):554-558, 2002
40. Mavragani CP, Moutsopoulos NM, Moutsopoulos HM: The management of Sjogren's syndrome. *Nat Clin Pract Rheumatol* **2**(5):252-261, 2006
50. Pijpe J et al: Clinical and histologic evidence of salivary gland restoration supports the efficacy of rituximab treatment in Sjogren's syndrome. *Arthritis Rheum* **60**(11):3251-3256, 2009

SECTION 28

The Skin in Inflammatory and Other Vascular Disorders

Chapter 162 :: Endothelium in Inflammation and Angiogenesis

:: Peter Petzelbauer, Robert Loewe, & Jordan S. Pober

ENDOTHELIUM AT A GLANCE

- All blood vessel endothelial cells (ECs) perform three important constitutive functions:
  - Maintaining homeostasis of the blood.
  - Forming a barrier that separates circulating blood from the tissue.
  - Regulating the extent of local blood flow.
- The cutaneous vasculature is divided into a superficial vascular plexus and a deep vascular plexus. The superficial vascular plexus is formed by parallel pairs of arterioles and venules connected via capillary loops that extend into the dermal papillae.
- ECs participate in innate and adaptive immune responses.
- Tumor necrosis factor-α and interleukin-1β are important modulators of EC function.
- Vascular ECs contribute to inflammation through distinctive patterns of adhesion molecule expression. In the skin, E-selectin, vascular adhesion molecule 1, and intercellular adhesion molecule 1 may be particularly important.
- Microvessels of the skin in situ basally express major histocompatibility complex (MHC) class I and II molecules at their luminal surfaces and may present antigen in an MHC-restricted manner to T cells.
- In the healthy adult, blood vessels are stable structures with very slow turnover of ECs. In chronic inflammation, tissue injury, wound healing, and tumor growth, new vessels are formed (angiogenesis) and existing vessels undergo remodeling.
- Keratinocytes produce a wide range of angiogenic factors, including members of the fibroblast or transforming growth factor protein family, platelet-derived growth factor, and vascular endothelial growth factor, as well as chemokines like cutaneous T cell-attracting chemokine. Vascular remodeling is a prominent feature of psoriasis.

OVERVIEW OF THE VASCULAR SYSTEM

The blood vascular system is a continuous series of hollow tubes that carry blood from the heart to the tissues and back again. Blood exits the heart through the aorta that gives rise to a series of diverging, progressively narrower muscular arteries and arterioles, delivering blood to all organs of the body. The terminal arterioles arborize into an interconnecting network of microvessels, mostly capillaries that nourish and cleanse the peripheral tissues. The capillary network empties into a series of converging venules and progressively larger veins that ultimately return the blood to the heart. All segments of this vascular system are lined by a one-cell-thick layer of epithelium-like cells called *endothelium* (Fig. 162-1). All vascular endothelial cells (ECs) share common features and functions, and hence may be collectively described as one cell type. However, ECs from one segment of the vascular system may differ in significant ways from the ECs

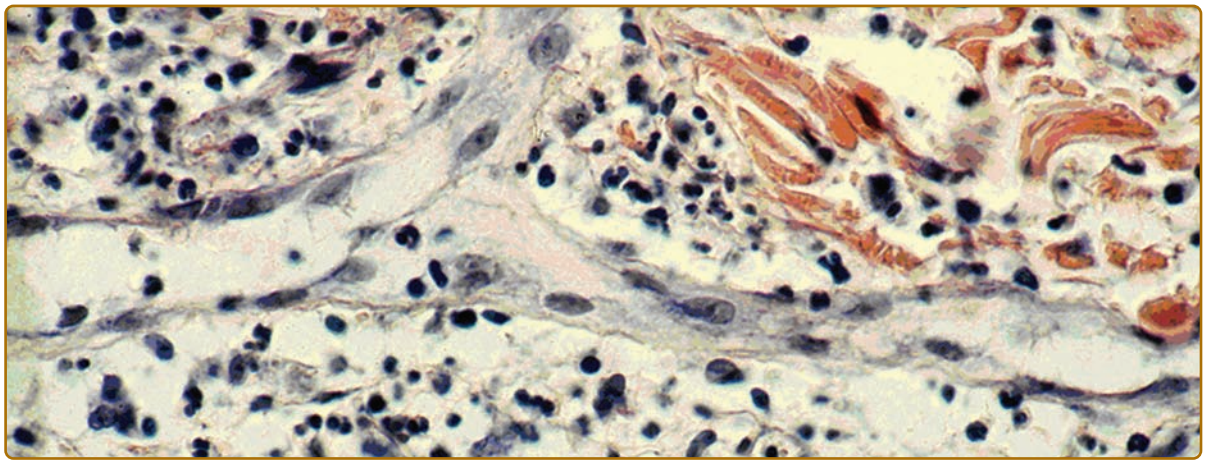

Figure 162-1 Endothelium. In this postcapillary venule, endothelial cells are seen to line a channel. Nuclei are seen en face and in cross-section, and activated endothelial cells appear to have an edematous cytoplasm, which increases their visibility. This specimen is from an inflammatory lesion (Sweet syndrome; see Chapter 32) without signs of vessel damage.

at other anatomic sites. Blood vessel ECs differ from lymphatic ECs, which are not discussed in this chapter.

Blood vessel ECs must perform three important constitutive functions. First, vascular ECs must maintain homeostasis of the blood, which consists of roughly equal volumes of fluid (plasma) and cellular elements (erythrocytes, leukocytes, and platelets). The plasma contains the proteins of the coagulation system. In addition, both leukocytes and platelets have membrane receptors that trigger cellular activation on contact with the extravascular environment. The EC lining prevents intravascular activation both of the coagulation system and of these responsive cellular elements, yet keeps both systems poised respond to wounding or infection.

Second, ECs must separate circulating blood from the tissues. The barrier formed by ECs permits limited passage of fluid and solutes, allowing the blood to nourish the tissues while displaying "permselectivity" for macromolecules and presenting a virtually impenetrable barrier for blood cells (except at specialized sites of high permeability and leukocyte trafficking). In other words, vascular ECs regulate rather than prevent interactions between blood and tissues.

Third, ECs must regulate local blood flow. Because ECs are arranged in alignment with flow, their contraction opens gaps between cells, enhancing permeability without altering flow (see Fig. 162-1). However, ECs indirectly regulate flow by acting on smooth muscle cells (SMCs), which are oriented almost parallel to the vessel's circumferential or radial axis.

ECs do so principally by the generation of SMC relaxants [e.g., nitric oxide (NO), prostaglandin E_2 or prostaglandin I_2 (PGI_2), and endothelium-derived hyperpolarizing factor] or contractants (e.g., endothelin) or by catalyzing the generation of vasoconstrictors from plasma protein-derived mediators (e.g., angiotensin II through the action of EC-expressed angiotensin-converting enzyme, which also inactivates bradykinin, a plasma protein-derived agonist that acts on ECs to generate NO.

In addition to these constitutive functions, ECs may be activated to induce additional functions, a topic discussed later in the chapter.

STRUCTURE AND FUNCTION OF THE SKIN VASCULATURE

Approximately three decades ago Irwin Braverman described the organization of the vascular network of human skin, which he summarized in 1989.[1] The human dermal vasculature consists of two interconnected systems—(1) a superficial and (2) a deep vascular plexus—with additional vascular networks surrounding sweat glands and hair follicles[2,3] (Fig. 162-2). The superficial vascular plexus (SVP) is comprised of paired arterioles and venules that form an interconnected network of vessels coursing on a plane parallel to and just beneath the epidermal surface.[3] Capillaries arise from the arterioles, extend upward within the papillary dermis at sites between the epidermal rete ridges, and then loop back down to the venules

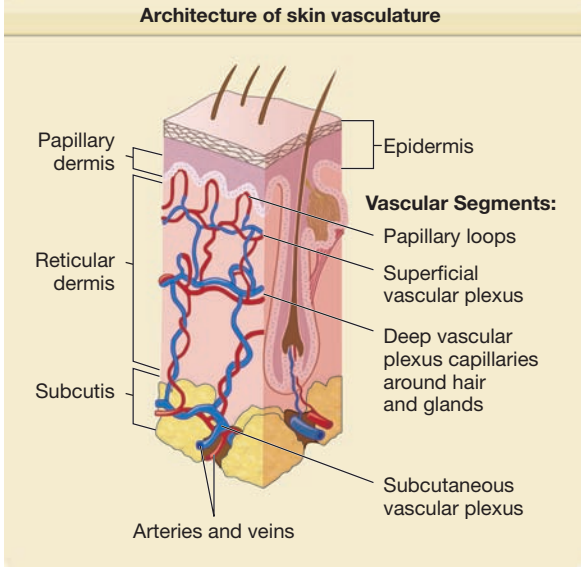

Figure 162-2 Schematic diagram of the architecture of the skin vasculature.

forming arcade-like structures. The basement membrane of the arterioles appears homogeneous by electron microscopy whereas that of the venules is multilayered. In normal skin, most of the capillary loop is invested with a basement membrane that resembles that of the arteriole, acquiring a venule-like investiture only at the level of the deepest rete just proximal to the anastomosis with the venule of the SVP.[2] There are no ultrastructural differences between capillary loops at different sites of the skin. Inflammatory leukocytes extravasate through the venule-like portions of the capillary and the venule proper but only rarely infiltrate through the arteriole-like portions of the capillary or the arteriole itself.

The arterioles and venules of the SVP are connected by short, straight vessels to the arterioles and venules of a deeper planar network of anatomizing vessels called the *deep vascular plexus* (DVP) (see Fig. 162-2). The plane of the DVP is parallel to that of the SVP and courses above the boundary between the reticular dermis and the underlying subcutis (see Fig. 162-2). The DVP is fed through penetrating vessels from the subcutis. The DVP is drained by valve-containing veins into the subcutaneous fat. The vessel wall in the SVP consists of discontinuous layers of elastic fibers and SMCs. The DVP contains arterioles and venules of larger caliber consisting of three layers: (1) an intima, (2) a media, and (3) an adventitia. Capillary networks connecting the arterioles and venules of the DVP provide nourishment for the adnexal structures within the reticular dermis. The venules of the DVP serve as portals of entry for leukocytes associated with inflammation of the adnexa or for inflammation within the reticular dermis itself, as occurs in erysipelas.

Dermal microvessels are surrounded by flat adventitial cells, ultrastructurally most closely resembling a fibroblast, called *veil cells*.[1] Veil cells are external to the wall, demarcating the vessel from the surrounding dermis. These cells lack leukocyte markers and are negative for HLA-DR and CD1a expression. They express glycoprotein Ib α, von Willebrand factor (vWF) receptor, and factor XIIIa, a coagulation transglutaminase, and are sometimes called *XIIIa-positive dendrocytes*. Factor XIIIa-positive dendrocyte rarefaction is found in the classic type of Ehlers–Danlos syndrome, but the significance of this finding is not clear. They should be distinguished from dermal dendritic cells, a population of specialized antigen-presenting leukocytes resident within the dermis.

Dermal microvessels, especially capillaries, contain, in addition to ECs, a population of contractile mesenchymal cells called *pericytes (PCs)*. Unlike veil cells, PCs are an integral component of the vessel wall. They extend long cytoplasmic processes over the abluminal surface of the ECs and make interdigitating contacts. The coverage of ECs by PCs varies considerably among different microvessel types. Communicating gap junctions, tight junctions, and adhesion plaques are present at these points of contact.

Because PCs are rich in contractile proteins and have complex interdigitations with ECs in postcapillary venules, it is assumed that they are responsible, at least in part, for gap formation in response to, for example, histamine or bradykinin (although cultured ECs are capable of contraction in the absence of PCs). Moreover, interaction between PCs and ECs is important for the maturation, remodeling, and maintenance of the vascular system via the secretion of growth factors or modulation of the extracellular matrix. There is also evidence that PCs are involved in the transport across the blood–brain barrier and the regulation of vascular permeability.

MORPHOLOGY AND MOLECULAR MARKERS

GENERAL MORPHOLOGY

ECs usually appear as flattened epithelium-like cells, with a thickness typically less than 10 μm and a surface area covering up to 1,000 μm^2 (see Fig. 162-1). In large vessels, ECs have an elongated shape, especially in regions of laminar flow, and have their long axis oriented in the direction of blood flow. ECs located in regions of disturbed flow (i.e., at branch points of the arterial tree) are often polygonal rather than elongated. Cultured ECs are typically polygonal but elongate when flowing medium is passed over them for periods of 24 hours or more.[4] Shear stress, the force imparted by viscous drag of flowing liquid, is responsible for inducing a cytoskeletal rearrangement and the change of shape from polygonal to elongated. Interestingly, the microtubular organizing center of ECs, located near the nucleus, is always oriented toward the heart (i.e., upstream of the nucleus in arteries and downstream of the nucleus in veins) regardless of the direction of blood flow.[5] Moreover, ECs have an apical/luminal polarization, integrin receptors for matrix macromolecules are concentrated on the basal/abluminal surface, and adhesion molecules for leukocytes are almost exclusively displayed on their apical surface, which faces the lumen of the blood vessel.[6]

SPECIALIZED ORGANELLES OF ENDOTHELIAL CELLS

The ultrastructure of a postcapillary venule is shown in Fig. 162-3. ECs have a number of characteristic organelles. The best described are Weibel–Palade bodies (WPBs), fenestrae, and the caveolar system. WPBs are elongated, membrane-bound organelles that display longitudinal striations by electron microscopy. WPBs are distributed randomly throughout the cytoplasm in vascular ECs of most vertebrates. WPBs constitutively contain vWF (also called *factor VIII-related antigen*), P-selectin (CD62P),[7] lysosomal membrane-associated glycoprotein 3 (or CD63),[8] 1,3-fucosyltransferase VI,[9] interleukin 8 (IL-8),[10] and angiopoietin 2 (Ang-2).[11] The longitudinal striations within the WPBs are formed by highly polymerized forms of vWF, reaching sizes of up to 20,000 kDa. On release, vWF polymers may attach to the basement membrane and stabilize platelet adhesion to the subendothelial matrix, particularly in

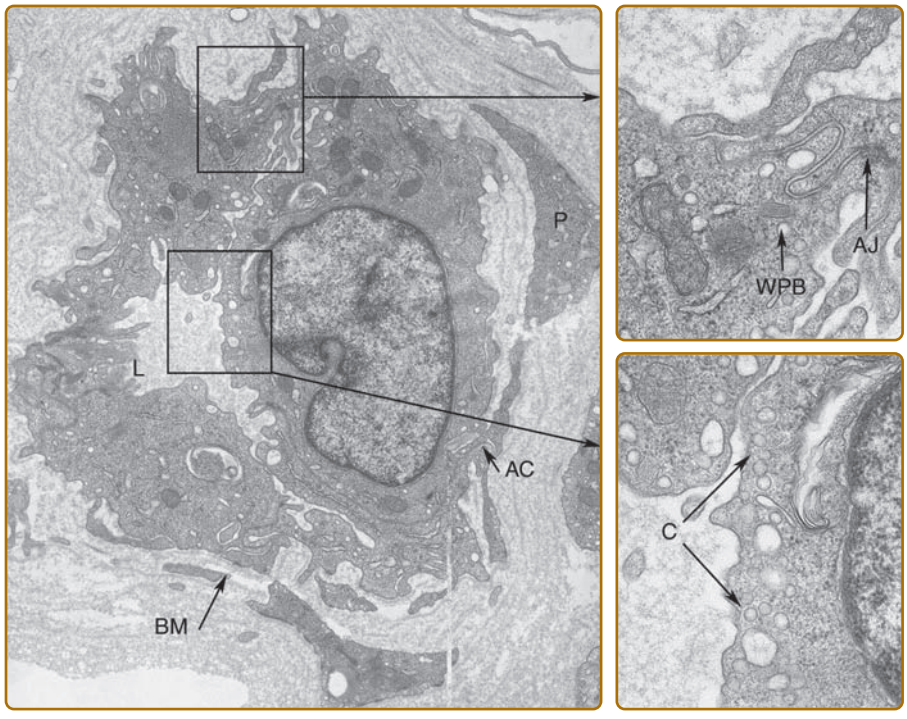

Figure 162-3 Ultrastructure of a postcapillary venule. AC = area of contact between endothelial cell and pericyte; AJ = adherens junction; BM = basement membrane; C = caveolae; L = lumen; P = pericyte; WPB = Weibel–Palade body.

high-velocity arterial flow. Although vWF is commonly used as an EC marker (see Section "Molecular Markers of Endothelial Cells"), it is also found in megakaryocytes, which appear to lack a physiologic mechanism of release, synthesizing vWF only for storage within the α granules of their platelet progeny. P-selectin is rapidly translocated to the cell surface as the WPB fuses with the plasma membrane, where it mediates leukocyte adhesion to ECs (see Section "Leukocyte Adhesion"). CD63 is a 53-kDa lysosomal membrane glycoprotein belonging to the tetraspanin superfamily; its function in the WPB is unknown.

Blood vascular ECs usually form a continuous monolayer, and most transendothelial transport takes place in the junctions between cells. One important exception is in the fenestrae of capillaries in lymph nodes, capillaries in the intestinal mucosa, renal glomerular ECs, and hepatic and bone marrow sinusoids. Fenestrae, uniquely found in ECs, are specialized annular patches of attenuated cytoplasm and membrane, about 175 nm in diameter, characterized by an increased concentration of anionic lipids.[12] They group into structures resembling sieve plates that occupy 6% to 8% of the surface capillaries. Fenestrated capillaries are much more permeable to water and small-molecular-size solutes than those of the continuous type. The anionic charge probably precludes the transfenestral passage of anionic plasma proteins. Various factors, such as pressure, alcohol, serotonin, nicotine, and infection, change the number and diameter of fenestrae, and ECs of the continuous type may become transiently fenestrated.

All ECs appear to contain numerous vesicles subjacent to the plasmalemma, both luminal and abluminal. On careful examination, most of these vesicles turned out to have narrow tubular connections to the plasma membrane. Such flask-shaped invaginations are called *caveolae*, literally "little caves," and are part of the surface membrane, either as a single caveola or as more complex racemose invaginations. In situ, they may account for 50% or more of the plasma membrane surface area of ECs. Caveolae arise from a late Golgi compartment and represent a stable membrane unit built up around caveolins, cholesterol, and glycosphingolipids. ECs are rich in caveolins 1 and 2. Caveolins bind to cholesterol and are required for caveolae formation; ECs in caveolin 1 knockout mice fail to form caveolae. Expression of caveolin 1 in some cell types normally lacking caveolae can cause their formation, but cultured ECs normally retain expression of caveolins yet lose their caveolae, with cholesterol and glycosphingolipids dispersing into submicroscopic lipid rafts on the now simplified plasma membrane, implying a key role for an as yet unidentified factor.

Caveolae can mediate vesicular transport, internalize certain plasma membrane proteins and provide a platform for the assembly of signaling complexes at the surface of the cell. Caveolins interact with a variety of downstream signaling molecules, including Src-family of tyrosine kinases, p42/44 mitogen-activated protein kinase, and endothelial NO synthase (eNOS). They hold these signal transducers in the inactive conformation until activation by an appropriate stimulus. For example, the amount of caveolin is inversely related to NO production by eNOS.[13] Mice lacking caveolin 1 have impaired NO and calcium signaling in the cardiovascular system, which causes aberrations in EC-dependent relaxation, contractility, and maintenance of myogenic tone.[14]

Caveolin 1 is associated with a number of growth factor receptors, including the epidermal growth factor receptor, the high affinity nerve growth factor receptor (TrkA), the insulin receptor, the platelet-derived growth factor receptor and transforming growth factor receptors I and II.[15,16] In addition, cytokine receptors like the tumor necrosis factor (TNF) receptor 1 (CD120a) and interferon receptors also localize to caveolae. For these receptors, the invaginated structure of caveolae provides an optimal environment for receptor function, forming a more stable signaling complex and allowing for cross talk with other receptors.

The lipid constituents of caveolae are the same as those of lipid rafts, but rafts are regions without membrane indentations and they are flat. A key limitation in a clear distinction between rafts and caveolae is due to methodical limitations to clearly separate them. Moreover, rafts and caveolae should be considered as dynamic entities that form and dissipate in response to various stimuli, and both may facilitate transport of entities to other cellular regions and across the cell.

Another organelle that is present in venular endothelium is so called vesicular–vacuolar organelle, grapelike structures of interconnected vesicles that extend throughout the cytoplasm. They show a wide variation in size and most vesicles do not contain caveolin. Consistent with this finding, they are present in normal size and numbers in caveolin null mice.[17] These organelles appear to be critically involved in acute vascular hyperpermeability, which typically involves the postcapillary venules, where these vesicular–vacuolar organelles are typically situated.

ENDOTHELIAL JUNCTIONS

Neighboring ECs connect to each other by forming interdigitating protrusions connected by junctions. Junctions possess different degrees of complexity along the vascular tree, reflecting different permeability for proteins and cells. Intercellular tight (occluding) junctions constitute the anatomic basis for the tightly regulated interfaces of the blood–testis and blood–brain barriers.[18] They consist of a continuous belt-like meshwork of six anastomosing junctional strands, which prevent the transport of macromolecules into the tissue. Arterial ECs also possess tight junctions[19]; however, they consist of only one or two junctional strands, and tight junctions are difficult to find in postcapillary venules. Tight junctions contain a complex of transmembrane (junctional adhesion molecule-1, occludin, and claudins) and cytoplasmic (zonula occludens-1 and -2, cingulin, AF-6, and 7H6) proteins linked to the actin cytoskeleton. The claudin multigene family encodes tetraspan membrane proteins that are crucial structural and functional components of tight junctions. In mammals, the claudin family consists of 24 members, which exhibit complex tissue-specific patterns of expression. Their extracellular loops interact with each other to seal the cellular sheet and regulate paracellular transport between the luminal and basolateral spaces. The transmembrane protein occludin is linked to ZO-1, a cytoplasmic protein that interacts with the cytoskeleton and appears involved in opening and closing of the junctions. Junctional adhesion molecules, called *JAMs*, members of the immunoglobulin superfamily, form homophilic adhesion sites in tight junctions and play a role in the generation of cell polarity, keeping luminal proteins from diffusing to the abluminal cell surface and vice versa.

Adherens junctions are found in all vascular ECs (see Fig. 162-3). They are multimeric protein structures that mediate homotypic cell adhesion. In endothelial cells, they are distributed along the cleft between neighboring cells and are frequently intermingled with tight junctions. During embryonic development, this type of junction promotes adhesion of identical cells and is important for organization and separation of tissues. In the adult, they maintain tissue homeostasis and contribute to paracellular permeability. Moreover, they confer cell-to-cell signals such as contact inhibition of cell growth, or resistance to apoptosis. They also regulate cell shape and polarity. Endothelial adherens junctions are principally organized by VE-cadherin [also called *cadherin 5* or *vascular endothelial cadherin (CD 144)*]. VE-cadherin-negative ECs derived by gene targeting fail to organize in vessel-like structures, blocking VE-cadherin interactions with monoclonal antibodies inhibits vessel formation.[20,21] Whereas VE-cadherin appears critical for initial formation of blood vessels, for maintenance and remodeling of blood vessels, a receptor-type phosphotyrosine phosphatase (RPTP) called *VE-PTP* appears essential. VE-PTP binds to VE-cadherin via the extracellular domain and supports adhesive functions of VE-cadherin.[22] Intracellularly, VE-cadherin is linked to a large cytosolic protein complex. This complex contains catenins, β-catenin, p120ctn, plakoglobin (also called γ-catenin), and α-catenin. Catenins β-catenin, p120ctn and plakoglobin contain homologous Armadillo repeats, whereas α-catenin is homologous to vinculin, which is another actin-binding protein. Moreover, this complex contains src, fyn and src homology-containing phosphatase (SHP)-1, and RPTP-μ and may associate with neighboring transmembrane receptors such as vascular endothelial growth factor receptor (VEGF-R)-2, angiopoietin receptor 1 (also known as Tie-2) and protease activated receptors (PAR)-3 and -6. Thus, adherens junctions integrate signals from neighboring cells and neighboring transmembrane receptor molecules and link these signals to the cytoskeleton and through focal adhesion kinase with integrin receptors to the basal matrix. This signaling pathway also functions retrograde from integrin receptors to adherens junctions. This network gets further input through RhoGTPases signaling to Rho kinase (ROCK) and leading to contraction of the cytoskeleton.[17,23–29]

ECs form gap junctions, demonstrated by transfer of microinjected small-molecular-weight tracers between adjacent ECs. In ECs, the relevant gap junctional proteins are connexin-43, connexin-37, and connexin-40. Interestingly, ECs also may form heterogap junctions with PCs or SMCs in the vessel wall and sometimes with adherent leukocytes.

ENDOTHELIAL CELL–MATRIX INTERACTIONS

ECs rest on a basal lamina, which is formed by EC itself and by surrounding cells. It consists of laminins, collagens, fibronectin, nidogen (entactin), and heparan sulfate proteoglycans. Interaction with these matrix molecules is essential for maintaining normal endothelial function. For example, the laminin A chain peptide supports endothelial branching and formation of new capillaries.[30] Furthermore, a 20-kDa *C*-terminal fragment of collagen XVIII specifically inhibits endothelial proliferation and angiogenesis,[31] which suggests that collagen XVIII is also a positive regulator of vessel growth. On the other hand, EC–collagen V interactions inhibit endothelial attachment and growth. ECs interact with these components of the basal lamina by numerous transmembrane adhesion molecules. The complexities of these interactions have only been partially characterized. Members of the integrin family are particularly important for this function. For example, $\alpha_6\beta_1$-, $\alpha_2\beta_1$-, $\alpha_5\beta_1$-, and $\alpha_V\beta_3$-receptor complexes are important for endothelial attachment to, and migration on, laminin, collagen, and tenascin, and therefore serve important roles in angiogenesis. In addition, integrin binding to matrix proteins also has a multitude of intracellular effects on the organization of the endothelial actin skeleton and on signaling processes within the cell.[3] Endothelial-cell growth factors have been shown to differentially upregulate the biosynthesis of α_2, α_5, β_1, and β_3 integrins, serving the different needs of endothelium during growth, spreading, and new vessel formation. Moreover, integrins show certain tissue-and vessel-restricted expression; for example, $\alpha_1\beta_1$ is found only in small blood vessels and capillaries but not in large vessel ECs. Matrix proteins such as thrombospondin 1, may also serve as inhibitors of angiogenesis.[33]

MOLECULAR MARKERS OF ENDOTHELIAL CELLS

ECs display a number of molecular markers that result in a characteristic profile detectable with antibodies, lectins, and other ligands (Table 162-1). In addition to containing molecules expressed on all endothelium, the skin vasculature shows several site-specific characteristics. Postcapillary venules of the SVP are $CD36^-$ and thus distinct from capillaries of the DVP and from capillaries of other tissues, which are $CD36^+$.[34] CD36 antigen is a cellular receptor for thrombospondin, collagen, low-density lipoproteins, long-chain fatty acids, and platelet-agglutinating protein p37.[35] Moreover, CD36 functions as one of the receptors that mediate the adhesion of *Plasmodium falciparum*-infected erythrocytes to microvascular EC. The functional consequences of the disparate CD36 expression on SVP and DVP endothelium are unknown. Microvessels are best characterized by expression of the pathologische anatomie Leiden-endothelium (PAL-E) antigen (which is identical with plasmalemmal vesicle 1 or fenestrated endothelial-linked structure protein),[36] N-cadherin, and CXC chemokine receptor 4 (CXCR4), and by their surrounding by smooth muscle actin-positive cells (which may be SMCs or PCs). Blood vascular ECs normally lack the lymphatic EC markers lymphatic vessel endothelial-1 [LYVE-1, (a hyaluronan receptor) and podoplanin], but may express these molecules when inflamed.[37,38] ECs express receptors for binding members of the VEGF family. Blood endothelial cells express VEGFR-2 and VEGFR-1, whereas lymphatic vessel endothelial cells express VEGFR-2 and VEGFR-3.[39–42] Neuropilins, another group of VEGF-binding membrane-bound receptors, are also differentially expressed in various types of vasculature. Whereas neuropilin-1 is strongly expressed in arterial endothelial cells, neuropilin-2 is expressed in veins and visceral lymphatic vessels.[43] Another important signaling system is the angiopoietin/Tie receptor system (see Section "Regulation of Angiogenesis and Vasculogenesis").

Postcapillary venules of the skin express toll-like receptor (TLR) family members and CD32 molecules (FcγRIIa).[44] CD32 binds complexed immunoglobulin G and is thought to function in the elicitation of type III (immune complex-mediated) hypersensitivity as well as in immune complex clearing. ECs of postcapillary venules express significantly higher levels of the histamine H_1 receptor than other ECs. Histamine produces increased albumin leakage and induces rolling of leukocytes, mediated in part by P-selectin expressed on the EC surface. PAR 2 expression at this site also plays a role in inflammatory reactions. PAR 2-activating peptides increase leukocyte rolling and adhesion to postcapillary venules. Finally, postcapillary vessels of the skin in situ constitutively express major histocompatibility complex (MHC) class I and II molecules at their luminal surfaces, which implies that ECs may directly participate in the elicitation of antigen-driven immune responses. As discussed later (see Section "Role of Endothelium in Adaptive Immunity"), skin microvessels in cell culture appear able to process and present antigen in an MHC-restricted manner to T cells.[45]

ENDOTHELIUM IN INFLAMMATION

INNATE IMMUNITY

Innate immunity, also called *natural* or *native immunity*, comprises the host's defense systems against microbes that are independent of T and B lymphocytes and their receptors for specific antigens (see Chapter 10). The innate immune system is much older in evolutionary terms than the T- and B-cell-specific immune system (often called *adaptive immunity* to distinguish it from innate immunity). The humoral component primarily involves the complement system. The primary cellular effectors of innate immunity in humans are neutrophils, mononuclear phagocytes, and natural killer cells, but ECs also participate.

Endothelial cells represent the initial target in many different types of infection.[46] For example, exposure to lipopolysaccharide, a major cell-wall constituent

TABLE 162-1
Molecular Markers of Endothelium

Marker	Location/Function	Expression Profile
VWF	WPB, biosynthetic organelles (Golgi, ER)	EC, megakaryocytes, platelets
CD31	Adhesion molecule, transmigration	EC, platelets, leukocytes
CD143 (angiotensin-converting enzyme)	Secreted then bound to cell surface	EC, macrophages
CD141	Anticoagulant thrombomodulin	EC, trophoblast of the placenta
Reactivity with the lectin UEA-1	Blood group H antigens	EC, erythrocytes, specialized epithelia
VEGFR-1 and VEGFR-2	Receptor tyrosine kinase	EC, macrophages, hematopoietic stem cells, motor neurons (R2)
Tie-1 and Tie-2	Receptor tyrosine kinase	EC, hematopoietic stem cells, peripheral nervous tissue (Tie-2)
ICAM-2	Adhesion molecule	EC
CD40, CD54, CD58, CD105	–	EC, broad expression pattern
CD9, CD13, CD31, C1q and C5a receptors, complement regulatory proteins	Common embryologic origin of the angioblast and the hematopoietic stem cell	EC, hematopoietic cells
CD26, CD40, CD44, CD47, CD54, CD58, CD146	—	EC, broadly expressed on other cell types
Class II MHC molecules	Antigen presentation	Constitutive on skin and kidney microvessels
Endoglin (CD105)	Surface receptor	EC, stromal cells
PAL-E antigen	Fenestrae	Microvessels and veins
CD34	Proteoglycan, adhesion molecule	Microvessels, hematopoietic cells
CD36	Proteoglycan	Microvessels except brain and some skin ECs
CD32	Fc receptor	Liver and skin microvessels, leukocytes
P-selectin	Prestored in WPB	EC
VCAM-1 (CD106)	Inducible adhesion molecule	EC, macrophages, follicular-dendritic cells
E-selectin (CD62E)	Inducible adhesion protein	EC
MAdCAM-1	Adhesion molecule, sialomucin	Microvessels of intestine and breast
GlyCAM-1	Adhesion molecule, sialomucin	Lymph nodes, high endothelial venules
Peripheral node addressing (antibody MECA-79)	L-selectin ligands	EC of peripheral nodes and skin
ICAM-3	Adhesion molecule	Tumor vessels

EC = endothelial cell; ER = endoplasmic reticulum; GlyCAM = glycosylation-dependent cell adhesion molecule; ICAM = intercellular adhesion molecule; MAdCAM = mucosal addressin cell adhesion molecule; MHC = major histocompatibility complex; PAL-E = pathologische anatomie Leiden-endothelium; UEA = ulex europaeus agglutinin; VCAM = vascular adhesion molecule; VEGFR = vascular endothelial growth factor receptor; vWF = von Willebrand factor; WPB = Weibel–Palade body.

of Gram-negative bacteria, results in endothelial activation through a receptor complex consisting of TLR-4, CD14, and MD2. Then, recruitment of the adaptor protein myeloid differentiation factor (MyD) 88 to the ligand-activated TLR-4 receptor initiates an MyD88-dependent pathway that culminates in the early activation of nuclear factor-κ B and the mitogen-activated protein kinases. In parallel, an MyD88-independent pathway using an alternative adaptor protein called TRIF results in a late-phase activation of nuclear factor-κ B as well as generation of interferons.[47,48] ECs also express TLR-2, which serves as a signaling receptor for Gram-positive cell-wall components, and intracellular TLRs that respond to various types of nucleic acids typically encountered during infections by viruses. Stimulation of TLR 2/6

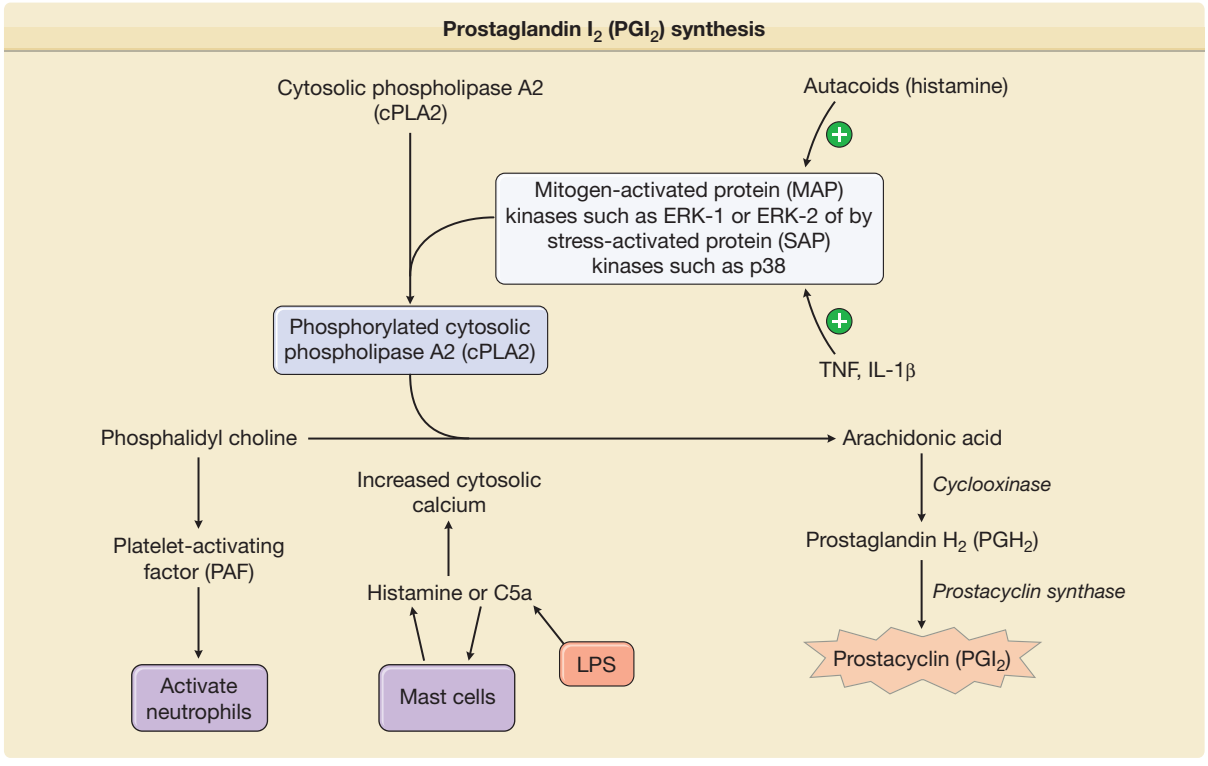

Figure 162-4 Prostaglandin I_2 (PGI_2) synthesis. ERK = extracellular signal-regulated kinase; IL = interleukin; LPS = lipopolysaccharide; TNF = tumor necrosis factor.

by bacterial lipopeptides also may promote angiogenesis and results in the secretion of GM-CSF.[49] Certain vascular beds express the macrophage mannose receptor (CD206), a receptor for oligosaccharides on the cell wall of bacteria, yeasts, and parasites. Other receptors of the innate immune system include a variety of lectin-type molecules, such as mannose-binding protein or galectins that recognize bacterial carbohydrates. Mannose-binding protein may stimulate the alternative pathway of complement activation.

TNF and IL-1 are the principal effector cytokines of the innate immune response to bacteria. In general, endothelial responses to TNF and IL-1 are similar and are considered together. The major isoform of IL-1 that is produced during innate immune responses is IL-1β, but IL-1α, the major isoform made by ECs, has indistinguishable actions, and we will simply refer to both isoforms as IL-1. At least five changes in the phenotype of ECs that promote inflammation, collectively called *endothelial activation*, have been described.

SYNTHESIS OF VASODILATORS.

TNF- or IL-1-treated ECs increase production of vasodilators, such as PGI_2 and NO, that relax smooth muscle cell tension, thereby producing vasodilation and increasing tissue perfusion. PGI_2, also called *prostacyclin*, is synthesized in ECs by a series of three sequential enzyme-catalyzed reactions.[52] ECs express one isoform of prostaglandin H synthase, PGHS-1, also called *cyclooxygenase 1*, that is constitutively active. Treatment of ECs with TNF or IL-1 dramatically increases PGHS activity by inducing de novo expression of a second isoform, PGHS-2, which is also called *cyclooxygenase 2*. This response markedly increases the capacity to make prostaglandin (PG)H_2 from arachidonic acid, and the increased PGH_2 is subsequently converted into PGI_2 (Fig. 162-4). Pharmacologic inhibition of the synthesis of PGH_2 is thought to contribute to the anti-inflammatory actions of aspirin and nonsteroidal anti-inflammatory drugs. NO is produced by conversion of arginine to citrulline through eNOS (Fig. 162-5). TNF exhibits opposing effects on vasodilation. Initially, it enhances eNOS function and NO synthesis through activation of Akt and by increasing the synthesis of tetrahydrobiopterin, a limiting cofactor for eNOS function.[53] At later times, TNF destabilizes eNOS mRNA and thereby inhibits NO production.

LEUKOCYTE ADHESION.

(Tables 162-2 and 162-3). TNF- or IL-1-treated ECs exhibit changes in the cell surface that favor the initial capture, rolling, and, ultimately, firm adhesion and spreading of leukocytes (Fig. 162-6). Adhesion is a necessary prelude to extravasation of leukocytes into the tissues. Capture and rolling are typically mediated by selectins expressed on the leukocyte or on the EC.[54] There are three structurally related selectin proteins: (1) L-selectin (CD62L), (2) E-selectin (CD62E), and (3) P-selectin (CD62P). In the presence of flowing blood, the leukocyte is propelled in the direction of blood flow, rapidly breaking and reforming selectin-mediated attachments. This

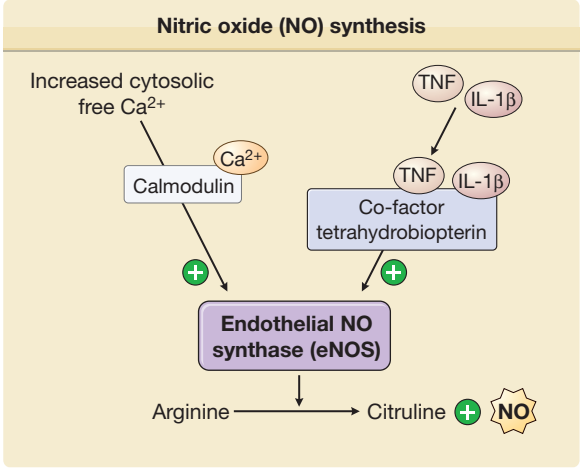

Figure 162-5 Nitric oxide (NO) synthesis. IL = interleukin; TNF = tumor necrosis factor.

results in rolling of the leukocyte along the EC surface (see Fig. 162-6). Ligands involved in selectin-mediated capture may not be the same as those involved in selectin-mediated rolling; for example, neutrophils may switch from L-selectin to E-selectin ligand (ESL)-1 as the principal E-selectin ligand during these two phases of the interaction.[55,56] Studies using blocking monoclonal antibodies or selectin knockout mice have confirmed that selectins are required for neutrophil rolling and subsequent recruitment in vivo. In mice, E- and P-selectin functions may be redundant (i.e., both molecules must be knocked out or inhibited for complete loss of rolling). Of note, whereas IL-1 and TNF upregulate both P- and E-selectin in mice, they induce only E- but not P-selectin in humans. In humans, E-selectin expression is largely regulated by de novo synthesis induced by cytokines whereas P-selectin is preformed and mobilized from WPBs to the cell surface in response to stimuli like thrombin, histamine, reactive oxygen species, and the like. Consequently, E- and P-selectin may not be redundant in humans. Selectin expression is rapid, within 5 min for P-selectin and 1 to 2 hours for E-selectin, but is often transient, peaking at 15 minutes for P-selectin and 4 to 6 hours for E-selectin, but may persist much longer on skin ECs. Another important mechanism initiating rolling of T lymphocytes on ECs is the interaction of the hyaluronan receptor CD44. CD44 is expressed on

TABLE 162-2
Adhesion Molecules

Adhesion Molecule	Expression	Ligand	Function
Selectins			
L-selectin (CD62L)	Leukocytes	Sialylated and fucosylated carbohydrates displayed on, for example, CD34, MAdCAM-1, or GlyCAM-1	Tether, rolling
E-selectin (CD62E)	EC	Sialylated Lewis X or A moieties such as CLA displayed on ESL-1, L-selectin or PSGL-1[58]	Tether, rolling
P-selectin (CD62P)	EC, platelets	Glycans and sulfated sialomucins displayed onPSGL-1[95]	Tether, rolling
Integrins			
LFA-1 ($\alpha_L\beta_2$ or CD11a/CD18)	Leukocytes	ICAM-1, ICAM-2[96]	Firm adhesion, diapedesis
Mac-1 ($\alpha_M\beta_2$ or CD11b/CD18)	Leukocytes	ICAM-1[96]	Firm adhesion, diapedesis
VLA-4 ($\alpha_4\beta_1$)	Monocytes, T cells, eosinophils, and basophils	VCAM-1	Firm adhesion
LPAM-1 ($\alpha_4\beta_7$)	Lymphocytes	VCAM-1, MAdCAM-1, fibronectin	Adhesion
$\alpha_1\beta_1$, $\alpha_2\beta_1$	EC	Collagens, laminins	Angiogenesis
$\alpha_V\beta_3$, $\alpha_V\beta_5$	EC	Fibronectin, vitronectin, fibrinogen, osteopontin, TSP	Angiogenesis
$\alpha_5\beta_1$	EC	Fibronectin	Angiogenesis
Junctional Proteins			
PECAM-1 (CD31)	EC, leukocytes	PECAM-1	Transmigration
CD99	EC, leukocytes	CD99	Transmigration
JAM-A, JAM-B, JAM-C	EC	Integrins	Transmigration
VE-cadherin	EC	E1 fragments of fibrin	Transmigration

CLA = cutaneous lymphocyte antigen; EC = endothelial cell; GlyCAM = glycosylation-dependent cell adhesion molecule; ICAM = intercellular adhesion molecule; JAM = junctional adhesion molecule; LFA = lymphocyte function-associated antigen; LPAM = lymphocyte Peyer patch adhesion molecule; MAdCAM = mucosal addressin cell adhesion molecule; PECAM = platelet/endothelial cell adhesion molecule; PSGL = P-selectin glycoprotein ligand; TSP = thrombospondin; VCAM = vascular adhesion molecule; VE-cadherin = vascular endothelial cadherin; VLA = very late antigen.

TABLE 162-3
Phenotype of Postcapillary Venules of the Superficial Vascular Plexus

Constitutive Markers in Normal Skin	Phenotypic Alterations in Acute Inflammation	Phenotypic Alterations in Chronic Inflammation
VWF	E-selectin (CD62E) low	E-selectin (CD62E) high
PECAM-1 (CD31)	P-selectin (CD62P)	P-selectin (CD62P)
CD34	VCAM-1 (CD106) low	VCAM-1 (CD106) high
VE-cadherin (CD144)	CXCR4 downregulated	MECA-79 reactive epitopes
N-cadherin PAL-E CXCR4 CD32 CCR10 low CD36 negative	CCR10 high	HECA-452 reactive epitopes

N-cadherin = neuronal cadherin; PECAM = platelet/endothelial cell adhesion molecule; PAL-E = pathologische anatomie Leiden-endothelium; VCAM = vascular adhesion molecule; VE-cadherin = vascular endothelial cadherin; vWF = von Willebrand factor.

endothelial cells and, under inflammatory conditions, binds hyaluronan, which then binds CD44 expressed on activated T lymphocytes and macrophages.[57]

Firm adhesion of leukocytes to ECs is generally mediated by leukocyte integrins. Leukocytes use two different types of integrins to interact with ECs. The first of these are the CD18 or β_2 integrins, including lymphocyte function-associated antigen-1 ($\alpha_L\beta_2$ or CD11a/CD18) and Mac-1 ($\alpha_M\beta_2$ or CD11b/CD18). The adhesion mediated by LFA-1 or Mac-1 recognition of intercellular adhesion molecule-1 (ICAM-1) is much stronger than that mediated by selectins, so that once these molecules have engaged ICAM-1, leukocytes no longer roll. In the case of neutrophils, integrin engagement results in a gradual slowing of rolling velocity. In contrast, lymphocytes abruptly convert from rolling to firm adhesion. Once adherent, leukocytes spread out and then slowly crawl along the EC surface until they reach a cell junction, where they undergo diapedesis through the vessel wall into the tissues (see Fig. 162-6). It is likely that LFA-1-mediated attachment, disengagement, and reattachment to ICAM-1 play a role in the spreading, crawling, and diapedesis of leukocytes. ICAM-1 is induced at slightly later times than E-selectin, but it remains elevated for days; it is initially (at 4 hours after treatment with TNF) upregulated diffusely on the luminal surface of the EC but then preferentially localizes to the intercellular junctions over the first few days.[6] Studies with blocking antibodies and in knockout mice confirm that β_2 integrins and ICAM-1 play a major role in leukocyte adhesion to ECs and in subsequent recruitment.

The second group of integrins on leukocytes that mediate attachment to ECs are the α_4 integrins (CD49d), which may pair with either β_1 (CD29) to form very late activation antigen-4 (VLA-4) ($\alpha_4\beta_1$) or with β_7 to form

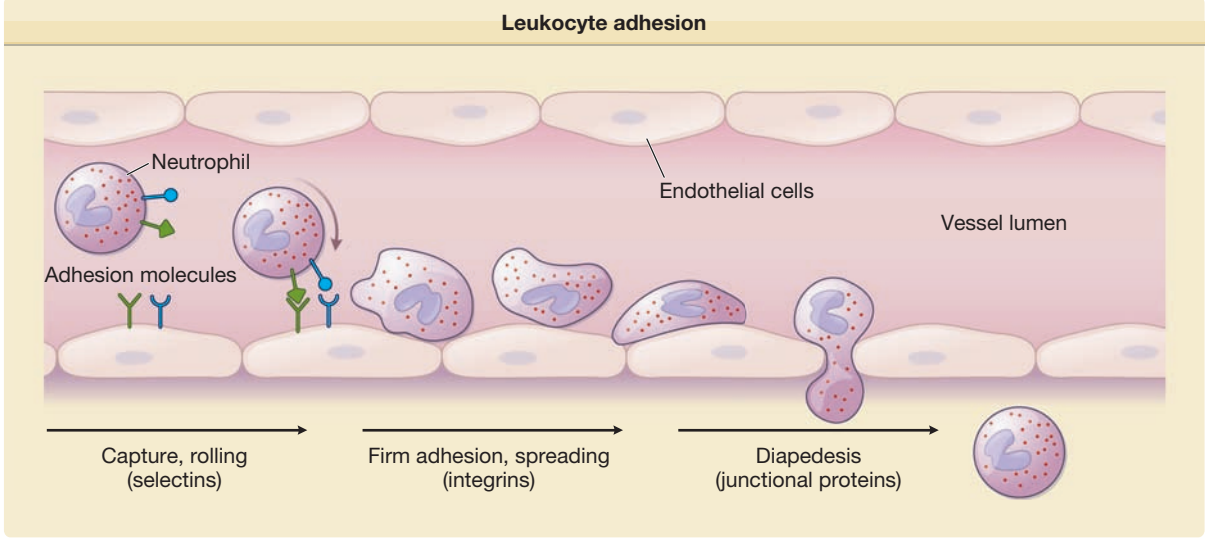

Figure 162-6 Leukocyte adhesion.

lymphocyte Peyer patch adhesion molecule-1 (LPAM-1) (integrin $\alpha_4\beta_7$). The principal EC ligand for VLA-4 is vascular adhesion molecule 1 (VCAM-1). This immunoglobulin superfamily member is not expressed on resting ECs under normal circumstances but is upregulated by TNF or IL-1 with a time course that peaks at about 24 hours. VCAM-1 may be selectively upregulated by IL-4, a cytokine associated with certain types of adaptive immunity, and IL-4 can act synergistically with TNF or IL-1. Although VCAM-1 expression is not responsive to interferon-γ (IFN-γ) itself, IFN-γ intensifies TNF-induced VCAM-1 expression.[60] Interestingly, VCAM-1 may support initial tethering and rolling of some leukocytes (e.g., of T cells but not of neutrophils), as well as firm adhesion, depending on whether the affinity/avidity of the leukocyte VLA-4 is increased by leukocyte activation. Antibody-blocking experiments confirm a role for these molecules in leukocyte recruitment in vivo.[61] True VCAM-1 knockout mice are embryonic lethals due to failure of placentation. Some VCAM-1 "knockouts" were made by disrupting the first exon. These animals make a truncated VCAM-1 protein, lacking the first Ig domain but express it at reduced ("hypomorphic") levels. These animals also confirm a role for VCAM-1 in leukocyte recruitment.

LEUKOCYTE ACTIVATION. TNF- or IL-1-treated ECs promote the activation of tethered or rolling leukocytes, triggering the transition from selectin-mediated low-affinity attachment to integrin-mediated firm adhesion and the transition from spherical, immotile leukocytes to spreading, migrating forms. In some experiments, engagement of selectins appears to be adequate by itself to trigger some of these changes, but most experiments indicate the requirement for a distinct signal. One candidate activator is the lipid mediator platelet-activating factor (PAF), which can be displayed in the EC plasma membrane. PAF synthesis is initiated by cytosolic phospholipase A2 activation, which is the same reaction that provides arachidonic acid for PGI_2 synthesis. It has been reported that IL-1β may promote PAF synthesis in ECs, but most studies emphasize the role of autacoids (e.g., histamine), rather than cytokines, as inducers of PAF synthesis.

The chemokines constitute an important group of TNF- or IL-1β-induced leukocyte activators that are defined by the presence and number of amino acids between two *N*-terminal cysteine residues (i.e., CC, CXC, etc.) (see Chapter 12). Chemokines induce migration and/or activation of various types of leukocytes through interaction with a group of seven transmembrane G protein-coupled receptors. The CXC chemokines (such as IL-8) are particularly important for neutrophil activation, and CC chemokines (such as MCP-1) are important for monocyte activation. IL-8 is stored in WPBs and released on stimulation with histamine or thrombin. Both IL-8 and MCP-1 are synthesized and secreted by TNF- or IL-1β-treated ECs. Furthermore, ECs can display their secreted chemokines in a complex with cell surface proteoglycans in a manner that renders them bioavailable to tethered or rolling leukocytes. The bound chemokines displayed by ECs could be made by ECs or could be captured and displayed once made by tissue cells or leukocytes. In addition, there is a transmembrane protein form of a chemokine called *fractalkine* that has its chemokine domain presented at the top of a mucinlike stalk. Fractalkine can be induced in vascular ECs and functions as an adhesion molecule. Accumulating evidence suggests that fractalkine mediates vascular injury in glomerulonephritis, allograft rejection, and atherosclerotic disease.[63–65] Chemokines may also play a role in activation and recruitment of specific lymphocyte subsets, as discussed later.

EXTRAVASATION OF LEUKOCYTES. The extravasation of leukocytes requires the preceding steps of tethering, rolling and adhesion followed by locomotion to junctions. Junctional proteins such as PECAM-1 (CD31), CD99 and junctional adhesion molecules (JAMs) contribute to leukocyte transmigration, and as noted earlier, activated ECs also concentrate adhesive ligands, such as E-selectin, ICAM-1, and VCAM-1, at these same junctions. The details of interaction between leukocytes and ECs during diapedesis in vivo are incompletely defined. The principal pathway for extravasation appears to be through the intercellular junctions (see Table 162-2). Antibodies to PECAM-1 and to CD99 inhibit this process. Of note, in PECAM-1 knockout mice, effects on leukocyte transmigration appear to be mouse strain specific. PECAM-1 at the border of endothelium forms homophilic interaction between PECAM-1 on leukocytes and triggers targeted recycling of membrane from a reticulum localized compartment close to the endothelial cell lateral border and is called lateral border recycling compartment. This compartment constitutively recycles and is mobilized to sites of junctions and surrounds the transmigrating leukocyte. This compartment also contains CD99 and JAM-1 but not VE-cadherin.[66] JAM proteins interact with leukocytes by binding to integrins. The integrin LFA-1 mediates neutrophil and T-cell adhesion to JAM-A; the integrin $\alpha_4\beta_1$ mediates leukocyte adhesion to JAM-B. JAM-2–$\alpha_4\beta_1$ interactions appear to be dependent on interactions between JAM-B and JAM-B. JAM-B binds to CD11b/CD18 on neutrophils, and this interaction is thought to be important for neutrophil transendothelial migration. It has been shown that VE-cadherin gap formation is required for leukocyte transmigration and p120 is a critical intracellular mediator of this process through its regulation of VE-cadherin expression at junctions.[67] In addition, VE-cadherin may interact with leukocytes through an interposed fragment of fibrin, which is formed through thrombin-induced fibrinogen activation followed by plasmin or urokinase digestion.[68]

In certain instances, leukocytes may extravasate through the EC body. The factors that determine whether leukocytes use the intercellular or transcellular pathway are unknown. The early stages of this process appear to involve phagocytosis of the leukocyte through membrane extensions enriched in ICAM-1 and VCAM-1. The transcellular diapedesis of monocytes and neutrophils also involves the lateral border recycling compartment within which PECAM-1, CD99

and JAM-A are the critically involved adhesion molecules. In addition, the rapid transmigration of T cells, but not other leukocyte subsets, appears to depend on the presence of venular levels of shear stress, which contribute by signaling to the T cell by "stretching" tethered adhesion molecules such as LFA-1. TNF- or IL-1-treated ECs secrete and activate matrix metalloproteinases (MMPs), which degrade the condensed region of connective tissue matrix, that is, the basement membrane that underlies the endothelial monolayer. ECs may also trigger leukocytes to synthesize or release MMPs, and the signals for this release may be cytokine-inducible molecules such as VCAM-1 or chemokines.[69]

T cells in the circulation are heterogeneous. Some have never encountered their cognate antigen and are said to be naïve. Memory T cells arise following encounters with antigen and may be divided into central memory and effector memory subpopulations. Effector memory $CD45RO^{+}$ $CCR7^{low}$ L-$selectin^{low}$ $CD4^{+}$ T cells transmigrate across endothelial monolayers in flow chambers in the presence of the IFN-γ-inducible protein-10 (IP-10) (CXCL10) whereas naive T cells or central memory T cells do not, despite the expression of CXCR3 on the latter cell type. In vitro assays established that the recognition of endothelial MHC class II by T cells blocks the response to IP-10 but causes delayed transendothelial migration of effector memory, but not of naïve or central memory $CD4^{(+)}$ T cells. Fractalkine, induced by TNF or IL-1 on microvessel EC, also contributes to the TCR-initiated response.[70] The TCR pathway also involves PECAM-1, which is not used by T cells responding to IP-10.

VASCULAR LEAKAGE AND PROVISIONAL MATRIX. Extravasation of plasma proteins into the tissue is a hallmark of inflammation. Autacoids such as histamine allow this to occur rapidly and transiently by causing ECs to contract their actin cytoskeleton, opening gaps between cells. VEGF may function similarly but also appears to have its primary effects on increasing fluid transit through vesiculovacuolar organelles. In contrast, TNF- or IL-1-treated ECs permit the nonspecific extravasation of fluid and plasma proteins, commonly called *vascular leak*, only after a delay of several hours in a process that depends on new protein synthesis. The loss of permselectivity (vascular leak) is a hallmark of inflammation. The principal purpose of this response is to allow plasma proteins, such as fibronectin and fibrinogen, to deposit in the tissues, where they form a provisional matrix that can be used by motile leukocytes. This is important because circulating leukocytes typically lack receptors that allow them to interact with the normal extracellular matrix, composed largely of interstitial collagens.

Collectively, these five TNF- or IL-1-mediated responses of ECs promote the development of an inflammatory infiltrate initially comprised of neutrophils and later of mononuclear phagocytes. The infiltrating leukocytes serve to phagocytose the eliciting microbes and clean up damaged tissue. Infiltrating phagocytes also can cause tissue damage through the same mediators and enzymes they use to eradicate microbes. These mechanisms can and often do injure local ECs, which is manifested by EC retraction and/or denudation and often accompanied by intravascular thrombosis. Intravascular thrombi exacerbate tissue ischemia and injury. Fortunately, TNF- or IL-1-treated ECs become more resistant to injury through expression of protective gene products such as detoxifying agents for reactive oxygen intermediates like manganese-superoxide dismutase and hemoxygenase, protease inhibitors like plasminogen activator inhibitor-1 and tissue inhibitors of metalloproteinases, and cytoprotective genes such as the zinc finger protein ubiquitinase/de-ubiquitinase enzyme A20 and Bcl-related antiapoptotic genes such as *A1*. These protective responses allow ECs to survive many inflammatory reactions without triggering thrombosis and consequent tissue infarction.

The acquisition of cytoprotective features has been observed in the ECs of organ grafts that have evaded transplant rejection.[71] However, these protective responses are not always adequate. Moreover, some other TNF- or IL-1-mediated endothelial responses, for example, induction of procoagulant proteins such as tissue factor coupled with loss of anticoagulant proteins such as thrombomodulin, may actually exacerbate tissue and vascular injury. This combination of neutrophil recruitment and alterations in the endothelial coagulation system may underlie the tissue injury seen in the local Shwartzman reaction or in Gram-negative septicemia.

In summary, ECs, through their responses to cytokines, can contribute to host defense reactions mediated by the innate immune system. However, these same effector mechanisms may lead to endothelial injury and exacerbate tissue damage.

ROLE OF ENDOTHELIUM IN ADAPTIVE IMMUNITY

ECs of microvessels constitutively express MHC molecules. To date, the only well-established function of class I and class II MHC molecules is to present peptides to T cells. Vascular ECs not only express MHC molecules but also express the proteins involved in generating peptides and loading these peptides into nascent class I and class II molecules.[72] The expression of class I genes (and the gene encoding the associated β_2-microglobulin molecule), as well as the proteins involved in peptide generation and class I MHC molecule peptide loading, are all upregulated by cytokines, particularly by IFNs, and by TNF.[73] Under basal culture conditions human ECs do not express class II MHC molecules or the proteins responsible for peptide loading of class II molecules, but these proteins are induced by IFN-γ. In humans, class II molecules are basally expressed on microvascular cells in vivo.[73,74] It is unclear whether this "constitutive" expression depends on low levels of circulating IFN-γ or is truly constitutive.

The typical diameter of a capillary lumen is less than 10 μm, i.e., narrower than the diameter of a circulating lymphocyte. Consequently, circulating T cells are

forced to encounter antigenic peptides complexed to both class I and class II MHC molecules displayed on the endothelial surface during the course of normal circulation. A key question is what effect this encounter has on the T cell. Studies of the consequences of T-cell recognition of antigen presented by ECs have largely used cell culture systems. Naive T cells ignore antigens presented by ECs whereas resting memory T cells or recently activated T blasts respond by cytokine gene expression and a limited degree of proliferation. This limitation correlates with the observation that human ECs are deficient in expressing certain costimulatory molecules, for example, CD80 and CD86, and primarily costimulate T cells with LFA-3 (CD58).[76] Naive T cells poorly express CD2, the receptor for LFA-3. Another factor may be that naive T cells lack the expression of adhesion molecules necessary to attach firmly to ECs. In addition to constitutive expression of LFA-3, human ECs display inducible expression of ligands for inducible T-cell costimulator, CD137, and CD134 that are typically associated with the stimulation or reactivation of memory T cells, as well as expression of molecules that inhibit T-cell activation, such as ligands for PD-1.[77–79]

Several nonexclusive roles have been proposed for presentation of antigen by ECs if it were to occur in vivo. The first is the maintenance of immunologic memory. Long-lived memory T cells may require periodic low-affinity signaling to survive, and the expression of MHC molecules bearing self-peptides by ECs may provide such low-affinity signals as these cells pass through the microcirculation. Recent data indicate that human blood ECs are able to present self-antigens in vivo[75], which may help sustain the viability of memory-cell populations. A second role might come into play when there is reinfection by a particular pathogen. In this case, ECs may present microbe-derived peptides in association with MHC molecules, providing an antigen-specific signal to circulating memory T cells that pathogen is present. This mechanism would contribute to the efficiency of immune surveillance. This is a potentially important function, because T cells specific for any one antigen, even among memory T cells expanded by prior encounter with antigen, are rare (less than 1 in 10,000–100,000). Presentation of antigen by ECs could markedly increase the likelihood that antigen is recognized in a timely manner and that memory T cells are recruited to sites of danger. A third possibility involves the postthymic induction and activation of $CD4^+25^+$forkhead box P3 regulatory T cells.[80] It has been shown that, in mice, alloantigen presentation by vascular ECs to $CD4^+$ T cells induces such regulatory T cells, which could be important for induction of tolerance. However, it must be noted that mouse ECs usually do not express class II MHC molecules in vivo and that cultured human T cells preferentially activate $CD4^+$ effector cells rather than regulatory T cells.

T cells may differentiate into specialized cytokine-producing subsets. For $CD4^+$ T cells, such responses may become polarized into T helper 1 (Th1, they produce IFN and lymphotoxin), or into T helper 2 (Th2, they produce IL-4 and IL-5). More recently, it has been appreciated that some effector $CD4^+$ T cells may selectively secrete IL-17, a proinflammatory cytokine. IL-17 producing helper T (Th17) cells bind via LFA-1 to ICAM-1, which is expressed on EC. IL-17 has been identified as an important proinflammatory mediator in various diseases like atopic dermatitis or bronchial asthma. In various models, IL-17 was also able to directly disrupt the blood–brain barrier as a direct effect of Th17 cells on ECs. Disruption of blood–brain barrier is an important step for the development of central nervous system inflammation as observed in diseases like multiple sclerosis.[81,82] On HUVEC, IL-17 induces expression of adhesion molecules like ICAM-1, VCAM-1, E-selectin[83] but the potency of IL-17 is markedly less than that of TNF or IL-1. Another subclass of specialized T cells, regulatory T cells (Treg; $CD4^+$/$CD25^+$/$FOXP3^+$) play an important role in inflammatory and neoplastic diseases.[84,85] ECs of tumor vessels express a specific addressin signature to guide Tregs into the tumor.[86]

Cytokines released by Th1 or Th2 cells may differentially shape EC activation patterns. For example, IFN-γ combined with lymphotoxin causes prolonged expression of E-selectin, an important ligand for Th1 T cells. Th1 cells, but not Th2 cells, are able to bind to P-selectin and E-selectin, and migration of Th1 cells into inflamed skin is blocked by antibodies against P- and E-selectin.[87] P-selectin glycoprotein ligand 1 appears to function as P- and E-selectin ligands for Th1 cells, which correlates with increased expression of the α_3-fucosyltransferases in Th1 cells.[87,88] In contrast, Th2-derived IL-4 increases VCAM-1 expression while suppressing E-selectin, a cell surface molecule that favors eosinophil and possibly also Th2-cell recruitment. In other words, T cell-derived cytokines may modify the innate EC responses in a way that biases leukocyte recruitment toward recruitment of specific effector cells. Finally, differential expression of chemokine receptors may also account for selective recruitment of T-cell subsets. For example, CCR5 and, to a lesser degree, CXCR3 are preferentially found on Th1 cells, whereas CCR4, CCR8, and, more controversially, CCR3 and CXCR4 are preferentially found on Th2 cells.

SKIN MICROVESSELS IN INFLAMMATION AND REPAIR

SKIN MICROVESSELS IN CUTANEOUS INFLAMMATION

It is clear that vascular ECs are important participants in the development of inflammatory responses and that ECs may be partially responsible for tissue-specific differences in inflammation. One mechanism by which vascular ECs may contribute to tissue-specific inflammatory patterns is through distinctive patterns of adhesion molecule expression, which results in selective recruitment and diapedesis of circulating leukocytes bearing the proper ligands. In the skin, E-selectin, VCAM-1, and ICAM-1 may be particularly important in this process, and they have

been extensively evaluated in normal and disease states[34,89–91] (see Table 162-3).

The induction of E-selectin appears to be particularly important in cutaneous inflammatory reactions. In addition to being readily inducible by cytokines and uniformly associated with leukocytic infiltration, E-selectin may play a role in the selective recruitment of lymphocytes to cutaneous sites of inflammation through binding to the cutaneous lymphocyte antigen (CLA).[92,93] CLA is a carbohydrate moiety on the surface of T cells closely related to sialylated Lewis X, which has homology to the core structure of P-selectin glycoprotein-1.[94] By using the identifying monoclonal antibody HECA-452, CLA has been found on 80% to 90% of skin infiltrating lymphocytes compared with 5% to 10% at other peripheral sites. CLA is also present on circulating precursor Langerhans cells and presumably plays a role in their eventual localization to the skin. The expression of E-selectin in cultured dermal microvascular ECs is relatively persistent compared to endothelium derived from other sources. This persistent expression of E-selectin in vivo has been proposed to be responsible for the preferential homing of CLA-positive lymphocytes to the skin. Work in a chimeric human mouse model of inflammation suggests that CLA-positive lymphocytes specifically migrate through the superficial, as opposed to the deep, vascular plexus.[95] It is unlikely that E-selectin–CLA interactions alone are sufficient to account for the homing of lymphocytes to the skin. The transmigration of CLA-positive lymphocytes across activated ECs is dependent on interactions with VCAM-1 and ICAM-1, in addition to E-selectin.

The induction of E-selectin on cutaneous microvessels also appears to play a role in immediate hypersensitivity reactions in atopic individuals. These reactions are characterized by an immunoglobulin E-dependent biphasic response. Within minutes after exposure, the relevant antigen cross-links immunoglobulin E, which is bound to the high-affinity FcRε receptors on the surface of mast cells, and results in histamine release. Histamine-dependent stimulation of ECs leads to vasodilation and increased vascular permeability, which produces the classic wheal-and-flare response that typically resolves within 30 to 90 minutes. This reaction, known as the *early-phase response*, is not accompanied by endothelial E-selectin upregulation or inflammatory cell recruitment. The late-phase reaction begins 3 to 4 hours after antigen challenge and is characterized by the infiltration of eosinophils, neutrophils, and mononuclear cells into the inflamed area. Granulocytes are most prominent at 6 to 8 hours, and, by 24 to 48 hours, the cellular infiltrate consists largely of mononuclear cells. The expression of E-selectin, which indicates endothelial activation, is detectable at the onset of infiltration. Although this E-selectin induction may simply be due to cytokine release from infiltrating inflammatory cells, there is evidence that the necessary mediators are first released from skin-resident cells. In skin organ culture, the addition of antigen either before or during the culture period results in significant E-selectin expression without inflammatory infiltrate.[96]

VCAM-1 may play a role in the specific homing of leukocytes to the skin through binding to the integrin $\alpha_4\beta_7$ on the surface of lymphocytes. This integrin is associated with the specific localization of lymphocytes to the gut through binding to mucosal addressin cell adhesion molecule 1 (Madcam-1) on ECs of intestinal microvessels.[91] Another ligand for $\alpha_4\beta_7$ includes fibronectin. $\alpha_4\beta_7$ has been found to be expressed on a high percentage of intraepidermal lymphocytes, particularly in cutaneous T-cell lymphoma (CTCL) and, to a lesser degree, in spongiotic dermatitis.[91] Interestingly, in CTCL, the expression of $\alpha_4\beta_7$ strongly correlated with the expression of integrin $\alpha_E\beta_7$. $\alpha_E\beta_7$ is also found on a high percentage of gut (intraepithelial) and intraepidermal lymphocytes.

In chronic inflammatory conditions such as psoriasis and CTCL, the cutaneous microvascular endothelium develops a "high endothelial venule" morphology similar to that seen in peripheral lymph nodes. This is accompanied by the expression of peripheral lymph node addressin identified by the antibody MECA-79, which serves as an L-selectin ligand. This has led to the speculation that peripheral node addressins in chronic T cell-mediated skin diseases are responsible for sustained lymphocyte recruitment. Interestingly, there is MECA-79 reactivity in the perifollicular vessels in non-inflamed skin.[97] This constitutive expression in normal skin may serve a function in continuous lymphocyte recirculation.[98]

Chemokines also play a role in the selective homing of T cells to the skin. CCR4 is expressed at high levels by CLA-positive memory T cells. The CCR4 receptor TARC is constitutively expressed on ECs in cutaneous postcapillary venules. In vitro TARC triggers CLA-positive T cells that are rolling on E-selectin to firmly adhere ICAM-1. Another skin-associated chemokine, CCL27 (cutaneous T cell-attracting chemokine), is produced by keratinocytes and also preferentially attracts CLA-positive memory T cells.[99]

NEW VESSEL FORMATION IN THE SKIN

DEFINITION OF ANGIOGENESIS AND VASCULOGENESIS.

In the healthy adult, blood vessels are stable structures with very slow turnover of ECs. In settings of chronic inflammation, tissue injury, or tumor growth, new vessels may be formed and existing vessels may undergo remodeling. Much of the process of vessel formation has been learned by the study of the formation of the vascular system during embryogenesis. In the embryo, ECs arise from angioblasts,[100,101] which migrate from their site of origin (initially blood islands, later liver, and ultimately bone marrow) to peripheral tissues, where they form primitive blood vessels (vasculogenesis). Subsequently, new blood vessels arise from preexisting ones (angiogenesis). Mesenchymal cells are then recruited into the vessel wall, where they subsequently differentiate into smooth muscle cells and pericytes, as part of a process called *vascular remodeling*. New vessels can be formed in the adult as part of chronic inflammation, as part of the repair of injured tissues or during tumor growth. In the adult,

new blood vessels develop through adult angiogenesis (sprouting from preexisting, mature blood vessels); it has been proposed that there may also be a contribution through recruitment of circulating endothelial progenitor cells, mesoangioblasts, and multipotent adult progenitor cells derived from the adult bone marrow (adult vasculogenesis).[102,103] However, it is unclear that such cells give rise to stable ECs and many such observations have now been reinterpreted to imply a role for monocytes that express EC markers, promote angiogenesis, and then disappear as the new vessels become stable. Stem cells and endothelial progenitor cells have been identified in vessel walls as resident cells. Such cells are thought to reside in a niche, awaiting appropriate stimuli like vessel injury to take part in the repair of damaged and the formation of new blood vessels. Among such vascular wall progenitor cells are $CD34^+/CD31^-$ cells that differentiate into endothelial cells.[108] Other resident vascular wall progenitor cells are smooth muscle-cell progenitors and mesenchymal stromal cells,[109] which may arise from PCs.

REGULATION OF ANGIOGENESIS AND VASCULOGENESIS. (Table 162-4). Molecules of the VEGF family, VEGF A through E, and their receptors, VEGFR-1 (Flt-1), VEGFR-2 (KDR or Flk-1), and VEGFR-3 (Flt-4), are required to initiate the formation of primitive vessels. Mice with a targeted disruption of *VEGF* or *VEGFR-2* genes fail to develop a vasculature. VEGFR-1 knockout mice have immature leaky vessels. Disruption of VEGFR-3 results in the disorganization of large vessels and lymphatic hypoplasia. A missense mutation in VEGFR-3 occurs in primary human lymphedema.[107,110,111] Fibroblast growth factors 1 and 2 (FGF-1 and FGF-2, also called *acidic* and *basic FGF*, respectively) mainly signal through FGF receptor I.[112] Knockout mice die before vasculogenesis starts; thus, specific evaluation of FGF function in vascular development is not possible in these animals. Both FGF-1 and FGF-2 are potent EC mitogens but they also act on SMCs, PCs and fibroblasts. FGFs "synergize" with VEGF in stimulation of cultured EC mitogenesis and in bioassays of angiogenesis. In the adult, FGF-1 and FGF-2 are stored in the cytoplasm of a variety of cells, which is consistent with the fact that these proteins lack the signal sequences required for efficient secretion. Stored FGFs are released when cells are injured, acting as "wound hormones" to stimulate local angiogenesis and connective tissue growth.[112] Other polypeptide factors have also been found to act on ECs in vivo and in vitro, including epidermal growth factor,[113] heparin-binding EGF-like growth

TABLE 162-4
Molecules Important in Vasculogenesis and Angiogenesis

Molecule	Function	Receptor
VEGF family ■ Five splice variants (VEGF A–E) ■ Homolog PlGF	Specific mitogen for ECs	Family of closely related receptor tyrosine kinases ■ VEGFR-1 (Flt-1) binds VEGF A and B, PlGF ■ VEGFR-2 (KDR or Flk-1), main mediator of VEGF-induced vascular development and angiogenesis, binds all isoforms of VEGF ■ VEGFR-3 (Flt-4) binds VEGF C and D
FGF-1 and FGF-2	Involved in vasculogenesis and angiogenesis in embryonic development	FGFR-I
Angiopoietins ■ Ang-1 ■ Ang-2 ■ Murine Ang-3 ■ Human Ang-4	Ang-1 positively affects vascular stability Ang-2 is a competitive inhibitor of Ang-1	Tie-1 and Tie-2 receptor tyrosine kinases ■ Tie-2 mediates dialog between primitive mesenchymal cells and EC of immature vessels ■ Tie-1 ligands not known
PDGF	Secreted by ECs, acts on mesenchymal cells to promote migration, matrix biosynthesis, and differentiation	Receptor tyrosine kinase
TGF-β	Secreted by ECs, acts on mesenchymal cells to promote migration, matrix biosynthesis, and differentiation	Protein serine/threonine kinase endoglin (CD105), important for vascular development
TSP-1	Antiangiogenic, inhibits MMP-9, activates TGF-β	Integrin $\alpha_v\beta_3$ CD36

Ang = angiopoietin; EC = endothelial cell; FGF = fibroblast growth factor; FGFR = fibroblast growth factor receptor; KDR = kinase insert domain protein receptor; MMP = matrix metalloproteinase; PDGF = platelet derived growth factor; PlGF = placental growth factor; TGF = transforming growth factor; TSP = thrombospondin; VEGF = vascular endothelial growth factor; VEGFR = vascular endothelial growth factor receptor.

factor,[114] and hepatocyte growth factor (HGF)/scatter factor (SF).[115] For vascular remodeling and stabilization, tyrosine kinase receptors 1 (Tie-1) and 2 (Tie-2; Tek) are required. Tie-2 mediates the dialogue between mesenchymal cells and the endothelium of the immature blood vessel through binding to angiopoietins (Ang-1, Ang-2, murine Ang-3, and its human ortholog Ang-4). In humans, Tie-2 mutations cause venous malformations typified by enlarged vascular channels lacking smooth muscle cells. Ang-2 appears to be a competitive inhibitor of Ang-1, and Ang-2 overexpression results in a phenotype resembling an Ang-1 knockout animal.[116] Ligands for Tie-1 are not known, but knockout of this receptor results in defective vascular maturation later in embryonic development.[107,117] The eph family of receptor tyrosine kinases (ephA1 to ephA8 and ephB1 to ephB6) and their corresponding ephrin ligands (ephrin-A1 to ephrin-A5 and ephrin-B1 to ephrin-B3) are membrane bound and appear to mediate bidirectional cell-to-cell signaling. Mice lacking ephrin-B2 and its ephB4 receptor have lethal defects in early angiogenic remodeling.[118] During vascular development ephrin-B2 marks the ECs of early arterial vessels and ephB4 marks the ECs of early veins.[119]

PDGF and TGF-β are secreted by ECs and promote migration of mesenchymal cells, matrix biosynthesis, and differentiation.[120] PDGF and TGF-β act through receptors equipped with tyrosine and serine/threonine kinase activities. TGF-β also uses nonsignaling receptors that present TGF-β to the signaling receptor, for example, endoglin (CD105). A truncation mutation in the *endoglin* gene in humans causes a hereditary form of vascular malformations (hereditary hemorrhagic telangiectasia type I),[121] and endoglin knockout mice die of defective vascular development.

Matrix glycoproteins such as fibronectin and laminin and receptors for matrix glycoproteins such as β_1 and β_3 integrins are also believed to play a role in vasculogenesis and angiogenesis.[122] This seems intuitive, because neither ECs nor mesenchymal cells can survive unless they interact with matrix proteins via integrin receptors. Knockout of most of these molecules causes early embryonic death, which prevents a direct test of their role in vascular embryology. An exception is the β_3-integrin knockout mouse, which shows normal development but enhanced tumor angiogenesis. Coagulation factors, like tissue factor or coagulation factor V, are implicated in vasculogenesis by observations of defective vascular development in knockout mice.[123] It is thought that these defects are an indirect result of defective thrombin production, because knockout of the thrombin receptor PAR-1 produces similar phenotypes.

CUTANEOUS ANGIOGENESIS AND VASCULOGENESIS. Cutaneous angiogenesis and vasculogenesis occur in wound healing, inflammation, and tumorigenesis. New vessel formation in the skin differs in several ways from that in other organs. Skin harbors hair follicles, which, besides having a role in forming hair shafts, appear to play a role in new vessel formation. The follicle contains a distinct population of presumptive follicular stem cells that express nestin, also a marker for neural stem cells. These nestin-expressing follicle cells are located in the follicular bulge region. During the follicular growth cycle, they differentiate into the various cell types of the hair follicle and, in addition, can form a variety of epidermal cells. It has been shown that these nestin-positive cells can also develop into cutaneous blood vessels that originate from hair follicles and form a follicle-linked vascular network. The quantitative contribution of hair follicle-derived angiogenesis compared with conventional angiogenesis through local sprouting is unknown.

Skin endothelium is also unique by virtue of its close proximity to keratinocytes, which form the overlying epidermis coating. Keratinocytes have been shown to express a wide range of angiogenic factors, including members of the fibroblast or TGF protein family, platelet PDGF, or VEGF.[124,125] Of note, not only ECs respond to VEGF, but also epithelial cancer cells possess receptors for and respond to VEGF.[126] Under conditions of injury, hypoxia, or inflammation, keratinocytes produce and release these growth factors. Concomitantly, VEGFR-2 is upregulated on ECs, which augments endothelial responses to VEGF.[127] Ang-1 and Ang-2 are also upregulated during injury, which is consistent with the role they are thought to play in the destabilization, followed by stabilization, of the vasculature. This allows a window for VEGF-mediated sprouting and elongation, followed by Ang-1-mediated remodeling.[68] FGF-2 is released in cutaneous wounds and is derived from ECs and from infiltrating macrophages. Antibodies against FGF-2 inhibit wound angiogenesis nearly completely.[128]

Adhesion molecules are necessary for physiologic angiogenesis in the skin. The expression of integrin $\alpha_V\beta_3$ on the tips of growing capillaries appears to facilitate endothelial migration and to be required for wound healing. In an in-vivo model in which human skin placed on immunodeficient mice was wounded, blocking antibodies directed to CD31 and VE-cadherin reduced wound vascularization and healing.[20] In a similar model, blocking antibodies directed against $\alpha_V\beta_3$ inhibited angiogenesis and wound healing.[129] Administering $\alpha_V\beta_3$ inhibitors reduce granulation tissue formation and wound-induced angiogenesis, which suggests that $\alpha_V\beta_3$ is required for proper wound healing. In contrast, mice lacking β_3 integrins show enhanced wound healing with complete reepithelialization several days earlier than do wild-type mice,[130] apparently due to an increase in TGF-β1 and enhanced dermal fibroblast infiltration into wounds of β_3-null mice. This suggests that the role of β_3 integrins is complex and that these molecules may influence both angiogenic and antiangiogenic effects.

Angiogenesis is also necessary in skin tumorigenesis to maintain adequate nutritive supply. Skin tumors are known to produce angiogenic factors such as VEGF, FGF-2, EGF, and HGF/SF.[131] Some of these growth factors play a role in the pathogenesis of both benign and malignant skin tumors. There is a significant vascular contribution to the growth and metastasis of cutaneous melanoma and increased number of vessels in primary melanomas compared with severely atypical nevi. This vascular proliferative response appears to

be in part mediated by FGF-2, which is produced by melanoma cells. Antisense oligonucleotides directed against FGF-2 inhibit the proliferation of both primary and metastatic melanoma.[132] HGF/SF and VEGF are also produced by melanoma cells and also contribute to vascularization. Peptide growth factors also appear to play a role in the pathogenesis of vascular tumors. The spindle cells of Kaposi sarcoma also produce large amounts of VEGF (see Chapter 128). When human ECs are cultured in the presence of HGF/SF, they acquire a Kaposi sarcoma cell-like morphology. In hemangiomas, high levels of FGF-2 and VEGF characterize the proliferative phase. However, there is also abundant FGF-2 expression in the involuting phase.

VASCULAR REMODELING IN THE SKIN. Vascular remodeling plays a role in the pathogenesis of some inflammatory skin diseases, notably psoriasis (see Chapter 18). Psoriatic vessels become tortuous and elongated, and the normally well-defined boundary between capillary ECs resting on an arteriole-like homogenous basement membrane and ECs on a venule-like laminated basement membrane becomes unclear. The intrapapillary portions of capillaries acquire a venular phenotype.[133] It is unknown whether this is due to metaplasia from arteriolar to a venular endothelium or to an elongation of the postcapillary venule. The first ultrastructurally visible alterations in eruptive guttate psoriasis lesions consist of gap formation within postcapillary venules, EC hypertrophy with a cuboidal shape similar to that seen in high endothelial venules, and compression of the vascular lumen, all of which precedes the invasion of inflammatory cells into the tissue.[133] This morphologic alteration is accompanied by altered endothelial function. For example, there is increased blood flow in perilesional psoriatic skin even in the absence of any microscopically detectable changes.[134] It has been suggested that these vascular alterations may, in part, be mediated by increased production of VEGF by keratinocytes. There is also increased expression of VEGFR-1 and VEGFR-2 on the papillary dermal microvascular ECs.[135] VEGF appears to directly upregulate expression of ICAM-1, VCAM-1, and E-selectin. The VEGF-mediated vascular leak and adhesion molecule upregulation can be inhibited by concurrent overexpression of Ang-1. The role of angiogenesis in inflammatory processes has been further exemplified by the anti-inflammatory effects of angiogenesis inhibitors.[136]

The skin is prone to frequent trauma. Therefore, vascular remodeling, angiogenesis, and vasculogenesis in the skin are most often caused by wound healing processes. Wound healing requires a complex interplay between resident cells (endothelial cells, fibroblasts, and smooth muscle-like cells), soluble mediators, infiltrating leukocytes, and extracellular matrix molecules.[137] The most important soluble factors in wound healing are members of the VEGF family of growth factors. VEGF acts as an EC mitogen, a regulator of vascular permeability, and a chemotactic agent.[138] VEGF in the wound healing situation is mainly produced by stromal fibroblasts. In situations where the VEGF production cannot be appropriately adjusted to the increased demands, as is the case in elderly or diabetic patients, vessel formation is strongly reduced and wound healing impaired.[139,140]

CONCLUSION

The skin vascular system is unique in several respects. It is organized into functionally distinct vascular segments: the loops within the tips of the papillae, the SVP and the DVP, and the subcutaneous vascular plexus. These segments may individually or conjointly respond to exogenous or endogenous stimuli, thereby influencing skin disease expression. Due to their proximity to the epidermis, ECs of the SVP may directly respond to keratinocyte-derived factors like cutaneous T cell-attracting chemokine or VEGF, which results in an altered vascular architecture, phenotype, and function. Moreover, skin EC may be directly exposed to environmental antigens. In this context, the constitutive expression of HLA class II molecules by postcapillary venules implies that ECs play a role in antigen presentation, which may increase the likelihood that antigen is recognized in a timely manner to efficiently recruit memory T cells to sites of danger.

KEY REFERENCES

Full reference list available at www.DIGM8.com

DVD contains references and additional content

1. Braverman IM: Ultrastructure and organization of the cutaneous microvasculature in normal and pathologic states. *J Invest Dermatol* **93**:2S-9S, 1989
2. Braverman IM, Yen A: Ultrastructure of the human dermal microcirculation. II. The capillary loops of the dermal papillae. *J Invest Dermatol* **68**:44-52, 1977

27. Beckers CM et al: Driving Rho GTPase activity in endothelial cells regulates barrier integrity. *Thromb Haemost* **103**:40-55, 2010
35. Febbraio M et al: CD36: A class B scavenger receptor involved in angiogenesis, atherosclerosis, inflammation, and lipid metabolism. *J Clin Invest* **108**:785-791, 2001
37. Groger M et al: IL-3 induces expression of lymphatic markers Prox-1 and podoplanin in human endothelial cells. *Journal of Immunology* **173**:7161, 2004
39. Kaipainen A et al: Expression of the fms-like tyrosine kinase 4 gene becomes restricted to lymphatic endothelium during development. *Proc Natl Acad Sci USA* **92**:3566, 1995
47. Dauphinee SM, Karsan A: Lipopolysaccharide signaling in endothelial cells. *Lab Invest* **86**:9-22, 2006
56. Springer TA: Adhesion receptors of the immune system. *Nature* **346**:425-434, 1990
63. Matsukawa A et al: Chemokines and innate immunity. *Rev Immunogenet* **2**:339-358, 2000
68. Petzelbauer P et al: The fibrin-derived peptide Bbeta15-42 protects the myocardium against ischemia-reperfusion injury. *Nat Med* **11**:298-304, 2005
93. Picker LJ et al: A unique phenotype of skin-associated lymphocytes in humans. Preferential expression of the HECA-452 epitope by benign and malignant T cells at cutaneous sites. *Am J Pathol* **136**:1053-1068, 1990

Chapter 163 :: Cutaneous Necrotizing Venulitis

:: Nicholas A. Soter

CUTANEOUS NECROTIZING VENULITIS AT A GLANCE

- Signature lesions are erythematous papules that do not blanch when the skin is pressed and are known as *palpable purpura.*
- Palpable purpura persists for 1 to 4 weeks and resolves at times with transient hyperpigmentation and/or atrophic scars.
- Macules, papules, urticaria/angioedema, pustules, vesicles, ulcers, necrosis, and livedo reticularis also may be present.
- May be characterized by episodes of recurrent and chronic urticaria and angioedema.
- Lesions may occur anywhere on the skin but are most common on the lower extremities or over dependent areas such as the back and gluteal regions.
- May be associated with connective-tissue diseases, notably rheumatoid arthritis, Sjögren syndrome, systemic lupus erythematous, and hypergammaglobulinemic purpura.
- There may be many precipitating causes but infections and drugs are most common.
- The most widely recognized subgroup of idiopathic cutaneous necrotizing vasculitis in children is Henoch–Schönlein purpura.
- Histopathologic criteria include necrosis of the blood vessels with the 'deposition of fibrinoid material and dermal cellular infiltrates that consist of neutrophils with nuclear debris, mononuclear cells, and extravasated erythrocytes.

Necrotizing angiitis or vasculitis comprises a diverse group of disorders that combine segmental inflammation with necrosis of the blood vessels. The vascular damage may result from immunologic and/or inflammatory mechanisms. Clinical syndromes are based on criteria that include the gross appearance and the histopathologic alterations of the vascular lesions, the caliber of the affected blood vessels, the frequency of involvement of specific organs, and laboratory abnormalities. Necrotizing vasculitis may be a primary disease, may develop as a feature of a systemic disorder, or may be idiopathic. There is no standard classification of the vasculitides; the American College of Rheumatology classification and the Chapel Hill consensus criteria are widely used.[1,2] These classifications are limited in clinical practice, owing to the lack of recognition of certain disorders, the overlap of clinical manifestations, and the lack of precision in the description of cutaneous features.

Necrotizing vasculitis in the skin predominantly involves venules and is known as *cutaneous necrotizing venulitis/vasculitis* (CNV), *cutaneous small-vessel vasculitis*, and *leukocytoclastic vasculitis.* The occurrence of CNV in association with systemic involvement of the small blood vessels has been termed *hypersensitivity angiitis/vasculitis, systemic polyangiitis,* and *microscopic polyangiitis* (see Chapter 164). CNV may be restricted to the skin, may occur in association with an underlying chronic disease, may be precipitated by infections or drugs, or may develop for unknown reasons (Table 163-1). Systemic forms of necrotizing vasculitis that affect larger blood vessels are considered in Chapter 164.

EPIDEMIOLOGY

The age of patients has a limited influence on CNV. An associated chronic disorder usually determines the age of the affected individual. CNV is most commonly described in children as Henoch–Schönlein purpura, with an incidence of 20/100,000 individuals less than age 17 in the United Kingdom.[3] CNV was the most common type of vasculitis presenting to a dermatology ambulatory department in India.[4] Antineutrophil cytoplasmic antibody (ANCA)-associated vasculitides are most common in patients older than 50 years of age. Geographic variations in vasculitis may reflect an environmental influence, and seasonal variations in the incidence of vasculitis may suggest an infectious etiology.[5]

ETIOLOGY AND PATHOGENESIS

Experimental studies in animal models and observations in humans implicate immune complexes as a major pathobiologic mechanism in the production of CNV. Data obtained in animal models suggest that the localization of immune complexes in venules is related to vasoactive amines and subsequent vasopermeability alterations. Additional factors that are operative in the localization of immune complexes include endothelial-cell surface receptors and the defective clearance of immune complexes by the reticuloendothelial system.

The most frequently postulated mechanisms in the production of CNV are the local deposition of circulating immune complexes that are formed during antigen excess or the formation of immune complexes in situ in the skin. Immune complexes may activate

TABLE 163-1
Cutaneous Necrotizing Venulitis

- Associated chronic disorders
  - Rheumatoid arthritis
  - Sjögren syndrome
  - Systemic lupus erythematosus
  - Hypergammaglobulinemic purpura
  - Paraneoplastic vasculitis
  - Cryoglobulinemia
  - Ulcerative colitis
  - Cystic fibrosis
  - Antineutrophil cytoplasmic or antiphospholipid antibody syndromes
- Precipitating events
  - Bacterial, viral, mycobacterial, and rickettsial infections
  - Therapeutic and diagnostic agents
- Idiopathic disorders
  - Henoch–Schönlein purpura
  - Acute hemorrhagic edema of infancy
  - Urticarial venulitis
  - Erythema elevatum diutinum
  - Nodular vasculitis
  - Livedoid vasculopathy
  - Genetic complement deficiencies
  - Eosinophilic vasculitis
  - Idiopathic

the complement system and lead to the generation of C5a anaphylatoxin that degranulates mast cells and attracts neutrophils, which release lysosomal enzymes that damage tissue. The neutrophil superoxide-generating system may produce reactive oxygen products, which also cause tissue injury. The generation of the chemoattractant leukotriene (LT) B_4 from infiltrating neutrophils enhances the influx of neutrophils. An infiltrate composed predominantly of neutrophils in the lesional skin of patients with CNV is consistent with tissue damage, which is induced by immune complexes that activate the complement system. The initial neutrophilic process contains few CD3, CD4, CD1a, and CD36 cells whereas these cells are prominent in the later phase, with the adhesion receptors intercellular adhesion molecule-1 (ICAM-1) and lymphocyte function-associated antigen-1 (LFA-1).[6] In Henoch–Schönlein purpura, the fragmentation of neutrophils was attributed to apoptosis on the basis of the detection of inducible nitric oxide synthase and nitrotyrosine in the infiltrates and the detection of interleukin-8 (IL-8) on vascular endothelial cells.[7] Long penetration PTX3, which inhibits phagocytosis of apoptotic neutrophils by macrophages, was detected in skin biopsy specimens of idiopathic CNV and of Henoch–Schönlein purpura about blood vessels and at sites of infiltrates with leukocytoclasia.[8]

In CNV, circulating immune complexes have been demonstrated in serum as mixed-type cryoglobulins and indirectly by assays that detect C1q precipitins, materials that bind to complement receptors on human lymphocytoid (Raji) cells, materials that bind to monoclonal rheumatoid factor, and substances that function in the antibody-dependent cellular cytotoxicity inhibition assay. The presence of immune complexes is inferred from the occurrence of serum hypocomplementemia with activation of the classic activating pathway and by the detection of increased plasma levels of C4a and C3a anaphylatoxins.

In CNV, immune complexes have been detected in lesional tissues by their ultrastructural observation as electron-dense subendothelial deposits; the membrane-attack complex, C5b-9, of the complement system has been detected on the surface of endothelial cells and infiltrating neutrophils. Decay-accelerating factor, a regulatory complement protein that prevents the assembly of the membrane-attack complex, was not present on the surface of endothelial cells of the superficial dermal microvasculature. Tissue immune complexes also have been detected by direct immunofluorescence techniques as deposited immunoglobulins and complement proteins. In time–course studies of the evolution of cutaneous vascular lesions, immune reactants have been identified in lesions that are less than 24 hours old. Antigens have been identified only in a few instances as bacterial, viral, mycobacterial, or rickettsial proteins by direct immunofluorescence techniques or by the polymerase chain reaction.

A role for lymphocytes, mononuclear cells, and Langerhans cells in the production of CNV is suggested by a perivenular infiltrate in skin lesions that is rich in lymphocytes with large and hyperchromatic nuclei and by a prominence of other types of mononuclear cells in the vascular skin lesions of patients with CNV and Sjögren syndrome. The lymphocytes express CD3, CD4, CD1a, CD36, ICAM-1, and LFA-1. Lymphocytes may be activated by immune complexes, by cellular immune mechanisms, and by primary activation in autoimmune disease to produce lymphokines. In cell-mediated immune responses in lymphocytic vasculitis, dendritic cells and lymphocytes contribute to the perpetuation of CNV.[9] In CNV, there were increased numbers of factor XIIIa+ derived dendrocytes, which are involved in antigen presentation to T cells.[10] Endothelial cells also can present antigens to and activate T lymphocytes. Activated macrophages secrete chemokines and lysosomal enzymes. γ/δ T cells have been detected in CNV with a neutrophil-rich pattern and with an infectious etiology.[11] In these specimens, a 72-kDa heat shock protein was expressed by endothelial cells and antigen-presenting cells.

The participation of mast cells in CNV is suggested by hypogranulated mast cells with shed extracellular granules and by the development of vascular lesions after the intracutaneous injection of histamine in patients with active episodes of CNV. Mast cells can be activated directly by immune complexes through FcγRIII or by C5a. Through the production of histamine, prostaglandin D_2, and cysteinyl LTs, the mast cell could alter venular permeability; interendothelial cell gaps have been noted in venules in patients with CNV. Eosinophils and neutrophils could be recruited by mast cell-derived chemotactic factors. The neutral proteases and acid hydrolases of mast cells may facilitate tissue damage, and the release of tumor necrosis factor-α (TNF-α) may increase expression of E-selectin on endothelial cells and facilitate neutrophil recruitment.

Evidence for the role of the mast cell also is provided by time–course analyses of the sequential histopathologic changes in individuals with physical urticaria. In a patient with circulating immune complexes and hypocomplementemia, in whom cold and trauma elicited CNV, initial mast cell degranulation was followed by the infiltration of neutrophils, the deposition of fibrin, and venular endothelial-cell necrosis. A postulated sequence of events would be the activation of the mast cell by physical stimuli, the release of vasoactive mediators, the deposition of circulating immune complexes with activation of the complement system, the influx of neutrophils, and the development of CNV.[12] Another example of the time–course analysis of CNV in human skin was provided by an individual with exercise-induced vasculitis.[13] At 3 hours, the number of mast cells decreased, and the eosinophil was the first cell to appear around the venules with the deposition of eosinophil peroxidase. TNF-α levels were elevated, E-selectin was expressed on endothelial cells, and an influx of neutrophils appeared with the deposition of neutrophil elastase and the development of CNV.

Early in the course of necrotizing venulitis, endothelial cells show increased expression of ICAM-1 and E-selectin without the expression of vascular cell adhesion molecule-1 (VCAM-1) in response to TNF-α (see Chapter 162). Because E-selectin is an adhesion molecule for neutrophils and for skin-homing, memory T lymphocytes, the increase in E-selectin is consistent with the appearance of an infiltrate of neutrophils that express CD11b within the first 24 hours.[14]

In the acute phase of Henoch–Schönein purpura, endothelin-1, serum insulin-like growth factor-1 (IGF-1), IGF-binding protein-3, plasma matrix metalloproteinase-9 (MMP-9), ICAM-1, VCAM-1, TNF- α, IL-I-β, IL-2 receptor, IL-6, IL-8, transforming growth factor-β, vascular endothelial-cell growth factor (VEGF), and urine leukotriene E4 levels were elevated,[15–20] and the interferon-γ-inducible protein 10 level was low.[21] However, the pathogenic roles of these mediators remain undefined. IgA antiendothelial cell antibodies bind to endothelial cells and enhance endothelial cell production of IL-8 via the mitogen-activated protein kinase (MEK)/extracellular signal-regulated kinase (ERK) pathway.[22]

In skin biopsy specimens from patients with idiopathic CNV, hypersensitivity vasculitis, urticarial vasculitis, and Henoch–Schönlein purpura, E-selectin was detected on endothelial cells of lesions that were less than 48 hours old and was associated with an infiltrate of neutrophils that expressed CD11b. The endothelial cells expressed human leukocyte antigen DR (HLA-DR) and very late activating antigen-1 but not P-selectin, and the perivascular cells expressed VCAM-1 and HLA-DR. Diminished cutaneous fibrinolytic activity with reduced release of plasminogen activator from venular endothelial cells occurs in patients with CNV; the subsequent reduction in fibrinolytic activity leads to fibrin deposition. Increased levels of plasma thrombomodulin, tissue-type plasminogen activator, and plasminogen activator inhibitor-1 were detected in patients with Henoch–Schönlein purpura.[23,24]

Cutaneous nerve fibers can release neuropeptides, such as substance P, neurokinin A, and calcitonin gene-related peptide (CGRP), that cause vasodilation (see Chapter 102). Substance P activates mast cells and macrophages and increases fibrinolytic activity that is mediated by plasminogen activator. CGRP induces expression of E-selectin on endothelial cells and is chemotactic for T lymphocytes.

Eosinophils are minor infiltrating cells in CNV except in eosinophilic vasculitis and drug-induced CNV.[25] Eosinophils produce LTC_4 and platelet-activating factor, which increase vascular permeability. Eosinophil granule proteins are toxic to endothelial cells and cause the release of mediators from mast cells.

Associations have been recognized between small-vessel necrotizing vasculitis and ANCAs, which have specificity for proteins of the cytoplasmic granules of neutrophils and the lysosomes of monocytes. Two forms are recognized: (1) cytoplasmic (c-ANCAs) that are directed against proteinase 3(PR3) and (2) perinuclear (p-ANCAs) that are directed against myeloperoxidase (MPO). TNF-α facilitates neutrophil activation and cell surface expression of PR3 and MPO, which bind to ANCAs and increase the adherence of neutrophils to endothelial cells resulting in endothelial cell injury. Antiendothelial-cell antibodies have been detected in the sera of patients with systemic vasculitis, rheumatoid arthritis with vasculitis, microscopic polyangiitis, and Sneddon syndrome.

An increased prevalence of the HLA haplotype HLA-A11, Bw35 in patients with CNV and associated connective-tissue disorders suggests that genetic factors may be operative. HLA-DRB1 genotype associations were detected in patients with CNV and Henoch–Schönlein purpura in Spain.[26]

CLINICAL FINDINGS

The skin lesions of CNV are polymorphous; however, erythematous papules that do not blanch when the skin is pressed, which are known as *palpable purpura*, are the signature lesions (Fig. 163-1A). Macules, papules, urticaria/angioedema, pustules, vesicles, hemorrhagic blisters (Fig. 163-1B), necrosis and ulcers (Fig. 163-1C), and livedo reticularis may be present. Occasionally, there is subcutaneous edema below the area of the dermal lesions.

The eruption most often appears on the lower extremities or over dependent areas, such as the back and gluteal regions. The lesions may occur anywhere on the skin but are uncommon on the face, palms, soles, and mucous membranes. The clinical lesions are episodic and may recur over weeks to years. Palpable purpura persists for 1 to 4 weeks and resolves at times with transient hyperpigmentation and/or atrophic scars. Lesional symptoms include pruritus or burning and, less commonly, pain.

An episode of cutaneous vascular lesions may be attended by fever, malaise, arthralgias, or myalgias irrespective of a defined underlying or associated disease. Systemic involvement of the small blood vessels most commonly occurs in the synovia, gastrointestinal

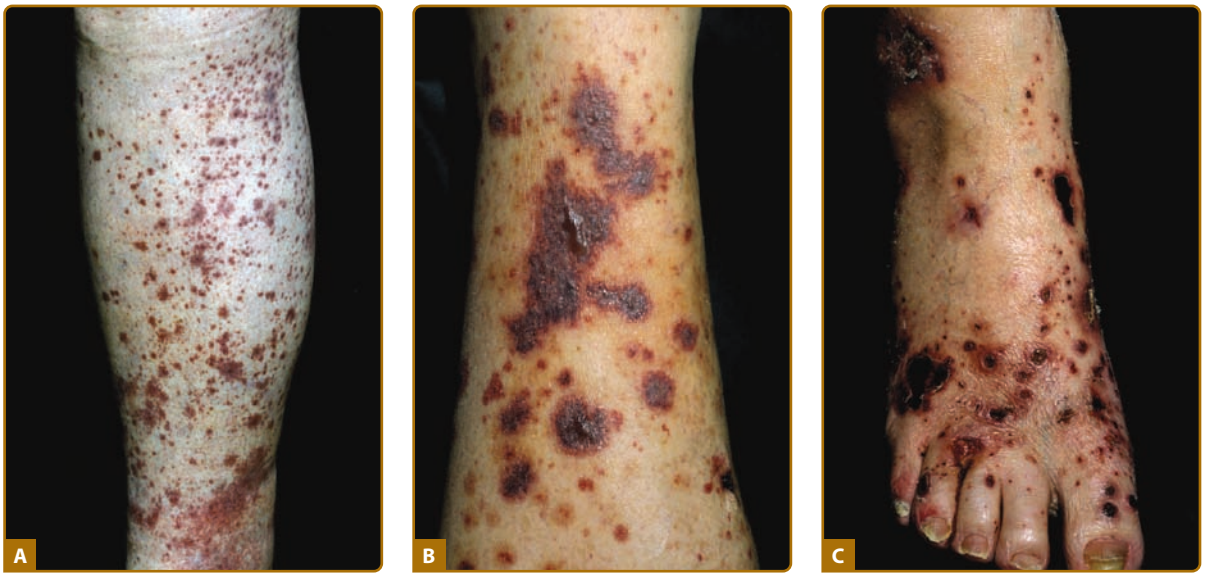

Figure 163-1 **A.** Palpable purpura on the lower leg in a patient with Henoch–Schönlein purpura. **B.** Palpable purpura with more severe tissue damage with hemorrhagic vesicles and bullae. **C.** With even more tissue damage, multiple necrosis, and ulcers.

tract, voluntary muscles, peripheral nerves, and kidneys.

ASSOCIATED CHRONIC DISORDERS

CNV is associated with connective-tissue diseases, notably rheumatoid arthritis, Sjögren syndrome, systemic lupus erythematosus (SLE), and hypergammaglobulinemic purpura. It rarely occurs in mixed connective-tissue disease, relapsing polychondritis, and scleroderma. In patients with rheumatoid arthritis and CNV, the development of vascular lesions is related to the severity of the disease, which is generally but not always seropositive, and the presence of anti-Ro antibodies. Subcutaneous nodules and cutaneous ulcers may be present. Patients with rheumatoid arthritis often have involvement of larger vessels with associated peripheral neuropathy, nail-fold infarcts, and digital gangrene.

In patients with SLE, CNV is a frequent manifestation[27] and is associated with exacerbations of the underlying disease. Patients with anti-Ro antibody have a greater risk for the development of CNV, with an Odds ratio 1.63.[28] Vasculitis, however, is rare in patients with subacute cutaneous lupus erythematosus. Some women with necrotizing vasculitis without connective-tissue disease have anti-Ro antibodies, and their infants may be born with neonatal lupus erythematosus.

In patients with Sjögren syndrome, the vascular lesions are located predominantly on the lower extremities and appear after exercise. Both hyperpigmentation and cutaneous ulcers are common features. Patients with Sjögren syndrome and CNV have a higher prevalence of articular involvement, peripheral neuropathy, Raynaud phenomenon, and renal involvement[29] as well as the presence of anti-Ro antibody. Hypergammaglobulinemic purpura occurs in older women and may be associated with Sjögren syndrome, SLE, or a lymphoproliferative disorder. Dermatomyositis in children, but not in adults, may be associated with vasculitis of the gastrointestinal tract.

Paraneoplastic vasculitis describes CNV with associated malignant conditions, which include Hodgkin lymphoma, lymphosarcoma, adult T-cell leukemia, mycosis fungoides, myelofibrosis, acute and chronic myelogenous forms of leukemia, B-cell chronic lymphocytic leukemia, multiple myeloma, IgA myeloma, diffuse large-cell leukemia, hairy-cell leukemia, squamous-cell bronchiogenic carcinoma, adenocarcinoma of the lung, prostatic carcinoma, renal carcinoma, bladder carcinoma, and colon carcinoma.[30] However, the association between CNV and neoplasia is rare. It is not necessary to evaluate all patients with CNV for associated malignant conditions.

Cryoglobulins (see Chapter 169), especially mixed types II and III, may be found in patients with idiopathic CNV and in patients with CNV that is associated with connective-tissue diseases, lymphoproliferative disorders, and hepatitis A, B, and C virus infections. Hepatitis C virus is the most common infection, especially when it is associated with cryoglobulinemia.[31,32] CNV occurs in patients with cystic fibrosis, inflammatory bowel diseases of the colon, and Behçet disease.[33]

ANCAs are associated with various forms of necrotizing vasculitis. ANCAs are present in patients with microscopic polyangiitis and cutaneous vasculitis with hepatitis C virus infection (see Chapter 164). The most common cutaneous feature in patients with ANCAs is palpable purpura. Microscopic polyangiitis is associated with small-vessel systemic vasculitis that involves the cutaneous venules and arterioles, the kidneys with necrotizing and crescentic glomerulonephritis,

the lungs with pulmonary hemorrhage or interstitial pneumonia, and p-ANCAs. Erythematous macules, purpura, and livedo reticularis are cutaneous manifestations in microscopic polyangiitis.[34,35] A male patient has experienced microscopic polyangiitis restricted to the skin and p-ANCAs for 20 years without progression to systemic vascular disease.[36] IgA ANCAs are present in acute Henoch–Schönlein purpura in children.

Anticardiolipin antibodies occur in patients with various forms of necrotizing vasculitis. IgA cardiolipin antibodies of the IgA class were detected in 6 of 10 patients with idiopathic CNV.[37] IgA anticardiolipin and IgA and IgM antiphosphatidyl serine–prothrombin complex antibody levels are elevated in adults with Henoch–Schönlein purpura and CNV that is restricted to the skin.[38] IgG and IgM anticardiolipin antibodies have been detected in some individuals with livedoid vasculitis.[39]

PRECIPITATING INFECTIONS AND DRUGS

Infections and drugs may precipitate episodes of CNV. The most commonly recognized infectious agents are β-hemolytic *Streptococcus*, *Staphylococcus aureus*, *Mycobacterium leprae,* and hepatitis B and C viruses. Transient episodes of urticaria may occur early in the course of hepatitis B virus infection and represent immune complex-induced vasculitis; episodes of palpable purpura may occur in patients with chronic active hepatitis. Cutaneous vasculitis has been recognized in a limited number of individuals with human immunodeficiency virus infection; the skin lesions consisted of palpable purpura, which at times had a follicular localization, and cutaneous ulcers.

Erythema nodosum leprosum (see Chapter 186), which appears as cutaneous nodules in lepromatous leprosy, is a form of necrotizing vasculitis that involves capillaries, venules, arterioles, small-to-medium-sized arteries, and veins. The vascular lesions occur spontaneously or are precipitated by the administration of chemotherapeutic agents. They may be accompanied by fever, malaise, arthralgias, lymphadenopathy, and polyneuritis.

Necrotizing vasculitis caused by the direct invasion of the blood-vessel wall occurs in septicemia due to *Neisseria meningitidis, Neisseria gonorrhoeae, Pseudomonas, Hemophilus influenzae*, rickettsia, candida, and infectious endocarditis; in Rocky Mountain spotted fever; and in infections localized at the site of a catheter.

Palpable purpura is one of the less common forms of drug reactions (see Chapter 41). The most commonly incriminated therapeutic agents were propylthiouracil, hydralazine, granulocyte colony-stimulating factor (G-CSF)/granulocyte-macrophage colony-stimulating factor (GM-CSF), allopurinol, cephaclor, minocycline, penicillamine, phenytoin, isotretinoin, and methotrexate in a Medline database search from 1965 to 1999.[40] Propylthiouracil[41] and hydralazine may cause vasculitis in association with ANCAs. Cutaneous vasculitis also has occurred after the administration of streptokinase, radiocontrast media, staphylococcal protein A column immunoadsorption therapy, drug additives, infliximab, etanercept, adalimumab, and rituximab.[42,43]

IDIOPATHIC DISORDERS

HENOCH–SCHÖNLEIN PURPURA. The most widely recognized subgroup of idiopathic CNV is Henoch–Schönlein purpura, which was formerly known as *anaphylactoid purpura*. It occurs predominantly in children, with a peak incidence at 5 to 6 years of age, but it may occur in adults.[44,45] Most cases occur in the autumn and winter and often are preceded by a history of a recent upper respiratory tract infections, especially with β-hemolytic *Streptococcus*, in up to 75% of individuals; however, Henoch–Schönlein syndrome has been associated with other infections.[46] Sites of involvement include the skin, synovia, gastrointestinal tract, and kidneys. Symptoms may include colicky abdominal pain, melena, arthralgia, and hematuria. Long-term morbidity from progressive renal disease depends on the degree of initial renal damage. The spread of purpura to the upper parts of the trunk is a predictive factor for renal involvement. Adults have a worse prognosis, owing to an increased risk of renal disease.

ACUTE HEMORRHAGIC EDEMA OF INFANCY. This uncommon disorder, which often goes unrecognized or has been confused with Henoch–Schönlein purpura, affects infants and children younger than 2 years of age. The lesions appear as painful, edematous petechiae and ecchymoses that affect the head and distal portions of the extremities. Facial edema may be the initial sign. The skin lesions may be associated with a target-like appearance and may develop bullae and necrosis. Infection, drugs, or immunization may be triggering factors. Acute hemorrhagic edema of infancy is distinguished from Henoch–Schönlein purpura by its occurrence in children aged 4 months to 2 years, by its lack of systemic features, and by its resolution within 1 to 3 weeks without sequelae.[47]

URTICARIAL VENULITIS. Episodes of recurrent and chronic urticaria and angioedema may be a clinical manifestation of CNV.[48,49] Known as *urticarial vasculitis/venulitis*, this edematous form of necrotizing venulitis occurs in patients with serum sickness, connective-tissue disorders, hematologic and other malignant conditions, an IgM_K M component, infections, and physical urticarias; after the administration of a variety of therapeutic agents; and as an idiopathic disorder. The term *hypocomplementemic urticarial vasculitis syndrome* (HUVS) has been used to describe patients with more severe systemic manifestations, hypocomplementemia, and an autoantibody to the collagen-like region of Clq.

The skin lesions appear as erythematous, occasionally indurated, wheals that may contain foci of purpura (Fig. 163-2; see Fig. 164-3 and Chapter 164). Other skin manifestations include angioedema,



Figure 163-2 Urticarial venulitis. Some of the wheals have been marked 24 hours previously to demonstrate persistent character of the urticaria.

macular erythema, livedo reticularis, nodules, and bullae. Although the individual urticarial lesions may last for fewer than 24 hours, they often persist for up to 3 to 5 days. The lesions are pruritic or possess a burning or painful quality; they usually resolve without residua although some individuals may develop contusions or hyperpigmentation. The episodes of urticaria are chronic, range in duration from months to years, and vary in frequency. Approximately 70% of affected individuals are women. The prevalence of this disorder remains unknown. General features include fever, malaise, and myalgia; the lymph nodes, liver, and spleen may be enlarged. Extracutaneous features involve the synovial, kidneys, gastrointestinal tract, lungs, eyes, heart, central nervous system, peripheral nerves, and blood vessels (Table 163-2). These extracutaneous features are more extensive in patients with HUVS.

The natural history of urticarial vasculitis is unknown although individuals have been described with historic episodes of cutaneous lesions for up to 25 years. In one series of patients followed for 1 year, 40% experienced complete resolution of skin lesions; in another series of individuals followed for as long as 14 years, resolution occurred in only one patient. Sjögren syndrome and SLE have developed. Deaths have been reported from pulmonary disease, sepsis, and myocardial infarction.

The prevalence of urticarial vasculitis in individuals with chronic idiopathic urticaria is unknown, although series have reported rates ranging from 1% to 50%. Most of these data have been reported from histopathologic studies in tertiary referral centers. The prevalence of urticarial vasculitis in a prospective clinical study in a university hospital in India was 11.4%.[50]

Necrotizing vasculitis of cutaneous venules has been described in isolated instances of dermographism, cold urticaria, delayed pressure urticaria, solar urticaria, and exercise-induced urticaria. However, the prevalence of necrotizing vasculitis in patients with physical urticaria is unknown, and the importance of this histopathologic finding for prognosis and therapy remains to be elucidated. Individuals with these physical urticarias have provided experimental models for time–course studies of the evolution of necrotizing vasculitis in human skin.

Schnitzler syndrome consists of episodes of urticarial vasculitis that occur in association with a monoclonal IgM_K M component. Associated features include fever, lymphadenopathy, hepatosplenomegaly, bone pain, a sensorimotor neuropathy, and renal failure. Evolution into hematologic malignant conditions has been reported in 15% of patients.[51]

TABLE 163-2
Extracutaneous Manifestations of Urticarial Venulitis

- General features
  - Fever
  - Malaise
  - Myalgia
- Specific organ involvement
  - Lymphadenopathy
  - Hepatosplenomegaly
  - Synovia (arthralgia, arthritis, Jaccoud arthropathy)
  - Kidneys (glomerulitis; glomerulonephritis with mesangioproliferative, membranoproliferative, or crescentic changes; interstitial nephritis; nephrotic syndrome; end-stage renal diseases)
  - Gastrointestinal tract (nausea, vomiting, pain, diarrhea)
  - Respiratory tract (laryngeal edema; dyspnea; chronic obstructive, restrictive, or interstitial pulmonary disease; emphysema; pulmonary hemosiderosis; tracheal stenosis; pleural effusion; pulmonary hemorrhage; vasculitis of the pulmonary venules)
  - Eyes (conjunctivitis, episcleritis, iridocyclitis, uveitis, vasculitis of the optic nerve and retina, blindness)
  - Central nervous system (headache, benign intracranial hypertension, seizures)
  - Peripheral nerves (neuropathy, cranial nerve paralysis)
  - Heart (arrhythmias, valvular heart disease, congestive heart failure, pericardial effusion, myocardial infarct)
  - Blood vessels (Raynaud phenomenon)

ERYTHEMA ELEVATUM DIUTINUM. Erythema elevatum diutinum occurs as symmetric, persistent, red–purple or red–brown plaques that are predominantly disposed over the joints of extensor surfaces and over the gluteal area (see Chapter 165).

NODULAR VASCULITIS. Nodular vasculitis (see Chapter 70) appears as tender, red, subcutaneous nodules over the lower extremities, especially the calves, without systemic manifestations (Fig. 163-3; see Fig. 70-5 and Chapter 70). At times, lesions develop on the thighs, buttocks, trunk, and arms, and ulcerated nodules may be present. Recurrent episodes are common. It is more common in women and has a peak incidence in individuals between 30 and 40 years of age. *Erythema induratum* is a form of nodular vasculitis, which has been



Figure 163-3 Nodular vasculitis with ulcers on lower legs (see Fig. 68-5).

associated with *Mycobacterium tuberculosis* infection, as demonstrated by polymerase chain reaction amplification for *M. tuberculosis* DNA in skin biopsy specimens.[52] Various sizes of blood vessels, which include venules, are affected.[53] Erythema induratum has been associated with hepatitis C virus infection.[54]

LIVEDOID VASCULOPATHY. Livedoid vasculopathy (Fig. 163-4), known also as *livedoid vasculitis*, *livedo vasculitis*, *segmental hyalinizing vasculitis*, and *atrophie blanche*, occurs as recurrent, painful ulcers of the lower extremities in association with a persistent livedo reticularis (*livedo racemosa*) that often is deep purple in color (see Fig. 164-11 and Chapter 164). Healing results in sclerotic pale areas that are surrounded by telangiectasias and designated atrophie blanche (Fig. 163-5). Many patients have arteriosclerosis or stasis of the lower extremities. Livedoid vasculitis is more common



Figure 163-4 Livedoid vasculitis with recurrent, painful ulcers and livedo reticularis.



Figure 163-5 Atrophie blanche over the medial malleolus with porcelain-white atrophy, telangiectases, and ulcers.

in women and may occur in patients with connective-tissue disorders, such as SLE, who develop central nervous system features; in malignant conditions; in hypercoagluable states; in thrombophilia; and as an idiopathic disorder. Protein C and S deficiencies,[55] factor V Leiden gene mutation, activated protein C resistance, prothrombin gene mutation, hyperhomocysteinemia, and antithrombin deficiency have been reported. Atrophie blanche, however, probably represents the end stage of a variety of forms of vascular damage in the skin (see Chapter 173). Elevated levels of fibrinopeptide A, homocystein, and plasminogen activator inhibitor[56] may occur in blood. Pathogenesis has focused on a hypercoagulable state with fibrin thrombi in the lumina of the superficial blood vessels. Some consider this condition to be a thrombogenic vasculopathy rather than a small-vessel vasculitis.[57] Antiphospholipid antibodies have been detected in a few individuals.[39]

Sneddon syndrome[58,59] is a condition in which livedo racemosa and livedoid vasculitis are associated with ischemic cerebrovascular lesions, hypotension, and extracerebral arterial and venous thromboses (see Fig. 173-9 in Chapter 173). Antiendothelial cell antibodies were detected in the serum in 35% of individuals; antiphospholipid antibodies, anti-β_2-glycoprotein antibodies, and antiprothrombin antibodies[60] were detected in some patients.

GENETIC COMPLEMENT DEFICIENCIES. Genetic C2 deficiency has been recognized in association with CNV in three children and in two siblings with HLA-A25, B18, DR2 (w15) haplotype. C4 deficiency was present in one child with CNV. Deficiencies of C4A and C4B isotypes were found in some children and adults with Henoch–Schönlein purpura. A partial C4B deficiency with C4 A1, A3, B1, and a null allele B*QO was reported in a 51-year-old woman with CNV.

EOSINOPHILIC VASCULITIS. Eosinophilic vasculitis has been described as an idiopathic syndrome in individuals with recurrent, pruritic, and purpuric papular skin lesions, urticarial plaques, and angioedema. Skin biopsy specimens showed an infiltrate composed of eosinophils expressing CD40[61] and VCAM-1 on endothelial cells of involved vessels. Eosinophilic vasculitis also has been described in some individuals with the hypereosinophilic syndrome (see Chapter 36) and in others with connective-tissue disorders.[62] There may be depressed complement levels, peripheral eosinophilia, elevated major basic protein levels, and a prolonged eosinophil survival time.

IDIOPATHIC. Individuals with CNV who do not meet the criteria for recognized syndromes are classified as idiopathic.

LABORATORY FINDINGS

The laboratory evaluation of patients with CNV depends on information obtained from the history and physical examination (Table 163-3). An elevated erythrocyte sedimentation rate is the most consistent abnormal laboratory finding. The platelet count is usually normal. Other abnormalities reflect either a coexistent chronic disorder or the involvement of additional organ systems. Occasionally, leukocytosis, anemia, thrombocytosis, an abnormal urine sediment, circulating immune complexes, rheumatoid factor, and antinuclear antibodies have been reported in idiopathic disease.

Serum complement levels are usually normal. Hypocomplementemia may develop in patients with concomitant connective-tissue diseases or cryoglobulinemia and reflects the associated disease or the composition of the cryoglobulin. Hypocomplementemia also occurs in some individuals with idiopathic CNV and in 40% of individuals with urticarial venulitis.

In patients with the HUVS, a low-molecular-weight 7s C1q precipitin, which has been identified as an IgG autoantibody against the collagen-like region of C1q, was detected. Autoantibodies to vascular endothelial cells were detected in patients with HUVS, in patients with SLE and urticarial vasculitis, and in patients with urticarial vasculitis alone.[63] In Henoch–Schönlein purpura, serum IgA1 levels are elevated, IgA ANCAs may be present, and urinary endothelin-1 levels may be elevated. In patients with CNV, various types of circulating immune complexes and IgA ANCAs[64] have been described. IgG autoantibodies to IgE and to FcεRIα also have been identified in some patients with urticarial venulitis.

TABLE 163-3
Laboratory Evaluation of Cutaneous Necrotizing Venulitis

- Erythrocyte sedimentation rate
- Complete blood count with differential analysis
- Platelet count
- Urinalysis
- 24-hour urine protein and creatinine clearance
- Blood chemistry profile
- Serum protein electrophoresis
- Immunoelectrophoresis
- Hepatitis B antigen and hepatitis A and C antibodies
- Cryoglobulins
- CH50
- Antinuclear antibody
- Rheumatoid factor
- Antineutrophil cytoplasmic antibodies
- Antiphospholipid antibodies
- Circulating immune complexes
- Stool guaiac test
- Skin biopsy

HISTOPATHOLOGY

In skin biopsy specimens of palpable purpura and urticarial vasculitis stained with hematoxylin and eosin (Fig. 163-6A), the histopathologic criteria requisite for

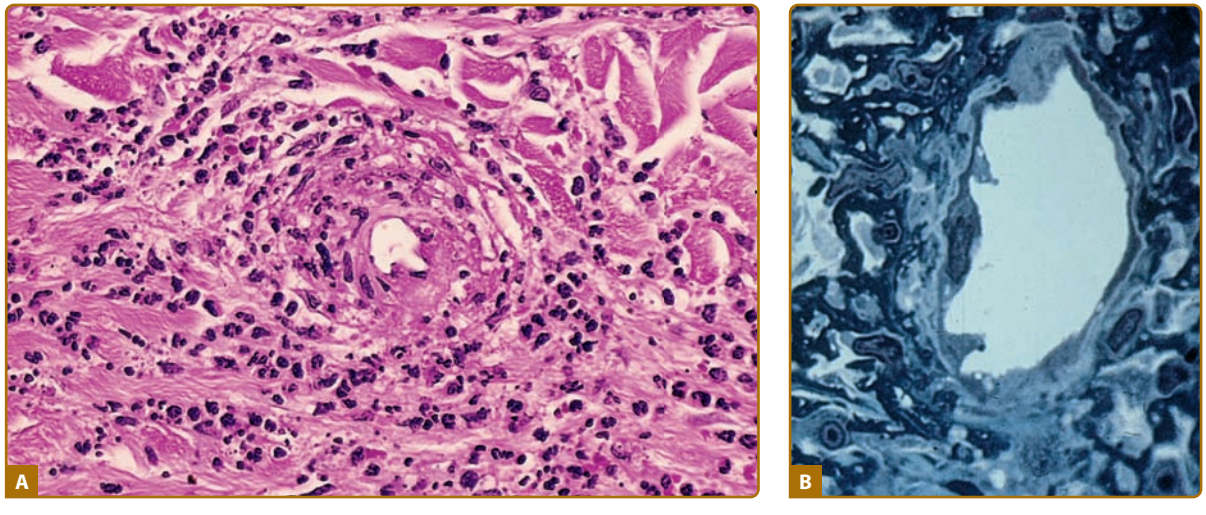

Figure 163-6 **A.** Perivenular infiltrate of neutrophils with fibrin deposition. (Hematoxylin and eosin stain, ×50 in the original magnification.) **B.** Endothelial-cell necrosis of a venule with perivenular fibrin and neutrophils. (1-µm section, Giemsa stain, ×1000 in the original magnification.)

the diagnosis of CNV include necrosis of the blood vessels with the deposition of fibrinoid material and dermal cellular infiltrates that consist of neutrophils with nuclear debris, mononuclear cells, and extravasated erythrocytes. The dermal inflammatory infiltrates vary in intensity and are usually perivenular in location, but at times they are dispersed widely. Some patients with connective-tissue disorders and cutaneous vasculitis have an infiltrate of inflammatory cells composed of eosinophils with deposited major basic protein and decreased numbers of mast cells.[62] Eosinophils may be present in increased numbers in drug-induced CNV.[25] The fibrinoid material consists of fibrin, necrotic endothelial cells, immunoreactants, and antigens.

Studies with 1-µm-thick sections (Fig. 164-6B) show two distinct cellular patterns in CNV: one rich in neutrophils and the other in lymphocytes.[65] The infiltrate of neutrophils regresses with the persistence of an infiltrate of mononuclear cells; repeat biopsy specimens in some patients consistently demonstrated an infiltrate of mononuclear cells. In a time–course study over 6 days of the evolution of experimentally induced CNV in a patient with physical urticarias,[12] the number of infiltrating neutrophils decreased without a concomitant increase in lymphocytes although the number of monocyte-macrophages was increased at 48 hours and 72 hours. Other features in both cell patterns of CNV include hypogranulated mast cells, macrophages containing debris, and the perivenular and interstitial deposition of fibrin. Venular alterations in both cell patterns consist of endothelial-cell swelling, activation of nuclei, wrinkling of nuclear membranes, necrosis (Fig. 163-6B), and basement-membrane reduplication and thickening. The arterioles are not affected.

By direct immunofluorescence techniques, fibrin deposition in venules is routinely identified in biopsy specimens, whereas the deposition of immunoglobulins and complement proteins varies widely. IgG is the most commonly deposited immunoglobulin although IgM and IgA also have been detected. IgA is deposited about blood vessels in the skin, intestines, and kidneys in Henoch–Schönlein purpura and has become an immunopathologic marker of this condition. In the skin in Henoch–Schönlein purpura, IgA1 is the dominant subclass deposited.[66] C3 is the only complement protein that has been sought with frequency in CNV.

DIFFERENTIAL DIAGNOSIS

Thrombocytopenia may result in purpura; however, these lesions are flat. Other causes of nonpalpable cutaneous purpura include local trauma to the skin of aged individuals with vascular fragility, chronic sun exposure, and endogenous or iatrogenic hypercorticism. Erythema elevatum diutinum may resemble Kaposi sarcoma (see Chapter 128) or multicentric reticulohistiocytosis (see Chapter 148). Scurvy may appear as hemorrhagic, follicular papules over the lower extremities. Various infectious agents may be associated with hemorrhagic skin lesions that arise from disseminated intravascular coagulation or septic emboli. The cutaneous manifestation of disseminated intravascular coagulation, which is known as *purpura fulminans,* appears as extensive areas of purpura with a slate-gray color (see Chapter 144). These lesions occur in patients with acute meningococcemia but also with Gram-positive coccal sepsis; skin biopsy specimens show thrombosis but not necrotizing venulitis. Septic emboli occur as finite numbers of hemorrhagic pustules, papules, and vesicles that are distributed over acral areas. Rarely, echo and coxsackievirus infections may cause purpuric papules. Rocky Mountain spotted fever typically begins as purpuric papules over the ankles and wrists that spread to include the trunk. Cholesterol embolization includes purpura, livedo reticularis, ulcers, and nodules. Calciphylaxis may appear as painful plaques with a reticulated or stellate pattern, induration, eschars, and ulcers.

The progressive pigmentary purpuric dermatoses (purpura simplex) (see Chapter 168), which include a number of disorders, appear as macular, petechial, pigmented, or lichenoid lesions.

The differential diagnosis of cutaneous nodules includes erythema nodosum, panniculitis, superficial forms of thrombophlebitis, fat necrosis associated with pancreatic disease, and systemic vasculitides, such as polyarteritis nodosa, granulomatosis with polyangiitis (Wegener's), and Churg–Strauss syndrome.

TREATMENT

Therapeutic approaches may be divided into removal of the antigen, treatment of an underlying disease, and treatment of CNV. Therapeutic approaches in the treatment of necrotizing vasculitis consist of prevention of the deposition of immune complexes, suppression of the inflammatory response, modulation of underlying immunopathologic mechanisms, and local therapy. When the eruption is associated with a precipitating event, withdrawal of the medication or treatment of the infection results in resolution of the cutaneous lesions. If a coexistent chronic disease is present, treatment of the underlying disease may be associated with improvement in the cutaneous vascular lesions. In many cases, CNV is a self-limited condition, and double-blind, placebo-controlled, prospective trials of therapeutic agents are usually lacking.

The treatment of CNV (Table 163-4) depends on an analysis of the cutaneous disability as well as on the toxicity and side effects of the therapeutic agents. H_1 antihistamines are used in patients with palpable purpura to alleviate lesional symptoms and perhaps to reduce tissue deposition of circulating immune complexes. Nonsteroidal anti-inflammatory agents are combined with the H_1 antihistamine. Depending on the therapeutic response, colchicine can be added to or substituted for these agents. However, colchicine was shown to have no significant therapeutic effect in a prospective, randomized, controlled trial. If there is no benefit, dapsone or hydroxychloroquine sulfate

TABLE 163-4
Treatment of Cutaneous Necrotizing Venulitis

- H_1 Antihistamines
- Nonsteroidal anti-inflammatory agents
- Colchicine
- Dapsone
- Hydroxychloroquine sulfate
- Systemic glucocorticoids
- Azathioprine
- Methotrexate
- Cyclosporin
- Mycophenolate mofetil
- Cyclophosphamide
- Intravenous gammaglobulin
- Plasmapheresis
- Infliximab
- Rituximab

can be used. If there still is no therapeutic response, a major decision must be made because the medications systemic glucocorticoids, azathioprine, methotrexate, cyclosporine, mycophenolate mofetil, cyclophosphamide, plasmapheresis, intravenous immunoglobulin,[67] infliximab,[68] and rituximab[69,70] are associated with serious side effects. Although all of these agents have been reported to benefit some patients, controlled clinical trials are not available. The administration of interferon-α is associated with clearing of cutaneous vasculitis in patients with hepatitis C virus infection.

The treatment of patients with urticarial vasculitis is similar to those with palpable purpura. Additional case reports exist on the treatment of patients with intramuscular gold therapy, cyclophosphamide-dexamethasone pulse therapy, mycophenolate mofetil,[71] thalidomide, anakinra, cinnarizine, and psoralen plus ultraviolet A (PUVA) photochemotherapy.

In patients with erythema elevatum diutinum, dapsone is the drug of choice. The treatment of nodular vasculitis consists of empiric trials of a variety of therapeutic agents that include a saturated solution of potassium iodide, nonsteroidal anti-inflammatory drugs, colchicine, and systemic glucocorticoids. Thalidomide is the treatment of choice for erythema nodosum leprosum.

In the treatment of livedoid vasculitis, support stockings are useful. Empiric trials of aspirin and dipyridamole, colchicine, dapsone, danazol, low-dose heparin, systemic glucocorticoids, nicotinic acid, low-molecular-weight dextran, phenformin and ethylestrenol, nifedipine, and pentoxifylline have been used. Infusions of prostacyclin, prostaglandin E_1, intravenous immunoglobulin, rituximab,[72] tissue plasminogen activator,[73] hyperbaric oxygen therapy,[74] and PUVA photochemotherapy have been used successfully in a few patients.

KEY REFERENCES

Full reference list available at www.DIGM8.com

DVD contains references and additional content

5. Watts RA et al: What is known about the epidemiology of the vasculitides? *Best Pract Res Clin Rheumatol* **19**:191, 2005
20. Yang Y-H et al: The immunobiology of Henoch-Schönlein purpura. *Autoimmun Rev* **7**:179, 2008
27. Ramos-Casals M et al: Vasculitis in systemic lupus erythematosus: Prevalence and clinical characteristics in 670 patients. *Medicine (Baltimore)* **85**:95, 2006
30. Solans-Laqué R et al: Paraneoplastic vasculitis in patients with solid tumors: Report of 15 cases. *J Rheumatol* **35**:294, 2008
40. ten Holder SM, Joy MS, Falk RJ: Cutaneous and systemic manifestations of drug-induced vasculitis. *Ann Pharmacother* **36**:130, 2002
43. Ramos-Casals M et al: Vasculitis induced by tumor necrosis factor-targeted therapies. *Curr Rheumatol Rep* **10**:442, 2008
44. Trapani S et al: Henoch Schönlein purpura in childhood: Epidemiological and clinical analysis of 150 cases over a 5-year period and review of literature. *Semin Arthritis Rheum* **35**:143, 2005
45. Diehl MP, Harrington T, Olenginski T: Elderly-onset Henoch Schonlein purpura: A case series and review of the literature. *J A Geriatr Soc* **56**:2157, 2008
48. Soter NA: Urticarial venulitis/vasculitis. In: *Urticaria and Angiodema*, edited by AP Kaplan, MW Greaves. New York, Informa Healthcare, 2009, p. 373
57. Khenifer S et al: Livedoid vasculopathy: Thrombotic or inflammatory disease? *Clin Exp Dermatol* **35**(7):693-698, 2010, epub 2009

Chapter 164 :: Systemic Necrotizing Arteritis

:: Peter A. Merkel & Paul A. Monach

SYSTEMIC VASCULITIS AT A GLANCE

- Heterogenous group of rare inflammatory conditions in which blood vessel walls are primarily targeted by an inflammatory reaction.
- Etiology unknown; geographic, environmental, and genetic factors may be important.
- Incidence up to 42 cases per million per year.
- Diagnosis often established in patients with multiple but variable organ involvement; supported by laboratory or radiologic studies and histologic evidence of inflammatory reaction in blood vessels.
- Cutaneous involvement can occur in any of the primary systemic vasculitic syndromes.
- Cutaneous features are often not sufficient to provide complete diagnosis and staging.
- Classification of the vasculitides is based on several factors including known etiology or disease association (primary vs. secondary forms), predominant size of involved vessels (small, medium, or large arteries), and additional clinical and laboratory data.
- Primary vasculitis is a diagnosis of exclusion after causes of secondary vascular inflammation have been ruled out.
- Determinants of prognosis and treatment include the specific vasculitic syndrome, whether critical organs are involved, the severity of involvement, and the rate of disease progression.
- Treatment often requires glucocorticoids and the use of other immunosuppressive drugs.

INTRODUCTION

The term "vasculitis" can be defined broadly to mean inflammation of blood vessels. However, from the perspective of the practicing clinician, "vasculitis" is most commonly used to describe a group of diseases in which inflammation of the blood vessels is the major, but not only, pathologic process. The vasculitides are a wide-ranging set of diseases that are mostly idiopathic, rare, and multisystemic. These diseases involve such a variety of clinical presentations and pathologies that all clinicians in every medical and surgical specialty will encounter such patients.

Vasculitis of the skin is a frequent manifestation in many forms of vasculitis, especially small- and medium-vessel arteritis where skin lesions may be the presenting symptom of a systemic illness.

This chapter will focus on skin disease in the systemic vasculitides. Isolated forms of skin vasculitis and some of the systemic vasculitides are covered in Chapter 163. In addition to outlining the skin manifestations of vasculitis in general and for specific types of vasculitis, this chapter will provide an approach to patients with skin disease in which vasculitis is a diagnostic consideration.

EPIDEMIOLOGY OF VASCULITIS

With the probable exception of drug/toxin-induced vasculitis, all forms of idiopathic vasculitis are considered rare, "orphan" diseases in the United States (prevalences of less than 200,000 people); similar designations exist in Europe and elsewhere.

Vasculitis occurs in people of both sexes, all ages, and all major racial/ethnic groups. However, some forms are more common in certain groups. For example, Takayasu arteritis is substantially more common in women than men, Kawasaki disease is almost exclusively a disease of young children, and giant cell arteritis is limited to older adults. Granulomatosis with polyangilis (GPA) mostly occurs in Caucasians and Behçet disease is markedly more common in countries in the Eastern Mediterranean as well as Japan and Korea. The demographic differences among the vasculitides are of scientific interest as clues to etiology and can be helpful diagnostically.[1] However, the epidemiologic tendencies are generally not so strong as to fully exclude the diagnosis of a specific form of vasculitis in any one person and exceptions to the typical epidemiology occur regularly.

CLASSIFICATION OF VASCULITIS

Multiple systems for classifying vasculitis exist, a situation that reflects a lack of clear understanding of the underlying pathophysiology and the overlap of clinical features among many types of vasculitis.[2–7] The most commonly accepted approach to classifying the vasculitides is to sort them by the size(s) of the predominant vessel involved (small, medium, or large) and then subdivide or group diseases, as appropriate (Fig. 164-1).

Classification criteria and definitions have been developed for many, but not all, specific types of vasculitis. These systems were designed for use in

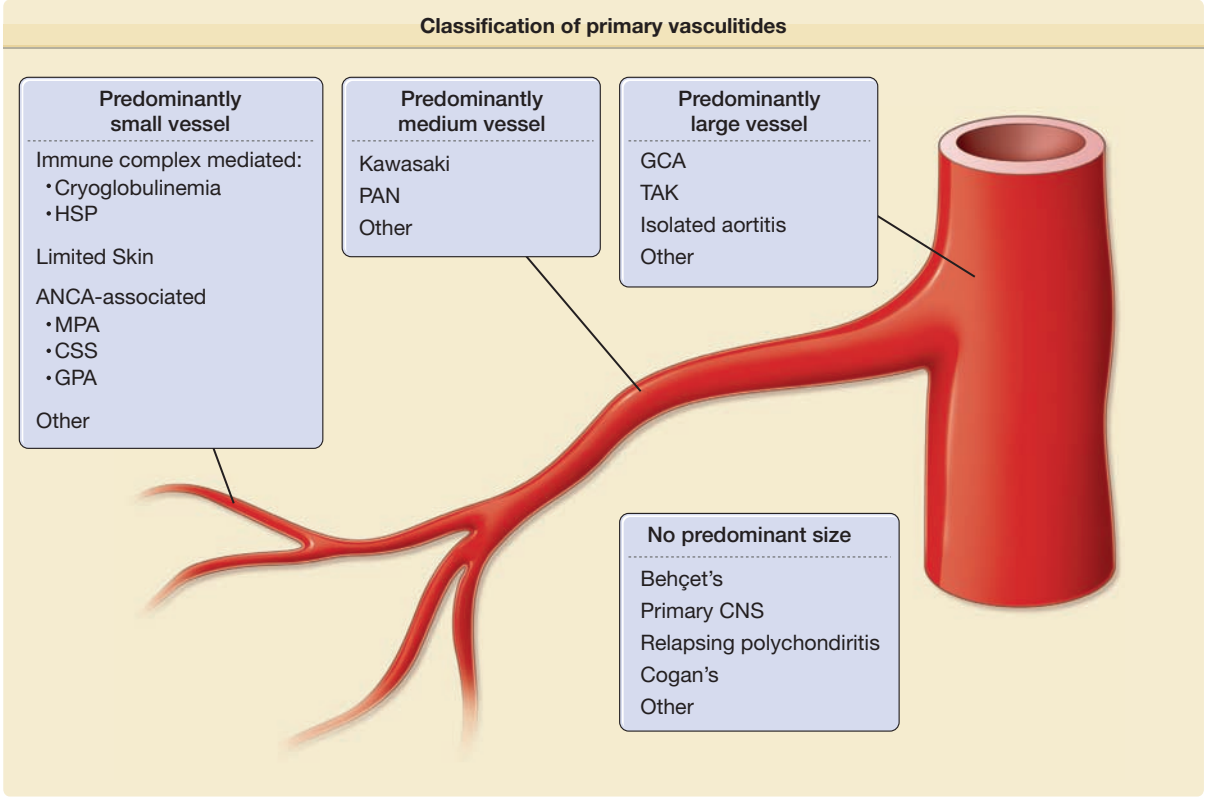

Figure 164-1 Classification of the primary vasculitides. ANCA = antineutrophil cytoplasmic antibodies; CSS = Churg–Strauss syndrome; GCA = giant cell arteritis; GPA = granulomatosis with polyangiitis (Wegener's); HSP = Henoch–Shönlein purpura; MPA = microscopic polyangiitis; PAN = polyarteritis nodosa; TAK = Takayasu's arteritis. (Redrawn from: Watts RA et al: Systemic vasculitis—Is it time to reclassify? *Rheumatology (Oxford)* Jul 20;2010.)

clinical research to create fairly homogenous study cohorts and were not meant to be used as "diagnostic" criteria.[3] Nonetheless, clinicians will find these criteria helpful. The most widely used criteria for vasculitis are from the classification criteria of the American College of Rheumatology[5–6] and the disease definitions of the Chapel Hill Consensus Conference.[7] However, these systems do not contain several forms of vasculitis, including some with frequent skin manifestations, such as Behçet disease and cryoglobulinemia, nor any "secondary" vasculitides (associated with another underlying disease such as systemic lupus erythematosus or an infection). Furthermore, some classes are no longer advised for use (e.g., "hypersensitivity vasculitis" is a term that has lost specific meaning). It should be emphasized that the term "leukocytoclastic vasculitis" does not refer to a specific disease but is a pathological description that often, but not always, applies to vasculitis in the skin or other organs. Similarly, "cutaneous vasculitis" is a vague name that could apply to any of several skin lesions seen in vasculitis and is not a distinct entity. There are also some separate sets of criteria for pediatric patients.[8]

A new international initiative is underway to reconsider the classification of the vasculitides and take into consideration data regarding the clinical and pathophysiological aspects of vasculitis not available when the prior systems were created; such new elements include testing for antineutrophil cytoplasmic autoantibodies (ANCA) and greater availability of advanced imaging techniques for large arterial disease.[3]

EVALUATION OF A PATIENT WITH POSSIBLE CUTANEOUS VASCULITIS

When a patient presents with skin lesions that are concerning for possible vasculitis, answers to three questions should be sought quickly:

1. Is the lesion due to vasculitis?
2. Are other organ systems involved in the illness?
3. Are there additional findings on medical interview, physical examination, laboratory testing, or radiographic imaging that can help establish a specific diagnosis?

   If a diagnosis of vasculitis is obtained, then it is imperative to ask two more questions:
4. Is it possible to make a diagnosis of a specific type of vasculitis for the patient?
5. Does the patient need immediate treatment and/or hospitalization?

A suggested approach to patients with skin lesions suspected of being due to vasculitis is shown in Fig. 164-2. The answer to the first question is often obtained by a skin biopsy, which is indicated in many cases of palpable purpura or other lesions when a diagnosis of vasculitis is not otherwise easily established. The second question is addressed by a thorough review of systems and physical exam and routine laboratory testing that can usually be completed rapidly. The third question is addressed

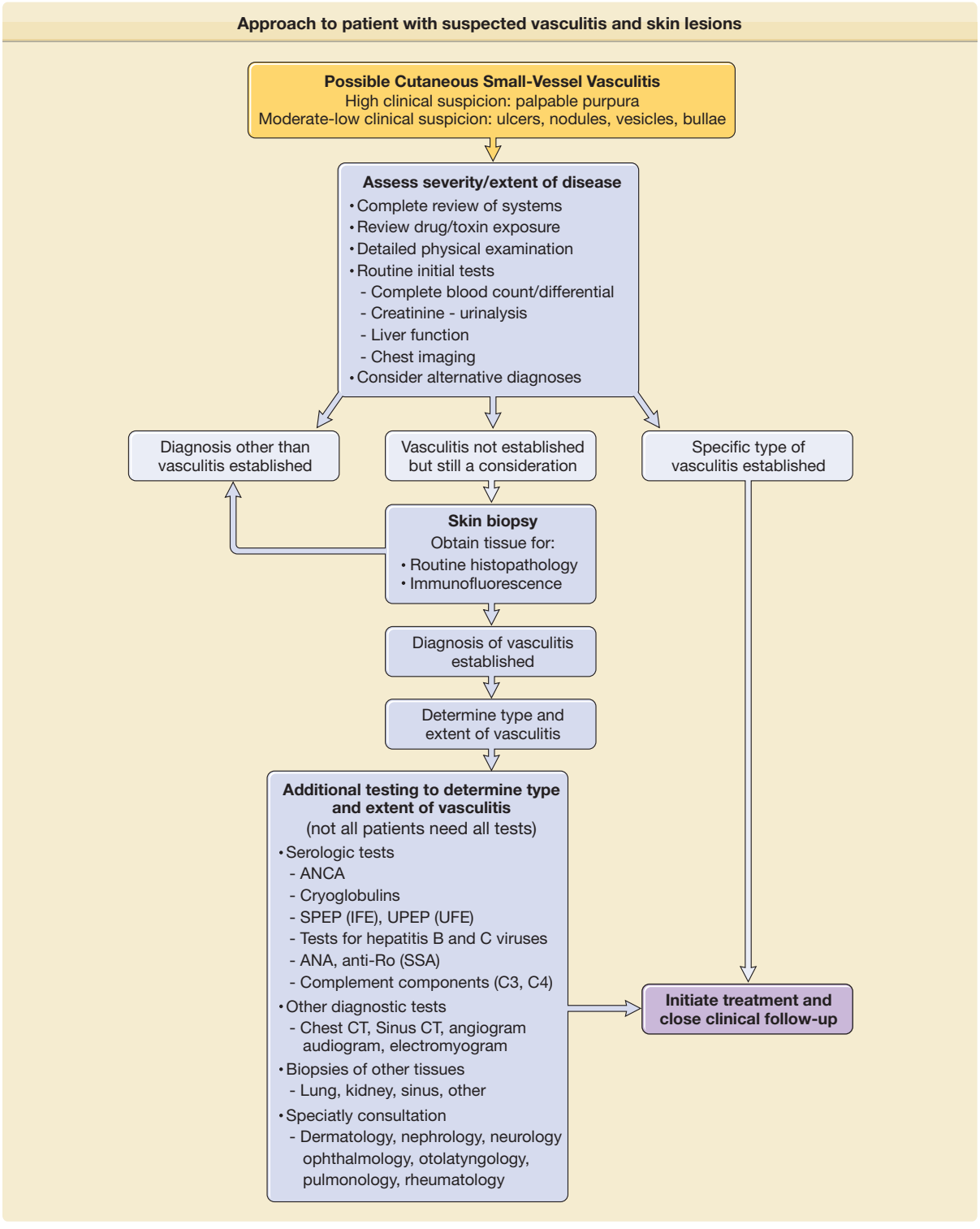

Figure 164-2 Approach to the patient with suspected vasculitis and skin lesions. ANCA = antineutrophil cytoplasmic antibodies; ANA = antinuclear antibodies; CT = computed tomography; IFE = immunofixation electrophoresis; SPEP = serum protein electrophoresis; SSA = susceptible *S. aureus*; UFE = uterine fibroid embolization; UPEP = urine protein electrophoresis.

by more specialized laboratory tests for which results typically take several days to return. It is important to quickly identify organ system involvement and how "sick" the patient is (or might soon be), since some causes of cutaneous vasculitis require no treatment, but others require immediate hospitalization for initiation of immunosuppressive and supportive therapy.

REVIEW OF SYSTEMS

A full review of systems with assessment of the overall severity of illness is the single most important component of the early evaluation of a patient suspected of having vasculitis. Together, the diseases that cause

TABLE 164-1
Major Signs, Symptoms, and Disease Processes of the Primary Vasculitides[a]

Organ System	Signs and Symptoms	Disease Process	Type of Vasculitis
General			
	Fever	Systemic inflammation	Many of the systemic vasculitides
	Fatigue/malaise,	Systemic inflammation	Most of the systemic vasculitides
	Weight loss	Systemic inflammation	Most of the systemic vasculitides
Eye			
	Red eye	Episcleritis, scleritis, uveitis, conjunctivitis	GPA, MPA, RPC, BD, others
	Acute visual loss or amaurosis fugax	Arterial insufficiency	GCA, TAK
	Proptosis	Orbital granuloma ("pseudotumor")	GPA
	Tearing	Dacrocystitis with lacrimal duct occlusion	GPA, CSS
Ear			
	Hearing loss	Sensorineural hearing loss	GPA, MPA, CSS, GCA
		Conductive hearing loss	GPA, CSS, RPC
	Ear pain and fullness	Mastoiditis and/or other inflammation of upper airway, auditory tube, middle ear	GPA, CSS
	External ear redness, tenderness, swelling	Chondritis	RPC, GPA, CSS
Nose and sinuses			
	Epistaxis, nasal crusting and discharge	Nasal mucosal inflammation	GPA, CSS
	Nasal bridge collapse (saddle nose deformity)	Nasal cartilage inflammation	GPA, RPC
	Nasal polyps	Eosinophilic nasal inflammation	CSS
	Facial pain/tooth pain	Sinusitis	GPA, CSS
	Anosmia	Olfactory epithelium/cells damage	GPA, CSS
Oral cavity			
	Painful oral ulcers	Aphthous ulcers	BD, GPA
	Gingival pain and swelling	Gingival inflammation	GPA
	Jaw claudication	Arterial insufficiency to muscles of mastication	GCA
Pulmonary			
	Hemoptysis	Alveolar hemorrhage	GPA, MPA
		Pulmonary artery rupture	BD
		Pulmonary embolus	GPA, MPA, CSS, BD
		Pulmonary nodules	GPA, CSS
		(See also causes of "Hemoptysis")	
	Dyspnea/cough	Pulmonary infiltrates	GPA, MPA, CSS
		Bronchitis/large airway collapse	GPA, RPC
		Pleuritis	GPA, CSS
		Subglottic stenosis	GPA, RPC
	Stridor/dyspnea	Asthma	CSS
	Wheezing	Large airway collapse	GPA, RPC
Cardiovascular			
	Angina	Coronary arteritis	TAK
	Congestive heart failure	Aortic root/valvular disease	TAK, GCA, BD, RPC
		Myocarditis	CSS, GPA
	Limb claudication	Aortic valve insufficiency	TAK, GCA
		Large artery stenosis	TAK, GCA
Gastrointestinal			
	Abdominal ischemic pain	Arterial insufficiency	PAN, HSP, GCA, TAK
	Lower GI bleeding	Muscoal ulcers or infarction	HSP, CSS, GPA, MPA, PAN
Renal			
	Gross hematuria	Renal infarction	PAN
		Glomerulonephritis (rare cause of gross hematuria)	GPA, MPA, CSS, HSP, Cryo

TABLE 164-1
Major Signs, Symptoms, and Disease Processes of the Primary Vasculitides[a] (Continued)

Organ System	Signs and Symptoms	Disease Process	Type of Vasculitis
Central nervous system	Headache, scalp tenderness	Cranial arteritis	GCA, TAK
	Lightheadedness/syncope	Arterial insufficiency to brain	GCA, TAK
	Cranial neuropathy	Inflammation of nerves; rarely mass lesion	GCA, GPA, MPA
Peripheral nervous system	Sensory/motor dysfunction	Inflammation of nerves; rarely mass lesion	CSS, GPA, MPA, PAN, Cryo
Musculoskeletal	Polyarthralgia	Polyarthritis	GPA, GCA, TAK, Cryo, HSP, BD
	Shoulder and hip girdle pain	Polymyalgia rheumatica	GCA
	Muscle weakness	Myositis	CSS
Skin	Purpura	Small-vessel vasculitis	GPA, MPA, CSS, PAN, HSP, Cryo
	Painful nodules, deep ulcers	Medium-vessel vasculitis	PAN, GPA, MPA, Cryo
	Digital ischemia/gangrene	Medium-large artery stenosis	GCA, TAK, PAN, GPA, MPA, Cryo
	Superficial nodules	Granulomas	GPA, CSS
	Papules, acne-like lesions	Papulopustular lesions	BD
	Painful, red nodules	Erythema nodosum	BD, TAK
	Peripheral edema	Deep vein thrombosis	GPA, MPA, CSS, BD

[a]This list is not inclusive of all manifestations for all diseases.
GPA = granulomatosis with polyangiitis (Wegener's), MPA = microscopic polyangiitis, CSS = Churg–Strauss syndrome, Cryo = cryoglobulinemic vasculitis, HSP = Henoch–Shönlein purpura; PAN = polyarteritis nodosa; BD = Behçet disease; RPC = relapsing polychondritis; GCA = giant cell arteritis; TAK = Takayasu's arteritis.

cutaneous vasculitis can affect all organ systems and, in most cases, that involvement will cause symptoms—renal disease being a prominent exception. Although some symptoms are clearly more concerning than others (hemoptysis vs. dry cough, painful red eye vs. mild arthralgias), even relatively mild symptoms can be a clue that disease is not limited to the skin. A list of important signs and symptoms of vasculitis is shown in Table 164-1.

PAST MEDICAL HISTORY, MEDICATION USE, AND EXPOSURES TO TOXINS OR INFECTIOUS DISEASES

It is critical to know the full medical history of any patient suspected of having vasculitis. Other diseases may either have vasculitis as a component of the illness (e.g., lupus) or may cause skin lesions that mimic vasculitis. Drug-induced vasculitis (DIV) is common and skin lesions, usually but not always purpura, are the most common manifestation of DIV.[9] The list of drugs reported to cause vasculitis is enormous with almost every class of medication implicated in possible cases of DIV. It is useful to ask about prescription, nonprescription, and "alternative" or herbal mediation use in the prior 6–12 months since the effect of some medications may persist after usage ends. Patients should also be asked about use of illegal or recreational drugs since several such agents, including methamphetamines, cocaine, and others have been implicated in cases of vasculitis. Occupational or other exposure to nondrug toxins should be asked about.

The patient should be asked about not only usual signs and symptoms of infection, but also recent travel, contacts with sick individuals, and risks for sexually transmitted diseases.

PHYSICAL EXAMINATION

Beyond a careful and full assessment of the skin, a multisystem examination is useful to determine whether symptoms are associated with objective abnormalities, or whether there are findings that a patient has not noticed. Vital signs are essential, but a patient with normal blood pressure can still have severe glomerulonephritis. The eyes should be inspected for redness and proptosis. The anterior nasal cavity can be easily visualized with an otoscope. Evidence of lymphadenopathy should be sought. Cardiac, lung, and abdominal examinations can give clues to underlying disease, but normal examinations do not rule out pathology. Similarly, absent pulses, asymmetric blood pressure readings, and bruits are helpful but imperfect measures to screen for large-vessel vasculitis. A complete joint examination is important and any findings suggestive of synovitis (joint swelling, warmth, redness) must be further investigated; however, many patients with vasculitis will have arthralgias without joint effusions. A full neurological examination is one of the most valuable components of the evaluation and

triage of a patient suspected of having vasculitis; subtle sensory and even motor abnormalities may be missed on initial evaluation.

The more detailed and expert examinations that can be performed by ophthalmologists and otolaryngologists are often extremely helpful in evaluating patients suspected of having vasculitis. Urgent referral is often indicated in patients with concerning symptoms such as new visual impairment, painful or red eyes, hoarseness or stridor, or hearing loss.

DIAGNOSTIC TESTING FOR SUSPECTED VASCULITIS

Given the broad range of entities that fall under the category "vasculitis", and the even larger number of diseases that are also reasonably considered when evaluating a patient suspected of having vasculitis, a vast number and range of diagnostic tests are often considered in such cases. However, obtaining a thorough medical history and conducting a detailed physical examination should enable the clinician to limit the types of vasculitis under consideration and prioritize the ordering of diagnostic tests. Not all tests need be ordered for all patients suspected of having vasculitis. This approach must of course be balanced by the possibility of atypical presentations of vasculitis as well as a range of infections, malignancies, and other diseases in the differential diagnosis of such patients. Evaluation for possible vasculitis usually occurs in parallel to evaluation for other processes.

SKIN BIOPSY. The method for diagnosing vasculitis depends on the type of vasculitis suspected, which is often based on the size of vessel involved. Vasculitides affecting the skin usually involve small- and medium-sized vessels and these vessels are amenable to biopsy (Fig. 164-3). Given the ease and low risk of skin biopsies, they play an important role in diagnosing vasculitis, and an equally important role in establishing a diagnosis other than vasculitis. A standard punch biopsy is sufficient to diagnose small-vessel vasculitis but a deeper and wider excision may be necessary to capture information on medium-sized vessels.[10,11] Lesions that should be approached with a deeper biopsy include subcutaneous nodules, livedo reticularis, or deep ulcers (Fig. 164-4). Many types of small-vessel vasculitis may also involve medium-sized skin vessels. It is important to realize that the difference between "small" and "medium" vessels is somewhat subjective and skin pathologists make such distinctions more often than might other pathologists who see larger biopsy specimens.

Sometimes the presence of a typical clinical syndrome makes biopsy unnecessary. For example, Henoch–Schönlein purpura in children is often



Figure 164-3 Different skin manifestations of systemic vasculitis. **A.** Purpura. **B.** Bullae. **C.** Ulcer.

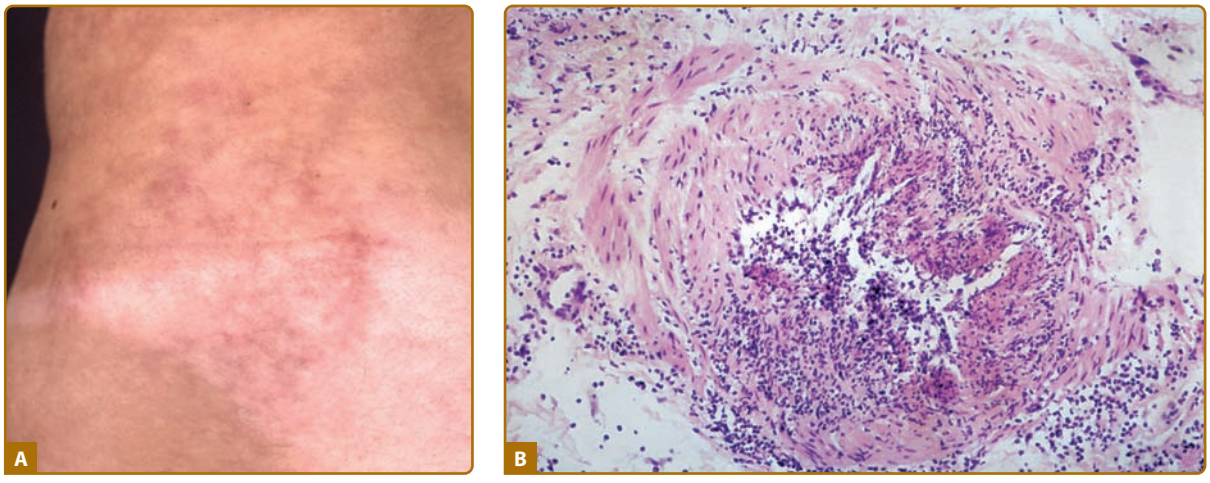

Figure 164-4 **A.** A patient with polyarteritis nodosa with "starburst" livedo made up of a cluster of nodular lesions. **B.** Histopathology of skin lesions in polyarteritis nodosa showing segmental necrotizing arteritis.

diagnosed on clinical grounds alone and some cases of ANCA-associated or cryoglobulinemic vasculitis can be diagnosed confidently by combining clinical features with specific serologic tests. Behçet disease and Kawasaki disease are diagnosed based on the clinical syndromes; biopsy is usually not performed on the skin lesions that are common in these diseases, and such biopsies are often nondiagnostic.

It is generally recommended to biopsy a skin lesion that has been clinically apparent for less than 48 hours, if possible, to maximize the chance of finding the typical features of acute neutrophilic vasculitis, including fibrinoid necrosis, extravasation of erythrocytes, extravasation of neutrophils with release of nuclear debris (leukocytoclasia), and the presence of immune deposits.[10,11] Processing of tissue is different for conventional histopathology or immunofluorescence testing; if immunofluorescence is desired, then either two specimens need to be obtained, or a single specimen needs to be divided before processing. The latter approach may however damage the tissue.[10]

As discussed throughout this chapter, the histologic finding of leukocytoclastic vasculitis is helpful in confirming the diagnosis of vasculitis but does nothing to establish an etiology from among the broad number of possibilities. Microscopy sometimes reveals features that are suggestive but not diagnostic of vasculitis, such as leukocytoclasia without fibrinoid necrosis. The finding of a perivascular infiltrate, particularly if it consists predominantly of mononuclear cells but even if it is neutrophilic, is also nonspecific. Certain features, when seen in addition to leukocytoclastic vasculitis, are strongly suggestive of particular diseases, such as extravascular granulomas with geographic necrosis (GPA), or eosinophil-rich extravascular granulomas (Churg–Strauss syndrome; CSS),[12] but these features are seen in a minority of biopsies in these diseases.

A predominance of IgA over IgG/IgM by immunofluorescence is suggestive but not diagnostic of Henoch–Schönlein purpura. The presence of deposits of IgG, IgM, and/or complement is suggestive of one of several immune-complex-mediated etiologies, including drug hypersensitivity, postinfectious vasculitis, cryoglobulinemia, and vasculitis secondary to systemic lupus erythematosus, Sjögren syndrome, or rheumatoid arthritis.[12]

OTHER BIOPSIES. Vasculitis is often diagnosed by biopsy of other organs, such as kidney, lung, muscle, or peripheral nerve or even from surgical specimens (Fig. 164-5). Kidney or lung biopsies are more likely than skin biopsies to show pathology diagnostic of a particular disease. Nonetheless, a skin biopsy establishing the diagnosis of vasculitis may preclude the need for more invasive biopsies.

LABORATORY TESTING. Although individual laboratory tests on their own are almost never diagnostic for vasculitis, such tests are essential in the evaluation of a patient in whom cutaneous vasculitis is being considered. Laboratory testing may identify organ systems involved in the disease process, especially renal disease. Furthermore, in the proper setting, selected serologic tests may establish an etiology for vasculitis. However, serologic tests usually complement rather than substitute for biopsy, particularly in a patient with skin lesions that can be readily biopsied.

Tests of Renal Function. Tests for renal disease are the most important laboratory tests to order in evaluating a patient suspected of having vasculitis since renal disease is common in many vasculitides and is rarely accompanied by signs or symptoms until end-stage renal failure occurs. Urinalysis, including both dipstick and microscopic examinations, should be performed on all patients in whom vasculitis is suspected, and repeatedly in patients in whom vasculitis of small- or medium-sized vessels is established in another organ system. The presence of any blood on the routine dipstick tests needs to be followed by an examination for red blood cell casts by someone specifically trained to look for casts (many nephrologists, some rheumatologists, but few laboratory technicians in North America). Measurement of serum creatinine

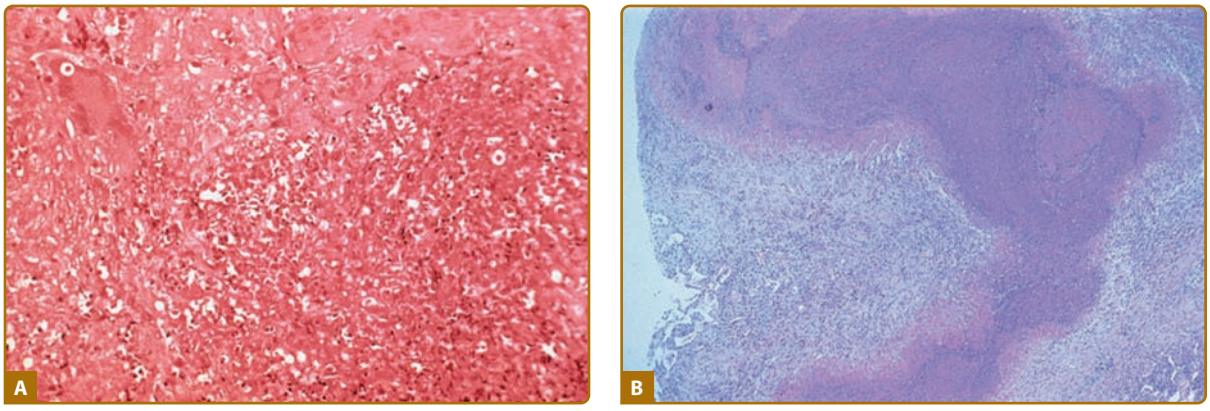

Figure 164-5 **A.** Lung histopathology from a patient with granulomatosis with polyangiitis (Wegener's) demonstrating necrosis, giant cells, and mixed cellular inflammation. **B.** "Geographic necrosis" in a low-power view of an open lung biopsy specimen from a patient with granulomatosis with polyangiitis (Wegener's).

is critical to estimate the glomerular filtration rate (GFR). Small changes in creatinine, even within the normal range, may be early evidence of decline in GFR. Although small-vessel vasculitis affecting the glomeruli is expected to produce hematuria, usually accompanied by red blood cell casts and proteinuria, vasculitis affecting only medium-sized vessels (e.g., polyarteritis nodosa) typically produces either isolated hematuria or a normal urinalysis. Urinalysis and serum creatinine are equally important tests and are complementary; neither alone is sufficient to exclude renal disease in vasculitis.

Tests of Liver Function. Vasculitis, particularly polyarteritis nodosa, can involve the liver, but significant hepatic dysfunction is rare. Liver function tests are thus of limited value in diagnosing vasculitis, but they do provide a baseline against which future values can be compared if, as is often the case, potentially hepatotoxic drugs are to be used for treatment. Liver function tests can also provide an early hint at infection with hepatitis B or C viruses, both of which are associated with vasculitis, but do not substitute for serologic testing for these infections. Normal liver function tests do not rule out infectious hepatitis.

Complete Blood Count. A complete blood count should be ordered on all patients suspected of having vasculitis. Many patients with active vasculitis have anemia and/or thrombocytosis, but the same is true of a wide range of inflammatory diseases. Severe anemia can be a clue to serious gastrointestinal involvement from various forms of vasculitis. The white blood cell count and differential can also be clues to the presence of infection or hematologic malignancy. However, leucocytosis is usually nonspecific and is also commonly caused by use of glucocorticoids. An elevated absolute eosinophil count is found in most untreated patients with CSS and a count greater than 1,000 cells/μL helps differentiate this disease from asthma and atopy.

Acute Phase Reactants. The erythrocyte sedimentation rate (ESR) and levels of C-reactive protein (CRP) are elevated in many patients with vasculitis, but the diagnostic sensitivity and specificity of these tests are not particularly high and thus these tests are not particularly helpful in either establishing or excluding a diagnosis of vasculitis. Furthermore, the levels of ESR and CRP do not correlate well with stage or severity of disease. ESR and CRP are often elevated in conditions that mimic vasculitis in the skin, as well as in many serious systemic diseases, including infections and malignancies. Patients with active vasculitis can have normal ESR and CRP values and patients may remain in clinical remission despite persistent elevation of these markers after treatment.

Autoimmune Serologies. Testing for autoantibodies is often a critical component of establishing the type of vasculitis present but it is important to recognize that serologic testing on its own is never diagnostic and should never substitute for clinical judgment.

Testing for ANCA and antiglomerular basement membrane (anti-GBM) antibodies, as well as antinuclear antibodies (ANA) to address the alternative possibility of systemic lupus erythematosus, is advised for any patient presenting with pulmonary hemorrhage and/or acute renal insufficiency with an active urinary sediment. ANCA-associated vasculitis and lupus can present with vasculitis of the skin, but anti-GBM disease does not, so the latter topic will not be discussed further.

Antineutrophil Cytoplasmic Antibodies. Approximately 90% of patients with microscopic polyangiitis, 75% of patients with GPA, and 40% of patients with CSS will test positive for ANCA.[13–16] Modern ANCA testing includes both immunofluorescence staining of neutrophils for the cytoplasmic (c-ANCA) or perinuclear (p-ANCA) patterns and ELISAs for specific autoantigens [proteinase-3 (PR3) and myeloperoxidase (MPO)].[16–18] Specificity of positive testing for anti-PR3 and anti-MPO antibodies for ANCA-associated vasculitis is quite high,[17–19] but specificity of p-ANCA staining in the absence of anti-MPO antibodies is low. Thus, positive tests for ANCA by ELISA are essential to consider ANCA testing positive for purposes of diagnosing vasculitis.

The predictive value of positive ANCA testing depends on the setting. In cases of biopsy-proven vasculitis or clinical "surrogates" of a biopsy of vasculitis, such as diffuse alveolar hemorrhage or acute renal failure with an "active" urinary sediment, positive testing for anti-PR3/MPO ANCA is highly specific. In the setting of nonspecific constitutional and musculoskeletal symptoms, the positive predictive value of ANCA testing is lower.

Anti-Nuclear Antibodies. Testing for ANA and related autoantibodies is useful when there is suspicion of systemic lupus or Sjögren syndrome. ANA testing is extremely sensitive (>95%) but not specific for the diagnosis of lupus. With the exception of anti-Ro (SSA) antibodies, additional tests for specific nuclear antigens, including double-stranded DNA, Smith, RNP, and La (SSB), should only be ordered if the ANA is positive and lupus is still under consideration. Only 80% of patients with Sjögren syndrome test positive for rheumatoid factor (RF), anti-Ro (SSA), or anti-La (SSB) antibodies, so negative tests do not rule out this diagnosis.

Rheumatoid Factor. Testing for rheumatoid factor is rarely useful in establishing either the diagnosis or specific type of vasculitis. The sensitivity and specificity of rheumatoid factor for Sjögren syndrome or cryoglobulinemic vasculitis are low. While at least 70% of patients with rheumatoid arthritis test positive for rheumatoid factor, the test is positive in more than 95% of patients with rheumatoid vasculitis.[20] However, since rheumatoid vasculitis typically occurs in patients with longstanding, severe rheumatoid arthritis, such testing has little additive value.

Paraproteins (Abnormal Immunoglobulins, Including Cryoglobulins). Cryoglobulins are immune complexes (immunoglobulins and their target antigens) that precipitate in the cold and are associated with clinical syndromes in which vasculitis is a prominent component (see Chapter 169). Cryoglobulinemia most commonly results from chronic infection with hepatitis C virus, but rheumatoid arthritis, systemic lupus erythematosus, Sjögren syndrome, and hematologic malignancies are also all associated with cryoglobulinemia. Testing for cryoglobulins requires careful attention to specimen handling and processing since incorrect practice at any one of several steps results in a high false-negative rate. Similarly, standard serum protein electrophoresis testing may not pick up some immunoglobulin clones, and immunofixation electrophoresis is a more comprehensive screen for clonal immunoglobulins.

Vasculitis has also been associated with monoclonal gammopathies (myeloma, plasmacytoma, or lymphoma) in the absence of cryoglobulinemia.[21]

Complement. Total hemolytic complement is measured using the CH50, but since this assay is cumbersome and suffers from variability between laboratories, measurement in serum of the complement proteins C3 and C4 is usually sufficient, and is useful for assessing patients with cutaneous vasculitis in several settings. In patients with cryoglobulinemic vasculitis C4 levels are usually severely depleted whereas C3 levels are less depleted or even normal.[22,23] One or both of these components are low in 70% of patients with rheumatoid vasculitis,[20] which is useful because rheumatoid arthritis is generally not associated with low circulating complement. In contrast, because systemic lupus erythematosus is commonly associated with low complement in a variety of settings, low complement helps raise the suspicion for lupus but is not specific for vasculitis in SLE. A subset of patients whose cutaneous vasculitis presents as urticaria (hence the term "urticarial vasculitis"), but who cannot be diagnosed with lupus or another underlying disease, have depletion of complement (see Chapter 163).

Selected Testing for Infectious Diseases. Many infections can cause skin lesions that either include vasculitis or mimic vasculitis. Chronic infection with hepatitis C virus is strongly associated with cryoglobulinemic vasculitis, and it can also be associated with polyarteritis nodosa in the absence of cryoglobulins.[24] Chronic hepatitis B virus infection was the cause of many cases of polyarteritis nodosa prior to the widespread adoption of vaccination programs.[25] Thus, patients with known or suspected vasculitis affecting small- or medium-sized arteries should be screened for hepatitis B and C infections.

Endocarditis can cause both true vasculitis, presumably through deposition of immune complexes, and lesions that mimic vasculitis, through septic emboli. Blood cultures are therefore appropriate to order for some patients suspected of small-vessel vasculitis.

Numerous and diverse infections have been implicated in causing secondary vasculitis, usually of small vessels and limited to the skin. Testing for specific organisms should therefore be based on a history of exposure or a suspicious clinical syndrome (e.g., sore throat or acute diarrhea).

Several uncommon infections directly infect and damage vascular endothelial cells and thus produce lesions that can either be regarded as vasculitis or as mimics of vasculitis; numerous organisms have been implicated, mostly in the form of case reports.

Screening for Drugs of Abuse. Toxicology screens for commonly used drugs of abuse may be appropriate for some clinical situations where vasculitis is suspected. In particular, both cocaine and methamphetamines have been associated with cutaneous vasculitis and/or arterial vasospasm, and nasal inhalation of cocaine can produce destructive nasal disease as severe as that seen in ANCA-associated vasculitis, although certain clinical features may help distinguish the two causes.[26,27]

DIAGNOSTIC IMAGING STUDIES

Chest Imaging. A chest radiograph is an appropriate screening test for any patient suspected of having vasculitis. For a patient with pulmonary symptoms, computed tomography (CT) is usually indicated, since plain radiographs will frequently not detect small

nodules or subtle but significant infiltrates. In patients diagnosed with GPA, microscopic polyangiitis, or CSS, a screening CT is indicated for staging purposes and to establish a baseline, even in asymptomatic patients.

If subglottic stenosis is suspected, CT of the neck/trachea can be a helpful adjunct to direct laryngoscopy.

Sinus Imaging. Sinus involvement is extremely common in GPA and CSS, and the ability to evaluate the sinuses on physical examination is limited even for an otolaryngologist. CT of the sinuses can help assess the possibility of GPA or CSS and is useful in staging and restaging disease once one of those diagnoses is made and treatment is initiated. However, the CT appearance of sinus inflammation in these diseases does not allow discrimination from other causes of sinusitis, and patients with prior damage from vasculitis often have persistent abnormalities. Nasal inflammation may be better assessed by physical exam than by CT.

Angiography. Angiography has a central role in the diagnosis and management of large- and medium-vessel vasculitis. Conventional catheter-based dye angiography has the highest resolution but is an invasive procedure and still does not allow visualization of most small vessels. Angiography based on CT and magnetic resonance (MR) is increasingly replacing the use of catheter-based angiography in large-vessel vasculitis (GCA and Takayasu's).[28]

The role of angiography in the diagnosis of vasculitis of the skin is limited to either establishing the underlying type of vasculitis (e.g., abdominal angiography demonstrating multiple aneurysms and stenoses in polyarteritis nodosa) or evaluating the arterial supply in patients with gangrene.

OTHER DIAGNOSTIC STUDIES

Nerve Conduction Studies and Electromyography. Nerve conduction studies should never replace a full neurologic examination and most patients with neurologic manifestations of vasculitis do not need such testing. Thus, nerve conduction testing is not recommended for screening asymptomatic patients, but can be useful for providing objective evidence of neuropathy and for distinguishing between compressive (i.e., mechanical) and noncompressive neuropathy, with the latter type including neuropathy due to vasculitis and many other medical causes. Electromyography (EMG) can establish the presence of myopathy, but usually not the cause. Nerve conduction studies are painful and require expertise not always readily available.

Audiology Testing. An audiogram is critical in diagnosing and distinguishing between conductive and/or sensorineural hearing loss. Hearing loss is a commonly missed manifestation of small-vessel vasculitis, including among elderly patients.[29] Sensorineural hearing loss is a cranial neuropathy and may rapidly lead to irreversible hearing loss. Although an audiogram is not generally indicated for screening an asymptomatic patient, a baseline audiogram is advised for all patients with an established diagnosis of ANCA-associated vasculitis (GPA, microscopic polyangiitis, or CSS).

SUMMARIES OF THE VASCULITIDES

MICROSCOPIC POLYANGIITIS

Microscopic polyangiitis (MPA) is a multisystem vasculitis of small vessels and sometimes also of medium-sized vessels.[30,31] Pauciimmune glomerulonephritis develops in the majority of patients, and pulmonary hemorrhage, peripheral and cranial neuropathy, musculoskeletal, and constitutional symptoms are also common; cardiac and gastrointestinal involvement are less common. Most patients with MPA are positive for ANCA, usually with specificity for antibodies to myeloperoxidase (MPO).[32] Although rapidly progressive glomerulonephritis and/or diffuse alveolar hemorrhage commonly lead to diagnosis, MPA often features a prolonged prodrome limited to musculoskeletal and constitutional symptoms.[33]

The skin is frequently involved in MPA.[15] The most common cutaneous lesion is palpable purpura and the pathology is indistinguishable from other types of leukocytoclastic vasculitis[12,34] (Fig. 164-6). Vasculitis of medium-sized vessels, leading to digital ischemia, subcutaneous nodules, livedo reticularis, and deep ulcers, can rarely occur in MPA.

GRANULOMATOSIS WITH POLYANGIITIS (WEGENER'S)

GPA encompasses all the features of microscopic polyangiitis but also many additional manifestations caused by necrotizing granulomatous inflammation and the two syndromes are currently considered distinct entities. Chronic inflammation of the upper airway (nasal cavity, sinuses, auditory tube, and middle ear) is present in about 90% of patients, often but not always as the initial manifestation.[13,35,36] Cavitary



Figure 164-6 Purpura in a patient with microscopic polyangiitis.



Figure 164-7 Skin ulcer in a patient with granulomatosis with polyangitis (Wegener's).

pulmonary nodules, orbital pseudotumor, and subglottic stenosis are also common and important features. Vasculitis of the eye (scleritis and episcleritis) is also much more common in GPA than in MPA.[13,30,35–37] Most patients with GPA who have involvement of multiple organ systems will test positive for ANCA.[37,38] The majority ANCA type in this disease is C-ANCA/antiproteinase-3 (PR3); however, P-ANCA/antimyeloperoxidase (MPO) is also not uncommon. Patients with disease seemingly restricted to the upper airway are only ANCA-positive in about 70% of cases, which can make diagnosis more challenging.[16,37]

In addition to palpable purpura and other presentations typical of small-vessel vasculitis, additional skin lesions occur in GPA and reflect a combination of vasculitis and necrotizing granulomatous disease, including neutrophilic and granulomatous dermatitis with papules (particularly on the extensor surfaces of the elbows), subcutaneous nodules, and ulcers[12,39–42] (Figs. 164-7 and 164-8). Vasculitis and extravascular granulomatous disease are sometimes seen in the same biopsy, facilitating diagnosis. As with MPA, manifestations attributable to involvement of medium-sized vessels can also be seen (Fig. 164-9).

CHURG–STRAUSS SYNDROME

CSS is often included among the ANCA-associated vasculitides since approximately 40% of patients test positive for ANCA,[43] and there is considerable overlap in features of CSS with both GPA and microscopic polyangiitis. However, CSS has unique features, the most prominent being a history of asthma (often severe or poorly controlled), and blood eosinophilia. Nasal polyps, constitutional symptoms, and rashes, all typical of atopy, are also common. The presence of pulmonary infiltrates on chest imaging (eosinophilic pneumonia) provides an important distinction from asthma. The most common presentation of severe vasculitis in CSS is acute peripheral neuropathy with involvement of the heart, gastrointestinal tract, brain, and eyes less common. Glomerulonephritis and pulmonary hemorrhage occur in about 10% and less than 5%, respectively, of patients with CSS.[14,44,45]

Cutaneous disease is more common in CSS than in GPA or microscopic polyangiitis.[14,44,45] Palpable and nonpalpable purpura, reflecting vasculitis histologically, comprise about 50% of cutaneous lesions.[12] Eosinophilic dermatitis and granulomatous dermatitis rich in both neutrophils and eosinophils are also common and produce erythematous macules, papules, and nodules. As with GPA, small-vessel vasculitis and extravascular eosinophilic and/or granulomatous disease are sometimes seen in the same biopsy. While the skin lesions of CSS often contain eosinophils, with or without vasculitis, eosinphil-rich skin biopsies are not unique to this disease and can be seen in other types of vasculitis.

CRYOGLOBULINEMIC VASCULITIS

See Chapter 169.

HENOCH–SCHÖNLEIN PURPURA

See Chapter 163.



Figure 164-8 Granulomatosis with polyangiitis (Wegener's). **A.** Palpable purpura **B.** Deep ulcer on the soft palate.

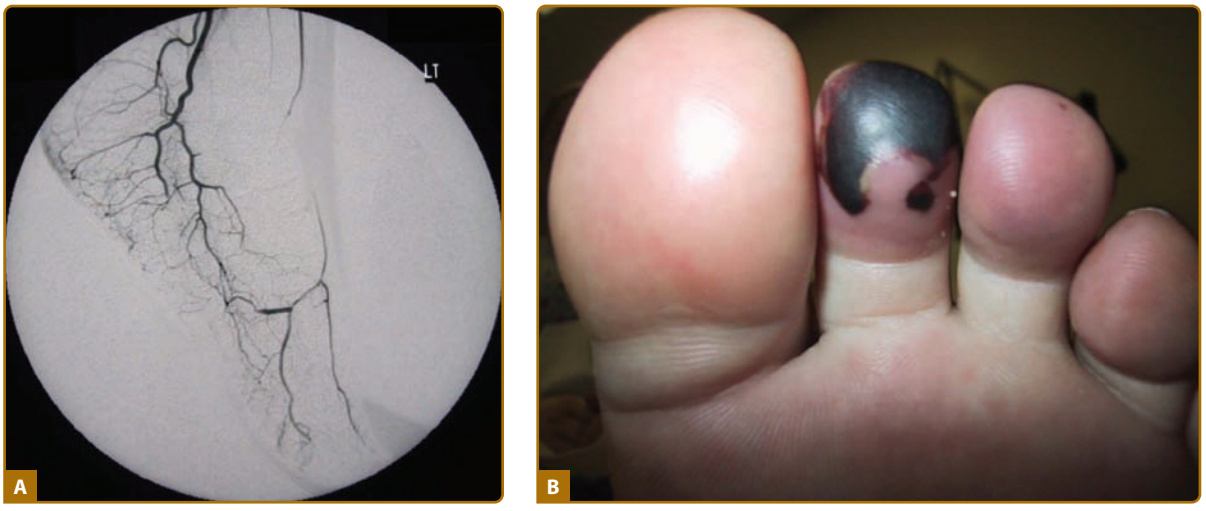

Figure 164-9 Granulomatosis with polyangitis (Wegener's). **A.** Vasculitis and occlusion of the dorsal pedal artery occlusion. **B.** Gangrenous toe secondary to the occlusion in panel **A**.

VASCULITIS ASSOCIATED WITH OTHER AUTOIMMUNE DISEASES

Vasculitis is seen relatively commonly in patients with systemic lupus (10%–36%)[46,47] and Sjögren syndrome (10%),[48] but is now extremely uncommon in rheumatoid arthritis.[49,50] Vasculitis in these diseases affects mostly small vessels, with some medium-vessel disease. The vasculitis may cause peripheral neuropathy, gastrointestinal ischemia, and central nervous system disease with other visceral involvement rare. Inflammatory bowel disease and relapsing polychondritis[51] have also been associated with vasculitis involving small, medium, or large vessels.

The cutaneous manifestations of systemic rheumatic diseases are covered in Chapters 155, 160, and 161. The cutaneous manifestations of small-vessel vasculitis (purpura, vesiculobullous lesions, shallow ulcers) and medium-vessel vasculitis (nodules, deep ulcers, digital gangrene) associated with connective-tissue diseases are generally similar to what is seen in other forms of cutaneous vasculitis (eFig. 164-9.1 in online edition).

MALIGNANCY-ASSOCIATED VASCULITIS

Vasculitis temporally associated with a solid malignancy has been reported in many case reports and in a few larger series.[52] A diverse set of malignancies has been implicated. Small-vessel vasculitis of the skin appears to be most common manifestation, and reports of remission of vasculitis after surgical resection of the tumor (and no other therapy) are suggestive of a causal relationship. Hematologic malignancies with or without associated paraproteinemias can result in vasculitis.[21] Furthermore, the often comprehensive medical testing and imaging associated with evaluating a patient with possible vasculitis can lead to discovery of a malignancy in a patient with vasculitis, and the two diagnoses may be unrelated.

CUTANEOUS LEUKOCYTOCLASTIC ANGIITIS

All of the diseases and syndromes described to this point are defined by a combination of clinical and laboratory parameters. Cutaneous leukocytoclastic angiitis, in contrast, is a histologic term defined by the absence of evidence of systemic disease and the term undoubtedly encompasses many etiologies, and appears in this list only to serve as a reminder that cutaneous vasculitis is not always a marker of systemic disease. If, and only if, a patient has biopsy-proven vasculitis, has no evidence of involvement of other organ systems by vasculitis, and has no clinical of laboratory evidence to support a specific form of vasculitis or a coexisting autoimmune inflammatory disease, should the diagnosis of cutaneous leukocytoclastic angiitis be tentatively made. This term appears in the nomenclature of the Chapel Hill Consensus Conference of 1994 to acknowledge that vasculitis limited to the skin is relatively common.[7] It has been estimated that about 20% of such cases follow infections, and another 20% are associated with drug exposure.[12] However, it is quite problematic to label skin-only vasculitis as a separate disease entity, and all such patients should be followed carefully for the possible evolution to a more systemic form of vasculitis.

DRUG-INDUCED VASCULITIS

Reactions to drugs have been implicated in about 20% of cases of cutaneous small-vessel vasculitis,[10] but the exact frequency of drug-induced disease is hard to establish due to incomplete reporting of cases and difficulty in firmly establishing causality of any one agent. Most categories of drugs have been implicated as causing vasculitis, but the number of reports for a given drug may represent reporting bias rather than relative risk.[9,53] Cutaneous small-vessel disease is the norm, but medium-vessel vasculitis and visceral involvement have been reported. The literature



Figure 164-10 Leukocytoclastic vasculitis after administration of granulocyte macrophage colony-stimulating factor for aplastic anemia.

is undoubtedly biased toward severe cases, but there are numerous reports of serious or fatal internal organ involvement (particularly renal, pulmonary, and hepatic). There is also a now well-accepted subset of drug-induced ANCA-associated vasculitis (antibodies usually directed against myeloperoxidase), especially involving propylthiouracil and related agents, hydralazine, but also other drugs.[54,55]

The cutaneous presentation of DIV is indistinguishable from other causes of small-vessel vasculitis (i.e., usually purpura but sometimes other lesions) (Fig. 164-10).

It is essential that a comprehensive review of all prescription, over-the-counter, illegal, and "alternative" drugs and supplements be undertaken for all patients suspected of having vasculitis.

Establishing a diagnosis of DIV may lead to avoidance of treatment with glucocorticoids and immunosuppressive agents in favor of clinical follow-up after drug discontinuation. However, two important caveats must be kept in mind in such cases: (1) drug discontinuation alone may not resolve the disease and severe disease may be present necessitating treatment; (2) the diagnosis of DIV may be wrong and the patient really has another form of vasculitis; thus, careful and prolonged follow-up of all patients is required.

BEHÇET DISEASE

See Chapter 166.

POLYARTERITIS NODOSA

Idiopathic vasculitis of medium-sized vessels (i.e., small- or medium-sized muscular arteries) can present in one or multiple organ systems. "Classic" polyarteritis nodosa involves multiple organ systems and presents with some combination of skin disease, myalgia, hypertension (from renal artery involvement), abdominal pain, neuropathy, and/or testicular pain. However, many patients do not present with the full set of manifestations, and diseases limited to muscle and nerve, single internal organs, or to the skin are

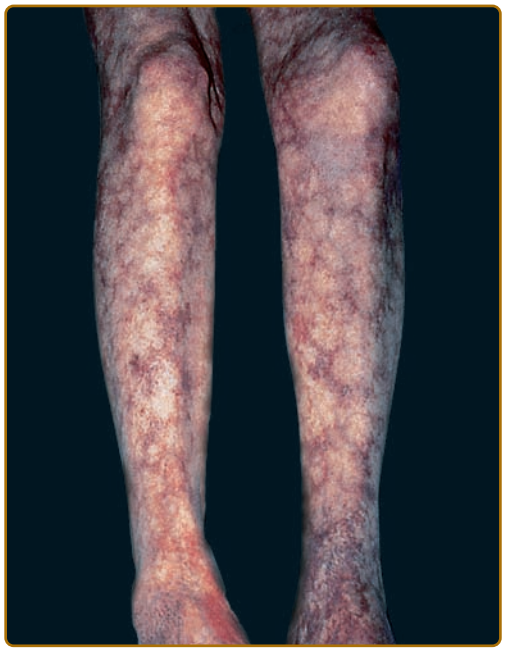

Figure 164-11 Livedo reticularis.

well-described variants. When the disease is limited to the skin, it is sometimes referred to as cutaneous poyarteritis nodosa; however, some of these patients will later manifest disease in other organs.

Interpreting the literature on poyarteritis nodosa is problematic since the term was formerly used to describe several forms of vasculitis now considered to be distinct diseases (particularly microscopic polyangiitis).[56,57] Historically, many cases of poyarteritis nodosa were associated with chronic infection with hepatitis B, but that association has declined markedly in countries in which vaccination against hepatitis B has become routine.[57] Whether the remaining, rare entity still known as poyarteritis nodosa represents one, a few, or many etiologies, or even whether there is a unified fundamental pathophysiology (e.g., immune complex disease), is unclear.

The most common cutaneous features of poyarteritis nodosa are livedo reticularis/racemosa (a lacy pattern of cutaneous blood vessels on the legs, and not always easy to distinguish from a benign consequence of vasoconstriction of more superficial vessels) (Fig. 164-11), painful cutaneous nodules or ulcers (Fig. 164-12), and digital ischemia.[58,59] These manifestations reflect vasculitis of "medium-sized" arteries in the subcutis, which are frequently too deep to be sampled in a routine punch biopsy.[10]

KAWASAKI DISEASE

See Chapter 167.

PRIMARY VASCULITIS OF THE CENTRAL NERVOUS SYSTEM

This rare disease is limited to the central nervous system (hence, no cutaneous findings) and presents with



Figure 164-12 Leg ulcer in a patient with polyarteritis nodosa.

symptoms of encephalopathy, multiple small strokes, and often headache.[60,61]

GIANT CELL ARTERITIS

Giant cell arteritis (GCA; temporal arteritis) is currently considered strictly a disease of adults older than 50 years of age that is markedly more common with advancing age. It is mostly a disease of people of Northern European ancestry. Cranial arteritis is a common feature with this term indicating stenosis or occlusion of one or more branches of the carotid artery to produce headache (70%–80%), jaw claudication (50%), and monocular (and rarely binocular) blindness (15%). Polymyalgia rheumatica, which includes pain and stiffness of the shoulder and hip girdles, is seen in at least 30%–40% of patients and may occur without cranial disease. Constitutional symptoms are common, including fever, malaise, and weight loss. Involvement of the aorta and its major branches produces symptoms similar to Takayasu arteritis in 15%–20% of patients. Diagnosis of GCA is usually confirmed by temporal artery biopsy (Fig. 164-13).

Palpable nodularity of the temporal artery is present in 30%–40% of cases and is the only cutaneous manifestation of GCA apparent on examination. Scalp necrosis and digital ischemia are rare complications.[62,63]

TAKAYASU ARTERITIS

Takayasu's is a rare form of vasculitis (prevalence <1:100,000) involving the aorta and its major branches.[64–69] Many patients are diagnosed as young adults, and 90% are female. The typical presentation of Takayasu's is limb claudication. Dizziness, constitutional symptoms, and severe hypertension (from renal artery stenosis) are also common. Cerebral infarction can occur. Coronary occlusions with angina or infarction and bowel ischemia are less common but life-threatening complication. Absent pulse(s), abnormal blood-pressure readings, and arterial bruits are common but not universal findings. Diagnosis is made by angiography.

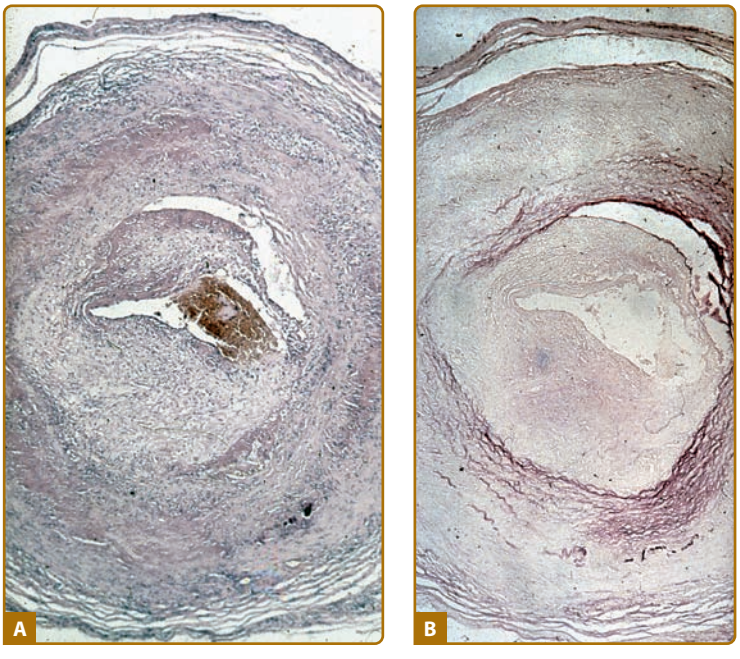

Figure 164-13 **A.** Histopathology of the temporal artery from a patient with giant cell arteritis shows necrosis of the media, inflammatory infiltrates consisting of lymphocytes, and giant cells. There is also subintimal proliferation of fibroblasts and fibrosis. **B.** Elastic tissue stain reveals destruction of the lamina interna and externa.

Lesions resembling erythema nodosum or pyoderma gangrenosum[70] have been described repeatedly in Takayasu's, with pathology of nodular lesions often, but not always, showing vasculitis and thereby differing from typical erythema nodosum.[71,72] Although complete occlusion of subclavian arteries is common, digital ischemia is rare.

TREATMENT AND MANAGEMENT OF VASCULITIS

GENERAL APPROACH TO TREATMENT OF SYSTEMIC VASCULITIS

When establishing a treatment regimen for a patient with vasculitis, consideration must be given to both the severity of the current presentation and the likelihood of disease progression and recurrence. For an increasing number of vasculitides, treatment is guided by results of relatively large, randomized, controlled trials. However, for many situations, clinicians still rely upon either extrapolation from trials in other diseases or empiric treatment based on small case series or personal experience.

For vasculitides expected to have extended courses and/or include severe manifestations, the general approach is to plan for two phases of treatment: remission induction and remission maintenance.[73,74] Remission induction usually involves use of high-dose glucocorticoids with steady dose taper combined with a short course (3–6 months) of a fairly rapid-acting and potent immunosuppressive agent. For example, cyclophosphamide, rituximab, and methotrexate all have roles in remission induction for ANCA-associated vasculitis. Remission maintenance usually involves prolonged use of non-cyclophosphamide-based regimens to allow for glucocorticoids to be either fully discontinued or maintained at a low dose (e.g., ≤10-mg prednisone daily). However, while the preceding approach is usual for the ANCA-associated vasculitides, polyarteritis nodosa, and some other forms of severe systemic disease for which there are data from clinical trials to guide treatment, it is less commonly used for other vasculitides in which glucocorticoids alone may suffice as therapy.

Clinicians must always remain alert to the possibilities of (1) a different diagnosis (either a different form of vasculitis or an entirely different disease); (2) development of additional manifestations of vasculitis; (3) treatment-related side effects, some of which can mimic vasculitis (infections, skin reactions, etc.).

An important aspect of caring for patients with vasculitis is determining who and when *not* to treat. "Watchful waiting" may be a reasonable management approach when (1) a diagnosis is not clear and no major organ system appears threatened; (2) there is an obvious cause or etiology for the vasculitis that is either reversible (toxin/drug) or self-limited (some infections); (3) uncertainly exists as to whether the patient's symptoms are due to a flare of disease or the result of either chronic damage or another process.

A critical component to the care of patients with vasculitis is close, regular clinical follow-up. Vasculitis often progresses rapidly and most forms of vasculitis have high rates of relapse. Depending on the form of vasculitis, regular office visits should be accompanied by laboratory and radiographic monitoring. Close follow-up should occur not only at the start of the disease process, but also for years following diagnosis.

TREATMENTS FOR SYSTEMIC VASCULITIS

A comprehensive list of drugs used in the treatment of the various systemic vasculitides and details of treatment regimens is beyond the scope of this chapter (additional information about specific agents is available in Chapters 224, 227, 233, and 234.

GLUCOCORTICOIDS. Glucocorticoids remain the mainstay of therapy for vasculitis given the rapidity of action, reliability of response, and physicians' familiarity with dosing and side effects. Glucocorticoids are usually the initial drug used to treat vasculitis and may be the only agent used for some forms of the disease. However, additional agents are often prescribed because either the dose of glucocorticoids needed to maintain disease control is unacceptably high or disease control is not attained by glucocorticoids alone. The acute and chronic toxicities are often underappreciated and the potential cumulative damage from chronic or recurrent use of glucocorticoids may be substantial.

OTHER IMMUNOSUPPRESSIVE AGENTS. A wide variety of additional immunosuppressive agents are used for treatment of the vasculitides. The proven effectiveness of the alkylating agent cyclophosphamide for the ANCA-associated vasculitides and, to a lesser extent, other forms of vasculitis, have helped establish this drug as the standard of care for initial treatment of severe forms of vasculitis.[35,75–77] Other alkylating agents are now rarely prescribed for vasculitis. Although effective in many, but certainly not all, cases, cyclophosphamide is also associated with serious toxicities, many of which are related to total cumulative dose (e.g., female and male infertility, bladder cancer). Therefore, the past three decades have seen the emergence of "cyclophosphamide-sparing" regimens[78] that usually have patients transition from an initial course of treatment with cyclophosphamide to a more prolonged course of a less toxic immunosuppressive agent, especially either methotrexate[79,80] or azathioprine[76,81]; mycophenolate, cyclosporine A, and other agents have also been used for maintenance therapy.

BIOLOGIC AGENTS. More recently, the so-called "biologic" agents, drugs created using recombinant DNA techniques to target specific components of the immune system, have been studied for use in treating vasculitis, often with a goal of being either cyclophosphamide

sparing or glucocorticoid sparing. The recent demonstration that rituximab, a B cell-depleting therapy, is as effective as cyclophosphamide for induction of remission in AAV is considered a major advance for the field.[82,83] However, studies examining the efficacy of anti-TNF agents for either GPA or giant cell arteritis have been highly disappointing.[84,85] There are many new biologic agents under consideration for use in the treatment of vasculitis, and clinical trials are needed to properly evaluate these new treatments.

OTHER TREATMENTS. Although a variety of other drug classes, including colchicine, antibiotics (dapsone and others), and "alternative" therapies have been promoted for treatment of various forms of vasculitis, good evidence is generally lacking for the efficacy of these agents.

The role of plasma exchange in the treatment of vasculitis remains controversial. There is some evidence for efficacy for plasma exchange for patients with AAV and severe renal disease[86] and possibly forms of cryoglobulinemic vasculitis. A large, international, randomized trial of plasma exchange for AAV is under way.

COMMON ERRORS IN THE DIAGNOSIS AND TREATMENT OF SYSTEMIC VASCULITIS

Given the huge spectrum of disease manifestations in vasculitis, the potential toxicities of treatments for vasculitis, and the serious ramifications of missing alternative diagnoses, especially infections, diagnostic misclassification is a major concern. Establishing a firm diagnosis of vasculitis based on physical examination and laboratory findings alone is a common problem. This is especially true for skin disease since not all purpura is due to vasculitis and not all skin disease in vasculitis is purpuric. Clinicians are cautioned against making a diagnosis of vasculitis in the skin without a biopsy; the exception to this guideline is if the patient has a clearly established diagnosis of vasculitis based on other evidence but, even then, it may be necessary to know what is causing a skin lesion. Many types of skin lesions improve with treatment with glucocorticoids; so, response to empiric use of this treatment is not diagnostically useful.

TABLE 164-2
Medical Emergencies Related to the Primary Vasculitides

Emergency Manifestations of Vasculitis	Type of Vasculitis
Ophthalmologic	
■ Threatened vision; monocular blindness	GCA, TAK
■ Scleritis	GPA, MPA, RPC
■ Uveitis	BD
Pulmonary	
■ Subglottic stenosis	GPA, RPC
■ Alveolar hemorrhage	GPA, MPA, CSS
■ Diffuse inflammatory infiltrates	GPA, MPA, CSS
■ Pulmonary embolus	GPA, MPA, CSS, BD
Cardiovascular	
■ Malignant hypertension–renal arterial stenoses	TAK, GCA, PAN
■ Rapid-onset cardiomyopathy/heart failure	CSS
■ Angina/myocardial infarction	TAK, GCA
■ Gangrene-digital ischemia	GCA, TAK, PAN, GPA, MPA
■ Aneurysm dissection (aorta or branches)	PAN, BD, GCA, TAK
Gastrointestinal	
■ Mesenteric ischemia	PAN, HSP, GCA, TAK
Renal	
■ Glomerulonephritis/rising creatinine/renal failure	GPA, MPA, CSS, HSP, PAN, Cryo
Neurologic	
■ Headache	GCA
■ Syncope	GCA, TAK
■ Stroke	GPA, MPA, CSS, BD, GCA, TAK
■ Sensorineural hearing loss or other cranial neuropathies	GPA, MPA
■ Mononeuritis multiplex	CSS, PAN, GPA, MPA
Other organ-threatening disease	Any systemic vasculitis

GPA = Granulomatosis with polyangiitis (Wegener's), MPA = microscopic polyangiitis, CSS = Churg–Strauss syndrome, Cryo = cryoglobulinemic vasculitis, HSP = Henoch Shönlein purpura; PAN = polyarteritis nodosa; BD = Behçet disease; RPC = relapsing polychondritis; GCA = giant cell arteritis; TAK = Takayasu's arteritis.

Undertreatment or delayed initiation of immunosuppressive therapy is a common problem for patients with systemic vasculitis. Undertreatment may take the form of failure to recognize multiorgan system disease, delay or reluctance to initiate immunosuppressive medications other than glucocorticoids for those forms of vasculitis for which such therapy has been shown to be useful, or underdosing of immunosuppressive agents.

Another common mistake is extending the course of treatment with medium–high doses of glucocorticoids beyond what is necessary to control an acute flare of vasculitis or the more serious manifestations.

MEDICAL EMERGENCIES RELATED TO THE PRIMARY VASCULITIDES

The systemic vasculitides vary greatly in their rate of progression and level of medical severity. However, it is imperative that all clinicians caring for patients with vasculitis understand that these diseases are often organ- and life-threatening and that progression to emergency situations may be rapid. Furthermore, vasculitis can accelerate rapidly even after a long period of slowly changing or even indolent disease. Table 164-2 outlines several of the most common situations in which patients require emergency care but this list is incomplete and clinicians must be vigilant about considering these and other potentially rapidly progressive problems.

KEY REFERENCES

Full reference list available at www.DIGM8.com

DVD contains references and additional content

9. Merkel PA: Drug-induced vasculitis. *Rheum Dis Clin North Am* **27**(4):849-862, 2001
10. Carlson JA, Ng BT, Chen KR: Cutaneous vasculitis update: Diagnostic criteria, classification, epidemiology, etiology, pathogenesis, evaluation and prognosis. *Am J Dermatopathol* **27**(6):504-528, 2005
13. WGET Research Group: Limited versus severe Wegener's granulomatosis: Baseline data on patients in the Wegener's granulomatosis etanercept trial. *Arthritis Rheum* **48**(8):2299-2309, 2003
14. Guillevin L et al: Churg-Strauss syndrome. Clinical study and long-term follow-up of 96 patients. *Medicine (Baltimore)* **78**(1):26-37, 1999
15. Guillevin L et al: Microscopic polyangiitis: Clinical and laboratory findings in eighty-five patients. *Arthritis Rheum* **42**(3):421-430, 1999
73. Mukhtyar C et al: EULAR recommendations for the management of primary small and medium vessel vasculitis. *Ann Rheum Dis* **68**(3):310-317, 2009

Chapter 165 :: Erythema Elevatum Diutinum

:: Nneka I. Comfere & Lawrence E. Gibson

ERYTHEMA ELEVATUM DIUTINUM AT A GLANCE

- Rare disease; unknown incidence.
- A chronic leukocytoclastic vasculitis typified by a distinctive clinical pattern.
- Symmetric, erythematous, violaceous, or yellow–brown papules/nodules/plaques.
- Most common sites of involvement are the extensor surfaces of the hands, fingers, elbows, knees, legs, and Achilles tendon. Trunk is usually spared.
- Co-occurring diseases include monoclonal paraproteinemias, lymphoproliferative disorders, chronic infection, autoimmune conditions, and connective tissue diseases.
- Pathology consists of leukocytoclastic vasculitis in early stage lesions and a granulation-tissue-like response with fibrosis in later stages.

Erythema elevatum diutinum (EED) is a chronic leukocytoclastic vasculitis (LCV) that was initially described by Hutchinson in 1888 and subsequently by Bury in 1889. The name *EED* was first used by Radcliff-Crocker and Williams who separated it into two groups.[1–3] The Bury type tended to occur more commonly in younger women with a history of underlying rheumatologic disease, and the Hutchinson type tended to occur in elderly males.

EPIDEMIOLOGY

The incidence of EED is unknown; however, it appears to be a rare disease. There is no significant mortality associated with EED. It presents predominantly in males, in the fourth to sixth decade of life.

ETIOLOGY AND PATHOGENESIS

The pathogenesis of EED is not entirely clear; however, the prevailing and traditional theories are based on immune complex deposition within vessel walls, complement fixation, inflammation, and subsequent vascular destruction.[1] The various disease associations seen in EED (see Section "Associated Diseases") have

provided further understanding of the underlying pathomechanism of EED.

Antineutrophil cytoplasmic antibodies (ANCA) of the immunoglobulin G (IgG) type have proven useful for the diagnosis and monitoring of disease activity in various systemic vasculitides, including granulomatosis with polyangiitis (Wegener's), microscopic polyangiitis (MPO), polyarteritis nodosa, and Churg–Strauss syndrome.[4]

There are reports in the literature documenting the occurrence of IgA ANCAs in patients with neutrophil-driven dermatoses such as Henoch–Schönlein purpura, inflammatory bowel disease, and various cutaneous vasculitides, including EED.[5,6] It seems likely that abnormal functioning or activation of the neutrophil, which is the primary inflammatory cell in EED, may represent the central event. Most importantly, some of the neutrophilic dermatoses, including EED, have been associated with underlying paraproteinemias (monoclonal and polyclonal IgA gammopathies)[7] and hematologic malignancies. The severity of EED does not, however, appear to be dependent on the total paraprotein levels. Nevertheless, immunoelectrophoresis screening for monoclonal gammopathies as a marker of EED has been recommended.[8] Hence, IgA ANCAs against yet unidentified neutrophilic antigenic targets may prove to be useful clinical markers in EED.[9]

In a recent analysis of the clinical, histopathologic, and immunohistochemical features in six patients with EED by Wahl et al,[8] the vascular endothelium of EED was immunoreactive for CD31, CD34, vascular endothelial growth factor, and factor VIIIa but nonimmunoreactive for factor XIIIa, transforming growth factor-β, and latency-associated nuclear antigen of human herpesvirus 8. The staining properties of the endothelium in EED were compared to endothelial staining in similar lesions, including LCV, urticarial vasculitis, dermatofibromas, and capillary hemangiomas. No significant differences in the immunohistochemical staining properties were observed. The authors concluded that the chronic and recurrent nature of EED is the primary means of distinguishing it from other entities that are similar clinically and histologically.[8]

CLINICAL FINDINGS

EED typically presents as multiple, persistent, symmetric, and erythematous to violaceous papules/nodules/plaques on the extensor surfaces of the hands (Fig. 165-1), elbows (Fig. 165-2), wrists, knees (Fig. 165-3), ankles, Achilles tendons, fingers (Fig. 165-4) and toes, buttocks (see eFig. 165-4.1 in online edition), face, ears, legs, forearms, and genitals.[1] The trunk, however, is usually spared, but may be involved rarely.[10] Other atypical sites of involvement include the retroauricular and palmoplantar regions.[1,2,10] Overlying epidermal changes, such as vesicles, bullae or ulcers, may be present. Lesions may be exacerbated by cold exposure and may become more raised, erythematous, and firm in the evening.[11–13]



Figure 165-1 Erythema elevatum diutinum. Nodular lesions on dorsal hand present for several years.

With time, the lesions may become firmer and develop a yellowish-brown coloration, resembling xanthomata (see Fig. 165-2). These eventually heal with dyspigmentation. The onset of new lesions may be associated with symptoms of pruritus, burning, stinging sensations, paresthesias, or may be completely asymptomatic. Constitutional symptoms, including fever and arthralgias, are seen commonly.[1,14]

The clinical presentation of EED in human immunodeficiency virus-infected (HIV-infected) individuals is somewhat different and can mimic lesions of Kaposi sarcoma and bacillary angiomatosis usually seen in immunosuppressive states.[15] Nodular lesions have been reported in HIV-infected patients.



Figure 165-2 Multiple erythematous scaly papules coalescing into plaques on extensor elbow.



Figure 165-3 Crusted brown and violaceous papules over knee and anterior thigh.

LABORATORY FINDINGS

For histopathology see Figure 165-5.

OTHER LABORATORY FINDINGS

(See Section "Associated Diseases" and Table 165-1)



Figure 165-4 Smooth, flesh-colored to slightly erythematous papules on extensor fingers over proximal interphalangeal joints.

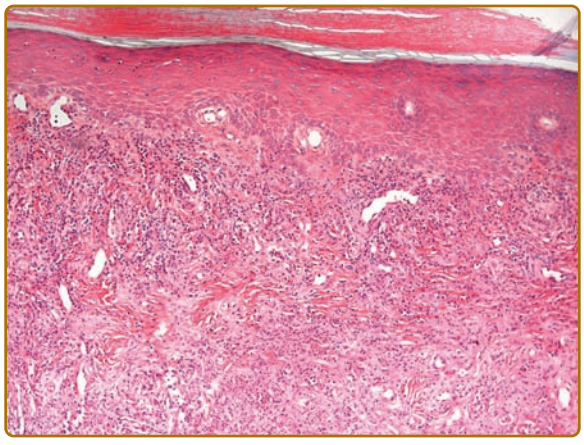

Figure 165-5 Early stage lesion of erythema elevatum diutinum: Focal leukocytoclastic vasculitis with a fairly dense perivascular and interstitial infiltrate composed of neutrophils, lymphocytes, histiocytes, and leukocytoclastic debris. Mild capillary proliferation is also evident.

ASSOCIATED DISEASES

EED has been reported in association with a wide range of disease processes (see Table 165-1). Notable associations include chronic bacterial infections, especially streptococcal infections; HIV infection; underlying monoclonal and polyclonal gammopathies; and connective tissue diseases. Some of these disease associations have provided further insight into the pathogenesis of EED.

The most frequent disease association with EED is IgA paraproteinemia. Lesions of EED have been noted to flare with increased IgA levels. Hence, IgA paraprotein levels have been proposed to be a useful clinical marker in EED.[23] Other notable associations have included chronic bacterial, viral, and parasitic infections. Bacterial infections, especially streptococcal infections, have been associated with EED, and typical skin lesions have been reproduced or exacerbated by the intradermal injection of streptococcal antigens.[1,3,23] Juxta-articular nodules of EED have been observed in patients with HIV infection. The histopathology of these nodules usually reveals a predominance of fibrosis rather than a neutrophilic infiltrate, probably secondary to the advanced/chronic stage of such lesions.[15,24,25] The role of infectious agents in the etiopathogenesis of EED is still unclear, but evidence suggests that perhaps these agents serve as antigenic triggers of a hypersensitivity response that manifests as EED.

Connective tissue diseases and autoimmune diseases have also been seen in association with EED.

TREATMENT

As is the case with cutaneous vasculitis, treatment is aimed at alleviating discomfort associated with the lesions, diminishing damage to the skin, and eradication/minimization of underlying/associated conditions. Reports in the literature on treatment options are primarily anecdotal or based on experience in small case

TABLE 165-1
Associated Entities

Infectious Diseases	Inflammatory Diseases	Connective Tissue Diseases/ Autoimmune Conditions	Malignancy	Medications	Miscellaneous
Chronic bacterial infections	Crohn disease	Cutaneous lupus erythematosus	Polycythemia vera	Rifampin	Pulmonary infiltrates
HIV, HIV-2	Mixed cryoglobulinemia	Relapsing polychondritis	Myelodysplasia	Pyrazinamide	Pleural effusions
Human herpesvirus 6	Pyoderma gangrenosum	Rheumatoid arthritis	IgA/IgG paraproteinemia (monoclonal gammopathy/ MGUS/myeloma)	Isoniazid	Mosquito bites
Measles virus		Systemic lupus erythematosus	Hairy-cell leukemia	Streptomycin	Insulin-dependent diabetes mellitus
Streptococcal infection/ rheumatic fever		Myasthenia gravis	Chronic lymphocytic leukemia		Hyperimmunoglobulinemia D syndrome
Syphilis		Celiac disease	B-cell lymphoma		Hypereosinophilic syndrome
Tuberculosis		Dermatitis herpetiformis	Lymphadenopathy-associated virus/ human T-cell lymphotrophic virus type 3		Acro-osteolysis
Hepatitis B		Autoimmune keratolysis of the eye			Hemophilia Peripheral ulcerative keratitis
		Sjogren syndrome[21]	Pulmonary lymphoepithelioma-like carcinoma[22]		

HIV = human immunodeficiency virus; Ig = immunoglobulin; MGUS = monoclonal gammopathy of undetermined significance.

series. Management of EED remains challenging due to the chronic and recurrent nature of the disease. In general, treatment of the underlying cause or infectious process may result in resolution of lesions.[1] Dapsone- and sulfone-based therapies are considered first-line treatment choices for EED.[1,3,14,26] Dramatic and rapid response is usually seen within 48 hours of initiation of therapy, with near complete resolution of lesions within weeks to months.[26] However, lesions may recur with discontinuation of therapy.[1,23] The responsiveness of EED and other neutrophil-driven dermatoses to dapsone and sulfonamides is not completely known but is thought to be secondary to its inhibitory effects on neutrophil chemotaxis and function.[13] In patients with HIV infection, treatment with a combination of antiretroviral agents and dapsone or sulfonamides may be beneficial.[1] Other reported treatments with variable success in EED include niacinamide and tetracycline,[27] colchicine,[28] intralesional, potent topical or oral corticosteroids,[3] phenformin,[29,30] clofazimine,[12] and cyclophosphamide.[31]

CONCLUSION

EED is a distinctive form of cutaneous vasculitis. It is the clinical pattern combined with the chronicity of this process that is unique to EED. Repeated antigenic stimulation or infection appears to play a key role in the pathogenesis. Although microscopic features of early lesions are shared with other cutaneous vasculitides, in the chronic phase of the disease, the microscopic pattern may resemble various other entities characterized by granulation response and healing skin. It is important to search for an underlying disease and to evaluate patients carefully for infection. Otherwise, treatment recommendations are anecdotal and similar to those used for other cutaneous vasculitides.

KEY REFERENCES

Full reference list available at www.DIGM8.com

DVD contains references and additional content

1. Gibson LE, El-Azhary R: Erythema elevatum diutinum. *Clin Dermatol* **18**:295, 2000
6. Rovel-Guitera P et al: IgA antineutrophil cytoplasmic antibodies in cutaneous vasculitis. *Br J Dermatol* **143**:99, 2000
8. Wahl CE, Bouldin MB, Gibson LE: Erythema elevatum diutinum: Clinical, histopathologic, and immunohistochemical characteristics of six patients. *Am J Dermatopathol* **27**:397, 2005
9. Ayoub N et al: Antineutrophil cytoplasmic antibodies of IgA class in neutrophilic dermatoses with emphasis on erythema elevatum diutinum. *Arch Dermatol* **140**:931, 2004
14. Yiannias JA, el-Azhary RA, Gibson LE: Erythema elevatum diutinum. A clinical and histopathologic study of 13 patients. *J Am Acad Dermatol* **26**:38, 1992
23. Woody CM, Lane JE, Davis LS: Erythema elevatum diutinum in the setting of connective tissue disease and chronic bacterial infection. *J Clin Rheumatol* **11**:98, 2005
25. LeBoit PE, Cockerell CJ: Nodular lesions of erythema elevatum diutinum in patients infected with the human immunodeficiency virus. *J Am Acad* **28**:919, 1993

Chapter 166 :: Adamantiades–Behçet Disease

:: Christos C. Zouboulis

ADAMANTIADES–BEHÇET DISEASE AT A GLANCE

- Rare disease with worldwide distribution but strongly varying prevalence; certain ethnic groups are mainly affected.
- A genetically determined disorder with a probable environmental triggering factor.
- Multisystem occurrence, with oral aphthous ulcers, genital ulcers, papulopustules, erythema nodosum-like lesions, uveitis, and arthropathy as most common signs.
- Inflammatory disease representing a neutrophilic vascular reaction or vasculitis.
- Chronic relapsing progressive course and potentially poor prognosis (especially in males with systemic presenting signs; mortality, 0–6%).

Adamantiades–Behçet disease is a multisystem inflammatory disease of unknown etiology, classified as systemic vasculitis involving all types and sizes of blood vessels and characterized clinically by recurrent oral aphthous and genital ulcers, skin lesions, and iridocyclitis/posterior uveitis, occasionally accompanied by arthritis and vascular, gastrointestinal, neurologic, or other manifestations[1,2] (Fig. 166-1).

HISTORICAL ASPECTS

Hippocrates of Kos (460–377 BC) used the designation "στοματα αφθωδεα, ελκωδεα" (oral aphthous ulcers) in a probable first description of a patient with the disease (*Epidemion Book III*, Case 7). The disease is named after Benediktos Adamantiades, a Greek ophthalmologist and Hulûsi Behçet, a Turkish dermatologist, who, in 1931 and 1937, respectively, described patients with the characteristic clinical complex insisting for a single clinical entity.[3] The first international multidisciplinary conference was organized by two dermatologists, Drs. M. Monacelli and P. Nazarro, 1964 in Rome, Italy.

EPIDEMIOLOGY

Adamantiades–Behçet disease presents a worldwide occurrence with varying prevalence, being endemic in the Eastern and Central Asian and the Eastern Mediterranean countries (along the so-called Silk Road) and rare in Northern European countries, Central and Southern Africa, the Americas, and Australia.[4] A prevalence of 80 to 420 patients per 100,000 inhabitants has been reported in Turkey,[5] 7 to 30 patients per 100,000 inhabitants in the rest of the Asian continent (Japan, 14–31:100,000; Korea, 7.3:100,000; Northern China, 14:100,000; Saudi Arabia, 20:100,000; Iran, 17:100,000) and 1.5–7.5:100,000 in Southern Europe. In Northern Europe (0.27–1.18:100,000) and the United States (0.12–0.33:100,000), the disease is rare.[4] In countries with several ethnic populations, including of Turkmen and Mongol descents, the latter are mainly affected. The increasing prevalence of the disease is due to its chronic character. Its annual incidence is low; 0.75 to 1.0 new cases per 100,000 inhabitants were assessed in Japan (1990) and Germany (2005).[6] Adamantiades–Behçet disease most often affects patients in their 20s and 30s; however, early and late onsets (first year of life to 72 years) have been reported. Juvenile disease rates are 2 to 21% in different ethnic groups; its prevalence was estimated to be 0.17:100,000 in France. In contrast to old Japanese and Turkish reports of male predominance, the male-to-female ratio drastically decreased

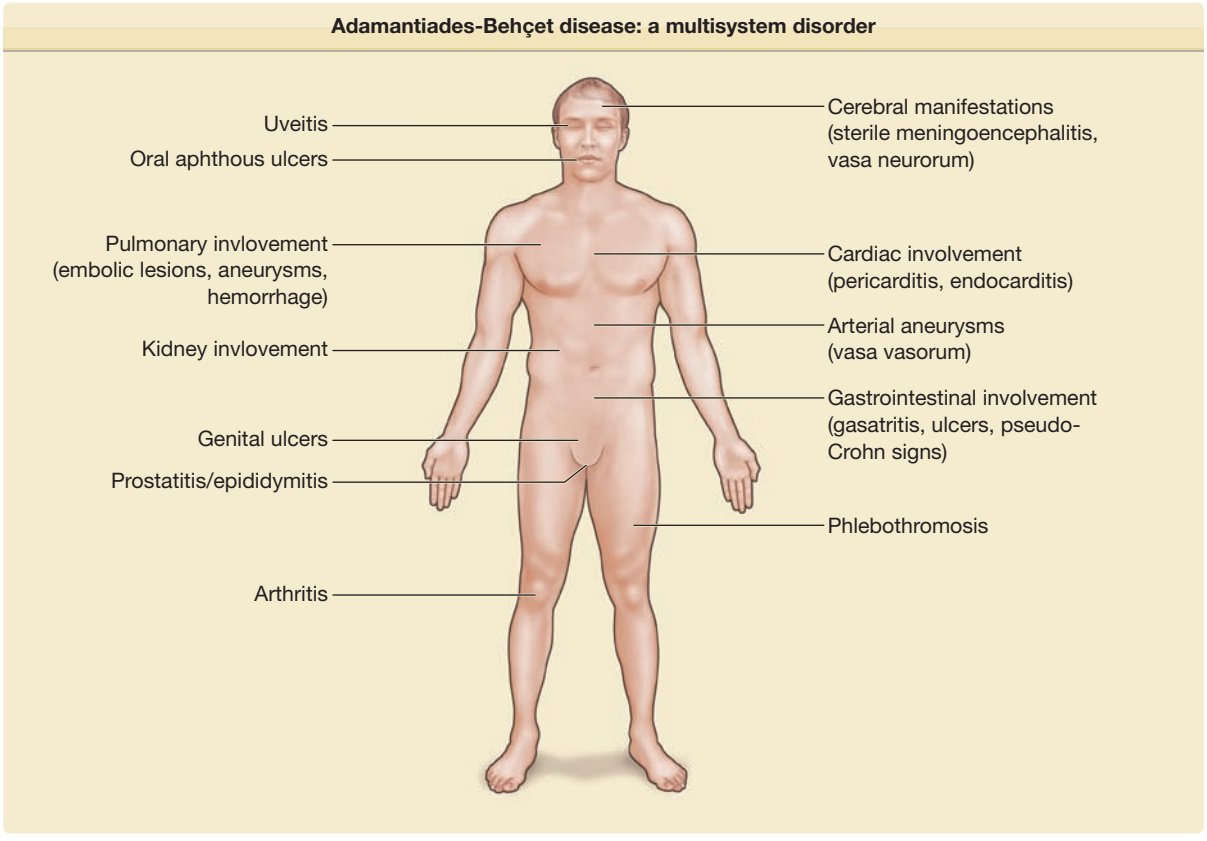

Figure 166-1 Adamantiades–Behçet disease: a multisystem disorder.

in the last 20 years. Currently, both genders are equally affected; a male predominance is still observed in Arab populations, whereas female predominance is evident in Korea, China, some Northern European countries, and the United States.

ETIOLOGY AND PATHOGENESIS

The etiology of the disease remains unknown, although genetic factors, infectious agents, environmental pollution, immunologic mechanisms, and endothelial and clotting factors have been implicated and studied intensively.[7,8] The endemic occurrence along the historical Silk Road, the major involvement of certain ethnic groups (mostly of Turkmen and Mongol descent), and associated immunogenetic data support the hypothesis that the disease followed the migration of these old nomadic tribes. On the other hand, the wide variation of the disease prevalence in the same ethnic group in association with different geographic areas of residence indicates an additional environmental triggering factor. Therefore, transfer of genetic material and/or of an unknown exogenous agent may have been responsible for the expansion of the disease.

GENETICS AND IMMUNOGENETICS

There is no specific mode of Mendelian transmission in Adamantiades–Behçet disease.[7,8] Familial occurrence with regional differences has been reported, being more frequent in Korea (15%) than in Japan or China (2–3%) and in Arab countries, Israel, and Turkey (2–18%) than in Europe (0–5%). An earlier disease onset in children compared with their parents and a higher frequency of familial cases in juveniles than in adults has been observed.

A significant association exists between the disease and human leukocyte antigen-B_{51} (HLA-B_{51}) in Japan, the Middle East, and the Mediterranean countries; however, this relationship is not as strong in Western countries.[9] The allele also seems to be associated with a more severe prognosis.[10] Its exact role in the disease mechanism is still unknown; however, it may be involved in the disease development through specific antigen presentation, molecular mimicry with microbial antigens, or participation in linkage disequilibrium with a presently unknown susceptibility gene.[11,12] Among the 24 currently described alleles, HLA-B_{5101} and -B_{5108} have most frequently been associated with Adamantiades–Behçet disease.[13] Shared amino acid residues (defining the Bw4 epitope) are crucial for antigen binding and natural killer cell interactions,[14] and Bw_4 was also reported to contribute to the severity of the disease.[15] Genes possibly associated with the disease have been localized on chromosome 6 in the region between the *tumor necrosis factor* gene and *HLA-B* or *HLA-C* genes, including the *major histocompatibility complex class I chain A* gene (A6 allele) and genes for heat shock proteins[8,11,13,16] (eFig. 166-1.1 in online edition). In addition, a novel susceptibility locus mapped to 6p22–23 was detected.[13] Lately, associations on chromosomes 1p31.3

[Interleukin (IL) 23R-IL12RB2] and 1q32.1 (IL10) were found by genome-wide association studies.[14,17] A haplotype association of *IL-8* gene with Adamantiades–Behçet disease was also detected.[18] Polymorphisms in gene encoding for host effector molecules may contribute to the disease susceptibility to and/or severity of the disease, such as in IL-23R reported in a Chinese Han population.[19]

INFECTIOUS PRECIPITANTS

Adamantiades–Behçet disease is not considered contagious as no horizontal transmission has ever been reported. However, viral and bacterial infections have been implicated in initiating immunopathologic pathways, leading to the onset of the disease.[7,8]

VIRAL AGENTS. Early theories of the pathogenesis of Adamantiades–Behçet disease proposed a viral or other infectious etiology.[3] Partial transcription of herpes simplex virus type 1 (HSV-1) DNA in patients' peripheral blood lymphocytes was reported.[7] HSV-1 DNA was detected in patients' saliva and oral and genital ulcers, and HSV-1 antibodies were found in patients' serum.

BACTERIAL AGENTS. The disease activity has been known to correlate with bacterial infection, particularly *Streptococci*.[7] *Streptococcus sanguinis (S. sanguinis)* dominates the flora of the oral mucosa in patients with the disease and appears to be the most relevant *Streptococcus* strain as a provoking factor for initiation of the disease.[20] *Streptococcus* antigens and antistreptococcal antibodies are frequently found in the oral mucosa and serum of patients. The involvement of immunoglobulin A protease-producing *S. sanguinis* is proposed as an explanation for a chronic infection leading to initiation of Adamantiades–Behçet disease. High titers of the immunogenic *S. sanguinis* antigen KTH-1 have been detected in patients. In addition, exposure of the patients to *Streptococcus* antigens may be a major provoking factor for disease activity. The lipoprotein of *Mycoplasma fermentans* MALP-404 was found in the serum of patients with Adamantiades–Behçet disease but not in healthy controls.[21] Interestingly, MALP-404 contains a peptide motif, which can be presented by HLA-B_{51}. A possible role for bacterial stimulation of monocytes via Toll-like receptor-2 producing neutrophil-stimulating proinflammatory factors in Adamantiades–Behçet disease was currently detected.[22]

IMMUNOLOGIC MECHANISMS

Immunologic mechanisms are considered to play a major role in the pathogenesis of Adamantiades–Behçet disease.[7,8,13,16] The disease has currently been classified among the autoinflammatory disorders,[23] which are caused by primary dysfunction of the innate immune system.

AUTOIMMUNE MECHANISMS. The major microscopic finding at most sites of active disease is an immune-mediated occlusive vasculitis. The pathergy reaction (see Section "Clinical Findings") is induced by the rapid accumulation of neutrophils (hyperchemotaxis) and later by T lymphocytes and monocytes/macrophages at the needle prick sites. T cells in the peripheral blood and in the involved tissues are increased, and a predominant T helper 1 immune response induced by IL-12 has been demonstrated.[24] Patients' lymphocytes also express CD29 molecules and bind to endothelial cells in active disease. In addition to defective T-cell immunity, B-cell activation is impaired. Circulating immune complexes, together with enhanced neutrophil migration, may be involved; diversity of T cells indicates that specific T-cell responses to several antigens may lead to the variety of symptoms.[25] Tropomyosins and the 160-kDa polypeptide kinectin have been detected as autoantigens in Adamantiades–Behçet disease.[26,27]

HEAT SHOCK PROTEINS. Increased levels of heat shock protein (HSP)-specific antibodies in serum have been found in Adamantiades–Behçet disease.[28,29] T cells respond to 60-kDa HSP, and four different peptide determinants within 60-kDa HSP identified by T-cell epitope mapping have been suggested to be involved in the pathogenesis of the disease.

CYTOKINE MEDIATORS. Various proinflammatory cytokines, such as IL-1, -8, -12, -17, -23, and tumor necrosis factor-α, are elevated in the sera of patients with Adamantiades–Behçet disease.[30–34] In particular, IL-8 seems to play an important role, can also be released by endothelial cells, has a potent effect on the inflammatory response, and is a sensitive marker of disease activity.[30–32] Cytokine release may be dependent on the involved organ.[30,31,33]

ENDOTHELIAL CELLS. The endothelium seems to be the primary target; however, it may just be subject to the bizarre behavior of the immune system.[35] An immunoglobulin M-type, 47-kDa cell surface HSP against endothelial α-enolase was identified in the serum of patients with Adamantiades–Behçet disease.[36] Plasma endothelin-1 concentrations were found significantly increased, perhaps indicating vasoconstriction and being the direct result of elevated synthesis by injured vascular endothelial cells. Thrombomodulin, a cell surface glycoprotein of vascular endothelium, which is also increased in the plasma of patients with active disease, potentially damages the endothelial cells.

CLINICAL FINDINGS

Adamantiades–Behçet disease is a chronic, recurrent, multisystem, and, occasionally, life-threatening disorder.[1,6] Recurrent oral aphthous ulcers, recurrent genital ulcers, skin manifestations, ocular lesions, and arthritis/arthropathy are the most frequent clinical manifestations. Vascular, gastrointestinal, neurologic, psychiatric, pulmonary, renal, and cardiac manifestations; epididymitis; and other findings can also occur. The clinical picture usually develops within a few months after the presenting sign; both an acute multisystem presentation and long-term development of the disease over years are possible.

APPROACH TO THE PATIENT WITH ORAL ULCERS, GENITAL ULCERS, OR IRIDOCYCLITIS/POSTERIOR UVEITIS

Diagnosis of Adamantiades–Behçet disease is based on clinical signs, as pathognomonic laboratory test or histologic characteristics are absent. There are several sets of diagnostic criteria, the most popular of them being the criteria of the International Study Group[37] and those of the Behçet Disease Research Committee of Japan.[38] However, there have been several problems with these criteria, including their performance in selectivity and specificity, so that both of them have currently been revised[2,39,40] (Tables 166-1, 166-2).

TABLE 166-1
Revised Diagnostic Criteria of the Behçet's Disease Research Committee of Japan[a]

- Main points
- Main symptoms
  - Recurrent oral aphthous ulcers
  - Skin lesions
    - a. Erythema nodosum (see eFig. 166-5.1B in online edition)
    - b. Superficial thrombophlebitis
    - c. Papules Skin hypersensitivity
  - Ocular lesions
    - a. Iridocyclitis or sequelae
    - b. Posterior uveitis or sequelae
- Genital ulcers
- Additional symptoms
  - Arthritis without deformity or sclerosis
  - Epididymitis
  - Gastrointestinal lesions represented by ileocecal ulcerations
  - Vascular lesions
  - Central nervous system lesions moderate or severe
- Criteria for diagnosis of disease types
  - Complete types: four main symptoms
  - Incomplete types: three main symptoms or two main and two additional symptoms or typical ocular lesions and another main symptom or two additional symptoms
  - Suspected disease: typical main symptoms not fulfilling the criteria for an incomplete type
  - Special lesions: certain gastrointestinal, vascular, and nervous system lesions
- Clinical laboratory data contributing to the diagnosis (not essential)
  - Negative or positive pathergy test
  - Negative or positive prick test to vaccinate for streptococci
  - Inflammatory response
  - Positive HLA-B51
  - Other pathologic findings
- Additional points
  - Nontypical symptoms should not be diagnosed as Behçet disease.
  - One of the criteria (a) to (c) of the skin lesions and (a) or (b) of the ocular lesions is enough for the diagnosis of the relevant symptom if the lesion occurs frequently

[a]In abbreviated form.
From Suzuki Kurokawa M, Suzuki N: Behçet's disease. *Clin Exp Med* **4**:10, 2004, with permission.

TABLE 166-2
Revised International Criteria for Behçet Disease (International Team for the Revision of ICBD; coordinator: F. Davatchi)[a]

Symptom	Points
Ocular lesions (recurrent)	2
Oral aphthosis (recurrent)	2
Genital aphthosis (recurrent)	2
Skin lesions (recurrent)	1
Central nervous system	1
Vascular manifestations	1
Positive pathergy test[b]	1

[a]BCD scoring: score ≥4 indicates Adamantiades–Behçet disease.
[b]Though the main scoring system does not include pathergy test, where pathergy testing *is* conducted, a positive result may be included for one extra point.
From Schirmer M et al: Evaluation and revision of the International Criteria for Behçet's Disease (ICBD). *Abstracts of the 14th International Conference on Behçet's Disease*, London, UK, 2010, p. 145, with permission.

MUCOCUTANEOUS LESIONS

Recurrent oral aphthous and genital ulcers are the most frequently observed mucosal manifestations. Oral aphthous ulcers are the presenting sign in more than 80% of the cases.[1,6,16] Although recurrent aphthous stomatitis is a common disorder, only a few patients progress to Adamantiades–Behçet disease, and it is not possible to determine in whom or when the transition may occur.[41] Typically, lesions are multiple, painful, 1–3 cm in diameter, and sharply margined with a fibrin-coated base and surrounding erythema (Fig. 166-2). Oral aphthous ulcers usually heal without scarring (92%). Genital ulcers may not recur as often and usually heal with a characteristic scar (64%–88%; Fig. 166-3). Spontaneous healing of aphthae occurs within 4 days to 1 month; genital ulcers may persist longer. Large oral ulcerations can also be associated with problems such as pharyngeal involvement, dysphagia, and dyspnea or fistulae involving the pharynx, larynx, trachea, or esophagus. Genital ulcers can occur on the penis, scrotum, vagina, labia, and urethra, and also in the anal, perineal, and inguinal regions.

Skin lesions that should be accepted as diagnostically relevant in Adamantiades–Behçet disease should be confined to pustular vasculitic lesions (including pathergy lesions), erythema nodosum-like lesions, Sweet-like lesions, pyoderma gangrenosum-like lesions, and palpable purpuric lesions of necrotizing venulitis (see Fig. 166-5). All of these lesions are characterized in their early stages by a neutrophilic vascular reaction. Acneiform lesions or follicle-based pustules should not be considered relevant.[42]



Figure 166-2 Single (**A**) and multiple (**B**) oral aphthous ulcers. (**A** from Altenburg A et al: Epidemiology and clinical manifestations of Adamantiades-Behçet disease in Germany—Current pathogenetic concepts and therapeutic possibilities. *J Dtsch Dermatol Ges* **4:** 49, 2006, with permission.)

SYSTEMIC LESIONS

Ocular involvement is the major cause of morbidity in patients with Adamantiades–Behçet disease. The most diagnostically relevant lesion is posterior uveitis (also called *retinal vasculitis*), which can lead to blindness (Fig. 166-4A). Other ocular lesions include anterior uveitis, hypopyon (pus in the anterior chamber of the eye, which is now—due to early treatment—uncommon; see Fig. 166-4B), and secondary complications such as cataract, glaucoma, and neovascular lesions.[43] Retinal inflammation can lead to vascular occlusion and, ultimately, tractional retinal detachment. Severe vitreous involvement, chronic cystoid macular edema, and possible—presumably also vasculitic—involvement of the optic nerve can result in vision loss. Recurrent vasculitic changes can ultimately lead to ischemic optic nerve atrophy.

The characteristic arthritis is a nonerosive, asymmetric, sterile, seronegative oligoarthritis; however, symmetric polyarticular involvement is common. Joint manifestations frequently occur first in one knee or ankle and then the other as migratory monoarthritis,

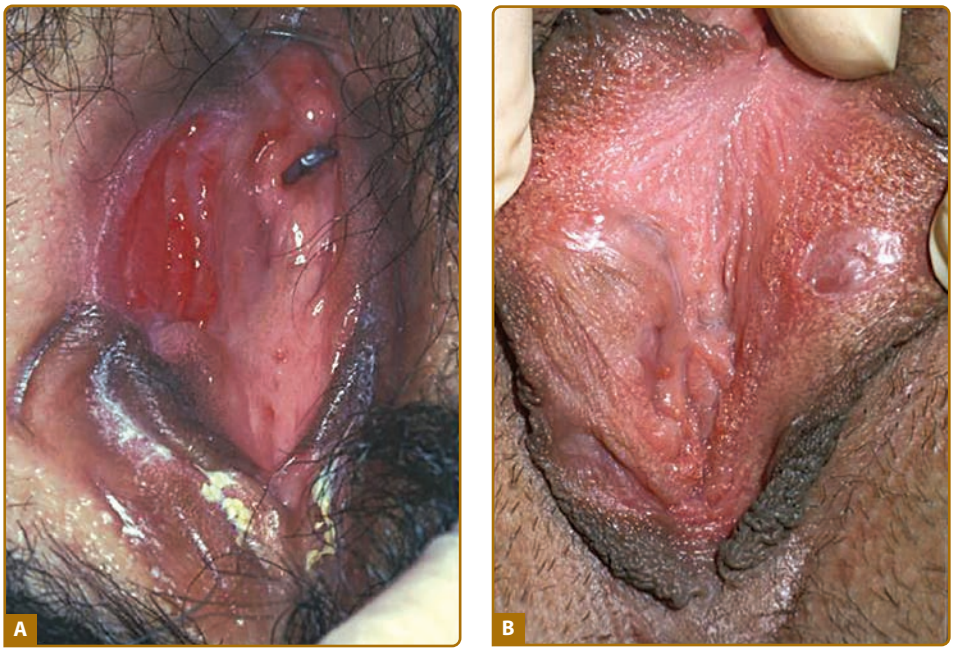

Figure 166-3 Genital ulcer (**A**) healing with a demarcated flat scar (**B**).

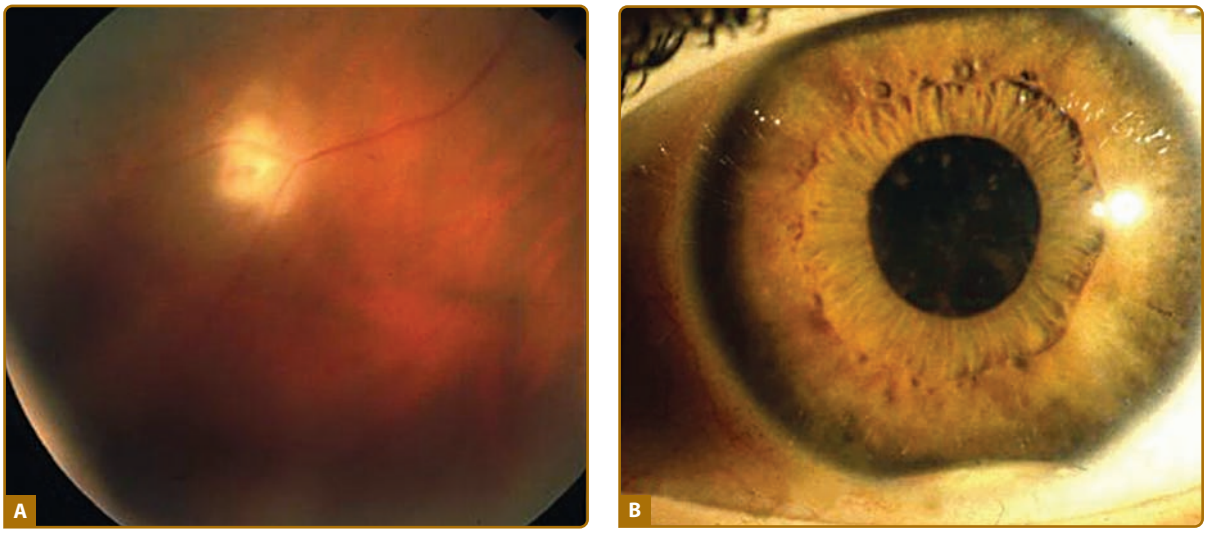

Figure 166-4 **A.** Posterior uveitis. **B.** Hypopyoniritis. (From Altenburg A et al: Epidemiology and clinical manifestations of Adamantiades-Behçet disease in Germany—Current pathogenetic concepts and therapeutic possibilities. *J Dtsch Dermatol Ges* **4:** 49, 2006, with permission.)

then in both joints simultaneously, and finally affecting nearly all joints. An HLA-B27-positive, erosive sacroiliitis has to be excluded.

Systemic vascular involvement can be significant and includes venous occlusions and varices, arterial occlusions, and aneurysms, often being migratory. Cases of large-vein thrombosis (inferior vena cava, cranial venous sinuses) or large-artery aneurysms are potentially fatal.[1,6] Arterial involvement is rather rare and usually presents in the form of thromboses and, less often, of aneurysms, resulting from multicentric arteritis. Pulmonary artery aneurysms are the principal feature of pulmonary involvement in Adamantiades–Behçet disease, occasionally resulting in coughing and hemoptysis. Cardiac involvement can include myocarditis, coronary arteritis, endocarditis, and valvular disease. A wide spectrum of renal manifestations can occur, varying from minimal change disease to proliferative glomerulonephritis and rapidly progressive crescentic glomerulonephritis. Immune complex deposition is thought to be responsible for the underlying pathogenesis in some cases of glomerulonephritis. Gastrointestinal complaints can be a symptom for aphthae throughout the gastrointestinal tract and can rarely result in perforation and peritonitis (0.5%). Inflammatory bowel disease has to be excluded. Sterile prostatitis and epididymitis can be present in male patients without genital ulcers.

Significant neurologic manifestations occur in approximately 10% of patients and may be delayed in onset. Meningoencephalitis, cerebral venous sinus thrombosis, benign intracranial hypertension, cranial nerve palsies, brainstem lesions, and pyramidal or extrapyramidal lesions have been described. Poor prognosis is associated with a progressive course, relapses after treatment, repeated attacks, and cerebellar symptoms or parenchymal disease. Neurologic manifestations usually present with severe headache. Further symptoms include gait disturbance, dysarthria, vertigo, and diplopia as well as hyperreflexia, epileptic seizures, hemiplegia, ataxia, or a positive Babinski reflex. Psychiatric symptoms, such as depression, insomnia, or memory impairment, are also signs of neurologic involvement.

HISTOPATHOLOGY

Characteristic histopathologic features of Adamantiades–Behçet disease are vasculitis and thrombosis (Fig. 166-5). Biopsies from early mucocutaneous lesions show a neutrophilic vascular reaction with endothelial swelling, extravasation of erythrocytes, and leukocytoclasia or a fully developed leukocytoclastic vasculitis with fibrinoid necrosis of blood vessel walls.[1,6] Although there are reports of lesions that consist primarily of a lymphocytic perivasculitis, most of these lesions are likely older. The neutrophilic vascular reaction should be considered the predominant histopathologic finding.[42] Aneurysms can also develop in large arteries as a result of vasculitis of the vasa vasorum with penetration of the lamina elastica.

SPECIAL TESTS

PATHERGY TEST

A positive pathergy test (hyperreactivity reaction) manifests within 48 hours as an erythematous papule (>2 mm) or pustule at the site of a skin needle prick or after intracutaneous injection of 0.1-mL isotonic salt solution using a 20-gauge needle without prior disinfection of the injection site (see eFig. 166-5.1A in online edition). The skin prick is generally placed at an angle of 45°, 3 to 5 mm intracutaneously on the volar forearm. Erythema without infiltration is considered a negative finding. Provoked oral aphthae and genital

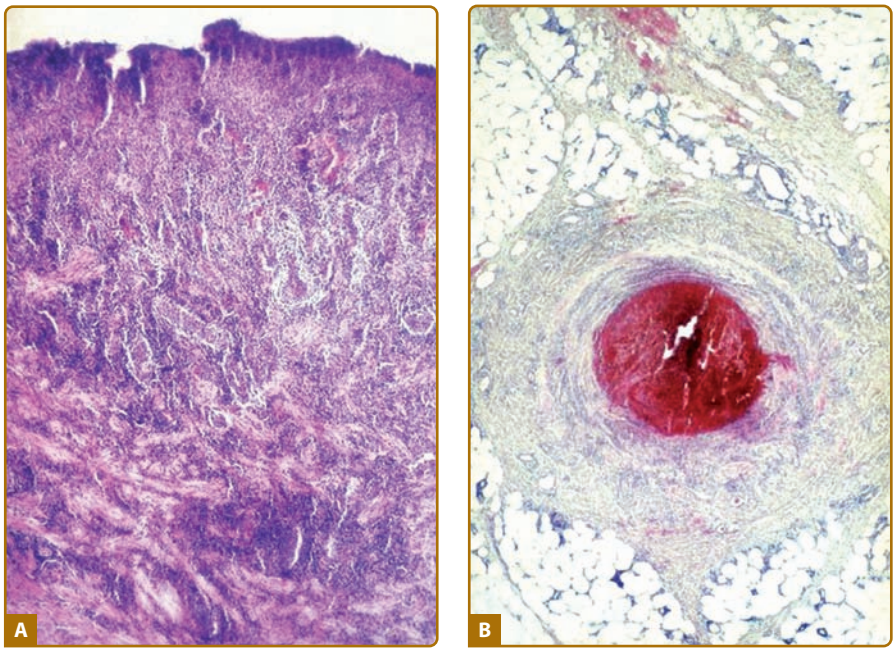

Figure 166-5 **A.** Abundant mixed inflammatory infiltrate dominated by neutrophils in an oral ulcer of Adamantiades–Behçet disease. **B.** Vessel thrombosis in an erythema nodosum-like lesion.

ulcers after injection or injury (such as chorioretinitis in the corneal region of the eye after photocoagulation of the ocular fundus region) can also be considered as positive pathergy phenomenon. Broader pathergy phenomena also include the occurrence of aneurysms around vascular anastomoses as well as local recurrence of ulcers after resection of affected bowel segments. Although a positive pathergy reaction is a sign of Adamantiades–Behçet disease, it is not pathognomic, as it can also occur in patients with pyoderma gangrenosum, rheumatoid arthritis, Crohn disease, and genital herpes infection.

RADIOLOGIC FINDINGS

Scintigraphic evidence of arthritis is found in 50% of the patients.[6] Cranial magnetic resonance imaging allows documentation of hypodense or atrophic changes in the brain. Electroencephalographic detection of diffuse α-waves is considered a positive finding. Vascular lesions can be detected by angiography.

DIFFERENTIAL DIAGNOSIS

(Box 166-1)[6,44]

CLINICAL COURSE AND PROGNOSIS

The clinical course of Adamantiades–Behçet disease is variable. There can be a delay of up to several years before the diagnosis is made, and this may influence the prognosis. Mucocutaneous and joint manifestations usually occur first. Recurrent erythema nodosum and $HLAB_{51}$ positivity are risk factors for the development of superficial thrombophlebitis and vision loss,[10,45,46] and superficial thrombophlebitis, ocular lesions, and male gender are risk factors for the development of systemic vessel involvement.[10,45,47] A severe course, including blindness, meningoencephalitis, hemoptysis, intestinal perforation, and severe arthritis, occurs in approximately 10% of patients. Blindness can often be prevented with early aggressive therapy of posterior uveitis. Lethal outcome has been seen in 0 to 6% of affected patients in different ethnic groups. Central nervous system and pulmonary and large vessel involvement, as well as bowel perforation, are the major life-threatening complications; death may also result as a complication of immunosuppressive therapy. Markers of severe prognosis include HLA-B_{51} positivity, male gender, and early development of systemic signs.[10] Onset in childhood does not necessarily predict a poor prognosis. Spontaneous remissions of certain or all manifestations of the disease have been observed. Ophthalmic and neurologic sequelae are leading causes of morbidity, followed by severe vascular and gastrointestinal manifestations, and their effects on morbidity may be cumulative.

TREATMENT

The choice of treatment for patients with Adamantiades–Behçet disease depends on the site and severity of the clinical manifestations of the disease. Recurrent aphthae are most often treated with palliative agents, such as mild diet, avoidance of irritating agents, and potent topical glucocorticoids and local anesthetics,[48,49] lately topical hyaluronic acid 0.2% gel 2 × /day over

BOX 166-1 DIFFERENTIAL DIAGNOSIS OF ADAMANTIADES–BEHÇET DISEASE

- Oculocutaneous/mucocutaneous syndromes
  - Erythema multiforme exudativum and variants, including Stevens–Johnson syndrome
  - Vogt–Koyanagi–Harada syndrome
  - Reiter disease
  - Bullous autoimmune diseases: Pemphigus vulgaris, cicatricial mucous membrane pemphigoid, epidermolysis bullosa acquisita
  - Viral infections (herpes, coxsackie, echo)
  - Syphilis
- Articulomucocutaneous syndromes
  - Systemic lupus erythematosus
  - MAGIC syndrome (*m*outh *a*nd *g*enital ulcers with *i*nflamed *c*artilage)
  - Yersiniosis
  - Arthropathic psoriasis
- Gastrointestinal/mucocutaneous syndromes
  - Ulcerative colitis, Crohn disease
  - Tuberculosis
  - Bowel-associated dermatitis-arthritis syndrome
- Aphthae
  - Recurrent aphthous stomatitis (RAS)
  - Cyclic neutropenia
  - Herpes simplex infection
- Genital ulcers
  - Ulcus vulvae acutum (Lipschütz ulcer)
  - Herpes simplex infection
  - Sexually transmitted infections
- Uveitis
  - Other forms of uveitis
- Arthritis
  - Ankylosing spondylitis
  - Juvenile rheumatoid arthritis
- Central nervous system manifestation
  - Multiple sclerosis
  - Neuro-Sweet disease
- Lung manifestation
  - Sarcoidosis

Adapted from Altenburg A et al: Epidemiology and clinical manifestations of Adamantiades-Behçet disease in Germany—Current pathogenetic concepts and therapeutic possibilities. *J Dtsch Dermatol Ges* **4:** 49, 2006, and Rogers RS 3rd: Pseudo-Behçet's disease. *Dermatol Clin* **21:** 49, 2003.

BOX 166-2 TOPICAL TREATMENT OF ORAL APHTHOUS ULCERS

- Mild diet
- Avoidance of hard, spicy, or salty nutrients and irritating chemicals, such as toasted bread, nuts, oranges, lemons, tomatoes, spices (pepper, paprika, curry), alcohol- or CO_2-holding drinks, mouthwashes, toothpastes containing sodium lauryl sulfate[a]
- Topical treatment of the aphthous oral ulcers includes:
  - Caustic solutions (silver nitrate, 1%–2%; tinctura myrrha, 5–10% weight/volume; H_2O_2, 0.5%; methyl violet, 0.5%) 1–2 ×/day
  - Antiseptic and anti-inflammatory preparations (amlexanox, 5% in oral paste[a]; triclosan, 0.1% mouthwash solution and in toothpastes[a]; amyloglucosidase- and glucoseoxidase-containing toothpastes[a]; hexetidine, 1%, chlorhexidine, 1–2% mouthwash solutions; benzydamine; camomile extracts); 3% diclofenac in 2.5% hyaluronic acid[a]; hyaluronic acid 0.2% gel; tetracycline mouthwash (as glycerine solution 250 mg/5 mL glycerine) 2 min 4–6 ×/day[a] (caveat: pregnancy); doxymycine in isobutylcanoacrylate[a]
  - Corticosteroids (triamcinolone mucosal ointment, dexamethasone mucosal paste, betamethasone pastilles) 4 ×/day or during the night (ointment/paste) or intrafocal infiltrations with triamcinolone suspension 0.1–0.5 mL per lesion
  - Anesthetics (lidocaine, 2–5%; mepivacaine, 1.5%; tetracaine, 0.5–1% gels or mucosal ointments) 2–3 ×/day (caveat: allergy)
  - 5-Aminosalicylic acid (5% cream) 3 ×/day (reduces the duration of lesions and the pain intensity)
  - Cyclosporine A, 500 mg solution for mouthwash 3 ×/day (effective as topical immunosuppressive drug)
  - Sucralfate suspension, 5 mL × 4/day[a] (for oral aphthous and genital ulcers)
- A close association of smoking with a decrease of recurrences of oral aphthous ulcers has been described.

[a]Small, randomized, double-blind, placebo-controlled trial against placebo.

30 days was found effective (Box 166-2).[50] For the topical treatment of genital ulcers and skin lesions, corticosteroid and antiseptic creams can be applied for up to 7 days. Painful genital ulcerations can be managed by topical anesthetics in cream. Corticosteroid injections (triamcinolone acetonide, 0.1–0.5 mL/lesion) can be helpful in recalcitrant ulcerations. They can also be beneficial on panuveitis and cystoid macular edema as a single intravitreal injection (triamcinolone acetonide 4 mg).[51,52]

Patients with mucocutaneous lesions resistant to topical treatment, those with systemic involvement, and patients with markers of poor prognosis are candidates for systemic treatment.[53,54] Several compounds have been found effective in randomized, double-blind, placebo-

BOX 166-3 SYSTEMIC TREATMENT OF ADAMANTIADES–BEHÇET DISEASE[a]

DRUG	DOSE	INDICATION	RCT
Methylprednisolone	40 mg/every 3-week IM	Erythema nodosum (but not orogenital ulcers)	55
Rebamipide	300 mg/day PO (caveat: pregnancy, lactation)	Oral ulcers	56
Colchicine	1–2 mg/day PO (caveat: pregnancy, lactation—induces oligozoospermia)	Oral aphthous ulcers, genital ulcers, folliculitis, erythema nodosum	57
		Erythema nodosum, arthritis, genital ulcers, (oral ulcers in females)	58
	1.5 mg/day	Ineffective	59
Dapsone	100 mg/day PO (caveat: pregnancy, lactation—methemoglobin increase: ascorbic acid, 500 mg/day)	Oral ulcers, genital ulcers, skin lesions, pathergy test	60
Azathioprine	2.5 mg/kg/day (caveat: pregnancy, lactation, severe liver disease, bone marrow depression, severe infection, children)	Recent onset ocular disease	61
Interferon-α 2a	6×10^6 IU/3 ×/week SC (caveat: pregnancy, lactation—induces psychotic signs, psoriasis, myopathy)	Oral ulcers, genital ulcers, papulopustular lesions	62
Interferon-α	1,000 and 2,000 IU/day PO	Ineffective	63
Thalidomide	100 mg/day or 300 mg/day (caveat: pregnancy, lactation—induces polyneuropathy: minimized at 25 mg/day)	Oral ulcers, genital ulcers, papulopustular lesions	64
Cyclosporine A	10 mg/kg/day PO (against colchicine, 1 mg/day PO) (caveat: lactation, renal insufficiency—induces pathologic central nervous system findings)	Ocular manifestations, oral ulcers, skin lesions, genital ulcers	65
	5 mg/kg/day PO (against cyclophosphamide pulses)	Visual acuity	66
	5 mg/day PO (against conventional treatment)	Ocular attacks	67
Etanercept	25 mg/2 ×/week PO (caveat: pregnancy, lactation)	Oral ulcers, nodular lesions, papulopustular lesions (not pathergy test)	68
Aciclovir	5 × 800 mg for 1 week + 2 × 400 mg/day for 11 week	Ineffective	69
Azapropazone	900 mg/day over 3 weeks PO	Arthritis	70

[a]Evidence grade A—randomized, double-blind, placebo-controlled trial (RCT) against placebo except otherwise mentioned.

controlled trials[55–70] (Box 166-3). Additional treatments have been successful in studies with a lower grade of evidence (eBox 166-3.1 in online edition).[2,16,48,71–83] Oral and intravenous prednisolone can be combined with other immunosuppressants, colchicine, dapsone, sulfasalazine, or interferon-α. A synergistic effect with cyclosporine A has been described in patients with ocular involvement. Prednisolone is one of the few medications that can be used during pregnancy. Colchicine can be combined with immunosuppressants and interferon-α. A rapid relapse often occurs after discontinuing cyclosporine A, interferon-α, dapsone or infliximab.[73,76,78]

PREVENTION

- Patients with severe or progressive recurrent aphthous stomatitis should be followed up for years as potential candidates for Adamantiades–Behçet disease, particularly those patients with familial occurrence of the disease.
- Patients with suspected Adamantiades–Behçet disease should be referred early for specialist advice.
- Male patients with systemic involvement as a presenting sign and/or an early age of onset should be treated systemically because of the poor prognosis.

KEY REFERENCES

Full reference list available at www.DIGM8.com

DVD contains references and additional content

1. McCarty MA, Garton RA, Jorizzo JL: Complex aphthosis and Behçet's disease. *Dermatol Clin* **21**:41, 2003
2. Suzuki Kurokawa M, Suzuki N: Behçet's disease. *Clin Exp Med* **4**:10, 2004
3. Zouboulis CC, Keitel W: A Historical review of early descriptions of Adamantiades-Behçet's disease. *J Invest Dermatol* **119**:201, 2002
4. Zouboulis CC: Epidemiology of Adamantiades-Behçet's disease. In: *Immunology of Behçet's Disease*, edited by M Zierhut, S Ohno. Lisse, Swets & Zeitlinger, 2003, p. 1
6. Altenburg A et al: Epidemiology and clinical manifestations of Adamantiades-Behçet disease in Germany—Current pathogenetic concepts and therapeutic possibilities. *J Dtsch Dermatol Ges* **4**:49, 2006
7. Zouboulis CC, May T: Pathogenesis of Adamantiades-Behçet's disease. *Med Microbiol Immunol* **192**:149, 2003
48. Zouboulis CC: Adamantiades-Behçet's disease. In: *European Handbook of Dermatological Treatments*, edited by AD Katsambas, TM Lotti, 2nd edition. Berlin Heidelberg, Springer, 2003, p16
53. Pipitone N et al: New approaches in the treatment of Adamantiades-Behçet's disease. *Curr Opin Rheumatol* **18**:3, 2006
54. Hatemi G et al: Management of Behçet disease: A systematic literature review for the European League Against Rheumatism evidence-based recommendations for the management of Behçet disease. *Ann Rheum Dis* **68**:1528, 2009

Chapter 167 :: Kawasaki Disease

:: Anne H. Rowley

KAWASAKI DISEASE AT A GLANCE

- Most common cause of acquired heart disease in children in developed nations.
- Highest incidence in Asian children; 1 in 100 Japanese children develops Kawasaki disease (KD) by age 5 years.
- KD is a multisystem inflammatory process of unknown but suspected infectious etiology.
- KD affects all blood vessels in the body, particularly medium-sized arteries such as the coronary arteries.
- Major symptoms are prolonged high fever, conjunctival injection, oral mucosal changes such as red lips and pharynx and strawberry tongue, redness and swelling of the hands and feet, erythematous polymorphic rash, and cervical lymphadenopathy.
- Inflammation in the coronary arteries can lead to aneurysms with subsequent myocardial infarction, aneurysm rupture, and sudden death.
- Treatment with intravenous immunoglobulin (IVIG) and aspirin, when given in the first 10 days of fever, reduces the prevalence of coronary artery abnormalities from 25% in those treated with aspirin alone, to 5% in those who receive IVIG with aspirin.
- Long-term complications are confined to the heart and vascular tree, primarily thrombosis and stenosis of the major coronary arteries with myocardial ischemia.

Kawasaki disease (KD), the leading cause of acquired heart disease in children in developed nations, is a multisystem inflammatory illness that particularly affects blood vessels, especially the coronary arteries. About 25% of untreated children develop coronary artery abnormalities, including dilatation and aneurysms that can lead to myocardial infarction and sudden death.[1,2] The etiology is unknown, but clinical and epidemiologic data support an infectious cause. In KD, an intense inflammatory cell response develops in a wide array of organs and tissues[3]; in medium-sized arteries such as the coronary arteries, this response can damage collagen and elastin fibers in the vessel walls and lead to loss of their normal structural integrity with resultant ballooning or aneurysm formation. Despite a limited understanding of KD pathogenesis, a very effective therapy exists in the form of IVIG and aspirin; when given in the first 10 days of fever, this therapy reduces the prevalence of coronary artery abnormalities from 25% in untreated patients to 5% in those who receive the therapy.[4] Because the etiology is unknown, no diagnostic test exists, and the diagnosis is made clinically. Classic KD is diagnosed in a patient with prolonged fever and four of five other clinical findings (Box 167-1). However, incomplete forms of illness are well-recognized, in which a child manifests prolonged fever with fewer than four other clinical features of the illness and subsequently develops coronary artery abnormalities. The existence of these incomplete forms of illness results in a major diagnostic dilemma for physicians in establishing the diagnosis accurately in children with prolonged fever of uncertain cause.

HISTORICAL ASPECTS

KD is named for Dr. Tomisaku Kawasaki, a Japanese pediatrician who first recognized the clinical features of the illness. He described 50 cases of a new illness in 1967 in the Japanese-language literature that he termed

BOX 167-1 DIAGNOSTIC CRITERIA FOR CLASSIC KAWASAKI DISEASE

Fever ≥5 days,[a] high spiking and intermittent, with at least four of the five clinical features[b]

1. Bilateral nonexudative conjunctival injection
2. Oral mucosal changes, including red, dry, cracked lips, pharyngeal erythema, and/or strawberry tongue
3. Changes of the hands and feet: erythema of palms and soles and/or swelling of the hands and feet during the acute phase, and/or periungual desquamation of the fingers and toes during the subacute phase
4. Rash: erythematous maculopapular, scarlatiniform, or erythema multiforme
5. Cervical lymphadenopathy ≥1.5 cm in diameter

[a]The diagnosis can be made before the fifth day of fever by experienced physicians if the patient has the other clinical features of the illness.
[b]In the absence of another explanation for the illness.

mucocutaneous lymph node syndrome.[5] It was not until later that some of the children with this newly described illness experienced sudden death; autopsy revealed myocardial infarction from thrombosis of coronary artery aneurysms. Prior to Dr. Kawasaki's description of the clinical features, KD was recognized only by pathologists at autopsy, who called the disease "infantile periarteritis nodosa."[6] Dr. Kawasaki described the illness in the English-language literature in 1974; this report was closely followed by a description of the same illness, observed independently in the early 1970s in Hawaii by Dr. Marian Melish and colleagues.[7,8] Since that time, it has become clear that although the attack rate of KD is highest in Asian, particularly Japanese, Korean, and Chinese children, all racial and ethnic groups around the world are affected by the illness.

EPIDEMIOLOGY

KD is predominantly an illness of young children, with 80% of cases occurring in children ages 6 months to 5 years.[9,10] However, infants less than 6 months of age can be affected, often manifest incomplete forms of the illness, and can have particularly severe KD.[11,12] Similarly, KD can occur in older children and teenagers, in whom the diagnosis is often delayed, and who may also have more severe KD with a higher prevalence of coronary artery abnormalities.[13–15] Therefore, the diagnosis must be considered in all pediatric age groups.

Boys are more commonly affected than girls at a ratio of 3:2. The incidence of KD is approximately tenfold higher in Japanese than in Caucasian children.[9,10] About 1 in 100 Japanese children develop KD by the age of 5 years; the peak age of illness is 9–11 months of age in both Japan and the United States.[9,16] The higher attack rate in Japanese children persists in those who adopt a Western diet and lifestyle, and is likely related to a genetic predisposition to KD among Asian children.[17] The risk of KD in siblings is tenfold higher than in the general population, and the incidence of KD in children born to parents who had KD is twice as high as in the general population.[18,19] Recurrence is rare, occurring in about 3% of cases in Japan.[16]

Many epidemiologic features of KD suggest an infectious agent is the cause. Among these are the well-described epidemics of illness[17,20–22] and the geographic wave-like spread of illness during an epidemic, compatible with spread of an infectious agent.[22] Cases in the United States are more common in the winter and spring.[9]

ETIOLOGY AND PATHOGENESIS

The etiology of KD remains unknown. The hypothesis that best fits the available clinical, immunologic, and epidemiologic data is that KD results from infection with a ubiquitous etiologic agent that usually results in asymptomatic infection, but causes KD in a small subset of genetically predisposed individuals. Genetic predisposition is a common theme in susceptibility and host response to infectious diseases. It is likely that KD is polygenic. Intensive investigation of genetic factors influencing susceptibility to KD is ongoing by several international collaborative groups. A functional polymorphism in the *ITPKC* gene, which is a negative regulator of T-cell activation, has been associated with KD susceptibility and risk of developing coronary artery abnormalities[23]; it is likely that other susceptibility genes will be discovered in the near future.

KD is often referred to as an autoimmune illness, but there is no compelling reason to classify it as such. The spontaneous resolution of the febrile phase of illness, the rarity of recurrent KD, and the fact that the highest incidence occurs in male infants, a group who rarely develop autoimmune diseases, all argue strongly against this possibility. Immune complexes, although detectable in serum in the subacute phase, are not deposited in tissues and do not appear to play a prominent role in pathogenesis. Although inflammation in KD results in tissue damage, the damage is likely to be primarily the result of an immune response targeting antigen(s) of an infectious agent in the tissue.

Many cytokines are upregulated in KD, which has led some investigators to propose a superantigen as the cause of the illness. However, cytokines are upregulated in many infectious diseases, and the cardinal feature of a superantigen-mediated illness, the paralysis of adaptive immunity,[24] is not observed in acute KD. Oligoclonal, antigen-driven CD8 T lymphocyte,[25] IgA plasma cell,[26] and IgM B lymphocyte[27] adaptive immune responses are detected in acute KD.

In KD, an intense inflammatory cell infiltrate is observed in many organs and tissues, particularly in the medium-sized arteries.[3] These inflammatory cells secrete matrix metalloproteinases and other enzymes that can disrupt collagen and elastin fibers in the coronary arteries, impairing the integrity of the arterial wall

and resulting in ballooning or aneurysm formation.[28] The initial insult that causes this immune response is unknown, but the nature of the inflammatory cell infiltrate provides clues. Although neutrophils contribute to the very early inflammatory-cell infiltrate in KD tissues, they are quickly replaced by large mononuclear cells and lymphocytes.[2] By two weeks after the onset of fever, the inflammatory infiltrate in the arterial walls largely consists of T lymphocytes (predominately CD8 T lymphocytes), macrophages, plasma cells (predominately of the IgA isotype), and eosinophils.[29,30] IgA plasma cells are increased in the respiratory tract, particularly in a peribronchial distribution.[31] The presence of IgA plasma cells and CD8 T cells as primary components of the inflammatory infiltrate in acute KD suggests an immune response to an intracellular pathogen with a respiratory portal of entry.[29] Sequencing of IgA genes in the arterial walls in acute KD shows an oligoclonal, or antigen-driven, response.[26] Synthetic versions of these oligoclonal IgA antibodies identify antigen in acute KD tissues.[32] Light and electron microscopic studies show that the antigen detected by KD synthetic antibodies resides in cytoplasmic inclusion bodies that are consistent with aggregates of viral protein and RNA.[33,34] Identification of the specific proteins and RNA in the inclusion bodies should lead to identification of the etiologic agent of KD. These studies are hampered by the lack of unfixed tissue specimens from fatal cases, and by the likelihood that the etiologic agent is an RNA virus without significant homology to known viruses, thereby making its RNA sequence difficult to identify.[34] It is hoped that advances in high throughput sequencing and bioinformatics analysis will yield the solution to the mystery of the etiology of KD in the near future.

CLINICAL FINDINGS

CLASSIC DIAGNOSTIC CRITERIA FOR KD

A diagnosis of classic KD is made in the presence of prolonged fever ≥5 days, with four of the following five clinical features in the absence of another explanation for the illness: (1) nonpurulent bulbar conjunctival injection (Fig. 167-1); (2) red, swollen, dry lips, which may crack and bleed (Fig. 167-1); (3) redness and swelling of the hands and feet; (4) rash; and (5) cervical lymphadenopathy, ≥1.5 cm in diameter. Experienced physicians can make a diagnosis of KD before the fifth day of fever in children with classic features. A patient with prolonged fever and fewer than four of the other features of the illness can be diagnosed with KD if coronary artery abnormalities develop. Incomplete (or atypical) KD refers to children with prolonged fever and fewer than four of the other features of illness who have a laboratory profile compatible with KD. Such patients should undergo echocardiography and be considered for treatment with IVIG because KD patients, particularly infants, do not always manifest classic diagnostic criteria during the acute febrile phase of illness, yet can develop coronary artery abnormalities (Box 167-1).

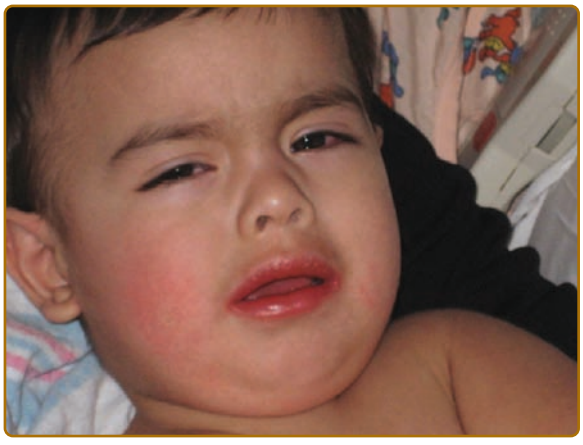

Figure 167-1 Typical facial features of acute Kawasaki disease showing conjunctival injection and red dry lips.

HISTORY

KD should be considered in the differential diagnosis of any child with prolonged fever without other explanation. In KD, all clinical features may not be present simultaneously. Therefore, it is important to query parents and physicians who saw the patient during the course of a prolonged febrile illness as to the presence of the other five clinical features of the illness: (1) conjunctival injection, (2) oral mucosal changes, (3) changes of the hands and feet, (4) rash, and (5) cervical adenopathy. Children with KD often have significant enough swelling and discomfort of the hands and feet that they will refuse to pick up objects or to walk. This is not commonly observed in children with most other illnesses in the differential diagnosis of KD and can provide an important clue to the diagnosis. Similarly, extreme irritability is common in KD and not as common in most other illnesses in the differential diagnosis. Without specific therapy, fever in KD is daily, high spiking, intermittent, and lasts for one to two weeks. The illness is often divided into three stages: (1) the acute febrile phase, (2) the subacute phase (that begins when fever resolves and continues until all clinical features have normalized), and (3) the convalescent phase (that follows the subacute phase and continues until the erythrocyte sedimentation rate (ESR) normalizes, usually at 6–8 weeks after the onset of fever).

CUTANEOUS FEATURES

Rash is commonly observed in KD, is most pronounced on the trunk and extremities, and generally takes one of three forms: (1) an erythematous maculopapular exanthema (Fig. 167-2), (2) erythema multiforme with typical target lesions, or (3) a scarlatiniform exanthema. Bullae, vesicles, and ulcerative lesions are not observed, but a fine micropustular rash, especially on the extensor surfaces, occasionally occurs. The rash may be pruritic. In the acute febrile phase of illness, groin erythema and desquamation are commonly observed (Fig. 167-3), and can be mistaken for candidal diaper dermatitis



Figure 167-2 Erythematous maculopapular exanthema observed in acute Kawasaki disease.

or even a staphylococcal scalded skin syndrome. The skin changes in the groin can be seen both in children in diapers and toilet-trained children. Classic periungual desquamation of the fingers and toes does not begin until the second to third week after fever begins, and can progress to involve the entire hand and foot (Fig. 167-4); treatment should be administered well before its appearance. In the third to sixth week after illness, transverse lines across the fingernails (Beau lines) are often apparent. These grow out with the nail.

In countries where BCG vaccine is routinely administered, such as in Japan, a common finding in children with KD is erythema and swelling at the site of BCG vaccine; the mechanism is unknown but the process resolves with treatment of KD. Although KD results in a vasculitis affecting all arteries and veins in the body, blood vessels in the skin are not prominently affected, and skin biopsy is not useful for diagnosis because pathologic findings are nonspecific.

RELATED PHYSICAL FINDINGS

Conjunctival injection in KD is bilateral and nonexudative. There may be limbal sparing (Fig. 167-5). Photophobia is a common accompanying feature. Oral findings include red, swollen, dry, cracked lips that may bleed, a "strawberry" tongue, and erythema of the mouth and throat. Oral ulcers are not a feature of KD. Palmar and plantar erythema is a common feature, and there can be an abrupt transition from marked erythema to normal skin at the wrists and ankles. The hands and feet can be edematous and painful. Cervical adenopathy is the least commonly observed clinical feature, occurring in only about 75% of children with classic KD, but can be the most prominent feature in a subset of patients, who are often treated with multiple different courses of antibiotic therapy without improvement before the correct diagnosis is made.[35] Cervical adenopathy is usually unilateral, may or may not be associated with superficial erythema and/or tenderness to palpation, and is nonfluctuant. Because KD is a multisystem inflammatory process, many organs and tissues are involved in the inflammatory process, leading to a variety of associated clinical features (Box 167-2). In particular, arthritis can occur during the acute febrile phase, involving the small interphalangeal joints and larger joints, or may occur during the subacute phase of illness, usually involving the larger joints such as the knees and ankles. Aseptic meningitis is a common finding in patients who undergo lumbar puncture.



Figure 167-3 Erythematous desquamating groin rash of acute Kawasaki disease.



Figure 167-4 Desquamation of the feet in the subacute phase of Kawasaki disease; this process began periungually and progressed to involve the entire soles.



Figure 167-5 Conjunctival injection with limbal sparing in acute Kawasaki disease.

BOX 167-2 ASSOCIATED CLINICAL FEATURES OF KAWASAKI DISEASE

CARDIOVASCULAR
- Coronary artery aneurysms
- Myocarditis
- Pericardial effusion
- Aneurysms of other medium-sized arteries (uncommon)
- Valvular disease (rare)
- Peripheral gangrene (rare)

RESPIRATORY
- Pneumonitis: interstitial or peribronchial infiltrates on chest X-ray, usually without respiratory distress
- Pulmonary nodules (rare)

GASTROINTESTINAL
- Hepatitis
- Obstructive jaundice
- Gallbladder hydrops
- Diarrhea

MUSCULOSKELETAL
- Arthritis

GENITOURINARY
- Urethritis
- Hydrocoele

NEUROLOGIC
- Marked irritability
- Aseptic meningitis
- Facial palsy (uncommon)
- Sensorineural hearing loss (uncommon)

OTHER
- Anterior uveitis
- Erythema and induration at the site of a Bacille Calmette-Guérin (BCG) vaccine

LABORATORY TESTS

In the absence of knowledge of the etiology of KD, a diagnostic test is not available. Laboratory findings in acute KD are nonspecific but quite characteristic. A complete blood count reveals either a normal or elevated white blood cell count with a neutrophil predominance. A low white blood cell count with lymphocyte predominance would be distinctly unusual in KD. A normochromic, normocytic anemia can be present, and resolves spontaneously with resolution of KD. The platelet count is normal in the first week of illness, although thrombocytopenia has been reported to be associated with a more severe outcome. Thrombocytosis, with platelet counts sometimes exceeding 1,000,000/mm^3, is characteristic of the subacute phase of KD, peaking in the second to third week after the onset of fever. This feature, like periungual desquamation, is not useful in making a diagnosis of KD in the first week of fever. Patients with anemia and low albumin levels may be at higher risk of developing coronary artery disease. A mild elevation of the liver transaminases is commonly observed in acute KD. Occasionally, obstructive jaundice occurs. Gallbladder hydrops, with accompanying right upper quadrant abdominal pain, resolves spontaneously and does not require surgical intervention. Sterile pyuria is also commonly observed. Acute-phase reactants such as the C-reactive protein (CRP) and the ESR are characteristically elevated in patients with acute KD, and the CRP is sometimes used to follow clinical response in patients refractory to IVIG therapy. Once IVIG is given, the ESR cannot be used to follow clinical response, because IVIG itself transiently increases the ESR.

SPECIAL TESTS

To determine whether a child with KD develops coronary artery dilatation, an echocardiogram should be performed at diagnosis, at 2–3 weeks after fever onset, and at 6–8 weeks after fever onset.[36] A complete blood count and CRP or ESR are also repeated at 2–3 weeks and 6–8 weeks after onset to monitor for resolution of inflammation. The peak time to detect coronary artery dilatation is 2–3 weeks after onset of fever, during the subacute phase of illness. Some centers perform an additional echocardiogram at 1 year after onset, but it is rare to find any evidence of coronary artery abnormalities at 1 year that were not present within the first two months after fever began. Electrocardiogram most often shows a prolonged PR interval and/or nonspecific ST- and T-wave changes.

DIFFERENTIAL DIAGNOSIS

The KD child with prolonged high fever, marked conjunctival injection, red, swollen hands and feet, erythematous rash, and red, cracked, bleeding lips who has a markedly elevated ESR and/or CRP and an elevated peripheral white blood cell count with a neutrophil predominance has a very distinctive illness and usually does not pose any difficulties in diagnosis. In other patients who have only some of the clinical features of KD, or in whom clinical findings are not as dramatic, other diagnoses must be carefully considered (Box 167-3).

In areas where measles is still prevalent, differentiating the two disorders can be difficult. Classically, patients with measles have rash that begins on the face behind the ears and Koplik spots in the mouth; neither of these features is observed in KD. Later in the course of measles infection, the rash becomes diffuse and Koplik spots are no longer visible. Conjunctival injection and edema of the hands and feet can be observed in both disorders. In uncomplicated measles, the peripheral white blood cell count and the erythrocyte sedimentation rate are generally low. The measles IgM antibody is virtually always

BOX 167-3 DIFFERENTIAL DIAGNOSIS OF KAWASAKI DISEASE

- Measles
- Adenovirus infection
- Enterovirus infection
- Scarlet fever
- Staphylococcal scalded skin syndrome
- Toxic shock syndrome
- Drug hypersensitivity reaction
- Juvenile rheumatoid arthritis

If Patient has Epidemiologic Risk Factor:

- Rocky Mountain spotted fever
- Leptospirosis

positive by the appearance of the measles rash, and is the best single test to differentiate the two conditions.

Group A streptococcal infection should be considered in the differential diagnosis of a KD patient with a scarlatiniform rash, and can be excluded by a negative throat culture. Diagnostic uncertainty could arise in a KD patient who is a group A streptococcal carrier. Administration of antibiotic therapy followed by reevaluation in 24–48 hours generally clarifies the diagnosis; children with group A streptococcal pharyngitis have a rapid response to therapy, while antibiotics are ineffective in KD. Adenovirus infection can mimic KD. The presence of exudative conjunctivitis and exudative pharyngitis suggests adenovirus as the most likely diagnosis. Other viruses can occasionally cause prolonged fever, such as enterovirus; in differentiating KD patients from those with uncomplicated viral infection, laboratory tests such as the ESR, CRP, and urinalysis can be helpful, as pyuria and markedly elevated acute-phase reactants are more typical of KD.

Drug hypersensitivity reactions can mimic KD. Oral and mucosal ulcers observed in Stevens–Johnson syndrome are absent in KD. Edema of the face, particularly around the eyes, is much more suggestive of drug reaction than KD. In general, the ESR and CRP are either normal or only mildly elevated in drug hypersensitivity reactions.

Staphylococcal scalded skin syndrome (SSSS) is easily distinguished by the classic finding of painful skin in SSSS, which is not observed in KD, and by Nikolsky sign, which is present in SSSS and absent in KD.

Although hypotension is unusual in KD, it occurs occasionally,[37,38] and toxic shock syndrome is in the differential diagnosis of such patients. Renal involvement and elevated creatinine phosphokinase are more likely to be observed in toxic shock syndrome than in KD. IVIG administered for a possible diagnosis of KD may serve as adjunctive therapy for toxic shock syndrome.

Juvenile rheumatoid arthritis is a diagnosis of exclusion, and an occasional patient with this disorder might initially be diagnosed with and treated for incomplete KD. The correct diagnosis may become apparent when fever recurs following reduction of high-dose aspirin therapy, implying an original clinical response to aspirin rather than to IVIG.

The following are in the differential diagnosis of KD in the appropriate epidemiologic context: (1) leptospirosis, which predominately occurs in tropical climates; (2) Rocky Mountain spotted fever, which tends to be highly regional in incidence; and (3) mercury poisoning, now quite rare.

DIAGNOSIS OF INCOMPLETE KD

The American Heart Association Committee on Rheumatic Fever, Endocarditis, and Kawasaki Disease has published an algorithm to assist the clinician in diagnosing incomplete KD.[36] This algorithm emphasizes the importance of combining clinical features, laboratory findings, and echocardiographic findings in making a diagnosis (see Box 167-4). In difficult cases, consultation with a KD expert should be considered. If the patient is not treated for KD but develops typical periungual desquamation after fever has resolved, and an alternative diagnosis that could explain this clinical finding has not been established (such as scarlet fever), an echocardiogram should be repeated. Infants ≤6 months of age can have mild or subtle clinical findings with KD, but have a high risk of developing coronary artery abnormalities. Therefore, infants with fever for a week or more without other explanation should have laboratory testing performed. If evidence of an inflammatory process is present, an echocardiogram should be ordered and KD considered, even in the absence of other clinical features of the illness.

COMPLICATIONS

KD can result in myocardial infarction, aneurysm rupture, and sudden death. Myocardial infarction can occur from thrombosis of an aneurysm, which is most common in the first few months after the onset, or from coronary artery stenosis, which occurs months to years following the illness. Aneurysm rupture is less common and usually occurs within the first month after the onset. More than 50% of KD patients have myocarditis during the acute febrile phase, manifested clinically as tachycardia out of proportion to fever, which generally improves rapidly with IVIG therapy. In the acute phase of illness, a pericardial effusion can be present; this resolves spontaneously. In patients with the most severe coronary artery aneurysms, aneurysms of other medium-sized arteries can also be observed, most commonly in the iliac, femoral, and axillary arteries. Rarely, valvulitis significant enough to require valve replacement has been reported. Although KD is a systemic inflammatory disease affecting multiple organs and tissues, there are no known long-term consequences of the disease outside of the heart and blood vessels.

PROGNOSIS/CLINICAL COURSE

About 85% of KD children treated with IVIG and aspirin within the first 10 days of illness respond with rapid

BOX 167-4 CRITERIA FOR DIAGNOSIS OF INCOMPLETE KAWASAKI DISEASE[a]

Fever for ≥5 days with two or three compatible clinical features of KD and

- ESR ≥40 mm/h and/or CRP ≥3.0 mg/dL
  - If patient has at least three compatible laboratory features,[b] perform echocardiogram and begin treatment
  - If patient has fewer than three compatible laboratory features,[b] but has dilated coronary arteries by echocardiogram (Z score of LAD or RCA ≥2.5), begin treatment
  - If patient has fewer than three compatible laboratory features[b] and LAD and RCA Z scores <2.5, but has at least three supportive echocardiographic features,[c] begin treatment.
  - If patient has fewer than three compatible laboratory features,[b] LAD and RCA Z scores <2.5, and fewer than three supportive echocardiographic features,[c] then follow patient and consider other diagnoses. If fevers persist and no other diagnosis is established, consider repeating laboratory tests and echocardiogram and consider consulting a KD expert. If fever resolves, KD is unlikely.
- ESR <40 mm/h and/or CRP <3.0 mg/dL
  - Follow patient. If fever continues, reevaluate clinically and consider repeating ESR and CRP. If fever resolves but patient develops typical periungual desquamation, perform echocardiogram.

[a]Adapted from Newburger JW et al: Diagnosis, treatment, and long-term management of Kawasaki disease: A statement for health professionals from the Committee on Rheumatic Fever, Endocarditis and Kawasaki Disease, Council on Cardiovascular Disease in the Young, American Heart Association. *Circulation* **110**(17):2747-2771, 2004

[b]Compatible laboratory features:
1. Albumin ≤3.0 g/dL
2. Anemia for age
3. Elevated alanine aminotransferase
4. Platelet count ≥450,000/mm^3 after the 7th day of illness
5. WBC ≥15,000/mm^3
6. Urinalysis with ≥10 WBC/high power field

[c]Supportive echocardiographic features:
1. Perivascular brightness
2. Lack of tapering
3. Decreased left ventricular function
4. Mitral regurgitation
5. Pericardial effusion
6. Z scores of LAD or RCA of 2–2.5

LAD = left anterior descending coronary artery
RCA = right coronary artery

resolution of fever and other clinical signs. Only 5% of KD patients treated within the first 10 days of fever develop coronary artery abnormalities.[4,39] Therefore, the vast majority of KD patients who are promptly diagnosed and treated do well, without developing cardiac complications. However, about 15% of KD children treated within the first 10 days of illness continue to have fever following a single infusion of IVIG with aspirin and require additional therapy; these patients have a higher risk of developing coronary artery abnormalities.[40,41] Long-term studies show that coronary artery abnormalities regress in 50% of patients by 1–2 years after the onset.[42] The larger the aneurysm, the less likely it is to regress. Giant coronary artery aneurysms, classically defined as those ≥8-mm internal diameter, almost never regress.[43] Regression of an aneurysm usually is accompanied by intimal proliferation, which can be significant enough in large aneurysms to lead to coronary artery stenosis and an increased risk of myocardial infarction.[44] In young infants and children, myocardial infarction usually presents as shock, emesis, and/or abdominal pain.[44] Patients with significant coronary artery disease may require catheter intervention procedures,[45] coronary artery bypass surgery,[46] or rarely, heart transplantation.[47] Cardiovascular risk assessment should be performed at intervals dependent upon the severity of coronary artery abnormalities.[36]

TREATMENT

A single infusion of 2 g/kg IVIG with aspirin (80–100 mg/kg/day given every 6 hours orally) should be administered to children with acute KD as soon as possible after diagnosis (Box 167-5).[39] This regimen, when administered to children with KD within the first 10 days of fever, reduces the prevalence of coronary artery abnormalities from 25% in untreated patients to 5% in those who receive the therapy. Most children experience rapid resolution of fever and other clinical signs following treatment, as well as improvement in acute-phase reactants. The mechanism of action of IVIG in KD is unknown.

Aspirin is given in high doses during acute KD for anti-inflammatory effect. It is generally continued at 80–100 mg/kg/day until the 14th illness day, or until the patient has been afebrile for at least 2–3 days. Aspirin is then reduced to 3–5 mg/kg/day given in a single daily dose, for its antithrombotic effect. Aspirin is discontinued at 6–8 weeks after onset if all echocardiograms have been normal and acute-phase reactants have normalized. If coronary artery abnormalities develop,

BOX 167-5 TREATMENT OF ACUTE KAWASAKI DISEASE

Intravenous gammaglobulin (IVIG) 2 g/kg infused over 10–12 hours; monitor vital signs carefully during infusion, with aspirin 80–100 mg/kg/day divided every 6 hours orally until the 14th illness day or until patient is afebrile for at least 2–3 days, then reduce dose to 3–5 mg/kg/day as a single daily dose. Aspirin is discontinued if echocardiograms at 2–3 weeks and 6–8 weeks are normal and when acute-phase reactants have normalized.

low-dose aspirin is continued. Depending upon the severity of coronary artery disease, other therapies such as clopidogrel or warfarin may be indicated[36]; such decisions should be made in consultation with a pediatric cardiologist. Intravenous methylprednisolone is not indicated for primary therapy of acute KD.[48]

IVIG and aspirin is also given to KD patients who present after the tenth day of illness if fever and/or clinical and laboratory signs of ongoing inflammation are present, although the efficacy of the therapy in this clinical situation is uncertain. About 15% of acute KD patients do not respond to initial therapy; optimal therapy for these patients with "refractory" KD is unknown. Most of these patients will respond to a second 2 g/kg IVIG infusion.[40,41] In those who remain febrile after a second IVIG infusion, intravenous methylprednisolone once daily for 3 days or infliximab have been given with apparent success.[49–51] More specific therapy awaits the identification of the cause of KD.

PREVENTION

Prevention of KD will not be possible until the etiology of the illness is identified.

KEY REFERENCES

Full reference list available at www.DIGM8.com

DVD contains references and additional content

9. Holman RC et al: Kawasaki syndrome hospitalizations in the United States, 1997 and 2000. *Pediatrics* **112**(3 Pt 1):495-501, 2003
10. Nakamura Y et al: Epidemiologic features of Kawasaki disease in Japan: Results from the nationwide survey in 2005-2006. *J Epidemiol* **18**(4):167-172, 2008
23. Onouchi Y et al: ITPKC functional polymorphism associated with Kawasaki disease susceptibility and formation of coronary artery aneurysms. *Nat Genet* **40**(1):35-42, 2008
33. Rowley AH et al: Cytoplasmic inclusion bodies are detected by synthetic antibody in ciliated bronchial epithelium during acute Kawasaki disease. *J Infect Dis* **192**(10): 1757-1766, 2005
36. Newburger JW et al. Diagnosis, treatment, and long-term management of Kawasaki disease: A statement for health professionals from the Committee on Rheumatic Fever, Endocarditis and Kawasaki Disease, Council on Cardiovascular Disease in the Young, American Heart Association. *Circulation* **110**(17):2747-2771, 2004
39. Newburger JW et al: A single intravenous infusion of gamma globulin as compared with four infusions in the treatment of acute Kawasaki syndrome. *N Engl J Med* **324**(23):1633-1639, 1991

Chapter 168 :: Pigmented Purpuric Dermatoses

:: Theresa Schroeder Devere, & Anisha B. Patel

PIGMENTED PURPURIC DERMATOSES AT A GLANCE

- A group of dermatoses characterized by petechiae, pigmentation, and, occasionally, telangiectasia.
- Are found most commonly on the lower extremities; however, the lesions may involve the upper body and rarely become generalized.
- Are benign, generally asymptomatic eruptions that tend to be chronic with remissions and flares.
- Share common histopathology features, including capillaritis, erythrocyte extravasation, and hemosiderin deposition.
- Clinical variation between eruptions led to their subclassification into eponymic groups.
- Frequent overlap may make differentiation difficult.

The pigmented purpuric eruptions are a group of dermatoses characterized by petechiae, pigmentation, and, occasionally, telangiectasia in the absence of associated venous insufficiency or hematologic disorders (Table 168-1). Synonyms include *persistent pigmented purpuric dermatitis*, *purpura simplex*, and *purpura pigmentosa chronica*. They are found most commonly on the lower extremities; however, the lesions may involve the upper body and rarely become generalized. There are reports of palm, sole, genital, and oral mucosal involvement. These benign, generally asymptomatic eruptions tend to be chronic, with remissions and flares. They share common histopathology features, including capillaritis, erythrocyte extravasation, and hemosiderin deposition.

EPIDEMIOLOGY

Pigmented purpuric eruptions are rare. There seems to be no ethnic or gender predisposition, and most patients are in their 30s and 40s (see Table 168-1), but children may be affected.

PATHOGENESIS

There are three different views of the pathogenesis of pigmented purpuric eruptions. The first is that they are

TABLE 168-1
Pigmented Purpuric Eruptions

	Schamberg	Majocchi	Gougerot and Blum	Doucas and Kapetanakis	Itching Purpura	Lichen Aureus
Average age	40s	30s	40s	40s	50s	20s–30s
Sex	M > F	F > M	M > F	F > M	M > F	M > F
Onset	Insidious	Abrupt	Insidious	Abrupt	Abrupt	Abrupt
Primary lesion	Red–brown macule	Annular purpuric, telangiectasia	Lichenoid papule	Red–brown macule + scale	Red–brown macule	Orange–brown papule or plaque

F = female; M = male.

due to a disturbance or weakness of the cutaneous blood vessels, leading to capillary fragility and erythrocyte extravasation. However, this does not account for the inflammatory infiltrate common to these disorders. The second proposed mechanism is humoral immunity. This suggested pathogenesis is supported by direct immunofluorescent studies showing vascular deposition of C3, C1q, immunoglobulin M, or immunoglobulin A. However, several cases have not shown these deposits. The third proposed mechanism is cellular immunity.[1,2] The infiltrate in pigmented purpuric dermatoses consists of lymphocytes, macrophages, and Langerhans cells. This inflammatory infiltrate leads to vascular fragility and subsequent leakage of erythrocytes. Aiba and Tagami used immunohistologic studies in eight cases of Schamberg disease to demonstrate that the dermal infiltrate was predominantly composed of helper–inducer T cells and OKT6-reactive cells,[3] whereas the epidermis showed intercellular staining with human leukocyte antigen (HLA)-DR antibody and OKT6 antibody. Based on this study, they concluded that a cellular immune reaction, specifically the Langerhans cell, likely plays an important role in the pathogenesis.

Pigmented purpuric dermatoses may be induced by drugs (Table 168-2),[4–17] but other causes have also been implicated (Table 168-3).[18–25] The mechanism behind drug-induced or other causes may be immune-mediated; however, this is unproven. There could be familial involvement, as was shown in a handful of cases, with one report consistent with an autosomal dominant inheritance pattern.[26] Gravity and increased venous pressure may account for the lesions localizing to the lower extremities.

TYPES OF PIGMENTED PURPURIC DERMATOSES

PROGRESSIVE PIGMENTARY DERMATOSIS (SCHAMBERG DISEASE)

Schamberg first described in 1901 a pigmented eruption on the legs of a 15-year-old boy that consisted of irregularly shaped reddish-brown patches with "pin head sized reddish puncta, closely resembling grains of cayenne pepper."[27]

Although described in children and adolescents, the average age of onset of Schamberg disease is in the fifth decade.[28] The lesions tend to develop insidiously on either or both lower legs. Lesions can involve the trunk or the upper extremities (Figs. 168-1 and 168-2). Schamberg disease is generally asymptomatic and persistent. Remissions and flares can occur indefinitely.

PURPURA ANNULARIS TELANGIECTODES (MAJOCCHI PURPURA)

The original case of purpura annularis telangiectodes, described by Majocchi in 1896, was a 21-year-old man with annular patches of follicular and punctate

TABLE 168-2
Drugs Implicated in Pigmented Purpuric Dermatoses

- Acetaminophen
- Aminoglutethimide
- Aspirin
- Bezafibrate
- Bufexamac
- Carbamazepine
- Carbromal
- Carbutamide
- Chlordiazepoxide
- Diltiazem
- Dipyridamole
- Topical fluorouracil
- Furosemide
- Glipizide
- Hydralazine
- Infliximab
- Interferon-α
- Medroxyprogesterone acetate
- Meprobamate
- Pseudoephedrine
- Raloxifene
- Reserpine
- Tartrazine (food additive)
- Thiamine
- Trichlormethiazide

TABLE 168-3
Other Implicated Causes of Pigmented Purpuric Dermatoses

- Contact dermatitis
  - Disperse dyes
  - Paraphenylenediamine
  - Black rubber
  - Cobalt
  - Benzoyl peroxide
  - Epoxy resin
  - Methylmethacrylate
  - Eutectic mixture of local anesthetics
- Venous stasis/acroangiodermatitis
- Step aerobics
- Rheumatoid arthritis
- Diabetes mellitus
- Benign hyperglobulinemic purpura (of Waldenstrom)/dysproteinemic purpura)
- Hodgkin disease
- Hepatitis B, C
- Odontogenic infection
- Polycythemia
- Purpuric mycosis fungoides



Figure 168-2 "Cayenne pepper" appearance of Schamberg disease. (Used with permission from S. Mallory, MD.)

reddish-brown macules, with telangiectasias and purpura on the lower extremities.[29] The annular pattern is the distinctive characteristic of this subtype (Fig. 168-3). The individual lesions may have central hypopigmentation and slight atrophy, with peripheral telangiectasias. Linear and irregularly shaped patterns may also occur. The lesions most often present symmetrically on the lower extremities; however, the upper extremities and trunk may be involved. The lesions are asymptomatic and usually last several months with relapses and remissions. This subtype occurs more commonly in young adult females.



Figure 168-1 Pigmented purpuric dermatosis: Schamberg disease. Multiple, discrete, and confluent nonpalpable, nonblanching purpuric lesions of many months' duration on the legs. Acute microhemorrhages resolve with deposition of hemosiderin, creating a disfiguring dark-brown peppered stain.



Figure 168-3 Pigmented purpuric dermatosis: Majocchi disease. Multiple nonpalpable, nonblanching purpuric lesions arranged in annular configurations and associated with tiny telangiectasias. Note brownish discoloration of older lesions.



Figure 168-4 Lichenoid dermatosis of Gougerot and Blum. (Used with permission from S. Mallory, MD.)

PIGMENTED PURPURIC LICHENOID DERMATOSIS (GOUGEROT AND BLUM)

In 1925, Gougerot and Blum reported a pigmented eruption on the lower extremity of a 41-year-old man.[30] The distinguishing feature of this subtype is the primary lesion, a reddish-brown polygonal or round lichenoid papule, in association with purpura or telangiectasia. Individual papules frequently coalesce into plaques with or without overlying scale. The term *lichenoid* describes the clinical appearance rather than a histologic feature. The color and morphology of the lesions can be mistaken clinically for Kaposi sarcoma (Fig. 168-4). Like the other subtypes, this eruption is found on the lower extremities and, occasionally, the arms. It occurs in males more often than females and has a chronic course.

ECZEMATID-LIKE PURPURA OF DOUCAS AND KAPETANAKIS

Doucas and Kapetanakis reported a group of patients with an asymptomatic seasonal eruption occurring in the spring and summer.[31] Its distinguishing quality is the mild scale overlying the typical patches and pinpoint erythematous macules. These spread rapidly over a period of 15–30 days, involving the legs and, occasionally, the upper body. This eruption fades without treatment over several months to years.



Figure 168-5 Disseminated pruriginous angiodermatitis (itching purpura). (Used with permission from S. Mallory, MD.)

ITCHING PURPURA (DISSEMINATED PRURIGINOUS ANGIODERMATITIS)

The acute onset and widespread involvement of orange–brown to purpuric macules with severe pruritus distinguishes itching purpura (Fig. 168-5).[32,33] It usually appears first on the lower extremities and may become generalized. This disorder also has a chronic course, but there can be spontaneous remissions. Middle-aged men are most commonly affected.

LICHEN AUREUS (LICHEN PURPURICUS)

Marten first coined the term "lichen purpuricus" in 1958,[34] and Calnan later termed the same eruption "lichen aureus."[35] In this condition, *lichen* refers to the clinical and histopathologic descriptions. A dense, band-like, dermal, inflammatory infiltrate differentiates lichen aureus from the other pigmented purpuric dermatoses. Clinically, there are circumscribed areas of confluent gold to copper-orange to, less commonly, purple macules or papules (Fig. 168-6). Although these lesions may be intensely pruritic, they are typically asymptomatic. They are most commonly unilateral and localized on the lower extremities, but they can affect the forearms and trunk. This disorder has a predilection for young adults, with a peak incidence in the second and third decades. The lesions tend to be chronic, remaining stable or progressing slowly. Spontaneous resolution rarely occurs in adults, but in children the eruption may be self-limited.



Figure 168-6 Lichen aureus. (Used with permission from S. Mallory, MD.)

UNILATERAL LINEAR CAPILLARITIS (SEGMENTAL PIGMENTED PURPURA)

Riordan et al reported a linear and pseudodermatomal distribution of pigmented purpura in four young men (average age, 22 years), which they called "unilateral linear capillaritis."[36] Both "segmental pigmented purpura" and "quadrantic capillaropathy" are considered variants of this linear pigmented purpura.[37,38] The patients all had a macular, pigmented, unilateral eruption involving the foot, leg, or buttock. Clinically, the lesions most closely represented lichen aureus; however, the pathology did not show a lichenoid infiltrate. Furthermore, all four cases resolved spontaneously in approximately 2 years, unlike the typically chronic course of lichen aureus. Two more cases were reported in a young woman and man, both in their 20s and both with involvement of their arms. The lesion in the male was self-resolving, similar to previously reported cases, and the female's lesion resolved with PUVA.[39] There are also several reported cases of segmental or zosteriform lichen aureus and Schamberg disease. Two cases have been associated with trauma, and one case preceded the development of localized morphea.[38,40–51]

GRANULOMATOUS PIGMENTED PURPURA

Saito and Matsuoka first reported a granulomatous variant of pigmented purpuric dermatosis in 1996,[52] and Wong reported two additional cases.[53] The mean age of onset was 59 years; all patients were of Asian descent, and all occurred only on the dorsum of the feet. Additional cases have been reported in a Caucasian female with lesions on her lateral ankles[54] and four more patients of Asian descent with involvement of the hands and wrists.[55] The scope of this variant appears to be expanding. Histopathologic examination showed a dense mononuclear cell infiltrate with granulomas in the papillary dermis, thickened capillaries, vascular proliferation, melanophages, and hemosiderin deposits. The duration of the lesions ranged from 2 months to 20 years.

PIGMENTED PURPURIC DERMATOSIS/ MYCOSIS FUNGOIDES OVERLAP

The first cases of pigmented purpura-like eruptions progressing to mycosis fungoides were reported in 1988 by Barnhill and Braverman.[56] Further, the first patient diagnosed with lichen aureus in the United States was later diagnosed with mycosis fungoides. Some evidence supports the idea that lichenoid variants of pigmented purpuric dermatoses may be precursors of mycosis fungoides, with similar histologic findings and clonal populations of lymphocytes.[57–64] Is there a relationship between the two disorders, or are these cases of mycosis fungoides merely mimicking pigmented purpura clinically? Although there is no clear connection between the two diseases, three different relationships have been reported: mycosis fungoides presenting as pigmented purpura, pigmented purpura evolving into mycosis fungoides, and pigmented purpura that simulates mycosis fungoides histologically. The latter may explain why similar treatments are used for both.[65] In a study of T-cell clonality and markers, T-cell monoclonality of PPD was most likely to predict a progression to mycosis fungoides. The absence of certain T-cell markers was less reliable predictor. Histologic clues were subtle, including greater lymphoid atypia in the intraepidermal lymphocytes as opposed to the dermal lymphocytes, but both subsets of PPD had a degree of lymphoid atypia, lichenoid infiltrates, and epidermotropism.[66] Differentiating between the two can be difficult, and clinical and histologic information, as well as immunophenotypic and genetic studies may be necessary.[65,67] Pigmented purpuric dermatoses with large areas of confluence, reticular arrangements, a superimposed violaceous hue, or pruritus that have been present or relapsing for several years are suspicious for mycosis fungoides. There is predominance for adult males as well.[56,68] Long-term follow-up of these patients is needed to determine if their lesions will evolve into mycosis fungoides.

HISTOPATHOLOGY

The pigmented purpuric dermatoses share similar histopathology. In early lesions, a lymphocytic perivascular infiltrate is found in the papillary dermis with extravasated erythrocytes (Fig. 168-7). The epidermis may show spongiosis and parakeratosis, especially in the pigmented purpuric lichenoid dermatitis of

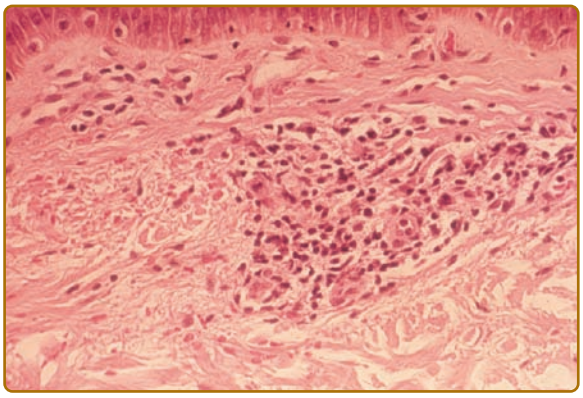

Figure 168-7 Pigmented purpuric dermatosis showing superficial perivascular lymphocytes and extravasated erythrocytes.

Gougerot–Blum and in the eczematid-like purpura of Doucas and Kapetanakis. In older lesions, there is less inflammation, and extravasated red cells may no longer be present. Hemosiderin is deposited primarily in macrophages. In lichen aureus, the mononuclear infiltrate in the upper dermis is distributed in a band-like fashion with a grenz zone.

DIAGNOSTIC STUDIES

Diagnosis is generally made clinically and supported by histopathologic examination. No consistent laboratory abnormalities have been identified. The clinical measurement of capillary fragility by application of a sphygmomanometer (Hess test) does not appear to be reliable, because some reports show an increased capillary fragility in pigmented purpuric eruptions, and others were normal. Review of the patient's medical history, medications, and potential contact allergens is advised. Skin biopsy may be indicated to rule out vasculitis, especially if the lesions are papular. Mycosis fungoides should be considered if the lesions are chronic and unremitting.

DIFFERENTIAL DIAGNOSIS

(Box 168-1)

BOX 168-1 DIFFERENTIAL DIAGNOSIS OF PIGMENTED PURPURIC DERMATOSES

- Contact dermatitis
- Cutaneous necrotizing vasculitis
- Stasis dermatitis and purpura
- Angioma serpiginosum
- Kaposi sarcoma (Gougerot–Blum)
- Mycosis fungoides

MANAGEMENT

Treatment is often ineffective, and most treatments are anecdotal. If the eruption is induced by a drug or contact allergen, discontinuation of the causative drug or contact allergen can lead to complete resolution. However, residual pigmentation may persist for years. Oral bioflavonoid (rutoside, 50 mg bid) and ascorbic acid (500 mg bid) given to three patients with chronic pigmented purpura in an open trial led to clearance in all three patients within 4 weeks.[69] Corticosteroids have been reported to be successful; in particular, triamcinolone spray or potent topical (fluorinated) steroids. Systemic corticosteroids and cyclosporine are often effective but are not indicated due to the benign nature of the disorder.[70] With both topical and systemic steroids, recurrence of the lesions is the rule when steroids are discontinued. Treatment with topical pimecrolimus twice daily cleared lichen aureus lesions in a 10-year-old boy.[71] In a pilot study, calcium dobesilate, 500 mg twice daily, was given to nine patients for 3 months.[72] Seven patients had some mild-to-moderate improvement that was sustained at 1 year after cessation of therapy. Griseofulvin, 500 mg to 750 mg daily, improved existing lesions within a week and stopped new lesions within a mean of 33 days in an open trial of six patients.[73] Colchicine, 0.5 mg twice daily, cleared a 28-year-old woman with recalcitrant Schamberg disease.[74] Minocycline has also been reported to be beneficial. Methotrexate was reported to clear a patient with Majocchi purpura with just 15 mg weekly dosing for 4 weeks, although she had recurrence when the medication was stopped. Again, aggressive therapy is not often warranted for this benign condition, but this patient was treated for her severe burning and pruritus.[75]

Pentoxifylline, which inhibits T-cell adherence to endothelial cells and keratinocytes, may be helpful. A randomized, investigator-blinded trial compared pentoxifylline, 400 mg thrice daily, with topical betamethasone dipropionate cream, 0.05 percent twice daily, for 2 months. Patients treated with pentoxifylline had significantly greater improvement than those treated with the topical steroid. However, the response was not sustained after discontinuation of the medication.[76] Psoralen and ultraviolet A light and narrow band ultraviolet B have both been reported to clear lesions.[77–80] In one case, phototherapy was used to maintain disease suppression while tapering oral prednisolone. The patient remained clear on once every 2-week dosing, but had recurrence when UVB was completely stopped.[81] In the second case, the patient cleared completely with just 30 UVB treatments and remained clear 8 months after stopping.[82] The phototherapy-induced immunosuppression of cell-mediated response is the proposed mechanism.[75] Photodynamic therapy has been reported as beneficial as it affects both immunomodulation and vascular destruction.[83] Supportive stockings should be worn when lesions are on lower extremities.

KEY REFERENCES

Full reference list available at www.DIGM8.com

DVD contains references and additional content

3. Aiba S, Tagami H: Immunohistologic studies in Schamberg's disease: Evidence for cellular immune reaction in lesional skin. *Arch Dermatol* **124**:1058, 1988
28. Torrelo A et al: Schamberg's purpura in children: A review of 13 cases. *J Am Acad Dermatol* **48**:31, 2003
54. Kerns MJ, Mallatt BD, Shamma HN: Granulomatous pigmented purpura: An unusual histological variant. *Am J Dermatopathol* **31**:77, 2009
75. Hoesly FJ, Huerter CJ, Shehan JM: Purpura annularis telangiectodes of Majocchi: Case report and review of the literature. *Int J Dermatol* **48**:1129, 2009
76. Panda S: Oral pentoxifylline vs topical betamethasone in Schamberg disease: A comparative randomized investigator-blinded parallel-group trial. *Arch Dermatol* **140**:491, 2004
81. Lasocki AL, Kelly RI: Narrowband UVB therapy as an effective treatment for Schamberg's disease. *Australas J Dermatol* **49**:16, 2008
82. Kocaturk E et al: Narrowband UVB treatment of pigmented purpuric lichenoid dermatitis (Gougerot-Blum). *Photodermatol Photoimmunol Photomed* **25**:55, 2009

Chapter 169 :: Cryoglobulinemia and Cryofibrinogenemia

:: Holger Schmid & Gerald S. Braun

CRYOGLOBULINEMIA AT A GLANCE

- Cryoglobulins are circulating immunoglobulin complexes found in plasma or serum that reversibly precipitate in cold temperatures.
- Cryoglobulinemia may be symptomless or cause a clinical syndrome involving the skin: purpura at distal sites is the hallmark. Livedo reticularis, acrocyanosis, ulceration, or gangrene may also be seen.
- Cryoglobulins are classified based on molecular properties into types I, II, III (Brouet classification).
- Type I cryoglobulins consist of a single monoclonal immunoglobulin (typically IgG) or light chain. They occur with hematologic malignancies such as multiple myeloma. If symptomatic, they present with a noninflammatory occlusive vasculopathy.
- Type II cryoglobulins consist of a monoclonal immunoglobulin (typically IgM) complexed with a polyclonal immunoglobulin (typically IgG).
- Type III cryoglobulins consist of purely polyclonal immunoglobulin complexes; type II–III refers to an intermediate state with oligoclonal immunoglobulin.
- Types II and III are also referred to as mixed cryoglobulinemias. They are caused by chronic hepatitis C virus (HCV) infection in >90% of cases, while in a minority of cases no etiology can be identified, designating them as "essential mixed" cryoglobulinemias. They present as the cryoglobulinemic vasculitis syndrome, i.e., an immune complex vasculitis involving the skin, neural, and renal tissues.
- Therapy primarily consists of controlling the underlying malignancy or HCV infection. In addition, immunosuppressants, plasma exchange, or targeting of cryoglobulin-producing B-cell clones may alleviate the cryoglobulin burden.

CRYOGLOBULINEMIA

EPIDEMIOLOGY

Cryoglobulinemia may be a symptomless phenomenon that is incidentally found, or it may produce a clinical syndrome involving the skin as a primary organ. In a historic large-scale examination, 11% of patient sera were shown to have cyoglobulinemia, but detection rates vary greatly with the patient population studied.[1] Reliable figures on the incidence or prevalence of cryoglobulinemia or symptomatic cryoglobulinemic syndrome are lacking. The epidemiologic study is hampered by factors such as selection bias from the referral of patients to tertiary care hospitals,

by the heterogeneity of clinical presentations inclusion criteria, and by the different geographic distribution of underlying etiologies such as HCV infection. There is a geographic predominance of cryoglobulinemia in Southern Europe as compared to Northern Europe or the United States that might be explained by this latter fact. The frequency distribution of different cryoglobulinemia subtypes among all types of cryoglobulinemia is approximately type I 25%, type II 25%, type III 50%, making the mixed cryoglobulinemias (types II and III) the most abundant form.[2] The vast majority (>90%) of mixed cryoglobulinemias occurs in association with chronic HCV infection. Thus, HCV-associated mixed cryoglobulinemia is the form among all cryoglobulinemias that has been studied best. On average, 30% of chronically HCV-infected subjects develop cryoglobulinemia, and this proportion can go up to 90% when patients with very longstanding disease are examined.[3–5] Development of cryoglobulins is more frequent with HCV genotype 1 as compared to genotypes 2 and 3.[6] However, on average, the symptomatic cryoglobulinemic vasculitis syndrome is present in only 2% to 5% of chronically HCV-infected patients[7] though figures as high as 15% have been proposed.[8,9] With a conservatively estimated prevalence of chronic HCV infection of ~1% in mind,[10] the calculated prevalence of HCV-associated cryoglobulinemic vasculitis in the USA would be 20–50 per 100,000. The true prevalence is probably on the lower end of this estimation. Given the increasing proliferation of HCV infection worldwide, rising figures might be expected on a global perspective.[11] The prevalence of "essential mixed cryoglobulinemia," i.e., mixed cryoglobulinemia without an identifiable cause, has been estimated to be 1:100,000 in former studies, with a female-to-male ratio of 3:1. However, this number is difficult to interpret since many cases that are nowadays recognized to be associated with HCV or other viruses were formerly attributed to be "essential."[12]

ETIOLOGY AND PATHOGENESIS

In 1933, Wintrobe and Buell first noted the in vitro phenomenon of cryoprecipitation, i.e., the cold-induced precipitation of plasma or serum proteins that is reversible upon rewarming at 37°C (98.6°F).[13] In 1947, Lerner and Watson described immunoglobulins and mixtures of immunoglobulins with other proteins that precipitate in the cold and called them cryoglobulins.[1] In 1974, Brouet introduced the classification of cryoglobulins based on molecular properties that is currently used.[2] Cryoglobulinemia describes the presence of cryoglobulins in a patient's serum (see Fig. 169-1). It can be asymptomatic, meaning that its presence usually goes undetected outside academic study screening protocols, or it can cause occlusive vasculopathy or the so-called cryoglobulinemic syndrome, which is characterized by immune-complex deposition causing vasculitis that involves the skin and mainly neural and renal tissues.

The classification scheme of Brouet, estimated frequency and composition of cryoglobulins is depicted in Table 169-1. Type-I cryoglobulins consist of a single monoclonal immunoglobulin (Ig), typically IgM, less commonly IgG or IgA or free Ig light chains (Bence Jones proteins). Complement components are not routinely found in type I cryoprecipitates. Type I cryoglobulins are often present in substantial amounts, ranging from 1 to 30 mg/mL. The large molecular size of monoclonal IgM and other molecular characteristics, such as absence of sialic acid moieties, deficient carbohydrate side chains, and weak noncovalent factors may predispose these Igs to precipitation.[14] Type I cryoglobulinemia is associated with hematologic disorders, such as Waldenström macroglobulinemia, multiple myeloma, or lymphoproliferative diseases (e.g., B-cell lymphoma).



Figure 169-1 Whitish cryoprecipitates after keeping tube at 4°C (39.2°F) for 48 hours and centrifugation.

Type II and type III cryoglobulins are immune complexes composed of polyclonal IgGs and mono- or polyclonal IgMs. Type II and type III cryoglobulins are typically present in relatively small amounts and generally result from chronic inflammatory states. Type II and type III cryoglobulins may fix complement.

Type II cryoglobulins represent a mixture of two Ig components: polyclonal Igs are associated with a monoclonal Ig that exhibits rheumatoid factor (RF) activity. Typically, a monoclonal IgM RF is complexed with a polyclonal IgG. HCV infection is the classical underlying disease.

A mixture of polyclonal Igs or polyclonal Ig-nonimmunoglobulin cryoprecipitates results in detection of type III cryoglobulins. Polyclonal IgM–IgG cryoglobulins with complement as an integral component are the most frequent scenario in type III cryoglobulinemia that is commonly associated with HCV infection or connective tissue diseases.

TABLE 169-1
Types of Cryoglobulins, Composition of Cryoprecipitates and Disease Associations

Type of Cryoglobulinemia (Estimated Frequency)	Composition of Cryoprecipitates	Disease Associations
Type I (25%)	Monoclonal IgM (sometimes IgG, IgA), immunoglobulin light chain, complexed to other proteins	Haematological disorders ■ Multiple myeloma ■ Waldenström macroglobulinemia ■ Plasma cell dyscrasias, monoclonal gammopathy of undetermined significance (MGUS) ■ Other lymphoproliferative diseases with M components
Type II (25%)	Combination of monoclonal (usually IgM with rheumatoid factor activity) and polyclonal (usually IgG)	Chronic infection ■ Viral (HCV) Autoimmune diseases ■ Sjögren syndrome ■ Cold agglutinin disease Haematological disorders ■ Waldenström macroglobulinemia ■ Chronic lymphocytic leukemia ■ B-cell non-Hodgkin lymphoma
Type III (50%)	Polyclonal Igs	Chronic infection ■ Viral (e.g., HCV, HIV, HBV) ■ Bacterial (e.g., subacute bacterial endocarditis, leprosy, spirochetal) ■ Fungal, parasitic Autoimmune diseases ■ Systemic lupus erythematosus ■ Rheumatoid arthritis ■ Dermatomyositis/polymyositis ■ Inflammatory bowel diseases ■ Biliary cirrhosis
Type II–III (frequency unknown)	Oligoclonal IgM, intermediate state between the entirely polyclonal type III and the monoclonal, polyclonal type II	Chronic infection (e.g., HCV) Autoimmune diseases Lymphoproliferative diseases Chronic liver disease Proliferative glomerulonephritis

Data from Crowson AN et al: Cutaneous vasculitis: A review. *J Cutan Pathol* **30**:161-173, 2003; and Kallemuchikkal U, Gorevic PD: Evaluation of cryoglobulins. *Arch Pathol Lab Med* **123**:119-125, 1999

A new type of cryoglobulins, called type II–III cryoglobulin, containing polyclonal IgG associated with a mixture of polyclonal and monoclonal (oligoclonal) IgM has recently been described.[15] This type of cryoprecipitate describes an intermediate, developing state between types III and II, suggesting a continuous transition from a purely polyclonal to a partially monoclonal composition by a process of successive clonal selection.

Types II and III cryoglobulinemias are classically referred to as "mixed cryoglobulinemias". Circulating mixed cryoglobulins are commonly detected in a great number of infectious or systemic disorders (see Table 169-1). The term "essential" is originally reserved for instances of mixed cryoglobulinemia in the absence of a well-defined underlying disease and, given the striking association between mixed cryoglobulinemia and HCV, is actually referred to only a minority of cryoglobulinemic patients.

Prevalence of serum anti-HCV antibodies and/or HCV RNA in cryoglobulinemic patients ranges from 70% to 100%. Type II cryoglobulinemia is more strongly associated with HCV than type III (90% vs. 70%, respectively). Presence of cryoglobulins increases with duration of HCV infection: cryoglobulins are found in 55%–90% of patients with longstanding infection. However, overt cryoglobulinemic syndrome develops in only 2%–5% of these cases (see also Section "Epidemiology"). The precise role of viral or host factors contributing to this discrepancy remains largely unknown. Specific HCV genotypes or distinct HLA subtypes, like HLA-DR11 or HLA-DR6 may predispose to extrahepatic systemic manifestations of cryoglobulinemia.[16,17] Pathogenesis of mixed cryoglobulinemia is probably a multifactorial and multistep process. Viral HCV antigens exert a chronic stimulus on the host immune system, resulting in specific immune dysregulatory mechanisms with B-cell proliferation and autoantibody production. HCV-related B-cell lymphoproliferative disorders comprise a spectrum of disease, ranging from asymptomatic clonal B-cell expansions to pathogenic cryoglobulinemia and

lymphoma.[18] From that perspective, HCV-associated mixed cryoglobulinemia is a benign lymphoproliferative B-cell disease with a potential for subsequent development of B-cell lymphoma.[19,20] Development of HCV-associated cryoglobulinemic vasculitis syndrome is associated with longstanding infection, old age, type II cryoglobulins, higher cryoglobulin levels, and clonal B-cell expansion.[21,22]

The group of non-HCV-induced mixed cryoglobulinemias is small. The following associations have been described: An association of cryoglobulinemia with various other infectious viral agents, for example, hepatitis B virus, cited as a major causative agent,[23] and HIV with or without HCV coinfection has also been demonstrated.[24] Parvovirus B19 has been implicated in a mild form of cryoglobulinemic syndrome.[25] Another important association is the one with Sjögren syndrome. According to one study, 16% of patients with primary Sjögren syndrome had cryoglobulins, and of those, 56% had cryoglobulinemic syndrome.[26,27] A study by the same group found cryoglobulinemia in 25% of patients with systemic lupus erythematosus.[28]

CLINICAL FINDINGS

APPROACH TO THE PATIENT. In almost all cases, the possibility of a diagnosis of cryoglobulinemia or cryoglobulinemic syndrome is primarily suggested by the presence of purpura of the distal extremities or by acral cyanosis and necrosis, depending on the potential presence of type I or types II and III cryoglobulinemia. Alternatively, the potential diagnosis may be suggested by the presence of a candidate underlying disease. A targeted review of systems and subsequent clinical examination will guide the physician towards the entire picture of organ involvement or differential diagnoses. The laboratory panel must include parameters relevant to both cryoglobulinemia and important differential diagnoses. Box 169-1 presents an algorithm for the diagnostic approach to the patient, including laboratory testing. eTable 169-1.1 in online edition summarizes the symptoms, signs, cutaneous, extracutaneous and laboratory findings of cryoglobulinemia. Of note, there are still only preliminary diagnostic criteria for the classification of mixed cryoglobulinemic patients (see eTable 169-1.2 in online edition).

CUTANEOUS LESIONS. Cutaneous lesions are the most frequent manifestations (Fig. 169-2). Type I cryoglobulinemia per se is often asymptomatic and cutaneous signs are related to hyperviscosity and/or thrombosis that induce ischemic vasculopathy presenting as Raynaud phenomenon, digital ischemia, livedo reticularis, or purpura. Type II and III cryoglobulinemic vasculitis is mediated by deposition of antigen–antibody complexes in small- and medium-sized arteries, leading to inflammation of vessel walls. Intermittent orthostatic palpable purpura, frequently observed late in the afternoon when highest cryoglobulin concentrations are present, is the most common presentation and particularly affects the lower extremities.[29] Dimension and diffusion of purpuric lesions can vary from sporadic isolated petechias or erythematous macules to severe vasculitic lesions with ulcerations. Leukocytoclastic vasculitis is the histopathological hallmark of mixed cryoglobulinemia and is easily detectable by skin biopsy (see Chapter 163 see also eFig. 169-2.1 in online edition). Nail-fold capillary abnormalities are common and include dilatation, altered orientation, capillary shortening, and neoangiogenesis.

RELATED PHYSICAL FINDINGS. *Renal involvement* is a serious complication, typically manifests early in the course of the disease and can present as a broad range of clinical findings, including hematuria with or without renal insufficiency (41%), isolated proteinuria, nephrotic syndrome (21%) or acute nephritic syndrome.[30] Chronic renal insufficiency without significant renal abnormalities and acute renal failure are less common. The incidence of renal disease in cryoglobulinemia varies from 5% to 60% and is typically immune complex mediated (type II and III), but may also occur secondary to thrombosis (type I) (for details see eTable 169-1.3 in online edition).

Neurological manifestations, typically affecting the sensory peripheral nervous system secondary to epineural vasculitis frequently complicate the clinical course. Patients typically describe paresthesias with burning symptoms in the lower limbs, often with nocturnal exacerbation, leading to severely compromised quality of life. Electromyographic and nerve conduction studies demonstrated peripheral neuropathy in up to 80% of patients with mixed cryoglobulinemia, but many symptom-based demographic studies report prevalence of only 5% to 45%. Peripheral neurologic disease manifests as a progressive, chronic distal mild sensory neuritis and only rarely as acute mononeuritis. Clinically apparent central nervous system dysfunction is rare.

Musculoskeletal complaints, typically arthralgias and myalgias, are described in more than 70% of persons with cryoglobulinemia, predominantly in type II and III disease. The association of cryoglobulinemia with palpable purpura, arthralgia and myalgia was referred to as Meltzer triad in the late 1960s. Arthralgias classically affect the proximal interphalangeal and metacarpophalangeal joints of the hands, the knees, and ankles. Clear clinical signs of myositis or arthritis are rare.

Abnormal liver function tests, hepatomegaly including signs of cirrhosis or abnormal histological results in liver biopsy were reported in up to 90%. Also, thyroid disorders and diabetes mellitus seem to be associated with cryoglobulinemia.[39]

Unspecific abdominal pain can affect 2% to 22%. Intestinal vasculitis of the small mesenteric vessels leading to acute abdomen has been reported.

Approximately 40% of patients are symptomatic with dyspnea, cough, or pleuritic pain. Pulmonary function tests often reveal evidence of small airways disease and chest radiographs sometimes show interstitial infiltrates or signs of subclinical alveolitis. Severe pulmonary disease, for example, bronchiolitis obliterans organizing pneumonia (BOOP) or pulmonary vasculitis are very uncommon.

BOX 169-1 APPROACH TO THE PATIENT ALGORITHM FOR PATIENTS WITH SUSPECTED CRYOGLOBULINEMIA

HISTORY AND EXAMINATION (INCLUDING OPTIONAL TECHNICAL METHODS)

Ask for

- Cold sensitivity
- Weakness, musculoskeletal complaints, arthralgia
- Alcohol consumption, hereditary liver disease, history of hepatitis
- Known infections (HCV, HBV, HIV)
- Urine abnormalities (hematuria, foamy urine, edema; any one suggesting renal involvement)
- Paresthesias
- Difficulties in concentrating (suggesting central neuronal involvement)

Look for

- Acrocyanosis, Raynaud phenomenon (suggesting type I cryoglobulinemia)
- Purpura of distal extremities (suggesting type II and III cryoglobulinemia)
- Peripheral neuropathy (consider electromyographic testing)
- Joint swelling (suggestive for rheumatoid arthritis, SLE)
- Lymph node enlargement (suggesting lymphoma)

Technical examination (optional)

- Ultrasound: Liver abnormalities, splenomegaly (suggesting lymphoma)
- EKG, echocardiography: Rule out cardiac involvement, e.g., suggesting SLE
- Ophthalmology: Eye involvement, chorioretinitis (suggestive for Behçet disease or sarcoidosis)

MANDATORY LABORATORY TESTING IN CRYOGLOBULINEMIA

- Cryoglobulins (establishing the diagnosis when positive; stringent laboratory workup at 37°C is needed)
- Complete blood count including differential blood count
- Creatinine, BUN
- Complement (C4 and possibly both C4 and C3 diminished)
- IgA level (suggestive for liver disease or Henoch-Schönlein Purpura)
- ANA, SS-B, SS-A (positive in SLE and Sjögren syndrome associated cryoglobulinemia)
- ANCA (possibly positive, or suggesting granulomatosis with polyangiitis [Wegener's] or microscopic polyangiitis)
- Rheumatoid factor RF (positive in Type II cryoglobulinemia with a very high titer)
- Urinalysis, if positive additional microscopic examination of urinary sediment
- Hepatitis A, B, C serology
- Look for other viruses, e.g., parvovirus B19, HIV if suspicion
- Further workup for hepatic failure if appropriate

HISTOLOGY

- Consider skin biopsy
  - To confirm leukocytoclastic vasculitis (stain for complement and immune complexes)
  - To rule out other forms of vasculitis
- Consider renal biopsy (discern between MPGN I and other forms)
- Consider hepatic biopsy

Hyperviscosity due to high levels of monoclonal cryoglobulins, typically seen in Waldenström macroglobulinemia and less frequently in multiple myeloma, can induce microcirculation impairment and reduced platelet function, leading to skin and mucosal bleeding. A variety of neurologic symptoms have been reported in hyperviscosity syndrome: blurring or loss of vision, headache, vertigo, nystagmus, dizziness, sudden deafness, diplopia, ataxia, confusion, dementia, disturbances of consciousness, stroke, seizures, somnolence or coma. A characteristic retinal venous engorgement ("sausaging") on funduscopic inspection can serve as a diagnostic clue.

LABORATORY TESTS. In clinical practice, cryoglobulin testing is underutilized, most probably due to the expenditure of time and stringent temperature requirements.

Serum must be obtained in warm tubes (37°C) in the absence of anticoagulants. After clotting and centrifugation at 37°C, the separated serum is stored at 4°C and inspected daily for a precipitate. Type I cryoglobulins

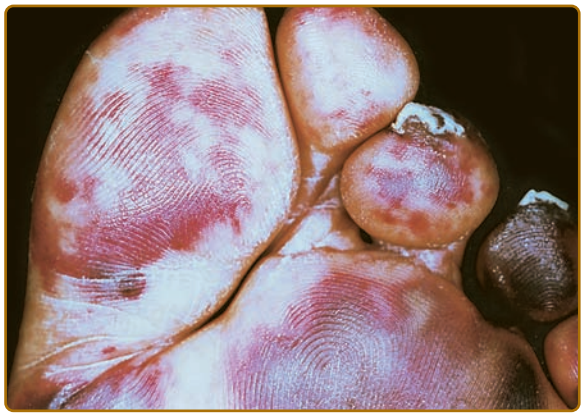

Figure 169-2 Leukocytoclastic vasculitis in a patient with mixed cryoglobulinemia manifested as palpable purpura and acrocyanosis. Patient with tuberculosis, positive antinuclear antibody, and hepatitis.

tend to precipitate within the first 24 hours (at concentrations >5 mg/mL), whereas type III cryoglobulins may require 7 days (see Fig. 169-1). For calculation of cryocrit (volume of packed cryoglobulins as percentage of original serum volume), the cryoprecipitate has to be spun in a graded (e.g., Wintrobe) tube. A cryocrit ≥2% is considered to be positive. Cryocrit levels usually do not correlate with severity and prognosis of disease.

Some authors recommend proof of reversibility of the cryoprecipitate by rewarming an aliquot at 37°C for 24 hours.[12] For phenotyping and identification of cryoglobulin components specific immunologic assays are performed at 37°C.

Clinical diagnosis of hyperviscosity can be established by measuring serum viscosity with an Oswald-type viscometer. Reference serum viscosity, measured as flow time through the viscometer of the patient's serum divided by that of water or saline, is between 1.4 and 1.8, while most symptomatic patients have values between 5 and 8. Again, clinical manifestations are often not proportional to serum viscosity.

As hypocomplementemia (with the typical pattern of low or undetectable C4 and normal or relatively normal C3 levels) occurs in up to 90% of patients with mixed cryoglobulinemia, C3 and C4 levels, usually measured in nephelometric immunoassays, should be routinely determined. A sudden increase in complement C4, raised to abnormally high levels can be observed in some patients developing a B-cell lymphoma.[40]

RF is often positive in type II and III cryoglobulinemia. Testing for antinuclear antibodies (ANAs, SS-A, SS-B) and other autoantibodies (e.g., anti-smooth-muscle Abs) is indicated upon clinical suspicion of underlying systemic connective tissue disease (e.g., SLE, Sjögren syndrome). Although the immunofluorescence ANA assay is the current diagnostic gold standard, titer and specificity of ANAs may vary considerably.

Particularly in patients with HCV-associated mixed cryoglobulinemia serum levels of IL-1β, IL-6, and TNF-α are significantly elevated.[41] Increased levels of the chemokines CXCL10 and CXCL13, also known as BCA-1 (B-cell-attracting chemokine-1), seem to be associated with active vasculitis.[42,43]

DIFFERENTIAL DIAGNOSIS

Starting from the symptom of purpura all small vessel cutaneous vasculitides, especially those involving the histopathological picture of leukocytoclastic vasculitis must be considered in the differential diagnosis of mixed cryoglobulinemia. Major differential diagnosis of vasculopathy, typical for type I cryoglobulinemia, includes diseases causing Raynaud syndrome, acrocyanosis, and acral ischemia.

See Box 169-2 for a complete overview on differential diagnosis of cryoglobulinemia (and cryofibrinogenemia).

COMPLICATIONS

Acute severe complications directly caused by cryoglobulins are rare with any type of cryoglobulinemia. The organs most vulnerable to complications are the nervous system and the kidneys. In Type I cryoglobulinemia, they are mostly related to an acute vaso-occlusive crisis caused by increased serum viscosity leading to acute acral ischemia and to cerebral and renal ischemia causing stroke or acute renal failure. In addition, the underlying hematologic disease of type I cryoglobulinemia can directly cause renal failure (e.g., myeloma kidney); see also eTable 169-1.3 in online edition. At advanced stages, complications are defined by the underlying hematologic disease itself: immunosuppression leading to infection and sepsis, coagulation disorders with severe bleeding, and side effects of hematologic disease-specific treatments. Mixed cryoglobulinemic vasculitis may involve the peripheral nerves leading to life-threatening situations or cause acute-on-chronic renal failure. Again, advanced stages of the underlying disease (mostly hepatitis C or other types of liver disease) can result in acute liver failure or problems associated with hepatic insufficiency, i.e., coagulation disorders, malnutrition, ascites, and the hepatorenal syndrome. Skin necrosis and vasculitic lesions can be entry sites for infection. Catastrophic individual patient courses have been described.[44]

PROGNOSIS AND CLINICAL COURSE

Prognosis is defined by the severity of the cryoglobulinemic syndrome and by the treatability of the underlying disease causing cryoglobulinemia. In type I cryoglobulinemia this will depend on the nature and stage of the hematological disease. A favorable prognosis in a patient with type I cryoglobulinemia can only be expected when control of the underlying disease can be achieved. In type II cryoglobulinemic vasculitis, data suggest that prognosis is generally benign in 50% of cases, but 30% have a moderate to severe course, especially because of renal and/or hepatic insufficiency.

BOX 169-2 DIFFERENTIAL DIAGNOSIS OF CRYOGLOBULINEMIA AND CRYOFIBRINOGENEMIA

Most likely

- Autoimmune disease
  - Lupus erythematosus
  - Dermatomyositis
  - Rheumatoid arthritis
  - Antiphospholipid antibody syndrome
- Vasculopathies
  - Thromboangiitis obliterans
  - Henoch-Schönlein purpura
  - *Atheroemboli*
  - Cholesterol emboli
  - Septic emboli
  - Calciphylaxis
- Primary cutaneous disorders
  - Urticaria
  - Livedo or livedoid vasculitis
  - Neutrophilic dermatoses
  - Lipodermatosclerosis panniculitis
  - Idiopathic perniosis (chilblains)
  - *Frostnip, pernio, frostbite*

Consider

- Autoimmune disease
  - Scleroderma
- Hematologic disorders
  - Inherited or acquired hypercoagulable states (e.g., protein C or S deficiency)
  - Thrombocytopenic disorders (e.g., thrombotic thrombocytopenic purpura, idiopathic thrombocytopenic purpura)
  - Disseminated intravascular coagulation
- Infection
  - Bacterial: *Rickettsia rickettsii* (Rocky Mountain spotted fever), *Neisseria meningitidis*
- Drug-related reactions
  - Raynaud (e.g., bleomycin, ergotamine)
  - Livedo reticularis (e.g., amantadine)
  - Purpura (e.g., heparin, warfarin)
- Other
  - Oxalosis

Always Rule Out

- Infection
  - Viral: HCV
- Vasculopathies
  - *Atherosclerotic peripheral vascular disease*

Consequently, 10-year-survival rates are significantly lower than in the normal population.[29,45,46] These data integrate a heterogeneous population that includes hepatitis C-associated cases that were treated by differing approaches ranging from symptomatic steroid therapy to antiviral treatment. It can be expected, however, that prognostic outlook will improve in the future since currently used antiviral treatment aimed at elimination of hepatitis C infection may cure or completely control HCV-associated mixed cryoglobulinemic vasculitis. In these patients, complications and side effects of antiviral treatment and the course of underlying hepatic disease will have a major impact on prognosis.[47]

Renal involvement is a poor prognostic sign in patients with cyroglobulinemic vasculitis with 15% progressing to end stage renal disease (ESRD).[29] MPGN I from any cause including noncyroglobulinemic ones has a poor prognosis: 50% of patients progress to ESRD within 10 years. Small studies report successful treatment of MPGN I by antiviral strategies.[48,49] The prognosis of cryoglobulinemia with no identified underlying disease (essential mixed cryoglobulinemia) is not well predictable, and, again, renal involvement is associated with poor prognosis (renal failure in 10% of patients).[50] The spectrum of renal disease in non-HCV mixed cryoglobulinemia has been recently studied.[51]

TREATMENT

Generally three levels of treatment can be considered when treating cryoglobulinemia: (1) etiologic treatment, which is aimed at the cure or safe containment of the underlying disease; (2) pathogenetic treatment, which is aimed at reducing the production of cryoglobulins while the underlying etiology remains untreated; and (3) symptomatic treatment that is aimed at reducing the cryoglobulin burden by removal from plasma or at mitigating the tissue's vasculitic reaction. Sometimes a combination of these approaches is used. The decision for initiation of a therapy should be informed by the severity of the symptoms with benefits outweighing risks. Cryoglobulinemia without symptoms does not justify treatment, unless there is an underlying condition that merits therapy. eTable 169-1.4 in online edition summarizes all available approaches, while integrated therapeutic concepts for typical clinical situations are presented here.

TYPE I CRYOGLOBULINEMIA

Etiologic treatment is the treatment of choice. The underlying hematologic disease, typically multiple myeloma, Waldenström macroglobulinemia or lymphoma must be treated with chemotherapy directed

by a hematologist according to current standards of care. In addition to this, severely symptomatic hyperviscosity syndrome of type I cryoglobulinemia can be reduced by repeated plasma exchange or by cryofiltration (see eFig. 169-2.3 in online edition). This may be necessary as a bridging therapy until therapy of the underlying disease shows an effect. In plasma exchange, the patient's plasma is removed by an apheresis membrane and substituted using approximately 3.5 L of donor plasma per session. Cryofiltration operates by passing the cooled patient's plasma through a specialized membrane unit designated at the removal of cryoprecipitates without necessitating plasma substitution. However, this latter approach may be hampered by rapid clogging of the membrane in the setting of high cryglobulin concentrations. In severe cases of type I cryoglobulinemia, it may be necessary that these removal procedures be performed daily over a period of two weeks or more. Intriguingly, the occurrence of plasmapheresis rebounds in disease activity has also been described.

HCV-ASSOCIATED TYPE II AND TYPE III CRYOGLOBULINEMIA IN PATIENTS WITH MILD-TO-MODERATE DISEASE

The primary therapeutic approach depends on disease severity. Patients with mild-to-moderate cryoglobulinemic vasculitis without major organ failure are best treated using antiviral agents. While the effects of the treatment exhibit some delay, the approach has the advantage of offering a potentially complete and sustained remission of the vasculitic syndrome. This has been shown by a series of pioneering studies employing regimens of interferon alone or in combination with ribavirin in patients with HCV and cryoglobulinemia.[55–63] Among those therapeutic regimens, the highest response rates were found using the current gold standard of therapy, PEGylated interferon α-2b and ribavirin[55,62]: recovery of purpura 87.5%, recovery of arthralgia 82%, recovery of peripheral neuropathy 74%, and recovery of nephropathy 50%. The rate of sustained viral response was similar to large patient study populations without cryoglobulinemia: 62.5%. The regimen is detailed in the current statements on the management of hepatitis C of the American Gastroenterological Association,[64,65] and it is briefly described in eTable 169-1.4 in online edition. There are several limitations of antiviral combination therapy. Applicability in renal insufficiency is reduced due to drug accumulation. Recommendations for dosage adjustment have been published in the current Kidney Disease: Improving Global Outcomes (KDIGO) guidelines of 2008[66] and are summarized in eTable 169-1.5 in online edition. While ribavirin is contraindicated at an estimated GFR <50 mL/min, it is a desirable drug rendering interferon therapy markedly more powerful.[62,64] Therefore a dosage regimen guided by plasma levels has been proposed that could allow for off-label administration in settings of a GFR <50 mL/min.[67] The contraindications and side effects of antiviral combination therapy are summarized in eTable 169-1.6 in online edition. Of note, ribavirin can cause hemolytic anemia requiring pausing or dosage adjustments. If in doubt, collaboration with a hepatologist and a nephrologist is recommended in order to apply this most promising of all approaches in HCV-related mixed cryoglobulinemic syndrome to as many eligible patients as possible.

HCV-ASSOCIATED TYPE II AND TYPE III CRYOGLOBULINEMIA IN PATIENTS WITH SEVERE DISEASE

In the case of organ failure such as overt renal failure, possibly accompanied by the nephrotic syndrome or neuropathy, initial pathophysiologic and symptomatic therapy are required in order to achieve a reasonably rapid response. Traditionally, an immunosuppressive combination therapy using steroids possibly followed by cyclophosphamide, azathioprine, or chlorambucil have been used.[68] Off-label use of the chimeric anti-CD20 (see also eTable 169-1.4 in online edition.) antibody, rituximab has recently emerged as a powerful alternative to classic immunosuppression.[69] The antibody targets B-lymphocytes leading to a depletion of 95% of the B-lymphocytic population. Thereby, the cryoglobulin-producing B lymphocytic clone is markedly reduced leading to marked cryoglobulin level reduction and consecutive remission. Taken together, this represents a pathophysiological approach to treatment (see eTable 169-1.4 in online edition). Since the B-cell depletion is only transient after one course, a relapse will usually occur.[70] As with classic immunosuppression, the therapy may lead to increased viral loads of HCV.[70] For long-term effects, repeated dosages of rituximab or maintenance therapy using classic immunosuppression would be required. The best option is to use these strategies to reduce acute cryoglobulinemic disease burden in order to bridge patients to a state where antiviral treatment, as outlined above, can be safely initiated.[68] Cases of successful remission of severe disease allowing for subsequent safe antiviral combination therapy have been reported.[71,72] As a bridging therapy, plasma exchange and cryofiltration can also be applied (see Section "Type I Cryoglobulinemia" for details). Though reported to be generally well tolerated in patients with cryoglobulinemic syndrome, rituximab has several limitations. It cannot be used in patients with overt skin ulceration due to interference with wound healing. Progressive multifocal leukencephalopathy under rituximab has been reported.[69] A recent report has pointed to a severe complication with worsening of cryoglobulinemic vasculitis syndrome on rituximab.[73] Yet, given the enormous potential of rituximab, the NIH has initiated a clinical research study on rituximab for the treatment of HCV-associated cryoglobulinemic vasculitis (Protocol number: 02-I-0096).

RELAPSE OF HCV-ASSOCIATED CRYOGLOBULINEMIC VASCULITIS

After initial successful antiviral treatment, relapses of HCV viremia with relapse of the vasculitic syndrome

have been described. The recent study by Cacoub and coworkers has concluded a protocol recommendation using another course of IFN + ribavirin in combination with rituximab to address this problem.[72] Another scenario of relapse after successful antiviral treatment has been described in one study where only the cryoglobulinemic vasculitis syndrome, but not the viremia reoccurred.[74] Such a scenario would call into question the concept of HCV as a cause for cryoglobulinemic vasculitis. However, in two-thirds of the study's patients, B-cell lymphoma was found on follow-up. This stresses the pivotal role of HCV in inducing B-cell lymphoma, as its occurrence is elevated 35-fold in patients with chronic HCV infection,[19,20] and stresses the importance of close medical follow-up in patients with a relapse of vasculitis despite successful clearance of the virus.

TYPE II AND TYPE III CRYOGLOBULINEMIC VASCULITIS NOT ASSOCIATED WITH HCV

In type II and III cryoglobulinemic vasculitis not associated with HCV classic immunosuppression using steroids and possibly steroid-sparing agents as outlined in eTable 169-1.4 in online edition continues to represent a major therapeutic approach. However, successful treatment has also been reported using rituximab.[69]

In any case, careful monitoring for development of B-cell lymphoma should be conducted which then would lead to specific treatment. Likewise specific treatment of the underlying disease remains key. Symptomatic therapy may also include nonsteroidal anti-inflammatory drugs.

CRYOFIBRINOGENEMIA

EPIDEMIOLOGY

CRYOFIBRINOGENEMIA AT A GLANCE

- Cryofibrinogenemia results from cryoprecipitation of patients native fibrinogen or fibrin by-products in plasma, but not serum.
- Cryofibrinogenemia is classified as essential or secondary (associated with malignancies, collagen vascular diseases, and thrombotic disorders).
- Cryofibrinogenemia is rare, but probably underestimated in clinical practice.
- Typical clinical features result from thrombosis (thrombotic phenomena of skin and viscera) and are often life threatening.

Cryofibrinogenemia is often clinically asymptomatic. Of note, 2% to 9% of healthy persons may have demonstrable amounts of cryofibrinogen, usually in concentrations less than 50 mg/L. In the past, cryofibrinogenemia was considered rare, but recent single-center studies indicate that this disorder is possibly underrecognized due to (1) the infrequency with which it causes symptoms and (2) inconsistencies in laboratory investigations producing falsely negative results. Initial studies noted the prevalence of cryofibrinogenemia among hospitalized patients between 3.4% and 13%, with a female (female–male ratio 4:1) but without age or racial prediction. In a study by Saadoun and coworkers, 2,312 hospitalized patients were tested for cryofibrinogenemia between 1996 and 2006.[75] A total of 515 (22.2%) patients had positive test results, of whom 88% had secondary and 12% had essential cryofibrinogenemia. Another retrospective single hospital 10-year report identified 61 patients having cryofibrinogenemia, which was essential in 18 (29.5%) and secondary in 43 (70.5%) patients.[76]

ETIOLOGY AND PATHOGENESIS

Precipitation of patients' native fibrinogen or fibrin by-products in plasma, but not serum, was first described by Korst and Kratochvil in 1955.[77] The so-called cryofibrinogenemia can be classified as primary (also named essential or idiopathic) or secondary. Diagnosis of primary cryofibrinogenemia requires the presence of cryofibrinogens in plasma, absence of cryoglobulins, and one or more compatible clinical features (e.g., cold-induced thromboses, increases in blood viscosity and/or vascular reactivity) in an otherwise healthy individual. Some authors hypothesize that essential cryofibrinogenemia might be a prerequisite for a secondary disease.

Secondary cryofibrinogenemia is diagnosed when an associated disease or drug is present. The most frequently associated disorders include malignancy, infections, connective tissue and autoimmune diseases (see Table 169-2).

Cryofibrinogen is characteristically composed of fibrinogen, fibrin, fibronectin and/or fibrin degradation products. Other components include albumin, cold insoluble globulin, factor VIII, and plasma proteins as well as the plasmin activity inhibitors α_1-antitrypsin, and α_2-macroglobulin. Pathology in cryofibrinogenemia is attributed to "in situ" thrombosis, leading to thrombotic occlusion of small- and medium-sized dermal vessels and resultant ischemia. Defects in the fibrinolysis process might lead to further clotting in small and medium arteries. Additional immunologic mechanisms may play a significant role in the pathophysiology of cryofibrinogenemia.

Some people with cryofibrinogenemia are asymptomatic, while others have clinical features resulting from thrombosis that can be life threatening when untreated.

Secondary forms of cryofibrinogenemia are significantly more frequent in patients with combined cryofibrinogenemia and cryoglobulinemia than in those with isolated cryofibrinogenemia (79 vs. 47%).[78] Among HCV-infected patients, cryofibrinogenemia is common, and closely correlated with cryoglobulinemia: in

TABLE 169-2
Cryofibrinogenemia Disease Associations

Endocrine Disorders
Diabetes mellitus
Hypothyroidism
Infection
Viral (e.g., VZV, EBV, HCV)
Bacterial (e.g., *Klebsiella pneumoniae*, *Mycoplasma pneumoniae*)
Severe sepsis
Malignancy
Adenocarcinoma (e.g., gastric, lung)
Hepatocarcinoma
Ovaric cancer
Prostate cancer
Haematological Disorders
Multiple myeloma
Lymphoma (follicular, B cell, T cell)
Chronic myelomonocytic leukemia
Autoimmune Diseases
Mixed connective tissue disease
Sjögren syndrome
Dermatomyositis
Drugs
Oral contraceptive agents

VZV = varicella-zoster virus; EBV = Epstein-Barr virus; HCV = hepatitis C virus.

a study of 143 patients with HCV infection, 53 (37%) had cryofibrinogen levels >50 mg/L. Forty-seven of these cryofibrinogen-positive patients (89%) had positive tests for cryoglobulins.[79]

CLINICAL FINDINGS

APPROACH TO THE PATIENT AND HISTORY TAKING.

Patients with cryofibrinogenemia typically report a temporal association between cold exposure and onset of symptoms. Nonspecific general complaints of fever and malaise are common. For all patients with cryofibrinogenemia, age-appropriate malignancy screening and evaluation for possible underlying infection or systemic inflammatory disease are indicated. However, diagnostic workup should always be directed by the patient's clinical presentation.

CUTANEOUS LESIONS.

Clinical signs in cryofibrinogenemia are mostly cutaneous and are typically located on cold-exposed areas (hands, feet, buttocks, ear, nose). These cold-sensitive lesions often reflect cold-induced thromboses, increased viscosity, and/or vascular reactivity. Palpable purpura with underlying leucocytoclastic vasculitis is the most frequent clinical presentation. Other cutaneous features can include painful ulcerations, livedo racemosa, Raynaud phenomenon, segmental swelling, lower extremity nodules, painful or pruritic erythema (perniosis) of the extremities and cold urticaria. Cryofibrinogenemia may clinically simulate calciphylaxis, presenting normally in patients with end-stage renal disease (ESRD).

RELATED PHYSICAL FINDINGS.

Cryofibrinogenemia has a broad spectrum of clinical manifestations including vessel, kidney, musculoskeletal and/or neuronal involvement. Various thrombotic events, nephritic or nephrotic syndrome, arthralgia, myalgia, multineuritis, and fever have been reported.[80] In a recent study, main clinical manifestations included purpura (46.6%), skin necrosis (36.6%), and arthralgia (31.6%) with cold sensitivity in 40% and overall thrombotic events occurring in up to 40% of cases. A high cryofibrinogen plasma concentration was a significant predisposing factor for thrombotic events.[75] Thrombotic events include cerebrovascular accidents (stroke, ocular thrombi including retinal arterial and/or venous occlusions), myocardial infarction, limb and bowel ischemia or infarction, and pulmonary emboli, although a causal relationship has not been proven for all described cases.[81]

LABORATORY TESTS.

Laboratory workup is critical for the accuracy of cryofibrinogen detection, and ideally includes separation in a temperature controlled centrifuge (see also Section "Laboratory Tests" under "Cryoglobulinemia").

The warm blood specimen should be anticoagulated with citrate, EDTA or oxalate, but not heparin, that nonspecifically precipitates fibrinogen. After centrifugation at 37°C, the plasma is placed in a Wintrobe tube, refrigerated at 4°C and observed for the formation of a precipitate for 72 hours. The cryocrit is quantitated by centrifuging the specimen while it remains cooled to 4°C. Each millimeter of visible precipitate in the Wintrobe tube represents 1% of cryocrit.

In parallel, a cryoglobulin test is simultaneously performed in a sample without anticoagulants, to ensure that the plasma precipitate is cryofibrinogen and not cryoglobulin.

Affinity-chromatography, immunodiffusion and/or electrophoresis are used for quantitation and/or identification of the individual cryofibrinogen components.

SPECIAL TESTS

Histological Features. Irrespective of the anatomic site, cryofibrinogenemia shows an occlusive thrombotic diathesis comprising eosinophilic refractile deposits within vessel lumina with extension into the vessel intima, with or without an accompanying characteristic granulomatous vasculitic component.[76,82] Cryofibrinogen precipitates have a cylindrical configuration in ultrastructural analysis, which is often displayed within the vessel lumina. Examination of renal deposits showed fibrillary material within glomerular capillary lumina and tubules with unique morphologic features not previously described.[80]

COMPLICATIONS

Typical complications due to thrombotic events include gangrene (5%), septicemia (5%), and leg amputation (3.3%).[75] In some cases essential cryofibrinogenemia might be a prerequisite for a secondary disease, particularly lymphomas[83]: in a 2008 report, 27% of

patients with primary cryofibrinogenemia developed lymphoma after a 5-year follow-up period.[76]

PROGNOSIS/CLINICAL COURSE

Clinical data regarding prognosis in cryofibrinogenemia are limited. In one study, 3 out of 60 patients with essential cryofibrinogenemia died after a mean follow-up of 85 months.

TREATMENT

Smoking cessation, avoidance of cold exposure and eliminating the use of vasoconstricting drugs are nonpharmacologic interventions that are recommended, but are only partially effective. In secondary cryofibrinogenemia, specific treatment of the underlying disease can lead to improvement in related symptoms.

For essential cryofibrinogenemia, various pharmacological agents including fibrinolytic approaches and immunosuppressive agents have been proposed. Oral stanozolol (2–4 mg twice daily), a synthetic derivative of testosterone with substantial fibrinolytic properties, has been effective after several days of treatment.[84] Streptokinase (sometimes in combination with streptodornase), given intravenously (e.g., 25,000–200,000 U/day) has a more rapid onset of action than stanozolol. Recently, the use of colchicine (0.6 mg twice daily) in combination with high-dose pentoxifylline (800 mg three times daily) has been described.[85]

Combinations of glucocorticoids (e.g., prednisone 10–60 mg/day) with other immunosuppressive agents (e.g., azathioprine 150 mg/day or chlorambucil 10 mg/day) have also been used in small studies with some benefit, including successful treatment of acute attacks.

Plasmapheresis might be considered when high levels of cryofibrinogens are present, and are associated with monoclonal proteins (e.g., myeloma, Waldenström macroglobulinemia), hyperviscosity, or clinically significant thrombosis. Long-term repeated plasmaphereses and anti-immunoglobulin adsorption improved the symptoms in one patient with secondary cryofibrinogenemia.[86]

KEY REFERENCES

Full reference list available at www.DIGM8.com

DVD contains references and additional content

7. Cacoub P et al: Extrahepatic manifestations of chronic hepatitis C. MULTIVIRC Group. Multidepartment Virus C. *Arthritis Rheum* **42**:2204-2212, 1999
12. Ferri C: Mixed cryoglobulinemia. *Orphanet J Rare Dis* **3**:25, 2008
20. Saadoun D et al: Increased risks of lymphoma and death among patients with non-hepatitis C virus-related mixed cryoglobulinemia. *Arch Intern Med* **166**:2101-2108, 2006
29. Ferri C et al: Mixed cryoglobulinemia: demographic, clinical, and serologic features and survival in 231 patients. *Semin Arthritis Rheum* **33**:355-374, 2004
55. Cacoub P et al: PEGylated interferon alfa-2b and ribavirin treatment in patients with hepatitis C virus-related systemic vasculitis. *Arthritis Rheum* **52**:911-915, 2005
75. Saadoun D et al: Cryofibrinogenemia: New insights into clinical and pathogenic features. *Am J Med* **122**:1128-1135, 2009

Chapter 170 :: Raynaud Phenomenon

:: John H. Klippel

RAYNAUD PHENOMENON AT A GLANCE

- Affects 10% of the population; 4:1 female–male ratio.
- Chronic episodic attacks of digital ischemia provoked by exposure to cold or emotional stress.
- Classified into primary (idiopathic) and secondary (underlying disease or cause present) forms; severity ranges from mild/benign to severe with loss of digital tissues.
- Connective tissue diseases—particularly systemic sclerosis—are the most common forms of secondary Raynaud.
- Both nonpharmacologic and drug therapies are used to reduce the frequency and severity of attacks.

EPIDEMIOLOGY

Studies of the epidemiology of Raynaud phenomenon are biased by underreporting (most patients with primary Raynaud never seek medical attention) and studies done by investigators interested in the secondary forms of the disorder. Surveys indicate that Raynaud phenomenon affects up to 10% of the general population.[1,2] Primary Raynaud phenomenon is estimated to be approximately twice as common as secondary Raynaud.[3] Symptoms most often first develop in the teenage years, and most series show a female predominance of the disorder (female–male = 4:1). Increases in the frequency and severity of attacks during menses suggest that female sex hormones may be involved in the pathogenesis.[4] Differences in seasonal skin temperatures, marital status, alcohol use, age, and smoking between women and men have also been suggested to contribute to the sex differences.[5,6] Familial aggregation has been identified in a number of studies and suggests the contribution of genetic factors.[7] Other associations reported in epidemiologic studies include

living in a cold climate, occupation, cardiovascular disease, low body–mass index, and use of vibratory tools.

ETIOLOGY AND PATHOGENESIS

The pathophysiology of the vasospasm is complex and only partially understood. Studies show significant reductions of peripheral blood flow throughout all phases of central body cooling and rewarming, suggesting impairments of central thermoregulatory control mechanisms.[8] Additional features which likely contribute to the development of Raynaud phenomenon include local defects of digital blood vessels causing abnormal vascular reactivity or reduced blood flow; an imbalance of locally produced vasoconstrictors or vasodilators; hyperreactivity of the sympathetic nervous system; and abnormal properties of the blood that compromise distal perfusion.

The gross histology of digital arteries in patients with primary Raynaud phenomenon is normal. Structural abnormalities of the digital microvasculature are frequently seen in patients with secondary forms of Raynaud phenomenon, particularly in the connective tissue diseases. Studies show a range of pathology, including intimal hyperplasia, narrowing or total occlusion of arteries, or thrombi. In most patients with systemic sclerosis, there exists evidence of activation and damage of the endothelium, fibrinolysis, and platelet activation.[9] Autoantibodies and microvascular damage appear to be independent predictive factors for the progression of Raynaud phenomenon to systemic sclerosis.[10]

Microcirculatory flow studies with laser Doppler in patients with scleroderma have shown marked reductions in blood flow and hand temperature during an attack, with prominent abnormalities during rewarming—findings that suggest a failure of the arteriovenous anastomoses to open.[11]

Serotonin is also incriminated as an important mediator in the induction of ischemic attacks of Raynaud phenomenon. Patients have an increased sensitivity to intra-arterial infusions of serotonin, and S2-serotonergic antagonists relieve but do not prevent the induction of attacks.

The evidence of direct central sympathetic nervous system hyperactivity is strongest in vibration-induced injury. The use of a vibration tool in one hand produces vasospasm in the other hand, and vasospasm can be inhibited by proximal nerve blockade.[12] In general, most studies of the sympathetic nervous system in patients with primary or other secondary forms of Raynaud phenomenon have failed to detect evidence of sympathetic hyperactivity. The results of microelectrode studies of skin sympathetic nervous activity during cold pressor tests are normal, and plasma levels of catecholamines are not increased in the venous drainage of the hands of patients with Raynaud phenomenon.

Consistent abnormalities in plasma fibrinogen, cold agglutinins, platelets, or cryoglobulins have not been demonstrated in primary Raynaud phenomenon, but are important in certain secondary cases, particularly scleroderma. Levels of von Willebrand's factor and soluble thrombomodulin, thromboxane B_2 and β-thromboglobulin, and tissue plasminogen activator inhibitor-1 are increased in patients with scleroderma, when compared to levels in patients with primary Raynaud phenomenon.[9]

Genetic studies with microsatellite markers of extended families affected with primary Raynaud phenomenon have identified several potential candidate genes.[13]

CLINICAL FINDINGS

A careful history and physical examination are important in the evaluation of a patient with suspected Raynaud phenomenon.

HISTORY

The history is important to elicit a clear description of the attacks and to screen for evidence of signs and symptoms suggestive of a secondary cause. Patients complain of episodic attacks of well-demarcated, white or blue digits induced by exposure to cold and sometimes by emotional stimuli (Fig. 170-1). Often only a portion of the digit is affected, and the thumbs are typically spared. A classic tricolor change of pallor, cyanosis, and hyperemia described in most textbooks is rarely volunteered by patients; most describe only blanching of the digits accompanied by numbness. During the attacks, one or more fingers or toes may be numb and be described as "dead." On rewarming, the digits may become bright red, and throbbing pain may occur. When pain is a prominent symptom in the ischemic phase, a secondary cause should be suspected. Attacks persist for minutes to hours. The fingers and toes are most commonly involved; however, the attacks may involve the nose, earlobes, or nipples.

A careful review of systems is important to screen for symptoms of connective tissue disease (arthralgias,



Figure 170-1 Ischemic phase of attack of Raynaud phenomenon with marked pallor of the ring and little fingers of the left hand and little finger of the right hand.

arthritis, dysphagia, heartburn, rash, photosensitivity, telangiectases, calcinosis, muscle weakness, shortness of breath, or sicca), a drug-related etiology, symptoms of obstructive arterial diseases (intermittent claudication), and exposure to vibratory tools or continuous finger trauma.

CUTANEOUS LESIONS

Attacks of Raynaud phenomenon, presumably stress induced, are commonly witnessed during the course of the history or physical examination. There is well-demarcated blanching or cyanosis of the digits extending from the tip to various levels of the digit (see Fig. 170-1). The skin distal to the line of ischemia is cold and pale, while the proximal skin is pink and warmer. On rewarming, blanched digits may become cyanotic, because of the low blood flow and deoxygenation, and then bright red, because of reactive hyperemia. Persistent ischemic discoloration of digits suggests a secondary cause.

The digits should be carefully examined for trophic or ischemic changes, which are signs of prolonged or severe attacks of Raynaud phenomenon. The skin may become atrophic, thin, and tight (sclerodactyly) and hair loss may occur over the dorsal surfaces. The nails may become brittle and deformed. Ulcerations, which can be extremely painful, particularly at night, may develop on the finger pads or around the nail bed. The ulcers heal slowly, leave characteristic small, pitted scars (Fig. 170-2), and may become infected. Gangrene of the distal aspects of the digit is rare.

RELATED PHYSICAL FINDINGS

The physical examination should pay attention to all pulses, and blood pressure should be obtained in both arms. Allen's test is useful to assess arterial and capillary function of the hands. Abnormal filling implies structural disease of the microcirculation and raises the suspicion of a secondary form of Raynaud phenomenon. In this test, the radial and ulnar arteries are simultaneously compressed by the examiner's thumbs, while the patient opens and closes the fist to induce blanching of the palm. Selective arterial filling is judged by the rate of color return as pressure is sequentially released from the radial and ulnar arteries. Vascular obstruction from the thoracic outlet syndrome should be assessed by the Adson maneuver, which tests for diminution in the radial pulse with exaggerated movements of the neck and shoulder. A careful neurologic examination should be performed to detect evidence of sympathetic hyperactivity, abnormal reflexes, muscular weakness or atrophy, or compression of the median nerve within the carpal tunnel. Skin changes, such as telangiectases, calcium deposits, changes in skin texture, rashes, or purpura, provide valuable clues to the presence of a connective tissue or hyperviscosity disorder.



Figure 170-2 Loss of pulp of the pad of the digit with pitting scars and ulcerations from chronic, severe Raynaud phenomenon.

LABORATORY TESTS

In all patients, a complete blood count, erythrocyte sedimentation rate, urinalysis, and antinuclear antibody test should be obtained. Additional laboratory studies should be directed by findings elicited by the history and physical examination. In patients with abnormal antinuclear antibody levels, tests for antibodies to specific nuclear antigens, such as Sm antigen or topoisomerase or centromere antigens, are helpful to detect early systemic lupus erythematosus or scleroderma (see Chapters 155 and 157). A routine chest radiograph should be obtained to look for a cervical rib or evidence of interstitial lung disease.

SPECIAL TESTS

Nail fold capillary microscopy is considered to be a useful procedure to distinguish primary from secondary Raynaud phenomenon.[14] Although mild capillary abnormalities may be observed in patients with primary Raynaud phenomenon, patients with connective tissue diseases may have enlarged, deformed capillary loops surrounded by avascular areas (Fig. 170-3).[15] Serial studies reveal progressive decreases in the total number of nail fold capillary loops in secondary, but not primary, forms of Raynaud phenomenon.[16] The patency of small arteries can be assessed by laser Doppler perfusion imaging.[17,18] Digital subtraction arteriography should be reserved for selected patients with prolonged, severe ischemia for whom arterial reconstruction is a consideration.

DIFFERENTIAL DIAGNOSIS

Raynaud phenomenon is subdivided into primary (idiopathic) and secondary forms based on whether an underlying cause or disease association can be identified.

PRIMARY RAYNAUD PHENOMENON

Primary Raynaud phenomenon is a disorder in which known causes of attacks of peripheral



Figure 170-3 Nail fold capillary microscopy, in a patient with scleroderma, showing capillary drop out with enlarged, dilated, tortuous capillary loops.

vasospasm cannot be found. Criteria for the diagnosis of primary Raynaud phenomenon have been developed by Allen and Brown[19] and LeRoy and Medsger[20] (Table 170-1).

Several studies have examined the long-term outcome of patients with primary Raynaud phenomenon.[3,21,22] Progression to a secondary form of Raynaud phenomenon, most commonly a connective tissue disease such as scleroderma, occurs in approximately 15% of patients during the first decade after onset. Variables predictive of a transition to a secondary form include nail fold capillary abnormalities, hand swelling, positive Allen's test, and antinuclear antibodies.

TABLE 170-1
Criteria for Primary Raynaud Phenomenon

- Vasospastic attacks precipitated by exposure to cold or emotional stimuli
- Bilateral involvement of extremities
- Normal vascular examination with symmetric peripheral pulses and normal nail fold capillary microscopy
- Absence of gangrene or, if present, limited to the skin of the fingertips
- No evidence of an underlying disease, drug, or occupational exposure that could be responsible for vasospastic attacks
- Negative antinuclear antibody test
- Normal erythrocyte sedimentation rate
- History of symptoms for at least 2 year

Combined criteria of Allen and Brown[19] and Le Roy and Medsger.[20]

SECONDARY RAYNAUD PHENOMENON

CONNECTIVE TISSUE DISEASES. The connective tissue diseases are the most common cause of secondary Raynaud phenomenon (Table 170-2). Among patients with scleroderma, 80%–90% manifest Raynaud phenomenon and/or persistent vasospasm. It is the presenting symptom in about one-third of patients and may be the only manifestation of the disease for years. Raynaud phenomenon occurs in about one-third of patients with systemic lupus erythematosus, idiopathic inflammatory myopathies, and systemic vasculitis. Although patients with rheumatoid arthritis often complain of cold hands with mottled red and white areas, true Raynaud phenomenon appears to be no more common in persons with rheumatoid arthritis than in the general population. Arteriograms of patients with connective tissue diseases usually show digital and sometimes, ulnar or radial artery obstructions.

OCCUPATIONAL. Raynaud phenomenon may be occupational in origin. It is especially common in

TABLE 170-2
Secondary Raynaud Phenomenon

- Connective tissue disease
  - Scleroderma
  - Systemic lupus erythematosus
  - Dermatomyositis and polymyositis
  - Undifferentiated connective tissue disease
  - Systemic vasculitis
  - Sjögren syndrome
  - Eosinophilic fasciitis
- Obstructive arterial disease
  - Atherosclerosis
  - Thromboangiitis obliterans (Buerger disease)
  - Thromboembolism
  - Thoracic outlet syndrome
- Neurologic disorders
  - Carpal tunnel syndrome
  - Reflex sympathetic dystrophy
  - Hemiplegia
  - Poliomyelitis
  - Multiple sclerosis
  - Syringomyelia
- Drugs and toxins
  - β-Adrenergic blockers
  - Ergotamines
  - Oral contraceptives
  - Methysergide
  - Bleomycin and vinblastine
  - Clonidine
  - Bromocriptine
  - Cyclosporine
  - Amphetamines
  - Fluoxetine
  - Interferon-α
- Occupation/environmental exposure
  - Vibration injury (lumberjacks, pneumatic hammer operators)
  - Posttraumatic injury (hypothenar hammer syndrome, crutch pressure)
  - Vinyl chloride disease
  - Cold injury
- Hyperviscosity disorders
  - Cryoproteins
  - Cold agglutinins
  - Macroglobulins
  - Polycythemia
  - Thrombocytosis
- Miscellaneous
  - Hypothyroidism
  - Infections (bacterial endocarditis, Lyme disease, viral hepatitis)
  - Neoplasms
  - Primary pulmonary hypertension
  - Arteriovenous fistula
  - Intra-arterial injections

individuals who use vibratory tools (e.g., air hammers, chain saws, rivet guns) and in those whose occupation requires prolonged exposure of the extremities to cold temperatures (e.g., butchers, ice cream workers, fish packers). Prevalence rates correlate with the vibration level of the tool and the duration of exposure; they can be as high as 90% in high-risk occupations such as logging or mining.[23]

NEUROLOGIC DISORDERS. Any neurologic condition that produces permanent disuse of a limb can be associated with sympathetic nervous system disturbances to that limb. Patients often develop persistent vasospasm with coldness, paleness or cyanosis, and even ulcerations of the limb, and Raynaud phenomenon may occur. Thermoregulatory abnormalities may be a prominent feature of reflex sympathetic dystrophy syndrome.[24] Nerve root pressure or nerve entrapment may produce Raynaud phenomenon. It is often present in patients with carpal tunnel syndrome and typically involves the first, index, and middle fingers, digits innervated by the median nerve. In addition, Raynaud phenomenon may occur as a result of neurovascular compression at the thoracic outlet. The compression may be caused by cervical ribs; abnormalities of the scalenus anticus muscle; bony abnormalities of the cervical vertebrae, clavicle, or first rib; or shoulder compression syndromes (the costoclavicular or hyperabduction syndrome).

DRUGS AND TOXINS. Propranolol, one of the most widely used β-adrenergic blockers for cardiovascular diseases and migraine headaches, is probably the most frequently used drug responsible for Raynaud phenomenon. Ergot preparations and methysergide used to treat migraine headaches may produce vasospasm. Intra-arterial use of many medications and recreational drugs can result in toxicity to endothelial cells with irreversible structural damage to the microvasculature of the extremities and be responsible for severe Raynaud phenomenon. The chemotherapeutic agents, bleomycin and vinblastine, also may cause the phenomenon.[25]

HYPERVISCOSITY. Patients with hyperviscosity from cryoglobulinemia, macroglobulins, cold agglutinins, and polycythemia can exhibit Raynaud phenomenon. Cryoglobulins are most commonly present in patients with multiple myeloma, but they also occur in patients with rheumatic diseases, chronic infections, leukemia, and lymphoma, and as an idiopathic condition.

MISCELLANEOUS. The most common endocrine disturbance associated with Raynaud phenomenon is hypothyroidism; symptoms usually remit with thyroid hormone replacement. Raynaud phenomenon may be a feature of various infectious disorders, including subacute bacterial endocarditis, Lyme disease, and viral hepatitis, presumably a reflection of systemic vasculitis. Peripheral vasospasm may also occur in association with malignant tumors, including pheochromocytoma, carcinoid, breast and ovarian carcinoma.

The major forms of vascular ischemia that must be distinguished from Raynaud phenomenon are cold digits, chilblain (pernio), livedo reticularis, and acrocyanosis (see Chapters 94 and 173). Many patients

complain of cold, sometimes painful digits without color changes. This condition likely represents one extreme of the spectrum of normal sympathetic nervous system activity. Chilblain is an inflammatory condition of the skin of the extremities induced by cold. Patients develop a bluish-red discoloration and edema, typically involving the lower limb and associated with warmth, erythema, and burning. In severe cases, hemorrhagic lesions, bullae, or ulcers may develop, and secondary infections may supervene. The lesions last from 7 to 10 days, often leaving a residual pigmentation of the skin. Livedo reticularis is a bluish discoloration of the skin of the extremities with a characteristic lacy, irregular appearance. The bluish discoloration becomes more intense on exposure to cold and may disappear in a warm environment. Most patients are entirely asymptomatic, although livedo reticularis may be a feature of the antiphospholipid syndrome, in which patients are at increased risk for venous and arterial thromboses, thrombocytopenia, and pregnancy losses. In acrocyanosis, the hands, and, less commonly, the feet, develop a persistent bluish discoloration. The blue color is intensified by exposure to cold and is converted into a purplish or red color by warming; a pallor phase is absent. The skin is cold, and the palms are often wet and clammy from sweat. Trophic changes or ulcerations are rarely observed.

TREATMENT

The management of Raynaud phenomenon is guided by the frequency and severity of attacks and the complications from ischemia (Table 170-3). Secondary forms of Raynaud phenomenon require treatment directed at the underlying medical disorder, discontinuation of drugs causing the vasospasm, or occupational modifications.

TABLE 170-3
Management of Raynaud Phenomenon

Infrequent or mild attacks	Preventive measures Cessation of smoking
Frequent or severe attacks	Calcium channel blockers (nifedipine, diltiazem) Antiadrenergic drugs (prazosin, reserpine) Topical nitroglycerin
Acute, severe ischemia	Intravenous prostaglandin E_1 or prostacyclin Digital sympathectomy Microvascular surgery
Digital ulcers	Antiseptic soaks, antibiotic ointments, occlusive dressing Calcium channel blockers (maximal doses) Intravenous prostaglandin E_1 or prostacyclin
Gangrenous, infected ulcers	Analgesics Antibiotics Surgical debridement Amputation

GENERAL MEASURES

Mild Raynaud phenomenon is generally easy to control with lifestyle changes to minimize exposure to the cold; dressing warmly with loose-fitting, layered clothing; and keeping the thermostat a few degrees higher than normal. Limiting time spent outdoors in winter, wearing insulated gloves, and using hand or foot warmers are usually helpful. Patients should be taught to recognize and terminate attacks promptly by returning to a warmer environment and applying local heat to the hands (e.g., by placing their hands in warm water or by using a hair dryer). Patients should be strongly encouraged to stop smoking and to avoid secondhand smoke, because nicotine induces cutaneous vasoconstriction. Stress modification and social support are valuable aspects of treatment to minimize vasoconstriction induced by hyperactivity of the sympathetic nervous system. Counseling, training in relaxation, or medications may be helpful. Some patients benefit from conditioning programs such as biofeedback training.

Digital ulcers from Raynaud phenomenon can be extremely painful and typically take weeks or months to heal completely. Pain control is an important part of therapy, because pain can lead to additional vasospasm and more ischemia. On occasion, narcotic pain medications may be necessary to control symptoms. The finger should be soaked in a tepid antiseptic solution (e.g., half-strength hydrogen peroxide) twice daily to soften or loosen the crust or eschar. After drying, an antibiotic ointment is applied to the ulcer, and the digit is covered with an occlusive dressing. Maximum drug therapy with a calcium channel blocker should be used throughout treatment. Infection is a common complication of digital ulcers and is typically manifest by increasing pain, erythema, swelling, or purulent drainage. Cultures usually demonstrate *Staphylococcus* sp., and treatment with dicloxacillin or cephalosporins is usually effective.

DRUG THERAPY

Various drugs have been used to treat Raynaud phenomenon, including vasodilators, platelet inhibitors, serotonin antagonists, and fibrinolytics. Drug therapy is usually reserved for patients with prolonged or frequent attacks that fail to respond to conservative measures. In general, improvements with drug therapy are more pronounced in patients with primary Raynaud phenomenon, presumably as a consequence of fixed, structural damage in patients with secondary forms.

The calcium channel blockers are by far the most widely used and effective drugs for treating Raynaud phenomenon.[26,27] Vasodilating properties vary among different agents. Nifedipine (10–20 mg tid or qid) reduces the severity and frequency of attacks; the

long-acting preparation of nifedipine is better tolerated but may be less effective. Diltiazem (60 mg tid or qid) may be substituted if nifedipine is ineffective or not well tolerated. Side effects of calcium channel blockers include fluid retention, light-headedness, and heartburn; these may limit therapy.

Sympatholytic drugs, including reserpine, methyldopa, phenoxybenzamine, and tolazoline, have been used in management, although they have not been well studied. In a pilot study, the selective serotonin reuptake inhibitor fluoxetine reduced the frequency and severity of Raynaud attacks.[28] Additional drug therapies reported to be beneficial in the treatment of Raynaud phenomenon include low molecular weight heparin,[29] prazosin,[30] the angiotensin II receptor antagonist losartan,[31] and stanozolol.[32] Topical nitroglycerin paste (2%) and a sustained-release transdermal glyceryl patch are helpful in selected patients[33]; although side effects such as headaches, dizziness, and skin irritation often limit therapy. Newer formulations of nitroglycerin appear to show promise.[34] Intravenous prostaglandin E_1 and prostacyclin (PGI_2) and iloprost (a PGI_2 analog) have been shown to have beneficial effects in patients with severe Raynaud phenomenon; however, the vasodilatory effects are not sustained and long-term therapy is required.[35–38] Oral prostaglandins are currently available only as investigational agents.

SYMPATHECTOMY

Sympathectomy may be a consideration for the management of patients with refractory, disabling attacks or with an acutely ischemic digit that is unresponsive to other measures.[39] A positive vasodilator response to a stellate ganglion block or epidural infusion should be documented before a permanent procedure is done. Lumbar sympathectomy has an important role in the management of severe Raynaud phenomenon of the feet, and selective digital sympathectomy may be used to relieve pain and heal digital ulcers in patients with ischemic digits.[40]

SEVERE VASOSPASM

Severe vasospasm with prolonged ischemia (dead-white finger) poses a threat of gangrene and amputation; it is considered a medical emergency. The patient should be hospitalized and the affected extremity put to rest. Nifedipine (10–20 mg tid) should be started immediately, as well as prostaglandin E_1 (6–10 ng/kg/minute) or PGI_2 (0.5–2 ng/kg), given by continuous intravenous infusion for several hours over three consecutive days. Intra-arterial phentolamine or tolazoline may reverse acute vasospasm, but monitoring of vital signs is essential, and these drugs need to be used with great caution. A digital (or stellate ganglion) block with lidocaine hydrochloride or bupivacaine hydrochloride (without epinephrine) relieves pain and produces a chemical sympathectomy that may reverse vasoconstriction. Sympathectomy (thoracic, lumbar, or digital) should be considered in patients who have a positive response. Arterial reconstruction should be reserved for patients with angiographically documented occlusive vascular disease.[40]

KEY REFERENCES

Full reference list available at www.DIGM8.com

DVD contains references and additional content

2. Gelber AC et al: Symptoms of Raynaud's phenomenon in an inner-city African-American community: Prevalence and self-reported cardiovascular comorbidity. *J Clin Epidemiol* **52**:441, 1999
19. Allen EV, Brown GE: Raynaud's disease: A critical review of minimal prerequisites for diagnosis. *Am J Med Sci* **183**:187, 1932
20. LeRoy EC, Medsger TA Jr: Raynaud's phenomenon: A proposal for classification. *Clin Exp Rheumatol* **10**:485, 1992
21. Spencer-Green G: Outcome in primary Raynaud phenomenon: A meta-analysis of the frequency, rates, and predictors of transition to secondary diseases. *Arch Intern Med* **158**:595, 1998
22. Hirschi M et al: Transition from primary Raynaud's phenomenon to secondary Raynaud's phenomenon identified by diagnosis of an associated disease. *Arthritis Rheum* **54**:1974, 2006
27. Thompson AE, Pope JE: Calcium channel blockers for primary Raynaud's phenomenon: A meta-analysis. *Rheumatology* **44**:145, 2005
40. Tomaino MM et al: Surgery for ischemic pain and Raynaud's phenomenon in scleroderma: A description of treatment protocol and evaluation of results. *Microsurgery* **21**:75, 2001

Chapter 171 :: Malignant Atrophic Papulosis (Degos Disease)

:: Dan Lipsker

MALIGNANT ATROPHIC PAPULOSIS AT A GLANCE

- A rare, primary vaso-occlusive disorder, affecting mainly the skin, the gastrointestinal tract, and the central nervous system.
- Diagnosis relies on clinicopathologic evaluation.
- Characterized by numerous typical porcelain-white, atrophic papules, with a rim of rosy erythema and/or telangiectases.
- Pathology shows a wedge-shaped area of dermal necrosis with edema and mucin deposition.
- Benign forms without extracutaneous involvement are possible.

In the early 1940s, Köhlmeier first described malignant atrophic papulosis, whereas Degos, Delort, and Tricot recognized it as a specific entity a year later.[1–3] We now know that the clinically distinctive lesion of the so-called *Degos disease* is a marker of a cutaneous thrombo-obliterative vasculopathy rather than of a specific disease per se. Indeed, such lesions can be found in at least two distinctive clinical settings: (1) as an apparent idiopathic disease, either classic Degos disease or its benign variant, or (2) as a surrogate clinical finding in some connective tissue diseases such as the antiphospholipid syndrome, lupus erythematosus, dermatomyositis, and systemic sclerosis.

EPIDEMIOLOGY

Classic Degos disease is rare, with about 200 reported cases. It almost always occurs in Caucasians, but cases have been observed in African-American patients and in Japan. The disease most commonly presents between the third and fourth decades, but can occur at any age. Men are more often affected than women (ratio, 3:1). The majority of cases are sporadic, but familial cases have been described, and most of these cases are consistent with an autosomal dominant pattern of inheritance.[4]

ETIOLOGY AND PATHOGENESIS

The etiology of Degos disease is unknown. The histopathologic findings in patients with malignant atrophic papulosis suggest a primary vaso-occlusive process. Thus, a vascular coagulopathy and/or endothelial cell damage should be considered as the major pathogenic mechanism. A combination of prothrombotic factors possibly plays a role in triggering the full-blown disease. Extensive studies of prothrombotic factors were performed in some patients with Degos disease, and no single abnormality was repeatedly identified. All patients should be screened for the presence of antiphospholipid antibodies/lupus anticoagulant and cryoglobulins, although Assier et al did not find the former in their series of 15 patients.[5] Inhibition of fibrinolysis and platelet abnormalities, including increased platelet adhesiveness and spontaneous aggregation, were reported in some patients.[5–8]

The lesions of Degos disease should be viewed as a cutaneous marker indicative of intraluminal thrombosis. Several disease processes may converge to produce those clinical and histologic findings.

CLINICAL FINDINGS

(Fig. 171-1)

HISTORY

Patients seek medical advice for the appearance of small cutaneous lesions that usually are neither pruritic nor painful. In some patients, history and/or review of systems will reveal signs indicative of extracutaneous involvement: abdominal pain, diarrhea, melena, nausea, blurred vision, hemiparesis, paresthesia, or any other sign indicative of an ischemic event. History can also give a clue to previous thromboembolic or obstetrical events suggestive of the antiphospholipid antibody syndrome.

CUTANEOUS LESIONS

Cutaneous lesions start as crops of 2–10 mm, largely asymptomatic or mildly pruritic, fleshy or rose-colored macules that soon become round, smooth, often dome-shaped firm papules (Fig. 171-2). Some lesions display central umbilication and/or necrosis (Fig. 171-3). These lesions evolve over days or weeks to porcelain-white, atrophic papules with a rim of rosy erythema and/or telangiectases (Fig. 171-4). A fully developed lesion therefore closely resembles lesions of atrophie blanche. In time, the reddish border disappears, and only a varicelliform white scar remains. Usually, the lesions are separated from each other, but they may coalesce, leading to polycyclic atrophic areas or to skin ulcerations.

The lesions are localized on the trunk and limbs. Palms, soles, face, scalp, and genitalia are usually

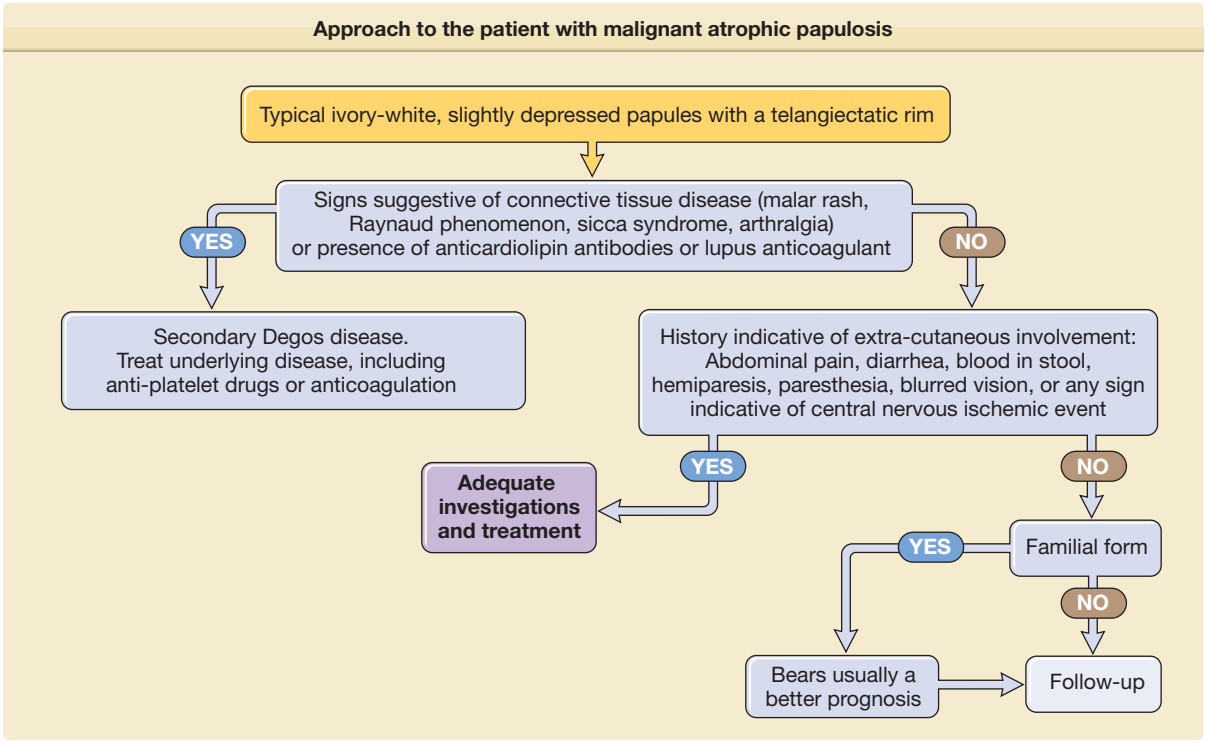

Figure 171-1 Approach to the patient with malignant atrophic papulosis.

spared, although there are exceptions. Exclusive acral localization is suggestive of connective tissue disease. A linear distribution was reported.[9] Eye involvement is possible, and the most common manifestation is an avascular patch on conjunctivae, but sclerae, episclera, retina, choroids, and optic nerves may be affected (see eFig. 171-4.1 in online edition).



Figure 171-2 Numerous typical papules of Degos disease in a young man.

CLASSIC DEGOS DISEASE. In classic Degos disease, the number of cutaneous lesions varies from a few to more than one hundred. Cutaneous findings usually precede the systemic manifestations that may involve the gastrointestinal tract, with bowel perforation and peritonitis, and/or the central nervous system, with hemorrhagic or ischemic stroke. Rarely, cutaneous lesions occur simultaneously or after gastrointestinal or central nervous system involvement. Postmortem studies have revealed small vessel thrombotic involvement of many organs, including kidney, bladder, prostate, liver, pleura, pericardium, lung, and eyes.[10] Some



Figure 171-3 Papule with central ulceration in patient with Degos disease.



Figure 171-4 Typical pathognomonic papules of Degos disease with a porcelain-white center and an erythematous raised border.

patients with classic Degos disease have antiphospholipid antibodies, and this raises the possibility of a relationship with a primary antiphospholipid syndrome.

BENIGN DEGOS DISEASE. A benign form of Degos is now widely recognized. In this form, only skin involvement is found, and most of the familial cases are benign.[4] Development during pregnancy has been reported in a patient with antiphospholipid antibodies,[11] as well as a case occurring in a patient with acquired immunodeficiency syndrome.[12] A patient developing Degos disease after interferon injections, a drug known to induce atrophie blanche-like lesions[13] and microangiopathy,[14] is known to the authors (L. Thomas, personal communication). There is no clear-cut distinction between the classic and the benign form of Degos disease, and there is no way by which one can predict which patients will or will not develop visceral involvement.

DEGOS DISEASE-LIKE LESIONS OR SECONDARY DEGOS DISEASE. Degos disease-like lesions can occur in patients with known lupus erythematosus, especially those with antiphospholipid antibodies, dermatomyositis, systemic sclerosis, granulomatosis with polyangiitis (Wegener's), Crohn's disease and during parvovirus B19 viremia, a virus with a known affinity for endothelial cells.[15,16–18]

LABORATORY TESTS

HISTOPATHOLOGY

Clinically, fully developed lesions reveal a cell-poor, wedge-shaped area of slight-to-severe dermal necrosis with dermal edema and copious mucin deposition, extending from the papillar dermis to the deep part of the reticular dermis (Fig. 171-5). At the base of the lesion, occluded vessels with occasional thrombosis, thickened vessel walls, proliferating endothelial cells, and sparse perivascular lymphocytic infiltrate can be found

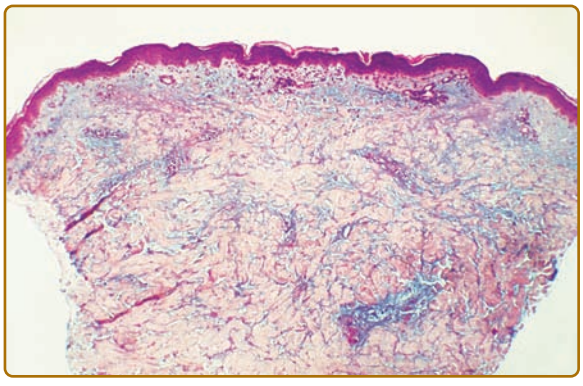

Figure 171-5 A wedge-shaped, cell poor, area of dermal necrosis, with copious mucin deposition, extending from the papillar dermis to the deep part of the reticular dermis hematoxylin-eosin-safran-Astra blue, ×40).

(Fig. 171-6). Yet, a full-blown leukocytoclastic neutrophilic vasculitis is never found in patients with malignant atrophic papulosis. This entity should therefore not be classified as vasculitis. Numerous secondary, epidermal changes can be found: hyperkeratosis, interface dermatitis, scattered necrotic keratinocytes, and atrophy. An associated sclerosing panniculitis was reported in one patient.[19] Results of direct immunofluorescence studies have been inconsistent. Electron microscopy occasionally revealed tubuloreticular aggregates within endothelial cells of uncertain significance.

Because some of those histopathologic findings, such as mucinous infiltration of the dermis, interface dermatitis, and perivascular lymphocytic dermal infiltrate, are shared by lupus erythematosus and dermatomyositis, Degos disease is considered by some authors as a possible variant of lupus erythematosus.[20]

OTHER LABORATORY TESTS AND SPECIAL TESTS

There is no diagnostic or prognostic marker of the disease. A search for antinuclear antibodies, lupus anticoagulant, and anticardiolipin antibodies should be

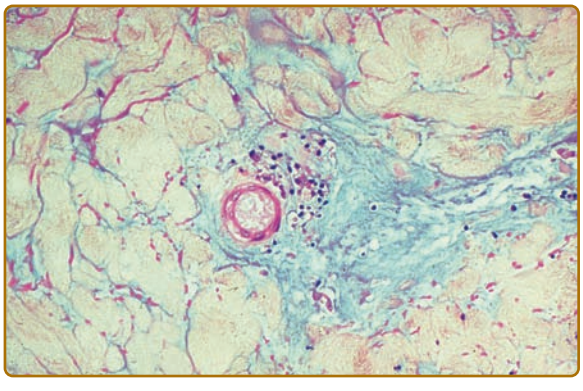

Figure 171-6 At the base of the dermal lesion, in the deep part of the reticular dermis, important mucin deposition and a slight lymphocytic infiltrate around a blood vessel (hematoxylin-eosin-safran-Astra blue, ×200).

performed in each patient. An extensive exploration of hemostasis will sometimes reveal abnormalities. When the disease starts with a sudden onset, a parvovirus B19 infection should be suspected and circulating viral DNA should be searched by PCR.[18]

Clinical evaluation can confirm secondary Degos disease if signs suggestive of connective tissue disease or antiphospholipid syndrome are present. If clinical evaluation reveals signs of intestinal or cerebral involvement (pain, diarrhea, hemiparesis, blurred vision, paresthesia), imaging studies including cerebral magnetic resonance imaging and/or endoscopic evaluation/laparoscopy are mandatory.

DIAGNOSIS

The diagnosis is usually established clinically, because of the distinctive skin lesion. A confirmatory biopsy should always be performed.

DIFFERENTIAL DIAGNOSIS

(Box 171-1)

COMPLICATIONS

Death related to an ischemic cerebral or gastrointestinal event is the major complication of Degos disease. Gastrointestinal hemorrhage, perforation, and peritonitis are the most frequent complications of the disease and are the major ominous events. Neurologic complications, including hemiparesis, aphasia, multiple cranial nerve involvement, monoplegia, sensory disturbances, and seizures, are less common. Rarely, progressive neurologic involvement can lead to death, especially in children. Exceptionally, death can result from respiratory failure or myocardial infarction.

BOX 171-1 DIFFERENTIAL DIAGNOSIS

Most Likely

- Atrophie blanche

Consider (Although Unlikely, Other Diseases with White and/or Necrotic Papules)

- Cutaneous lichen sclerosus
- Pityriasis lichenoides
- Lymphomatoid papulosis
- Syphilids, tuberculids
- Cutaneous Kikuchi disease (histiocytic necrotizing lymphadenitis)
- Clear cell papulosis
- Calcinosis cutis
- Fibroelastolytic papulosis of the neck
- White lentiginosis
- Scar, artifactual disease

Always Rule Out

- Connective tissue disease with Degos-like lesions, Crohn's disease, granulomatosis with polyangiitis (Wegener's), and parvovirus B19 infection.

PROGNOSIS AND CLINICAL COURSE

Although absence of visceral involvement 2 years after diagnosis portends a better prognosis, systemic involvement can occur up to many years after initial cutaneous lesions and thus it is impossible to predict the outcome. Lethality is above 50% if patients present with extracutaneous involvement, and most of these patients die within 2–3 years mainly because of severe intestinal involvement. Familial Degos disease bears a better prognosis.[4]

TREATMENT

Due to the rarity of Degos disease, there are no controlled clinical trials, but only anecdotal reports. Yet, in some aspects, Degos disease resembles livedoid vasculopathy, and, therefore, some treatments reported to be efficient in patients with the former entity are worth trying.

Secondary Degos disease occurring in patients with known connective tissue disease should involve, in our opinion, the introduction of antiplatelet agents in addition to the standard treatments otherwise required by those patients.

Patients with classic Degos disease should be screened for all known preventable cardiovascular risk factors. Patients should cease smoking, and their lipid levels should be screened and lowered, if necessary, using statins.

First-line treatment of patients with Degos disease should include platelet aggregation inhibitors (aspirin, clopidogrel, dipyridamole) (Box 171-2). A substantial number of patients responded to aspirin and dipyridamole.[6,7,12] A number of anecdotal treatments,

BOX 171-2 TREATMENT OF MALIGNANT ATROPHIC PAPULOSIS (DEGOS DISEASE)

First line	Aspirin (100–325 mg) and dipyridamole (3 × 400 mg)
Second line	Heparin and other anticoagulation strategies
Unresponsive or acutely ill patients	Intravenous immunoglobulins (1g/kg/day for 2 days or 0.4 g/kg/day for 5 days)
Adjunctive measures	Control of cardiovascular risk factors

including antibiotics, chloroquine, immunosuppressive agents, phenylbutazone, and fibrinolytics, have been reported with variable success. Systemic steroids have been reported to exacerbate the disease and should not be prescribed.[21] Heparin and other anticoagulation strategies such as antivitamin K (warfarin, fluindione) have variable success rates. Yet, by analogy to livedoid vasculopathy, low-molecular-weight heparin as well as the newer anticoagulants might warrant a trial in the acutely ill patient not responding to antiplatelet agents.[22] Intravenous immunoglobulins should be considered in patients not responding to other treatments or in the acutely ill.[18,23]

ACKNOWLEDGMENT

The author thanks Jean-Hilaire Saurat for his work on this chapter in previous editions.

KEY REFERENCES

Full reference list available at www.DIGM8.com

DVD contains references and additional content

1. Köhlmeier W: Multiple hautnekrosen bei thrombangiitis obliterans. *Arch Dermatol Syphil* **181**:783, 1941
3. Degos R, Delort J, Tricot R: Papulose atrophiante maligne (syndrome cutaneo-intestinal mortel). *Bull Mem Soc Med Hôp Paris* **64**:803, 1948
4. Pinault AL et al: Forme familiale bénigne de maladie de Degos. *Ann Dermatol Venereol* **131**:989, 2004
6. Caux F et al: Anomalies de la fibrinolyse dans la maladie de Degos. *Ann Dermatol Venerol* **121**:537, 1994
7. Drucker CR: Malignant atrophic papulosis: Response to antiplatelet therapy. *Dermatologica* **180**:90, 1990
8. Torrelo A et al: Malignant atrophic papulosis in an infant. *Br J Dermatol* **146**:916, 2002
9. Kirkup ME et al: Inflammatory linear vasculopathy mimicking Degos' disease. *Br J Dermatol* **150**:1212, 2004
10. Howsden SM et al: Malignant atrophic papulosis of Degos. *Arch Dermatol* **112**:1582, 1976
11. Bogenrieder T et al: Benign Degos' disease developing during pregnancy and followed for 10 years. *Acta Derm Venereol* **82**:284, 2002
12. Requena L, Farina C, Barat A: Degos disease in a patient with acquired immunodeficiency syndrome. *J Am Acad Dermatol* **38**:852, 1998
13. Bugatti L et al: Atrophie blanche associated with interferon-alfa adjuvant therapy for melanoma: A cutaneous side effect related to the procoagulant activity of interferon? *Dermatology* **204**:154, 2002
14. Zuber J et al: Alpha-interferon-associated thrombotic microangiopathy. A clinicopathologic study of 8 patients and review of the literature. *Medicine* **81**:321, 2002
15. Stephansson EA et al: Lupus anticoagulant and the skin. A longterm follow-up study of SLE patients with special reference to histopathological findings. *Acta Derm Venereol* **71**:416, 1991
18. Dyrsen ME et al: Parvovirus B19-associated catastrophic endotheliatis with a Degos-like presentation. *J Cutan Pathol* **35**:20-25, 2008
19. Grilli R et al: Panniculitis mimicking lupus erythematosus profundus: A new histopathologic finding in malignant atrophic papulosis (Degos disease). *Am J Dermatopathol* **21**:365, 1999
21. Burg G et al: Maligne atrophische papulose (Morbus Köhlmeier-Degos). *Hautarzt* **40**:480, 1989
22. Hairston BR et al: Treatment of livedoid vasculopathy with low-molecular-weight heparin: Report of 2 cases. *Arch Dermatol* **139**:987, 2003

Chapter 172 :: Vascular Malformations

:: Laurence M. Boon & Miikka Vikkula

VASCULAR MALFORMATIONS AT A GLANCE

- Worldwide prevalence: roughly 0.3%.
- Congenital, diversified but localized and well-demarcated lesions of malformed vessels of various types: capillary, venous, lymphatic, and arteriovenous.
- Histologically consist of enlarged, tortuous vessels of various types.
- Can be isolated, combined, or part of a syndrome.
- Management: multidisciplinary approach.

EPIDEMIOLOGY

Vascular malformations are believed to be due to errors of development of vessels that occur during the fourth and tenth weeks of intrauterine life. Most vascular malformations are sporadic, although several families with inherited forms have been identified. They are very heterogeneous and affect about 0.3% of the population. Vascular malformations are mostly congenital, even if they may be diagnosed only later in life.

ETIOLOGY AND PATHOGENESIS

Although several genes have been identified as the cause of inherited forms of vascular malformations, the etiology of the most common sporadic lesions is unknown.[1–3] Histologically, vascular malformations consist of enlarged, tortuous vessels with

quiescent endothelium. In contrast to hemangioma, there is neither parenchymal mass nor cellular proliferation.

CLASSIFICATION

For many years, vascular anomalies were grouped under the term *angioma*, hampering precise classification and leading to incorrect diagnosis and improper management. For example, the term *hemangioma* has been used both for vascular malformations, often of venous type (cavernous hemangioma) as well as for vascular tumors (strawberry hemangioma). This nomenclature changed in 1982 with the development of a biologic classification by Mulliken and Glowacki. It divided vascular anomalies into two major categories: (1) vascular tumors (with cellular proliferation; hemangioma being the most common) (see Chapter 126), and (2) vascular malformations (structural anomalies of blood vessels) that are subsequently subdivided, depending on the affected vessel type, into arterial, capillary, lymphatic, or venous malformations.[4,5] In 1996, this classification was adopted and further developed by the International Society for the Study of Vascular Anomalies (ISSVA) (Table 172-1).[6] Vascular malformations mostly affect only one vessel type, yet combined malformations also exist. They are named according to the affected vessel types, (e.g., capillary-venous or venolymphatic malformation). In addition to isolated forms, vascular malformations occur in syndromes such as Klippel–Trenaunay (KT) (capillary-lymphaticovenous malformation with limb hypertrophy), Maffucci syndrome (multiple enchondromas associated with multiple venous anomalies and high incidence of malignancy)[7], Cloves syndrome (congenital lipomatous overgrowth with vascular malformations, epidermal nevi, and scoliosis)[8,9], or Parkes Weber syndrome (high-flow vascular malformation of the extremity with soft tissue hypertrophy).[10]

TABLE 172-1
Classification of Vascular Tumors and Malformations

Vascular Tumors	Vascular Malformations
Hemangioma Hemangioma of infancy (HOI) Congenital Rapidly involuting congenital hemangioma (RICH) Noninvoluting congenital hemangioma (NICH)	**Capillary** Capillary malformation (CM) (Port-wine stain) Telangiectasia (hereditary benign telangiectasia, essential telangiectasia) Hereditary hemorrhagic telangiectasia (HHT) Capillary malformation-arteriovenous malformation (CM-AVM) Sturge–Weber syndrome
Hemangioendotheliomas Kaposiform hemangioendothelioma Tufted angioma	**Venous** Venous malformation (VM) Familial form: cutaneomucosal Mucocutaneous VM venous malformation cutaneomucosal (VMCM) Glomuvenous malformation (GVM) Blue rubber bleb nevus or Bean syndrome (BRBN)
Angiosarcoma	**Lymphatic** Lymphatic malformation (LM) Primary Lymphedemas **Arterial** Arteriovenous malformation (AVM) Capillary malformation-arteriovenous malformation (CM-AVM) Arteriovenous fistula (AVF) **Syndromic Malformations** Slow-flow Klippel–Trenaunay syndrome CLVM[1] (capillary-lymphaticovenous malformation with limb hypertrophy) Maffucci syndrome CLOVES syndrome Fast-flow Parkes Weber syndrome

CLINICAL FINDINGS

Vascular malformations grow proportionately with the patient. Usually they do not regress. Most frequently, they are well demarcated and localized (Fig. 172-1). In rare instances, they can be the stigmata of deep lesions. Vascular malformations are rheologically divided into *slow-flow* (capillary, lymphatic, venous, and combined) and *fast-flow* (arterial, arteriovenous, and combined). Doppler ultrasound is the best noninvasive radiologic examination that provides clues into the differentiation of the various types. Magnetic resonance imaging (MRI) details the extension and precise location of the lesion (Table 172-2).[11]

TREATMENT

Treatment of vascular malformations depends on the affected vessel type, the location of the lesion, and the symptoms. As many lesions are extensive, patients should be aware that a complete cure is often not possible. Treatment is difficult and can have severe complications. Extensive and/or complex lesions should always be managed by a multidisciplinary team.



Figure 172-1 Vascular malformations of various vessel types: **A.** capillary malformation of left lower extremity and genitalia; **B.** subcutaneous lymphatic malformation invading the cubital nerve; **C.** extensive venous malformation of right lower extremity causing pain, swelling, and coagulopathy; **D.** arteriovenous malformation of sole; and **E.** note nidus of the lesion on arteriography.

CAPILLARY MALFORMATIONS (CM)

EPIDEMIOLOGY

Capillary malformation (CM), commonly called *port-wine stain*, is a slow-flow vascular malformation with an incidence of 0.3% (Fig. 172-2).[12] Other blanchable pinkish patches, known as *stork bite, angel's kiss, salmon patch, or nevus flammeus neonatorum*, are often confused with CM. They are located on the nape of the neck (81%), the eyelids (45%), or the glabella (33%).[13] When located on the occiput, it is called *Unna nevus* (see eFig. 172-2.1 in online edition). These patches have a much higher incidence (42%) in white infants than in black infants (31%).[14] They are also present in various syndromes such as Beckwith–Wiedemann and Rubinstein–Taybi. These lesions disappear spontaneously around the ages of 1–4 years.

CAPILLARY MALFORMATIONS AT A GLANCE

- Worldwide occurrence: roughly 0.3% of the population affected.
- Congenital slow-flow malformations of the capillary bed.
- Pinkish red to purple in color. Tend to darken and thicken with time.
- In most cases, a cosmetic problem.
- Can be part of syndromes, such as Sturge–Weber or Klippel–Trenaunay.
- Pathology: capillaries that are increased in size and number with abnormal innervation.

TABLE 172-2
Diagnostic Features of Vascular Malformations

	Capillary Malformation	Venous Malformation	Lymphatic Malformation	Arteriovenous Malformation
Skin color	Pinkish-red to purple	Normal-bluish-purple GVM: red (neonates) to dark-blue-purple (adult)	Normal-yellowish-purple	Normal-red
Aspect	Flat	Flat-raised	Raised-vesicular	Flat-raised
Temperature	Normal	Normal	Normal	Warm
Palpation	Normal	Compressible GVM: nodular, painful	Firm, non compressible	Thrill, bruit
Associations	Hypertrophy pyogenic granulation	Phleboliths, deformation	–	Ulceration, deformation
Radiology	No-flow	Slow-flow	Slow-flow, cyst	Fast-flow
Histology	Dilated capillaries D2–40 negative	Thin-walled venous channels Relative lack of smooth muscle cells D2–40 negative	Cystic lymphatic channels D2–40 positive	Arterialized veins D2–40 negative
Etiology	?	VMCM: TIE2 GVM: Glomulin Sporadic VM: 50% somatic TIE2 mutations	LM: ? Primary lymphedema: SOX18, VEGFR3, FOXC2, CBR2	AVM: ? CM-AVM: *RASA1* HHT: endoglin, Activin-like receptor tyrosine kinase, SMAD4 PTHS: PTEN
Treatment	Pulsed-dye laser	Sclerotherapy, surgery	Surgery, sclerotherapy	Embolization followed by surgical resection of nidus



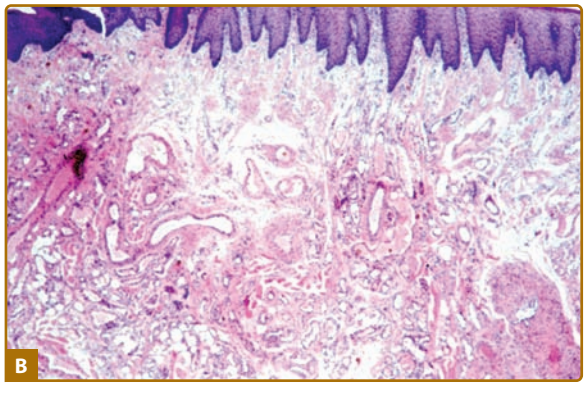

Figure 172-2 A. Extensive capillary malformation of upper extremity. **B.** Histologically, capillary malformation is characterized by dilated capillaries of normal number on the papillary and upper reticular dermis in combination with areas of increased number of normal-looking capillaries (hematoxylin and eosin staining).

CM are mainly sporadic, although there are well-documented pedigrees showing autosomal dominant inheritance.[15] When inherited, they are usually multiple and part of the CM-AVM phenotype, that associates atypical CM with arteriovenous malformation (AVM) (see Section "Arteriovenous Malformations").[16–19] No sex preponderance is noted.

ETIOLOGY AND PATHOGENESIS

Etiology of CM is currently unknown. Facial CM is thought to be due to clonal expansion of abnormal cells originating from the neural crest.[20] The identification of the affected gene (*RASA1*) in CM-AVM (see Section "Arteriovenous Malformations") might help unravel the cause of the more common sporadic CM. Histologically, CM is characterized by dilatation of normal numbers of capillaries of the papillary and upper reticular dermis combined with areas of increased number of normal-looking capillaries (see Fig. 172-2). Endothelial cells are flat. Factor VIII, fibronectin, and basement membrane protein are normal but S100 staining shows abnormal innervation.[21,22]

CLINICAL FINDINGS

CUTANEOUS LESIONS. (see Figs. 172-2 and 172-3). CM is a red homogenous congenital lesion that is often unilateral, sometimes bilateral, but usually not median. CMs involve skin and subcutis, and sometimes mucosa. Their color varies from pinkish red to deep purple with a geographic contour or a dermatomal distribution. Lesions are flat and painless, do not bleed spontaneously, and are never warm on palpation. They can extend throughout the entire body. Fifty percent of CMs are located on the face where they follow the distribution of the trigeminal nerve: ophthalmic branch V1 (front and upper eyelid), maxillary branch V2 (lower eyelid, cheek, and upper lip) (see Fig. 172-3B), or mandibular V3 (lower lip, chin, and mandibule). In combination with another vascular malformation, CM can be part of a syndrome, such as Sturge–Weber, phakomatosis pigmentovascularis (PPV), Klippel–Trenaunay (KT), Servelle–Martorell, etc. None of these syndromes is inherited. In rare instance, CM can be the cutaneous hallmark of occult spinal dysraphism, especially if located in the lumbosacral area.[23]

Sturge–Weber Syndrome. Sturge–Weber Syndrome (SWS) is a neuro-oculocutaneous syndrome consisting of a CM located on the opthalmic branch of the trigeminal nerve, a homolateral leptomeningeal capillary-venous malformation, often on the parieto-occipital area, and choroid "angioma" causing glaucoma and sometimes buphthalmos and retinal detachment (Fig. 172-4). Calcifications are frequently seen on the choroid plexus, and anomalies of the venous drainage of the encephalon can occur.[24] This malformation can cause epilepsy, leading to neural death, cerebral atrophy, and mental retardation.

Phakomatosis Pigmentovascularis. Phakomatosis pigmentovascularis (PPV) is thought to be an embryogenic anomaly affecting the vasomotor nerves and the melanocytes, both derived from neural crest. Clinically, PPV manifests as a large capillary malformation, which is metameric in distribution and mainly located on the trunk or the extremities, in association with pigmented cutaneous lesions, such as a pigmented nevus, a nevus spilus, a café au lait patch, or an atypical Mongolian spot (see Chapter 75) that is not located on the sacrum (eFig. 172-4.1 in online edition).[25] Nevus anemicus can also be seen in the vicinity as a twin spot.[26] These cutaneous lesions can be associated with systemic, visceral (e.g., larynx hypoplasia, intestinal polyposis), muscular (scoliosis), neurologic (mental retardation, epilepsy, intracranial calcification, cerebral atrophy), or ocular involvement (anomaly of the iris).

Klippel–Trenaunay Syndrome. Klippel–Trenaunay syndrome (KTS) is an eponym used for the presence of a capillary-lymphaticovenous malformation located on the extremity with hypertrophy of the affected limb (Fig. 172-5). Venous varicosities on the lateral side of the leg, first described by Servelle,



Figure 172-3 Several aspects of capillary malformations: light red lesions involving half of the body (**A**), dark red lesions on the face with mucosal involvement and soft tissue hypertrophy (**B**), and more localized on shoulder and arm (**C**).

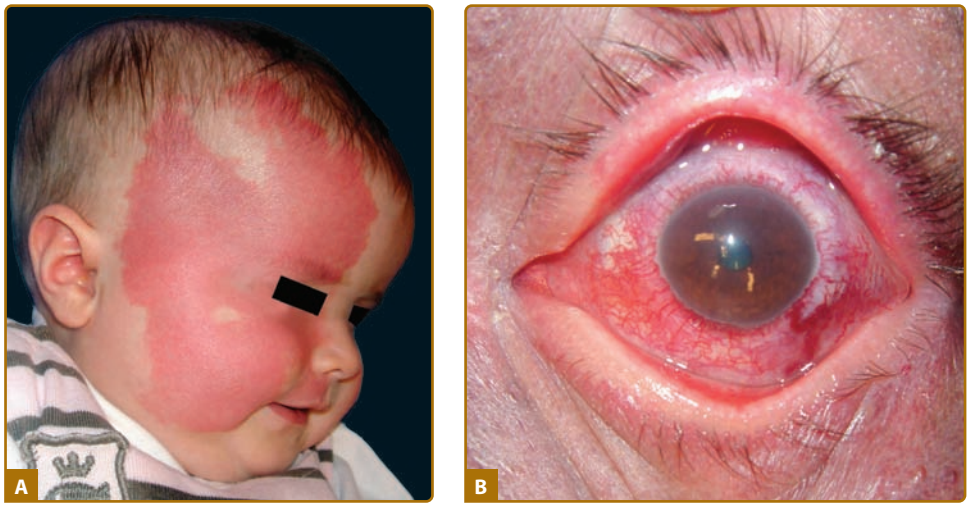

Figure 172-4 Extensive right facial capillary malformation (**A**) involving the ophthalmic and maxillary branches of the trigeminal nerve in a 6-month-old girl affected with Sturge–Weber syndrome. Choroid capillary-venous malformation (**B**) causing vision loss in a 50-year-old man with Sturge–Weber syndrome.

are very common and is specific for this syndrome in 80% of cases.[27] It is thought to be due to the persistence of embryologic veins. Valvular incompetence of deep venous system is common. Lower extremities are most commonly affected (95%), although upper limb, thorax, abdomen, and genitalia can also be involved. Lymphatic dermal vesicles cause frequent oozing. Lymphedema can be seen and tends to progress with time. Infection is common after trauma or secondary to small ulceration. VM is often seen in the underlying muscles. Hypertrophy of the limb is another sign of this disorder. It is already present at birth and occasionally evolves after puberty. Evolution toward ulceration, infection, bleeding, and thrombosis is common. Protein-loosing enteropathy can be seen with abdominal involvement. Pulmonary embolism can sometimes lead to death.



Figure 172-5 Capillary-lymphaticovenous malformation of the right lower extremity with soft tissue hypertrophy (Klippel–Trénaunay syndrome).

IMAGING STUDIES. No imaging studies are mandatory except in some rare situations. If a so-called *CM* is painful, warm, or spontaneously bleeds, Doppler ultrasound is indicated to exclude the diagnosis of a fast-flow malformation, such as an AVM, a Parkes Weber syndrome, or a proliferating hemangioma. CM located in the frontopalpebral area, especially if the inner part of the upper eyelid is involved, can be part of SWS. Therefore, a brain MRI and an ophthalmic examination have to be performed during the first months of life and repeated once a year until puberty, even if normal at younger age.[28] MRI of the spinal cord is needed in presence of a lumbosacral CM. In patients with PPV, ophthalmologic, neurologic, and orthopedic follow-up is mandatory due to the common association of CM with systemic lesion. In patients with KTS, leg length is evaluated radiologically after the age of 2 years and, if abnormal, followed once a year until the end of puberty. Doppler ultrasound evaluation of the venous status is mandatory to identify varicose veins in KTS. MRI is sometimes useful before management of the lesion.[27]

DIFFERENTIAL DIAGNOSIS

(Box 172-1)

AVF = arteriovenous fistula; AVM = arteriovenous malformation; CM = capillary malformation; CM-AVM = capillary malformation-arteriovenous malformation; CMTC = cutis marmorata telangiectatica congenita; HHT = hereditary hemorrhagic telangiectasia; M-CM = macrocephaly cutis marmorata

BOX 172-1 DIFFERENTIAL DIAGNOSIS OF CM

Differential Diagnosis of CM

Most Likely

Faint pinkish median patch
- Unna nevus
- Nevus flammeus neonatorum

Multiple, inherited
- CM of CM-AVM

Telangiectatic patch
- CMTC[a] [29]
- HHT[a] [30]
- Essential telangiectasia
- Unilateral naevoid telangiectasia

Warm on palpation
- Proliferating hemangioma
- AVM
- AVF

Ulcerated or painful
- AVM
- AVF

Rule Out

Small, multiple
- Mastocytosis
- CM of CM-AVM
- Tufted angioma [31]

Differential Diagnosis of CM (site specific)

Most Likely

Occiput
- Unna nevus

Glabella, upper eyelid, nape of neck
- Storke bite, angel's kiss, salmon patch

Consider

Extremity
- CMTC
- Klippel–Trenaunay syndrome
- Parkes Weber syndrome

Faint on trunk
- M-CM[a] [32]

Rule Out

Scalp
- Adams–Oliver syndrome [33]
- Multiple telangiectasia near canthus
- Ataxia telangiectasia [34]

[a]CMTC = Cutis Marmorata Telangiectatica Congenita; HHT = Hereditary Hemorrhagic Telangiectasia; M-CM = Macrocephaly-Capillary Malformation

COMPLICATIONS

The major concern for a patient affected with CM is cosmetic due to the visible discoloration. Hypertrophy of soft tissue can occur with time, especially when CM is located on V2 and V3 dermatomes or on the extremities. In rare instances, CM can be the stigmata of underlying anomalies such as lumbar dysraphism when located at sacrum.

PROGNOSIS AND CLINICAL COURSE

CM never regresses. It is present at birth, and slowly thickens and darkens with time. It often becomes raised and nodular.[35] Pyogenic granuloma can occur with time as well as soft tissue or bony hypertrophy.[36] (Fig. 172-6).

TREATMENT

Many therapeutical approaches have been used for CM, such as electrocoagulation, tattooing, dermabrasion, cryosurgery, and cosmetic makeup. Camouflage using Covermark is still effectively used (see eFig. 172-6.1 in online edition). Laser treatment is the gold standard for most CM. Pulsed-dye laser with its specific wavelength (585 nm) and a short pulse duration (400 ms) currently gives the best results in infants and children. There are few complications. Multiple sessions (6–12) are needed, and general anesthesia may be necessary as the procedure is painful. Laser treatment is more efficient on the cervicofacial and trunk area than on the extremities. Early treatment during childhood does not reduce the number of laser sessions.[37] The use of a dynamic cooling system to avoid heating the epidermis allows increasing of laser fluences, resulting in optimal lightening of the lesion.[38] Recurrence can occur after cessation of therapy. Laser has no impact on associated hypertrophy. Contour resection is needed mainly to treat complications such as pyogenic granuloma or lip hypertrophy.

Treatment of patients with KTS is conservative and mainly consists of elastic stockings to alleviate pain due to venous congestion. Surgical resection of varicose veins cannot be done if the deep venous system is abnormal (aplasia, incompetence). In the presence of leg discrepancy, an early-adapted shoe lift is needed to prevent scoliosis, and is followed by epiphysiodesis. If cutaneous bleeding occurs from capillary-lymphatic cutaneous vesicles,



Figure 172-6 Clinical course of capillary malformation: darkening and thickening with time: at age of 6 months (**A**), and at age of 33 years (**B**). Development of pyogenic granuloma (**C**), soft tissue (**D**), and mucosal hypertrophy (**E**).

neodymium:yttrium-aluminum-garnet laser coagulation, sclerotherapy, or skin grafting can be helpful.

PREVENTION

In patients with SWS, ophthalmic follow-up, started immediately after birth and continued until the end of puberty, is essential, as visual impairment will depend on the promptness of treatment. Prophylactic antiepileptic medication to prevent neural cell death has been advocated by some clinicians.[39,40]

VENOUS ANOMALIES

EPIDEMIOLOGY

Venous anomalies are the most common vascular malformations referred to specialized center [41]. They are mainly sporadic, although 1% are inherited (VMCM) and 5% are inherited glomuvenous malformations (GVM). No sex preponderance is reported.[42] Both VMCM and GVM have an age-dependant variation in penetrance, which reaches its maximum by 20 years of age (87% for VMCM and 92.7% for GVM).[43] Large VMCMs and GVMs are present at birth. However, 17% of affected individuals develop new small lesions over time.[42]

VM is a congenital defect on the skin or mucosa, but can involve any structure (subcutis, muscles, bones, and nerves) and any organ [central nervous system, gastrointestinal (GI) tract]. Fifty percent of VMs are located in the cervicofacial area and 37% on the extremities. VMs are mainly isolated, but can be part of complex vascular disorders of unknown etiology, such as KTS, and Maffucci and blue rubber bleb nevus (BRBN) syndromes.[44]

HISTOLOGY

VMs consist of ectatic vascular channels of venous type with flat endothelium and thin walls due to a variable number of mural smooth muscle cells that stain positive for smooth muscle cell-α-actin.[45] In contrast, GVM is characterized by distended venous channels surrounded by mural glomus cells that are aberrant

VENOUS MALFORMATIONS AT A GLANCE

- Most common referrals to specialized centers for vascular anomalies. Incidence unknown, but lower than for CM.
- Congenital slow-flow malformation of the venous bed.
- Bluish in color, localized or extensive, solitary or multifocal.
- Compressible on palpation, presence of phleboliths.
- Histologically consists of ectatic venous-like channels with anomalies in mural cells.
- Mainly sporadic but can be inherited as an autosomal dominant trait.
- Inherited venous anomalies: cutaneomucosal venous malformation (VMCM) (1%), glomuvenous malformation (GVM) (>5%).
- Syndromic venous malformation: Klippel–Trenaunay (KT), blue rubber bleb nevus (BRBN), Maffucci.

smooth muscle cells. Glomus cells are round or polygonal, instead of elongated like the normal vascular smooth muscle cells.[46] By immunohistochemistry, glomus cells stain positively for smooth muscle-α-actin and vimentin, whereas they are negative for desmin, von Willebrand factor and S100 neuronal marker.[47] By in situ hybridization, they are also negative for glomulin.[48]

PATHOGENESIS

The etiopathogenesis of at least 50% of sporadic VM are due to somatic mutations in the tyrosine kinase domain of the angiopoietin receptor TIE2, which was previously identified as the causative gene for inherited mucocutaneous VM (VMCM).[49] However, the mutations differ from the inherited ones, as the most common one (L914F) has never been identified as an inherited mutation and vice versa, the most common inherited mutation (R849W) has never been identified as a sporadic one, suggesting that sporadic mutations probably cause lethality in germline and that inherited one have weaker effects that require additional changes.[49]

VMCM is caused by amino acid substitutions in the *TIE2* gene. These gain-of-function mutations induce phosphorylation of the receptor.[50,51] GVM is genetically linked to a locus on 1p21, and caused by loss-of-function mutations in the *glomulin* gene.[43] Currently, there is no correlation between the position of a mutation in the *glomulin* gene and the characteristics of the disorder, such as the number of glomus cells in the lesion, the extent of the lesion, or the number of lesions. Moreover, for the same mutation, the expressivity is variable from patient to patient.[52] So far, a mutation in glomulin has been found in almost all GVM families tested, demonstrating locus homogeneity (Brouillard et al, unpublished).[48,52] Among the 30 different mutations found, eight are detected in several families, making efficient genetic diagnosis possible in more than 75% of patients. Several observations suggest a paradominant mode of inheritance for GVM, instead of a simple autosomal dominant transmission. A somatic double-hit mutation has been identified in one GVM resected from a patient with a known inherited glomulin mutation (Aerts et al, in preparation).[43] The combination of an inherited and a somatic mutation in the tissue suggests that a complete loss of glomulin is needed for GVM development.[43] This could explain the variation in size and location of GVMs, depending on the time of occurrence of the postzygotic second-hit mutations. The low frequency of extensive lesions (>5 cm) and the high frequency of localized lesions (<5 cm) support this model.[42]

CLINICAL FINDINGS

(Table 172-3; Fig. 172-7; and see eFig. 172-7.1 in online edition)

VMs are usually solitary, but can be multifocal, suggesting an inheritable disorder. Cutaneous VMs are congenital light-to-dark bluish lesions. Deep VM has a normal overlying skin color and is often diagnosed only at puberty or later in life with the onset of pain. Cutaneous VMs are detected early because they are usually clinically visible. Size varies from small spongy blebs to large lesions of several centimeters in diameter. VMs can easily be emptied by compression or by positioning in a non-dependent position. Skin temperature is normal. There is no thrill or bruit. Depending on size and location, VMs can cause pain, particularly in the morning on awakening, anatomic distortion, and even threaten life because of bleeding, expansion, or obstruction of vital structures. Palpation is not painful unless thrombosis occurs.[42] Local thrombosis is responsible for acute pain that lasts for 10 days and causes phleboliths, which can be identified by palpation or by radiography. VM never cause pulmonary embolism. Facial VM is usually unilateral causing asymmetry and progressive deformation and possibly dental malalignment (see Fig. 172-7 and eFig. 172-7.1 in online edition). Migraine is a common feature, if VM is located in the temporal muscle. Oropharyngeal VM can impair speech, whereas pharyngeal or laryngeal location will compromise the airway and cause snoring and even sleeping apnea. On extremities, VMs often involve muscles and joints (see eFig. 172-7.1 in online edition). They cause muscle weakness, hypotrophy, and sometimes hypertrophy, resulting in leg length discrepancy, which is less severe than in KTS. Intra-articular bleeding, if the malformation is located in the knee joint, lead to early-onset arthrosis.[53] Genital VM often occurs with limb VM and can be responsible for dyspareunia. GI VM is often diagnosed in patients with chronic anemia.

TABLE 172-3
Diagnostic Features of Venous Anomalies

	VM	VMCM	GVM	BRBN	Maffucci Syndrome
Location	50% head and neck	Extremities, mucosa	70% extremities	Especially palms and soles	Extremities
Skin color	Normal-bluish-purple	Bluish	Bluish-red-purple	Bluish-dark-blue	Normal-bluish
Aspect	Flat-raised	Raised dome-shaped	Raised, cobblestone Plaque like, hyperkeratotic	Dome shaped, nipple-like	Exophytic
	Single large	Multiple, small	Multiple	Multiple, small often + 1 large lesion	Multiple, important deformation of hands and feet
Palpation	Phleboliths	Compressible	Non compressible Painful	Firm, rubbery, Spongy	Firm
Associated	Coagulopathy	–	–	Visceral venous malformation, coagulopathy	Multiple enchondromas High risk of cancer
Radiologic	Phleboliths	Venous channels	No phlebolith	Venous channels	Venous channels Enchondromas
Tissue involved	Often deep location	Cutis and subcutis	Cutis and subcutis	Often deep component	Deep location
Histology	Thin-walled venous channels	Thin-walled venous channels	Glomus cells	Thin-walled venous channels	Spindle cells Hemangioendothelioma
Inheritance	Sporadic	Autosomal dominant	Autosomal dominant	Sporadic	Sporadic
Cause	50% somatic TIE2 mutations	Gain of function mutation in TIE2	Loss of function mutation in Glomulin	?	?

BOX 172-2 DIFFERENTIAL DIAGNOSIS OF VM

Differential Diagnosis of VM

Most Likely

Bluish subcutaneous mass, noncompressible
- Infantile hemangioma
- Lymphatic malformation

With multiple enchondromas
- Maffucci syndrome

Consider

Hyperkeratotic
- GVM, if on extremity
- HCCVM of CCM

Rule Out

Superficial, collateral normal veins
- Deep venous insufficiency, iatrogenic stenosis or congenital agenesis

Bluish non vascular lesion
- Bluish non vascular lesion such as bluish nevus

Differential Diagnosis of VM (Site Specific)

Consider

Base of the nose
- Normal prominent veins

Scalp or forehead
- Sinus pericranii
- Underlying Galen malformation

Subungual
- Solitary glomus tumor

Cheek
- Bluish nevus

Brain
- Developmental venous anomaly
- CCM

Rule Out

Neck; deep mass
- Thyroglossal duct
- Bronchogenic cyst

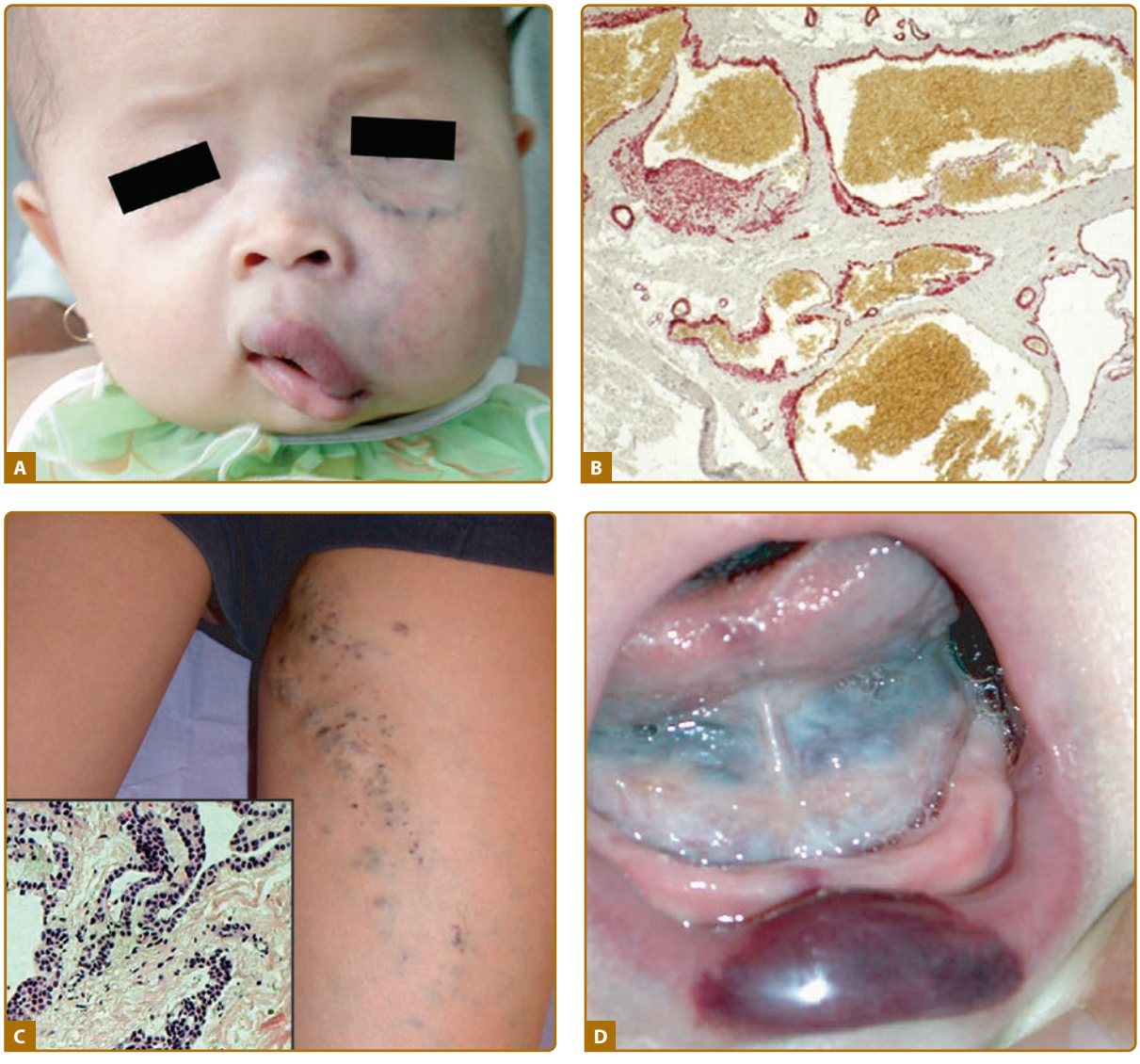

Figure 172-7 **A.** Venous anomalies: extensive hemifacial venous malformation (VM) causing soft-tissue hypertrophy and lip deformation in a 6-month-old boy. **B.** Histologically, VM consists of ectatic venous-like channels with anomalies in mural cells (hematoxylin and eosin). **C.** Superficial glomuvenous malformation of the inner thigh. Note the presence of mural glomus cells on histology (hematoxylin and eosin). **D.** Mucosal VM involving the lower lip and the floor of the mouth.

LYMPHATIC MALFORMATIONS

EPIDEMIOLOGY

Lymphatic malformation (LM) is a congenital disorder of unknown incidence. It consists of vesicles or large cysts filled with lymphatic fluid. Macrocystic LM can be diagnosed in utero as early as the first trimester of pregnancy.[83] However, most LMs are diagnosed during infancy, before the age of 2 years. Some can manifest only at puberty or during adulthood. Macrocystic LMs are often located on the neck, axilla, chest wall, or groin, whereas microcystic lesions are commonly seen in the face. LMs occur sporadically in contrast to primary lymphedema that can be inherited as an autosomal dominant trait in up to 20% of cases. Rare families with recessive inheritance have also been

LYMPHATIC MALFORMATIONS AT A GLANCE

- Worldwide occurrence is unknown.
- Congenital sporadic slow-flow malformations of the lymphatic vessels.
- Primary lymphedema can be inherited as an autosomal trait.
- LMs consist of micro- or macrocysts filled with lymphatic fluid.
- Infection is the most common complication that can lead to septicemia.
- Histologically consist of dilated lymphatic channels with flat endothelium that stains for D2-40.

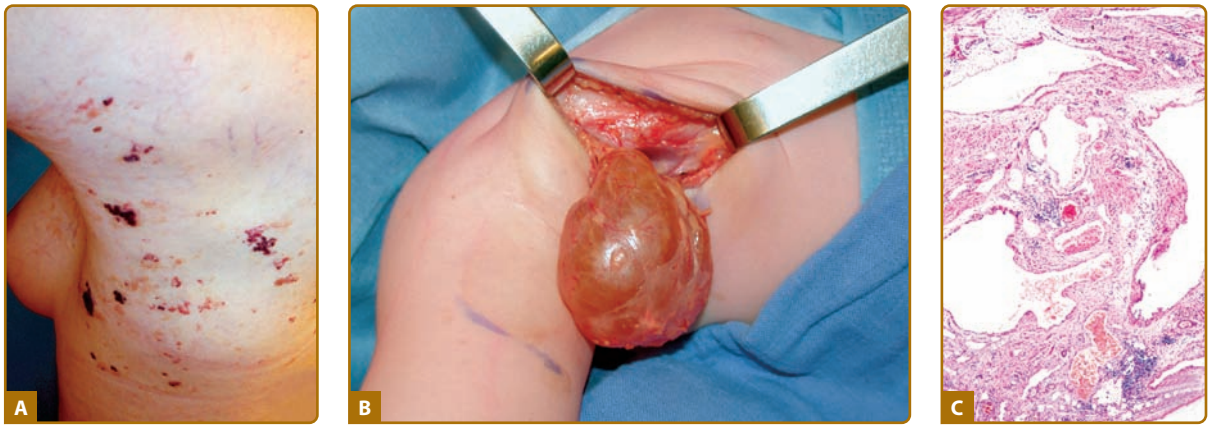

Figure 172-8 **A.** Microcystic, dermal lymphatic malformation (LM) consisting of clear and dark-red vesicles. **B.** Intraoperative view of a macrocystic LM of the axilla showing a well-delineated cyst filled with clear lymph fluid. **C.** Histologically, LM consists of dilated lymphatic channels with flat endothelium (hematoxylin and eosin).

identified.[84] Primary lymphedema is divided into congenital (present at or soon after birth) (Milroy disease, OMIM #153100) and late onset (present at puberty) (Meige disease OMIM #153200). It can be isolated or part of a syndrome, such as Turner and Noonan syndromes.[85]

ETIOLOGY AND PATHOGENESIS

LMs are errors in morphogenesis of the lymphatic vessels. The etiology is unknown. In contrast, several genes have been identified that lead to or cause lymphedema. Milroy disease is caused by a mutation that leads to loss of phosphorylation of vascular endothelial growth factor receptor 3 (VEGFR3),[86,87] whereas lymphedema distichiasis is caused by loss-of-function mutations in the FOXC2 transcription factor. Hypotrichosis-lymphedema-telangiectasia (HLT) that has an autosomal dominant or recessive pattern of inheritance, is caused by mutations in *SOX18*.[84] Hennekam syndrome is an autosomal recessive generalized lymphatic dysplasia, which is characterized by intestinal lymphangiectasia with severe and progressive lymphedema of the limbs, genitalia, and face and sever mental retardation (OMIM #235510).[88] Mutations in the Ccbe1 (collagen and calcium-binding EGF domains 1) have been identified.[89,90]

Histologically, LMs are characterized by dilated flat endothelium-lined channels of variable wall thickness. No blood cells are seen in these spaces, except after intracystic bleeding (Fig. 172-8) or in the presence of a combined lymphaticovenous malformation. Macrocystic LM shows single or multiple lymphatic cysts surrounded by thick fibrous membrane. These cysts do not communicate with each other. Endothelial vessels express specific lymphatic markers, such as podoplanin, D2-40, VEGFR-3.[91] Lymphedema is characterized by abnormalities in collecting lymphatic vessels in the affected limb (VEGFR3 and FOXC2 patients) and extensive dermal fibrosis.

CLINICAL FINDINGS

LMs are composed of microcysts (previously *lymphangioma* circumscriptum; Fig. 172-9) and/or macrocysts (larger than 1-cm diameter, previously known as cystic hygroma) that grow proportionally with the child. They are filled with clear or serosanguineous fluid (see Fig. 172-9). Macrocystic LM manifests as a soft, multilobulated, well-defined mass, whereas microcystic LMs are ill defined and often invade adjacent structures. Skin can be normal in color or, due to intracystic bleeding, have a bluish discoloration (see eFig. 172-9.1 in online edition). Dermal LMs can manifest as small millimeter-sized vesicles, clear (see Fig. 172-9 and eFig. 172-9.1 in online edition) or dark red (if intracystic bleeding) that can bleed and become purple and nodular.

Facial asymmetry, especially of the mandibule, is commonly associated with microcystic LM (see eFig. 172-9.1 in online edition). Intraorbital LM is responsible for ocular dystopia and exophthalmia as well as orbital enlargement. LM on the tongue impairs speech and produces oozing and halitosis. Airway obstruction is common when affecting the base of the tongue or the cervicofacial area.[92] Extension into the pleura can occur and cause



Figure 172-9 Lymphatic malformation. Frog-spawn-like confluent grouped "vesicles" filled with a serosanguineous fluid.

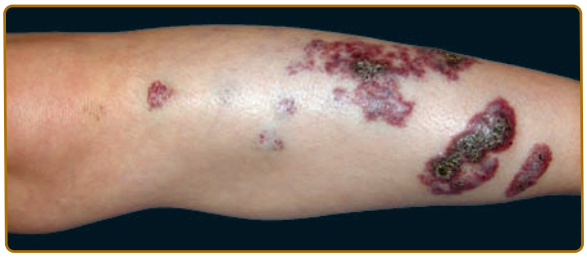

Figure 172-10 Capillary-lymphatic malformation (angiokeratoma circumscriptum) on the lower extremity, causing oozing. It is purple–red in color and slightly raised, with hyperkeratosis.

chylothorax. Abdominal lesions are associated with chylous ascites. Extensive limb LM can cause elephantiasis.

ANGIOKERATOMA CIRCUMSCRIPTUM. Angiokeratoma circumscriptum, or capillary-lymphatic malformation (CLM), is a combined, well-demarcated lesion often located on the extremity. This lesion is pink to bluish red in color, slightly raised, and usually hyperkeratotic (Fig. 172-10). Dilated capillaries and lymphatic vessels located on the superficial dermis and associated with hyperkeratosis can be seen histologically. Clinically, angiokeratoma circumscriptum (see Fig. 172-10), angiokeratoma of Mibelli



Figure 172-11 Various types of congenital primary lymphedema characterized by lymphedema of lower limb, below the knees (**A**), with papillomatosis (**B**), and with upslanting toenails (**C**), that can evolve into elephantiasis (**D**).

(circumscribed, dark-red, and hyperkeratotic plaques on the distal extremities; see eFig. 172-10.1 in online edition), and angiokeratoma of Fordyce (very common hyperkeratotic, blue–black papules on the scrotum of elderly males; see eFig. 172-10.2 in online edition) are recognized (see Table 136-2). They have to be differentiated from the angiokeratomas of Fabry disease (see Chapter136).

GORHAM–STOUT SYNDROME. Gorham–Stout syndrome ("vanishing bone disease") is an osteolytic disorder characterized by progressive demineralization and destruction of bones, which are replaced by lymphatic vessels and capillaries.[93] Depending on the location, this syndrome manifests as bone pain, muscular atrophy, fractures, pleural effusion, ascites, and cerebrospinal fluid rhinorrhea. Lethality occurs in 16% of cases.

LYMPHEDEMA. Lymphedema is characterized by swelling of the affected body part, usually the lower extremity, and caused by accumulation of lymphatic fluid into the extracellular space due to intrinsic lymphatic dysfunction (Fig. 172-11). Various phenotypes depending on the age of onset, location and associated anomalies.[90]

Congenital lymphedema. Congenital lymphedema or Milroy disease is suspected in the presence of swelling of the dorsum of the feet with familial history of lymphedema. Lymphedema is present at birth, often bilateral and affects the lower limbs, below the knees.[94] Other features can be associated with congenital lymphedema, such as hydrocele (37% of males), prominent veins (23%), upslanting toenails (14%), papillomatosis (10%), or urethral abnormalities in males (4%). Cellulitis is a common complication affecting 20% of cases.[94] Rare occurrence of pleural effusion even in utero, hydrops fetalis, and chylous ascites have been observed.[95,96] Spontaneous resorption of limited localized lymphedema has also been noted.[87,95] Moreover, in some patients ($n = 2/12$), sporadic hydrops fetalis and/or generalized subcutaneous edema was caused by a VEGFR3 mutation.[97] At birth, they had only limited edema of the lower extremities. The presence of a VEGFR3 mutation in this frequently lethal fetal condition may thus be a positive prognostic factor.

DIFFERENTIAL DIAGNOSIS

(Box 172-3)

COMPLICATIONS

LM can suddenly enlarge in response to fever, cough, or viral or bacterial infection or to intralesional bleeding (see eFig. 172-11.1 in online edition). Recurrent cellulitis is the major complication, as it can evolve into septicemia if not promptly treated. Local redness and warmth will appear and the lesion will become painful. Visceral LM can cause protein-loosing enteropathy and hypoalbuminemia.

BOX 172-3 DIFFERENTIAL DIAGNOSIS OF LM

Differential Diagnosis of LM

Most Likely

Rapid growth after birth

- Fibro- or rhabdomyosarcoma[100]

Consider

Subcutaneous mass

- Infantile hemangioma
- Venous malformation
- Teratoma[101]
- Fibrosarcoma

Differential Diagnosis of LM (Site Specific)

Rule Out

Vulvar

- Acquired lymphangiectasia due to radiotherapy
- Acquired lymphangiectasia due to Crohn disease

PROGNOSIS AND CLINICAL COURSE

LM usually grows with the child. LM often causes asymmetry with bony overgrowth. Increase in size can be seen during infection of intralesional bleeding. Episodic reports of spontaneous involution exist. As the regression is usually seen after local infection, it could be that this evolution is due to postinflammatory pseudosclerosis.

TREATMENT

Intralesional bacterial infection as well as early cellulitis should be monitored with prolonged antibiotics first given intravenously. Pain medication and anti-inflammatory drugs may be required. Immune-modifying medications, such as interferon and corticosteroids, are not effective. Neodymium:yttrium-aluminum-garnet laser or carbon dioxide laser photocoagulation has been used to treat dermal LM vesicles that cause oozing (see eFig. 172-11.2 in online edition). Macrocystic LM is treated with fluid aspiration followed by percutaneous, intralesional injection of sclerosing agents performed by an interventional radiologist. Several sclerosing agents have been used, such as sodium tetradecyl sulfate, pure ethanol, OK432 (extract from a killed strain of group A *Streptococcus pyogenes*: picibanil), doxycycline, or bleomycin. Side effects include fever, erythema, and oedema.[102,103]

Surgical resection is another alternative for LM.[104] Results depend on the anatomical site and extension of the lesion (See eFig. 172-11.3 in online edition). Recurrence is frequent since it is difficult to differentiate microcystic LM from adjacent normal tissue. This leads to either incomplete resection or unnecessary sacrifice of normal structures. One should always try to treat completely one region at a time.[105]

Lymphedema is best treated with elastic stocking, massage, and pneumatic compression devices. Family and patient education regarding the etiology and treatment is necessary, as lymphedema can be inherited.

ARTERIOVENOUS MALFORMATIONS

ARTERIOVENOUS MALFORMATIONS AT A GLANCE

- Worldwide occurrence: rare, but exact frequency unknown.
- Congenital fast-flow malformations that can be hidden until puberty.
- Histologically consist of direct communications between arteries and veins.
- Usually sporadic, but can have a genetic predisposition as in capillary malformation-arteriovenous malformation or hereditary hemorrhagic telangiectasia.
- Can be part of syndromes, such as Parkes Weber or PTEN hamartoma tumor syndrome
- Most difficult vascular malformations to treat; need a multidisciplinary approach.

Fast-flow cutaneous vascular malformations are mainly AVM and rarely arteriovenous fistula (AVF). AVF is usually traumatic. AVM is characterized by the presence of a "nidus," the epicenter of the lesion that is composed of direct communications between multiple feeding arteries and draining veins without intervening the normal capillary bed. Histologically, AVM consists of distorted arteries and veins with thickened muscle walls due to arteriovenous shunting and fibrosis (Fig. 172-12).

EPIDEMIOLOGY

The incidence of AVM is unknown. It is a rare, usually sporadic, fast-flow vascular malformation. It can affect any tissue and any organ. Seventy percent of AVMs are located on the head and neck area. AVMs are present at birth, but often manifest later in life during puberty or after trauma. They never regress. Hereditary hemorrhagic telangiectasia (HHT) is an autosomal inherited disorder with a prevalence of 1 in 10,000 individuals.

ETIOLOGY AND PATHOGENESIS

The etiology of AVM is currently unknown. An underlying predisposing genetic defect exists for these fast-flow vascular malformations when part of CM-AVM (OMIM #608354), HHT (OMIM #187300), or PTHS (OMIM #153480 and 158350). CM-AVM associates multiple, small, atypical CMs with fast-flow lesions (AVM or AVF). It is inherited as an autosomal dominant disorder with a penetrance of about 95%.[16,17,19] It is caused by loss-of-function mutations in the *RASA1* gene.[16,18] The high intrafamilial phenotypic variability could be explained by the necessity of a second hit, a somatic mutation, to occur. Prevalence of CM-AVM is unknown.

Molecules implicated in the transforming growth factor-β signaling pathway predispose to the formation of AVM/AVF, as loss-of-function mutations in endoglin and activin-like receptor tyrosine kinase cause hereditary hemorrhagic telangiectasia with fast-flow lesions in skin, mucosa and viscera (lung, brain, and liver) (OMIM # 187300).[106,107]

AVM can also be caused by loss-of-function mutation in PTEN, a tumor suppressor gene, as seen in most patients with PTHS (OMIM# 158350 & 153480).[108] This rare congenital, autosomal dominant disorder is characterized by the triad of macrocephaly, multiple lipomas and AVMs, which are often multifocal, associated with ectopic fat, and cause destruction of tissue architecture.[109,110]

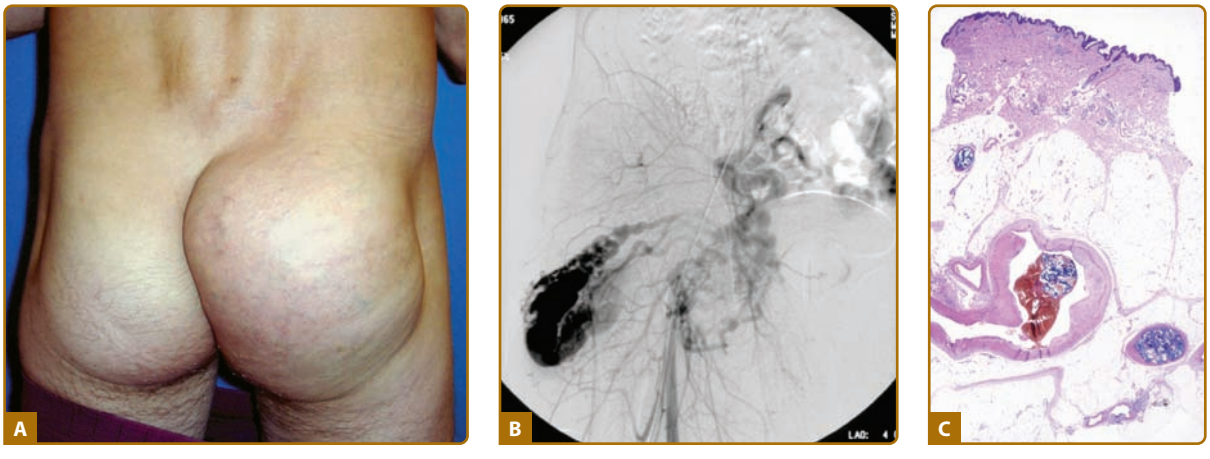

Figure 172-12 Extensive arteriovenous malformation deforming the right buttock (**A**). Arteriography showing the nidus of the malformation (**B**). Histology shows a direct connection between artery and vein, with thrombotic material secondary to the embolization procedure (**C**).

TABLE 172-4
AVM Staging: Schobinger Classification

STAGE 1	Local mass, blush or red stain Doppler ultrasound: increased vascularization
STAGE 2	+ Prominent draining veins, pulsation, thrill Doppler ultrasound: arteriovenous shunting
STAGE 3	+ Dystrophic changes
STAGE 4	+ Congestive heart failure

CLINICAL FINDINGS

During childhood, AVM is often mistaken for a CM or a hemangioma, as, at birth, AVM usually manifests as a faint, ill-defined, macular red stain. However palpation reveals its fast-flow component as it is warm. About one third of AVMs are present at birth, another one-third appear during childhood or at puberty, and the rest in adulthood. Puberty and trauma usually trigger the growth of an AVM. AVMs are staged using the Schobinger classification (Table 172-4). AVMs manifest as cutaneous, red-to-purple warm masses with a thrill, a bruit, or a pulsation of increased amplitude. They worsen with time evolving from stage I to III or even IV, never regressing spontaneously (Fig. 172-13).

CM-AVM. CM-AVM manifests as multiple atypical CM associated with fast-flow lesions in 18% to 20% of patients: AVM, AVF, Parkes Weber syndrome. The expressivity is highly variable within families, from small, asymptomatic CMs to life-threatening AVM. In contrast to sporadic CM, CMs in CM-AVM are often multiple and randomly distributed. Their size is variable: from a few millimeters to several centimeters in diameter. They are round-to-oval, pink, red or brown, and sometimes with a narrow pale halo (Fig. 172-14). The lesions are well-circumscribed and blanch on pressure with a glass. Some of them are present at birth, whereas others appear later. They grow with the child and are asymptomatic. Fast-flow lesions (AVM or AVF) are either cutaneous, subcutaneous with or without intramuscular and intraosseous involvement, intraspinal (A novel association between *RASA1* mutations and spinal arteriovenous anomalies[111], or intracerebral.[16,17,19] About 10%–15% of the CM-AVM individuals have Parkes Weber syndrome either on the lower (two-thirds) or the upper extremity (one-third). The AVMs can be asymptomatic but complications occur depending on their location and size.

HEREDITARY HEMORRHAGIC TELANGIECTASIA. Hereditary Hemorrhagic Telangiectasia (HHT) manifests as multiple cutaneous and mucosal telangiectasias that are associated with visceral, pulmonary, and cerebral fast-flow lesions. Epistaxis is a common clinical sign and can be life-threatening (ref 25).

PTEN HAMARTOMA TUMOR SYNDROME. PTEN hamartoma tumor syndrome (PTHS) regroup patients with Bannayan–Riley–Ruvalcaba syndrome (BRRS) and Cowden syndrome, as 60% and 81% of them, respectively, have a mutation in the *PTEN* gene.[110] These patients typically have macrocephaly, penile freckling, multiple developmental venous anomalies in the brain, fast-flow vascular malformations (54%) and an increased risk of malignancy. The vascular



Figure 172-13 Stage 2 arteriovenous malformation (AVM) (**A**) evolving into stage 3 AVM (**B**).



Figure 172-14 Small atypical capillary malformations of capillary malformation-arteriovenous malformation (**A–D**). Note the pale halo (**D**).

malformations are often multifocal (57%) and musculoskeletal, and associated with ectopic fat deposition and disruption of the normal tissular architecture.

PARKES WEBER SYNDROME. Parkes Weber syndrome (OMIM # 608355) was first described by F. Parkes Weber in 1918. This condition is characterized by a large, congenital, cutaneous, vascular stain on an extremity in association with soft tissue and skeletal hypertrophy of the affected limb, and with underlying multiple arteriovenous microfistulas.[10] The affected extremity is longer and larger than the contralateral one. The signs and symptoms worsen with age. When young, these patients can develop congestive heart failure.

BONNET–DECHAUME–BLANC OR WYBURN–MASON SYNDROME. Bonnet–Dechaume–Blanc or Wyburn–Mason syndrome, is a sporadic syndromic AVM located in the centrofacial and/or hemifacial area, with oculo-orbital and cerebral involvement.[112] AVM is present at birth and worsens with time. Patients can exhibit epistaxis, exophthalmos, and hemianopia. Mental retardation can occur.

COBB SYNDROME. Cobb syndrome is another sporadic syndromic AVM that associates cutaneous and spinal cord AVMs of the same metamere.[113] It manifests in childhood with neurological complications (pain, sensory and motor disturbances and a neurogenic bladder) that depend on the location and extension of the AVM. Treatment consists of complete surgical resection of the spinal cord AVM nidus, whenever possible.

IMAGING STUDY

Ultrasonography and Color Doppler show no mass, but an aggregation of high-velocity arterial and pulsatile venous flow with low resistance. Vessels are tortuous. On extremities, noninvasive follow-up is performed by comparing the arterial outflow of the affected limb with the unaffected one. Computed tomography scan has been replaced by MRI, which better shows the extent of AVM and allows differentiation from hemangioma and VM. Flow voids, corresponding to fast-flow vessels, are pathognomonic of AVM. Arteriography

BOX 172-4 DIFFERENTIAL DIAGNOSIS OF AVM

Differential Diagnosis of AVM

Most Likely

At birth

- Congenital hemangioma
- Infantile fibrosarcoma
- Other sarcoma

Rapid growth after birth

- Infantile hemangioma

Rule Out

On top of a scar

- Sarcoïdosis

Differential Diagnosis of AVM (Site Specific)

Rule Out

Ear, nose

- Lupus erythematosus tumidus
- Sarcoidosis
- Dabska tumor

Lip

- Melkersson–Rosenthal syndrome

is needed before any treatment to determine feeding arteries and the nidus (see Fig. 172-12).

DIFFERENTIAL DIAGNOSIS

(Box 172-4)

PROGNOSIS AND CLINICAL COURSE

AVMs tend to worsen with time, causing local destruction and/or life-threatening bleeding. Puberty and trauma trigger growth. Bony hypertrophy is a common feature that causes common facial asymmetry. AVM of an extremity commonly causes peripheral ischemia due to blood flow steel phenomenon. Cardiac failure is rare (Schobinger stage IV), especially during childhood. Improper management, often due to misdiagnosis, such as ligation of feeding arteries, or partial resection of the nidus, can have dramatic consequences and expansion of the AVM (see Fig. 172-13). The CMs in CM-AVM are harmless, and usually of only cosmetic importance.

TREATMENT

This fast-flow vascular malformation is the most complex and difficult vascular anomaly to treat. Its management is multidisciplinary. AVM should be followed by periodic evaluation. In a limb AVM or multiple AVFs, elastic stockings can stabilize the lesion and protect the skin. The goal of cure of an AVM is based on obliteration (by embolization) and complete removal of the nidus or the epicenter. Early intervention for "quiescent AVM" (Schobinger Stage I) is debatable but should be considered only if complete resection is possible.[114] In contrast to AVF, superselective arterial embolization alone is only palliative and is done only in unresectable complicated AVM. The embolized particles need to reach the epicenter of the lesion to avoid refilling of the nidus through new collaterals.[115] Direct puncture of the nidus is another possibility in patients with previous arterial ligation or embolization.[116] Surgical resection is usually done only after embolization, to minimize perioperative bleeding.[117] AVM needs to be widely excised. Reconstruction often necessitates microsurgical free flap transfer.[118] At least 5-year follow-up by annual Doppler ultrasound and/or MRI is mandatory after any treatment. For patients with Parkes Weber syndrome, the treatment should be as conservative as possible (e.g., elastic stockings). Epiphysiodesis may be necessary to control leg length discrepancy. However, this procedure can sometimes aggravate the AVM.[10]

For patients with HHT, multiple treatments have been tried to reduce bleeding, for example, topical application of anti-inflammatory drugs, laser, or surgery. Due to the extensiveness of the lesions, they all give limited free symptoms-intervals. Thalidomide has recently been successfully used to reduce the frequency and duration of nosebleeds in patients with HHT.[119]

KEY REFERENCES

Full reference list available at www.DIGM8.com

DVD contains references and additional content

1. Brouillard P, Vikkula M: Vascular malformations: Localized defects in vascular morphogenesis. *Clin Genet* **63**(5):340-351, 2003
9. Alomari AI: CLOVE(S) syndrome: Expanding the acronym. *Am J Med Genet A* **149A**(2):294; author reply 295, 2009
10. Enjolras O, Chapot R, Merland JJ: Vascular anomalies and the growth of limbs: A review. *J Pediatr Orthop B* **13**(6):349-357, 2004
17. Boon LM, Mulliken JB, Vikkula M: RASA1: Variable phenotype with capillary and arteriovenous malformations. *Curr Opin Genet Dev* **15**(3):265-269, 2005
24. Boukobza M et al: [Sturge-Weber syndrome. The current neuroradiologic data]. *J Radiol* **81**(7):765-771, 2000
42. Boon LM et al: Glomuvenous malformation (glomangioma) and venous malformation: Distinct clinicopathologic and genetic entities. *Arch Dermatol* **140**(8):971-976, 2004
44. Dompmartin A, Vikkula M, Boon LM: *Phlebology* **25**(5): 224-235, 2010
45. Wassef M, Enjolras O: [Superficial vascular malformations: Classification and histopathology]. *Ann Pathol* **19**(3):253-264, 1999
49. Limaye N et al: Somatic mutations in angiopoietin receptor gene TEK cause solitary and multiple sporadic venous malformations. *Nat Genet* **41**(1):118-124, 2009
53. Hein KD et al: Venous malformations of skeletal muscle. *Plast Reconstr Surg* **110**(7):1625-1635, 2002
63. Sirvente J et al: Frequency and phenotypes of cutaneous vascular malformations in a consecutive series of 417 patients with familial cerebral cavernous malformations. *J Eur Acad Dermatol Venereol* **23**(9):1066-1072, 2009
73. Dompmartin A et al: Elevated D-dimer level is diagnostic for venous malformations. *Arch Dermatol* **145**: 1239-1244, 2009
79. Konez O, Burrows PE: Magnetic resonance of vascular anomalies. *Magn Reson Imaging Clin N Am* **10**(2):363-388, vii, 2002

80. Hammer FD et al: Ethanol sclerotherapy of venous malformations: Evaluation of systemic ethanol contamination. *J Vasc Interv Radiol* **12**(5):595-600, 2001
97. Ghalamkarpour A et al: Recessive primary congenital lymphoedema caused by a VEGFR3 mutation. *J Med Genet* **46**(6):399-404, 2009
102. Mathur NN et al: Bleomycin sclerotherapy in congenital lymphatic and vascular malformations of head and neck. *Int J Pediatr Otorhinolaryngol* **69**(1):75-80, 2005
105. Greene AK et al: Periorbital lymphatic malformation: Clinical course and management in 42 patients. *Plast Reconstr Surg* **115**(1):22-30, 2005
114. Liu AS et al: Extracranial arteriovenous malformations: Natural progression and recurrence after treatment. *Plast Reconstr Surg* **125**(4):1185-1194, 2010
115. Burrows PE, Fellows KE: Techniques for management of pediatric vascular anomalies. In: *Current Techniques in Interventional Radiology*, vol 2. Philadelphia, Current Medicine, 1995, pp. 12-27
117. Wu JK et al: Auricular arteriovenous malformation: Evaluation, management, and outcome. *Plast Reconstr Surg* **115**(4):985-995, 2005

Chapter 173 :: Cutaneous Changes in Peripheral Arterial Vascular Disease

:: Veerendra Chadachan, Steven M. Dean, & Robert T. Eberhardt

OBSTRUCTIVE PERIPHERAL ARTERIAL DISEASE

OBSTRUCTIVE PERIPHERAL ARTERIAL DISEASE AT A GLANCE

- Most commonly due to atherosclerosis of the vessels supplying the lower extremity.
- Affects 15% of the US adult population over the age of 65 years.
- Stenosis or obstruction of the large arteries to the lower extremities leading to supply demand mismatch, initially with exertion but may progress to occur at rest.
- Intermittent claudication with exertional muscle pain or fatigue, critical limb ischemia with rest pain or tissue compromise, and acute limb ischemia.
- Cutaneous findings from hypoperfusion ranging from dry skin, hair loss, and malformed toenails to ulceration and gangrene.

EPIDEMIOLOGY

Although atherosclerotic obstructive peripheral arterial disease (PAD) has a prevalence of only 3% in patients of age 40–59 years, this rises to 15% in the age group older than 65 years. This translates into approximately 9 million cases in the United States in 2005, and this number is expected to increase along with the aging demographics of our population.[1,2] PAD is often unrecognized clinically and more than one-half of all patients are asymptomatic. Gender predisposition shows preponderance in males, although the incidence in females rises rapidly after menopause. Anatomically, superficial femoral artery disease predominates, with development of symptoms typically in the seventh decade. Interestingly, symptoms from aortoiliac disease usually present a decade earlier.

ETIOLOGY AND PATHOGENESIS

Atherosclerotic risk factors are similar to those identified for coronary artery disease and include diabetes mellitus, hypertension, hyperlipidemia, smoking, family history of vascular disease, and obesity. Among these, diabetes mellitus and smoking are the most significant and are associated with a fourfold and doubling of relative risk, respectively. Patients with diabetes mellitus develop the disease at an earlier age than nondiabetics and have more severe and progressive disease. The anatomic distribution of obstruction differs from nondiabetics with less aortoiliac involvement and more extensive disease of the runoff vessels below the knees; however, superficial femoral artery disease is similar in both populations. Approximately 50% of patients have hyperlipidemia. PAD is also more commonly encountered in patients with hypertension.

The pathologic findings in atherosclerosis occur in large- and medium-sized arteries, and are morphologically diverse, with focal accumulation of lipids and lipoproteins, mucopolysaccharides and collagen, smooth muscle cells and macrophages, and calcium deposits in variable quantities. Localized areas of intimal thickening secondary to smooth muscle cell proliferation and lipid-laden macrophages are seen in early stages with disruption of the internal elastic lamina. The media is often atrophic with thin strands of smooth muscle, lipid pools, collagen tissue, and calcium deposits. Enlarging plaques

encroach on the lumen despite dilation of the artery, and the plaques may ulcerate. Hemorrhages occur in the arterial wall. Thrombi may form and occlude the narrowed arterial lumen.

The etiology of atherosclerosis is complex and multifactorial, but progressive buildup of plaque narrows the vessel lumen, and complete occlusion may develop acutely secondary to thrombosis. Because disease progression is usually over an extended time period, collateral blood vessels have time to develop and are usually robust. Tissue perfusion to the affected limb is often adequate at rest, but the blood pressure distal to the occlusions is decreased secondary to high resistance and limited flow through collateral vessels. Under resting conditions, normal blood flow to extremity muscle groups averages 300–400 mL/min. Once exercise begins, blood flow increases up to tenfold owing to the increase in cardiac output and compensatory vasodilation at the tissue level. When exercise ceases, the blood flow returns to normal within minutes. In patients with PAD, resting blood flow may be similar to that of a healthy person. However, during exercise, blood flow cannot maximally increase in muscle tissue because of fixed proximal arterial stenoses. When the metabolic demands of the muscle exceed blood flow, claudication symptoms ensue. At the same time, a longer recovery period is required for blood flow to return to baseline once exercise is terminated. Dermatologic changes imply severe compromise of tissue perfusion, often secondary to tandem high-grade stenoses or occlusions present at multiple levels in the arterial tree.

CLINICAL FINDINGS

(Fig. 173-1)

HISTORY. The most classical symptom of PAD is intermittent claudication, which is usually described as pain, fatigue, or tiredness in the muscles distal to the diseased

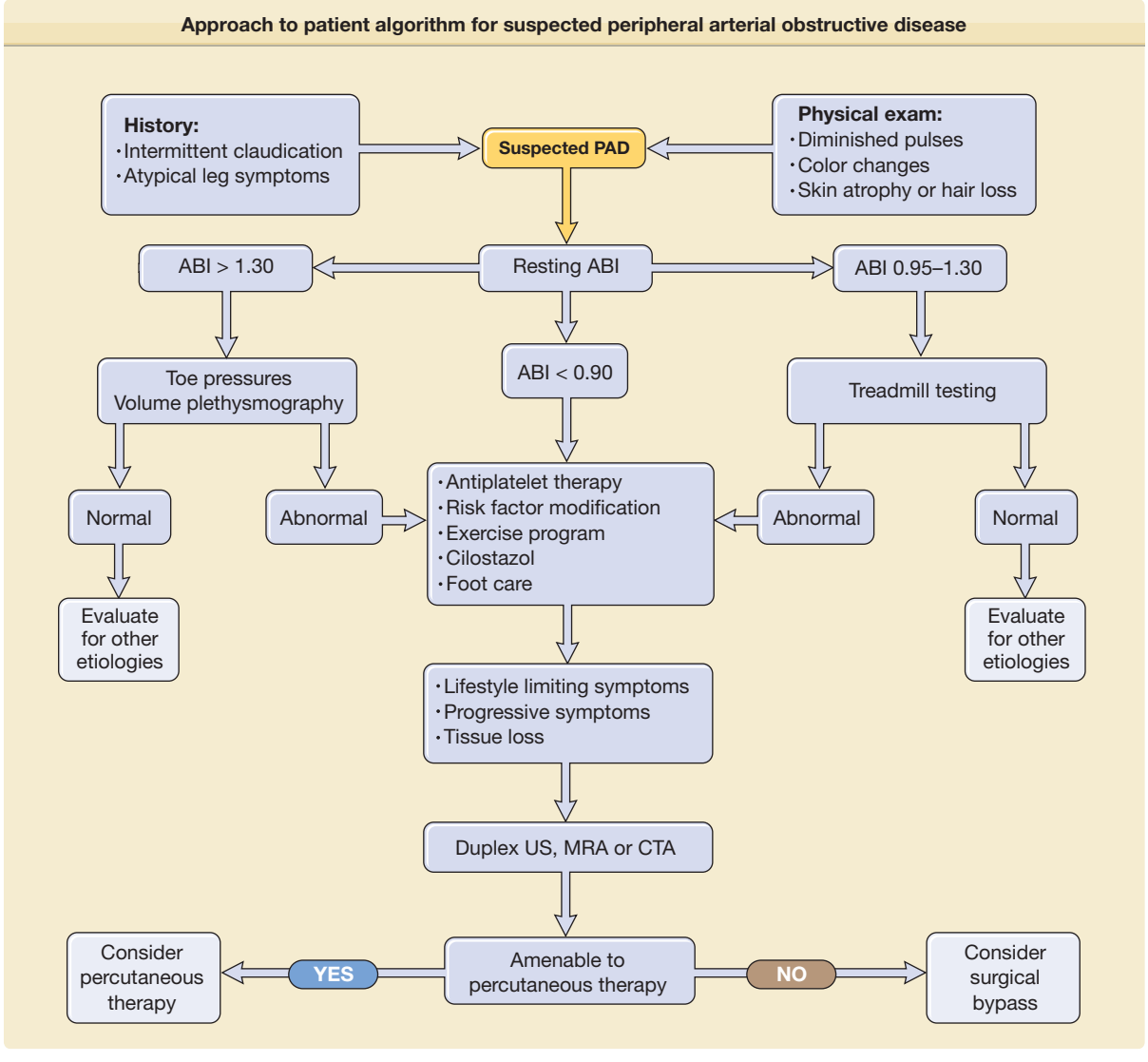

Figure 173-1 Approach to patient algorithm for suspected peripheral arterial obstructive disease. ABI = ankle–brachial index; CTA = computed tomographic angiography; MRA = magnetic resonance angiography.

BOX 173-1 ACUTE LIMB ISCHEMIA: SIX Ps

1. Pain
2. Pallor
3. Pulselessness
4. Paresthesia
5. Paralysis
6. Poikilothermia

vascular segment on walking. The location of the pain differs depending on the anatomical location of the arterial lesions. Since the disease is most common in the distal superficial femoral artery, patients most commonly present with claudication in the calf muscle area (the muscle group just distal to the arterial disease). When the disease affects the more proximal aortoiliac vessels, thigh and buttock muscle claudication predominates. The discomfort tends to be highly reproducible within the same muscle groups and is precipitated by the same level of exertion. It is crucial to determine the amount of walking distance before the onset of symptoms; this helps to quantify patients with some standard measure of walking distance before and after therapy. Resolution within several minutes of rest is an expected finding. Patients with inadequate collateral circulation may complain of cold extremities, hyperesthesia, rest pain, discolored toes, or skin breakdown. Ischemic rest pain typically affects the foot and may interfere with sleep or necessitate sleeping with the leg in a dependent position. Peripheral edema may then occur.

Acute limb ischemia secondary to vessel thrombosis or embolism presents more dramatically with (1) severe pain, usually persistent at rest, (2) pallor, (3) pulselessness, (4) paresthesias, and (5) paralysis (the five Ps). Poikilothermia (a cold extremity) may be added to this pentad of clinical findings (Box 173-1). The presence of neurologic symptoms indicates severe ischemia and need for emergent evaluation.

Since atherosclerosis is a systemic disease process, patients who present with claudication due to PAD can be expected to have atherosclerosis elsewhere. Hence, it is common for patients to present with symptoms related to disease affecting the other vascular territories.

TABLE 173-1
Cutaneous Findings in Peripheral Arterial Disease

- Pallor
- Coolness of the extremities
- Dependent rubor
- Subcutaneous atrophy
- Hair loss
- Brittle toenails
- Absence of sweating
- Ulceration
- Gangrene
- Tenderness
- Regional edema

CUTANEOUS FINDINGS. The cutaneous findings in PAD will vary depending on the severity of arterial obstruction and tissue ischemia (Table 173-1). Limbs in patients with intermittent claudication may appear normal, although associated clinical findings may include hair loss, coldness, and cyanosis, or thickened and malformed toenails. In patients with severe ischemia, the skin is apt to be atrophic, dry, and shiny. In patients with rest pain, the foot is usually bright red and cold in dependency. Ulcerations most often start at the tips of the toes or on the heel of the foot and are extremely painful except when diabetic neuropathy is also present (Fig. 173-2). Ulcers also occasionally start on the lower calves or lateral aspect of the heel. They frequently demonstrate irregular borders and a pale base. The heels may show cracks in the skin with numerous fissures. When gangrene occurs, usually one or more toes become black, dry, and mummified (Fig. 173-3). Superimposed infection is a major concern, and important associated signs include purulent discharge or decay (wet gangrene) or surrounding tissue erythema and swelling.

RELATED PHYSICAL FINDINGS. The hallmark characteristic is decreased or absent pulses distal to the stenotic arterial segment, and there may be bruits on auscultation over the diseased segment of vessel secondary to turbulent flow. It is also possible to find normal palpable pulses in a patient who presents with a history consistent with typical intermittent claudication. In such a case, the clinician can have the patient walk around



Figure 173-2 Obstructive peripheral arterial disease. An ulcer is seen on the medial aspect of the foot at the base of the great toe. **A.** Foot pallor with elevation of limb suggests severe ischemia. **B.** Foot erythema with the leg in a dependent position, termed dependent rubor, also suggests severe ischemia.



Figure 173-3 Necrotic toe in a patient with peripheral arterial obstructive disease. There is marked dependent rubor of the toes and distal aspect of the foot.

the office (or perform toe raises) until the symptoms are reproduced and then palpate for pulses. The exercise may "unmask" a stenosis causing the atherosclerotic lesion to become significant and should diminish the strength of the pulses distal to the lesion. The collateral circulation to limbs affected by PAD can be evaluated by simple bedside exam. With the patient supine, elevation of the limb at a 45° angle for 2 minutes should not produce pallor. Collateral circulation is deemed inadequate if the toes and feet become pale. The patient then assumes a sitting position with the legs dependent and the times for filling of the foot veins and flushing of the feet measured. The veins should fill within 20 seconds and the feet flush immediately in a warm environment. When these times exceed 30 seconds, the collateral circulation is deemed inadequate, and the patient must be observed frequently for the development of rest pain, ulcers, or gangrene. Venous filling times are of limited value when varicose veins coexist.

SPECIAL TESTS

A simple objective test comparing systolic blood pressure in the arms and ankles is sufficient to document the severity of arterial obstruction. The ankle systolic pressure in the supine position should be equal to or greater than the brachial artery systolic pressure. An ankle-to-arm systolic pressure ratio is calculated (ankle-brachial index, or ABI); values greater than 0.9 are generally considered normal, whereas those less than 0.4 are indicative of severe disease (see Chapter 174 for details of ABI measurements). This information is of prognostic use for determination of wound healing or the need for revascularization. One important caveat to note is that occasional patients with heavily calcified or "noncompressible" vessels, most commonly diabetics, may have falsely elevated ABIs (greater than 1.3) despite the presence of significant PAD. Under this circumstance, alternate tests, including toe pressures (as smaller vessels are rarely affected) or segmental volume plethysmography, are helpful. Duplex ultrasound scanning can be time-consuming, but further helps to define physiology and anatomic extent of disease. Magnetic resonance angiography (MRA) and computed tomographic angiography are competitive technologies used to demonstrate precise anatomic location and extent of disease in the arteries but supply limited hemodynamic information. MRA is often preferred because of lack of ionizing radiation or need for iodine-based contrast dye, but may not be tolerated by claustrophobic individuals. Conventional catheter-based arteriography is usually reserved for definitive evaluation in patients about to undergo vascular surgery or as a necessary component of percutaneous angioplasty or stenting procedures (Fig. 173-4).

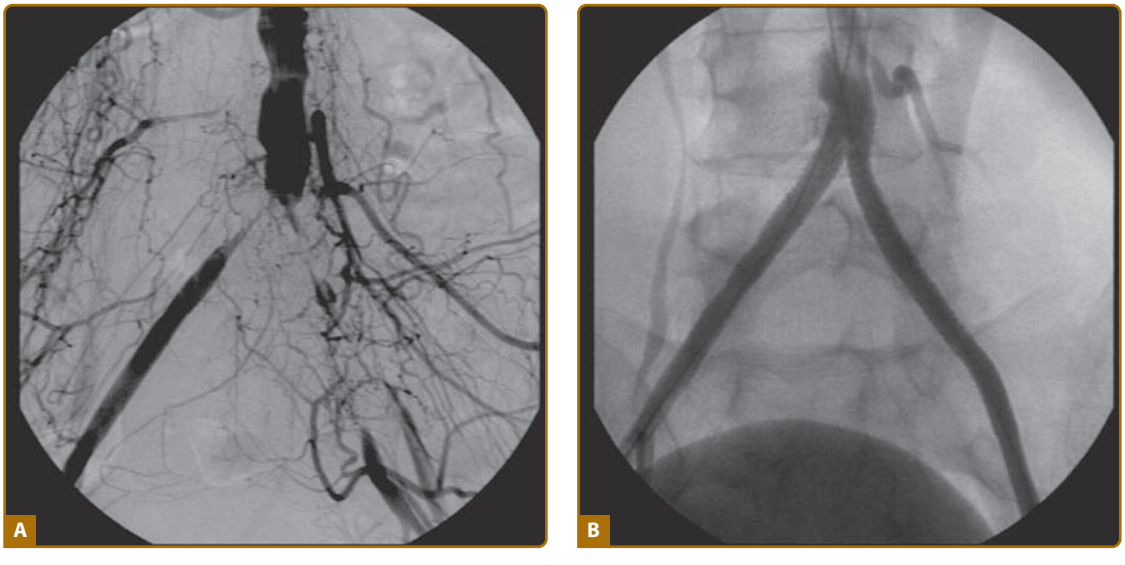

Figure 173-4 **A.** Contrast angiography demonstrating extensive peripheral artery occlusive disease involving the bilateral iliac arteries with stenoses and occlusions. **B.** Recanalization of the iliac arteries after placement of bilateral iliac artery stents.

BOX 173-2 DIFFERENTIAL DIAGNOSIS OF OBSTRUCTIVE PERIPHERAL ARTERIAL DISEASE

LOCAL FACTORS

- Trauma (including iatrogenic)
- Arterial dissection
- Cystic adventitial disease
- Thrombosed popliteal artery aneurysm
- Arterial entrapment syndromes
- Extrinsic compression

SYSTEMIC DISEASE

- Primary thrombotic disorder (thrombophilia)
- Embolism
- Thromboangiitis obliterans
- Fibromuscular dysplasia
- Vasculitic disorders (particularly giant cell arteritis or Takayasu arteritis)

DIFFERENTIAL DIAGNOSIS

The diagnosis of PAD can usually be made by the typical history of intermittent claudication and palpation for diminished or absent pulses in the limbs. The ABI is usually diminished, although occasional patients may have normal values at rest. When the diagnosis remains in doubt, a helpful provocative maneuver to increase blood flow is to exercise the patient. Postexercise blood flow may be limited by the arterial obstructive disease, and repeat ABI will then be diminished. The differential diagnosis of PAD includes both local factors and systemic disorders (Box 173-2). Arterial obstructive disease is just one of several potential etiologies for the development of a foot ulcer (Box 173-3). In some patients with diabetes mellitus or other disease resulting in neuropathy, ulcers may develop on the heel, toes, or anterior calf in the presence of normal pulses. These painless (neurotrophic) ulcers are due to repetitive trauma not noticed by the patient because of the peripheral neuropathy. Surrounding callus formation is a typical finding.

Thromboangiitis obliterans also causes intermittent claudication, ulcers, and gangrene. It occurs in young smokers (onset of symptoms before the age of 45 years) and is often associated with superficial thrombophlebitis and vasospasm. In contrast to PAD, it affects medium and smaller arteries and the upper extremities more commonly.

Occlusive vascular disease confined to focal anatomic locations in young patients with minimal traditional risk factors for atherosclerosis should raise suspicion for alternative etiologies. For example, popliteal artery occlusion may occur secondary to entrapment by calf muscles or cystic adventitial disease. In the former, an abnormal anatomical insertion of the medial gastrocnemius muscle head causes compression of the popliteal artery, with the tibial pulses disappearing on plantar (or dorsi) flexion of the foot and full extension of the knee. Pain is aggravated with walking but less with running because knee extension is not as severe with running. In the latter condition, adventitial cysts of unclear etiology compress the vessel lumen, most commonly in the popliteal artery (85%) or rarely, in the external iliac or femoral arteries, presenting as intermittent claudication. Surgical excision of the cysts usually alleviates symptoms although, in the event of complete vessel occlusion, an interposition graft may be necessary.

Neurogenic claudication (pseudoclaudication) is often a difficult diagnosis to distinguish and is due to compression or intermittent ischemia of the lower spinal cord or cauda equina with exercise. Etiologic factors are prolapsed intervertebral discs, congenital stenosis, or hypertrophic bony ridging of the spinal canal. In contrast to PAD, leg pain may occur in the erect position without exercise and be affected by changes in posture, neurologic signs may be present before or after exercise, and peripheral pulses are normal. The pain is frequently relieved by leaning forward against a solid surface or by sitting. Dilemmas in diagnosis and management can occur when both conditions coexist. MRI or computed tomography scan of the spine is used to confirm the diagnosis.

BOX 173-3 DIFFERENTIAL DIAGNOSIS OF FOOT ULCERS

- Obstructive peripheral arterial disease
- Microvascular disease
- Chronic venous insufficiency
- Neuropathic (particularly diabetic)
- Infection (diabetes or fungal)
- Trauma

COMPLICATIONS

The major direct complications of PAD relate to limb loss from progressive severe ischemia or superimposed infection. In patients with rest pain or tissue loss, the risk of infection is high and wound healing slow or absent. Under these circumstances, the need for revascularization is more urgent to avoid the need for amputation. Superimposed infection needs to be aggressively treated with antibiotics, wound débridement, and local foot care and, if rapidly progressive, presents a medical emergency.

PROGNOSIS AND CLINICAL COURSE

The most feared consequence of PAD is a severe limb-threatening ischemia leading to amputation. Fortunately, the peripheral vascular outcomes in patients with intermittent claudication as a consequence of

PAD tend to be relatively benign, with studies showing that 60%–90% of such patients remained stable over a period of 5–9 years.[3] In a large prospective study of 1,440 patients with intermittent claudication, only 12.2% patients were reported to require amputation during a follow-up period of 10 years. Occasional patients show spontaneous improvement in symptoms, most likely secondary to enhanced collateral blood flow, although plaque regression is possible. However, patients with diabetes mellitus tend to have progressive disease, and their amputation rate is fourfold greater than for patients without diabetes. In patients with diabetic neuropathy, trauma to the limbs must be avoided, and special shoes may be required. Ongoing smokers also have greater amputation and vascular graft occlusion rates than nonsmokers.

In contrast with the limb-related outcomes, because patients with PAD often have advanced atherosclerosis present in multiple vascular beds, the risk of associated cardiovascular morbidity and mortality is high.[1,2] The 5-year mortality in patients with intermittent claudication is 30%, with death largely attributed to cardiovascular causes. In addition, another 20% of patients will incur a nonfatal myocardial infarction or stroke. The association between PAD and cardiovascular morbidity and mortality has been shown to be independent of prior history of cardiovascular disease and independent of known cardiovascular risk factors. Studies have also shown that more severe PAD, as indicated by a lower ABI value, is associated with greater risk of cardiovascular mortality than mild PAD, as evidenced by a higher ABI value. It should be emphasized that PAD of any severity (as documented by an abnormal ABI) may be used to identify the individuals with an increased risk of cardiovascular events and mortality.[4]

TREATMENT

The goal of medical management should include measures to halt the progression of the disease in addition to alleviating the symptoms. The measures to halt the progression of disease include cessation of smoking and optimization of risk factors, such as diabetes mellitus, hypertension, and hyperlipidemia. For patients with symptoms of intermittent claudication, an exercise program is often the treatment of choice (Box 173-4).[2] Patients are instructed to exercise to the threshold of tolerable pain, briefly rest, and then exercise again for a total duration of 30–60 minutes a day in excess of their normal activity. The exercise period must be performed in one session, with walking being the preferred modality. Drawing on data from several studies, approximately 80% of patients may be expected to show significant improvements in exercise tolerance through these techniques. While the exact mechanism for improvement in walking distance with exercise remains unknown, regular exercise is thought to condition the muscles to work more efficiently (more extraction of blood) and increase collateral vessel formation. The magnitude of benefit associated with exercise programs for claudication appears to be greater than that reported for clinical trials of pharmacologic therapy. Patients should be further instructed to keep their feet warm, clean, and dry; and extremes of temperature should be avoided because ischemic tissue is more susceptible to burning and to frostbite than normal tissue. Cuts or severe bruises of the limbs or feet should be treated immediately. Conventional vasodilators appear to have no value in treatment.

BOX 173-4 TREATMENT OF OBSTRUCTIVE PERIPHERAL ARTERIAL DISEASE

	Symptom Relief	Risk Reduction
First line	Exercise regimen Cilostazol (Pletal)	Smoking cessation Statin therapy (target low-density lipoprotein <100 mg/dL) Aspirin Glycemic control Antihypertensive therapy
Second line	Pentoxifylline (Trental) Percutaneous revascularization (angioplasty, stent, atherectomy, cryotherapy) Surgical revascularization (endarterectomy or bypass)	Other lipid therapy Clopidogrel (Plavix)

Two agents have been approved for the indication of intermittent claudication in the United States. Cilostazol, a phosphodiesterase inhibitor with antiplatelet and vasodilatory properties, has been shown in several studies to have consistent benefits on treadmill walking distance and quality of life.[5] However, its benefits are balanced by high frequency of side effects, principally gastrointestinal symptoms or headaches. Furthermore, it is contraindicated in patients with congestive heart failure. Pentoxifylline affects red cell deformability and blood viscosity but has been shown to be relatively ineffective in the treatment of claudication[2]. Other agents, such as propionyl-L-carnitine an agent with metabolic effects, are under study in the United States for this indication.

Endovascular intervention with angioplasty or stenting is highly effective for aortoiliac disease and is often indicated for moderate, or lifestyle-limiting claudication. Angioplasty or stenting of the superficial femoral artery is technically feasible but limited in applicability by high restenosis rates, particularly in the setting of long occlusions, a common scenario in this location. Despite this limitation, it is a valid therapeutic option for patients with focal disease, severe claudication, or tissue loss. Endovascular management of infrapopliteal (below the knee) disease is associated with extremely high restenosis rates, and is

usually a temporizing measure to allow increased blood flow for wound healing. Surgical bypass techniques are effective but are generally high-risk procedures in a population with frequent comorbidities and are usually reserved for patients with severe intermittent claudication or rest pain, or to allow healing of ulcers and gangrene. Sympathectomy is not of value for intermittent claudication, but has been used in the past to allow small ulcers or areas of gangrene to heal. In patients with rest pain, ulcers, or gangrene who are technically unrevascularizable or very high risk for surgery, treatment options are limited. A period of rest with legs dependent may improve some patients, but amputation is a frequent outcome. Parenterally administered prostacyclin or prostaglandin E_1 despite some favorable reports of success, has not yet been thoroughly evaluated and is an expensive mode of therapy.

Dry gangrene of the digits or lower limbs should be allowed to spontaneously demarcate. Soaking or ointments are unnecessary. The edges of the gangrenous areas should be kept open if possible and observed frequently for infection. Pain medication is usually necessary for 2–3 months with digital gangrene. A conservative approach and patience will save many digits and extremities. Infected (wet) gangrenous areas must be actively débrided and appropriate antibiotics administered. Amputations may be necessary.

PREVENTION

The grim statistics regarding cardiovascular outcomes in these patients emphasize the need for aggressive secondary prevention by modifying appropriate cardiovascular risk factors when possible. Tobacco smoking is absolutely contraindicated. Continued smoking has been identified as the most consistent adverse risk factor associated with the progression of the disease. Smoking even one or two cigarettes a day can interfere with PAD treatments. Smoking is also associated with significantly higher rates of amputation compared with nonsmokers. The rate of in-hospital amputation was shown to be 23% in smokers and 10% in nonsmokers. On the other hand, quitting smoking has been shown to slow the progress of PAD and also to reduce the rates of amputation required. Hypertension and diabetes mellitus should be controlled, and hyperlipidemias should be treated with a target low-density lipoprotein <100 mg/dL (or <70 mg/dL with uncontrolled or multiple risk factors) as per recent guidelines for secondary prevention. Evidence is accumulating that aggressive lipid management will prevent progression of PAD, in addition to prevention of myocardial infarction and stroke. Similarly, antiplatelet use with aspirin is used for prevention of cardiovascular events but some controversy of effectiveness in diabetics with PAD. The use of thienopyridines such as clopidogrel (Plavix) may be of additional benefit, but may be associated with higher bleeding rates (particularly with combined therapy) and expense. Use of antiplatelet therapy is a must for those with PAD but should be individualized.

ATHEROMATOUS EMBOLISM

ATHEROMATOUS EMBOLISM AT A GLANCE

- Atheromatous embolism is the embolization of small pieces of atheromatous debris from the more proximal arteries to the smaller arteries.
- Synonyms include *cholesterol embolism, atheroembolism, blue toe syndrome,* and even *pseudovasculitis syndrome.*
- More common with advanced age and after invasive procedures.
- Manifestations include blue or discolored toes, livedo racemosa, gangrene, necrosis, ulceration, and fissure.
- Renal failure and stroke from systemic involvement.
- Diagnosis confirmed by cholesterol clefts in skin or muscle biopsies.
- Treatment focuses on prevention during invasive procedures and elimination of the embolic source. Medical therapy may include antiplatelet therapy and statin agents, while the use of anticoagulation is controversial and often avoided.

EPIDEMIOLOGY

The epidemiology of atheromatous embolism is poorly defined due to underreporting and difficulties establishing a clinical diagnosis.[6] Routine autopsy series of the adult population suggest an incidence of atheromatous embolism of between 0.15% and ~4%. The incidence increases dramatically in the presence of severe atherosclerotic disease. Atheromatous embolism has been found in more than 20% of deaths following cardiac surgery or angiography. However, it should be emphasized that the rate of clinically detected atheromatous embolism appears to be reasonably low (less than 1%). The atheromatous embolism appears to be more common in males than in females with a reported male-to-female ratio of approximately 3.4:1. It is strongly associated with older age, with the mean age reported to range from 66 to 72 years.

ETIOLOGY AND PATHOGENESIS

The pathogenesis of atheromatous embolism involves the occlusion of small arteries and arterioles (of 50–900 μm in diameter) by atheromatous debris (or

so-called *cholesterol crystals*) that are dislodged from a proximal atherosclerotic plaque, with this material inciting an inflammatory cascade characterized by leukocyte infiltration followed by monocytes. This inflammatory process leads to further occlusion with thrombus formation, endothelial cell proliferation, and intimal fibrosis, which may result in ischemia, infarction, and necrosis. The clinical picture is characterized by impaired perfusion of the skin and muscle due to small vessel occlusion, although nearly any organ of the body may be involved.

The major risk factor for the development of atheromatous embolism is atherosclerotic disease of the thoracic or abdominal aorta. The risk is higher with more extensive atheroma burden (defined by increased thickness above 4 mm) or unfavorable plaque features such as protruding mobile plaque.[7] Coexistent vascular disease including coronary artery disease, PAD, and even an abdominal aortic aneurysm are risk factors. The more traditional atherosclerotic risk factors also increase the risk of atheromatous embolism, with older age (more than 60 years) being prominent.

Atheromatous embolism often occurs after an invasive procedure.[8] Angiography, endovascular procedures, and both cardiac and vascular surgeries may create mechanical trauma to the vessel and destabilize an atherosclerotic plaque. Anticoagulation, primarily with Coumadin, and even thrombolytic therapy are potential risk factors. It has been postulated that anticoagulation may delay the healing of irregular or ulcerated plaque. Embolic events may occur spontaneously although minor stressors such as coughing or straining may be provocative factors.

CLINICAL FINDINGS

HISTORY. The clinical presentation of atheromatous embolism, although it can occur spontaneously, usually follows an invasive procedure such as an invasive angiographic or vascular surgical procedure. The clinical manifestations may be immediate, or delayed by several days to weeks after the inciting event. The precise clinical syndrome depends on the location of the source of embolism and the pattern and distribution of flow downstream. This may range from subtle clinical findings to catastrophic systemic embolic complications. Nearly any organ of the body may be involved. Involvement of the ascending aorta may result in systemic complications including transient ischemic attacks, strokes, or retinal manifestations, while involvement of the descending or abdominal aorta may lead to lower extremity ischemia, renal failure, mesenteric ischemia, or hemorrhagic pancreatitis. Since more common sites for severe atheromatous disease are in abdominal aorta and iliac arteries, the signs and symptoms more commonly result from embolism to the lower half of the body. The lower extremity involvement typically presents with manifestations of discolored or ulcerated painful toes and tender calf muscles.

In addition, constitutional symptoms including fever and weight loss may be seen due to hypermetabolism associated with the inflammatory process.

TABLE 173-2
Cutaneous Findings in Atheromatous Embolism

- Blue or purple toes
- Livedo racemosa
- Gangrenous digits
- Ulcers
- Fissures
- Nodules
- Petechiae
- Purpura
- Splinter hemorrhages

CUTANEOUS LESIONS. The dermatologic manifestations are often the presenting complaint (Table 173-2). The most common of these findings are related to tissue or digital ischemia and include cyanosis, necrosis, gangrene, ulcerations, and fissures. The finding of tender, cool, blue, or purple toes with normal pulses, found in the "blue toe syndrome," is common (Fig. 173-5A). About 50% of patients will have livedo racemosa, which typically involves the foot and leg but may extend into the trunk or buttocks. Erythematous lesions are often seen on the lateral aspect of the foot and calcaneal region. Although advanced ischemic manifestations such as ulcers or gangrene may be present (see Fig. 173-5B), the surrounding areas are normally perfused tissue. There may be other cutaneous manifestations, often hemorrhagic in nature, including petechiae, ecchymosis, purpura, and splinter hemorrhages. Raised painful inflammatory nodules may occur.

RELATED PHYSICAL FINDINGS. Examination of the vascular system often reveals normal pedal and proximal pulses, but systolic bruits may be heard on auscultation over the aorta or common femoral arteries. Tenderness of skeletal muscles, particularly in the calf, may be detected. Funduscopic examination revealing Hollenhorst plaques is a specific but insensitive finding because most atheromatous emboli arise from a source distal to the aortic arch. Fever may be present.

LABORATORY TESTS

The laboratory tests are typically nonspecific and depend upon the organ involved and the severity of disease. An elevated erythrocyte sedimentation rate, thrombocytopenia, hypocomplementemia, leukocytosis, and anemia may all been seen due to the systemic inflammatory response. With renal involvement azotemia, proteinuria, microscopic hematuria, eosinophilia, and even eosinophiluria may be seen. Transient eosinophilia has been reported in up to 80% of those with renal involvement. Involvement of the gastrointestinal tract may lead to anemia and blood in the stools. Injury to the liver, gallbladder, or pancreas may lead to abnormal liver function tests and elevated pancreatic enzymes.



Figure 173-5 **A.** Typical appearance of blue toes due to multiple atheromatous emboli to the lower limbs in a patient with extensive atheromatous disease of the aorta. **B.** Development of ulceration of the tip of the toes due to atheromatous embolism with a faint reticular pattern on the forefoot typical of livedo racemosa.

SPECIAL TESTS

Contrast angiography may reveal diffuse atherosclerotic involvement of the vessels proximal to the lesions, but is typically avoided due to the risk of precipitating further embolic events. Noninvasive imaging techniques such as computed tomographic angiography or MRA are useful to evaluate for atherosclerotic disease within the aorta or other large vessels. Although stenotic atherosclerotic disease is the most common finding, aneurysmal disease may also be present. Transthoracic echocardiography is often helpful to evaluate for a cardiac source, but the more definitive transesophageal echocardiography can also assess the thoracic aorta for plaque.

Definitive diagnosis of cholesterol embolization requires demonstration of cholesterol crystals, which are birefringent under polarized light. However, due to the solubility of cholesterol with typical solvents used in processing of tissue for histopathology, cholesterol crystals appear as empty clefts. Skin, muscle, or renal biopsies may reveal these characteristic elongated, needle-shaped clefts in small arterial vessels. There may also be inflammatory infiltrates, intimal thickening, and perivascular fibrosis as well as giant cells. The sensitivity of the biopsy depends upon the site. Muscle biopsy seems to be the most sensitive test, reportedly being positive in >95% of cases, but is technically difficult, painful, and risky to obtain. The sensitivity of skin biopsy has varied from 40% to 90%. Skin biopsies offer maximum yield when obtained directly from areas of suspected emboli, such as those with livedo racemosa, but should be cautiously obtained or avoided in areas of more overt ischemic injury.

DIFFERENTIAL DIAGNOSIS

Because of its clinical similarity to other systemic diseases, atheromatous embolism is often misdiagnosed. The diagnosis of atheromatous emboli is suggested by blue or ulcerated painful digits, livedo racemosa, petechiae, and tender calf muscles in the presence of normal pulses. However, it is difficult to establish the diagnosis, when the clinical features are subtle and nonspecific. Thus, a high index of suspicion is needed, especially in the setting of a history of preexisting atherosclerotic disease and a specific precipitating event. Definitive diagnosis can be made by skin, muscle, or even renal biopsies. Several other entities must be considered in the differential diagnosis of atheromatous embolism (Box 173-5).

Moreover, among patients who develop acute renal failure, it is important to distinguish from contrast nephropathy, which is typically reversible. Renal failure due to atheromatous emboli usually develops over

BOX 173-5 DIFFERENTIAL DIAGNOSIS IN ATHEROMATOUS EMBOLISM

- Antiphospholipid antibodies
- Atrial myxoma
- Calciphylaxis
- Chilblains (or pernio)
- Cryoglobulinemia
- Heparin-induced thrombocytopenia
- Malignancies
- Multiple myeloma
- Nonbacterial thrombotic endocarditis
- Polyarteritis nodosa
- Subacute bacterial endocarditis
- Thrombocytopenia, polycythemia
- Thrombotic embolism
- Vasculitis
- Warfarin-induced skin necrosis

1–4 weeks after angiographic procedure and shows partial recovery, whereas contrast-induced renal failure typically appears soon after testing and begins to recover within 3–5 days.

COMPLICATIONS

There are numerous ischemic complications depending upon the organ involved. These include the kidneys, mesenteric circulation, and central nervous system. Renal atheroembolic disease is a consequence of showering of emboli to the renal parenchymal branch vessels. An intense inflammatory process may ensue, producing glomerular sclerosis, tubular atrophy, and interstitial fibrosis. Although there is a variable timing of onset and progression of disease, there typically is a several-week delay after the inciting event before the development of renal dysfunction. New onset of hypertension or overt renal failure may ensue. It is rare to develop gross hematuria or frank renal infarction. The development of renal failure is one of the more ominous complications with a high mortality in affected individuals.

The central nervous system is another feared site of involvement with atheromatous embolism. There is concern for ischemic manifestations such as transient ischemic attacks, stroke, and paralysis. However, other less readily appreciated manifestations may ensue, such as a confusional state or a progressive neurologic decline.

The gastrointestinal tract is perhaps the third most common organ system involved with atheromatous embolism. The manifestations may be nonspecific abdominal complaints such as abdominal pain, nausea, vomiting, or diarrhea. More severe ischemic manifestations may be seen with gastrointestinal bleeding or bowel infarction. The colon is the most common site in the gastrointestinal tract to be affected. Establishing a diagnosis may be difficult as endoscopy findings are often nonspecific, and biopsy may miss the classic findings. Splenic infarction, cholecystitis, gangrene of the gall bladder, pancreatitis, and pancreatic necrosis have also been reported.

PROGNOSIS AND CLINICAL COURSE

The prognosis of cholesterol embolism is generally poor, in part because of the severe underlying atherosclerosis. The outcome also depends upon the organ system affected with the emboli. Estimates of mortality range from 20% to 30% for 1-year mortality. The poorest outcomes have been reported in those with emboli arising from a suprarenal location.

The syndrome usually subsides, and lesions heal following successful surgical or medical treatment, although spontaneous resolution may occur. Recurrent embolism may result in limb loss in the absence of surgical or interventional management options. In the "malignant multisystem" disease, most patients die within 1 year if treatment is unsuccessful. The prognosis is extremely poor in the presence of systemic complications, particularly renal failure or stroke. The development of end-stage renal disease due to atheromatous embolism is a strong predictor of death.

TREATMENT

Early recognition is essential to minimize end-organ damage and improve the clinical outcomes.[6] Preventing further ischemic insult, supportive care, and removal of the atheromatous source are the mainstays of therapy.[9] Elimination of the source of the emboli can often be accomplished by surgical bypasses or endarterectomy although many of these patients have contraindications to major surgery. Endovascular procedures with covered stents may also be considered; however, this approach may carry significant risk with the potential to exacerbate further embolization.

Medical therapies have not been well studied, and recommendations are based on the results from small series or anecdotal reports. Antiplatelet agents, such as aspirin, dipyridamole, or clopidogrel, are most often tried and, if successful, should be continued long term. Antithrombotic therapy such as subcutaneous heparin or low-molecular-weight heparin may be beneficial with some, suggesting that these agents may reduce the secondary small vessel thrombosis. Warfarin is usually avoided due to potential for exacerbating the process, but this concern has limited basis. There is even a proposed beneficial effect of long-term anticoagulation to prevent embolic events in those with extensive mobile aortic atheroma. The use of statins may aid in plaque stabilization and has clear established benefits in prevention of cardiovascular ischemic events in those with vascular disease. Other agents such as iloprost and cilostazol have limited evidence to suggest benefit but have been tried in those with renal dysfunction and cutaneous lesions, respectively. Systemic corticosteroids are not recommended. Since most of these patients have severe underlying atherosclerosis, they should be aggressively treated for secondary prevention of cardiovascular disease with optimization of the risk factors.

PREVENTION

Because of the rarity of the disease and the difficulties in establishing the diagnosis, increased awareness of the problem is important. Primary prevention in high-risk patients, targeted to avoid the development of atherosclerotic plaque, should be performed. Once atherosclerosis develops, avoiding unnecessary invasive procedures is advised. When angiography is necessary, more cautious techniques with the use of soft-tipped guidewires and more flexible catheters help to reduce the risk. In addition, protective devices such as filters, baskets, and balloon occlusion have been used. In patients with atheromatous disease of abdominal aorta and iliac arteries, use of brachial artery approach is often considered. Surgical techniques have also been refined with less aortic manipulation and circulation arrest, which may help to minimize the chance of developing this disorder.

THROMBOANGIITIS OBLITERANS (BUERGER DISEASE)

THROMBOANGIITIS OBLITERANS AT A GLANCE

- Rare inflammatory occlusive disease affecting medium and small arteries and veins, most commonly in the extremities.
- Predominantly affects males, at age 20–40 years.
- Extremely strong association with smoking; often abates with smoking cessation.
- Clinical manifestations include ischemia, cold sensitivity, or claudication of foot, leg, or hand.
- Ischemic ulcers, peripheral cyanosis, gangrene, or superficial thrombophlebitis.

EPIDEMIOLOGY

The prevalence of this disease is greatest in the Mediterranean, Middle East, and Asia, and it is relatively less common in people of northern European descent.[10] Males are afflicted with a higher prevalence than females (with a male-to-female ratio of 3:1), although an increased incidence in females has occurred in recent years, likely reflecting the pattern of tobacco use. Patients are usually between the ages of 20 and 40 years. Over the last three decades, there has been a marked decline in the reported prevalence of thromboangiitis obliterans in the United States, possibly reflecting the impact from adoption of strict diagnostic criteria for this disease entity, although declining smoking prevalence may also play a role. In 1947, the prevalence of the disease in the United States was estimated at 104 cases per 100,000, however, more recently the prevalence has been estimated at 12–20 cases per 100,000.[11]

ETIOLOGY AND PATHOGENESIS

The etiology of thromboangiitis obliterans remains unknown. The disease occurs almost exclusively in smokers and often abates with the cessation of tobacco smoking. An increased cellular sensitivity to types I and III collagen has been reported in comparison to a group of normal individuals and patients with atherosclerotic disease. An increased prevalence of HLA-A9, HLA-A54, and HLA-B5 has been observed in these patients, suggesting a genetic component to the disease.[12] Tissue ischemia is produced by an inflammatory reaction involving medium and small arteries of the extremities and superimposed obstruction by thrombi. Despite the inflammatory process, thromboangiitis obliterans is considered serologically silent, and even during active disease inflammatory markers, such as erythrocyte sedimentation rate and C-reactive protein levels, are usually normal. In one report, serum antiendothelial cell antibody titers were found to be high, and impaired endothelial-dependent vasodilation to acetylcholine has been demonstrated to occur even in nonobstructed limbs. Veins may also be involved. Occasionally, cardiac, intestinal, and cerebral vessels are involved.

CLINICAL FINDINGS

(Fig. 173-6)

HISTORY. The most common initial complaints are claudication of the foot or lower calf, digital cyanosis or gangrene, or rest pain. Involvement of multiple limbs is typical. Patients may present with ulcers of the toes or fingers. Although the lower extremities are affected most often, more than one-third of patients have upper-extremity involvement. Ulcerations or gangrenous areas are characteristically extremely painful. Superficial thrombophlebitis, often migratory, may occur in up to 40% of patients. Cold sensitivity or even classical Raynaud phenomenon may be observed.

CUTANEOUS FINDINGS. The cutaneous findings of thromboangiitis obliterans are similar to that of PAD. Common findings include ulceration or gangrene of digits (feet worse than hands) (Fig. 173-7), peripheral cyanosis or Raynaud phenomenon, and superficial thrombophlebitis, often migratory, with indurated red nodules.

RELATED PHYSICAL FINDINGS. The hands and feet of patients with the disease are usually cold and mildly edematous. They may develop cyanotic, ulcerated, or gangrenous, and very painful digits. Typically, the distal pulses (dorsalis pedis, posterior tibial, and ulnar pulses) are often absent, while the more proximal pulses are preserved. During episodes of thrombophlebitis, small-indurated red, tender nodules will be found, which follow the course of superficial veins and are common on the thigh or calf. Typical changes of Raynaud phenomenon, with well-demarcated pallor or cyanosis of the digits, may be seen on exposure to cold; one or more extremities may be involved. Sensory abnormalities reflecting ischemic neuropathy have been observed in advanced cases. Nail fold examination with capillaroscopy may reveal multiple dilated capillary loops.

TREATMENT

There is no specific treatment (Box 173-6) other than smoking cessation. Local wound care is imperative, and adequate analgesic therapy is emphasized. In the absence of data from large randomized trials, antiplatelet agents and vasodilators may play a role and are usually initiated. Similarly, pentoxifylline or cilostazol, both agents used for improving walking

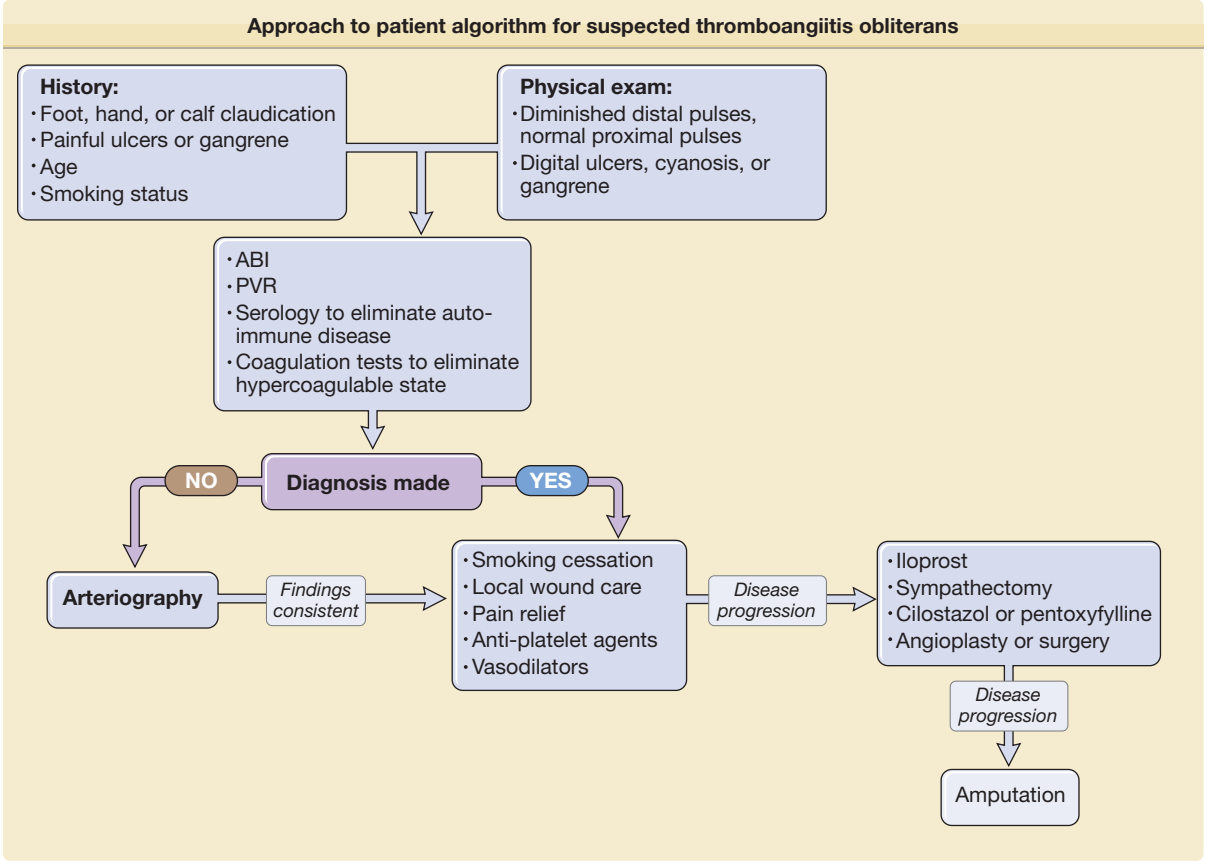

Figure 173-6 Approach to patient algorithm for suspected thromboangiitis obliterans. ABI = ankle–brachial index; PVR = pulse-volume recording.

distances in claudicants with atherosclerotic disease, may be tried. In one study, daily intravenous infusions of iloprost, a prostaglandin analog, were shown to relieve rest pain, heal ulcers, and prevent amputation more frequently than aspirin. Bypass surgery or angioplasty have been reported but are suboptimal therapeutic options because of the small size and distal location of the vessels affected. Sympathectomy may help patients with a prominent vasospastic component. Vascular endothelial growth factor gene therapy may prove of value, but has not been well studied yet. In



Figure 173-7 Necrotic toe in a patient with thromboangiitis obliterans; this appearance may be seen with other arterial occlusive processes.

BOX 173-6 TREATMENT OF THROMBOANGIITIS OBLITERANS

	Improve Blood Flow	Symptom Relief
First line	Smoking cessation	Local wound care Analgesics
Second line	Antiplatelet agents Oral vasodilators Cilostazol (Pletal) Pentoxifylline (Trental)	
Third line	Iloprost Angioplasty Surgical endarterectomy or bypass	Sympathectomy Amputation

those with refractory disease with nonhealing ulcers, gangrene, or intractable pain, surgical amputation of the affected distal limbs is often unavoidable.

PREVENTION

Absolute discontinuation of tobacco use is the only strategy proven to prevent the progression of thromboangiitis obliterans. Smoking as few as one or two cigarettes daily, using chewing tobacco, or even using nicotine replacements may keep the disease active.[14] The following strategies are important in prevention of complications from the disease: use of well-fitting protective footwear to prevent foot trauma and thermal or chemical injury, avoidance of cold environments, and avoidance of drugs that lead to vasoconstriction.

LIVEDO RETICULARIS AND LIVEDO RACEMOSA

LIVEDO RETICULARIS AND LIVEDO RACEMOSA AT A GLANCE

- Livedo is an ischemic dermopathy characterized by a violaceous reticular or "net-like" mottling of the skin.
- Imperative to differentiate benign livedo reticularis from pathologic livedo racemosa.
- Livedo reticularis is a primary disorder affecting young to middle-aged females that is benign. The livid conical discoloration is symmetric, reversible, and uniform.
- Livedo racemosa is a secondary disorder that is pathologic and permanent. The livid conical discoloration is asymmetric, irreversible, and "broken."
- Antiphospholipid antibody testing should be obtained on all patients presenting with livedo racemosa.

EPIDEMIOLOGY

Livedo reticularis is typically a primary disorder that affects young to middle-aged females (20–50 years of age) who are otherwise healthy.[15] Amantadine-induced livedo reticularis is also more common in females. The epidemiologic factors of livedo racemosa are dependent on the underlying condition. It is the most frequent dermatologic manifestation in patients with antiphospholipid syndrome, present in 25% of patients with primary APS and in up to 70% of patients with SLE-associated APS.[16] The distinction between livedo racemosa and livedo reticularis is an evolving concept, which is not universally quoted, and is not referred to in most of the older literature.

ETIOLOGY AND PATHOGENESIS

In both disorders, the characteristic ring-like mottling results from (patho)physiologic changes within the cutaneous microvascular system. Anatomically, the dermis is perfused via perpendicularly oriented ascending arterioles. Individual arterioles arborize into a capillary bed at the skin surface. Ultimately, the capillary beds empty into a conical appearing, peripherally located subpapillary venous plexus.

Pathophysiologically, livedo arises from either deoxygenation or venodilatation within the venous plexus.[17] Decreased arteriolar perfusion is the predominant cause of deoxygenation within the venous plexus. Diminished arteriolar flow can result from vasospasm, hyperviscosity, and/or thrombosis. Physiologic arteriolar vasospasm produces the reversible cutaneous discoloration of livedo reticularis. The livedo reticularis can occur as a physiological reaction to cold exposure, when it is known as cutis marmorata, or the skin color changes may be unrelated to ambient temperature. Protracted arteriolar vasospasm, thrombosis, and/or hyperviscosity underlie the pathologic skin changes of livedo racemosa. Venodilatation of the venous plexus may be provoked by hypoxia or autonomic dysfunction.

A possible role for the endothelial cells (EC) has also been suggested in the subset of patients of APS with livedo racemosa. The interaction of aPL antibodies with EC could induce livedo racemosa and also lead to increased production of procoagulant substances such as tissue factor (TF), plasminogen activator inhibitor 1, and endothelin. Increased TF expression on EC induced by aPL could be responsible, in part, for hypercoagulability and might explain the thrombosis in both arterial and venous circulation that characterizes these patients.

Amantadine-induced livedo reticularis has traditionally been ascribed to catecholamine provoked arteriolar vasospasm; however, an interaction between amantadine and *N*-methyl-D-aspartic acid receptors in the skin may be responsible in some unexplained fashion.[18]

Livedoid vasculopathy is a rare ulcerative subtype of livedo racemosa due to fibrinolytic abnormalities and microcirculatory thrombosis.

CLINICAL FINDINGS

HISTORY. With the exception of a subjective feeling of coldness, the majority of patients with livedo reticularis are asymptomatic. Patients often present with concerns regarding their skin discoloration. A minority describes mild pain and numbness. The symptoms are worse during winter months. Livedo



Figure 173-8 Symmetric and relatively uniform, conical rings of primary, reversible livedo reticularis (cutis marmorata).

racemosa-associated symptoms are related to the causative secondary disorder.

CUTANEOUS LESIONS. In livedo reticularis, a symmetric, fishnet-like red or purple mottling surrounds a pallorous conical core (Fig. 173-8). This discoloration is aggravated by cold exposure and may completely dissipate with warming. The livid rings are most pronounced on the lower extremities yet the abdomen and upper extremities can be affected.

In contradistinction to the symmetric and uniform reticular pattern of livedo reticularis, the discoloration of livedo racemosa is asymmetric, irregular, and "broken" (Fig. 173-9). Although it may improve with warming, it does not resolve completely. Attendant skin manifestations of livedo racemosa may include purpura, nodules, macules, ulcerations, and/or atrophie blanche-type scarring. When associated with livedoid vasculitis, painful ulcerations about ankles and forefeet may occur.

In both livedo reticularis and racemosa, the skin is palpably cool.

RELATED PHYSICAL FINDINGS. Livedo reticularis and livedo racemosa are often associated with vasospastic digits or acrocyanosis. With exception of the characteristic skin changes, the examination in livedo reticularis is otherwise unremarkable. Patients with livedo racemosa may have concurrent abnormal physical findings related to their underlying disease (e.g., aphasia and lateralizing neurologic signs associated with Sneddon syndrome).



Figure 173-9 Permanent and "broken" rings of secondary livedo racemosa on the buttocks and thighs in a woman who had cerebrovascular thrombosis. This is an example of Sneddon syndrome.

LABORATORY AND SPECIAL TESTS

In livedo reticularis, laboratory testing is typically negative and consequently is unwarranted. An antiphospholipid antibody panel should be obtained on all patients presenting with livedo racemosa. A complete thrombophilia panel is warranted in the rare patient with livedoid vasculopathy (see Chapter 163). The need for additional laboratory analysis in a patient with livedo racemosa should be directed by the clinical assessment.

A skin biopsy is not required in livedo reticularis as the findings are nonspecific. A large punch or wedge biopsy of the deep reticular dermis and subcutaneous fat is sometimes helpful in identifying the secondary cause of livedo racemosa. Selection of the correct biopsy site (seemingly uninvolved skin in the center of the lesion) is essential for detection of relevant vascular pathology. The biopsy findings are highly variable and reflect the associated livedo racemosa etiology. For instance, cholesterol clefts suggest atheroembolic disease, calcification of the vessels and interstitium indicate calciphylaxis, noninflammatory arteriolar obstruction occurs with Sneddon syndrome, livedoid vasculopathy is associated with extensive fibrin deposition and microthrombi (see Chapter 163), whereas fibrinoid necrosis is present in polyarteritis nodosa (see Chapter 164).

DIFFERENTIAL DIAGNOSIS

The diagnosis of livedo is easily made by identifying the characteristic mottled skin discoloration. It is paramount that the clinicians distinguish between livedo reticularis and livedo racemosa. Once a diagnosis of livedo racemosa is established, the secondary cause (Table 173-3) should be sought by appropriate clinical laboratory tests. Diagnostic difficulties may occur when no other pathological signs except livedo racemosa are found. This clinical condition, known as "idiopathic livedo racemosa," may represent a very early stage of Sneddon syndrome.

TABLE 173-3
Conditions Associated with Livedo Racemosa

- Antiphospholipid antibody syndrome
- Sneddon syndrome
- Livedoid vasculopathy
- Vasculitis (especially polyarteritis nodosa)
- Collagen vascular disease
- Myeloproliferative syndromes (polycythemia vera, essential thrombocytosis)
- Paraproteinemias
- Cryoglobulinemia/cryofibrinogenemia/cold agglutinin disease
- Atheroembolic disease
- Calciphylaxis
- Hyperoxaluria
- Atrial myxoma
- Erythema ab igne
- Chronic pancreatitis
- Infections

PROGNOSIS AND CLINICAL COURSE

The prognosis for livedo reticularis is excellent as this is primarily a cosmetic condition. Livedo racemosa-associated prognosis is less favorable and parallels the associated disease. Of interest, livedo racemosa has been identified as a marker for predicting multisystem thrombosis in the antiphospholipid antibody syndrome. Additionally, up to 40% of patients manifest livedo racemosa as the initial sign of the antiphospholipid antibody syndrome.[19] In addition, increased rate of pregnancy loss has been recognized in patients with widespread livedo racemosa who were seronegative for antiphospholipid antibodies, suggesting that livedo racemosa may be an independent risk factor for pregnancy loss in the absence of APS. Livedoid vasculopathy tends to be a relapsing condition marked by recurrent painful ulcerations and subsequent atrophie blanche-type scars.

TREATMENT

Other than cold avoidance, medical treatment for primary livedo reticularis is typically unwarranted. As a last resort, vasodilator therapy may be tried in the patient that is socially inhibited by the cosmetic appearance of the disorder. The symptoms may improve spontaneously with age.

Therapy of livedo racemosa should be directed toward the underlying disorder. Patients with livedo racemosa and the antiphospholipid antibody syndrome with thrombosis require anticoagulation. Treatment of livedoid vasculopathy is often unsatisfactory but potentially beneficial medications include anticoagulants, antiplatelet agents, immunosuppressants, pentoxifylline, danazol, and tissue plasminogen activator. Alternatively, hyperbaric oxygen and psoralen and ultraviolet A light therapy have also been successfully utilized to treat livedoid vasculopathy.

ERYTHROMELALGIA (ERYTHERMALGIA)

ERYTHROMELALGIA AT A GLANCE

- Intense, burning pain with marked erythema, typically of the lower extremity.
- Typically intermittent. May be precipitated by exercise.
- Primary disorder or secondary to a myeloproliferative disorder.
- Cutaneous manifestations are often a result of attempts to alleviate the symptoms with immersion and thermal injury.
- Aspirin may be effective for secondary erythromelalgia.

EPIDEMIOLOGY

This is a rare disorder with limited epidemiologic data available.[20] In Norway, the incidence is estimated to be 0.25 for 100,000 population with a prevalence of 2 per 100,000. In the United States, extrapolation from a series of erythromelalgia patients at the Mayo Clinic suggests an incidence of 1 case per 40,000 patients; however, this could overestimate the incidence in general population. Primary erythromelalgia may occur at any age with an uncertain gender predilection, although recent studies seem to suggest a female predominance.[21] In contrast, secondary erythromelalgia has an equal sex distribution and occurs mostly after the third decade.

ETIOLOGY AND PATHOGENESIS

The etiology and pathogenesis of the erythromelalgia are unknown. Several mechanisms have been postulated for primary erythromelalgia, including arteriovenous shunting and a small fiber neuropathy. It has been speculated that precapillary sphincters may be constricted while arteriovenous shunts are open, leading to an increased total perfusion but a deficient nutritive blood flow.[22] Substances produced by local hypoxia lead to increased local blood flow, warmth, redness, and pain. In contrast, the genetics of erythromelalgia appears to be supporting a neuropathic basis. A mutation in a voltage-gated sodium channel of sensory nerves has been reported in inherited erythromelalgia.

Secondary erythromelalgia occurs in polycythemia, thrombocythemia, and autoimmune disorders and is hypothesized to be caused by platelet breakdown products based on the response to aspirin therapy.

CLINICAL FINDINGS

HISTORY. The disorder is characterized by red, hot, painful extremities with characteristic intense burning pain. It most commonly affects the lower extremities but may affect the upper extremities as well as other body parts, such as the face and ears. Involvement is usually symmetric, although it can be unilateral in secondary cases. The symptoms are typically intermittent in nature but may be constant. Their onset may be gradual or abrupt, usually precipitated by activities that increase the body temperature, such as exercise, ambient temperature, or the use of heavy blankets at night. The episodes can also be triggered by dependency of the limb, wearing socks, or tight shoes, and sometimes with the ingestion of alcohol or spicy foods. There are also reports of episodes triggered by ingestion of some drugs, such as pergolide, bromocriptine, and calcium channel blockers (nifedipine, felodipine, and nicardipine). In contrast, cold exposure (e.g., standing on a cold floor) or immersion in ice water often relieves the flares.

Patients have also been described who have both erythromelalgia and Raynaud phenomenon. During the hyperemic phase of Raynaud phenomenon, patients often complain of erythromelalgic-like symptoms. It is postulated that both syndromes have a common basis in a dysfunction of the regulation of vasomotor tone.[23]

CUTANEOUS LESIONS. Examination during attacks reveals warm, red, extremely sensitive extremities with normal pulses (Fig. 173-10). Between flares, the extremities may appear normal. The constant use of ice water leads to maceration of the skin, secondary infection, ulcers, and necrosis.

PHYSICAL FINDINGS. Physical examination is usually unremarkable in primary type of erythromelalgia, however may reveal signs of an underlying disorder in the secondary erythromelalgia. The peripheral pulses are usually normal or bounding.



Figure 173-10 Intense erythema of the feet with associated burning pain typical of erythromelalgia.

PROGNOSIS AND CLINICAL COURSE

The natural history of erythromelalgia is extremely variable.[24] Symptoms may be mild for several years or totally disabling within weeks. It has been reported that with long-term follow-up, symptoms were worse in 32%, unchanged in 27%, improved in 31%, and resolved in 10% of patients. Many patients become disabled being unable to work or carry on daily activities. As a result of the profound impact upon their life with intractable symptoms, patients have even been known to commit suicide. There is a decrease in survival compared with age- and gender-matched controls.

TREATMENT

There are limited data available to guide therapy, primarily based upon case reports or small series.[24] Behavioral modifications should include efforts to keep the limbs cool and avoid the use of ice water or prolonged soaking. Additional measures including biofeedback and even hypnosis have been tried. Pharmacologic therapy has varied but often has focused on vasoactive drugs and drugs that affect the nervous system. Most vasoactive drugs, including calcium-channel blockers and β blockers, have been minimally effective in treating this disorder. Drugs used to treat neuropathy, such as serotonin reuptake inhibitors, tricyclic antidepressants, and gabapentin, have been used and may provide some relief. Aspirin is often of great benefit but only in secondary cases. Topical therapies, such as lidocaine patch or capsaicin cream, may reduce the pain. The prostaglandin E_1 analog misoprostol has been evaluated in a double-blind, crossover trial and found to be superior to placebo. Numerous other agents, including lorazepam, cycloheptadine, methysergide, piroxicam, and pizotifen, have been tried in selected cases. Surgical or medical sympathectomies have also been tried but have been found to have mixed results.

PREVENTION

There are no established measures to prevent the development of erythromelalgia. The focus has been to prevent flares once the disorder occurs. The key to prevention is to avoid exacerbating factors and to prophylactically cool the involved extremity. The other preventive measures are to prevent the development of secondary complications often as a result of prolonged soaking in ice water. It is important to limit the duration of soaking and to use cool, not ice-cold, water.

KEY REFERENCES

Full reference list available at www.DIGM8.com

DVD contains references and additional content

1. Hirsch AT et al: ACC/AHA 2005 guidelines for the management of patients with peripheral arterial disease (lower extremity, renal, mesenteric, and abdominal aortic): A collaborative report from the American Association for

Vascular Surgery/Society for Vascular Surgery, Society for Cardiovascular Angiography and Interventions, Society for Vascular Medicine and Biology, Society of Interventional Radiology, and the ACC/AHA Task Force on Practice Guidelines (Writing Committee to Develop Guidelines for the Management of Patients With Peripheral Arterial Disease). *J Am Coll Cardiol* **47**:1239, 2006
2. Hiatt WR: Medical treatment of peripheral arterial disease and claudication. *N Engl J Med* **344**:160, 2001
6. Liew YP, Bartholomew JR: Atheromatous embolization. *Vasc Med* **10**:309, 2005
10. Olin JW, Shih A: Thromboangiitis obliterans (Buerger's disease). *Curr Opin Rheumatol* **18**:18, 2006
13. Olin JW: Thromboangiitis obliterans (Buerger's disease). *N Engl J Med* **343**:864, 2000
15. Kraemer M, Linden D, Berlit P: The spectrum of differential diagnosis in neurological patients with livedo reticularis and livedo racemosa. *J Neurol* **252**:1155, 2005
19. Toubi E et al: Livedo reticularis is a marker for predicting multi-system thrombosis in antiphospholipid syndrome. *Clin Exp Rheum* **23**:499, 2005
20. Cohen JS: Erythromelalgia: New theories and new therapies. *J Am Acad Dermatol* **43**:841, 2000
24. Davis MD, Rooke T: Erythromelalgia. *Curr Treat Options Cardiovasc Med* **8**:153, 2006

Chapter 174 :: Cutaneous Changes in Peripheral Venous and Lymphatic Insufficiency

:: Craig N. Burkhart, Chris Adigun, & Claude S. Burton

VENOUS DISEASE AT A GLANCE

- One percent to 3% of US health care expenses are for peripheral venous diseases and their complications.
- Venous ulcers are the most common.
- Risk factors include genetics, obesity, female gender, pregnancy, occupations requiring prolonged standing, surgery, trauma, and malignancies.
- Peripheral venous disease should be considered part of a spectrum including the following:
  - Early signs: tenderness, edema, hyperpigmentation, and varicose veins.
  - Late signs: atrophie blanche, lipodermatosclerosis, and venous ulcers.
- Venous ulcers are located exclusively below the knee after venous pump failure, most often secondary to prior thrombosis.
- Treatment for all stages includes leg elevation, compression, treatment of infection, and dermatitis.
- Deep venous disease is associated with thromboembolism.

CHRONIC VENOUS DISEASE

Chronic disease of the peripheral veins includes a spectrum of diseases ranging from edema and tenderness to venous ulceration (Box 174-1).

EPIDEMIOLOGY

Chronic venous disease is extremely common. Although estimated costs and time lost from work have not been objectively assessed in over two decades, estimates state that 6–7 million people in the United States have evidence of venous stasis and that it accounts for 1% to 3% of the total health care budgets in countries with developed health care systems.[1]

Risk factors for chronic venous disease include heredity, age, female sex, obesity, pregnancy, prolonged standing, and greater height.[2]

ETIOLOGY AND PATHOGENESIS

Venous ulcer occurs after failure of the calf muscle pump (Fig. 174-1). The heart pumps blood down to the foot; the calf muscle pump (when upright), returns venous blood to the heart. Venous blood from the skin and subcutis collects in the superficial venous system including the greater and lesser saphenous veins and its tributaries, moves through the fascia in a series of "perforating" or "communicating" veins, and fills the muscle-enveloped deep venous system. With muscle contraction, the deep veins are compressed; one-way valves in the deep system allow the now high pressure flow to move against gravity, and one-way valves in the perforators close to prevent

BOX 174-1 COMMON SIGNS AND SYMPTOMS OF PERIPHERAL VENOUS DISEASE

SYMPTOMS

- Leg fullness
- Aching discomfort
- Heaviness
- Nocturnal leg cramps
- Bursting pain on standing

SIGNS

Very Early

- Tenderness to palpation

Early

- Edema
- Hyperpigmentation
- Stasis dermatitis
- Varicose veins

Late

- Venous ulcers
- Atrophie blanche
- Lipodermatosclerosis
- Acroangiodermatitis of Mali
- Postphlebitic syndrome



Figure 174-2 Extensive varicose veins on the calf and thigh.

pressure injury in the skin (see Fig. 174-1). In all patients with venous disease there is failure of these one-way valves and this can result in varicose veins (Fig. 174-2). The severity of venous disease is influenced by the number

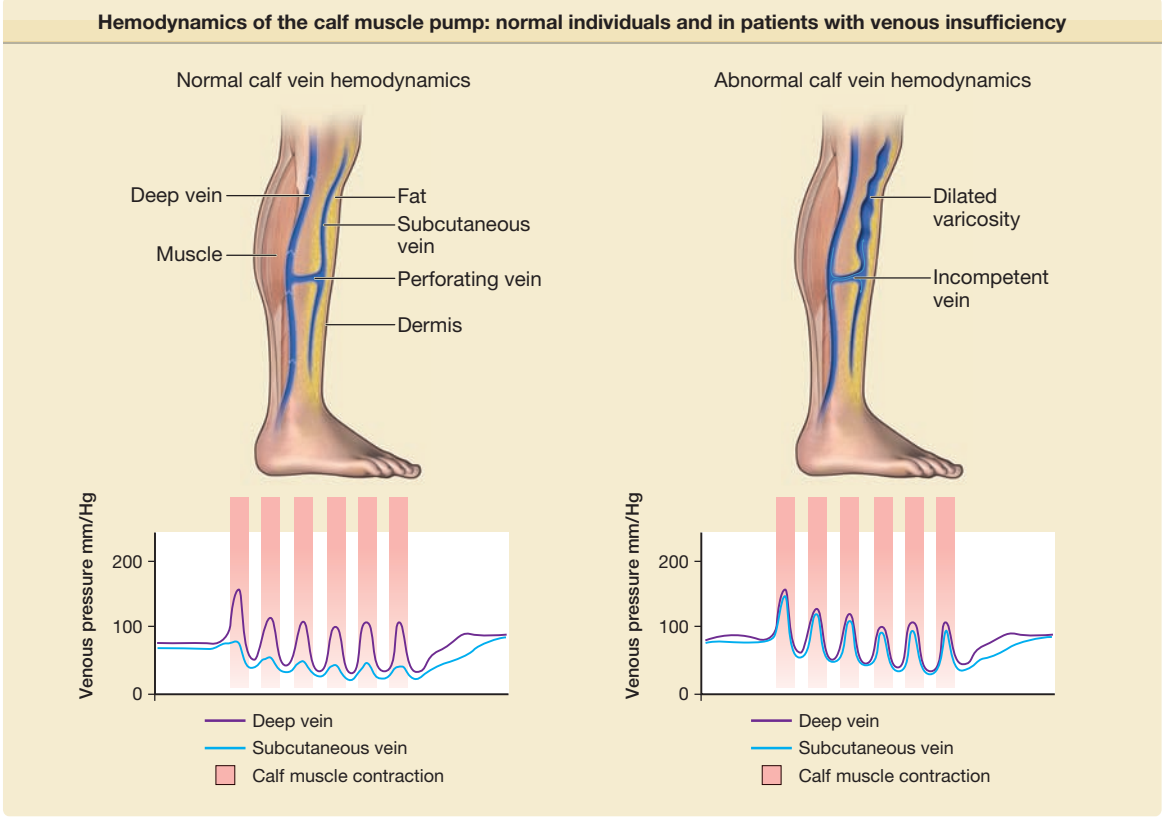

Figure 174-1 Anatomy and hemodynamics of the calf muscle pump in normal individuals and in patients with venous insufficiency. The latter is characterized by high pressure reflux from deep veins into the superficial veins and small vessels of the skin.

and distribution of incompetent valves and is worsened by any impairment of leg muscle function or ankle joint range of motion—all critical components of the calf muscle pump. Any obstruction to venous return (thrombosis, radiation fibrosis, etc.), or elevation of right atrial pressure (pulmonary hypertension, heart failure, etc.), further compromises venous return. A more detailed description of the anatomy and hemodynamics of the venous system of the lower extremities is found in Chapter 249.

The most common cause of valvular failure is thrombosis. The nidus for venous thrombosis is typically the valve cusp, and when the thrombus is lysed by plasmin, valve function is often lost as well. Calf muscle pump failure after deep venous thrombosis (DVT) is often referred to as the *postphlebitic syndrome*.[3]

Once valves fail, especially those in the perforators, high pressure blood in the deep system refluxes into the unsupported veins of the skin, there is vascular leakage of fibrinogen producing "fibrin cuffs" that may interfere with tissue nourishment, and white blood cell trapping leading to soft tissue injury, inflammation, and eventually fibrosis, as the subcutaneous fat is replaced by scar in a process described by the term *lipodermatosclerosis* (see Section "Cutaneous Lesions").

CLINICAL FINDINGS

HISTORY. An approach to the analysis of patients with ulcers is in Fig. 174-3.

Trauma frequently triggers the nonhealing venous ulcer. The events preceding ulceration happen insidiously over many years and may be ignored by the patient. A history of thrombosis may be missing because most episodes of lower extremity venous thrombosis are clinically silent. Relevant inquiry related to thrombosis risk should include a family history of similar problems (suggesting perhaps a familial thrombotic tendency), any episode of leg immobilization including knee or hip surgery and fractures, and any head injury associated with loss of consciousness.

Most patients complain of leg swelling, and many have been given diuretics, though the edema of venous disease, unlike the edema in salt-retaining states, like heart failure, cirrhosis, and nephrotic syndrome, does not respond to diuretics. An edematous leg not responsive to diuretic therapy is a strong clue to the diagnosis. Venous ulcers may or may not be painful.

CUTANEOUS LESIONS. All of the clinical syndromes described are secondary to the initial valvular syndrome and are grouped into clinical categories. Once there is venous valvular failure, a rather predictable series of changes occur in the skin. The earliest (though not universal) physical finding is soft tissue tenderness, even of normal appearing skin, discovered when checking for the presence of edema by palpation. Its association with other cutaneous signs of chronic venous disease is common.

The soft tissue injury that precedes ulceration begins in the subcutis, and visible changes may not appear for some time. Frequently one notes the appearance of petechial lesions, which have the appearance of cayenne pepper sprinkled about the gaiter area. As the hemoglobin in the petechial lesions breaks down, the iron remains in the skin as hemosiderin and may lead to impressive discoloration (Fig. 174-4).

Stasis dermatitis, characterized by erythema, scaling, pruritus, erosions, oozing, crusting, and occasional

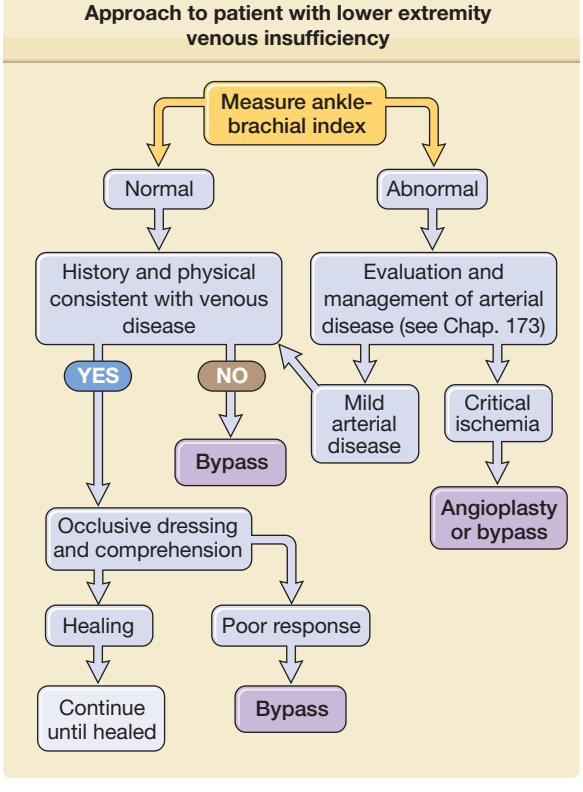

Figure 174-3 Approach to patient with lower extremity venous insufficiency.



Figure 174-4 Bilateral venous disease with dermatitis and extensive hemosiderosis.

vesicles may occur during any stage of chronic venous insufficiency (see Fig. 174-4). It typically occurs in the medial supramalleolar region where microangiopathy is most intense. Over time, lesions may lichenify. As 58% to 86% of patients with venous leg ulcers develop contact sensitization to topical therapies, it is important to evaluate for coexisting allergic contact dermatitis.

In lipodermatosclerosis (sclerosing panniculitis, hypodermatitis sclerodermiformis) pliable subcutaneous fat is gradually replaced by fibrosis, and the skin begins to feel indurated. This is a fibrosing panniculitis (see Chapter 70) characterized by a bound-down, indurated plaque that begins at the medial ankle and extends circumferentially around the entire leg.[4] As the fibrosis increases, it may constrict and strangle the lower leg further, impeding venous and lymphatic flow and leading to brawny edema above and below the fibrosis. These late changes resemble an inverted champagne bottle (Fig. 174-4).

Varicose veins, especially noticeable when the patient is standing, and smaller varicosities appear about the dorsum of the foot and ankle (see Chapter 249). Although they are usually asymptomatic, patients may complain of symptoms of aching, cramping, itching, fatigue, and swelling that are worse with prolonged standing.

Atrophie blanche refers to skin overlying areas of fibrosis that often appears porcelain white and atrophic. Fully established lesions of atrophie blanche consist of irregular, smooth, atrophic plaques with surrounding hyperpigmentation and telangiectasias (Fig. 174-5). Although mostly related to venous stasis, atrophie blanche may also be associated with an underlying disorder of coagulation (e.g., antiphospholipid syndrome, inherited coagulopathies) livedoid vasculitis (see Chapter 163) or autoimmune disease (e.g., scleroderma, lupus erythematosus).[5] Acroangiodermatitis (pseudo-Kaposi sarcoma, congenital dysplastic angiopathy, arteriovenous malformation with angiodermatitis) has purple macules, nodules, or verrucous plaques on the dorsal feet and toes of patients

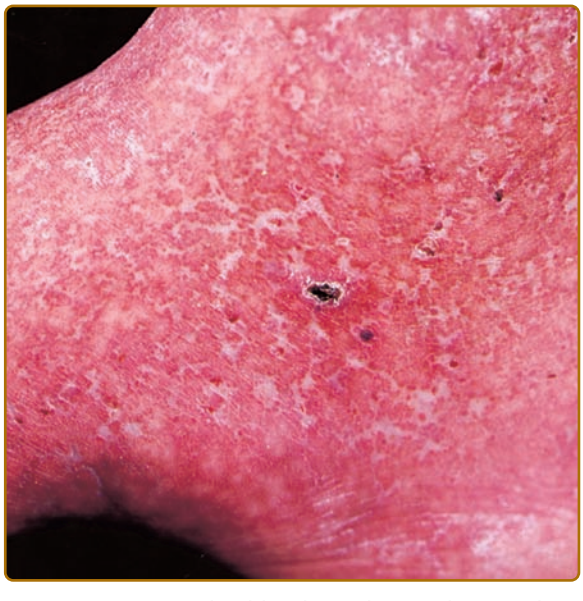

Figure 174-5 Atrophie blanche with irregular porcelain-white atrophic scars, small ulcerations, and crusting.



Figure 174-6 Venous ulceration in an area of lipodermatosclerosis, hemosiderosis, inflammation, and varicosities on the foot. Note lipodermatosclerosis constricts lower leg below the calf ("inverted champagne bottle").

with long-standing venous insufficiency and mimics Kaposi sarcoma clinically and histologically. Identical lesions have been described in arteriovenous malformations of the legs, arteriovenous shunts for hemodialysis, paralyzed limbs, and amputation stumps (http://www.accessmedicine.com/iedetect.aspx#2994638).

Occasionally, acute inflammation of the subcutaneous fat develops in patients with venous disease, and histologically one finds an acute septal panniculitis in this setting (see Chapter 70).

Though ulceration is classically located in the gaiter area (see Fig. 174-6), *venous ulcers* have been described anywhere below the knee. Venous ulcers are typically tender, shallow, irregular, red-based ulcers that are always located below the knee (Figs. 174-6 and 174-7). They are usually located on the medial ankle or along



Figure 174-7 Venous ulceration with stasis dermatitis, edema, and varicosities.

BOX 174-2 DIFFERENTIAL DIAGNOSIS OF LEG ULCERS

- Vascular diseases
  - Arterial (hypertensive atherosclerotic, vasospastic)
  - Venous (venous stasis ulcer)
  - Lymphedema
- Metabolic disorders
  - Diabetes mellitus
  - Necrobiosis lipoidica diabeticorum
  - Porphyria cutanea tarda
  - Gout
  - Pancreatitic (pancreatitis, carcinoma)
- Infections
  - Bacterial (especially *Staphylococcus aureus*, *Streptococcus*)
  - Spirochetal (syphilis)
  - Fungal (deep fungal, mycetoma)
  - Opportunistic in immunocompromised
  - Viral
- Vasculitis
  - Hypersensitivity vasculitis
  - Polyarteritis
  - Systemic lupus erythematosus
  - Rheumatoid vasculitis
  - Granulomatosis with polyangiitis (Wegener's)
  - Lymphomatoid granulomatosis
- Lymphedema
  - Congenital
  - Postinfectious
  - Postsurgical
  - Postirradiation
- Drugs
  - Halogens (bromide, iodide)
  - Ergotism
  - Drug-induced vasculitis
  - Anticoagulant necrosis (Coumadin, heparin)
  - Hydrea
- Hematologic abnormalities
  - Hypercoagulable states (protein C, protein S, antithrombin III deficiency, activated protein C resistance, prothrombin gene polymorphism)
    - Lupus anticoagulant syndrome
    - Paroxysmal nocturnal hemoglobinuria
  - Sickle cell anemia
  - Thalassemia
  - Polycythemia vera
  - Leukemia
  - Dysproteinemia (cryoglobulinemia, macroglobulinemia)
- Tumors
  - Cutaneous (basal cell cancer, squamous cell cancer, sarcoma, malignant melanoma, Merkel cell)
  - Secondary (metastatic carcinoma, lymphoma)
  - Kaposi sarcoma
- Miscellaneous
  - Pyoderma gangrenosum
  - Trauma (including factitial)
  - Burns
  - Pressure ulcers, neuropathic ulcers
  - Insect bites (brown recluse spider)
  - Ulcerative lichen planus
  - Bullous diseases (epidermolysis bullosa)
  - Sweet syndrome
  - Idiopathic

the line of the long or short saphenous veins. Clinical distinction should be made with other common ulcers of the lower extremity as discussed later in this chapter and as shown in Box 174-2.

HISTOPATHOLOGY

Histologic signs of venous hypertension include hemosiderin deposition, lobular superficial and/or deep dermal neovascularization, and fibrosis of the dermis and subcutaneous tissue in later stages. These histologic findings are found in all clinical manifestations of chronic venous disease.

LABORATORY TESTS AND IMAGING STUDIES

It is crucial to evaluate arterial blood flow. A useful bedside screening test is to calculate the ratio of the systolic blood pressure in the ankle (as measured by Doppler) to the systolic pressure in the brachial artery (also measured by Doppler). This "ankle/brachial index" is greater than or equal to one in normal individuals. Anything less than one is an indication of peripheral arterial disease. The lower the ratio, the more severe the arterial obstruction (see Fig. 174-3). An ankle/brachial index is reliable except in the presence of calcified vessels, which are noncompressible and therefore a true systolic pressure cannot be measured. Having excluded arterial disease as a cause of ulceration, a clinical diagnosis is sufficient for the initiation of empiric therapy in most cases. When the diagnosis is in doubt, skin biopsy may be useful. Functional testing of calf muscle pump function and venous valvular function using plethysmography is occasionally useful. Duplex Doppler ultrasonography can be useful to document valvular incompetence and to evaluate patients for possible sclerotherapy or surgery (see Chapter 249).

DIFFERENTIAL DIAGNOSIS

(See Box 174-2)

COMPLICATIONS

Recurrent ulceration is frequent. Any open wound provides a portal of entry for bacteria, and cellulitis, though infrequent, may develop at any time. Given that venous dermatitis may be extremely pruritic, and that these patients are easily sensitized to the topical agents they apply, contact dermatitis, especially due to topical antibiotics, is common. The skin is easily excoriated and may become infected.[6] The advent of methicillin-resistant *Staphylococcus aureus* is a threat to this population. The dermatitis of venous disease may become generalized as an id reaction (see Chapter 17) and may rarely produce an exfoliative erythroderma (see Chapter 23). Many of these individuals are predisposed to thrombi, and recurrent episodes of venous thrombosis are not uncommon.

All patients with advanced venous disease have some degree of lymphatic impairment, though lymphatic impairment may also result from inherited defects in lymphatic development or destruction of lymphatics after cellulitis lymphangitis, surgical interruption, or radiation.[7] Loss of lymphatic drainage from the lower leg may lead to verrucous changes and cutaneous hypertrophy, elephantiasis nostras (see Section "Acquired Lymphedema").

PROGNOSIS AND CLINICAL COURSE

The prognosis for healing areas of ulceration and inflammation is excellent in the absence of comorbid illness that interferes with healing. The vast majority of uncomplicated patients respond well to ambulatory outpatient therapy as outlined in the section "Treatment." Permanent changes include hemosiderosis and fibrosis that develop before the initiation of therapy. Loss of valvular function is irreversible. In the absence of continual lifelong cutaneous support in the form of inelastic wraps or elastic stockings, skin and soft tissue injury continues.

TREATMENT

Treatment of chronic venous insufficiency is outlined in Box 174-3. Treatment for all clinical manifestations of chronic venous insufficiency includes therapies that lower venous pressure and improve venous and lymphatic flow by mechanical means, dressings, drugs, and surgery.

Given the limitations of bed rest as an effective therapy, the focus is now on an ambulatory outpatient approach to the management of venous ulceration. Most experts agree on the essential role of compression in treating chronic venous insufficiency.[8] Hence, unless there are contraindications (arterial occlusive disease or abnormal ankle–arm indexes), compression therapy should remain part of any treatment regimen for chronic venous disease.

Toward the end of the nineteenth century, Paul Gerson Unna recognized that by providing a compression bandage to the distal extremity he could heal venous ulcers in an ambulatory patient population using zinc impregnated gauze wrap, the "Unna boot." Though the literature over the years continued to document the success of this approach, it proved difficult to achieve graduated compression with this wrap, and compliance was poor. Eventually, the addition of a self-adherent second layer (Coban™, for example) over a zinc wrap was introduced as the "Duke boot" and has proven to be easy to apply with reproducible graduated inelastic compression (Fig. 174-8) bandaging to

BOX 174-3 TREATMENT OF CHRONIC VENOUS INSUFFICIENCY

- Mechanical
  - Leg elevation
  - Compression stockings
  - Compression bandages
  - Intermittent pneumatic compression pumps
- Drug therapy
  - Aspirin
  - Pentoxifylline
  - Topical steroids (for stasis dermatitis)
  - Horse chestnut seed extract
- Dressings
  - Wet and dry nonadherent dressings
  - Occlusive hydrocolloid or gel dressings
  - Zinc paste-impregnated bandages (Unna boot)
- Surgery
  - Sclerotherapy
  - Long saphenous vein stripping
  - Saphenofemoral/saphenopopliteal junction disconnection
  - Calf varicosity avulsions
  - Subfascial endoscopic perforator vein ligation
  - Endovenous laser therapy
  - Radiofrequency ablation



Figure 174-8 Compression bandage using a zinc paste primary layer (Unna boot) followed by Coban™ at full stretch.

counter the outflow from perforator incompetence is the cornerstone of venous ulcer management.[9]

In 1962, George Winter reported the use of an occlusive layer enhanced healing in a pig model of acute wounds. His data suggested a roughly 100% improvement in the rate of wound healing simply by providing a moist environment. The impact on wound care has been dramatic. There are now thousands of such dressings on the market and although they differ in composition, absorption, gas exchange, and cost, all provide a moist environment (see Chapter 248). Underneath such dressings, fibrinopurulent and necrotic debris, aided by host and bacterial enzymes, dissolves painlessly (eFig. 175-8.1 in online edition). One can take advantage of these dressings to provide the best local environment for the wound, followed by a compression wrap to address the underlying hemodynamic disturbance.

The dressings should be changed weekly, or more often for heavily exudating wounds. New tissue is vulnerable to the cytotoxic effects of most topical antiseptics, and these agents are to be avoided. One should not put anything in a wound that you would not be willing to put in your eye. A gentle rinse with tap water or saline is sufficient. It is preferable to have the patient supine during dressing changes if at all possible.

Mechanical therapy is the mainstay of treatment for all clinical manifestations of chronic venous insufficiency. A Cochrane review found that "the use of elastic compression stockings to treat postthrombotic syndrome cannot be supported on the basis of the currently available data," but did find some evidence for a beneficial effect for intermittent pneumatic compression units (http://www.accessmedicine.com/iedetect.aspx#2994643). Nevertheless, daily use of elastic compression stockings has been shown to reduce swelling in some patients with postthrombotic syndrome (http://www.accessmedicine.com/iedetect.aspx#2994644); prevent worsening of established postthrombotic syndrome (http://www.accessmedicine.com/iedetect.aspx#2994635); and may reduce recurrence of healed venous (ulcershttp://www.accessmedicine.com/iedetect.aspx#2994645).

Each pharmaceutical therapy targets a specific clinical aspect of chronic venous insufficiency. Diuretics may be used in the short term for treating severe edema. Horse chestnut seed extract (often standardized to 50 mg escin twice daily) is an herbal remedy that appears to be safe and effective as a short-term treatment for leg pain and swelling.[10] Aspirin (300–325 mg/day)[11] and pentoxifylline[12] may improve healing of chronic venous ulcers. Finally, topical steroids and emollients aid resolution of stasis dermatitis.

Although all wounds harbor potential pathogens, there is no evidence that routine use of antibiotics is helpful in patients with venous ulcer. If cellulitis is suspected, empiric therapy with coverage for *S. aureus* and *Streptococci* is warranted. Topical antibiotics, especially mupirocin, are useful for folliculitis due to *S. aureus* and *Streptococci.* With the increasing incidence of community acquired methicillin-resistant *S. aureus* in this population, culture and sensitivity are suggested for suspected skin and soft tissue infections.

Venous disease is progressive and irreversible. Patients must be educated about the need for continual hemodynamic support after the wound has healed. Graduated stockings that provide a minimum of 30–40 mmHg at the ankle should be carefully fitted to all patients and worn for their lifetime. It is a mistake to place elastic stockings on edematous limbs, especially those that are tender. One should use compression bandaging until all edema, inflammation, and tenderness have resolved before fitting the patient with stockings.

In carefully selected cases, sclerotherapy or surgical techniques, especially endovenous ablation, may close incompetent perforators and correct the hemodynamic abnormalities that lead to venous ulcer (see Chapter 249).[13,14]

PREVENTION

Prevention of venous thrombosis prevents venous insufficiency. Because many thrombotic traits are genetic, it is likely those patients at extra risk for thrombosis may be identified and treated for this risk before an event, and efforts to prevent thrombosis during elective surgery and hospitalization should reduce the numbers of postphlebitic limbs. Once a patient develops venous thrombosis, elastic compression stockings are the only proven method to reduce the risk of postthrombotic syndrome.[15]

Valvular failure may develop during pregnancy. Therefore, the use of supportive stockings throughout maternity, although not proven, can be recommended. If one's occupation or lifestyle involves long periods of immobility (long-distance flights appear to be especially risky), stockings are advisable.

OTHER VENOUS DISEASES

DEEP VEIN THROMBOSIS

DVT is important for at least two reasons: (1) the thrombosed veins are the sources of pulmonary embolisms, and (2) the thrombosed leg may progress to chronic venous disease that has already been discussed.[16] Superficial thrombophlebitis has associations with internal diseases as well.

For details, see online edition of this book.

LYMPHEDEMA

Edema is an excess of fluid in the body tissues. Although most of this fluid is in the interstitial spaces, there is usually excess fluid both in the vascular bed and within cells. When this becomes chronic, inflammatory cells and their cytokines lead to an irreversible state. This chronic accumulation of protein-rich fluid may occur due to conditions that predispose to chronic edema, such as venous stasis; or it may occur due to lymphatic failure secondary to trauma, malignancy, disease, or genetic mutations that give rise to nonfunctional lymphatics. Lymphedema refers specifically to

LYMPHEDEMA AT A GLANCE

- Lymphatics are essential for the clearing of extravascular fluids and debris and as transport of immunocompetent cells during the initiation of an immune response.
- Specific markers of lymphatic endothelia exist.
- Genetic defects causing lymphedema in childhood or early adult life are often caused by defects in a vascular growth factor receptor (*VEGFR3*) and *FoxC2*, a transcription factor.
- Lymphedema acquired in adult life is often related to chronic venous disease, after mastectomy with radiation and node removal, and, in certain geographic locations, filariasis.
- Cellulitis may complicate all forms of lymphedema and should be aggressively treated.



Figure 174-9 Lymphedema of the left leg in a 47-year-old fireman. The extreme swelling began at birth and was painless. Note the lack of stasis pigmentation or ulceration. The patient functioned normally at work and wanted no treatment.

swelling of a part of the body due to impaired lymph transport capacity as a consequence of a malformation or malfunction of the lymphatics.

The typical clinical presentation of lymphedema is an edematous extremity without concurrent pain or inflammation. Acquired lymphedema leaves legs feeling heavy and the patient tired. Although the limb swells during the day, indentations from socks can be seen on the leg at nighttime, returning toward normal during the night, but the leg stays swollen, and initially concerns may be cosmetic in nature. The foot is often involved first and initially lesions pit with pressure. With time, lesions become woody or lardaceous and do not pit. The toe contours are eventually lost. The Kaposi–Stemmer sign, a feature of chronic lymphedema, appears as an inability to pinch up a fold of skin between the second and third toe on the dorsum of the foot. This condition develops due to chronic thickening of the skin overlying the digits.

Primary lymphedema is a congenitally determined intrinsic or constitutional fault in lymphatic drainage. This is most commonly due to mutations in specific genes that are critical to lymphatic development or function, but may arise as a result of a developmental abnormality due to unknown causes in utero. Depending on the cause, primary lymphedema may present at any age (Fig. 174-9).

Secondary lymphedema occurs when previously normal lymphatics suffer an external insult such as disease, infection (repeated episodes of erysipelas), trauma, or surgery, and subsequently lose their functional capability, giving rise to lymphedema. It is due most commonly worldwide to parasitic infection. In industrialized countries, secondary lymphedema occurs following trauma, infection, postsurgery, malignancy, or postradiation.[17]

In all the clinical disorders discussed, lymphedema may be transient and pitting with pressure but, with time, becomes fixed, and is accompanied by adipose tissue hypertrophy, fibrosis (Fig. 174-9), and epidermal hyperplasia (Fig. 174-10) that eventually makes pitting less evident.[18]



Figure 174-10 Verrucous skin changes in chronic lymphedema.

Patients with lymphedema are susceptible to recurrent erysipelas, physical impairment, and psychosocial stigmatization, and may be at increased risk of malignancy such as lymphangiosarcoma.

PRIMARY LYMPHEDEMA. Emberger syndrome is an autosomal dominant primary lymphedema syndrome caused by mutations in GATA2, a transcription factor involved in gene regulation during vascular development and hematopoietic differentiation.[20] Patients with this syndrome may have a low CD4/CD8 ratio, immune dysfunction (widespread cutaneous warts), sensorineural deafness, and genital lymphedema in addition to lymphedema of the lower limbs. These patients require monitoring due to their predisposition to AML (acute myeloid leukemia).

Milroy Syndrome

Etiology and Pathogenesis. Milroy syndrome is an autosomal dominant disease that characteristically has a mutation in *VEGFR3* (also called the *FLT4 gene*). This causes impaired tyrosine kinase activity of the VEGFR3 receptor, which disrupts lymphangiogenesis. Penetrance is relatively high (80%), but not complete, suggesting a role of additional genetic or environmental factors. There is a 2.3:1.0 female predominance in pedigrees; this sex ratio may be due to a more severe disease in males that leads to hydrops fetalis and fetal death.

Clinical and Radiologic Findings. Lymphedema is almost always from birth and is confined to the legs with deep creases over the toes and small deformed ("ski jump") toenails, and is typically characterized by hypoproteinemia from intestinal loss of albumen, chylous ascites, and scrotal edema.[21] Thickening of the skin overlying the digits leads to a positive Kaposi–Stemmer sign.[18]

Prenatal ultrasound can show edematous legs in the fetus. Skin biopsy from swollen feet of patients that possess the VEGFR3 mutation reveals abundant skin lymphatics that are confirmed to be nonfunctional by fluorescence microlymphangiography.[22] Interestingly, lymphangiography also demonstrates dysplastic lymphatics in both clinically affected and clinically normal extremities, emphasizing the complexity of the pathophysiology that ultimately leads to disease.

Lymphedema-Distichiasis

Etiology and Pathogenesis. Autosomal dominant nonsense and frameshift mutations in the forkhead transcription factor FoxC2 (MFH1 or mesenchyme forkhead-1), cause abnormalities in morphogenesis of the lymphatic valves in this disease.[23] Radiographic studies of patients with lymphedema-distichiasis show lymph and venous reflux of the lower limbs, illustrating the primary valve failure. Distichiasis, a double row of eyelashes, develops as a result of failure of proper differentiation of eyelid follicles into Meibomian glands.[18] Although the *FoxC2* mutation is specific for lymphedema-distichiasis,[24] further investigation has illustrated that lymphedema with ptosis may actually be one of the variable manifestations of *FoxC2* mutations, rather than a distinct disorder.[25]

Clinical and Radiologic Findings. Lymphedema typically develops during puberty, but may be delayed until early adulthood, especially in females. The lymphedema will commonly worsen in severity over time, and may be complicated by recurrent infection and eventual papillomatosis. Aberrant eyelashes are present arising along the posterior border of the eyelid margin, which frequently leads to eyelash irritation of the cornea and photophobia. Other associated findings of this syndrome include cardiac defects, cleft palate, spinal extradural cysts, and other ophthalmologic complications. Given the complexity of this disorder, and possibility of systemic involvement, treatment of this disorder frequently requires a multidisciplinary approach, including dermatologists, pediatricians, and geneticists.[18,21,26,27]

DISORDERS AFFECTING BOTH LYMPHATICS AND VEINS

SECONDARY LYMPHEDEMA

The most common cause of secondary, or acquired, lymphedema worldwide is due to lymphatic disruption and obstruction by infection with the nematode *Wuchereria bancrofti*, also known as filariasis (see Chapter 207). In the industrialized world, the most common cause is malignancy and malignancy-associated therapeutic interventions, such as surgery and radiotherapy.[17]

EPIDEMIOLOGY. Chronic edema in a community sample in London had a prevalence of 1.33 per 1,000 and was 5.4 per 1,000 for those older than the age of 65 years.[32] Twenty-five percent of chronic edema was related to malignancy; and 29% of patients had at least one episode of cellulitis over the year before the survey; 70% to 80% of patients were female.

Worldwide lymphedema due to filariasis is estimated to affect 100 million individuals[33,34] and is considered to be the second leading cause of permanent disability in the world.

For epidemiology, and clinical manifestations and treatment of filariasis see Chapter 207.

Other infectious diseases with lymphedema are much less common and include lymphogranuloma venereum, granuloma inguinale (see Chapters 203 and 204), and tuberculosis (see Chapter 184).

In regions of tropical Africa, Central America, and the Indian subcontinent where filariasis is uncommon, there is a condition of chronic lymphedema that is called podoconiosis, or nonfilarial elephantiasis. This condition causes edematous feet and legs, and is usually bilateral. Podoconiosis is not infectious in origin. It is caused by chronic inoculation of microparticles of silica through the soles of barefoot walkers.[17]

BOX 174-4 COMMON SIGNS AND SYMPTOMS OF LYMPHEDEMA

SYMPTOMS

- Edematous extremity
- Painless
- Heaviness
- Indentations from socks on standing
- Indentations improve overnight

SIGNS

Early

- Pitting edema
- Erysipelas

Late

- Nonpitting edema
- Thickened, woody skin
- Papillomatosis
- Verrucous tissue overgrowth
- "Ski-jump" upturned toe nails
- Infections (bacterial, fungal, viral warts)

CLINICAL FINDINGS. Typically, patients will present with a persistently edematous extremity without concurrent pain or inflammation (Box 174-4). The foot is often involved first, and initially lesions pit with pressure. Patients presenting later in the disease course may present with nonpitting edema. Feet may illustrate swollen toes with upturned nails. Thickening of the skin over the digits may be present, as may be the Kaposi–Stemmer sign. If the condition has been long-standing, the skin overlying the affected extremity may show generalized thickening, papillomatosis, or verrucous tissue overgrowth (Fig. 174-10). Fungal infections, erysipelas, or viral warts may also be present.

Unilateral lymphedema suggests localized obstructing factors, but bilateral lymphedema does not rule out anatomic obstruction, as the obstruction may be in the pelvis or abdomen.

Inflammation as manifested by redness, pain, and swelling is not lymphedema, but can be pyogenic infection, most commonly with *S. aureus* or *Streptococcus pyogenes*. Systemic antibiotics should be started before waiting for red lymphangitic streaking. A common complication is contact dermatitis from the use of topical antibiotics or multiple emollients and anti-inflammatory creams.

DIAGNOSIS. Chronic venous insufficiency can present with very similar features of early lymphedema. In this clinical context, both conditions will have pitting edema, and the characteristic skin changes in late-stage lymphedema have not yet developed. However, chronic venous insufficiency is typically bilateral, rather than unilateral as in lymphedema. It is imperative to exclude medical causes of lower extremity swelling, such as renal failure, hypoalbuminemia, congestive heart failure, protein-losing nephropathy, pulmonary hypertension, obesity, pregnancy, and drug-induced edema, among others. An uncommon clinical mimic to lymphedema is lipedema of the leg. This syndrome is due to bilateral adipose deposition, usually in the buttocks and lower extremities. This leads to enlargement that stops abruptly at the level of the malleoli, characteristically sparing the feet. This distinctive clinical presentation is referred to as "armchair legs."[17] This condition predominates among overweight women who spend the majority of their time with their legs in a dependent position. Chronic immobility leads to decreased lymphatic drainage and subsequent lymphedema.

SPECIAL TESTS. Diagnosis of filariasis includes assays to detect filarial antigens, and ultrasound to visualize living adult worms, even in the absence of microfilaremia.[34]

If there is doubt regarding the clinical diagnosis of lymphedema, especially when trying to differentiate from edema, there are various studies that may be employed for diagnostic confirmation. These include isotopic lymphoscintigraphy or, if necessary, radiocontrast lymphangiography.[35,36] Computed tomography (CT) and magnetic resonance imaging (MRI) are other radiographic options, though not ideal. MRI is preferred over CT because of its ability to detect water. These modalities should reveal the characteristic "honeycomb" pattern of the subcutaneous tissue present in chronic lymphedema. This pattern is not present in other types of edema. If there is suspicion for concurrent deep venous thrombosis or venous disease, a venous duplex ultrasound is often required.[17]

COMPLICATIONS. Prolonged lymphedema leads to fibrosis and epidermal hyperplasia with verrucous hyperkeratosis (Fig. 174-10). Ulceration rarely occurs, although the edema and hyperkeratotic changes may be profound. Lymphangiosarcoma, the Stewart–Treves syndrome when associated with postmastectomy lymphedema, is the common lesion in chronically lymphedematous locations (see Chapter 126).

TREATMENT. Drug therapy for lymphedema, in general, has been inadequate. Diuretics are frequently prescribed, and not only do they not alleviate the symptoms, they may actually worsen the condition. Diuretics thus should not be used as a primary treatment for lymphedema. There is some evidence to suggest the efficacy of coumarin therapy. Coumarin apparently reduces capillary filtration as well as reduces fibrotic tissue deposition.[17]

A combination of elevation, exercise, compression garments/devices, skin care aimed to prevent infection, and manual lymphatic drainage, usually via massage, are the mainstay in management of lymphedema.[17] In patients with primary and secondary lymphedema, in the absence of venous or arterial disease, manual lymphatic drainage and sequential pneumatic pumps, in addition to compression wraps and garments, may be useful.

Cellulitis or recurrent lymphangitis is a significant problem in lymphedematous sites, and there is both a rationale and results that encourage long-term antibiotic use (e.g., 2.4 million units of benzathine-penicillin G intramuscularly every 2 weeks).[37]

Microsurgery of lymphatics to bypass obstructed nodes can be considered if nonsurgical treatments are not successful. This procedure is not commonly performed in the United States because it is still considered experimental, but the literature from studies of this procedure performed in Europe is considerable. The surgery consists of the formation of multiple end-to-end lymphatic–venous anastomoses.[38] Congenital lymphatic disorders have been treated with this intervention in the early childhood years with dramatic results.[39,40]

Low-level laser therapy (LLLT), either in combination with pneumatic compression or as a solo intervention, has been studied in patients with postoperative lymphedema, primarily in postmastectomy lymphedema. Results are encouraging, and patients have had improvements in the total volume of affected limbs at follow-up analysis of up to 1 year.[41]

Excisional or suction-assisted lipectomy (liposuction) may be an option in selected patients in whom are not eligible for other treatment options, or in whom other therapeutic modalities have failed.

PREVENTION. Any patient with lymphedema, whatever the cause, should keep their feet dry, nails trimmed, and prevent and aggressively treat pyogenic infection. Lymph moves faster during limb activity and exercise (e.g., walking should be encouraged). A combination of flexibility training, aerobic training, and strengthening exercises—while wearing compression garments or devices—have shown to have significant improvement in lymphedema.[17]

LOCALIZED AREAS OF LYMPHEDEMA

Lymphedema is common in some locations, especially on the face, vulva and penis, and can lead to superficial lesions termed lymphangiectasia. These focal areas of lymphedema occur from obstruction of usually previously normal lymphatics, progressing to lymphatic valve incompetence, lymph reflux, and retrograde lymph flow to the skin. This leads to blister-like lesions full of lymphatic fluid called lymphangiectasias. These most commonly occur after trauma, treatment for malignancy, or infection. These lesions are highly symptomatic and distressing, and frequently are painful, pruritic, and exudative.[42,43] A current favored treatment modality for superficial lesions is with carbon dioxide laser ablation. Because the underlying obstructed lymph vessels are not corrected by the superficial laser, recurrences commonly occur.[43] Other options for treatment include surgical excision and superficial radiotherapy and sclerotherapy.[44]

KEY REFERENCES

Full reference list available at www.DIGM8.com

DVD contains references and additional content

2. Bergan JJ et al: Chronic venous disease. *N Engl J Med* **355:**488, 2006
7. Ko DS et al: Effective treatment of lymphedema of the extremities. *Arch Surg* **133:**452, 1998
8. Douglas WS, Simpson NB: Guidelines for the management of chronic venous leg ulceration. Report of a multidisciplinary workshop. British Association of Dermatologists and the Research Unit of the Royal College of Physicians. *Br J Dermatol* **132:**446, 1995
9. Marston WA et al: Healing rates and cost efficacy of outpatient compression treatment for leg ulcers associated with venous insufficiency. *J Vasc Surg* **30:**491, 1999
14. Chaby G et al: Refractory venous leg ulcers: A study of risk factors. *Dermatol Surg* **32:**512, 2006
17. Kerchner K, Fleischer A, Yosipovitch G: Lower extremity lymphedema update: pathophysiology, diagnosis, and treatment guidelines. *J Am Acad Dermatol* **59**(2):324-331, 2008; [Epub May 29, 2008]
18. Damstra RJ, Mortimer PS: Diagnosis and therapy in children with lymphoedema. *Phlebology* **23**(6):276-286, 2008 Review
19. Damstra RJ et al: Erysipelas as a sign of subclinical primary lymphoedema: A prospective quantitative scintigraphic study of 40 patients with unilateral erysipelas of the leg. *Br J Dermatol* **158**(6):1210-1215, 2008; [Epub Mar 20, 2008]
22. Connell F, Brice G, Mortimer P: Phenotypic characterization of primary lymphedema. *Ann N Y Acad Sci* **1131:**140-146, 2008

Disease Due to Microbial Agents, Infestations, Bites, and Stings

PART 9



Bacterial Disease

Chapter 175 :: General Considerations of Bacterial Diseases

:: Noah Craft

BACTERIAL SKIN DISEASES AT A GLANCE

- Bacteria cause disease by direct invasion of tissues, by secreting toxins, and by causing immunologic consequences that result in disease.
- The innate immune system is critical in the initial defense against bacterial entry into the skin.
- The virulence and pathogenicity of bacteria is related to their ability to avoid activating the innate immune system or resisting killing within immune effector cells.
- Immunosuppression, especially neutropenia, puts the host at high risk for bacterial infections; some infections are rare except in the immunocompromised host.
- Consideration of host factors and pathogen virulence factors are critical to choose a safe and effective therapy against bacterial infections.
- There are many noninfectious conditions that can mimic the clinical presentations of bacterial infections. Consider the noninfectious differential diagnoses carefully.
- The use of up-to-date computer based resources for antibiotic resistance trends and best-practice guidelines is important when choosing empiric antimicrobial therapy.

The microbes that live on or in the human body are collectively referred to as the human microbiome. Some microbes of the human microbiome cause disease and others do not (commensals). The skin microbiome is a complex and diverse population of organisms that includes many bacteria, both commensals and pathogenic. The Human Microbiome Project includes recent work using metagenomic sequencing that describes the skin microbiome in previously inconceivable detail. The effects of multiple factors, including sebum secretion, body location, lipid content, pH, and sweat production significantly influence the growth of bacteria on the skin.[1] The effects of skin diseases such as psoriasis also dictate the composition of the skin microbiome.[2] It is clear there are many more bacteria normally living on our skin than previously imagined. Understanding the factors that contribute to healthy skin and skin disease will lead to improved treatment and prevention of

skin infections and perhaps many noninfectious skin diseases.

The relationship of bacteria and the skin may be considered in four major categories[1]: (1) primary skin infections,[2] (2) secondary infection of a primary skin disease (e.g., infected atopic dermatitis),[3] (3) the skin lesions as manifestations of primary infection in some other organ system, usually the blood, and[4] (4) reactive skin conditions resulting from bacterial infection elsewhere (e.g., erythema nodosum due to streptococcal pharyngitis). Thus, the balance of host immunity and the growth of the skin bacteria determine the disease state of the skin. Controlling a disease state, like atopic dermatitis, clearly reduces the number of skin infections that arise in the broken skin barrier. Conversely, controlling skin infections with dilute bleach baths and mupirocin ointment can lead to decreased atopic dermatitis flare as well.[3]

When considering the patient, it is important to remember that not all skin infections are suppurative but may present as reactive responses (e.g., erythema nodosum). Equally important, not all suppurative skin problems are primary skin infections (e.g., hidradenitis suppurativa). Notably, many erythematous skin lesions are not infectious at all (e.g., stasis dermatitis). The importance of the skin as a mirror of systemic infection cannot be overemphasized, especially when classic clinical findings are distorted as in immunocompromised patients. The timely recognition of the cutaneous clues of bacteremia may prevent the rapid spread of life-threatening infections due to organisms such as *Pseudomonas aeruginosa*, *Vibrio vulnificus*, *Salmonella typhi*, *Staphylococcus aureus*, and *Neisseria meningitidis*.

PATHOGENESIS OF BACTERIAL INFECTION OF THE SKIN

The development and evolution of bacterial infection involve three major factors[1]: (1) the portal of entry and skin barrier function,[2] (2) the host defenses and inflammatory response to microbial invasion, and[3] (3) the pathogenic properties of the organism.

PORTAL OF ENTRY

Normal intact pediatric and adult skin is relatively resistant to infection and most skin infections occur when there is disruption of the skin barrier. Maceration, shaving, chronic wounds, excoriation of pruritic insect bites, and disruption of the epidermal barrier by other pathogens are some of the ways bacteria can breach the skin barrier. For example, skin trauma, interdigital maceration, or tinea pedis can be predisposing factors for lower leg cellulitis in an otherwise healthy person without venous incompetence or a leg ulcer.[4]

The character of the cutaneous inflammatory response to bacteria will be influenced by how the organisms reach the involved area. Local inflammation and suppuration commonly accompany direct bacterial infection of the skin. In septicemia, the vascular wall is often the primary site of skin involvement; hemorrhage, or thrombosis with infarction is the initial manifestation leading to ulceration or eschar. Certain bacteria can produce bacteremia or distant lesions without evoking an obvious inflammatory response at the portal of entry [e.g., *Yersinia pestis*, *Streptobacillus moniliformis* (rat-bite fever)], even in a healthy host. Occasionally, a devastating *Streptococcus pyogenes* septicemia has followed closely on an innocuous pinprick or abrasion that has not induced a significant local lesion.

NATURAL RESISTANCE OF THE SKIN

The normal skin of healthy individuals is highly resistant to invasion by the wide variety of bacteria to which it is constantly exposed. It is difficult to produce localized infections such as impetigo, furunculosis, or cellulitis, if the integument is intact.[5] Pathogenic organisms such as *S. pyogenes* (group A streptococcus, GAS) and *S. aureus* produce characteristic lesions of cellulitis and furunculosis in hosts with normal defenses usually because there is a disruption of the normal skin barrier. The presence of a silk suture reduces by a factor of 10,000, in the case of *S. aureus*, the number of organisms needed to produce an abscess in the human skin.[6]

Bacteria are unable to penetrate the keratinized layers of normal skin and, when applied to the surface, rapidly decrease in number. Maceration and occlusion, which result in increased pH, higher carbon dioxide content, and higher epidermal water content, result in dramatic increases in bacterial flora.[7] Some bacteria, such as those that are Gram negative, can only be found in such sites, suggesting that normal skin conditions prevent them from colonizing the skin. The relative dryness of normal skin specifically contributes to the marked limitation of growth of bacteria, especially Gram-negative bacilli.

Lipids found on the skin surface also may have antibacterial properties.[8,9] Reduction of skin surface lipids with topical solvents prolongs the survival time of *S. aureus* on the skin. The free fatty acids, and linoleic and linolenic acids, are more inhibitory for *S. aureus* than for coagulase-negative staphylococci, a component of the normal skin flora. Sphingosine, glucosylceramides, and *cis*-6-hexadeconic acid have been demonstrated to have antimicrobial activity against *S. aureus*. Bacterial interference (the suppressive effect of one bacterial species on colonization by another) exerts a major influence on the overall composition of the skin flora.

The organisms that characteristically survive and multiply in various ecologic niches of the skin constitute the "normal cutaneous flora." As an example, the distribution of different species of coagulase-negative staphylococci varies among different anatomic areas, and their relative numbers can depend on age. In adults, *Staphylococcus epidermidis* is the principal staphylococcal species isolated from the scalp, face, chest, and axilla. In a study of the skin microbiome of healthy adults, over 98% of skin bacteria belonged to four phyla: (1) Actinobacteria (51.8%), (2) Firmicutes (24.4%), (3) Proteobacteria (16.5%), and (4) Bacteroidetes (6.3%). Although 205 genera were identified on

only 20 individuals, three were associated with more than 62% of the sequences: (1) *Corynebacteria* (22.8%; Actinobacteria), (2) *Propionibacteria* (23.0%; Actinobacteria), and (3) *Staphylococci* (16.8%; Firmicutes).[10]

ANTIMICROBIAL PEPTIDES. Human skin contains a wide range of proteins with inherent antimicrobial properties. These antimicrobial peptides (AMPs) are expressed on the skin surface as well as in eccrine sweat and saliva.[11] Activated keratinocytes produce AMPs. The AMPs produced in keratinocytes are delivered to the skin surface in the lamellar bodies, and their appearance on the skin surface is closely tied to the production of normal skin stratum corneum lipids (see Chapter 47). These small proteins have as a characteristic physical property: the presence of an amphipathic organization, with one portion being cationic and capable of binding to microbial membranes, and another being hydrophobic allowing for insertion into the bacterial lipid membrane. The insertion into the membrane results in membrane disruption and microbial death. The second principle of AMPs is that they are processed after release by enzymes on the skin surface, resulting in multiple peptides each with different activities and different targets. The third principle of AMPs is that they not only kill microbes directly, but they are also potent activators of the host immune response. There are dozens of AMPs with activity on the human skin.[12] The two major AMPs studied to date on the skin are (1) the cathelicidins (LL-37) and (2) the defensins. The marked decrease of these molecules on the inflamed skin of patients with atopic dermatitis may be related to the susceptibility of atopic patients to infections with *S. aureus*, herpes simplex virus, and vaccinia virus.[13] T-helper 2 cytokines specifically suppress the production of these AMPs, a possible explanation for why psoriatic skin has normal or elevated AMP content and is less susceptible to bacterial and viral infections.[14]

SPECIFIC FEATURES OF HOST INFLAMMATORY RESPONSE TO CUTANEOUS INFECTION. The adaptive immune system, which requires the development of targeted cells and antibodies, is highly effective in protecting humans from infection once the effector cells and antibodies have been produced. However, this takes days, and bacteria replicate and invade in hours. The discovery of the "innate" immune system explains the ability of organisms to mount an effective and targeted immune response to microbes before the adaptive immune system comes into play (see Chapter 10). The innate immune system is present in plants, invertebrates, and vertebrates. This system relies on a series of pattern recognition receptors (PRRs) that recognize pathogen-associated molecular patterns (PAMPS) that are not present on "self".[15] Binding of the PRRs to the PAMPs results in opsonization and activation of the complement system as well as induction of inflammatory signaling pathways. This process involves at least three PRRs[1]: (1) the AMPs discussed in Antimicrobial Peptides,[2] (2) Toll-like receptors (TLRs), and[3](3) the complement system. These three systems engage bacteria once they enter the skin and, by intercommunication and by signaling neutrophils and other immune cells, are vital in bringing to the site of infection the cells required to destroy the pathogen.

TLRs are a repertoire of pattern recognition receptors (see Chapter 10).[16] They occur on cell membranes and recognize certain exogenous ligands that are unique to invading microorganisms and not found in the host. They play a prominent role as primary sensors for invading pathogens. For instance, TLR2 recognizes the peptidoglycan on the surface of Gram-positive bacteria, TLR4 recognizes the lipopolysaccharide on Gram-negative bacteria, and TLR5 recognizes flagellin, unique to flagellated bacteria. These structural elements of the invading organism are essential for its pathogenicity and therefore are hard to eliminate on an evolutionary basis. The TLRs not only engage the invader, but they also orchestrate what type of immune response is generated for that specific pathogen. TLRs do this by instructing antigen-presenting cells that have engaged the organism to secrete appropriate cytokines to generate the desired immunologic milieu and eventual adaptive immune response (see Chapter 10). Alternative downstream signaling pathways can result in different immune responses from engagement of the identical TLRs.

Complement (see Chapter 37) is activated when mannin-binding lectin binds to carbohydrate patterns on bacteria and activates C2 and C4.[17] Activation of C3 liberates C3a and C3b. C3b on membranes leads to opsonization and enhanced phagocytosis. In addition, the cleavage of C5 leads to C5a, a potent activator of neutrophils and a stimulator of proinflammatory cytokines, including interleukin 1 (IL-1) and IL-8. The "membrane attack complex" is formed by completion of the complement cascade and kills invading microbes. Not surprisingly, complement components also modulate the immune system, and alter TLR stimulation of some activation pathways. Through an extensive repertoire of outcome options, the human host has the ability to develop an organism-specific response to a wide variety of infectious agents that the host has not previously encountered. In addition, the innate immune system through complement and TLR orchestrates the adaptive immune system to appropriately respond to the invading microbe. This elaborate innate immune response explains the variety of rather distinctive clinical responses to various bacterial infections that have been described. The infectious agent, the anatomic site of the infection, and the attendant inflammatory response pattern create the clinical lesion.

PATHOGENICITY OF THE MICROORGANISM

To effectively invade a host, the microbe must initially gain access. *S. aureus* uses teichoic acid and other surface proteins that promote adherence to the nasal mucosa. The bacteria are then available to contaminate any breaches in the skin, binding to fibronectin in wounds. The disease-producing capacity of bacteria is termed *virulence*. The genetic material encoding virulence factors and toxins are carried on mobile genetic elements called *pathogenicity islands*. Bacteriophages

carry genetic elements from one bacterium to the next (Panton–Valentine leukocidin for example). Panton–Valentine leukocidin is a cytotoxin directed against human immune cells. It is associated with deep-seated and more inflammatory furunculosis, and now has been correlated with methicillin resistant *S. aureus* (MRSA). Importantly, up to 37% of patients with purulent CA-MRSA infections are colonized at another anatomical location with the organism.[18] In addition, many bacterial species contain DNA elements within their own genome that specifically are designed to escape, inactivate, or suppress the host's innate immune response, especially by resisting killing by neutrophils and excreted products. These gene products that respond to the host's immune attack are usually composed of a two-protein interaction cascade involving a sensor and a response protein. This is called a *two-component gene regulatory system*. In the case of *S. aureus*, numerous specific substances target each element of the innate immune attack by the host. Staphylokinase (SAK) inactivates defensins. Aureolysin A cleaves LL-37. The *oatA* gene encodes a membrane protein that imparts lysozyme resistance. *S. aureus* is catalase positive, and the yellow pigment of *S. aureus* (carotenoids) protects it from oxidative killing by neutrophils. SAK also activates plasminogen to plasmin. Surface plasmin cleaves C3b and immunoglobulin G, removing important opsonin molecules from the bacterial surface. Chemotaxis inhibitory protein of *S. aureus* binds to C5a blocking neutrophil activation. Staphylococcal complement inhibitor binds to C3 convertase on the bacterial surface preventing it from cleaving C3 and activating the complement cascade. SAKS, chemotaxis inhibitory protein of *S. aureus*, and staphylococcal complement inhibitor are carried on the same pathogenicity islands.[19–22]

Although it is useful to distinguish between disease caused by toxins and those caused by direct invasion and virulence factors, most bacterial infections result from the combination of the invasive and toxigenic properties of the organism. Examples in which locally secreted toxins are instrumental in creating the characteristic lesions are infections with *S. aureus* (bullous impetigo), *Corynebacterium diphtheriae*, and *Bacillus anthracis* (see Chapter 177). Systemic manifestations of toxin secretion are seen in staphylococcal scalded skin syndrome and tetanus. In the case of *Clostridium perfringens*, elaboration of a variety of extracellular toxins and enzymes (α-toxin or lecithinase, proteases, collagenases) appears to play an important role in the rapidly spreading skin lesions and the systemic manifestations of clostridial myonecrosis (see Chapter 179). *S. pyogenes*, specifically GAS, also contains numerous genes that help it evade the innate immune system. These include those within the genome, such as the M protein, which prevents phagocytosis by neutrophils, and those transmitted on prophages such as exotoxin A. The production of DNase SdaD2 protects GAS from extracellular killing by neutrophils in neutrophil extracellular traps and is important in skin infections. Tissue invasion and systemic spread are enhanced by streptokinase. GAS streptokinase is active only against human plasminogen, which may be critical in restricting GAS infection to humans. The proclivity of streptococcus to share the genetic material containing these virulence factors across strains has blurred the restrictions of streptococcal types to certain disease patterns. Now, for instance, in some regions, group G streptococcus is a major cause of pharyngitis and contains the same virulence genes that gave GAS the ability to cause this condition.[23,24]

Gram-negative bacteria (*Escherichia coli*, *S. typhi*, *N. meningitidis*, *Neisseria gonorrhoeae*, *Brucella melitensis*, and others) contain endotoxin, or complex phospholipid-polysaccharide macromolecules (LPS), as an integral part of the bacterial cell envelope (see Chapter 180). Endotoxins, unlike exotoxins, are released only upon breakdown of the bacterial cell. Their toxicity appears to be linked principally to the lipid fraction, whereas their antigenic determinants reside with the polysaccharide component. Much is now known of the mechanisms by which LPS exerts its biologic effects in systemic infections due to Gram-negative bacteria or in major localized infections that may also be capable of producing the sepsis syndrome. The effects are both toxic and immunologic. The two cytokines most important in the toxic and proinflammatory effects of LPS are produced by LPS-activated macrophages: (1) tumor necrosis factor (TNF-α) and (2) IL-1. TNF-α initiates a proinflammatory cytokine cascade (see Chapter 11). TNF-α activates the coagulation system through its effects on vascular endothelium, and decreases blood pressure and tissue perfusion by reducing myocardial contractility and by relaxing smooth muscle. High circulating levels of TNF-α are demonstrable in patients with meningococcemia and other forms of severe sepsis.[25] Infusion of high concentrations of purified TNF-α alone can produce shock and death. The ability of LPS, through TNF-α production, to induce leukocyte adherence to capillary endothelium and to induce fibrin deposition has been suggested as the basis for development of the hemorrhagic necrotic skin lesions (with or without direct bacterial invasion) that sometimes occur during the course of Gram-negative bacteremias and particularly in meningococcemia. Purpura fulminans develops in 10%–20% of cases of marked meningococcal sepsis, and severe cases may develop thrombosis of large vessels with infarction of digits (see Chapters 144 and 180).

CHANGING PATTERNS OF BACTERIAL INFECTIONS OF THE SKIN

Three factors have resulted in an increase in the prevalence and virulence of bacterial infections. First, new pathogens such as *Bartonella* spp. that were not previously known to cause human disease were discovered (see Chapter 182). Second, bacteria themselves have become more difficult to treat via the acquisition of virulence factors and antibiotic resistance. Third, there is an ever increasing number of immunocompromised patients due to increasing numbers of the elderly and debilitated, the human immunodeficiency virus-infected, and the iatrogenically immunosuppressed. In addition to the usual pathogens, a variety of "non-pathogenic" members of the cutaneous microbiome are

capable of producing disease in debilitated patients and in individuals with altered humoral or cellular defenses. For example, ecthyma gangrenosum due to local or systemic destructive invasion of the skin by *Pseudomonas aeruginosa* is seen virtually always in the setting of neutropenia (see Chapter 179). In the immunocompetent host, a transient and self-healing folliculitis ("hot-tub folliculitis) is caused by the same organism. *Bartonella henselae* causes cat-scratch disease, a self-healing disorder in the immunocompetent host (see Chapter 182). In patients with advanced AIDS (CD4 <50), *B. henselae* leads to bacillary angiomatosis and systemic involvement that is fatal without treatment (see Chapters 182 and 198).

INFLUENCE OF HYPERSENSITIVITY TO BACTERIAL ANTIGENS ON INFLAMMATORY REACTION IN SKIN

The ability of bacteria to induce immunologic events on the part of the host explains certain syndromes. The flares of atopic dermatitis induced by *S. aureus* may be due to shifts in cytokine profile in the lesions induced by the bacterial infection. Similarly, streptococcal infection of the pharynx can induce an immunologic response that triggers guttate psoriasis via activation of the immune system.

NEUTROPHILIC CONDITIONS AS A CUTANEOUS RESPONSE TO SYSTEMIC INFECTION

Inflammatory changes in and about small blood vessels in the skin may occur in a variety of bacteremic infections in the absence of obvious localization of bacteria at these sites. The papular and petechial lesions of chronic meningococcemia, and at times in disseminated gonococcal infection (see Chapters 180 and 205), and the development of leukocytoclastic vasculitis following adequate treatment of endocarditis (probably induced by circulating immune complexes) are examples. The lesions of Sweet syndrome (see Chapter 32) and early erythema nodosum (see Chapter 70) can have prominent tissue neutrophilia, even though the initiating infection (e.g., streptococcal pharyngitis) is distant. The Osler nodes and petechiae of subacute bacterial endocarditis, caused by viridans streptococci, probably provide the best examples of this association of small-vessel vasculitis with bacteremia (see Chapter 181). Histologically, these lesions are more suggestive of vasculitis than of emboli. The occasional development of such lesions in profusion, localized to the lower extremities, supports the concept of cutaneous vascular inflammation rather than embolization.

CLASSIFICATION OF BACTERIAL INFECTIONS OF THE SKIN

The discovery of specific bacteria as the cause of skin infections has led, in most cases, to classification of skin diseases based on the pathogenic bacteria rather than by morphology. In many cases, however, the infectious agent will be identified by culture, and the results not known for at least 1 day. In addition, impetigo (see Chapter 176), cellulitis, and necrotizing fasciitis (see Chapter 179) are three examples where multiple pathogens are capable of causing the same clinical pattern and require treatment decision based on the most likely pathogens. Therefore, morphologic classification of skin lesions is still important and can guide initial diagnostic testing and empiric antibiotic treatment. To this end, the classification of skin findings caused by bacterial infections as[1] primary infections (pyodermas),[2] secondary infections,[3] cutaneous manifestations of systemic bacterial disease, and[4] reactive conditions resulting from distant infection, seems warranted. Primary bacterial infections are produced by the invasion of ostensibly normal skin by a single species of pathogenic bacteria. In such infections, there is usually no doubt as to the primary etiologic role of the specific agent in the pathogenesis of the lesion. Treatment aimed at the bacterial pathogen almost universally results in cure of the lesion. Impetigo, erysipelas, and furunculosis (see Chapter 176) are familiar examples of primary cutaneous infections. In contrast, secondary infections develop in areas of already damaged skin. Although the bacteria present did not produce the underlying skin disorder, their proliferation and subsequent invasion of surrounding areas may aggravate and prolong the disease. Such secondary infection may occur when the integrity of the skin has been broken, or the local immune milieu is altered by the primary skin condition, allowing infection by bacteria. In contrast to the primary infections, the secondary infections at times show a mixture of organisms on culture, and not infrequently, it is impossible to determine which, if any, play the major role. It is important to know in which conditions recovery of a bacterial pathogen is important, and in which it is less predictable of response to antibiotic treatment. In flares of atopic dermatitis (see Chapter 14), decreasing the numbers of *S. aureus* on the skin surface with antibiotics is often associated with improvement of the dermatitis. In contrast, even experts in the field disagree on the significance of culturing bacterial "pathogens" from chronic leg ulcers. In the case of secondary infections, the morphology of the primary skin disease may be minimally altered, and the presence of an exacerbating bacterial pathogen may only be suspected by poor response to treatment or an otherwise unexplained flare of the condition.

DIAGNOSTIC STRATEGIES

DIRECT EXAMINATION OF ASPIRATES AND BIOPSIES

Identification of bacteria from skin lesions may provide important information as to the cause of cutaneous infections. Although not practical in many settings, examination of a Gram-stained smear of material from a suspected skin infection can guide decisions on

early antibiotic therapy before a cultural diagnosis is made. For these reasons, bacteriologic investigation is an important part of the initial evaluation of patients with skin lesions and includes[1] appropriate sampling,[2] interpretation of Gram-stained smears, and[3] use of selective growth media for culturing.

Gram staining provides a very rapid method of examining a sample for number and type of bacteria, as well as for the character of the inflammatory exudate in sterile pustules. Obtaining an appropriate specimen for microscopic study and culture requires care to avoid contamination. Bacterial cultures from cellulitis and erysipelas are generally unrewarding. Aspirates or biopsies from the advancing edge of cellulitis yielded positive cultures in an average of 16% of patients.[26] Although not routinely performed, findings on needle aspiration, when positive, can provide an immediate useful guide to therapy. If sterile saline is injected into a lesion for diagnostic culture, solutions without bacteriostatic additives should be employed. In circumstances in which no data are available from needle aspiration, a surgical biopsy may yield information that is life saving. In the bioterrorism-associated outbreak of anthrax infections in the United States, rapid specific diagnosis of cutaneous disease was accomplished by punch biopsy of an erythematous, indurated plaque and tissue Gram stain demonstrated Gram-positive rods, confirmed as *B. anthracis* by immunohistochemical analysis (see Chapter 183).[27] Local lesions of the skin and subcutaneous tissues in immunocompromised patients should always be biopsied if aspiration fails to define a pathogen. Encouraging results have been reported in patients with suspected necrotizing fasciitis (see Chapter 179) who had biopsies done to confirm the diagnosis early in the course of this devastating infection.[28]

OTHER DIAGNOSTIC PROCEDURES

FLUORESCENT ANTIBODY. The practical use of this procedure in bacterial diseases of the skin is currently of limited applicability. Spirochetes can be demonstrated (by the direct or indirect techniques) in chancres, (see Chapter 200). *N. gonorrhoeae*, *Actinomyces israelii*, *Legionella* sp., *Francisella tularensis*, *B. anthracis*, and *Y. pestis* have been identified by this rapid direct fluorescent antibody staining method. Its greatest use is in the specific diagnosis of uncommon but serious infections.[29]

OTHER IMMUNOLOGIC METHODS. A variety of serologic tests may be helpful in the diagnosis of bacterial infections of the skin. These tests are particularly important in conditions where the cutaneous manifestations are secondary to systemic disease (e.g., "rose spots" of typhoid fever). *Bartonella* infections are routinely diagnosed in this manner.

POLYMERASE CHAIN REACTION. Polymerase chain reaction (PCR) technology can be applied to diagnosis of material obtained on skin punch biopsy of lesional tissue or aspirates from a vesiculobullous lesion just as it has been used in diagnosis of infection in body fluids (cerebrospinal fluid, pleural fluid, blood). Appropriate precautions to exclude contamination during the acquisition of the specimen must be taken. The use of this procedure is most helpful when one particular rare bacterial species is being considered, and appropriate primers are available. Such was the case in a patient with a cutaneous lesion during the bioterrorism-induced anthrax outbreak.[25,29]

ANTIBIOTIC THERAPY

(See Chapter 230)

The selection of the appropriate antibiotic should be made initially on the basis of the appearance of the skin lesion, the characteristics of any systemic illness, and a Gram-stained smear of material from a lesion, if available. Culture results and susceptibility testing of the isolated pathogen(s) are usually available within 24–48 hours. Additional epidemiologic factors (current hospitalization or residence in a nursing home, recent antibiotic use, neutropenia, and immune status) should be considered in the choice of initial antimicrobial therapy. Also, it is important to make the choice based on the latest data from the local area and from frequently updated sources in view of the rapidly changing patterns of antimicrobial resistance of various bacterial species. The use of computerized decision support, infectious disease reference systems, best-practice guidelines, or pharmacologic databases should be considered when choosing empiric therapy for bacterial infections.

DOSAGE: METHODS OF ADMINISTRATION—EXCRETION

Primary cutaneous infections of mild to moderate severity can be treated with local measures, topical drugs, oral antibiotics, or by a combination of these methods. Extensive infections of the skin, with or without systemic manifestations, should be vigorously treated with parenteral antibiotics in adequate dosages. In the immunocompromised host, parenteral treatment of cutaneous infections is virtually always recommended.

A number of factors must be considered in administering antibiotics: oral treatment may be limited by absorption and gastrointestinal disturbances; hypotension and extensive skin disease can prohibit the intramuscular route; and the proper drug selected may be suitable for administration only by a specific route. The metabolism profile of a given antibiotic should always be considered to avoid underdosing or toxic accumulation in the face of specific organ malfunction (e.g., hepatic or renal impairment).

TOXICITY

The toxicity of antibiotics should be considered on an individual basis but some problems are applicable

to all antibiotics. Hypersensitivity reactions are relatively common and can include skin rashes, fever, or more severe manifestations such as acute anaphylaxis or exfoliative erythrodermas. The penicillins and sulfonamides are particularly likely to produce these problems. Questions regarding previous drug allergy should be asked whenever any antibiotic is to be administered. All antibiotics can alter the indigenous flora, especially broad-spectrum agents such as the cephalosporins. Gastrointestinal disturbances and oral mucous membrane lesions are the major problems encountered with alteration of the flora. There are numerous other potential drug reactions (renal, hematologic, hepatic, nervous system) to antibiotics that may represent acceptable risks if the reasons for use of these drugs are compelling. It is the physician's responsibility to be aware of the usual and unusual manifestations of toxicity of any of the antibiotics used and to be alert to possible novel effects in individual patients. The use of electronic medical records with physician alerting systems will help improve these potential negative outcomes.

ANTIBIOTIC RESISTANCE

Transferable resistance to multiple antibiotics has emerged as a widespread problem. The mechanisms of acquired resistance can occur in several ways.[30] Foreign DNA containing an antibiotic resistance gene can be transferred by (a) horizontal gene transfer into a recipient by several paths; (b) cell-to-cell conjugation; (c) transformation by naked DNA plasmid or linear fragments released by dead cells; or (d) phage-mediated transduction. Antimicrobial resistance can also arise by de novo mutation. Efforts should be made to minimize the overuse of antibiotics and to use agents with the narrowest spectrum of antimicrobial coverage when appropriate.

TOPICAL ANTIBACTERIAL AGENTS

(See Chapter 218)

Topical antibacterial agents are frequently used to prevent, as well as to suppress, bacterial growth in open lesions and surgical wounds. In the case of sutured dermatologic wounds, topical antibiotics are often no better than petrolatum and have limited effect in reducing wound infections.[31] Additionally, topical neomycin and bacitracin commonly precipitate contact dermatitis and should be avoided. Contact dermatitis is especially common when these topical antibiotics are applied to venous insufficiency leg ulcers.

Among the most useful topical antibacterial agents are acetic acid (1%–5% for *Pseudomonas* nail and toe web infections, gentamicin (0.17% cream) may be useful in selected patients when mixed Gram-negative bacteria require local suppression (e.g., Erosio interdigitalis blastomycetica) and mupirocin (2% cream or ointment) with antibacterial activity against various streptococci and *S. aureus*. A number of broad-spectrum antiseptics are also available for topical use. Povidone-iodine (Betadine) is effective against most Gram-positive and Gram-negative bacteria but does not persist in the skin to provide a residual action. Chlorhexidine gluconate (4% solution) combines broad antibacterial properties with prolonged action. An alcoholic preparation is especially effective, is not appreciably absorbed into the blood, and generally is not irritating to the skin. These broad-spectrum antiseptics can be used prophylactically or to treat local wounds and superficially infected dermatoses.

ACKNOWLEDGMENT

The author thanks Timothy G. Berger, MD, for his excellent work on this chapter in the previous edition.

KEY REFERENCES

Full reference list available at www.DIGM8.com

DVD contains references and additional content

1. Grice EA et al: Topographical and temporal diversity of the human skin microbiome. *Science* **324**(5931):1190-1192, 2009
3. Huang JT et al: Treatment of Staphylococcus aureus colonization in atopic dermatitis decreases disease severity. *Pediatrics* **123**(5):e808-e814, 2009
12. Schauber J, Gallo RL: Antimicrobial peptides and the skin immune defense system. *J Allergy Clin Immunol* **124**(3 Suppl 2):R13-R18, 2009
13. de Jongh GJ et al: High expression levels of keratinocyte antimicrobial proteins in psoriasis compared with atopic dermatitis. *J Invest Dermatol* **125**(6):1163-1173, 2005
16. Kang SS, Kauls LS, Gaspari AA: Toll-like receptors: Applications to dermatologic disease. *J Am Acad Dermatol* **54**(6):951-983; quiz 83-86, 2006
19. Rooijakkers SH, van Kessel KP, van Strijp JA: Staphylococcal innate immune evasion. *Trends Microbiol* **13**(12):596-601, 2005
30. Andersson DI, Hughes D: Antibiotic resistance and its cost: Is it possible to reverse resistance? *Nat Rev Microbiol* **8**(4):260-271, 2010

Chapter 176 :: Superficial Cutaneous Infections and Pyodermas

:: Noah Craft

PYODERMAS AT A GLANCE

- Bacterial skin infections (pyodermas) are primarily caused by *Staphylococcus aureus* and *Streptococcus* sp.
- Twenty percent of individuals are continuously colonized with *S. aureus*, and occasional carriage is found in 60% of healthy people. This represents a common source of many infections.
- Contributing factors: immunosuppression, atopic dermatitis, preexisting tissue injury, and inflammation.
- Local manifestations include: folliculitis, furunculosis, ecthyma, and impetigo.
- Systemic reactions include: staphylococcal toxic shock syndrome and scarlatiniform eruption.
- Not particularly localized to one anatomic area.
- Pathology: abundant neutrophilic infiltration admixed with lymphocytes.
- Treatment: topical, oral, or parenteral antibiotics; change predisposing conditions, if possible. When planning therapy, consider local and current antimicrobial resistance patterns.

Normal human skin is colonized soon after birth by a large number of bacteria that live as commensals on the epidermis and epidermal appendages (the skin microbiome). Coagulase-negative *Staphylococci* (*Staphylococcus epidermidis*) are inoculated during vaginal passage and coryneform bacteria take up residence on neonatal skin shortly after birth. Within several weeks after birth, the microbiome of neonatal skin is similar to that of adults and includes many species of bacteria and fungi (see Chapter 175).

The majority of the primary and secondary pyodermas (cutaneous bacterial infections) are caused by either *S. aureus* or group A *Streptococcus*. These bacteria cause a broad clinical spectrum of infection ranging from superficial pyodermas to invasive soft-tissue infections (STIs; see Chapter 179) depending on the organism, the anatomic location of infections, and on host factors.

STAPHYLOCOCCAL SKIN INFECTIONS

EPIDEMIOLOGY

Staphylococci are classified into two major groups: (1) the coagulase-negative *Staphylococci* and (2) coagulase-positive (*S. aureus*) *Staphylococci*. Individuals carry a minimum of 10–24 combined temporary and resident strains of *S. epidermidis*, the most common coagulase-negative strain. *S. epidermidis* is a common colonizer of the skin but is capable of causing superficial and invasive infections (particularly about implants and catheters).

S. aureus permanently colonizes the anterior nares in approximately 20% of the population. Carriage is transient or intermittent in other individuals. Approximately 60% of healthy individuals have occasional carriage of *S. aureus* at some site.[1] Other sites of colonization include the axillae, perineum, pharynx, and hands. Conditions predisposing to *S. aureus* colonization include atopic dermatitis, diabetes mellitus (insulin dependent), dialysis (hemo- and peritoneal), intravenous drug use, liver dysfunction, and human immunodeficiency virus (HIV) infection. Colonization by *S. aureus* is found at some body site in up to 37% of patients presenting with purulent community associated methicillin resistant *S. aureus* (MRSA) infections.[2]

S. aureus is an aggressive pathogen and the most common cause of primary pyodermas and STIs, as well as of secondary infections on disease-altered skin. *S. aureus* in pyodermas or STIs can invade the bloodstream, producing bacteremia, metastatic infection such as osteomyelitis, and acute infective endocarditis. Some strains of *S. aureus* also produce exotoxins, which can cause constellations of cutaneous and systemic symptoms such as staphylococcal scalded-skin syndrome (SSSS) and staphylococcal toxic shock syndrome (TSS).

Transfer of organisms to patients occurs predominantly via the hands of personnel rather than through the air. This appears to be particularly true in newborn nurseries. Any individuals with open staphylococcal infections are high-risk potential carriers and transmitters of infection. Nasal carriage of *S. aureus* appears to be a major risk factor for wound infection after cardiac surgery, resulting in higher mortality rates and longer postoperative stays.[3] The rate of *S. aureus* bacteremia is also higher in nasal carriers of *S. aureus*.[4] Good nursery technique, careful handling of patients, strict handwashing procedures, and isolation of patients with open draining staphylococcal infections are important in the reduction of transmission of *Staphylococci*. In older adults, *S. aureus* accounts for 9% of nosocomial

infections and follows only *Escherichia coli, Pseudomonas aeruginosa*, and *Enterococci* in prevalence.[5]

ETIOLOGY AND PATHOGENESIS

Colonization by *S. aureus* may be transient or represent a prolonged carrier state. *S. aureus* produces many cellular components and extracellular products that may contribute to its pathogenicity. Host factors such as immunosuppression, glucocorticoid therapy, and atopy may play a major role in the pathogenesis of staphylococcal infections. Preexisting tissue injury or inflammation (surgical wound, burn, trauma, dermatitis, retained foreign body) is of major importance in the pathogenesis of staphylococcal disease.

Some strains produce one or more exoproteins, including the staphylococcal enterotoxins (SEA, SEB, SECn, SED, SEE, SEG, SEH, and SEI), and the exfoliative toxins (ETA and ETB), TSS toxin-1 (TSST-1), and leukocidin. These toxins have unique potent effects on immune cells and other biologic effects as well, ultimately inhibiting host immune response.

TSST-1 and the staphylococcal enterotoxins are also known as *pyrogenic toxin superantigens*. These molecules act by binding directly to constitutively expressed HLA-DR molecules (major histocompatibility complex II) on antigen-presenting cells without antigen processing. Although conventional antigens require recognition by all five elements of the T-cell-receptor complex, superantigens require only the variable region of the β-chain. As a result, 5%–30% of resting T cells may be activated, whereas the "normal" antigenic response is only 0.0001%–0.01% of T cells.[6] Nonspecific T-cell activation leads to massive systemic release of cytokines, especially interleukin 2, interferon-γ, and tumor necrosis factor-β from T cells and interleukin 1 and tumor necrosis factor-α from macrophages.[7] Superantigen stimulation of T cells also results in activation and expansion of lymphocytes expressing specific T cell-receptor variable region of the β-chain. They may activate B cells, leading to high levels of immunoglobulin E (IgE) or autoantibodies.[8] Also, there is evidence that superantigens selectively induce cutaneous lymphocyte-associated antigen on T cells, thereby "homing" them to the skin.[8]

There are several other mechanisms by which *S. aureus* evades immune clearance. Approximately 60% of *S. aureus* strains secrete the chemotaxis inhibitory protein of *Staphylococci*, which inhibits neutrophil chemotaxis. Additionally, protein A, staphylokinase, capsular polysaccharide, fibrinogen binding protein, and clumping factor A all act to aid in avoidance of being opsonized and phagocytosed. Staphylokinase and aureolysin bind and cleave antimicrobial peptides, respectively, resulting in increased survival in vitro and probably in vivo.[1]

DRUG RESISTANCE. A major problem in treating staphylococcal infections has been the emergence of antibiotic-resistant strains. With ever-increasing use of penicillins, methicillin-resistant *S. aureus* (MRSA) strains have become a major epidemiologic problem since the 1980s. Resistance to methicillin indicates pan resistance to all β-lactam antibiotics. Recently, intermediate-level resistance of MRSA to vancomycin has emerged and constitutes a potential further problem in treatment. Although *S. aureus* infection prevalence has not changed much, the percentage of MRSA isolates of these infections has significantly increased in some countries. Today, MRSA can be divided into Hospital-Associated (HA) or Community-Associated (CA) MRSA. In many areas, the prevalence of CA-MRSA strains is over 50%.[9]

Attempts to eradicate MRSA have generally been unsuccessful. Treatment of anterior nares and wounds with mupirocin ointment has been shown to decrease *S. aureus* colonization but in one study did not decrease the rate of transmission to a roommate in a long-term care facility.[10] Although there are many other reports of the use of topical mupirocin to reduce colonization of MRSA and methicillin-sensitive *S. aureus*, indiscriminate use of topical mupirocin must be avoided because significant mupirocin resistance has already emerged.

IMMUNITY. The primary defense against *S. aureus* infections is the innate immunity provided by neutrophils.[11] A major component of the innate response is antimicrobial peptides. These peptides can be found in various locales and include dermicidin, LL-37, protegrin, α-defensins and β-defensins, lactoferricin, and cascocidin. However, *S. aureus* also has the ability to thwart the immune system in several ways. One of the main virulence factors of *S. aureus* is the production of adhesins that facilitate binding to host epithelial cell surfaces. The almost universal presence in adults of circulating antibodies to one or more cell-wall antigens or extracellular toxins substantiates the high prevalence of staphylococcal infections. However, these antibodies are not the primary determinants of resistance to such infections. Recent evidence demonstrates that *S. aureus* can invade and survive in many types of host cells, suggesting that a cell-mediated immune response may be required for killing intracellular organisms.

CLINICAL FINDINGS

SUPERFICIAL STAPHYLOCOCCAL PYODERMAS. Pyodermas are infections in the epidermis, just below the stratum corneum or in hair follicles. In industrialized nations, *S. aureus* is the most common cause of superficial pyodermas (Box 176-1), but group A *Streptococcus* continues to be a common cause of pyoderma in developing countries. If untreated, pyodermas can extend to the dermis, resulting in ecthyma and furuncle formation.

Impetigo. Two clinical patterns of impetigo are recognized: (1) bullous and (2) nonbullous. Bullous impetigo is caused by *S. aureus*. Currently, in industrialized nations, nonbullous impetigo is most commonly caused by *S. aureus* and less often by group A *Streptococcus*. Group A *Streptococcus* remains a common cause of nonbullous impetigo in developing nations.

BOX 176-1 INFECTIONS AND TOXIN SYNDROMES INVOLVING THE SKIN AND SOFT TISSUES CAUSED BY *STAPHYLOCOCCUS AUREUS*

SITES OF COLONIZATION (CARRIER STATE)
- Anterior nares
- Throat
- Axillae, perineum
- Hands
- Involved skin in individuals with atopic dermatitis

SITES OF COLONIZATION IN NEONATES (AND SITES OF INFECTION)
- Skin
- Umbilicus
- Circumcision site
- Conjunctivae

SUPERFICIAL PYODERMAS
- Primary pyodermas
  - Skin
    - Impetigo
    - Bullous impetigo
    - Erythema
    - Botryomycosis
  - Hair follicles
    - Superficial folliculitis (follicular or Bockhart impetigo)
    - Folliculitis (sycosis barbae)
    - Furuncle (boil)
    - Carbuncle
  - Intertriginous sites
    - Perianal dermatitis
  - Digital infections
    - Paronychia
    - Blistering distal dactylitis
  - After skin disruption
    - Trauma (physical, thermal)
    - Foreign body (intravascular catheter, prosthetic device)
- Secondary pyodermas
  - Impetiginization of dermatoses such as atopic dermatitis, herpes simplex (superinfection)
  - Pyodermas associated with systemic disease
  - Job syndrome
  - Chédiak–Higashi syndrome
  - Chronic granulomatous disease

INVASIVE INFECTIONS
- Lymphangitis, lymphadenitis
- Erysipelas
- Cellulitis
- Streptococcal gangrene
- Pyomyositis
- Bacteremia, septicemia

METASTATIC SKIN INFECTIONS ASSOCIATED WITH BACTEREMIA (OFTEN *S. aureus* ACUTE INFECTIONS ENDOCARDITIS)
- Abscesses (superficial and deep)
- Septic vasculitis (pustular purpura)

PURPURA FULMINANS
- Disseminated intravascular coagulation associated with staphylococcal bacteremia
- Meningococcemia-like syndrome

STAPHYLOCOCCAL TOXIN-ASSOCIATED SYNDROMES
- Staphylococcal scarlet fever
- Staphylococcal scalded-skin syndromes
- Staphylococcal toxic-shock syndrome

Nonbullous Impetigo. The nonbullous type of impetigo accounts for more than 70% of cases of this form of pyoderma. It occurs in children of all ages as well as in adults. Intact skin is usually resistant to colonization or impetiginization, possibly due to absence of fibronectin receptors for teichoic acid moieties on *S. aureus* and group A *Streptococcus*. Production of bacteriocins, produced by certain *S. aureus* strains (phage group 71) and highly bactericidal to group A *Streptococcus*, may be responsible for the isolation of only *S. aureus* from some lesions initially caused by *Streptococci*.

History. In a typical sequence, *S. aureus* spreads from nose to normal skin (approximately 11 days later) and then develop into skin lesions (after another 11 days). Lesions commonly arise on the skin of the face (especially around the nares) or extremities after trauma. Nasal carriers of *S. aureus* can present with a very localized type of impetigo confined to the anterior nares and the adjacent lip area (Fig. 176-1); pruritus or soreness of the area is a common complaint (Fig. 176-2). Conditions that disrupt the integrity of the epidermis, providing a portal of entry of impetiginization, include insect bites, epidermal dermatophytoses, herpes simplex, varicella, abrasions, lacerations, and thermal burns.

Differential Diagnosis. See Box 176-2 for differential diagnosis of nonbullous impetigo.

Cutaneous Lesions. The initial lesion is a transient vesicle or pustule (see Fig. 176-2) that quickly evolves into a honey-colored crusted plaque that can enlarge to greater than 2 cm in diameter (see Fig. 176-1). Surrounding erythema may be present. Constitutional symptoms are absent. Regional lymphadenopathy may be present in up to 90% of patients with prolonged, untreated infection. If untreated, the lesions may slowly enlarge and involve new sites over several weeks. In some individuals, lesions resolve spontaneously;



Figure 176-1 *Staphylococcus aureus*: impetigo. Erythema and crusting on the nose and moustache area (**A**), which can spread to involve the entire centrofacial region (**B**).

in others, the lesions extend into the dermis, forming an ulcer (see Section "Staphylococcal Ecthyma").

Bullous Impetigo. Three types of skin eruptions can be produced by phage group II *S. aureus*, particularly strains 77 and 55: (1) bullous impetigo, (2) exfoliative disease (SSSS), and (3) nonstreptococcal scarlatiniform eruption (staphylococcal scarlet fever). All three represent varying cutaneous responses to extracellular exfoliative toxins ("exfoliatin") types A and B produced by these *Staphylococci* (see Chapter 177). Exfoliative toxin A acts as a serine protease of desmoglein 1, the desmosomal cadherin that is also the target of autoantibodies in pemphigus foliaceus.[12]

In a study of bullous impetigo, 51% of patients had concurrent *S. aureus* cultured from the nose or throat, and 79% of cultures grew the same strain from both sites.



Figure 176-2 *Staphylococcus aureus*: nasal carriage with impetigo. Erythema with a small pustule on the tip of the nose and nares in individual whose nares are colonized by *S. aureus*.

Cutaneous Lesions. Bullous impetigo occurs more commonly in the newborn and in older infants, and is characterized by the rapid progression of vesicles to flaccid bullae (Fig. 176-3). Decades ago, extensive bullous impetigo (archaic term: *pemphigus neonatorum* or *Ritter disease*) occurred in epidemics within neonatal nurseries.

BOX 176-2 DIFFERENTIAL DIAGNOSIS OF NONBULLOUS IMPETIGO

Consider

- Seborrheic dermatitis
- Atopic dermatitis
- Allergic contact dermatitis
- Epidermal dermatophyte infections
- Tinea capitis
- Herpes simplex
- Varicella
- Herpes zoster
- Scabies
- Insect bite reaction
- Burns
- Erythema multiforme
- Pemphigus foliaceous
- Cellulitis
- Pediculosis capitis

Always Rule Out

- Herpes simplex
- Herpes zoster
- Scabies

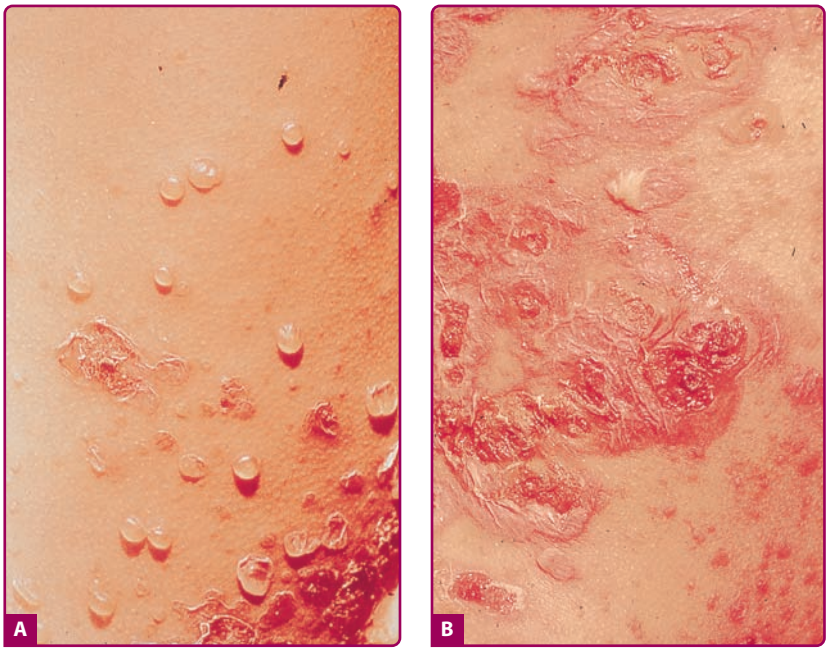

Figure 176-3 *Staphylococcus aureus*: bullous impetigo. **A**. Multiple vesicles with clear and turbid contents that rapidly coalesce to form flaccid bullae (**B**).

Bullae usually arise on areas of grossly normal skin. The Nikolsky sign (sheet-like removal of epidermis by shearing pressure) is not present. Bullae initially contain clear yellow fluid that subsequently becomes dark yellow and turbid (see Fig. 176-3A), and their margins are sharply demarcated without an erythematous halo. The bullae are superficial, and within a day or two, they rupture and collapse, at times forming thin, light-brown to golden-yellow crusts (see Fig. 176-3B). So-called *bullous varicella* represents superinfection by *S. aureus* (phage group II) of varicella lesions (bullous impetiginization).

Laboratory Tests. Gram stain of exudates from bullous impetigo reveals Gram-positive cocci in clusters. *S. aureus* belonging to phage group II can be cultured from the contents of intact bullae.

Histologically, the lesions of bullous impetigo show vesicle formation in the subcorneal or granular region, occasional acantholytic cells within the blister, spongiosis, edema of the papillary dermis, and a mixed infiltrate of lymphocytes and neutrophils around blood vessels of the superficial plexus.

Differential Diagnosis. See Box 176-3 for differential diagnosis of bullous impetigo.

Prognosis and Clinical Course. If untreated, invasive infection can complicate *S. aureus* impetigo with cellulitis, lymphangitis, and bacteremia, resulting in osteomyelitis, septic arthritis, pneumonitis, and septicemia. Exfoliatin production can lead to SSSS in infants and in adults who are immunocompromised or have impaired renal function.

Treatment. See Box 176-4. Local treatment with mupirocin ointment or cream, removal of crusts, and good hygiene is sufficient to cure most mild to moderate cases.[13] Retapamulin 1% ointment is also effective for localized impetigo and secondarily impetiginized dermatitis as well, although decreased efficacy against MRSA was noted in some trials.[14] Fusidic acid is an equally

BOX 176-3 DIFFERENTIAL DIAGNOSIS OF BULLOUS IMPETIGO

Consider

- Contact dermatitis
- Bullous insect bites
- Bullous tinea
- Bullous fixed drug reaction
- Bullous drug eruption
- SSSS
- Thermal burns
- Pemphigus vulgaris
- Bullous pemphigoid
- Erythema multiforme
- Dermatitis herpetiformis

Always Rule Out

- Herpes simplex
- Varicella
- Bullous tinea
- Bullous fixed drug reaction
- Bullous drug eruption
- SSSS

SSSS = staphylococcal scalded-skin syndrome.
Note: Any of these disorders may occur primarily and become secondarily impetiginized with *Staphylococcus aureus* or group A *Streptococcus*.

BOX 176-4 TREATMENTS FOR IMPETIGO[a]

	TOPICAL		SYSTEMIC	
First line	Mupirocin Retapamulin Fusidic acid (not available in United States)	bid bid bid	Dicloxacillin Amoxicillin plus clavulanic acid; cephalexin	250–500 mg PO qid for 5–7 days 25 mg/kg tid; 250–500 mg qid
Second line (penicillin allergy)			Azithromycin Clindamycin Erythromycin	500 mg × 1, then 250 mg daily for 4 days 15 mg/kg/day tid 250–500 mg PO qid for 5–7 days
If CA-MRSA is suspected	Mupirocin	bid	TMP-SMX Clindamycin Tetracycline Doxycycline, Minocycline	160/800 mg PO bid for 7 days 15 mg/kg/day tid 250–500 mg PO qid for 7 days 100 mg PO bid for 7 days

[a]Washing and hygiene are important in all regimens.

effective topical agent for localized impetigo and has very few adverse effects topically. However, it is currently unavailable in the United States.[15] Systemic antibiotics may be required in extensive cases. The frequency of isolation of group A *Streptococcus* makes such therapy a reasonable approach in most patients who have a significant degree of involvement. There is no role for general disinfectant treatments or bacitracin.[16]

Staphylococcal impetigo responds quite promptly to appropriate treatment. In an adult with extensive or bullous lesions, dicloxacillin (or similar penicillinase-resistant semisynthetic penicillin), 250–500 mg orally (PO) four times daily (qid), or erythromycin (in the penicillin-allergic patient), 250–500 mg PO qid, should be given. Treatment should be continued for 5–7 days (10 days if *Streptococci* are isolated). Also, a single course of oral azithromycin (in adults 500 mg on the first day, 250 mg daily on the next 4 days) has been shown to be equally as effective as dicloxacillin for skin infections in adults and children. For impetigo caused by erythromycin-resistant *S. aureus*, which is commonly isolated from impetigo lesions of children, amoxicillin plus clavulanic acid [25 mg/ kg/day given three times a day (tid)], cephalexin (40–50 mg/kg/day), cefaclor (20 mg/kg/day given tid), cefprozil (20 mg/kg once daily), or clindamycin (15 mg/kg/day tid or qid) given for 10 days are effective alternative therapies. If CA-MRSA is likely, consider the following therapies: TMP-SMX and rifampin (100%), clindamycin (95%), and tetracycline (92%). Inducible resistance to clindamycin should be excluded by performing a D-zone disk-diffusion test.

Staphylococcal Ecthyma. Ecthyma is a cutaneous pyoderma characterized by thickly crusted erosions or ulcerations. Ecthyma is usually a consequence of neglected impetigo and classically evolves in impetigo occluded by footwear and clothing. Thus, it is a lesion, typically occurring in the homeless and soldiers in combat on maneuver in a humid and hot climate. *S. aureus* and/or group A *Streptococcus* can be isolated on culture. Untreated staphylococcal or streptococcal impetigo can extend more deeply, penetrating the epidermis, producing a shallow crusted ulcer (Fig. 176-4). Ecthymatous lesions can evolve from a primary pyoderma or within a preexisting dermatosis or site of trauma. Ecthyma gangrenosum is a cutaneous ulcer caused by *P. aeruginosa* and resembles staphylococcal or streptococcal ecthyma (see Chapter 180).

Ecthyma occurs most commonly on the lower extremities of children, or neglected elderly patients, or individuals with diabetes. Poor hygiene and neglect are key elements in pathogenesis.



Figure 176-4 *Staphylococcus aureus*: ecthyma. Multiple thickly crusted ulcers on the leg of a patient with diabetes and renal failure. Ecthymatous lesions were also present on the other leg, the arms, and the hands.

The ulcer has a "punched-out" appearance when the dirty grayish-yellow crust and purulent material are debrided. The margin of the ulcer is indurated, raised, and violaceous (see Fig. 176-4), and the granulating base extends deeply into the dermis. Untreated ecthymatous lesions enlarge over weeks to months to a diameter of 2–3 cm or more.

The lesions are slow to heal, requiring several weeks of antibiotic treatment for resolution. Problems of spread by autoinoculation or by insect vectors and of poststreptococcal sequela (glomerulonephritis) are the same as with impetigo.

Management of ecthyma is usually systemic and includes the same agents used for staphylococcal impetigo (see Box 176-4).

Folliculitis. Folliculitis is a pyoderma that begins within the hair follicle, and is classified according to the depth of invasion (superficial and deep), and microbial etiology (Box 176-5).

Superficial Folliculitis. Superficial folliculitis has also been termed *follicular* or *Bockhart impetigo*. A small, fragile, dome-shaped pustule occurs at the infundibulum (ostium or opening) of a hair follicle, often on the scalps of children and in the beard area (Fig. 176-5), axillae, extremities, and buttocks of adults. Isolated staphylococcal folliculitis is common on the buttock of adults. *Periporitis staphylogenes* refers to secondary infection of miliaria of the neonate by *S. aureus*. Staphylococcal blepharitis is an *S. aureus* infection of the eyelids, presenting with scaling or crusting of the eyelid margins, often with associated conjunctivitis; the differential diagnosis includes seborrheic dermatitis and rosacea of the eyelid.

S. aureus folliculitis must be differentiated from other folliculocentric infections. Also, three noninfectious, inflammatory, follicular disorders are more common in black men: (1) pseudofolliculitis barbae, which occurs on the lower beard area (Fig. 176-6); (2) folliculitis keloidalis or acne keloidalis nuchae, on the nape of the neck; and (3) perifolliculitis capitis, on the scalp. *S. aureus* can cause secondary infection in these inflammatory disorders. Exposure to mineral oils, tar products, and cutting oils can cause an irritant folliculitis. Acne vulgaris, drug-induced acneiform



Figure 176-5 *Staphylococcus aureus*: superficial folliculitis. Multiple pustules confined to the beard area.



Figure 176-6 Pseudofolliculitis barbae. Multiple papules in the lower beard area caused by ingrowing of the curved hair shaft in a black man who shaves. If pustules are present, secondary *Staphylococcus aureus* infection must be ruled out.

BOX 176-5 CLASSIFICATION OF INFECTIOUS FOLLICULITIS

BACTERIAL FOLLICULITIS

- *Staphylococcus aureus* folliculitis
  - Periporitis staphylogenes
  - Superficial (follicular or Bockhart impetigo)
  - Deep (sycosis) [may progress to furuncle (boil) or carbuncle]
- *Pseudomonas aeruginosa* folliculitis ("hot tub" folliculitis)
- Gram-negative folliculitis (occurs at the site of acne vulgaris, usually the face, with long-term antibiotic therapy)
- Syphilitic folliculitis (secondary; acneiform)

FUNGAL FOLLICULITIS

- Dermatophytic folliculitis
  - Tinea capitis
  - Tinea barbae
  - Majocchi granuloma
- *Pityrosporum* folliculitis
- *Candida* folliculitis

VIRAL FOLLICULITIS

- Herpes simplex virus folliculitis
- Follicular molluscum contagiosum

INFESTATION

- Demodicidosis



Figure 176-7 Sycosis barbae. Deep staphylococcal folliculitis of the mustache region.

eruptions, rosacea, hidradenitis suppurativa, acne necrotica of the scalp, and eosinophilic folliculitis of HIV disease must be distinguished from infectious folliculitis as well. Also, "hot tub" folliculitis may be caused by *P. aeruginosa* (see Chapter 180).

Deep Folliculitis. Sycosis barbae is a deep folliculitis with perifollicular inflammation occurring in the bearded areas of the face and upper lip (Fig. 176-7). If untreated, the lesions may become more deeply seated and chronic. Local treatment with warm saline compresses and local antibiotics (mupirocin or topical clindamycin) may be sufficient to control infection. More extensive cases require systemic antibiotic therapy. Dermatophytic folliculitis must be differentiated from *S. aureus* folliculitis. In fungal infections, hairs are usually broken or loosened, and there are suppurative or granulomatous nodules rather than pustules. Also, in dermatophytic folliculitis plucking of hairs is usually painless (see Chapter 188).

Lupoid sycosis is a deep, chronic form of sycosis barbae associated with scarring, usually occurring as a circinate lesion. A central cicatrix surrounded by pustules and papules gives the appearance of lupus vulgaris (see Chapter 184).

Furuncles and Carbuncles. A furuncle or boil is a deep-seated inflammatory nodule that develops around a hair follicle, usually from a preceding, more superficial folliculitis and often evolving into an abscess. A carbuncle is a more extensive, deeper, communicating, and infiltrated lesion that develops when suppuration occurs in thick inelastic skin when multiple, closely set furuncles coalesce.

Furuncles. Furuncles arise in hair-bearing sites, particularly in regions subject to friction, occlusion, and perspiration, such as the neck, face, axillae, and buttocks. They may complicate preexisting lesions such as atopic dermatitis, excoriations, abrasions, scabies, or pediculosis, but occur more often in the absence of any local predisposing causes. In addition, a variety of systemic host factors is associated with furunculosis: obesity, blood dyscrasias, defects in neutrophil function (defects in chemotaxis associated with eczema and high levels of IgE, defects in intracellular killing of organisms as in chronic granulomatous disease of childhood), treatment with glucocorticoids and cytotoxic agents, and immunoglobulin deficiency states. The process is often more extensive in patients with diabetes. The majority of patients with problems of furunculosis appear to be otherwise healthy.

Cutaneous Lesions. A furuncle starts as a hard, tender, red folliculocentric nodule in hair-bearing skin that enlarges and becomes painful and fluctuant after several days (i.e., undergoes abscess formation; Fig. 176-8A). Rupture occurs with discharge of pus, and often a core of necrotic material. The pain surrounding the lesion then subsides, and the redness and edema diminish over several days to several weeks. Furuncles



Figure 176-8 **A.** Furuncle of the upper lip. The lesion is nodular, and the central necrotic plug is covered by purulent crust. Several small pustules are seen lateral to the center of the lesion. **B.** Multiple furuncles. Multiple abscesses on the buttocks of long standing in a young man with inflammatory bowel disease. The lesions healed with scarring after a prolonged course of dicloxacillin.

BOX 176-6 DIFFERENTIAL DIAGNOSIS OF FURUNCULOSIS

- Cystic acne
- Kerion (see Chapter 188)
- Hidradenitis suppurativa
- Ruptured epidermal inclusion cyst
- Furuncular myiasis
- Apical dental abscess
- Osteomyelitis

may occur as solitary lesions or as multiple lesions in sites such as the buttocks (see Fig. 176-8B).

Differential Diagnosis. See Box 176-6 for differential diagnosis of furunculosis.

Carbuncles. A carbuncle is a larger, more serious inflammatory lesion with a deeper base, characteristically occurring as an extremely painful lesion at the nape of the neck, the back, or thighs (Fig. 176-9). Fever and malaise are often present, and the patient may appear quite ill. The involved area is red and indurated, and multiple pustules soon appear on the surface, draining externally around multiple hair follicles. The lesion soon develops a yellow–gray irregular crater at the center, which may then heal slowly by granulating, although the area may remain deeply violaceous for a prolonged period. The resulting permanent scar is often dense and readily evident.

Laboratory Tests. Extensive furunculosis or a carbuncle may be associated with leukocytosis. *S. aureus* is almost always the cause with CA-MRSA being more than likely in most geographic locations. Histologic examination of a furuncle shows a dense polymorphonuclear inflammatory process in the dermis and subcutaneous fat. In carbuncles, multiple abscesses, separated by connective-tissue trabeculae, infiltrate the dermis and pass along the edges of the hair follicles, reaching the surface through openings in the undermined epidermis. The diagnosis is made on the basis of the clinical appearance. Gram stain of pus, clusters of Gram-positive cocci, or isolation of *S. aureus* on culture confirms the diagnosis.



Figure 176-9 Carbuncle. This lesion represents multiple confluent furuncles draining pus from multiple openings.

Prognosis and Clinical Course. The major problems with furunculosis and carbuncles are bacteremic spread of infection and recurrence. Lesions about the lips and nose raise the specter of spread via the facial and angular emissary veins to the cavernous sinus. Invasion of the bloodstream may occur from furuncles or carbuncles at any time, in an unpredictable fashion, resulting in metastatic infection such as osteomyelitis, acute endocarditis, or brain abscess. Manipulation of such lesions is particularly dangerous and may facilitate spread of infection via the bloodstream. Fortunately, these complications are not common. Recurrent furunculosis is a troublesome process that may continue for many years.

Treatment. Simple furunculosis may be aided by local application of moist heat. A carbuncle or a furuncle with surrounding cellulitis, or one with associated fever, should be treated with a systemic antibiotic (as for MRSA impetigo; see Box 176-4). For severe infections or infections in a dangerous area, maximal antibiotic dosage should be employed by the parenteral route. CA-MRSA should be suspected in all serious purulent infections. Vancomycin (1.0–2.0 g intravenously daily in divided doses) or other systemic parenteral agents that have anti-CA-MRSA activity are indicated for these patients. Antibiotic treatment should be continued for at least 1 week.

When the lesions are large, painful, and fluctuant, then incision and drainage are the most important actions that one should take in a timely manner. If the infection is recurrent or complicated by comorbidities, a culture can be sent. Antimicrobial therapy should be continued until all evidence of inflammation has regressed and altered appropriately as culture results become available. Draining lesions should be covered to prevent autoinoculation and diligent hand washing performed. Patients with recurrent furunculosis present a special and frequently exasperating problem (Box 176-7).

Abscess. As discussed in Section "Furuncles and Carbuncles," abscesses caused by *S. aureus* commonly occur in folliculocentric infections—that is, folliculitis, furuncles, and carbuncles. Abscesses can also occur at sites of trauma, foreign bodies, burns, or sites of insertion of intravenous catheters. The initial lesion is an erythematous nodule. If untreated, the lesion often enlarges, with the formation of a pus-filled cavity (Fig. 176-10). CA-MRSA should be suspected in all patients with abscess.

The initial and most important treatment of an abscess is incision and drainage. Antibiotic usage after incision and drainage is only recommended if the lesion is severe or associated with cellulitis, there are signs of systemic illness, there are comorbid factors or immune suppression, the patient is very young or very old, if the abscess is in a body location that is difficult to drain, there is associated septic phlebitis, or there is no response to incision and drainage alone.[9]

Botryomycosis. (See Chapter 185, Table 185-1). Botryomycosis is a rare pyogenic disease, possibly related

BOX 176-7 MANAGEMENT OF RECURRENT FURUNCULOSIS

- Careful evaluation for underlying causes.
- Systemic processes: previously discussed.
- Specific localized predisposing factors: industrial exposure to chemicals, oils; poor hygiene; obesity; hyperhidrosis; ingrown hairs; pressure from tight clothing or belts.
- Sources of staphylococcal contact: pyogenic infections in the family, contact sports such as wrestling, autoinoculation.
- Nasal carriage of *Staphylococcus aureus*: this is the site from which dissemination of the organism may occur to other body sites. The frequency of nasal carriage varies: 10%–15% in infants 1 year of age, 38% in college students, 50% in hospital physicians and military trainees.
- General skin care: the aim of these measures is to reduce the numbers of *S. aureus* on the skin. General skin care of both hands and body with water and soap is important (an antimicrobial soap solution, such as 4% chlorhexidine solution, may be used to decrease staphylococcal skin colonization). The patient should avoid trauma to the skin as well as potential skin irritants such as strong soaps and deodorants. A separate washcloth (and towel) should be used and carefully washed in hot water before use.
- Care of clothing: loose, lightweight, porous clothing should be worn as much as possible. Large numbers of *Staphylococci* are frequently present on the sheets and underclothing of patients with furunculosis and may cause reinfection of the patient and infection of other members of the family. In problem cases, it is not unreasonable to recommend that these items be carefully and separately washed in boiling water and changed daily.
- Care of dressings: dressings should be changed frequently if purulent drainage collects. They should be carefully discarded in a paper bag that can be sealed and disposed of immediately.
- General measures: despite the above measures, some patients continue to have recurrent cycles of lesions. Sometimes, the problem can be ameliorated or abolished by removing the patient from the regular routine of work. This is particularly pertinent in individuals who are under considerable emotional stress and physical fatigue. A vacation for several weeks, ideally in a cool, dry climate, may help considerably by providing rest and also the time needed for carrying out the program of careful skin care.
- Measures aimed at elimination of nasal (and skin) carriage of *S. aureus* (methicillin susceptible or methicillin resistant).
- Local use of ointment in the nasal vestibule reduces nasal carriage of *S. aureus* and secondarily reduces the "shedding" of organisms on the skin, a process that may contribute to recurrent furunculosis. Intranasal application of a 2% mupirocin calcium ointment in a white, soft, paraffin base for 5 days can eliminate *S. aureus* nasal carriage in 70% of healthy individuals for up to 3 months. In immunocompetent staphylococcal carriers with recurrent skin infections, a 5-day course of nasal mupirocin ointment every month for 1 year resulted in positive nasal cultures in only 22% of patients as compared with 83% in the placebo group. The nasal culture-negative patients also had significantly fewer skin infections during the treatment period. Staphylococcal resistance to mupirocin was observed in only 1 patient out of 17. Prophylaxis with fusidic acid ointment in the nares twice daily every fourth week for the patient and family members who are nasal carriers of the infecting strain (along with peroral antistaphylococcal antibiotic for 10–14 days for the patient) has been used with some success.
- Oral antibiotics (e.g., rifampin, 600 mg orally daily for 10 days) have been effective in eradicating *S. aureus* from most nasal carriers for periods of up to 12 weeks. Such a use of rifampin for a brief period to eradicate nasal carriage of *S. aureus* and interrupt a continuing cycle of recurrent furunculosis might be reasonable in a patient in whom other measures have failed. However, selection of rifampin-resistant strains can occur rapidly with such therapy. The addition of a second drug (dicloxacillin for methicillin-susceptible *S. aureus*; trimethoprim-sulfamethoxazole, ciprofloxacin, or minocycline for methicillin-resistant *S. aureus*) has been used to reduce the emergence of rifampin resistance and to treat recurrent furunculosis.

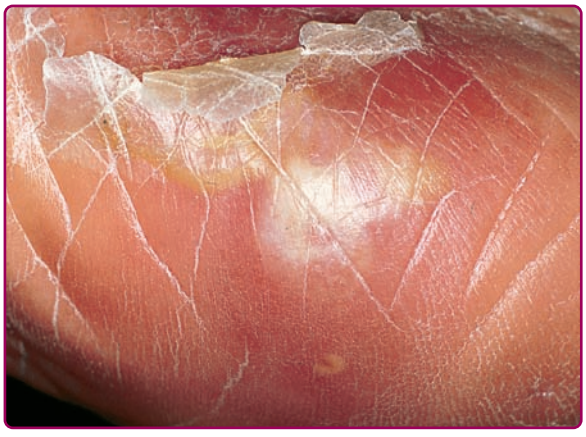

Figure 176-10 *Staphylococcus aureus* abscess. A large painful abscess on the heel of a patient with diabetes improved clinically; however, the severe pain persisted. X-ray films of the heel revealed a broken-off sewing needle. The patient had sensory neuropathy and was unaware of stepping on this foreign body.

to a balance between numbers of organisms and host defenses, presenting as a purulent chronic, subcutaneous infection. Predisposing factors include trauma, immunosuppression (HIV disease, hyper-IgE syndrome), chronic alcoholism, and diabetes mellitus. Lesions (usually solitary) can occur in skin, bone, and liver.

Cutaneous botryomycosis usually presents as a solitary lesion or a few lesions, often occurring in the genital area. The lesion has the gross appearance of a ruptured epidermal inclusion cyst (an erythematous circumscribed tender nodule), or prurigo nodularis (Fig. 176-11). In the majority of reported cases, a foreign body (fish bone, broom straw, etc.) has played a role in initiating or perpetuating the lesion. For diagnosis and treatment, see Chapter 185.



Figure 176-11 *Staphylococcus aureus* botryomycosis. A plaque on the chest had been present for several months in this human immunodeficiency virus-infected individual. The diagnosis was confirmed on lesional biopsy findings and culture.

Staphylococcal Paronychia. Individuals exposed to hand trauma or chronic moisture are predisposed to staphylococcal paronychia, as well as to other causes of paronychia (e.g., *Candida, Pseudomonas, Streptococcus,* dermatophytes). *S. aureus* is the major infectious cause of acute paronychia, usually around the fingernails, often originating from a break in the skin, such as a hangnail. Clinically, skin and soft tissue of the proximal and lateral nail fold are red, hot, and tender, and, if not treated, can progress to abscess formation (Fig. 176-12).

In contrast, chronic or recurrent paronychia caused by *Candida albicans* is an infection of the space created by separation of the proximal dorsal nail plate and the undersurface of the proximal nail fold. Candidal paronychia is most common in individuals who have their hands in water for a great deal of time (see Chapter 189).

Management of paronychia caused by *S. aureus* includes oral and topical antibiotics, and incision and drainage of abscesses.

Staphylococcal Whitlow (Felon). A whitlow is a purulent infection or abscess involving the bulbous distal end of the finger. The most common causes are *S. aureus* and herpes simplex virus. The portal of entry of *S. aureus* is a traumatic injury or possible extension of an acute paronychia. This infection is usually very painful. An obvious portal of entry is often apparent. The finger bulb is red, hot, tender, and edematous,



Figure 176-12 *Staphylococcus aureus* paronychia. An abscess is seen in the dorsum of the finger, beginning in a small break in the cuticle. In contrast, *Candida* paronychia is a space infection, occurring in the space created by the separation of the proximal dorsal nail plate and the overlying proximal nail fold.



Figure 176-13 *Staphylococcus aureus* whitlow (felon). A pyogenic granuloma arose 1 week after trauma to the bulb of the thumb. A week later, the bulb became swollen, erythematous, and very tender. Abscess formation is seen with loculation of pus. X-ray films showed early osteomyelitis complicating the whitlow.

with possible abscess formation (Fig. 176-13). In contrast, individuals with herpetic whitlows usually have a history of lesions occurring in the same site and present with grouped hemorrhagic vesicles, which may become confluent and form a single bulla (see Chapter 193). Management of a staphylococcal whitlow requires surgical drainage of loculated abscess(es) within the tissue and intravenous antibiotic therapy. X-ray examination of the involved finger is indicated to determine the presence of osteomyelitis. CA-MRSA should be suspected in all cases.

SYNDROMES CAUSED BY STAPHYLOCOCCAL EXOTOXINS. SSSS, staphylococcal scarlatiniform eruption, TSS, recalcitrant erythematous, desquamating disorders (red disorders), and recurrent toxin-mediated perineal erythema are syndromes caused by staphylococcal exotoxins and are discussed in Chapter 177.

STREPTOCOCCAL SKIN INFECTIONS

GENERAL FEATURES

EPIDEMIOLOGY. Group A *Streptococci* are usually spread by transfer of organisms from an infected person or carrier through close personal contact. The major source of such spread is from patients with infections in the upper respiratory tract. Approximately 10% of the normal population carry group A *Streptococcus* asymptomatically—a higher percentage of adults than of children in the oropharynx and less commonly in the nares and anus. Although the carriage rate of group A *Streptococcus* on normal skin is less than 1%, a variety of skin lesions and puerperal sepsis may also be the source of intrahospital spread of infection. Group A *Streptococci* introduced into the operating room in the form of a minor skin infection, or even through perianal carriage by a surgeon or anesthetist, may be responsible for an epidemic of streptococcal wound infections.

The major factor in the spread from a carrier or an infected person is the proximity to the individual disseminating the organisms. Because many patients with group A streptococcal (GAS) skin infections harbor the same organism in their pharynxes, they are, for both reasons, potential sources for spread of infection in a hospital. Particular care must be taken to prevent spread of infection by isolating such patients until antibiotic therapy has rendered them noncontagious.

The overall incidence of streptococcal disease has surged since the mid-1980s.[17] Reports of invasive GAS infections often associated with shock and multiorgan failure have increased globally. Localized epidemics continue to appear and, during such outbreaks, the carrier and infection rates in the community increase. After recovery (without antibiotic treatment) from streptococcal pharyngitis, some individuals may carry the organism for prolonged periods. The carrier state may also occur in the absence of overt antecedent infection. Fifteen percent to twenty percent of schoolchildren carry group A *Streptococci* in the throat. Some have hypothesized that the genetic predisposition to develop psoriasis may have been associated with an improved survival outcome in times of epidemic streptococcal infections.[18]

ETIOLOGY AND PATHOGENESIS. The Lancefield classification of streptococcal groups (A–T) is based on the C carbohydrate antigens of the cell wall. Although essentially all GAS strains are β-hemolytic *Streptococci*, not all *Streptococci* producing β-hemolysis belong to group A. Because serologic grouping of *Streptococci* is not generally available, a reasonably accurate presumptive test for group A *Streptococci* is necessary. Bacitracin disk ("Taxos S") sensitivity has been widely used; group A *Streptococci* are, almost without exception, susceptible to the low concentration of bacitracin contained in the disk, whereas *Streptococci* of other groups are often resistant. Subtyping of group A *Streptococci* can be performed according to their M protein antigenicity (see below). Certain M protein serotypes appear to correlate with greater virulence of the organism. The M protein inhibits phagocytosis, promotes adherence to host cells and allows bacterial growth in human blood.[19] The M protein is highly polymorphic, with more than 150 variants coded for by the *emm* gene. Other virulence factors are cell surface molecules, including the hyaluronic acid capsule, C5a peptidase, opacity factor, and streptococcal inhibitor of complement. Secreted proteins playing a role in virulence include streptolysins O and S, cysteine proteinase, pyrogenic exotoxins, streptokinase, hyaluronidase, and other enzymes. It should be noted that horizontal gene transfer in GAS strains is a

very common event. This transfer results in the rapid development of new and more virulent strains.[20]

The primary invasive streptococcal pyodermas are due almost exclusively to group A *Streptococcus*, which is usually considerably more invasive than of other *Streptococci*. Nonsuppurative postinfectious complications have been limited mostly to those produced by group A *Streptococcus*. Thus, GAS infections merit antibiotic treatment and eradication.

The hallmarks of invasive GAS infection are profuse edema, rapid spread through tissue planes, and a relatively thin exudative response. Infection may spread via the lymphatic or hematogenous routes and result in a fulminant clinical course.

The presence of *Streptococci* of groups other than A in skin lesions may represent either surface colonization or actual secondary infection in preexisting dermatoses. Group C and group G *Streptococci* have occasionally been implicated in impetiginous lesions, secondarily infected dermatitis, wound infections with lymphangitis, and even in erysipelas and cellulitis (see Chapter 178). *Streptococci* of groups B and D have been isolated from infections of skin lesions secondary to ischemia or venous stasis and have particularly involved the perineal area and operative wound sites. As with most secondary infections, those due to group B and group D *Streptococci* are frequently mixed infections with enteric bacteria or *S. aureus*. Group B *Streptococci* may cause cellulitis and otitis in neonates and, sometimes, in adults. Group L *Streptococci* (often carried by pigs, cattle, and poultry) have been responsible for impetigo, secondarily infected wounds, and paronychias in meat handlers.

The incidence of invasive complications (lymphangitis, suppurative lymphadenitis, bacteremia) of streptococcal infections of the skin has decreased in the antibiotic era. Other than these pyogenic complications, a variety of nonsuppurative complications (acute rheumatic fever, acute glomerulonephritis, erythema nodosum) may follow GAS infections. Distinct differences exist between acute rheumatic fever and acute glomerulonephritis in the site of the antecedent infection, the length of the latent period, and the streptococcal serotypes involved. Acute rheumatic fever may be a complication of GAS pharyngitis or tonsillitis, but it does not occur after streptococcal skin infections. In contrast, acute nephritis may follow infection of either the skin or the upper respiratory tract. The latent period between streptococcal pharyngitis and the onset of rheumatic fever is 2–3 weeks; whereas the latent period for pharyngitis-associated nephritis is approximately 10 days. A longer latent period of approximately 3 weeks is characteristic of acute nephritis associated with streptococcal pyoderma.

Group A *Streptococci* are classified into over 80 subtypes, based on the antigenicity of their M proteins (fibrillar structures extending out from the cell surface). Although there is no strong evidence of an association between infection with any specific group A serotypes and the subsequent development of rheumatic fever as yet, several serotypes (particularly mucoid strains of types 1, 3, and 18) have been implicated in a few outbreaks of streptococcal sore throat complicated by this sequela.[21] However, there is a clear relationship between infection with certain serotypes and the subsequent occurrence of nephritis—the so-called *nephritogenic serotypes*. Type 12 is the classic serotype responsible for pharyngitis-associated acute nephritis, but other serotypes, such as 1, 4, 25, and 49, have been implicated. The pyoderma-associated nephritogenic strains generally belong to different serotypes: types 2, 49, 42, 55, 56, 57, and 60.[22,23] Unlike the pharyngitis strains, the pyoderma serotypes produce lipoproteinase or opacity factor, illustrating a fundamental difference between the two.[17] The skin rather than the pharynx is the principal site of antecedent streptococcal infection causing nephritis, and impetigo is now the most common form of such predisposing skin infections.

The frequency of acute glomerulonephritis after infection with a known nephritogenic strain is 10%–15%; the frequency of rheumatic fever after an unrecognized or inadequately treated pharyngeal infection by any serotype of group A *Streptococcus* is 2%–3% or less. The distinction between nephritogenic and other strains of *Streptococci* that might be associated with rheumatic fever can be seen in studies from Trinidad, a hyperendemic area for pyoderma-associated nephritis. There the streptococcal serotypes causing outbreaks of nephritis differed from the serotypes associated with sporadically occurring cases of acute rheumatic fever in the same population.[21]

It has been suggested that several biologic properties are associated with broad categories of group A *Streptococci*. Most M proteins fall into one of two antigenic classes based on the presence (class I) or absence (class II) of a highly conserved antigenic domain. Almost all rheumatic fever outbreak-associated strains belong to serotypes of class I and require a precursor nasopharyngeal infection. However, because many class I serotypes are associated with impetigo as well, and because class II serotypes are responsible for both upper respiratory and skin infections, the class of M protein alone is not a determinant of tissue tropism. Current evidence indicates differences among class I organisms that may relate to their capacities to induce rheumatic fever: class I nasopharyngeal isolates appear to lack human IgG-binding activity, whereas nearly all impetigo isolates of the same class bear human IgG receptors.[24]

As in *S. aureus*, there are several GAS superantigens that have been identified. These include streptococcal pyrogenic exotoxin (or erythrogenic exotoxin) A–C, F, and G–J, streptococcal superantigen, and streptococcal mitogenic exotoxin Z. These superantigens are associated with disease.[25]

ANTIBODY RESPONSE AND IMMUNITY.

The immune response to GAS infection depends to a large measure on the site of infection. *Streptococcal infection* is usually defined as a positive throat culture with a serologic response to group A *Streptococcus* and the streptococcal carrier state by a positive throat culture and no serologic response. After streptococcal pharyngitis, specific antibodies develop to many of the extracellular enzymes of the *Streptococci*. Eighty-five percent

of patients with acute rheumatic fever and a proven preceding streptococcal infection have an elevated or increasing antistreptolysin O titer. The serologic demonstration of an antecedent streptococcal infection in this situation can be increased to virtually 100% by the simultaneous testing for several other antibodies (antihyaluronidase, anti-DNase B). Antibodies to extracellular products, with the exception of antibody to the erythrogenic toxin of scarlet fever, appear to have no effect on the manifestations of illness. Streptococcal immunity is type specific (but not group specific), long lasting, and depends on the production of bactericidal antibodies to the specific M proteins of the over 80 different serotypes of group A organisms. Although recurrent pharyngeal infections caused by the same serotype are most unusual, repeated clinical infections caused by different types are not uncommon. Early treatment of streptococcal upper respiratory tract disease with antibiotics may suppress the appearance of type-specific antibody (and immunity), as well as the development of antibody to the extracellular products of the organism.

In contrast to pharyngeal infections, the antistreptolysin O response with streptococcal skin infections or pyoderma-associated nephritis is weak. To define the latter serologically, anti-DNase B titers are much more reliable. Although pyoderma strains of *Streptococci* produce M proteins, and although type-specific antibody may develop in patients with pyoderma-associated nephritis, the frequency of production of such antibodies and their role in protection against reinfection are unclear. Although pharyngeal reinfection with the same streptococcal serotype is probably unusual, some evidence suggests that the same serotype can be associated with repeated episodes of pyoderma.

Specific diseases caused by group A (and other) *Streptococci* are listed in Box 176-8. Streptococcal pyodermas include all types of superficial streptococcal skin infections except erysipelas—that is, impetigo, ecthyma, and secondary infections of preexisting skin lesions (e.g., insect bites, abrasions, eczema). Streptococcal intertrigo such as streptococcal perianal "cellulitis" can occur primarily or secondarily in underlying conditions such as inverse psoriasis.

BOX 176-8 INFECTIONS AND TOXIN SYNDROMES CAUSED BY GROUP A *STREPTOCOCCI*

SUPERFICIAL PYODERMAS
- Nonintertriginous skin
  - Impetigo
  - Ecthyma
  - Blistering distal dactylitis
- Intertriginous skin
  - Perianal streptococcal cellulites
  - Streptococcal vulvovaginitis
  - Streptococcal intertrigo

INVASIVE INFECTIONS
- Acute lymphangitis
- Erysipelas
- Cellulitis
- Streptococcal gangrene
- Bacteremia, septicemia

TOXIN-ASSOCIATED SYNDROME
- Scarlet fever
- Streptococcal toxic-shock-like syndrome
- Streptococcal gangrene

NONSUPPURATIVE COMPLICATIONS
- Rheumatic fever
- Glomerulonephritis

OTHER ASSOCIATED CUTANEOUS REACTION PATTERNS
- Erythema nodosum
- Erythema multiforme
- Guttate-pattern psoriasis
- Vasculitis

IMPETIGO

EPIDEMIOLOGY. Impetigo caused by group A *Streptococcus* is a highly communicable infection and occurs predominantly in preschool-aged children (usually before the age of 2 years except in highly endemic areas). It is more common in warmer, more humid climates than in temperate zones. Its peak seasonal incidence is in the later summer and early fall. Nongroup A (groups B, C, and G) *Streptococci* may be responsible for rare cases of impetigo; group B *Streptococci* are associated with impetigo in the newborn. Whereas, many different serotypes of group A *Streptococci* may cause pharyngitis, a limited number of newly described types predominate in impetigo (types 49, 52, 53, 55, 56, 57, 59, and 61).

ETIOLOGY AND PATHOGENESIS. Group A *Streptococci* appear on normal skin of children approximately 10 days before the development of impetigo, and they are not recovered from the nose and throat of the same patients until 14–20 days after skin acquisition of the organism. *Streptococci* are recovered from the respiratory tract of approximately 30% of children with skin lesions, but there is no clinical evidence of streptococcal pharyngitis. Thus, the sequence of spread in a given patient is from normal skin to lesions and eventually to the respiratory tract.[26] In contrast, the sequence of spread of *S. aureus* (in cases of impetigo in which it is the only organism isolated) is from nose, to normal skin, to skin lesions (see Section "Impetigo").

When exposed to an infectious contact, preexisting lesions, such as scabies, varicella, or eczema, predispose to the appearance of infected lesions. Crowding, poor hygiene, and neglected minor skin trauma contribute to the spread of streptococcal impetigo in families. Minor outbreaks have also occurred among athletes involved in contact sports. Although the majority of cases occur in children, particularly of preschool age, young adults are also affected. The inflammatory process of impetigo is superficial, with a unilocular vesicopustule located

between the stratum corneum above and the stratum granulosum below. This is usually situated near the opening of a hair follicle. Organisms, as well as leukocytes and cell debris, fill the vesicle.

CLINICAL FINDINGS

Cutaneous Lesions. Impetigo caused by group A *Streptococcus* presents as a crusted superficial infection of the skin; an initial vesicular phase has been described but is rarely detected. Lesions are clinically indistinguishable from impetigo caused by *S. aureus*, with the exception of bullous impetigo (see Section "Nonbullous Impetigo" and Figs. 176-1 to 176-3). Pruritus and burning may occur, but the lesions are usually painless. Systemic response is minimal unless complications occur.

Laboratory Tests. A slight leukocytosis may occur. A Gram-stained smear of early vesicle fluid reveals Gram-positive cocci in chains. Culture of the weeping area or of the area beneath an unroofed crust reveals group A *Streptococci* or a mixture of *Streptococci* and *S. aureus* (particularly from older crusted lesions).

PROGNOSIS AND CLINICAL COURSE. If untreated, the process may persist and new lesions may develop over the course of several weeks; thereafter, the infection tends to resolve spontaneously unless there is some underlying cutaneous disorder such as eczema. If untreated, some lesions become chronic and deeper, such as ecthyma (see Section "Staphylococcal Ecthyma"). Complicating erysipelas, cellulitis, or bacteremia are unusual. The major serious sequela is acute poststreptococcal glomerulonephritis.

TREATMENT. Topical treatment (removal of dirt, crusts, and debris by soaking with soap and water) is a valuable adjunct. Mupirocin ointment appears to be as effective as parenteral or oral penicillin for treatment of impetigo.[27] Retapamulin 1% ointment is also effective for localized impetigo and secondarily impetiginized dermatitis as well, although decreased efficacy against MRSA was noted in some trials.[14]

In superficial pyodermas known to be caused by group A *Streptococcus*, penicillin is the drug of choice, administered either as a single injection of long-acting benzathine penicillin (300,000–600,000 units for children; 1.2 million units for adults) or orally (25,000–100,000 units/kg/day in divided doses q6h for 10 days). Although penicillin treatment clears the lesions of GAS impetigo and prevents recurrence for a short time, *Streptococci* can persist on or newly colonize unaffected skin in spite of this therapy. Erythromycin (30–50 mg/kg/day PO in divided doses q6h for children; 250–500 mg PO q6h for adults administered for 10 days) is a suitable alternative drug in patients allergic to penicillin. However, it should be noted that 20% or more of GAS strains became resistant to erythromycin in areas (Japan, Finland) where this antibiotic had been extensively used for a variety of indications.[28] There is still no evidence to suggest that treatment of GAS pyoderma can prevent subsequent nephritis in any individual. Although the latent period after impetigo is longer than that after pharyngeal infection, the mildness of the illness delays or negates the seeking of medical attention.

Practically, however, the majority of cases of nonbullous impetigo are caused by *S. aureus*, and topical or systemic antimicrobial treatment should be directed at that pathogen (see Box 176-4).

STREPTOCOCCAL ECTHYMA

See Section "Staphylococcal Ecthyma."

INTERTRIGINOUS STREPTOCOCCAL INFECTIONS

Streptococcal pyodermas occur much less commonly in occluded sites such as the perineum/perianal region, vulva/vagina, axillae (Fig. 176-14), inframammary region, groin, preputial sac, and web spaces of the feet. Perianal (group A) streptococcal "cellulitis" occurs principally in children, presenting with intense perianal erythema (Fig. 176-15), pain on defecation, blood-streaked stools associated with anal fissures, and chronicity if untreated.[29] It is often confused with psoriasis, candidiasis, seborrheic dermatitis, inflammatory bowel disease, pinworm infection, or a behavioral problem. The infection can also involve the penis and vulva. Treatment options include oral antibiotics or topical mupirocin. Guttate psoriasis has also occurred in children, associated with perianal streptococcal infection.[30]



Figure 176-14 Group A streptococcal intertrigo. A sharply marginated erythematous and oozing plaque in the axilla, which was also present in the other axilla, inframammary area, and inguinal folds, was painful in this human immunodeficiency virus-infected woman.



Figure 176-15 Group A streptococcal intertrigo—perianal streptococcal cellulitis. Well-demarcated erosive erythema in the perianal region and perineum in an 8-year-old boy who complained of soreness.

BLISTERING DISTAL DACTYLITIS. Group A *Streptococcus* is responsible for the majority of cases of blistering distal dactylitis, also called *bulla repens*, usually occurring in children and adolescents. However, group B *Streptococcus* can also cause this infection. A large, tense blister develops, filled with seropurulent fluid, over the volar skin pad of distal fingers or toes (Fig. 176-16). The blisters are often surrounded by an erythematous base. The lesion may be more proximally located on the finger or extend to involve the nail folds. Group A *Streptococcus* may be cultured from the vesicle fluid. Blistering distal dactylitis may be treated with oral penicillins or erythromycin and release of subungual pus is often required. Staphylococcal blistering distal dactylitis has been reported with an identical clinical picture.[31]



Figure 176-16 Group A streptococcal blistering dactylitis. A blister is seen on a toe adjacent to the nail fold; the patient also had group A streptococcal intertrigo of an abdominal skin fold.

ACUTE LYMPHANGITIS. Acute lymphangitis is an inflammatory process involving the subcutaneous lymphatic channels. It is most often caused by group A *Streptococci*, but occasionally may be caused by *S. aureus*; rarely, STIs with other organisms, such as *Pasteurella multocida* or herpes simplex virus may be associated with acute lymphangitis.

CLINICAL FINDINGS

History. The portal of entry is commonly a wound on an extremity, an infected blister, or a paronychia. The systemic manifestations of infection may occur either before any evidence of infection that is present at the site of inoculation or after the initial lesion has subsided. The patient may notice pain over an area of redness proximal to the original break in the skin. Systemic symptoms are often more prominent than expected from the degree of local pain and erythema.

An unusual spread of streptococcal infection of the thumb (paronychia) or of the interdigital webs between the thumb and index finger may occur occasionally. Lymphatic drainage from this area can bypass the lymph nodes at the elbow and drain into the axillary nodes, which, in turn, communicate with the subpectoral nodes and the pleural lymphatics. As a consequence, subpectoral abscesses and pleural effusion can develop. The subpectoral infection may dissect downward and appear over the lower chest and upper abdomen as an area of cellulitis. This is a very serious illness. The clinical clues to the development of this sequence of events are provided by the location of the original infection on the thumb or medial surface of the index finger and the early occurrence of axillary pain.

Cutaneous Lesions. Red linear streaks, which may be a few millimeters to several centimeters in width, extend from the local lesion toward the regional lymph nodes, which are usually enlarged and tender (Fig. 176-17).

DIFFERENTIAL DIAGNOSIS. In the upper extremities, acute lymphangitis usually can be differentiated from subacute or chronic sporotrichoid syndrome caused by organisms such as *Sporothrix schenckii*. In the lower extremities, superficial thrombophlebitis may produce somewhat similar linear areas of tender erythema. The absence of a portal of entry and of tender regional adenopathy is helpful in distinguishing this process from lymphangitis.

LABORATORY TESTS. The peripheral white blood cell count is elevated, with a marked increase in polymorphonuclear cells. The offending organism



Figure 176-17 Acute lymphangitis of forearm due to *Staphylococcus aureus*. There is a tender linear streak extending proximally from a small area of cellulitis on the volar wrist.

cannot be cultured from the skin, as the infection is restricted to the lymphatic channels. However, the primary portal of entry or a suppurative lymph node, if overt infection is present, may reveal the etiologic agent.

PROGNOSIS AND CLINICAL COURSE. The frequent development of bacteremia with metastatic infection in various organs makes this a potentially serious disease. The infection responds readily to penicillin therapy if instituted promptly.

INVASIVE STREPTOCOCCAL INFECTIONS

Erysipelas, cellulitis, and streptococcal gangrene are invasive streptococcal infections and are discussed in Chapter 178.

STREPTOCOCCAL TOXIN SYNDROMES

Scarlet fever and toxic streptococcal syndromes are streptococcal toxin syndromes and are discussed in Chapter 177.

CUTANEOUS MANIFESTATIONS OF SUBACUTE BACTERIAL ENDOCARDITIS

(See Chapter 181)

POSTSTREPTOCOCCAL (GROUP A) NONSUPPURATIVE CUTANEOUS SEQUELAE

ERYTHEMA NODOSUM. (See Chapter 70)

ERYTHEMA MARGINATUM (CUTANEOUS LESIONS OF ACUTE RHEUMATIC FEVER). (See Chapter 160)

PURPURA FULMINANS. (See Chapters 144 and 181)

OTHER SKIN LESIONS ACCOMPANYING OR FOLLOWING GROUP A STREPTOCOCCAL INFECTIONS

Erythema Multiforme-Like Lesions. Round erythematous macules, up to 1.5 cm in diameter, some developing bright borders and subsequently showing clearing in the center, may occur during bacteremia caused by group A *Streptococci* (or *S. aureus*) in infants and young children (see Chapter 39).

Acute Guttate Psoriasis. Rarely, erythematous, papulosquamous, guttate psoriasiform lesions may develop during or after GAS pharyngitis, perianal streptococcal infection, or other skin infections. Children appear to be most commonly affected. Clearing of the lesions may occur within weeks of antimicrobial therapy of the streptococcal infection. Although the temporal relation of the two processes is striking, a direct causal connection has not been established. There is no strong evidence to support the use of antibiotics in the treatment of guttate psoriasis.

MANAGEMENT OF GROUP A STREPTOCOCCAL SKIN INFECTIONS

GENERAL PRINCIPLES. Penicillin G is the drug of choice in the treatment of known GAS skin infections. When the etiology is not known immediately (e.g., in cellulitis) and when *S. aureus* is also a distinct consideration, a semisynthetic penicillin (nafcillin or oxacillin) should be employed initially. Penicillin treatment should be continued for at least 10 days to ensure eradication of the infection. Prophylactic penicillin therapy is indicated for close family contacts (particularly children) of patients with streptococcal pharyngitis.

ANTIMICROBIAL THERAPY. Mild instances of infections, such as impetigo, scarlet fever, or certain cases of erysipelas and cellulitis, may be treated with oral penicillin V (250–500 mg qid). When staphylococcal infection is suspected, dicloxacillin (250–500 mg PO qid) should be substituted. In adults allergic to penicillin, erythromycin (250–500 mg PO qid) is a reasonable alternative. Other alternatives include azithromycin, clarithromycin, and clindamycin (Box 176-9).

PREVENTION OF SPREAD. Patients hospitalized with GAS infections should be isolated until the

BOX 176-9 TREATMENT OF STREPTOCOCCAL PYODERMAS[a]

	TOPICAL (FOR MILD IMPETIGO)	SYSTEMIC	
First line	Mupirocin bid	Penicillin V	250–500 mg PO qid for 5–7 days
		Dicloxacillin (if *Staphylococcus aureus* is suspected)	250–500 mg qid for 5–7 days
Second line (penicillin allergy)	Retapamulin bid	Azithromycin	500 mg × 1 then 250 mg daily for 4 days
		Clindamycin	15 mg/kg/day tid
		Erythromycin	250–500 mg PO qid for 5–7 days

[a]Washing and hygiene are important in all regimens.

organisms have been eradicated by antibiotic treatment. Individuals with recurrent episodes of GAS infections can be treated with dicloxacillin or erythromycin, 250 mg twice daily (penicillin-allergic individuals), as secondary prophylaxis.

SOFT-TISSUE STREPTOCOCCAL INFECTIONS

(See Chapter 178)

CUTANEOUS INFECTIONS CAUSED BY MICROCOCCUS: PITTED KERATOLYSIS

Pitted keratolysis involves the stratum corneum of the web spaces and plantar surface. Originally named *keratoma plantare sulcatum* by Castellani in 1910, this disease has become more commonly called by its current name after Taplin and Zaias coined it in 1967. The disease was first seen in those who went barefooted during the rainy season.

ETIOLOGY AND PATHOGENESIS. The likely causative organism is *Micrococcus sedentarius*, which is a Gram-positive *Staphylococcus*-related bacterium that invades the stratum corneum softened by sweat and moisture. *Corynebacterium* sp. may also be involved. Pitted keratolysis tends to be much more severe in tropical climates than in temperate ones.

Pitted keratolysis occurs in adults and children of both sexes, but adult males with sweaty feet are most susceptible (96% of cases).[32] Sliminess of the skin, often manifest by the foot sticking to the socks, is also a common complaint (70% of cases). The feet are typically very malodorous (89%) and may be mildly pruritic (8%).

CLINICAL MANIFESTATIONS. Pitted keratolysis presents as a superficial erosion of the stratum corneum, composed of numerous small crateriform pits coalescing to form a large discrete defect with serpiginous borders on the plantar surface of the foot. The pits are usually larger than 0.7 mm in diameter, but at times are smaller than 0.5 mm. The pits have elongated configurations along the plantar furrows and are located predominantly on the pressure-bearing areas, such as the ventral aspect of the toe, ball of the foot, and the heel, but they are also seen on nonpressure-bearing areas.[32] The web spaces between the toes are also commonly involved sites, and may be the only manifestation (Fig. 176-18). The diagnosis is made clinically.

DIFFERENTIAL DIAGNOSIS. Interdigital tinea pedis can present with erosive lesions in the web spaces. Erythrasma in the web spaces is usually hyperkeratotic but can be erosive.

LABORATORY FINDINGS. Gram staining of scrapings may detect the microorganism more readily than potassium hydroxide examination. Histologically, the organisms are present in the walls and bases of the crateriform defects in the upper layer of the stratum corneum. The organisms appear as coccoid and filamentous forms with branches and septa.



Figure 176-18 Pitted keratolysis. The web spaces between the toes are sharply eroded. Interdigital tinea pedis and erythrasma may occur concurrently.

TREATMENT. Prophylactic measures are aimed at keeping the feet as dry as possible. Inert antiseptic foot powders often help. Aluminum chloride 20% solution is an effective astringent. A benzoyl peroxide wash and 5% gel are effective therapy in most cases as well. Other commonly used topical adjunctive agents include clindamycin and erythromycin solutions. Systemic use of these agents can be attempted in severe cases.[33]

INFECTIONS CAUSED BY CORYNEBACTERIUM

ERYTHRASMA. Erythrasma is a common superficial bacterial infection of the skin characterized by well-defined but irregular reddish-brown patches, occurring in the intertriginous areas, or by fissuring and white maceration in the toe clefts. It is commonly misdiagnosed as tinea cruris for many months before proper diagnosis is made.

Etiology and Epidemiology.

Corynebacterium minutissimum, the etiologic agent of erythrasma, is a short, Gram-positive rod with subterminal granules. The infection is more common in tropical than in temperate climates. In a study in a temperate climate, 20% of randomly selected subjects were found to have erythrasma by Wood's lamp examination. The generalized disease is much more common in the tropics. Erythrasma is more common in men and may occur in asymptomatic form in the genitocrural area.

Clinical Findings

History. Symptoms vary from a completely asymptomatic form, through a genitocrural form with considerable pruritus, to a generalized form with scaly lamellated plaques on the trunk, inguinal area, and web spaces of the feet. When pruritic, irritation of lesions may cause secondary changes of excoriations and lichenification.

Cutaneous Lesions. The most common site of involvement is the web spaces of the feet, where erythrasma presents as a hyperkeratotic white macerated plaque



Figure 176-19 Erythrasma. Hyperkeratosis with a yellowish hue in the web space of the foot. The three lateral web spaces of both feet were involved. The potassium hydroxide preparation was negative; the Wood's lamp examination showed a bright coral red fluorescence.

(Fig. 176-19), especially between the fourth and fifth toes. In the genitocrural, axillary, and inframammary regions, the lesions present as well-demarcated, reddish-brown, superficial, finely scaly, and finely wrinkled patches (Fig. 176-20). In these sites, the patches have a relatively uniform appearance as compared with tinea corporis or cruris, which often have central clearing.

Wood's lamp examination of erythrasma reveals a coral-red fluorescence caused by coproporphyrin III. The fluorescence may persist after eradication of the *Corynebacterium* as the pigment is within a thick stratum corneum.

Differential Diagnosis. Tinea versicolor is distinguished from erythrasma by the lesions on the trunk being most numerous at nonintertriginous sites. Tinea cruris tends to have an active scaling border with central clearing. Inverse psoriasis usually presents as sharply demarcated plaques with a shiny red color in the intergluteal cleft, inguinal folds, and axillae.

Laboratory Findings. Culture of the specific *Corynebacterium* in abundance from the lesion corroborates

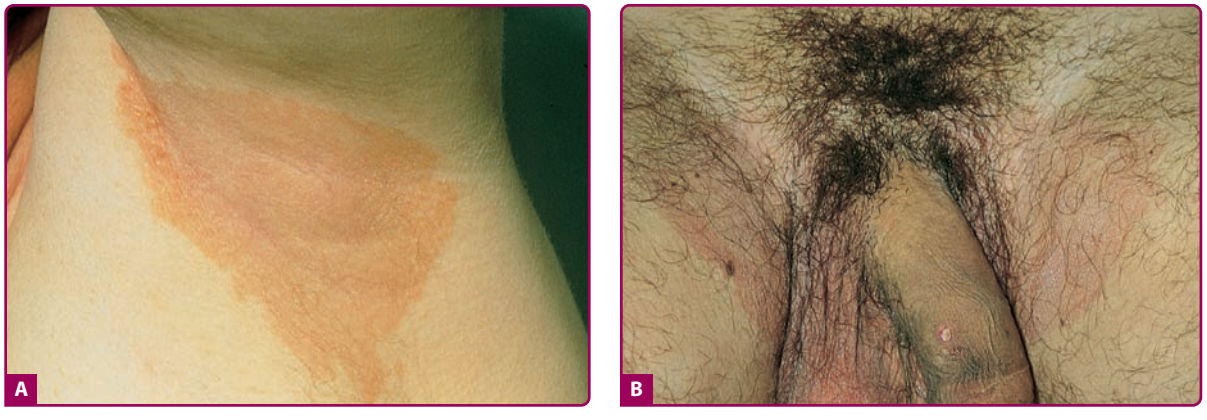

Figure 176-20 Erythrasma. Well-demarcated reddish-brown patches in the axilla (**A**) and groin (**B**). The potassium hydroxide preparations were negative; the Wood's lamp examination showed a bright coral red fluorescence.

the diagnosis. Gram-stained imprints of the horny layer of the skin show rod-like, Gram-positive organisms in large numbers.

The diagnosis is strongly suggested by the location and superficial character of the process, but must be confirmed by demonstration of the characteristic "coral-red" fluorescence with Wood's lamp illumination.

Prognosis and Clinical Course. The disease may remain asymptomatic for years or may undergo periodic exacerbations. Relapses occasionally occur even after successful antibiotic treatment.

Treatment. For localized erythrasma, especially of the web spaces of the feet, benzoyl peroxide wash and 5% gel are effective in most cases. Clindamycin or erythromycin (2% solution) or azole creams are several of the many effective topical agents. Fusidic acid has been used outside the United States. For widespread involvement, oral erythromycin is effective. A 1-g single dose of clarithromycin has been used successfully.[34] For secondary prophylaxis, an antibacterial benzoyl peroxide bar when showering is effective.

TRICHOMYCOSIS AXILLARIS AND PUBIS.

Trichomycosis axillaris, a bacterial infection of the hair shaft (not fungal as the name implies), is characterized by what appears to be nodular thickenings on the hair shaft, composed of colonies of aerobic *Corynebacterium*. The condition occurs both in the axillae and pubic areas, and not just in the axillae, as the name implies. The bacteria produce various pigments, giving the nodules a range of colors. The concretions on the hair shaft are usually a tan color but may be reddish, yellow, or black (Fig. 176-21). Lesions are most dense and may be present only in the central portion of the axillary hair. Trichomycosis is asymptomatic except for the patient's concern regarding the lesions themselves and because they are malodorous.

The diagnosis is usually made on the basis of the physical findings. The concretions can be visualized using a potassium hydroxide preparation. Pediculosis pubis infestation with multiple eggs on the hair shaft should be ruled out.

The involved hair can be removed by shaving. Benzoyl peroxide wash and gel are effective as treatment and prevention against recurrence of trichomycosis. Topical clindamycin or erythromycin solutions can be used as well.



Figure 176-21 Trichomycosis axillaris. Tan-yellow concretions on the hair shafts of the axilla.

KEY REFERENCES

Full reference list available at www.DIGM8.com

DVD contains references and additional content

1. Foster TJ: Immune evasion by staphylococci. *Nat Rev Microbiol* **3**(12):948-958, 2005
9. Deleo FR et al: Community-associated meticillin-resistant Staphylococcus aureus. *Lancet* **375**(9725):1557-1568, 2010
11. DeLeo FR, Diep BA, Otto M: Host defense and pathogenesis in Staphylococcus aureus infections. *Infect Dis Clin North Am* **23**(1):17-34, 2009
12. Amagai M et al: Toxin in bullous impetigo and staphylococcal scalded-skin syndrome targets desmoglein 1. *Nat Med* **6**(11):1275-1277, 2000
13. Gisby J, Bryant J: Efficacy of a new cream formulation of mupirocin: Comparison with oral and topical agents in experimental skin infections. *Antimicrob Agents Chemother* **44**(2):255-260, 2000
16. Koning S et al: Interventions for impetigo. *Cochrane Database Syst Rev* (2):CD003261, 2004
18. McFadden JP et al: Psoriasis and streptococci: The natural selection of psoriasis revisited. *Br J Dermatol* **160**(5):929-937, 2009
20. Currie BJ: Group A streptococcal infections of the skin: Molecular advances but limited therapeutic progress. *Curr Opin Infect Dis* **19**(2):132-138, 2006
33. Blaise G et al: Corynebacterium-associated skin infections. *Int J Dermatol* **47**(9):884-890, 2008

Chapter 177 :: Gram-Positive Infections Associated with Toxin Production

:: Jeffrey B. Travers & Nico Mousdicas

GRAM-POSITIVE INFECTIONS ASSOCIATED WITH TOXIN PRODUCTION AT A GLANCE

- Caused by *Staphylococcus aureus* and/or group A *streptococcus* toxin-producing bacteria.
- Three characteristic syndromes (all with skin manifestations):
  - Predominantly cutaneous.
    - Local: bullous impetigo.
    - Generalized: staphylococcal scalded skin syndrome.
  - Cutaneous and systemic:
    - Local: recurrent toxin mediated erythema—recurrent perineal erythema.
    - Generalized: recalcitrant erythematous desquamating disorder.
    - Other abortive hybrids of predominantly systemic manifestations disorder.
- Predominantly systemic:
  - Generalized: toxic shock syndrome *Staphylococcus* (predominantly) or *Streptococcus.*
  - Scarlet fever—*Streptococcus* (predominantly) or *Staphylococcus*.

Skin infections with the Gram-positive bacteria *Staphylococcus aureus* and group A *streptococcus* (*Streptococcus pyogenes*) are an important source of morbidity and even mortality. These bacteria produce toxins that can induce characteristic syndromes, including staphylococcal scalded-skin syndrome (SSSS) and toxic shock syndrome (TSS). Moreover, the production of these toxins is thought to underlie the ability of infection with these bacteria to initiate and/or to propagate inflammatory skin diseases.

EPIDEMIOLOGY

All conditions discussed here are relatively rare but have high morbidity, and some have considerable mortality.

FACTORS IN TOXIN-MEDIATED DISEASE

Staphylococcal and streptococcal pathogenicity is due to the production of a range of immunomodulatory proteins including toxins, exoenzymes, and adhesins.[1] Among the best characterized are the toxins (Table 177-1).

Many risk factors play a role in the ability of a toxin-forming *Staphylococcus* or *Streptococcus* to produce disease. The development of disease is related to the resistance of the host to infection and to the virulence of the organism. Host resistance depends, among other factors, on intact skin and mucous membranes functioning as barriers to invasion and the host's ability to mount an immune response (e.g., neutralizing antibodies) against such toxins. Colonization by virulent *Staphylococcus* or *Streptococcus* toxin-producing organisms exposed to optimal, focal conditions for growth and toxin production (e.g., menstruation + tampon use or abscess) allows these bacteria to initiate and/or propagate infection.

Minor defects in these barriers such as those produced by superficial excoriations, toe web fungal infections or alternatively, major defects produced by surgery, trauma, burns, or foreign substances (packing, sutures, intravascular catheters, shunts) increase the risk of infection. The role of host response cannot be overstated. For example, if a patient has an underlying immunodeficiency and cannot produce adequate neutralizing antibodies; or, as in chronic granulomatous disease where neutrophils lack the oxidative burst to destroy catalase-positive bacteria (e.g., *S. aureus*), the patient is at increased risk for colonization and infection by toxin-producing bacteria. Finally, the types of immune cells that are activated play an important role in the subsequent host response, especially as it relates to toxins that act as superantigens. The ability of a superantigen to activate numerous T cells is based upon the variable region of the T-cell receptor. This could result in various types of responses depending on the specificity of the individual T cell that happened to become activated. Table 177-2 provides an overview of Gram-positive coccal toxin related diseases.

DISEASES CAUSED BY EXFOLIATIVE TOXINS: STAPHYLOCOCCAL SCALDED-SKIN SYNDROME

S. aureus-mediated production of exfoliative toxin also results in a spectrum of blistering skin disorders ranging from localized bullous impetigo (see Chapter 177)

TABLE 177-1
Toxins and Diseases Due to Staphylococcus aureus and Group A Streptococcus

Bacteria	Toxin	Toxin Type	Clinical Disease
Staphylococcus aureus	Exfoliatin type A	Epidermolytic	Bullous impetigo SSSS
	Exfoliatin type B	Epidermolytic	SSSS Bullous impetigo
	TSS toxin 1	Superantigen	TSS (menstrual > nonmenstrual), food poisoning
	Staphylococcal enterotoxins A–C	Superantigen	TSS (nonmenstrual > menstrual), food poisoning
Streptococcus pyogenes	Streptococcal pyrogenic exotoxins A, C	Superantigen	TSS (nonmenstrual), scarlet fever

SSSS = staphylococcal scalded-skin syndrome; TSS = toxic shock syndrome.

to a severe generalized form, SSSS. The syndrome is a generalized exanthematous disease consisting of cutaneous tenderness and widespread superficial blistering and denudation.

ETIOLOGY AND PATHOGENESIS

Exfoliative toxins (ETs) are made by certain strains of *S. aureus* (usually phage group 2). Exfoliatin A and B (ETA and ETB) are two serologically distinct proteins produced by *S. aureus*.[2] ETs are serine proteases that bind to the cell adhesion molecule desmoglein 1 and cleave it, resulting in a loss of cell–cell adhesion.[3] Consistent with the expression pattern of desmoglein 1, which is expressed in the upper part of the epidermis, the epidermolysis takes place usually between the stratum spinosum and granulosum. This results in a very thin-walled, flaccid blister that is easily disrupted, exhibiting a positive Nikolsky sign. The pathophysiology of ET resembles that of the autoimmune blistering disease pemphigus foliaceus, with desmoglein 1 targeted in both diseases. Presumably, staphylococcal bacteria have evolved this toxin to allow the bacteria to proliferate and spread beneath the barrier of the skin. There are two forms of ET-mediated disease: (1) localized bullous impetigo and (2) systemic SSSS. Recent studies suggest that the majority of cases of localized bullous impetigo are due to ETA, and systemic forms such as SSSS are due to ETB, possibly due to a lower titer of anti-ETB neutralizing antibodies in the general population.[4] Although some reports suggest that ET can also act as superantigens (see Section "Diseases Caused by Superantigenic Toxins") in addition to their epidermolytic activities,[5] this has been called into question.[6]

CLINICAL FEATURES

LOCALIZED FORM (BULLOUS IMPETIGO).

Infection of the upper part of the skin (epidermis) by *S. aureus* or *S. pyogenes* results in impetigo contagiosa (Figs. 177-1 and 177-2). Impetigo, which may account for up to 10% of all pediatric skin disease, consists of honey-colored crusts on an erythematous base. Approximately one-fourth of cases of impetigo are bullous, with local ET-expressing *Staphylococcus* and without hematogenous dissemination. As is the case with SSSS, bullous impetigo is usually a disease of children (see Chapter 177), although adult cases can also occur. The early lesions of bullous impetigo are cloudy vesicles or bullae surrounded by an erythematous rim (see Fig. 177-2). These blisters often rupture leaving superficial erosions. Lesions at various stages can often be seen. The lesions tend to be found around exposed parts of the body and around orifices (see Fig. 177-1). Diagnosis is usually based upon clinical appearance. In contrast to SSSS, confirmation of diagnosis can be easily obtained by aspiration of blister fluid for Gram stain and cultures will reveal *S. aureus*.

GENERALIZED FORM.

The clinical features of SSSS were first described in 1878 by the German physician Gotfried Ritter von Rittershain, who reported almost 300 cases of "dermatitis exfoliativa neonatorum" among young children.[7] Outbreaks of SSSS tend to occur in clusters as a consequence of cross infection. Typically neonatal or maternity hospital staff colonized or infected with ET-producing *Staphylococci* are the source of these outbreaks. Although more commonly seen in infants/children, SSSS can also be seen in adults. The risk factors for adults include a compromised immune response allowing for growth of the *S. aureus* and possibly impaired amounts of toxin-neutralizing antibodies or renal insufficiency, which decreases the clearance of the toxin. Affected individuals initially have a faint, orange–red macular exanthem or uniform erythema (Fig. 177-3) sparing mucosal surfaces in association with a purulent conjunctivitis, otitis media, nasopharyngeal infection, or, occasionally, pyogenic skin infection such as bullous impetigo or that which arises from an umbilical stump or boil (carbuncle). These are the staphylococcal foci from which the toxin is released. Periorificial (see Fig. 177-3A) and flexural (see Fig. 177-3B) accentuation of the exanthema is often noted.

Although the early rash is not distinctive in appearance, the concomitant cutaneous tenderness is usually present at this early stage. Tenderness can often be so severe that infants will refuse to lie down or allow

TABLE 177-2

Gram-Positive Coccal Infections Associated with Toxin Production

- Caused by *Staphylococcus aureus* and/or Group A *Streptococcus* Toxin-Producing Bacteria
- Characteristic syndromes (all with skin manifestations): can be divided into three categories depending on the predominant clinical presentation
  1. Predominantly cutaneous
     - Local: bullous impetigo
     - Generalized: staphylococcal scalded-skin syndrome
  2. Intermediate cutaneous and systemic
     - Local: recurrent toxin-mediated erythema (recurrent perineal erythema)
     - Generalized
     - Recalcitrant erythematous desquamating disorder
     - Other abortive hybrids of predominantly systemic manifestations
  3. Predominantly systemic
     - Generalized
       - Toxic shock syndrome—*Staphylococcus* (predominantly) or *Streptococcus*
       - Scarlet fever—*Streptococcus* (predominantly) or *Staphylococcus*

Predominantly Cutaneous	Intermediate Cutaneous and Systemic	Predominantly Systemic
■ Exfoliative toxins	■ Unidentified toxins	■ Superantigens
Clinical Features		
■ Erythema local or generalized ■ Tenderness ■ Nikolsky sign ■ Bullae ■ Exfoliation	■ Erythema generalized ■ Fever and hypotension ■ Desquamation ■ Mucosal involvement ■ Prolonged disease ■ Some but not all toxic shock syndrome criteria met ■ Recurrences	■ Erythema generalized with or without sandpaper characteristics ■ Toxic ■ Fever and hypotension ■ Mucosal involvement ■ Swelling of hands and feet ■ Organ failure ■ Exfoliation or desquamation
Foci of Bacterial Colonization/Infection		

■ Bullous impetigo
  ■ Local skin
■ *Staphylococcus* scalded-skin syndrome
■ Conjunctiva
■ Middle ear
■ Nasopharyngeal
■ Umbilical stump
■ Carbuncle or boil
	■ Recurrent perineal erythema
	  ■ Nasopharyngeal
	■ Recalcitrant erythematous desquamating disorder
	■ Human immunodeficiency virus-associated
	■ Nonhuman immunodeficiency virus associated
	  ■ Search for occult *Staphylococcus*/*Streptococcus* infection
		■ Toxic shock syndrome—*Staphylococcus aureus*
		  ■ Menstrual associated
		  ■ Vagina
		  ■ Nonmenstrual
		  ■ Surgical wounds
		  ■ Sinusitis
		  ■ Osteomyelitis
		  ■ Influenza
		  ■ Intravenous drug use
		  ■ Burn wounds
		  ■ Gynecologic-postpartum
		■ Toxic shock syndrome—*Streptococcus*
		  ■ Skin in 80% of cases
		  ■ Cellulitis
		  ■ Necrotizing fasciitis
		■ Scarlet fever—streptococcal
		  ■ Nasopharyngeal
		  ■ Surgical wounds
		  ■ Uterine infections
		  ■ Special clinical features of scarlet fever
		  ■ Circumoral pallor
		  ■ White and red strawberry tongue
		  ■ Forchheimer's spots
		  ■ Pastia's sign
		■ Scarlet fever—staphylococcal
		  ■ All arise from skin (e.g., furuncle/carbuncle)
		  ■ Special clinical features of *Staphylococcus*, scarlet fever
		  ■ Absences of pharyngitis in a patient with generalized erythroderma with sandpaper texture



Figure 177-1 Bullous impetigo in a child. Blisters are initially filled with cloudy fluid and later rupture, resulting in erosions and crusting.

anyone to hold them. Within 1–2 days the rash progresses from an exanthematous scarlatiniform to a blistering eruption (Fig. 177-4; see Fig. 177-3C and eFig. 177-4.1 in online edition). Very superficial tissue paper-like wrinkling of the epidermis, which is characteristic, progresses to large flaccid bullae in flexural and periorificial surfaces. A positive Nikolsky sign can be elicited by stroking the skin, which results in a superficial blister (see Fig. 177-4A and B and eFig. 177-4.1 in online edition). Large sheets of the epidermal surface are typically shed, revealing a moist underlying erythematous base. At this stage, the disease looks very worrisome, resembling a generalized scalding burn. Although fevers are often present and outwardly the signs of SSSS may look serious, the infants and children do not usually appear toxic unless they have developed complications such as septicemia or pneumonia. The cutaneous process usually resolves spontaneously or faster with antibiotics and superficial desquamation, with healing completed within 5–7 days (Fig. 177-5; see eFig. 177-5.1 in online edition). Cultures obtained from an intact blister are usually sterile, consistent with the pathogenesis of a hematogenously disseminated toxin originating from a distant focus of infection.



Figure 177-2 Bullous impetigo in a child. Note blisters filled with cloudy fluid and lesions that have ruptured, leading to erosions and crusting.

Although most cases of SSSS occur in infants and children, the syndrome can also rarely be seen in adults, particularly when there is renal failure (see eFig. 177-5.2 in online edition). Histopathology shows acantholysis in the granular layer and subcorneal cleft formation in early lesions (Fig. 177-6B) and an intact viable epidermis with shedding of the stratum corneum in the desquamative stage.

INTERMEDIATE (ABORTIVE) FORMS. In addition to localized bullous impetigo and generalized SSSS, intermediate forms of staphylococcal-mediated eruptions, in which blistering can be apparent, can be encountered. One scenario is localized bullous impetigo that evolves to produce regionally limited bullae and denuded areas that may or may not actually harbor *S. aureus*. A possibly abortive form of SSSS has been described. It is known as the *scarlatiniform variant* and has features of the early erythrodermic and final desquamative stages, yet very little blister formation is present (see "Staphylococcal Scarlet Fever").[8] Again, because *S. aureus* bacterial strains can produce both exfoliative and other superantigenic toxins, and ETs could have superantigenic activity,[5] it is not surprising that overlap syndromes with features of toxic shock and scalded skin can infrequently be observed.

DIAGNOSIS AND DIFFERENTIAL DIAGNOSIS

All forms of SSSS are characterized by intraepidermal cleavage with splitting beneath and within the stratum granulosum. The cleavage space may contain either partially or totally unattached acantholytic cells. However, the remainder of the epidermis is usually unremarkable, and the dermis contains few inflammatory cells (see Fig. 177-6B). In localized bullous impetigo, more inflammatory cells, including neutrophils, can be often visualized (see Fig. 177-6A).

The principal diagnostic problem is distinguishing generalized SSSS from toxic epidermal necrolysis (TEN) (see Chapter 40). It should be noted that the cases that represented Lyell's first description of TEN actually included some that were probably SSSS.[9] The age distribution between SSSS (neonates, children) and TEN tends to be different, yet much overlap occurs. In contrast to TEN, SSSS never has mucosal erosions. Using a Tzanck smear that will show acantholytic cells in SSSS but not in TEN (see eFig. 177-6.1 in online edition) and the use of frozen sections that can rapidly differentiate the superficial subgranular acantholysis in SSSS versus the characteristic full-thickness epidermal necrosis and dermal–epidermal separation seen in TEN aid in the differential diagnosis.

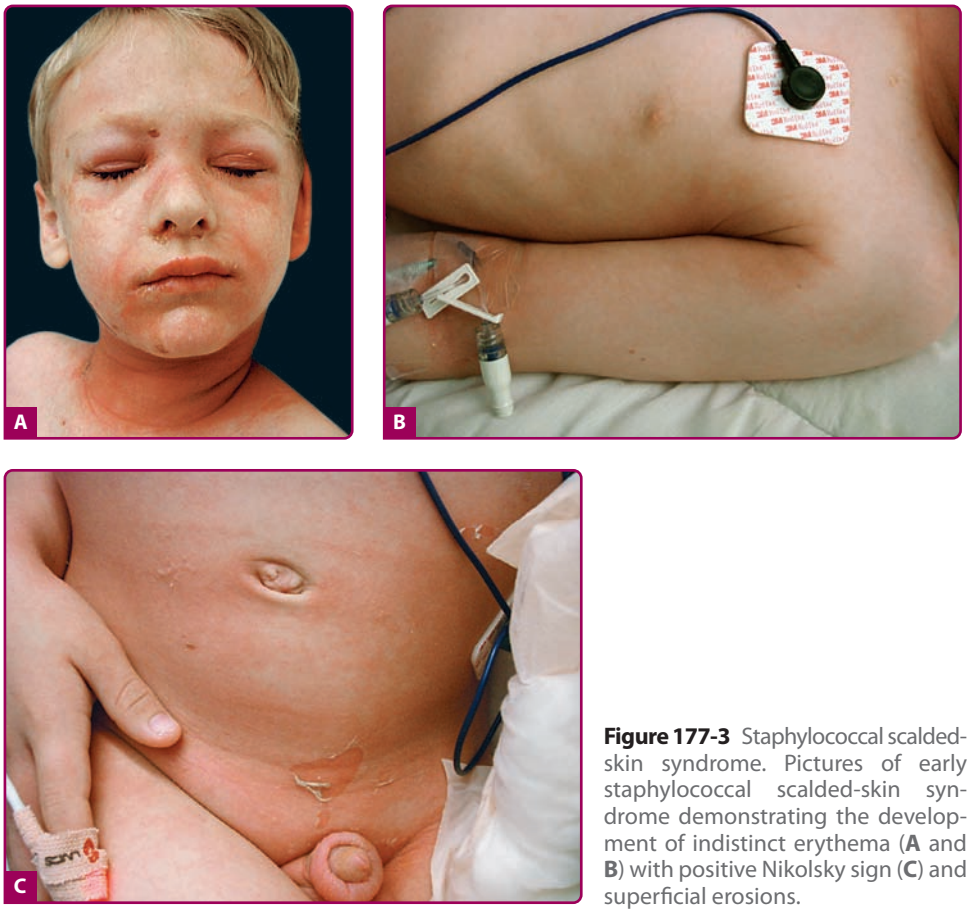

Figure 177-3 Staphylococcal scalded-skin syndrome. Pictures of early staphylococcal scalded-skin syndrome demonstrating the development of indistinct erythema (**A** and **B**) with positive Nikolsky sign (**C**) and superficial erosions.

TREATMENT AND PROGNOSIS

Therapy for bullous impetigo may include topical mupirocin ointment therapy alone and/or oral antibiotics. Prognosis for recovery is excellent. Therapy for SSSS should be directed toward eradication of *S. aureus*, which generally requires hospitalization and intravenous antistaphylococcal antibiotics. For uncomplicated cases, oral antibiotics can usually be substituted after several days. The use of suitable antibiotics, combined with supportive skin care and management of potential fluid, and electrolyte abnormalities due to the widespread disruption of barrier function, will usually be sufficient to ensure rapid recovery. Neonates benefit from incubators to maintain body temperature and humidity. The use of nonadherent dressings, including petrolatum-impregnated gauze, to the widespread areas of superficial blistering are helpful. Antibiotic mupirocin ointment applied several times per day to clearly impetiginized areas, including the original source, is often a helpful adjunct to systemic antibiotic therapy.

Major complications of SSSS are serious fluid and electrolyte disturbances. The mortality in uncomplicated pediatric SSSS is very low (2%) and is not usually associated with sepsis. Adult mortality is higher (approximately 10%) due to concomitant morbidity factors and increased likelihood of sepsis.

DISEASES CAUSED BY SUPERANTIGENIC TOXINS

ETIOLOGY AND PATHOGENESIS

Superantigens are a group of microbial and viral proteins that differ in several important respects from conventional peptide antigens (Fig. 177-7).[10,11] First, unlike conventional protein antigens, which are taken up and processed by antigen presenting cells, superantigens exert their effects as globular intact proteins. Similar to peptide antigens, they are presented by class II major histocompatibility complex (MHC) molecules; however, they do not interact with the MHC peptide β-antigen binding groove, but instead bind to conserved amino acid residues that are on the outer walls of the peptide antigen-binding groove. Thus, whereas recognition of conventional peptide antigens by the T-cell receptor is restricted by MHC alleles, recognition of superantigens is generally not MHC restricted. Second, superantigens primarily recognize and bind to the variable region of the T-cell receptor β chain (Vβ). This is in contrast to nominal peptide antigens, which require recognition by all five variable elements (i.e., Vβ, Dβ, Jβ, Vα, Jα) of the T-cell receptor. Therefore, the responding frequency of a superantigen for resting T cells is several orders of magnitude greater



Figure 177-4 Staphylococcal scalded-skin syndrome (SSSS). Pictures of later SSSS demonstrating (**A**) the same patient in **Fig. 177-3A** 24 hours later with erythema, more superficial blisters with desquamation of large sheets. **B.** Superficial erosions around the eye with underlying denuded skin. **C.** Characteristic crusting with superficial erosions noted on face of this 10-month-old child with SSSS.



Figure 177-5 Late stage of staphylococcal scalded-skin syndrome. Generalized desquamation with large sheets.

(up to 20%–30%) than a conventional peptide antigen (0.01%–0.1%) The unique ability of a superantigen to bind directly to (and signal through) MHC class II molecules, and cross-link (and thus activate) a large percentage of T cells expressing relevant T-cell receptor Vβ chains, provides an explanation for the potent immune stimulation seen with these molecules. Of note, in comparison to nominal antigens, superantigen-mediated T-cell activation tends to generate increased numbers of T cells expressing the skin homing receptor cutaneous lymphocyte antigen (CLA).[12] Given that CLA-positive T cells are the T-cell type that traffics readily to the skin, the increased numbers of CLA-positive T cells generated by these agents is thought to be responsible for the high propensity of cutaneous manifestations in these conditions. Superantigens lead to a massive release of cytokines, including tumor necrosis factor-α, interleukin 1, and interleukin 6. This cytokine "storm" is in great part responsible for a capillary leak syndrome and accounts for the majority of the clinical manifestations seen in superantigen-mediated diseases. The prototypical disease due to superantigens is TSS caused by staphylococcal or streptococcal toxins. Although specific syndromes such as TSS and

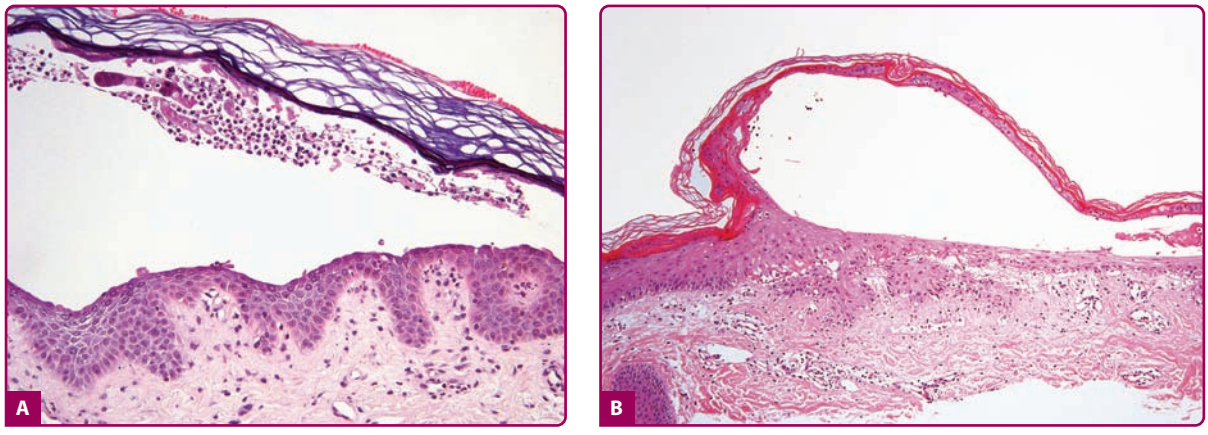

Figure 177-6 Histology of bullous impetigo (200×) (**A**) vs. staphylococcal scalded-skin syndrome (100×) (B). In both conditions, the intraepidermal cleavage induced by the epidermolytic toxin occurs within or just below the stratum granulosum. Note paucity of cells in generalized disease (staphylococcal scalded-skin syndrome) (**B**) in comparison to the large numbers of leukocytes found in the localized form (bullous impetigo) (**A**). In both, cleavage occurs in the granular layer and is due to acantholysis. Note: free-floating acantholytic cells in **A** and compacted acantholytic cells in the blister roof of **B**.

scarlet fever have characteristic findings, overlap syndromes have been described. Because the individual clinical findings are the summation of amount and type(s) of toxins and the types of cells responding to activation, it should not be surprising that heterogeneity in clinical presentations occurs.

Unlike syndromes associated with ETs that usually do not have significant systemic symptoms, those due to superantigens are characterized by systemic manifestations. Superantigen-mediated toxin syndromes can be divided into intermediate cutaneous and systemic and predominantly systemic due to the relative amounts of systemic toxicity. Disorders that have predominantly systemic manifestations are scarlet fever and the most ominous toxin-mediated disease, TSS. The intermediate cutaneous and systemic category includes syndromes such as recalcitrant erythematous desquamating disorder (REDD) and toxin-mediated erythema, which are less systemic versions of TSS and scarlet fever, respectively. All of these superantigen-mediated disorders are diagnosed based upon clinical findings and can be due to toxins produced by either *S. aureus* or group A *Streptococcus* (see Table 177-2).

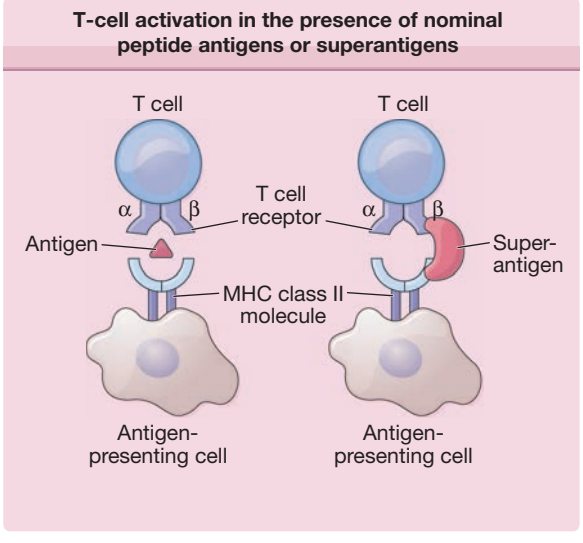

Figure 177-7 T-cell activation in the presence of nominal peptide antigens (*left*) or superantigens (*right*). The peptide antigen binds in the groove of the major histocompatibility complex (MHC) class II molecule and activates only antigen-specific T cells through the T-cell receptor. In contrast, a superantigen is a large globular protein that binds to the MHC class II molecule outside the antigen-binding groove and directly cross-links the MHC class II molecule and the Vβ chain of the T-cell receptor, leading to polyclonal T-cell activation.

TOXIC SHOCK SYNDROME

(See Table 177-2)

TSS is an inflammatory response characterized by fever, rash, hypotension, and multiorgan involvement representing the severe end of the spectrum of superantigen-mediated diseases. Although first described in 1978 in a series of children with *S. aureus* infection,[13] TSS became more broadly recognized with reports of epidemics associated with use of highly absorbent tampons in menstruating women in the early 1980s.[14] Presumably, the tampon served as a nidus for infection: the blood added protein and neutralized the normally bacteriocidal acidic vaginal pH. Since the first descriptions of the disease, TSS has been shown to be associated with many types of staphylococcal and streptococcal infections.

CLINICAL FINDINGS

Staphylococcal Toxic Shock Syndrome. The most common staphylococcal toxin associated with TSS is TSS toxin-1 (TSST-1), and it is the predominant toxin associated with menstrual-associated cases. TSST-1

appears unique among superantigens in its ability to cross-mucosal surfaces. With the removal of highly absorbent tampons from the market along with patient education, the incidence of menstruation-associated TSS decreased steadily, and at present the incidence of nonmenstrual TSS exceeds that of menstrual-associated cases. Nonmenstrual TSS is associated with postsurgical wounds, sinusitis, osteomyelitis, influenza, intravenous drug use, burn wounds, and gynecologic infection (especially in the postpartum period). Other staphylococcal toxins, including staphylococcal enterotoxins B and C (SEB and SEC), can also be found, and the latter two superantigenic toxins comprise approximately 50% of nonmenstrual TSS. The host response is an important factor in the development of TSS, as studies have shown an increased susceptibility in patients who do not have neutralizing antibodies against TSST-1.[15]

The symptoms of TSS begin with the acute onset of fever, sore throat, and myalgia. Diarrhea is common, and vomiting may also occur. The rash is most often a macular erythema but a scarlatiniform type can also sometimes be seen. The eruption usually begins on the trunk and spreads to extremities and can involve palms and soles (Fig. 177-8). If the patient is hypotensive, the eruption tends to be more prominent on the trunk than extremities. Symptoms of hypotension include orthostatic dizziness, fainting, or overt shock. Nonpurulent conjunctival hyperemia, pharyngeal inflammation, and strawberry tongue (see "Scarlet Fever") are invariably present. Signs of decreased mentation can also occur. The rash will desquamate within 1–2 weeks after it appears. The Centers for Disease Control and Prevention criteria for TSS are listed in Table 177-3. Cases of lesser severity that do not meet the full definition probably do occur frequently, especially with earlier recognition and treatment. In nonmenstruation cases, especially those associated with postoperative infections, the classic signs of a localized infection such as erythema, pain, and purulence can be absent. This is often in contrast to streptococcal TSS.



Figure 177-8 Toxic shock syndrome (TSS). Patient in intensive care unit with TSS due to *Staphylococcus aureus*. Note patient's eruption is nonspecific erythema around intertriginous areas and face. The eruption associated with staphylococcal TSS varies and could be morbilliform, scarlatiniform, or even pustular.

Streptococcal Toxic Shock Syndrome. Streptococcal TSS was described in the late 1980s as a disease similar to staphylococcal TSS, but caused by invasive group A *Streptococcus*. Recent reports have suggested streptococcal TSS is more commonly encountered than the staphylococcal form. The majority of cases of streptococcal TSS are due to streptococcal pyrogenic exotoxin A (SPEA), yet other superantigenic toxins including SPEB, SPEC, and involvement of other nongroup A *Streptococcus* have also been reported. Although not associated with tampon use, streptococcal TSS can result from nearly any type of group A streptococcal infection. The most common types of infections appear to be wounds, and streptococcal TSS has been well described as a complication of varicella and influenza A. However, in many cases the route of infection cannot be determined. In contrast to staphylococcal TSS, disease induced by group A *Streptococcus* is from skin in 80% of cases. The initial presentation is skin pain that is localized to an extremity in many cases. The localized pain often progresses over several days to localized erythema (see Chapter 179) and edema. Then cellulitis associated with necrotizing fasciitis and myositis with concomitant streptococcal invasion of the bloodstream develops. It should be noted that blood cultures are positive in more than one-half of patients with streptococcal TSS, in contrast to only one-tenth of patients with staphylococcal TSS. Thus, a patient with signs of TSS and a localized cellulitis should suggest streptococcal TSS as soft-tissue infections are not usually seen with staphylococcal TSS. Although very young, elderly, diabetic, or immunocompromised patients would be more susceptible to streptococcal TSS, the majority of cases have occurred in otherwise healthy adults.

DIFFERENTIAL DIAGNOSIS.

The differential diagnosis of staphylococcal TSS includes septic shock, staphylococcal exfoliative syndromes, Rocky Mountain spotted fever, viral hemorrhagic shock, measles, leptospirosis, and Stevens–Johnson syndrome. Although Kawasaki syndrome has many similar clinical findings, including swelling of extremities and desquamation of palms and soles during convalescence, Kawasaki syndrome differs in that the course of fever is prolonged, and there is absence of diarrhea and hypotension. Streptococcal-mediated syndromes including scarlet fever and especially streptococcal TSS can mimic staphylococcal TSS.

In a patient with fever, rash, and hypotension, a thorough search for possible sites of staphylococcal and streptococcal infection is critical. Surgical wounds should be carefully examined even if no clinical signs of infection are apparent. Vaginal examination and removal of tampon or other foreign body should be done, and vaginal irrigation with saline or povidone iodine has been recommended.

TREATMENT AND PROGNOSIS.

The treatment of TSS is supportive (and usually in the intensive care setting) and focused on eradicating the offending *S. aureus*. Large doses of a β-lactamase-resistant, antistaphylococcal antibiotics (e.g., nafcillin) have

TABLE 177-3
Centers for Disease Control and Prevention Case Definition of Staphylococcal Toxic Shock Syndrome

Major Criteria (All Four Must Be Met)	Multisystem Involvement (Three or More Must Be Met)	Normal Test Results (If Performed)

▪ Fever
  ▪ Temperature >38.9°C (102°F)
▪ Rash
  ▪ Diffuse macular erythroderma
▪ Desquamation
  ▪ 1–2 week after onset of illness, particularly on palms/soles
	▪ Gastrointestinal
	  ▪ Vomiting or diarrhea at onset of illness
	▪ Muscular
	  ▪ Severe myalgia or creatine kinase level twice upper limit of normal
	▪ Mucous membrane
	  ▪ Oropharyngeal, conjunctival, or vaginal hyperemia
		▪ Blood, throat, or cerebrospinal fluid cultures (blood cultures may be positive for *Staphylococcus aureus*)
		▪ No rise in titer in antibody tests for Rocky Mountain spotted fever, leptospirosis, or measles

▪ Hypotension
  ▪ Systolic blood pressure <95 mm Hg for adults, or less than fifth percentile by age for children <16 years of age, or orthostatic syncope
	▪ Renal
	  ▪ Blood urea nitrogen or creatinine level twice upper limit of normal, or >5 white blood cells per high-power field in urine in absence of urinary tract infection
	▪ Hepatic
	  ▪ Total bilirubin, aspartate aminotransferase, or alanine aminotransferase level at least twice upper limit of normal
	▪ Hematologic
	  ▪ Platelets <100,000/mm^3
	▪ Central nervous system
	  ▪ Disorientation or alterations in consciousness without focal neurologic signs when fever and hypotension are absent	

been used historically. Because these agents have been known to increase TSST-1 in vitro (probably as a result of cell lysis), concomitant clindamycin (which will inhibit bacterial protein toxin production) is often prescribed. Because of the increasing frequency of methicillin-resistant *Staphylococci* in the community, vancomycin is often recommended. β-lactamase-resistant penicillins are of lesser value, not only because of emerging resistance, but also they are less effective with high levels of bacteria (in contrast to clindamycin or vancomycin). Todd has recommended a combination of vancomycin and clindamycin for suspected serious staphylococcal infections pending culture and sensitivity.[16] Recently intravenous immunoglobulin (IVIG; which presumably acts in part via neutralizing antibodies against toxins) has been used and appears to have significant promise.[17] At present, IVIG is used in severe or recalcitrant cases. Contraindications to IVIG include previous hypersensitivity to it or immunoglobulin A deficiency. Systemic corticosteroids are controversial and probably have less impact than considered, as superantigen-mediated immune cell activation is associated with corticosteroid resistance.

Staphylococcal TSS is clearly a life-threatening disease but the mortality rate is only approximately 5%, most likely because the majority of cases occur in otherwise healthy young individuals. Unfortunately, recurrence can be seen in up to 20%. Women who have had TSS should avoid using tampons during menstruation as it will increase the likelihood of reinfection. Diaphragms and contraceptive sponges should also be avoided in this population.

The treatment of streptococcal TSS is similar to that for staphylococcal TSS. For cases associated with necrotizing fasciitis/myositis, rapid recognition and surgical débridement are imperative. IVIG is becoming increasingly recognized as an important part of treatment of streptococcal TSS, especially because the mortality rate in this disease can be greater than 30%.[18]

RECALCITRANT ERYTHEMATOUS DESQUAMATING DISORDER

(See Table 177-2)

A new presentation of a toxin-mediated disorder, termed *recalcitrant erythematous desquamating disorder*, was first described in 1992.[19] The clinical findings include fever and hypotension. The rash of REDD consists of diffuse macular erythema with delayed desquamation. Other findings in common with TSS include ocular and oral mucosal injection and strawberry tongue. *Staphylococci* producing TSST-1, staphylococcal enterotoxin A or B (SEA, SEB), have been isolated from various places, including nasal sinuses, soft tissues, or blood. Although the majority of patients described to date have had acquired immunodeficiency syndrome, some REDD patients without acquired

immunodeficiency syndrome have been reported. In contrast to TSS, this is a prolonged disease (measured in weeks to several months) in which only several of the TSS criteria are met. The diagnosis is often established by careful examination for occult colonization and/or infection in a susceptible individual.

SCARLET FEVER

(see Table 177-2)

Scarlet fever is a syndrome characterized by exudative pharyngitis, fever, and scarlatiniform rash. It is most commonly due to pyrogenic exotoxin-producing group A *Streptococcus*, although staphylococcal infections can produce a similar-appearing disease. The exact mechanism by which toxins produce the symptom complex is unclear. Compelling studies by Schlievert demonstrated that the scarlatiniform eruption could only be induced in mice that were previously sensitized against toxins. This suggests that a combination of conventional delayed type and superantigen-mediated processes are occurring.[20] It should be noted that streptococcal toxins, especially SPEA, have areas of significant homology with collagen, which could provide a mechanism for rare autoimmune sequelae of streptococcal scarlet fever, including renal failure and rheumatic fever.[21] Scarlet fever is no longer the major public health threat it was in the past because of antibiotic treatment, and because most streptococcal isolates causing scarlet fever express the less virulent SPEB and SPEC rather than SPEA.

CLINICAL FINDINGS

Streptococcal Scarlet Fever. Streptococcal scarlet fever is a childhood disease that occurs most commonly in winter and early spring. It is estimated that up to 10% of childhood group A streptococcal pharyngitis patients develop scarlet fever. Approximately 12 hours to 5 days after exposure, an abrupt prodrome consisting of pharyngitis, headache, vomiting, abdominal pain, and fever develops. The rash appears 1–2 days after onset of the illness, first on the neck and then extending to the trunk and extremities, although it spares the palms and soles. The exanthem texture is usually coarse, like fine-grade sandpaper, and the erythema blanches with pressure (Fig. 177-9). The skin can be mildly pruritic but usually



Figure 177-9 Scarlet fever. **A.** Exanthematous rash with a sandpaper texture in the axilla. **B.** Exanthematous rash with a sandpaper feel on the chest. **C.** Perioral pallor and strawberry tongue. **D.** Poststreptococcal desquamation.

is not painful. A few days after generalization of the exanthem, the rash becomes more intense around skin folds and lines of confluent petechiae, due to increased capillary fragility (Pastia's sign), can be seen. The generalized exanthem begins to fade 3–4 days after onset and a desquamative phase begins, usually starting on the face. Peeling from the palms and fingers and, sometimes, soles occurs approximately 1 week later and can last for up to 1 month (see Fig. 177-9D).

Oral findings of streptococcal scarlet fever include edematous, erythematous tonsils sometimes covered with a yellow, gray, or white exudate. Tender anterior cervical lymphadenopathy is common. Petechiae and punctate red macules are seen on the soft palate and uvula (Forchheimer's spots). A flushed face with circumoral pallor is also commonly noted (see Fig. 177-9C). In scarlet fever, the tongue demonstrates characteristic changes. During the first 2 days of the disease, the tongue has a white coat through which the red and edematous papillae project (white strawberry tongue). After 2 days, desquamation occurs, resulting in a red tongue with prominent papillae (red strawberry tongue) (see Fig. 177-9C).

The diagnosis of scarlet fever is made by the characteristic clinical signs and confirmed by the rapid streptococcal test or throat culture. Scarlet fever usually follows a benign course, and any undue morbidity or mortality is likely due to suppurative complications, including peritonsillar abscess, sinusitis, pneumonia, and meningitis or nonsuppurative complications associated with immune-related rheumatic fever or glomerulonephritis. The risk of acute rheumatic fever following an untreated group A streptococcal infection has been estimated to be approximately 3% in epidemics and 0.3% in endemic circumstances. Glomerulonephritis can occur in up to 10%–15% after infection with nephritogenic group A streptococcal strain. In addition to pharyngitis, group A streptococcus can cause scarlet-fever-like eruptions from skin (often surgical wounds) or uterine infections.

Scarlet fever is treated by antibiotics (penicillin or erythromycin for a 10-day course) and supportive care. Fever usually abates within 12–24 hours after initiation of antibiotic therapy. Recurrences are common.

Staphylococcal Scarlet Fever. Staphylococcal scarlet fever, also known as *scarlatiniform erythroderma or rash*, was first described almost 90 years ago and, until recently, was considered to be a milder or abortive form of SSSS. Patients usually develop a generalized erythroderma with a roughened, sandpaper-like texture very much like in streptococcal scarlet fever. However, the exanthem of staphylococcal scarlet fever tends to be more tender than corresponding streptococcal scarlet fever. Systemic signs including malaise and fever are invariably present. Within a few days of initiation of the rash, thick flakes develop, and the entire skin desquamates over the subsequent week. Unlike generalized SSSS, the scarlatiniform eruption is not associated with the formation of bullae or superficial exfoliation and can be very difficult to differentiate from other infectious erythrodermal causes such as TSS and streptococcal scarlet fever. Scarlet fever induced by *Staphylococci* differs from streptococcal-mediated disease by the lack of pharyngitis. A recent study by Wang and colleagues examined the clinical characteristics and toxin detected in 20 children with staphylococcal scarlet fever.[22] They found that all of the patients' staphylococcal infections arose from the skin; 16 of 20 cases from furuncles/carbuncles; and two each from abscesses or wound infections. All of the *S. aureus* strains expressed SEB. Of note, SEB shows significant protein sequence homology with SPEA, a known exotoxin associated with streptococcal scarlet fever. Yet other studies have implicated other staphylococcal enterotoxins.[23] One explanation for this heterogeneity of toxins associated with this disorder is that the diagnosis is made upon clinical grounds. It is indeed possible that staphylococcal scarlet fever represents an incomplete form of TSS, in which toxins spread from the skin, thus activating the skin-associated lymphoid tissue rather than mucosal-associated lymphoid tissue. Because most cases of streptococcal scarlet fever arise from a pharyngitis, the lack of a pharyngitis in a patient with characteristic rash and other clinical signs of scarlet fever should alert the clinician to look for a localized nidus of infection (e.g., furuncle) that could be cultured to establish the diagnosis.

DIFFERENTIAL DIAGNOSIS. The diagnosis of scarlet fever is made on clinical grounds with supporting positive bacterial cultures. The differential diagnosis should include other toxin-mediated disorders including SSSS. Although Kawasaki syndrome (see Chapter 167) has many similar clinical findings including mucosal involvement (e.g., strawberry tongue), swelling of extremities, and desquamation of palms and soles during convalescence, Kawasaki syndrome differs in that the course of fever is prolonged and cultures would be expected to be negative. Atypical drug hypersensitivity reactions can have some cutaneous features, but would lack the mucosal signs. There is usually a history of offending drug and peripheral eosinophilia. Scarlet fever from group A *Streptococcus* can usually be differentiated from that induced by *S. aureus* as the usual nidus of infection in streptococcal scarlet fever is from a pharyngitis while the staphylococcal variant usually has its infectious nidus in the skin.

TREATMENT AND PROGNOSIS. The treatment of scarlet fever includes antibiotics to eradicate the offending bacteria. If the localized nidus of infection is an abscess or furuncle/carbuncle, it should be drained. Acute rheumatic fever or glomerulonephritis is not associated with staphylococcal scarlet fever. For situations in which more systemic signs resemble TSS, the treatment should be that of TSS.

TOXIN-MEDIATED ERYTHEMA (RECURRENT TOXIN-MEDIATED PERINEAL ERYTHEMA)

(See Table 177-2)

In 1996, Manders and colleagues recognized a previously unreported toxin-mediated disorder, they termed

recurrent toxin-mediated perineal erythema.[24] Recurrent toxin-mediated perineal erythema is characterized by a striking diffuse macular perineal erythema that occurs within 24–48 hours after a pharyngitis with a toxin-producing group A *Streptococcus* or *S. aureus*. Clinical findings seen in scarlet fever, including a strawberry tongue, as well as erythema, edema, and later, palmoplantar desquamation, are commonly found in recurrent perineal erythema. Fever, hypotension, and other systemic signs of scarlet fever or TSS are characteristically absent although diarrhea is a common feature. Recurrences are more frequently found in this localized form. It has been proposed by Manders that that the term *toxin-mediated erythema* be used to describe the following clinical settings in which a toxin-producing *Staphylococcus* or *Streptococcus* can be found: recurrent erythroderma associated with a preceding bacterial pharyngitis, isolated episodes of toxin-mediated erythema without recurrences, and patients with episodic mild hypotension, fever, and typical mucocutaneous findings in the absence of full criteria for TSS.[25]

DISEASES INITIATED AND/OR EXACERBATED BY SUPERANTIGENS

In addition to the ability of superantigens to induce characteristic diseases including TSS, scarlet fever, and gastroenteritis, recent evidence is accumulating, which indicates that these potent immunomodulatory agents can initiate or exacerbate other skin disorders.

PSORIASIS. (See Chapter 18). Psoriasis is an autoimmune T-cell-driven keratinocyte hyperproliferative disease involving skin and rarely joints. Superantigens have been implicated in psoriasis in at least two settings: (1) the guttate (acute eruptive) form and (2) in situations where psoriasis flares in response to secondary infection.[11]

The acute guttate form of psoriasis is characterized by the rapid onset of small erythematous psoriasiform papules that can be generalized. This form can develop during or most commonly, right after a group A streptococcal infection (usually pharyngitis). More commonly found in children and young adults, guttate psoriasis has been estimated to be the initiation of psoriasis in up to 20% of patients. Studies examining a series of guttate psoriasis patients have demonstrated the association of a SPEC-expressing group A *Streptococcus* along with expansion of the appropriate T-cell receptor B Vβ pattern in the skin lesions and in perilesional skin.[26] These and other supporting studies do suggest that the superantigen-mediated systemic activation of T cells and MHC II-expressing accessory cells, resulting in the uncovering of the specific oligoclonal activation seen in chronic lesions is a plausible explanation for how infection could initiate this form of psoriasis.

In addition to the ability of systemic activation by a superantigen to initiate psoriasis, accumulating evidence has emerged that a localized infection with a superantigen-secreting microbe could be the trigger for worsening of psoriasis. For example, subjects with psoriasis have an increased cutaneous reactivity to the topical application of small (nanogram) amounts of superantigens, which is due to the increased levels of keratinocyte MHC II expression seen in subjects with activated psoriasis.[27] Thus, guttate psoriasis and flaring of existing psoriasis should prompt a careful examination and treatment for microbial infections. In women, a history of possible menstrual-associated flares of psoriasis (especially with tampon use) should prompt appropriate investigations and treatment.

AUTOECZEMATIZATION (ID) RESPONSE. (See Chapter 17). The autoeczematization (id) response is an acute, generalized skin reaction to a variety of stimuli. This stimulus may be a preexisting or new dermatitis (most often on the lower leg), or skin infection with fungi, bacteria, viruses, or parasites. The erythematous and papular pruritic rash often develops at distant sites and tends to be symmetric. No concomitant systemic toxicities are usually seen. One common clinical scenario is a patient with known stasis dermatitis who develops an allergic skin reaction to a topical agent (neomycin-containing antibiotic) used on the leg. Because of the ability of superantigens to stimulate significantly high numbers of T cells that tend to home to the skin, localized bacterial infection with a superantigen-producing *S. aureus* or group A *Streptococcus* could result in an autoeczematization response. Thus, careful examination for a microbial trigger is warranted in any patient with an autoeczematization response.

ATOPIC DERMATITIS. (See Chapter 14). Secondary infection with *S. aureus* or group A *Streptococcus* is a well-known trigger of atopic dermatitis.[28] It is estimated that *S. aureus* can be cultured from essentially all subjects with atopic dermatitis.[28] Recent studies have demonstrated that skin from subjects with active atopic dermatitis has decreased levels of antimicrobial proteins.[29] This lack of antimicrobial proteins may provide one explanation for the almost universal bacterial infection associated with flaring atopic dermatitis. Moreover, superantigen-expressing *S. aureus* have been associated with steroid-resistant AD cases.[30] The mechanisms by which bacterial infection can worsen atopic dermatitis is an active area of study, and not surprisingly, superantigens have been implicated. In addition to the "usual" mechanism of cross-linking T-cell receptor and MHC-II molecules, it has been shown that many atopic dermatitis patients have immunoglobulin E antibodies that recognize these globular proteins.[31] Thus, in addition to being a superantigen, these toxins can act as allergens in this population.

KEY REFERENCES

Full reference list available at www.DIGM8.com

DVD contains references and additional content

1. Dinges MM, Orwin PM, Schlievert PM: Exotoxins of Staphylococcus aureus. *Clin Micrbiol Rev* **13**:16, 2000

10. McCormick JK, Yarwood JM, Schlievert PM: Toxic shock syndrome and bacterial superantigens: An update. *Annu Rev Microbiol* **55**:77, 2001
11. Leung DY et al: The role of superantigens in human diseases: Therapeutic implications for the treatment of skin diseases. *Br J Dermatol* **53**(Suppl.):17, 1998
14. Shands KN et al: Toxic shock syndrome in menstruating women: Association with tampon use and Staphylococcus aureus and clinical features in 52 cases. *N Engl J Med* **303**:1436, 1980
16. Todd JK: Staphylococcal infections. *Pediatr Rev* **26**:444, 2005
27. Travers JB et al: Epidermal HLA-DR and the enhancement of cutaneous reactivity to superantigenic toxins in psoriasis. *J Clin Invest* **104**:1181, 1999
29. Ong PY et al: Endogenous antimicrobial peptides and skin infections in atopic dermatitis. *N Engl J Med* **347**:1151, 2002

Chapter 178 :: Non-Necrotizing Infections of the Dermis and Subcutaneous Fat: Cellulitis and Erysipelas

:: Adam D. Lipworth, Arturo P. Saavedra, Arnold N. Weinberg, & Richard Allen Johnson

NON-NECROTIZING INFECTIONS OF THE DERMIS AND SUBCUTANEOUS TISSUE AT A GLANCE

- Approximately 7%–10% of hospitalizations in North America are due to skin and soft-tissue infections (SSTI), including cellulitis and erysipelas.
- The incidence of SSTI is increasing, paralleling the rise of methicillin-resistant *Staphylococcus aureus*.
- A high index of suspicion for resistant organisms shoamaintained for cases that do not improve rapidly with empiric therapy, or in areas where resistant strains have been reported.
- Newer antibiotics are currently available or undergoing testing to treat resistant infections caused by methicillin-resistant or vancomycin-resistant strains.
- Microbiologic data from various culture techniques is helpful, but swabs, aspirations, and tissue cultures generally have a low yield for uncomplicated cellulitis and erysipelas.
- Non-necrotizing soft-tissue infections are treated with antibiotics and supportive measures, with drainage of collections as needed.

EPIDEMIOLOGY

Skin and soft tissue infections (SSTI) are characterized by clinical findings that include an acute, tender, spreading, edematous, suppurative inflammation of the skin, subcutaneous fat, or muscle, often associated with systemic symptoms of malaise, fever, chills, and local pain. Cellulitis is an infection of the dermis and subcutaneous fat, while erysipelas is a more superficial variant affecting the superficial dermal lymphatics and adjacent tissues. Along with the pyodermas (see Chapter 176), cellulitis and erysipelas, are the predominant forms of non-necrotizing SSTI, which account for 7%–10% of hospitalizations in North America.[1] Over the past two decades, the incidence of SSTI has increased faster than the incidence of other acute infections, paralleling the rise of methicillin-resistant *Staphylococcus aureus* (MRSA) rates.[2]

Cellulitis and erysipelas are usually caused by *S. aureus* or β-hemolytic *Streptococci* [primarily group A *Streptococcus* (GAS)] (see Table 178-1). Factors that increase the likelihood of SSTI include exposure to pathogenic organisms, local breach of the skin barrier function (including atopic dermatitis, and less often, allergic contact dermatitis, psoriasis, trauma, intravenous drug use, surgical and cosmetic procedures, toe-web intertrigo, arthropod bites, and chronic ulcers), immunocompromise (including acquired immunodeficiency syndrome [AIDS], diabetes, end-stage renal disease/dialysis, neutropenia, cancer, and immunosuppressive medications), obesity, and circulatory compromise (see Chapter 175).

Several risk factors, relatively specific to erysipelas, include extremes of age (children and the elderly), diabetes mellitus, and nephrotic syndrome.[3] In the adult patient with erysipelas, lymphedema (including

TABLE 178-1
Etiology of Non-necrotizing Soft-Tissue Infections

Type of Infection	Most Common Cause (s)	Uncommon Causes
Erysipelas	Group A *Streptococcus*	Group B, C, and G *Streptococci*, *Staphylococcus aureus*
Cellulitis	*S. aureus*, group A *Streptococcus*	Group B, C, and G *Streptococci; Streptococcus iniae; Pneumococcus; Haemophilus influenzae* (children); *Escherichia coli; Proteus*, other Enterobacteriaceae; *Campylobacter jejuni; Moraxella; Cryptococcus neoformans; Legionella pneumophila, Legionella micdadei; Bacillus anthracis* (anthrax); *Aeromonas hydrophila; Erysipelothrix rhusiopathiae; Vibrio vulnificus, Vibrio alginolyticus, Vibrio cholera non-01*
Cellulitis in children Facial/periorbital cellulitis Perianal cellulitis	*S. aureus*, group A *Streptococcus* *S. aureus*, group A *Streptococcus* Group A *Streptococcus*	Group B *Streptococcus* (neonates) *Neisseria meningitides, H. influenzae* (young children) *S. aureus*
Cellulitis secondary to bacteremia	*Pseudomonas aeruginosa*	*V. vulnificus; Streptococcus pneumoniae;* group A, B, C and G *Streptococci*
Cellulitis associated with water exposure	*E. rhusiopathiae* (*erysipeloid*)	*V. vulnificus, A. hydrophila, Mycobacterium marinum* (nodular lymphangitis), *Mycobacteria fortuitum* complex

congenital lymphedema), venous stasis, web intertrigo, and obesity are common risk factors. Lymphedema in particular may be an important feature in erysipelas even when subclinical and only evident by lymphosyntigraphy.[4]

For all variants of cellulitis, there is less predictability in immunocompromised hosts where organisms may include a range of traditional and rare pathogens, usual commensals, yeast, fungi, and parasites. Because traditional patterns of symptoms and physical findings may be lacking or nonspecific in immunocompromised patients, determining an etiologic diagnosis is especially important.[5] In both immunocompetent and immunocompromised hosts, bullae, necrosis, or gas-forming bacterial infections signal urgency in establishing the location of infection and in defining the cause (see Chapter 179).

ETIOLOGY, MICROBIOLOGY, AND PATHOGENESIS

Pathogens isolated from cellulitis are split primarily between *S. aureus* and GAS; the best estimates place the rate of *S. aureus* cellulitis at approximately 50%, and GAS at approximately 35%.[6] However, microbiologic studies are limited by the low yield of cultures from cellulitis (see Section "Diagnostic Studies"), and anecdotal experience suggests that *S. aureus* may now be a far more common cause of cellulitis than GAS. *Haemophilus influenzae* is an important cause of cellulitis in much of the world, but the widespread use of the *Haemophilus influenza type b* vaccine has greatly decreased the incidence in the United States.

The remainder of cellulitis cases are caused primarily by groups B and G *Streptococcus*,[7,8] enteric-Gram-negative rods,[9] coagulase-negative *Staphylococcus*,[10] and *Streptococcus pneumoniae*.[11] These unusual pathogens are particularly common and problematic in association with extremes of age, prolonged hospitalization, percutaneous intravascular lines, diabetes, obesity, immunocompromised states, and glucocorticoids.[8] Liposuction and percutaneous drug use are reported risk factors that may also lead to cellulitis from less common organisms.

Erysipelas is a distinct type of superficial cutaneous cellulitis with marked dermal lymphatic vessel involvement. GAS has classically been considered the predominant cause of erysipelas, but erysipelas may also be caused by *S. aureus* and group C or G *Streptococcus*.

VIRULENCE MECHANISMS

Both *S. aureus* and GAS possess effective mechanisms of bypassing the immune system and establishing infection. GAS appears capable of inactivating cathelicidin LL-37, thereby mediating resistance to the innate immune system.[12] Although it is classically regarded as an extracellular pathogen, GAS also appears able to evade immune detection and antibiotic therapy by entering macrophages and endothelial cells.[13,14] Both GAS and *S. aureus* may produce exotoxins that result in systemic toxic reactions, including toxic shock syndrome (see Chapter 177). Panton–Valentine Leukocidin (PVL) is a β-pore forming toxin produced by many strains of *S. aureus* that damages leukocytes and predisposes to severe SSTI and other infections.[15]

ANTIMICROBIAL RESISTANCE

METHICILLIN-RESISTANT *STAPHYLOCOCCUS AUREUS* (MRSA), AND RELATED PATHOGENS. Antibiotic resistance is of increasing concern, particularly in the case of MRSA, which, in many series across disparate geographic areas in the United States and Europe, now accounts for more than

50% of cellulitis from which a pathogen could be cultured.[16–19] Healthy individuals are frequently affected, but certain populations appear to be at particular risk for MRSA skin infections, including those with immunosuppression, chronic illness (including end-stage renal disease), prisoners,[17] athletes,[20] and men who have sex with men.[21] Other risks noted in the literature include youth, recent sexual contact, presence of abscess, low body mass index, spontaneity of infection, and group home living.[16]

Methicillin resistance arises from the *mecA* gene, a component of a mobile genetic element, the staphylococcal cassette chromosome (SCC*mec*). This gene results in the production of an altered penicillin-binding protein (PBP2a), with a lower affinity for β-lactam groups, resulting in a minimum inhibitory concentration (MIC) to oxacillin of at least 4 μg.[22] This mechanism imparts resistance to all β-lactam antibiotics currently available, including penicillins, cephalosporins, monobactams, and carbapenems. Similar resistance mechanisms to β-lactams have been increasing in several important pathogenic strains of coagulase-negative *Staphylococcus* species, including *S. sciuri* and *S. haemolyticus*.[23,24]

Relative to infection with Methicillin-sensitive *S. aureus* (MSSA) and other pathogens, infection with MRSA is associated with a higher rate of adverse outcome and treatment failure,[25] as well as higher economic costs of care.[26] These unfavorable outcomes likely arise from the virulence factors closely associated with dominant MRSA strains in both community and nosocomial settings. Many MRSA strains, including the CA300 strain, which has emerged as the dominant community-acquired (CA) strain in the United States, have a very high rate of PVL expression,[27,28] and they also appear to be more effective colonizers than MSSA strains.[29]

Both hospital-acquired (HA) and CA-MRSA strains have accumulated mutations that result in resistance to other classes of antibiotics, including macrolides, tetracyclines, fluoroquinolones, and sulfonamides, though the resistance patterns to these non-β-lactam antibiotics vary widely by region. With increased use of mupirocin and chlorhexidine as adjunctive therapies for MRSA, or as part of decolonization regimens, resistance to these topical agents is also on the rise, topping 10% in some settings.[30,31] Resistance to mupirocin has been associated with increased resistance to other antibiotics,[30] and with poor outcome measures, including increased mortality in at least one study of MRSA in an intensive care unit setting.[32] In addition, resistance to the drugs often considered "salvage" medications, including vancomycin[19] and linezolid,[33] is of increasing prevalence and concern.

VANCOMYCIN-RESISTANT *ENTEROCOCCUS* (VRE). Vancomycin-resistant *Enterococcus* is most often a colonizing organism in SSTI, but it may act as a pathogen in nosocomial SSTI in immunocompromised patients.[34] Despite its relatively low virulence, VRE is of increasing concern because of its ability to transmit resistance to other bacterial species, and because of the increasing prevalence of immunocompromised patients worldwide from HIV disease/AIDS and immunosuppressive medications.[35]

SKIN SIGNS AND SYMPTOMS

CLASSICAL CELLULITIS

Cellulitis presents with erythema, pain, firm and tender induration, and less commonly, fluctuance. The erythema may rapidly intensify and spread. The margins are generally indistinct. In some cases of cellulitis, the overlying epidermis undergoes bulla formation or necrosis, resulting in extensive areas of epidermal sloughing and superficial erosion (Figs. 178-1 and 178-2). Regional lymphadenopathy may be associated with cellulitis on an extremity. In older individuals, thrombophlebitis may complicate lower leg cellulitis. Systemic symptoms, such as fever, chills, and malaise are variable, and sometimes may antedate localizing complaints and signs of SSTI. In a study of 50 patients with cellulitis, only 26% had fever higher than 38°C (100.4°F). A potential portal of entry was identified in 66% of patients.[36]

The infection may also cause deeper necrosis, resulting in dermal and subcutaneous abscess formation, fasciitis, and myonecrosis. Pain in the absence of erythema, or out of proportion to the appearance of the local area, should raise suspicion for an early



Figure 178-1 Cellulitis with swelling, erythema, and tenderness. **A.** Note the blistering and crusting on the lower extremity. **B.** The cellulitis is emanating from an upper extremity abscess.



Figure 178-2 **A.** Cellulitis after puncture trauma. The forearm is swollen, erythematous, and tender; there is abscess formation. **B.** Cellulitis arising at the site of a surgical excision: *Staphylococcus aureus*. Note discharge of pus.

deep-seated infection. Crepitus is a rare sign that signifies a gas-forming pathogen (see Chapter 179).

Cellulitis usually presents at the site of an antecedent lesion, including acute and chronic ulcers, traumatic wounds (abrasions, lacerations, animal and human bites), surgical procedure sites, dermatoses, or percutaneous catheters. Less commonly, bacteremia from systemic infections such as osteomyelitis and diverticular abscesses may cause SSTI.

ERYSIPELAS

Although erysipelas shares many clinical features with classical cellulitis (pain, tenderness, erythema, and edema), the plaque-like edema has a more sharply defined margin to normal tissue, and the erythema is classically bright red (Fig. 178-3). The surface findings are often described as *peau d'orange* (skin of an orange) in appearance. In the presence of antecedent edema or other anatomic abnormalities, the margin between normal and diseased soft tissue may be more obscure, much as in primary cellulitis.

Seventy-five to 90% of cases involve the lower extremities, while the face is affected in 2.5%–10% of cases.[37] Facial erysipelas begins unilaterally but may spread by contiguity over the nasal prominence to involve the face symmetrically (Fig. 178-4). There may not be an obvious portal of entry, and skipped areas may confuse the nature of the process. The oropharynx is a common portal of entry, and throat culture may show GAS. Inflammatory edema can extend to the eyelids, but orbital complications are rare.

Fever may precede local signs, and occasionally before distal extremity findings, patients complain of groin pain caused by swelling of femoral lymph nodes. Lymphangitis and abscess are not common, but the process may spread rapidly from the initial lesion. Infrequently, bullae or epidermal sloughing may occur in the involved area.[38]

CELLULITIS COMPLICATING SURGICAL WOUNDS

Surgical wound infections are the most common adverse events in hospitalized patients undergoing surgery and are classified as incisional (superficial) or deep.[39] Incisional wound infections involve the skin, subcutaneous tissue, and/or muscle (see Fig. 178-2B). Up to 80% of wound infections are incisional. A wound is considered to be infected if there is drainage of purulent material and evidence of inflammation. Incisional infections present with erythema, pain, tenderness,



Figure 178-3 Erysipelas. There is painful, warm erythema of the lower extremity with well-defined borders.

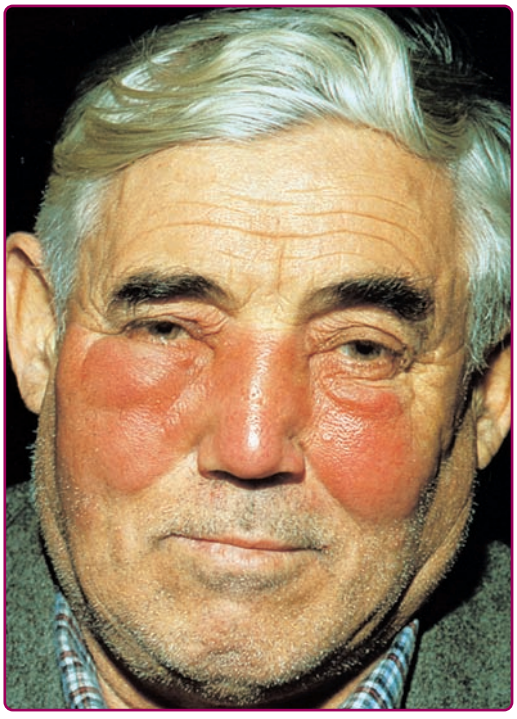

Figure 178-4 Erysipelas. Painful, edematous erythema with sharp margination on both cheeks and the nose. There is tenderness, and the patient has fever and chills.

local swelling and often, with low-grade fever. Cultures of the purulent drainage most often grow *S. aureus*. However, the microbiologic profile of cellulitis complicating surgery may reflect the structures incised during the procedure, such as an Enterobacteriaceae cellulitis after a genitourinary operation.[40]

Deep infections involve structures adjacent to the surgical wound that were entered or exposed during the procedure, such as subfascial layers, viscera, and/or spaces within the peritoneum, thorax, or joints. Deep-wound infections may be more subtle and delayed, and often present as fever of uncertain cause. Progressive bacterial synergistic gangrene and other variants of gangrenous cellulitis can arise in surgical wounds or around sutures (see Chapter 179).

The complications of superficial and deep-wound infections include poor healing, bacteremia, local and systemic effects of prolonged hospitalization, poor nutrition, residual compromised tissue integrity, and the consequences of prolonged antibiotic therapy. Additionally, wounds infected with toxin-producing *S. aureus* or GAS may result in systemic complications such as toxic shock syndrome or scarlet fever (see Chapter 177).

CELLULITIS COMPLICATING PRESSURE ULCERS

Pressure ulcers, particularly those located in the sacrum of elderly, frail, malnourished individuals, become contaminated by a variety of facultative and anaerobic microorganisms from the skin and the bowel, including *S. aureus, Enterococci*, *Pseudomonas aeruginosa,* and *Bacteroides fragilis*. In addition to pain and cellulitis, the ulcer may eventually be complicated by bacteremia, often polymicrobial, or the underlying bone can become infected. Given a high burden of colonizing organisms, the identity of the active pathogen(s) may be difficult to determine. Pressure ulcers complicated by cellulitis or sepsis should be urgently debrided.[41]

CELLULITIS COMPLICATING HUMAN AND ANIMAL BITES

Domestic dog and cat bites are common and can give rise to cellulitis caused by *Pasteurella multocida, Capnocytophaga canimorsus* (especially in asplenic individuals), and a host of other aerobes and anaerobes from the animal's mouth or the skin of the infected individual. Dog bites are often accompanied by a crush injury that devitalizes tissues. The bite of cats can inject organisms (via sharp incisors) deep into tissues, including joint spaces, tendon sheaths, or bone (see Chapters 180 and 209).

With rates of cellulitis approaching 15%, human bites have a higher incidence of infection than do animal bites because of the mix of oral bacteria (aerobes and anaerobes), as well as the crush injury imparted by the bite.[42,43] Organisms include various *Streptococci*, *S. aureus, Eikenella*, *Corynebacterium*, and the anaerobic *Peptostreptococci* and *Peptococci*. Cellulitis from bites should be monitored carefully for progression to a necrotizing infection.

PROGNOSIS AND CLINICAL COURSE

Acute cellulitis, with or without abscess formation, has a tendency to spread through the lymphatics and bloodstream and may be a serious disease, if not treated early. In patients with chronic edema, the process may spread extremely rapidly and recovery may be slow, despite drainage and sterilization of the lesions by antibiotics.

Uncomplicated erysipelas remains confined primarily to the lymphatics and subcutaneous tissues. Even in the days before antibiotic therapy, it was often a self-limited process, subsiding over 7–10 days. Occasionally, untreated erysipelas or cellulitis may be complicated by bulla formation, abscess, necrotizing fasciitis, and bacteremia with sepsis or metastatic infection in various organs. Prompt diagnosis and treatment prevents both suppurative and nonsuppurative complications. However, in young infants and elderly debilitated patients, and in individuals receiving glucocorticoids, the disease may progress with devastating rapidity to a fatal outcome.

Both classical cellulitis and erysipelas tend to recur in the same area, probably as a result of chronic lymphatic obstruction and persistent edema. Recurrent infection may specifically be seen along the lines of venectomy following saphenous vein harvest (with tinea pedis as a portal of entry). Irradiation and nodal dissection with mastectomy predisposes to recurrent

cellulitis and erysipelas over the nodal basin, or involving any part of limb distal to the procedure.

Recurrent erysipelas may produce persistent swelling of the lips (macrocheilia), cheeks (particularly the lax tissues beneath the eyes), abdomen, and lower extremities, sometimes resulting in elephantiasis nostra verrucosa (see Chapter 174). The resultant edema predisposes to further bouts of recurrent erysipelas or cellulitis, creating a cycle that can be difficult to break.[37]

Early pathogen identification, therapy, and prolonged elevation of the affected area can help to preserve better tissue resistance to reinfection. Historically, some patients with frequently recurrent GAS erysipelas have benefited from prophylactic antibiotics, usually monthly benzathine penicillin injections, but recurrences may persist in cases of noncompliance, unusual pathogens, or inappropriate antibiotic selection or dosage.[44]

DIFFERENTIAL DIAGNOSIS

Dermatologists are frequently called upon to differentiate between cellulitis and many other conditions with similar clinical presentations, including both infectious and noninfectious mimickers of cellulitis[45,46] (see Box 178-1).

DIAGNOSTIC STUDIES

STAINS AND CULTURES

The typical appearance of an SSTI, coupled with epidemiologic and clinical data, may guide antimicrobial therapy but is not completely reliable, particularly in patients who are immunocompromised. Cultures and stains from swabs, aspirates, tissue biopsies, and blood may provide valuable microbiologic data in select situations. This data can be particularly helpful with the rise of resistant bacteria and resultant uncertainty over appropriate empiric therapy.

CULTURE OF SURFACE SWABS, NEEDLE ASPIRATES, AND PUNCH BIOPSIES. Epidermal swabs are rarely helpful in cases of simple cellulitis or erysipelas, since any organism found is likely to be a colonizer or contaminant rather than a true pathogen.[47]

Needle aspirates may be of greater utility, yielding a likely pathogen at published rates of between 2% and 40% of cases.[48,49] The procedure is performed by injecting nonbacteriostatic saline into the advanced border of the infected site, followed by aspiration of tissue fluid, which is then subjected to staining and culture. Sampling the most inflamed area of the lesion, rather than the advancing edge, may increase the yield of cultures.[50] Open lesions such as postsurgical, traumatic, and pressure ulcers, may contain multiple organisms, some of which may be significant whereas others are contaminants.[51]

While the yield of needle aspirates varies widely in the literature, punch biopsies for culture can predictably identify a pathogen from a plaque of simple cellulitis in 20%–30% of the cases.[48] The Gram stain may help initially to identify the morphology of most significant staining bacteria, but cultures with sensitivities are ultimately more useful when the stains reveal bacteria with potential resistance to the commonly used antibiotics.

BLOOD CULTURES. Most studies that include only immunocompetant patients with uncomplicated, nonnecrotizing cellulitis or erysipelas demonstrate positive blood cultures in only 2%–5% of patients, suggesting that blood cultures should not necessarily be part of the routine evaluation for all simple SSTI, especially because the rate of false-positive contaminants approaches the rate of true pathogens identified.[37,48,52,53] However, the risk of bacteremia is notably higher in patients with comorbid HIV disease/AIDS and other forms of immunocompromise (approximately 25%), and in patients with an abscess, lymphedema, fever, or clinical evidence of a necrotizing or otherwise severe infection. Other factors that may signal a higher utility for blood cultures include proximal location of the infection, duration of symptoms for less than 2 days, multiple comorbid factors, and lack of pretreatment with antibiotics.[54]

HISTOPATHOLOGY

In addition to direct stains and cultures, pathologic investigation with special staining can be very useful. Histologically, erysipelas is characterized by intense edema, marked lymphatic and vascular dilatation of the superficial dermis, and a profuse infiltration of tissue spaces and lymphatic channels with *Streptococci* and neutrophils. The *Streptococci* are not found in the blood vessels, but their presence in the lymphatics produces an inflammatory reaction about these vessels. Histiocytes and granulation tissue may be seen in chronic lesions. Edema may cause dermal pallor and epidermal spongiosis.

Direct immunofluorescent techniques have been reported to identify streptococcal pathogens in 19 of 27 cases of erysipelas and in 10 of 15 cases of cellulitis, yielding a sensitivity of 70% for in situ detection of *Streptococci*.[55] Lesional skin punch biopsy is often helpful in ruling out a cellulitis-simulating noninfectious inflammatory lesion or a coexisting diagnosis such as erythema nodosum, vasculitis, or eosinophilic cellulitis.

IMAGING

Imaging modalities in the setting of SSTI are most commonly employed to rule out abscess, necrotizing fasciitis, pyomyositis, and gas forming anaerobic bacterial infections (see Chapter 179). The most common feature of cellulitis noted on MRI or ultrasound is subcutaneous tissue thickening.[56]

TREATMENT

ANTIBIOTICS

ANTIBIOTICS FOR INFECTIONS IN WHICH *STAPHYLOCOCCUS AUREUS* IS SUSPECTED (INCLUDING MRSA). Empiric therapy for patients with suspected or potential staphylococcal infections

BOX 178-1 DIFFERENTIAL DIAGNOSIS OF ERYSIPELAS AND ACUTE CELLULITIS

NONINFECTIOUS

- Connective Tissue Diseases
  - Lupus erythematosus
  - Dermatomyositis
  - Scleroderma
  - Relapsing polychondritis
- Vascular/Circulatory disorders
  - Deep venous thrombosis
  - Superficial thrombophlebitis
  - Lymphedema
  - Lipodermatosclerosis
  - Leukocytoclastic vasculitis
- Neutrophilic dermatoses
  - Sweet syndrome
  - Pyoderma gangrenosum
  - Neutrophilic eccrine hidradenitis
- Neoplastic
  - Cutaneous lymphoma
  - Carcinoma erysipeloides
  - Paget disease
- Eczematous disorders
  - Contact dermatitis
  - Atopic dermatitis
  - Stasis dermatitis
- Follicular occlusion syndromes
  - Acne conglobata
  - Dissecting cellulitis
  - Hidradenitis suppurativa
- Iatrogenic
  - Fixed drug eruption
  - Generalized drug hypersensitivity
  - Radiation dermatitis
  - Warfarin necrosis
- Granulomatous diseases
  - Sarcoidosis
  - Foreign body reactions
  - Metastatic Crohn's disease
- Miscellaneous
  - Eosinophilic cellulitis
  - Familial Mediterranean Fever
  - Insect bites and stings
  - Erythromelalgia
  - Scleredema
  - Gout
  - Panniculitides (including erythema nodosum)

INFECTIOUS

- Bacterial
  - Dental abscess/sinus
  - Phlegmon
  - Necrotizing soft tissue infection
  - Erysipeloid
  - Erythema migrans
  - Cutaneous anthrax
- Mycobacterial
  - Tuberculosis cutis verrucosa
  - Atypical mycobacterial infections
- Viral
  - Early herpes zoster
  - Parvovirus B19
- Fungal
  - Dermatophytoses
  - Cutaneous candidiasis
  - Deep fungal infections
- Parasitic
  - Leishmaniasis
  - Onchocerciasis

has changed in recent years with the increased prevalence of MRSA infections. Traditionally, simple cellulitis not requiring hospital admission has most commonly been treated with a penicillinase-resistant penicillin (e.g., dicloxacillin), or an oral cephalosporin (e.g., cephalexin) (see Box 178-2). In areas where MRSA rates are highest, clindamycin, trimethoprim-sulfamethoxazole, fluoroquinolones, and tetracyclines such as doxycycline and minocycline have recently played a more significant role in empiric therapy. However, each of these agents has deficiencies worth considering when choosing an empiric agent. The great majority

BOX 178-2 ANTIMICROBIAL TREATMENT OF NON-NECROTIZING INFECTIONS (ERYSIPELAS, CELLULITIS)

DISEASE		DRUG OF FIRST CHOICE	ALTERNATIVE DRUGS
Erysipelas	Simple, outpatient	Penicillin V[a] Intramuscular procaine penicillin Amoxicillin Vancomycin	Cefoxitin, cephalexin Dicloxacillin Amoxicillin/clavulanate Clindamycin Azithromycin
Cellulitis	Severe, hospitalized patient	Ampicillin/sulbactam Ticarcillin/clavulanate Piperacillin/tazobactam Imipenem/cilastatin, meropenem	Vancomycin Clindamycin Linezolid
	Simple, outpatient	Cephalexin Dicloxacillin	Clindamycin Azithromycin Clarithromycin
	Severe, hospitalized patient[b]	Ampicillin/sulbactam Cefazolin Piperacillin/tazobactam Ticarcillin/clavulanate Imipenem/cilastatin, meropenem	Vancomycin Linezolid Aminoglycoside + metronidazole
	Refractory, high likelihood of MRSA infection	Vancomycin Linezolid	Daptomycin Quinupristin-dalfopristin Tigecycline

MRSA: Methicillin Resistant *Staphylococcus aureus*.
[a]Penicillin V or amoxicillin only if known group A *Streptococcus*, without suspicion for *Staphylococcus aureus*.
[b]Consider empiric MRSA therapy in any severely ill patient.

of CA-MRSA and most HA-MRSA, remains susceptible to trimethoprim-sulfamethoxazole, but this drug is largely ineffective against GAS. *Streptococci*, MRSA, and MSSA, all have significant resistance to clindamycin, fluoroquinolones, and tetracyclines in some areas.[57,58]

Moreover, data supporting a switch to non-β-lactam empiric therapies of outpatient SSTI is lacking at this time. A cost-effectiveness analysis modeling the use of cephalexin, clindamycin, and trimethoprim-sulfamethoxazole for simple SSTI found cephalexin to be the most cost-effective choice in most clinical situations, including situations reflective of even the highest rates of MRSA documented in the literature currently.[59] A retrospective study of cellulitis in Philadelphia-area pediatric practices found that failure of empiric therapy was more likely with trimethoprim-sulfamethoxazole than with either cephalexin or clindamycin. Other factors associated with therapeutic failure across all three antibiotics included markers of infection severity, such as fever, abscess, or presentation to an emergency department; while not always statistically significant, cephalexin had the lowest failure rate in every clinical situation examined.[60] A multicenter retrospective study from Idaho found no statistically significant difference between the clinical effectiveness of β-lactam antibiotics compared with MRSA empiric coverage for outpatient cellulitis cases, but the non-β-lactams were associated with higher rates of adverse effects.[61]

The retrospective nature of these studies does not generally account for the reasons empiric MRSA coverage was selected in some cases and not others, and so these studies do not rule out the possibility that non-β-lactam drugs are more effective empiric coverage in some situations. However, at this time, despite the shift in prescribing practices to favor therapy that may cover MRSA, the data appears to favor continued use of penicillinase-resistant β-lactam antibiotics in most cases of simple SSTI not requiring hospitalization.

More severe cases of cellulitis requiring hospitalization are usually treated with parenteral antibiotics; the same controversy over whether to use a β-lactam or empiric MRSA coverage is important for hospitalized patients, but the risks of choosing an inappropriate initial therapy are potentially greater in cases of more severe infections, perhaps shifting the balance in favor of empiric MRSA-coverage, especially vancomycin, in

many situations. The most common agents chosen are intravenous semisynthetic penicillinase-resistant penicillins (e.g., nafcillin 2 g intravenously every 4 hours) and cephalosporins (e.g., cefazolin 1g intravenously every 8 hours), or vancomycin (1g intravenously twice daily) when MRSA is suspected, or when the patient has a history of an immediate type reaction (immunoglobulin E mediated) to penicillin or cephalosporin. A recent abstract presented compelling retrospective data supporting use of vancomycin over β–lactam antibiotics as empiric therapy for cellulitis in hospitalized patients.[62] Carbapenems have very broad coverage and are useful agents for severe infections when MRSA is not suspected, or when combined with anti-MRSA therapy.[63]

Linezolid (600 mg orally twice daily) is an oxazolidinone that has emerged as an effective oral alternative for infections caused by MRSA, MSSA, GAS, and VRE,[64] but linezolid resistance, while still rare, is increasing.[33] In outpatients, its use is limited largely by cost, though it may prove cost effective in many inpatient situations because it has been shown to decrease hospitalization times when compared to vancomycin.[65]

Other agents, approved by the US Food and Drug Administration (FDA) for the treatment of SSTI, include quinupristin-dalfopristin, daptomycin, and tigecycline. Use of quinupristin-dalfopristin (a streptogramin combination antibiotic) is limited by the large volumes of intravenous infusions required to achieve adequate cutaneous penetration. Daptomycin (4 mg/kg/day) is a bactericidal lipopeptide that achieves very good concentrations in the skin, and has been shown to be equivalent to vancomycin and other antibiotics in the treatment of SSTI.[66] In addition, given its novel mechanism of action, which is poorly understood but includes disruption of bacterial membrane electric potential, less chance for bacterial resistance is postulated.[67] Tigecycline, a new generation glycylcycline derived from minocycline, overcomes existing tetracycline resistance mechanisms and is broadly effective against Gram-negative and Gram-positive bacteria (including MRSA), as well as anaerobes and some atypical pathogens.[68]

Newer agents include oritavancin, dalbavancin, and telavancin, new lipoglycopeptides with long half-lives that belong to the same class as vancomycin.[69–71] More recently, two novel cephalosporins with activity against MRSA have been developed—(1) ceftaroline and (2) ceftobiprole.[72,73] Finally, a new diaminopyrimidine dihydrofolate reductase inhibitor related to trimethoprim, iclaprim, is under review by the FDA.[74]

ANTIBIOTICS FOR PREDOMINANTLY STREPTOCOCCAL INFECTIONS. It is rare in current practice that *S. aureus* can be ruled out with sufficient confidence to empirically treat with antistreptococcal drugs alone, without drugs that cover *Staphylococcus* well, but mild cases of early erysipelas known to be caused by GAS can be treated on an outpatient basis with either oral or intramuscular penicillin (See Box 178-2). Dicloxacillin or cephalexin (both 500 mg four times a day) is more commonly used because it is so difficult to rule out *S. aureus* clinically (see Box 178-2). Macrolides and clindamycin can be used in penicillin-allergic individuals, but increasing resistance of *Streptococcus pyogenes* to erythromycin has been reported.[75,76] Severe streptococcal SSTI, or SSTI complicated by comorbidities including diabetes, should be treated with high dose intravenous aqueous penicillin G (1–2 million units every 4–6 hours), but it is now rare to administer penicillin alone for cutaneous infections, without tissue culture proving monomicrobial streptococcal infection.

ADJUNCTIVE THERAPIES

Care of the local lesions of erysipelas and cellulitis includes bed rest and elevation of the involved area to reduce local edema. Cool, sterile saline dressings decrease the local pain and are particularly indicated in the presence of bullous lesions. The application of moist heat may aid in the localization of an abscess in association with cellulitis. Surgery is not generally needed for erysipelas or cellulitis unless an abscess or necrotizing infection is suspected. When present, an abscess should be drained and cultured (see Chapter 176).

PREVENTION

Education of health care providers, adherence to infection-control measures, and judicious use of antimicrobials are paramount to SSTI prevention. Decolonization strategies have thus far failed to demonstrate consistent efficacy, and development of further resistance from these protocols is a feared complication.[77] Several vaccines have been developed against *S. aureus*, which in theory circumvent staphylococcal resistance mechanisms, but so far, none has proven effective beyond phase III trials.[78] Antistaphylococcal IgG was also found to be ineffective in late testing.[79] Vaccines against the M-protein of GAS are being investigated.[80]

KEY REFERENCES

Full reference list available at www.DIGM8.com

DVD contains references and additional content

1. Vinh DC, Embil JM: Rapidly progressive soft tissue infections. *Lancet Infect Dis* **5**:501-513, 2005
19. Rice LB: Antimicrobial resistance in Gram-positive bacteria. *Am J Infect Control* **34**:S11-S19; discussion S64-S73, 2006
25. Davis SL et al: Epidemiology and outcomes of community-associated methicillin-resistant Staphylococcus aureus infection. *J Clin Microbiol* **45**:1705-1711, 2007
32. Jones JC et al: Mupirocin resistance in patients colonized with methicillin-resistant Staphylococcus aureus in a surgical intensive care unit. *Clin Infect Dis* **45**:541-547, 2007
37. Lopez FA, Lartchenko S: Skin and soft tissue infections. *Infect Dis Clin North Am* **20**:759-772, v-vi, 2006
45. Kroshinsky D, Grossman ME, Fox LP: Approach to the patient with presumed cellulitis. *Semin Cutan Med Surg* **26**:168-178, 2007

46. Falagas ME, Vergidis PI: Narrative review: Diseases that masquerade as infectious cellulitis. *Ann Intern Med* **142**:47-55, 2005
50. Swartz MN: Clinical practice. Cellulitis. *N Engl J Med* **350**:904-912, 2004
59. Phillips S, MacDougall C, Holdford DA: Analysis of empiric antimicrobial strategies for cellulitis in the era of methicillin-resistant Staphylococcus aureus. *Ann Pharmacother* **41**:13-20, 2007
60. Elliott DJ et al: Empiric antimicrobial therapy for pediatric skin and soft-tissue infections in the era of methicillin-resistant Staphylococcus aureus. *Pediatrics* **123**:e959-e966, 2009

Chapter 179 :: Necrotizing Soft Tissue Infections: Necrotizing Fasciitis, Gangrenous Cellulitis, and Myonecrosis

:: Adam D. Lipworth, Arturo P. Saavedra, Arnold N. Weinberg & Richard Allen Johnson

NECROTIZING SKIN AND SOFT-TISSUE INFECTIONS AT A GLANCE

- Necrotizing skin and soft-tissue infections include necrotizing fasciitis, gangrenous cellulitis, and myonecrosis, and related diseases that cross soft-tissue planes.
- Necrotizing skin and soft tissue infections are locally destructive and frequently have severe systemic complications. They must be recognized rapidly and treated aggressively to minimize mortality.
- Tissue cultures have more utility in necrotizing infections than in simple cellulitis and erysipelas.
- Necrotizing soft-tissue infections require a combination of surgical treatment and antibiotics.
- Radiographic imaging may be helpful in crepitant infections but should not delay surgical therapy in cases where necrotizing infections are suspected.

EPIDEMIOLOGY

Necrotizing skin and soft tissue infections (SSTI) include gangrenous cellulitis, necrotizing fasciitis, and anaerobic myonecrosis. All of these conditions are highly destructive locally, and they frequently have severe or lethal systemic complications; they must be recognized early and treated aggressively, usually with a combination of antibiotics, surgical debridement, and supportive measures. However, the infrequency of these infections, coupled with the relatively nonspecific clinical findings early in their course, makes rapid diagnosis difficult; up to 85% of these patients do not have an accurate diagnosis at the time of admission to the hospital.[1]

Necrotizing fasciitis, especially the monomicrobial form, frequently affects young, healthy patients. However, increased age, immunocompromise including acquired immunodeficiency syndrome (AIDS), chronic illness, alcoholism, and percutaneous drug use are risk factors.[2] A chart review from New Zealand found that features common to a high proportion of necrotizing fasciitis patients included diabetes mellitus, gout, congestive heart failure, and recent surgical procedures. However, statistical analysis to assess the validity of these associations was not presented.[3] Necrotizing fasciitis arising at sites of recent tattoos[4,5] and sclerotherapy has been reported.[6] Finally, the role of nonsteroidal anti-inflammatory drugs (NSAIDS) is controversial; many studies have found an association between NSAIDS and necrotizing SSTI, but prospective studies have failed to confirm the speculation that NSAIDS may promote infection progression or delay diagnosis by obscuring early symptoms.[7]

Clostridial necrotizing SSTI, including anaerobic cellulitis and myonecrosis, arise either from deep traumatic or surgical inoculation, or from hematogenous spread from an internal infectious focus.[8] These infections are rare in healthy patients; common associations include malignancy, neutrophil dysfunction, bowel ischemia, and hemolytic-uremic syndrome.[9]

ETIOLOGY, MICROBIOLOGY, AND PATHOGENESIS

The most common pathogens mediating necrotizing SSTI are group A β-hemolytic *Streptococcus* (GAS) in

TABLE 179-1
Etiology of Necrotizing Skin and Soft-Tissue Infections

Type of Infection	Most Common Cause(s)	Uncommon Causes
Gangrenous Cellulitis		
Clostridial anaerobic cellulitis	*C. perfringens*	*C. novyi*, *C. sordellii*, *C. septicum*
Non-clostridial crepitant cellulitis	*Bacteroides* sp., Peptostreptococci	*E. coli*, other enterobacteriaceae
Gangrenous cellulitis in the immunosuppressed individual	*P. aeruginosa* (ecthyma gangrenosum) *Mucor*, *Rhizopus*, *Aspergillus*	*Bacillus* sp., other bacterial and fungal sp.
Necrotizing Fasciitis		
Type I Polymicrobial infection with mix of anaerobes and facultative species	Anaerobes: *Peptostreptococcus* or *Bacteroides* sp. Facultative species: non–group A streptococci, Enterobacteriaceae	Groups B, C, and G streptococcus
Type II	Group A streptococcus	
Necrotizing Fasciitis Variants that Involve Extra-Fascial Cutaneous Structures		
Synergistic Necrotizing Cellulitis: Polymicrobial with facultative and anaerobic organisms that originate in the intestine:	Facultative coliform organisms: *E. coli*, *Proteus*, *Klebsiella* Anaerobic organisms: *Bacteroides* sp., or *Peptostreptococcus*	
Progressive Bacterial Synergistic Gangrene (Meleney Gangrene)	*S. aureus* and *Peptostreptococcus* sp.	
Infectious myositis		
Pyomyositis	*S. aureus* β-hemolytic streptococcus	*S. pneumonia* *H. influenzae* Enterobactereciae Mycobacteria Fungi
Anaerobic myonecrosis (Gas gangrene)	*C. perfringens*	*C. septicum*

the case of necrotizing fasciitis type II, and anaerobes such as clostridial species in the case of gangrenous cellulitis and myonecrosis. However, other relatively common organisms that cause necrotizing SSTI include *Staphylococcus aureus*, non-group A streptococcal species, *Pseudomonas*, *Pasteurella*, *Vibrio*, and Enterobacteriaceae (such as *Escherichia coli*).[8,10] These infections are often polymicrobial, with a mix of both pathogens and contaminants (see Table 179-1).

The microorganisms associated with necrotizing cutaneous infections in the normal host are joined by a variety of other traditionally pathogenic and nonpathogenic bacteria, as well as fungi, in immunocompromised patients. In the presence of thermal burns, hematogenous *Pseudomonas aeruginosa* may infect normal skin, producing ecthyma gangrenosum (see Chapter 180), or may be attracted to burn areas, leading to extensive bacteremic pseudomonas gangrenous cellulitis. Mucormycotic gangrenous cellulitis can engraft onto thermal burns or complicate percutaneous catheter areas in immunosuppressed individuals. In the immunocompromised host, it becomes mandatory to biopsy any necrotic cellulitic lesions and to be alert to the possibility of a wide range of bacterial, viral, fungal, and even parasitic pathogens.

The pathophysiology of necrotizing fasciitis has not been fully elucidated, but the bacteria capable of producing this infection, including GAS, appear to share the ability to produce enzymes that degrade fascia and allow rapid proliferation at the level of the superficial fascia. This proliferation results in local thrombosis, progressive ischemia, liquefaction necrosis, and ultimately, more superficial gangrene.[11]

Mechanisms of clostridial virulence are better understood. Clostridial species are large spore-forming Gram-positive bacilli that produce more toxins than any other known bacteria.[12] Clostridial α-toxin, a pore-forming lecithinase that mimics the function of phospholipase C, hydrolyzes cell membranes, and increases capillary permeability and platelet aggregation, thereby mediating hemolysis and dermonecrosis. This exotoxin has been shown to be both sufficient and necessary for gas gangrene in mouse models; injection of *Bacillus subtilis* carrying a gene for the toxin produces myonecrosis, and immunizing mice against the α-toxin prevents the infection.[13] Nevertheless, other clostridial toxins do appear to play a role in human SSTI disease, including θ-toxin (containing perfringolysin O), ε-toxin, and multiple collagenases. *Clostridium perfringens* accounts for approximately 80% of clostridial SSTI; less common causes of gangrenous clostridial SSTI include *Clostridium septicum*, *Clostridium novyi*, and *Clostridium sordellii*.[12,14]

TABLE 179-2
Findings in Necrotizing Skin and Soft-Tissue Infections

Feature	Progressive Bacterial Synergistic Gangrene	Synergistic Necrotizing Cellulitis	Streptococcal Gangrene	Clostridial Myonecrosis (gas gangrene)	Necrotizing Infections in Immunosuppression
Microbiology	Streptococci, *Staphylococcus aureus*	Mixture of organisms: *Bacteroides*, peptostreptococci, or *Escherichia coli*	Group A streptococci	*Clostridium perfringens*	*Rhizopus, Mucor, Absidia, Pseudomonas aeruginosa*
Predisposing conditions	Surgery or draining sinus	Diabetes	Diabetes or abdominal surgery	Trauma	Diabetes, corticosteroid use, immunosuppression, burns
Fever	Minimal	Moderate	High	Moderate to high	Low in fungal, high in pseudomonal
Pain	Prominent	Prominent	Prominent	Prominent	Mild
Anesthesia	Absent	Absent	May occur	Absent	May occur
Crepitus	Absent	May occur	Absent	Present	Absent
Course	Slow	Rapid	Very rapid	Extremely rapid	Rapid

Modified with permission from Pasternack MS, Swartz MN: Cellulitis, necrotizing fasciitis, and subcutaneous tissue infections, in *Principles and Practice of Infectious Diseases*, 7th ed, edited by Mandell GL et al. Churchill Livingstone/Elsevier, Philadelphia, 2010, p 1301.

CLINICAL PRESENTATION, DIAGNOSIS, PROGNOSIS

Necrotizing infections of soft tissues may be localized to the muscle, fascia, or the overlying skin and subcutis, or they may cross these layers; the structural layers involved provide a useful framework for categorizing these infections into gangrenous cellulitis (affecting the dermis and subcutaneous tissue), necrotizing fasciitis (predominantly affecting the fascia), and pyomyositis and myonecrosis (affecting the muscle) (Table 179-2).

NECROTIZING FASCIITIS

HISTORY

Necrotizing fasciitis infections are often more extensive than the overlying skin changes would suggest. Early in the disease (stage 1), the involved area may be painful at first and then evolve with objective findings: swelling, erythema, warmth, and tenderness, resembling simple cellulitis.[11] Constitutional symptoms with high fever and toxicity are characteristic of early progression, but at least one study of necrotizing fasciitis patients found fever in only half of patients, and hypotension in only 18%.[15] It is possible that systemic manifestations are delayed or obscured by widespread use of broad-spectrum antibiotics at the first sign of a SSTI, when the disease is often thought to be a simple cellulitis.[16] Within several days, induration worsens and bullae develop (stage 2). Ultimately, the skin color becomes purple and frank cutaneous gangrene ensues (stage 3) (Fig. 179-1). At this advanced stage, the involved area is no longer tender but has become anesthetic as a result of occlusion of small blood vessels and destruction of superficial nerves in the subcutaneous tissues.[11,16–18]



Figure 179-1 Fournier's gangrene (type 1 necrotizing fasciitis of genitalia) with progressive necrosis of the pubic, perigenital, and perianal tissue.

The classification of necrotizing fasciitis can be confusing because different variants have been described in the literature using unrelated criteria, including microbiologic features, anatomic location, and etiology.

VARIANTS DEFINED BY MICROBIOLOGIC CHARACTERISTICS

TYPE I NECROTIZING FASCIITIS. Type I necrotizing fasciitis, a polymicrobial infection, is caused by a mix of facultative and anaerobic microbes, often delivered into the subcutaneous tissues after surgery, trauma, bowel perforation from neoplasm or diverticulitis, or injecting drug abuse via skin popping. It is by far the most common form of necrotizing fasciitis, accounting for nearly 90% of cases, often occurring in patients compromised by diabetes or malnutrition. Organisms include at least one anaerobic organism recovered in a mix of facultative microbes: nongroupable *Streptococci*, *Enterococci*, anaerobic *Streptococci* and *Staphylococci*, *Bacteroides*, and Enterobacteriaceae including *E. coli*, as well as various aquatic bacteria. Often, three to five species contribute to the infection, which may have a slower pace than GAS in evolving to a full-blown process with cutaneous manifestations.[19,20]

Type I necrotizing fasciitis most commonly occurs on an extremity, abdominal wall, perineum, or near operative wounds (see Fig. 179-1). It is important to recognize that when this infection presents in the thigh (dissection along the psoas muscle) or abdominal wall, it may be secondary to an intestinal source (occult diverticulitis, rectosigmoid neoplasm). Crepitus often develops, particularly in patients with diabetes mellitus if gas-forming anaerobes, such as *Bacteroides*, are causative.

TYPE II NECROTIZING FASCIITIS AND STREPTOCOCCAL GANGRENE. Type II necrotizing fasciitis is caused by a monomicrobial infection, usually GAS, which in this setting has been referred to as "flesh eating bacteria" by the lay press. If the process is not limited to the fascia, it is referred to as streptococcal gangrene. Occasionally, in the neonatal period, and very rarely in adults, group B *Streptococci* have been recovered.[21] Other streptococcal species have been reported to cause monomicrobial necrotizing fasciitis, including groups C and G *Streptococci*, as well as *Streptococcus pneumoniae*.[22] In addition, monomicrobial necrotizing fasciitis caused by methicillin-resistant *S. aureus* (MRSA) may be much more common than previously thought, with one recent study finding it to be the cause of nearly 40% of necrotizing fasciitis patients between 2001 and 2006.[23]

Patients may be immunocompromised by age or illness such as diabetes, alcoholism, or cirrhosis, but are usually healthy individuals. The location of the necrotizing lesion is most often an extremity and rarely, the face. The clinical presentation is usually indistinguishable from type I necrotizing fasciitis, but necrosis of the overlying skin can be particularly rapid and dramatic, revealing deeper structures, including tendon sheaths and muscle. Though lymphangitis is rare, metastatic abscesses can occur. Bacteremia is documented in approximately two-thirds of patients, and patients often develop a streptococcal toxic shock syndrome (see Chapter 177).[24]

VARIANTS DEFINED BY EXTRAFASCIAL STRUCTURES AFFECTED

SYNERGISTIC NECROTIZING CELLULITIS. Synergistic necrotizing cellulitis is a mixed infection of anaerobes and facultative bacteria generally classified as a type I necrotizing fasciitis because of prominent fascial involvement, but it actually may infect all soft-tissue structures, including skin and muscle. It is painful, progressive, and highly lethal, primarily affecting frail, elderly, diabetic, or obese patients, almost always with compromising cardiovascular and renal disease. The process may begin with only mild pain and low-grade fever, evolving slowly over 7–10 days. The initial skin lesion is a small reddish-brown bulla or patch on the perineum (near a perirectal or ischiorectal abscess) or lower extremity, with extreme local tenderness; the superficial appearance belies the widespread destruction of the deeper tissues. Skin sinuses (with surrounding areas of blue–gray gangrene) form, draining a foul-smelling thin pale "dishwater" exudate containing fragments of necrotic fat. Gas can be palpated in approximately one-fourth of patients. Half of the patients become bacteremic. Extensive gangrene of the superficial tissues and fat can be visualized by direct inspection through open skin areas or with skin incisions.[25–27]

Frequently isolated organisms include anaerobes (*Streptococci* and/or *Bacteroides*) and facultative bacteria, especially Enterobacteriaceae (*E. coli*, *Proteus*, and *Klebsiella* species).[25,28] Rapid and extensive surgical debridement with antibiotics guided by the Gram stain is essential; nevertheless, the mortality rate remains in the 40%–50% range.[27]

PROGRESSIVE BACTERIAL SYNERGISTIC GANGRENE (MELENEY GANGRENE). Progressive bacterial synergistic gangrene is a specific polymicrobial infection, perhaps best categorized as a form of synergistic necrotizing cellulitis, which presents with a necrotic ulcer at the site of abdominal or thoracic incisions, wire-stay sutures, or fistulous tracts. The infection typically develops insidiously, within a week or two of a procedure. It is called synergistic because by definition, two or more bacteria must coinfect to create the clinical appearance, as demonstrated by Meleney who reproduced these ulcers by injecting microaerophilic *Streptococci* and *S. aureus* into animal skin; the infection did not develop when either pathogen was injected alone.[27]

VARIANTS DEFINED BY ANATOMIC LOCATION

CERVICAL AND CRANIOFACIAL NECROTIZING FASCIITIS. These two variants of necrotizing fasciitis may be classified as either type I or type II, but

they are defined and named by their anatomic location and etiology, rather than by their microbiologic profiles. Cervical necrotizing fasciitis is usually a type I infection (polymicrobial etiology), but GAS can be the single etiologic agent in rare cases, particularly in the setting of peritonsillar abscess formation. Most commonly, cervical necrotizing fasciitis originates from dental or pharyngeal sources. Crepitus may develop as the infection spreads to the face. This is in contradistinction to craniofacial necrotizing fasciitis, which starts in the face and is most commonly caused by GAS after a traumatic episode. Cervical necrotizing fasciitis carries a much higher mortality rate than the craniofacial variant.[29–31]

FOURNIER'S GANGRENE. Fournier's gangrene is a localized gangrenous SSTI involving the genitalia. The infection tends to be limited to skin and subcutaneous tissue of the genitals, but it may spread along fascial planes to the perineum and abdominal wall. It is usually caused by a mix of facultative and anaerobic organisms, and therefore is best categorized as a form of synergistic necrotizing cellulitis or type I necrotizing fasciitis. In rare cases, GAS as the single pathogen has been implicated, and this may be related to rectal ring carriage or to oral–genital sex. The average age at onset is 50–60 years of age. Most men have underlying diseases or a history of procedures. These include diabetes mellitus, ischiorectal abscess, perineal fistula, bowel disease (rectal or colon carcinoma, diverticulitis), scrotal or penile trauma, prior hemorrhoidal or urogenital surgery, pressure ulcers of the scrotum and perineum, paraphimosis and, rarely, obscure causes, such as dissection of pancreatic secretions through the retroperitoneum and into the scrotum in acute pancreatitis.[32–34]

The onset of Fournier's gangrene can be insidious, with a discrete area of edema, erythema, and necrosis on the scrotum. Ultimately, skin necrosis begins to proceed rapidly over 1–2 days (Fig. 179-2). Pain, swelling, and crepitus in the scrotum, perineum, or suprapubic region may be marked. Foul-smelling drainage occurs, indicating a contribution from anaerobes. Purple discoloration of the scrotum, an initial "red flag," progresses to frank gangrene. The testes, glans penis, and spermatic cord are usually spared, as they have a separate blood supply. The infection may progress and invade the abdominal panniculus in obese patients, especially those with diabetes mellitus, leading to rapid and extensive destruction of tissue and requiring wide debridement and prolonged hospitalization. Fournier's gangrene carries 20% mortality even with treatment.[32–34]



Figure 179-2 Fournier gangrene. There is painful erythema with marked edema, superficial desquamation, and areas of necrosis in the inferior aspect of the scrotum.

DIAGNOSTIC STUDIES (CULTURES, HISTOPATHOLOGY, IMAGING)

The gold standard for diagnosing necrotizing fasciitis is open surgical exploration with direct visualization and palpation of the necrotic fascia, which appears grayish and does not bleed; blunt dissection reveals foul-smelling discharge and a lack of usual adherence of the superficial fascia to underlying tissues.[11] Short of open exploration, no test is specific for necrotizing infection, but several laboratory, microbiologic, histopathologic, and imaging studies have been shown to be useful in differentiating bacterial necrotizing SSTI from non-necrotizing infections or noninfectious causes of soft-tissue necrosis (see Box 179-1).

LABORATORY RISK INDICATOR FOR NECROTIZING FASCIITIS (LRINEC). In 2004, Wong et al performed a retrospective analysis to determine independent predictive factors of necrotizing fasciitis at time of presentation, and converted these factors into a scoring system they called Laboratory Risk Indicator for Necrotizing Fasciitis (LRINEC). The variables included in the score are elevated C-reactive protein, leukocytosis, anemia, hyponatremia, renal failure, and hyperglycemia; each is assigned a weight depending on the degree of abnormality. In this initial study, a score of at least six had a positive predictive value of 92%, and a score of at least eight was strongly predictive of necrotizing fasciitis. The negative predictive value for a score less than six was 96%.[35] This system may be useful for stage 1 disease, when the clinical presentation is generally identical to cellulitis, but a recent analysis of the LRINEC in a tropical tertiary care center found significantly lower sensitivity (80%) and specificity (67%) at a cutoff value of six.[36]

Another diagnostic test that has shown some promise is tissue oxygen monitoring by near-infrared spectroscopy. A cutoff oxygen saturation of less than 70% was found to be highly sensitive (100%) and specific (97%) for necrotizing fasciitis in patients without

BOX 179-1 DIFFERENTIAL DIAGNOSIS OF INFECTIOUS NECROTIZING BACTERIAL SKIN AND SOFT-TISSUE INFECTIONS

NONINFECTIOUS

- Arteriolar occlusion with cutaneous necrosis (retiform purpura with necrosis)
  - Leukocytoclastic vasculitis
  - Calciphylaxis, oxalosis
  - Warfarin necrosis
  - Disseminated intravascular coagulation
  - Hemolytic uremic syndrome
  - Thrombotic thrombocytopenic purpura
  - Hypercoagulable state
  - Emboli (cholesterol, fat, amniotic fluid, etc.)
- Panniculitides with liquefaction necrosis
  - Pancreatic panniculitis
  - α-1-antitrypsin deficiency
- Follicular occlusion syndromes
  - Acne conglobata
  - Dissecting cellulitis
  - Hidradenitis suppurativa
- Neutrophilic dermatoses
  - Pyoderma gangrenosum
  - Sweet syndrome
- Iatrogenic
  - Fixed drug eruption
  - Radiation dermatitis
- Miscellaneous causes
  - Insect bites/stings (esp. brown recluse bite)
  - Irritant contact dermatitis with necrosis
  - Sterile spontaneous diabetic myonecrosis
  - Trauma with hematoma formation
  - Metastatic Crohn's disease

INFECTIOUS

- Non-necrotizing bacterial SSTI
  - Cellulitis
  - Erysipelas
  - Abscess, furuncle
- Septic emboli/ septic vasculitis
  - Endocarditis
  - Internal organ abscess
  - Meningitis (*Neisseria meningitides*)
  - Bacteremia/Sepsis
- Herpes zoster and herpes simplex
- Deep Fungal infection
- Atypical mycobacterial infection
- Bursitis, arthritis, osteomyelitis

SSTI = skin and soft-tissue infections.

known chronic venous stasis, peripheral vascular disease, shock, or systemic hypoxia.[37]

BIOPSY FOR CULTURE AND HISTOPATHOLOGY. Tissue from a biopsy or surgical specimen is far more likely to demonstrate an organism on stain or culture in necrotizing SSTI than in simple cellulitis. One study of 198 necrotizing SSTI was able to obtain microbiologic data in 189 of the samples.[38]

Deep incisional biopsy and histopathologic examination on frozen section has been shown to decrease mortality in necrotizing fasciitis by rapidly establishing the diagnosis and thus defining the need for surgical debridement.[39] Indications for an open exploration and a biopsy include confusion, pain and tenderness, tachycardia, tachypnea, ketoacidosis/hyperglycemia, bullous or gangrenous skin changes, bronzing of the skin, spreading areas of anesthesia, thin reddish discharge with undermining of wound edges, crepitus, and an abscess with multiple tracts.

In streptococcal gangrene, the prominent angiitis and focal dermal necrosis with spread along fascial planes suggest that the disease is fundamentally gangrene of the subcutaneous tissues followed by necrosis of the overlying skin. Microscopically, fibrinoid necrosis is present in the media of many arteries and veins passing through the edematous and damaged fascia.[40] Fibrin thrombi and coagulation necrosis may be present throughout the fascia and skin. Numerous polymorphonuclear leukocytes and mononuclear cells infiltrate the lesion, and the upper layers of the dermis contain large numbers of Gram-positive cocci.

IMAGING. Several imaging modalities, including magnetic resonance imaging (MRI), computed tomography (CT), and ultrasound have all been shown to demonstrate distinctive imaging features of necrotizing fasciitis lesions, but their role in diagnosis is still controversial. All three of these modalities can show fascial thickening, as well as fluid and gas in

the adjacent tissue planes.[11] MRI is the most sensitive of these studies, and may also show a hyperintense T2-weighted signal in the muscle, and a deep dermal, dome-shaped area of increased signal.[11,41] However, the sensitivity of MRI is higher than the specificity, resulting in an excellent negative predictive value, but a relatively high false-positive rate, resulting in some unnecessary surgical explorations.[42] While these studies, especially MRI, can be helpful in ruling-out necrotizing fasciitis, or in differentiating early disease from simple cellulitis, radiographic testing should never delay open surgical examinations in cases with a high index of suspicion.

PROGNOSIS AND CLINICAL COURSE

Although subacute variants have been described, necrotizing fasciitis generally follows a hyperacute progression that results in rapid shock and multiorgan failure.[1] The mortality rate ranges in the literature from 17%–49%.[43,44] The wide range of mortality for necrotizing fasciitis and all necrotizing SSTI depends largely on the underlying health and immune status of the patients, and on the extent of diagnostic delay.

Histopathologic features can predict prognosis, with mortality increasing as the bacteria in the tissue increase and the number of neutrophils decrease.[16] Delay in diagnosis and comorbid streptococcal toxic shock syndrome are associated with particularly poor survival.[43] Other factors associated with decreased survival in individual studies include age greater than 50, tachycardia, fever, leukocytosis, renal failure, hematocrit greater than 50%,[45] APACHE II score of at least 13,[44] congestive heart failure, and a history of gout.[3]

GANGRENOUS CELLULITIS

NONCLOSTRIDIAL CREPITANT CELLULITIS

The patient with nonclostridial crepitant cellulitis may have experienced a traumatic or surgical injury that was inadequately debrided or had an underlying local infection, a poorly performed needle stick, or skin popping (injecting drug use into dermal or subcutaneous tissue).[46,47] Underlying diabetes, glucocorticoid or NSAID use, and granulopenia may be present. The clinical presentation is often insidious, with low-grade fever, mild pain, and tenderness, but with early palpable gas and edema. Anaerobic nonspore-forming isolates may include *Bacteroides* sp. or *Peptostreptococci*, often with facultative Gram-negative bacilli. In uncontrolled diabetes mellitus, the presence of gas may result from metabolism of glucose by *E. coli*, *Klebsiella*, *Aeromonas*, and other microorganisms[10] (see Chapter 180).

CLOSTRIDIAL ANAEROBIC CELLULITIS

The histotoxic clostridia are responsible for a variety of infections that involve the subcutaneous and muscular tissues, often with abrupt and dramatic changes in the overlying skin.

Clostridial anaerobic cellulitis begins as an infection of the more superficial subcutaneous zone, but it may progress to involve deeper structures including deep fascia and muscle. The human gut commensal, *C. perfringens*, with or without other bacteria, is the most common cause. The cellulitis usually arises in tissues that are already devitalized, such as dirty or inadequately debrided wound several days after injury, needle stick, or surgery. The clostridia are able to grow in the wound and extend rapidly through tissue planes with attendant formation of large quantities of gas that is both readily palpable and visible on conventional X-ray. A thin, dark-gray to brown, foul, serous discharge is often produced.[48] Gram stain of the drainage reveals short, plump, blunt-ended, "box-car" shaped Gram-positive rods with a variable number of polymorphonuclear leukocytes and, occasionally, other bacterial forms.[8]

Compared with anaerobic myonecrosis, anaerobic cellulitis is more indolent, produces less surface change and relatively little local pain, edema, or toxemia. At surgery, gas may be readily evident throughout the exudate. Anaerobic cellulitis can be distinguished from anaerobic myonecrosis by inspection of muscle to avoid needless mutilating surgery and amputations.

Other variants of anaerobic cellulitis are more commonly associated with toxemia. *C. novyi* and *C. sordellii* are specifically associated with infected wounds from intravenous drug use, childbirth, and medical abortions. Patients develop toxic shock and gangrenous cellulitis, though fever is not universally seen. The organism can usually be cultured from wounds, but blood cultures may remain negative.[49,50] The environmentally resident *C. septicum* can cause a toxic anaerobic cellulitis arising via hematogenous spread from a gastrointestinal source.

INFECTIOUS MYOSITIS

Infectious myositis is a broad term for skeletal muscle infection with any pathogen, including viruses, bacteria, fungi, and parasites. Bacteria and fungi tend to cause a local myositis, which is referred to as pyomyositis in the presence of a purulent collection. Cases of pyogenic myositis are generally divided into clostridial and nonclostridial etiologies.[51] The most common nonclostridial causes of pyomyositis and myonecrosis are *S. aureus* and β-hemolytic streptococcal species. GAS may cause myositis with severe muscle edema, necrosis, compartment syndrome, and overlying skin changes from deep ischemia.[52,53] Other potential pathogens include *S. pneumoniae*, *Haemophilus influenza*, Gram-negative bacilli, *Mycobacteria*, and fungi.[10,43,54] Bacteremia is documented in 5%–30% of pyomyositis cases.[43]

Clostridial myositis can produce a crepitant myonecrosis, often referred to as "gas gangrene." Uncommonly, nonclostridial pathogens such as *Aeromonas hydrophila*, *Peptostreptococcus*, and *Bacteroides* species can cause a similar crepitant myonecrosis.[54]

CLASSICAL ANAEROBIC (CLOSTRIDIAL) MYONECROSIS (GAS GANGRENE)

Anaerobic myonecrosis (gas gangrene) is a rapidly progressing, toxemic, potentially lethal infection involving muscle but with secondary changes in the overlying skin. Gas gangrene may also occur in the uterus, intraperitoneal viscera, brain, and eye, sometimes in the absence of bacteremia. The infection may develop as a complication of a traumatic dirty wound with extensive muscle and soft-tissue damage,[31] or after surgery on the bowel or gallbladder. *C. perfringens* is the most common pathogen in the classic presentation of anaerobic myonecrosis.

The incubation period of anaerobic myonecrosis is often short (12–24 hours) but may be delayed, rarely developing after anaerobic cellulitis. The first symptom is usually severe local pain followed by fever, tachycardia, and hypotension. Gas formation is present but not prominent in subcutaneous tissues, and may be obscured by edema of the superficial tissues. Radiography reveals extensive dissection of gas through the deep soft tissue structures.[55]

The skin often takes on a dark yellow or bronze discoloration with tense blebs or bullae containing dark brown fluid. A serosanguineous exudate can be expressed from the wound or aspirated from a bulla. Gram stain of the exudate reveals plump Gram-positive rods and rare or absent white blood cells, even with a systemic leukocytosis. This paucity of leukocytes is notable on muscle biopsy as well, perhaps a result of the θ-toxin (perfringolysin O), which appears to inhibit recruitment of neutrophils.[56] The overlying skin may develop patchy necrosis and desquamation, as a result of vascular compromise and local ischemia. At surgery, the process in the muscle is evident, with gray pallor, absence of bleeding, presence of gas, and failure of the muscle to respond to direct stimuli.[8,43,54]

Published mortality rates are generally in the 20%–30% range, but this rate increases dramatically in older patients, or in those with comorbid conditions or delayed diagnosis.[57,58]

SPONTANEOUS, NONTRAUMATIC ANAEROBIC MYONECROSIS

In the absence of an external wound, septicemic gas gangrene may occur spontaneously, usually caused by *C. septicum* and often associated with hematologic malignancies or occult colon cancer, especially in the cecal area. Spontaneous *C. septicum* gas gangrene is a fulminant disease, with a mortality approaching 100% and marked by a precipitous onset and progression, often with subcutaneous gas, myonecrosis, and high-grade septicemia. Overlying skin of an involved area becomes red–brown and the epidermis sloughs early in the illness. In addition, the organism may be aerotolerant and thus lacks susceptibility to hyperbaric oxygen. No controlled treatment trials exist for this disease.[59–61]

Spontaneous gas gangrene from *E. coli* has also been reported. All three patients had cirrhosis, and no obvious source of bacteremia was noted.[10] In addition, sterile, spontaneous diabetic myonecrosis is important to consider in the differential diagnosis, although these patients are usually not febrile and do not appear toxic. This entity is most common in women with late-stage diabetes mellitus, complicated by nephropathy and retinopathy, and it usually affects the quadriceps and thigh muscles, occasionally with slight elevation in muscle enzymes.[62]

TREATMENT

Treatment of all necrotizing SSTI involves a combination of urgent debridement, antibiotics, and often, adjunctive therapies.

ANTIBIOTICS

Antimicrobial treatment decisions for patients with crepitant or gangrenous SSTI must be based on a rapid or presumptive identification of the etiologic agent(s) (see Box 179-2). Until definitive microbiologic data is obtained, high-dose parenteral broad-spectrum antibiotics should be given to cover any pathogens on the clinical differential. An organism found on blood culture does not rule out the possibility of a polymicrobial infection, and should not necessarily prompt narrowing of the antimicrobial coverage until reliable cultures from the wound are obtained.

As a general rule, streptococcal infections should be treated with a regimen that includes penicillin G. Clindamycin should be added if toxic shock syndrome is suspected (see Chapter 177). Staphylococcal species should be treated with a penicillinase-resistant β-lactam, such as nafcillin, or with vancomycin, if MRSA is suspected. Alternative agents for empiric coverage of suspected MRSA include linezolid, daptomycin, tigecycline, and quinupristin-dalfopristin, as well as several agents still under development (see Chapter 178). Once cultures with susceptibility data are obtained, fluoroquinolones, sulfonamides, and other antibiotic classes may have a role. Clostridial infections should be treated with a combination of parenteral penicillin G and either clindamycin or metronidazole. Clindamycin-resistant *C. perfringens* SSTI has been reported.

SURGICAL DEBRIDEMENT

Treatment of all types of necrotizing SSTI requires early and complete surgical debridement of necrotic tissue, including any skin, fascia, or muscle involved. In some cases, amputation of a limb can be rapidly accomplished and may be lifesaving in selected patients. Intraoperative inspection can help determine the depth of the infection, and should also provide material for bacterial and pathologic study. Re-exploration and debridement should be performed as necessary to ensure that all necrotic tissue has been removed.

BOX 179-2 ANTIMICROBIAL TREATMENT OF NECROTIZING INFECTION OF SKIN, FASCIA, AND MUSCLE

ORGANISM	DRUG OF FIRST CHOICE	ALTERNATIVE DRUGS
Mixed infection	Ampicillin/sulbactam Imipenem/cilastatin, meropenem Ticarcillin/clavulanate Vancomycin (if suspicion for MRSA)	Cefoxitin, clindamycin, or metronidazole + an aminoglycoside
Streptococcus (A, C, G, B)	Penicillin G (+ clindamycin for toxic shock syndrome or necrotizing fasciitis)	Ceftriaxone + clindamycin Vancomycin Linezolid
Enterococcus (systemic Infection)	Penicillin G or ampicillin + aminoglycoside	Vancomycin + aminoglycoside Linezolid Quinupristin/dalfopristin Daptomycin
Staphylococcus aureus	Nafcillin (or oxacillin) Vancomycin (for methicillin-resistant strains)	Cefazolin Amoxicillin/clavulanate Clindamycin Quinupristin/dalfopristin Linezolid Daptomycin
Clostridium perfringens	Penicillin G + clindamycin	Metronidazole + carbapenem Ceftriaxone Chloramphenicol

MRSA = methicillin-resistant *Staphylococcus aureus.*

ADJUNCTIVE THERAPIES

Preoperative hyperbaric oxygen (HBO) has emerged as an important adjunctive therapy for several necrotizing SSTI, especially anaerobic infections such as clostridial cellulitis and myonecrosis.[63] It has been postulated that HBO acts synergistically with many antibiotics, and that it restores the free radical-mediated antibacterial mechanisms of leukocytes in hypoxic tissue.[64] It also appears to cease clostridial production of α-toxin and to directly suppress clostridial growth, and has been demonstrated by retrospective analysis to decrease mortality.[65]

Other adjunctive considerations in treatment of SSTI include the use of intravenous γ globulin for type II necrotizing fasciitis caused by GAS, but evidence for its benefit in the absence of toxic shock syndrome is lacking. There may be a role for granulocyte-stimulating stem cell factor,[9] calcium–channel blockers, glycoprotein IIb/IIIa inhibitors,[66] and photodynamic therapy,[67] but data for all of these adjunctive therapies is limited.

As discussed above, there is some evidence that NSAIDs should be avoided in patients suspected of incubating or expressing early bacterial infections, but this remains controversial since prospective studies have failed to confirm the link between NSAIDs and severe SSTI thus far. *C. perfringens* antitoxins are no longer available for use in humans.

KEY REFERENCES

Full reference list available at www.DIGM8.com

DVD contains references and additional content

1. Puvanendran R, Huey JC, Pasupathy S: Necrotizing fasciitis. *Can Fam Physician* **55**:981-987, 2009
8. Vinh DC, Embil JM: Rapidly progressive soft tissue infections. *Lancet Infect Dis* **5**:501-513, 2005
11. Wong CH, Wang YS: The diagnosis of necrotizing fasciitis. *Curr Opin Infect Dis* **18**:101-106, 2005
16. Wang YS, Wong CH, Tay YK: Staging of necrotizing fasciitis based on the evolving cutaneous features. *Int J Dermatol* **46**:1036-1041, 2007
25. Stone HH, Martin JD Jr: Synergistic necrotizing cellulitis. *Ann Surg* **175**:702-711, 1972
27. Pasternack MS, Swartz MN: *Cellulitis, Necrotizing Fasciitis, and Subcutaneous Tissue Infections*. 7th ed. Philadelphia, PA: Churchill Livingstone/Elsevier; 2010
35. Wong CH et al: The lrinec (Laboratory Risk Indicator for Necrotizing Fasciitis) score: A tool for distinguishing necrotizing fasciitis from other soft tissue infections. *Crit Care Med* **32**:1535-1541, 2004
36. Holland MJ: Application of the Laboratory risk indicator in necrotising fasciitis (Lrinec) score to patients in a tropical tertiary referral centre. *Anaesth Intensive Care* **37**:588-592, 2009
42. Blankenship RB, Baker T: Imaging modalities in wounds and superficial skin infections. *Emerg Med Clin North Am* **25**:223-234, 2007
43. Lopez FA, Lartchenko S: Skin and soft tissue infections. *Infect Dis Clin North Am* **20**:759-772, v-vi, 2006

Chapter 180 :: Gram-Negative Coccal and Bacillary Infections

:: Myron S. Cohen, William A. Rutala, & David J. Weber

The Gram stain is used to differentiate among different types of bacteria based on the biochemical properties of their cell walls.[1] The stain is named after Danish scientist Hans Christian Gram (1853–1938) who developed the method to differentiate between two causes of pneumonia (*Streptococcus pneumoniae* and *Klebsiella pneumoniae*).[2] The demonstration of Gram-negative cocci in sterile sites usually indicates infection due to *Neisseria meningitides* or *N. gonorrhoeae*. Gram-negative bacilli may be described as fusiform (e.g., *Fusobacterium nucleatum*, *Capnocytophaga* spp.), curved (e.g., *Vibrio* spp., *Campylobacter* spp., *Helicobacter* spp.), coccobacilli (e.g., *Haemophilus* spp., *Brucella* spp.), or rods (e.g., *Escherichia coli*, *Klebsiella* spp.).

Many of the characteristic cutaneous manifestations of infection with Gram-negative organisms are due to direct microbial invasion of the skin or subcutaneous tissues. In addition, responses of host cytokines, chemokines, receptor molecules (e.g., Toll-like receptors), and other effector cells and factors may contribute to fever, hypotension, and a variety of cutaneous manifestations.[3–7]

INFECTIONS DUE TO *NEISSERIA MENINGITIDIS* (*MENINGOCOCCUS*)

MENINGOCOCCUS INFECTIONS AND THE SKIN AT A GLANCE

- In the United States up to 2,800 cases of meningococcal disease occur annually.
- Skin lesions associated with meningococcemia result from damage to small dermal blood vessels.
- Three clinical syndromes are associated with meningococcal disease: (1) meningitis, (2) meningococcemia, and (3) chronic meningococcemia.
- Purpura and gross hemorrhage correlate with higher numbers of organisms in the bloodstream and indicate a poorer prognosis.

Three clinical syndromes associated with cutaneous involvement occur in meningococcal disease: (1) meningitis, (2) acute meningococcemia, and (3) chronic meningococcemia. Skin lesions are frequently the most dramatic manifestations of these infections. The presence of areas of purpura or gross hemorrhage is associated with higher numbers of organisms in the bloodstream and indicates a poorer prognosis than for a petechial eruption. The epidemiology, pathogenesis, and clinical presentations of these processes have been reviewed.[3,5,6,8,9]

BACTERIOLOGY AND PATHOGENESIS

Neisseria are aerobic, encapsulated, Gram-negative, bean-shaped cocci. *Neisseria meningitidis* grows well on blood-enriched media in 5%–10% CO_2. With potentially mixed bacterial exudates, these organisms should be grown on a selective medium (e.g., modified Thayer-Martin). They can be distinguished from *Neisseria gonorrhoeae* by their fermentation of both glucose and maltose rather than of glucose alone. *Meningococci* are separable on the basis of capsular antigens, of which A, B, C, Y, and W-135 are the major human pathogenic groups. Outer membrane proteins that can identify serotypes are helpful in epidemiologic studies.[5] In an epidemic of meningococcal disease, a shift of capsular group can occur (e.g., from group B to group C and vice versa), which facilitates evasion of host antibodies.[10] Persons with late terminal complement deficiencies are especially prone to systemic infections with *N. meningitides*.[11]

Skin lesions associated with meningococcemia result from damage to small dermal blood vessels. Light and electron microscopy reveal bacteria within endothelial and polymorphonuclear cells in needle aspirate or punch biopsy specimens.[12,13] Endothelial damage, thrombosis, and necrosis of the vessel walls occur. Immunoglobulins and complement are present, even in early lesions.[5,12] Edema, infarction of overlying skin, and extravasation of red blood cells are responsible for the characteristic macular, papular, pustular, petechial, hemorrhagic, and bullous lesions. Many of the cutaneous hemorrhagic lesions may be caused directly by the effects of lipopolysaccharide (LPS) endotoxin or indirectly by stimulation of lease of outer membrane vesicles (blebs) has been observed on electron microscopy of *meningococci* in the plasma of patients with very high levels of circulating endotoxin in fatal meningococcal septicemia.[14] Another contribution to the dermal inflammatory vascular injury, independent of immune complexes and cytokine activity, may be the interaction between vascular endothelium (intercellular adhesion molecule 1) and an adhesion glycoprotein (CD18) on leukocytes, the so-called *dermal (localized) Shwartzman reaction* (LSR).[15] Mouse neutrophils express a surface protein, gp 49 B1, that prevents neutrophil-dependent vascular injury in response to LPS; humans have a leukocyte analog. The LSR requires a priming dose of LPS followed by a systemic challenge 18–24 hours later. A single

intradermal injection of LPS into gp 49 B1-null mice produces an exaggerated microangiopathy in the LSR not seen in wild-type gp 49 B1 mice.[16] LSR and the generalized Shwartzman reaction (in which both doses of LPS are administered systemically) serve as models for the thrombohemorrhagic vasculopathy, purpura fulminans, of meningococcal sepsis. The profound effects on small blood vessels, caused directly by bacterial invasion or indirectly by LPS, host cytokines, or LSR, may lead to diminished blood volume, lowered cardiac output, anoxia, myocardial failure, hypotension, acidosis, and diffuse intravascular coagulation (DIC).[6] Purpura fulminans, the cutaneous manifestation of DIC (see Chapter 144), occurs in 10%–20% of children with meningococcal septic shock and is associated with functional impairment of protein C activation.[8] The latter is thought to result from (1) downregulation of thrombomodulin and endothelial protein C receptor on endothelial surfaces to which protein C binds for its activation, (2) shedding of thrombomodulin from the endothelial surface, and (3) enzymatic cleavage of the thrombin-coupled protein C activation complex.[17]

Chronic meningococcemia is an uncommon disease, which usually begins as a nonspecific febrile illness over the course of weeks to months. It then establishes a pattern of recurrent fever, joint pain, and skin lesions that are present in over 90% of patients. *Meningococci* can usually be isolated from blood during the periodic fevers and rash. As with acute invasive meningococcal infection, chronic infection has been linked to absence of terminal complement components (see below).[18,19] The chronic course of chronic meningococcemia, the lack of endotoxin-like manifestations, and the potential for eventual complications such as meningitis or endocarditis suggest that an unusual host-parasite relationship is central to this rare infection.

EPIDEMIOLOGY

Humans are the only known natural hosts of *N. meningitidis*. Nasopharyngeal carrier rates vary with age: 1% in young children, 5% in those 14–17 years of age, and 20%–40% in adults. In the United States, there are 1,400–2,800 cases of meningococcal disease annually for a case rate of 0.5–1.1 in 10^5 total population.[20] In schools and military camps, or when a carrier of a new strain develops disease in a day care or family setting, carrier rates can increase dramatically.[21,22]

Globally, group A strains have been responsible for epidemics of meningitis, especially in sub-Saharan Africa, where it accounts for about 80%–85% of all cases. In Europe and the Americas, groups B and C have predominated, and in the United States, a recent surge in the group Y disease has been reported. There is increasing evidence of serogroup W-135 being associated with outbreaks of considerable size. For example, in 2000 and 2001 several hundred pilgrims attending the Hajj in Saudi Arabia were infected with *N. meningitides* W-135.[23]

In most industrialized countries, a few clonal serogroup B electrophoretic types (e.g., ET-5 strains) have predominated during recent decades. Similarly, clonal complex ET-37 strains, usually expressing the serogroup C capsule but sometimes expressing serogroup B, W-135, or Y, are found around the world.[5] Adult family members probably introduce the organism into the household, but secondary cases are most frequently spread from ill children to other family members in the same age group, especially under crowded conditions.[24] Household spread is 500–800 times more frequent than the occurrence of secondary cases in the community, and there is an increased incidence of secondary cases in day care centers where large numbers of susceptible children congregate.[6,20] Microbiologists who are exposed to droplets or aerosols containing *N. meningitides* (e.g., by spinning CSF) are also at higher risk of meningococcal disease.[25] The absence of the spleen has been associated with fulminant meningococcal disease.[20]

Immunity to *Meningococci* increases with age, and protective bactericidal antibodies, both IgG and IgM, are found in 70%–95% of young adults. Newborns are often resistant to meningococcal disease until they are 3–6 months of age.[26] Underlying immune defects that confer a predisposition to invasive meningococcal infection include functional or anatomic asplenia, a deficiency of properdin, and a deficiency of terminal complement components.[6] Overall, 75%–85% of identified systemic bacterial infections occurring in individuals with complement deficiencies are cause by *meningococci*.[11]

The quadrivalent vaccine containing polysaccharides of groups A, C, Y, and W-135 had been the only licensed vaccine against meningococcal disease until 2005. Its inadequate protective efficacy in infants led to the development of protein polysaccharide conjugate vaccines that has high protective efficacy in children similar to the *Haemophilus influenzae* type b conjugate vaccine.[27,28] Further, the vaccine has been associated with a reduction of carriage of the vaccine types included in the vaccine. The group B capsular polysaccharide, a polysialic acid polymer similar to fetal neural tissue, does not induce protective immunity. Efforts continue to develop a vaccine using outer membrane proteins of group B organisms and clinical trials are ongoing.[29]

ACUTE MENINGOCOCCEMIA AND MENINGITIS

CLINICAL MANIFESTATIONS

History. The disease often follows a mild upper respiratory tract infection associated with headache, influenza-like complaints, nausea, and muscle soreness. These symptoms can be so short lived that fever, obtundation, and other manifestations of meningitis are the initial findings. In fulminant meningococcemia, vomiting, stupor, precipitous development of a hemorrhagic rash, and hypotension may be evident within a few hours of the onset of symptoms. Milder cases develop at a slower pace.

Cutaneous Lesions. Skin findings in acute meningococcal infections are characteristically petechial, but transient macular or papular lesions (Fig. 180-1A),



Figure 180-1 *Neisseria meningitidis* infection. Acute meningococcemia. **A.** Transient macular and papular lesions on the upper chest. **B.** Discrete pink-to-purple macules and papules, as well as purpura, on the face of a young child. These lesions represent early diffuse intravascular coagulation (DIC). **C.** Map-like gray-to-black areas of cutaneous infarction are seen in this child with DIC.

which can resemble those seen in viral exanthems, may be evident.[30] The petechiae are small and irregular with a "smudged" appearance. Although most often located on the extremities and trunk, lesions can also be found on the head (see Fig. 180-1B), palms, soles, and mucous membranes. Extensive hemorrhagic lesions with central necrosis (suggillations) and bullae can develop. Gangrenous hemorrhagic areas (indistinguishable from purpura fulminans; see Chapter 144) can appear in severe meningococcemia, often with DIC (see Fig. 180-1C). Skin lesions and bacteremia are rarely seen with meningococcal pneumonia.[31] Cellulitis has been noted occasionally, especially in children with meningococcal conjunctivitis (see Section "Primary Meningococcal Conjunctivitis").

Other Physical Findings. Patients with meningitis display signs of meningeal irritation and altered consciousness. Cranial nerve palsies, long-tract signs, seizures, and alterations in vital signs associated with changes in intracranial pressure may be present.

Obtundation and hypotension without meningeal signs, associated with the syndrome of DIC, are characteristic features of fulminant meningococcemia. Rarely, meningococcemia may result in septic foci in other areas: (1) septic arthritis, (2) purulent pericarditis with enlarging cardiac silhouette and findings of tamponade, and (3) bacterial endocarditis. More commonly, a delayed immune complex-mediated syndrome results in a sterile arthritis, pericarditis, or episcleritis.[5] The acute arthritis–dermatitis syndrome, characterized by petechiae and nontraumatic arthritis, has traditionally been identified with disseminated *N. gonorrhoeae* infection (see Chapter 205). There has been a decline of gonococcal cases and an increase in cases of this syndrome caused by *N. meningitidis*.[32]

LABORATORY FINDINGS. A polymorphonuclear leukocytosis is present in peripheral blood and cerebrospinal fluid (CSF) in meningitis. The CSF glucose value is commonly reduced. Characteristic organisms may be seen on Gram-stained smears of fluid, and *Meningococci* are usually isolated from the CSF. *N. meningitidis* may be isolated from the blood of approximately one-third of patients with meningitis and from almost 100% of patients with acute meningococcemia. Demonstration of organisms in cutaneous lesions has been variable, and the presence of Gram-negative commensal organisms on the skin requires cautious interpretation. Reports describe positive results for 50%–80% of aspirates, skin film samples, and punch biopsy specimens of petechial lesions.[12,33]

In patients already exposed to antimicrobial agents, the development of rapid, accurate, and inexpensive procedures for detection of soluble antigens in the CSF has been a major advance. The latex agglutination method and enzyme-linked immunosorbent assay methods are sensitive and very specific, but their clinical usefulness in most situations has been questioned.[34] More recently, the polymerase chain reaction (PCR)

has been used to detect *N. meningitides* in cerebrospinal fluid and/or blood.[35] Further, PCR can be used to type strains, a useful adjunct in epidemic situations. However, PCR is not widely available.

HISTOPATHOLOGY. Endothelial swelling is seen, a perivascular infiltrate of polymorphonuclear leukocytes is present, thrombi occlude capillaries and postcapillary venules, and the walls of capillaries and venules are destroyed, as in leukocytoclastic vasculitis (see Chapter 163).

DIFFERENTIAL DIAGNOSIS. Meningococcal infection warrants consideration in a patient with fever and a petechial or purpuric eruption, even in the absence of clinical meningitis (Box 180-1). Occasionally, the characteristic rash is absent, which delays consideration of meningococcal disease.

COURSE AND PROGNOSIS. If untreated, acute meningococcal disease usually ends fatally. With treatment, recovery occurs in 90% of patients with meningitis.

In severe meningococcemia, especially with the rapid emergence of cutaneous hemorrhages, hypotension, and DIC, the entire course from onset to death can be measured in hours. In patients with sepsis-associated DIC, cutaneous thrombotic hemorrhages on the distal extremities may lead to skin and digital necroses that necessitate amputation.[36] Rarely, young children with meningococcal sepsis, shock, and DIC suffer thrombotic injury that causes growth plate arrest.[37] Myocardial dysfunction often occurs in meningococcal septic shock and is associated with high circulating levels of interleukin 6.[38] These cases are often associated with massive adrenal hemorrhage (*Waterhouse–Friderichsen syndrome*). Children who die from meningococcal septic shock have relatively low cortisol levels (but not in the range expected in adrenal insufficiency).[39] The mortality rate for meningococcal septic shock approaches 100%. Gradations in the severity of meningococcal disease make it difficult to assign an accurate prognosis, although a bedside predictive model has been proposed.[6,40]

BOX 180-1 DIFFERENTIAL DIAGNOSIS OF ACUTE MENINGOCOCCEMIA

- Acute bacteremias and endocarditis: in endocarditis, mucous membrane and conjunctival lesions, as well as subungual "splinter" hemorrhages, occur. Very infrequently, numerous petechial and purpuric lesions occur in patients with acute *Staphylococcus aureus* endocarditis. Usually, a few skin lesions in a patient with acute *S. aureus* endocarditis are purulent purpura. In acute gonococcemia, the skin lesions are usually acral, nodular, hemorrhagic, and few in number (see Chapter 205). Occasional patients with *Haemophilus influenzae* or *Streptococcus pneumoniae* bacteremia develop petechial eruptions.
- Cutaneous necrotizing vasculitis (see Chapter 163): here, lesions are usually palpable. Renal involvement and hypertension may be present.
- Enteroviral infections: fever, petechial eruptions, and aseptic meningitis are frequent features.
- Rocky Mountain spotted fever: the history of exposure to ticks in an endemic area, absence of an antecedent respiratory infection, and delay in appearance of the rash are clues (see Chapter 199).
- Toxic shock syndrome (see Chapter 177).
- Purpura fulminans (see Chapters 144 and 181).
- Weil disease (leptospirosis) (see Chapter 183).

CHRONIC MENINGOCOCCEMIA

CLINICAL MANIFESTATIONS

History. The manifestations of chronic meningococcemia are vague at onset but tend to establish a pattern over a period of weeks or months.[18,41,42] Initially, there may be an acute febrile illness, but it wanes and leaves the patient with intermittent muscle aches, joint soreness, mild headache, and anorexia with weight loss. The simultaneous emergence of a localized rash with several days of fever and joint soreness is characteristic. As fever recedes, the rash fades, and the patient may be totally free of skin manifestations for days or weeks. This pattern of recurring fever and rash may last from a few weeks to 6 or 8 months. Untreated cases may eventually evolve into acute meningococcemia, meningitis, or endocarditis. Several case reports have related this syndrome to the absence of a terminal component of complement, a finding also observed in sporadic and recurrent acute meningococcal infections.

Cutaneous Lesions. Skin lesions are usually distributed about one or more painful joints or on pressure areas in contrast to the acral distribution in gonococcemia. They may vary in appearance and size (1–20 mm) from one crop of lesions to the next and include (1) pale to rose-colored macular and papular lesions (the most common type), (2) slightly indurated and tender erythema nodosum-like nodules, (3) petechiae of variable size, (4) petechiae with vesicular or pustular centers, (5) hemorrhage (minute) with an areola of paler erythema, and (6) grossly hemorrhagic areas with pale blue–gray centers.

Other Physical Findings. Aside from the rash, the physical findings of chronic meningococcemia are minimal, except for occasional joint swelling and tenderness.

HISTOPATHOLOGY. The skin lesions differ pathologically from those in acute meningococcemia in that bacteria are absent, and fluorescent antibody techniques do not detect meningococcal antigens. Also, thrombi do not occlude capillaries and venules,

endothelial cell swelling is absent, and the perivascular infiltrate consists of mixed polymorphonuclear and mononuclear cells.

DIAGNOSIS AND DIFFERENTIAL DIAGNOSIS. During febrile periods, blood cultures frequently reveal *Meningococci* and provide the specific diagnosis. Recently, a novel *i-Neisseria menigitidis* specific PCR assay was used to identify *N. menigitidis* in skin biopsy specimens even though blood cultures remained negative.[43]

A number of diseases with periodic fever, skin lesions, and joint involvement resemble chronic meningococcemia:

- Subacute bacterial endocarditis: a prolonged febrile course with a pleomorphic petechial rash, joint symptoms, and no overt focus make subacute bacterial endocarditis an important consideration. A prominent heart murmur, evidence of renal impairment, and blood cultures help establish the diagnosis.
- Acute rheumatic fever: when fever is prolonged, joint findings are prominent, and macular and papular rashes appear, the diagnosis may be acute rheumatic fever (see Chapter 160).
- Henoch–Schönlein purpura: the petechial hemorrhagic rash in Henoch–Schönlein purpura is more often symmetric, usually only on the lower extremities, and does not have the periodicity of the rash of chronic meningococcemia (see Chapter 163).
- Rat-bite fever, also referred to as *Haverhill fever*, may be acute (mimicking acute meningococcemia) or chronic (resembling chronic meningococcemia). Intermittent fever, rash, and joint manifestations are hallmarks of an illness that follows a rodent bite or ingestion of contaminated milk (see Chapter 183).
- Erythema multiforme: the iris-type configuration of lesions suggests erythema multiforme (see Chapter 39).
- Gonococcemia (chronic): the cutaneous and joint manifestations of chronic gonococcemia may continue for many days or weeks (see Chapter 205), and tenosynovitis in gonococcemia can be an important clue.

COURSE AND PROGNOSIS. Some patients with chronic meningococcemia recover spontaneously without specific therapy, whereas others develop serious systemic complications, such as endocarditis or meningitis. The prognosis for treated infection is excellent.

PRIMARY MENINGOCOCCAL CONJUNCTIVITIS

N. meningitidis is responsible for up to 2% of cases of bacterial conjunctivitis. The source of infection is either direct inoculation of airborne organisms from close contact with carriers or manual contact with secretions from the patient's own nasopharynx.[44]

TREATMENT AND PROPHYLAXIS

CHEMOTHERAPY. Widespread emergence of sulfonamide-resistant strains, approximately 40 years ago, has complicated therapy for meningococcal infections. Initially, these strains belonged predominantly to serogroup B, but in recent years, they have been from serogroups A to C. More recently, increasing penicillin resistance has led to the recommendation to use a third-generation cephalosporin (ceftriaxone or cefotaxime) as primary therapy.[45] Alternatives (provided the strain is susceptible) include penicillin G, ampicillin, fluoroquinolone, or aztreonam.[45]

The usual adult dosage of ceftriaxone is 2 g every 12 hours or cefotaxime 2–3 gm every 6 hours. Penicillin G (adult dose, 4 MU every 4 hours) or ampicillin (adult dose, 2 g every 4 hours) may be used if the penicillin MIC is less than 0.1 μg/mL. The usual duration of therapy is 7 days. Similar therapy should treat chronic meningococcemia. In highly penicillin-allergic adults, administration of chloramphenicol (1 g IV every 6 hours) is preferable to risking cross-reactions with a third-generation cephalosporin. However, increasing resistance of meningococcal strains to chloramphenicol worldwide could change this recommendation.[46] All meningococcal isolates from blood, CSF, or other normally sterile body cavities should be tested for penicillin susceptibility.[6] Immune complex-associated complications (fever, sterile arthritis, vasculitis, pericarditis, episcleritis) can occur in 15% of patients 4–10 days after initiation of antimicrobial therapy for severe meningococcal disease.[47]

SUPPORTIVE THERAPY. Although it has been postulated that hypotension in acute meningococcemia may be due to adrenal failure associated with Waterhouse–Friderichsen syndrome (adrenal hemorrhage), blood cortisol levels and corticosteroid secretion rates have been found to be elevated or in the low normal range (not in the range associated with adrenal insufficiency).

The modern treatment of shock in sepsis begins with a number of well-accepted measures, including antibiotic selection, drainage procedures for abscesses, appropriate use of volume expanders, administration of β-adrenergic-stimulating drugs such as dopamine or isoproterenol, correction of severe acidosis, and, in selected patients, use of peripheral vasodilators. Therapies still considered experimental include those that neutralize host cell-mediated cytokines (e.g., interleukin 1, tumor necrosis factor) and protein C. Although numerous studies of glucocorticoid therapy have been completed, results have been variable, and on balance glucocorticoids do not appear to be indicated for septic shock.

Because of the impaired conversion of protein C to its activated form through the downregulation of thrombomodulin by inflammatory cytokines during sepsis, intravenous recombinant human activated protein C (drotrecogin alfa activated) has been evaluate for its efficacy as an adjunct in treating sepsis. However, a placebo-controlled randomized clinical trial in adults[48] with severe sepsis and a low risk of death, and a placebo-controlled randomized trial in children[49] with

severe sepsis failed to demonstrate benefit. Neither of these trials included substantial numbers of patients with meningococcal sepsis. In an earlier randomized trial of patients with severe sepsis, recombinant human activated protein C reduced the mortality rate from 30.8% in the placebo group to 24.7% in those receiving drotrecogin alfa.[50] The incidence of serious bleeding was 3.5% in the drotrecogin alfa group compared with 2.0% in the placebo group. Any patients with meningococcal infection with disseminated intravascular coagulation (DIC) should be closely monitored for increased bleeding. Severe meningococcal infections can be complicated by the syndrome of DIC. The basis for the diagnosis is usually a composite of associated hematologic abnormalities, including thrombopenia and hypofibrinogenemia, prolongation of the prothrombin time and partial thromboplastin time, and the presence of fibrin split products. If bleeding occurs, it may be necessary to administer fresh frozen plasma. Treatment for each case must be individualized, because therapy may be harmful and produce more problems than the DIC syndrome. Data on the use of heparin in treating DIC remain unconvincing, and because of potential adverse effects, this drug is no longer recommended. Investigators continue to study antibodies to various cytokines whose levels are elevated in meningococcal septicemia and immunomodulatory therapies.[51]

CHEMOPROPHYLAXIS. There is a critical need for reliable chemoprophylaxis to rapidly protect children exposed in a day care nursery, contacts in a crowded household, and institutional groups, because secondary cases can emerge, often within 24–48 hours of an index case.[21,52]

Rifampin, ceftriaxone, ciprofloxacin, and azithromycin are appropriate drugs for chemoprophylaxis in adults. The drug of choice for most children is rifampin (>1 month of age, 10 mg/kg, maximum 600 mg, orally, every 12 hours for 2 days).[53] However, rifampin resistance occurs and reports have documented the development of invasive meningococcal disease. Fortunately, ciprofloxacin and ofloxacin are effective single-dose substitutes, and ceftriaxone is available for parenteral single-dose use in children as well as adults. Azithromycin has demonstrated the ability to clear carriage in one study.

IMMUNIZATION. The meningococcal conjugate vaccine (MCV4 which contains groups A, C, Y, and W-135) is preferred for children, adolescents, and adults less than 55 years of age. MCV 4 is indicated for children 2 through 10 years of age with persistent complement component deficiency, anatomic or functional asplenia, and certain other conditions placing them at high risk. It is also indicated for all adolescents at 11 or 12 years of age (catch period, 13 through 18 years of age). MCV4 is indicated for adults less than 55 years of age who have the following risks: anatomic or functional asplenia, persistent complement component deficiencies, first year college students living in dormitories, microbiologists routinely exposed to isolates of *N. meningitides*, military recruits, and persons who travel to or live in countries in which meningococcal disease is hyperendemic or epidemic.

The polysaccharide vaccine (groups A, C, Y, and W-135 *N. meningitidis*) is safe and effective in preventing meningococcal disease in adults and is preferred for adults who are 56 years of age or older. Indications are the same for adults of 55 years of age or younger.

Elucidation of the complete genome of *N. meningitidis* has identified several conserved proteins that, in an experimental mouse model, have been protective against challenge with all pathogenic *N. meningitidis* organisms.

SPECIAL CONSIDERATIONS FOR THE HEALTHCARE WORKER. Patients, who present with cutaneous findings that are consistent with acute meningococcal infection, represent a medical emergency. Because the course of the disease is so rapid, it is imperative that appropriate diagnostic samples (i.e., blood and cerebrospinal fluid) be collected in an expedient manner and then the patient started immediately on empiric antibiotic therapy. If cerebrospinal fluid cannot be rapidly obtained, then the patient should be started on empiric therapy and the cerebrospinal fluid obtained as soon as feasible. All patients with known or suspected invasive meningococcal infection should be placed on Droplet Precautions (private room, healthcare providers wear a surgical mask when in the room). If the patient is in an open area (e.g., emergency department), a surgical mask should be placed over the patient's mouth and nose (if possible). Droplet precautions should be continued until the patient has been on appropriate therapy for at least 24 hours.

INFECTIONS DUE TO *PSEUDOMONAS AERUGINOSA*

PSEUDOMONAS AERUGINOSA INFECTIONS AND THE SKIN AT A GLANCE

- The ubiquitous Gram-negative bacillus *Pseudomonas aeruginosa* can cause serious infections, usually in individuals who have altered defenses, who are receiving intense antibiotic therapy, or who are in the hospital.
- Cutaneous manifestations of *Pseudomonas* infections are common and characteristic.
- These cutaneous manifestations may represent the overt finding in septicemia (ecthyma gangrenosum) or may be the localized focus of serious infections of the ear.
- *Pseudomonas* infection can produce trivial cutaneous lesions involving the nails, toe webs, other skin areas, and external auditory canal.

BACTERIOLOGY AND PATHOGENESIS

Pseudomonas aeruginosa is a nonfermentative, obligately aerobic, Gram-negative bacillus. Some strains produce a blue pigment (pyocyanin), a water-soluble yellow–green substance (fluorescein), or black pyomelanin. With Wood's lamp, the presence of organisms in lesions of skin or nails can be detected if the infecting strain produces fluorescein. The pigments impart a characteristic greenish color to the surrounding growth media or the tissue substrate involved in clinical disease (e.g., "green nail" syndrome, Fig. 180-2). In addition, an odor of grapes, characteristic of trimethylamine, often accompanies the growth of these microorganisms.

Organisms gain entry at sites of maceration, dermatophytic foci, trauma, or foreign bodies (e.g., indwelling venous catheters), or via aspiration into the respiratory tract. Infections in otherwise healthy individuals are unusual; when they occur, the involved regions are often areas with increased moisture (e.g., toe webs, the external auditory canal). Infection may begin in the base of the nail in persons who frequently have their hands or feet in water. This can progress to paronychia, followed by development of a green–blue discoloration of the nail due to local pigment production. The ability of this organism to infect healthy, but moistened, skin is evidenced by the occurrence of disseminated papules and pustules on areas of skin of people immersed in hot tubs ("hot tub folliculitis," Fig. 180-3), wading pools, and swimming pools.[52] These ubiquitous organisms can sometimes be aggressive secondary invaders in open wounds, in decubitus and other skin ulcerations, or in association with thermal burns. Rarely, a superficial pyoderma due solely to *Pseudomonas* is engrafted on a generalized or localized dermatitis, such as tinea pedis or eczema, producing irregular pustular areas with macerated borders.[64] Serious invasive infections occur in debilitated patients; malnourished infants; individuals whose normal bacterial flora has been suppressed by antibiotics; patients with neoplastic diseases, granulocytopenias, or impaired circulating or cellular immunity, including that associated with acquired immunodeficiency syndrome (AIDS)[65]; and individuals requiring mechanical respiratory assistance. These organisms frequently colonize body surfaces and survive exposure to antibiotics. *P. aeruginosa* can spread widely via the bloodstream, producing a disseminated infective vasculitis in which organisms can appear in the adventitia and media of vessels without luminal clots. Occasionally, features of the generalized Shwartzman reaction are found, but less frequently than in infections due to *N. meningitidis* or *Enterobacteriaceae*.



Figure 180-2 *Pseudomonas aeruginosa* infection. "Green nails." This 36-year-old bartender noted a greenish yellow discoloration of 8 of 10 fingernails during the preceding year. Several of the fingers show chronic candidal paronychia as well.



Figure 180-3 *Pseudomonas aeruginosa* infection. "Hot tub folliculitis." This 22-year-old woman noted the appearance of erythematous, pruritic papules and pustules on the trunk, buttocks, and upper thighs several days after bathing in a hot tub. The eruption resolved without antibiotic therapy.

EPIDEMIOLOGY

Because *P. aeruginosa* is widely distributed in nature, it is not surprising that it may contaminate plants, vegetables, hot tubs, and swimming and wading pools. Moist regions of skinfolds and the external auditory canal are the most common sites of colonization (3%–5% of cases). *P. aeruginosa* is found in small numbers in the feces of 10%–20% of the population.

Any activity that leads to excessive local moisture—laundry work, dishwashing, or hiking for long periods in wet terrain—will enhance the growth of these organisms. Moist or weeping cutaneous lesions

(e.g., thermal burns) encourage the growth of *Pseudomonas* as well as of other Gram-negative bacteria. Increased environmental humidity is frequently associated with overgrowth of these organisms. Synthetic sponges easily become contaminated with Gram-negative bacteria and have served as vehicles of transmission.

Systemic infection with *P. aeruginosa* depends primarily on altered susceptibility of the host rather than on spread from individual to individual or on increased pathogenicity. However, exceptions may be seen in newborn nurseries, respiratory care units, and occasionally urology wards, where dissemination from a primary source may occur. Neutropenic or immunocompromised hospitalized patients are more likely to become colonized and develop invasive disease. *P. aeruginosa* is the sixth most common pathogen in healthcare-associated infections (ranks seventh for central line-associated bloodstream infections, fourth for catheter-associated urinary tract infections, second for ventilator-associated pneumonia, and fifth for surgical site infections).[66]

LOCAL AND SECONDARILY INFECTED LESIONS

Pseudomonas produces a number of characteristic lesions. In addition, colonization by these organisms complicates other skin diseases and open wounds.[51]

CLINICAL MANIFESTATIONS

History. Painful paronychial lesions, with or without characteristic green discoloration of the nails, occur most often in women with a history of continual immersion of the hands in water with soaps and detergents. People with toe web infection characteristically work in an atmosphere of high humidity, often have wet feet, and experience soreness and scaling of web tissues. There are numerous reports of the appearance of skin rashes in healthy individuals within 1–5 days after the use of public bathing facilities such as therapeutic or recreational whirlpools, hot tubs, or swimming pools (see Fig. 180-3).[67] *P. aeruginosa* organisms have been isolated in large numbers from pool water. The rash usually clears without therapy within 1 week but is often accompanied by malaise, low-grade fever, external otitis, and mastitis. *P. aeruginosa* folliculitis has also occurred after shower or bath exposure or exposure to contaminated bath articles.[68] Hot-foot syndrome caused by *P. aeruginosa* contamination of a wet surface exemplifies the organism's opportunism in infecting the ventral surfaces of feet abraded by a roughened floor.[69,70]

Cutaneous Lesions. In addition to a tender paronychial lesion, patients with green nail syndrome may have a nail that is partly or entirely green. The color may be in horizontal bands, representing intermittent activity of the infection at the nail base (see Fig. 180-2). Individuals with toe web *Pseudomonas* infections have thick, macerated, scaling, foul smelling discolored areas between the toes. Hot-foot syndrome is characterized by tender, painful, red plantar nodules that develop within 1–2 days of exposure to an abrasive wet surface, such as a wading pool.[70]

In acute diffuse external otitis, the lesion has a swollen, macerated appearance in the local area without involving the eardrum. Often referred to as *swimmer's ear*, the condition produces intense swelling and discoloration with excruciating pain on movement of the pinna. The most common pathogen causing swimmer's ear is *P. aeruginosa*, although other organisms can cause the syndrome including *Proteus vulgaris*, *E. coli*, *Staphylococcus aureus*, *Streptococci*, *Enterobacter aerogenes*, *K. pneumoniae* and *Citrobacter* spp.[71] If the skin is traumatized, local infection can spread to the pinna, producing perichondritis and chondritis with intense tender swelling. Cartilaginous necrosis may result unless immediate drainage with through-and-through incisions and appropriate antibiotic therapy are instituted.[72] The most severe form of *Pseudomonas* infection, malignant external otitis, has a high mortality rate if therapy is delayed or inadequate.[73,74] It usually occurs in elderly people with diabetes but may also be seen in healthy elderly people after surgery or minor trauma, such as water irrigation of the external canal, and in patients with AIDS.[75] The onset and early progression are insidious, with swelling, erythema, moderate discharge, and pain without fever or constitutional symptoms. As the surface breaks down, *Pseudomonas* invades the soft tissues at the junction of cartilage and bone; the process then advances to involve cartilage, mastoid, and temporal bone. Inflammation at the stylomastoid and jugular foramina can lead to seventh nerve palsy followed by palsy of the ninth to eleventh nerves. Diagnosis is made clinically if granulation tissue can be seen erupting at the cartilage-bone interface in the posterior inferior canal wall. The pinna is often swollen, and pain is intense.[74]

In patients who develop folliculitis, the rash can be localized if only a limb has been immersed, or generalized, or in intertriginous areas. The rash begins as erythematous papules, evolves to papulopustules (see Fig. 180-3), and eventually heals with fine desquamation and occasional pigmented macules. Pruritus and pain may accompany the lesions along with localized areas of mastitis and external otitis. Serotype 0–11 of *P. aeruginosa* is most commonly involved.

A small outbreak of *P. aeruginosa* 0–11 folliculitis occurred in granulocytopenic patients in a cancer treatment center, but the lesions in these patients, in contrast to those in healthy individuals with swimming pool folliculitis, rapidly became widespread and progressed to bullae, which became necrotic (ecthyma gangrenosum like) unless systemic antibiotic treatment was begun immediately.[76] Thus, ecthyma gangrenosum (see Section "Septicemia and Cutaneous Involvement") can result from progression of initial folliculitis in an immunocompromised patient as well as from *P. aeruginosa* bacteremia.

Although gangrene of the genitalia and perineum (Fournier gangrene) is almost always caused by a polymicrobial (facultative species and anaerobes) or group A streptococcal infection, exceptional cases have been attributed to *P. aeruginosa*.[77] Necrotizing

fasciitis generally has similar causes, but in rare cases monomicrobial *P. aeruginosa* necrotizing fasciitis has occurred, usually involving the vulva or abdominal wall, in children with acute lymphoblastic leukemia.[78] Such patients are febrile; the infected area is painful, erythematous, and edematous, with subsequent skin necrosis; and bacteremia is present. Necrotizing fasciitis due to *P. aeruginosa* has also occurred in an immunocompetent infant.[79]

In secondarily infected skin areas, irregular, superficial pustular lesions may be superimposed on underlying skin disease; the margins of these regions are usually sharply defined and may exhibit the characteristic grape-like odor and pigmented exudate.[80] *P. aeruginosa* infection of a chronic ulcer occasionally progresses to *Pseudomonas* cellulitis.[81]

DIAGNOSIS AND DIFFERENTIAL DIAGNOSIS.

Nail and skin lesions, resulting from *Pseudomonas* infection, are recognized by the characteristic pigment. The organisms can be identified as thin Gram-negative rods, or a mixed infection (e.g., with *Candida*) may be observed. Fluorescence, demonstrated with a Wood's lamp, can support the diagnosis. Occasionally, *Aspergillus* infection of the nails produces a greenish color, and there is usually no associated paronychia. A subungual hematoma may superficially resemble *Pseudomonas* nail infection.

COURSE AND PROGNOSIS.

Patients with minor *Pseudomonas* infections (e.g., onychia and paronychia, toe web inflammation, whirlpool-associated skin rash, and external otitis) usually improve rapidly with topical therapy and drying of the affected area. Malignant external otitis requires the systemic administration of antibiotics directed against *Pseudomonas*, including a fluoroquinolone with or without an antipseudomonal β-lactam antibiotic (e.g., ceftazidime, cefepime, imipenem or meropenem). High dosages and prolonged therapy are combined with surgical debridement to limit spread to bone and nervous system.[82]

SEPTICEMIA AND CUTANEOUS INVOLVEMENT

CLINICAL MANIFESTATIONS

History. In individuals with suspected *Pseudomonas* septicemia, history taking is most frequently centered around the underlying problem and antecedent therapy. A premature infant may have required resuscitation and treatment of a nonspecific pneumonitis before developing high fever, obtundation, and macular or hemorrhagic vesicular skin lesions. Infants may present initially with omphalitis or severe diarrhea, followed by septicemia and skin lesions. Urinary tract infections complicating exstrophy of the bladder may predispose the infant to bacteremia. In adults, there is usually a background of antibiotic therapy, immunoglobulin deficiency, diabetes mellitus, treatment with glucocorticoid hormones or antitumor agents, or the use of percutaneous catheters. Frequently, the patient is granulopenic, has already had a significant febrile illness, and may still be receiving antibiotics when one of the characteristic cutaneous manifestations develops. The local lesions are rarely painful. Occasionally, hemorrhagic manifestations may develop secondary to platelet reduction or DIC.

Pseudomonal involvement of the gastrointestinal tract, particularly in the tropics, may produce the picture of an acute enteric infection, with headache, high fever, diarrhea, and rose spots (Shanghai fever) resembling typhoid fever. The same enteric syndrome with ecthyma gangrenosum has occurred in previously healthy infants.[82]

Cutaneous Lesions. Skin lesions, the most characteristic physical findings in *Pseudomonas* septicemia, consist of four types[83]:

1. *Vesicles and bullae*. Singly or in clusters, these lesions spread in random fashion over the skin. They become hemorrhagic as they evolve. Occasionally, in infants they may be surrounded by large erythematous halos and be mistaken for erythema multiforme.
2. *Ecthyma gangrenosum*. This lesion starts with an erythematous or purpuric macule and develops rapidly into a hemorrhagic bulla that ruptures; becomes a gunmetal gray, infarcted lesion with surrounding erythema (Fig. 180-4); and evolves into a necrotic black or gray–black eschar and surrounding erythema (Fig. 180-5). Frequently, the lesion is in the anogenital or axillary region. Noma neonatorum, a gangrenous process of the nose, eyelids, oral cavity, or anal area and genitalia, occurs in premature newborns and other infants.[84] It is similar in appearance to noma, which occurs in young debilitated infants. Whereas the infecting agent in noma is *Fusobacterium*, noma neonatorum is caused *by P. aeruginosa*.



Figure 180-4 *Pseudomonas aeruginosa* infection. Ecthyma gangrenosum. Gunmetal gray, painless, infarcted lesions with surrounding erythema.



Figure 180-5 *Pseudomonas aeruginosa* infection. Ecthyma gangrenosum. This 32-year-old man with human immunodeficiency virus infection noted the onset of a very tender plaque on the right buttock associated with fever and malaise. **A.** Five-day-old lesion with a central infarcted, necrotic area surrounded by erythema. **B.** At 5 weeks, the lesions had improved after ciprofloxacin treatment, which was discontinued because of an adverse drug reaction. Without antibiotic treatment, the necrotic area enlarged and was associated with bacteremia. Eventually, the lesion reepithelialized, but the patient died of pseudomonal pneumonia.

3. *Gangrenous cellulitis*. Sometimes presenting as a sharply demarcated, superficial, painless, necrotic lesion, gangrenous cellulitis may resemble a decubitus ulcer. However, it is located in a nonpressure area and may complicate a prior area of injury, such as a thermal burn. Also, it may begin abruptly, producing local pain, swelling, and erythema, and involving deep subcutaneous tissue and fascia. Local injury or bacteremia may introduce the infection.
4. *Macular or papular nodular lesions*. These lesions are small, oval, and painless, located predominantly over the trunk. They resemble the rose spots of typhoid fever.

Another cutaneous manifestation of *Pseudomonas* septicemia, usually occurring after days or weeks, is suppurative panniculitis. The lesions are red, warm, and sometimes fluctuant, but often situated deeply enough to feel solid. Surgical incision reveals suppuration, and *P. aeruginosa* can be isolated.[83,85] A variation of this manifestation consists of numerous red, nonfluctuant, hot, nontender, subcutaneous nodules that may be accompanied by other characteristic lesions, such as hemorrhagic bullae and ecthyma gangrenosum. Such lesions may be treated successfully by combination antipseudomonal antibiotic therapy.

Other lesions that may appear in systemic *Pseudomonas* infection include petechiae, ecchymoses, dermal Shwartzman-like reactions, and purpura fulminans.

Other Physical Findings. Patients with *Pseudomonas* septicemia frequently exhibit physical findings associated with their underlying diseases: malnutrition, mucous membrane ulcerations, glossitis secondary to antibiotic therapy and granulocytopenia, urinary tract infections, proctitis, adenopathy, hepatosplenomegaly, and hemorrhagic bronchopneumonia.

LABORATORY FINDINGS.

Hematologic examination may reveal leukocytosis or leukopenia, based on the underlying illness. Platelet levels may be diminished, and levels of fibrinogen and other clotting factors may be reduced in association with DIC, liver disease, or profound malnutrition.

Characteristically, in *Pseudomonas* septicemia aspirated material from bullae, areas of cellulitis, and papular or nodular lesions reveals numerous organisms but few leukocytes, even in patients with leukocytosis. Cultures of these lesions and of blood show *Pseudomonas*.

PATHOLOGY.

The distinctive finding in *Pseudomonas* lesions is a necrotizing vasculitis in which a myriad of bacteria invade the walls of small arteries and veins.[79] Extravasation occurs around the vessels, edema and bland necrosis in the perivascular and adventitial regions are extensive, and blood flow supplied by the affected vessel is decreased. Organisms tend to spread along the exterior surfaces of vessels and invade the skin. Similarly, bacterial invasion of the blood vessel walls in lungs, liver, and other organs produces nodular necrotic lesions.

DIAGNOSIS AND DIFFERENTIAL DIAGNOSIS.

Ecthyma gangrenosum skin lesions in an acutely ill patient suggest the diagnosis of *Pseudomonas* septicemia. The finding of abundant Gram-negative rods with rare granulocytes in vesicle fluid or in association with gangrenous or hemorrhagic cellulitis constitutes further presumptive evidence.

The differential diagnosis of *Pseudomonas* septicemia includes other infections that can produce ecthyma gangrenosum and other skin lesions through direct involvement of blood vessels (e.g., those caused by *N. meningitidis*, *Aeromonas hydrophila*, *Escherichia coli*, *Klebsiella pneumoniae*, *Citrobacter freundii*, *Morganella* sp., *Vibrio vulnificans*, *Burkholderia cepacia*, *Stenotrophomonas*

maltophilia, *Moraxella* sp., and fungi of the *Aspergillus*, *Fusarium*, and *Rhizopus* groups).[86] *Chromobacter violaceum*, a saprophyte present in water and soil in tropical and subtropical (e.g., Southeastern United States) environments, is a rare cause of ecthyma gangrenosum in the setting of chronic granulomatous disease of childhood, a condition predisposing to infections with this microorganism.[87] Pyoderma gangrenosum and gangrenous herpes simplex may mimic ecthyma gangrenosum.[88]

COURSE AND PROGNOSIS.

Pseudomonas septicemia is frequently the terminal event in a patient with malignant disease or altered defense mechanisms. Therapy may be effective and recovery complete in some instances when septicemia occurs in patients with more favorable underlying problems, such as urinary tract infections, or in patients with venous catheters.

TREATMENT AND PROPHYLAXIS

Local Infections. Superficial skin and toe web infections and onychia usually respond to application of acetic acid, silver nitrate, or gentian violet compresses two to three times daily between long periods of drying. Paronychia is best treated by surgical drainage, nail trimming, and application of 4% thymol in chloroform. Acetic acid, polymyxin (0.1%) in acetic acid, or glucocorticoids with neomycin are effective for otitis externa. When acetic acid is used topically on chronic ulcers, a 2%–5% solution is often effective.[71] In addition, topical silver nitrate (0.5%) or silver sulfadiazine may eradicate these organisms in burn patients (see Chapter 95).

Systemic Infections. *Pseudomonas* septicemia requires early systemic bactericidal antimicrobial therapy. Effective agents include the aminoglycosides (gentamicin, tobramycin, amikacin). One of these drugs is combined with ceftazidime or cefepime, an antipseudomonal penicillin (e.g., piperacillin-tazobactam), or a carbapenem (imipenem or meropenem or doripenem) and given IV to patients who are acutely ill. In the presence of hypotension or any renal impairment, the dosage of aminoglycoside must be reduced; aminoglycoside serum levels should guide therapy.

In addition to the parenteral administration of antibiotics, surgical drainage is appropriate for nodular and fluctuant lesions. Acute *P. aeruginosa* gangrenous cellulitis/fasciitis requires debridement (often extensive), sometimes with a surgical "second look" 1 or 2 days later. *P. aeruginosa* infections are especially serious in neutropenic patients. A number of different vaccines and monoclonal antibodies have been developed in the past decade for active and passive immunization against *P. aeruginosa* but all remain experimental at the present time.[89]

SKIN INFECTIONS DUE TO OTHER *PSEUDOMONAS* SPECIES

Pseudomonas putrefaciens, now renamed *Shewanella putrefaciens*, is a rare cause of cellulitis, particularly chronic infected ulcers of the lower extremities.[90] The natural habitat of the organism is water and soil, and it is a rare cause of cellulitis and bacteremia after contamination of a laceration.[91]

INFECTIONS DUE TO *HAEMOPHILUS INFLUENZAE*

HAEMOPHILUS INFECTIONS OF THE SKIN AT A GLANCE

- *Haemophilus influenzae* cellulitis involves the face, neck, or upper extremities.
- Most cases occur in young children (6–24 months of age), but the infection can occur in adults.
- Because of immunization with *H. influenzae* conjugate vaccines, invasive *H. influenzae* disease has nearly disappeared in industrialized countries, but it persists as a major problem in developing countries.

BACTERIOLOGY AND PATHOGENESIS

Haemophilus influenzae is a small, pleomorphic Gram-negative coccobacillus with fastidious growth requirements, including the presence of heme and nicotinamide nucleoside. There are rough and encapsulated forms, the latter of which are divided into six types (a through f) based on capsular polysaccharide antigens.

Most invasive infections with *H. influenzae*, including meningitis, epiglottitis, and cellulitis, are caused by encapsulated type b strains (Hib). Rough strains do not cause cellulitis, but are involved in acute otitis media, exacerbations of chronic bronchitis, and pneumonia.[92] A hyperacute disease, Brazilian purpuric fever, characterized by fever, purpura, and shock, is caused by nontypeable *H. influenzae* biogroup aegyptius strains producing an extracellular hemagglutinin that may be a virulence factor.[93] Fever often reaches 39.4°C–40.6°C (103°F–105°F) by the end of the first week. During the second week, rose spots may appear on the trunk, and diffuse abdominal cramping becomes prominent, sometimes accompanied by diarrhea.

Most Hib skin infections are preceded by an upper respiratory tract infection or acute otitis media. The characteristic localization of the cellulitis to the upper part of the body argues for the sequence of upper respiratory tract infection, fallout onto or invasion of the skin locally, and then bacteremia. This sequence is evident in adult as well as in pediatric cases. A primary bacteremic mechanism with secondary localization in the skin would be favored by a more random and widespread distribution of lesions than is seen. Localization of a subclinical bacteremia could follow

trauma and has been suggested as a possible predisposing event.

EPIDEMIOLOGY

Humans are the only known natural host for *H. influenzae*. These potentially pathogenic bacteria are carried in the oropharynx and nasopharynx, especially in children up to age 5 years, as part of the normal indigenous flora. However, early immunization using conjugate Hib vaccines has markedly decreased nasopharyngeal carrier rates, increased herd immunity, and caused a dramatic decline in invasive clinical disease.[94] Cellulitis, meningitis, pneumonia, and epiglottitis due to *H. influenzae* type b have all but disappeared in vaccinated populations.[95] There is growing evidence for strain replacement with increased cases of invasive infection due to nontypeable strains of *H. influenzae* as well as serotypes a and f.[96,97]

CLINICAL MANIFESTATIONS

HISTORY. Typically, a nonimmunized young infant or child develops an area of swelling and discoloration on the face or arm after several days of coryza and abruptly rising temperature. Rarely, a similar process occurs in adults as a complication of upper respiratory tract infection.[98]

CUTANEOUS LESIONS. The typical lesion is a single, circumscribed, indurated area usually located on the face, neck, upper chest, or upper extremity. Although described in infants as characteristically blue–red to purple–red and surrounded by a zone of edema, the early lesion may be an area of pale edema or erythema (Fig. 180-6). The margins are indistinct, in contrast to the sharply defined borders of erysipelas. Regional adenopathy is rarely present. Occasionally, in children with Hib buccal cellulitis, erythematous buccal mucosal lesions appear on the side of the affected cheek, which suggests direct bacterial spread from the oropharynx into buccal soft tissues.[99]

When *H. influenzae* cellulitis occurs in adults, the infection follows a striking sequence: marked pharyngitis at first, high fever, then rapidly progressive anterior neck swelling, tenderness, erythema, and dysphagia.[98]

OTHER PHYSICAL FINDINGS. Associated otitis media, sinusitis, or epiglottitis as well as pneumonia may occur; occasionally, metastatic infections such as septic arthritis or meningitis develop.



Figure 180-6 Cellulitis caused by *Haemophilus influenzae*. Erythema and edema of the face in a child. (Used with permission from Richard A. Johnson, MD.)

LABORATORY FINDINGS

The white blood cell count is elevated, usually in the 20,000/mm^3 range. Results of blood cultures are positive in approximately 50% of cases. Aspiration and culture of specimens taken from the margin of the cellulitis have yielded positive results in about half of patients.

DIAGNOSIS AND DIFFERENTIAL DIAGNOSIS

H. influenzae cellulitis should be suspected when a child aged 3–24 months develops an acute facial (buccal) cellulitis with high fever. Immediate confirmation of the diagnosis may be possible from inspection of Gram-stained smears of an aspirate of the lesion. Although upper body cellulitis caused by other microorganisms is more common in adults, Hib should also be considered in patients with respiratory infections, especially adults or young children not fully immunized.

Streptococcal (group A, C, or G) or pneumococcal cellulitis may produce discoloration of the skin similar to that in Hib infection. Erysipelas, which occurs rarely in infants, is usually homogeneously erythematous, and the margins of the plaque-like swelling are distinct, whereas the lesion borders in *H. influenzae* cellulitis are indefinite. The presence of pustules or boils is helpful in identifying *S. aureus* as the etiologic agent.

COURSE AND PROGNOSIS

Most patients do well with antibiotic therapy, even though the disease is often associated with bacteremia. The abrupt onset of high fever and easily observed cellulitis indicates the urgency of the situation. Constant vigil must be maintained for suppurative complications in the upper airways, meninges, lungs, bones, joints, and other organs.

TREATMENT AND PROPHYLAXIS

Third-generation cephalosporins (ceftriaxone or cefotaxime) are currently the drugs of choice in the treatment

of Hib disease because of their activity against both ampicillin-susceptible and β-lactamase-producing strains of *H. influenzae* and because of their efficacy in treating any complicating meningeal spread of infection. Infections caused by β-lactamase-negative isolates can be treated with ampicillin given IV in four to six divided doses daily. Many Hib strains now show plasmid-mediated ampicillin resistance.[100] For this reason, therapy should begin with a third-generation cephalosporin.

The use of Hib conjugate vaccine (capsular polysaccharide covalently linked to a protein moiety) has dramatically decreased the incidence of invasive Hib disease in the developed world. These vaccines stimulate the production of protective antibodies when given to infants before 6 months of age.[101]

CUTANEOUS MANIFESTATIONS OF *SALMONELLA* INFECTIONS (ENTERIC FEVER)

SALMONELLA INFECTIONS AND THE SKIN AT A GLANCE

- *Salmonella* organisms are widespread in nature.
- Carried by cold- and warm-blooded animals, they contaminate foods derived from animals and are global in distribution.
- *Salmonella* infections manifest as gastroenteritis, enteric fever, or septicemia.
- Rose spots are the classic skin lesions of systemic *Salmonella* infection.
- These lesions occur in 10%–60% of natural (untreated) typhoid fever cases but less frequently in cases of enteric fever caused by other *Salmonella* sp.

BACTERIOLOGY AND PATHOGENESIS

Isolation of salmonellae from stool is made difficult by the fact that, when present, they represent only a small part of the fecal flora. Extragastrointestinal isolates are easier to identify, because they are usually pure cultures of a given *Salmonella* sp. The use of selective media (e.g., MacConkey agar, *Salmonella–Shigella* agar) that inhibit the growth of Gram-positive organisms, as well as many Gram-negative species, facilitates isolation of the organisms from stool. Salmonellae are Gram-negative bacilli that do not ferment lactose. In stool bacteriologic testing, initial selection of nonlactose-fermenting colonies is followed by biochemical and serologic (agglutination) procedures for identification. There are over 2,400 serovars determined by surface and flagellar antigens. Modern molecular biology has established a revised nomenclature, with *Salmonella enterica* the single species, and all others serovars (serotypes) of this single species (e.g., *S. enterica* serotype Typhimurium). Because habits are difficult to change, organisms are usually still referred to as familiar species [e.g., *Salmonella typhi*, *Salmonella paratyphi* (A, B or C), *Salmonella enteritidis*] rather than as serotypes of *S. enterica*.

EPIDEMIOLOGY

People acquire *S. typhi* and other *Salmonella* species causing enteric fever by ingestion of contaminated water or food, often during travel in developing countries. A history of recent travel and of suspicious food or water encounters should be sought in a patient with appropriate clinical manifestations.

Humans are the only hosts for *S. typhi* and *S. paratyphi*. The chronic carrier state that may follow clinical typhoid fever is almost always asymptomatic, except for manifestations of gallbladder disease, if cholelithiasis and active cholecystitis are present. Other serotypes of *Salmonella* can occasionally produce an enteric fever syndrome similar to, but usually milder than, that of typhoid fever. Unlike *S. typhi*, these other *Salmonella* serotypes are ubiquitous in nature (occurring in animals, reptiles, and poultry).

CLINICAL MANIFESTATIONS

HISTORY. Symptoms begin several days to several weeks after the ingestion of contaminated water or food. Headache, fever, generalized aching, abdominal discomfort, cough, and constipation are common. Delirium or mental torpor is not unusual, especially with high fever. Heart rate may be slower than expected for the magnitude of the fever. Symptoms increase in intensity and fever rises in a stepwise fashion. During the second week abdominal pain and rash often occurs. Finally, the third week of typhoid fever is characterized by hepatosplenomegaly and intestinal bleeding. Intestinal perforation and/or peritonitis may occur.

CUTANEOUS LESIONS. After 7–10 days of high fever, the rose spots characteristic of *S. typhi* infection may appear. These lesions are 2–3 mm, slightly raised, nontender, pink maculopapules that blanch on pressure. Appearing in crops of approximately 10–20 lesions, they are often located between the nipple area and the umbilicus on the anterior trunk, rarely on the back or extremities. Without therapy, the spots usually become brownish as they fade and disappear in 3–4 days. New lesions emerge over the ensuing 2–3 weeks in untreated patients. Their presence in 63% of a group of 62 patients should encourage careful observation for this subtle rash.[102] Early institution of antimicrobial therapy may be responsible for the decreasing incidence of rose spots. The rash is less frequently reported in people of color, but this may be

because of the difficulty in detecting the small lesions on dark skin. Rose spots occur infrequently in enteric fevers caused by other *Salmonella* sp.

Other skin changes have been noted during the acute phase of enteric fever. Erythema typhosus, an erythematous confluent rash, may occur during the first week. Erythema nodosum and urticarial lesions have been observed. In several reports from the Indian subcontinent, subcutaneous and cutaneous abscesses and skin ulcers have been described.[103,104] It is distinctly uncommon to observe herpes labialis in enteric fever.

OTHER PHYSICAL FINDINGS. During the time cutaneous lesions are appearing, the patient may be disoriented and have signs of pneumonia. The abdomen is often distended, tympanitic, and diffusely tender, with some localization to the right lower quadrant. The spleen is often enlarged but may be difficult to palpate because of abdominal distension and guarding.

LABORATORY FINDINGS

Leukopenia is often present, but values range from 3,000 to 20,000/mm^3. The percentage of mononuclear cells may be increased, and atypical lymphocytes can appear in small numbers, which suggests a viral illness. Thrombocytopenia and, rarely, hemolysis may occur. During the initial week of illness, blood culture results are usually positive for *Salmonella*. During the second week, or when diarrhea begins, stool culture results become positive for *Salmonella*, and the white blood cell count may increase. Isolation of *S. enterica* serotype Typhi from the blood is the gold standard for diagnosis of typhoid fever.

HISTOPATHOLOGY

Histologic examination of a rose spot reveals gross dilatation of capillaries. There is considerable edema and abundant pericapillary infiltration with macrophages. Organisms may be present within these cells.[92]

DIAGNOSIS AND DIFFERENTIAL DIAGNOSIS

The diagnosis of *Salmonella* enteric fever may be difficult in a sporadic case, especially if the characteristic rash and gastrointestinal symptoms have not yet appeared and there is no history of travel in an endemic area. Headache, cough, and high fever are not very specific findings. However, when these symptoms are associated with delirium, relative bradycardia, and leukopenia with increased numbers of circulating mononuclear cells, the diagnosis of enteric fever should be considered. The diagnosis is usually made by performing blood cultures, which yield positive results for *Salmonella* in approximately 80% of untreated cases during the first 10 days. Results of Widal's tests are usually negative during the early phase of the illness. Likewise, enteric fever due to *S. enterica* serotypes other than serotype Typhimurium can usually be diagnosed through blood cultures. Culture of other material (e.g., bone marrow, rose spots) may be important, especially in patients who have had prior antibiotic therapy. PCR testing of blood may have a role in the latter.

Differential diagnosis includes a wide range of diseases. Prominent cough and severe headache in the early phases may suggest a viral or atypical pneumonia. Typhus and Rocky Mountain spotted fever can usually be excluded by geographic and epidemiologic considerations, serologic studies, the characteristic petechial component of the rash, and its distribution on the distal parts of the extremities. Miliary tuberculosis may begin as an acute febrile illness with similar symptoms, leukopenia, and splenomegaly. The diagnosis may be delayed until a secondary complication such as meningitis occurs. Infectious mononucleosis is suggested by headache, fever, lymphadenopathy, splenomegaly, and a blood profile with leukopenia and some atypical mononuclear cells.

Malaria and toxoplasmosis are two parasitic illnesses that deserve consideration. Epidemiologic information plus intermittency of symptoms usually suggest the former. In generalized toxoplasmosis, manifestations may be very similar to those of early enteric fever: prominent cough, high fever, lymphadenopathy, and a truncal rash. The rash tends to be more florid than in enteric fever and has a petechial component. Diagnosis usually requires identification of *Toxoplasma gondii* in biopsy material or a rising antibody titer.

COURSE AND PROGNOSIS

The response of patients with enteric fever to antibiotic therapy is usually gradual, with 3–6 days needed for the temperature to return to normal. With prolonged treatment, the incidence of relapse has declined. The major complications in the preantibiotic era were bowel perforation and hemorrhage. Although rare, these complications still occur and are responsible for 75% of mortality. Deaths have been reduced from 10% to 1% to 2% with antibiotic therapy, although mortality is higher in immunocompromised patients. After recovery from typhoid fever, 1%–4% of patients continue to harbor organisms in the gallbladder and to excrete them in the stools, becoming a potential source for spread.

TREATMENT AND PREVENTION

The emergence of multidrug-resistant *Salmonella*, including *S. typhi*, in many areas of the world has essentially eliminated the use of chloramphenicol, ampicillin, and trimethoprim-sulfamethoxazole as first-line antimicrobials.[105] The fluoroquinolones (ciprofloxacin, ofloxacin) are active against drug-susceptible and multidrug-resistant *S. typhi* or other salmonellae causing enteric fever but are not approved for use in persons under 18 years of age. Blood cultures become sterile promptly on treatment with ciprofloxacin, and this drug has become the treatment of choice for typhoid fever. Ciprofloxacin is administered in 500–750-mg

doses given orally (or 400 mg given IV) every 12 hours in adults for 7–14 days. Other active drugs include ceftriaxone, cefotaxime, and azithromycin.

SKIN INFECTIONS DUE TO NONTYPHOIDAL *SALMONELLA* SEROTYPES

Skin infections due to nontyphoidal abscesses. Very uncommonly, *Salmonella* necrotizing fasciitis has been reported, usually in the setting of immunosuppression.[106]

INFECTIONS WITH OTHER GRAM-NEGATIVE BACILLI THAT HAVE CUTANEOUS MANIFESTATIONS

OTHER GRAM-NEGATIVE BACILLARY INFECTIONS AND THE SKIN AT A GLANCE

- An acute cellulitis, with or without production of gas, may be caused by *Escherichia coli*, *Proteus* sp., *Klebsiella* sp., *Enterobacter* sp., *Serratia marcescens*, and other organisms.
- These infections occur often, but not exclusively in the very elderly; in individuals with diabetes; in patients after trauma surgery, bowel or perineal inflammation; and in immunocompromised individuals.
- The infectious process may be limited to the superficial soft tissues or found primarily in the deep fascia.
- Drug addicts develop such infections after "skin popping," which lead to cellulitis and necrotizing fasciitis.
- Rhinoscleroma is a granulomatous infection caused by *Klebsiella pneumoniae* subspecies *rhinoscleromatis*. It has a slowly progressive course and may involve the upper airway and tracheobronchial tree.

ENTERIC GRAM-NEGATIVE BACILLI

EPIDEMIOLOGY

Cellulitis usually follows contamination of adjacent tissues by bowel contents or a breakdown of skin. Predisposing conditions include (1) bowel perforation, (2) colon surgery, (3) chronic edema, (4) vascular insufficiency, (5) injection of addictive drugs,[114] (6) decubitus ulcers, (7) presence of percutaneous lines, and (8) superficial perineal dermatitis. Poorly controlled diabetes, altered host defenses, and poor nutrition often further predispose to such infections in these patients. Crepitant (gas-containing) cellulitis results from infection with gas-forming strains of bacteria (*E. coli*, *Klebsiella*, *A. hydrophila*), especially in patients with diabetes, or in the presence of *Bacteroides* sp. or anaerobic *Streptococci*.[115,116]

CLINICAL MANIFESTATIONS

HISTORY. Diabetes mellitus, malnutrition, or a chronic condition (e.g., paraplegia with decubitus ulcers) is usually present at the time of infection. The onset may be insidious or abrupt. Pain, often severe, frequently precedes local skin changes, especially if the infection is at the level of the deep fascia. High fever, shaking chills, increasing pain, and falling blood pressure may follow. Rectal or perineal pain can indicate a local process that may be especially devastating in a patient deficient in granulocytes.

CUTANEOUS LESIONS. In the early stages, the skin is rarely discolored beyond a pink hue, and vesicles or bullae are almost never present. At this juncture, unless pain is present, the process may easily be overlooked. As the cellulitis progresses, edema and redness increase; tenderness, crepitus, and hemorrhagic bullae may develop; and areas of cutaneous gangrene may appear. The cellulitis may remain localized to the skin and superficial subcutaneous tissues, but progression to the deep fascia with necrosis of fat and increasing pain and toxicity suggests a diagnosis of necrotizing fasciitis[117] (see Chapter 179). Although most cases of Gram-negative bacillary necrotizing fasciitis are polymicrobial in etiology, a striking monomicrobial form caused by *Klebsiella* sp. occasionally occurs, almost always in individuals with diabetes mellitus.[118] *Klebsiella* necrotizing fasciitis results from direct inoculation or commonly from hematogenous spread from another site.

SUPERFICIAL NASAL LESIONS. *K. pneumoniae* subspecies *rhinoscleromatis* is the etiologic agent of a hypertrophic, granulomatous infection of the external nares known as *rhinoscleroma*. It often produces changes in the overlying nasal skin (Fig. 180-7) and the contiguous surfaces of the respiratory, sinus, and posterior pharyngeal regions. Most cases seen in the United States have been in patients who have emigrated from specific areas of Eastern and Central Europe, Africa, the Near East, and parts of Central and South America.[119] Dissemination of the organism is by prolonged close contact. Infected individuals can shed organisms for years. The disease has been reported in patients with AIDS.[120] As in leprosy, the disease rarely becomes clinically apparent until early adulthood. Patients complain of fetid, purulent nasal discharge, epistaxis and obstructive symptoms, cutaneous nasal masses, and eventual scarring of nasal passages. Diagnosis depends on biopsy-based identification of characteristic vacuolated Mikulicz



Figure 180-7 *Klebsiella pneumoniae* subspecies *rhinoscleromatis* infection. Rhinoscleroma. The nasal passages and nose are infected, which results in obstructed respiration.

cells and isolation of the organism on routine cultures. If untreated, rhinoscleroma has a slowly progressive course over many years and may extend to involve any portion of the upper airway and tracheobronchial tree.[121]

K. pneumoniae subspecies *rhinoscleromatis* is susceptible to ciprofloxacin, 250–500 mg administered twice daily for 1–3 months. Alternatively, the combination of rifampin plus trimethoprim-sulfamethoxazole for 6 months may be used.

OTHER PHYSICAL FINDINGS. The clinical course is often dominated by systemic manifestations of the underlying illness or decreased mental alertness, hypotension, and dehydration. Abdominal distension and other manifestations of localized or generalized peritonitis may be present. Extreme tenderness of the rectum, with or without a mass, can indicate the local source of a perineal process.

LABORATORY FINDINGS

The leukocyte count is usually elevated but may be markedly diminished in the presence of Gram-negative septicemia. Elevated blood glucose values and findings of ketoacidosis are not unusual. In crepitant cellulitis, radiographs or magnetic resonance imaging of the soft tissue may show the depth and extent of the gas-forming process.[122]

PATHOLOGY

Edema, gangrene of overlying skin, fat necrosis, and exudate containing polymorphonuclear leukocytes are usually present. Gas may be evident in the subcutaneous tissues. Blood vessels are often involved in a necrotic, obliterative, inflammatory reaction. Underlying muscle is usually not involved unless there is septicemia associated with major vascular thrombosis or there is myonecrosis due to an organism such as *A. hydrophila*.

DIAGNOSIS AND DIFFERENTIAL DIAGNOSIS

A bacteriologic diagnosis can be made by analysis of specimens from needle aspiration of the cellulitis or an overlying bleb. Several Gram-positive as well as Gram-negative organisms may be present. When gas is present, anaerobic cocci and *Clostridia* must also be considered. A foul, fetid odor may accompany the presence of anaerobes in the exudate. Radiologic and surgical evaluation can be helpful in determining a descriptive diagnosis such as crepitant cellulitis or necrotizing fasciitis.

COURSE AND PROGNOSIS

The process may be indolent and may respond quickly to effective antibiotic therapy. In obese diabetic patients with perineal lesions, the progression of necrotizing fasciitis may be astonishingly rapid, even with vigorous antibiotic and surgical therapy. When the process is located centrally, in the perineal–gluteal area, the mortality rate is often as high as 50%. Infection of an extremity is frequently treated by antibiotics, drainage, and debridement, or by amputation, with more favorable results. The course is often prolonged and complex.

TREATMENT

Immediate antibiotic therapy and surgical drainage, guided by Gram-stained smears of the exudate and determinations of the extent of the process, are essential. Incision and drainage of focal collections associated with cellulitis are indicated. In necrotizing fasciitis, debridement of involved skin and subcutaneous tissues should be extended until normal fascia is reached. The adjunctive use of hyperbaric oxygen therapy for necrotizing fasciitis is controversial but may have some rationale in selected cases with a polymicrobial etiology in which anaerobes play an important role.[123] Judgment and experience are vital in surgical decisions.

Patients with necrotizing fasciitis or gangrenous cellulitis should receive initial combination antimicrobial therapy (modified by specific findings of Gram-stained smears and culture): ampicillin, gentamicin and clindamycin; ampicillin, gentamicin, and metronidazole; ampicillin–sulbactam plus gentamicin; or meropenem or imipenem or doripenem plus gentamicin. Fluoroquinolones can substitute for aminoglycosides in patients with renal impairment. If *P. aeruginosa*, *Klebsiella*, or *Serratia* is suspected in certain hospital-acquired infections, tobramycin or amikacin may be preferred to gentamicin, and a broad-spectrum penicillin (e.g., piperacillin-tazobactam) or cephalosporin (ceftazidime or cefepime) added in place of ampicillin if *Pseudomonas* is a major pathogen. If methicillin-susceptible *S. aureus* is suspected, nafcillin is included; if resistant *Enterococci* or methicillin-resistant *Staphylococci* are suspected, then vancomycin is included.

KEY REFERENCES

Full reference list available at www.DIGM8.com

DVD contains references and additional content

4. Kingston ME, Mackey D: Skin clues in the diagnosis of life-threatening infections. *Rev Infect Dis* **8**:1, 1986
6. Rosenstein NE et al: Meningococcal disease. *N Engl J Med* **344**:1378, 2001
8. Betrosian AP, Berlet T, Agarwal B: Purpura fulminans in sepsis. *Am J Med Sci* **332**:339, 2006
9. Stephens DS, Greenwood B, Brandtzaeg P: Epidemic meningitis, meningococcaemia, and *Neisseria meningitis*. *Lancet* **369**:2196, 2007
11. Figueroa JF et al: Infectious diseases associated with complement deficiencies. *Clin Microbiol Rev* **4**:359, 1991
28. Cohn AC et al: Changes in *Neisseria meningitides* disease epidemiology in the United States, 1998–2007: Implications for prevention of meningococcal disease. *Clin Infect Dis* **50**:184, 2010
29. Tan LKK, Carlone GM, Borrow R: Advances in the development of vaccines against *Neisseria meningitides*. *New Engl J Med* **362**:1511, 2010
40. Barquet N et al: Prognostic factors in meningococcal disease. *JAMA* **278**:491, 1997
45. Tunkel AR et al: Practice guidelines for management of bacterial meningitis. *Clin Infect Dis* **39**:1267, 2004
52. Stephens DS: Uncloaking the meningococcus: Dynamics of carriage and disease. *Lancet* **353**:941, 1999
59. Rice PA: Gonococcal arthritis (disseminated gonococcal infection). *Infect Dis Clin North Am* **19**(4):853-861, 2005
60. Miller KE: Diagnosis and treatment of *Neisseria gonorrhoeae* infections. *Am Fam Phys* **73**:1770, 2006
64. Agger WA, Mardan A: Pseudomonas aeruginosa infections of intact skin. *Clin Infect Dis* **20**:302, 1995
69. Yu Y et al: Hot tub folliculitis or hot hand-foot syndrome caused by pseudomonas aeruginosa. *J Am Acad Dermatol* **57**:596, 2007
71. Wang E-C et al: Ear problems in swimmers. *J Chin Med Assoc* **68**:347, 2005
73. Ali T et al: Malignant otitis extern: Case series. *J Laryngol Otol* **14**:1, 2010 (Epub ahead of print)
74. Carfrae MJ, Kesser BW: Malignant otitis externa. *Otolaryngol Clin NA* **41**:537, 2008
76. El Baze P et al: Pseudomonas aeruginosa 0–11 folliculitis: Development into ecthyma gangrenosum in immunosuppressed patients. *Arch Dermatol* **121**:873, 1985
80. Silvestre JF, Betlloch MI: Cutaneous manifestations due to pseudomonas infection. *Int J Dermatol* **38**:419, 1999
83. Bodey GP: Dermatologic manifestations of infections in neutropenic patients. *Infect Dis Clin North Am* **8**:655, 1994
89. Doring G, Pier GB: Vaccines and immunotherapy against pseudomonas aeruginosa. *Vaccine* **26**:1011, 2008
107. Janda JM et al: The genus Aeromonas: Taxonomy, pathogenicity, and infection. *Clin Microbiol Rev* **23**:35, 2010
111. Kumamoto KS et al: Clinical infections of vibrio vulnificus: A case report and review of the literature. *J Emerg Med* **16**:61, 1998
115. Brook I, Frazier EH: Clinical features and aerobic and anaerobic microbiological characteristics of cellulitis. *Arch Surg* **130**:786, 1995
119. Andraca R et al: Rhinoscleroma: A growing concern in the United States? Mayo Clinic experience. *Mayo Clinic Proc* **68**:1151, 1993

Chapter 181 :: The Skin in Infective Endocarditis, Sepsis, Septic Shock, and Disseminated Intravascular Coagulation

:: Laura Korb Ferris & Joseph C. English

INFECTIVE ENDOCARDITIS, SEPSIS, SEPTIC SHOCK, DIC, AND THE SKIN AT A GLANCE

- Infective endocarditis: staphylococcal or streptococcal bacteria most common cause in intravenous drug use setting.
- Sepsis: Gram-positive bacteria most common cause; tenth leading cause of death in the United States.
- Disseminated intravascular coagulation: most commonly from sepsis; results from systemic activation of the coagulation cascade.
- Cutaneous manifestations of these entities include: splinter hemorrhages, Janeway lesions, Osler nodules, erythroderma, cellulitis, purpura, hemorrhage, purpura fulminans, and skin necrosis.

INFECTIVE ENDOCARDITIS

EPIDEMIOLOGY

In the United States, the incidence of native-valve endocarditis is 1.7–6.2 cases per 100,000 person-years. The highest rate of infective endocarditis (IE) is seen in intravenous drug users, with an incidence estimated at 150–2,000 per 100,000 person-years. The risk of prosthetic valve IE decreases with time following valve implantation and the cumulative risk is about 2%–3% after 60 months.[1]

ETIOLOGY AND PATHOGENESIS

IE can be subdivided by native valve versus prosthetic valve. The causative organisms in most cases of IE are *Staphylococci* or *Streptococci*, implicating skin as the initial site of infection in many cases. Native valve endocarditis occurs most commonly in the setting of valvular disease or in people who use intravenous

drugs. Rheumatic valve disease has been replaced by aortic stenosis and mitral regurgitation, as the most common settings in which native valve endocarditis is encountered. At sites of endothelial injury, a sterile thrombus can occur which is particularly susceptible to seeding of bacteria from transient episodes of bacteremia. This can result in the development of valvular vegetations that can cause local tissue destruction and embolic events.

Intravenous drug users are particularly susceptible to IE even though most have no preexisting structural heart disease. More than half of the cases of IE in injection drug users are right sided, involving the tricuspid valve. The most common causative organism is *Staphylococcus aureus*.

Prosthetic valve endocarditis can be classified as early (in the first 2 months following valve replacement) or late (2 months or later). The newly placed prosthetic valve is particularly susceptible to bacterial colonization because the process of endothelialization does not occur until 2–6 months following surgery. Early prosthetic valve endocarditis is most commonly caused by *Staphylococcus epidermidis* followed by *S. aureus*. Late prosthetic valve endocarditis can be due to a variety of organisms including the so-called HACEK organisms (*Haemophilus parainfluenzae*, *Haemophilus aphrophilus*, *Actinobacillus actinomycetemcomitans*, *Cardiobacterium hominis*, *Eikenella corrodens*, and *Kinsella kinasae*).

Most cases of nosocomial endocarditis are secondary to indwelling catheters or to surgical procedures, and are caused by *Streptococci*. However, nosocomial endocarditis in dialysis patients is most commonly due to *S. aureus*. Other less common causes of IE include fungi, *Pseudomonas*, *Coxiella burnetii*, *Bartonella quintana*, and *Proprionobacteria acnes*.

CLINICAL FINDINGS

HISTORY. Patients with IE generally present with noncardiac complaints of fever, malaise, and anorexia. The presence of a murmur that is new or has changed in character is often present. Unexplained fever in a patient with a prosthetic heart valve should prompt an evaluation for endocarditis. The Duke criteria,[2] (Box 181-1 are helpful in making the diagnosis of IE.

CUTANEOUS LESIONS. Cutaneous signs of IE are nonspecific but may help the clinician in making the appropriate diagnosis. Cutaneous findings are caused either by embolic events, thrombosis, or focal vasculitis.

Splinter hemorrhages (Fig. 181-1) are 1–2 mm red–brown longitudinal streaks under the nail plate. They are seen in about 15% of patients with IE and are considered to be of greater diagnostic value if proximally located. Splinter hemorrhages associated with IE are the result of small capillary vasculitis, or from microemboli. In the absence of other signs or symptoms of IE, the mere presence of splinter hemorrhage is not specific enough evidence to warrant a workup. Crops of petechiae are commonly seen in the buccal membrane, soft palate, and extremities.

BOX 181-1 MODIFIED DUKE CRITERIA FOR IE[a2]

Major Criteria

1. Microbiological
   a. Two separate blood cultures positive for typical microorganism
   OR
   b. Persistently positive blood culture for typical microorganism
   OR
   c. Single positive blood culture for *Coxiella burnetii* or a phase I IgG antibody titer to *Coxiella burnetii* greater than 1:800
2. Evidence of endocardial involvement
   a. New valvular regurgitation
   OR
   b. Positive echocardiogram showing oscillating echogenic intracardiac mass at the sire of endocardial injury, a periannular abscess, or new dehiscence of a prosthetic valve

Minor Criteria

1. Predisposition to infective endocarditis
2. Fever
3. Vascular phenomena such as Osler nodes or Roth spots
4. Immunologic factors such as a positive rheumatoid factor or glomerulonephritis
5. Serologic evidence of active infection not meeting microbiological major criteria

[a]Clinically definite case is defined as fulfilling 2 major, 1 major plus 3 minor, or 5 minor criteria.
Clinically suspicious case is defined as fulfilling 1 major and 1 minor, or 3 minor criteria.



Figure 181-1 Globular proximal splinter hemorrhage and several distal linear splinter hemorrhages in a patient with IE. (Photo used with permission from William James, MD and James Fitzpatrick, MD).

Janeway lesions are painless, irregular, nonblanchable, erythematous maculopapules that appear on the palms and soles and last days to weeks (eFig. 181-1.1 in online edition). Histologically, thrombi are found in small vessels in the absence of vasculitis. Neutrophilic microabscesses can be seen in the dermis with occasional Gram-positive organisms. Osler's nodes present as painful red papulonodules with a pale center on the fingertips lasting days to weeks (eFig. 181-1.2 in online edition). Osler's nodes are painful, perhaps due to involvement of the glomus bodies located in the fingertips. Histologically, neutrophilic microabscesses are present in the dermis, and arteriolar microemboli may contain Gram-positive cocci.

Septic emboli of valvular vegetation fragments can cause ischemia of distal extremities. Toes are most commonly involved, followed by fingers, and this condition presents as reticulated purpura similar to that seen in cholesterol emboli syndrome (see Chapter 174). While this condition generally resolves without sequelae, tissue necrosis or gangrene can result.

RELATED PHYSICAL FINDINGS. The most common noncutaneous finding in IE is fever. Signs and symptoms related to the bacterial infection and septic emboli may include splenomegaly, microscopic hematuria, pneumonitis, cerebral vascular accident, meningoencephalitis, brain abscess, retinal hemorrhages (Roth spots), acute abdomen, myocardial infarction, pericarditis and congestive heart failure, arthralgias and arthritis, or chronic wasting disease.

LABORATORY TESTS

A positive blood culture is the most helpful laboratory test in making the diagnosis of IE. Other tests that may be abnormal in this setting include a positive rheumatoid factor, elevated erythrocyte sedimentation rate, C reactive protein, leukocytosis, or a urinalysis showing hematuria. Subacute bacterial endocarditis can be associated with the presence of antineutrophilic cytoplasmic antibodies (ANCAs).

SPECIAL TESTS

Echocardiography allows the visualization of the valves and can provide information as to the level of myocardial involvement. Transthoracic echocardiography (TTE) is less invasive and less expensive than transesophageal echocardiography (TEE). However, the sensitivity and specificity of TTE are 60%–70% and 98%, respectively, whereas the sensitivity of TEE is 75%–95% without a compromise in specificity.

DIFFERENTIAL DIAGNOSIS

The differential diagnosis of splinter hemorrhages is reviewed in Box 181-2. Janeway lesions and Osler nodes can be similar in appearance to septic emboli and neutrophilic eccrine hidradenitis. Cases of culture-negative, ANCA-positive subacute bacterial endocarditis, particularly in the presence of cutaneous manifestations such as purpura, may mimic ANCA-associated vasculitis.

BOX 181-2 DIFFERENTIAL DIAGNOSIS OF SPLINTER HEMORRHAGE[3]

- Trauma
- Atopic dermatitis
- Psoriasis
- Thyrotoxicosis
- Internal malignancy
- Drug induced
- Vascular endothelial growth factor receptor (VEGFR) inhibitors[4]
- Tetracyclines
- Scurvy
- Trichinosis
- Idiopathic

COMPLICATIONS

Cardiac complications of IE include congestive heart failure, extension of disease to the myocardium and pericarditis. Embolic complications include stroke, mycotic intracranial aneurisms and splenic abscess.[1]

PROGNOSIS AND CLINICAL COURSE

The overall mortality for IE has dropped by about 50% over the past 40 years and is currently about 28%.[2] Prognosis depends on age, the nature of the responsible microorganism, the presence of emboli, and the extent of cardiac damage. Early diagnosis and treatment improve outcome.

TREATMENT

Appropriate antibiotic therapy should be initiated in suspected cases of IE after blood cultures have been drawn. Long-term (4–6 weeks) parenteral antibiotics, usually with a penicillin derivative, are used to treat streptococcal or staphylococcal IE. Antibiotic treatment has been shown to reduce the risk of subsequent embolism. Treatment of infective endocarditis caused by other organisms is reviewed elsewhere.[5] Indications for surgical treatment include persistent bacteremia, despite 7 days of parenteral antibiotic therapy, prosthetic valve endocarditis, the presence of large vegetations, severe valvular dysfunction, and infection with *Pseudomonas*, *C. burnetii*, or fungus.[6]

PREVENTION

Currently, prophylactic antibiotics for skin surgery are not indicated for procedures performed on noninfected, surgically scrubbed skin regardless of cardiac history.

Guidelines issued by the American Heart Association in May 2007 shifted from recommending antibiotic prophylaxis for patients at increased risk for IE, to recommending IE prophylaxis for patient who have a high risk of an adverse outcome associated with IE who are to have a procedure that involves a contaminated or infected wound, or surgery on oral or nasal mucosa.[7] For dermatologists, this would include patients with a prosthetic heart valve, a personal history of IE, valvulopathy in a cardiac transplant patient, or an unrepaired cyanotic heart defect.

SEPSIS AND SEPTIC SHOCK

EPIDEMIOLOGY

Sepsis, most commonly from Gram-positive bacteria, is the 10th leading cause of death in the United States. A review of approximately 750 million hospitalizations over 22 years in the United States showed that sepsis accounts for 1.3% of all hospital admissions. The incidence of sepsis has been steadily increasing since 1971 although the mortality rate has been dropping.[8]

ETIOLOGY AND PATHOGENESIS

The prevailing presumption has been that sepsis is a result of uncontrolled activation of the inflammatory response to pathogens. This increased inflammation leads to uncontrolled coagulation, which in turn causes the release of more inflammatory mediators. Sepsis is often characterized by an initial burst of immunologic activation, including a surge in TNF-α production. This is thought to be mediated by binding of specific pathogen-associated molecules to toll-like receptors found on cells of the immune system. Toll-like receptors activate signaling through transcription factors such as nuclear factor-κB (NF-κB) that activate the expression of a cascade of inflammatory cytokines. However, this is followed by a relative decrease in immunity with impaired delayed type hypersensitivity, a loss of critical cells of the immune response including B cells, $CD4^+$ helper T cells, and dendritic cells, and the inability to clear infection.[9]

Sepsis is often complicated by impaired organ function. Autopsy studies revealed that even in the setting of profound organ dysfunction, cell death is minimal and not sufficient to account for the clinical picture. Thus, sepsis appears to activate a state of cellular hibernation in which cells reduce their activities to only those required for cell survival. This would explain why organ function is often regained in those patients who recover from sepsis.

CLINICAL FINDINGS

HISTORY. The septic patient is usually febrile, or in some cases hypothermic, with tachycardia and tachypnea. Patients with severe sepsis can also have dysfunction of major organ systems and those in septic shock develop hypotension that is refractory to the administration of fluid.

CUTANEOUS LESIONS. The causative organism in sepsis is not always identifiable by routine culture. In some cases, the cutaneous exam can provide clues to the identity of the responsible pathogen, providing a valuable clinical tool in the management of the septic patient.

Erythroderma in the septic patient suggests staphylococcal or streptococcal toxic shock syndrome (TSS). Patients with TSS are usually young and otherwise healthy. Patients with staphylococcal TSS are much more likely to be erythrodermic but much less likely to have positive blood culture than are patients with streptococcal TSS. Streptococcal TSS is commonly associated with a soft tissue infection.

The finding of pustules on the skin of a septic patient, particularly in the neonate or immunocompromised individual, may be suggestive of fungal infection, particularly with *Candida* species. Congenital candidiasis, most often seen in infants born to mothers with vaginal candidiasis, is generally a skin-limited disease. However, in the septic infant with pustules, candidemia should be considered.

The vasculitis and coagulopathy that can occur in the septic patient may cause purpura, sometimes prominent in the nail fold small capillaries (Fig. 181-2). Purpura is particularly prominent in those patients with thrombocytopenia. Such infections are seen most commonly in oncology patients undergoing bone marrow transplantation. In the immunocompromised host, opportunistic fungal infection, such as with *Aspergillus* sp., *Fusarium* sp., and *Candida* sp., often presents as erythematous papules, petechiae, or pustules that progress to purpuric lesions (Fig. 181-3).

Pustules due to disseminated gonococcemia are acrally located, typically tender and a characteristic gun-metal gray color, hemorrhagic or black, and are most commonly seen in the otherwise healthy adolescent or young adult (eFig. 181-3.1 in online edition).



Figure 181-2 Proximal nail fold purpura from leukocytoclastic vasculitis due to *Clostridium difficile* sepsis.



Figure 181-3 Petechiae from *Fusarium* sepsis in an immunosupprressed patient.

Gram stain of the pustule will reveal intracellular Gram-negative diplococci. In its most extreme form, meningococcemia can cause purpura fulminans (see below). Pustules may also be secondary to a local inoculation site, as in the case of staphylococcal sepsis.

Cellulitis is characterized by intense local inflammation in the presence of relatively few infectious organisms and blood cultures are rarely positive (see Chapter 179). Most commonly occurring on the legs, the affected extremity is typically erythematous, hyperemic, and edematous. The most common causes of cellulitis are *S. aureus* and Group A *Streptococcus*. Rarely, anaerobic organisms including clostridial species and other anaerobic bacteria species such as *Bacteroides*, *Peptostreptococcus*, or *Peptococcus* are the causative organism. In immunosuppressed patients, *Cryptococcus neoformans* can also cause cellulitis, particularly in the setting of AIDS. Patients with liver compromise can develop cellulitis from *Vibrio vulnificus*, a Gram-negative bacterium that lives in warm marine environments and becomes concentrated in filter-feeding shellfish. Infection occurs either via consumption of contaminated organisms such as raw oysters, or through contact with infected waster. Mortality rates exceed 40% in those with *V. vulnificus* sepsis.[10]

A more aggressive local soft tissue infection, necrotizing fasciitis, can be associated with positive blood cultures later in the course of the disease due to hematogenous seeding by the organisms. Clinically, necrotizing fasciitis is rapidly progressive, initially painful, and accompanied by fever and leukocytosis (see Chapter 179). Blood cultures are frequently positive. After several days, the involved area may become anesthetic secondary to destruction of cutaneous nerves.[11]

Ecthyma gangrenosum (see Chapter 180) begins as an erythematous papule that expands and eventually becomes a necrotic bulla. Lesions are most commonly seen between the umbilicus and the knees. Classic ecthyma gangrenosum represents cutaneous seeding of bacteria, usually *Pseudomonas aeruginosa*, from a hematogenous source, and is seen almost exclusively in neutropenic patients, often in association with an underlying malignancy. Nonclassical cases have been reported with *Aeromonas hydrophila*, *Escherichia coli*, *Citrobacter freundii*, and *Corynebacterium diptheriae*, fungal infection including *Candida*, *Aspergillus*, *Fusarium*, and mucormycosis-causing species, and even herpes simplex virus.[12]

RELATED PHYSICAL FINDINGS. Sepsis is defined as infection plus systemic inflammation and is characterized by hyper- or hypothermia, tachycardia and tachypnea. Sepsis is further subdivided into severe sepsis, which is defined as infection with systemic inflammation and organ dysfunction. The organ systems commonly affected in sepsis include the renal, hepatic, central nervous, pulmonary, gastrointestinal, and cardiovascular systems. Septic shock occurs when patients with severe sepsis also have hypotension (SBP <90) refractory to fluid administration.

LABORATORY TESTS

The septic patient will generally have a white blood cell count greater than 12×10^9/L or less than 4×10^9/L, or a bandemia of greater than 10%. Elevated CRP and procalcitonin levels are common. Organ dysfunction can manifest as low cardiac output, elevated creatinine, thrombocytopenia, and elevated INR or PTT, or hyperbilirubinemia.[13] Blood cultures can be helpful in guiding treatment of the septic patients, however, only 30%–50% of septic patients will have positive blood cultures.[14]

SPECIAL TESTS

Special tests including imaging studies and culture of suspected involved tissue can sometimes be helpful in identifying the source of infection in the septic patient.

DIFFERENTIAL DIAGNOSIS

The differential diagnosis of skin findings in the septic patient is reviewed in Box 181-3.

COMPLICATIONS

Complications of sepsis include death, loss of limbs due to hypoperfusion and permanent organ dysfunction.

PROGNOSIS AND CLINICAL COURSE

There are over 750,000 cases of sepsis each year in the United States and mortality rate from severe sepsis and septic shock is 30%–60%.[15]

BOX 181-3 DIFFERENTIAL DIAGNOSIS OF SKIN FINDINGS IN THE SEPTIC PATIENT

- Erythroderma
- Staphylococcal or streptococcal scalded skin syndrome
- Drug reaction
- Cutaneous T cell lymphoma
- Psoriasis
- Papules
- Drug reaction
- Contact Dermatitis
- Pustules
- Candidemia
- Disseminated gonococcemia
- Folliculitis
- Miliaria
- Steroid acne
- Acute generalized exanthematous pustulosis
- Purpura
- Invasive fungal infection, especially in thrombocytopenic patient
- Disseminated intravascular coagulation
- Vasculitis (infectious, neoplastic, drug induced, or autoimmune)
- Trauma induced
- Heparin or coumadin necrosis
- Thrombotic thrombocytopenic purpura
- Cryoglobulinemia
- Cellulitis
- Infectious cellulitis
- Necrotizing fasciitis
- Stasis dermatitis
- Ecthyma gangrenosum
- Pseudomonal ecthyma gangrenosum
- Nonpseudomonal bacterial or fungal ecthyma gangrenosum
- Herpes simplex infection in immunosupressed patient
- Necrotizing vasculitis
- Cryoglobulinemia

TREATMENT

Treatment of sepsis is usually done in an intensive care unit and involves the use of antimicrobial drugs, chosen empirically or on the basis of the culture of a particular microorganism started as soon as possible, but no longer than one hour after the diagnosis of severe sepsis or septic shock is mad. Choice of antibiotic therapy should be reevaluated on a daily basis to minimize toxicity and maximize efficacy. The administration of activated drotrecogin-α has been shown to reduce mortality in cases of sever sepsis. Patient outcomes in sepsis haven been shown to improve with the use of standardized treatment protocols. Supportive care is important to preserve organ function.

PREVENTION

The prevention of sepsis in a hospital setting is achieved by the implementation of basic infection control measures including routine hand washing and the minimization and regular replacement of indwelling catheters. In patients who are immunocompromised, particularly in the setting of organ transplantation or AIDS, the use of prophylactic antibiotics can help to reduce the incidence of sepsis.

DISSEMINATED INTRAVASCULAR COAGULATION

EPIDEMIOLOGY

The incidence of disseminated intravascular coagulation (DIC) is not known. Approximately 15% of septic patients may develop DIC.

ETIOLOGY AND PATHOGENESIS

DIC represents systemic activation of the coagulation cascade. This leads to fibrin deposition in the vasculature, which can cause organ ischemia and death. In addition, the consumption of platelets and coagulation factors can lead to bleeding. DIC occurs most commonly secondary to an underlying disorder as listed in Box 181-4.

In DIC, coagulation activation is tissue factor dependent (i.e., extrinsic or factor VIIa pathway). Inflammatory cytokines, such as TNF-α, promote damage to endothelial cells and activation of mononuclear cells. These cells then produce tissue factor that binds to factor VIIa and activates downstream coagulation cascades. Thrombin generation is amplified by defective

BOX 181-4 SETTINGS IN WHICH DIC CAN OCCUR

- Sepsis
- Trauma
- Malignancy
- Obstetrical complication (amniotic fluid embolism, placental abruption)
- Vascular abnormalities
- Hepatic failure
- Immunologic reaction to drugs or toxins
- Transfusion reactions
- Transplant reaction
- Protein C or S deficiency

anticoagulant mechanisms and results in increased fibrin deposition. The fibrin that is generated fails to be degraded by the fibrinolytic system. In the healthy state, antithrombin regulates thrombin activity. In DIC, antithrombin levels are low due to continuous consumption, degradation by neutrophil elastase and impaired synthesis due to liver failure in some settings. Fibrinolysis is inhibited by plasminogen activator inhibitor type I (PAI-1). Studies show that individuals with high plasma levels of PAI-1 are at higher risk of mortality in DIC. This correlates with a mutation in PAI-1 that is associated with higher PAI-1 plasma concentrations. Thus, some individuals may be genetically predisposed to fatal outcomes from DIC due to a point mutation in PAI-1.[16]

The infection, most commonly associated with DIC, is meningococcal sepsis. However, DIC has been reported following viral and other bacterial infections. Many recent reports suggest an emergence of sepsis due to *Staphylococcus*, particularly those isolates containing exotoxins including, staphylococcal enterotoxin serotypes B and C (SEB and SEC), toxic shock syndrome toxin-1 (TSST-1), and Panton–Valentine leukocidin (PVL), a leukocyte toxin believed to be important in the pathophysiology of skin and soft-tissue infections and necrotizing pneumonia, as a factor in initiating DIC.[17]

DIC can also be associated with obstetric complications including preeclampsia, abruption, and amniotic fluid embolism. In these cases, the placenta appears to play a central role in the hemostatic pathway.

CLINICAL FINDINGS

HISTORY. DIC is always secondary to an underlying condition or disorder, and thus the patient will generally first present with the antecedent condition. Often, patients with DIC will develop simultaneous bleeding, thrombosis, and multiorgan failure. Platelet count is not useful in predicting a patient's risk of thrombosis as clots can form even in the setting of thrombocytopenia. The onset of DIC in the neonatal period is suggestive of protein C or S deficiency.

CUTANEOUS LESIONS. The most characteristic cutaneous finding in DIC is noninflammatory purpura with extensive microvascular occlusion referred to as purpura fulminans (Fig. 181-4). Patients will have diffuse bleeding, hemorrhagic necrosis of tissue, and skin necrosis (eFig 181-4.1 in online edition). Patients with purpura fulminans may present with ischemic digits or extremities that, if left untreated, can progress to gangrene.

RELATED PHYSICAL FINDINGS. In its most extreme form, patients with DIC will develop the Waterhouse–Friderichsen syndrome, most commonly seen in meningococcal sepsis (see Chapter 180). This is a syndrome of multiorgan failure characterized by a petechiae or purpura, coagulopathy, cardiovascular collapse, and bilateral adrenal hemorrhage.



Figure 181-4 Purpura fulminans from *Escherichia coli* sepsis.

LABORATORY TESTS

DIC is characterized by laboratory evidence of massive activation of the coagulation cascade and the destruction of platelets. Platelet counts are generally less than 100,000. Platelet counts tend to be lowest in acute sepsis-associated DIC and increased in chronic DIC associated with malignancy. Because of the high conversion of fibrinogen to fibrin, soluble fibrin monomers and the D-dimer assay are usually elevated. The prothrombin time is usually prolonged to at least 1.2 times the upper limit of normal as well. Several scoring systems exist that assign numerical values to particular laboratory findings and allow the calculation of a single numerical score that is helpful in predicting the presence of and mortality from DIC as reviewed elsewhere.[18]

DIFFERENTIAL DIAGNOSIS

The differential diagnosis of DIC includes other conditions causing small and midsize vessel thrombotic occlusions leading to organ failure and microangiopathic hemolysis. This includes thrombocytopenic thrombotic purpura, the hemolytic uremic syndrome, and the HELLP (hemolysis, elevated liver enzymes, low platelets) syndrome seen in obstetric patients.

COMPLICATIONS

Complications of DIC include tissue necrosis and infection, often requiring amputation of limbs or digits, multiorgan failure (particularly the Waterhouse–Friderichsen syndrome), and death.

PROGNOSIS/CLINICAL COURSE

The mortality risk is doubled in patients with DIC who are septic or have experienced trauma.

TREATMENT

Because DIC is always secondary to another condition, the most important factor in the management of DIC is treatment of the underlying cause. However, replacement of components consumed during DIC and inhibition of the coagulation cascade has an important role as well. Despite the conventional wisdom that replacement of platelets and coagulation factors in the patient with DIC adds "fuel to the fire", more recent clinical trials have not shown this to be the case. These studies have demonstrated a survival benefit to treating patients with DIC with low-dose heparin or activated protein C.[18] Asymptomatic DIC is treated with low molecular weight heparin, synthetic protease inhibitor (SPI), or antithrombin. The marked bleeding type of DIC is treated with SPI; fresh-frozen plasma and platelets are added in cases of severe bleeding. Finally, in organ failure type DIC, antithrombin is used in addition to supportive care.

There is very little published experience regarding the treatment of the cutaneous necrosis seen in DIC. Skin necrosis secondary to DIC is similar to that seen in full thickness cutaneous burns. Excision of necrotic tissue and coverage with autografts, and/or amputation of extremities are possible treatment options.[19]

PREVENTION

Most interventions in DIC are aimed at minimizing organ damage and bleeding. Prevention of DIC itself can be achieved by the prompt diagnosis and treatment of its causes, particularly sepsis.

KEY REFERENCES

Full reference list available at www.DIGM8.com

DVD contains references and additional content

1. Mylonakis E, Calderwood SB: Infective endocarditis in adults. *N Engl J Med* **345**(18):1318-1330, 2001
2. Leblebicioglu H, et al: Characteristics and analysis of risk factors for mortality in infective endocarditis. *Eur J Epidemiol* **21**(1):25, 2006
3. McDonald JR: Acute infective endocarditis. *Infect Dis Clin North Am* **23**(3):643-664, 2009
5. Wilson W et al: Prevention of infective endocarditis: guidelines from the American Heart Association: A guideline from the American Heart Association Rheumatic Fever, Endocarditis, and Kawasaki Disease Committee, Council on Cardiovascular Disease in the Young, and the Council on Clinical Cardiology, Council on Cardiovascular Surgery and Anesthesia, and the Quality of Care and Outcomes Research Interdisciplinary Working Group. *Circulation* **116**(15):1736-1754, 2007
11. Riedemann NC, Guo RF, Ward PA: The enigma of sepsis. *J Clin Invest* **112**(4):460-467, 2003
14. Levi M: Disseminated intravascular coagulation. *Crit Care Med* **35**(9):2191-2195, 2007
18. Saladi RN et al: Idiopathic splinter hemorrhages. *J Am Acad Dermatol* **50**(2):289, 2004

Chapter 182 :: Bartonellosis

:: Timothy G. Berger & Francisco G. Bravo

BARTONELLOSIS AT A GLANCE

- Cat-scratch disease, trench fever/bacteremia, bacillary angiomatosis, and Carrion disease are all caused by different species of the Bartonella family.
- *Bartonella* sp. are able to live inside erythrocytes, explaining the presence of bacteremia in many of the clinical conditions.
- *Bartonella bacilliformis* are the primary host for humans. Immunocompetent patients develop a systemic disease and an eruptive phase.
- Cat-scratch disease is mainly a zoonosis. Infected humans will mostly develop a lumphocutaneous syndrome.
- Bacillary angiomatosis, which is analogous to the eruptive phase of Carrion disease, mostly occurs in immunosuppressed hosts, especially acquired immunodeficiency syndrome patients.
- Diagnosis often made by histologic examination or serology due to the difficulty in culturing these bacteria.

Bartonella are Gram-negative bacilli, with the remarkable capacity for intraerythrocyte persistence and the production of bacteremia. Until the 1980s, *Bartonella* were felt to only cause a rather exotic illness, Carrion disease. Since the description of a peculiar vascular proliferation in patients infected with Human Immunodeficiency Virus (HIV) infection, the number of identified *Bartonella* sp. has been rapidly expanding.

The genus includes three important species that are human pathogens: (1) *Bartonella henselae*, the cause of most cases of cat-scratch disease (CSD) as well as some cases of bacillary angiomatosis (BA), hepatic and splenic peliosis (cystic blood-filled spaces in hepatic lobules or the splenic parenchyma), and endocarditis; (2) *Bartonella quintana*, the cause of trench fever, urban trench fever, BA, and endocarditis; and (3) *Bartonella bacilliformis*, the cause of Carrion disease and its eruptive phase known as verruga peruana (VP). Other potential human pathogens are *Bartonella elizabethae* and *Bartonella vinsonii*, which cause endocarditis, *Bartonella grahamii*, a cause of neuroretinitis, and *Bartonella washoesis*, which causes myocarditis (Table 182-1).[1] Infections caused by most *Bartonella* are associated with arthropod vectors that may simultaneously carry several species. Adaptation to specific vectors and reservoirs seems to be a common strategy of *Bartonellae* for transmission and host diversity. At least one mammal host is known for every one of the *Bartonella* species identified to date.[2] Human beings are the exclusive hosts for *B. bacilliformis* and *B. quintana*, whereas in the case of *B. henselae*, the cat is the host of choice with man being a more accidental host. Asymptomatic bacteremia rates in primary vertebrate (reservoir) hosts may exceed 50%. This suggests high prevalence of infection and prolonged and persistent bacteremia as characteristics of *Bartonella* infection. The extent of disease caused by *B. henselae* will depend on the integrity of the immune system: if the person affected is immune competent, the clinical presentation can be a lymphocutaneous syndrome. If the person affected is immune deficient, the disease will be systemic and very similar to that seen in Carrion disease. [3]

The genus *Bartonella* contains organisms previously in the genuses *Rochalimaea* and *Grahamella*. *Bartonella* organisms are small aerobic, fastidious, pleomorphic, Gram-negative bacteria; they are difficult to culture from clinical samples. Initial clinical isolates grow slowly and visible colonies may not be detected for weeks, but subsequent passages grow much more rapidly. The organisms are short rods, ranging from 0.3 to 0.5 µm wide by 1.0–1.7 µm long. The organisms are best visualized in tissue using modified silver stains (Warthin–Starry). Polymerase chain reaction (PCR) and immunohistochemistry can also detect infection.[4,5]

The family of Bartonella keeps expanding. A new species, *Bartonella rochalimae*[6] has recently been described as causing a febrile illness with splenomegaly in a tourist visiting Peru.

CAT-SCRATCH DISEASE

CAT-SCRATCH DISEASE AT A GLANCE

- Vast majority of cases caused by *Bartonella henselae.*
- Transmitted by the scratch or bite of a cat.
- Most common cause of localized, chronic lymphadenopathy in children.
- Diagnosis established serologically.

EPIDEMIOLOGY

Approximately 29.2 million households (31%) in the United States own a cat, averaging close to two cats per household, for a total household cat population

TABLE 182-1
***Bartonella* Species and the Diseases They Cause**

Species	Human Disease	Risk Group	Reservoir	Vector
Bartonella henselae	Cat-scratch disease Bacillary angiomatosis Endocarditis	IC ICD IC	Cat Cat Cat	Cat flea[a] Cat flea[a]
Bartonella quintana	Trench fever Urban trench fever and endocarditis Bacillary angiomatosis	IC IC, alcoholic, homeless ICD	Human Human Human	Body louse Body louse Body louse
Bartonella bacilliformis	Oroya fever Verruga peruana	IC	Human	Sandfly
Bartonella elizabethae	Endocarditis			
Bartonella vinsonii	Endocarditis			
Bartonella grahamii	Neuroretinitis			
Bartonella washoesis	Myocarditis			
Bartonella rochalimae	Febrile illness	IC	Unknown	Unknown

IC = immunocompetent; ICD = immunocompromised.
[a]The cat flea transmits *Bartonella henselae* from cat to cat, but not cat to human.

of 57 million. This large population of domestic cats explains the more than 22,000 cases of CSD reported annually. Although cats behave as adapted hosts, they also can develop a systemic bacteremic illness. CSD affects persons of all ages, although 60%–90% of classic cases are reported in children and young adults. CSD is seen worldwide and does not appear to have a racial prevalence. Veterinarians may be a particular group at risk.[7] Most patients with CSD recall a history of cat contact, but this is not absolute (90.3%–99.1%). The incidence of CSD is slightly higher in males and it occurs seasonally, mostly between July and October.[8–10]

CSD is associated with exposure to a cat, usually a kitten. The method of spread from cat to human is usually a scratch or bite. In California, 39.5% of cats are bacteremic for *B. henselae* with a single sampling, indicating a very high infection rate. Infection in cats is a worldwide phenomenon, as shown by seroprevalence studies in cats in Sao Paulo, Brazil revealing 46% reactivity to *Bartonella* spp.[7] Bacteremic cats were more likely to be stray cats, young (less than 1 year old), and flea infested. Seroprevalence for *B. henselae* is as high in pet cats as in shelter and feral cats.[11] The seroprevalence of *B. henselae* among pet cats in North America is 27% overall but highly variable, with a higher seroprevalence in warm rainy regions. When the geographic seroprevalence of *B. henselae* is compared with predicted estimates of cat flea populations on the basis of temperature and humidity, there is considerable overlap, supporting the role of the cat flea (*Ctenocephalides felis*) as the arthropod vector among cats. *B. henselae* can be transmitted from cat to cat via the cat flea, cat fleas contain *Bartonella* organisms after feeding on infected cats, cat flea feces contains viable *Bartonella*, and cats can be experimentally infected by the intradermal injection of infected cat flea feces.[12] The cat flea has not been demonstrated to spread *Bartonella* infection from cats to humans. Rather, the disease transmission to human is a consequence of traumatic or subclinical inoculation. Cats' claws and teeth may be contaminated by infected flea feces during scratching and grooming allowing for transmission to humans by scratches.

ETIOLOGY AND PATHOGENESIS

B. henselae causes the vast majority (more than 95%) of cases of CSD. Two main genogroups have been identified in human and cats: (1) Houston-1 and (2) Marseille (also known as genotype II). These two geno groups are further subdivided into 4 variants: (1) Marseille, (2) CAL-1, (3) Houston-1, and (4) ZF-1.[13] The disease caused by all variants is clinically identical.

CLINICAL FINDINGS

CUTANEOUS LESIONS. The clinical spectrum of CSD has expanded since serologic diagnosis has become possible. Less than 10% of patients have a fever higher that 39°C, and one third are afebrile.[13] Typical CSD exhibits two components: (1) the primary inoculation papule and (2) adenopathy proximal to the inoculation site. The papule appears at the site of inoculation within 3–10 days of exposure and progresses through an edematous or vesicular and crusted stage. The primary inoculation papule lasts 1–3 weeks. The lymphadenopathy, seen in at least 90% of patients with typical CSD, develops on average 2 weeks after inoculation (range, 3–50 days; Fig. 182-1). The inoculation papule is still present in 60%–90% when the adenopathy develops, making it a valuable diagnostic finding.[14] The most commonly affected lymph nodes are axillary, epitrochlear, cervical, submandibular, and groin,[13] with 98% of patients having involvement of only one anatomic region. The nodes are generally firm, tender and between 1 and 5 cm in diameter (Fig. 182-2). The lymphadenopathy usually remits spontaneously after



Figure 182-1 Bartonellosis: cat-scratch disease with axillary adenopathy. Acute, very tender, axillary lymphadenopathy in a child; cat scratches were present on the dorsum of the ipsilateral hand. (Used with permission from Howard Heller, MD.)



Figure 182-2 Bacillary angiomatosis. Multiple, grouped, dusky-red, and violaceous papules and nodules that resemble pyogenic granulomas.

several months, although in 20% of cases, the adenopathy lasts longer than 6 months. Recurrences are uncommon.

Suppuration of clinical significance occurs in less than 10% of cases, but when affected nodes are followed with ultrasonography, suppuration is found to be the natural course of resorption of affected nodes in nearly all cases.[14] Surgical drainage is seldom necessary.

RELATED PHYSICAL FINDINGS. With improved diagnosis, atypical cases of CSD have increased from fewer than 5% of cases to more than 30% of cases in some series.[15] The exact prevalence of these atypical presentations is not known, as they are often reported as single cases, and the total number of CSD cases from which they come is unknown. In one pediatric series, a picture of "atypical mononucleosis" with pharyngitis and bilateral cervical adenopathy and thrombocytosis was a common presentation of *B. henselae* infection.[16] One recent study identified *B. henselae* as the third leading cause of FUO in children, after Epstein–Barr virus infection and osteomyelitis. Exposure to cats is not uniformly reported by patients with fever and *Bartonella* infection.[13] Endocarditis, hepatic and splenic granulomatosis, and massive lymph node enlargement resembling lymphoma are less common presentations.[15] Involvement of the terminal ileum may rarely mimic inflammatory bowel disease and intra-abdominal lymphadenopathy may very rarely obstruct the portal vein.[17,18]

Ocular complications of *B. henselae* infection have been frequently reported. The Parinaud oculoglandular syndrome consists of fever, regional lymphadenopathy, and follicular conjunctivitis, and is the most common presentation of ocular *B. henselae* infection. Other manifestations include neuroretinitis, focal retinochoroiditis, arterial and venous occlusion, iridocyclitis, and macular hole.[19,20] The most common neurologic complication of CSD is acute encephalopathy, presenting with seizures in 66% and status epilepticus in 10% of patients.[21–23]

In one study, up to 20% of immunocompetent patients with serologically confirmed CSD had PCR positivity for *B. henselae* in peripheral blood, suggesting bacteremia may be common.[24] Not surprisingly, hematogenous dissemination of *B. henselae* complicating CSD in immunocompetent persons has been reported to affect bone (osteomyelitis), liver and spleen, lungs (pneumonia, pleural effusion, pulmonary nodules), and the optic nerve.[25–27] These lesions may be markedly symptomatic, or, in one case of pulmonary involvement, completely asymptomatic.[25] *B. henselae* not infrequently causes endocarditis in persons with known valvular heart disease, usually affecting the aortic valve, and 90% of patients require valvular surgery as a consequence of severe damage.[28]

Reactive conditions of the skin and joints may be seen in patients with CSD. Two percent of CSD patients develop erythema nodosum.[29] Three percent of patients with CSD suffer a rheumatoid-factor-negative arthropathy of the larger joints of the extremities.[30] These patients are older than 20 years of age and two-thirds are female. Twenty percent have lesions of erythema nodosum. In 80%, the arthropathy resolved in 6 weeks, but in 20%, there is a more chronic course averaging 2.5 years.

LABORATORY TESTS

Routine laboratory findings are nonspecific and usually not helpful, except to exclude other diseases. Patients with CSD may have a slightly elevated white blood cell count and elevated erythrocyte sedimentation rate during the acute phase. Blood cultures are rarely positive when using current testing techniques. PCR of affected lymph nodes may be positive in 30% of cases. Between 80% and 90% of cases of CSD have positive serology for *B. henselae* at the time of presentation, and many of the seronegative cases are positive 2–8 weeks later. Serologic testing has replaced the CSD skin test as the confirmatory test of choice in cases of CSD. The 2 major serologic diagnostic methods used are indirect fluorescence assay (IFA) and enzyme immune-assay (EIA). Titer levels seems to correlate with the type of disease: titers of IgG >1:50 suggest a diagnosis of acute infection, such as CSD, whereas IgG titers >1:800 suggests a diagnosis of endocarditis.[31]

HISTOPATHOLOGY

Histopathologic examination of CSD lymph node lesions is not specific. Lymph nodes undergo three stages in the formation of a granuloma: (1) enlargement with hypertrophy of the germinal centers and thickening of the cortex; (2) formation of granuloma with invasion of lymphocytes and epithelioid cells; and (3) necrosis and infiltration with neutrophils—all of which may be simultaneously present within a single lymph node. Abscess formation may occur. Organisms can be detected in lymph nodes and primary skin lesions, often in clumps or filaments, usually in or adjacent to areas of necrosis.

In primary skin lesions, microscopic examination reveals necrosis of the epidermis and upper dermis, and dermal inflammation ranging from neutrophil and macrophage infiltration to granuloma formation. Conjunctival lesions have similar histological findings. In a few cases, conjunctival lesions produce proliferating blood vessels and a homogenous eosinophilic to basophilic granular appearance in the background—features similar to those of BA.

DIFFERENTIAL DIAGNOSIS

(Box 182-1)

TREATMENT

Virtually all cases of CSD remit spontaneously without therapeutic intervention. In a retrospective study of 202 patients with CSD who were treated with antibiotics, commonly prescribed antibiotics, including

BOX 182-1 DIFFERENTIAL DIAGNOSIS[32]

Most Likely

- Atypical *Mycobacteria* (especially *Mycobacterium Marinum*)
- Sporotrichosis

Consider

- Syphilis
- Tularemia
- Primary inoculation tuberculosis

Rule Out

- Lymphoma

macrolides, tetracycline derivatives, and cephalosporins, were ineffective.[28] However, antibiotic susceptibility studies have shown that *B. henselae* is highly sensitive to macrolides, tetracycline derivatives, and second- and third-generation cephalosporins, and is variably sensitive to quinolones. The failure of antibiotics in classic CSD in the immunocompetent host may relate to the small infectious burden and the frequent initiation of therapy, once the disease is already improving spontaneously (in its lymphatic phase). In a prospective randomized trial, azithromycin for 5 days was demonstrated to reduce the lymph node volume during the first 30 days of observation. Half of azithromycin-treated patients reached 20% of baseline lymph node volume by 1 month, as opposed to 7% of untreated patients. However, there was no difference in any other symptoms or findings, or in the long-term outcome, and some treated patients had increase in lymph node size after treatment.[14] For complicated CSD of the eye or central nervous system, doxycycline 100 mg twice daily plus rifampin 300 mg twice daily is recommended. In children less than 8 years of age, erythromycin may be substituted for doxycycline.

TRENCH FEVER, URBAN TRENCH FEVER, AND BACTEREMIA/ ENDOCARDITIS

TRENCH FEVER, URBAN TRENCH FEVER, AND BACTEREMIA/ ENDOCARDITIS AT A GLANCE

- Infection transmitted by the body louse.
- Etiology: *Bartonella Quintana*.
- Systemic symptoms: headache, fever, and shin and back pain.
- Endocarditis.

EPIDEMIOLOGY

B. quintana is the etiologic agent of trench fever, a disease that affected more than 1 million troops of the German and Allied armies during World War I.[33] In the last three decades, *B. quintana* has been identified as a cause of bacteremia and endocarditis in the United States and France (urban trench fever).[28,33] Virtually all of the patients are human immunodeficiency virus-negative, homeless, alcoholic men. Moreover, in cities where urban trench fever has been described, from 15% to 50% of the indigent alcoholic inner city male population has serologic evidence of infection with *B. quintana*.[34]

ETIOLOGY AND PATHOGENESIS

Trench fever is caused by *B. quintana*. As opposed to most other *Bartonella* species, humans are the only known reservoir for this organism. The disease is transmitted from human to human by the human body louse (*Pediculus humanus corporis*). Close body contact and unsanitary conditions are associated with outbreaks. The incubation period ranges from 5 to 20 days. The organism can be isolated from patients with the disease and can be transmitted from person to person by direct inoculation or through lice. Recovered patients may be bacteremic for weeks.[33] *Bartonella* are the only bacterial pathogens that are able to invade and live inside the human erythrocyte. This may be the reservoir of bacteria in persistently infected persons.[1]

CLINICAL FINDINGS

Classic trench fever is characterized by a fever lasting approximately 1 week, followed by recurrent fevers every 4–8 days, most commonly every 5 days (quintana fever). Clinically, patients complain of severe headaches and neck, back, and shin pain (shin bone fever). There are no specific cutaneous manifestations. Although significant morbidity is associated with the disease, fatalities are rare.

LABORATORY TESTS

The diagnosis is usually made by blood culture, which is >90 percent positive if done specifically to isolate *Bartonella*, and before any antibiotic therapy. After even a single dose of antibiotics, blood cultures are usually negative. All patients are serologically negative at presentation but become positive after several weeks, making this a useful delayed confirmatory test, but of no value in the acute setting.

TREATMENT

For uncomplicated bacteremia, 4 weeks of doxycycline 100 mg bid plus gentamicin 3 mg/kg/day intravenously for 2 weeks is recommended.[1] For documented *Bartonella* endocarditis, doxycycline 100 mg bid for

6 weeks plus gentamicin 3 mg/kg/day for 2 weeks is recommended.[1]

BARTONELLA INFECTION IN THE IMMUNOSUPPRESSED (BACILLARY ANGIOMATOSIS; PELIOSIS OF THE LIVER AND SPLEEN)

BACILLARY ANGIOMATOSIS AT A GLANCE

- Etiology: *Bartonella henselae or B. Quintana*.
- Acquired from infected cats or body lice respectively.
- Most commonly in patients with acquired immunodeficiency syndrome but also in other forms of immunosuppression.
- Pyogenic granuloma-like and subcutaneous nodules.
- Hyperpigmented plaques in African-Americans.
- May be associated with hepatic and systemic lesions.
- Treatment: erythromycin or doxycycline.

EPIDEMIOLOGY

BA is most commonly seen in patients with acquired immunodeficiency syndrome (AIDS) and a CD4 count less than 50 cells/mm, with an incidence of 1.2 cases per 1,000 at-risk patients.[35] Patients with other forms of immunosuppression, including patients with leukemia and recipients of organ transplants, have been reported.[36] Uncommonly, human immunodeficiency virus-negative and nonimmunosuppressed persons develop BA.[37] Although, in the cases of BA in immunocompetent persons, the lesions were proliferative vascular papules, they were limited in number, the affected persons had limited or no systemic involvement and a benign course. There is no predisposition in terms of race, sex, or age.

ETIOLOGY AND PATHOGENESIS

Both *B. henselae* (the CSD bacillus) and *B. quintana* (the agent of trench fever) have been identified as causative agents of BA. At one end of the clinical spectrum, classic CSD is seen in young, immunocompetent hosts as a limited infection. At the other end, BA is seen in patients who are severely immunocompromised as a systemic disease. Thus, it is the immune-competence of the host and the bacterial load that dictates the clinical manifestations of the disease. The presence of intracellular bacilli in endothelial cells leads to intracellular hypoxia. Hypoxia induces Hypoxia-Inducible Factor-1 (HIF-1) that in turn induces vascular endothelial cell growth factor, leading to vascular proliferation.[38] BA caused by *B. henselae* is acquired from infected cats and is a manifestation of CSD in the immunecompromised host. Peliosis hepatitis is exclusively associated with *B. henselae* infection.[39] In contrast, patients with BA caused by *B. quintana* develop subcutaneous masses and lytic bone lesions.

CLINICAL MANIFESTATIONS

CUTANEOUS LESIONS. The incubation period for BA is unknown. In AIDS patients, the clinical constellation includes fever, cutaneous or subcutaneous vascular lesions, lymphadenopathy, and/or abdominal symptoms. The most common cutaneous morphologies of BA are (1) pyogenic granuloma-like lesions, (2) subcutaneous nodules, and (3) hyperpigmented indurated plaques. The same patient may have several morphologies. Lesions resembling pyogenic granuloma can range in size from 1 mm to many centimeters and are dusky red in color with a collarette of scale and peripheral satellite lesions (Fig. 182-2). The lesions are firm, bleed easily, and are often tender. They occur on skin and mucosa. Subcutaneous nodules can range from distinct nodules to diffuse swellings with or without induration and are also often tender. Hyperpigmented plaques are most commonly seen in African-Americans with BA and are oval in shape; they are several centimeters in diameter with indistinct borders. Large, fungating masses rarely occur. Patients with BA may have few to thousands of lesions with the number of lesions gradually increasing over time. Additional immunosuppression with chemotherapeutic agents may be followed by a shower of miliary skin lesions.

RELATED PHYSICAL FINDINGS. In addition to cutaneous lesions, other organ systems may be affected. Hepatic and splenic vascular lesions can occur concomitantly with or independent of cutaneous lesions and can be a cause of significant blood loss and anemia. *Bartonella* infection, especially that caused by *B. quintana,* can affect bone and soft tissues. Lesions of the central nervous system have been reported and can result in neurologic and psychiatric disorders. Bacteremia, chronic fevers, and pulmonary and gastrointestinal lesions have also been reported. Radiologic studies usually identify areas of systemic involvement. Ocular vascular proliferative lesions can produce loss of vision.[40]

There are several reports of patients with other cutaneous diseases concomitant with BA, as well as the simultaneous existence of BA and another infection within the same lesion. Several patients have been reported with both BA and Kaposi sarcoma. Cytomegalovirus, Epstein–Barr virus, *Cryptococcus neoformans,*

BOX 182-2 DIFFERENTIAL DIAGNOSIS OF BACILLARY ANGIOMATOSIS

Most Likely

- Pyogenic granuloma
- Kaposi sarcoma
- Angioma

Consider

- Chronic herpes simplex
- Hypertrophic scars
- Nocardiosis

Always Rule Out

- Amelanotic melanoma
- Squamous cell carcinoma
- Basal cell carcinoma
- Dermatofibroma protuberans
- Merkel cell carcinoma

and *Mycobacterium avium-intracellulare* have been found within lesions of BA.

DIFFERENTIAL DIAGNOSIS

(Box 182-2)

LABORATORY FINDINGS

Patients with AIDS and BA are anemic and may have elevated liver function tests (characteristically, lactic acid dehydrogenase and alkaline phosphatase are more elevated than hepatocellular enzymes). Blood cultures are positive for *Bartonella* sp. in approximately one-half of BA patients. *B. henselae* or *B. quintana* can be cultured from skin lesions. The organisms grow slowly and may not be detected without prolonged culture (more than 1 month). PCR of affected tissue is virtually always positive if lesions are histologically characteristic. The vast majority of cases are diagnosed histologically, with identification of the causative bacteria by Warthin–Starry staining.

HISTOPATHOLOGY

Lesions of BA have the general features of a lobular capillary hemangioma (pyogenic granuloma) (Fig. 182-3A), but in contrast to a pyogenic granuloma, the endothelial cells are often larger and polygonal; they may have marked atypia. There is a prominent inflammatory infiltrate, with significant numbers of neutrophils as well as leukocytoclastic debris (see Fig. 182-3B). Polymorphous-clear leukocytes (PMNs) are scattered throughout the lesion, as opposed to classic pyogenic granuloma lesions in which the PMNs are at or near the surface, even if the pyogenic granuloma is eroded and impetiginized. There is usually a finely granular pink to purple material

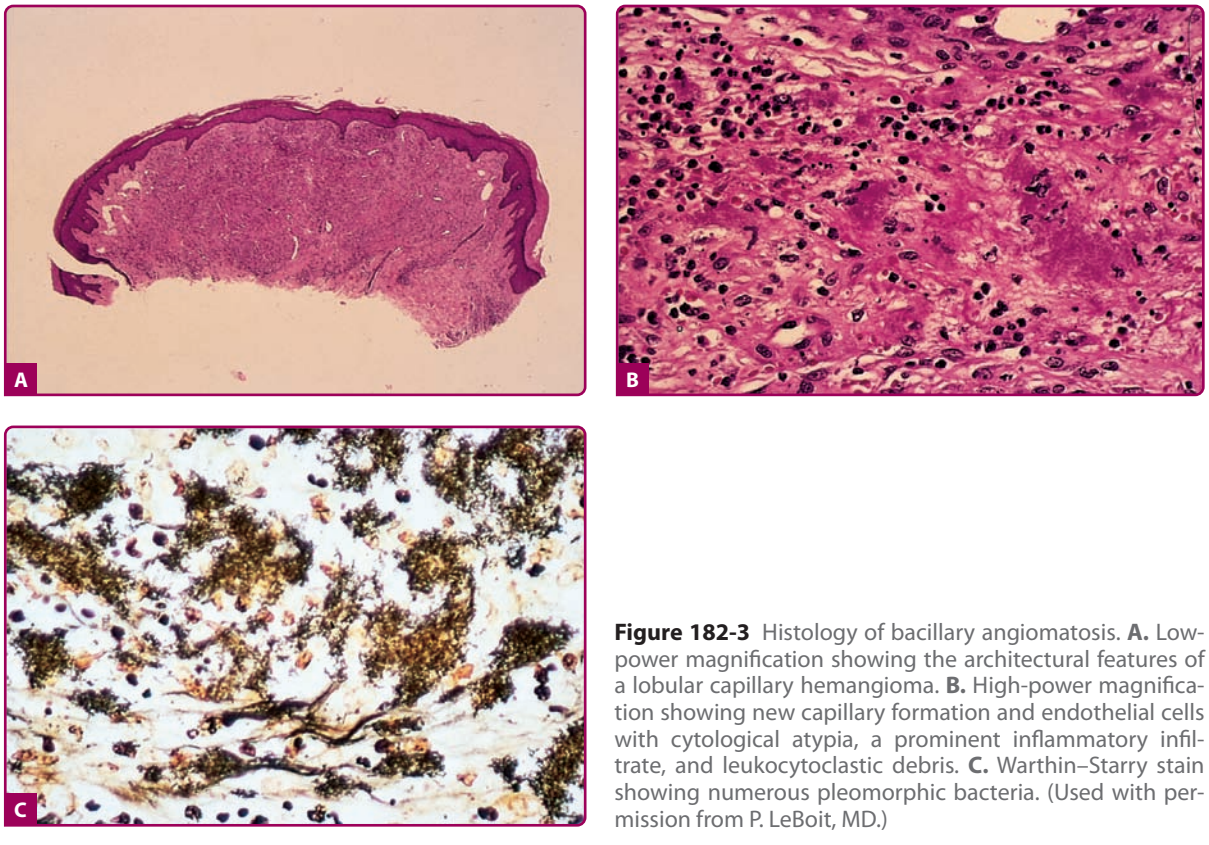

Figure 182-3 Histology of bacillary angiomatosis. **A.** Low-power magnification showing the architectural features of a lobular capillary hemangioma. **B.** High-power magnification showing new capillary formation and endothelial cells with cytological atypia, a prominent inflammatory infiltrate, and leukocytoclastic debris. **C.** Warthin–Starry stain showing numerous pleomorphic bacteria. (Used with permission from P. LeBoit, MD.)



Figure 182-4 Bartonellosis (verruga peruana). Multiple small papules on the extremities. The lesions may ulcerate.

in areas of PMN infiltration adjacent to blood vessels. This represents large clumps of bacteria, best visualized with a modified Warthin–Starry stain (see Fig. 182-4C). Standard tissue Gram stain and the Warthin–Starry stain used for syphilis do not stain the organisms. If the diagnosis cannot be confirmed with special stains, electron microscopy may be used. The histological findings are identical to those seen in VP, except for the number of bacilli that can be seen on special stains (bacilli are sparse in VP). The lack of spindle cells, atypically shaped vascular channels, and hyaline globules distinguish BA from Kaposi sarcoma. Lesions of BA in tissues other than liver show similar histological features.

CLINICAL COURSE

In the immunocompromised host, the natural history of untreated BA is gradually progressive disease, with increasing numbers of skin lesions and involvement of many visceral organs. If untreated, severely immunocompromised patients may die of their infection.

TREATMENT

Erythromycin, 500 mg four times a day, or doxycycline, 100 mg twice a day for 3 months, is the treatment of choice for BA. Other antibiotics thought to be effective are minocycline, tetracycline, chloramphenicol, azithromycin, and roxithromycin. For peliosis hepatitis, 4 months of treatment is recommended. Some patients require life-long suppressive therapy. Relapses have been reported, especially with shorter treatment courses[39] A Jarisch–Herxheimer reaction, not uncommonly, occurs after initiation of therapy. Most patients respond rapidly to antibiotic therapy. The disappearance of the vascular lesions may relate to the effects of the macrolides and tetracyclines on protein synthesis, stopping the production of vascular growth factors. Patients not treated for a sufficient period are likely to relapse, despite the fact that their skin lesions vanish after a few weeks of treatment. The additional treatment is required to sterilize visceral or hematologic reservoirs of bacteria.

CARRION DISEASE, INCLUDING OROYA FEVER AND VERRUGA PERUANA

CARRION DISEASE AT A GLANCE

- Etiology: *Bartonella bacilliformis*.
- Arthropod vector: Sandfly—Lutzomyia.
- Geographically restricted to South American Andes and lower highland jungles.
- Biphasic disease: acute hematic phase (Oroya fever) and eruptive phase (verruga peruana).

EPIDEMIOLOGY

Carrion disease was the first and for many years the only *Bartonella* infection known. The disease has two well-defined phases: (1) a systemic febrile illness, described historically as Oroya Fever (OF), and (2) an eruptive phase, most relevant to dermatologist, known as verruga peruana. The disease is restricted to the South American Andes, from 2°5′ latitude north to 13° south of the equator, including southern Colombia, parts of Ecuador, and Peru. Most cases have been reported in regions of altitude ranging from 500 to 3,200 meters above sea level. Recent epidemics have been reported in previously nonendemic areas of Peru, suggesting that the endemic area is expanding to lower highland jungle areas near the Amazon basin.[41] Sea surface temperature warming is associated with higher minimum daily temperatures, and an increase in the arthropod vectors. El Niño-related climate changes resulted in up to a fourfold increase in *B. bacilliformis* infection in some geographic regions.[42] Humans are the only known reservoir for *B. bacilliformis*, and asymptomatic bacteremia occurs in 0.5% of persons in endemic regions. In one endemic area, the annual incidence of infection was 12.7% in the overall population, 38% in children, and 1% in those 60 years of age or older. Cases cluster in households.[41]

ETIOLOGY AND PATHOGENESIS

The disease is named after Daniel A. Carrión, who, as a Peruvian medical student in 1885, inoculated himself with a lesion of VP and died after developing the systemic illness known as Oroya fever, demonstrating that

both diseases are in fact caused by the same agent. The causative organism is *B. bacilliformis*. The arthropod vector is most commonly a sandfly, particularly *Lutzomyia verrucarum*, the same vector that transmits *Leishmania peruviana*, an agent of cutaneous leishmaniasis.

CLINICAL MANIFESTATIONS

Carrion disease had been considered a biphasic disease with an acute form (acute hematic bartonellosis or Oroya fever) and a chronic form with skin lesions called verruga peruana. With the ability to culture the causative organism and do serologic testing, the disease spectrum has expanded. In a prospective study in an endemic area, 1% of patients presented with acute hematic disease, 37% with VP and symptoms of acute hematic disease, 32% with VP without systemic symptoms, and 20% have an asymptomatic infection with seroconversion only. Only a minority of patients will manifest both phases of the disease.

After an incubation period between 10 and 210 days (average, 60 days), the acute stage (acute hematic bartonellosis) develops. Patients have severe fevers, headache, abdominal pain, malaise, adenopathy, and a profound paleness. Other signs of hemolysis may also be present. Patients may develop signs of neurologic involvement, including coma. During the acute state, the patients are extremely susceptible to superinfection, either bacterial (classically *Salmonella*) or parasitic (classically *Toxoplasma*). After acute hematic bartonellosis, the patients may experience recurring episodes of fever and transitory bone, joint, and muscle pain.

Patients often present with the eruptive lesions of VP having had no preceding acute phase. VP are highly vascular lesions, identical to pyogenic granuloma or BA (see Fig. 182-4). Three patterns of cutaneous lesions have been described: (1) miliary, (2) nodular, and (3) mular. In the miliary form, lesions are about 3 mm in diameter. Mular lesions are larger, fewer in number, and either sessile or pedunculated, with superficial erosion. Nodular lesions are deep dermal or subcutaneous papules and nodules may not have overlying erythema. Mucosal lesions may occur.

LABORATORY FINDINGS

During the acute hemolytic phase, a profound anemia may be present. Red blood cell counts can fall below $106/mm^3$ (two-thirds of patients have a hematocrit below 20). Oroya fever is one of the few bacterial diseases in which the agent can actually be seen on peripheral blood smears. On Giemsa stained smears, the organisms are seen as blue-colored extraerythrocytic and intraerythrocytic bacilli or coccobacilli. Although B bacilliformes may parasitize up to 100% of the red blood cells, sensitivity of this method for diagnostic purposes can be as low as 36% in unskilled hands.[43] The microorganism can be isolated from peripheral blood during the acute phase and less commonly during the eruptive phase. The isolation of *B. bacilliformis* from patients with lesions of VP underlies the role of such patients as reservoir for the microorganism in endemic areas. Serological tests, such as enzyme-linked immunosorbent assay (ELISA), immunoglobin IgM or IgG indirect inmunofluorescence, hemagglutination test, inmunoblotting of specific 17 or 18 kDa antigen, Western blotting, and polymerase chain reaction are available in reference laboratories, but are not part of routine practice in the remote endemic areas.

HISTOPATHOLOGY

Lesions of VP are histologically identical to those of BA, showing the distinct angioproliferative pattern with areas of neutrophilic collection within the stroma. The pattern of proliferation varies with the type of lesion. In miliary lesions, it is in the papillary and superficial reticular dermis, and in nodular and mular lesions, it is in the deeper dermis. Old verrugas tend to lose the inflammatory component, retaining the vascular frame. At that point, the lesion may look very similar to a pyogenic granuloma. In contrast to BA, the purple bodies of bacteria are hardly seen in VP lesions. However, the organisms can be seen in the tissue with modified silver stain techniques.

DIFFERENTIAL DIAGNOSIS

(Box 182-3)

TREATMENT

If untreated, Oroya fever is a fatal disease in 40%–90% of cases. Because of the frequent concomitant infection with *Salmonella*, the treatment of choice for Oroya fever is chloramphenicol (50–75 mg/kg/day, maximum 3 g/day) for 14 days plus a β-lactam antibiotic. Ciprofloxacin, 500 mg bid for 10 days, also appears effective. Rifampin, 600 mg daily in adults and 10 mg/kg/day in children for 14–21 days, is the treatment of choice for VP, although the macrolides and tetracyclines are also effective. Oral azithromycin, 500 mg daily for 7 days or ciprofloxacin, 500 mg bid for 7–10 days, are considered valid alternatives.[1,43] VP may also regress spontaneously.

BOX 182-3 DIFFERENTIAL DIAGNOSIS OF VERRUGA PERUANA

Most Likely
- Pyogenic granuloma
- Bacillary angiomatosis

Consider
- Cutaneous tuberculosis
- Nocardiosis
- Any angiomatous proliferation

Always Rule Out
- Angiosarcoma
- Skin cancer (especially melanoma)

KEY REFERENCES

Full reference list available at www.DIGM8.com

DVD contains references and additional content

1. Rolain JM et al: Recommendations for treatment of human infections caused by *Bartonella* species. *Antimicrob Agents Chemother* **48**:1921, 2004
10. Reynolds MG et al: Epidemiology of cat-scratch disease hospitalizations among children in the United States. *Pediatr Infect Dis J* **24**:700, 2005
11. Guptill L et al: Prevalence, risk factors, and genetic diversity of *Bartonella henselae* infections in pet cats in four regions of the United States. *J Clin Microb* **42**:652, 2004
23. Massei F et al: *Bartonella henselae* infection associated with Guillain-Barré syndrome. *Pediatr Infect Dis J* **25**:90, 2006
34. Guibal F et al: High seroprevalence to *Bartonella quintana* in homeless patients with cutaneous parasitic infestations in downtown Paris. *J Am Acad Dermatol* **44**:219, 2001
41. Chamberlin J et al: Epidemiology of endemic *Bartonella bacilliformis:* A prospective cohort studying a Peruvian mountain valley community. *J Infect Dis* **186**:983, 2002

Chapter 183 :: Miscellaneous Bacterial Infections with Cutaneous Manifestations

:: Scott A. Norton

This chapter focuses on a group of unrelated bacterial diseases that are rarely encountered in a conventional urban or suburban setting but are acquired after a distinctive environmental exposure, such as saltwater immersion, animal bites, handling of an infected animal carcass, or travel to specific areas around the world. Several of these diseases present primarily as cutaneous disorders with rare systemic involvement (e.g., erysipeloid); others present primarily as systemic disorders with rare cutaneous involvement (e.g., brucellosis). Several of the pathogens can be aerosolized and disseminated for respiratory transmission, naturally or with human intervention. The ease of dissemination and the potential virulence of several organisms make them suitable for intentional spread as biologic weapons. The intentional spread of these diseases is discussed in greater detail in Chapter 213.

In this chapter, these infections are grouped by their most common, natural means of transmission to humans: atraumatic exposure to animals, animal bites, and contact with contaminated water (Fig. 183-1).

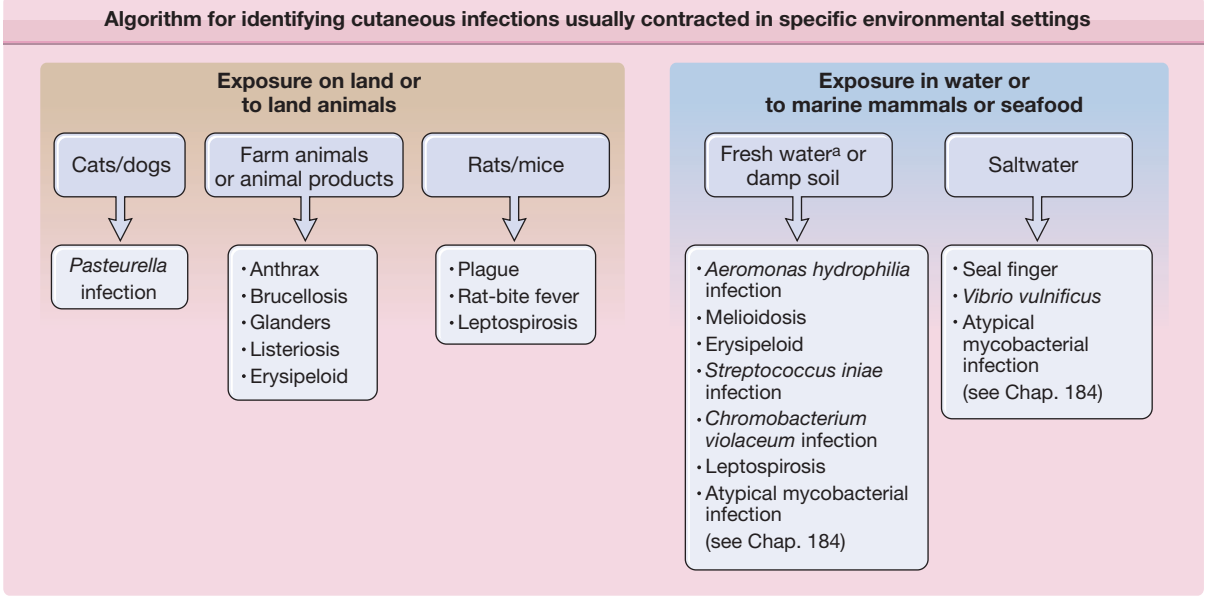

Figure 183-1 Algorithm for identifying cutaneous infections usually contracted in specific environmental settings. [a]Brackish water may harbor the same organisms.

ANTHRAX

ANTHRAX AT A GLANCE

- A large Gram-positive rod, *Bacillus anthracis*, changes into dormant spores under environmentally harsh conditions. Spores are infectious particles that revert to active bacillary form in host tissues.
- Natural pathogen of livestock, especially sheep, goats, and cattle. Most human diseases are occupationally related to exposure to live animals or animal products.
- Cutaneous anthrax is the most common form and is associated with the lowest morbidity. Inhalational and gastrointestinal anthrax are more virulent and frequently lethal.
- Cutaneous lesions arise from percutaneous spore inoculation, usually unnoticed. They present as painless edematous papules or plaques that develop jet-black central eschars.
- The organism is a Centers for Disease Control and Prevention Category A bioweapon in aerosolizable micropowder form. There is no human-to-human transmission.

ETIOLOGY AND EPIDEMIOLOGY

Anthrax is a zoonotic infectious disease caused by *Bacillus anthracis*, a large aerobic, spore-forming Gram-positive rod.[1] Anthrax occurs naturally in ruminant mammals, such as sheep, cattle, and goats. Human disease is seen most often in agrarian, livestock-dependent regions. Consequently, human anthrax usually follows agricultural or industrial exposure, either through direct handling of infected animals or contaminated soil or through the processing of hides, wool, hair, or meat.[2] Anthrax has potential as a class A bioweapon (Table 183-1; see also Chapter 213).

The clinical presentation of human anthrax depends on the route of inoculation. In 95% of human cases, the disease is acquired through percutaneous inoculation of anthrax spores. Human anthrax can also be acquired as inhalational and gastrointestinal disease. Recent cases in the United States of both forms have been associated with recreational use of drums made of unprocessed animal hides imported from West Africa.[3,4] Each of anthrax's form has distinctive clinical, epidemiologic, and prognostic features.[5]

Outbreaks still occur in endemic areas.[6–11] During the late twentieth century, thousands of people in the African nations of Zambia and Zimbabwe developed anthrax.[12] More than 90% of cases were cutaneous and the remainder represented an equal mix of inhalational and gastrointestinal disease. Dying animals typically release vegetative bacilli into the environment, which then convert into the dormant, yet infectious, spores. There are ongoing outbreaks of animal anthrax among free-ranging wood bison (Athabaskan buffalo) in Northern Canada,[13] several species of antelope in Zambia,[14] hippopotami in Uganda, and domesticated grazing animals in North Dakota.[15]

CLINICAL FINDINGS

HISTORY. After an incubation period of 1–7 days, patients may experience low-grade fever and malaise and develop a painless papule at the exposed site. As the lesion enlarges, the surrounding skin becomes increasingly edematous. Pain, if present, is usually due to edema-associated pressure or secondary infection.

CUTANEOUS LESIONS. Cutaneous anthrax develops when spores enter minor breaks in the skin, especially on exposed parts of the hands, legs, and face (Fig. 183-2). In the hospitable environment of human skin, spores revert to their rod forms and produce their toxins. A dermal papule, often resembling an arthropod bite reaction, develops over several days, and then progresses through vesicular, pustular, and escharotic phases. Lesions are surrounded by varying degrees of edema. Depending on the manner of inoculation, one to several lesions may appear, and there may be regional lymphadenitis, malaise, and fever. Individual lesions may appear pustular, leading to the name "malignant pustule," but they do not suppurate. In anthrax, true pustules are rare; a primary pustular lesion is unlikely to be cutaneous anthrax.

The lesion enlarges into a glistening pseudobulla that becomes hemorrhagic with central necrosis and may be umbilicated (see Fig. 183-2). The necrotic ulcer is usually painless, which is an important feature in differentiating it from a brown recluse spider bite. There may be small satellite papules and vesicles that may extend along lymphatics in a sporotrichoid manner. An area of brawny, nonpitting edema ("malignant edema") often surrounds the main lesion. Lesional progression is due to toxins and is unaffected by antibiotic therapy. Fatigue, fever, chills, and tender regional adenopathy may cause an ulceroglandular syndrome. The eschar dries and separates in 1–2 weeks.[16–20]

RELATED PHYSICAL FINDINGS. Cutaneous anthrax may cause fever, tachycardia, and hypotension.

HISTOPATHOLOGY

The prominent features are hemorrhagic edema, dilated lymphatics, and epidermal necrosis. Bacilli

TABLE 183-1
Overview of Bacterial Infections

Infection	Expected Demographic Distribution	Typical Presentation (Skin)[a]	Typical Exposure	Bioweapon Potential[b]	Treatment
Anthrax	Worldwide, especially developing agrarian areas	Painless edematous plaque with central black ulcer or eschar	Goats, sheep, cattle, or products made from them	A	PCN, doxycycline, ciprofloxacin
Tularemia	North America, Europe	Ulceroglandular: painful papule that ulcerates and forms eschar	Tick bites, rabbits, rodents	A	Aminoglycoside, fluoroquinolone, doxycycline.
Plague	Worldwide, especially United States Southwest, India	Buboes (tender regional lymphadenopathy) followed by purpura and gangrene	Flea bites, spread from infected rodents	A	Aminoglycoside, doxycycline, cotrimoxazole
Brucellosis	Worldwide, especially developing agrarian areas	Variable; skin manifestations present in <5% of patients	Cattle, sheep, goats, or untreated milk	B	Doxycycline plus aminoglycoside or rifampin
Glanders	Rare and focal in Asia, Middle East	Nodule with cellulitis that ulcerates; later, deep abscesses and sinuses	Donkeys, mules, horses	B	Sulfadiazine, gentamycine, doxycycline
Pasteurella infection	Worldwide	Rapid onset of cellulitis at bite site followed by necrosis	Dog or cat bite	NR	Amoxicillin plus CA
Rat-bite fever (streptobacillary)	Worldwide, especially Asia	Morbilliform eruption with fever followed by arthritis	Rats or their excreta	NR	Amoxicillin plus CA
Seal finger	Cool coastal regions worldwide	Extremely painful nodule on finger	Seals or sea lions	NR	TCN, ceftriaxone
Listeriosis	Worldwide	In neonates, generalized petechiae, papules, and pustules	In neonates, infected mother with transfer in utero or shortly after birth	NR	Ampicillin or PCN IV
Vibrio vulnificus infection	Worldwide	Necrotizing fasciitis, hemorrhagic bullae often beginning as a wound infection	Warm saltwater or brackish water or undercooked seafood	NR	Doxy and ceftazidime IV, debridement of lesions
Aeromonas hydrophila infection	Worldwide	Cellulitis evolving to abscess formation, often beginning as a wound infection	Fresh or brackish water, contaminated fish	NR	Third-generation cephalosporins, fluoroquinolones; debridement
Melioidosis	Wet tropical areas, especially Southeast Asia and northern Australia	Indolent abscesses; suppurative parotitis (in children)	Wet soil (classically rice paddies), flooded regions	B	Ceftazidime plus a carbipenem IV, then prolonged oral amoxicillin CA or TMP-SMX
Erysipeloid	Worldwide	Tender violaceous plaque on hand at site of injury	Contaminated fish, shellfish, poultry, meat, and animal products	NR	PCN, ampicillin, ceftriaxone, fluoroquinolone
Streptococcus iniae infection	Worldwide, especially freshwater fish farms	Rapid onset of hand cellulitis following a puncture wound	Contaminated farm-raised fish	NR	PCN, cephalosporin
Leptospirosis	Worldwide, especially the tropics	Papules, petechiae, jaundice	Contaminated freshwater, moist soil, or animal urine	NR	Doxy, PCN
Diphtheria	Worldwide where immunization is not practiced	Pustule or superinfected abrasion, evolving to an ulcer with gray membrane at base	Asymptomatic human carriers	NR	PCN IV or erythromycin plus antitoxin

[a]For many entities, multiple presentations are possible depending on the route of inoculation (percutaneous entry, oral ingestion, or inhalation). See text.
[b]If aerosolized, per criteria of the Centers for Disease Control and Prevention.
A = highest (systemic disease, often fatal); B = substantial (severe systemic disease, sometimes fatal); CA = clavulanic acid; doxy = doxycycline; genta = gentamicin; IV = intravenously; NR = not rated; PCN = penicillin; TCN = tetracycline; TMP-SMX = trimethoprim-sulfamethoxazole.



Figure 183-2 Anthrax. The classic cutaneous lesion of a primary infection in anthrax is a painless papule that evolves into a hemorrhagic bulla with surrounding brawny nonpitting edema. Note the typical localization on the hand. The name *anthrax* comes from the Greek word ανθραξ *(anthrax)*, meaning coal, which refers to the coal-black hue of the lesions of cutaneous anthrax.

may be found in the eschar. Anthrax is toxin-mediated and induces scant inflammatory infiltrate. Immunohistochemical stains are quite useful.[21]

TREATMENT

Naturally occurring anthrax is treated with penicillin or doxycycline. Weaponized anthrax, on the other hand, may be resistant to these antibiotics, and, therefore, a fluoroquinolone is recommended for the initial treatment of confirmed or suspected bioterrorism-associated anthrax, even in pregnant women and children. Once drug sensitivities have been established, the patient may be switched to another antibiotic as clinically indicated. Antibiotics will kill activated *B. anthracis* bacilli but will not alter tissue damage already caused by toxins.[22,23] To neutralize the anthrax toxins, the Centers for Disease Control and Prevention (CDC) now possesses human antianthrax immunoglobulin and monoclonal antibodies directed against the toxins are in development.

Although cutaneous anthrax is usually an uncomplicated and readily treatable infection, public health concerns warrant hospitalization. Standard universal precautions are appropriate but specific measures against secondary respiratory transmission are unnecessary because anthrax is not transmitted from person-to-person.

Parenteral crystalline penicillin G (2 million units every 6 hours) was the treatment of choice prior to the 2001 bioterrorism outbreak. In one study, smears and cultures from vesicles or from the necrotic tissue beneath the eschar became negative within 6 hours of initiation of penicillin therapy. Treatment of primary cutaneous anthrax is continued with parenteral therapy until the local edema disappears or the lesion dries up over 1–2 weeks. When the edema resolves, the patient may complete the 60-day treatment with oral therapy.

Other than to obtain material for culture or histopathology, incision and debridement of the cutaneous lesion is unnecessary. First of all, the lesions contain no purulent material needing evacuation and, second, without effective antibiotics, these procedures increase the risk of bacteremic spread of the disease.

PROGNOSIS AND CLINICAL COURSE

Untreated cutaneous anthrax, particularly if nonedematous, is a largely self-resolving disease. In contrast, some lesions, especially ones with massive edema, pose the risk of bacteremia with subsequent septicemia. Thus, the mortality rate of untreated cutaneous anthrax is roughly 5%–20%. With prompt and appropriate antibiotics, there is rapid defervescence and clinical improvement. Massive facial edema associated with cutaneous lesions of the head or neck may lead to respiratory compromise, requiring intubation or tracheostomy and systemic corticosteroids. Palpebral lesions may scar the eyelids and edema-associated seventh-nerve palsy may occur.[24] Hospitalization in an intensive care unit is recommended for any patient with inhalational or gastrointestinal anthrax.

PREVENTION

In nonendemic areas, any case of anthrax requires immediate reporting to public health authorities and a prompt public health response because of the threat of intentional criminal or terroristic release. Although anthrax is a dangerous disease, it is not transmitted from person-to-person. Instead, the spore is the infectious propagule. Therefore patients with anthrax—of whatever clinical presentation—do not require isolation.

An anthrax vaccine has been in use since 1954 for people with occupational exposure to natural anthrax (e.g., veterinarians, wildlife biologists). The CDC recently released new guidelines on its use in the post-9/11 era for routine occupational use and for pre- and postoutbreak exposure use.[25]

Although cutaneous anthrax is usually an uncomplicated and readily treatable infection, public health concerns warrant hospitalization. Standard universal precautions are appropriate but specific measures against secondary respiratory transmission are unnecessary because anthrax is not transmitted from person-to-person.

TULAREMIA (*FRANCISELLA TULARENSIS* INFECTIONS)

TULAREMIA AT A GLANCE

- Caused by *Francisella tularensis*, a Gram-negative coccobacillus found in rabbits, rodents, other mammals, and their immediate environments in temperate and cold regions of North America.
- Has diverse clinical presentations related to route of transmission. Ulceroglandular disease after tick bites is most common.
- Bacteria are easily aerosolized and highly infectious in small inocula; therefore, tularemia poses risks of laboratory accidents or use as a bioweapon.

ETIOLOGY AND EPIDEMIOLOGY

Tularemia is a zoonotic infectious disease caused by *Francisella tularensis*, a pleomorphic Gram-negative coccobacillus found in many species of mammals, most important, lagomorphs (rabbits and hares) and rodents, and in their immediate environments. The bacteria are highly infectious, can be transmitted in many ways, and cause at least eight different patterns of disease.

Tularemia occurs solely in temperate and cold regions of the Northern Hemisphere. The most common form in the United States is ulceroglandular disease in which organisms are inoculated directly into the skin by minor trauma or by bites of infected arthropods that maintain the enzootic cycle. Before 1950, most US infections occurred in hunters who handled infected rabbits and hares. Two incidence peaks each year corresponded with summer and winter hunting seasons. Currently, 100–150 US cases occur each year, mostly in Arkansas, Missouri, and Oklahoma, with transmission of the organism largely via tick bites. The most common tick vectors are *Dermacentor variabilis*, *Amblyomma americanum*, and, in Europe, *Ixodes* sp.[26–30]

Of several subspecies, the most virulent (*F. tularensi* subspecies *tularensis*) lives only in the North America. A more benign one (*F. tularensis* subspecies *holarctica*) is the only subspecies in Eurasia. Although these bacteria do not produce spores, they can survive environmentally—and maintain infectivity—for months.[28,29]

Tularemia is transmitted in other ways, too. Other arthropod vectors include the deerfly (*Chrysops discalis*) in the Western United States, and mosquitoes in Scandinavia and the Baltic region.[31] An outbreak of pulmonary tularemia on Martha's Vineyard, Massachusetts, was associated with springtime mowing of tall grass.[32] The precise environmental source was not clear, perhaps aerosolization of animal excreta in the grass. Domestic cats may spread the organism via direct contact, bite, or aerosol. In parts of Europe, aquatic rodents (muskrats and beavers), household rodents, and drinking water contaminated by these animals are the major sources of infection. Rarely, direct inoculation into conjunctivae or ingestion of poorly cooked, contaminated meat causes infection. There is no human-to-human transmission. A second species, *Francisella philomiragia*, can infect patients with inherited defects in phagocytosis such as chronic granulomatous disease (OMIM #306400).

CLINICAL FINDINGS

HISTORY. Duration of incubation varies with size of inoculum, ranging from 2–10 days. All forms of tularemia present as a sudden flu-like illness characterized by fever, headache, malaise, and myalgias.

CUTANEOUS LESIONS. In ulceroglandular tularemia, a painful red papule appears at the inoculation site (Fig. 183-3). It enlarges rapidly and evolves into a necrotic chancriform ulcer often covered by a black eschar. Regional lymph nodes are large and tender.[32] Bacteremia may cause sepsis and virulent pneumonia. In two recent Scandinavian outbreaks with the less virulent *holarctica* type of tularemia, due primarily to mosquito-borne ulceroglandular disease, approximately one-third of nearly 300 patients developed nonspecific secondary cutaneous manifestations, such as erythema nodosum, erythema multiforme, or an asymptomatic id-like papular eruption on the extremities.[31,33]

RELATED PHYSICAL FINDINGS. In oculoglandular tularemia, organisms are introduced directly



Figure 183-3 Tularemia. A chancre-like ulcer with raised margins on the dorsum of the fourth digit with accompanying axillary lymphadenopathy. The rash on the chest is unrelated and is pityriasis versicolor.

into the conjunctivae, for example, after handling an infected tick or rabbit. This causes purulent conjunctivitis with pain, edema, and local adenopathy. In a recent outbreak in Bulgaria, more than 90% of cases were oropharyngeal, reflecting transmission via contaminated well water. Swallowing the organism may cause ulcerative pharyngotonsillitis with cervical adenopathy or may cause "typhoidal" tularemia.[34] Pulmonary tularemia may be primary (i.e., due to inhalation of organisms) but is more often because of bacteremic spread from another focus.

LABORATORY FINDINGS

Laboratories should be notified of suspected tularemia so that cultures can be set under biohazard conditions to avoid aerosolization. *F. tularensis* grows best on cysteine-supplemented blood agar, producing nonmotile, nonsporulating, pleomorphic, Gram-negative coccobacilli. Some reference laboratories also use animal inoculation techniques.

HISTOPATHOLOGY

The pathogen survives intracellularly in phagocytes, and small granulomas develop in lymph nodes, liver, and spleen. Some lesions may caseate and progress to frank abscess formation. Hepatic granulomas may resemble tuberculosis or brucellosis.

DIFFERENTIAL DIAGNOSIS

The primary lesion of tick-transmitted tularemia resembles a furuncle, paronychia, common ecthyma, the initial lesion of anthrax, *Pasteurella multocida* infection, or sporotrichosis. Prominent regional adenopathy may suggest cat-scratch disease, plague, or melioidosis. Fever after a tick bite might suggest Rocky Mountain spotted fever, but that usually has an exanthem rather than a chancriform lesion. Other tick-borne febrile diseases include other rickettsioses, ehrlichiosis, babesiosis, and viral tick fevers. *F. tularensis* is difficult to grow so the diagnosis is usually made by serologic tests showing a rise in titers. Although the subspecies of *F. tularensis* are clinically and epidemiologically distinct, they are serologically indistinguishable.[28]

TREATMENT

A presumptive diagnosis of tularemia on clinical and epidemiologic grounds is sufficient to initiate treatment while awaiting serologic confirmation (see Table 183-1). Treatment consists of an aminoglycoside antibiotic, such as gentamicin, or a fluoroquinolone; these should be given for at least 10 days. A tetracycline antibiotic, such as doxycycline, given for at least 15 days is an acceptable alternative. Patients improve within 24–48 hours, but treatment should continue for at least 7–10 afebrile days to reduce the risk of relapse.

COURSE, PROGNOSIS, AND COMPLICATIONS

Untreated pulmonary and typhoidal tularemia have mortality rates of about 30%. Without antibiotics, ulceroglandular disease lasts many weeks and has a mortality rate of 5%. Brief courses of antibiotics may permit relapse but, with proper treatment, uncomplicated recovery is expected.

PREVENTION

Hunters and animal handlers should wear impervious gloves when handling game, especially rabbits. Game meat should be cooked thoroughly, even if stored frozen for long periods. A live-attenuated (but rarely used) vaccine was developed in Russia; the US government is currently funding vaccine research. The disease is reportable in the United States and any cluster of pulmonary tularemia cases should raise concerns of bioterrorism.[29,35]

PLAGUE

PLAGUE AT A GLANCE

- Focal enzootic sites worldwide, including the Southwestern United States. Human disease is caused by bites from infected fleas or direct contact with rodent reservoirs.
- The bubonic form is the most common, producing large tender lymph nodes (buboes) proximal to the site of fleabite. All forms can lead to sepsis, distal gangrene (origin of the term *black death*), and death.
- Pneumonic plague because of respiratory spread of aerosolized *Yersinia pestis* has a high mortality and is a possible weapon of bioterrorism.

ETIOLOGY AND EPIDEMIOLOGY

Plague is a severe, acute, febrile zoonosis caused by the aerobic Gram-negative bacillus *Yersinia pestis*. Plague exists in an enzootic cycle, infecting humans through contact with rodent reservoirs or flea vectors. Human plague has three clinical forms: (1) bubonic; (2) bubonic septicemic, a more virulent form due to secondary bacteremia and sepsis; and (3) pneumonic (fulminant disease due to respiratory spread). Distal purpura and gangrene associated with septicemic plague likely gave rise to the term *black death*. The plague bacillus likely evolved from the fecal–oral pathogen, *Y pseudotuberculosis*, by acquiring several virulence plasmids.[36]

Endemic or sylvatic plague occurs in wild rodents in the Western United States, parts of South America,

much of sub-Saharan Africa, and across Southern Asia. In most places, plague is sporadic but Madagascar currently has epidemic plague.[37,38] There are several thousand cases of plague worldwide each year and the disease prevalence is increasing across Africa; Madagascar alone account for nearly half the number of human cases each year.[36,39]

In this country, human disease is almost always transmitted by fleas. Direct handling of infected rodents, rabbits, or their carcasses can also transmit plague. Some cases are transmitted by direct contact with pet dogs or cats that become ill after contact with infected wild animals. Between 1990 and 2005, 107 plague cases, more than 80% bubonic, were reported in the United States, averaging seven per year, mostly in summertime. In Western States, winter cases are often linked with handling of animal carcasses while hunting. In recent years, epizootics have occurred among prairie dogs, and sporadic human cases were seen on several Indian reservations, associated with ground squirrels. Rarely, bacteremic bubonic disease may evolve into pneumonic plague and further initiate respiratory spread to others.[40,41]

The flea associated with epidemic plague in the Old World is *Xenopsylla cheopis*, but fleas in other genera (e.g., *Anomiopsyllus*, *Aetheca*, *Pulex*) are also vectors in the United States.

Because *Y. pestis* can be aerosolized, is devastatingly lethal, and can spread from person-to-person, it is considered a Category A biologic weapon (see Table 183-1). *Y. pestis* produces an intracellular toxin and virulence factors (see Chapter 213).

CLINICAL FINDINGS

HISTORY. Bubonic plague incubates for roughly 2–6 days, followed by the sudden onset of high fever, prostration, malaise, myalgias, backache, and tachycardia. Primary pneumonic plague has a shorter incubation time.

CUTANEOUS LESIONS. In bubonic plague, the initial skin lesion is related to the fleabite and may appear as papular urticaria. However, the hallmark of bubonic plague is prominent, exquisitely tender regional lymphadenopathy with extensive subcutaneous edema. Inguinal buboes are most common in adults; cervical and axillary buboes are more common in children.[36]

Any form of plague can lead to overwhelming endotoxic septicemia accompanied by disseminated intravascular coagulopathy (DIC) (see Chapter 144 and 181). Subsequent purpura and gangrene are most severe on distal extremities.[42]

RELATED PHYSICAL FINDINGS. Primary septicemic plague lacks buboes and presents with typical Gram-negative sepsis. Many patients also have severe abdominal pain, nausea, vomiting, and bloody diarrhea. Pneumonic plague has an abrupt onset with high fever, tachycardia, tachypnea, chest pain, and dyspnea. Within 24 hours of onset, the patient is critically ill and producing bloody sputum laden with *Y. pestis*. Meningitis may complicate all forms of plague.

DIFFERENTIAL DIAGNOSIS

Most patients with bubonic plague present with the rapid onset of a toxic febrile illness, painful buboes, and evidence of an arthropod bite without surrounding cellulitis. Bubonic plague should be distinguished from tularemia, lymphogranuloma venereum, cat-scratch disease, chancroid, Kikuchi's disease, and suppurative lymphadenitis due to staphylococcal or streptococcal infections. Pneumonic plague must be differentiated from other acute bacterial pneumonias. Epidemiologic considerations and the tempo of the illness are major points in the differential diagnosis. The diagnosis is made by examining Gram-stained (or specific fluorescent antibody stained) smears of infected material or by culturing organism from blood, sputum, or aspirated buboes. Serologic methods help retrospectively by demonstrating a fourfold or greater rise in titers. A convalescent passive hemagglutination titer of >1:16 suggests the diagnosis.

TREATMENT

Because the original drug of choice, streptomycin, is not widely available, another aminoglycoside antibiotic, gentamicin, is the preferred treatment (although the US Food and Drug Administration has not approved it for this indication) (see Table 183-1). Doxycycline is also effective and maybe the treatment of choice when oral therapy is required or to use as postexposure prophylaxis. Cotrimoxazole is useful when combination therapy is desired.[43] Patients with pneumonic plague must be placed in respiratory isolation to prevent further transmission. The course of treatment, irrespective of medication, is 10 days. Ordinarily, buboes should not be drained until they are well-localized and antibiotic therapy has been started.[46]

PROGNOSIS AND CLINICAL COURSE

Pneumonic and septicemic plague, if untreated, are nearly always fatal. Untreated bubonic plague has a mortality rate of roughly 50% but early antibiotic therapy has reduced this to 5%–10%. Because primary septicemic plague lacks telltale buboes, the clinical suspicion of plague is often delayed, hence antibiotics are started late and mortality is high.

PREVENTION

Most cases in the United States are acquired peridomestically so it is important in endemic areas to control rodents around homes. Children should be taught to avoid rodent nests, burrows, and dead animals. Pets should be given regular flea treatments, examined properly when ill, and trained not to hunt small mammals or eat sick or dead mammals. Rabbit hunters should wear gloves when handling carcasses. With pneumonic cases, respiratory isolation is mandatory and close contacts should receive antibiotic prophylaxis

with doxycycline or cotrimoxazole. Plague vaccine is no longer available. Because the disease is a zoonosis, it is considered ineradicable, so prevention through rodent control is the most important way to prevent plague.[36,39]

BRUCELLOSIS

BRUCELLOSIS AT A GLANCE

- Zoonosis transmitted by contact with infected animals or consumption of contaminated dairy products.
- May be transmitted via aerosolized bacteria, hence the concern regarding the use of *Brucella* in bioterrorism.
- Usually presents with undulant fever and can involve all organ systems, especially the joints, reproductive organs, liver, and central nervous system. Endocarditis can be fatal.
- Cutaneous lesions are seen in fewer than 5% of patients, usually children. Variable morphologies include vasculitis, erythema nodosum, panniculitis, abscesses, and polymorphous papules, pustules, and papulosquamous lesions. Children with acute brucellosis may have a violaceous papulonodular eruption primarily on the trunk and lower extremities.

GLANDERS

GLANDERS AT A GLANCE

- Rare zoonosis caused by the Gram-negative bacillus *Burkholderia mallei* (formerly *Pseudomonas mallei*), found focally in Asia and the Middle East.
- Animal glanders occurs in horses, mules, and donkeys. Humans are infected through direct occupational exposure to animal reservoirs.
- Most human cases are acquired by direct inoculation into skin or contact of open skin with an infected animal or its secretions. Inhalational transmission is rare.
- A cutaneous ulcer develops after a 1–5-day incubation period, followed by several presentations: ulceroglandular syndrome, localized abscesses (acute or chronic), or bacteremic dissemination (often fatal).

PASTEURELLA MULTOCIDA INFECTIONS

PASTEURELLA MULTOCIDA INFECTIONS AT A GLANCE

- Normal flora in oropharynx of many domestic animals. Most human infections are due to dog or cat bites.
- Local pain and swelling appear rapidly, usually less than 2 days after exposure.
- Gram-negative organism; nevertheless, infection is treated with penicillin or presumptively with amoxicillin/clavulanic acid.

ETIOLOGY AND EPIDEMIOLOGY

P. multocida is a small, ovoid, Gram-negative rod that can cause local skin infection with regional adenitis after a superficial animal bite, scratch, or lick,[65] or septic arthritis and osteomyelitis after a deeper animal bite. Respiratory infections unassociated with trauma occur in rare cases, and bacteremia may accompany meningitis or osteomyelitis.

P. multocida commonly colonizes the oropharynx and nasopharynx of healthy cats, dogs, rats, mice, pigs and other livestock, and poultry. Nearly all patients with *P. multocida* infection have had animal exposure, most commonly a dog or cat bite. Cat teeth are often longer and sharper than those of dogs and therefore may penetrate more deeply to cause septic arthritis or osteomyelitis. Compromising conditions such as cirrhosis, malignancy, and chronic obstructive pulmonary disease coexist in most severe cases.[66–71]

Neonatal pasteurellosis can be acquired by exposure to animals, usually pet dogs and cats in the household, even without known or recognized traumatic contact, possibly via respiratory droplets from the animal, or via vertical transmission from an asymptomatic mother.[72]

CLINICAL FINDINGS

HISTORY. Local pain and swelling occur within a few days of an animal bite or contact exposure. Fever is uncommon.

CUTANEOUS LESIONS. Redness, swelling, ulceration, and seropurulent drainage develop at the bite site. Cellulitis may progress rapidly and extensively, producing lymphangitis. Local necrosis may follow, and necrotizing fasciitis with septic shock has been reported.[66,73]

RELATED PHYSICAL FINDINGS. Regional adenopathy may be present. Deep bites may introduce organisms into a joint or beneath periosteum and cause septic arthritis or osteomyelitis.

LABORATORY FINDINGS

Mild leukocytosis is present. After several weeks, a radiograph of underlying bone may show osteomyelitis. The organism is Gram-negative, and Wright–Giemsa stain reveals a bipolar appearance. Histopathologically, an acute pyogenic response is seen.[67]

DIFFERENTIAL DIAGNOSIS

The diagnosis is suspected when a painful infection develops rapidly (<2 days) at the site of an animal bite. Approximately 75% of infected cat bites are caused by *P. multocida*. Local ulceration and proximal lymphadenitis mimic ulceroglandular tularemia, but *P. multocida* characteristically produces a necrotizing cellulitis and not chancriform syndrome. The diagnosis is confirmed by isolation of the organism, although treatment is often initiated according to an animal bite protocol or based on the history of a rapidly appearing painful cellulitis after a dog or cat bite.[73,74]

TREATMENT

Because most animal bite wounds show polymicrobial contamination, an amoxicillin/clavulanic acid preparation should be started after a dog or cat bite. Although *P. multocida* is a Gram-negative organism, most strains are susceptible to penicillin, which is the drug of choice if only *Pasteurella* is cultured. If one suspects that the bite reached periosteum, parenteral penicillin should be given until the local lesion is well healed. *P. multocida* is also susceptible to doxycycline, later-generation cephalosporins, and trimethoprim-sulfamethoxazole (see Table 183-1).

PROGNOSIS AND CLINICAL COURSE

Infection usually responds promptly to antibiotic therapy. Osteomyelitis, abscesses, and remnant foreign bodies should be treated surgically as well as medically. *P. multocida* infections may be more severe or lead to sepsis in immunocompromised or acquired immunodeficiency syndrome (AIDS) patients.

PREVENTION

A great many animal bites are unprovoked by family pets onto a child's hand, therefore judicious selection of pets and instruction to children are useful, but not guaranteed, ways to reduce domestic animal bites.[75]

RAT-BITE FEVER

RAT-BITE FEVER AT A GLANCE

- Rat-bite fever refers to two clinically similar zoonoses caused by *Streptobacillus moniliformis* and *Spirillum minus*.
- Infection is usually acquired through rat bite or ingestion of rat-contaminated food or drink.
- The disease is characterized by the classic triad of fever, polyarthralgias, and rash.

SEAL FINGER

SEAL FINGER AT A GLANCE

- Occupational zoonosis after contact with seals or sea lions. Occurs worldwide in marine environments.
- Usually presents as an exquisitely painful nodule on the distal phalanx of the finger that may progress to tenosynovitis or joint destruction.
- The pathogen is likely to be a marine *Mycoplasma* found in the seal's normal oropharyngeal flora. The infection responds quickly to tetracyclines.

LISTERIOSIS (*LISTERIA MONOCYTOGENES* INFECTIONS)

LISTERIOSIS AT A GLANCE

- Caused by anaerobic Gram-positive bacillus transmitted in fecal–oral manner through consumption of contaminated dairy products.
- Human listeriosis is most common in pregnant women, neonates, and patients with acquired immunodeficiency syndrome, and in food-borne outbreaks. May cause miscarriages, stillbirths, and virulent neonatal infections.
- Generalized petechiae, papules, or pustules may be seen in neonatal listeriosis, especially in meconium-stained newborns.

ETIOLOGY AND EPIDEMIOLOGY

L. monocytogenes is an anaerobic Gram-positive bacillus found widely in soil, water, vegetation, and the gut flora of humans and other animals. Exposure to this organism occurs through fecal–oral contamination, but the disease has an opportunistic nature, appearing in very young, very old, pregnant, or immunocompromised individuals. *L. monocytogenes* is found in the feces of many domestic and wild animals and birds, and is therefore widespread in the environment.[90] Typically, livestock become infected by eating manure-contaminated silage; this can cause abortions, septicemia, and a peculiar form of encephalitis called *circling disease*.[91]

Human listeriosis is uncommon but occurs in three typical settings: (1) sporadic disease in pregnant women and neonates; (2) sporadic disease in AIDS patients; and (3) food-borne outbreaks.[92] Humans usually become infected by eating contaminated, unpasteurized, or improperly pasteurized dairy products. In adults, the disease can present as septicemia, meningitis, vaginal infection, pneumonitis, or oculoglandular syndrome and can cause miscarriages and stillbirths.[62] Infantile listeriosis presents acutely with septicemia, meningitis and meningoencephalitis, and septic granulomatosis.

Approximately 5% of humans are fecal carriers of *Listeria*. Higher rates of carriage have been observed in family contacts of patients with listeriosis. Several outbreaks have implicated unpasteurized soft cheeses imported from Mexico or vegetables from farms that fertilize crops with manure.[93]

The highest incidence of human listeriosis is seen among infants in the perinatal period, which suggests that the transmission occurs in utero or at birth. One-fourth of adult cases occur in pregnant women. Many other adult cases occur in patients with altered cellular immunity, such as those with Hodgkin disease, leukemia, or AIDS or those who have undergone organ transplantation. Hepatic disorders such as cirrhosis and iron overload also predispose to infection. Recent reports suggest that biological therapies that interfere with tumor necrosis factor activity, such as treating psoriatic arthritis with infliximab, may increase the risk for listeriosis.[94]

CLINICAL FINDINGS

HISTORY. Early-onset neonatal listeriosis develops in infants infected in utero by untreated bacteremic mothers shortly before labor begins. Findings are evident at birth or become apparent within the first few days. These neonates are acutely ill and have generalized pustular, papular, or petechial skin lesions. Late-onset neonatal listeriosis occurs several weeks after a healthy birth, is presuably acquired postpartum, and usually presents as meningitis.[93,95,96]

Listeriosis from food-borne organisms usually causes outbreaks of acute gastroenteritis in families or communities. Patients have fever, vomiting, and nonbloody diarrhea, but this form lacks skin lesions.

CUTANEOUS LESIONS. In septic infants, cutaneous lesions appear as generalized petechiae, papules, or pustules. Veterinarians or farmers who handle infected bovine fetuses may develop an acute febrile illness with headache, malaise, and regional adenopathy. Tender red papules develop on exposed surfaces and may evolve into pustules over 2–3 days. These contain the characteristic Gram-positive rods.

RELATED PHYSICAL FINDINGS. Neonates with early onset listeriosis are often meconium-stained at birth, lethargic, and have an enlarged liver and spleen. Central nervous system listeriosis has a spectrum of neurologic manifestations, ranging from typical acute bacterial meningitis, abscesses, encephalitis, and infarcts.[96]

LABORATORY FINDINGS

L. monocytogenes is a small pleomorphic bacillus that often appears coccoid in infected tissues and body fluids. Pustules, meconium, cerebrospinal fluid (CSF), or blood cultures reveal the characteristic Gram-positive rods. The organism is β-hemolytic when cultured on sheep blood agar and exhibits a characteristic tumbling motility when grown in broth. In adults with meningitis, the CSF contains neutrophils, but about one-third of meningitic infants have a mononuclear response.

HISTOPATHOLOGY

Skin lesions show focal necrosis, neutrophilic infiltrates, and monocytes around blood vessels. In septic patients, viscera may show abscesses and granulomas.

DIFFERENTIAL DIAGNOSIS

Neonatal listeriosis should be suspected in a meconium-stained newborn with intrauterine growth retardation who develops a papular skin eruption or subsequently failure to thrive. The differential diagnosis includes other in utero neonatal infections such as toxoplasmosis, cytomegalovirus infection, rubella, disseminated herpes simplex infection, and disseminated bacterial infections, such as those caused by group B *Streptococci*, *Escherichia coli*, *Salmonella*, and *Pseudomonas*.

TREATMENT

Neonates with listeriosis should be treated with intravenous ampicillin (or penicillin) (see Table 183-1). Penicillin-allergic patients may be treated with cotrimoxazole or erythromycin. Cephalosporins are generally ineffective.[90]

PROGNOSIS, CLINICAL COURSE, AND COMPLICATIONS

In neonatal septicemia or meningitis, mortality is around 50%, even with treatment. In adults, prompt treatment is usually effective, unless there is a severe underlying debility. Pregnant woman, even if treated, are at risk for miscarriage.

PREVENTION

Prepartum strategies to reduce neonatal group B streptococcal infections may also reduce risk of neonatal listeriosis.[96]

Farmers should not feed contaminated silage to livestock nor use untreated manure to fertilize crops. Still, it is almost impossible to guarantee *Listeria*-free foods. Therefore, people at greatest risk should avoid foods typically linked to listeriosis, such as raw (unpasteurized) dairy products, unwashed vegetables, and poorly cooked meats. Veterinarians and farmers should use gloves and protective garments when handling aborted fetuses or placentae.[95]

VIBRIO VULNIFICUS INFECTIONS

VIBRIO VULNIFICUS INFECTIONS AT A GLANCE

- Noncholera *Vibrio* organisms are found in warm saltwater worldwide. Exposures occur via percutaneous injury, often minor (e.g., while ocean fishing) or via ingestion of filter-feeding shellfish, which concentrate organisms.
- Severe illness presents with necrotizing fasciitis, hemorrhagic bullae, and hypotensive shock. Cirrhosis and other liver diseases predispose to a virulent, often fatal, course.

ETIOLOGY AND EPIDEMIOLOGY

Vibrio are facultatively anaerobic, pleomorphic, Gram-negative rods found in marine waters, estuaries, brackish lakes, and their sediments wherever the water temperature is above 20°C (68°F). The most well-known vibriosis is cholera, caused by antigenic strains of *Vibrio cholerae*. Although cholera organisms do not infect the skin, many other *Vibrio* do. The most important of these, *V. vulnificus* can cause fulminant cellulitis, myositis, necrotizing fasciitis, and death.[97]

People become infected with *V. vulnificus* through oral or percutaneous exposure. After eating contaminated raw or undercooked seafood, people who have chronic liver disease or diabetes mellitus, or who are otherwise immunocompromised, are at risk for primary septicemia. Percutaneous infections are acquired by handling raw seafood, by entering saltwater with an open wound, or by experiencing skin trauma while in or around saltwater. Immunocompromised individuals are again at increased risk for secondary septicemia.[98,99]

V. vulnificus lives in warm seawater, where it colonizes the skin of fish and is concentrated in filter-feeding shellfish, such as oysters. Infections are particularly common along the Gulf of Mexico and, because of global warming, are now found in increasingly higher latitudes, such as on the Baltic Sea.[100–102]

Most cases of wound infection are sporadic and depend more on host susceptibilities than environmental conditions. However, after Hurricane Katrina struck the Gulf Coast in 2005, thousands of people were exposed to brackish floodwaters. There were 18 known cases of *Vibrio* wound infections—14 due to *V. vulnificus*, 3 due to *V. parahaemolyticus*, and 1 unspeciated case.[103]

CLINICAL FINDINGS

HISTORY. There is nearly always a history of contact with saltwater, injury while ocean fishing, or consumption or handling of shellfish. After oral exposure, primary septicemia often begins with watery diarrhea, fever, chills, nausea, vomiting, and abdominal pain. People with wound infections usually recall an open skin lesion present before the saltwater exposure or a percutaneous injury during the exposure. *Vibrio* cellulitis is painful and has a rapid onset within 12–24 hours of exposure. Secondary bacteremia with sepsis may occur several days later.[104]

CUTANEOUS LESIONS. Infected wounds may present as pustules, lymphangitis, or cellulitis. These infections may be mild or may develop into rapidly progressive, painful cellulitis with extensive skin necrosis, myositis, and necrotizing fasciitis (Fig. 183-4).



Figure 183-4 *Vibrio vulnificus* cellulitis with hemorrhagic plaque and bullae on the legs of an older diabetic patient with cirrhosis.

Secondary bacteremia may cause metastatic cutaneous lesions.[98,105] In septic patients, large hemorrhagic bullae commonly arise on the extremities or trunk and usually progress to necrotic ulcers and necrotizing fasciitis (see Table 183-1; see also Chapter 179).

RELATED PHYSICAL FINDINGS. *V. vulnificus* septicemia causes high fever, tachycardia, and hypotension. One-third of patients develop Gram-negative septic shock.

LABORATORY FINDINGS

In primary septicemia, leukopenia is more common than leukocytosis. Thrombocytopenia is typical and may be part of disseminated intravascular coagulation. Usually, there is laboratory evidence for the person's predisposing condition (e.g., diabetes). All *Vibrio* species can be grown in regular blood culture media and cause hemolysis on sheep blood agar, but only *V. vulnificus* ferments lactose on MacConkey's agar. Histopathology shows noninflammatory bulla, epidermal necrosis, hemorrhage, and bacteria in dermal vessels. Radiographic studies show accumulations of nonspecific soft tissue edema.

DIFFERENTIAL DIAGNOSIS

A cirrhotic or diabetic patient with fever, shock, and hemorrhagic bulla within several days of saltwater exposure or eating raw oysters should alert the physician to possible *Vibrio* septicemia, especially along the American Gulf Coast.

Similar presentations include disseminated intravascular coagulation, clostridial myonecrosis, meningococcemia, purpura fulminans, any form of necrotizing fasciitis, and other aggressive soft tissue infections. Wound infections sustained in fresh water suggest infection with *Aeromonas* rather than *Vibrio*. Clostridial myonecrosis may present with necrotizing fasciitis and shock, but is further suggested by local wound crepitus and the finding of Gram-positive rods.

TREATMENT

Primary or secondary septicemia due to *V. vulnificus* (or other *Vibrio* sp.) requires prompt management of hypotensive shock, parenteral administration of antibiotics, and vigorous debridement of necrotic lesions. Amputation of the affected limb may be necessary. The antibiotics of choice are a combination of doxycycline and ceftazidime (see Table 183-1). Alternatives to doxycycline include chloramphenicol, ciprofloxacin, and minocycline. Alternatives to ceftazidime include cefotaxime. Application of compresses with modified Dakin's solution (0.025% sodium hypochlorite) may help arrest the progression of the cutaneous lesions.[106]

PROGNOSIS, CLINICAL COURSE, AND COMPLICATIONS

The mortality rate for *V. vulnificus* primary septicemia is approximately 50%, about three times higher than the mortality for wound infections caused by the same organism.

PREVENTION

People with cirrhosis, diabetes, AIDS, and other immunocompromising illnesses should not eat raw shellfish and, if they have open skin wounds, should not enter seawater, estuaries, or brackish lakes. If an at-risk individual exposes open skin to saltwater, the site should be cleansed promptly with soap and clean water. Similarly, these individuals should not handle raw fish and shellfish. Vigilant attention to onset of illness is then required. Some authorities consider of a course of prophylactic oral doxycycline for an immunocompromised person with a high-risk exposure.

OTHER CUTANEOUS *VIBRIO* INFECTIONS

The most common other *Vibrio* to cause wound infections are *Vibrio parahaemolyticus* and nontoxigenic *Vibrio cholerae* (i.e., antigenic strains other than 01 and 139). Usually, these *Vibrio* cause an infection after oral exposure, producing an acute but self-limited noninflammatory gastroenteritis. Wound infections may occur after open skin is exposed to saltwater. The disease course is usually less severe than that of *V. vulnificus* although in an immunocompromised host, it may cause hemorrhagic bulla, shock, and necrotizing fasciitis.

AEROMONAS HYDROPHILA INFECTIONS

AEROMONAS HYDROPHILA INFECTIONS AT A GLANCE

- Caused by a facultatively anaerobic Gram-negative bacillus found in fresh and brackish water worldwide.
- Usually presents as cellulitis after exposure to fresh or brackish water but may cause necrotizing fasciitis or myonecrosis.
- Sepsis risk in cirrhotic and immunocompromised patients.

MELIOIDOSIS

MELIOIDOSIS AT A GLANCE

- Caused by *Burkholderia pseudomallei* (formerly *Pseudomonas pseudomallei*), a Gram-negative aerobic bacillus that lives as a saprophyte in freshwater and damp soil.
- Occurs in humans and animals, primarily in wet tropical areas such as Southeast Asia and coastal northern Australia. People who develop melioidosis elsewhere usually had prior exposure in endemic areas.
- Rice farmers, particularly if compromised by diabetes mellitus or chronic renal disease, are most susceptible.
- The disease is acquired after exposure to contaminated soil or water, either directly via the skin or through inhalation of particulate soil or dust.
- Clinical presentation ranges from focal indolent cutaneous and subcutaneous abscesses to fulminant pneumonia with septicemia.
- On the Centers for Disease Control and Prevention's Category B list of possible bioweapon agents.

ERYSIPELOID

ERYSIPELOID AT A GLANCE

- An occupational zoonosis is caused by *Erysipelothrix rhusiopathiae* and associated with percutaneous trauma while handling raw fish or poultry.
- Classic dermatologic presentation is localized nonsuppurative purple–red plaques on the dorsal hands. Rare chronic and bacteremic forms exist.

ETIOLOGY AND EPIDEMIOLOGY

Erysipeloid, an acute infection of traumatized skin caused by *Erysipelothrix rhusiopathiae* (formerly *Erysipelothrix insidiosa*), occurs most frequently in fishermen, butchers, kitchen workers, and others who handle raw fish, poultry (especially turkey), and meat products.[136,137,141–143] The disease is especially common in pigs, where it is known as swine erysipelas. In humans, erysipeloid occurs primarily during the summer months and can be considered an occupational dermatosis.

E. rhusiopathiae is a thin, Gram-positive, microaerophilic, nonmotile bacillus that is hardy enough to survive putrefaction of tissue and exposure to saltwater or freshwater. The organism is found in rats, birds, the slime on saltwater fish, and crabs and other shellfish, and is associated with poultry, meats, hides, and bones.

In humans, organisms usually enter broken skin on the hands and takes one of the four clinical forms: (1) a local nonsuppurative cutaneous infection (erysipeloid of Rosenbach); (2) a diffuse chronic cutaneous form consisting of multiple plaques with sharply defined angular borders; (3) subacute bacterial endocarditis, particularly of the aortic valve; or (4) a bacteremic form without endocarditis, usually found only in immunocompromised patients. The disease does not seem to confer lasting immunity.[144]

CLINICAL FINDINGS

HISTORY. The patient is usually employed in the fishing or animal product industry. After inoculation, there is an incubation period of 2–7 days. Initially, burning pain occurs at the injured site, then a violaceous dermal plaque develops. Lymphangitis and regional adenopathy occasionally occur, as well as low-grade fever and malaise. Bacteremia and endocarditis are rare but serious sequelae. Untreated, erysipeloid usually heals on its own within 3 weeks.

CUTANEOUS LESIONS. The distinctive erysipeloid lesion is usually on a finger or the back of the hand; is violaceous, warm, and tender; and has well-defined, raised margins with an angular or polygonal border (Fig. 183-5). It often involves the web spaces



Figure 183-5 Erysipeloid. Characteristically, the violaceous, sharply marginated lesion is composed of macules and plaques and is located on the hand.

but spares the terminal phalanges and does not progress beyond the wrist. The borders usually expand, whereas the central region clears without desquamation or ulceration. Rarely, multiple lesions distant from the original site of injury arise, presumably through bacteremic spread. Postinflammatory hyperpigmentation may persist after the lesion resolves.

RELATED PHYSICAL FINDINGS. Arthritis may be associated with the local lesion, and, in rare cases, distant joints are involved. Sepsis produces typical peripheral stigmata, including signs of endocarditis.[142]

LABORATORY FINDINGS

Gram stains rarely show *E. rhusiopathiae* although culturing tissue from the advancing edge may reveal the organism. Growth occurs best on serum-fortified media between 30°C and 37°C under hypercapnic conditions. Agar-gel diffusion precipitation or fluorescent antibody techniques are helpful in establishing the diagnosis.[136,137]

HISTOPATHOLOGY

The findings are nonspecific but may include marked superficial dermal edema, vascular dilation, and mixed lymphocytic and neutrophilic perivascular infiltrates.

DIFFERENTIAL DIAGNOSIS

The character of the local lesion in a person handling fresh meat or fish products suggests the diagnosis. As its name suggests, erysipeloid resembles other forms of bacterial cellulitis or erysipelas. It may resemble a severe, acute irritant contact dermatitis. In erysipelas, the central area is most affected region compared with central clearing in erysipeloid. "Seal finger" may be mistaken for erysipeloid.

TREATMENT

The treatment of choice for erysipeloid is high-dose penicillin or ampicillin for 7–10 days. Patients who cannot take penicillins may be treated with a third-generation cephalosporin (such as ceftriaxone), imipenem, or ciprofloxacin (see Table 183-1). This recommendation is based primarily on in vitro studies, not clinical experience. If arthritis, septicemia, or endocarditis is present, the penicillin dosage should be increased and the drug should be administered intravenously for several weeks.[142]

PROGNOSIS, CLINICAL COURSE, AND COMPLICATIONS

Untreated lesions usually last for 2–3 weeks but may have waxing and waning cycles over several months. Improvement is often dramatic and recurrence is rare if penicillin is administered. The prognosis in systemic infections depends on early and appropriate treatment. The bacteremic form occasionally leads to endocarditis with its attendant morbidity and mortality.

PREVENTION

Erysipeloid can be prevented by wearing gloves when handling live animals or animal products and by washing skin wounds promptly with soap and water.

STREPTOCOCCUS INIAE INFECTIONS

STREPTOCOCCUS INIAE INFECTIONS AT A GLANCE

- Caused by a recently recognized streptococcal species that colonizes or infects freshwater fish, such as tilapia, grown in intense aquaculture.
- Most human clinical cases present as cellulitis of the hand after an accidental puncture wound during preparation of live fish for cooking.
- Bacteremia commonly occurs.

PREVENTION

Aquaculture farms are becoming increasingly aware of *S. iniae* infections in their produce and have an economic incentive to maintain healthy fish. Nevertheless, cooks who prepare live-bought, aquaculture-raised fish will continue to be exposed to this pathogen.

LEPTOSPIROSIS

LEPTOSPIROSIS AT A GLANCE

- Waterborne zoonosis with worldwide distribution caused by serovars of *Leptospira interrogans*, which are excreted in urine of reservoir animals, especially rodents. Outbreaks during rainy seasons or after flooding in areas with poor sanitation.
- Most human cases are mild or subclinical. In severe cases there may be fever, hepatic and renal failure, jaundice, hemorrhage, and death.
- Cutaneous findings include jaundice, conjunctival suffusion, petechiae, and nonspecific papules.

ETIOLOGY AND EPIDEMIOLOGY

Leptospirosis is a waterborne zoonosis caused by *Leptospira interrogans*. The disease is found worldwide, except in the Polar Regions, wherever animal urine can contaminate bodies of freshwater. Rodents are the most important reservoirs, although over 160 species of mammals are known to harbor *Leptospira*, including wild, farm, pet, and laboratory animals. Infected humans can also serve as transient reservoirs, particularly in urban slums in the wet tropics. Reservoir animals excrete leptospires in their urine, which contaminate the environment. Humans generally acquire the disease through broken skin after direct contact with an infected animal or exposure to contaminated water or soil. People are infected less commonly through mucous membranes, ingestion of contaminated water, or inhalation of fomites.[154, 155]

L. interrogans thrives in warm fresh water, so leptospirosis has its highest incidence in tropical areas, particularly those with inadequate sanitation and where people go barefoot. Leptospirosis is an important cause of undifferentiated fever in the developing world, along with dengue, malaria, and typhoid. Serological surveys in some endemic regions suggest that >80% of people had prior infection.[156] The disease is most prevalent among children who play or swim in contaminated water and among adults with occupational exposures (e.g., sugarcane workers or rice farmers) to infected animals or to contaminated soil and water. Travelers to hyperendemic areas, particularly ecotourists or adventure travelers who are exposed to contaminated water, are at increased risk. Many outbreaks of leptospirosis have been reported after heavy rains and floods as they cause sewers to overflow.[157,158] Hawaii has the highest incidence in the United States.[157,159,160]

CLINICAL FINDINGS

HISTORY. Patients usually have had recent occupational or recreational contact with contaminated water or mud. Most human infections are asymptomatic, self-limited, and detectable only on serologic surveys. Ill patients have one of two clinical forms of the disease: (1) a mild anicteric form that resolves without complications, or (2) a severe, icteric form (Weil disease). Both forms typically have two phases: the acute bacteremic phase, followed by the delayed immune or convalescent phase. Incubation usually takes 5–14 days and then the leptospiremic phase begins suddenly with headache, fever, chills, nausea, vomiting, abdominal pain, and myalgias (particularly of the calves and thighs). This initial nonspecific phase continues for about a week, then defervescence occurs.[159]

After several relatively asymptomatic days, the second phase of illness begins with low-grade fever. In severe cases rash, meningitis, uveitis, and hepatic and renal failure may develop.

CUTANEOUS LESIONS. In the first week of illness, the conjunctivae become suffused (red but not exudative). Skin lesions occur in fewer than 50% of cases. These consist of nonspecific macules, papules, urticaria, and petechiae, mostly on the trunk. Desquamation and infarcts have been observed on the hands or feet of some infected children. Weil disease has prominent hepatic (jaundice) and renal (hematuria, azotemia) components. Hemorrhages occur in a variety of organs, including the skin, and petechiae are common on the palate. A variant called *pretibial fever* or *Fort Bragg fever*, caused by *L. interrogans* serovariant *autumnalis*, has a distinctive rash that appears on the fourth or fifth day of illness, consisting of slightly raised, 1- to 5-cm, tender, erythematous papules on the shins. The rash subsides within 4–7 days.[155]

RELATED PHYSICAL FINDINGS. Most patients present with a fever of unknown origin without localizing signs. Other physical findings depend on the severity of the presentation, ranging nuchal rigidity in aseptic meningitis; or jaundice, hepatomegaly, and interstitial nephritis in Weil's disease. Some patients have generalized hemorrhages with epistaxis, hematuria, and gastrointestinal bleeding, and pretibial fever with splenomegaly.

LABORATORY FINDINGS

Laboratory tests help establish the diagnosis and the disease's severity. Direct isolation of leptospires is possible from the blood or CSF during the acute phase or from urine during the convalescent phase. A recently developed serum dipstick assay rapidly detects anti-leptospire immunoglobulin M or IgM antibodies. Thrombocytopenia is common but the white blood cell count is widely variable, reaching levels up to 40,000/mm^3 in Weil's disease. A CSF pleocytosis, with up to several hundred mononuclear cells, may be present. Liver function abnormalities and jaundice are common. Azotemia and hematuria occur in patients with renal involvement.[159,161]

TREATMENT

Public health authorities in endemic areas recommend starting antibiotic therapy early, perhaps presumptively, to reduce the risk of severe disease while laboratory confirmation is awaited. Doxycycline is effective and can be taken prophylactically for short-term exposure in a hyperendemic area. Penicillin has also been recommended, although controlled studies are lacking, and it may precipitate a Jarisch–Herxheimer reaction (see Table 183-1).

PROGNOSIS, CLINICAL COURSE, AND COMPLICATIONS

Perhaps 90% of patients have either asymptomatic or mild anicteric disease. Both forms resolve spontaneously without complications. In Weil's disease,

close attention must be given to fluid and renal status. Untreated Weil's disease has a mortality rate of 5%–40%, usually due to renal failure, less often due to cardiopulmonary failure or pulmonary hemorrhage. Late sequelae among survivors of untreated illness include neuropsychiatric diseases.[162]

PREVENTION

Water sanitation and rodent control measures will reduce the incidence of leptospirosis in a community. There is no vaccine against leptospirosis. Individuals who expect frequent contact with contaminated water or soils (e.g., military personnel or adventure travelers) should consider protective clothing and other ways to limit exposures or they may decrease the risk of disease by taking prophylactic doxycycline 200 mg, once weekly during these periods.[158,162]

DIPHTHERIA

DIPHTHERIA AT A GLANCE

- Classic diphtheria produces adherent gray membranous pharyngeal lesions, which may cause lethal airway obstruction. Exotoxin may cause latent peripheral neuritis or lethal cardiomyopathy.
- Cutaneous diphtheria usually affects the legs and begins as tender pustules that break down to punched-out ulcers covered by gray membranes. It is primarily found in the tropics or in travelers returning from these areas.
- Diphtheria can be prevented with toxoid immunization. It is treatable with antibiotics and antitoxin.

Chapter 184 :: Tuberculosis and Infections with Atypical *Mycobacteria*

:: Aisha Sethi

Tuberculosis is still an important worldwide disease. There were an estimated 9.27 million incident cases globally of TB in 2007.[1] This is an increase from 9.24 million cases in 2006, to 8.3 million cases in 2000 and 6.6 million cases in 1990. Most of the estimated number of cases in 2007 were in Asia (55%) and Africa (31%), with small proportions in the Eastern Mediterranean region (6%), the European region (5%) and the Americas (3%). The five countries that ranked first to fifth in terms of total numbers of cases in 2007 were India, China, Indonesia, Nigeria, and South Africa. Of the 9.27 million incident cases in 2007, an estimated 1.37 million (14%) were HIV positive; 79% of these HIV-positive cases were in the African region.

In 2008, a total of 12,898 incident tuberculosis (TB) cases were reported in the United States; the TB rate declined 3.8% from 2007 to 4.2 cases per 100,000 population, the lowest rate recorded since national reporting began in 1953. In 2008, the TB rate in foreign-born persons in the United States was 10 times higher than in US-born persons. TB rates among Hispanics and blacks were nearly eight times higher than among non-Hispanic whites, and rates among Asians were nearly 23 times higher than among non-Hispanic whites. To ensure that TB rates decline further in the United States, especially among foreign-born persons and minority populations, TB prevention and control capacity should be increased. Additional capacity should be used to (1) improve case management and contact investigations; (2) intensify outreach, testing, and treatment of high-risk and hard-to-reach populations; (3) enhance treatment and diagnostic tools; (4) increase scientific research to better understand TB transmission; and (5) continue collaboration with other nations to reduce TB globally.[2]

HIV-positive people are about 20 times more likely than HIV-negative people to develop TB in countries with a generalized HIV epidemic, and between 26 and 37 times more likely to develop TB in countries where HIV prevalence is lower.

The so-called atypical *Mycobacteria* (*Mycobacteria* other than *Mycobacteria tuberculosis*, or MOTT) cause skin disease more frequently than does *M. tuberculosis*. They exist in various reservoirs in the environment. Among these organisms are obligate and facultative pathogens as well as nonpathogens. In contrast to the obligate pathogens, the latter do not cause disease by person-to-person spread.

MYCOBACTERIA AND THE ACQUIRED IMMUNODEFICIENCY SYNDROME PANDEMIC

The pandemic of acquired immunodeficiency syndrome (AIDS), with its profound and progressive suppression of cellular immune functions, has led to a resurgence of tuberculosis and the appearance

or recognition of new mycobacterial pathogens. The *Mycobacterium avium*-intracellulare (MAI) complex is the most common cause of disseminated bacterial infections in patients with AIDS in the United States, but is much less frequently so in Europe. In AIDS patients, *Mycobacterium kansasii* is more common than *M. tuberculosis*. The incidence of tuberculosis in patients with AIDS is almost 500 times than that in the general population. Cutaneous disease in AIDS patients is frequently caused by MOTT.

TUBERCULOSIS OF THE SKIN

TUBERCULOSIS AT A GLANCE

- Infection with *Mycobacterium tuberculosis* or other very closely related strains, as well as the inflammatory reaction of the host define, the disease (tuberculosis, or TB).
- One-third of the world's population is infected with TB.
- TB is the main cause of death of patients infected with human immunodeficiency virus.
- TB usually affects the lung, but virtually all other organ systems may be involved.
- TB of the skin is a relatively rare manifestation with a wide spectrum of clinical findings depending on the source of infection and the immune status of the host.
- Diagnosis is based on clinical manifestations, histopathologic analysis, demonstration of the relevant *Mycobacteria* in tissue or in culture and host reaction to *M. tuberculosis* antigen.
- Treatment is with standard multidrug regimens; cases of multidrug-resistant (MDR) TB or extensively multidrug-resistant (XDR) TB require special attention.
- Course and prognosis depend on the immune status of the host. Treatment is curative except for patients with a severely compromised immune system.

EPIDEMIOLOGY

Tuberculosis of the skin has a worldwide distribution. Once more prevalent in regions with a cold and humid climate, it now occurs mostly in the tropics. Cutaneous TB incidence parallels that of pulmonary TB and developing countries still account for the majority of cases in the world. The emergence of resistant strains and the AIDS epidemic have led to an increase in all forms of TB (Table 184-1).



Figure 184-1 Scrofuloderma in an Ethiopian patient. (Used with permission from Dr. Kassahun Bilcha.)

The two most frequent forms of skin tuberculosis are lupus vulgaris (LV) and scrofuloderma (Fig. 184-1). In the tropics, LV is rare, whereas scrofuloderma and verrucous lesions predominate. LV is more than twice as common in women than in men, whereas tuberculosis verrucosa cutis is more often found in men. Generalized miliary tuberculosis is seen in infants (and adults with severe immunosuppression or AIDS), as is primary inoculation tuberculosis. Scrofuloderma usually occurs in adolescents and the elderly, whereas LV may affect all age groups.

THE *MYCOBACTERIUM*. *Mycobacteria* multiply intracellularly, and are initially found in large numbers in the tissue.

M. tuberculosis, *M. bovis*, and, under certain conditions, the attenuated BCG organism cause all forms of skin tuberculosis.

In LV, the bacteria often have virulence as low as that of the BCG. Large number of bacteria can be found in the lesions of a primary chancre or of acute miliary tuberculosis; in the other forms, their number in the lesions is so small that it may be difficult to find them.

M. tuberculosis may become dormant in the host tissue.

New diagnostic tools are emerging,[4,5] as described below.

THE HOST. The human species is quite susceptible to infection by *M. tuberculosis*, with big differences among populations and individuals. Populations that have been in long-standing contact with tuberculosis are, in general, less susceptible than those who have come into contact with *Mycobacteria* more recently, presumably reflecting widespread immunity from subclinical infection. Age, state of health, environmental factors, and particularly the immune system are of importance. In Africans, tuberculosis frequently takes an unfavorable course, and tuberculin sensitivity may be more pronounced than in whites.

TUBERCULIN REACTION (KOCH PHENOMENON). An extract of *M. tuberculosis* (tuberculin) was shown to produce a different skin reaction in sensitized individuals than in naive individuals, and this

TABLE 184-1
Classification of Cutaneous Tuberculosis

	Host Immune Status	Clinical Disease
Exogenous infection	Naive Immune	 Primary inoculation tuberculosis Tuberculosis verrucosa cutis
Endogenous spread	High Low	Lupus vulgaris Scrofuloderma Acute miliary tuberculosis Orificial tuberculosis Metastatic tuberculous abscess (tuberculous gumma)
Tuberculosis due to Bacille Calmette-Guérin	Naive	Normal primary complex-like reaction Perforating regional adenitis Postvaccination lupus vulgaris
Tuberculids	Not clear	Tuberculids: Lichen scrofulosorum Papulonecrotic tuberculid Facultative tuberculids: Nodular vasculitis Erythema nodosum

difference became the basis of a widely used diagnostic test. This reaction is a delayed-type hypersensitivity reaction, induced by *Mycobacteria* during primary infection. This "old tuberculin" has now been replaced by purified protein derivative (PPD). More recently, purified species-specific antigens have been developed.[6]

Local intradermal injection (the method most widely used) leads to the local tuberculin reaction, which usually reaches its maximum intensity after 48 hours. It consists of a sharply circumscribed area of erythema and induration, and in highly hypersensitive recipients or after large doses, a pallid central necrosis may appear.

In an attempt to quantify the tuberculin reaction, an assay known as the QuantiFERON®-TB Gold test was developed to measure specific antigen-driven interferon-γ synthesis by whole blood cells and was approved by the FDA in 2005.

Tuberculin sensitivity usually develops 2–10 weeks after infection and persists throughout life. The state of sensitivity of an individual infected with *M. tuberculosis* is of considerable significance in the pathogenesis of tuberculosis skin lesions.

In patients with clinical tuberculosis, an increase in skin sensitivity usually indicates a favorable prognosis, and in tuberculous skin disease accompanied by high levels of skin sensitivity, the number of bacteria within the lesions is small. Tuberculin sensitivity (skin reactivity) is not necessary for immunity, however, and sensitivity and immunity do not always parallel each other.

ROUTE OF INFECTION. Cutaneous inoculation leads to a tuberculous chancre or to tuberculosis verrucosa cutis (Fig. 184-2), depending on the immunologic state of the host.

Spread of *Mycobacteria* may occur by continuous extension of a tuberculous process in the skin (scrofuloderma) by way of the lymphatics (LV), or by hematogenous dissemination (acute miliary tuberculosis of the skin or LV).

HISTOPATHOLOGY

The hallmark of tuberculosis and infections with some of the slow-growing atypical *Mycobacteria* is the tubercle: an accumulation of epithelioid histocytes with Langhans-type giant cells among them and a varying amount of caseation necrosis in the center, surrounded by a rim of lymphocytes and monocytes. Although this tuberculoid granuloma is highly characteristic of several forms of tuberculosis, it may be mimicked by deep fungal infections, syphilis, and leprosy, as well as other diseases. As in leprosy, the histopathologic features of skin tuberculosis may be reflective of the host's immune status.



Figure 184-2 Tuberculosis Verrucosa cutis on the foot of an Ethiopian patient. (Used with permission from Dr. Kassahun Bilcha.)

POLYMERASE CHAIN REACTION PROCEDURE

The polymerase chain reaction (PCR) procedure has been used increasingly to ascertain the presence of mycobacterial DNA in skin specimens.[7] Although the detection of specific DNA in tissues has yielded valuable information and will conceivably gain importance in the future, interpretation of the results of these tests in individual patients is still problematic.[8] In one study, samples from 16 of 20 patients with sarcoidosis contained mycobacterial DNA, both tuberculous and nontuberculous.[9] In another study of patients with confirmed or highly probable cutaneous tuberculosis or with erythema induratum, believed to indicate a host response to the infection, PCR testing showed 100% sensitivity and specificity in multibacillary disease. In paucibacillary disease, PCR testing showed 55% sensitivity and specificity, and only 80% of PCR-positive patients responded to antituberculosis therapy.[7]

QUANTIFERON®-TB GOLD (QFT-G) TEST

In 2005, the FDA approved QFT-G as an in vitro diagnostic aid. In this test, blood samples are mixed with antigens and controls. For QFT-G, the antigens include mixtures of synthetic peptides representing two *M. tuberculosis* proteins: (1) ESAT-6 and (2) CFP-10. After incubation of the blood with antigens for 16–24 hours, the amount of interferon-γ (IFN-γ) is measured.

If the patient is infected with *M. tuberculosis*, their white blood cells will release IFN-γ in response to contact with the TB antigens. The QFT-G results are based on the amount of IFN-γ that is released in response to the antigens.

Although more sensitive than the tuberculin skin test, the QFT-G may be negative in patients with early active tuberculosis and indeterminate results are more common in immunocompromised individuals and young children. Another similar assay, the T-SPOT®.*TB* test, measures the number of IFN-γ-producing T cells and is currently available in Europe. QFT-G testing is indicated for diagnosing infection with *M. tuberculosis*, including both TB disease and latent TB infection. Whenever *M. tuberculosis* infection or disease is being diagnosed by any method, the optimal approach includes coordination with the local or regional public health TB control programs.

SKIN DISEASES CAUSED BY *MYCOBACTERIUM TUBERCULOSIS/BOVIS* INFECTION

Infection with *M. tuberculosis* used to be thought to result in characteristic clinical features.[10] However, with increasing number of cases in immunocompromised individuals and improved diagnostic tools, many uncharacteristic manifestations have been discovered.

PRIMARY INOCULATION TUBERCULOSIS (TUBERCULOUS CHANCRE, TUBERCULOUS PRIMARY COMPLEX)

EPIDEMIOLOGY. Tuberculous chancre and affected regional lymph nodes constitute the tuberculous primary complex in the skin. The condition is believed rare, but its incidence may be underestimated. In some regions with a high prevalence of tuberculosis and poor living conditions, primary inoculation tuberculosis of the skin is not unusual. Children are most often affected.

ETIOLOGY AND PATHOGENESIS. Tubercle bacilli are introduced into the tissue at the site of minor wounds. Oral lesions may be caused by bovine bacilli in nonpasteurized milk and occur after mucosal trauma or tooth extraction. Primary inoculation tuberculosis is initially multibacillary, but becomes paucibacillary as immunity develops.

CLINICAL FINDINGS. The chancre initially appears 2–4 weeks after inoculation and presents as a small papule, crust, or erosion with little tendency to heal. Sites of predilection are the face, including the conjunctivae and oral cavity, as well as the hands and lower extremities. A painless ulcer develops, which may be quite insignificant or may enlarge to a diameter of more than 5 cm (Fig. 184-3). It is shallow with a granular or hemorrhagic base studded with miliary abscesses or covered by necrotic tissue. The ragged edges are undermined and of a reddish-blue hue. As the lesions grow older, they become more indurated, with thick adherent crusts.



Figure 184-3 Primary inoculation tuberculosis. Note tuberculous chancre on the thigh and regional lymphadenopathy. A positive tuberculin reaction is noted on the arm.

Wounds inoculated with tubercle bacilli may heal temporarily but break down later, giving rise to granulating ulcers. Mucosal infections result in painless ulcers or fungating granulomas. Inoculation tuberculosis of the finger may present as a painless paronychia. Inoculation of puncture wounds may result in subcutaneous abscesses.

Slowly progressive, regional lymphadenopathy develops 3–8 weeks after the infection (Fig. 184-3) and may rarely be the only clinical finding. After weeks or months, cold abscesses may develop that perforate to the surface of the skin and form sinuses. The lymph nodes draining the primary glands may also be involved. Body temperature may be slightly elevated. The disease may take a more acute course, and in half of the patients, fever, pain, and swelling simulate a pyogenic infection. Early, there is an acute nonspecific inflammatory reaction in both skin and lymph nodes, and *Mycobacteria* are easily detected by Fite stain. After 3–6 weeks, the infiltrate and the regional lymph nodes acquire a tuberculoid appearance and caseation may occur.

DIAGNOSIS. Any ulcer with little or no tendency to heal and unilateral regional lymphadenopathy in a child should arouse suspicion. Acid-fast organisms are found in the primary ulcer and draining nodes in the initial stages of the disease. The diagnosis is confirmed by bacterial culture. The PPD reaction is negative initially and later converts to positive (Fig. 184-3).

DIFFERENTIAL DIAGNOSIS. The differential diagnosis encompasses all disease with a primary complex (Box 184-1).

COURSE. If untreated, the condition may last up to 12 months. Rarely, LV develops at the site of a healed tuberculous chancre. The regional lymph nodes usually calcify.

The primary tuberculous complex usually produces immunity, but reactivation of the disease may occur. Hematogenous spread may give rise to tuberculosis of other organs, particularly of the bones and joints. It may also lead to acute miliary disease with a fatal outcome. Erythema nodosum occurs in approximately 10% of cases.

BOX 184-1 DIFFERENTIAL DIAGNOSIS OF PRIMARY INOCULATION TUBERCULOSIS

Most Likely
- Syphilis
- Sporotrichosis

Consider
- Tularemia
- Bartonellosis

Always Rule Out
- Other mycobacterioses

TUBERCULOSIS VERRUCOSA CUTIS (WARTY TUBERCULOSIS, PROSECTOR'S WART, LUPUS VERRUCOSUS)

ETIOLOGY AND PATHOGENESIS. Tuberculosis verrucosa cutis is a paucibacillary disorder caused by exogenous reinfection (inoculation) in previously sensitized individuals with high immunity.

Inoculation occurs at sites of minor wounds or, rarely, from the patient's own sputum. Members of professional groups handling infectious material are at risk. Children may become infected playing on contaminated ground.

CLINICAL FINDINGS. Lesions usually occur on the hands or, in children, on the lower extremities as a small asymptomatic papule or papulopustule with a purple inflammatory halo. They become hyperkeratotic and are often mistaken for a common wart. Slow growth and peripheral expansion lead to the development of a verrucous plaque with an irregular border (Fig. 184-4). Fissures discharging pus extend into the underlying brownish-red to purplish infiltrated base. The lesion usually is solitary, but multiple lesions may occur. Regional lymph nodes are rarely affected.

Lesions progress slowly and, if untreated, persist for many years. Spontaneous involution eventually occurs, leaving an atrophic scar.

HISTOPATHOLOGY. The most prominent histopathologic features are pseudoepitheliomatous hyperplasia with marked hyperkeratosis, a dense inflammatory infiltrate, and abscesses in the superficial dermis or within the pseudoepitheliomatous rete pegs. Epithelioid cells and giant cells are found in the upper and middle dermis. Typical tubercles are uncommon, and the infiltrate may be nonspecific.



Figure 184-4 Tuberculosis verrucosa cutis on the back of the hand.

BOX 184-2 DIFFERENTIAL DIAGNOSIS OF TUBERCULOSIS VERRUCOSA CUTIS

Most Likely
- Warts or keratoses
- Hyperkeratotic lupus vulgaris
- Blastomycosis
- Hypertrophic lichen planus

Consider
- Chromomycosis
- Bromoderma
- Tertiary syphilis

Always Rule Out
- Lesions due to other *Mycobacteria*

DIFFERENTIAL DIAGNOSIS. (Box 184-2)

LUPUS VULGARIS (TUBERCULOSIS LUPOSA)

EPIDEMIOLOGY. LV is an extremely chronic, progressive form of cutaneous tuberculosis occurring in individuals with moderate immunity and a high degree of tuberculin sensitivity. Once common, LV has declined steadily in incidence. It has always been less common in the United States than in Europe. Females appear to be affected two to three times as often as males; all age groups are affected equally.

ETIOLOGY AND PATHOGENESIS. LV is a postprimary, paucibacillary form of tuberculosis caused by hematogenous, lymphatic, or contiguous spread from elsewhere in the body. Spontaneous involution may occur, and new lesions may arise within old scars. Complete healing rarely occurs without therapy.

CLINICAL FINDINGS. Lesions are usually solitary, but two or more sites may be involved simultaneously. In patients with active pulmonary tuberculosis, multiple foci may develop. In approximately 90% of patients, the head and neck are involved. LV usually starts on the nose, cheek, earlobe, or scalp and slowly extends onto adjacent regions. Other areas are rarely involved.

The initial lesion is a brownish-red, soft or friable macule or papule with a smooth or hyperkeratotic surface. On diascopy, the infiltrate exhibits a typical apple jelly color. Progression is characterized by elevation, a deeper brownish color (Fig. 184-5), and formation of a plaque (see Fig. 184-5). Involution in one area with expansion in another often results in a gyrate outline border. Ulceration may occur. Hypertrophic forms appear as a soft nodule (see eFig. 184-3.1 in online edition) or plaque with a hyperkeratotic surface (eFig. 184-3.2 in online edition). The mucosae may be primarily involved or become affected by the extension of skin lesions. Infection is manifest as small, soft, gray or pink papules, ulcers, or friable granulating masses.

After a transient impairment of immunity, particularly after measles (thus the term lupus postexanthematicus), multiple disseminated lesions may arise simultaneously in different regions of the body as a consequence of hematogenous spread from a latent tuberculous focus. During and after the eruption, a previously positive tuberculin reaction may become negative but will usually revert to positive as the general condition of the patient improves.

HISTOPATHOLOGY. The most prominent histopathologic feature is the formation of typical tubercles. Secondary changes may be superimposed: epidermal



Figure 184-5 **A.** Slightly raised, brownish plaque of lupus vulgaris. **B.** Large plaque of lupus vulgaris of 10 years' duration involving the cheek, jaw, and ear.

thinning and atrophy or acanthosis with excessive hyperkeratosis or pseudoepitheliomatous hyperplasia. Acid-fast bacilli are usually not found. Nonspecific inflammatory reactions may partially conceal the tuberculous structures. Old lesions are composed chiefly of epithelioid cells and may be impossible to distinguish from sarcoidal infiltrates (see eFig. 184-4.1 in online edition).

DIAGNOSIS. Typical LV plaques may be recognized by the softness of the lesions, brownish-red color, and slow evolution. The apple jelly nodules revealed by diascopy are highly characteristic; finding them may be decisive, especially in ulcerated, crusted, or hyperkeratotic lesions. The result of the tuberculin test is strongly positive except during the early phases of postexanthematic lupus. Bacterial culture results may be negative, in which case the clinical diagnosis can usually be supported by positive PCR results for *M. tuberculosis.*

DIFFERENTIAL DIAGNOSIS. (Box 184-3)

COMPLICATIONS. Involvement of the nasal or auricular cartilage may result in extensive destruction and disfigurement (Fig. 184-6). Atrophic scarring, with or without prior ulceration, is characteristic, as is recurrence within a scar. Fibrosis may be pronounced and mutilating.

Dry rhinitis is often the only symptom of early nasal LV, but lesions may also destroy the cartilage of the nasal septum. Scarring of the soft palate and laryngeal stenosis also occur.

COURSE. LV is a very long-term disorder and without therapy progresses over many years to functional impairment and disfiguration (see Fig. 184-6). Long-standing LV may lead to the development of carcinoma (see Fig. 184-6). Squamous cell carcinomas outnumber basal cell carcinomas by far, and the risk of metastases is high. In 40% of patients, there is associated tuberculous lymphadenitis, and 10%–20% have active pulmonary tuberculosis or tuberculosis of the bones and joints.[11] Pulmonary tuberculosis is 4–10 times more frequent in patients with LV than in the general population.

BOX 184-3 DIFFERENTIAL DIAGNOSIS OF LUPUS VULGARIS

Most Likely
- Sarcoidosis
- Discoid lupus erythematosus

Consider
- Lymphocytoma
- Tertiary syphilis
- Leprosy
- Lupoid leishmaniasis

Always Rule Out
- Blastomycosis or other deep mycotic infections



Figure 184-6 Lupus vulgaris of long duration that has led to the destruction of the nose. Ulcerating squamous cell carcinoma has developed on the upper lip.

SCROFULODERMA (TUBERCULOSIS COLLIQUATIVA CUTIS)

EPIDEMIOLOGY. Prevalence is higher among children, adolescents, and the aged.

ETIOLOGY AND PATHOGENESIS. Scrofuloderma is subcutaneous tuberculosis leading to cold abscess formation and a secondary breakdown of the overlying skin. It may be either multibacillary or paucibacillary.

Scrofuloderma represents contiguous involvement of the skin overlying another site of infection (e.g., tuberculous lymphadenitis, tuberculosis of bones and joints, or tuberculous epididymitis).

CLINICAL FINDINGS. Scrofuloderma most often occurs in the parotidal, submandibular, and supraclavicular regions and may be bilateral. It first presents as a firm, subcutaneous nodule, usually well defined, freely movable, and asymptomatic. As the lesion enlarges, it softens. After months, liquefaction with perforation occurs, causing ulcers and sinuses (Fig. 184-7). The ulcers are linear or serpiginous with undermined, inverted, bluish edges and soft, granulating floors. Sinusoidal tracts undermine the skin. Clefts alternate with soft nodules. Scar tracts develop and bridge ulcerative areas or even stretches of normal skin. Tuberculin sensitivity is usually pronounced.

HISTOPATHOLOGY. Massive necrosis and abscess formation in the center of the lesion are nonspecific.



Figure 184-7 Scrofuloderma in the clavicular region. Note abscess formation, ulceration, and extrusion of purulent and caseous material.

However, the periphery of the abscesses or the margins of the sinuses contain tuberculoid granulomas.

DIAGNOSIS. If there is an underlying tuberculous lymphadenitis or bone and joint disease, the diagnosis usually presents no difficulty. Positive results on culture confirm the diagnosis.

DIFFERENTIAL DIAGNOSIS. (Box 184-4)

COURSE. Spontaneous healing does occur, but the course is very protracted, and it may be years before lesions have been completely replaced by scar tissue. Presence of the typical cribriform scars permits a correct diagnosis, even after the process has become quiescent. LV may develop at or near the site of scrofuloderma.

BOX 184-4 DIFFERENTIAL DIAGNOSIS OF SCROFULODERMA

Most Likely
- Sporotrichosis
- Hidradenitis suppurativa

Consider
- *Mycobacterium scrofulaceum* infection
- Syphilitic gummas
- Actinomycosis
- Severe forms of acne conglobata

Always Rule Out
- *Mycobacterium avium*-intracellulare lymphadenitis

ORIFICIAL TUBERCULOSIS (TUBERCULOSIS ULCEROSA CUTIS ET MUCOSAE, ACUTE TUBERCULOUS ULCER)

ETIOLOGY AND PATHOGENESIS. Orificial tuberculosis is a rare form of tuberculosis of the mucous membranes and orifices that is caused by autoinoculation of *Mycobacteria* from progressive tuberculosis of internal organs.

The underlying disease is far advanced pulmonary, intestinal, or, rarely, genitourinary tuberculosis. *Mycobacteria* shed from these foci in large numbers are inoculated into the mucous membranes.

CLINICAL FINDINGS. A small yellowish or reddish nodule appears on the mucosa and breaks down to form a soft ulcer with a typical punched-out appearance, undermined edges, and circular or irregular border (Fig. 184-8). The ulcer floor often exhibits multiple yellowish tubercles and bleeds easily. The surrounding mucosa is edematous and inflamed. Lesions may be single or multiple and are extremely painful, resulting in dysphagia.

The tongue is most frequently affected, particularly the tip and the lateral margins, but the soft and hard palates are also common sites. In advanced cases, the lips are involved, and the oral condition often represents an extension of ulcerative tuberculosis of the pharynx and larynx. In patients with intestinal tuberculosis, lesions develop around the anus, and in females with active genitourinary disease, the vulva is involved.

HISTOPATHOLOGY. There is a massive nonspecific inflammatory infiltrate and necrosis, but tubercles with caseation may be found deep in the dermis. *Mycobacteria* are easily demonstrated.



Figure 184-8 Orificial tuberculosis in advanced cavitary pulmonary tuberculosis.

BOX 184-5 DIFFERENTIAL DIAGNOSIS OF ORIFICIAL TUBERCULOSIS

Most Likely
- Aphthous ulcers

Consider
- Syphilitic lesions (not painful)

Always Rule Out
- Squamous cell carcinoma

DIFFERENTIAL DIAGNOSIS. (Box 184-5)

COURSE. Orificial tuberculosis is a symptom of advanced internal disease and usually portends a fatal outcome.

SEQUELAE OF BACILLE CALMETTE–GUÉRIN INOCULATION

Vaccination with attenuated bovine BCG appears to protect infants and young children from the more serious forms of tuberculosis, but its ability to prevent disease in adults remains uncertain. In the United States, guidelines for BCG immunization have been developed.[12,13]

In the normal course of BCG vaccination, an infiltrated papule develops after approximately 2 weeks, attains a size of approximately 10 mm after 6–12 weeks, ulcerates, and then slowly heals, leaving a scar. Vaccination may provoke an accelerated reaction in a previously infected person. The regional lymph nodes may enlarge, but usually heal without breaking down. Tuberculin sensitivity appears 5–6 weeks after vaccination.

The true incidence of complications caused by the BCG organism is difficult to ascertain, but it is extremely low in comparison to the great number of vaccinations performed in Europe in the past 50 years.[14] Problems include the following:

- LV at or near the vaccination site (latency of months to years)
- Koch phenomenon in individuals sensitive to tuberculin [see Section "Tuberculin Reaction (Koch Phenomenon)"]
- Regional adenitis, sometimes severe and with systemic symptoms, more often in children
- After deep injection, local abscesses, excessive ulceration
- Scrofuloderma with suppuration for 6–12 months
- Generalized tuberculid-like reactions (rare)
- Generalized adenitis, osteitis, organ tuberculosis (e.g., in the joints) occasionally

THE TUBERCULIDS

Lichen scrofulosorum, erythema induratum, papulonecrotic tuberculids, lupus miliaris disseminatus faciei, and other eruptions with rather exotic designations were originally included in the tuberculids (Table 184-2).

TABLE 184-2
Tuberculids

Terminology: Relationship to Tuberculosis	Entities
Tuberculids: conditions in which *Mycobacterium tuberculosis/bovis* appears to play a significant role	Lichen scrofulosorum Papulonecrotic tuberculid
Facultative tuberculids: conditions in which *M. tuberculosis/bovis* may be one of several pathogenic factors	Nodular vasculitis/erythema induratum of Bazin Erythema nodosum
Nontuberculids: conditions formerly designated as tuberculids; there is no relationship to tuberculosis	Lupus miliaris disseminatus faciei Rosacea-like tuberculid Lichenoid tuberculid

With the sharp decline in incidence and the effective treatment of tuberculosis in developed countries, the tuberculids also became rare. However, this does not apply to areas in which tuberculosis is still common, and with the recent resurgence of tuberculosis associated with AIDS in some Western countries, some tuberculids are also being observed again.

The pathogenic relationship of the tuberculids to tuberculosis is still poorly understood. Although there is no doubt that such a relationship exists for some tuberculids, in other cases it appears highly unlikely.

PCR testing revealed *M. tuberculosis* DNA in skin lesions of erythema induratum/nodular vasculitis and papulonecrotic tuberculid in one series of patients, but in another, results were uniformly negative.[18,19] Thus, *M. tuberculosis* infection may be responsible directly or indirectly for some cases of these diseases but not all, and the usefulness of lesional PCR testing may vary among clinical settings. Consistent with this statement, antituberculosis drugs are beneficial in some cases but not all; spontaneous involution may occur, and some patients appear to respond well to other therapies. It should be noted that, although not considered a tuberculid, sarcoidosis has been postulated to result from an immunologic reaction to mycobacterial antigens.[20]

The following discussion includes only those conditions for which a preponderance of the evidence supports a tuberculous etiology (see Table 184-2).

LICHEN SCROFULOSORUM

EPIDEMIOLOGY AND PATHOGENESIS. Lichen scrofulosorum is an uncommon lichenoid eruption ascribed to hematogenous spread of *Mycobacteria* in an individual strongly sensitive to *M. tuberculosis*. Usually associated with chronic tuberculosis of the lymph nodes, bones, or pleura, it has also been observed after BCG vaccination and in association with *M. avium-intracellulare* infections.[21]

BOX 184-6 DIFFERENTIAL DIAGNOSIS OF LICHEN SCROFULODERMA

Most Likely
- Lichen planus
- Lichen nitidus

Consider
- Lichenoid secondary syphilis
- Micropapular forms of sarcoidosis

CLINICAL FINDINGS. Lesions are usually confined to the trunk and occur most often in children and adolescents with active tuberculosis. The lesions are asymptomatic, firm, follicular or perifollicular flat-topped yellowish or pink papules, sometimes with fine scale. Lichenoid grouping is pronounced, and lesions may coalesce to form rough, discoid plaques. Lesions persist for months, but spontaneous involution eventually occurs. Antituberculosis therapy results in complete resolution within weeks.

HISTOPATHOLOGY. Superficial tuberculoid granulomas develop around hair follicles or independent of the adnexa. *Mycobacteria* are not seen in the sections and cannot be cultured from biopsy material.

DIFFERENTIAL DIAGNOSIS. (Box 184-6)

PAPULONECROTIC TUBERCULID

EPIDEMIOLOGY. Papulonecrotic tuberculid is a symmetric eruption of necrotizing papules, appearing in crops and healing with scar formation that occurs preferentially in children or young adults. It is rarely reported but may not be uncommon in populations with a high prevalence of tuberculosis.

ETIOLOGY AND PATHOGENESIS. As a rule, bacteria cannot be demonstrated in lesions. In most cases, the tuberculin test shows a positive reaction, and associated pulmonary or extrapulmonary tuberculosis is common. LV has been reported to evolve with papulonecrotic tuberculid. Lesions are reported to respond promptly to antituberculosis therapy whether or not a tuberculous focus is identified.

In studies of skin lesions in patients with papulonecrotic tuberculid, *M. tuberculosis* DNA was detected in approximately 50% of the skin biopsies (11 out of 22 samples).[22,23,24] *M. kansasii* infection was documented in one patient.[25]

Some cases of papulonecrotic tuberculid have been associated with discoid lupus erythematosus, arthritis, or erythema nodosum. Although papulonecrotic tuberculid is classified as an id reaction and therefore, by definition, is not due to direct involvement of the skin by the organism, some of the lesions have been positive on culture. It seems most likely that papulonecrotic tuberculid is a reaction to particulate tuberculous antigen and, in some cases, to living organisms as well.[26]



Figure 184-9 Papulonecrotic tuberculid on the forearm.

CLINICAL FINDINGS. Sites of predilection are the extensor aspects of the extremities, buttocks, and lower trunk (Fig. 184-9), but the eruption may become widespread. Distribution is symmetric, and consists of disseminated crops of livid or dusky red papules with a central depression and an adherent crust over a crater-like ulcer. There is spontaneous involution, which leaves pitted scars.

HISTOPATHOLOGY. Characteristically, a wedge-shaped necrotic area in the upper dermis extends into the epidermis. The inflammatory infiltrate surrounding this necrotic area may be nonspecific, but is usually tuberculoid. Involvement of the blood vessels is a cardinal feature and consists of an obliterative and sometimes granulomatous vasculitis leading to thrombosis and complete occlusion of the vascular channels.

DIFFERENTIAL DIAGNOSIS. (Box 184-7)

NODULAR VASCULITIS/ERYTHEMA INDURATUM OF BAZIN

(See Chapter 70)

ERYTHEMA NODOSUM

(See Chapter 70)

BOX 184-7 DIFFERENTIAL DIAGNOSIS OF PAPULONECROTIC TUBERCULID

Most Likely
- Pityriasis lichenoides et varioliformis acuta
- Prurigo

Consider
- Lichen urticatus
- Secondary syphilis

Always Rule Out
- Leukocytoclastic necrotizing vasculitis

TREATMENT OF CUTANEOUS TUBERCULOSIS

In general, the management of cutaneous tuberculosis is similar to that of tuberculosis of other organs.[27–30] Chemotherapy is usually the treatment of choice (Table 184-3A and eTable 184-3B in online edition), but ancillary measures may be required. Vaccines against *M. tuberculosis* have been attempted,[27] but are still not available.

Although they are not yet established as a therapeutic option, cytokines such as interleukin 2, interferon-γ,

TABLE 184-3A
Therapy Guidelines for *Mycobacterium tuberculosis* Infections

Initial Phase			Continuation Phase			Range of Total Doses (Minimal Duration)	Rating (Evidence)[a,b]	
Regimen	Drugs	Interval and Doses[c] (Minimal Duration)	Regimen	Drugs	Interval and Doses[c,d] (Minimal Duration)		HIV⁻	HIV⁺
1	INH RIF PZA EMB	7 days per week for 56 doses (8 weeks) or 5 days per week for 40 doses (8 weeks)[e]	1a 1b 1c[f]	INH/RIF INH/RIF INH/RPT	7 days per week for 126 doses (18 weeks) or 5 days per week for 90 doses (18 weeks)[e] Twice weekly for 36 doses (18 weeks) Once weekly for 18 doses (18 weeks)	184–130 (26 weeks) 92–76 (26 weeks) 74–58 (26 weeks)	A (I) A (I) B (I)	A (II) A (II)[c] E (I)
2	INH RIF PZA EMB	7 days per week for 14 doses (2 weeks), then twice weekly for 12 doses (6 weeks), or 5 days per week for 10 doses (2 weeks)[e], then twice weekly for 12 doses (6 weeks)	2a 2b[f]	INH/RIF INH/RPT	Twice weekly for 36 doses (18 weeks) Once weekly for 18 doses (18 weeks)	62–58 (26 weeks) 44–40 (26 weeks)	A (II) B (I)	B (II)[c] E (I)
3	INH RIF PZA EMB	Three times weekly for 24 doses (8 weeks)	3a	INH/RIF	Three times weekly for 54 doses (18 weeks)	78 (26 weeks)	B (I)	B (II)
4	INH RIF EMB	7 days per week for 56 doses (8 weeks) or 5 days per week for 40 doses (8 weeks)[e]	4a 4b	INH/RIF INH/RIF	7 days per week for 217 doses (31 weeks) or 5 days per week for 155 doses (31 weeks)[e] Twice weekly for 62 doses (31 weeks)	273–195 (39 weeks) 118–102 (39 weeks)	C (I) C (I)	C (II) C (II)

[a]Definitions of evidence ratings: A = preferred; B = acceptable alternative; C = offer when A and B cannot be given; E = should never be given.
[b]Definitions of evidence ratings: I = randomized clinical trial; II = data from clinical trials that were not randomized or were conducted in other populations; III = expert opinion.
[c]DOT, Directly Observed Therapy. Among patients with extrapulmonary tuberculosis, regimen 1 is recommended as initial therapy unless the organisms are known or strongly suspected of being resistant to the first-line drugs. If PZA cannot be used in the initial phase (i.e., regimen 4), the continuation phase must be increased to 7 months. Doses of medications (maximum dose) when given daily: INH, isoniazid 5 mg/kg (300 mg); RIF, rifampin 10 mg/kg (600 mg); PZA, pyrazinamide 25 mg/kg (2000 mg); EMB, ethambutol 18 mg/kg (1600 mg); RPT, rifapentine, which is given once weekly at 10 mg/kg.
When DOT is used, drugs may be given 5 days/week and the necessary number of doses adjusted accordingly. Although there are no studies that compare five with seven daily doses, extensive experience indicates this would be an effective practice.
[d]Patients with cavitation on initial chest radiograph and positive cultures at completion of 2 months of therapy should receive an 8-month (31-week; either 217 doses [daily] or 62 doses [twice weekly]) continuation phase.
[e]Five-day-a-week administration is always given by DOT. Rating for 5 day/week regimens is AIII.
Not recommended for HIV-infected patients with CD4+ cell counts <100 cells/ml.
[f]Options 1c and 2b should be used only in HIV-negative patients who have negative sputum smears at the time of completion of 2 months of therapy and who do not have cavitation on initial chest radiograph. For patients started on this regimen and found to have a positive culture from the 2-month specimen, treatment should be extended an extra 3 months.
From American Thoracic Society, CDC, and Infectious Disease Society of America: Treatment of tuberculosis. *MMWR Recomm Rep* 2003; **52**:1-77

interleukin 12, and granulocyte-macrophage colony-stimulating factor may help to control intracellular pathogens and thereby shorten the duration of therapy and overcome drug resistance.[31] The immunomodulatory drug thalidomide (see Chapter 235) may prove to be useful in controlling problems related to the inflammatory response that may follow treatment of multibacillary infection and could become a useful adjunctive drug, as it is in the treatment of leprosy.

SPECIAL CONSIDERATIONS IN TREATING TUBERCULOSIS OF THE SKIN

In contrast to systemic infection, for which triple-drug therapy is recommended, tuberculosis verrucosa cutis and localized forms of LV without evidence of associated internal tuberculosis may be treated with isoniazid alone for up to 12 months. Because viable *Mycobacteria* have been found in clinically healed lesions, treatment should be continued for at least 2 months after complete involution of the lesions. Surgical intervention is quite helpful in scrofuloderma, because it reduces morbidity and shortens the required length of chemotherapy. Small lesions of LV or tuberculosis verrucosa cutis are also best excised, but tuberculostatics should be given concomitantly. Plastic surgery is important as a corrective measure in cases of long-standing LV with mutilation.

Extensively drug resistant (XDR) TB is defined as resistance to at least rifampicin and isoniazid from among the first line anti-TB drugs (which is the definition of MDR TB) in addition to resistance to any fluoroquinolone, and to at least one of the three injectable second-line anti-TB drugs used in TB treatment [(1) capreomycin, (2) kanamycin, and (3) amikacin]. The CDC and WHO have outlined that XDR TB poses a grave global public health threat and has a higher risk of death as it renders patients virtually untreatable with currently available drugs.[32]

DISEASES CAUSED BY *MYCOBACTERIA* OTHER THAN *M. TUBERCULOSIS*

MOTT were identified as human pathogens in 1938 (*Mycobacterium fortuitum*), in 1948 (*Mycobacterium ulcerans*), and in 1954 (*Mycobacterium marinum*). However, overshadowed by the infectious disease burden due to *M. leprae* and *M. tuberculosis*, the pathogenic potential of slow-growing MOTT species has been recognized only in recent decades. Because MOTT infections usually closely mimic infections with *M. tuberculosis*, and the bacteria have strict and often unusual requirements for culture, they are still probably underdiagnosed.

IDENTIFICATION OF *MYCOBACTERIA* OTHER THAN *M. TUBERCULOSIS*

As with other infectious diseases, the diagnosis of mycobacterial infection depends on the identification of the microorganism isolated from the host. Specimens for culture should be sent to a special laboratory familiar with the special growth requirements of these organisms.

Antigens for intradermal skin testing (PPDs) for many of the clinically relevant mycobacterial species have been prepared in analogy to PPD from *M. tuberculosis*, but their accessibility is very limited and they are therefore little used.

Histopathologic analysis is supportive but cannot distinguish among mycobacterial species, because all share similar histopathologic features.[33]

Treatment is summarized in Table 184-4. Importantly, some MOTT organisms are resistant to standard tuberculosis therapy. PCR testing for mycobacterial DNA is not yet reliable enough to play a role in the diagnosis of disease but can sometimes be useful in distinguishing among species.

DISEASES CAUSED BY *MYCOBACTERIA* OTHER THAN *M. TUBERCULOSIS* AT A GLANCE

- A heterogeneous group of diseases caused by a variety of obligate or facultatively pathogenic *Mycobacteria* other than those of the *Mycobacterium tuberculosis* complex.
- Involvement depends on the type of *Mycobacterium*, the route of infection, and the immune status of the host.
- Various organs may be involved.
- *Mycobacteria* other than *M. tuberculosis* (MOTT) are more often the cause of skin disease than *M. tuberculosis*.
- Diagnosis relies on histopathologic analysis and the results of culture.
- Incidence is unknown, but endemic areas exist for certain types of MOTT.
- Treatment is unlike that of tuberculosis, and no strict international guidelines have been developed. Effective antibiotics are known for each mycobacterial species but should be checked by sensitivity testing.

ETIOLOGY AND PATHOGENESIS. MOTT are widely distributed in nature and are usually commensals or saprophytes, rather than pathogens. Atypical *Mycobacteria* are usually acquired from environmental sources such as water or soil, and their role in disease reflects their natural distribution and, possibly, local lifestyles. These organisms are thought to cause mycobacterial skin disease more often than does *M. tuberculosis*. Cases tend to be sporadic, but certain types of exposures may lead to small community outbreaks.[3,34] Any organ or organ system may be affected (Table 184-5), but MOTT seem much less likely to disseminate than *M. tuberculosis*, and infections usually run a more benign

TABLE 184-4
Treatment of Infections with *Mycobacteria* Other Than *M. tuberculosis*

	Mycobacterium Species							
Treatment	**Ulcerans**	**Marinum**	**Kansasii**	**Intracellulare-avium**	**Scrofulaceum**	**Haemophilum**	**Chelonae**	**Fortuitum**
Amikacin			+				+	+
Ansamycin				+				
Azithromycin				+				
Cefoxitin								+
Ciprofloxacin								+
Clarithromycin				+	+		+	
Clofazimine	+			+				
Co-trimoxazole	+							
Cycloserine			+					
Dapsone	+							
Doxycycline		+					+	
Erythromycin							+	
Ethambutol[a]	+	+	+	+				
Ethionamide			+	+				
Imipenem								+
Isoniazid			+	+	+			
Kanamycin			+					
Minocycline	+	+	+	+		+[b]		
Rifampicin	+	+	+	+	+			
Rifamycin			+	+		+		
Streptomycin[a]	+		+	+				
Tobramycin								+
Surgery	+				+		+	+

[a]Usual antituberculosis drugs.
[b]Alone or in combination with ciprofloxacin or rifampicin.

TABLE 184-5
Organ Involvement in Infections with Atypical *Mycobacteria*

	Organ Involvement	
Mycobacterial Species	**Skin, Subcutis**	**Lymph Nodes, Other Organs**
Mycobacterium tuberculosis/bovis complex (including *Mycobacterium africanum* and Bacille Calmette-Guérin)	+	+
Mycobacterium marinum	+	–
Mycobacterium ulcerans	+	–
Mycobacterium gordonae	+	–
Mycobacterium haemophilum	+	–
Mycobacterium kansasii	+	+
Mycobacterium avium-intracellulare complex (including *Mycobacterium scrofulaceum*)	+	+
Fast growers: *Mycobacterium fortuitum*, *Mycobacterium chelonae*, *Mycobacterium abscessus*	+	–



Figure 184-10 Verrucous plaque of "spam" disease on the knee of a Pacific Islander patient. (Used with permission from Dr. Joseph Lillis.)

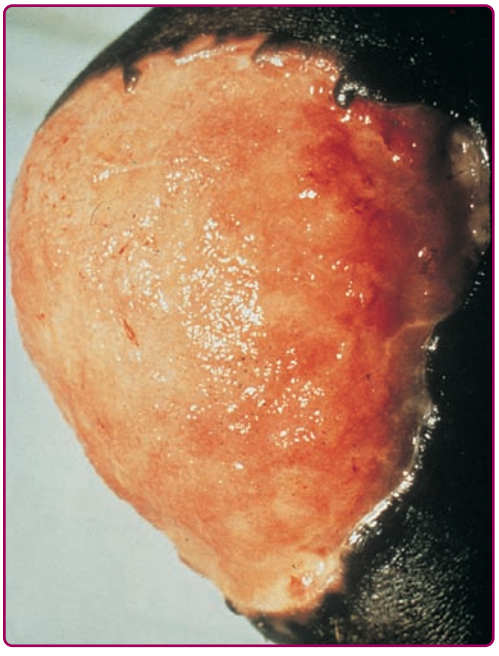

Figure 184-11 *Mycobacterium ulcerans* infection in a child in Uganda. The knee bears an ulcer with an infiltrated undermined margin and a base of necrotic adipose and connective tissue. (Used with permission from M. Dietrich, MD.)

and limited course. As a rule, MOTT are much less responsive to antituberculosis drugs but may be sensitive to other chemotherapeutic agents.

Only two organisms, *M. ulcerans* and *M. marinum*, produce a characteristic clinical picture. An immunosuppressed state of the host or damage to a particular organ (e.g., in *M. kansasii* infection of the lung) facilitates these infections.

New mycobacterial pathogens are described from time to time, which suggests that their full pathogenic potential is not yet appreciated. Recently, an outbreak of skin disease caused by a nontuberculous *Mycobacteria* in Pacific Islanders from Satowan was reported in the literature.[35] These patients presented with long-standing verrucous and keloidal plaques (locally known as "spam" disease) (Fig. 184-10). Histopathological and PCR data demonstrated a nontuberculous mycobacterial infection as the cause.

SKIN INFECTIONS WITH *MYCOBACTERIA* OTHER THAN *M. TUBERCULOSIS*

MYCOBACTERIUM ULCERANS (BURULI ULCER DISEASE).

The natural habitat of *M. ulcerans* is still not known, and it has never been found outside the human body, but *M. ulcerans* infection occurs in wet, marshy, or swampy areas and seems to have to do with contaminated water. *M. ulcerans* is the third most frequent mycobacterial pathogen, after *M. tuberculosis* and *M. leprae*.

Clinical Findings. The disease is found most often in children and young adults, and affects females more often than males. A subcutaneous nodule gradually enlarges and eventually ulcerates. A blister may develop before ulceration. The ulcer is deeply undermined, and necrotic fat is exposed (Fig. 184-11). The preceding nodule as well as the ulcer is painless, and the patient continues to feel well. The painless nature of the ulcer has been attributed to nerve damage and tissue destruction caused by the toxin mycolactone. The lesions may occur anywhere on the body but tend to be limited to the extremities in adults. They may be large, involving a whole limb. The ulceration may persist for months and years, and healing and progression of the ulceration may occur in the same patient. This process may lead to appreciable and sometimes disabling scarring and lymphedema. Neither lymphadenopathy nor any constitutional signs appear at any time unless the disease process is complicated by bacterial superinfection.

Differential Diagnosis. (Box 184-8)

MYCOBACTERIUM MARINUM (*MYCOBACTERIUM BALNEI*, FISHTANK/SWIMMING POOL GRANULOMA).

M. marinum occurs in freshwater and saltwater, including swimming pools and fish tanks.

Clinical Findings. Risk factors for *M. marinum* infection are a history of trauma and water- or fish/seafood-related hobbies and occupations. The disease begins as a violaceous papule at the site of a trauma 2–3 weeks after inoculation. Patients may have a nodule or a psoriasiform or verrucous plaque at the site of inoculation, usually the hands, feet, elbows, or knees (Fig. 184-12). The lesions may ulcerate. Usually, the

BOX 184-8 DIFFERENTIAL DIAGNOSIS OF *MYCOBACTERIUM ULCERANS* LESIONS

EARLY LESIONS	LATE LESIONS
Most Likely	
Foreign body granuloma	Blastomycosis or other deep fungus infection
Sebaceous cyst	Pyoderma gangrenosum
Consider	
Phycomycosis	Suppurative panniculitis
Nodular fasciitis	
Appendageal tumor	
Always Rule Out	
Panniculitis	Necrotizing cellulitis
Nodular vasculitis	

BOX 184-9 DIFFERENTIAL DIAGNOSIS OF *MYCOBACTERIUM MARINUM* LESIONS

Most Likely
- Blastomycosis
- Coccidioidomycosis
- Sporotrichosis

Consider
- Histoplasmosis
- Nocardiosis
- Tertiary syphilis
- Yaws

Always Rule Out
- Other mycobacterial infections

lesions are solitary, but occasionally lymphocutaneous spread occurs. They may heal spontaneously within 1–2 years, with residual scarring. Occasionally, the lesions are suppurative, rather than granulomatous, and may be multiple in both normal or immunosuppressed hosts.

Differential Diagnosis. (Box 184-9)

MYCOBACTERIUM KANSASII .

M. kansasii is the atypical *Mycobacterium* most closely related to *M. tuberculosis*. It is usually acquired from the environment. Endemic areas include Texas, Louisiana, the Chicago area, California, and Japan. Skin disease caused by *M. kansasii* usually occurs in adults, and is more common in individuals with underlying immunosuppression caused by Hodgkin disease, treatment for organ transplantation, or AIDS. Inoculation is usually attributable to minor trauma such as a puncture wound.

Clinical Findings.

M. kansasii infection may present in several forms. Most frequently, there are papules in a sporotrichoid distribution. Sometimes, subcutaneous nodules extend to deeper structures and may result in a carpal tunnel syndrome or joint disease. An ulcerated plaque may also develop as a metastatic lesion. Disseminated disease caused by *M. kansasii* infection occurs in immunosuppressed patients, and such patients have cellulitis and abscesses rather than granulomatous lesions. The most commonly affected organ is the lung, usually in patients with other pulmonary



Figure 184-12 **A.** *Mycobacterium marinum* infection on the back of the hand. Granulomatous nodular lesion with central ulceration at the site of inoculation. (Used with permission from A. Kuhlwein, MD.) **B.** Verrucous, violaceous plaque with central spontaneous clearing occurring at the site of an abrasion sustained in a fish tank. The lesion was caused by *M. marinum*.

BOX 184-10 DIFFERENTIAL DIAGNOSIS OF *MYCOBACTERIUM KANSASII* LESIONS

Most Likely
- Sporotrichosis

Consider
- Tuberculosis

Always Rule Out
- Other granulomatous infections of the skin

conditions (silicosis, emphysema). Infection may also cause cervical lymphadenopathy. As with *M. tuberculosis*, *M. kansasii* present in nasopharyngeal secretions can lead to periorificial cutaneous infection. These infections usually progress slowly, although a chronic stable lesion or even spontaneous regression may occur. Drug therapy should be initiated as soon as the diagnosis is made.

Differential Diagnosis. (Box 184-10)

MYCOBACTERIUM SCROFULACEUM. *Mycobacterium scrofulaceum* is widely distributed in the environment.

Clinical Findings. The usual manifestation of *M. scrofulaceum* infection is cervical lymphadenitis, frequently unilateral, in children, mainly between the ages of 1 and 3 years. Submandibular and submaxillary nodes are typically involved, rather than the tonsillar and anterior cervical nodes, as is characteristic for *M. tuberculosis* infection. There are no constitutional symptoms. Involved lymph nodes enlarge slowly over several weeks, and eventually ulcerate and develop fistulae. There is rarely an evidence of lung or other organ involvement. In most cases, the disease is benign and self-limited.

Differential Diagnosis. The differential diagnosis includes other forms of bacterial lymphadenitis; viral infections, including mumps and mononucleosis; and malignancy, including solid tumors, lymphoma, and leukemia.

MYCOBACTERIUM AVIUM-INTRACELLULARE. *M. avium*-intracellulare encompasses organisms with a wide variety of microbiologic and pathogenic properties. Well over 20 subtypes can be separated by immunologic techniques, although this is not necessary for clinical purposes.

These organisms are usually grouped together with *M. scrofulaceum* in the so-called *M. avium*-intracellulare-scrofulaceum complex, but are separated here for clinical reasons. Whereas *M. scrofulaceum* produces only a benign, self-limited lymphadenopathy with no organ involvement, *M. avium*-intracellulare infection usually causes lung disease or, less frequently, osteomyelitis. It may also produce a cervical lymphadenitis with sinus formation that is clinically indistinguishable from tuberculous scrofuloderma.

Clinical Findings. Primary skin disease caused by *M. avium*-intracellulare has been reported in rare instances, presenting as single or multiple painless, scaly yellowish plaques, sometimes resembling LV, or as subcutaneous nodules with a tendency to ulceration and a slowly progressive, chronic course. Sometimes, skin involvement occurs secondary to disseminated infection with *M. avium*-intracellulare. Skin lesions have included generalized cutaneous ulcerations, granulomas, infiltrated erythematous lesions on the extremities, pustules, and soft-tissue swelling. *M. avium*-intracellulare infections are an important cause of morbidity in patients with AIDS (see Chapter 198).

MYCOBACTERIUM SZULGAI, MYCOBACTERIUM HAEMOPHILUM, MYCOBACTERIUM GENAVENSE. *Mycobacterium szulgai*, *Mycobacterium haemophilum*, and *M. genavense* are rarely found to cause human disease in cases of otherwise unexplained cervical lymphadenitis, cellulitis, draining nodules and plaques, bursitis, pneumonia, and subcutaneous granulomatous eruptions.

MYCOBACTERIUM FORTUITUM, MYCOBACTERIUM CHELONAE, MYCOBACTERIUM ABSCESSUS. *M. fortuitum, Mycobacterium chelonae, and Mycobacterium abscessus*—three species of fast-growing, facultative pathogenic *Mycobacteria*—were previously grouped in the *M. fortuitum* complex but are now recognized as distinct species. These organisms seem to be widely distributed and can commonly be found in soil and water. Contamination of various materials, including surgical supplies, occurs but does not always result in clinical disease.

Clinical Findings. *M. fortuitum, M. chelonae, and M. abscessus* cause similar clinical diseases. Infection usually follows a puncture wound or a surgical procedure. The disease manifests itself as a painful red infiltrate at the site of inoculation; there are no signs of dissemination and no constitutional symptoms. Cold postinjection abscesses, especially in the tropics, may also be caused by fast-growing *Mycobacteria*. Recent cases in the United States have followed after pedicures and water immersion in salons.

The lesion is a dark red nodule, often with abscess formation and clear fluid drainage. Healthy children and adults may become infected, but disseminated disease usually occurs in hemodialysis patients or other immunologically compromised individuals. The disease course consists of multiple recurrent episodes of abscesses on the extremities or a generalized macular and papular eruption. Internal organs may be involved.

Histopathology. There is simultaneous occurrence of polymorphonuclear leukocyte microabscesses and granuloma formation with foreign body-type giant cells, the so-called dimorphic inflammatory response. There is usually necrosis but no caseation. Acid-fast bacilli may occasionally be found within microabscesses.

Diagnosis. Organisms of the *M. fortuitum* complex may be identified by special laboratories to permit a rational treatment.

ACKNOWLEDGMENT

The author thanks Bernard Naafs, MD, for his work on this chapter in the previous editions of this book.

KEY REFERENCES

Full reference list available at www.DIGM8.com

DVD contains references and additional content

1. WHO report 2009 – Global Tuberculosis Control. http://www.who.int/tb/publications/global_report/2009/key_points/en/index.html. Last accessed on March 13 2010
2. Center for Disease Control. MMWR weekly – Trends in Tuberculosis, United States 2008. http://www.cdc.gov/mmwr/preview/mmwrhtml/mm5810a2.htm?s_cid=mm5810a2_e#tab. Last accessed on March 13 2010
3. Rastogi N et al: The mycobacteria: An introduction to nomenclature and pathogenesis. *Rev Sci Tech* **20**:21, 2001
4. Pai M, Kalantri S, Dheda K: New tools and emerging technologies for the diagnosis of tuberculosis: Part II. Active tuberculosis and drug resistance. *Expert Rev Mol Diagn* **6**:423, 2006
34. Saiman L: The mycobacteriology of non-tuberculous mycobacteria. *Paediatr Respir Rev* **5** (Suppl A):S221, 2004
35. Lillis JV et al: Sequelae of World War II: An outbreak of chronic cutaneous nontuberculous mycobacterial infection among Satowanese islanders. *Clin Infect Dis* **48**(11):1541-1546, 2009
36. American Thoracic Society, CDC, and Infectious Disease Society of America: Treatment of tuberculosis. *MMWR Recomm Rep* **52**:1-77, 2003

Chapter 185 :: Actinomycosis, Nocardiosis, and Actinomycetoma

:: Francisco G. Bravo, Roberto Arenas & Daniel Asz Sigall

Actinomyces and *Nocardia* are a group of filamentous bacteria belonging to the same class, Actinobacteria, and same order, Actinomycetales. They cause human disease with prominent skin involvement. Microorganisms under this category were wrongly classified as fungi for a long time, because of their tendency to produce branching filaments, mimicking radiating hyphae (from the Greek *actino*, meaning sun). Their taxonomy is still evolving, resulting in continuous reclassification of different species in old and new families. Anaerobic endogenous *Actinomyces*, part of our normal respiratory, intestinal, and genitourinary flora, will cause localized suppurative disease with fistula formation that is analogous to the lumpy jaw of cattle. Aerobic environmental *Nocardia* sp. cause diseases ranging from cellulitis to paronychia to abscesses, with the most striking presentation being a lymphocutaneous, sporotrichoid syndrome. In addition, other aerobic environmental species of *Nocardia* and *Actinomyces* will cause one of the two known forms of mycetoma, the actinomycetoma.

The sulfur granule or grain, a clumping of filamentous bacteria seen in infected living tissue, is considered characteristic of the infection by these microorganisms, but is not always present and is also not specific (Table 185-1). Practicing dermatologists should be aware of the various morphologic variants of these diseases, so that measures may be taken to ensure the appropriate culturing techniques required for isolation.

ACTINOMYCOSIS

ACTINOMYCOSIS AT A GLANCE

- Worldwide distribution, relatively uncommon.
- *Actinomyces* are part of normal upper respiratory, intestinal, and genitourinary flora.
- *Actinomyces israelii* is the most common causative agent, usually mixed with Gram-positive cocci and anaerobes.
- Classical presentation is a chronic, localized infiltrative process with abscess fistula formation and draining sinuses.
- Most common location is cervicofacial (related to dental pathology), followed by abdominal, pelvic, and chest wall involvement.
- Pathologic findings include a chronic inflammatory infiltrate with granulation tissue or granuloma formation.
- Grains (sulfur granules) are characteristic but neither invariably present nor pathognomonic.

TABLE 185-1
Infectious Diseases with Production of Grains

Disease	Actinomycosis	Nocardiosis	Actinomycetoma	Eumycetoma	Botryomycosis
Clinical pattern	Lump with draining sinuses	Sporotrichoid, cellulitis	Lump with draining sinuses	Lump with draining sinuses	Lump with draining sinuses
Site	Cervicofacial, thorax, abdomen, pelvic	Extremities (upper > lower)	Feet, back, extremities	Feet mainly	Hand, head, feet
Source	Endogenous flora	Environment	Environment	Environment	Endogenous and environment
Most common causative agent	*Actinomyces israelii*	*Nocardia brasiliensis* *Nocardia asteroides*	*Nocardia brasiliensis* *Actinomadura madurae* *Actinomadura pelletieri* *Streptomyces somaliensis*	*Madurella mycetomatis* *Magnaporthe grisea* *Pseudallescheria boydii*	*Staphylococcus aureus* *Escherichia coli* *Pseudomonas aeruginosa*
Presence of grains, clinically or in tissue	Common	Rare (only disseminated)	Always	Always	Always
Content of grains	Filamentous bacteria	Filamentous bacteria	Filamentous bacteria	Hyphae	Cocci
Staining	Gram-positive	Gram-positive Weak acid-fast bacillus	Gram-positive Weak acid-fast bacillus (only if *Nocardia*)	Periodic acid-Schiff, Grocott	Gram-positive

EPIDEMIOLOGY

Described by Israel in 1878, the disease has a worldwide distribution. It is more commonly seen in males, ages 20–60, with females affected at a younger age. In the preantibiotic era, the incidence in the Netherlands and Germany was 1:100,000 inhabitants/year; in the 1970s, the reported incidence in Cleveland, Ohio, was 1:300,000 inhabitants/year, and in 1984, in Cologne, Germany, it was estimated to be 1:40,000 inhabitants/year.[1] Recently, an increased incidence of genitourinary actinomycosis has been described in females, related to the use of intrauterine devices (IUDs). Nowadays, there is a tendency of subtle cases with more limited involvement, many of them restricted to the oral cavity. Diagnosis in such circumstances requires a high index of suspicion.

ETIOLOGY AND PATHOGENESIS

The term *actinomycosis* implies disease produced by endogenous, anaerobic, or microaerophile, Gram-positive, nonspore-forming bacteria, belonging to the families Actinomycetaceae and Propionibacteriaceae, of the order Actinomycetales; and Bifidobacteriaceae, of the order Bifidobacteriales.[1] Their normal habitat is human or animal mucosal surfaces, with considerable host specificity, from the mouth to the upper respiratory, gastrointestinal, and female genital tract. Species known to cause disease in humans include *A. israelii*, *Actinomyces naeslundii*, *Actinomyces gerencseriae*, *Actinomyces viscosus*, *Actinomyces odontolyticus*, and *Actinomyces meyeri*, as well as *Propionibacterium propionicum* and *Bifidobacterium dentium*. The disease in most cases is mixed with other microorganisms sharing the same habitat, so it should be considered a synergistic infection, with the *Actinomyces* playing the role of guiding organism, defining the course, the symptoms, and the ultimate prognosis. Accompanying organisms may vary in number, from one to nine different species, and may include coagulase negative staphylococci, *Staphylococcus aureus*, α- and β-hemolytic streptococci, microaerophile and anaerobic streptococci, *Fusarium* and *Bacteroides* spp., and even *Propionibacterium* sp. other than *P. propionicum*.[1] This concomitant flora may be in part responsible for the disease course. If pyogenic bacteria are involved, such as *S. aureus* or β-hemolytic streptococci, the lesion will be acutely inflammatory and painful. If, on the contrary, anaerobes predominate, the course will be subacute and insidious. A distinctive more chronic course is seen when *A. israelii* or *A. gerencseriae* is accompanied by *Actinobacillus actinomycetemcomitans*. In recent years, with better culturing techniques, more than one *Actinomyces* have been isolated from one single lesion in several patients, stressing the possibility that single bacterial isolation, common in the past, was a technical artifact.

The infection has its portal of entry at a break on a mucous membrane. Most cervical and facial cases originate from periapical abscesses or after dental procedures. *Actinomyces* bacteremia seems to occur quite commonly after dental procedures.[2] Thoracic cases represent involvement of the chest wall by continuity

either from pleural or lung disease acquired by obstruction or aspiration. The same mechanism of spreading applies to disease of the abdominal wall, secondary to gut or genital pathology, following appendicitis, diverticulitis, surgery, or trauma. Perineal disease occurs as a consequence of involvement of the internal organs of the pelvis, often secondary to use of an intravaginal device or IUD. The only exception to the endogenous origin of the infection is hand involvement that follows fist or bite trauma.[3]

In tissue, the bacteria cluster in filamentous aggregates, the so-called *sulfur granules* (grains; see Table 185-1). They are commonly surrounded by acute and chronic inflammation, usually neutrophils, granulation tissue, and fibrosis. Granuloma formation is unusual. The fistula formation may give way to drainage of granules, their presence at once should not be considered specific for this disease.

CLINICAL FINDINGS

Actinomycosis should always be suspected when dealing with one of three features: (1) a mass-like inflammatory infiltrate of the skin and subcutaneous tissue, (2) sinus formation with drainage, and (3) a relapsing or refractory clinical course after short-term therapy with antibiotics. Actinomycotic granules may be seen macroscopically. Although most patients are immunocompetent, a recent series underlies the importance of *Actinomyces* as an emerging pathogen in patients with chronic granulomatous disease.[4]

Cervical actinomycosis is the most frequent form of disease,[5] accounting for approximately 55% of cases. Commonly, there is a history of poor dental hygiene, dental or periodontal disease, dental procedure, surgery, or penetrating trauma through the oral mucosa. Most of the infections start as a periapical abscess. The most common location is on the jaw angle and high cervical area (60%), followed by the cheek (16%), the chin (13%), and less commonly, the temporomandibular joint and the retromandibular area. The lesion starts as a solid mass in any of those locations, and initially may be confused with a neoplastic process (Fig. 185-1). It may progress to form recurring abscesses and later will spread to adjacent structures, not respecting anatomic planes. Propagation to lymph nodes is uncommon but eventually may involve the orbit, cranium, spine, and even vascular structures. The lesion is sometimes reported as painless, but pain may be present, as well as fever and leukocytosis. With extension to the skin surface, sinus tracts appear (Fig. 185-2). The overlying skin may have a purplish red hue. Trismus may develop. Bone involvement, mostly of the jaw, is present in 10% of cases. More limited disease may produce a mass or an ulcer, affecting any structure in the mouth or the nasopharyngeal region. Extension to the ear may present as chronic otitis media or mastoiditis. In addition to orbital involvement, there are reported cases of lacrimal canaliculitis and endophthalmitis.

Thoracic actinomycosis comprises 15% of cases. The common source of infection is the aspiration of microorganism from the oropharynx, although other routes



Figure 185-1 Cervicofacial actinomycosis. A solid mass on the mandibular angle that can be confused with a neoplastic process.

are possible, such as propagation of cervicofacial disease to the mediastinum. The disease may involve the lung, pleura, mediastinum, and chest wall. The course is indolent, with chest pain, fever, weight loss, cough, and less frequently, hemoptysis, mimicking tuberculosis. Radiologically, the disease will present as a mass or pneumonia, with pleural involvement by continuity. Relevant to dermatologists, up to 26% of cases will have chest wall involvement[5] with the developing of a cutaneous abscess and sinus formation (Fig. 185-3). Parenchymal, pleural, and chest wall disease occurring



Figure 185-2 Typical cervicofacial actinomycosis: a lump with sinus formation. (Used with permission from Wilson Delgado, DDS; and Lepoldo Meneses, DDS; Universidad Peruana Cayetano Heredia, Lima.)



Figure 185-3 Thoracic actinomycosis from a patient who died from disseminated disease.

together will make actinomycosis a most likely diagnosis. Mediastinal actinomycosis may show either as anterior chest wall disease (rarely sternal involvement), or paraspinal abscess. Involvement of breast tissue and breast implants has also been described.

Abdominal actinomycosis represents about 20% of all cases. It is as a consequence of spreading from the gastrointestinal tract or from the female genital tract. Appendicitis and diverticulitis are common precipitating events. Any organ in the peritoneal cavity may be affected; by continuity, the disease may spread to the abdominal wall. An inflammatory mass may appear in the skin surface of the abdominal region or the perineum, with later development of sinuses. In the perianal area, multiple abscesses and fistula formation may occur. From there on, spreading to buttocks, thigh, scrotum, or groin may follow.

Primary pelvic disease most commonly originates from ascending infection from the female genital tract and less commonly from abdominal disease. The role of IUD as a risk factor has been well-established and infection is usually associated with prolonged use, 8 years on average.

Punch or fist actinomycosis represents a particularly uncommon but interesting clinical presentation. It usually follows blunt trauma of a closed fist against an adversary's mouth; similar findings may originate from a human bite. It usually involves the proximal phalanges and metacarpal bones. First a soft tissue infection, it will eventually spread to the bony structures. Grains are commonly seen in this particular form.

Actinomycosis of the central nervous system (CNS) may present as brain abscess, meningitis, meningoencephalitis, subdural empyema, actinomycoma, and spinal abscess. It is usually secondary to hematogenous spread.

LABORATORY FINDINGS

Laboratory tests considered useful include direct examination of draining material, culture, and biopsy. Direct examination will show the presence of filamentous *Actinomyces* on Gram stain. The isolation of *Actinomyces* in culture should be considered diagnostic, if coming from a sterile site. However, positive culture rates are as low as 35% in some series. The processing should be done in anaerobic conditions, and when all techniques available today are used, the percentage of isolates that cannot to be identified is as low as 2.8%.[1] Needle aspiration has been recently reported as an additional diagnostic procedure.[6]

The best material to culture is tissue, pus, or microscopic granules, and avoidance of any antibiotic treatment is recommended. Appropriate culture media include thioglycolate with 0.5 sterile rabbit serum at 35°C (95°F) for 14 days. Colonies may appear within 5–7 days, but up to 2 weeks may be required. *A. israelii* classically will produce a "molar tooth" colony on agar and will look clumpy on broth. *A. odontolyticus* colonies are red or rusty in color. *Actinomyces* are indole negative. The microbiologic identification of different species occurs only in a minority of cases. Tests for urease, catalase, gelatin hydrolysis, and fermentation of cellobiose, trehalose, and arabinose may also be performed, as well as gas liquid chromatography, indirect immunofluorescence testing, and sequencing or restriction analysis of amplified 16S ribosomal DNA.

The presence of granules, either microscopically or macroscopically, is very relevant, especially if obtained from tissues not connected to mucosal surfaces. Grains are usually yellow (hence the name *sulfur granules*), but can be white, pinkish gray, gray, or brown. In tissue samples, special stains, such as Brown–Brenn, Gram, Giemsa, or Gomori stains, are required to demonstrate filamentous structures. The number of grains is usually scanty: only one single granule was identified from 25% of specimens in a study of 181 cases.[5] The microscopic examination of the granules may reveal the Splendore–Hoeppli phenomena, a rim of eosinophilic material surrounding the granules in tissue sections. The lack of staining with Fite-modified acid-fast stain separates *Actinomyces* from *Nocardia* sp. Eumycetoma granules stain positive with periodic acid-Schiff and Gomori stains, whereas granules from Botryomycosis should show clumps of bacteria. Direct immunofluorescent staining is available for some species, including *A. israelii* (see Table 185-1).

DIFFERENTIAL DIAGNOSIS

Depending on the site affected, the differential diagnosis will include infections such as tuberculosis, noninfectious inflammatory processes such as hidradenitis or inflammatory bowel disease, and neoplasia (Box 185-1).

BOX 185-1 DIFFERENTIAL DIAGNOSIS OF ACTINOMYCOSIS (SITE SPECIFIC)

Most Likely

- Face: tuberculosis, odontogenic abscesses, parotid tumors
- Chest: tuberculosis, neoplasm, pyogenic infections
- Abdomen and pelvis: tuberculosis, inflammatory bowel disease, hidradenitis suppurativa, neoplasm

Consider

- Face: lupus panniculitis, granuloma inguinale
- Pelvis: granuloma inguinale

PROGNOSIS AND THERAPY

There is general agreement that the treatment of actinomycosis requires high-dose antibiotics to be given for a long period. The treatment of choice is penicillin G, 18–24 million units intravenously for 2–6 weeks, followed by oral penicillin or amoxicillin, to be given for 6–12 months. Cervicofacial disease or any more limited disease can receive a shorter course of therapy. A good rule to follow is to treat until there is full resolution of clinical disease. Alternative treatment for those allergic to penicillin includes tetracycline, doxycycline, erythromycin, and clindamycin. Imipenem has been used successfully as short-term therapy. Chloramphenicol is the alternative to penicillin in cases of CNS involvement. Risk factors for death or relapse include duration of disease longer than 2 months, lack of antibiotic therapy or surgical therapy, and needle aspiration rather than open drainage or excision.

With early diagnosis and more limited disease, as compared to the bulky disease of the past, treatment can be shorter: 30 days for cervicofacial disease and 3 months for pelvic or thoracic disease.[7] Periapical actinomycosis can be successfully treated with curettage and 10 days of antibiotic therapy.

Surgery is indicated for bulky disease involving the chest, abdomen, pelvis, and CNS. It should be directed to resection of necrotic tissue, excision of sinus tracts, draining of empyemas and abscesses, and curettage of bone, always accompanied by antibiotic therapy.

Antibiotics effective against synergistic microbes that accompany the *Actinomyces* can reasonably be included in the initial therapy.

PREVENTION

Good oral hygiene and prevention of periodontal disease may decrease colonization by *Actinomyces*. Physicians managing patients using an IUD should be aware of the risk of developing the disease.

NOCARDIOSIS

NOCARDIOSIS AT A GLANCE

- Aerobic Gram-positive filamentous bacteria.
- Worldwide distribution, environmentally acquired infection, due to primary traumatic inoculation.
- Pulmonary infections mostly in immunocompromised patients and skin infections mostly in immunocompetent patients.
- Skin disease mostly caused by *Nocardia brasiliensis*; less commonly *Nocardia asteroides*, *Nocardia otitidiscaviarum*, and *Nocardia farcinica*.
- Cutaneous nocardiosis can take the form of either cellulitis or more characteristic lymphocutaneous nodules in a sporotrichoid pattern; skin lesions also occur in disseminated disease.
- Diagnosis is based on Gram stain of clinical specimen showing thin, Gram-positive branching bacteria, weakly positive with acid-fast staining; microbiologic isolation of *Nocardia* sp. is diagnostic, but requires keeping cultures under observation 5–7 days.
- Treatment: sulfonamides.

EPIDEMIOLOGY

The *Nocardia* sp. are aerobic, Gram-positive, filamentous, higher bacteria found worldwide in soil and decaying organic plant matter. They can be found in house dust, beach sand, garden soil, and swimming pools. They are able to cause disease in many organs, including the skin. Approximately 1,000 cases of nocardiosis occur annually in the United States.[8] Cutaneous disease comprises 5%–22% of all cases.[8] A higher incidence of primary cutaneous nocardiosis in Europe may be explained on the basis of more frequent isolation of *Nocardia brasiliensis* in the environment. Patients have also been reported in India and Argentina.[9] Disease occurs more commonly in males.

Immunocompromised patients account for 50% of cases, mostly pulmonary, systemic, and CNS infections. They are commonly seen in transplant patients, patients with acquired immunodeficiency syndrome (AIDS)[8] or malignancy, or those receiving steroids. Primary cutaneous disease is most commonly seen in immunocompetent patients and has been reported

rarely in children in United States, mostly in the south and southwestern part of the country.[10]

ETIOLOGY AND PATHOGENESIS

The *Nocardia* sp. of medical importance includes *Nocardia asteroides*, most commonly associated with lung and systemic disease, and *N. brasiliensis*, most commonly associated with skin infection. Other species include *Nocardia farcinica*, *Nocardia otitidiscaviarum*, *Nocardia nova*, *Nocardia pseudobrasiliensis*, *Nocardia transvalensis*, and *Nocardia abscessus*. It is only recently that many of these species have been completely separated, especially those of the *N. asteroides* group, including *N. farcinica* and *N. nova*. It is interesting to note that *Nocardia* sp. belong to a subgroup of bacteria called the *aerobic nocardioform actinomycetes* that also include *Mycobacterium*, *Corynebacterium*, *Rhodococcus*, and *Gordona*. All these microorganisms have mycolic acid as constituent of their cell wall, which explains the varying acid fastness on appropriate staining. The proposed etiologic agent for Whipple disease, *Tropheryma whippelii*, also belongs to this group.

The usual inflammatory response in infected tissue is neutrophilic, with branching, beading filamentous bacteria within abscesses. Sulfur granules are uncommon in primary cutaneous nocardiosis; they have been described in disseminated disease. They are more commonly seen when the clinical picture is that of mycetoma (see Section "Actinomycetoma").

Certain virulent strains of *Nocardia* are resistant to neutrophil-mediated killing.[11] They can inhibit phagosome–lysosome fusion in vitro, giving rise to L-forms able to survive inside macrophages. The existence of cell wall deficient L-forms may explain the occasional late relapse. The presence of superoxide dismutase in growth media is characteristic of the more virulent strains. Complex cell wall glycolipids also contribute to virulence.[11]

The initial neutrophilic reaction is followed by a more cell-related immune response that is responsible for clearing the infection from the lung tissue and prevents dissemination. If this fails, a chronic neutrophilic response results in a more indolent course. Reduced cellular immunity predisposes transplant and AIDS patients to infection, with transplant patients accounting for up to 13% of cases in the United States.[9] Some species are considered more difficult to treat: *N. farcinica* has a high degree of resistance to various antibiotics, especially third-generation cephalosporins and aminoglycosides. Another recently described species, *N. pseudobrasiliensis*, has a higher rate of dissemination.

CLINICAL FINDINGS

Cutaneous involvement by *Nocardia* can manifest either as cellulitis or more characteristically, as lymphocutaneous nodules in a sporotrichoid pattern. Disseminated disease can also present in the skin as a consequence of hematogenous spread. In most series, skin disease is second only to pulmonary involvement in frequency. Mycetoma due to *Nocardia* is discussed in Section "Clinical Findings" under "Actinomycetoma."

Predisposing factors for primary cutaneous nocardiosis include soil or sand exposure while gardening or farming; or superficial injury from domestic shrubbery, outdoor falls, or accidents. The frequent history of thorn injury or gardening may suggest incorrectly a diagnosis of sporotrichosis. Cat scratches or insect bites may be also the portal of entry, especially in children.[7]

The most common cause of primary cutaneous nocardiosis is *N. brasiliensis*, but *N. asteroides*, *N. otitidiscaviarum*, *N. nova*, and *N. farcinica* have also been implicated. Most patients are immunocompetent, but *Nocardia* cutaneous infection may also occur in the context of immunosuppression. A recent series of nocardial infection in AIDS patients showed skin lesions in 11% of cases, most commonly cutaneous abscesses and suppurative adenitis.[8] Nocardiosis has recently described in patients receiving antitumor necrosis factor (TNF) biologic therapy for Crohn's disease.[12]

The disease has been also described in ulcerobullous, linear/keloid, and nodulopustular forms (Fig. 185-4A) that may evolve into the more typical sporotrichoid pattern (see Fig. 185-4B). Patients

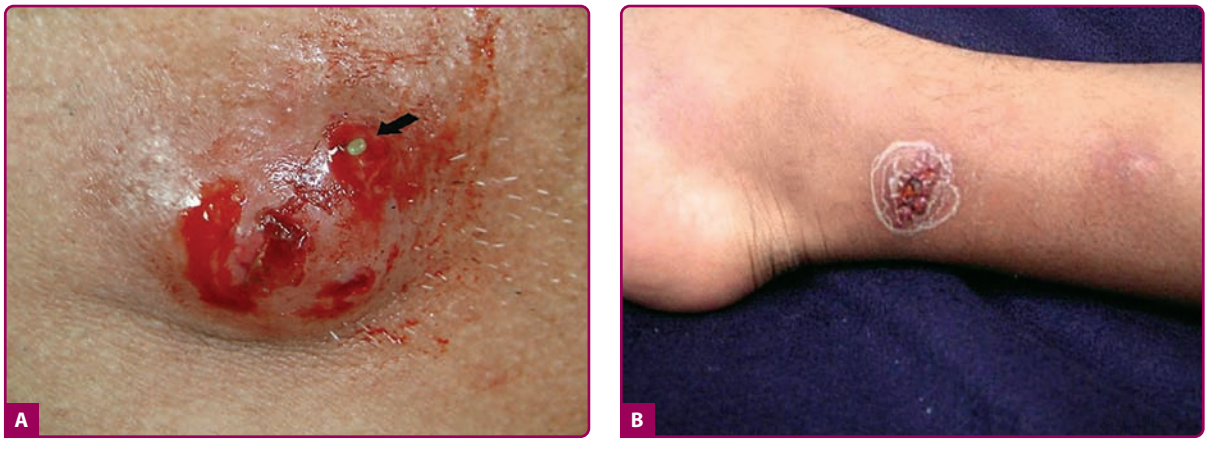

Figure 185-4 **A.** Early lesions of lymphocutaneous nocardiosis. **B.** Lymphocutaneous nocardiosis: typical sporotrichoid pattern. (Used with permission from Marcia Karam, Daniel Asz, and Roberto Arenas, Hospital Manuel Gea González, Mexico City.)

may also present acutely with eccrine hidradenitis, or chronically with hyperkeratotic plaques. Cutaneous nocardiosis may begin suddenly, reactivate after months to years, or follow a chronic course for up to 10 years. A case of simultaneous infection in a husband and wife has been described. Very rarely, pure cutaneous disease may lead to systemic illness. The cellulitic form most commonly affects the lower extremities, as compared to sporotrichoid form, in which the upper extremities are most commonly involved. Children frequently present with cellulitis, abscesses, and lymphadenitis affecting lower extremities and trunk; 20% of cases will have lesions at multiple sites.[10]

Lymphocutaneous forms may account for 24% of all *Nocardia* cutaneous infections (see Fig. 185-4B).[13] The first case proven to be because of *N. brasiliensis* was described by Alarcon[14]; the patient developed acute nodular suppurative lymphadenitis after injuring the finger with a rose thorn. Although the upper extremity is the most common location, disease of lower extremity and cervicofacial region have also been reported. A common history is appearance of a solitary papule or nodule on the upper limbs, 2–4 weeks after cutaneous inoculation. Then, proximal nodules develop along lymphatic drainage. The primary lesion is initially warm and tender, then becomes fluctuant and later ulcerates. Macroscopic grains may be seen, but draining sinuses are rare. Systemic symptoms are mild. Regional lymphadenitis is common but lymphangitis is unusual.

Sternal wound infections usually develop 1 month after thoracic surgery. The symptoms include erythema, clear-to-purulent drainage, wound dehiscence, and/or fever. Diabetes mellitus seems to be the only identifiable risk factor. At least in one outbreak, the hands of an anesthesiologist were culture positive for *N. farcinica*. In another case of sternal osteomyelitis and mediastinal abscess, the patient's occupation (carrying wooden crates loaded with vegetables) may have been the relevant risk factor for infection.

Pulmonary disease is the most common form of clinical infection, but, compared to primary cutaneous diseases, is often due to different species (*N. asteroides* predominates). The disease may take the form of an acute pneumonia or a chronic process with bronchopneumonia, abscesses, and development of cavities. Ten percent of pulmonary infections disseminate to the skin.

Bacteremia due to *Nocardia* is seen in debilitated patients with concomitant malignancy, and *N. asteroides* is the agent most commonly isolated. Cutaneous or subcutaneous nodules and abscesses occur in many patients, and the skin may be the portal of entry in some cases. Catheter-associated nocardemia is well-documented.

LABORATORY FINDINGS

Laboratory tests considered useful include direct examination of clinical specimens, culture, and biopsy. The importance of direct microscopic examination for the presence of granules cannot be overemphasized. Organisms are detected as Gram-positive, branched filamentous "hyphae," and branching at right angles is diagnostic. Acid-fast stains, including Fite Faraco and the modified Kinyoun technique, show the filamentous bacteria. For isolation, cultures should be kept for up to 2–3 weeks. The microorganisms grow satisfactorily on most of the nonselective media used for isolation of bacteria, mycobacterium, and fungi. Because slow growth of *Nocardia* colonies over 2 days to 2 weeks on routine culture media allows bacterial overgrowth, isolation of this organism from soil and nonsterile sites may be difficult. *Nocardia* do not survive the digestive procedures used routinely in mycobacterial culture. Thayer–Martin and buffered charcoal–yeast extract agar may be used and pretreatment of specimens with a low pH potassium chloride-hydrochloric acid solution for 4 minutes is required.

After initial isolation, subcultures should be incubated at 25°C (77°F), 35°C (95°F), and 45°C (113°F). *N. asteroides* grows best at 35°C (95°F). Aerial hyphae, giving a chalky appearance, may be seen macroscopically in cultures; however, in the early stages of growth, they are only seen with the microscope. *N. asteroides* complex colonies vary from salmon pink to orange, whereas *N. brasiliensis* are usually orange, and *N. otitidiscaviarum* are usually pale. Identification of genus can be achieved by microscopic and colonial morphology, growth requirements, metabolism of glucose, arylsulfatase production, growth in lysozyme, and phenotypic molecular characteristics. Genotyping methods, including polymerase chain reaction, DNA hybridization, and sequencing of 16 ribosomal RNA, are useful, if available.

Histologic patterns described on histology include monocytic infiltrates, fibrinopurulent exudates, granuloma formation, chronic nodular dermatitis, microabscess formation, and coccobacillary organisms; the presence of granules has been described in disseminated cases.[9]

DIFFERENTIAL DIAGNOSIS

In cases of cellulitis, the differential diagnosis is extensive, including both infectious and noninfectious etiologies. However, in the lymphocutaneous form, the differential diagnosis can be approached more systematically. The sporotrichoid pattern should be differentiated from the more acute ulceroglandular syndrome, as is seen in tularemia and cat-scratch disease (Box 185-2).

PROGNOSIS AND CLINICAL COURSE

Primary cutaneous nocardiosis is usually subacute or chronic but has a good prognosis when treated appropriately. However, the disease has the potential to disseminate; sternal wound infections may be complicated with osteomyelitis.[9] Systemic disease, especially sepsis, has a high mortality rate, 44%–85%, if the patient is nocardemic.[11]

TREATMENT

The treatment of *Nocardia* infection is appropriate antimicrobial therapy and surgical drainage and debridement.

BOX 185-2 DIFFERENTIAL DIAGNOSIS OF LYMPHOCUTANEOUS NOCARDIOSIS

Most Likely

- Sporotrichosis
- *Mycobacterium marinum* infection
- Leishmaniasis
- Pyoderma due to *Staphylococcus aureus*

Consider

- Cryptococcosis
- Tuberculosis
- *Mycobacterium kansasii, Mycobacterium chelonae,* and *Mycobacterium fortuitum*
- Cysticercosis

Rule Out

- Epithelioid sarcoma
- Metastatic disease

Factors to consider include site and severity of infection, the immune status of the host, potential for interactions and the species of *Nocardia* involved. The current standard for sensitivity testing is by the broth microdilution method.

Sulfonamides, alone or in combination with trimethoprim (TMP), are the cornerstone of therapy for *Nocardia* infections, but are ineffective against *N. otitidiscaviarum*.[11] For primary cutaneous nocardiosis of mild to moderate intensity, sulfonamide (either sulfadiazine or sulfisoxazole) alone has been considered adequate therapy,[11] but other authors consider TMP–sulfamethoxazole (SMX) the treatment of choice, despite lack of controlled trials. This is based on synergistic activity of these drugs in vitro against *Nocardia*. The commercially available preparation has a fixed ratio of 1:5, and the dose recommended at the present time is 5–10 mg/kg TMP and 25–50 mg/kg SMX in two to four divided doses. For primary cutaneous nocardiosis, 5 mg/kg of TMP should be sufficient. Clinical improvement should be seen within 3–10 days, and 1–4 months of treatment should be curative for sporotrichoid nodules and cutaneous ulcers. Prolonged therapy is required for immunosuppressed patients. Minocycline 100–200 mg twice a day is considered the alternative treatment in cases of sulfonamide hypersensitivity or poor tolerance.

In more severe cases or disease involving other organs, a combination of sulfonamide with a second agent is recommended. The second-line drugs most recommended are amikacin, imipenem, and ceftriaxone. Alternative second-line drugs include amoxicillin clavulanate and linezolid. Immunosuppression is a good indication for a two-drug regimen, including amikacin; 88% cure rate has been reported when this drug is used.[9] Sternal infections due to *N. asteroides* have responded to oral ofloxacin therapy.[8] *N. farcinica* has a high degree of resistance to various antibiotics, especially third-generation cephalosporin and imipenem, and combined therapy is highly recommended. Extended treatment for extracutaneous nocardiosis, with parenteral therapy followed by an oral regimen is necessary. Surgery is indicated in cases of abscesses (drainage) or extensive necrosis (debridement). Spontaneous resolution or good clinical response despite inappropriate therapy has been seen in children with *Nocardia* cellulitis or lymphadenitis.[10]

PREVENTION

The low incidence of *Nocardia* infections in immunodeficient states does not justify prophylactic use of antibiotics. AIDS patients receiving TMP–SMX for *Pneumocystis* are already protected against *Nocardia*.

ACTINOMYCETOMA

(See also Chapter 185)

ACTINOMYCETOMA AT A GLANCE

- Actinomycetoma is caused by bacteria, as opposed to eumycetoma, which is caused by fungi.
- More commonly seen in the tropics.
- Several microorganisms cause the disease. Some species are specific for some geographic areas. In the Americas, *Nocardia brasiliensis* predominates.
- More common in men and in lower extremities.
- Visceral involvement has bad prognosis.
- Characterized by inflammation, tumefaction, and discharging sinus tracts.
- Macroscopic or microscopic grains are usually white. Gram staining shows filamentous bacteria.

EPIDEMIOLOGY

Mycetomas are chronic infections of the skin, underlying tissues, sometimes bones, and rarely viscera, caused by both bacteria (actinomycetomas) and fungi (eumycetomas).[10] Only actinomycetoma is discussed further in this chapter (for eumycetomas, see Chapter 185). The disease has a worldwide distribution but it is more frequent in the tropics, especially in India, Sudan, Somalia, Mexico, and Venezuela. *Actinomadura pelletieri* and *Actinomadura madurae* are common agents in Senegal.[15] Occasional cases are seen in the United States, particularly in the south. Actinomycetoma

affect mainly men, but frequency before 15 years of age is similar in both sexes.[16]

ETIOLOGY AND PATHOGENESIS

Microorganisms reported to cause actinomycetomas include *N. brasiliensis*, *A madurae*, *A. pelletieri*, *Streptomyces somaliensis*, and less commonly, *N. asteroides*, *N. otitidiscaviarum*, *Nocardiopsis dassonvillei*, and *N. transvalensis*.[17] *N. pseudobrasiliensis*, *Nocardia veterana, Nocardia mexicana and Sesamia sudanensis* sp. have also been reported. The new taxon *N. pseudobrasiliensis* has been associated with invasive or disseminated infections.[18] The infection most commonly affects people living in rural areas in developing countries.

Recent studies using DNA hybridization and ribosomal RNA sequencing have confirmed marked heterogeneity among the genera of aerobic actinomycetes.

In North America (Mexico), South America, and Australia, *N. brasiliensis* is the leading cause of actinomycetomas; in Africa, Saudi Arabia, and India, *S. somaliensis* and *A. madurae* predominate; this species is also identified as the etiologic agent in 10%–15% of cases in Mexico and Venezuela.[19]

Cell-mediated immunity may influence mycetoma pathogenesis; $CD8^+$ lymphocytes and macrophages are the main cells implicated. *N. brasiliensis* as an intracellular bacterium modulates macrophage cytokine production, which aids survival of the pathogen.[20] In patients with actinomycetoma the levels of IgG1, IgG2, IgG3, IgG4, and IgM have demonstrated to be higher than in a control group. These findings suggest that the increase or deficiency of a determined immunoglobulin class, as well as the relationship between different subclasses, play a role in the pathogenesis of actinomycetoma.



Figure 185-5 Actinomycetoma of the lower leg. Multiple, indolent, coalescing nodules.



Figure 185-6 Mycetoma of the foot produced by *Nocardia* sp.: typical location, with multiple draining sites.

CLINICAL FINDINGS

Actinomycetoma is a chronic, localized, slowly progressive, painless disease of the skin and subcutaneous tissue. The pathologic process usually begins with a minor injury. Walking barefooted or wearing sandals may be considered a risk factor for these infections in rural communities. The lower limbs are involved in 64% of the cases (Fig. 185-5), the foot being the most common site (Fig. 185-6 and 185-7). The lower leg, knee, and thigh, as well as the hand, forearm (Figs. 185-8 and 185-9), face, neck, and abdominal wall, may also be affected. In Mexico, the upper back (Figs. 185-10 and 185-11) is involved in 17%–25% of cases in relation to occupational activity such as firewood collection. Actinomycetoma caused by *Nocardia* sp. is a very inflammatory process characterized by tumefaction, destructive granuloma with a nodular appearance, deformity, and discharging sinus tracts with communicating channels that exude pus. Ulceration, crusting, and scarring are also observed.[14] Mycetoma due to *A. madurae*, *A. pelletieri*, and *S. somaliensis* are less inflammatory with smaller sinus tracts; *A. madurae* is mainly seen in women with plantar involvement.[19] With all these agents, the granules may be seen with the naked eye (see Table 185-1), usually in a cream color; the exception will be *A. pelletieri*, in which the granules are red.



Figure 185-7 Mycetoma of the foot by *Actinomyces* sp.: this is a less inflammatory form that what is seen in *Nocardia* cases.



Figure 185-8 Mycetoma of the hand and wrist caused by *Nocardia brasiliensis*. Note gross deformity. (Used with permission from Roberto Arenas, MD, Hospital Manuel Gea González, Mexico City.)

The course is chronic and progressive, with potential involvement of bones, lung, and abdominal viscera. In women, mycetomas increase in size during pregnancy and spontaneously improve after delivery. Advanced cases may cause functional disability. Atypical clinical forms include the cryptic mycetoma (without sinus tracts), the so-called *mini-mycetoma* (single or multiple small lesions observed mainly in children and adolescents), and the occasional inguinal "metastatic" lesions from a primary mycetoma of the foot.[14]

LABORATORY FINDINGS

Skin biopsy plays an important role in the diagnosis of actinomycetoma. Typically, in hematoxylin and eosin stained tissue sections, there is a suppurative reaction characterized by the presence of polymorphonuclear cells, fibrosis, neovascularization, and rarely, a granulomatous reaction with a tuberculoid granuloma.[14] *Nocardia* infection is characterized by granules 30–200 m in diameter, partially basophilic to amphophilic, with an amorphous, eosinophilic, radially arranged material on the periphery (the so-called *Splendore–Hoeppli phenomenon*). Granules of *A. madurae* are soft and bigger (1–3 mm diameter), purple with a cartographic shape and an eosinophilic fringe (Fig. 185-12). *A. pelletieri* granules are firm and red with a diameter of 200–500 m. Granules of *S. somaliensis* are rounded, hard, pale, and 1.5–10.0 mm in diameter.[14] These organisms stain in tissue with Gomori methenamine silver, periodic acid-Schiff, and the Brown–Brenn modification of the Gram stain.



Figure 185-9 Radiograph from patient in **Fig. 185-6** shows associated marked destruction of bones and underlying soft tissues. (Used with permission from Roberto Arenas, MD, Hospital Manuel Gea González, Mexico City.)



Figure 185-10 Mycetoma of the shoulder caused by *Nocardia brasiliensis*. (Used with permission from Maria Cecilia Albornoz, MD, Instituto de Biomedicina, Caracas.)

Clinical specimens should be sent for direct examination (Gram stain) and culture. On direct examination, *Nocardia* granules are microscopic with a yellowish color. Granules produced by other agents are macroscopic: those of *A. madurae* are white, yellow, or cream, whereas grains from *A. pelletieri* are red and those of *S. somaliensis* are cream to brown color. Fine needle aspiration cytology has been reported as a good diagnostic tool. The cell block technique of mycetoma aspirates can be use for cytodiagnosis, showing findings similar to histopathologic sections.[21]

The microorganisms can be cultured on Sabouraud's dextrose agar or Lowenstein–Jensen at room temperature; *Nocardia* strains are white–yellow hard colonies. Microscopically, its very thin filaments are Gram-stain positive and acid-fast with the Kinyoun's stain. *A. madurae* produce slowly growing beige or pink colonies; *A. pelletieri* colonies are red. *S. somaliensis* produce beige or tanned colonies. All *Actinomyces* and *Streptomyces* sp. are acid-fast negative.[14]

Biochemistry can be used for identification. *N. brasiliensis* hydrolyzes casein and tyrosine, but not xanthine;



Figure 185-11 **A.** Huge scapulothoracic mycetoma caused by *Nocardia brasiliensis*. Note multiple fistulae. **B.** Close-up. Note doughnut-shaped masses and purulent drainage. (**B,** Used with permission from Maria Cecilia Albornoz, MD, Instituto de Biomedicina, Caracas.)

N. otitidiscaviarum is negative to casein and tyrosine and positive to xanthine testing; *N. asteroides* is negative to all these tests.

An enzyme-linked immunosorbent assay has been described for the diagnosis of mycetoma due to *N. brasiliensis*; it has been proposed as a method to predict the response to therapy. This test detects antibodies against two immunodominant antigens (24 and 26 kDa). An additional advantage of this particular assay might be its demonstrated cross-reactivity with *N. asteroids*.[22]

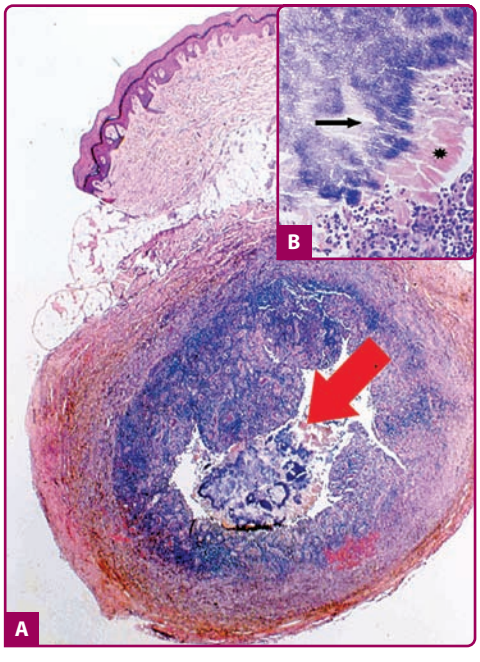

Figure 185-12 **A.** Skin biopsy of an *Actinomadura* mycetoma shows the granule (*red arrow*) inside the inflammatory reaction (hematoxylin and eosin, 20×). **B.** The contrast between the blue fibrillary material (*black arrow*), representing bacteria, and the eosinophilic proteinaceous material of the Splendore–Hoeppli phenomenon (*star*) (hematoxylin and eosin, 100×).

The most common radiographic abnormalities are soft tissue swelling, periosteal reaction and sclerosis and bone cavities.[23] Ultrasonography is also a useful modality. The utility of helical computed tomography (HCT) especially in trunk mycetomas provides evidence about the grade of invasion such as visceral, muscular, and vascular systems, and calculation of the affected area.[24]

DIFFERENTIAL DIAGNOSIS

The differential diagnosis includes other infections causing fistulae; such as eumycotic mycetoma, actinomycosis, botryomycosis, scrofuloderma, and atypical mycobacterial infections (Box 185-3). Botryomycosis is a condition that can mimic actinomycetoma and eumycetoma, both clinically and histologically. The disease can be caused by several organisms, most commonly *S. aureus*, *Escherichia coli*, *Pseudomonas aeruginosa*, *Proteus vulgaris*, *Actinobacillus* sp., *Streptococcus* sp., Gram-negative coccobacilli, *Propionibacterium* acne, and other anaerobic bacteria. The cutaneous form accounts for 75% of the cases; visceral involvement, mainly the lung, is rare. The disease is characterized by localized areas of infiltration, with mass effect and draining sinuses. Extension to the underlying structures, including bone, is not uncommon. Most commonly affected areas are exposed surfaces, such as hands, head, and feet. Patients usually have a predisposing

BOX 185-3 DIFFERENTIAL DIAGNOSIS OF ACTINOMYCETOMA

- Eumycotic mycetoma
- Actinomycosis
- Botryomycosis
- Scrofuloderma
- Atypical mycobacterial infections

factor such as local trauma, a foreign body, diabetes, or HIV infection. Botryomycosis is also characterized by the presence of granules, which can be seen macroscopically and microscopically. As in mycetoma, the center of the granule will show agglomeration of the causal agent, most commonly, Gram-positive cocci. Splendore–Hoeppli phenomenon may also be seen around the granules.

TREATMENT

Therapy for patients with actinomycetoma should be individualized. Economic considerations may influence the choice of therapy, particularly in developing countries.

Molecular identification of the causal agents and development of genetic markers for disease can improve management. Cure may be defined by a lack of clinical activity, absence of grains and negative cultures. The cure rates vary between 60% and 90%. Treatment periods are very long, especially with bone and visceral involvement, for which prognosis is poor.[25]

Combined antibiotic therapy prevents the development of drug resistance and eradicates any residual infection. The treatment of choice in actinomycetoma caused by *N. brasiliensis* is diaminodiphenylsulfone (Dapsone) 100–200 mg/day (3–5 mg/kg) plus TMP–SMX 160/800 mg twice a day for several months in initial cases; treatment should continue for up to 2 years.[14] Dapsone can also be combined with streptomycin, 1 g/day; clofazimine, 100 mg/day; rifampin, 300 mg twice/day; tetracycline, 1 g/day; or isoniazid, 300–600 mg/day; alternative drugs include kanamycin and phosphomycin. Some resistant cases have been treated with amoxicillin, 500 mg, plus clavulanic acid, 125 mg/day for 5 months.

Amikacin alone or combined with imipenem are powerful antibiotics used as alternative treatments for severe or multiresistant mycetomas, especially those with bone and visceral involvement. In adults, amikacin is administered 15 mg/kg/day (500 mg intramuscularly twice a day) for 3 weeks; ototoxicity and nephrotoxicity may develop.[26] Carbapenems as imipenem and meropenem have a broad microbicidal activity refractory to hydrolysis by β-lactamases. They have demonstrated good in vitro and in vivo activity against *Nocardia* asteroides complex, good in vitro sensitivity against *A. madurae*, and apparent low in vitro activity against *N. brasiliensis*. Imipenem has been proposed as a suitable option for severe *N. brasiliensis* infection refractory to other drug therapies.[27] Patients treated with intravenous imipenem must be hospitalized; the drug can be given as monotherapy at 500 mg three times daily, or in combination with intravenous amikacina in a dose of 500 mg twice daily (15 mg/kg) in cycles of 21 days, especially in patients with pulmonary or peritoneal involvement.[25]

Ramam et al[28] used a two-step regimen consisting of an intensive phase of therapy with intravenous penicillin (1,000,000 IU every 6 hours), intravenous gentamicin (80 mg twice a day), and oral TMP–SMX (80–400 mg twice a day) for 5–7 weeks. Linezolid, a new oxazolidinone, has shown in vitro antimicrobial activity against *N. brasiliensis*; it also has demonstrated efficacy in patients with nocardiosis. Its main disadvantage of this alternative is the cost. It is available as intravenous and oral preparations.

The use of clindamycin, ciprofloxacin, and moxifloxacin has been suggested in *Nocardia* infections.[29]

Patient follow-up is always important, and improvement can be monitored by clinical assessment as well as by laboratory tests: hemoglobin level, white cell count, C-reactive protein, erythrocyte sedimentation rate, enzyme-linked immunosorbent assay (when available), biopsy, and culture.

Amputation is not indicated in actinomycetoma because the very low risk of lymphangitic or hematogenous dissemination. Functional impairment is common with osseous, pulmonary, or abdominal visceral involvement. The disease may be fatal.

KEY REFERENCES

Full reference list available at www.DIGM8.com

DVD contains references and additional content

1. Pulverer G, Schutt-Gerowitt H, Schaal KP: Human cervicofacial actinomycoses: Microbiological data for 1997 cases. *Clin Infect Dis* **37**:490, 20031
7. Sudhakar SS, Ross JJ: Short-term treatment of actinomycosis: Two cases and a review. *Clin Infect Dis* **38**:444, 20045
9. Lederman ER, Crum NF: A case series and focused review of nocardiosis: Clinical and microbiologic aspects. *Medicine (Baltimore)* **83**:300, 2004
10. Fergie JE, Purcell K: Nocardiosis in South Texas children. *Pediatr Infect Dis J* **20**:711, 2001
11. Lerner PI: Nocardiosis. *Clin Infect Dis* **22**:891, 1996
14. Arenas R, Lavalle P: Mycetoma (Madura foot). In: *Tropical Dermatology*, edited by Arenas R, Estrada R. Landes: Georgetown; 2001, p. 51
16. Bonifaz A et al: Actinomicetomas en niños y adolescentes. *Monografías en Dermatología* **19**:17, 2006
19. Davila MR et al: Epidemiología de los micetomas por Actinomadura madurae en el Estado de Guanajuato, México. *Monografías en Dermatología* **19**:24, 2006
27. Ameen M et al: Efficacy of imipenem therapy for Nocardia actinomycetomas refractory to sulfonamides. *J Am Acad Dermatol* **62**(2):239-246, 2010

Chapter 186 :: Leprosy

:: Delphine J. Lee, Thomas H. Rea, & Robert L. Modlin

LEPROSY AT A GLANCE

- Definition: a chronic granulomatous infection and caused by *M. leprae*.
- Involvement: affecting primarily skin and nerves.
- Diagnosis: acid-fast bacilli in tissue or classic peripheral nerve abnormality.
- Incidence: approximately 250,000–500,000 new cases yearly, worldwide.
- Long-term morbidity: despite curative antibacterial treatment, one-quarter to one-third of patients will have a debilitating and permanent neurological deficit.
- A clinical challenge: diverse manifestations result from a granulomatous spectrum, and are further increased by superimposed, reactional states.
- An immunologic opportunity: an exemplary model for the understanding of cell-mediated immunity in humans.

ETIOLOGY AND PATHOGENESIS

Risk factors are birth or residence in a known endemic area, a family member with leprosy, reflecting common genetic susceptibility, environmental exposure, or both, and, as with many other infections, poverty. Therapeutic use of anti-tumor necrosis factor (TNF) antibodies and the immune reconstitution inflammatory syndrome (IRIS) of highly active antiretroviral therapy (HAART) have been associated with the onset of leprosy.[15,16]

Mycobacterium leprae, the cause of leprosy, is a non-cultivable, Gram-positive, obligate intracellular, acid-fast bacillus. Sequencing of the bacillary genome[17] revealed gene deletion and decay leaving *M. leprae* with few respiratory enzymes, providing an explanation for the failure to cultivate the organism in cell-free media, as well as for its obligatory intracellular environment. In tissues or smears, *M. leprae* is quantified by the biopsy index (BI), a logarithmic scale as to the numbers of bacilli per oil immersion field (OIF): a BI of 6 is 1,000 or more bacilli/OIF; a BI of 5 is 100–1,000/OIF; a BI of 4 is 10–100/OIF; a BI of 3 is 1–10/OIF; a BI of 2 is 1 bacillus/1–10 OIFs; a BI of 1 is 1 bacillus/10–100 OIFs; and a BI of 0 is no bacilli in 100 OIFs. Because a BI of 6 indicates 10^9 bacilli per gram of granuloma, tissue with a BI of 0, may have as many as 10^3 organisms per gram.

The bacillary cell wall consists of a peptidoglycan backbone linked to arabinogalactan and mycolic acids. Immunogenic proteins are associated with the cell wall, and also are present in the cytoplasm. The cell-wall-associated lipoproteins, ligands for pattern recognition receptors (PRRs) such as TLR2 and NOD2 of the innate immune system, probably initiate the host's first response *M. leprae*. This response may be important in determining the eventual clinical outcome.[18] A lipoglycan target of both antibody and cellular immune responses, lipoarabinomannan, courses through the outer membrane and inserts into the cell membrane. Phenolic glycolipid I is a major, species specific and immunogenic constituent of the highly nonpolar outer layer of the bacillus. Entry into nerves is mediated by the binding of the species-specific trisaccharide in phenolic glycolipid I to laminin-2 in the basal lamina of Schwann cell–axon units,[19] providing a rationale for why *M. leprae* is the only bacterium known to invade peripheral nerves.

A twin study has provided compelling evidence that both genetic and environmental factors are important in determining disease susceptibility and expression.[20] A region on chromosome 10p13, including the PARK2 and PACRG, loci for susceptibility to Parkinson's disease, has been found to also contain a risk factor for the development of leprosy.[21] This includes both tuberculoid and lepromatous forms, and has been identified in a number of genetically diverse populations, but not all. Major histocompatibility complex class II antigens appear to influence the clinical presentation, but not disease susceptibility,[22] while PRRs such as the TLRs and NOD2 may influence both.[23–27] The great majority of people exposed to *M. leprae* are presumed to make a curative immunologic response, while the clinical presentation of the granulomatous spectrum of leprosy provides an immunologic spectrum of host defense, thus providing an exemplary model for examining cell-mediated immunity (CMI) in humans.

CLINICAL FINDINGS

HISTORY

For physicians practicing in nonendemic areas, learning that the patient has risk factors for leprosy, i.e., birth or residence in an endemic area, or a blood relative with leprosy may lead to a correct diagnosis of leprosy.

Historic data or symptoms that should elicit further suspicion of leprosy include complaints referable to peripheral neuropathy, persistent nasal stuffiness, ocular symptoms, and, in young men, loss of sexual drive or infertility.

CUTANEOUS LESIONS

THE GRANULOMATOUS SPECTRUM. Ridley and his associates provided the most detailed description of the granulomatous spectrum of leprosy,[28,29] integrating both clinical and histologic changes. Ridley's construct is a six-member spectrum, ranging from high to low resistance, TT (polar tuberculoid), BT (borderline tuberculoid), BB (borderline), BL (borderline lepromatous), LLs (subpolar lepromatous), and, finally, LLp (polar lepromatous):

$$\text{TT} \leftarrow \text{BT} \leftrightarrows \text{BB} \leftrightarrows \text{BL} \leftrightarrows \text{LLs LLp}$$

Conceptually, TT and LLp are clinically stable, but, between the poles, the host response may change, as indicated by the arrows, upgrading (or reversing) to a state of higher resistance, often with devastating inflammation, or downgrading to a posture of lower resistance, usually silent but occasionally inflammatory. BT patients may upgrade to TT, thus, becoming stable, but LLs patients do not downgrade to LLp nor do LLp patients upgrade. ("LL" includes both LLs and LLp patients.) The host's granulomatous response is the result of the degree of CMI directed against *M. leprae*. The classification is determined primarily by clinical and histologic changes, bacillary numbers being a secondary consideration. Patients along the clinical spectrum of leprosy are presumed to be manifestations of evolving immune responses, which, based on environmental and genetic factors, will eventually gravitate toward one of the two poles.

In comparison of pre-Ridley and Ridley terminology, "tuberculoid" corresponds to TT and BT, "borderline" or "dimorphic" to BB and BL, and "lepromatous" to LLs and LLp. In virtually all TT patients, and in most BT cases, acid-fast bacilli (AFB) cannot be found, whereas in BB, BL, LLs, and LLp, bacilli are demonstrable with ease. Ridley's construct is useful in classifying patients, especially for immunity.

PERIPHERAL NERVE CHANGES. Five types of peripheral nerve abnormalities are common in leprosy. (1) Nerve enlargement (usually perceived as asymmetry), particularly in those close to the skin, generally thought to be due to the fact that those locations are coolest in temperature, such as the great auricular, ulnar, radial cutaneous, superficial peroneal, sural, and posterior tibial. (2) Sensory impairment in skin lesions. (3) Nerve trunk palsies either with signs and symptoms of inflammation or without such overt manifestations, that is, silent neuropathy,[30] usually with both sensory and motor loss (weakness and/or atrophy) and, if long standing, also with contracture. (4) Stocking-glove pattern of sensory impairment (S-GPSI), with a slow loss of type C fibers, involving heat and cold discrimination before loss of pain or light touch, beginning in acral areas and, over time, extending centrally but initially sparing the palms. (5) Anhidrosis on palms or soles suggests sympathetic nerve involvement.



Figure 186-1 A solitary, anesthetic, and annular lesion of polar tuberculoid leprosy (TT), which had been present for 3 months. Its sharp margins, erythema, and scale are more evident than its elevation. The central red dots are the sequelae or "footprints" of testing for pinprick perception when it is absent. (If present, the patient withdraws, preventing overly purpuric consequences.) The central portion of the lesion was slightly hypopigmented as compared to the surrounding normal skin.

Polar Tuberculoid Leprosy. In TT leprosy immunity is strong as manifested by spontaneous cure and the absence of downgrading to a posture of less host resistance. The primary skin lesion of TT is a sharply marginated plaque, often annular secondary to peripheral propagation and central clearing. Typically, the lesion is firmly indurated, elevated, erythematous, scaly, dry, hairless, and hypopigmented (Fig. 186-1), but clinically, considerable variation is encountered (eFig. 186-1.1 in online edition).

A nearby sensory nerve may or may not be enlarged (eFig. 186-1.1 in online edition), but the lesion itself is characteristically anesthetic and anhidrotic. Skin lesions are often solitary, particularly in those patients who are TT de novo, as contrasted to those who upgrade to TT from BT, where multiple lesions, usually no more than three, may be found. In both groups, immunity is sufficient to affect cure, thus, placing an upper limit of 10 cm on lesion size, but antibiotic therapy is recommended.

TT Histology. In de novo TT lesions, small, well-developed epithelioid tubercles are surrounded by large lymphocytic mantles, but are uncommonly seen. In TT upgrading from BT, abundant Langhans-type giant cells and a brisk exocytosis into the epidermis are usually found in addition to the lymphocytic mantle (Fig. 186-2). Rarely caseation necrosis is seen, and, if present, warrants the classification of TT (eFig. 186-2.1 in online edition). AFB are not found.

Borderline Tuberculoid Leprosy. In BT disease (Fig. 186-3 and eFigs. 186-3.1 and 186-3.2 in online edition), immunologic resistance is strong enough to restrain the infection, in that the disease is limited and bacillary growth retarded, but the host response is

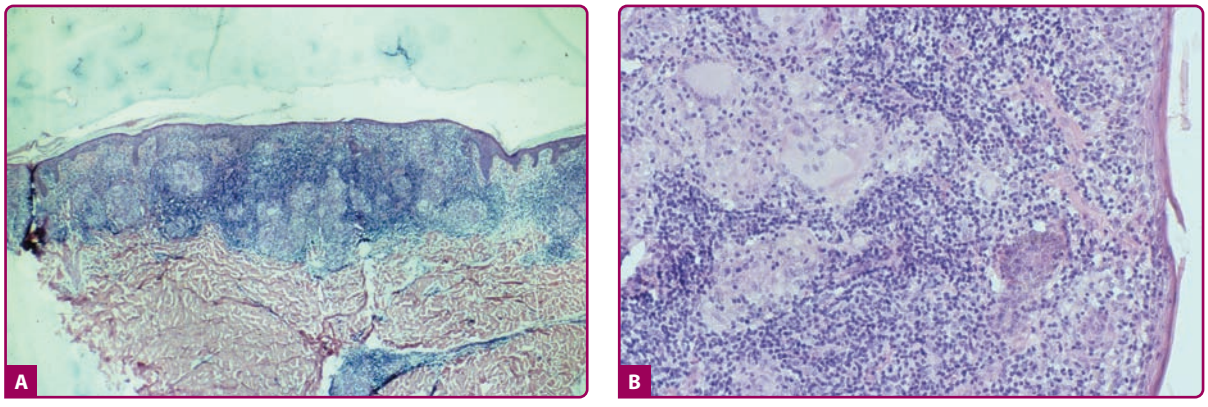

Figure 186-2 Two views of the histology of a TT lesion. **A.** The lower power view looks a lot like that of lupus vulgaris, which is the origin of the term "tuberculoid" leprosy. (H&E, 10· objective.) **B.** The high-power view of the same lesion shows abundant Langhan's giant cells, epithelioid tubercles, a dense lymphocytic infiltrate and a brisk exocytosis into the epidermis. (H&E, 20· objective.)

insufficient to self-cure. These patients are somewhat unstable—resistance may increase, upgrading to TT, or decrease, downgrading to BL.

The primary skin lesions of BT are plaques and papules (Box 186-1). As in TT, an annular configuration is common and both borders are sharply marginated but annular lesions or plaques may have sharply marginated satellite papules (Fig. 186-3). Hypopigmentation may be conspicuous in darkly pigmented patients (eFig. 186-3.1 in online edition). In contrast to TT, typically, there is little or no scaling, less erythema, less induration, and less elevation, but lesions may become much larger, that is, well over 10 cm in diameter, a single lesion sometimes involving an entire extremity over time (eFig. 186-3.1 in online edition). Multiple, asymmetric lesions are the rule, but solitary lesions are not rare. Impairment of sensation in skin lesions is the rule and nerve trunk involvement, enlargement or palsies, usually in no more than two and asymmetric, are common. Nerve abscesses, when they occur, are most often seen in males with BT disease (eFig. 186-3.2 in online edition).



Figure 186-3 One of several lesions of borderline tuberculoid leprosy (BT), which had an incompletely annular configuration with satellite papules. Compared to the TT lesion in **Fig. 186-1**, there is less erythema, no evident scales, but the sharp margination, and the "footprints" of absent pinprick perception are well developed. The lesional histology is shown in **eFig. 186-8.2** in online edition.

BT Histology. In BT tissues, well-organized epithelioid tubercles are present but the lymphocytic mantles are less well developed than in TT disease (eFigs. 186-3.3 and 186-3.4 in online edition). Also, Langhans-type giant cells are inconstant. Epidermal exocytosis, if present at all, is focal. AFB are only rarely seen in BT. The presence of AFB or plasma cells in what otherwise appears to be BT warrants consideration of a reversal reaction.

Borderline Leprosy. BB is the immunologic midpoint or midzone of the granulomatous spectrum, being its most unstable area, with patients quickly up- or downgrading to a more stable granulomatous posture with or without a clinical reaction. Characteristic skin changes are said to be annular lesions with sharply marginated interior and exterior margins, large plaques with islands of clinically normal skin within the plaque, giving a "Swiss cheese" appearance, or the classic dimorphic lesion. Because of instability, the BB posture is short lived and such patients are rarely seen. For example, we have yet to see a nonreactional patient meeting both clinical and histologic criteria.

BB Histology. In BB, the epithelioid differentiation remains, but lymphocytes are sparse, giant cells are absent, and bacilli are easily found.

Borderline Lepromatous Leprosy. In BL disease, resistance is too low to significantly restrain bacillary proliferation, but still sufficient to induce tissue destructive inflammation, especially in nerves. Thus, BL patients have the worst of both worlds. The

BOX 186-1 DIFFERENTIAL DIAGNOSIS

PRIMARY LESIONS

- **Macules and patches.** The hypopigmentation of pityriasis alba and indeterminate leprosy mimic each other. If the patient was born in, or had resided in, an endemic area, then the distinction between the two may be made by neurological or histological examination. Hypopigmented BL plaques can be so faintly indurated as to mimic patches. Telangiectasias may be eruptive or present as mats on the face and upper trunk.
- **Papular to nodular lesions.** In the dermis, leprosy may mimic, or be mimicked by dermatofibromas, histiocytomas, lymphomas, sarcoidosis, and other granulomas. Eruptive and recurrent inflammatory subcutaneous nodules may be ENL, erythema nodosum, erythema induratum, and vasculitis. Palpable, but not visible, subcutaneous nodules in Latapi's lepromatosis may mimic lipomas.
- **Plaques.** Erythematous plaques may mimic mycosis fungoides. Plaques without pigmentary change may be wheal like in appearance, causing confusion with urticaria. Hypopigmented plaques may mimic papulosquamous eruptions. Islands of normal skin within a plaque may suggest psoriasis.
- **Polymorphous vesiculobullous eruption/Dermoepidermal separation.** They may occur in ENL. Up to 30% of LL patients may have an antibody directed to desmoglein 1, giving rise to bullous lesions. Also, IgM is deposited not uncommonly at the epidermal basement membrane in LL. These antibodies are not necessarily pathogenic but may confuse diagnosis.
- **Annular lesions.** Leprosy may mimic, or be mimicked by, annular erythemas, sarcoidosis, syphilis, or tinea.

SECONDARY LESIONS

- **Infarcts.** Lucio's phenomenon lesions and necrotic ENL mimic septic infarcts.
- **Ulcers.** Ulcers occur in Lucio's phenomenon and ENL secondary to vascular occlusion. In patients with nerve destruction, neurotrophic ulcers occur on the plantar surface, patients with Leg ulcers secondary to venous insufficiency are seen in Latapi's lepromatosis.

CLINICAL CONSTELLATIONS

- **Systemic lupus erythematosus-like changes.** Fusiform fingers, swan neck deformity, false positive syphilis tests, antiphospholipid antibodies, lupus anticoagulant, hyperglobulinemia, and anemia.
- **Vasculitis.** A true vasculitis may occur in ENL, Lucio's reaction, and Latapi's lepromatosis. Clinically, leprosy lesions of a nodular character may be misdiagnosed as "vasculitis."

BL category is highly variable in its clinical expression (eFigs. 186-3.5 in online edition and Fig. 186-4). Although seen in only a third of BL patients, the classic dimorphic lesion is the most characteristic, having an annular configuration with a poorly marginated outer border (lepromatous like) but a sharply marginated inner one (tuberculoid like), hence, having both morphologies thus "dimorphic leprosy." Variation may be considerable in one patient and even greater across the entire BL population. Poorly or sharply marginated plaques with "punched out" or "Swiss cheese" sharply marginated areas of normal skin in the interior of the plaque are also characteristic, and can be thought of as a variant of the classic dimorphic lesion (eFig. 186-3.5 in online edition). Annular lesions with sharply marginated exterior and interior borders are not uncommon. Lepromatous-like, poorly defined papules and nodules may be numerous, but are usually accompanied by sharply marginated lesions somewhere.

Lesions range in number from solitary to numerous and widespread. Generally, the annular and plaque lesions are asymmetrically distributed, but the lepromatous-like nodules, if numerous, are symmetric (Fig. 186-4). Skin lesions are often hypesthetic or anesthetic, but not necessarily so. Nerve trunk palsies have their highest prevalence in BL disease, but are variable in number, ranging from none to serious neurologic deficits, both motor and sensory, in all four extremities. Involvement of both median and ulnar nerves, not infrequently bilateral, is characteristic. When disease is extensive, BL patients may also develop S-GPSI.



Figure 186-4 Multiple lesions in a patient with borderline lepromatous leprosy (BL). The annular lesions vary in size and are asymmetrically distributed. In contrast, the poorly defined papular and nodular lesions are roughly symmetric. Impaired sensation was present in most lesions.

Untreated BL patients have slow relentless progression of skin and nerve changes. With or without treatment, this course may be altered by a reactional state (see section below), upgrading or reversal reactions being more common than erythema nodosum leprosum (ENL). Also, BL patients may silently downgrade to an LLs granulomatous posture.

Borderline Lepromatous Histology. One classic BL dermal response is a relatively dense lymphocytic infiltrate restricted to the space occupied by the macrophages (eFig. 186-4.1 in online edition). The macrophages are often foamy, but undifferentiated macrophages may be common. The epidermis is undisturbed. In nerves, the other classic BL response is lamination of the perineurium with infiltration by inflammatory cells (eFig. 186-4.2 in online edition). In BL, as contrasted to LLs, the inflammatory infiltrate is so dense as to obscure the lamination. An alternative BL pattern is that of a chronic lymphohistiocytic infiltrate (eFigs. 186-4.3 and 186-4.4A in online edition). Plasma cells may be present. Bacilli are easily found, and globi are not unusual.

Lepromatous Leprosy. In lepromatous leprosy (LL) the diminished CMI toward *M. leprae* permits unrestricted bacillary replication and widely disseminated, multiorgan disease. Diffuse dermal infiltration is always present subclinically and, may be overtly manifested by enlargement of ear lobes, widening of the nasal root, fusiform swelling of the fingers, and the skin being thrown into folds. Poorly defined nodules are the most common lesions, usually up to 2 cm in diameter, and are symmetrically distributed. A conjunction of skin folding and nodule formation produces the "leonine faces."

Dermatofibroma-like or histiocytoma-like lesions, usually multiple, are sharply marginated erythematous papules or nodules, sometimes confluent into plaques (Fig. 186-5A and 186-5B). These were first identified in relapsing patients as "histoid" leprosy, but are not unusual as presenting lesions. Less common presenting skin lesions include digitate, barely indurated patches of erythema (Fig. 186-6), which in light-skinned patients are sometimes followed by a mild hyperpigmentation, a veil of melanin concealing the erythema; in dark-skinned patients multiple hypopigmented macules may be seen. Also, rarely, a dense dermal infiltrate may mimic a nevoid lesion (see eFig. 186-6.1 in online edition).

A clinical clue of LLs is a sharply marginated region in a lesion, perhaps the residual of a BL lesion in a patient who has downgraded to LLs, or the presence of dermatofibroma-like lesions. The distinction between LLs and LLp is usually made histopathologically.

Hair loss is most common in the eyebrows (eFig. 186-6.2 in online edition), where it may progress medially to laterally or be patchy. Hair loss may also occur on the eyelashes and extremities, and may be partially reversible if treated early. Scalp involvement is rare. Loss of eccrine sweating from sympathetic nerve involvement is common, as manifested by dry palms or soles. Any given skin lesion may or may not be hypoesthetic but generally, in each patient, some are. Nerve trunk palsies occur, but are less common than in BL. The stocking glove pattern of sensory impairment



Figure 186-5 **A.** Multiple dermatofibroma-like papules, with some confluence to form plaques. **B.** Multiple dermatofibroma-like and histiocytoma-like lesions in a patient who had sought no help for these, until taken to the hospital from an automobile accident. The senior pathologist who reviewed the case suggested a Fite stain. The skin between such nodules is diffusely infiltrated.



Figure 186-6 These multiple, barely palpable, erythematous, and asymptomatic lesions had been erupting over the previous 2 months in an LLs patient. With treatment, as the lesions remitted they became mildly hyperpigmented. Here, the accentuation of the normal skin markings is in contrast to their effacement, as shown in **Fig. 186-4.**

is common and may be so severe as to lead to debilitating trophic changes of the hands or feet.

Untreated LL disease is relentlessly progressive, but this course may be altered by reactional states. LLs and LLp subjects frequently develop erythema nodosum leprosum (ENL). LLp patients do not develop reversal reactions (see below), whereas LLs patients may.

LL Histology. LLs and LLp have many histologic features in common. (1) Nodular lesions, consisting mainly of foamy or undifferentiated macrophages, have replaced much of the dermis, with loss of appendages. The epidermis is attenuated by the nodule, but a thin layer of dermis (grenz zone) separates the two and a Fite stain shows numerous bacilli. (2) Clinically normal skin will show a variably dense infiltrate of foamy or undifferentiated macrophages, often scant in a perivascular and periappendageal distribution, but the epidermis is undisturbed (eFig. 186-6.3 in online edition). (3) Both LLs and LLp may show small but dense aggregates of lymphocytes, which may be B-cells. (4) The appearance of the macrophages varies with the age of the lesion, ranging from undifferentiated to foamy cells (eFigs. 186-6.4 and 186-6.5 in online edition). (5) Endothelial AFB are not uncommon in LLs and LLp. (6) Plasma cells and mast cells, the latter often easily identified by the AFB counter stain, are sometimes increased. (7) In older lesions, foreign-body giant cells may be common, probably arising in response to the death of macrophages containing many dead AFB (eFig. 186-6.6 in online edition).

In LLs, lymphocytes are sparsely distributed generally, and the perineurium is laminated, but sparsely infiltrated by inflammatory cells making the laminations conspicuous (see eFig. 186-6.7 in online edition). In LLp, lymphocytes are fewer than in LLs, and the perineurium is undisturbed (see eFig. 186-6.8 in online edition). In our experience, the dermatofibroma-like lesions have all been in LLs patients, may resemble dermatofibromas histologically as well as clinically (eFig. 186-6.9 in online edition).

Indeterminate Leprosy. Indeterminate leprosy is a term with nearly as many meanings as it has users. We prefer the definition of Khanolkar,[31] designating an early lesion appearing before the host makes a definitive immunologic commitment to a curative or overt granulomatous response. Clinically, the indeterminate lesion is a hypopigmented macule or patch, with or without an associated sensory deficit in or near the defect, and AFB, if found, are present in very small numbers. Such lesions are rare. The term is sometimes used, inappropriately in our opinion, to describe lesions rich in bacilli but having neither typical tuberculoid nor lepromatous histological patterns. Such patients are usually BL or occasionally LL.

Indeterminate Leprosy Histology. The indeterminate lesions usually show a patchy infiltrate in both the papillary and reticular dermis, consisting of lymphocytes and a few macrophages. Bacilli are rare or are not found. If bacilli are present in good numbers then BL or LL disease is much more likely than "indeterminate leprosy."

RELATED PHYSICAL FINDINGS

Insensitivity of the cornea is common in all forms of leprosy. In BL and LL diseases, numerous changes in the cornea and anterior chamber are possible. Iritis is a common serious change, occurring de novo or in association with reactions. Also, beading of the corneal nerves is common, and may be a helpful diagnostic sign.

In all LL patients and in BL with extensive disease, wide dissemination of the infection is the rule. In the upper respiratory tract involvement is from the tip of the nose through the vocal cords, manifesting as rhinitis, septal perforation, nasal collapse and hoarseness. As judged by elevated FSH and LH levels, testicular involvement with loss of testosterone production is common in LL men, less so in BL men, and is clinically manifested by complaints of impotence and infertility, and, on examination, by atrophy. Involvement of liver, spleen, peripheral lymph nodes, and bone marrow is common, but clinically evident organ injury is unusual. With effective chemotherapy, chronic disability from ocular or upper respiratory tract involvement is less common than previously, but has not disappeared. Ophthalmologists and otolaryngologists are still vital to evaluate and treat acute changes, and to prevent chronic changes in patients with leprosy.

PREGNANCY AND POSTPARTUM. Pregnancy is said to be a precipitating factor for leprosy in 10%–25% of women patients, presumably because of altered immunity. When pregnant, LL and BL patients are predisposed to develop ENL, but in the postpartum period, they are predisposed to develop reversal reactions, putatively due to reduced immunity in the former and restored immunity in the latter.[32] Untreated lactating BL and LL patients have viable bacilli in their milk, but no increased risk of disease transmission has been identified in infants ingesting such bacilli.[33] Dapsone in mother's milk may produce hemolysis in the baby.

ACQUIRED IMMUNODEFICIENCY SYNDROME OR AIDS. In contrast to the high incidence of tuberculosis and *M. avium*-intracellulare infections in AIDS or HIV patients, leprosy has not been regarded as an opportunistic infection in these individuals, perhaps as a consequence of *M. leprae* being an obligatory intracellular parasite. For example, in one study AIDS or HIV did not appear to influence disease expression (tuberculoid versus lepromatous) or the frequency of reactional states, but was a risk factor for recurrent DTH reactions.[34] However, recent reports of leprosy presenting as DTH reactions in the setting of highly active antiretroviral therapy (HAART) (eFig. 186-6.10 in online edition) suggest that the current views may need revision.[35]

RELAPSING LEPROSY. "Multibacillary" patients who are noncompliant or who develop drug resistance are prone to relapse. Such individuals present in several ways, including (1) a reprise of their initial presentation, (2) florid dermatofibroma-like lesions (histoid lesions), (3) a reactional state, and (4) a clinical state of higher resistance than their initial presentation, for example, an initially LLs individual having BL or even BT disease. LLp patients do not develop reversal reactions.

REACTIONAL STATES

The reactional states of leprosy are distinctive, tissue destructive, inflammatory processes that are putatively immunologically driven. They greatly increase the morbidity of the disease and, because of the experience required for optimal patient care, justify leprology as a clinical subspecialty. When present, a reactional state is superimposed upon the underlying granuloma, but the reactional state usually dominates the clinical picture. Too often, the reactional states are dismissed as complications of treatment, but they may occur before treatment is initiated or after it has been completed. They distress the patient who correctly complains, "I did every thing the doctor advised, but I got worse."

REVERSAL REACTION (JOPLING'S TYPE I REACTION). Reversal reactions are particularly common in BL patients, but are not rare in LLs, BB, or BT.[36] Reversal reactions are supported by substantial evidence to be a delayed-type hypersensitivity (DTH) response and are also known as DTH reactions. Though theoretically patients may upgrade to a more-resistant granulomatous posture, remain unchanged, or downgrade to a less-resistant posture. Downgrading is rarely if at all ever observed, and type I reactions are associated with reversal (upgrading). Therefore, reversal reaction is often synonymous with "upgrading" resulting in improved CMI or DTH "reactions." LLp patients do not develop DTH reactions.

Clinically, DTH reactions are characterized by the abrupt conversion of previously torpid plaques to tumid lesions, and new tumid lesions arising in clinically normal skin with or without an abrupt onset of neuritis. A purplish dusky erythematous color is characteristic (eFigs. 186-6.10 and Figs. 186-7A and 186-7B in online edition). Morphologic variants include annular, concentric and eczematous changes (eFigs. 186-7.1–186-7.3 in online edition). Lesions are rarely solitary, as can happen in BT upgrading to TT, often multiple, and occasionally myriad, as in BL or LLs upgrading to BT (eFig. 186-6.10 in online edition). Iritis and lymphedema (eFig. 186-7.4 in online edition) (elephantiasis graecorum) may be concomitant changes. Neuritis also ranges from mild to severe, and is potentially disastrous, particularly if involving multiple nerves. For example, in LL commonly, and in BL occasionally, a withering away of the type C pain fibers results in diminished pain perception and in severe cases may result in loss of the protective pain sensation. This may be referred to as a "stocking glove pattern of sensory impairment." Motor loss with nerve involvement in addition to loss of sensation may occur in distal arms and legs.

Patients often present with DTH reactions, and DTH reactions occurring soon after presentation and the



Figure 186-7 **A.** Some of the initial presenting lesions in a patient with a DTH reaction, who had BL leprosy. The tumidity, purplish hue and sharp margination strongly suggest a reversal reaction. The lesions were neither painful nor tender. The differences between these lesions and those shown in **eFig. 186-2.3** in online edition emphasize that the DTH reaction, not the underlying BL disease, dominates the clinical picture. **B.** The patient also had, in the left foot, an irreversible foot drop of recent onset. The redness in the skin of the left foot and leg reflects the associated loss of sympathetic nerves.

initiation of treatment may well have been DTH reactions from the beginning.[37] Presumably, the increased prominence of signs and symptoms motivate patients to seek medical attention. Most common in the first year of treatment, DTH reactions may occur 7 years or longer after starting therapy, and well after treatment has stopped. The diagnosis of a DTH reaction is primarily clinical, but histologic confirmation, if available, should be sought.

REVERSAL REACTION HISTOLOGY. Biopsies of reversal reaction tissues, when compared with prereactional biopsies in the same patient, occasionally do not differ. However, the most common change is edema (eFig. 186-7.5 in online edition). Other common changes are enhanced epithelioid differentiation of macrophages, increased lymphocytes, Langhans-type and foreign-body giant cells often mixed together, epidermal thickening, and, occasionally, enhanced bacteriolysis (eFigs. 186-7.5–186-7.6 in online edition). Nerve histology may change rapidly in a reversal reaction, in which nerves may be destroyed by a granulomatous infiltrate (eFig. 186-7.7 in online edition). Edema and well-developed epithelioid tubercles associated with AFB, plasma cells, or a mixture of Langhans and foreign-body giant cells should arouse suspicion of a reversal reaction.

ERYTHEMA NODOSUM LEPROSUM (JOPLING'S TYPE II REACTION). ENL occurs most often in LL, in up to 75% of cases, but is not rare in BL patients. ENL is not erythema nodosum occurring in leprosy; it is a leprosy-specific response, which has some clinical and histologic features in common with erythema nodosum. It may occur before, during, or after chemotherapy. Excluding untreated patients who present because of ENL, the median time of onset of ENL is close to 1 year after onset of treatment. Clinically, this reaction is characterized by crops of painful and tender, bright pink, dermal and subcutaneous nodules in clinically normal skin, in association with fever, anorexia, and malaise. Arthralgias and arthritis are more common in ENL than are neuritis, adenitis, orchitis/epididymitis, or iritis, but each may rarely be the initial presentation. Involvement of both upper and lower extremities is the rule and facial lesions occur in half the patients. Lesions may be targetoid, vesicular, pustular, ulcerative, or necrotic (Fig. 186-8 and eFigs. 186-8.1–186-8.5 in online edition). A neutrophilic leukocytosis is often present, occasionally leukemoid in degree. Severe episodes can be associated with an abrupt fall in hemoglobin level, up to 5 g/dL, easily mistaken for dapsone-induced hemolysis. The improvement in response to thalidomide is dramatic in more than 90% of patients, perhaps qualifying as a diagnostic criterion. When leprosy presents as ENL, there may be few or no stigmata of the underlying disease. ENL may be precipitated by pregnancy or pyogenic infections.

Although episodes of ENL may be sporadic, in the more severely involved patients, episodes can be frequent to virtually unremitting. In the latter, brawny induration of the anterior thighs and preaxial portion of the arms is characteristic, perhaps a reversible fibrosis. The course of ENL is often prolonged, the median duration of anti-inflammatory treatment being approximately 5 years. If the diagnosis of ENL is considered, it is usually not difficult, as the clinical and histologic features and the response to thalidomide therapy are highly characteristic.



Figure 186-8 Papular ENL lesions occurring on the face and arms of an LL patient. Some papules are becoming confluent, forming a plaque. In contrast to nodular ENL lesions, in the papular ENL lesion the dermis is more extensively involved than the subcutis.

ENL HISTOLOGY. A "bottom-heavy" pattern is a low-power feature of most ENL lesion, showing a gradient of inflammatory cells, scant in the papillae and heavy in the deep dermis or subcutis (eFig. 186-8.6 in online edition). An uncommon alternative histology is a pan-dermal infiltrate with marked edema of the papillary dermis (eFig. 186-8.7 in online edition). In ENL lesions, neutrophils are the "signature" cells, but may not be found if older lesions are sampled. The extent of the neutrophil infiltrate is highly variable, being so dense as to form a small abscess (eFig. 186-8.8 in online edition), or very scarce. Other common features are an increase in lymphocytes, epidermal thickening, lobular panniculitis, and fibrosis. An uncommon but not rare finding is vasculitis (eFig. 186-8.9 in online edition) that appears focal in distribution.

LUCIO'S PHENOMENON. This is an often dramatic onset of hemorrhagic infarcts on the skin, most prevalent in Mexico and the Caribbean region and restricted to patients with Latapi's lepromatosis (Lucio's leprosy).

When fully developed, Latipi's lepromatosis features diffuse infiltration of the skin, as well as a purplish suffusion of the hands and feet, telangiectatic mats or eruptive telangiectasias, nasal septum perforation, total alopecia of eye brows and eye lashes, and often a stocking glove pattern of sensory impairment. Firm subcutaneous nodules are palpable but not visible. Ocular sparing is the rule.

Lucio's phenomenon usually occurs after Latapi's lepromatosis is well developed and, with few exceptions, before treatment is initiated. Hemorrhagic infarcts, arising in crops, have serrated margins characteristic of septic infarcts and are painful but not tender (eFigs. 186-8.10 and 186-8.11 in online edition). Lesions usually crust and may heal with scarring.

Some lesions are bullous. Ulceration is common, especially below the knees. Lesions vary in size and extent, ranging from a few small lesions on the ankles to many large ulcerations that are life threatening. With dapsone alone, lesions may worsen, but in our experience, with one exception, new lesions ceased within 1 week of beginning rifampin.

LABORATORY TESTS

Polymerase chain reaction (PCR) testing for diagnosis of leprosy is not used in clinical practice, as in AFB-negative BT tissue a positive signal occurs less that half the time. Most laboratory abnormalities occur in LL or extensive BL disease. Hyperglobulinemia is the most common, giving an elevated sedimentation rate. A biologic false-positive serologic test for syphilis, anemia of chronic disease, and mild lymphopenia are also common. Clinically insignificant antiphospholipid antibodies are present in 50% of LL patients, and may give rise to a lupus anticoagulant or agglutination of sheep erythrocytes (Rubino factor).[53] If sought, the stained smear of the buffy coat shows bacilli up to 10^5/mL. Elevated serum lysozyme and angiotensin-converting enzyme values reflect the extensive accumulation and activation of macrophages synthesizing these proteases. Proteinuria, not uncommon, is associated with a focal glomerulonephritis, seen mostly in patients with ENL. Low testosterone levels, accompanied by high serum follicle-stimulating hormone (FSH) and luteinizing hormone (LH) values indicating testicular disease, occur in a majority of men with LL, but in a minority of men with BL.

DIAGNOSIS

A firm diagnosis of leprosy requires demonstration of a consistent peripheral nerve abnormality or the demonstration of AFB in tissues.

In nonendemic areas the diagnosis is missed only because the possibility of leprosy is not considered. There is no test to exclude leprosy.

Because *M. leprae* does not grow in cell-free media, demonstration of mycobacteria by their acid-fast property is used most commonly in diagnosis. AFB in tissue sections are best shown by carbolfuchsin staining, using modifications of the Ziehl–Neelsen method, collectively called Fite–Farraco stains. *M. leprae,* like *Nocardia* species, is only weakly acid-fast. In smears, either the Ziehl–Neelson method or auramine–rhodamine staining with fluorescent microscopy is satisfactory. Because of characteristic clinical and histologic changes, positive specification of *M. leprae* is rarely required. The presence of *M. leprae* in nerves or the presence of epithelioid cell granulomas within nerves are diagnostic, while characteristic histologic changes may suggest or corroborate the diagnosis of leprosy.

BOX 186-2 ANTIBACTERIAL TREATMENT OF LEPROSY RECOMMENDATIONS

RECOMMENDING ORGANIZATION	DISEASE TYPE	RIFAMPIN	DAPSONE	CLOFAZIMINE	DURATION	FOLLOW UP
World Health Organization	PB (1–5 lesions)	600 mg/ month	100 mg/day	—	6 months	No mandated follow up. To return prn
	MB (>5 lesions)	600 mg/ month	100 mg/day	50 mg/day 300 mg/month	1 year	No mandated follow up To return prn
U.S. Public Health Service	PB (1–5 lesions)	600 mg/day	100 mg/day	—	1 year	At 6 months intervals for 5 years
	MB (>5 lesions)	600 mg/day	100 mg/day	50 mg/day	2 years	At 6 months intervals for 10 years

OTHER MICROBICIDAL AGENTS	DOSE
Clarithromycin	500 mg/day
Minocycline (substitute for dapsone or clofazimine)	100 mg/day
Ofllaxacin	400 mg/day

BOX 186-3 MEDICAL MANAGEMENT OF REACTION STATES

	THALIDOMIDE	PREDNISONE OR PREDNISOLONE	DURATION	OTHER AGENTS OF UNPROVEN VALUE
Reversal reactions (type 1 reactions)	Of no value	0.5–1.0 mg/kg Rifampin may increase their catabolism Taper slowly Alternate-day treatment may be well tolerated	Usually needed for 6 months—2 years. May be longer or shorter	Nonsteroidal anti-inflammatory agents
Erythema nodosum leprosum (type II reactions)	The most efficacious drug if available and not contraindicated Initially 1 dose of 100–200 mg qd hs Maintainable dose range 50 mg every other day to 500 mg daily	If thalidomide not available, 0.5–1.0 mg/kg/day.	Median duration of treatment is approximately 5 years. Can persist for 10 years	Pentoxifylline clofazimine
Lucio phenomenon (usually ceases with use of a microbicidal agent)	Of no value	May be helpful	—	Plasmapheresis reported as helpful in unremitting patients

COMPLICATIONS

The common complications of leprosy arise from peripheral nerve injury, venous insufficiency, or scarring. Approximately one-quarter to one-third of newly diagnosed patients with leprosy have, or will eventually have, some chronic disability secondary to irreversible nerve injury, usually of the hands or feet, or from eye involvement. Exposure keratitis may result from a variety of factors including a dry eye, corneal insensitivity, and lagophthalmos. This keratitis and the anterior chamber lesions (including involvement of iris, sclera or corneal nerves) may result in blindness. Venous insufficiency, secondary to endothelial involvement of deep vein valves, leads to stasis dermatitis and leg ulcers. Destruction of joints (Charcot joints) may occur due to loss of the protective pain sensation. Sympathetic nerve involvement results in decreased hidrosis, leading to dry palms and soles. This in combination with repetitive cycles of skin injury from diminished protective pain results in hyperkeratosis, fissuring and bacterial superinfection. Collapse of the nose in LL is from the contracture of the scar tissue, which has replaced the bone and cartilage. Uncommon complications of Lucio's phenomenon include septicemia from extensive ulceration and contracture secondary to scar formation.

Nerve injury leading to loss of muscle innervation may lead to weakness. Repetitive cycles of injury and bacterial superinfection, permitted by loss of protective pain sensation, are the sources of severe tissue destruction in leprosy. Contracture, secondary to muscle weakness or scar formation, may produce further deformity. Management and prevention of the problems arising from nerve injury may require the skills of orthopedic surgeons, ophthalmologists, podiatrists, plastic surgeons, physical therapists, orthotists, and/or occupational therapists.

PROGNOSIS AND CLINICAL COURSE

The only leprosy patients who will cure themselves without therapy are those with TT, or BT patients who upgrade to TT. Otherwise the disease will be progressive, with morbidity due to nerve injury and/or superimposed reactional states. Treatment arrests much of disease activity but the stocking-glove pattern of sensory impairment may progress. Peripheral neuritis of resent onset may improve with corticosteroid treatment. Like the postpolio syndrome, late arising sensory impairment is sometime seen and is difficult to understand and to manage.

KEY REFERENCES

Full reference list available at www.DIGM8.com

DVD contains references and additional content

8. World Health Organization: Global leprosy situation, 2007. *Wkly Epidemiol Rec* **82**:225-232, 2007
17. Cole ST et al: Massive gene decay in the leprosy bacillus. *Nature* **409**(6823):1007-1011, 2001
19. Ng V et al: Role of the cell wall phenolic glycolipid-1 in the peripheral nerve predilection of Mycobacterium leprae. *Cell* **103**(3):511-524, 2000
20. Chakravartti MR, Vogel F: A twin study on leprosy. In: *Topics in Human Genetics*, edited by PE Becker. Stuttgart, Georg Thieme, 1973, pp. 1-124
27. Zhang FR et al: Genomewide association study of leprosy. *N Engl J Med* **361**:2609-2618, 2009
28. Ridley DS: Histological classification and the immunological spectrum of leprosy. *Bull World Health Organ* **51**:451-465, 1974
36. Scollard DM et al: The continuing challenges of leprosy. *Clin Microbiol Rev* **19**:338-381, 2006
42. Yamamura M et al: Defining protective responses to pathogens: Cytokine profiles in leprosy lesions. *Science* **254**:277-279, 1991
52. Lee DJ et al: Integrated pathways for neutrophil recruitment and inflammation in leprosy. *J Infect Dis* **201**:558-569, 2010
54. Worobec SM: Treatment of leprosy/Hansen's disease in the early 21st century. *Dermatol Ther* **22**:518-537, 2009

Chapter 187 :: Lyme Borreliosis

:: Meera Mahalingam, Jag Bhawan, Daniel B. Eisen, & Linden Hu

LYME DISEASE AT A GLANCE

- Lyme disease is caused by *Borrelia burgdorferi*, a spirochete.
- Clinical course can be prolonged and may involve multiple organ systems.
- Cutaneous hallmarks are erythema migrans and acrodermatitis chronica atrophicans.
- Diagnosis is typically made on clinical grounds, identification of the organism from tissue sections and/or serologic testing.
- Early treatment with antibiotics (doxycycline, amoxicillin, or cefuroxime) is highly successful.

Lyme borreliosis, or Lyme disease, is the most commonly reported arthropod-borne illness in both the United States and Europe.[1] It was first recognized in the 1970s after epidemiologic investigations of a clustering of cases of oligoarthritis among children in eastern Connecticut established a probable microbial etiology for the disease.[2] In 1981, Burgdorfer isolated a new spirochetal bacterium, *Borrelia burgdorferi*, from the midgut of the *Ixodes dammini* tick (now *Ixodes scapularis*).[3] Recovery of the organism subsequently from cutaneous lesions, cerebrospinal fluid (CSF), and blood specimens of patients with Lyme disease in both the United States[4,5] and Europe[6–8] definitively linked the disease with *B. burgdorferi*.

EPIDEMIOLOGY

The existence of *B. burgdorferi* in the Northeastern United States likely predates the presence of European settlers by several thousand years.[9] The incidence and range of the organism has steadily grown since its recognition in the 1970s. Deer and birds are thought to be the primary drivers in dispersal of infected ticks into new areas. In the United States, the Centers for Disease Control and Prevention (CDC) initiated surveillance for Lyme disease in 1982, and the Council of State and Territorial Epidemiologists made Lyme disease a nationally notifiable disease in 1991. Since 1992, 248,074 cases have been reported to the CDC.[10] In 2006, the number of new cases in the United States was 19,931(national median incidence 0.5 cases per 100,000 people). This represents a 101% increase in annual incidence since 1992. There is believed to be significant underreporting of Lyme disease, and the real number of new cases each year in the United States is actually thought to approach 150,000. For the 15-year period for which the CDC has data, approximately 93% of reported cases occurred in ten states located in the Northeastern, mid-Atlantic, and North Central regions: Connecticut, Delaware, Maine, Maryland, Massachusetts, Minnesota, New Hampshire, New Jersey, New York, Pennsylvania, Rhode Island, and Wisconsin. Nearly all states have reported cases of Lyme disease at some point during the past 15 years, though average incidence varies markedly from 0.0 for Colorado, Montana, and Hawaii to 73.6 per 100,000 people for Connecticut. Disease in many of the states with low incidence represents travelers infected during travel to more endemic regions.

Lyme disease is also widely distributed in Europe, with an estimated 120,000 new cases each year.[11] The

highest reported frequencies occur in forested areas of central and Northern Europe (Germany, Austria, Slovenia, and Sweden).[12,13] The infection is also found in Eastern Russia, China, Korea, and Japan.[14]

ETIOLOGY

ORGANISM

Borrelia burgdorferi sensu lato, the agent of Lyme borreliosis, belongs to the eubacterial phylum of Spirochaetales, which are vigorously motile, corkscrew-shaped bacteria. The borrelial genome is made up of a linear chromosome and more than 20 circular and linear plasmids, the largest number known for any bacterium.[15] Some of the plasmids can be considered minichromosomes, as they are required for survival of the organism. Among the interesting characteristics of the organism are the large number of lipoproteins (more than 150). *B. burgdorferi*'s genome encodes no toxins or other identified virulence factor. *Borrelia* also lack biosynthetic machinery to produce many essential nutrients (e.g., amino acids and fatty acids) suggesting that *B. burgdorferi* is highly dependent on its host for obtaining crucial nutrients.[15]

Eleven *Borrelia* spp. have been described worldwide within the *B. burgdorferi sensu lato* family. Only three—(1) *B. burgdorferi sensu stricto*, (2) *Borrelia afzelii*, and (3) *Borrelia garinii*—have been confirmed to be pathogenic in humans and to cause Lyme borreliosis, although other species are under investigation for their relationship to human diseases (including *Borrelia bissettii*[16,17] and *Borrelia lonestari*[18]).

In the United States, the etiologic agent of Lyme disease is exclusively *B. burgdorferi sensu stricto*. *B. afzelii* and *B. garinii* cause the majority of Lyme disease in Europe, although *B. burgdorferi sensu stricto* is also present.[19] In Asia, only *B. afzelii* and *B. garinii* have been confirmed to exist.

ENZOOTIC LIFE CYCLE OF THE AGENT OF DISEASE

B. burgdorferi is maintained in nature through a cycle involving small rodents, birds, and ticks of the *Ixodes* species.[20,21] Although not important reservoirs for *B. burgdorferi*, deer are an important feeding source for adult ticks and reductions in deer populations can lead to significant decreases in the tick population.[22]

Ixodes ticks have a 2-year, three-stage (larval, nymphal, and adult) life cycle. Larval ticks acquire *B. burgdorferi* organisms by taking a blood meal from an infected animal and maintain the infection during the subsequent molting to the nymphal and adult stages. *B. burgdorferi* remain dormant in the tick's midgut between feedings.[23] Each tick life stage takes one blood meal: larval ticks feed in late summer, nymphal ticks feed the subsequent spring and early summer, and adult ticks feed in the fall and early winter. The major reservoirs for *B. burgdorferi* are small rodents and birds that are fed on by larval and nymphal ticks. Adult ticks feed on larger mammals (e.g., deer) that are not important reservoirs for *B. burgdorferi*. Humans are incidental hosts not important in maintaining *B. burgdorferi* in the wild. Most cases of human illness occur in the late spring and summer months when the ticks are most active and human outdoor activity is greatest.

Of clinical relevance, certain *Ixodes* ticks are vectors of other tick-borne illnesses in addition to Lyme disease: *I. scapularis* ticks in the United States and *Ixodes ricinus* ticks in Europe may transmit *Babesia microti* (a red blood cell parasite) or *Anaplasma phagocytophilum* (formerly referred to as the agent of human granulocytic ehrlichiosis).[24,25] *I. ricinus* in Europe and *Ixodes persulcatus* in Asia are also vectors of tick-borne encephalitis virus.[26]

PATHOGENESIS

Once in the host's skin, *B. burgdorferi* begins to spread from the initial inoculation site rapidly into the bloodstream where it disseminates to multiple sites. Time from inoculation to dissemination varies from as little as 3 days to weeks.[5]

B. burgdorferi has developed strategies to adapt to and survive in markedly different microenvironments.[27] The organism expresses a variety of proteins during its life cycle, facilitating binding to different host proteins, migration within host tissues, transmission, and evasion of the host immune response.[28,29] A well-documented example of host adaptation is the variable expression of outer-surface proteins (Osp) A and C. OspA, primarily expressed while the spirochete is dormant in the tick's midgut,[30] is thought to serve as an anchor by binding the tick midgut protein, TROSPA.[31] When the tick engorges on a host, *B. burgdorferi* downregulates OspA, releases from the midgut, and begins to multiply and travel to the salivary glands. This process takes between 24 and 48 hours, which explains why removal of the tick before 24 hours of attachment prevents transmission of disease.[32]

As the organism downregulates OspA, it upregulates OspC, which facilitates migration from the tick's gut to its salivary glands. OspC binds to a tick salivary protein, Salp15, which protects the organism from clearance by host immune defenses.[33] Immunosuppressive characteristics of tick saliva also aid in the establishment of early infection. For example, tick saliva contains proteins that bind host chemokines.[34] These proteins, termed evasins, help suppress recruitment of inflammatory cells into the area where the tick is feeding allowing the tick to better feed and incidentally providing protection to organisms such as *B. burgdorferi* that are transmitted during feeding.

B. burgdorferi also bind host factor H to protect itself from complement-mediated killing.[35,36] Specificity of strains of *B. burgdorferi* for factor H from different animal species may, in part, explain differences in host range between the species. *B. burgdorferi* have been shown to upregulate host proteases such as matrix metalloproteinases in the skin and joints which may play a role in pathogenesis by digesting extracellular matrix proteins and allowing dissemination, but this requires further clarification.[37]

IMMUNOLOGY

Both innate and acquired host immune defenses have important roles in the control of *B. burgdorferi* infection; however, neither can typically eradicate the disease.[38,39] Phagocytosis, both complement mediated and noncomplement mediated, is the first line of host defense against *B. burgdorferi*.[40,41] Natural antibodies (polyclonal IgM antibodies) may also function as a first line of defense against *B. burgdorferi*, killing spirochetes in the tick midgut during the blood meal and limiting pathogen burden before the development of a specific adaptive immune response.

Once inside the host, *B. burgdorferi* is a strong inducer of inflammation. Its outer surface lipoproteins are potent inflammatory stimuli.[42–44] Recognition of borrelial lipoproteins occurs through binding to Toll-like receptor 1 and 2 heterodimers, which initiates a cascade of intracellular signaling events culminating in the production of proinflammatory cytokines, chemokines, and other molecules important in host defense. Studies using Toll-like receptor-deficient mice have shown that other signaling pathways are also activated by *B. burgdorferi* and result in release of inflammatory mediators. Among the other innate immune receptors recognizing *B. burgdorferi* and mediating inflammation are integrin receptors.[45,46]

Development of a specific humoral immune response generally occurs over weeks to months.[47,48] The IgM response usually peaks between 3 and 6 weeks after disease onset and may remain elevated for months to years; the immunoglobulin G (IgG) response usually follows the IgM response by several weeks so that approximately 90% of patients have detectable IgG levels 4–6 weeks into the infection. The development of the humoral antibody response typically heralds a significant decrease in the number of organisms and decrease in the level of inflammation. Of note, the acquired humoral response is not typically protective against reinfection, in part due to significant sequence variability in protective antigenic epitopes between *B. burgdorferi* strains and the lack of expression of less variable protective antigens (e.g., OspA) in the mammalian host.[49]

CLINICAL MANIFESTATIONS

The clinical course of Lyme disease is typically described in stages that parallel that of another spirochetal disease, syphilis: early localized, early disseminated, and late disseminated. Localized disease closely follows the bite of an infected tick and is characterized by the erythema migrans (EM) rash with or without constitutional symptoms. Early disseminated Lyme disease presents days to months after onset of infection as a number of distinct clinical entities affecting the skin, joints, nervous system, and heart. Late-disseminated Lyme disease typically presents in only a subgroup of untreated patients months to years later, and manifests as chronic symptoms localized most often to the skin, joints, and nervous system. A minority of patients go on to develop prolonged posttreatment syndromes. These include a syndrome of antibiotic-resistant arthritis thought possibly to be autoimmune in nature, and, separately, a constellation of symptoms with similarities to fibromyalgia and chronic fatigue syndrome. The relationship of these latter symptoms to infection with *B. burgdorferi* is still debatable.

The disease caused by each species of *B. burgdorferi* is largely the same but certain clinical manifestations are more closely associated with infection due to a particular species.[19,50] For instance, *B. burgdorferi sensu stricto* is the most arthritogenic of the three *Borrelia* species.[51] For this reason, Lyme arthritis is the most frequent presentation of late Lyme disease in North American patients. Similarly, because *B. afzelii* is the species that has most often been associated with late skin manifestations; some dermatologic conditions [e.g., acrodermatitis chronica atrophicans (ACA) and borrelial lymphocytoma] are nearly exclusively found in Europe. Finally, *B. garinii*, the most neurotropic of the three species, causes a wide range of neurologic abnormalities.

EARLY CUTANEOUS MANIFESTATIONS OF LYME DISEASE

ERYTHEMA MIGRANS

Clinical Features. In early case reports, EM lesions were reported in 50%–80% of patients with Lyme disease. More recent studies have shown lower rates of EM, likely due to improved patient education. Definite history of tick bite at the site of the lesion is obtained in only a small proportion of patients.[52] The lesion itself is believed to be the result of the direct presence of the spirochete, corroborated by reports showing aspiration and cultivation of the organism from the lesion (see Fig. 187-1). EM lesions develop within 3–30 days of the tick bite (median, 7 days).[53]

EM may be seen anywhere on the body but is most common on the lower extremities, inguinal and axillary regions of adults (Fig. 187-2), and on the face in children ("slapped cheek" appearance) reflecting sites of predilection of the tick.[2] Although no definite sex predilection has been noted in the United States, women are reported to be more commonly affected in European studies.[8]

The skin lesion has a characteristic and pathognomonic appearance (see Fig. 187-2) of an expanding erythema encircling the bite site, with the transition between the central zone and periphery being less well demarcated than between that of the periphery and adjacent skin.[52] The border is usually continuous and not patchy. Cases in which the erythema appears stationary or even linear are reported.[5] Typically described as round, the lesion in reality is more oval with the "long line of the oval parallel to the lines of least skin tension" (Langer lines) (see Fig. 187-2).[54] As migration of the lesion proceeds, distortion of this configuration occurs.[55] The center fades after a few weeks leaving only the annular border erythematous (see eFigs. 187-2.1 and 187-2.2 in online edition).

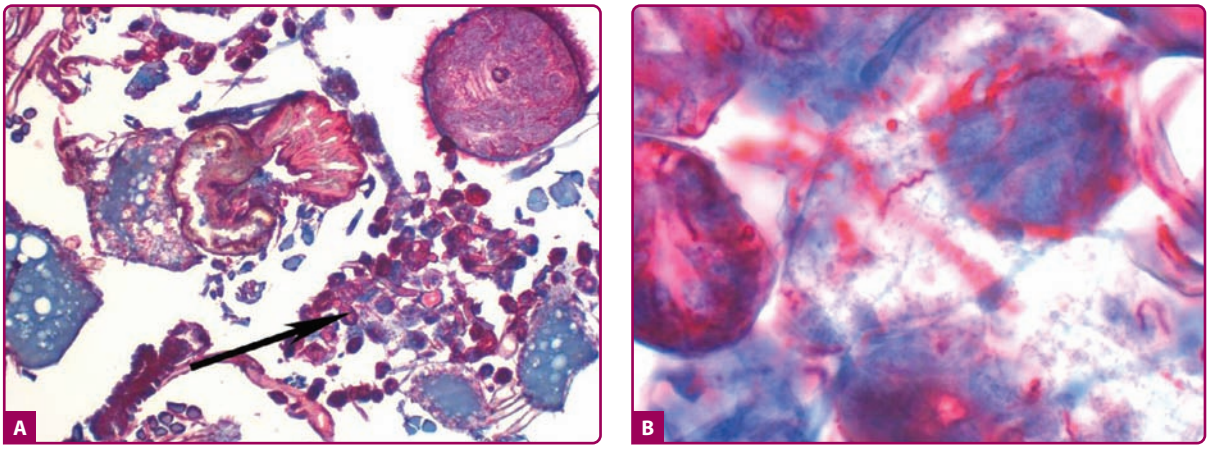

Figure 187-1 Tick with *Borrelia* (**A**) 10× and (**B**) 100×. (Used with permission from Dr. K Eisendle, Innsbruck Medical University.)

In very large lesions, only a portion of the erythematous border can be seen (see eFig. 187-2.3 in online edition).

Uncommon presentations include the entire lesion being homogenously erythematous ("solidly erythematous") (10%), forms with marked central necrosis, minimal size EM (size of the ring less than 5 cm at initial presentation) (2%), and the vesicular variant (5%).[56–58]

The lesion in itself is usually asymptomatic, but 50% of patients report mild tingling or itching.[59] Systemic manifestations, reported in approximately 50% of patients, may appear before, during, or after the classic lesion.[52,55]

EM has an excellent prognosis, attributable in part to the activation of proinflammatory cytokines such as interferon-γ.[60] EM usually heals spontaneously, but may persist for as long as 6–12 months; median duration in the United States is approximately 4 weeks and in Europe is approximately 10 weeks.[8,19,59]

Multiple EM-like lesions occur in between 1% and 17% of patients.[52] The reported prevalence of multiple lesions is believed to be higher in the United States (25%–48%) than in Europe (8% or less).[61] The spatial relationship of multiple lesions to the initial lesion indicates that they may be the consequence of hematogenous dissemination. Secondary EM lesions number from 2 to more than 80, usually occur away from the original lesion, and are usually smaller and less migratory (occur in "crops" of similar size, color, and shape) in comparison to classic EM.[52] Lesions are usually asymptomatic and if untreated spontaneously resolve over weeks to months. Like the primary lesion, secondary EM expands over days to weeks resulting in both solid and annular erythema. Primary EM may still be present but more often a primary lesion is not found. Constitutional symptoms are usually more severe than those associated with classic EM.[56]



Figure 187-2 Lyme borreliosis. Erythema migrans in the groin with expanding margin at the site of the tick bite of a week's duration. (Reprinted with permission from *Dermatopathology Interactive Atlas*, edited by J Bhawan, P Sau, HR Byers, 2001; http://www.dermpathatlas.com.)

Histopathologic Features. Histopathologic findings vary with the biopsy site[55] and age of the lesion. Biopsies of early lesions show papillary dermal edema and a mixed infiltrate of lymphocytes, neutrophils, a few plasma cells, and a few eosinophils (Fig. 187-3). Biopsies of older lesions display a variably dense perivascular and interstitial infiltrate of lymphocytes and plasma cells (Fig. 187-4). Helpful, albeit nonspecific, clues include the presence of plasma cells and mast cells in the infiltrate.[62] The presence of plasma cells and eosinophils in the same specimen is reported to be much less common than the presence of either alone.[55]

Immunohistochemical studies indicate the infiltrate to be composed of $CD4^+$ T lymphocytes with the exception of those seen in association with HIV infection in which the infiltrate is mainly $CD8^+$ T lymphocytes, reflective of the CD4 lymphopenia of HIV infection.[63]

Histopathologic features of multiple lesions of EM are identical to primary EM.

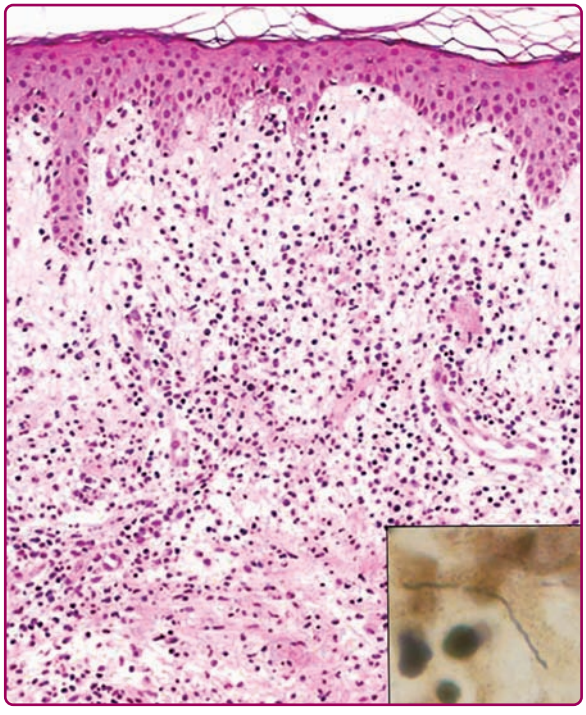

Figure 187-3 Histopathology of erythema migrans. Papillary dermal edema, mixed infiltrate of lymphocytes, neutrophils, few plasma cells, and few eosinophils (hematoxylin and eosin stain). *Inset* shows a spirochete in same biopsy stained with Warthin–Starry stain (oil immersion). (Reprinted with permission from *Dermatopathology Interactive Atlas*, edited by J Bhawan, P Sau, HR Byers, 2001.)

Diagnosis and Differential Diagnosis. The diagnosis of EM is typically made on clinical appearance in patients in an endemic area. From biopsy specimens, spirochetes, detected using special stains, are best located in the papillary dermis and may be short or elongate at this stage of the disease (see Fig. 187-3 inset).[55] Direct detection of the spirochete from biopsy specimens using newer modified immunohistochemical methods such as focus floating microscopy have a better yield in detection of organisms from EM cases. Both sensitivity and specificity are higher than for culture or polymerase chain reaction (PCR)-based techniques.[64,65]

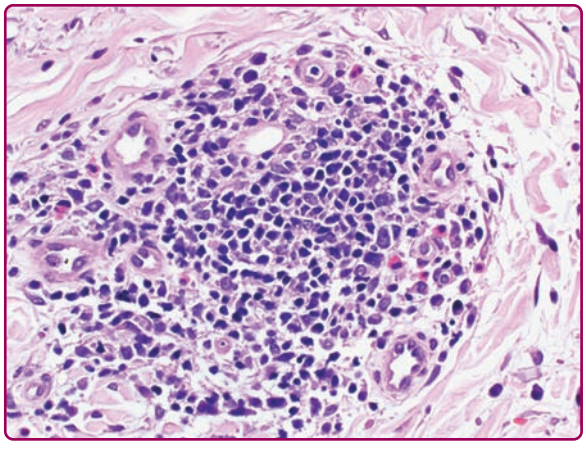

Figure 187-4 Histopathology of erythema migrans. Dense nodular perivascular lymphoid cell infiltrate with many plasma cells and few eosinophils in a biopsy from a later stage of erythema migrans. (Hematoxylin and eosin stain, ×40.)

Atypical lesions exist and broaden the clinical differential diagnosis to include cellulitis, tinea, other contact dermatitis, or a fixed drug reaction (Table 187-1). The differential diagnosis of vesicular EM includes poison ivy, contact dermatitis, cellulitis, herpes simplex, and impetigo.

LATE CUTANEOUS MANIFESTATIONS OF LYME DISEASE

ACRODERMATITIS CHRONICA ATROPHICANS

Clinical Features. Observed mainly in elderly patients in Europe, ACA has an insidious onset and appears to have predilection for females.[66] Rare cases of ACA have been reported in children.[67] The time interval from the spirochete inoculation to the onset of symptoms of ACA is extremely difficult to evaluate. Most patients do not recall the specific tick bite that initiated the disease.[8,68] That the spirochete can survive for decades is favored by reports indicating recovery of the spirochete from biopsies of skin from ACA patients even after 20 years.[8]

An inflammatory phase characterizes the early clinical stages of this biphasic disease.[69] The inflammatory phase presents as a bluish-red discoloration on the extensor aspect of fingers, hands, joints, and lower extremities (see eFigs. 187-4.1 and 187-4.2 in online edition).

Joints commonly involved include the elbows and knees. Infiltrated purple bands of varying widths may be observed adjacent to involved joint(s). Associated findings include a cushion-like ("doughy") swelling of the dorsum of the hands and feet (see eFig. 187-4.2 in online edition).[69]

The extremities are most commonly involved, although extensive lesions on the trunk have also been documented. Lesions typically extend from the distal to the proximal portion of the extremity involved. The erythema and swelling initially vary in intensity ("waxes and wanes"), and swelling of the posterior aspect of the lower extremities is believed by some to be particularly indicative of Lyme disease.[59]

Cutaneous atrophy (Fig. 187-5), characteristic of the later clinical stage, is not an obligatory sequel to the inflammatory phase of ACA.[69] Rarely, coexistence of both kinds of lesions at different sites in the same patient has been documented. The atrophic phase is characterized by lesions with a "cigarette paper-like" appearance and a prominence of superficial veins (see Fig. 187-5).

Extracutaneous Features. Central and peripheral nervous system involvement has also been documented in approximately 45% of patients with ACA.

TABLE 187-1
Cutaneous Manifestations of Lyme Disease

	Onset	Diagnosis/Differential Diagnosis
Common Manifestations		
Erythema migrans	Days to weeks (early)	Arthropod bite, erythema multiforme granuloma annulare, urticaria, erysipelas, brown recluse spider bite, fixed drug eruption
Acrodermatitis chronica atrophicans	Months to years (late)	Venous insufficiency, lichen sclerosus, scleroderma, physiologic age-related atrophy, corticosteroid-induced atrophy
Uncommon Manifestations		
Cutaneous scleroborrelioses	Months to years (late)	
Morphea		Primary morphea
Lichen sclerosus		Primary lichen sclerosus
Periarticular fibrous nodules		Rheumatoid nodule, gouty tophi
Progressive facial hemiatrophy		Primary progressive facial hemiatrophy/Parry–Romberg syndrome
Eosinophilic fasciitis		Primary eosinophilic fasciitis/Shulman syndrome
Cutaneous atrophoborrelioses	Months to years (late)	
Anetoderma		Primary anetoderma
Cutaneous lymphoborrelioses	Months to years (late)	
B-cell dominant (including B-cell lymphoma)		Arthropod bite reaction, response to vaccination, granulomas, neoplasm
T-cell dominant		Pityriasis lichenoides, polymorphous light eruption
Other cutaneous lesions	Weeks to months to years (early or late)	
Panniculitis		Erythema nodosum
Granuloma annulare		Insect bite reaction
Erythema multiforme		Drug eruption
Syphilis-like papulosquamous eruption		Secondary syphilis



Figure 187-5 Acrodermatitis chronica atrophicans. Typical end-stage cutaneous atrophy with prominence of superficial veins.

Thirty percent to 45% of patients suffer from a polyneuropathy, often most pronounced in the limb with cutaneous involvement.[61] Chronic joint and bone involvement, attributed to persistence of spirochetes in cutaneous lesions, is most often seen in patients with long-standing ACA or an untreated lesion of EM/ACA and is typically restricted to the extremity involved. The characteristic symptom, exhibited in approximately one-third of patients in one study, was a swollen or painful foot and heel.[61] Other symptoms include subluxation of small joints, bursitis, arthritis, and cortical thickening of bone. Solitary or multiple fibrotic lesions near joints, particularly in the olecranon area, may develop in some patients.[69]

Histologic Features. All three species of *B. burgdorferi* that infect humans have been found in ACA lesions.[70] Histopathologic features of biopsied lesions vary with the clinical phase of ACA. In inflammatory lesions, three layers are typically described: an atrophic epidermis, a zone of uninvolved papillary dermis, and a layer of inflammatory cells composed of lymphocytes and plasma cells.[71] The presence of plasma cells in the infiltrate is documented mainly from studies from Europe, as American reports indicate that few or no plasma cells are found.[68,69] The infiltrate may be

deep with extension into the subcutis.[59] Occasionally, interface dermatitis has been reported. Unusual findings include the presence of vacuoles, either singly or in groups, at different levels of the dermis.[72] Although some believe these represent mature adipocytes, others believe them to be an expression of lymphedema, given that they are mainly observed from biopsies of markedly edematous sites. In favor of the latter hypothesis is the absence of such vacuoles from the same site posttreatment.

Phenotypic studies indicate the lymphocytes in the infiltrate are mainly of the CD4 phenotype, favoring the concept that ACA is a T cell-mediated immune response.[73] Further in support of this theory is the expression of adhesion molecules, such as intracellular adhesion molecule-1, on endothelial cells, lymphocytes, and basal keratinocytes in the inflammatory infiltrate.[74] Chronicity of the lesions may be partially explained by downregulation of major histocompatibility complex class II molecules on Langerhans cells.[75]

Diagnosis and Differential Diagnosis. Detection of the spirochete using special stains, novel immunohistochemical techniques such as focus floating microscopy or PCR-based techniques substantiates the infective etiology, further supported by positive serologic findings.[65] Serology is of great utility in the diagnosis of ACA. Antibodies to *B. burgdorferi* can be detected in almost all of patients with ACA even years after treatment.

Lesions of ACA are notoriously overlooked or misinterpreted. In those with a relevant clinical history, the onset appears to be related to an untreated lesion of EM and/or neurologic manifestations. In one study, a history of EM months to years earlier on the same side was found in approximately 18% of patients.[75] Differential diagnoses are listed in Table 187-1.

CUTANEOUS SCLEROBORRELIOSES

Clinical Features. Sclerotic skin lesions clinically indistinguishable from primary lichen sclerosus (LS) or morphea (see eFig. 187-5.1 in online edition) develop not only in association with other dermatoborrelioses [approximately 10% of patients with ACA and borrelial lymphocytoma (see Section "Uncommon Cutaneous Manifestations of Lyme Disease")] but also in the absence of other cutaneous manifestations of Lyme disease.[56,76,77]

Periarticular ("ulnar") fibrous nodules (Fig. 187-6), described in association ACA, may also occur in the absence of dermatoborrelioses.[78] They usually present as hard nodules on the elbows, knees, and on the lateral aspect of the digits near joints and have been reported to be provoked by trauma, surgery, and electromagnetic radiation.[79]

Uncommon sclerotic disorders associated with Lyme disease include progressive facial hemiatrophy (Parry–Romberg syndrome) and eosinophilic fasciitis (Shulman syndrome) (see Chapter 157).[80] In support of an infectious etiology is the clinical similarity of the cutaneous lesions, positive history of tick bite, and, in rare cases, antiborrelial serologic evidence and positive culture and PCR from lesions.[81,82] Eosinophilic fasciitis associated with borrelial infection has been termed *borrelial fasciitis*, reflective of the infectious nature of these lesions.[80] Patients with borrelial fasciitis lack the peripheral blood eosinophilia typical of patients with Shulman disease.



Figure 187-6 Lyme borreliosis. Fibrotic nodules and multiple large, firm subcutaneous nodules on both elbows.

Histologic Features. A unifying feature of LS- and morphea-like scleroborrelioses is the abundance of plasma cells in the inflammatory infiltrate.[69] Unusual histologic findings include a scleromyxedema-like picture with increased dermal mucin and fibroblast proliferation.[78]

Histopathologic examination of a periarticular fibrous nodule reveals relatively well-circumscribed nodules of broad hyalinized bundles of collagen with macrophages and plasma cells.[79,83] Adjacent capillaries may be occluded by similar deposits.

Progressive facial hemiatrophy and eosinophilic fasciitis show variable dermal sclerosis, loss of appendages, and a perivascular infiltrate composed predominantly of lymphocytes and plasma cells with scattered histiocytes.[69] In borrelial fasciitis, eosinophilic infiltration of the fascial planes is not as impressive as in the idiopathic disorder, Shulman disease.[80]

Diagnosis and Differential Diagnosis. (See Table 187-1). In the absence of other dermatoborrelioses, definitive diagnoses can only be made by positive evidence of infection in the form of identification of the spirochete using special stains in tissue sections positive cultures, or positive serology.[84] (Identification of the organism in periarticular nodules has been reported despite the lengthy delay following the tick bite). Conflicting evidence regarding serologic findings in patients with scleroderma or LS-like lesions exists.[77] Although some reports indicate a

high frequency of elevated titers of anti-*Borrelia* antibodies, others suggest that such serologic evidence is minimal.

CUTANEOUS ATROPHOBORRELIOSES

Clinical Features. Atrophic lesions indistinguishable from primary anetoderma (see Chapter 67) may also occur in the absence of other dermatoborrelioses.[69,84] When associated with ACA, these lesions are usually seen at the periphery of an extensive lesion.[85]

Histologic Features. Biopsy specimens from atrophic or anetoderma-like skin lesions show abnormal elastic tissue fibers in association with a perivascular infiltrate of lymphocytes with occasional histiocytes, neutrophils, or eosinophils.[69] Spirochetes may be found with difficulty in histologic sections.

Diagnosis and Differential Diagnosis. (See Table 187-1). Definitive diagnosis is made by identification of the spirochete in tissue sections, positive cultures, or positive serology in combination with a compatible clinical presentation.[84]

UNCOMMON CUTANEOUS MANIFESTATIONS OF LYME DISEASE

CUTANEOUS LYMPHOBORRELIOSES (B- AND T-CELL LYMPHOID HYPERPLASIAS)

Clinical Features. Lymphocytic infiltrates associated with *Borrelia* are the least common of the cutaneous hallmarks of Lyme disease (1%) and may present either as single borrelial lymphocytoma (lymphadenosis benigna cutis, LABC) or as multiple lesions.[59] The coexistence of lymphocytoma with other dermatoborrelioses led to the suggestion of a unifying causative organism, favored by the development of EM-like lesions following passive inoculation of an infiltrate from a lesion of LABC.[8,86] Lymphocytoma has been reported solely in Europe. However, all three species of *B. burgdorferi sensu lato* have been associated with lymphocytoma, so it is unclear whether the lack of US cases is related to strain differences.[70]

More common in children than in adults, lymphocytoma clinically presents as a nodulopapular lesion on the ear lobe (Fig. 187-7) or scrotum (see eFig. 187-7.1 in online edition) in children and the nipple-areolar area in adults.[56] The precise reason for this predilection is not known but is believed to be tissue temperature related.[59] It can occur in other locations. (see eFig. 187-7.2 in online edition).

As with the other dermatoborrelioses, most patients are not aware of a preceding tick bite. The incubation period varies anywhere from a few weeks to 10 months. The duration of an untreated solitary lesion can vary from months to years (average, 5 years). Spontaneous resolution may occur, but typically lesions resolve more rapidly with antibiotic therapy.[61] Lesions of multiple lymphocytomas can be entirely subcutaneous, may last for decades, and typically have



Figure 187-7 Borrelial lymphocytoma of ear lobe, 3 months' duration.

no specific site predilection or associations with other dermatoborrelioses.

Discoid lesions that start as small papules and expand peripherally with central clearing and that wax and wane have also been described in association with borrelial infection.[87] The name given for these lesions is *benign lymphocytic infiltrates* of the skin (Jessner–Kanof) (see Chapter 146). More common in men, they tend to be located on the face, neck, and upper trunk. Annular lesions clinically resembling EM have also been described.

Several reports suggest an association of low-grade cutaneous B-cell lymphoma with *B. burgdorferi* infection.[88,89] Clinical presentation of *Borrelia*-associated B-cell lymphoproliferative disease is varied and consists of multiple ill defined, slowly progressive plaques and nodules presenting on the trunk, extremities, or both, of usually older patients. The highest frequency of infection with *Borrelia* has been found in marginal zone lymphoma (20%–52%), followed by follicular center lymphoma (15%–26%) and diffuse large B-cell lymphoma (15%–16%; see Chapters 145 and 146).[88,90] That antigenic drive by *Borrelia* may be a pathogenic factor in more than one subtype is supported by the association of *B. burgdorferi* in patients who subsequently present with multiple subtypes of cutaneous B-cell lymphoma. Demonstration of the organism in the skin before development of overt cutaneous B-cell lymphoma serves to confirm the temporal progression of *B. burgdorferi*-associated B-cell lymphoproliferative disease. Clinical regression of marginal zone lymphoma ("pseudolymphoma") after eradication of *B. burgdorferi* argues in favor of a benign process.[89,91,92]

Histologic Features. Histopathologic findings of benign B- and T-cell dominant hyperplasias are essentially similar to benign lymphoid hyperplasias (Fig. 187-8) secondary to an arthropod bite, vaccination, or other causes (see Chapter 146). Definitive classification of *Borrelia*-associated B-cell lymphoma is confounded by the immunohistochemical profile. Expression of CD5 and CD10 (common acute lymphoblastic leukemia antigen), antigens typically associated with centrocytic lymphoma, are absent in *Borrelia*-associated B-cell lymphoma.[88]

Diagnosis and Differential Diagnosis. (See Table 187-1). Positive history of tick bite and presence

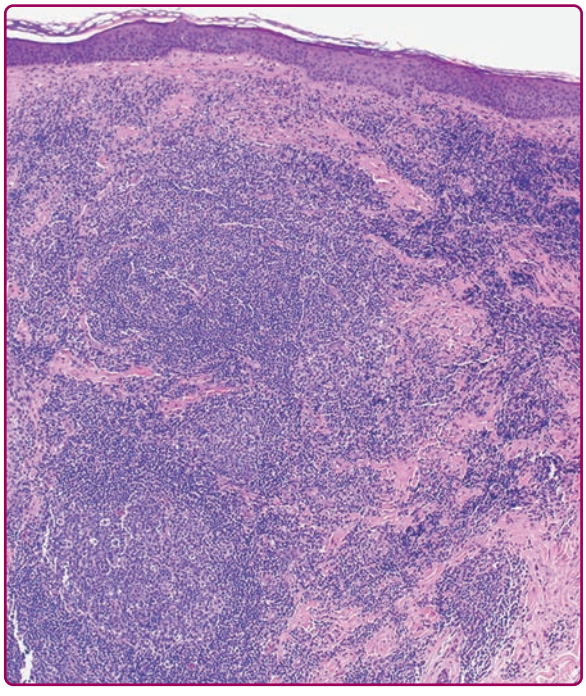

Figure 187-8 Cutaneous borrelial lymphocytoma with definitive history of tick bite. Nodular and diffuse dense lymphohistiocytic infiltrate with prominent germinal center (hematoxylin and eosin stain).

of other dermatoborrelioses are helpful, given that the histologic findings of cutaneous lymphoborrelioses are not diagnostic. Direct evidence of an infective etiology has been provided from studies demonstrating the presence of fragmented spiral forms suggestive of *B. burgdorferi* in lesions of benign lymphocytic infiltrates[87] and has been confirmed by immunofluorescence using species-specific monoclonal antibodies. Spirochetes may be cultured directly from biopsy specimens or *B. burgdorferi* DNA may be detected by PCR. High titers of antiborrelial antibodies have been reported in more than 50% of patients with LABC solitaria.[86] The common denominator in patients with *Borrelia*-associated lymphoma appears to be a high titer of antibodies, typical of the chronic stage of the infection, against *B. burgdorferi*.[88]

OTHER CUTANEOUS LESIONS. Other cutaneous lesions reported in patients with documented Lyme disease include panniculitis, vasculitis, granuloma annulare, erythema multiforme, and a syphilis-like papulosquamous eruption (see Table 187-1), but *B. burgdorferi* has not been directly recovered from any of these lesions, arguing against routine molecular analysis of these disorders for the presence of *Borrelia*.[65]

NONCUTANEOUS MANIFESTATIONS OF LYME DISEASE

NERVOUS SYSTEM MANIFESTATIONS. *B. burgdorferi* can cause early disseminated neurologic disease in 10%–15% of patients in the United States who have not received antibiotics.[93] Meningitis, cranial neuropathy, and radiculopathy are the most common neurologic manifestations and can manifest as soon as 1 week after EM.[94] Facial palsy is the most characteristic neuropathy of early Lyme disease in the United States, occurring in 40%–50% of patients with borrelial neurologic involvement, usually within 4 weeks after onset of EM. Bilateral facial palsy should immediately raise suspicion for Lyme disease, as it is uncommon in most other causes of facial palsy. Involvement of other cranial nerves has been reported, but is relatively rare.[94] The triad of lymphocytic meningitis, cranial palsy (often facial), and radiculoneuritis, known as *Bannwarth syndrome*, is pathognomonic for Lyme disease. It is frequently reported in Europe but is rare in the United States.[95,96] Acute or subacute myelitis leading to spastic paraparesis and CSF pleocytosis, mononeuritis, and a Guillain–Barré-like syndrome may also occur in early disseminated disease.[94,97] Late neurologic manifestations include encephalomyelitis, encephalopathy, and chronic polyneuropathies.[97,98]

CARDIAC MANIFESTATIONS. Cardiac involvement occurs in 4%–10% of untreated patients in the United States and in 0.3%–4.0% of European patients. It usually occurs within several weeks after the onset of infection, although it can occur as early as 1 week and as late as 7 months into the infection.[99,100] Within the heart, *B. burgdorferi* has a predilection for the atrioventricular node, resulting in atrioventricular block. Acute myopericarditis and left ventricular dysfunction can also occur, but are usually self-limited and mild, only sometimes resulting in transient cardiomegaly or pericardial effusion.[101] *B. burgdorferi* has been isolated from endomyocardial biopsy samples from several European patients with chronic dilated cardiomyopathy, a complication observed less frequently in the United States.[102,103]

MUSCULOSKELETAL MANIFESTATIONS. Early musculoskeletal manifestations of *B. burgdorferi* infection are typically nonspecific. Inflammatory arthritis is the most frequent clinical sign of late-disseminated Lyme disease in the United States, occurring in 50%–70% of patients with untreated or incompletely treated infection. It usually presents 1 or more months after the onset of Lyme disease as asymmetric mono- or oligoarthritis of large joints, most often of the knee.[93] Migratory arthritis is also relatively common.[5,51] Bouts of arthritis are generally frequent and short at first, becoming longer and less frequent with time, each lasting from several days to 1 year.

OTHER MANIFESTATIONS OF LYME DISEASE. Ophthalmic complications in the form of conjunctivitis, keratitis, iridocyclitis, retinal vasculitis, choroiditis, and optic neuropathy are rare manifestations of Lyme disease. They are believed to be the direct result of tissue inflammation by *B. burgdorferi* and are usually associated with other signs and symptoms of disease.[104,105] The eye may also be affected by extraocular manifestations of Lyme disease, such as cranial nerve pareses and orbital myositis. Findings

in other organ systems (gastrointestinal, lymphatic, respiratory, urinary, and genital) have been reported, but the associations with borrelial infection are loose.

PERINATAL LYME DISEASE. Studies in both human and animal models indicate that *B. burgdorferi* can cross the placenta during the initial spirochetemia, but evidence of a fetal immune response or an adverse neonatal outcome are not definitively established.[106]

LYME DISEASE IN CHILDREN. Other than differences in localization of EM lesions (more typically in the head and neck), pediatric Lyme disease is similar to that of adults. Of note, however, is that in children optic nerve involvement may lead to blindness.[107]

PROGNOSIS AND CLINICAL COURSE

Virtually all manifestations of Lyme disease resolve over time, even in the absence of antibiotic therapy. Antibiotic therapy can hasten resolution of some (EM, arthritis), but not all (facial palsy, radiculitis) manifestations, and early antibiotic therapy can clearly prevent late manifestations.

Dual infection with *B. burgdorferi* and either of *Babesia microti* or *A. phagocytophilum* occurs at different frequencies depending on the geographic location, and may alter the clinical presentation of Lyme disease in some patients. Some studies suggest more severe disease in patients who are coinfected, but this remains uncertain.[108–110]

COMPLICATIONS

A small number of patients have symptoms that persist for years despite appropriate antibiotic therapy. Up to 10% of patients with Lyme arthritis treated with appropriate antibiotics may have continued arthritis that persists for years.[111,112] Arthritis in these patients does typically respond to immunosuppressive agents (methotrexate, antitumor necrosis factor therapies), which has led to suggestions that these patients may have an infection-induced autoimmune syndrome. Molecular mimicry of borrelial antigens with host proteins has been proposed as one possible mechanism, but this remains unproven.[113]

There have been many reports of patients who develop a fibromyalgia-like syndrome including profound fatigue, depression, myalgias, polyarthralgias without arthritis, and paresthesias, as well as neurocognitive difficulties involving memory, concentration (particularly auditory), and impaired verbal fluency after infection with *B. burgdorferi*.[43,114,115] This syndrome is often referred to as *chronic Lyme disease*. The linkage of these symptoms with *B. burgdorferi* infection remains controversial and several large epidemiologic studies have shown that patients who have contracted Lyme disease are no more likely to suffer from these symptoms than persons in the general population.[116,117]

DIAGNOSIS OF LYME DISEASE

Physical findings, a history of potential exposure, known tick bites, or symptoms consistent with the typical multisystem presentation of Lyme disease can all be helpful in making a diagnosis. In the presence of classic EM or of Bannwarth syndrome, the diagnosis of Lyme disease can be made on clinical grounds alone. Diagnostic conundrums arise in presentations that involve other compatible skin, cardiac, neurologic, or musculoskeletal symptoms in the absence of a history of EM or tick exposure.

LABORATORY TESTS

DIRECT DETECTION OF *B. BURGDORFERI*. The organism is notoriously difficult to detect even with the use of special stains that include silver impregnation techniques such as Warthin–Starry, modified Dieterle or Bosma–Steiner.[118] More recently, focus floating microscopy (FFM), a novel modified immunohistochemical detection method has been shown to be reliable in detecting the organism from formalin-fixed paraffin-embedded tissue with a sensitivity surpassing that of PCR-based methods (96.0% vs. 45.2%) and a comparable specificity nearly equaling its sensitivity (99.4% vs. 100%).[65] The technique takes into consideration the scant presence of these spirochetes in tissue sections and their tiny size (0.2 µm thick) (Fig. 187-9). Added advantages of FFM include the fact that it is a fairly rapid, robust and relatively inexpensive method.

The gold standard for diagnosis of Lyme disease is culture of *B. burgdorferi*. However, the need for specialized media and the slow growth of the organism make it impractical in most clinical settings. *B. burgdorferi* can readily be cultured from biopsies of EM and ACA[64] as well as from CSF samples in patients with meningitis.[119,120] Recent studies have also demonstrated that the organism can be recovered from the blood in up to 50% of untreated adult patients with EM.[121] However, cultures are generally insensitive in patients with



Figure 187-9 Immunohistochemical staining for *Borrelia* using focus floating microscopy. (Used with permission from Dr. K Eisendle, Innsbruck Medical University.)

extracutaneous manifestations of Lyme borreliosis, particularly in later stage disease.

PCR-based assays, although utilized in detecting *B. burgdorferi* DNA in skin biopsy and synovial fluid specimens from patients with EM and Lyme arthritis, respectively, have varied sensitivities (30%–90%) based on the *Borrelia* strains, substrate (fresh frozen tissue or formalin-fixed paraffin-embedded tissue) and primers (specific for human pathogenic strains) used.[122] However, PCR testing for *B. burgdorferi* DNA has not been approved by the U.S. Food and Drug Administration (FDA), and its routine use is not recommended.[7]

SEROLOGIC DIAGNOSIS OF LYME DISEASE.

Immunologic diagnosis is the main laboratory modality used to support a clinical diagnosis of Lyme disease. In the United States, the FDA has approved more than 70 different immunoassays for Lyme disease[123]—mainly enzyme-linked immunoabsorbent (ELISA) and western immunoblot assays. ELISA tests use whole-cell lysates of *B. burgdorferi sensu lato* or, less commonly, purified *B. burgdorferi* antigens to capture either anti-*B. burgdorferi* IgG and/or IgM antibodies present in a given sample. Although relatively sensitive, ELISA tests are associated with a high rate of false-positive results.[124,125] Patients with autoimmune diseases (lupus, rheumatoid arthritis), Epstein–Barr virus, bacterial endocarditis, and other tick-borne diseases appear to be at an increased risk for false-positive IgM serologic testing; syphilis; patients with systemic lupus erythematosus, ehrlichiosis, and babesiosis or infections with H. pylori for false-positive IgG serologic testing.[125–127] A newer ELISA test that uses only a small peptide of the constant region of *B. burgdorferi* VlsE protein appears to have greater specificity than traditional whole cell ELISA testing. This test, also known as the *C6 peptide test*, measures only IgG antibody, but IgG antibody to the C6 peptide develops early in the course of disease and sensitivity of the assay in patients with early disease has been equivalent to that seen with IgM whole cell ELISA tests.[128,129] Western immunoblot assays are more specific because they enable detection of antibodies to individual components of *B. burgdorferi*. Currently, there are no widely accepted standard tests or criteria for serodiagnosis of Lyme disease in either Europe or Asia, in part because of the presence of multiple strains of *B. burgdorferi* that have only partial antigen cross-reactivity in a research setting.

Other Available Tests for the Diagnosis of Lyme Disease

Current Recommendations for Use of Serologic Testing for Lyme Disease. Because of its limitations, particularly high false-positive results within the general population, serologic testing should be initiated based on the pretest probability of disease and serve only to support a clinical diagnosis.[7] It is most helpful in patients with an intermediate pretest probability of Lyme disease—namely those who reside in endemic areas and who present with signs and symptoms consistent with, but not diagnostic of, Lyme disease (e.g., facial palsy, arthritis, or atrioventricular nodal conduction abnormalities in the absence of an EM lesion). Patients who reside in areas of high endemicity and have clear EM lesions should be diagnosed on clinical grounds alone without laboratory testing. Testing should be avoided in patients with low suspicion for disease (patients not living in endemic areas, or with nonspecific systemic symptoms, or after a tick bite) as the rates of false-positive tests greatly outnumber true positive tests in this setting. An algorithm for workup of patients presenting with an eruption suspicious for EM is shown in Fig. 187-10.

Once the decision is made to obtain serologic testing, current recommendations are for two-stage testing, starting with a highly sensitive ELISA test first. If the ELISA is negative, the likelihood of Lyme disease is low, and further testing is not generally recommended. However, if the test is positive or indeterminate, a western immunoblot assay with high specificity should be used to confirm the results. The specificity of this two-step approach is thought to be 99%–100% in late-stage Lyme disease.[130] If testing is negative early in the course of disease, the tests can be repeated in 3–4 weeks. However, antibiotic therapy, if given very early, may abort antibody development. It is important to note that in patients with untreated disease for longer than 1 month, IgM testing should not be performed. A positive IgM western blot with a negative IgG western blot in this setting is considered a negative result due to the high false positivity rate of IgM testing. Misuse or misinterpretation of the IgM tests one major factor in overdiagnosis of Lyme disease. Seronegativity in patients suspected of having late Lyme disease practically excludes the diagnosis.[7] Finally, because IgG and IgM antibody titers may persist for years despite antibiotic therapy,[131,132] persistent seropositivity is not in itself an indication of treatment failure, nor is it proof of recent infection or reinfection. Currently, there is no test that allows confirmation of successful clearance of the organism after treatment.

Some recent studies have suggested that the use of two-step testing for Lyme disease may result in underdiagnosis of Lyme disease. The performance of traditional ELISA tests against nonisogenic genotypes of *B. burgdorferi* is poor and early in the course of the disease results in lower sensitivity in patients infected with these strains.[133] The C6 antibody test appears to function better across genotypes of *B. burgdorferi* and with the European strains *B. garinii* and *B. afzelii*. Newer strategies incorporating C6 as a single step test or utilizing a C6 band in the second step western blot IgG test[134] have shown promising results but require further confirmation before they can be recommended.

TREATMENT RECOMMENDATIONS

Treatment is indicated for all stages of Lyme disease, even though most manifestations resolve over time without therapy. Patients may not be asymptomatic at the time of completion of the antibiotic course but this is not an indication for extending length of therapy; symptoms generally continue to improve steadily over

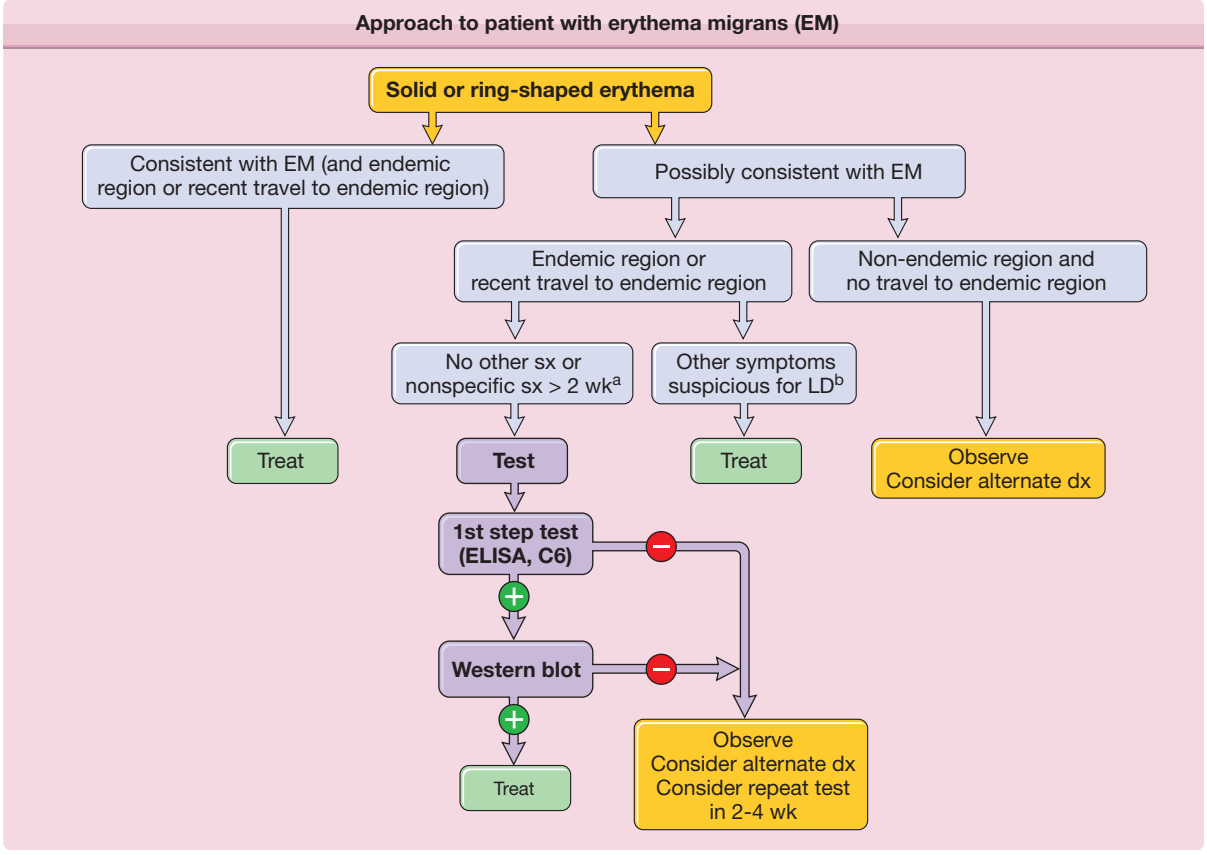

Figure 187-10 Approach to patient with erythema migrans (EM). [a]Fever, chills, fatigue. [b]Bell palsy, radiculoneuritis, meningitis, arthritis. dx = diagnosis; ELISA = enzyme-linked immunosorbent assay; LD = Lyme disease; sx = symptoms; dx = diagnosis.

time. Of note, Jarisch–Herxheimer reactions (fevers, chills, and worsening arthralgias and myalgias) are sometimes reported after the initial dose of antibiotics; the reaction is thought to be caused by host reaction to the dying organisms.

The Infectious Disease Society of America has published guidelines for the treatment of all manifestations of Lyme disease,[135] although many of the recommendations are based on expert opinion and not on rigorously controlled clinical trials. Treatment patterns differ among countries, but no data suggest differences in either the efficacy of specific antibiotics or in the optimal duration of therapy between patients in North America and Europe.

Treatment of all of the cutaneous manifestations of Lyme disease should initially be with oral antibiotics (Table 187-2). Doxycycline is generally considered as first-line therapy, because it has excellent penetration into the central nervous system and is also effective against *A. phagocytophilum*, the agent of human granulocytic ehrlichiosis. Amoxicillin should be used in children and pregnant women. Cefuroxime is a more expensive first-line agent. These three agents have been found to be equally effective.[26,135–137] Macrolides are second-line agents and some evidence suggests that they are less effective than the first-line agents.[135] Duration of therapy is generally recommended to be 14–21 days; a recent study showed similar outcomes in patients with EM treated with either a 10- or a 20-day course of oral doxycycline.[138]

Intravenous antibiotics (ceftriaxone, cefotaxime, or penicillin G) may be recommended for patients with cutaneous manifestations that are accompanied by neurologic disease (meningitis, encephalopathy) or high degree heart block. Intravenous antibiotics are also sometimes used for patients with refractory ACA or arthritis.

Treatment of patients with nonspecific fibromyalgia-like disease after infection with *B. burgdorferi* is controversial. There are no controlled trials supporting the use of long-term antibiotic therapy.[139]

PREVENTION

Prompt removal of the tick is the most effective measure in preventing disease, as the tick must usually be attached for 24–48 hours for transmission to occur. For adult or nymphal *I. scapularis* ticks that have attached for longer than 36 hours within an endemic area, a single 200-mg dose of doxycycline within 72 hours of tick removal is 87% effective in preventing early cutaneous manifestations.[135,140]

TABLE 187-2
Treatment of Lyme Disease

Presentation[a]			Treatment (Alternate)	Treatment Length (Days)	Comments
Early Lyme disease	Skin	Erythema migrans	A (B)	14 (14–21)	Can consider treating for 10 days if using doxycycline
		Lymphocytoma	A (B)	14 (14–21)	
	Cardiac	First and second degree AV block	A (B)	14 (14–21)	Consider IV antibiotics, temporary pacemaker if symptomatic
		Third degree AV block	C (D)	14 (14–21)	Consider temporary pacemaker
	Neurological	Cranial nerve palsy	A (B, C)	14 (14–21)	Consider lumbar puncture to exclude central nervous system involvement
		Meningitis	C (D)	14 (14–28)	
		Radiculopathy	C[b] (D)	14 (14–28)	Response to treatment usually is slow and may be incomplete; do not repeat antibiotics unless objective relapse
Late Lyme disease	Skin	Acrodermatitis	A (B)	21 (14–28)	If persistent or recurrent joint swelling, repeat 28-day course of oral antibiotics or 14–28-day course of IV ceftriaxone. If arthritis persists despite two courses of antibiotics: nonsteroidal antiinflammatory drugs, disease-modifying antirheumatic drugs, arthroscopic synovectomy
	Rheumatological	Arthritis	A (B, C/D)	28	
	Neuro	Encephalopathy	C (D)	28 (14–60)	Use 14–28 days initially. If no improvement, may consider a second course of similar duration
		Radiculopathy	C (D)	14 (14–28)	

Treatment (doses need to be adjusted in children):
A: First-line oral: Doxycycline[c] (100 mg PO bid), or Amoxicillin[d] (500 mg PO tid), or Cefuroxime (500 mg PO bid)
B: Alternative oral[e]: Azithromycin (500 mg PO qd), or Erythromycin (500 mg PO qid), or Clarithromycin (500 mg PO bid)
C: First-line parenteral: Ceftriaxone (2 g IV qd)
D: Alternative parenteral: Penicillin G (18–24 M units/day divided into doses given q4h),[f] or Cefotaxime (2 g IV q8h), or Doxycyline (200–400 mg/day IV in two divided doses)

[a]If several manifestations of Lyme disease are present, the route (PO or IV) and length of therapy should be as for the manifestation with the longest and most aggressive (e.g., IV >PO) recommendation.
[b]According to some small studies, oral doxycycline has been found to be effective.
[c]Also effective against *Anaplasma phagocytophilum*, the agent of human granulocytic ehrlichiosis. Relatively contraindicated during pregnancy or lactation and for children younger than 8 years.
[d]Preferred choice in children and pregnant women.
[e]Reserved for patients who are intolerant of first-line agents.
[f]Assuming normal renal function.

In 2002, the only FDA-approved Lyme disease vaccine for humans, a recombinant form of OspA, was withdrawn by the manufacturer despite an 80% efficacy in preventing Lyme disease in North America.[141,142] Withdrawal of the vaccine was related to concerns linking the emergence of autoimmune arthritis with host immune responses to OspA.[143] Recently, trials of an OspA vaccine lacking the epitope thought to be linked to autoimmune arthritis have begun in Europe.[144]

Available preventive measures in Lyme disease endemic areas include use of repellents, such as DEET or picaridin, or permethrin treatment of clothing; routine checks for ticks; and landscaping practices to create an inhospitable environment for ticks (removing brush and leaf litter, creating buffer zones of wood chips or gravel between forest and lawn, and application of pesticides to yards). Novel approaches under investigation include biologic agents (fungi) to kill the ticks, the use of devices to target acaricides to rodents and deer without harming them, the development of vaccines to eradicate disease in the wild reservoirs and vaccinations to prevent tick feeding. The control of infection on a larger scale by the eradication of deer or widespread use of acaricides have had limited public acceptance.[1,145]

KEY REFERENCES

Full reference list available at www.DIGM8.com

DVD contains references and additional content

26. Steere AC: Lyme disease. *N Engl J Med* **345**:115, 2001
37. Zhao Z et al: Selective up-regulation of matrix metalloproteinase-9 expression in human erythema migrans skin lesions of acute lyme disease. *J Infect Dis* **188**:1098, 2003
59. Duray PH, Asbrink E, Weber K: The cutaneous manifestations of human Lyme disease: A widening spectrum. *Adv Dermatol* **4**:255; discussion 276, 1989
60. Mullegger RR et al: Differential expression of cytokine mRNA in skin specimens from patients with erythema migrans or acrodermatitis chronica atrophicans. *J Invest Dermatol* **115**:1115, 2000
61. Asbrink E, Hovmark A: Early and late cutaneous manifestations in Ixodes-borne borreliosis (erythema migrans borreliosis, Lyme borreliosis). *Ann N Y Acad Sci* **539**:4, 1988
62. Duray PH: Clinical pathologic correlations of Lyme Disease. *Rev Infect Dis* **11**:S1487, 1989
64. Berger BW et al: Cultivation of Borrelia burgdorferi from erythema migrans lesions and perilesional skin. *J Clin Microbiol* **30**:359, 1992
71. Duray PH: The surgical pathology of human Lyme disease. An enlarging picture. *Am J Surg Pathol* **11**(Suppl. 1):47, 1987
80. Granter SR, Barnhill RL, Duray PH: Borrelial fasciitis: Diffuse fasciitis and peripheral eosinophilia associated with Borrelia infection. *Am J Dermatopathol* **18**:465, 1996
82. Abele DC, Anders KH: The many faces and phases of borreliosis. I. Lyme disease. *J Am Acad Dermatol* **23**:167, 1990
89. Goodlad JR et al: Borrelia burgdorferi-associated cutaneous marginal zone lymphoma: A clinicopathological study of two cases illustrating the temporal progression of B. burgdorferi-associated B-cell proliferation in the skin. *Histopathology* **37**:501, 2000

SECTION 30

Fungal Diseases

Chapter 188 :: Superficial Fungal Infection

:: Stefan M. Schieke & Amit Garg

SUPERFICIAL FUNGAL INFECTIONS AT A GLANCE

- Dermatophyte species are contained in three genera: *Epidermophyton*, *Microsporum*, and *Trichophyton*. They are divided further according to three natural habitats (humans, animals, and soil).
- Dermatophytes infect keratinized tissue including skin, hair, and nails.
- Microscopic examination, culture, Wood's light evaluation and histopathology may all be useful in confirming a dermatophytosis.
- *Trichophyton* is the most common species isolated in the US.
- Several topical preparations (imidazoles and allylamine) and oral agents (griseofulvin, itraconazole, fluconazole, and terbinafine) serve as effective antifungal therapeutic options for dermatophytoses.
- Tinea nigra is a superficial dermatophyte infection that may mimic acral lentiginous melanoma.
- Piedra, which consists of white and black forms, is an asymptomatic superficial fungal infection of the hair shaft.

MYCOSES

Mycoses are divided among three forms: (1) *superficial*, involving stratum corneum, hair, nails, (2) *subcutaneous*, involving dermis and/or subcutaneous tissue, and (3) *deep/systemic*, representing hematogenous spread of organisms including opportunistic pathogens in immunocompromised hosts. The focus of this chapter is the superficial mycoses and their patterns of integumentary infections (Table 188-1). A glossary of terms used in this chapter is contained in Table 188-2.

TABLE 188-1
Patterns of Integumentary Infections by Superficial Mycoses

Genera	Skin	Hair	Nails
Trichophyton	×	×	×
Microsporum	×	×	
Epidermophyton	×		×
Tinea Nigra	×		
Black Piedra		×	
White Piedra		×	

TABLE 188-2
A Glossary of Terms

Anthropophilic—preferring humans over other animals as natural habitat

Arthroconidia—asexual spore produced by segmentation of hyphae

Dematiaceous—melanin in the cell walls of its conidia, hyphae, or both results in a darkly colored fungus

Ectothrix—dermatophyte growth pattern with spores forming a sheath on the outside of the hair shaft

Endothrix—dermatophyte growth pattern with spore formation within the hair shaft

Favus—dermatophyte growth pattern with hyphae and air spaces within the hair shaft

Geophilic—preferring the soil over humans and animals as natural habitat

Hyphae—long, filamentous fungus cells forming a branching network called mycelium

Macroconidia—asexual large multinucleate spores produced by vegetative reproduction

Microconidia—asexual small spores produced by vegetative reproduction

Zoophilic—preferring animals over humans as natural habitat

DERMATOPHYTES

The universe of fungi comprises more than 1.5 million species worldwide. Dermatophytes (term derived from the Greek words for "skin plant") are contained in the family of arthrodermataceae and are represented by approximately 40 species divided among the three genera: *Epidermophyton*, *Microsporum*, and *Trichophyton*. In the United States, *Trichophyton* species, and namely *T. rubrum* and *T. interdigitale*, represent the most common species isolated. Dermatophytes are classified further according to their natural habitats—humans, animals, or soil. Their ability to attach to and invade keratinized tissue of animals and humans and to utilize degradation products as nutritional sources form the molecular basis for superficial fungal infections of skin, hair, and nails, termed *dermatophytoses*.[1]

TAXONOMY AND EPIDEMIOLOGY

Recent modifications to the taxonomical system of dermatophytes affecting clinical practice require mention. While previous taxonomy was based largely on phenotypical characteristics of dermatophytes, recent inclusion of genotypical analyses necessitated regrouping of some taxa since many of these genotypical differences were not reflected phenotypically, and *vice versa*.[2] Current taxonomy includes a synthesis of new data based on sequencing of variable genomic regions such as the internal transcribed spacer (ITS) regions of fungal ribosomal DNA as well as classic phenotypical characterizations. The difficulty in devising such a taxonomical system for dermatophytes relates to reduced genetic diversity due to recent speciation and population of the same ecological niches. Phenotypically, this is reflected by similar clinical manifestations being caused by multiple taxonomically different dermatophyte species. It should be noted, however, that the current framework is still a work in progress, and the taxonomy will likely undergo further refinements in the future. Table 188-3 lists the most commonly encountered dermatophyte pathogens including the new taxonomy according to their natural habitats and reservoirs. The current medical literature on dermatophytes and infections, however, does not stringently follow the new taxonomy.

TABLE 188-3
Habitats and Hosts of Common Dermatophytes

Habitat	Dermatophyte	Host
Anthropophilic	*Trichophyton rubrum*	Humans
	Trichophyton tonsurans	
	Trichophyton interdigitale (syn: Trichophyton mentagrophytes var. interdigitale)	
	Trichophyton schoenleinii	
	T. rubrum (syn: Trichophyton megninii, Trichophyton gourvilii)	
	Trichophyton soudanense	
	Trichophyton violaceum (syn: Trichophyton yaoundei)	
	Trichophyton concentricum	
	Microsporum audouinii	
	Microsporum ferrugineum	
	Epidermophyton floccosum	
Zoophilic	*T. mentagrophytes (syn: T. mentagrophytes var. quinckeanum)*	Rodents
	T. interdigitale (syn: T. mentagrophytes var. mentagrophytes, T. mentagrophytes var. granulosum)	Rodents
	Trichophyton erinacei	Hedgehogs
	Trichophyton simii	Primates
	Trichophyton verrucosum	Cattle
	Microsporum canis (syn: Microsporum distortum, Microsporum equinum)	Cats, dogs, horses
	Microsporum amazonicum	Rodents
	Microsporum gallinae	Poultry
	Microsporum nanum	Pigs
	Microsporum persicolor	Rodents
Geophilic	*Microsporum gypseum*	Soil
	Microsporum cookie	
	Microsporum persicolor	
	Trichophyton vanbreuseghemii	
	Trichophyton eboreum	
	Trichophyton terrestre	

In order to avoid confusion over the dynamic status of the taxonomy as well as to remain reflective of the current nomenclature in the literature, this chapter will use both nomenclatures, resulting in some apparent contradictions. The authors hope that a more unified nomenclature is accepted for future editions of this chapter.

The additional classification of superficial fungi according to natural habitat is clinically relevant, since anthropophilic, zoophilic, and geophilic dermatophytoses provide important information about the source of infection and demonstrate varied clinical features.

ANTHROPOPHILIC. species are typically restricted to human hosts and are transmitted via direct contact. Infected skin or hair retained in clothing, combs, caps, socks, and towels, for example, also serve as source reservoirs. Unlike the sporadic geophilic and zoophilic infections, anthropophilic infections are often epidemic in nature. These dermatophytes have adapted to humans as hosts and as such elicit a mild to noninflammatory host response.

ZOOPHILIC. species are transmitted to humans from animals. Cats, dogs, rabbits, guinea pigs, birds, horses, cattle and other animals are common sources of infection. Transmission may occur through direct contact with the animal itself, or indirectly via infected animal hair. Exposed areas such as the scalp, beard, face, and arms are favored sites of infection. *Microsporum canis* is often transmitted to humans from cats and dogs, while guinea pigs and rabbits are a frequent source of human infection with zoophilic strains of *T. interdigitale.* While host adaptation by zoophilic dermatophytes may lead to relatively silent infections, these dermatophytes tend to produce acute and intense inflammatory responses in humans.[1]

GEOPHILIC. fungi cause sporadic human infection upon direct contact with the soil. *Microsporum gypseum* is the most common geophilic dermatophyte cultured from humans. There is a potential for epidemic spread due to the higher virulence of geophilic strains as well as an ability to form long-lived spores that may reside in blankets or grooming tools. As with zoophilic infections, geophilic dermatophytes typically result in intense inflammatory responses.[3]

Clinical presentations of dermatophytoses depend not only on the source, but also on host factors. Immunocompromised individuals are more susceptible to refractory dermatophyte infections or to deep mycoses.[4,5] Interestingly, only the severity of dermatophytosis appears to be increased with HIV infection, and not the prevalence.[6] Other host factors such as age, sex, and race appear to be additional epidemiologic factors for infection, although their relationship to dermatophyte susceptibility remains unclear. As an example, dermatophyte infections are five times more prevalent in males than females.

Superficial fungal infections are a worldwide problem that affects more than 20%–25% of the population.[7] Some species demonstrate ubiquitous distribution whereas others are geographically limited. Accordingly, predominant species reflect considerable geographic differences, as in the case of tinea capitis. In the United States, *Trichophyton tonsurans* has replaced *Microsporum audouinii* as the most common cause of tinea capitis in the second half of the 20th century, and *M. canis* has now become the second most common cause.[8] In Europe, *M. canis* remains the most common cause of tinea capitis despite a significantly increased incidence of *T. tonsurans*.[9] The etiologic profile is quite different in Africa where *M. audouinii*, *Trichophyton soudanense*, and *Trichophyton violaceum* are the most prevalent pathogens.[10] However, human travel and migration results in dynamic patterns of infection. As an example, *T. soudanense* and *T. violaceum*, typically restricted to Africa, were isolated in US cases of tinea capitis in 2007.[11] Finally, local customs may also influence rates and patterns of dermatophytoses. The use of macerating occlusive footwear, for example, in industrialized nations has made tinea pedis and onychomycosis much more common in these regions.[6]

PATHOGENESIS

Dermatophytes exhibit a broad armamentarium of enzymes (keratinolytic proteases, lipases etc.) that act as virulence factors to allow adherence and invasion of skin, hair, and nails, and also to utilize keratin as a source of nutrients for survival. The initial steps in dermatophyte infections are adherence to keratin followed by invasion and growth of mycelial elements. As a consequence of keratin degradation and subsequent release of proinflammatory mediators, the host develops an inflammatory response of varying degree. The classic "ringworm," or annular morphology of tinea corporis results from an inflammatory host response against a spreading dermatophyte followed by a reduction or clearance of fungal elements from within the plaque, and in many cases by spontaneous resolution of the infection.

ADHERENCE. Dermatophytes overcome several lines of host defense before hyphae begin to thrive in keratinized tissues. The first step is successful adherence of arthroconidia, asexual spores formed by fragmentation of hyphae, to the surface of keratinized tissues.[12] Early nonspecific lines of host defense include fungistatic fatty acids in sebum as well competing bacterial colonization.[13,14] Several recent studies have focused on the molecular steps involved in arthroconidial adherence to keratinized surfaces. Dermatophytes have been shown make selective use of their proteolytic armamentarium during adherence and invasion.[15,16] The basis for this highly concerted attack may be explained partially by specific upregulation of multiple genes induced by contact with keratin, as has been shown by differential gene expression analysis in *T. rubrum.*[17] Following several hours of successful adherence, the spores begin to germinate in preparation for the next step in the infective chain of events, invasion.

INVASION. Trauma and maceration facilitate penetration of dermatophytes through the skin. Invasion of germinating fungal elements is further accomplished

through secretion of specific proteases, lipases and ceramidases, the digestive products of which also serve as fungal nutrients.[18] Interestingly mannans, which are components of the fungal cell wall, show inhibitory effects on keratinocyte proliferation and cell-mediated immunity.[19,20]

HOST RESPONSE. Dermatophytes encounter a range of host responses from several lines of nonspecific mechanisms including fungistatic fatty acids, increased epidermal proliferation, and secretion of inflammatory mediators to cell mediated-immunity. In the line of defense mechanisms, keratinocytes represent the first frontier of living cells to encounter invading fungal elements. The key position of keratinocytes is reflected by their complex response to invasion including proliferation to increase shedding as well as secretion of antimicrobial peptides including human β defensin-2[21] as well as proinflammatory cytokines (IFN-α, TNFα, IL-1β, 8, 16, and 17) that further activate the immune system. Once deeper layers of epidermis are involved, new nonspecific defenses such as competition for iron by unsaturated transferrin emerge. The degree of host inflammatory reaction depends on the host's immune status as well as the natural habitat of the dermatophyte species involved. Interestingly, anthropophilic dermatophytes induce secretion of a limited cytokine profile from keratinocytes in vitro compared to zoophilic species.[22,23] This difference may reflect the augmented inflammatory response generally observed with zoophilic species.

The next level of defense is cell-mediated immunity resulting in a specific delayed type hypersensitivity response against invading fungi. The inflammatory response associated with this hypersensitivity is associated with clinical resolution, while defective cell-mediated immunity may result in chronic or recurrent dermatophytoses. The Th2 response does not appear to be protective, since patients with elevated fungal antigen antibody titers are observed to have widespread dermatophyte infections.[24] A possible role for the Th17 response to dermatophyte infections is suggested by the recent discovery of binding of hyphal elements to Dectin-2, a C-type lectin pattern recognition receptor on dendritic cells, critical for inducing Th17 responses.[25,26] However, the relative importance of the Th17 immune response to dermatophytosis remains to be elucidated.

GENETICS

Despite epidemiological observations suggesting a genetic predisposition to fungal infections, molecular insight confirming this hypothesis has been lacking. Recently, however, two families with increased susceptibility to fungal infections and mutations in the C-type lectin fungal pattern recognition pathway have been described. In addition, mutations in CARD9, an adaptor molecule downstream of Dectin-1 and Dectin-2, which result in failure of Th17 activation, were associated with susceptibility to chronic mucocutaneous candidiasis along with chronic dermatophyte infections.[27]

DIAGNOSTIC PROCEDURES

(Table 188-4)

The clinical diagnosis of a dermatophyte infection can be confirmed by microscopic detection of fungal elements, by identification of the species through culture, or by histologic evidence of the presence of hyphae in the stratum corneum. In addition, fluorescence patterns under Wood's light examination may support a clinical suspicion.

MICROSCOPIC EXAMINATION

Although microscopic evaluation of potassium hydroxide (KOH)-treated samples of scale does not allow for speciation or characterization of the susceptibility profile, it is used (or underused) as a quick and inexpensive bedside tool to provide evidence of dermatophytosis. In dermatophytosis involving the skin, hair or nails, septate and branching hyphae without constriction (Fig. 188-1) may be visualized under microscopic examination with 10%–20% KOH preparation. All superficial dermatophytes appear identical when visualized in this manner. Because KOH examination may yield false-negative results in up to 15% of cases,[28] patients suspected of having dermatophytosis on clinical impression should be treated. Culture confirmation should be considered whenever systemic treatment is warranted, such as in the case of tinea capitis.

Scale from skin should be collected by scraping the involved area with a dull edge outward from the advancing margins. Full thickness nail clippings should involve the dystrophic portion, as proximal from the distal edge as possible without causing injury. Hairs should be plucked (not cut), placed on a glass slide and prepared with 10%–20% KOH and covered with a coverslip. Slightly warming the slide with a low intensity flame allows better penetration of the KOH solution into keratin. Low-power microscopy will reveal three possible patterns of infection (Fig. 188-2): (1) Ectothrix—small or large arthroconidia forming a sheath around the hair shaft, (2) Endothrix—arthroconidia within the

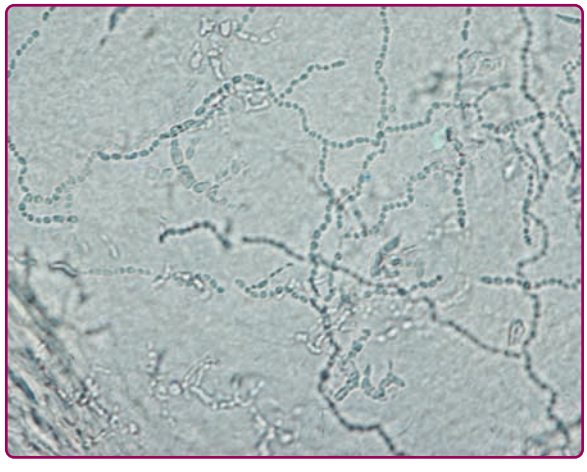

Figure 188-1 Microscopic examination of skin scrapings (scales) revealing septate, branching hyphae.

TABLE 188-4
Common Laboratory Dermatophyte Identification Methods

Laboratory Test	Method	Function	Findings
Potassium hydroxide preparation	Scales from the advancing border, subungual debris, or affected hair removed and placed on a glass slide. KOH 10% dropped on specimen and covered with a cover slip. The undersurface of the glass slide may be gently heated with a low-lit flame.	KOH solution and gentle heating softens keratin and highlights the dermatophyte.	Long narrow septated and branching hyphae
Culture	Sabouraud medium (4% peptone, 1% glucose, agar, water)	Facilitates growth of dermatophytes	Microscopic morphology of microconidia and macroconidia, along with culture features including surface topography and pigmentation. The reader is referred to http://www.mycology.adelaide.edu.au/ for a comprehensive characterization of fungal colonies. Common colonies are characterized in Table 188-5.
	Modified Sabouraud medium (addition of chloramphenicol, cycloheximide, and gentamicin)	Facilitates growth of dermatophytes and inhibits growth of non-*Candida albicans*, *Cryptococcus*, *Prototheca* species, *P. werneckii*, *Scytalidium* species, *Ochroconis gallopava*	
Dermatophyte test medium	Scales from the advancing border, subungual debris or affected hair embedded in the medium.	Medium contains the pH indicator phenol red. Dermatophytes utilize proteins resulting in excess ammonium ion and an alkaline environment.	Incubation at room temperature for 5–14 days results in change in color of medium from yellow to bright red in the presence of a dermatophyte.
Histolopathology special stains: periodic acid-Schiff and Grocott's methenamine silver	Tissue may be obtained by skin or nail biopsy techniques	Stains fungal cell wall to detect fungal elements in tissue sections	Pink (PAS) or black (GMS) fungal elements noted in the stratum corneum

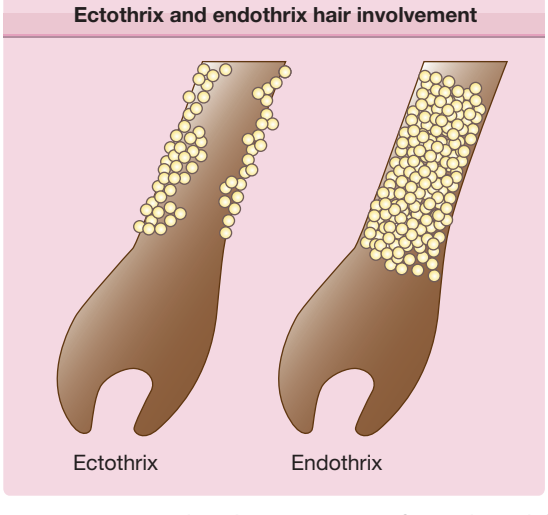

Figure 188-2 Graphic demonstration of ectothrix (*left*) and endothrix hair involvement.

hair shaft, or (3) Favus—hyphae and air spaces within the hair shaft.

CULTURE

Speciation of superficial fungi is based on macroscopic, microscopic and metabolic characteristics of the organism. While some dermatophytes are readily identified on the basis of their primary isolation cultures, most require further differentiation through subcultures on specific media (identification culture) or through specific biochemical tests.

Sabouraud's dextrose agar (SDA) is the most commonly used isolation medium for dermatophytes and it serves as the medium on which most morphologic descriptions are based. Elimination of contaminant molds, yeast and bacteria is achieved by the addition of cycloheximide and chloramphenicol (+/−gentamicin) to the medium making it highly selective for the

isolation of dermatophytes. The development of colonies can take 5–7 days in the case of *Epidermophyton floccosum* and up to 4 weeks for *Trichophyton verrucosum*. Cultures are incubated at room temperature (20°C–25°C) for at least 4 weeks before being finalized as no growth. Dermatophyte test medium (DTM) is an alternative isolation medium that contains the pH indicator phenol red. The medium turns red when dermatophyte proteolytic activity increases the pH to 8 or above, and it remains amber with the growth of most saprophytes. Nondermatophyte acidic byproducts turn the medium yellow. While DTM serves as a good alternative for isolation of dermatophytes, it may not allow for their direct identification due to altered growth and thus morphology of dermatophytes in DTM. Table 188-5 describes general microscopic features of microconidia and macroconidia of the three genera of dermatophytes, while Table 188-6 describes

TABLE 188-5
Microscopic Features of Dermatophyte Microconidia and Macroconidia

Genera	Microconidia	Macroconidia
Trichophyton	Smooth walled. Used for identification.	Absent or nondiagnostic.
Microsporum	Absent or nondiagnostic.	Rough walled. Used for identification.
Epidermophyton	Absent.	Smooth walled. Used for identification.

TABLE 188-6
Colony and Microscopic Morphology Features of the Most Common Dermatophytes

Organism	Colony Morphology		Microscopic Appearance
Epidermophyton floccosum 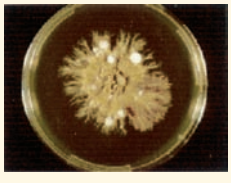	Flat feathery colonies with a central fold and yellow to dull gray–green pigment. Yellow to brown reverse pigment.	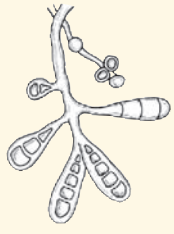	Numerous thin and thick-walled, club-shaped macroconidia.
Microsporum audouinii 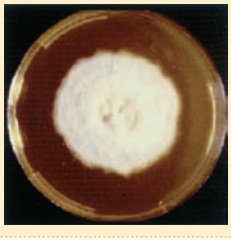	Flat and white to gray with widely spaced radial grooves. Tan to salmon reverse pigment. Salmon-pink pigment on PDA. No growth on polished rice.		Terminal chlamydoconidia and pectinate (comb-like) hyphae.
Microsporum canis 	Flat, white to light yellow, coarsely hairy, with closely spaced radial grooves. Yellow to orange reverse pigment. Yellow on PDA. Growth on polished rice.		Numerous thick walled and echinulate spindle shaped macroconidia with terminal knobs and greater than 6 cells.
Microsporum gypseum 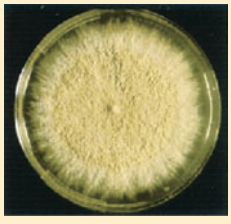	Flat and granular with tan to buff pigment, no reverse pigment.	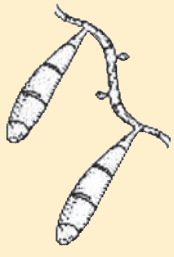	Numerous thin-walled pickle shaped macroconidia without knobs and fewer than 6 cells.

TABLE 188-6
Colony and Microscopic Morphology Features of the Most Common Dermatophytes (Continued)

Organism	Colony Morphology		Microscopic Appearance
Ticrosporum interdigitale 	White to creamy with a cottony, mounded surface. None to light brown reverse pigment. No pigment on PDA. Urease positive, which helps to distinguish it from *T. rubrum*.		Grape-like clusters of round microconidia, rare cigar-shaped macroconidia, occasional spiral hyphae. Hair perforation positive, which helps to distinguish it from *T. rubrum*.
Ticrosporum rubrum 	Mounded white center with maroon periphery. Maroon reverse pigment. Cherry red on PDA. Urease negative.	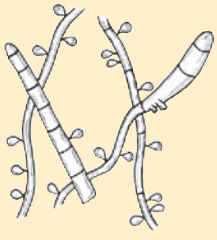	Few tear-shaped microconidia, rare pencil-shaped macroconidia. Hair perforation negative.
Ticrosporum schoenleinii 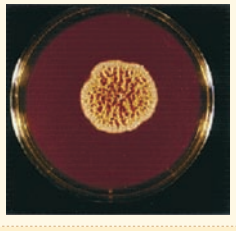	Heaped or folded and whitish. Colorless to yellow-tan reverse pigment.	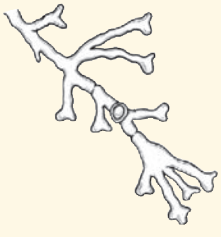	Knobby antler-like hyphae (favic chandeliers), numerous chlamydoconidia.
Ticrosporum tonsurans 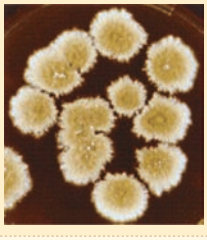	Suede-like center with feathery periphery, white to yellow or maroon color. Reverse pigment usually dark maroon, sometimes none to yellow. Partial thiamine requirement.	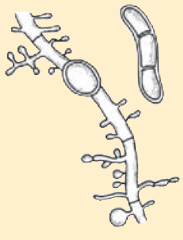	Numerous multiform microconidia and rare cigar-shaped macroconidia.
Ticrosporum verrucosum 	Small and heaped, although sometimes flat, white to yellow–gray. Reverse pigment none to yellow. Requires thiamine and usually inositol for growth.	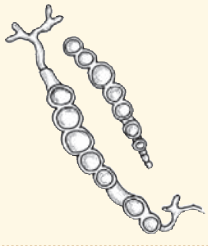	Chains of chlamydoconidia on SDA. Long and thin "rat-tail" macroconidia with thiamine.
Ticrosporum violaceum 	Waxy and heaped, deep purplish-red. Purple reverse pigment. Partial thiamine requirement.	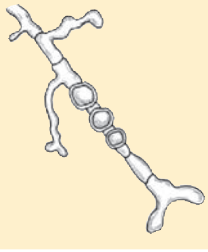	Irregular hyphae with intercalary chlamydoconidia. No micro- or macroconidia on SDA, rare micro- and macroconidia with thiamine.

PDA = potato dextrose agar; SDA = Sabouraud's dextrose agar.
Used with permission from David Ellis, PhD.

TABLE 188-7
***Trichophyton* Nutritional Growth Requirements**

Urease test	Differentiates *Trichophyton. interdigitale* (positive result) from *Trichophyton rubrum* (negative result)	
Hair erforation est	Differentiates *T. interdigitale* (positive result) from *T. rubrum* (negative result)	
Nutritional requirement	Differentiates *Trichophyton* species	
	Thiamine	*Trichophyton tonsurans* *Trichophyton concentricum* *Trichophyton violaceum*
	Thiamine + inositol Nicotinic acid Histidine	*Trichophyton verrucosum* *Trichophyton equinum* *Trichophyton megninii*
Growth on polished rice	Differentiates *Microsporum* species	
	Good growth Poor growth	*Mrichophyton canis* *Mrichophyton audouinii* *Mrichophyton distortum*

TABLE 188-8
Pattern of Hair Infection and Fluorescence

Pattern	Dermatophyte	Fluorescence
Endothrix	*Trichophyton soudanense*	None
	Trichophyton violaceum	None
	Trichophyton tonsurans	None
	Trichophyton gourvilii	None
	Trichophyton yaoundei	None
Ectothrix	*Mrichophyton canis*	Yellow–green
	Mrichophyton audouinii	Yellow–green
	Mrichophyton distortum	Yellow–green
	Mrichophyton ferrugineum	Yellow–green
	Mrichophyton fulvum	None
	Mrichophyton gypseum	None
	Trichophyton megninii	None
	Trichophyton interdigitale	None
	Trichophyton rubrum	None
	Trichophyton verrucosum	None
Favus	*Trichophyton schoenleinii*	Blue–gray, occasional

colony and microscopic features of the most common dermatophyte species.

Identification of isolated fungi is facilitated by subculture on specific media such as potato dextrose agar (PDA) or Borelli's lactrimel agar (BLA) that stimulate sporulation, production of pigment and development of typical morphology. Finally, dermatophytes may be differentiated further by their ability to grow on autoclaved polished rice, perforate short strands of hair in vitro or hydrolyze urea (urease test), or require nutritional supplementation for growth (Table 188-7).

HISTOPATHOLOGY

Skin biopsy is not often employed in the workup of typical dermatophytoses. Localized cutaneous eruptions suspected to represent dermatophytosis with equivocal KOH examination are often treated despite the lack of confirmation. Biopsy may confirm the diagnosis when a systemic agent is being considered for treatment of a recalcitrant or more widespread eruption. Biopsy may be used to aid in the diagnosis of Majocchi's granuloma in which KOH examination of scale on the surface may more often be negative. Biopsy is also sometimes useful in confirming the presence of hyphae involving hair shafts on the scalp in tinea capitis, although culture is necessary to allow speciation of the pathogen. When present, hyphae may be appreciated in the stratum corneum on hematoxylin and eosin staining. However special stains, most commonly periodic acid-Schiff (PAS) and methenamine silver stains, highlight hyphae that may otherwise be subtle in appearance on routine staining. Whereas culture is the most specific test for onychomycosis, PAS examination of nail clippings is the most sensitive[29] and it obviates the need to wait weeks for a result.

WOOD'S LIGHT FLUORESCENCE

Examination of involved hair bearing areas, such as the scalp or beard, with a Wood's lamp (365 nm) may reveal pteridine fluorescence of hair infected with particular fungal pathogens. Hairs that fluoresce should be selected for further examination, including culture. While ectothrix organisms *M. canis* and *M. audouinii* will fluoresce on Wood's light examination, the endothrix organism *T. tonsurans* will not fluoresce. *T. tonsurans*, which is now the most common cause of tinea capitis in the United States, thus limits the use of Wood's light examination. Table 188-8 lists common patterns of dermatophyte hair involvement and fluorescence.

DERMATOPHYTOSES

TINEA CAPITIS

Tinea capitis describes dermatophyte infection of hair and scalp, typically caused by *Trichophyton* and *Microsporum* species, with exception of *Trichophyton concentricum*.

EPIDEMIOLOGY. Tinea capitis is most commonly observed in children between 3 and 14 years of age. The fungistatic effect of fatty acids in sebum may help to explain the sharp decrease in incidence after puberty.[30] Overall prevalence of the carrier state is around 4% in the United States with a peak prevalence of approximately 13% in girls of Sub-Saharan African American descent.[31] In general, tinea capitis is more common among children of African descent for unknown reasons. Transmission is increased with decreased personal hygiene, overcrowding and low socioeconomic status. The anthropophilic dermatophyte *T. tonsurans* is the most prevalent species found in the United States, while *M. canis* remains the

most common cause of tinea capitis in Europe.[32] Organisms responsible for tinea capitis have been cultured from fomites such as combs, caps, pillowcases, toys and theater seats. Even after shedding, hairs may harbor infectious organisms for more than 1 year.[33] The high prevalence of asymptomatic carriers thwarts eradication of the disease.

PATHOGENESIS. Infection of hair by dermatophytes follows 3 main patterns—ectothrix, endothrix and favus. Dermatophytes establish infection in the perifollicular stratum corneum and spread around and into the hair shaft of mid- to late-anagen hairs before descending into the follicle to penetrate the cortex. With hair growth, the infected part of the hair rises above the surface of the scalp where it may break because of its increased fragility.

In *ectothrix* infections (see Fig. 188-2), only the arthroconidia on the surface of the hair shaft may be visualized, although hyphae are also present within the hair shaft. The cuticle is destroyed. On Wood's lamp examination, a yellow–green fluorescence may be detected, depending on the causative organism. In *endothrix* infections (see Fig. 188-2), arthroconidia and hyphae remain within the hair shaft and leave the cortex and cuticle intact. This pattern of tinea capitis is associated with the appearance of "black dots" which represent broken hairs at the surface of the scalp. *Endothrix* organisms do not show fluorescence on Woods lamp exam. *Favus* is characterized by longitudinally arranged hyphae and air spaces within the hair shaft. Arthroconidia are not usually noted in infected hairs.

CLINICAL FINDINGS. (Table 188-9). The clinical appearance of tinea capitis depends on the causative species as well as other factors such as the host immune response. In general, dermatophyte infection of the scalp results in hair loss, scaling and varying degrees of an inflammatory response.

TABLE 188-9
Pathogens Associated with Clinical Types of Tinea Capitis

Inflammatory	*Microsporum audouinii* *Microsporum canis* *Microsporum gypseum* *Microsporum nanum* *Trichophyton interdigitale* *Trichophyton schoenleinii* *Trichophyton tonsurans* *Trichophyton verrucosum*
Noninflammatory	*M. audouinii* *M. canis* *Microsporum ferrugineum* *T. tonsurans*
Black dot	*T. tonsurans* *T. violaceum*
Favus	*T. schoenleinii* *Trichophyton violaceum* *Trichophyton mentagrophytes*

Note: A single dermatophyte may have more than one presentation.



Figure 188-3 Tinea capitis "gray patch" type. A large, round hyperkeratotic plaque of alopecia due to breaking off of hair shafts close to the surface, giving the appearance of a mowed wheat field on the scalp of a child. Remaining hair shafts and scales exhibit a green fluorescence when examined with a Wood's lamp. *Microsporum canis* was isolated on culture.

Noninflammatory Type. Also called the seborrheic form of tinea capitis since scale is the predominant feature,[34] noninflammatory tinea capitis is seen most commonly with anthropophilic organisms such as *M. audouinii* or *Microsporum ferrugineum.* Arthroconidia may form a sheath around affected hairs turning them gray and causing them to break off just above the level of the scalp. Alopecia may be imperceptible or in more inflammatory cases there may be circumscribed erythematous scaly patches of nonscarring alopecia with breakage of hairs ("gray patch" type; Fig. 188-3). Patches often occur on the occiput.[33] When involving an ectothrix pattern, infected hairs may exhibit green fluorescence under Wood's light (see Table 188-8).

"Black Dot" Tinea Capitis. (Fig. 188-4). The "black dot" form of tinea capitis is typically caused by the anthropophilic endothrix organisms *T. tonsurans* and *T. violaceum*. Hairs broken off at the level of the scalp leave behind grouped black dots within patches of polygonal shaped alopecia with finger-like margins. Normal hairs also remain within patches of broken hairs. Diffuse scaling is also often present. While "black dot" tinea capitis tends to be minimally inflammatory, some patients may develop follicular pustules, furuncle-like nodules, or in rare cases kerion—a boggy, inflammatory mass studded with broken hairs and follicular orifices oozing with pus.[35]

Inflammatory Type. Zoophilic or geophilic pathogens, such as *M. canis*, *M. gypseum*, and *T. verrucosum*, are more like to cause an inflammatory type of tinea capitis. Inflammation, which is the result of a hypersensitivity reaction to the infection, in this setting ranges



Figure 188-4 "Black dot" tinea capitis caused by *Trichophyton tonsurans*.

from follicular pustules to furunculosis (Fig. 188-5) or kerion (Fig. 188-6). Intense inflammation may also result in scarring alopecia. The scalp is usually pruritic or tender. Inflammatory tinea capitis is often associated with posterior cervical lymphadenopathy, which serves as a clinical pearl in differentiating tinea capitis from other inflammatory disorders involving the scalp.

DIFFERENTIAL DIAGNOSIS. (Box 188-1)

LABORATORY TESTS. (See Tables 188-4, 188-6)

HISTOPATHOLOGY. (See Table 188-4). In tinea capitis, PAS and methenamine silver stains readily reveal hyphae around and within hair shafts. The dermis demonstrates a perifollicular mixed cell infiltrate with lymphocytes, histiocytes, plasma cells, and eosinophils. Follicular disruption leads to an adjacent foreign-body giant cell reaction. Markedly inflammatory lesions such as a kerion demonstrate an acute infiltrate of polymorphonuclear leukocytes within the dermis and follicle.[36] Organisms may not be visualized in kerion since the intense host response destroys many of the fungal organisms. However, fungal antigens may be detectable with immunofluorescent techniques.[37]



Figure 188-5 Inflammatory tinea capitis caused by *Microsporum canis*. Along with alopecia, there are inflammatory papules, pustules and nodules. This patient also had posterior cervical lymphadenopathy.



Figure 188-6 Kerion of the scalp.

TINEA FAVOSA

Tinea favosa or favus (Latin, "honeycomb") is a chronic dermatophyte infection of the scalp rarely involving glabrous skin, and/or nails characterized by thick yellow crusts (scutula) within the hair follicles which leads to scarring alopecia.

EPIDEMIOLOGY. Favus is usually acquired before adolescence, although it may extend into adulthood.[38] Associated with malnutrition and poor hygiene, favus has become geographically limited over the past century, and it is now seen almost exclusively in Africa, the Middle East and parts of South America. Even in these regions, its incidence has declined dramatically, and studies from South Africa, Lybia, and Arabia suggest disappearance of favus over the last few decades.[39–41]

ETIOLOGY. *Trichophyton schoenleinii* is the most common cause of human favus, although *T. violaceum* and *M. gypseum* are also rare isolates.[42] Although favus occurs in animals including domesticated birds (*Microsporum gallinae*) and mice (*Trichophyton mentagrophytes* formerly *T. mentagrophytes var. quinckeanum*), there exist only a few reports of humans infected by the pathogens responsible for animal favus.[43]

CLINICAL FINDINGS. Early favus (first 3 weeks of infection) is characterized by patchy perifollicular

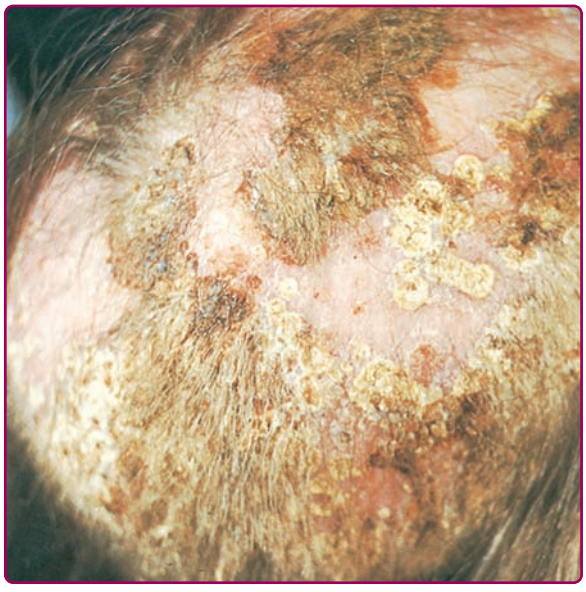

Figure 188-7 Favus caused by *Trichophyton schoenleinii*. Note the numerous yellow scutula.

erythema with slight scaling and matting of the hair. Progressive hyphal invasion distends the follicle, first producing a yellow–red follicular papule and then a yellow concave crust (scutulum) around a single dry hair (Fig. 188-7) that is less brittle than hair of endothrix infections. The scutulum may reach 1 cm in diameter, engulfing surrounding hairs and coalescing with other scutula to form large adherent mats with an unpleasant cheese-like or musky odor. Over several years, the plaques advance peripherally leaving behind central, atrophic areas of alopecia.[42]

DIFFERENTIAL DIAGNOSIS. (Box 188-1)

LABORATORY TESTS. (See Tables 188-4, 188-6).

T. schoenleinii exhibits subtle, blue–gray fluorescence along the entire hair with Wood's lamp examination. Microscopy with KOH preparation reveals hyphae arranged lengthwise around and within the hair shaft, rare arthroconidia, and vacant air spaces.[42]

BOX 188-1 DIFFERENTIAL DIAGNOSIS OF TINEA CAPITIS

Most Likely

- Seborrheic dermatitis, contact dermatitis, pustular or plaque psoriasis, atopic dermatitis, bacterial pyodermas, folliculitis decalvans, lichen planopilaris, and dissecting cellulitis of the scalp

Consider

- Alopecia areata, trichotillomania, pseudopelade

Rule Out

- Subacute cutaneous lupus erythematosus, syphilis

HISTOPATHOLOGY. (See Table 188-4)

TINEA BARBAE

EPIDEMIOLOGY.

Tinea barbae, as its name would imply, occurs predominantly in males. The incidence of tinea barbae has decreased as improved sanitation has reduced transmission by contaminated barbers' razors. Direct exposure to cattle, horses, or dogs is now the more common mode of acquisition, and this accounts for a shift in prevalence toward farmers or ranchers in rural settings.

ETIOLOGY.

Tinea barbae is most commonly caused by the zoophilic strains of *T. interdigitale* (former *T. mentagrophytes var. mentagrophytes)*, *T. verrucosum*, and less commonly *M. canis*. Among the anthropophilic organisms, *T. schoenleinii*, *T. violaceum* and certain strains of *T. rubrum* (former *T. megninii*), cause tinea barbae in endemic areas.[42]

CLINICAL FINDINGS.

Tinea barbae affects the face unilaterally and involves the beard area more often than the moustache or upper lip. Two forms exist.

Superficial Type. Caused by anthropophiles such as *T. violaceum*, this form of tinea barbae is less inflammatory and resembles tinea corporis or bacterial folliculitis. The active border shows perifollicular papules and pustules accompanied by mild erythema (Fig. 188-8A). Alopecia, if present, is reversible.

Inflammatory Type. Usually caused by *T. interdigitale* (zoophilic strains) or *T. verrucosum*, inflammatory tinea barbae is the most common clinical presentation. It presents analogously to kerion formation in tinea capitis with boggy-crusted plaques and a seropurulent discharge (Fig. 188-8B). Hairs are lusterless, brittle, and easily epilated to demonstrate a purulent mass around the root. Perifollicular pustules may coalesce and eventuate in abscess-like collections of pus, sinus tracts, and scarring alopecia.

DIFFERENTIAL DIAGNOSIS. (Box 188-2)

LABORATORY TESTS. (See Tables 188-4, 188-6)

HISTOPATHOLOGY. (See Table 188-4)

BOX 188-2 DIFFERENTIAL DIAGNOSIS OF TINEA BARBAE

Most Likely

- Bacterial folliculitis (sycosis vulgaris), pseudofolliculitis barbae, acne vulgaris, rosacea, contact dermatitis, perioral dermatitis, candidal folliculitis

Rule Out

- Herpes simplex, halogenoderma



Figure 188-8 Tinea barbae. **A.** Superficial type. Scattered follicular papules, pustules and small nodules that may be easily mistaken for *Staphylococcus aureus* folliculitis. **B.** Kerion type. Sharply demarcated red edematous nodule studded with multiple yellowish weeping pustules. Note hairs have been lost from this nodule.

TINEA CORPORIS

Tinea corporis refers to any dermatophytosis of glabrous skin except palms, soles, and the groin.

EPIDEMIOLOGY. Tinea corporis may be transmitted directly from infected humans or animals, via fomites, or it may occur via autoinoculation from reservoirs of dermatophyte colonization on the feet.[44] Children are more likely to contract zoophilic pathogens, especially *M. canis,* from dogs or cats. Occlusive clothing and a humid climate are associated with more frequent and severe eruptions.[45] Wearing of occlusive clothing, frequent skin-to-skin contact, and minor traumas such as the mat burns competitive wrestling create an environment in which dermatophytes flourish. "Tinea corporis gladiatorum" is caused most commonly by *T. tonsurans*, and it occurs most frequently on the head, neck, and arms.[46]

ETIOLOGY. Although any dermatophyte may cause tinea corporis, it is caused most commonly by *T. rubrum*. *T. rubrum* is also the most likely candidate in cases with concomitant follicular involvement.[35] *Epidermophyton floccosum*, *T. interdigitale* (anthropophilic and zoophilic strains), *M. canis*, and *T. tonsurans* are also common pathogens.[1] Tinea imbricata, caused by *T. concentricum*, is limited geographically to areas of the Far East, South Pacific, and South and Central America.

CLINICAL FINDINGS. The classic presentation is that of an annular ("ring-worm"-like; Fig. 188-9A) or serpiginous plaque with scale across the entire active erythematous border. The border, which may be vesicular, advances centrifugally. The center of the plaque is usually scaly but it may exhibit complete clearing. Whereas concentric vesicular rings suggest tinea incognito, often caused by *T. rubrum*, the erythematous concentric rings of tinea imbricata demonstrate little to no vesiculation. *T. rubrum* infections may also present as large, confluent polycyclic (Fig. 188-9B) or psoriasiform (Fig. 188-9C) plaques, especially in immunosuppressed individuals.

Majocchi's granuloma is a superficial and subcutaneous dermatophytic infection involving deeper portions of the hair follicles that presents as scaly follicular papules and nodules that coalesce in an annular arrangement (Fig. 188-10). It is caused most commonly by *T. rubrum, T. interdigitale,* and *M. canis*. Majocchi's granuloma is observed on the legs in women who become inoculated after shaving or who apply topical corticosteroids to the involved area, which facilitates infection. It is also observed increasingly among immunocompromised patients.[47]

DIFFERENTIAL DIAGNOSIS. (Box 188-3)

LABORATORY TESTS. (See Tables 188-4, 188-6)

HISTOPATHOLOGY. (See Table 188-4)

BOX 188-3 DIFFERENTIAL DIAGNOSIS OF TINEA CORPORIS

Most Likely

- Erythema annulare centrifugum, nummular eczema, psoriasis, tinea versicolor, subacute cutaneous lupus erythematosus, cutaneous candidiasis

Consider

- Contact dermatitis, atopic dermatitis, pityriasis rosea, seborrheic dermatitis

Rule Out

- Mycosis fungoides, parapsoriasis, secondary syphilis



Figure 188-9 Tinea corporis. **A.** Annular. Tinea corporis demonstrating the classic annular or "ring worm" like configuration and advancing raised erythematous and scaly border. Note that because the dorsum of the foot is predominantly involved, this eruption is considered tinea corporis and not pedis. **B.** Polycyclic. Tinea corporis demonstrating multiple polycyclic red erythematous plaques with a raised scaly border. **C.** Psoriasiform. Tinea corporis resembling psoriasis.

TINEA CRURIS

Tinea cruris is a dermatophytosis of the groin, genitalia, pubic area, and perineal and perianal skin. The designation is a misnomer, because in Latin "cruris" means of the leg. It is the second-most common type of dermatophytosis worldwide.



Figure 188-10 Majocchi's granuloma. Follicular papules and nodules with scale coalescing to form an annular shaped plaque on the leg of a woman applying topical corticosteroids to the area.

EPIDEMIOLOGY. Much like tinea corporis, tinea cruris spreads via direct contact or fomites, and it is exacerbated by occlusion and humid climates. Autoinfection from distant reservoirs of *T. rubrum* or *T. interdigitale* on the feet, for example, is common.[44] Tinea cruris is three times more common in men, and adults are affected more commonly than children.

ETIOLOGY. Most tinea cruris is caused by *T. rubrum* and *E. floccosum*, the latter being most often responsible for epidemics.[42] *T. interdigitale* and *T. verrucosum* are implicated less commonly.

CLINICAL FINDINGS. Tinea cruris presents classically as a well-marginated annular plaque with a scaly raised border which extends from the inguinal fold on to the inner thigh, often bilaterally. Erythematous scaly patches with papules and vesicles involving the inner thighs is also a common but perhaps less obvious presentation. Pruritus is common, as is pain when plaques are macerated or secondarily infected. Plaques in tinea cruris due to *E. floccosum* are more likely to demonstrate central clearing, and are more often limited to the genitocrural crease and the medial upper thigh. In contrast, plaques in tinea cruris due to *T. rubrum* coalesce with extension to the pubic, perianal, buttock, and lower abdominal areas (Fig. 188-11). Genitalia including the scrotum are infrequently affected.[42]



Figure 188-11 Tinea cruris. Annular eythematous plaques with a raised scaling border expanding from the inguinal on the inner thighs and pubic region.

DIFFERENTIAL DIAGNOSIS. (Box 188-4)

LABORATORY TESTS. (See Tables 188-4, 188-6)

HISTOPATHOLOGY. (See Table 188-4)

TINEA PEDIS AND TINEA MANUUM

Tinea pedis denotes dermatophytosis of the feet, whereas tinea manuum involves the palmar and interdigital areas of the hands. Infection of the dorsal aspects of feet and hands is considered to be tinea corporis.

EPIDEMIOLOGY. Occurring worldwide, tinea pedis and tinea manuum are the most common dermatophytoses. High prevalence, estimated to be around 10%, is attributed primarily to modern occlusive footwear, although increased worldwide travel has also been implicated.[42] Incidence of tinea pedis is higher among those using communal baths, showers or pools. With the ubiquitous presence of dermatophytes in the environment, however, it may be that host factors such as an individual's immune response to dermatophytes, in addition to exposure, play a determining role in the acquisition of tinea pedis. The authors, however, are not aware of any studies formally addressing this question.

Tinea manuum is acquired through direct contact with an infected person or animal, the soil, or via autoinoculation. Most commonly only one hand (*singular*: tinea manus) is involved, concomitant with infection of feet and toenails for which the term "*two feet–one hand*" syndrome has been coined. This classic presentation of tinea manus represents a secondary infection of the hand acquired from excoriating and picking infected feet and toenails.[48] Tinea manuum should be suspected in individuals who have fine dry scaling of the palm or palms, often accentuated in the creases.

BOX 188-4 DIFFERENTIAL DIAGNOSIS OF TINEA CRURIS

Most Likely

- Erythrasma, cutaneous candidiasis, intertrigo, contact dermatitis, psoriasis, seborrheic dermatitis, lichen simplex chronicus, folliculitis

Consider

- Familial benign pemphigus, Darier-White disease, histiocytosis

ETIOLOGY. Tinea pedis and tinea manuum are caused predominantly by *T. rubrum* (most common), *T. interdigitale*, and *E. floccosum*.

CLINICAL FINDINGS. Tinea pedis may present as any of four forms, or combinations thereof.

Interdigital Type. The most common presentation of tinea pedis begins as scaling, erythema and maceration of the interdigital and subdigital skin of the feet, and in particular between the lateral third and fourth and fourth and fifth toes (Fig. 188-12A).



Figure 188-12 Tinea pedis. **A.** Interdigital type. The inderdigital space is macerated with opaque white scales and has erosions. **B.** Moccasin type. Patchy erythema and scaling in a moccasin distribution on the foot. The arciform pattern of scales is characteristic. **C.** Bullous type. Ruptured bullae, erosions and erythema on the plantar aspect of the great toe. Hyphae were detected on KOH 10% preparation obtained from epithelial cell on the roof of the inner aspect of the bulla.

Under appropriate conditions, the infection will spread to the adjacent sole or instep, but it rarely involves the dorsum. Occlusion and bacterial coinfection (*Pseudomonas*, *Proteus*, and *Staphylococcus aureus*) soon produce the interdigital erosions with pruritus and malodor that are characteristic of the dermatophytosis complex, or "athlete's foot."

Chronic Hyperkeratotic (Moccasin) Type. In chronic hyperkeratotic type tinea pedis, there is patchy or diffuse scaling on the soles and the lateral and medial aspects of the feet, in a distribution similar to a moccasin on a foot (Fig. 188-12B). The degree of erythema is variable, and there may also exist few minute vesicles that heal with collarets of scale less than 2 mm in diameter. The most common pathogen is *T. rubrum* followed by *E. floccosum* and anthropophilic strains of *T. interdigitale*.

Vesiculobullous Type. Vesiculobullous type of tinea pedis, typically caused by zoophilic strains of *T. interdigitale* (former *T. mentagrophytes var. mentagrophytes*), features tense vesicles larger than 3 mm in diameter, vesiculopustules, or bullae on the soles and periplantar areas (Fig. 188-12C). This type of tinea pedis is uncommon in childhood but has been caused by *T. rubrum*.[49]

Acute Ulcerative Type. Tinea pedis with zoophilic *T. interdigitale* along with rampant bacterial superinfection with Gram-negative organisms produces vesicles, pustules and purulent ulcers on the plantar surface. Cellulitis, lymphangitis, lymphadenopathy and fever are frequently associated.

Vesiculobullous and acute ulcerative types commonly produce a vesicular Id reaction, either on the lateral foot or toes, or on the lateral aspects of the fingers.

Tinea manus, dermatophyte infection of the hand, usually has a noninflammatory presentation with diffuse dry scaling and accentuation in the creases (Fig. 188-13). However, vesicles, pustules and exfoliation may be present, especially when zoophilic dermatophytes involved. Tinea manus commonly occurs in association with moccasin type tinea pedis and onychomycosis, which should also be treated to minimize relapse.[50]



Figure 188-13 Tinea pedis and manus. "Two feet–one hand" presentation of *Trichophyton rubrum*. Scaling in the involved (*right*) hand is accentuated in the creases.

BOX 188-5 DIFFERENTIAL DIAGNOSIS OF TINEA PEDIS

Most Likely

- Interdigital: erosio interdigitalis blastomycetica, erythrasma, bacterial coinfection
- Hyperkeratotic: dyshidrosis, psoriasis, contact dermatitis, atopic dermatitis, hereditary or acquired keratodermas
- Vesiculobullous: dyshidrosis, contact dermatitis, pustular psoriasis, bacterid, palmoplantar pustulosis, bacterial pyodermas, scabies

Consider

- Pityriasis rubra pilaris

Rule Out

- Reactive arthritis

DIFFERENTIAL DIAGNOSIS. (Box 188-5)

LABORATORY TESTS. (See Tables 188-4, 188-6).

KOH examination of blister roofs (vesicules or bullae) yields the highest rate of positive findings.

HISTOPATHOLOGY. (See Table 188-4).

In tinea pedis, fungal organisms are highlighted in the stratum corneum by PAS or methenamine silver stains and are sometimes accompanied by foci of neutrophils.

There may also be a sparse, chronic, superficial perivascular infiltrate in the dermis. The vesiculobullous type demonstrates subcorneal or spongiotic intraepithelial vesiculation.

DERMATOPHYTID (ID) REACTION

These inflammatory reactions, named apparently after the instinctual component of the psyche as defined by Freud, occur in 4%–5% of patients with dermatophytosis at sites distant from the primary inflammatory fungal infections such as tinea pedis or kerion.[51] Although the precise mechanism is unknown, the Id reaction is associated with a DTH response to the *Trichophyton* test and may involve a local DTH response to systemically absorbed fungal antigen.[52] Id reactions appear polymorphic, ranging in morphology from follicular or nonfollicular papules and vesicles of the hands and feet to reactive erythemas including erythema nodosum, erythema annulare centrifugum, or urticaria.[53–56] Unlike the primary eruption, the Id eruption is KOH examination and culture negative. Criteria for establishing the presence of an Id eruption are the following: (1) dermatophytosis on another part of body, (2) absence of fungal elements from the id eruption, and (3) resolution of the id eruption with clearing of the primary dermatophyte infection.

ONYCHOMYCOSIS

Onychomycosis describes fungal infection of the nail caused by dermatophytes, nondermatophyte molds, or yeasts. Tinea unguium refers strictly to dermatophyte infection of the nail. Clinically, different three types of onychomycosis are distinguished: (1) distolateral subungual onychomycosis (DLSO), (2) proximal subungual onychomycosis (PSO), (3) white superficial onychomycosis (WSO).

EPIDEMIOLOGY.

Onychomycosis is the most prevalent nail disease and accounts for approximately 50% of all causes of onychodystrophy. It affects up to 14% of the population with both an increasing prevalence among older individuals.[57] and an overall increasing incidence.[58] Onychomycosis is also increasing in incidence among children and adolescents and accounts for up to 20% of dermatophyte infections diagnosed in children.[59] Risk factors for nail infection include nail trauma, immunosuppression such as HIV infection, diabetes mellitus, and peripheral vascular insufficiency.[60] The increasing prevalence of this disease may be secondary to wearing of tight shoes, increasing numbers of individuals on immunosuppressive drugs, and an increased use of communal locker rooms. The dermatophytosis commonly begins as tinea pedis before extending to the nail bed, where eradication is more difficult. This site serves as a reservoir for local recurrence or for infections spreading to other areas. Up to 40% of patients with toenail onychomycosis show concomitant skin infections, most commonly tinea pedis (30%).[61]

ETIOLOGY.

In the majority of cases, onychomycosis is caused by dermatophytes, and *T. rubrum* and *T. interdigitale* are responsible for approximately 90% of all cases. *T. tonsurans* and *E. floccosum* are also well documented causative agents.[62] Yeast and nondermatophyte molds such as *Acremonium*, *Aspergillus*, *Fusarium*, *Scopulariopsis brevicaulis*, and *Scytalidium* are the source of approximately 10% of toenail onychomycosis. Interestingly, *Candida* species are responsible for up to 30% of fingernails cases, whereas nondermatophyte molds were not detected in diseased fingernails.[63]

CLINICAL FINDINGS

Distolateral subungual type. DLSO is the most common form of onychomycosis and may be caused by any of the organisms listed above. It begins with invasion of the stratum corneum of the hyponychium and distal nail bed, forming a whitish to brownish–yellow opacification at the distal edge of the nail (Fig. 188-14A). The infection then spreads proximally up the nail bed to the ventral nail plate. Hyperproliferation or altered differentiation of the nail bed in response to the infection results in subungual hyperkeratosis, while progressive invasion of the nail plate results in an increasingly dystrophic nail.

Proximal Subungual Type. (Fig. 188-14B). PSO results from infection of the proximal nail fold primarily with *T. rubrum* and *T. megninii* and is apparent as a white to beige opacity on the proximal nail plate. This opacity gradually enlarges to affect the entire nail and eventuates in subungual hyperkeratosis, leukonychia, proximal onycholysis, and/or destruction of the entire nail. Patients with PSO should be screened for HIV, as PSO has been considered a marker for this disease.[6,64]

White Superficial Type. (Fig. 188-14C). WSO results from direct invasion of the dorsal nail plate resulting in white to dull yellow sharply bordered patches anywhere on the surface of the toenail. It is usually caused by *T. interdigitale*, although nondermatophyte molds such as *Aspergillus*, *Scopulariopsis*, and *Fusarium* are also known pathogens. *Candida* species may invade the hyponychial epithelium to eventually affect the entire thickness of the nail plate.[65]

DIFFERENTIAL DIAGNOSIS. (Box 188-6)

LABORATORY TESTS. (See Tables 188-4, 188-6).

Although onychomycosis is responsible for 50% of dystrophic nails, laboratory diagnostic confirmation prior to treatment with potentially toxic oral, antifungal treatments is judicious. KOH examination of subungual debris, culture of the nail plate and accompanying debris on SDA (with and without antimicrobials),



Figure 188-14 Tinea unguium. **A.** Distal subungual type. Discoloration, thickening and subungual debris of the distal aspect of the toenails. **B.** Proximal subungual type. Discoloration and thickening of the proximal nail in a patient with acquired immunodeficiency syndrome; Kaposi sarcoma is also seen on the fourth toe. **C.** White superficial type. Irregular opaque white patches on various parts of the nail plates.

BOX 188-6 DIFFERENTIAL DIAGNOSIS OF ONYCHOMYCOSIS

Most Likely

- Psoriasis, lichen planus, trauma, onychogryphosis

Consider

- Pachyonychia congenita, acquired and congenital leukonychias, Darier-White disease, Yellow Nail syndrome

Rule Out

- Melanoma

and PAS staining of a nail clipping are most useful. However, KOH examination is often negative even when clinical suspicion is high, and nails with hyphae reported on KOH examination often yield negative cultures. The simplest measure to minimize false-negatives caused by sampling error is to maximize sample size and repeat collections. The following guidelines are suggested to discern pathogens from contaminants: (i) if a dermatophyte is isolated on culture, it is considered a pathogen; (ii) a nondermatophyte mold or yeast cultured is significant only if hyphae, spores, or yeast cells are seen on microscopic examination, and (iii) there is repeated heavy growth of a nondermatophyte mold without concurrent isolation of a dermatophyte.[66] Whereas culture is the most specific test for onychomycosis, PAS examination of nail clippings is the most sensitive[29] and it obviates the need to wait weeks for a result.

HISTOPATHOLOGY. (See Table 188-4). Hyphae are seen between the nail laminae parallel to the surface and have a predilection for the ventral nail and stratum corneum of the nail bed.[67] The epidermis may show spongiosis and focal parakeratosis, and there is a minimal dermal inflammatory response. In WSO, the organisms are present superficially on the dorsal nail and display unique "perforating organs" and "eroding fronds." In candidal onychomycosis there is invasion of pseudohyphae throughout the entire nail plate, adjacent cuticle, granular layer, and stratum spinosum of the nail bed, as well as the hyponychial stratum corneum.[65]

TREATMENT OF DERMATOPHYTES

(Table 188-10)

Multiple systemic and topical antifungal agents are available to treat dermatophytoses of skin, hair and nails.

TINEA CAPITIS AND FAVUS

Infections involving hair-bearing skin usually necessitate oral antifungal treatment since dermatophytes penetrating the follicle are usually out of reach for topically applied agents. Griseofulvin along with the allylamine (terbinafine) and oral triazoles (itraconazole and fluconazole) are considered safe and effective in the treatment of tinea capitis.

GRISEOFULVIN. Griseofulvin along with terbinafine in patients older than 4 years are systemic treatments for tinea capitis approved by the US Food and Drug Administration. The previously recommended pediatric dosage was 10–20 mg/kg/day in divided doses for 6–8 weeks taken with a fatty meal to facilitate absorption.[33] However, high failure rates with this regimen resulted in the current dosage recommendation of griseofulvin 20–25 mg/kg/day of the microsize form, and 15 mg/kg/day in divided doses of the ultramicrosize form for 8 weeks.[68] Although the current recommendation is not based on outcomes of controlled trials, the collective clinical experience suggests its high therapeutic efficacy. Disadvantages of griseofulvin include poor compliance related to length of treatment and its bitter taste in liquid form. Common side effects include photosensitivity, headache, and gastrointestinal upset.[69] Griseofulvin also is a potent inducer of cytochrome P450 enzymes.

TERBINAFINE. Doses of 3–6 mg/kg/day of terbinafine can cure *Trichophyton* tinea capitis in 2–4 weeks; however, 4–8 weeks of treatment may be required for eradication of *Microsporum*.[68] Two randomized trials confirmed the increased efficacy of terbinafine (5–8 mg/kg/day) in the treatment of *T. tonsurans* infection with significantly higher cure rates compared to lower dose griseofulvin (10–20 mg/kg/day). However, even at this lower dose range, griseofulvin showed significantly higher cure rates for *M. canis* infections.[70] Further, it is not clear that terbinafine (5–8 mg/kg/day) has a therapeutic advantage in curing tinea capitis over the higher dose regimen of griseofulvin (20–25 mg/kg/day). Terbinafine may cause gastrointestinal upset. As with itraconazole, there are reports of liver failure in patients using terbinafine. Terbinafine has an inhibitory effect on the CYP 2D6 subset of the cytochrome P450 system. While fewer medications are metabolized through this CYP 2D6 subset as than through the CYP 3A4 subset inhibited by itraconazole and ketoconazole, notable interactions still exist with β-blockers and tricyclic antidepressants.

ITRACONAZOLE. At doses of 5 mg/kg/day for 2–4 weeks, itraconazole effectively eradicates tinea capitis caused by either *Microsporum* or *Trichophyton*.[68] Pulse therapy at 5 mg/kg/day for 1 week out of each month for one to three cycles is also effective. Possible adverse effects of itraconazole include gastrointestinal upset, diarrhea with the liquid formulation, and peripheral edema, especially when used in conjunction with calcium channel blockers. Itraconazole is better absorbed in the presence of food, which results in secretion of gastric acid and lower gastric pH. On the contrary, antacids such as H_2 blockers may decrease the absorption of itraconazole by increasing the gastric pH. Like with fluconazole, hepatotoxicity with itraconazole occurs at lower rates than with ketoconazole.[35]

TABLE 188-10
Treatment of Dermatophytes

Disease	Topical Treatment	Systemic Treatment
Tinea capitis	Only as adjuvant Selenium sulfide 1% or 2.5% Zinc pyrithione 1% or 2% Povidone iodine 2.5% Ketoconazole 2%	Adults: Griseofulvin, 20–25 mg/kg/day · 6–8 weeks Terbinafine, 250 mg/day · 2–8 weeks Itraconazole, 5 mg/kg/day · 2–4 weeks Fluconazole, 6 mg/kg/day · 3 weeks Children: Terbinafine, 3–6 mg/kg/day · 2–8 weeks all others are the same
Tinea barbae	Only as adjuvant Topical antifungals	Griseofulvin, 1 g/day · 6 weeks Terbinafine, 250 mg/day · 2–4 weeks Itraconazole, 200 mg/day · 2–4 weeks Fluconazole, 200 mg/day · 4–6 weeks
Tinea corporis/cruris	Allylamines Imidazoles Tolnaftate Butenafine Ciclopirox	Adults: Terbinafine, 250 mg/day · 2–4 weeks Itraconazole, 100 mg/day · 1 week Fluconazole, 150–300 mg/week · 4–6 weeks Griseofulvin, 500 mg/day · 2–4 weeks Children: Terbinafine, 3–6 mg/kg/day · 2 weeks Itraconazole, 5 mg/kg/day · 1 week Griseofulvin, 10–20 mg/kg/day · 2–4 weeks
Tinea pedis/manuum	Allylamine Imidazoles Ciclopirox Benzylamine Tolnaftate Undecenoic acid	Adults: Terbinafine, 250 mg/day · 2 weeks Itraconazole, 200 mg twice daily · 1 week Fluconazole, 150 mg/week · 3–4 weeks Children: Terbinafine, 3–6 mg/kg/day · 2 weeks Itraconazole, 5 mg/kg/day · 2 weeks
Onychomycosis	Ciclopirox Amorolfine	Adults: Terbinafine, 250 mg/day · 6–12 weeks Itraconazole, 200 mg/day · 2–3 months Fluconazole, 150–300 mg/week · 3–12 months Children: Terbinafine, 3–6 mg/kg/day · 6–12 weeks Itraconazole, 5 mg/kg/day · 2–3 months Fluconazole, 6 mg/kg/week · 3–6 months

Itraconazole has also rarely been linked to congestive heart failure. Itraconazole is an inhibitor of the CYP 3A4 subset of cytochrome P450 system.

FLUCONAZOLE. Available as both tablets and a pleasant-tasting liquid, fluconazole at doses of 6 mg/kg/day for 20 days is effective in curing tinea capitis.[68] Alternatively, fluconazole can be administered as a pulse, once weekly, regimen with 6 mg/kg/day for 8–12 weeks.[71] Absorption of fluconazole is not affected by gastric pH, and gastrointestinal side effects are less common. Hepatitis has been reported but it occurs less frequently than with ketoconazole.[35] Fluconazole is a potent inhibitor of cytochrome P450 enzymes, in particular CYP 2C9 and 2C19. Since most medications metabolized by the cytochrome P450 system are through the CYP 3A4 subset, fluconazole has less potential to interact with medications than other systemic imidazoles.

ADJUVANT THERAPY. Selenium sulfide (1% and 2.5%), zinc pyrithione (1% and 2%), povidone iodine (2.5%), and ketoconazole (2%) are shampoo preparations that help eradicate dermatophytes from the scalp of children. Adjunctive use of these shampoos is recommended 2–4 times weekly for 2–4 weeks.[72] The use of ketoconazole 2% shampoo or selenium sulfide 2.5% three times weekly by all household members also reduces transmission by decreasing the shedding of spores.[69]

Oral glucocorticoids may reduce the incidence of scarring associated with markedly inflammatory varieties of tinea capitis. Although there is no consistent evidence for improved cure rates with use of oral glucocorticoids, they appear to relieve pain and swelling associated with infections. The usual regimen prednisone is 1–2 mg/kg each morning during the first week of therapy.

TINEA BARBAE

Like tinea capitis, an oral antifungal is usually necessary in the treatment of tinea barbae. Ultramicronized griseofulvin 500 mg twice daily for 6 weeks, terbinafine 250 mg daily for 2–4 weeks, itraconazole 200 mg daily for 2–4 weeks, and fluconazole 200 mg daily for 4–6 weeks are regimens that have been used effectively. Systemic glucocorticoids used for the first week of therapy are helpful in cases with severe inflammation.

TINEA CORPORIS AND TINEA CRURIS

For isolated plaques on the glabrous skin, topical allylamines, imidazoles, tolnaftate, butenafine, or ciclopirox are effective. Most are applied twice daily for 2–4 weeks. Oral antifungal agents are reserved for widespread or more inflammatory eruptions. Comparative studies in adults show that terbinafine 250 mg daily for 2–4 weeks, itraconazole 200 mg daily for 1 week, and fluconazole 150–300 mg weekly for 4–6 weeks are preferable over griseofulvin 500 mg daily until cure is reached.[73] Safe and effective regimens for children include terbinafine 3–6 mg/kg/day for 2 weeks, itraconazole 5 mg/kg/day for 1 week, and ultramicrosize griseofulvin 10–20 mg/ kg/day for up to 2–4 weeks.

TINEA PEDIS AND TINEA MANUUM

Mild interdigital tinea pedis without bacterial involvement is treated topically with allylamine, imidazole, ciclopirox, benzylamine, tolnaftate, or undecenoic acid based creams.[74] Terbinafine cream applied twice daily for 1 week is effective in 66% of cases.[75] The dosing schedule of oral terbinafine is 250 mg daily for 2 weeks. Itraconazole in adults is given 400 mg daily for 1 week, 200 mg daily for 2–4 weeks, or 100 mg daily for 4 weeks with similar efficacies of all regimens,[76] whereas itraconazole in children is administered at 5 mg/kg/day for 2 weeks. Fluconazole 150 mg weekly for 3–4 weeks is also effective.[71] Topical or systemic corticosteroids may be helpful for symptomatic relief during the initial period of antifungal treatment of vesiculobullous tinea pedis. Maceration, denudation, pruritus, and malodor obligate a search for bacterial coinfection by Gram stain and culture, the results of which most often demonstrate the presence of Gram-negative organisms including *Pseudomonas and Proteus*. Patients suspected of having Gram-negative coinfections should be treated with a topical or systemic antibacterial agent based on the culture and sensitivity report. Associated onychomycosis is common; if present, more durable treatment of the onychomycosis is necessary to prevent recurrence of tinea pedis. Newer oral antifungal agents have replaced griseofulvin as the treatments of choice for severe or refractory tinea pedis when this infection is also accompanied by onychomycosis.

ONYCHOMYCOSIS

The management of onychomycosis depends on several factors including the severity of nail involvement, associated tinea pedis, along with efficacy and potential adverse effects of any treatment regimen. While it seems reasonable not to treat minimal nail involvement, concurrent tinea pedis should always be treated, particularly in the setting of diabetes mellitus, to prevent cellulitis.

TOPICAL THERAPY. In those patients with distal nail involvement and/or contraindication for systemic treatment, topical therapy should be considered. Ciclopirox 8% lacquer applied daily for 48 weeks achieved mycologic cure in 29%–36% of cases and clear nails (clinical cure) in 7% of mild to moderate cases of onychomycosis caused by dermatophytes.[77] Despite its much lower efficacy compared with oral antifungal agents, use of topical ciclopirox avoids risk of drug interactions. Amorolfine 5% applied twice weekly is another agent specifically prepared for use as a nail lacquer. It is the first member of a new class of antifungal drugs, the morpholine derivatives, which show activity against yeasts, dermatophytes and molds that cause onychomycosis. Amorolfine may have higher mycologic cure rates (38%–54% after 6 months of treatment) compared to ciclopirox lacquer; however, prospective controlled trials validating a significant difference are needed.[78]

SYSTEMIC THERAPY. An oral antifungal is required for onychomycosis involving the matrix area, or when a shorter treatment regimen or higher chance for clearance or cure is desired. Selection of the antifungal agent should be based primarily on the causative organism, the potential adverse effects, and the risk of drug interactions in any particular patient.

Terbinafine is fungistatic and fungicidal against dermatophytes, *Aspergillus*, and less so against *Scopulariopsis*. Terbinafine is not recommended for candida onychomycosis since it demonstrates variable efficacy against *Candida* species. A course of terbinafine 250 mg daily for 6 weeks is effective for most fingernail infections, while a minimum 12-week course[12–16] is required for toenail infections. Most adverse effects are gastrointestinal such as diarrhea, nausea, taste disturbance, and elevation of liver enzymes. Evidence suggests that a 3-month continuous regimen of terbinafine is the most effective oral treatment for onychomycosis of the toenails available today.[79] Clinical cure rates among different studies are approximately 50%, although the success rate is lower in patients over 65 years.[80] Itraconazole is fungistatic against dermatophytes,

nondermatophyte molds and yeasts. Safe and effective schedules include pulse dosing with itraconazole 400 mg daily for 1 week per month or a continuous dose of 200 mg daily, both of which require 2 months or 2 pulses of treatment for fingernails and at least 3 months or 3 pulses for toenails.[73] Itraconazole is dosed by weight in children at 5 mg/kg/day.[81] Elevated liver enzymes occur in 0.3%–5% of patients during therapy and return to normal within 12 weeks of discontinuation. Although itraconazole has a broader spectrum of activity than terbinafine, studies have shown a significantly lower rate of cure (about 25% vs. 50%) and higher relapse rate (about 50% vs. 20%) with itraconazole compared with terbinafine.[82,83] Fluconazole is fungistatic against dermatophytes, some nondermatophyte molds, and Candida. The usual regimen for fluconazole is 150–300 mg once weekly for 3–12 months.[73] Griseofulvin is no longer considered standard treatment for onychomycosis because of its prolonged treatment course, potential for adverse effects and drug interactions, and its relatively low cure rates.

Combination therapy regimens may have a higher clearance rate than either oral or topical treatments alone. Oral terbinafine combined with amorolfine nail lacquer was shown to result in clinical cure and negative mycology in 59% of patients compared to 45% of patients treated with oral terbinafine alone.[84] However, another study failed to show any additional benefit of combining oral terbinafine with ciclopirox 8% solution.[85]

In vitro fungicidal activity demonstrated by thymol, camphor, menthol, and oil of *Eucalyptus citriodora*[86,87] offers the potential for additional therapeutic strategies to treat onychomycosis. Thymol 4% prepared in ethanol may be used as drops applied to the nail plate and hyponychium. The application to nails of commercially available topical preparations with thymol, such as Vicks VapoRub™, has anecdotally led to success. Final options for refractory cases include surgical avulsion or chemical removal of the nail with 40% urea compounds in combination with topical or oral antifungals.

TINEA NIGRA

Tinea nigra is a superficial dermatomycosis caused by dematiaceous, darkly pigmented, *Hortaea werneckii* (formerly named *Phaeoannellomyces werneckii* and *Exophiala werneckii*).[88]

EPIDEMIOLOGY. Tinea nigra occurs in tropical or subtropical areas, including Central and South America, Africa, and Asia. Its incidence is low in the United States and Europe. While the majority of the approximately 150 North American cases reported since 1950 were associated with tropical travel,[42] endemic foci exist in the coastal southeastern United States and in Texas. Person-to-person transmission is rare.[89] Tinea nigra has a female/male predilection of 3:1.

ETIOLOGY. Tinea nigra is almost always caused by *H. werneckii*, although other dematiaceous fungi such as *Stenella araguata* may produce the same clinical picture. Dematiaceous fungi are commonly found in soil, sewage, and decaying vegetation.[89] Tinea nigra arises after trauma to the skin, subsequent inoculation and a typical incubation period of 2–7 weeks.



Figure 188-15 Tinea nigra palmaris. An irregular, brownish-black patch on the palm caused by *Phaeoannellomyces werneckii*. (Used with permission from Stuart Salasche, MD.)

CLINICAL FINDINGS. Tinea nigra is found on otherwise healthy people and presents typically as an asymptomatic, mottled brown to greenish-black macule or patch with minimal to no scale on the palms or soles (Fig. 188-15). The macule is often darkest at the advancing border. Because of its coloration and location on palms and soles, tinea nigra is frequently misdiagnosed as acral lentiginous melanoma.

DIFFERENTIAL DIAGNOSIS. (Box 188-7)

LABORATORY TESTS. KOH examination of scrapings from the macule reveals brown to olive-colored, thick branching hyphae, along with oval to spindle-shaped yeast cells that occur singly or in pairs with

BOX 188-7 DIFFERENTIAL DIAGNOSIS OF TINEA NIGRA

Most Likely
- Junctional nevus, dysplastic nevus, melanoma

Consider
- Chemical exposure

Rule Out
- Addison disease, syphilis, yaws

a central transverse septum. Cultures performed on SDA with cycloheximide and chloramphenicol grow within 1 week. The colony is initially yeast-like with a brown to shiny black color and appears as typical two-celled yeast forms under microscopic examination. With time, mycelial growth predominates creating a fuzzy grayish-black colony.

TREATMENT. Tinea nigra responds readily to topical therapy with a keratolytic (Whitfield's ointment, 2% salicylic acid), tincture of iodine, or topical antifungal.[90,91] Treatment should be continued for 2–4 weeks after clinical resolution in order to prevent relapse. Although oral ketoconazole, itraconazole and terbinafine are also effective, systemic therapies are rarely indicated.[88]

PIEDRA

Piedra is an asymptomatic superficial fungal infection of the hair shaft also known as trichomycosis nodularis. Black piedra is caused by *Piedraia hortae*, whereas white piedra is caused by pathogenic species of the *Trichosporon* genus, namely *Trichosporon asahii*, *Trichosporon ovoides*, *Trichosporon inkin*, *Trichosporon mucoides*, *Trichosporon asteroides*, and *Trichosporon cutaneum*.[88]

EPIDEMIOLOGY. Black piedra is seen commonly in humans and primates of tropical areas of South America, the Pacific Islands, and the Far East, and less commonly in Africa and Asia. *P. hortae* is present in the soil and in stagnant water and crops. Scalp hair is most commonly affected. In fact, infection is encouraged for religious and esthetic reasons by some indigenous cultures.[92]

White piedra is most common in temperate and semitropical climates of South America and Asia, the Middle East, India, Africa, and Japan. It occurs infrequently in the United States and Europe. White piedra affects facial, axillary, and genital hair more commonly than scalp hair. *T. ovoides* is found more commonly on scalp hair, *T. inkin* on pubic hair and *T. asahii* on other body surfaces. Person-to-person transmission is rare, and infection has not been associated with travel to endemic areas.[93]

CLINICAL FINDINGS. Black piedra is characterized by firmly attached, hard or gritty, brown–black colored concretions on the hair shaft that vary in size from the microscopic range to a few millimeters in size. Concretions are most commonly noted on frontal portions of the scalp. Black piedra weakens the hair shaft and results in hair breakage.

White piedra consists of softer and less adherent whitish to beige colored concretions that are discrete or may coalesce into sleeve-like structures along the hair shaft. These concretions affect the outer layers of the hair shaft and may be easily detached. Broken hairs, although sometimes present, are less common than in black piedra.[88]

Microscopy readily differentiates piedra from nits, hair casts, developmental hair shaft defects, and trichomycosis axillaris. In addition, the nodules of trichomycosis axillaris are usually smaller and may fluoresce under a Wood's lamp.

BOX 188-8 DIFFERENTIAL DIAGNOSIS OF PIEDRA

Most Likely

- Pediculosis, trichomycosis axillaris, tinea capitis

Consider

- Monilethrix

DIFFERENTIAL DIAGNOSIS. (Box 188-8)

LABORATORY TESTS. Nodules of black piedra examined by KOH preparation display a periphery of aligned hyphae and a well-organized center of thick-walled cells packed closely together, sometimes termed pseudoparenchyma. These nodules are mostly outside of the hair shaft. *P. hortae* grows well, albeit slowly, on most laboratory media and is uninhibited by cycloheximide.

The nodules of white piedra have a less organized and more intrapilar appearance than do nodules of black piedra. Hyphae are arranged perpendicularly to the hair shaft. *T. asahii* thrives on SDA and it is inhibited by cycloheximide.

TREATMENT. Shaving the infected hair is curative and represents the best treatment for both black and white piedra, although this approach should be supplemented with a topical azole preparation. Because of high relapse rates as well as evidence for intrafollicular organisms in white piedra, some advocate the use of systemic antifungal agent such itraconazole.[93]

KEY REFERENCES

Full reference list available at www.DIGM8.com

DVD contains references and additional content

2. Graser Y, Scott J, Summerbell R: The new species concept in dermatophytes-a polyphasic approach. *Mycopathologia* **166**:239, 2008
10. Seebacher C, Bouchara JP, Mignon B: Updates on the epidemiology of dermatophyte infections. *Mycopathologia* **166**:335, 2008
20. Dahl MV: Dermatophytosis and the immune response. *J Am Acad Dermatol* **31**:S34, 1994
32. Patel GA, Schwartz RA: Tinea capitis: Still an unsolved problem? *Mycoses* **54**(3):183–188, 2011
58. Ghannoum MA et al: A large-scale North American study of fungal isolates from nails: The frequency of onychomycosis, fungal distribution, and antifungal susceptibility patterns. *J Am Acad Dermatol* **43**:641, 2000
71. Gupta AK, Cooper EA: Update in antifungal therapy of dermatophytosis. *Mycopathologia* **166**:353, 2008
80. de Berker D: Clinical practice. Fungal nail disease. *N Engl J Med* **360**:2108, 2009
88. Schwartz RA: Superficial fungal infections. *Lancet* **364**:1173, 2004

Chapter 189 :: Yeast Infections: Candidiasis, Tinea (Pityriasis) Versicolor, and *Malassezia* (*Pityrosporum*) Folliculitis

:: Roopal V. Kundu & Amit Garg

CANDIDIASIS

YEAST INFECTIONS AT A GLANCE

- *Candidiasis* refers to a diverse group of acute and chronic integumentary or disseminated yeast infections, most commonly caused by *Candida albicans*.
- *Candida* species are the most common cause of fungal infection in immunocompromised persons.
- *Malassezia* yeast, although normal flora in most healthy individuals, cause a wide spectrum of superficial cutaneous disease, including tinea versicolor and *Malassezia* folliculitis.
- Common predisposing factors associated with *Candida* and *Malassezia* infection include a warm, humid environment; hyperhidrosis; occlusion of skin and hair follicles; oral contraceptive, antibiotic and systemic corticosteroid use; diabetes mellitus; and immunosuppression.
- Potassium hydroxide preparation of skin scrapings demonstrates the characteristic fungal elements that identify *Candida* and *Malassezia*.
- Multiple topical and systemic agents are effective in treating infection with *Candida* and *Malassezia*; however, recurrences are common.

The genus *Candida* is comprised of a heterogeneous group of over 200 yeast species.[1] *Candida* species are ubiquitous yeast-like fungi that form true hyphae, pseudohyphae, and budding yeasts. *Candidiasis* (or *candidosis*) refers to a diverse profile of yeast infections caused by members of the genus *Candida*, and predominantly by *Candida albicans*. *Candida* species are among the most common fungal pathogens to affect humans. While the skin, nails, mucous membranes, and gastrointestinal tract are typical sites of infection, *Candida* may involve any part of the body. Although considered opportunistic human pathogens, *Candida* species may also exist as commensal organisms of skin and mucosal membranes of the gastrointestinal, genitourinary, and respiratory tracts.

EPIDEMIOLOGY

FREQUENCY. *Candida* are usually limited to human and animal hosts, however they have also been recovered from the hospital environment: countertops, air-conditioning vents, floors, respirators, and on medical personnel. Oropharyngeal colonization with *Candida* is observed in up to 50% of healthy individuals [2] and may also be detected in 40%–65% of normal stool samples. In addition, *C. albicans* exists as a commensal organism in the vaginal mucosa of 20%–25% of asymptomatic, healthy women[3] and up to 30% of healthy pregnant women.[4] Vulvovaginal candidiasis (VC) is the second most common cause of vaginitis in women.

Candida species are the most common cause of fungal infection in immunocompromised persons. More than 90% of persons infected with HIV not receiving highly active antiretroviral therapy (HAART) develop oropharyngeal candidiasis and 10% of these patients develop esophageal candidiasis.[5–6] *Candida* species are now the fourth most commonly isolated pathogens from blood cultures in patients with systemic infections.[7]

MORTALITY/MORBIDITY

Most candidal infections are mucocutaneous. While in few cases there may be pronounced effect on morbidity, these infections do not lead to death. However, immunocompromised patients including hospitalized patients, may develop candidemia and disseminated candidiasis which have a 30%–40% mortality rate. In fact, systemic candidiasis causes more case fatalities than any other systemic mycosis.

SEX. Neither sex is predisposed to candidal colonization.

AGE. Neonates and adults >65 years of age are most susceptible to candidal colonization and mucocutaneous candidiasis.

ETIOLOGY AND PATHOGENESIS

Responsible for 50%–60% of all candidal infections, *C. albicans* is the most common candidal pathogen identified.[8] *C. albicans* has its own virulence factors including adhesion molecules that permit attachment

of the organism to other structures, proteinase secretions [aspartyl proteinases (SAP1-9)] that facilitate damage to cell envelopes, as well as the ability to convert to the hyphal form which is thought to be important for the virulence of *C. albicans*.[9]

The relative prevalence of *C. albicans* in clinical isolates is declining, and other species such as *Candida glabrata*, *Candida parapsilosis*,[1,10] *Candida tropicalis*, *Candida krusei*,[1,11] and *Candida dubliniensis*[12] are increasingly being encountered as pathogens.[13] *C. glabrata* and *C. albicans* account for approximately 70%–80% of *Candida* species recovered from patients with candidemia or invasive candidiasis. Other species of *Candida* have gained importance because of their frequent intrinsic resistance to systemic antifungal therapy. Certain patient populations are more susceptible to specific *Candida* species: the presence of *C. parapsilosis* should be considered in hospitalized patients and those with vascular catheters or prosthetic devices, while *Candida tropicalis* has been observed to cause candidemia in patients with leukemia and in those who have undergone bone marrow transplantation.

CLINICAL MANIFESTATIONS

The mucocutaneous manifestations of candidiasis are represented by several distinct clinical syndromes.

MUCOCUTANEOUS CANDIDIASIS

ORAL CANDIDIASIS

Acute pseudomembranous candidiasis or thrush is the most common form of oral candidiasis. Predisposing factors include diabetes mellitus, systemic steroid and antibiotic use, pernicious anemia, malignancy, radiation to head and neck, and cell-mediated immunodeficiency[2,15–16] (Table 189-1). Thrush appears as discrete white patches that may become confluent on the buccal mucosa, tongue, palate, and gingivae (Fig. 189-1A). This friable pseudomembrane resembles cottage cheese or milk curds and consists of desquamated epithelial cells, fungal elements, inflammatory cells, fibrin, and food debris (Figs. 189-1A–189-1C). Scraping the patches exposes a brightly erythematous surface underneath. Microscopic examination of this material reveals masses of tangled pseudohyphae and blastospores (Fig. 189-2). In severe cases, the mucosal surface may ulcerate.

Acute atrophic candidiasis (erythematous candidiasis), which occurs after sloughing of the thrush pseudomembrane,[15] is observed most often in the setting of broad-spectrum antibiotic or systemic glucocorticoid therapy and human immunodeficiency virus infection.[2] The most common location is on the dorsal surface of the tongue, where depapillated atrophic patches with minimal pseudomembrane formation are noted. There are both asymptomatic and symptomatic variants, the latter characterized by burning or pain.[17]

Chronic atrophic candidiasis (denture stomatitis) (Fig. 189-1B) is a common form of oral candidiasis seen in 24%–60% of denture wearers,[18] and more commonly occurs in women. Chronic erythema and edema of the palatal mucosal surface in contact with the dentures is present. Presumably, the chronic low-grade trauma and occlusion caused by dentures predispose to candidal colonization and subsequent infection.[19]

TABLE 189-1
Factors Predisposing to *Candida* Infections

MECHANICAL FACTORS
- Dentures
- Local occlusion (dressings or garments), moisture, and/or maceration
- Obesity
- Trauma

NUTRITIONAL FACTORS
- Avitaminosis (vitamin A and C)
- Generalized malnutrition
- Iron deficiency (chronic mucocutaneous candidiasis)
- Parenteral hyperalimentation

PHYSIOLOGIC ALTERATIONS
- Extremes of age
- Menses
- Pregnancy

SYSTEMIC ILLNESSES
- Acrodermatitis enteropathica
- Down syndrome
- Endocrine disease
- Cushing disease
  - Diabetes mellitus
  - Hypoadrenalism
  - Hypoparathyroidism
  - Hypothyroidism
- Acute and chronic renal failure (hemodialysis)
- Bone marrow transplantation
- Malignancy (especially hematologic, thymoma)
- Solid organ transplantation (liver, kidney)
- Immunodeficiency
  - Acquired immunodeficiency syndrome
  - Severe combined immunodeficiency syndrome
  - Myeloperoxidase deficiency
  - Chédiak–Higashi syndrome
  - Hyperimmunoglobulinemia E syndrome
  - Chronic granulomatous disease
  - DiGeorge syndrome
  - Nezelof syndrome
  - Hypocomplementemia
  - Granulocytopenia

IATROGENIC
- Indwelling catheters and intravenous lines
- Prolonged hospitalizations
- X-ray irradiation
- Medications
  - Corticosteroids
  - Other immunosuppressive agents
  - Antibiotics (especially broad spectrum, metronidazole)
  - Oral contraceptives (especially estrogen dominant)
  - Colchicine
  - Phenylbutazone
  - Chemotherapy



Figure 189-1 **A.** Pseudomembranous candidiasis or thrush. Note the characteristic white patches on the palate. **B.** Atrophic candidiasis under dentures. Edema and erythema at the site of contact with dentures. **C**. *Candida* perlèche with erythema and fissuring at the corners of the mouth. **D.** Hyperplastic candidiasis of the tongue.

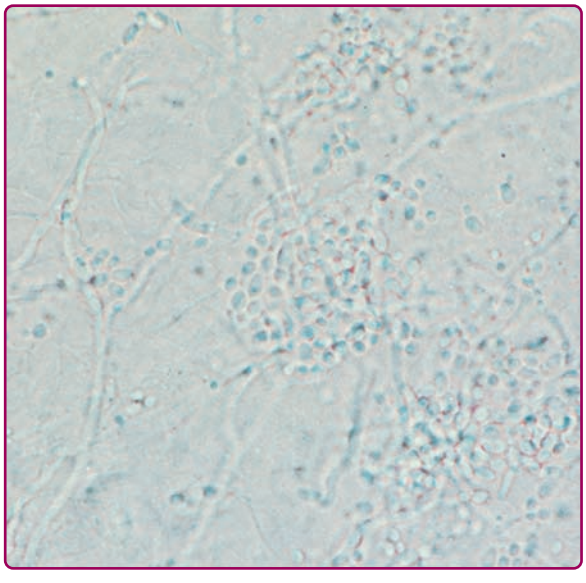

Figure 189-2 *Candida* in potassium hydroxide preparation. Pseudomycelia in clusters of grape-like yeast cells.

Candidal cheilosis (angular cheilitis or *perlèche)* is characterized by erythema, fissuring, maceration, and soreness at the angles of the mouth (Fig. 189-1C). This condition is commonly encountered in habitual lip lickers and in elderly patients with sagging skin at the oral commissures. Loss of dentition, poorly fitting dentures, malocclusion, and riboflavin deficiency also predispose one to cheilosis. Cheilosis is often associated with chronic atrophic candidiasis in denture wearers.[15]

The differential diagnosis for oral candidiasis is summarized in Box 189-1.

VAGINAL AND VULVOVAGINAL CANDIDIASIS

VC is the second most common cause of vaginitis, and approximately three-fourths of all women will experience an episode of VC in their lifetime. *C. albicans* causes 80%–90% of VC and is followed by *C. glabrata* in frequency.[20] Risk factors for VC include systemic antibiotic or steroid use, diabetes mellitus, presence

BOX 189-1 DIFFERENTIAL DIAGNOSIS OF ORAL CANDIDIASIS

Most Likely
- Lichen planus
- Aphthous stomatitis
- Erythema multiforme
- Pernicious anemia

Consider
- Mucositis due to chemotherapy
- Lupus erythematosus
- Histoplasmosis
- Salicylate toxicity

Rule Out
- Glucagonoma
- Zinc deficiency
- Pemphigus vulgaris

of an intrauterine device, wearing of tight-fitting and synthetic clothing, and immunosuppression.[21,22] These factors disrupt vaginal flora of lactobacilli that serve to inhibit overgrowth of *Candida*.[20]

Recurrent VC, defined as four or more episodes per year, occurs in up to 10% of women.[20] Changes in hormone levels during pregnancy and the luteal phase of the menstrual cycle may induce relapses. Use of genital cleansing solutions or douche may elicit a hypersensitivity response and increase susceptibility to *Candida*. Frequent sexual intercourse, resulting in vaginal abrasions and involving semen allergy, may also predispose women to recurrent VC.[23] When none of the above mentioned factors is involved in VC, one should consider use of antibiotics, immunosuppression, or diabetes mellitus as potential contributors.[24]

Patients with VC present with a vaginal discharge associated with vulvar pruritus, burning, and occasional dysuria or dyspareunia. Examination shows thick curd-like whitish plaques on the vaginal wall with underlying erythema and surrounding edema that may extend to the labia and perineum. The cervix is normal upon speculum examination.[25]

BALANITIS AND BALANOPOSTHITIS

Candida spp. cause 30%–35% of infectious balanitis. Factors predisposing to candidal balanitis include diabetes mellitus, an uncircumcised state, and candidal vaginal infection in sexual partners. Occasionally, patients with balanitis complain of transient erythema and burning occurring shortly after intercourse. The eruption involving the penis is pruritic. Physical findings include white patches on the glans or prepuce. Small papules or fragile vesiculopustules on the glans or along the coronal sulcus (Fig. 189-3) break to leave erythematous erosions with a collarette of whitish scale. Infection may spread to the scrotum, gluteal folds, buttocks, and thighs. In diabetic or immunosuppressed patients, a severe edematous, ulcerative balanitis may occur.



Figure 189-3 Candidal balanoposthitis. Multiple discrete pustules on the glans penis and inner aspect of the foreskin.

CUTANEOUS CANDIDIASIS

INTERTRIGO

C. albicans has a predilection for colonizing skin folds, intertriginous zones in which the local environment is moist and warm. Usual locations for candidal intertrigo include the genitocrural, gluteal, interdigital, inframammary (Fig. 189-4) areas, and beneath the pannus and axillary areas. Predisposing conditions include obesity, diabetes mellitus, wearing of occlusive clothing and occupational factors.[26] The pruritic eruption appears as macerated red erythematous patches and thin plaques with satellite vesiculopustules. These pustules enlarge and rupture, leaving an erythematous base with a collarette of easily detachable scale that contributes to further maceration and fissuring. Cutaneous candidal infection is diagnosed by the typical appearance of the eruption and confirmed by KOH examination and, when necessary, culture. See Box 189-2 for the differential diagnosis of intertriginous candidiasis.

Several clinical variants of *Candida* intertrigo deserve special mention. Candidal diaper dermatitis results from yeast colonization of the gastrointestinal tract and chronic occlusion with wet diapers. The eruption with pronounced red erythema first appears in the perianal region and spreads to the perineum and inguinal creases (Fig. 189-4C).[27] *Erosio interdigitalis blastomycetica* refers to interdigital candidal or polymicrobial infection of the hands or feet, usually affects the third or fourth interdigital space, where moisture trapping is thought to underlie the condition (Fig. 189-4D). *Candida* miliaria affects the back in bedridden patients. The eruption begins as isolated vesiculopustules containing



Figure 189-4 Candidal intertrigo. **A.** Erythematous, eroded, pustular papules coalescing to plaques involving the scrotum and inguinal area with satellite lesions. Collarette-like scales where pustules have eroded. **B.** Confluent and discrete erythematous, eroded areas with pustular and erosive satellite lesions. **C.** Red, partially eroded plaques on the vulva surrounded by a delicate collarette in an infant. Outside the main lesions are a few pustular satellite lesions. **D.** Erosio interdigitalis blastomycetica. Erythematous eroded areas between the fingers.

BOX 189-2 DIFFERENTIAL DIAGNOSIS OF INTERTRIGINOUS CANDIDIASIS

Most Likely
- Intertrigo, irritant contact dermatitis
- Dermatophytosis (e.g., tinea cruris)
- Psoriasis
- Erythrasma
- Seborrheic dermatitis

Consider
- Familial benign pemphigus
- Flexural Darier disease
- Leiner disease

Rule Out
- Glucagonoma
- Extramammary Paget disease
- Secondary syphilis
- Zinc deficiency

yeast, which spread over occluded regions on the back. *Candida* also colonizes and infects skin around wounds covered with occlusive dressings (Fig. 189-5). Broad-spectrum topical antibiotics contribute to these *Candida* wound infections.[28]

GENERALIZED CUTANEOUS CANDIDIASIS

This is an unusual form of cutaneous candidiasis that manifests as a diffuse eruption beginning as individual vesicles and spreading into confluent areas involving the trunk, thorax, and extremities. The associated generalized pruritus is increased in severity in the genitocrural folds, anal region, axillae, and hands and feet (Fig 189-6).

CANDIDA FOLLICULITIS

Superficial infection involving the infundibulum of hair follicles occurs also in the predisposed patient,

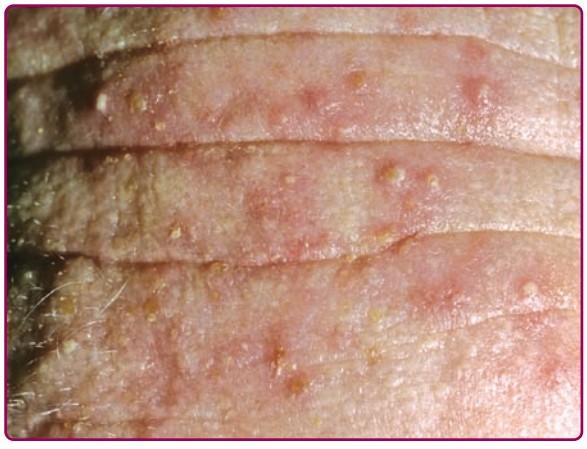

Figure 189-5 *Candida* miliaria on the forehead of a diabetic patient that arose after use of a semiocclusive dressing for headache.



Figure 189-6 Cutaneous candidiasis. Erythematous, unroofed vesicles and vesiculopustules coalescing into plaques involving the lower back and buttocks. Collarette-like scales where vesicles have eroded.

most commonly in the setting of diabetes mellitus or immunocompromised states. KOH examination of the contents of follicular pustules distinguishes this condition from bacterial folliculitis.

CANDIDAL PARONYCHIA AND ONYCHOMYCOSIS

Candidal infection of the nails and paronychial folds occurs most often in those with diabetes mellitus or who habitually immerse their hands in water (i.e., housekeepers, bakers, fishermen, and bartenders). In paronychia, there is initial redness, swelling and tenderness of the proximal and lateral nailfolds with retraction of the cuticle toward the proximal nail fold (Fig. 189-7). Pain and erythema may extend along the entire nail plate and nail bed.[29,30] Candidal paronychia should be differentiated from acute bacterial paronychia or paronychia associated with hypoparathyroidism, celiac disease, acrodermatitis enteropathica (Chapter 130), reactive arthritis syndrome (Chapter 20), acrokeratosis paraneoplastica, and retinoid therapy. Candidal onychomycosis is associated with secondary nail thickening, ridging, whitish discoloration, and occasional nail loss.

CHRONIC MUCOCUTANEOUS CANDIDIASIS

Chronic mucocutaneous candidiasis (CMC) is characterized by chronic, treatment-resistant, superficial candidal infections of the skin, hair, nails, and mucous membranes. There is virtually no propensity for disseminated visceral candidiasis.



Figure 189-7 Chronic onychia and paronychia caused by *Candida albicans*. **A.** Note the warm but not hot, slightly tender, edematous nail fold with some onycholysis. This is very often misdiagnosed as staphylococcal paronychia. **B.** This is a chronic inflammatory condition with pustulation of the nail fold that also can involve the nail plate.

CMC is frequently associated with endocrinopathies including hypoparathyroidism, hypoadrenalism, and hypothyroidism, as well as conditions associated with specific abnormalities in cell-mediated immunity, such combined immune deficiency syndrome, DiGeorge syndrome, or patients with severely impaired T-cell function (i.e., AIDS). CMC first appearing in adulthood is often associated with thymoma.[31] There are several more or less distinct clinical syndromes of CMC (Table 189-2)[32–34] in which

TABLE 189-2
Classification of Chronic Mucocutaneous Candidiasis

Clinical Syndrome	Inheritance	Age at Onset	Distribution of Lesions	Endocrinologic Abnormality	Associated Findings	Notes
Chronic oral candidiasis	Sporadic	Any	Mucosa of tongue, lips, buccal cavity; perlèche; no skin or nail involvement	None	Esophagitis	Denture stomatitis is a variant
Chronic candidiasis with endocrinopathy (APECED)	Autosomal recessive	Childhood	Mucous membranes, skin, and/or nails	Frequent (hypoadrenalism, hypothyroidism, hypoparathyroidism, or polyendocrinopathy)	Alopecia totalis, thyroiditis, vitiligo, chronic hepatitis, pernicious anemia, gonadal failure, malabsorption, diabetes mellitus	Endocrinopathy may be delayed in onset
Chronic candidiasis without endocrinopathy	Autosomal recessive	Childhood	Mucous membranes, perlèche, and nail involvement; less common skin involvement	None	Blepharitis, esophagitis, laryngitis	–
	Autosomal dominant	Childhood		None	Dermatophytosis, loss of teeth, recurrent viral infections	–
Chronic localized mucocutaneous candidiasis	Sporadic	Childhood	Mucous membranes, skin, and/or nails	Occasionally	Pulmonary infections, esophagitis	Hyperkeratotic lesions (*Candida*), granuloma
Chronic diffuse candidiasis	Autosomal recessive	Childhood	Widespread on mucous membranes, skin and nail involvement	None	–	Erythematous, serpiginous skin lesions
		Adolescence	Widespread on mucous membranes, skin and nail involvement	None	History of frequent course of antibiotics	–
Chronic candidiasis with thymoma	Sporadic	Adulthood (after third decade)	Mucous membranes, nails, and skin	None	Thymoma, myasthenia gravis, aplastic anemia, neutropenia, hypogammaglobulinemia	Chronic mucocutaneous candidiasis often precedes diagnosis of thymoma



Figure 189-8 Mucocutaneous candidiasis. Well-demarcated serpiginous lesions with massive scaling. Lesions look like psoriasis.



Figure 189-9 Invasive candidiasis with candidemia. Multiple erythematous papules on the hand of a febrile patient with granulocytopenia associated with treatment of acute myelogenous leukemia. The usual source of the infection is the gastrointestinal tract. *Candida tropicalis* was isolated on blood culture. Candidal forms were seen in lesional skin biopsy specimens.

candidal infections cause oral thrush, diaper dermatitis, angular cheilitis (perlèche), lip fissures, nail and paronychial involvement, vulvovaginitis, and cutaneous involvement. The cutaneous eruption may appear with an erythematous, serpiginous border, or areas of brownish desquamation on a background of mild erythema (Fig. 189-8). Nail involvement is characterized by markedly thickened and dystrophic nail plates in which the entire thickness is invaded by *Candida*. The paronychial folds are red and edematous, there may be pus, and the fingertips are often bulbous (Fig. 189-7B).

DISSEMINATED CANDIDIASIS

The incidence of disseminated candidiasis is steadily rising as the prevalence of immunosuppressed patients with longer life spans has also increased. The responsible organisms, *C. albicans, C. tropicalis, C. glabrata,* and *C. parapsilosis,*[35] gain hematogenous access from the oropharynx or gastrointestinal tract when mucosal barrier function is compromised (e.g., by mucositis secondary to chemotherapy), or when intravenous catheters become contaminated. Multiple organ systems including gastrointestinal and respiratory may become involved.[36] Recognition of a candidal eruption in the context of disseminated infection may be important to early diagnosis, as ante-mortem blood cultures are negative in a high percentage of patients with autopsy-proven systemic candidiasis.[36] Approximately 10% of patients with disseminated candidiasis develop metastatic 0.5–1.0-cm nontender erythematous papules with a hemorrhagic or pustular center (Fig. 189-9) over the trunk and extremities associated with fever and myalgias.[37] Some papules may be necrotic in appearance. The differential diagnosis for disseminated candidiasis is provided in Box 189-3.

LABORATORY FINDINGS

Direct microscopic examination of specimens for the presence of yeast or isolation of yeast in culture confirms infection. In superficial candidal infections, the diagnosis can be confirmed by microscopic examination skin scrapings or smears obtained from skin, nails, or mucosal surfaces that reveal hyphae, pseudohyphae, or budding yeast cells (Fig. 189-2). Potassium hydroxide smear, or Gram or methylene blue

BOX 189-3 DIFFERENTIAL DIAGNOSIS OF DISSEMINATED CANDIDIASIS

Most Likely

- Bacterial sepsis (e.g., gonococcal, meningococcal, staphylococcal)

Consider

- Pityrosporum folliculitis
- Miliaria
- Deep fungal infections (e.g., cryptococcosis, Torulopsis, or sporotrichosis)

Always Rule Out

- Disseminated fungal infections (e.g., aspergillosis)
- Disseminated Varicella Zoster or Herpes infections

stain is useful for direct demonstration of fungal cells. Cultures from affected nails may help identify the etiologic agent responsible for onychomycosis (dermatophyte vs. yeast). *C. albicans* readily produce whitish mucoid colonies within 2–5 days on Sabouraud's agar with added antibiotics.

In systemic candidiasis associated with an eruption, the diagnosis may be confirmed from histopathologic examination and tissue culture of lesional skin. Blood cultures are positive in only 50%–60% of cases of disseminated infection.[35] Serologic studies using immunodiffusion, counterimmunoelectrophoresis, and latex agglutination methods are fraught with false-negative and false-positive reactions which limit their utility in confirming diagnosis. Newer techniques to detect circulating candidal antigens (e.g., mannan or enolase) or metabolic products (e.g., arabinitol) show improved sensitivities and specificities in serial testing.[38] Specifically, the serum (1,3)β-D-glucan detection assay (Glucatell, Fungitell) is a nonculture assay that measures level of β-glucan, a component of the fungal cell wall. In a large multicenter study, the assay yielded high sensitivity (75%–100%), specificity (88%–100%) and positive predictive value with highly reproducible results.[39]

MICROSCOPIC STUDIES

Since *Candida* sp. may infect virtually any organ system, specimens for laboratory examination will vary from body fluids to tissue samples. Direct microscopic examination of scrapings from mucosa, skin or nails for the presence of yeast provides bedside evidence to support the clinical diagnosis. Body fluids such as urine and cerebrospinal fluid should be centrifuged and the sediment examined directly to increase the probability of detecting yeast. Specimens must be treated with a clearing agent such as 10% KOH and ink before the material is examined. *Candida* appears as oval budding cells, elongated filamentous cells connected end-to-end (pseudohyphae), or septate hyphae (Fig. 189-2).

PATHOLOGY

Superficial candidiasis is characterized by subcorneal pustules on histopathological examination. Organisms are seldom seen within the pustules but rather are highlighted in the stratum corneum with periodic acid-Schiff (PAS) staining. Examination of a candidal granuloma shows marked papillomatosis and hyperkeratosis and a dense dermal infiltrate consisting of lymphocytes, granulocytes, plasma cells, and multinucleated giant cells. In systemic candidiasis with skin involvement, foci of yeast are observed in the dermis and within dermal vessels. Organisms are identified using PAS, methenamine silver, or methylene blue stains.

TREATMENT

Treatments used to manage *Candida* infections may vary based on species of *Candida* responsible for infection, sensitivity to specific antifungal drugs, anatomic location of infection, underlying disease, and immune status of the patient.

Guidelines in the management of candidiasis were updated in 2009 by the Infectious Disease Society of America.[40] These guidelines include recommendations on the appropriate use of echinocandins, caspofungin, micafungin, and anidulafungin, along with voriconazole and posaconazole, as well as lipid formulations of amphotericin B. Fluconazole is still considered a first-line agent in nonneutropenic patients with candidemia or suspected to have invasive candidiasis. Therapeutic options in the management of invasive candidiasis and candidemia include triazoles as well as newer agents such as echinocandins.[41,42] A brief discussion on the treatment of candidal infections is included herein. For a detailed review on current therapeutic strategies, please refer to Chapter 232.

ORAL CANDIDIASIS. Uncomplicated oral candidiasis may be treated with nystatin suspension 400,000–600,000 units four times per day, or clotrimazole troches 10 mg dissolved in the mouth five times per day. For recurrent cases, oral azoles (see Chapter 232) are proven to be more effective.

CANDIDAL VULVOVAGINITIS AND BALANITIS. Two therapeutic approaches exist when considering treatment for candidal vaginitis. Topical imidazole preparations available over the counter, such as butoconazole, miconazole, and clotrimazole, as well as those available by prescription, including tioconazole, econazole, and terconazole are easy to use and effective over 3–7 days of treatment.[24] These agents are also safe to use during pregnancy.[43] Oral fluconazole, itraconazole, and ketoconazole offer efficacy similar to that of topical therapy (see Chapter 219). Prophylactic regimens to prevent recurrences include weekly clotrimazole 500-mg tablet used intravaginally or fluconazole 150 mg/week orally.[24] The recommended treatment for candidal balanitis is topical clotrimazole cream or a single oral 150-mg dose of fluconazole.

CUTANEOUS. Candidal intertrigo has been treated successfully with topical antifungals (e.g., clotrimazole, econazole, ciclopirox, miconazole, ketoconazole, and nystatin). Powder preparations also keep dry otherwise moist environments that facilitate candidal infections. Systemic antifungal therapy is recommended for extensive cutaneous infections, follicular involvement, or infections in immunocompromised patients.

CANDIDAL PARONYCHIA. Chronic paronychia due to *Candida* is often resistant to therapy. The most important aspects of therapy include minimizing contributing factors such as water exposures, as well as drainage of any abscess. Topical imidazole in solution form should be considered initially.[26] Four percent thymol in ethyl alcohol (compounded by the pharmacy, as it is not commercially available) is drying to candida, and thus may be a suitable alternative. Oral azoles may also be used in otherwise refractory cases.[29]

CANDIDAL ONYCHOMYCOSIS. Oral itraconazole or fluconazole (triazoles) appear to be most efficacious for candidal onychomycosis. Two treatment regimens are available: the daily dose or pulsed-dose regimen. Itraconazole, which is approved for use for onychomycosis in the United States, may be administered at 200 mg daily for 6 weeks for fingernails and for 12 weeks for toenails. It may also be administered in pulse therapy, 200 mg twice daily for 1 week per month, for a total of two pulses for fingernails and three pulses for toenails.[44]

DISSEMINATED CANDIDIASIS. Amphotericin B, available in newer lipid-based formulations, as well as caspofungin are effective in treating disseminated candidiasis (see Chapter 232).[45]

CHRONIC MUCOCUTANEOUS CANDIDIASIS. Oral azoles are first line agents in the treatment of CMC. Regimens include fluconazole 100–400 mg/d or itraconazole 200–600 mg/d used until there is clinical improvement. Initial therapy for acute infection should always be followed by maintenance therapy with the same azole for life.

PITYROSPORUM INFECTIONS OF THE SKIN: TINEA VERSICOLOR AND *PITYROSPORUM* FOLLICULITIS

The genus *Malassezia*, formerly known as *Pityrosporum*, currently includes twelve species of lipophilic basidiomycetous yeast: *Malassezia furfur*, *Malassezia pachydermatis*, *Malassezia sympodialis*, *Malassezia globosa*, *Malassezia restricta*, *Malassezia slooffiae*, *Malassezia obtusa*, *Malassezia dermatitis*, *Malassezia nana*,[46] *Malassezia yamatoensis*,[47] *Malassezia japonica*,[48] and *Malassezia equi*.[49,50] In 1996, a new taxonomic classification [51] based specifically on morphologic, physiologic and ultrastructural features detected by molecular techniques allowed for the addition of several new species to the *Malassezia* genus.

The species of *Malassezia* may be differentiated by their nutritional requirements, morphology, and molecular biology.[49,51] All *Malassezia* species require lipids for growth, because with the exception of *M. pachydermatis* which has the ability to produce phospholipase, they do not synthesize C14–C16 saturated fatty acids.[52] Although previously recognized as a zoophilic organism, *M. pachydermatis* has been identified only recently as a human pathogen. In one study, the organism caused a series of infections in a neonatal care nursery, where *M. pachydermatis* was presumably spread to patients from health care workers whose pet dogs were colonized with the fungus.[53] It was later shown that the vast majority of dog owners tested positive for *M. pachydermatis* on their hands.[54] Other members of the genus, including *M. sympodialis* and *M. slooffiae*, are part of the normal skin flora.[55] A few studies also linked *M. sympodialis* with neonatal cephalic pustulosis, also known as neonatal acne.[56,57]

Cutaneous infections with *Malassezia* take two main primary forms: (1) pityriasis versicolor and (2) *pityrosporum* folliculitis. However, *Malassezia* may also play some role in the course of other common skin diseases such as seborrheic dermatitis, atopic dermatitis, and psoriasis.[49,58]

TINEA (PITYRIASIS) VERSICOLOR

EPIDEMIOLOGY. The prevalence of tinea versicolor in the United States is estimated to be 2%–8% of the population. The infection occurs more frequently in regions with higher temperatures and relative humidity. Tinea versicolor has a worldwide prevalence of up to 50% in the hot and humid environments and as low as 1.1% in colder climates.

Incidence of tinea versicolor is the same in all races, but the eruption is often more apparent in darker-skinned individuals due to resulting alteration in skin pigmentation. No sex predominance is apparent. Tinea versicolor is most common among adolescents and young adults, in whom lipid-producing sebaceous glands are more active.

Etiology and Pathogenesis. *M. furfur* can be cultured from both affected and normal skin and is considered part of the normal flora, particularly in sebum-rich areas of the body.[59] Experimental inoculation of *Malassezia* under occlusion has resulted in infection.[59] The resulting increase in humidity, temperature and CO_2 tension appear to be important factors contributing to infection.[60] While removal of occlusion promotes healing of the eruption, the organism may still be cultured from clinically uninvolved areas.[60] Furthermore, this colonization of follicular structures facilitates a high recurrence rate.

M. furfur is a dimorphic, lipophilic organism that grows in vitro only with the addition of C12–C14 fatty acids such as olive oil and lanolin. Under appropriate conditions, it converts from the saprophytic yeast to the predominantly parasitic mycelial form, which causes clinical disease. Factors predisposing to mycelial transition include a warm, humid environment, hyperhidrosis, oral contraceptive, and systemic corticosteroid use, Cushing's disease, immunosuppression, and a malnourished state.[59,61]

The yeast may filter natural sunlight and interfere with normal tanning.[62] Mayser et al discussed a specific compound synthesized by *Malassezia* called *pityriacitrin* that absorbs ultraviolet light.[63] Other metabolites of *M. furfur* are listed on Box 189-4. Specifically, via lipases *Malassezia* metabolizes various fatty acids such as arachidonic or vaccenic acids and subsequently releases azelaic acid as one of the metabolites. Azelaic acid inhibits the action of the tyrosinase in the melanin production pathway, which results in persistent hypopigmentation of affected skin for months, and sometimes years.[64] This hypopigmentation may be accentuated further in summer months if surrounding unaffected skin becomes tan.

While *M. furfur* had long been identified as the fungus causing tinea versicolor, *M. globosa* is now thought

BOX 189-4 *MALASSEZIA* FURFUR METABOLITES

Azelaic acid: a dicarboxylic acid that inhibits tyrosinase
Malassezin: an aryl hydrocarbon receptor agonist that induces apoptosis in melanocytes
Pityriacitrin: a yellow compound that absorbs UV light
Pityrialactone: an indole alkaloid (tryptophan derivative) that fluoresces under 366 nm UV light
Pityriarubins: red indole alkaloids that inhibit the neutrophil respiratory burst in vitro in a dose dependent manner and inhibit 5-lipoxygenase activity

to be the predominant species involved in its pathogenesis.[65]

CLINICAL FINDINGS

The typical presentation of tinea versicolor is scaly oval to round macules scattered over characteristic areas of the body, including the upper trunk, neck, and upper arms (Fig. 189-10). The macules often coalesce forming irregular shaped patches of pigmentary alteration. The color of patches varies from almost white to pink to reddish brown or fawn colored (Fig. 189-10C). The scale is characteristically described as dust-like or furfuraceous (Fig. 189-10D). Extensive scaling can be produced by lightly scraping a #15 scalpel blade over the involved skin.[66] Patches may have a wrinkled surface appearance (Fig. 189-11) and this feature serves as a useful clinical pearl for the diagnosis. The presenting concern often relates to the cosmetic appearance of the eruption rather than any symptoms, since pruritus is usually mild or absent. The diagnosis made on clinical grounds is supported by Wood's light (365 nm) examination which may show yellow–orange fluorescence thought to be due to the presence of pteridine and is confirmed by microscopic KOH examination of the scale. Tinea versicolor tends to recur in warmer months of the year.

An inverse form of tinea versicolor is encountered predominantly in flexural areas.[67] These sharply demarcated confluent pink erythematous patches may be confused with inverse psoriasis, seborrheic dermatitis, erythrasma, candidiasis, and dermatophytic infections. The differential diagnosis of tinea versicolor is presented in Box 189-5.

LABORATORY TESTS

Potassium hydroxide (KOH) preparation of skin scrapings demonstrates the characteristic fungal spores and short cigar-butt hyphae ("spaghetti and meatballs"). Visualization of fungal elements may be enhanced by the addition of methylene blue stain to the KOH preparation. Culture is rarely necessary and requires a lipid-containing medium (i.e., olive oil) to demonstrate growth.

BOX 189-5 DIFFERENTIAL DIAGNOSIS OF TINEA VERSICOLOR

Most Likely
- Pityriasis alba
- Pityriasis rosea
- Seborrheic dermatitis
- Dermatophyte infections

Consider
- Erythrasma
- Vitiligo
- Psoriasis
- Pityriasis rubra pilaris
- Confluent and Reticulated Papillomatosis of Gougerot and Carteaud

Always Rule Out
- Secondary syphilis
- Hypopigmented mycosis fungoides

PATHOLOGY

While the yeast may be identified with hematoxylin and eosin staining alone, visualization is enhanced through PAS stain. Microscopic examination reveals clusters of oval budding yeast cells 3.5 × 4.5 µm long with short, septate, and occasionally branching hyphae (Fig. 189-12) inhabiting the stratum corneum.

DIAGNOSIS. The clinical appearance of tinea versicolor is usually characteristic, and KOH examination is confirmatory. A Wood's lamp examination may show orange–yellowish fluorescence of involved skin, suspected to be a due to pteridine. In some cases, however, the eruption may appear darker, rather than more fluorescent, than unaffected skin under the Wood's light.

Treatment

Tinea Versicolor. Several topical agents are useful in treating tinea versicolor, and these include selenium sulfide, zinc pyrithione, sodium sulfacetamide,[68] ciclopiroxolamine,[69] as well as azole[70] and allylamine antifungal preparations.

A widely used and inexpensive protocol involves using selenium sulfide lotion 2.5%, which is applied liberally to affected areas for 7–10 minutes prior to rinsing. While daily use may be considered for extensive cases, application 3–4 times per week is adequate, and this frequency may be tapered further to once or twice monthly and used as a maintenance regimen to prevent recurrences. Alternatively, ketoconazole shampoo 2% is lathered on to affected areas and left for 5 minutes prior to rinsing; this treatment is repeated for three consecutive days.[71] Terbinafine solution 1% applied twice daily to affected areas for 7 days has yielded cure rates of more than 80%.[72]

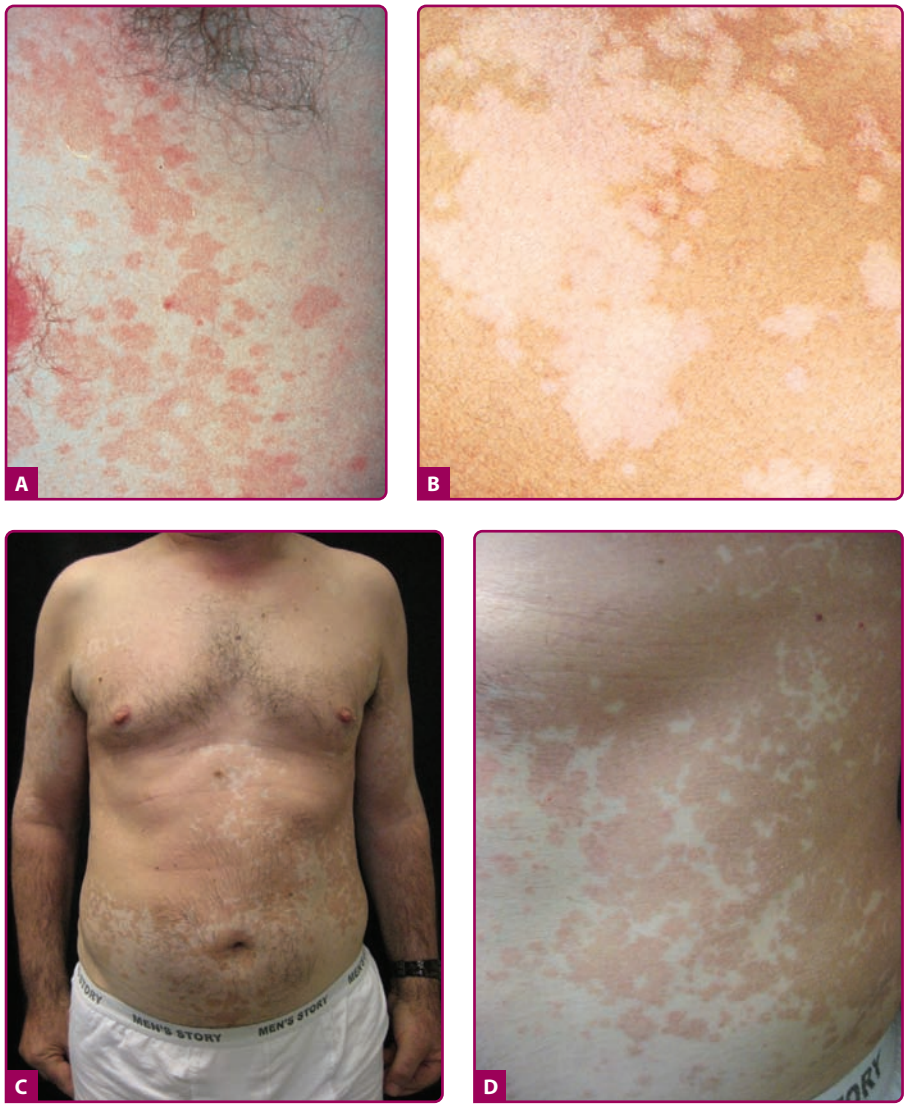

Figure 189-10 Pityriasis (tinea) versicolor. **A.** These lesions are darker because of hyperemia secondary to inflammatory response and increased melanin. **B.** There are sharply marginated, uniformly hypopigmented macules with fine, sometimes barely perceptible scales, which are easily scraped off with a glass slide. When the lesions are very large, as on the left, they can be confused with vitiligo. **C.** Salmon-colored finely scaled macules coalescing into large patches. **D.** Fine, dust-like scale seen on closeup.



Figure 189-11 Pityriasis (tinea) versicolor. Macules and patches may have a wrinkled surface appearance.

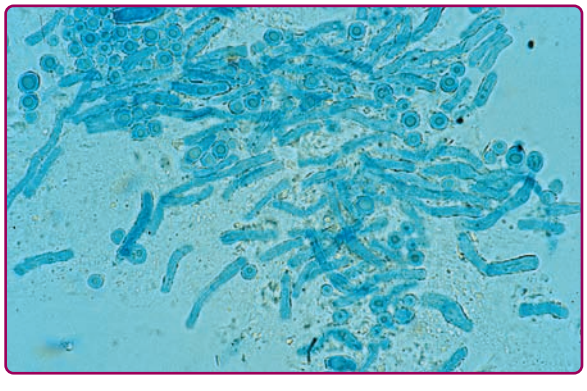

Figure 189-12 "Spaghetti and meatballs" appearance of *Malassezia* in a KOH preparation.

Although topical therapy is ideal for localized or mild infections, systemic treatment may be necessary for patients with extensive disease, frequent recurrences, or for whom topical agents have failed.[73] Ketoconazole, fluconazole, and itraconazole are the preferred oral agents, and various dosing regimens are effective.[74] Oral ketoconazole 200 mg daily for 7 or 10 days, or oral itraconazole 200–400 mg daily for 3–7 days is almost universally effective.[75–76] Oral ketoconazole administered as a single 400 mg dose is an easy to use regimen with comparable results.[75] Similarly, a single dose of oral itraconazole 400 mg has been shown to be more than 75% effective, and in one study, just as effective as itraconazole given for 1 week.[77] Fluconazole is also effective when administered as a single oral dose of 400 mg.[78] Oral terbinafine, an allylamine, is not recommended in the treatment of *Malassezia* related disorders, since the drug is not delivered efficiently to the skin's surface. The potential for drug toxicity and interactions via the influence of azoles on cytochrome p450 isoenzyme activity should be addressed when considering the use of oral azole agents to treat tinea versicolor.[79]

Prevention. Recurrence is common and regular maintenance application of any of the topical agents helps to reduce high rates of recurrence. While the condition does not leave any permanent scar or pigmentary changes, skin tone may take several months to return to normal. Prevention of recurrences is helpful in limiting long-lasting dyschromia. A regimen of one tablet a month of ketoconazole, fluconazole, and itraconazole has been used successfully to prevent recurrences.[80]

PITYROSPORUM (*MALASSEZIA*) FOLLICULITIS

EPIDEMIOLOGY. *Malassezia* organisms are observed as skin flora in 75%–98% of healthy people. Colonization by *M. furfur* begins soon after birth and peaks during adolescence and young adulthood, concomitant with an increase in sebaceous gland activity. No known racial or gender differences exist. Those living in warm and humid climates have higher incidences of *Malassezia* folliculitis.[81]

Etiology and Pathogenesis. *Malassezia* yeasts are classified as superficial mycoses that by definition do not invade past the cornified epithelium. However, in *Pityrosporum* folliculitis, follicular ostia, and central and deep segments of the hair follicle are involved by *Malassezia*, most commonly *M furfur*.[82]

Clinical Features. The chronic pruritic eruption of *Malassezia (Pityrosporum)* folliculitis appears as numerous monomorphic 2–4 mm follicular papules and papulopustules with perifollicular erythema on the upper trunk, neck, and upper arms of young and middle-aged adults (Fig. 189-13A). Some may have concomitant seborrheic dermatitis or tinea versicolor, and there have also been cases of associated recalcitrant acne vulgaris.[83] KOH examination or culture may be required to distinguish this infection from the more common bacterial folliculitis. On occasion, histologic evaluation via skin biopsy may be necessary for diagnosis. Routine staining with hematoxylin and eosin may identify organisms, although *Malassezia* may be more easily visualized through PAS stain (Fig. 189-13B). Systemic diseases and pharmacologic agents that hasten growth of yeast, possibly through alterations in host immunity, facilitate infections of hair follicles. Some of these risk factors include pregnancy, diabetes mellitus, Hodgkin disease,[84] cancer treated with epidermal growth factor receptor inhibitors,[85] HIV infection, and therapy with oral antibiotics, corticosteroids and/or immunosuppressants. Other contributing factors include high heat and humidity and occlusion of the skin and hair follicles with cosmetics, lotions, sunscreens, emollients, olive oil, or clothing.[86] As in the case of pityriasis versicolor, recurrence of *Malassezia* folliculitis is common. See Box 189-6 for the differential diagnosis of *Malassezia* folliculitis.

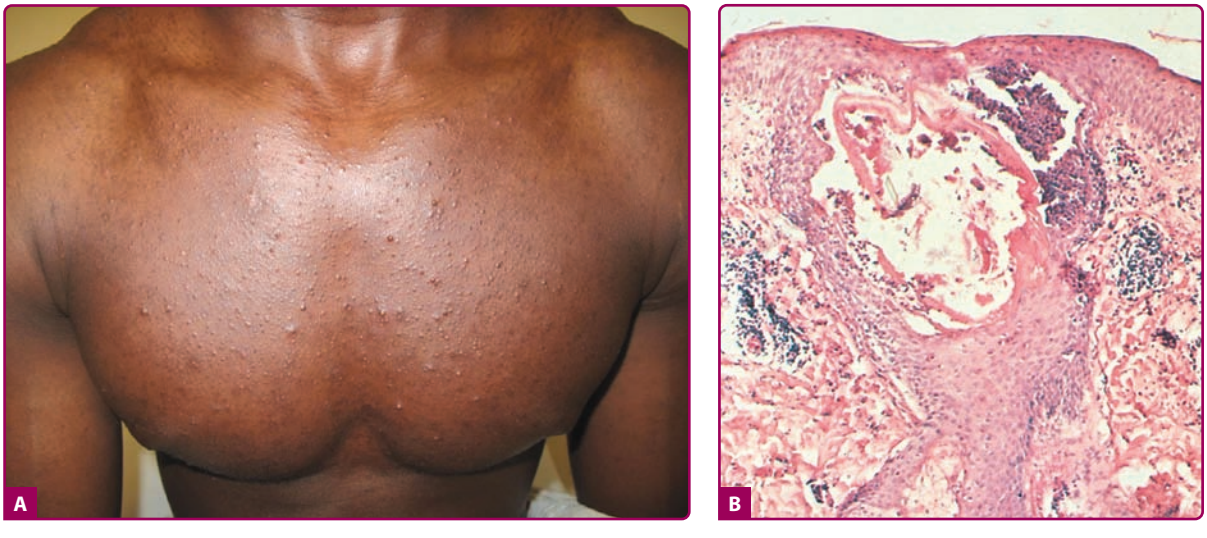

Figure 189-13 **A.** *Pityrosporum* folliculitis on the anterior chest. **B.** Histopathology. Note the organisms in the follicular ostia on staining with hematoxylin and eosin.

BOX 189-6 DIFFERENTIAL DIAGNOSIS OF *PITYROSPORUM* FOLLICULITIS

Most Likely
- Acne vulgaris
- Bacterial folliculitis

Consider
- Candidal folliculitis
- Eosinophilic folliculitis
- Steroid folliculitis

Always Rule Out
- Disseminated candidiasis
- Pustular drug eruption

Laboratory Findings. To identify the *Malassezia* yeast forms, scale from involved skin should be scraped with a #15 scalpel blade onto a glass slide and treated with 10% KOH. Alternatively, cellophane tape used to pick up scales from the skin may be mounted on a glass slide with methylene blue that selectively stains the organisms.[87] The microscopic appearance of the yeast is classically described as "spaghetti and meatballs" (Fig. 189-12), with fungal spores and short cigar-butt pseudohyphae.

Pathology. *Malassezia* organisms are noted in dilated follicular units, which may show keratin plugging and cellular debris (Fig. 189-10B). Staining with PAS or methenamine silver will reveal the oval single-budding yeast. When follicular walls rupture, there is a resulting mixed inflammatory infiltrate of lymphocytes, histiocytes, and neutrophils surrounding follicles. Microscopic examination of pustules usually shows budding yeast forms and spores, not hyphae.

Diagnosis. Diagnosis of *Malassezia* folliculitis is made on clinical grounds, and confirmed by KOH examination of scrapings. Skin biopsy is rarely necessary to make the diagnosis.

Treatment and Prognosis

***Malassezia* Folliculitis.** Both topical and oral antifungal agents are effective agents in the treatment of *Malassezia* folliculitis and are commonly combined to hasten resolution and maintain clearance. Topical regimens include daily use of ketoconazole shampoo 2%, selenium sulfide lotion 2.5%, and ciclopirox olamine cream 0.77%. There are limited data on the use of systemic agents in treating *Malassezia* folliculitis. Commonly used regimens include oral ketoconazole 200 mg daily for 4 weeks, fluconazole 150 mg weekly for 2–4 weeks, and itraconazole 200 mg daily for 2 weeks.[49,87] Oral terbinafine is not recommended in the treatment of *Malassezia* related disorders, since the drug is not delivered efficiently to the skin's surface.

PREVENTION

Recurrence is common. Because relapses almost always occur after treatment is complete, topical agents are continued indefinitely at reduced frequency as a preventative measure. Topical protocols used in the prevention of *Malassezia* folliculitis include selenium sulfide 2.5% lotion once weekly, ketoconazole 2% cream once weekly, and ketoconazole 2% shampoo 2–3 times weekly. Maintenance therapies with systemic agents include oral itraconazole 400 mg once monthly and oral fluconazole 200 mg once monthly.

KEY REFERENCES

Full reference list available at www.DIGM8.com

DVD contains references and additional content

1. Segal E: Candida, still number one–what do we know and where are we going from there? *Mycoses* **48**(Suppl 1):3-11, 2005
7. Pfaller MA, Diekema DJ: Epidemiology of invasive candidiasis: A persistent public health problem. *Clin Microbiol Rev* **20**(1):133-163, 2007
17. McCullough MJ, Savage NW: Oral candidosis and the therapeutic use of antifungal agents in dentistry. *Aust Dent J* **50**(4 Suppl 2):S36-S39, 2005
25. Sobel JD: Vulvovaginal candidosis. *Lancet* **369**(9577):1961-1971, 2007
40. Pappas PG et al: Clinical practice guidelines for the management of candidiasis: 2009 update by the Infectious Diseases Society of America. *Clin Infect Dis* **48**(5):503-535, 2009
49. Gupta AK et al: Skin diseases associated with Malassezia species. *J Am Acad Dermatol* **51**(5):785-798, 2004
50. Batra R et al: Malassezia Baillon, emerging clinical yeasts. *FEMS Yeast Res* **5**(12):1101-1113, 2005
64. Mendez-Tovar LJ: Pathogenesis of dermatophytosis and tinea versicolor. *Clin Dermatol* **28**(2):185-189, 2010
65. Crespo-Erchiga V, Florencio VD: Malassezia yeasts and pityriasis versicolor. *Curr Opin Infect Dis* **19**(2):139-147, 2006
82. Akaza N et al: Malassezia folliculitis is caused by cutaneous resident Malassezia species. *Med Mycol* **47**(6):618-624, 2009

Chapter 190 :: Deep Fungal Infections

:: Roderick J. Hay

Deep fungal infections comprise two distinct groups of conditions, the subcutaneous and systemic mycoses. Neither are common, and the subcutaneous mycoses, with some exceptions, are largely confined to the tropics and subtropics. In recent years, the systemic mycoses have become important opportunistic infectious complications in immunocompromised patients, including those with acquired immunodeficiency syndrome (AIDS) and patients receiving treatment for malignancies. They also include a group of primary respiratory infections, such as histoplasmosis and coccidioidomycosis, which may affect otherwise healthy individuals and those with underlying illness. The fungi that cause these respiratory infections are usually dimorphic or exist in a different morphologic phase (e.g., yeast or mold) at different stages of their life cycle.

Patients with subcutaneous fungal infections often present to a physician with signs of skin involvement. By contrast, patients with systemic mycoses only occasionally have skin lesions, either following direct involvement of the skin as a portal of entry or after dissemination from a deep focus of infection. There are a number of excellent texts about fungi and the diseases they cause.[1–4]

Treatment of these conditions remains difficult in many cases, although there is now a wide range of antifungal drugs with different modes of action.

SUBCUTANEOUS MYCOSES

SUBCUTANEOUS MYCOSES AT A GLANCE

- Are usually sporadic.
- Are contracted in the tropics and subtropics.
- May cause chronic disability.
- Are best diagnosed by histopathology, except for sporotrichosis.
- Often require months of successful antifungal treatment.

The subcutaneous mycoses, or mycoses of implantation, are infections caused by fungi that have been introduced directly into the dermis or subcutaneous tissue through a penetrating injury, such as a thorn prick. Although many are tropical infections, others, such as sporotrichosis, are also prevalent in temperate climates; any of these infections may present as an imported disease in a patient who has originated from an endemic area, sometimes after a lapse of many years. The most common subcutaneous mycoses are sporotrichosis, mycetoma, and chromoblastomycosis. Rarer infections include lobomycosis and subcutaneous zygomycosis.

SPOROTRICHOSIS

Sporotrichosis is a subcutaneous or systemic fungal infection caused by the dimorphic fungus *Sporothrix schenckii*.[5,6] The fungus occurs in the natural environment, presumably in mold (cells growing in a chain) form, but develops as a yeast (cells growing as single cells) in infections. The most frequent site of this infection is the dermis or subcutis. There is also a systemic form of sporotrichosis whose clinical features range from pulmonary infection to arthritis or meningitis. One important characteristic of the diagnosis of cutaneous lesions is the scarcity of organisms in tissue, making confirmation of the diagnosis by microscopy potentially difficult.[6] Sometimes in tissue, fungal cells are surrounded by an eosinophilic refractile fringe, the asteroid body, that is a characteristic of the organism, although a similar phenomenon may occur with other infectious organisms (e.g., Schistosome eggs).

EPIDEMIOLOGY. Infections occur in both temperate and tropical countries. They are seen in North, South, and Central America, including the Southern United States and Mexico, as well as in Africa, Egypt, Japan, and Australia.[6] The countries where the highest rates of infection occur are Mexico, Brazil, and South Africa. However, sometimes hyperendemic areas are found where large numbers of cases occur.[7] In the United States, infections are most common in the Midwestern river valleys. Infections are now rare in much of Europe. In nature, the fungus grows on decaying vegetable matter such as plant debris, leaves, and wood. Although it is usually a cause of sporadic infection, *S. schenckii* also may affect groups of workers exposed to the organism, such as those using straw as a packing material, gardeners, forestry workers, and those whose recreational activities bring them into contact with plant debris. A recent outbreak of sporotrichosis in Brazil has accentuated the role of exposure to other courses of infection, in this case domestic or feral cats. The organism is thought to be introduced into the skin through a local injury.

CLINICAL FINDINGS. The two clinical varieties of sporotrichosis are the subcutaneous and systemic forms of disease.[5,8,9] Subcutaneous sporotrichosis is by far the more common and includes two main forms: (1) lymphangitic and (2) fixed infections. The lymphangitic form is the more common and usually develops on exposed skin sites such as hands or feet. The first



Figure 190-1 Sporotrichosis. An ulcerated nodule is seen on the thumb, with proximal lymphangitic spread represented by subcutaneous nodules. (Used with permission from Takeji Nishikawa, MD.)

sign of infection is the appearance of a dermal nodule that breaks down into a small ulcer. Draining lymphatics become inflamed and swollen, and a chain of soft secondary nodules develops along the course of the lymphatic (Fig. 190-1); these also may break down and ulcerate. In the fixed variety, which accounts for about 15% of cases, the infection remains localized to one site, such as the face, and a granuloma develops that subsequently may ulcerate. Satellite nodules or ulcers may form around the rim of the primary lesion. Other clinical variants of subcutaneous sporotrichosis may mimic mycetoma, lupus vulgaris, and chronic venous ulceration. In some cases, deep extension of the infection may affect joints or tendon sheaths. Patients with AIDS who develop sporotrichosis often have multiple cutaneous lesions[9] without prominent lymphatic involvement, but deep infections, such as arthritis, are also reported.

In the much rarer systemic form of sporotrichosis, lesions can develop almost anywhere, although chronic lung nodules, with cavitation, arthritis, and meningitis have been described most frequently. These may coexist with cutaneous lesions of sporotrichosis.

DIFFERENTIAL DIAGNOSIS. Conditions commonly confused with sporotrichosis are mycobacterial (see Chapter 184) and primary cutaneous *Nocardia* infections (see Chapter 185) and leishmaniasis (see Chapter 206). The nontuberculous mycobacterial infection due to *Mycobacterium marinum* (fish-tank granuloma), in particular, closely resembles lymphangitic sporotrichosis.

LABORATORY TESTS. The best sources of diagnostic material are smears, exudates, and biopsies. *S. schenckii* is seen very rarely in direct microscopic examination because yeasts are usually present only in small numbers; the organism can be isolated readily on Sabouraud's agar. In primary culture, the fungus grows as a mold, with compact, white colonies that darken with age. Microscopically, the hyphae produce small oval or triangular conidia either on specialized hyphae or elsewhere on the mycelium. Ideally, the organism should be converted to yeast phase on enriched media such as brain-heart infusion agar at 37°C (98.6°F) to complete the identification.

Pathologically, sporotrichosis causes a mixed granulomatous reaction with neutrophil microabscesses. The fungus, if present, is usually in the form of small (3–5 μm) cigar-shaped or oval yeasts that may, on occasion, be surrounded by a thick, radiating eosinophilic fringe forming the distinctive asteroid body. Organisms are usually sparsely distributed in lesions, and it may be necessary to scan several sections to identify a single yeast. An intradermal sporotrichin skin test is available in some countries and may have a role to play in allowing the physician to identify the most appropriate laboratory investigations to instigate.

TREATMENT. Although spontaneous remissions may occur, most patients are treated with antifungal chemotherapy.[10] Treatments include itraconazole, 200 mg daily, and terbinafine, 250 mg daily, which are better tolerated, and intravenous amphotericin B for deep infection; at present there has been little experience with voriconazole or posaconazole. In all cases, treatment is continued for at least 1 week after clinical resolution. A cheaper alternative is potassium iodide (saturated solution), 4–6 mL tid, which is effective in the cutaneous types of sporotrichosis and should be continued for 3–4 weeks after clinical cure. The daily dose is built up slowly from 1 mL tid over 2–3 weeks to avoid side effects such as hypersalivation and nausea. This is an inexpensive form of therapy, but it is unpalatable.

MYCETOMA (MADUROMYCOSIS, MADURA FOOT)

Mycetoma is a chronic localized infection caused by different species of fungi or actinomycetes. It is characterized by the formation of aggregates of the causative organisms, known as *grains* that are found within abscesses. These either drain via sinuses onto the skin surface or involve adjacent bone, causing a form of osteomyelitis. Grains are discharged onto the skin surface via these sinuses. The disease advances by direct spread, and distant metastatic sites of infection are very rare. Mycetomas caused by species of fungi are known as *eumycetomas*, and those caused by aerobic actinomycetes or filamentous bacteria are known as *actinomycetomas* (see Chapter 185). The organisms are usually soil or plant saprophytes[11] that are only incidental human pathogens.

EPIDEMIOLOGY. Mycetomas are mainly, but not exclusively, found in the dry tropics where there is low annual rainfall.[11,12] They are sporadic infections that are seldom common, even in endemic areas.[13] Occasionally, nonimported cases are reported from temperate climates, although in these cases, the most common organism is *Scedosporium apiospermum*. Actinomycetomas due to *Nocardia* sp. are most common in Central America and Mexico. In other

parts of the world, the most common organism is a fungus, *Madurella mycetomatis*. The actinomycete *Streptomyces somaliensis* is isolated most often from patients originating from Sudan and the Middle East. The causative organisms of mycetoma have been isolated or detected by molecular methods from either soil or plant material, including Acacia thorns, in endemic areas.

The organisms are implanted subcutaneously, usually after a penetrating injury. It is unusual to find any underlying predisposition in patients with mycetoma, and the persistence of the organism after the initial inoculation appears to be related to its ability to evade host defenses through a variety of adaptations such as cell wall thickening and melanin deposition.[14]

CLINICAL FINDINGS. The clinical features of both fungal and actinomycete mycetomas are very similar.[12] They are most common on the foot, lower leg, or hand, although head or back involvement also may occur. Infection of the chest wall is most characteristic of *Nocardia* infections (see Chapter 185). The earliest stage of infection is a firm, painless nodule that spreads slowly with the development of papules and draining sinus tracts over the surface (Fig. 190-2). Local tissue swelling, chronic sinus formation, and later bone involvement distort and deform the original site of infection (Figs. 190-3 and 190-4). Lesions are seldom painful except in the late stages and where sinus tracts are about to emerge onto the skin surface. Dissemination from the initial site is exceptionally rare, although local lymphadenopathy may occur.

X-ray changes include periosteal erosion and proliferation, as well as the development of lytic lesions in the bone. Bone scans or magnetic resonance imaging may identify bone lesions at an earlier stage.



Figure 190-2 Mycetoma. Brawny edema and crusted papules on the plantar surface.



Figure 190-3 Eumycetoma caused by *Scedosporium* leading to significant distortion of the forefoot.

DIFFERENTIAL DIAGNOSIS. Chronic bacterial or tuberculous osteomyelitis may resemble mycetoma. Actinomycosis (see Chapter 185) is also similar but usually develops close to certain sites, such as the mouth or the cecum, where the causative organisms are sometimes commensal.

LABORATORY TESTS. Finding the mycetoma grains is the key to establishing the diagnosis, and these are generally discharged from the openings of sinus tracts. However, they may also be obtained by removing the surface crust from a pustule or sinus tract with a sterile needle and gently squeezing the edges. Grains are 250–1,000-µm white, black, or red particles that can be picked out with the naked eye (Table 190-1). Direct microscopy of grains is important because it will show whether the grain is composed of the small actinomycete or broader fungal filaments. In general, it is not possible to distinguish the fine actinomycete filaments in potassium hydroxide (KOH) mounts or, for that matter, in hematoxylin and eosin-stained material. In addition, black grains are always caused by fungi; red grains, by actinomycetes (see Table 190-1).

Final identification requires isolation of the causal agent in culture. In view of the number of possible species, a series of different culture media and conditions of incubation should be used. Morphologic and physiologic characteristics are used to distinguish between the genera and species. There are now a few examples where the organism has been identified using specific primers through use of the polymerase chain reaction. Serology is diagnostically helpful only in some cases (e.g., in *S. somaliensis)*, and even then, more as a guide to therapeutic response. In a few centers, molecular tools are used to identify organisms.



Figure 190-4 Mycetoma. Chronic fibrotic involvement of the foot with lymphatic spread to the popliteal fossa.

TABLE 190-1
Macroscopic and Histopathologic Features of Mycetoma Grains[a]

Organisms	Hematoxylin and Eosin Section Appearances
Eumycetoma	
Dark grains	
Madurella mycetomatis	Cement present, vesicles sometimes prominent
M. grisea	Cement absent, compact outer layer
Leptosphaeria senegalensis	Cement in outer zone, dark periphery with vesicular center
Exophiala jeanselmei	Cement absent, often hollow
Pyrenochaeta romeroi	Cement lacking, compact outer layer
Pale grains	
Fusarium sp., *Acremonium*, *Scedosporium apiospermum*, *Aspergillus nidulans*, *Neotestudina rosati*	Compact, pigment lacking, interwoven fungal filaments (*Scedosporium apiospermum* may have prominent vesicles)
Actinomycetoma	
Pale (white to yellow) grains	
Actinomadura madura	Basophilic-stained fringe in layers
Nocardia brasiliensis	Small, pale blue, eosinophilic fringe
Yellow to brown grains	
Streptomyces somaliensis	Grains fractured, basophilic, or pink
Red to pink grains	
A. pelletieri	Small, basophilic layers

[a]Helpful rules of thumb:
Black or dark grains are always produced by fungi.
Red grains are always produced actinomycetes.
But pale (white) grains may be produced by either fungi or actinomycetes.

Histologically, there is a chronic inflammatory reaction with neutrophil abscesses and scattered giant cells and fibrosis.[11] Grains are found in the center of the inflammation. Their size and shape may help in the identification, although with nonpigmented (pale or white grain) eumycetomas, this is seldom sufficient (Fig. 190-5).

TREATMENT. Of the fungal causes of mycetoma, some cases of *M. mycetomatis* infection respond to ketoconazole, 200 mg, itraconazole 200 mg or voriconazole 200–400 mg daily over several months. For the others, a trial of therapy with griseofulvin, or terbinafine, is worth attempting. However, responses to chemotherapy are unpredictable, although antifungals may slow the course of infection. Surgery, usually amputation, is the definitive procedure and may have to be used in advanced cases. However, the value of major surgery in a disfiguring but nonlife-threatening infection has to be weighed against the availability of appropriate prosthetic limbs.

Actinomycetomas (see Chapter 185) generally respond to antibiotics such as a combination of dapsone with streptomycin or sulfamethoxazole-trimethoprim plus rifampin or streptomycin. Amikacin or imipenem also may be used in recalcitrant *Nocardia* infections. The responses in all but a few cases are good.[15]

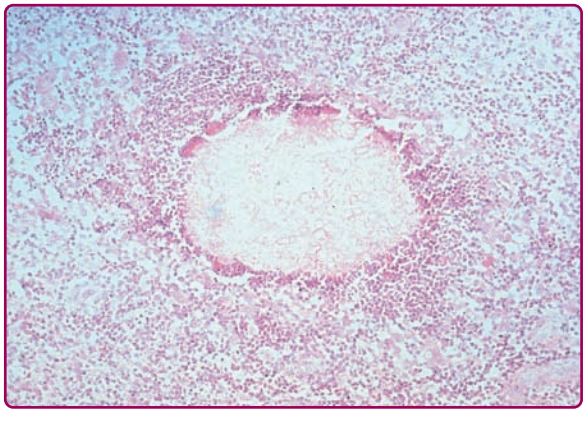

Figure 190-5 Pale eumycetoma grain (hematoxylin and eosin stain).

CHROMOBLASTOMYCOSIS (CHROMOMYCOSIS)

Chromoblastomycosis is a chronic fungal infection of the skin and subcutaneous tissues caused by pigmented (dematiaceous) fungi that are implanted into the dermis from the environment. In the ensuing inflammation, they form thick-walled single cells or cell clusters (sclerotic or muriform bodies), and these may elicit a marked form of pseudoepitheliomatous hyperplasia often accompanied by transepidermal elimination of organisms. The infection can be caused by a number of different pigmented fungi, the most common being *Phialophora verrucosa*, *Fonsecaea pedrosoi*, *Fonsecaea compactum*, *Wangiella dermatitidis*, and *Cladophialophora carrionii*.[16]

EPIDEMIOLOGY. The fungi that cause chromoblastomycosis can be isolated in the environment from wood, plant debris, or soil.[17] The vast majority



Figure 190-6 Chromoblastomycosis. A solitary, large, verrucous plaque surrounded by a halo of erythema is seen on the calf. (Used with permission from Ted Rosen, MD, and Howard Rubin, MD.)

of infections are caused by *F. pedrosoi* and *C. carrionii*. As with other subcutaneous mycoses, infection follows implantation through a tissue injury. The infection is found as a sporadic condition in Central and South America, although rarely in North America. It occurs in the Caribbean region, Africa (particularly Madagascar), Australia, and Japan. It also may occur as an imported infection outside the usual endemic areas. The disease is most frequent in male rural workers.

CLINICAL FINDINGS. The initial site of the infection is usually on the feet, legs, arms, or upper trunk. The clinical features vary.[17] The initial lesion is often a warty papule that expands slowly over months or years (Figs. 190-6 and 190-7). Alternatively, lesions may be plaque-like with an atrophic center. The more common verrucous form spreads slowly and locally. Individual lesions may be very thick and often develop secondary bacterial infection. Satellite lesions around the initial site of infection are local extensions of the infection and usually are produced by scratching. Complications of chromoblastomycosis include local lymphedema, leading to elephantiasis and squamous carcinomas in some chronic lesions.



Figure 190-7 Closeup view of chromoblastomycosis. Note hyperkeratosis with pigmentation.

DIFFERENTIAL DIAGNOSIS. The disease must be differentiated from podoconiosis or chronic tropical lymphedema with hyperplasia (mossy foot) which is due to a reaction to soil microparticles. Other chronic verrucous lesions, such as tuberculosis and blastomycosis, are often more extensive. The identification of organisms in the lesions of chromoblastomycosis is essential.

LABORATORY TESTS. The typical sclerotic or muriform fungal cells can be seen in skin scrapings taken from the surface of lesions, particularly areas where there is a small dark spot on the skin surface, using KOH mounts. The lesions also should be biopsied because the pathologic changes and presence of muriform cells are typical. The histology shows a mixed granulomatous response, with small neutrophil abscesses and often exuberant epidermal hyperplasia.[18] The organisms, which are often seen either in giant cells or in neutrophil abscesses, appear singly or in small groups of brown pigmented cells, often with a single or double septum and thick cell wall.

In culture, these fungi are very similar in gross macroscopic appearance, producing black colonies with a downy surface. Their cultural identification depends on demonstrating the presence of different but specific types of sporulation, and either single or multiple sporulation mechanisms may be seen in each organism. Accurate differentiation between the different fungi may be difficult. At this stage, the choice of treatment does not depend critically on correct identification of the organisms, although there may be differences in the speed of response to azole drugs (see Section "Treatment").

TREATMENT. The main treatments for chromoblastomycosis are itraconazole, 200 mg daily;[19] terbinafine, 250 mg daily;[20] and, in extensive cases, intravenous amphotericin B (up to 1 mg/kg daily). Lesions can be spread by surgery, which should be used only as an adjunctive therapy after drug treatment. The local application of heat may be helpful in some instances. The responses of these fungi to different antifungal agents do not appear to differ significantly, although there is some evidence that *C. carrionii* responds more rapidly to terbinafine and itraconazole. In any event, treatment is continued until there is clinical resolution of lesions, which usually takes several months. Extensive lesions often respond poorly to conventional treatment and combinations of antifungal drugs have been used, for example, amphotericin B and flucytosine or itraconazole and terbinafine.

PHAEOHYPHOMYCOSIS (PHAEOMYCOTIC CYST, CYSTIC CHROMOMYCOSIS)

Phaeohyphomycosis is a rare infection characterized by the formation of subcutaneous inflammatory cysts or plaques. It is caused by dematiaceous fungi, the most common of which are *Exophiala jeanselmei* and *W. dermatitidis*, but some 103 species have been described as causal agents.[21] However, unlike in chromoblastomycosis, these organisms form short, irregular, pigmented hyphae in tissue. The infection may occur in any climatic area, although it is more common in the tropics. It also may appear in immunosuppressed patients, particularly those receiving long-term glucocorticoid therapy. The lesions present as cysts and may be mistaken for other similar structures such as synovial or Baker's cysts. The diagnosis is usually made after surgical excision. Histologically, the cyst wall consists of palisades of macrophages and other inflammatory cells surrounded by a fibrous capsule, and the fungal hyphae are found in the macrophage zone. Although the fungi in tissue lesions are usually pigmented, this is not always the case; cystic lesions caused by nonpigmented fungi being called hyalohyphomycotic cysts. The treatment is surgical excision, although relapse can occur, particularly in immunocompromised patients.

LOBOMYCOSIS (KELOIDAL BLASTOMYCOSIS, LOBO DISEASE)

Lobomycosis is an uncommon infection seen in Central and South America, often in remote rural areas. The source of the organism is unknown, although similar lesions have been found on freshwater dolphins. Lobomycosis is characterized by the appearance of keloid-like skin lesions on exposed sites.[22] Although it cannot be cultured in vitro, it is caused by a fungus, *Lacazia loboi*, that forms chains of rounded cells in tissue, each joined by a small tubule. Lesions may occur anywhere on the body but usually are found on exposed parts such as the legs, arms, and face. They can spread from site to site by autoinoculation. Antifungal drugs are not effective, and surgical removal is the main treatment.

SUBCUTANEOUS MUCORMYCOSIS [BASIDIOBOLOMYCOSIS, SUBCUTANEOUS PHYCOMYCOSIS AND CONIDIOBOLOMYCOSIS, (RHINO)-ENTOMOPHTHOROMYCOSIS]

Subcutaneous mucormycosis is a rare tropical subcutaneous mycosis characterized by the development and spread of a chronic, firm swelling involving subcutaneous tissue. There are two main varieties caused by different organisms.[23] The first, most often caused by *Basidiobolus ranarum* (*B. haptosporus*), is more common in children. It occurs in a wide variety of countries and environments from South America to Africa and Indonesia. The organism can be found in plant debris and in the intestinal tracts of reptiles and amphibians. Lesions usually develop around limb girdle sites and present with a firm, slowly spreading, woody cellulitis. The second form, caused by *Conidiobolus coronatus*, is seen in adults. The organism can be isolated from soil, plant debris, and some insects. The early infection starts in the region of the inferior turbinates of the nose. Spread involves the central part of the face, and once again, the swelling is hard and painless. It may cause very severe deformity of the nose, lips, and cheeks. These infections are distinct to those caused by related fungi.

Histopathologically, a chronic granulomatous response with large numbers of eosinophils can be seen. The fungi are present as large, strap-like hyphae without cross walls or septa. They are also often surrounded by refractile eosinophilic material (Splendore–Hoeppli phenomenon). The organisms can be cultured readily on Sabouraud's agar. Ketoconazole (400 mg daily) and itraconazole (100–200 mg daily) also may be useful in this condition, although experience to date is limited to a few cases. Lesions also respond to oral treatment with potassium iodide, given in similar doses to those used in sporotrichosis (see Section "Treatment" under "Sporotrichosis").

RHINOSPORIDIOSIS

Rhinosporidiosis is a chronic infection caused by the organism *Rhinosporidium seeberi*, which causes the development of polyps affecting the mucous membranes. The organism has never been cultured, and it is now thought to be an aquatic protist and a member of the Mesomycetozoea. Rhinosporidiosis is seen most often in Southern India and Sri Lanka. Cases also have been described in South America, the Caribbean, and South Africa. Exposure to water (lakes, pools) has been associated with the infection. The main site affected is the nasal mucosa, but the conjunctival mucosa also may be affected.[24] The infection causes the development of polyps that are studded with white flecks; these are small cysts or sporangia containing small spores. These are best seen in histopathologic sections, where the large sporangia or spore sacs in different phases of development are readily seen. The only treatment is surgical excision.

SYSTEMIC MYCOSES

The systemic mycoses are fungal infections whose initial portal of entry into the body is usually a deep site such as the lung, gastrointestinal tract, or paranasal sinuses. They have the capacity to spread via the bloodstream to produce a generalized infection. In practice, there are two main varieties of systemic mycosis: (1) the opportunistic mycoses and (2) the endemic respiratory mycoses.

The chief opportunistic systemic mycoses seen in humans are systemic or deep candidiasis, aspergillosis, and systemic zygomycosis. These affect patients

ENDEMIC AND OPPORTUNISTIC SYSTEMIC MYCOSES AT A GLANCE

- Where the patient has lived or visited is important for diagnosis.
- History of underlying disease states and their treatment is critical.
- Erythema nodosum may be caused by some endemic mycoses (e.g., coccidioidomycosis).
- Skin biopsy is important in making the diagnosis.
- Positive fungal culture must be interpreted with caution, as the organism identified may simply be colonizing the site.
- Warn the laboratory if you are sending material from a suspected endemic mycosis case for culture, as these are dangerous pathogens and require containment facilities.
- Treatment usually requires prolonged therapy with intravenous drugs such as amphotericin B, voriconazole, or caspofungin.

with severe underlying disease states, such as AIDS, or with neutropenia associated with malignancy, solid-organ transplants, or extensive surgery. With the use of combination antiretroviral therapy, the incidence of systemic mycoses in patients infected with human immunodeficiency virus (HIV) has dropped considerably. In the neutropenic patient in particular, other fungi also may cause infection occasionally. Different underlying conditions predispose to different mycoses, and a scheme for this is shown in Table 190-2. Generally, skin involvement is not common with most of these opportunistic infections, which can occur in any climate and environment. The clinical manifestations of the opportunistic mycoses are also variable because they depend on the site of entry of organism and the underlying disease.

The endemic respiratory mycoses are histoplasmosis (classic and African types), blastomycosis, coccidioidomycosis, paracoccidioidomycosis, and infections due to *Penicillium marneffei*. The clinical manifestations of these infections are affected by the underlying state of the patient, and many develop in the presence of particular immunodeficiency states, notably AIDS. However, they follow similar clinical patterns in all infections. These infections also may affect otherwise healthy individuals. They have well-defined endemic areas determined by factors that favor the survival of the causative organisms in the environment, such as climate. The usual route of infection is via the lung (Fig. 190-8).

TABLE 190-2
Underlying Predisposition and Opportunistic Systemic Mycoses

Predisposition	Infection
Neutropenia (whatever cause) functional neutrophil defects	Aspergillosis, oropharyngeal, and/or systemic candidiasis, mucormycosis, infections due to rare organisms
CD4 lymphopenia (e.g., acquired immunodeficiency syndrome)	Oropharyngeal candidiasis, cryptococcosis, and endemic respiratory mycoses such as histoplasmosis, nocardiosis
Diabetes mellitus	Mucormycosis
Heart valve surgery	Various but mainly *Candida albicans* and non-*albicans Candida* sp.
Abdominal surgery	Candidiasis

In practice, because of the tendency for both groups of infections to develop in predisposed patients, the distinction between opportunistic and endemic mycoses is blurred. This is particularly the case with cryptococcosis, which shares clinical and pathologic features of the two main types of respiratory systemic mycoses but is mainly seen now in untreated AIDS patients.

HISTOPLASMOSIS

Fungi of the dimorphic genus *Histoplasma* cause a number of different infections in animals and humans. These range from equine farcy, or equine histoplasmosis, a disseminated infection of horses caused by *Histoplasma farciminosum* to two human infections known as (1) classic or small-form histoplasmosis and (2) African histoplasmosis. These are caused, respectively, by two variants of *Histoplasma capsulatum*: (1) *H. capsulatum* var. *capsulatum* and (2) *H. capsulatum* var. *duboisii*. They can be distinguished because their respective yeast phases differ in size, the *capsulatum* variety producing cells from 2 to 5 µm in diameter and the *duboisii* form producing cells of 10–15 µm in diameter. The other important differences are in their epidemiology and clinical manifestations. They also show minor antigenic differences that are apparent in serodiagnosis but their mycelial phases are identical. The two types of human infections will be referred to as histoplasmosis and African histoplasmosis because this nomenclature is used most widely.

SMALL-FORM OR CLASSIC HISTOPLASMOSIS OR HISTOPLASMOSIS CAPSULATI.

Histoplasmosis results from infection with the dimorphic fungus *H. capsulatum* var. *capsulatum*. A sexual state of this fungus, *Ajellomyces capsulatus*, also has been described. The infection starts as a pulmonary infection that, in most individuals, is asymptomatic

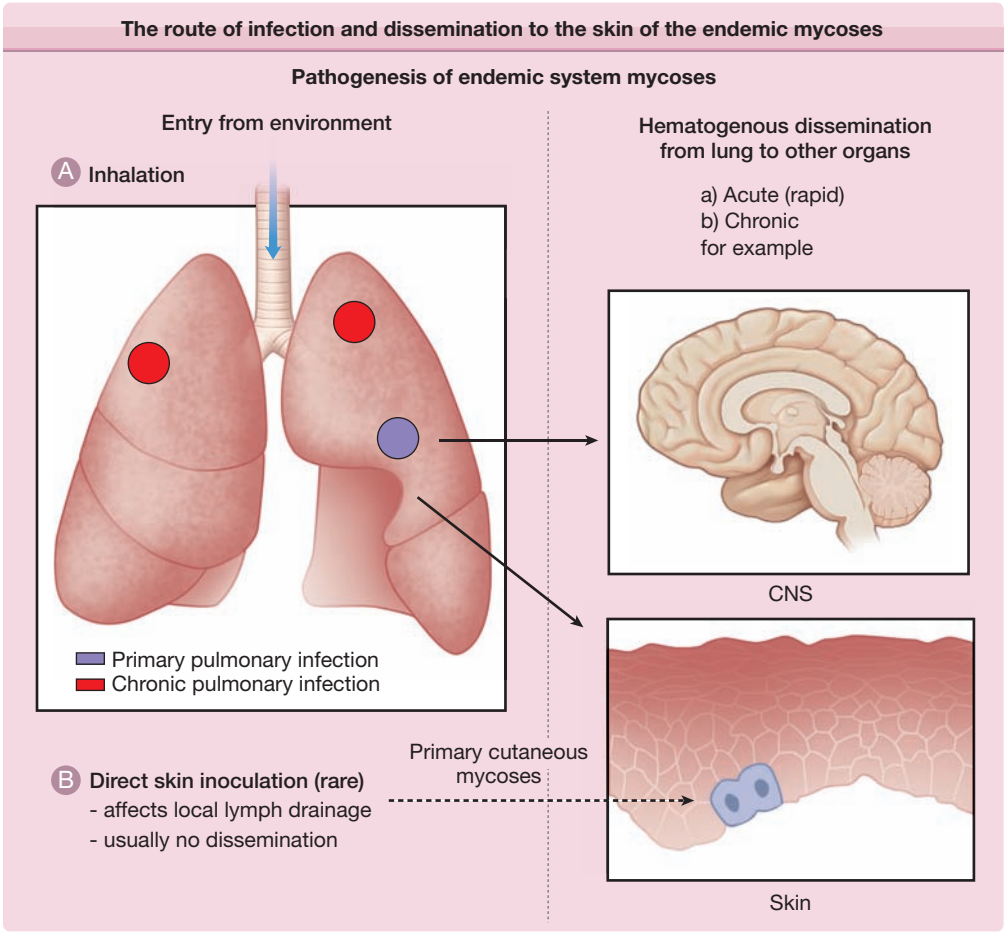

Figure 190-8 The route of infection and dissemination to the skin of the endemic (respiratory) mycoses. CNS = central nervous system.

and heals spontaneously, the only evidence of exposure being the development of a positive intradermal skin test reaction to a fungal antigenic extract, histoplasmin.[25] However, in addition, there is a symptomatic disease that includes respiratory infections and acute or chronic pulmonary histoplasmosis, as well as a disseminated infection that may spread to affect the skin or mucous membranes. Direct inoculation into the skin may occur as a result of a laboratory accident.

Epidemiology. Histoplasmosis occurs in many countries from the Americas to Africa, India, and the Far East. In the United States, it is endemic in the Mississippi and Ohio River valleys, where often more than 80% of the population may have acquired the infection asymptomatically. Exposure rates are usually lower in all other endemic areas, although high rates are also found in Northern South America and some Caribbean islands. Histoplasmosis is not found in Europe. *H. capsulatum* is an environmental organism that can be isolated from soil, particularly when it is contaminated with bird or bat excreta. The disease is acquired by inhalation of spores, and epidemics of respiratory infection may occur in persons exposed to a spore-laden environment when exploring caves or cleaning sites heavily contaminated with bird droppings, such as bird roosts or barns. Although any person can acquire histoplasmosis through inhalation, it causes a distinctive disseminated infection in patients with disease affecting cellular immune capacity, such as AIDS or lymphoma.[26,27]

Clinical Findings. The spectrum of histoplasmosis includes asymptomatic as well as benign symptomatic infections and a progressive disseminated variety with bloodstream spread to multiple organs.[25] Skin lesions may develop as a result of immune-complex formation in the primary infection (erythema multiforme) or from direct spread after dissemination from the lungs; rarely, infections may develop at a point of inoculation into the skin.

Asymptomatic forms of histoplasmosis are, by definition, without signs or symptoms, but those exposed usually have a positive histoplasmin skin test. The percentage of skin test reactors in the community indicates the chances of exposure, and, in endemic areas, this may range from 5% to 90%. Occasionally, asymptomatic pulmonary nodules removed at surgical exploration or autopsy are found to contain *Histoplasma*.

Acute Pulmonary Histoplasmosis. In acute pulmonary histoplasmosis, patients are often exposed to large quantities of spores such as may be encountered in a cave or after cleaning a bird-infested area. Patients present with cough, chest pain, and fever, often with accompanying joint pains and rash—toxic erythema, erythema multiforme, or erythema nodosum. These skin rashes are not common, occurring in fewer than 15% of patients, but they may be precipitated by treatment of the acute infection. On chest X-ray, there is often diffuse mottling, which may calcify with time.

Chronic Pulmonary Histoplasmosis. Chronic pulmonary histoplasmosis usually occurs in adults and presents with pulmonary consolidation and cavitation, closely resembling tuberculosis. Skin involvement is not seen.

Acute Progressive Disseminated Histoplasmosis. In patients with acute disseminated histoplasmosis, there is widespread dissemination to other organs such as the liver and spleen, lymphoreticular system, and bone marrow. Patients present with progressive weight loss and fever. This form is the type that is most likely to occur in untreated AIDS patients, who often develop skin lesions as a manifestation of disseminated infection (Fig. 190-9).[28] There are papules, small nodules, or small molluscum-like lesions that subsequently may develop into shallow ulcers. These skin lesions are more common in HIV positive patients than in others with disseminated histoplasmosis. Diffuse micronodular pulmonary infiltrates also may develop. Patients have progressive and severe weight loss, fever, anemia, and hepatosplenomegaly.

The distinction between acute and chronic dissemination in histoplasmosis is somewhat artificial because these merely represent extremes of behavior, with progression occurring over a few months, on the one hand, and over several years, on the other. Intermediate forms occur, and other organs such as the meninges and heart may be affected.



Figure 190-9 Histoplasmosis, disseminated. Multiple erythematous keratotic papules and small plaques resembling guttate pattern psoriasis are seen on the chest and arm of a man with advanced human immunodeficiency virus disease. (Used with permission from J. D. Fallon, MD.)

Chronic Progressive Disseminated Histoplasmosis. Chronic disseminated histoplasmosis may appear months or years after a patient has left an endemic area. The most common clinical presenting features are oral or pharyngeal ulceration, hepatosplenomegaly or adrenal insufficiency (Addison disease) due to adrenal infiltration. The mouth ulcers are often large, irregular, and persistent and may affect the tongue as well as the buccal mucosa. The patients otherwise may appear well, but it is important to investigate for evidence of infection elsewhere (e.g., by abdominal computed tomography scan). Adrenal infection in particular should be excluded.

Primary Cutaneous Histoplasmosis. Primary cutaneous histoplasmosis is rare and follows inoculation of the organism into the skin, for instance, after accidental laboratory- or postmortem room-acquired infection. The primary lesion is a nodule or indurated ulcer, and there is often local lymphadenopathy.

Differential Diagnosis.

The organism is the same size as a number of others causing deep mycoses such as *P. marneffei* and small forms of *Blastomyces* and *Cryptococcus* (see Section "Laboratory Tests"). It is also similar in size to *Leishmania* sp., and in the tropics, kala-azar is an important part of the differential diagnosis. These observations emphasize the importance of carrying out appropriate laboratory tests to confirm the diagnosis.

Laboratory Tests.

The diagnosis of histoplasmosis is established by identifying the small intracellular yeast-like cells of *Histoplasma* in sputum, peripheral blood, bone marrow, or biopsy specimens. *Histoplasma* must be separated from *P. marneffei* because the two organisms are of a similar size, although the latter shows characteristic septa formation. The identity of the organism should be confirmed by culture; it grows as a mold at room temperature. The white, cottony colonies develop at room temperature on Sabouraud's glucose agar to produce two types of spores, the larger (8–15 µm), rounded, tuberculate macroconidia being typical; the smaller microconidia are infectious. Confirmation of the identity should be obtained by demonstrating ribosomal RNA using a DNA probe. Mycelial-phase cultures of *H. capsulatum* are very infectious, and laboratories receiving specimens should be warned about the suspected diagnosis.

The intradermal histoplasmin skin test is an epidemiologic tool that is of no help in diagnosis. In patients with disseminated histoplasmosis, it is often negative. By contrast, serology is often useful in diagnosis. A rising complement-fixation titer indicates dissemination. Precipitins detected by immunodiffusion are also valuable because the presence of antibodies to specific H and M antigens correlates well with active or recent infection.[28] A new development, particularly helpful

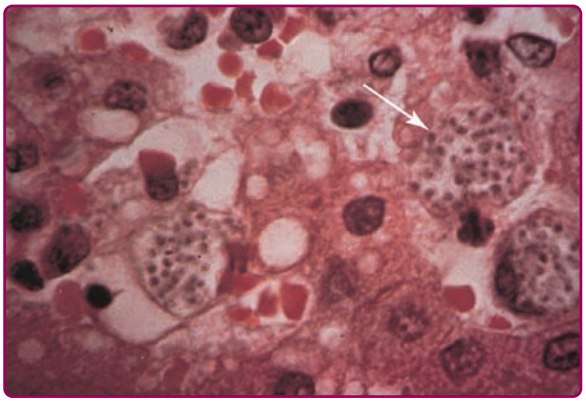

Figure 190-10 Histoplasmosis, disseminated. Lesional biopsy specimen shows dermal macrophages packed with dozens of tiny yeast forms of *Histoplasma capsulatum* (*arrow*).

in AIDS patients, has been serologic or urine tests for the detection of circulating *Histoplasma* antigens.[29] In histopathologic sections, *H. capsulatum* is an intracellular parasite often seen in macrophages. The cells are small (2–4 µm in diameter) and oval in shape with small buds (Fig. 190-10). Mycelial forms are seen rarely in tissue.

PCR based molecular diagnostic methods are available in some centers.

AFRICAN HISTOPLASMOSIS (LARGE-FORM HISTOPLASMOSIS OR HISTOPLASMOSIS DUBOISII). African histoplasmosis is sporadic and uncommon even in AIDS patients.[30] It is seen in patients from areas south of the Sahara and north of the Zambezi River in Africa. Infections seen outside Africa are all imported. The most common clinically involved sites are the skin and bone, although lymph nodes and other organs, including the lungs, may be affected. Skin lesions range from small papules resembling molluscum contagiosum to cold abscesses, draining sinuses, or ulcers. It is not clear if there is an asymptomatic form of African histoplasmosis as in classic histoplasmosis. The diagnosis is confirmed by culture and microscopy (direct microscopy or histopathology). The organisms of *H. capsulatum* var. *duboisii* are different from the smaller *capsulatum* forms. They are usually 10–15 µm in diameter, slightly pear-shaped, and clustered in giant cells. *Histoplasma* serology, using conventional tests, is often negative in African histoplasmosis.

Treatment. The choice of therapy for histoplasmosis depends on the severity of the illness. For patients with some disseminated or localized forms of the disease, oral itraconazole (200–400 mg daily) is highly effective. It also has been used for long-term suppressive treatment of the disease in AIDS patients after primary therapy either with itraconazole or amphotericin B.[31] However, there is now evidence that provided CD4 counts do not fall in patients on highly active antiretroviral therapy (HAART) therapy (see Chapter 198), suppressive treatment can be discontinued. In AIDS, some patients receiving treatment for histoplasmosis, an immune reconstitution syndrome has been reported after commencing HAART therapy with intestinal obstruction, uveitis, and arthralgia. Intravenous amphotericin B (up to 1 mg/kg daily) is given to patients with widespread and severe infections and is the main alternative used. Ketoconazole and fluconazole are effective in some cases. In African histoplasmosis, itraconazole is also the treatment of choice, but once again, in severe cases amphotericin B may be used.[30]

BLASTOMYCOSIS (NORTH AMERICAN BLASTOMYCOSIS)

Blastomycosis is a chronic mycosis caused by the dimorphic pathogen *Blastomyces dermatitidis*.[32] Its chief sites of involvement are the lungs, but disseminated forms of the infection may affect skin, bones, central nervous system, and other sites.

EPIDEMIOLOGY. Blastomycosis is found in North America and Canada.[33] Most cases, though, come from the Great Lakes region and southern states of the United States. It also occurs sporadically in Africa, with the largest numbers of cases coming from Zimbabwe,[34] and cases also have been reported from the Middle East and India.

It is thought that the natural habitat of *Blastomyces* is in some way related to wood debris and is close to rivers or lakes or in areas subjected to periodic flooding. However, it is difficult to isolate *Blastomyces* from the natural environment.[35] Blastomycosis also may affect domestic animals such as dogs.

CLINICAL FINDINGS. As with histoplasmosis, there is a subclinical form of the infection; its prevalence has not been defined in detail because of lack of a commercial *Blastomyces* skin test antigen and the extent of antigenic cross-reactivity with fungi such as *Histoplasma*. Primary cutaneous blastomycosis is also very rare and follows trauma to the skin and the subsequent introduction of fungus, for instance, in laboratory workers or pathologists.[36] After inoculation, an erythematous, indurated area with a chancre appears in 1–2 weeks with associated lymphangitis and lymphadenopathy.

Pulmonary blastomycosis is very similar in clinical presentation to pulmonary tuberculosis.[33,36,37] There may be no symptoms, or there may be low-grade fever, chest pain, cough, and hemoptysis, and unlike histoplasmosis, it often coexists with disseminated disease. Skin lesions are a common presenting feature of disseminated blastomycosis.[36,38] They are often symmetric and usually affect the face and extremities. The early lesion is a papule or nodule, which may ulcerate and discharge pus. With time, this enlarges to form a hyperkeratotic lesion, often with central ulceration and/or scarring (Figs. 190-11 and 190-12). Oral lesions are less common. Multiple skin lesions are often found in disseminated infection. Other patients may present with nodules and abscesses, and in many patients



Figure 190-11 Blastomycosis. Inflammatory plaque with ulceration resembling pyoderma gangrenosum on the calf. (Used with permission from Elizabeth M. Spiers, MD.)

lesions of different morphologies are present. African patients with blastomycosis have a higher frequency of skin and bone involvement.[34] Although blastomycosis can affect almost any organ, other common sites for dissemination include the bone, the epididymis, and the adrenal gland. Less commonly, there is widespread rapid dissemination with multiple organ involvement, and *B. dermatitidis* can produce a form of adult respiratory distress syndrome. Skin lesions in widespread disseminated disease are usually papules, abscesses, or small ulcers. Widespread blastomycosis has been described in AIDS patients, but it is not common.[39]



Figure 190-12 Blastomycosis. Chronic verrucous plaque on the cheek.



Figure 190-13 Direct preparation (potassium hydroxide) of *Blastomyces* (*arrows*).

DIFFERENTIAL DIAGNOSIS. The chronic skin granulomas must be differentiated from those due to tuberculosis, other deep mycoses, nonmelanoma skin cancers, pyoderma gangrenosum, and drug reactions due to bromides and iodides.

LABORATORY FINDINGS. The fungus can be found in KOH mounts of pus, skin scrapings, or sputum as thick-walled, rounded refractile spherical cells with broad-based buds (Fig. 190-13). In culture, the fungus grows as a mycelial fungus at room temperature. It produces small, rounded, or pear-shaped conidia. At higher temperature [37°C (98.6°F)] and on enriched media, it produces yeast forms with the characteristic buds. Molecular probes will confirm the identity. In tissue sections, the typical organisms with broad buds may be found although it may be necessary to search several fields to find the characteristic cells. These are often found in giant cells or surrounded by neutrophils (Fig. 190-14). Precipitating antibodies to *B. dermatitidis* are often present in the sera of infected patients, and a characteristic precipitin line, the E band, has been described in a high proportion of proven cases; there is also an enzyme-linked immunosorbent assay for blastomycosis. There is also an antigen detection system that is most accurate in urine samples.

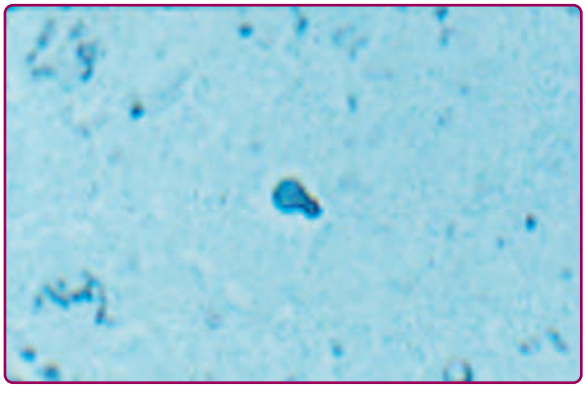

Figure 190-14 Blastomycosis. Lesional biopsy specimen shows a budding yeast form (Gomori methenamine silver stain).

TREATMENT. Treatment is similar to that used for histoplasmosis; itraconazole (200–400 mg daily) is used in the less severe forms of the infection or when there is only localized spread. Voriconazole is also active against this infection. Treatment is usually given for at least 6 months. Follow-up surveillance is necessary because relapse can occur, particularly where there are deep sites of infection or the patient is immunosuppressed. Amphotericin B (up to 1 mg/kg daily) is generally used for the treatment of widespread disseminated forms of blastomycosis.

COCCIDIOIDOMYCOSIS (COCCIDIOIDAL GRANULOMA, VALLEY FEVER, SAN JOAQUIN VALLEY FEVER, DESERT RHEUMATISM)

Coccidioidomycosis is the infection caused by the fungal species *Coccidioides immitis* and *Coccidioides posadasii*; the latter is phenotypically identical and produces identical disease but is mainly found outside California. They shows an unusual form of dimorphism, with a mold form at room temperature and the development of large, spore-containing structures, spherules, in infected tissue. As with other endemic mycoses, there are asymptomatic, acute and chronic pulmonary, and disseminated forms. The disease can affect otherwise healthy individuals or predisposed patients, including those with AIDS.

EPIDEMIOLOGY. *C. immitis* is endemic in some semidesert areas of the Southwestern states of the United States (e.g., California,) and *C. posadasii* elsewhere (Arizona, New Mexico, and Texas) and in parts of Mexico and Central and South America. The climate of the endemic areas is marked by very high summer temperatures and low annual rainfall, demonstrated by a characteristic vegetation with cacti and mesquite bushes. Skin tests with coccidioidin show that the incidence of exposure in endemic areas may be as high as 95%. The fungus is found in soil and can affect other animals as well as humans. Exposure may result from a brief visit to an endemic area, and local weather can determine exposure rates.[40] For instance, dust storms may cause infection in large numbers of individuals. The usual route of infection is respiratory, although direct implantation into the skin can occur rarely.

CLINICAL FINDINGS. As with other systemic mycoses, there is an asymptomatic or subclinical form of coccidioidomycosis that is common in endemic areas, judging by the percentages of skin test reactors to coccidioidin in the healthy population. The primary pulmonary form, which is the most common clinical type, presents as a chest infection with fever, cough, and chest pain. Complications such as pleural effusion may occur. Erythema multiforme or erythema nodosum,[40] often accompanied by arthralgia or anterior uveitis, occurs from the third to the seventh week in about 10%–15% of patients and is more common in females. Sometimes an early, generalized, macular and erythematous rash is seen in some patients.



Figure 190-15 Coccidioidomycosis, disseminated. Two intact and ulcerated papules/nodules are seen on the cheek and nose of this comatose patient with coccidioidomycotic meningitis. (Used with permission from Francis Renna, MD.)

The chronic pulmonary form of the disease presents with chronic cough and resembles tuberculosis. Skin lesions normally do not occur in this phase.

In the rare primary skin infection,[41] after inoculation, there is an indurated nodule that develops 1–3 weeks after local trauma. This is followed by regional lymphadenopathy. Disseminated coccidioidomycosis develops in fewer than 0.5% of infected individuals. It is mainly seen in patients from certain ethnic backgrounds (American blacks, Filipinos, or Mexicans),[40] apparently independent of occupational exposure or socioeconomic class, in pregnant women, and in immunosuppressed patients, including those with AIDS.[42,43] In disseminated disease, lesions may develop in the skin, subcutaneous tissues, bones, joints, and all organs. The skin lesions (Fig. 190-15) are papules, nodules, abscesses, granulomas, ulcers, or discharging sinuses in which there is underlying bone or joint disease. Some lesions appear as flat plaques with central atrophy. Meningitis is an important complication of dissemination and is usually not associated with signs of infection in other sites. In AIDS patients, persistent pneumonia, skin lesions, and widespread dissemination can all occur.

DIFFERENTIAL DIAGNOSIS. Physicians in endemic areas should be aware of the connection between erythema nodosum and coccidioidomycosis. It also may occur in visitors to endemic areas after only a short stay.

LABORATORY TESTS. A characteristic of the laboratory findings is the ability of *Coccidioides* to form spore-containing spherules. These are large (up to 250 μm) and can be seen in KOH mounts of sputum, cerebrospinal

fluid (CSF), or pus. In culture, colonies of *Coccidioides* are mycelial, fast growing, white, and cottony. On microscopy, there are chains of arthrospores at intervals on the older mycelium. *Coccidioides* in the mold phase is highly infectious, and cultures should be handled carefully. There is, as yet, no commercial molecular test for coccidioidomycosis.

A variety of serologic tests are of value in the diagnosis and prognosis of coccidioidomycosis.[44] Precipitins develop in about 90% of infected individuals within 2–6 weeks but are short-lived, complement-fixing antibodies are characteristic of more severe infections and, in active infection, increase to a maximum after 6 months. Skin tests with coccidioidin are of little value in diagnosing infections. Spherulin is an antigen obtained from spherules of *C. immitis* and may be better than coccidioidin for detecting sensitization. However, in severe infections, cutaneous anergy to both is common.

Spherules containing large endospores can be seen in tissue sections, although there are a variety of less distinct intermediate stages in spherule formation that also can be seen. Before endospores form, the cytoplasm of the immature spherule is basophilic and subsequently breaks up into spores. Mycelium is seen rarely in histopathologic sections.

TREATMENT. No specific therapy apart from rest is necessary in the primary pulmonary infection, and there is little evidence that the symptoms are either improved or shortened by giving an oral azole drug, even though it is widespread practice. For disseminated disease, the results of treatment are still variably, but amphotericin B (1 mg/kg daily), itraconazole (200–400 mg daily), or fluconazole (200–600 mg daily) can all be given.[45] Experience with the newer antifungal agents, such as voriconazole and posaconazole, is limited at present. It is important to follow patients carefully, given the frequency of relapse. Meningitis and progressive disseminated infection involving multiple sites are all particularly refractory to therapy. Generally, soft-tissue coccidioidomycosis (skin and joint) has a better prognosis, and the mortality in patients who present with such lesions is low.

PARACOCCIDIOIDOMYCOSIS (SOUTH AMERICAN BLASTOMYCOSIS, PARACOCCIDIOIDAL GRANULOMA)

Paracoccidioides brasiliensis is a dimorphic fungus that causes a respiratory infection with a tendency to disseminate to the mucous membranes and lymph nodes. It is confined to Central and South America.[46]

EPIDEMIOLOGY. Paracoccidioidomycosis has been reported from most Latin American countries, but the infection is found most commonly in parts of Brazil, Colombia, and Argentina. The infection does not occur in the United States, although it has been reported in Mexico. Exposure rates can be estimated by skin test reactivity and appear to be equal in both males and females, although the prevalence of positive reactors in endemic areas seldom exceeds 25%; work with a skin test derived from purified glycoprotein 43 antigen generally demonstrates that exposure rates are higher than previously believed. The active infection is seen predominantly in males. The mechanism is thought to be connected to the presence of a cytoplasmic estrogen receptor on the fungus, and in vitro, estradiol suppresses the conversion of mycelium to yeast.[47] The ecologic niche of the organisms is unknown, but the condition is much more frequent in rural areas; exposure has been associated with proximity to water or areas of high atmospheric humidity.[48]

CLINICAL FINDINGS. There are a number of different clinical patterns of paracoccidioidomycosis infection that depend on the predominant site of clinical involvement. These include the lung (pulmonary form), the mucous membranes (mucocutaneous form), and the lymph nodes (lymphatic form). Many patients have a mixed type of infection with involvement of different organ groups.[46]

Patients rarely present with an acute form of pulmonary infection although this has been observed rarely and reported to subside while dissemination occurs. More usually, pulmonary infection tends to be chronic and slowly progressive with weight loss and chronic cough. The lesions may be bilateral and nodular on chest X-ray, and there is often extensive fibrosis. Other sites of involvement include mucocutaneous areas. Oral or circumoral lesions are common in the mucocutaneous forms of paracoccidioidomycosis; lesions also occur in the nose, conjunctivae, or around the anus. These lesions may be small granulomas or ulcers. They heal with scarring, which may cause considerable deformity.

The cervical lymph nodes are sometimes enlarged, tender, and tethered to the overlying skin; they rarely suppurate. Other systemic sites of involvement include the spleen, intestines, lungs, and liver. Paracoccidioidomycosis is uncommon in AIDS patients, although there is a widespread variety that is a more rapidly progressive form of disseminated infection occurring in young adults or older children without recognizable predisposition.[49]

DIFFERENTIAL DIAGNOSIS. Differential diagnosis includes tuberculosis, leishmaniasis, and other deep mycoses.

LABORATORY TESTS. Sputum, exudates, and scrapings can be screened using KOH. They show numbers of round yeasts with a characteristic form of multiple budding in which a parent cell is surrounded by large numbers of smaller buds. The organism is dimorphic and produces a cottony mycelial-phase growth on primary isolation at room temperature. Once again, the characteristic yeast phase can be induced on enriched media such as brain–heart infusion agar at 37°C (98.6°F). Serology is very helpful in confirming the diagnosis, the main tests being the immunodiffusion assay and a complement-fixation test. Recently, antibodies to pb27 and 87-kDa antigens

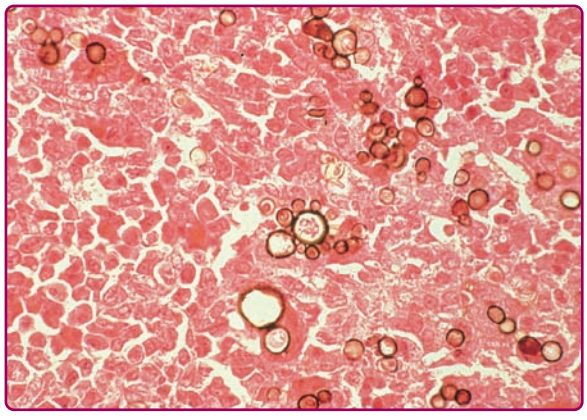

Figure 190-16 Biopsy of oral mucosal lesion showing multiple budding *Paracoccidioides brasiliensis*.

have been found to be highly specific for this infection in immunoblotting. There are also antigen-detection tests useful in monitoring patients with disseminated disease. Histopathologically, there is a mixed granulomatous response with fibrosis. The organisms can be seen with special fungal stains such as methenamine silver (Grocott modification). In tissue, the characteristic budding pattern can be seen, although it may be necessary to search several fields to find the most typical structures (Fig. 190-16). In widespread infections, masses of small yeast forms may be mistaken for *Histoplasma*.

TREATMENT. The treatment of choice in most cases is itraconazole, which can produce remissions in 3–6 months.[50] Voriconazole produces similar responses. Relapses can occur, and, where possible, patients should be reviewed periodically after primary therapy. In very extensive infections and in severely ill patients, such as those with the progressive disseminated type of infection, intravenous amphotericin B may be necessary. Severe pulmonary or intraoral fibrosis may remain after treatment.

INFECTIONS DUE TO *P. MARNEFFEI* (PENICILLIOSIS, *PENICILLIOSIS MARNEFFEI*)

P. marneffei infection is a more recently recognized disease found in Southeast Asia. *P. marneffei* is a member of the common genus *Penicillium*.[51] It shows an unusual pattern of dimorphism in that it develops yeast-like cells that reproduce with septal formation, dividing the cells into two. It is inhaled via the lungs, and it is not known whether there is a primary cutaneous form of the infection.

EPIDEMIOLOGY. The natural source of *P. marneffei* is unknown. Infections are confined to Southeast Asia, particularly Thailand, South China, and Vietnam. However, there are reports in other Asian countries, including Northeast India, and imported cases are seen in Europe and the United States. Natural infections are known to occur in bamboo rats of the genus *Cannomys*, which are large burrowing rodents. The infection affects otherwise healthy individuals as well as those with immune defects and is most common after the rainy season.[52] Patients with AIDS appear to be particularly susceptible to this infection.

CLINICAL FINDINGS. There has been no work to demonstrate that there is a subclinical form of *Penicillium* infection, even though this is likely. Patients usually present with localized pulmonary or disseminated disease. The chest signs are those of chronic pulmonary disease.[53,54] More than 50% of AIDS patients with this infection have multiple skin lesions, which are umbilicated papules that may enlarge and ulcerate. They are usually widely scattered on the face and trunk. Other organs, including the liver, gastrointestinal tract, spleen, and bone marrow, may be affected.

DIFFERENTIAL DIAGNOSIS. The main differential diagnosis is with other disseminated mycoses, such as histoplasmosis and cryptococcosis, which also can be found in the endemic area in AIDS patients. Biopsy and, when necessary, culture will distinguish between the different causes.

LABORATORY TESTS. *P. marneffei* forms characteristic yeast-like cells that are divided by a septum in tissue and are best seen in histopathologic sections stained with methenamine silver. These cells are small (2–4 μm) and difficult to see in blood films or skin or bone marrow smears, but they may be highlighted with stains such as leishmanin. In culture, *P. marneffei* is a green or grayish mold that produces typical *Penicillium* conidiophores and a diffusible red pigment. There is no commercial serologic test as yet, although antigen detection systems and polymerase chain reaction have both been used in diagnosis, the latter for identification of cultures.

TREATMENT. In severe cases, amphotericin B is necessary. In many cases, however, there is a good response to itraconazole (200–400 mg daily). In AIDS patients, this is continued after initial therapy to prevent relapse.[54]

CRYPTOCOCCOSIS

Cryptococcosis is the infection caused by the encapsulated yeast *C. neoformans*. Although the main portal of entry is through inhalation into the lungs, the disease usually presents with signs of extrapulmonary dissemination such as meningitis. Cutaneous lesions can develop as a result of dissemination or, rarely, through inoculation. It is associated with HIV infection.[55]

EPIDEMIOLOGY. Cryptococcosis has a worldwide distribution although exposure rates probably differ markedly in different countries. *C. neoformans* has three variants: (1) *C. neoformans* var. *neoformans*, (2) *C. neoformans* var. *grubii*, and (3) *C. neoformans* var. *gattii*.

These correspond to three clusters of serotypes: (1) D, (2) A, and (3) B or C.[56] The *neoformans* and *grubii* varieties can be isolated from pigeon excreta and are more common in AIDS patients; the *gattii* form is found in the debris of certain eucalyptus trees in the tropics and California, but it is less often isolated from AIDS patients. Two sexual varieties called *Filobasidiella neoformans* and *F. bacillispora* correspond to the *neoformans/grubii* and *gattii* varieties, respectively. Clinically the main differences to be seen are those between the *neoformans* and *gattii* varieties. Patients with certain immunodeficiency states caused by AIDS, malignant lymphomas, sarcoidosis, collagen disease, carcinoma, and those receiving systemic glucocorticoid therapy are particularly susceptible. The incidence of cryptococcosis in patients with established untreated AIDS varied in different countries from 3% to 6% in the United States, to 3% in the United Kingdom, to more than 12% in parts of Africa (e.g., Democratic Republic of the Congo). However, with the widespread use of HAART therapy the incidence has declined. Strains of serotype D are more likely to be found in skin lesions, which occur in 10%–15% of cases of disseminated cryptococcosis.

CLINICAL FINDINGS. The advent of the AIDS epidemic has affected the epidemiology of cryptococcosis considerably, and in areas such as Northern Thailand, it is one of the main secondary complications of HIV infection.[55] There is probably a subclinical form of cryptococcosis because unaffected individuals may have positive skin tests. However, the most common clinical manifestation of disease is meningoencephalitis. This presents with classic signs of meningismus, changes in consciousness, mental changes, and nerve palsies. In AIDS patients, these signs may be only weakly expressed. Pulmonary infection can be found in about 10% of those with meningitis. Chest signs include the appearance of nodular shadows, cavitation, and pleural effusion. Patients with AIDS often present with fever and mild headache and few other features of infection.[55] Cutaneous lesions may develop in about 10% of cases but are seldom pathognomonic.[57–60] Acneiform papules or pustules progressing to warty or vegetating, crusted plaques, ulcers, and hard infiltrated plaques or nodules are characteristic of widespread systemic infection (Fig. 190-17). Cold abscesses, cellulitis, and nodular lesions also occur. In otherwise healthy patients or those with sarcoidosis, lesions may be solitary, and in such patients, they may be the only clinical manifestation of infection.

In primary cutaneous cryptococcosis with direct inoculation of organisms into the skin, the skin lesions are usually solitary nodules that break down and ulcerate. Local lymphadenopathy also develops. The term *primary cutaneous cryptococcosis* is also used loosely to describe solitary lesions of cryptococcosis, but in many such cases there is also evidence of dissemination to other internal organs. It is important to investigate all patients who present with cutaneous lesions for evidence of dissemination to other sites.[58]

DIFFERENTIAL DIAGNOSIS. Cryptococcal skin lesions may mimic a range of other conditions, particularly other systemic mycoses in AIDS patients. It is important to biopsy and culture suspicious lesions in immunocompromised patients.



Figure 190-17 Cryptococcosis, disseminated. Multiple, discrete, skin-colored papules, and nodules resembling molluscum contagiosum are seen on the face of a male with advanced human immunodeficiency virus disease. (Used with permission from Loïs Vaillant, MD.)

LABORATORY TESTS. Cryptococci are large (5–15 μm), budding cells with capsules that are best observed by direct microscopy of India ink or Nigrosin mounts (Fig. 190-18). The organism is not difficult to grow in culture. Various biochemical features, such as the production of urease and the ability to pigment on Guizotia seed medium, are characteristic: or molecular probes can be used to confirm the identity Serologic tests are rapid and specific. The main test is an antigen-detection assay using latex agglutination or enzyme-linked immunosorbent assay, and this is simple and



Figure 190-18 Cryptococcosis. India ink preparation of cerebrospinal fluid.

very rapid to perform on blood or CSF. Very high titers are found in AIDS patients in serum and CSF. Non-AIDS patients with single, localized skin lesions are often antigen negative.

In tissue sections, the large pleomorphic yeasts stimulate either a granulomatous reaction or very little inflammation. The capsules of the cells can be stained using the mucicarmine or Alcian blue stains.

TREATMENT. The most frequently used drug regimen in the non-AIDS patient is intravenous amphotericin B combined with flucytosine. In patients with single skin lesions and no other signs of infection, alternatives such as fluconazole or itraconazole can be used. In AIDS patients, there is a very high relapse rate, and the usual policy is to give a 10–14-day course of amphotericin B with or without flucytosine, followed by long-term fluconazole.[61] However, it may be possible to stop long-term suppressive therapy in patients receiving HAART. Fluconazole given on its own is an alternative approach.

CUTANEOUS ASPECTS OF SYSTEMIC OPPORTUNISTIC MYCOSES

Skin lesions are not common with the opportunistic fungal infections, but they can occur in some, particularly in certain predisposed groups. When they occur, their presence may be very helpful because it is possible to biopsy easily accessible lesions in order to establish the diagnosis.

SYSTEMIC CANDIDIASIS

(See Chapters 189 and 198)

Systemic candidiasis follows dissemination of *Candida* sp. from the gastrointestinal tract or via the bloodstream. Skin lesions may occur particularly in two situations: (1) in neutropenic patients, there is often a severe disseminated disease with widespread skin nodules and associated muscle pains,[62] and (2) in intravenous drug abusers, candidiasis may present with a follicular, pustular rash in the beard area and scalp. Other lesions include retinal and vitreal deposits and abscesses around the costochondral junctions.[63]

Systemic candidiasis is usually treated with intravenous amphotericin B (conventional or lipid-associated), caspofungin or fluconazole. Resistance to some azole drugs, such as fluconazole and ketoconazole, is more common with certain non-*albicans Candida* sp., and these antifungal agents should be avoided in infections caused by these species.

MUCORMYCOSIS (PHYCOMYCOSIS, ZYGOMYCOSIS)

Mucormycosis is a rare disease caused by zygomycete fungi such as *Rhizomucor*, *Absidia*, and *Rhizopus*. *Cunninghamella bertholletiae* and *Saksenaea vasiformis* are less common causes. These fungi cause disease in patients with poorly controlled diabetes, neutropenia, or renal disease. Direct invasion through abrasions has been reported following trauma due to a natural disaster (e.g., during a mud slide or tsunami).[64] They can invade necrotic burned areas or involve the facial skin secondary to invasive infection of the paranasal sinuses (Fig. 190-19). Mucormycosis also has been caused by close apposition of the skin with contaminated dressing materials in the case of *R. rhizopodiformis*[65] or with wooden tongue depressors in the case of *R. microsporus*.[66] These fungi have a tendency to invade blood vessels, causing widespread infarction. Infections may respond to intravenous amphotericin, and recent results with lipid-associated amphotericin B formulations have been encouraging.

OTHER OPPORTUNISTIC MYCOSES

Other fungi causing systemic infections also may produce skin lesions in the process of bloodstream dissemination. The best known of these organisms are *Aspergillus*, *Scedosporium*, *Trichosporon*, and *Fusarium*. Skin infection is seen mainly in severely immunocompromised patients such as those with neutropenia.

Aspergillus may produce large necrotic lesions such as ecthyma gangrenosum, but smaller papules and cold abscesses also can occur.[67] *Fusarium* infections may produce widely distributed target-like lesions that may undergo central necrosis and, in some cases, digital cellulitis and superficial white onychomycosis.[68] Treatment for all these infections is usually amphotericin B; although voriconazole is increasingly used with aspergillosis.

LABORATORY FINDINGS. Laboratory confirmation of the diagnosis is fraught with difficulties chiefly because many of the organisms are also commensals in human sites; because they occur in severely ill patients, the capacity to produce diagnostic antibody titers is compromised. The interpretation of laboratory data is consequently difficult and has to be related to the clinical state of the patient. Ideally, a histologic diagnosis should be made, although biopsy may be impossible because of the risk of bleeding.

General Treatment. In many cases, the diagnosis of a systemic mycosis is presumptive, and treatment therefore is given empirically.

ACTINOMYCOSIS AND NOCARDIOSIS

Actinomycosis is an infection caused by filamentous bacteria that form large granules (sulfur granules) in abscess cavities. Draining sinuses communicate from the center of the abscess to the skin or mucosal surface. Nocardiosis is an acute and chronic infection also caused by filamentous bacteria. These lead to localized skin, subcutaneous, and systemic infections. Actinomycosis and nocardiosis are discussed in detail in Chapter 185 and in the online edition.



Figure 190-19 Mucormycosis. **A.** The face of this young woman with diabetes mellitus shows proptosis, unilateral facial edema, and a right-sided facial palsy associated with infection beginning in the right maxillary sinus. **B.** Ulcer. **C.** Hyphae in tissue.

KEY REFERENCES

Full reference list available at www.DIGM8.com

DVD contains references and additional content

2. Merz WG, Hay RJ: *Topley and Wilson's Microbiology and Microbial Infections: Medical Mycology*. London, Hodder Arnold, 2005
4. Dismukes WE et al: *Clinical Mycology*. New York, Oxford University Press, 2003
5. Ramos-e-Silva M et al: Sporotrichosis. *Clin Dermatol* **25**:181, 2007
11. Fahal AH: Mycetoma: A thorn in the flesh. *Trans R Soc Trop Med Hyg* **98**:3, 2004
17. López Martínez R, Méndez Tovar LJ: Chromoblastomycosis. *Clin Dermatol* **25**:188, 2007
25. Kauffman CA: Histoplasmosis: A Clinical and Laboratory Update. *Clin Microbiol Rev* **20**:115, 2010
33. Bradsher RW et al: Blastomycosis. *Infect Dis Clin N Am* **17**:21, 2003

33. Bradsher RW et al: Blastomycosis. *Infect Dis Clin N Am* **17**:21, 2003

42. Crum NF et al: Coccidioidomycosis: A descriptive survey of a reemerging disease. Clinical characteristics and current controversies. *Medicine* **83**:149, 2004
46. Ramos-E-Silva M, Saraiva Ldo E: Paracoccidioidomycosis. *Dermatol Clin* **26**:257, 2008
53. Lu PX et al: Acquired immunodeficiency syndrome associated disseminated Penicillium marneffei infection: Report of 8 cases. *Chin Med J* **118**:1395, 2005
60. Pomar V et al: Disseminated cryptococcosis resembling milliary tuberculosis in an HIV-1-infected patient. *Lancet Infect Dis* **5**:189, 2005
62. Bae GY et al: Clinicopathologic review of 19 patients with systemic candidiasis with skin lesions. *Int J Dermatol* **44**:550, 2005

SECTION 31

Viral and Rickettsial Diseases

Chapter 191 :: General Considerations of Viral Diseases

:: L. Katie Morrison, Ammar Ahmed, Vandana Madkan, Natalia Mendoza, & Stephen Tyring

VIRAL DISEASES AT A GLANCE

- Cutaneous lesions are an extremely common and often the only manifestation of viral infections.
- Viruses can produce skin lesions by direct replication in the epidermis, as is the case with papillomaviruses, poxviruses, and several herpesviruses; or as a secondary manifestation of replication elsewhere in the body.
- The direct effects of viral replication on epidermal cells and the inflammatory immune response both contribute to cutaneous lesions.
- Viral latency followed by reactivation occurs with certain viruses. Neoplastic transformation is possible with some latent viruses.
- Laboratory diagnostic techniques include viral culture, microscopy, detection of viral nucleic acids or viral antigens, and serologic testing.
- Many effective antiviral drugs exist, and others are currently in development.
- Preventive techniques are currently the most effective means for decreasing the morbidity of viral infections. Vaccines are a key component of preventative measures.

Cutaneous manifestations are a prominent feature in many viral infections and may arise from a direct result of viral replication in the epidermis or secondarily from viral replication in other organs. In the latter case, the cutaneous manifestations may be the presenting sign of a systemic infection requiring further evaluation. Although most viral infections with cutaneous involvement are mild and self-limited, occasionally severe or life-threatening complications can develop, especially in immunocompromised hosts. Developments in laboratory testing have improved diagnosis of viral infections in the skin. In addition antiviral medications have improved clinical management and outcomes for many of these viral illnesses. While specific diagnosis of the etiologic viral agent is not always feasible, laboratory diagnosis may also be important epidemiologically. Preventive vaccines are available for certain viruses and are currently the most effective strategy for decreasing morbidity and mortality associated with these diseases. Prophylactic vaccines led to the eradication of smallpox, and now include newer vaccines against herpes zoster virus and human papillomaviruses.

DEFINITION

Viruses are unique and fascinating small subcellular agents that require host cells to replicate their genetic material.[1] They contain genomic nucleic acid, a protein coat, and some viruses also have a lipid envelope. Lacking functional ribosomes or other organelles, viruses require host cellular machinery for replication of their genetic material.[1,2] This dependence on the host cell for transcription and replication is why viruses are often referred to as *obligate intracellular parasites*. The intracellular location of the virus provides survival benefit to the virus against some of the host's immune mechanisms.

Viruses are an important means of horizontal gene transfer and evolutionary genetic diversity.[3,4] Historically, there have been many discussions regarding the etiology and categorization of viruses. Most experts currently view viruses as biological particles that can interact with cells, as opposed to biological organisms or life forms.[3] Viruses have features of both of these groups, which accounts for some of their enigma, but

TABLE 191-1
Selected Virus Groups

Group	Size (nm)	Shape	Envelope	Nucleic Acid	Capsid Assembly	Examples of Viruses
Herpesvirus	120–200	Icosahedral	Yes	DNA	Nucleus	Herpes simplex virus (types 1 and 2), varicella zoster virus, cytomegalovirus, EBV, HHV-6, 7, and 8
Papillomavirus	50–55	Icosahedral	No	DNA	Nucleus	Papillomaviruses
Polyomavirus	45–50	Icosahedral	No	DNA	Nucleus	SV40, JC virus, Merkel cell polyomavirus
Poxvirus	240 × 300	Complex	Yes	DNA	Cytoplasm	Molluscum contagiosum, orf, milker's nodules virus, variola virus, vaccinia virus
Retrovirus	80–120	Spherical	Yes	RNA	Cytoplasm	HIV, HTLV
Paramyxovirus	150–300	Helical	Yes	RNA	Cytoplasm	Measles virus, mumps virus
Togavirus	40–60	Icosahedral	Yes	RNA	Cytoplasm	Rubella virus, Chikungunya virus, some arboviruses
Parvovirus	20	Icosahedral	No	DNA	Nucleus	Parovirus B19 (agent of Erythema infectiosum)
Hepadnavirus	40–50	Icosahedral	No	DNA	Nucleus	Hepatitis B virus
Adenovirus	70–80	Icosahedral	No	DNA	Nucleus	Multiple human serotypes
Picornavirus	20–30	Icosahedral	No	RNA	Cytoplasm	Enterovirus (coxsackievirus, echovirus, poliovirus), rhinovirus
Bunyavirus	90–100	Helical	Yes	RNA	Cytoplasm	Some arboviruses
Arenavirus	85–120	Spherical	Yes	RNA	Cytoplasm	Lassa virus
Flavivirus	40–50	Spherical	Yes	RNA	Cytoplasm	Yellow fever virus, Dengue virus, hepatitis C virus, West Nile virus

lack some of the defining features of living organisms and are not classified taxonomically amongst the kingdoms of life.

The viral nucleic acid contains the genetic information necessary for directing the host cell to replicate the virus. The assembled virus is referred to as a *virion*, and contains a highly organized protein coat or *capsid*.[5] The protein coat protects the viral nucleic acid from extracellular environmental insults such as nucleases and it facilitates virion attachment to the membrane of the host cell.[6] After the virion has infected a cell, the now intracellular viral genetic information is usually found in a nonparticulate form. The various virion components are synthesized in separate pieces within the cell and assembled to form progeny particles. This assembly type of replication is characteristic of viruses.[7]

CLASSIFICATION

Viruses are grouped based upon their type of genomic nucleic acid, DNA or RNA, and by the number of strands of nucleic acid within each virion.[2] Other traditional categorization has focused on viral size, morphology, and presence of an envelope, as shown in Table 191-1. A given family of viruses usually shares functional, genetic, biochemical, and immunologic features as well. Other features that may be evaluated in viral categorization are antigenic cross reactivity and host cell tropism. With the advent of more sophisticated techniques, recent viral classification has focused on relatedness of genome sequences.[8]

On a morphological basis viruses can be grouped as helical, icosahedral, or complex as determined by the type of capsomer and overall shape of the virus.[9] In certain virus families (such as herpesviruses and retroviruses), the capsids are located inside an envelope (composed of lipid, protein, and carbohydrate), which is required for infectivity[5] (see Table 191-1). The viral envelope is sensitive to drying, so that infectivity is lost with drying. The virions of some other viruses (e.g., papillomaviruses) do not possess an envelope, so their capsids are called *naked*. Because the capsid proteins are usually stable in dry environments, viruses whose virions lack an envelope typically remain infectious for long periods after drying.[10]

Figure 191-1 shows examples of virions from the three main families of viruses that multiply in the epidermis and appendageal structures (papillomaviruses,

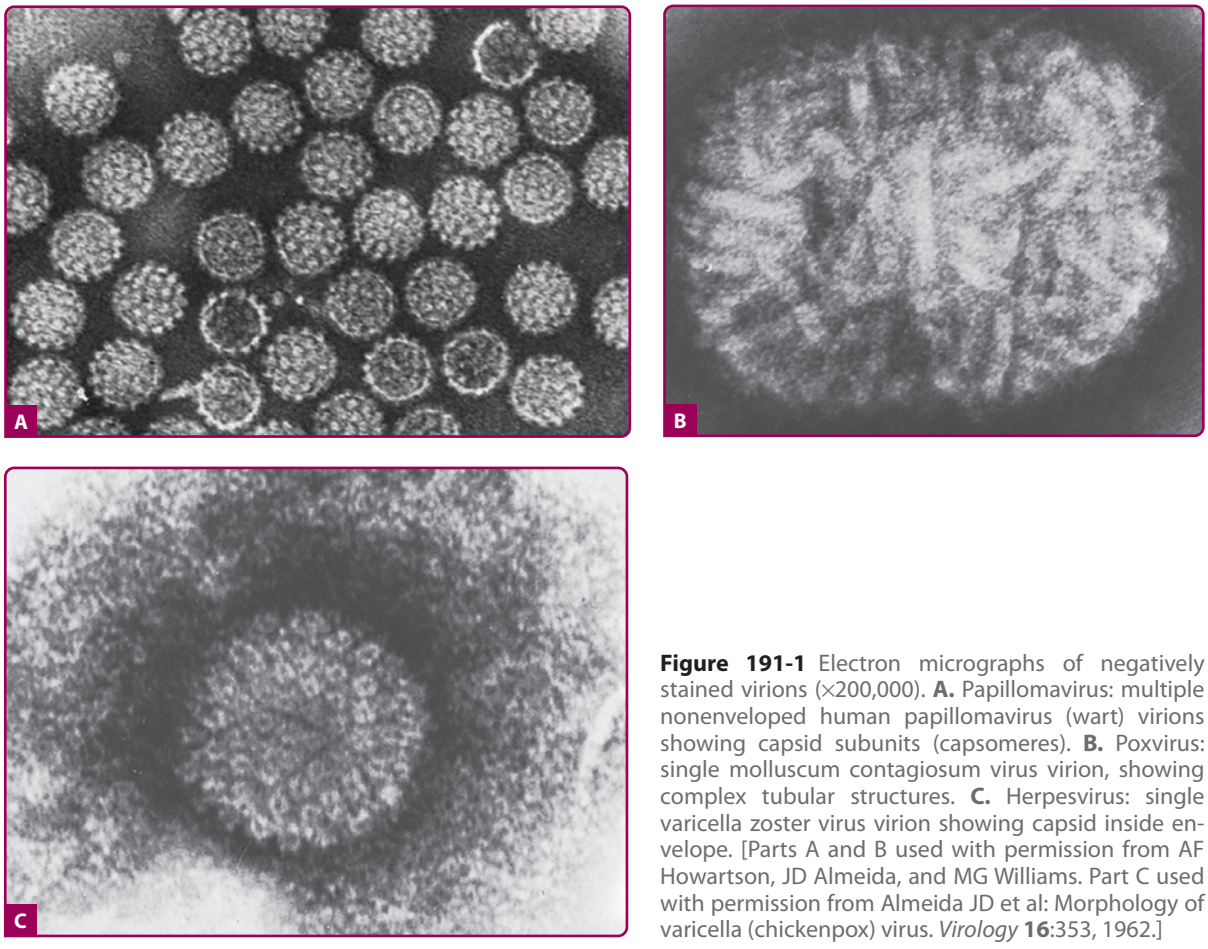

Figure 191-1 Electron micrographs of negatively stained virions (×200,000). **A.** Papillomavirus: multiple nonenveloped human papillomavirus (wart) virions showing capsid subunits (capsomeres). **B.** Poxvirus: single molluscum contagiosum virus virion, showing complex tubular structures. **C.** Herpesvirus: single varicella zoster virus virion showing capsid inside envelope. [Parts A and B used with permission from AF Howartson, JD Almeida, and MG Williams. Part C used with permission from Almeida JD et al: Morphology of varicella (chickenpox) virus. *Virology* **16**:353, 1962.]

herpesviruses, and poxviruses). The viral genomes of these three families are composed of DNA. As noted earlier, papillomaviruses possess naked (nonenveloped) capsids, and herpesviruses have enveloped virions. Poxvirus virions are large, have a very complex structure, and are enveloped, but their envelope is not required for their virions to be infectious. Hence, poxviruses can remain infectious even after drying.[11]

VIRAL REPLICATION

Viral particles do not multiply through cell division because they are acellular. Instead, replication of viruses requires certain host cell genes, proteins, and organelles. The viral replication cycle involves several steps: adsorption, cellular uptake, uncoating, biosynthesis, virion assembly, and release.[5]

Adsorption proceeds with the attachment of virions to cells, involving a specific interaction between the viral capsid, or envelope, and host cell surface receptors. The specificity of this interaction between the viral protein and host receptor defines and limits the species and cell type that a particular virus can infect.[6] Cells that lack the appropriate cell surface receptors for a particular virus are not susceptible to cellular viral entry and infection. For example, human immunodeficiency virus (HIV) enters cells via an interaction between viral envelope protein and two classes of receptors: cellular CD4 receptors and chemokine receptors.[12] While the majority of people are known to be susceptible to HIV infection, rare genetic modifications of specific chemokine receptors have been identified which render hosts relatively resistant to HIV infection or the development of acquired immunodeficiency syndrome.[13,14]

After adsorption, the coat of enveloped viruses may fuse with the host cell membrane and release the virus nucleocapsid into the host cytoplasm. Alternately some viruses may enter the cell through invagination of the cell membrane forming vesicles in the cell cytoplasm.[6] Uncoating subsequently occurs with release of the viral genome from its protective capsid, which begins the nonparticulate phase of the virus life cycle. The nucleic acid can now be transported within the cell.

In the genomic activation or biosynthetic phase, messenger RNA (mRNA) is transcribed typically from viral DNA and translated by the host cell under regulation by the virus. DNA viruses, such as papillomaviruses and herpeviruses typically replicate in the nucleus. (Figs. 191-2 and 191-3) RNA viruses mainly replicate in the cytoplasm. However this is not absolute,

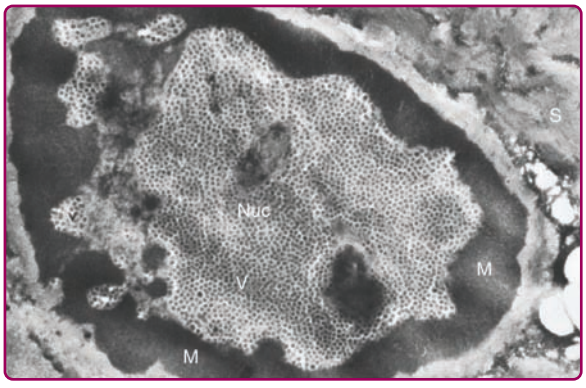

Figure 191-2 Papillomavirus-infected cell. Electron micrograph (×20,000). Nucleus (Nuc) of a stratum corneum cell, filled with papillomavirus virions (V); chromatin is marginated (M). Mature keratin can be seen in an adjacent cell (S).

as exemplified by poxviruses that contains DNA but replicate in the host cell's cytoplasm[15] (Fig. 191-4).

Early viral proteins are usually nonstructural and may code for important enzymes, while later proteins tend to be structural components for the virion. Nonvirion proteins (proteins that are not structural components of the mature virion) of certain viruses may redirect the cell to synthesize proteins required by the virus at the expense of those required for normal function of the cell, essentially hijacking the host's replication and transcription processes.[15]

Assembly of the viral nucleocapsids is the next step. This may occur in the nucleus, as it does with herpes viruses, or in the cytoplasm with polioviruses, or even at the cell surface with viruses such as influenza.[16]

Release of new infectious virions may occur by several mechanisms. The virions of most viruses, including papillomaviruses, herpesviruses, and poxviruses, are released upon cell lysis.[10] Some virions are released by budding from the cell surface and contain a host cell membrane coat. This can occur when virus proteins and nucleic acid condense adjacent to the cell membrane with subsequent budding off of the cell. Virions with resultant cell membranes have a survival advantage of decreased antigenic stimulation and decreased activation of the host's immune system.[10] Alternatively some viruses utilize the host cell's cellular secretory pathway via *Golgi*-derived transport vesicles and fuse with the cell membrane to exit the cell.

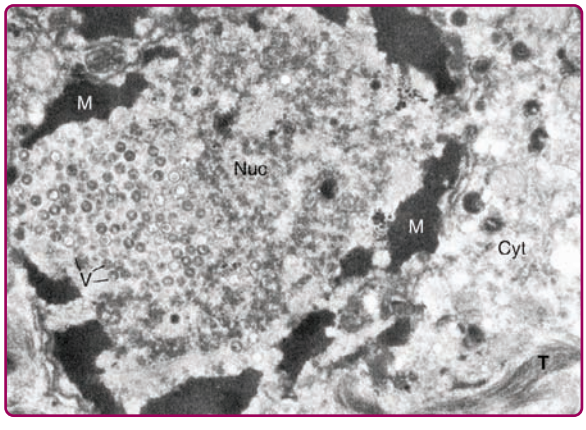

Figure 191-3 Cell infected with varicella zoster virus (a herpesvirus). Electron micrograph (×24,000). Portion of cell of the stratum spinosum. The nucleus (Nuc) contains varicella zoster virions (V). Chromatin is marginated at (M). Virions (V) and tonofilaments (T) are shown in the cytoplasm (Cyt).

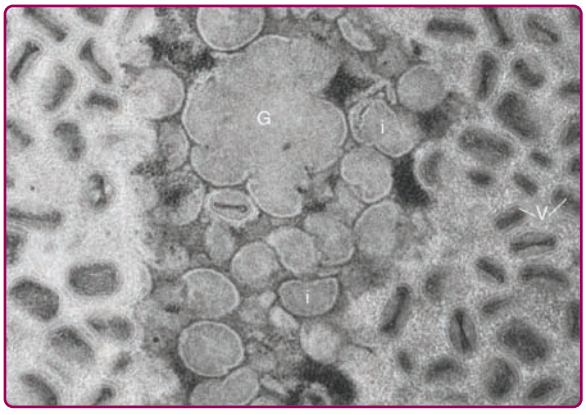

Figure 191-4 Cell infected with molluscum contagiosum (a poxvirus). Electron micrograph (×45,000). Cytoplasm of a spinosum cell filled with mature molluscum contagiosum virions (V), immature virus forms (i), and viroplasm in a gyrate pattern (G).

Typically, hundreds or thousands of new virions are produced from each infected cell, which can then go on to infect other cells. One cycle of viral replication may last from 3 to 36 hours, depending on the virus and cell type involved. Interruption of any step in viral cellular entry, uncoating, synthesis, assembly, or release may prevent the development of new infectious virions. Viruses can also establish several alternate pathways in the host cell, discussed further in the next section.

Each virus has specificity for cell type(s) it can infect. Human papillomaviruses can productively infect a very narrow range of cells, namely, certain differentiating human epidermal cells.[17] Other viruses can infect a much broader range of cells. Herpes simplex viruses (HSVs) can replicate in many different human and nonhuman cell types.[18]

Even within a given tissue, a virus may be infectious only for cells with a specific degree of differentiation. The important role of the differentiated state of the cell in determining whether or not a virus will undergo replication is seen in the skin lesions caused by the molluscum contagiosum virus (MCV). Because MCV particles are sometimes found in cells of the upper dermis, the virus must be capable of attachment to and penetration of these cells. MCV does not, however, replicate in dermal cells, which indicates that an intracellular block to MCV synthesis in the dermal cells. MCV particles are also found in the basal layer of epidermal cells, but synthesis of new viral components does not begin until the cells reach the suprabasal layers, implying that MCV replication can take place only in partially differentiated epidermal cells.[11]

Individual viruses are discussed further in their respective chapters.

CELLULAR CONSEQUENCES OF VIRAL INFECTION

Most viral infections eventually result in the host cell death as a result of cell lysis or alterations to the cell's normal surface membrane leading to cellular apoptosis.[9] Infections of this type are known as lytic or *cytocidal*. However certain enveloped viruses can replicate without causing irreversible damage to the host cell. In noncytocidal infections other possible interactions with the host cell are persistent infection, viral latency, and tumor transformation.[19]

Persistent cellular viral infections without mass cell destruction are possible and occur when there is survival of the infected cell, or only a few host cells are initially infected. This can occur with cytomegalovirus or papillomavirus infections.[17]

Latent infections, via viral integration into the host genome or into the host cell episomally, are another possibility. Viral DNA replication thus proceeds with the cell's genome but does not result in acute mass viral replication or cell lysis.[20] Viral latency is a mechanism for evading the host immune response and may have consequences for the cell. Latently infected cells either produce very small numbers of new virions so that spread to uninfected cells is minimal or they synthesize no virions but retain an intact and potentially inducible viral genome.[20] Ultimately, the state of latent infections can become disrupted with production of new virions. This is commonly seen with herpes viruses HSV-1, HSV-2, and VZV; reactivation of the virus can ensue under conditions that allow viral genome induction.[18]

Tumor viruses possess the ability to alter the normal control of cellular proliferation and transform cells. The phenomenon of latent viral integration with expression of viral proteins known to have an effect on cell cycle regulation has been demonstrated with several viruses, most recently the Merkel cell polyomavirus (MCPyV).[21,22] In many of the genomically evaluated cases to date, the MCPyV DNA sequence has demonstrated a mutation resulting in loss of viral replication ability but retained ability to establish latency in the host cell and express viral proteins.[22,23] Among the viral proteins that have been found to be expressed are those involved in regulation of the host cell, which is a common feature of tumor viruses. Papillomaviruses similarly can encode nonvirion proteins that increase cell growth and lead to inappropriate control of cell division.[17]

The link between certain viruses and cancer was a pivotal discovery in the past century. The viral infectious nature of specific tumors has important implications for prevention, diagnosis, and therapy. Viral induced neoplasia is discussed in greater detail in subsequent chapters.

In addition to complete cellular destruction or transformative consequences for the cell, characteristic effects of a particular virus infection can be microscopically visualized. Cytopathic effects can be pathognomonic for the specific viral infection. These cell effects are typically the result of viral protein synthesis or subcellular degeneration, and can be seen as membrane blebbing, multinucleated giant cell formation, and inclusion body formations, to name a few.

PATHOGENESIS OF VIRAL INFECTIONS IN THE SKIN

Since a virus must grow within a host cell, the virus must be viewed together with its host in any consideration of pathogenesis, epidemiology, host defenses, or therapy. Transmission of an infecting virus to a susceptible individual can occur through several routes. In warts, herpes simplex, primary varicella infections, herpes zoster, molluscum contagiosum, and smallpox, viral shedding from human skin lesions represents an important source in the transmission of virus to other people. For other viruses with cutaneous manifestations, respiratory secretions, blood, genital secretions, or animal vectors are involved in carrying virus to susceptible individuals. Skin involvement may occur by three different routes: direct inoculation, systemic infection, or local spread from an internal focus. The resulting skin lesions may be due to the direct effect of viral replication on infected cells, the host response to the virus, or the interaction of replication and host response.

The viruses of warts, MCV, vaccinia, orf, milker's nodules, and (primary) herpes simplex, all of which infect the skin by direct inoculation, replicate in the epidermis.[10] Their viral cytopathic effects account for the appearance of early lesions. The immune system presumably contributes to the evolution of these lesions by inducing an inflammatory response. The incubation period is generally short, because the lesions develop at the site of inoculation. For warts, however, the incubation period is longer, presumably because the virus replicates slowly or cellular spread of virus is limited.

In systemic infections, the skin is infected during viremia, so that the dermis is generally infected earlier than the epidermis. It is unclear what determines the specific cutaneous distribution of viral exanthemas. In primary varicella infections and smallpox, the lesions seen are a secondary result of the cytocidal damage that the viral infection produces.[18] In contrast, there is some evidence from patients with impaired cellular immunity that suggests that cutaneous manifestations of rubella and measles result at least partly from a cell-mediated immune response to the virus. The basis of most viral exanthemas, such as with enteroviral infections, remains to be established.

Recurrent HSV and herpes zoster represent the local spread of virus to the skin after reactivation of the latent virus present in sensory nerve ganglia. Cytocidal activity is involved in the pathogenesis of these viral associated cutaneous lesions, although the immune response appears to also be an etiologic factor in the blister formation.[18]

HOST RESPONSE

The severity of illness induced by a particular virus has considerable intraspecies variation. The size of the viral inoculum and the portal of entry play some role in the clinical manifestation of disease, but it is believed that host factors usually account for the majority of clinical variation. Both innate and adaptive immunity play key roles in the coordinated immune response to viral infection.[24] Conversely, viral infection may interrupt the normal functioning of the immune system, especially infection with those viruses that target lymphoid cells, such as Epstein–Barr virus and HIV.

Viral proteins have reactive epitopes, which are important for host cellular interaction during infection and replication.[6] The host's defense mechanisms are directed against the viral antigenic epitopes. Antibody responses to viral infection represent the major host defense against reinfection by the same virus. The prophylactic administration of type-specific antibodies can prevent or modify some primary viral infections, even in patients with impaired cellular immunity. There are several mechanisms by which antibodies may inhibit the spread of virus. These include opsonization of virus and prevention of attachment to target cell receptors (which may be increased by complement), enhancement of phagocytic cell activity, and complement-mediated immune destruction of virally infected cells. However, humoral immunity is not believed to contribute substantially to the recovery from most primary viral infections. Viral infections in patients with isolated humoral immune deficiencies usually follow a normal course.

Cell-mediated immunity (CMI) is also elicited during viral infections, controlling viral spread and promoting viral clearance. CMI is a specific response to infection involving T cell recognition of viral fragments displayed on infected cell membranes. This leads to targeting for destruction by natural killer T cells. Some viruses such as HIV can effectively evade CMI by inducing variation in the amino acid sequence of virion surface proteins.[25]

Patients with impaired CMI often have difficulty handling primary or recurrent viral infections. Such patients are at risk of developing severe primary virus infections, problematic reactivations of dormant viruses such as VZV and CMV, and persistent warts, herpes simplex eruptions, and other viral cutaneous lesions. Virus-specific cytotoxic lymphocytes, natural killer cells, and antibody-dependent cell-mediated cytotoxicity all can inhibit infection under experimental conditions and are thought to be the primary players in clearing viral infections. Such genetic alterations in CMI have provided insights into how the immune system responds to viral infections.

Inflammatory cells may produce some of their antiviral effects via the production of interferons, a unique family of closely related cytokines that are active against viruses. Interferon, which can be induced by foreign RNA or DNA (including viral nucleic acids), is secreted into the extracellular fluid. Resistance to viral infection is increased in those cells that come in contact with interferon. Virtually all viruses are capable of inciting an interferon response and are susceptible to its action. However, there is great variability amongst viruses in the degree of interferon induction and the sensitivity to its effects.

Host genetic factors also play a role in the outcomes of viral infection. In animal models, cellular genes greatly influence the susceptibility to viral infection at several levels, including virion attachment to cells, viral replication, and viral-induced immune responses.

CLINICAL MANIFESTATIONS

Viral infections can produce a wide spectrum of mucocutaneous lesions, from single papules to generalized pustulation to large, fungating tumors. Table 191-2

TABLE 191-2
Viral Exanthems

Type of Rash	Associated Virus
Macular/Morbilliform	Rubella Echovirus (especially 9, 16) Coxsackievirus (especially A5, A9, A16, B5) Epstein–Barr virus (infectious mononucleosis) Human herpesvirus 6 (roseola) Rubeola virus Arbovirus (dengue fever) Parvovirus B19 (erythema infectiosum) Hepatitis B and C viruses Human immunodeficiency virus 1
Papular	Human papillomaviruses Orf virus Human herpesvirus 8 (Kaposi sarcoma) Milker's nodule virus Molluscum contagiosum Human immunodeficiency virus 1
Patches	Epstein–Barr virus (oral hairy leukoplakia)
Petechial/purpuric	Coxsackieviruses A5, A9 Hemorrhagic fever viruses Rubella virus (congenital infection) Cytomegalovirus (congenital infection) Echovirus 9 Epstein–Barr virus
Urticarial	Human immunodeficiency virus 1 Hepatitis B virus Coxsackieviruses A5, A9 Epstein–Barr virus
Vesicular/ vesiculopustular	Varicella zoster virus Vaccinia virus Variola virus Herpes simplex virus types 1 and 2 Coxsackievirus (hand-foot-and-mouth disease) (herpangina) Vesicular stomatitis virus Echovirus

lists the viruses that most commonly cause a number of distinguishable skin lesions. Also, for many viruses with cutaneous manifestations, the combination of the exanthem with other clinical and systemic findings, when present, can be characteristic for a specific virus. Human herpesvirus 6 induced roseola subitum in a well appearing child after days of a very high fever or measles exanthem with its characteristic oral lesions, are examples.

There are several cutaneous eruptive diseases for which a virus is highly suspected as the etiologic agent, but this viral causation has not been proven. Asymmetrical periflexural exanthem of childhood and pityriasis rosea are two such diseases (although evidence does link pityriasis rosea to human herpesvirus 7 infection).[26,27]

In certain viral infections the lesions are very specific (e.g., the verrucous papules seen with papillomavirus infection), and a diagnosis can be made without any further testing. However, even during an acute viral infectious episode there is often considerable clinical evolution and variation in the lesions. For example, in many infections due to HSV, VZV, or coxsackievirus, the lesions begin as papules with erythema, progress to frank vesicles, and are followed by pustules, crusts, or shallow ulcers.

In other viral infections the lesions are either rather nonspecific (e.g., urticaria or erythema multiforme) and cannot be accurately distinguished from lesions of nonviral etiology, or semispecific for a limited number of viral diagnoses (e.g., the vesicles seen in HSV, VZV, coxsackievirus, and echovirus infections). In both of these circumstances additional diagnostic procedures may help clarify the cause. Evaluation of systemic signs and symptoms is crucial in formulating a differential diagnosis of skin eruptions and is particularly valuable in infections by viruses that do not replicate in the epidermis, such as Epstein–Barr virus and CMV.

DIAGNOSIS OF VIRAL INFECTIONS

Several laboratory methods are used for diagnosis of viral infections. These are methods based upon viral detection including viral culture and detection of viral antigens, and indirect techniques such as microscopic evaluation and serology. Molecular diagnostic techniques, which are based upon detection of viral nucleic acids, are a newer method increasingly used for laboratory diagnosis of viral infections. The results of any diagnostic method must be interpreted in the context of the clinical setting. Coincidental infection with a virus unrelated to the illness should always be considered. For many viruses, rapid molecular-based assays that are sensitive and specific are now commercially available.

Viral culture is the traditional diagnostic gold standard. If necessary, more precise identification of the cultured virus can be carried out with specific tests for viral nucleic acid or viral antigen. Culture techniques for HSV are quite sensitive, with diagnostic changes in cells often appearing within 1–2 days of inoculation.[18] The closely related VZV is much more difficult to grow in culture, which frequently leads to false-negative results.[18]

When viral culture is of interest, specimens from an acute episode early in the disease process often yield more accurate results than samples taken from the later stages. In vesicular conditions, fluid from an early vesicle is typically a good source of virus. Lesional specimens are less likely to give positive results with nonvesicular exanthemas. Specimens are collected in a sterile tube with 2–5 mL of a buffered isotonic balanced salt solution containing penicillin and streptomycin. Preferably, they should be transported on ice immediately to the laboratory. Alternatively, specimens should be frozen if possible [–70°C (–94°F)]. The suspected pathogen(s) should be indicated, because it may determine the type of cell culture or test animal to be inoculated.[28]

Other diagnostic tests are available that can yield faster results than culturing the virus. This approach may be especially useful for detecting those viruses difficult to propagate in culture and those such as papillomaviruses for which no reproducible culture system is available. Direct microscopic analysis may identify characteristic cells, as with Tzanck smears for herpesviruses (this test will not distinguish between HSV and VZV) or characteristic inclusion bodies with CMV-infected cells. For those lesions that contain large numbers of viral particles, electron microscopy of a lesion or its extract may provide morphologic identification of the virus, although this method is labor intensive, costly, and not readily available.

Rapid diagnostic tests for viral antigens are useful and widely available. Fluorescent antibody detection is commonly used to identify and distinguish between HSV-1, HSV-2, and VZV infections. Radioimmunoassay, enzyme-linked immunosorbent assay, immunoelectron microscopy, and immunoperoxidase techniques are other methods of identifying viral antigen by the use of virus-specific antibody.

Serologic studies to detect viral antibodies may be important for epidemiologic purposes, for identification of infection with viruses such as HIV and hepatitis B virus, and for those situations in which acute sera contain diagnostic antibodies, as with heterophile antibodies in infectious mononucleosis. In general, the most accurate serologic method of diagnosing this acute viral illness is comparison of immunoglobulin G antibody titers from acute and convalescent sera. This comparison is limited to retrospective diagnosis. A single positive titer for immunoglobulin M antibody can also suggest acute illness. Acute specimens should be taken as early in the illness as possible and convalescent specimens 2–4 weeks later. Serum should be separated immediately from the coagulated blood and refrigerated or preferably frozen at –20°C (–4°F) until antibody tests can be run simultaneously on both specimens.[28] A fourfold or greater rise in antibody titer between acute and convalescent sera generally indicates recent infection. A variety of assays are used to measure antibody levels, each detecting a certain type of antigen–antibody reaction, with the type of virus partly determining the utility of any particular assay.

Culture systems possess some virus-specific constraints, but any virus should theoretically be detectable by recognition of viral nucleic acid if sufficient

probes or primers can be obtained for the specific virus(es) of interest. Molecular-based diagnostic assays have had an important impact in direct laboratory identification as well as in improving our understanding of the role of microbes in certain diseases. Most commonly these molecular tests are based upon polymerase chain reaction (PCR) techniques, but many other molecular techniques can be used to diagnosis viral infections including Southern hybridization and in situ hybridization techniques.

Assays based on PCR and related techniques are extremely sensitive, often being able to detect as few as 1 infected cell in 10,000, and highly specific. The main pitfall of PCR is that its great sensitivity makes it very susceptible to yielding false-positive results via cross contamination with minute quantities of viral nucleic acid. Meticulous attention to detail and appropriate controls as well as closed system techniques that are increasingly available can usually overcome this potential liability. In situ PCR, which combines the sensitivity of PCR with histologic localization, is an even more sophisticated technique for viral detection.[29]

Cutaneous manifestations of viral infections are often sufficient for clinical diagnosis. The exact laboratory diagnostic method chosen, if any, will depend on a combination of factors such as resources, clinical disease suspicion, differential diagnosis, immediacy of results, and test accuracy.

THERAPY AND PREVENTION

Viruses are difficult to target therapeutically because of their replication only within host cells, relying on the host cell's biosynthetic processes. Specificity of antiviral therapy to target the virus without consequence to the host can be challenging. Strategies aimed at unique viral functions or proteins are critical for correct diagnosis, treatment, and prevention of disease. Effective treatment requires knowledge of the viral cycle and viral proteins.

More than 40 drugs are approved for the treatment of viral infections, and several of these have a key role in the treatment of cutaneous viral infections. The majority of these drugs are virostatic, not virocidal. Viral enzyme inhibitors, viral receptor inhibitors, chemotherapeutic agents, and immunomodulatory drugs are among the systemic and topical medications used to treat such infections.[10] Our improved understanding of specific viral cycles, the viral interaction with the host cells, and the host immune response, has improved treatment for several viral infections. Specific antiviral treatments are covered in the respective disease chapters.

Although significant progress has occurred in antiviral therapy in recent decades, especially in the treatment of HIV, herpesviruses, and influenza virus infections, strategies aimed at prevention of viral infection have thus far proved more successful than the specific treatment of established infection for most viruses. Vaccines have been extremely useful in the prevention of a variety of viral illnesses and represent one of the premier medical achievements of the twentieth century. In 2006, the US Food and Drug Administration approved two new antiviral vaccines: a prophylactic VZV vaccine for the prevention of herpes zoster in persons 60 years of age and older, and a prophylactic vaccine against genital human HPV infection in women for prevention of cervical cancer caused by HPV-16 and HPV-18 and genital warts caused by HPV-6 and HPV-11. A second vaccine for the prevention of cervical cancer secondary to HPV-16 and HPV-18 (but not HPV-6 or HPV-11) was approved in 2009.[30,31] A number of other vaccines are currently being researched for HSV, cytomegalovirus, dengue virus, West Nile virus, and HIV, among others.[32]

Recombinant DNA techniques are making it possible to develop effective, noninfectious subunit vaccines composed only of viral protein (as with the vaccines against HPV and hepatitis B virus), rather than traditional vaccines, which contain either an attenuated strain of the pathogen or an inactivated preparation of the entire virus. In addition to vaccines that induce active immunity, the passive administration of type-specific antibody soon after exposure is useful in select clinical situations, for example, in immunocompromised children exposed to varicella, and in acute rabies infections. Sensitive procedures for the detection of hepatitis B virus, hepatitis C virus, and HIV in potential blood donors has drastically reduced the incidence of transmission of these agents by transfusion. Public health measures such as safer sex, single use of needles, control of mosquitoes, and proper hand washing continue to be paramount in the prevention of viral disease.

KEY REFERENCES

Full reference list available at www.DIGM8.com

DVD contains references and additional content

2. Condit R: *Principles of Virology*, vol. 1, 5th edition. Philadelphia, Lippincott Williams & Wilkins, 2007
10. Dimmock N, Easton A, Leppard K: *Introduction to Modern Virology*, 6th edition. Malden, MA, Blackwell Publishing, 2007
19. Efstathiou S, Preston CM: Towards an understanding of the molecular basis of herpes simplex virus latency. *Virus Res* **111**(2):108-119, 2005
21. Feng H et al: Clonal integration of a polyomavirus in human Merkel cell carcinoma. *Science* **319**(5866):1096-1100, 2008
22. Shuda M et al: T antigen mutations are a human tumor-specific signature for Merkel cell polyomavirus. *Proc Natl Acad Sci U S A* **105**(42):16272-16277, 2008
23. Garneski KM, DeCaprio JA, Nghiem P: Does a new polyomavirus contribute to Merkel cell carcinoma? *Genome Biol* **9**(6):228, 2008
27. Drago F, Broccolo F, Rebora A: Pityriasis rosea: An update with a critical appraisal of its possible herpes viral etiology. *J Am Acad Dermatol* **61**(2):303-318, 2009
30. Printz C: CancerScope: FDA Advisory Committee supports second HPV vaccine. *Cancer* **115**(22):5130, 2009
31. Cervarix–a second HPV vaccine. *Med Lett Drugs Ther* **52**(1338):37-38, 2010

Chapter 192 :: Exanthematous Viral Diseases

:: Leah T. Belazarian, Mayra E. Lorenzo, Andrea L. Pearson, Susan M. Sweeney, & Karen Wiss

MEASLES

EPIDEMIOLOGY

Measles, or rubeola, is a highly contagious disease with worldwide distribution that remains a leading cause of vaccine-preventable deaths in children.[1] The peak incidence of infection occurs during the winter and spring months in temperate areas.[2] The risk of mortality is highest in developing countries, with most deaths due to complications of the disease.[3] In the United States, measles-related deaths occur in 1–3 of every 1,000 reported cases.[2]

Before the development of a vaccine, measles epidemics in the United States usually occurred in preschool and young school aged children.[2,4] A successful immunization program for children and adolescents, particularly in urban areas, has resulted in a greater than 99% decrease in the reported incidence of indigenous measles since the vaccine was first licensed in the early 1960s.[2] Yet, cases of measles continue to occur as a result of viral transmission from importation into the United States.[2]

Improved immunization programs in developing countries have also prevented outbreaks and reduced measles-associated morbidity and mortality. From 2000–2008, global mortality attributed to measles decreased by 78%, from 733,000 to 164,000 deaths.[5] However, the reduction in mortality has leveled off and concerns exist regarding the ability of many countries with a high burden of measles mortality to continue effective measles eradication strategies.

ETIOLOGY AND PATHOGENESIS

Measles virus, a member of the Paramyxoviridae family, is a heat-labile virus with an RNA core and outer lipoprotein envelope.[2,4] Humans are the only natural hosts of the measles virus.[2] Measles is spread by direct or airborne droplet exposure. The incubation period is typically 8–12 days, with patients being contagious from 1 to 2 days before onset of symptoms to 4 days after appearance of the rash.[2] Both humoral and cell-mediated immunity are needed to control measles virus infection. Immunoglobulin M (IgM) antibodies are detected initially with onset of the rash, followed by a rise in measles-specific IgG titers. The humoral response controls viral replication and confers antibody protection, whereas the cell-mediated response eliminates infected cells.[4] A transient immunosuppression occurs during measles virus infection, causing depressed delayed-type hypersensitivity and T-cell counts as well as an increased risk of bacterial infections.[4] This process, as well as long-term immunity against measles, is not well understood but may be due to a weak T helper 1 response to the virus.[6] Measles virus may use dendritic cells to target lymphoid tissue (CD150 lymphocytes) and disseminate virus throughout the body.[7]

CLINICAL FINDINGS

HISTORY. The prodrome is typically characterized by fever (up to 40.5°C), malaise, conjunctivitis (palpebral, extending to lid margin), coryza, and cough (brassy or barking), which may last up to 4 days.[2,4] Koplik spots, the pathognomonic enanthem of measles, begin as small, bright red macules that have a 1–2-mm blue–white speck within them. They are typically seen on the buccal mucosa near the second molars (Fig. 192-1 and eFig. 192-2.1 in online edition) 1–2 days before and lasting 2 days after the onset of the rash (see eFig. 192-1.1 in online edition).[2,4] Individuals with preexisting partial immunity (e.g., patients who received exogenous immunoglobulin) may have less severe symptoms but a prolonged incubation period (14–20 days). Conversely,

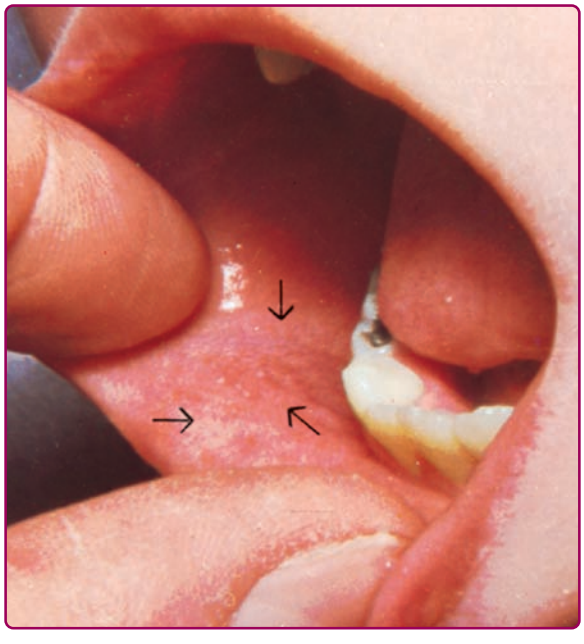

Figure 192-1 The pathognomonic Koplik spots appear as tiny white lesions surrounded by an erythematous halo—"grains of sand." They precede the generalized rash by 1–2 days.



Figure 192-2 The morbilliform eruption of measles in a toddler.

immunosuppressed patients may have more severe disease and can present without the typical rash.[2]

CUTANEOUS LESIONS. The exanthem is characterized by erythematous, nonpruritic macules and papules that begin on the forehead and behind the ears (Fig. 192-2). The rash quickly progresses to involve the neck, trunk, and extremities (Fig. 192-3 and eFig. 192-3.1 in online edition). The hands and feet are involved. Lesions may coalesce, especially on the face and neck (see Fig. 192-3.2 in online edition). The rash usually peaks within 3 days and begins to disappear in 4–5 days. Desquamation may occur as the rash resolves.



Figure 192-3 Measles. Classic morbilliform exanthem with red papules spreading from forehead and postauricular to neck, trunk, and then extremities.

RELATED PHYSICAL FINDINGS. The entire illness may last up to 10 days, with some individuals also having vomiting, diarrhea, abdominal pain, splenomegaly, pharyngitis, otitis media, and generalized lymphadenopathy.[4] Immunosuppressed patients are at higher risk for pneumonitis, acute encephalitis (1:1000 cases), and other fatal complications.[4,8] Viral shedding may also be more persistent in these individuals.[2,9]

Atypical measles infection is rare, but seen in individuals who received formalin-inactivated measles vaccine (1963–1967) and were subsequently exposed to wild-type virus.[4] Symptoms are often more severe with high fever, interstitial pneumonia, pleural effusions, extremity edema, hepatitis, and hyperesthesias occurring more commonly. Coryza, conjunctivitis, and Koplik spots are usually not present. The rash may be maculopapular, hemorrhagic, vesicular, or urticarial and spreads centripetally, making it difficult to distinguish from Rocky Mountain spotted fever.[4]

LABORATORY TESTS

The laboratory diagnosis of measles is based on virus detection or positive serologic findings.[7] During the prodrome stage, virus can be found in nasopharyngeal secretions, blood, and urine. Viral culture has a low sensitivity for finding the virus but viral immunofluorescence tests may quickly detect measles in throat or nasopharyngeal specimens.[10] Indirect enzyme linked immunoassay (ELISA), polymerase chain reaction (PCR), and reverse transcription-PCR assays can detect measles virus in clinical specimens such as nasopharyngeal secretions, oral fluid, serum, dried blood spots collected on filter paper and urine.[7,11] Genotyping of viral isolates can determine patterns of transmission and importation. Genome sequencing can differentiate wild type and vaccine virus infection.[2]

Serologic studies demonstrate measles virus infection with a documented presence of measles IgM antibody and/or a significant increase in measles IgG antibody concentration in paired acute and convalescent titers. IgM antibody increases with the onset of the rash and lasts approximately 1 month. It may be absent or only transient in patients immunized with two vaccine doses.[2,12] As the sensitivity of measles IgM assays may vary during the first 3 days after onset of rash, the test should be repeated in any suspected patient with a negative measles IgM assay and a generalized rash lasting more than 72 hours.[2] IgG antibody appears 2 weeks after rash onset and peaks 4–6 weeks later.[2] In the United States, measles should be reported to the local or state health department.

DIFFERENTIAL DIAGNOSIS

(Box 192-1)

COMPLICATIONS

Age-specific rates of complications are highest among children less than 5 years old and adults over

BOX 192-1 DIFFERENTIAL DIAGNOSIS OF MEASLES

Most Likely

- Drug hypersensitivity reaction
- Rubella

Consider

- Rocky Mountain spotted fever (atypical cases)
- Henoch–Schönlein purpura (atypical cases)
- Other viral infection (parvovirus, enterovirus, adenovirus, human herpesvirus-6, Epstein–Barr virus)

Always Rule Out

- Kawasaki disease
- Graft-versus-host disease (recent bone marrow transplant)

20 years. The most common complications of measles virus infection are otitis media, pneumonia, laryngotracheobronchitis, and diarrhea.[2,13] Hepatitis, thrombocytopenia, and encephalitis occur less commonly. Thrombocytopenia-associated purpura may be severe. Pneumonia is the most common fatal complication of measles in children and the most common complication overall in adults.[4,14] The disease severity is worse in immunocompromised and malnourished individuals, often resulting in the development of Hecht giant cell pneumonia.[15]

Subacute sclerosing panencephalitis (SSPE), a rare degenerative central nervous system disease that occurs 7–10 years after wild-type measles infection, is marked by seizures and behavioral and intellectual deterioration.[2]

PROGNOSIS AND CLINICAL COURSE

Clinical diagnosis of measles is typically made with onset of the characteristic rash as the prodromal symptoms can mimic influenza-like illnesses. Uncomplicated measles is self-limited, lasting 10–12 days. Malnutrition, immunosuppression, poor health, and inadequate supportive care can worsen the prognosis in any patient. In developing nations, measles is a major cause of infant mortality.

TREATMENT

Treatment for measles in the majority of cases is supportive, particularly to maintain good hydration. Patients should be on standard and airborne transmission precautions for 4 days after rash onset (entire duration of illness in immunocompromised patients).[2] Patients with secondary bacterial infections need to be treated with appropriate antibiotics. Ribavirin may be considered, as it has been shown to inhibit measles virus in tissue culture and reduce the severity and duration of measles in some cases.[2,4,16] In trials of patients with subacute sclerosing panencephalitis, however, no benefit was noted with the use of ribavirin.

Malnutrition and vitamin A deficiency can depress cell-mediated immunity in children, increasing the risk and severity of childhood infections. Measles virus infection decreases serum levels of vitamin A and can lead to higher risk of mortality from disease. The World Health Organization (WHO) and the United Nations International Children's Emergency Fund (UNICEF) issued a joint statement that vitamin A should be administered to all children with measles in communities where vitamin A deficiency is known or where measles mortality is at least 1%.[2,17] A 2005 Cochrane review of vitamin A supplementation to treat measles in children found an association between using two doses of vitamin A on two consecutive days and a reduced risk of measles mortality in children less than 2 years old.[2,18]

All individuals at risk (infants less than 1 year of age, pregnant women, unimmunized, and immunocompromised) should receive immunoglobulin prophylaxis within 6 days of exposure to measles virus.[2] If given within 72 hours of exposure, the individual may not be infected with the virus.[4] Healthy individuals should receive 0.25 mL/kg of intramuscular immunoglobulin, and immunocompromised patients require 0.5 mL/kg.[2] Exposed patients (excluding pregnant women and those with impaired immune systems) should also be given the measles vaccine 5–6 months later to confer lasting protection (Box 192-2).

PREVENTION (IMMUNIZATIONS)

The incidence of measles has decreased worldwide as a direct result of immunization. Two doses of the live attenuated measles vaccine (with first dose at or after 12 months of age) produces detectable levels of antibody in 99% of individuals, conferring lifelong immunity.[2,4] Exposure to measles is not a contraindication to immunization. Measles vaccine may even provide protection in some cases if given within 72 hours of the exposure.[2]

Common potential side effects of measles vaccine include fever, local injection site reaction and transient morbilliform rash (7–10 days after vaccination; lasts

BOX 192-2 TREATMENTS FOR MEASLES

- First line
  - Supportive care
  - Treat secondary infections
  - Vitamin A[a]
  - Immune globulin, IM[a]
  - Measles vaccine
- Second line
  - Ribavirin[a]

[a]In select cases, please see text.

2 days) that resolve without treatment. Less common adverse reactions include thrombocytopenia and transient neurologic reactions.[2,19]

Measles vaccine administration is contraindicated in individuals who have a moderate to severe illness as well as those who have had an immediate anaphylactic reaction to a previous measles vaccine. It is also contraindicated in pregnant women and those with impaired immune systems (human immunodeficiency virus infection, immunosuppressive therapy). Hypersensitivity reactions can occur to components of the vaccine such as gelatin, neomycin, or egg white cross-reacting proteins.[2,20]

There have been many unconfirmed, unsubstantiated but widely publicized reports suggesting a potential link between measles-mumps-rubella (MMR) vaccine and the development of autism and possibly inflammatory bowel disease and atopic disorders. Current scientific evidence does not support a causal link between MMR vaccine and autism, inflammatory bowel disease or atopic disorders.[21–25]

RUBELLA

RUBELLA AT A GLANCE

- German measles, 3-day measles.
- Epidemic disease; worldwide distribution.
- Short prodrome; rash of 2- to 3-day duration.
- Enlargement of cervical, suboccipital, and postauricular glands.
- High risk of fetal malformations with congenital infection (microcephaly, congenital heart disease, and deafness), particularly in the first trimester.

EPIDEMIOLOGY

Rubella virus has a worldwide distribution with outbreaks occurring most frequently in late winter and early spring months. Humans are the only hosts for infection.[26] School-aged children, adolescents, and young adults most often develop the disease. Epidemics occasionally occur in developing countries, especially where vaccines are unavailable.

Since introduction of the rubella vaccine in the United States in 1969, the incidences of rubella and congenital rubella syndrome have drastically declined with no widespread epidemics occurring in the United States. Since 2003, fewer than 20 cases are reported annually in the United States.[27] Occasional outbreaks have largely been attributed to failure to vaccinate susceptible individuals. Yet, recent serologic surveys indicate that approximately 10% of the United States-born population >5 years old is susceptible to rubella.[26,27] Epidemiologic studies have identified that individuals born outside the country or in a vaccine-poor area also have an increased risk of rubella.[26]

ETIOLOGY AND PATHOGENESIS

Rubella is an enveloped positive-stranded RNA virus in the Togaviridae family that is spread through direct or droplet contact from nasopharyngeal secretions.[26] Infected individuals shed virus for 5–7 days before and up to 14 days after onset of rash,[28] with viremia unlikely after the rash occurs. In most individuals, infection leads to lifelong immunity.

Congenital rubella occurs when a nonimmunized, susceptible, pregnant woman is exposed to the virus. Transplacental infection of the fetus occurs during the viremic stage. The risk is greatest to a fetus exposed to the virus in the first trimester. Congenitally infected infants may shed the virus through urine, blood, and nasopharyngeal secretions for up to 12 months after birth, thus being a potential source of viral exposure to other susceptible individuals.[26,28]

CLINICAL FINDINGS

HISTORY. Primary rubella infection is typically a mild, subclinical disease, particularly in adults.[26,28] The prodrome is characterized by low-grade fever, myalgias, headache, conjunctivitis, rhinitis, cough, sore throat, and lymphadenopathy; symptoms that may last up to 4 days and often resolve with appearance of rash. Up to 50% of children with primary rubella infection may have a subclinical infection[29] or present only with lymphadenopathy or rash (no prodrome).[28] Conversely, older adults may have more severe and persistent prodromal symptoms that may make distinction from rubeola difficult in some situations. The presence of Koplik spots in the mouth favors rubeola. As the prodrome resolves and the rash begins to appear, some patients develop an enanthem consisting of tiny red macules on the soft palate and uvula (Forschheimer spots).[30] This enanthem is not diagnostic for rubella.

CUTANEOUS LESIONS. The exanthem, occurring 14–17 days after exposure, is characterized by pruritic pink to red macules and papules that begin on the face, quickly progressing to involve neck, trunk, and extremities (Fig. 192-4 and "Rubella At a Glance" image).[28] Lesions on the trunk may coalesce, whereas those on the extremities often remain more discrete. The rash usually begins to disappear in 2–3 days, unlike rubeola, which can be more persistent and clears the head and neck first. Desquamation may follow resolution of the rash.

RELATED PHYSICAL FINDINGS. Lymphadenopathy is usually most severe in the posterior cervical, suboccipital, and postauricular lymph nodes



Figure 192-4 Rubella. Erythematous macules and papules appearing initially on the face and spreading to trunk, arms, and legs within 24 hours.

and is noted up to 7 days before the rash appears.[26] Enlargement of the nodes may persist for several weeks.

Adults, particularly women (up to 70%), may develop arthritis with rubella infection.[26] Both small and large joints may be affected. Joint symptoms often first appear as the rash fades and can last several weeks. In some individuals, the symptoms may become persistent or recurrent. Joint swelling may progress to form a joint effusion.

LABORATORY TESTS

Diagnosis is typically made using serology to detect rubella-specific IgM antibody (up to 8 weeks after infection) or to document a fourfold rise in antibody titer in acute and convalescent-phase serum.[26,30] Hemagglutination inhibition (less common), complement fixation, immunofluorescence assay, and ELISA are some of the methods used to detect antibodies.[11] As with measles, rubella cases should be reported to local or state health departments.

Viral culture (nose, throat, blood, urine, CSF, and synovial fluid) is sensitive but often difficult due to the influence of timing, collection procedure and transport on the specimen.[11] Reverse transcription PCR may be used to detect rubella virus from throat swab or oral fluid with subsequent genotyping of strains to identify a source during outbreaks.[11,31] Complete blood cell count usually shows leukopenia with relative neutropenia. Increased numbers of atypical lymphocytes or abundant plasma cells may be noted as well. Patients with meningeal involvement have lymphocytes in the cerebrospinal fluid (CSF).

CONGENITAL RUBELLA SYNDROME

Women who are infected with rubella during pregnancy may only exhibit minor clinical symptoms. The effects, however, of rubella infection on the fetus can be profound,[28] with the greatest risk of fetal malformation in the early stages of pregnancy. Up to 85% of fetuses exposed to rubella within the first 12 weeks of gestation develop serious sequelae such as: microcephaly with mental retardation, congenital heart disease (ventricular septal defect, patent ductus arteriosus, pulmonary artery stenosis), sensorineural deafness, cataracts, glaucoma, low birth weight, and fetal death.[27,28,30] Neonatal manifestations of congenital infection include: growth retardation, interstitial pneumonitis, radiolucent bone disease, hepatosplenomegaly, thrombocytopenia, and dermal erythropoesis "blueberry muffin lesions."[26]

Diagnosis of congenital rubella infection is obtained by isolating rubella virus in the throat, cataracts, urine, or CSF of the affected neonate. Serologic testing is not as sensitive but is easily available for confirmatory testing. IgM antibody can be detected from birth to 1 month of age; IgG antibody titers may be stable or increase over several months. Laboratory confirmation of congenital infection in children >1 year old is difficult as viral isolation is rare.[26,28]

DIFFERENTIAL DIAGNOSIS

(Box 192-3)

COMPLICATIONS

Rarely, rubella infection may lead to encephalitis (1 in 6,000 cases),[30] with mortality rates varying from 0% to 50%.[30] Other rare complications include: peripheral neuritis, optic neuritis, myocarditis, pericarditis, hepatitis, orchitis, and hemolytic anemia.[28] Transient thrombocytopenia has been described in 1 in 3,000 children (usually girls); first appearing within days of rash onset and lasting days to months.[28,32] Recently, cases of rubella-associated hemophagocytic syndrome

BOX 192-3 DIFFERENTIAL DIAGNOSIS OF RUBELLA

Most Likely
- Drug hypersensitivity reaction
- Rubeola (measles)

Consider
- Other viral infection (enterovirus, adenovirus, parvovirus, human herpesvirus-6)

Always Rule Out
- Streptococcal scarlet fever

For differential diagnosis of congenital rubella syndrome with blueberry muffin lesions, see Box 192-9.

and encephalitis have been described.[33,34] Congenital rubella syndrome may predispose patients to developing diabetes mellitus.[35]

PROGNOSIS AND CLINICAL COURSE

Rubella is typically a self-limited disease. Infants who have congenital rubella are infectious until viral shedding from the nasopharynx and urinary tract ends. The majority of infants (85%) infected in utero excrete virus in the first month of life; 1%–3% continue to excrete virus in the second year of life.[26,30] Pregnant women caring for these infants are at risk for developing rubella. Clinical course depends on how severely affected the fetus is from intrauterine infection.

TREATMENT

Treatment of primary, uncomplicated rubella is supportive. Standard and droplet precautions are recommended for patients with rubella for 7 days after rash onset.[26] In nonpregnant individuals, rubella vaccine administration within 3 days of exposure may theoretically prevent illness, though this is yet to be proven.[26] Limited data indicate that intramuscular immune globulin (0.55 mL/kg) as postexposure prophylaxis of rubella-susceptible patients may decrease infection, viral shedding and rate of viremia.[26] However, absence of clinical signs after administration of immune globulin in a pregnant woman does not assure that congenital infection did not occur. IgM antibody can be used to detect maternal infection after exposure, even after immune globulin administration.[26]

Neonates with congenital rubella syndrome require supportive care as well as appropriate attention to significant health issues. These infants are contagious and should be isolated to prevent transmission to susceptible individuals.[26,28] Contact isolation is recommended for these infants until they are at least 12 months old or if repeated cultures are negative after 3 months of age.[26]

PREVENTION (IMMUNIZATIONS)

Rubella vaccine is typically administered as part of a threefold vaccine (MMR) or fourfold vaccine (MMRV) at 12–15 months of age and again at 4–6 years of age. Seroconversion after a single dose of MMR vaccine occurs in 95% of individuals.[26,27] It is imperative that individuals at risk for rubella infection are immunized, such as health care workers, military recruits, college students, and recent immigrants.[26] Individuals are considered immune to rubella if they have documented vaccination with a live MMR on or after their first birthday, serologic evidence of rubella immunity, or were born after 1957 (except women of child-bearing age).[26,30]

Potential adverse reactions to rubella vaccine occur in susceptible individuals and include: fever (6–12 days after vaccine), morbilliform rash, lymphadenopathy, and arthralgia.[26] Febrile seizures occur more frequently in children 1–2 years old when receiving the first MMR vaccine.[26]

Pregnant women should not receive the rubella vaccine due to theoretical risk to the fetus.[36] Any woman receiving the rubella vaccine should not become pregnant for 28 days. Infants of vaccinated breast-feeding mothers may become infected with rubella via breast milk. Typically, they develop a mild erythematous exanthem of macules and papules with no serious effects.[30] As rubella infection confers lifelong immunity, a woman who is reexposed during pregnancy has a low risk of having her fetus contract congenital rubella. Concern about possible infection can be addressed by looking for IgM antibodies in fetal serum (cordocentesis).

ERYTHEMA INFECTIOSUM AND PARVOVIRUS B19 INFECTION

PARVOVIRUS B19 AT A GLANCE

- Causes erythema infectiosum, fifth disease.
- Fifth disease in children with "slapped cheeks" followed by an erythematous, lacy eruption on the trunk and extremities.
- Symmetric polyarthritis, particularly of the small joints.
- Causes papular purpuric gloves-and-socks syndrome with pruritic erythema, edema, and petechiae of the hands and feet, fever, and oral erosions in adolescents.
- Aplastic crisis in patients with increased red blood cell turnover, chronic anemia in immunocompromised persons, and fetal hydrops.

EPIDEMIOLOGY

Erythema infectiosum (fifth disease) is worldwide in distribution, can occur throughout the year, and can affect all ages. It tends to occur in epidemics, especially associated with school outbreaks in the late winter and early spring. Serologic studies show increasing prevalence of antibodies with age. Various studies indicate that from 15% to 60% of children 5–19 years of age and 30%–60% of adults are seropositive.[37] Seroprevalence increases to greater than 90% in the elderly.[37] Previous infection with B19 seems to confer lifelong immunity.

The incubation period for erythema infectiosum is from 4 to 14 days.[38] After intranasal inoculation of parvovirus-infected serum to healthy volunteers, low-grade fever and nonspecific complaints occurred at the time of viremia, 6–14 days after inoculation, and the rash appeared at day 17 or 18.[39] Parvovirus B19 is thought to be transmitted primarily by the respiratory route via aerosolized droplets during the viremic phase, and B19 DNA has been found in respiratory secretions of viremic patients.[39] After the rash of

erythema infectiosum appears, B19 is not found in respiratory secretions and is usually not present in the serum. This suggests that persons with erythema infectiosum are infectious only before the onset of the rash.

The virus seems to be effectively spread after close contact. The secondary attack rate among susceptible household contacts is approximately 50%. Transmission may occur via blood transfusion, from blood products, and vertically from mother to fetus.[40] The transmission of B19 through blood transfusion is particularly problematic because the nonenveloped virus is not killed by the solvent detergents or heat that are used to inactivate HIV and hepatitis viruses.[41]

ETIOLOGY AND PATHOGENESIS

The B19 virus belongs to the family Parvoviridae and the genus *Erythrovirus*.[42] B19 lacks an envelope and contains single-stranded DNA. It is the smallest single-stranded DNA-containing virus known to infect humans, measuring 18–26 µm in diameter. Parvoviruses are widespread in veterinary medicine, but animal parvoviruses are not thought to be transmissible to humans.[41]

The pathogenesis of erythema infectiosum is unknown, but the mechanism may involve immune complexes. The more serious manifestations of parvovirus infection relate to the fact that the virus infects and lyses erythroid progenitor cells. Evidence suggests that the blood group P antigen (globoside) is a receptor of parvovirus. Because some individuals lack P antigen, they are not susceptible to infection with B19.[43] In patients with increased red blood cell destruction or loss who depend on compensatory increase in red cell production to maintain stable red cell indices, B19 infection may lead to transient aplastic crisis. Such patients include those with anemia associated with acute or chronic blood loss. When parvovirus infects the erythroblasts in a developing fetus with decreased red cell survival, the result may be hemolysis and anemia.[44] Anemia may trigger congestive heart failure, edema (fetal hydrops), and possibly fetal death.

CLINICAL FINDINGS

PARVOVIRUS B19 IN CHILDREN. Most infections caused by B19 are asymptomatic and unrecognized. Fifth disease, the most common clinical picture associated with the virus, usually begins with nonspecific symptoms such as headache, coryza, and low-grade fever approximately 2 days before the onset of the rash.[45] Patients may have headache, pharyngitis, fever, malaise, myalgias, coryza, diarrhea, nausea, cough, and conjunctivitis coinciding with the rash. Approximately 10% of children with erythema infectiosum develop arthralgias or arthritis. Large joints are affected more often than small joints.[45] Occasionally, children may present with chronic joint complaints suggestive of juvenile idiopathic arthritis.[46]

The characteristic rash begins with confluent, erythematous, edematous plaques on the malar eminences, the "slapped cheeks" (Fig. 192-5). As the facial rash fades over 1–4 days, pink to erythematous macules or papules appear on the trunk, neck, and extensor surfaces of the extremities. These lesions have some central fading, giving them a lacy or reticulated appearance (Fig. 192-6).[45] The rash can be morbilliform, confluent, circinate, or annular, and there have been reports of palmar and plantar involvement.[38] The eruption typically lasts 5–9 days, but can recur for weeks or months with triggers such as sunlight, exercise, temperature change, bathing, and emotional stress. In some outbreaks, pruritus is a major feature of the rash in children.[38]



Figure 192-5 Erythema infectiosum. Child with the characteristic "slapped cheeks."

There have been occasional reports of parvovirus B19 associated with vascular purpura, including Henoch–Schönlein purpura.[47] An enanthem consisting of erythema of the tongue and pharynx and red macules on the buccal mucosa and palate can occur.

PARVOVIRUS B19 IN ADULTS. Acute arthropathy is the primary manifestation of B19 viral infection in adults.[48] It occurs mainly in women and affects the small joints of the hands and, knees. Other joints, such as the spine and costochondral joints, are occasionally involved. This symmetric polyarthritis is usually of sudden onset and is self-limited but can be persistent or recurrent for months. It may mimic Lyme arthritis or rheumatoid arthritis.

The constitutional symptoms are usually more severe in adults than in children.[49] Fever, adenopathy, and a mild arthritis without a rash is the usual course. Women are more likely than men to have joint complaints and rash, whereas men often present with only a flu-like illness.[48] Some adults may have fatigue, malaise, and depression for weeks after the infection. Asymptomatic infection can certainly occur in adults

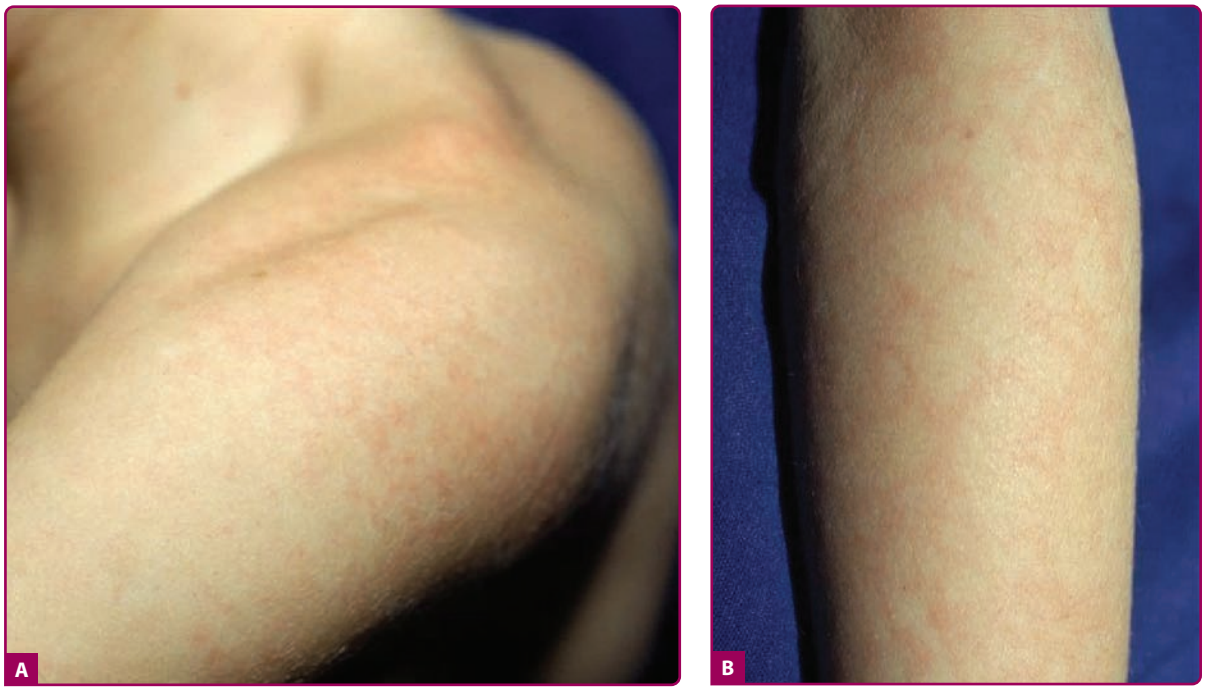

Figure 192-6 **A** and **B.** Erythema infectiosum. **A**. Lacy, reticulated macules and papules on proximal extremities. **B**. Lacy macules on leg.

as well as in children. In one outbreak, 26% of adults were reported to be asymptomatic.[48] Parvovirus B19 can cause numbness and tingling of the fingers with or without other features of fifth disease.[50] Pruritus that is sometimes severe can occur with or without a rash. It has been suggested that if pruritus is a complaint in a patient with acute-onset arthritis, parvovirus should be considered as a possible cause.

The rash in adults, if present at all, is usually macular and blotchy or lacy, often on the extremities, and rarely demonstrates the characteristic slapped-cheek appearance.[48] Other cutaneous manifestations associated with B19 infection in adults include purpura, vesicles and pustules, palmoplantar desquamation, a morbilliform exanthem with Koplik spots, and livedo reticularis.

PAPULAR PURPURIC GLOVES-AND-SOCKS SYNDROME. In 1990,[51] a unique syndrome of pruritic erythema and edema of the hands and feet with petechiae, fever, and oral erosions was described. This rare exanthem, now known as *papular purpuric gloves-and-socks syndrome,* seems to affect teenagers and adults. However, it can affect children also.[52] Patients usually have mild prodromal symptoms of fatigue and low-grade fever, myalgias, and arthralgias. Subsequently, itchy, painful, symmetric edema and erythema of the distal hands and feet occurs.[53] Purpuric papules appear on the hands and feet with abrupt demarcation at the wrists and ankles. The enanthem, if present, arises on the lips, soft palate, and buccal mucosa. The syndrome resolves spontaneously within 2 weeks. Although many viruses have been implicated as causative agents for papular purpuric gloves-and-socks syndrome, B19 is the virus proven to cause the syndrome.[54] Importantly, papular purpuric gloves-and-socks syndrome is contagious when the eruption is present, in contrast to erythema infectiosum.

LABORATORY TESTS

In patients with erythema infectiosum, laboratory results are usually normal, including reticulocyte count, hematocrit, and tests of liver and renal function. Patients with aplastic crisis have reticulocytopenia and anemia, the severity of which depends on the degree of underlying anemia. Reticulocytopenia, anemia, lymphopenia, neutropenia, and thrombocytopenia can occur in healthy individuals with B19 infection, although these are usually not significant enough to cause clinical symptoms. The erythrocyte sedimentation rate is rarely elevated, and rheumatoid factor has been positive in some cases of parvovirus-associated arthritis.

Detection of recent infection is usually performed with assays for IgM antibody. Radioimmunoassay or ELISA techniques can detect IgM within a few days after onset of illness. IgM can be measured for up to 6 months in many cases, although there is a decline in titer in the second month after onset. IgG can be identified with the same techniques by the seventh day of illness and lasts for years and is therefore best for documenting past infection. Parvovirus antibody is often not detectable in immunodeficient persons.

SPECIAL TESTS

Histologic examination of various tissues demonstrates homogeneous, intranuclear inclusions with peripheral condensation of chromatin in erythroid precursor

cells.[55] Electron microscopy of these inclusions reveals parvovirus-like particles.[55] In fetal tissues, a leukoerythroblastic reaction may also be seen. The histopathologic changes in the skin of patients with erythema infectiosum include a sparse superficial perivascular lymphocytic infiltrate that is not considered diagnostic.

PCR is used to detect B19 DNA.[56] This technique is considered one of the most sensitive approaches for detection of the virus within a number of different specimens including serum or plasma, amniotic fluid, placental or fetal tissue, or bone marrow. It is considered the test of choice in an immunocompromised patient. Immunohistochemical techniques can be used to detect B19 parvovirus antigen in a number of different tissues.

DIFFERENTIAL DIAGNOSIS

(Box 192-4)

COMPLICATIONS

As more attention is focused on parvovirus B19, an increasing number of complications are recognized. Subclinical infection is quite common. However, this virus can be responsible for a variety of hematologic, rheumatologic, and neurologic abnormalities.

TRANSIENT APLASTIC CRISIS. Parvovirus B19 is the most common cause of transient aplastic crisis in patients with chronic hemolytic anemias.[57] This has been demonstrated in sickle cell anemia, hereditary spherocytosis, heterozygous β-thalassemia, pyruvate kinase deficiency, and autoimmune hemolytic anemia, as well as in other conditions of decreased red cell production or increased red cell destruction. The aplastic crisis may be the initial manifestation of the underlying hematologic disease.[58] Patients typically have fever and constitutional complaints, followed 1 week later by fatigue, pallor, and worsening anemia.[59] Cutaneous manifestations are rarely seen with the aplastic crisis. The hemoglobin may fall below 4 μg/dL and is not associated with reticulocyte production. Bone marrow examination shows hypoplasia or aplasia of the erythroid series. Red blood cell transfusion may be necessary, and most patients recover in 1 week, although the problem can be fatal if untreated. Transient red cell aplasia can occur in healthy persons without underlying hematologic abnormalities.[60] It is likely that the aplasia is missed in individuals without disorders of shortened erythrocyte survival because the hemoglobin does not drop low enough to cause symptoms.

CHRONIC B19 INFECTION. In immunocompromised patients, B19 infection can cause a serious, prolonged anemia from persistent lysis of red blood cell precursors.[60] Parvovirus-related chronic anemia has been reported in HIV-infected patients, as well as in transplant recipients and those with congenital immunodeficiencies, acute leukemias, lupus erythematosus, and during the first year of life without immunodeficiency. These patients respond dramatically to intravenous γ globulin, suggesting that antibody is the main defense to human parvovirus infection.[61]

FETAL B19 INFECTION. Fetal infection with B19 may result in either an unaffected fetus or spontaneous abortion (especially in the first half of pregnancy), hydrops fetalis in the second half of pregnancy, congenital anemia, and even late fetal death.[62] Nonimmune fetal hydrops is the most common complication of intrauterine infection with B19. Because B19 virus can infect erythroid precursors, extensive hemolysis can occur in the fetus, leading to severe anemia, tissue anoxia, high-output heart failure, and generalized edema. The fetus may show ultrasonographic evidence of subcutaneous edema, ascites, pleural effusion, pericardial effusion, placental edema, and polyhydramnios. The overall risk of fetal death is not clearly known, but recent studies suggest that this risk is approximately 6.5% with maternal infection.[62] The risk of fetal death for a woman with unknown serologic status is estimated to be less than 2.5% after a household exposure and less than 1.5% after a significant work exposure. It seems that in B19-infected pregnant women, most fetuses are not infected; if they are infected, usually there is not an adverse outcome.[63] Furthermore, approximately one-half of women of childbearing age are immune to parvovirus infection because of prior infection.

Because parvoviruses are known teratogens in animals, there has been much concern about whether they cause birth defects in humans. In sera collected from 253 infants with a wide range of congenital abnormalities, there was no parvovirus-specific IgM detected to suggest recent infection.[64] There has been one report of a B19-infected abortus with eye abnormalities,[65] and another of

BOX 192-4 DIFFERENTIAL DIAGNOSIS OF PARVOVIRUS B19 INFECTION

Most Likely
- Erythema infectiosum
- Drug reaction
- Enteroviral infection
- Erysipelas on the cheek
- Papular purpuric gloves-and-socks syndrome
- Hand-foot-mouth disease

Consider
- Erythema infectiosum
- Roseola
- Rubella
- Measles
- Collagen vascular disease (systemic lupus erythematosus, dermatomyositis)
- Papular purpuric gloves-and-socks syndrome
- Atypical measles

Always Rule Out
- Scarlet fever
- Rocky Mountain spotted fever
- Kawasaki disease

an infected abortus with cleft lip, cleft palate, and micrognathia.[66] Rare reports describe cardiac abnormalities.[67] neurologic problems,[68] and "blueberry muffin" nodules.[69] It has been concluded from these few studies that parvovirus B19 is not a common cause of birth defects.

OTHER COMPLICATIONS. There are reports of B19 infection causing encephalitis, meningitis, brachial neuritis, a myasthenia-like syndrome, and motor weakness. Parvovirus infection has been blamed for a granulomatosis with polyangiitis (Wegener's) illness,[70] polyarteritis nodosa,[71] Kawasaki disease,[72] and a systemic lupus erythematosus-like picture.[73] In addition, there are reports of other hematologic complications including idiopathic thrombocytopenic purpura, transient neutropenia, myocarditis, a hemophagocytic syndrome, and the Blackfan–Diamond syndrome.

PROGNOSIS AND CLINICAL COURSE

Parvovirus B19 infection in healthy individuals is self-limited. The eruption of erythema infectiosum and the parvovirus arthropathy usually resolve in 1–2 weeks, but can recur or persist for months. If untreated, transient aplastic crisis can be fatal, but most patients recover in 1 week. Chronic anemia from B19 usually resolves if treated with γ globulin. Fetal hydrops can lead to fetal death if not treated.

TREATMENT

There is no specific treatment available for parvovirus B19 infection. Erythema infectiosum is a benign condition, and usually no treatment is necessary. Supportive therapy for relief of fatigue, malaise, pruritus, and arthralgia may be needed. The chronic anemia of persistent B19 infection may be treated successfully with commercially available intravenous immunoglobulin, which contains neutralizing anti-B19 antibodies. Transient aplastic crisis, which can be life threatening, may require oxygen therapy and blood transfusion.

Serologic testing for B19 IgG and IgM should be offered to pregnant women who are exposed to parvovirus B19. Infected pregnant women are followed by frequent ultrasonograms. Evidence of hydrops fetalis warrants umbilical cordocentesis to check for anemia, viral DNA, IgG, and IgM. The management of infected fetuses is controversial. Some physicians advocate observation because spontaneous resolution is common. Fetuses with severe anemia and compromise are usually managed with intrauterine exchange transfusion, but this procedure does carry risk (Box 192-5).

PREVENTION

There is currently no vaccine to prevent parvovirus B19 infection. Candidate vaccines are in clinical trials.[74] It is not known whether immunoglobulin given around the time of exposure prevents infection or alters the course of the disease.

BOX 192-5 TREATMENTS FOR PARVOVIRUS B19 INFECTIONS

▪ Erythema infectiosum	Supportive treatment of fatigue, malaise, pruritus, arthralgias
▪ Chronic anemia	IV immune globulin
▪ Transient aplastic crisis	Oxygen and/or blood transfusion may be necessary
▪ Hydrops fetalis	Possible intrauterine exchange transfusion

Because patients with erythema infectiosum are no longer infectious by the time they develop the illness, control measures directed toward these individuals are not likely to be effective. If these persons are hospitalized, no special precautions need to be taken. Because the virus is transmitted before the rash appears, the disease is easily spread in situations of close prolonged contact such as schools, day care centers, workplaces, and homes.

Patients with aplastic crisis or immunosuppression with chronic B19 anemia may have high-titer viremia and are particularly infectious. These individuals should be placed in respiratory and contact isolation if hospitalized, and pregnant health care providers should not care for them directly. Hospital workers are at risk of contracting nosocomial infections from these patients[75] and could spread the virus to patients if adequate precautions are not taken.

EPSTEIN–BARR VIRUS

EPSTEIN–BARR VIRUS AT A GLANCE

- Human herpesvirus 4.
- In developed countries, primary infection most often occurs during adolescence/early adulthood.
- Infectious mononucleosis characterized by the triad of fever, lymphadenopathy, and pharyngitis.
- Morbilliform exanthem with primary infection; most common after administration of ampicillin/amoxicillin.
- Oral hairy leukoplakia, nasopharyngeal carcinoma, Burkitt lymphoma, Hodgkin disease, Kikuchi histiocytic necrotizing lymphadenitis, and certain types of cutaneous T-cell lymphoma associated with Epstein–Barr virus infection.

EPIDEMIOLOGY

Epstein–Barr virus (EBV) is a worldwide pathogen with more than 90% of adults latently infected.[76] In developed countries, most cases of primary infection occur during adolescence or early adulthood, and clinically may present as infectious mononucleosis.[77] Primary infection may occur during childhood; however, is often subclinical, probably because children are better able to clear the infection. In developing countries, most of the population is infected during childhood, thus infectious mononucleosis is much less common.

EBV is transmitted primarily by saliva through close contact.[78] Viral replication occurs during primary infection, allowing infectious viral particles to be shed from the oropharynx. There are also reports of EBV acquired via blood transfusion.[79] It is also thought that EBV may be transmitted through breast milk[80] and genital secretions.[81]

ETIOLOGY AND PATHOGENESIS

EBV, also called *human herpesvirus 4 (HHV-4)*, belongs to the Herpesviridae family and is approximately 180–200 nm in diameter.[78] The double-stranded DNA genome encodes approximately 100 proteins and is enclosed within a capsid. The capsid is surrounded by an envelope, composed primarily of glycoprotein gp350. CD21 is present on the surface of B cells and binds with gp350, allowing entry of EBV into the cell.

EBV infects B lymphocytes directly within the oral mucosa or infects mucosal epithelial cells, which then infect the B lymphocytes.[82–84] The infected B cells are activated, and their population is expanded. These B lymphocytes allow dissemination of the virus throughout the lymphoreticular system.[85] A clonal expansion of cytotoxic T lymphocytes allows recovery from primary infection and is the source of the atypical lymphocytes associated with EBV infection.[86] Symptoms likely result from this immunologic response.

EBV establishes an indefinite latent infection within the B cells, during which time low levels of the latent proteins are produced.[86] The previously linear DNA forms a circular structure, called an episome. Thereafter, B cells may reactivate and reinfect the oropharynx; replication and shedding of the viral DNA allows transmission of the virus to new hosts.[78,85]

CLINICAL FINDINGS

HISTORY. There is an incubation period of 30–50 days. Primary infection with EBV in adolescents and adults typically results in infectious mononucleosis, or the "kissing disease." The classic triad of fever, lymphadenopathy, and pharyngitis are noted in more than 50% of patients.[78] The fever may range from 37.5°C (99.5°F) to 40.5°C (104.9°F) and lasts 1–3 weeks. Lymphadenopathy is tender and characteristically found in the posterior cervical chain. Examination of the posterior pharynx may vary from mild erythema to grossly enlarged tonsils with white exudates.[85]

CUTANEOUS LESIONS. Seventy percent to 100% of patients with infectious mononucleosis develop an eruption when antibiotics, specifically ampicillin, are administered.[83] Similar rashes have been reported with other antibiotics, such as amoxicillin, cephalexin, erythromycin, and levofloxacin. The rash typically begins 7–10 days after the initial administration of antibiotics. A pruritic, erythematous, morbilliform, or scarlatiniform eruption is noted on the trunk and extremities. The rash has been described as copper colored. Coalescence may be observed on the extensor surfaces and dependent areas. (Fig. 192-7 and see eFig. 192-7.1 in online edition). The palms, soles, or oral mucosa may be involved. Clearance, which is usually within 7 days,[87] is accompanied by prominent desquamation.[86] The rash is thought to be a result of EBV-induced antibodies that are produced in response to the administered drug; these antibodies subsequently form immune complexes, which fix complement.[83] This exanthem does not usually indicate a permanent allergy to the medication.[87]

An exanthem due to EBV alone occurs in a minority of cases (approximately 5%–15%),[83,87] and can similarly be morbilliform and pruritic; however, usually it commences during the first few days of illness and resolves faster, typically in 1–6 days.[86,87] Periorbital and eyelid edema may be seen in up to 50% of those with infectious mononucleosis.[89] In approximately 25% of cases, an enanthem is noted. Six to 20 petechiae, measuring 0.5–1.0 mm, may be visualized at the junction of the hard and soft palate. Lesions may coalesce forming larger lesions.

Erythema multiforme, erythema nodosum, acrocyanosis, erythema annulare centrifugum, pityriasis lichenoides, palmar dermatitis, cold urticaria, and granuloma annulare have all been reported during infection with EBV.[86]

Genital ulcers may occur during primary infection with EBV (Fig. 192-8).[90,91] They may occur prior to the onset of other features of infectious mononucleosis or occasionally after the fever and lymphadenopathy.[92] They are well circumscribed, painful, and deep with a red-violaceous border. The base of the ulcer can be clear, seropurulent, or with granulation tissue. They frequently occur on the labia minora.[93] If bilateral, they are often symmetric with a "kissing" pattern. It is unclear at this point whether the ulcer is caused directly by the virus or whether it is due to a host immune response. Biopsy is typically nonspecific and nondiagnostic. The ulcers heal in approximately 2–3 weeks, and treatment is symptomatic.

EBV is currently the most common cause of Gianotti–Crosti syndrome.[94] In children, primary infection with EBV is often mild or asymptomatic; as a result, typical features of infectious mononucleosis are usually not observed.[86]

RELATED PHYSICAL FINDINGS. Associated symptoms and signs may include fatigue, rigors, headache, and hepatosplenomegaly.[95]



Figure 192-7 **A**. Epstein–Barr virus mononucleosis. Copper-colored papules on trunk and extremities after taking oral amoxicillin. **B**. Closer view of rash with Epstein–Barr virus mononucleosis. (Used with permission from Helmut Hintner, MD.)

LABORATORY TESTS

Most patients with infectious mononucleosis demonstrate lymphocytosis, with lymphocytes often accounting for more than 50% of the absolute white blood cell count.[96] Atypical lymphocytes are a hallmark, and typically represent more than 10% of total lymphocytes; most of these cells represent activated T cells responding to infected B cells.[78] Mild, transient neutropenia[97] and thrombocytopenia[98] are common. Transaminases are elevated in more than 80% of patients with infectious mononucleosis.[99]



Figure 192-8 Two scrotal ulcerations in a patient with documented EBV infection.

The presence of heterophile antibodies confirms most cases of infectious mononucleosis.[100] Heterophile antibodies recognize antigens on the erythrocytes from a number of different species, including horses, sheep, bulls, and humans; however, they do not recognize EBV. They are thought to be a result of polyclonal stimulation during the viral infection,[101] and can occasionally be detected (false positives) in other illnesses such as lymphoma, hepatitis, or autoimmune disease.[100] Heterophile antibodies typically appear within 1 week of the onset of symptoms, peak within 2–5 weeks, and may persist for up to 1 year. They are not the ideal diagnostic test in children less than 4 years old, as sensitivity is quite low.[95] In the past, the Paul–Bunnell test had been used with sheep erythrocytes.[100,96] Currently, the more sensitive monospot test is used, which is a latex agglutination assay with horse erythrocytes to look for heterophile antibodies. Up to 10% of patients with EBV mononucleosis never develop heterophile antibodies; this is referred to as heterophile-negative mononucleosis.

A number of antibodies specific to EBV develop in the course of disease as well.[100,95] Measurement of these specific antibodies may be warranted if infectious mononucleosis is suspected and heterophile antibodies are negative. IgM and IgG antibodies form to viral capsid antigen (VCA) and are both present at onset of disease. IgM VCA antibodies wane after approximately 3 months; IgG VCA antibodies persist for life and are a marker for previous infection. IgG antibodies to EBV nuclear antigen develop 6–12 weeks into the course of disease and also persist for life. IgG to early antigen develops at the onset of disease and is made up of two subsets of antibodies, anti-D and

anti-R. The presence of anti-D antibodies suggests recent infection, although 30% of patients do not produce antibodies at all. Anti-R antibodies have no clinical significance. Thus, primary infection may be most easily diagnosed in the presence of IgM and IgG VCA antibodies as well as negative IgG EBV nuclear antigen antibodies.[102]

HISTOPATHOLOGY

The morbilliform exanthem associated with EBV demonstrates nonspecific histopathologic findings.[103] There is usually a mild perivascular infiltrate of inflammatory cells. Specific cutaneous manifestations may show their characteristic pathologies.

DIFFERENTIAL DIAGNOSIS

(Box 192-6)

COMPLICATIONS

Complications of infectious mononucleosis occur in approximately 20% of patients and include airway obstruction, autoimmune hemolytic anemia or thrombocytopenia, neutropenia,[85] myocarditis, and hepatitis.[80] Neurologic complications occur in approximately 5% of patients.[85] Examples include encephalitis, meningitis, and Guillain–Barré syndrome.[78] The risk of splenic rupture is estimated at 0.1% and is spontaneous in greater than one-half of cases.[104] Between 3% and 30% of patients with infectious mononucleosis also have concomitant group A streptococcal pharyngitis.[96] Finally, in some patients, fatigue and hypersomnia can persist up to 6 months.[105]

BOX 192-6 DIFFERENTIAL DIAGNOSIS OF INFECTIOUS MONONUCLEOSIS

Most Likely
- Group A streptococcal infection
- Cytomegalovirus mononucleosis
- Toxoplasmosis

Consider
- Viral hepatitis
- Measles
- Rubella
- Enterovirus
- Adenovirus

Always Rule Out
- Primary exanthem of human immunodeficiency virus
- Drug rash with eosinophilia and systemic symptoms syndrome

PROGNOSIS AND CLINICAL COURSE

Recovery from infectious mononucleosis is typically over 2–3 weeks without specific treatment.[100] Disease may be more protracted in older adults. Chronic active EBV infection occurs rarely.[78] It begins as a primary EBV infection and persists for more than 6 months with severe illness and histologic evidence for organ disease. EBV DNA or antigens can be demonstrated from tissue, and usually EBV antibody titers are significantly elevated.

TREATMENT

Treatment for uncomplicated infectious mononucleosis is symptomatic (Box 192-7).[95] Acetaminophen or nonsteroidal anti-inflammatory agents may be useful in treating the fever or throat discomfort. Because splenomegaly is often an associated finding, contact sports should be avoided until the spleen has returned to its normal size to avoid splenic rupture.

Systemic corticosteroids may decrease the duration of fever or pharyngeal symptoms, but in general, are not recommended for uncomplicated disease.[77]

There have been complications such as encephalitis or meningitis associated with steroid treatment of infectious mononucleosis. Oral steroids may be considered in patients showing signs of impending airway obstruction, thrombocytopenia, or hemolytic anemia.

A meta-analysis of five randomized controlled trials evaluating acyclovir in the treatment of infectious mononucleosis showed that there was decreased oropharyngeal shedding of the EBV; however, there was no overall clinical benefit demonstrated.[106] A multicenter, double-blind, placebo-controlled study involving 94 patients with acute infectious mononucleosis revealed that acyclovir and prednisolone also reduced oropharyngeal replication of virus but did not affect duration of symptoms.[107]

BOX 192-7 TREATMENT FOR EPSTEIN–BARR VIRUS INFECTIOUS MONONUCLEOSIS

First line	Fever, throat discomfort, myalgias, headache. Splenomegaly	Acetaminophen/nonsteroidal anti-inflammatory drugs. Avoid contact sports until spleen size normalizes to prevent splenic rupture
Second line	Impending airway obstruction, thrombocytopenia, hemolytic anemia	Systemic corticosteroids

PREVENTION

Because infectious mononucleosis is often mistaken for a bacterial infection, antibiotics may initially be used to treat. Antibiotics should be avoided in infectious mononucleosis as an exanthem is much more likely to occur in this setting.

Vaccinations are currently being investigated and may prove to be helpful in preventing EBV infections in the future, particularly in high-risk patients.[78]

LYMPHOPROLIFERATIVE DISEASE AND MALIGNANCY

The latent infection established by EBV has been linked to the development of several malignancies, including nasopharyngeal carcinoma, Burkitt lymphoma, and Hodgkin lymphoma.[78] EBV-associated malignancies occur mainly in patients who are immunocompromised due to HIV infection, congenital immunodeficiencies, or those who receive immunosuppressant therapy such as organ transplant recipients. It is thought that the latent infection of B cells allows transformation and immortalization, allowing the development of a neoplasm to occur.[114] Different EBV genes are expressed in each type of malignancy and the biology is quite complex.

Nasopharyngeal carcinoma occurs sporadically in the United States and in Western Europe, is common among Alaskan Eskimos, and is endemic in Southern China, Southeast Asia, and in the Mediterranean basin.[115] This neoplasm may clinically present with bloody nasal drainage, otitis media, or cranial nerve palsies. Metastasis to the lymph nodes occurs early; thus lymphadenopathy of the head or neck may be the initial presentation. Skin metastases can rarely be the presenting sign, usually appearing as dermal or subcutaneous nodules.[116] Clubbing and dermatomyositis have rarely been reported in association with nasopharyngeal carcinoma. EBV is present in the malignant epithelial cells yet is not found in the lymphocytes.[78]

African Burkitt lymphoma is a mature B-cell neoplasm endemic to Equatorial Africa that involves overexpression of the c-myc oncogene.[117] It typically affects children and presents with tumors of the jaw or facial bones.[117,118] A sporadic subtype in Western Europe or the United States demonstrates abdominal involvement. The immunodeficient subtype typically occurs in HIV-positive patients and appears most frequently in the abdomen. Virtually all cases of endemic Burkitt lymphoma are associated with EBV as well as a previous malarial infection, whereas the sporadic variant is associated with EBV is less than 20% of cases.[118,119] Dissemination to the skin is extremely rare; however, marked lymphadenopathy is commonly observed.[118] Biopsy of lesions show a neoplasm of medium-sized cells with abundant basophilic cytoplasm, as well as apoptotic debris and macrophages ingesting apoptotic tumor cells, creating the "starry sky" appearance.

Hodgkin disease is a malignant lymphoma with bimodal age distribution.[120] In developed countries, the peaks are in young adulthood and in older adults. In developing countries, children as well as older adults are more frequently affected. EBV is associated with Hodgkin lymphoma in 30%–50% of cases. EBV is linked to Hodgkin disease more commonly in developing countries, in children, and in the setting of immunodeficiency. The majority of patients have a painless mass, frequently in the neck.[121] Hodgkin disease has associated skin lesions in 17%–53% of patients.[122] The majority of cutaneous findings are nonspecific and considered paraneoplastic in nature. Examples include severe pruritus, eczema, ichthyosis, urticaria, erythroderma, erythema nodosum, and associated mycosis fungoides. Cutaneous infiltration by Hodgkin disease is rarer, and typically occurs in the setting of advanced disease. Findings may include ulcerated nodules, plaques, tumors, papules, or erythroderma. Pathology consists predominantly of an inflammatory infiltrate with scattered characteristic Reed–Sternberg cells, which are $CD30^+$, $CD15^+$, binucleate large cells with eosinophilic nuclei.[120] Treatment is radiotherapy, chemotherapy, or a combination.

Certain types of cutaneous T-cell lymphoma have been found to be associated with the EBV. Chronic ulcers, subcutaneous nodules, and violaceous tumors have been noted in patients with angiocentric T/natural killer-cell lymphomas, T large-cell lymphomas, and systemic T-cell lymphoma with cutaneous involvement.[123] Necrotic nasal masses, which may affect surrounding skin as well, can also occur in angiocentric T/natural killer-cell lymphomas. EBV may also be associated with subcutaneous panniculitic T-cell lymphoma, which clinically presents as a panniculitis.[124] Histologically, there are atypical lymphocytes in the lobules of the fat as well as phagocytizing "beanbag cells" (eFig. 192-8.1 in online edition).

Vesiculopapular lesions on the face of a child, resembling hydroa vacciniforme, may be associated with EBV and have a malignant potential. Hypersensitivity to mosquito bites with erythematous swellings or ulcers may also be linked to latent EBV infections. This phenomenon may indicate high risk for progression to a malignant neoplasm.

GIANOTTI–CROSTI SYNDROME

GIANOTTI–CROSTI SYNDROME AT A GLANCE

- Papular acrodermatitis of childhood.
- Common, self-limited dermatosis.
- Monomorphic dome-shaped or flattopped papules symmetrically distributed on face and extensor extremities.
- Associated with multiple viral triggers and immunizations.
- Historically associated with hepatitis B infection, but now more often triggered by Epstein–Barr virus.

EPIDEMIOLOGY

Gianotti–Crosti Syndrome, also known as infantile papular acrodermatitis and papular acrodermatitis of childhood, is a common, self-limited dermatosis seen worldwide. It affects infants and children between the ages of 6 months and 12 years with the peak age of presentation being 1–6 years of age. Cases have a seasonal predilection, most often occurring in spring and early summer. In children, there is neither an ethnic nor sexual predilection.[129,130] There have been only scattered case reports in adults, exclusively in women.

ETIOLOGY AND PATHOGENESIS

GCS is a cutaneous reaction pattern associated with viruses, bacteria, and vaccines. The exact pathogenesis is unclear. However, there is some suggestion that immunizations or immune imbalance may enhance the risk of developing the exanthem following certain infections. A recent study showed an increased incidence of a personal or family history of atopy in children with GCS.[131]

Historically, it was thought to be induced exclusively by hepatitis B, but over time other infectious triggers have been identified. When hepatitis B is the causative agent, subtype ayw is most frequently seen.[132] However, with widespread immunization against Hepatitis B, most cases found in Europe, India, the United States, and Canada are not associated with Hep B infection. EBV is the most common cause in the United States and can be due to initial infection or reactivation.[133] Other associated viruses include cytomegalovirus, enterovirus, respiratory syncytial virus, rotavirus, adenovirus, echovirus, pox virus, poliovirus, coxsackie virus (A16, B4, and B5), parvovirus B19, HIV, hepatitis A, hepatitis C, mumps virus, HHV-6, vaccinia virus, rubella virus and parainfluenza virus. Bacterial pathogens include *Mycoplasma pneumoniae*, *Borrelia burgdorferi*, *Bartonella henselae*, and group A β-hemolytic streptococcus. Immunizations that have been associated include influenza, diptheria-pertussis-tetanus (DPT), bacillus Calmette–Guérin, *Haemophilus influenzae* type b, MMR, hepatitis B, Japanese encephalitis and oral polio vaccine. Although many groups have tried using both electron microscopy and immunohistochemistry, neither viral particles nor viral antigens have been demonstrated in skin lesions of GCS.[134,135] Thus, today it is accepted that the mechanism of lesion development does not involve a direct local interaction between viral antigens and immune-competent cells in the skin.

CLINICAL FINDINGS

HISTORY. Before the onset of the exanthem, a nonspecific prodrome of upper respiratory tract symptoms with fever and pharyngitis plus lymphadenopathy may be present.

CUTANEOUS LESIONS. Regardless of the cause, the clinical features in all cases tend to be the same. Typically, patients abruptly develop multiple coalescing, monomorphous, flat-topped or dome-shaped, red–brown papules and papulovesicles (Fig. 192-9 and see eFig.192-9.1 and eFig. 192-9.2 in online edition). Lesions can be pruritic and, rarely, hemorrhagic. Papules vary from 1 to 10 mm in diameter (see Fig. 192-9B) and are distributed symmetrically on the cheeks, extensor surfaces of the extremities, and the buttocks. The trunk, palms, and soles are usually, but not always, spared. Occasionally, the small papules coalesce into large plaques. Cutaneous lesions evolve over a few days and last for 2–8 weeks.

RELATED PHYSICAL FINDINGS. Constitutional symptoms, including malaise, low-grade fevers, and diarrhea, are sometimes seen at time of presentation, but are usually mild. Patients can develop lymphadenopathy, especially of the cervical, axillary, and inguinal chains.[136]

LABORATORY TESTS

In most patients, the diagnosis is established on clinical findings and no further diagnostic testing



Figure 192-9 **A** and **B**. Erythematous edematous monomorphous dome-shaped papules on the extensor extremities in an toddler with Gianotti–Crosti syndrome.

BOX 192-8 DIFFERENTIAL DIAGNOSIS OF GIANOTTI–CROSTI SYNDROME

Most Likely
- Papular urticaria
- Pityriasis rosea

Consider
- Erythema multiforme
- Lichen planus
- Lichenoid drug eruption
- Pityriasis lichenoides et varioliformis acuta
- Molluscum contagiosum
- Hand-foot-mouth disease
- Follicular eczema
- Erythema infectiosum

Always Rule Out
- Infectious mononucleosis
- Henoch–Schönlein purpura
- Scabies

is necessary. In patients with hepatomegaly, further diagnostic testing, including complete blood cell count and liver enzymes, may be warranted. Lymphocytosis or lymphopenia are common and do not require further diagnostic evaluation. If there are elevations in the liver enzymes, evaluation for hepatitis or EBV should be performed. If hepatitis is suggested, checking anti-hepatitis A IgG and IgM, hepatitis B surface antigen and core antibody, and anti-hepatitis C IgG is indicated.

DIFFERENTIAL DIAGNOSIS

(Box 192-8)

COMPLICATIONS

Complications are rare with the majority of cases having a self-limited and mild course. On rare occasions, when GCS is associated with hepatitis B infection, chronic liver disease with subsequent liver failure can occur.[137]

PROGNOSIS AND CLINICAL COURSE

In the vast majority of cases, GCS is a self-limited, benign process that usually resolves within 3–4 weeks. The course is quite variable, with the skin findings lasting anywhere from 5 days to 12 months.[136,138] Lesions heal without scarring, and, rarely, postinflammatory hypopigmentation or hyperpigmentation is seen. Lymphadenopathy can last for several months.[132] In cases associated with hepatitis B, an anicteric viral hepatitis evolves and may not be seen until 2 weeks after cutaneous lesions are seen. Most of the time, the hepatitis is self-limited.

TREATMENT

No treatment is necessary in the majority of cases. In some patients, medium potency topical steroids may decrease the duration of lesions when applied once daily for 1–2 weeks. However, patients should be monitored closely because worsening of findings with topical steroid use has been documented.[139] In severe cases, systemic, pulsed corticosteroids may be administered.[140] Oral antihistamines or topical anti-itch lotions may diminish severe pruritus.

PREVENTION

There is no known way to prevent GCS.

HUMAN CYTOMEGALOVIRUS

CYTOMEGALOVIRUS AT A GLANCE

- Human herpesvirus 5.
- High prevalence in the population.
- Establishes latent infection and capable of reactivation in immunosuppressed states.
- Primary infection is mainly asymptomatic; it is the cause of severe morbidity and mortality in utero and in immunocompromised patients.
- Petechiae and blueberry muffin syndrome with congenital infection.
- Congenital infection is major cause of hearing loss.
- Infected cells are cytomegalic with intranuclear inclusions.

EPIDEMIOLOGY

Human cytomegalovirus (HCMV) is ubiquitous around the world. The seroprevalence in the population increases with age, with 10%–20% of children infected before they reach puberty.[141] By adulthood, the prevalence of HCMV is 40%–100%. For unclear reasons, there is a higher prevalence in developing countries and areas of low socioeconomic status. HCMV is the most common congenital viral infection in humans with an incidence of 0.2%–2.2% of live births in the United States.[142] Five percent to 17% of congenital infections exhibit neurodevelopmental sequelae.[143] Nearly all HIV-infected patients are infected with HCMV.[144] It is a significant cause of morbidity in bone marrow

transplant (BMT) and solid organ transplant (SOT) patients, with 50%–90% of patients infected.[142]

CLINICAL FINDINGS

CONGENITAL HUMAN CYTOMEGALOVIRUS INFECTION

History. Congenital HCMV (cytomegalic inclusion disease of the newborn) occurs mostly in children of primiparous women with primary infection during pregnancy. Fifty-five percent of maternal primary HCMV infections results in intrauterine HCMV infection of the fetus, and approximately one-third of those are symptomatic.[149] Reactivation or secondary HCMV infection of a HCMV-immune woman during pregnancy rarely results in symptomatic HCMV infection for the baby.[149]

Cutaneous Lesions. Cutaneous findings in the newborn include a petechial rash secondary to thrombocytopenia, jaundice due to hepatitis and blueberry muffin lesions (Fig. 192-10) from dermal erythropoiesis. In one study, approximately 70% of children with symptomatic congenital HCMV infections had petechiae and jaundice.[150] Dermal erythropoiesis, also known as thrombocytopenic purpura or blueberry muffin syndrome, can also be seen with congenital rubella,[151] toxoplasmosis, and blood dyscrasias. These purpuric lesions are present at birth and evolve during the first 24–48 hours of life. They are papular and range from 2 to 10 mm in diameter. Lesions are initially dark blue to violaceous and fade to red or copper–brown. They regress during the first 6 weeks of life despite continued presence of the virus. Histology shows plaque-like aggregates of nucleated cells and nonnucleated erythrocytes in the reticular dermis.[152]



Figure 192-10 Newborn with congenital HCMV infection: "blueberry muffin baby." (From Groark SP, Jambel RM: Violaceous papules and macules in a newborn. Dermal erythropoiesis associated with congenital cytomegalovirus infection. *Arch Dermatol* **114**:116, 1989, with permission.)

Related Physical Findings. Related findings include hepatosplenomegaly in virtually all newborns, microcephaly, periventricular calcifications, ventriculomegaly, encephalitis, chorioretinitis, hearing loss or neurodevelopmental sequelae, intrauterine growth retardation, and postnatal failure to thrive. Studies show that 22%–65% of symptomatic and 6%–23% of asymptomatic children have hearing loss after congenital HCMV infection.[153]

PERINATAL HUMAN CYTOMEGALOVIRUS INFECTIONS

History. Perinatal infection with HCMV is very different from congenital HCMV infection, without diffuse visceral or central nervous system involvement.[149] Transmission of the virus occurs via cervical secretions, breast milk, or blood transfusions between 4 and 16 weeks of age. It is usually asymptomatic, although it may be manifested by self-limited lymphadenopathy, hepatosplenomegaly, or afebrile pneumonitis.

Cutaneous Lesions. There are usually no cutaneous findings with perinatal HCMV infection. Uncommon presentations for HCMV infection in infants and children include scleroderma, Giartti–Crosti syndrome[128,154] gray pallor, hepatosplenomegaly with self-limited respiratory deterioration in preterm infants,[155] and cutaneous vasculitis.[155] Perineal ulcers have been reported in an immunocompetent preterm infant.[156]

HUMAN CYTOMEGALOVIRUS INFECTION IN IMMUNOCOMPETENT ADULTS AND CHILDREN

History. Although primary HCMV infection in the immunocompetent patient is usually asymptomatic, some can present with an infectious mononucleosis-like picture.[157] Approximately 10% of infectious mononucleosis cases are caused by HCMV. Symptoms and signs are indistinguishable from EBV-induced mononucleosis, including fever, malaise, splenomegaly, hepatitis, peripheral, and atypical lymphocytosis. Unlike EBV mononucleosis, HCMV-induced mononucleosis patients do not typically have pharyngitis and lymphadenopathy.[158] Given the lack of heterophile antibodies, HCMV mononucleosis is also known as heterophile-negative mononucleosis. Postperfusion syndrome is the term used when HCMV mononucleosis occurs between 3 and 6 weeks after exposure to blood products.[159]

Reactivation of various herpesviruses including HCMV, EBV, HHV6, and HHV7 has been reported in the setting of drug induced hypersensitivity syndrome (DIHS), which, in some cases, might lead to multiorgan failure after the offensive drug is discontinued.[160]

Cutaneous Lesions. A few patients with HCMV mononucleosis develop a rubelliform or morbilliform eruption; if given ampicillin, 80%–100% develop a

morbilliform rash within 1 week (see eFig. 192-10.1 in online edition).[161] There have been reports of erythema nodosum[162] and urticaria[83] associated with acute HCMV mononucleosis. Cutaneous ulcers due to CMV have been reported in patients with severe cases of DIHS.[163]

HUMAN CYTOMEGALOVIRUS AND THE IMMUNOCOMPROMISED

History. Immunocompromised patients are at risk for HCMV primary infection as well as reactivation resulting in persistent viremia and disseminated systemic disease.[164] Immunosuppressive agents such as azathioprine and cyclophosphamide alone can reactivate HCMV disease, as can systemic corticosteroids in conjunction with other immunosuppressive agents.

Solid Organ Transplant Recipients. SOT recipients not infected with HCMV receive an organ from an HCMV-positive individual are at highest risk of developing HCMV disease posttransplantation. Other risk factors include therapy with anti-T-cell antibody (OKT3)[165] and those who undergo HHV-6 seroconversion.[166] Initial infection of the transplanted organ is followed by pneumonitis, enteritis, hepatitis, retinitis, and central nervous system disease.[167]

Bone Marrow Transplant Patients. The risk of HCMV disease in BMT patients is lower with the use of seronegative donors and use of leukocyte-depleted blood products.[168] Risk factors for reactivation include a seropositive recipient, graft-versus-host disease (GVHD), and T-cell depletion of allograft. Pneumonitis has a 60%–80% mortality without treatment and 50 % mortality with antiviral treatment and cytomegalovirus immune globulin.

Human Immunodeficiency Virus-Infected Patients. HCMV retinitis was seen in up to 25% of HIV-infected patients before the use of highly active antiretroviral therapy (HAART).[169] Now, immune recovery vitreitis with posterior segment inflammation is seen as CD4 counts recover after initiation of HAART.[170] Encephalopathy, peripheral polyradiculopathy, pneumonitis,[167] and colitis[171] may occur.

Cutaneous Lesions. Cutaneous manifestations of HCMV disease in immunocompromised patients are rare compared with involvement of other organs. Perianal and rectal ulceration are most common (Fig. 192-11).[172] Also seen are indurated hyperpigmented nodules or plaques,[173] papular and purpuric eruptions,[172] vesiculobullous lesions,[174] purpura, petechiae,[175] indurated plaques, and nodules (see eFig. 192-11.1 in online edition). Verrucous and necrotic nodules have been reported in HIV-infected patients.[164] Some of these cutaneous manifestations may be caused by infection of the endothelium of cutaneous blood vessels.[176]



Figure 192-11 Infant with AIDS and diaper dermatitis-like disseminated HCMV. (From Thiboutot DM et al: Cytomegalovirus diaper dermatitis. *Arch Dermatol* **127**:396,1991, with permission.)

LABORATORY TESTS

The gold standard for diagnosis of HCMV infection is viral culture from blood using human fibroblasts. Infection is determined by cytopathic effect. However, it takes days to several weeks to see the cytopathic effect in culture. The diagnosis of congenital HCMV infection can be made by detection of virus in urine or saliva via culture or PCR (Fig. 192-12).[177]

The characteristic histologic feature of cytomegalovirus (CMV) infection is cytomegalic cells with nuclear inclusions. In the skin, enlarged endothelial cells with large intranuclear inclusions and a clear halo (owl's eye cells) are seen in small dermal vessels.[178] Cytopathic changes seen in the vascular lumen vary according to the stage of infection of each cell, including intranuclear and intracytoplasmic inclusions (Figure 192-13). Histologic diagnosis is specific but sensitivity is low.[179]

Various fast and reliable methods for detection of HCMV antigens and nucleic acids in cells and tissue are available. These include HCMV antigenemia assay (detects pp65 in peripheral blood neutrophils), hybrid capture assay (detects HCMV DNA in leukocytes), and quantitative and qualitative PCR. In immunocompetent individuals, IgM is usually positive during primary infection. The reported sensitivity of commercially available ELISA for HCMV IgM varies. Rheumatoid factor and EBVIgM may yield false-positive results.[180] IgG may be negative during active infection, but subsequent fourfold rise in IgG titer is indicative of infection.

The diagnosis of invasive CMV disease can be challenging because the presence of the virus does not mean causality given that the virus establishes latency after primary infection.

DIFFERENTIAL DIAGNOSIS

(Boxes 192-9 and 192-10)

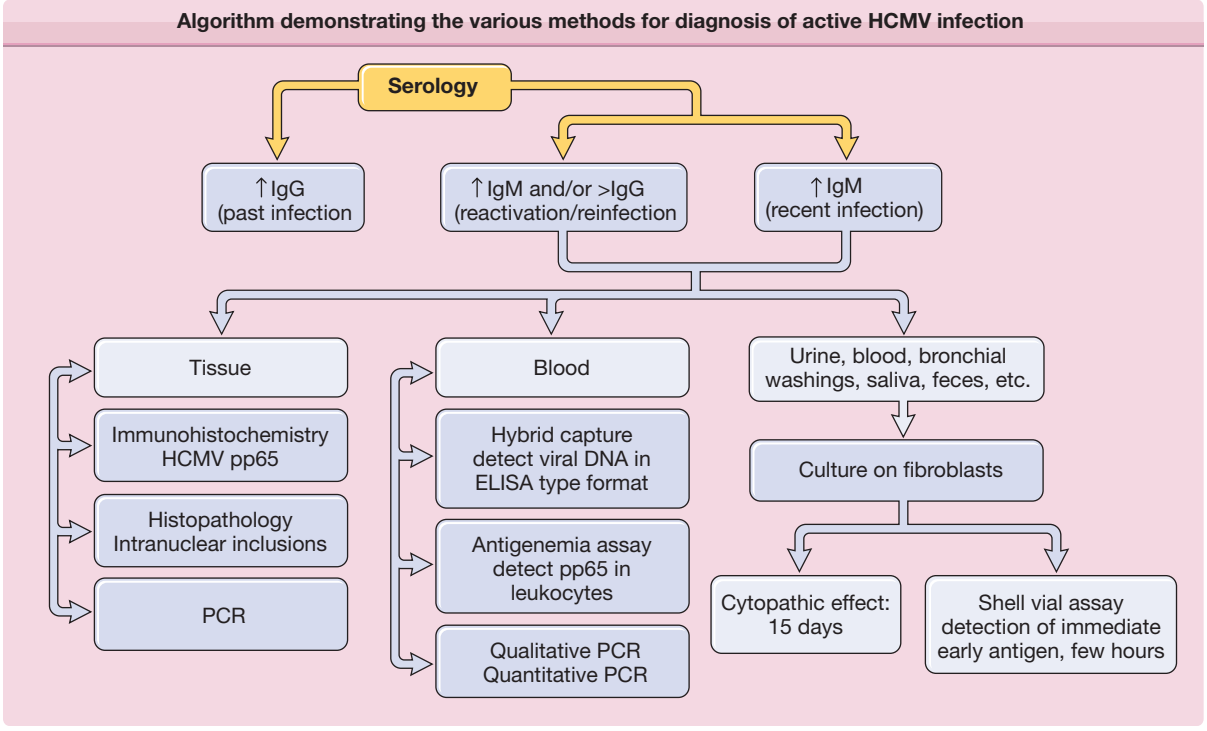

Figure 192-12 Algorithm demonstrating the various methods for diagnosis of active HCMV infection.

COMPLICATIONS

Possible complications of postnatal HCMV infection include interstitial pneumonia, hemolytic anemia, splenic infarction, thrombocytopenia and hemolytic anemia, hepatitis, Guillain–Barré syndrome, meningoencephalitis, myocarditis, arthritis, and gastrointestinal/genitourinary syndromes (i.e., colitis, esophagitis, cervicitis, and urethral syndromes).[143,149]

PROGNOSIS AND CLINICAL COURSE

HCMV disease in immunocompetent individuals is usually self-limited. In immunocompromised patients with systemic HCMV disease, the prognosis is poor and mortality 85%.[181]

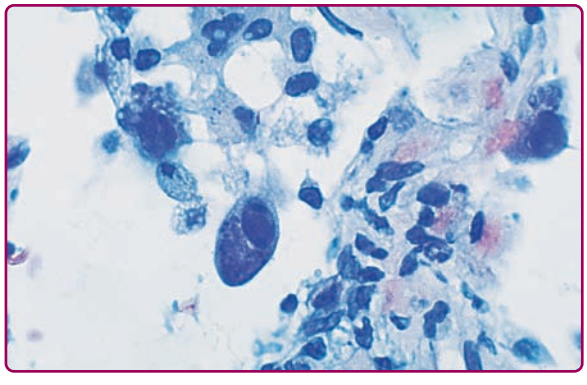

Figure 192-13 Intracellular inclusions in a cell infected by human cytomegalovirus. (From Konstadt JW et al: Disseminated cytomegalovirus infection with cutaneous involvement in a heart transplant patient. *Clin Cases Dermatol* **2**:2,1990, with permission.)

TREATMENT

HCMV infection in immunocompetent hosts is usually asymptomatic or self-limited, not requiring

BOX 192-9 DIFFERENTIAL DIAGNOSIS OF CONGENITAL HUMAN CYTOMEGALOVIRUS (BLUEBERRY MUFFIN SYNDROME)

Most Likely

- Causes of dermal (extramedullary) hematopoiesis
  - Congenital infection
    - Rubella
    - Toxoplasmosis
    - Herpes simplex virus infection
    - Enterovirus
  - Twin-twin transfusion syndrome
  - Hereditary spherocytosis
  - Rhesus and ABO incompatibility

Consider

- Langerhans cell histiocytosis
- Neonatal lupus erythematosus

Always Rule Out

- Congenital leukemia
- Neuroblastoma with skin metastases

BOX 192-10 DIFFERENTIAL DIAGNOSIS OF HUMAN CYTOMEGALOVIRUS MONONUCLEOSIS

Most Likely

- Epstein–Barr virus mononucleosis

Consider

- Toxoplasmosis
- Viral hepatitis

Always Rule Out

- Lymphoma

treatment with antiviral drugs. Ganciclovir, valacyclovir, foscarnet, and cidofovir have been approved for systemic treatment of HCMV disease.[182] HAART is effective in suppressing HCMV viremia and preventing CMV retinitis in acquired immunodeficiency syndrome patients without end-organ disease.[183] Ganciclovir and valacyclovir are also used for HCMV prophylaxis.[143,182] None of these drugs is recommended for treatment of symptomatic congenital HCMV infection.

PREVENTION

Prevention of HCMV infection in transplanted patients can be achieved with use of blood and tissues from HCMV-negative donors.[168] Preemptive (at time of high risk for disease but before symptoms) or prophylactic treatment can be used for immunocompromised individuals at risk of infection from blood transfusions or organ transplantation with ganciclovir.[149] Risk factors evaluated for preemptive therapy include CMV viremia and GVHD. The use of prophylactic versus preemptive therapy remains controversial.[184–186]

HUMAN HERPESVIRUS 6

HUMAN HERPESVIRUS 6 AT A GLANCE

- Causes exanthema subitum (roseola infantum, sixth disease).
- Febrile seizures often without rash in children.
- High seroprevalence in general population by 1 year of age.
- Reactivation in immunocompromised individuals is cause of morbidity.

EPIDEMIOLOGY

HHV-6 has been identified as a causative agent for exanthem subitum (ES), also known as roseola infantum and sixth disease.[187] ES is usually seen in children ages 6 months to 4 years.[188–190] The seroprevalence of HHV-6 in the adult population is greater than 95%.[189] Seroprevalence is high in the first few weeks of life and subsequently declines as maternal antibodies wane. It rises again by 1 year of age, with its peak between 3 and 5 years of age, and declines with advancing age.[190,192–194] There is a discrepancy between the seroprevalence of HHV-6 and the incidence of ES, mainly thought to be due to the varied clinical manifestations of HHV-6 infection and subclinical HHV-6 infection.[195] Primary HHV-6 infection in children can result in a subclinical infection or an acute febrile illness without cutaneous manifestations.[196–197] There is seasonal variation of HHV-6 infection with highest incidence in spring; summer and fall epidemics have also been reported.[191]

ETIOLOGY AND PATHOGENESIS

HHV-6 is a member of the β-Herpesviridae subfamily. There are two distinct variants by restriction enzyme analysis, HHV-6a and -6b.[198] They are different in their immunologic, biologic,[199] and genetic[198] characteristics. HHV-6b causes ES, but it is unclear what diseases, if any, are caused by HHV-6a.[200]

The cellular receptor for HHV-6 is CD46.[201] The mode of transmission is proposed to be via nasopharyngeal viral shedding from healthy individuals.[202] Airborne transmission is likely via saliva.[203] HHV-6 has been isolated from the saliva of healthy individuals[188–190] and viral shedding is intermittent, not associated with changes in antibody titers.[188] HHV-6 DNA is found in the cervix of infected women,[204] raising the question of possible perinatal infection, although children of mothers with positive swabs do not acquire early HHV-6 infection. HHV-6 DNA has also been found in fetal tissue from spontaneous abortions.[205,206] HHV-6 is not transmitted through breast milk.[191] Transmission in transplant patients can occur via the grafted organ.[207,208] The incubation period for HHV-6 infection is 5–15 days, with an average of 10 days. Viremia in immunocompetent children lasts 3–4 days in ES, whereas viremia from HHV-6 reactivation in allogeneic BMT patients lasts weeks.[209]

HHV-6 replicates in salivary glands,[210] where it can establish a persistent infection.[191] It is tropic for $CD4^+$ T lymphocytes in vitro[211,212] and establishes latency in human peripheral blood monocytes/macrophages[213] and early bone marrow progenitors.[214] HHV-6 genome is able to integrate into the host cell DNA at the ends of chromosomes 1, 17, and 22.[191]

HHV-6 can reactivate from latency in immunosuppressed individuals.[191,206,215] A synergistic effect on disease of HHV-6 and CMV has been described in renal transplant recipients.[216,217] HIV and HHV-6 also appear

to be synergistic. The clinical importance of this finding remains to be elucidated. Unlike in transplant patients, there does not seem to be one specific clinical syndrome of HHV-6 infection in HIV-infected patients.[191]

CLINICAL FINDINGS

HISTORY. Primary infection with HHV-6 results in an acute febrile illness typically in children 6 months to 1 year of age.[191] The fever lasts approximately 3–7 days[191] and can be followed by the characteristic rash of roseola in a minority of children.[197,218,219]

HHV-6 infection is seen in 40%–50% of transplant recipients (BMT more than SOT) and peaks at 2–4 weeks posttransplantation. Approximately one-half of these infections result in symptomatic disease with bone marrow suppression.[220]

CUTANEOUS LESIONS

Exanthem Subitum. Palpebral edema can be evident from the first to third day of fever, resulting in a "sleepy" appearance, and resolves after a day of the exanthema.[221] Erythematous papules on the soft palate (Nagayama spots) may precede the viral exanthema.[221] The exanthem is seen from 1 day before to 1–2 days after the fever fades and lasts for 3–5 days.[221] It is characterized by rose red macules or papules 2–5 mm in diameter, surrounded by a white halo. These are distributed mainly on the neck and trunk and sometimes on the face and proximal extremities (Fig. 192-14). Desquamation is not usually seen.

Transplant Recipients. A rash similar to acute GVHD has been described in pediatric patients undergoing BMT who have HHV-6 reactivation.[222,223] Fever and/or rash are the most common manifestations of HHV-6 infections in SOT recipients.[191]

Human Immunodeficiency Virus Patients. HHV-6 can be an opportunistic pathogen in HIV patients, causing encephalitis and pneumonitis in some cases.[191] But most case reports do not show one consistent clinical syndrome in HIV patients.[191]

PITYRIASIS ROSEA. (See Chapter 42 and Section "Human Herpesvirus 7").

Rosai–Dorfman Disease
(See Chapter 148). HHV-6 genome has been detected in tissue from patients with sinus histiocytosis with massive lymphadenopathy or Rosai–Dorfman disease,[224] and immunohistochemical studies suggest a possible pathogenic involvement.[225]

RELATED PHYSICAL FINDINGS. Patients with ES may have high fever, malaise, inflamed tympanic membranes, conjunctival injection, gastrointestinal and respiratory tract symptoms, cervical lymphadenopathy, and bulging fontanelle.[221,226] A mononucleosis-like infection, which is EBV- and CMV-negative, has been attributed to HHV-6 in children and adults.

LABORATORY TESTS

Although laboratory results may be variable in HHV-6 primary infection, one can see leukopenia (between 3,000 and 6,000 cells/mm^3) with an increased percentage of lymphocytes between days 3 and 6 of the illness. White blood cell count elevation can be seen at



Figure 192-14 **A** and **B.** Exanthem subitum in an infant showing truncal pink macules and some papules that appeared one day after defervescence.

the beginning of the febrile phase. HHV-6 infection is usually benign and self-limited; however, in atypical cases, serologic studies may be valuable. This can be done by ELISA or by indirect immunofluorescence. Anti-HHV-6 IgM antibodies are a marker of recent infection or reactivation, but 5% of adults may be IgM seropositive at any time. IgM develops after 5–7 days of infection, peaks at 2–3 weeks, and disappears in 2 months. IgM alone is not reliable.[227] A fourfold IgG increase between acute and convalescent sera IgG indicates active infection.

Laboratory tests vary in their ability to distinguish latent virus from actively replicating virus. PCR detection of HHV-6 DNA in cell-free serum, plasma, or CSF indicates active replication, whereas a positive PCR from cellular material does not indicate active replication because the virus can be found latent in cells. Viral culture is not used routinely because it is technically difficult and may take more than 1 week. A combination of a positive serum IgM with positive PCR of whole blood DNA in patients older than 3 months of age has excellent specificity and sensitivity, and positive and negative predictive value for primary infection.[196,228] Although not routinely available, quantitative PCR allows fast, sensitive, and absolute quantitation of viral load, making it a method of choice.

COMPLICATIONS

Febrile seizures are thought to occur in 10% of children with primary HHV-6 infection.[191] Rarely, encephalitis has been reported in children with fatal or severe sequelae such as hemiparesis.[196] Although usually a benign infection, rare complications include hepatitis, hemophagocytic syndrome, pneumonitis, and thrombocytopenia.[191,195] Hemophagocytic syndrome has been reported on reactivation of HHV-6 in an immunocompetent adult.[229]

HHV-6 infection or reactivation in the immunocompromised can also result in hepatitis,[208] pneumonitis,[230,231] bone marrow suppression,[232,233] and graft dysfunction or rejection.[215] Reactivation of HHV-6 in the immunocompromised host can result in encephalitis and/or encephalopathy.[191] There have been reports of fulminant multifocal demyelinating disease in both immunocompetent and immunocompromised patients. The contribution of HHV-6 infection to progressive multifocal leukoencephalopathy or multiple sclerosis is being studied.[191]

PROGNOSIS AND CLINICAL COURSE

ES is benign and self-limiting. Treatment may be necessary for atypical cases with complications and in immunosuppressed patients. Primary infection can be fatal in the immunocompromised host.

TREATMENT

There are no controlled clinical trials, and no compounds have been formally approved for treatment of HHV-6 infection. The same drugs used for HCMV treatment and prophylaxis have been used for HHV-6. The activities of various antiviral compounds against HHV-6 have been tested in vitro.[234,235] Several case reports support the clinical effectiveness of ganciclovir in HHV-6 treatment and prophylaxis.[191] Foscarnet and cidofovir might also prove to be useful.[189] New antiherpesvirus drugs are being developed, although most are not active against HHV-6.[191] Further studies are needed before treatment and prophylaxis can be recommended.

PREVENTION

Prophylaxis with ganciclovir may prevent HHV-6 reactivation in BMT and stem cell transplant recipients,[236] but low-dose prophylaxis may facilitate the development of resistance. Preemptive therapy (treatment after systemic detection of virus but before clinical symptoms of disease) has been proposed instead.[191]

HUMAN HERPESVIRUS 7

HUMAN HERPESVIRUS 7 AT A GLANCE

- Causes a small subset of cases of exanthem subitum.
- Primary infection typically occurs later in life than human herpesvirus 6 infection.

EPIDEMIOLOGY

In seroconversion studies, 10% of ES cases are caused by HHV-7.[237] Primary infection occurs during childhood, but later than[238] and at a slower rate than infection with HHV-6[239]; both viruses are ubiquitous in adulthood. HHV-7 can be isolated from saliva samples of healthy seropositive adults.[240]

ETIOLOGY AND PATHOGENESIS

HHV-7 is a member of the β-Herpesviridae family. It has significant homology to HHV-6; however, it is serologically and biologically distinct. It was initially isolated from $CD4^+$ T lymphocytes from a healthy adult [241] has been identified as the cellular receptor for HHV-7.[242]

HHV-7 establishes persistent infection in salivary glands,[243] transmission might be through saliva.[195] Latent virus can be activated in vitro from peripheral blood mononuclear cells[244] and its DNA can be found in $CD4^+$ T cells. Similar to many other herpesviruses,[245,246] HHV-7 can downregulate expression of CD4[247] and major histocompatibility complex class I,[248] which may play a role in establishment of latency or pathogenesis.

Reactivation of HHV-7 occurs more often than reactivation of HHV-6.[239]

CLINICAL FINDINGS

EXANTHEM SUBITUM. HHV-7 causes a small subset of ES cases. When HHV-7 is associated, ES tends to occur later in life than when HHV-6 is associated.[196] The rash associated with HHV-7 is lighter in color and occurs later in the course of the disease than HHV-6-associated ES.[249]

PITYRIASIS ROSEA. (See Chapter 42). HHV-7 DNA has been isolated from skin biopsy specimens, peripheral blood mononuclear cell, and plasma of patients with pityriasis rosea and not controls.[250] However, these findings have not been confirmed by other studies.[251–254] It is possible that the inflammatory milieu in pityriasis rosea activates HHV-7 and HHV-6 within the lesions, but there is no evidence for causality.

LICHEN PLANUS. HHV-7 DNA and virion-like structures have been found in lesional lichen planus skin samples compared to nonlesional skin and psoriatic skin samples.[255] Although suggestive, further studies are needed to establish a causal relationship. HHV-7 has also been found to be the associated with febrile seizures in children.[256]

LABORATORY TESTS

There is limited cross reactivity between HHV-7 and HHV-6 in serologic studies.[257] Due to high prevalence, a single positive IgG is not sufficient to establish a diagnosis. Culture from peripheral blood mononuclear cells takes 1–3 weeks, and it is not widely available. PCR is more widely available and is useful for timely diagnosis. Diagnosis of active infection by PCR can only be made from acellular material such as CSF, serum, or plasma, because the virus is latent in peripheral blood mononuclear cells and tissue. Immunohistochemical studies for viral antigens in biopsy specimens can be performed.[258]

DIFFERENTIAL DIAGNOSIS

(Box 192-11)

BOX 192-11 DIFFERENTIAL DIAGNOSIS FOR HUMAN HERPESVIRUS 6 AND HUMAN HERPESVIRUS 7 ASSOCIATED EXANTHEM SUBITUM

Most Likely
- Human herpesvirus-associated exanthem subitum
- Drug hypersensitivity reaction
- Enterovirus (including coxsackie, echovirus)

Consider
- Rubella (German measles)
- Measles/rubeola
- Adenovirus
- Epstein–Barr virus
- Fifth disease (erythema infectiosum, parvovirus)

Always Rule Out
- Scarlet fever
- Kawasaki disease

COMPLICATIONS

Complications of HHV-7-associated ES include acute hemiplegia and febrile seizures with CSF findings consistent with encephalitis[259] and hepatitis.

PROGNOSIS AND CLINICAL COURSE

ES is a self-limiting disease, which does not require specific antiviral treatment. Disease in immunocompromised can be more serious and require treatment.

TREATMENT

Treatment for HHV-7 has not been evaluated in clinical trials but could be guided by treatment recommendations for HHV-6.

ENTEROVIRUSES

Human enteroviruses may cause a variety of exanthems and clinical syndromes. They are small, single-stranded RNA picornaviruses and include echovirus, coxsackievirus A and B, enterovirus, and poliovirus.[260] Most enteroviral infections are benign. However, nonpolio enteroviruses are the most common cause of aseptic (viral) meningitis.[261] Enteroviruses can also cause life-threatening infections with encephalitis, myocarditis, and sepsis.[261] These are more common in neonates and immunocompromised individuals. Enteroviral infections are seen throughout the year, but many epidemics occur in the summer and fall. The viruses are primarily spread via the fecal–oral route or more rarely oral–oral or respiratory routes. Common source water exposures may also be responsible. Typical incubation period is 3–6 days.

The exanthems seen with enteroviruses are often nonspecific and not very dramatic, with small pink macules and papules that resolve in a few days. Petechiae and purpura are frequently present (Figs. 192-15A and 192-15B). When a petechial rash due to an enterovirus accompanies high fever and meningeal signs and symptoms, the clinical picture may mimic meningococcemia.



Figure 192-15 **A** and **B.** Purpuric macules and papules in a 4-year-old girl with enteroviral infection.

HAND-FOOT-MOUTH DISEASE

HAND-FOOT-MOUTH DISEASE AT A GLANCE

- Viral exanthem seen mostly commonly in children in summer and fall.
- Erosions in the mouth and papulovesicles on the palms and soles.
- Caused by enteroviruses including coxsackievirus A16 and enterovirus 71.
- Self-resolving without serious sequelae in the majority of cases but may have serious complications when caused by enterovirus 71.

EPIDEMIOLOGY. Hand-foot-mouth disease (HFMD) is the best-recognized enteroviral exanthem with worldwide distribution that is usually self-limited. There is a slight male predominance. Children less then 10 years of age are most frequently affected and infected adults rarely show signs of infection. Similar to exanthems caused by other enteroviruses, HFMD occurs more during summer and fall in temperate climates and throughout the year in the tropics.[170,262–268] Outbreaks may be sporadic or in epidemics. The largest recorded epidemic was in Taiwan in 1998. This epidemic was caused by enterovirus 71 and affected over 120,000 people and caused 78 deaths.[269] Children under the age of 5 years were the most severely affected and the majority of deaths were secondary to pulmonary edema and hemorrhage.

Transmission is via the fecal–oral route and, less commonly, respiratory inhalation. There is a high transmission rate among household contacts as has been documented with studies of epidemics.[268] Once inhaled or ingested, virus replication ensues in the oropharynx and/or gastrointestinal tract with subsequent viremia. The incubation period of HFMD is believed to be short, lasting 3–6 days, with viral shedding lasting up to 5 weeks.[270]

ETIOLOGY AND PATHOGENESIS. HFMD is caused by a number of nonpolio enteroviruses, including coxsackieviruses A5, A7, A9, A10, A16, B1, B2, B3, B5, echoviruses, and other enteroviruses. The most common causes are coxsackie A16 and enterovirus 71. Enteroviruses belong to the Picornaviridae family, which are single-stranded RNA viruses.

CLINICAL FINDINGS

History. After an incubation phase of 3–6 days, affected individuals may complain of a low-grade fever, malaise, abdominal pain, and upper respiratory tract symptoms.

Cutaneous Lesions. Nearly all cases of HFMD have painful oral lesions. These are generally few in number and are found on the tongue (Figs. 192-16A and 192-17A), buccal mucosa, hard palate, and, less frequently, the oropharynx. The lesions start as bright pink macules and papules that progress to small 4–8 mm vesicles with surrounding erythema. These quickly erode and form yellow to gray erosions surrounded by an erythematous halo. The time between



Figure 192-16 **A.** Toddler with vesicles and surrounding erythema on the tongue from hand-foot-mouth disease. **B** and **C.** Elliptical, "football-shaped" vesicles with halo of erythema on the palms and soles in the same patient.



Figure 192-17 **A.** Hand-foot-mouth disease is clinically identical in adults. Shallow ulcerations on the tongue that are part of the oral lesions of hand-foot-mouth disease caused by coxsackievirus A16 infection. **B** and **C.** Vesicular lesions on the fingers and feet.

vesicle and erosion is short, and most patients have erosions by the time they visit their physician.

Cutaneous peripheral lesions are present in two-thirds of patients and appear soon after the oral lesions.[271] The lesions are most common on the palms, soles (see Figs. 192-16B and 192-16C and 192-17B and 192-17C), sides of hands and feet, buttocks (see eFig. 192-17.1 in online edition) and, occasionally, external genitalia, and on the face and legs. They evolve similarly to the oral lesions, starting as red macules that become clear oval, elliptical (football shaped), or triangular vesicles with surrounding red halos (see Figs. 192-16 and 192-17) The number of lesions ranges from few to numerous and run parallel to the skin lines on fingers and toes. After crusting, they heal in 7–10 days.

Related Physical Findings. HFMD usually begins with a nonspecific prodrome, including low-grade fever [38°C–39°C (100.4°F–102.2°F)] that lasts 1–2 days, malaise, and, occasionally, abdominal pain or upper respiratory tract symptoms. Sore throat or sore mouth is common and may lead to poor oral intake and dehydration. Cervical and submandibular lymphadenopathy may be present.

LABORATORY TESTS.

No laboratory tests are indicated. If an epidemic is suspected, stool and throat cultures may be helpful in determining the strain and, therefore, possible complications.

SPECIAL TESTS.

Historically, enteroviral infection was verified by viral culture, which lacked sensitivity, and suckling mouse inoculation, which detected neutralizing antibodies. Confirmation of enteroviral infection can be done by using viral culture or PCR-based assays. Virus can be recovered from skin vesicles as well as throat and stool swabs. PCR is most widely employed for CSF samples and can help to identify serotypes in severe enteroviral infection.

Skin biopsies are not typically performed. Nonspecific findings such as intraepidermal blister formation from vacuolar and reticular degeneration of keratinocytes is seen as in other viral blisters.

DIFFERENTIAL DIAGNOSIS.

(Box 192-12)

BOX 192-12 DIFFERENTIAL DIAGNOSIS OF HAND-FOOT-MOUTH DISEASE

Most Likely
- Herpangina

Consider
- Varicella
- Aphthous stomatitis
- Drug eruption
- Erythema multiforme

Always Rule Out
- Herpes gingivostomatitis

COMPLICATIONS.

Patients rarely experience complications from HFMD. One rare complication, called eczema coxsackium, occurs in individuals with eczema. These patients develop disseminated cutaneous viral infection similar to that seen in eczema herpeticum.[272] The most common serious complication associated with HFMD is aseptic meningitis. Aseptic meningitis is rarely life threatening, and patients do not develop permanent sequelae. Epidemics in Taiwan of enterovirus 71 have resulted in severe disease with encephalitis, encephalomyelitis, polio-like syndromes, myocarditis, pulmonary edema, pulmonary hemorrhage, and death.[266,267,273] Serious complications are less frequent in cases associated with coxsackievirus A16 than with enterovirus 71.[266]

PROGNOSIS AND CLINICAL COURSE.

HFMD is usually a benign, self-limited illness that resolves within 7–10 days. Occasionally, cases associated with more prolonged fever, systemic symptoms, diarrhea, and joint pains have been reported.[274]

TREATMENT.

Treatment is typically supportive with attempts to reduce discomfort. Early treatment with milrinone, a cyclic phosphodiesterase inhibitor, has the potential to significantly reduce mortality in the management the enterovirus 71-induced illness.[275] Intravenous administration of human IgG has been used in China since 2000, with some success, to treat severe cases of enterovirus 71 infection.[276]

PREVENTION.

During epidemics, public health measures should be instituted to decrease morbidity. Measures such as universal precautions, dissuading attendance at childcare centers or kindergarten, and isolating affected individuals have been suggested.[277] Vaccine development is underway.[276]

HERPANGINA

HERPANGINA AT A GLANCE

- A viral enanthem seen in small children in summer and fall in temperate climates.
- Papulovesicles on the tonsillar pillars, uvula, and soft palate that progress to erosions.
- Caused by enteroviruses, including coxsackievirus and echoviruses.
- Self-resolving over several days without serious sequelae in the majority of cases.

EPIDEMIOLOGY.

Herpangina is a self-limited exanthem seen in children around the world. There is no ethnic or sexual predilection. Children are affected most commonly between 3 and 10 years of age. Most outbreaks in temperate climates are seen in the

summer and fall. Herpangina is caused by multiple types of coxsackie viruses (most frequently subtypes A8, A10, and A16), echoviruses, and enteroviruses.[278] Transmission is via fecal–oral, respiratory inhalation, or oral–oral spread in the majority of cases.

ETIOLOGY AND PATHOGENESIS. Enteroviruses belong to the family of Picornaviridae, which are single-stranded RNA viruses. Herpangina may occur sporadically or in epidemics. Epidemics have been traced to coxsackievirus A types 1, 2, 3, 4, 5, 6, 8, 10, 22, and B1 as well as echovirus types 16 and 25 and enterovirus 71. Replication ensues in the pharynx and gastrointestinal tract, with subsequent viremia. The incubation period is about 4 days,[279] and viral shedding may continue for days to months.

CLINICAL FINDINGS

History. The presenting signs and symptoms of herpangina are sudden onset of fever, chills, sore throat, headache, dysphagia, and body aches. The fever ranges from 37.5°C to 41.5°C (99.5°F–106.7°F). There may be a prodrome of listlessness, irritability, and anorexia a few hours before the onset of fever.

Cutaneous Lesions. Lesions are 1–2 mm, yellow–white papulovesicles with surrounding erythema that progress to erosions (Fig. 192-18). They are seen most frequently on the anterior pillars of the tonsillar fauces (or tonsillar pillars), followed by the uvula, tonsils and soft palate. They are less frequently seen on the tongue and buccal mucosa. The number of lesions may vary from very few to numerous. They can occur in small clusters and later coalesce and ulcerate leaving a shallow, punched out grayish–yellow crater 2–4 mm in diameter. Resolution occurs over 5–10 days.

LABORATORY TESTS. No laboratory tests are indicated.

SPECIAL TESTS. Historically, enteroviral infection has been verified by viral culture that lacked sensitivity and suckling mouse inoculation looking for neutralizing antibodies. Recently, PCR has been found to be very effective in detection and identification of enterovirus serotypes. PCR could be very useful if it were to become widely available.[280]

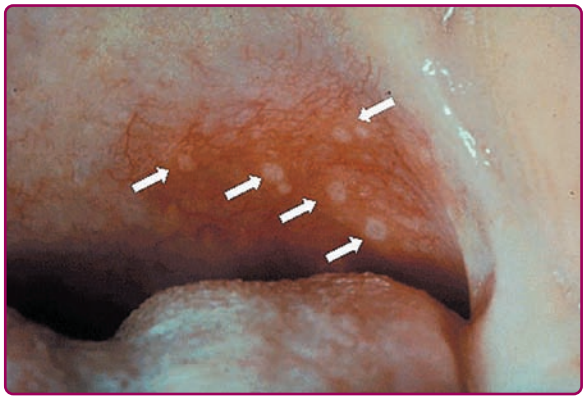

Figure 192-18 Typical appearance of the oropharyngeal lesions of herpangina. Acute, multiple papulovesicular lesions quickly progress to from shallow ulcerations with brisk marginal erythema.

BOX 192-13 DIFFERENTIAL DIAGNOSIS OF HERPANGINA

Most Likely
- Hand-foot-mouth disease

Consider
- Infectious mononucleosis
- Lymphonodular pharyngitis
- Aphthous stomatitis
- Oral candidiasis
- Varicella
- Diphtheria
- Nutritional deficiency
- Hematologic disorders

Always Rule Out
- Herpetic gingivostomatitis

DIFFERENTIAL DIAGNOSIS. (Box 192-13). Herpangina is located in the posterior oropharynx. Herpetic gingivostomatitis more commonly presents with labial and skin involvement.

COMPLICATIONS. Occasionally, patients suffer febrile seizures associated with the fever that is present in the first few days of infection. There have been rare case reports of serious complications, including myocarditis, encephalitis, meningitis, and pulmonary edema.

TREATMENT. The main goal of treatment is pain management. Viscous lidocaine, antihistamine mouthwashes and allopurinol mouthwash may be of benefit in relieving symptoms. Adequate fluid intake is encouraged to prevent dehydration.

PROGNOSIS AND CLINICAL COURSE. The fever rarely lasts longer then 4 days, whereas oral lesions spontaneously resolve several days after their eruption. The prognosis is good, and the course is most often benign.

PREVENTION. Once infected, a person has lifelong immunity to that particular strain. Recurrence of herpangina may occur but would be from one of the other strains.

ERUPTIVE PSEUDOANGIOMATOSIS

Cherry et al first described a syndrome in 1969 in which four children with acute echovirus infection (two with echovirus 25 and two with echovirus 32) developed small 2–4 mm red papules that resembled angiomas on the face and extremities.[281] The papules blanched on pressure and were surrounded by a small 1–2 mm halo. The eruption was short lived and typically resolved

within 10 days. Patients often had associated fever, malaise, headache, diarrhea, and respiratory complaints.

Other children and adults have been described with similar outbreaks. Although a virus is likely to cause eruptive pseudoangiomatosis, echoviruses have not been consistently confirmed as the causative agent.[282–284]

BOSTON EXANTHEM DISEASE

Named for its occurrence as an epidemic in Boston, this exanthem was found to be caused by echovirus 16. Clinical manifestations ranged from a light pink "roseola-like" exanthem to morbilliform or vesicular exanthems in more severe cases. Lesions were mostly localized to the face, chest and back and rarely the extremities. Small ulcerations were also found on the soft palate and tonsils.[285,286]

ROTAVIRUS

ROTAVIRUS AT A GLANCE

- Occurs worldwide; peak occurs in the winter.
- Transmission occurs primarily by fecal–oral route; major cause of diarrhea in children under age 2 years of age.
- Belongs to the Reovirus family.
- Skin manifestations may include exanthems, Gianotti–Crosti syndrome, and acute hemorrhagic edema of infancy.

EPIDEMIOLOGY

Rotavirus is a major cause of diarrheal illness in children under 2 years of age.[287] Rotaviral infections occur worldwide, affecting children in both developing and developed countries.[288] In the United States, the peak of rotaviral infections occurs in the winter. Typically, rotavirus appears in the Southwestern United States in November and reaches the Northeast by March.

Rotavirus is transmitted primarily by the fecal–oral route.[289] It has also been postulated that transmission via respiratory droplets and contaminated water is possible. The virus may survive on hands for at least 4 hours, and, in addition, ten infectious rotaviral particles may be all that is needed to transmit the infection. Once transmitted, viral shedding may commence as early as 48 hours before the development of symptoms and continue for 4–7 days thereafter. Asymptomatic shedding is also common.[290] Because of frequent diaper changing and contact between infected toddlers, day care centers often have outbreaks.[289] The fact that soap and water alone are relatively ineffective in removing virus from contaminated hands allows easier transmissibility.[291]

Children between the ages of 6 months and 2 years are most often affected. There is a male predominance that is poorly understood.[292] Adults can also become infected; they are often household members of infected children.[293]

CLINICAL FINDINGS

HISTORY. After an incubation period of 1–3 days, symptoms of rotaviral infection commence.[289] Typically, fever and vomiting are followed by nonbloody diarrhea (often 10–12 episodes per day), which occasionally results in moderate to severe dehydration.[292,297,298] Respiratory symptoms and otitis media may be present. In general, illness is less severe in adults.[294] Vomiting and diarrhea are usually present; however, fever and respiratory symptoms are absent.[293]

CUTANEOUS LESIONS. Rotaviral infections are not associated with specific dermatologic manifestations; however, several clinical pictures have been reported.[300] A generalized exanthem possibly related to rotavirus has been described.[299–301] Pink–red macules and papules appear 3–6 days after the onset of the diarrhea and as defervescence occurs. The asymptomatic rash progresses from the trunk to the extremities and, finally, to the face within hours. The exanthem then fades over approximately 3 days in the same order as it appeared.

Other dermatologic manifestations have been described. GCS occurs in response to a number of different viruses. Two toddlers had GCS with diarrhea 4 and 7 days before the eruption, and rotavirus was isolated from the stool cultures.[302] A third case of Gianotti–Crosti was reported without gastrointestinal symptoms.[303] Rotavirus was isolated from the stool culture, and all other suspected viruses yielded negative results. A child with acute hemorrhagic edema of infancy was found to be associated with a rotaviral infection.[303]

RELATED PHYSICAL FINDINGS. It has been noted that rotavirus is associated with respiratory symptoms and otitis media in up to 50% of cases.[289]

LABORATORY TESTS

Laboratory values may be unremarkable; however, it is not unusual to find a mild hyperchloremic metabolic acidosis.[304] Occasionally, liver transaminases may be mildly elevated. Hypernatremia, elevated albumin, and elevated uric acid, when detected, are likely the result of dehydration. Fecal leukocytes may be detected; however, they are usually not significant.[304]

COMPLICATIONS

Rotaviral infections may lead to persistent gastrointestinal symptoms, including diarrhea, gastroparesis, and lactose deficiency. Immunosuppressed patients and malnourished patients in developing countries are most at risk for protracted disease.[309] In addition, there have

been many associated conditions/syndromes reported, including seizures,[310] encephalopathy,[311] aseptic meningitis,[312] hepatic abscess,[313] acute myositis,[314] pneumonia,[315] sudden infant death syndrome,[316] Reye syndrome,[317] biliary atresia,[318] and Kawasaki disease.[319] It has also been suggested that rotaviruses have been associated with necrotizing enterocolitis[320] and intussusception.[321]

PROGNOSIS AND CLINICAL COURSE

Rotaviral infection in the United States resolves, on average, within 5–7 days, without any sequelae.[297,304] In developing countries, where poverty and malnutrition are common, children are most likely to experience chronic symptoms.[309] Death from rotaviral infection is not uncommon in developing countries due to dehydration.[295]

TREATMENT

Because there are no specific antiviral agents directed against the rotavirus, therapy is aimed at correcting dehydration and electrolyte imbalance. Oral rehydration is necessary. The World Health Organization recommends the oral rehydration solution, which consists of an isotonic salt solution with glucose supplementation or oral rehydration solution light, which has reduced osmolarity.[322] Intravenous fluids may be necessary if the patient is unable to rehydrate orally or if there is severe dehydration and should ideally consist of lactated Ringer or normal saline. Antibiotics are ineffective, and antimotility agents are not recommended for young children.

PREVENTION

Infection control is an important means of preventing rotaviral infections.[322] It is important to disinfect contaminated surfaces with quaternary ammonium compounds that contain 40% alcohol[273,305] or chlorhexidine gluconate in 70% ethanol.[289] Currently, two orally administered live rotavirus vaccines are available in the United States.[323]

UNILATERAL LATEROTHORACIC EXANTHEM

UNILATERAL LATEROTHORACIC EXANTHEM AT A GLANCE

- Asymmetric periflexural exanthem of childhood.
- Children 1–5 years of age.
- Pink papules that start in a large flexural region, become bilateral, but remain asymmetric.
- Probably viral etiology.

EPIDEMIOLOGY

Unilateral laterothoracic exanthem (ULE), also known as asymmetric periflexural exanthem of childhood (APEC), has a seasonal variation and occurs most frequently in late winter and early spring.[307] It typically occurs in children from 1 to 5 years of age but may be seen from 8 months to 10 years.[324] Rare cases in adults have been reported.[325] There is a slight female predominance and it is more common in Caucasians.

ETIOLOGY AND PATHOGENESIS

The etiology is unknown, but because of its seasonality and associated viral symptoms and lack of response to antibiotics, a viral trigger is suspected. The distinct clinical presentation may be a manifestation of a variety of infectious agents. The pathogenesis is also unknown.

CLINICAL FINDINGS

HISTORY. Mild upper respiratory tract, low-grade fever, or gastrointestinal tract symptoms precede the eruption in a majority of patients.

Conjunctivitis and fatigue may be present.

CUTANEOUS LESIONS. The lesions are usually 1–2-mm pinpoint, pruritic, pink papules that begin in a large flexural region like the axillae or groin and spread centrifugally (Fig. 192-19 and eFig. 192-19.1 in online edition). A variety of morphologies have been described, including macules, papules, morbilliform, annular, scarlatiniform, and annular. The initial lesion is often a pink papule with a surrounding pale halo.[307] The eruption typically becomes bilateral and more widespread within 5–15 days, but a unilateral and asymmetric distribution remains. The eruption is often quite pruritic.

RELATED PHYSICAL FINDINGS. Lymphadenopathy is seen in 70% of patients. This often manifests



Figure 192-19 Rough pink papules in the right axilla characteristic of unilateral laterothoracic exanthem. (Used with permission from Antonio Torrelo, MD.)

BOX 192-14 DIFFERENTIAL DIAGNOSIS OF UNILATERAL LATEROTHORACIC EXANTHEM

Most Likely
- Allergic or irritant contact dermatitis
- Scarlet fever

Consider
- Other viral exanthems

Always Rule Out
- Herpes zoster
- Atopic dermatitis

as a large (1–3 cm) mobile lymph node at the site where the rash starts.

LABORATORY TESTS

No laboratory tests are indicated.

DIFFERENTIAL DIAGNOSIS

(Box 192-14)

COMPLICATIONS

There has not been documentation of complications after ULE.

PROGNOSIS AND CLINICAL COURSE

The rash typically lasts from 2 to 6 weeks but may last as long as 2 months. Resolution is spontaneous and without scarring. During the healing stage, desquamation and postinflammtory pigment change may also be present as the exanthem resolves.

TREATMENT

Treatment for ULE is typically focused on controlling pruritus. This can be done with topical corticosteroids, antiitch lotions, and oral antihistamines.

PREVENTION

There is no known way to prevent ULE.

KEY REFERENCES

Full reference list available at www.DIGM8.com

DVD contains references and additional content

2. Pediatrics, A.A.o: Rubella. In: *Red Book: 2009 Report of the Committee on Infectious Diseases*, edited by LK Pickering, CJ Baker, DW Kimberlin, SS Long. Elk Grove Village, IL, American Academy of Pediatrics, 2009, p. 444
4. Stalkup JR: A review of measles virus. *Dermatol Clin* **20**:209, 2002
26. CDC: Rubella. In: *Red Book: 2009 Report of the Committee on Infectious Diseases*, edited by LK Pickering, CJ Baker, DW Kimberlin, SS Long. Elk Grove Village, IL: American Academy of Pediatrics, 2009, p. 579
28. Vander Straten MR, Tyring SK: Rubella. *Dermatol Clin* **20**:225, 2002
30. CDC: Control and prevention of rubella: Evaluation and management of suspected outbreaks, rubella in pregnant women, and surveillance for congenital rubella syndrome. *MMWR Recomm Rep* **50**:1, 2001
45. Feder HM Jr, Anderson I: Fifth disease. A brief review of infections in childhood, in adulthood, and pregnancy. *Arch Intern Med* **149**:2176, 1989
62. Levy R et al: Infection by parvovirus B 19 during pregnancy: A review. *Obstet Gynecol Surv* **52**:254, 1997
78. Cohen JI: Epstein-Barr virus infection. *N Engl J Med* **343**:481, 2000
83. Ikediobi NI, Tyring SK: Cutaneous manifestations of Epstein-Barr virus infection. *Dermatol Clin* **20**:283, 2002
130. Brown J, Rentiers R: The Gianotti-Crosti syndrome: A distinctive exanthem. *Can Med Assoc J* **4**:773, 1969
158. Horwitz CA et al: Clinical and laboratory evaluation of cytomegalovirus-induced mononucleosis in previously healthy individuals. Report of 82 cases. *Medicine (Baltimore)* **65**:124, 1986
172. Lee JY: Cytomegalovirus infection involving the skin in immunocompromised hosts. A clinicopathologic study. *Am J Clin Pathol* **92**:96, 1989
175. Lesher JLq Jr: Cytomegalovirus infections and the skin. *J Am Acad Dermatol* **18**:1333, 1988
176. Pariser RJ: Histologically specific skin lesions in disseminated cytomegalovirus infection. *J Am Acad Dermatol* **9**:937, 1983
191. De Bolle L, Naesens L, De Clercq E: Update on human herpesvirus 6 biology, clinical features, and therapy. *Clin Microbiol Rev* **18**:217, 2005
193. Leach CT, Sumaya CV, Brown NA: Human herpesvirus-6: Clinical implications of a recently discovered, ubiquitous agent. *J Pediatr* **121**:173, 1992
237. Hidaka Y et al: Exanthem subitum and human herpesvirus 7 infection. *Pediatr Infect Dis J* **13**:1010, 1994
266. Chang LY et al: Comparison of enterovirus 71 and coxsackie-virus A16 clinical illnesses during the Taiwan enterovirus epidemic, 1998. *Pediatr Infect Dis J* **6**:1092, 1999
269. Ho M et al: An epidemic of enterovirus 71 infection in Taiwan. Taiwan Enterovirus Epidemic Working Group. *N Engl J Med* **4**:929, 1999
274. Fields JP et al: Hand, foot, and mouth disease. *Arch Dermatol* **6**:243, 1969

Chapter 193 :: Herpes Simplex

:: Adriana R. Marques & Jeffrey I. Cohen

HERPES SIMPLEX AT A GLANCE

- Herpes simplex viruses (HSVs) are common human DNA viral pathogens that intermittently reactivate. After replication in the skin or mucosa, the virus infects the local nerve endings and ascends to the ganglia where it becomes latent until reactivation.
- There are two types of HSV: HSV-1 and HSV-2. HSV-1 is mostly associated with orofacial disease, whereas HSV-2 usually causes genital infection, but both can infect oral and genital areas and cause acute and recurrent infections.
- Most of the adult population is seropositive for HSV-1, and the majority of infections are acquired in childhood. About one-fourth of adults are infected with HSV-2 in the United States. Acquisition of HSV-2 correlates with sexual behavior.
- Most primary HSV infections are asymptomatic or not recognized, but they can also cause severe disease. Most recurrences are not symptomatic (asymptomatic shedding), with most transmissions occurring by asymptomatic shedding.
- Genital herpes is the most prevalent sexually transmitted disease worldwide and is the most common cause of ulcerative genital disease, and it is an important risk factor for acquisition and transmission of human immunodeficiency virus.
- HSV can cause diseases involving the eye, central nervous system, and neonatal infection. Cellular immunity defects are a risk factor for severe and disseminated disease.
- Diagnosis is made by polymerase chain reaction, viral culture, or serology, depending on the clinical presentation.
- Treatment is with acyclovir, valacyclovir, or famciclovir. Regimens and dosages vary with the clinical setting. Resistance is rare in other than immunocompromised patients.

EPIDEMIOLOGY

Herpes simplex virus (HSV) infections are common worldwide and are caused by two closely related types of HSV. Their main clinical manifestations are mucocutaneous infections, with HSV type 1 (HSV-1) being mostly associated with orofacial disease, whereas HSV type 2 (HSV-2) is usually associated with genital and perigenital infection.

The incidence of primary infection with HSV-1, which is responsible for the vast majority of recurring labial herpes, is greatest during childhood, when 30%–60% of children are exposed to the virus. Rates of infection with HSV-1 increase with age and reduced socioeconomic status, the majority of persons age 30 or older are seropositive for HSV-1.[1,2] From 20% to 40% of the population have had episodes of herpes labialis.[3] The frequency of recurrent episodes is extremely variable, and, in some studies, averages about once per year,[4] but there is evidence that the frequency and severity of recurrent HSV-1 disease decrease over time.

Acquisition of HSV-2 correlates with sexual behavior and the prevalence of the infection in the pool of one's potential sexual partners. Antibodies to HSV-2 are rare in people before the onset of intimate sexual activity and rise steadily thereafter. HSV-2 seroprevalence in the United States is 22% in persons 12 years of age or older.[5] The rate of HSV-2 seropositivity declined in the United States from 21% in 1988–1994 to 17% in 1999–2004, and rate of HSV-1 seropositivity declined from 62% to 58% during the same period.[6]

Although most patients infected with HSV-1 or HSV-2 are asymptomatic, they still can transmit the virus. Studies using DNA polymerase chain reaction (PCR) assays show that rates of detecting HSV-2 DNA in genital secretions of people who have never recognized herpes outbreaks (asymptomatic persons) are similar to the rates of shedding viral DNA in people who have experienced symptomatic genital herpes but who are not symptomatic at the moment of testing (subclinical shedding).[7] In one study, 21% of genital swabs were positive for HSV-2 by PCR and 12% of oral swabs were positive for HSV-1 PCR in HSV-2 and HSV-1 seropositive persons, respectively.[8] It is estimated that more than 70% of transmission of HSV-2 is associated with asymptomatic and subclinical reactivation and shedding. The rate of transmission is no higher is persons with frequent symptomatic recurrences than those with infrequent recurrences.[9] The average risk of transmission for couples discordant for genital herpes (i.e., one partner has genital herpes and the other does not) varies from 5% to 10% per year.[10,11] As with other sexually transmitted infections, the rate of acquisition of HSV-2 infection is higher for women than for men (6.8 vs. 4.4 cases per 100 person-years;

relative risk, 1.55). Asymptomatic HSV-2 infection is more common among men and persons who are also seropositive for HSV-1, suggesting that prior infection with HSV-1 reduces one's likelihood of experiencing symptomatic HSV-2 infection.[12] Studies have shown that genital HSV infections significantly increase the risk for acquisition and transmission of human immunodeficiency virus (HIV). Randomized trials with acyclovir reduced the frequency of genital ulcers and slightly reduced HIV viral loads, but did not reduce transmission of HIV.[13,14]

ETIOLOGY AND PATHOGENESIS

THE VIRUS

HSV-1 and HSV-2 are members of the Herpesviridae family, a group of lipid-enveloped double-stranded DNA viruses. Both serotypes of HSV are members of the α-Herpesviridae virus subfamily. α-Herpesviruses infect multiple cell types in culture, grow rapidly, and efficiently destroy the host cells. Infection in the natural host is characterized by lesions in the epidermis, often involving mucosal surfaces, with spread of virus to the nervous system and establishment of latent infections in neurons, from which virus periodically reactivates. HSV-1 and HSV-2 have a high degree of genetic and antigenic homology. An analysis of herpesvirus phylogeny estimated that the two HSV types diverged from an ancestral protoherpesvirus approximately 8 million years ago.[15]

Herpesvirus replication is a carefully regulated process. Shortly after infection, immediate-early genes are transcribed whose proteins upregulate expression of early proteins that are required for genome replication. The late [HSV-2→HSV] genes encode virion structural components including the glycoproteins.

In vivo, HSV infections can be divided into three stages: (1) acute infection, (2) establishment and maintenance of the latency, and (3) reactivation of virus. During acute infection, virus replicates at the site of inoculation on mucocutaneous surfaces, resulting in primary lesions from which virus rapidly spreads to infect sensory nerve terminals, where it travels by retrograde axonal transport to neuronal nuclei in regional sensory ganglia. In a subset of infected neurons, a latent infection is established in which viral DNA is maintained as an episome and HSV gene expression is severely restricted: of all of the viral genes, only one is abundantly transcribed during latency. In the last stage, replication reactivates with concomitant anterograde axonal transport of newly assembled virus to a peripheral site, at or near the original portal of entry (see eFig. 193-0.1 in online edition).

HSV-1 reactivates most efficiently and frequently from trigeminal ganglia, whereas HSV-2 reactivates primarily from sacral ganglia. The rate of reactivation of HSV appears to be influenced by the quantity of latent viral DNA in the ganglia.[16] Reactivation is induced in experimentally infected animals by exposure to ultraviolet irradiation, by hyperthermia, by local trauma, and by other physiologic stressors.

IMMUNE RESPONSE

Host immunity to HSV clearly influences the risk of acquiring the infection, the severity of disease, and the frequency of recurrences. The risk of severe HSV disease and the recurrence rate correlates with the level of cellular immune competence of the host. Patients with mild decreases in cellular immunity may experience only an increased number of recurrences and a slower resolution of lesions, whereas severely compromised patients are more likely to develop disseminated, chronic, or drug-resistant infections.

Studies of humans and mice have implicated a role for both $CD8^+$ and $CD4^+$ T lymphocyte subsets, natural killer cells, and inflammatory cytokines like interferon-γ in mediating protection against HSV. However, the contribution of each cell subset and cytokine in the control of HSV infection has not been clearly defined. Innate immunity is also important and polymorphisms in *TLR2* are associated with increased rates of genital lesions in seropositive persons.[17]

Patients with defects in humoral immunity have no increase in HSV disease severity, but the humoral immune response is important in reducing virus titers at the site of inoculation and in regional neural tissues during primary infection. Animals are effectively protected from disseminated and neurologic disease by passive transfer of polyclonal or monoclonal antibodies and by antibody responses elicited actively through vaccination. Moreover, the transfer of HSV-specific antibodies from the mother to the child is a key factor in protecting against neonatal herpes.

The mechanisms of immunity required to sustain latency and limit reactivation of HSV are less clear. There is evidence that constant immune surveillance and engagement are required to maintain latency, mainly by HSV-specific $CD8^+$ lymphocytes and low levels of viral proteins produced in neurons.[18] T cells reactive to HSV-1 are clustered around latently infected neurons in ganglia from HSV-1 seropositive persons.[19] HSV-specific $CD8^+$ lymphocytes localize to site of reactivation and persist in the skin for weeks after lesions are cleared.[20]

CLINICAL FINDINGS

The clinical manifestations of HSV infection depend on the site of infection and, as indicated in Immune Response (above), the immune status of the host. Primary infections with HSV, namely those that develop in persons without preexisting immunity to either HSV-1 or HSV-2, are usually more severe, frequently with systemic signs and symptoms, and they have a higher rate of complications, than recurrent episodes.

OROFACIAL INFECTIONS

Herpetic gingivostomatitis (Fig. 193-1) and pharyngitis are most commonly associated with a primary HSV-1 infection. The symptoms of primary oral herpes may resemble those of aphthous stomatitis and include



Figure 193-1 Primary herpetic gingivostomatitis. (Used with permission from Clyde S. Crumpacker, MD.)

ulcerative lesions involving the hard and soft palate, tongue, and buccal mucosa, as well as neighboring facial areas. Patients with pharyngitis exhibit ulcerative and exudative lesions of the posterior pharynx that can be difficult to differentiate from streptococcal pharyngitis. Other common symptoms are fever, malaise, salivation, myalgias, pain on swallowing, irritability, and cervical adenopathy.

Reactivation of virus from these primary infections involves the perioral facial area, mainly the lips, with the outer one-third of the lower lip being the most commonly affected (Fig. 193-2 and see eFig. 193-2.1 in online edition). Other facial locations include the nose, chin, and cheek, and account for less than 10% of the cases (Fig. 193-3). Two-thirds of labial lesions involve the vermilion border, whereas the rest occur at the junction of the border with the skin. In patients with frequent recurrences, lesions may differ slightly in location with each episode. Immunocompetent patients tend not to experience recurrent intraoral lesions, but can present with clusters of tiny vesicles and ulcers, or linear fissures on the gingivae and anterior hard palate that are mildly symptomatic. Prodromal symptoms precede herpes labialis in 45%–60% of



Figure 193-2 Herpes simplex virus infection: recurrent herpes labialis.



Figure 193-3 Recurrent facial herpes simplex with grouped vesicles and crusting. (Used with permission from Clyde S. Crumpacker, MD.)

episodes. Patients experience pain, burning, or itching at the site of the subsequent eruption. Even in the immunocompetent patient, the severity of recurrent herpes labialis is extremely variable and may vary from that of prodromal symptoms alone without the subsequent development of lesions (aborted episodes) to extensive disease induced by severe local sunburn.

The progression of the classical herpes lesions has been divided according to the following stages based on their features: prodromal, erythema, and papule (the developmental stages); vesicle, ulcer, and hard crust (disease stages); followed by dry flaking and residual swelling (resolution stages). The lesions usually resolve within 5–15 days.

Trigger factors for oral herpes recurrences include emotional stress, illness, exposure to sun, trauma, fatigue, menses, chapped lips, and the season of the year.[21] Other well-documented triggers include exposure to ultraviolet irradiation, trigeminal nerve surgery, oral trauma, epidural administration of morphine, and abrasive, laser, and chemical facial cosmetic procedures. The exact mechanism by which these diverse factors trigger HSV reactivation is unknown.

HSV-2 causes a primary orofacial infection that is indistinguishable from that associated with HSV-1 except that it is usually in adolescents and young adults and following genital–oral contact. Moreover, HSV-2 orolabial infections are 120 times less likely to reactivate than is orolabial HSV-1 disease. For the differential diagnosis of orofacial herpes see Box 193-1.

GENITAL INFECTION

Genital herpes is the major clinical presentation of HSV-2 infection, but it may also result from HSV-1 in 10%–40% of the cases, primarily following oral–genital contact.[22] Because of their epidemiology,

BOX 193-1 DIFFERENTIAL DIAGNOSIS OF OROLABIAL AND GENITAL HERPES

Disease	Differences from Orolabial Herpes
Aphthous ulcers	Not preceded by vesicles, only on mucosa
Syphilis	Painless, not preceded by vesicles
Herpangina	Posterior portion of mouth (soft palate, tonsils)
Stevens Johnson syndrome	Disseminated lesions

Disease	Differences from Genital Herpes
Chancroid	Deep ulceration with exudate
Syphilis	Painless, not preceded by vesicles
Lymphogranuloma venereum	Painless ulcer, unimpressive primary lesions
Granuloma inguinale	Painless ulcer, exuberant lesions

acquisition of HSV-1 in a person with prior HSV-2 infection is unusual, but HSV-2 acquisition in the presence of previous HSV-1 infection is common, and infection of the genital tract with both HSV-1 and HSV-2 has been described. Patients with previously known HSV-1 genital infection who develop frequent genital herpes recurrences should be tested for HSV-2 infection.[23] Viremia occurs in about 25% of persons during primary genital herpes.[24]

The clinical course of acute first-episode genital herpes among patients with HSV-1 and HSV-2 infections is similar. These infections are associated with extensive genital lesions in different stages of evolution, including vesicles, pustules, and erythematous ulcers that may require 2–3 weeks to resolve (Fig. 193-4). In males, lesions commonly occur on the glans penis or the penile shaft; in females, lesions may involve the vulva, perineum, buttocks, vagina, or cervix. There is accompanying pain, itching, dysuria, vaginal and urethral discharge, and tender inguinal lymphadenopathy. Systemic signs and symptoms are common and include fever, headache, malaise, and myalgias. Herpetic sacral radiculomyelitis, with urinary retention, neuralgias, and constipation, can occur. HSV cervicitis occurs in more than 80% of women with primary infection. It can present as purulent or bloody vaginal discharge, and examination reveals areas of diffuse or focal friability and redness, extensive ulcerative lesions of the exocervix, or, rarely, necrotic cervicitis. Cervical discharge is usually mucoid, but it is occasionally mucopurulent.

The rates of recurrence for genital HSV-2 infections vary greatly among individuals and over time within the same individual. Infections caused by HSV-2 reactivate approximately 16 times more frequently than HSV-1 genital infections, and average 3–4 times per year, but may appear virtually weekly.[3] Recurrences tend to be more frequent in the first months to years after first infection. The classical clinical manifestations



Figure 193-4 **A.** Primary genital herpes with vesicles. (Used with permission from Clyde S. Crumpacker, MD.) **B.** Primary herpetic vulvitis.



Figure 193-5 **A.** Genital herpes: recurrent infection of the penis. Group of vesicles with early central crusting on a red base arising on the shaft of the penis. This "textbook" presentation, however, is much less common than small asymptomatic erosions or fissures. **B.** Genital herpes: recurrent vulvar infection. Large, painful erosions on the labia. Extensive lesions such as these are uncommon in recurrent genital herpes in an otherwise healthy individual.

of recurrent HSV-2 infection include multiple small but grouped vesicular lesions in the genital area (Fig. 193-5), but it can occur anywhere in the perigenital region, including the abdomen, groin, buttocks, and thighs (Fig. 193-6), and the lesions may recur at the same site or change location. The recurrence of genital lesions may be heralded by a prodrome of tenderness, itching, burning, or tingling, and the outbreaks are less severe than primary infection. Without treatment, the lesions usually heal in 6–10 days. Herpetic cervicitis is less common in recurrent disease, occurring in 12% of patients. It may present without external lesions. Signs and symptoms that are less classical for genital HSV infection, and which may divert one from the correct diagnosis include small erythematous lesions, fissures, pruritus, and urinary symptoms. HSV can cause urethritis, usually manifested only as a clear mucoid discharge, dysuria, and frequency. Occasionally, HSV can be associated with endometritis, salpingitis, or prostatitis. Symptomatic or asymptomatic rectal and perianal infections are common. Herpetic proctitis presents with anorectal pain, anorectal discharge, tenesmus, and constipation, with ulcerative lesions of the distal rectal mucosa. Genital herpes can recur at nongenital sites as well. For the differential diagnosis of genital herpes, see Box 193-1.



Figure 193-6 Recurrent genital herpes on the abdomen (zosteriform herpes simplex).

OTHER CUTANEOUS INFECTIONS

HSV can infect any skin site (Fig. 193-6). The common theme among virtually all of these cutaneous presentations is the requirement that virus has penetrated otherwise normal and well-keratinized tissues. Herpetic whitlow (Fig. 193-7) is infection of the fingers by HSV acquired by direct inoculation or by direct spread from mucosal sites at the time of primary infection. Thus, a typical presentation of whitlow would be in children who suck their fingers during a primary gingivostomatitis outbreak. It is also a well-documented occupational hazard for medical personnel. It is usually caused by HSV-1, but HSV-2 whitlow may develop as a manifestation of primary inoculation following manual–genital contact with an infected partner. The infected region becomes erythematous and edematous. Lesions are usually present at the fingertip and can be pustular and very painful. Fever and local lymphadenopathy are common. Whitlow is often misdiagnosed as a bacterial paronychial infection, but the surgical drainage, often needed for a bacterial infection, is unnecessary and potentially harmful, while antiviral therapy speeds healing. Whitlow may recur.



Figure 193-7 Herpes simplex virus infection: herpetic whitlow. Painful, grouped, confluent vesicles on an erythematous edematous base on the distal finger were the first (and presumed primary) symptomatic infection.

Cutaneous herpes can be transmitted between athletes involved in contact sports, such as wrestling (herpes gladiatorum) and rugby (herpes rugbiaforum or scrum pox), and may occur as outbreaks or small epidemics among team members. In these instances, multiple herpetic lesions may appear across the thorax, ears, face, arms, and hands, in which infection is facilitated by trauma to the normally keratinized skin during sport activities (Fig. 193-8A). Concomitant ocular herpes can occur.

Eczema herpeticum (Kaposi varicelliform eruption; Fig. 193-8B and eFig. 193-8.1 in online edition) results from widespread infection following inoculation of virus to skin damaged by eczema. It is usually a manifestation of primary HSV-1 infection in a child with atopic dermatitis, and the expression of cathelicidins in the skin may be a factor in controlling susceptibility to eczema herpeticum in these patients.[25] Mycosis fungoides, Sèzary syndrome, Darier disease, various bullous diseases of the skin (particularly if patients are receiving immunosuppressive therapy), and burns of second or third degree can also be complicated by cutaneous dissemination of HSV. The severity of eczema herpeticum ranges from mild to fatal, with mortality rates of up to 10% being reported before antiviral therapy was available. Mortality was usually primarily caused by bacterial superinfection and bacteremia. Common pathogens include *Staphylococcus aureus*, *Streptococcus*, and *Pseudomonas*. In a typical severe primary attack, several days after exposure vesicles develop in large numbers over areas of active or recently healed atopic dermatitis, particularly the face, and continue to appear in crops for several more days. The vesicles become pustular and markedly umbilicated. Patients commonly have high fever and adenopathy. Viremia with infection of internal organs can be fatal. Recurrences are usually far milder than these first infections. Arriving at the correct diagnosis can be delayed because of secondary impetigo involving the lesions, but it always should be considered in children with infected eczema, particularly if the child is more systemically ill than one might anticipate with impetigo. Eczema herpeticum of the young infant is a medical emergency, and early treatment with acyclovir can prove lifesaving.

Recurrent HSV infection is the most common precipitating event in cases of recurrent erythema multiforme (see Chapter 39). HSV-associated erythema multiforme is usually an acute, self-limited, recurrent disease. The duration of the disease is usually about



Figure 193-8 **A.** Herpes simplex gladiatorum with lesions on the neck. **B.** Herpes simplex virus infection: eczema herpeticum on face. Confluent and discrete crusted erosions associated with erythema and edema of the face of a man with atopic dermatitis.

3 weeks. The lesions are usually disseminated and symmetric, occurring on acral extremities and the face, and there is grouping of the lesions over the elbow and knees, as well as nail fold involvement. Mucosal involvement is usually mild and restricted to the mouth. Constitutional symptoms are rare, and the skin lesions heal without scarring.

LABORATORY TESTS

The method of choice for diagnosis of HSV infection depends on the clinical presentation. In many instances, the history and clinical findings may be sufficient, but the social, emotional, and therapeutic implications of a diagnosis dictate that it be confirmed by laboratory testing when possible. For patients with lesions, virus can be isolated in cell culture. In culture, HSV causes typical cytopathic effects, and most specimens will prove positive within 48–96 hours after inoculation. The sensitivity of the culture depends on the quantity of the virus in the specimen. Even in the most experienced centers, only approximately 60%–70% of fresh genital lesions are culture-positive. Isolation of the virus is most successful when lesions are cultured during their vesicular stage and when specimens are taken from immunocompromised patients or from patients suffering from a primary infection.

PCR is more sensitive than viral isolation and has become the preferred method for diagnosis. PCR has been extensively used for the diagnosis of central nervous system infections and in neonatal herpes. It is also useful for the detection of HSV in late-stage ulcerative lesions. Both viral culture and PCR assays enable typing of the isolate as HSV-1 or HSV-2. This information helps to predict the frequency of reactivation after a first-episode of HSV infection.

Direct fluorescent antibody staining of lesion scrapings and antigen detection assays can also be used but sensitivity is lower than viral culture.[26] The Tzanck smear can be helpful in the rapid diagnosis of herpesvirus infections, but it is less sensitive than culture and staining with fluorescent antibody, with positive results in fewer than 40% of culture-proven cases. It is performed by scraping the base of a freshly ruptured vesicle and staining the slides with Giemsa or Wright stain (the Papanicolaou staining method can also be used), followed by examination for the multinucleated giant cells that are diagnostic of herpetic infection (Fig. 193-9). Both HSV and varicella-zoster virus (VZV) will cause these changes. In skin biopsy specimens, epithelial cells are enlarged, swollen, and often separated. Multinucleated cells with intranuclear eosinophilic inclusion bodies (Cowdry type A inclusions) can be seen.

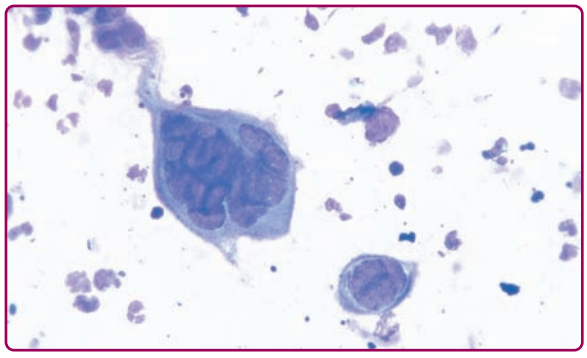

Figure 193-9 Herpes simplex virus: positive Tzanck smear. A giant, multinucleated keratinocyte on a Giemsa-stained smear obtained from a vesicle base. Compare size of the giant cell to that of neutrophils also seen in this smear. Another smaller multinucleated acantholytic keratinocyte is seen as well as acantholytic keratinocytes. Identical findings are present in lesions caused by varicella-zoster virus.

Serologic detection of antibodies to HSV can be helpful in certain settings, but the results are often misinterpreted. Its main function is in differentiating a primary episode from a recurrent infection (Table 193-1). A positive serologic test result can be useful in patients with

TABLE 193-1
Classification of Herpes Simplex Infections According to Viral Isolation and Paired Serologic Test Results

Classification	Virus Isolated	Serology (Acute)		Serology (Convalescent)	
		HSV-1	HSV-2	HSV-1	HSV-2
Primary HSV-1	HSV-1	–	–	+	–
Primary HSV-2	HSV-2	–	–	–	+
Primary HSV-1 plus previous HSV-2 infection[a]	HSV-1	–	+	+	+
Primary HSV-2 plus previous HSV-1 infection	HSV-2	+	–	+	+
Recurrent HSV-1	HSV-1	+	– or +	+	– or +
Recurrent HSV-2	HSV-2	– or +	+	– or +	+

HSV = herpes simplex virus; – = negative; + = positive.
[a]Rare.

recurrent, genital lesions that are not present at times of examination and, therefore, a positive culture cannot be obtained. Serologic testing can also be helpful for counseling patients with initial episodes of disease and their partners, especially during pregnancy, and in counseling partners of patients with genital herpes about their risk of acquiring HSV.

Type-specific serologic assays based on antigenic differences between HSV-1 and HSV-2 glycoprotein G, are available.[27] These tests should be used by practitioners who are prepared to counsel patients about the meaning of the test results in terms of the natural history of the disease, available treatment regimens, disease transmission, and the emotional and social implications of the diagnosis.[28]

COMPLICATIONS

IMMUNOCOMPROMISED HOST

All manifestations of HSV infection seen in the immunocompetent host can also be seen in immunocompromised patients but they are usually more severe, more extensive, and difficult to treat; for many of them, recurrences are more frequent as well. Patients with defects of T cell immunity, such as those with AIDS or transplant recipients, are at particular risk for progressive mucocutaneous or visceral infections, but the degree of dissemination depends on the level of immunodeficiency of the host. Recurrent and persistent ulcerative HSV lesions are among the most common and defining opportunistic infections in patients with acquired immunodeficiency syndrome. Genital herpes is very common in patients with HIV and can be persistent and severe. Oropharyngeal HSV in immunocompromised patients can present with widespread involvement of skin (Fig. 193-10), the mucosa, and extremely painful, friable, hemorrhagic, and necrotic lesions, similar to mucositis caused by cytotoxic agents. The lesions can spread locally to involve the esophagus. Esophagitis presents with odynophagia, dysphagia, substernal pain, and multiple ulcerative lesions. Esophagitis can also arise directly by reactivation of HSV and its spread to the esophagus via the vagus nerve. Tracheobronchitis can also occur by spreading of the virus from oropharyngeal HSV.

HSV can reactivate from visceral ganglia of the autonomic nervous system or disseminate hematogenously to other visceral organs (causing pneumonitis, hepatitis, pancreatitis, or meningitis) and other portions of the gastrointestinal tract, as well as causing adrenal necrosis. Most of these severe infections are caused by HSV-1, but HSV-2 can do so as well. Few are ever diagnosed except at autopsy.

OCULAR INFECTIONS

HSV is a leading cause of recurrent keratoconjunctivitis and it is associated with corneal opacification and visual loss. It is usually caused by HSV-1, except in neonates in whom HSV-2 is more prevalent. The majority of HSV eye disease is caused by reactivation of the virus in the trigeminal ganglia, but primary infections of the eye can also occur. Usually, the initial manifestation of herpetic eye disease is a superficial infection of the eyelids and conjunctiva (blepharoconjunctivitis), or corneal surface (dendritic or geographic epithelial ulcer with pain and blurred vision). Deeper involvement of the cornea (stromal keratitis) or anterior uvea (iritis) represents more serious forms of the disease and can cause permanent visual loss. Acute retinal necrosis is a rare but rapidly progressive disease characterized by retinal arteriolar sheathing, uveitis, and peripheral retinal opacification with variable pain and visual loss. Bilateral involvement may occur, and retinal detachment is common. It is usually associated with HSV-1 infection, but HSV-2 retinitis has been described, and VZV causes a similar process.[29]



Figure 193-10 Herpes simplex virus infection: chronic ulcer in an immunocompromised host. Multiple, slowly spreading, deep ulcers with central necrosis and hemorrhagic crusts on the lips, cheeks, and nose of a woman with leukemia.

NEUROLOGIC DISORDERS

All HSV infections involve the nervous system, as neurons are the sole proven site of virus latency. Neurologic manifestations of HSV infections, however, are not universal, but highly variable in their presentation and severity. HSV meningitis is manifested by headache, fever, stiff neck, and mild photophobia, with lymphocytic pleocytosis in the cerebrospinal fluid (CSF). Most cases result from HSV-2 infection.[30] It resolves spontaneously in 2–7 days. It is usually seen in association with primary genital HSV-2 infection. Recurrent lymphocytic meningitis (Mollaret meningitis) is associated with HSV-2 reactivation, often without

symptomatic genital disease. Involvement of the sacral nerves with autonomic nervous system dysfunction, numbness, pelvic pain, tingling, urinary retention, constipation, and CSF pleocytosis have been reported in association with HSV infection. Symptoms usually resolve in a few days, but in some cases, the neurologic residua take weeks to months to disappear, occasionally becoming permanent. Rare cases of transverse myelitis and Guillain-Barrè syndrome after HSV infection have been reported. Bell palsy is an acute, peripheral facial paresis of unknown cause and is thought to result from inflammation and subsequent mechanical compression of the facial nerve in the temporal bone. Reactivation of HSV and VZV are implicated in the pathogenesis of the disease.[31]

HSV encephalitis is the most commonly identified acute, sporadic viral encephalitis in the United States, accounting for 10%–20% of all cases. Nearly all of the cases arising after the neonatal period (see Section "Neonatal Herpes") are caused by HSV-1. HSV encephalitis usually presents with acute onset of focal neurologic symptoms and fever. Involvement of the temporal lobe is a characteristic feature of this disease, but overall, it is difficult to differentiate HSV encephalitis clinically from other viral encephalitides. PCR of the CSF for HSV DNA is the most sensitive noninvasive technique to help in the diagnosis, but it can occasionally be negative very early in the course of the disease.[32] Patients with presumed HSV encephalitis should be treated empirically with intravenous acyclovir until the diagnosis is confirmed or an alternative diagnosis is made. However, even with therapy, neurologic sequelae are frequent.[33]

NEONATAL HERPES

The neonate is a special category of immunodeficient host. The incidence of neonatal herpes varies from 1 case per 12,500 to 1 per 1,700 live births.[34] The category of maternal infection plays a significant role in defining the risk of neonatal herpes. Primary genital herpes is associated with a risk of neonatal infection of 25%–50% for vaginally delivered babies, and accounts for 50%–80% of cases of neonatal HSV infection. In contrast, recurrent maternal infection is associated with a risk of transmission of less than 3%, and transplacental antibodies are likely to play a role in decreasing the risk of infection.[35] Other risk factors for development of neonatal herpes include vaginal delivery, presence of cervical HSV infection, use of invasive monitors, and isolation of HSV from the genital tract.[36] Prolonged rupture of the membranes is also a risk factor.

Neonatal herpes infections manifest in one of the three forms: (1) skin, eye, and mouth involvement; (2) encephalitis; or (3) disseminated disease (Fig. 193-11). The latter two forms account for more than 50% of cases of neonatal herpes. It is important to remember that more than 20% of neonates with neurologic and disseminated disease do not develop cutaneous vesicles. Without therapy, the overall mortality of neonatal herpes is 65%, and fewer than 10% of untreated neonates



Figure 193-11 Neonatal herpes simplex virus 2.

with central nervous system infection will develop normally. With current therapeutic modalities, most babies with skin, eye, and mouth disease survive and have normal development at 1 year. For treated babies with encephalitis, mortality is 6%, with about 30% developing normally after 1 year. For babies with disseminated disease, mortality is 30%, with about 80% of the survivors apparently developing normally after 1 year.[34]

TREATMENT

All sexually active persons should be educated regarding the nature and risks of acquiring and transmitting sexually transmitted infections, including HSV. Studies show that about one-half of the patients with asymptomatic HSV-2 infection have mild, unrecognized disease and can be taught to recognize their symptoms and signs of genital herpes. Also, patients should be counseled regarding safer sex practices. It must be emphasized that the majority of transmission occurs in asymptomatic phases and from people who have no classical lesions. Patients with genital herpes should be counseled to refrain from sexual intercourse during outbreaks and for 1–2 days after and to use condoms between outbreaks. Suppressive antiviral therapy is also an option for individuals concerned about transmission to a partner (see Section "Antiviral Therapy under Prevention").

Pregnant women who are known to have genital herpes should be reassured that the risk of transmitting herpes to the baby during childbirth is extremely low. Recommendations for the management of pregnant women with recurrent genital herpes include clinical evaluation at delivery, with

delivery by Cesarean section indicated if there are signs and symptoms of active infection (including prodrome). But Cesarean section delivery may not reliably prevent neonatal HSV infection when membranes are ruptured for long periods (≥24 hours). Women with primary HSV infection during pregnancy should be treated with antiviral therapy. For women at or beyond 36 weeks of gestation who are at risk for recurrent HSV infection, suppressive antiviral therapy has been recommended, (1) as this decreases viral shedding, the incidence of active lesions near term, and the need of Cesarean delivery due to HSV.[37,38] Close follow-up, sequential[70] PCR or cultures for HSV of infants born to seropositive mothers who are shedding virus at the time of delivery, prophylactic therapy with intravenous acyclovir for infants born to mother with primary infection, and intravenous acyclovir if HSV is detected in infants of seropositive mothers have also been suggested.[34]

Women who are known by history and serologic tests not to have genital herpes should be counseled about signs and symptoms of HSV and how to avoid acquiring the infection during pregnancy. Serology is helpful in counseling a couple in which the male partner has recurrent genital herpes and the pregnant wife is susceptible.

ANTIVIRAL THERAPY

(See Chapter 231)

Many HSV infections require no specific treatment at all. Keeping the lesions clean and dry while they heal by themselves may be all that is required. Treatment is warranted for infections that are likely to prove protracted, highly symptomatic, or complicated. Acyclovir, an acyclic guanosine analogue, has a highly favorable therapeutic index because of its preferential activation in infected cells and preferential inhibition of the viral DNA polymerase. It must be phosphorylated to be active, and it requires the viral thymidine kinase (TK) for initial phosphorylation. Acyclovir inhibits HSV-1 and HSV-2 replication by 50% at a concentration of 0.1 and 0.3 μg/mL (range, 0.01–9.9 μg/mL), respectively, but is toxic at concentrations of >30 μg/mL. Any strain that requires more than 3 μg/mL of acyclovir to be inhibited is said to be relatively drug resistant.

Valacyclovir, the L-valyl ester of acyclovir, is an oral prodrug of acyclovir that achieves three- to fivefold higher bioavailability after oral administration, and it can be used in a more convenient dosage regimen. Famciclovir is the well-absorbed oral form of the related guanosine analogue penciclovir. Similar to acyclovir, famciclovir is converted by phosphorylation to its active metabolite penciclovir triphosphate. The efficacy and adverse effect profile of famciclovir is comparable to that of acyclovir. Penciclovir 1% cream is approved by the U.S. Food and Drug Administration (FDA) for the treatment of herpes simplex labialis. Docosanol 10% cream is approved by the FDA for over-the-counter treatment of recurrent herpes labialis. Docosanol is a long-chain saturated alcohol that inhibits entry of lipid-enveloped virus into the cell. It decreased the healing time by 18 hours when compared with placebo.[39]

The current recommendations for antiviral treatment depend on the clinical disease, on host immune status, and whether one is treating a primary or recurrent episode or considering suppressive therapy (Boxes 193-2, 193-3, 193-4, and 193-5).[84] For disseminated or severe herpes infections, the treatment of choice remains intravenous acyclovir 5–10 mg/kg every 8 hours. Some experts use acyclovir 15 mg/kg intravenously every 8 hours for life-threatening HSV infection, including encephalitis. The dose of intravenous acyclovir for neonatal herpes is 20 mg/kg per dose given every 8 hours.

For first episodes of genital HSV-2 infections, oral acyclovir, famciclovir, and valacyclovir all speed the healing and resolution of symptoms, and decrease viral shedding. When compared with placebo, acyclovir decreases time of healing from 16 to 12 days, the duration of pain from 7 to 5 days, and the duration of constitutional symptoms from 6 to 3 days.[51] Valacyclovir was compared with acyclovir in the treatment of primary episodes and shown to be equivalent.[52] Antiviral treatment of initial herpes episodes does not decrease subsequent recurrences, probably because HSV establishes latent infection within hours after inoculation and days before symptoms evolve.

Treatment of recurrent episodes of genital herpes with famciclovir, acyclovir, or valacyclovir has been shown to reduce the time of healing from about 7 to 5 days, time of cessation of viral shedding from 4 to 2 days, and duration of symptoms from 4 to 3 days when compared with placebo. Valacyclovir and acyclovir are equivalent[54,56]; valacyclovir was similar to famciclovir in one study,[57] but slightly superior to famciclovir to suppress genital herpes in another study.[67] A regimen of patient-initiated, 1-day famciclovir 1,000 mg twice daily was not different from placebo in immunocompetent black adults in a recent study, but this finding warrants further investigation.[85] For persons with frequent or complicated genital recurrences, long-term suppressive therapy with acyclovir or its analogues is the most effective management strategy.[71,86,87] Suppressive therapy was effective during the first year after acquisition of genital herpes.[69,70] Suppressive therapy reduces the rate of shedding in healthy persons and those with HIV.[60,70,88,89] Suppressive therapy with valacyclovir was more effective to reduce the burden of genital herpes disease than episodic therapy.[90] Because genital herpes is not progressive in the normal host and because the rate of recurrences varies over time and may decrease after some years, it is wise to recommend a "holiday" from treatment every year or so to reassess the person's continuing need for treatment.

The use of antiviral suppressive therapy during the late phase of pregnancy to avoid neonatal herpes has also been advocated, but a formal study of the approach would require a very large number of participants because of the rare incidence of neonatal herpes. A more achievable goal is to decrease the

BOX 193-2 RECOMMENDED REGIMENS FOR THE TREATMENT OF OROFACIAL HERPES SIMPLEX INFECTIONS

	ACCEPTABLE REGIMEN ALTERNATIVES[a]			
Disease	**Adults**	**Pediatric[b]**	**Duration**	**Comments**
Primary infection	Acyclovir, 200 mg orally five times a day. Acyclovir, 400 mg orally three times a day. Valacyclovir, 1,000 mg orally two times a day. Famciclovir, 250 mg orally three times a day.	15 mg/kg of acyclovir orally five times a day.[40]	7–10 days or until resolution of symptoms.	IV acyclovir for severely ill individuals. No studies have been done in adults: regimens are extrapolated from their effectiveness in primary genital herpes.
Recurrent infection: episodic treatment	Topical penciclovir, 1% cream q2h while awake.[41] Topical docosanol 10% cream five times a day.[39] Acyclovir, 400 mg orally five times a day.[42] Famciclovir, 500 mg orally two or three times a day.[43,44] Valacyclovir, 2,000 mg orally twice a day for 1 day.[45] Famciclovir, 1,500 mg single dose or 750 mg twice a day for 1 day.[46]	4–5 days or until lesions are healed. Valacyclovir and famciclovir were used for only 1 day.		Generally not warranted.
Recurrent infection: prophylaxis	Acyclovir, 400 mg orally twice a day.[47]			Start just before and during precipitating event, such as intensive ultraviolet exposure.
Recurrent infection: suppression of confirmed frequent recurrences	Acyclovir, 400 mg orally twice a day.[48] Valacyclovir 500 mg once a day.[49] Valacyclovir 1,000 mg once a day.[50]	There are no pediatric studies, but children with confirmed frequent recurrences may benefit from suppressive oral acyclovir therapy.		

[a]The doses are for patients with normal renal function.
[b]Oral dosage of acyclovir in children should not exceed 80 mg/kg/day. Children 40 kg and above should receive the adult dose.
Note: Neither valacyclovir nor famciclovir is approved by the US Food and Drug Administration for use in children.

need for Cesarean deliveries caused by herpes recurrences during labor. Studies have shown that antiviral therapy in late pregnancy (beginning at 36 weeks) prevent clinical recurrences, Cesarean sections due to genital herpes, and the risk of HSV viral shedding at delivery.[91]

Orolabial HSV infections warrant antiviral treatment less often than do the genital infections. Primary HSV gingivostomatitis should be treated with oral acyclovir. The pediatric dose is 15 mg/kg of acyclovir suspension orally five times a day for 7 days. When it is started within 3 days of onset of the disease, this regimen decreases the duration of oral and extraoral lesions, fever, and eating and drinking difficulties. Valacyclovir and famciclovir may be equally effective, but they have not been studied in this setting and are not currently approved for use in children. Severely ill children may need to be hospitalized for hydration, and intravenous acyclovir may be necessary.

Treatment of recurrent herpes labialis with antiviral drugs in immunocompetent hosts has shown

BOX 193-3 RECOMMENDED REGIMENS FOR THE TREATMENT OF GENITAL HERPES SIMPLEX INFECTIONS

	ACCEPTABLE REGIMEN ALTERNATIVES[a]			
Disease	**Adults**	**Pediatric[b]**	**Duration**	**Comments**
Primary infection	Acyclovir, 200 mg orally five times a day.[51] Acyclovir, 400 mg orally three times a day.[52] Valacyclovir, 1,000 mg orally twice a day.[52] Famciclovir, 250 mg orally three times a day.	Acyclovir, 40–80 mg/kg/ day orally divided in three to four doses (maximum 1 g/d).[53]	7–10 days or clinical resolution occurs.	
Recurrent infection	Acyclovir, 400 mg orally three times a day. Acyclovir, 200 mg orally five times a day.[54] Acyclovir, 800 mg orally twice a day.[55] Valacyclovir, 500 mg orally twice a day.[56,57,58,59] Valacyclovir, 1,000 mg orally once a day.[58] Valacyclovir, 1,000 mg orally twice a day.[60,61,c] Famciclovir, 500,[c] 250, 125 mg orally twice a day.[44,62–63] Famciclovir, 1,000 mg orally twice a day for 1 day (patient initiated).[57,59,64] Famciclovir, 500 mg, then 250 mg twice daily for 2 days.[63]	For children ≥12 years of age: acyclovir, 200 mg orally five times a day.[53] Acyclovir 800 mg orally twice a day.[53] Acyclovir 800 mg three times a day for 2 days.[53]	5–10 days or until clinical resolution occurs.	
Suppression of recurrences	Acyclovir, 400 mg orally twice a day.[65] Acyclovir, 800 mg orally once a day.[66] Valacyclovir, 500, 1,000 orally once a day.[67,68,d] Valacyclovir, 250 mg orally twice a day.[65,d] Valacyclovir, 500 mg twice a day or 1,000 mg orally once a day.[60,61,69,70,c;] Famciclovir, 250 orally twice a day.[71,72,73] Famciclovir, 125 mg, 250 mg orally three times a day.[74]	For children ≥12 years of age: acyclovir, 400 mg orally twice a day.[53]		Duration of the therapy is controversial. Some authorities will offer treatment for 1 year and then reassess the need to resume it.
Suppression of recurrences in pregnant women	Acyclovir, 400 mg orally three times a day from 36 weeks of gestation until delivery.[75,76] Valacyclovir 500 mg twice a day from 36 weeks of gestation until delivery.[77,78]			
Reduction of transmission	Valacyclovir, 500 mg orally once a day.[11]			Safer sex practices should continue to be used.

[a]The doses are for patients with normal renal function.
[b]Oral dosage of acyclovir in children should not exceed 80 mg/kg/day. Children 40 kg and above should receive the adult dose.
[c]Human immunodeficiency virus patients.
[d]The high once-a-day and twice-daily doses of valacyclovir are more effective in patients who present with more than 10 recurrences per year.
Note: Neither valacyclovir nor famciclovir is approved by the US Food and Drug Administration for use in children.

BOX 193-4 RECOMMENDED REGIMENS FOR THE TREATMENT OF OCULAR AND OTHER CUTANEOUS HERPES SIMPLEX INFECTIONS

		ACCEPTABLE REGIMEN ALTERNATIVES[a]			
Disease		**Adults**	**Pediatric[b]**	**Duration**	**Comments**
Ocular herpes	Therapy	1% trifluridine drop—1 drop q2h during day (maximum, 9 drops/day). until corneal ulcer has healed, followed by 1 drop every 4 h while awake (minimum 5 drops/day) for an additional 7 days (to not exceed 21 days) 3% vidarabine ointment—q3h during day (five times daily); after reepithelialization, treat for an additional 7 days at a reduced dose (such as twice daily) Acyclovir 3% ophthalmic ointment five times daily for 7–10 days Ganciclovir ophthalmic gel 0.15% 1 drop into affected eye five times daily until healed; then 1 drop three times daily for 7 days Acyclovir, 400 mg orally five times a day. Valacyclovir, 1,000 mg orally two times a day.[79]			Undertake in consultation with an ophthalmologist. The combination of interferon and an antiviral may speed healing.[80]
	Suppression of recurrences	Acyclovir, 400 mg orally twice a day.[81,82] Valacyclovir 500 mg daily[81]	For children ≥12 years of age: acyclovir, 400 mg orally twice a day.[53]		Undertake in consultation with an ophthalmologist.
Other cutaneous herpes (herpes gladiatorum, herpetic whitlow, etc.)	Treatment	Acyclovir, 200 mg orally five times per day. Acyclovir, 400 mg orally three times a day. Valacyclovir, 1,000 mg orally twice a day. Famciclovir, 250 mg orally three times a day.	Acyclovir, 4–80 mg/kg/day orally divided into three to four doses (maximum 1 g/day)[53]	7–10 days or until resolution of symptoms.	No studies have been done. Regimens are extrapolated from the treatment of genital herpes. Consider suppressive antiviral therapy for patients with frequent recurrences.

[a]The doses are for patients with normal renal function.
[b]Oral dosage of acyclovir in children should not exceed 80 mg/kg/day. Children 40 kg and above should receive the adult dose.
[c]Human immunodeficiency virus patients.
[d]The high once-a-day and twice-daily doses of valacyclovir are more effective in patients who present with more than 10 recurrences per year.
Note: Neither valacyclovir nor famciclovir is approved by the U.S. Food and Drug Administration for use in children.

BOX 193-5 RECOMMENDED REGIMENS FOR THE TREATMENT OF NEONATAL HERPES, DISSEMINATED INFECTION, ENCEPHALITIS AND ECZEMA HERPETICUM

	ACCEPTABLE REGIMEN ALTERNATIVES[a]			
Disease	**Adults**	**Pediatric[b]**	**Duration**	**Comments**
Neonatal herpes		IV acyclovir, 20 mg/kg every 8 hours.[83]	14–21 days.	The value of long-term suppression after initial treatment is being evaluated.
Disseminated infection	IV acyclovir, 10–15 mg/kg three times a day.	IV acyclovir, 10 mg/kg three times daily.[53]	14–21 days.	
Encephalitis	IV acyclovir, 10–15 mg/kg three times a day.	IV acyclovir, 15–20 mg/kg three times daily.[53]	14–21 days.	
Eczema herpeticum	Acyclovir, 200 mg orally five times a day. Acyclovir, 400 mg orally three times a day. Valacyclovir, 1,000 mg orally twice a day. IV acyclovir, 10–15 mg/kg three times a day.	Acyclovir, 40–80 mg/kg/ day orally divided in three to four doses (maximum, 1.2 g/d). IV acyclovir, 10 mg/kg three times daily.[53]	14–21 days.	No studies have been done. Use IV acyclovir in severely ill individuals. Consider suppressive antiviral therapy for patients with recurrences. Ocular involvement should be treated in consultation with an ophthalmologist.

[a]The doses are for patients with normal renal function.
[b]Oral dosage of acyclovir in children should not exceed 80 mg/kg/day. Children 40 kg and above should receive the adult dose.
Note: Neither valacyclovir nor famciclovir is approved by the U.S. Food and Drug Administration for use in children.

only modest benefits so far. The infections are inherently briefer and less symptomatic than genital herpes. Treatment is only effective if used very early in the disease, especially in the prodromal or erythema lesion stages. Patients who wish treatment should have the medication available and be vigilant for the earliest signs and symptoms of recurrence. When treatment is felt to be required, the therapy of choice is penciclovir 1% cream every 2 hours while awake, for 4 days.[41] Treatment should be initiated as early as possible. When initiated within 1 hour of first symptoms of recurrence, penciclovir sped the healing of lesions (4.8 days vs. 5.5 days) and decreased the duration of pain (3.5 days vs. 4.1 days). This regimen is approved by the FDA. Docosanol 10% cream is approved by the FDA for over-the-counter treatment of herpes simplex labialis. It is to be applied five times a day at the first sign of recurrence of herpes simplex labialis. There has been no direct comparison with topical penciclovir. Oral acyclovir, 400 mg five times a day for 5 days, affords marginal benefit if begun in the earliest hour or two of the outbreak. Famciclovir, 500 mg three times a day for 5 days, when started within 48 hours after experimental ultraviolet radiation, decreased the median time of healing from 6 to 4 days[43] but is not useful for the more usual sporadic cases of herpes labialis. A 1-day regimen of valacyclovir (2 g twice daily for 1 day) decreased the mean duration of cold sore episodes by 1 day when compared with placebo, if started in the prodrome period. Similarly, a single dose of famciclovir reduced time of healing of herpes labialis lesions by approximately 2 days compared with placebo.[46] Creams and ointments containing 5% and 10% acyclovir are not beneficial in recurrent herpes labialis.

The use of suppressive acyclovir for herpes labialis is controversial. In one small study, oral acyclovir, 400 mg twice a day, was effective in decreasing recurrences of herpes labialis.[48] In another study, suppressive therapy with valacyclovir was more effective than episodic therapy with valacyclovir for herpes labialis.[50] In studies with skiers (who have significant sun exposures), acyclovir 400 mg twice a day, was shown to reduce recurrences in one study,[47] whereas acyclovir, 800 mg bid, failed to prevent recurrences in another study.[92] Both perioperative famciclovir (125 or 250 mg orally twice daily given 1–2 days before to 5 days after the procedure) and valacyclovir (500 mg twice daily

for 14 days, starting either a day before or the day of the procedure) appeared to reduce the recurrence of orofacial HSV in patients undergoing facial laser resurfacing.[93,94] Valacyclovir has also been shown to suppress recurrences of herpes gladiatorum.[95]

Herpetic eye disease should always be treated in consultation with an ophthalmologist. Options usually involve topical antivirals, including vidarabine, trifluridine, acyclovir, or ganciclovir. Topical antivirals are effective in shortening the duration of dendritic and geographic keratitis, and are used to prevent corneal epithelial disease in patients with blepharitis and conjunctivitis, as well as patients on topical steroid therapy for corneal stromal inflammation and iridocyclitis.[80] Oral acyclovir is also effective for dendritic and geographical epithelial keratitis. Suppressive antiviral therapy reduces the rates of all types of recurrent ocular HSV disease, and it is most important for patients with a history of HSV stromal keratitis because it can prevent additional episodes and potential loss of vision.[81,82]

ANTIVIRAL RESISTANCE

Virtually all clinically relevant drug resistance has been seen in immunocompromised patients. The primary mechanism of acyclovir resistance is selection of viral mutants defective or deficient in TK expression. Most mutants that are TK deficient are somewhat attenuated for virulence in vivo.

The treatment of resistant HSV infection is complicated. First, one must make the diagnosis. Very few people who claim to be "resistant" to one of the antiviral drugs actually harbor resistant virus. There is a common misconception that treatment prevents all recurrences. One should suspect resistance only in people who continue to have culture-proven outbreaks of unaltered frequency and severity, especially if the lesions do not heal by themselves. When resistance is suspected, virus should be recovered and tested specifically for sensitivity to acyclovir. These tests are expensive but are available through commercial reference laboratories. Second, the options for patients with true resistance are few and far from ideal due to the lack of alternatives that are safe and easy to administer. Foscarnet inhibits replication of all known herpesviruses in vitro and does not require activation by TK or other kinases, and therefore can be effective in the treatment of acyclovir-resistant HSV. Foscarnet requires intravenous therapy and can cause numerous adverse reactions including nephrotoxicity, electrolyte disturbances, anemia, and seizures. Also, foscarnet-resistant HSV strains have been described.

Cidofovir does not require the viral TK for its intracellular phosphorylation to the active form. Cidofovir has been tested in cases of acyclovir-resistant HSV and topical cidofovir has been used with success to treat progressive herpetic lesions.[96] Intravenous cidofovir is associated with considerable nephrotoxicity and requires the coadministration of saline hydration and probenecid. A few patients with acyclovir-resistant genital herpes have responded to imiquimod 5% cream.[97] Imiquimod caused severe inflammation in some patients with recurrent herpes labialis.[98] Resiquimod reduced the rate of new lesions in one study of persons without drug-resistant virus,[99] but had no effect on genital herpes in another study.[100] Long-term suppressive acyclovir therapy reduced the rate of drug-resistant HSV disease in hematopoietic stem cell transplant recipients.[101]

PREVENTION

Strategies to prevent HSV infection have proved inadequate. HSV infection can be prevented by total abstinence, as indicated by very low seroprevalence rates in cloistered nuns. Condoms reduce rates of transmission if used routinely.[102,103] Male circumcision reduced the rate of HSV-2 infection from 10% in the control group to 7.8% in the circumcised group.[103] Other than these public health approaches, most efforts involve antiviral therapy and vaccines directed at genital herpes.

ANTIVIRAL THERAPY

Acyclovir, famciclovir, and valacyclovir decrease both symptomatic and subclinical shedding of HSV-2, from about 8% of the days in the placebo group to 0.3%–0.6% of the days in the treatment group, when assessed by culture.[67,74,88,104,105] Once daily valacyclovir reduced shedding by PCR from 14% to 3% in patients with newly diagnosed genital herpes.[106] Valacyclovir 500 mg once daily was shown to be effective in reducing the transmission of HSV-2 between partners by 48%, and reduced clinical disease in the susceptible partner by 75% in a randomized, placebo-controlled trial involving immunocompetent, heterosexual couples in stable relationships.[11] This therapy can be recommended for individuals concerned about transmission to a partner, in conjunction with the use of condoms. Regarding other groups (e.g., homosexual couples, nonmonogamous individuals, immunocompromised, and persons with asymptomatic HSV-2 infection), it is uncertain if the use of antiviral therapy (and which regimen) would be adequate to decrease transmission.

Vaginal microbicides are also being studied, mostly focusing on decreasing HIV transmission, but some of the compounds also have anti-HSV activity and may also affect HSV transmission.[107]

VACCINES

The best public health strategy to reduce infection and morbidity associated with HSV infection is development of effective vaccines. Unfortunately, no vaccine has proved to protect adequately against acquisition of HSV (prophylactic) or to reduce the number of recurrent episodes (therapeutic), although there are hopeful developments in these directions.

Recombinant glycoprotein vaccines containing immunogenic HSV proteins have been developed and

tested by multiple pharmaceutical and biotechnological companies. In a preliminary study, a recombinant HSV-2 glycoprotein D vaccine with alum adjuvant decreased the frequency of symptomatic outbreaks in patients with genital herpes. A modified form of the vaccine (with added glycoprotein B and a lipid emulsion adjuvant known as MF59) did not decrease the number of recurrences in patients with genital herpes, but did decrease the duration and severity of a subsequent study outbreak of genital herpes.[108] Two phase III studies of the effect of this vaccine (one in monogamous seronegative partners of individuals with genital herpes, and the other in seronegative persons attending clinics for sexually transmitted diseases) failed to prevent acquisition of genital herpes infection or disease.[109] A recombinant gD2 vaccine that uses monophosphoryl lipid-A as adjuvant was protective against HSV-2 genital disease (but had limited protection against infection) in HSV-1 and HSV-2 seronegative women but not in males or HSV-1 seropositive females.[110] A double-blind, randomized controlled study in HSV-1 and HSV-2 seronegative women found that the vaccine was not effective in preventing genital herpes disease.

A major theoretical limitation of recombinant HSV vaccines is their inability to induce broad and protective cellular immune responses, and therefore genetically engineered live vaccines have been developed. Replication-defective viruses are capable of only a single round of replication, and therefore have no pathogenic potential while potentially inducing the full spectrum of immune responses. The use of replication-defective HSV mutants has been tested with success as a candidate vaccine in animal models. A glycoprotein H-deficient virus had no effect on reducing HSV reactivation and clinical disease among individuals with recurrent genital HSV-2 infection.[111] Another replication-defective mutant, defective in ICP8 (a single-stranded DNA binding protein) and part of the helicase/primase complex, has demonstrated to be immunogenic and protective in animals but has not been tested in humans yet. DNA vaccines for HSV have also shown promising results in animal models, but resulted in very limited induction of HSV-specific cellular immune responses in a phase I human study.[112]

ACKNOWLEDGMENT

This chapter is dedicated to the memory of Stephen E. Straus, a coauthor of this chapter in the seventh edition.

KEY REFERENCES

Full reference list available at www.DIGM8.com

DVD contains references and additional content

6. Xu F et al: Trends in herpes simplex virus type 1 and type 2 seroprevalence in the United States. *JAMA* **296**(8):964-973, 2006
8. Mark KE et al: Rapidly cleared episodes of herpes simplex virus reactivation in immunocompetent adults. *J Infect Dis* **198**(8):1141-1149, 2008
11. Corey L et al: Once-daily valacyclovir to reduce the risk of transmission of genital herpes. *N Engl J Med* **350**(1):11-20, 2004
12. Langenberg AG et al: A prospective study of new infections with herpes simplex virus type 1 and type 2. Chiron HSV Vaccine Study Group. *N Engl J Med* **341**(19):1432-1438, 1999
20. Zhu J et al: Virus-specific CD8+ T cells accumulate near sensory nerve endings in genital skin during subclinical HSV-2 reactivation. *J Exp Med* **204**(3):595-603, 2007
22. Gupta R, Warren T, Wald A: Genital herpes. *Lancet* **370**(9605):2127-2137, 2007
34. Corey L, Wald A: Maternal and neonatal herpes simplex virus infections. *N Engl J Med* **361**(14):1376-1385, 2009
37. Money D, Steben M: SOGC clinical practice guidelines: Guidelines for the management of herpes simplex virus in pregnancy. Number 208, June 2008. *Int J Gynaecol Obstet* **104**(2):167-171, 2009
46. Spruance SL et al: Single-dose, patient-initiated famciclovir: A randomized, double-blind, placebo-controlled trial for episodic treatment of herpes labialis. *J Am Acad Dermatol* **55**(1):47-53, 2006
84. Cernik C, Gallina K, Brodell RT: The treatment of herpes simplex infections: An evidence-based review. *Arch Intern Med* **168**(11):1137-1144, 2008

Chapter 194 :: Varicella and Herpes Zoster

:: Kenneth E. Schmader & Michael N. Oxman

VARICELLA AND HERPES ZOSTER AT A GLANCE

- Varicella (chickenpox) and herpes zoster (shingles) are distinct clinical entities caused by a single member of the herpesvirus family, varicella-zoster virus (VZV).
- Varicella, an acute, highly contagious exanthem that occurs most often in childhood, is the result of primary VZV infection of a susceptible individual.
- The rash usually begins on the face and scalp and spreads rapidly to the trunk, with relative sparing of the extremities. Lesions are scattered rather than clustered, and progress from rose-colored macules to papules, vesicles, pustules, and crusts. In varicella, in contrast to smallpox, lesions in all stages are usually present on the body at the same time.
- In normal children, systemic symptoms are usually mild and serious complications are rare. In adults and immunologically compromised persons of any age, varicella is more likely to be associated with life-threatening complications.
- Where use of varicella vaccine in susceptible children and adults is widespread, the incidence of varicella is markedly reduced, although breakthrough varicella may occur.
- Herpes zoster is characterized by unilateral, dermatomal pain, and rash that results from reactivation and multiplication of endogenous VZV that had persisted in latent form within sensory ganglia following an earlier attack of varicella.
- The erythematous, maculopapular, and vesicular lesions of herpes zoster are clustered rather than scattered because virus reaches the skin via sensory nerves rather than viremia.
- Herpes zoster is most common in older adults and immunosuppressed individuals.
- Pain is an important clinical manifestation of herpes zoster, and the most common debilitating complication is chronic pain or postherpetic neuralgia (PHN).
- Antiviral therapy and analgesics reduce acute pain; lidocaine patch (5%), high dose capsaicin patch, gabapentin, pregabalin, opioids, and tricyclic antidepressants may reduce the pain of PHN.
- A live attenuated zoster vaccine reduces the incidence of herpes zoster by one-half and the incidence of PHN by two-thirds.

EPIDEMIOLOGY

EPIDEMIOLOGY OF VARICELLA

Varicella is distributed worldwide, but its age-specific incidence differs in temperate versus tropical climates, and in populations that have received varicella vaccine. In temperate climates in the absence of varicella vaccination, varicella is endemic, with a regularly recurring seasonal prevalence in winter and spring, and periodic epidemics that depend upon the accumulation of susceptible persons. In Europe and North America in the prevaccination era, 90% of cases occurred in children younger than 10 years of age and fewer than 5% in individuals older than the age of 15.[1] From 1988 to 1995, there were approximately 11,000 hospitalizations and 100 deaths caused by varicella each year in the United States.[2–4] The risk of hospitalization and death was much higher in infants and adults than in children, and most varicella-related deaths occurred in previously healthy people.[5] In tropical and semitropical countries, the mean age of varicella is higher and susceptibility among adults to primary VZV infection is significantly greater than in temperate climates. High levels of susceptibility to varicella among adult immigrants from tropical climates are well documented in the US military, where many recruits from Puerto Rico and the Philippines have been seronegative. This is important for hospitals, where susceptible healthcare workers may pose a significant risk of nosocomial varicella.

Widespread use of the varicella vaccine has markedly altered the epidemiology of varicella. In the United States, vaccine coverage rates among susceptible children increased from 0% in 1995, when varicella vaccine was licensed, to 88% in 2004.[6] This has resulted in a marked decline in varicella cases

and varicella-related hospitalizations. From 1995 through 2000, varicella cases reported to the Centers for Disease Control (CDC) declined by 71%–84%, depending upon surveillance area; by 2005 the incidence of varicella had decreased by 90%, with a comparable decline in varicella-related hospitalizations.[7–11] The decline was greatest among children aged 1–4 years, but cases declined in all age groups, including unvaccinated infants and adults, reflecting herd immunity. Varicella-related mortality has also declined substantially after introduction of the varicella vaccine. From 1990 to 1994, mortality from varicella decreased by 66% in all age groups under 50 years, with the greatest reduction (92%) among children 1–4 years of age.[4]

Varicella is highly contagious. Attack rates of 87% among susceptible siblings in households and nearly 70% among susceptible patients on hospital wards have been reported. More than 95% of cases of varicella are clinically apparent, although occasionally the exanthem may be so sparse and transient as to pass unnoticed. A typical patient is infectious for 1–2 days (rarely, 3–4 days) before the exanthem appears, and for 4 or 5 days thereafter, that is, until the last crop of vesicles has crusted. The immunocompromised patient, who may experience many successive crops of lesions for a week or more, is infectious for a longer period of time. The mean incubation period of varicella is 14 or 15 days, with a range of 10–23 days. It is often prolonged in patients who develop varicella after passive immunization with varicella-zoster immune globulin (VZIG) or zoster immune plasma (ZIP), or after postexposure immunization with live attenuated Oka strain varicella vaccine.[11]

The major route by which varicella is acquired and transmitted is thought to be the respiratory tract, but infection may also be spread by direct contact. Varicella crusts are not infectious, and the duration of infectivity of droplets containing virus is probably quite limited. Although the infectiousness of patients with varicella is thought to depend largely upon virus shed from the mucous membranes of the upper respiratory tract, VZV has only rarely been cultured from pharyngeal secretions; however, VZV DNA can be detected in the oropharynx of the majority of patients using polymerase chain reaction (PCR)-based assays.[12]

Natural varicella (i.e., varicella caused by wild-type VZV) generally confers life-long immunity to the disease. Re-exposure to the virus boosts humoral and cell-mediated immune responses, but rarely leads to clinical illness. Most reported second attacks of varicella involve incorrect diagnoses; others may represent cutaneous dissemination in patients with herpes zoster (see below). With severe immunocompromise, reinfections manifested as varicella have been observed. In addition, persons who develop modified varicella (e.g., because they are infected early in infancy in the presence of maternal antibody or have been immunized with live attenuated varicella vaccine) may respond to exogenous exposure by developing a second, usually mild, episode of "breakthrough" varicella.

EPIDEMIOLOGY OF HERPES ZOSTER

Herpes zoster occurs sporadically throughout the year without seasonal prevalence. The occurrence of herpes zoster is independent of the prevalence of varicella, and there is no convincing evidence that herpes zoster can be acquired by contact with other persons with varicella or herpes zoster. Rather, the incidence of herpes zoster is determined by factors that influence the host-virus relationship.

One strong risk factor is older age (Fig. 194-1A). The incidence of herpes zoster is 1.5–3.0 per 1,000 person-years in all ages and 7–11 per 1,000 per year in persons over 60 years of age in European and North American studies.[13–22] It is estimated that there are more than a million new cases of herpes zoster in the United States each year, more than half of which occur in persons ≥60 years of age, and this number will increase as the population ages.[14,17,21,23]

Another major risk factor is cellular immune dysfunction. Immunosuppressed patients have a 20–100 times greater risk of herpes zoster than immunocompetent individuals of the same age. Immunosuppressive conditions associated with high risk of herpes zoster include HIV infection, bone marrow transplant, leukemia and lymphoma, use of cancer chemotherapy, and use of corticosteroids. Herpes zoster is a prominent and early "opportunistic infection" in persons infected with HIV, in whom it is often the first sign of immune deficiency. Thus, HIV infection should be considered in individuals who develop herpes zoster.

Other factors reported to increase the risk of herpes zoster include female sex,[20] physical trauma in the affected dermatome,[24] IL-10 gene polymorphisms,[25] and white race.[19,20] Exposure to children and contact with cases of varicella have been reported to increase levels of VZV-CMI and confer protection against herpes zoster.[20,26]

Second episodes of herpes zoster are uncommon in immunocompetent persons, and third attacks are very rare. Persons suffering more than one episode may be immunocompromised. Immunocompetent patients suffering multiple episodes of herpes zoster-like disease are likely to be suffering from recurrent zosteriform herpes simplex virus infections.[27]

Patients with herpes zoster are less contagious than patients with varicella. The rate at which susceptible household contacts develop varicella after exposure to herpes zoster appears to be about one-third of the rate observed following exposure to varicella.[14] Virus can be isolated from vesicles and pustules in uncomplicated herpes zoster for up to 7 days after the appearance of the rash, and for much longer periods in immunocompromised individuals. Patients with uncomplicated dermatomal zoster appear to spread the infection by means of direct contact with their lesions. Airborne transmission has also been documented.[28] Patients with disseminated herpes zoster may also transmit the infection via aerosols, so that airborne precautions, as well as contact precautions, are required for such patients.

The effect of the marked reduction in the incidence of varicella, due to widespread varicella vaccination of

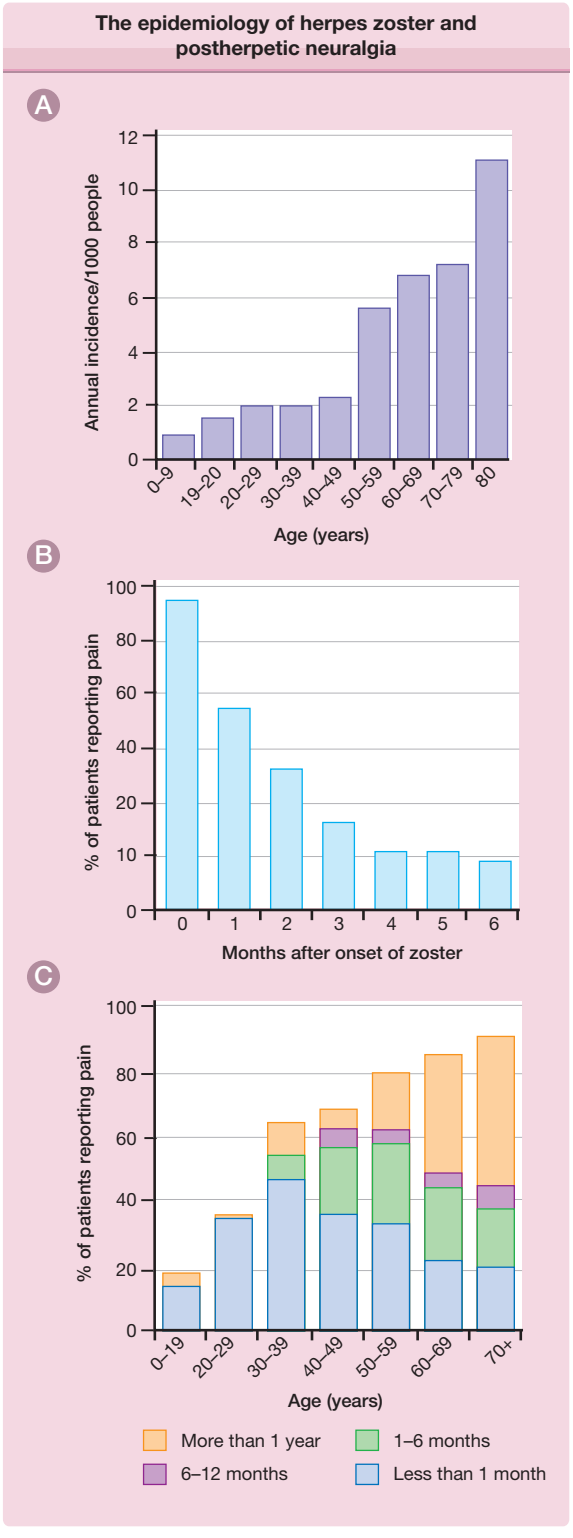

Figure 194-1 **A.** The epidemiology of herpes zoster and postherpetic neuralgia. The annual incidence of herpes zoster per 1,000 persons in a general medical practice. **B.** The percentage of patients with pain persisting after the onset of the herpes zoster rash. These data are from the placebo recipients in one large, double-blind treatment study. **C.** The proportion of patients with postherpetic neuralgia according to age. (From Kost RG, Straus SE: Postherpetic neuralgia: Pathogenesis, treatment, and prevention. *N Engl J Med* **335**:32, 1996 with permission.)

children, on the epidemiology of herpes zoster is unclear. In the long term, the incidence of herpes zoster is likely to decline as the cohorts of children now receiving varicella vaccine become adults; vaccine virus-associated herpes zoster will probably be less frequent and less severe in older adults than wild-type virus-associated herpes zoster because the vaccine virus is highly attenuated. In the short term, the incidence of herpes zoster could increase because a decline in the incidence of varicella will reduce the adult population's exposure to VZV thereby reducing immune boosting, hastening the age-related decline in immunity to VZV, and thus increasing the age-specific risk of herpes zoster. However, recent studies of herpes zoster in populations with high rates of varicella vaccination have shown little or no increase in the incidence of herpes zoster.[8,15,29,30]

ETIOLOGY AND PATHOGENESIS

VZV is a member of the herpesvirus family.[31] Other members pathogenic for humans include herpes simplex viruses type 1 (HSV-1) and type 2 (HSV-2); cytomegalovirus (CMV); Epstein–Barr virus (EBV); human herpesvirus-6 (HHV-6) and human herpesvirus-7 (HHV-7), which cause roseola; and Kaposi's sarcoma-associated herpesvirus, also called human herpesvirus type 8. All herpesviruses are morphologically indistinguishable and share a number of properties, including the capacity to establish latent infections that persist for life.

The VZV genome encodes about 70 unique genes, most of which have DNA sequence and functional homology to genes of the other herpesviruses.[32] Immediate early (IE) gene products regulate VZV replication. Early gene products, such as the virus-specific thymidine kinase and the viral DNA polymerase, support viral replication. Late genes encode virus structural proteins that serve as targets for neutralizing antibodies and cellular immune responses.

There is only one VZV serotype. However, there are multiple VZV genotypes that display geographic segregation and recombination, and minor variations in their nucleotide sequences allow one to distinguish wild type from vaccine virus strains, and to "fingerprint" viruses isolated from individual patients.[32,33]

PATHOGENESIS OF VARICELLA

Entry of VZV is through the mucosa of the upper respiratory tract and oropharynx. Initial multiplication occurs at this portal of entry, where VZV infects tonsillar T cells, which disseminate virus via the blood and lymphatics (the primary viremia). Infected T cells carry virus to the reticuloendothelial system, the major site of virus replication during the remainder of the incubation period, and to the skin, where innate immune responses delay VZV replication and rash formation.[32,34–36]

The incubating infection is partially contained by innate host defenses [e.g., interferon, natural killer (NK) cells] and by developing VZV-specific immune responses. In most individuals, virus replication eventually overwhelms these developing host defenses, so

that about 2 weeks after infection, a much larger (secondary) viremia and associated symptoms and lesions occur. Skin lesions appear in successive crops, reflecting a cyclic viremia, which in the normal host is terminated after about 3 days by VZV-specific humoral and cellular immune responses. Virus circulates in mononuclear leukocytes, primarily lymphocytes. Even in uncomplicated varicella, the secondary viremia results in the subclinical infection of many organs in addition to the skin. Effective host immune responses terminate viremia and limit the progression of varicella lesions in the skin and other organs. Humeral immunity to VZV protects against varicella. People with detectable serum antibody resulting from wild-type VZV infection do not usually become ill after exogenous exposure. Cell-mediated immunity to VZV also develops during the course of varicella, persists for many years, and protects against severe infections.[37,38]

PATHOGENESIS OF HERPES ZOSTER

During the course of varicella, VZV passes from lesions in the skin and mucosal surfaces into the contiguous endings of sensory nerves and is transported centripetally up the sensory fibers to the sensory ganglia. Infected T cells may also carry virus to sensory ganglia hematogenously. In the ganglia, the virus establishes a latent infection that persists for life. Herpes zoster occurs most often in dermatomes in which the rash of varicella achieves the highest density—those innervated by the first (ophthalmic) division of the trigeminal nerve and by spinal sensory ganglia from T1 to L2.[39]

Although the latent virus in the ganglia retains its potential for full infectivity, reactivation is sporadic and infrequent, and infectious virus does not appear to be present during latency. The mechanisms involved in reactivation of latent VZV are unclear, but reactivation has been associated with immunosuppression; emotional stress; irradiation of the spinal column; tumor involvement of the cord, dorsal root ganglion, or adjacent structures; local trauma; surgical manipulation of the spine; and frontal sinusitis (as a precipitant of ophthalmic zoster). Most important, though, is the decline in VZV-specific cellular immunity that occurs with increasing age.[40]

VZV may also reactivate without producing overt disease. The small quantity of viral antigens released during such contained reactivations would be expected to stimulate and sustain host immunity to VZV.[14,41]

When VZV-specific cellular immunity falls below some critical level, reactivated virus can no longer be contained.[14] Virus multiplies and spreads within the ganglion, causing neuronal necrosis and intense inflammation, a process that is often accompanied by severe neuralgia.[42,43] Infectious VZV then spreads antidromically down the sensory nerve, causing intense neuritis, and is released from the sensory nerve endings in the skin, where it produces the characteristic cluster of zoster vesicles. Spread of the ganglionic infection proximally along the posterior nerve root to the meninges and cord may result in local leptomeningitis, cerebrospinal fluid pleocytosis, and segmental myelitis. Infection of motor neurons in the anterior horn and inflammation of the anterior nerve root account for the local palsies that may accompany the cutaneous eruption, and extension of infection within the central nervous system (CNS) may result in rare complications of herpes zoster (e.g., meningoencephalitis, transverse myelitis). Viremia also occurs during herpes zoster.[44]

PATHOGENESIS OF PAIN IN HERPES ZOSTER AND POSTHERPETIC NEURALGIA

Pain is a major symptom of herpes zoster. It often precedes and generally accompanies the rash, and it frequently persists after the rash has healed—a complication known as postherpetic neuralgia (PHN). A number of different but overlapping mechanisms appear to be involved in the pathogenesis of pain in herpes zoster and PHN (Fig. 194-2).[45,46]

Injury to the peripheral nerve and to neurons in the ganglion triggers afferent pain signals. Inflammation in the skin triggers nociceptive signals that further amplify cutaneous pain. The abundant release of excitatory amino acids and neuropeptides induced by the sustained barrage of afferent impulses during the prodrome and acute phase of herpes zoster may cause excitotoxic injury and the loss of inhibitory interneurons in the spinal dorsal horn. Damage to neurons in the spinal cord and ganglion, and to the peripheral nerve, is important in the pathogenesis of PHN. Damaged primary afferent nerves may become spontaneously active and hypersensitive to peripheral stimuli, and also to sympathetic stimulation. Excessive nociceptor activity and ectopic impulse generation may, in turn, sensitize CNS neurons, augmenting and prolonging central responses to innocuous as well as noxious stimuli. Clinically, these mechanisms result in allodynia (pain and/or unpleasant sensations elicited by stimuli that are normally not painful, e.g., light touch) with little or no sensory loss.

The anatomic and functional changes responsible for PHN appear to be established early in the course of herpes zoster. This would explain the correlation of initial pain severity and the presence of prodromal pain with the subsequent development of PHN, and the failure of antiviral therapy to fully prevent PHN (see below).

CLINICAL FINDINGS

CLINICAL FINDINGS OF VARICELLA

PRODROME OF VARICELLA. In young children, prodromal symptoms are uncommon. In older children and adults, the rash is often preceded by 2–3 days of fever, chills, malaise, headache, anorexia, severe backache, and, in some patients, sore throat and dry cough.

RASH OF VARICELLA. In unvaccinated persons, the rash begins on the face and scalp and spreads rapidly to the trunk, with relative sparing of the extremities (Fig. 194-3). New lesions appear in successive crops, but their distribution remains central. The rash tends

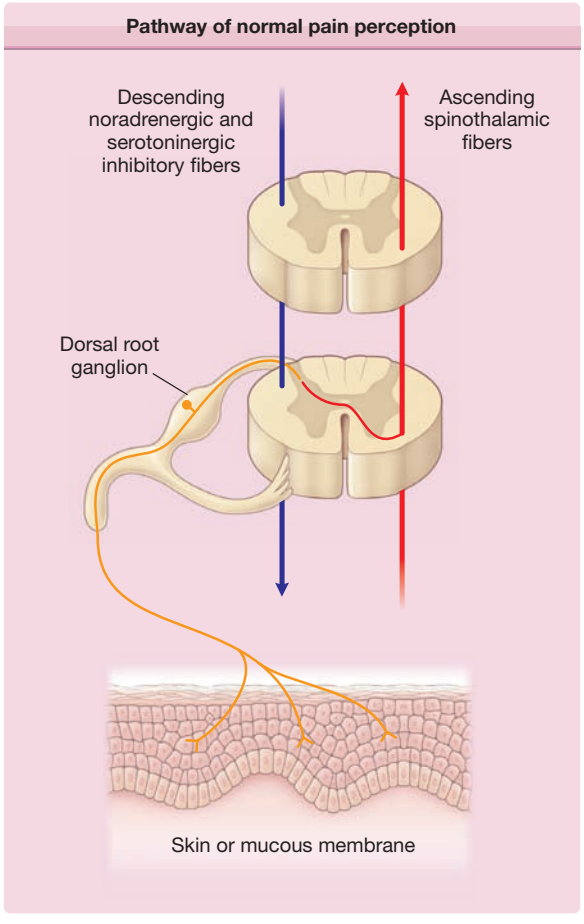

Figure 194-2 Pathway of normal pain perception. Noxious stimuli activate free nerve endings in the skin to generate signals that are conveyed through unmyelinated C fibers (*red*) and small Aδ fibers to the neuronal bodies in the segmental dorsal root ganglia, then proximally to the dorsal horn of the spinal cord, where they form synapses with second-order neurons. Spinal cord neurons are subject to powerful descending inhibitory signals from the brain (*green*), mediated by the biogenic amines serotonin and norepinephrine. Drugs that potentiate the central effects of biogenic amines, such as tricyclic antidepressant drugs, may act by enhancing these descending pathways. Endogenous opiates also contribute to descending inhibitory input. The net result of peripheral afferent input and descending inhibitory input is projected cephalad, joining other ascending fibers in the contralateral spinothalamic tract (*orange*). Information from the spinothalamic tract is integrated with input from brainstem and cortical areas for the perception of specific aspects of pain as well as more general affective components of pain perception.

to be denser in the small of the back and between the shoulder blades than on the scapulae and buttocks and more profuse on the medial than on the lateral aspects of the limbs. It is not uncommon to have a few lesions on the palms and soles, and vesicles often appear earlier and in larger numbers in areas of inflammation, such as diaper rash or sunburn.

A striking feature of varicella lesions is their rapid progression, over as little as 12 hours, from rose-colored macules to papules, vesicles (Fig. 194-3A), pustules, and crusts. The typical vesicle of varicella is 2–3 mm in diameter and elliptical, with its long axis parallel to the folds of the skin. The early vesicle is superficial and thin-walled, and it is surrounded by an irregular area of erythema, which gives the lesions the appearance of a "dewdrop on a rose petal." The vesicular fluid soon becomes cloudy with the influx of inflammatory cells, which convert the vesicle to a pustule (Fig. 194-3B). The lesion then dries, beginning in the center, first producing an umbilicated pustule and then a crust. Crusts fall off spontaneously in 1–3 weeks, leaving shallow pink depressions that gradually disappear. Scarring is rare unless the lesions were traumatized by the patient or superinfected with bacteria. Healing lesions may leave hypopigmented spots that persist for weeks to months; if scars occur they are depressed, pox-like.

Vesicles also develop in the mucous membranes of the mouth, nose, pharynx, larynx, trachea, gastrointestinal tract, urinary tract, and vagina. These mucosal vesicles rupture so rapidly that the vesicular stage may be missed. Instead, one sees shallow ulcers 2–3 mm in diameter.

A distinctive feature of varicella is the simultaneous presence, in any one area of the skin, of lesions in all stages of development. Careful prospective studies have shown that the average number of lesions in healthy children ranges from 250 to 500; secondary cases resulting from household exposure are more severe than primary cases resulting from exposure at school, presumably because more intense and prolonged exposure at home results in a higher virus inoculum.

Fever usually persists as long as new lesions continue to appear, and its height is generally proportional to the severity of the rash. It may be absent in mild cases or rise to 40.5°C (105°F) in severe cases with extensive rash. Prolonged fever or recurrence of fever after defervescence may signify a secondary bacterial infection or another complication. The most distressing symptom is pruritus, which is usually present throughout the vesicular stage.

The varicella vaccine alters the natural history of the rash. A small percentage of vaccinees develop "breakthrough" varicella after exposure to people with active VZV infections. The usual breakthrough rash is predominately maculopapular with fewer lesions (i.e., less than 60) and fewer vesicles than the rash of natural varicella. The incidence and severity of fever is also less than that in natural varicella.[47]

CLINICAL MANIFESTATIONS OF HERPES ZOSTER

PRODROME OF HERPES ZOSTER. Pain and paresthesia in the involved dermatome often precede the eruption by several days and vary from superficial itching, tingling, or burning to severe, deep, boring, or lancinating pain. The pain may be constant or intermittent and it is often accompanied by tenderness and hyperesthesia of the skin in the involved dermatome. The preeruptive pain of herpes zoster may simulate pleurisy, myocardial infarction, duodenal ulcer, cholecystitis, biliary or renal colic, appendicitis, prolapsed intervertebral disk, or early glaucoma, and this may lead to serious misdiagnosis and misdirected interventions. Prodromal pain is uncommon in



Figure 194-3 Varicella. **A.** A full spectrum of lesions—that is, erythematous papules, vesicles ("dewdrops on rose petals"), crusts, and erosions at sites of excoriation—is seen in a child with a typical case of varicella. **B.** A wider range of lesions, including many large pustules, is seen in a 21-year-old female who was febrile as well as "toxic" and had varicella pneumonitis.

immunocompetent persons under 30 years of age, but it occurs in the majority of persons with herpes zoster over the age of 60 years. A few patients experience acute segmental neuralgia without ever developing a cutaneous eruption—a condition known as *zoster sine herpete*.[48]

RASH OF HERPES ZOSTER. The most distinctive feature of herpes zoster is the localization and distribution of the rash, which is nearly always unilateral and is generally limited to the area of skin innervated by a single sensory ganglion (Fig. 194-4A). The area supplied by the trigeminal nerve, particularly the ophthalmic division, and the trunk from T3 to L2 are most frequently affected; the thoracic region alone accounts for more than half of all reported cases, and lesions rarely occur distal to the elbows or knees.[14,18,39]

Although the individual lesions of herpes zoster and varicella are indistinguishable, those of herpes zoster tend to evolve more slowly and usually consist of closely grouped vesicles on an erythematous base, rather than the more discrete, randomly distributed vesicles of varicella. This difference reflects intraneural spread of virus to the skin in herpes zoster, as opposed to viremic spread in varicella. Herpes zoster lesions begin as erythematous macules and papules that often first appear where superficial branches of the affected sensory nerve are given off, for example, the posterior primary division and the lateral and anterior branches of the anterior primary division of spinal nerves.[39] Vesicles form within 12–24 hours and evolve into pustules by the third day. These dry and crust in 7–10 days. The crusts generally persist for 2–3 weeks (Fig. 194-4B). In normal individuals, new lesions continue to appear for 1–4 days (occasionally for as long as 7 days). The rash is most severe and lasts longest in older people, and is least severe and of shortest duration in children.

Between 10% and 15% of reported cases of herpes zoster involve the ophthalmic division of the trigeminal nerve (Fig. 194-4C).[49] The rash of ophthalmic zoster may extend from the level of the eye to the vertex of the skull, but it terminates sharply at the midline of the forehead. When only the supratrochlear and supraorbital branches are involved, the eye is usually spared. Involvement of the nasociliary branch, which innervates the eye as well

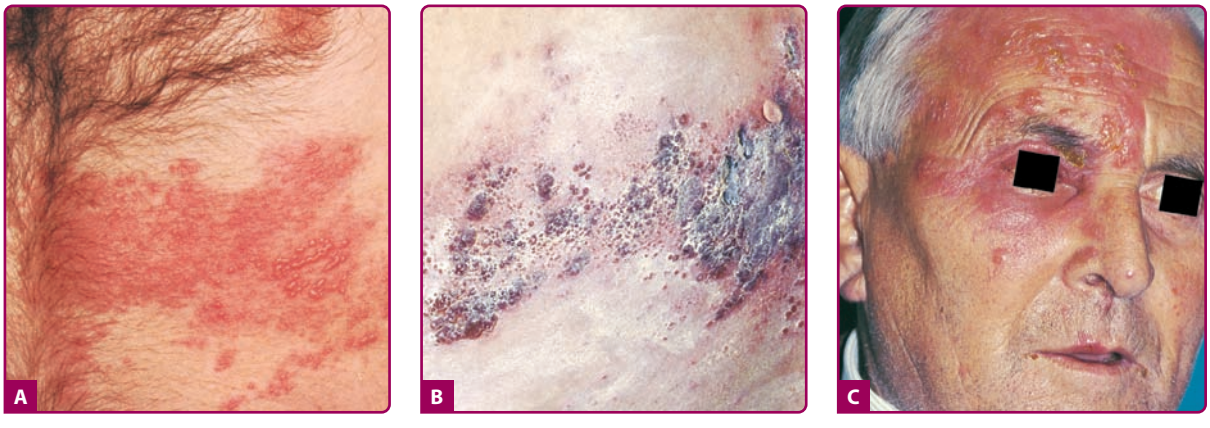

Figure 194-4 Herpes zoster. **A.** Early involvement of a thoracic dermatome with erythema within the dermatome and areas of grouped vesicle formation. **B.** Later involvement with crusted sites on the back, where the eruption first appeared, and many confluent hemorrhagic vesicles and bullae on the lateral chest wall, where the eruption appeared more recently; some vesicles are also seen outside the involved dermatome, representing hematogenous dissemination, a not uncommon occurrence. **C.** Ophthalmic zoster. Note the involvement of the tip of the nose, which frequently signals involvement of the eye.

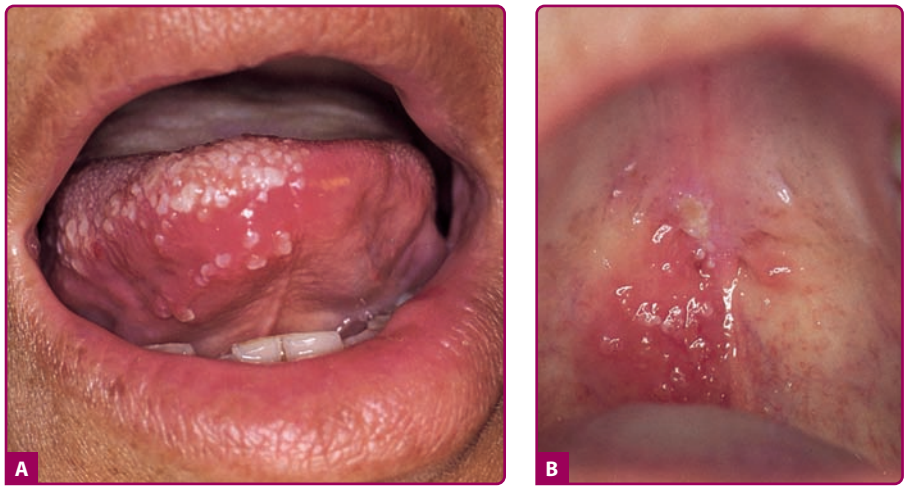

Figure 194-5 Cephalic herpes zoster with facial palsy (Hunt syndrome). A 60-year-old female with right-sided facial palsy and vesicles on her (**A**) *tongue* and (**B**) *soft palate.*

as the tip and side of the nose, provides VZV with direct access to intraocular structures. Thus, when ophthalmic zoster involves the tip and the side of the nose, careful attention must be given to the condition of the eye. The eye is involved in 20%–70% of patients with ophthalmic zoster. Corneal sensation is generally impaired and when impairment is severe, it may lead to neurotrophic keratitis and chronic ulceration.

Herpes zoster affecting the second and third divisions of the trigeminal nerve as well as other cranial nerves may produce symptoms and lesions in the mouth (Fig. 194-5), ears, pharynx, or larynx. The so-called Ramsay Hunt syndrome (facial palsy in combination with herpes zoster of the external ear or tympanic membrane, with or without tinnitus, vertigo, and deafness), results from involvement of the facial and auditory nerves.

PAIN OF HERPES ZOSTER. Although the rash is important, pain is the cardinal problem posed by herpes zoster, especially in the elderly. Most patients experience dermatomal pain or discomfort during the acute phase (The first 30 days following rash onset) that ranges from mild to severe. Patients describe their pain or discomfort as burning, deep aching, tingling, itching, or stabbing. For some patients, the pain intensity is so great that words like horrible or excruciating are used to describe the experience. Acute herpes zoster pain is associated with decreased physical functioning, emotional distress, and decreased social functioning.[50,51]

HERPES ZOSTER IN THE IMMUNOCOMPROMISED HOST. Except for PHN, most serious complications of herpes zoster occur in immunocompromised persons. These complications include necrosis of skin and scarring (Fig. 194-6) and cutaneous dissemination (Fig. 194-7) with an incidence as high as 25%–50%. Patients with cutaneous dissemination also manifest widespread, often fatal, visceral



Figure 194-6 **A.** Acute, necrotic herpes zoster involving the first and second distributions of the fifth cranial nerve in a woman with lymphoma receiving cytotoxic chemotherapy. **B.** Dense scar formation and temporal muscle wasting several weeks later. (From Straus SE et al: Varicella-zoster infections: Biology, natural history, treatment and prevention. *Ann Intern Med* **108**:221, 1988 with permission.)



Figure 194-7 The back of a patient with chronic lymphocytic leukemia and disseminated herpes zoster. (From Straus SE et al: Varicella-zoster infections: Biology, natural history, treatment and prevention. *Ann Intern Med* **108**:221, 1988 with permission.)

dissemination, particularly to the lungs, liver, and brain.

HIV-infected patients are fairly unique in their tendency to suffer multiple recurrences of herpes zoster as their HIV infection progresses; herpes zoster may recur in the same or different dermatomes or in several contiguous or noncontiguous dermatomes. Herpes zoster in patients with AIDS may be severe, with cutaneous and visceral dissemination. Patients with AIDS may also develop chronic verrucous, hyperkeratotic, or ecthymatous cutaneous lesions caused by acyclovir-resistant VZV (Fig. 194-8) (see also Chapter 198).

DIFFERENTIAL DIAGNOSIS

(See Box 194-1)



Figure 194-8 Chronic verrucous lesions of herpes zoster despite long-term acyclovir treatment in a patient with advanced AIDS. (Used with permission from David Paar, MD.)

BOX 194-1 DIFFERENTIAL DIAGNOSIS OF VARICELLA AND HERPES ZOSTER

VARICELLA

Most Likely
- Vesicular exanthems of coxsackieviruses and echoviruses
- Impetigo
- Insect bites
- Contact dermatitis
- Rickettsialpox

Consider
- Papular urticaria
- Erythema multiforme
- Drug eruptions
- Disseminated herpes simplex
- Scabies

Always Rule Out
- Secondary syphilis
- Disseminated herpes zoster
- Dermatitis herpetiformis
- Smallpox and other poxviruses

HERPES ZOSTER

Most Likely
- Zosteriform herpes simplex
- Contact dermatitis
- Insect bites
- Burns

Consider
- Papular urticaria
- Erythema multiforme
- Drug eruptions
- Scabies

Always Rule Out
- Bullous pemphigoid
- Pemphigus vulgaris
- Dermatitis herpetiformis
- Epidermolysis bullosa herpetiformis

CLINICAL DIAGNOSIS OF VARICELLA

Varicella can usually be diagnosed readily on the basis of the appearance and evolution of its characteristic rash (see Fig. 194-3), particularly when there is a history of exposure within the preceding 2–3 weeks.

Disseminated herpes zoster may be mistaken for varicella when there is widespread dissemination of VZV from a small, painless area of herpes zoster or from the affected sensory ganglion in the absence of an obvious dermatomal eruption. This is not infrequent in profoundly immunosuppressed, seropositive persons (Fig. 194-7).

Disseminated HSV infections may resemble varicella; however, there is often an obvious concentration of lesions at and surrounding the site of the primary or recurrent infection (e.g., the mouth or external genitalia) and there may be marked toxicity and encephalitis.

The remaining differential diagnoses of varicelliform rashes are listed in Box 194-1. The character, distribution, and evolution of the lesions, together with a careful epidemiologic history, usually differentiate these diseases from varicella. When any doubt exists, the clinical impression should receive laboratory confirmation.

CLINICAL DIAGNOSIS OF HERPES ZOSTER

In the preeruptive stage, the prodromal pain of herpes zoster is often confused with other causes of localized pain. Once the eruption appears, the character and dermatomal location of the rash, coupled with dermatomal pain or other sensory abnormalities, usually makes the diagnosis obvious (Figs. 194-4 and 194-5).

A cluster of vesicles, particularly near the mouth or genitals, may represent herpes zoster, but it may also be recurrent HSV infection.[27] Zosteriform herpes simplex is often impossible to distinguish from herpes zoster on clinical grounds. A history of multiple recurrences at the same site is common in herpes simplex but does not occur in herpes zoster in the absence of profound and clinically obvious immune deficiency.

Box 194-1 lists other considerations in the differential diagnosis of herpes zoster.

LABORATORY DIAGNOSIS

The lesions of varicella and herpes zoster are indistinguishable by histopathology (Fig. 194-9). The presence of multinucleated giant cells and epithelial cells containing acidophilic intranuclear inclusion bodies (Fig. 194-9B) distinguishes the cutaneous lesions produced by VZV from all other vesicular eruptions (e.g., those caused by variola and other poxviruses, and by coxsackieviruses and echoviruses) except those produced by HSV. These cells can be demonstrated in Tzanck smears prepared at the bedside; material is scraped from the base of an early vesicle, spread on a glass slide, fixed in acetone or methanol, and stained with hematoxylin-eosin, Giemsa, Papanicolaou, or Paragon multiple stain.

Punch biopsies provide more reliable material for histologic examination than Tzanck smears and facilitate diagnosis in the prevesicular stage and in atypical lesions such as the chronic verrucous lesions produced by acyclovir-resistant VZV in patients with AIDS (Fig. 194-8).

The definitive diagnosis of VZV infection, as well as the differentiation of VZV from HSV, is accomplished by the isolation of virus in cell cultures inoculated with vesicle fluid, blood, cerebrospinal fluid or infected tissue, or by the direct identification of VZV antigens or nucleic acids in these specimens. Virus isolation is the only technique that yields infectious VZV for further analysis, such as determination of its sensitivity to antiviral drugs; however, VZV is extremely labile, and only 30%–60% of cultures from proven cases are generally positive. To maximize virus recovery, specimens should be inoculated into cell culture immediately. It is important to select new vesicles containing clear fluid for aspiration, because the probability of isolating VZV diminishes rapidly as lesions become pustular. VZV is almost never isolated from crusts.

VZV can be isolated and propagated in vitro in monolayer cultures of a variety of human (and certain simian) cells. The cytopathic effects induced by the replicating virus in such cell cultures are characterized by the formation of acidophilic intranuclear inclusion bodies and multinucleated giant cells similar to those seen in the cutaneous lesions of the disease. These changes are indistinguishable from those produced by HSV, but whereas HSV rapidly spreads to infect the remaining cells in the culture, the cytopathic effect of VZV remains focal. Cytopathic effects of VZV are generally not apparent until several days after specimen inoculation. Modifications of the cell culture assay in which vesicle fluid or lesion scrapings are centrifuged onto cells growing on coverslips at the bottom of thin glass-walled "shell" vials followed 24–72 hours later by fixation and staining with fluorescein- or enzyme-labeled monoclonal antibodies to VZV proteins, can confirm the presence of VZV relatively quickly, well before cytopathic effects are evident in conventional cell cultures.[52]

Immunofluorescent or immunoperoxidase staining of cellular material from fresh vesicles or prevesicular lesions has become the diagnostic method of choice

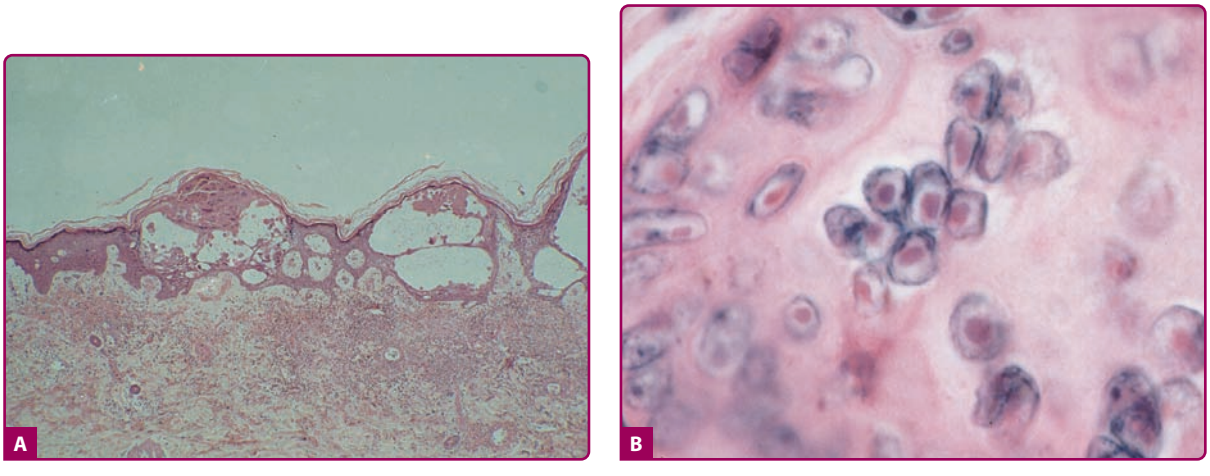

Figure 194-9 Herpes zoster, histopathology. **A.** Intraepidermal vesicle, acantholysis, reticular degeneration; underlying dermis shows edema and vasculitis. **B.** Multinucleated giant cells with characteristic nuclear changes.

in many centers; it can detect VZV significantly more often and faster than virus culture, even relatively late in the disease when cultures are no longer positive.[52] Enzyme immunoassays provide another rapid and sensitive method for antigen detection.

Detection of VZV DNA in clinical specimens following amplifications by PCR provides the greatest assay sensitivity, very high specificity and rapid turnaround time. It has revolutionized the diagnosis of VZV infections, and can distinguish among wild type and Oka vaccine strains of VZV and HSV.[52,53]

Serologic tests permit the retrospective diagnosis of varicella and herpes zoster when acute and convalescent sera are available for comparison.[52] These assays can also identify susceptible individuals who may be candidates for isolation or prophylaxis. The technique most commonly used is a solid-phase enzyme-linked immunosorbent assay (ELISA). However, this assay often lacks sensitivity and specificity, failing to detect antibody in people who are immune and sometimes yielding false-positive results in susceptible individuals. Several more sensitive techniques have been developed to measure humoral responses to VZV. These include an immunofluorescence assay for antibody to VZV-induced membrane antigens [fluorescent antibody to membrane antigen (FAMA)] that reliably distinguishes immune from susceptible adults and a latex agglutination test that is comparable in sensitivity and specificity to FAMA assays, but is much simpler to perform.[54]

COMPLICATIONS

COMPLICATIONS OF VARICELLA

In the normal child, varicella is rarely complicated. The most common complication is the secondary bacterial infection of skin lesions, usually by *Staphylococci* or *Streptococci*, which may produce impetigo, furuncles, cellulitis, erysipelas, and, rarely, gangrene.[55] These local infections often lead to scarring and, rarely, to septicemia with metastatic infection of other organs. Bullous lesions may develop when vesicles are superinfected by *Staphylococci* that produce exfoliative toxins. Invasive group A streptococcal infections are particularly virulent. In the absence of varicella vaccination, up to one-third of varicella is associated with invasive group A streptococcal infections; they usually occur within 2 weeks of the onset of the varicella rash.[56] Widespread varicella vaccination appears to have markedly reduced the percentage of invasive group A streptococcal hospitalizations associated with varicella in the United States.[57]

Secondary bacterial pneumonia, otitis media, and suppurative meningitis are rare complications and typically respond to appropriate antibiotic therapy. However, bacterial superinfection is common and potentially life threatening in leukopenic patients. Other complications reflect a basic defect in the capacity of the host to limit VZV replication and dissemination.

In adults, fever and constitutional symptoms are more prominent and prolonged, the rash of varicella is more profuse, and complications are more frequent. High rates of complications have been reported in adults not born in the United States (i.e., adults born in Mexico).[58] Primary varicella pneumonia is the major complication of adult varicella. Some patients are virtually asymptomatic, but others develop severe respiratory embarrassment, with cough, dyspnea, tachypnea, high fever, pleuritic chest pain, cyanosis, and hemoptysis 1–6 days after onset of the rash. The severity of the symptoms usually exceeds the physical findings, but the roentgenogram typically reveals diffuse, peribronchial nodular densities throughout both lung fields with a tendency to concentrate in the perihilar regions and at the bases. The mortality in adults with frank varicella pneumonia has been estimated to be between 10% and 30%, but it is less than 10% if immunocompromised patients are excluded.[59]

Varicella during pregnancy is a threat to both mother and fetus.[60] Disseminated infection and varicella pneumonia may result in maternal death, but neither the incidence nor the severity of varicella pneumonia appear to be significantly increased by pregnancy. The fetus may die as a consequence of premature labor or maternal death caused by severe varicella pneumonia, but varicella during pregnancy does not, otherwise, substantially increase fetal mortality. Nevertheless, even in uncomplicated varicella, maternal viremia can result in intrauterine (congenital) VZV infection, and a characteristic constellation of congenital abnormalities.[60] Perinatal varicella (i.e., varicella occurring within 10 days of birth) is more serious than varicella in infants infected even a few weeks later.

The morbidity and mortality of varicella are markedly increased in immunocompromised patients. In these patients, continued virus replication and dissemination result in a prolonged high-level viremia, a more extensive rash, a longer period of new vesicle formation, and clinically significant visceral dissemination. Immunosuppressed and glucocorticoid-treated patients may develop pneumonia, hepatitis, encephalitis, and hemorrhagic complications of varicella, which range in severity from mild febrile purpura to severe and often fatal purpura fulminans and "malignant" varicella.

CNS complications of varicella occur in fewer than 1 in 1,000 cases; they include several distinct syndromes. Varicella-associated Reye syndrome (acute encephalopathy with fatty degeneration of the liver) typically occurs 2–7 days after the appearance of the rash. In the past, from 15% to 40% of all cases of Reye syndrome occurred in association with varicella, with mortality as high as 40%, particularly when aspirin was administered for fever.[61] Acute cerebellar ataxia is more common than the other neurologic complications of varicella, occurring in 1 in 4,000 cases, and is more benign.[62] Encephalitis is much less common, occurring in 1 in 33,000 cases, but it frequently causes death or permanent neurologic sequelae. The pathogenesis of cerebellar ataxia and encephalitis remains obscure, but in many cases it is possible to detect VZV antigens, VZV antibodies, and VZV DNA in the cere-

brospinal fluid of patients, suggesting direct infection of the CNS.

Although elevated aminotransferase levels are common, clinical hepatitis is rare except as a complication of progressive varicella. Other rare complications of varicella include myocarditis, glomerulonephritis, orchitis, pancreatitis, gastritis and ulcerative lesions of the bowel, arthritis, Henoch-Schönlein vasculitis, optic neuritis, keratitis, and iritis. The pathogenesis of many of these complications has not been delineated, but direct parenchymal or endovascular VZV infection, or vasculitis induced by VZV antigen-antibody complexes, appear to be responsible in most cases.

COMPLICATIONS OF HERPES ZOSTER

(See Table 194-1)

The sequelae of herpes zoster include cutaneous, ocular, neurologic, and visceral complications.[39] Most complications of herpes zoster are associated with the spread of VZV from the initially involved sensory ganglion, nerve, or skin, either via the bloodstream or by direct neural extension. The rash may disseminate after the initial dermatomal eruption has become apparent. When immunocompetent patients are carefully examined, it is not uncommon to have at least a few vesicles in areas distant from the involved and immediately adjacent dermatomes. The disseminated lesions usually appear within a week of the onset of the segmental eruption and, if few in number, are easily overlooked. More extensive dissemination (with 25–50 lesions or more), producing a varicella-like eruption (generalized herpes zoster; Fig. 194-7), occurs in 2%–10% of unselected patients with localized herpes zoster, most of whom have immunologic defects as a result of acquired immunodeficiency, as seen with HIV infection, underlying malignancy (particularly lymphomas), or immunosuppressive therapy. If the rash spreads widely from a small, painless area of herpes zoster, the initial dermatomal presentation may go unnoticed, and the ensuing disseminated eruption may be mistaken for varicella.

When the dermatomal rash is particularly extensive, as it often is in severely immunocompromised patients, there may be superficial gangrene with delayed healing and subsequent scarring (Fig. 194-6). Secondary bacterial infection may also delay healing and cause scarring.

The eye is involved in 20%–70% of patients with ophthalmic zoster, with a wide range of possible complications.[49] VZV is also the principal cause of acute retinal necrosis (ARN), a fulminant sight-threatening disease observed primarily in otherwise healthy individuals.[46,63,64]

Herpes zoster may be attended by a variety of neurologic complications (Table 191-1), of which PHN is the most common and important.[65] PHN has been variably defined as any pain after rash healing or any pain 1 month, 3 months, 4 months, or 6 months after rash onset.[66,67] In clinic and community studies, the overall incidence of PHN is 8%–15% depending on the definition (Fig. 194-1A).[21,68,69] Age is the most significant risk factor for PHN (Fig. 194-1C). Clinically significant pain lasting 3 months or more is rare in immunocompetent persons younger than 50 years of age, but complicates 12%–15% of cases of herpes zoster in persons 60 years of age and older.[17] Other risk factors for PHN include the presence of prodromal pain, severe pain during the acute phase of herpes zoster, greater rash severity, more extensive sensory abnormalities in the affected dermatome and, possibly, ophthalmic (as opposed to thoracic or abdominal) herpes zoster.[70] Increasing age, greater acute pain severity, presence of prodromal pain, and greater rash severity have each been reported to be independent predictors of PHN.[67] The positive predictive value of each factor alone was low, but, together, the positive predictive value was almost 50%. PHN usually remits spontaneously over several months but, as with PHN itself, the risk of long-lasting PHN increases with increasing age.

Patients with PHN may suffer from constant pain (described as "*burning, aching, throbbing*"), intermittent pain ("*stabbing, shooting*"), and/or stimulus-evoked pain, including allodynia ("*tender, burning, stabbing*"). Allodynia (pain elicited by stimuli that are normally not painful) is a particularly disabling component of the disease that is present in approximately 90% of patients with PHN. Patients with allodynia may suffer severe pain after even the lightest touch of the

TABLE 194-1
Complications of Herpes Zoster

Cutaneous	Visceral	Neurologic
■ Bacterial superinfection ■ Scarring ■ Zoster gangrenosum ■ Cutaneous dissemination	■ Pneumonitis ■ Hepatitis ■ Esophagitis ■ Gastritis ■ Pericarditis ■ Cystitis ■ Arthritis	■ Postherpetic neuralgia ■ Meningoencephalitis ■ Transverse myelitis ■ Peripheral nerve palsies ■ Motor ■ Autonomic ■ Cranial nerve palsies ■ Sensory loss ■ Deafness ■ Ocular complications ■ Granulomatous angiitis (causing contralateral hemiparesis)

affected skin by things as trivial as a breeze or a piece of clothing. These subtypes of pain may produce disordered sleep, depression, anorexia, weight loss, chronic fatigue, and social isolation, and they often interfere with dressing, bathing, general activity, traveling, shopping, cooking, and housework.

TREATMENT

ANTIVIRAL AGENTS. (See also Chapter 231). The nucleoside analogues acyclovir, famciclovir, valacyclovir, and brivudin and the pyrophosphate analog foscarnet show efficacy in treating VZV infections. Acyclovir is a guanosine analogue that is selectively phosphorylated by VZV thymidine kinases (it is a poor substrate for cellular thymidine kinase) and thus is concentrated in infected cells. Cellular enzymes then convert acyclovir monophosphate to acyclovir triphosphate, which interferes with viral DNA synthesis by inhibiting viral DNA polymerase. VZV is approximately tenfold less sensitive to acyclovir than herpes simplex virus.

Two prodrugs, valacyclovir and famciclovir, are better and more reliably absorbed than acyclovir following oral administration. Thus, they produce much higher blood levels of antiviral activity and permit less frequent dosing than acyclovir. Valacyclovir is a valine ester of acyclovir that is converted enzymatically to acyclovir after absorption. Famciclovir is a prodrug of penciclovir, a nucleoside analogue similar to acyclovir in mechanism of action and antiviral activity against VZV and HSV. Famciclovir is converted enzymatically to penciclovir after absorption.

Brivudin is a uracil analogue with very high activity against VZV. Although effective in the treatment of herpes zoster, and licensed for such use outside the United States, it is not licensed in the United States, in part because of a potentially lethal interaction with 5-fluorouracil.

Foscarnet is an analogue of inorganic pyrophosphate that inhibits the replication of all known herpesviruses in vitro. It exerts its antiviral activity by selective inhibition at the pyrophosphate-binding site of virus-specific DNA polymerases and reverse transcriptases at concentrations that do not affect cellular DNA polymerases. Foscarnet does not require phosphorylation by thymidine kinase to be activated and is therefore active against acyclovir-resistant VZV mutants that have reduced or altered thymidine kinase activity.

Topical antiviral therapy lacks efficacy in patients with varicella and herpes zoster and is not recommended. Systemic therapy, either oral or parenteral, is required. Because of their superior pharmacokinetics, the lower sensitivity of VZV compared to HSV, and the existence of barriers to the entry of antiviral agents into tissues that are sites of VZV replication, famciclovir or valacyclovir are preferred to acyclovir for oral therapy of VZV infections. Acyclovir-resistant VZV has been documented in varicella and herpes zoster in patients with advanced AIDS (Fig. 194-8). Because of the mechanism of acyclovir resistance (mutations in the viral thymidine kinase gene), these acyclovir-resistant mutants are cross-resistant to ganciclovir, valacyclovir, famciclovir, and penciclovir. They usually respond to foscarnet, 40 mg IV every 8 hours; however, the infections commonly recur after treatment has ended.

TREATMENT OF VARICELLA

TOPICAL THERAPY. In normal children, varicella is generally benign and self-limited. Cool compresses or calamine lotion locally, tepid baths with baking soda or colloidal oatmeal (three cups per tub of water) and oral antihistamines may relieve itching. Creams and lotions containing glucocorticoids and occlusive ointments should not be used. Antipyretics may be needed, but salicylates must be avoided because of their association with Reye syndrome. Minor bacterial infections are treated with warm soaks. Bacterial cellulitis requires systemic antimicrobial therapy that is effective against *Staphylococcus aureus* and group A β-hemolytic streptococcus.

ANTIVIRAL THERAPY

Normal Children. (See Table 194-2). A large randomized, controlled trial of acyclovir treatment of healthy children 2–12 years of age found that early treatment (within 24 hours of the appearance of rash) with oral acyclovir (20 mg/kg four times a day for 5 days) modestly reduced the maximum number of lesions, the time to cessation of new lesion formation, and the duration of the rash, fever, and constitutional symptoms when compared to placebo.[71] Treatment initiated more than 24 hours after rash onset was not effective. Because varicella is a relatively benign infection in children and the clinical benefits of treatment are modest, routine antiviral treatment is not recommended in otherwise normal children[30,72,73]; however, many have favored its use where cost is not a concern, where it can be begun in time to benefit the patient (within 24 hours of rash onset), and where there is a perceived need to speed resolution of the infection so that parents can comfortably return to work. Because secondary cases among susceptible children in the household are generally more severe than the index cases, and because early initiation of treatment is more readily accomplished in secondary cases, treatment with acyclovir seems reasonable for such secondary cases.

The American Academy of Pediatrics recommends oral acyclovir for persons aged >12 years, persons with chronic cutaneous or pulmonary disorders, persons receiving long-term salicylate therapy, and persons receiving short, intermittent, or aerosolized courses of corticosteroids because these individuals are at increased risk for moderate-to-severe varicella.[73]

Normal Adolescents and Adults. A randomized, controlled trial of acyclovir treatment of healthy adolescents 13–18 years of age found that early treatment with oral acyclovir (800 mg five times a day for 5 days) reduced the maximum number of lesions and time to cessation of new lesion formation compared to placebo.[74] A randomized, placebo-controlled trial of

TABLE 194-2
Antiviral Treatment of Varicella in the Normal and Immunocompromised Host

Patient Group	Regimen
Normal[a]	
Neonate	Acyclovir 10 mg/kg or 500 mg/m^2 every 8 h for 10 days
Child (2 to <18 years of age)	Symptomatic treatment alone, or Valacyclovir 20 mg/kg every 8 h for 5 days[b] (not to exceed 3 g/day) or Acyclovir 20 mg/kg po four times a day × 5 days (not to exceed 3200 mg/day)
Adolescent (≥40 kg) or adult, especially with mild immune compromise (e.g., use of inhaled glucocorticoids)	Valacyclovir 1 g po every 8 h for 7 days or Famciclovir 500 mg po every 8 h for 7 days or Acyclovir 800 mg po five times a day for 7 days
Pneumonia	Acyclovir 10 mg/kg IV every 8 h × 7–10 days[b]
Pregnancy	Routine use of acyclovir is not recommended. If there are complication (e.g., pneumonia) treat pneumonia as per recommendation above.
Immunocompromised	
Mild varicella or mild compromise	Valacyclovir 1 g po every 8 h for 7–10 days or Famciclovir 500 mg po every 8 h for 7–10 days or Acyclovir 800 mg po five times a day for 7–10 days
Severe varicella or severe compromise	Acyclovir 10 mg/kg IV every 8 h for 7–10 days
Acyclovir resistant (advanced AIDS)	Foscarnet 40 mg/kg IV every 8 h until healed

[a]Oral acyclovir or preferably, famciclovir or valacyclovir, should be considered for otherwise healthy persons at increased risk for moderate-to-severe varicella (e.g., persons aged >12 years, persons with chronic cutaneous or pulmonary disorders, persons receiving long-term salicylate therapy, and persons receiving short, intermittent, or aerosolized courses of corticosteroids). (From Marin M et al: Prevention of varicella: Recommendations of the Advisory Committee on Immunization Practices (ACIP). *MMWR Recomm Rep* **56**:1-40, 2007.)
[b]Must prepare suspension by grinding 500-mg valacyclovir caplets and suspending in cherry-flavored Suspension Structural Vehical USP-NF (SSV) at 25 mg/mL or 50 mg/mL in lots of 100 mL at time of dispensing.

oral acyclovir in healthy young adults with varicella showed that early treatment (within 24 hours of rash onset) with oral acyclovir (800 mg five times a day for 7 days) significantly reduced the time to crusting of lesions, the extent of disease, and duration of symptoms and fever.[59] Thus, routine treatment of varicella in adults seems reasonable. Although not tested, it is likely that famciclovir 500 mg PO q8h or valacyclovir 1,000 mg PO q8h would be convenient and appropriate substitutes for acyclovir in normal adolescents and adults. Many physicians do not prescribe oral acyclovir in uncomplicated varicella during pregnancy because the risk to the fetus of treatment is unknown. Other physicians recommend oral antiviral therapy for infections in the third trimester when organogenesis is complete, when there may be a heightened risk of varicella pneumonia, and when infection can be spread to the newborn. Intravenous acyclovir is often considered for pregnant women with varicella who have extensive cutaneous and/or systemic disease.

Complications of Varicella in Normal Persons. Uncontrolled trials in immunocompetent adults with varicella pneumonia suggest that early treatment (within 36 hours of hospitalization) with IV acyclovir (10 mg/kg q8h) may reduce fever and tachypnea and improve oxygenation.[75] Other serious complications of varicella in the immunocompetent host, such as encephalitis, meningoencephalitis, myelitis, and ocular complications, should be treated with IV acyclovir.

Immunocompromised Patients. Controlled trials in immunocompromised patients with varicella demonstrated that treatment with IV acyclovir decreased the incidence of life-threatening visceral complications when treatment was initiated within 72 hours of rash onset.[76] Immune compromise, however, is a continuum ranging from minimal to severe. Intravenous acyclovir has been the standard of care for varicella in patients with substantial immunodeficiency. Although oral therapy with famciclovir or valacyclovir might suffice for patients with mild degrees of immune impairment, there are no controlled clinical trials to guide the decision.

TREATMENT OF HERPES ZOSTER

TOPICAL THERAPY. During the acute phase of herpes zoster, the application of cool compresses, calamine lotion, cornstarch, or baking soda may help to alleviate local symptoms and hasten the drying of vesicular lesions. Occlusive ointments should be avoided, and creams or lotions containing glucocorticoids should not be used. Bacterial superinfection of local lesions is uncommon and should be treated with warm soaks; bacterial cellulitis requires systemic antibiotic therapy. Topical treatment with antiviral agents is not effective.

ANTIVIRAL THERAPY. The major goals of therapy in patients with herpes zoster are to (1) limit the extent, duration, and severity of pain and rash in the primary

TABLE 194-3
Antiviral Treatment of Herpes Zoster in the Normal and Immunocompromised Host

Patient Group	Regimen
Normal	
Age <50 years	Symptomatic treatment alone, or Famciclovir 500 mg PO every 8 h for 7 days or Valacyclovir 1 g PO every 8 h for 7 days or Acyclovir 800 mg PO 5 times a day for 7 days[a]
Age ≥50 years, and patients of any age with cranial nerve involvement (e.g., ophthalmic zoster)	Famciclovir 500 mg PO every 8 h for 7 days or Valacyclovir 1 g PO every 8 h for 7 days of Acyclovir 800 –mg PO 5 times a day for 7 days[a]
Immunocompromised	
Mild compromise, including HIV-1 infection	Famciclovir 500 mg PO every 8 h for 7–10 days or Valacyclovir 1 g PO every 8 h for 7–10 days or Acyclovir 800 mg PO 5 times a day for 7–10 days[a]
Severe compromise Acyclovir resistant (e.g., advanced AIDS)	Acyclovir 10 mg/kg IV every 8 h for 7–10 days Foscarnet 40 mg/kg IV every 8 h until healed

[a]Famciclovir or valacyclovir are preferred because their greater and more reliable oral bioavailability result in higher blood levels of antiviral activity, the lower susceptibility of VZV (compared to HSV), and the existence of barriers to the entry of antiviral agents into tissues that are sites of VZV replication.

dermatome; (2) prevent disease elsewhere; and (3) prevent PHN.

Normal Patients. Table 194-3 lists the current recommendations for treatment of herpes zoster. Randomized controlled trials indicate that oral acyclovir (800 mg five times a day for 7 days), famciclovir (500 mg q 8 hours for 7 days), and valacyclovir (1 g three times a day for 7 days) reduce time to rash healing, and the duration and severity of acute pain in older adults with herpes zoster who are treated within 72 hours of rash onset.[77] In some studies, the duration of chronic pain was also reduced, but the FDA has not approved these agents for the prevention of PHN.[78,79] Randomized controlled trials comparing acyclovir to valacyclovir, acyclovir to famciclovir, and valacyclovir to famciclovir demonstrated equivalent results in rash healing, acute pain, and the duration of chronic pain.[80–82] All three drugs are acceptable agents for older adults, with cost and dosing schedule determining the choice of agent. However, the reduced sensitivity of VZV compared with HSV, the existence of barriers to the entry of antiviral agents into tissues that are sites of VZV replication, and the higher and more reliable blood levels of antiviral activity achieved, make famciclovir or valacyclovir preferable to acyclovir for oral treatment of herpes zoster.

Because of the lower risk of PHN, antiviral therapy is less valuable or necessary for treatment of uncomplicated herpes zoster in healthy people younger than 50 years of age. The utility of antiviral agents is unproven if treatment is initiated more than 72 hours after rash onset. Nevertheless, we believe that it is prudent to initiate antiviral therapy even if more than 72 hours have elapsed after rash onset in patients who have herpes zoster involving cranial nerves (e.g., ophthalmic zoster) or who continue to have new vesicle formation.[77,79]

Ophthalmic zoster represents a special therapeutic challenge because of the risk of ocular complications. Examination by an ophthalmologist should be sought in most cases. Oral acyclovir has been shown in a randomized, controlled trial to be effective in preventing ocular complications of ophthalmic zoster.[83] Famciclovir and valacyclovir appear to have efficacy comparable to that of acyclovir in the treatment of ophthalmic zoster, and are preferred for the reasons cited above.[84,85]

Immunocompromised Patients. A randomized, double-blind, placebo-controlled trial in immunocompromised patients with herpes zoster showed that IV acyclovir (500 mg/m^2 q8h for 7 days) halted progression of the disease, both in patients with localized herpes zoster and in patients with cutaneous dissemination prior to treatment.[86] Acyclovir accelerated the rate of clearance of virus from vesicles and markedly reduced the incidence of visceral and progressive cutaneous dissemination. Pain subsided faster in acyclovir recipients, and fewer reported PHN, but these differences were not statistically significant. Clinical trials comparing IV acyclovir to IV vidarabine for the treatment of herpes zoster in immunocompromised patients showed that acyclovir was significantly more effective and less toxic.[86,87] In patients with mild immunocompromise and localized herpes zoster, oral acyclovir, valacyclovir, or famciclovir will usually suffice.[88,89] A randomized, controlled trial of oral famciclovir versus oral acyclovir in patients with localized herpes zoster following bone marrow or organ transplantation or cancer chemotherapy showed that the two treatments were equivalent in rash healing and loss of acute pain, and that both were well tolerated.[89]

ANTI-INFLAMMATORY THERAPY. The possibility that PHN might be caused by inflammation of the sensory ganglion and contiguous neural structures provided the rationale for the use of glucocorticoids during the acute phase of herpes zoster in an attempt to further reduce acute pain and prevent PHN.

Randomized controlled trials, however, showed that the addition of glucocorticoids to acyclovir did not change the incidence of chronic pain.[90–92] However, glucocorticoids did reduce acute pain in most trials, and in one trial of acyclovir and prednisone, the time to uninterrupted sleep, return to baseline daily activity, and cessation of analgesic therapy was reduced in patients who received glucocorticoids.[91] Consequently, some experts advocate oral glucocorticoids for otherwise healthy older adults whose rash is complicated by moderate-to-severe pain and who have no contraindications to glucocorticoids.[77] Others believe that the common adverse effects of glucocorticoids argue against their routine use in older patients with herpes zoster. We agree and do not recommend the use of glucocorticoids in this setting. Glucocorticoids, in combination with effective antiviral therapy, may improve motor outcomes and acute pain in VZV-induced facial paralysis and cranial polyneuritis, where compression of affected nerves may contribute to disability.

ANALGESICS. Greater severity of acute pain is a risk factor for PHN, and acute pain may contribute to central sensitization and the genesis of chronic pain. Therefore, aggressive pain control is both reasonable and humane.[77] The severity of acute herpes zoster pain should be determined using simple standardized pain scales. Clinicians should prescribe nonopiate or opiate analgesics with the goal of limiting the severity of pain to less than 3 or 4 on a 0-to-10 scale, and to a level that does not interfere with sleep. The choice, dosage, and schedule of drugs are governed by the patient's pain severity, underlying conditions, and response to specific drugs. A randomized controlled trial of oxycodone, gabapentin, or placebo in older adults with herpes zoster showed that oxycodone, but not gabapentin, provided significantly greater pain relief than placebo in patients with moderate-to-severe pain.[93] This trial was not powered to analyze PHN, and there are no other controlled trials of the effect of treatment with opioids or gabapentin during the acute phase of herpes zoster on the subsequent development of PHN. A crossover study of a single dose of 900 mg of gabapentin during the acute phase of herpes zoster showed greater pain relief than placebo.[94] If pain control remains inadequate, regional or local anesthetic nerve blocks should be considered for acute pain control.[77,95] A randomized controlled trial demonstrated that a single epidural injection of corticosteroids and local anesthetics in the acute phase of herpes zoster did not prevent the subsequent development of PHN.[95]

TREATMENT OF POSTHERPETIC NEURALGIA

Once established, PHN is difficult to treat. Fortunately, it resolves spontaneously in most patients, although this often requires several months (Fig. 194-1B). Clinicians have advocated a wide range of treatments, including many oral and topical medications, epidural injection of local anesthetic and glucocorticoids, acupuncture, biofeedback, subcutaneous injections of triamcinolone, trans-epidermal electric nerve stimulation (TENS), spinal cord stimulators, and systemic administration of a variety of compounds, but most have not been validated by controlled trials. The results of randomized controlled trials demonstrated efficacy for pain relief in PHN for the following drugs: gabapentin, pregabalin, tricyclic antidepressants (TCAs), opioid analgesics, tramadol, lidocaine patch 5%, and high-concentration capsaicin patch.[96–101] The choice of these medications should be guided by the adverse event profiles, potential for drug interactions, and patient comorbidities and treatment preferences. On average, these agents provide adequate pain relief (defined as reduction of pain to below 4 on a 0–10 point scale or by 50% on a visual analog or Likert scale) in 30%–60% of patients. These modalities are now recommended as evidence-based pharmacotherapy for PHN in practice management guidelines.[96–98]

TOPICAL THERAPY. Topical anesthesia delivered by means of a 5% lidocaine patch has been shown in controlled clinical trials to produce significant pain relief in patients with PHN. The 10 × 14-cm lidocaine patch contains 5% lidocaine base, adhesive, and other ingredients on a polyester backing. It is easy to use and is not associated with systemic lidocaine toxicity.[102] Up to three patches are applied over the affected area for 12 hours a day. The disadvantages of the patch are application site reactions, such as skin redness or rash, and substantial cost. Eutectic mixture of local anesthetics (EMLA) cream applied once a day over the affected area under an occlusive dressing is an alternative method of delivering topical anesthesia.

A single 1-hour application of a high-concentration capsaicin patch (8%) compared with a low-concentration control patch significantly reduced pain from PHN from the second week after the capsaicin application throughout a subsequent 12-week period.[99] The high-concentration patch was generally well tolerated. Adverse events include increases in pain associated with patch application (usually transient) and application-site reactions (e.g., erythema). The role of the high-concentration capsaicin patch in the treatment of PHN is yet to be clearly established, partly because its long-term benefits are not yet known. However, this intervention has promise because a single 1-hour application may yield several weeks of pain reduction.

ORAL AGENTS. Gabapentin has been shown to produce moderate or greater pain relief in 41%–43% of patients with PHN compared to 12%–23% in patients receiving placebo.[103,104] Frequent adverse effects of gabapentin include somnolence, dizziness, and peripheral edema. Pregabalin has been shown to produce 50% or greater pain relief in 50% of patients with PHN compared to 20% in placebo recipients.[105,106] Dizziness, somnolence, and peripheral edema were also the most common adverse effects reported for pregabalin.[105–107] Pregabalin has a less complicated dose titration schedule and a faster onset of action than gabapentin.

TCAs have been shown to produce moderate-to-good pain relief in 44%–67% of elderly patients with

PHN in several randomized, controlled trials.[96,97,100,108] Nortriptyline and desipramine are preferred alternatives to amitriptyline because they cause fewer cardiac adverse effects, sedation, cognitive impairment, orthostatic hypotension, and constipation in the elderly.[109]

Treatment with scheduled opioids may also reduce PHN. In a randomized, placebo-controlled crossover trial of sustained-release oxycodone in patients with PHN, patients reported significant pain relief when treated with opioid compared to placebo.[110] In a crossover study in patients with PHN, both controlled-release morphine and TCAs provided significant pain relief compared to placebo.[111] In this trial, patients preferred treatment with opioid analgesics to either TCAs or placebo, despite a greater incidence of adverse effects and more dropouts during opioid treatment.

The use of combinations of these drugs for PHN is common in clinical practice and undergoing increasing investigation. In a crossover trial, patients with diabetic polyneuropathy or PHN were randomized to daily active placebo (lorazepam), sustained-release morphine, gabapentin, and a combination of gabapentin and morphine.[112] Combination therapy with morphine and gabapentin produced greater pain relief than either agent alone or placebo, but with an increase in adverse effects (constipation, sedation, and dry mouth). In a crossover trial, patients with diabetic polyneuropathy or PHN were randomized to receive one of three sequences of daily oral gabapentin, nortriptyline, and a combination of the two.[113] Combination therapy with gabapentin and nortriptyline produced greater pain relief than either agent alone. The most common adverse event was dry mouth secondary to nortriptyline. These results suggest that combination therapy may benefit some individuals with PHN who have responded to one of the agents chosen, but at the risk of increased adverse effects than with either drug alone.

PREVENTION

PREVENTION OF VARICELLA

VARICELLA VACCINE. Several studies conducted in Europe, Japan, and the United States from the early 1970s through the early 1990s demonstrated that live attenuated (Oka strain) VZV vaccines were immunogenic and efficacious in protecting susceptible children against varicella. Although breakthrough cases of varicella were observed following subsequent exposure to wild-type VZV, they were relatively mild.[30] Similar results were obtained in adults when two doses were given 4–8 weeks apart. Vaccinated children and adults developed breakthrough varicella caused by wild-type VZV at a rate of 1%–3% per year compared to an attack rate of 8%–13% per year in unvaccinated children. On the basis of these data, the FDA licensed the Oka/Merck varicella vaccine in the United States in 1995. In 2005, the FDA approved a combined measles, mumps, rubella, and varicella vaccine (MMRV) for routine immunization of children 12 months to 12 years of age.

Because of the frequency of breakthrough varicella caused by wild-type VZV, the Advisory Committee on Immunization Practices (ACIP) now recommends two 0.5-mL doses of varicella vaccine for healthy children aged ≥12 months, adolescents, and adults without evidence of immunity.[30] For children aged 12 months—to 12 years, the recommended minimum interval between the two doses is 3 months, although the second dose may be administered as soon as 28 days after the first. For persons aged >13 years, the recommended minimum interval is 4 weeks. Single-antigen varicella vaccine is approved for use among healthy persons aged ≥12 months. Combination MMRV vaccine is approved for use among healthy children aged 12 months to 12 years. Because of the increased severity of varicella in adults, susceptible adults should be identified and vaccinated. High priority should be given to vaccinating adults who may be at increased risk for exposure or transmission and who do not have evidence of immunity, including (1) health care providers, (2) household contacts of immunocompromised persons, including susceptible pregnant women, (3) persons who live or work in environments in which transmission of VZV is likely (e.g., teachers, day care employees, residents, and staff in institutional settings), (4) persons who live or work in environments in which transmission has been reported (e.g., college students, inmates and staff members of correctional institutions, and military personnel), (5) nonpregnant women of childbearing age, (6) adolescents and adults living in households with children, and (7) international travelers. Second dose catch-up varicella vaccination is recommended for children, adolescents, and adults who previously received only one dose.[30,114]

The immunity to varicella induced by varicella vaccine is not as solid as that induced by wild-type VZV infection, and the duration of vaccine-induced immunity is not yet known. However, a high percentage of children followed long-term have remained seropositive.[115] Recent experience in clinical practice indicates that vaccine efficacy in children is modestly lower than that reported in clinical trials, and outbreaks of breakthrough varicella in schools and day care centers do occur.[114,116–118] In a prospective, population-based study, vaccine effectiveness for prevention of all disease was 78.9% (95% CI, 69.7%–85.3%); for prevention of moderate disease was 92% (50–500 lesions) and for prevention of severe disease and physician visits was 100%.[118] A CDC analysis of 10 years of surveillance data for varicella (1995–2004) showed that the annual rate of breakthrough varicella significantly increased with the time since vaccination, from 1.6 cases per 1,000 person-years (95% CI, 1.2–2.0) within 1 year after vaccination to 9.0 per 1,000 person-years (95% CI, 6.9–11.7) at 5 years and 58.2 per 1,000 person-years (95% CI, 36.0–94.0) at 9 years.[119] Although most breakthrough varicella in children are characterized by mild disease, more recent reports indicate that 25%–30% of breakthrough cases are not mild and are clinically similar to varicella in unvaccinated children.[120] Interestingly, cases of breakthrough varicella in household settings were half as contagious as cases of varicella in unvaccinated persons, although the minority of breakthrough cases

with 50 lesions or more were as contagious as cases in unvaccinated persons. In adults, approximately 20% of vaccinees lose detectable antibodies to VZV over time, but continue to be partially protected.[114,116–118] Of the 48 million doses of varicella vaccine distributed between 1995 and 2005, there were 25,306 adverse events reported (52.7/100,000 doses distributed) to the FDA's Vaccine Adverse Event Reporting System and the Centers for Disease Control and Prevention (CDC)[121] 95% of which were nonserious events, mainly minor rashes and injection site reactions.[121] Serious adverse events were rare (2.6/100,000 doses distributed) and, in the majority, a causal relationship between the serious adverse event and varicella vaccine could not be established.

Herpes zoster has been reported in vaccinees, but it occurs at a significantly lower frequency than herpes zoster in persons of similar age following varicella caused by wild-type VZV. Cases of laboratory-confirmed herpes zoster in vaccinees from several studies included some cases caused by reactivation of the vaccine virus and others caused by reactivation of wild-type virus acquired prior to vaccination as a consequence of unrecognized varicella.

POSTEXPOSURE PROPHYLAXIS AND INFECTION CONTROL. Patients with varicella and herpes zoster may transmit VZV to susceptible individuals. Preventive measures include the varicella vaccine, investigational high-titer zoster immune globulin (VariZIG), and postexposure chemoprophylaxis with acyclovir.

Active immunization with the live attenuated varicella vaccine is effective in preventing illness or modifying varicella severity in children if used within 3 days after exposure.[122] Whereas protection afforded by zoster immune globulin is transient, varicella vaccine induces long-lasting (active) immunity to VZV and protection against subsequent exposures. Therefore, the ACIP recommends varicella vaccine for postexposure prophylaxis in unvaccinated persons without evidence of immunity.[30]

Passive immunization with VZIG was an effective preventive strategy, but the production of VZIG has been discontinued in the United States. An investigational VZIG, VariZIG, is available under an investigational new drug application (IND).[123] The investigational VariZIG is a purified human immune globulin prepared from plasma containing high levels of antibody to VZV (immunoglobulin class G [IgG]). This product can be requested for patients who have been exposed to varicella and who are at increased risk for severe disease and complications.[123]

Chemoprophylaxis with acyclovir also has been studied in susceptible children following household exposure to varicella. Children who received postexposure treatment with acyclovir experienced fewer and less severe cases of varicella than children in the control group.[124] However, appropriate timing is critical, and immunity to varicella may not be achieved, especially with early postexposure treatment. In addition, there is concern that resistant strains of VZV may be selected by promiscuous application of this approach. Hence, postexposure antiviral chemotherapy is not recommended for routine use in children.

Infection control practices for VZV increase in importance with the age and compromised immune status of the exposed, susceptible individual. There is no need to prevent exposure of susceptible normal children to VZV, but careful isolation procedures should be enforced to prevent infection of susceptible immunocompromised patients, newborn infants, and adults, particularly women of childbearing age. Exposure of susceptible immunocompromised patients to VZV warrants reduction in the dosage of glucocorticoids and other immunosuppressive drugs, and administration of investigational VariZIG. Hospital and long-term care facility personnel without a clear history of varicella or herpes zoster should be tested for antibody to VZV, and susceptible personnel vaccinated against varicella. Appropriate leave from work should be instituted following VZV exposure of any susceptible personnel who are not vaccinated. In hospitals, airborne and contact precautions are recommended until all lesions are crusted for patients with varicella, immunocompromised patients with localized herpes zoster, and any patient with disseminated herpes zoster.[125,126] Contact precautions are recommended for immunocompetent patients with localized herpes zoster.

PREVENTION OF HERPES ZOSTER

ZOSTER VACCINE. Until universal varicella vaccination greatly reduces the number of people latently infected with wild-type VZV, prevention of herpes zoster must be aimed at preventing reactivation and spread of the latent wild-type VZV. Long-term suppressive acyclovir treatment is only practical in immunocompromised patients at proven risk of developing herpes zoster within a defined time period, for example, in the year following bone marrow or solid organ transplantation. Other strategies must be devised for the general population.

One approach to the prevention of herpes zoster is the stimulation of immunity to VZV, which wanes in the elderly and in other high-risk individuals.[40,127] Studies of healthy adults over 55 years of age with a history of varicella have demonstrated an increase in VZV-specific T lymphocytes and humoral immunity after vaccination with live attenuated VZV vaccine that is similar to the increase observed after an episode of herpes zoster.[128] These findings suggested that vaccination of older persons may be useful in preventing herpes zoster and its complications.[33,127] A recent VA Cooperative Study (the Shingles Prevention Study) tested the hypothesis that vaccination against VZV would decrease the incidence and/or severity of herpes zoster and PHN among older adults.[17] The study enrolled 38,546 adults 60 years of age or older in a randomized, double-blind, placebo-controlled trial of a live attenuated Oka/Merck VZV vaccine of much greater potency than the currently licensed varicella vaccine. A total of 957 confirmed cases of herpes zoster (315 among vaccine recipients and 642 among placebo recipients) and 107 cases of PHN (27 among

vaccine recipients and 80 among placebo recipients) were included in the efficacy analysis. The zoster vaccine reduced the burden of illness due to herpes zoster by 61.1% (P <0.001), reduced the incidence of PHN by 66.5% (P <0.001), and reduced the incidence of herpes zoster by 51.3% (P <0.001). Reactions at the injection site were more frequent among vaccine recipients but were generally mild. The proportion of subjects reporting serious adverse events, and rates of hospitalization and death were comparable in vaccine and placebo recipients.[129] Furthermore, the zoster vaccine neither caused nor induced herpes zoster in recipients. This landmark study showed that the zoster vaccine markedly reduced morbidity from herpes zoster and PHN among older adults. The FDA licensed the zoster vaccine for the prevention of herpes zoster in adults 60 years of age and older in 2006. The ACIP of the CDC unanimously recommended the vaccine for the prevention of herpes zoster and its complications, including PHN, in immunocompetent adults 60 years of age and older, irrespective of a history of herpes zoster.[23] Zoster vaccine has now been added to the US schedule of routinely recommended adult immunizations.[23]

The zoster vaccine may be administered without screening for a history of varicella or herpes zoster, nor should one conduct serologic testing for varicella immunity before vaccination.[23] Persons known to be VZV seronegative should be vaccinated against varicella according to current recommendations.[30] Older adults who have PHN or who have a current episode of herpes zoster may ask to be vaccinated, but zoster vaccination is not indicated to treat acute herpes zoster or PHN. Some patients may want to receive zoster vaccine after a recent episode of herpes zoster has resolved. The optimal time to immunize an individual after a recent episode of herpes zoster is unknown, and the clinical diagnosis of herpes zoster is not always correct. The authors believe that an interval of 3–5 years after the onset of a well-documented case of herpes zoster is reasonable.

A history of anaphylactic reaction to any of the vaccine components is a contraindication to the vaccine.[23] Neomycin is a vaccine component but contact dermatitis due to neomycin does not represent anaphylaxis and therefore is not a contraindication to zoster vaccination. The zoster vaccine should not be given to persons who have severe acute illness, including active untreated tuberculosis, until the illness has subsided. Persons with leukemia, lymphomas, or other malignant neoplasm affecting the bone marrow or lymphatic system, or with AIDS or other clinical manifestations of HIV infection, including those with $CD4^+$ T-lymphocyte counts ≤200 per mm^3 and/or ≤15% of total lymphocytes should not receive zoster vaccine.[23] Persons on immunosuppressive therapy, including high-dose corticosteroid therapy, should not receive the vaccine. The ACIP defines high-dose corticosteroids as 20 mg or more per day of oral prednisone or equivalent for 14 days or more.[130] Low doses of methotrexate (≤0.4 mg/kg/week), azathioprine (≤3.0 mg/kg/day), or 6-mercaptopurine (≤1.5 mg/kg/day) are not considered to have significant immunosuppression.[23]

When considering the zoster vaccine, older adults may express concerns about transmission of vaccine virus to other individuals. Transmission of VZV requires the development of a vesicular rash containing vaccine virus after vaccination. If there is no rash, there is no transmission. Zoster vaccine-associated vesicular rashes are very unusual. In the Shingles Prevention Study, vesicular lesions at the injection site were observed in 20 of 19,270 vaccine recipients a median of 3–4 days after vaccination and in 7 out of 19,276 placebo recipients. Neither vaccine virus nor wild-type VZV were detected by DNA PCR testing in the few specimens that were available for testing. Transmission of vaccine virus from recipients of zoster vaccine to susceptible household contacts has not been documented. Thus, immunocompetent older adults in contact with immunosuppressed patients should receive zoster vaccine to reduce the risk that they will develop herpes zoster and transmit wild-type VZV to their susceptible immunosuppressed contacts.[23,33] For the same reasons, adult contacts of susceptible pregnant women and infants should receive zoster vaccine. Zoster vaccine recipients with susceptible pregnant or immune compromised contacts need not take any special precautions following vaccination, except in the rare situation that a vesicular rash develops, in which case standard contact precautions are adequate. Eligible residents and personnel in nursing homes and other facilities housing older adults should also be vaccinated against herpes zoster. However, VZV-seronegative persons (e.g., health care workers from tropical countries who have not had varicella) should be vaccinated against varicella. These recommendations are consistent with those of the ACIP.[23] In the unlikely event that an immunocompromised contact develops a significant illness caused by vaccine virus, he/she may be treated with standard anti-VZV agents (acyclovir, valacyclovir, or famciclovir).

With the development of the varicella and zoster vaccines, antiviral therapy, and neuropathic pain treatments, clinicians now have multiple effective tools to reduce human suffering from varicella and herpes zoster.

ACKNOWLEDGMENT

Dedicated to the memory of Stephen E. Straus, a coauthor of this chapter in previous editions.

KEY REFERENCES

Full reference list available at www.DIGM8.com

DVD contains references and additional content

4. Nguyen HQ, Jumaan AO, Seward JF: Decline in mortality due to varicella after implementation of varicella vaccination in the United States. *N Engl J Med* **352**:450, 2005
7. Seward JF et al: Varicella disease after introduction of varicella vaccine in the United States, 1995–2000, *JAMA* **287**:606, 2002
8. Jumaan AO et al: Incidence of herpes zoster, before and after varicella-vaccination-associated decreases in the

incidence of varicella, 1992–2002. *J Infect Dis* **191**:2002, 2005
14. Hope-Simpson RE: The nature of herpes zoster: A long-term study and a new hypothesis. *Proc R Soc Med* **58**:9, 1965
17. Oxman MN et al: A vaccine to prevent herpes zoster and postherpetic neuralgia in older adults. *N Engl J Med* **352**:2271, 2005
19. Schmader KE, George LK, Hamilton JD: Racial differences in the occurrence of herpes zoster. *J Infect Dis* **171**:701, 1995
23. Harpaz R, Ortega-Sanchez IR, Seward JF: Advisory Committee on Immunization Practices (ACIP) Centers for Disease Control and Prevention (CDC). Prevention of herpes zoster: Recommendations of the Advisory Committee on Immunization Practices (ACIP). *MMWR Recomm Report*. **57**(RR-5):1-30, 2008
27. Kalman CM, Laskin OL: Herpes zoster and zosteriform herpes simplex infections in immunocompetent adults. *Am J Med* **81**:775, 1986
30. Marin M et al: Prevention of varicella: Recommendations of the Advisory Committee on Immunization Practices (ACIP). *MMWR Recomm Rep* **56**:1-40, 2007
32. Cohen JI, Straus SE, Arvin AM: V aricella-zoster virus replication, pathogenesis and management. In: *Fields Virology*, Vol. 2, 5th edition, edite by D Knipe, X Howley, eds. Philadelphia, Lippincott Williams & Wilkins, 2007, p. 2744
33. Oxman MN: Zoster vaccine: Current status and future prospects. *Clin Infect Dis* **51**:197, 2010
38. Arvin AM: Humoral and cellular immunity to varicella-zoster virus: An overview. *J Infect Dis* **197**:S58, 2008
40. Levin MJ et al: Decline in varicella-zoster virus (VZV)-specific cell-mediated immunity with increasing age and boosting with a high-dose VZV vaccine. *J Infect Dis* **188**:1336-1344, 2003
43. Watson CPN et al: Postherpetic neuralgia: Further postmortem studies of cases with and without pain. *Pain* **44**:101, 1991
50. Katz J et al: Acute pain in herpes zoster and its impact on health-related quality of life. *Clin Infect Dis* **39**:342, 2004
51. Schmader KE et al: The impact of acute herpes zoster pain and discomfort on functional status and quality of life in older adults. *Clin J Pain* **23**:490, 2007
59. Wallace MR et al: Treatment of adult varicella with oral acyclovir: A randomized, placebo-controlled study. *Ann Intern Med* **117**:358, 1992
60. Enders G et al: Consequences of varicella and herpes zoster in pregnancy: Prospective study of 1739 cases. *Lancet* **343**:1548, 1994
67. Jung BF et al: Risk factors for postherpetic neuralgia in patients with herpes zoster. *Neurology* **62**:1545, 2004
72. Klassen TP et al: Acyclovir for treating varicella in otherwise healthy children and adolescents. *Cochrane Database Syst Rev* (4):CD002980, 2005
77. Dworkin RH et al: Recommendations for the management of herpes zoster. *Clin Infect Dis* **44**:S1, 2007
79. Gnann JW Jr, Whitley RJ: Herpes zoster. *N Engl J Med* **347**:340, 2002
90. Wood MJ et al: A randomized trial of acyclovir for 7 days or 21 days with and without prednisolone for treatment of acute herpes zoster. *N Engl J Med* **330**:896, 1994
91. Whitley RJ et al: Acyclovir with and without prednisone for the treatment of herpes zoster: A randomized, placebo-controlled trial. The National Institute of Allergy and Infectious Diseases Collaborative Antiviral Study Group. *Ann Intern Med* **125**:376, 1996
92. He L et al: Corticosteroids for preventing postherpetic neuralgia. *Cochrane Database Syst Rev* (1):CD005582, 2008
93. Dworkin RH et al: Oxycodone or gabapentin for acute pain in herpes zoster: A randomized, placebo-controlled trial. *Pain* **142**:209, 2009
95. van Wijck AJ et al: The PINE study of epidural steroids and local anaesthetics to prevent postherpetic neuralgia: A randomised controlled trial. *Lancet* **367**:219, 2006
97. Dubinsky RM et al: Practice Parameter: Treatment of postherpetic neuralgia. *Neurology* **63**:959, 2004
99. Backonja M et al: NGX-4010, a high-concentration capsaicin patch, for the treatment of postherpetic neuralgia: A randomised, double-blind study. *Lancet Neurology* **7**:1106, 2008
100. Hempenstall K et al: Analgesic therapy in postherpetic neuralgia: A quantitative systematic review. *Plos Med* **2**:e164, 2005
112. Gilron I et al: Morphine, gabapentin, or their combination for neuropathic pain. *New Engl J Med* **352**:1324, 2005
113. Gilron I et al: Nortriptyline and gabapentin, alone and in combination for neuropathic pain: A double-blind, randomized controlled crossover trial. *Lancet* **374**:1252, 2009
120. Chaves SS et al: Varicella disease in vaccinated persons: Clinical and epidemiologic characteristics, 1997–2005. *J Infect Dis* **197**:S127, 2008
121. Chaves SS et al: Safety of varicella vaccine after licensure in the United States: Experience from reports to the vaccine adverse event reporting system, 1995–2005. *J Infect Dis* **197**:S170, 2008
125. Garner JS: Guideline for isolation precautions in hospitals. The Hospital Infection Control Advisory Committee. *Infect Control Hosp Epidemiol* **17**:53, 1996
126. Bolyard EA et al: Guidelin for Infection Control in Health Care Personnel. *AJIC* **26**:289, 1998
129. Simberkoff MS et al: Safety of zoster vaccine in the shingles prevention study: A randomized trial. *Ann Intern Med* **152**:545, 2010
130. Kroger AT et al: Advisory Committee on Immunization Practice (ACIP) Centers for Disease Control and Prevention (CDC). General recommendations on immunization: Recommendations of the Advisory Committee on Immunization Practices (ACIP). *MMWR Recomm Rep* **55**(RR-15);1-48, 2006

Chapter 195 :: Poxvirus Infections

:: Caroline Piggott, Sheila Fallon Friedlander, & Wynnis Tom

POXVIRUSES

POXVIRUSES AT A GLANCE

- Poxviruses are the largest animal viruses; they can cause disease of varying severity in humans.
- Smallpox is the only poxvirus for which humans are the sole reservoir, which allowed its eradication.
- The smallpox vaccine virus, vaccinia, has its own adverse effects.
- Monkeypox is a zoonotic infection endemic in Africa, but it has recently appeared in the Western Hemisphere.
- Milker's nodule and orf mainly cause localized cutaneous infections.
- Molluscum contagiosum is generally a benign cutaneous disease most frequently seen in children and immunocompromised individuals.
- Histopathologic features of poxviral cutaneous lesions include the presence of intracytoplasmic eosinophilic inclusion bodies.

Poxviruses are double-stranded DNA viruses that replicate in the cytoplasm of host cells (Table 195-1). These "brick-shaped" viruses constitute the largest known animal viruses and can be seen with light microscopy.[1] The poxviruses that cause significant disease in humans are reviewed here. Their effects on the host range from systemic disease to localized infection to epithelial cell proliferation alone.

ORTHOPOXVIRUS INFECTIONS

SMALLPOX (VARIOLA)

Variola virus is the pathogen responsible for smallpox, a disease that devastated humankind in catastrophic epidemics for over 3,000 years. This poxvirus scarred and killed millions of people in both the Old and New Worlds, affecting entire populations on every continent.

SMALLPOX AT A GLANCE

- Smallpox is an illness with mortality rates of over 30% in its major form.
- It is transmitted mainly by the respiratory route; viremia leads to cutaneous and visceral involvement.
- The eruption consists of papules that progress simultaneously to vesicular and pustular lesions in a centrifugal pattern.
- The disease has not been seen since 1978, but the potential use of aerosolized variola virus for bioterrorism is of significant concern.
- Smallpox vaccination has been reinstituted on a selective basis for response in the case of an outbreak.

Edward Jenner altered the course of history in 1796 when he created the first vaccine by inoculating patients with cowpox virus in order to protect patients against the related smallpox virus. Utilizing this method of protection, smallpox could be prevented, and an intensive global effort at vaccination and tracking of cases led to its eradication in 1980.[2] It subsequently appeared an illness of merely historical interest until threats of bioterrorism in recent years renewed the need for knowledge about smallpox and its features, along with the development of improved vaccines and treatments for use should the disease arise again.

EPIDEMIOLOGY. Unlike other diseases caused by members of the family Poxviridae, smallpox affects only humans and thus cannot be acquired from another species. Transmission is generally via respiratory droplets and requires close contact. Outbreaks occur in the winter and early spring seasons when conditions of low humidity and low temperature favor survival of the aerosolized virus.[3] Smallpox is less infectious than other diseases spread by the respiratory route, including measles, varicella, and influenza. Secondary attack rates for unvaccinated contacts are estimated to range from 37% to 88%.[4] Secondary cases are often limited to family members or health care workers. Spread of smallpox is enhanced when there are large quantities of virus in the aerosolized droplets, an increased number and extent of exposures between infected individuals and contacts, and a higher population density. The very young, elderly, and pregnant women are more susceptible to infection.[5] Individuals

TABLE 195-1
Poxviruses with Humans as Hosts

Genus	Species	Hosts	Main Portal of Entry	Clinical Features
Orthopoxvirus	Variola virus	Humans	Respiratory tract	High fever and myalgias precede oropharyngeal enanthem and centrifugal exanthem. Simultaneous progression of skin lesions from macules to papulovesicles, pustules, and crusts, resulting in significant scars. Last reported case in 1978; concern for use in bioterrorism.
	Vaccinia virus	Humans	Skin	Used as vaccine for smallpox and monkeypox. Vaccination site progresses from papule to vesicle, pustule, and crust, leaving scar. Adverse events occur when virus spreads locally or in a generalized manner, more severe in individuals with disruption of the skin barrier or immunocompromise.
	Monkeypox virus	Rodents, humans, monkeys, anteaters	Skin	Clinical presentation similar to that of smallpox but more prominent lymphadenopathy and lower mortality.
	Cowpox virus	Rodents, cats, humans, cattle	Skin	Contact with infected animal host gives rise to papule that becomes vesicular, hemorrhagic, pustular, and ulcerative; resulting eschar heals over 3–4 weeks with scarring. Pustular stage: often umbilicated with surrounding zone of erythema and edema. Constitutional symptoms and lymphangitis common. Can be extensive or severe if skin barrier disrupted.
Parapoxvirus	Orf virus	Sheep, goats, humans	Skin	Contact with infected animal or fomite leads to papule(s) that forms pustules or nodules with central umbilication and surrounding gray-white or violaceous ring and outer zone of erythema; lesion usually occurs on hand. Lesions become weepy then dry and crust. Healing occurs over 4–8 weeks, usually without scarring. Constitutional symptoms/lymphangitis occur less commonly.
	Paravaccinia virus	Cattle, humans	Skin	Transmission by contact with infected teats/mouths of cattle. Clinical findings and course similar to those of orf; differentiated by their different animal hosts.
	Bovine papular stomatitis virus	Cattle, humans	Skin	Transmitted by contact with infected mouths of cattle. Clinical findings and course similar to those of orf and paravaccinia.
Molluscipox-virus	Molluscum contagiosum virus	Humans, chimpanzees (one report)	Skin	Discrete firm, dome-shaped papules; central umbilication. Can be extensive in individuals with atopic dermatitis or immunocompromise. Most cases self-resolve in 9–12 months but lesions often treated to speed resolution; can be persistent/refractory in immunocompromised individuals.
Yatapoxvirus	Tanapox virus	Humans, monkeys	Possibly skin	Uncertain mode of transmission, possible mosquito vector from infected monkeys to humans. Short fever precedes eruption of one to multiple pruritic, indurated papules with surrounding edema. Become necrotic and/or ulcerative then heal within 6 weeks with scarring.

with more severe clinical disease are reported to be more infectious, but these same people also tend to be toxemic and confined to bed.

Because no significant subclinical carrier state exists, eradication was possible and was accomplished in 1980. After its eradication, the responsible virus was presumed to be limited to two World Health Organization (WHO)-approved laboratories in the United States and the former Soviet Union (Russian Federation). A theoretical concern exists that these or other

unreported stocks of virus may be in the hands of countries or groups with terrorist relationships and could be aerosolized for use as a biologic weapon (see Chapter 213). The possibility of genetically altering variola or other similar viruses for increased virulence further heightens concerns regarding misuse.[6] The majority of the population would be susceptible to smallpox disease as routine vaccination of civilians was discontinued in the United States in 1972 and worldwide in the 1980s. Those vaccinated before 1972 have uncertain levels of immunity remaining. Until 2003, laboratory workers handling nonhighly attenuated orthopoxviruses were the only individuals recommended to receive routine vaccination. Since that time, military personnel and a small group of US civilians who would serve as first-line responders in a possible outbreak have been vaccinated.[7] The risk of untoward effects from the vaccine, particularly in immunocompromised patients and individuals with atopic dermatitis or other diseases where a skin barrier defect exists, caused health authorities to hesitate before implementing mass vaccination policies.

ETIOLOGY AND PATHOGENESIS.

Smallpox is caused by the variola virus, a linear, double-stranded DNA virus of the genus *Orthopoxvirus*. Variola virus measures approximately $300 \times 250 \times 200$ nm and has an oval- or brick-shaped appearance on electron microscopy (see eFig. 195-0.1 in online edition). Strains of the virus fall into two main groups: (1) variola major and (2) variola minor. Although their genomes share approximately 98% homology, their virulence is markedly different, with 30% or higher mortality associated with the major type and less than 1% mortality associated with the minor type.[2,8]

Humans are the only natural reservoir of the variola virus and the reason for this strict tropism is not fully understood.[9] The disease process begins following close, prolonged exposure to an infected individual. The usual portal of entry is the oropharyngeal or respiratory tract, either by inhalation of aerosolized droplets or direct contact with infected mucous membranes.[10] After entry, the virus attaches to respiratory epithelial cells, travels to regional lymph nodes, and replicates at these sites. Transient primary viremia with uptake of the virus by macrophages occurs, and the variola virus spreads to the reticuloendothelial organs, where asymptomatic replication continues. A massive secondary viremia follows and causes the onset of symptoms (the prodromal period). The virus spreads to the skin and mucosa, along with other organs and tissues such as the liver and kidneys.[11] Variola virus is transmissible beginning in the late prodromal phase through aerosolization of viral particles from the oropharynx. It is most infectious during the first 7–10 days after onset of the viral rash and remains transmissible until the scabs fall off of skin lesions.[11,12]

Variola virus is less commonly spread via accidental inoculation into the skin, through the conjunctiva, and through contact with infected body fluids or highly contaminated fomites. Rarely, it has been transmitted transplacentally and by long-range airborne or suspended viral particles in enclosed areas.[6]

CLINICAL FINDINGS

History. The infected individual remains asymptomatic during the incubation period of viral replication. A prodrome of high fever [39°C–41°C (102.2°F–105.8°F)], chills, myalgias, and severe headache develops within 7–17 days of exposure, with an average incubation of 12 days for variola major and a few days longer for variola minor. The person is usually severely ill and bedridden during the prodromal period, which lasts 2–4 days. Children may develop seizures.[4,10]

Cutaneous Lesions. Evanescent, nonspecific urticarial or morbilliform lesions can develop during the prodrome. These occur mainly in previously vaccinated individuals at the vaccination site and the axillae, popliteal, and groin areas.[2] Approximately 1 day after the onset of fever, an enanthem develops. The earliest viral lesions are red macules on the mouth, tongue, and oropharynx that subsequently vesiculate and ulcerate, releasing high concentrations of transmissible virus particles in respiratory secretions. A skin rash (exanthem) erupts two to several days after the onset of fever, at about the same time that the mucosal lesions ulcerate. The fever usually declines with appearance of the rash.[6,13] The exanthem varies depending on viral dose and strain, vaccination status, level of immunity, and nutritional status.[5] The outbreak is categorized into two clinical forms: (1) variola major and (2) variola minor.

Forms of variola major are more common than variola minor. One classification divides variola major into five clinical types.[14] Ordinary, common or classic smallpox is the most common type and accounts for over 90% of cases of smallpox in unvaccinated individuals. Skin lesions begin as macules on the face and upper extremities that then spread quickly to the trunk and lower extremities. Involvement of all parts of the body, including palms and soles, occurs within 24–48 hours. The macules become raised papules within 1 day and then form vesicles, often with central umbilication, after 4–5 days (see eFig. 195-0.2 in online edition). Fever recurs as the lesions become firm pustules around day 7 (Fig. 195-1) and persists until all lesions have crusted and scabbed at day 14 (Fig. 195-2). Scabs separate by 3–4 weeks after the onset of the rash. Key features of smallpox skin lesions are their prominence peripherally on the face and extremities and their simultaneous progression in a centrifugal pattern, with all lesions in any one area exhibiting the same morphology.[10,15] After their resolution, pitted scars ("pockmarks") often persist and can be disfiguring (Fig. 195-3). Scarring is most common on the face, where there are larger and more numerous sebaceous glands, which are particularly susceptible to infection and destruction by variola virus.[2]

Modified smallpox has as severe a prodromal illness as ordinary smallpox, but the clinical course of cutaneous lesions is accelerated. Lesions are fewer in number and tend not to progress to vesicles or pustules, crusting by day 10. This form occurs mainly in vaccinated individuals and does not cause death. Flat smallpox (also called *malignant smallpox*) is an uncommon form of variola major in which the macules barely raise. It



Figure 195-1 Pustular smallpox lesions with characteristic highest density on the face and extremities. [From the Centers for Disease Control and Prevention (CDC) Public Health Image Library, Atlanta, GA, USA.]



Figure 195-3 Scars and pockmarks remain after the crusts have fallen off. [From the Centers for Disease Control and Prevention (CDC) Public Health Image Library, Atlanta, GA, USA and contributed by J. Noble, Jr., MD.]

usually occurs in children and unvaccinated individuals lacking cellular immunity. Those affected become severely ill with toxic fever, and most die with hemorrhagic lesions and pneumonia.[4] The hemorrhagic, or fulminant, type of variola major is equally common in unvaccinated and vaccinated persons. It is divided into two forms: early and late. The early form consists of petechial hemorrhages into the skin or mucous membranes during the prodromal period. Massive hemorrhage from mucosal surfaces leads to death within 8 days of onset, before any appearance of the typical rash of smallpox, with a case fatality of 100%. Women, especially if pregnant, are more susceptible to this form. In the late form, hemorrhage appears after onset of the typical rash, death occurs by 12 days after onset, and men and women are equally affected.[16] The last type of variola major is variola sine eruptione, in which vaccinated individuals come in contact with affected individuals and develop fever and other symptoms (e.g., headache, conjunctivitis) but no rash. In this type, the illness lasts 48 hours or less. Serologic studies do show a rise in antibody titers against smallpox virus.[4,14]



Figure 195-2 Crusted lesions on the foot at day 21 of the rash of smallpox. [From the Centers for Disease Control and Prevention (CDC) Public Health Image Library, Atlanta, GA, USA and contributed by Paul B. Dean, MD.]

Variola minor is clinically indistinguishable from cases of modified smallpox and from cases of ordinary smallpox in which lesions are discrete rather than confluent. Occasionally, the lesions are nonumbilicated. In the pre-eradication period, the diagnosis of variola minor was given only after assessment of the severity of an outbreak, if the case fatality rate was low (1% or less).[8] Molecular virologic differentiation between major and minor viral strains is now available.

Related Physical Findings. Variola virus spreads via the blood to affect other noncutaneous systems. It can infect the metaphyses of growing bones and lead to arthritis in up to 2% of affected children. Osteomyelitis variolosa occurs less frequently than arthritis, but may also cause bone deformities.[17] Swelling of the eyelids and a mild conjunctivitis are common findings. Cough and bronchitis may be seen in some cases of smallpox. A degree of encephalopathy often occurs, with symptoms ranging from headache and hallucinations to delirium and psychosis.[2] Gross hematuria can occur with the hemorrhagic type of variola major.[16]

LABORATORY TESTS.

The white blood cell count may increase as the skin lesions of smallpox become pustular. Severe thrombocytopenia occurs in both early and late hemorrhagic smallpox. A marked decrease in the level of factor V (accelerator globulin) and increase in thrombin time are noted in the early form, likely from

disseminated intravascular coagulation. The late form has a smaller degree of these coagulation disturbances.[2]

Histopathology. Skin biopsy specimens from early papules show edema and dilation of the capillaries of the papillary dermis with a perivascular infiltrate of lymphocytes, histiocytes, and plasma cells. With progression, the cells of the epidermis become vacuolated and swollen and undergo ballooning degeneration. These vesicles have characteristic intracytoplasmic inclusion bodies called *Guarnieri bodies*. Pustules form with migration of polymorphonuclear cells into the vesicles. Eventually, the pustule becomes a crust, with new epithelium growing to repair the surface. Mucous membrane lesions show similar changes but also have extensive necrosis of the epithelial cells leading to rapid ulceration rather than vesiculation.[18]

Special Tests. For diagnosis, specimens (skin lesions, tonsillar swab, blood, skin biopsy) should be collected by someone recently vaccinated and sent to designated high-containment facilities.

Scrapings of skin lesions can be examined via electron microscopy to assess for the typical oval or brick shape of orthopoxviruses. Serologic testing for orthopoxviruses with paired samples can be performed; this identifies the presence of a member of the genus but is not specific for variola virus. Polymerase chain reaction (PCR) methods are used to definitively identify variola virus and can also characterize the viral strain. Variola virus can be cultured in several commonly used cell lines and can be identified by the formation of characteristic pocks on chorioallantoic membranes of chicken embryos.[6,19]

DIFFERENTIAL DIAGNOSIS.

(Box 195-1). The exanthem of smallpox is most often confused with that of varicella (chickenpox). Smallpox lesions are initially centrifugal with simultaneous progression of all lesions. In contrast, varicella lesions have a more truncal (centripetal) distribution, the vesicles are more superficial, and lesions are present at different stages. Varicella also has a shorter disease course, with only a 1–2-day prodrome and with all lesions crusting in 4–6 days from their initial appearance.[11] Human monkeypox clinically resembles smallpox but often manifests lymphadenopathy. It is a zoonotic disease and is not spread as easily between persons. The morbilliform prodromal rash of smallpox can be confused with measles or coxsackievirus infections. Secondary syphilis should be considered, especially when there are lesions on the palms and soles, but these lesions do not progress. Other eruptions in the differential diagnosis are listed in Box 195-1. The lesions of hemorrhagic smallpox can be similar to those of meningococcemia, viral hemorrhagic fevers such as Ebola, dengue or rift valley fever, severe acute leukemia, and other acute hemorrhagic eruptions such as those associated with coagulopathies.

COMPLICATIONS.

Secondary bacterial infection occurs commonly in skin lesions as well as at regional lymph nodes, affecting 5% of individuals. A temperature spike occurring 3–5 days after the start of the prodrome may indicate secondary infection.[13] Keratitis and corneal ulceration, common in malnourished individuals, result in blindness in 1% of cases. Either variola virus or bacterial superinfection can lead to respiratory complications, including pneumonia, at day 8–10 of illness. Both arthritis and osteomyelitis can lead to limb deformities, including bone shortening, subluxation, and flail joints. Orchitis is less common and usually unilateral. Encephalitis is reported in 0.2% of cases.[2]

PROGNOSIS AND CLINICAL COURSE.

The most common form of variola major, common smallpox, is associated with a mortality rate ranging from

BOX 195-1 DIFFERENTIAL DIAGNOSIS OF SMALLPOX AND MONKEYPOX

Most Likely

- Papulovesicular eruption
  - Varicella
  - Disseminated zoster
  - Generalized vaccinia
- Prodromal morbilliform eruption
  - Measles
  - Drug eruption
- Hemorrhagic lesions (smallpox only)
  - Meningococcemia
  - Disseminated intravascular coagulation
- Mucosal lesions
  - Hand-foot-and-mouth disease
  - Stevens-Johnson syndrome

Consider

- Papulovesicular eruption
  - Kaposi varicelliform eruption
  - Eczema vaccinatum
  - Extensive molluscum contagiosum (human immunodeficiency virus infection)
  - Drug eruption
  - Bullous impetigo
  - Pityriasis lichenoides et varioliformis acuta
  - Rickettsialpox
- Prodromal morbilliform eruption
  - Coxsackievirus infection
  - Other viral infections
- Hemorrhagic lesions (smallpox only)
  - Acute leukemia
  - Viral hemorrhagic fevers
- Mucosal lesions
  - Oral herpes simplex

Always Rule Out

- Papulovesicular eruption
  - Secondary syphilis
- Hemorrhagic lesions (smallpox only)
  - Acquired coagulopathy
- Mucosal lesions
  - Stevens–Johnson syndrome

less than 10% when lesions are discrete to 50%–75% when lesions are confluent. Death often occurs between days 10 and 16 of illness. Modified smallpox is associated with less than 10% mortality. In contrast, flat smallpox has a case fatality rate of over 90%, and hemorrhagic forms have nearly 100% mortality. The overall mortality rate for variola major is 30%, compared to less than 1% for variola minor.[14] Those who survive either disease have lifetime immunity. Death from smallpox is thought to be secondary to toxemia associated with immune complexes and variola antigens, which induce hypotension/shock and multiorgan failure. Encephalitis is an important factor in death from variola minor but not from variola major.[2,4]

TREATMENT. There is currently no specific treatment for smallpox. A patient suspected of having the disease should be isolated in a negative-pressure room and given supportive care. Precautions should be taken to prevent secondary infection and appropriate antibiotics administered should it occur. Research on antiviral agents is ongoing. Intravenous cidofovir, a nucleotide analog approved for treatment of cytomegalovirus infection, is available from the Centers for Disease Control and Prevention (CDC, Atlanta, GA, USA) through an Investigational New Drug protocol. It has been found to have activity against variola, vaccinia, and other orthopoxviruses in in vitro and animal studies, but lacks clinical trial data and does carry a risk of nephrotoxicity.[20] Lipid-soluble cidofovir-derivatives, such as CMX001, are under study.[21] In addition, the oral drug ST-246 (Tecovirimat, SIGA Technologies, Corvallis, OR, USA) appears to inhibit the function of a major envelope protein (p37) required for extracellular egress of orthopoxviruses and prevent viral spread. It has been used by Emergency Use Authorization since 2008, and has shown efficacy against variola, monkeypox, and other orthopoxviruses in animal studies, and is now in Phase II trials.[22] Topical idoxuridine may be used to treat corneal lesions, although its efficacy has not been proven.

PREVENTION. Because of the development of lifelong immunity after recovery from natural smallpox infection, the first efforts at prevention were to introduce crusts or fluid from lesions to unaffected individuals to induce mild disease. This process of variolation did reduce morbidity and mortality but also caused full infection and spread in some cases. In 1796, Dr. Edward Jenner developed vaccination, using the cowpox virus to introduce cross-immunity against the variola virus. Vaccinia virus later became the virus used. Vaccination is 90%–96% effective in preventing smallpox disease when given before exposure to variola virus. For postexposure prophylaxis, smallpox vaccination within 2–3 days of exposure can protect against severe disease. Vaccination within 4–5 days may protect against death.[2,23] However, vaccination does not give lifelong immunity. The duration and degree of protection over time are subjects of debate. Most estimates suggest that primary vaccination gives full protection for 3–5 years and some but declining immunity at 10 years and after. Revaccination may give significant protection for at least 30 years.[12,24]

VACCINIA AND SMALLPOX VACCINATION

The vaccinia virus is also of the genus *Orthopoxvirus*. Its origins are unknown, but it is most similar to the cowpox virus in this family. In the nineteenth century, it replaced cowpox as the agent used for smallpox vaccination. Discussion here focuses on its features as the smallpox vaccine, as vaccinia virus is not known to cause natural infection. Because of significant homology with other poxviruses, vaccination with vaccinia virus provides not only protection against smallpox, but also against closely related orthopoxviruses such as monkeypox, camelpox, and cowpox.[2]

EPIDEMIOLOGY. Eradication of smallpox was made possible by intensive tracking of cases of infection with ring vaccination of primary and secondary contacts. The last known case of natural infection was one of variola minor in Somalia in 1977. One final case of accidental laboratory infection occurred in 1978, and the WHO declared eradication in 1980. Routine vaccination of civilians was discontinued in the United States in 1972 and worldwide in the 1980s. Vaccination of US military personnel initially ceased in 1990 and laboratory workers handling nonhighly attenuated orthopoxviruses were the only group still recommended to receive periodic vaccination.[25] But with the postal anthrax and World Trade Center attacks in 2001 and other threats of bioterrorism, vaccination was reinitiated in the United States in late 2002 for the military and a small group of voluntary public health and health care workers who would be first-line responders in a possible outbreak.[26]

Vaccination made eradication of smallpox possible, but given that vaccinia is a live virus, it does carry its own set of adverse effects. Most adverse events can occur at any age, but infants and children younger than the age of 5 years tend to be particularly affected. Adverse reactions are ten times more common with primary vaccination than revaccination. Individuals with atopic dermatitis, or other diseases with skin barrier dysfunction can acquire a severe eruption, eczema vaccinatum, from secondary contact more often than from direct vaccination.[4,26]

ETIOLOGY AND PATHOGENESIS. Smallpox vaccination involves the introduction of vaccinia virus into the outer layers of the intact skin. There are many strains of the virus, with the less pathogenic New York City Board of Health (NYCBH) and Lister-Elstree strains being used during the global smallpox eradication campaign. The previous vaccine licensed and used in the United States was a lyophilized, calf-lymph vaccine (Dryvax, Wyeth Laboratories, Marietta, PA, USA) produced from the NYCBH vaccinia strain.[12] In 2007, the United States transitioned to the new ACAM2000 vaccine (Acambis, Cambridge, MA, USA), formulated using a clone of Dryvax and modern cell-culture technology.[27] ACAM2000 was developed for a number of reasons: the possibility of contamination of the Dryvax vaccine with bovine spongiform encephalopathy from

calves, expiration of available Dryvax vaccine, rising concerns of the use of variola for bioterrorism and having an adequate vaccine supply, and risk of hypersensitivity reactions with Dryvax.[27] ACAM2000 has thus far shown comparable safety and efficacy to its predecessor in clinical trials and is currently used by the US Department of Defense for military and laboratory worker immunizations.[28–30]

After injection of vaccine into the skin by a bifurcated needle (see eFig. 195-3.1 in online edition), the virus rapidly multiplies locally and occasionally at regional lymph nodes. Viable, transmissible vaccinia virus is present at the resulting skin lesion until the lesion scabs and separates. The area heals with scarring at the injection site. Infection is usually limited by the host response with the development of antibody- and cell-mediated immunity.[11] Adverse events and complications occur when the virus spreads outside of the local area, either by transfer or a host inability to contain the response.

CLINICAL FINDINGS

History. Soreness is almost universal at the vaccination site. Systemic symptoms can occur and are considered normal reactions. These include fever [greater than 37.7°C (99.9°F) and more common in children], chills, headache, myalgias, and malaise. They generally peak at days 8–10 and last 1–3 days. Approximately 30% of vaccinees feel too ill to carry out normal activities.[31]

Cutaneous Lesions. The normal local skin reaction to vaccination begins 3–5 days after administration, starting with a papule that then develops into a vesicle (Jennerian vesicle) followed by a pustule around day 7–9. It crusts and scabs over at day 10–14, with the scab detaching at day 17–21 and leaving a residual scar (Fig. 195-4). A robust take, in which the local reaction is 10 cm or larger in diameter, occurs in 2%–16% of first-time vaccinees (see eFig. 195-4.1 in online edition). This can be mistaken for bacterial cellulitis, but it occurs 8–10 days after vaccination and self-improves without antibiotic therapy in 24–72 hours.[32] In contrast, secondary bacterial infections usually occur within the first 5 days or 30 days after vaccination.

Previously vaccinated individuals have a milder reaction with an accelerated time course. Those with substantial residual immunity may have only erythema with revaccination. Minor local reactions that can occur near the primary site include nearby satellite lesions that progress at the same rate, lymphadenopathy/lymphangitis, and intense surrounding erythema or edema.[12]

Adverse Reactions. Adverse cutaneous reactions associated with smallpox vaccination can be localized or generalized. Secondary bacterial infection, usually by *Staphylococci* or group A *Streptococci*, can occur at the primary site. Accidental vaccinia is the autoinoculation of vaccinia virus from the vaccination site to another area. It is the most common adverse event seen

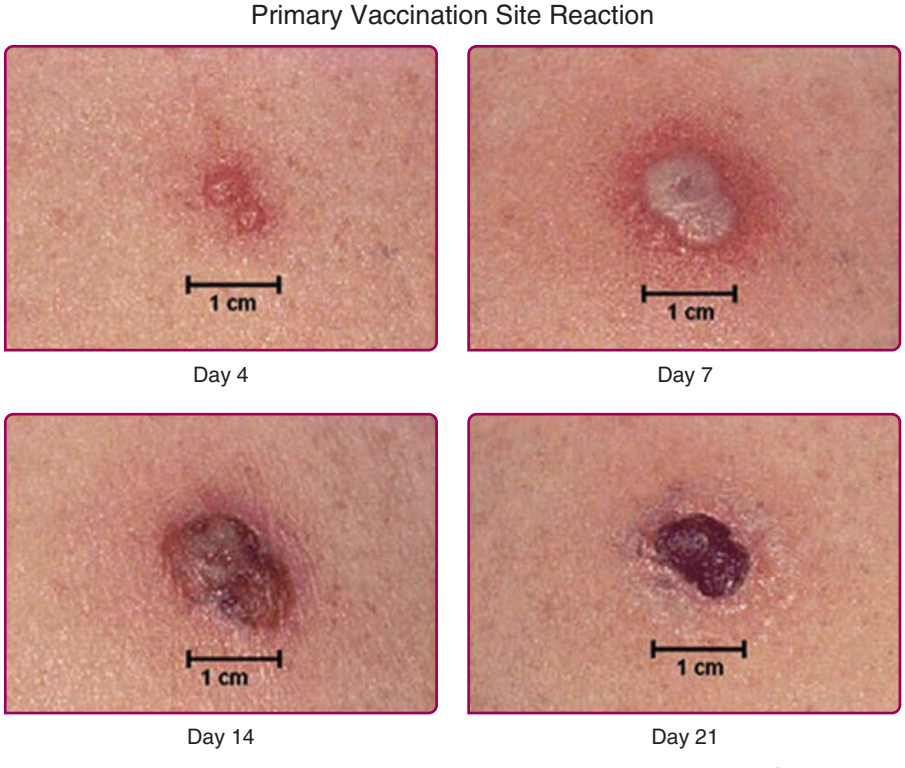

Figure 195-4 Normal progression seen at the smallpox vaccination site. [From the Centers for Disease Control and Prevention (CDC), Atlanta, GA, USA.]

and accounts for about half of all adverse events. The most common sites of transfer are the eyelids (see eFig. 195-4.2 in online edition), nose, mouth, and genitalia. Lesions are seen at these areas 7–10 days after vaccination, and they usually follow the time course of the original primary lesion. The lesions may be more attenuated if autoinoculation occurs more than 5 days after vaccination as the host immune response is developing.[33] Accidental inoculation to the eyes can lead to conjunctivitis, keratitis, or iritis.

Generalized adverse eruptions can be nonspecific, immune-mediated reactions, including morbilliform and roseola-like rashes. Hypersensitivity reactions such as erythema multiforme can also develop (see eFig. 195-4.3 in online edition). These rashes typically self-resolve over several days. In rare cases, Stevens–Johnson syndrome can develop and require hospitalization and supportive care. Vaccination can also lead to generalized vaccinia, in which macular, papular, or, less commonly, vesicular lesions can be disseminated to normal skin without evidence of autoinoculation. Generalized vaccinia can be limited or extensive and can occur anywhere on the body (Fig. 195-5). It is thought to be caused by spread of vaccinia virus via the bloodstream and usually occurs 6–9 days after primary vaccination. The lesions progress, as do other vaccinial lesions. The condition is self-limited in immunocompetent individuals but is often more severe in the setting of immunodeficiency.[34]

Eczema vaccinatum is the localized or generalized spread of vaccinia virus in individuals affected with atopic dermatitis or, less frequently, other chronic dermatoses such as Darier disease. The individual feels ill with fever, malaise, and lymphadenopathy. It can occur in the primary vaccinee with onset usually at the same time or soon after the appearance of lesions at the vaccination site. Papules, pustules, or vesicles can occur anywhere on the body but have a predilection for areas with prior lesions of atopic dermatitis (see Fig. 195-6). Lesions can range from several to hundreds; the most serious cases result in substantial loss of the skin barrier. The severity of eczema vaccinatum is independent of the severity or activity of the atopic dermatitis or other underlying skin disease. It can also be acquired by secondary transmission, usually by children in contact with a recently vaccinated family member.[10,35]



Figure 195-5 Generalized vaccinia in an 8-month-old infant. [From the Centers for Disease Control and Prevention (CDC) Public Health Image Library, Atlanta, GA, USA and contributed by Allen W. Mathies, MD of the California Emergency Preparedness Office, Immunization Branch.]



Figure 195-6 Eczema vaccinatum with lesions in areas of active dermatitis.

Vaccination of individuals with severe impairment of the immune system leads to progressive vaccinia, also called *vaccinia necrosa* and *vaccinia gangrenosa*. In these individuals, the primary lesion at the site of vaccination does not heal but instead enlarges and progresses to a painless ulcer with central necrosis (see eFig. 195-6.1 in online edition). Viral replication is not halted and viremia occurs, with similar metastatic lesions developing at distant sites in the skin, bone, and/or viscera. Most cases have occurred in individuals with defective cell-mediated immunity, but cases have also been described in those with humoral defects.[4] The degree of immune impairment may correlate with the risk for development of progressive vaccinia, but the precise protective level is unknown.[32]

Related Physical Findings. In addition to the skin, other organ systems can be affected by smallpox vaccination. Central nervous system complications can occur in previously healthy individuals. Postvaccinial encephalopathy most commonly affects children younger than 2 years of age, causing cerebral edema without inflammation. Symptoms develop abruptly 6–10 days after vaccination and can include fever, headache, seizures, hemiplegia, aphasia, and transient amnesia. Postvaccinial encephalitis and encephalomyelitis occur 11–15 days after vaccination, with fever, malaise, vomiting, and headache that progress

to confusion, seizures, amnesia, spinal cord signs, and coma.[36] These complications are thought to be autoimmune reactions, because vaccinia virus is not found in sampled cerebrospinal fluid or tissue. Higher rates of central nervous system complications are seen with non-NYCBH vaccinia strains. Other neurologic events reported to occur in temporal association with smallpox vaccination include transverse myelitis, paralysis, seizures, and polyneuritis, but causality has not been established.[2,37]

Cardiac events, including myopericarditis, can also occur with vaccination. With the Dryvax vaccine, the rate of myopericarditis among US military vaccinees was elevated 3.6-fold compared to the rate in unvaccinated personnel.[38] In clinical trials with ACAM2000, suspected cases of myopericarditis were noted at an approximate rate of 1 in every 175 primary vaccinees, with no cases in revaccinees.[28] Since reinitiation of smallpox vaccination in the United States in 2002, ischemic cardiac events as well as nonischemic dilated cardiomyopathy have been reported for the first time. Whether these events are caused by smallpox vaccination or are coincidental occurrences is not yet clear.[10]

LABORATORY TESTS. Recent studies suggest that IgM antibodies, detected as early as day 4, may play a role in preventing potentially deadly early viral spread.[39] Neutralizing IgG antibodies and cellular immunity start to become detectable around day 7 of vaccination and are responsible for maintaining the long-term host-immune response to the virus. Vaccinia virus can be detected at the primary vaccination site and sites of accidental vaccinia, generalized vaccinia, eczema vaccinatum, and progressive vaccinia.

COMPLICATIONS. Vaccinia keratitis can cause corneal ulceration with scarring and visual loss. Eczema vaccinatum can be so severe that the affected individual loses a substantial amount of the cutaneous barrier, much like a burn victim. Individuals with postvaccinial encephalopathy, encephalitis, or encephalomyelitis may recover in approximately 2 weeks, but one-fourth of survivors are left with residual sequelae (e.g., mental impairment, paralysis).[40]

Smallpox vaccination of a woman during pregnancy can rarely lead to fetal, or congenital, vaccinia, with about 50 cases reported in the literature. Transmission to the fetus can occur at any time during the pregnancy and results in lesions on the skin, mucous membranes, and placenta. The appearance can be similar to that of generalized vaccinia or progressive vaccinia, and lesions can be extensive (see eFig. 195-6.2 in online edition). It is unknown whether infection is through the blood or by direct contact with infected amniotic fluid. No reliable intrauterine diagnostic test exists to confirm fetal infection.[37]

PROGNOSIS AND CLINICAL COURSE. The potentially fatal adverse reactions from smallpox vaccination are eczema vaccinatum, progressive vaccinia, and postvaccinial central nervous system disease. Progressive vaccinia is universally fatal if untreated. Central nervous system complications have a 15%–25% case fatality rate. Most fatal cases from secondary transmission occur in infants younger than 1 year of age and are from contact eczema vaccinatum. Fetal vaccinia often results in fetal or neonatal death.[10,40]

Myopericarditis was reported in the pre-eradication era and was thought to cause the rare cases of cardiac-associated deaths after vaccination. Since reinstitution of vaccination in the United States in 2002, cases of myocarditis have been reported (as discussed above) but no deaths have occurred to date. Several ischemic cardiac deaths have occurred.[28,41]

TREATMENT. Symptomatic treatment alone is needed for the normal systemic symptoms and minor local events (robust take, lymphangitis, intense erythema, or edema) occurring after vaccination. Secondary infections should be treated with appropriate antimicrobial therapy. Uncomplicated cases of accidental vaccinia do not require therapy. Extensive cases can be treated by intravenous administration of vaccinia immune globulin (VIG) or cidofovir to speed recovery. VIG is a sterile solution of the immunoglobulin fraction of plasma from persons vaccinated with the smallpox (vaccinia) vaccine. Topical antiviral medications can be used in moderate-to-severe cases of ocular vaccinia. Vidarabine ointment has been effective in the past, but supplies are likely very limited because it is no longer manufactured. Trifluridine eyedrops can be tried, but there are no clinical data regarding successful treatment. It should not be administered for longer than 14 days, because it can cause a reversible superficial punctate keratopathy. VIG can exacerbate vaccinia keratitis and should not be used in cases of isolated keratitis.[32]

Generalized vaccinia usually requires only symptomatic treatment, but if severe, such as in those with immunodeficiency, VIG may be of benefit. With severe eczema vaccinatum in which there is significant loss of the skin barrier, meticulous skin care with volume and electrolyte repletion are needed. Early treatment with VIG has been shown to reduce mortality from eczema vaccinatum (from 30% to 40% down to 7%, based on pre-eradication era data).[32] VIG administration and care in an intensive care unit also reduces the case fatality rate of progressive vaccinia from 100% to 20%–30%.[40] In 2009, a US military vaccinee diagnosed with acute myelogenous leukemia several weeks after primary vaccination developed progressive vaccinia at the vaccination site; he was treated with VIG, CMX001, topical imiquimod, and oral and topical ST-246 during his course to achieve improvement.[42] Treatment for neurologic complications is supportive care; there is no evidence that VIG is effective in these cases. Given the rarity of fetal vaccinia, inadvertent vaccination during pregnancy is not ordinarily a reason for termination. There is also no indication for prophylactic administration of VIG to the pregnant woman, but it might be considered for a viable infant born with vaccinial lesions.[34,43]

PREVENTION. The vaccination site should be covered with gauze and an overlying semipermeable membrane bandage. Observing contact precautions

and washing the hands frequently when caring for the site should be emphasized.

A higher proportion of persons are at risk for adverse vaccine reactions today than during the era of routine smallpox vaccination. Atopic dermatitis as well as immunocompromise have increased in prevalence.[44] To reduce the incidence of adverse events, smallpox vaccination in the United States is currently limited to the select groups discussed earlier (see Section "Epidemiology"). There are no absolute contraindications to vaccination should an actual outbreak occur. Current recommendations and contraindications in the absence of a known exposure risk are listed in Box 195-2. More detailed guidelines are available from the CDC.

Safer vaccines remain under research and development to prevent the adverse effects and complications of smallpox vaccination. Tissue and cell-culture vaccines, including the new ACAM2000 and a different cell-cultured smallpox vaccine (DynPort, Frederick, MD, USA) under clinical trial, are the current generation of smallpox vaccines in the United States. Production involves the sterile growth of cell lines that host the vaccinia virus. By increasing purity and reducing contamination, these vaccines may help avoid the allergic and autoimmune reactions thought to stem from the nonvaccinia material in calf-lymph vaccines. These reactions include hypersensitivity reactions, erythema multiforme, and possibly the encephalitic and cardiac reactions. But because they are live viruses similar in immunogenicity to Dryvax, their safety profiles are not significantly different with regard to adverse events specifically associated with vaccinia exposure.[24,28,29] For other strategies, see online edition of this book.

Another strategy is the development of vaccines using strains of vaccinia attenuated by serial passage through nonhuman tissue. This leads to a reduced capacity for replication and potentially reduced adverse effects. The modified vaccinia Ankara strain is produced by passage through chick embryo fibroblasts. No significant complications were reported with its use in Germany and Turkey in the 1970s to help people at high risk for side effects (such as those with atopic dermatitis/eczema, etc.) tolerate the standard smallpox vaccine; efficacy against actual disease, however, was never proven. The LC16m8 vaccine also uses an attenuated vaccinia strain, with passage of the Lister vaccinia strain through rabbit kidney cells. Studies in Japan in the 1960s and 1970s found it to have less local and systemic reactogenicity but similar protective immunity to conventional smallpox vaccines. Further clinical study of the modified vaccinia Ankara-based and Lc16m8 vaccines is under way.[6,10,45] Finally, advances in modern molecular immunology have introduced the idea of subunit vaccines with genes or proteins from vaccinia virus. These are under laboratory investigation as future vaccine candidates.[11,46]

BOX 195-2 VACCINATION AGAINST SMALLPOX USING VACCINIA VIRUS

Indications

- Pre-exposure prevention of smallpox
- Postexposure prophylaxis against severe disease and death

Contraindications

- Contraindications in the pre-exposure setting
  - Presence of atopic dermatitis or other eruptions with disruption of the skin barrier
  - Immunosuppression, including human immunodeficiency virus infection/acquired immunodeficiency syndrome (HIV/AIDS), inherited and acquired cellular immunodeficiencies, and severe autoimmune disease
  - Known heart disease or significant cardiac risk factors
  - Serious allergy to components of the vaccine diluent (polymyxin, neomycin, streptomycin, chlortetracycline)
  - Age younger than 12 months
  - Pregnancy or breast-feeding
- Contraindications in the postexposure setting
  - No absolute contraindications in the case of an actual smallpox outbreak

MONKEYPOX

In contrast to smallpox, which was described in writings as far back as 340 AD, monkeypox is a relatively recently recognized disease. It was first identified in 1958 as an illness of cynomolgus monkeys, hence its name. Monkeypox was first documented to cause human illness in 1970 in Zaire (the present Democratic Republic of the Congo), when an illness similar to smallpox was noted after eradication of the latter.

EPIDEMIOLOGY. Human monkeypox is a disease acquired mainly from infected animals. It is endemic in the rain forest countries of Central and West Africa, occurring in sporadic outbreaks. The majority of cases are in children. Despite its recent recognition, monkeypox has presumably caused illness for thousands of years.[47] Transmission occurs mainly during handling of infected animals or contact with the animals' body fluids. Person-to-person spread via respiratory droplets and close contact can occur as with smallpox, but usually in a more limited manner. Outbreaks in the Democratic Republic of the Congo in 1996–1997 showed sustained human-to-human transmission for the first time. This may reflect decreased immunity secondary to the discontinuation of routine smallpox vaccination.[48] In spring 2003, the first cases of human monkeypox in the Western Hemisphere occurred in the Midwest region of the United States (72 reported cases, 37 laboratory confirmed). All cases are thought to be associated with contact with ill pet prairie dogs previously housed with African rodents imported from Ghana.[49]

The longest documented chain of person-to-person transmission is eight generations, which suggests that monkeypox has little potential for the type of

epidemic spread seen with smallpox.[48] However, possible genetic alteration to produce greater virulence or transmissibility is a concern.

ETIOLOGY AND PATHOGENESIS.

Monkeypox is caused by the monkeypox virus, a zoonotic virus. Like variola and vaccinia viruses, it is also of the genus *Orthopoxvirus* and has an oval or brick shape on electron microscopy. The monkeypox viral genome is 96% identical to that of the variola virus at the central region, which encodes essential enzymes and structural proteins. The end regions that encode virulence and host-range factors are substantially different, and the range of hosts for the monkeypox virus is much wider than that for variola virus.[49] In addition to humans, hosts for monkeypox include cynomolgus and other monkeys, other primates (apes, gorillas, chimpanzees, orangutans), and nonprimate animals such as rabbits, mice, guinea pigs, and giant anteaters. The natural reservoir is unknown but is thought to be wild rodents such as the squirrel.[1,50]

Monkeypox is mainly transmitted through abraded skin after a bite or scratch from an infected animal or by contact with their infected body fluids. The virus multiplies locally at the site of injury; then it is rapidly transported to regional lymph nodes, where multiplication continues. Invasion of the bloodstream disseminates the virus to distant sites. The monkeypox virus is also transmissible from person-to-person via aerosolization of the virus or contact with lesions or body fluids during the first week of the rash, although this transmissibility is significantly lower than that for smallpox.[49] Monkeypox may also rarely be transmitted by contaminated fomites.[51]

CLINICAL FINDINGS

History. Monkeypox is difficult to differentiate from smallpox based on clinical findings alone.[52] Subclinical cases of monkeypox can occur in individuals with and without prior smallpox vaccination. In those with illness, symptoms manifest after a 10–14-day incubation period. A prodrome of fever, chills, malaise, headache, myalgias, and back pain occurs, lasting 2–3 days. Some individuals experience sore throat, cough, or shortness of breath. Diarrhea and abdominal pain may also be reported.[2,48]

Cutaneous Lesions. A rash generally develops 1–3 days after the onset of fever, initially consisting of monomorphic macules and papules. Most commonly, the eruption begins on the face and/or trunk, with the lesions spreading in a centrifugal pattern to become generalized. They then progress over 14–21 days to vesicles and pustules that umbilicate, crust, and desquamate (see eFigs. 195-6.3 and 195-6.4 in online edition). Dyspigmented and pitted scars result. Monkeypox lesions can involve the oral and genital mucous membranes.[47] No hemorrhagic form of monkeypox like that of smallpox has been described in humans.

In the outbreak in the United States, only one patient (a child) had a generalized rash as extensive as that seen in cases in Africa. The other affected individuals had only localized lesions, mostly on the hands, associated with direct contact with the infected animals from Ghana (Fig. 195-7 and see eFig. 195-7.1 in online edition). This likely reflects the fact that West African strains of monkeypox virus are less virulent than those of Central Africa.[48,49]



Figure 195-7 The primary inoculation site of monkeypox virus in a 3-year-old child, 14 days after being bitten by a prairie dog. (Used with permission from the Marshfield Clinic, Marshfield, WI, USA.)

Related Physical Findings. Significant lymphadenopathy develops 1–2 days before the onset of the rash, usually in submandibular, cervical, or inguinal areas (Fig. 195-8). Conjunctivitis and keratitis may occur. Confusion and seizures are rare.[53,54]



Figure 195-8 Significant postauricular lymphadenopathy with pustular skin lesions in a 2-year-old female with monkeypox. (Used with permission from the Armed Forces Institute of Pathology, Washington, DC, USA, http://www.afip.org/Departments/infectious/mp/.)

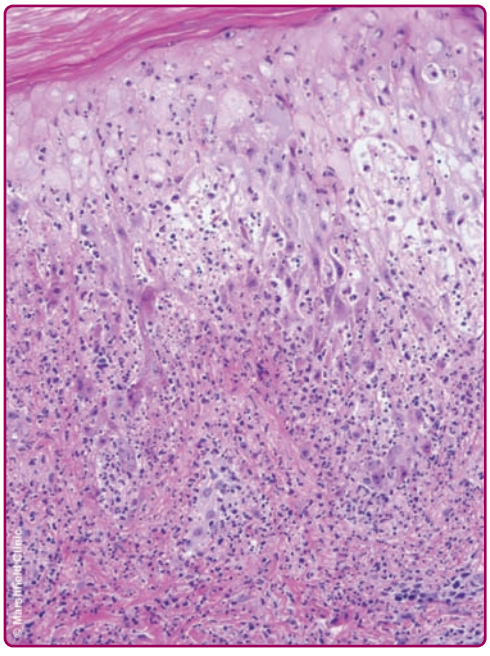

Figure 195-9 Histopathology of a monkeypox lesion with dermal papillary edema, acute inflammation, and ballooning degeneration of keratinocytes. (H&E; Used with permission from the Marshfield Clinic, Marshfield, WI, USA.)

LABORATORY TESTS. Leukocytosis, elevated transaminase levels, and low blood urea nitrogen levels are often seen. Lymphocytosis and thrombocytopenia occur with less frequency.[55]

Histopathology. On examination of skin biopsy specimens, the features are indistinguishable from those of smallpox. There is similar dermal papillary edema, acute inflammation, and ballooning degeneration of keratinocytes (Fig. 195-9). Cytoplasmic eosinophilic inclusion bodies (Guarnieri bodies) are also seen (see eFig. 195-9.1 in online edition). Focal necrosis may occur.[53]

Special Tests. Electron microscopy of material from scabs or fluid from skin lesions can be used to determine the presence of an orthopoxvirus, but it cannot distinguish among them. Assays for specific antibodies against monkeypox can differentiate it from other poxviruses. Monkeypox virus has good growth in RK13 cells and causes pocks on chorioallantoic membranes at 39°C (102.2°F). Isolation of the virus on mammalian cell culture and characterization by PCR and sequencing can definitively identify monkeypox virus and can differentiate Central African from West African monkeypox.[19,50,52]

DIFFERENTIAL DIAGNOSIS. (See Box 195-1). The features of monkeypox are clinically similar to but less severe than those of ordinary smallpox (variola major). Lymphadenopathy is a distinctive hallmark of monkeypox not usually seen in smallpox. It is observed in 90% of cases in which the individual has never received the smallpox vaccine and in approximately 53% of those who have been vaccinated.[2] Varicella has a milder and shorter viral prodrome, with pleomorphic lesions evolving in a centripetal distribution. Lymphadenopathy is also infrequent with varicella. Orf and bovine stomatitis, caused by poxviruses of family Parapoxviridae, can produce similar skin lesions but these are localized. Also in the differential diagnosis are drug eruptions, eczema herpeticum, and rickettsialpox (see Box 195-1). Persons with human immunodeficiency virus (HIV) infection may develop extensive molluscum lesions that can look similar.

COMPLICATIONS. Secondary skin and soft tissue infections may occur (approximately 20% of cases). Affected individuals may also develop pneumonitis (12%), encephalitis (fewer than 1%), and ocular complications, including scarring with corneal lesions.[47]

PROGNOSIS AND CLINICAL COURSE. The scars left by the rash may improve over time. In Africa, mortality ranges from 1% to 10% and mainly occurs in children. Death is generally in the second week of disease and is secondary to bacterial superinfection, gastrointestinal complications, or pulmonary complications. These are likely compounded by poor nutrition and inaccessibility of medical care.[2,49] All affected individuals recovered without any deaths during the outbreak in the United States in 2003.[56]

TREATMENT. Currently, there is no specific treatment for monkeypox. Symptomatic treatment should be instituted. Cidofovir may be considered in severe cases, but there is no available data on its clinical efficacy in humans. VIG administration can also be considered in severe cases, but its benefits are unknown. ST-246 has been shown to prevent disease and death from monkeypox virus in mice and nonhuman primate models and it is now in Phase II clinical trials.[22]

PREVENTION. Global eradication of monkeypox is more difficult than smallpox eradication, because the wide range of hosts for monkeypox virus allows it to maintain an animal reservoir while sporadically causing human disease. Vaccination with the calf-lymph-derived smallpox vaccines (vaccinia virus) was found to be effective in preventing human monkeypox. Observation of cases in Africa showed 85% protection against monkeypox; cases that do occur are milder and even subclinical when they occur in vaccinated individuals.[53] The newer ACAM2000 has similar immunogenicity to Dryvax and showed equal protective efficacy against monkeypox virus in a nonhuman primate model.[29,57]

The CDC currently recommends pre-exposure vaccination for investigators of animal or human monkeypox cases and health care providers who may care for or be in close contact with patients with monkeypox, provided they have no contraindication to smallpox vaccination (Box 195-3). The role of postexposure vaccination is less clear, but it is recommended for those within 4 days of direct exposure to monkeypox virus

BOX 195-3 VACCINATION AGAINST HUMAN MONKEYPOX USING VACCINIA VIRUS

Indications

- Pre-exposure vaccination for investigators of animal or human monkeypox cases and health care providers who may care for or be in close contact with patients with monkeypox
- Postexposure vaccination for those within 4 days of direct exposure to monkeypox virus, should be considered up to 14 days after exposure

Contraindications

- Contraindications in the pre-exposure setting
  - Presence of atopic dermatitis or other eruptions with disruption of the skin barrier
  - Immunosuppression, including human immunodeficiency virus infection/acquired immunodeficiency syndrome (HIV/AIDS), inherited and acquired cellular immunodeficiencies, and severe autoimmune disease
  - Known heart disease or significant cardiac risk factors
  - Serious allergy to components of the vaccine diluent (polymyxin, neomycin, streptomycin, chlortetracycline)
  - Age younger than 12 months
  - Pregnancy or breast-feeding
- Contraindications in the postexposure setting
  - Immunosuppression, including HIV/AIDS, inherited and acquired cellular immunodeficiencies, and severe autoimmune disease
  - Life-threatening allergy to components of the vaccine diluent (polymyxin, neomycin, streptomycin, chlortetracycline)

and should be considered up to 14 days after exposure, including in children under the age of 12 months, pregnant women, and people with skin conditions. Those with impaired immune systems or life-threatening allergy to latex or vaccine components should not receive the ACAM2000 vaccine even if exposed to monkeypox, but VIG can be considered for postexposure prophylaxis.[47,48]

The newer smallpox vaccines under research and development are also being studied for efficacy against monkeypox virus and may in the future allow prevention of human monkeypox with fewer adverse effects.

PARAPOXVIRUS INFECTIONS

Unlike the orthopoxviruses, members of family Parapoxviridae tend to cause localized rather than systemic disease in healthy individuals.

MILKER'S NODULE

EPIDEMIOLOGY.

Milker's nodule, also called *paravaccinia* and *pseudocowpox*, occurs worldwide but is prevalent only in individuals in close contact with cattle. It is an occupational disease of milkers, veterinarians, and workers in the meat industry. Most cases are in newly employed milkers who have not developed immunity.[1] Cases are mostly sporadic, but small epidemics have been reported. No natural cases of human-to-human transmission have been reported, only experimentally transmitted cases in the laboratory setting.[58]

ETIOLOGY AND PATHOGENESIS.

Milker's nodule is caused by the paravaccinia virus (also called *pseudocowpox virus*), a member of family Parapoxviridae. It is a 260 ×160-nm cylindrical virus with spirally arranged tubules. The virus typically is found at the teats and mouth of cattle but may also occur on the trunk and legs. Humans are accidental hosts following contact with infected animals or contaminated fresh meat. Paravaccinia virus is transferred by direct inoculation into the skin, often through a break in the skin barrier.[59] Cases of transmission from contaminated fomites to individuals with burn injury have been reported.[60] (see Fig. 195-10B).

CLINICAL FINDINGS

History. The incubation period for milker's nodule is 4–7 days. In a minority of cases, the infected individual develops mild systemic symptoms such as a transient low-grade fever.[61]

Cutaneous Lesions. The sites of inoculation of paravaccinia virus are usually the hands and, on occasion, the face. After the incubation period, skin lesions develop. One to several lesions usually appear, but they may occasionally be numerous. Lesions begin as red and occasionally pruritic macules that become raised papules (see eFig. 195-9.2 in online edition). They can then form papulovesicles with a target-like appearance—a red center surrounded by a white or gray ring and outer red halo. The lesions then develop into bluish or violaceous tender nodules. Some ulcerate or have a central depression (Fig. 195-10), which results in formation of eschars with crust. Lesions often take 4–8 weeks, and sometimes longer, to heal.[58,59]

Related Physical Findings. Lymphangitis is often present in the skin surrounding the primary lesion(s). Lymphadenopathy is not common.

LABORATORY TESTS

Histopathology. The histopathologic findings of milker's nodule depend on the stage of the lesion. Early lesions show vacuolization and ballooning of cells in the upper third of the epidermis, which sometimes leads to multilocular vesicles. Intracytoplasmic inclusion bodies may be seen, with rare intranuclear inclusions. Epidermal necrosis may be observed



Figure 195-10 **A.** Firm, eroded milker's nodule. **B.** Multiple lesions at the site of a second-degree scalding burn sustained in a milking barn.

focally with ulceration and crust as the lesion progresses. Neutrophils are seen in the epidermis and superficial papillary dermis with epidermal necrosis. Mature lesions have finger-like epidermal projections, papillary dermal edema, and a mixed inflammatory infiltrate that includes lymphocytes, histiocytes, and eosinophils. Regressing lesions have decreasing acanthosis and inflammation.[58,62]

Special Tests. Electron microscopy of blister fluid or crusts can identify the characteristic cylindrical shape of parapoxviruses. Paravaccinia virus is slow growing on tissue culture. Viral DNA hybridization or PCR procedures may be used to distinguish paravaccinia virus from other parapoxviruses.[63]

DIFFERENTIAL DIAGNOSIS.

Milker's nodules appear very similar to the lesions of orf, another parapoxvirus. Attention to clinical history usually allows differentiation, with cattle the source of infection for milker's nodules and sheep or goats for orf. Tissue cultures can aid in diagnosis if needed. Bovine papular stomatitis virus causes disease in cattle with lesions around the animal's mouth. Transmission to people produces lesions similar to milker's nodules, and some believe the etiology of both of these conditions may actually be the same virus.[64] Milker's nodules must also be differentiated from cowpox. Cowpox is very rare in humans. It has a longer incubation period, causes more pain and lymphadenopathy, and has led to death in persons with immunocompromise or atopic dermatitis. Large lesions of milker's nodule can be confused with anthrax, pyogenic granuloma, giant herpetic lesions, and keratoacanthoma (Box 195-4).

COMPLICATIONS.

Secondary bacterial infection can occur but is rare. Erythema multiforme, morbilliform eruptions, and erythema nodosum have been reported in cases of milker's nodule.

PROGNOSIS AND CLINICAL COURSE.

Milker's nodule is a self-limited illness. Most cases heal without scarring. Infection produces lifelong immunity.

TREATMENT.

Because the disease is self-limited, treatment, if needed, is symptomatic. Surgical curettage of large lesions may help speed healing.[61,65]

PREVENTION.

There is no cross-immunity between orthopoxviruses and parapoxviruses, and thus smallpox vaccination (vaccinia virus) has no effect on this illness. Prevention mainly consists of isolation of infected animals and contact precautions.[66]

BOX 195-4 DIFFERENTIAL DIAGNOSIS OF MILKER'S NODULE AND ORF

Most Likely
- Few to multiple lesions
  - Bovine papular stomatitis
  - Cowpox
  - Herpetic whitlow
- Solitary lesion
  - Pyogenic granuloma
  - Pyoderma

Consider
- Few to multiple lesions
  - Atypical mycobacterial infection
  - Sporotrichosis
- Solitary lesion
  - Tularemia
  - Giant herpetic lesion
  - Giant molluscum
  - Erysipeloid

Always Rule Out
- Few to multiple lesions
  - Anthrax
  - Primary inoculation tuberculosis
- Solitary lesion
  - Keratoacanthoma
  - Syphilitic chancre

ORF

Contagious pustular dermatosis, infectious pustular dermatitis, scabby mouth disease, and sore mouth disease are all synonyms for orf, a self-limited zoonotic viral infection that usually involves the hands of people handling infected animals. The offending Orf virus is a member of the *Parapoxvirus* genus. It is an endemic disease in sheep and goats that usually affects the area around the lips and nostrils of the animal, as well as the teats of ewes suckling young. It is transmitted to humans through contact with infected tissue or fomites, and human infections have been noted after vaccination of sheep herds.[67,68] Orf shares clinical characteristics with other infectious diseases and may be mistaken for more serious and life-threatening disorders such as tularemia, anthrax, and erysipeloid (Box 195-4). Although clinical appearance and history of ruminant exposure are usually diagnostic, real-time PCR testing, which is available through the CDC, is the most rapid and accurate way to make the diagnosis when clinical uncertainty exists.[68]

EPIDEMIOLOGY. Human disease is more commonly seen in farmers and shepherds, but anyone who has contact with small ruminants is at risk. Although sheep and goats are the more common sources of infection, the virus has also been found in camels, mountain goats, gazelles, and musk oxen. Disease can occur after contact with animals or fomites such as barn doors, feeding troughs, wire fencing, and bottles. The virus is quite hardy and can survive heating, drying, and certain solvents such as ether and chloroform. Vaccination of animals with unattenuated virus leads to milder disease in the animal, but can result in infection of humans exposed to the vaccinated animal.[67]

ETIOLOGY AND PATHOGENESIS. Orf virus is the prototypic species of the genetically heterogeneous *Parapoxvirus* genus.[69] It is an ovoid cross-hatched particle of approximately 250 × 160 nm with a twine-like structure. Electron microscopic analysis can distinguish this *Parapoxvirus* from *Orthopoxviruses* such as variola (smallpox). Virulence proteins elaborated by the virus aid in evading host immunity.

CLINICAL FINDINGS

Cutaneous Lesions. Five to six days after inoculation, a slightly elevated red papule appears, which subsequently vesiculates (Table 195-2). The lesions then evolves into a targetoid nodule with a red center, white ring, and peripheral rim of erythema (Fig. 195-11). A weeping stage (see eFig. 195-11.1 in online edition) is followed by a dry stage and finally a dry crust and scab, which generally resolves without scarring. Multiple lesions are sometimes present, and giant lesions occasionally occur.[70]

Related Physical Findings. Systemic findings are uncommon in immunocompetent individuals but can include lymphadenopathy and lymphangitis. Rarely fever and malaise may occur.

TABLE 195-2
Clinical Manifestation of Orf

Time After Exposure	Clinical Manifestations	Laboratory Analysis	Other Notes
3–7 days	One to four papules on hand (typically only one lesion): begin as a red maculopapular lesion ↓ Vesicle ↓	Can confirm by histology, viral culture, increase in serologic titers, or complement fixation. Electron microscopy of lesional skin shows brick-shaped viral particles (200–380 nm in length); intranuclear inclusions are occasionally seen.	Systemic symptoms are rare, but may include lymphadenopathy and lymphangitis, fever, rigors, drenching sweat, malaise, and urticaria.
10–14 days	Target lesion, with red center, white middle ring, and red halo ↓		
14–21 days	Acute weeping stage ↓		Lesions are relatively painless.
21–28 days	Regenerative dry stage with black dots ↓		
28–35 days	Papillomatous stage ↓		
35 days	Regressive stage with dry crust and eventual shedding of the scab		Typically no scarring occurs.

From Diven DG: Poxvirus. In: *Mucocutaneous Manifestations of Viral Disease*, edited by SK Tyring. New York, Infarma Healthcare, 2002, p. 39, with permission.



Figure 195-11 The target phase of orf shows a white circle with central and peripheral erythema.

LABORATORY TESTS

Histopathology. In the target stage, intranuclear and intracytoplasmic inclusions are present in vacuolated epidermal cells, with an accumulation of neutrophils, basophils, dendritic cells, and lymphocytes (see eFig. 195-11.2 in online edition). Papillomatosis and acanthosis subsequently develop, and marked finger-like downward projections of the epidermis may be seen (see eFig. 195-11.3 in online edition).

Special Tests. Electron microscopy may be helpful in distinguishing between *parapoxviruses* and other types of poxviruses but is not diagnostic for orf; similar limitations exist with serologic testing. Tissue culture is possible but time consuming. The most rapid and sensitive means of making the diagnosis is PCR testing, and real-time PCR procedures, in particular, appear extremely sensitive.[68]

DIFFERENTIAL DIAGNOSIS.

A variety of bacterial and infectious diseases can present with findings similar to those of orf (see Box 195-4). Exposure history is important, because many of these disorders (milker's nodules, cowpox, monkeypox, etc.) are associated with exposures to animals other than sheep or goats.[63] The lesion of anthrax is more hemorrhagic with rapid progression to an eschar. Tularemia and syphilis are associated with chancres. Sporotrichosis begins as a single necrotic nodule but is followed by multiple nodules arising in a linear fashion along the lymphatics. Primary innoculation tuberculosis and atypical mycobacterial infection can give rise to ulcerative lesions that may take months to years to heal.

COMPLICATIONS.

Secondary bacterial infection, swelling, lymphadenitis, and fever can occur. Erythema multiforme,[71] vesicular eruptions,[72] and secondary spread within active atopic dermatitis skin lesions have been reported.[72] Bullous pemphigoid has also rarely been reported after orf infection.[73]

PROGNOSIS AND CLINICAL COURSE.

Orf is usually a self-limited disease that resolves within 4–6 weeks. Typically scarring does not occur. Immunocompromised individuals can develop progressive destructive lesions that may require interventions such as débridement or antiviral therapy such as cidofovir cream.[65,74]

TREATMENT.

Supportive care is the most appropriate intervention for immunocompetent patients. Application of compresses, culture of lesion specimens, and antibiotic coverage may be appropriate if secondary bacterial infection is suspected. Immunocompromised patients may require medical intervention (see Section "Prognosis and Clinical Course").

PREVENTION.

Barrier precautions such as use of gloves and good hand hygiene are recommended. Patients with an impaired skin barrier from either abrasions or intrinsic skin disease (e.g., atopic dermatitis) should be particularly vigilant regarding avoidance of contact with infected animals or potential fomites.

MOLLUSCIPOXVIRUS INFECTION: MOLLUSCUM CONTAGIOSUM

Molluscum contagiosum (MC) is a benign but nonetheless frequently troublesome viral infection that most often affects young children. It is characterized by smooth, dome-shaped, discrete, opalescent papules with a central core that occasionally develops surrounding areas of scale and erythema (molluscum dermatitis). Patients and families are bothered by this infection because of its often prolonged course, as it may persist for months to years. MC is a greater concern in immunocompromised individuals and those with atopic dermatitis, in whom the extent and duration of infection may be more extreme. Sexually transmitted disease occurs in adults but is extremely unlikely in children.

EPIDEMIOLOGY

MC virus (MCV) infection occurs worldwide and appears specific to humans. The prevalence of MCV infection has risen significantly in the past several decades, with an 11-fold increase noted in one US study of patient visits for this disorder over a two-decade span.[75] This rise appears to parallel the overall increase in sexually transmitted diseases. Although a prevalence rate of less than 5% in US children is often cited,[76] the rate varies by location, and it is thought that subclinical infection may be more common than overt disease. A representative Australian study documented an overall seropositivity rate of 23%, which supports the view that subclinical or mild



Figure 195-12 Molluscum contagiosum. **A.** Discrete, solid, skin-colored papules, 1–2 mm in diameter with central umbilication. **B.** Multiple, scattered, and discrete lesions, some of which are inflamed.

unrecognized disease exists in the population. HIV-infected individuals are at higher risk for extensive prolonged disease, and individuals with atopic conditions appear more likely to have increased numbers of lesions and experience a more prolonged disease course.[76]

Transmission may occur via direct skin or mucous membrane contact, or via fomites. Bath towels, swimming pools, and Turkish baths have all been reported as sources of infection, and individuals involved in close contact sports (e.g., wrestling) also appear at higher risk.[77,78] Autoinoculation and koebnerization also play a role in the spread of lesions. Recent reports also document the possibility of vertical transmission from mother to neonate during the intrapartum period.[79]

ETIOLOGY AND PATHOGENESIS

MCV is a large, brick-shaped poxvirus that replicates within the cytoplasm of cells. It shares a number of genomic similarities with other poxviruses, and approximately two-thirds of the viral genes are similar to those of vaccinia and variola virus.[80] There are four subtypes of MCV, but they all appear identical clinically. Ninety-eight percent of disease in the United States is caused by MCV genotype 1 and it is the main cause of MC in children.[80,81] MCV-2 is primarily seen in adults and immunocompromised individuals, with sexual contact being the most common mode of transmission. Serial transmission of the virus has not yet been achieved in culture. An incubation period of 2–7 weeks has been observed.

Virus replicates within the cytoplasm of epithelial cells, and infected cells replicate at twice the baseline rate. There are many MCV genes that may contribute to an impaired immune response to this virus, including (1) a homolog of a major histocompatibility class 1 heavy chain, which may interfere with antigen presentation; (2) a chemokine homolog that may inhibit inflammation; and (3) a glutathione peroxidase homolog that may protect the virus from oxidative damage by peroxides.[82,83]

CLINICAL FINDINGS

CUTANEOUS LESIONS. MC often presents with extremely small pink, pearly, or flesh-colored papules that then enlarge, occasionally reaching sizes of up to 3 cm ("giant molluscum"). As they enlarge, a dome-shaped, opalescent morphology may become more apparent. The lesions may have a central dell or umbilication (Fig. 195-12), within which a white curd-like substance can be seen that can be expressed with pressure. Most patients develop multiple papules, often in intertriginous sites, such as the axillae, popliteal fossae, and groin. Genital and perianal lesions can develop in children and are only rarely associated with sexual transmission in this population.[75]

Lesions may be grouped in clusters or appear in a linear array. The latter often results from koebnerization or development of lesions at sites of trauma. Erythema and eczematous changes may occur around lesions; this is termed *molluscum dermatitis*. Papules may become erythematous (Fig. 195-12B), which is believed to be an immune response to the infection. Patients with acquired immunodeficiency syndrome may develop large and extensive lesions involving both genital and extragenital sites.[82] (see Chapter 198)

SPECIAL TESTS

Diagnosis is usually straightforward. Evaluation of the central contents using a crush preparation and Giemsa staining can be carried out when necessary (eFig. 195-12.1 in online edition), and histopathologic evaluation can be performed as needed. Some clinicians recommend that an adult with new-onset MC infection

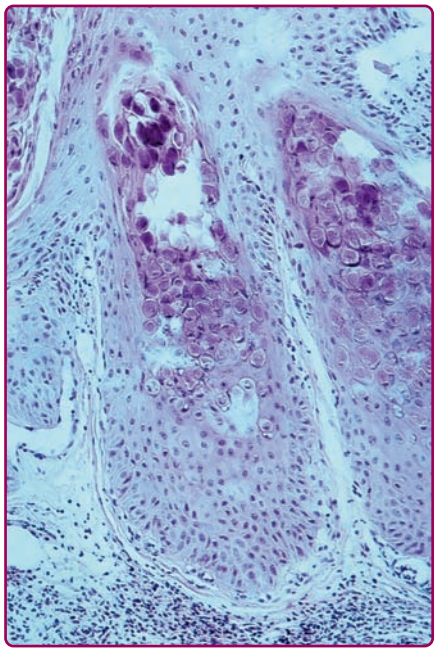

Figure 195-13 Molluscum contagiosum. Histopathology (skin biopsy, H&E) shows downgrowth of infected epidermal cells bearing large eosinophilic cytoplasmic inclusion bodies (Henderson-Paterson bodies).

undergo evaluation for HIV infection and/or other causes of an immunocompromised state.[84]

Histopathologic examination reveals a hypertrophied and hyperplastic epidermis. Above the basal layer, enlarged cells containing large intracytoplasmic inclusions (Henderson-Paterson bodies) can be seen (Fig. 195-13). These increase in size as the cells reach the horny layer.

DIFFERENTIAL DIAGNOSIS

The differential diagnosis includes verrucae, pyogenic granulomas, amelanotic melanoma, basal cell carcinomas, and appendageal tumors. Fungal infections caused by *Cryptococcus*, histoplasmosis, and *Penicillium* must be considered in immunocompromised hosts (Box 195-5).

COMPLICATIONS

Although many patients are asymptomatic, pruritus is sometimes a significant problem, particularly in those patients with underlying atopic dermatitis. Chronic conjunctivitis and punctate keratitis may develop in patients with eyelid lesions. Secondary bacterial infection can occur, particularly if patients scratch their lesions.

PROGNOSIS AND CLINICAL COURSE

Spontaneous clearance occurs, but often over a prolonged period of months to years. Most families prefer treatment if lesions persist more than a month or two.

BOX 195-5 DIFFERENTIAL DIAGNOSIS OF MOLLUSCUM CONTAGIOSUM

Most Likely
- Verrucae

Consider
- Pyogenic granuloma
- Papular granuloma annulare
- Epidermal inclusion cyst
- Sebaceous hyperplasia

Always Rule Out
- Appendageal tumors
- Basal cell carcinoma
- Amelanotic melanoma
- Cryptococcosis/histoplasmosis/penicilliosis

In patients with HIV, MC infection is usually indicative of a more advanced state of HIV, with higher viral load and lower $CD4^+$ T-cell count.[84]

TREATMENT

It is important to discuss the risks and benefits of individual therapies with families before embarking on treatment for this essentially benign condition, which will generally resolve without complication in the immunocompetent individual (Table 195-3). For some children, no treatment is the best option as the child's native immune response may clear the MC without additional intervention. Many experts use cantharidin 0.7% or 0.9% liquid for treatment of MC. This extract of the blister beetle, *Cantharis vesicatoria*, induces vesiculation at the dermoepidermal junction when applied topically to the skin. It must be applied with care and washed off 2–6 hours later. Use on the face or genital areas is not recommended, and families must be counseled regarding the small risk of extreme reaction or scarring.

Other traditional therapies have included curettage and cryotherapy; however, both of these treatments are painful. The use of topical anesthetic agents may ameliorate some of the associated pain, but patients generally find topical cantharidin treatment the most efficient and least painful. Other topical therapeutic modalities include retinoid creams, imiquimod cream, salicylic acid, trichloroacetic acid, cidofovir, and silver nitrate paste and tape stripping. Oral cimetidine has also been used with some success.[85] However, a 2009 Cochrane Database analysis of treatments for MC, which identified only 11 therapeutic studies of high quality, found that no single intervention is convincingly effective for the treatment of MC.[86]

PREVENTION

Prevention of spread may be enhanced by avoiding trauma to the sites of involvement as well as avoiding

TABLE 195-3
Treatment of Molluscum Contagiosum

		Considerations	Level of Evidence[a]
Watchful waiting	Spontaneous resolution occurs over months to years in immunocompetent individuals.	Risk of autoinoculation, associated dermatitis, secondary bacterial infection	3
Topical therapies	Cantharidin (0.7% or 0.9%)	Rarely severe blistering and scarring of concern	2, 3
	Podophyllin (10%–25% resin) (0.3% or 0.5% cream)	Rarely severe blistering and scarring of concern	1, 2, 3
	Cryotherapy/liquid nitrogen	Rarely severe blistering and scarring of concern	3
	Curettage	Painful	3
	Imiquimod cream (5%)	Painful, scarring possible	1, 2, 3
	Topical retinoids	Irritation common	3
	Silver nitrate paste	Irritation common	2
	Trichloroacetic acid (25%–35%)	Rarely severe blistering and scarring of concern	2, 3
	Topical cidofovir (1%, 3% gel; 1%, 3% cream)	Expensive	2, 3
Systemic therapies	Oral cimetidine (40 mg/kg/day)	Recommended only for immunocompromised individuals, expensive	2, 3
	Oral cidofovir		3
	Subcutaneous interferon-α	Recommended only for immunocompromised individuals	3

[a]1 = double-blind studies; 2 = open-label prospective studies; 3 = case reports.

scratching, with the use of antipruritics as necessary. Autoinoculation may be decreased by treating all existing lesions.

KEY REFERENCES

Full reference list available at www.DIGM8.com

DVD contains references and additional content

1. Diven DG: An overview of poxviruses. *J Am Acad Dermatol* **44**(1):1-16, 2001
4. Breman JG, Henderson DA: Diagnosis and management of smallpox. *N Engl J Med* **346**(17):1300-1308, 2002
7. Cohen J: Bioterrorism. Smallpox vaccinations: How much protection remains? *Science* **294**:985, 2001
30. Cono J, Casey CG, Bell DM: Smallpox vaccination and adverse reactions. Guidance for clinicians. *MMWR Recomm Rep* **52**:1-28, 2003
38. Tom WL, Kenner JR, Friedlander SF: Smallpox: Vaccine reactions and contraindications. *Dermatol Clin* **22**(3):275-289, 2004
45. Ligon BL: Monkeypox: A review of the history and emergence in the Western hemisphere. *Semin Pediatr Infect Dis* **15**(4):280-287, 2004
47. Di Giulio DB, Eckburg PB: Human monkeypox: An emerging zoonosis. *Lancet Infect Dis* **4**(1):15-25, 2004
56. Werchniak AE et al: Milker's nodule in a healthy young woman. *J Am Acad Dermatol* **49**(5):910-911, 2003
60. Lewis-Jones S: Zoonotic poxvirus infections in humans. *Curr Opin Infect Dis* **17**(2):81-89, 2004
79. Smith K, Yeager J, Skelton H: Molluscum contagiosum: Its clinical, histopathologic, and immunohistochemical spectrum. *Int J Dermatol* **38**:664-672, 1999
84. van der Wouden JC et al: Interventions for cutaneous molluscum contagiosum. *Cochrane Database Syst Rev* **4**:CD004767, 2009

Chapter 196 :: Human Papilloma Virus Infections

:: Elliot J. Androphy & Reinhard Kirnbauer

PAPILLOMAVIRUS INFECTIONS AT A GLANCE

- Very common infection of skin and mucosa of children and adults.
- Papules of variable size often with a rough scaly surface.
- Caused by human papillomaviruses (HPV), a subset of which are associated with cervical, penile, anal, and other epithelial malignancies.
- Treatment often requires physical or immune mediated destruction of infected epithelial cells.
- A prophylactic vaccine effectively protects from infection with HPVs most commonly identified in cervical cancer and genital warts.

Papillomaviruses (PVs) cause benign cutaneous and mucosal epithelial proliferations commonly called warts or verrucae. PV infections do not produce acute local or systemic signs or symptoms but induce slow, focal accumulations of keratinocytes. Lesions may remain subclinical for long periods or may enlarge into fulminating masses that persist for months or even years. Persistent lesions caused by certain types of human PV (HPV) can undergo neoplastic transformation.

ETIOLOGY AND PATHOGENESIS

(See Also Chapter 191)

PVs comprise a large family of small DNA viruses that infect humans and many other species.[1] PVs are highly host-specific, meaning that those from one species do not induce papillomas in heterologous species, so HPVs infect only humans. Rabbit, bovine, and canine PVs have been used in animal models of viral infection because biologic experiments cannot be performed in humans using HPVs due to their oncogenic potential.

The PV genome is present within the viral particle as a single, covalently closed circle of double-stranded DNA. Each genome is composed of approximately 8,000 nucleotide base pairs and is approximately one-twentieth the size of a herpesvirus genome. Based on their DNA sequences, most human and animal PVs share a similar genetic organization (Fig. 196-1) that encodes only eight to nine related proteins.[2] PV proteins are labeled as E (early) and L (late).[3] The E proteins are necessary for viral DNA replication and are not incorporated into the infectious virus particle. Because the E genes do not encode a DNA polymerase or thymidine kinase, PV replication is not selectively susceptible to inhibition by nucleoside analogues. Rather, PVs use host cell enzymes and factors to replicate their DNA genomes. The *L1* and *L2* genes encode the structural proteins that form the outer protein shell or capsid of the infectious viral particle, which is called the *virion*. The spherical virion measures approximately 55 nm in diameter and packages the viral DNA (Fig. 196-2).

More than 100 HPV genotypes have been isolated and sequenced; the actual number of HPV genotypes is even higher.[1,4] By convention, two HPV isolates are classified as the same type when a highly conserved sequence within their *L1* genes are at least 90% identical.[5] A new HPV genotype is recognized based on less than 90% homology to all other known HPVs within this DNA sequence.[4] A subtype has 91%–98% identity, whereas a natural variant has less than 2% divergence to a known type in this region of *L1*.

Often associated with distinct regional predilection, histopathology, and biology, HPVs are often categorized as cutaneous (nongenital) and include genotypes such as HPV-1, -2, -3, and -4, whereas HPV-6, -11, -16, and -18 predominate in genital and mucosal infections. A large variety of HPV types such as HPV-5 and -8 have been isolated in epidermodysplasia verruciformis (EV), immunosuppressed individuals, and are

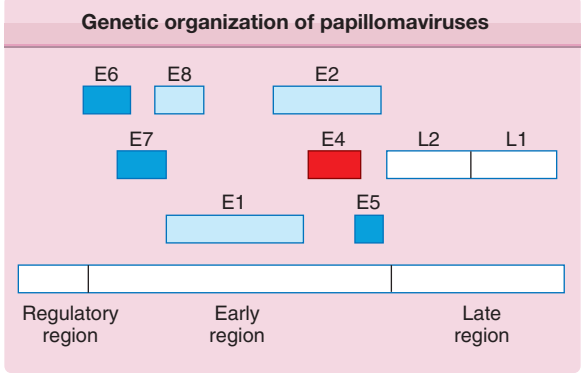

Figure 196-1 All papillomaviruses genomes are composed of approximately 8,000 nucleotide base pairs, represented as a linear sequence but actually a closed circle of double-stranded DNA. The boxes depict the viral genes, each of which encodes a protein. The regulatory region does not encode proteins but is a DNA segment that controls expression of viral genes and replication of the viral genome. *E6*, *E7*, and *E5* represent transforming genes; E1 and E2 coordinate replication and transcription of the viral genome; and the L1 and L2 proteins form the viral capsid. E4 encodes a protein that may be involved in the release of the virus from the cell's keratin framework.

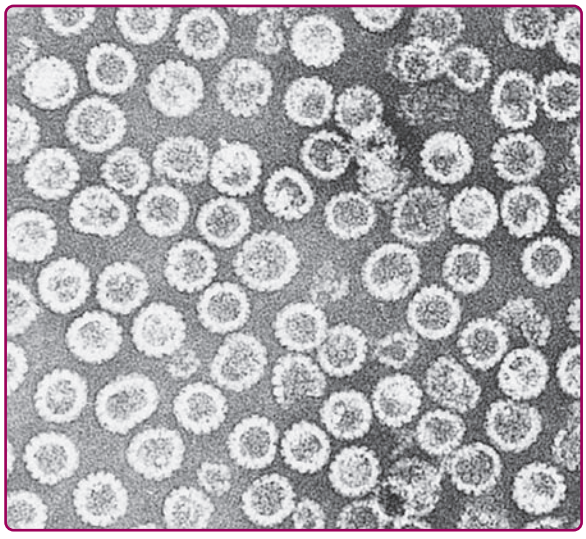

Figure 196-2 Transmission electron micrograph of human papillomavirus type 16 virus-like particles composed of the L1 and L2 proteins. These proteins were synthesized in cell culture and self-assembled into 55-nm particles that are morphologically similar to natural infectious virus except that they do not contain the viral DNA. The particles in the electron micrograph were purified from the cells. (Micrograph used with permission from Heather Greenstone.)

also found to be present in normal skin (Table 196-1). PVs have also been classified by phylogenetic organization based on their DNA sequence relationships.[6,7] The α genus includes a large set of cutaneous and genital-mucosal types and the β genus is primarily comprised of EV-types. Other genus classifications include more distantly related human and animal PV species. HPVs closely related by DNA sequence tend to induce similar lesions. Examples include highly related types such as 3 and 10, which induce flat warts; types 6 and 11, which cause genital–mucosal warts (condylomata acuminata); and types 5 and 8, which appear as scaly patches in EV.

Another important distinction is that specific HPV genotypes have malignant potential. This was first noted in EV. Warts that contain HPV types -5 and -8 undergo a high rate of malignant degeneration, whereas those induced by other HPV types, even in the same patient, tend to remain benign.[8] Similarly, approximately 50% of cervical carcinomas contain HPV-16, with HPV-18, -45, -31, -33, -52 and -58 accounting for an additional 35%.[9] Less frequent HPVs account for the remainder of cervical malignancies. This group is collectively referred to as *high-risk* types, whereas the *low-risk* types such as HPV-6 and -11 are isolated from benign cervical disease and genital warts, and identified in <1% of cervical malignancies.

HPV infection occurs through inoculation of virus into the viable epidermis through breaks in the epithelial barrier. Maceration of the skin is probably an important predisposing factor, as suggested by the increased incidence of plantar warts in swimmers who frequently use public pools. In rodent models of cervical HPV infection, mechanical disruption of the epithelium or inclusion of the mild detergent nonoxynol-9 dramatically increased the incidence of infection.[10] Animal models using HPV virions demonstrate that attachment to heparan sulfate proteoglycans on the basement membrane is a required initial step in natural infection. A furin protease then cleaves L2, inducing a conformation change that allows binding to an unidentified basal cell receptor.[11] This experimental model explains how PVs reserve infection for

TABLE 196-1
Clinical Associations of Human Papillomavirus (HPV) Types

HPV Type	Most Common Clinical Lesion	Less Frequent Lesion	Potential Oncogenicity
1	Deep plantar/palmar warts	Common warts	
2, 4, 27, 29	Common warts	Plantar, palmar, and mosaic warts	
3, 10, 28, 49	Flat warts	Flat warts in EV	HPV-10 rare in cervical and vulvar carcinomas
7	Butcher's warts		
13, 32	Oral focal epithelial hyperplasia		
5, 8, 9, 12, 14, 15, 17, 19–26, 36, 47, 50	EV, warts in immunosuppression	Normal skin (?)	HPV-5, -8, -9 isolated from SCCs
6, 11	Anogenital warts, cervical condylomata	Bowenoid papulosis, oral warts; respiratory papillomatosis	Buschke-Löwenstein tumor; rare in penile, vulvar, cervical, and other urogenital tumors; "low risk"
16, 18, 31, 33–35, 39, 40, 51–60	Cervical condylomata; anogenital warts; bowenoid papulosis	Common warts	Genital and cervical dysplasias and carcinomas; rare in SCC of the digit; "high risk"

EV = epidermodysplasia verruciformis; SSC = squamous cell carcinoma.



Figure 196-3 **A.** Common wart, periungual. Multiple, confluent, keratotic papules around the proximal periphery of the fingernails. **B.** Common wart, verruca plantaris with black dots of thrombosed capillaries. **C.** Common wart, mosaic plantar. A large hyperkeratotic plaque is seen on the heel, made up of multiple small coalescing warts.

and specifically target epithelial basal cells. To establish persistent infection, the virus presumably must enter a stem cell or convert the infected cells to one with stem-like properties. After entry, a single copy or at most a few copies of the viral genome are maintained as an extrachromosomal plasmid or episome within the infected epithelial basal cell's nucleus. When these cells divide, the viral genome also replicates and partitions to the progeny cell, which transports the viral infection into the differentiating layers of the epithelium. Viral RNA expression (transcription) is extremely low until the upper Malpighian layer, where viral DNA synthesis and genome amplification typically results in hundreds to thousands of copies per cell. The viral capsid proteins L1 and L2 (see Fig. 196-1) are synthesized in these upper epithelial strata and assemble into a tightly packed, very stable protein capsid. The newly synthesized viral DNA is packaged in the capsid, and mature virions accumulate in the nuclei of these upper level cells (see Fig. 196-2). The viral E1-E4 protein (the product of a spliced RNA from the *E1* and *E4* genes) may induce collapse of the cytoplasmic keratin filament network that surrounds the residual nucleus that contains assembled viruses.[12] This is postulated to facilitate release of the virions from the cross-linked cytoskeleton of keratinocytes/corneocytes so that virus can be inoculated into another site or desquamated into the environment.

PV virions exfoliate along with the residual epidermal cells. PVs do not bud from the nuclear or plasma membrane as do many viruses such as herpes simplex or human immunodeficiency virus (HIV). Therefore, HPVs do not possess a lipoprotein envelope that leads to susceptibility to environmental conditions such as freezing, heating, or dehydration with alcohol that inactivate enveloped viruses. In contrast, PV virions are resistant to desiccation and to the detergent nonoxynol-9, although exposure of virions to formalin, strong detergents such as sodium dodecyl sulfate or prolonged high temperature reduces their infectivity.[13,14] PVs can remain infectious for years when stored in glycerol at room temperature or in liquid nitrogen.

After experimental PV inoculation, a verruca usually appears within 2–9 months. This observation implies a relatively long period of subclinical infection that may act as an inapparent source of infectious virus. The rough surface of a wart can disrupt adjacent skin and enable inoculation of virus into adjacent sites, with the development of new warts over a period of weeks to months. Autoinoculation of virus into apposed skin is commonly seen on adjacent digits (see Fig. 196-3), mucosa (see Fig. 196-4), and in the anogenital region. Each new lesion results either from the initial exposure or spread from other warts. There is no convincing evidence for blood-borne dissemination.

The relative abundance of virus particles in a wart varies with the clinical setting and the HPV type. Newer lesions tend to contain more virions than do older verrucae. Plantar warts containing HPV-1 produce a high number of virions; anogenital verrucae typically have trace quantities of mature virus particles; common warts usually have intermediate numbers.

Because the viral episomes are at low copy and the L1 and L2 capsid proteins are not expressed in the lower epithelial levels in warts, the differentiation state of the infected epithelial cell influences viral transcription, signals initiation of viral DNA synthesis, and



Figure 196-4 Multiple mucosal warts extending to the vermillion border where they become highly keratinized.

permits virion assembly. Further support for the belief that the production of virus particles depends on the state of epithelial differentiation is the fact that virion production decreases as benign papillomas progress toward dysplasia. Capsid proteins are never observed in HPV-infected malignant cells. The propagation of limited amounts of HPVs in cultured cells results from the ability to reproduce the physiologic milieu required for differentiation.[15,16] Although it is possible to isolate infectious HPVs from cultured epithelial cells, the process is time-consuming, technically challenging, expensive, and limited to research laboratories. Therefore, laboratory culture for detection of HPV is not a practical diagnostic test.

EPIDEMIOLOGY

Acquisition of HPV depends on several factors, including the location of lesions, the quantity of infectious virus present, the degree and nature of the contact, and the general and HPV-specific immune status of the exposed individual. The roles of immunity and genetic susceptibility to PV infection are incompletely understood. The decrease in the frequency of warts with age implies that resistance to infection develops over time, and much of this resistance may be immunologic. In experimental PV infection in animals, resistance to virus challenge correlates with the presence of neutralizing anti-capsid antibodies. Serum or immunoglobulin G from resistant animals can provide protection through passive transfer.[17,18] It is therefore likely that neutralizing antibodies account for at least some of the resistance to reinfection. Serum antibodies to viral capsids are detectable in some patients with current warts or a history of warts. These antibodies, as well as other host factors, may help to limit the spread of warts to new sites. Although humoral immunity may contribute to resistance to acquisition of infection, host cellular immune reactivity plays a critical role in wart regression. Individuals with impaired cell-mediated immunity are particularly susceptible to persistent HPV infection, and their infections are notoriously resistant to treatment. Warts are common in renal and solid organ transplant patients on immunosuppressive therapy, which may contribute to their increased risk of cutaneous malignancy.[19,20] Although there are instances in which treatment of one or a few warts leads to resolution of many or all warts in nonimmunosuppressed patients, this outcome is the exception rather than the rule.

The reservoir of HPV is believed to be individuals with clinical and subclinical infection, as well as virus present in the environment. It is now apparent that HPV DNA is resident at very low levels on normal skin and in hair follicles. Using ultrasensitive polymerase chain reactions (PCR), a wide range of HPV, often of the β genus, is detected in the majority of individuals with both normal and suppressed host immunity.[21–23] Whether this HPV DNA represents a subclinical state rather than true "latency" (i.e., nonreplicating and transcriptionally inactive virus) is unknown. Whether HPV DNA persists in a latent state in the epithelium after successful treatment of immunocompetent individuals also remains an unresolved issue. However, the fact that HPV DNA becomes undetectable in the majority of cervical infections, even by exquisitely sensitive PCR techniques, implies that complete viral clearance is possible.

Nongenital warts occur most frequently in children and young adults, in whom the incidence may exceed 10%.[24,25] The age-specific incidence of nongenital warts differs from that of anogenital warts, which are uncommon in children. Anogenital warts behave as a sexually transmitted condition, and partners can transmit the virus with high efficiency.[26] Penile lesions occur frequently in sexual contacts of women with cervical intraepithelial neoplasia.[27,28]

Although genital warts in children may be a consequence of sexual abuse, such warts in infants and children commonly result from virus inoculation at birth or from incidental spread from cutaneous warts (see Chapter 106). In contrast to anogenital lesions in adults, a significant proportion of genital warts in children contain HPV types that are usually isolated from nongenital warts.[29–31]

In addition to causing lesions on the external genitalia, genital-mucosal HPV types also infect the uterine cervix.[32,33] This sexually transmitted infection, which may involve low- or high-risk HPV types, is especially common in sexually active women younger than 25 years of age. The majority of HPV DNA positive cervical infections are transient and remain histologically normal. Thus, even normal-appearing genital skin or mucosa may represent a reservoir for contagion. Studies of large populations throughout the world have documented the natural history of cervical infection and the association of high-risk HPV with cervical cancer. Persistence of HPV DNA strongly correlates with an increased risk for progression to cervical dysplasia and invasive cancer. High-risk HPV DNA has also been detected in clinically normal penile skin, although less is known of the epidemiology of genital HPV infection in men.[34]

The majority of respiratory (laryngeal) papillomas occur in infants and young children. The HPVs isolated from respiratory tract papillomas are often the same types as those of genital warts, especially HPV-6 and -11,[35] and respiratory papillomatosis in young children is thought to result from seeding of the larynx and oropharynx during parturition.[36] Although the epidemiologic correlation of condyloma in mothers of infants with respiratory papillomas has been documented,[37] cervical and genital warts are common in the childbearing age women and respiratory papillomatosis of infants is rare. Because Cesarean section has attendant risk and is not fully protective, this is not routinely recommended for expectant mothers. Instead, treatment efforts should be aimed at reducing HPV infection before delivery. Oral and respiratory warts in adults are usually the consequence of oral–genital contact and is a significant risk factor for development of HPV-associated oropharyngeal cancers, most commonly with HPV-16.[38]

Approximately 50% of EV cases are inherited, usually with an autosomal recessive pattern. Studies to identify the HPV genotype in EV wart lesions are limited to research laboratories. In contrast to the finding of β-HPV types on normal skin, large numbers of these

viruses are easily detected in EV lesions. Mutations in the *EVER* genes are reported to be present in a subset of EV individuals.[39,40]

CLINICAL FINDINGS

HISTORY

The typical history is of a newly acquired, slowly expanding, persistent, and often scaly papule of the skin. Over several weeks to months, the appearance of additional nearby lesions indicates local spread and infers the diagnosis of HPV infection.

CUTANEOUS WARTS

Warts are often classified by their anatomic location or morphology. As shown in Figs. 106-3 to 106-8, the physical appearance of warts varies. *Common warts* (verruca vulgaris) are scaly, rough, spiny papules or nodules (see Table 196-1). These may occur as single or grouped papules on the hands and fingers (see Figs. 196-3A and 196-5) or elsewhere (Fig. 196-7). Verrucae may be *filiform* and resemble cutaneous horns (Fig. 196-6). *Flat warts* (verruca plana) are 1–4 mm, slightly elevated, flat-topped papules that have minimal scale (see Fig. 196-8). These are most frequent on the face, hands, and lower legs. *Plantar and palmar warts* are thick, endophytic, and hyperkeratotic papules, which may be painful with pressure (see Figs. 196-3B and C). Punctate black dots ("seeds") that represent thrombosed capillaries become evident after shaving off the outer keratinous surface. *Mosaic warts* result from coalescence of plantar or palmar warts into large plaques (see Fig. 196-3C). Some individuals with an apparently normal immunologic state develop exuberant warts of the palms or soles that are refractory to treatment. *Butcher's warts* are verrucous papules, usually multiple, on the dorsal, palmar, or periungual hands and fingers of meat cutters, and may be infected with HPV-7.

Anogenital warts (also known as condylomata acuminata, genital warts, or venereal warts) consist of epidermal and dermal papules or nodules on the perineum, genitalia, crural folds, and anus (196-9A,B,C and E). They vary in size and can form large, exophytic, cauliflower-like masses, especially in the moist environment of the perineum. Discrete 1- to 3-mm sessile warts may occur on the penile shaft. Lesions that resemble common



Figure 196-6 Common warts. Filiform warts on the chin and lips of a child.



Figure 196-5 Common wart. A giant wart on the dorsum of the hand in a renal transplant recipient; the lesions were resistant to treatment but resolved spontaneously when immunosuppressive therapy was discontinued.



Figure 196-7 The large, scaly, and horny warts contain human papillomavirus (HPV)-2. The smaller, flatter, less scaly papules are warts that contain HPV-3.



Figure 196-8 Plane warts, verruca plana. **A.** Multiple pink flat warts on the face of an 11-year-old girl. **B.** Many flat-topped papules occur in a linear configuration resulting from self-inoculation.

warts also occur in this region but are unusual. Warts may extend internally into the vagina, urethra, and perirectal epithelium.

Bowenoid papulosis and erythroplasia are clinicopathologic entities in which high-risk HPVs have been identified.[41] In bowenoid papulosis, papules, often multiple, appear as 2–3-mm lesions on the external male and female genitalia (see Chapters 77 and 78). Erythroplasia is characterized by a velvety, erythematous mucosal plaque with distinct borders (Fig. 196-9B). Histologically, there is cellular atypia resembling Bowen disease or squamous cell carcinoma (SCC) in situ. These lesions are usually infected with HPV-16, which suggests that bowenoid papulosis and erythroplasia may represent a precursor of penile and vulvar cancer. Erythroplasia can progress to invasive SCC (Fig. 196-9B). However, in bowenoid papulosis the rate of transition to frank malignancy is much lower for the external genitalia than for the cervix. These small papules should be treated also because they may represent a reservoir for the transmission of potentially oncogenic HPVs.

EPIDERMODYSPLASIA VERRUCIFORMIS

EV usually manifests in childhood with persistent and often widespread warts that do not regress due to unique susceptibility to specific HPV types. Individual lesions typically have either the appearance of flat warts (Fig. 196-10) or flat scaly red-brown macules that resemble pityriasis versicolor, particularly if the occur on the trunk. The presence of warts on large areas of the body is suggestive but not necessary to consider this diagnosis. Involvement of the cervix and oropharynx is rare. Failure to clear lesions despite adequate treatment is another indication of potential EV. Because warts in EV almost always recur after treatment, this implies a failure to mount an effective immune response to the HPV infection. Individuals with EV do not usually have frequent bacterial or other viral infections. Immunocompromised individuals, such as those with HIV infection, may have multiple warts that contain EV and other β-HPV types and are difficult to eradicate, but this susceptibility is acquired.[42,43] SCCs in EV and immunosuppression usually arise in pityriasis-like lesions on sun-exposed areas (Fig. 196-11). Regional and distant metastases may occur. Although pityriasis-like lesions caused by any EV type are at risk of becoming malignant, this is higher for those caused by HPV-5 and -8.

EXTRACUTANEOUS (MUCOSAL) INFECTIONS

Oral warts are usually small, slightly elevated, soft, often pink or white papules that may be found on the buccal, gingival, labial mucosa (Fig. 196-4), tongue or hard palate. Verrucous, horny papillomas may occur on the palate. Mucosal lesions of the oropharynx, termed focal epithelial hyperplasia, also contain HPVs. In oral florid papillomatosis, multiple large verrucae appear within the oral cavity (see Fig. 196-9D). Progression to verrucous carcinoma may occur. Oral warts may result from genital contact. Warts may also occur in the urethra, usually when meatal warts are present. They may spread to the urinary bladder.

In respiratory (laryngeal) papillomatosis, multiple warts usually involve the larynx and may extend to the oropharynx and bronchopulmonary epithelia. Presenting symptoms commonly include hoarseness and stridor. Cases typically occur in infants or young children in whom the lesions may block the airway, but the condition may develop at any age. These HPV-associated papillomas may spontaneously remit, especially at puberty, but recurrences are frequent.

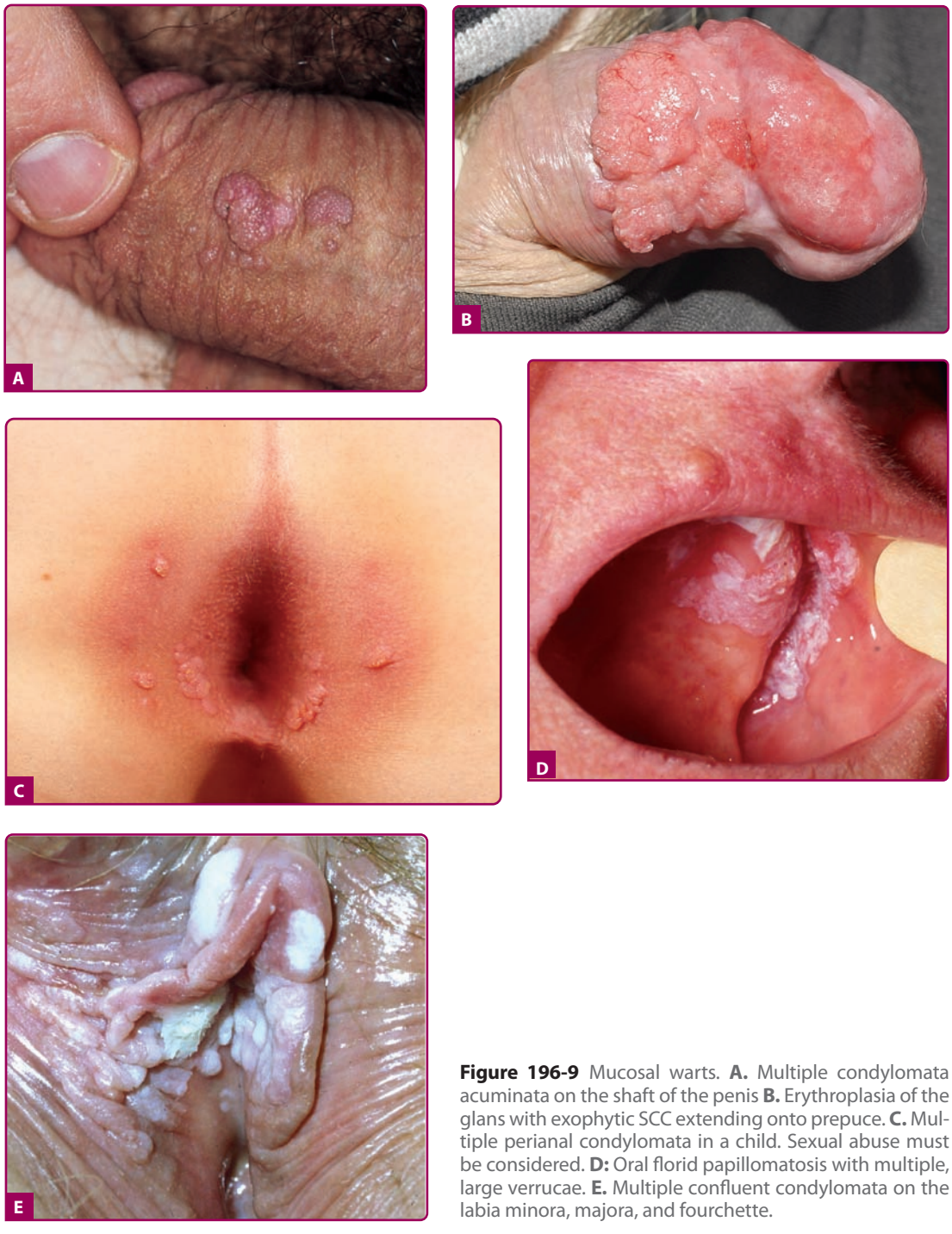

Figure 196-9 Mucosal warts. **A.** Multiple condylomata acuminata on the shaft of the penis **B.** Erythroplasia of the glans with exophytic SCC extending onto prepuce. **C.** Multiple perianal condylomata in a child. Sexual abuse must be considered. **D:** Oral florid papillomatosis with multiple, large verrucae. **E.** Multiple confluent condylomata on the labia minora, majora, and fourchette.

Cervical lesions are usually flat or slightly elevated and visualization may require colposcopy and enhancement after acetic acid application, which makes them appear as white patches (Fig. 196-12).

HISTOPATHOLOGY

Verrucae consist of an acanthotic epidermis with papillomatosis, hyperkeratosis, and parakeratosis (Fig. 196-13). The elongated rete ridges often point toward the center of a wart. The dermal capillary vessels are prominent and may be thrombosed. Mononuclear cells may be present. Large keratinocytes with an eccentric, pyknotic nucleus surrounded by a perinuclear halo (koilocytotic cells or koilocytes) are characteristic of HPV-associated papillomas. Koilocytes visualized in a Papanicolaou (Pap) smear represent a hallmark of HPV infection. PV-infected cells may have small, eosinophilic granules and dense clumps of basophilic keratohyaline granules. These granules may be composed of or associated with the PV E4 (E1-E4) protein



Figure 196-10 Epidermodysplasia verruciformis. Plane wart-like lesions on the dorsa of the hands and forearms, associated with human papillomavirus-5 and -8. The lesions are numerous, flat, reddish, and partly confluent.

and are not conglomerates of virus particles. Flat warts have less acanthosis and hyperkeratosis and do not display parakeratosis or papillomatosis. Koilocytotic cells are usually abundant, indicating the viral origin of the lesion. Anogenital warts may have slight or extensive acanthosis and parakeratosis: they lack a granular layer as they are within or adjacent to a mucosal surface. The rete ridges often form thick bands extending extensively into the underlying, highly vascular dermis.

Flat warts have a similar histologic appearance whether in the general population or in patients with EV (Fig. 196-14). The granular and upper spinous layers contain many cells with perinuclear vacuolization. In EV, lesions containing HPV-5 or -8 have a characteristic basket weave hyperkeratosis with many large clear cells in the granular and spinous layers (Fig. 196-15).



Figure 196-11 Invasive cancer in an epidermodysplasia verruciformis patient infected with numerous human papillomavirus (HPV) types, including HPV-5, -8, -9, -14, and others. In the tumor cells, HPV-5 DNA was detected in a high copy number. This large squamous cell carcinoma did not metastasize and did not recur after surgery. There are numerous actinic keratoses on the forehead.

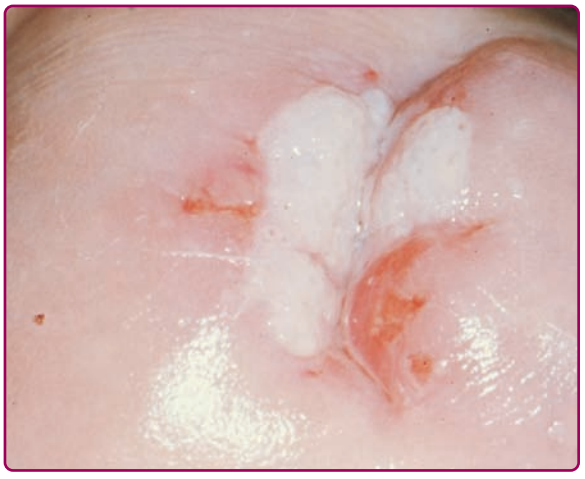

Figure 196-12 Colposcopic view of cervical condyloma after treatment with acetic acid for visualization as white, elevated patch.

DIFFERENTIAL DIAGNOSIS

The clinical appearance and history of acquired, slowly enlarging papules usually lead to the diagnosis of viral wart. Histologic examination can be used to confirm the diagnosis. Application of 3%–5% acetic acid to genital warts enhances visualization of these lesions, particularly with colposcopic magnification (Fig. 196-12), although the diagnosis should not rest only on the presence of white lesions as the test is nonspecific. Detergent-disrupted PV particles expose L1 and L2 antigens shared among most PVs. Immunohistochemistry using antibodies can detect these capsid proteins in clinical materials, including formalin-fixed tissue,

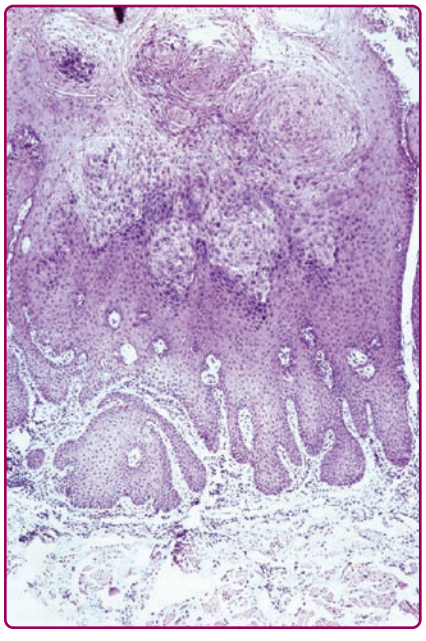

Figure 196-13 Verruca vulgaris. The process is one of extensive hyperplasia, and the hyperplastic cells contain both intranuclear and intracytoplasmic inclusion bodies.

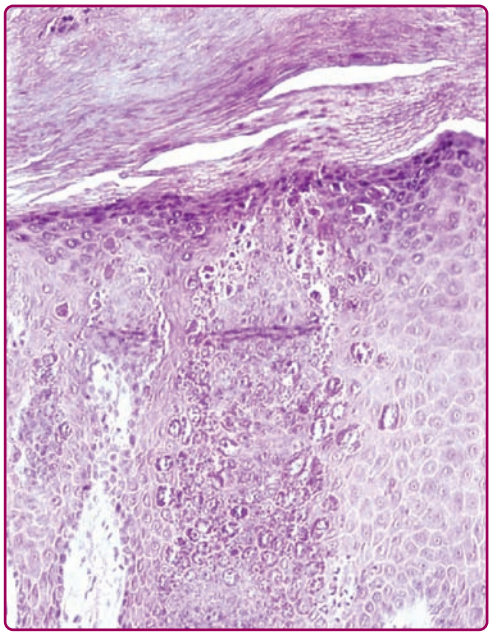

Figure 196-14 Human papillomavirus-3–associated plane wart-like lesion in patient with epidermodysplasia verruciformis. Numerous cells show perinuclear vacuolization in the granular and upper spinous layers.

but is insensitive and not routine. In situ hybridization using HPV specific probes is much more sensitive and can be used on pathologic specimens. PCR techniques detect cutaneous or EV type HPVs but are generally limited to research and diagnostic laboratories. Highly sensitive and specific diagnostic hybridization tests to identify genital–mucosal HPV types are commercially available (Digene Hybrid Capture 2; Roche Amplicor HPV and Linear Array HPV Genotyping Tests).[44,45]

Cutaneous warts are commonly found in all age groups. Multiple warts that do not spontaneously resolve, always recur after treatment, persist for years, or have an unusual morphology (especially if familial) suggest EV. HPV typing may be of benefit in confirming the diagnosis of EV and will disclose whether the patient is infected with a type that is associated with cutaneous malignancy. Immunocompromised patients, such as those with acquired immunodeficiency syndrome, lymphoproliferative disorders, or drugs to prevent transplant rejection, often have multiple warts.

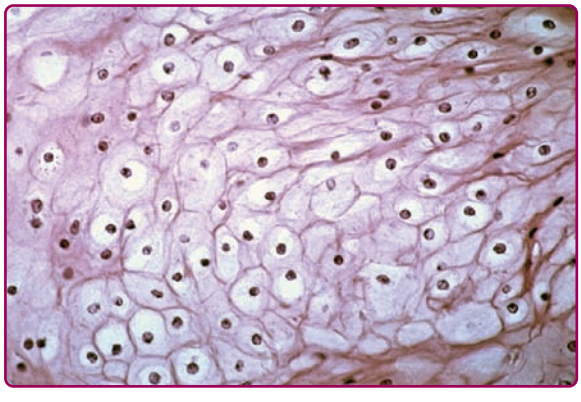

Figure 196-15 Characteristic cytopathic effect of epidermodysplasia verruciformis-specific human papillomavirus (HPV) in a patient found to be infected with HPV-5, -8, and -9. Very abundant clear large cells with small pyknotic nuclei replace almost the entire epidermis.

Common lesions such as seborrheic and solar keratoses, nevi, acrochordons, sebaceous hyperplasia, clavi, small pyogenic granuloma, or SCC may resemble a verruca. The differential diagnosis varies considerably with the type of lesions and the site of involvement (Box 196-1).

Papules of lichen planus may resemble flat warts; the former may be differentiated by their color, polygonal shape, Wickham's striae, and buccal involvement (Box 196-2). Acrokeratosis verruciformis is characterized by verrucous papules on the extremities. Warts in epidermodysplasia may resemble pityriasis versicolor but are not transient.

Nevi, benign keratoses, cysts, or ectopic sebaceous glands may resemble penile and vulvar warts (Box 196-3). A history of increasing number of acquired, grouped lesions is suggestive of warts. Syphilitic condylomata must be ruled out.

COMPLICATIONS

PAPILLOMAVIRUSES AND CANCER

Viral genome amplification occurs in upper levels of the epithelium composed of nondividing keratinocytes. Therefore, all PVs must block terminal differentiation and activate the cellular machinery necessary for synthesis of viral DNA. Most molecular studies of viral gene functions use the high-risk types, since these generally exert more pronounced phenotypes in cell culture models. In one assay, primary human keratinocytes or cervical cells proliferate and differentiate as a stratified epithelium at the air-media interface on a floating collagen raft.[46] Introduction of high-risk HPV-16 or -18 DNA into these organotypic keratinocyte cultures induces a disorganized pattern of differentiation with suprabasal mitotic figures resembling SCC in situ, whereas the keratinocytes expressing low-risk HPV-6 or -11 DNA retain a normal pattern of stratification.[47,48] In another model, the high-risk HPV-16 or -18, *E6* genes were found to induce resistance of keratinocytes to calcium-induced differentiation.[49] Expression of high-risk E6 and E7 together in primary keratinocytes, which have a limited lifespan in culture, efficiently blocks replicative senescence with the cells able to sustain serial passage and becoming "immortal."[50,51] Low-risk HPVs are much less effective in immortalization assays.[52,53] These experiments highlight the oncogenic properties of high-risk *E6* and *E7* genes and rationalize why these genes always retained and expressed in cervical cancers. Metastatic tumors in cervical cancer and EV express *E6* and *E7*, implying their retention is necessary for maintenance of the malignant phenotype. Thus, for the genital–mucosal HPVs, there is

BOX 196-1 DIFFERENTIAL DIAGNOSIS OF WARTY LESIONS ON HANDS AND FEET

	SINGLE LESIONS	MULTIPLE LESIONS
Palms and soles	***Consider*** ▪ Verruca vulgaris ▪ Callus, corn, clavus ▪ Epidermal inclusion cyst ▪ Milkers nodules (palms) ▪ Orf (palms) ***Rule Out*** ▪ Amelanotic acrolentiginous melanoma ▪ Carcinoma cuniculatum	***Consider*** ▪ Arsenical keratoses ▪ Verruca vulgaris ▪ Palmoplantar keratoderma ▪ Pyogenic granuloma ▪ Psoriasis ▪ Pits in basal cell nevus syndrome ***Rule Out*** ▪ Secondary syphilis
Dorsum of hands and feet	***Consider*** ▪ Verruca vulgaris ▪ Periungual warts ▪ Actinic keratosis ***Rule Out*** ▪ Squamous cell carcinoma ▪ Keratoacanthoma ▪ Tuberculosis verrucosa cutis ▪ Fish tank granuloma	***Consider*** ▪ Verruca vulgaris ▪ Verrucae planae ▪ Actinic keratosis ▪ Acrokeratosis verruciformis ▪ Stucco keratosis

an excellent correlation between their ability to induce cell transformation in vitro and their association with malignancy.[54]

The E6 and E7 proteins (see Fig. 196-1) have evolved multiple mechanisms to the cellular DNA replication program and inhibit apoptosis, which is the innate protective death response to cell stress and DNA damage.[55–57] Studies demonstrate that E6 and E7 each have distinct protein targets in the cell.[58,59] High-risk E7 binds to and induces degradation of the retinoblastoma family of tumor suppressors. These proteins restrict entry into cell cycle, and their inactivation by E7 allows infected cells to enter cell cycle and initiate DNA synthesis.[60] Low-risk E7 are less effective at retinoblastoma protein inactivation and also more restricted in their effects on certain members of this family.[61]

The best-known property of high-risk E6 proteins is their ability to bind to and induce ubiquitination of p53.[59,62] This results in degradation of this tumor suppressor and inhibition of p53 mediated growth arrest, apoptosis, and autophagy pathways in response to cell stresses such as DNA damage. However, the E6 proteins from low-risk HPV and those types associated with malignancies in EV and immunosuppression do not directly bind p53. These viruses may prolong the life span and restrict tumor suppressor pathways by alternate mechanisms.[59,63] Another remarkable activity of high-risk and several other E6 proteins is their ability to increase expression of hTERT, the catalytic subunit of telomerase.[64–66] Telomerase is expressed in immortal stem cells and many cancers. This enzyme protects chromosome ends from progressive deterioration during replication, which normally limits a cell's lifespan. In addition, high-risk E6 bind to several factors in the programmed cell death pathway, including tumor necrosis factor receptor (TNF-R), fas-associated death domain (FADD), and caspase-8, and in this manner interferes with apoptotic signaling.[62,67] Cutaneous β- and high-risk α-type HPV E6 proteins target Bak

BOX 196-2 DIFFERENTIAL DIAGNOSIS OF PLANE WARTS

FACE	HAND	TRUNK, EXTREMITIES
▪ Perioral dermatitis ▪ Adenoma sebaceum (mild) ▪ Syringomas ▪ Flat seborrheic keratosis ▪ Actinic keratosis ▪ Trichoepitheliomas	▪ Acrokeratosis verruciformis ▪ Lichen planus ▪ Stucco keratosis ▪ Seborrheic keratosis	▪ Epidermodysplasia verruciformis ▪ Pityriasis versicolor ▪ Superficial actinic porokeratosis ▪ Seborrheic or verrucous keratosis

BOX 196-3 DIFFERENTIAL DIAGNOSIS OF GENITAL WARTS

FLAT OR PAPULAR

Consider

- Condylomata acuminata
- Bowenoid papulosis
- Seborrheic keratosis
- Pearly penile papules
- Lichen planus
- Lichen sclerosus et atrophicus

Rule Out

- Erythroplasia
- Extramammary Paget disease
- Condylomata lata of secondary syphilis

NODULAR

Consider

- Nevi
- Sebaceous glands
- Angiokeratoma
- Skin tags

Rule Out

- Squamous cell carcinoma
- Amelanotic melanoma

for degradation, thereby abrogating its activity in the mitochondrial pathway of apoptosis.[68–71] The E5 oncoproteins activates growth factor receptors. For bovine PV, which induces fibropapillomas, E5 appears to preferentially activate the receptors for platelet-derived growth factor, whereas HPV-16 E5 may stimulate the epidermal growth factor receptor.[72,73]

Robust epidemiologic and molecular studies confirm that infection with high-risk HPVs is the cause of almost all cases of cervical cancer. Even with high-risk HPVs, most cervical infection have a benign outcome.[32,33] Persistent infection with high-risk or other HPV types is a major risk factor. The critical determinants of whether HPV infection of the cervix is transient or persistent and thus at high-risk for malignant progression are not known. Individuals with impaired cellular immune function, such as renal transplant recipients or HIV infection and acquired immunodeficiency syndrome, are at greater jeopardy for persistent HPV infection that can progress to dysplasia and to cancer.[74]

In the genital–mucosal HPVs, transcription of E6 and E7 is regulated by the viral E2 protein, which has been shown to repress their expression. Loss of E2 function may alleviate repression and lead to increased levels of the E6 and E7 oncoproteins and stochastic mutations of E2 are found in many cervical cancers.[75] Furthermore, E2 binds to the viral E1 protein, and this complex is necessary for viral genome replication as an episome or plasmid.[76] Loss of E2 would obligate HPV genome integration into the infected cells DNA, and this would also alter the viral transcription program. Furthermore, HPV integration assures persistence of the viral infection in the basal cell population, for as these cells divide, viral episomes could otherwise partition during mitosis to the progeny cells and be lost as these migrate up through the epithelium and ultimately exfoliate. While interruption of E2 and HPV integration is likely an important step in neoplastic transformation of the cervix, it is not absolutely required, for approximately 15% or more of cervical cancers contain only viral episomes.[77,78]

While E6 and E7 contribute to the malignant state, cervical cancers develop from benign or dysplastic precursor lesions over a span of years to perhaps a decade or more. Not all warts in EV become cancerous. These observations imply the requirement for oncogenic cofactors in addition to continued expression of E6 and E7. Skin cancers in EV usually appear in sun-exposed regions. The benign but locally obstructive verrucae in respiratory papillomatosis, if treated by X-rays, often progress to invasive SCC. In cervical cancer, chromosomal mutations and deletions have been reported, with the most common being on chromosomes 3 and 4.[79–82] Small doses of chemical carcinogens convert benign warts in rabbits induced by the Shope cottontail rabbit PV into invasive SCC. In cattle, esophageal papillomas induced by bovine PV type 4 become malignant if the infected animals graze on bracken fern, which contains a potential carcinogen. These phenomena indicate that oncogenic PVs do not induce malignant tumors directly but predispose the infected cell to tolerate genetic damage and select for mutations that promote cell survival and continuous cell division.

Epidemiologic and molecular evidence has clearly linked a subset of penile, vulvar, vaginal, anal, and oropharyngeal carcinomas with HPV infection.[83,84] As with cervical cancer, these tumors are associated primarily with high-risk HPV types. High-risk HPVs, especially HPV-16, have been identified in some periungual cutaneous tumors. The giant condyloma acuminatum, also called the Buschke–Lowenstein tumor, is a low-grade, locally invasive SCC. Low-risk HPVs, such as types 6 and 11, are usually found in these tumors. Epithelioma cuniculatum, another rare type of verrucous carcinoma, is found on the sole and is thought to arise from a plantar wart (see Chapter 114).

Many studies have detected low levels of HPV DNA, often of EV or β-HPV types, in actinic keratoses, basal cell carcinoma (BCC) and SCC, psoriasis, and other skin lesions.[85–89] These genomes are present at extremely low levels, usually much less than one copy per cell. RNA expression of HPV genes has been difficult to detect in these cutaneous lesions. It is possible that HPV genes induce an altered transitional state, and their presence and expression becomes unnecessary in cutaneous cancers ("hit and run"). In contrast, all cells within cervical tumors express E6 and E7, and continuous expression of these two viral genes is necessary for their continued proliferation. Furthermore, because PCR detects persistent HPV DNA in 50%–90% of normal skin and hair follicle samples,[23,90,91] contamination by incidental HPV from normal skin is possible.[92] For example, a broad spectrum of HPV types has been reported to be detected in cutaneous melanomas, but the evidence for HPV as causative is very weak.[93] Therefore, the causal role of HPV in the pathogenesis of these benign, premalignant, and malignant epithelial lesions remains unresolved.[85,94–96]

TREATMENT

The management of warts depends on the degree of physical and emotional discomfort, the extent and duration of lesions, the patient's immunologic status, the patient's desire for therapy, and the risk of contagion to other persons.[97,98] Recurrences are common with all treatment modalities.

Most treatments for verrucae involve physical destruction of the infected cells. The existence of multiple treatment modalities reflects the fact that none is uniformly effective or directly antiviral. In general, there are few adequately controlled studies of HPV treatment. The choice of treatment depends on the location, size, number and type of wart, as well as on the age and cooperation of the patient. Pain, inconvenience, risk of scarring, and the benefit to the patient should be considered. Children with common warts may not require treatment as spontaneous regression is frequent. However, new warts may appear and virus can be spread to other areas or susceptible individuals. In patients with anogenital warts (including bowenoid papulosis), sexual partners should be examined, the cervix should be evaluated and a Pap smear obtained; male contacts of women with cervical disease should also be examined. Anogenital warts in sexual contacts should be treated.

Cryotherapy using liquid nitrogen applied with a cotton tip or a spray canister to achieve a halo of ice in and around the lesion is a standard and effective treatment for most warts.[99,100] A single freeze is sufficient for most warts. Caution must be used near the nail matrix when treating periungual warts. Aggressive cryotherapy with a spray canister can injure underlying structures such as nerves and therefore its use on the lateral surfaces of the digits and genitalia mandates caution. Warts on the elbows and knees of children may be particularly susceptible to scarring with cryotherapy; although effective, this modality should be used in moderation in these patients.

Warts may be curetted or surgically excised, particularly large anogenital warts unresponsive to topical treatments. Electrodesiccation of condyloma acuminata requires local anesthesia but is also effective. Laser treatment in several different energy formats, including photodynamic therapies, can be useful for destroying warts that are treatment resistant or those that require careful control of width and depth, such as large periungual warts. Use of a surgical mask should be routine because infectious PV has been identified in the vapor plume with laser or with electrocoagulation of warts.[101] Mohs micrographic surgery has been useful in the treatment of verrucous carcinoma. X-irradiation of verrucae is contraindicated because of its association with the development of malignancy in respiratory papillomatosis and EV. Avoidance of and protection from sun exposure is critical in EV.

Chemotherapeutic agents are commonly used to treat warts. Although topical podophyllin resin has been widely used for anogenital warts, the potency of podophyllin preparations is variable. Podophyllin is contraindicated during pregnancy. Purified podophyllotoxin (Condylox) has activity that is uniform from batch to batch and is approved for treatment of genital and perianal warts.[102] Topical 5-fluorouracil has been used to treat cutaneous and genital warts, and has been reported to be highly effective with occlusion in the treatment of plantar warts.[103] Intralesional bleomycin may eradicate verrucae, but should be used cautiously because of the possibility of extensive tissue necrosis.[104] Anecdotal reports suggest topical application of the nucleotide analog cidofovir may be effective in the treatment of warts, however, pain and ulceration are significant side effects.[105,106]

Caustics and acids such as salicylic acid, lactic acid, and trichloroacetic acid, destroy and peel off infected skin. Home use of salicylic acid preparations can be particularly efficacious in young children who cannot tolerate other modalities. Retinoic acid has been used topically for flat warts and probably has a similar mechanism of action. Oral isotretinoin has also been used in the treatment of extensive cutaneous warts but carries the same cautions as its use for acne. Cantharidin is an extract of the green blister beetle that is painlessly applied and causes delayed blistering and focal destruction of epidermis.

Immunotherapies have been attempted in various forms. Induction of allergic contact dermatitis with diphenylcyclopropenone or squaric acid dibutylester allows localization of inflammation to warts on which the allergen is painted; it has been speculated that this treatment stimulates local immunity.[107,108] Cimetidine has been associated with the resolution of cutaneous warts, particularly in children. Although this regimen has its supporters, a double-blind controlled study failed to confirm a beneficial outcome.[109] Interferon has been effective in short-term studies, reducing warts in laryngeal papillomatosis and EV, but lesions return when therapy is stopped. Recombinant interferons have been used by intralesional injection of refractory genital warts.[110] Imiquimod, a potent stimulator of the release of several proinflammatory cytokines that acts at least in part by activation of Toll-like receptors 7 and 8,[111] is approved for patient-applied therapy treatment of genital warts, although some report cure rates are lower than treatments with physical modalities, other studies have found greater than 90% resolution.[112,113] Imiquimod is less effective for cutaneous warts. A small double-blind study of oral zinc sulfate for cutaneous warts reported a 78% response rate that was durable to 6 months.[114] Home application of 5% potassium hydroxide solution has induced regression of genital warts in men.[115] Anecdotal reports suggest that intralesional injections of candidal extracts induce wart regression.[116–118] Because yeast and viruses share no homologous proteins, the mechanism of action is obscure but thought to be due to induction of a localized immune response. Imiquimod and low-dose retinoids appear to reduce the development of cutaneous malignancies in transplant recipients.[119,120]

PREVENTION

For nongenital warts, direct exposure to lesions or to fomites that contain virus represent likely sources of infection. The risk for acquisition of new genital or cervical HPV infection correlates with the number of sexual partners. The risk of genital infection appears to be lower in circumcised males and in their sexual partners,[121] and there is evidence that regular use of condoms may partially protect against the acquisition of genital HPV infection.[122] Widespread Pap smear screening in the United States and other developed countries has greatly reduced the incidence of invasive cervical cancer.

The prophylactic HPV vaccine represents the newest approach to preventing genital HPV infection. The vaccine, which is noninfectious, is based on self-assembly of the L1 protein into virus-like particles (VLPs) that morphologically and antigenically resemble authentic capsids (see Fig. 196-2). VLP immunization induces high titers of type-specific neutralizing antibodies.[123] In human clinical trials, the L1 VLP vaccine, which is administered intramuscularly, induced seroconversion in more than 99% of vaccines and resulted in serum antibody titers 40 times or more than those that develop after natural infection, with nearly 100% protection against the development of cervical infections attributable to the HPV types in the vaccine.[124–127] A quadrivalent vaccine (Gardasil) composed of L1 VLPs from HPV-6, -11, -16, and -18, is approved by the US Food and Drug Administration for females and males ages 9–26 (in Europe in males only 9–15 years). A bivalent HPV-16 and -18 VLP vaccine (Cervarix) is also marketed as a vaccine to prevent cervical cancer. Both are administered as three intramuscular injections over a 6-month period. Headache, fever, and pain, itching, redness, swelling, and bruising at the injection site, were the most common side effects observed. Because the quadrivalent vaccine includes HPV-6 and -11 VLP, it offers reduction in the occurrence of genital warts. Despite nearly 100% efficacy in preventing HPV infection, these vaccines do not have therapeutic activity against established infection. Another limitation is that protection appears to be primarily type-specific, with limited cross-protection against very closely related types, so most infections caused by HPV types other than those in the vaccine will not be prevented. However, HPV-16 and -18 account for approximately 70% of cervical cancer worldwide. Thus, the prophylactic VLP vaccines should protect against the majority of HPV infections that lead to cervical cancer.

KEY REFERENCES

Full reference list available at www.DIGM8.com

DVD contains references and additional content

1. de Villiers EM et al: Classification of papillomaviruses. *Virology* **324**(1):17-27, 2004
9. Munoz N et al: Epidemiologic classification of human papillomavirus types associated with cervical cancer. *N Engl J Med* **348**(6):518-527, 2003
20. Moloney FJ et al: A population-based study of skin cancer incidence and prevalence in renal transplant recipients. *Br J Dermatol* **154**(3):498-504, 2006
23. Hazard K et al: Cutaneous human papillomaviruses persist on healthy skin. *J Invest Dermatol* **127**(1):116-119, 2007
27. Bleeker MC et al: Penile lesions and human papillomavirus in male sexual partners of women with cervical intraepithelial neoplasia. *J Am Acad Dermatol* **47**(3):351-357, 2002
54. McLaughlin-Drubin ME, Munger K: Oncogenic activities of human papillomaviruses. *Virus Res* **143**(2):195-208, 2009
90. Boxman IL et al: Detection of human papillomavirus DNA in plucked hairs from renal transplant recipients and healthy volunteers. *J Invest Dermatol* **108**(5):712-715, 1997
91. de Koning MN et al: Prevalence and associated factors of betapapillomavirus infections in individuals without cutaneous squamous cell carcinoma. *J Gen Virol* **90**(Pt 7):1611-1621, 2009
92. Forslund O et al: High prevalence of cutaneous human papillomavirus DNA on the top of skin tumors but not in "Stripped" biopsies from the same tumors. *J Invest Dermatol* **123**(2):388-394, 2004
98. Lipke MM: An armamentarium of wart treatments. *Clin Med Res* **4**(4):273-293, 2006
123. Kirnbauer R et al: Papillomavirus L1 major capsid protein self-assembles into virus-like particles that are highly immunogenic. *Proc Natl Acad Sci U S A* **89**(24):12180-12184, 1992
126. Villa LL et al: Immunologic responses following administration of a vaccine targeting human papillomavirus Types 6, 11, 16, and 18. *Vaccine* **24**(27-28):5571-5583, 2006

Chapter 197 :: Human T-Lymphotropic Viruses

:: Erwin Tschachler

HUMAN T-LYMPHOTROPIC VIRUS 1-INDUCED SKIN DISEASES AT A GLANCE

- An estimated 10–20 million people are infected by human T-cell lymphotropic virus type 1 (HTLV-1) worldwide, with endemic pockets of high prevalence in Southern Japan and the Caribbean islands.
- Infective dermatitis is a recalcitrant form of eczema occurring in HTLV-1-infected children in the Caribbean.
- Adult T-cell leukemia (ATL) shows monoclonal HTLV-1 provirus integration in tumor cells and occurs in four clinical variants, all of which tend to show skin involvement:
  - Smoldering ATL—5% of all cases.
  - Chronic ATL—15% of all cases.
  - Lymphoma-type ATL—20% of all cases.
  - Acute ATL—60% of all cases.
- The prognosis of lymphoma-type and acute ATL is very poor despite chemotherapy, with a projected 4-year survival of 5%.

The first known pathogenic human retrovirus was isolated in 1980 from the lymphocytes of a patient with cutaneous T-cell lymphoma (CTCL) by Poiesz and coworkers.[1] Independently, Miyoshi and co-workers later isolated an identical retrovirus from a Japanese leukemia patient.[1] The name *human T-cell leukemia virus type 1* (HTLV-1) is used now for all isolates previously called *adult T-cell leukemia virus* in Japan and *HTLV* in the United States.

EPIDEMIOLOGY

An estimated 10–20 million individuals are infected by HTLV-1 worldwide,[2–4] with an endemic pattern in Southern Japan, the Caribbean islands, and some countries in equatorial Africa. In some of these locations, most notably the Japanese islands Shikoku, Kyushu, and Okinawa, the seroprevalence reaches 36%.[2–4] Small clusters of HTLV-1/HTLV-2 seropositive populations have been reported in restricted areas in South America, among Australian aborigines, and in the Middle East.[2–4] In the United States and Europe, the incidence of HTLV-1 infection is below 0.1%, and clusters are found predominately among immigrants from endemic areas, especially those from the West Indies and Africa.[2–4]

Sexual intercourse is the main mode of horizontal transmission of HTLV-1.[2–4] In vertical transmission, breast-feeding plays a more important role than perinatal or intrauterine transmission.[2–4] Parenteral transmission of HTLV-1 is also possible, and approximately one-half of patients who received transfusions from an HTLV-1-infected donor seroconvert,[2–4] however, the transmission risk by blood transfusion in low prevalence countries is minimal.[4,5] Transfusion-mediated HTLV-1 infection in Japan has been virtually eliminated by mass screening of donated blood. In contrast to blood transfusions, cell-free, fresh, frozen plasma appears not to be infectious.[5] Parenteral transmission via needle sharing very likely accounts for clusters of HTLV-1/HTLV-2 seropositivity in intravenous drug users in certain areas of the United States and Europe.[6]

ETIOLOGY AND PATHOGENESIS

HTLV-1 together with HTLV-2, a virus that has not yet been clearly associated with any human disease, and bovine leukemia virus form their own genus within family Retroviridae.[2] Many strains of HTLV-1 have been isolated in different areas of the world, including the United States, the Caribbean islands, Africa, and Japan.[3] The overall nucleic acid sequence variation among different HTLV-1 strains does not exceed 7%. By comparison, the nucleotide sequence conservation between HTLV-1 and HTLV-2 is only approximately 55%. In addition to genes coding for viral structural proteins, both the HTLV-1 and HTLV-2 genomes contain an extra sequence of approximately 1.6 kilobases between the *env* and the 3′ LTR, which contains several regulatory genes. These include the transregulatory proteins Tax (transactivator in the region x) and Rex (regulator in the region x), whose functions have been elucidated, but the function of the other proteins of the pX region—p21Rex, $p12^{I}$, $p13^{II}$, and $p30^{II}$—still awaits full clarification.[2,7–9]

Infection of human, monkey, and rabbit T lymphocytes by HTLV-1 in vitro leads to their continuous growth in tissue culture and the development of cell lines with growth characteristics of transformed cells. In infected patients, HTLV-1 is present mainly in $CD4^{+}$ T cells.[10] The steps leading from virus infection to the development of the different HTLV-1-associated diseases are still only partly understood. Only a small percentage of patients infected with HTLV-1 ultimately develop adult T-cell leukemia (ATL), and the time from infection to the appearance of leukemia is usually several decades.[2,4]

Tax, the viral transactivator, is necessary for the transformation of T cells. It interferes with at least two inhibitors of cell cycle progression, including the tumor suppressor protein $p16^{ink}$ and p53.[2,8] In the transformed state, HTLV-1-infected T cells proliferate in the absence of exogenous growth factors. This event correlates with both the constitutive activation of the Janus kinase/signal transducer and activator of transcription (Jak/STAT) signaling pathway[8] and the constitutive activation of the cyclin E/cyclin-dependent kinase 2 complex. The in vitro model of T-cell transformation appears to mirror the event that leads to leukemogenesis. In most cases of ATL, genetic mutation or deletion of p53 or $p16^{ink}$ occurs,[8] and the leukemic cells of 70% of patients display constitutive activation of the Jak3 and STAT proteins.[8] An antisense transcript of HTLV-1 from the 3′ long terminal repeat and called HTLV-1 bZIP factor (HBZ) has been identified, its expression was documented HTLV-1-infected cells as well as in all ATL cases studied and its expression is correlated with proviral load.[11] HBZ mRNA promotes proliferation of ATL cells and is thought to play a critical role in leukemogenesis.

Although HTLV-2 has been less well studied than HTLV-1, most of the properties described for the latter, including the transformation of T cells in vitro and the presence and importance of transregulatory genes, are also true for the former.[2]As noted above, no disease has been associated with HTLV-2 infection, to date.

HUMAN T-LYMPHOTROPIC VIRUS 1 INFECTION AND CLINICAL DISEASES

ADULT T-CELL LEUKEMIA/LYMPHOMA

Uchiyama and co-workers first described ATL in 1977 as a distinct malignancy of mature T cells occurring primarily in patients born in Southwestern Japan.[1–4,12] At the beginning of the 1980s, HTLV-1 was linked to ATL by virus isolation from leukemic cells, by the demonstration of oligoclonal or monoclonal integrated HTLV-1 provirus in leukemic cells, and by extensive seroepidemiologic studies.[1,2,4,8] Besides Japan, the West Indies are a major region where HTLV-1 infection and ATL are endemic.[2–4]

Although the presence of HTLV-1 is a prerequisite for ATL development, infection with this virus does not necessarily lead to the occurrence of leukemia. More than 90% of infected individuals remain asymptomatic carriers.[2,12] The annual incidence rate of ATL among HTLV-1 carriers older than 40 years is approximately 0.6–1.7 in 1000.[13] The cumulative incidence rate of ATL in HTLV-1 carriers approximates 2–5%. The latent period from infection to outbreak of leukemia is 20 years or longer, as concluded from studies in migrants.[14] Interestingly, the average age of onset of ATL differs in patients in Japan (56 years) and in the Caribbean (43 years).[15]

According to the World Health Organization's lymphoma classification, ATL is a peripheral T-cell lymphoma. Based on the clinical course and laboratory parameters, ATL is classified into four subtypes—(1) smoldering (5% of cases), (2) chronic (15%), (3) lymphoma type (20%), and (4) acute or prototypic ATL (60%)—for which diagnostic criteria have been formulated (Box 197-1).[16,17]

Acute, prototypic ATL is a fatal malignancy of adult onset with a clinical presentation that appears to be identical in all endemic areas.[54,12,16,17] It is characterized by the variable combination of multiorgan involvement,

BOX 197-1 DIAGNOSTIC CRITERIA FOR ADULT T-CELL LEUKEMIA (ATL)

FEATURES COMMON TO ALL ATL SUBTYPES

- Positive results on serologic testing for HTLV-1
- Clonal integration of HTLV-1 in tumor cells
- Expression of CD25 and HLA class II antigens by tumor cells

DISTINGUISHING FEATURES OF ATL SUBTYPES

- Smoldering ATL
  - Normal lymphocyte counts with 1%–5% leukemic cells present
  - Skin lesions and/or lung lesions possible but not essential, no other visceral involvement
  - No lymphadenopathy, no hypercalcemia
  - Serum LDH level up to 1.5× the normal upper limit
- Chronic ATL
  - Lymphocytosis ($>4 \times 10^9$/L) with 5% or more leukemic cells present
  - Skin, liver, lung, or lymph node involvement possible but not essential; other viscera not involved
  - No hypercalcemia
  - Serum LDH level above 2× the normal upper limit
- Lymphoma-type ATL
  - Normal lymphocyte counts with <1% leukemic cells present
  - Possible involvement of multiple visceral organs, lymphadenopathy
  - Possible hypercalcemia
  - Serum LDH level strongly elevated
- Acute ATL
  - Lymphocytosis ($>4 \times 10^9$/L) Large numbers of leukemic cells present in peripheral blood
  - Involvement of multiple visceral organs with organomegaly
  - Frequently hypercalcemia with osteolytic lesions
  - Serum LDH level strongly elevated

HTLV-1 = human T-cell lymphotropic virus type 1; LDH = lactic acid dehydrogenase.

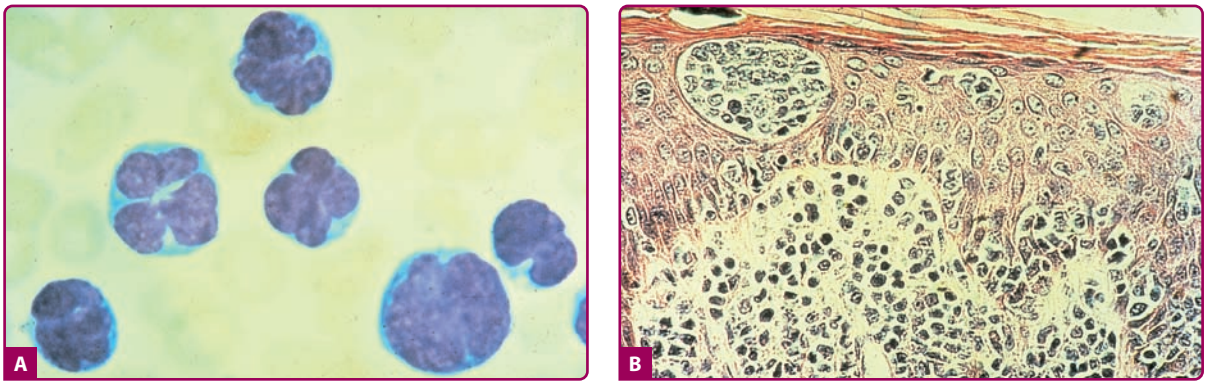

Figure 197-1 **A.** Abnormal lymphocyte with multilobated nucleus ("flower cell") from a patient with adult T-cell leukemia (ATL). (Used with permission from K. Takatsuki, MD, Kumamoto University, Japan.) **B.** ATL tumor cells infiltrate the epidermis, creating Pautrier's microabscesses. (Used with permission from B. Hanchard, MD, University of the West Indies, Kingston, Jamaica.)

including hepatosplenomegaly, systemic lymphadenopathy, central nervous system involvement, and skin lesions, with the massive presence of multilobated leukemic cells in the peripheral blood (Fig. 197-1A). The presence of leukemic infiltrates in different organs determines the clinical presentation and the morbidity: central nervous system involvement may alter the mental status of the patient; lymphoma within the liver may lead to abnormalities in liver function test results and jaundice; and lung involvement may lead to tachypnea, cyanosis, and dyspnea.

A striking feature in a high percentage of patients with acute ATL is refractory hypercalcemia, which may be the first sign of the disease and indicates an aggressive course.[4,12,16–18] Patients may have weakness, lethargy, polyuria, and polydipsia. Lytic bone lesions resembling those of multiple myeloma are often present at the time of diagnosis, and levels of alkaline phosphatase may be elevated.[4,18] Parathyroid hormone levels and 1,25-dihydroxyvitamin D levels are normal in ATL patients with hypercalcemia. Factors produced by leukemic cells themselves have been suggested to account for the hypercalcemia and bone resorption in ATL patients.

Lymphoma-type ATL also shows severe organ involvement and high serum levels of lactic acid dehydrogenase and may be associated with hypercalcemia. Unlike in acute ATL less than 1% leukemic cells are present in the peripheral blood. Both lymphoma-type and acute ATL have a poor prognosis, with a projected 4-year survival of no more than 5%.[4,12,17]

Smoldering and chronic ATL have more protracted courses; however, they may convert into acute ATL.[4,12,16,17]

The skin involvement in ATL varies considerably among patients and is present to a variable degree in all forms of ATL.[4,12,19–21] Skin lesions may appear as uncharacteristic erythematous patches, as papules and nodular tumors (Fig. 197-2), and as erythroderma. Nonspecific skin lesions may precede the onset of acute ATL by up to two decades.[21] Specific skin infiltrates may occur as the first manifestations of ATL, and monoclonality of skin-infiltrating cells may be evident by the criteria of both T-cell receptor rearrangement and integration of HTLV-1 DNA. This occurs at a time when circulating T cells of these patients still appear unaffected.[20] To designate this latter situation, the term *cutaneous-type ATL* has been proposed.[20] However, it is questionable whether this form represents an independent type of ATL or should be included in the smoldering form. Alternatively, it may reflect very early detection of prototypic or chronic ATL as a result of improved diagnostic methods.

DIAGNOSIS AND DIFFERENTIAL DIAGNOSIS OF ADULT T-CELL LEUKEMIA.

Not only does prototypic ATL show a characteristic clinical course but examination of the leukemic cells yields a characteristic picture: numerous multilobated cells called *ATL cells* or *flower cells* (see Fig. 197-1A) are present in peripheral blood and can usually be readily distinguished from cells of other T-cell leukemias by light microscopy, although sometimes occasional cells indistinguishable from Sézary cells may be present.[4,12,16,17] In smoldering-type ATL and chronic-type ATL, multilobated cells are less frequent, and in lymphoma-type ATL they may comprise fewer than 1% of lymphocytes (see Box 197-1). Monoclonal integration of HTLV-1 DNA[4,12,16,17] in leukemic cells as well as in affected organs is a diagnostic criterion. Immunophenotyping shows that leukemic cells display predominantly a mature $CD2^+/CD3^+/CD4^+/CD8^-/CD25^+$ phenotype.[4,12,16,17] Although most of these T-cell markers can be found in other T-cell malignancies, the strong expression of the interleukin 2 receptor α chain (CD25) can be regarded as a distinguishing marker differentiating ATL and Sézary syndrome.[12,16,17,22]

The histopathologic features seen in affected organs and lymph nodes are more variable than the signs in peripheral blood, and ATL is associated with lymphomas of several histologic subtypes. Differentiation of ATL from other peripheral T-cell lymphomas, especially HTLV-1-positive and HTLV-1-negative cases, on morphologic grounds is not possible. No specific pathologic finding distinguishes ATL from other forms of non-Hodgkin lymphoma. Difficulties can also be encountered in differentiating the skin manifestations of ATL from mycosis fungoides (MF) and Sézary



Figure 197-2 Skin manifestations of adult T-cell leukemia (ATL). **A.** Generalized papular infiltrates in a patient from Jamaica with prototypic ATL. **B** and **C.** Nodular skin tumors in Japanese ATL patients. (Used with permission from K. Takatsuki, MD, Kumamoto University, Japan.)

syndrome, because focal epidermal infiltration by T cells or Pautrier's microabscesses (see Fig. 197-1B) can be present in skin lesions of ATL.[21,23,24] Indeed, the diseases of patients from whom the original US HTLV-1 isolates were obtained were originally classified as Sézary syndrome and CTCL.[1] Four diagnostic criteria have been put forward that must be fulfilled to unequivocally establish the diagnosis of HTLV-1-associated ATL[4,12,16,17]: (1) a histologically or cytologically proven lymphoid malignancy with T-cell surface antigens must be present; (2) abnormal T lymphocytes must be detected in peripheral blood, except in the lymphoma type; (3) anti-HTLV-1 serum antibodies must be present; and (4) the clonality of HTLV-1 proviral DNA must be demonstrated.

The fact that the first HTLV-1 isolates were obtained from patients misclassified as having MF and Sézary syndrome, together with the earlier reports regarding the presence of retroviral particles in the skin and lymph nodes of patients with these diseases, has prompted an intensive search for HTLV-1 in CTCL. Although several reports claimed that HTLV-1 DNA sequences were detectable in tumor tissue and in cell lines derived from MF patients, an overwhelming majority of investigators, studying patients from the same geographic regions with comparable methods, were unable to find HTLV-1 DNA in CTCL samples.[25] It is now well accepted by most that HTLV-1 is not involved in the pathogenesis of CTCL (see Chapter 145).

PROGNOSIS AND TREATMENT OF ADULT T-CELL LEUKEMIA.

The prognosis of ATL depends largely on the subtype. In the most extensive study on the course of ATL to date, 818 Japanese patients newly diagnosed with the disease were studied for a median follow-up time of 13.3 months.[12,15] Median survival time was 6.2 months for those with the acute type, 10.2 months for those with the lymphoma type, and 24.3 months for those with the chronic type. Projected 2- and 4-year survival rates were, respectively, 16.7% and 5.0% for the acute type, 21.3% and 5.7% for the lymphoma type, 52.4% and 26.9% for chronic type, and 77.7% and 62.8% for the smoldering type. The presence of hypercalcemia, high levels of lactic acid dehydrogenase, and an excessively high white blood cell count are prognostic factors[4,12,15–17,26] associated with poor survival.

Treatment of ATL remains disappointing. Combination cytotoxic therapy used to treat non-Hodgkin lymphoma has little effect on prototypic ATL and ATL lymphoma. Although complete remission can be achieved in up to 40% of patients with different combinations of conventional chemotherapy, most of the patients experience relapse within weeks or months, and the 4-year overall survival rate is below 10%.[4,12,15–17,26] Frequent complications of treatment include septicemia and opportunistic infections, which result from chemotherapeutic intensification of the immune suppression already present in ATL patients. Besides conventional chemotherapy, the combination of interferon-α and zidovudine, a nucleoside analog used against human immunodeficiency virus type 1 (see Chapter 231), has shown some effect in the treatment of acute and lymphoma-type ATL.[15–17,26] Allogeneic hematopoietic stem-cell transplantation that has been used in several clinical trials ATL,[26] holds some promise for the future. Other therapeutic approaches,[17,26] including the use of monoclonal antibodies against surface molecules of leukemic cells, arsenic trioxide, proteasome inhibitors, and angiogenesis inhibitors, have been under study; however, to date no breakthrough has been reported.

The course of smoldering and chronic ATL is less dramatic, internal organ involvement and hypercalcemia are observed less frequently than in ATL lymphoma and acute ATL, and the prognosis is better.[4,12,15–17,26] Because chemotherapy-associated immunosuppression increases the immunosuppression caused by the disease itself, early chemotherapy may be more harmful than beneficial for patients with smoldering and chronic ATL. Therefore, these patients should not be treated with chemotherapy unless they enter a more aggressive phase of their disease. The combination of zidovudine and interferon-α has been suggested as a possible treatment for these clinical variants.

NONMALIGNANT SEQUELAE OF HUMAN T-LYMPHOTROPIC VIRUS 1 INFECTION

NEUROLOGIC DISEASE. HTLV-1 infection is associated with chronic progressive myelopathy, which is referred to as *tropical spastic paraparesis* (TSP) in the Caribbean and *HTLV-1-associated myelopathy* (HAM) in Japan.[27] Patients with TSP/HAM are generally younger at disease onset than ATL patients. The latent period from infection to development of clinical neurologic symptoms has been described to be very short in individual cases. The lifetime risk for developing TSP/HAM has been estimated at 1%.[28] In contrast to ATL, which is associated with HTLV-1 infection very early in life, TSP/HAM frequently occurs in patients who became infected only in adolescence. In particular, the acquisition of HTLV-1 by blood transfusion has been reported to play an important role in the development of TSP/HAM.

INFECTIVE DERMATITIS. Infective dermatitis (Fig. 197-3) is a severe, chronic, relapsing eczema in Jamaican children[29] associated with infection by *Staphylococcus aureus* and β-hemolytic *Streptococci*.[29] An association between infective dermatitis and HTLV-1 infection has been reported. Bacterial infection in infective dermatitis is difficult to control, and although it responds to antibiotic treatment, prolonged therapy is necessary and relapses are common after discontinuation. The characteristic clinical picture, the recalcitrant course, and HTLV-1 seropositivity sets infective dermatitis apart from other forms of recurrent eczema, including atopic eczema.[29] Immunosuppression observed in HTLV-1 carriers, as well as in ATL patients,[30] may play a role in the pathogenesis of infective dermatitis. Although HTLV-1-infected individuals are overrepresented among patients hospitalized for infectious diseases in Japan, infective dermatitis has rarely been reported in regions outside the Caribbean. Regional, cultural, or genetic factors may play an additive role in the occurrence of infective dermatitis. Evidence that infective dermatitis in childhood might be associated with subsequent development of ATL comes from studies of HTLV-1 infection and infective dermatitis in Jamaica.[31,32] In addition to infective dermatitis, several other infectious and noninfectious skin disorders are frequently observed in HTLV-1-infected individuals.[33]



Figure 197-3 Dermatitis in a Jamaican girl infected with human T-cell lymphotropic virus type 1. (Used with permission from L. LaGrenade, MD, University of the West Indies, Kingston, Jamaica.)

OTHER DISORDERS. In addition to the diseases described in the previous sections, certain types of uveitis, polymyositis, chronic inflammatory arthropathy, and peripheral neuropathy have been suggested to be associated with HTLV-1 infection.[4] However, future epidemiologic and virologic studies will be necessary to establish the causative role of the virus in the pathogenesis of these diseases.

KEY REFERENCES

Full reference list available at www.DIGM8.com

DVD contains references and additional content

1. Matsuoka M, Jeang KT: Human T-cell leukemia virus type I at age 25: A progress report.*Cancer Res* **65**:4467, 2005
4. Gonçalves DU et al: Epidemiology, treatment, and prevention of human T-cell leukemia virus type 1-associated diseases. *Clin Microbiol Rev* **23**:577, 2010
9. Nicot C et al: Human T-cell leukemia/lymphoma virus type 1 nonstructural genes and their functions. *Oncogene* **24**:6026, 2005
12. Taylor GP, Matsuoka M: Natural history of adult T-cell leukemia/lymphoma and approaches to therapy. *Oncogene* **24**:6047, 2005
17. Tsukasaki K et al:. Definition, prognostic factors, treatment, and response criteria of adult T-cell leukemia-lymphoma: A proposal from an international consensus meeting. *J Clin Oncol* **27**:453, 2009
23. DiCaudo DJ et al: Clinical and histologic spectrum of human T-cell lymphotropic virus type I-associated lymphoma involving the skin. *J Am Acad Dermatol* **34**:69, 1996
26. Uozumi K: Treatment of adult T-cell leukemia. *J Clin Exp Hematop* **50**:9, 2010
31. Maloney EM et al: A cohort study of health effects of human T-cell lymphotropic virus type I infection in Jamaican children. *Pediatrics* **112**:136, 2003
33. Nobre V et al: Dermatological findings in 3 generations of a family with a high prevalence of human T cell lymphotropic virus type 1 infection in Brazil. *Clin Infect Dis* **43**:1257, 2006

Chapter 198 :: Cutaneous Manifestations of Human Immunodeficiency Virus Disease

:: Lily Changchien Uihlein, Arturo P. Saavedra, & Richard Allen Johnson

HUMAN IMMUNODEFICIENCY VIRUS (HIV) INFECTION AND ACQUIRED IMMUNE-DEFICIENCY SYNDROME (AIDS) AT A GLANCE

- As of 2008, more than 30 million people were living with HIV infection/AIDS.
- HIV-1 and HIV-2 are human lymphotropic retroviruses that principally infect $CD4^+$ T lymphocytes and $CD4^+$ cells of monocytic lineage.
- An individual is deemed to have AIDS if he or she is HIV-seropositive with a $CD4^+$ T cell count <200/μL, a $CD4^+$ T cell percentage <14, or any of several diseases deemed to be indicative of a severe defect in cell-mediated immunity.
- The broad and diverse spectrum of dermatologic disease in HIV infection/AIDS includes inflammatory, infectious, neoplastic, and medication-related disorders.
- Specific stages of HIV disease (acute HIV syndrome, immune reconstitution, clinically latent disease, and advanced disease) tend to be associated with different dermatologic disorders.
- Dermatologic disease may help to estimate the level of immunosuppression in HIV infection/AIDS, particularly in resource-limited settings.
- As there are many dermatologic disorders that are seen in HIV infection/AIDS, this chapter focuses on those diseases that are the most closely associated.

The introduction of antiretroviral therapy (ART) has markedly altered the life expectancy and quality of life for many of the 33.4 million individuals worldwide infected with human immunodeficiency virus (HIV).[1] However, the number of newly diagnosed infections remains high, and many individuals in areas of high HIV prevalence remain unaware of their infection. Globally, 2.7 million new infections were estimated to have developed in 2008, while 56,300 new infections were estimated to have occurred in United States in 2006.[1, 2] It is estimated that 21% of the 1.1 million infected HIV individuals in the United States are currently undiagnosed.[2,3] This suggests that identification of HIV infection/acquired immune-deficiency syndrome (AIDS)-associated dermatoses has the potential to facilitate the diagnosis of HIV infection not only in resource-limited settings but in relatively resource-abundant ones.

Cutaneous disorders occur in nearly every patient during the course of HIV disease, either as a result of acquired immunodeficiency or from treatment. The spectrum of dermatologic manifestations of HIV disease is broad and diverse.[4] Individuals who have access to combination ART have a markedly altered course of disease if immune restoration is successfully achieved.[5] In most cases, there is a marked reduction in the incidence of opportunistic infections and neoplasms. Globally, however, the majority of HIV-infected individuals lack access to ART and, consequently, many of the cutaneous manifestations associated with HIV disease become chronic and progressive.

ETIOLOGY

HIV is a lymphotropic human retrovirus, which is predominantly transmitted through sexual contact. Other

important means of transmission include exposure to infected blood (including needles shared by injecting drug users and "skin popping") and transmission from an infected mother to her infant during pregnancy, delivery, or breastfeeding. HIV-1 is the most common cause of HIV infection globally, whereas HIV-2 infection has been detected mainly in West Africa. Although both HIV subtypes cause clinically similar disease, HIV-2 is associated with slower progression of immunosuppression, decreased infectivity, and resistance to non-nucleoside reverse transcriptase inhibitors.[6–8]

PATHOGENESIS

The profound immunosuppression that defines HIV disease results from progressive depletion of $CD4^+$ T lymphocytes. Efficient infection of a target cell by HIV requires not only expression of a CD4 molecule on that cell's surface, but also the presence of a co-receptor (such as CCR5 or CXCR4). Although HIV infects primarily $CD4^+$ T lymphocytes and $CD4^+$ cells of monocytic lineage, any cell that expresses CD4 and an appropriate co-receptor may be infected by HIV.[9] The depletion of $CD4^+$ T cells in HIV disease is believed to be multifactorial, and includes direct infection and destruction of $CD4^+$ T cells by HIV, as well immune exhaustion and apoptosis of T cells due to persistent and aberrant activation of the immune system.[9]

NATURAL HISTORY

HIV disease is a continuum that progresses from primary infection to death via a sequence of opportunistic infections and neoplasms that mark the gradual deterioration of the immune system (Table 198-1 and Fig. 198-1). Increased availability of ART has dramatically altered the course of HIV disease in many individuals—by delaying the development of symptomatic disease, reducing the burden of opportunistic disease, and prolonging life expectancy. The field of HIV medicine continues to rapidly evolve, and excellent Web resources that are frequently updated include http://www.aidsinfo.nih.gov and http://www.cdcnpin.org.

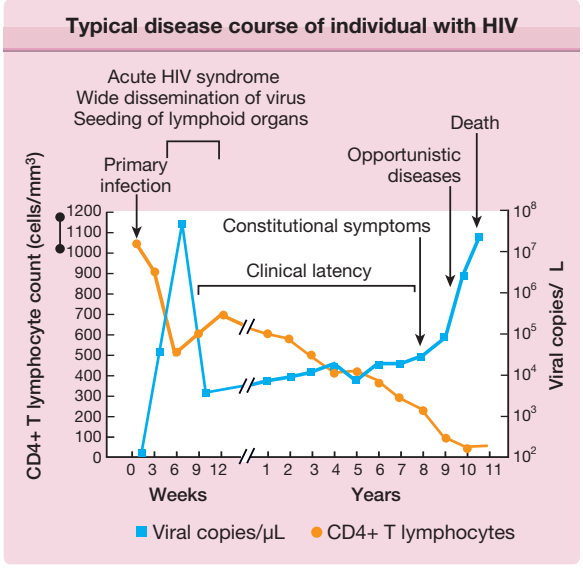

Figure 198-1 Typical disease course in an individual with human immunodeficiency virus (HIV) infection (From Fauci A et al: Immunopathogenic mechanisms of HIV infection. *Ann Intern Med* **124**:654, 1996.)

ACUTE HIV SYNDROME

About 3–6 weeks following primary infection, the majority of individuals infected with HIV develop an acute mononucleosis-like syndrome, which is referred to as *acute retroviral syndrome*. Clinical manifestations include fever, lethargy, rash (Fig. 198-2), myalgias/arthralgias, cervical and axillary lymphadenopathy, pharyngitis, night sweats, and nausea/vomiting/diarrhea. Less commonly reported findings include leukopenia, thrombocytopenia, weight loss, aseptic meningitis, anorexia, abnormal liver function tests, and oral and genital ulcers.[10] Symptoms generally

TABLE 198-1
Stages of Human Immunodeficiency Virus Disease

Stage and Clinical Features	Typical Duration	$CD4^+$ Cell Range (Cells/μL)
Acute retroviral syndrome (brief mononucleosis-like illness)	1–2 weeks	1000–500
Asymptomatic (no symptoms or signs other than lymphadenopathy)	>10 years	750–500
Early symptomatic (non–life-threatening infections, chronic or intermittent illness)	0–5 years	500–100
Late symptomatic (acquired immunodeficiency syndrome; increasingly severe symptoms, life-threatening infections and cancers)	0–3 years	200–50
Advanced (increasing risk of death, fewer transferable opportunistic infections)	1–2 year	50–0



Figure 198-2 Exanthem of acute retroviral syndrome: discrete, erythematous macules and papules on the trunk and arm. Associated findings were fever, scrotal ulcers, erythematous macules on the palate, and lymphadenopathy.

last an average of 2–3 weeks and resolve gradually as levels of plasma viremia decrease. It is important to maintain a high index of suspicion in individuals with a suggestive constellation of symptoms. Studies have documented that up to 25% of those with HIV infection are not tested, despite suggestive symptoms.[11] In fact, 2% of individuals thought to have Epstein–Barr virus were found to have HIV when tested retrospectively in one study, and roughly half of those had acute primary HIV infection.[12]

The laboratory diagnosis of HIV-1 infection is typically made by either identification of antibodies to HIV or direct detection of HIV antigens or nucleic acids (Table 198-2). A delay of 3–4 weeks typically occurs between newly acquired HIV-1 infection and development of antibodies, which is referred to as the "window period." However, core structural protein p24 antigen may be detected several weeks prior to seroconversion. The viral-RNA assay detects infection up to 5 days earlier than the p24 assay, and appears to be more sensitive.[11]

COURSE AFTER PRIMARY INFECTION

The length of time between initial infection and the development of symptomatic disease varies significantly, and is now augmented by ART in many cases. This period of clinical latency does not necessarily imply disease latency. Viral replication may persist, and $CD4^+$ T cell levels progressively decline (Fig. 198-1). The more severe and life-threatening complications of HIV disease typically occur when $CD4^+$ T cell counts fall below 200/μL. The World Health Organization published in 2006 criteria for clinical staging in individuals with confirmed HIV infection, while the US Centers for Disease Control and Prevention (CDC) published a revised classification system for HIV infection in 1993.[13,14] The AIDS is defined by the CDC as an HIV-seropositive individual with a $CD4^+$ T cell count <200/μL, a $CD4^+$ T cell percentage <14, or any of several diseases considered to be indicative of a severe defect in cell-mediated immunity.[14] Conditions deemed by the CDC to be AIDS-defining in a patient with a confirmed HIV infection are listed in Box 198-1.

CLINICAL FINDINGS IN HIV DISEASE

(See Table 198-3)

CUTANEOUS FINDINGS IN ACUTE HIV SYNDROME

The majority of individuals with acute retroviral syndrome develop a mucocutaneous eruption, typically consisting of distinct, well-demarcated, nonpruritic macules and papules favoring the upper chest and back (particularly the clavicular region), forehead,

TABLE 198-2
Laboratory Diagnosis of Human Immunodeficiency Virus (HIV) Infection[5]

Test	Component Tested	Window Period	Role in Diagnosis
Enzyme-linked immunosorbent assay[a]	Antibodies (IgM and IgG)	3–6 weeks	Screening
Antigen capture[b]	HIV p24 antigen	2–3 weeks	Screening
Western blotting	Antibody (IgG)	3 weeks	Confirmatory
Immunofluorescence	Antibody (IgG)	3 weeks	Confirmatory
Nucleic acid testing	HIV RNA or DNA	2 weeks	Confirmatory
Viral culture	Virus, usually from peripheral blood mononuclear cells, not serum or plasma	—	Confirmatory, research

Ig = immunoglobulin.
[a]Rapid tests as well as particle agglutination tests are also available.
[b]Detection can be increased with the use of immune complex dissociation techniques.
Modified from Maldarelli F: Diagnosis of human immunodeficiency virus infection. In: *Principles and Practice of Infectious Diseases*, edited by GL Mandell et al. Philadelphia, Elsevier, 2005, p. 1506, with permission.

BOX 198-1 AIDS-DEFINING CONDITIONS IN HIV-INFECTED INDIVIDUALS >13-YEARS-OLD[14]

Candidiasis of bronchi, trachea, or lungs
Candidiasis, esophageal
Cervical cancer, invasive
Coccidioidomycosis, disseminated or extrapulmonary
Cryptococcosis, extrapulmonary
Cryptosporidiosis, chronic intestinal (>1 month's duration)
Cytomegalovirus, extrapulmonary
Cytomegalovirus disease (other than liver, spleen, or nodes)
Cytomegalovirus retinitis (with loss of vision)
Encephalopathy, HIV-related
Herpes simplex: chronic ulcers(s) (>1 month's duration); or bronchitis, pneumonia, or esophagitis
Histoplasmosis, disseminated or extrapulmonary
Isosporiasis, chronic intestinal (>1 month's duration)
Kaposi sarcoma
Lymphoma, Burkitt or immunoblastic (or equivalent term)
Lymphoma, primary, of brain
Mycobacterium tuberculosis, any site (pulmonary or extrapulmonary)
Mycobacterium, other species or unidentified species, disseminated or extrapulmonary
Pneumocystis jiroveci pneumonia
Pneumonia, recurrent
Progressive multifocal leukoencephalopathy
Salmonella septicemia, recurrent
Toxoplasmosis, brain
Wasting syndrome due to HIV

and scalp (Fig. 198-2).[23] Diffuse urticaria and pustular/vesicular eruptions have also been reported, though less commonly. Noninfectious ulcerations of the oral, genital, and anal mucosa are another common finding, and have been reported in up to 6%–28% of patients. Cutaneous symptoms are often accompanied by fever, lethargy, lymphadenopathy, and joint pain. The eruption of acute retroviral syndrome typically presents 3–6 weeks after initial infection, and persists for about 5–8 days. The differential diagnosis of acute retroviral syndrome includes Epstein–Barr virus infection, cytomegalovirus infection, primary herpes simplex infection, viral hepatitis, secondary syphilis, and systemic drug hypersensitivity. As acute infection with HIV-1 has been associated with a high degree of viremia within 2–6 weeks of infection, identification of individuals with acute retroviral syndrome provides the opportunity to prevent secondary transmission during a period of significant viremia prior to seroconversion.

CUTANEOUS FINDINGS IN IMMUNE RECONSTITUTION

Initiation of ART typically results in partial recovery of the immune system, as measured by an increase in $CD4^+$ T cell counts and decrease in plasma HIV viral load. In general, this leads to clinical improvement; however, in a small subset of individuals, a paradoxical clinical deterioration occurs. Termed immune restoration disease or immune reconstitution inflammatory syndrome (IRIS), this phenomenon typically presents within the first 3 months of ART initiation with either symptoms of a new infectious or inflammatory condition or clinical worsening of an existing infectious or inflammatory condition. It is believed that IRIS results from an exaggerated immune

TABLE 198-3
Correlation of Mucocutaneous Manifestations of Human Immunodeficiency Virus Infection with CD4 T Cell Counts[13,15–22]

CD4 T Cell Count >500/μL	500/μL >CD4 T Cell Count >250 μL	CD4 T Cell Count <200/μL
Acute retroviral syndrome	Dermatophyte infections, recurrent or persistent	Bacillary angiomatosis
Herpes zoster infection (nondisseminated)	Oral candidiasis	Hyperkeratotic scabies
Seborrheic dermatitis	Oral hairy leukoplakia Herpes zoster infection, disseminated	Cutaneous miliary tuberculosis Eosinophilic folliculitis
		Herpes simplex virus infection (>1 month's duration)
		Idiopathic pruritus
		Invasive fungal infections
		Kaposi's sarcoma
		Molluscum contagiosum, large facial lesions
		Papular pruritic eruption of HIV

BOX 198-2 DERMATOLOGIC MANIFESTATIONS OF IMMUNE RECONSTITUTION SYNDROME[27–32]

INFECTIOUS
- Mycobacterial infection
- Cytomegalovirus
- Viral hepatitis
- Varicella zoster virus
- Herpes simplex virus
- Human papillomavirus
- Cryptococcosis
- Histoplasmosis
- Leishmaniasis

INFLAMMATORY
- Sarcoidosis
- Rheumatoid arthritis
- Systemic lupus erythematosus
- Tumid lupus
- Dyshidrotic eczema
- Eosinophilic folliculitis

NEOPLASTIC
- Kaposi sarcoma
- Dermatofibroma

response to preexisting microbial, host, or other antigens at a time when $CD4^+$ T cell counts are rapidly increasing. IRIS has been reported in 15%–25% of individuals initiating ART, with an incidence of 15%–45% in individuals who also have a documented underlying opportunistic infection.[24] Risk factors associated with the development of IRIS include male gender, a shorter interval between initiating treatment of an opportunistic infection and starting ART, a rapid fall in HIV viral load after initiation of ART, a lower baseline $CD4^+$ T cell count, and a higher baseline viral load during ART.[25,26] IRIS has been reported in association with a broad range of infections, inflammatory disorders, and neoplasms (Box 198-2).[27,29] If a patient presents with paradoxical worsening of an existing disease in the setting of starting ART, it is important to consider the possibility of IRIS, in addition to treatment nonadherence, antimicrobial resistance, and tachyphylaxis. Although most cases of IRIS are self-limited and typically last weeks to months, IRIS can be associated with severe morbidity and, in rare cases, even mortality.

Management of IRIS consists of continuation of antiretroviral medications and initiation of appropriate therapy for the underlying infectious or inflammatory condition. In addition, systemic steroids have been reported to be beneficial in some cases.[33] In severe cases of IRIS, discontinuation of ART should be considered and weighed against the risk of development of viral resistance or HIV progression.

CUTANEOUS FINDINGS IN CLINICALLY LATENT HIV INFECTION

The introduction of ART has markedly altered the natural history of HIV infection by allowing for immune reconstitution, thereby significantly reducing the incidence of both opportunistic infections and neoplasms. As a result, many of the common skin manifestations of clinically latent HIV consist of cutaneous disorders normally seen in immunocompetent individuals, such as seborrheic dermatitis, psoriasis, drug hypersensitivity reactions, skin cancers, and human papillomavirus infections. In addition, increasing availability of ART has brought with it an increase in the prevalence of cutaneous side effects of antiretrovirals.

INFLAMMATORY DERMATOSES

Seborrheic Dermatitis. (See Chapter 22). Seborrheic dermatitis is one of the most common dermatologic manifestations of HIV disease, affecting as many as 83% of HIV-infected individuals during the course of their disease.[34] Seborrheic dermatitis may occur during all stages of HIV disease, and frequently occurs early in HIV-infection ($CD4^+$ T cell count >500/μL).[15] As is the case in immunocompetent adults, HIV-infected individuals with seborrheic dermatitis typically present with erythema and greasy scale involving the scalp, eyebrows, nasolabial folds, and posterior auricular regions. However, more disseminated forms of seborrheic dermatitis are often seen in advanced HIV disease. The forehead and malar areas, as well as the chest, back, axillae, and groin may be involved. In fact, erythroderma arising from seborrheic dermatitis may be an initial presenting sign of HIV infection in developing countries. Treatments commonly include low-potency topical steroids and topical antifungals, though more widespread forms tend to be more refractory to standard therapy.

Psoriasis Vulgaris. (See Chapter 18). Although psoriasis may develop at any stage of HIV infection, the severity of psoriasis tends to correlate with worsening immune function. For some individuals, psoriasis may be the initial presenting symptom of HIV infection, and new onset psoriasis in an individual at risk for HIV is an indication for HIV testing (Box 198-3). All clinical subtypes of psoriasis are observed in HIV-infected individuals, though guttate, inverse and erythrodermic psoriasis are the most common.[35] There are no randomized trials evaluating treatments for psoriasis in HIV-infected individuals. However, based on case reports and case series, topical therapies (such as calcipotriol, corticosteroids, and tazarotene) have been recommended as first-line therapy for mild to moderate psoriasis.[35] For moderate to severe psoriasis, phototherapy and ART have been recommended as first-line agents, whereas oral retinoids such as acitretin have been suggested as second-line treatment.[35,36] For severe and refractory disease, methotrexate, etanercept, and infliximab have been effective, but are associated with a higher risk of opportunistic infection.[35]

BOX 198-3 MUCOCUTANEOUS DISORDERS THAT ARE INDICATIONS FOR HIV SEROTESTING

Highly Indicative of HIV Infection (correlated with risk factors for HIV infection)

- Exanthem of acute retroviral syndrome
- Proximal subungual onychomycosis
- Herpetic ulcers of >1 month's duration
- Oral hairy leukoplakia
- Kaposi's sarcoma
- Eosinophilic folliculitis
- Multiple facial molluscum contagiosum in an adult
- Papular pruritic eruption of HIV

Strongly Associated with HIV Infection (correlated with risk factors for HIV infection)

- Any sexually transmitted disease (suggestive of "unsafe" sexual practices)
- Herpes zoster
- Signs of injecting drug use
- Candidiasis (oropharyngeal or recurrent vulvovaginal)

May be Associated with HIV Infection (correlated with risk factors for HIV infection)

- Generalized lymphadenopathy
- Seborrheic dermatitis (extensive, refractory to therapy)
- New Onset Psoriasis B

OPPORTUNISTIC INFECTIONS

Human Papillomavirus Infections. (See Chapter 196). Although the incidence of opportunistic infections in general has declined markedly since the introduction of ART, the incidence of human papillomavirus (HPV) infections has not significantly decreased and may actually have increased.[37–39] HPV infections are commonly seen at all stages of HIV disease, and anogenital and oral HPV infections have been reported to occur at a higher rate in HIV-infected individuals compared to that in the general population.[40,41]

Common Warts. As immunodeficiency progresses, common warts may become larger, more numerous, confluent, and more refractory to treatment. HPV-5 can cause an unusual pattern of extensive verruca plana and pityriasis (tinea) versicolor-like lesions, similar to that seen in epidermodysplasia verruciformis.[42]

Anogenital Warts. Clinically, anogenital warts appear similar to those seen in immunocompetent individuals; however, condyloma may be more numerous or extensive, and are often less responsive to therapy. As in immunocompetent individuals, anogenital warts in HIV-infected individuals most commonly result from infection by HPV-6 and HPV-11. Although anogenital warts are commonly considered to be benign lesions, anogenital warts in HIV-infected individuals are more likely to reflect infection with multiple HPV types, including high-risk oncogenic types -16, -18, -31, -51, -53, -56, and -58 as well as low-risk types -6 and -11.[43] One study found that the majority of anogenital warts in HIV-infected individuals represent coinfection by both low-risk and high-risk HPV types.[44] In another series, histologic evidence of low-grade anal intraepithelial neoplasia was found in about 50% of apparently benign anogenital warts in HIV-infected individuals.[45]

Management of external anogenital HPV infection in HIV-infected individuals is directed toward identifying high-grade dysplasia before progression to invasive squamous cell carcinoma (SCC). All HIV-infected individuals should be examined annually for evidence of HPV infection, especially those with a history of HPV infections. Application of 5% acetic acid may help to highlight subclinical dysplastic lesions. Based on the principles of cervical cytology, periodic anal cytology testing (via Papanicolaou smears) every 1–2 years has been proposed as a means of early detection of anal cancer.[46] The sensitivity of anal cytology has been reported to range from 69%–93%, while specificity ranges from 32% to 59%.[47] However, both sensitivity and specificity are reported to be higher for identification of disease within the anal canal compared to that of the external anogenital area, likely because of lower yield of cells from hyperkeratotic surfaces.[48] High-resolution anoscopy/coloposcopy with biopsy should be performed in all patients with abnormal cytology. Individuals with documented external anogenital dysplasia should be followed by periodic examinations every 4–6 months, with biopsy of any new lesions at those sites.

Oral HPV Infections. HPV-induced oropharyngeal lesions typically present as pink or white verrucous papules, resembling anogenital condyloma. If lesions are extensive, they may coalesce to form multiple large plaques, which may transform to verrucous carcinoma (oral florid papillomatosis). Oral HPV infection has also been associated with a subset of oropharyngeal SCC, which sometimes arises from the base of the tongue and tonsils.[49,50] Interestingly, advanced markers of HIV disease such as low $CD4^+$ T cell count have not been shown to be predictive of oral HPV infection.[51] Electrosurgery is effective for treatment of oral HPV-induced lesions.

HPV-Induced Dysplasia and Invasive SCC. The risk of HPV-induced dysplasia and malignancy is significantly higher in HIV-infected individuals compared to that in the general population. One large prospective cohort study estimated that the incidence of anal SCC in HIV-infected individuals was 42.9 times that in the general population, whereas the incidence of cervical cancer in HIV-infected women was 12.2 times that in the general population.[52] A low $CD4^+$ T cell count has been associated with a significantly increased risk of anal SCC in men, but not cervical or vulvar SCC in women.[53] The effect of ART on the incidence of HPV-induced in situ and invasive SCC varies. The introduction of ART has been associated with an increase in the incidence of anal cancer in HIV-infected individuals;

however, ART has also been associated with decreased incidence of cervical cancer.[52]

Anogenital dysplasia has been successfully treated with ablative therapies, such as surgery, electrocautery, laser, and infrared coagulation. Topical therapy is another approach, and options include imiquimod, podophyllotoxin, 80% trichloroacetic acid, and liquid nitrogen. In one small study of HIV-infected men with anal intraepithelial neoplasia, subjects were treated with imiquimod cream three times a week for 16 weeks. Nearly 80% of subjects showed complete clearance of lesions at the end of therapy.[54] However, 26% of individuals who had completely cleared after imiquimod therapy experienced a recurrence after a mean follow up of 30 months.[55] For minimally invasive SCC arising on the anal verge (nonkeratinized to keratinized epithelium) or on external anogenital sites (such as the penis, vulva, and perineum), surgical excision with adequate margins is recommended. Invasive SCC of the anus (transformation zone) is generally treated by radiation therapy and chemotherapy.

Staphylococcus Infections. *Staphylococcus aureus* is a common bacterial pathogen causing cutaneous and systemic infections at all stages of HIV disease. No unique staphylococcal infections occur in HIV disease. Rather, HIV-infected individuals tend to present a wide range of primary skin and soft tissue infections that are normally seen in immunocompetent individuals (see Chapters 176, 178, 179, 180, 181). Secondary infection of underlying dermatoses, particularly in those colonized with *S. aureus*, is frequently seen in individuals with atopic dermatitis. Secondary infection of herpetic ulcers and molluscum may occur (see Chapters 193, 195).

Risk factors for staphylococcal infection in HIV-infected individuals include nasal carriage of *S. aureus*, the presence of an indwelling vascular catheter, and a $CD4^+$ T cell count <100/μL.[56] Interestingly, a prevalence of *S. aureus* carriage in the nares of 30%–50% has been documented in both symptomatic and asymptomatic HIV-seropositive individuals.[56,57]

More recently, an increase in methicillin-resistant *S. aureus* (MRSA) strains has been noted in the United States and Europe, particularly those acquired from the community.[58,59] Risk factors associated with MRSA skin infections include recent hospitalization, receipt of systemic antibiotics within the past 6 months, history of injection drug use, high-risk sexual practices, and previous incarceration.[58,60] The prevalence of MRSA infections does not appear to be correlated with $CD4^+$ T cell count or viral load.[60]

Management of staphylococcal infections should be directed at treatment of the acute infection, treatment of any underlying dermatoses, eradication of nasal carriage of *S. aureus* with mupirocin ointment, and chronic oral prophylaxis for recurrent infections (See Chapter 176). Given the current prevalence of MRSA infection, culture and sensitivities of lesions and the nares are imperative.

Herpes Simplex Virus 1 and 2 Infections. (See Chapter 193). Herpes simplex virus (HSV) infection is commonly associated with HIV disease. Chronic herpetic ulcers of greater than 1 months' duration are an AIDS-defining condition. HSV infection in HIV disease may present with severe, painful ulcerations of the perioral region, anogenital region, and digits (Fig. 198-3). Atypical morphologies, such as hyperkeratotic, verrucous papules and nodules, are sometimes observed in advanced HIV disease.[61] In more advanced HIV disease, lesions typically respond less promptly to oral antiviral therapy and recur more frequently.



Figure 198-3 Herpes simplex virus infection. Chronic herpetic ulcers and ulcerated tumor on the penis, scrotum, and pubic area in a patient with human immunodeficiency virus infection. The herpes simplex virus was acyclovir resistant, and lesions resolved after treatment with topical cidofovir.

Foscarnet and cidofovir may be administered intravenously for infections caused by acyclovir-resistant HSV.[62] Cidofovir gel has been effective as a topical therapy of acyclovir-resistant HSV infections.[63] Imiquimod 5% cream is also an effective topical treatment for cutaneous herpetic infections, including those caused by acyclovir-resistant HSV strains.[64]

Varicella Zoster Virus Infections. (See Chapter 194). In HIV-infected individuals, varicella zoster virus infection (VZV) may present as severe varicella (primary VZV infection), persistent varicella, dermatomal herpes zoster (see eFig. 198-3.1 in online edition), disseminated herpes zoster, and chronic or recurrent herpes zoster.[65] In advanced HIV disease, herpes zoster may present atypically. Disseminated herpes zoster infection may manifest with scattered vesicles in the absence of dermatomal lesions. Persistent ecthymatous ulcerations and verrucous papules in the absence of a vesicular stage have also been described.[66,67] Management of HIV-infected individuals with primary VZV infection should include evaluation for visceral disease. If evidence of visceral involvement is present, treatment with intravenous acyclovir (10 mg/kg every 8 hours, renally adjusted) should be initiated.[68] Management of herpes zoster is based on extent of

disease and degree of immunocompromise of the patient. Individuals with early HIV disease and localized cutaneous involvement may be treated with oral acyclovir, valacyclovir, or famciclovir for 7–10 days.[68,69] Those with advanced HIV disease ($CD4^+$ T cell count <200/μL), disseminated disease, visceral disease, or ocular involvement should be treated with intravenous acyclovir.[68] Acyclovir-resistant VZV is rare.[70]

Sexually Transmitted Diseases. (See Chapters 200, 202, 203, 204.) Given that the vast majority of HIV infections are sexually transmitted, individuals with HIV infection should also be screened for other sexually transmitted diseases such as Chlamydia, gonorrhea, and genital ulcerative diseases (e.g., syphilis, herpes, and chancroid).

MEDICATION-RELATED EFFECTS

Adverse Cutaneous Drug Eruptions. (See Chapter 41.) The incidence of adverse cutaneous drug eruptions is estimated to be as much as 100 times more common in individuals with untreated HIV disease compared to that in the general population, and may become more frequent with advancing immunodeficiency.[71] Morbilliform eruptions are by far the most common manifestation, accounting for about 75%–95% of cases (see eFig. 198-3.2 in online edition).[72,73] Urticaria, erythema multiforme major, erythema multiforme minor, lichenoid eruption, vasculitis, and fixed drug eruption are also reported, though far less frequently.[72,73] About 20% of cases are associated with systemic symptoms, such as fever, headache, myalgias, and arthralgias.[72] Severe bullous eruptions appear to be more common in HIV disease. In one study of toxic epidermal necrosis (TEN) patients over a 6-year period, the incidence of TEN in HIV-infected individuals was found to be 375 times greater than that in the general population.[74] TEN was more common in patients with advanced HIV disease and was associated with a 21% mortality rate.[74]

Sulfonamide drugs and penicillins are common causative agents of cutaneous drug eruptions, accounting for 75% of cases in one study.[72] Factors that have been associated with increased risk of drug eruptions include female gender, $CD4^+$ T cell count <200/μL, $CD8^+$ T cell count >460/μL, and a history of having had drug eruptions in the past.[72,75,76] In addition, individuals who are sulfa-allergic are at increased risk of more severe reactions to sulfa drugs in the setting of immune reconstitution following initiation of ART.

Management of a cutaneous drug eruption should include discontinuation of all potentially causative drugs if possible. In the absence of mucosal involvement and systemic symptoms, a causative medication may be continued with close clinical monitoring. However, if early symptoms of urticaria/angioedema or Stevens–Johnson syndrome/TEN are present, the drug should be immediately discontinued. Oral corticosteroid therapy has been reported to be helpful in decreasing the risk of cutaneous drug eruptions, and short-term corticosteroid therapy appears to be safe in most HIV-infected individuals.[75,77] One placebo-controlled trial randomized 41 asymptomatic HIV-infected individuals (median $CD4^+$ T cell count 131/μL, all but one was undergoing treatment with ART) to 8 weeks of oral prednisolone (0.5 mg/kg) or placebo to examine the immunologic consequences of corticosteroid use in HIV disease. After 8 weeks of therapy, no major side effects or HIV disease-related events had occurred, and HIV RNA levels remained stable.[78] Desensitization is an option for individuals with a history of uncomplicated cutaneous drug eruptions, and has been successfully accomplished in individuals allergic to trimethoprim-sulfamethoxazole (TMP-SMZ).[79]

Adverse Effects of Antiretroviral Therapy. There are currently six classes of antiretroviral medications: (1) non-nucleoside reverse transcriptase inhibitors (NNRTIs), (2) protease inhibitors, (3) nucleoside reverse transcriptase inhibitors (NRTI), (4) integrase inhibitors, (5) chemokine receptor 5 antagonists, and (6) entry inhibitors (see also Chapter 231). These medications are associated with a variety of cutaneous adverse effects, including hypersensitivity reactions, lipodystrophy, retinoid-like effects, hyperpigmentation, nail changes, and injection site reactions (Table 198-4).

Lipodystrophy Syndrome and Metabolic Syndrome. (See also Chapter 71.) HIV-related lipodystrophy is characterized by abnormal fat distribution, which may include lipohypertrophy, lipoatrophy or both. Lipohypertrophy presents with central obesity, cushingoid habitus ("buffalo hump"), increased neck girth (Fig. 198-4), increased abdominal girth due to intraabdominal fat ("protease pouch" or "crix belly"),



Figure 198-4 Lipohypertrophy. The subcutaneous fatty tissue of the cervicothoracic region as well as the preauricular cheeks and neck are strikingly enlarged.

TABLE 198-4
Adverse Effects of Antiretroviral Drugs[9,80–84]

Drug	Mechanism	Nonmucocutaneous Side Effects	Mucocutaneous Side Effects
Nucleoside Reverse Transcriptase Inhibitors			
Abacavir (ABC) Didanosine (ddI) Emtricitabine (FTC) Lamivudine (3TC) Stavudine (d4T) Tenofovir (TDF) Zidovudine (AZT) Zalcitabine (ddC)	Nucleoside analogs that act by incorporating themselves into the growing viral DNA chain, which eventually induces termination of viral DNA elongation.	■ Pancreatitis, peripheral neuropathy, lactic acidosis, and hepatotoxicity with didanosine, stavudine, and zalcitabine ■ Hepatotoxicity with emtricitabine and lamivudine ■ Renal toxicity with tenofovir ■ Anemia, granulocytopenia, myopathy, lactic acidosis, hepatotoxicity, and nausea with zidovudine	■ Hypersensitivity, with rare instances of Stevens Johnson syndrome/toxic epidermal necrolysis (SJS/TEN) ■ Systemic hypersensitivity reactions in up to 5%–8% with abacavir, associated with HLA-B5701/HLA-DR7/HLA-DQ3; incidence reduced by prescreening for HLA-B5701 ■ Leukocytoclastic vasculitis, pancreatitis, and peripheral neuropathy with didanosine ■ Hyperpigmentation of the nail bed, palms, and soles with emtricitabine ■ Hyperpigmentation of the nails (including multiple longitudinal and transverse bands), diffuse hyperpigmentation of the skin and oral mucosa, leukocytoclastic vasculitis, and hypertrichosis with zidovudine ■ Lipohypotrophy with stavudine and zidovudine ■ Paronychia with nailfold pyogenic granuloma with lamivudine and zidovudine ■ Oropharyngeal and esophageal ulcerations with zalcitabine
Non-nucleoside Reverse Transcriptase Inhibitors			
Delavirdine Efavirenz Etravirine Nevirapine	Non-nucleosides that directly bind to reverse transcriptase to prevent conversion of viral RNA to DNA.	■ Hepatotoxicity ■ Somnolence and depression with efavirenz	■ Hypersensitivity reactions are common within the first 6 weeks of therapy, with rare progression to systemic hypersensitivity or SJS/TEN (highest incidence with nevirapine)
Protease Inhibitors			
Amprenavir Atazanavir Darunavir Fosamprenavir Indinavir Lopinavir Nelfinavir Ritonavir Saquinavir Tipranavir	Prevents cleavage of protein precursors essential for HIV maturation, infection of new cells and replication	■ Nausea, vomiting, diarrhea, headaches, lipid anomalies, and hyperglycemia ■ Oral paresthesias with amprenavir ■ PR prolongation and hyperbilirubinemia with atazanavir ■ Hepatotoxicity and intracranial hemorrhage with tipranavir ■ Nephrolithiasis and hyperbilirubinemia with indinavir ■ Ritonavir may affect levels of many other medications, including saquinavir	■ Hypersensitivity reactions with rare progression to SJS, particularly with amprenavir, fosamprenavir and tipranavir ■ Acute exanthematous pustulosis ■ Lipohypertrophy, most commonly with indinavir ■ Dose-dependent retinoid-like effects (xerosis, cheilitis, alopecia, lateral nailfold pyogenic granuloma, curly hair, and recurrent paronychia), acute porphyria, "frozen shoulder," and venous thrombosis with indinavir ■ Spontaneous bleeding and hematomas, particularly with ritonavir ■ Rare cases of fixed drug eruptions with saquinavir ■ Darunavir, tipranavir, fosamprenavir, and amprenavir contain sulfa moieties and should be used with caution in sulfa allergic patients
Fusion Inhibitors			
Enfuvirtide	Inhibits binding of HIV to CD4 cells by binding to and inhibiting the action of gp40, a HIV protein that induces structural changes needed for fusion of HIV to host CD4 cells	■ Increased frequency of bacterial pneumonia	■ Systemic hypersensitivity reactions in <1%
Integrase Inhibitors			
Raltegravir	Inhibits HIV integrase, a viral enzyme that catalyzes the integration of HIV DNA into host chromosomal DNA	■ Nausea	■ Pruritus
Chemokine Receptor 5 (CCR5) Antagonists			
Maraviroc	Binds to the CCR5 receptor, a HIV co-receptor on CD4 cells, and thereby blocks attachment of HIV envelope proteins and HIV entry into host cells	■ Hepatotoxicity, nasopharyngitis, cough, abdominal pain, dizziness, musculoskeletal symptoms	■ Injection site reactions in up to 98% of patients, requiring discontinuation in only 3%

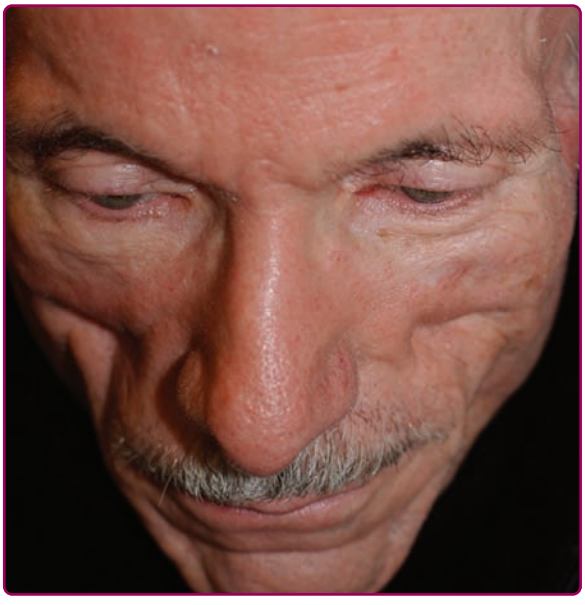

Figure 198-5 Lipoatrophy. The cheeks are hollowed, secondary to loss of subcutaneous fat. This caused significant cosmetic concern for this patient with human immunodeficiency virus infection who was on antiretroviral therapy. Lipohypertrophy was also present on the neck and upper central back.

and breast enlargement. Lipoatrophy of subcutaneous fat produces a pseudoathletic appearance, and often presents with a prominent venous pattern and musculature on the extremities, buttocks, and face (Fig. 198-5). Abnormal fat distribution is often accompanied by metabolic abnormalities, such as fasting glucose levels, fasting insulin levels, hypertriglyceridemia, hypercholesterolemia, and decreased high-density lipoprotein.[85] In a study of 581 HIV-infected individuals (of which 95% were currently treated with or had previously undergone treatment with ART), the overall prevalence of lipodystrophy was 38%, whereas the prevalence of lipoatrophy alone was 16% and lipohypertrophy alone was 12%. The prevalence of lipid anomalies was 49% and the prevalence of glucose disorders was 20%.[86]

Lipohypertrophy is most commonly associated with protease inhibitor therapy, whereas lipoatrophy is frequently associated with NRTIs, particularly the thymidine analogues stavudine and zidovudine. It should be noted, however, that HIV infection by itself may induce changes in fat distribution and metabolic anomalies such as insulin resistance.[87,88]

Management of lipodystrophy remains challenging. Substitution of regimens containing stavudine and zidovudine has been shown to be of partial benefit for lipoatrophy. For example, one study showed a significant increase in limb fat when stavudine or zidovudine was substituted with abacavir.[89] Although switching individuals to NRTI sparing regimens have produced modest results in lipoatrophy, the improvement in fat distribution may come at the expense of lipid anomalies if patients are switched to protease inhibitors.[90] Thiazolidinediones, such as rosiglitazone, have been shown to increase limb fat in small studies of individuals with HIV-associated lipodystrophy and insulin resistance.[91] However, concern about the risk of cardiovascular events, particularly with rosiglitazone, may limit the use of thiazolidinediones.[92] Facial lipoatrophy has been treated with soft tissue fillers, such as poly-L-lactic acid or calcium hydroxylapatite, with varying degrees of success.[93,94] Liposuction has been used to treat the dorsocervical lipomatosis, but results are often unsatisfactory.

OPPORTUNISTIC NEOPLASMS

Cutaneous Cancers. A 3–5 fold increased incidence of nonmelanoma skin cancer has been reported in HIV-infected individuals, as is the case with immunosuppressed solid organ transplant recipients.[95] However, the ratio of SCC to basal cell carcinoma (BCC) in HIV-infected individuals is 1:7, which is markedly different from a ratio of approximately 2:1 in transplant patients.[96] In HIV-infected individuals, SCCs tend to favor the head and neck, as they do in the general population.[97] However, they tend to appear at a younger age and may follow a more aggressive course with a higher risk of local recurrence, metastasis, and mortality (Fig. 198-6).[98] Superficial BCCs of the trunk have been reported to be the most common type of BCCs in HIV-infected individuals; however, an increased frequency of more aggressive subtypes of BCCs have been reported, including metastatic BCC and multiple infundibulocystic BCC.[99–101] As is the case for the general population, risk factors for the development of nonmelanoma skin cancer in HIV-infected individuals include sun exposure, blond hair, blue eyes, and a



Figure 198-6 Human papillomavirus-induced invasive squamous cell carcinoma in a 32-year-old man with human immunodeficiency virus infection. The perianal tumor had been present for several months, and histology was consistent with squamous carcinoma.

family history of skin cancer.[100] CD4+ T cell count and ART have not found to be significantly associated with the incidence of nonmelanoma skin cancer.[97]

The incidence of malignant melanoma in HIV-infected individuals has been reported to be 2.6 times that of the general population in one study.[52] However, neither CD4+ T cell count nor ART was significantly associated with the incidence of melanoma.[52] In fact, the incidence of melanoma has been reported to have significantly increased since the introduction of ART, suggesting the role of other factors, such as behavioral and lifestyle factors.[52] As in immune-suppressed solid organ transplant recipients, the incidence of Merkel cell carcinoma is higher in HIV-infected individuals.[102]

CUTANEOUS FINDINGS ASSOCIATED WITH SYMPTOMATIC AND ADVANCED HIV INFECTION

More than 90% of HIV-infected individuals will experience dermatologic symptoms of HIV during the course of their disease.[103] These symptoms tend to occur with greater frequency as immune function deteriorates. Specific cutaneous disorders that correlate with lower CD4+ T cell counts (<300/μL) include dermatoses (such as eosinophilic folliculitis and papular pruritic eruption of HIV), opportunistic malignancies (such as Kaposi sarcoma), and opportunistic infections (such as *Mycobacteria* infections, oropharyngeal candidiasis, molluscum contagiosum, and deep fungal infections).

INFLAMMATORY DERMATOSES

Pruritus and Pruritic Eruptions of HIV Disease. Pruritus is a common complaint in individuals with late symptomatic and advanced HIV disease.

In the majority of cases, primary or secondary dermatoses rather than metabolic disorders are the cause of pruritus.[104] The differential diagnosis of pruritus in an HIV-infected individual is listed in Box 198-4.

An atopic-like diathesis may become manifest in individuals with advanced HIV disease and pruritus, even in the absence of a prior history of atopy. Changes secondary to chronic rubbing and scratching are often seen, including excoriations, lichen simplex chronicus, and prurigo nodularis. Secondary *S. aureus* infection (impetiginization, furunculosis, or cellulitis) may also occur in traumatized lesions. Ichthyosis vulgaris and xerosis are common in advanced HIV disease and may be associated with mild pruritus. Protease inhibitors (particularly indinavir) may cause a retinoid dermatitis. These changes typically occur relatively soon after initiation of therapy. Idiopathic pruritus is associated with CD4+ T cell counts <200/μL and viral load >55,000 copies/mL, whereas ART has been associated with a decrease in idiopathic pruritus.[105]

Eosinophilic Folliculitis. Eosinophilic folliculitis is a chronic pruritic dermatosis occurring in persons with advanced HIV disease.[16] In one retrospective study of HIV-infected individuals, low CD4+ T cell counts (<200/μL) were associated with the development of eosinophilic folliculitis, independent of ART status.[16] Clinically, eosinophilic folliculitis presents with extremely pruritic small pink to red, edematous, folliculocentric papules, and less commonly pustules. Lesions tend to develop symmetrically above the nipple line on the chest, proximal arms, head, and neck (Fig. 198-7). Secondary changes are common, and include excoriations, lichen simplex chronicus, and prurigo nodularis, as well as secondary infection with *S. aureus*. In individuals with darker skin, postinflammatory hyperpigmentation often produces significant cosmetic disfigurement. The histologic findings of eosinophilic folliculitis are relatively specific, and demonstrate an inflammatory infiltrate of lymphocytes and eosinophils at the level of the isthmus and sebaceous glands.[106] Peripheral eosinophilia is seen in about 25%–50% of patients.[106,107]

The most effective therapy for eosinophilic folliculitis is prednisone (starting with an initial dose of 70 mg daily, and tapered by 5 or 10 mg over 7 or 14 days). However, in the majority of persons with successfully treated eosinophilic folliculitis, lesions recur within a few weeks of discontinuation of prednisone. In individuals with severe symptoms, prednisone may be given on alternate days or weekly. Itraconazole 200 mg daily has also been reported to be effective. If no response or only a partial response is seen after 2 weeks, the dose may be increased to 300 mg or 400 mg daily.[108] A third alternative is oral isotretinoin 40–80 mg daily.[109] When lesions and symptoms resolve, the dose

BOX 198-4 DIFFERENTIAL DIAGNOSIS OF PRURITUS IN A HIV-POSITIVE INDIVIDUAL

Inflammatory
- Papular pruritic eruption of HIV
- Eosinophilic folliculitis
- Atopic dermatitis
- Psoriasis
- Seborrheic dermatitis

Infectious
- Scabies
- Arthropod assault
- Viral hepatitis

Systemic and Metabolic Disorders
- Obstructive liver disease
- Renal failure
- Lymphoma

Miscellaneous
- Xerosis
- Ichthyosis vulgaris
- Dermatographism
- Allergic contact dermatitis
- Photodermatitis
- Adverse cutaneous drug eruptions



Figure 198-7 Eosinophilic folliculitis. **A.** Multiple erythematous pruritic papules and a few pustules in an individual with a CD4 cell count of 50/μL. **B.** Close-up showing urticaria papules, pustules, and crusted erosions secondary to rubbing.

may then be tapered to 40 mg daily for several weeks, and then to 20 mg daily or 40 mg every other day. Isotretinoin can raise serum triglyceride levels, which are often high in HIV-infected individuals. As a result, serum lipids should be monitored regularly. Phototherapy with narrow-band ultraviolet B (UVB) and ultraviolet A with or without psoralen is considered to be a safe and effective treatment modality in HIV-infected persons, and does not have a significantly deleterious effect on viral load.[110–112] High-potency topical corticosteroid preparations may reduce the formation of new lesions as well as treat eczematous dermatitis, thus providing symptomatic relief. Topical preparations containing 4% hydroquinone are relatively ineffective in treating postinflammatory hyperpigmentation.

Papular Pruritic Eruption of HIV. Papular pruritic eruption (PPE) of HIV has been considered to be within the spectrum of pruritic papular disorders in HIV, which includes eosinophilic folliculitis and nonspecific pruritus. The primary lesion is a firm urticarial papule, though sterile pustules have been described as well. The eruption is usually symmetric and distributed primarily on the extremities, and less commonly on the trunk and face. Lesions are occasionally but not always folliculocentric. Because the eruption is intensely itchy, the eruption is typically associated with multiple excoriations, marked postinflammatory hyperpigmentation, and scarring (Fig. 198-8).

PPE is rarely reported in Europe and North America. However, the prevalence of PPE is estimated to be between 18%–46% in Africa and Haiti, where it is frequently the initial presenting sign of HIV disease.[113,114] In fact, PPE appears to be a marker of severe immunosuppression as more than 80% of HIV-infected individuals with PPE have been reported to have $CD4^+$ T cell counts <100/μL.[17] The etiopathogenesis of PPE is unclear, but it has been suggested that PPE may represent a hypersensitivity reaction to arthropod bites.[115] PPE is extremely difficult to treat effectively and is only moderately responsive to antihistamines and topical steroids. Immune reconstitution with ART is an effective treatment for PPE, though several months of therapy may be required for lesions to resolve. UVB is also an effective therapy, though its utility is limited by the lack of treatment centers in resource-limited settings where the prevalence of PPE is highest.

Photosensitivity. Photosensitivity in HIV-infected individuals has been reported in association with other diseases such as porphyria cutanea tarda, chronic actinic dermatitis, lichenoid photoeruption, and



Figure 198-8 Papular pruritic eruption of human immunodeficiency virus infection. There are multiple, disseminated excoriated papules, postinflammatory pigmentation, and small scars. (Used with permission of Anisa Mosam, MD.)

photosensitive granuloma. Idiopathic photosensitivity is an uncommon phenomenon in HIV disease but may be the presenting complaint of advanced disease.[116] Clinically, photosensitive eruptions tend to present with two distinct morphologies: (1) photodistributed lichenoid eruptions and (2) photodistributed eczematous eruptions.[117] Risk factors for development of photosensitivity include African American ethnicity (6.7-fold risk) and ART (2.8-fold risk).[117]

Erythroderma. (See Chapter 23). Erythroderma in HIV disease may be related to drug hypersensitivity, atopic dermatitis, psoriasis, seborrheic dermatitis, photosensitivity dermatitis, coexisting human T-cell lymphotrophic virus-1 infection, pityriasis rubra pilaris, or cutaneous T cell lymphoma.[118]

DISORDERS OF THE OROPHARYNX.

Nearly all untreated HIV-infected individuals experience disorders of the oropharynx during the course of their disease.[119] In about 10% of cases, oropharyngeal disorders have been reported to be the first sign of HIV disease.[120] Thus, the presence of persistent oropharyngeal disorders may be an indication for HIV testing (Box 198-3). In a study of oropharyngeal disorders in advanced HIV disease, candidiasis was the most common finding, diagnosed in more than 90% of subjects.[121] Other common oropharyngeal disorders included herpetic ulcers, xerostomia, exfoliative cheilitis, oral hairy leukoplakia, Kaposi sarcoma, patchy depapillation of the tongue, and ulcers of unclear etiology.[121] Individuals treated with ART have been found to have a decreased prevalence of oral disorders compared to individuals that are untreated.[122]

ORAL HAIRY LEUKOPLAKIA.

(See Chapter 76). Oral hairy leukoplakia is a benign infection of epithelial cells of oral mucosa with Epstein–Barr virus. A common oral manifestation of HIV disease, oral hairy leukoplakia is marker of moderate to advanced immunosuppression.[123] However, the incidence of oral hairy leukoplakia has been noted to have decreased with ART.[122] Clinically, oral hairy leukoplakia presents with asymptomatic hyperplastic, whitish plaques on the bilateral aspects of the lateral tongue. Lesions are typically asymmetric, and have corrugations accentuating the normal tongue ridges (Fig. 198-9). Treatment may not be necessary as the lesions are often asymptomatic. However, acyclovir and valacyclovir are sometimes effective. Podophyllin has also been reported to be helpful.[124]



Figure 198-9 Oral hairy leukoplakia. White plaques with vertical corrugations on the inferolateral aspect of the tongue. The lesions are fixed unlike those of oral candidiasis, which can be brushed off.

OPPORTUNISTIC INFECTIONS

Bartonella. (See Chapter 182). Bacillary angiomatosis, caused by *Bartonella henselae* and *Bartonella quintana,* occurs most commonly in the setting of advanced HIV disease ($CD4^+$ T cell count <200/μL).[18] Clinically, the cutaneous lesions of bacillary angiomatosis are red to violaceous, dome-shaped papules, nodules, or plaques that may resemble cherry angioma, pyogenic granuloma, or Kaposi sarcoma. Lesions may be tender to palpation, and range in size from a few millimeters up to 2–3 cm in diameter (Fig. 198-10). Less commonly, domed subcutaneous masses may develop without the characteristic red color of more superficial vascular lesions.[125] Lesions may be solitary or multiple—in rare cases, totaling more than 1,000 lesions. Nearly any cutaneous site may be involved, but the palms, soles, and oral cavity are usually spared. The spectrum of internal disease caused by *B. henselae* and *B. quintana,* following hematogenous or lymphatic dissemination, includes soft tissue masses, bone marrow involvement, lymphadenopathy, splenomegaly, and hepatomegaly. Hepatic infection, in the form of *Bartonella*-associated



Figure 198-10 Bacillary angiomatosis. Cherry hemangioma-like papules and a larger pyogenic granuloma-like nodule on the skin of a patient with advanced human immunodeficiency virus infection. Subcutaneous nodules were also present.

peliosis hepatitis, has been reported in a number of HIV-infected individuals.[126]

Currently, the prevalence of bacillary angiomatosis in North America and Western Europe is low because of widespread availability of ART and prophylaxis given for infections such as *Mycobacteria avium* complex. The antibiotics of choice for bacillary angiomatosis are erythromycin (250–500 mg PO qid) or doxycycline (100 mg bid), for at least 4 weeks or until the lesions resolve.[127] Secondary prophylaxis is indicated in patients with recurrent bacillary angiomatosis.

Cutaneous Tuberculosis. (See Chapter 184). Although tuberculosis infections are a common opportunistic infection in HIV disease particularly in developing countries, cutaneous tuberculosis is rare.[128] Tuberculosis of the skin is caused by *Mycobacterium tuberculosis*, *Mycobacterium bovis*, and the BCG vaccine. Various manifestations of cutaneous tuberculosis have been described in HIV-infected individuals, including scrofuloderma, lichen scrofulosorum, disseminated miliary tuberculosis, gummatous tuberculosis, and tuberculous abscess.[19,128,129] Cutaneous miliary tuberculosis—a previously rare form of cutaneous tuberculosis that arises from hematogenous spread of bacilli to the skin from an internal focus of infection—has been reported in multiple individuals with advanced HIV disease ($CD4^+$ T cell count <100/μL).[19,130] Clinically, cutaneous miliary tuberculosis may initially present with red–brown pinpoint macules, papules, and papulovesicles. Lesions often develop into small flat-topped papules that crust over centrally. The eruption tends to be asymmetrically distributed, and favors the buttocks, thighs, and extensor surfaces. The cutaneous findings of cutaneous miliary tuberculosis are nonspecific, and may resemble a bacterial folliculitis.[19] Pulmonary symptoms may be present, though radiographic findings may be nonspecific as well. Cutaneous military tuberculosis is treated with multidrug antituberculosis therapy; however mortality rates are high (>50%), particularly in the case of multidrug resistant organisms.[130]

Candidiasis. (See Chapter 189). *Candida* colonization of the oropharynx is common in HIV-infected individuals, and has been reported in up to 90% of individuals with advanced disease.[120] Oropharyngeal candidiasis typically presents in four different clinical patterns: (1) pseudomembranous (thrush), (2) hyperplastic, (3) erythematous (atrophic), and (4) angular cheilitis. Pseudomembranous candidiasis typically involves the tongue, and presents with yellow–white plaques that are removable by scraping. Hyperplastic candidiasis usually involves the buccal mucosa, and consists of white plaques that are not removable by scraping. Erythematous candidiasis commonly presents with erythematous patches of the palate and the dorsal tongue with associated depapillation. Angular cheilitis manifests as erythema with curdlike flecks or painful fissures at the angles of the lips.

A number of studies have documented a higher incidence of vulvovaginal candidiasis in HIV-infected women, particularly in those with advanced HIV disease. For instance, in one prospective study, women with $CD4^+$ T cell counts <200/μL had a fourfold increased risk of symptomatic vulvovaginal candidiasis compared to immunocompetent women.[131] In a study of 200 HIV-infected women in North America, recurrent vaginal candidiasis was the most common initial clinical manifestation of HIV infection in 37% of subjects.[132] Children with HIV infection often experience oral candidiasis, diaper area candidiasis, and intertrigo of the axillae and neck folds.[133]

Dermatophyte Infections. (See Chapter 188). As is the case for immunocompetent individuals, *Trichophyton rubrum* and *Trichophyton mentagrophytes* are the most common dermatophytes seen in HIV-infected individuals. In HIV disease, dermatophyte infections of the epidermis, commonly caused by *T. rubrum* may be more extensive, and are often asymptomatic. Disseminated disease may sometimes present atypically. For instance, disseminated *T. rubrum* has been reported to mimic Kaposi sarcoma.[134] Infections of the nails are also common. *T. rubrum* frequently causes distal and lateral subungual onychomycosis in both HIV-infected and immunocompetent individuals. However, *T. rubrum* also causes proximal subungual onychomycosis (infection of the undersurface of the proximal nail plate), which is seen almost exclusively in individuals infected with HIV.[135] As a result, the diagnosis of proximal subungual onychomycosis is an indication for HIV testing (Box 198-3). Unless immunocompetence is restored, dermatophyte infections are often chronic and recurrent. ART has markedly diminished the incidence of these infections, and adverse drug interactions between ART and antifungal medication appear to be less clinically significant than previously believed.[135]

Invasive Fungal Infections. (See Chapter 190). Disseminated fungal infections in advanced HIV disease may arise either by (1) local invasion of the skin or mucosa with secondary lymphatic or hematogenous dissemination or (2) reactivation of a latent pulmonary focus of infection. Cutaneous findings commonly resemble multiple molluscum contagiosum lesions, which tend to favor the face and upper trunk.

Cryptococcosis. Disseminated infection by the encapsulated yeast *Cryptococcus neoformans* is probably the most common life-threatening fungal infection associated with advanced HIV disease. Disseminated disease typically involves the brain, kidney, prostate, bone, and pericardium. Disseminated cryptococcus is more commonly seen in individuals with a $CD4^+$ T cell count <50/μL.[136,20] The most common clinical presentation of cutaneous cryptococcosis is umbilicated skin-colored or pink papules or nodules of the head and neck that mimic molluscum contagiosum. Less frequently seen are subcutaneous nodules, cellulitis, herpetiform ulcers, palpable purpura, violaceous plaques mimicking Kaposi sarcoma, and pyoderma gangrenosum–like lesions.[137,138] Skin lesions may develop many weeks or months prior to onset of systemic symptoms.

Coccidioidomycosis. *Coccidioides immitis* is dimorphic fungus endemic to the Southwestern United States, Mexico, and Central and South America. The cutaneous lesions of disseminated coccidioidomycosis are usually asymptomatic, and typically begin as papules that evolve to pustules, plaques, or nodules with minimal surrounding erythema. Lesions often resemble molluscum contagiosum lesions. In time, lesions may enlarge and become confluent with the formation of abscesses, multiple draining sinus tracts, ulcers, cellulitis, verrucous plaques, and granulomatous nodules.[139,140] Unlike histoplasmosis and cryptococcosis, the oral mucous membranes are typically spared.[140]

Histoplasmosis. *Histoplasma capsulatum* is a dimorphic soil fungus. Endemic areas include the river valleys of the Midwestern and Southeastern United States, Southeastern South America, and Southern and East Africa. Disseminated histoplasmosis is more commonly seen in individuals with advanced HIV disease ($CD4^+$ T cell count <50/μL) and presents with fevers, weight loss, pulmonary symptoms, lymphadenopathy, hepatosplenomegaly, and rash. The skin findings associated with disseminated histoplasmosis may consist of lesions of multiple morphologies, including erythematous papules, necrotic umbilicated papules and nodules mimicking molluscum, folliculitis, acneiform eruptions, rosacea-like eruptions, psoriasiform eruptions, ulcers, vegetative plaques, and pyoderma gangrenosum-like lesions (Fig. 198-11).[141,142] Lesions occur most commonly on the face, followed by the extremities and trunk. The oral mucosa may also be affected, and nodules and ulcerations of the soft palate, oropharynx, epiglottis, and nasal vestibule are sometimes seen. HIV-infected individuals already on systemic antifungal therapy may develop a subtle widespread exanthematous or psoriasiform eruption.



Figure 198-11 Histoplasmosis. A young woman from South Africa with advanced untreated HIV/AIDS presented with disseminated skin-colored umbilicated papules, papulopustules, and ulcerated nodules of varying sizes (Used with permission of Adam Lipworth, MD).

Aspergillosis. Invasive aspergillosis is rare in HIV disease, and is a complication primarily seen in individuals with $CD4^+$ T cell count <50/μL.[21] Primary cutaneous aspergillosis typically arises from direct inoculation and are sometimes seen at the site of intravenous catheters.[143] Secondary cutaneous aspergillosis is commonly the result of hematogenous spread or direct extension to the skin from a pulmonary focus. Risk factors for invasive aspergillosis in HIV disease include neutropenia, corticosteroid use, and intravenous drug use.[21,144] Skin lesions commonly consist of skin-colored to pink umbilicated papules and nodules resembling molluscum contagiosum, fluctuant papules, deep-seated pustules, vesiculopustular plaques, and nonhealing ulcers.[143] Mortality in invasive aspergillosis remains high even with appropriate treatment. Therapy with voriconazole has been reported to be associated with improved survival and fewer side effects, compared to amphotericin B.[145]

Penicilliosis. The dimorphic fungus *Penicillium marneffei* is the third most common HIV-associated opportunistic infection in South East Asia, and is endemic to Northeastern India, Vietnam, Thailand, Indonesia, and Southern China.[146] The clinical presentation of penicilliosis varies, though it often presents with fever, weight loss, anemia, and lymphadenopathy in patients with $CD4^+$ T cell count <50/μL. Skin lesions are present in about 70% of patients, and typically consist of umbilicated papules favoring the face, pinnae, upper trunk, and arms (Fig. 198-12).[147,148]



Figure 198-12 Penicilliosis. A 27-year-old Vietnamese man with advanced untreated HIV/AIDS presented with fever, weight loss, and hundreds of skin-colored umbilicated papules and nodules of varying sizes, many with central erosion and crust (Used with permission of Hoang Van Minh. From Wolff K, Johnson RA: *Fitzpatrick's Color Atlas and Synopsis of Clinical Dermatology*, 6th edition. New York, McGraw-Hill, 2009.)



Figure 198-13 Molluscum contagiosum infection. A patient with advanced HIV/AIDS presented with multiple large facial mollusca causing significant cosmetic disfigurement.

Pustules, subcutaneous nodules, and acne-like lesions have also been reported.[147] Treatment with amphotericin or itraconazole is often effective, though relapse is common. Secondary prophylaxis with itraconazole in patients is indicated until immune reconstitution with ART.[149]

Molluscum Contagiosum. (See Chapter 195). Molluscum contagiosum lesions are caused by poxvirus infection, and are a cutaneous marker for advanced HIV disease ($CD4^+$ T cell count <100/μL).[18,22] Commonly seen in children, molluscum infections in HIV-infected individuals may present with pearly skin-colored umbilicated papules characteristically seen in immunocompetent individuals. However, lesions that are large, confluent and predominantly facial are characteristic of advanced HIV disease (Fig. 198-13). Atypical lesions are also common, and may resemble folliculitis, abscesses, warts, furuncles, and cutaneous horns. The differential diagnosis of molluscum-like lesions in an HIV-infected individual is listed in Box 198-5. In a study conducted during the pre-ART area, molluscum lesions were detected in 30% of individuals with a $CD4^+$ T cell count of <100/μL.[22] After initiation of ART, molluscum infections often resolve completely.[150,151]

In HIV-infected individuals, molluscum infections tend to be progressive and recurrent. Electrofulguration with repeated curettage is effective for multiple large and confluent lesions. For cases refractory to standard therapies, imiquimod 5% cream may be effective in both children and adults.[152,153] Topical cidofovir, a nucleotide analogue with activity against several DNA viruses, is also reported to be efficacious.[154,155]

BOX 198-5 DIFFERENTIAL DIAGNOSIS OF UMBILICATED PAPULES IN A HIV-POSITIVE INDIVIDUAL

Most Likely

Molluscum contagiosum

Consider

Cryptococcosis
Coccidioidomycosis
Histoplasmosis
Penicilliosis
Aspergillosis
Varicella zoster infection
Basal cell carcinoma
Arthropod bites
Lymphomatoid papulosis

Human T Cell Lymphotrophic Virus. (See Chapter 197). Human T cell lymphotrophic virus-1 (HTLV-1) is a human retrovirus that is associated with adult T cell leukemia, a slowly progressive neurologic disorder (HTLV-1-associated myelopathy/tropical spastic paraparesis), uveitis, and a chronic eczematous dermatitis referred to as "infective dermatitis." The skin findings of HTLV-1 infection mimic chronic atopic dermatitis, typically presenting with erythematous, scaly, crusted plaques of the scalp, neck, and groin in children and adolescents. Periorbital papules with seborrheic scale may be seen near the eyebrows.[156] Retroauricular fissuring and generalized ichthyosis are seen in a minority of cases. The exudative nature of these lesions may help to differentiate HTLV-1 from atopic dermatitis.[156]

High rates of HTLV-1 seroprevalence are found in Japan, the Caribbean, Africa, and South America (particularly Brazil). The exact rate of HTLV-1 and HIV coinfection is not clear, though one study of HIV infected individuals in Brazil documented a HTLV-1 coinfection rate of 12.5%.[157] In HIV-infected adults, an increased incidence of inflammatory dermatoses including seborrheic dermatitis and prurigo has been reported with HTLV-1 coinfection.[157] In addition, HIV and HTLV-1 coinfection has been associated with higher $CD\text{-}4^+$ T cell counts as well as more advanced clinical disease than HIV infection alone, suggesting that the higher $CD4^+$ T cell counts may not offer immunologic benefit in the setting of HTLV-1 coinfection.[158]

Scabies. (See Chapter 208). Scabies, a parasitic infection caused by the mite *Sarcoptes scabiei* var. *hominis*, is included in the differential diagnosis of pruritus in HIV disease. In HIV-infected individuals, scabies may present with more typical symptoms but individuals with advanced HIV disease, who are not

able to control mite replication, are at risk for developing crusted scabies. Crusted scabies commonly presents with extensive thick hyperkeratotic plaques with dirty gray brown scale, involving atypical locations such as the scalp, beard area, palms, and soles. Lesions are often not pruritic, or only minimally pruritic. While an immunocompetent host is estimated to harbor 10–15 mites, a gram of crust from an individual with crusted scabies may harbor thousands of mites.[159,160] For this reason, crusted scabies is extremely contagious. *S. aureus* superinfection may occur, but is rarely complicated by bacteremia. For classic scabies, a topical scabicide or oral ivermectin (200 µg/kg weekly) ×2 doses is usually effective.[161] For crusted scabies, multiple doses of ivermectin (200 µg/kg weekly) may be necessary (3–7 doses, depending on the severity of the infection), and should be combined with a topical scabicide (every 2–3 days × 1–2 weeks) and a keratolytic cream to improve penetration of the agent.[161]

Leishmania. (See Chapter 206). The rate of HIV and leishmania coinfection varies; however, studies have reported rates ranging from 2% to as high as 30% in endemic areas.[162,163] HIV infection has been reported to increase the risk of developing visceral leishmaniasis by 100–2,320-fold in endemic areas, as well as the risk of recurrent disease[162] Conversely, leishmaniasis is believed to increase HIV infectivity and promote progression of HIV disease, likely through upregulation of HIV-1 replication.[162,163] HIV-infected individuals with leishmaniasis tend to have lower cure rates, higher recurrence rates, and higher mortality rates than those of immunocompetent individuals.[162,164] See Chapter 206 for a discussion of treatment of leishmaniasis.

OPPORTUNISTIC NEOPLASMS. Individuals with HIV disease have been reported to have a higher prevalence of the AIDS-defining malignancies, Kaposi sarcoma (see Chapter 128), in situ and invasive cervical SCC, and non-Hodgkin lymphoma.[52,97,165] However, HIV-infected individuals have also been noted to have an increased incidence of in situ and invasive anal SCC, vulvar/vaginal SCC, Hodgkin lymphoma, primary liver cancer, lung cancer, melanoma, nonmelanoma skin cancers, oropharyngeal cancer, and leukemia.[52] Since the introduction of ART, the incidence of some opportunistic neoplasms, such as Kaposi sarcoma and non-Hodgkin lymphoma, have declined dramatically.[52,97,165] However, the incidence of many non-AIDS defining cancers (such as anal SCC, nonmelanoma skin cancers, melanoma, and Hodgkin lymphoma) have not decreased despite the introduction of ART, and there is evidence that the incidence may have actually increased in some cases.[52,97] The etiology of the higher incidence of malignancy among HIV-infected individuals is likely multifactorial. Contributing factors may include diminished immune-mediated tumor surveillance, concomitant infection with oncogenic viruses (such as Epstein–Barr, HPV, and human herpesvirus-8), and associated behavior and lifestyle factors.

KEY REFERENCES

Full reference list available at www.DIGM8.com.

DVD contains references and additional content

2. Hall HI et al: Estimation of HIV incidence in the United States. *JAMA* **300**(5):520-529, 2008
15. Lapins J et al: Mucocutaneous manifestations in 22 consecutive cases of primary HIV-1 infection. *Br J Dermatol* **134**(2):257-261, 1996
18. French MA et al: Immune restoration disease after the treatment of immunodeficient HIV-infected patients with highly active antiretroviral therapy. *HIV Med* **1**(2):107-115, 2000
41. Patel P et al: Incidence of types of cancer among HIV-infected persons compared with the general population in the United States, 1992–2003. *Ann Intern Med* **148**(10):728-736, 2008
62. Coopman SA et al: Cutaneous disease and drug reactions in HIV infection. *N Engl J Med* **328**(23):1670-1674, 1993
63. Saiag P et al: Drug-induced toxic epidermal necrolysis (Lyell syndrome) in patients infected with the human immunodeficiency virus. *J Am Acad Dermatol* **26**(4):567-574, 1992
89. Zancanaro PC et al: Cutaneous manifestations of HIV in the era of highly active antiretroviral therapy: An institutional urban clinic experience. *J Am Acad Dermatol* **54**(4):581-588, 2006
92. Rosenthal D et al: Human immunodeficiency virus-associated eosinophilic folliculitis. A unique dermatosis associated with advanced human immunodeficiency virus infection. *Arch Dermatol* **127**(2):206-209, 1991
128. Venkatesan P, Perfect JR, Myers SA: Evaluation and management of fungal infections in immunocompromised patients. *Dermatol Ther* **18**(1):44-57, 2005

Chapter 199 :: The Rickettsioses, Ehrlichioses, and Anaplasmoses

:: Sandra A. Kopp, Analisa V. Halpern, Justin J. Green, & Warren R. Heymann

RICKETTSIAL, EHRLICHIAL, AND *ANAPLASMA* INFECTIONS AT A GLANCE

- Rickettsiae primarily target vascular endothelial cells, causing febrile illness and rash in the mammalian host.
- Transmission is predominantly via tick bites, with certain pathogens transmitted by human body lice and mites.
- Fever, headache, myalgia, and malaise are common to rickettsial, ehrlichial, and *Anaplasma* infections; rash is common in rickettsial disease, occasional in ehrlichial infection, and rare in anaplasmosis.
- The early signs and symptoms of infection are often nonspecific and can mimic self-limited viral illnesses or other life-threatening illnesses.
- Early empiric treatment with doxycycline should be considered in highly suspicious cases until rickettsial infection is definitively ruled out, as delayed treatment can lead to severe sequelae and high mortality rates.

Rickettsial diseases are curable infections that, if unrecognized, can be readily lethal. Early nonspecific symptoms can mimick benign viral illnesses and should be considered in any patient who presents with constitutional symptoms, fever, headache, and a characteristic petechial rash. The advent of modern molecular technologies, including genetic analysis, has allowed for significant taxonomic reclassification of the rickettsiae including moving the family *Bartonella* (see Chapter 192) and the genus *Coxiella* out of the order Rickettsiales to the orders Rhizobiales and Legionellales, respectively. "Rickettsiae" now includes a polyphyletic group of microorganisms in the class Proteobacteria, comprising species belonging to the genera *Rickettsia*, *Orientia*, *Ehrlichia*, *Anaplasma*, and *Neorickettsia*. Several non-rickettsial agents that were historically included in the group of infections loosely termed the *rickettsioses* remain incorporated in the discussion of rickettsial disease herein to reflect that precedent.[1]

Historically rickettsiae and *Rickettsia*-like organisms (e.g., *Coxiella burnetii*) were endemic pathogens, however the rise of international travel has allowed for the spread of rickettsial infections to nonendemic areas. *Rickettsia prowazekii and C. burnetii,* agents of epidemic typhus and Q fever, respectively have emerged as potential agents of bioterrorism.[2]

RICKETTSIAE

ETIOLOGY AND PATHOGENESIS OF SPOTTED FEVER AND TYPHUS GROUPS

Rickettsiae are obligate, intracellular, Gram-negative bacteria. They are pleomorphic 0.3–1 µm coccobacilli composed of DNA and RNA and reproduce through binary fission. Rickettsiae are propagated by arthropod vectors that use mammals (and sometimes the arthropods themselves) as reservoirs of infection. Rickettsiae are separated into the spotted fever group and the typhus group on the basis of common genetics, immunologic patterns, and intracellular growth characteristics. The typhus group lives entirely within the cell cytoplasm, whereas the spotted fever group can reside within the cytoplasm or nucleus. Rickettsiae are differentiated by unique antigenic structures on cell surface proteins. *Rickettsia rickettsii* has two major surface proteins, outer membrane protein A (OmpA) and B (OmpB), which are the main targets for serological testing.

Infection occurs through arthropod-induced breaks in the skin allowing access of the pathogen to the blood and lymph. Spotted fever rickettsiae are injected into the host through the saliva of the feeding tick, whereas typhus group rickettsiae enter through the feces of infected human body lice or fleas. Manipulation of the bite site, a long attachment of the arthropod, and exposure to arthropod hemolymph during tick removal aid in the transmission of pathogenic organisms. The rickettsial organisms then spread via the hematogenous and lymphatic systems, attach to endothelial cell membranes, and are phagocytosed. Spotted fever group rickettsiae stimulate host cells to produce reactive oxygen species and cause actin polymerization that aid in bacterial extrusion. In contrast, typhus group rickettsiae replicate intracellularly until the host cell bursts.[3] The severe clinical manifestations of rickettsial infection (e.g., hypovolemia, purpura, pulmonary and cerebral edema) are caused by proliferation of bacteria within the vascular endothelium resulting in a multifocal, systemic vasculitis and microvascular leakage.[4]

SPOTTED FEVER GROUP

ROCKY MOUNTAIN SPOTTED FEVER. Rocky Mountain Spotted Fever (RMSF) was first recognized in 1896 in the Snake River Valley of Idaho and was originally called *black measles* because of the characteristic appear-

ance of the rash. Caused by the tick-borne *R. rickettsii*, it is the most frequently reported rickettsial infection in the United States. Fatal outcomes have been reported in 5% of treated cases, and as high as 20% of untreated cases.[5]

Epidemiology. The vector largely responsible for RMSF in the eastern two-thirds of the United States is the American dog tick, *Dermacentor variabilis*, whereas the Rocky Mountain wood tick, *Dermacentor andersoni*, is prevalent in the Western United States (Fig. 199-1). RMSF is most prevalent in the Southeastern and South Central states, during spring and early summer. Historically, children younger than 10 years of age had the highest incidence of RMSF; however, surveillance data in the United States during 2003 demonstrate a higher age-specific incidence in persons aged 40–64 years.[6] The principal epidemiologic characteristics of RMSF are outlined in Table 199-1.



Figure 199-1 Tick species responsible for transmission of *Rickettsia*, *Ehrlichia*, and *Anaplasma*. **A.** *Dermacentor variabilis*. **B.** *Dermacentor andersoni*. **C.** *Amblyomma americanum*. **D.** *Ixodes scapularis*. **E.** *I. pacificus*. **F.** *Rhipicephalus sanguineus*. **G.** Comparison of *I. scapularis*, *A. americanum*, and *D. variabilis* by life stage. (A US dime is shown to approximate relative size.) (From the Centers for Disease Control and Prevention (http://www.cdc.gov).)

TABLE 199-1
Epidemiologic Features, Prognosis and Treatment of *Rickettsia*, *Ehrlichia* and *Anaplasma* Infection

Disease (Agent)	Primary Vector(s)	Epidemiology	Incubation Period	Risk Factors[a]	Prognosis	First Line Treatment	Second Line Treatments
Rocky Mountain spotted fever (*Rickettsia rickettsii*)	*Dermacentor variabilis* (American dog tick), *Dermacentoandersoni* (Rocky Mountain wood tick), *Amblyomma americanum* (lone star tick), *Rhipicephalus sanguineus* (brown dog tick), *Amblyomma cajennense* (Central and South America), *Haemaphysalis leporispalustris* ticks	Widespread in the United States, concentration in South Atlantic and South-Central states; Argentina, Brazil, Columbia, Costa Rica, Mexico, Panama, Canada Spring–Summer	>2–14 days	Males; adults 40–64 years, children <10 years; rural dwelling	Severe disease: G6PD deficiency (rapid decompensation, fulminant disease with higher incidence of necrosis), males, elderly, neurologic disease, hepatitis, jaundice, thrombocytopenia, acute renal failure, sulfa medications, delayed diagnosis and treatment.	Adults[b]: Doxycycline 100 mg po q12h × 5–10 days Children[c]: Doxycyline 2.2 mg/kg po q12h × 5–10 days Pregnancy[c]: Doxycycline 100 mg po q12h for 5–10 days	Adults: Chloramphenicol, 50–75 mg/kg po q6h × 5–10 days *or* Tetracycline 500 mg q6h po × 5–10 days Children: Chloramphenicol, 12.5–25 mg/kg po q6h × 5–10 days Pregnancy[d]: Chloramphenicol
Mediterranean spotted fever (*Rickettsia conorii*)	*R. sanguineus* (brown dog tick)	Endemic to Southern Europe, Middle East, Southwest Asia, India, and Africa Summer	5–7 days	Exposure to dogs	Mild disease (mainly in children) has good prognosis. Severe disease "malignant Mediterranean spotted fever": Alcoholics, elderly, G6PD deficiency, diabetes mellitus, heart disease, delayed diagnosis and treatment.	Adults: Doxycycline 200 mg po q12h × 1 day *or* 100 mg po q12h for 2–5 days Children[c]: Doxycyline 2.2 mg/kg po q12h × 5–10 days Pregnancy: Azithromycin 500 mg po daily × 3 days	Adults: Tetracycline 500 mg po q6h × 10 days *or* Ciprofloxacin 750 mg q12h for 8 days Children: Clarithromycin, 15 mg/kg/day divided q12h for 7 days *or* Azithromycin, 10 mg/kg/day daily × 3 days Pregnancy[d]: Chloramphenicol
Rickettsialpox (*Rickettsia akari*)	*Liponyssoides sanguineus (Allodermanyssus sanguineus)* (house mouse, *Mus musculus*, mite)	United States (mainly eastern seaboard), South Africa, Korea, Ukraine, Croatia Sporadic	~ 7 days (eschar), ~ 7–24 days (systemic symptoms and rash)	Males; urban dwellers (likely from mice exposure); intravenous drug users	Excellent.	Self-limiting	Doxycycline can be used for severe cases
Endemic typhus (*Rickettsia typhi; Rickettsia felis*)	*Xenopsylla cheopis* (rat flea), *Ctenocephalides felis* (cat flea)	Southeast United States, Gulf region, Southern California; worldwide most cases in Africa (reported on all continents except Antarctica) Summer	1–2 weeks (~12 days)	Exposure to fleas, poverty, poor hygiene	Excellent prognosis with treatment. Complicated disease occurs with alcoholism, elderly, hematologic disorders, and exposure to sulfa-containing drugs.	Adults: Doxycycline 100 mg po q12h for 7–14 days Children[c]: Doxycyline 2.2 mg/kg po q12h × 5–10 days Pregnancy[c,d]: Chloramphenicol *or* Doxycycline	Adults: Chloramphenicol, 80–100 mg/kg/day po divided q6h Children: Chloramphenicol, 12.5–25 mg/kg po q6h for 5–10 days Pregnancy: Azithromycin

Epidemic typhus (*Rickettsia prowazekii*)	*Pediculus humanus var. corporis* (human body louse), *Neohaematopinus sciuropteri* lice, *Orchopeas howardii* fleas	United States, Eastern Europe, Africa, Central and South America, China, Himalayan region Sporadic (increased in Winter)	~1–2 weeks (8 days, average)	Wartime, poor hygiene, natural disasters, cold weather	Good prognosis with treatment. Fever abates in 2 weeks (without treatment) and 48 hours (with treatment). Recovery of strength in 2–3 months	Adults[e]: Doxycycline 200 mg single dose (or until afebrile for 24 h) Children[c]: Doxycyline 2.2 mg/kg po q12h × 5–10 days Pregnancyc,[d]: Chloramphenicol *or* Doxycycline	Adults: Chloramphenicol, 80–100 mg/kg/day po divided q6h Children: Chloramphenicol, 12.5–25 mg/kg po q6h for 5–10 days Pregnancy: Azithromycin
Human monocytic ehrlichiosis (*Ehriichia chaffeensis*)	*A. americanum* (lone star tick), *D. variabilis* (American dog tick), *Ixodes pacificus* ticks	South and Mid-Atlantic, North/South-Central United States, isolated areas of New England[f] Spring and summer (peak in May–July	5–14 days	Males; adults >70 years	Poor prognosis: Immunosuppression (HIV, transplantation, glucocorticoids); cough, lymphadenopathy, diarrhea; use of trimethoprim-sulfamethoxazole.	Adults: Doxycycline 100 mg po q12h for 5–14 days Children[c]: Doxycyline 2.2 mg/kg po q12h × 5–14 days Pregnancy[c]: Doxycycline 100 mg po q12h for 5–14 days	Adults: Tetracycline 500 mg po q6h × 5–14 days *or* Rifampin 300 mg po q12h x7–10 days Children: Tetracycline 25–50 mg/kg/day po divided q6h × 5–14 days *or* Rifampin 10 mg/kg po q12h × 7–10 days Pregnancy: Rifampin 300 mg po q12h x7–10 days
Human granulocytic anaplasmosis *(Anaplasma phagocytophilum)*	*Ixodes scapularis* (Eastern United States) and *I Ixodes pacificus* (Western United States), *Ixodes ricinus* (Europe) (black-legged ticks)	New England, upper Midwest United States, Mid-Atlantic, Northern California and Europe[g] Spring and summer (peaks in July and November	5–21 days	Males; adults 60–69 years	Poor prognosis: Elderly, marked lymphopenia, anemia, immunosuppression (HIV, transplantation, glucocorticoids); development of opportunistic infections (e.g., *Aspergillosis,* disseminated candidiasis, etc.).	Adults[h]: Doxycycline 100 mg po q12h for 5–14 days Children[c,h]: Doxycyline 2.2 mg/kg po q12h × 5–14 days Pregnancy[c,h]: Doxycycline 100 mg po q12h for 5–14 days	Adults: Tetracycline 500 mg po q6h × 5–14 days *or* Rifampin 300 mg po q12h x7–10 days Children: Tetracycline 25—50 mg/kg/day po divided q6h × 5–14 days *or* Rifampin 10 mg/kg po q12h × 7–10 days Pregnancy: Rifampin 300 mg po q12h x7–10 days

G6PD = glucose-6-phosphate dehydrogenase; HIV = human immunodeficiency virus.
Children = <45 kg.
Tetracycline maximum daily dose = 2 grams.
Chloramphenicol maximum daily dose = 4 grams.
[a]Males appear to be at higher risk of all tick-borne rickettsial diseases, presumably because of greater recreational and occupational exposure. Disease occurs in all age groups; numbers reflect highest age-specific incidence.
[b]Treat for 3 days after fever subsides and until clinical improvement is noted, typically for a minimum of 5–7 days. More severe illness may require longer duration of therapy.
[c]In severe, life-threatening cases, or when rocky mountain spotted fever cannot be ruled out, doxycycline should be considered first line in any age and during pregnancy.
[d]Use with caution in the third trimester of pregnancy as chloramphenicol may cause gray baby syndrome in neonates (abdominal distention, pallor, cyanosis, vasomotor collapse). Doxycycline should be considered in near-term gravidas.
[e]For recrudescent disease (Brill-Zinsser), a second course of antibiotics is usually curative.
[f]In 2003, 70% of cases of human monocytic ehrlichiosis were reported from seven states: Arkansas, Georgia Missouri, Maryland, North Carolina, Oklahoma, and Tennessee.
[g]In 2003,71% of cases of human granulocytic anaplasmosis were reported from four states: Massachusetts, Minnesota, New York, and Rhode Island.
[h]Treatment is extended to treat potential coinfection with Lyme disease.
Data from Parola P, Paddock CD, Raoult D: Tick-borne rickettsioses around the World: Emerging diseases challenging old concepts. *Clin Microbiol Rev* **18**:719, 2005, and Dana AN: Diagnosis and treatment of tick infestation and tick-borne diseases with cutaneous manifestations. *Dermatol Ther* **22**:293-326, 2009.

Clinical and Laboratory Findings. A high index of suspicion is important to the diagnosis of RMSF. One or two classic symptoms, outlined in Table 199-2, may be seen at presentation, but only about 60% of patients will have the complete clinical triad of fever [>39.5°C (102°F)], headache, and rash. Fever usually presents within the first 3 days of the illness, followed by a characteristic rash 2–4 days after the onset of fever. The rash usually starts on the wrists and ankles, spreading centripetally over the next 6–18 hours. Palms and soles are typically involved with relative sparing of the face.[6] Cutaneous lesions are initially blanchable red macules that become papular and display evidence of petechiae or purpura (Fig. 199-2). Atypical "spotless" fever, seen in approximately 20% of cases does not imply milder disease, and is more common in the elderly and darker-skinned individuals.[4] Periorbital edema, confusion, abdominal pain mimicking an acute abdomen, conjunctival injection, palatal petechiae, edema of dorsal hands, and calf pain are sometimes appreciated. Necrosis from overwhelming vasculitis is rare and preferentially occurs in peripheral locations such as the digits, penis, and scrotum (Fig. 199-3).[7]

TABLE 199-2
Clinical and Diagnostic Findings in Rocky Mountain Spotted Fever (RMSF), Human Monocytic Ehrlichiosis (HME), and Human Granulocytic Anaplasmosis (HGA)

	RMSF	HME	HGA
Tropism	▪ Endothelial cells.	▪ Monocytes.	▪ Granulocytes.
Common initial signs and symptoms	▪ Fever to 38.9°C, chills, malaise, myalgia, nausea, vomiting, anorexia, headache. ▪ Periorbital edema, abdominal pain mimicking appendicitis (children >adults), conjunctival injection, palatal petechiae, edema of dorsal hands, calf pain.	▪ Fever, chills, headache, malaise, myalgia, nausea, vomiting, anorexia, photophobia. ▪ Abdominal pain mimicking appendicitis (children >adults), conjunctival injection, palatal petechiae, edema of dorsal hands, calf pain.	▪ Malaise, fever, myalgia, headache. ▪ Less common: Arthralgia, nausea, vomiting, diarrhea, cough.
Rash	▪ Erythematous blanching macules and/or papules 2–4 days after fever onset; starts at wrists/ankles and spreads centripetally; may involve palms, soles. Rash evolves over few days to petechial and purpuric lesions.	▪ Erythematous macules and/or papules, petechiae, or diffuse erythema approximately 5 days after onset of systemic symptoms	▪ Rare
Common laboratory abnormalities	▪ Common: Thrombocytopenia, anemia, mild hyponatremia. ▪ Variably elevated: Liver transaminases, lactate dehydrogenase, creatine kinase, bilirubin, alkaline phosphatase, blood urea nitrogen, creatinine. ▪ Cerebrospinal fluid: Leukocytosis, moderately elevated protein, and a normal glucose level.	▪ Leukopenia, lymphopenia, thrombocytopenia, transaminitis, and anemia	▪ Thrombocytopenia, transaminitis, leukopenia, anemia, elevated creatinine. ▪ Neutropenia is more common than lymphopenia.
Systemic sequelae	▪ Cardiovascular: Hypotension, hypovolemia, peripheral edema, inappropriate tachycardia, myocarditis, arrhythmias. ▪ Gastrointestinal: Bleeding, perforation, hepatomegaly, jaundice ▪ Neurologic: Confusion, delirium, stupor, meningismus, coma, motor deficits, cranial nerve palsy, deafness, photophobia, hallucinations, seizures, Guillain-Barré syndrome. ▪ Other: Conjunctivitis, acute renal failure, adult respiratory distress syndrome.	▪ Respiratory: Cough, dyspnea, respiratory insufficiency/ adult respiratory distress syndrome. ▪ Neurologic: Meningoencephalitis, altered mental status, cranial or peripheral motor nerve paralysis, sudden transient deafness. ▪ Other: Acute renal failure, disseminated intravascular coagulation, and pericarditis.	▪ General: Septic or toxic–shock-like syndrome (see Chapter 177), coagulopathy, disseminated intravascular coagulation (see Chapter 144), rhabdomyolysis, pancreatitis. ▪ Respiratory: Adult respiratory distress syndrome. ▪ Neurologic: Brachial plexopathy, demyelinating polyneuropathy, cranial nerve paralysis. ▪ Other: Acute abdominal syndrome, myocarditis, acute renal failure, hemorrhage, opportunistic infections.



Figure 199-2 **A.** Early macular blanchable macules and papules on the ankle and sole. No truncal lesions were present at this time. **B.** Truncal and facial hemorrhagic macules and papules 7 days after the onset of the rash. **C.** Erythematous macular lesions on the palm may develop into a petechial rash that spreads centrally. (Reprinted from Collins SP: Cutaneous conditions. In: *Atlas of Emergency Medicine*, 2nd edition, edited by KJ Knoop, LB Stack, AB Storrow. New York, NY, McGraw-Hill, 2002, p. 382.) **D.** Petechial lesions on the arm of a child with fulminant Rocky Mountain spotted fever. (Used with permission from MMWR, Diagnosis and Management of Tick-borne Rickettsial Diseases: Rocky Mountain Spotted Fever, Ehrlichiosis, and Anaplasmosis—United States. March 13, 2006/55(RR04); 1-27, http://www.cdc.gov/mmwr.)

Thrombocytopenia, anemia, mild hyponatremia, and mild transaminitis may be present. The white blood cell count is typically normal, however an increase in bands may be observed.[6] Severe and life-threatening cardiac, gastrointestinal, hepatic, neurologic, ophthalmologic, renal, and pulmonary manifestations can occur with delayed or inadequate treatment. In patients with severe RMSF who survive the acute illness, long-term sequelae are usually the result of neurologic deficits or acral necrosis. In a case series by Buckingham et al, of 92 children diagnosed with RMSF, the median delay between seeking medical attention and antibiotic therapy was 6 days, with only 49% reporting a tick bite.[8] Table 199-2 outlines the cutaneous and systemic manifestations of RMSF, as well as common laboratory abnormalities.

Pathology. Histopathologic examination shows a septic vasculitis (Fig. 199-4). Early lesions demonstrate dermal edema with a predominantly perivascular lymphohistiocytic infiltrate and extravasated erythrocytes. Lymphohistiocytic vasculitis can progress to



Figure 199-3 Gangrene of the toes in Rocky Mountain spotted fever. (Used with permission from Gary Marshall, MD and MMWR, Diagnosis and Management of Tick-borne Rickettsial Diseases: Rocky Mountain Spotted Fever, Ehrlichiosis, and Anaplasmosis—United States. March 13, 2006/55(RR04);1–27. http://www.cdc.gov/mmwr.)

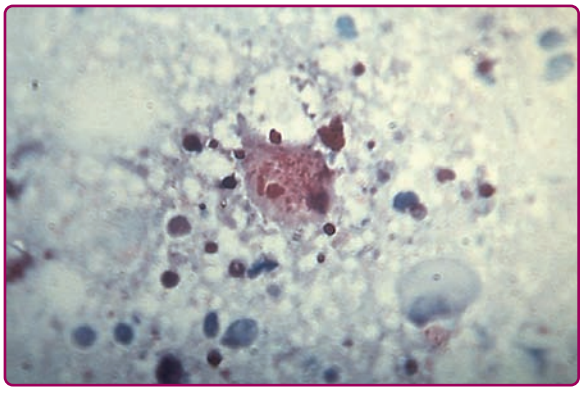

Figure 199-5 Gimenez stain of Rocky Mountain spotted fever in tick lymph cells. [From the Centers for Disease Control and Prevention (http://www.cdc.gov/ncidod/dvrd/rmsf/organism.htm.)]

leukocytoclastic vasculitis. Basal cell vacuolization, lymphocytic exocytosis, fibrin thrombi, and capillary wall necrosis can also be appreciated. Immunohistology reveals positive staining for *R. rickettsii* in infected endothelial cells and tick hemolymph. (Fig. 199-5.) Most rickettsial diseases share a similar histology.

Diagnosis and Differential Diagnosis. Serologic examination using the indirect immunofluorescence assay (IFA) is the gold standard for diagnosis of RMSF. It detects convalescent antibodies (at a diagnostic titer of ≥64 IgG and ≥32 IgM) but is seldom diagnostic before the seventh day of disease, and often not until far into the second week. An effective treatment for RMSF should begin by the fifth day of illness. It is vital to begin empiric therapy while awaiting serologies. Because of inferior sensitivity and specificity, the Weil–Felix test (agglutination of certain *Proteus* sp.) and complement fixation tests have been largely supplanted by newer diagnostic methods. Immunohistochemical staining of skin or organ tissue biopsy and polymerase chain reaction (PCR) may also confirm the diagnosis.[9]

When a patient presents without a rash, the differential diagnosis for RMSF is broad (Boxes 199-1 and 199-2). Macules and papules, petechiae, or purpuric lesions may sometimes develop in these diseases as well, further precluding the ability to distinguish them from RMSF on clinical grounds alone.

Treatment. Tetracyclines, specifically doxycycline, are the drugs of choice for all rickettsial diseases in patients of all ages, even during pregnancy. The use of tetracyclines in children with RMSF is no longer a subject of controversy. Although repeated exposure to tetracycline increases the risk of tooth staining, studies suggest that limited use of this antibiotic in children during the first 6–7 years of life has a negligible effect on the color of permanent incisors.[10] Sulfa-based medications are not recommended, as they may result in a more complicated disease course.[11]

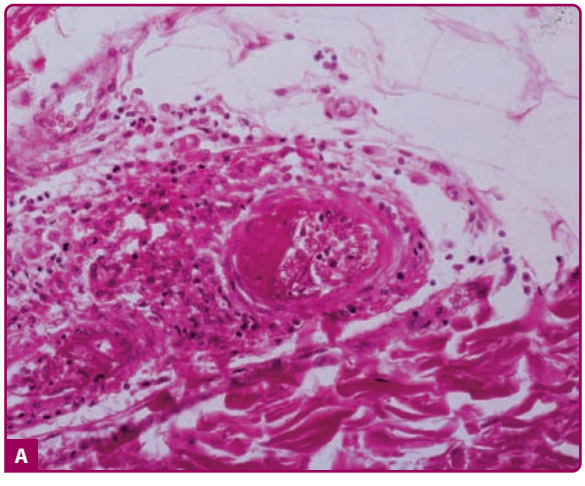

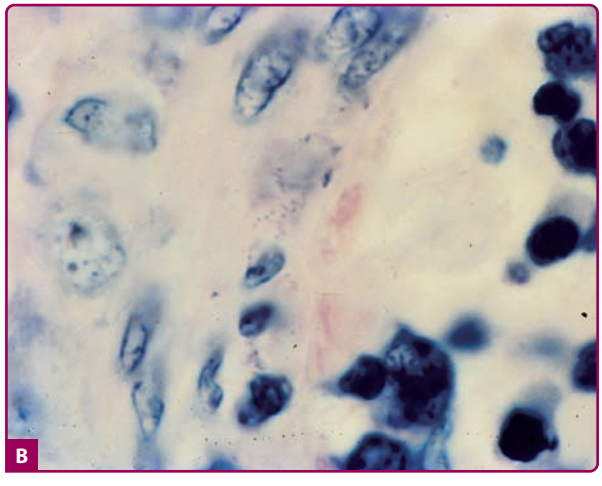

Figure 199-4 **A.** Vascular lesion of Rocky Mountain spotted fever as seen in an arteriole in the skin. An early thrombus is present. **B.** Rickettsiae are seen in endothelial cells from a biopsy of a cutaneous lesion.

BOX 199-1 DIFFERENTIAL DIAGNOSIS OF RICKETTSIAL AND EHRLICHIAL DISEASES

Most Likely

- Enteroviral infection (e.g., coxsackievirus, echovirus)
- Roseola infantum (human herpesvirus 6)
- Drug eruption
- Group A streptococcal pharyngitis
- Vasculitis
- Kawasaki disease
- Measles (coryza, Koplik's spots, cough)
- Epstein–Barr virus/infectious mononucleosis

Consider

- Viral meningoencephalitis
- *Mycoplasma pneumoniae* infection
- Parvovirus B19
- Tularemia
- Leptospirosis
- Immune complex mediated illness
- Atypical erythema multiforme
- Typhoid fever
- Dengue
- Viral hemorrhagic fevers (Ebola, Marburg, Lassa)

Always Rule Out

- Meningococcemia (more rapid-onset rash and leukocytosis, but both may show gangrenous lesions)
- Disseminated gonococcal infection
- Lyme disease
- Tick-borne viral fevers (e.g., Colorado tick fever)
- Thrombotic thrombocytopenic purpura and immune thrombocytopenic purpura
- Toxic shock syndrome
- Stevens–Johnson syndrome
- Secondary syphilis

Chloramphenicol may be used if tetracyclines are contraindicated because of allergies. Side effects include aplastic anemia, reversible bone marrow suppression, and gray baby syndrome in near-term gravidae,[12] Aggressive supportive care is crucial, with particular attention to electrolyte and fluid balance. Treatment and management strategies for RMSF are listed in Table 199-1 and Box 199-3.

Fulminant RMSF leading to more rapid decompensation has characteristically been reported in chronic alcoholics and black males with glucose-6-phosphate dehydrogenase deficiency. These patients have a higher risk of cutaneous necrosis.[3] Prompt empiric administration of appropriate antibiotic therapy is recommended, as it is the most important factor affecting survival.

Prevention. Avoiding tick exposure, wearing protective clothing, performing tick checks regularly while in tick-infested areas, and proper tick extractions are important for lowering the risk of infection. Chemical repellants, such as diethyltoluamide (DEET) in concentrations up to 35%, are safe for use in adults and children. Prophylactic antibiotics after tick exposure are not recommended. Despite its life-threatening nature, vaccine development remains to be a low priority because of the availability of safe and effective antibiotics,[13]

OTHER SPOTTED FEVERS

Tick-Bite Associated

Mediterranean Spotted Fever and African Tick Bite Fever. Several other tick-borne rickettsial species are pathogenic to humans. Mediterranean spotted fever (MSF), also known as *Boutonneuse fever* or *Marseille fever*, caused by *Rickettsia conorii*, was first documented as a cause of human rickettsial disease is 1932. MSF is the prototypical illness of the non-RMSF spotted fever group. African tick bite fever (ATBF), caused by *Rickettsia africae*, is a distinct clinical entity.

Epidemiology. *R. conorii* is transmitted by an infected *Rhipicephalus sanguineus* tick (see Fig. 199-1) and is endemic throughout Africa, the Middle East, and Southern Europe. Contact with dogs is reported in up to 90% of cases of MSF. Epidemiologic characteristics of MSF are summarized in Table 199-1. *R. africae* is transmitted by an infected *Amblyomma* tick endemic to sub-Saharan Africa.

Clinical and Laboratory Findings. The constitutional symptoms, systemic complications, and laboratory abnormalities of the tick-bite–associated spotted fevers are similar to those of RMSF. The classic cutaneous hallmark of this group is the tache noir, occurring in about 13%–68% of patients with *R. conorii* infection (Fig. 199-6A).[14] The tache noir occurs at the site of inoculation as an erythematous, indurated papule with a central necrotic eschar that represents locally aggressive endothelial invasion by rickettsiae. Temporal and morphologic pattern of the rash in this group of spotted fevers is similar to RMSF; however, the eruption may be more diffuse and is less frequently petechial or purpuric (see Fig. 199-6B). The presence of multiple tick bites, multiple eschars (seen in 50% of patients with ATBF), and lymphadenitis, distinguish ATBF from MSF,[1] although children with MSF may have cervical lymphadenopathy.[14]

Diagnosis and Differential Diagnosis. Like RMSF, diagnosis of MSF or ATBF is by IFA. Biopsy from an eschar for immunohistochemistry is particularly sensitive in MSF. PCR or western blot analysis can be used to differentiate between *R. conorii* and *R. africae.* Newer serologic assays and PCR have been useful in identifying the numerous emerging agents of spotted fever around the globe, including *Rickettsia japonica* (Japanese spotted fever) and *Rickettsia slovaca*.[1] *R. slovaca*, along with *Rickettsia raoultii* have been associated with TIBOLA/DEBONEL (tick-borne lymphadenopathy/*Dermacentor*-borne necrosis erythema and lymphadenopathy), a recently recognized

BOX 199-2 SELECTED DIFFERENTIAL DIAGNOSIS OF FEVER AND ERYTHEMATOUS OR PETECHIAL RASH

DISEASE	AGENT	SEASON	ONSET	CLINICAL FEATURES
Rocky Mountain spotted fever	*Rickettsia rickettsii*	Spring to summer	Fever, headache, malaise, gastrointestinal symptoms, rash after 2–4 days; rapid progression to severe systemic illness	Rash starting on ankles/wrists, spreads centripetally, may involve palms/soles, progresses from erythematous macules to petechiae
Endemic (murine) typhus	*Rickettsia typhi*	Sporadic	Fever, malaise, headache, rash after 4–5 days	Erythematous macules and/or papules involving trunk >extremities
Human monocytic ehrlichiosis	*Ehrlichia chaffeensis*	Spring to summer	Fever malaise, headache, rash in ~30% of patients	Erythematous macules and/or papules, or petechial rash; more common in children >adults
Meningococcal disease	*Neisseria meningitidis*	Year-round, but more common late winter to early spring	Fever and rash within 24 h, rapid progression to severe systemic illness.	Erythematous macules and/or papules, petechiae usually beginning on lower extremities and spreads centripetally. Toxic appearing.
Group A streptococcal pharyngitis	*Streptococcus pyogenes*	Fall to winter	Abrupt onset of fever and sore throat, malaise; rash follows acute illness	May cause petechial rash in children who appear well
Fifth disease (erythema infectiosum)	Human parvovirus B19	Late winter to early summer	Low fever and mild constitutional signs before rash onset	"Slapped cheek" appearing erythematous rash on face, lacy erythematous rash on trunk. Papular-purpuric gloves and socks syndrome—young adults
Roseola infantum	Human herpesvirus 6	Year-round	Fever 3–5 days, then rash, commonly in children <2 years of age	Morbilliform rash begins on trunk, spreads and fades rapidly
Enteroviral infection	Echovirus, coxsackie viruses, other non-polio enteroviruses	Summer to early fall most commonly, but occurs year-round	Nonspecific febrile illness, with or without rash	Fine morbilliform rash at fever onset; begins on face and spreads caudally; occasionally petechial

Adapted from MMWR, Centers for Disease Control and Prevention: Diagnosis and Management of Tickborne Rickettsial Diseases: Rocky Mountain Spotted Fever, Ehrlichioses, and Anaplasmosis—United States. March 31, 2006/55(RR04), p 1–27, http://www.cdc.gov/mmwr/preview/mmwrhtml/rr5504a1.htm.



Figure 199-6 **A.** Mediterranean Spotted Fever. Tache noire with eschar at the site of the mite bite. **B.** Multiple disseminated red papules in the same patient as in part A. (Used with permission from VisualDx. Copyright Logical Images, Inc.)

BOX 199-3 MANAGEMENT OF RICKETTSIAL, EHRLICHIAL, AND *ANAPLASMA* INFECTIONS

- Delays in treatment can lead to severe sequelae and fatal outcome.
- Clinical history, symptoms, physical exam, and laboratory findings should guide approach to management and treatment.
- Clinicians may consider a "watch-and-wait" approach for 24–48 h for patients early in the course of illness who have nonsupporting history, nonspecific clinical signs, and normal lab findings.
- Doxycycline is the drug of choice for the treatment of presumptive or confirmed rickettsial disease in both adults and children.
- Limited courses of tetracycline-class antibiotics (e.g., doxycycline) do not pose a substantial threat of tooth staining in children.
- Tetracyclines are typically contraindicated in pregnancy but may be warranted in life-threatening cases of Rocky Mountain spotted fever when clinical suspicion arises.
- When early invasive meningococcal infection cannot be ruled out, antibiotics for *Neisseria meningitides must be started.*
- Prophylactic use of antibiotics after a tick bite is not recommended, as atypical presentations may result, delaying adequate diagnosis and treatment. If prophylaxis is given, a full 10-day course should be administered.
- In patients for whom tetracyclines are absolutely contraindicated, chloramphenicol can be used for rickettsial disease; rifampin or rifabutin may be considered for the ehrlichioses/anaplasmosis.
- When treating ehrlichial infections, consider continuation for 14–21 days to allow for adequate treatment of concomitant Lyme disease in areas endemic for *Borrelia burgdorferi.*

Adapted from MMWR, Centers for Disease Control and Prevention: Diagnosis and Management of Tickborne Rickettsial Diseases: Rocky Mountain Spotted Fever, Ehrlichioses, and Anaplasmosis—United States. March 31, 2006/55(RR04), p 1–27, http://www.cdc.gov/mmwr/preview/mmwrhtml/rr5504a1.htm.

rickettsial disease associated with eschar formation at the tick-bite site and painful lymphadenopathy. TIBOLA/DEBONEL is usually seen in the pediatric population with tick-bites involving the scalp.[15]

The rash of MSF generates a similar differential diagnosis as that of RMSF. If a tache noir is seen, one must also consider brown recluse spider bite, cutaneous anthrax, scrub typhus, rickettsialpox, aspergillosis, or mucormycosis.

Treatment. Guidelines for the treatment of MSF are outlined in Table 199-1. Overall, non-RMSF spotted fevers run a less aggressive course than RMSF. However, MSF has been reported to cause severe cardiac, renal and neurologic complications, as well as death in about 1% of cases.[14] In general, all non-RMSF spotted fevers are treated similarly to MSF. Macrolide antibiotics may offer a better risk/benefit ratio than tetracyclines in the pediatric age group, however, doxycycline is still first-line therapy.[16]

Mite-Bite Associated

Rickettsialpox. Rickettsialpox is an acute, self-limited, febrile disease so named because of its clinical resemblance to varicella (chickenpox). Its etiologic agent is *Rickettsia akari*. *Mus musculus*, the house mouse, is the reservoir, and the vector is the rodent mite, *Liponyssoides sanguineus* (formerly *Allodermanyssus sanguineus*).[17] The colorless rodent mite inflicts a painless bite and is too small to be readily recognized by the victim.

Epidemiology. Most cases of rickettsialpox in the United States have occurred in large metropolitan areas of the Northeastern United States, with approximately one-half of the cases reported from New York City alone. Table 199-1 describes the salient epidemiologic features of rickettsialpox.

Clinical and Laboratory Findings. A primary lesion occurs at the site of the mite bite as early as 1–2 days after transmission. It consists of a painless, erythematous, indurated papule ranging in size from 0.5–3.0 cm. Vesicle formation is followed by desiccation which produces an eschar to form the characteristic tache noir (Fig. 199-7). Regional lymphadenopathy is common. Resolution of the primary lesion occurs within 1 month.

Approximately 7 days after the primary lesion appears, fever, chills, diaphoresis, myalgia (often manifesting as backache), malaise, and headache begin. The fever persists with remissions for about 1 week before abating. Two to three days after the onset of systemic symptoms, a generalized papulovesicular eruption occurs (Fig. 199-7B). Small vesicles or pustules appear with subsequent central crust formation. Roughly 5–40 lesions may be found, typically resolving in 1 week. Less frequently, an enanthem, photophobia, generalized lymphadenopathy, and gastrointestinal symptoms may be noted. Thrombocytopenia is common during the acute febrile illness, and a mild leukopenia with a relative lymphocytosis may be seen.

Pathology. In contrast to RMSF, MSF, ATBF, and typhus group Rickettsioses, the perivascular macrophage, not the endothelial cell, appears to be the target of *R. akari*. Primary lesions are characterized by extensive necrosis and an acute inflammatory infiltrate. Secondary papulovesicular lesions display a subepidermal split with superficial edema, and a perivascular lymphohistiocytic infiltrate that can become vasculitic.

Diagnosis and Differential Diagnosis. Antibody titers peak after 3–4 weeks and could be delayed for up to 8 weeks with antibiotic use. Biopsy for direct immunofluorescence (DIF) with anti-*R. rickettsii* immunoglobulin is highly sensitive; however, due to cross-reactivity among the spotted fever group rickettsiae, confirmatory cross-adsorption testing may be

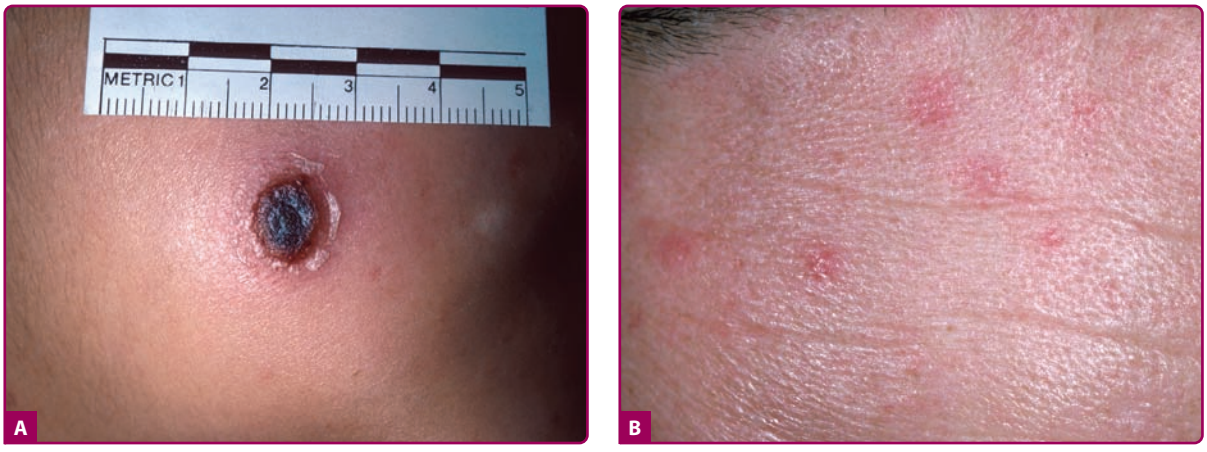

Figure 199-7 **A.** Rickettsialpox: Tache noir. A crusted, ulcerated lesion with eschar and a faint red halo at the site of the mite bite. **B.** Mediterranean spotted fever, 32-year-old Caucasian male with eschar on thigh, followed by fever, and erythematous papules and small pustules. (Used with permission from VisualDx. Copyright Logical Images, Inc.)

considered with *R. akari* and *R. rickettsii* antigens. Tissue for DIF should be taken from a primary eschar, as lesions from the generalized eruption do not contain enough inoculum to become positive by DIF. If immunohistochemistry is inconclusive, PCR can be used to confirm infection.[18]

The differential diagnosis includes varicella, smallpox, gonococcemia, infectious mononucleosis, echovirus (types 9 and 16), and coxsackievirus infection (A9, A16, and B5), in addition to those diseases discussed under the differential diagnosis of MSF. In varicella, one observes a "dewdrop on a rose petal," referring to a primarily vesicular lesion surrounded by macular erythema. This is distinct from the erythematous papule surmounted by a vesicle seen with rickettsialpox.[17] Fever occurs with the rash of varicella but precedes the eruption of rickettsialpox.

Treatment. Rickettsialpox is self-limited. Even without antibiotics, it will resolve within 2 weeks. In the rare severe case, tetracycline antibiotics continued for up to 5 days are the most effective therapy; defervescence is typical within 48 hours.[17]

TYPHUS GROUP

ENDEMIC TYPHUS (MURINE OR FLEA-BORNE TYPHUS).

Endemic typhus is caused mainly by *Rickettsia typhi*, and is classically transmitted to humans by the rat flea (*Xenopsylla cheopis*), with rats serving as the reservoir. *Rickettsia felis* has recently emerged as an important agent of endemic typhus with characteristics of both the typhus and spotted fever group rickettsiae. *R. felis* has been identified in peridomestic cats, dogs, opossums, and their fleas (e.g., cat flea, *Ctenocephalides felis*) in parts of southern Texas, southern California, and Mexico.[19,20]

Epidemiology. Murine typhus has been reported from all continents except Antarctica, although most cases today occur in Africa. It is most likely underdiagnosed and mistaken for a viral illness since flea bites are not usually recalled and most cases are self-limited.[21] Epidemiologic characteristics are outlined in Table 199-1.

Clinical and Laboratory Findings. Most infected persons experience fever, headache, backache, and joint pain 6–14 days after contact with an infected flea. Nonspecific gastrointestinal symptoms may be present, especially in children.[22] Extremely high fever, 41.1°C (106°F), may last up to 2 weeks. Commonly, a rash begins on the chest and spreads to the sides and back. The palms and soles are rarely involved. The rash may last only a few hours and consists of erythematous macules and/or papules. Petechiae are found infrequently. Rash is seen in less than 20% of patients at presentation. Fifty to sixty percent of patients will develop a rash over the course of the illness, with a median onset of 6 days after the onset of fever.[19] More severe complications are uncommon but may include seizures, meningoencephalitis, retinitis, acute hepatitis, endocarditis, renal insufficiency, pneumonia, and respiratory failure. Thrombocytopenia, transaminitis, and hyponatremia are common, though usually mild.

Diagnosis and Differential Diagnosis. Diagnostic IFA titers are present in 50% of patients by day 7, virtually in 100% of patients by day 15; however, these may not distinguish between endemic and epidemic typhus. Western blot and cross-adsorption studies can differentiate the two diseases, however, they require expensive, specialized laboratories.[21] The differential diagnosis of endemic typhus is broad as a result of the nonspecific nature of the cutaneous eruption (see Box 199-2).

Treatment. Treatment for endemic typhus is similar to that of RMSF (see Table 199-1). With institution of appropriate antibiotics, fever typically resolves in 2–3 days. Spontaneous recovery often occurs within 2 weeks in untreated patients. Prior infection with *R. typhi* provides lifelong immunity to subsequent infection.

EPIDEMIC (LOUSE-BORNE) TYPHUS.

Epidemic typhus (also called *prison fever, famine fever*, or

ship fever) is caused by *R. prowazekii*, and is transmitted to humans primarily via the body louse (*Pediculus humanus* var. *corporis*). Epidemic typhus may result in long-term latent asymptomatic infection. A re-emergence of the illness known as Brill–Zinsser disease (BZD) can occur in survivors who may suffer recrudescent infection, even decades after the initial infection.

Epidemiology. Louse infestation occurs when cold weather, poor hygiene, crowding, and poverty are prevalent. These conditions are most commonly found today in refugee camps, and among the homeless and imprisoned. The most recent outbreak of epidemic typhus occurred in refugee camps in Burundi during the mid-1990s.[23] Table 199-1 details the epidemiologic characteristics of epidemic typhus.

The major reservoir for disease is humans, with lice acquiring the infection by feeding on persons with primary illness or BZD. The lice are spread through close personal contact or infested clothing. The infected louse will defecate while taking a blood meal, and the organisms in the feces are then scratched into the skin, enabling transmission. Lice die of infection within 3 weeks, however, their feces can be infectious for up to 100 days, therefore allowing human-to-human transmission through clothes or close contact. Contact with southern flying squirrels (*Glaucomys volans*) is associated with outbreaks of epidemic typhus in the Eastern United States, where the fleas or lice from these rodents can be important vectors.[24]

Clinical and Laboratory Findings. After an incubation period of 1–2 weeks, abrupt onset of intractable headache, fever [to 40°C (104°F)], chills, and myalgia occurs. If left untreated, prostration due to overwhelming hypotension and vascular collapse may ensue. Typically, a rash begins in the axillary folds and upper trunk on the fifth day of illness. Initial lesions consist of erythematous macules that become papular and petechial over several days. In contrast with most rickettsial diseases, the eruption spreads centrifugally but spares the face, palms, and soles. Complications include acral gangrene, cerebral thrombosis, and other neurologic sequelae, multiorgan system failure, and death. Laboratory abnormalities include thrombocytopenia, elevated transaminases, and elevated lactate dehydrogenase. Leukocytosis is seen in a minority of patients.

BZD occurs as a recrudescence of previous infection with *R. prowazekii*. Provocation by immunologic stress induced by poor living conditions may play a role. The illness is usually milder than the primary disease. In the United States it was most commonly seen in those who were exposed to epidemic typhus in World War II.

Diagnosis and Differential Diagnosis. Techniques for diagnosis are identical to those used for other rickettsial diseases, with the IFA test the most widely used method. The differential diagnosis is similar to that of endemic typhus. The diagnosis of epidemic typhus should be considered when the appropriate clinical characteristics are seen in the setting of known or suspected louse infestation, or, in the United States, when a history of an exposure to flying squirrels is elicited. The centrifugal spread, lack of eschar, and predilection for colder months helps differentiate epidemic typhus from other rickettsial infections. Endemic typhus is typically less severe than epidemic typhus. When lice and rats are both prevalent (poor hygienic conditions, prison, etc.), a risk exists for both diseases. In such situations, it is critical to discriminate between *R. typhi* and *R. prowazekii* infections, as the latter has markedly greater epidemic potential.

Treatment. Fatal illness is rare if proper therapy is initiated early (see Table 199-1). Although a single dose of doxycycline may be curative, optimal therapy should be continued for 2–3 days after defervescence. BZD is treated identically to primary epidemic typhus. Therapy failures have been documented with azithromycin for BZD.[25]

Prevention. Prevention begins with regular bathing and clothes washing. Delousing with appropriate agents, such as permethrin, malathion, lindane or DDT, is effective. A vaccine is available, but recommended only for high-risk groups.

SCRUB TYPHUS.

Scrub typhus (*Tsutsugamushi fever* or *chigger fever)*, is a mite-transmitted zoonosis caused by *Orientia tsutsugamushi*. The vector is the larval stage (chigger) of the trombiculid mite (*Leptotrombidium deliense* and other *Leptotrombidium* sp.). The mites and the rodents that carry them serve as the major reservoirs.

Epidemiology. Named for the type of vegetation that harbors the mite vector, scrub typhus is endemic to a region spanning the Indian subcontinent to Eastern Asia and the Western Pacific Rim (Japan, Korea, India, Pakistan, Taiwan, Southeast Asia, and Australia). Scrub vegetation is a transitional terrain between tall forests and cleared land, composed of plantations, fields, groves, and tall grass. Accordingly, the illness is more common in rural settings and is a common occupational disease. Because of the long incubation period, scrub typhus can present in travelers returning to nonepidemic areas.

Clinical and Laboratory Findings. An erythematous papule appears within 2 days of the chigger bite and undergoes ulceration and eschar formation in one-half to two-thirds of patients. The eschar may be absent in intertriginous areas. Regional lymphadenopathy is followed by generalized lymphadenopathy. One to 2 weeks after the bite, there is a sudden onset of high fever [40°–40.6°C, (104°–105°F)]. Chills, headache, cough, myalgia, anorexia, nausea, diarrhea, dyspnea, ocular pain, and conjunctival injection are variably present. A centrifugal macular and then papular eruption occurs in approximately 35% of cases about 4–5 days after the fever begins. The eruption starts on the trunk, spreads to the extremities, and fades within a few days. Hepatosplenomegaly and a relative bradycardia may be appreciated. Severe complications include adult respiratory distress syndrome, myocarditis, pericarditis, disseminated intravascular

coagulation, hemophagocytic syndrome, retinal vein occlusion, renal failure, and hepatitis. Nuchal rigidity, meningoencephalitis, tremors, slurred speech, deafness, and tinnitus are seen rarely. Examination of the cerebrospinal fluid in these cases reveals only a slight monocytosis.

Diagnosis and Differential Diagnosis. The differential diagnosis is similar to that for endemic typhus. Enzyme-linked immunosorbent assay, dot blot urine immunoassay, rapid immunochromatographic flow assay, and PCR have the greatest sensitivity and specificity but are limited by their availability in endemic areas. Diagnostically, IFA remains the gold standard. Conclusive diagnosis is based on a fourfold increase in titer of paired samples drawn at least 2 weeks apart. A single acute titer of more than 1:50 can be used as a preliminary diagnostic cutoff in travelers returning from endemic areas.[26] In 2009, an association was reported between high *O. tsutsugamushi* DNA loads determined by PCR and disease severity.[27]

Treatment. Although single dose or short courses (3 days) of doxycycline may prove to be efficacious, treatment is recommended for 14 days. Naturally occurring doxycycline- and chloramphenicol-resistant strains of *O. tsutsugamushi* have been found in Northern Thailand, Azithromycin, rifampin, and ciprofloxacin are alternatives in this setting.[28] With the institution of proper antibiotics, defervescence occurs abruptly, usually within 24 hours. In untreated patients, fever lasts for about 2 weeks. Vaccine development has yielded disappointing results; however, is crucial in this era of antibiotic resistance.[29]

Prevention. DEET applied to the skin or impregnated into clothing is effective at preventing transmission. Chemoprophylaxis with weekly doxycycline may be efficacious when traveling to endemic areas. Rodent control may paradoxically increase the risk of human disease as chiggers lose their natural host and target humans.

THE EHRLICHIOSES.

The ehrlichial pathogens were reclassified following the identification in 1994 of the so-called *HGE* agent responsible for causing human granulocytic ehrlichiosis. Based on distinct phylogenetic and pathogenic characteristics, this organism was assigned its own genus, *Anaplasma*, and the disease associated with it was renamed human granulocytic anaplasmosis (HGA).[6]

Epidemiology. Human disease attributed to ehrlichial organisms has been reported in the United States since 1986. The causative agent of human monocytic ehrlichiosis (HME) is *Ehrlichia chaffeensis*, and the main reservoirs are deer, dogs, and coyote. The white-footed mouse (*Peromyscus leucopus*) and white-tailed deer (*Odocoileus virginianus*) are the principal reservoirs for *Anaplasma phagocytophilum*, the causative agent of HGA. Table 199-1 describes the principal epidemiologic characteristics of HME and HGA.

HGA infection occurs in a geographic pattern identical to that of Lyme disease (*Borrelia burgdorferi*) (see Chapter 187), namely in the Northeastern United States, parts of the Pacific Northwest, and the upper Midwest United States. The vector for both HGA and Lyme is the *Ixodes* tick (see Fig. 199-1D and E). In addition to *A. phagocytophilium* and *Borrelia burgdorferi*, *Ixodes* ticks can transmit *Babesia microti*, *Borrelia afzelii*, and *Borrelia garinii*. Not surprisingly, most cases of HGA are found in areas with high incidences of Lyme disease and babesiosis.

The lone star tick (*Amblyomma americanum*) and the American dog tick (*D. variabilis*), the vectors of *E. chaffeensis*, also transmit *R. rickettsii* and *Francisella tularensis*, the causative agents of RMSF and tularemia (see Chapter 180), respectively (see Fig. 199-1). It is essential to consider possible coinfection with these potentially life-threatening organisms in patients with known or suspected ehrlichial disease. Though mainly a tick-borne disease, HGA has been reported after blood transfusions, whereas HGE has been believed to occur after contact with contaminated animal tissue.[30,31]

Etiology and Pathogenesis. Ehrlichiae and Anaplasmodiae are small, obligate intracellular bacteria. *E. chaffeensis* is trophic for monocytic cells, whereas *A. phagocytophilum* prefer myeloid or granulocytic cells. The organisms grow within membrane-bound vacuoles, and form intracytoplasmic microcolonies called morulae, which may be seen in peripheral blood smears.[6,32]

Clinical and Laboratory Findings. There is substantial overlap in the clinical presentation and laboratory evaluation of patients with HME, HGA, and RMSF (see Table 199-2). Patients give a history of a tick bite in only about 68% of cases of ehrlichiosis. The clinical course ranges from asymptomatic seroconversion to multisystem organ failure and death (see Table 199-2) The rash of HME is often indistinguishable from that of RMSF, and can present as erythematous macules and papules, petechiae, or as a diffuse erythema. It is observed in approximately 33% of adults and 66% of children with HME. Rash is rare in HGA, the absence of a rash in a patient with systemic findings suggestive of RMSF should prompt consideration of anaplasmosis. Conversely, if a rash is present in a patient with anaplasmosis, coinfection with meningococcus, *R. rickettsii*, or *B. burgdorferi* should be considered. Laboratory abnormalities include leukopenia (often with a left shift), thrombocytopenia, and elevated transaminases. Despite similar presentations, HME usually has a more severe progression and higher case fatality ratio, whereas HMA has a higher prevalence of opportunistic infections.[33]

Pathology. In contrast to the rickettsioses, endothelial cell injury or frank vasculitis are not a typical feature. A single retrospective case study suggests HME may rarely be associated with cutaneous vasculitis such as polyarteritis nodosa.[34]

Diagnosis and Differential Diagnosis. Clinical illness nearly always precedes laboratory diagnosis by any method. Morulae stained with Wright or Giemsa stains are occasionally observed inside the leukocytes

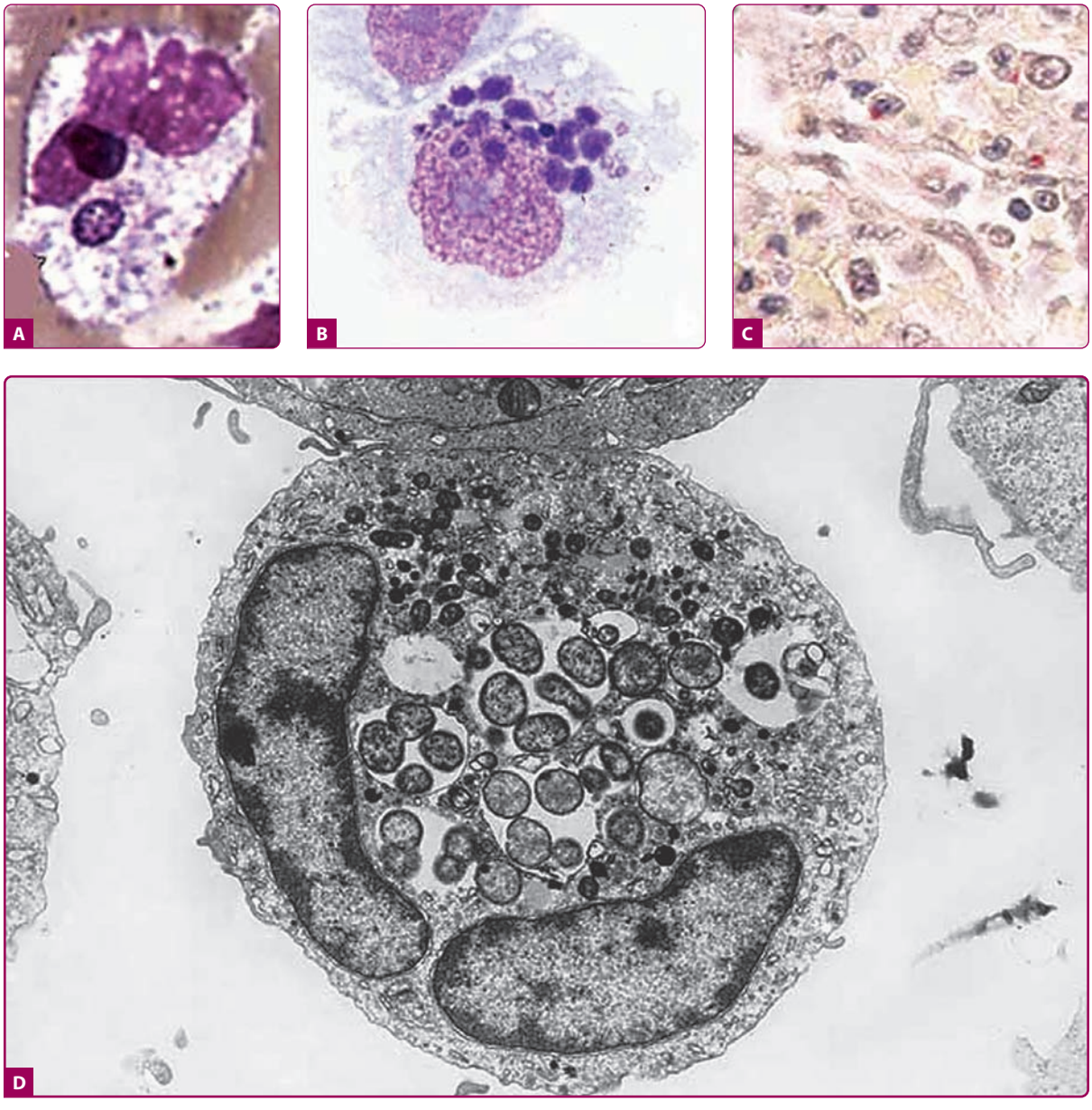

Figure 199-8 **A.** *Anaplasma phagocytophilum* in human peripheral blood band neutrophil (Wright stain, original magnification × 1000). **B.** *A. phagocytophilum* in THP-1 myelomonocytic cell culture (Leukostat stain, original magnification × 400). **C.** *A. phagocytophilum* in neutrophils infiltrating human spleen (immunohistochemistry with hematoxylin counterstain; original magnification × 100). **D.** *A. phagocytophilum* ultrastructure by transmission electron microscopy in HL-60 cell culture (original magnification × 21,960). (Used with permission from Dumler JS et al: Human granulocytic anaplasmosis and Anaplasma phagocytophilum. *Emerg Infect Dis* **11**:1828, 2005. Available from http://www.cdc.gov/ncidod/EID/vol11no12/05–0898.htm.)

in peripheral blood smears, buffy coat preparations, or cerebrospinal fluid, usually during the first week of infection (Fig. 199-8). Smear sensitivities are low and variably dependent upon the experience of the microscopist.[32] Therefore, a negative smear should not delay treatment. False positives can occur with toxic granulation, superimposed platelets, and Döhle's bodies.

Confirmatory testing should be performed with serologic assays available through commercial and state public health laboratories. The sensitivity of the IFA is dependent on the timing of collection and is estimated to be 94%–100% sensitive after 14 days. Paired serum samples taken 2–3 weeks apart should demonstrate a fourfold rise in titers. PCR of whole blood may be more useful than tissue biopsy in HME and HGA, as these pathogens are trophic for circulating leukocytes. Immunohistochemical staining of formalin-fixed, paraffin-embedded tissue may be useful for documenting infection in the first 48 hours of disease.[6]

The differential diagnosis is extensive and similar to RMSF (see Boxes 199-1 and 199-2). The presence of a rash, normal white blood cell count, lack of morulae, and pathologic evidence of vasculitis is more consistent with RMSF.

Treatment. The median duration of disease is 1–2 weeks with treatment. Defervescence usually occurs within 1–2 days. Table 199-1 and Box 199-3 detail appropriate therapy. Treatment with doxycycline for 5–14 days is generally effective, but continued therapy for 14–21 days is indicated if coinfection with *B. burgdorferi* is suspected.[6,32]

Prevention. Preventive measures include avoidance of tick exposure, use of chemical repellants such as DEET, light-colored clothing (to visualize ticks), and careful removal of attached ticks.

KEY REFERENCES

Full reference list available at www.DIGM8.com

DVD contains references and additional content

1. Parola P, Paddock CD, Raoult D: Tick-borne rickettsioses around the World: Emerging diseases challenging old concepts. *Clin Microbiol Reviews* **18**:719, 2005
4. Walker DH, Raoult D: *Rickettsia rickettsii* and other spotted fever group rickettsiae (Rocky Mountain spotted fever and other spotted fever). In: *Principles and Practice of Infectious Diseases*, vol. 2, 5th edition, edited by GL Mandell, JE Bennett, R Dolin. Philadelphia, Churchill Livingstone, 2000, p. 2035
5. Chapman AS et al: Diagnosis and management of tickborne rickettsial diseases: Rocky Mountain spotted fever, ehrlichioses, and anaplasmosis—United States: A practical guide for physicians and other health-care and public health professionals. *MMWR Recomm Rep* **55**:1-27, 2006
6. Bakken JS et al: Centers for Disease Control and Prevention. Diagnosis and management of tickborne rickettsial diseases: Rocky Mountain spotted fever, ehrlichioses, and anaplasmosis—United States. *MMWR Morb Mortal Wkly Rep* **5**5:1, 2006
9. Dana AN: Diagnosis and treatment of tick infestation and tick-borne diseases with cutaneous manifestations. *Dermatologic Therapy* **22**:293-326, 2009
13. Dantas-Torres F: Rocky Mountain spotted fever. *Lancet Infect Dis* **7**:724-732, 2007
14. Rovery C, Raoult D: Mediterranean spotted fever. *Infect Dis Clin North Am* **22**:515-530, 2008
17. Heymann WR: Rickettsialpox. *Clin Dermatol* **14**:279, 1996
32. Dumler JS et al: Human granulocytic anaplasmosis and *Anaplasma phagocytophilum*. *Emerg Infect Dis* **11**:1828, 2005. Available at: http://www.cdc.gov/eid.
33. Dumler SJ et al: Ehrlichiosis in humans: Epidemiology, clinical presentation, diagnosis, and treatment. *Clin Infect Dis* **45**:S45-S51, 2007

SECTION 32

Sexually Transmitted Diseases

Chapter 200 :: Syphilis

:: Kenneth A. Katz

SYPHILIS AT A GLANCE

- A disease caused by the spirochete *Treponema pallidum* subspecies *pallidum* that is usually sexually transmitted.
- In the United States, syphilis disproportionately affects men who have sex with men and blacks.
- The most common and recognizable manifestations are usually cutaneous.
- Syphilis passes through four distinct clinical phases:
  1. Primary stage, characterized by a chancre.
  2. Secondary stage, characterized typically by skin eruption(s) with or without lymphadenopathy and organ disease.
  3. A latent period of varied duration, characterized by the absence of signs or symptoms of disease, with only reactive serologic tests as evidence of infection.
  4. Tertiary stage, with cutaneous, neurologic, or cardiovascular manifestations.
- The recommended treatment for most types of syphilis is benzathine penicillin G, with dose and administration schedule determined by disease stage.
- Persons with human immunodeficiency virus infection are at higher risk of treatment failure and to neurosyphilis.

Syphilis is an infection caused by *Treponema pallidum* subspecies *pallidum*. It can cause serious disease in persons who acquire it after birth and especially devastating disease in persons who acquire it in utero. Many of its manifestations are cutaneous, making it of interest and importance to dermatologists, especially as morbidity from syphilis rises in the developed world and continues in the developing world.

HISTORY

Whether syphilis arose in the New World, the Old World, or both remains a controversial subject.[1–3] Pandemics of syphilis began in the Old World in Naples, Italy, 1 year after Columbus returned from the New World.[2,4,5] Syphilis was much more virulent then, earning it the monicker "great pox,"[4] to distinguish it from another virulent disease with cutaneous manifestations, smallpox. The disease takes its name from a poem, called *Syphilis, Sive Morbus Gallicus* (*Syphilis, or the French Disease*), written in 1530 by Giralomo Fracastoro, a physician and poet of Verona. Part of the poem recounts the story of a shepherd, named Syphilus, who, as punishment for angering Apollo, was afflicted with the disease known as syphilis.[5] Other names besides Morbus Gallicus and the Great Pox by which the disease has been known include lues, the Great Mimic, the Great Masquerader, the Great Imitator, and the Neapolitan disease.[5] The cause of syphilis, the bacterium *T. pallidum*, was discovered by Schaudinn and Hoffman in 1905.[6] Darkfield microscopy and serologic testing for syphilis were pioneered, respectively, in 1906 by Landsteiner and in 1910 by Wasserman.[4]

Syphilis historically has been of major interest to dermatologists, who were leaders in syphilis research and treatment in Europe and the United States.[7–12] One of the leading American dermatology journals, currently called *Archives of Dermatology*, was before 1955 called *Archives of Dermatology and Syphilology*. An editorial explaining the jettisoning of "Syphilology" from the journal's title stated as follows:

> *The diagnosis and treatment of patients with syphilis is no longer an important part of dermatologic practice. The papers on syphilis that are now submitted to the Archives are few and far between. Few dermatologists now have patients with syphilis; in fact, there are decidedly fewer patients with syphilis, and so continuance of the old label, "Syphilology," on this publication seems no longer warranted.*

Elsewhere in the world, however, the link between dermatology and syphilology (and other sexually transmitted diseases) remains stronger.[13,14]

Treatments for syphilis in the prepenicillin era included burning sores with hot irons, rubbing mercury-containing ointments on lesions and other parts of the body, administering mercury orally, and treating with arsenicals, including salvarsan (also called "606" or arsphenamine), which was discovered by Ehrlich and Hata in 1909.[4] Heat treatments were also used. Recognition that *T. pallidum* was heat sensitive led the Viennese psychiatrist Julius Wagner von Jauregg to develop syphilis malariotherapy in 1917,[15] an accomplishment for which he received the Nobel Prize in Medicine in 1927.[16] That therapy involved inoculating syphilis patients with malaria, allowing them to experience, optimally, between 10 and 12 febrile episodes, and then treating them with quinine.[10,16–18] The treatment reportedly led to complete or partial remission of general paresis in a substantial proportion of patients, though it killed an estimated 10% of those receiving the therapy.[17] Heat therapy through malaria inoculation and through other means was practiced in the United States until the early 1950s, when use of penicillin became widespread.[10]

Two studies have provided the most insight into the natural history of syphilis. The first was a retrospective study of approximately 2,000 persons with syphilis in Oslo, where mercury treatments standard in other places were not used.[18] The second was the infamous Tuskegee syphilis study, in which 399 black men with late syphilis from Alabama were prospectively followed from 1932 to 1972.[19] The men were denied treatment for syphilis, even after the discovery of the effectiveness of penicillin for the disease. There were multiple other serious ethical lapses in the study. The aftermath of the study lead to major changes in ethical requirements for conducting clinical research in the United States.[20]

In addition to being more virulent than it is currently, syphilis was also much more common. Of historical interest, persons said to have suffered from syphilis include Ivan the Terrible, Henry VIII, Henri de Toulouse-Lautrec, and Al Capone,[4] and among many others.[21] Osler, aware of the high prevalence and protean manifestations of syphilis, has been quoted as saying "He who knows syphilis knows medicine."[4] By the early 1930s, it was estimated that approximately 10% of Americans had syphilis, with 500,000 new infections and 60,000 cases of congenital syphilis per year.[22] In 1937, Sugeon General Thomas Parran, keenly interested in syphilis, published a book, titled *Shadow on the Land*,[23] that focused on the substantial public health harms of the then-prevalent disease.[22] Parran prioritized syphilis prevention and control, emphasizing screening, treatment, community involvement, and education.[22,24] Nevertheless, syphilis remained prevalent until penicillin, discovered by Fleming in 1928 and first used to treat syphilis in 1943, became widely available in the postwar era.[4] Syphilis incidence then declined sharply in the 1950s, followed by a modest rebound through the mid-1980s. In the late 1980s and early 1990s syphilis reemerged in the United States in the South and in large cities, disproportionately affecting black Americans.[2,25] Incidence then fell to a postwar nadir in 2000, when 5,979 cases (2.1 cases per 100,000 residents) of primary and secondary syphilis were reported nationally. As syphilis incidence waned, CDC released the National Plan to Eliminate Syphilis from the United States in 1999.[26]

EPIDEMIOLOGY

Unfortunately, syphilis incidence in the United States began increasing in late 2000, and that increase has continued nationally through 2009.[2,27] The current syphilis epidemic in the United States and other parts started, and has continued, primarily among men who have sex with men (MSM).[2,28] Incidence of syphilis and other sexually transmitted diseases (STDs) among MSM had declined during the AIDS epidemic, and the subsequent increased incidence among MSM has been attributed to a number of factors, including a decrease in safe sex practices resulting from successful HIV treatments, use of the Internet to meet sex partners, serosorting (i.e., attempting to choose sex partners who share the same HIV status), and an increase in use of recreational drugs, including methamphetamine and erectile-dysfunction medicines.[2,28,29] Of all primary and secondary syphilis cases reported to CDC during 2009, 2% occurred in MSM,[27] of whom an estimated 30%–74% were coinfected with HIV.[27,29] The male-to-female rate ratio for primary and secondary syphilis cases, which measures the extent to which transmission is occurring among MSM, was 5.6 in 2009, an increase compared with 1.2 in 1996 and 5.1 in 2008.[27] The male-to-female rate ratio varies greatly geographically, however, being generally lower in the South and higher in larger cities nationwide. Outbreaks among heterosexual men and women continue to occur sporadically,[30,31] and syphilis among heterosexuals has reemerged as a public health problem.[31] Compared to persons who have never had syphilis, Persons with a history of syphilis are at increased risk of repeat syphilis.[32,33]

In 2009 44,828 cases of syphilis overall were reported to CDC, a 3% decrease from 2008.[27] Those included 13,997 primary and secondary cases (4.6 per 100,000 residents) as well as 13,066 early latent cases and 17,338 late and late latent cases. Ten of the 13 states with rates of primary and secondary syphilis greater than the national average (4.6/100,000 population) were in the South, which accounted for 53% of primary and secondary cases nationwide in 2009. The other three states were New York, California, and Illinois. The rate in the District of Columbia, which reported 163 cases in 2009, was 27.5, higher than that of any state. Of those counties and independent cities that accounted for 50% of reported primary and secondary syphilis cases in 2009, Los Angeles had the highest number of cases (768) and Jefferson County, Texas, had the highest rate (65.0/100,000 population). Rates of primary and secondary syphilis nationwide were highest in persons 20–29 years old. Blacks are disproportionately affected by primary and secondary syphilis, with rates over nine times higher than rates among non-Hispanic whites in 2009 overall, including 8 and 20 times higher among black males and females, respectively,

compared with white males and females.[27] In 2009, there were 427 reported cases of congenital syphilis in the United States.[27] The incidence of congenital syphilis increased 22% from 2005 to 2009, concurrent with an increase in the rate of primary and secondary syphilis among females. Rates have increased primarily in the South and among infants born to black mothers.[34]

Based on those epidemiologic data and other factors, the CDC recommends screening (i.e., testing of asymptomatic persons) for syphilis in the United States for the following groups[38]:

- MSM who have been sexually active within the past year at least annually, and more frequent screening (every 3-6 months) for MSM with multiple or anonymous partners or who have sex in conjunction with illicit drug use (particularly methamphetamine use) or whose partners have sex in conjunction with those activities;
- Pregnant women, at the first prenatal visit, and early in the third trimester for women who are at high risk for syphilis, live in areas of high syphilis morbidity, or are previously untested;
- Persons in correctional facilities, if syphilis screening is justified on the basis of epidemiology in the locality and in the correctional institution.

Internationally, morbidity from syphilis remains substantial. Each year an estimated 12 million new cases of syphilis occur, and 1 million pregnancies are complicated by syphilis.[2]

BIOLOGY AND PATHOPHYSIOLOGY

Treponema pallidum subspecies *pallidum* is a motile, spiral-shaped bacterium for which humans are the only natural host.[16] *T. pallidum* ranges in size from 5 to 16 μm in length and is 0.2 to 0.3 μm in diameter.[35] (Fig. 200-1) The bacterium is surrounded by a cytoplasmic membrane, which is itself enclosed by a loosely associated outer membrane. Between those membranes lies a thin layer of peptidoglycan, which provides structural stability and houses endoflagella, organelles that are responsible for *T. pallidum's* characteristic corkscrew motility. Microscopically the bacterium is indistinguishable from other pathogenic treponemes that cause nonvenereal diseases, including *T. pallidum* subspecies *endemicum* (bejel), *T. pallidum* subspecies. *pertenue* (yaws), and *T. pallidum* subspecies *carateum* (pinta). The *T. pallidum* genome, sequenced in 1998,[36] is 1.14 Mb in length, relatively small for a bacterium.[16]



Figure 200-1 Early chancre presenting as an ulcer with a smooth, clean base on the shaft of the penis.

The bacterium has very limited metabolic capabilities, making it reliant on host pathways for many of its metabolic needs.[16,37] *T. pallidum* does not survive more than a few hours to days outside its host and cannot be cultured in vitro for sustained periods, complicating efforts to understand the organism.[16,37] Instead, it must be propagated in mammals, with rabbits the preferred species because, following testis inoculation, rabbits experience disease manifestations,[37] unlike mice.[16] *T. pallidum* divides slowly, taking from 30 to 50 hours in vitro. That slow reproduction rate has important implications for treatment, which must be present in the body for a long period in order to assure effectiveness against the bacterium.[38]

Following inoculation, *T. pallidum* attaches to host cells, including epithelial, fibroblast-like, and endothelial cells, likely by binding to fibronectin, laminin, or other components of host serum, cell membranes, and the extracellular matrix. It can invade rapidly into the bloodstream—within minutes of inoculation, based on rabbit models—and can cross many barriers in the body, such as the blood–brain barrier and the placental barrier, to infect many tissues and organs. That dissemination leads ultimately to manifestations of syphilis distant from the site of the initial chancre(s) in an infected person and in a developing fetus.

T. pallidum lacks virulence factors common to many other bacteria, including lipopolysaccharide endotoxin.[16] It does, however, produce a brisk immune response, mediated by membrane lipoproteins,[39] that begins shortly after infection. Infection at all stages leads to infiltration by lymphocytes, macrophages, and plasma cells.[37] $CD4^+$ T cells predominate in chancres, and $CD8^+$ T cells predominate in lesions of secondary syphilis.[37] Infection leads also to elaboration of Th1 cytokines, including IL-2 and IFN-γ, although downregulation of the Th1 response during secondary syphilis, coincident with the peaking of antibody titers,[37] might contribute to the organism's ability to evade the host immune response.[40,41] Subtyping studies of *T. pallidum* have linked certain strains of the organism to neurosyphilis.[42]

The humoral immune response begins with production of IgM antibodies approximately 2 weeks after exposure, followed 2 weeks thereafter by IgG antibodies.[39] IgM in addition to IgG continues to be produced during infection and can lead to immune-complex formation.[39] Antibody titers peak during bacterial dissemination, in secondary syphilis.[37] Some antibodies crossreact with other treponemal species, and some are specific for *T. pallidum* subspecies *pallidum*. The immune response is somewhat active against the organism, helping block attachment of the organism to host cells, conferring passive immunity in rabbit models, and enhancing phagocytosis in vitro.[37]

The immune response is sufficient to prevent syphilis reinfection in persons who have untreated syphilis.

In other words, in what is called Colles' law or "chancre immunity," persons with untreated syphilis will not experience another episode of primary syphilis as long they remain untreated.[37] However, the immune response is insufficient to eradicate *T. pallidum* from the host. In addition to suppressing the Th1 response, the organism is thought to evade those host defenses by taking harbor in immune-privileged tissues (e.g., central nervous system, eye, and placenta), failing to be present in sufficient quantities (e.g., during latent infection) to trigger a host response, varying its surface proteins during infection through gene conversion, and overcoming host attempts to prevent bacterial access to iron, which is necessary for bacterial growth.[16,37] The immune response is also not adequate to prevent reinfection after a person is cured of syphilis, although it might modify the course of reinfection. Compared with persons with syphilis for the first time, for example, reinfected persons are less likely to have manifestations of primary or secondary syphilis and more likely to be diagnosed with latent syphilis.[43]

The immune response is also likely responsible for the tissue damage caused in syphilis.[16] Damage to axons located near the site of a chancre might explain why that lesion, although ulcerative, is typically painless.[44]

Interest in a vaccine for syphilis continues, with focus on using outer membrane protein antigens to elicit an immunoprotective response.[45] However, a number of barriers to vaccine development exist. Those include variability in outer membrane protein antigens, the limited number of antigens on *T. pallidum* to which immunoprotective antibodies could bind, the possibility that the formation of a host protein coat around *T. pallidum* might prevent antibody binding, and a potential lack of commercial incentive to produce a vaccine.[45]

CLINICAL COURSE

The natural history of syphilis is presented in Table 200-1. Of note, when considering syphilis in the differential diagnosis in a patient, clinicians must consider the epidemiology and routes of transmission of the disease.

TABLE 200-1
Stages of Syphilis

Contact (⅓ become infected) ↓ (10–90 days) Primary (chancre) ↓ (3–12 weeks) Secondary (mucocutaneous lesions, organ involvement) ↓ (4–12 weeks) Early latent → Relapsing (1/4) (1 year from contact) ↓	
Late latent (more than 1 year)	↘
Remission (⅔)	Tertiary (⅓) Late benign (16%) Cardiovascular (10%) Neurosyphilis (5–10%)

That requires taking a complete sexual history, including ascertaining genders of sex partners and the types of sexual behaviors engaged in with those partners.[46] From a clinical perspective specific behaviors with specific partners are more important than sexual orientation (e.g., gay or straight), because some persons who engage in same-sex sexual behavior do not self-identify as gay.[47]

EXPOSURE AND INCUBATING SYPHILIS

Syphilis is most commonly acquired sexually, when a person comes in contact with infectious lesions of syphilis on another person. Infectious lesions of syphilis in adults, which include chancres, condyloma lata, and mucous patches, can be present anywhere on the body but are typically located in or around the genital, anal, or oral area. Direct contact with infectious lesions during oral, vaginal, or anal sex, or during other sexual activities, can result in inoculation and infection. Lesions on keratinized skin (e.g., palmoplantar lesions and maculopapular rash on the trunk) typically do not contain sufficient treponemes to be infectious, and prophylaxis for persons exposed to noninfectious lesions such as those is neither necessary nor indicated. Infectious lesions of congenital syphilis includes discharge from rhinitis ("snuffles") and bullous lesions on the skin.

Syphilis can also be acquired through nonsexual contact,[48] blood transfusion,[49] accidental inoculation in an occupational setting (e.g., laboratory or healthcare worker[50]) or nonoccupational setting (e.g., tattooing[51]), or through exposure in utero.[52]

Estimates of the risk of acquisition of syphilis following exposure to a person with infectious syphilis are varied and have been derived in two types of sources.[53] The first source are data from three prospective placebo-controlled trials of prophylactic treatment, in which 9%,[54] 28%,[55] or 63%[56] of contacts to syphilis acquired syphilis. The second source is from studies of persons identified as sex contacts in contact-tracing interviews of persons diagnosed with syphilis, in which 18%–88% of contacts acquired syphilis.[53] Nevertheless, the relatively high estimates of syphilis acquisition following exposure underscores the importance of prompt treatment and testing of sex contacts, as discussed later in this chapter. Persons recently exposed to and infected with syphilis who have yet to manifest signs or symptoms of the disease are said to have incubating syphilis.

PRIMARY SYPHILIS

As defined by CDC surveillance case definitions, primary syphilis is a stage of syphilis characterized by one or more chancres, in the presence of laboratory evidence from tissues or sera consistent with syphilis.[57] As with all CDC syphilis surveillance case definitions presented in this chapter, classification by a clinician with expertise in syphilis may take precedence over surveillance case definitions.[57]



Figure 200-2 Chancre on the penile shaft, demonstrating a clean base and elevated borders on the shaft of the penis.



Figure 200-4 Multiple chancres coalescing on the foreskin.

At the inoculation site, a chancre develops after an incubation period that ranges from 10 to 90 days (average, 3 weeks). The chancre starts as a dusky red macule that evolves into a papule and then a round-to-oval ulcer (Figs. 200-1 and 200-2). The typical chancre, also called a Hunterian chancre or "ulcus durum" (hard ulcer), ranges in diameter from a few millimeters to 2 cm and is sharply demarcated with regular, raised borders that are indurated, giving the lesion a cartilaginous feel. The base is usually clean, and the chancre is classically not painful. Up to 35% of chancres, however, are reportedly painful,[58] and multiple chancres (Figs. 200-3 and 200-4) have been reported in 32%–47% of cases.[59] The absence of any of the typical features of a chancre does not rule out syphilis, however. Variations in clinical presentation can result from the number of spirochetes inoculated, the patient's immune status, concurrent antibiotic therapy, and impetiginization.[40,60,61] Patients might not be aware of chancres, especially if painless and located in areas that are not visible, such as the anus, vagina, cervix, or oral cavity.[62]

Common genital locations for a chancre in men include the glans, the coronal sulcus, and the foreskin.[62,63] Retraction of the foreskin when a chancre is present on the underside causes the foreskin to flip suddenly, a sign known as the *dory flop*, after the movement of a dory, a small wooden fishing boat, which flips suddenly when overturned.[63,64] The dory flop sign can help distinguish chancres from other nonindurated causes of genital ulcer disease, such as herpes simplex virus infection and chancroid, that present without the induration that leads to the sudden flip of the foreskin. Uncommon presentations include giant necrotic chancre, phagedenic chancre (a deep, bright-red, necrotic ulcer with a soft base and exudate, resulting from secondary bacterial infection associated with immunosuppression), phimosis resulting from adherence of a chancre on the foreskin to the glans, and balanitis.[65]

Common genital locations in women, in decreasing order, include the cervix, labia majora, labia minora, fourchette, and urethra (Fig. 200-5).[66] Chancres in women can be more edematous than indurated.[63]



Figure 200-3 Multiple chancres on the glans and foreskin.



Figure 200-5 Chancre in a female. An ulcer covered with fibrin and necrotic slough at the orifice of the urethra.



Figure 200-6 Chancre in the perianal area. Fecal material is also present in the area.



Figure 200-7 Chancre on the penis in a man who also had plantar papules (see Fig. 200-8).

Edema indurativum is a unilateral labial swelling with rubbery consistency and intact surface, indicative of a deep-seated chancre.

Extragenital chancres in many areas of the body have been reported.[67,68] Oral sex was identified as the likely mode of syphilis acquisition in 14% of cases overall, and in 20% of cases in MSM, in Chicago during 1998–2002.[69] Other studies have attributed even higher proportions of infections among MSM to exposures during oral sex.[70] Anal sex can lead to development of chancres in the perianal (Fig. 200-6) or anal areas that can be difficult to detect on routine physical examination.[58,71] Digital or other[72,73] contact with the oral, genital, or anal areas or receiving a bite (e.g., on the nipple during sex[74]) can also lead to infection.

The chancre heals in 3–6 weeks without treatment and 1–2 weeks with treatment. Scarring typically does not occur, although thin atrophic scars may occur.[62] Coinfection with herpes simplex virus or *Haemophilus ducreyi*, the causative organism of chancroid, can be present in rare cases.[75–77] Relapses of primary syphilis, called *monorecidive syphilis* or *chancre redux*, arise in the setting of untreated or inadequately treated syphilis and are rare.[78]

In 60%–70% of cases of primary syphilis, painless regional lymphadenopathy arises 7–10 days after the chancre appears, especially when the chancre's location is genital. Unilateral lymphadenopathy is more common earlier in the course of disease, with bilateral involvement later in the course.[78]

A differential diagnosis for chancres is presented in Box 200-1.

BOX 200-1 DIFFERENTIAL DIAGNOSIS OF PRIMARY SYPHILIS

INFECTIOUS

- Herpes simplex
- Chancroid
- Granuloma inguinale
- Vaccinia
- Lymphogranuloma venereum
- Aphthous ulcer
- Erosive candidal vulvitis or balanitis

NON-INFECTIOUS

- Traumatic erosion or ulcer
- Behçet disease
- Squamous cell carcinoma
- Basal cell carcinoma
- Fixed-drug eruption

SECONDARY SYPHILIS

As defined by CDC surveillance case definitions, secondary syphilis is a stage of syphilis characterized by localized or diffuse mucocutaneous lesions, often with generalized lymphadenopathy, in the presence of laboratory evidence from tissues or sera consistent with syphilis. The chancre may still be present.[57]

Lesions of secondary syphilis, classically called "syphilids" or, when affecting the skin, "syphiloderms,"[63] typically erupt 3–12 weeks after the chancre appears (up to 6 months after exposure). In up to 25% of cases lesions of the secondary syphilis develop while the chancre is still present[59,61] (Figs. 200-7 and 200-8), with overlap more common among HIV-infected



Figure 200-8 Plantar lesions of secondary syphilis in a man who also had a penile chancre (see Fig. 200-7).



Figure 200-9 Macular syphilis (roseola syphilitica) with a subtle presentation of nonscaling, oval pink, ill-defined macules and patches on the trunk.



Figure 200-11 Lichenoid syphilitic eruption with pink to violaceous, planar, polygonal papules resembling lichen planus.

persons.[61] Rash is present in nearly all cases of secondary syphilis, although the specific type of rash varies.[59,60,79] Erythematous macules (roseola syphilitica) or maculopapules are commonly present symmetrically on the trunk and extremities in 40%–70% of cases (Fig. 200-10), with papular, papulosquamous, or lichenoid (Fig. 200-11) presentations less common.[59,79] A white scaly ring on the surface of papulosquamous lesions, called Biette's collarette (Fig. 200-12), is characteristic but not pathognomonic for syphilis. The face is typically spared in these generalized syphilids, although seborrheic dermatitis-like lesions around the hairline, termed the Crown of Venus or corona veneris, can form a crown-like pattern.[62] Lesions are not usually pruritic,[63] although pruritus was reported in up to 40% of patients in one study.[63] The presentation of the rash overall can be subtle or florid, or can develop from subtle macules to more florid papules over time.[80] Erythematous to copper-colored round papules, well demarcated and sometimes with an annular scale, are



Figure 200-10 Macular syphilis with a more florid presentation of nonscaling, oval pink, ill-defined macules and patches on the trunk.

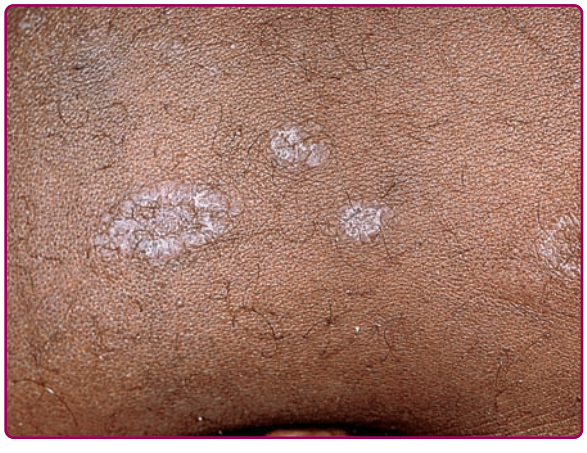

Figure 200-12 Papulosquamous syphilitic eruption with erythematous, well-demarcated, flattened plaques covered with scales (Biette's collarette).



Figure 200-13 Characteristic secondary syphilis lesions on the palms (**A**) and soles (**B**). Palmoplantar lesions may be macular or papular, discrete or diffuse, and nonscaling, slightly scaly, or hyperkeratotic ("syphilitic corn").

present on the palms and soles in nearly 75% of cases (Figs. 200-13A and 200-13B).[59] Plantar lesions can be variously mistaken for calluses (clavi syphilitici). Plantar lesions can also extend to the lateral and posterior aspects of the foot (Fig. 200-14).

Other dermatologic manifestations include a patchy nonscarring alopecia, described as "moth-eaten" (Fig. 200-15) or, less commonly, a diffuse alopecia of the scalp. Loss of lateral third of the eyebrows can occur. Annular papules and plaques can be present around the mouth and nose, in a presentation colloquially referred to as "nickels and dimes"[63] (Fig. 200-16). Papules and plaques, sometimes annular and occasionally papulosquamous, can also be present on the penis and scrotum (Figs. 200-17 and 200-18). Mucous patches are white-to-yellow erosions on the tongue that efface lingual papillae[63] (Fig. 200-19). Confluence of mucous patches on the tongue has been termed *plaques fauches en prairie*. Mucous patches can be present elsewhere in the oral cavity, on other mucous membranes, or at the corners of the mouth, where they appear as "split papules," with an erosion traversing the center (Fig. 200-20). Mucous patches are teeming with spirochetes and, hence, highly infectious. Also highly infectious are condyloma lata, which present as moist, flat, well-demarcated papules or plaques with macerated or eroded surfaces in intertriginous areas, commonly in the labial folds in females or in the perianal region in all patients[63] (Figs. 200-21 and 200-22). However, any moist intertriginous area of the body can harbor condyloma lata, including the axillae, web spaces between toes, and the folds under breasts or an abdominal panniculus. Mucous patches and condyloma lata have been reported in 8% and 17% of patients with secondary syphilis, respectively.[59] Malignant lues is a rare manifestation that presents as crusted or scaly papules and plaques that can ulcerate or become necrotic, with an oyster shell-like surface (Fig. 200-23). These lesions, described as rupioid, are often seen in association with high nontreponemal titers and systemic symptoms.[81] Nail changes including fissuring, onycholysis, Beau's lines, and onychomadesis have been reported.[62] Less common presentations of secondary syphilis include lichenoid, nodular, follicular, pustular, framboesiform, and corymbose eruptions and



Figure 200-14 Plantar lesions of secondary syphilis extending to the lateral aspect of the foot.



Figure 200-15 Moth-eaten alopecia of secondary syphilis, which is more common than diffuse alopecia. Irregular, patchy, nonscarring alopecia is present more frequently on the occipital scalp and occasionally affects the eyebrows and beard.



Figure 200-16 Annular plaques of secondary syphilis on the face, colloquially referred to as "nickels and dimes," in a transgender woman.



Figure 200-18 Papules of secondary syphilis on the penis.

palmoplantar keratodermas.[65,82–85] With the exception of mucous patches and condyloma lata, cutaneous manifestations of secondary syphilis do not contain a substantial number of treponemes and, therefore, are not typically infectious.

The maculopapular rash of secondary syphilis can resemble almost any generalized or localized maculopapular eruption (Box 200-2); mucous membrane lesions resemble mucosal manifestations of other dermatoses, and syphilitic hair loss has to be separated from other etiologies of alopecias.

Without treatment, the secondary stage typically recedes in 4–12 weeks. Scarring typically does not occur although pigmentary changes (leukoderma colli syphiliticum or, if on the neck, "necklace of Venus") can result[62] from inhibition of melanogenesis. Dermal atrophy, possibly related to elastin degradation, may occur. Absence of syphilids in cinnabar-containing red tattoos has been reported as well, possibly resulting from the antitreponemal effect of mercury in cinnabar.[86] In addition to neurosyphilis, discussed later, patients with secondary syphilis can experience systemic symptoms that include (in roughly descending order of prevalence) sore throat, malaise, headache, weight loss, fever, musculoskeletal aches, visual disturbances, and hoarseness.[79] Pharyngitis and tonsillitis,[87] laryngitis,[88] uveitis,[89] gastritis,[90] hepatitis,[90] renal disease (membranous glomerulopathy),[91] and periostitis[92] have all been



Figure 200-17 Annular papules and papulosquamous plaques of secondary syphilis on the penis.



Figure 200-19 Mucous patches of the tongue in secondary syphilis. Note lack of typical lingual papillae in affected areas.



Figure 200-20 Split papule, a type of mucous patch of secondary syphilis that can be present at the angle of the mouth, with a characteristic slit traversing its center.



Figure 200-21 Condyloma lata, presenting as papules and plaques in the perianal area.



Figure 200-22 Condyloma lata, presenting as moist, flat-topped plaques on the scrotum.



Figure 200-23 Sharply marginated, necrotic ulcers of secondary syphilis described as "rupioid," covered by thick, dirty crusts (like oyster shells), which are characteristic of malignant syphilis (lues maligna).

reported in secondary syphilis, as have hematologic abnormalities including lymphopenia, anemia, and elevated erythrocyte sedimentation rate.[93]

LATENT SYPHILIS

The secondary stage is followed by an asymptomatic stage with no clinical findings, with seroreactivity by definition the only evidence of infection. Latent syphilis therefore is a diagnosis of exclusion, after signs of syphilis, including those that can be present on accessible mucosal surfaces (e.g., oral cavity, perineum,

BOX 200-2 DIFFERENTIAL DIAGNOSIS OF THE MACULOPAPULAR RASH OF SECONDARY SYPHILIS

Most Likely

- Pityriasis rosea
- Condyloma acuminata (condyloma lata)
- Drug eruption
- Viral eruption
- Psoriasis

Consider

- Lichen planus
- Eczema
- Sarcoid
- Cutaneous T-cell lymphoma
- Erythema multiforme
- Balanitis
- Vulvitis
- Granuloma annulare
- Lupus erythematosus
- Dermatophytosis

perianal area, underneath the foreskin, labia, vaginal walls, cervix), have been excluded.[38] Latency may remain indefinitely, be interrupted by a relapse of secondary syphilis, or progress to the tertiary stage.

For disease surveillance purposes, CDC divides latent syphilis into three subcategories, early latent, late latent, and latent syphilis of unknown duration. Clinical management of patients with late latent syphilis and latent syphilis of unknown duration is identical and differs from clinical management of patients with early latent syphilis.

Early latent syphilis can be diagnosed if, within the year preceding discovery of the reactive serologic test, a person had one of the following[57]:

1. Documented seroconversion or fourfold or greater increase in titer of a nontreponemal test;
2. Unequivocal symptoms of primary or secondary syphilis;
3. A sex partner documented to have primary, secondary, or early latent syphilis; or
4. Reactive nontreponemal and treponemal tests from a person whose only possible exposure occurred within the previous 12 months.

To make a diagnosis of early latent syphilis based on the first or third criterion above, clinicians often need, and should seek, the assistance of the local health department. Because syphilis diagnoses and results of reactive serologic tests for syphilis are reportable in every state and territory of the United States, local or state health departments compile (or attempt to compile) records of all syphilis diagnoses and reactive serologic titers for persons residing in the jurisdiction. Clinicians can contact the "reactor desk" of their local or state health jurisdiction, where syphilis diagnostic and titer histories are maintained, to inquire about a patient's titer history and prior diagnoses and treatments, so that a patient can be staged as having early latent syphilis according to the first criterion above. Public health workers can also search diagnostic and titer histories in their databases for the names of sex partners identified by seroreactive patients, to enable staging patients with early latent syphilis under the third criteria above.

Latent syphilis of unknown duration is a subcategory of latent syphilis that is diagnosed in patients aged 13–35 years who have a nontreponemal titer ≥32 and in whom early latent syphilis cannot be diagnosed according to the criteria previously mentioned.[57] This category is meant to capture persons with syphilis who do not meet criteria for early latent syphilis but who, on the basis of their relatively young age and high titer, are thought to have acquired syphilis—and, possibly, have transmitted it to sex partners—more recently than persons with late latent syphilis.[38] Differentiating persons with latent syphilis of unknown duration from those with late latent syphilis is important for two reasons. First, sex partners of those with latent syphilis of unknown duration are managed like partners of those with primary, secondary, or early latent syphilis, while partners of those with late latent syphilis are managed less aggressively, as discussed later. Second, public health agencies prioritize contact-tracing investigations of persons with latent syphilis of unknown duration over persons with late latent syphilis, since the persons with latent syphilis of unknown duration are likely to have been more recently infectious to sex partners. Elicitation of and follow up with partners of persons with latent syphilis of unknown duration compared with late latent syphilis, is more likely to contribute to syphilis prevention and control efforts.

Late latent syphilis, the final subcategory of latent syphilis, is diagnosed in a patient with latent syphilis who cannot be diagnosed with one of the other two subcategories.[57]

TERTIARY SYPHILIS

Although not a formal stage of syphilis, as defined by CDC surveillance case definitions, "tertiary syphilis" is a commonly used term clinically.[57] A CDC case definition does exist for disease manifestations clinically considered "tertiary syphilis." That case definition is for "syphilis, late, with clinical manifestations other than neurosyphilis (late benign syphilis and cardiovascular syphilis)," which is characterized by inflammatory lesions of the cardiovascular system, skin, bone, and rarely, other structures, in the presence of laboratory evidence from tissues or sera consistent with syphilis.[57] Although neurosyphilis can occur at any stage of disease, as discussed later, late manifestations of neurosyphilis have historically been considered to be a manifestation of tertiary syphilis.

Historically, on the basis of information from the Oslo and Tuskegee studies, approximately one-third of patients with untreated latent syphilis progressed to tertiary syphilis, typically after 15–40 years, while the other two-thirds remain in latency. Because of effective antibiotic therapy, progression to tertiary syphilis is now very rare in the developed world.

Late benign syphilis refers to signs and symptoms of syphilis that occur after secondary syphilis that do not involve the cardiovascular or nervous systems. Lesions of late benign syphilis are caused by delayed type hypersensitivity responses to the small number of treponemes present in the involved tissue or organ.[40]

The hallmark of late benign syphilis is the gumma, a granulomatous nodular lesion with variable central necrosis, which most commonly affect the skin or mucous membranes (80% of gummas).[40] Gummas are nontender pink to dusky-red nodules or plaques that vary in size from millimeters to many centimeters in diameter.[21] They favor sites of previous trauma and may arise anywhere in the body but are more common on the scalp, forehead (Fig. 200-24), buttocks, and presternal, supraclavicular, or pretibial areas. The nodule is initially firm but develops a gummy consistency due to accumulation of necrotic tissue. Gummas may grow horizontally as well as vertically, and many assume geometric configurations. Small ulcers and abscesses may be present within the lesions. As the central gumma heals, new lesions may develop on the periphery, forming scalloped borders. In contrast to noduloulcerative lesions, gummas are deeper and more destructive (Fig. 200-25). Tissue necrosis eventuates in cylindrical, punched-out ulcers with clean granulomatous bases covered with adherent yellow–white slough



Figure 200-24 Disfiguring gummatous infiltration of the glabella and forehead with scattered ulcerations in a 60-year-old woman with late benign syphilis.



Figure 200-26 Two deep, punched-out ulcers in the popliteal fossa covered with an adherent yellow slough at the base. This is the classical appearance of nodular gummas.

(Fig. 200-26). The ulcer may enlarge, remain unchanged, or heal spontaneously even as the gumma enlarges. Superficial gummas heal with atrophic scars, whereas deeper lesions leave thickened, pitted, ridged scars. The lesions are rarely contagious, but infection following contact with gummas has been reported. Pseudochancre redux refers to a solitary gumma of the penis.

Gummas involving the mucous membranes typically affect the palate, nasal mucosa, tongue, tonsils, and pharynx. The lesions ulcerate and can be disfiguring, as when they cause a saddle-nose deformity from destruction of nasal cartilage and bone, or perforation of the nose or palate[40] (Figs. 200-27A and 200-27B). Chronic interstitial glossitis can develop even after penicillin treatment and may undergo malignant degeneration (Fig. 200-28). Besides the skin and mucous membranes, gummas can affect practically any organ, but especially the bones, liver, heart, brain, stomach, and upper respiratory tract.[16] Gummas do not heal without appropriate antibiotic therapy, but in the setting of appropriate therapy respond briskly, leaving scars.[16]

Other manifestations of late benign syphilis affecting the skin include granulomatous nodular and noduloulcerative lesions and psoriasiform plaques.[62] Nodular and noduloulcerative lesions are superficial,



Figure 200-25 Aggressive gumma of the forehead causing destruction of the calvarium, mimicking advanced, destructive basal cell carcinoma.

BOX 200-3 DIFFERENTIAL DIAGNOSIS OF TERTIARY SYPHILIS

Consider

- Sarcoid
- Metastatic carcinoma
- Sarcomas
- Lymphomas
- Granulomatosis with polyangiitis (Wegener's)
- Leishmaniasis
- Vasculitis
- Deep fungal infections
- Lupus vulgaris
- Psoriasis



Figure 200-27 Destruction of the nasal cartilage and bone by a gumma leads to a saddle nose (**A**) and to the perforation of the nasal cartilage and skin and thus to considerable mutilation (**B**).

firm, painless, dull-red, shiny, flat nodules that range in size from several millimeters to 2 cm (Fig. 200-29). They appear in a grouped configuration, can coalesce into large plaques (Fig. 200-30) or ulcerate and can resemble granuloma annulare.[94,95] Psoriasiform plaques are most commonly seen on the arms, back, and face (Fig. 200-31).

The differential diagnosis of tertiary syphilis is shown in Box 200-3.

Historically, cardiovascular manifestations of tertiary syphilis affected 10%–40% of those infected and were thought to be responsible for most deaths caused by syphilis.[16] Syphilis typically causes syphilitic aortitis, leading to aortic regurgitation in 10% of individuals with untreated disease,[96] and can also cause coronary ostial stenosis and saccular aneurysm.[97] *T. pallidum* DNA has been detected in an aortic aneurysm, demonstrating that infection of the aorta leads to direct damage to the tissue.[98]



Figure 200-28 Premalignant, chronic, interstitial glossitis secondary to gummatous infiltration of the tongue.

NEUROSYPHILIS

Neurosyphilis—literally, infection of the central nervous system (CNS) by *T. pallidum*—is commonly considered to be a manifestation of "tertiary syphilis," although neurosypyhilis can in fact occur during any stage of infection. CDC case definitions for neurosypyhilis are divided into confirmed (any stage of infection and a reactive CSF-VDRL), and probable (any stage of



Figure 200-29 A noduloulcerative tertiary syphilitic lesion is a sharply defined and irregularly shaped flat nodule of a dull red color, firm consistency, and superficial ulcerations.



Figure 200-30 Crusted and scaly noduloulcerative tertiary syphilis plaques with characteristic serpiginous borders and scarring.

infection, a nonreactive CSF-VDRL, elevated protein or white blood count without other known causes of those abnormalities, and clinical symptoms or signs of neurosyphilis without other known causes for those symptoms or signs).[27]

"Neuroinvasion," in which *T. pallidum* disseminates to cerebrospinal fluid and meninges, occurs very early in syphilis.[99] Neuroinvasion can be transient, with the body clearing the infection, or more sustained, in which case it is called asymptomatic neurosyphilis, defined by CSF abnormalities. Asymptomatic neurosyphilis, if discovered, is usually treated to prevent progression to symptomatic neurosyphilis, although benefits of treatment for asymptomatic neurosyphilis are not well documented.



Figure 200-31 Plaque of tertiary syphilis may be brick-red in color, covered with scales, and may be indistinguishable from psoriasis.

Early symptomatic neurosyphilis typically manifests as meningitis, resulting in meningismus, fever, or cranial nerve abnormalities (especially cranial nerves II, III, IV, VI, VII, and VIII), or meningovasculitis, resulting in meningitis with stroke, usually affecting the portion of the brain supplied by the middle cerebral artery.[99] Uveitis is the most common ophthalmic manifestation of early neurosyphilis, presenting as eye pain, redness, and photophobia, and sensorineural hearing loss is the most common manifestation of otologic syphilis. Ophthalmic and otologic manifestations of early neurosyphilis are managed in the same way as neurologic manifestations.[38,99]

Early symptomatic neurosyphilis is not uncommon. A review of syphilis cases among HIV-infected men in four large US cities during 2002–2004 showed that almost 2%, including persons at each stage of infection, had symptomatic early neurosyphilis. Ocular abnormalities were most common among those affected, followed by other cranial nerve involvement, acute meningitis, other syndromes (headache, altered mental status, or both), and cerebrovascular accidents. Of those with symptomatic early neurosyphilis, nearly one-third had persistent neurologic deficits 6 months after receiving appropriate treatment.[100]

The two syndromes commonly associated with late neurosyphilis are general paresis of the insane, also known as dementia paralytica, and tabes dorsalis.[99] General paresis presents as a rapidly progressive dementia, accompanied by personality changes. Tabes dorsalis presents with sensory ataxia and bowel and bladder dysfunction, resulting from damage to the posterior columns of the spinal cord. Tabes dorsalis can be accompanied by an Argyll–Robertson pupil (which accommodates but does not react to light) and optic atrophy. These syndromes are now very rare in the developed world.

Clinicians diagnosing a person with syphilis should perform a neurologic review of systems and perform a neurologic examination. According to CDC recommendations, indications for CSF examination in persons with syphilis include neurologic, ophthalmic, or otologic signs or symptoms; evidence of active tertiary syphilis; or treatment failure; HIV infection in and of itself is not an indication for CSF examination.[38] Some experts have recommended a CSF examination on all patients with a nontreponemal serologic test titer ≥1:32 or who are HIV-infected with a $CD4^+$ count ≤350 cells/μL.[101] Because benzathine penicillin G does not cross the blood–brain barrier, treatment with that form of penicillin does not interfere with subsequent CSF examination and should not be delayed on that basis. CSF examinations to assess treatment response are recommended,[38] although serologic response can be used as a proxy for CSF normalization in many cases.[102]

CONGENITAL SYPHILIS

Congenital syphilis refers to syphilis caused by infection in utero with *T. pallidum*. CDC defines a confirmed case of congenital syphilis as signs of disease in an infant or child with specific laboratory evidence of infection with *T. pallidum*.[27] A probable case is defined as a condition affecting an infant whose mother had untreated or inadequately treated syphilis at delivery, regardless of signs in the infant, or an infant or child who has a reactive treponemal test for syphilis and evidence of congenital syphilis on physical examination or radiographs of long bones, a reactive CSF-VDRL, an elevated CSF cell count or protein (without other known cause), or a reactive FTA-ABS IgM antibody test or IgM enzyme-linked immunosorbent assay.[57]

Transplacental fetal infection can occur at any time during pregnancy and at any stage of maternal infection.[103] Probability of transmission of infection depends on the stage of infection in an untreated mother, ranging from 70%–100% in primary syphilis, 40% for early latent syphilis and 10% for late latent syphilis.[104] Because infection is spread hematogenously, a chancre is not present on the fetus or infant.[103] In 30%–40% of cases, congenital syphilis results in stillbirth.[52] Of infants who survive, two-thirds are asymptomatic at delivery and only later develop symptoms.[103] Clinical findings in symptomatic infants are similar to congenital infections caused by cytomegalovirus, toxoplasmosis, herpes simplex virus, rubella, and other infections.[52] The most prominent manifestations of early congenital syphilis, defined as syphilis in a child aged <2 years, include fever, rash, hepatosplenomegaly, and persistent rhinitis ("snuffles").[103] Hydrops fetalis (edema), lymphadenopathy, neurosyphilis, leukocytosis, thrombocytopenia, and periostitis and osteochondritis may also be present, with the pain associated with osteochondritic lesions causing the infant to refuse to move the affected anatomic area ("pseudoparalysis of Parrot").[52,103] If present at delivery, the rash is usually bullous ("syphilitic pemphigus") (Fig. 200-32) and very infectious.[103] Rash that presents at two weeks or more after birth, however, is typically maculopapular, with small copper-red lesions similar to lesions of secondary syphilis most commonly affecting the hands and feet.[52] Desquamation and crusting can then occur.[105] Other cutaneous lesions present can include condyloma lata, mucous patches, fissures around the lips, nares, or anus, and petechiae from thrombocytopenia.[52] The skin of the syphilitic neonate is often dry and wrinkled and, in newborns with fair skin, may have a café-au-lait hue (Fig. 200-33).



Figure 200-32 Bullous eruptions on the soles of a newborn with early prenatal syphilis. Bullae have ruptured and now present as erosions ("syphilitic pemphigus").



Figure 200-33 Early prenatal syphilis in a newborn. The skin is dry and wrinkled, with a yellowish-brownish hue. There is hemorrhagic rhinitis. This is what Diday described as "a little wrinkled potbellied (not seen here) old man with a cold in his head." Note also the aged appearance of the fingers in this newborn.

Late congenital syphilis is defined as disease occurring in a child at least 2 years old that typically manifests over the first two decades of life.[52] Many manifestations of late congenital syphilis result from damage caused during early infection and are not reversible with treatment. Those manifestations include scars ("rhagades") (Fig. 200-34) resulting from



Figure 200-34 Perioral rhagades are linear scars that result from ulcerations that appear during early congenital syphilis and persist to adulthood.



Figure 200-35 The presence of small, notched, peg-shaped upper incisors (Hutchinson teeth) is also part of the late congenital syphilis triad.

cutaneous fissures; a saddle-nose deformity, resulting from destruction of nasal cartilage from snuffles; frontal bossing (Olympian brow), thickening of the sternoclavicular portion of the clavicle (Higoumenakis sign), anterior bowing of the midtibia (saber shins), and scaphoid scapula, all resulting from chronic periostitis; and peg-shaped notched central incisors (Hutchinson teeth) (Fig. 200-35) and mulberry molars, resulting from syphilis vasculitis in developing tooth buds. Other manifestations include eighth nerve deafness and eye abnormalities, including interstitial keratitis, glaucoma, or corneal scarring. Hutchinson's triad refers to Hutchinson teeth, interstitial keratitis, and eighth nerve deafness.[52]

Of note, as with any sexually transmitted disease, the diagnosis of syphilis in a child beyond the neonatal period should raise the question of child abuse.[38]

SYPHILIS AND HUMAN IMMUNODEFICIENCY VIRUS INFECTION

(See Chapter 198)

The interaction of syphilis and HIV infection is complex.[29] The clinical presentation of syphilis varies in minor ways between HIV-infected and HIV-uninfected persons.[29] HIV-infected persons are more likely to present with >1 chancre and with larger and deeper chancres in primary syphilis,[61,106] and are more likely to manifest signs of secondary syphilis while a chancre (or chancres) are present.[61,107] Atypical and aggressive presentations of syphilis in HIV-infected persons might also be more common, although those presentations are not thought to be unique to HIV coinfection.[29,106]

Syphilis has been shown in most studies to transiently increase HIV viral load and decrease $CD4^+$ T cell count during infection, with resolution following treatment.[108–114] Those changes might facilitate HIV transmission by HIV-infected patients coinfected with syphilis.[29,114] An effect of syphilis on progression to AIDS or mortality has not been found.[115] Syphilis has also been associated with HIV acquisition,[116] and all persons presenting with syphilis who are not known to be infected with HIV should be tested for HIV.[38] The disruption of epidermal or mucosal barriers caused by syphilis ulcers, and the migration to these lesions of inflammatory cells that are targets for HIV are two biological mechanisms that might account for the synergy between the two infections. Common behavioral factors (e.g., lack of condom use) also likely contribute to risk of coinfection. All HIV-infected persons entering HIV care should have a serologic test for syphilis, which should be repeated yearly thereafter, or more frequently if indicated (e.g., MSM, pregnant women).[117] HIV infection has also been associated with repeat syphilis infection.[32]

Because of its effect on the immune system, HIV infection is thought to increase risk of neurosyphilis,[29,99] based on studies correlating abnormal cerebrospinal fluid (CSF) findings with advanced HIV disease[101] and failure to normalize CSF-VDRL test results in the presence of HIV infection,[118] especially with lower CD4 cell counts. Additionally, HIV-infected persons with syphilis can experience "neurorelapse," meaning the development of neurosyphilis following appropriate treatment for primary, secondary, or early latent syphilis and declines in nontreponemal titers consistent with cure.[99]

HIV infection can sometimes complicate serologic diagnosis of syphilis and subsequent follow-up, since unusual serologic responses have been observed in HIV-infected persons with syphilis.[38] False-negative serologic test results in the setting of the prozone phenomenon[119] and seronegative syphilis[120] have been reported. Also, serofast reactions (i.e., persistently reactive nontreponemal test results, even following appropriate treatment) can occur in up to 40%.[121] When syphilis is suspected clinically and serology is nonreactive, skin biopsy can be useful diagnostically, as can darkfield microscopy[35] or polymerase chain reaction (PCR)-based assays for *T. pallidum*,[75] if available.

CDC treatment recommendations for syphilis do not depend on HIV infection status, supported by limited data indicating that outcomes are not improved with more intense or prolonged treatment.[29,38,117,122] Titers might decline more slowly in appropriately treated HIV-infected persons,[29,38,123] particularly those who have lower titers on initial diagnosis.[124] Compared with HIV-uninfected persons, HIV-infected persons with primary or secondary syphilis should have more frequent follow-up (Table 200-2).[117]

DIAGNOSTIC TESTS

Diagnosis of syphilis depends on clinical suspicion combined with laboratory testing to directly or indirectly detect infection with *T. pallidum*. Of note, in cases where clinical suspicion for syphilis is high, clinicians should not wait for the results of laboratory testing before administering appropriate treatment.

DIRECT DETECTION OF *T. PALLIDUM*

DARKFIELD MICROSCOPY. Darkfield microscopic examination is the diagnostic test of choice in chancres, moist lesions of secondary syphilis (condylomata lata and mucous patches), and the discharge

TABLE 200-2
CDC Recommendations for Treatment and Follow-up of Adults with Primary, Secondary, or Early Latent Syphilis[38]

Stage of Disease	HIV Status of Person	Recommended Treatment	Alternative Treatment for Penicillin-allergic Persons (Non-Pregnant Women Only[a])	Schedule for Follow-up After Treatment[b]	Timeframe to Expect Fourfold Decline in Titer[c]
Primary or secondary	HIV-uninfected	Benazthine penicllin G, 2.4 million units, administered intramuscularly in a single dose	Doxycycline 100 mg orally twice daily for 14 days	6 and 12 months	6–12 months
	HIV-infected	Benazthine penicllin G, 2.4 million units, administered intramuscularly in a single dose	Doxycycline 100 mg orally twice daily for 14 days	3, 6, 9, 12, and 24 months	6–12 months
Early latent	HIV-uninfected	Benazthine penicllin G, 2.4 million units, administered intramuscularly in a single dose	Doxycycline 100 mg orally twice daily for 14 days	6, 12, and 24 months after treatment	12–24 months
	HIV-infected	Benazthine penicllin G, 2.4 million units, administered intramuscularly in a single dose	Doxycycline 100 mg orally twice daily for 14 days	6, 12, 18, and 24 months	12–24 months

[a]Pregnant women must not be treated with doxycycline. If allergic to penicillin, pregnant women must be desensitized and then treated with benzathine penicllin G.
[b]In practice, many experts advocate follow-up every 3 months for all persons. Additionally, some persons (e.g., MSM or women who become pregnant) should be screened appropriately in addition to being followed at the recommended intervals to assess clinical and serologic response to treatment.
[c]If titers have not declined fourfold after the stated time frame, consider reinfection, treatment failure, or neurosyphilis. If at any time after treatment signs or symptoms of syphilis appear, also consider those same three possibilities.
Note that initial treatment is the same for HIV-uninfected and HIV-infected persons.

from rhinitis in congenital syphilis. Darkfield examination will often be positive before serologic tests become reactive.[125] Because nonpathogenic treponemes are normally present in the oral cavity and can be mistaken for *T. pallidum*, darkfield microscopy cannot be used to test oral lesions. The number of *T. pallidum* organisms in secondary syphilis lesions except for mucous patches and condyloma lata is generally not sufficient to allow darkfield diagnosis.

Universal precautions must be used when collecting and handling darkfield specimens, since lesions of syphilis suitable for darkfield examination are very infectious. Darkfield specimens are prepared by removing crusts from the surface of the lesion, cleaning the surface of the lesion with a sterile saline-soaked gauze, squeezing the base of the lesion with two gloved fingers to induce the presence of a serous exudate on the surface, and collecting the exudate with a glass slide, cover slip, or bacteriological loop. Only if the amount of exudate is insufficient to prevent the slide from drying out prior to microscopic examination should a drop of nonbacteriostatic normal saline be added before covering the slide with a cover slip. The slide is examined within 5–20 minutes by a trained microscopist, using a darkfield microscope, for the presence of organisms with the characteristic morphology and motility of *T. pallidum*.[35] Sensitivity is approximately 74%–79%, but declines as minutes elapse, as dead treponemes cannot exhibit the motility required for diagnosis.[35] Of note, prior application of a topical antibiotic to a lesion can yield a false-negative darkfield specimen.

DIRECT FLUORESCENCE ANTIBODY TEST.

The lesional exudate is smeared on a glass slide and

stained with fluorescein-labeled anti-*T. pallidum* immunoglobulin. In contrast to darkfield microscopic examination, the smear can be held for later evaluation and oral or anal lesions can be examined because only *T. pallidum* is stained. The sensitivity of the test is 73%–100%.[35]

MOLECULAR TESTS. In research settings, PCR-based methods have been used to detect *T. pallidum* DNA from lesions.[75]

HISTOPATHOLOGIC EXAMINATION

Histopathologic examination is not essential for a diagnosis of syphilis, which can in many cases be made on the basis of clinical findings, serologic testing, and, for appropriate lesions and if available, darkfield microscopy. In unusual or questionable cases, however, histopathologic examination can be useful.

PRIMARY SYPHILIS. At the edge of a chancre, the epidermis shows changes similar to those of secondary syphilis, discussed later.[126] The papillary dermis shows edema and a perivascular and interstitial infiltrates characterized by lymphocytes (predominantly $CD4^+$ T cells), histiocytes, and plasma cells, with neutrophils admixed. *T. pallidum* organisms can be visualized along the dermal–epidermal junction and in and around blood vessels, using Levaditis or Warthin–Starry stains or by immunofluorescent techniques.[126]

SECONDARY SYPHILIS. Although clinically different in appearance, lesions of primary and secondary syphilis share many histologic features, with changes more marked in papular lesions and less so in macular lesions.[126] In the epidermis those changes include psoriasiform hyperplasia, exocytosis of lymphocytes, spongiform pustulation, and parakeratosis, in the dermis marked papillary dermal edema and perivascular and/or periadnexal infiltrate composed of lymphocytes and/or histiocytes, sometimes granulomatous, and most intense in the papillary dermis. Plasma cells are present in three-fourths of cases, and *T. pallidum* organisms can be seen on appropriately stained sections in one-third of cases, usually in the epidermis and less commonly around superficial dermal blood vessels.[126]

TERTIARY SYPHILIS. Histopathologically, gummatous lesions are characterized by granulomas with central zones of acellular necrosis. Endarteritis obliterans and angiocentric plasma cell infiltrates of dermal blood vessels can also be present. Nodular lesions show small granulomas in the dermis, accompanied by islands of epithelioid cells, multinucleated giant cells, lymphocytes, and plasma cells.[126]

SEROLOGY

Serologic tests for syphilis include nontreponemal tests, which detect IgG and IgM antibodies to lipoidal material released from damaged host cells and possibly from *T. pallidum,* and treponemal tests, which detect antibodies to *T. pallidum* itself. Accurate serologic diagnosis of syphilis requires both types of test. Sensitivity and specificity of selected serologic tests for syphilis are shown in Table 200-3.

NONTREPONEMAL SEROLOGIC TESTS. The two most widely used nontreponemal tests are the Venereal Disease Research Laboratory (VDRL) and rapid plasma reagin (RPR) tests. The VDRL and RPR begin to become reactive 4–5 weeks after infection, with 100% sensitivity by approximately 12 weeks, and revert to nonreactive in 25%–30% of cases during late latent syphilis. Cases of seronegative secondary

TABLE 200-3
Sensitivity and Specificity of Serologic Tests for Syphilis

Test	Sensitivity (%)				Specificity (%)
	Primary	Secondary	Latent	Tertiary	
Nontreponemal tests					
RPR[35]	86 (77–99)	100	98 (95–100)	73	98 (93–99)
VDRL[35]	78 (74–87)	100	95	71 (37–94)	99 (98–99)
Treponemal tests					
TPPA[35]	88 (86–100)	100	100	NA	96 (95–100)
MHA-TP[35]	76 (69–90)	100	97 (97–100)	94	99 (98–100)
FTA-ABS[35]	84 (70–100)	100	100	96	97 (94–100)
TPHA[139]	77 (53–86)	100	99 (99–100)	100	96–99
EIA[a][140]	85–97	97–100	100 (early latent) 75–100 (late latent)	NA	99–100

[a]Various EIAs from different manufacturers were tested. See citation for details.
RPR = rapid plasma reagin; VDRL = venereal disease research laboratory; TPPA = *Treponema pallidum* particle agglutination; MHA-TP = microhemagglutination assay for *T. pallidum*; FTA-ABS = fluorescent treponemal antibody absorption assay; TPHA = *T. pallidum* hemagglutination; EIA = enzyme immunoassay.

syphilis in HIV-infected persons have been reported.[120] Results can be qualitative (reactive/nonreactive) or quantitative. Quantitative results are reported as titer, which refers to serial dilutions of serum by a factor of 2 (1:2, 1:4, 1:8, and so on). The reported titer represents the most dilute sample that gives a reactive result. RPR and VDRL titers cannot be directly compared, and even for the same test, reported titers may differ slightly between laboratorians and laboratories. Because of the importance of using nontreponemal titers to assess response to treatment, a titer for each person diagnosed with syphilis must be obtained on the day-of-treatment. Without a day-of-treatment titer, it is very difficult to interpret subsequent titers to determine whether the person has responded to treatment appropriately.

In most persons, following appropriate treatment, nontreponemal titers will revert to nonreactive. In persons treated for primary syphilis, nontreponemal tests become nonreactive in 60% by 4 months and in nearly all patients by 12 months.[127] In persons treated for secondary syphilis, the tests usually become nonreactive 12–24 months after treatment. If therapy is administered in the early latent stage, nontreponemal tests may remain reactive in low titers for up to 5 years or longer. Persons with late latent syphilis may have nonreactive nontreponemal test results, even without a history of treatment. In some persons nontreponemal antibodies can persist at a low titer for long periods, and sometimes for life, in what is called a serofast reaction which, as mentioned previously, might be more common in HIV-infected persons.[121]

False-negative results occur during very early infection or in latent and late syphilis. In a small percent of secondary syphilis cases, very high antibody titers inhibit test reactivity, producing a false-negative result, called the prozone phenomenon. To exclude the prozone phenomenon the test must be repeated with diluted serum. Many laboratories do not routinely check for the prozone phenomeon, so clinicians must request rule out of the prozone phenomenon in the appropriate setting (e.g., a patient with a suspicious rash and a negative nontreponemal test result).

Biologic false-positive results constitute approximately 1% of reactive nontreponemal tests and usually have low titers (<1:8). Causes of biologic false-positive results are shown in Table 200-4.

TREPONEMAL SEROLOGIC TESTS. Examples of treponemal serologic tests include the *T. pallidum* particle agglutination (TPPA) test, the microhemagglutination assay for *T. pallidum* (MHA-TP), the fluorescent treponemal antibody absorption assay (FTA-ABS), the T. pallidum haemagglutination test (TPHA), and various treponemal enzyme immunoassays (EIAs) and immunochemiluminescence assays. These tests, which use whole or fragments of *T. pallidum* as antigen, directly detect infection with *T. pallidum*. Compared with nontreponemal tests, they are more cumbersome to perform—except for treponemal EIAs—but have greater sensitivity in the primary and late stages and slightly higher specificity. They have historically been used, and in many setting are still used, to confirm syphilis, since a reactive treponemal test result essentially rules out the possibility of a biologic false positive reaction on a nontreponemal test. A reactive nontreponemal test result followed by a reactive treponemal test result, hence, confirms a diagnosis of syphilis. The test results must be interpreted in light of clinical findings and prior serologic test results in order to determine whether the case of syphilis is new or old, and, if the latter, previously treated successfully or not.

Persons who have had syphilis usually will have reactive treponemal test results for life, even after successful treatment, making a reactive treponemal test in a person with a history of syphilis generally not useful clinically. However, 15%–25% of treponemal tests become nonreactive between 2 and 3 years after treatment of primary syphilis.[128] The tests are highly specific and sensitive during the secondary and the late phases of the disease. Treponemal test titers do not correlate with, and are not used to monitor, disease activity. Sensitivity is low in the weeks after infection but is nearly 100% by 12 weeks. Importantly, treponemal tests can become reactive within 12 weeks of infection, before nontreponemal tests are reliably positive, and clinicians should consider ordering treponemal tests for persons suspected of early infection even if a nontreponemal test result is nonreactive. False-positive results in treponemal tests are also rare but have been associated with infections, autoimmune or connective tissue disease, or narcotic addiction.[39,128,129]

Historically, nontreponemal tests have been less expensive to perform than treponemal tests and, as a result, have been used as the first step of the laboratory algorithm for syphilis diagnosis. However, the automation of EIA tests, a form of treponemal test, has made EIAs less expensive for large-volume laboratories to perform.[39,130] As a result, some large-volume laboratories have begun to use EIAs rather than nontreponemal tests as the first step of the algorithm for laboratory diagnosis of syphilis.[39] In this newer algorithm, a treponemal EIA is performed first. If and only if that EIA result reactive, a nontreponemal test is performed. Reactive results on both tests confirm a diagnosis of syphilis. Again, knowledge of clinical findings and results of prior serologic tests for syphilis is necessary to appropriately interpret the results. In approximately 3% of cases, a reactive treponemal EIA result is followed by a nonreactive nontreponemal test result. In those cases, a tie-breaker test, usually consisting of an alternate treponemal test, can be performed, with data combined with clinical suspicion to determine diagnosis and treatment.[130] Of note, numerous rapid, point-of-care serologic tests for syphilis are available worldwide and have high sensitivity and specificity, although none have been cleared for use in the United States.[39]

CONGENITAL SYPHILIS

Transplacental transfer of maternal nontreponemal and treponemal IgG antibodies to the fetus

TABLE 200-4
Causes of Biologic False-Positive Nontreponemal Tests

	Acute	Chronic
Physiologic	Pregnancy[a]	Advanced age
Spirochete	Leptospirosis	Endemic syphilis
Infection	Lyme disease Rat-bite fever Relapsing fever	Pinta Yaws
Viral infection	Cytomegalovirus Infectious mononucleosis Hepatitis Herpes simplex Herpes zoster-varicella infection Measles Mumps *Mycoplasma* pneumonia Toxoplasmosis Viral sepsis	Human T-cell leukemia/lymphoma virus 1 Human immunodeficiency virus infection
Bacterial infection	Pneumonia	Lepromatous leprosy Lymphogranuloma venereum Tuberculosis
Protozoan infection	Malaria	Kala azar Trypanosomiasis
Autoimmune		Autoimmune hemolytic syndrome
Disease		Autoimmune thyroiditis Idiopathic thrombocytopenic purpura Mixed connective-tissue disease Polyarteritis nodosa Primary biliary cirrhosis Rheumatoid arthritis Sjögren syndrome Systemic lupus erythematosus
Other		Drug abuse Dysproteinemias Hepatic cirrhosis Malnutrition Malignancy Lymphoproliferative disorders

[a]Note: Evidence for pregnancy as a cause of biologic false-positive reactions is limited and concern persists for clinicians failing to diagnosis syphilis in pregnancy.

complicates serologic diagnosis of congenital syphilis.[38] Infants born to mothers with reactive nontreponemal and treponemal tests should be evaluated with a quantitative nontreponemal serologic test performed on infant serum, as umbilical cord blood might be contaminated with maternal blood, yielding a false-positive result. According to CDC, no treponemal test is necessary and none can be recommended, although some experts advocate use of a treponemal EIA for IgM (Captia Syphilis-M EIA), which has been cleared by FDA for diagnosis of congenital syphilis.[39] If possible, suspicious lesions or body fluids (e.g., nasal discharge) should be tested using darkfield microscopy or direct fluorescent antibody (DFA).[38]

CEREBROSPINAL FLUID EXAMINATION

CSF should be tested for VDRL reactivity, white blood cell count, and protein level,[38] as well as with other tests that would suggest other diseases in the differential diagnosis.

TREATMENT AND FOLLOW-UP

Based on extensive data from case series and clinical trials as well as clinical experience,[131] parenteral penicillin G is the recommended treatment for all stages of syphilis, with the preparation, dose, and length of

treatment dependent on the clinical manifestations, stage of disease, and age of the patient.[38] Benzathine penicillin G, the recommended preparation of penicillin for most stages of syphilis, has a long half-life, which is critical therapeutically because of the slow dividing time of *T. pallidum*. The choice of penicillin formulation is important in assuring adequate treatment. In the United States, the only penicillin product that is appropriate for treatment of primary, secondary, or latent syphilis is Bicillin L-A®, which contains only benzathine penicillin G. Another similarly packaged product, Bicillin C-R®, contains procaine penicillin G in addition to benzathine penicillin G and is not an appropriate treatment. Substantial confusion and errors relating to those two products have been reported.[132,133]

Penicillin-allergic persons with syphilis who are not pregnant and do not have neurosyphilis may be treated with doxycycline. Pregnant women who are penicillin-allergic must be desensitized to and treated with penicillin, which is the only drug that is known to cross into the placenta and treat infection in the fetus.[38] Reports of treatment failures and emergence in *T. pallidum* of resistance to macrolides including azithromycin, at one point a convenient alternative to penicillin because of its oral formulation, now precludes use of that class of drug in the U.S. and much of the world,[134–136] although it may still be used with caution in some areas.[137] As discussed previously, CDC-recommended treatment regimens do not differ on the basis of a person's HIV infection status.[38]

CDC recommendations for treatment and follow-up of adults with primary, secondary, or early latent syphilis are shown in Table 200-2. For information on children and for congenital syphilis and neurosyphilis, CDC treatment guidelines should be consulted.[38]

Clinical and serologic follow-up is important to monitor response to treatment (Table 200-2). Treatment success is generally defined as a fourfold decline in serologic nontreponemal titer (or reversion to nonreactive result) following appropriate treatment, in the absence of persistent signs or symptoms of syphilis, and within a specified timeframe depending on stage of infection and HIV infection status of the infected person.[38] An example of a fourfold decline in titer is a 1:64 titer declining to 1:16 or lower, or a 1:16 titer declining to 1:4 or lower. CDC recommends follow-up at 6 month intervals until a fourfold decline is documented, except for HIV-infected persons with primary or secondary syphilis, for whom follow-up every 3 months during the first year is recommended, and congenital syphilis, for whom follow-up every 2–3 months is recommended.[38] In practice, however, many experts recommend follow-up at 3-month intervals.

A fourfold titer increase following appropriate treatment indicates reinfection or treatment failure—the latter in some cases associated with neurosyphilis—with treatment depending on which of those is believed to have caused the increase. Reinfection must be assessed by clinical history and physical examination. If treatment failure cannot be ruled out, the patient should be treated with 7.2 millions units of benzathine penicillin G (divided in three weekly doses); CSF examination should be performed to determine whether neurosyphilis is present, and, if it is, the patient should be treated for neurosyphilis as well.

COMPLICATIONS OF TREATMENT

The Jarisch–Herxheimer reaction is a self-limited clinical syndrome consisting of fever, headache, flare of mucocutaneous lesions, tender lymphadenopathy, pharyngitis, malaise, myalgias, and leukocytosis. It occurs within 12 hours of initiating therapy and resolves within 24–36 hours. The fever peaks 6–8 hours after the onset, usually around 39°C (102.2°F), but it can be as high as 42°C (107.6°F). Patients should be warned about the possibility of developing this reaction before receiving treatment. Acetaminophen can be used to attempt to diminish the reaction, although very little evidence of its effectiveness exists.[138] The patient should be encouraged to rest, maintain fluid intake, and seek medical attention if symptoms are severe. The pathogenesis of the Jarisch–Herxheimer reaction is unknown, but is thought to result from cytokine release mediated by the release of lipoproteins from dying *T. pallidum* organisms.[138] In pregnant patients, the Jarisch–Herxheimer reaction may lead to premature contractions or loss of fetal movement, events that should prompt the patient to seek evaluation. However, given the potentially devastating effects of congenital syphilis, prompt treatment of maternal syphilis is critical.[38]

Anaphylaxis from administration of penicillin injection is a life-threatening emergency that is managed by intramuscular injection of epinephrine and diphenhydramine with hydrocortisone intravenously along with emergent transfer to a monitored setting.[47]

At the time of initial treatment, patients should be educated to distinguish an allergic reaction, which precludes further treatment with penicillin or related drugs, from a Jarisch–Herxheimer reaction, which does not.

DISEASE REPORTING AND MANAGEMENT OF PERSONS EXPOSED TO SYPHILIS

As reflected by the efforts to eliminate syphilis in the United States, prevention and control of syphilis are of substantial public health interest in the United States and worldwide.[2,26] Syphilis is a nationally notifiable disease in the United States, meaning that both clinicians and laboratories are mandated by law to report cases or laboratory results diagnostic of or suspicious for syphilis to their local or state public health authorities.[57] Clinicians should contact their local or state health department to familiarize themselves with local reporting requirements, including required forms and need for paper-based or electronic reports, for syphilis and other reportable diseases.

Local or state public health authorities maintain databases of syphilis diagnoses, laboratory results, and

treatments for persons diagnosed with syphilis. That information is available to clinicians taking care of persons with suspected syphilis and can be helpful in staging infections (e.g., determining if criteria for early latent syphilis are met) and assuring appropriate treatment. Clinicians should routinely encourage persons diagnosed with syphilis to inform their sex partners of exposure to syphilis and follow-up with patients to assure that disclosure has occurred. Identifying which sex partners are at risk of infection depends both on the elapsed time since last exposure and stage of infection in the source patient. This risk period is 3 months plus duration of symptoms for primary syphilis, 6 months plus duration of symptoms for secondary syphilis, and 1 year for early latent syphilis and latent syphilis of unknown duration. Clinicians should also inform persons they diagnose with syphilis that the case will be reported to the public health authority and that, in many cases, health department workers (sometimes called Communicable Disease Investigators [CDIs] or Disease Intervention Specialists [DIS]) will contact the person to ensure that treatment was adequate, provide education about syphilis, solicit contact information for sex partners, and inquire about sexual behaviors so that prevention and control resources can be targeted to affected populations. It is a principle of public health practice, including in syphilis contact-tracing investigations, to protect the confidentiality of the source partner.

Management of at-risk sex partners of persons diagnosed with syphilis also depends on elapsed time since exposure.[57] Sex partners exposed during the 90 days preceding the diagnosis of primary, secondary, or early latent syphilis should be examined and tested for syphilis. However, regardless of results of the physical examination and laboratory tests, those partners should be treated presumptively because of the high efficacy of prophylactic treatment and the likelihood (up to 63%) that they been infected but have yet to show clinical or laboratory evidence of disease. Persons exposed >90 days before the diagnosis of primary, secondary, or early latent syphilis should also be examined and tested and treated presumptively if serologic test results are not available immediately and the opportunity for follow-up is uncertain. Sex partners of persons with late latent syphilis should be evaluated and tested, and then managed on the basis of those findings.

KEY REFERENCES

Full reference list available at www.DIGM8.com

DVD contains references and additional content

2. Fenton KA et al: Infectious syphilis in high-income settings in the 21st century. *Lancet Infect Dis* **8**:244-253, 2008
16. Lafond RE, Lukehart SA: Biological basis for syphilis. *Clin Microbiol Rev* **19**:29-49, 2006
19. Jones JH: *Bad Blood: The Tuskegee Syphilis Experiment*. New York, Free Press, 1993
26. CDC: *The National Plan to Eliminate Syphilis From the United States*. Atlanta, GA, Dept. of Health and Human Services, Centers for Disease Control and Prevention, 2006
27. CDC: *Sexually Transmitted Disease Surveillance, 2008*. Atlanta, GA, U.S. Department of Health and Human Services, 2009
28. Peterman TA, Furness BW: The resurgence of syphilis among men who have sex with men. *Curr Opin Infect Dis* **20**:54-59, 2007
38. CDC: Sexually transmitted diseases treatment guidelines, 2010. *MMWR Recomm Rep* **59 (RR-12)**:1-110, 2010
39. Sena AC, White BL, Sparling PF: Novel Treponema pallidum Serologic Tests: A Paradigm Shift in Syphilis Screening for the 21st Century. *Clin Infect Dis* **51**:700-708, 2010
45. Cullen PA, Cameron CE: Progress towards an effective syphilis vaccine: The past, present and future. *Expert Rev Vaccines* **5**:67-80, 2006
46. Klausner JD: The sexual history. In: *Current Diagnosis & Treatment of Sexually Transmitted Diseases*, edited by JD Klausner, EW Hook III. New York, McGraw-Hill, 2007, pp. 229-231
57. CDC. Case definitions for infectious conditions under public health surveillance. *MMWR Recomm Rep* **46**(No. RR-10):1-55, 1997
62. Lautenschlager S: Cutaneous manifestations of syphilis: Recognition and management. *Am J Clin Dermatol* **7**:291-304, 2006
63. Crissey JT, Denenholz DA: Clinical picture of infectious syphilis. *Clin Dermatol* **1**:39-61, 1984
99. Marra CM: Update on neurosyphilis. *Curr Infect Dis Rep* **11**:127-134, 2009
100. CDC: Symptomatic early neurosyphilis among HIV-positive men who have sex with men–four cities, United States, January 2002-June 2004. *MMWR Morb Mortal Wkly Rep* **56**:625-628, 2007
126. Crowson AN, Magro C, Mihm M: Treponemal diseases. In: *Lever's Histopathology of the Skin*, 9th edition, edited by DE Elder. Philadelphia, Lippincott Williams & Wilkins, 2005, pp. 591-602
130. CDC: Syphilis testing algorithms using treponemal tests for initial screening–four laboratories, New York City,2005–2006. *MMWR Morb Mortal Wkly Rep* **57**:872-875, 2008
134. Katz KA, Klausner JD: Azithromycin resistance in Treponema pallidum. *Curr Opin Infect Dis* **21**:83-91, 2008

Chapter 201 :: Endemic (Nonvenereal) Treponematoses

:: Nadine Marrouche & Samer H. Ghosn

ENDEMIC TREPONEMATOSES AT A GLANCE

- Pinta, yaws, and endemic syphilis (bejel) are nonvenereal infections usually acquired by skin-to-skin-contact.
- They are caused by *Treponema pallidum* subspecies or closely related treponemes.
- They are mostly endemic in rural areas within tropical and subtropical regions of selected countries.
- Like venereal syphilis, these infections are clinically characterized by three successive stages separated by periods of latency.
- Although not fatal, they are disfiguring and disabling.
- Penicillin therapy is highly effective for both the cutaneous and systemic lesions.

INTRODUCTION

The endemic, or nonvenereal, treponematoses are infections caused by bacteria that are closely related to *Treponema pallidum pallidum*, the etiologic agent of venereal syphilis. These include *Treponema carateum* (pinta), *Treponema pallidum pertenue* (yaws), and *Treponema pallidum endemicum* (bejel or endemic syphilis). The diseases are distinguished from venereal syphilis by mode of transmission, age of acquisition, geographic distribution, and clinical features. Unlike syphilis, they are transmitted mostly among children living in tropical and subtropical climates, chiefly by casual contact rather than sexual contact, and congenital infection is unusual. As many as 2.5 million persons are believed to be infected with nonvenereal treponematoses. However, a significant proportion of infected persons remain asymptomatic. Like venereal syphilis, the diseases progress through successive clinical early (primary and secondary) and late stages usually separated by periods of latency.[1]

Without treatment, patients remain potentially infectious indefinitely, although the skin lesions may become inconspicuous or subclinical. Patients do not develop lifelong immune resistance. Cross-immunity is absent in the early stages of endemic syphilis, yaws, and pinta but is variable in late stages. Notably, patients with late pinta are resistant to syphilis, but those with yaws or syphilis at any stage are susceptible to pinta. The level of cross-protection may be proportional to the severity of the initial infection.[1] Untreated treponematoses are nonfatal but may cause cutaneous lesions and deformities of the bone and cartilage. This potentially leads to significant disfigurement, pain, disability, and social isolation, thus incurring a significant economic burden on already disadvantaged populations.

MICROBIOLOGY

The different treponemal species causing venereal and nonvenereal treponematoses are morphologically and serologically identical and induce comparable histopathological changes. This reflects the high antigenic relatedness among these organisms and justifies the long-standing controversy about the origin of these diseases. Some authors had even claimed that the morphologically identical treponemes represent the same organism causing different clinical manifestations under different climatic conditions.[2] Over the past two decades, evidence from molecular studies has accumulated supporting the argument for species specificity. Molecular data have allowed the elucidation of genetic features differentiating *T. pallidum pallidum* from the nonvenereal treponemes.[3–7] It was not until recently that Centurion et al identified subspecies-specific genetic signatures in the *trp* gene family that allow differentiation among the *T. pallidum* subspecies.[8]

PINTA (CARATE, MAL DE PINTA, AZUL)

EPIDEMIOLOGY AND ETIOLOGY

Pinta is an ancient disease that was first described in the sixteenth century in Amerindians.[9] The causative organism is *T. carateum*, which is the least antigenically related to the other human treponemes as it is a separate species from *T. pallidum*. The name of the organism derives from the Colombian word for the disease ("carate"), in reference to the color changes seen in persons having the disease. The organism can be propagated only in primates, and no isolates are known to exist.[10] Consequently, much less is known about this treponeme than any of the others.

The incidence of the disease has remarkably decreased over the last few decades. Today, pinta remains prevalent in scattered foci in rural areas of Central and South America (Southern Mexico, Brazil, Colombia, Venezuela, Peru, and Ecuador), where people still live in crowded, unhygienic conditions. People of all ages may be infected. However, half of

all patients are younger than 15 years of age.[11] The exact mechanism of disease transmission is not fully elucidated, but repeated direct lesion-to-skin contact is the most likely mode. Transmission through insects is unlikely.[1] Because cell-mediated immunity is not completely effective against this organism, untreated infection persists indefinitely.

CLINICAL FINDINGS

Pinta is the most benign of the endemic treponematoses with the skin being the only organ of involvement. As in syphilis, there are three distinct clinical stages. Lesions at different stages may be present in a single patient. Lymphadenopathy may develop during any stage.

PRIMARY STAGE. A small number (1–3) of erythematous macules or papules appear at the site(s) of inoculation after an incubation period of 1–8 weeks. Primary lesions are usually nonpruritic and do not ulcerate. Sites of predilection include exposed areas of the extremities in addition to the face and neck. The initial lesions expand or coalesce with other lesions over several weeks to months, forming irregular scaly lichenified plaques that can reach a diameter of up to 20 cm (Fig. 201-1).[12] Over time, the center of the lesions becomes hypochromic, grayish, light blue, or pale mauve.[1] Eventually, lesions may heal spontaneously with residual depigmentation[13] or may persist for years.

SECONDARY STAGE. After several months and occasionally up to 10 years after the initial infection, secondary lesions (pintids) start to appear. These are highly infectious lesions teeming with spirochetes.[12] Like the primary lesions, pintids start as erythematous scaly papules that enlarge and coalesce into psoriasiform plaques. However, they tend to be smaller and more extensive than the primary lesions. They may encircle the sites of the primary lesions or erupt generally on the body. Pintids may occur on the palms, soles, and groin.[1] Some lesions may be circinate or annular with raised borders where the number of treponemes is highest. Over time, lesions display remarkable variation in color ranging from copper colored to gray to slate blue.[11]



Figure 201-1 Lichenified patch in primary pinta with dyschromic changes.



Figure 201-2 Depigmented and hyperpigmented, mottled patches in late pinta.

TERTIARY STAGE. Late lesions usually develop 3 months to 10 years after the appearance of the secondary lesions. Typically, patients have dyschromic patches that are hyperchromic, hypochromic, and achromic, which impart a mottled pattern with a variegated palette of white, brown, blue, red, and violet. The lesions have irregular borders and vary in size. The most commonly involved areas are the wrists, palms, ankles, and elbows as well as the skin around and within old lesions (Fig. 201-2). It is common for periarticular lesions of pinta to exhibit scarring and atrophy ("cicatricial lesions of pinta").[9] This is in contrast to extensor surface plaques that tend to be hyperkeratotic.[14] Patients with only late-stage lesions may appear to have vitiligo ("vitiligo of pinta").

DIFFERENTIAL DIAGNOSIS

(Box 201-1)

YAWS (FRAMBOESIA TROPICA, PIAN, BUBA, PARU, PARANGI)

EPIDEMIOLOGY AND ETIOLOGY

Yaws is caused by *T. pallidum pertenue*. The spirochete can be propagated in laboratory animals, and various strains have been isolated for investigation.[1] The infection affects rural populations along the tropical belt in areas with high humidity, heavy rain, and annual temperatures at and above 27°C.[15] The spread of the spirochete is facilitated in the setting of poor hygiene, scanty clothing, and overcrowding.[11]

Yaws is the most prevalent nonvenereal treponematosis. An estimated average of 50 million persons was infected in the early 1950s. Massive WHO supported treatment campaigns were carried from the

BOX 201-1 DIFFERENTIAL DIAGNOSIS OF PINTA

Most Likely

- Leukodermas
- Eczema (early lesions)

Consider

- Pityriasis alba
- Pellagra and other vitamin deficiencies
- Tinea versicolor
- Melasma
- Lichen planus (early lesions)
- Tuberculoid leprosy (early lesions)
- Tinea corporis
- Psoriasis (early lesions)
- Lupus erythematosus (early lesions)
- Atrophic lichen planus
- Yaws (early lesions)
- Syphilis
- Leprosy

Always Rule Out

- Vitiligo (late depigmented stage)
- Erythema dyschromicum perstans

mid-1950s to the early 1960s, which resulted in a dramatic decrease in the prevalence of the disease.[16] However, due to relaxed surveillance and control measures, under-diagnosis, and the persistence of poor sanitary conditions, a resurgence of yaws has been documented in regions of Africa and Southeast Asia. Sizable foci have been reported in several tropical regions of western and central Africa (Ghana, Togo, Benin, and the Central African Republic), and residual foci remain in South America (Colombia, Guyana, Peru, Ecuador, and Brazil), Haiti, Dominica, Southeast Asia, Indonesia, Papua New Guinea, and the Solomon Islands.[11] Approximately 75% of new cases arise in children younger than 15 years of age.[17,18] Currently, at least 100 million children are estimated to be at risk of becoming infected.[1]

The main route of transmission of yaws is direct skin-to-skin contact and via contact with open wounds, excoriations, or bites.[19] Some experts claim that the disease can be transmitted through domestic utensils or by the eye flies (eye gnats) that are 1.5–2.5 mm long and do not bite but rather feed on body fluids of various animals including humans.[1]

CLINICAL FINDINGS

Yaws shares numerous clinical characteristics with venereal syphilis. In contrast to pinta, the disease is not skin-limited. Among the nonvenereal treponematoses, the disease is characterized by the most destructive and disfiguring skeletal involvement.

PRIMARY STAGE. In the primary stage, skin lesions appear after an incubation period of 10–90 days (on average 3 weeks). Classically, the initial presentation is a single nontender but often pruritic erythematous infiltrated papule (mother yaw or buba madre) that often acquires a papillomatous surface.[1] Its location often indicates the site where the spirochete penetrated the skin, usually the legs, feet, or buttocks.[20] Satellite papules may be present. Over time, the mother yaw enlarges radially reaching up to 5 cm in diameter and occasionally merges with the smaller satellite lesions forming a larger plaque. It often ulcerates, forming the "chancre of yaws", and develops a yellow–brown crust which ultimately sloughs off, uncovering a moist soft base that is often likened to a raspberry, hence the synonym "framboesia" (Fig. 201-3). The ulcer is very rich in treponemes. Fever, regional lymphadenopathy, and arthralgias may accompany this stage.[14] The mother yaw heals over 3–6 months but sometimes remains through the secondary stage of the disease. It typically leaves a depigmented pitted scar with dark margins.[21]

SECONDARY STAGE. The lesions of secondary yaws, known as "daughter yaws" or pianomas, may appear while the mother yaw is still present, but may take up to 2 years to develop.[1] These lesions resemble the mother yaw but are smaller (up to 2 cm) and more disseminated (Fig. 201-4A). They are often accompanied by constitutional symptoms such as fever, malaise, and generalized lymphadenopathy. Over time, daughter yaws may ulcerate and secrete a fibrinous exudate teaming with infectious treponemes (Figs. 201-4B and 201-4C).

The exudate attracts flies, which can cause great suffering to the affected person. Lesions usually favor perioroficial locations, such as around the mouth and nose.[14] In addition to the characteristic exudative papillomas,



Figure 201-3 Ulcerated primary-stage nodule (mother yaw). The genital location is unusual.



Figure 201-4 **A**. Early secondary lesions of yaws (daughter yaws) appearing as eroded and crusted papules and plaques. **B**. Warty secondary-stage papillomas (daughter yaws). **C**. Eroded papillomas covered by fibrinous exudate. (**B** and **C** used with permission from H.J.H. Engelkens, MD, J. van der Stek, MD, and E. Stolz, MD.)

dry papulosquamous patches (pianides), comparable to those seen in venereal syphilis, may appear on any body part.[20] Occasionally, central clearing results in an annular morphology simulating a fungal infection and these have been called "tinea yaws."[14] In the body folds, secondary lesions simulate condyloma lata. More rarely, the mucous membranes, especially the oral cavity, are involved in the form of hypertrophic mucous patches.[1] Hyperkeratotic lesions, affecting mainly palms and soles, are characteristic. They are referred to as "crab yaws" because they get fissured and infected resulting in a painful "crablike" debilitating gait (Fig. 201-5).[17] Periungual hyperkeratosis results in a paronychia which is known as "pianic onychia."[22] Of special interest is the influence of the climate on the clinical expression of yaws. During wet seasons, lesions tend to be more florid and diffuse whereas they are less exudative and confined to the moist intertriginous areas in the setting of a dry climate.[11] They also tend to assume atypical morphologies in dry seasons. Some reports describe an attenuated, less contagious form of yaws in areas of low disease prevalence. This form is less florid with few (even single), small, dry, lesions that are often limited to skin folds.[1]



Figure 201-5 Fissured hyperkeratotic plantar keratoderma in secondary yaws (crab yaws).

Bone and joint manifestations may already occur during this early stage of the disease.[23] These consist of painful osteoperiostitis of the forearm or leg, in addition to the proximal phalanges of the hands or feet. The characteristic "ghoul (monster) hands" appearance reflects swelling of the proximal two phalanges.[1] Some of the early bone changes can be seen on radiographs. Periosteal thickening can often be palpable.[24] Lesions of secondary yaws tend to resolve spontaneously without scarring over weeks to months. The disease then enters a latent stage during which relapses, usually one or two, are common. In relapsing yaws, lesions tend to be confined to the perioral, perianal, and periaxillary areas. Recurrences are possible for as long as 5 years after the initial infection. This is followed by either elimination of the organisms or in most cases a lifelong latency period.[1]

TERTIARY STAGE. Tertiary yaws is estimated to develop in approximately 10% of cases around 5–10 years after inoculation.[11] This stage is characterized by irreversible soft tissue and skeletal deformities. Gummatous suppurative nodules may involve the skin and subcutaneous tissues (gumma framboesiodes). These often break down and coalesce into serpiginous ulcers characterized by significant necrosis. Eventually, keloidal scarring and debilitating contractures ensue.[11,14] Hyperkeratotic lesions on the palms and soles, similar to those occurring in early yaws, are another common cutaneous manifestation of this stage and may lead to palmoplantar keratoderma. Mottled depigmentation of the hands, over the wrists, and along the shins has been described in older adults.[1]

Different forms of skeletal involvement lead to variable manifestations. Hypertrophic periostosis can result in unilateral or bilateral exostosis of the nasal process of the maxillae called "goundou."[25] Destructive ostitis can lead to curvature of the tibia (saber tibia) or, rarely (in 1% of untreated persons), to the dreaded mutilating rhinopharyngitis obliterans, also known as "gangosa." The latter results from massive ulcerative

BOX 201-2 DIFFERENTIAL DIAGNOSIS OF YAWS

Most Likely

- Frambesiform leishmaniasis (pianomas, gangosa)
- Paracoccidioidomycosis (pianomas)

Consider

- Psoriasis (pianides)
- Impetiginized eczema (pianides)
- Pyoderma vegetans (pianomas)
- Arthropod bites (pianides)
- Myiasis (pianides)
- Scabies (pianides)
- Dermatophytosis (pianides)
- Pyoderma (pianomas)
- Lupus vulgaris (gangosa)
- Atypical mycobacterial infection
- Deep fungal infections (gangosa)
- Tuberculoid leprosy (pianides)
- Ecthyma (pianomas)
- Vitiligo (late dyschromic stage)
- Pinta (late dyschromic stage)
- Keratodermas
- Plantar Verrucae
- Rhinosporidiosis (gangosa)
- Rhinoscleroma (gangosa)
- South American Blastomycosis (gangosa)
- Bacterial osteomyelitis (bone lesions)
- Sickle cell anemia (bone lesions)

Always Rule Out

- Frambesiform syphilis (pianides, pianomas)

destruction of the nasal cartilage and other midfacial structures.[9] Joint manifestations include the development of juxta-articular subcutaneous nodules which can ulcerate. These are not to be confused with the nodules of early yaws.[11] Although very rare, ocular (optic disc atrophy), CNS (myeloneuropathy), and cardiovascular (aneurysms) abnormalities have been reported in late yaws.[1,26] Some have even suggested that all known complications of venereal syphilis can occur in yaws.[27]

DIFFERENTIAL DIAGNOSIS

(Box 201-2)

ENDEMIC SYPHILIS (BEJEL, FIRJAL, LOATH, BISHEL, BELESH, NJOVERA)

EPIDEMIOLOGY AND ETIOLOGY

Bejel is the name given by the Arab Bedouins of Syria and Iraq to endemic syphilis.[14] The causative organism is *T. pallidum endemicum*. It is prevalent among rural communities in dry and arid climates, under conditions of crowding and poor hygiene.[11] For centuries, it was encountered in Northern Europe, Southeast Asia, and Southern Africa. Nowadays however, it is mostly prevalent among nomads and semi-nomads in the Arab Peninsula (Iraq, Syria, and Saudi Arabia), and along the Sahel (Southern border of the Sahara desert).[11,14] The recent literature points toward a marked resurgence of the disease in North Burkina Faso,[28] Turkey,[29] and Niger.[30] In endemic areas, children under 15 years of age represent around 80% of all cases and serve as an important disease reservoir.[31] Transmission occurs via direct contact with infectious lesions on the skin and mucous membranes. One study demonstrated the presence of treponemes on a drinking flask, supporting indirect transmission through sharing food and fomites.[32,33]

CLINICAL FINDINGS

Like yaws, the clinical features of bejel resemble those of venereal syphilis, except that mucosal involvement tends to predominate. Although joint pain and bone changes are common, they tend to be less severe than the skeletal manifestations seen in yaws.

PRIMARY STAGE. Early lesions of endemic syphilis start to appear after an incubation period of 2–4 weeks. In contrast to other nonvenereal treponematoses, primary lesions often go unnoticed because they usually involve the oral and nasopharyngeal mucosa. These present as painless, small papules that may become eroded and ulcerated. Lesions on the nipples of breastfeeding women can also be seen. Primary lesions usually resolve in 1–6 weeks.[12]

SECONDARY STAGE. This stage develops around 6 months postinoculation. It is characterized by both mucocutaneous and skeletal manifestations. Painless, often macerated and eroded mucous patches develop on mucosal membranes of the oral cavity, nasopharynx, and might even reach the larynx. Angular stomatitis (also known as split papules) appear at the labial commissures.[1] Skin lesions include vegetating condyloma lata in the moist intertriginous areas of the axillae and groin. These are comparable to those seen in yaws and venereal syphilis.[11] In up to 15% of cases, a diffuse skin rash with generalized lymphadenopathy may develop. As in secondary syphilis, the rash can assume different morphologies such as macular, papular, or annular lesions. Painful periostitis of the long bones and hands, as in yaws, may occur at this stage leading to nocturnal lower extremity pain.[14] Untreated, secondary lesions continue to appear for up to 9 months postinoculation. This is followed by a latent stage of variable length (up to 15 years). Occasionally, it may last for only few months leading to the development of the tertiary stage at a very young age.[21]

TERTIARY STAGE. Tertiary bejel is characterized by mucocutaneous and skeletal manifestations in the



Figure 201-6 Cutaneous gummas in late endemic syphilis. Note the involvement of the elbow.

BOX 201-3 DIFFERENTIAL DIAGNOSIS OF ENDEMIC SYPHILIS

Most Likely

- Condylomata acuminata
- Molluscum contagiosum
- Oral herpes simplex
- Aphthous ulcers
- Angular cheilitis

Consider

- Seborrheic dermatitis (papulocircinated lesions)
- Psoriasis (papulocircinated lesions)
- Dermatophytosis (papulocircinated lesions)
- Deep fungal infection (gummas)
- Leishmaniasis (gummas)
- Mycobacterial infection (gummas)
- Lymphomas and sarcomas (gummas)
- Granulomatous diseases (gummas)

Always Rule Out

- Venereal syphilis

form of deforming gummas that tend to be generally less mutilating than those of yaws (Fig. 201-6). In the skin, destructive ulcers result eventually in the formation of depigmented scars with hyperpigmented borders. Mucosal involvement may eventuate in disfiguring complications such as saddle-nose deformity, palate perforation, and gangosa.[12] The larynx has been reported to be solitarily involved.[34] Although joint pain and bone changes are common, they tend to be less severe than the skeletal manifestations seen in yaws. They are often only noticeable by plain radiography. Uveitis, optic atrophy, and even chorioretinitis have been reported.[35] Cardiac involvement seems to be extremely rare and has been reported in the form of aortitis and saccular aneurysms of the aortic arch.[12] An attenuated form of endemic syphilis with fewer, more rapidly healing cutaneous lesions but more frequent periostitis has been reported. As in attenuated yaws, this milder form has been attributed to better nutrition and hygiene, and earlier access to antibiotic therapy.[14]

DIFFERENTIAL DIAGNOSIS

(Box 201-3)

DIAGNOSIS OF THE NONVENEREAL TREPONEMATOSES

A presumptive diagnosis of pinta, yaws, or endemic syphilis in a given patient should be suspected on the basis of the clinical findings in the setting of an endemic area (Table 201-1). However, this task is difficult at times, especially in view of the occurrence of sporadic cases outside areas of endemicity. Health care providers with limited experience in recognizing these diseases frequently misdiagnose them as impetigo, psoriasis, mycobacterial infection, or tropical ulcer, among other diseases. The diagnosis is confirmed by detection of the treponemes under darkfield microscopic examination or with a direct fluorescent antibody (DFA) test, by serology, or by histologic examination. Darkfield microscopy allows microscopic examination of the serous exudates of lesions and permits a rapid demonstration of treponemes; however, it necessitates expertise and is not readily available. DFA test allows a more sensitive and specific microscopic diagnosis. However, this technique is only available in central laboratories.[1] The same serological tests used in the diagnosis of venereal syphilis are used to diagnose the endemic treponematoses; however, no single test is yet available that can differentiate endemic treponematoses from each others or from venereal syphilis. These tests are affordable, readily available, and can be particularly helpful when microscopic tools are nonrevealing or unavailable.[11] Nontreponemal serological tests are usually used for screening, whereas treponemal tests are used for diagnosis confirmation. Nontreponemal tests, including the Venereal Disease Research Laboratory test and the Rapid Plasma Reagin test, use a nonspecific cardiolipin antigen that is cross-reactive among the various treponemes. Positivity indicates either a recent or a current infection. In yaws and endemic syphilis, nontreponemal tests yield reactive results in 2–3 weeks after the onset of the primary lesion. In pinta, these tests give reactive results in 80% of cases within 3 months after the appearance of primary lesions and in essentially all patients with the late stage of the disease.[36] After treatment, serological titers of the nontreponemal tests decrease, which makes them valuable in monitoring

TABLE 201-1
Nonvenereal Treponematoses—Clinical Manifestations

	Pinta	Yaws	Endemic Syphilis
Causative organism	*Treponema carateum*	*Treponema pallidum pertenue*	*Treponema pallidum endemicum*
Transmission	Skin-to-skin contact	Skin-to-skin contact, via eye flies (?)	Skin or mucosal contact, via drinking flasks (?)
Peak ages	1–15 years	1–15 years	Months–15 years
Incubation	7–60 days	10–90 days	15–30 days
Primary lesions	Erythematous papules become psoriasiform plaques	Vegetating, soft, ulcerating papule (mother yaws) with satellites	Small eroded mucosal papule (often overlooked)
Secondary lesions	Erythematous scaly and psoriasiform plaques (pintids); dyschromia	Warty or frambesiform nodules (pianomas), papulosquamous plaques (pianides), palmoplantar plaques, pianic onychia	Mucous patches (split papules), condylomata lata, syphilis-like eruptions
Tertiary lesions	Dyschromic, hypochromic, achromic, and polychromic patches	Serpiginous gummas, pintoid dyschromia, juxta-articular nodes, gangosa, goundou, keratoderma	Gummas, gangosa, juxta-articular nodes on elbows only
Reactive serologic test result	2–3 months after primary lesion	2–3 weeks after primary lesion	2–3 weeks after primary lesion
Treatment	Penicillin	Penicillin	Penicillin

patients post-therapy. The specific treponemal tests, which use *T. pallidum* as an antigen, include the fluorescent treponemal antibody absorption (FTA-ABS) and the microagglutination assays for antibodies to *T. pallidum* (MHA-TP) tests. They are important in excluding false-positive nonspecific tests. In contrast to the nontreponemal tests, they may not only indicate a current or recent infection, but would remain reactive even after adequate treatment, indicating as such a past infection ("serological scar").[1] Other treponemal tests, including enzyme immunoassays, have not shown greater specificity than the FTA-ABS test but may be less expensive.[36] A finger-prick indirect hemagglutination test is advantageous for screening children.[37]

Although serological tests are still the most practical diagnostic tool, they are not subspecies specific. Recent identification, by molecular testing, of reliable genetic signatures for the different treponemal subspecies, may prove in the near future to be a valuable tool not only for research but also for diagnostic purposes.

HISTOPATHOLOGIC FEATURES OF THE NONVENEREAL TREPONEMATOSES

In early pinta, the epidermis shows only mild acanthosis, spongiosis, and lymphocytic exocytosis. The basal cell layer exhibits decreased keratinocyte pigmentation and liquefactive necrosis. In the dermis, melanophages are numerous and there is a mixed perivascular inflammatory cell infiltrate consisting mainly of plasma cells and lymphocytes, with scattered histiocytes and neutrophils. Unlike in venereal syphilis, endothelial cells only occasionally exhibit mild swelling. Identification of treponemes using silver staining or immunofluorescence techniques is possible in the early stages. In the tertiary stage, the epidermis might become atrophic. Langerhans cells are noted to be increased.[38] The inflammatory infiltrate becomes sparse or even absent, especially in the depigmented lesions. Visualization of treponemes becomes more difficult, particularly in hypo/depigmented patches.[11,14]

Findings of yaws are similar to those of pinta, but yaws usually causes ulcer formation. In early yaws, acanthosis, papillomatosis, focal spongiosis, and neutrophilic exocytosis/microabscesses are the main epidermal changes.[39] Throughout the stages of the disease, a diffuse inflammatory cell infiltrate composed mostly of plasma cells is usually seen in the dermis. This is in contrast to venereal syphilis, where a T-cell dermal infiltrate has been identified in the early disease stage.[40] Yaws spirochetes exhibit striking epidermotropism in contrast to venereal syphilis where the spirochetes favor the dermal compartment. Blood vessels show little or no endothelial cell proliferation. Endarteritis is a feature of late lesions.[11,14]

The changes seen in bejel closely resemble those of venereal syphilis particularly with regard to the presence of giant cell granulomas. The epidermal changes seen in secondary bejel lesions resemble those of

BOX 201-4 TREATMENT OF THE NONVENEREAL TREPONEMATOSES

First Line	Benzathine penicillin G	>10 years	1.2 million units IM	Single dose
		<10 years	0.6 million units IM	Single dose
Second Line	Oral erythromycin	Adults	500 mg qid	15 days
		Children <8 years	8–10 mg/kg qid	15 days
	Oral doxycycline	Adults	100 mg bid	15 days
	Oral tetracycline	Adults	500 mg qid	15 days
		Children >8 years	250 mg qid or 25 mg/kg/day	15 days

condyloma lata; however, the dermal infiltrate in bejel is more diffuse rather than perivascular as in syphilis. Organisms are present in primary and secondary stages but not in late disease stages.[11,14]

The dyschromic patches seen in treponematoses may reveal variable alterations in basal keratinocyte pigmentation or melanocytes' number and are, as such, hard to be distinguished histologically from primary dyschromic disorders (such as vitiligo). Therefore, clinical parameters (history, physical exam, and epidemiology) are, when combined, important factors that help differentiate syphilis and the nonvenereal treponematoses from primary pigmentary disorders.

TREATMENT AND PREVENTION OF THE NONVENEREAL TREPONEMATOSES

The WHO recommends a single intramuscular injection of benzathine penicillin for the treatment of early and late stages of the endemic treponematoses (Box 201-4). With proper penicillin therapy, cure rates up to 97% are possible and lesions become noninfectious within 24 hours. In addition, the titers of the nontreponemal serological tests show a gradual decline and eventually become negative. In pinta, the achromic patches persist for life.[1] Treatment failures with penicillin have been reported in a few cases in Papua New Guinea, Colombia, and Ecuador. However, in such cases, reinfection should always be ruled out.[1,41] Erythromycin is indicated for the treatment of infections in those who are allergic to penicillin. Other macrolide antibiotics are also probably effective, despite a scarcity of reported experience. In persons allergic to penicillin, other alternatives may include tetracycline and doxycycline.[14] Close contacts should also receive therapy.

Mass treatment programs constitute an important strategy devised by the WHO to control the endemic treponematoses. Recommendations for prophylactic treatment depend on the number of seropositive children younger than 6 years of age[1] and are as follows:

1. If the prevalence is more than 50%, treatment is given to the entire population.
2. If the prevalence ranges between 10% and 50%, treatment is given to patients, their contacts, and all children under the age of 15 years.
3. If the prevalence is less than 10%, then treatment is administered only to patients and their close contacts.

Eradication campaigns have been effective using a 7- to 10-day course of oral penicillin, at a dose of 50 mg/kg per day in four divided doses up to 1,200 mg daily. However, experience has shown that mass treatment campaigns alone are insufficient.[42] Treatment of those infected and those at risk must be followed by periodic clinical follow-up, serosurveillance, and screening campaigns.[43]

Concurrent infection with human immunodeficiency virus appears to exacerbate nonvenereal treponematosis, and based on the experience with venereal syphilis, it appears prudent to screen persons at risk for human immunodeficiency virus infection.[44]

ACKNOWLEDGMENT

The authors would like to acknowledge Dr. Miguel Sanchez, the author of the seventh edition of the chapter, for his complete and comprehensive review of the topic.

KEY REFERENCES

Full reference list available at www.DIGM8.com

DVD contains references and additional content

1. Antal GM, Lukehart SA, Meheus AZ: The endemic treponematoses. *Microbes Infect* **4**(1):83-94, 2002
14. Farnsworth N, Rosen T: Endemic treponematosis: Review and update. *Clin Dermatol* **24**(3):181-190, 2006
31. Parish JL: Treponemal infections in the pediatric population. *Clin Dermatol* **18**(6):687-700, 2000

Chapter 202 :: Chancroid

:: Stephan Lautenschlager

CHANCROID AT A GLANCE

- A sexually transmitted acute ulcerative disease usually localized at the anogenital area and often associated with inguinal adenitis or bubo.
- *Haemophilus ducreyi*—a Gram-negative, facultative anaerobic coccobacillus—is the causative agent.
- Although the number of cases is decreasing overall, chancroid is still common in many developing countries (Africa, the Caribbean Islands, and Southwest Asia).
- Painful, soft ulcers with ragged undermined margins develop 1–2 weeks after inoculation (usually prepuce and frenulum in men and vulva, cervix, and perianal area in women).
- Nonsexual transmission has been reported recently.
- Chancroid facilitates the transmission of HIV.
- Laboratory culture of *H. ducreyi* is problematic, but greater sensitivity can be expected by DNA amplification methods, which are currently not routinely available.
- Azithromycin and Ceftriaxone are recommended as single-dose treatment, enhancing compliance.

EPIDEMIOLOGY

Chancroid is most common in developing countries, especially in Africa and Asia, where it was isolated from over 50% of patients with genital ulcers until the 1990s.[1–3] These endemic regions also have some of the highest rates of HIV infection in the world, and chancroid is common in all 18 countries where adult HIV prevalence surpasses 8%.[4] More recent reports from Southeast Asia and Africa suggest that the incidence of chancroid may be declining in the face of a rapidly rising incidence of genital herpes.[5–9] Chancroid outbreaks have been reported in a number of cities in industrialized countries during the last two decades, predominantly in the United States.[10] After an epidemic in California in 1981, the number of cases peaked in 1987 at 5,035 cases. In a ten city study, chancroid was confirmed in 12% of genital ulcers in Chicago and 20% in Memphis.[11] In contrast, only 23 cases of chancroid were reported to the Centers for Disease Control and Prevention (CDC) in 2007.[12] The true incidence in most areas remains unclear and is probably vastly underreported because confirmatory culture media or DNA amplification methods are not commercially available.[13] The global epidemiology of chancroid is so poorly documented that it is not included in WHO estimates of the global incidence of curable sexually transmitted diseases.[4] Overall, chancroid accounted for 8 cases (3%) of genital ulcers in a sexually transmitted infection (STI) clinic in Paris from 1995 to 2005.[14]

The prevalence of chancroid is higher in lower socioeconomic groups. Recent epidemics in the industrialized countries have usually been associated with commercial sex work, the use of crack cocaine, with syphilis and an increased risk of HIV infection.[15,16] Lower-class prostitutes appear to be a reservoir in all reported outbreaks of this disease and men have a markedly higher incidence of chancroid than women.[10] Several studies in Africa showed that chancroid-ulcer is an important risk factor for the heterosexual spread of HIV-1.[17,18] In West Africa, it has been shown that 2% of female sex workers were carrying the organism asymptomatically.[19] The duration of infectivity in the absence of treatment was estimated to be 45 days for women. The transmission rate from females to males is not known, in contrast to a reported transmission rate from males to females of 70% per sex act.[20] Nonsexual transmission has been recently reported.[21,22]

CLINICAL FINDINGS

The incubation period is between 3 and 7 days, rarely more than 10 days. No prodromal symptoms are known. The chancre begins as a soft papule surrounded by erythema. After 24–48 hours it becomes pustular, then eroded and ulcerated (Fig. 202-1); vesicles are not seen. The edges of the ulcers are often ragged and undermined (Fig. 202-2). The ulcer is usually covered by a necrotic, yellowish-gray exudate (eFig. 202-2.1 in online edition), and its base is composed of granulation tissue that bleeds readily on manipulation. In contrast to syphilis, chancroid ulcers are usually tender and or painful not indurated (soft chancre). The diameter varies from 1 mm to 2 cm. Half of the males present with a single ulcer and most lesions are found on the external or internal surface of the prepuce, on the frenulum, or on the glans (eFig. 202-2.2 in online edition). Meatus and shaft of the penis and the anus (eFig. 202-2.3 in online edition) are involved less frequently. Edema of the prepuce is often seen. Rarely, if the chancre is localized in the urethra, *Haemophilus ducreyi* causes purulent urethritis.[33]

In females the lesions are mostly localized on the vulva (Fig. 202-3), especially on the fourchette, the



Figure 202-1 Early sharply circumscribed ulcer in the *coronal sulcus*.

labia minora, and the vestibule. Vaginal, cervical, and perianal ulcers have also been described. Extragenital lesions of chancroid have been reported on the breasts, fingers, thighs, and inside the mouth. Trauma and abrasion may be important for such extragenital manifestations.

Painful inguinal adenitis (bubo) occurs in up to 50% of patients within a few days to 2 weeks (average 1 week) after onset of the primary lesion (Fig. 202-4). The adenitis is unilateral in most patients, and erythema of the overlying skin is typical. Buboes can become fluctuant and may rupture spontaneously. The pus of bubo is usually thick and creamy. Buboes are less common in female patients. Besides the common types of chancroid described above, a number of clinical variants have been reported (Table 202-1). Mild systemic symptoms can rarely accompany chancroid, but systemic infection by *H. ducreyi* has never been observed. The significance of the recent detection of genetic material of *H. ducreyi* in oesophageal lesions of HIV patients[34] requires further study.



Figure 202-2 Ragged edges of a soft ulcer.



Figure 202-3 Vulvar chancroid with undermined edges.

DIFFERENTIAL DIAGNOSIS

The three classic etiologic agents for genital ulceration are (1) *H. ducreyi*, (2) *Treponema pallidum*, and (3) herpes simplex. The clinical appearance of the diseases caused by these three organisms can be extremely variable in both men and women, and therefore, clinical diagnosis of genital ulcer disease can be made with reasonable certainty only for a minority of patients.[45] The etiology of genital ulcers (Table 202-2)[46] also differs considerably by geographic region. In industrialized countries, isolated painful chancres are most likely due to herpes simplex virus.[47] In a high percentage of genital ulcers, no pathogen can be isolated but coinfections with syphilis (*ulcus mixtum*) or herpes simplex are not uncommon as well.[5,8]



Figure 202-4 Small soft ulcer on the internal surface of the prepuce with painful, fluctuant inguinal adenitis (bubo).

TABLE 202-1
Clinical Variants of Chancroid

Giant Chancroid	Single lesion extends peripherically and shows extensive ulceration.
Large Serpiginous Ulcer	Lesion that becomes confluent, spreading by extension and autoinoculation. The groin or thigh may be involved (*Ulcus molle serpiginosum*).
Phagedaenic Chancroid	Variant caused by superinfection with fusospirochetes. Rapid and profound destruction of tissue can occur (*Ulcus molle gangraenosum*).
Transient Chancroid	Small ulcer that resolves spontaneously in a few days may be followed 2–3 weeks later by acute regional lymphadenitis (French: *chancre mou volant*).
Follicular Chancroid	Multiple small ulcers in a follicular distribution.
Papular Chancroid	Granulomatous ulcerated papule may resemble donovanosis or condylomata lata (*Ulcus molle elevatum*).

COMPLICATIONS

In about half of the untreated patients, the course is that of spontaneous resolution without complications. Due to delay in treatment, various complications may occur (Box 202-1).

PROGNOSIS AND CLINICAL COURSE

The disease is self-limited and systemic spread does not occur. Occasionally, without treatment, genital ulcer and inguinal abscess have been reported to persist for years. Local pain is the most frequent complaint. If no clinical improvement is evident 1 week after the start of therapy, incorrect diagnosis, coinfection with another STI, concomitant HIV infection, poor compliance, or a resistant strain of *H. ducreyi* must be considered.

Infections do not confer immunity and reinfections are possible. To avoid reinfections, patients must be instructed to use condoms properly.

TABLE 202-2
Differential Diagnosis of Chancroid

	Disease	Etiological Agent
Most Likely	Genital herpes Syphilis Lymphogranuloma venereum	*Herpes simplex* virus type 1 and 2 *Treponema pallidum* *Chlamydia trachomatis* Serovars L1–L3
Consider	Other bacterial STI: Donovanosis (formerly Granuloma inguinale) Other bacterial infections: Viral infections: Acute HIV infection *Ulcus vulvae acutum* Genital herpes zoster Parasitic infections: Amebiasis Leishmaniasis Scabies Inflammatory diseases: Behçet's disease Aphthosis Crohn's disease Pyoderma gangraenosum Drug induced: Fixed drug eruption Toxic Traumatic and self-induced genital ulcers and neoplasms	*Klebsiella granulomatis* (formerly *Calymmatobacterium granulomatis*) *Streptococcus species*, staphylococcal and fusospirillary infections, *Mycobacterium tuberculosis*, *Corynebacterium diphtheriae* (very rare) HIV Epstein–Barr virus, Cytomegalovirus Varicella-zoster virus *Entamoeba histolytica* *Leishmania species* *Sarcoptes scabiei* e.g., Trimethoprim-sulfamethoxazole e.g., Foscarnet
Always Rule Out	Genital herpes Syphilis HIV infection	*H. simplex virus* type 1 and 2 *Treponema pallidum*

BOX 202-1 COMPLICATIONS OF CHANCROID

Painful inguinal adenitis (up to 50%)[48] (Fig. 202-4)

Spontaneous ruptures of inguinal buboes with occurrence of large abscesses and fistula formation (rare)

Spreading of *Haemophilus ducreyi* to distant sites (kissing ulcers (Fig. 202-5) and/or extragenital lesions due to autoinoculation) (in 50% of male patients)

Esophageal lesions in HIV patients[34]

Acute conjunctivitis (very rare)[49]

Bacterial superinfection (including anaerobs) leading to extensive destruction (rare)

Scarring leading to phimosis (rare)

Erythema nodosum (very rare)[50]

Enhanced HIV transmission (3–10-fold increased risk)



Figure 202-5 Spreading of *Haemophilus ducreyi* by autoinoculation (kissing-ulcer) from the frenulum to the glans.

TREATMENT

Since the 1970s, β-lactamase-producing strains of *H. ducreyi* emerged and treatment failures were common. Subsequently, further plasmid-mediated resistance to tetracycline, sulfonamides, chloramphenicol, and aminoglycosides also has been reported.[51] Little is known about chromosomally mediated resistance in *H. ducreyi*, but decreased susceptibilities to various antibiotics in the absence of identifiable resistance plasmids suggests such mechanisms.[51] Based on in vitro susceptibility, the most active drugs against *H. ducreyi* are Azithromycin, Ceftriaxone, Ciprofloxacin, and Erythromycin. Worldwide, several isolates with intermediate resistance to either Ciprofloxacin or erythromycin have been reported. Regimens actually recommended by the CDC, by WHO, and by the European STD guidelines (revised in 2011) are listed in Table 202-3.[52–54] Antibiotic combinations (e.g., Ceftriaxone and Streptomycin) showed synergy in an animal model and may be promising to improve single-dose treatment, but clinical evaluation is needed.[55] Local treatment consists of antiseptic dressings (i.e., povidone-iodine). Suppurative nodes should not be incised; if necessary, they can be punctured to prevent spontaneous rupture and sinus tract formation. A large syringe should be used and the fluctuant buboes entered laterally through normal skin. In patients with phimosis, a circumcision may be necessary when all active lesions have healed. In pregnancy, Ceftriaxone is the preferred drug, but Azithromycin can be used as well.[56]

Even after correct treatment, relapses occur in about 5% of patients and retreatment with the original regimen is recommended. Usually reinfection by an untreated sexual partner is the suspected cause of relapse.

HIV infection and lack of circumcision appear to be associated with increased likelihood of infection with *H. ducreyi* and treatment failure.[57] In resource-poor areas of the world, syndromic management can be recommended, but local epidemiology must be considered.[37,53] Flow charts for the management of genital ulcers have been developed that do not require laboratory identification of the causative pathogen.[37] If a patient complains of one or more small blisters or an ulcer with a history of recent blisters, then herpes management should be followed. If an isolated small

TABLE 202-3
Regimens Actually Recommended by the CDC, WHO[a] and by the European STD Guidelines (2011)*

Antibiotics	Dosage	Limitations
Azithromycin	1 g orally in a single dose	High cost, limited availability
Or		
Ceftriaxone	250 mg IM in a single dose	Parenterally, may perform less well in HIV-positive patients
Or		
Ciprofloxacin	500 mg orally bd for 3 days	High cost, compliance, pregnancy
Or		
Erythromycin base	500 mg orally qds for 7 days	Compliance, gastrointestinal intolerance QT interval prolongation

[a]WHO recommends as alternative therapy only.
*M. Kemp et al. European guideline for the management of chancroid, 2011. *Int J STD & AIDS* **22:** 241-241, 2011

ulcer and painful matted gland is present, lymphogranuloma venereum, chancroid, and syphilis should be treated, and if only an ulcer is present, syphilis and chancroid should be treated.[37]

RELATION BETWEEN HIV INFECTION AND CHANCROID

Over the past decade, renewed interest in chancroid has led to evidence that genital ulcers promote the heterosexual transmission and acquisition of HIV-1.[58–62] Effective treatment of genital ulcers can reduce the incidence of HIV-1, and this strategy has become a cornerstone of HIV prevention programs in many parts of the world.[63]

Furthermore, it was shown that concomitant HIV infection has clinically significant effects on the course of the chancroid disease, and failure of single-dose[17] or short-course[59] therapy for chancroid in men is associated with HIV-1 seropositivity. A wide variation of the clinical picture of chancroid has been observed in HIV-infected patients.[59]

Epidemiologic control of chancroid may be a very important strategy to interrupt the heterosexual spread of HIV in some parts of the world. Accordingly, patients with chancroid should also be tested for HIV antibodies. HIV-seropositive patients with culture-proven chancroid should be monitored closely and treated with a multiple-day regimen.

PREVENTION

The augmentation of the HIV epidemic by *H. ducreyi* has made chancroid control an urgent priority. Patients should be advised to abstain from sexual activity until all clinical lesions have cleared. Sexual contacts of the patient (within ten days of symptom presentation) should be examined and treated regardless of whether symptoms of the disease are present, since asymptomatic carriage of *H. ducreyi* is possible.[19] Antibiotics may provide some protection from reinfection, since a single dose of azithromycin lasted as long as 2 months after treatment.[64] Chancroid survives in populations in which many men are having sex with a few women. As a result of increased condom use and social programs such as presumptive treatment plans, the cases of chancroid in Nairobi, Kenya, have decreased dramatically to less than 10% of genital ulcers.[4] In Thailand, a decrease of 95% (from 30,000 to less than 2,000 cases) was achieved in the 1990s.[4,65] On the basis of these results, eradication of chancroid seems to be a feasible public health objective.[4]

KEY REFERENCES

Full reference list available at www.DIGM8.com

DVD contains references and additional content

11. Mertz KJ et al: Etiology of genital ulcers and prevalence of human immunodeficiency virus coinfection in 10 US cities. The Genital Ulcer Disease Surveillance Group. *J Infect Dis* **178**:1795-1798, 1998
14. Hope-Rapp E et al: Etiology of genital ulcer disease. A prospective study of 278 cases seen in an STD clinic in Paris. *Sex Transm Dis* **37**:153-158, 2010
18. Mohammed TT, Olumide YM: Chancroid and human immunodeficiency virus infection—A review. *Int J Dermatol* **47**:1-8, 2008
32. Janowicz DM, Li W, Bauer ME: Host-pathogen interplay of Haemophilus ducreyi. *Curr Opin Infect Dis* **23**:64-69, 2010
37. Lewis DA: Chancroid: Clinical manifestations, diagnosis, and management. *Sex Transm Infect* **79**:68-71, 2003
52. Centers for Disease Control and Prevention (CDC): Sexually transmitted diseases treatment guidelines, 2006. *MMWR Morb Mortal Wkly Rep* **55**:RR-11, 2006

Chapter 203 :: Lymphogranuloma Venereum

:: Rim S. Ishak & Samer H. Ghosn

LYMPHOGRANULOMA VENEREUM `AT A GLANCE

- Systemic sexually transmitted disease caused by L serovars of *Chlamydia trachomatis*.
- Endemic in Africa, Southeast Asia, and South and Central America, and rare in developed countries.
- Recent outbreaks among men who have sex with men in Europe and North America.
- Clinically manifest as inguinal and anorectal syndromes, in three stages.
- Hematogenous spread with manifestations of systemic infection.
- Diagnosis by identification of organism and by serology or genotyping.
- Doxycycline or erythromycin treatment curative if given early.

EPIDEMIOLOGY

Lymphogranuloma venereum (LGV) is a sexually transmitted disease due to specific *Chlamydia* variants that is rare in developed countries. It is endemic in East and West Africa, India, Southeast Asia, South and Central America, and some Caribbean Islands; and accounts for 7%–19% of genital ulcer diseases in areas of Africa and India.[1,2] The peak incidence occurs in persons 15–40 years of age, in urban areas, and in individuals of lower socioeconomic status. Men are six times more likely than women to manifest clinical infection.[3] The incidence of LGV is low in the developed world where cases are usually limited to travelers or military personnel returning from endemic areas. Since 2003, however, outbreaks of LGV have appeared in Europe, Australia, and North America, particularly in the form of proctitis, among human immunodeficiency virus (HIV) positive men who have sex with men (MSM).[4–11]

LGV is contracted by direct contact with infectious secretions, usually through any type of unprotected intercourse, whether oral, vaginal, or anal. Transmission efficiency is unknown.[12,13] Sexual practices such as fisting and sex-toy sharing may be other routes of transmission.[4] In a recent study that compared sexual behaviors in men with LGV and men with non-LGV chlamydial proctitis, fisting was a major predisposing factor.[14] An epidemic of LGV has been reported among "crack" cocaine users in the Bahamas.[15]

Due to underdiagnosis and underreporting, the epidemiology of LGV remains poorly understood. Common diagnostic laboratory methods are nonspecific and not readily available in endemic areas. Even in industrialized countries, only a few laboratories offer specific assays to LGV serovars. Without such assays, many LGV cases are misdiagnosed as common chlamydial urogenital infection. Underdiagnosis of LGV is also largely due to the presence of an asymptomatic carrier state. Women, in particular, may harbor asymptomatic persistent infection in the cervical epithelium, thus serving as reservoirs of the infection as they do for other urogenital chlamydial infections and gonorrhea. Recently, a large study conducted in the United Kingdom found that only 6% of MSM were asymptomatic carriers of LGV *Chlamydia* serovars; the majority of cases of LGV in the rectum and urethra were symptomatic.[16] Infectivity in men usually ceases after healing of the primary mucosal lesion. Interestingly, most of the detected cases in the recent outbreaks are in men who practice receptive anal sex, suggesting that a high proportion of men who practice insertive anal sex are mis- or undiagnosed. The reasons behind this are unclear but may be organism-related, host-related (sexual practices such as fisting and the use of sex toys, intravenous drug use, HIV status, etc.) or physician-related (failure to diagnose genital LGV). The resurgence of LGV as a health problem may simply reflect increased awareness rather than increased incidence.

ETIOLOGY AND PATHOGENESIS

LGV (tropical or climatic bubo, lymphopathia venerea, Nicolas–Favre disease) is caused by *Chlamydia trachomatis* serovars (serologic variants) L1, L2, and L3.[17] Most of the recent outbreaks are caused by a number of strains of *C. trachomatis* L2 serovar (L2b), suggesting that these outbreaks most likely represent increased awareness of a slowly evolving endemic.[7–9,16,18,19]

Chlamydiae are obligate intracellular bacteria characterized by two distinct morphologic forms: (1) the small metabolically inactive and infectious elementary body, and (2) the larger metabolically active and noninfectious reticulate body. (eFig. 203-0.1 in online edition). *C. trachomatis* has been subdivided into several serovars that differ in their major outer membrane proteins, and which are associated with several diseases. Serovars A, B, and C are the causes of trachoma ocular infections, whereas serovars D-K are responsible for ocular, genital and respiratory infections.[20] In contrast to the A-K serovars that remain confined to the mucosa, LGV serovars are more invasive and have a high affinity for macrophages.[17] After being inoculated onto the mucosal surface, the organisms replicate within macrophages, and find their way to the draining lymph nodes (LNs), and cause lymphadenitis.

CLINICAL FINDINGS

CUTANEOUS LESIONS AND RELATED PHYSICAL FINDINGS

Clinical manifestations are protean, depending on the sex of the patient, acquisition mode, and the disease stage. Three clinical stages characterize LGV. Nonspecific cutaneous lesions such as erythema nodosum, erythema multiforme, urticaria, and scarlatiniform exanthema may occur with any of these stages.[21]

PRIMARY STAGE. Three to 30 days after infection, 5- to 8-mm painless erythematous papule(s) or small herpetiform ulcers appear at the site of inoculation (Fig. 203-1). Painful ulcerations[22] and nonspecific urethritis[23] are less common. In males, the lesion is usually found on the coronal sulcus, prepuce, or glans penis; and in females on the posterior wall of the vagina, vulva, or, occasionally, the cervix. Inoculation may also be rectal or pharyngeal. The primary lesion is transient, often heals within a few days, and may go unnoticed.

SECONDARY STAGE. A few weeks after the primary lesion appears, marked LN involvement and hematogenous dissemination occur, manifested by variable signs and symptoms, including fever, myalgia, decreased appetite, and vomiting. Photosensitivity may develop in up to 35% of the cases, often 1–2 months after bubo formation.[24] Less commonly, patients may develop meningoencephalitis, hepatosplenomegaly, arthralgia, and iritis.[25,26] The lymphadenitis episodes often resolve spontaneously in 8–12 weeks. Depending on the mode of transmission, two major syndromes are distinguished.



Figure 203-1 Lymphogranuloma venereum: soft painless erosion on the prepuce.

The acute genital syndrome (GS) or inguinal syndrome is characterized by inguinal and/or femoral LN involvement and is the major presentation in men. Initially, the skin overlying the affected LN is erythematous and indurated. Over the subsequent 1–2 weeks, the LN enlarge and coalesce to form a firm and tender immovable mass (bubo) (Fig. 203-2),



Figure 203-2 Early bubo consisting of unilateral enlargement and coalescence of inguinal lymph nodes. The overlying skin is erythematous and indurated. Note the absence of the primary lesion in this case. (Used with permission from Shukrallah Zaynoun, MD.)



Figure 203-3 Lymphogranuloma venereum: bilateral, firm, immovable masses above Poupart's ligament.

which may rupture and drain through the skin, forming sinus tracts. Bilateral involvement occurs in one-third of the cases (Fig. 203-3). Nodal enlargement on either side of the inguinal ligament, the "groove sign," is pathognomonic of LGV, but only presents in 10%–20% of cases[27] and is rarely bilateral.[28] In women, inguinal lymphadenitis is unusual because the lymphatic drainage of the vagina and cervix is to the deep pelvic/retroperitoneal LN. When these nodes are involved, low abdominal/back pain that exacerbates upon lying supine and pelvic adhesions may ensue.

The acute anorectal syndrome (ArS) is characterized by perirectal nodal involvement, acute hemorrhagic proctitis, and pronounced systemic symptoms. It is the most common presentation in women and in homosexual men who practice anal sex. The major source of rectal spread in women is the internal lymphatic drainage of the lower two-thirds of the vagina. Patients may complain of anal pruritus, bloody rectal discharge, tenesmus, diarrhea, constipation, and lower abdominal pain.[5,29] In a recent study, 96% of MSM patients presented with signs and symptoms of proctitis.[30] Despite affecting mostly HIV-positive MSM, LGV has not behaved as an opportunistic infection in the recent outbreak, and clinical features have not differed between HIV-positive and HIV-negative cases.[31]

TERTIARY STAGE. This stage is more seen in women with untreated ArS, and includes rectal strictures (most common) and abscesses, perineal sinuses, rectovaginal fistulae (leading to "watering can perineum"), and "lymphorrhoids" (perianal outgrowths of lymphatic tissue). Esthiomene (Greek, "eating away") is a rare primary infection of the external genitalia (mostly in women), leading to progressive lymphangitis and genital destruction. Infertility and "frozen pelvis" are potential sequelae of ruptured deep pelvic nodes in women. Late sequelae of the GS are less common and include urethral strictures and genital elephantiasis with ulcers and fistulas (in 4% of cases).[32] Penile deformities such as the saxophone penis may also occur.[33]

OTHER UNUSUAL MANIFESTATIONS

Extragenito-anal inoculation of LGV is rare. Oropharyngeal infection may manifest initially as pinhead-sized vesicles on the lip, and later on as cervical lymphadenopathy with constitutional symptoms, closely mimicking lymphoma. Tonsillitis, supraclavicular and mediastinal lymphadenopathy, and pericarditis rarely occur.[34–38] Ocular autoinoculation of infected discharges may lead to conjunctivitis with marginal corneal perforation, often with preauricular lymphadenopathy.[39] Inhalation of LGV serovars L1 and L2 may accidentally occur in laboratory workers and lead to pneumonitis with mediastinal and supraclavicular lymphadenopathy.[40]

LABORATORY TESTS

Diagnosis of LGV may be difficult, but LGV should be suspected in any patient with infected sexual contacts, genital ulcer, perianal fistula, or bubo. The accuracy of clinical diagnosis has been reported to be as low as 20%.[41] Therefore, laboratory tests are important to establish the diagnosis and are usually divided into two broad categories: (1) nonspecific tests that do not distinguish between LGV and (2) non-LGV serovars, and specific LGV tests. In practice, a positive test on LN aspirate is considered diagnostic of LGV, in contrast to a positive test on primary genital lesion where further specific testing is required to rule out common chlamydial urogenital infections.

SPECIFIC TESTS FOR LYMPHOGRANULOMA VENEREUM

Nucleic acid amplification using polymerase chain reaction (PCR) may be performed on all specimens, and has been the diagnostic method of choice in the recent outbreak. Several generations of PCR analysis have been developed over the past decade; however, most of them lacked the ability to differentiate between LGV and non-LGV strains. In 2008, a new diagnostic technique with a quadriplex reverse transcriptase PCR assay was developed. This unique technology can detect individual LGV and non-LGV infection, as well as mixed infections in rectal specimens. However its main disadvantage is that it is available only in the Centers for Disease Control and Prevention and in a few US laboratories.[42] Other newly introduced biomolecular techniques exploring immune-mediated lysis,[23] heparin sulfate lysis,[43,44] use of pooled antibody,[18] and structural genetic differences[45] seem to be promising.

NONSPECIFIC CHLAMYDIAL TESTS

The complement fixation test is the most commonly used test. Titers greater than 1:256 are highly suggestive of LGV and titers below 1:32 exclude the diagnosis unless the disease is in its early stages.[46] The microimmunofluorescence test for the L-type serovar is more sensitive & specific but less readily available.[47] In addition, culture studies may be preformed; however, they do not distinguish between LGV and non-LGV serovars, are tedious, and require special growth media. Nevertheless, a positive culture without centrifugation is highly suggestive of LGV.

In addition, direct fluorescence microscopy using conjugated monoclonal antibody against *C. trachomatis* on smears from bubo material or genital swab can be done.[48] Serology assays are sensitive but nonspecific due to cross reactivity with other chlamydial infections. In addition, they do not differentiate current from prior infection. Frei test, the earliest diagnostic modality to identify LGV, consists of an intradermal skin test assessing delayed hypersensitivity to chlamydial antigens. It is no longer used because of its low sensitivity and limited specificity due to cross reaction with *C. trachomatis* D-K.[17] Finally, other non specific laboratory findings include mild leukocytosis, false-positive VDRL, cryoprecipitates, rheumatoid factor, and high serum levels of immunoglobulin A and immunoglobulin G.[49]

DIAGNOSTIC PROCEDURES

Bubo aspiration to obtain material for culture and direct microscopy should be performed through a lateral approach, and may require injection of 2–5 mL of sterile saline before the aspiration due to the paucity of milky fluid.[48] Proctoscopic examination reveals, in the setting of the ArS, multiple discrete and irregular superficial ulcerations and friable granulation tissue, usually confined to the distal 10 cm of the anorectal canal.[50,51]

HISTOPATHOLOGIC EXAMINATION

Primary lesions reveal nonspecific ulceration with granulation tissue, and endothelial swelling. Organisms are rarely demonstrated using Giemsa stain. Biopsy of affected LN reveals suppurative granulomatous inflammation. Necrotic foci may enlarge into stellate abscesses, which, in turn, may coalesce into discharging sinuses. These findings are not specific to LGV and can be found in chancroid, cat-scratch disease, tularemia, and some deep fungal infections. The pathology of LGV-proctocolitis is similar to that of Crohn disease and includes crypt distortion, submucosal fibrosis, and follicular inflammation with occasional granuloma formation.[50]

DIFFERENTIAL DIAGNOSIS

(See Box 203-1)

In contrast to LGV primary stage, chancroid ulcers are usually larger and more painful, and granuloma inguinale ulcers have abundant friable granulation tissue without associated lymphadenitis. Acute GS may be hard to differentiate from chancroid. Buboes

BOX 203-1 DIFFERENTIAL DIAGNOSIS OF LYMPHOGRANULOMA VENEREUM (STAGE SPECIFIC)

- Primary stage
  - Ulcerogenital diseases (herpes simplex virus, chancre, chancroid, granuloma inguinale)
  - *Neisseria gonorrhoeae* and/or common chlamydial urogenital infection
  - Noninfectious causes: trauma, Zoon balanitis, fixed drug eruption
- Secondary stage
  - Acute genital syndrome
    - Ulcerogenital diseases with lymphadenopathy (syphilis, chancroid, herpes simplex virus)
    - Incarcerated inguinal hernia
    - Reactive inguinal lymphadenitis to a lower extremity focus of infection
    - Bubonic plague (in endemic areas)
    - Acquired immunodeficiency syndrome
    - Kaposi sarcoma
    - Tularemia
    - Mycobacterial infections
  - Acute anorectal syndrome
    - Inflammatory bowel disease
  - Oropharyngeal lymphogranuloma venereum
    - Lymphoma
    - Infectious mononucleosis
    - Cat-scratch disease
- Tertiary stage
  - Malignancy
  - Filariasis and other parasitic infections
  - Pseudoelephantiasis (no lymphadenitis) of tuberculosis and granuloma inguinale
  - Deep fungal infection
  - Hidradenitis suppurativa
  - Trauma

containing little or no pus are, however, more likely to be caused by LGV.[44] Suspecting LGV proctitis in HIV-positive MSM who present with signs and symptoms of Crohn's disease is important, even in the absence of LGV pathognomonic findings. Both conditions have similar proctoscopic findings; however, Crohn's disease is more proximally localized.

COMPLICATIONS

In addition to the complications seen in the tertiary stage, the ulcerative nature of LGV may facilitate the acquisition and transmission of blood-borne pathogens such as HIV[52] and hepatitis C.[17] LGV may also lead to immune disturbances ranging from mild gammaglobulinemia to rare but fatal immunoblastic lymphoma.[53] Recently several case reports have described an association between LGV and sexually acquired reactive arthritis (SARA) in HLA-B27 positive individuals.[54,55]

PROGNOSIS AND CLINICAL COURSE

Antibiotic treatment, if given early, is curative, with the acute ArS responding more dramatically than the acute GS.

TREATMENT

Oral doxycycline, 100 mg twice daily for 3 weeks, is the treatment of choice. When contraindicated, oral erythromycin base, at a dose of 500 mg four times a day for 3 weeks, may be given. Treatment with azithromycin (1 g once weekly for 3 weeks or in a single dose)[56] is likely curative but still lacks data regarding its efficacy and safety in pregnancy. It should be noted that the duration of treatment needed to eradicate *C. trachomatis* is longer for the LGV serovars compared with the other less invasive serovars of *C. trachomatis*. Therefore, when in doubt about the *Chlamydia* serovar, a 3-week course of antibiotics is advised. Therapy may be prolonged in HIV-positive patients and, in general, should not be stopped until the complete resolution of all signs and symptoms (Box 203-2).

Surgery is often required in late stages and includes lateral aspiration of buboes through intact skin (direct incision has a high risk of fistula formation), rectal stricture dilatation, abscess drainage, rectovaginal fistula repair, genital reconstruction, and colostomy. Avoidance of sexual activity until complete resolution of signs and symptoms is important.[57]

PREVENTION

LGV seems to be a rapidly spreading universal problem. Effective control should include periodic evaluation of high-risk individuals, reinforcement of health

BOX 203-2 TREATMENT OF LYMPHOGRANULOMA VENEREUM

First line	Oral doxycycline	100 mg bid	3 weeks
Second line	Oral erythromycin	500 mg qid	3 weeks
Third line	Oral azithromycin	1 g once weekly	3 weeks

education aiming at early recognition and counseling, improving community and clinician awareness of LGV, and increasing the availability of specific diagnostic tests. All sexual contacts should be traced and treated. LGV case reporting should be mandatory by law for more reliable monitoring of prevalence trends.[8]

KEY REFERENCES

Full reference list available at www.DIGM8.com

DVD contains references and additional content

2. Goeman J, Piot P: The epidemiology of sexually transmitted diseases in Africa and Latin America. *Semin Dermatol* **9**(2):105-108, 1990
8. Blank S, Schillinger JA, Harbatkin D: Lymphogranuloma venereum in the industrialised world. *Lancet* **365**(9471):1607-1608, 2005
16. Ward H et al: The prevalence of lymphogranuloma venereum infection in men who have sex with men: Results of a multicentre case finding study. *Sex Transm Infect* **85**(3):173-175, 2009
17. Kapoor S: Re-emergence of lymphogranuloma venereum. *J Eur Acad Dermatol Venereol* **22**(4):409-416, 2008
42. Chen CY et al: A real-time quadriplex PCR assay for the diagnosis of rectal lymphogranuloma venereum and non-lymphogranuloma venereum Chlamydia trachomatis infections. *Sex Transm Infect* **84**(4):273-276, 2008
57. Workowski KA, Berman SM: Centers for Disease Control and Prevention sexually transmitted diseases treatment guidelines. *Clin Infect Dis* **44**(Suppl 3):S73-S76, 2007

Chapter 204 :: Granuloma Inguinale

:: Abdul-Ghani Kibbi, Ruba F. Bahhady, & Myrna El-Shareef

GRANULOMA INGUINALE AT A GLANCE

- Granuloma inguinale or donovanosis is a chronic ulcerative debilitating disease that mainly affects the genital organs.
- Caused by the Gram-negative bacteria *Klebsiella granulomatis*.
- Affects mostly people of lower socioeconomic status living in the tropical and subtropical areas.
- Diagnosis is made by demonstrating intracellular Donovan bodies on histology.

EPIDEMIOLOGY AND MODE OF TRANSMISSION

The mode of transmission of granuloma inguinale (GI) is controversial. It is generally considered sexually transmitted, but fecal contamination and autoinoculation remain a possibility, especially in the setting of infected children and adults without sexual activity and primary involvement of remote extragenital sites.[1,2] Transmission rate between sexual partners is low compared with other sexually transmitted diseases and was found to be not more than 50%. The incidence of GI is also relatively low among both prostitutes and their conjugal partners. Nevertheless, this disease predominantly affects sexually active individuals.[3] Moreover, donovanosis, being an ulcerative disease, increases the risk of human immunodeficiency virus (HIV) transmission.[4–6] Transvaginal transmission of donovanosis during delivery has been reported, with an apparent predilection to ear structures of the newborn.[7,8] Patients tend to belong to the low socioeconomic classes. No racial predilection has been proved,[9–11] and both male and female predominance have been reported.[5,6,11] Afflicted people are likely to delay seeking medical attention due to the painless nature of the ulcers and the possible embarrassment or fear from medical or surgical intervention. Late cases can be very debilitating and are much more difficult to manage.[12]

GI is endemic in warm, moderately humid areas like South Africa, India, Southern China, and Brazil.[5,13] There are new endemic areas of donovanosis, mainly South and Central America, India, and Papua New Guinea,[12] but the overall incidence of GI seems to be decreasing, especially in Papua New Guinea.[1] The disease has nearly been eradicated from Australia, with only five cases reported in 2004,[14] and is rare in North America and Europe.[15–17]

ETIOLOGY

Donovanosis is caused by the organism *Klebsiella granulomatis*, previously called *Calymmatobacterium granulomatis*. The name has been changed after sequencing the *phoE* and 16S ribosomal RNA genes and demonstrating close homology with *Klebsiella pneumoniae* and *Klebsiella rhinoscleromatis*.[5,12]

K. granulomatis is a Gram-negative, nonmotile, pleomorphic bacterium that stains well with Giemsa,

Wright's, or silver stains but is periodic acid-Schiff-negative. The mature form is encapsulated, while the immature form is not. The immature nonencapsulated form may assume a closed-safety-pin appearance due to bipolar chromatin densities.

It is difficult to culture and store this organism; however, it may be cultured using embryonic chick heart or chick embryo amniotic fluid. It has also been cultured in human peripheral blood mononuclear cells after decontaminating the specimen with amikacin, vancomycin, and metronidazole,[12] and in HEp-2 cells after adding gentamicin and cycloheximide.[5]

K. granulomatis is a facultative organism that resides in the cytoplasm of large mononuclear cells. It is pathogenic only to humans and the developing chick embryo. It was isolated from the feces of two out of four patients with donovanosis, although it has not been successfully cultured from feces. It is still unknown if this organism has a natural habitat.[18]

CLINICAL FINDINGS: HISTORY AND CUTANEOUS LESIONS

The incubation period extends from 3 days to 3 months but is usually 2–3 weeks. Single or multiple papules or nodules later develop and grow into a painless ulcer that may extend to the adjacent tissues and moist folds, forming "kissing lesions." The penis, scrotum, and glans are the most commonly affected sites in males; and the labia and perineum are most commonly affected in females.[11] Vaginal and cervical involvement has also been reported and sometimes mistaken for squamous cell carcinoma.[5] In one case report, GI has mimicked ovarian cancer presenting as a pelvic mass.[19] The anus and colon may be infected, especially in homosexual males.[5,20]



Figure 204-1 Granuloma inguinale on the inner prepuce. Two beefy red, erosive plaques that bleed easily. (Used with permission from Shukrallah Zaynoun, MD.)

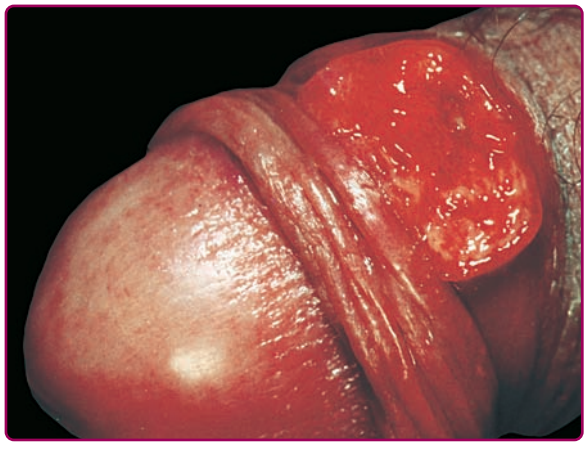

Figure 204-2 Granuloma inguinale. Nodular variety evolving into a large, exuberant ulcer. (Used with permission from A. Eichmann, MD.)

GI most commonly presents as beefy red, easily bleeding, foul-smelling ulcers with granulation tissue[5] (Fig. 204-1). The ulcers may have hypertrophic or verrucous borders resembling condylomata acuminata.[16] It may also present as soft, red nodules that eventually ulcerate (Fig. 204-2). In long-standing donovanosis, the lesions may be necrotic, quite destructive of tissue, and have a copious gray, foul-smelling exudate (Fig. 204-3).[5,16] The tissue overlying the regional lymph nodes may evolve into an abscess or pseudobubo that later ulcerates.[5] The lymph nodes per se are rarely involved unless there is a bacterial superinfection.[16] In the rare dry cicatricial form, the nonbleeding ulcers form band-like scars and lead to digital lymphedema due to constriction.[16]

HIV coinfection may alter the clinical presentation of GI. The natural history is usually more rapid, and ulcers may persist for longer periods, lead to more

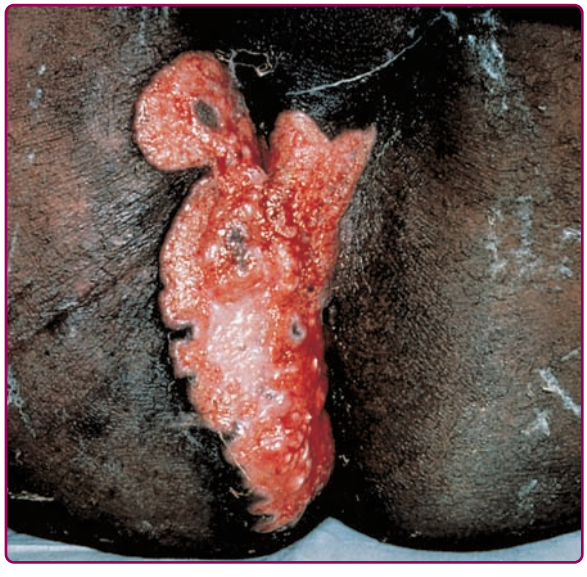

Figure 204-3 Granuloma inguinale. Large ulcerovegetative type.

tissue destruction, and need more prolonged antibiotic treatment. In addition, HIV patients with GI may have concomitant infection with other organisms such as those causing malacoplakia (most commonly *Escherichia coli*), which has been reported in GI of the cervix in two AIDS patients.[21] Furthermore, extragenital dissemination of GI has been reported in HIV-positive patients.[15]

DIAGNOSIS AND LABORATORY TESTS

Demonstrating the Donovan bodies on smear or biopsy specimen makes the diagnosis of GI, although they are more easily visualized with properly done smears rather than biopsy (Fig. 204-4).[16] Secondary bacterial infection and debris may affect the smear result; thus, it is recommended to wipe the ulcers gently with cotton swabs first before taking the smear but not to clean the ulcers with saline first.[1] Tissue for smear or crush preparations are better taken from the advancing edge of the ulcer, and tissue preparation should be made immediately, before the desiccation of histiocytes.

Serology is not helpful in making the diagnosis. Polymerase chain reaction has so far only been used for research purposes.[22] Histologically, the epidermis may exhibit pseudoepitheliomatous hyperplasia and/or ulcerations, depending on the site biopsied. In the dermis, a dense mixed inflammatory cell infiltrate is usually seen composed of polymorphonuclear cells, plasma cells, histiocytes, and rare lymphocytes. Edema and endothelial cell swelling are often noted. The hypertrophic and the cicatricial forms of GI may exhibit fibrosis.[3,20] Clusters of Donovan bodies are seen in the vacuolated cytoplasm of the large mononuclear cells. Using Giemsa, Wright's, or silver stains, these Donovan bodies appear as safety-pin-like structures measuring 1–2 µm × 0.5–0.7 µm. Rapi-Diff may also be used as a modified version of Giemsa preparation for a quick diagnosis.[23] These Donovan bodies may also be occasionally found extracellularly or within neutrophils.[20]

BOX 204-1 DIFFERENTIAL DIAGNOSIS OF GRANULOMA INGUINALE

Most Likely

- Primary syphilis (hard indolent ulcer) with indolent lymphadenopathy
- Secondary syphilis (pale, white, moist plaques)
- Lymphogranuloma venereum (prominent inguinal lymphadenopathy)
- Chancroid (painful ulcers with painful lymphadenopathy)
- Malacoplakia
- Note that the above diseases may coexist.

Always Rule Out

- Long-standing necrotic lesions of the penis, vulva, or cervix
  - Squamous cell carcinoma
  - Genital amebiasis
  - Chronic herpes simplex of the immunosuppressed
- Extragenital involvement
  - Leishmaniasis
  - Scrofuloderma
  - Deep mycosis
  - Pyoderma gangrenosum
  - Paracoccidioidomycosis
  - Mediofacial granuloma
  - Langerhans cell histiocytosis
- Disseminated form with bone involvement
  - Tuberculosis

The differential diagnosis of Donovan bodies (Box 204-1) includes the Frisch bacilli in Mikulicz cells of rhinoscleroma, the amastigotes of leishmania, the chlamydial inclusion bodies of lymphogranuloma

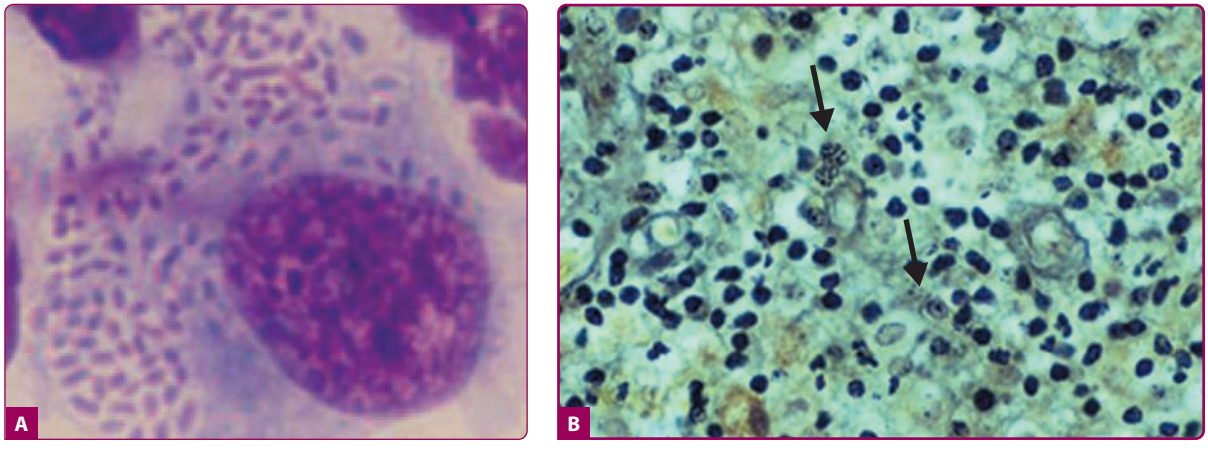

Figure 204-4 Granuloma inguinale. **A:** Pund cell stained by rapid Giemsa (RapiDiff) technique showing numerous Donovan bodies. **B:** Donovan bodies are readily stained with Giemsa stain. (Part A from O'Farrell N: Donovanosis. In: *Harrison's Principles of Internal Medicine*, 18th ed, edited by Longo DL, Fauci AS, Kasper DL, et al. New York, McGraw-Hill, 1321, 2012.)

venereum, histoplasmosis, and the Michaelis–Gutmann bodies of Malacoplakia.[20,21,23]

COMPLICATIONS

Genital complications of donovanosis include genital swelling that may progress to pseudoelephantiasis, phimosis, paraphimosis, and progressive tissue destruction that may lead to the destruction of the whole penis or other involved organs.[6,24] There is also an increased risk of squamous cell carcinoma in long-standing cases.[5,11] More recently, squamous cell carcinoma (SCC) has developed in GI ulcerations of shorter duration in an HIV-infected patient.[25]

Extragenital involvement has been reported in around 6% of the cases, occurring either as a primary infection or by spreading from a genital site by autoinoculation or systemic hematogenous dissemination.[6,13] Primary extragenital sites reported include particularly the oral mucosa, and also the neck, scalp, chest, arms, and legs. Oral involvement usually presents as swelling, ulcerations, and bleeding of the gum and palate. Bone involvement may lead to loss of teeth. Long-standing infection results in fibrosis, gum and cheek adhesions, and microstomia.[5,6] Hematogenous dissemination may present with fever, anorexia, and weight loss. It may lead to the involvement of bones, notably, and visceral organs like including the bowel, liver, spleen, and lungs. The most commonly affected bone is the tibia, comprising more than 50% of reported cases. There are few reported cases of GI manifesting as otitis media with mastoiditis, psoas abscess, and cervical lymphadenopathy.[2,7,26]

In addition, the fact that GI ulcers are painless and bleed easily upon contact increases the risk of HIV transmission remarkably.[9,27]

PROGNOSIS AND CLINICAL COURSE

GI shows no tendency for spontaneous healing. If left untreated, GI may extend to internal organs, including the ovaries, adnexa, uterus, epididymis, and bladder. Fistulas may form and lead to genital fibrosis and deformity.[5,11] Systemic dissemination may be fatal, especially in cases of misdiagnosis.[6]

TREATMENT

Untreated ulcers do not resolve spontaneously. Appropriate antibiotic therapy should be initiated once a diagnosis is established to avoid complications that could result in serious sequelae (Box 204-2).[28,29]

It is presumed that the inclusion of azithromycin in the WHO recommendation as a first-line treatment despite its high cost is advantageous because it can be administered intermittently and on a weekly basis, while patients are under supervision. The patient should continue treatment for at least 3 weeks and until all clinically visible ulcers have completely healed. Serial biopsy specimens may be needed.[11] If the patient does not improve within the first few days of treatment, the addition of gentamicin 1 mg/kg intravenously every 8 hours needs to be considered.

The Centers for Disease Control and Prevention recommend the same treatment regimens for HIV-positive patients with GI, although there have been a few reports of failure of such treatment.[28] The Centers for Disease Control and Prevention also strongly recommend gentamicin 1 mg/kg intravenously every 8 hours for HIV-infected patients with GI if there is no improvement within the first few days.

Beyond the recommended protocol of treatment, a trial with thiamphenicol has resulted in complete

BOX 204-2 TREATMENT OF GRANULOMA INGUINALE

	CDC (2006)	WHO (2003)
Recommendations[a]	Doxycyline 100 mg twice daily	Azithromycin, 1 g on first day, then 500 mg once a day OR Doxycycline, 100 mg twice daily
Alternatives[a]	Azithromycin 1 g orally once per week Ciprofloxacin 750 mg orally twice a day Erythromycin base 500 mg orally four times a day Trimethoprim-sulfamethoxazole one double-strength (160 mg/800 mg) tablet orally twice a day	Erythromycin, 500 mg orally, four times daily Tetracycline, 500 mg orally, four times daily Trimethoprim 80 mg/sulfamethoxazole 400 mg, two tablets orally, twice daily for a minimum of 14 days

[a]Duration of treatment with any regimen is for at least 3 weeks and until the lesions heal.

resolution of GI penile ulcers in eight out of ten patients; two of whom were HIV-infected patients. All patients were reevaluated regularly 3 months after treatment ended and were still disease-free.[30] Pregnant or lactating patients with GI are to avoid doxycycline and ciprofloxacin in their treatment regimens.

Relapse may occur **6–18 months** after apparently effective treatment, requiring follow-up by the physician. Long-standing cases may be complicated by secondary bacterial infections or by fistulas and abscess formation, which require surgical intervention and render antibiotic treatment alone ineffective.[13]

PREVENTION

All partners who had sexual contact with a patient with GI within 60 days before the onset of symptoms need to be examined. Sexual partners need not be treated unless they develop signs and symptoms of GI.

Children born to mothers with untreated donovanosis need to receive prophylactic azithromycin at a dose of 20 mg/kg for 3 days.[8]

KEY REFERENCES

Full reference list available at www.DIGM8.com

DVD contains references and additional content

1. O'Farrel N: Donovanosis. *Sex Transm Inf* **78**:452, 2002
11. Lupi O et al: Tropical dermatology: Bacterial tropical diseases. *J Am Acad Dermatol* **54**:559, 2006
12. Birley H et al: Sexually transmitted diseases: Microbiology and management. *J Med Microbiol* **51**:793, 2002
18. Carter J et al: phylogenetic evidence for reclassification of Calymmatobacterium granulomatis as Klebsiella granulomatis. *Int J Sys Bacteriol* **49**:1695, 1999
19. Barroso LF et al: Donovanosis presenting as a pelvic mass mimicking ovarian cancer. *South Med J* **102**(1):104-105, 2009
20. Richens J: The diagnosis and treatment of donovanosis. *Genitourin Med* **67**:441, 1991
23. Velho PE et al: Donovanosis. *Braz J Infect Dis* **12**(6):521-525, 2008
25. Sardana K et al: Malignant transformation of donovanosis (granuloma inguinale) in a HIV-positive patient. *Dermatol Online J* **14**(9):8, 2008
28. Centers for Disease Control and Prevention: 2006 Sexually transmitted diseases treatment guidelines. *MMWR Recomm Rep* **55**:RR-11, 2006

Chapter 205 :: Gonorrhea, Mycoplasma, and Vaginosis

:: Ted Rosen

GONORRHEA, MYCOPLASMA AND VAGINOSIS DISEASES AT A GLANCE

- More than 20 million new sexually transmitted diseases (STDs) occur annually in the United States.
- In the United States, chlamydia is currently the most common reported STD. It is also the most common cause of pelvic inflammatory disease in women.
- Urethritis is a common presenting symptom of STDs in both men and women.
- Diagnosis can usually be made through direct microscopy, culture, and/or newer diagnostic methods such as nucleic acid amplification tests.
- Early and appropriate antimicrobial therapy of STDs results in good prognosis.
- Prevention of STDs includes sexual abstinence or safe sex practices.

GONORRHEA

EPIDEMIOLOGY

More than 600,000 people are estimated to acquire new gonococcal infections in the United States yearly according to the Centers for Disease Control and Prevention (CDC), although only about half are actually reported through the public health system. This makes gonorrhea the second most commonly reported infectious disease in the United States, second only to chlamydia. The rate of new infections declined after the implementation of a national gonorrhea control program in the United States during the mid-1970s and continued to decrease through the late 1990s. It has since stabilized at near 100 cases per 100,000 population.[1] The prevalence of infection may have decreased due to sexually transmitted disease (STD) screening programs that have incorporated immediate, on-site, single-dose treatment, when indicated. Safer sex practices in response to the human immunodeficiency virus (HIV) epidemic may also be a factor contributing to the decline of new gonorrheal infections. The highest rate of reported gonococcal infections is among sexually active teenagers and young adults, aged 15–24. There is notable ethnic disparity, with the reported gonorrhea rate in African-Americans being twenty times

higher and in Hispanics twice as high when compared to Caucasians.[1] Such racial disparity is multifactorial and may be due to differences in accessibility to health care, lack of use of available resources, and sexual partner preferences. Risk factors for acquisition of gonorrheal infection include new or multiple sex partners, younger age, unmarried status, commercial sex work, minority ethnicity, substance and alcohol abuse, lower socioeconomic and educational levels, inconsistent condom use, and any previous STD infection. Prior gonorrhea is an especially important risk factor for acquisition of a new gonococcal infection, as recidivism is particularly common.[2] As is true of most STDs, alcohol ingestion to the point of inebriation is associated with risky sexual behavior, including unprotected intercourse and sex with multiple partners, and is thus a major factor in acquisition of gonorrhea.[3]

Since the 1980s, prevalence rates among men and women have been similar in all age categories, although for any given age range, the prevalence will be slightly higher in women. The highest rates in women are for those between the ages of 15 and 19 years and in men between the ages of 20 and 24 years.[1] However, one should never exclude the diagnosis of any STD based upon age alone. A relatively high divorce rate and the wide availability of drugs to treat erectile dysfunction have both contributed to a resurgence of STDs (including gonorrhea) amongst those middle-aged and older individuals living in industrialized countries.[4] A higher rate of new infections among men having sex with men (MSM) has also been reported in some major cities.[5]

ETIOLOGY AND PATHOGENESIS

Albert Ludwig Sigismund Neisser first discovered the causative agent of gonorrhea in 1879. This infection is due to *Neisseria gonorrhoeae*, a Gram-negative, aerobic coccus-shaped bacterium typically found in pairs. The organisms are usually visualized intracellularly, located within polymorphonuclear leukocytes (Fig. 205-1). Gonorrhea is acquired through sexual contact, or, much less commonly, as a result of poor hygiene or the complementary/alternative "medical" use of urine. It can also be transmitted vertically from mother to child during normal vaginal birth, characteristically causing an inflammatory eye infection (ophthalmia neonatorum).

Pathogenesis involves bacterial attachment to columnar epithelial cells via pili or fimbriae. The most common sites of attachment include the mucosal cells of the male and female urogenital tracts. Outer membrane proteins, PilC and Opa, on the bacteria aid in attachment and local invasion. Invasion is mediated by bacterial adhesins and sphingomyelinase, which contribute to the process of endocytosis. Gonococci also induce upregulated target cell integrins, which prevent mucosal cell shedding, a natural defense mechanism. Certain gonococcal strains produce immunoglobulin A proteases that cleave the heavy chain of the human immunoglobulin and block the host's normal bactericidal immune response. Once inside the cell, the organism undergoes replication and can grow in both aerobic and anaerobic environments. After cellular invasion, the organism replicates and proliferates locally, inducing an inflammatory response. Outside the cell, the bacteria are susceptible to temperature changes, ultraviolet light, drying, and other environmental factors. The outer membrane contains lipooligosaccharide endotoxin, which is released by the bacteria during periods of rapid growth and contributes to its pathogenesis in disseminated infection. Delays in proper antibiotic treatment, physiologic changes in host defenses, resistance to immune responses, and highly virulent strains of bacteria contribute to hematogenous spread and disseminated infection. Humans are the only natural hosts of *N. gonorrhoeae*.[6]

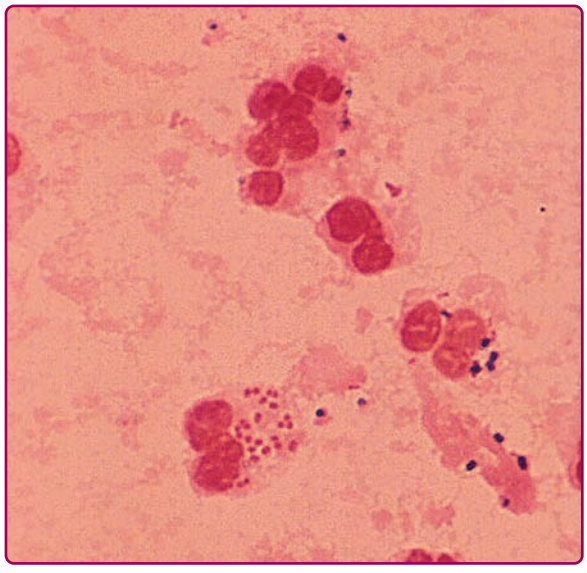

Figure 205-1 Diagnostic Gram-stained smear of urethral discharge of a man with acute gonorrhea. Gonococci (*red*) within a polymorphonuclear leukocyte. There are also some Gram-positive cocci in this smear (*dark blue*). (Used with permission from Angelika Stary, MD.)

CLINICAL FINDINGS: HISTORY AND PHYSICAL FINDINGS

N. gonorrhoeae infection tends to involve mucous membranes predominantly lined by columnar epithelial cells. The urethra, cervix, rectum, pharynx, and conjunctiva are the areas most commonly involved.

LOCALIZED DISEASE (MEN). The incubation period in men is typically from 2 to 8 days, although it may rarely be longer since most infections are symptomatic by 2 weeks following exposure. Only about 10% of infections are asymptomatic in men. The most common manifestation of gonococcal infection in men is urethritis, characterized by a spontaneous, often profuse, cloudy or purulent discharge from the penile meatus. (Fig. 205-2). Mucosal membrane inflammation in the anterior urethra leads to pain or burning upon urination and meatal erythema and swelling

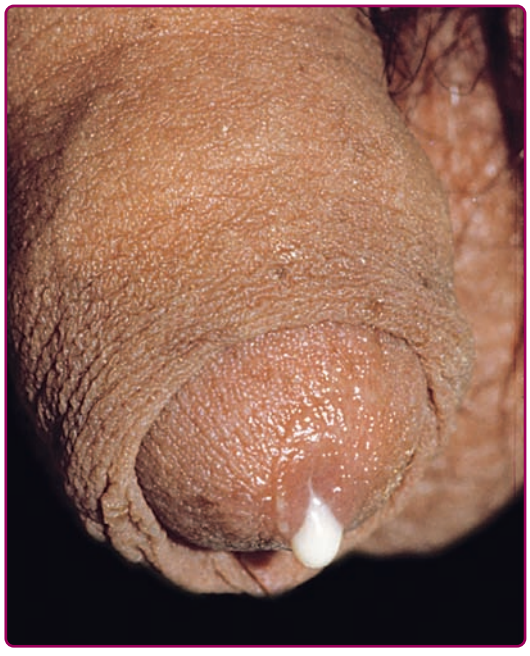

Figure 205-2 Acute gonorrhea in a male manifesting as creamy purulent discharge from the urethra.

(Fig. 205-3). In some cases, there is so much soft tissue inflammation that the entire distal penis becomes swollen, so-called "bull head clap." (Fig. 205-4) Testicular pain and swelling may indicate epididymitis or orchitis and may be the only presenting symptom. However, epididymitis is more commonly caused by *Chlamydia trachomatis* or by combined infection with *N. gonorrhoeae*. There have been rare instances of genital skin furuncles due to gonorrhea.[7]

Proctitis is a manifestation of gonococcal infection manifesting in those who practice unprotected anoreceptive intercourse. Thus, it is most common in MSM. Symptoms may include a rectal mucopurulent discharge, pain on defecation, constipation, and



Figure 205-3 Acute gonorrhea in a noncircumcised male. There is a purulent discharge from the urethra and concomitant inflammation of the prepuce and glans.



Figure 205-4 Swelling of the distal shaft characterizes "bull head clap," which is actually a manifestation of urethral gonococcal infection.

tenesmus. As a result of gonococcal proctitis, MSM are at a higher risk of acquiring HIV infection due to both damaged anorectal epithelial integrity and local recruitment of HIV-target cell types (CCR5/CD4$^+$ T cells and DC-SIGN+ dendritic cells).[8]

Pharyngitis caused by *N. gonorrhoeae* was once thought to be rare. However, the commonplace practice of fellatio amongst heterosexual adolescents and young adults, as well as among MSM, often in lieu of penetrative intercourse, has made pharyngeal gonorrhea much more common.[9] While it may be asymptomatic, pharyngeal disease may serve as a source for disseminated gonococcal disease. When present, symptoms range from cervical lymphadenopathy and mild-to-moderate pharyngeal erythema to severe ulceration with pseudomembrane formation.[10]

LOCALIZED DISEASE (WOMEN). Fifty percent of women infected with *N. gonorrhoeae* are asymptomatic. Appropriate screening, prompt diagnosis, and treatment are crucial in women due to serious complications that can result in sterility. The endocervix is a common site of local infection. Symptoms of urethritis include mucopurulent discharge, vaginal pruritus, and dysuria. However, vaginitis does not occur except in prepuberal girls or postmenopausal women because the vaginal epithelium of sexually mature women does not support growth of *N. gonorrhoeae*. Other sites of infection include Bartholin's and Skene's glands, which results is swelling and tenderness.[7] Organisms may invade the upper genital tract, including the uterus, fallopian tubes, and ovaries, resulting in pelvic inflammatory disease (PID).

PID occurs in about 10%–40% of uncomplicated gonorrheal infections in women and is characterized by fever, lower abdominal pain, back pain, vomiting, vaginal bleeding, dyspareunia, and adnexal or cervical tenderness during movement associated with a pelvic examination. Sequelae of untreated infection include tubo-ovarian abscesses, subsequent ectopic pregnancies, chronic pelvic pain, and infertility due to chronic inflammation with resultant scarring. Symptoms tend to occur or worsen at the time of menses and cannot be

distinguished from nongonococcal etiologies.[11,12] Fitz-Hugh–Curtis syndrome, involving inflammation of the liver capsule, is associated with genitourinary tract infection and may be present in up to one-fourth of women with PID caused by either *N. gonorrhoeae* or *C. trachomatis*. Presenting symptoms include right upper quadrant pain and tenderness with abnormal liver function tests.[13] This syndrome must be distinguished from acute viral hepatitis.

Women may also develop proctitis through autoinoculation from cervical discharge or as a result of direct contact from an infected partner's penile secretions. As is true in men, symptoms may include rectal mucopurulent discharge, pain on defecation, constipation, and tenesmus. The incidence of gonococcal pharyngitis is higher than that in men due to the common practice of fellatio, especially among adolescents. It is estimated that, in adolescent women, 11%–26% of cases of gonorrhea are comprised solely of asymptomatic pharyngeal infection.[9]

NEWBORNS AND CHILDREN. Neonates may acquire *N. gonorrhoeae* during passage through the birth canal from contact with infected secretions. Such ocular infections are known as ophthalmia neonatorum, and are characterized by profuse, purulent ocular discharge.[14] and can lead to severe corneal perforation or scarring. Most states, by law, require the prophylactic use of silver nitrate drops, erythromycin, or tetracycline ophthalmic ointment for prevention of ophthalmia neonatorum. However, the efficacy of prophylactic ocular antibiotics has been recently questioned, and its use in low-risk patient populations may someday be discontinued.[15] Pharyngeal or genital gonococcal infection in children is often a sign of sexual abuse and warrants further investigation.[14]

DISSEMINATED DISEASE. Spread of infection from the primary site of inoculation to other parts of the body through the bloodstream leads to disseminated gonococcal infection (DGI), also known as gonococcemia. Disseminated disease occurs in 0.5%–3% of cases and is associated with a classic triad of dermatitis, migratory polyarthritis, and tenosynovitis. Pain and swelling may occur in a single joint or in multiple joints asymmetrically. True septic arthritis due to gonorrhea is more typically monoarticular or pauciarticular, whereas polyarticular disease is most often associated with active bacteremia.[16]

Skin findings consist of small- to medium-sized macules or, most typically, hemorrhagic vesicopustules on an erythematous base located on palms and soles (Fig. 205-5) or on the trunk and elsewhere on the extremities. Skin lesions may develop necrotic centers. The concurrence of some degree of hemorrhage and necrosis led to the term "gun metal gray" to describe the cutaneous lesions of DGI. On the palms and soles, lesions may be tender, but in other sites they tend to be both nonpruritic and painless. Skin lesions disappear after appropriate treatment has been administered. Cutaneous lesions may be present in 40%–70% of cases of disseminated disease. Histologically, perivascular neutrophilia, dermal vasculitis, and epidermal neutrophil infiltration may be seen.



Figure 205-5 Disseminated gonococcal infection. Tender, hemorrhagic, and necrotic pustules on the fingers and palms.

LABORATORY TESTS

Organisms are Gram-negative, intracellular diplococci visualized microscopically inside polymorphonuclear cells. Because of high specificity (>99%) and sensitivity (>95%), a Gram stain of a urethral specimen that demonstrates polymorphonuclear leukocytes with intracellular Gram-negative diplococci can be considered diagnostic for infection with *N. gonorrhoeae* in symptomatic men.[17] However, because of lower sensitivity, a negative Gram stain can not be considered sufficient for ruling out gonococcal infection in asymptomatic men at high risk for infection. In addition, Gram stains of endocervical specimens, pharyngeal, or rectal specimens also are not sufficient to detect infection, and, therefore, are not recommended.[17] Vaginal specimens are never recommended for diagnostic purposes, since the vaginal mucosa resists gonococcal invasion.

Bacterial culture has been the "gold standard" diagnostic test for years, although newer and more specific tests are now being widely used. Culturing *N. gonorrhoeae* requires media containing heme, nicotinamide adenine dinucleotide, yeast extract, carbon dioxide, and other supplements required for isolation. Culture can be performed on modified Thayer-Martin medium. In men, culture and Gram stain are performed on secretions or urethral swabs. Endocervical and endourethral specimens for culture and Gram's stain yield accurate results in women. Cultures on pharyngeal and rectal swabs may also be performed if infection is suspected in these areas.

The US Food and Drug Administration has approved certain chemiluminescent DNA probes that can be used on endocervical or urethral specimens for diagnosis of gonorrhea. However, distinguishing gonococcal from nongonococcal infection may be difficult with DNA probes. Newer techniques include the use of nucleic acid amplification tests, such as polymerase chain reaction (PCR), transcription-mediated amplification, and strand displacement amplification on urine or urethral specimens. Overall, nucleic acid

BOX 205-1 DIFFERENTIAL DIAGNOSIS FOR ALL MUCOSAL-BASED VENEREAL DISEASES

LOCALIZED

- Urinary tract infection
- Chlamydia
- Gonorrhea
- Pelvic inflammatory disease
- Trichomoniasis
- Herpes simplex virus
- Bacterial vaginosis
- Vaginitis
- Endometriosis
- Mycoplasmal infection
- Orchitis and epididymitis
- Lymphatic occlusion due to pelvic neoplasm

SYSTEMIC

- Septic arthritis
- Rheumatoid arthritis
- Psoriatic arthritis
- Bowel-bypass syndrome
- Hepatitis B and C
- Behçet disease
- Reiter syndrome
- Lyme disease
- Rheumatic fever

ALWAYS RULE OUT

- Tubo-ovarian abscess
- Ectopic pregnancy
- Pregnancy
- Appendicitis
- Meningococcemia
- Coinfection with syphilis and HIV
- Sexual abuse (in children)

amplification tests are highly sensitive and specific and may be able to detect even the presence of one organism.[18] However, the precise test considered "optimal" in terms of specificity, sensitivity, practicality, and cost effectiveness remains to be determined and is subject to ongoing controversy.[19] Even nucleic acid detection tests may yield false positive and false negative results. In addition, diagnosis via any nonculture method does not allow for antibiotic sensitivity testing.

In DGI, cultures, and if available, nucleic acid amplification testing, should be done on blood, joint fluid, and skin lesions. Synovial fluid from affected joints must be analyzed for cell count, Gram stain, and culture. Of necessity, diagnosis may rely on clinical suspicion and pertinent findings, because tests for DGI yield positive results only in a small number of cases.

DIFFERENTIAL DIAGNOSIS

Box 205-1 shows the differential diagnosis for all mucosal-oriented venereal diseases.

COMPLICATIONS

Permanent sequelae of gonococcal infection in women may be infertility as a result of untreated PID. Untreated DGI can lead to septic arthritis, yielding permanent joint damage. Meningitis and endocarditis are rare manifestations of DGI, which can lead to death or permanent disability due to central nervous system or cardiac damage.

PROGNOSIS AND CLINICAL COURSE

Prognosis is excellent if infection is treated early with appropriate antibiotics. Previously treated gonococcal infection does not reduce the risk of reinfection. DGI has a good prognosis if treated appropriately and before permanent damage to joints or organs occurs.

TREATMENT

Ten percent to 30% of people with gonococcal infection are coinfected with *Chlamydia*. Thus, routine dual therapy with doxycycline or azithromycin has been recommended and shown to be cost effective. Dual therapy also decreases the development of antimicrobial resistance. Box 205-2 shows current CDC recommendations, as revised in 2010, for uncomplicated cervical, urethral, pharyngeal, and

BOX 205-2 TREATMENT OF LOCALIZED, UNCOMPLICATED GONOCOCCAL INFECTION OF CERVIX, RECTUM, PHARYNX OR URETHREA

- Single dosage of any of the following:
  - Ceftriaxone, 125 mg IM
  - Cefixime, 400 mg PO

Alternate single-dose cephalosporin re`gimens may be considered on an individual basis, and include: Ceftizoxime 500 mg IM, Cefotaxime 500 mg IM, Cefoxitin 2.0 g IM administered with probenecid 1.0 g PO

Some evidence exists that the following single-dose regimens might also be effective: Cefpodoxime 400 mg PO and Cefuroxime axetil 1.0 g

- For patients allergic to cephalosporins, spectinomycin, 2 g in a single IM dose.
- In dual therapy for chlamydia, add either:
  - Azithromycin, 1 g orally in a single dose
  - Doxycycline, 100 mg orally twice a day for 7 days

TABLE 205-1
Management of Disseminated Gonococcal Infection

Recommended Regimen	
Ceftriaxone	1 g IM or IV every 24 hours (intravenous route preferred)
Alternative Regimens	
Cefotaxime	1 g IV every 8 hours
Or	
Ceftizoxime	1 g IV every 8 hours
Or	
Spectinomycin	2 g IM every 12 hours
Following clinical improvement, parenteral therapy may be switched to oral therapy for seven additional days:	
Cefixime	400 mg BID PO
Or	
Cefpodoxime	400 mg BID PO

rectal gonococcal infections.[20] Due to the increased prevalence of antimicrobial resistance, quinolones are no longer recommended for the routine treatment of any gonococcal infections.[21] Spectinomycin, the recommended alternative to cephalosporins, has had an inconsistent history of availability and as of 2010, is not available in the United States. However, dosage regimens for spectinomycin are maintained in Box 205-2 should this situation change in the near future.

Patients with DGI may require hospitalization due to septic arthritis, meningitis, or endocarditis. The recommended regimen for DGI is ceftriaxone, 1 g intramuscularly (IM) or intravenously (IV) every 24 hours, continuing for 24–48 hours after improvement is noted. Treatment may then be switched to oral doses of the antibiotics listed in Table 205-1. Treatment of gonococcal meningitis should consist of ceftriaxone, 1–2 g IV every 12 hours for 10–14 days. Therapy for gonococcal infections in neonates is shown in Box 205-3. Gonococcal ophthalmia neonatorum should be treated with ceftriaxone, 25–50 mg/kg IV or IM, not to exceed 125 mg in a single dose. For treatment regimens of PID and epididymitis, the reader is referred to a CDC Web site.[20]

Sexual partners of those found to have gonococcal infections should be evaluated. However, since this is not always feasible, empiric treatment may be advisable. In general, treatment of partners of female or heterosexual male patients diagnosed with gonorrhea empirically is as or more effective than the traditional reliance on referral, testing and as needed treatment.[22] One way of doing this is via expedited partner therapy (having the index patient deliver therapy to the partner); such expedited therapy decreases the risk of persistent or recurrent infection in the index patient.[23] No studies have evaluated empiric treatment of gonorrhea (or chlamydia) in MSM. State laws vary with regard to expedited partner therapy and must be considered. Moreover, this type of empiric therapy misses the opportunity to counsel partners and treat comorbid disease, when detected.

BOX 205-3 TREATMENT OF GONOCOCCAL INFECTION IN NEONATES

- Ceftriaxone, 25–50 mg/kg/day IV or IM in a single daily dose for 7 days, or for 10–14 days if meningitis is documented

Or

- Cefotaxime, 25 mg/kg IV or IM every 12 hours for 7 days, or for 10–14 days if meningitis is documented

CONTRAINDICATIONS

Patients with documented allergy to later generation cephalosporins can be managed with spectinomycin. Fluoroquinolones can be considered, but only if documented sensitivity to this class of drugs has been established by culture.

CHLAMYDIA

EPIDEMIOLOGY

Infection with *C. trachomatis* is the most common reported STD in the United States, with more than 1.2 million reported cases in 2009.[1] Due to a high rate of asymptomatic infection, the prevalence of infection may actually be much higher. The national rate of chlamydial infection is 409.2 per 100,000 population, representing a 3% increase from the prior reporting year.[1] This may be as a result of wider screening and more sensitive and specific tests. The highest rates of infection reported are in women between the ages of 15 and 24 years. Following the expanded availability of less invasive urine testing for chlamydia, men are getting evaluated with greater frequency, resulting in an increase of over 45% in the chlamydia rate among men between 2004 and 2009.[1] While the overall rate of reported chlamydia among men is lower than among women, the CDC estimates that the actual overall prevalence of chlamydia is similar among men and women. Infection rates among African-Americans have been eight times higher and in Hispanics three times higher than those reported in same-gender Caucasians.[1] Chlamydial infection is also disproportionately high among Native American and Eskimo populations. Risk factors are similar to those related to gonococcal infections, and include young age, new or multiple sex partners regardless of age, unprotected sexual intercourse, inconsistent condom use, commercial sex work, and low socioeconomic and educational status.

ETIOLOGY AND PATHOGENESIS

The Greek-derived word *chlamys* means "cloak draped around the shoulder." This refers to the draping of intracytoplasmic inclusions containing *C. trachomatis* around the nucleus of an infected cell. *C. trachomatis* is a nonmotile, Gram-negative, obligate intracellular organism with 15 serotypes: A through C cause chronic conjunctivitis and are endemic in Africa and Asia, D through K cause urogenital tract infections, and L1 though L3 cause lymphogranuloma venereum (see Chapter 203). The bacteria have a two-phase life cycle. The infectious form is known as the *elementary body*, which enters host cells through endocytosis. Replication through binary fission occurs inside the host cell, using host-derived adenosine triphosphate, with formation of reticulate bodies. Large intracytoplasmic inclusions inside cells are made up of hundreds of reticulate bodies, which then convert back to infectious elementary bodies to be released from the cell.

Urogenital tract infection is the area most commonly affected in men and women. Transmission is through oral, anal, or vaginal intercourse with symptoms occurring 1–3 weeks after exposure. However, asymptomatic infection occurs in up to 80% of women and 50% of men. Coinfection with other STDs occurs frequently, most commonly with gonorrhea. Various serotypes have been associated with an increased risk of cervical squamous cell carcinoma, suggesting that *Chlamydia* species may act as a cofactor with oncogenic, high-risk HPV in neoplastic transformation.[24,25] Newborns can be infected from passage through the birth canal of an infected mother.[26]

CLINICAL FINDINGS: HISTORY AND PHYSICAL FINDINGS

The most common manifestation of disease is urethritis, characterized by a watery or mucoid discharge from the urethra that may be accompanied by variably severe dysuria in both men and women. Note that the discharge due to *Chlamydia* is classically less purulent, less profuse, and less spontaneous when compared to urethral gonorrhea. However, there is considerable clinical overlap, and neither the nature of the discharge nor the severity of accompanying dysuria can be reliably used to make a specific diagnosis. Rectal infection may result in proctitis in both men and women; symptoms resemble those seen with gonococcal proctitis (detailed previously). Infection due to specific serovars (L1–L3) may also present as lymphogranuloma venereum.[27] (For further details on LGV, see Chapter 203).

In men younger than age 35 years, *C. trachomatis* is the most common cause of epididymitis. Thus, aside from urethral discharge, men may also present with unilateral scrotal pain and swelling. It remains questionable whether chlamydial species commonly cause prostatitis. In a recent large-scale study that utilized very sensitive detection technology, only 3% of chronic prostatitis patients were found to harbor *C. trachomatis* infection.[28]

In women, the columnar epithelium of the endocervix is commonly affected. Other symptoms, beside those of urethritis, include intermenstrual or postcoital bleeding and vague but persistent lower abdominal pain. As with gonococcal infection, a severe complication in women that can result in sterility is PID, with ascending infection to the uterus and fallopian tubes. In the United States, chlamydial species are currently the most common causes of PID. Symptoms may include fever, lower abdominal pain, back pain, vomiting, vaginal bleeding, dyspareunia, and adnexal or cervical motion tenderness on physical examination. Sequelae of untreated infection include tubo-ovarian abscesses, ectopic pregnancies, chronic pelvic pain, and infertility due to chronic inflammation with resultant scarring. Five to ten percent of women with chlamydial PID may develop perihepatitis.

Newborns may develop conjunctivitis and pneumonia after being infected from passage through the birth canal of an infected mother. Signs of ophthalmia neonatorum may include injected conjunctivae, purulent discharge, or swollen eyelids. Subacute, afebrile pneumonia as a consequence of neonatal chlamydial infection usually presents after 1–3 months. Symptoms include cough and wheezing.[29] Animal experiments suggest that neonatal respiratory chlamydial infection predisposes to asthma later in life.

LABORATORY TESTS

Traditionally, chlamydial infection was diagnosed by tissue culture with specimens obtained from the endocervix in women, urethra in men, and rectum, or conjunctivae, as indicated. More rapid and sensitive tests have replaced culture in recent years. A direct fluorescent antibody test, which is highly specific, can be performed on endocervical and penile urethral specimens with rapid results (Fig. 205-6). Enzyme immunoassays, which are less specific than the direct fluorescent antibody test, can be used to detect chlamydial antigens through the formation of a color change. Less invasive tests involving nucleic acid hybridization and nucleic acid amplification, such as PCR and ligase chain reaction, are more commonly being used to detect even

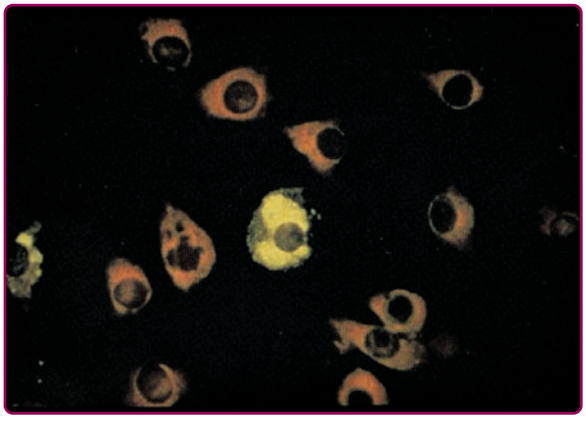

Figure 205-6 Detection of *Chlamydia trachomatis* by direct immunofluorescence with monoclonal antibodies.

small amounts of chlamydial DNA in urethral, vaginal, endocervical swabs and in first voided urine samples. At least one recent meta-analysis suggested that nucleic acid amplification tests are considerably more sensitive that point-of-care rapid diagnostic tests.[30] It should be noted that the nucleic acid amplification and hybridization tests are less accurate for chlamydial detection from rectal and oropharyngeal sites than from genital sites.

There is also some debate about exactly who should receive chalmydial testing, aside from those whose symptoms suggest that diagnosis. The CDC recommends annual screening of all sexually active women under the age of 25 and for older women with risk factors (e.g., those who have a new sex partner or multiple sex partners). Studies done in the 1990s point to a reduced prevalence of infection and reduced rate of subsequent PID following institution of routine *C. trachomatis* screening. However, a recent meta-analysis suggests that the benefits attendant to widespread screening for *Chlamydia* are greatly exaggerated.[31] Evidence is also insufficient to recommend routine screening for *C. trachomatis* in sexually active young men, based on feasibility, efficacy, and cost-effectiveness. Screening in MSM is controversial, although in high-prevalence locales, this is probably advisable.

COMPLICATIONS

Reactive arthritis (see Chapter 20) can occur up to 1 month after symptoms of nongonococcal urethritis (NGU), including NGU due to chlamydia. The classic triad associated with this syndrome is NGU, arthritis, and conjunctivitis. Additional symptoms may include fever, malaise, myalgias, asymmetric joint stiffness, lower back pain, cutaneous lesions involving the genitals, and aortic regurgitation as a result of inflammation around the aortic valve. Individuals with the haplotype HLA-B27 are at increased risk of developing the reactive arthritis syndrome. Upper genital tract complications in women have already been detailed above.

PROGNOSIS AND CLINICAL COURSE

Early treatment with appropriate antibiotic therapy results in excellent prognosis and reduces the risk of long-term complications, such as infertility from PID. It is important to complete an appropriate course of antibiotics. First-time therapy with antibiotics has been shown to be up to 95% effective in eradicating infection. It is important to counsel patients on the risks of coinfections with other STDs and to arrange for partner referral.

TREATMENT

The treatment of chlamydial infection is summarized in Box 205-4. Although azithromycin and doxycycline are considered equipotent, in patients who have erratic health-care-seeking behavior, poor treatment compliance, or unpredictable follow-up, azithromycin is more cost-effective in treating chlamydia because it enables the provision of a single-dose of directly observed therapy. Sexual contact should be avoided until treatment is completed. The CDC recommends that sex partners of those infected with *Chlamydia* also receive treatment in order to prevent prompt reinfection of the original patient. Recent studies have shown that many young heterosexual women who have been diagnosed with chlamydia became reinfected by male partners who were neither diagnosed nor treated.[32,33] CDC guidelines call for infected men and women to be retested for chlamydia approximately 3 months after initial treatment. For heterosexuals, the CDC recommends that, where feasible and allowed by state law, antibiotic treatment be delivered by patients to their partners (expedited therapy) if other strategies for reaching and treating partners are not likely to succeed.[1]

BOX 205-4 TREATMENT OF *CHLAMYDIA* INFECTION

- Azithromycin, 1 g PO in a single dose

Or

- Doxycycline, 100 mg PO twice a day for 7 days

Alternative regimens:

- Erythromycin base 500 mg PO, four times daily for 7 days

Or

- Erythromycin ethylsuccinate 800 mg PO, four times daily for 7 days

Or

- Ofloxacin 300 mg PO, twice daily for 7 days

Or

- Levofloxacin 500 mg daily for 7 days

Recommended treatment for pregnant women:

- Azithromycin 1 g PO as a single dose
- Amoxicillin, 500 mg PO three times a day for 7 days

Recommended treatment for ophthalmia neonatorum:

- Erythromycin base or ethylsuccinate 50 mg/kg/day orally, divided into four doses daily, for 14 days

GENITAL MYCOPLASMAS

EPIDEMIOLOGY

Species of *Mycoplasma* are the smallest, free-living, self-replicating bacteria. These organisms developed by degenerative evolution from lactobacilli, and lack a cell wall. These organisms have retained the ability to colonize the respiratory and urogenital tracts of humans. *Mycoplasma* sp. and other *Ureaplasma* sp. are referred to as the genital mycoplasmal organisms and may be found in the lower urogenital tracts of sexually

active adults. Seven mycoplasmal strains have been isolated from the genital tract: (1) *Mycoplasma hominis* and (2) *Mycoplasma genitalium* are commonly identified, while (3) *Mycoplasma fermentans,* (4) *Mycoplasma penetrans,* (5) *Mycoplasma pneumoniae,* (6) *Mycoplasma primatum,* and (7) *Mycoplasma spermatophilum* are rare at this site.[34] Molecular biological findings have made it possible to distinguish between two species of *Ureaplasma*: (1) *Ureaplasma urealyticum* and (2) *Ureaplasma parvum*. Risk factors for genital mycoplasmas include: multiple partners, younger age, ethnic minority, and past or present bacterial vaginosis (BV).

Forty percent to 80% of sexually active women in the United States have urogenital colonization with *Ureaplasma* organisms. *M. hominis* has also been isolated in 20%–50% of sexually active women. Rates of colonization tend to be lower in men, except in the setting of HIV coinfection. The rates of colonization in children and nonsexually active adults are even lower yet. Newborns may be infected by passage through the birth canal of an infected mother. While the most common cause of symptomatic NGU remains *Chlamydia* sp., the genital mycoplasmas may also cause this disorder. *Ureaplasma* organisms have been found to be the cause of over 20% of nonchlamydial NGU, while *M. genitalium* accounts for 10%–20% of cases of nonchlamydial NGU.[35] The detection of *M. hominis* in a urethral smear is irrelevant to NGU, as numerous studies have isolated *M. hominis* independently of symptoms.[34]

ETIOLOGY AND PATHOGENESIS

The bacteria can attach to and penetrate epithelial cells by adhesion proteins on the back of the cell body. The structure and function of adhesion proteins for *M. genitalium* (P110 and P140) and *M. hominis* (P100) are well characterized. The abundance of urea to metabolize predisposes ureaplasmas to the urinary tract. The specific adhesion proteins for *Ureaplasma* sp. are still unknown. All genital mycoplasmas multiply as parasites, as they are unable to complete various metabolic reactions. Cholesterol is required for growth and is taken from the epithelial cell; ureaplasmas need urea as well. Because of their parasitic nature and specific nutritional requirements, *Mycoplasma* species tend to remain localized to mucosal surfaces. Disseminated infection is rare and tends to occur only in immunocompromised hosts or in cases of epithelium severely traumatized by instrumentation.

M. genitalium and *Ureaplasma* sp. have been isolated from the lower urogenital tracts of men with urethritis and in 10% of women with cervicitis and 10%–20% of women with PID.[34] *M. hominis* has been isolated from a few cases of salpingitis. There is no clear relationship between genital mycoplasma and epididymitis and/or prostatitis. In cases of bacterial vaginitis (see below), coinfection with *Mycoplasma* species (particularly *M. hominis*) may worsen the condition. *Ureaplasma* sp. and *M. hominis* have been isolated from the blood of febrile women postpartum and postabortion.

CLINICAL FINDINGS: HISTORY AND PHYSICAL FINDINGS

Patients with genital mycoplasmal infections may go undiagnosed as such because these organisms may produce symptoms that are usually attributed to other, more common causative agents such as *Chlamydia*. This may also be due to the high rate of coinfection with such organisms. As with chlamydia, various genital mycoplasmas infections can result in urethritis, cervicitis, PID, endometritis, salpingitis, and chorioamnionitis. Other species can cause respiratory infection, septic arthritis, surgical wound infections, neonatal pneumonia, and meningitis. Infection with these organisms needs to be considered if workup for the more commonly isolated organisms is negative. Physical findings and symptomatology are indistinguishable from those seen with chlamydial NGU.

LABORATORY TESTS

Laboratory tests for genital mycoplasmas may be limited because most specimens must be sent to reference laboratories. Culture specimens should be obtained from the urethra or first voided urine in men, and from the cervix, urethra, and vagina in women. *M. hominis* and *U. urealyticum* can be cultured on special media, which is enriched with horse serum as a nutrient source. PCR assay is required to detect *M. genitalium,* and may also optionally be used by laboratories to identify other *Mycoplasma*. First voided urine is actually the preferred specimen to submit when the reference laboratory plans to utilize nucleic acid amplification testing.[34] While various commercial tests are available for antibodies (CBR, hemagglutination, immunofluorescence), the mere detection of *Mycoplasma* antibodies is not sufficient, to verify infection due the possibility of prior colonization and cross reactions. Increased titer levels may be a sign of acute infection. Because *Mycoplasma* does not possess a cell wall, Gram stain will not detect these organisms.

COMPLICATIONS

Invasion by different species of *Mycoplasma* and *Ureaplasma* can cause disseminated disease, especially in immunocompromised hosts who have deficiencies in antibody production. Disseminated disease may result in respiratory tract invasion, osteomyelitis, or infectious arthritis. Bacteremia as a result of *M. hominis* has been shown after renal transplantation. *M. hominis* has also be found in surgical wound infections, pericardial effusions, prosthetic heart valves, subcutaneous abscesses, and in synovial fluid of people with rheumatoid arthritis.

There is an increased frequency of *M. hominis* and ureaplasmas in cervical cultures from women who are unable to conceive, suggesting a causative role in infertility. The role of *M. genitalium* in infertility is not well studied in this regard. While this may represent

an overinterpretation, for some cases of premature rupture of the fetal membranes, preterm labor, intraamniotic infection, and chorioamnionitis, the presence of genital mycoplasmas suggests that these organisms may play a role in the pathogenesis of these complications of pregnancy.[36]

PROGNOSIS AND CLINICAL COURSE

Prognosis in immunocompetent hosts is excellent with prompt diagnosis and appropriate treatment.

TREATMENT

Because these organisms lack a cell wall, they are inherently resistant to β-lactam and cephalosporin antibiotics. Treatment for genital mycoplasmas is similar to treatment for chlamydia. *M. genitalium* is the most difficult of these organisms to treat, with failure rates ranging from 67% (levofloxacin) to 16% (single-dose azithromycin).[34]

Trichomonas vaginalis

EPIDEMIOLOGY

Trichomonas vaginalis causes a condition called trichomoniasis, which affects about 2–3 million women annually in the United States. Worldwide, it has been estimated to affect more than 180 million women. It is difficult to estimate the number of men infected because most infections in men are asymptomatic. However, 30%–40% of men who are exposed have detectable organisms in the lower genitourinary tract. It is currently not a reportable disease, making epidemiologic estimates crude.

ETIOLOGY AND PATHOGENESIS

Trichomoniasis is an STD caused by parasitic protozoan that infects mucosal epithelium, causing microulceration. In women, organisms may be isolated from the vagina, urethra, cervix, Bartholin and Skene glands, and bladder. In men, organisms may be found in the external genital area, anterior urethra, epididymis, prostate, and semen. The incubation period before symptomatic infection is usually between 4 and 28 days. In women, manifestation of infection ranges from an asymptomatic carrier state to inflammatory vaginitis. Due to the increase in vaginal acidity, a situation favorable for parasitic growth and reproduction, symptoms tend to occur during or after menstruation. Most men are asymptomatic carriers.

CLINICAL FINDINGS: HISTORY AND PHYSICAL FINDINGS

Women who are infected may complain of a malodorous, yellow–green vaginal discharge, vulvar pruritus, swelling and erythema, dyspareunia, lower abdominal discomfort, or dysuria. Infection tends to occur in sexually active women and men. Men are usually asymptomatic, although some may complain of urethral discharge and dysuria or urinary frequency. Both men and women may be asymptomatic carriers. Newborns may become infected from passage through the birth canal of an infected mother. Infection in a child may be a sign of sexual abuse.

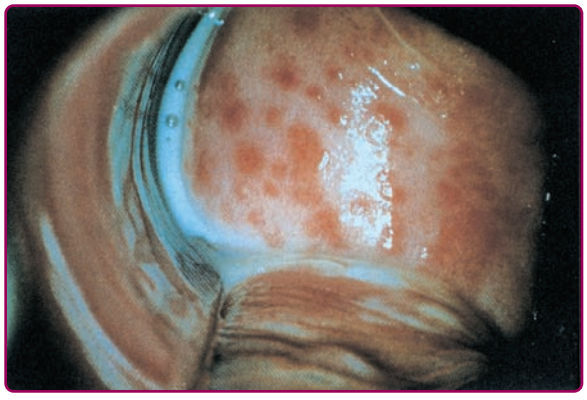

Figure 205-7 *Trichomonas vaginalis* infection: "strawberry" appearance of cervix with punctuate bleeding erosions. (Used with permission from U. Lauper, MD.)

On physical examination, punctate hemorrhages may be seen on the vaginal wall and cervix. A term commonly associated with such hemorrhages is "colpitis macularis" or "strawberry cervix" (Fig. 205-7). This is a specific sign of trichomoniasis, but is also seen in 1%–2% of women during a regular pelvic exam. It may be visualized in up to 45% of cases through the use of colposcopy. Findings consistent with the generic diagnoses of balanitis, epididymitis, and prostatitis rarely may be present in men. Coinfection with other STDs may produce a more complex presentation.

LABORATORY TESTS

Vaginal pH tends to be elevated above 4.5 in trichomoniasis, as well as in BV, thereby making this a nonspecific finding. There are three basic methods to search for the causative parasite. A saline wet mount of a vaginal discharge specimen is the simplest, least costly, and therefore the most common diagnostic test. The ovoid-shaped protozoa can be visualized microscopically, best by phase contrast or dark-field examination (Fig. 205-8). Direct microscope examination, while highly specific, is only 60%–70% sensitive.[37] The most sensitive test is anaerobic culture, which usually is positive within 48 hours, and is the preferred (albeit most costly) detection method. There are now several commercially available, rapid result, point-of-care tests that can be performed on vaginal discharge specimens: an immunochromatographic test (OSOM Trichomoas Rapid Test), with results available in 10 minutes and a nucleic acid probe test (Affirm VP III), which requires 45 minutes to complete.[37] The latter test has the advantage of simultaneously searching for and identifying the presence of *T. vaginalis*, *Gardnerella vaginalis*, and

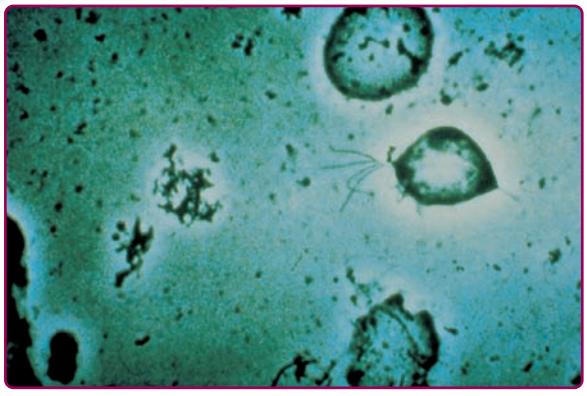

Figure 205-8 *Trichomonas vaginalis*, phase contrast microscopy. (Used with permission from U. Lauper, MD.)

Candida albicans. Both of these rapid result tests share a sensitivity of about 83% and specificity of over 97%.[37] Several additional PCR-based laboratory tests (Amplicor and APTIMA) have recently been approved that represent modifications of existing *Chlamydia*/GC detection techniques, although their sensitivities are lower than the point-of-care tests. For diagnosing infection in men, urethral, first void urine or semen cultures may be performed.

COMPLICATIONS

Recently, studies have shown a link between *T. vaginalis* infection and complications in pregnancy, such as premature delivery, early rupture of membranes, and low birth weight in newborns. Trichomoniasis has also been associated with an increased risk of HIV transmission.[38] Less commonly, it has been linked to atypical PID.[39]

PROGNOSIS AND CLINICAL COURSE

Prognosis is excellent with resolution of infection occurring after appropriate treatment. Treatment of sexual partners may help avoid reinfection. Persistent infection despite appropriate treatment with metronidazole may require susceptibility testing. This can be obtained from the CDC. Specimens for such testing by the laboratory service of the CDC Division of STD Prevention should be submitted through the clinician's own state health department.

TREATMENT

Treatment is summarized in Box 205-5. The nitroimidazoles metronidazole and tinidozoleare the only agents approved for treatment of trichomoniasis, the clinical efficacy of both drugs being identical.[40] It should be noted that alcohol ingestion during and for 24 hours after the last dose of metronidazole (72 hours after tinidazole) may be associated with a sensitivity reaction consisting of nausea, vomiting, flushing, and tachycardia. There is also a propensity for drug–drug interactions with cimetidine, warfarin, phenytoin, and lithium; appropriate adjustments must be made to ensure safe use of the nitroimidazoles when these other agents are being used. While safety of nitroimidazole use in pregnancy is uncertain, most experts condone this practice.[41]

BOX 205-5 TREATMENT OF TRICHOMONIASIS

- Metronidazole, 2 g PO in a single dose

Or

- Tinidazole, 2 g PO in a single dose

Alternative recommendations

- Metronidazole, 500 mg PO twice a day for 7 days

BACTERIAL VAGINOSIS

EPIDEMIOLOGY

BV is the most common vaginal infection in women of childbearing age. It is estimated that approximately 16% of pregnant women in the United States may have BV at a given time. Incidence rates are difficult to determine due to the high prevalence of asymptomatic infection and lack of screening methods. Risk factors appear to include sex at an early age, new or multiple sex partners, smoking, and douching or use of bidet toilets.[42,43] Some studies have shown an increased prevalence among women who have sex with women, perhaps based on transfer of pathogenic vaginal flora related to frequent use of lubricant and shared vaginal sex toys.[44] Women who have never had sex are extremely rarely affected.

ETIOLOGY AND PATHOGENESIS

BV is a polymicrobial syndrome that occurs when there is an imbalance of the bacterial flora normally present in the vagina. The shift occurs from hydrogen peroxide-producing lactobacilli to a greater concentration of bacterial organisms including *G. vaginalis*, *Mobiluncus* sp., *M. hominis*, anaerobic Gram-negative rods belonging to the genera *Prevotella*, *Porphyromonas*, and *Bacteroides*, and *Peptostreptococcus* sp.[45] It is not known to be transmitted through sexual contact, and the exact etiology has not been defined.

CLINICAL FINDINGS: HISTORY AND PHYSICAL FINDINGS

As many as 50%–75% of women with BV may be asymptomatic.[46,47] Women with BV may complain of a fishy odor and thin, white or gray vaginal discharge. Vulvo-vaginal pruritus and inflammation are rare. On physical examination, a milky, homogenous vaginal coating may be seen adherent to the vaginal wall.

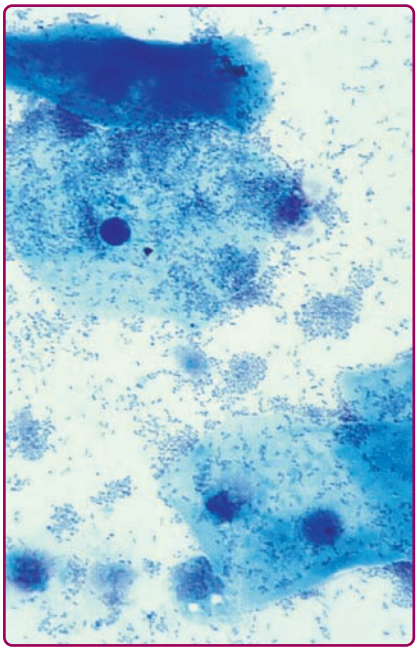

Figure 205-9 Bacterial vaginosis. Clue cells are large epithelial cells covered with bacteria. (Used with permission from Angelika Stary, MD.)

LABORATORY TESTS

According to the Amstel criteria for diagnosing BV, three of the following four must be present:[1] (1) thin, homogenous vaginal discharge;[2] (2) a positive whiff test, which involves the production of a fishy odor when mixing vaginal fluid with 10% potassium hydroxide;[3] (3) vaginal fluid pH greater than 4.5; and[4] (4) the presence of clue cells (epithelial cells covered with bacteria) on microscopic examination (Fig. 205-9).[47] Clue cells, being the most reliable indicator of BV, must make up at least 20% of the epithelial cells on saline wet mount. Another diagnostic test involves the use of Gram staining to distinguish between the normal bacterial flora of Gram-positive rods and lactobacilli from the Gram-negative morphotypes seen in BV. Due to the variety of bacterial species, culture is not a reliable diagnostic test. However, a DNA probe-based test (affirm VP III) and a newly developed immunochromatographic test (OSOM BVBlue) disclose high concentrations of *G. vaginalis*, which is suggestive of this diagnosis.

COMPLICATIONS

BV has been shown to be a risk factor for premature labor and preterm birth in pregnancy.[48] BV has also be associated as a risk factor for transmission and acquisition of HIV.[49] Studies have produced conflicting data as to whether BV is associated with a higher risk of acquiring cervical intraepithelial neoplasia.[50,51] Some studies have linked BV to postpartum fever, postpartum endometritis, postoperative gynecologic complications, and postabortal infections; however, more studies are needed to investigate the relationship between BV and possible sequelae.[52]

PROGNOSIS AND CLINICAL COURSE

BV has a good prognosis with appropriate treatment. Some infections may resolve on their own without therapy. A large number of infections are asymptomatic, and complications are rare. Many of the reported complications remain debatable as to whether they are true sequelae of BV. Recurrent infections have been reported, and a longer treatment regimen may be warranted in such cases.

TREATMENT

Treatment of BV is summarized in Box 205-6. The established benefits of therapy for BV in nonpregnant women are to (1) relieve vaginal symptoms and signs of infection and (2) reduce the risk for infectious complications after a variety of gynecological procedures (endometrial biopsy, hysterectomy, hysterosalpingography, placement of an IUD, cesarean section, uterine curettage, and abortion) In pregnant women, treatment of BV also reduces the risk of portpartum infectious complications as well as the risk of preterm labor.[53,54]

PREVENTION

Obviously, the best prevention against STD acquisition is abstinence until the establishment of a monogamous

BOX 205-6 TREATMENT OF BACTERIAL VAGINOSIS

- Metronidazole, 500 mg PO twice daily for 7 days

Or

- Metronidazole gel, 0.75%, 5 g intravaginally once daily for 5 days

Or

- Clindamycin cream, 5%, 5 g intravaginally qhs for 7 days

In pregnant women:

- Metronidazole, 250 mg PO three times daily for 7 days

Or

- Metronidazole 500 mg PO twice daily for 7 days

Or

- Clindamycin, 300 mg twice daily for 7 days

Alternative regimens

- Tinidazole 2.0 g orally once daily for 3 days

Or

- Tinidazole 1.0 g orally once daily for 5 days

Or

- Clindamycin 300 mg twice daily for 7 days

Or

- Clindamycin ovules, 100 g intravaginally qhs for 3 days

sexual relationship. However, clearly this is not a pragmatic suggestion for a majority of individuals in present day society. Some 60% of high school students will have had sex before graduation[55]; "one night stand" and "sex on the first date" mentalities are common among young adults; a longer life span in general insures that some older individuals will take new sex partners later in life. As an alternative, it is important for clinicians to educate their patients about how STDs are acquired, the possible adverse short- and long-term sequelae of STDs and the details of safe(r) sex practices. This is especially true for those individuals who fall into high-risk demographic groups. Routine screening for the various mucosal-based venereal diseases should be performed by appropriate health care providers when indicated to facilitate timely diagnosis and therapy, thereby reducing the likelihood of continued transmission.

ACKNOWLEDGMENT

The author thanks Annabelle L. Garcia, Vandana K. Madkan, and Stephen K. Tyring, who were authors of this chapter in the seventh edition.

KEY REFERENCES

Full reference list available at www.DIGM8.com

DVD contains references and additional content

1. Centers for Disease Control and Prevention: *Sexually transmitted diseases in the United States, 2009*, http://www.cdc.gov/std/stats09/trends.pdf, accessed Nov 27, 2010
3. Nicoletti A: The STD/Alcohol connection. *J Pediatr Adolesc Gynecol* **23**:53, 2010
9. Giannini CM et al: Culture of non-genital sites increases the detection of gonorrhea in women. *J Pediatr Adolesc Gynecol* **23**:246, 2010
17. Centers for Disease Control and Prevention: *Sexually Transmitted Diseases Treatment Guidelines 2006; Diseases Characterized by Urethritis and Cervicitis*, http://www.cdc.gov/std/treatment/2006/urethritis-and-cervicitis.htm#uc6, accessed Nov 4, 2010
19. Whiley DM et al: Exploring "best practice" for nucleic acid detection of Neisseria gonorrhoeae. *Sex Health* **5**:17, 2008
20. Centers for Disease Control and Prevention: Sexually transmitted diseases treatment guidelines, 2010. *MMWR Morb Mortal Wkly Rep* **59**(RR-12):1-114, 2010
22. Saperstein AK, Firnhaber GC: Should you test or treat partners of patients with gonorrhea, chlamydia, or trichomoniasis? *J Fam Prac* **59**:46, 2010
23. Trelle S et al: Improved effectiveness of partner notification for patients with sexually transmitted infections: Systematic review. *BMJ* **334**:354, 2007
30. Hislop J et al: Systematic review of the clinical effectiveness and cost-effectiveness of rapid point-of-care tests for the detection of genital chlamydia infection in women and men. *Health Technol Assess* **14**:1, 2010
31. Low N et al: Effectiveness of chlamydia screening: Systematic review. *Int J Epidemiol* **38**:435, 2009
35. Martin DH: Nongonococcal urethritis: New views through the prism of modern molecular microbiology. *Curr Infect Dis Rep* **10**:128, 2008
39. Soper D: Trichomoniasis: Under control or undercontrolled? *Am J Obstet Gynecol* **190**:281, 2004
41. Okun N, Gronau KA, Hannah ME: Antibiotics for bacterial vaginosis or Trichomonas vaginalis in pregnancy: A systematic review. *Obstet Gynecol* **105**:857, 2005
54. Ugwumadu A et al: Natural history of bacterial vaginosis and intermediate flora in pregnancy and effect of oral clindamycin. *Obstet Gynecol* **104**:114, 2004
55. Centers for Disease Control and Prevention: Trends in HIV and STD-related risk behaviors among high school students-United States, 1991–2007. *MMWR* **57**:817, 2008

SECTION 33

Infestations, Bites, and Stings

Chapter 206 :: Leishmaniasis and Other Protozoan Infections

:: Joelle M. Malek & Samer H. Ghosn

LEISHMANIASIS AND OTHER PROTOZOAN INFECTIONS AT A GLANCE

- A complex of diseases caused by the protozoa *Leishmania* and transmitted by the bite of infected phlebotomine sandflies.
- Four major human diseases: (1) localized cutaneous leishmaniasis, (2) diffuse cutaneous leishmaniasis, (3) mucocutaneous leishmaniasis, and (4) visceral leishmaniasis.
- Resulting disease dependent mainly on interaction between *Leishmania* species and the immunologic status of the host.
- Diagnosis by organism isolation or by serology but species identification only possible with isoenzyme analysis and new molecular techniques.
- Management ranging from observation to systemic therapy, primarily with antimonials, and vaccines in development.

LEISHMANIASIS

EPIDEMIOLOGY[1]

Leishmaniasis, a truly ancient disease,[2] was recognized on Amerindian pottery drawings dating back to the first century AD.[3] It was named after W.B. Leishman who identified organisms in smears taken from the spleen of a patient who died from "dum-dum fever" in India in 1901. The disease burden remains important in the twenty-first century with up to 2 million individuals developing systemic disease annually and accounting for around 70,000 deaths per year.[4]

The various types of leishmaniasis are confined primarily to the Mediterranean basin, Southern Europe, Central Africa, and parts of Southern and Central Asia [Old World (OW)], and Central and South America [New World (NW)]. The infection is endemic in 88 countries, 72 of which are developing countries.

In Western countries, the incidence is increasing due to human immunodeficiency virus (HIV)-*Leishmania* coinfection, military appointment, and tourism in endemic countries.[5,6] New Zealand, Antarctica, and the Pacific islands are *Leishmania*-free. Australia was thought to be devoid of *Leishmania* species until 2004, when it was discovered in red kangaroos that had developed ulcers over their limbs or ears, raising the possibility of imported species becoming endemic, or of a current still unrecognized human form of the disease.[7]

More than 90% of localized cutaneous leishmaniasis (LCL) cases occur in Afghanistan, Algeria, Iran, Iraq, Saudi Arabia, Syria, Brazil, and Peru.[8] In the United States, most LCL cases are imported; however, the Southern and Central parts of Texas are considered endemic for *Leishmania mexicana*.[9,10]

The World Health Organization (WHO) has classified leishmaniasis as a category 1 disease (emerging and uncontrolled). The recent geographic spread is attributed to massive rural-urban migration and agro-industrial development projects that bring nonimmune urban residents into endemic rural areas. Other incriminated factors include natural disasters, cessation of malaria spraying leading to increased sandfly population, reconstructions, control programs, global warming, wars, and deforestation.

Risk factors for contracting the disease include residing in an endemic area and in a ground floor, the design and construction material of the house, and the presence of domesticated animals. The prevalence of the disease increases until the age of 15 then seems to stabilize, probably reflecting development of immunity.[11] In general, males have greater likelihood of developing the disease. This can be explained by behavioral differences in exposure as well as by hormonal modulation of disease susceptibility or resistance.[12]

See Box 206-1 for various forms of leishmaniasis and their abbreviations.

BOX 206-1 ABBREVIATIONS USED FOR VARIOUS FORMS OF LEISHMANIASIS

- LCL: localized cutaneous leishmaniasis
- DCL: diffuse cutaneous leishmaniasis
- VL: visceral leishmaniasis
- VTL: viscerotropic leishmaniasis
- MCL: mucocutaneous leishmaniasis
- PKDL: post-kala-azar dermal leishmaniasis
- LR: leishmaniasis recidivans

ETIOLOGY AND PATHOGENESIS[13]

ETIOLOGY AND LIFE CYCLE. The genus *Leishmania* consists of parasitic protozoa of the phylum Sarcomastigophora, order Kinetoplastida, and family Trypanosomatidae. At least 21 species are pathogenic for humans and all are essentially transmitted by the bite of an infected female phlebotomine sandfly.[4] Cases of venereal[14] and vertical[15,16] transmission, as well as transmission from infected blood transfusion[17] or needles[18–22] have, however, been reported.

Leishmania are dimorphic parasites; in the gut of the sandfly or in culture, they exist in the spindle-shaped motile (single anterior flagellum) promastigote form (10–20 µm). In the cells of the host reticuloendothelial system, *Leishmania* exist in the oval nonmotile amastigote form (2–6 µm) that has a relatively large basophilic nucleus and a smaller rod-shaped kinetoplast of extranuclear DNA at the base of the lost flagellum.[23] Infected macrophages are ingested by the fly during a blood meal and the amastigotes are released into the stomach of the insect where they immediately transform into the promastigote form. The latter migrate to the alimentary tract of the fly, multiply extracellularly by binary fission, and in few days, reach the esophagus and the salivary glands of the fly where they change into infective metacyclic promastigotes, which will be released into the skin at next bite. They are then phagocytosed by host macrophages where they transform into amastigotes that multiply by binary fission and get released following cellular burst to infect other macrophages (eFig. 206-0.1 in online edition)

RESERVOIR HOSTS.[24,25] Leishmaniasis is mostly zoonotic, being incidentally transmitted to humans from wild and domestic animals (primary reservoir hosts) (Table 206-1).[24,26–29] However, visceral leishmaniasis (VL) caused by *Leishmania donovani* and OW-cutaneous leishmaniasis (OW-CL) caused by some *Leishmania tropica* strains are anthroponotic diseases (i.e., humans are the primary reservoir hosts).

INSECT VECTORS.[30] The insect vector of leishmaniasis, the female phlebotomine sandfly, is grouped under the Suborder Nematocera of the order Diptera. Three genera [(1) *Phlebotomus* in the OW, and (2) *Lutzomyia* and (3) *Psychodopygus* in the NW], and around 70 species are implicated as vectors.[31] They are widely distributed and have predilection to intertropical and warm temperate zones. Only the female sandfly is hematophagus. Phlebotomine sandflies are less than 3 mm long, and do not fly far from their breeding site. Their activity is mostly crepuscular or nocturnal while the host is asleep. They rest during the day and lay their eggs in dark, cool, humid, and organic matter-rich places such as rodent burrows, bird's nests, and house wall fissures. Being exophilic and exophagic, they prefer to rest and to have their meal outdoors, which limits their control through house spraying.

PATHOGENESIS.[31] The resulting disease depends on the fate of the phagocytosed amastigotes. This in turn is function of numerous parasite- and host-related factors, as well as other factors that may account for geographical differences.[8,32]

In general, parasites interfere with the signaling pathways, intracellular kinases, transcription factors, and gene expression of macrophages, compromising their ability to generate leishmanicidal substances. In addition, they impair dendritic cell activation, migration, and ability to secrete T helper 1 (Th1) cytokines.

PARASITE-RELATED FACTORS.[33] Sandfly saliva is increasingly recognized as an essential element in the pathogenesis of the disease. Besides containing vasodilators, anticoagulants, and immunomodulators, it may also increase the inoculum size and the diameter of the lesion.[34] Intraspecific variations of sandfly saliva may even affect the overall clinical outcome of *Leishmania infantum*-induced disease by shifting the adaptive immunity from a Th1 to a Th2 immune response. The development of anti-saliva antibodies after exposure may account for the decline with age of susceptibility to the infection in endemic areas.[11]

Other parasite-related factors include infectivity, pathogenicity, virulence, and tissue tropism.[35–39] These differ from one species to the other. For example, lipophosphoglycan and gp63 are two important promastigote virulence factors that impair infected cells' overall functions with the former being clearly involved in *Leishmania major* disease but absent in *L. mexicana*.[11]

Although viscerotropic species tend to spread to the reticuloendothelial system, they may become dermotropic as a consequence of treatment such as seen in post-kala-azar dermal leishmaniasis (PKDL).[40] Similarly, *L. tropica*, classically dermotropic, may cause visceral disease.[41,42]

HOST-RELATED FACTORS.[11,31,43] Malnutrition, immunosuppression, and host genetic background influence host susceptibility as well as resistance to the disease. The output of acquired T cell immunity, which depends on the net effect of the opposing Th1 and Th2 responses, largely determines the course and the therapeutic response of the infection. A dominant Th1 response resulting in the production of interferon-γ (IFN-γ) and nitric oxide leads to a leishmanicidal state of macrophages, and accounts for subclinical infection or self-healing LCL

TABLE 206-1
***Leishmania* Species, Major Vector and Host Reservoirs**

	Leishmania Species	Vector	Main Reservoir Hosts	Disease Caused	Geographic Location
Old World (OW) Leishmaniasis					
OW Leishmaniasis	*Leishmania major*	*Phlebotomus*	▪ The great gerbil *Rhombomys opimus* ▪ The fat sand rat *Psammomys obesus* ▪ *Meriones* spp. ▪ Rodents	LCL DCL (1 isolate in Ethiopia)	▪ Central Asia ▪ West Asia (Jordan, Israel, Palestine, Syria, Saudi Arabia) and North Africa (Libya) ▪ Pakistan, India ▪ Sub-Saharan Africa
	Leishmania tropica		▪ Humans ▪ Hyraxes? ▪ Unknown	LCL, LR, VTL	▪ West and Central Asia ▪ East Africa ▪ West Mediterranean Basin
	Leishmania aethiopica		Hyraxes	LCL, DCL, MCL (rarely)	East Africa (Kenya, Sudan, Ethiopia)
	Leishmania donovani		Humans, dogs	LCL, VL, PKDL	India, Sudan, Kenya, China, Pakistan, Nepal, Tanzania,
New World Leishmaniasis					
Leishmania mexicana complex	*L. mexicana*	*Lutzomyia*	Rodents Wood rat in Texas	LCL, DCL LCL, LR, MCL, DCL, VL	Central America, Mexico, Texas South America
	Leishmania amazonensis		Spiny rats Less commonly: rodents, marsupials, and carnivores		
	Leishmania pifanoi		Unknown	LCL	Venezuela, South America
	Leishmania venezuelensis		Domestic cat?	LCL	
	L garnhami		Opossum	LCL	
Leishmania (Viannia) or *Leishmania braziliensis* complex	*L. (V) braziliensis*	*Lutzomyia Psychodopygus*	Rodents Less commonly: canids, felids, equines	LCL, MCL, LR, uta	South America, Central America, Mexico
	Leishmania (Viannia) panamensis	*Lutzomyia*	Sloths Less commonly: marsupials, rodents	LCL, LR, MCL, DCL	Central America, Colombia, Ecuador
	L. (Viannia) peruviana		Domestic dogs Less commonly: humans, rodents, Marsupials	LCL	Peruvian Andes
	L. (Viannia) Guyanensis		Sloths Less commonly: anteaters and opossums	LCL, LR, MCL (rarely)	Guyana, Brazil
	L. (Viannia) lainsoni		Lowland Paca, brown capuchin monkeys	LCL	Brazil, Bolivia, Peru
	L. (Viannia) colombiensis		Sloths Less commonly: anteaters and armadillos	LCL, VL (rarely, reported in Venezuela)	Colombia, Venezuela
OW and NW Leishmaniasis					
	Leishmania chagasi/ Leishmania infantum	*Lutzomyia, Phlebotomus*	Dog, fox, opossum, porcupine	LCL, infantile VL	Mediterranean basin; Middle East and Central Asia to Pakistan ; China; Central and South America

LCL = localized cutaneous leishmaniasis; DCL = diffuse cutaneous leishmaniasis; LR = Leishmaniasis recidivans; VTL = viscerotropic leishmaniasis; MCL = mucocutaneous leishmaniasis; VL = visceral leishmaniasis; PKDL = post-kala-azar dermal leishmaniasis.

and the positive Montenegro skin test (that assesses delayed-type hypersensitivity to leishmanial antigen). A dominant Th2 response accounts for progressive disease such as diffuse cutaneous leishmaniasis (DCL), and is characterized by anergy to leishmanial antigen (negative Montenegro skin test). Mucosal leishmaniasis patients will have both Th1 and Th2 responses, with slight predominance of Th2 immunity, explaining persistence of the disease. To summarize, T-cell immunity would be intact in LCL, defective in DCL, and pathologically exuberant in mucocutaneous leishmaniasis (MCL). Humoral immunity seems to play little or no role in determining the course of the infection. High titers of anti-leishmanial IgG correlate more with chronic, nonhealing, and visceral disease.



Figure 206-1 **A**. Acute Old World-localized cutaneous leishmaniasis: multiple nodules on the arm caused by *Leishmania major*. **B.** Multiple, nodular, ulcerated lesions on the trunk at the site of sand fly bites. Note that the ulcerated nodules look similar to volcanoes seen from above ("volcano sign").

CLINICAL FINDINGS

The clinical spectrum includes cryptic infection, LCL, and other forms including disseminated infection [DCL, MCL, VL, VTL (viscerotropic leishmaniasis), PKDL, leishmanid].[31]

CRYPTIC LEISHMANIASIS. Both cutaneous and visceral infection can remain subclinical or manifest with mild, nonspecific, and transient symptoms.[8,31,44,45]

LOCALIZED CUTANEOUS LEISHMANIASIS.[46] LCL constitutes 50%–75% of all incident cases. It is the mildest form of *Leishmania* diseases and the one that prevails in the OW.[3] It can be caused by all *Leishmania* species. Most cases heal spontaneously within 1 year and are characterized as acute LCL. Disease lasting more than 1 year is termed chronic LCL.

ACUTE LCL

Old World Localized Cutaneous Leishmaniasis. OW-CL (*Aleppo boil, Baghdad boil, Oriental sore, leishmaniasis tropica, Biskra button, Delhi boil, Bouton d'orient, Lahore sore, Rose of Jericho, Kandahar sore, the little sister*) is caused mainly by *L. major, L. tropica, Leishmania aethiopica*, and to a lesser extent *L. infantum* (Table 206-1).[24,26–29] Two major types, (1) the moist type (caused by *L. major*) (Fig. 206-1) and (2) the dry type (caused by *L. tropica*), are identified (Table 206-2).[47–50] Both types may coexist in the same patient.[40]

TABLE 206-2
Major Types of Old World-Localized Cutaneous Leishmaniasis

		Moist Type	Dry Type
Synonyms		Zoonotic cutaneous leishmaniasis	Anthroponotic cutaneous leishmaniasis
Species		*Leishmania major*	*Leishmania tropica*
Areas		Rural	Urban
Incubation Period		2–8 weeks	Up to 8 months
Clinical Picture	**Number of Lesions**	Multiple (Up to 100 insect bite-like lesions on exposed body parts, most of them resolve and only few evolve into LCL)	Single lesion over face
	Ulceration	More prominent and early, hemorrhagic crust	Less prominent and late, serous crust
Period of Healing		6 months (3–12 months)	Twice as long as moist type
Course/Outcome		Mild, self-limited, atrophic scars	Risk of progression to chronic LCL, Leishmaniasis recidivans or VL
Treatment		Observation or local treatment	Systemic treatment often required

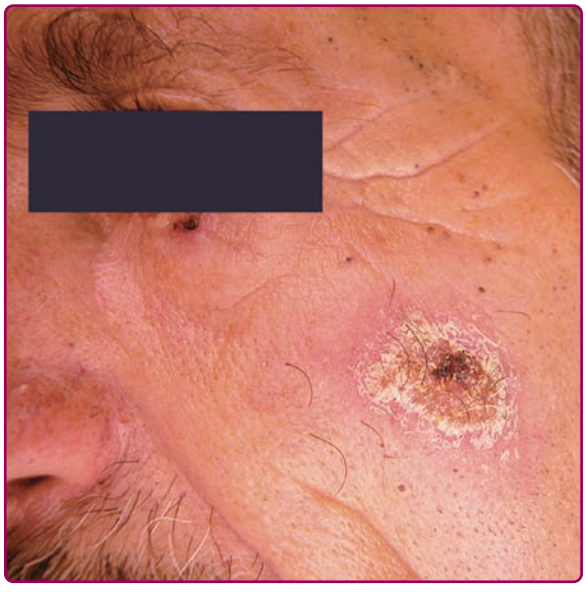

Figure 206-2 Acute Old World-localized cutaneous leishmaniasis. Single crusted erythematous plaque over the cheek.

L. aethiopica may cause a similar cutaneous disease to *L. tropica* but carries a higher risk of evolving into DCL in up to 20% of affected individuals.[47] *L. infantum*, the causative agent of Mediterranean VL in children, may cause a self-limited skin disease in adults.[51–53] Species identification cannot be made clinically and requires biochemical/molecular techniques.

The morphologic spectrum of OW-LCL is wide. Lesions start as erythematous papules that enlarge over few weeks to form nodules/plaques and often ulcerate and become crusted (Figs. 206-2–206-4; eFigs. 206-4.1 and 206-4.2 in online edition). The "volcanic" noduloulcerative morphology is characteristic and consists of painless crateriform ulcer with a rolled margin and a necrotic base that is often covered with an adherent crust (Fig. 206-5). Other presentations include "iceberg nodules,"[54] and eczematoid, psoriasiform,[50] erysipeloid,[55,56] zosteriform, paronychial,



Figure 206-3 Acute Old World-localized cutaneous leishmaniasis. Crusted erythematous nodule over the right perioral area in a young Middle Eastern girl.

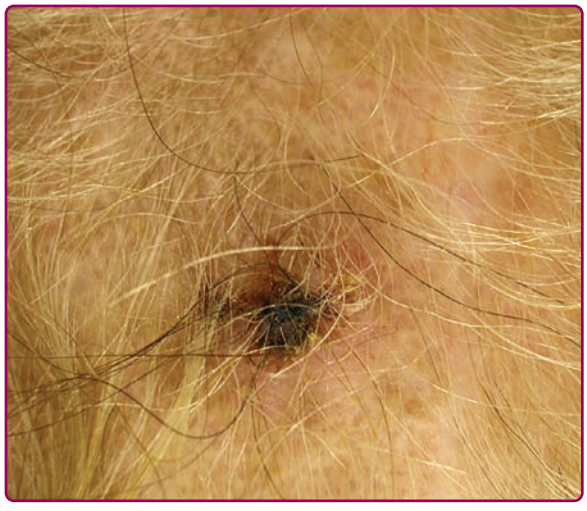

Figure 206-4 Acute Old World-localized cutaneous leishmaniasis. Crusted and ulcerated erythematous papule over the scalp.

chancriform, annular, palmoplantar,[57] verrucous, and keloidal[58] lesions. Satellitosis (Fig. 206-6), regional lymphadenopathy, localized lymphadenitis,[59] sporotrichoid lymphatic spread (eFig. 206-6.1 in online edition), subcutaneous lymphatic nodules,[54,60] and localized hypoesthesia[61] may occur. Mature lesions may be elongated and oriented parallel to skin creases.[54] Secondary bacterial infection is common.[62]

New World Localized Cutaneous Leishmaniasis (NW-LCL). NW-LCL (*valley sickness, Andean sickness, white leprosy, chiclero ulcer, uta, pian bois, and bay sore*) is caused by *L. mexicana and Leishmania (Viannia) braziliensis* complexes mainly (Table 206-1). Infection with *L. mexicana* or *Leishmania (Viannia) guyanensis* causes only cutaneous disease in contrast to infection with *L. (V) braziliensis* and *Leishmania (Viannia) panamensis*, which may, in 40%–80% of the cases, progress to MCL. Pure cutaneous disease is very similar to OW-LCL and isolated ulcers in exposed areas are the most common presentations. The progression of the lesions gives rise to a characteristic scar consisting of thin pale skin at the ulcer site with a hyperpigmented border.[3] About 50% of the lesions caused by *L. mexicana* heal within 3 months, whereas those caused by *L. braziliensis* persist much longer and are often associated with lymphadenopathy.[63,64] *L. mexicana*, however, is the causative organism of chiclero ulcer, a chronic mutilating infection of the pinna of the ear of forest workers in Mexico and Central America. (Fig. 206-7) *Lutzomyia flaviscutellata* is the major vector. In Brazil, the lower limbs are commonly affected, causing the typical Bauru ulcers.[3] Uta, the Andean cutaneous form of leishmaniasis, is caused by *L. braziliensis* and predominantly affects exposed areas in children. Its principal vector is *Lutzomyia peruensis*. An atypical nodular form of NW-CL caused by *Leishmania d. chagasi* has been reported from Honduras[65,66] and Nicaragua.[67] Unusual clinical pictures have been reported, especially in immunosuppressed patients.[3,68]

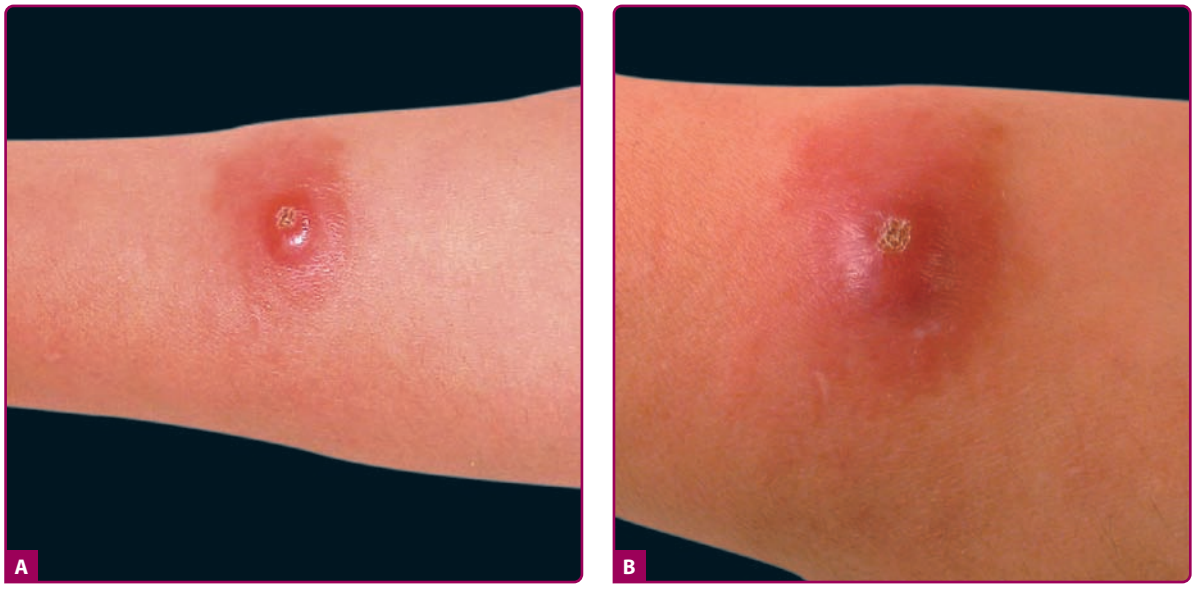

Figure 206-5 **A** and **B.** Acute Old World-localized cutaneous leishmaniasis. Classical "volcaniform" noduloulcerative lesion over the forearm.

Complications of LCL. Common complications include permanent scarring, disfigurement, and social stigma. Autoinoculation or koebnerization following trauma, tattooing, or surgery have been reported.[69] Major complications of LCL include chronic LCL, DCL, and MCL (in NW-LCL). Acute immunodeficiency syndrome (AIDS) and other immunosuppressive conditions increase the risk of mucocutaneous and visceral dissemination,[70–73] and of recurrence following therapy.[74] Disseminated cutaneous leishmaniasis, defined as more than ten pleomorphic lesions in noncontiguous areas of the body, has been reported in increasing frequency to complicate NW-LCL and HIV-associated OW-LCL.[69]

CHRONIC LCL. Typically, the lesions evolve from papules to chronic disfiguring indurated nodules/plaques that are larger than average acute LCL lesions and may exhibit variable degrees of scaling, ulceration, verrucosity, and scarring. (Fig. 206-8) The diagnosis may be challenging because of the paucity of organisms seen on histologic examination.

Leishmaniasis Recidivans. Leishmaniasis recidivans (LR) is a rare form of chronic LCL and accounts



Figure 206-6 Acute Old World-localized cutaneous leishmaniasis. Large volcaniform lesion and surrounding small satellite erythematous papules. (Used with permission from Raj Kubba, MD.)



Figure 206-7 New World-localized cutaneous leishmaniasis chiclero ulcer. A deep ulcer on the helix at the site of a sandfly bite. (From Wolff K, Johnson RA: *Fitzpatrick's Color Atlas and Synopsis of Clinical Dermatology*, 6th edition. New York, McGraw-Hill, 2009.)



Figure 206-8 Chronic-localized cutaneous leishmaniasis. Verrucous, scaly, erythematous plaque with focal ulceration and crusting. (Used with permission from Raj Kubba, MD.)



Figure 206-9 Disfiguring lupoid leishmaniasis of several years duration in a Middle Eastern man.

for 3%–10% of all LCL cases. It is caused mostly by *L. tropica* in the OW, and less commonly by *L. (V) braziliensis* in the NW as well as *Leishmaniasis amazonensis*, *L. (V) panamensis, and L. (V) guyanensis*. Erythematous scaly papules, often with apple jelly appearance, at the borders of a completely or partially healed CL lesion, are characteristic. It may complicate vaccination with a live strain of *Leishmania*[75] and usually occurs in the setting of hyperactive T-cell immunity and low antibody titers. Reactivation of dormant infection (up to 15 years after apparent resolution) after an unknown stimulus such as trauma or topical corticosteroids, rather than reinfection with different strains, is believed to account for most of the cases. In fact, several studies have demonstrated persistence of the intracellular living organisms in "healed" *Leishmania* lesions, this being more likely to occur if therapy was incomplete or deficient.[76,77]

Lupoid Leishmaniasis. Lupoid leishmaniasis shares similar etiology and clinical picture with LR; however, the former is not a recurrent lesion.[62] The lesion characteristically occurs over the face and may resemble clinically lupus vulgaris or discoid lupus erythematosus.[78] In the absence of molecular identification of parasites, the diagnosis may be delayed for several years leading to mutilation (Fig. 206-9).[79]

OTHER FORMS OF LEISHMANIASIS

DIFFUSE CUTANEOUS LEISHMANIASIS. DCL, also called pseudolepromatous leishmaniasis, is an anergic rare form of cutaneous leishmaniasis that occurs in the setting of deficient cell-mediated immunity and mimics clinically and histologically lepromatous leprosy. It is usually caused by *L. aethiopica* in the OW and by *L. amazonensis* and *L. mexicana* in the NW. Immunosuppressed patients, especially HIV-infected individuals, may develop a severe form of DCL (>200 lesions) with no species-specific relation.[4,80,81] Following a classical LCL lesion, dissemination occurs (immediately in 30% of cases but up to 11 years in others)[47] in the form of nonulcerated and parasite-laden nodules (eFig. 206-9.1 in online edition) with predilection for exposed areas of the body such as the face, where lesions may coalesce leading to leonine facies. Viscera are not involved. A progressive/chronic course with relapse after therapy is classical.

MUCOCUTANEOUS LEISHMANIASIS. MCL may complicate up to 10% of LCL patients and is characterized by the chronic and progressive spread of lesions to the nasal, pharyngeal, and buccal mucosa; lesions appear 1–5 years after resolution of the primary lesion(s), or less commonly while they are still present. It is often a complication of NW-LCL caused by *L. (V) braziliensis*, *L. (V) panamensis*, *L. amazonensis, and L. (V) guyanensis.* Ninety percent of cases occur in Bolivia, Brazil, and Peru.[82] In the OW, similar mucosal lesions caused by *L. aethiopica* may be seen but have a better prognosis.[4,83,84]

MCL results from direct extension or hematogenous/lymphatic spread to the upper respiratory tract, and rarely ocular and genital mucosa, and liver.[40] Bony structures are usually spared. Stuffy nose, epistaxis, coryza, hyperemia, and nasal septum crusting and ulceration are frequent presenting symptoms and signs. If untreated, the disease evolves into either septal perforation with resulting collapse of the nasal bridge and free hanging nose (tapir nose or parrot beak) or partial/total naso-oropharyngeal mutilating ulceration (espundia) (Fig. 206-10). In rare cases, the lips, cheeks, soft palate, or larynx are involved.[11] Lymphadenopathy is common in *L. braziliensis*-induced disease and may be associated with hepatomegaly and systemic symptoms.[4]



Figure 206-10 Mucocutaneous leishmaniasis, South American. Painful, mutilating ulceration with destruction of portion of the nose.

The major causes of mortality are secondary infection, pharyngeal obstruction, and respiratory failure. Cure rates decrease with advanced disease.[4]

VISCERAL LEISHMANIASIS.[3] VL (*Sikari disease*, *Burdwan fever*, *Shahib's disease*, *tropical splenomegaly*, *kala-azar*, *death fever*, *dum-dum fever*) is endemic in the tropical and subtropical parts of the world. Ninety percent of cases occur in Bangladesh, Ethiopia, India, Nepal, Brazil, and Sudan.[82] The causative agents are *L. donovani* and *L. chagasi/infantum* and to a lesser extent *L. amazonensis*, *and Leishmania (Viannia) colombiensis*. Infection with *L. donovani* occurs in the OW (India and Sudan), is anthroponotic and highly endemic, and involves *Phlebotomus argentipes* as a vector. Other infections are zoonotic and dogs are the major reservoir hosts. *L. infantum* afflicts mainly malnourished children in China, Africa, the Middle East, and the Mediterranean basin.

Hematogenous dissemination of the parasite to the reticuloendothelial system follows skin inoculation. However, congenital (transplacental) transmission may occur.[16] Most infections remain subclinical. The incubation period and the duration of the disease are variable. The cardinal features of VL are persistent high undulating fever, leucopenia, anemia, splenomegaly, and hypergammaglobulinemia. Other findings include emaciation, burning feet (peripheral neuropathy), hepato-gastrointestinal disturbances, epistaxis, thrombocytopenia, and lymphadenopathy. Skin lesions develop later in the course of the disease and consist of ashy hyperpigmented patches on the temple, around the mouth, and on the abdomen, hands, and feet in light skin-persons; hence, the name kala-azar (in Hindi, black sickness). Other findings include hair and skin depigmentation (in Kenyan patients),[40] cutaneous nodules and mucosal ulcers (in Sudanese patients),[40] trichomegaly (Pitalugo's sign), petechiae, and jaundice.[40]

Without treatment, the fatality rate in developing countries approaches 100% in 2 years with the major complications being cachexia, secondary infections, enteritis, and pneumonia. Hemolytic anemia, acute renal damage, and severe mucosal hemorrhage are less common.

VL/HIV Coinfection.[85] Most coinfection cases have intravenous (IV) drug use as a common denominator[86] and represent diagnostic and therapeutic challenges, since VL precipitates the onset of AIDS and HIV increases the risk of VL. The problem is mostly described in Spain, Italy, France, and Portugal.[82,86–89] *L. infantum* is the major causative agent; however, other *Leishmania* species that do not normally visceralize have been isolated.[80,81,90] MCL-, PKDL-, and DCL-like pictures may result[91] and cutaneous lesions are highly variable.[71] Multiple dermatofibroma- and Kaposi's sarcoma-like papulonodular lesions may occur,[86] and should be differentiated from parasitic colonization of Kaposi's sarcoma.[92] The presence of amastigotes in atypical locations tend to correlate with the degree of immunosuppression.[93] People with both conditions have worse prognosis, shortened survival time, higher relapse rate and inferior response to treatment compared with HIV-negative patients. VL is now being proposed to be integrated in the Centers for Disease Control and Prevention (CDC) clinical category C as an AIDS-defining illness.[3]

POST-KALA-AZAR DERMAL LEISHMANIASIS.[94] PKDL is extremely rare in the NW and is mostly seen, in two major forms, in Sudan and India (eTable 206-2.1 in online edition). As the name implies, it is a cutaneous manifestation of VL that usually develops months to years after resolution of VL, and rarely during its treatment.[96,98] In India, PKDL is the most common skin manifestation of leishmaniasis (eFigs. 206-10.1 and eFigs. 206-10.2 in online edition). Affected patients are the major reservoirs of the infection.[98] High blood concentration of the immunosuppressive cytokine interleukin-10 in VL patients is predictive of PKDL development. The parasite count is low and detection of organisms is not always possible. With polymerase chain reaction (PCR) technique, however, *Leishmania* parasites are recovered in skin lesions in up to 83% and 94% of Sudanese and Indian PKDL, respectively. The development of skin lesions in PKDL is closely linked to *Leishmania*-specific lymphocyte reactivity, or in HIV patients, to immune reconstitution during HAART treatment. The reason behind the two major clinical forms of PKDL remains essentially unclear.[94]

VISCEROTROPIC LEISHMANIASIS.[41] Caused by *L. tropica*, this variant has been described among American veterans of Operation Desert Storm. Visceral infection manifests as fever, malaise, and variable hematologic and hepato-gastrointestinal findings. Classic signs of VL are absent and the skin is usually not involved; however, a recent report in a young Afghani refugee living in the United States demonstrated cutaneous lesions.[99] Positive culture from bone-marrow aspirates and good response to antimonials are typical.

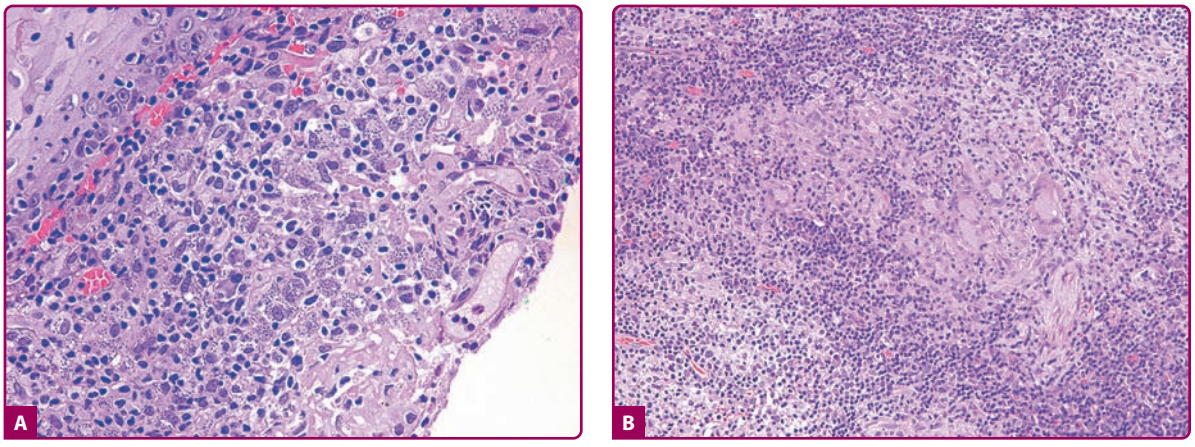

Figure 206-11 Histologic examination (hematoxylin and eosin). **A.** Acute cutaneous leishmaniasis. Moderately dense lymphohistiocytic infiltrate with numerous parasitized macrophages containing amastigotes (Leishman bodies). **B.** Chronic cutaneous leishmaniasis. Tuberculoid granulomatous dermatitis. Note the presence of multinucleated giant cells, the surrounding lymphoplasmacytic infiltrate, and the absence of parasites.

LEISHMANID. This term refers to an id reaction consisting of a diffuse, asymptomatic, and symmetric papular eruption in the setting of acute LCL or LR.[100] It typically resolves within 8 weeks of its appearance. Leishmanid may develop during treatment and is not an indication to withhold therapy.[47]

DIAGNOSIS[101,102]

Given the potential treatment toxicity, confirmation of the diagnosis is always mandatory. Even when smear, histology, and culture results are combined, the parasite may not be detected in 10%–20% of cases.[40,54] The diagnostic challenge is often greater in NW disease and in chronic lesions.[63,103] The sensitivity of both tissue smear and culture approaches 90% when specimens are taken during the first weeks of infection.[3] The best approach is to use several diagnostic methods.

Taken from the infiltrated margin, a skin biopsy may be divided into three parts: one for an impression smear, one for histological examination, and another one for culture.

Several smear techniques may be used with a success rate ranging between 50% and 80%.[40] They are obtainable from fine needle aspirates or tissue scrapings, air-dried, fixed with methyl alcohol, stained with Giemsa stain, and viewed under oil-immersion microscopy. Impression smears, made by gently pressing the skin biopsy against a glass slide 2–5 times, provide better sensitivity than H&E examination.[104]

The histopathologic examination of early lesions of LCL reveals a dense and diffuse mixed inflammatory cell infiltrate composed predominantly of histiocytes, and scattered multinucleated giant cells, lymphocytes, and plasma cells[105] (sometimes with intracytoplasmic homogenous eosinophilic immunoglobulin material called Russell bodies). The hallmark of the disease (in around 70% of the cases) is the presence of numerous extracellular and intracellular (within histiocytes) amastigotes (also known as Leishman–Donovan bodies) (Fig. 206-11A).[40] Giemsa stain stains the parasite nonmetachromatically and the kinetoplast bright red. The organisms may also be highlighted by the Wright and Feulgen stains. Monoclonal antibodies such as G2D10 can identify amastigotes and promastigotes in smear, biopsy or culture specimens, constituting a rapid screening test for leishmaniasis.[106] The histologic differential diagnosis includes diseases characterized by parasitized macrophages. The presence of halo surrounding the yeasts in Histoplasmosis, safety pin-like encapsulated Donavan bodies in Granuloma inguinale, and Mikulicz cells in Rhinoscleroma distinguishes these conditions from Leishmaniasis. Other considerations are blastomycosis, paracoccidiomycosis, toxoplasmosis, and trypanosomiasis. As the lesion evolves, the number of amastigotes per section decreases and the histology approaches that of chronic LCL where the predominant histologic pattern is nodular/diffuse noncaseating tuberculoid granulomatous dermatitis (Fig. 206-11B). Epidermal hyperplasia and ulceration are variable. Scarring with marked loss of elastic fibers may be seen.

In DCL, a diffuse infiltrate composed of vacuolated macrophages with numerous intra- and extracellular amastigotes is characteristic. The major differential diagnosis is lepromatous leprosy. In MCL, the histopathologic findings are similar to those of LCL but organisms are usually sparse. In PKDL, Pautrier-like epidermal microabscesses and a dense lymphoplasmacytic infiltrate with papillary dermal edema (in early lesions) are characteristic.[47]

Culture (at room temperature), by means of a biphasic medium such as Novy-Mac-Neal-Nicolle (NNN) or chick embryo medium, is the gold standard of diagnosis, but with a sensitivity of only 50%.[40] It can be performed using aspirates, scrapings or fresh skin biopsies.[69] Promastigotes often appear after several days but occasionally may take few weeks. Species identification is not possible based on their morphology.

Molecular techniques using species-specific oligonucleotide probes for kinetoplast DNA may be used on all specimens. PCR methods are particularly useful and offer superior specificity and sensitivity in the diagnosis of cutaneous leishmaniasis, MCL, and VL, especially in cases where organisms are scarce.[107–111] Their widespread use, however, is hindered by cost as well as by the technical expertise they require. False-positive reactions and species identification in NW-CL may be at times problematic.[11]

Isoenzyme analysis is currently considered to be the gold standard for *Leishmania* speciation. It consists of enzyme electrophoresis of cultured promastigotes and is based on the fact that morphologically similar promastigotes of different species have different enzyme profiles; however, it is lengthy and costly.

Serology in cutaneous leishmaniasis is not useful due to its low sensitivity (antibodies present in low titre[112]) and specificity (due to cross-reaction with leprosy, malaria, and other trypanosomal infections).

The Montenegro skin test (Leishmanin) is analogous to the tuberculin test and consists of phenol-killed promastigotes injected in the dermis.[3] This allows the detection of exposure to *Leishmania* without distinguishing between past and active infection.[113] Up to 50% of people living in endemic areas may test positive without a history of previous or active disease. The test is positive once crusting has developed, and negative in anergic states such as DCL and PKDL or often in lesions (less than 3-months-old).

Laboratory animal inoculation (xenodiagnosis) is useful when the parasite load is low.[40] Electron microscopy offers no advantage over light microscopy and its use is limited.[40]

In VL, microscopic detection and/or culture of parasites in tissue aspirates from spleen (sensitivity >97%), lymph nodes (sensitivity 60%), or bone marrow (sensitivity 55%–97%) is diagnostic. However, as these techniques are invasive, several serologic and molecular methods have been developed. Anti-K39 antibody based on a recombinant antigen from *L. chagasi* has high sensitivity and specificity. It is an immunochromatographic strip test using finger prick blood and is helpful in resource-poor regions. As a last resort, PCR of peripheral blood or tissue aspirate can be done and is extremely sensitive.[114]

DIFFERENTIAL DIAGNOSIS

(Box 206-2)

PROGNOSIS AND CLINICAL COURSE[31]

The clinical course is disease dependent. In general, lifelong species-specific immunity follows drug-induced cure or natural resolution.[115] Cross-species immunity may also develop.[116] Sterile immunity does not occur and persistent tissue infection seems to be the rule even following adequate therapy.[39,117–119]

BOX 206-2 DIFFERENTIAL DIAGNOSIS OF VARIOUS TYPES OF LEISHMANIASIS

- ACUTE LCL
  - Arthropod bite
  - Infections (pyoderma, Majocchi granuloma, tuberculosis, and atypical mycobacterial and deep fungal infections)
  - Sarcoidosis
  - Pyoderma gangrenosum
  - Malignancy: basal cell/squamous cell carcinoma, keratoacanthoma, lymphoma
  - Foreign body granulomas
  - Pseudolymphoma
- CHRONIC LCL
  - Infections: lupus vulgaris, leprosy
  - Sarcoidosis
  - Discoid lupus
  - Lymphoma and reactive lymphoid hyperplasia
- DCL
  - Infections: lepromatous leprosy, deep fungal infections
  - Xanthomas
  - Lymphoma
- MCL
  - Infection: leprosy, syphilitic gumma, yaws, tuberculosis, deep fungal infections such as paracoccidioidomycosis
  - Granulomatosis with polyangiitis (Wegener's)
  - Malignancy: nasopharyngeal carcinoma, squamous cell carcinoma and lymphoma
- VL
  - Infections: malaria, syphilis, tuberculosis, typhoid fever, brucellosis, histoplasmosis, schistosomiasis
  - Systemic lupus erythematosus
  - Leukemia/lymphoma
  - Tropical splenomegaly syndrome
- PKDL
  - Infections: syphilis, yaws, leprosy

LCL = localized cutaneous leishmaniasis; DCL = diffuse cutaneous leishmaniasis; MCL = mucocutaneous leishmaniasis; VL = visceral leishmaniasis; PKDL = post-kala-azar dermal leishmaniasis.

TREATMENT[120–123]

Given the clinical diversity of leishmaniasis and the lack of adequately controlled therapeutic trials, each case needs to be individualized based on the parasite species (Table 206-3), extent of the disease, host immune and nutritional status, presence of intercurrent diseases, geographic region, and cost, availability and toxicity of the various therapeutic options. In general, NW-CL tends to be more severe and progressive than OW-CL. In addition, NW-CL caused by

TABLE 206-3
Treatment Options Based on *Leishmania* Species

OW-CL	*Leishmania major*	Expectant observation Local therapy
	Multiple, progressive or sporotrichoid	Systemic therapy
	Leishmania tropica *Leishmania aethiopica* *Leishmania infantum*	Systemic therapy
NW-CL	*Leishmania mexicana* complex	Expectant observation Systemic therapy
NW-MCL	*Leishmania braziliensis* Complex	Systemic therapy

OW = Old World; CL = cutaneous leishmaniasis; NW = New World; MCL = mucocutaneous leishmaniasis.

L. braziliensis may eventuate into "espundia," thus necessitating systemic therapy. As a rule, patients should be monitored until the lesions have completely healed. Follow up at 6 months is appropriate.

Since most lesions caused by *L. major* and *L. mexicana* heal spontaneously within 4 months, an expectant approach is favored as it may confer protective immunity. Multiple, persistent, progressive, deep, sporotrichoid, and secondarily infected lesions should, however, be treated as well as lesions on cosmetically or functionally important sites such as joints.

Local therapy (Box 206-3) is appropriate for small, noninflamed and localized lesions that are not at risk to progress to MCL. Topical imiquimod alone is ineffective.[141] Systemic therapy is reserved for complicated CL such as DCL and CCL, MCL, VL, relapsing disease, or disease complicated by HIV coinfection. In general, OW-CL requires shorter courses compared to NW-CL. Systemic therapies used for leishmaniasis are summarized in Table 206-4. Sodium stibogluconate and meglumine antimoniate are pentavalent antimony derivatives with slightly differing antimony concentrations and comparable efficacy and safety profiles. They are the mainstay of systemic treatment.[178] Indian VL is treated with 20 mg/kg/day intramuscularly or IV once daily for 40 days versus 28 days if the disease is contracted elsewhere. Antimony resistance is a serious issue in India and in Iran.[179–182] Resistant cases may benefit from combining antimonials with pentoxifylline,[156] allopurinol,[183–186] paromomycin,[187,188] azithromycin,[189–191] IFN-γ,[192–194] granulocyte-macrophage colony-stimulating factor,[195] and topical imiquimod.[196,197]

BOX 206-3 LOCAL THERAPY FOR LEISHMANIASIS

- Excision/curettage or laser ablation.[97]
- Cryotherapy,[124] thermotherapy,[36] electrotherapy,[125] photodynamic therapy.[126]
- Intralesional antimonial,[127–130] combined with cryotherapy.[131]
- Paromomycin ointment[127,132,133] alone or combined with 12% methylbenzethonium chloride.[126]
- Topical azoles.[134]
- Others: ethanolic formulation of amphotericin B,[135,136] topical glyceryl trinitrate,[137] hypertonic sodium chloride,[138,139] intralesional metronidazole,[140] intralesional interferon-γ,[11] topical or intralesional zinc sulfate.[11]

PREVENTION AND VACCINES

Essential to prevention is the promotion of personal protective measures through the use of protective clothing, insect repellents containing 30%–35% DEET, permethrin-treated bed nets and clothing; the avoidance of endemic areas; and staying on higher floors of buildings in the evening.[198] One way of reservoir control of *L. major* was achieved by destroying burrows made by the rodent host. In endemic areas where dogs could be hosts of parasites, a dog collar coated with deltamethrin could be a useful way to control transmission.[11] Targeting anthroponotic foci that are at the origin of deathly epidemics, suspecting leishmaniasis in persons with skin lesions or febrile illnesses returning from endemic areas, and deferring prospective blood donors from donating blood for at least 1 year after their return are other measures. Control of HIV in Southern Europe where leishmaniasis is closely associated with HIV has generated positive outcome.[114]

New diagnostic tests, drugs, and vaccines are in development.[116,199,200] Vaccine development for tropical diseases is often limited by the lack of financial return.[201] "Leishmanization," the self-inoculation of the live parasite in inconspicuous areas of the body, has been practiced in endemic areas to prevent disfiguring facial lesions, but was later abandoned due to its complications. Killed promastigotes vaccines with and without adjuvant BCG seem to be useful in some endemic areas.[116,202] Adjuvants such as BCG are important to prime a Th1 response. Attenuated live parasites- and plasmid DNA-based vaccines using leishmanial antigens have shown efficacy in mouse models.[116] Experimental vaccines containing a component of sandfly saliva proteins appear to be promising.[203] Despite being experimentally successful, a safe nonliving prophylactic vaccine has not yet been able to confer significant protection in humans.[204] The recent sequencing of the *Leishmania* genome might lead the way to new ways for prevention, control, and treatment of the condition.[205–207]

AFRICAN TRYPANOSOMIASIS[208,209]

EPIDEMIOLOGY

African trypanosomiasis (Af-T) afflicts humans (sleeping sickness) and cattle (nagana), and affects up to half

TABLE 206-4
Systemic Therapies for Leishmaniasis[3,11,69,126,142–144]

Systemic Treatment/ Dose	Mechanism of Action	Indications	Effectiveness	Adverse Effects
Pentavalent antimonials: sodium stibogluconate (Pentostam) IV and meglumine antimoniate (Glucantime) IM/IV 20 mg/kg/day for 20–30 days	Inhibition of glycolysis and oxidation of fatty acids of the parasite	Complicated OW-LCL, NW-LCL with potential of mucosal dissemination, DCL, MCL, VL.	Superior to all other drugs except pentamidine in NW-LCL. Cure rate variable depending on species and disease: ranges from 35%–95%. High treatment failure in India and Iran.	Dose dependant and resolve after discontinuation of drug. Pain at injection site, myalgias (68%), pancreatitis (18%), hepatitis, marrow suppression, QT prolongation, fatigue, headache, rash, and nausea.
Pentamidine[143] 2–4 mg/kg/day IV or IM or every other day for 4–7 days.	Not established yet	NW-LCL in French Guyana (first-line treatment), MCL.	Superior to all other drugs in NW-LCL.	Risk of diabetes mellitus in high-dose course, nephrotoxicity, hypotension, arrhythmias, nausea, vomiting, diarrhea, pancytopenia, cough, bronchospasm, confusion, and hallucinations.
Amphotericin B 1 mg/kg every other day for up to 30 days IV 15 mg/kg total dose.	Binding to sterols present in parasite's membrane causing a change in permeability	Second-line therapy when other treatments fail LCL, MCL.	>97% efficacy for VL in all regions.	Hyperpyrexia, hypotension, thrombophlebitis, renal complications, anemia, and hepatitis
Liposomal amphotericin B[145] 3 mg/kg/day IV for 5 days, then on day 10.	Same as above	VL not yet studied for LCL.	100% cure rate against *Leishmania braziliensis* Single dose (10 mg/kg) as efficacious as conventional Amphotericin B (1 mg/kg every other day for 15 doses) for VL in India.	Less renal toxicity than amphotericin B
Imidazoles:[6,146–151] Itraconazole 200 mg/day orally for 6 weeks. Fluconazole 200 mg/day orally for 42 days. Ketoconazole 600 mg/day for 28–30 days.	Inhibition of demethylation of lanosterol, blocking ergosterol synthesis.	LCL	Oral itraconazole: good efficacy against *Leishmania tropica* Oral fluconazole: efficacy against *Leishmania major* Oral ketoconazole: 89% efficacy against both *L. major and L. tropica*, and 76% against *Leishmania panamensis*.	No significant side effects, hepatotoxicity.
Miltefosine[152] 2.5 mg/kg/day for 28 days orally	Inhibits phosphatidylcholine biosynthesis in parasites.	VL (Indian) LCL	94% efficacy in Indian VL, less efficacy in African VL.	Diarrhea, vomiting, reproductive toxicity in animals.
Paromomycin sulfate[153] 15 mg/kg daily for 21 days IM	Inhibition of protein synthesis	Indian VL	94% efficacy in Indian VL, 59% efficacy against *L. braziliensis* and *L. mexicana*, under investigation for VL in Africa.	Rarely: nephrogenic, ototoxic, hepatotoxic.
Zinc sulfate[154,155] 2.5–10 mg/kg/day orally for 30–40 days	Boosting of Th1 reaction as well as phagocytosis of parasites	LCL	84%–97% efficacy against *L. major* or *L. tropica*	Necrosis at injection site
Pentoxifylline 400 mg orally 2–3 times/day (with pentavalent antimony)[156,157]	Inhibits TNF-α	MCL, LCL	Reduces healing time as well as need for second course of pentavalent antimony, is effective for MCL patients resistant to pentavalent antimony, Can prevent renal functional alterations induced by meglumine antimonate in rats	No significant side effects related to pentoxifylline

Other reported systemic therapies: Terbinafine,[158] Metronidazole,[140,159,160] Dapsone,[161,162] interferon-γ, [163] Allopurinol, [164–167] Trimethoprim-sulfamethoxazole,[168,169] Rifampin,[170] Nifurtimox,[171,172] Quinolones,[173] Pyrimethamine,[174] Anti-interleukin-10 (experimentally lead to sterile cure),[118] Azithromycin.[175–177]
IV = intravenous; IM = intramuscular; OW = Old World; LCL = localized cutaneous leishmaniasis; NW = New World; DCL = diffuse cutaneous leishmaniasis; MCL = mucocutaneous leishmaniasis; VL = visceral leishmaniasis; Th1 = T helper 1; TNF = tumor necrosis factor.

a million people every year in the middle latitudes of Africa, where the vector is found. Fatality rate is close to 100% in untreated patients. The disease is very rare in the United States.[209]

ETIOLOGY AND PATHOGENESIS

Trypanosoma brucei, a unicellular organism, enters the bloodstream of a mammalian host via the bite of a blood-feeding infected male or female tsetse fly of the genus *Glossina*. Other ways to contract the disease, although uncommon, include placental transmission, blood transfusion, and sexual contact.[210,211]

The tsetse flies are attracted by dust clouds of moving objects and animals, as well as black and blue colors. They bite most during early daylight and at dusk, and ingest trypomastigotes from infected blood meals (eFig. 206-11.1 in online edition).

Trypomastigotes have a glycoprotein-coated surface that has a protective role against lytic factors found in human plasma. Furthermore, the extensive antigenic variation of the glycoprotein present on the parasite's surface allows evasion from humoral immunity. This also explains why a vaccine targeting trypanosomes would be extremely difficult to develop.[212]

CLINICAL FINDINGS

Af-T presents in two distinct forms. West African or Gambian trypanosomiasis (GT) (caused by *Trypanosoma b. gambiense*) is a chronic predominantly anthroponotic disease present in rural areas west of the Rift Valley. East African or Rhodesian trypanosomiasis (RT) (caused by *Trypanosoma b. rhodesiense*) is an acute fatal disease (within weeks, if untreated) that infects mainly livestock/game animals east of the Rift Valley, and sporadically herdsmen, hunters, photographers, and tourists.[213–215] Water requirements of the *palpalis* group of tsetse flies and the savannah habitat of *Glossina morsitans* determine the geographic distribution of GT and RT, respectively. This ecological separation, however, is not as strict as it was in the past with an overlap of the two forms of the disease in Uganda.[212]

In RT, a painful chancre develops at the site of the tsetse bite and resolves within 1–3 weeks leaving no scar. It consists of a circumscribed, rubbery, indurated, 2–5 cm dusky red nodule, often with a central eschar (Fig. 206-12). In GT, however, the initial lesion consists of a single nonspecific nodule that is often mistaken for an insect bite or a folliculitis.[3]

Afterward, Af-T will evolve in two stages: (1) the hemolymphatic or early stage and (2) the meningoencephalitic or late stage. In contrast to the late stage, when the skin is not involved, cutaneous changes may be seen in the early stage and are more commonly observed in RT and in light-skin patients. Perhaps for this reason, skin lesions are rarely reported in native Africans.

The hemolymphatic stage occurs 3–10 days after the initial bite development with the parasites entering the circulation and causing irregularly spiking



Figure 206-12 East African trypanosomiasis. The trypanosome chancre consists of erythematous nodule with central bulla and ulceration. This patient was treated with Suramin and survived. (From Case Records of the Massachusetts General Hospital, Case 20–2002. *N Engl J Med* **346**:2069, 2002, with permission of the Massachusetts Medical Society.).

fever. Hepatosplenomegaly, constitutional symptoms, normocytic anemia, thrombocytopenia, and pruritus (especially presternal) develop, and may be related to circulating immune complexes.[3] Local lymphadenopathy progresses to generalized lymphadenopathy in virtually all African natives and in about half of Europeans patients. Involvement of the posterior cervical (Winterbottom's sign) and supraclavicular lymph node (LN) is characteristic only of GT. The disease is more severe in RT where severe parasitemia, myocarditis and rarely, fatal disseminated intravascular coagulopathy develop.[209] Trypanids are distinctive eruptions that develop 6–8 weeks after the onset of fever in approximately half the light-skin patients, and consist of poorly defined, centrally pale, evanescent, annular, targetoid, or blotchy erythematous macular, hemorrhagic, urticarial, or erythema nodosum-like lesions, commonly on the trunk.[216] These lesions might be due to a type III hypersensitivity reaction.[3] A sensation of formication may be associated. The eruption waxes and wanes over weeks with accentuation upon exposure to cold, heat, or sweat. Painless swelling of the face (imparting a sad look), and of the hands and feet may occur. Other findings include ichthyosis, acroparesthesias, icterus, petechiae, and generalized flushing.

The late stage is characterized by central nervous system (CNS) involvement weeks to months after exposure in RT, and months to years after exposure in GT and occurs when parasites cross the blood–brain barrier. Severe headache develops then chronic meningoencephalitis, somnolence, coma, and death

ensues. Delayed bilateral pain out of proportion to a sharp squeeze applied to soft tissues, known as Kerandel's deep delayed hyperesthesia, is characteristically found in European patients but is uncommon in African patients.[217] Patients may also develop behavioral changes, psychosis and focal neurologic symptoms. Marked weight loss can ensue.[212]

DIAGNOSIS

Diagnosis of Af-T is via detection of trypanosomes in blood film or Giemsa-stained thick smears, chancre/LN aspirate, buffy coat, bone marrow, or CSF. Histologically, long, thin trypanosomes are best seen using Giemsa stain, in the midst of a perivascular lymphoplasmacytic infiltrate. Because of antigenic variability, serologic tests lack sensitivity and specificity.[213] Differentiation of RT from GT is usually based on epidemiology. PCR is the method of choice but cost limits its use in African countries.[218] New diagnostic tools are being developed.[219–221]

Control of Af-T in endemic areas is highly cost-effective and entails case detection and treatment, keeping tsetse populations at low levels,[221] and mass screening of at-risk populations.

TREATMENT

A lumbar puncture is essential for the differentiation between the early and late stages because treatment will vary accordingly.[216] Four registered drugs are currently provided free of charge by the WHO.[141,164,165,206] Suramin and pentamidine are the drugs of choice for early-stage RT and early stage GT, respectively. Melarsoprol, an arsenical, is a powerful trypanocide able to cure both RT and GT in all stages; however, due to its toxicity mostly on the central nervous system, its use is restricted to late-stage disease of both forms. Eflornithine is cytostatic and can only be used in GT. Of concern, HIV-positive patients receiving treatment for RT may succumb to full-blown AIDS.[218] Other drugs that can be used for late stage disease include nitrofurazone and difluoromethylornithine.[3] Combination therapy of the available drugs was investigated and all trials showed better results than monotherapy. Of note, combination therapy containing melarsoprol leads to severe drug reactions. A multicountry study comparing nifurtimox (registered for the treatment of Chagas disease) and eflornithine to eflornithine alone was undertaken for late-stage GT. The combination therapy resulted in fewer infusions, shorter treatment duration, and fewer adverse effects.[222,223]

CHAGAS' DISEASE (AMERICAN TRYPANOSOMIASIS)[224]

EPIDEMIOLOGY

American trypanosomiasis (Am-T) is a zoonotic disease caused by *Trypanosoma cruzi* and transmitted to humans by blood-sucking triatomine bugs (kissing bugs, assassin bugs, reduviid bugs). It is endemic in many rural areas of Central and South America and Mexico. In the United States, up to 300,000 individuals are affected and up to 45,000 have the clinical disease.[225,226]

ETIOLOGY AND PATHOGENESIS

Triatomine bugs are large (3–4 cm), "cone-nosed" bedbugs that thrive in poor housing conditions and become infected with *T. cruzi* by feeding on contaminated blood. An infected triatomine bug takes a blood meal usually at night, and releases trypomastigotes in its feces near the site of the bite wound, usually a mucocutaneous junction. Human infection occurs when mucous membranes especially the conjunctiva or skin breaks are contaminated with the feces upon rubbing/scratching (eFig. 206-12.1 in online edition). Other reported ways of transmission of the disease seem to be via the intake of reduviid feces-contaminated fruits and fruit products.[3] Congenital (transplacental) transmission[227] and transmission by blood transfusion and organ transplantation[224,228–230] may also occur.

CLINICAL FINDINGS

Am-T progresses in three stages (Box 206-4).

DIAGNOSIS

Diagnosis and treatment are problematic. In the first stage, diagnosis involves microscopic demonstration of trypomastigotes in blood specimens especially thin smears, hemoculture, or xenodiagnosis. Thereafter, detection of organisms becomes difficult, and diagnosis relies more on serologic testing or PCR. The WHO recommends using at least two antigen detection tests for confirmation of the disease.[237]

TREATMENT

Treatment is indicated for acute infections, congenital infections, patients who are immunosuppressed or children with chronic disease.[237] Both drugs that are available, benznidazole and nifurtimox, are toxic[238] and most effective when given during the first stage of the infection or in congenital infections. Because of their toxicity, potential carcinogenic risk, decreased efficacy in chronic disease, and the presumably autoimmune nature of the latter, treatment of chronic disease has long been considered controversial. Later studies, however, revealed the persistence of the parasite in heart muscle as well as digestive tissue in patients with the chronic condition.[235,239] In addition, patients with chronic cardiomyopathy who were given benznidazole had less clinical deterioration a decade later as well as lower serologic titers. Therefore, chemotherapeutic intervention at any stage of the disease is currently recommended.[240] Allopurinol and itraconazole have also been tried for chronic disease.[3]

BOX 206-4 CLINICAL STAGES OF CHAGAS DISEASE

The acute phase (first stage)	Transient parasitemia: usually asymptomatic or associated with fever, lymphadenopathy, mild hepatosplenomegaly, and morbilliform/urticarial rash; lasting for about 8 weeks.
	Chagoma: painful inflammatory reaction at the site of inoculation: 1–3 cm erythematous, often ulcerated nodule with a surrounding pale halo. Local lymphadenopathy often present.
	Schizotripanides or transient skin rash resembling measles.
	Romaña's sign (or ophthalmoganglionar complex): Unilateral conjunctivitis with palpebral edema (from conjunctival inoculation).
	May be fatal in young children or immunosuppressed individuals.
The indeterminate phase (second stage)	Low levels of the parasite in blood and other tissues → chronic asymptomatic and infectious state.
	Reactivation of the infection following organ transplantation (disseminated painful subcutaneous and/or ulcerated nodules [224,231,232]).
The symptomatic chronic phase (third stage)	In 10%–30% of patients often many years after initial infection Lethal dilated cardiomyopathy, arrhythmias, megaesophagus, and megacolon
	Pathogenesis: was thought to be mediated by molecular mimicry;[233,234] however, parasites persistence in tissues were recently demonstrated by PCR and in situ hybridization.[235]
	Genetic variability of *Trypanosoma cruzi* might determine the clinical presentation of chronic disease.[236]

Preventive measures are aimed to eradicate the vectors, improve diagnostic tests, develop less toxic and more efficient drugs, and implement serologic screening of organ donors and recipients. Control programs have reduced the incidence of Am-T by 70% in some countries of South America.[241]

CUTANEOUS AMEBIASIS[242]

EPIDEMIOLOGY

Entamoeba histolytica, of the class Sarcodina and genus *Entamoeba*, is a pathogenic ameba that can cause intestinal and extraintestinal diseases. Amebiasis is the second leading cause of death from parasitic diseases. Higher incidence is reported in Mexico and in developing tropical countries.[243] In developed countries, risk groups include male homosexuals, travelers, immigrants, and institutionalized patients.

ETIOLOGY AND PATHOGENESIS

Entamoeba exists in two forms: (1) the capsuled cyst (10–15 µm) or infective stage, and (2) the mobile trophozoite or tissue-invasive stage. Both forms are passed in the feces. Human beings are the only natural hosts and infection generally occurs by ingestion of mature cysts in fecally contaminated food, water, or hands. Anal sex and contaminated enema equipment are other modes of transmission.[242]

Trophozoites have marked phagocytic, proteolytic, and cytolytic capabilities, releasing proteases, collagenase, hyaluronidase, N-acetylglucosaminidase, phospholipase-A, and secretagogues.[244] They can therefore invade human colonic mucosa, and occasionally penetrate through to the portal circulation, reaching the liver and other organs, and causing fatal lesions. Some mammalian cells are resistant to trophozoite adherence.[242] Most cases of asymptomatic noninvasive "luminal amebiasis" are caused by *Entamoeba dispar*, rather than *E. histolytica*.[245]

CLINICAL FINDINGS

Depending on the extent of invasion and the transmission mode, the clinical spectrum includes three major presentations:

1. Invasive intestinal disease (dysentery, colitis, and amebomas).
2. Invasive extraintestinal disease (liver abscess, peritonitis, and pleuropulmonary abscess).
3. Cutaneous disease can be either primary or secondary:
   - In primary cutaneous amebiasis, an extremely rare condition, the skin is affected without underlying intestinal or extraintestinal disease. It is thought to be secondary to direct inoculation from scratching with contaminated fingers in areas with poor hygiene. Penile lesions are often acquired through anal intercourse with infected individuals.[243,246]
   - In secondary cutaneous amebiasis, the skin can be infected following extension from an underlying/contiguous intestinal or extraintestinal abscess, draining catheter, fistula, colostomy or laparotomy incision.[243,246,247] Trophozoites can also spread through contaminated stool to the anogenital



Figure 206-13 Cutaneous amebiasis. (From Weinberg S, Kristal L, Prose NS: *Color Atlas of Pediatric Dermatology*, 4th edition. New York, McGraw-Hill, 2007.)

skin. This is often seen in children with diarrhea following direct and prolonged contact with infected feces in their diapers.[244,248] Autoinoculation via contaminated hands may account for more distal lesions.[249–251]

Both types of cutaneous transmissions are rare and result in rapidly progressive, foul smelling, and painful punched-out ulcers with glairy, hemopurulent, raw beef-like base; necrotic, cordlike and undermined borders; and surrounding erythema (Fig. 206-13). Lesions may reach up to 20 cm in diameter and are often destructive if untreated. Chronic urticaria may be associated[252] and local lymphadenopathy is common. Without prompt diagnosis and treatment, the prognosis is poor. In rare cases, even primary cutaneous amebiasis has a fatal outcome.[246]

DIAGNOSIS

The diagnosis relies on identification of cysts and/or trophozoites in infected stool, mucosa, or skin. This method, however, cannot distinguish between *E. histolytica* and *E. dispar.* Enzyme-linked immunosorbent assays are useful in this regard. Stool culture and PCR are only available as research tools. Serology may be helpful but false-negativity may occur in early infection. Skin biopsy reveals ulceration, mixed inflammatory cell infiltrate, and areas of necrosis where trophozoites may be identified as round or oval cells (20–50 µm) with basophilic cytoplasm, an eccentric nucleus with central karyosome, and often displaying erythrophagocytosis (sign of pathogenicity).[253]

TREATMENT

For symptomatic intestinal or extraintestinal disease, the drug of choice is oral or intravenous metronidazole (250–800 mg every 8–12 hours for 10 days), followed by treatment with one of the luminal agents iodoquinol, paromomycin, diloxanide furoate, dehydroemetine, or chloroquine.[123]

OPPORTUNISTIC AMEBAS

EPIDEMIOLOGY AND ETIOLOGY

The free-living amebas belonging to the genera *Naegleria, Acanthamoeba, Balamuthia* and lately described *Sappinia* are ubiquitous in air, soil, and water; they rarely cause disease in immunocompetent patients; reported presentations include acanthamebic keratitis (in contact lens wearers) and primary amebic meningoencephalitis (caused by *Naegleria fowleri*). Immunocompromised AIDS and organ transplant patients are at risk of disseminated disease[254] as well as at risk of developing granulomatous amebic encephalitis, a rare gradually progressive fatal neurologic disease caused by *Acanthamoeba* species.[255–259] Free-living amebas can also harbor bacteria, such as *Legionella, Mycobacterium avium, Burkholderia* spp., *Escherichia coli, and Vibrio cholerae*, possibly serving as vectors of bacterial infections in humans.[260]

The portal of entry of the amebas is usually the nasal mucosa, from which they can reach the CNS. They can also enter through a skin break or through the respiratory tract with subsequent hematogenous dissemination to the CNS.[257]

CLINICAL FINDINGS

Cutaneous lesions have been mainly reported in *Acanthamoeba*-induced disease, mostly in HIV-positive patients. *Balamuthia mandrillaris*-related skin involvement, however, is being increasingly reported. In HIV-positive patients, skin lesions are the most common (75%–90% of the cases) and sometimes the sole manifestation of disseminated disease.[255,261] The extremities (lower more than upper) and the face are commonly involved. Numerous widely distributed papules, plaques, nodules, pustules, as well as cellulitis, nonhealing ulcers with rolled borders, eschars, and palatal ulceration have been described. Lymphadenopathy may be present.[262] An asymptomatic plaque over the central face with possible satellite lesions along with neurologic symptoms is a characteristic presentation of *B. mandrillaris* disease.[3]

One study suggested that the immunologic state of the patient determines the clinical outcome of cutaneous acanthamebiasis. Unexpectedly, immunocompromised patients were found to develop multiple subacute skin lesions without CNS involvement and to respond better to therapy. On the other hand, immunocompetent patients had a worse prognosis with slowly progressive cutaneous lesions and more CNS involvement.[262]

DIAGNOSIS

Histopathologically, a dermal and/or subcutaneous predominantly neutrophilic infiltrate is present, sometimes with vasculitic, and granulomatous changes.[255,263]

The identification of 20–30 µm trophozoites with abundant vacuolated cytoplasm, and central nuclear karyosome is diagnostic but may be difficult because of their macrophage-like appearance.[255] Gomori methenamine silver and periodic-acid-Schiff stains may highlight the organisms. *B. mandrillaris* may occasionally exhibit more than one nucleolus distinguishing it from *Acanthamoeba*. Definite diagnosis and speciation is possible using indirect immunofluorescence, culture or PCR.[3]

TREATMENT

The disease is often fatal but early treatment using a combination of IV pentamidine and oral fluconazole, sulfadiazine, isethionate, or 5-fluorocytosine may improve the outcome. HIV patients may benefit from antiretroviral therapy.[254]

TOXOPLASMOSIS[264–267]

ETIOLOGY

Toxoplasmosis, caused by the parasitic protozoan *Toxoplasma gondii* (class Sporozoa), is one of the most common human infections worldwide. The main reservoirs of *T. gondii* infection are members of the cat family (Felidae), which become infected by carnivorism; dogs and rabbits can also host the parasite. Viable organisms invade the feline intestinal epithelium where they undergo an asexual cycle followed by a sexual cycle and then form oocysts, which are excreted in large numbers and are resistant to harsh environmental conditions and disinfectants. Human infection results mainly from ingestion of cyst-containing undercooked meat or milk, but can also result from ingestion of the oocytes from fecally contaminated hands or food, organ transplantation,[268] blood transfusion,[269] or transplacental transmission.[270] The parasites become tachyzoites and form tissue cysts, mostly in skeletal muscle, myocardium, brain, eye and placenta, and may remain asymptomatic. Invasion of the reticuloendothelial/endothelial systems results in suppuration and granuloma formation.

CLINICAL DIAGNOSIS

Three major clinical forms are identified:

1. Congenital toxoplasmosis occurs in 1 per 1,000 live births in the United States. The risk of transmission is highest in the third trimester; however, the disease is more severe if transmitted in early pregnancy.[3] Approximately 10% of affected newborns will have chorioretinitis and blindness, and 20% will have generalized or CNS disease. Infection may manifest as abortion,[270] stillbirth, microcephaly, tram-track intracerebral calcifications,[271,272] deafness, hydrocephalus, mental retardation, or seizures. Skin lesions include purpura, jaundice, blueberry muffin lesions (dermal erythropoiesis), and erythroderma. Untreated subclinical infection may reactivate during the second to third decade of life, mostly in the form of retinochoroiditis.[273]
2. Acquired toxoplasmosis in immunocompetent persons is often asymptomatic in 80%–90% of cases.[274,275] However, 10%–20% of patients, preferentially including pregnant women, develop cervical or occipital lymphadenopathy and a flu-like illness. Rarely, myocarditis, pneumonitis, encephalitis, and polymyositis may occur. Cutaneous manifestations are protean reflecting the heterogeneous immune responses to the organism,[264] and include among others dermatomyositis-like syndrome[276–281] and pityriasis lichenoides (Box 206-5).[275,282–285] Toxoplasmosis should be sought in patients with an acute dermatomyositis-like picture. Both conditions share a common underlying pathogenic mechanism related to the expression on muscle fibers of human leukocyte antigen class I as well as production of certain cytokines.[3]
3. Toxoplasmosis in immunodeficient patients is often secondary to reactivation of latent infection and presents as disseminated disease. Toxoplasmic encephalitis is the most common cause of intracerebral lesions in AIDS patients. Disseminated papular/nodular eruption may occur.[85,264,294–296] Rare cases of graft-versus-host disease-like rash have been reported in patients who underwent hematopoietic stem cell transplant. Histology may not be helpful in differentiating between the two conditions.[297] A high degree of suspicion of toxoplasmosis and molecular confirmation are important to distinguish between the two conditions.[298]

BOX 206-5 SPECTRUM OF CUTANEOUS LESIONS SEEN IN ACQUIRED TOXOPLASMOSIS IN IMMUNOCOMPETENT PERSONS

- Dermatomyositis-like syndrome.[276–281]
- Pityriasis lichenoides.[275,282–285]
- Cellulitis.[279–281]
- Others: Sweet's syndrome,[286] cold urticaria,[287] erythroderma,[288] palmoplantar maculopapular rash,[267] morphea,[289] mastocytosis,[290] lichen planus pilaris, pityriasis rubra pilaris, capillaritis, papular acantholytic dermatosis, keratosis lichenoides chronica,[291] chronic prurigo,[279] scarlatiniform eruption, panniculitis,[292] erythema-multiforme,[293] roseola, papular urticaria.[3]

DIAGNOSIS

Diagnosis is routinely made by serology. Protozoa may be identified in bronchoalveolar lavage or LN specimens,

or skin biopsies. Tachyzoites, visualized with Wright or Giemsa stains, are crescent-shaped and have a prominent, centrally placed nucleus. The most common histologic finding is subacute histiolymphocytic vasculitis with demonstration of trophozoites within macrophages.[293] Epidermotropic infection and neural infiltration may occur.[299] Immunoperoxidase stains are specific and are particularly helpful when small tissue specimens are submitted. PCR-based testing has a high diagnostic value in acute disease and has become the preferred method of diagnosis, particularly in prenatal diagnosis of toxoplasmosis and in immunocompromised patients with disseminated toxoplasmosis. PCR detection of the parasite in fluid specimens (blood, amniotic fluid, CSF, urine, vitreous, and aqueous fluid.) as well as fetal and brain tissues is indicative of active infection.[300–303]

TREATMENT

Treatment should be initiated in all patients with acute or active disease or congenital infection, and in immunosuppressed individuals.[3] Sulfadiazine and pyrimethamine act synergistically and together provide effective therapy.[123] Clindamycin can be used in sulfonamide-allergic patients. Co-trimoxazole was recently reported to be effective in the treatment of toxoplasmic lymphadenitis.[304]

KEY REFERENCES

Full reference list available at www.DIGM8.com

DVD contains references and additional content

3. Lupi O et al: Tropical dermatology: Tropical diseases caused by protozoa. *J Am Acad Dermatol* **60**(6):897-925, 2009; quiz 926-898
4. David CV, Craft N: Cutaneous and mucocutaneous leishmaniasis. *Dermatol Ther* **22**(6):491-502, 2009
11. Reithinger R et al: Cutaneous leishmaniasis. *Lancet Infect Dis* **7**(9):581-596, 2007
69. Bailey MS, Lockwood DN: Cutaneous leishmaniasis. *Clin Dermatol* **25**(2):203-211, 2007
126. Gonzalez U et al: Interventions for Old World cutaneous leishmaniasis. *Cochrane Database Syst Rev* (4):CD005067, **2008**
142. Khatami A et al: Treatment of acute Old World cutaneous leishmaniasis: A systematic review of the randomized controlled trials. *J Am Acad Dermatol*. **57**(2):335 e331-e329, 2007
143. Palumbo E: Current treatment for cutaneous leishmaniasis: A review. *Am J Ther* **16**(2):178-182, 2009
212. Brun R et al: Human African trypanosomiasis. *Lancet* **375**(9709):148-159
239. Wilkinson SR, Kelly JM: Trypanocidal drugs: Mechanisms, resistance and new targets. *Expert Rev Mol Med* **11**:e31, 2009
260. da Rocha-Azevedo B, Tanowitz HB, Marciano-Cabral F: Diagnosis of infections caused by pathogenic free-living amoebae. *Interdiscip Perspect Infect Dis* **2009**:**251**406, 2009

Chapter 207 :: Helminthic Infections

:: Kathryn N. Suh & Jay S. Keystone

HELMINTHIC INFECTIONS AT A GLANCE

- Helminthic infections are a major cause of morbidity and mortality, particularly in tropical and developing countries.
- The majority of infected individuals have a low worm burden and are asymptomatic.
- Dermatologic symptoms and cutaneous findings may be associated or presenting features of helminthic infections.
- Dermatologic manifestations may differ in returning travelers and in immigrants from endemic areas.
- Migratory lesions, subcutaneous masses, papular eruptions, urticaria, and pruritus are the most common presenting dermatologic symptoms of helminthic infections.
- Cutaneous larva migrans is the most common helminthic dermatosis identified.
- Recognition of skin findings or helminthic infections and an appropriate epidemiologic history can guide appropriate investigations and effective therapy.

Helminths (worms) are variably sized multicellular parasites that can infect a wide range of mammals, including humans. Those causing human disease belong to three groups: (1) nematodes (roundworms), (2) trematodes (flukes), and (3) cestodes (tapeworms) (Table 207-1); trematodes and cestodes are collectively referred to as platyhelminths (flatworms). This chapter focuses only on those helminths that more commonly cause dermatologic disease.

TABLE 207-1
Helminths Causing Infection in Humans

Helminth	Disease	Portal of Entry	Source of Infection
Nematodes (Roundworms)—Intestinal			
Ancylostoma duodenale, Necator americanus	Hookworm	Skin	Larvae in soil, occasionally in food
Ascaris lumbricoides	Ascariasis	Gastrointestinal	Eggs from contaminated food, soil
Enterobius vermicularis	Enterobiasis (pinworm)	Gastrointestinal	Eggs in environment
Strongyloides stercoralis	Strongyloidiasis	Skin	Larvae in soil
Nematodes (Roundworms)—Tissue			
Ancylostoma braziliense, Ancylostoma caninum	Cutaneous larva migrans	Skin	Larvae in soil
Dirofilaria spp.	Dirofilariasis	Skin	Infective mosquitoes
Dracunculus medinensis	Dracunculiasis	Gastrointestinal	Infective copepods in water
Filariae			
Brugia malayi, Brugia timori	Filariasis	Skin	Infective mosquitoes
Mansonella ozzardi, Mansonella perstans, Mansonella streptocerca	Filariasis	Skin	Infective midges and/or flies
Loa loa	Loiasis	Skin	Infective deer flies
Onchocerca volvulus	Onchocerciasis	Skin	Infective black flies
Wuchereria bancrofti	Filariasis	Skin	Infective mosquitoes
Gnathostoma spinigerum, others	Gnathostomiasis	Gastrointestinal	Larvae in animal flesh (raw fish, amphibians)
Toxocara canis, Toxocara cati	Visceral larva migrans	Gastrointestinal	Eggs in contaminated food, soil
Trichinella spiralis	Trichinosis	Gastrointestinal	Larvae in animal flesh (usually pork, bear)
Trematodes (Flukes)			
Clonorchis sinensis	Clonorchiasis	Gastrointestinal	Metacercariae in seafood (raw fish)
Fasciola hepatica, others	Fascioliasis	Gastrointestinal	Metacercariae on watercress, in water
Fasciolopsis buski	Fasciolopsiasis	Gastrointestinal	Metacercariae on plants, in water
Heterophyes heterophyes	Heterophyiasis	Gastrointestinal	Metacercariae in seafood (raw fish)
Metagonimus yokogawai	Metagonimiasis	Gastrointestinal	Metacercariae in seafood (raw fish)
Paragonimus westermani, others	Paragonimiasis	Gastrointestinal	Metacercariae in seafood (crabs, crayfish)
Schistosoma mansoni, Schistosoma japonicum, others	Schistosomiasis	Skin	Cercariae in water
Schistosomes, non-human (avian)	Cercarial dermatitis	Skin	Cercariae in water
Cestodes (Tapeworms)			
Diphyllobothrium latum (fish tapeworm)	Diphyllobothriasis	Gastrointestinal	Larvae in seafood (raw fish)
Echinococcus spp.	Echinococcosis (hydatid disease)	Gastrointestinal	Eggs in contaminated food
Hymenolepis nana (dwarf tapeworm)	Hymenolepiasis	Gastrointestinal	Eggs in contaminated food, water
Spirometra mansonoides, others	Sparganosis	Gastrointestinal	Larvae in contaminated water or animal flesh (snakes, amphibians, fish)
Taenia multiceps, others	Coenurosis	Gastrointestinal	Eggs in contaminated food, water
Taenia saginata (Beef tapeworm)	Taeniasis	Gastrointestinal	Larvae in contaminated food (beef)
Taenia solium (Pork tapeworm)	Taeniasis; cysticercosis	Gastrointestinal	Larvae in contaminated food (pork)

EPIDEMIOLOGY

Globally, helminthic infections are among the most common diseases of humans. However, the true prevalence of helminthiases is difficult to determine, particularly since the majority of infected individuals harbor relatively few worms and are asymptomatic. Large worm burdens and symptomatic disease affect a relatively small proportion of those who are infected.

While some helminths such as *Enterobius vermicularis* and *Toxocara canis* are found worldwide, others are more geographically restricted (eTable 207-1.1 in online edition). Most infections occur in developing tropical or subtropical countries, where environmental conditions are conducive to the completion of the life cycle of many helminths, and the requisite animal hosts and vectors for ongoing transmission exist. In addition, the high population density, poverty, and poor sanitation

commonly found in these areas further facilitate the transmission of these diseases. Knowledge of the geographic distribution of specific helminths is important for the clinician, and will help to direct appropriate investigations and management.

Helminthic infections are less prevalent in temperate and northern climates, although some diseases are endemic even in these regions (eTable 207-1.1 in online edition). In developed countries and colder climates, helminthic diseases are more often imported by travelers to or immigrants from endemic areas. Less frequently, helminthic infections in developed nations can be locally acquired (e.g., trichinellosis resulting from improperly prepared food) or transmitted via person-to-person spread (e.g., enterobiasis).

SKIN DISEASES IN TRAVELERS

Dermatologic disorders are the third most common illness in travelers.[1] In several observational studies, 5%–17% of travelers to varied destinations developed a dermatologic condition during or after travel.[2–6] These figures cannot necessarily be generalized to all travelers; however, as the studies included travelers assessed only in specialty (travel and tropical medicine) clinics, and may also have been subject to geographic biases (due to the specific population of travelers studied and/or the more common travel destinations among these travelers).

Infections, including tropical skin diseases, are common causes of dermatoses among travelers. Insect bites, allergic reactions, and other rashes are among the most prevalent noninfectious dermatologic diagnoses in travelers. Of the helminthic skin infections, cutaneous larva migrans (CLM) is by far the most commonly reported in travelers and accounts for 5%–25% of all skin diseases in this group.[6–8] Most other helminthic infections that may be associated with dermatologic findings are relatively rare in travelers.

SKIN DISEASES IN IMMIGRANTS AND REFUGEES

The prevalence of dermatologic conditions in immigrants and refugees has not been exhaustively studied. Two studies suggest that skin conditions among these populations occur no more frequently[3] or, in one study, much less commonly[5] than in travelers; however, these studies are subject to the same biases noted above.

The helminths that cause skin findings in this population, and the clinical presentation, may also differ from those in travelers. For example, filarial infections are more commonly encountered in individuals who have resided in endemic areas for prolonged periods rather than in travelers,[8] since they usually require repeated exposures to insect vectors in order for effective transmission to occur. Strongyloidiasis is also more prevalent in immigrants from endemic areas, particularly Southeast Asia, and often presents with eosinophilia or nonspecific abdominal symptoms.[9] Acute onchocerciasis may occur in short-term (at least



Figure 207-1 Onchocercal dermatitis. (Used with permission from Herman Zaiman, MD.)

1 month) visitors to endemic areas and characteristically presents with a hyperimmune response manifest by pruritus and rash (Fig. 207-1),[10,11] in spite of low-parasite loads. In contrast, infected immigrants more commonly have chronic onchodermatitis, chronic skin changes including atrophy, hypopigmentation and lichenification, and onchocercal nodules (Fig. 207-2).

LIFE CYCLE AND TRANSMISSION OF HELMINTHS

All helminths have complex life cycles that include maturation from eggs (or other infective forms) to larvae (or other immature forms) to adults. Human disease results from ingestion of eggs or other infective forms or, alternatively, exposure of the skin to infective forms (larvae or cercariae) by direct contact or via the bite of



Figure 207-2 Onchocercal nodule over iliac crest. (Used with permission from Jay S. Keystone, MD, FRCPC.)

an insect vector. Humans may be the primary hosts for some helminths (e.g., *Strongyloides stercoralis*), or may be incidental or accidental hosts (e.g., avian schistosomes, animal hookworm, and *T. canis*). Helminths that are well adapted to humans can mature from the infective stage into adult forms in the human host; infection generally persists for the lifespan of the adult worm, which in some cases can be for many years. In contrast, animal helminths cannot mature into adult forms in humans (who in this setting are therefore "dead-end" hosts), although infection can still cause tissue damage and clinical findings.

In general, helminths do not multiply in the human host. Most helminths (with the notable exception of *S. stercoralis*) are incapable of completing an entire life cycle in the human host, and depend on the environment (e.g., soil, water), plants, or other animal hosts or insects, for their survival. Consequently, transmission of infection requires the presence of appropriate environmental conditions, specific intermediate hosts (in whom only the asexual reproductive cycle occurs) and/or specific insect vectors, explaining in large part the localized geographic distributions of many helminthic diseases.

Examples of helminthic diseases acquired by ingestion of infective forms (eggs or metacercariae) in contaminated food or water include *Ascaris lumbricoides* and *Fasciola hepatica*. In ascariasis (eFig. 207-2.1 in online edition), swallowed eggs are consumed, larvae are released within the gastrointestinal tract, and migrate through the portal-systemic circulation to the lungs, from where they are swallowed. Skin disease such as urticaria may occur during the larval migration phase. Once in the gastrointestinal tract, larvae mature into adult worms where sexual reproduction may take place; either eggs or adult worms can be shed in stool. Eggs must mature in soil before releasing infective larvae. In fascioliasis, infective metacercariae excyst in the small intestine and migrate through the intestinal wall and peritoneum to their target tissue, the biliary tract, where they become adults. Again, skin findings typically occur as immature forms migrate. Eggs produced by adult flukes are passed in feces and become infective for humans only after maturation in a suitable (intermediate) snail host.

Schistosomiasis results from penetration of intact skin by infective cercariae (eFig. 207-2.2 in online edition). Dermatologic findings in early disease manifest either at the time of cercarial penetration (swimmer's itch or cercarial dermatitis), or during migration of immature forms (schistosomulae) from the skin and through tissue to the venous systems of their target organs (which may vary depending on the infecting species), where they mature into adults. Migration of schistosomulae in previously unsensitized individuals (usually travelers) can result in acute illness (Katayama fever) consisting of fever, myalgias, cough, and wheezing, and may be accompanied by urticaria. Sexual reproduction leads to the release of eggs into the local circulation. En route to the bladder or bowel, eggs may sometimes become trapped in ectopic tissues, including skin, where they cause a granulomatous reaction. In skin, this may lead to a chronic papular eruption. Eggs excreted in urine or feces hatch in fresh water, releasing cercariae, which must undergo further maturation in one of several intermediate snail hosts in order to infect humans.

Infection can also result from penetration of intact skin by larvae, exemplified by human hookworm infection (eFig. 207-2.3 in online edition). Larval skin penetration may cause localized papular or vesicular lesions, or creeping eruption. Larvae then migrate to the circulatory system where they are carried to the lungs, penetrate the alveoli, and ascend the bronchial tree, are swallowed, and enter the gastrointestinal tract. Skin findings may also occur during larval migration to the lungs. Maturation into adult worms occurs in the small intestine, where they reproduce and release eggs into stool. Under the appropriate environmental conditions, eggs mature into infective larvae in soil. In contrast, larvae of animal hookworms (e.g., *Ancylostoma braziliense*) cannot mature beyond the larval stage in humans and tunnel aimlessly in the skin before the infection eventually extinguishes itself.

Larvae can also be introduced through intact skin by insect bites (e.g., in filarial infections). The insect vector and the target tissue both vary according to the infecting species; cutaneous disease may be seen during either migration of larval forms through tissue, or as a result of adult worms in tissue. Microfilariae released from mature adult worms are taken up by an insect during a subsequent blood meal, and then undergo maturation to infective forms within the insect before being introduced into another human host.

ETIOLOGY AND PATHOGENESIS

A variety of helminths can infect humans and cause cutaneous findings (Table 207-2). Cutaneous manifestations can be seen at every phase of the helminth life cycle in humans: by larvae or cercariae during skin penetration; during larval migration and tissue invasion; and due to the presence of eggs and adult worms in skin and soft tissues. Skin lesions also may occur during either early (acute) or chronic infection.

The pathogenesis of skin lesions in helminthic infections is varied. Direct penetration of skin may lead to a localized immune response, as seen in CLM or cercarial dermatitis. Migration of helminths can cause a generalized immune response (urticaria; maculopapular eruptions), particularly due to migration of larvae or immature forms (e.g., with *Ascaris* or *Toxocara* infection); a local inflammatory reaction to adult worms or eggs may also develop, as occurs with cutaneous nodules due to *Onchocerca volvulus* and in schistosomiasis. Skin changes can also result from disruption of the normal skin structures due to lymphedema, as with filarial infections. Finally, ill-defined systemic immune reactions such as erythema nodosum (EN) or erythema marginatum, rarely reported manifestations of several helminthic infections, may also be present. Skin findings of helminthic infections do not generally result from hematogenous spread of parasites, in contrast to many bacterial and viral infections.

Helminths induce a dramatic expansion of the T helper 2 (Th2) lymphocyte subset, with elevated levels of immunoglobulin E (IgE), peripheral eosinophilia,

TABLE 207-2
Helminths Causing Cutaneous Disease: Common Dermatologic Findings

Species	Localized Edema	Migratory Skin Lesions	Nodules or Masses	Papules	Petechiae	Pruritus	Urticaria	Ulcer	Vesicle/Bulla
Nematodes (Roundworms)									
Ancylostoma braziliense, Ancylostoma caninum		X		X		X	X		X
Ancylostoma duodenale, Necator americanus (human hookworm)		X				X	X		X
Ascaris lumbricoides						X	X		
Dirofilaria spp.		Rare	X						
Dracunculus medinensis	X[a]	X						X	X
Enterobius vermicularis						X			
Filariae									
Brugia spp. (*malayi, timori*)	X[b]		X						
Loa loa	X[a]	X	X			X	X		
Mansonella spp. (*ozzardi, perstans, streptocerca*)	X[b]			X		X			
Onchocerca volvulus	Rare[a]		X	X		X	X		X
Wuchereria bancrofti	X[b]		X						
Gnathostoma spinigerum, others	X[a]	X	X			X	X		
Strongyloides stercoralis		X		X	X[c]	X	X		
Toxocara spp. (*canis, cati*)						X	X		
Trichinella spiralis	X[a]		X		X	X	X		
Trematodes (Flukes)									
Fasciola hepatica		X				X	X		
Paragonimus westermani		X	X			X	X		
Schistosoma spp. (human and avian)			X	X		X	X		
Cestodes (Tapeworms)									
Echinococcus spp. (*granulosis, multilocularis*)			X						
Spirometra mansonoides, others (sparganosis)		X	X						
Taenia multiceps, others (coenurosis)			X						
Taenia solium (cysticercosis)			X						

[a]Focal or localized edema.
[b]Lymphedema with filarial infections.
[c]Disseminated strongyloidiasis.

and an increase in tissue mast cells. It is unclear whether these Th2-derived responses are important in the protective immune response against the parasite, are responsible for immune-mediated pathology, or both.[12] Despite high levels of IgE and other features of Th2 cell activation, allergic responses are rarely observed in infected individuals except during the invasive phase of infection, when pruritus and/or urticaria may occur. Infected hosts have evolved elaborate immune evasion strategies that permit long-lived helminthic infections, including the induction of tolerance to parasite antigens.

APPROACH TO THE PATIENT

With the exception of CLM, most travelers and immigrants who present with dermatologic complaints will not have a diagnosis attributable to a helminthic infection. However, clearly these must be considered if the epidemiologic and exposure history and clinical findings are consistent with a helminthic infection, since these are treatable infections that have important clinical implications, such as disseminated strongyloidiasis in an immunocompromised host.

As with all diseases of travelers and immigrants, a thorough history is essential in order to direct the clinician toward the correct diagnosis. The history should focus on aspects related to travel (or residence in endemic areas), general medical conditions, and medications. In addition, specific details of the dermatologic complaints must also be obtained. Finally, the clinician should be knowledgeable about (or know how to find out about) outbreaks of disease that may have been ongoing during an individual's travel or residence in a given area.

EXPOSURE HISTORY: TRAVEL AND AREAS OF RESIDENCE

The travel history (or history of residence in endemic areas) must be thorough in order to elucidate likely exposures to helminths. Specific details may be more readily obtained in recently returned travelers than immigrants, although immigrants are much more likely to be aware of local and endemic diseases (albeit often by local names). Details to be obtained include the exact dates, durations, and locations of travel or residence; purpose of travel; activities or occupations, inquiring specifically about those that would increase exposure to specific helminths (Table 207-3); dietary intake; a history of similar signs and symptoms in other family members or fellow travelers; and the use of preventive measures.

The exact destinations of travel (urban vs. rural), not only the country or countries visited, are important to obtain. Although some diseases may be endemic throughout a world region or area (eTable 207-1.1 in online edition), the prevalence of others may vary greatly, sometimes within a given country. For example, onchocerciasis and loiasis are endemic in West Africa, but generally not in other parts of Africa, and both infections are found only in rural areas, unlike Bancroftian filariasis (*Wuchereria bancrofti*) that is often transmitted in urban centers. The risk of disease may not be present in all areas of a country in which a disease is considered to be endemic; for example, schistosomiasis is found in Brazil, but only in the northeastern region. Duration of travel or residence in an endemic area (and hence duration of exposure) is relevant for some diseases; schistosomiasis can be acquired after a single exposure to infective cercariae in freshwater, whereas filariasis is often acquired only after numerous bites, and therefore is rare among short-term travelers to endemic areas.

The purpose of travel is also correlated with the likelihood of exposure to specific pathogens. Rural and adventure travelers are more likely to be exposed to helminthic infections than are business travelers, travelers whose itineraries are limited to urban areas, and those whose travels are of shorter durations.

Certain activities and occupations will place individuals at greater risks of helminthic infections while abroad (Table 207-3). Examples of common exposures and associated diseases include barefoot walking or walking in open shoes (sandals) (e.g., CLM, strongyloidiasis); freshwater swimming in Africa (e.g., schistosomiasis); and dietary indiscretions such as consumption of salads or undercooked or contaminated meat or fish (e.g., ascariasis, echinococcosis, fascioliasis, gnathostomiasis). Although direct exposure to animals is not a risk factor for helminthic infections, the risk of CLM is greater in areas with a higher prevalence of stray dogs and cats. For those infections that are vector borne, such as filarial infections transmitted by mosquitoes, black flies, and deer flies, the use of preventive measures such as appropriate clothing, insect repellent, and bed nets can reduce the risk of infection.

GENERAL MEDICAL HISTORY

In addition to the travel history, a general medical history should be obtained. Skin findings may be related to underlying medical conditions, or to any associated treatment for these. The differential diagnosis of skin lesions in a returned traveler or immigrant also includes noninfectious disorders such as contact dermatitis (including to jewelry), drug eruptions, and photosensitivity reactions (that may be precipitated by travel-related medications such as doxycycline). A list of prescription and nonprescription medications or supplements should be obtained, in particular those that may have been started recently and/or prescribed abroad, as well as any recent use of topical medications or products.

DERMATOLOGIC HISTORY AND PHYSICAL FINDINGS

The dermatologic history should include details regarding the initial presentation, morphology, and anatomic distribution of skin lesions; the progression and duration of lesions; time of onset relative

TABLE 207-3
Exposures to Helminthic Infections

Exposure or Activity	Disease/Syndrome	Comments
Barefoot walking or walking in open shoes (sandals)	Cutaneous larva migrans Human hookworm (*Ancylostoma duodenalis*, *Necator americanus*) Strongyloidiasis	
Swimming or water exposure	Schistosomiasis (human) Cercarial dermatitis (schistosomiasis, avian)	Freshwater exposure in Africa, Arabian peninsula (*Schistosoma mansoni* and *Schistosoma hematobium*); or South America (*S. mansoni*) Freshwater or saltwater exposure
Dietary indiscretion Contaminated food or water (also via contaminated fingers) Contaminated water Raw or undercooked meat Raw or undercooked seafood, crustaceans, amphibians, reptiles Contaminated plants	 Ascariasis Enterobiasis (pinworm) Toxocariasis Dracunculiasis Sparganosis Cysticercosis (*Taenia solium*) Sparganosis Trichinellosis Gnathostomiasis Paragonimiasis Sparganosis Fascioliasis	 Infected pork Infected rodent meat Infected meat (mainly pork, but other wild and domestic meats) Watercress
Insect bites[a] Mosquito Fly	 Dirofilariasis Lymphatic filariasis (*Brugia* spp., *Wuchereria bancrofti*) Filariasis (*Mansonella* spp.) Loiasis Onchocerciasis	 Use of personal protective measures (insect repellent, bed nets) can be protective
Other Topical poultices	 Sparganosis	 Poultices containing infected amphibian, reptile, or rodent meats

[a]History of bites is not reliable.

to potential exposures; and any associated local and systemic signs and symptoms. Although some manifestations of helminthic infections, such as urticaria or maculopapular eruptions, are nonspecific, the differential diagnosis of helminthic dermatoses can often be narrowed based on the description and morphology of the lesion(s) present. For some diseases such as CLM, skin findings are virtually pathognomonic and the diagnosis can be established by history and careful examination of skin lesions, often without the need for additional investigations.

MORPHOLOGIC CHARACTERISTICS AND DISTRIBUTION OF SKIN LESIONS DUE TO HELMINTHIC DISEASES.

Skin lesions due to helminthic infections can assume a variety of morphologies. The most commonly encountered problem is that of migratory skin lesions. CLM (creeping eruption) is the most common cause of migratory lesions in general. Subcutaneous nodules, papular eruptions, and urticaria and pruritus are also common manifestations of helminthic infections.

Migratory Skin Lesions. Migratory lesions can be caused by multiple helminths. Migratory lesions can be linear (serpiginous) or may be more ill-defined areas of erythema and swelling, and may be painless, painful, or pruritic. Table 207-4 lists the most common



Figure 207-3 Cutaneous larva migrans. (Used with permission from Jay S. Keystone, MD, FRCPC.)

TABLE 207-4
Differential Diagnosis of Migratory Skin Lesions

Helminth	Morphology of Lesion	Description	Most Common Location
Ancylostoma braziliense, Ancylostoma caninum	Serpiginous (CLM)	Typically one to three serpiginous lesions, 3 mm wide and up to 20 cm in length; intensely pruritic, may be vesicobullous; movement up to several cm per day	Feet, buttocks
Ancylostoma duodenale, Necator americanus (human hookworm)	Serpiginous	Pruritic tracks due to larval migration	Feet
Dracunculus medinensis	Localized area of edema or swelling with movement beneath	Moving mass may be seen just before emergence of adult worm through skin	Feet
Fasciola hepatica	Migratory subcutaneous swellings	Erythematous, painful, pruritic subcutaneous nodules may have a migratory component; larval track marks may also be seen	Abdomen, back, extremities
Loa loa	Migratory subcutaneous swelling or serpiginous	Migration of adult worm across conjunctivae or under skin	Skin, eye
Gnathostoma spinigerum	Serpiginous (CLM) Migratory subcutaneous swellings (eosinophilic panniculitis)	Migration of larvae can cause creeping eruption; movement 1 cm/hour Intermittent single or multiple erythematous swellings; may be migratory, pruritic or painful; last 1–4 weeks, with recurrences in different anatomic areas after variable asymptomatic periods	Trunk, upper body Thighs
Paragonimus westermani	Migratory subcutaneous swellings or nodules	Firm migratory swellings or nodules, may be migratory; slightly tender and slightly mobile, up to 6 cm diameter; swellings contain immature flukes	Lower abdomen, inguinal region
Spirometra mansonoides, others (sparganosis)	Migratory subcutaneous swellings	Slow-growing, typically painful swellings that may be migratory; may be pruritic	Abdomen, lower extremities
Strongyloides stercoralis (larva currens)	Serpiginous (larva currens)	Movement at 5–10 cm/hour; intensely pruritic, transient, but recurrent	Buttocks, groin, trunk, thighs

CLM = cutaneous larva migrans.

helminthic causes of migratory lesions, as well as characteristic features of these lesions.

Serpiginous and linear lesions are most commonly due to CLM (most frequently caused by *A. braziliense* and *Ancylostoma caninum*; see also Section "Hookworm-Related Cutaneous Larva Migrans"). Usually one to three (or more) erythematous, serpiginous, and intensely pruritic lesions due to intradermal larval migration are present (Fig. 207-3); bullae and vesicles may also be present (Fig. 207-4). Lesions usually measure 3 mm in width and 15–20 cm in length. Lesions of CLM may rarely be accompanied by severe folliculitis, or may present as papules alone without a linear element (papular larva migrans). Serpiginous skin lesions in *S. stercoralis* infection, a pathognomonic manifestation of strongyloidiasis known as larva currens, typically present as recurrent, transient, and rapidly moving skin lesions (Fig. 207-5). Larval migration may occur at rates of 5–10 cm/hour, and the lesions usually disappear within hours only to recur over subsequent weeks to years. Lesions typically occur on the buttocks and in the perianal region, as larvae exit the



Figure 207-4 Cutaneous larva migrans with vesicular and bullous lesions. (Used with permission from Jay S. Keystone, MD, FRCPC.)

gastrointestinal tract and reinfect the host by penetrating the perianal skin. Linear migratory lesions can also be seen occasionally in human hookworm infection (*Ancylostoma duodenale* and *Necator americanus*) at the site of larval penetration, and in gnathostomiasis (usually relatively slow migration at 1 cm/hour). Linear migratory lesions can also be seen in *Loa loa* infection, and result from movement of the adult worm (not larvae) in tissue, typically under the skin or also across the bulbar conjunctivae (Fig. 207-6).



Figure 207-5 Larva currens in chronic strongyloidiasis. Multiple serpiginous, inflammatory lesions are visible on the buttocks.

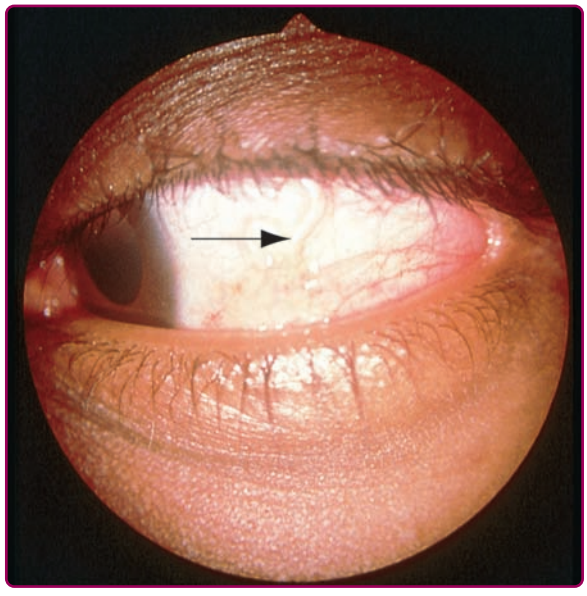

Figure 207-6 Loiasis. Adult worm crossing bulbar conjunctiva of the eye (*arrow*). (Used with permission from Murray Wittner, MD, PhD.)

Migratory subcutaneous swellings and nodules are characteristic of infections due to *Fasciola*, *Gnathostoma*, and *Paragonimus*, and in sparganosis (*Spirometra* species). Lesions may be painful or pruritic. Migratory swelling due to the movement of adult worms is also seen in dracunculiasis, in which movement within a bullous, vesicular, or edematous lesion on the foot is often noted prior to eruption of the skin lesion and egress of the adult worm (Fig. 207-7). Since the implementation of global eradication and drinking water monitoring



Figure 207-7 Dracunculiasis. (Used with permission from Jay S. Keystone, MD, FRCPC.)

TABLE 207-5
Differential Diagnosis of Nodular Skin and Subcutaneous Lesions

Helminth	Description of Nodular Lesion	Most Common Location
Brugia malayi	Hydrocele/scrotal mass due to lymphatic obstruction.	Scrotum
Dirofilaria spp.	Single erythematous, well-defined firm nodule or mass, usually 1–5 cm diameter; usually asymptomatic but may be tender; rarely may be migratory (usually not).	Head and neck, breasts, extremities, scrotum
Dracunculus medinensis	Edematous lesion/mass may be seen just before emergence of adult worm through skin; movement underneath lesion due to movement of adult worm	Feet
Echinococcus spp.	Firm subcutaneous (or muscular) nodules or masses; usually single but may be multiple; may feel fluctuant; nontender. Rarely with fistulization and inflammation of skin (*Echinococcus multilocularis*). True cutaneous lesions are rare.	Abdomen
Gnathostoma spinigerum	Intermittent single or multiple erythematous swellings; may be migratory, pruritic or painful; last 1–4 weeks, with recurrences in different anatomic areas after variable asymptomatic periods.	Trunk, upper body, thighs
Loa loa	Calabar swelling—localized angioedema, 5–20 cm diameter, usually lasting 2–4 days but recurrent; due to migration of adult worms.	Eyelid, upper extremities, periarticular regions (especially knee, wrist)
Mansonella perstans	Calabar swellings—localized swellings lasting 1–4 days, recurrent.	Face, upper extremities (especially forearms), hands
Onchocerca volvulus	Well-defined, fixed painless nodules containing adult worms in deep dermis and subcutaneous tissue.	Over bony prominences including skull (South America), ribs, iliac crest (Africa), others
Paragonimus westermani	Firm swellings or nodules, may be migratory; slightly tender and slightly mobile, up to 6 cm diameter; swellings contain immature flukes.	Lower abdomen, inguinal region
Spirometra mansonoides, others (sparganosis)	Slow-growing, typically painful swellings that may be migratory; may be pruritic.	Abdomen, lower extremities
Taenia multiceps, others (coenurosis)	Solitary subcutaneous (or muscular) nodule, usually 2–6 cm diameter; painless	Trunk (especially intercostal regions), anterior abdominal wall; head, neck, extremities less commonly
Taenia solium (cysticercosis)	Painless, fixed, well-circumscribed rubbery subcutaneous nodules in 50% of patients with cysticercosis; may be single or multiple; average size 2 cm in diameter.	Trunk, extremities
Wuchereria bancrofti	Hydrocele/scrotal mass due to lymphatic obstruction.	Scrotum

programs in endemic countries, cases of dracunculiasis have decreased dramatically and the disease has almost been eliminated.[13]

Subcutaneous Nodules and Masses. Subcutaneous and soft tissue masses may have variable characteristics, including overlying erythema, pain or tenderness, and pruritus. They may be single or multiple, and fixed or mobile. The more common etiologies of nodular lesions are listed in Table 207-5.

Solitary nodules or masses are found in echinococcosis, filariasis due to *Brugia malayi* and *W. bancrofti* (both of which may cause scrotal masses in men, due to lymphatic obstruction), dirofilariasis, and coenurosis. *Multiple nodules* are typical of cysticercosis (*Taenia solium* infection), in which small, painless subcutaneous or intramuscular nodules are present, although single nodules can also occur. Subcutaneous cysticercosis, although reported in over 50% of infected individuals in older case series,[14] currently occurs in less than 10% of cases. Most other helminths that manifest as subcutaneous nodules or masses may present with single or multiple lesions. *Painless nodules* are most characteristic of coenurosis, cysticercosis, dirofilariasis, echinococcosis, and onchocerciasis. *Painful nodules* are seen in paragonimiasis and sparganosis. Transient painful lesions that resolve and subsequently recur in different anatomic areas are characteristic of *Gnathostoma* infection and loiasis. *Fixed lesions* are typical of cysticercosis, echinococcosis, and onchocerciasis.

Papular and Macular Lesions. Papules and macules occur in relatively few helminthic infections

TABLE 207-6
Differential Diagnosis of Papular and Macular Lesions

Helminth	Description	Most Common Location
Ancylostoma braziliense, caninum (CLM)	Pruritic erythematous papule(s) within days of larval penetration; may be vesicular; also papular larva migrans.	Feet, buttocks
Ancylostoma duodenale, Necator americanus (human hookworm)	Ground itch: in sensitized individuals, pruritic papular lesions at sites of larval entry; may be vesicular.	Feet, hands
Mansonella perstans, streptocerca	Multiple pruritic papules; hypopigmented and hyperpigmented macules and lichenification may be present.	Upper chest (M. streptocerca)
Onchocerca volvulus	Acute: multiple pruritic papules, may become vesicular or pustular; may be erythematous and edema may be present. Chronic: intensely pruritic, flat papules (3–9 mm) or macules, may be hyperpigmented or lichenified.	Face, trunk, extremities Shoulders, buttocks, waist, extremities
Schistosoma species (avian)	Erythematous papular or maculopapular lesions, may be vesicular or urticarial; intensely premitotic; onset within 24 hours of saltwater or freshwater exposure, lasts 1–3 weeks.	Any surface exposed to water
Schistosoma species (human)	Acute: erythematous papular and urticarial lesions in previously sensitized individuals; onset within hours of freshwater exposure, lasting 1 week. Chronic: bilharziasis cutanea tarda; slightly pigmented 2–4 mm firm, pruritic, oval papules or papulonodular lesions, may be verrucous or polypoid; may appear in crops; due to granulomatous reaction to eggs in skin.	Any surface exposed to water Trunk, especially periumbilical region; buttocks, genitalia

CLM = cutaneous larva migrans.

(Table 207-6). Papular lesions may occur at sites of skin penetration by infective larvae or cercariae in CLM and schistosomiasis. In CLM, papules are typically in the feet or buttocks, similar to the distribution of migratory lesions. In schistosomiasis, exposure to infected freshwater (for avian or human schistosomes) or salt water (avian schistosomes) may cause pruritus, which is followed rapidly by a papular eruption in previously sensitized individuals. Chronic papular lesions (bilharziasis cutanea tarda) may be present in chronic schistosomiasis. Papular lesions may also be manifestations of acute or chronic infection with *O. volvulus*, and have been reported in disseminated and chronic strongyloidiasis.

Urticaria and Pruritus. *Pruritus* (Table 207-7) may be present in the absence of skin findings, either as a primary symptom of infection (e.g., filariasis due to *Mansonella perstans*), or before the onset of skin lesions (e.g., schistosomiasis). Pruritus is a common feature of most helminthic infections, with the noteworthy exceptions of lymphatic filariasis (e.g., due to *Brugia* species and *W. bancrofti*) and tapeworm infections. *Pruritus ani* is characteristic of strongyloidiasis and enterobiasis (pinworm infection).

Urticaria are often present in the acute phase of infection, during which larvae or other immature forms actively invade human tissues. Helminths that infect humans by penetration of skin may cause a local urticarial rash at the sites of penetration. Migration of immature forms in the circulation may cause a generalized hypersensitivity reaction; urticaria is common during this phase of infection by many helminths (Table 207-7).

Localized Edema. Although edema or swelling may be an associated feature of many helminthic skin lesions, localized edema is highly suggestive of the presence of certain infections.

Eyelid edema in particular may be seen in gnathostomiasis and onchocerciasis (Calabar swelling), and violaceous periorbital edema is characteristic of trichinosis. *Limb edema* is highly suggestive of lymphatic filariasis (due to *Brugia* species and *W. bancrofti*). Rarely, limb edema ("gros bras camerounais") may occur with acute onchocerciasis, usually in conjunction with

TABLE 207-7
Helminthic Infections Causing Urticaria and Pruritus

Helminth	Comments
Nematodes (Roundworms)	
Ancylostoma braziliense, *Ancylostoma caninum*	Pruritus and urticaria after skin penetration and during larval migration
Ancylostoma duodenale, *Necator americanus* (human hookworm)	Pruritus and urticaria after skin penetration and during larval migration
Ascaris lumbricoides	Pruritus and urticaria during larval migration (with Loeffler's syndrome)
Enterobius vermicularis	Pruritus ani
Filariae	
Loa loa	Pruritus and urticaria
Mansonella spp. (*ozzardi*, *perstans*, *streptocerca*)	Pruritus occurs early, may be only symptom
Onchocerca volvulus	Pruritus and urticaria in acute or chronic disease
Gnathostoma spinigerum, others	Pruritus and urticaria during larval migration
Strongyloides stercoralis	Pruritus and urticaria after skin penetration and during larval migration, including with chronic infection; pruritus ani
Toxocara spp. (*canis*, *cati*)	Pruritus and urticaria during larval migration
Trichinella spiralis	Pruritus and urticaria during larval migration
Trematodes (Flukes)	
Fasciola hepatica	Urticaria during migration of adult flukes
Paragonimus westermani	Urticaria during larval migration
Schistosoma spp. (human and avian)	Transient urticaria with pruritus within 24 hours of exposure to cercariae; urticaria with Katayama fever (acute schistosomiasis)

pruritus, and typically only after exposures in travelers and expatriates visiting West and Central Africa.[15,16]

Changes In Skin Texture or Pigmentation. *Hypopigmentation* of skin can be a feature of chronic infection caused by *O. volvulus* ("leopard skin"), *M. perstans*, and *Mansonella streptocerca*. Hypopigmented macules are the most common cutaneous findings in streptocerciasis.[17] In onchocerciasis, depigmentation is characterized by perifollicular pigmentation within macular or minimally depressed areas, with yellow-brown hypopigmentation, and is particularly noticeable in dark-skinned individuals (see Section "Onchocerciasis" in Chapter 75). *Hyperpigmentation* can also occur with mansonellosis due to *M. streptocerca*, as well as in chronic schistosomiasis. *Lichenification* in the context of chronic pruritus is a feature of onchocerciasis ("sowda" in Arabic), and to a lesser extent mansonellosis; hyperpigmented plaques eventually coalesce and become lichenified over time, particularly over the lower extremities and in young adults in Yemen and Sudan. *Verrucous lesions* may be seen in chronic schistosomiasis (bilharziasis cutanea tarda). *Ichthyosis* may also be present in chronic onchocerciasis.

Other Cutaneous Manifestations. *Petechiae* may be present with trichinellosis and are frequently seen in disseminated strongyloidiasis, in which they are particularly prominent on the trunk. *Vesicles or bullae* may be seen at the site of larval skin penetration in up to 15% of patients with CLM, in human hookworm infection, and occasionally in dracunculiasis, onchocerciasis, and strongyloidiasis. *Ulcers* are uncommon findings in most helminthiases with the exception of dracunculiasis, in which multiple ulcers are common. Ulcerative genital lesions, particularly in women, may occasionally be present in schistosomiasis and tend to occur more often with acute disease (e.g., in travelers).[18]

EN is rare in helminthic infections, but has been described as a clinical finding with hookworm infection,[19] and in visceral larva migrans,[20] sparganosis,[21] and lymphatic filariasis. It has also been reported in one patient in conjunction with *A. lumbricoides* infection,[22] although EN in this patient may also have been due to concomitant *Chlamydia pneumoniae* pneumonia. *Erythema multiforme* has been reported in CLM.[23] *Eosinophilic panniculitis* has been documented in gnathostomiasis[24] and toxocariasis.[25,26] *Eosinophilic cellulitis* (Well's syndrome) may occur in ascariasis,[27] onchocerciasis, and toxocariasis.[28] *Eosinophilic folliculitis* due to helminths has rarely been described in CLM and in toxocariasis.[29] *Exfoliative dermatitis* of the affected limb may occur during the resolution phase of *W. bancrofti* infection.

INTERVAL BETWEEN EXPOSURE AND ONSET OF SYMPTOMS. The time of onset of skin disease (and other key symptoms) relative to travel and likely exposures can be helpful in establishing a diagnosis (Table 207-8). Some infections such as acute schistosomiasis or CLM become evident within hours to days of exposure, whereas others may not present until months to years after infection.

PROGRESSION AND DURATION OF SKIN LESIONS. Skin lesions due to helminthic infections can persist for variable durations (Table 207-8). For those helminths that cause infection by penetration of skin, local dermatologic findings last only for a short time during infection by human helminths, but may persist longer with animal helminths (e.g., CLM). During the chronic phase of infection, however, the duration of cutaneous manifestations varies depending on the infecting helminth. For infections in which skin findings are the result of inflammatory reactions to larvae or eggs in tissues (e.g., onchocerciasis and schistosomiasis, respectively), clinical manifestations can persist for the lifespan of the adult worms, which in some cases may be years. Even with appropriate therapy for chronic infections, chronic skin changes may not resolve completely.

TABLE 207-8
Interval from Exposure to Onset, and Duration, of Cutaneous Symptoms

Species	Typical Interval Between Exposure and Onset of Cutaneous Symptoms	Typical Duration of Symptoms
Nematodes (Roundworms)		
Ancylostoma braziliense, Ancylostoma caninum	Usually 1–5 days, typically within one month	2–14 weeks, rarely longer (up to 2 years)
Ancylostoma duodenale, Necator americanus (human hookworm)	Ground itch—1–2 days Urticaria—1–3 weeks	1–2 weeks
Ascaris lumbricoides	Urticaria—10–14 days	Several weeks
Dirofilaria spp.	Subcutaneous nodules— several months	
Dracunculus medinensis	Edema, vesicle or bulla formation, ulceration with worm protrusion—1 year	Several weeks
Enterobius vermicularis	Pruritus ani—weeks to months	30–45 days (self-limited), or until treated
Filariae		
Brugia spp. (*malayi, timori*)	Hydrocele—years	Years
Loa loa	Calabar swelling, urticaria: >6 months to years Adult worm migration—years	Several days to weeks Years
Mansonella spp. (*ozzardi, perstans, streptocerca*)	Pruritus, dermatitis, hypopigmentation—unknown	Years
Onchocerca volvulus	Onchodermatitis—months to years Onchocercoma—years	Years Years
Wuchereria bancrofti	Hydrocele—years	Years
Gnathostoma spinigerum, others	Creeping eruption—1–2 days Migratory masses—3–4 weeks	Up to 3 months 1–2 weeks, but recur for years
Strongyloides stercoralis	Larva currens—months to years Chronic urticaria, larva currens—years Petechiae, purpura (in disseminated disease)—variable	Hours, but recur for years Years —
Toxocara spp. (*canis, cati*)	Urticaria—weeks to months	Years
Trichinella spiralis	Eyelid edema, petechiae—1–3 weeks	2–3 weeks
Trematodes (Flukes)		
Fasciola hepatica	Urticaria—6–12 weeks (with abdominal pain, fever, weight loss)	Several weeks to months
Paragonimus westermani	Urticaria—2 days to 2 weeks Subcutaneous nodules—2–3 weeks	Several weeks Years
Schistosoma spp. (human and avian)	Swimmer's itch: <24 hours Urticaria—2 weeks to months Bilharziasis cutanea tarda— years	Days to 3 weeks 2–10 weeks Years
Cestodes (Tapeworms)		
Echinococcus spp. (*granulosis, multilocularis*)	Years	Years
Spirometra mansonoides, others (sparganosis)	20 days to 3 years	Years
Taenia multiceps, others (coenurosis)	Months to years	Years
Taenia solium (cysticercosis)	Variable—months to years	Years

COMPLICATIONS OF CUTANEOUS HELMINTHIC INFECTIONS

Secondary complications including excoriation and secondary superinfection are not uncommon, especially when pruritic lesions are present. Skin changes such as lichenification and pigment changes, as noted above, may be persistent. Other significant complications of cutaneous helminthic diseases are addressed in the discussion of specific helminths.

ASSOCIATED SYMPTOMS AND RELATED PHYSICAL FINDINGS

Apart from the skin, symptoms of helminthic infections tend to most frequently involve the respiratory, gastrointestinal, and neurological systems, and the eye. Disease may also occur in many other tissues due to aberrant migration of larvae and adult worms.

Because the skin lesions of many helminthic infections tend to occur in acute (larval) infection, and

nondermatologic symptoms often result from the presence of adult helminths or their products of reproduction, it is important to appreciate that skin findings often precede other manifestations of disease. However, dermatologic and nondermatologic symptoms may coexist in some acute infections, as well as in chronic infections.

PULMONARY DISEASE. Helminthic diseases in which pulmonary symptoms and skin disease may be present are listed in eTable 207-8.1 in online edition. *Loeffler's syndrome*, a hypersensitivity syndrome consisting of dyspnea, wheezing, cough, and fever, typically results from larval migration through lung tissue and may be seen in infection caused by human hookworms, *Ascaris*, and *Strongyloides*. Because these symptoms are due to larval migration, they begin shortly after infection and may occur coincidentally with an urticarial rash. Loeffler's syndrome typically lasts for 1–2 weeks.

Other pulmonary symptoms are generally not simultaneous with dermatologic symptoms, occurring after larvae have matured into adult forms. *Hemoptysis* is uncommon; among helminthic infections it is most frequently a feature of paragonimiasis, but can also be a symptom of echinococcal disease and disseminated strongyloidiasis. *Pleural effusions* also occur rarely, and in helminthic infections are more likely to be eosinophilic. The most common parasitic etiology is *Paragonimus*, but effusions can also be caused by a variety of other helminths (eTable 207-8.1 in online edition).[30–32]

GASTROINTESTINAL DISEASE. Helminthic infections causing gastrointestinal symptoms are listed in eTable 207-8.2 in online edition. *Abdominal pain* is most commonly seen in ascariasis and human hookworm infection, after dermatologic manifestations have resolved, and in strongyloidiasis. Abdominal pain in strongyloidiasis is typically epigastric in location. Because *S. stercoralis* can complete its entire life cycle within the human host, larvae and adult worms may coexist simultaneously, and thus abdominal symptoms may be coincident with larva currens and pruritus ani. Right upper quadrant abdominal pain may also be a manifestation of acute fascioliasis, caused by larval penetration of the hepatic capsule; urticaria may also be present during this phase. *Diarrhea* can be a symptom of strongyloidiasis, and rarely of schistosomiasis.[33] *Hepatitis* may be seen in acute fascioliasis. *Liver masses* or abdominal masses may be the presenting symptom of echinococcosis. *Hepatomegaly* is one of the classic findings of visceral larva migrans (toxocariasis), typically occurring in children and usually in conjunction with fever, respiratory symptoms (wheezing), and occasionally urticaria. Hepatomegaly has also been reported as a finding of several other helminthiases. *Granulomatous hepatitis* may also cause hepatomegaly, and is most commonly encountered in schistosomiasis (due to granuloma formation around eggs in the periportal circulation), but can also be a feature of ascariasis (eggs), strongyloidiasis (larvae), and toxocariasis (larvae). *Biliary disease* may be due to either occlusion of the biliary tract by adult worms or flukes (e.g., ascariasis, fascioliasis, strongyloidiasis) or due to compression of the biliary tract by a mass lesion (e.g., echinococcosis). *Hepatic fibrosis* can be a complication of chronic schistosomiasis.

NEUROLOGIC DISEASE. Helminthic infections most commonly affecting the central nervous system include neurocysticercosis and strongyloidiasis. *Seizures*, typically focal but sometimes generalized, are the most common presentation of neurocysticercosis. Neurocysticercosis should be considered in the presence of subcutaneous cysticercosis. The clinical presentation of neurocysticercosis is determined by the number, size, and location of intracranial lesions, as well as the viability of cysts (dying cysts produce more inflammation and are more likely to be associated with seizures). Globally, neurocysticercosis is among the most common causes of seizure disorders. Seizures may also occur with infection due to *Schistosoma* species, *Paragonimus*, and in sparganosis. *Meningitis* can be seen in strongyloidiasis. *S. stercoralis* larvae may be visualized in cerebrospinal fluid, but more commonly meningitis is a result of Gram-negative bacteremia, due to Gram-negative enteric organisms that are carried across the bowel mucosa during larval penetration in disseminated disease; abdominal petechiae or purpura are often present. *Eosinophilic meningitis or meningoencephalitis* may be a feature of cysticercosis, gnathostomiasis, paragonimiasis, schistosomiasis, toxocariasis, and less commonly strongyloidiasis, among others.[34] *Mass lesions or cysts* can be caused by *Echinococcus* spp., *Paragonimus, Taenia* spp. causing coenurosis, and *Toxocara*. In schistosomiasis, intracranial infection is most commonly associated with *Schistosoma japonicum* infection and may result from the development of granulomas around ectopic eggs. Other central nervous system manifestations of helminthic infections, including brain abscesses, transverse myelitis and myelopathy, and intracranial hemorrhage, may occasionally be seen.

OCULAR DISEASE. While ocular involvement is most frequently associated with infections due to *Loa loa* and *O. volvulus* (river blindness), disease involving the conjunctiva, sclera, and all chambers of the eye can be occasional features of most helminthic infections. Onchocerciasis is one of the major causes of blindness worldwide. Ocular symptoms and findings are often related to the presence of larvae or microfilariae migrating through and causing inflammatory reactions in various chambers of the eye and the retina. Onchodermatitis is common in chronic infection, and skin findings and eye disease may be present simultaneously. Ocular disease is also one of the most frequent presentations of sparganosis; in one case series in Thailand,[35] ocular disease accounted for half of all cases.

Conjunctivitis is the typical ocular manifestation of gnathostomiasis and sparganosis, but has also been reported in a variety of other infections. *Keratitis* is most commonly present in onchocerciasis and coenurosis. *Uveitis* is characteristic of onchocerciasis and schistosomiasis. *Retinitis or chorioretinitis* may be present in onchocerciasis. *Migration of adult worms* through the eye may be seen in loiasis and dirofilariasis, and

less commonly fascioliasis and gnathostomiasis, and gives rise to a foreign body sensation in the eye. *Granulomatous nodules* in the eye or conjunctivae may be present in schistosomiasis and *M. perstans* infection.[36] *Eyelid swelling* (Calabar swelling) may be due to onchocerciasis, and to filariasis caused by *M. perstans.*

LYMPHADENOPATHY. Lymphadenopathy is an uncommon finding in helminthic infections, with the exception of filarial infections. *Regional lymphadenopathy* can be present with lymphatic filariasis (due to infection with *Brugia* spp. and *W. bancrofti*), as well in loiasis, mansonellosis due to *M. streptocerca*, and onchocerciasis. *Generalized lymphadenopathy* may be present in lymphatic filariasis, and in acute schistosomiasis (Katayama fever).

OTHER SYMPTOMS. *Fever* and urticaria can be features of Loeffler's syndrome (eTable 207-8.1 in online edition), which may be the initial manifestation of infection due to *A. lumbricoides*, human hookworm, *S. stercoralis*, and in toxocariasis. Fever in acute trichinellosis usually occurs in conjunction with other symptoms including myalgias. Fever is also a finding in acute schistosomiasis (Katayama fever) and may also be present in other helminthiases, typically during larval migration. *Gram-negative sepsis* may occur in disseminated strongyloidiasis (see Sections "Neurologic Disease and Strongyloidiasis").

LABORATORY EVALUATION

Results of routine blood tests, including eosinophilia, are neither sensitive nor specific for diagnosing helminthic infections. While most hematological and biochemical tests are nonspecific, the presence of eosinophilia can be suggestive of specific diseases when combined with clinical findings and/or the exposure history, and should prompt additional investigations.[37,38] Diagnosis of helminthic infections may also be aided by results of ancillary investigations (e.g., chest radiography, abdominal imaging).

EOSINOPHILIA. Eosinophilia, defined as an absolute eosinophil count of greater than 500 eosinophils/mm^3, should prompt appropriate investigations for helminthic infections as noted above. Eosinophilia is not typical of infections due to most pathogens other than helminths; helminth antigens are effective stimuli for inducing eosinophilia. Levels of eosinophils in the blood can be affected by host factors including the response to other bacterial, viral or fungal coinfections (which lower eosinophil counts), the use of systemic steroids (which lower eosinophil counts), and an immunosuppressed state. In helminthic infection, eosinophil counts vary according to the stage of infection and the infecting helminth. Eosinophilia is not a feature of infection due to intestinal lumen dwelling helminths, except during the larval migration phase for those helminths in which this occurs; in contrast, helminthic infections in which adults, larvae, or eggs persist in tissues are typically associated with eosinophilia. Eosinophil counts are typically normal during the penetration phase and reach their highest levels (often markedly elevated) during the invasive phase of the cycle. Eosinophilia often accompanies the urticarial rash during the invasive stage of infection; thereafter, the eosinophil count often decreases slowly and may fluctuate more or less above the normal value during the chronic phase of infection. A transient hypereosinophilia may be also observed approximately 10 days after the start of effective antihelminthic treatment, and eosinophilia may persist for 1–2 months after successful helminth eradication.

Helminths typically causing eosinophilia are listed in Table 207-9. Severe or high-grade eosinophilia (an eosinophil count of >3,000/mm^3) is suggestive of infection caused by relatively few of these parasites (Table 207-9).

ADDITIONAL LABORATORY TESTS. Other laboratory tests may be abnormal but may not aid with establishing a specific diagnosis. Other than leukocytosis, which may reflect only the presence of eosinophilia, hematologic studies obtained when skin lesions are present are unlikely to be helpful. Evidence of disseminated intravascular coagulation may be present in disseminated strongyloidiasis. Iron deficiency anemia due to chronic low-grade intestinal bleeding is a feature of established hookworm infection but occurs well after the resolution of cutaneous disease.

Biochemical testing may reveal abnormal liver function tests and enzymes in acute fascioliasis and toxocariasis, when urticaria may be present. Granulomatous hepatitis may be suggested by an obstructive picture, with a disproportionately elevated alkaline phosphatase. Most biochemical tests are otherwise

TABLE 207-9
Helminthic Infections that May Be Associated with Eosinophilia

Disease	Comments
Ascariasis[a]	Marked eosinophilia in early infection
Cysticercosis	
Dirofilariasis	
Dracunculiasis	
Fascioliasis[a]	Marked eosinophilia in early infection
Filariasis[a]	Eosinophilia may be marked especially in loiasis and with pulmonary symptoms
Gnathostomiasis[a]	
Hookworm infection (CLM)[a]	Can be marked during larval migration
Paragonimiasis[a]	Marked eosinophilia in early infection
Schistosomiasis[a]	Especially during early infection (Katayama fever)
Sparganosis	
Strongyloidiasis[a]	Eosinophilia may be moderate in chronic infection
Toxocariasis (VLM)[a]	

[a]Marked eosinophilia (eosinophil count >3,000/mm^3) may be present.
CLM = cutaneous larva migrans; VLM = visceral larva migrans.

nonspecific and are of limited use in determining the correct diagnosis.

RADIOLOGIC INVESTIGATIONS. Symptomatic patients with Loeffler's syndrome and acute schistosomiasis will typically have diffuse patchy infiltrates on chest radiographs; urticaria may be present at this time. Radiologic findings consistent with acute respiratory distress syndrome may be present in disseminated strongyloidiasis. Chest X-rays may also be abnormal in paragonimiasis (cystic lesions, pleural effusion). Pleural effusions may be present in infection due to other helminths as well (eTable 207-8.1 in online edition). A solitary pulmonary nodule may be noted in dirofilariasis.

Abdominal imaging [ultrasound, computed tomography (CT), or magnetic resonance imaging (MRI)] should be directed by abdominal symptoms and is suggestive of a diagnosis in relatively few helminthic infections. Septated hepatic cysts are characteristic of echinococcosis, and hepatic masses or nodules (hypodense lesions up to 10 mm in size) may be visualized on ultrasound or CT scan in fascioliasis. Tracts or tunnels representing migration of immature flukes through the liver may also be noted in fascioliasis.[39,40]

Imaging studies of the central nervous system are diagnostic in neurocysticercosis, in which CT or MRI usually reveals parenchymal cysts and occasionally intraventricular cysts.

DIAGNOSIS OF HELMINTH INFECTIONS

The definitive diagnosis of most helminthic infections rests on identification of one or more of the various stages of the helminth (e.g., larvae, eggs, adult worms) in tissue specimens, blood, or excretions (stool or urine). Occasionally adult worms may be observed during medical procedures (e.g., endoscopy, or during surgery). In many helminthic infections causing skin disease, however, cutaneous findings occur during the larval migration phase, and hence precede the presence of adult worms and the production of eggs or larvae. The diagnosis of a helminthic infection is therefore often difficult during the penetration and acute phase of the disease; diagnosis may be suspected because of associated epidemiologic and clinical findings. In chronic infection, the diagnosis can be established based on the identification of parasite eggs or larvae, or occasionally adult worms, but the sensitivity of stool examination can also vary depending on the parasite.

Serologic assays are available for many helminthic infections, but vary greatly in their sensitivity and specificity; their utility is also limited by cross-reactivity of tests among the various helminths. Another significant limitation to serologic testing relates to the delayed appearance of antibodies after acute infection. Although antibody production typically begins during the invasive (acute) phase of disease, when skin lesions are clinically apparent, titers may be negative at this time. Serologic tests may need to be repeated several weeks later, after resolution of cutaneous findings; an increase in titers (seroconversion) retrospectively supports or establishes the clinical diagnosis. Similarly, positive antibody titers may reflect prior infection but do not necessarily imply active or acute disease, although a decrease in antibody titer may be seen following appropriate therapy in some infections, notably strongyloidiasis.

Additional diagnostic tests may include pathologic examination of tissue specimens or blood (for microfilariae), microscopic examination of other specimens (e.g., bronchoscopy specimens in disseminated strongyloidiasis), or molecular testing. Diagnostic tests for helminthic infections are summarized in eTable 207-9.1 in online edition.

TREATMENT

Recommended and alternate therapies for treatment for helminthic infections causing cutaneous findings can be found in recent reviews and guidelines,[41,42] and in eTable 207-9.2 in online edition.

SPECIFIC HELMINTHIC DISEASES OF MAJOR IMPORTANCE

Sections that follow below describe key features of the most common and important helminthic infections. CLM syndrome and enterobiasis (pinworm infection) are encountered relatively frequently by clinicians in developed countries. Strongyloidiasis, although not as commonly seen, must be considered in the appropriate clinical context; failure to diagnose and treat the infection may have significant clinical consequences for immunocompromised patients in particular, in whom disseminated strongyloidiasis carries a significant mortality risk. For these reasons, these three infections will be described below. An outline of the other helminthic infections that may present with dermatologic findings is available online.

CUTANEOUS LARVA MIGRANS SYNDROME

The terms CLM and creeping eruption are often used interchangeably when referring to disease caused by animal hookworms. Technically, however, CLM refers to a syndrome in which the larvae of any animal nematode infect humans AND in which the infected human is a dead-end host. These nematodes include animal hookworms, *Gnathostoma* species, and agents of zoonotic filariases including *Spirulina* X,[43] *Pelodera strongyloides*, and zoonotic *Strongyloides* species. By definition, CLM syndrome does NOT include diseases in which creeping eruption is due to: (1) nonlarval forms of parasites (e.g., dracunculiasis, loiasis); (2) larval forms of human nematodes such as *S. stercoralis* (larva currens); or (3) larval forms of trematodes such as *Fasciola gigantica*. Creeping eruption refers to the clinical finding (sign) of a migratory serpiginous lesion but does not denote the etiology of the lesion.

Clinically, the hallmark of CLM is a creeping eruption. The different helminthic diseases causing creeping eruption can often be distinguished based on the epidemiologic and exposure history, the characteristics of the cutaneous trail(s) (location, number, width and length, rate of movement) (Table 207-4), and the duration of symptoms (Table 207-8), in addition to other clinical and laboratory findings. The correct diagnosis is required for appropriate treatment.

HOOKWORM-RELATED CUTANEOUS LARVA MIGRANS. Hookworm-related (Hr) CLM (creeping verminous dermatitis, sandworm eruption, plumber's itch, duck hunter's itch) is most commonly caused by animal hookworms, and in particular *A. braziliense*. Other skin-penetrating hookworm larvae that produce similar disease include *A. caninum, Uncinaria stenocephala* (hookworm of European dogs), and *Bunostomum phlebotomum* (hookworm of cattle). *A. caninum* causes eosinophilic enteritis as well as cutaneous disease. Cats and dogs are hosts for *Ancylostoma ceylanicum* and *A. caninum*.

HrCLM is widely distributed but is most commonly found in tropical and subtropical areas, especially the Southeastern United States, Caribbean, Africa, Central and South America, India, and Southeast Asia. Contact with sand or soil contaminated with animal feces is required for infection to occur; infection can be prevented by avoiding skin contact with fecally contaminated soil. Larvae penetrate human skin and migrate up to several centimeters a day, usually between the stratum germinativum and stratum corneum. This induces a localized eosinophilic inflammatory reaction. Most larvae are unable to undergo further development or invade deeper tissues, and die after days to months.

Typical skin lesions appear 1–5 days after exposure. The characteristic lesion of HrCLM is an erythematous, raised, and vesicular, linear, or serpentine cutaneous trail (Fig. 207-3).[44] Vesicular or bullous lesions may be seen at the site of larval skin penetration in up to 15% of patients with CLM (Fig. 207-4).[7,45] Lesions are approximately 3 mm wide and may reach 15–20 cm in length. They can be single or multiple, are intensely pruritic, and may be painful. The hookworm larvae advance a few millimeters to a few centimeters daily. The most common anatomic sites (usually 3–4 cm from the penetration site) include the feet (Fig. 207-3) and buttocks (Fig. 207-8), although other sites may be affected. Excoriation and impetiginization are uncommon (10% of cases). Skin lesions usually last between 2 and 8 weeks, but have been reported to last for up to 2 years. Systemic signs and symptoms (wheezing, dry cough, urticaria) have been reported in some patients.[46]

A less frequent but well reported clinical presentation is that of hookworm folliculitis, consisting of 20–100 eosinophilic follicular papules and pustules confined to a particular area of the body, usually the buttocks.[47–49] Patients with folliculitis usually also have creeping eruption. Papular lesions without CLM (papular larva migrans) are a less common presentation.[50] Other cutaneous signs related to the subcutaneous migration of helminth larvae have been occasionally described, such as urticaria and panniculitis.[26]



Figure 207-8 Cutaneous larva migrans of the buttocks. (Used with permission from Jay S. Keystone, MD, FRCPC.)

The diagnosis of HrCLM is based on clinical findings. Hookworm folliculitis can also be diagnosed clinically when creeping eruption is also present; if not, skin biopsy may be required. Histopathologic findings include larvae trapped within the follicular canal, the stratum corneum, or the dermis, together with an inflammatory eosinophilic infiltrate.[47] Skin scrapings in patients with folliculitis may reveal live and dead larvae when examined by light microscopy with mineral oil.

Both albendazole (400 mg po daily for 3 days) and ivermectin (200 µg/kg daily for 1 or 2 days) are effective therapies for HrCLM.[51] Treatment of hookworm folliculitis may require repeated treatments. Topical therapy with thiabendazole or 10% albendazole may also be used. Because larvae have usually migrated beyond the end of the visible skin lesion and their location cannot be reliably determined, surgical excision or cryotherapy are not recommended.

ENTEROBIASIS (PINWORM INFECTION)

Enterobiasis (threadworm, pinworm or seatworm infection; oxyuriasis) is caused by *E. vermicularis*. It is among the most widely distributed helminthic infections and is found worldwide. Transmission is by the fecal-oral route; infection results from ingestion of *E. vermicularis* eggs (e.g., by contact with contaminated fomites or via contaminated fingers) and rarely by inhalation and ingestion of aerosolized eggs in dust. The highest rates of infection are among children. Infection can be prevented by treatment of infected cases and good personal hygiene.

Nocturnal anal and perianal pruritus is the primary clinical feature. The worm may be seen around the anus. The skin may become impetiginized, and cellulitis may occur as a complication. Women may rarely develop vulvovaginitis; a nodular lesion of the vulva has also been described.[52] Nondermatologic extraintestinal manifestations are rare but have been reported. Epidemiologically, enterobiasis is often associated with an intestinal protozoan, *Dientamoeba fragilis*, which may produce gastrointestinal upset. The differential diagnosis includes strongyloidiasis, atopic dermatitis, contact dermatitis, and neurodermatitis.

The diagnosis is established by identification of *E. vermicularis* eggs in the perianal area, most effectively by the sticky tape method. A piece of tape, sticky side out, can be attached to a wooden tongue depressor and firmly pressed against the perianal skin immediately on waking in the morning, before defecation or bathing. The tape is removed and placed sticky side down on a slide, and examined under a microscope. Sensitivity of this method is 70% with three specimens and increases to almost 100% with seven specimens. Eggs are found in stool in only 10%–15% of infections. Occasionally, the adult worm (white, up to 4 mm in length) is found in the perianal area, vulva, vagina, or underclothes. When ectopic sites are involved, the parasite may be identified in tissue sections.

Enterobiasis is self-limited if reinfection does not occur. Treatment with one dose of albendazole 400 mg, mebendazole 100 mg, or pyrantel pamoate 11 mg/kg, is effective. Treatment of household members is also recommended as household transmission is common. Treatment should be repeated once, 2 weeks after the first course of therapy, since medications are relatively ineffective against developing larvae and newly ingested eggs. Specific personal hygiene measures are also important for eradication of infection.

STRONGYLOIDIASIS

Strongyloidiasis is caused by *S. stercoralis*, which is endemic to Africa, Asia, Southeast Asia, and Central and South America. Disease is also found in the Caribbean, and to a much lesser extent in Europe, Japan, Australia, and parts of the Southern United States. Humans are the only hosts. Infection caused by *Strongyloides fuelleborni*, found sporadically in Africa and Papua New Guinea, is relatively rare. The prevalence of infection can be high in endemic areas, as well as among institutionalized mentally impaired persons, in former prisoners of war, and in refugees and immigrants from endemic areas. Infection results from penetration of skin or mucous membranes by infective larvae, usually from soil; the risk of infection is high for persons with frequent soil contact (e.g., walking barefoot) in warm, moist areas contaminated by human feces. Appropriate sanitation and avoidance of soil contact by skin in endemic areas reduce the risk of infection. Persons infected with human T-cell lymphotrophic virus type 1 (HTLV-1) and those receiving immunosuppressive therapy may develop hyperinfection (disseminated disease). Persons with a history of prior residence or activities that place them at an increased risk for strongyloidiasis should be evaluated for presence of the infection, and should be treated even if asymptomatic. This is especially important in persons who receive or will receive immunosuppressive therapy.

Most infected persons have low worm burdens and are persistently infected for life, often with minimal or no symptoms. If symptoms are present they are generally intermittent, with long asymptomatic periods between episodes. Cutaneous manifestations may be seen at any phase of infection. Following skin penetration, an urticarial eruption or larva currens may develop. Larva currens, a migratory serpiginous and intensely pruritic lesion caused by intradermal migration of larvae, can be differentiated from CLM by the high rate of movement (up to 5–10 cm/hour). Larva currens typically disappears within a few hours, only to recur over the course of weeks to years. During the invasive phase of the infection, transient pulmonary manifestations (cough, wheezing, infiltrates) are of pulmonary migration and may be associated with urticaria. Chronic strongyloidiasis gives rise to nonspecific gastrointestinal complaints (epigastric pain, nausea, vomiting, diarrhea, constipation, malabsorption, weight loss). Perianal larva currens may be present (Fig. 207-5) and is pathognomonic of chronic infection. Persons chronically infected with *Strongyloides* may also experience pruritus ani and chronic urticaria, which may be complicated by prurigo nodularis or lichen simplex chronicus.[53]

Hyperinfection syndrome most often occurs in the presence of impaired cellular immunity, typically because of the use of systemic steroids but also with other immune compromised states including HTLV-1 infection. Interestingly, human immunodeficiency virus infection is not associated with an increased risk of disseminated disease. Insidious gastrointestinal symptoms may be present. Pulmonary disease is the most common extraintestinal manifestation of hyperinfection syndrome and is characterized by diffuse pulmonary infiltrates with dyspnea, cough, wheezing, or hemoptysis. Diarrhea and abdominal pain occur frequently, with inflammation leading to small bowel wall edema; ileus may develop in late stages. In uncontrolled hyperinfection, filariform larvae also penetrate organs not normally involved in the life cycle, including the urinary tract, liver, brain, and skin. The finding of larvae in stool may be an early sign of hyperinfection even in those with minimal symptoms. The dermatologic manifestation of hyperinfection and disseminated strongyloidiasis is a rapidly and progressively diffuse petechial and purpuric eruption, often with a reticular pattern, typically involving the trunk and proximal extremities (Fig. 207-9).[54–56] The



Figure 207-9 Disseminated strongyloidiasis, with nonpalpable purpura on the abdominal wall. (Reprinted with permission from Grossman ME, Roth J: *Cutaneous Manifestations of Infection in the Immunocompromised Host*. Baltimore, Williams & Wilkins, 1995.)

"thumbprint sign," a unique pattern of periumbilical purpura resembling multiple thumbprints,[57] may also be seen. Gram-negative bacillary infections including bacteremia, peritonitis, meningitis, and sepsis may result from the concurrent migration of bacteria and larvae across the bowel wall. The mortality rate for disseminated disease is approximately 50%.

Peripheral eosinophilia is present in up to 80% of patients with intestinal disease, and may be high-grade during larval migration, but it is rarely a feature of disseminated infection (although pulmonary eosinophilia may be noted in the latter), and may be absent in patient on systemic steroids and who are otherwise severely immunocompromised. In chronic disease, the eosinophil level fluctuates and is often mildly elevated (mild to moderate increase) but may be normal. Hence, the absence of eosinophilia does not rule out strongyloidiasis.

The diagnosis of larva currens is based on its characteristic clinical features. The identification of larvae in the stool, small bowel contents, and, rarely, in other body fluids confirms the diagnosis. Larvae first appear in the stool 2–4 weeks after exposure. Multiple stool examinations are often necessary to make the diagnosis; a single stool specimen may fail to detect larvae in up to 70% of cases, although sensitivity approaches 100% with seven consecutive stool samples. The agar plate method, in which a stool sample is placed on solid bacterial medium, incubated, and subsequently examined for bacterial tracks created by larvae dragging enteric bacteria as they migrate across the plate, is more than 90% sensitive.[58] Serologic testing has a sensitivity of approximately 90% but lacks specificity, may cross-react with other helminthic infections (in particular filariasis, ascariasis, and acute schistosomiasis), and cannot reliably distinguish between recent and treated infection since antibodies may persist for years following effective treatment. However, since several recent studies have shown that antibody levels drop significantly over the first year following successful therapy, serology is often used to determine test of cure. Skin biopsy of the larva currens eruption often fails to reveal larvae, whereas they may be visualized in biopsy specimens of purpuric and petechial lesions with hyperinfection.

Treatment of strongyloidiasis in asymptomatic individuals is often successful. Ivermectin 200 µg/kg daily for 2 days is the recommended therapy. Albendazole 400 mg twice daily for 7 days is an alternative, although data are more limited and the drug is not approved by the US Food and Drug Administration for this indication. In contrast, patients with disseminated disease may require prolonged or repeated courses of therapy; some experts also suggest that combination therapy with ivermectin and albendazole be used in this setting. If possible, immunosuppressant therapy should be discontinued in those with hyperinfection.

OTHER HELMINTHIC DISEASES

The sections below briefly describe helminths that can cause dermatologic disease that are not covered in the hard copy textbook. Diagnosis of all infections outlined below is summarized in eTable 207-9.1 in online edition, and treatment in eTable 207-9.2 in online edition, and will not otherwise be discussed in detail.

INTESTINAL NEMATODES (ROUNDWORMS)

ASCARIASIS (*Ascaris lumbricoides*). Ascariasis (roundworm infection) is usually caused by *A. lumbricoides* and rarely *Ascaris suum*. It is distributed worldwide, with a higher prevalence in tropical and subtropical climates. Infection occurs via the fecal–oral route; humans become infected by ingesting infective eggs in contaminated food and water, and on contaminated hands. Disease can be prevented by proper sanitation and avoidance of ingestion of fecally contaminated soil.

Urticaria occurs only during the invasive phase of the disease and may be associated with the pulmonary manifestations of Loeffler's syndrome (cough, wheezing, and dyspnea), which occurs 10–14 days after ingestion of eggs. Urticaria resolve spontaneously at the end of this phase. Gastrointestinal symptoms occur much later and in the absence skin findings. Eosinophilia may accompany the invasive stage. The mainstay of diagnosis is the identification of eggs in feces, which does not occur until after dermatologic manifestations have resolved, approximately 6–8 weeks after onset of infection.

Differential Diagnosis. The differential diagnosis includes other causes of urticaria.

HOOKWORM INFECTION (*Ancylostoma duodenale, Necator americanus*). Humans are the main reservoir for *A. duodenale* and *N. americanus*, and become infected when infective larvae penetrate intact skin (e.g., when walking barefoot on contaminated soil). The disease is most common in rural tropical and subtropical areas but can also occur in temperate areas when sanitation is poor. Infection can be prevented by proper sanitation, and avoidance of barefoot walking.

Cutaneous manifestations may be seen at two stages of infection. Within 1–2 days after contact, the area of skin penetrated by the larvae may have localized erythema, edema, and papular or papulovesicular lesions (ground itch).[59] This eruption is most commonly located on the feet and lasts 1–2 weeks. The pulmonary migration phase, seen in a minority of patients, begins 1–3 weeks after infection and presents with cough, wheezing, and shortness of breath; urticaria may be present and disappear spontaneously at the end of this phase. Peripheral eosinophilia begins as early as 2–3 weeks after initial infection, and may be high-grade during the invasive phase. The diagnosis is made by identification of eggs in stool, but eggs are not passed until after skin findings have resolved, approximately 6–8 weeks after onset of infection. In chronic infection, abnormal laboratory values include iron deficiency anemia, hypoalbuminemia, and gross or occult blood in feces.

Differential Diagnosis. Ground itch may be confused with cellulitis, a cellulitis-like reaction after an arthropod bite or sting, and folliculitis. For the differential diagnosis of acute urticaria, see Chapter 38.

TISSUE NEMATODES (ROUNDWORMS)

DIROFILARIASIS (*Dirofilaria immitis*).

Dirofilariasis (dog heartworm infection) is most prevalent in North and South America, Australia, Europe, Japan, India, and China. Sporadic infections with other *Dirofilaria* spp.—*Dirofilaria tenuis* (raccoon), *Dirofilaria repens* (dog), and *Dirofilaria ursi* (bear)—have been reported from all continents.[60]

The characteristic cutaneous finding in dirofilariasis is a solitary, erythematous to flesh-colored, well-defined, firm subcutaneous nodule or mass.[61] The lesion is usually 1–5 cm in diameter and may be tender; rarely, the lesion is migratory.[62] Nodules most commonly occur in the head, neck, breast, extremities, and scrotum. *Dirofilaria immitis* also causes pulmonary disease (most often asymptomatic but may cause cough, chest pain, low-grade fever, and occasionally hemoptysis). In pulmonary dirofilariasis, chest X-rays demonstrate a solitary coin lesion that may be calcified.

Differential Diagnosis. Other helminthic causes of nodular lesions (Table 207-5), as well as epidermal inclusion cysts, lipomas, other benign tumors, and malignant tumors make up the differential diagnosis of subcutaneous dirofilariasis.

DRACUNCULIASIS (*Dracunculus medinensis*).

Dracunculiasis (Guinea worm disease, Medina worm infection) is transmitted by ingestion of infective copepods in water. The disease was endemic in Sub-Saharan Africa but as a result of a widespread water filtration and monitoring program,[13,63] the disease has been almost completely eliminated. In 2009, only 3,190 cases were reported worldwide, compared with 25,000 in 2006.[13]

Symptoms associated with the migration of the worm may precede the emergence of the worm. The characteristic clinical findings include a bullous lesion, typically on the foot, that ruptures and ulcerates after contact with water (Fig. 207-7). Cellulitis and abscess formation can occur. Most infected individuals harbor multiple worms, but usually fewer than six. The adult worm may be palpated or can be seen emerging from the ulcer, and typically dies after reaching the skin and releasing larvae.

Differential Diagnosis. The differential diagnosis includes causes of localized cutaneous bullae, ulcers, and carbuncles.

FILARIAL INFECTIONS.

Filarial infections have been broadly grouped into three categories of disease based on their location of disease: (1) lymphatic, (2) cutaneous, and (3) body cavity.[64] Morbidity is almost entirely attributable to those species that cause lymphatic disease, and to a lesser extent cutaneous disease. Body cavity infection, due to *Mansonella ozzardi*, is usually asymptomatic and will not be discussed below. Filarial infections are summarized in eTable 207-9.3 in online edition.

Lymphatic Filariasis (*Brugia malayi and Brugia timori; Wuchereria bancrofti*). Lymphatic filariasis is caused mainly by *W. bancrofti* (Bancroftian filariasis), which causes 90% of disease, and *B. malayi* (Malayan filariasis), which accounts for only 10% of all cases.[65] Infection caused by *B. timori* is rare. Lymphatic filariasis is widely distributed in both urban and rural areas of tropical and subtropical areas, with the largest number of infections occurring in India, South Asia, East Asia, the Pacific Islands (eFig. 207-9.1 in online edition), and Sub-Saharan Africa. *W. bancrofti* is also endemic in northern parts of South America (Guyana, Surinam, and some coastal regions of Brazil). In developed countries, infections are seen primarily in immigrants and persons with prolonged visits to endemic areas.

Infection is transmitted to humans by mosquitoes, and can be prevented by avoidance of mosquito bites. The incubation period is usually 5–18 months, during which time microfilariae migrate to the lymphatic system, mature into adults, mate, and release microfilariae (larvae); occasionally symptoms develop within 3 months of exposure. Lymphatic filariasis is first acquired in childhood, often with as many as one-third of children in endemic areas infected before the age of 5.[66] However, the characteristic symptoms typically occur years after infection and the prevalence of clinical disease increases after age 20 in endemic areas. Adult worms live an average of 10–15 years, and microfilariae probably 6–12 months. Symptoms and sequelae can persist after the death of all parasites.

Clinical manifestations may be acute, chronic, or recurrent.[67] Initial infection may be subclinical but may also cause recurrent lymphangitis with characteristic retrograde progression, lymphadenitis, orchitis, epididymitis, or occasionally fever. Lymphangitis typically recurs 6–10 times per year, with each episode lasting 3–7 days. The affected body part clinically appears normal between early episodes, although during the resolution of the acute phase of *W. bancrofti* filariasis, there may be extensive exfoliation of the skin of the affected limb. Intermittent fevers and adenolymphangitis can recur during the lifetime of the adult worm. Travelers (>1 month) to endemic areas less frequently acquire infection but may present with more intense inflammatory reactions to filarial parasites. The findings may include lymphangitis, lymphadenitis, groin pain from the associated lymphatic inflammation, urticaria, and peripheral eosinophilia.

Chronic disease with sequelae of lymphatic obstruction (lymphedema, elephantiasis, hydrocele, and chyluria), becomes evident 10–15 years after infection. The skin over the involved area can become hypertrophic, verrucous, and fibrotic with redundant skin folds (Fig. 207-10). Fissures, ulceration, secondary bacterial infection, and gangrene may occur. The lower extremity, scrotum, and penis are most commonly affected, and less frequently the upper extremity, breast, and vulva are involved. Treatment does not reverse the late findings of scarring and lymphatic obstruction.



Figure 207-10 Lymphatic filariasis. (Used with permission from Jay S. Keystone, MD, FRCPC.)

Eosinophilia, sometimes high-grade, and elevated IgE levels are common. Infiltrates may be present on chest radiography in individuals with tropical pulmonary eosinophilia. The diagnosis is made by demonstrating microfilariae at night in blood, urine, and other body fluids, and tissue. However, persons with active filarial infection may not be microfilaremic. Inguinal lymph node ultrasound may show active microfilariae ("filarial dance sign"), more commonly seen in men than in women. Lymph node biopsy is contraindicated.

Differential Diagnosis. Acute infection may resemble bacterial lymphangitis and other causes of nodular lymphangitis (e.g., sporotrichosis, leishmaniasis). Other causes of lymphedema and elephantiasis must be considered during evaluation of chronic disease.

Cutaneous Filariasis: Loiasis (*Loa loa*). Loiasis is endemic in rural areas of Central and West Africa, affecting an estimated 3–13 million residents. *Loa loa* is transmitted by the day-biting *Chrysops* fly; infection can be prevented by avoiding bites from *Chrysops* in endemic areas, diethylcarbamazine chemoprophylaxis, and treatment of infected humans to reduce source of parasites. Symptoms usually begin an average of 24 months after exposure, but can begin as early as 4 months or as late as a decade or more after infection. Microfilariae first appear in the bloodstream 5–6 months after the person becomes infected. The adult worm can live longer than 20 years in the human host.

The characteristic finding of loiasis is the Calabar swelling (Fig. 207-11),[68] a localized area of angioedema due to migration of adult worms through subcutaneous tissues. Calabar swellings usually begin years after infection, typically around joints of the upper extremities, generally last 2–4 days, and may be associated with pruritus or pain. They range in size from 5–20 cm in diameter and may be recurrent. Fatigue, myalgias, arthralgias, and fever are rare. A rapidly moving creeping eruption that usually lasts only a few hours may occur when the adult worm migrates under the skin; adult worms may also be seen moving across the bulbar conjunctiva of the eye (Fig. 207-6). Pruritus may also occur. Peripheral eosinophilia (high-grade), leukocytosis, and elevated IgE are often present.



Figure 207-11 Calabar swelling in loiasis. (Used with permission from Jay S. Keystone, MD, FRCPC.)

Differential Diagnosis. The differential diagnosis includes all of the causes of migratory and nodular skin lesions (Tables 207-4 and 207-5).

Cutaneous Filariasis: Mansonelliasis (*Mansonella perstans, Mansonella streptocerca*). Infection due to both *M. perstans* and *M. streptocerca* is often asymptomatic, but symptoms when present are primarily cutaneous. *M. perstans* is endemic in Sub-Saharan Africa, as well as parts of Central and South America. It is transmitted by biting *Culicoides* midges. Like lymphatic filariasis, infection during childhood is common, and reinfection may occur.[69] In highly endemic areas, the prevalence of infection may be as high as 80%.[70] Cutaneous manifestations include Calabar-like swellings, typically in the forearms, hands and face, and pruritus with or without a papular rash.[71] The exact interval between infection and onset of symptoms is unclear.

M. streptocerca is endemic in forested areas of West and Central Africa. Transmission is also by infected midges. Cutaneous manifestations of *M. streptocerca* infection include pruritus, papular lesions, and hypopigmented, hyperpigmented, or lichenified macules, typically found on the upper chest.

Eosinophilia is often present in *Mansonella* infections, but may also be due to the high prevalence of coinfection with other filarial or helminthic infections.

Cutaneous Filariasis: Onchocerciasis (*Onchocerca volvulus*). Onchocerciasis (river blindness; *erysipelas de la costa* in Mexico and Guatemala; *sowda* in Arabic speaking areas; *craw-craw* in West Africa) is concentrated in rural areas of Equatorial Africa and the Arabian peninsula (eFig. 207-11.1 in online edition), and in Latin America (eFig. 207-11.2 in online edition). Onchocercia-

sis is transmitted by black flies of the genus *Simulium*. In the human, infective larvae mature to adult worms that are encapsulated in fibrous tissue and reside in nodules in the subcutaneous tissue and deep fascia. The incubation period is usually 1–2 years with a range of months to several years, although microfilariae may first appear 3–15 months after exposure; symptoms may precede microfilaremia but often develop only after months or years of infection. Microfilariae can survive in humans for up to 2–3 years, and adult worms for 10–15 years. The primary means of preventing onchocerciasis is through vector control and mass treatment with ivermectin of the population in endemic areas.

Infected individuals may be asymptomatic. Clinical manifestations most commonly involve the skin and eye. Six different patterns of skin changes have been described in onchocerciasis: (1) acute papular onchodermatitis and (2) chronic papular onchodermatitis (Fig. 207-1), (3) lichenified onchodermatitis, (4) atrophy, (5) depigmentation (see Section "Onchocerciasis" in Chapter 75), and (6) onchocercal nodules (Fig. 207-2). More than one pattern of skin involvement may be present simultaneously, or one pattern of skin involvement may evolve into another pattern.

Pruritus is often the first symptom of infection. Acute papular onchodermatitis most often involves the face, extremities, and trunk, and includes widespread small pruritic papules, vesicles and pustules, sometimes with associated erythema and edema. Short-term visitors to endemic regions typically present with acute pruritus and rash (Fig. 207-1),[11] and demonstrate immune hyperresponsiveness despite low levels of parasites[10]; skin nodules and eye involvement are usually absent. After exposures in forested areas of West and Central Africa, travelers and expatriates may have an acute form of onchocerciasis characterized by acute pruritic and erythematous swelling of a limb known as *gros bras camerounais*[15] or onchocerciasis-associated limb swelling.[16]

The skin lesions of chronic papular onchodermatitis are macules and lichenoid papules varying in size from 3–9 mm in diameter. Pruritus is common, and postinflammatory hyperpigmentation may be present. The most commonly affected anatomic areas are the buttocks, shoulders, and waist (Fig. 207-1). Palpable asymptomatic onchocercal nodules containing the adult worm involve the deep dermis and subcutaneous tissue (Fig. 207-2), and occur over bony prominences such as the skull, iliac crest, knee, rib, sacrum, scapula, and trochanter.

Peripheral eosinophilia and elevated IgE levels are common findings.

Differential Diagnosis. Acute onchodermatitis may resemble miliaria, insect bites, scabies, or eczema. Chronic onchodermatitis may resemble a chronic or lichenoid eczema or atopic dermatitis. Skin changes resembling lichenified onchodermatitis can be due to conditions causing significant pruritus or rubbing. Atrophic changes resemble those associated with aging. Onchocercal depigmentation may be confused with postinflammatory hypopigmentation or depigmentation. The differential diagnosis for onchocercal nodules includes other parasitic causes of nodules (Table 207-5) and epidermal inclusion cysts.

GNATHOSTOMIASIS (*Gnathostoma spinigerum*)

Gnathostomiasis is caused by *Gnathostoma spinigerum* and less commonly other *Gnathostoma* species.[72] It is endemic in Southeast Asia, especially Thailand and Japan. Since the 1970s, the prevalence of gnathostomiasis has increased in Peru, Ecuador, and Mexico. Sporadic cases have been reported in the Americas, Africa, Europe, and Australia. In the last two decades, an increase has been noted in the cases in travelers returning from endemic countries.[73–75] Infection is acquired by ingestion of larvae in undercooked or raw flesh of infected animals (typically fish, amphibians, and reptiles) or contaminated water. Imported fish and other animal flesh can be a source of infection outside of endemic areas.

The penetration phase occurs within 1–2 days of larval ingestion and includes acute urticaria and fever, malaise, anorexia, nausea, vomiting, diarrhea, and epigastric pain, which resolve spontaneously within 2 days.[76] Migration of the larvae in the skin and subcutaneous tissue causes migratory swellings (eosinophilic panniculitis), creeping dermatitis (1 cm/hour), papules, and nodules.[77] Solitary or multiple migratory swellings usually occur 3–4 weeks after infection, are intermittent, and associated with erythema, pruritus, and pain (Fig. 207-12). The swellings develop rapidly, persist for 1–4 weeks, then resolve, only to reappear in a different anatomic location after an asymptomatic interval of weeks to months. Over time, episodes become less frequent, less intense, and shorter in duration, but may continue for months to years. Rarely, infection may present as a papular lesion or limb swelling. The most common anatomic locations include the trunk, upper body, and thighs. Peripheral eosinophilia may be high-grade during larval migration.

Differential Diagnosis. The differential diagnosis includes causes of migratory lesions (Table 207-4), panniculitis, limb swelling (e.g., loiasis, onchocerciasis, eosinophilic cellulitis, other), and skin nodules (Table 207-5).



Figure 207-12 Subcutaneous swelling of gnathostomiasis. (Used with permission from Jay S. Keystone, MD, FRCPC.)

TOXOCARIASIS (*Toxocara canis, Toxocara cati*).

Toxocariasis (visceral larva migrans) is most commonly caused by the dog roundworm *T. canis*. It is most prevalent in tropical and temperate climates where humans and dogs coexist, but is found worldwide. Transmission is via the fecal–oral route, with the highest rates of infection in children and individuals with pica.

Most infections are asymptomatic or mild. Severe illness can occur, with disease involving the liver, heart, brain, spinal cord, eyes, and muscle. The most common cutaneous symptoms include urticaria during larval migration, and chronic pruritus or prurigo.[78,79] In acute infection, urticaria is often accompanied by other symptoms including fever, abdominal pain, wheezing, and myalgias. Since larvae can survive and wander through tissues for 10 years or more, urticaria may also persist after resolution of acute symptoms. Other less common cutaneous manifestations include eosinophilic panniculitis,[25,26] eosinophilic cellulitis (Well's syndrome),[28] and eosinophilic folliculitis.[29] Henoch–Schonlein purpura[80] and subcutaneous granulomas[81] have also been reported. Peripheral eosinophilia, often high-grade, may be persistent, and liver enzymes may be elevated during acute infection.

Differential Diagnosis. The differential diagnosis mainly includes other causes of urticaria.

TRICHINOSIS (*Trichinella spiralis*).

Trichinosis (trichinellosis) is present in most countries, but there is marked variation in the incidence. Humans are accidental dead-end hosts and become infected by eating raw or undercooked flesh of animals infected with *Trichinella*, most commonly bears or boars. Human infection can be sporadic or epidemic. Sporadic infections can occur worldwide by shipment of contaminated meat.

Infection may be asymptomatic. Symptomatic disease occurs during larval migration and varies in severity. Death is uncommon (1%–2% of recognized infections) and is usually related to neurologic or cardiac involvement.

Abdominal pain, diarrhea, and vomiting occur during the first week of infection. Ten days after the ingestion of larvae, fever (in 90% of the cases), cutaneous manifestations (75% of cases),[82] fatigue, and severe myalgia develop. The most frequent skin findings are periorbital and facial edema (75%–95% of cases), conjunctivitis, and less commonly a macular or papular (sometimes urticarial) rash. Hand swelling and volar surface erythema followed by desquamation have been reported.[83] Subconjunctival and subungual hemorrhages can occasionally be seen (eFig. 207-12.1 in online edition). Peripheral eosinophilia may be marked and may persist for months. Muscle enzymes (creatine phosphokinase, CPK) are increased.

The diagnosis is usually based on the epidemiological history (e.g., an ongoing epidemic, or suspected dietary exposure), the clinical triad (fever, facial edema, myalgias), and laboratory findings (eosinophilia, increased CPK). A definitive diagnosis is possible after the 17th day and relies on the identification of the parasite in muscle.

Differential Diagnosis. The differential diagnosis includes allergic reactions, dermatomyositis, vasculitis, causes of urticaria, and eosinophilia–myalgia syndrome.

TREMATODES (FLUKES)

FASCIOLIASIS (*Fasciola hepatica, Fasciola gigantica*).

Fascioliasis caused by *F. hepatica* is found worldwide in sheep- and cattle-raising areas[84,85] and has been reported from all continents. Disease due to *F. gigantica* is rare. Infection, which may be asymptomatic, results from ingestion of encysted cercariae on water plants (e.g., watercress).

Symptomatic acute infection presents with fever, abdominal pain, nausea, and diarrhea, which occur during the migration of immature flukes. Urticaria and wheezing may be present during the invasive phase. Less commonly, ectopic subcutaneous nodules may develop; lesions are typically erythematous, pruritic and painful, occurring on the abdomen, back, and extremities. Rarely, eosinophilic panniculitis may be present. Chronic infection does not typically involve the skin. Eosinophilia is typically present during the invasive phase. The identification of eggs in stool only occurs well after symptoms of invasive disease have subsided. Serology may be helpful.

PARAGONIMIASIS (*PARAGONIMUS WESTERMANI*).

Paragonimus westermani is widely distributed in East and Southeast Asia and Africa. Other species of *Paragonimus* can infect humans and are found in Asia, Africa, and the Americas.[86–88] Worldwide, an estimated 10 million persons are infected with paragonimiasis. Infection is prevalent in Asia, where raw, undercooked, salted, pickled, or marinated crustaceans are frequently eaten.

Infection is often asymptomatic. Urticaria may occur early. Migratory subcutaneous nodules containing immature flukes may appear as early as 2 weeks, and are present in 10% of those with *P. westermani* infection and 20%–60% of patients with *Paragonimus skrjabini* and *Paragonimus szechuanensis* infection. Lesions may be up to 6 cm in diameter, are migratory, firm, slightly mobile, and tender to palpation. The lesions are most commonly located on the lower abdomen and inguinal region. Pulmonary involvement is common in chronic infection, but often asymptomatic. Peripheral eosinophilia may be present.

SCHISTOSOMAL INFECTIONS

Cercarial Dermatitis. Cercarial dermatitis (swimmer's itch) occurs worldwide and may be acquired by contact with infective cercariae of many species of non-human schistosomal parasites, in both freshwater and salt water. Attack rates during outbreaks usually range from 55%–100% of those exposed, with highest attack rates in those with a history of previous cercarial dermatitis.[89]

Clinical findings are confined to the skin and are usually distributed on skin surfaces exposed directly to water. Pruritus may begin while swimming, followed rapidly by the appearance of an erythematous macular rash that persists for several hours. Ten to fifteen hours after exposure, papules, vesicles, and urticaria develop. Marked pruritus is characteristic. Symptoms peak 48–72 hours after exposure, and gradually resolve spontaneously over the next several weeks.

Schistosomiasis (*Schistosoma hematobium, Schistosoma intercalatum, Schistosoma japonicum, Schistosoma mansoni, Schistosoma mekongi*). An estimated 200 million people worldwide are infected with schistosomiasis (bilharziasis) and over half-a-billion live in endemic areas (eFigs. 207-12.2 and 207-12.3 in online edition). Humans are the only important reservoir for *S. haematobium*. Infection can be acquired after a brief exposure in an endemic area; many outbreaks have been reported in travelers,[90,91] typically after swimming, wading, rafting, or bathing in slow-moving freshwater in endemic areas. Attack rates in nonimmune exposed persons (e.g., travelers) can be as high as 100%. Cutaneous manifestations can be seen at every phase of the infection.

Cercariae penetrate intact skin within 30 seconds to 10 minutes and may elicit a local inflammatory response (penetration phase). The first exposure to cercariae typically results in erythema and pruritus that resolve within hours. In those previously sensitized, a pruritic, erythematous, papular, and urticarial rash develops, usually lasting 1 week. Migration of the larvae (schistosomulae) in the body usually occurs 2–6 weeks after exposure and leads to an acute parasitic toxemia with a hypersensitivity reaction and circulating immune complexes. This invasive phase (Katayama fever) has historically been described with *S. japonicum* (Katayama fever, sensu stricto), *S. mansoni,* and, to a lesser extent, with *S. haematobium*. Symptoms of Katayama fever are most prominent in primary infection in nonimmune persons and include fever, fatigue, myalgia, and headache that may persist for several weeks. Abdominal symptoms and diarrhea may also be present. Urticaria, purpura, subungual hemorrhages, and edema of the face, the extremities, genitals, and trunk may be seen during the invasive phase.

Chronic schistosomiasis (bilharziasis cutanea tarda) may begin after years of infection and result from a granulomatous inflammatory reaction to the deposition of eggs in the dermis (Fig. 207-13), which may continue for the lifespan of the adult worm (up to 10 years). It is seen primarily in persons who have lived in endemic regions. Lesions are skin-colored or slightly pigmented, 2- to 4-mm firm, pruritic, oval papules that appear in crops and clusters, typically on the trunk and especially the periumbilical region, and remain unchanged without treatment. Lesions also appear in the genital area buttocks, especially on the vulva in women and the scrotum and penis in men. Chronic lesions may also include painless, skin-colored, pink or brown eroded papules and warty, vegetative, polypoid lesions that may be ulcerated and necrotic, with fistulous tracts. Chronic disease can be complicated by lymphedema and elephantiasis, secondary bacterial infection, and squamous cell carcinoma.



Figure 207-13 Ectopic deposition of *Schistosoma mansoni* eggs.

Prominent eosinophilia may be present in early infection, especially during the invasive phase, and subsequently fluctuates more or less above the normal value during the chronic phase. Onset of eosinophilia may lag behind appearance of clinical symptoms. Acute disease can be suspected based on the history of exposure and cercarial dermatitis. Identification of eggs in the stool occurs only after the acute phase of infection.

Differential Diagnosis. The differential diagnosis during acute disease includes other causes of urticaria. Bilharziasis cutanea tarda of the genitals and buttocks must be differentiated from syphilis, condyloma latum, condyloma acuminatum, other granulomatous diseases, malignancy, and hemorrhoids.

CESTODES (TAPEWORMS)

COENUROSIS (*Multiceps multiceps, Multiceps serialis*).

Reported human cases of coenurosis, caused most commonly by *Multiceps multiceps* and less often by *Multiceps serialis*, are rare and sporadic, with the majority from Africa.[92] Infections have occurred in Asia, Europe, and North America,[93] particularly in areas where sheep are common. Intramuscular and subcutaneous cysts are the most common presentation, especially in cases from Africa,[92] but disease may also involve the eye and the central nervous system.[93]

CYSTICERCOSIS (*Taenia solium*).

T. solium (pork tapeworm) is a common parasite in Central and South America, Africa, parts of Asia, and Eastern Europe, although domestic acquisition of infection

has also been well documented in the United States. Cysticercosis is the most common helminthic infection of the central nervous system. Humans acquire cysticercosis by ingesting eggs in food, water, or on fingers contaminated with human feces, but may also acquire intestinal disease from eating undercooked or raw pork containing cysts with infective larvae.

Humans can have either form of disease, or both; intestinal taeniasis is found in up to 50% of patients with cysticercosis.

Less than 10% of patients with cysticercosis present with subcutaneous nodules, although earlier studies reported a detection rate of 50%.[14] Nodules are mobile, well-defined and characteristically nontender, measuring 2 cm in size on average, and commonly found on the extremities and the trunk. The time from infection to the appearance of subcutaneous nodules is highly variable and may be from months to years. Neurocysticercosis is frequently asymptomatic; symptomatic disease presents with seizures in more than two-third of cases.[94] Ectopic disease in other sites is less common.

Differential Diagnosis. The differential diagnosis of subcutaneous nodules includes benign cysts, soft-tissue tumors, and other parasitic causes of nodules (Table 207-5).

ECHINOCOCCOSIS (*Echinococcus granulosus, Echinococcus multilocularis*).

Echinococcus granulosus (cystic hydatid disease) is prevalent in southern South America, the Mediterranean region, parts of the former Soviet Republic, the Middle East, Asia, and Northern and Eastern Africa. Infections are sporadic in other world regions, except Antarctica. *Echinococcus multilocularis* (alveolar hydatid disease) is more limited in distribution, and has been documented in North America, Europe, Asia, India, and Iran. Infection caused by other species (*Echinococcus vogeli, Echinococcus oligarthrus*, and others) is rare. Humans are incidental intermediate hosts who become infected by ingesting infective eggs (shed in feces of dogs or, for *E. multilocularis*, foxes) in contaminated food or water.

Most echinococcal infections are asymptomatic; symptoms develop years after infection and are related to the location and size of cysts. Cysts are usually single, but in 25% of cases multiple cysts are present. Most cysts are hepatic (50%–75%) and pulmonary (20%–30%), with other sites infrequently involved. Typically, the signs and symptoms include an enlarging firm but fluctuant, nontender abdominal mass (Fig. 207-14), epigastric and right upper quadrant pain, jaundice, hepatomegaly, nausea, and vomiting. True skin and soft-tissue manifestations are rare except when cyst leakage occurs. Significant leaks may produce an "anaphylactoid reaction" with eosinophilia, urticaria, and wheezing. Urticaria alone may occur alone in mild cases. Echinococcal cysts implant in soft tissues in less than 2% of infected patients.[95] Infection with *E. multilocularis* has been reported to cause supraumbilical cutaneous and subcutaneous nodules with ulceration, surrounding inflammation, and painless cutaneous fistulae resulting from extension of an underlying visceral lesion.[96] Eosinophilia is usually absent, except in the case of cyst leakage.



Figure 207-14 Abdominal bulge due to intraperitoneal echinococcosis. (Used with permission from Jay S. Keystone, MD, FRCPC.)

Differential Diagnosis. The differential diagnosis includes other cutaneous nodules (Table 207-5) and other cystic lesions of soft tissues.

SPARGANOSIS (*Spirometra mansoni, Spirometra erinacei, Spirometra mansonoides*).

Spirometra species are found in animals on all continents, but most reported human cases are from China, Japan, and Southeast Asia. Cases have also been reported from Africa, Australia, the Caribbean, Southern Europe, and the Americas. Infection is acquired by ingestion of infective tapeworm larvae in contaminated water or animal (fish, amphibian, reptile) flesh, or by use of infected flesh in topical poultices.

The severity of infection depends on the route of infection, the number of parasites, and the anatomic locations involved.[97] Ingestion of larvae leads to a slow-growing subcutaneous or intramuscular nodule (Fig. 207-15), which is occasionally migratory, 3 weeks

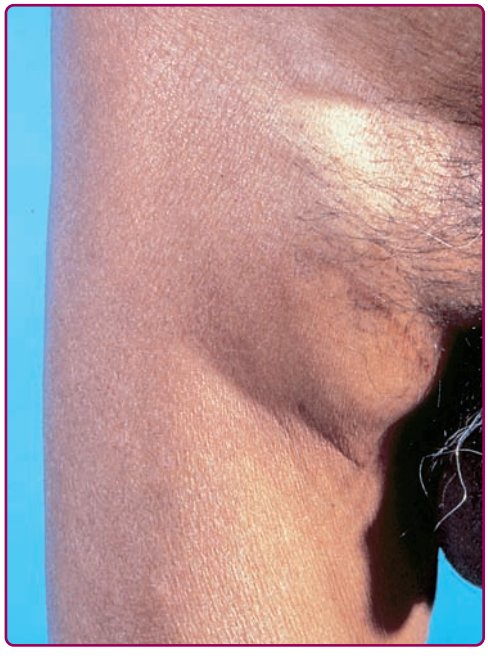

Figure 207-15 Soft tissue swelling of sparganosis. (Used with permission from Jay S. Keystone, MD, FRCPC).

to 14 months after ingestion. The lesion may be pruritic and tender or nontender and may persist for years. Sparganosis due to the application of poultices made with infected flesh is characterized by localized pruritus, erythema, edema, and subcutaneous nodules that are painful to palpation

SUMMARY

Helminthic infections can cause a spectrum of cutaneous disease. Migratory lesions of CLM are most likely to be encountered by clinicians in the developed world. Recognition of specific dermatologic findings, in conjunction with a thorough epidemiologic and exposure history, can establish the diagnosis and/or direct further investigations, and lead to appropriate therapy.

KEY REFERENCES

Full reference list available at www.DIGM8.com

DVD contains references and additional content

1. Caumes E: Skin Diseases. In: *Travel Medicine*, 2nd edition, edited by JS Keystone, PE Kozarsky, DO Freedman, HO Nothdurft, BA Connor. Philadelphia, Elsevier Limited, 2008, p. 523.
4. Freedman DO et al: Spectrum of disease and relation to place of exposure among ill returned travelers. *N Engl J Med* **354**:119, 2006
6. Lederman ER et al: Dermatologic conditions of the ill returned traveler: An analysis from the GeoSentinel Surveillance Network. *Int J Infect Dis* **12**:593, 2008
8. Ansart S et al: Spectrum of dermatoses in 165 travelers returning from the tropics with skin diseases. *Am J Trop Med Hyg* **76**:184, 2007
56. Galimberti R et al: Disseminated strongyloidiasis in immunocompromised patients—Report of three cases. *Int J Dermatol* **48**:975, 2009

Chapter 208 :: Scabies, Other Mites, and Pediculosis

:: Craig N. Burkhart & Craig G. Burkhart

SCABIES

SCABIES AT A GLANCE

- Human infestation caused by host-specific itch mite that lives its entire life cycle within the epidermis.
- Causes a diffuse, pruritic eruption after an incubation period of 4–6 weeks.
- Is transmitted by close physical contact or by fomites.
- Topical therapy is most popular, but oral ivermectin is effective.
- Because of the common occurrence of asymptomatic mite carriers in the household, all family members and close contacts should be treated simultaneously.

EPIDEMIOLOGY

Scabies is worldwide and affects all ages, races, and socioeconomic levels. Prevalence varies considerably with some underdeveloped countries having rates from 4% to 100% of the general population.[1] An infested host usually harbors between 3 and 50 oviparous female mites,[2] but the number may vary considerably among individuals. For example, patients with crusted formerly "Norwegian" scabies (Fig. 208-1) who have a defective immunologic or sensory response (i.e., leprosy, paraplegic, or HIV-infected patients) harbor millions of mites on their skin surface, with minimal pruritus.

It has been well established that close personal contact is a prime route of transmission. Although sometimes considered a sexually transmitted disease, the equally high prevalence in children attests that casual contact or sharing of objects among children and other



Figure 208-1 Crusted scabies. Hyperkeratotic plaques populated with thousands of mites.

family members is also sufficient to transmit the disease. Transmission via inanimate objects has been best demonstrated with crusted scabies. This condition is notoriously contagious, and anyone roaming within the general vicinity of these patients risks acquiring the infestation. Indeed, 6,000 mites/g of debris from sheets, floor, screening curtains, and nearby chairs have been detected.[3] Mites are also prevalent in the personal environment of normal scabies patients.[4,5] In one study, live mites were recovered from dust samples taken from bedroom floors, overstuffed chairs, and couches in every patient's dwelling.[5]

ETIOLOGY AND PATHOGENESIS

Scabies is an infestation by the highly host-specific mite, *Sarcoptes scabiei* var. *homini*, family Sarcoptidae, class Arachnida. The mite is pearl-like, translucent, white, eyeless, and oval in shape with four pairs of short stubby legs. The adult female mite is 0.4 × 0.3 mm with the male being slightly smaller—just slightly too small to be seen by the naked eye. The scabies mite is able to live for 3 days away from the host in a sterile test tube, and for 7 days if placed in mineral oil mounts.[4,6] Mites cannot fly or jump.

The life cycle of mites is completed entirely on human skin. The female mite by a combination of chewing and body motions is able to excavate a sloping burrow in the stratum corneum to the boundary of the stratum granulosum.[7,8] Along this path, which can be 1 cm long, she lays two to three eggs a day during her life span of 30 days. Eggs hatch in 10 days and larvae leave the burrow to mature on the skin surface. The male mite lives on the surface of the skin and enters burrows to procreate.

CLINICAL FINDINGS

The diagnosis of scabies is suspected by pruritus associated with a characteristic distribution of lesions and epidemiologic history. Pruritus typically appears 4–6 weeks after initial infestation; with subsequent reinfestations, symptoms develop within 2 days.[9] Similar to the human response to other insects such as fleas, yellow jackets, and mosquitoes, there is a wide range of clinical responses to an infestation with scabies and some individuals remain asymptomatic despite being infested. These individuals are considered "carriers."

On physical examination, patients display excoriations and eczematous dermatitis that favors the interdigital webs (Fig. 208-1), sides of fingers, volar aspects of the wrists and lateral palms (Fig. 208-2), elbows, axillae, scrotum, penis (Fig. 208-3), labia, and areolae in women. The head and neck are usually spared in healthy adults, but in infants, elderly, and immunocompromised, all skin surfaces are susceptible. Indurated, crusted nodules can be seen in children on intertriginous areas. In crusted scabies, (Fig. 208-1) hyperkeratotic plaques develop diffusely on the palmar and plantar regions, with thickening and dystrophy of the toenails and fingernails.



Figure 208-2 Scabies. Several thread-like burrows are present in the web spaces of the fingers and on the knuckles, a common location for these lesions in scabies. Longitudinal scraping of a burrow will often reveal the mite or mite products under microscopic examination.

The pathognomonic lesion is a burrow, which is a thin, thread-like, linear structure (Fig. 208-2) 1–10 mm in length. It is a tunnel caused by the movement of the mite in the stratum corneum. When present, the burrow is best seen in the interdigital webs and wrists; however, it can be difficult to find in early stages of the condition, or after the patient has extensively excoriated the lesions. Identification of a burrow can be facilitated by rubbing a black felt-tip marker across an affected area. After the excess ink is wiped away with an alcohol pad, the burrow appears darker than the surrounding skin because of ink accumulation in the burrow.

A definitive diagnosis is made by microscopic identification of the scabies mites, eggs, or fecal pellets (scybala). This is accomplished by placing a drop of mineral oil over a burrow and then scraping longitudinally with a number 15 scalpel blade along the length of the burrow or a suspicious skin area, being careful not to cause bleeding. The scrapings are then applied to a glass slide and examined under low power (Fig. 208-3). Confocal microscopy and dermoscopy can also be used to examine the mite in vivo[10,11] and a skin biopsy can be diagnostic, if the mite happens to be transected

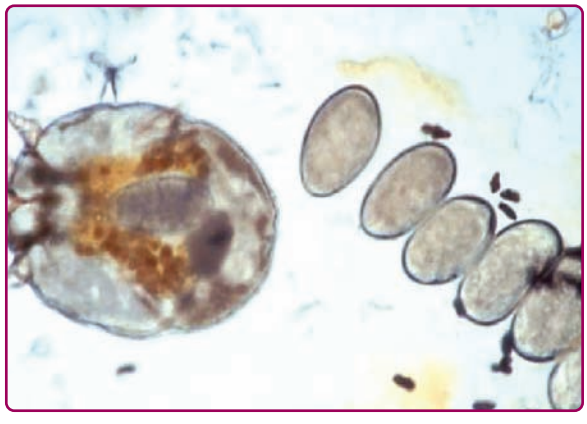

Figure 208-3 Scabies. Microscopic examination of a mineral oil preparation after scraping a burrow reveals a gravid female mite with oval, gray eggs and fecal pellets.

in the stratum corneum (see eFig. 208-3.1 in online edition). An enzyme-linked immunosorbent assay has been developed for serologic testing of other mite infestations in animals; however, no serologic tests for scabies exist for humans.[12] Despite the possibility of confirming the presence of mites via multiple methods of testing, the diagnosis usually is based on clinical impression, and solidified by response to treatment.

DIFFERENTIAL DIAGNOSIS

(See Box 208-1)

COMPLICATIONS

Secondary impetiginization may occur and poststreptococcal glomerulonephritis has resulted from scabies-induced pyodermas caused by *Streptococcus pyogenes*. Lymphangitis and septicemia have also been reported in crusted scabies (see eFig. 208-3.2 in online edition). Finally, scabies infestation can also trigger bullous pemphigoid.[13,14]

TREATMENT

Scabies is treated by a combination of a scabicide and fomite control. With all insecticidal therapies, a second application, usually a week after the initial treatment, is required to reduce the potential for reinfestation from fomites as well as to kill any nymphs that may have hatched after treatment as a result of a semiprotective environment within the egg. All household and close contacts must be simultaneously treated to prevent reinfestation from asymptomatic carriers.

Topical scabicides are applied overnight to the entire skin surface with special attention to finger and toe creases, cleft of the buttocks, belly button, and beneath the fingernails and toenails. In adults, one can exclude treating the scalp and face. Most treated individuals experience relief from symptoms within 3 days, but patients must be informed that even after adequate scabicidal therapy, the rash and pruritus may persist for up to 4 weeks. The itching experienced during this time period is commonly referred to as "postscabetic itch." Patients should be educated that excessive washing of the skin with harsh soaps will aggravate their skin irritation. Instead, oral antihistamines and emollients can be beneficial. The treatments for scabies are summarized in Box 208-2 but a few comments are warranted:

- Lindane has received a "black box" warning as well as restrictive labeling changes by the US Food and Drug Administration (FDA) to greatly restrict its

BOX 208-1 DIFFERENTIAL DIAGNOSIS OF SCABIES

Most Likely

- Atopic dermatitis
- Dyshidrotic eczema
- Pyoderma
- Contact dermatitis
- Insect bite reaction

Consider

- Dermatitis herpetiformis
- Psoriasis
- Bullous pemphigoid
- Drug eruption
- Systemic causes of pruritus
- Delusions of parasitosis

BOX 208-2 TREATMENT FOR SCABIES

DRUG	DOSE	COMMENTS
Permethrin 5% cream	Apply for 8 hours, repeat in 7 days	Most common treatment presently; pregnancy category B, tolerance seems to be developing
Lindane 1% lotion	Apply for 8 hours, repeat in 7 days	US Food and Drug Administration "black box" warning now in effect[a]; banned in California
Crotamiton 10% cream	Apply for 8 hours on days 1, 2, 3, and 8	Has antipruritic qualities; effectiveness is marginal
Precipitated sulfur 5%–10%	Apply for 8 hours on days 1, 2, 3	Considered safe in neonates and during pregnancy; limited efficacy data; inexpensive
Benzyl benzoate 10% lotion	Apply for 24 hours	Not available in United States
Ivermectin 200 µg/kg	Taken orally on day 1 and 8	Highly effective with good safety profile; not recommended for children less than 15 kg or for pregnant or lactating women

[a]Black box warns against usage in premature infants and individuals with known uncontrolled seizure disorders, as well as cautious usage in infants, children, the elderly, and individuals with other skin conditions, such as dermatitis and psoriasis, and people who weigh less than 110 lbs (50 kg) as they may be at risk of serious neurotoxicity.

usage.[15,16] Moreover, it is banned in California.[17] A physician should write a prescription for lindane only when cognizant of all the caveats are noted by the FDA.[18] (See Box 208-2 footnote.)

- There are no documented cases of scabies resistance to permethrin, but tolerance is beginning to develop.[19] Pregnant females, breast-feeding mothers, and children under 2 years should limit their two applications (1 week apart) to 2 hours only when using permethrin.
- Crotamiton is considerably less effective than all other options offered.
- Five to ten percent sulfur is messy, malodorous, tends to stain, and can produce irritant dermatitis, but is inexpensive and may be the only choice in areas of the world in which a lack of funds dictates therapy.[20] The efficacy and toxicity of sulfur has not been critically evaluated in recent years, but many feel that it is the safest choice for neonates and pregnant females.[21]

Ivermectin is an anthelmintic agent derived from a class of compounds known as avermectins. It has been used in veterinary medicine since 1981, and has excellent antiparasitic properties.[22,23] Ivermectin has been approved since 1996 by the FDA for treatment of two diseases, namely onchocerciasis and strongyloides. Clinical efficacy for scabies has been impressive at a dosage of 200 µg/kg given twice 1 week apart.[24,25] Given that millions of people have been treated for onchocerciasis worldwide without significant side effects, it appears to be extremely safe. Nevertheless, because the drug acts on nerve synapses utilizing glutamate or γ- aminobutyric acid, and because the blood–brain barrier is not fully developed in young children, it is not recommended for use in children less than 15 kg (33 lbs) or in pregnant or lactating women. Success rates approach 100% in studies where entire households and close contacts of infested individuals are treated while maintaining strict fomite controls.[23,26]

In crusted scabies, the combination of oral ivermectin and a topical scabicide are recommended as the oral medication will not penetrate into the thickness of the keratinous debris under the nails.

PREVENTION

Several measures should be considered to reduce the potential of reinfestation by fomite transmission. Because of the common occurrence of asymptomatic mite carriers in the household, all family members and close contacts should be treated simultaneously. After treatment, treated individuals should wear clean clothing, and all clothing, pillow cases, towels and bedding used during the previous week should be washed in hot water and dried at high heat. Nonwashables should be dry-cleaned, ironed, put in the clothes dryer without washing, or stored in a sealed plastic bag in a warm area for 2 weeks. Floors, carpets, upholstery (in both home and car) play areas, and furniture should be carefully vacuumed. Fumigation of living spaces is not recommended. Pets also do not need to be treated because they do not harbor the human scabies mite.

OTHER MITES BESIDES SCABIES

OTHER MITES AT A GLANCE

- Scabies and *Demodex* live in the skin, most other mites drop off human host after feeding.
- Some species are vectors of human disease.
- Chiggers can cause pruritic vesicular, papular, or granulomatous lesions.

There are 45,000 described species of mites that belong to the subclass Acarina and the class Arachnida. Some of the mites that can affect humans are listed in Table 208-1. Human infestation by these mites occurs only accidently (save for *Demodex* species).

Demodex folliculorum hominis and *Demodex brevis* are the only mites that routinely live on humans. These organisms reside in the hair follicle and the infundibulum of the sebaceous gland, respectively. Their presence has been linked with rosacea, perioral dermatitis, and suppurative folliculitis, although a causal role for mites in these diseases has not been established.

Although animal and fowl mites are not primary parasites of humans, *Pyemotes* sp. can cause straw itch, oak leaf eruption, or itch mite eruptions. These mites can cause epidemics of dermatitis with outbreaks in the last decade occurring in several Midwestern States. *Pyemotes ventricosus* and *Pyemotes tritici* occur in animal handlers, farmers participating in harvesting of grain, and those exposed to decorative grain.[27,28] *Pyemotes herfsi*'s normal host is the leaf galls on oak trees, and therefore this eruption characteristically occurs in people who spend time outdoors in or near wooded areas. Typical bites appear on exposed skin as red macules with a small blister center 10–16 hours after contact.

Harvest mites (also called berry bugs, red bugs, scrub-itch mites, and chiggers) are in the family Trombiculidae and are distributed worldwide.[29] In the United States they inhabit mostly the southeast, south, and midwest, in areas of grasslands, forest, and damp areas along lakes and streams. Humans are susceptible to the larvae from April until the first frost. The minute, reddish larvae of Trombicula are less than 0.5 mm long and feed on skin cells of animals, including humans. Rather than sucking blood, these mites inject digestive enzymes into the skin breaking down cells, which can subsequently cause severe reactions and swelling. Each bite has a characteristic red papule with a white, hard central area. After feeding, they drop off their hosts and mature into adults, which are harmless to humans. Rarely does a victim realize when the bite is occurring, as itching from a chigger bite does not develop until 1–2 days after the bite. Chiggers prefer warm covered areas of the body, and thus the bites are often clustered behind the knees, or beneath tight undergarments such as socks, underwear, or brassieres.

TABLE 208-1
Mites (Besides Scabies)

Type of Mite	Scientific Name	Clinical Features/Disease Association
Follicle	*Demodex folliculorum hominis* and *Demodex Brevis*	Associated with rosacea, idiopathic facial burning
Fowl	*Dermanyssus gallinae* and *Demodex Avium*	Pruritic papules, sometimes with a hemorrhagic center
Straw itch	*Pyemotes tritici* and *Pyemotes ventricosus* and *Pyemotes herfsi*	Patchy dermatitis on trunk and arms during and after harvesting
Harvest or red (Chiggers)	Genus *Trombicula Eurotrombicula Alfreddugesi* and *Eurotrombicula Splendidus*	Scrub typhus vector; papular to vesicular lesions found on ankles, waist, or warm skinfolds most common in United States
Animal	*Ornithonyssus bacoti*, *Liponyssoides sanguineus*, *Cheyletiella* sp. "walking dandruff"	Endemic/murine typhus vector; rickettsialpox vector; nonspecific pruritic eruption on body parts in close contact with infested pets
House dust	*Dermatophagoides* sp.	Atopic dermatitis, allergies

The house dust mite is a cosmopolitan guest in human habitation and feeds off flakes of shed human skin. The mites are harmless, but their bodies and excreta are believed to play a role in human disease. They are a common precipitant of asthma, hay fever, and allergic respiratory symptoms worldwide. In addition, atopic dermatitis may be exacerbated in some patients by dust mite allergens.[30,31]

PEDICULOSIS

Pediculosis, the infestation of man by lice, has been a human affliction since antiquity. Three species of lice infest humans: (1) *Pediculus humanus capitis*, the head louse, (2) *Pediculus humanus humanus*, the body or clothing louse, and (3) *Phthirus pubis*, the pubic, or crab, louse.

PEDICULOSIS CAPITIS (HEAD LICE)

PEDICULOSIS CAPITIS AT A GLANCE

- Infestation occurs worldwide affecting hairs of the scalp most commonly in children between the ages of 3 and 12.
- Presence of 0.8 mm eggs (nits) firmly attached to scalp hairs is most common sign of infestation.
- Spread by close physical contact and sharing of headgear, combs, brushes, and pillows.
- Resistance to traditional over-the-counter preparations is growing; topical malathion and ivermectin should be considered in resistant cases.

EPIDEMIOLOGY. Head lice infestations occur worldwide and are most common in children between the ages of 3 and 12.[32] Based on pediculicide sales in the United States, an estimated 10–12 million children are infected each year. Head lice affect all levels of society, and all ethnic groups; however, the incidence is low among African-Americans in the United States, possibly due to an anatomic inability of female lice in America to deposit eggs on coarse curly hair.[33]

Transmission is by means of direct head-to-head contact or by indirect (fomite) transmission through combs, brushes, blow-dryers, hair accessories, upholstery, pillows, bedding, helmets, or other headgear.[34–36–39] Lice can be dislodged by air movement, blow-dryers, combs, and towels, and passively transferred to fabric, facilitating new infestations.[29–33]

ETIOLOGY AND PATHOGENESIS. Head lice are blood-sucking, wingless, highly host-specific insects belonging to the order Anoplura. They are almost 2 mm long with three pairs of claw-like legs that are well adapted for grasping hair. Their entire life cycle is on the scalp. More than 95% of infested individuals have fewer than 100 adult lice in their scalps. The female louse lays 5–10 eggs per day during her 30-day life span. After 10 days, the eggs hatch producing larvae, which are referred to as nymphs or "instars." Instars look like miniature adult louse and go through three stages of development that take 14 days for full maturation. The eggs are laid about 1 cm from the scalp surface, firmly attached to individual hairs with a proteinaceous glue that closely resembles the amino acid composition of the human hair shaft itself.[40,41]

Lice typically survive less than 2 days away from the scalp, although under favorable conditions of heat and humidity, survival has been reported at 4 days. Nits can survive for 10 days away from the scalp.

CLINICAL FINDINGS. Pediculosis capitis is confined to the scalp with nits (Fig. 208-4) found most readily in the occipital and retroauricular regions.



Figure 208-4 Nit sheath. Microscopic view of an egg, containing an unhatched louse, attached to a hair shaft.

Most patients experience pruritus. The average incubation before symptoms is 4–6 weeks. Some individuals remain asymptomatic despite infestation, and can be considered "carriers."

Bites of the mites may produce 2 mm erythematous macules or papules, but usually an examiner only finds excoriations, erythema, and scaling. Other findings may include a low-grade fever, regional lymphadenopathy, and irritability.

Infestations are diagnosed by demonstrating egg capsules (nits) and live lice. Nits are readily seen by the naked eye and are an efficient marker of past or present infestation. They can be differentiated from dandruff, hair casts and the like, as nits are not easily removed from the hair shaft.[42] The color of newly laid or viable eggs is tan to brown; the remains of eggs that have hatched are clear, white, or light in color. The presence of adult lice confirms active infestation. However, lice are fast, avoid light, and blend in with the hair, making them difficult to find. Finding live adult lice or immature nymphs is best achieved with fine combing the hair with a nit comb. Wet combing, in which water and conditioner are applied to the hair prior to using the nit comb, increases the yield by prying the adult lice from the hair follicles.[41,42]

DIFFERENTIAL DIAGNOSIS. See Box 208-3.

COMPLICATIONS.

Secondary bacterial infections can occur with *pediculosis capitis*. In fact, head lice are thought to be the most common cause of pyodermas of the scalp in the developed world.[43]

Head lice and body lice are closely related, so it is not surprising that head lice can serve as host for rickettsiae and have the potential of transmitting diseases.[44,45] Head lice in laboratory experiments have been readily infected with *Rickettsia prowazekii*.[46] *Bartonella quintana*, which causes trench fever, has also been isolated in head lice.[47,48,71,72] Transmission of these infections to humans by pediculosus capitis, however, has never been described and it is highly unlikely to occur outside of experimental conditions.

BOX 208-3 DIFFERENTIAL DIAGNOSIS OF HEAD LICE

- Seborrheic dermatitis (dandruff)
- Insect bites
- Eczema
- Psoriasis
- Hair gel hair spray
- Piedra (a fungal infection)
- Pseudonits (desquamated epithelial cells with sebaceous plugs encircling the hair)
- Delusions of parasitosis

TREATMENT.

Standard treatment recommendations for pediculosis capitis utilize a two-step process of confirming active infestation with live lice and then treating with an over-the-counter or prescription pediculocidal therapy. Pediculocide choice is typically based on local resistance patterns and access of patients to a physician for prescription medications.[49] However, with increasing resistance to pediculocides, a multimodal approach, similar to *Staphylococcus aureus* therapy, is warranted to prevent widespread resistance to currently available products (see Fig. 208-5).[50] This is especially important when treating with prescription pediculocides.

Physical methods to treat infestations, including shaving one's head to avoid infestation, dates back to the sixth century BC, when priests and wealthy Egyptians removed scalp hair and wore wigs. The routine of head shaving for military services today was founded on the same principle. While a buzz haircut may be a solution for boys, such an approach would be traumatic psychologically for girls. Combing out nits is difficult, tedious, time-consuming, and somewhat painful. While wet combing can be an adjuvant to topical insecticidal therapy, is not by itself sufficient in most situations.[44]

Pediculicides remain the most effective treatment for head lice.[51–58] Given (1) variable ovicidal activity, (2) possible lack of patient compliance, (3) growing resistance to pediculocides, and (4) the potential of fomite reinfestation, it is recommended to repeat treatment with all insecticidal treatments in 1 week.

The array of treatments for head lice is summarized in Box 208-4. One of the leading factors for the increasing number of infestations is resistance of lice to topical therapies.[59–65] Since the introduction of insecticides years ago, the louse has adapted by several genetic alterations. The agents with the highest success rates, namely malathion and ivermectin, are prescription products. One trial has shown oral ivermectin given

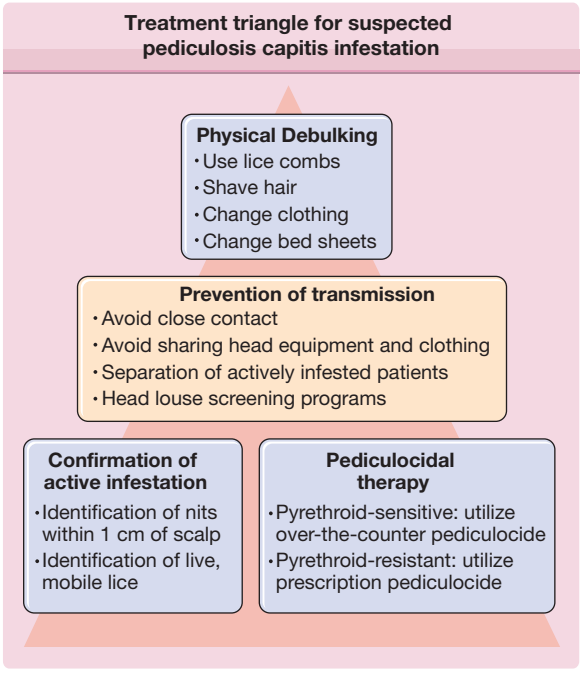

Figure 208-5 Treatment triangle for suspected pediculosis capitis infestation. Although including all items within this figure is impractical for many patients, utilizing one to two elements from each aspect of the entire regimen will increase the efficacy of therapy and reduce the spread of resistance. (Modified from Grayson ML: The treatment triangle for staphylococcal infections. *N Engl J Med* **355**(7):724-727, 2006.)

twice at a 7-day interval to be more effective than topical malathion lotion.[66] However, both pediculocides are highly effective and treatment decisions should be based on local resistance patterns and individual patient characteristics.

There are a number of anecdotal and market-driven reports with occlusive and suffocation methods (such as with application of petrolatum, mayonnaise, dimethicone, vegetable oil, mineral oil, hair pomade, and olive oil).[67,68] To accurately evaluate pediculicidal activity of any compound, one must appreciate that head lice have the ability to "resurrect" from a state of seeming death, in which respiratory and motor function appear to have ceased.[69,70] These insects are less dependent than mammals for continuous nervous control of respiration and circulation, and the exact point of death is not readily defined. Indeed, the World Health Organization recommends pediculicidal testing to be read 24 hours after application of insecticide since otherwise mortality rates are overestimated.[71] Not following these guidelines has lead to overestimates of the efficacy of several alternative treatments with occlusive agents and essential oils from health food stores. Such products slow the movements of adult lice and may allow them to be more easily combed out of their scalps, but these substances are usually not lethal to lice.

Patients should be counseled in at least some effective measures to prevent reinfestation by fomite transmission. After treatment, treated individuals should wear clean clothing, and all clothing, hats, pillow cases, towels and bedding used during the previous week should be washed in hot water and dried at high heat. Nonwashables should be dry-cleaned, ironed, put in the clothes dryer without washing, or stored in a sealed plastic bag in a warm area for 2 weeks. Combs and brushes may be washed in very hot water (65°C) or may be coated with the pediculicide for 15 minutes. Floors, carpets, upholstery (in both home and car) play areas, and furniture should be carefully vacuumed to remove any hairs with viable eggs attached. Fumigation of living spaces is not recommended and pets do not need to be treated because they do not harbor the human head louse. There is no reliable evidence that strict "no nit"

BOX 208-4 TREATMENT OF HEAD LICE AND CRAB LICE

	ADMINISTRATION	RISK FACTORS
Pyrethrins synergized (RID, Pronto, etc.)[a]	Topically for 10 minutes[b]	Allergy to chrysanthemums, ragweed, or related plants
Permethrin 1%[a] (Nix)	Topically for 10 minutes[b]	None
Permethrin 5%	Topically overnight[b]	None
Malathion 0.5%	Topically overnight	High flammability; burning/stinging at sites of eroded skin
Carbaryl 0.5%	Topically overnight	Not available in United States
Lindane 1%	Topically for 4 minutes[b]	US Food and Drug Administration "black box" warning now in effect;[c] banned in California
Topical ivermectin	Topically for 10 minutes	Not currently commercially available
Ivermectin, oral 200 µg/kg	Orally on days 1, 8, and 15	Very good efficacy on adult lice; not ovicidal, hence nits are safe until they hatch; not recommended for pregnant females or children weighing less than 15 kg

[a]Available over-the-counter.
[b]Application to dry scalp and hair followed by adequate wash out with non-medicated shampoo (head lice).
[c]See Box 208-2.

policies at schools are necessary to prevent spread of the infestation, and they should be abandoned in favor of family education regarding effective treatment.

PEDICULOSIS CORPORIS (BODY LICE)

PEDICULOSIS CORPORIS AT A GLANCE

- Infestations most commonly found in homeless, refugees, and victims of war and natural disasters.
- Diagnosis made by presence of nits in lining of clothing, particularly the seams.
- Infections transmitted by body lice include epidemic typhus, trench fever, and relapsing fever.

ETIOLOGY AND PATHOGENESIS. *Pediculus humanus humanus*, body lice, have a very similar morphology to head lice, except they are 30% larger. The body louse's lifespan is 20 days during which the female may lay up to 300 eggs. The lice lay their eggs in the seams of clothing, while obtaining their blood meals from the host. The body louse can survive without a blood meal for up to 3 days.

EPIDEMIOLOGY. Pediculosis corporis requires exposure to the louse and favors an inability to wash and change clothing. Thus, it is most commonly found on homeless individuals, refugees, victims of war and natural disasters, or those forced into crowded living condition with poor hygiene. The infestation is usually transmitted by contaminated clothing or bedding. After exposure, the inability to wash or change clothes allows the infestation to persist.

CLINICAL FINDINGS. Symptomatically, patients complain of pruritus. Most commonly, the only sign of body lice is excoriations, often linear and primarily on the back, neck, shoulders, and waist. Postinflammatory pigmentation is seen in chronic cases. Adult lice are not easily seen except in heavy infestations. Diagnosis is made by closely examining the lining of the clothing, particularly at the seams, for the presence of nits. The clothing may also be shaken over a sheet of white paper, at which time the lice may be seen moving about on the paper.

DIFFERENTIAL DIAGNOSIS. Box 208-5.

COMPLICATIONS. Several important human diseases are transmitted by the body louse. The major diseases include epidemic typhus (caused by a rickettsiae, *R. prowazekii*), murine typhus (caused by *Rickettsia typhi*), trench fever (caused by *B. quintana*), and relapsing fever (caused by a spirochete, *Borrelia recurrentis*).[73–77] Lice obtain organisms, such as rickettsiae and spirochetes, from ingestion of blood meals from infested hosts. Transmission of microorganisms from body lice is not from the louse bite, but rather by (1) contaminated fecal material being scratched into excoriated skin of bite sites, (2) inhalation of dry, powdery louse feces from handling typhus-contamined bedding or clothing or (3) infected lice having its gut ruptured, allowing an infective blood meal to enter excoriations on the skin. In addition, excoriation can lead to secondary infection with *S. aureus*, *S. pyogenes*, and other bacteria.

BOX 208-5 DIFFERENTIAL DIAGNOSIS OF BODY LICE

- Scabies
- Atopic dermatitis
- Contact dermatitis
- Drug reaction
- Viral exanthem
- Other animal parasites
- Systemic causes of pruritus
- Delusions of parasitosis

TREATMENT. The most important treatment of body lice is disinfestation of all clothing and bedding. Beds should be burned or sprayed with lice sprays, because the body louse may lay eggs on the seams of the mattress or couch. Clothing is best treated like biohazardous waste, bagged, and tightly sealed in specially marked, plastic, biohazard bags. The waste is handled separately from other trash until it can be incinerated, maintaining a temperature of 65°C for 30 minutes. If this is not possible, clothing and bedding should be fumigated, machine washed in hot water, and dried on high heat or dry-cleaned. Hot ironing of the seams of upholstered furniture should also be performed and exposure to infested items should be strictly avoided for 2 weeks. The patient should be treated from head to toe with a topical insecticide or given oral ivermectin.

PEDICULOSIS PUBIS (CRAB LICE)

PEDICULOSIS PUBIS AT A GLANCE

- Best to call "crab lice" (rather than "pubic lice") as infestations may involve other hair-bearing sites such as mustache, beard, axillae, eyelashes, eyebrows, and scalp hair.
- Transmitted by sexual or close contact as well as via fomites (contaminated clothing, towels, and bedding).
- Topical therapy options similar to pediculosis capitis, but ivermectin orally, is preferred for this infestation.

ETIOLOGY AND PATHOGENESIS. Pediculosis pubis is caused by infestation of the body with *Phthirus pubis*. Crab lice range from 0.8 to 1.2 mm in length and have wide, short bodies resembling tiny crabs. They have a serrated edge on their first claw, which gives them traction on flat, hairless, surfaces; thus, they can navigate across the entire body surface. They most commonly are found in the pubic and perianal region, but occasionally they also reside in mustache, beard, axillae, eyelashes, eyebrows, and scalp hair. In hirsute individuals, they are also found on the short hairs of the thighs and trunk. The louse has a lifespan of less than 3 weeks during which time the female will lay about 25 eggs on human hairs. The adult crab louse can survive for 36 hours off the human host, while the eggs are viable for up to 10 days.

EPIDEMIOLOGY. Crab lice can be found in all levels of society and all ethnic groups. Patients with crab lice often have another concurrent sexually transmitted disease. Although pediculosis pubis is considered a sexually transmitted disease, transmission has been documented to occur from contaminated clothing, towels, and bedding.

CLINICAL FINDINGS. In the case of crab lice, all hairy parts of the body should be examined, especially the eyelashes, eyebrows, and perianal area. Many individuals have two different hair-bearing sites infested.[78] These lice can be mistaken for scabs or moles, or can blend in with skin color making them difficult to detect. Infested patients have an average of 10–25 adult organisms on their body. Nits can also be identified near the base of hairs (Fig. 208-6). The diagnosis can be confirmed by microscopic examination of the plucked hair to identify the nits and/or adult lice. Although rare, skin lesions named maculae caerulea (eFig. 208-6.1 in online edition), representing hemorrhage, can be seen with pubic lice with slate gray to bluish, irregular-shaped macules about 1 cm in diameter. Pediculosis palpebrarum, or phthiriasis palpebrarum, is the infestation of the eyelashes with crab lice.



Figure 208-6 Pediculosis pubis. Several lice and their dot-like nits attached to the hair shafts can be seen in the pubic area of this patient. (Used with permission from D.A. Burns, MD.)

BOX 208-6 DIFFERENTIAL DIAGNOSIS OF PUBIC LICE

- Excoriations
- Scabies
- Contact dermatitis
- Piedra
- Trichomycosis pubis
- Hair casts
- Nevi

DIFFERENTIAL DIAGNOSIS. Box 208-6.

TREATMENT. Shaving is not curative as the louse will seek another hairy area of the body to reside. Crab lice are treated with the same topical therapy as that for pediculosis capitis (Box 208-4).[79] In vitro and in vivo resistance to pyrethrins have been shown.[80] There is a lack of appreciation for their tendency to inhabit rectal hair.[78] Unless the physician is certain that only one body area is involved, all hairy areas of the body should be treated because (1) it is not uncommon to have other areas infested, and (2) lice can migrate away from a treated areas to other hair-bearing locations. For this reason, oral ivermectin is recommended for this entity.[71] However, as ivermectin treatment relies on the insect obtaining a blood meal, so the nits are not affected and the patient requires repeat oral ivermectin on day 8 and day 15.

Phthiriasis palpebrarum (Fig. 208-7) has traditionally been treated with petrolatum (Vaseline), but this treatment is slow and needs to be applied at least five times a day for weeks. Ivermectin is the first-line therapy for this condition.[81]

Fomite precautions mirror those discussed previously for pediculosis capitis. Treatment failure is



Figure 208-7 Pediculosis pubis. Eyelash infestation with Pthirus pubis. Nits can be seen attached to the eyelashes. (Used with permission from D.A. Burns, MD.)

usually a result of failure to treat all hairy areas (especially perirectally) or reinfestation from neglecting to treat sexual contacts. Other household members are also infested occasionally and should be carefully questioned for symptoms and/or examined.

KEY REFERENCES

Full reference list available at www.DIGM8.com

DVD contains references and additional content

5. Arlian LG, Estes SA, Vyszenski-Moher DL: Prevalence of *Sarcoptes scabiei* in the environment of scabietic patients. *J Am Acad Dermatol* **21**:806-811, 1988
9. Bergstrom FC et al: Scabies mite inactivated serine protease paralogs inhibit the human complement system. *J Immunol* **182**:7809-7817, 2009
24. Meinking TL, Taplin D, Hermida JL: The treatment of scabies with ivermectin. *N Engl J Med* **333**:26-30, 1996
33. Carter D: *Insect egg glue. Ph.D. Thesis*, Department of Applied Biology, Cambridge University, 1990
40. Burkhart CN et al: Molecular composition of the louse sheath. *J Parasitol* **85**:559-561, 1999
72. Sasaki T et al: First molecular evidence of *Bartonella quintana* in *Pediculus humanus capitis* (Phthiraptera: Pediculidae) collected from Nepalese children. *J Med Entomol* **43**:110-112, 2006

Chapter 209 :: Bites and Stings of Terrestrial and Aquatic Life

:: Jennifer S. Daly & Mark Jordan Scharf

BITES AND STINGS AT A GLANCE

- Dog bites account for 80%–90% of all mammalian bites involving humans, but cat bites are more likely to become infected.
- Whether or not postexposure prophylaxis with rabies immunoglobulin and human diploid cell rabies vaccine is needed depends on the circumstances surrounding the bite.
- In the United States, there are approximately five to six deaths from snakebites and probably 6,000 to 7,000 snakebite envenomations each year.
- Most stingray injuries occur when bathers, waders, or fishermen accidentally step on rays as they lie partially covered with sand in shallow waters. The extreme pain caused by the venom may be relieved by soaking the affected body part in very warm water.

Humans are a part of the environment and ideally live peacefully with other animals and plants. However, sometimes the interactions between man and the environment prove harmful to one or the other. The first two sections of this chapter consider the harmful effects of land-borne animal bites, as well as the bacterial and viral infections they may transmit. The last section reviews bites and stings and other forms of injury that may be inflicted by marine life.

BITES OF LAND ANIMALS

EPIDEMIOLOGY

Dog bites account for 80%–90% of all mammalian bites involving humans. Four to five million dog bites are estimated to occur each year in the United States, and, in 2001, it was estimated that 368,245 persons were treated for dog bite-related injuries.[1] The human victim is often a 5– 9-year-old boy who may have been teasing or playing with the dog. Sometimes the bite occurs when a person is trying to break up a pair of fighting dogs or trying to aid an animal. In the United States 4%–5% of dog bites are work related and include bites sustained by postal carriers. Overseas, a higher percentage are produced by untamed animals.[2–4] Most dog bite injuries involve the upper extremities, especially the hands. Cat bites are the second most common type of mammalian bite after dog bites, but the wounds following a cat's bite are nearly twice as likely to become infected as wounds from dog bites.[5]

CLINICAL APPROACH (PATHOGENESIS AND TREATMENT)

The evaluation and treatment of all bite wounds should include taking a careful history of the incident, the type of animal, the site of the bite, and the geographic setting. Hand wounds, puncture wounds, and crush injuries are likely to become infected. Specimens from infected bites should be cultured and a Gram-stained smear prepared; the wound should then be washed, well-irrigated, and left open. Most patients with bites on the hands, deep cat bites, deep cat scratches, and sutured wounds should be treated with amoxicillin/clavulanic acid or ceftriaxone because of the risk of

Pasteurella multocida infection; if the patient is allergic to these agents a quinolone or a tetracycline should be used. Evidence that the use of prophylactic antibiotics is of benefit exists only for bites of the hand. However, once the patient has an infection, intravenous antibiotics and surgical drainage are often required.[4,6–8] Tetanus immune status should be evaluated, and rabies prophylaxis should be considered, depending on the type of animal, local epidemiologic factors, and ability to quarantine the animal for 10 days.[9]

Human bites and monkey bites deserve special mention, because 30% become infected with aerobic or anaerobic mouth organisms. Infection caused by anaerobes may spread through the metacarpal–phalangeal space and causes severe damage. The same procedure should be followed as for other animal bites; that is, culture and Gram stain, thorough washing, and debridement. Wounds, especially hand wounds, should be left open if possible. Evidence suggests that patients with human bites that penetrate the epidermis should be treated prophylactically with amoxicillin/clavulanic acid for 7–10 days or, if the patient is allergic to penicillins, with a fluoroquinolone plus an antianaerobic agent such as clindamycin.[7,10] Clenched-fist injuries should be evaluated by a hand surgeon because of the high likelihood of infectious complications, including septic arthritis and osteomyelitis.[2]

SPECIFIC BACTERIAL INFECTIONS CAUSED BY ANIMAL BITES

Pasteurella multocida INFECTION.

(See Chapter 183). An organism commonly infecting bite wounds is *P. multocida,* a bacterium present in the nasopharynx in 50%–66% of dogs and 70%–90% of cats. The most common pattern is that of local infection with adenitis after a dog or cat bite or scratch. *P. multocida* is the most common pathogen in cat bite infections and may also complicate 26% of dog bite wounds.[5] The infection usually presents within 24–48 hours, often within several hours. In patients with a cat bite, the infection may be followed by tenosynovitis or osteomyelitis as a result of inoculation of the organism into the periosteum by the long, sharp tooth of the animal. *Pasteurella* infections have also been reported after bites of large cats such as lions and tigers.

Systemic infection may also occur as bacteria may enter the respiratory tract through the inspiration of contaminated barn dust, or by inhalation of infectious droplets sprayed by the sneeze of an animal. In such cases, the bacteria probably colonize the respiratory tract and in some patients cause active infection. Bronchiectasis, emphysema, peritonsillar abscess, and sinusitis have all been described with this organism. Finally, systemic infection with bacteremia or meningitis may occur.

P. multocida is a small, Gram-negative, ovoid bacillus that grows well on blood agar but does not grow on selective Gram-negative media such as MacConkey agar. Because of the superficial resemblance of *P. multocida* to *Haemophilus influenzae* and *Neisseria* organisms, infections of the respiratory tract and central nervous system with this bacillus may be misdiagnosed initially.

Treatment of the patient with presumptive *P. multocida* infection should consist of careful washing of the wound and an attempt to leave it open. The empiric antibiotic of choice is amoxicillin/clavulanic acid orally for 7–10 days, with careful follow-up examination of the wound. *P. multocida* is susceptible to penicillin alone, and patients may be switched to penicillin if they have a pure infection with this organism. A fluoroquinolone, a tetracycline, and a trimethoprim-sulfamethoxazole are alternatives. In most patients, the antibiotic is aimed at both the patient's skin flora (such as *Staphylococcus aureus*) and organisms from the animal's mouth. Given the increasing prevalence of community acquired methicillin resistant *S. aureus* (MRSA), patients should be treated with vancomycin, clindamycin, tetracycline, or trimethoprim-sulfamethoxazole if MRSA is suspected (see Chapters 176 and 177).[11]

Staphylococcus intermedius INFECTION.

S. intermedius is an organism associated with dogs weighing more than 40 lb. It is more commonly found in canine gingival flora than is *S. aureus* (39% vs. 10%).[12] It is a Gram-positive, coagulase-positive coccus that can be differentiated from *S. aureus* in the laboratory by biochemical testing. In comparison with *S. aureus*, *S. intermedius* does not produce acetoin from glucose and has β-galactosidase activity. If these tests are not performed (i.e., if only a latex assay is use to identify *Staphylococci*), the laboratory may incorrectly report an isolate as *S. aureus* or unspecified *Staphylococcus*. Antibiotic treatment is the same as that for infections with *S. aureus*, although resistance to oxacillin is uncommon in *S. intermedius* and is growing in importance for *S. aureus*.[11]

Capnocytophaga canimorsus INFECTION.

C. canimorsus is a capnophilic ("carbon dioxide-loving"), facultatively anaerobic, slow-growing, Gram-negative rod associated with dog bites.[13–16] The organism has been found in the oral cavity of 17% of cats and 24% of dogs. Most infections occur in splenectomized or immunocompromised hosts, although fatal infections including meningitis have been reported in immunocompetent hosts and present as overwhelming sepsis.

INFECTION BY *Porphyromonas* SPECIES.

Porphyromonas sp. are slow-growing anaerobic bacteria found in the deep gingival pockets of animal and humans. The organism is difficult to culture, requiring 4–6 days for colony formation as well as vitamin K and hemin in the media.[17,18] Citron and co-workers[19] found *Porphyromonas* sp. in 28% of culture specimens from patients with infected dog and cat bite wounds.

CAT SCRATCH DISEASE.

Bartonella henselae is the most common etiologic agent of cat scratch disease. *Afipia felis* and other *Bartonella* species may cause some cases (see Chapter 182).

PLAGUE.

(See Chapter 183).

TULAREMIA. (See Chapter 183).

RAT-BITE FEVER. (See Chapter 183).

SPECIFIC VIRAL INFECTIONS CAUSED BY ANIMAL BITES

RABIES

Epidemiology. The most notorious viral disease to occur after an animal bite is rabies, which is caused by a Rhabdovirus. Its epidemiology has changed in the past few years as a result of improved control of rabies in the domestic animal population. Now, nonimmune dogs and domestic animals account for only 8% of cases, whereas sylvatic animals, such as skunks, raccoons, red and gray foxes, and bats, represent the greatest potential danger. Rodents, such as squirrels and hamsters, are probably inconsequential as sources of rabies. However, cases of rabies in cattle are increasing.[20] Postexposure prophylaxis, which is nearly 100% effective, has reduced the number of cases of human rabies from more than 100/year a century ago to an average of 1–4 cases a year in the United States today. In 2004, of the eight cases in the 49 states and Puerto Rico, four were acquired as a result of patients' receiving transplanted organs from an infected donor.[20,21] While in the United States death in humans from rabies is rare, WHO estimates that 55,000 deaths occur each year in developing countries, half in children under 15 years.[22]

Live virus is introduced into nerve tissue at the time of the bite, multiplies at the site, and then spreads to the central nervous system. It replicates in gray matter and then spreads along autonomic nerves to the salivary glands, adrenal glands, and heart. The incubation period varies with the site of the bite from 5 days to as long as several years. Clinical features include a prodromal period of 1–4 days, followed by high fever, headache, and malaise. Paresthesia at the site of inoculation occurs in 80% of patients. The next sequence of events is familiar: agitation, hyperesthesia, dysphagia, excessive thirst, paralysis, and death.

Diagnosis. The diagnosis of clinical rabies is difficult and is often not made until after the death of the patient. Viral isolation methods may yield positive results for specimens of saliva or cerebral spinal fluid during the first 2 weeks of the illness, and saliva is infectious, so isolation precautions are needed. Serum antibodies may be detected as early as day 6 and usually by day 13. The fluorescent antibody method for detection of the viral antigen is the most rapid and sensitive means of making the diagnosis, and no matter where the actual bite site is, once patients have central nervous system disease, the diagnosis can be made from a biopsy of skin from the highly innervated hair-covered area of the neck or from brain tissue.

Prevention and Treatment. The most effective prevention for rabies is to avoid contact with any wild animal or any unfamiliar domestic animal. Persons at risk of unavoidable contact with rabies, such as spelunkers, veterinarians, virologists, and travelers spending time in countries where rabies is enzootic, should receive preexposure prophylaxis with the human diploid cell rabies vaccine (HDRV) series (three intramuscular injections on days 0, 7, and 21 or 28) given in the deltoid muscle and repeated every 2 years. In persons vaccinated intradermally (using a lower intradermal dose), the neutralizing antibody titer should be followed, because the immune response may not be fully protective.[23]

The need for postexposure prophylaxis can be determined by the answers to the following questions: (1) What is the status of animal rabies in the locale where the exposure took place? (2) Was the attack provoked or unprovoked? (3) Of what species and size was the animal? (4) What was the state of health and vaccination record of the animal? (5) Will the brain of the animal be examined within 48 hours? (6) Can the animal be effectively quarantined? Most animals transmit rabies virus in saliva only a few days before becoming ill themselves; bats, however, may harbor the virus for many months.

BITES BY HOUSEHOLD PETS. If the dog or cat responsible for the bite is healthy and available for observation for 10 days, the patient should not be treated unless the animal develops rabies. At the first sign of rabies in the animal, the patient should be treated with rabies immunoglobulin (RIG) and the vaccine HDRV. The symptomatic animal should be killed and tested as soon as possible. If the animal is rabid or suspected of being rabid, or if it does not have up-to-date vaccination records, the patient should be treated with RIG and HDRV (see Section "Specifics of Treatment").[24]

BITES BY WILD ANIMALS. All skunks, bats, groundhogs, foxes, coyotes, raccoons, bobcats, and other carnivores should be regarded as rabid unless laboratory test results prove negative. The patient should be treated with RIG and HDRV.

BITES BY OTHER ANIMALS. Bites by other animals (livestock, rodents, lagomorphs such as rabbits and hares, and ferrets) should be considered individually.[23] Local and state public health officials should be consulted about the need for prophylaxis. Bites by squirrels, hamsters, guinea pigs, gerbils, chipmunks, rats, mice, and other small rodents almost never call for anti-rabies prophylaxis.

SPECIFICS OF TREATMENT. The most important step is to cleanse the wound immediately with a brush and soap to remove as much virus as possible. The wound should be rinsed well and then scrubbed a second time with green soap or 70% alcohol, which is rabicidal. If vaccine treatment is indicated, both RIG and HDRV should be given as soon as possible, regardless of the interval after exposure, unless the patient has been previously vaccinated and a serologic assay shows current immunity. In this case, only HDRV is needed and should be given on day 0 and day 3. For nonimmune hosts, administration of RIG

is the most urgent. If HDRV is not immediately available, RIG should be started and HDRV given as soon as it is obtained. RIG (20 IU/kg) should be given immediately—50% around the site of the bite and 50% in the thigh or the arm. This passive immunization will result in the early appearance of antibody but will also inhibit development of the active antibody from HDRV, hence the need for a 28-day series. Active immunization is accomplished using HDRV, given intramuscularly for a total of five doses on days 0, 3, 7, 14, and 28. Serum for rabies antibody testing should be collected 2 weeks after the fifth dose. If there is no antibody response, an additional booster should be given.

MANAGEMENT OF THE PATIENT WITH CLINICAL RABIES. In the rare cases in which a patient is admitted with the clinical diagnosis of rabies, several steps should be taken immediately. First, the diagnosis must be suspected and the patient placed on isolation precautions while the diagnosis is made rapidly by fluorescent antibody staining of specimens from various tissues, as well as immunofluorescence staining of the source animal's brain tissue. Elevated antibody titers in the absence of immunization are clear evidence of infection. The first signs of clinical rabies are usually nonspecific, such as malaise, anorexia, fatigue, headache, and fever. The acute neurologic illness that follows is most commonly characterized by intermittent episodes of hyperactivity. In some cases, however, a progressive paralysis occurs. The usual period from onset of symptoms to onset of coma is 10 days. Risk of exposure for hospital staff includes contact with open wounds or mucous membranes with saliva or other potentially infectious material such as neurologic tissue, spinal fluid, or urine. Blood, serum, and stool are not considered infectious.

Basic clinical management consists of anticipating and preventing all treatable complications of the rabies infection and induction of coma to manage the patient until the patient generates an immune response.[25] Pulmonary hypoxia should be prevented by tracheostomy at the first sign of respiratory difficulty, monitoring of actual partial pressure of oxygen, and use of supplemental oxygen. There are no specific antiviral treatments for rabies, although ribavirin has been tried.[25] Anticonvulsant therapy should also be instituted. Extreme increases in intracranial pressure may be prevented by insertion of a cerebrospinal fluid reservoir that allows withdrawal of the intraventricular fluid and measurement of intracranial pressure. Cardiac arrhythmias may be anticipated with careful monitoring. Rabies had been regarded as uniformly fatal, but there have been patients who have survived with prolonged cardiorespiratory support, and there is serologic evidence that some animals have survived. An aggressive approach to treatment of the patient with known rabies infection is worthwhile. In 2004, a 15-year-old girl without a history of prior rabies vaccination survived after her physicians used a treatment based on induced coma as well as other supportive measures and antiviral agents.[20,25] The World Health Organization has complied information regarding treatment and prevention accessible on their Web site.[22]

HERPESVIRUS SIMIAE (B VIRUS) INFECTION. Herpesvirus simiae (B virus) is enzootic in Old World monkeys, especially rhesus, cynomolgus, and other macaques. The illness in monkeys is similar to that caused by herpes simplex in humans, and asymptomatic monkeys may shed the virus in saliva. Most cases in humans have occurred after direct exposure to macaque monkeys or monkey tissue through bites, scratches, or cuts.[26] A vesicular lesion develops at the wound site with progressive lymphadenitis and fever. Over the next few days to weeks patients develop a severe illness, which is characterized by rapidly progressive ascending neuropathy and encephalitis. The illness is rare and before the availability of antiviral therapy, 72% of cases were fatal. A cluster of four cases occurring in 1987 in Pensacola, Florida, were treated with acyclovir. The two patients who received acyclovir when their infections were localized responded well to therapy and were maintained on oral acyclovir. All macaques should be presumed to be shedding B virus and should be handled accordingly. All monkey-inflicted injuries should be cleansed, specimens should be collected for viral culture, and a physician should evaluate the patient. Clinical and serologic monitoring is critical, and high-risk or infected patients should be treated according to established guidelines. The use of acyclovir or ganciclovir initially and acyclovir for years has led to improved survival in infected patients.

SNAKEBITES

In the United States, there are approximately five to six deaths from snakebites and probably 6,000 to 7,000 snakebite envenomations each year.[26] The largest number of venomous snakebites occur in the Southwestern States. Worldwide as many as 125,000 fatal snakebites may occur each year.[27] Because of regional differences in varieties of snakes, management recommendations including specific antivenom recommendations differ by geographic area. The World Health Organization has published guidelines to help insure the quality and availability of antivenom immunoglobulins worldwide, and has an online database that can be used to explore the global distributions of venomous snake species, and access information on antivenom products and their manufacturers.[28]

The two major poisonous snakes in the Americas are the pit viper (family Viperidae, subfamily Crotalinae, which includes the rattlesnake, water moccasin, and copperhead) and the coral snake (family Elapidae). Poisonous snakes are found in all states of the United States except Maine, Hawaii, and Alaska.[29] The northern copperhead, also called the highland moccasin, is pink or reddish brown and is marked with large chestnut brown barrels resembling dumbbells or hourglasses (Fig. 209-1). The bite is painful but rarely fatal. The timber rattler is dark brown with chevrons of black and brown (Fig. 209-2).

The degree of toxicity of a snakebite depends on the potency of the venom, the amount injected, the size and condition of the snake, and the size of the



Figure 209-1 Northern copperhead.



Figure 209-3 Copperhead snakebite.

person bitten. Pain occurs at the site of the bite (usually within 5 minutes). Signs and symptoms at the bite site include wheal with local edema, numbness, and, within moments, ecchymosis and painful lymphadenopathy (Fig. 209-3).

Nausea, vomiting, sweating, fever, drowsiness, and slurred speech may develop. Bleeding of the gums and hematemesis are common hemorrhagic manifestations. If edema and erythema have not developed within 8 hours after the bite, it can be assumed that significant envenomation did not occur. Estimated mortality rates for victims who receive antivenom in a health care facility are less than 1% and probably less than 0.1%.

For proper treatment, it is extremely important to establish that the bite is from a poisonous snake. Many patients experience symptoms related to fear that may mimic symptoms from venom. The patient should have distinct fang punctures and immediate local pain, followed by edema and discoloration within 30 minutes. It is helpful to inspect the snake, because those that are poisonous may be differentiated from those that are not by the presence of fangs and the shape of the pupils (Fig. 209-4). Availability of a photograph of snakes common to a specific geographic area is important for all hospital emergency wards to aid practitioners in deciding if the patient has been bitten by a poisonous snake.

Although there are still insufficient evidence-based criteria for first aid and out-of-hospital treatment for snakebite envenomations, a rational approach is outlined in Table 209-1.[30] In summary, the patient should be stabilized and transported as rapidly as possible to a health care facility capable of administering antivenom, and the affected site should be immobilized below the level of the heart. Constricting bands such as watches or jewelry should be removed; the routine use of venous compression bands is not recommended.[29] The patient should be kept as immobilized as possible.[29] Venous compression techniques are designed to impede the return of venous and lymphatic flow from the bite site without sacrificing blood flow to the extremity. In cases in which there is likely to be a significant delay in transport and the victim is developing systemic signs of envenomation such as hypotension, these techniques may be of value.[30] Arguments against the use of venous compression techniques include the time that it takes to apply the treatments, which



Figure 209-2 Timber rattlesnake.

TABLE 209-1
First Aid and Out-of-Hospital Treatment for Snakebite Envenomation

1. The patient should be stabilized and transported as rapidly as possible to a health care facility capable of administering antivenom. Consult the CDC and WHO Web sites for updated information on antivenom availability and use.[28]
2. The affected site should be immobilized below the level of the heart, constricting bands such as watches or jewelry should be removed, and the patient should be kept as immobile as possible.[29]
3. The use of venous compression bands or pressure immobilization is not recommended,[29] although there is controversy surrounding their use if there is likely to be a significant delay in transport and the victim is developing systemic signs of envenomation such as hypotension, and in such a case these techniques may be of value.[30]
4. The value of using a suction device to extract venom is debated in the literature.[29] If such a device is applied in the field and fluid is accumulating in the suction cup, it can be left in place until the patient reaches a medical facility.[30]
5. The use of cryotherapy, incision, or excision of the bite site, arterial tourniquets, and electroshock therapy as part of emergency field therapy should be discouraged.

CDC = Centers of Disease Control and Prevention; WHO = World Health Organization.

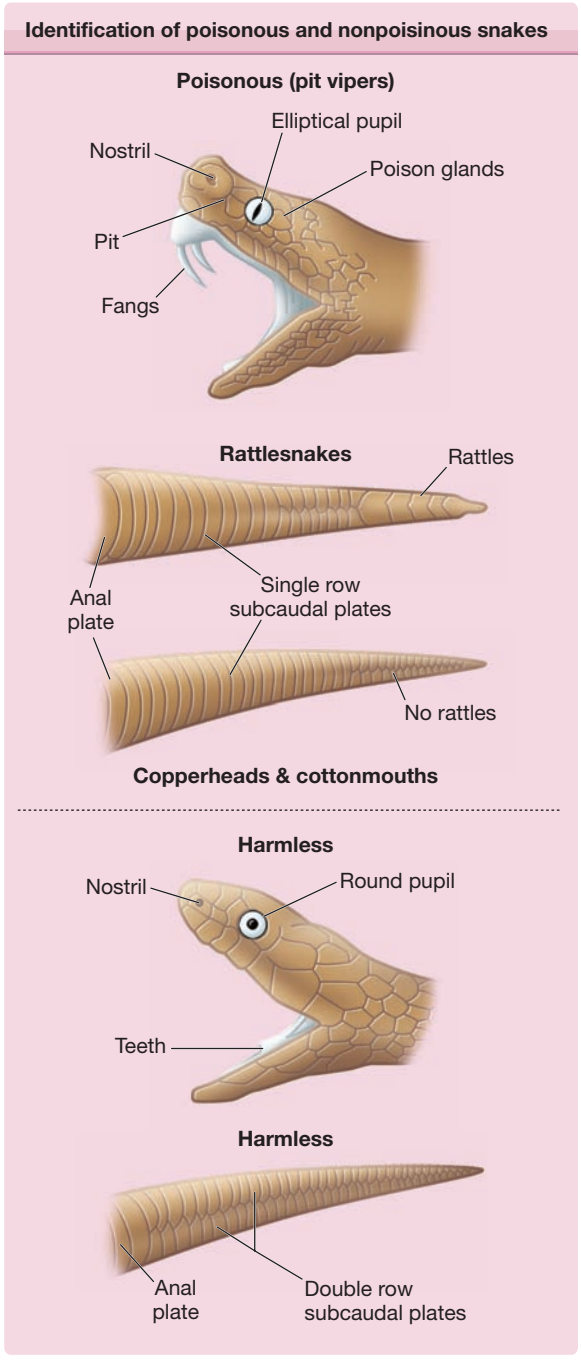

Figure 209-4 Identification of poisonous and nonpoisonous snakes. (From Wingert WA, Wainschel W: A quick handbook on snake bites. *Resid Staff Physician*, 1977, p 56, with permission.)

may further delay transport time. Additional arguments against the use of these techniques include the potential for concentrating the venom in the affected limb, which may worsen local necrosis, along with the possibility of a bolus effect when the compression is released.[30] Another possible disadvantage of the use of these compression techniques is the potential for them to cause arterial compression if the affected limb swells in reaction to the toxin. If a decision is made to use a venous compression band in the field, arterial pulses should be palpable distal to the ligature, and the dressing should be checked frequently to make sure that it is has not become too tight. If a venous compression dressing has been applied in the field and is not causing vascular compromise, it should be left in place until the patient reaches a health care facility and antivenom is at the bedside.[30]

The role of surgical intervention in the treatment of snakebite envenomations is limited in most cases. Surgery is appropriate only if medical treatment fails. This includes elevation of the bitten body part in conjunction with the administration of four to six vials of Crotalidae polyvalent immune Fab (ovine) (FabAV) over the course of 1 hour, fails.[29] Debridement of truly necrotic skin and subcutaneous tissues is recommended 4–5 days after envenomation. In cases of bites to a digit, if there is severe swelling and the finger is tense, blue, or pale, a digit dermotomy may be of use. True compartment syndrome involving an extremity is a rare complication of snakebite envenomation. Fasciotomy should be used only in cases of increased compartment pressure that has not responded to prompt and sufficient treatment with antivenom.[31]

The primary treatment for crotaline snake venom poisoning is prompt and adequate dosing with antivenom. Antivenom is most effective if given within 4 hours of the snakebite (Box 209-1).

FabAV should be used for all severe American crotaline snakebites, but not those of the coral snake. The dosage should be guided by the severity and progression of local changes and systemic clinical signs. Because some patients develop recurrent manifestations of envenomation after initial treatment, both a loading dose of four to six vials of FabAV and then, once initial control has been achieved, three maintenance doses 6, 12, and 18 hours later are recommended.[29]

Supportive treatment is indicated, including hospitalization with careful evaluation of baseline hematocrit, platelet count, and prothrombin time. Coagulopathy should be corrected by using antivenin, because fresh frozen plasma is ineffective.[29] The wound should be cleansed and covered. Antitetanus therapy and antibiotic prophylaxis with penicillin, ampicillin/sulbactam, or tetracycline should be initiated for severe bites.

BOX 209-1 ANTIVENOM FOR CROTALINE SNAKE BITES

- Emergency information and antivenom are available in the United States through the nationwide poison control center network, which can be reached 24 hours a day by calling 800-222-1222.[29]
- The World Health Organization Web site has a database with information and pictures to aid providers in finding the correct antivenom[28]: http://apps.who.int/bloodproducts/snakeantivenoms/database/.

BITES AND STINGS OF AQUATIC ORGANISMS

SEAL BITE

Normally, a seal bite occurs on the finger of a trainer or a seal hunter—thus the term *seal finger* or *spaek finger*.[32,33] The etiologic agent is unclear and is controversial. One study suggests that a virus similar to that causing Orf may be the culprit,[33] although *Mycoplasma* sp. have been isolated, and some patients respond to tetracycline (see Chapter 183). The incubation period of 4–8 days is followed by throbbing pain, erythema at the site, and swelling of the joint proximal to the bite. Untreated, seal finger progresses to cellulitis, tenosynovitis, and arthritis. Tetracycline, 500 mg orally four times a day for 10 days, remains the antibiotic of choice.[30,32] It is also helpful to immobilize and elevate the finger as well as soak it several times a day (see Chapter 183).

INJURIES CAUSED BY JELLYFISH, PORTUGUESE MAN-OF-WAR, SEA ANEMONES, AND CORALS

Stings caused by jellyfish, Portuguese man-of-war, sea anemones, and corals are the most common envenomations experienced by humans in marine environments. All of these creatures are members of the phylum Cnidaria, formerly known as *Coelenterata*. They are divided into three major classes. The first class, Hydrozoa, includes the Portuguese man-of-war, fire corals, and hydroids. Jellyfish belong to the second class, Scyphozoa. The third class, Anthozoa, encompasses sea anemones and true corals. Approximately 100 of the 9,000 species of Cnidaria that have been identified may cause injury to humans.[34]

Cnidarians are radially symmetric animals with body walls formed by an inner and outer layer of cells enclosing a jelly-like substance. They may be either free floating in the water like jellyfish or sessile like corals.[34] Almost all cnidarians possess nematocysts, or stinging capsules, which are usually concentrated on some form of tentacle. Each nematocyst contains a toxin or group of toxins and a coiled thread-like apparatus with a barbed end that functions like a flexible hypodermic syringe (Fig. 209-5). When the nematocyst comes into contact with a victim, the barbed end is discharged, and the toxin is injected into the skin.

Cnidarian stings range from mild, self-limited irritations to extremely painful and serious injuries, depending on the toxin of the species involved and the magnitude of the envenomation. Stings from certain species such as the cubomedusae, or box jellyfish, can be fatal.

In most cases, jellyfish stings elicit toxic reactions that may be localized and/or systemic. Although immediate-type hypersensitivity reactions, including urticaria, angioedema, and anaphylaxis, occur less frequently, they require prompt medical intervention, because shock and death may ensue in highly sensitized individuals. Allergic contact dermatitis, delayed and persistent hypersensitivity reactions, granuloma annulare, and erythema nodosum are other possible cutaneous reactions to jellyfish stings.[35]

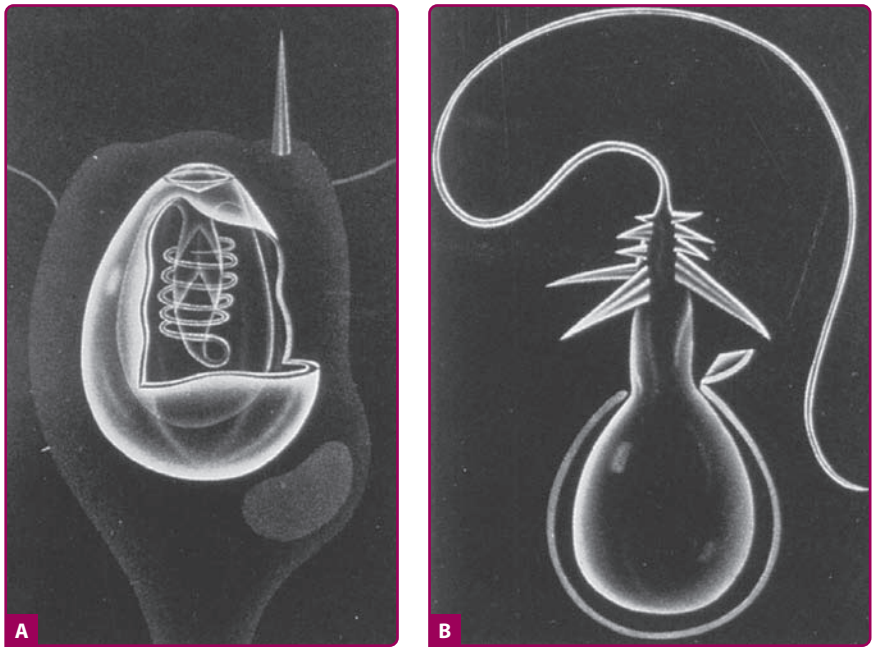

Figure 209-5 From left to right, a diagrammatic view of an intact and discharged coelenterate nematocyst. (R Kreuzinger, used with permission from World Life Research Institute.)



Figure 209-6 *Cyanea capillata*, also known as *sea nettle* or *lion's mane*, is a common cause of jellyfish stings. (BW Halstead, used with permission from World Life Research Institute.)



Figure 209-7 *Chrysaora fuscescens* is commonly known as the Pacific Sea Nettle or West Coast Sea Nettle. Its sting causes much discomfort but only rarely does the patient require medical attendtion.

INJURIES CAUSED BY JELLYFISH

Sea Nettles. Among the organisms most commonly causing jellyfish stings are the sea nettles, which comprise two different species, both of which inhabit Atlantic as well as Indo-Pacific waters. *Cyanea capillata* and its relatives are the larger of the two species, with a bell measuring up to 1 m and numerous tentacles reaching 30 m in length (Fig. 209-6).[36] *Chrysaora fuscescens* (Fig. 209-7) is found in the Pacific waters off the coast of California. *Chrysaora quinquecirrha* is smaller, with a white or rusty bell that may reach 30 cm with four digestive tentacles hanging from it. Although sea nettle stings are seldom lethal, they can be quite painful.[37] Initially the victim experiences a sharp burning pain in the area contacted by the tentacles. Within minutes, the sting area develops a zigzag, whip-like pattern of raised red welts 2–3 mm wide (Fig. 209-8). The duration of acute pain may vary, but the pain often begins to abate in 30 minutes. The wheals usually subside by 1 hour, but purplish brown petechial and postinflammatory pigmentation may persist for several days.

Portuguese Man-of-War. *Physalia physalis* is the species name for the Portuguese man-of-war, which is a member of the class Hydrozoa and is therefore not a true jellyfish. *P. physalis* is encountered in both Atlantic and Mediterranean waters, and is easily recognized by its translucent blue to pink or purple bladder-like float with multiple tentacles (Fig. 209-9). *P. physalis* is distinguished from its Pacific ocean relative *Physalia utriculus*, commonly known as the *blue bottle*, by its larger bell, which ranges in size from 10 to 30 cm, and multiple fishing tentacles extending up to 30 m; in contrast, *P. utriculus* has only a single tentacle that rarely exceeds 5 m.[38] These tentacles are armed along their entire length with hundreds of thousands of nematocysts arranged in stinging batteries, with each battery containing hundreds of nematocysts. The nematocysts remain active even after portions of the tentacles are broken off in storms or when these animals are stranded on the shoreline by high winds or waves.



Figure 209-8 Whip-like sting pattern caused by *Cyanea capillata* in a young boy. (JH Barnes, used with permission from World Life Research Institute.)



Figure 209-9 *Physalia physalis*, the Portuguese man-of-war, is distinguished by its bladder-like float and numerous trailing tentacles. (BW Halstead, used with permission from World Life Research Institute.)



Figure 209-10 This diver surfaced directly under a large Portuguese man-of-war and suffered a severe sting with bulla formation and tissue necrosis. (S Anderson, used with permission from World Life Research Institute.)

A beached Portuguese man-of-war can cause a severe sting when stepped on or touched. Children who are stung after handling these animals and then cry and rub their eyes may develop an acute conjunctivitis.

Stings of *P. physalis* are more painful and severe than those caused by sea nettles and are more extensive and serious than those caused by *P. utriculus*. At the moment of contact with the tentacles of *P. physalis*, the victim experiences a sharp, shock-like, burning pain. There may be painful paresthesias or numbness in the sting area. Initially, the sting area appears as an irregular single line or multiple lines composed of red papules, beaded streaks, or erythematous welts that correspond to the areas of tentacle contact. The wheals resolve in hours but may progress to vesicular, hemorrhagic, necrotic, or ulcerative stages before healing (Fig. 209-10).[39]

Postinflammatory striae may persist for weeks to months. Severe localized complications of *P. physalis* stings may also include arterial spasm in the sting site that can result in distal digital gangrene.[40,41]

Within 10–15 minutes of a *Physalia* sting, the victim may develop symptoms of an envenomation reaction characterized by nausea, abdominal cramps, muscular pains, backache, irritability, dyspnea, and chest tightness. Intravascular hemolysis and acute renal failure were reported in a 4-year-old girl after a severe sting by *P. physalis*.[42] Most reports of death due to stings of *P. physalis* are not well-documented, but well-substantiated case reports of human fatalities do exist.[43–45]

Cubomedusae (Class Cubozoa): Box Jellyfish. Of all the species of jellyfish that cause painful stings and distress to swimmers, the species with the most established record of lethality are the cubozoans. *Chironex fleckeri* or box jellyfish causes at least one death each year in Australia.[46] The fatality is usually a child, presumably because the size of the victim and the total area of the sting determine the likelihood of death. Until recently, most of the published cases of *C. fleckeri* stings involved fatal or nearly fatal envenomations, but less serious stings do occur in endemic areas.[47–49]

C. fleckeri (commonly known as the *sea wasp*) is an advanced species of jellyfish, with a semitransparent cubic bell that may grow to a volume of 9 L and weigh more than 6 kg (Fig. 209-11).[46] Trailing from the bell are up to 60 stinging tentacles, which may reach 2–3 m in length. When a human comes into contact with a box jellyfish, some of the tentacles are torn off and adhere to the skin. Rescuers of *C. fleckeri* sting victims must exercise caution, because they also are at risk of envenomation until the tentacles have been neutralized and removed.

The stings appear initially as linear welts that give the patient the appearance of having been whipped.[46] Fresh stings of *C. fleckeri* are easily recognized because they have a diagnostic, frosted, cross-hatched, or ladder-like appearance (Fig. 209-12). Microscopic diagnosis is also possible from blade scrapings or tape-strippings from the sting site. The intense pain may persist for many hours. Severely stung areas of skin take on a dusky cyanotic appearance and blister formation and necrosis may occur. The healing process is slow and may be complicated by bacterial superinfection and scarring.

Death may ensue within minutes due to cardiotoxic and neurotoxic agents in the venom that can produce ventricular arrhythmias and cardiac arrest, and respiratory failure, respectively.[48] Intravascular hemolysis caused by the toxin can precipitate acute renal failure. First aid for these victims frequently



Figure 209-11 The deadly box jellyfish, *Chironex fleckeri*, is found in Indo-Pacific waters off the coast of Northern Australia. (Used with permission from R Hartwick.)

involves cardiopulmonary resuscitation. Intravenous verapamil has been proposed for both treatment and prophylaxis of ventricular arrhythmias.[50,51] Antivenom is available for *C. fleckeri* stings, and its early use in severe envenomations may be lifesaving and significantly reduces the pain and inflammation at the sting site.[47]



Figure 209-12 Characteristic frosted cross-hatched tentacle marks diagnostic of a sting caused by *Chironex fleckeri*. (Used with permission from Townsville General Hospital, Department of Medical Illustration, Townsville, Queensland, Australia.)

TABLE 209-2
Prevention of Jellyfish Stings

1. Swim only at patrolled beaches with properly trained lifeguards and adequate treatment facilities.
2. Avoid swimming in infested waters, especially after a storm, because stings may result from remnants of floating damaged tentacles.
3. Beware of apparently dead or beached jellyfish.
4. When snorkeling or scuba diving, wear protective clothing such as a wet suit, long-sleeved shirt, pants, or long woolen underwear, and gloves. In areas where Irukandji syndrome occurs, wear a Lycra stinger suit.
5. Use sunblock containing jellyfish and "sea lice" repellent.
6. Bathing beaches should be closed during periods of high jellyfish infestation.

Irukandji syndrome is a severe and delayed response (usually 30 minutes but between 5 and 40 minutes) to the sting of a small box jellyfish, termed the *Irukandji jellyfish*, that has resulted in the death of two tourists in the Cairns–-Port Douglas region of Australia.[52] The classic syndrome consists of local signs of inflammation together with severe back pain, excruciating muscle cramps, piloerection, sweating, nausea, vomiting, headache, and palpitations. The most severe cases may progress to include extreme hypertension and cardiac failure. Only one species, *Carukia barnesi*, has been clearly linked to this syndrome, but it is thought that at least six different species of small jellyfish, each with only one tentacle arising from each corner of the bell (carybdeids), may be etiologic agents. The stings most often occur in deep water. Treatment includes application of vinegar to discharge nematocysts and victim transport for medical attention including pain control and α-blockade, because the venom is thought to act as a presynaptic neuronal sodium agonist and to stimulate norepinephrine release.

Prevention and Treatment of Jellyfish Stings. Tables 209-2–209-4 give details on the prevention of jellyfish stings and first aid for and treatment of the stings. Systemic reactions may occur, and the treatment for these includes support of vital

TABLE 209-3
First Aid Treatment of Jellyfish Stings

1. Remove or rescue the victim from the water.
2. Stabilize vital functions: Airway, breathing, circulation.
3. Immobilize the affected part to prevent further envenomation by adherent tentacles.
4. Identify the type of jellyfish sting by considering locale, time of year, and indigenous species and by observing the sting pattern. Preserve a portion of the tentacle for future identification. Tape-strip or scrape the sting site for microscopic analysis of the nematocysts if no tentacles are available.
5. To prevent further envenomation of the victim and to reduce the chance of a sting to the rescuer, disarm the nematocysts before removing the adherent tentacles.

TABLE 209-4
Organism-Specific and Follow-up Treatment of Jellyfish Stings

1. If *Chironex fleckeri* or other box jellyfish species that cause the Irukandji syndrome are suspected, douse or spray dilute acetic acid (3%–10%) or household vinegar over all areas of tentacle contact for at least 30 s.
2. For sea nettles, mix sodium bicarbonate (baking soda) with water to form a slurry and pour over the affected area or apply the powder directly to the tentacles.
3. For *Physalia physalis* stings, a slurry of baking soda is indicated. Vinegar had been reported to neutralize nematocysts of *P. physalis*, but work with species from Australia indicate that it may cause a discharge of nematocysts in some cases.
4. If vinegar or baking soda is unavailable, papain, available as a powdered meat tenderizer, may be applied directly as a powder or mixed in water as a slurry to sting areas and tentacles of both sea nettles and Portuguese man-of-war.
5. If nothing else is available, the tentacles can be rinsed off with seawater.
6. Do not use fresh water, methylated spirits, or alcohol in any form to deactivate tentacles, because these all may cause a rapid massive discharge of nematocysts.
7. After the tentacles have been disarmed, they may be carefully removed with a forceps or gently scraped away from the skin with shaving cream and a razor or a plastic card, shell, or knife.

functions with cardiopulmonary resuscitation, oxygen, and intravenous fluids.[53,54] Application of a venous-lymphatic constriction bandage proximal to the wound site should be considered in the case of severe stings when systemic reactions are present or likely to occur, when topical deactivation of tentacles is not possible, and when transport to receive specific antivenin for *C. fleckeri* stings is available. The antivenin is prepared from sheep serum and may therefore pose a risk of allergic reaction in sensitive individuals.[35,37] The preferred route of administration is intravenous, but the antivenin may be given intramuscularly. In severe stinging, it has proved lifesaving. It is also the only treatment that can alleviate the intense pain and may reduce inflammation at the sting site and decrease the chance of scarring. Intravenous administration of verapamil has been advocated for both treatment and prophylaxis of arrhythmias.[50,51] For pain in severe stinging, parenteral narcotic analgesics and ice packs, as well as antivenin, should be considered. Local reactions may be treated with topical anesthetic ointments, creams, lotions, or sprays to relieve itching or burning pain.[34] For delayed-type hypersensitivity reactions, which may occur days to weeks after the stinging (see Fig. 209-13), topical glucocorticoids, topical tacrolimus, antihistamines, and systemic glucocorticoids should be used as necessary.[36]

Secondary infections should be treated with the appropriate parenteral antibiotics, and antitetanus therapy should be considered. Application of ice or cold packs can relieve the pain of mild to moderate stings of many types of jellyfish, and aspirin or acetaminophen, alone or in combination with codeine, can be used to relieve persistent pain.



Figure 209-13 Delayed-type hypersensitivity reaction occurring about 2 weeks after jellyfish stings on the leg.

SEA ANEMONE DERMATITIS. Sea anemones are members of the phylum Cnidaria, class Anthozoa. They are sessile creatures with flowery tentacles armed with nematocysts (Fig. 209-14). The stings of sea anemones may cause dermatitis in sponge fishermen, sponge divers, and beachcombers who gather snails and crabs from rocky hollows along the shore. Their toxicity to humans depends on the species. After the immediate reaction has subsided, delayed-type hypersensitivity reactions can develop at the site of a sting from a sea anemone (Fig. 209-15).

The genus *Sagartia* is the cause of sponge fisherman's disease.[34] This anemone lives at the base of sponges sought by commercial fishermen. When they harvest or sort the sponges with their bare hands or forearms, they are likely to come into contact with the tentacles of *Sagartia*. Itching and burning occur at the sting site within minutes, accompanied by erythema, edema, and vesicles.[34]

Treatment of sea anemone stings is similar to that of jellyfish envenomations (see Section "Prevention



Figure 209-14 The flowery tentacles of the sea anemone can cause envenomations similar to jellyfish stings. (Used with permission from Marty Gilman, Worcester, MA.)



Figure 209-15 Delayed-type hypersensitivity reaction to a presumed sea anemone sting. This 11-year-old girl stepped into a hole while wading in shallow waters on the South Carolina coast. She experienced an immediate burning pain with erythema and swelling of both lower legs that subsided within a day. Several days later she developed a pruritic linear eruption. A diagnosis was made of a delayed-type hypersensitivity reaction that developed in the sting site and corresponded with the tentacle marks from what was presumed to be a sea anemone envenomation.

and Treatment of Jellyfish Stings").[56] The tentacles should be removed carefully.[34] Both vinegar and Stingose (an aqueous solution of 20% aluminum sulfate and 11% surfactant) have been suggested for application to neutralize the sites of anemone stings.[57] Sea anemone sting sites often heal slowly and may require treatment with antibiotics.

INJURIES CAUSED BY FIRE CORAL AND CORAL CUTS. Corals are colonial organisms belonging to the phylum Cnidaria. Coral injuries may be caused by nematocyst stings or lacerations. Both injuries may occur at the same time and may be complicated by foreign-body reactions, bacterial infections, and localized eczematous reactions. For most true corals nematocyst envenomation is a relatively innocuous experience, resulting in mild pruritic erythema that requires little if any treatment. Calamine lotion or antipruritic lotions may bring relief.[58]

In contrast to the stings of true corals, the sting of the fire coral, *Millepora alcicornis*, is quite painful, as many scuba divers and snorkelers from the Florida Keys to the Caribbean will attest (Fig. 209-16). The wet mucous membrane or slime surrounding the organism contains numerous nematocysts that readily discharge on contact with the skin, causing immediate burning and stinging pain. Within 1 to several hours a pruritic erythematous papular eruption appears, which in severe



Figure 209-16 The mustard-colored finger-like outcropping in the upper left quadrant of this formation of coral and hydroids is a typical example of fire coral.

cases may become pustular and, in rare cases, may progress to necrosis and eschar formation.[58] Lesions heal in 1–2 weeks, often with postinflammatory hyperpigmentation. A delayed and persistent allergic contact dermatitis has also been reported to occur from a fire coral sting in the Red Sea.[59]

Fire coral stings should be rinsed with seawater to remove undischarged nematocysts. The sting area can then be compressed with either 5% acetic acid (vinegar) or 40%–70% isopropyl alcohol for 15–30 minutes or until the pain is relieved.[37,60] Seawater compresses, hot to the point of tolerance, are also reported to inactivate the toxin. A topical steroid cream or ointment may relieve pruritus and promote healing.

Coral cuts, lacerations caused by the razor-sharp exoskeletons of coral, are notorious for their slow-healing and propensity for secondary infection. Factors that complicate healing include the following: (1) wounds often involve the lower extremities and these generally heal more slowly because of decreased tissue blood supply; (2) wound edges are often irregular, contused, crushed, and abraded; (3) contamination of wounds is likely because of pathogenic bacteria in shore waters; and (4) foreign bodies, including marine algae growing on the coral or portions of the coral itself, may be implanted in the wound.

Treatment of coral cuts should begin with vigorous cleansing of the wound with soap and water with a soft brush or rough towel, followed by copious irrigation with saline to remove foreign bodies. If the wound is extensive, local anesthesia may be required to allow adequate cleansing, exploration, and debridement and to achieve good hemostasis. Hydrogen peroxide washing of the wound before dressing it is recommended.

The decision whether to perform primary closure of a coral cut wound or to allow it to heal by secondary intention depends on the location of the wound, the degree of tissue trauma at the wound margins, and the likelihood of subsequent infection. Tape-stripping is preferable to suturing of leg wounds, because sutured leg wounds have a high chance of abscess formation. Once the wound is closed, antibiotic ointment and rest are advisable. Tetanus prophylaxis should be given according to immunization history.



Figure 209-17 The poison bun sponge, *Fibula nolitangere*, can cause a severe irritant or toxin-induced contact dermatitis.



Figure 209-19 Purple sea urchin, *Strongylocentrotus purpuratus,* commonly found along the Pacific coast of the United States.

DERMATITIS FROM SPONGES

Sponges are members of the phylum Porifera, class Desmospongiae. They are simple multicellular animals that live attached to the sea bottom. Sponges grow by forming a series of hollow-centered branching tubes composed of a fibrous material called *spongin*, which contains spicules of calcium carbonate or silica.[34,61,62] Spicules of certain species of sponges are capable of penetrating the skin, causing a localized irritant or foreign-body reaction. Treatment of sponge spicule dermatitis involves tape-stripping of the affected area.

At least 13 species of sponges can cause a toxic dermatitis. Of these, the most commonly encountered are the West Indian and Hawaiian fire sponge, *Tedania ignis*; the poison bun sponge, *Fibula nolitangere* (Fig. 209-17); and the red sponge, *Microciona prolifera*, found in the Northeastern United States.[63] These creatures are covered by a surface secretion, or slime, that produces an irritant or toxin-induced dermatitis when contacted by bare skin.[62]

Symptoms of itching, prickling, stinging, or burning appear within minutes of exposure and are followed within a few hours by pain, swelling, and stiffness. If the fingers are involved, they often become immobile within 24 hours. The first cutaneous sign of sponge poisoning is local erythema, which progresses to a papular, vesicular, or bullous eruption with weeping of a serous or purulent fluid.[62,63] Desquamation of the site occurs within several days. Erythema multiforme and anaphylactoid reactions have been reported in highly sensitized individuals. Treatment of sponge dermatitis is similar to that of severe poison ivy.[63]

INJURIES CAUSED BY ECHINODERMS: SEA URCHINS, STARFISH, AND SEA CUCUMBERS

SEA URCHINS. Sea urchins are spiny creatures that belong to the phylum Echinodermata, class Echinoidea. They are encased in a fragile, roughly spherical, calcareous shell, which is protected by a formidable array of mobile spines and pincer-like organs known as *pedicellariae* (Fig. 209-18).[64,65]

Bathers, surfers, divers, and fishermen are all at risk for sea urchin injuries. These creatures, such as the purple sea urchin, hide in rocks in low tide zones along the Pacific coast between Alaska and Mexico (Fig. 209-19).

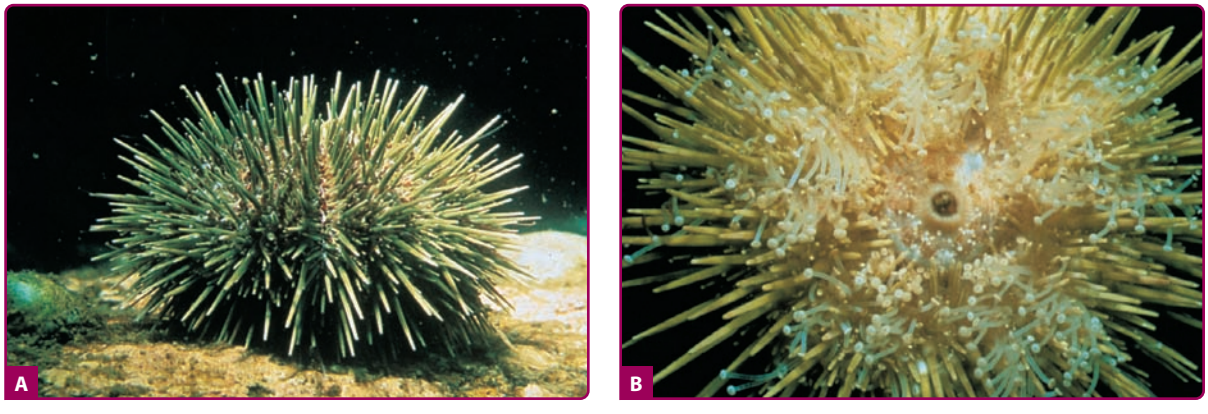

Figure 209-18 Lateral (**A**) and ventral (**B**) views of a sea urchin demonstrate this animal's protective spines and venomous pedicellaria underneath. (Used with permission from Marty Gilman, Worcester, MA.)

Injuries may occur when the victim steps on an urchin, driving the spines into an unprotected foot, or as a result of loss of balance or wave action, in which case the hands or other body parts may be impaled. Sea urchin spines are composed of calcium carbonate and are covered with a proteinaceous membrane.[62] Injuries from sea urchins may be inflicted either by penetrating wounds from the animals' spines, which often break off and become imbedded in the wound, or by bites from the pedicellaria. In certain species, the spines or pedicellaria are venomous. This fact may explain why the pain of some sea urchin wounds is so excruciating and out of proportion to the apparent injury.

Encounters with sea urchins can result in both immediate and delayed reactions. Immediate reactions are usually localized and are initially manifested by a severe burning pain at the wound site, which quickly becomes red and swollen and may bleed profusely. There may be a black or purple discoloration at the site of the spine penetration due to either retained spines in the wound or to a tattoo-like effect from dye released by spines that have exited intact, but this discoloration will likely disappear within 48–72 hours.[60] Paresthesias may develop at the wound area. Systemic symptoms are not common but can occur in injuries due to particularly venomous species. Symptoms may include nausea, syncope, paresthesias, ataxia, muscle cramps, paralysis, and respiratory distress.[63]

Delayed-type hypersensitivity reactions may occur with erythema and intense pruritus days after the initial injury.[66] In one of these cases, the diagnosis was confirmed by patch testing with extracts of the ground sea urchin spines.[67] Nodular reactions are localized to the area of spine penetration and are not usually painful. Nodules may take on colors from the dye in the spines[64] and may have a central umbilication or a keratotic surface[64] (Fig. 209-20).

The diffuse form more commonly involves the fingers or toes and is manifested by a fusiform swelling of the affected digit with accompanying pain and loss of function.[63,64] In addition to joint synovitis and arthritis, osteoarticular complications of sea urchin spine penetration may include tenosynovitis with or without destruction of the underlying bone, fasciitis, and bursitis.[68] Sea urchin spine wounds may also cause direct mechanical injuries to nerves and may be complicated by secondary infection.[69]

Initial first aid for the pain from immediate reactions is to soak the affected area in hot water [43°C to 46°C (110°F to 115°F)] for 30–90 minutes until maximal relief is obtained. Infiltration of the wound site with 1%–2% lidocaine without epinephrine may be required in some cases to produce significant pain relief.[70] Spines protruding from the wound may be carefully removed. They are very fragile; therefore, it is difficult to extract the entire spine intact. Tumescence of the skin with a local anesthetic may allow superficially imbedded spines to be extracted when radiographs demonstrate no evidence of joint or bony impingement.[65] More invasive attempts at spine removal should not be made without the benefit of aseptic surgical facilities and radiographs to confirm the spine locations. Removal of the spines may be aided by the use of an operating microscope. Antibiotics are indicated for secondary infections, and tetanus prophylaxis should be given if indicated.

STARFISH. Certain species of starfish may produce puncture wound injuries similar to those caused by sea urchins. The crown-of-thorns starfish, *Acanthaster planci*, accounts for most severe starfish envenomations.[63] The ice pick-like spines of *A. planci*, which may reach 4–6 cm in length, are covered with a thin skin and glandular tissue that produce a poisonous slime.[70] The resulting wound is quite painful and may be accompanied by numbness and paresthesias. Systemic symptoms including nausea, vomiting, and muscle weakness are infrequent and short lived.[63] Fragments of spines and their surrounding integument may become imbedded in the wounded area, resulting in granulomatous reactions.

Treatment is similar to that of sea urchin wounds.



Figure 209-20 **A** and **B.** Nodular reactions to imbedded sea urchin spines. (Used with permission from Karen Rothman, MD.)

SEA CUCUMBERS. Sea cucumbers are sausage-shaped, bottom-feeding echinoderms that can produce a papular contact dermatitis by means of a toxic liquid substance, known as *holothurin*, that is secreted from their body walls.[34] Conjunctivitis, even blindness, can result from corneal involvement if the toxin comes in contact with the eyes.[63] Prevention of sea cucumber dermatitis involves protecting the skin and eyes from contact with these creatures and educating children and curious divers about the risk of handling them. Treatment consists of washing the affected area with soap and water to remove the toxin and then treating as for a mild contact dermatitis.

DERMATITIS AND BITES FROM MARINE WORMS

BRISTLEWORM DERMATITIS. Bristleworms are multisegmented marine worms of the phylum Annelida, class Polychaeta (which means "many bristles"; Fig. 209-21). Each segment of the worm is armed with rows of silky or bristle-like, hollow, venom-filled setae that can easily penetrate and break off in the unprotected skin of a victim as do cactus spines.[70] Contact with the bristleworm results in an erythematous papular or urticarial eruption at the site, accompanied by symptoms of paresthesias, intense itching, or burning pain.[34,70] The bristles are too small and fragile in most cases to be removed with a forceps; however, tape-stripping with cellophane adhesive tape can be effective. After the setae have been removed, the application of ammonia soaks or alcohol or water compresses may bring symptomatic relief.

LEECH BITES. Leeches are another class of segmental worms whose bites may be encountered in freshwater or saltwater as well as on land. Although freshwater leeches are capable of attaching painlessly to their human hosts, saltwater leeches produce bites with pain similar to that of a bee sting. Leeches inject a powerful anticoagulant, hirudin, into the wound, as well as other antigenic substances that are capable of eliciting allergic reactions (including anaphylaxis) in sensitized individuals. Local symptoms of leech bites include bleeding from the puncture marks, pain, swelling, redness, and severe pruritus; urticarial, bullous, or necrotic reactions may occur in sensitized persons.[34]

Severe ulcerations may result if the leech is removed forcibly and its mouth parts are left behind in the bite site. Leeches must be induced to fall off by applying a noxious agent (such as alcohol, vinegar, brine, or a match flame) to their site of attachment.



Figure 209-21 *Hermodice carunculata*, the West Indian bristleworm, can inflict a painful wound with its hollow, venom-filled bristle-like setae. (Used with permission from Marty Gilman, Worcester, MA.)

CERCARIAL DERMATITIS (CLAM DIGGER'S ITCH). Cercarial dermatitis, also known as *schistosome dermatitis* or *swimmer's* or *clam digger's itch*, is an acute pruritic eruption resulting from penetration of the skin by the cercarial forms of certain parasitic flatworms of the family Schistosomatidae.

Symptoms of cercarial dermatitis begin with urticaria-like lesions and a prickling sensation of the skin, which lasts about half an hour after exposure to cercaria-infested waters. Severe pruritus of the affected area occurs 10–12 hours later. Within 24 hours, erythematous papules appear that may progress to vesicles and later to pustules. Pain and swelling of the area accompanies the intense itching, which usually peaks in 48–72 hours. Headache, fever, and superinfection with lymphangitis are occasionally present.

In the Great Lakes region, several species of *Schistosoma cercariae* that cause swimmer's itch have been reported, and many other such species have been discovered throughout the world in both freshwater and saltwater.[71,72] A severely disabling form of cercarial dermatitis affects the paddy workers and rice farmers of the Far East. Cercarial dermatitis has also been described in individuals exposed to shallow coastal waters, notably on Long Island Sound where the condition affects clam diggers, giving rise to the name, *clam digger's itch* (Fig. 209-22). There is one reported case of cercarial dermatitis occurring on the hands and arms of a patient after he cleaned the aquarium in which he kept native water snails.[73]

Humans are accidental hosts in the life cycle of dermatitis-producing schistosomes. The cycle begins when the primary host, a waterfowl, marsh bird, finch, muskrat, mouse, or deer, passes schistosomal eggs in its feces into a body of water. Each egg hatches in 10–15 minutes, releasing a secondary stage miracidium. The miracidia are free-swimming and must locate and infect their definitive snail host within 12 hours or they will die. The miracidia migrate to the snail's digestive gland, where they develop into multiple sporocysts. In about 5 weeks, the sporocysts give rise to hundreds of fork-tailed cercariae that measure 0.75 mm in length. The cercariae are released from the snail under favorable conditions of light and heat, and are carried toward the shore by prevailing winds and currents.[72] When an appropriate host is encountered, the cercaria attach to the skin with their oral suckers and penetrate the epidermis and dermis by means of histolytic enzymes. They lose their tails in this process and are now called schistosomula. The schistosomula



Figure 209-22 Intensely pruritic papulovesicles suggestive of a severe reaction to flea bites in a patient with clam digger's itch. The left hand, which was not in the water and was holding the pail for collecting the clams, was spared.

migrate via the blood vessels through the heart and lungs to the intrahepatic veins, where they mature into adult male and female trematode flukes. When the worms mate, they pass in pairs through the mesenteric venules of the intestinal wall where the female lays hundreds of eggs.[72] The eggs then penetrate the gut wall and are discharged in the feces, and the cycle is repeated.

When cercariae that do not cause schistosomiasis in humans accidentally attach to the skin, they may penetrate the epidermis but are unable to reach the bloodstream. The organisms die in the superficial papillary dermis and undergo total histolysis within 3–4 days. The cercarial protein residua stimulate a delayed-type hypersensitivity response, which may increase in severity with repeated exposures. Skin biopsies taken at 3–4 days reveal an amorphous eosinophilic mass at the site of the dissolved cercaria, with an intense lymphocytic infiltrate. Later, histiocytes appear in the middle and deep papillary dermis.

The differential diagnosis of cercarial dermatitis includes insect bites from chiggers, mosquitoes, and fleas; contact dermatitis from poison ivy; and the stings of other marine coelenterates. In Africa, Asia, South America, and Puerto Rico, swimmer's itch must be distinguished from the dermatitis associated with human schistosomiasis, which produces an eruption with very similar but milder and more transient symptoms.[74] Swimmer's itch must also be distinguished from sea bather's eruption (SE), which is discussed in the next section.

Prevention of cercarial dermatitis in waters where swimmer's itch is known to be a problem is difficult. Coating the skin with petrolatum and various chemical repellents has been tried, but the effectiveness of these methods remains unproven. Clothing barriers may be of some help.

Treatment of cercarial dermatitis is largely symptomatic. In mild cases, antipruritic or drying lotions, oatmeal or starch baths, and antihistamines may alleviate pruritus. Aspirin may be helpful for the pain and swelling, and a bedtime sedative may be required to allow the patient much-needed sleep. Proper washing and hygiene should be maintained to prevent bacterial superinfection. In severe cases, potent topical glucocorticoids and occasionally systemic glucocorticoids may be required.

SEA BATHER'S ERUPTION

SE, also known as *marine dermatitis* and often misnamed *sea lice infestation*, is an acute dermatitis that begins shortly after bathing in seawater. SE is often confused with swimmer's itch (cercarial dermatitis, see previous section), not only because they both occur after exposure to water but also because the common names of these two conditions are easily confused. For many years, the cause of SE remained a mystery, but it is now known that the responsible agents in at least two types of SE are the larval forms of marine coelenterates. In waters off the coast of Florida and in the Caribbean, the tiny larvae of the thimble jellyfish, *Linuche unguiculata*, are to blame.[75] Off the coast of Long Island, New York, researchers found that the larval forms of the sea anemone *Edwardsiella lineata* were responsible for the eruption.

In addition to having a different etiology, SE can be distinguished from cercarial dermatitis by several other characteristics: SE primarily involves areas of the body covered by bathing suits from which water evaporates slowly, as opposed to uncovered areas as is typical of swimmer's itch. Most symptoms are not noted until the bather has left the water (although some of those affected have complained of a prickling sensation while still in the water).

The eruption is caused by minute stings from the nematocysts of the coelenterate larvae, which become trapped underneath swimwear or may adhere to hairy areas of the body. In addition to SE after contact with the larvae, which are most abundant in May and June, swimmers and bathers may also develop SE after contact with the other two free-swimming stages of *L. unguiculata*, the ephyrae and medusae stages.[76]

The lesions begin within 4–24 hours after exposure as erythematous macules, papules, or wheals that may itch or burn (Fig. 209-23).[34] These lesions may progress to vesiculopapules, which crust over and heal in 7–10 days. Associated systemic symptoms may include chills and a low-grade fever as well as nausea, vomiting, diarrhea, headache, weakness, muscle spasms, and malaise. Febrile and systemic symptoms are more common in children and adolescents.[77] In the presence of such constitutional symptoms, caregivers who fail to recognize the pattern of the eruption or who fail to take a history of exposure to saltwater may mistakenly make the diagnosis of a viral syndrome.



Figure 209-23 Sea bather's eruption in a young girl after a swim at a Florida beach. (Used with permission from Karen Rothman, MD.)

In waters along the coast of South Florida, the season for SE is between March and August with a peak in May. The incidence among bathers during May and June 1993 in Palm Beach County was reported to be 16%.[77] The strongest risk factor for developing SE is a previous history of the condition, which is consistent with the theory that SE represents a hypersensitivity response to the nematocyst stings. Other risk factors include age younger than 16 years and surfing. Showering with swimwear removed was found to be a protective measure.[77]

Prevention of SE includes the measures listed in Table 209-5. Treatment of SE is symptomatic and includes the use of antipruritic lotions, colloidal baths with starch or oatmeal, antihistamines, and topical glucocorticoids. Severe unremitting cases may warrant systemic glucocorticoid therapy.[75] Secondary bacterial infections may complicate the condition and should be diagnosed and treated appropriately.

TABLE 209-5
Prevention of Seabather's Eruption

1. Bathers should remove their swimwear and shower as soon as possible after leaving the water. Because fresh water may cause discharge of the nematocysts, it is important that the suits be removed before showering begins.
2. Bathing suits should be rinsed with soap and water and heat dried, because the eruption can recur when the suit is air-dried.
3. T-shirts should not be worn in the water. Women may consider wearing a two-piece suit to reduce the surface area under which larvae may be trapped.
4. Whole-body Lycra swimsuits or wet suits with snug-fitting collars and cuffs may be protective, but the eruption may still occur along the collar or cuff edges.
5. Highly sensitized individuals should avoid swimming in infested waters during outbreaks of seabather's eruption.

INJURIES CAUSED BY MOLLUSKS

CONE SHELL ENVENOMATIONS. Cone shells are univalvular gastropods whose ornate cone-shaped shells are highly prized by shell collectors and divers. A number of species have a highly developed venom apparatus that can inflict a lethal sting. Most of the dangerous cone shell species are found in the shallow waters of the Indo-Pacific. Cone shells are carnivorous. They live on the ocean bottom and, depending on the species, may hunt worms, other mollusks, or fish. Cone shells kill their prey by means of a spear-like venomous radular tooth that is thrust out from the animal's proboscis. Cone shell venom contains several different kinds of neurotoxins, and death may result from respiratory paralysis. There is so far no antivenin for cone shell toxin, and mortality rates after envenomations from the more dangerous species (*Conus geographicus* and *C. magus*) may be as high as 15%–20%.[34]

Injuries from cone shells are of the puncture wound variety. The degree of pain is variable, ranging from a mild stinging sensation, similar to that of an insect bite, to excruciating pain. Early symptoms may include edema, ischemia, numbness, and paresthesias of the wound site. Paresthesias may become widespread, with the lips and mouth commonly affected.[34,63] Localized muscular paralysis may progress to generalized weakness or paralysis with eventual respiratory distress and cardiopulmonary failure.[78] Neurotoxic symptoms that indicate severe envenomation include diplopia, blurred vision, aphonia, dysphagia, and coma. Rare cases of disseminated intravascular coagulation have been reported after cone shell envenomation.

Great care must be exercised in handling live cone shells. Thick protective gloves should be worn, and the soft under portion of the animal should be avoided. Cone shells should never be placed in pockets of clothing or swimwear, because they have been known to sting through clothing.[55]

Treatment of cone shell envenomations is supportive. The victim should be kept at rest and the sting area kept dependent and immobilized. A compression dressing should be applied to occlude lymphatic-venous, but not arterial, flow.[55] Local suction may be helpful if it can be applied immediately to the wound site with a plunger device, such as the Extractor Vacuum Pump (Sawyer Products, Safety Harbor, Florida).

OCTOPUS BITES. Octopuses are an advanced group of mollusks belonging to the class Cephalopoda. The octopus bites with a parrot-like chitinous beak located on the ventral side of the head in the middle of its eight tentacles (Fig. 209-24). Species of octopi range in size from a few centimeters to 1–2 m in diameter.[79] They are shy and reclusive creatures that tend to avoid encounters with humans; however, bites can occur when curious divers, fishermen, or beachgoers encounter these animals and handle them carelessly. Most octopus bites are not life threatening to humans.

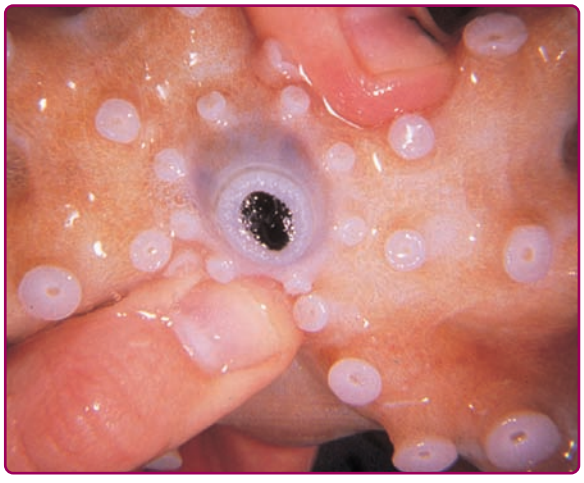

Figure 209-24 Ventral view of the underside of an octopus exposing the animal's centrally located mouth and parrot-like beak. (From Fulghum DD: Octopus bite resulting in granuloma annulare. *South Med J* **79**:1434, 1986, with permission.)

The bite site may be immediately painful, as after a bee sting, and is recognized by the presence of two small puncture wounds, which may bleed profusely.[55] Symptoms from octopus bites are usually mild and transient and consist of redness, swelling, and itching.[79]

The most dangerous species of octopus, the Australian blue-ringed octopus, *Hapalochlaena maculosa*, is found in Australian coastal waters. Mortality rates after bites from *H. maculosa* may be as high as 25%. *H. maculosa* produces a toxin in its salivary glands that is introduced into the bite site by the animal's powerful beak and contains a fraction identical to tetrodotoxin; this toxin blocks peripheral nerve conduction and results in paralysis of the victim with subsequent respiratory failure. The bite of the blue-ringed octopus may or may not be painful, so that victims may not realize they have been bitten until neurologic symptoms develop.[63]

There is no antivenin for bites of *H. maculosa.* Treatment is supportive and similar to that recommended in the previous section for severe cone shell envenomations.

INJURIES CAUSED BY VENOMOUS FISH SPINES

Ichthyoacanthotoxicosis is the proper term for envenomations as a result of puncture wounds or lacerations inflicted by the spines of venomous fish. There are more than 200 species of venomous fish in the world that can cause injury to humans.[63] The most notorious of these species are the stingrays, catfish, lionfish, scorpionfish, stonefish, weevers, toadfish, and spiny dogfish. All of these fish have in common a venom apparatus consisting of a single spine or multiple spines, in various locations, which are covered by an integumentary sheath enclosing various forms of venom glands. When the spine of the animal penetrates the victim, the sheath is torn and the venom glands release their toxins into the wound. The toxins from some of these fish may remain potent for 24–48 hours after the death of the fish.[80]



Figure 209-25 A close-up view of a stingray stinger without its outer membrane and venom glands, demonstrating the retroserrated spine. (Used with permission from David Fulghum, MD.)

STINGRAYS. Stingrays are one of the most common causes of venomous fish stings confronting humans, with as many as 1,500 to 2,000 stingray attacks reported each year in the United States alone.[70,81] Rays are grouped into one of four categories: (1) gymnurid (butterfly rays), (2) urolophid (round stingrays), (3) myliobatid (bat or eagle rays), and (4) dasyatid (proper stingrays). The groupings are based on their relative stinging ability, which depends on the size, number, and location of the caudal stinging appendages. The most dangerous group, the dasyatid or true stingrays, have the largest spines located further out on their tails, which makes them the most potent striking weapons. The spines have retroserrated teeth, so that removal is difficult (Fig. 209-25).

Most stingray injuries occur when bathers, waders, or fishermen accidentally step on rays as they lie partially covered with sand in shallow waters.[82,83] Severe lacerations and puncture wounds are inflicted by the ray as it defensively whips its tail upward and forward when stepped on or threatened (Fig. 209-26).[82,83] The majority of wounds, therefore, are located on the dorsum of the foot or lower leg. Penetrating wounds to other locations have occurred to fishermen stung while attempting to remove rays from their lines or nets. Rarely these injuries are fatal. Soaking in warm water relieves the pain.

CATFISH. Both freshwater and saltwater catfish are armed with stout, sharp spines located immediately in front of the soft rays of their dorsal and pectoral fins. Catfish defensively lock these spines into an extended position when they are handled or threatened. Bathers may sustain stings on their feet or legs if they step on a catfish, but most catfish stings involve the hand or upper extremity of fishermen or seafood processors.[84] To prevent these injuries, it has been suggested that the offending spines be removed with a pair of pliers before cleaning of the fish is attempted.

Swimmers and bathers in the Amazon River are at risk for urologic injuries if they encounter a very



Figure 209-26 Stingrays reflexively swing their barbed tails up when stepped on, causing painful lacerations and puncture wounds. (The leg used for this photograph was a prosthesis; the stingray was alive.) (Used with permission from David Fulghum, MD.)

small species of catfish called the *candiru*, which has the ability to enter the human urethra. Barbs on the head of this fish prevent it from swimming backward out of the orifice, and surgical intervention is often required to extract the fish.

SCORPIONFISH. Scorpionfish, family Scorpaenidae, are divided into three main groups on the basis of their stinging apparatus. All have venomous spines of varying sizes and toxicity, which may be found in dorsal, pelvic, and anal locations, depending on the species.

Scorpionfish, genus *Scorpaena*, have stings that are of intermediate severity. They are bottom dwellers with superior camouflage abilities that allow them to blend in almost invisibly with their surroundings (Fig. 209-27).



Figure 209-27 *Scorpaena plumieri*, a species of scorpion fish, is found in the waters of the West Indies. Its camouflage abilities are exceeded only by its painful sting.

Their spines are long and heavy and have moderate-sized venom glands.

Stonefish, genus *Synanceja*, are the most dangerous members of the scorpionfish family. They live in shallow waters, sometimes partially buried in sand or mud, or in holes of rocky shoals, reef areas, or tidal pools.[70] Injuries occur when a wader steps on the erect venomous dorsal spine that the stonefish raises in defense. Stonefish spines are short and thick and have very large and well-developed venom glands. The wounds caused by stonefish are quite severe and may be fatal. A stonefish antivenin is available.

WEEVERFISH. In European coastal waters, the weeverfish is one of the most common and serious causes of venomous fish spine injuries.[85] These fish are equipped with between five and eight venomous dorsal spines and two venomous opercular spines (one on each side of the head near the gill plate).[86] Waders and bathers are at risk when they step on weeverfish that lie partly buried in mud or sand in shallow waters.

LOCAL AND SYSTEMIC SYMPTOMS OF FISH SPINE ENVENOMATIONS. The toxicity of a given venomous fish sting depends on a number of factors, including the species of fish involved, the location and severity of the wound, the amount of venom released, and the first aid and subsequent medical care provided to the victim. In general, these wounds produce pain out of proportion to the apparent severity of the injury. The pain is immediate and intense. In the case of scorpionfish stings, the pain may be so severe as to cause the victim to thrash about wildly, scream, and finally lose consciousness.

Initially, the sting site may appear pale or cyanotic. The area around the wound may be anesthetic or hyperesthetic. Erythema and edema soon develop, giving the appearance of a cellulitis. Vesicles may form. In severe stinging, especially those caused by stonefish, the wounded area may become indurated and develop areas of ischemic necrosis with subsequent sloughing and ulcer formation.

Systemic effects from toxic fish spine envenomations may range from mild to severe, depending on the species involved and the amount of venom entering the wound. They can include headache, nausea, vomiting, diarrhea, abdominal cramps and pain, fever, local lymphangitis and lymphadenitis, joint aches, muscle weakness, diaphoresis, peripheral neuropathy, limb paralysis, restlessness, delirium, seizures, cardiac arrhythmias, myocardial ischemia, pericarditis, hypotension, and respiratory distress, and can lead to death.[78,84,87,88]

PREVENTION. Prevention of toxic fish spine wounds begins with knowledge of and appreciation for the various venomous species that may be encountered in a given area. Waders and bathers should shuffle their feet to scare away and avoid stepping on rays or scorpionfish. Fishermen must exercise care when removing rays or catfish from their fishing lines or when cleaning fish with venomous spines. Fish hobbyists and divers should wear protective clothing and avoid handling venomous species.

TREATMENT. Puncture wounds and lacerations from venomous fish spines should be irrigated immediately with sterile saline or water, if available, and with seawater as a last resort.[55] The wounded area should then be soaked as quickly as possible in hot (not scalding) water of approximately 43°C to 46°C (110°F to 115°F) for 30–90 minutes or until maximal pain relief is achieved. Hot soaks may be repeated if the pain returns. Because the wound or extremity may be partially anesthetic, the person administering first aid must test the water's temperature for the victim.[54,89] One source of hot water that is often overlooked and may be useful in an emergency is hot seawater from a boat motor's cooling system.

Local infiltration of the wound with 1%–2% lidocaine without epinephrine may bring about significant pain relief and allow exploration of the wound after radiographs have been obtained to locate retained portions of spines.[60,70] Longer-acting anesthetics such as procaine and bupivacaine may be chosen to provide a longer period of pain relief. The wound should be thoroughly cleaned to remove any remnants of integumentary sheath. Abdominal and thoracic wounds and deep wounds to the hands, feet, or fascial compartments of the legs should be explored in the operating room.[70] Debridement of necrotic tissues may be required at the time of exploration, and sequential debridement may be necessary. In general, these wounds should be left open or closed loosely with tape or suture to allow for adequate drainage and to prevent abscess formation.

Tetanus prophylaxis should be administered if indicated, and antibiotics are recommended if the wound is more than 6-hours-old, is extensive, or involves deep puncture injuries to the hand or foot. The choice of antibiotic should be based on the bacteriology of the marine environment in which the wound occurred and, subsequently, on results of deep wound or tissue cultures. Empiric antibiotic therapy for infections of wounds occurring in saltwater should include coverage for *Vibrio* species. Before final wound culture results are known, initial choices of parenteral antibiotics include intravenous ciprofloxacin, imipenem-cilastatin, a third-generation cephalosporin, gentamicin, tobramycin, or trimethoprim-sulfamethoxazole.

Stonefish stings complicated by severe reactions may be treated with antivenin by slow intravenous infusion. Antivenom is not usually required for the stings of lionfish and other species of scorpionfish except for stonefish.[70] Stonefish antivenom is available from the Australian Commonwealth Serum Laboratory, Melbourne, Australia.

FISH BITES

There are many species of fish whose bites are dangerous to humans. Among the best known are the sharks and barracudas, whose bites may cause severe injuries.

Although they are well-publicized by the news media, shark attacks are relatively rare events. The average number of shark attacks worldwide is between 50 and 100 annually.[90] Only 32 of the 400 known species of sharks have been reported to attack humans. Most shark attacks involve surfers, scuba divers, and swimmers. Because sharks are attracted to bright or shiny objects, as well as to those with contrasting colors, these items should not be worn in the water. Sharks are also attracted by any sort of blood in the water; therefore, women who are menstruating should refrain from water sports in areas in which sharks may be prevalent, and no one should swim with an open bleeding wound. Spear fishermen should never tie their catch to themselves, and they should place their catch in the dive boat as soon as possible. Although most shark bites are not life-threatening, more severe attacks may cause extensive soft-tissue loss with massive hemorrhage, which, in the worst cases, can result in amputation of a limb or death.[91,92]

Barracuda attacks are even rarer than shark bites. They tend to occur in turbid waters where these predators may mistake jewelry or other brightly colored objects worn by bathers for the baitfish on which they feed. Barracuda bites typically produce straight or V-shaped lacerations.

Divers and aquarium hobbyists must be careful when feeding or handling moray eels, which have powerful jaws and knife-like teeth. Although they are not considered venomous by most sources, they can produce deep puncture wounds and lacerations (Fig. 209-28).[55] When biting, moray eels tend to lock onto their prey; decapitation of the eel or disarticulation of its jaw may be required to release the victim.[93] As with all deep puncture wounds or lacerations, victims of moray eel bites should receive tetanus prophylaxis. Empiric antibiotic therapy for prophylaxis or treatment can include ciprofloxacin or cefuroxime for coverage of *Vibrio* or *Pseudomonas* species.[93]

WATERBORNE INFECTIONS

A variety of infections may result from exposures to aquatic environments. Pathogenic organisms may be actively introduced into the bite, sting, or laceration wounds caused by marine life; preexisting wounds may be passively infected when exposed to contaminated waters. *V. carchariae*, a halophilic (saltwater-loving)



Figure 209-28 Moray eel bites are uncommon, but their incidence has increased because divers feed these animals at popular dive sites. (Used with permission from Marty Gilman, Worcester, MA.)

TABLE 209-6
Wound Infections Associated with Waterborne Organisms

Organism	Clinical Features
Aeromonas hydrophilia	Cellulitis (may be bullous), fasciitis, myonecrosis, bacteremia.
Edwardsiella tarda	Cellulitis, abscess, osteomyelitis, bacteremia.
Erysipelothrix rhusiopathiae	Slowly progressive cellulitis without adenopathy or lymphangitis, almost always involving the hand; septic arthritis; subacute bacterial endocarditis.
Mycobacterium balnei or *Mycobacterium marinum*	Swimming pool granuloma; fish fancier's finger; chronic cellulitis and culture-negative ulcers; often the primary lesion is on the hand and then a series of lesions develop in draining lymphatics.
Pfisteria piscicida	Raw, red pock-marked lesions in fish in polluted waterways; in humans, rashes, respiratory problems, and memory deficits.
Protothecosis	Papular or eczematoid dermatitis in immunosuppressed patients; localized infection of the olecranon bursa.
Pseudomonas species	Trench foot; Gram-negative toe web space infections; swimmer's ear; hot tub folliculitis.
Streptococcus iniae	Cellulitis and bacteremia after skin injuries during the handling of fresh fish raised by aquaculture.
Vibrio vulnificus, other *Vibrio* sp.	Cellulitis, sometimes with bulla formation; may progress to septicemia, especially in alcoholics, diabetics, and immunosuppressed patients; metastatic cellulitis, meningitis, and death may result from fulminant infections.

Gram-negative bacillus, was reported as the cause of a wound infection after a shark bite.[94] Table 209-6 lists those organisms commonly associated with waterborne infections (see also Chapter 183). A host of other agents, such as *Streptococcus* and *Staphylococcus* sp., *Bacteroides fragilis*, *Clostridium perfringens*, *Escherichia coli*, *Salmonella enteritidis*, marine *Vibrio* sp., *Chromobacterium violaceum*, and *Chlorella*, also require consideration when dealing with infections associated with aquatic settings.[70]

CUTANEOUS MANIFESTATIONS OF SEAFOOD INGESTION AND SEAFOOD POISONING

Dermatologic reactions may appear after the ingestion of seafood. Urticaria, angioedema, and, rarely, leukocytoclastic vasculitis may occur in individuals sensitized to fish or shellfish. Many seafoods, such as kelp, contain large amounts of iodine, which may cause acneiform eruptions.

Scombroid food poisoning involves the ingestion of spoiled fish from the Scombridae family of fish, such as tuna, mackerel, and Bonita. If these fish are not kept cold enough after being caught, their flesh develops scombrotoxins as a consequence of the bacterial breakdown of histidine into histamine, saurine, and possibly other toxic by-products. These can cause striking erythema and flushing of the face, neck, and upper trunk, as well as pruritus and urticarial and angioedematous eruptions. Antihistamines can provide symptomatic relief in severe cases.

Ciguatera toxin, which is produced during blooms of toxic dinoflagellates, is incorporated into the marine food chain and concentrated in the flesh of a variety of fish. It is heat stable, and symptoms may occur after eating cooked or raw fish containing the toxin. Dermatologic symptoms of ingesting these fish may include generalized pruritus and diffuse erythematous macular and papular exanthems, which may progress to blister formation and desquamation.

ACKNOWLEDGMENT

The authors wish to thank Dr. Bruce Halstead of the World Life Research Institute, Colton, California, for allowing us to reprint the photographs from the first and second editions of *Poisonous and Venomous Marine Animals of the World*.

KEY REFERENCES

Full reference list available at www.DIGM8.com

DVD contains references and additional content

1. CDC: Nonfatal dog bite–related injuries treated in hospital emergency departments—United States, 2001. *MMWR Morb Mortal Wkly Rep* **52**:605, 2003
2. Griego RD et al: Dog, cat, and human bites: A review. *J Am Acad Dermatol* **33**:1019, 1995
9. Rupprecht, CE, Gibbons, RV: Clinical practice. Prophylaxis against rabies. *N Engl J Med* **351**:2626, 2004
10. Talan DA et al: Clinical presentation and bacteriologic analysis of infected human bites in patients presenting to emergency departments. *Clin Infect Dis* **37**:1481, 2003
22. World Health Organization (WHO): *Rabies and Envenomings: A Neglected Public Health Issue: Report of a Consultative Meeting*, 2007, http://www.who.int/bloodproducts/animal_sera/Rabies.pdf, accessed 2010
25. Willoughby RE Jr et al: Survival after treatment of rabies with induction of coma. *N Engl J Med* **352**:2508, 2005
27. World Health Organization (WHO): *WHO Guidelines for the Production, Control and Regulation of Snake Antivenom Immunoglobulins*, 2010, http://www.who.int/bloodproducts/snake_antivenoms/snakeantivenomguideline.pdf, accessed 2010
28. World Health Organization (WHO): *Venomous Snakes and Antivenoms Search Interface*, 2010, http://apps.who.int/bloodproducts/snakeantivenoms/database/default.htm, accessed 2010
34. Fisher AA: Aquatic dermatitis, Part I. Dermatitis caused by coelenterates. *Cutis* **64**:84, 1999

36. Burnett JW et al: Local and systemic reactions from jellyfish stings. *Clin Dermatol* **5**:14, 1987
39. Halstead BW: Coelenterate (cnidarian) stings and wounds. *Clin Dermatol* **5**:8, 1987
52. Collated by CRC Reef on behalf of the Queensland Government Irukandji Jellyfish Responce Task Force, Current Status of Knowledge and Action on Irukandji, v.8.3. 6/1/**2006**:6/1/2006, http://www.reef.crc.org.au/discover/plantsanimals/pdf/StatusofKnowledgeandActionPaperSep2002.pdf, accessed Nov 22, 2011
55. Halstead BW, Auerbach PS, eds: *Dangerous Aquatic Animal of the World: A color Guide, with Prevention, First Aid, and Emergency Treatment Procedures*. Princeton, NJ, Darwin Press, 1990
60. Auerbach PS: *Diving Medicine Articles: I Have Been Stung: What Should I do?* [updated 2004], 2004, Divers Alert Network, accessed November 22, 2011
61. Isbister GK, Hooper JN: Clinical effects of stings by sponges of the genus Tedania and a review of sponge stings worldwide. *Toxicon* **46**:782, 2005
75. Tomchik RS et al: Clinical perspectives on seabather's eruption, also known as 'sea lice'. *JAMA* **269**:1669, 1993
82. Meyer PK: Stingray injuries. *Wilderness Environ Med* **8**:24, 1997
89. Atkinson PR et al: Is hot water immersion an effective treatment for marine envenomation? *Emerg Med J* **23**:503, 2006

Chapter 210 :: Arthropod Bites and Stings

:: Robert A. Schwartz & Christopher J. Steen

ARTHROPOD BITES AND STINGS AT A GLANCE

- Many arthropod species are capable of inflicting bites and stings on humans.
- Reactions to arthropod assaults can range from mild to life threatening.
- Arthropods also serve as vectors for systemic diseases.
- The terrestrial arthropods of medical importance include the orders Arachnida (arachnids), Chilopoda (centipedes), Diplopoda (millipedes), and Insecta (insects).

Arthropod bites and stings are a significant cause of morbidity worldwide. Although many arthropod attacks produce only mild, transient cutaneous changes, more severe local and systemic sequelae can occur, including potentially fatal toxic and anaphylactic reactions. Arthropods also serve as vectors for numerous systemic diseases. The medically significant classes of nonaquatic arthropods are Arachnida, Chilopoda, Diplopoda, and Insecta (Fig. 210-1).[1]

HISTOPATHOLOGY

Many arthropod bites produce a similar histologic reaction pattern. In the acute phase, there is a superficial and deep, perivascular and interstitial inflammatory infiltrate, which is characteristically wedge shaped. The infiltrate is usually mixed in composition with an abundance of lymphocytes and eosinophils, although neutrophils and histiocytes can also be seen. Neutrophils may predominate in reactions to fleas, mosquitoes, fire ants, and brown recluse spiders. Over the most prominent superficial infiltrates, spongiosis can be seen, sometimes with progression to vesicle formation or epidermal necrosis. Older, excoriated areas are usually altered by the effects of scratching, with the development of parakeratosis, serum exudates, and a dermal infiltrate with neutrophils and more abundant lymphocytes. Although not commonly seen on histology, insects or insect parts, including burrowed scabies mites, eggs, feces, or the retained mouthparts of ticks, may be visible. Chronic lesions, which most often result when arthropod parts are retained in the skin, may have a pseudolymphomatous appearance (see Chapter 146).

TREATMENT PRINCIPLES

The morbidity from arthropod bites and stings varies with the species inflicting the injury. Although species-specific clinical findings and treatment will be discussed in further detail, there are several applicable general treatment principles. Local wound care is essential following arthropod assault. Wounds should be cleansed; any remaining arthropod parts, including stingers, should be removed expeditiously. Patient discomfort should be addressed and can involve a variety of treatment modalities, including the use of ice packs, application of topical corticosteroids and antipruritics, injection of local anesthetics, and, less frequently, the use of systemic analgesics. Supportive measures for systemic toxic and allergic reactions, including anaphylaxis, should be instituted when necessary. Secondary infection should be treated with appropriate antibiotics. Bites from several terrestrial arthropods species may require tetanus prophylaxis. Severe envenomation from particular species, such as the black widow spider, may require antivenom administration. Documented hypersensitivity to some species can be treated with desensitization immunotherapy.

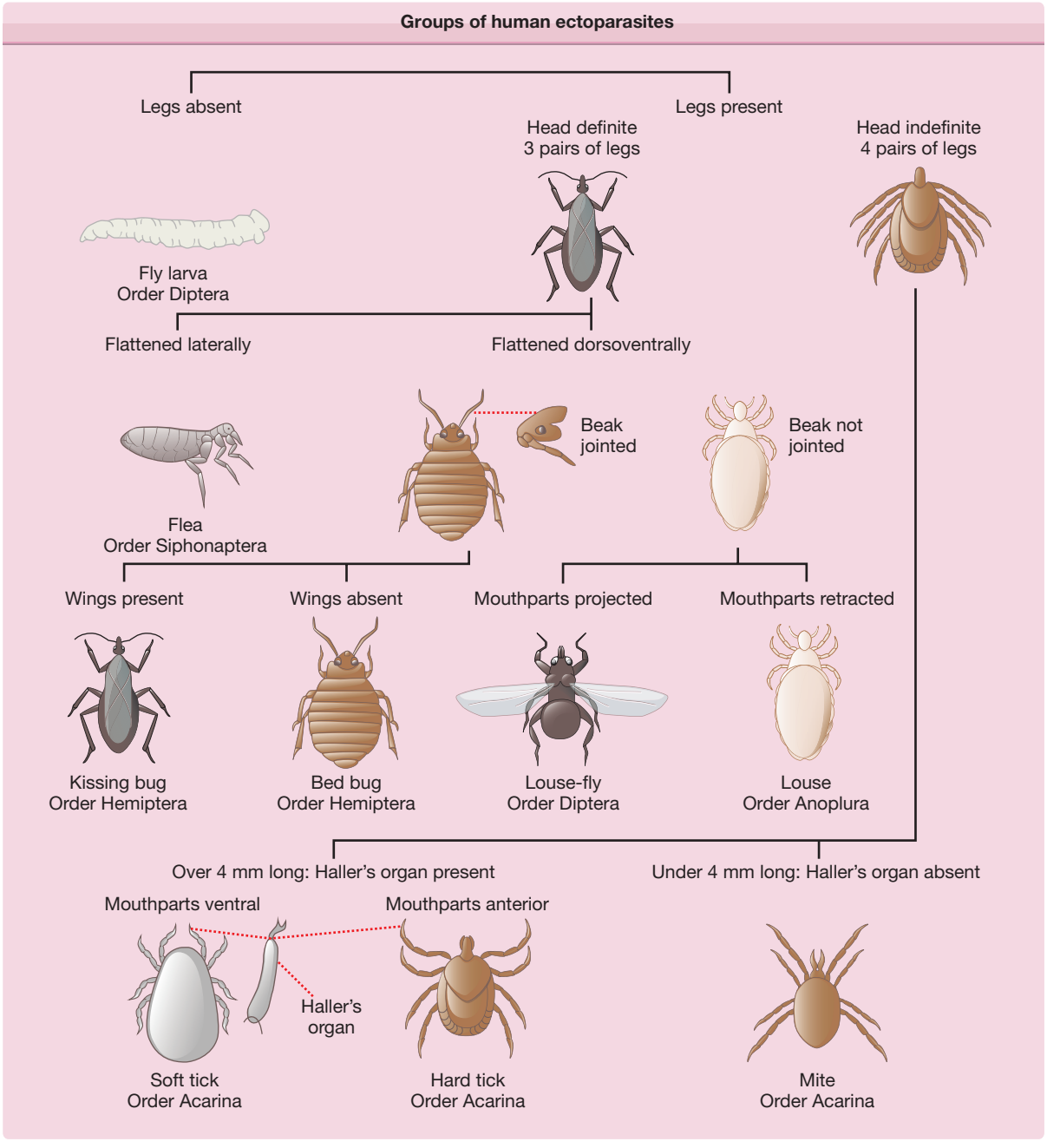

Figure 210-1 Pictorial key to groups of human ectoparasites. (Used with permission from C.J. Stojanovich and H.G. Scott, US Department of Health, Education, and Welfare, Public Health Service.)

Awareness of the potential arthropod-borne illnesses spread by each species is also important.

DIFFERENTIAL DIAGNOSIS

(Box 210-1)

ARACHNIDA

The class Arachnida contains three orders of medical significance: (1) Araneae (spiders), (2) Acarina (ticks and mites), and (3) Scorpiones (scorpions). Arachnids are distinguished anatomically from other arthropods by a lack of wings or antennae and the presence of four pairs of legs and two body segments. Larval ticks, which only have three pairs of legs, are an exception to this rule (see Fig. 210-1).

ARANEAE

Spiders are carnivorous members of the animal kingdom that use webs and venom to capture and kill prey. Within the United States, three genera contain species

BOX 210-1 DIFFERENTIAL DIAGNOSIS OF ARTHROPOD BITES AND STINGS

- Black widow bite: acute abdomen (appendicitis, etc.), meningitis, tetanus, drug withdrawal, acute renal failure, acute myocarditis, acute coronary syndrome, other arthropod bite
- Brown recluse bite: hobo spider bite, chemical burn, Lyme disease, cutaneous anthrax infection, pyoderma gangrenosum, ecthyma, trauma, vasculitis, neoplasm, other arthropod bite
- Scorpion sting: other arthropod bite, tetanus, botulism, Guillain–Barré, organophosphate toxicity, medication overdose
- Centipede bite: other arthropod bite, cellulitis
- Millipede "burn": contact dermatitis, conjunctivitis
- Insect bites (flies, fleas, bedbugs, kissing bugs): other arthropod bites (scabies, lice), atopic dermatitis, contact dermatitis, papular urticaria, delusions of parasitosis
- Hymenoptera bite/sting: other arthropod bite, anaphylaxis
- Lepidopterism: other arthropod bite, contact dermatitis, atopic dermatitis, phytodermatitis

whose bites are toxic to man: (1) *Latrodectus*, (2) *Loxosceles*, and (3) *Tegenaria*. The American Association of Poison Control Centers reported over 15,000 spider bites in the United States in 2004.[2] In the same year, only one death was attributed to spider envenomation in the United States.

LATRODECTUS. Members of the *Latrodectus* genus, or widow spiders, are often black in color and have a red, hourglass-shaped marking on their abdomens (Fig. 210-2). Although there are more than 20 species of widow spiders, *Latrodectus mactans*, the Southern black widow spider, is the most common and notorious in the United States and can be found in all but the most northern parts of the country. Other widow spiders encountered in the United States include *Latrodectus various* (Northern black widow), *Latrodectus hesperus* (Western black widow), *Latrodectus bishopi* (red-legged widow), and *Latrodectus geometricus* (brown widow). Members of the *Latrodectus* genus are nonaggressive, trapping spiders that spin webs in protected areas and await their prey. Human bites are often the result of accidental or deliberate provocation. Webs are typically found on the corners of doors and windows, underneath woodpiles, in garages and sheds, and on the undersides of eaves. Webs can also be found around outdoor toilet seats, a location that has led to bites on or near the genitalia.[3]



Figure 210-2 Black widow spider with characteristic red hourglass marking on the underside of its abdomen.

Clinical Findings. Bites of the black widow spider (*L. mactans*), which are often painful, usually only result in mild dermatologic manifestations. Within the first 30 minutes, localized erythema, piloerection, and sweating may appear at the wound site. A sensation of numbness or aching pain may develop shortly after the bite. Urticaria and cyanosis may occur at the bite site. Black widow venom contains the neurotoxin α-latrotoxin, which acts by opening ion channels at presynaptic nerve terminals, thereby causing an irreversible release of acetylcholine at motor nerve endings and catecholamines at adrenergic nerve endings.[4] Consequently, black widow bites may produce agonizing crampy abdominal pain and muscle spasm that may mimic an acute abdomen.[4] Other signs and symptoms include headache, paresthesias, nausea, vomiting, hypertension, lacrimation, salivation, seizures, tremors, acute renal failure, and sometimes, paralysis; fortunately, death is uncommon. Based on the spectrum of symptoms, black widow bite may be misdiagnosed as drug withdrawal, appendicitis, meningitis, or tetanus, to name a few.[4]

Management. Although many widow spider bites require only local wound care, more serious reactions may necessitate hospitalization. Those patients at increased risk for serious complications include the very young, very old, and those with underlying cardiovascular disease. Current treatments for black widow envenomation include intravenous calcium gluconate (10%), narcotic analgesics, muscle relaxants, and benzodiazepines.[5] *L. mactans* antivenom prepared from equine serum is also available. Additionally, there appears to be an effective cross-reactivity among antivenom for a number of other *Latrodectus* species.[6–8] The benefits of the antivenom in treating complications of widow bites should be weighed against the potential for allergic reaction to the antivenom. Patients should also be up to date on tetanus immunization.

LOXOSCELES. Members of the *Loxosceles* genus, also called *recluse spiders* or *fiddle-back spiders*, are nonaggressive spiders characterized by a dark brown marking on their cephalothorax in the shape of a fiddle or violin (Fig. 210-3). The brown recluse spider, *Loxosceles reclusa*, is the most well-known member of this genus



Figure 210-3 Brown recluse spider with characteristic fiddle-shaped marking on cephalothorax.

and is most abundant in the American Midwest and Southeast. Other medically significant members of this genus include *Loxosceles deserta* (desert recluse), *Loxosceles rufescens* (Mediterranean recluse), *Loxosceles kaiba* (Grand Canyon recluse) and *Loxosceles arizonica* (Arizona recluse). Recluse spiders are so named because they will often seek out shelter in undisturbed places such as closets, attics, and storage areas for bedding and clothing. Bites usually occur when the spider feels threatened or provoked, such as when someone tries to put on clothing that contains the spider.[1]

Clinical Findings. Bites of the brown recluse spider (*L. reclusa*) vary from mild, local reactions to severe ulcerative necrosis, a reaction known as *necrotic arachnidism*. After a bite, transient erythema may develop with the formation of a central vesicle or papule. The hallmark "red, white, and blue" sign of a brown recluse bite is characterized by a central violaceous area surrounded by a rim of blanched skin that is further surrounded by a large asymmetric erythematous area (Fig. 210-4A). In a small percentage of cases, the initial wound may progress to necrosis (see Fig. 210-4B), which usually begins 2–3 days after the bite, with eschar formation occurring between the fifth and seventh days.[9] Eventually deep ulcers develop (see eFig. 210-4.1 in online edition). The bite reaction may mimic pyoderma gangrenosum or erythema migrans of Lyme disease.[10] Cutaneous anthrax and chemical burns have been mistaken for a brown recluse spider bite.[11,12] The potential for misdiagnosis has led to the development of a sensitive enzyme-linked immunosorbent assay for *Loxosceles* species venom that may eventually be available for clinical application.[13]

Brown recluse venom contains a number of proteins, including sphingomyelinase D, esterase, hyaluronidase, and alkaline phosphatase, which all contribute to tissue destruction. Sphingomyelinase D, the major component of the venom, cleaves sphingomyelin to form cermade-1-phosphate and choline and also hydrolyzes lysophosphatidylcholine to produce lysophosphatidic acid.[14] Lysophosphatidic acid then triggers a proinflammatory response and causes platelet aggregation and increased vascular permeability.[14] Sphingomyelinase D is also capable of inducing complement-mediated hemolysis.[15] Systemic symptoms may develop within 1–2 days after envenomation and include nausea, vomiting, headache, fever, and chills. Rare but serious sequelae of brown recluse bites include renal failure, hemolytic anemia, hypotension, and disseminated intravascular coagulation.[16,17]

Management. General treatment measures for recluse bites include cleansing the bite site and the application of cold compresses. Patients may also require analgesics to control pain. Antibiotics may be useful in reducing secondary bacterial infection of the wound site. Warm compresses and strenuous exercise should be avoided. Although *Loxosceles* antivenom

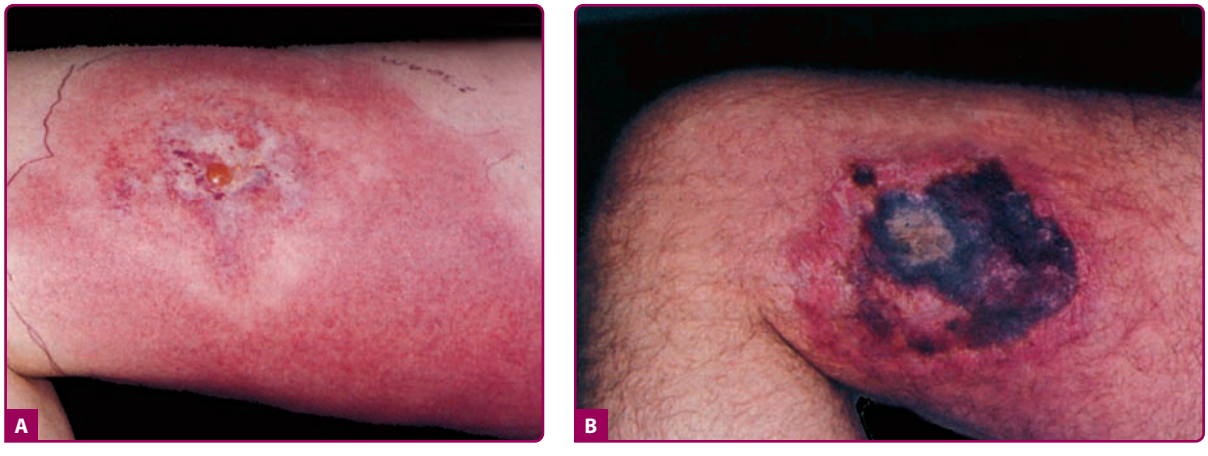

Figure 210-4 **A.** Clinically typical brown recluse spider bite showing the "red, white, and blue" sign. **B.** Late brown recluse spider bite with overlying eschar.

have been developed and are frequently used in South America, there is little evidence to support their effectiveness, particularly against local cutaneous effects.[8] A number of treatment modalities have been suggested, including hyperbaric oxygen, dapsone, intralesional and systemic corticosteroids, colchicine, and diphenhydramine.[18,19] However, one study that used a rabbit model to compare dapsone, colchicine, intralesional triamcinolone, and diphenhydramine showed no effect on eschar size from any of these medications.[18] Necrotic wounds heal slowly, sometimes over many months, and may require surgical excision and reconstruction to close the resulting defect. Surgical interventions should be delayed until the wound has stabilized.

TEGENARIA. *Tegenaria agrestis*, the hobo spider or "aggressive house spider," is the predominant cause of necrotic arachnidism in the Pacific Northwest of the United States and can be found in an area ranging from Alaska to Utah.[20] Although *Loxosceles* species are not typically found in the same geographic distribution, bites from hobo spiders are often mistaken for brown recluse bites. These spiders are brown in color with a gray herringbone pattern on the abdomen.[21] The hobo spider typically builds funnel-shaped webs in crawl spaces, basements, wood piles, and bushes. Most hobo spider bites occur from July to September when the more venomous male spiders are seeking mates.

Clinical Findings. The local cutaneous effects after envenomation by the hobo spider, which can range from mild to serious, are similar to those caused by the brown recluse.[22] The initial bite is often painless. Induration and paresthesia of the bite site may develop within 30 minutes. A large erythematous area may form around the site. Vesicle formation often occurs during the first 36 hours. Eschar formation may follow in severe cases, with necrosis and sloughing of the underlying tissue.

Management. Wounds usually heal within several weeks. The most common systemic symptom after a hobo spider bite is a severe headache, which can persist for up to 1 week.[23] Other symptoms may include fatigue, nausea, vomiting, diarrhea, paresthesias, and memory impairment. Although rare, death may ensue due to severe systemic effects, including aplastic anemia.[23]

TARANTULA. Tarantulas are indigenous to certain regions of the United States and are also kept as exotic pets. Tarantulas are members of the family Theraphosidae and are hair covered and larger than many other types of spider, with leg spans of up to 12 inches reported in certain species. Unlike the other venomous spiders discussed, tarantula bites generally only produce mild local symptoms. However, more serious reactions can be caused by urticating hairs on the spider's abdomen. When threatened, tarantulas may rub their back legs together in a motion that flicks these hairs off. These hairs may become embedded in the skin or eyes. Cutaneous responses to the hairs range from mild, local pruritus to granulomatous reactions. Ocular sequelae from hairs embedded in the cornea range from conjunctivitis and keratouveitis to corneal granulomas and chorioretinitis.[24–27] Although cutaneous reactions can be treated with topical corticosteroids, ocular involvement requires ophthalmologic evaluation.

SCORPIONES

The order Scorpiones (scorpions) comprises terrestrial arachnids most commonly encountered in tropical or arid regions, including the southwestern United States, northern Africa, Mexico, and the Middle East. These nocturnal creatures seek shelter under stones and bark during the day. As with other arachnids, scorpions are generally shy and sting humans only when provoked. Although capable of producing significant local wounds, the potential for serious, even lethal, cardiovascular complications following a scorpion sting remains of primary concern.[1] The scorpion of principal interest in the United States is *Centruroides exilicauda* (formerly *Centruroides sculpturatus*), whose sting is potentially fatal (Fig. 210-5). *Centruroides* species possess a small spine at the base of the stinger, a feature which may help distinguish them from other species of scorpion.[28,29]

CLINICAL FINDINGS. Scorpion stings usually produce an immediate, sharp, burning pain. This may be followed by numbness extending beyond the sting site. Regional lymph node swelling, and, less commonly, ecchymosis and lymphangitis, may develop. *C. exilicauda* venom contains a powerful neurotoxin, capable of producing muscle spasticity, nystagmus, blurred vision, slurred speech, excessive salivation, respiratory distress, pulmonary edema, and myocarditis.[30–35]



Figure 210-5 *Centruroides* scorpion.

Infants and young children are at the greatest risk for serious complications.[29]

MANAGEMENT. Mild scorpion envenomations may only require symptomatic treatment, including analgesics and local ice compresses. Any child stung by a scorpion, especially if identified as *C. exilicauda*, should be hospitalized for close monitoring of respiratory, cardiac, and neurologic status.[36] Specific antivenom is the treatment of choice for severe envenomation. Critically ill children with neurotoxic effects of scorpion envenomation can benefit greatly and promptly with intravenous administration of scorpion-specific F(ab')(2) antivenom.[29] Lack of it may have serious consequences. Studies indicate that *C. exilicauda* antivenom is safe, with a low incidence of anaphylactic reaction following infusion and a rapid onset of symptom relief.[34,37] Although serum sickness is common after antivenom infusion, it is usually self-limited and can be managed with antihistamines and corticosteroids.[34,37]

ACARINA

The order Acarina contains ticks and mites (see Fig. 210-1). Ticks are the most numerous members of this order, with approximately 800 known species. They are important worldwide as vectors of systemic disease, capable of transmitting viruses, rickettsia, spirochetes, bacteria, and parasites to humans.

MITES. (See Chapter 208).

TICKS. Ticks are divided into two families: (1) Ixodidae (hard ticks) and (2) Argasidae (soft ticks). Hard ticks are responsible for the majority of tick-related disease. Ticks pass through multiple stages during their life cycle, including egg, larva, nymph, and adult, and require blood meals for transition between the latter three stages. Ticks are distinguished from other mites by the presence of a barbed hypostome, which is inserted into the skin for feeding (Fig. 210-6). Ticks ingest blood from a diversity of vertebrate hosts including birds, reptiles, and mammals.[38] Adult hard ticks are capable of ingesting several hundred times their unfed body weight when taking a blood meal and may survive for months without feeding. When searching for a suitable host, hard ticks exhibit a unique behavior called "questing" during which the tick crawls to the edge of a leaf or blade of grass and holds its front pair of legs stretched out in order to grab onto a passing host.[39–41] Humans often become infested by contact with tall grass or brush that harbors the unfed ticks or by their association with domestic animals like cats or dogs. Ticks are attracted to the smell of sweat, the color white, and body heat. Once on a host, a tick may spend up to 24 hours in search of a protected site to feed, such as a skin fold or the hairline. Tick feeding time ranges from 2 hours to 7 days, with the tick dropping off of the host once fully engorged.

Many different tick species are responsible for local tick bite reactions and transmission of disease in human



Figure 210-6 *Dermatocentor variabilis* feeding. The tick has been attached for 24 hours.

hosts. In the United States, *Ixodes scapularis* (deer tick or black-legged tick), *Dermacentor andersoni* (American wood tick), *Dermacentor variabilis* (American dog tick), *Ixodes pacificus* (Western black-legged tick), and *Amblyomma americanum* (Lone Star tick) are among the most common. In the Eastern Hemisphere, important tick species include *Ixodes ricinus* (castor bean tick or sheep tick) and *Ixodes persulcatus* (Taiga tick). Among the diseases transmitted by ticks are Lyme disease (see Chapter 187), ehrlichiosis, babesiosis, Rocky Mountain spotted fever (see Chapter 199), Colorado tick fever, Q fever, and tularemia (see Chapter 180).

Clinical Findings. The majority of tick bites occur in the spring and summer, coinciding with the life cycle of the tick. Tick bites are usually painless, as the tick introduces an anesthetic and anticoagulant substance when biting. Often, a person will not even know he or she has been bitten, but will see or feel an attached tick while scratching or bathing. Tick bites may incite foreign body granuloma formation, reactions to injected toxins and salivary secretions, and other hypersensitivity responses. Rarely, delayed hypersensitivity reactions occur with fever, pruritus, and urticaria.[42] A red papule is usually seen at the bite site, and may progress to localized swelling and erythema.[42,43] A cellular response to the bite can lead to induration and nodularity after a few days. Foreign-body reactions may occur when mouthparts are retained in skin after incomplete removal of the tick. Chronic tick bite granulomas may present diagnostic problems and persist for months to years.

Tick paralysis is a potentially lethal complication of tick infestation and is thought to be caused by a neurotoxin contained within tick salivary secretions. The illness may start with headache and malaise and rapidly progress to an acute ascending lower motor neuron

paralysis, similar to that of Guillain–Barré syndrome, which may result in respiratory failure and death.[44,45] Several species of tick are capable of causing tick paralysis, including *D. andersoni*, *D. variabilis*, and *A. americanum*. Typically, the onset of symptoms occurs 4–6 days after attachment of the tick. Symptoms resolve once the tick is removed from the patient. Supportive measures, including mechanical ventilation, may be required until symptoms resolve.

Management. After potential exposure, the skin should be inspected for ticks to remove them before they begin feeding and risk transmitting disease. Once a tick has inserted its hypostome into the skin, it must be forcibly removed. Although many methods have been suggested for removing ticks, physical methods, such as slow, steady pulling on the tick, are probably the safest and most useful. Retained tick parts should be removed surgically if necessary to prevent development of foreign body granulomas. Antibiotic prophylaxis after tick bites is controversial. Although there is some evidence that prophylaxis may help prevent acquisition of Lyme disease and other vector-borne illnesses, the risks of antibiotic therapy must be weighed against the risks and prevalence of vector-borne illnesses in a particular region. In areas highly endemic for Lyme disease, the benefits of prophylactic treatment may outweigh the risks, especially in cases in which the tick has been attached to the host for an extended period of time and can accurately be identified as a vector for Lyme borreliosis. In these cases, the authors suggest a course of oral doxycycline (see Chapter 187).

CHILOPODA AND DIPLOPODA

The arthropod classes Chilopoda and Diplopoda are composed of centipedes and millipedes, respectively. Centipedes and millipedes are terrestrial arthropods with multiple body segments.

CENTIPEDES

Centipedes, which have one pair of legs per body segment, are nocturnal carnivores that may produce extremely painful bites with a pair of poisonous claws. The *Scolopendra* species is found throughout the southwestern United States and may attack when its habitat is disturbed. In addition to severe pain and erythema following a bite, localized sweating, edema, secondary infection, and ulceration may be seen. There are also case reports of proteinuria, acute coronary ischemia, and myocardial infarction following centipede bite.[46–50] Treatment consists of analgesia, including injection of local anesthetics, antihistamines, and tetanus prophylaxis. Antibiotics may be required to treat secondary infection.

MILLIPEDES

Millipedes, which have two pairs of legs per body segment, usually feed on living and dead plant matter. They lack poison claws and neither bite nor sting. However, millipedes possess repugnatorial glands on either side of each segment and may emit a toxic substance if threatened. The oily, viscous liquid can cause a brownish discoloration of the skin that can persist for months and may produce burning and blistering.[51–53] Severe reactions are mainly seen in tropical species. Some species are capable of squirting the toxin several inches. This can result in various eye lesions including periorbital edema, periorbital discoloration, conjunctivitis, and keratitis.[54] Although ophthalmologic evaluation should be considered for eye exposures, thorough immediate cleansing with soap and water is usually adequate for skin contact.

INSECTA

The class Insecta contains several orders of medical importance: Anoplura (lice; see Chapter 208), Diptera (flies, mosquitoes), Coleoptera (beetles), Hemiptera (bedbugs, kissing bugs), Siphonaptera (fleas), Hymenoptera (ants, bees, wasps), and Lepidoptera (butterflies and moths). Insects can be distinguished from other arthropods by the presence of three body segments, a pair of compound eyes, paired antennae, and six legs.

DIPTERA

The order Diptera, or true flies, contains several important families: Culicidae (mosquitoes), Simuliidae (black flies), Ceratopogonidae (biting midges), Tabanidae (horse flies and deer flies), Psychodidae subfamily Phlebotominae (sandflies), and Glossinidae (tsetse flies). Not only do members of this order inflict cutaneous injury with their bites, they are also, collectively, responsible for the transmission of more disease worldwide than any other arthropod order.

The family Culicidae contains more than 2,000 species of mosquito, many of which transmit disease. Several genera of mosquito, including *Anopheles*, *Culex*, and *Aedes*, serve as vectors for malaria, yellow fever, dengue fever, filariasis, and encephalitis viruses, including West Nile virus, which caused the largest arboviral meningoencephalitis outbreak ever recorded in North America.[55] Because male mosquitoes lack piercing mouthparts, female mosquitoes inflict all human bites. Mosquito bites incite the formation of pruritic wheals and papular lesions, which form in response to irritating salivary secretions that are injected by the mosquito to prevent coagulation. Mosquito bites may have an urticarial, vesicular, eczematous, or granulomatous appearance. Bite reactions usually subside over several days.

Other biting flies include midges, black flies, horseflies, tsetse flies, and sandflies. Black flies of the family Simulidae are vectors for onchocerciasis (African river blindness, see Chapter 207) and tularemia (see Chapter 180). Within the Tabanidae family, *Tabanus* species (horse flies) also serve as vectors for tularemia, and *Chrysops* species (deer flies or mango flies) are responsible for transmission of *Loa loa* filariasis (see Chapter 207) and tularemia. Cutaneous myiasis (Fig. 210-7) may



Figure 210-7 Cutaneous myiasis: a domed nodule resembling a furuncle at the site of deposition of a botfly larva. The lesion has a central pore through which the posterior end of the larva intermittently protrudes. The inset shows the larva that has been extracted.

be caused by the deposition of fly larvae into intact skin or open wounds by several species, including *Dermatobia hominis* (human botfly).[56,57] Numerous species of sandflies also spread disease with *Phlebotomus* species transmitting Old World leishmaniasis (see Chapter 206) and *Lutzomyia* species transmitting New World leishmaniasis and Carrión disease (bartonellosis; see Chapter 206). *Glossina* species (tsetse flies) serve as vectors for African trypanosomiasis (see Chapter 206).

Diptera bites should be cleansed thoroughly with soap and water to avoid secondary infection. A short course of topical steroids and systemic antihistamines may be used to control pruritus. Rare allergic reactions should be treated aggressively. Cutaneous myiasis is often best treated with local surgical excision of the larva and involved surrounding tissue. The antihistamines cetirizine or ebastine taken prophylactically as a single 10-mg dose have been demonstrated in studies to decrease wheal formation and subsequent pruritus following mosquito bites.[58,59]

COLEOPTERA

The Coleoptera order is the largest order in the animal kingdom, containing over 300,000 species of beetles. Although beetles generally do not bite or sting humans, many species of beetle contain chemicals that can cause blistering of human skin.[60] Although some beetles are capable of emitting these chemicals, most cases of blister beetle dermatosis are the result of a beetle being crushed against the skin. The most well-known beetle to cause blister beetle dermatosis is *Lytta vesicatoria*, the Spanish fly, which is found in Southern Europe and contains the chemical cantharidin. Cantharidin, which causes vesiculation of the skin, is used in the treatment of warts and molluscum contagiosum. Several other species of beetle found in different regions of the world, including the central and southeastern United States, contain similar chemicals and can cause blistering.[61,62] *Paederus* species (rove beetles) contain the vesicant pederin and are another cause of beetle dermatitis.[62] Washing of affected areas immediately after exposure may help prevent vesiculation. Blisters should be treated with local wound care until resolved.

Another beetle with dermatologic significance is the carpet beetle. The most common species found in the United States are *Attagenus megatoma* (black carpet beetle) and *Anthrenus scrophulariae* (common carpet beetle). Although adult carpet beetles are of little clinical importance, cutaneous exposure to carpet beetle larvae, which feed on wool, carpets, clothing, and other organic material, can cause an allergic papulovesicular dermatitis.[63]

HEMIPTERA

The Hemiptera order encompasses two families of clinical significance: (1) the Cimicidae, which includes *Cimex lectularius* (bedbugs), and (2) the Reduviidae, which includes *Triatoma* species (kissing bugs). Although most members of this order are herbivores, these two families are frequent human parasites.

CIMICIDAE. The common bedbug (*C. lectularius*; see Fig. 210-1) has been a scourge of mankind for centuries. The bedbug is a nocturnal feeder that stays hidden during the day in cracks and crevices of headboards, in picture frames, behind loose wallpaper, or any other dark place that accommodates its flattened body.[1] After a potential victim has gone to bed, the insects come out of hiding for a blood meal. They are attracted to the warmth and carbon dioxide production of their victim. Bedbugs usually complete their meal in a matter of minutes and then return to hiding. Although bedbugs can survive for 1 year or more without feeding, they usually seek a blood meal every 5–10 days.[1] Bedbugs are common and are distributed worldwide. They can be spread in clothing and baggage of travelers and visitors, on secondhand mattresses, and via laundry.

Along with other blood-sucking arthropods, the role of bedbugs in infectious disease transmission has gained increasing interest in recent years. Although laboratory studies have shown that these insects are capable of incubating and shedding pathogens such as hepatitis B virus for several weeks after feeding on an infected bloodmeal, there is currently no convincing evidence that *Cimex* species act as vectors in their natural state.[64]

Bedbug bites are usually painless and may be overlooked unless large numbers of bites are present. Bites are usually multiple and may be grouped in a linear fashion. A row of three bedbug bites is sometimes referred to as *breakfast, lunch, and dinner*[65] (Fig. 210-8). Reactions to the bites consist of wheals and papules, often with a small hemorrhagic punctum at the center. Bullous reactions to bites are also possible in sensitized individuals, and hypersensitivity reactions have been reported.[65–67] Flecks of blood may also be found on bed linens. Minimal symptomatic treatment of bites and good local wound care to prevent pruritus and secondary infection are sufficient in most cases.[67] In the presence of a secondary infection, topical antiseptic



Figure 210-8 Papular urticaria: bedbug bites. These are pruritic urticarial papules, arranged in a row (breakfast, lunch, and dinner).

lotion or antibiotic cream should be applied.[66] Topical corticosteroids and oral antihistamines may be used for pruritus. Once a bedbug infestation has been diagnosed, a professional exterminator is often necessary to eradicate the insects. Evidence for disease transmission is lacking.

REDUVIIDAE. The kissing bug, or assassin bug, belongs to the family Reduviidae and is distinguished by a triangular shape on its back formed by the meeting of the membranous wings. All reduviid bugs possess piercing mouthparts used to feed on blood. Most species of Reduviidae are found in the Americas, with a few species located in Africa, Asia, and Europe. Within the United States, these insects are found in the Southwest from Texas to California.[68] Reduviidae are of great clinical significance because they act as vectors for *Trypanosoma cruzi*, the causative agent of Chagas disease, which affects an estimated 15 million to 20 million people living in South America and Central America (see Chapter 206). Kissing bugs earned their name for their predilection to bite on or near the lips. After taking a blood meal, reduviids characteristically turn around and defecate immediately. The trypanosomes are inoculated when the victim subsequently scratches the infected feces into the wound.[1]

Although they are nocturnal feeders and usually prey on rodents, during periodic flights they move toward the lights of desert homes. Defensive bites of reduviids are extremely painful. The painless bite of a feeding reduviid occurs only while the host is sleeping, because the blood meal takes several minutes to complete. Bites have been associated with papular, urticarial, and bullous reactions. A small proportion of victims may develop generalized, acute allergic reactions that cause the victim to awaken with sudden onset anaphylactic signs and symptoms.[69] Defensive bites may incite more severe local cutaneous reactions, including necrosis and ulceration.

SIPHONAPTERA

Fleas belong to the insect order Siphonaptera (see Fig. 210-1). These small bloodsucking insects are wingless and are capable of jumping to a height of 18 centimeters. Members of the family Pulicidae, most notably the rat fleas (*Xenopsylla cheopis* and *Xenopsylla brasiliensis*), transmit bubonic plague (*Yersinia pestis*) (see Chapter 180). Other members of this family are also capable of transmitting disease, including the cat flea (*Ctenocephalides felis*), which is a vector for bubonic plaque and endemic typhus (*Rickettsia prowazekii*).

Fleabites produce minimal irritation in nonsensitized individuals, typically resulting in linear or clustered urticarial papules, frequently found on the lower legs (Fig. 210-9). In sensitized individuals, most often young children, the antigenic saliva is capable of producing papular urticaria, an eruption characterized by recurrent or chronic pruritic papules occurring on exposed skin areas.[1,70] Bullous reactions to fleabites may also develop in patients with hypersensitivity (see eFig. 210-9.1 in online edition.) Conservative topical therapy with corticosteroids and antipruritics, along with oral antihistamines, is usually sufficient for most fleabites. Antibiotics may be necessary should secondary bacterial infection develop. Once a flea infestation occurs, complete eradication of the insects is necessary to prevent additional bites.

The Tungidae family contains a tropical flea species called *Tunga penetrans* (the sand flea, chigoe flea, or jigger) that is the etiologic agent of tungiasis, an infestation caused by penetration of the adult female flea into human skin to lay eggs.[71] The usual sites of attachment are feet, particularly plantar surface, subungul or periungal skin or web spaces, and legs, but any body surface in contact with ground can be affected. Solitary or multiple erythematous papules slowly enlarge over a few weeks to 4–10 mm in diameter (Fig. 210-10). A fully developed as white or yellowish firm somewhat translucent nodule may be painful,



Figure 210-9 Papular urticaria: fleabites. Multiple, pruritic urticarial papules, usually <1 cm in diameter; they may be topped by a vesicle. Here, they occur on the legs of a child.



Figure 210-10 Tungiasis: a necrotic periungual papule on the fifth toe. The larva can be visualized by removing the overlying crust.

especially if subungual, or the pain may reflect secondary impetigo and rarely lymphangitis and septicemia. Dermoscopy facilitates visualization of ovoid eggs, and thus the diagnosis of tungiasis.[72] Tungiasis may be also be associated with pain, pruritus, and, sometimes, autoamputation of toes.[73] Death from tetanus has also been reported. One need elicit a history of travel or residence in an endemic area. Treatment options include surgical excision of the affected area or killing the adult female flea with cryotherapy or topical agents. Tetanus prophylaxis is recommended, and systemic antibiotics should be used when necessary. Prevention can be enhanced in endemic areas by avoiding walking along beaches barefoot or in sandals and not sitting or lying in the sand in parts of Nigeria, the Caribbean, India, and Brazil.

HYMENOPTERA

The order Hymenoptera contains the families Apidae and Bombidae (bees), Vespidae (wasps), and Formicidae (ants). Many members of this order have evolved poison glands used for defense and/or hunting. Aside from local cutaneous reactions, Hymenoptera stings are an important problem because of their high incidence and ability to produce fatal anaphylactic reactions.[74]

All Hymenoptera stings are inflicted by female insects via a modified ovipositor or egg-laying apparatus. Most Hymenoptera stings occur when the nest or individual insects are threatened. The honeybee stings with a barbed ovipositor, which it leaves impaled into the skin. The honeybee dies after stinging because it eviscerates itself to expel its paired venom sacs. The stinger should be removed as swiftly as possible after a sting because the musculature attached to the stinger can continue to pump venom into the skin. If possible, the stinger should not be squeezed during removal with fingers or tweezers as additional venom can be injected into the victim. One method for removal is to scrape the edge of a credit card or the dull blade of a butter knife along the skin at an angle almost parallel to the surface. This will dislodge the stinger while minimizing the injection of additional venom. Other Hymenoptera species lack a barbed stinger and may sting repeatedly.

Imported fire ants (*Solenopsis invicta*), originally from Brazil, are an aggressive species that has become well established in the southeastern United States. *Solenopsis* venom contains a nonproteinaceous, hemolytic factor identified as a dialkylpiperidine, solenopsin D, which induces mast cell degranulation.[75] Imported fire ants often attack in groups. Their sting results in an intense inflammatory, wheal-and-flare reaction that becomes a sterile pustule and may progress to localized necrosis and scarring. Sensitized individuals may experience significant bullous reactions following a sting. When attacking, the ants tend to bite the flesh with their powerful jaws and then pivot and sting in a circular pattern, resulting in ring-shaped lesions.

CLINICAL MANIFESTATIONS. Hymenoptera stings typically produce immediate burning and pain, followed by the development of an intense, local, erythematous reaction with swelling and urticaria. This "typical" reaction to hymenoptera stings usually subsides within several hours. However, more severe local reactions can occur, including extensive swelling at the sting site and prolonged induration lasting for up to 1 week. A cell-mediated immune response has also been implicated in these reactions.[76] Generalized systemic reactions to hymenoptera stings occur in approximately 0.4% to 3.0% of patients. Anaphylactic reactions may be evident as generalized urticaria, angioedema, and bronchospasm.

MANAGEMENT. Treatment of a Hymenoptera sting is governed by the severity of the reaction. Mild local cutaneous reactions may only require local cleansing, application of ice, and possible injection of local anesthetic to control pain. Oral or parenteral diphenhydramine may help control urticaria and pruritus. Anaphylaxis must be treated vigorously with subcutaneous epinephrine (0.5 mL of 1:1000 dilution) and the institution of intramuscular epinephrine, exit to an emergency room, and the supportive measures. Individuals with known Hymenoptera hypersensitivity should always carry a preloaded epinephrine-filled syringe for emergency self-administration. Desensitization therapy should be considered for any patient with a positive intradermal skin test to Hymenoptera venom and a history of sting-induced anaphylaxis. Fire ant hypersensitivity is a potentially deadly condition for which rush immunotherapy may be a good option to achieve protection quickly.

LEPIDOPTERA

The Lepidoptera order is the second largest order of insects and contains over 100,000 species of caterpillars, moths, and butterflies. An estimated

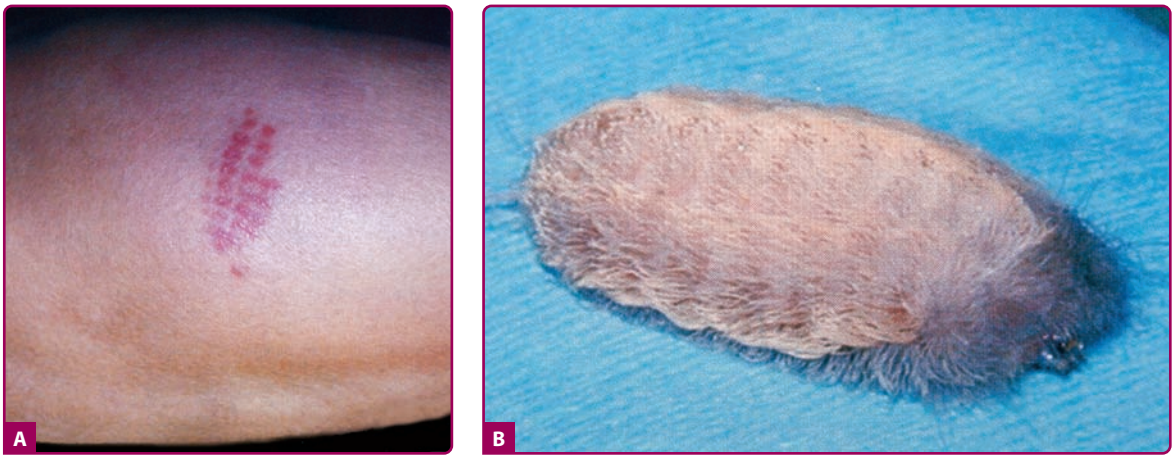

Figure 210-11 **A.** Cutaneous reaction from contact with a puss caterpillar showing the typical grid-like pattern. **B.** Pus caterpillar (*Megalopyge opercularis*) demonstrating the corresponding grid-like pattern of its hairs.

100–150 species within this order are thought to produce *lepidopterism*, the term used to describe the aggregate of medical effects caused by caterpillars, moths, and butterflies.[77,78] Multiple theories regarding the mechanisms of lepidopterism have been proposed, including mechanical irritation by pointed hairs (setae), toxin injection through hollow setae, and cell-mediated hypersensitivity to the hairs. One well-known cause of erucism or caterpillar dermatitis is *Lymantria dispar* (gypsy moth caterpillar).[79,80] Cutaneous contact with hairs from this caterpillar may produce a pruritic dermatitis characterized by multiple erythematous papules often arranged in linear streaks. Urticaria, angioedema nad anapylaxis may occur with processionary caterpillars (genus *Thaumetopoea*). Wind-borne hairs may produce keratoconjunctivitis and respiratory symptoms. *Megalopyge opercularis* (asp or puss caterpillar), which can inject venom through its hollow syringe-like hairs, is capable of inflicting an intensely painful sting, and may produce a characteristic train-track pattern of purpura at the sting site (Fig. 210-11).[81,82] Other species that cause lepidopterism in the Americas include *Automeris io* (io moth), *Euproctis chrysorrhoea* (brown-tailed moth), *Sibine stimulate* (saddleback moth), and *Hemerocampa pseudotsugata* (Douglas-fir tussock moth).

Treatment for lepidopterism is largely symptomatic. Systemic antihistamines, topical preparations containing menthol and camphor, and moderate to high potency topical corticosteroids can be used to control pruritus. Systemic steroids may be beneficial for severe reactions. The intractable pain caused by the sting of the puss caterpillar may require oral or parenteral narcotic analgesics. Embedded setae can be removed from the skin by "stripping" with adhesive tape. There is an antivenom available that should be employed for potentially fatal Lonomia genus caterpillar envenomation, still responsible for deaths in southern Brazil.[83]

PREVENTION

Several relatively simple steps can be taken to minimize the occurrence of arthropod bites. Spider bites can be reduced by wearing gloves while working in crawl spaces, garages, or basements or when manipulating woodpiles or rubbish piles. In scorpion endemic areas, shaking out clothing and footwear before putting them on is advisable. Wearing appropriate clothing with good coverage and avoiding rubbing against high brush and grass may help avoid tick bites. Bright colors and artificial scents like perfume, which are attractants for mosquitoes and other flying insects, are best avoided on warm summer nights. In tropical regions, proper footwear is essential to preventing tungiasis. Infestations of living areas by arthropods, including fleas and bedbugs, are difficult to eliminate and may require the assistance of a professional exterminator.

Chemical repellents are also useful in preventing arthropod bites. Several different chemical compounds have been studied, including *N*,*N*-diethyl-3-methylbenzamide (DEET, previously diethyltolu-amide), picaridin (KBR 3203), and *p*-menthane-3,8-diol (Eucalyptus oil). The most effective repellent for all biting flies, including mosquitoes, is DEET, which is available in many products in concentrations up to 100%. Generally, a product containing 10% to 30% DEET provides adequate protection for most outdoor activities, with higher concentrations of DEET providing longer protection times. Although DEET has an excellent safety record, there are reports of encephalopathy developing, particularly in children, after exposure to this chemical.[84,85] For this reason, only products with DEET concentrations of less than 10% should be used on children. Permethrin, an insecticide often used to treat pediculosis and scabies, is available as a tick repellent that can be sprayed on clothing and fabrics, including tents and sleeping bags, and remains effective through

several wash cycles. Combined use of permethrin-treated clothing and DEET applied to the skin provides the maximum protection.

KEY REFERENCES

Full reference list available at www.DIGM8.com

DVD contains references and additional content

1. Steen CJ, Carbonaro PA, Schwartz RA: Arthropods in dermatology. *J Am Acad Dermatol* **50**:819; quiz 842, 2004
3. Carbonaro PA, Janniger CK, Schwartz RA: Spider bite reactions. *Cutis* **56**:256, 1995
35. Carbonaro PA, Janniger CK, Schwartz RA: Scorpion sting reactions. *Cutis* **57**:139, 1996
43. Bhate C, Schwartz RA: Lyme disease: Part I. Advances and perspectives. *J Am Acad Dermatol* **64**(4):619-636; quiz 637-638, 2011
67. Thomas I, Kihiczak GG, Schwartz RA: Bedbug bites: A review. *Int J Dermatol* **43**:430, 2004
70. Stibich AS, Schwartz RA: Papular urticaria. *Cutis* **68**:89, 2001
74. Steen CJ et al: Insect sting reactions to bees, wasps, and ants. *Int J Dermatol* **44**:91, 2005
80. Beaucher WN, Farnham JE: Gypsy-moth-caterpillar dermatitis. *N Engl J Med* **306**:1301, 1982
83. Hossler EW: Caterpillars and moths. Part II. Dermatologic manifestations of encounters with Lepidoptera. *J Am Acad Dermatol* **62**:13, 2010

Occupational Skin Diseases and Skin Diseases Due to Biologic Warfare

PART 10



Occupational Skin Diseases

Chapter 211 :: Occupational Skin Diseases Due to Irritants and Allergens

:: Golara Honari, James S. Taylor, & Apra Sood

OCCUPATIONAL SKIN DISEASES DUE TO IRRITANTS AND ALLERGENS AT A GLANCE

- Skin disorders are the second most commonly reported occupational disease, accounting for approximately 20% of occupational disorders.
- Irritant and allergic contact dermatitis comprise a significant number of cases of occupational skin disease. The majority involve workers in the manufacturing and service industries.
- Chronic cumulative irritant contact dermatitis is the most common form of occupational irritant contact dermatitis.
- Approximately 80% of individuals with occupational contact dermatitis have hand involvement.
- Patch testing should be performed to rule out an allergic contact dermatitis in all cases in which an initial chronic irritant dermatitis is suspected.

Occupational dermatoses are any abnormal conditions of the skin caused or aggravated by substances or processes associated with the work environment. Occupational skin diseases (OSDs) are a major public health problem because they are common, are often chronic, and have significant economic impact on society and on workers.[1] A thorough knowledge of potential irritants, allergens, and other causative factors in the workplace, as well as the workers' compensation system, is essential for the dermatologist dealing with occupational dermatoses.

EPIDEMIOLOGY

The US Department of Labor publishes annual incidence statistics on the safety and health of employees in private industry (http://www.bls.gov/). In 2008, of the 3.8 million nonfatal job related injuries and illnesses reported among the private industry establishments, 5.1% (193,800 cases) were work-related illnesses, of these, skin disorders were the second most common reported illness, accounting for almost 38,000 cases.[2] Occupational contact dermatitis is the most commonly reported OSD, and in most countries, the reported incidence of occupational contact dermatitis varies from

5 to 19 cases per 10,000 full-time workers per year.[3] Incidence rates also vary based on the specialty of the reporting physicians; rates are six to eight times higher in some studies when cases are reported by occupational physicians rather than by dermatologists.[4]

The number of OSD cases has declined,[5] especially in the past 8 years, possibly due to better prevention, the ease with which workers' compensation cases are accepted, and a change in reporting patterns of employees or employers.[6] However, a large number of minor or transient cases still go unreported or untreated, so the exact incidence is not known. Occupational skin disease still accounts for a significant percentage of days away from work. In 2008, dermatitis led to 3,170 (8.4%) of the skin disease cases resulting in days away from work and 2,630 (83%) of these cases were caused by contact dermatitis.[2]

Distribution of nonfatal occupational injury and illness cases by category is demonstrated in Figure 211-1. Surface wounds and bruises and trauma-induced injuries are not considered among the skin disease and illnesses. Surface wounds and bruises accounted for 11,2870 (12.24%) of all traumatic injuries and disorders cases involving days away from work in 2008.[7]

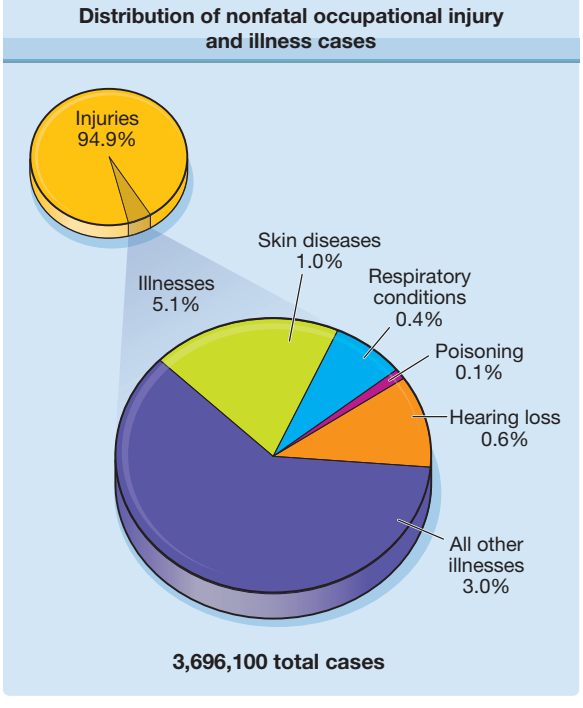

Figure 211-1 Distribution of nonfatal occupational injury and illness cases by category of illness; private industry; 2008. Only 5% of injury and illness cases reported among private industry establishments in 2008 were illnesses. Nearly 6 in 10 illnesses were categorized as "all other illnesses," which includes such things as repetitive motion cases and other systemic diseases and disorders. (Adapted from US Bureau of Labor Statistics: *2008 Survey of Occupational Injuries & Illnesses*, http://www.bls.gov/iif/oshwc/osh/os/osch0039.pdf, accessed Feb 7, 2009.)[41]

IRRITANT CONTACT DERMATITIS

(See Chapter 48.)

Irritant contact dermatitis (ICD) is a nonimmunologic inflammatory reaction of the skin to contact with a chemical, physical, or biologic agent. ICD is the most common OSD, accounting for up to 80% of cases, although some authors have found a relatively equal distribution of ICD and allergic contact dermatitis (ACD).[3] Chapter 48 discusses ICD in detail. Exogenous and endogenous factors influencing ICD are listed in Tables 48-1 and 48-2. In addition to the more common acute and chronic eczematous reactions, the clinical spectrum of ICD includes ulceration, folliculitis, acneiform eruptions, miliaria, pigmentary alterations, alopecia, contact urticaria, and granulomatous reactions (Table 211-1).[8]

MAJOR CATEGORIES OF IRRITANT CONTACT DERMATITIS

The two major types of occupational ICD are acute ICD and cumulative ICD. These and the many other subtypes are discussed in Table 48-3, which summarizes their time onset and prognosis.

ACUTE IRRITANT CONTACT DERMATITIS, INCLUDING CHEMICAL BURNS. Acute eczematous dermatitis after exposure to a potent irritant, often an acid or alkali, may overlap with chemical burns. Highly irritating chemicals may induce a reaction in anyone if the concentration and duration of action are sufficient. The intrinsic nature of the chemical is also important. Common irritants in the workplace are discussed in Common Occupational Irritants later in the chapter. In national statistics for work-related injuries, acute ICD reactions are often classified as chemical burns (Fig. 211-2).

CUMULATIVE IRRITANT CONTACT DERMATITIS. Cumulative ICD, the most common type of ICD, develops slowly after multiple subthreshold exposures to mild irritants (soap, water, detergents, industrial cleansers, solvents, etc.) under a variety of conditions.[9] Some of the high-risk occupations for ICD are listed in Table 211-2. For a comprehensive list, see the sources presented in eTable 211-0.1 in online edition. The other categories of ICD, as well as predisposing factors, including exogenous as well as endogenous factors, are discussed in Chapter 48. Atopic individuals have an increased susceptibility to skin irritation and account for a large percentage of workers' compensation dermatitis claims.

LOW-HUMIDITY DERMATITIS. Workers, especially atopic individuals who are subjected to low relative humidity at work (Table 211-3),[10] are also at risk for developing dermatitis, especially with the presence of other irritants. When relative humidity is below 35%–40%, the stratum corneum becomes drier and more brittle, and shows increasing permeability to marginal

TABLE 211-1
Clinical Features of Irritant Contact Dermatitis and Suggested Etiology

- **Eczema** (acute and cumulative irritant exposure)
  - Industrial cleaners
  - Water, soaps, and detergents
  - Weak acids and alkalies
  - Oils and organic solvents
  - Oxidizing agents (H_2O_2, benzoyl peroxide)
- **Ulcerations and burns**
  - Strong acids, especially chromic, hydrofluoric, nitric, hydrochloric, sulfuric
  - Strong alkalis, especially calcium oxide, sodium hydroxide, potassium hydroxide, ammonium hydroxide, calcium hydroxide, sodium metasilicate, sodium silicate, potassium cyanide, trisodium phosphate
  - Salts, especially arsenic trioxide, dichromates
  - Solvents, especially acrylonitrile, carbon bisulfide
  - Gases, especially ethylene oxide, acrylonitrile
- **Folliculitis and acneiform eruptions**
  - Arsenic trioxide
  - Glass fibers
  - Oils and greases
  - Tar
  - Asphalt
  - Chlorinated naphthalenes
  - Polyhalogenated biphenyls
  - 2,3,7,8-Tetrachlorodibenzo-*p*-dioxin (TCDD)
  - Polyhalogenated dibenzofurans
- **Miliaria**
  - Occlusive clothing
  - Adhesive tape
  - Ultraviolet and infra-red radiation
  - Aluminum chloride
- **Pigmentary changes**
  - **Hyperpigmentation**
    - Any irritant or allergen, especially phototoxic agents such as psoralens, tar, asphalt, phototoxic plants, others
    - Metals,[a] such as inorganic arsenic (systemically), silver, gold, bismuth, mercury
    - Radiation: ultraviolet, infra-red, microwave, ionizing
  - **Hypopigmentation**[a]
    - *p*-tert-Amylphenol and butylphenol
    - Hydroquinone
    - Monobenzyl and monomethyl ether of hydroquinone
    - *p*-tert-Catechol
    - *p*-Cresol
    - 3-Hydroxyanisole
    - Butylated hydroxyanisole
    - 1-tert-Butyl-3,4-catechol
    - 1-Isopropyl-3,4-catechol
    - 4-Hydroxypropriophenone
  - **Alopecia**
    - Borax
    - Chloroprene dimers
  - **Urticaria**
    - Numerous chemicals, cosmetics, animal products, foods, plants, textiles, woods
  - **Granulomas**[b]
    - Keratin
    - Silica
    - Beryllium
    - Talc
    - Cotton fibers
    - Bacteria
    - Fungi
    - Parasites and parasite parts

[a]Also potential allergens.
[b]some listed agents are also allergens.
Adapted from Lammintausta K, Maibach H: Contact dermatitis due to irritation. In: *Occupational Skin Disease*, 2nd edition, edited by RM Adams. Philadelphia: WB Saunders, 1990, p. 11.



Figure 211-2 Acute irritant contact dermatitis on the hand caused by an industrial solvent. There is massive blistering on the palm.

irritants. Symptoms such as pruritus and burning may be the only complaints and are more distressing than physical signs, which may involve exposed or covered areas. Differential diagnosis includes irritation from airborne substances, other dermatoses, and psychogenic causes.

AIRBORNE IRRITANT DERMATITIS. Airborne irritants are an important cause of contact dermatitis. The pattern is fairly characteristic, with subjective symptoms of stinging, burning, or smarting sensations. Objective findings range from barely visible diffuse lesions to more severe dermatitis of the eyelids, cheeks, nasal folds, and neck. Some airborne irritant particles cause symptoms only if occluded under clothing in the flexures and other intertriginous body areas.

The most frequent causes are irritating dusts and volatile chemicals, such as solvents, ammonia, formaldehyde, epoxy resins and their hardeners, cement dust, fibrous glass, and sawdust, especially from irritating woods.[11] See Table 48-4 for a list of other airborne irritants.

TABLE 211-2
Occupations at Increased Risk for Irritant or Allergic Contact Dermatitis[8,9,14,21,31,42,43]

Occupation	Irritants	Allergens
Agricultural workers	Fertilizers, germicides, dust, diesel, gasoline, oils, pesticides, plants, solvents, wet-work	Pesticides, animal feeds, barley and oats, fungicides, germicidal products, cement, plants, veterinary medications, wood dust, preservatives, wool
Bakers	Acids, flour, spices, soaps and detergents, oven cleaners, essential oils, yeast, enzymes	Ammonium persulfate; benzoyl peroxide; dyes; essential oils; enzymes; flavors; flour; some fruits
Construction workers	Acids, fibrous glass, concrete, solvents, hand cleaners	Cement, chromium, chromium compounds, cobalt, epoxy resins, nickel, resins, rubber allergens, wood dust
Cooks	Wet work, soaps and detergents, vegetable and fruit juices, raw meat and fish, spices, sugar and flour, heat	Flavors and spices, formaldehyde, garlic, sodium metabisulfite (antioxidant for vegetables)
Cosmetologists	Soaps and detergents, bleaches, solvents, permanent wave solutions, shampoos, wet-work	Dyes, amine-based products including parphenylene diamine, glyceryl monothioglycolate (perming solution), rosin, preservatives, rubber allergens, ethylmethacrylate, methylmethacrylate
Dentists and Dental technicians	Wet work, adhesives (epoxy and cyanoacrylates), essential oils, orthodontic plasters, amalgam mixtures, solvents	Dental impression material, eugenol, anesthetics, mercury, disinfectants, methacrylates, latex, rubber accelerators
Florists	Wet work, soaps and detergents, fertilizers, herbicides, pesticides, mechanical and chemical plant irritants	Plants, pesticides, insecticides
Health care workers	Wet work, soaps and detergents, alcohol, ethylene oxide, medications	Latex gloves, anaesthetics, antibiotics and antiseptics, phenothiazines, formaldehyde, glutaraldehyde, chloroxylenol
Housekeepers	Wet work, soaps and detergents, cleaners, polishes, oven cleaners, disinfectants	Potassium dichromate, preservatives, rubber accelerators, latex
Machinists	Solvents, coolants, cutting oils, degreasers, acids, corrosion inhibitors, heat, soaps and detergents, metal filings and swarf	Additives/preservatives in cutting fluids, chromium, nickel
Automobile Mechanics	Abrasive skin cleaners, diesel, gasoline, greases, oils, solvent, transmission fluid, motor oils	Chromium, cobalt, epoxy resin; nickel
Painters	Paints, solvents, adhesives, paint removers, paintbrush cleaners, soaps and detergents	Turpentine, thinners, chromium, formaldehyde, epoxy products, polyester resins

DIAGNOSIS OF IRRITANT CONTACT DERMATITIS

The diagnosis of ICD is based on a history of exposure to a known potential irritant, the clinical appearance, and the distribution of lesions.[12] Subacute and chronic irritant dermatitis are almost always diagnoses of exclusion. Patch testing (see Chapter 13) helps to distinguish ACD from ICD or to diagnose a superimposed ACD or ICD. More detailed criteria for the clinical diagnosis of ICD are discussed in Chapter 48 and especially Boxes 48-1 and 48-2 and Table 48-7.

TABLE 211-3
Low-Relative-Humidity Environments That Increase Risk of Dermatitis[44,45]

- Soft contact lens manufacturing workers
- Silicon chip manufacturing workers
- Aircraft crews on long-distance flights
- Office workers
- Resident staff in hospitals and hotels
- Traveling salespersons (from automobile heaters)

COMMON OCCUPATIONAL IRRITANTS

SOAPS AND DETERGENTS. Soaps and detergents are weak skin irritants; however, excessive use can cause cumulative insult dermatitis in susceptible individuals. The choice of cleanser varies with the job for which it is intended; for example, machinists and auto mechanics need a cleanser with a high detergent and abrasive action. The inappropriate use of products intended as industrial cleansers can also result in dermatitis.

TABLE 211-4
Selected Chemical Burns That Require Unique Therapies[14,74,75,76]

Chemical	Treatment Basics (Then Transport to Hospital Emergency Department for Further Evaluation and Treatment)
Burning metal fragments of sodium, potassium, and lithium	Extinguish with Class D fire extinguisher (containing sodium chloride, sodium carbonate or graphite base) or with sand; cover with mineral oil; extract metal particles mechanically.[a]
Hydrofluoric acid	Flush with running water; then administer calcium gluconate gel (2.5%) followed by intralesional injection, if needed.
White Phosphorus	Remove particles mechanically; wash with soap and water; then apply copper ($CuSO_4$) sulfate in water for several minutes, remove black copper phosphide, and wash with water. Vigorous water irrigation and removal of phosphorus particles mechanically; The use of a Wood lamp (ultraviolet light) results in the fluorescing of the white phosphorus and may facilitate its removal. A brief rinse with 1% copper sulfate solution may be helpful. Copper sulfate combines with phosphorus to form a dark-copper phosphide coating on the particles that makes them easier to see and debride, and also impedes further oxidation. However, copper sulfate can cause hemolysis and hemoglobinuria, and should be used with caution.[74] More recently Kaushik and Bird recommend vigorous water washing rather than using copper sulfate.[75]
Phenolic compounds	Decontaminate with undiluted 200–400 molecular weight polyethylene glycol (PEG), which can be located in the chemical section of hospital pharmacies, followed by copious water irrigation. Isopropanol or glycerol may be substituted if PEG is not available.[76] initial soap and water washing followed by treatment with polyethylene glycol 300 or 400 or ethanol (10%) in water.
Bromine or iodine	Wash frequently with soap and water followed by treatment with 5% sodium thiosulfate.

[a]Use of water to extinguish burning metal fragments is contraindicated because of the formation of highly alkaline hydroxides.

WATERLESS HAND CLEANERS. Waterless hand cleaners are formulated to remove tough oil and grease stains and are widely used at work sites where there is no convenient source of water. They should be applied sparingly because they may contain petroleum-derived solvents and may result in dermatitis if overused. Instant hand sanitizers, which often contain high concentrations of alcohol, can be drying to the skin.

ACIDS AND ALKALIS, INCLUDING CHEMICALS THAT CAUSE BURNS. Chemical burns are an important cause of occupational injury.[13] Copious irrigation is the primary method of treating all chemical burns; however, certain types of burns require specific antidotes and therapies (Table 211-4).[14]

Inorganic Acids. Inorganic acids are used in large quantities in industry; some of the occupations at risk for exposure are listed in Table 211-5. Acids are common causes of chemical burns and can cause erythema, blistering and necrosis, and discoloration of the skin. Mechanisms of action of common industrial irritants, including acids, are listed in Table 211-6.

Organic Acids. Organic acids, such as acetic, acrylic, formic, glycolic, benzoic, and salicylic acids, are less irritating than some other acids but can cause chronic irritant dermatitis after prolonged exposure. Formic acid has greater corrosive potential than other organic acids. Fatty acids, such as palmitic, oleic, and stearic acids tend to have low irritant potential.

Hydrofluoric Acid. Hydrofluoric acid (HF) is extremely irritating, even in low concentrations (15%–20%). Fluoride ions penetrate deep into the tissues and bind to calcium and magnesium ions, causing severe tissue damage including bone destruction, especially of the terminal digits of the hand.[14] After exposure to lower concentrations of HF, the onset of symptoms may be delayed until release of fluoride ions occurs in deep tissues. Exposure to HF is a medical emergency requiring topical or subcutaneous administration of calcium gluconate after lavage to bind the fluoride ions (see Table 211-4).

Chromic Acid. Chromic acid is highly irritating, causing ulcerations of the skin ("chrome holes") and perforation of the nasal septum. It can be absorbed and lead to renal failure.[15]

Alkalis. Alkalis saponify surface lipids and penetrate easily, leading to severe and extensive tissue destruction, including deep ulcerations that heal very slowly (see Table 211-5).

Cement. Exposure to wet cement may cause severe alkaline and thermal burns due to the exothermic reaction of calcium oxide with water to form calcium hydroxide.[16] Kneeling in wet cement for prolonged periods leads to deep burns of the knees ("cement knees") and shins.[17] Burns may also result from the trapping of wet cement in gloves and boots.

TABLE 211-5
Industrial Chemicals Presenting Risk for Burns and Acute Irritant Reactions[9,13–21,31,42,46]

Chemical	Industries Presenting Risk
Acids	
Sulfuric	Manufacture of fertilizers, inorganic pigments, textile fibers, explosives, pulp and paper
Hydrochloric	Production of fertilizers, dyes, paints, and soaps
Formic	Textile industry (dyeing and finishing), leather manufacture (delimer and neutralizer), production of natural latex (coagulant)
Acrylic	Manufacture of acrylic plastics (monomer)
Chromic	Chrome plating, copper stripping, and aluminum anodizing operations
Hydrofluoric	Etching and frosting of glass, rust removal, dry cleaning (spot cleaning)
Alkalis	
Calcium, sodium, and potassium hydroxides	Manufacture of bleaches, dyes, vitamins, plastics, pulp and paper, and soaps and detergents
Others	
Arsenic	Smelting of copper, gold, lead, and other metals; semiconductor industry
Beryllium	Aerospace and other industries involved in the production of hard, corrosion-resistant alloys
Cobalt	Manufacture of alloys, ceramics, electronics, magnets, paints and varnishes, or cosmetics; electroplating
Mercury	Industries involved in the manufacture or use of bactericides, dental amalgams, and catalysts
Phosphorus	Manufacture of insecticides and fertilizers

TABLE 211-6
Mechanisms of Action of Common Industrial Irritants[47]

Action	Irritant
Keratin and protein dissolution	Alkalis, soaps
Lipid dissolution	Organic solvents
Dehydration	Inorganic acids Anhydrides Alkalis (calcium oxide)
Oxidation	Bleaches
Reduction	Salicylic acid Formic acid Oxalic acid
Keratogenesis	Arsenic Tars Petroleum

From Birmingham DJ: Dermatoses in occupational diseases. In: *Occupational Diseases: A Guide to their Recognition*, edited by MM Key et al. NIOSH Publication No. 77-181. Washington, DC, US Government Printing Office, 1977.

OTHER CHEMICALS AND AGENTS

Phosphorus. Phosphorus can cause deep, destructive burns. It ignites spontaneously on exposure to air. The affected area should be kept moist until the chemical is completely removed. Severe metabolic derangements have been reported after phosphorus burns, and patients should be closely monitored for multiorgan failure.[18]

Ethylene Oxide. Ethylene oxide burns may result from contact with porous materials and devices that have been sterilized with ethylene oxide but not properly aerated.[19] Ethylene oxide may cause delayed irritant reactions (see Table 48-5). Rarely, allergic contact dermatitis is reported to ethylene oxide.[66]

Phenol. Phenol is rapidly absorbed through intact skin and can cause local necrosis and nerve damage.

Solvents. The chief uses of solvents are in the manufacture of other chemicals and as carriers for chemical reactions, as pressure transmitters for hydraulic systems, and as coatings, industrial cleaners, printing inks, and pharmaceuticals. After water, the most common solvents are aliphatic and aromatic hydrocarbons, esters, ethers, ketones, amines, and nitrated and chlorinated hydrocarbons (eTable 211-6.1 in online edition).[20,21] Volatile solvents, in particular, act by dissolving the intercellular lipid of the epidermis, causing transient "whitening" of the skin and a feeling of dryness.

Fibrous Glass. Glass fibers, or man-made vitreous fibers, cause a highly pruritic contact dermatitis that may resemble scabies. Fibers larger than 3.5 m are generally responsible. Contact can be direct, indirect (through clothing), or through the air. Fibers may cause simple mechanical irritation by penetration into the skin, or secondary ACD from the associated finishing resins (e.g., epoxy).

Fabrics. Wool and rough synthetic clothing can cause irritant dermatitis, especially in atopic individuals. Fire-retardant fabrics, "NCR" paper (carbonless copy paper), and paper facemasks, such as are used in the semiconductor and other industries, can also induce irritation.

Plants. Florists, horticulturists, gardeners, nursery personnel, farm workers, grocery store workers, and outdoor workers are at risk for developing dermatoses caused by plants (see also Chapters 13 and 48). eTable 211-6.2 in online edition lists the various clinical types of plant dermatoses.

ALLERGIC CONTACT DERMATITIS

(See Chapter 13.)

ACD is reported less frequently than ICD in the work environment, possibly because most workers are not patch-tested, and thus the disorder is not diagnosed and reported. In a multicenter study conducted by the North American Contact Dermatitis Group that examined 839 cases identified as occupational dermatitis (29% of 2,889 patients referred for evaluation of contact dermatitis), 54% were primarily allergic dermatitis, 32% were irritant dermatitis, and 14% were conditions other than contact dermatitis that were aggravated by work.[22] In this series, ACD was seen most commonly in nurses; the other occupational groups represented were assemblers, nurse's aides and orderlies, machinists, students, machine operators, auto mechanics, those performing compressing and compacting jobs, and cooks. Allergens strongly associated with occupational exposure were rubber (thiuram and carbamate accelerators), epoxy resin, and ethylenediamine. The recent increase in the use of computers has led to an increase in computer-related skin diseases; including ACD caused by plasticizers and possibly neoprene and rubber accelerators in the equipment.[23]

The principal occupational contact allergens are listed in Table 211-7. Additional more recently reported occupational allergens are discussed in eTable 211-7.1 and eTable 211-7.2 in online edition describes difficulties in the diagnosis of ACD.

The mechanism of ACD and its clinical manifestations are described in Chapter 13. It is important to remember that if a worker develops ACD 2 or 3 days after initial contact with an allergen, the induction of sensitivity must have occurred previously, perhaps during an earlier job.

CONTACT URTICARIA AND IMMEDIATE CONTACT REACTIONS

(See Chapter 38)

Contact urticaria syndrome (CUS) comprises a heterogeneous group of inflammatory reactions that usually appear within minutes after cutaneous or mucosal contact with the eliciting agent and disappear within 24 hours, usually within a few hours. CUS has four stages: stage 1—localized urticaria, dermatitis, or itching, tingling, or burning; stage 2—generalized urticaria; stage 3—rhinoconjunctivitis, asthma, or gastrointestinal symptoms; and stage 4—anaphylaxis.

There are three varieties of contact urticaria (CU): (1) nonimmunologic CU, (2) immunologic CU, and (3) CU of uncertain mechanism (see also Chapter 38).

TABLE 211-7
Major Occupational Contact Allergens[42,48]

- Acrylics
- Biocides—isothiazolinones, formaldehyde releasers
- Chromate
- Cobalt
- Colophony
- Dyes
- Epoxy resin systems (may need to test with specific resin worker uses)
- Formaldehyde
- Formaldehyde resins
- Fragrances and essences
- Nickel (initial sensitization is usually nonoccupational)
- *para*-Phenylenediamine (PPD)
- Plants and woods
- Rubber-processing chemicals

NONIMMUNOLOGIC CONTACT URTICARIA

In nonimmunologic CU, exposed individuals develop reactions without previous sensitization. Depending on the nature of the substance, its concentration, the area of skin exposed, and the mode of exposure, the reaction usually remains localized; and systemic symptoms of wheezing, rhinorrhea, and syncope do not occur. Causative urticants include benzoic acid, sorbic acid, cinnamic acid, cinnamic aldehyde, and nicotinic acid esters.[24,25]

Affected occupational groups and the causative agents to which they may be exposed include the following: gardeners—nettles, various plants, caterpillar hairs, moths, and other insects; cooks—fish, mustard, cayenne pepper, and thyme; and medical and related personnel—alcohol, balsam of Peru, benzocaine, methyl salicylate, tar extracts, tincture of benzoin, witch hazel, and dimethyl sulfoxide.

IMMUNOLOGIC CONTACT URTICARIA

(See Chapter 38.)

Immunologic CU, an immunoglobulin E-mediated immediate allergic reaction, occurs in persons previously sensitized to a specific agent. Atopic individuals, especially those with atopic dermatitis, are more susceptible. The prototype is natural rubber latex (NRL) allergy, which results from a reaction to one or more proteins present in NRL.[26] The highest prevalence of NRL allergy is in individuals with spina bifida. Also affected are health care workers; kitchen workers; cleaners; others who wear NRL gloves; and workers involved in the manufacture of rubber bands, surgical gloves, and latex dolls.

The next most common cause of immunologic CU is food items such as raw potato and meat. Other causes are antibiotics and other medications, preservatives, disinfectants, fragrances, epoxy resin hardeners, several woods, birch pollen, and formaldehyde in clothing.

CONTACT URTICARIA OF UNCERTAIN MECHANISM

CU of uncertain mechanism includes reactions to ammonium persulfate, which is used as a booster in bleaching hair. The dermatitis, which occurs mostly in clients, has a sudden onset and is characterized by

erythema, edema, severe itching, urticaria, and occasionally syncope, with wheezing and dyspnea. Hairdressers should be made aware of the seriousness of this problem. Both nonimmunologic and immunologic mechanisms have been demonstrated to be present in the immediate reactions to ammonium persulfate.

DIAGNOSIS OF CONTACT URTICARIA

Other than for NRL allergy, there are few statistical data on CU. Data from Finland indicate that farmers (from exposure to cow dander) account for the most cases but that the highest incidence is found among bakers.[25] Recent data from Australia included 143 cases of occupational CU diagnosed over 12 years, which represented 8.3% of 1,720 cases of occupational skin diseases. Natural rubber latex allergy in health care workers accounted for the majority of cases, followed by foodstuffs in food handlers and ammonium persulfate utilized in hair dressers. The most frequently affected sites of CU were the hands, all of which were occupational, followed by the arms and face.[69] Diagnosis of immunologic CU typically involves skin testing with the suspected substance and serologic assays for specific immunoglobulin E. When a chemical hapten is the suspected cause, it must be conjugated with a protein, usually human serum albumin, a nonstandard procedure.[71]

CU occurs from direct contact with skin (most cases) or mucosa (e.g., latex and chlorhexidine; the latter may be associated with systemic toxicity), or from contact with airborne allergen (e.g., cinchona, mulberry, xylene). Exposure may be accidental or caused by equipment failure (e.g., xylene). Standard ingredients (e.g., Tinofix) or trace contaminants or impurities (e.g., an anhydride present in sorbitan sesquioleate) may be responsible. CU may be associated with other urticaria such as delayed pressure urticaria. Occasionally, only erythema, burning, and itching occur, but at least some people should develop urticaria at the application site for the agent to be regarded as causing CU. Combined CU and delayed allergic eczematous reactions may occur.[27]

DIAGNOSIS OF OCCUPATIONAL SKIN DISEASE

ASPECTS OF EVALUATION

Making medical determinations in cases of putative occupational skin disorders and in workers' compensation cases confronts the physician with several challenging tasks: (1) weighing patient assertions and demands concerning the work relatedness of the disease, job changes, and job modifications; (2) serving as gate keeper with regard to time off from and date of return to work; (3) dealing with lack of adequate workplace information—job description, list of chemicals used at the workplace, and exposures, including material safety data sheets; (4) balancing clinical judgment against technology (e.g., determining whether hand eczema in a machinist is work related when patch test results are negative); (5) establishing causation in the legal sense, which usually requires only probability of work association (within reasonable certainty or more than 50% medical certainty), rather than absolute certainty, such as fulfilling Koch's postulates.[28,29]

The medicolegal essentials in evaluating OSD in the workplace consist of the following:

1. Making an accurate diagnosis, including taking a detailed medical and occupational history, performing a complete skin examination, and ordering diagnostic tests as indicated (Table 211-8).
2. Determining causation. Mathias[30] has proposed that a Yes answer to four of the following seven questions is adequate to establish occupational causation and aggravation in contact dermatitis cases:
   a. Is the clinical appearance compatible with contact dermatitis?
   b. Are there workplace exposures to potential irritants or allergens?
   c. Is the anatomic distribution of the eruption compatible with job exposure?

TABLE 211-8
Diagnostic Workup for Occupational Irritant and Allergic Contact Dermatitis[49–51]

History
- Duration, site of onset, progression, symptoms (itching, burning, pain), improvement away from work, treatment to date including response, history of any overt contact allergies
- Occupational history, including current job and process description, changes in current job, previous employment, protective clothing used if any, other workers affected
- Hobbies and part-time jobs
- Medical history, including medical, dermatologic, and surgical history, especially any history of atopic dermatitis, seasonal allergies, and asthma
- Family history of atopy, psoriasis, or other chronic skin conditions

Examination
- Site(s) of eruption
- Morphology of lesions (erythema, eczema, lichenification, pigmentary changes, urticaria, etc.)
- Pattern of involvement

Diagnostic Tests (if indicated)
- Patch testing
- Photopatch testing
- Tests for immediate hypersensitivity (see Fig. 211-3)
  - Radioallergosorbent assay test (RAST)
  - Open and semiopen patch tests (read at 10 and 45 minutes)[49]
  - Prick test
  - Scratch-chamber test[50]
- Repeat open-application "use" test
- Potassium hydroxide examination for fungi, glass fibers
- Fungal, bacterial, and viral smears and cultures
- Skin biopsies
- Dimethylglyoxime test for detecting nickel, other tests (detection of chromates and formaldehyde)
- Chemical analysis

d. Is the temporal relationship between exposure and onset consistent with contact dermatitis?
e. Have causal nonoccupational exposures been excluded or made highly unlikely?
f. Does the dermatitis improve away from work exposure to the suspected irritant or allergen?
g. Do patch or provocation tests identify a probable cause?

The Mathias criteria were found to be valid and useful in a study of occupational contact dermatitis and the concepts are applicable to other occupational dermatoses.[70]

3. Providing recommendations for treatment, prevention, disability status (if any), job placement, rehabilitation, and use of other resources (industrial hygiene consultation and consultations with other medical specialists, such as allergists, pulmonologists, or occupational medicine physicians).

DIAGNOSTIC TESTING

PATCH TESTING. Because of the importance of ACD in the etiology of OSD, patch testing (see Chapter 13) should be performed in almost all cases of contact dermatitis, even in patients who are thought to have only ICD. Testing should be performed using commercially prepared allergens. Further testing with substances in the worker's environment, including topical medications, protective equipment such as gloves, sensitizing ingredients in cleansers or other products, and occasionally the products themselves (e.g., cutting oils), is sometimes indicated. eTable 211-8.1 in online edition lists additional patch testing series that may be useful in making a diagnosis. Slodownik et al recently showed that in 1,532 patients who were patch tested for occupational dermatoses, 101 patients (6.6%) reacted to their own products, which in 20 (1.3%) of these patients was the only clue for detecting the responsible allergen.[42] Testing with irritants such as most solvents, soaps, cement, and the like should not be done, and patch testing with other environmental chemicals should be performed only by knowledgeable individuals to avoid false-positive irritant reactions. Standard texts can be consulted for patch test concentrations. See eTable 211-0.1 in online edition.

TESTS FOR IMMEDIATE HYPERSENSITIVITY. If type I immediate hypersensitivity is suspected, testing of agents in nonirritating concentrations can be carried, out (Fig. 211-3). Radioallergosorbent tests and skin prick testing, including to the patients own food samples, are recommended as part of the routine assessment of patients in high risk occupations for OCU, particularly if the hands are affected and there is a history of atopy and exposure to urticants.[69]

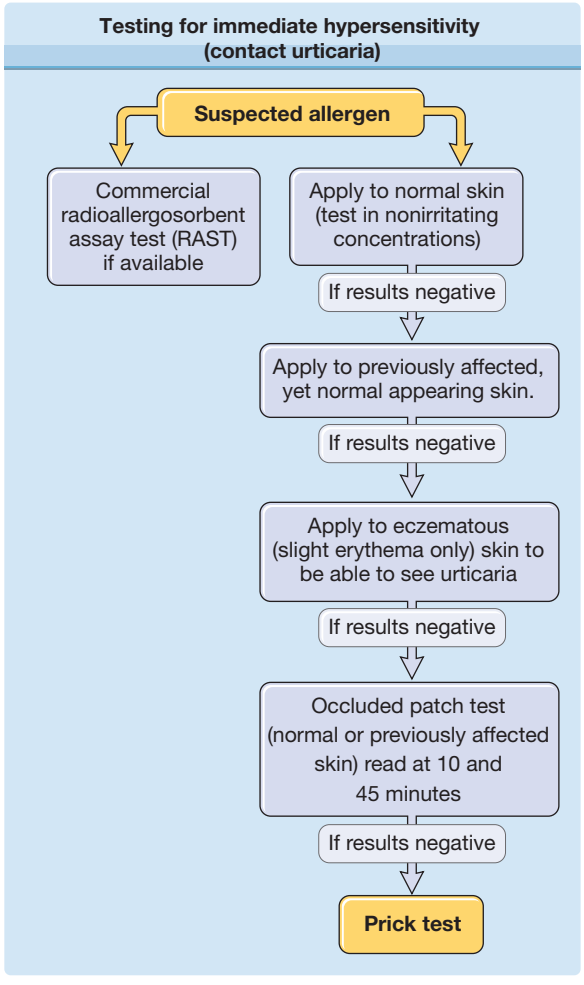

Figure 211-3 Testing for immediate hypersensitivity (contact urticaria). (Adapted from Taylor JS et al: Contact urticaria. In: *Occupational Skin Disease*, 3rd edition, edited by RM Adams. Philadelphia, WB Saunders, 1999, p. 111.)

TREATMENT AND PREVENTION

Initial treatment for OSDs depends on the cause and is essentially the same as that for diseases of nonoccupational origin. However, it is important that patients be told the specific cause(s) of their disease and methods to avoid recurrences, and be given information on the appropriate use of skin cleansers, topical treatments, and protective clothing as well as on other preventive measures. Most occupational skin disorders are preventable, and their avoidance requires environmental, personal, and medical methods.[31]

ENVIRONMENTAL METHODS AND WORKPLACE VISITS

Environmental methods are the preferred control measures, but they are sometimes also the most expensive measures to implement. Environmental methods involve industrial hygiene and environmental engineering interventions such as the following:

1. Hazard identification: workplace visits are an important but often overlooked part of the evaluation of workers with OSD. Hazard identification and assessment of means of

exposure can be evaluated by direct observation and may be required for problem solving, especially when more than one worker is affected.
2. Substitution of less irritating and allergenic chemicals [e.g., rubber gloves without thiurams and carbamates, an alternative resin (phenolic or polyester) for epoxy resins, an alternative metalworking fluid without a sensitizing additive].
3. Isolation and enclosure of the process.
4. Local exhaust ventilation.
5. Chemical dispensers.
6. Good housekeeping.

PERSONAL METHODS

BARRIER CREAMS. Barrier creams have been called *invisible gloves*, but they are an inadequate substitute for protective clothing and are often used when gloves, sleeves, and facemasks cannot be conveniently or safely used. Several types are available: ordinary emollient creams, water-repellant creams, oil- and solvent-resistant creams, and products for use against poison ivy and poison oak. The most effective barrier creams are sunscreens and sunblocks, which ideally should be worn by all outdoor workers. Problems associated with the use of barrier creams are a false sense of security, improper selection and use, allergy to an ingredient (often a preservative or fragrance), potential for increased absorption of occupational chemicals, and inadequate or infrequent application.

SKIN CLEANSERS. Skin cleansers are discussed in Section "Common Occupational Irritants."

PROTECTIVE CLOTHING. Protective clothing ranges from gloves, aprons, hoods, boots, and work shoes to full-body clothing. Fabrics that resist heat, cold, acids, alkalis, solvents, and ultraviolet radiation are available. Certain types are resistant to mildew and fire. Personal protective equipment is addressed by the Occupational Safety and Health Administration in specific standards for general industry, shipyards, marine terminals, and long-shoring, including the US Government Code of Federal Regulations (29 CFR Part 1910).[32] Manufacturers of personal protective equipment provide catalogs with guidelines for the selection of clothing for various exposures. Forsberg provides a handy reference guide.[33] eTable 211-8.2 in online edition lists major glove materials and present general guidance regarding their suitability for use in handling certain chemicals.

MEDICAL METHODS

Physicians often overlook certain medical aspects of prevention. Basic principles consist of the following:

1. Initial and subsequent employment physical examinations should include appraisals of the skin and evaluation of fitness for work.
2. Workers with skin disease may require accommodation in the workplace.
3. Potentially sensitizing topical preparations (neomycin, bacitracin, benzocaine, etc.) should be avoided when treating OSD.
4. Well-motivated workers should undergo medical and vocational rehabilitation; this is covered by many workers' compensation plans.

FITNESS FOR WORK AND WORKPLACE ACCOMMODATION

The Americans with Disabilities Act of 1990 brought to the fore issues of job placement and accommodation. Most individuals with chronic skin conditions can perform normal work activities, but in some instances accommodation in the workplace is required.[34]

PROGNOSIS AND PERSISTENCE

Although the prognosis of chronic OSD is guarded, there has been improvement, with clearance reported in 70%–84% of cases.[35] Minimizing workplace exposure and maximizing patient knowledge regarding potential irritants and allergens is one of the most important factors in improving prognosis.[35,36] Certain conditions, such as chromium sensitivity, have a poor prognosis and are notoriously long lasting. Atopic dermatitis, especially in occupations in which there is frequent or prolonged contact with water, soaps, and detergents, is also associated with a poor prognosis.

Of the several causes of persistence of OSD, the most important is an incomplete or incorrect diagnosis. Other factors include failure to eliminate the cause(s), improper job placement, improper therapy, the presence of secondary diagnoses (e.g., allergy to topical medications or multiple contact allergies), exposure to cross-reacting substances at home or in vocational activities, and improper cleansing of the skin. Some workers develop an ongoing dermatitis termed *persistent postoccupational dermatitis* for which there is no obvious present cause, precipitated by prior occupational dermatitis. This has significant implications for prognosis and workers' compensation.[37,38]

IMPAIRMENT AND DISABILITY EVALUATION

Evaluation of patients with OSD is discussed in more detail in other sources.[28,29,72] However, dermatologists should be aware of the *Guides to the Evaluation of Permanent Impairment*, published by the American Medical Association.[73] The *Guides* chapter on skin disease has been used for more than 30 years to evaluate patients with permanently impairing skin disorders (diseases that have reached maximum medical improvement—often after 6–12 months' duration) of both occupational and nonoccupational origin. The *Guides* are used by a number of state workers' compensation authorities

and provide examples of five classes of impairment ranging from 0% to 95%.

HEALTH RISK ASSESSMENT

The current scientific approach to risk reduction in occupational health is based on risk assessment, which is separated into four basic elements: (1) hazard identification, (2) dermal exposure assessment, (3) dose-response assessment, and (4) risk characterization.[39,40]

HAZARD IDENTIFICATION

Hazard identification involves determining whether exposure to an agent can cause disease or injury using material safety data sheets. Material safety data sheets provide information only about substances considered hazardous; those present in concentrations of less than 1% are not required to be listed, and the physician may need to call for additional information.

DERMAL EXPOSURE ASSESSMENT

Dermal exposure assessment determines the nature and size of populations exposed to a chemical agent via the skin, as well as the magnitude and duration of the exposure. Considerations regarding exposure include the method of exposure: spills, contaminated tools or rags, aerosols or sprays, or permeation of protective clothing. Thus, work activity (e.g., task duration and frequency, amount of chemical used), work substance (molecular weight, particle size, solubility, volatility, etc.), and worker (e.g., surface area exposed, personal hygiene, presence of dermatitis) are three major factors.

DOSE-RESPONSE ASSESSMENT

Dose-response assessment describes the quantitative relationship between the dose at the target and the toxicologic effect. Persons with atopic dermatitis have increased transepidermal water loss and enhanced reactivity to irritants.

RISK CHARACTERIZATION

Risk characterization involves the integration of the data to determine safe exposure by comparing exposure levels with levels at which no adverse effects are observed, while allowing for a safe margin of error. With the exception of nickel and chrome exposure, few skin exposures have been characterized in this way, and it may be difficult to do so. Also, attention must be given to percutaneous absorption as well as to dermal exposure.

MEDICO-LEGAL REPORTS

Physicians may be asked to report on patients with putative occupational skin diseases. These may range from brief diagnosis and treatment medical reports to more complex impairment and disability evolutions for workers compensation authorities, or attorneys. Evaluation guidelines may be provided by the authority or attorney requesting the report; if not physicians should consult their own state's workers compensation guidelines, if any, or the federal government in case of federal employees. Dermatologists are usually asked to evaluate "outlying" claims such as persistent and recurrent hand eczema persisting despite job change or modification, contested claims for work-related causation or percentage of disability, and transient skin complaints with few objective findings. Workers compensation claims become more difficult to resolve the longer the patient remains out of work. References by Clark and Zirwas and by Taylor provide further information and guidance for impairment and disability evaluation for dermatologic conditions.[28,29,72,73]

Formal return to work guidelines is primarily utilized for musculoskeletal complaints rather than skin disorders. Workers with severe enough dermatitis to miss work often are eligible for temporary total disability which is typically short term, less than 6 months. For disorders lasting longer than 6 months, the AMA Guides to the Evaluation of Permanent Impairment may be utilized, but states differ on which edition of the Guides is accepted. Unduly restrictive limitations upon return to work, such as avoiding all contact with chemicals, may jeopardize a worker's job. Before writing such recommendations they should be discussed with the patient/employee and employer. Change of jobs does not always result in clearing of a worker's dermatitis and some union–management contracts may restrict worker placement. Some skin diseases become chronic and do not clear with treatment and allergen and irritant avoidance. Possible reasons are listed in Section "Prognosis and Persistence." eTable 211-8.3 in online edition discusses fitness to work with skin disease and lists selected conditions that may disqualify an individual for work. eTable 211-8.4 in online edition lists some work-aggravated skin disorders that may require accommodation by an employer.

A physician's report should list and summarize all diagnoses. A summary statement regarding causation is then made; for example, within a reasonable degree of medical certainty (51% or greater) the disease is (or is not) related to work. A physician is not required to have such an opinion and in some cases may not be able to make a determination of probable cause. Impairment is then discussed including a description of specific clinical findings related to impairment; if permanent refer to the specific section of the AMA Guides.[73] Specific recommendations for medical and pharmaceutical therapy should be included along with a brief explanation of the treatment. Recommendations for prevention including work restrictions are made next, including suggestions for environmental modification (exhaust ventilation, splash guards, etc.) and personal protective equipment. The effect of future exposures to chemical, physical and biological agents should be addressed, along with any need for rehabilitation. Some states and insurance carriers may provide rehabilitation services.

KEY REFERENCES

Full reference list available at www.DIGM8.com

DVD contains references and additional content

3. Belsito DV: Occupational contact dermatitis: Etiology, prevalence, and resultant impairment/disability. *J Am Acad Dermatol* **53**(2):303-313, 2005
9. Frosch PJ, John SM: Clinical aspects of irritant contact dermatitis. In: *Contact Dermatitis*, 4th edition, edited by PJ Frosch, T Menne, JP Lepoittevin. Berlin, Springer-Verlag, 2006, p. 255
33. Forsberg K, Mansdorf SZ: *Quick Selection Guide to Chemical Protective Clothing*, 5th edition. New Jersey, Wiley, 2007
38. Keogh SJ, Gawkrodger DJ: Persistent post-occupational dermatitis: Report of five cases. *Acta Derm Venereol* **86**(3):248-249, 2006
58. Foti C et al: Occupational allergic contact dermatitis associated with dimethyl fumarate in clothing. *Contact Dermatitis* **61**(2):122-124, 2009
69. Williams JD et al: Occupational contact urticaria: Australian data. *Br J Dermatol* **159**:125-131, 2008

Chapter 212 :: Occupational Noneczematous Skin Diseases Due to Biologic, Physical, and Chemical Agents: Introduction

:: Paul X. Benedetto, James S. Taylor, & Apra Sood

OCCUPATIONAL SKIN DISEASES DUE TO BIOLOGIC, PHYSICAL, AND CHEMICAL AGENTS AT A GLANCE

- Certain occupations are associated with an increased risk of infection (viral, bacterial, fungal, parasitic), arthropod bites and stings, or infestations.
- Mechanical trauma is common in the workplace and can have skin manifestations.
- Preexisting skin conditions may be aggravated by work-related mechanical trauma.
- Occupational skin granulomas can be immunogenic (e.g., beryllium induced) or nonimmunogenic (e.g., silica induced).
- Occupational skin diseases can result from excessive heat, cold, and other atmospheric factors such as low humidity in the workplace.
- Exposure to silica, vinyl chloride, and other chemical agents can cause systemic sclerosis and limited scleroderma-like disease.
- Occupational chloracne is one of the most sensitive indicators of toxic exposure to halogenated aromatic hydrocarbons such as dioxins and PCBs.
- Occupational skin cancers due to exposure to chemical carcinogens or to ultraviolet light are a major health concern.

Noneczematous skin diseases caused by biologic, physical, and chemical agents in the workplace are discussed in this chapter. Trauma-related eczema is also included. For epidemiology, incidence, and management of occupational skin diseases, refer to Chapter 211.

SKIN DISEASES DUE TO BIOLOGIC AGENTS

Workers in healthcare, food services, cleaning and maintenance, and outdoor occupations are at a risk of developing skin infections. Table 212-1 lists some of the occupations associated with increased risk of certain infections.[1]

Establishing a definite relationship between work and a specific infection is not always simple. Laboratory isolation of the infective organism and a supporting medical history and physical examination are helpful.

Another area of particular concern is the rise in incidence of multidrug-resistant organisms. This has been a growing problem for many years with the dilemma playing a particularly important role in the management of wounded military personnel. With an increased number of troops being deployed overseas to active combat in Iraq and Afghanistan, the issue of antibiotic resistance complicates wound management in situations where resources may be relatively sparse.[2] The most frequently identified strains of resistant organisms contaminating battlefield wounds are *Staphylococcus aureus*, *Acinetobacter baumanii*, *Klebsiella pneumonia*, and *Pseudomonas aerugenosa*.[3,4]

TABLE 212-1
Occupational Skin Infections[1–27]

Occupational Groups at Risk[137]	Infections
Agricultural workers, farmers, shepherds, cattle workers, ranchers, animal scientists, animal breeders, veterinarians	Orf, milker's nodules, tinea barbae dermatophyte infections, mycetoma, chromoblastomycosis, sporotrichosis, cutaneous larva migrans
Athletes (wrestlers, surfers, swimmers, football, hockey and beach volleyball players, triatheletes)	Herpes gladiatorum, tinea corporis gladiatorum, impetigo, furunculosis, seabather's eruption, swimming pool granuloma (*M. marinum*), pseudomonas ("hot tub") folliculitis, acne mechanica, cutanea larva migrans
Butchers, meat handlers, abattoir workers[138]	Staphylococcal and streptococcal infections, cutaneous anthrax, viral warts, erysipeloid, tularemia, brucellosis, leptospirosis
Construction and other outdoor workers	Blastomycosis, coccidioidomycosis, arthropod bites
Cooks, bakers, food handlers, dishwashers, cannery workers, bartenders, others doing wet work	Candidal intertrigo, paronychia, pseudomonas folliculitis
Fish merchants and fishermen	Staphylococcal, streptococcal infections, erysipeloid, vibrio vulnificus, aeromonas hydrophilia
Foresters, hunters	Tularemia, Lyme disease
Gardeners	Sporotrichosis
Hairdressers, manicurists	Staphylococcal and streptococcal infections
Healthcare workers (physicians, nurses, dentists, physician and dental assistants, respiratory therapists, paramedics)	Herpes simplex (herpetic whitlow), HIV infection, hepatitis, staphylococcal and streptococcal infections, candidiasis
Laboratory workers	Brucellosis, tularemia, HIV infection, hepatitis, monkeypox
Military personnel	Staphylococcal and streptococcal infections, dermatophyte infections, arthropod bites, leishmaniasis
Pet shop workers, aquarium handlers, fish tank cleaners	Fish tank granuloma (*Mycobacterium marinum*), monkeypox
Veterinarians	Cutaneous tuberculosis, cutaneous anthrax, brucellosis, tularemia, orf

HIV = human immunodeficiency virus.

BACTERIAL INFECTIONS

STAPHYLOCOCCAL AND STREPTOCOCCAL INFECTIONS. (See Chapter 176.) Secondary bacterial skin infections due to *Staphylococcus* and *Streptococcus* are common complications of abrasions, lacerations, burns, and puncture wounds. Butchers and meat handlers are likely to develop infected cuts and scratches, paronychia, abscesses, and lymphangitis. Folliculitis and boils are common in farm workers and construction workers. Workers in hot, humid, and dirty environments[5] (see eFig. 212-0.1 in online edition) or those working in close contact with infected persons, such as nurses, hairdressers, and manicurists, are at risk. Metalworking and other industrial fluids contaminated with bacteria are another potential source of infection for workers and have even been implicated in an outbreak of *Pseudomonas folliculitis*.[5,6] The increase in multidrug-resistant bacterial strains and the emergence of community-acquired methicillin-resistant *S. aureus*[7] may present a therapeutic challenge.

Infectious eczematoid dermatitis frequently follows contact dermatitis that is untreated and in an area where there is constant rubbing. In this case, the patient was a logger working in an area with poor access to medical attention.

ANTHRAX. (See Chapters 183 and 213.) Anthrax, caused by *Bacillus anthracis*, is primarily seen in cattle, sheep, horses, goats, and wild herbivores. Occupational exposure to infected animals or their products (such as skin, wool, and meat) is the usual pathway of exposure for humans. Agricultural workers, stockbreeders, butchers, and meat processors can become infected by contact with diseased animals. Contaminated hides, goat hair, wool, and bones can infect dockworkers, freight handlers, warehouse workers, and employees of processing plants that handle these products. Tanners, carpet makers, and upholsterers are also at risk, as well as laboratory workers handling specimens.[8]

Anthrax also poses a particular risk to the general population and military personnel as an agent of germ warfare owing to the highly infectious nature of its spores (see Chapter 213).[9–11] Closely following the attacks of September 11, 2001, a series of anthrax exposures were reported, the result of contaminated letters sent via the United States Postal Service. A total of 22 cases, including 10 cases of inhalational anthrax and

12 cases of cutaneous anthrax, occurred over a 1 month period.[12] During the ongoing investigation conducted by the FBI and the CDC, a laboratory worker assigned to the case was exposed to the organism via infected vials and contracted cutaneous anthrax.[13] These attacks highlighted the dangers of infectious agents as potential weapons of biological warfare and renewed interest in appropriate administration of the anthrax vaccine.

MYCOBACTERIAL INFECTIONS

Cutaneous Tuberculosis. (See Chapter 184.) Tuberculosis verrucosa cutis, a slow-growing warty papule or plaque caused by the exogenous inoculation of *Mycobacterium tuberculosis* or *Mycobacterium bovis* in previously sensitized individuals, has been reported in pathologists and morgue attendants (prosector's or anatomist's wart).[14] Surgeons, veterinarians, farmers, and butchers are also at risk, although the condition is rare at the present time.

The Bacille Calmette–Guérin (BCG) vaccine, prepared using live attenuated *M. bovis*, is given to prevent the development of tuberculosis. There have been reports of scrofuloderma, with skin changes overlying cold abscess formation in the underlying subcutaneous tissue at the site of inoculation. Additionally lupus vulgaris (LV), or paucibacillary cutaneous infection caused by hematogenous, lymphatic or contiguous spread from the site of inoculation[15] has occurred after an extended latency period of up to 17 years after administration of the vaccine.[16] Although the United States has never routinely administered the BCG vaccine, in some instances, individuals who are at particularly high risk (e.g., healthcare workers repeatedly exposed to drug-resistant strains of *M. tuberculosis*) may receive the vaccine.[17] Furthermore, it was standard policy to inoculate school-aged children even in the United Kingdom until 2005. Given reports of long latency between vaccine administration and occurrence of lupus vulgaris, continued awareness and surveillance is advisable when caring for UK citizens.

Nontuberculous Mycobacterial Infections. Numerous atypical (i.e., nontuberculous) mycobacteria cause cutaneous and systemic disease. *Mycobacterium marinum* causes swimming pool or fish tank granuloma, a solitary or disseminated granulomatous infection seen in fishermen, fish tank cleaners, aquarium workers (eFig. 212-0.2 in online edition), and workers cleaning contaminated swimming pools.[18] Surgeons are also at risk. Granulomas also may form in a linear fashion along lines of lymphatic drainage (so-called sporotrichoid spread).

Less common atypical mycobacteria may cause infection in the setting of immunosuppression (such as AIDS), as well as in immune competent hosts with high-risk exposure in an occupational setting. There have been case reports of *Mycobacterium simiae* causing a cutaneous granulomatous infection in animal handlers scratched by primates.[19] Infection with this particular mycobacterium is complicated by its multidrug resistance and requires culture and susceptibility testing.[20] There are also reported cases of veterinarians and livestock handlers contracting cutaneous mycobacterial infections, such as cutaneous infection with *M. bovis* caused by exposure to an infected alpaca and lupus vulgaris caused by *M. bovis* sp. *caprae* caused by exposure to dairy cattle.[21,22]

BRUCELLOSIS. (See Chapter 183.) Brucellosis is a zoonosis transmitted to humans via contact with infected animals or ingestion of untreated milk or milk products. Farmers, livestock breeders, meatpackers, veterinarians, and laboratory workers are at risk.[23] An epidemic caused by sniffing bacterial cultures has been reported.[24]

TULAREMIA. (See Chapter 183.) Tularemia is caused by *Francisella tularensis*, a Gram-negative bacillus transmitted by ticks, fleas, and deerflies. Animal reservoirs include wild rabbits, squirrels, birds, sheep, beavers, muskrats, and domestic dogs and cats. Tularemia is seen in hunters, trappers, game wardens, butchers, fur handlers, and laboratory workers. It is highly infectious, and great care should be exercised in handling infected tissues and excreta. All laboratory personnel who may handle samples from a case of suspected tularemia should be forewarned.

ERYSIPELOID. (See Chapter 183.) Erysipeloid is almost always an occupational disease and is caused by *Erysipelothrix rhusiopathiae*, a Gram-negative rod that infects freshwater and saltwater fish, ducks, emus, turkeys, chickens, and other farmed animals such as sheep.[25] Butchers, fishermen, scuba divers, and retailers of fish and poultry are commonly affected.[26]

VIRAL INFECTIONS

HERPES SIMPLEX. (See Chapter 193.) Infection with herpes simplex virus (HSV) is the most common viral infection of occupational origin. Infections due to HSV type 1 or 2 are seen in occupations in which there is exposure to infected secretions from the mouth or the respiratory tract. Dentists, dental assistants, nurses, and respiratory technicians are particularly vulnerable, and herpetic whitlow is a common problem.[27] Infection with HSV-1 after a needle-stick injury has also been reported.[28] Herpes labialis is a common problem in woodwind and brass instrumentalists.[29] HSV infection on the body surfaces of wrestlers and rugby players, known as herpes gladiatorum, is temporarily disqualifying for infected athletes. In healthcare professions, the implementation of universal precautions has led to a significant reduction in the prevalence of infection.[30]

HEPATITIS AND HUMAN IMMUNODEFICIENCY VIRUS INFECTION. Needle-stick injuries are a well-recognized occupational hazard for healthcare workers, putting them at risk of acquiring an infectious disease from blood-borne pathogens. The average risk of human immunodeficiency virus (HIV) transmission after a percutaneous exposure to HIV-infected blood has been estimated to be approximately 0.3%.[31,32] For hepatitis B, the risk of clinical hepatitis if the blood was positive for both hepatitis B surface antigen and hepatitis B envelope antigen is reported to be 22% to

31%; the risk is 1% to 6% if the blood was positive for hepatitis B surface antigen but negative for hepatitis B envelope antigen.[32] A 95% decline in hepatitis B virus infection in healthcare workers was noted from 1983 to 1995, largely due to widespread immunization of healthcare workers with the hepatitis B vaccine.[33] The average incidence of antihepatitis C virus seroconversion after accidental percutaneous exposure to a hepatitis C virus-positive source is 1.8% (range, 0%–7%).[32] The most accurate data on needle-stick and sharps injuries are derived from prospective studies, which yield an estimated annual incidence ranging from 562 to 839 injuries per 1,000 healthcare workers per year.[34] Nurses have the most patient contact, and it is not surprising that this occupational group accounts for most reported cases.[34,35] Immediate evaluation of the injured employee is necessary to assess the risk related to exposure and the need for postexposure prophylaxis (antiretroviral therapy for HIV, immunoglobulins and vaccination for hepatitis B virus). A substantial reduction in needle-stick injuries with the use of needleless systems or newer safety needle devices and blunt suture needles has been noted, though still not widely implemented due to questions of relative efficacy compared to older technology.[33,36] Examples of needleless systems include, but are not limited to, intravenous delivery systems that administer medication or fluids through a catheter port or connector site using a blunt cannula or other nonneedle connection, and jet injection systems that deliver subcutaneous or intramuscular injections of liquid medication through the skin without the use of a needle.

The CDC has published guidelines for the management of postexposure prophylaxis (PEP) in the setting of occupational exposure to HIV.[37] The indication for PEP depends on the type of exposure, such as percutaneous injury versus mucous membrane and nonintact skin exposure, as well as the severity of injury and the volume of fluid exposure. In cases of less high-risk exposure, such as solid needle superficial injuries and mucous membrane or nonintact skin exposures from HIV-positive individuals who are asymptomatic or known to have low viral loads, a basic two-drug PEP regimen is the current CDC recommendation. In higher risk exposures, such as deep puncture wounds and wounds from large-bore hollow needles from symptomatic individuals and those with high viral load or in acute seroconversion, the current recommendation is a three-drug postexposure prophylaxis regimen. Ideally, drugs in the regimen are chosen from different classes of antiretrovirals and exert their effects at different stages in the viral replication cycle, thus increasing efficacy and reducing or prolonging potential drug resistance. The drug classes include nucleoside reverse transcriptase inhibitors (NRTI), nucleotide analogue reverse transcriptase inhibitors (NtRTI), nonnucleoside reverse transcriptase inhibitors (NNRTI), protease inhibitors (PI), and fusion inhibitors (FI).

VIRAL WARTS. (See Chapter 196.) Handlers of meat, poultry, and fish have a high prevalence of viral warts, which is likely attributable to the acquisition of minor cuts and abrasions during work. Human papillomavirus 7 has been isolated more frequently in this group of patients.[38]

MOLLUSCUM CONTAGIOSUM. (See Chapter 195.) Professional wrestlers and boxers are prone to developing molluscum.

ORF (ECTHYMA CONTAGIOSUM). (See Chapter 195.) Orf, caused by a parapoxvirus, is endemic in sheep and goats, and is easily transmitted to humans through direct contact. Veterinarians, farmers, and shepherds are at risk.[39]

MILKER'S NODULES. (See Chapter 195.) The paravaccinia virus, which infects the udders of cows and produces ulcers in the mouths of calves, can be transmitted to dairy farmers and veterinarians, causing milker's nodules (or pseudocowpox)[40] (see eFig. 212-0.3 in online edition).

MONKEYPOX. (See Chapter 195.) An outbreak of human monkeypox in the United States in 2003 was traced to a shipment of infected exotic African rodents, some of which escaped, that produced secondary infection in wild prairie dogs housed at the same pet store. Exposure to these infected prairie dogs resulted in 37 human infections involving exotic pet dealers, pet owners, and veterinary care workers.[41] Although human-to-human transmission rate of monkeypox virus is thought to be low, the Centers for Disease Control and Prevention recommends strict contact, droplet, and airborne precautions for healthcare workers. The case-fatality rate has been less than 10% in Africa, with children being more vulnerable to fatal infection.[42] Smallpox vaccination is recommended for healthcare workers and household contacts of confirmed monkeypox cases per Centers for Disease Control and Prevention guidelines.

FUNGAL INFECTIONS

DERMATOPHYTIC SKIN INFECTIONS. (See Chapter 188.) Dermatophytic skin infections are seen more frequently in farmers and animal husbandry workers.[43] Infections with *Trichophyton rubrum* and *Trichophyton mentagrophytes*, which are seen in the general population, may occur in work situations involving increased perspiration and occlusion. *Microsporum gypseum*, *T. mentagrophytes*, and *verrucosum verrucosum* cause infection in agricultural and other outdoor workers (see eFig. 212-0.4 in online edition). *M. canis* infects veterinarians and laboratory workers. Physiotherapists who perform hydrotherapy are also more likely to develop fungal skin infections.[44] An unusual tinea corporis infection in a scientist due to a laboratory strain of *Arthroderma benhamiae* has been reported.[45] There is a report of a laboratory worker developing erythema multiforme secondary to cutaneous infection with *T. mentagrophytes* contracted from contact with research animals.[46]

CANDIDIASIS. (See Chapter 189.) Infection with *Candida albicans* is common in occupations that expose

the skin to moisture and occlusion, such as those that require wearing gloves for long periods of time. Food handlers, surgeons and nurses, dental assistants, dishwashers, laundry workers, and tollbooth attendants are at risk.

SPOROTRICHOSIS. (See Chapter 190.) Sporotrichosis, caused by *Sporothrix schenckii*, is acquired by inoculation through puncture wounds from thorns, sticks, or splinters. It is seen in farmers, nursery and forestry workers, and those in other outdoor occupations. Gardeners working with sphagnum moss used for packing plant roots may also be at risk. There have been reports of disseminated and bilateral sporotrichosis mimicking sarcoidosis and prurigo nodularis, respectively.[47,48]

MYCETOMA (MADURA FOOT). (See Chapters 185 and 190.) Mycetoma, caused by various species of fungi and actinomycetes, is seen mainly in farmers and outdoor workers in tropical and subtropical countries; walking barefoot is a risk factor.

CHROMOBLASTOMYCOSIS. (See Chapter 190.) Chromoblastomycosis, a deep mycosis, often follows a puncture wound or other trauma during which soil-inhabiting fungi of *Phialophora*, *Hormodendrum*, and *Fonsecaea* species are injected deep into the tissues. Agricultural and other outdoor workers are at risk.

BLASTOMYCOSIS. (See Chapter 190.) Those at risk of blastomycosis include agricultural, forestry, and construction workers, farmers, and persons working with heavy earth-moving equipment in endemic areas, such as the Mississippi and Ohio River basins.[49]

COCCIDIOIDOMYCOSIS. (See Chapter 190.) Coccidioidomycosis is acquired by the inhalation of dust containing the spores of *Coccidioides immitis*. Farmers, construction workers, bulldozer and heavy equipment operators, and laboratory workers are susceptible.

PARASITIC DISEASES

(See Chapters 206 and 207.)

There has been an increase in the incidence of cutaneous leishmaniasis in the US military personnel who were deployed to southwest or central Asia or other areas in which leishmaniasis is endemic, with hundreds of cases having been reported to date.[50–52] The larvae of *Ancylostoma braziliense* and *Necator americanus* cause creeping eruption (cutaneous larva migrans) in agricultural workers, fishermen, sewer workers, and lifeguards. Skin divers, lifeguards, dockworkers, and caretakers who maintain lakes and ponds are prone to development of swimmer's itch caused by the cercariae of a schistosome; there is also a report of swimmer's itch developing after cleaning of an aquarium.[53] Dogger Bank itch is seen in fishermen and dockworkers in the North Sea, who are exposed to the marine bryozoan *Alcyonidium gelatinosum*.

In contrast to swimmer's itch, lifeguards, swimmers and professional divers can develop seabather's eruption, commonly called "sea lice," which is papulopustular dermatosis caused by the thimble jellyfish, *Linuche unguiculata*. The life cycle of *L. unguiculata* has three distinct stages: (1) larva (planula), (2) ephyra, and (3) adult (medusa). The eruption appears to be a hypersensitivity reaction to the venomous nematocysts discharged by the larval form of the jellyfish becoming trapped under clothing, and occurs most frequently from spring through summer. There have been reports of the eruption being caused by nematocysts discharged by adult jellyfish as well.[54,55]

ARTHROPOD STINGS, BITES, AND INFESTATIONS

(See Chapters 209 and 210.)

The bites of bees, wasps, hornets, ants, ticks, mites, centipedes, and millipedes frequently cause work-related skin disease. Outdoor workers, food handlers, chicken farmers (chicken mites), workers in food-processing plants, restaurant workers, and dockworkers may be affected. Epidemics of scabies have occurred in nursing homes, hospitals, and other residential facilities for the aged[56] Lyme disease (see Chapter 187) is transmitted through a tick bite and can affect outdoor construction workers, loggers, ranchers, and park rangers in wilderness areas.[57]

SKIN DISEASES DUE TO PHYSICAL AGENTS

MECHANICAL TRAUMA-INDUCED SKIN DISORDERS

The skin may be subjected to friction, pressure, cuts, lacerations, and abrasions in the workplace. Repeated mechanical trauma such as low-intensity pressure or friction, the most common mechanical trauma, leads to hyperpigmentation and lichenification, whereas heavier and persistent friction leads to hyperkeratosis and callus formation (eFig. 212-0.5 in online edition). Sudden shearing forces may lead to the formation of friction blisters, erosions, or ulcers.[58] Prolonged and excessive pressure may produce hyperpigmentation and thickening, characteristic as the stigmata of various occupations[59] (Fig. 212-1). Besides calluses and corns, occupational marks include discolorations, telangiectasias, tattoos, and deformities. Greater automation and better protective clothing, especially a wider selection of gloves, have decreased the incidence of occupational marks. In musicians, clinical presentation and location of skin lesions are usually specific for the instrument used (e.g., fiddler's neck, cellist's chest, guitar nipple, flautist's chin).[60] In athletes, repetitive trauma from running may lead to black heel or talon noir as well as blisters and jogger's toe.[60] Corns may also develop due to extreme pressure associated with bony deformities, poor foot mechanics, or improper footwear.[61] A new group of skin disorders related to prolonged computer use leading to repetitive trauma (mousing callus)



Figure 212-1 Nail dystrophy in a slaughterhouse worker. While holding a knife in his right hand to cut off the hide, he pulled and tugged on the hide with his left hand. Note the calluses over the distal interphalangeal joints on the left.

and prolonged pressure (computer palms) has been described.[62,63] Underlying skin conditions in patients such as psoriasis and lichen planus may be aggravated by occupational trauma (koebnerization). Preexisting dermatitis caused by friction and pressure may predispose to the development of allergic sensitization.[64]

Hyperkeratotic hand eczema is a chronic hyperkeratotic, scaly, fissured dermatitis involving the palms seen in workers engaged in manual work involving repeated friction and pressure (Fig. 212-2). Pulpitis may be seen on the fingertips in women engaged in domestic work as a dry, scaly, fissuring, painful dermatitis.[65] A similar condition may be seen in dental personnel allergic to acrylates, in which paresthesias of the fingertips are reported. Posttraumatic eczema (dermatitis in loco minoris resistentiae) is dermatitis at the site of cutaneous trauma. The eczema usually develops within a few weeks of the acute injury and may persist or recur for long periods of time.[65] The damage and functional alteration of the skin is thought to play a role in precipitating the eczema. Table 212-2 lists the types of posttraumatic eczema and provides some examples.[66]



Figure 212-2 Chronic hypertrophic dermatosis of the palms in a 59-year-old machinist. He was transferred to work in a storeroom, where he continually handled tools, and was forced to retire because of persistence of the dermatosis with its fissuring and bleeding.

TABLE 212-2
Clinical Classification of Posttraumatic Eczema

1. Idiopathic reaction (endogenous eczema absent) (e.g., thermal burn on hand followed by eczema 1 mo later)	1. Idiopathic reaction (endogenous eczema absent) (e.g., thermal burn on hand followed by eczema 1 mo later)
2. Isomorphic reaction	2. Isomorphic reaction
a. Primary (precedes endogenous eczema) (e.g., laceration on finger followed by finger eczema and later by flexural atopic eczema)	a. Primary (precedes endogenous eczema) (e.g., laceration on finger followed by finger eczema and later by flexural atopic eczema)
b. Secondary (follows endogenous eczema) (e.g., irritant hand eczema followed by finger puncture and finger eczema, which persists after hand eczema clears)	b. Secondary (follows endogenous eczema) (e.g., irritant hand eczema followed by finger puncture and finger eczema, which persists after hand eczema clears)

From Mathias CGT: Post-traumatic eczema. *Dermatol Clin* **6**:35, 1988.

GRANULOMAS

Granulomas may form due to penetration of the skin by foreign material; they may be immunogenic or nonimmunogenic. Table 212-3 lists the causes of occupational skin granulomas.[67] The penetration of human hair into the interdigital spaces of barbers and of cow and sheep hair into the hands of animal tenders can produce foreign-body granulomas.[68]

THERMAL BURNS AND OTHER HEAT-INDUCED SKIN DISORDERS

Workers are at risk for thermal burns as a result of scalding; contact with liquid metal, hot equipment,

TABLE 212-3
Classification of Occupational Granulomas

Causative Substance (Setting)

Immunogenic granulomas
- Beryllium (metal production, X-ray screen production)
- Zirconium (steel working)
- Cadmium (paint and rubber industry)

Nonimmunogenic granulomas
- Silica (sandblasting, mining, land mine explosions)
- Starch (occupations requiring the use of surgical gloves)
- Cactus spines (farming, outdoor work)
- Sea urchin spines (diving)
- Wood splinters (farming, forestry)
- Hair (hairdressing, farming, animal handling)
- Sheep wool (sheep raising)
- Metal (metal fragment/chainsaw blade/shrapnel)[139]

Adapted from Goh CL: Non-eczematous occupational contact reactions. In: *Condensed Handbook of Occupational Dermatology*, edited by L Kanerva et al. Berlin, Springer-Verlag, 2004, p. 135.

and tar; and flame burns after explosions. Kitchen workers and adolescents working in fast food restaurants may develop scalds from hot grease.[69] Roofers frequently incur hot tar burns, whereas explosives and flammable liquids cause most industrial burns. Persons working in foundries and smelting plants are at risk for molten metal burns. Firefighters are also at risk, although the use of protective gear reduces the extent of burn injuries.[70] Workers experiencing prolonged or repeated exposure to heat and those using laptops on their laps for prolonged periods can develop erythema ab igne.[71] Acne vulgaris, rosacea, and herpes simplex may be aggravated by the heat of open furnaces, heat torches, ovens, and stoves. Heat-induced cholinergic urticaria may result from strenuous physical exercise or a very warm work environment.

ELECTRICAL BURNS

In industrial settings, electrical burns are usually high-voltage injuries, which may result in serious tissue destruction. Outdoor workers are at a risk for lightening burns, which show characteristic fern-like patterns (see Chapter 95).

COLD-INDUCED SKIN DISORDERS

(See Chapter 94.)

Frostbite, chilblains, immersion foot, and cold urticaria are common in workers employed in cold environments, such as military personnel stationed in cold climates, ski patrolmen and mountain rescue workers. Icemakers, liquefied gas makers, refrigeration workers, and persons engaged in winter sports are also at risk.

VIBRATION SYNDROME

The vibration of hand-held tools may induce a type of vascular spasm in the fingers and hands known as white fingers or vibration-induced white finger.[72] Operators of vibrating impact and power tools such as jackhammers, pounding machines, riveting hammers, chain saws, and hand grinders may develop this condition, especially in cold climates. The vascular symptoms may be associated with neuromuscular symptoms and even with bony changes, collectively known as hand-arm vibration syndrome.[73] Earlier symptoms are mild and consist of numbness and tingling, followed by blanching and stiffness of one or more fingers, with paresthesias and weakening of intrinsic muscles developing in the later stages. Vibration frequencies between 30 and 300 Hz are most strongly associated. Smoking is also considered a risk factor. Improvements in the design of chain saws and other vibrating tools have resulted in a decrease in the prevalence of vibration-induced symptoms.

SKIN DISEASES DUE TO CHEMICAL AGENTS AND RADIATION

CHEMICAL HYPOPIGMENTATION/ LEUKODERMA

(See also Table 212-1.)

Most cases of occupational leukoderma are caused by either chemical or thermal burns, or as a postinflammatory effect of irritant or allergic contact dermatitis in which tissue injury is enough to destroy melanocytes. A third category, chemical leukoderma, may follow cutaneous exposure to a number of phenolic or catecholic derivatives, which structurally resemble tyrosine, an amino acid precursor of melanin synthesis. These include monobenzylether of hydroquinone, *p*-tert-butylphenol, *p*-tert-butyl catechol and congeners along with a number of other chemicals, which cause pigment loss in humans and in animal models. At low doses these substances simply inhibit melanin synthesis, but at higher doses may be cytotoxic to melanocytes, resulting in irreversible pigment loss. These chemicals may be present in industrial and consumer products. The essential chemical requirement for melanocyte toxicity appears to be a nonpolar side chain in the para position on the phenolic or catecholic ring structure. Depigmentation is not always preceded by inflammation of the affected skin, but is frequently associated with allergic contact dermatitis to the same chemical responsible for the pigment loss.

Chemical leukoderma may appear identical to idiopathic vitiligo with similar anatomic distribution. Scalp hair is rarely involved and eye color is not changed. Time from exposure to onset of pigment loss ranges from 2 weeks to 6 months. Wood's light exam of the entire skin is important to detect nascent areas of involvement.

Diagnosis is more easily made when a number of cases are clustered in a factory with a history of exposure to a known depigmenting agent. Patch testing with putative depigmenting chemicals may be preferable on covered areas such as the buttocks and may result in leukoderma at sites of positive or negative tests for up to six weeks after application. Satellite depigmentation may occur after patch testing strong depigmenting chemicals. Black guinea pigs have been used as an alternative test method.

A detailed history is important to exclude other causes of depigmentation. Differentiation from vitiligo may be impossible, and many authorities believe chemical leukoderma may evolve into vitiligo, presumably in genetically predisposed individuals. Most cases occur by direct contact but inhalation or ingestion may be operative. More recent causes have included paraphenylenediamine containing and semipermanent hair colors, Indian *bindi* (PTBP), *alta*, and *roli* (cause unknown), and rubber shoes and synthetic wallets (MBEH).[74–78]

OCCUPATIONAL CONNECTIVE TISSUE DISORDERS

Raynaud phenomenon and scleroderma-like skin lesions with osteolytic changes in the bones of the

fingers are well described in vinyl chloride workers (see also Chapters 157 and 170).[79] The syndrome has been called occupational acro-osteolysis. Exposure to other organic solvents, such as chlorinated hydrocarbons, polyvinyl acetate glues, has also been reported to cause scleroderma-like disease (eTable 212-3.1 in online edition).[79–81] Systemic sclerosis and scleroderma-like skin changes after silica exposure with or without associated pulmonary silicosis is eponymously referred to as Erasmus syndrome and has been described in underground miners (coal, gold, uranium, lead miners), stone masons, and those in related occupations.[82] The simultaneous operation of vibrating tools during mining may contribute to the development of the disease.

OCCUPATIONAL AND ENVIRONMENTAL ACNE

OIL ACNE. (See Chapter 80.) Oil acne is a folliculitis occurring on skin that comes in contact with oils, especially heavy industrial oils or straight cutting oils used by machinists. Areas with the greatest exposure to oil-soaked clothing, such as the arms and thighs, are most frequently involved. Oil acne is also caused by airborne oil mist.[83] Oil acne is treated with the usual topical and systemic modalities for acne vulgaris. Systemic antibiotics are often needed, as is isotretinoin in severe cases. Key factors in preventing oil acne are avoiding contact with oils and grease, including practicing good personal hygiene. Work clothes should be changed daily and frequent cleansing of the skin at risk with soap and water is advised. With better engineering controls and protective clothing, the occurrence of oil acne has decreased.[84]

COAL TAR AND PITCH ACNE. (See Chapter 80.) Coal tar oils, creosote, and pitch can produce a comedonal type of acne, with a predilection for exposed areas, particularly the malar regions.[85] Coal tar plant workers, roofers, road maintenance workers, and construction workers are at risk. Coal tar derivatives are not only acnegenic but also carcinogenic and photosensitizing. A phototoxic reaction may also occur and cause hyperpigmentation, known as coal tar melanosis. Pitch and tar papillomas, keratoses, and acanthomas may develop as a late complication.[86] Pitch acne is also treated with standard acne vulgaris therapies. Prevention includes good exhaust ventilation systems in the workplace and wearing clean uniforms and protective coverings, as well as showering at the end of shifts.

ACNE MECHANICA. Repeated or prolonged physical insults to the skin from pressure, occlusion, friction, rubbing, or heat may provoke acne lesions by inducing the rupture of microcomedones, an eruption that can be strikingly inflammatory. Occupational cases may appear under face masks in hospital workers or cleanroom workers in the semiconductor industry, and under belts, straps, tight-fitting work clothing, football shoulder pads and helmets, hats and telephones. Fiddler's neck and violinist's neck is also a variant.[87]

Clinically, crops of inflammatory papules and pustules appear in affected areas of skin. Deep, inflammatory nodules may result from prolonged pressure. It has been emphasized that acne mechanica is a complication of acne vulgaris and that external physical forces merely exacerbate the underlying disease focally.[88] Improvement of mechanical acne may occur promptly after removing the source of mechanical and physical factors. Skin washing and use of topical cleansing agents may reduce the risk of acne mechanica.

CHLORACNE. (See Chapter 80.) Chloracne, the most clinically striking form of acne, is one of the most sensitive indicators of occupational or environmental exposure to toxic halogenated aromatic hydrocarbons, which share relative molecular planarity, and which typically occur as trace contaminants during synthesis of industrial chemicals. Exposure can be percutaneous or by inhalation or ingestion and is a cutaneous sign of potential systemic toxicity. One of the most potent inducers of chloracne is 2,3,7,8-tetrachlorodibenzo-*p*-dioxin (TCDD), which has been identified in multiple industrial outbreaks as well as in putative poisoning cases in Austria and the Ukraine.[89,90] Other chloracnegenic chemicals include other halogenated dioxins, naphthalenes, biphenyls, dibenzofurans, azobenzenes, and azoxybenzenes, with the chloracnegenic potential being closely correlated with the potential to induce the enzyme aryl hydrocarbon hydroxylase (AHH)91 and are listed in eTable 212-3.2 in online edition.[92]

In 2009, a new chloracnegen was reported from the United Kingdom in an outbreak of chloracne among seven male pharmaceutical discovery chemists, who synthesized novel polycyclic halogenated chemical compounds classified as triazoloquinoxalines. As with dioxins, the triazoloquinoxalines were synthetic intermediates in the project, being synthesized in small-scale (mg/g) quantities. Toxicological investigations found that the triazoloquinoxalines showed high activity in the chemically activated *luciferase* gene expression (CALUX) cell bioassay for estimation of dioxin-like activity and were several times more chloracnegenic than dioxins on a weight for weight basis. Triazoloquinoxalines also showed the basic structural features and physiochemical properties that are typical of chloracnegens, such as high metabolic stability, a polycyclic structure, a lipophilic nature, and the potential to be halogenated.[93]

Clinically, the distribution is characteristic, with multiple closed comedones and straw-colored cysts primarily over the malar crescents and retroauricular folds, sparing the nose; the posterior neck, trunk, and extremities as well as the buttocks, scrotum, and penis may also become involved. TCDD impairs differentiation of keratinocytes.[94] Polychlorinated biphenyls (PCBs) and TCDD cause follicular hyperkeratosis and palmoplantar hyperhidrosis. PCBs can also cause skin, mucus membrane, and nail hyperpigmentation, as well as conjunctivitis. Ingestion alone of PCBs and their thermally degraded polychlorinated dibenzofurans (PCDFs) caused chloracne in two mass nonoccupational "oil-poisoning" episodes, one in Japan in 1968 and the other in Taiwan in 1979, the largest

epidemics of chloracne to date. Subsequent clinical studies showed that the causative PCBs and furans were transplacental dermato- and neuroectodermal toxins causing nail dystrophy and dental abnormalities and growth and developmental delays.[95–97]

Findings in the pathogenesis of chloracne include a reduction in sebum excretion as a hallmark of the disorder along with fewer *Propionibacterium acnes* organisms in the follicles as compared with acne vulgaris.[98] Dioxins, for example, TCDD have been shown to impede androgen action possibly through interfering with androgen receptors.[93] The biological mechanisms of chloracne induction are still debated but it was suggested that dioxins exert their chloracnegenic effect by activating skin stem cells and shifting the differentiation commitment of the stem cell progeny.[99]

One of the most important initial steps in chloracne pathogenesis and toxicity of dioxins is the activation of the AHH receptor, a transcription factor that binds to the Ah receptor nuclear translocator (ARNT) to regulate the transcription of numerous genes, including *cytochrome P450 CYP1A1*, *GSTA1*, and *TGF*-α. These changes of gene expression play critical roles in the cornification and epidermal barrier of the skin and may disturb normal proliferation and differentiation of human epidermal cells.[100,101]

It has been demonstrated that all of these responses are opposed by ligand-activation of the epidermal growth factor (EGF) receptor (R), an important regulator of keratinocyte cell fate. EGF represses the dioxin-mediated gene transcription induction of *CYP1A1* in cultured normal human keratinocytes by inhibiting the recruitment of the transcriptional coactivator protein p300 to the *CYP1A1* gene. EGF also inhibits the dioxin-dependent induction of certain parameters in keratinocytes that are reflective of dioxin-induced chloracne. This EGFR signaling may modulate the incidence and severity of chloracne and be of potential therapeutic relevance to human poisonings by dioxin.[102]

Chloracne tends to resolve slowly upon cessation of chemical exposure. Its duration correlates with the severity of the disease that usually reflects the degree and extent of exposure. Dioxins are highly lipophilic, have a long half-life in fat tissue and low turnover rate in the body.

The modalities that are useful in acne vulgaris are often ineffective in chloracne. Topical application of retinoic acid (0.005%–0.3% concentration) gel or cream is of some benefit in controlling comedones, but other topical agents are of little use.[103] A combination of tetracycline and short courses of orally administered prednisone may help with severe inflammatory cases. There are anecdotal reports of both unsuccessful and efficacious use of oral 13-*cis*-retinoic acid (isotretinoin),[103] which, if instituted early, may prevent cyst formation. Local therapy with acne surgery and dermabrasion has been reported. Light cautery following topical anesthesia with EMLA cream has been used successfully in six patients with resistant chloracne lesions.[104]

Olestra, a nonabsorbable, nondigestible, lipophilic dietary fat substitute has been reported to accelerate the patients' intestinal excretion of TCDD by eight- to tenfold. Sufficiently to reduce the normally observed elimination half life of TCDD from about 7 years to 1 to 2 years.[105]

Based on clinical findings alone, it may be difficult to differentiate chloracne from early acne vulgaris (eTable 212-3.3 in online edition) and solar comedones (Favre–Racoucht syndrome). Scarring may be mild to severe, depending on the degree of chemical exposure and skin involvement.[106,107] eTable 212-3.4 in online edition differentiates chloracne from other types of environmental acne such as oil folliculitis, pitch acne, and tropical acne.[53]

OCCUPATIONAL SKIN CANCER

The first cancer to be linked to an environmental exposure was scrotal cancer in chimney sweeps, reported by Sir Percivall Pott in 1775. The percentage of skin cancers induced by the work environment is disputed; some studies suggest that it is as high as 70% to 80%,[108] but other studies indicate a much lower percentage.[109] The common causative agents implicated in occupational skin cancers and occupations with potential exposure are listed in Table 212-4.

ULTRAVIOLET LIGHT. (See Chapters 112 and 113.) Ultraviolet (UV) radiation acts as both a tumor initiator and tumor promoter. Most studies report a significant association between work-related sun exposure and skin cancer[110] as well as actinic keratoses[111] (see eFig. 212-2.1 in online edition), but other studies have found no definite association[112] or a very slight increased risk,[113] perhaps because of greater self-selection for indoor jobs among those with fair skin and a tendency to burn compared to those with less-susceptible skin types.[114]

Exposure to UV radiation, particularly UVB light, is thought to play a critical role in the pathogenesis of malignant melanoma (see Chapter 124),[115] although some studies do not show an increased risk of

TABLE 212-4
Agents Inducing Occupational Skin Cancers and Industries Presenting Exposure Risk[51–75]

Causative Agent	Industries/Activities with Potential Exposure
Polycyclic aromatic hydrocarbons	Coal gasification, aluminum production, iron and steel foundries, coke production, shale oil extraction, tar distilling, asphalt and roofing material work, wood impregnation
Arsenic	Glass working; copper, zinc, and lead smelting; pesticide and herbicide production; semiconductor industry
Ultraviolet light	Outdoor work, welding
Ionizing radiation	Nuclear power plants, radiography, uranium mining

developing melanoma in outdoor workers compared to indoor workers.[116] This is consistent with the epidemiologic link of melanoma to intermittent intense UV exposures, more often experienced in association with vacations or recreational activities than employment. However, a recent study of patients diagnosed with melanoma residing in close proximity to one another in Connecticut attempted to assess the impact of chronic ambient ultraviolet B radiation in the development of their cancers. The study quantified average UV radiation at that latitude utilizing calibrated meteorological equipment and controlled for intermittent sun exposure based on patient history and utilizing regression analysis. The authors concluded that chronic exposure to UV radiation may play an additive role to intermittent intense sun exposure and may indeed be an independent risk factor for the development of melanoma.[117] No large studies of a clear association of malignant melanoma with occupational exposure corroborate these findings. Nonoccupational exposures to nonsolar radiation, such as UV lamps and tanning beds, is reportedly associated with an increased risk of melanoma.[118]

A recent review found a statistically significant increased risk of malignant melanoma in patients who worked at petroleum-refining plants and were exposed to petroleum hydrocarbons and solvents such as polycyclic aromatic hydrocarbons (PAHs), polychlorinated biphenyls (PCBs), benzene, aromatic hydrocarbons, and heavy oils.[119] A potentially causal relationship between the occupational exposure and melanoma was postulated given the higher prevalence of melanoma in these workers on nonsun-exposed sites. In another longitudinal analysis from 1946 to 2002 conducted at one of the world's largest tar refineries, an increased prevalence of nonmelanoma skin cancers, and cancers developing in atypical sites such as the nasal epithelium, was documented. The study also reported several cases of malignant melanoma in these workers, but it is unclear if their rate of developing melanoma was higher than expected in the general population.[120]

The association between squamous cell carcinoma (see Chapter 114) and cumulative UV exposure is stronger, which makes outdoor occupations a significant risk factor. However, other occupational exposures, such as exposure to chemical carcinogens, may also play a critical role,[121] and an additive effect cannot be excluded.

To determine the role of the workplace in the development of actinic skin damage and skin cancer, one must consider a detailed occupational history with job descriptions from earliest employment, as well as nonoccupational activities, hobbies and sports, and other recreational pursuits, including those in which the patient engaged at a younger age.

POLYCYCLIC AROMATIC HYDROCARBONS. Exposure to polycyclic aromatic hydrocarbons (PAHs) accounts for most of the reported occupational skin tumors.[122] PAHs are hydrophobic, nonpolar compounds that form DNA adducts[120] and act as complete carcinogens.[123] Coal tar and petroleum products such as tar, pitch, coke, carbon black (soot), creosote, anthracene, crude paraffin, asphalt, fuel and diesel oils, lubrication and coolant oils, and untreated mineral oils, as well as oils, waxes, and tars from the distillation products of shale oil and lignite, contain PAHs.[124] High occupational exposures to PAHs can occur in several industries and occupations (see Table 212-4), and workers can be exposed to PAHs through inhalation or skin contact. The risk for melanoma, as well as internal cancers, has been reported to be increased in oil refinery workers.[125]

An association between scrotal cancers and the use of cutting oils has been noted, probably related to the addition of shale oil.[126] Used engine oil has also been associated with a case of extramammary Paget disease of the scrotum and groin in a patient with longstanding occupational exposure.[127] Creosote used in wood treatment has been suggested as a cause of skin and lip cancer when associated with sunlight exposure.[128] Roofers and road pavers are also at increased risk for skin cancers and internal cancers due to the potential carcinogenicity of bitumen and of PAHs from coal tar products.[129] Tar refinery workers are at increased risk of developing nonmelanoma skin cancers, mainly on facial areas, forearms, and hands.[130] Use of topical tar products to treat dermatologic disease has been suggested to pose a skin cancer risk but has never been documented to do so.

ARSENIC. Arsenic-containing drinking water is clearly associated with various skin and internal organ malignancies.[131] The methylated, trivalent form of arsenic is more toxic than the pentavalent form.[132] Although arsenic induces chromosomal abnormalities in experimental systems and human tissues, it does not induce cancers in animal models.

Long-term arsenic exposure may lead to arsenical keratosis, squamous cell carcinoma, basal cell carcinomas, and Bowen disease. Merkel cell carcinoma has also been reported in a person with chronic arsenicalism.[133] Table 212-4 lists occupations at risk for exposure to arsenic.

IONIZING RADIATION. (See Chapter 240.) Exposure to ionizing radiation has been known to be a cause of occupational skin cancer since the early 1900s. Atomic bomb survivors have an increased risk of developing basal cell carcinoma.[134] X-ray-induced skin cancers appear to be associated with a higher frequency of multiple skin lesions, recurrences, and major surgical sequelae[135] (Fig. 212-3). There have been reports of a high prevalence of melanoma among airline pilots and flight attendants exposed to cosmic radiation; however, some observers feel that this association is due to lifestyle effects.[136]

DIAGNOSIS, TREATMENT, AND PREVENTION

General concepts in the diagnosis, treatment, and prevention of occupational skin disorders are discussed in Chapter 211.



Figure 212-3 Radiodermatitis and squamous cell carcinoma in a woman who had worked as an X-ray technician for years, holding young patients still during X-ray examinations, including fluoroscopy, but without protection.

KEY REFERENCES

Full reference list available at www.DIGM8.com

DVD contains references and additional content

26. Haddad V Jr. et al: Tropical dermatology: Marine and aquatic dermatology. *J Am Acad Dermatol* **61**(5):733-750; quiz 751–752, 2009
37. Centers for Disease Control and Prevention: Updated U.S. Public Health Service guidelines for the management of occupational exposures to HIV and recommendations for postexposure prophylaxis. *MMWR* **54**(RR-9)1-17, 2005; http://www.cdc.gov/mmwr/PDF/rr/rr5409.pdf
66. Mathias CGT: Post-traumatic eczema. *Dermatol Clin* **6**:35, 1988
83. Bjorkner BE: Industrial airborne dermatoses. *Dermatol Clin* **12**:501, 1994
87. Omohundro C, Taylor JS: Occupational acne. In: *A Colour Handbook of Occupational Dermatology*, edited by JSC English. London, Manson, 1998, pp. 121-134
101. Tang NJ et al: Expression of AhR, CYP1A1, GSTA1, c-fos and TGF-alpha in skin lesions from dioxin-exposed humans with chloracne. *Toxicology Letters* **177**(3):182-187, 2008
136. Ramirez CC, Federman DG, Kirsner RS: Skin cancer as an occupational disease: The effect of ultraviolet and other radiation. *Int J Dermatol* **44**:95, 2005

SECTION 35

The Skin in Bioterrorism and Biologic Warfare

Chapter 213 :: Cutaneous Manifestations of Biologic, Chemical, and Radiologic Attacks

:: Scott A. Norton & Jeffrey N. Lackey

BIOLOGIC, CHEMICAL, AND RADIOLOGIC TERRORISM ATTACKS AT A GLANCE

- Potential biologic weapons are classified by the Centers for Disease Control and Prevention into Category A, B, and C levels of risk.
- Category A comprises smallpox, anthrax, plague, tularemia, botulism, and viral hemorrhagic fevers.
- Category B comprises a large number of pathogens ranging from *Brucella* and *Listeria* to the toxins produced by *Clostridium perfringens*.
- Category C comprises a number of viruses, rickettsioses, multidrug-resistant tuberculosis, and rabies.
- Chemical weapons are categorized into blistering agents (such as sulfur mustard), nerve agents, blood agents, urticating agents, and incapacitating agents.
- Radiologic weapons include what is called a *dirty bomb*, which produces low levels of radiation contaminating an entire zone.

The bombings of the World Trade Center's twin towers on September 11, 2001, and the spate of anthrax cases that soon followed introduced new responsibilities to the medical and public health communities.[1–3] Physicians now have a societal responsibility to know the principles of responding to outbreaks of disease caused by biologic weapons. The dermatologist's role in recognizing bioterrorism is particularly significant because many pathogens produce illnesses with prominent cutaneous findings.[4,5] The dermatologic aspects of smallpox, for example, are the most obvious and dramatic aspects of the disease. Other conditions, such as anthrax, frequently—although not always—manifest in the skin. It is likely that the diagnosis of an index case of a bioterror outbreak will rest on dermatologic findings, subtle or overt.

Public health authorities recognize that terrorism may involve other sorts of unconventional weapons, including chemical and radiologic weapons. This chapter provides an overview of the manifestations of unconventional weapons that terrorists might use.

BIOLOGIC WEAPONS

The Centers for Disease Control and Prevention (CDC) stratified potential bioweapons into three levels of risk (Tables 213-1, 213-2 and 213-3) based on ease of manufacture, ease of dissemination, subsequent person-to-person transmission, lethality, and psychosocial effects (literally, how terrified a community will be). When an organism is intentionally dispersed as part of warfare, terrorism, or criminal activity, a goal is to infect huge numbers of people. Hence, the dispersal system may be engineered to disseminate the disease widely, often as airborne spread that results in pulmonary or inhalational disease. Some—but not all—of the pathogens are then transmissible from person to person, thereby potentiating the public health effects of—and the terror associated with—biologic weapons.

CATEGORY A AGENTS AND DISEASES

(Table 213-1)

ANTHRAX. (See Chapter 183.) In late 2001, an outbreak of 22 cases in several states along the Eastern Seaboard of the United States was due to an intentional, criminal act of bioterrorism.[10,11] The outbreak occurred when envelopes of spores were distributed through the postal system, contaminating many offices and infecting mail handlers and letter recipients. Initially, it was thought the anthrax spores were finely engineered into an easily aerosolized form, but more recent examinations suggest that even crudely milled spores can cause such an outbreak. The Federal Bureau

TABLE 213-1

Biologic Agents or Diseases Most Likely to be Used in Terrorism or Warfare (Centers for Disease Control and Prevention and National Institutes of Health Category A Agents or Diseases)[a]

Disease	Pathogen or Agent	Weaponized Route of Transmission	Cutaneous Findings	Percent with Cutaneous Findings in Bioterror Attack	Chapter in *Dermatology in General Medicine*
Smallpox	*Variola*	Airborne, then person to person.	Enanthem followed by classic vesicopustular eruption.	All	195
Anthrax	*Bacillus anthracis*	Airborne. No person-to-person transmission.	Edematous papule or plaque evolving into an ulcer surmounted by a black eschar.	Roughly 50%, based on 2001 experience	183
Plague	*Yersinia pestis*	Airborne, then person to person.	None in pure pulmonary form. Distal purpura and gangrene in septicemic form. Buboes in bubonic form.	Not known	183
Tularemia	*Francisella tularensis*	Airborne without subsequent person-to-person transmission.	None in pure pulmonary form. Membranous pharyngitis and oropharyngeal ulcers in oropharyngeal form. Ulceroglandular syndrome.	Not known	183
Botulism	Toxin produced by *Clostridium botulinum*	Airborne, less likely through intentional contamination of food or water. No person-to-person transmission.	Cranial nerve palsies followed by descending paralysis that spares sensation and cognition. Xerostomia, facial palsies, pupils fixed and dilated.	Possibly 100% will have xerostomia, facial palsies, and fixed and dilated pupils	183
Viral hemorrhagic fevers	Examples include filoviruses, such as Ebola and Marburg; arenaviruses, such as Lassa, Junin, and Machupo; flaviviruses, such as dengue; and bunyaviruses, such as hantavirus and Rift Valley fever	Airborne, then possible subsequent transmission depending on agent. Dengue, e.g., is transmitted by the mosquito *Aedes aegypti*.	Petechiae, purpura, and frank hemorrhage.	Not known	—

[a]Category A diseases or agents are the highest priority because they can be easily disseminated or transmitted from person to person, result in high mortality rates and have the potential for major public health impact, might cause public panic and social disruption, and require special action for public health preparedness.

TABLE 213-2
Centers for Disease Control and Prevention and National Institutes of Health Category B Agents or Diseases[a]

Disease	Pathogen or Agent	Cutaneous Findings	Chapter in *Dermatology in General Medicine*, 8th Edition
Brucellosis	*Brucella* sp.		183
Glanders	*Burkholderia mallei*		183
Melioidosis	*Burkholderia pseudomallei*		183
Typhus	*Rickettsia prowazekii*		199
Water safety threats	Examples include bacteria (e.g., *Vibrio cholerae)*, viruses (e.g., Norwalk virus) and protozoa (e.g., *Cryptosporidium parvum*)	Usually none	
Food safety threats	Examples include *Listeria monocytogenes* and *Escherichia coli* O157:H7	Rare	
Psittacosis	*Chlamydia psittaci*	None	
Q fever	*Coxiella burnetii*	None	
Ricin poisoning	Prepared from *Ricinus communis* (castor beans)	None	
Staphylococcal enterotoxin B		None	
Viral encephalitis	Examples include α viruses that cause equine encephalitides	Rare	
Clostridium perfringens toxin	Epsilon toxin of *C. perfringens*	None	

[a]Category B diseases and agents are the next highest priority because they are moderately easy to disseminate; result in moderate morbidity rates and low mortality rates; and are not part of the Centers for Disease Control and Prevention's routine surveillance system.[6–8]

of Investigation now believes that the perpetrator was a scientist working at the US Army's infectious disease laboratory at Fort Detrick, MD. The motive, however, remains unknown.

THE EASY WEAPONIZATION OF THIS HIGHLY LETHAL AGENT MAKES IT ONE OF THE MOST FEARED BIOLOGIC WEAPONS.

During the Cold War, several nations were known to have produced massive quantities of weaponized anthrax, evidence of which became widely known after a 1979 mishap at the Soviet Union's Sverdlosk bioweapon facility. A cloud of anthrax spores was accidentally released and dozens of people downwind died from inhalational anthrax. The Sverdlosk disaster, however, led to the notion that weaponized anthrax caused only inhalational illness. The letter-borne anthrax incidents of late 2001 showed otherwise when only 11 of the 22 victims had inhalational disease, four of whom died. The others had cutaneous anthrax.

Clinical Findings. Inhalational disease can have longer incubation periods than cutaneous disease, perhaps as long as 40–60 days. If a person is on antibiotics (for another reason or for anthrax prophylaxis), *Bacillus anthracis* may remain in its more protected spore form until the antibiotics are discontinued. The initial symptoms of inhalation anthrax are flu-like and nonspecific, characterized by fever, fatigue, and malaise, but soon followed by chills, high fever, nonproductive cough, and dyspnea. Cyanosis, shock, multiorgan failure, and death may ensue. Chest radiographs characteristically show symmetric mediastinal widening due to hemorrhagic lymphadenitis of mediastinal nodes. In inhalational disease, as well as in septicemic anthrax, which may follow cutaneous or gastrointestinal anthrax, bacteremia may lead to fulminant meningitis.[10,11,14,15]

Patients with inhalational anthrax often present initially with a flu-like illness that progresses virulently into severe febrile illness accompanied by tachypnea, stridor, and cyanosis. In inhalation anthrax, the chest X-ray shows significant mediastinal widening and hilar adenopathy because of edema and hemorrhagic necrosis of draining nodes. The pulmonary parenchyma is usually spared; hence, the disease is identified as *inhalational anthrax*, not pulmonary anthrax.[12]

Diagnosis. The acute onset of a painless edematous noduloulcerative lesion with a black eschar should elicit the possible diagnosis of cutaneous anthrax, especially in the epidemiologic setting of exposure to imported animal products, recent travel to endemic areas, or presence of known use of weaponized anthrax (see Fig. 183-1 and eBox 213-0.1 in online edition).[16]

TABLE 213-3

Examples of Centers for Disease Control and Prevention and National Institutes of Health Category C Agents or Diseases[a]

- Nipah virus
- Hanta virus
- Tick-borne hemorrhagic fever virus, specifically Crimean–Congo hemorrhagic fever[b]
- Tick-borne encephalitis complex
- Yellow fever[b]
- Avian influenza virus and severe acute respiratory syndrome virus[c]
- Multidrug-resistant tuberculosis
- Rabies
- Other rickettsioses (e.g., those caused by *Rickettsia typhi, Rickettsia conori, Rickettsia rickettsia, Orientia tsutsugamushi*)

[a]Category C agents or diseases include emerging pathogens that could be engineered for mass dissemination in the future because of availability, ease of production and dissemination, and potential for high morbidity and mortality rates and major public health impact.[6,7,9] Category C agents and diseases generally lack specific dermatologic findings.

[b]Yellow fever virus and most hantaviruses can cause thrombocytopenia, hemorrhage, and hemodynamic instability that can lead to mucosal bleeding.

[c]The H5N1 strain of influenza A virus (avian influenza) and severe acute respiratory syndrome virus have the potential for rapid, widespread, human-to-human transmission, with high morbidity, mortality, and disruption to societal order.

An additional clinical clue is the presence of edema vastly out of proportion to the observed size of the cutaneous lesion. Diagnostic steps include obtaining swabs of exudates for Gram stain and culture, biopsy specimens for histopathology and immunohistochemical staining, and to draw blood samples for culture and serology. *The CDC requests that practitioners notify local or state health departments before attempting a laboratory diagnosis of cutaneous anthrax.*

The diagnosis is usually suspected on the basis of the character of the lesion and the occupational history, hobby exposure, or likelihood of bioterrorism. Demonstration of large Gram-positive rods in aspirated fluid from beneath the eschar, or on skin punch biopsy, also using a direct fluorescent antibody technique supports the diagnosis. Definitive diagnosis requires culture of the organism and demonstration of its susceptibility to specific bacteriophage lysis. Occasionally, the organism can be isolated from the blood during the acute cutaneous illness as well as in disseminated anthrax. Retrospective serodiagnosis is possible with the demonstration of a titer rise in electrophoretic immunotransblots of antibody to protective antigen and enzyme-linked immunosorbent assay for detection of antibodies to a particular toxin called *lethal factor*.

Therapy. Naturally occurring anthrax is susceptible to penicillin and doxycycline but weaponized anthrax may have been engineered to be resistant to these antibiotics. Therefore, a fluoroquinolone such as ciprofloxacin is recommended for initial treatment of confirmed or suspected anthrax, even in pregnant women and children in whom this class of antibiotic is rarely administered. Once drug sensitivities have been established, the patient may be switched to another antibiotic as clinically indicated. Current treatment of cutaneous anthrax in adults in the setting of bioterrorism involves the use of ciprofloxacin (500 mg po bid) or doxycycline (100 mg po bid) for 60 days because possible coexposure to inhaled anthrax spores.[10,11] Antibiotics kill activated *B. anthracis* bacilli but do not reverse the effects of toxins already produced. For that, one must use anthrax Immunoglobulin (AIG).

Two types of vaccine are available for immunization against anthrax.[7] The first vaccine (anthrax vaccine adsorbed, AVA) is licensed for human use in the United States to protect workers in occupations that might expose them to *B. anthracis*. Since 1998, it has often been given to members of the Armed Forces of the United States. It can also be used as part of a postexposure prophylactic regimen. The vaccine is a sterile culture filtrate (composed primarily of protective antigen) of an attenuated strain of *B. anthracis* adsorbed to an aluminum hydroxide adjuvant and administered in five doses over 18 months. The second vaccine is for immunization of livestock against anthrax and consists of viable spores of an attenuated, nonencapsulated, toxigenic strain.

PLAGUE. (See Chapter 183.) Plague is caused by *Yersinia pestis*, an aerobic Gram-negative bacillus with "safety-pin" bipolar staining (see Chapter 183). In nature, plague is usually limited to enzootic cycles between rodent reservoirs and flea vectors. Most human infections occur via fleabites and typically lead to bubonic plague, which is highly lethal but generally not communicable to others. In naturally occurring disease, human-to-human transmission occurs mainly if the patient's condition changes from bubonic form of plague to the pneumonic form. Once in the lungs, the pathogens are dispersed within droplets that others inhale, leading to additional cases of pneumonic plague. This form of plague is more deadly than bubonic, having a fatality rate among untreated cases that approaches 100%. Hence, deliberate spread of aerosolized plague bacteria could kill massive numbers of people.[19,20]

The Japanese military tested plague as a biological weapon during the occupation of Manchuria before and during World War II. Rather than spreading the bacteria via airborne routes, the Japanese allegedly distributed common fleas—*Pulex irritans*—that had been infected with *Yersinia pestis*.[19]

Pneumonic plague does not produce buboes, which are the result of transcutaneous transmission via fleabites. Instead, pneumonic plague produces skin lesions if it evolves into septicemic plague. Then the patient may develop acral ecchymoses and distal gangrene, often accompanied by disseminated intravascular coagulation. These lesions resemble purpura fulminans, septic emboli, or meningococcemic purpura, and possibly gave rise to the term *Black Death*.

Plague in any form is a reportable disease in every jurisdiction worldwide. Confirmatory laboratory tests include culture of *Y. pestis* from a clinical specimen or

detection by polymerase chain reaction. Serologic tests are not useful in the acute setting.[21]

In the event of an outbreak of pneumonic plague, the keystone of protection is isolation of cases and the use of prophylactic antibiotics, specifically doxycycline, a quinolone such as ciprofloxacin, chloramphenicol, or cotrimoxazole. The human vaccine against plague has been withdrawn. For cases, the preferred regimen is parenteral gentamicin combined with oral (see Table 180-1).

TULAREMIA. (See Chapter 183.) Tularemia, like plague, ordinarily exists in enzootic cycles and infects humans most commonly after an arthropod bite. The usual arthropod vector to transmit tularemia is a tick (such as *Dermacentor andersoni, D. variabilis*, or *Amblyomma americanum*) and less commonly a deerfly, *Chrysops discalis*, or in Northern Europe, certain mosquitoes. Furthermore, like plague, tularemia occasionally presents in a pulmonary form, with the pathogens entering the lungs either through septicemic spread from a lymphocutaneous focus, or directly through the inhalation of aerosolized bacteria. The infectious inoculum for *Francisella tularensis* is extremely small, perhaps as few as 50 organisms.[22,23] Because pneumonic tularemia is highly lethal, the intentional dispersal of airborne organisms has the potential to cause devastating outbreaks of disease. Unlike pneumonic plague, however, pulmonary tularemia cannot be spread from person to person.

Clinical Findings. Tularemia can be acquired through several routes and present in several clinical forms. Pulmonary tularemia, which presumably would be the main form seen after intentional airborne spread, lacks cutaneous lesions. Airborne spread could, however, lead to other forms of the disease, such as oculoglandular and gastrointestinal, which in some cases have mucocutaneous findings.

Treatment. Tularemia is a reportable disease and any pulmonary case or cluster of other cases should launch an epidemiologic investigation. In the event of an outbreak of pneumonic tularemia, health authorities should consider community prophylaxis with doxycycline or ciprofloxacin. Streptomycin (or in its absence, gentamicin) treats all forms of tularemia successfully when administered early in the course of the disease. Clinical improvement is evident within 24–48 hours, but treatment should be continued for at least 7–10 afebrile days. Tetracycline and chloramphenicol are acceptable alternatives but should be given for longer periods than 21 and 14 days, respectively, to reduce the risk of relapse.[23] In the United States, the National Institutes of Health and the Department of Defense are funding development of a newer vaccine.

SMALLPOX. For epidemiology, etiology, and pathogenesis, clinical manifestations, prognosis, and vaccination see Chapter 195.[24–27]

After the World Health Organization declared that naturally occurring smallpox was eradicated, laboratories worldwide destroyed their stocks of variola—except for a few facilities that maintained small amounts of virus, putatively for research purposes. With the collapse of the Soviet Union and the dismantling of its military medical research system, there have been concerns that rogue states or terrorist organizations have obtained unmonitored stocks of virus. Any recurrence of smallpox represents a catastrophic medical, public health, and criminal event of extraordinary proportions.

The differential diagnosis of smallpox and varicella is described in eBox 213-0.2 in online edition.

The CDC has an algorithm for the evaluation of suspected smallpox and offers a differential diagnosis. The algorithm, *Evaluating patients for smallpox: acute, generalized vesicular or pustular rash illness protocol* (available at http://www.bt.cdc.gov/agent/smallpox/diagnosis/pdf/spox-poster-full.pdf), identifies three features at the core of a clinical diagnosis of smallpox (Box 213-1).[28]

Dermatologists who serve as bioterrorism resources for their communities or hospitals must become familiar with smallpox vaccination programs. Vaccinia, an orthopoxvirus related to smallpox and to the cowpox originally used in Jenner inoculations, can produce several cutaneous adverse effects, which require some expertise to diagnose and manage. These conditions are reviewed in detail in Chapter 195.

BOX 213-1 CORE FEATURES IN THE CLINICAL DIAGNOSIS OF SUSPECTED SMALLPOX

- Febrile prodrome occurring 1–4 days before rash onset with fever ≥38.3°C (101°F) and at least one of the following: prostration, headache, backache, chills, vomiting, or severe abdominal pain.
- Classic smallpox lesions are deep-seated, firm or hard, round, well-circumscribed vesicles or pustules that are sharply raised and feel like small, round objects embedded under the skin. As they evolve, the lesions may become umbilicated or confluent.
- Lesions in the same stage of development: On any one part of the body (e.g., face or arm), all lesions are in the same stage of development—that is, all are vesicles or all are pustules.

CATEGORY B AGENTS AND DISEASES WITH POSSIBLE CUTANEOUS MANIFESTATIONS

(Table 213-2.)

BRUCELLOSIS. (See Chapter 183.) Brucellosis is a zoonotic infectious disease that is usually transmitted to humans by direct contact with infected animals or animal products or by ingestion of contaminated dairy products. It can also be transmitted via aerosolized

propagules and requires a small inoculum, perhaps 10–100 organisms, to cause human disease. Hence, it is regarded as a possible biologic weapon. Indeed, during the Cold War, the United States and other nations allegedly experimented with the weaponization of *Brucella suis*.[8,29,30]

Deliberate spread of aerosolized bacteria would cause pulmonary disease, which has a mortality rate, even when untreated, of less than 5%. The disease can cause profound fatigue and requires prolonged treatment; hence, victims could be incapacitated for months. Subsequent human-to-human transmission will not occur. Cutaneous manifestations of brucellosis are uncommon and nonspecific and are discussed in detail in Chapter 183.

MELIOIDOSIS AND GLANDERS. (See Chapter 183.) Melioidosis and glanders are clinically similar diseases caused by the related bacteria *Burkholderia pseudomallei* and *Burkholderia mallei*, respectively. The clinical presentations of the two illnesses are similar but the pathogens have markedly different environmental niches. Glanders naturally occurs in horses, donkeys, mules, and other equids—although it is extremely rare worldwide today. Melioidosis is found in fresh water and damp soils in tropical regions, notably Southeast Asia, particularly Singapore and northeast Thailand, and in the coastal areas of northern Australia.[31,32]

As biologic weapons, these organisms would be disseminated in aerosols to cause respiratory outbreaks. Only a small inoculum of either is required to cause illness. The incubation period is roughly 10–14 days, and the subsequent pulmonary disease has a mortality rate of more than 95% untreated or approximately 40% when treated with appropriate antibiotics. Pulmonary disease can lead to bacteremia or septicemia, which can produce cutaneous and subcutaneous abscesses (see Chapter 183).[32–34]

The first case of human glanders in the United States in more than 50 years was reported in 2002 in a microbiologist who was inadvertently exposed at an Army Research Laboratory. He developed axillary lymphadenopathy and bacteremic infection with hepatic and splenic abscesses but responded well to prolonged treatment with imipenem and doxycycline.[35]

CATEGORY C BIOWEAPONS

(See Table 213-3.)

Category C is an expanding list of diseases, mostly caused by emerging pathogens that could possibly be engineered for mass dissemination and major public health impact.[9] The number of diseases in Category C continues to expand as new diseases, such as severe acute respiratory syndrome, avian flu (caused by the H5N1 strain of influenza A virus), and Nipah virus infection are recognized for their potential for high morbidity, mortality, and societal disruption.[9]

Most diseases currently in Category C lack specific dermatologic findings. In nature, many are arthropod-borne viral hemorrhagic fevers that present with the systemic effects of vascular compromise, widespread hemorrhage, and hypovolemic shock. These conditions are often accompanied by cutaneous manifestations of thrombocytopenia and hemorrhage, namely petechiae, purpura, and frank bleeding from orifices and mucosal surfaces. The most severe of these, Crimean–Congo hemorrhagic fever caused by a bunyavirus, is usually transmitted by hard ticks in the genus *Hyalomma*. Several other pathogens, such as yellow fever virus, are transmitted by mosquitoes. If—or when—used for bioterrorism, Category C pathogens will likely be transmitted by aerosolization, contamination of drinking or food supplies, or in ways yet to be engineered.

CHEMICAL WEAPONS

(Table 213-4.)

Chemical weapons were used on a grand scale during World War I by the Imperial German Army and then by the Allied Forces in response. The morbidity, mortality, and terror associated with these weapons exceeded that of any known conventional weapon.[36] Soon after the 1918 Armistice, international treaties limited—then ultimately banned—the use of chemical agents during warfare. Although these prohibitions are regarded as international law, not all nations have signed and ratified the various treaties. Furthermore, the ban on chemical weapons specifies use during declared wars with adversary nations. The treaties do not, however, explicitly forbid the use of chemical weapons against noncombatants or within one's own country.

The Japanese cult, Aum Shinrikyo, used another chemical weapon, the nerve agent sarin, in Tokyo's subways in an act of domestic terrorism. Although no one was killed, this attack underscores the fact that rogue organizations can obtain or develop their own unconventional weapons.

Chemical weapons are divided somewhat loosely into categories based on their effects on human victims: blister agents, nerve agents, blood agents, urticating agents, choking agents, and incapacitating agents. Table 213-4 identifies prototypical members of the major categories and describes mechanistic and clinical features of these agents. The class with the most severe effects on the skin is that of blister agents.[36,38]

Blister agents, notably sulfur mustard (HD), are the most commonly used chemical weapons. HD was first used during World War I in battles around Ypres, Belgium, hence its other name, *yperite*. Because of a mustard- or garlic-like odor, the compound is often called *mustard gas*. Saddam Hussein's Iraqi military forces used HD against the Iranian army (1980–1988) and against Iraqi citizens in Kurdish villages, such as Halabja.

HD is a relatively simple compound; it can be synthesized by combining two moieties, sulfur dichloride and ethylene. It is inexpensive to manufacture, stable in storage, and can be delivered by many means—therefore, it is likely to be the chemical weapon of choice for a terrorist organization.

HD is an amber-colored, viscous liquid that is lipid soluble, thereby passing easily into and through

TABLE 213-4
Major Categories of Chemical Weapons and Their Major Effects

Class of Agent	Example of Agent	Physical Form of Weaponized Substance	Mechanism of Action	Route of Exposure	Time to Onset of Signs and Symptoms	Nondermatologic Signs and Symptoms	Cutaneous Reactions	Immediate Treatment[a] Includes	Definitive Treatment Includes	Differential Diagnosis
Blood agent	Hydrogen cyanide	Liquid or vapor	Inactivates cytochrome oxidase, thereby preventing cells from using oxygen.	Inhalation, cutaneous, mucosal	Seconds to minutes	Low dose: dizziness, nausea, headache, eye irritation. High dose: loss of consciousness; cessation of respiration.	Often with cherry red skin.	Remove from environment. Remove clothing. Flush skin with copious water. Oxygen.	Oxygen. Amyl nitrite or sodium nitrite, followed by sodium thiosulfate. Respiratory support.	Carbon monoxide poisoning. Hydrogen sulfide (sewer gas) poisoning
Blistering agent	Mustard gas, mustard agent, yperite, sulfur mustard	Liquid or vapor	Alkylating agent (related to medical nitrogen mustard) but precise mechanism in the skin is not known.	Inhalation, cutaneous, mucosal	Hours to days	Red, irritated eyes with conjunctivitis and lid edema. Vomiting. Nasal irritation, cough.	Erythema, pruritus, blistering.	Remove from environment. Remove clothing. Flush skin with copious water or hypochlorite. Irrigate eyes with saline.	No antidote exists. Definitive eye care. Pain relief. Respiratory support. If the blister agent is Lewisite rather than sulfur mustard, use Dimercaprol (British antilewisite).	Exposure to other irritants (e.g., caustics, ammonia, sodium hydroxide)
Nerve agent	Tabun, sarin, VX	Liquid or gas	Inhibits acetylcholinesterase, allowing excess acetylcholine to accumulate (which overstimulates muscles, glands, and nerves) and allowing unrestrained parasympathetic (specifically muscarinic) activity.	Inhalation, cutaneous, mucosal	Vapor: seconds to minutes Liquid: minutes to hours	Pinpoint pupils, lacrimation, asthma-like wheezing, fasciculating muscles, perspiration, hypersalivation, diarrhea. Higher doses: seizures, apnea, loss of consciousness.	Perspiration and piloerection.	Remove from environment. Remove clothing. Flush with copious amounts of water or warm soapy water. Atropine and pralidoxime.	Repeated doses of atropine to reduce secretions. Pralidoxime as needed. Consider diazepam to prevent seizures, inc atropine-induced seizures. Respiratory support.	Organophosphate pesticide poisoning

(continued)

TABLE 213-4
Major Categories of Chemical Weapons and Their Major Effects (Continued)

Class of Agent	Example of Agent	Physical Form of Weaponized Substance	Mechanism of Action	Route of Exposure	Time to Onset of Signs and Symptoms	Nonderma-tologic Signs and Symptoms	Cutaneous Reactions	Immediate Treatment[a] Includes	Definitive Treatment Includes	Differential Diagnosis
Urticating agent	Phosgene, nettle gas, oxime	Gas	Not known.	Inhalation, cutaneous, mucosal	Seconds to minutes	Burning eyes, rhinorrhea, hoarseness, dyspnea, cough.	Immediate pain and severe burning on skin contact. Soon, urticaria-like edema, followed by blisters on day 2. May cause deep necrosis of skin.	Remove clothing. Flush with copious amounts of water or sodium bicarbonate solution.	Supportive burn care.	Exposure to other irritants (e.g., caustics, ammonia, sodium hydroxide)
Choking agent	Phosgene, carbonyl chloride, carbonic acid dichloride	Gas or liquid that vaporizes easily	Not known. Increases permeability of alveolar capillaries leading to noncardiogenic pulmonary edema.	Inhalation	Hours	Dyspnea, chest tightness, wheezing, red mucosa; erythema, causes noncardiac pulmonary edema.	None	Remove from environment. Oxygen. Consider intubation. Flush eyes with water.	Oxygen, respiratory support.	Industrial gas exposure (e.g., ammonia, hydrochloric acid)

[a]Personal protective measures [e.g., chemical hazard suit and protective mask (gas mask)] are usually necessary before one can assist a victim of a chemical weapon attack.

the skin. If HD lands on someone's skin, roughly 80% evaporates quickly, 10% passes through the skin and enters systemic circulation, and 10% remains in the skin. Victims first experience an irritated, gritty feeling in their eyes. This progresses over hours to a chemical conjunctivitis and massive lid edema. Ocular effects can last several weeks and may destroy the cornea or even rupture the globe. Victims also suffer severe nausea and vomiting within several hours of exposure.

The skin starts itching within hours and then develops a diffuse nonspecific erythema later on the first day. Blisters begin to appear at 1–2 days, starting as small vesicles that coalesce to form large, extensive bullae.

HD penetrates the skin within minutes and there is no antidote. Therefore, for decontamination to be effective, it must be started immediately. Responders must don full protective gear (chemical hazard suit and a protective breathing mask) and remove the victim from the contaminated environment. The victim's clothes must be removed completely and the body washed—flooded—with copious amounts of water. Warm soapy water is better and a hypochlorite solution (one part household bleach to nine parts water) is best. The eyes must be flushed with saline.

Subsequent care is largely supportive and the patient feels better when given nonsteroidal anti-inflammatory drugs to counter inflammation and placed in a cool environment. It is necessary to manage fluids and electrolytes and to remain vigilant for secondary infection. In-vivo animal studies suggest that débridement of blisters increases the rate of wound healing, but human studies have not been conducted. Healing is largely a matter of time and leaves persistent dry, itchy, discolored (hypo- and hyperpigmented) skin at the affected areas.[36–42]

RADIOLOGIC WEAPONS

Terrorist organizations are unlikely to possess true nuclear weapons but may have what is known as a *dirty bomb*. This type of weapon presents a radiation hazard by using conventional explosives, such as dynamite, to scatter radioactive debris or dust, which then contaminates an area. Dirty bombs do not trigger nuclear chain reactions but instead produce low levels of radiation. Accordingly, exposed individuals are unlikely to experience acute radiation injury. The immediate effects of a dirty bomb will most likely be due to the force of the blast, which can harm people and destroy property. The lasting effects of a dirty bomb include contamination of a zone, rendering it uninhabitable until the difficult task of area decontamination is complete.

Individuals exposed to radiation from a dirty bomb must rid themselves of lingering radioactive dust or debris. Ideally, this will be conducted at a designated decontamination station. Victims must remove all clothes and then wash their entire bodies thoroughly with soap and water. The decontamination station should contain, collect, and dispose of the clothes and water in a manner that is safe and appropriate for radioactive waste.

In the event of a suspected attack with a chemical or radiologic weapon, medical personnel must coordinate with public health and law enforcement agencies at the local, state, and federal level.[36,40–45]

KEY REFERENCES

Full reference list available at www.DIGM8.com

DVD contains references and additional content

1. Rotz LD et al: Public health assessment of potential biological terrorism agents. *Emerg Infect Dis* **8**(2):225-230, 2002
12. Wright JG: Use of anthrax vaccine in the United States: Recommendations of the Advisory Committee on Immunization Practices (ACIP), 2009. *MMWR Recomm Rep* **59**(RR-6):1-30, 2010
16. Carucci JA et al: Cutaneous anthrax management algorithm. *J Am Acad Dermatol* **47**(5):766-769, 2002
20. Butler T: Plague into the 21st century. *Clin Infect Dis* Sep 1;**49**(5):736-742, 2009
27. Moore ZS, Seward JF, Lane JM: Smallpox. *Lancet* **367**(9508):425-435, 2006
39. CDC: *Cutaneous Radiation Injury (CRI)*, http://www.bt.cdc.gov/radiation/criphysicianfactsheet.asp, accessed Nov 21, 2011.

This page intentionally left blank

PART 11 Therapeutics



Topical Therapy

Chapter 214 :: Principles of Topical Therapy

:: Aieska De Souza & Bruce E. Strober

PRINCIPLES OF TOPICAL THERAPY AT A GLANCE

- The efficacy of a topically applied drug depends on its inherent potency and on its ability to penetrate skin.
- Some factors that affect penetration include: concentration of medication, thickness and integrity of the stratum corneum, frequency of application, occlusiveness of the vehicle, and compliance.
- Topical formulations (vehicles) are meant to enhance the beneficial effects of the medication.
- Either the vehicle or its active ingredient(s) may cause local toxicity.
- Topical medications may induce systemic toxicity.

Sensible topical drug therapy involves not only the selection of an appropriate agent, but also a thoughtful consideration of the areas of the body affected, the state of the diseased skin, the concentration of the drug, the type of vehicle (e.g., ointment, cream, lotion), the method of application, and a defined duration of use that both maximizes efficacy and minimizes adverse side effects. Behind each of these considerations are basic principles that help guide the practitioner toward a rational plan of therapy.

CUTANEOUS DRUG DELIVERY

The therapeutic efficacy of a topical drug relates to both its inherent potency and the ability of that drug to penetrate the skin.[1] In fact, many potent agents, such as hydrocortisone and fluocinolone acetonide, are quite poorly absorbed after topical application. Conversely, many well-absorbed agents with weak potency have negligible therapeutic use. Percutaneous absorption necessitates passage through the stratum corneum, epidermis, papillary dermis, and into the bloodstream. (See Chapter 215 for information on the pharmacokinetics of topical therapy.)

In contrast to many orally administered drugs that are nearly completely absorbed within a few hours, topical medicines generally have a poor total absorption and a very slow rate of absorption. For example, less than 2% of a topically applied corticosteroid such as hydrocortisone is absorbed after a single application left on the skin for more than 1 day. Furthermore, peak rates of absorption are reached up to 12–24 hours after application. Fortunately, low absorption does not necessarily translate into low efficacy. Drugs such as topical corticosteroids are effective because of their inherent potency and can exert clinically significant effects in spite of low absorption. In this light, absorption represents only one of many facets of efficacy.

OTHER FACTORS THAT AFFECT ABSORPTION

STRATUM CORNEUM

The stratum corneum is the rate-limiting barrier to percutaneous drug delivery. This cornified layer is composed of ceramides, free fatty acids, and cholesterol in a 1:1:1 molar ratio. By weight, the stratum corneum consists of 50% ceramides (acylceramides being the most abundant), 35% cholesterol, and 15% free fatty acids. The stratum corneum thickness and, thus, drug penetration will vary depending on body site.[2] Box 214-1 lists varying body sites and their relative resistance to percutaneous absorption.

There are two main routes for permeation through the stratum corneum: (1) the transepidermal and (2) the transappendageal pathways. The transappendageal, or shunt route, involves the flow of molecules through the eccrine glands and hair follicles via the associated sebaceous glands.[3] In the transepidermal route, molecules pass between the corneocytes via the intercellular micropathway, or through the cytoplasm of dead keratinocytes and intercellular lipids, defined as the *transcellular micropathway*.[3,4] The intercellular pathway is considered the most important route for cutaneous drug delivery.

An important consideration in topical therapy is that diseased skin may have an altered (increased, decreased, or absent) stratum corneum, thus changing the body site's barrier function. Abraded or eczematized skin presents less of a barrier. Solvents, surfactants, and alcohols can denature the cornified layer and increase penetration; as a result, topical medications with these components may enhance absorption. Importantly, simple hydration of the stratum corneum enhances the absorption of topically applied steroids by four to five times.[5]

OCCLUSION

Occlusion via closed, airtight dressings or greasy ointment bases increases the hydration and temperature of the stratum corneum, limits rub-off/wash-off of the drug and, consequently, enhances drug penetration. Occlusion techniques range from application under an airtight dressing such as vinyl gloves, plastic wrap, and hydrocolloid dressings to occlusion with cotton gloves or socks at night for treatment of hands and feet, to application of a medication already impregnated into an airtight dressing, as seen in flurandrenolide tape. To derive the greatest benefit from occlusion, the patient should hydrate the skin by immersion in water for approximately 5 minutes before the application of a cream or ointment. Clinically, this may correspond to application immediately after bathing and before drying completely. With many drugs, occlusion increases drug delivery by 10–100 times the amount of drug delivered when not occluded.[6] This approach can lead to more rapid onset times and increased efficacy when compared with topical application alone. On the other hand, occlusion may also lead to a more rapid appearance of the drug's adverse effects, such as the ability of topical corticosteroids to induce local skin atrophy or suppression of the hypothalamus–pituitary–adrenal axis. Occlusion may promote infection, folliculitis, or miliaria. In the case of topical anesthetics such as lidocaine and prilocaine, occlusion hastens absorption into both the skin and the bloodstream, which has led in rare cases to cardiac complications from lidocaine toxicity or methemoglobinemia from prilocaine toxicity.

BOX 214-1 REGIONAL DIFFERENCES IN PENETRATION[a]

1. Mucous membrane
2. Scrotum
3. Eyelids
4. Face
5. Chest and back
6. Upper arms and legs
7. Lower arms and legs
8. Dorsa of hands and feet
9. Palmar and plantar skin
10. Nails

[a]Most penetration with number 1 and less penetration with increasing numbers.

FREQUENCY OF APPLICATION

The frequency of drug application likely has little effect on increasing a topical drug's overall efficacy.[6,7] One daily application is enough for most topical glucocorticoids, for example, but the nonspecific emollient or protective effect of creams and ointments are likely enhanced by more frequent applications. Regardless, increasing the contact time for a topical drug augments its total absorption.

QUANTITY OF APPLICATION

The quantity of the drug applied likely has a negligible effect on drug absorption. Obviously enough drug must be dispensed and spread to cover the affected areas. Further, the quantity of drug applied might affect patient adherence to the prescribed regimen. For example, too much applied drug might negatively alter the subjective experience of having a medication on the skin, i.e., the drug may feel "wrong" (greasy, caked, chalky, etc.) or is cosmetically unattractive (shiny, white color). Regardless, the amount prescribed must be adequate to treat the affected body surface area for the necessary length of time. In this regard, patient education is critical to prevent wasteful overuse or ineffective underuse of the medication. The amounts of topical medications to dispense, based on the estimated body surface area, frequency of application, and duration of therapy, are presented in Table 214-1. For topical medications like sunscreens that are used over large areas, underapplication is a problem

TABLE 214-1
Suggested Amounts of Topical Medications to Dispense—Cream or Ointment

Area Treated	Estimated% Body Surface Area	Single Application (g)	Twice a Day for 1 Week (g)	Three times a Day for 1 Week (g)
Face	3	1	15	20
Scalp	6	2	30	45
One hand	3	1	15	20
One arm	7	3	45	60
Anterior trunk	14	4	60	90
Posterior trunk	16	4	60	90
One leg including foot	20	5	70	100
Anogenital area	1	1	15	20
Whole body	100	30–40	450–500	600–1,000

From New York University's Dermatologic Formulary—Skin and Cancer Unit.

for most patients. However, for smaller areas, patients may apply a large amount of an ointment, for example, leading to complaints of greasiness or rubbing off on clothing, which can be minimized by using an appropriate amount.

ADHERENCE

Topical medication adherence is a critical although often overlooked aspect of medication efficacy. Generally, adherence to a treatment regimen is associated with female gender, employment, being married, and low prescription costs. Lower adherence is seen for patients with extensive disease, and paradoxically, disease on the face.[8] One 8-week survey using electronic monitoring showed that adherence to treatment for a twice-daily topical prescription decreased from 84% the first week to 51% during the eighth week, with topical nonadherence being especially notable on weekends.[9] Furthermore, adherence is negatively affected by depression, which is common in people with chronic skin conditions and found in up to 20% of patients with psoriasis.[10]

TACHYPHYLAXIS. Defined as the decrease in drug response when used over a prolonged period of time, tachyphylaxis is commonly observed during corticosteroid topical therapy. It is now thought that adherence may be a contributing factor, rather than loss of corticosteroid receptor function.[5,11] Increase in adherence may be achieved by asking patients to use it only on weekends (weekend therapy) or specific days of the week (pulse therapy).[5]

REBOUND EFFECT. Worsening of preexisting dermatoses can occur in patients who have been using topical potent corticosteroids for prolonged regimens.[5] Either tapering down the corticosteroid strength to moderate- or low-potency corticosteroids or increasing the duration of time between applications of the topical drug might prevent the rebound effect.

MISCELLANEOUS FACTORS

Vigorous rubbing or massaging of the drug into the skin not only increases the surface area of skin covered, but also increases blood supply to the area locally, augmenting systemic absorption. It may cause a local exfoliative effect that will also enhance penetration. The presence of hair follicles on a particular body site also enhances drug delivery, with the scalp and beard areas presenting less of a barrier when compared with the relatively hairless body sites. Although having a thinner stratum corneum, the skin of older individuals is poorly hydrated, with fewer hair follicles and, therefore, may impede drug delivery.

Reducing the particle size of the active ingredient increases its surface area–volume ratio, allowing for a greater solubility of the drug in its vehicle. This forms the basis for the increased absorption of certain micronized drugs.[12]

CLASSIFICATION AND CLINICAL APPLICATION OF TOPICAL FORMULATIONS

The vehicle is the inactive part of a topical preparation that brings a drug into contact with the skin. Before the mid-1970s pharmaceutical companies performed limited testing of the impact of the vehicle on the potency of a given formulation. The lack of a scientific analysis of the vehicle led to the marketing of topical drugs that, while having different concentrations of the same active ingredient, nevertheless exhibited similar bioavailability and potency. For example, older preparations of triamcinolone acetonide showed no real

BOX 214-2 VEHICLE INGREDIENTS COMMONLY USED IN TOPICAL PREPARATIONS

- Emulsifying agents
  - Cholesterol
  - Disodium mono-oleamidosulfosuccinate
  - Emulsifying wax
  - Polyoxyl 40 stearate
  - Polysorbates
  - Sodium laureth sulfate
  - Sodium lauryl sulfate
- Auxiliary emulsifying agents/emulsion stabilizers
  - Carbomer
  - Catearyl alcohol
  - Cetyl alcohol
  - Glyceryl monostearate
  - Lanolin and lanolin derivatives
  - Polyethylene glycol
  - Stearyl alcohol
- Stabilizers
  - Benzyl alcohol
  - Butylated hydroxyanisole
  - Butylated hydroxytoluene
  - Chlorocresol
  - Citric acid
  - Edetate disodium
  - Glycerin
  - Parabens
  - Propyl gallate
  - Propylene glycol
  - Sodium bisulfite
  - Sorbic acid/potassium sorbate
- Solvents
  - Alcohol
  - Diisopropyl adipate
  - Glycerin
  - 1,2,6-Hexanetriol
  - Isopropyl myristate
  - Propylene carbonate
  - Propylene glycol
  - Water
- Thickening agents
  - Beeswax
  - Carbomer
  - Petrolatum
  - Polyethylene
  - Xanthan gum
- Emollients
  - Caprylic/capric triglycerides
  - Cetyl alcohol
  - Glycerin
  - Isopropyl myristate
  - Isopropyl palmitate
  - Lanolin and lanolin derivatives
  - Mineral oil
  - Petrolatum
  - Squalene
  - Stearic acid
  - Stearyl alcohol
- Humectants
  - Glycerin
  - Propylene glycol
  - Sorbitol solution

differences in potency among the 0.025%, 0.1%, and 0.5% concentrations. By contrast, modern drug development attempts to maximize drug bioavailability by optimizing vehicle formulation. Additionally, during the current drug development process, dose-response studies determine the maximal effective concentration within a given vehicle, above which any further increase in concentration serves no therapeutic benefit.

The vehicle of a topical formulation often has beneficial nonspecific effects by possessing cooling, protective, emollient, occlusive, or astringent properties. Rational topical therapy matches an appropriate vehicle that contains an effective concentration of the drug. The vehicle functions optimally when it is stable both chemically and physically and does not inactivate the drug. The vehicle also should be nonirritating, nonallergenic, cosmetically acceptable, and easy to use. Additionally, the vehicle must release the drug into the pharmacologically important compartment of the skin. Finally, the patient must accept using the vehicle or else compliance will be poor. For example, although ointments are often pharmacodynamically more effective than creams, patients generally prefer creams to ointments, and thus, it is no surprise that more prescriptions are written for cream-based formulations. Box 214-2 lists many commonly used ingredients in topical preparations. Many of these compounds may serve more than one function in a particular formulation.

POWDERS

Powders absorb moisture and decrease friction. Because they adhere poorly to the skin, their use is mainly limited to cosmetic and hygienic purposes. Generally, powders are used in the intertriginous areas and on the feet. Adverse effects of powders include caking (especially if used on weeping skin), crusting, irritation, and granuloma formation. Further, powders may be inhaled by the user. Most powders contain zinc oxide for its antiseptic and covering properties, talc (primarily composed of magnesium silicate) for its lubricating and drying properties, and a stearate for improved adherence to the skin. Calamine is a popular skin-colored powder composed of 98% zinc oxide

and 1% ferric oxide and acts as an astringent to relieve pruritus. Other drugs formulated as powders include some over-the-counter antifungals.[12]

POULTICES

A poultice, also referred to as a *cataplasm*, is a wet solid mass of particles, sometimes heated, that is applied to diseased skin. Historically, poultices contained meal, herbs, plants, and seeds. The modern poultice often consists of porous beads of dextranomer. Poultices are used as wound cleansers and absorptive agents in exudative lesions such as decubiti and leg ulcers.[12]

OINTMENTS

Ointments are semisolid preparations that spread easily. They are petrolatum-based vehicles, capable of providing occlusion, hydration, and lubrication. Drug potency often is increased by an ointment vehicle due to its ability to enhance permeability.[5] Ointment bases used in dermatology can be classified into five categories: (1) hydrocarbon bases, (2) absorption bases, (3) emulsions of water-in-oil, (4) emulsions of oil-in-water, and (5) water-soluble bases. Dermatologists commonly refer to the hydrocarbon bases and absorption bases as *ointments* and the water-in-oil/oil-in-water emulsion bases as *creams*. In pharmaceutical terms, all of these preparations are ointments and are specifically indicated for conditions affecting the glabrous skin (palms and soles) and lichenified areas.[5]

HYDROCARBON BASES. Also called *oleaginous bases*, hydrocarbon bases are often referred to as *emollients* because they prevent the evaporation of moisture from the skin and are composed of a mixture of hydrocarbons of varying molecular weights, with petrolatum being the most commonly used (white petrolatum, except for being bleached, is identical to yellow petrolatum). They are greasy and can stain clothing. The silicon ointments are composed of alternating oxygen and silicon atoms bonded to organic groups, such as phenyl or methyl, and are excellent skin protectants. They can be used for diaper rash, incontinence, bedsores, and colostomy sites. Hydrocarbon bases are generally stable and do not contain preservatives. They cannot absorb aqueous solutions, and thus are not used for water-soluble drugs.[12]

ABSORPTION BASES. Absorption bases contain hydrophilic substances that allow for the absorption of water-soluble drugs. The hydrophilic (polar) compounds may include lanolin and its derivatives, cholesterol and its derivatives, and the partial esters of polyhydric alcohols such as sorbitan monostearate. These ointments are lubricating and hydrophilic, and they can form emulsions. They function well as emollients and protectants. They are greasy to apply but are easier to remove than the hydrocarbon bases. They do not contain water. Examples include anhydrous lanolin and hydrophilic petrolatum.[12]

WATER-IN-OIL EMULSIONS (CREAMS). Emulsions are two-phase systems involving one or more immiscible liquids dispersed in another, with the assistance of one or more emulsifying agents. A water-in-oil emulsion, by definition, contains less than 25% water, with oil being the dispersion medium. The two phases may separate unless shaken. The emulsifier (or surfactant) is soluble in both phases and surrounds the dispersed drops to prevent their coalescence. Examples of surfactants used include sodium lauryl sulfate, the quaternary ammonium compounds, Spans (sorbitan fatty acid esters), and Tweens (polyoxyethylene sorbitan fatty acid esters). Preservatives are frequently added to increase the emulsion's shelf life. Water-in-oil emulsions are less greasy, spread easily on the skin, and provide a protective film of oil that remains on the skin as an emollient, while the slow evaporation of the water phase provides a cooling effect.[8]

OIL-IN-WATER EMULSIONS. An oil-in-water emulsion contains greater than 31% water. In fact, the aqueous phase may comprise up to 80% of the formulation. This type of formulation is the one most commonly chosen to deliver a dermatologic drug. Clinically, oil-in-water emulsions spread very easily, are water washable and less greasy, and are easily removed from the skin and clothing. Invariably, they contain preservatives, such as the parabens, to inhibit the growth of molds. Additionally, oil-in-water emulsions contain a humectant (an agent that draws moisture into the skin), such as glycerin, propylene glycol, or polyethylene glycol (PEG), to prevent the cream from drying out. The oil phase may contain either cetyl or stearyl alcohol (paraffin alcohols) to impart a stability and velvety smooth feel upon application to the skin. After application, the aqueous phase evaporates, leaving behind both a small hydrating layer of oil and a concentrated deposit of the drug.[12]

WATER-SOLUBLE BASES. Water-soluble bases consist either primarily or completely of various PEGs. Depending on their molecular weight, PEGs are either liquid (PEG 400) or solid (PEG 4,000). These formulations are water soluble, will not decompose, and will not support the growth of mold, and therefore require no preservative additives. They are much less occlusive than water-in-oil emulsions, nonstaining, greaseless, and easily washed off of the skin. Without water, this ointment poorly delivers its coformulated drug. Therefore, it will be useful in scenarios where the practitioner desires a high surface concentration and low percutaneous absorption of the drug. For example, topical antifungal drugs and topical antibiotics (e.g., mupirocin) are formulated in this type of base.

Gels are made from water-soluble bases by formulating water, propylene glycol, and/or PEGs with a cellulose derivative or carbopol. A gel consists of organic macromolecules uniformly distributed in a lattice throughout the liquid. After application, the aqueous or alcoholic component evaporates, and the drug is deposited in a concentrated form. This provides a faster release of the drug independent of its water solubility.

Gels are popular because of their clarity and ease of both application and removal. They are suitable for facial or hairy areas because after application little residue is left behind.[5] Nevertheless, they lack any protective or emollient properties. If they contain high concentrations of alcohol or propylene glycol, they tend to be drying or cause stinging. Gels require preservatives.[12] Newer gel formulations may contain the humectant glycerin, the emollient dimethicone, or the viscoelastic polysaccharide hyaluronic acid, which can mitigate some of the associated irritation. Nonaqueous gels, with bases such as glycerol, may be used for poorly solubilized therapeutics such as 5-aminolevulonic acid.[13]

Microspheres, or microsponges, are formulated in an aqueous gel. Medication, in this case tretinoin, is combined into porous beads 10–25 μm in diameter. The beads are made up of methyl methacrylate and glycol dimethacrylate.

PASTES

Pastes are simply the incorporation of high concentrations of powders (up to 50%) into an ointment such as a hydrocarbon base or a water-in-oil emulsion. The powder must be insoluble in the ointment. Invariably, they are "stiffer" than the original ointment. The powders commonly used are zinc oxide, starch, calcium carbonate, and talc. Pastes function to localize the effect of a drug that may be staining or irritating (i.e., anthralin). They also function as impermeable barriers that serve as protectants or sunblocks. Pastes are less greasy than ointments, more drying, and less occlusive.[12]

LIQUIDS

Liquids can be subdivided into solutions, suspensions, emulsions (discussed in Section "Ointments"), and foams.

SOLUTIONS. A solution involves the dissolution of two or more substances into homogenous clarity. The liquid vehicle may be aqueous, hydroalcoholic, or nonaqueous (alcohol, oils, or propylene glycol). An example of an aqueous solution is aluminum acetate or Burow solution. A hydroalcoholic solution with a concentration of alcohol of approximately 50% is called a *tincture*. A collodion is a nonaqueous solution of pyroxylin in a mixture with ether and ethanol, and is applied to the skin with a soft brush. Flexible collodions have added castor oil and camphor and are used, for example, to deliver 10% salicylic acid as a keratolytic agent. Liniments are nonaqueous solutions of drugs in oil or alcoholic solutions of soap. The base of oil or soap facilitates application to the skin with rubbing or massage. Liniments can be used as counterirritants, astringents, antipruritics, emollients, and analgesics.[12]

SUSPENSIONS (LOTIONS). A suspension, or lotion, is a two-phase system consisting of a finely divided, insoluble drug dispersed into a liquid in a concentration of up to 20%. Nonuniform dosing can result if the suspended particles coalesce and separate out of a homogeneous mixture, therefore shaking of the lotion before application may be required. Examples include calamine lotion, steroid lotions, and emollients containing urea or lactic acid. The applied lotion leaves the skin feeling cooler via evaporation of the aqueous component. Lotions are easier to apply and allow for uniform coating of the affected area, and are often the favorite preparation in treating children. Lotions are more drying than ointments, and preparations with alcohol tend to sting eczematized or abraded skin.[12] Lotions are suitable for application to large surface areas due to their ability to spread easily.[5]

SHAKE LOTIONS. Shake lotions are lotions to which a powder is added to increase the surface area of evaporation. As a result of the increased evaporation, the application of shake lotions effectively dries and cools wet and weeping skin. Generally, shake lotions consist of zinc oxide, talc, calamine, glycerol, alcohol, and water, to which specific drugs and stabilizers may be added. Shake lotions tend to sediment, and derive their name from the need to shake the preparation before each use to obtain a homogeneous suspension. In addition, after water has evaporated from the lotion, the powder component may clump together and become abrasive. Therefore, patients should be instructed to remove the residual particles before the reapplication of shake lotions.[12]

FOAMS. Foams are triphasic liquids composed of oil, organic solvents and water, which are kept under pressure in aluminum cans. Foams are formulated with a hydrocarbon propellant, either butane or propane.[14] The foam lattice is formed when the valve is activated. Once in contact with the skin, the lattice breaks down, the alcohol evaporates within 30 seconds, and leaves minimal residue in the skin. The alcohol component of the foam is thought to act as a penetration enhancer, momentarily altering the barrier properties of the stratum corneum and increasing drug delivery through the intercellular route.[14] Previous studies have demonstrated that foam vehicles are highly effective in delivering greater amount of active drug at an increased rate when compared to other vehicles that traditionally depend upon hydration of the intercellular spaces within the stratum corneum.[14] Foams have not been associated with an increase in the adverse events and compliance seams to be better with this formulation, especially for localized conditions affecting the scalp.[14]

AEROSOLS

Topical aerosols may be used to deliver drugs formulated as solutions, suspensions, emulsions, powders, and semisolids. Aerosols involve formulating the drug in a solution within a pure propellant. Usually, the propellant is a blend of nonpolar hydrocarbons. When applied to abraded or eczematized skin, aerosols lack the irritation of other formulations, especially when the quality of the skin makes direct application painful or difficult. Furthermore, aerosols dispense a drug as a thin layer with minimal waste, and the unused portion

cannot be contaminated. Aerosol foams, a relatively new vehicle for drug delivery, are commonly used to deliver corticosteroids such as betamethasone valerate and clobetasol propionate. The foam contains the drug within an emulsion formulated with a foaming agent (a surfactant), a solvent system (such as water and ethanol), and a propellant. On application, a foam lattice forms transiently until it is broken by both the heat of the skin and the heat of rubbing the foam onto the skin. Foams that are alcohol based leave very little residue within seconds of their application. Furthermore, a given corticosteroid formulated in a foam vehicle demonstrates comparable potency when compared with the same corticosteroid in other vehicles.[1,15] Although aerosols allow for the ease of application (especially to hair-bearing areas) and high patient satisfaction, they suffer from the disadvantages of being expensive and potentially ecologically damaging.[12]

PENETRATION ENHANCERS

CHEMICAL ENHANCERS. A penetration enhancer is a compound that is able to promote drug transport through the skin barrier. Skin hydration and interaction with the polar head group of the lipids are mechanisms for increasing penetration. Water, alcohols (mainly ethanol), sulphoxides (dimethylsulphoxide/DMSO), decylmethylsulphoxide/DCMS, azones (laurocapram), and urea are some of the most commonly used compounds.[4] Urea is thought to act as a penetration enhancer due to its keratolytic properties and by increasing the water content in the stratum corneum. Other substances that may also act as enhancers include propylene glycol, surfactants, fatty acids, and esters.

Vesicular systems are widely used in dermatologic and cosmetic fields to enhance drug transport into the skin through the transcellular and follicular pathways. Examples of vesicular systems include liposomes (phospholipid-based vesicles), niosomes (nonionic surfactant vesicles), proliposomes and proniosomes, which, respectively, are converted to liposomes and niosomes upon hydration.[16]

PHYSICAL ENHANCERS. Physical methods such as the application of a small electric current (iontophoresis), ultrasound energy (phono- or sonophoresis) and the use of microneedles increase cutaneous drug penetration.[4] Microdermoabrasion is the application of crystals (generally aluminum oxide) on the skin and the collection of such crystals and skin debris under vacuum suction. This technique enhances drug permeation and facilitates drug absorption by altering the architecture of the stratum corneum.[17]

STABILIZERS

Stabilizers are nontherapeutic ingredients and include the preservatives, antioxidants, and chelating agents. Preservatives protect the formulation from microbial growth. The ideal preservative is effective at a low concentration against a broad spectrum of organisms, nonsensitizing, odor free, color free, stable, and inexpensive. Unfortunately, the ideal preservative does not exist. The parabens are the most frequently added preservatives, and are active against molds, fungi, and yeasts, but less effective against bacteria. Alternative agents include the halogenated phenols, benzoic acid, sodium benzoate, formaldehyde, the formaldehyde-releasing agents, and previously, thimerosal. Most commonly used preservatives may act as contact sensitizers.

Antioxidants or preservatives prevent the drug or vehicle from degrading via oxidation. Examples include butylated hydroxyanisole and butylated hydroxytoluene, used in oils and fats. Ascorbic acid, sulfites, and sulfur-containing amino acids are used in water-soluble phases. Chelating agents, such as sodium EDTA and citric acid, work synergistically with antioxidants by complexing heavy metals in aqueous phases.

THICKENING AGENTS

Thickening agents increase the viscosity of products or suspend ingredients in a formulation. Examples include bees-wax and carbomers. In addition to functioning as an ointment vehicle, petrolatum may be added to an emulsion to increase its viscosity. As in this example, an ingredient may have a therapeutic effect as well as acting as part of a vehicle.

TOXICITY OF TOPICAL DRUGS

LOCAL EFFECTS

Either the vehicle or its active ingredients may cause local toxicity to the applied site. Local adverse effects are usually minor and reversible. Major cutaneous side effects include irritation, allergenicity, atrophy, comedogenicity, formation of telangiectases, pruritus, stinging, and pain. The mechanism of toxicity may be as simple as the desiccation of the stratum corneum (the removal of sebum and oils by the preparation's emulsifiers, for example), or involve a more complex effect on either the cells of the epidermis or dermis and the structures these cells comprise (i.e., epidermis, adnexae). Local damage may occur either directly at, or within close proximity to, the treated site. Further, irritation and damage may appear even after a drug has been discontinued. Often the therapeutic effects of the active ingredient mask or immediately treat the toxic effects of the formulation so that acutely toxic effects are transient.[18] For example, an allergic contact dermatitis to a preservative in a topical steroid may be masked by the effects of the steroid itself.

IRRITANT CONTACT DERMATITIS. Irritation is driven less by drug penetration and more by drug concentration. Thus, lowering the concentration of an irritating drug may lower the risk of side effects. However, a change in formulation may reduce the

preparation's efficacy. Nevertheless, often using a less concentrated preparation over a greater period of time is as therapeutically efficacious while minimizing adverse effects; for example, the use of benzoyl peroxide 2% to 5% preparations in contrast to 10% preparations.[18] In some instances, though, skin irritancy might be central to drug efficacy. For example, although not conclusively shown, the power of immunomodulating agents such as imiquimod might rely on an increased innate (inflammatory or irritant) immune response.

SUBJECTIVE OR SENSORY IRRITANT CONTACT DERMATITIS. Patients may detect burning or stinging sensations without any signs of cutaneous irritation after applying a topical medication.[19,20] Several compounds may induce sensory irritant contact dermatitis in predisposed individuals, such as tacrolimus,[21] sorbic acid, propylene glycol, benzoyl peroxide hydroxy acids, mequinol, ethanol, lactic acid, azelaic acid, benzoic acid, and tretinoin.[19,20]

ALLERGIC CONTACT DERMATITIS. In contrast to local irritation, contact allergy development depends on local penetration. Allergy, of course, is driven by antigen recognition and presentation, and thus, percutaneous absorption of the drug must be at a level that guarantees interaction with the immune effector cells of the skin. Therefore, the contact allergenicity of a drug relates most significantly to percutaneous absorption. In some instances, cutaneous allergy may be therapeutic, for example, the treatment of patients with cutaneous T-cell lymphoma with topical nitrogen mustard. The shift in malignant T cells from T helper (Th) 2 to Th1-type cytokine expression is believed to lead to apoptosis of the malignant T cells and tumor regression.[22]

MALIGNANCIES. Rarely, topical therapy may result in neoplasia. For example, the risk of secondary malignancies, such as keratoacanthomas, basal and squamous cell carcinomas, lentigo maligna and primary melanoma have been reported with the long-term use of nitrogen mustard.[22]

OTHERS. The application of topical corticosteroids to the periorbital skin has been reported both to induce cataracts and increase in intraocular pressure.[5]

SYSTEMIC EFFECTS

One should be aware of the potential systemic toxicities of topical drugs. Although generally safer than the other routes of administration, topical application can result in systemic toxicities ranging from end-organ toxicity (central nervous system, cardiac, renal, etc.), teratogenicity, and carcinogenicity to drug interactions. These outcomes may relate to the drug itself, its metabolites, or even a component of the vehicle.

The kinetics of topically applied drugs differ significantly from those administered by other routes. One important consideration is the lack of hepatic first-pass metabolism of a topical drug. This is especially relevant to drugs such as salicylic acid that are relatively innocuous when given enterally, but may manifest central nervous system toxicity when applied topically. Additionally, acting as a reservoir, the stratum corneum may store large amounts of a topical drug, and a subsequently long diffusion period of many days may ensue, delivering a steady supply of drug to the systemic circulation.

Percutaneous toxicity directly relates to percutaneous absorption. Therefore, factors that modulate absorption also influence toxicity: the concentration of the drug, its vehicle, the use of occlusion, the body site and area treated, frequency of use, the duration of therapy, and the nature of the diseased skin. For example, 6% salicylic acid in Eucerin used for 11 days in the treatment of psoriasis has been associated with epistaxis and deafness, while the same concentration of salicylic acid in hydrophilic cream under occlusion for 4 days for the treatment of dermatitis (involving the same amount of body surface area) may result in hallucination.[18] Similar to their effect on systemically administered drugs, renal and hepatic diseases, by influencing drug clearance, also contribute to an increased potential for drug toxicity.

Young children have a greater surface area–volume ratio, and thus are at greater risk of percutaneous toxicity than adults. This phenomenon necessitates alternative drugs, formulations, and dosing schedules for children with widespread cutaneous disease. Patients with acute flares of cutaneous illness (for example, psoriasis or atopic dermatitis) may require the treatment of a larger body surface area in a relatively abbreviated period of time. These patients may also increase their dose and frequency of application during such flares. Coupled with the likely increased percutaneous absorption of the diseased skin, these scenarios exponentially increase the possibility of systemic toxicity, and patient education is vital to prevent adverse outcomes.[12] To reduce the risk of toxicity from topical drugs and to increase treatment efficacy, many practitioners will rationally advocate systemic approaches (i.e., methotrexate, cyclosporine, injectable or infusable biologics, or ultraviolet radiotherapy) to patients whose disease involves an extensive body surface area.

TYPE I HYPERSENSITIVITY REACTIONS. In rare instances, anaphylactic shock can be precipitated by topical drug application. For example, when applied to diseased or abraded skin, bacitracin ointment can induce an immediate-type (type I) hypersensitivity reaction in susceptible individuals. Such reactions might be represented by a local and then subsequently generalized pruritus leading to cardiopulmonary arrest.[12] Nonimmunologic acute toxicity results from substances such as pesticides and chemical warfare agents that rapidly diffuse through the skin and reach target organs.

MALIGNANCIES. Systemic calcineurin inhibitors have been associated with increased risk of lymphoma and nonmelanoma skin cancer. But the topical use of such drugs does not appear to be related

to cancer.[23,24] In fact, the risk for lymphoma with the use of topical calcineurin inhibitors was assessed in animal studies that demonstrated an increased risk only when blood levels were 30 times higher than those measured after topical application in human subjects.[24] Numerous studies have demonstrated the efficacy and safety of topical calcineurin inhibitors. More than 50 cases of lymphoma have been reported, although the topical calcineurin inhibitor use may be coincidental. Nevertheless, there is a clear need for additional follow-up information to establish the long-term safety profile of this class of drugs. Two long-term trials currently being conducted might help address these concerns.[24]

ENDOCRINE SYSTEM. Topical corticosteroids can rarely cause hypothalamic–pituitary–adrenal axis suppression, growth retardation, hyperglycemia, iatrogenic Cushing syndrome and femoral head osteonecrosis.[5] Factors that enhance drug absorption are directly related to an increase in these side effects; therefore, carefully monitoring must be ensured when prescribing usage in large surfaces areas, prolonged use of potent corticosteroids, usage under occlusion, high potency corticosteroids, or use for the pediatric age group (due to their increased surface to body mass ratio).

Transdermal drug delivery, in contrast to topical drug delivery, uses topical application of therapeutic drug as a delivery system for systemic therapy. Transdermal patches have been approved by the US Food and Drug Administration since 1981 (scopolamine being the first) for the delivery of 13 different medications, with more seeking approval. The most commonly used patches are for nitroglycerin and fentanyl. Advantages of this approach include controlled release, a steady blood-level profile with zero-order kinetics, lack of a plasma peak, and, in some cases, improved patient compliance. These patches remain on the skin for 12 hours to 1 week. A patch consists of a plastic backing, a reservoir of medication, either a rate-controlling membrane or a polymer matrix system for controlled diffusion, followed by an adhesive facing the skin. The most common adhesives used are acrylates, silicones, and polyisobutylenes. These patches have been tested and are approved for use on the thighs, buttocks, lower abdomen, upper arms, and chest; application to other sites can lead to either sub- or supratherapeutic blood levels. Adverse effects of patches include local irritation and allergic contact dermatitis to either an adhesive or to the drug itself and may necessitate discontinuation. Topical therapies are a mainstay of treatment for the dermatologist. An understanding of the interactions between a drug's concentration, penetration, availability, and treatment of diseased skin allows physicians to maximize both efficacy and tolerability of topical therapy. An understanding of local and systemic toxicities allows selection of appropriate, safe therapy for patients and minimizes unwanted effects. Appropriate selection of topical agents and patient education on proper use can optimize therapeutic outcomes.

KEY REFERENCES

Full reference list available at www.DIGM8.com

DVD contains references and additional content

2. Feldman RJ, Maibach HI: Regional variation in percutaneous penetration of 14C cortisol in man. *J Invest Dermatol* **48**:181, 1967
4. Trommer H, Neubert RH: Overcoming the stratum corneum: The modulation of skin penetration. *Skin Pharmacol Physiol* **19**:106-121, 2006
7. Eaglstein WH, Farzad A, Capland L: Topical corticosteroid therapy: Efficacy of frequent application. *Arch Dermatol* **110**:955, 1974
8. Zaghloul SS, Goodfield MJ: Objective assessment of compliance with psoriasis treatment. *Arch Dermatol* **140**:408, 2004
12. Ricciatti-Sibbald D, Sibbald RG: Dermatologic vehicles. *Clin Dermatol* **7**:11, 1989
14. Huang X et al: A novel foam vehicle for delivery of topical corticosteroids. *J Am Acad Dermatol* **53**:S26-S38, 2005
23. Bashir SJ, Maibach HI: Topical drug testing. In: *Comprehensive Dermatologic Drug Therapy*, edited by Wolverton SE. Philadelphia, W.B. Saunders Company, 2001, p. 911

Chapter 215 :: Pharmacokinetics and Topical Applications of Drugs

:: Hans Schaefer, Thomas E. Redelmeier, Gerhard J. Nohynek, & Jürgen Lademann

PHARMACOKINETICS AT A GLANCE

- Compounds applied topically to the skin surface migrate along concentration gradients.
- The drug or its formulation may affect the skin barrier, resulting in time-dependent changes of the barrier function.
- There are significant regional variations in the barrier properties of the skin.
- Formulations differ in their physicochemical properties—this influences the kinetics of release and/or absorption and the onset, duration, and extent of a biologic response.
- The primary compartment that limits the percutaneous absorption of compounds is the stratum corneum.
- Diffusion within the viable tissue, as well as metabolism and resorption, also influence the bioavailability of compounds in specific skin compartments.
- Metabolic activity is a primary consideration in the design of prodrugs and may influence the bioavailability of drugs delivered via dermatologic or transdermal formulations.

Pharmacokinetics related to topical applications of drugs describes the time-dependent drug concentration following the application of the drug to the skin surface, its subsequent passage through the skin barrier into the underlying skin layers, and its distribution into the systemic circulation. The subject continues to hold the attention of research scientists and clinicians alike because of its relevance to dermatologic therapy and the possibility of topical application of current systemic medication that cannot be administered orally, such as peptides or proteins. However, this is an inherently complex subject, despite the advent of new insights into the principal factors that govern diffusion of a drug into and across the skin.

The major difficulty in developing an accurate description of the percutaneous absorption of a drug is related to the size of the compartments. A topical application of a cream or ointment is generally spread to a thickness of not greater than 10 µm. The thickness of the stratum corneum is also approximately 10 µm, whereas the viable epidermis, dermis, and, to a greater extent, the systemic compartment, represent a large sink in which absorbed drugs undergo dilution to levels that often remain undetectable to all but the most sensitive techniques. The determination of the time-dependent changes in the concentration of a drug in individual compartments is technically challenging. After topical application of a drug formulation, several parameters can affect this process (Box 215-1).

DIFFUSION

LAWS OF DIFFUSION

Compounds applied topically to the skin surface migrate along concentration gradients according to well-described laws governing diffusion of solutes in solutions and/or their diffusion across membranes. For a detailed discussion of relevant equations, readers are referred to several comprehensive reviews.[1–4]

FICK'S LAWS

Diffusion of uncharged compounds across a membrane or any homogeneous barrier is described by Fick's first and second laws. The first law

$$J = -D\,(\Delta C/\Delta \delta)$$

BOX 215-1 PARAMETERS THAT AFFECT DRUG AMOUNTS IN SKIN COMPARTMENTS

- Formulations may undergo drastic changes in composition and structure.
- Drug or formulation may affect the skin barrier, resulting in time-dependent changes of the barrier function.
- Skin barrier may be affected by the type and progression of a disease.
- Regional variations in the barrier properties of the skin.
- Skin may respond to topical drug, enhancing or retarding percutaneous absorption.
- Metabolic capacity of skin may lead to exposure of skin or systemically to both parent drug and pharmacologically active metabolite(s).

states that the steady-state flux of a compound (J = moles/cm/s) per unit path length (δ, cm) is proportional to the concentration gradient (ΔC) and the diffusion coefficient (D, cm^2/s). The negative sign indicates that the net flux is in the direction of the lower concentration. This equation applies to diffusion-mediated processes in isotropic solutions under steady-state conditions. Fick's second law predicts the flux of compounds under nonsteady-state conditions. Diffusion is an effective transport mechanism over very short distances, but not over long ones. The relationship between the time (Δt) it takes for a molecule to migrate along a path length (x) and its diffusion coefficient is governed by the equation:

$$\Delta t = x^2/2D.$$

For example, the diffusion coefficient for water in an aqueous solution is: 2.5×10^{-5} cm^2/s, suggesting that a water molecule would migrate over a 10-μm path (the equivalent of the width of the stratum corneum) in 0.4 ms. However, because diffusion depends upon the square of the distance, longer distances are not efficiently covered; a 100-μm path would take 40 ms.

THREE-COMPARTMENT MODEL

Although pharmacokinetic analysis of topical preparations may require the description of a relatively large number of compartments, this discussion is confined to the three outlined in Figure 215-1: (1) the skin surface, (2) the stratum corneum, and (3) the viable tissue. The formulation itself forms a reservoir, from which the compound must be released; in order to undergo percutaneous absorption, the compound then must penetrate the stratum corneum, diffuse into and through

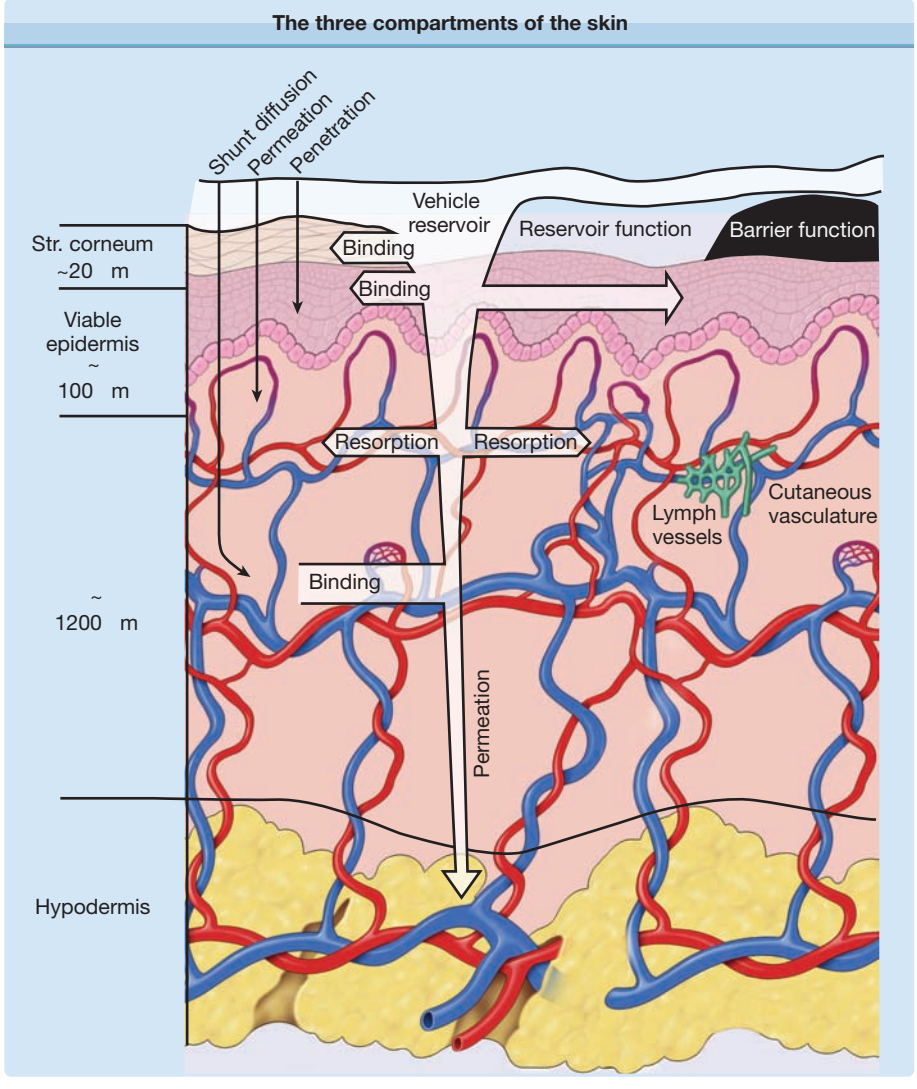

Figure 215-1 Diagrammatic representation of three compartments of the skin: surface, stratum (Str.) corneum, and viable tissues. After surface applications, evaporation and structural/compositional alterations in the applied formulation may play an important role in determining the bioavailability of drugs. The stratum corneum, the outermost layer, plays the most significant role in determining the diffusion of compounds into the body. After absorption, compounds may bind or diffuse within the viable tissues, or become resorbed by the cutaneous vasculature.

TABLE 215-1
Compartments Encountered by Substances Undergoing Percutaneous Absorption: General Relevance of Processes to Bioavailability

Compartment	Processes	General Relevance to Bioavailability
Vehicle	Diffusion	++
	Thermodynamic activity	++
	Evaporation	+
	Precipitation	±
Stratum corneum	Reservoir function	+++
	Diffusion	+++
	Binding	+
	Metabolism	–
Epidermis	Diffusion	±
Cutaneous vasculature	Metabolism	±
	Binding	++
	Resorption	+
Underlying tissues including dermis	Diffusion	±
	Metabolism	±
	Binding	–

– = although theoretically possible, this process is probably not of general relevance; ± = this process is of direct relevance, but only in a restricted number of cases; + = the process is in general relevant, but not as important as ++ or +++.

the viable epidermis into the dermis, and, finally, gain access to the systemic compartment through the vascular system. In addition, the substance may diffuse through the dermal and hypodermal layers to reach underlying tissues. As summarized in Table 215-1, within each compartment, the compound may diffuse down along its concentration gradient, bind to specific components, or be metabolized. The size or characteristics of each compartment may alter with time, and the factors determining diffusion within each compartment may be affected by disease state as well as the nature or the pharmacologic/biologic activity of the drug or its excipients.

THE SKIN SURFACE

SURFACE APPLICATIONS OF FORMULATIONS. Formulations differ in their physicochemical properties, and, as discussed in Section "Formulations," this influences the kinetics of release and/or absorption. However, the principal consideration is that topically applied drug products represent a physically small compartment, which limits the amount of compound that can be applied to the skin surface. When a patient applies a dermatologic preparation, the layer of a formulation covering the skin is very thin (approximately 0.5–2.0 mg/cm^2). Thicker layers are felt as "unpleasant" and are consciously or subconsciously rubbed off or spread to larger surfaces. This restricts the amount of an active compound that can effectively come in contact with the skin surface to approximately 5–20 µg/cm^2 for a 1% (wt/wt) topical formulation.

However, even after being rubbed in, formulations do not remain homogeneous over the time course of penetration. For example, topical applications containing water, alcohol, or similar solvents undergo rapid evaporation.[5] This phenomenon is readily recognized by patients as a cooling sensation. The evaporation results in rapidly increasing concentrations of nonvolatile substances on the skin surface, which may result in the formation of supersaturated "solutions" or, alternatively, precipitation of active ingredients. Formulations may also mix with skin-surface lipids or undergo time-dependent changes in their composition as excipients and drugs undergo absorption. Altogether, these considerations suggest that dramatic changes in the composition and structure of formulations may occur following surface application, all of which may determine the subsequent bioavailability of active ingredients.

RESERVOIR. The reservoir function was first described by Vickers,[6] who observed that simple occlusion leads to the renewed onset of a glucocorticoid-mediated vasoconstriction several hours after it had declined. He interpreted this effect as renewed liberation of the glucocorticoid from a "reservoir" stored in the upper skin layers.

We define as *reservoir* the amount of an active ingredient that is still in contact with the nonvolatile constituents of its formulation after the latter had been massaged into the skin surface. The compound has not yet penetrated, but it cannot be removed by simple rubbing or contact with clothing or other tissues.

The reservoir thus adheres to the skin surface and resides in the wrinkles and the upper layers of the stratum corneum. Reservoirs on eczematous skin may become even more prominent because of the scaliness of the skin. Recently, we discovered that the upper volume of the follicular channels serves also as a reservoir, which may result in a relative increase in absorption through appendages. In-vivo laser scanning microscopy measurements found that the hair follicles represent an efficient reservoir for topically applied formulations, which can be compared with the reservoir of the stratum corneum on several body sites.[7,8] This phenomenon may be increased in formulations that contain particles or precipitates, given the evidence that appropriately sized particles can rapidly penetrate along the shafts of hair follicles to a depth of up to 100–500 µm.[9–12]

The optimum size of the particles for penetration into hair follicles is between 300 and 600 nm, which corresponds to the cuticular structure of the hairs.[13,14] It was assumed that the rigid hair shaft acts as a geared pump, because this effect could only be observed in the case of moving hairs.[14] The follicular reservoir may result in a relative increase in the absorption of topically applied substances. No evidence has been found that topically applied substances penetrate efficiently into the sweat glands. This may be due to sweat outflow or other, unknown reasons.

FORMULATIONS. Formulations can be differentiated on the basis of whether they are designed to remain on the skin surface (sunscreen products and cosmetics), to be delivered to compartments in the skin (topical formulations), or to migrate across the skin into the central compartment (transdermal formulations).

Formulations may affect the kinetics and the degree of percutaneous absorption and, subsequently, the onset, duration, and extent of a biologic response. In the context of percutaneous absorption, there are several different parameters that should be considered when selecting a formulation[1,15]: the thermodynamic activity of the active ingredient[16]; the amount of compound that can be incorporated into the formulation[17]; the stability of the formulation on the skin surface (e.g., emulsions may break easily)[18]; the partition coefficient of the active ingredient between the vehicle and the stratum corneum[19]; and the enhancer activity.

In general, percutaneous absorption is proportional to the thermodynamic activity of the compound. Thus, the greatest flux is observed at the active ingredient's maximum solubility in a vehicle. Vehicles that are very good solvents should be avoided because they may retain the active ingredient on the skin surface.

LIPOSOMES AS TRANSDERMAL DELIVERY SYSTEMS. Liposomes are microscopic spheres comprising a bilayer that encloses an inner aqueous core. A wide variety of cosmetics contain liposomes. Liposome-based formulations have proved to be safe, cosmetically attractive, and well accepted. There is considerable evidence that, at least for some preparations, application of liposomes is mildly occlusive and improves the hydration level of the stratum corneum. Interest in the use of liposomes to enhance the delivery of drugs across the skin has been spurred by several observations in animal models: liposome formulations were believed to enhance the penetration of compounds across the skin or to optimize the retention of bioactive compounds in target tissues.[20] However, these early studies, which relied largely on animal models, were followed by relatively few in-vivo studies for humans[17] conducted under standard conditions.

The action mechanism of liposomes is based on a partly damaged liquid layer of the stratum corneum, so that the liposomes can penetrate efficiently into the skin barrier. Deep in the stratum corneum, the liposomes get damaged and release their drug, which has to pass through the last cell layers of the stratum corneum by itself to reach the living cells.[21]

There is no clear evidence that liposomes can pass the skin barrier as intact structures, but intact liposomes can penetrate along the hair shaft and this route may be appropriate for delivery of bioactive compounds into sebaceous glands or hair follicles.[7,8] Rigid liposomes penetrate better into the hair follicles than flexible liposomes, which supports the assumption that the moving hairs act as a geared pump.[21]

THE SKIN BARRIER

(See Chapter 47.)

The primary compartment that limits the percutaneous absorption of compounds is the stratum corneum. This thin (10–20 µm) layer effectively surrounds the body and represents a highly differentiated structure that determines the diffusion of compounds across the skin. The physical description of the stratum corneum is well documented,[22] and it can be accurately described as "bricks" of bundled, water-insoluble proteins, embedded in a "mortar" of intercellular lipid.

The stratum corneum is a highly organized, differentiated structure. To participate fully in forming an effective barrier to diffusion, the biogenesis of the corneocytes as well as the synthesis and processing of the intercellular lipid must proceed in an orderly manner. Disruption in the kinetics of skin barrier formation by accelerating the division of the keratinocytes in the underlying layers will lead to a disruption in the barrier properties of the skin.[23] Thus, the concept of dead or dying skin forming a passive barrier to diffusion is now replaced by a model of the stratum corneum as a highly differentiated structure with unique properties that are particularly suited for its role in forming the skin barrier (see Chapter 47).[24]

APPENDAGES. A variety of appendages penetrate the stratum corneum and epidermis, facilitating thermal control and providing a protective covering. Appendages are potential sites of discontinuity in the integrity of the skin barrier. The density of the hair follicles varies on different body sites. Hair follicles represent a reservoir that may store topically applied substances. A detailed analysis of the reservoir of the hair follicles showed that the highest reservoir is

on the scalp, followed by the forehead and the calf.[25] On the forehead, there are a high number of small follicles, while the calf contains fewer but larger hair follicles. These reservoirs are comparable to the reservoir of the stratum corneum on these body sites. The percentage of the hair follicles on the total skin surface varies between 0.2% and 1.3%, depending on the body site.[25] Differences in the follicular penetration were observed in different ethnic groups.[26] Hair follicles appear to present an important pathway for percutaneous absorption in nondiseased skin.[11,12] This can be explained by the fact that only the upper wall of the follicular apparatus (the acroinfundibulum) is protected by a coherent stratum corneum, whereas in the lower part (infrainfundibulum), the corneocytes appear undifferentiated, and protection is incomplete, if not absent. Even solid particles may enter deep into the follicular orifice,[9,10,22] a phenomenon that lends itself to the concept of follicular targeting of drugs.[22]

It follows that in relationship to the integral protection against the passage of xenobiotics in general, and drugs specifically, the barrier function of the interfollicular stratum corneum is even more potent than previously believed, whereas more research is needed relative to the follicular pathway. Recent investigations hint to the presence of active follicles (open to penetration) and passive ones.[11]

PENETRATION PATHWAYS. In principle, three penetration pathways are possible: (1) the intercellular penetration, inside the lipid layers around the corneocytes; (2) the follicular penetration; and (3) the intracellular penetration. Although in the past, the transcorneal penetration was assumed to be the only penetration pathway, recent investigations, as cited above in Appendages, have demonstrated that penetration via the hair follicles should be taken into consideration.[25–27]

Up to the present time, no evidence is available that topically applied substances pass the skin barriers by means of the intracellular route.

Pathways across the Stratum Corneum. Several studies have directly visualized penetration pathways across the stratum corneum by electron microscopy. For example, osmium vapor can be used to precipitate *n*-butanol that has penetrated the stratum corneum.[28] After a brief (5–60 s) exposure of murine or human stratum corneum, the alcohol was found to be enriched in the intercellular spaces (threefold), although significant levels were also found in the corneocytes. By using a different approach that involved rapid freezing, water, ethanol, and cholesterol were also found preferentially concentrated in the intercellular lipid spaces.[29] Similarly, the penetration of mercury chloride through the intercellular lipid can be detected following precipitation with ammonium sulfide vapor.[30]

However, in most of these investigations, there was also significant localization of compounds in the corneocytes, more prevalent in the upper layers (stratum disjunctum). Thus, corneocytes undergoing desquamation appear to be relatively permeable, even to rather bulky ions such as mercury. There is additional evidence that other compounds can and do penetrate corneocytes. It is well established, for example, that occlusion or immersion of skin in a bath leads to swelling of the corneocytes, consistent with the entry of water. Other compounds have also been localized in corneocytes, such as the anionic surfactants that are bound to keratins. Low-molecular-weight moisturizers such as glycerol are likely to partition into the corneocytes and alter their water-binding capacity. Thus, the penetration of compounds into corneocytes cannot be excluded from considerations of percutaneous absorption pathways. The relevance of this step relates to whether it is rate determining, i.e., whether the diffusion of compounds within the intercellular lipid is restricted by the corneocytes.

Pathways across the Hair Follicles. Using the method of differential stripping—a combination of tape stripping with cyanoacrylate surface biopsies—the amount of formulation stored in the hair follicles can be quantified.[31] It was found that nanoparticles were stored 10 times longer in the hair follicles than in the stratum corneum.[14] It should be noted that when topically applied substances penetrate into the hair follicles, they do not necessarily penetrate through the skin barrier into the living tissue, because the hair follicles also have barrier properties.

On the other hand, the particles can be used as efficient carrier systems for drug delivery into the hair follicles. The hair follicles represent an important target structure because they are surrounded by a close network of blood capillaries. Additionally, they are hosting the stem and dendritic cells which are important for regenerative medicine and monomodulation.

For optimal action, the drug should be released from the particles after having penetrated deep into the hair follicles. The pharmacokinetics is determined mainly by the process of the drug release from the particles in this case.[61]

In the past, there have been several attempts to detect follicular penetration.[32–34] Experiments were performed on animal and human skin, with different densities of the hair follicles. Unfortunately, in all cases, the properties of the stratum corneum had also changed.

The analysis of the follicular penetration became possible after the development of a method that artificially closes the hair follicles in vivo.[35] Using this method, it was demonstrated that the small molecules, such as caffeine, may penetrate through the skin barrier not only by the transcorneal, but also by the follicular routes.[36]

INTER- AND INTRAINDIVIDUAL VARIATION IN SKIN BARRIER FUNCTION. Finally, it is worthwhile to consider the level of inter- and intraindividual variation in skin barrier activity, including that of follicles. The most accurate and reproducible measurement of skin barrier activity is transepidermal water loss.[37] The extent of variation of this parameter for the same individual is estimated to be 8% by site and 21% according to the day of measurement. The variations

between individuals are reported to be somewhat larger, ranging from 35%–48%.[38] There appear to be no significant gender- or ethnic-dependent differences in skin barrier activity. The skin barrier activity of premature babies[39] is markedly impaired, although skin barrier function appears normal for full-term infants. There seems to be no significant alteration in skin barrier activity as a function of age. Differences in skin barrier activity among different sites have been observed; barrier function can be ranked as arm ~ abdomen > postauricular > forehead.[37]

VIABLE TISSUE

Although the primary barrier to percutaneous absorption lies within the stratum corneum, diffusion within the viable tissue, as well as metabolism and resorption, also influence the bioavailability of compounds in specific skin compartments. These processes are interrelated, and factors that increase the rate of one of these processes inevitably influence the others. Because the development of dermatologic formulations is often focused on "targeted" delivery to living tissues, the manipulation of these processes offers a clear-cut rationale for increasing the therapeutic efficacy of dermatologic drugs.

The passage of compounds from the stratum corneum into the viable epidermis results in a substantial dilution. This is not only the relatively larger volume of the epidermis as compared with that of the stratum corneum, but also the lower resistance to diffusion within viable tissues, approximately corresponding to that of an aqueous protein gel.[38] Drug concentrations of 10^{-4}–10^{-6} M may be attained in the epidermis and dermis for substances that permeate readily. Although the actual concentration gradient of a compound is affected both by the physicochemical properties of the compounds as well as by the duration of application, a concentration gradient is present at all times. In other words, strategies to enhance percutaneous absorption generally result in a relatively uniform and parallel increase in the concentration of compounds in all compartments.

SKIN METABOLISM

The skin contains a wide range of enzymatic activities, including phase I oxidative, reductive, hydrolytic, and phase II conjugation reactions, as well as a full complement of drug-metabolizing enzymes.[40,62] Metabolic activity is a primary consideration in the design of prodrugs and may influence the bioavailability of drugs delivered via dermatologic or transdermal formulations. Alterations in skin metabolism have been implicated in a range of diseases, including hirsutism and acne, and they may be relevant to the risk of topical exposure to carcinogens. Metabolic processing of antigens by Langerhans cells is involved in the presentation of allergens to the immune system. Thus, metabolism in skin compartments plays a significant role in determining the fate of a topically applied active compound.

Significant cutaneous metabolism has been demonstrated for a wide variety of compounds of differing physicochemical properties, including the steroid hormones estrone, estradiol, and estriol, as well as glucocorticoids, prostaglandins, retinoids, benzoyl peroxide, aldrin, anthralin, 5-fluorouracil, nitroglycerin, theophylline, and propranolol.[27] Recently, it has been shown that arylamine-type hair dye ingredients are also subject to metabolism in human and animal skin, resulting in *N*-acetylated metabolites.[41–43] The enzyme responsible is believed to be epidermal *N*-acetyltransferase-1.[41] For example, cutaneous metabolism reduces the systemic bioavailability of nitroglycerin administered in a transdermal drug formulation in rhesus monkeys by 16%–21% and hydrolyzes virtually 100% of a salicylate diester.[44] It is convenient to classify metabolic reactions in terms of their cofactor dependence.[63] Processes that require cofactors are likely to be energy dependent, and these are located within viable tissues. Among the best-studied examples are the interconversion of steroids (e.g., estrone and estradiol), and the oxidation of polycyclic aromatic hydrocarbons with mixed-function mono-oxygenases. In contrast, cofactor-independent processes involve catabolism and may be located outside of viable tissues, i.e., in the transition region between the stratum corneum and stratum granulosum. The best characterized of these involve hydrolytic reactions such as nonspecific ester hydrolysis.

Metabolic activity is found in (1) skin-surface microorganisms, (2) appendages, (3) the stratum corneum, (4) the viable epidermis, and (5) the dermis. In considering the site of the most significant metabolism, one has to take into account the relevant enzymes and their specific activity, as well as their capacity relative to the size of the compartment. Thus, although the level of many enzymes is highest in the epidermis, the relatively large size of the dermal compartment may result in a significant role in the metabolism of topically applied substances. A further consideration is that enzymes involved in cutaneous metabolism may be induced upon exposure to xenobiotics. This has been well described for various mixed-function monooxygenases.[45] Finally, the qualitative and quantitative extrapolation of results from animal models to humans is uncertain, owing to the significant species differences in the metabolism of compounds.

Percutaneous absorption and metabolism of compounds can be viewed as two events in kinetic competition with each other.[46] Generally, compounds that remain in the skin for longer periods of time undergo significantly more metabolism. Furthermore, the type of metabolism of a substance may also be influenced by the nature of its formulation, as illustrated by investigations on the metabolism of several transdermal nitroglycerin formulations.[47] The inclusion of enhancers in the formulation not only increased the bioavailability of the nitroglycerin but also the ratio of one metabolic compound (1,2-glyceryl dinitrate) in relation to another (1,3-glyceryl dinitrate). This may limit the suitability of in-vitro experiments for estimating the significance of cutaneous metabolism because the vasculature is not functional in vitro. It further emphasizes that it is difficult to extrapolate quantitatively the

level of metabolism obtained for different formulations. This has significant implications for the estimation of bioequivalence.

However, despite the variety of skin-associated metabolic processes, the extent of metabolism is normally modest, i.e., 2%–5% of the absorbed compounds, although for *N*-acetylation of arylamines, metabolism may be quantitative.[43] Metabolism is limited not only by the relatively short period of time that a compound spends in the viable layers of the skin, but also by the overall low level of enzyme activity. Thus, under many circumstances, the available enzymes are saturated by the level of compound undergoing percutaneous absorption.[40]

RESORPTION

Resorption, defined as the uptake of compounds by the cutaneous microvasculature, is directly related to the surface area of the exchanging capillaries as well as their blood flow. Total blood flow to the skin may vary up to 100-fold, a process primarily regulated by vascular shunts, but also by recruitment of new capillary beds. It is estimated that, under resting conditions, only 40% of the blood flow passes via exchanging capillaries capable of acting as a sink for absorbed compounds. However, this value demonstrates considerable variation between body sites, individuals, and species and is influenced by disease states and environmental conditions. In particular, changes in temperature and humidity as well as the presence of vasoactive compounds may directly influence skin blood flow.[48]

For most compounds and situations, resorption does not limit the delivery of compounds to the central compartment after topical applications. This is a result of the relatively high resistance to diffusion within the stratum corneum as compared with uptake by the vasculature. However, for compounds or situations in which diffusion across the stratum corneum is rapid, resorption limits the maximum rate of absorption.[48] The evidence that resorption can limit the delivery of compounds to the central compartment comes primarily from studies that examined the influence of blood flow on this process. The percutaneous absorption of methyl salicylate is increased by elevated ambient temperature or strenuous exercise, an observation consistent with increased resorption as a result of cutaneous blood flow.[49] Moreover, intravenously administered nicotine (a vasoconstrictor) reduces the percutaneous absorption of topically applied nicotine.[50] Regional differences in the percutaneous absorption of piroxicam, a nonsteroidal anti-inflammatory agent, are dependent upon the local vasculature rather than upon skin barrier function.[51] Perhaps the most convincing evidence that resorption can limit delivery to the vasculature comes from in-vitro studies on the perfused porcine skin flap.[52]

An additional consideration is that the rate of resorption may indirectly influence the diffusion of compounds to the underlying musculature, tissues, and joints.[53] The principle of locally enhanced delivery to underlying musculature has been demonstrated for piroxicam as well as several local anesthetic preparations.[54]

INFLUENCE OF PATHOLOGIC PROCESSES ON SKIN BARRIER FUNCTION

Reduced skin barrier function has been observed in a number of pathologic conditions, including the ichthyoses,[55,56] psoriasis,[22,57] atopic dermatitis,[58] and contact dermatitis.[59] It is generally accepted that this is attributable to structural alterations in the stratum corneum.[22] These structural deficiencies may arise from an absence of an enzyme or structural protein in the underlying viable tissues or may be related to the improper formation of the stratum corneum resulting from an increase in keratinocyte proliferation.[64] Thus, in individuals predisposed to a defective barrier, a minor perturbation may become amplified as the skin "attempts to compensate" by increasing keratinocyte proliferation.[60] A further consideration is that the homeostatic mechanisms responsible for recovery of barrier activity after perturbation may be altered in some diseases or physiologic states.

For example, whereas the skin of aged people exhibits normal barrier function, the recovery of barrier activity after perturbation is markedly reduced.[55,56] This kinetic basis for reduced barrier function may also account for interindividual variation in barrier function and/or the apparently increased susceptibility of certain individuals to contact dermatitis.[59]

KEY REFERENCES

Full reference list available at www.DIGM8.com

DVD contains references and additional content

13. Lademann J et al: Hair follicles—A long term reservoir for drug delivery. *Skin Pharm* **19**:232, 2006
61. Menon GK, Brandsma JL, Schwartz PM: Particle-mediated gene delivery and human skin: Ultrastructural observations on stratum corneum barrier structures. *Skin Pharmacol Physiol* **20**(3):141-147, 2007
62. Rolsted K et al: Cutaneous in vivo metabolism of topical lidocaine formulation in human skin. *Skin Pharmacol Physiol* **22**(3):124-127, 2009; [Epub Jan 8, 2009]
63. Novotný J et al: Dimethylamino acid esters as biodegradable and reversible transdermal permeation enhancers: effects of linking chain length, chirality and polyfluorination. *Pharm Res* **26**(4):811-821, 2009; [Epub Nov 14, 2008]
64. O'Regan GM, Irvine AD: The role of filaggrin loss-of-function mutations in atopic dermatitis. Review. *Curr Opin Allergy Clin Immunol* **8**(5):406-410, 2008

Chapter 216 :: Topical Corticosteroids

:: Isabel C. Valencia & Francisco A. Kerdel

TOPICAL CORTICOSTEROIDS AT A GLANCE

- Most frequently prescribed of all dermatologic drug products.
- Are effective at reducing the symptoms of inflammation, but do not address the underlying cause of the disease.
- Topical glucocorticoid research has focused on strategies to optimize potency while minimizing side effects.
- The new molecules have an overall higher anti-inflammatory effect, good compliance (only once daily application), rarely induce cross-sensitivity reactions and have weak atrophogenic properties.

MECHANISM OF ACTION

Corticosteroids have specific and nonspecific effects that are related to different mechanisms of action, including anti-inflammatory, immunosuppressive, antiproliferative, and vasoconstrictive effects. Most of their actions are mediated by an intracellular receptor called the glucocorticoid receptor. The glucocorticoid receptor α-isoform is located in the cytosol, binds glucocorticoids, and translocates to a region of the nuclear DNA known as the corticosteroid responsive element, where it is then able to stimulate or inhibit transcription of the adjacent genes, thus regulating the inflammatory process.[1] The glucocorticoid receptor β-isoform does not bind glucocorticoids, but is able to bind the antiglucocorticoid/antiprogestin compound RU-486 to regulate gene expression.[2] The glucocorticoid receptor β can attenuate the ligand-mediated transactivation of hormone-sensitive genes by the α-isoform and may be an important marker of steroid insensitivity.[3]

ANTI-INFLAMMATORY EFFECTS

Corticosteroids are thought to exert their potent anti-inflammatory effects by inhibiting the release of phospholipase A_2, an enzyme responsible for the formation of prostaglandins, leukotrienes, and other derivatives of the arachidonic acid pathway. Corticosteroids also inhibit transcription factors, such as activator protein 1 and nuclear factor κβ, which are involved in the activation of proinflammatory genes. Genes known to be upregulated by corticosteroids and that play a role in the resolution of inflammation include lipocortin and p11/calpactin-binding proteins, both involved in the release of arachidonic acid.[1,4,5] Lipocortin I inhibits phospholipase A_2, reducing the release of arachidonic acid from phospholipids.[1,6,7] Corticosteroids also decrease the release of interleukin-1α (IL-1α), an important proinflammatory cytokine, from keratinocytes.[1,8] Other proposed mechanisms for the anti-inflammatory effects of corticosteroids include inhibition of phagocytosis and stabilization of lysosomal membranes of phagocytizing cells.[9]

IMMUNOSUPPRESSIVE EFFECTS

The effectiveness of corticosteroids is, in part, also due to their immunosuppressive properties. Corticosteroids suppress the production and effects of humoral factors involved in the inflammatory response, inhibit leukocyte migration to sites of inflammation, and interfere with the function of endothelial cells, granulocytes, mast cells, and fibroblasts.[1,10–12] Several studies have shown that corticosteroids can cause mast cell depletion in the skin.[13] Experiments have also shown that topical corticosteroids cause local inhibition of chemotaxis of neutrophils in vitro, and decrease the number of Ia+ Langerhans cells in vivo.[14,15] Corticosteroids reduce eosinophilia in patients with asthma. They also reduce T-cell proliferation and induce T-cell apoptosis, in part from inhibition of the T-cell growth factor IL-2.[1,16] In addition, several cytokines are directly affected by corticosteroids, including IL-1, tumor necrosis factor-α, granulocyte-macrophage colony-stimulating factor, and IL-8. These effects may also be a result of the steroid action on antigen presenting cells.[17]

ANTIPROLIFERATIVE EFFECTS

The antiproliferative effect of topical corticosteroids is mediated by inhibition of DNA synthesis and mitosis, partly explaining the therapeutic action of these drugs in scaling dermatoses.[18] They are known to reduce the keratinocyte size and proliferation. Fibroblast activity and collagen formation are also inhibited by topical corticosteroids.[19]

VASOCONSTRICTION

The mechanism by which corticosteroids induce vasoconstriction is not yet completely clear. It is thought to be related to inhibition of natural vasodilators such as histamine, bradykinins, and prostaglandins.[1,20,21] Topical steroids cause capillaries in the superficial dermis to constrict, thus reducing erythema. The ability of a given corticosteroid agent to cause vasoconstriction usually correlates with its anti-inflammatory potency, and thus, vasoconstriction assays are often used to

predict the clinical activity of an agent. These assays, in combination with double-blind clinical trials, have been used to separate the topical corticosteroids into seven classes based on potency. Class 1 includes the most potent, while class 7 contains the least potent. eTable 216-0.1 in online edition lists many of the available topical corticosteroids according to this classification. Notice that the same drug can be found in different potency classifications depending on the delivery vehicle used.

PHARMACOKINETICS

Corticosteroids have a basic skeletal structure comprising 17 carbon atoms arranged in three six-membered rings and one five-membered ring. Modifications of cortisol (Fig. 216-1), by addition or alteration of functional groups at certain positions, have led to compounds with variable anti-inflammatory potency, glucocorticosteroid versus mineralocorticoid activity, and adverse effects.[22]

Topical corticosteroid research has focused on strategies to optimize potency while minimizing side effects. One strategy is to develop compounds with enhanced anti-inflammatory effects and minimal unwanted atrophogenic and adrenal suppressive effects. In this sense, progress has been made with the development of glucocorticoid molecules that, while retaining high activity in the skin following topical application, are quickly broken down into inactive metabolites, thereby mitigating systemic and possibly some local toxic effects ("soft" glucocorticoids). Some of these compounds include the diesters 17,21-hydrocortisone aceponate and hydrocortisone 17-butyrate-21-propionate, prednicarbate, mometasone furoate, methylprednisolone aceponate, alclometasone dipropionate, and carbothioates such as fluticasone propionate.[1,23] This last agent is classified as a potent corticosteroid with lower potential to cause skin atrophy and adrenal suppression due to its high lipophilicity, high glucocorticoid receptor binding and activation and rapid metabolism in the skin.[24] It offers the advantage of once daily application and infrequent local allergic reactions. Mometasone furoate also has highly anti-inflammatory effects with low incidence of adrenal suppression.[1] Hydrocortisone aceponate, prednicarbate, and methylprednisolone aceponate have significant anti-inflammatory effects, but the least capacity to induce skin atrophy; therefore, they can be used to treat areas such as the face, the scrotum, and large body surface areas in children, with minimal adverse effects.[1,25]

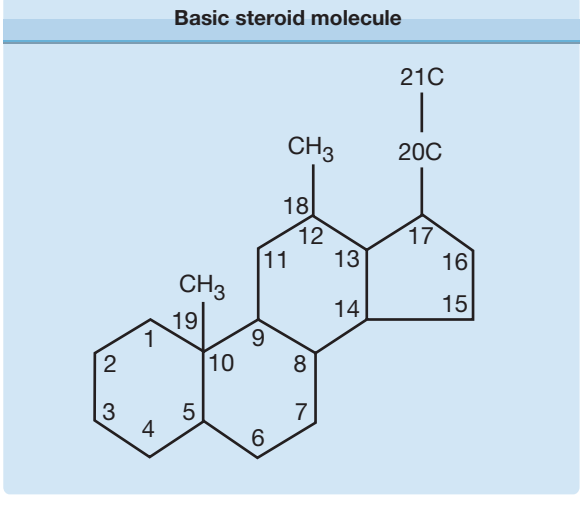

Figure 216-1 Basic steroid molecule.

Before choosing a topical glucocorticoid preparation, one must consider the patient-related and drug-related factors that can affect its systemic absorption. The age of the patient, the extent and location of the body surface area to be treated and the presence or absence of skin inflammation, greatly affect the activity of the topical agent. Penetration of the glucocorticoid varies according to the skin site, which, in turn, is related to the thickness of the stratum corneum and the vascular supply to the area. For example, penetration of topical steroids through the eyelids and scrotum is four times greater than for the forehead and 36 times greater than for the palms and soles. Inflamed, moist, and denuded skin also shows increased penetration. Areas of the body where the skin is inherently thin not only allow for increased penetration of the drug but also are more susceptible to develop side effects than other areas where the skin is thick. Potent topical steroids (classes 1 and 2) should rarely, if ever, be used in the areas with the highest level of penetration, such as the eyelids. The concentration of the therapeutic agent used, the duration of the application, the use of occlusive dressings, the elected vehicle, and the intrinsic characteristics of the chosen molecule, can also affect the absorption and the degree of adverse effects.[26,27] The target site for topical corticosteroids is the viable epidermis or dermis, and clinical response to a formulation is directly proportional to the concentration of corticosteroid achieved at the target site. A comparison study of skin concentrations after topical versus oral corticosteroid treatment found that most topical corticosteroids have the potential to achieve greater effective drug levels in the superficial layers of the skin than those achieved with standard doses of oral prednisone. Therefore, the apparently greater efficacy of oral corticosteroid therapy may be due in part to poor patient compliance with topical therapy.[28]

Topical corticosteroids are compounded in several formulations and with varying strengths. Recent research has emphasized the importance of treatment adherence in the management of skin conditions. As such, newer formulations including spray, foam, lotion, hydrogel, and shampoo formulations have been developed to improve patient convenience and acceptance, without sacrificing the efficacy, safety and tolerability of the traditional ointment and cream formulations. A recent systematic review of the literature found that while there are few direct comparison studies between clobetasol propionate, a class 1 steroid, in different vehicles, the efficacy rates for more recent formulations is roughly comparable to that of clobetasol ointment in the treatment of psoriasis. The most common adverse effect was mild and transient stinging/burning at the lesion site, which may be due to the

alcohol content found in these formulations.[29] None of the clinical trials directly compared these formulations with one another.[30,31]

Increasing hydration of the stratum corneum can enhance absorption of topical corticosteroids by four to five times. Absorption is also enhanced by ten times with occlusion.[32] A retrospective study of wet dressings used with topical corticosteroids (hydrocortisone 1% cream to the face and folds and triamcinolone 0.1% cream from the neck down) for adults with recalcitrant pruritic dermatoses of different etiologies, alleviated the pruritus in 98% of the patients at dismissal. The enhanced corticosteroid penetration is only one of the numerous benefits of the wet dressings.[33]

INDICATIONS

Topical corticosteroids are recommended for their anti-inflammatory activity in inflammatory skin diseases, but they can also be used for their antimitotic effects and their capacity to decrease the synthesis of connective tissue molecules.[1] Certain variables must be considered when treating skin disorders with topical glucocorticoids. For example, the responsiveness of diseases to topical glucocorticoids varies. In this setting, diseases can be divided into the three categories shown in Table 216-1: (1) highly responsive, (2) moderately responsive, and (3) least responsive.

PEDIATRIC USES

Topical glucocorticoids are highly effective, and few side effects are observed when a low-potency preparation is used for brief periods of time without occlusion in children. However, children and, in particular, infants, are at an increased risk of absorbing topical corticosteroids for several reasons. They have a higher ratio of skin surface area to body weight and application to a given area results in a greater potentially systemic dose of steroid. Infants may also be less able to metabolize potent glucocorticoids rapidly.[34] Premature infants are especially at risk because their skin is thinner and the penetration rate of topically applied drugs is greatly increased.[35] Application of topical steroids to the diaper area results in occlusion of the steroid by the diaper, and increased penetration occurs. Excess absorption of topical glucocorticoids can suppress endogenous cortisol production. Consequently, subsequent cessation of topical steroid therapy after an extended treatment period can, albeit rarely, result in an addisonian crisis. Deaths from addisonian crisis have been reported with the use of topical steroids, and the risk of this occurring is greater in children.[36] Chronic suppression of cortisol production can also lead to growth retardation. A morning plasma cortisol level can be performed to screen for adrenal suppression, although ACTH stimulation testing with cosyntropin is more accurate. If suppression is present, the child should be slowly weaned from the steroids to prevent these complications.

Corticosteroids have been used with success for atopic dermatitis for several decades. Placebo-controlled trials have found them effective in 75% or more of patients with atopic dermatitis when compared with fewer than 30% of placebo-treated patients.[37] They are important for managing acute flares. As with other skin conditions, selecting the appropriate strength according to the body site, the extent of involvement and the flare intensity is essential for treatment success.[27] Education of the patients and caregivers is critical to improve adherence to the prescribed medication and optimize compliance. Results from large-scale surveys show that patients/caregivers overestimate the actual risks of topical corticosteroids ("steroid phobias") leading to treatment noncompliance.[38,39] Adequate time should be spent transmitting the important role of intermittent topical corticosteroid therapy, and the beneficial risk-benefit ratio with their appropriate use.[40]

Hemangiomas of infancy show a good or partial response to treatment with ultrapotent topical glucocorticoids in 74% of infants. The majority reported accelerated cessation of growth. Small, superficial hemangiomas, particularly at sites prone to ulceration, disfigurement or both, and small periocular lesions that have not yet caused significant visual impairment

TABLE 216-1
Responsiveness of Dermatoses to Topical Application of Corticosteroids

Highly Responsive	Moderately Responsive	Least Responsive
■ Psoriasis (intertriginous)	■ Psoriasis	■ Palmoplantar psoriasis
■ Atopic dermatitis (children)	■ Atopic dermatitis (adults)	■ Psoriasis of nails
■ Seborrheic dermatitis	■ Nummular eczema	■ Dyshidrotic eczema
■ Intertrigo	■ Primary irritant dermatitis	■ Lupus erythematosus
	■ Papular urticaria	■ Pemphigus
	■ Parapsoriasis	■ Lichen planus
	■ Lichen simplex chronicus	■ Granuloma annulare
		■ Necrobiosis lipoidica diabeticorum
		■ Sarcoidosis
		■ Allergic contact dermatitis, acute phase
		■ Insect bites

are the best candidates for therapy.[41] The mechanism of action by which corticosteroids act in hemangiomas to decrease proliferation is unknown. Intralesional corticosteroid injection of hemangiomas before and after treatment, have revealed an increase in mast cells, reduced transcription in several cytokines and enhanced transcription of *cytochrome b* gene.[42]

GERIATRIC USES

Elderly patients similarly can have thin skin, which allows for increased penetration of topical glucocorticoids. They are also more likely to have preexisting skin atrophy secondary to aging and may be diaper dependent, so the same precautions used in the treatment of infants should be used when treating elderly patients.

USES IN PREGNANCY

Appropriate human studies using topical glucocorticoids in pregnancy have never been undertaken. Studies in animals, however, show that topical steroids are systemically absorbed and may cause fetal abnormalities, especially when used in excessive amounts, under occlusive dressings, for prolonged periods of time, or when the more potent agents are used. Most topical steroids are rated by the US Food and Drug Administration as category C drugs, which imply that caution must be exercised when used in pregnancy. A recent, systematic review of the safety of topical corticosteroids in pregnancy performed by Chi et al, found that the current data is inconclusive and limited and unable to detect an association between topical corticosteroids and congenital abnormalities, preterm delivery, mode of delivery or stillbirth. The current evidence shows no statistically significant effects for pregnant women who use topical corticosteroids compared with unexposed women. However, in a small cohort study of participants from a single maternity center, there appears to be an association of highly potent corticosteroids with low birth weight. Most of the previous studies only assessed the risk for congenital abnormality or orofacial cleft. Further cohort studies with comprehensive outcome measures (including fetal growth, preterm birth, and birth death), consideration of corticosteroid potency, dosage and indications, and a large sample size are required in order to detect a small risk.[43] It is currently unknown whether topical glucocorticoids are excreted in breast milk; however, they should be used with caution in breastfeeding mothers and should never be used on the breasts before breastfeeding.

DOSING REGIMEN

The frequency of topical application of corticosteroids was developed in an empirical manner, with most textbooks and physicians recommending twice-daily use. For superpotent corticosteroids, once-daily application is considered as beneficial as twice-daily application. Likewise, there is at best a slight difference with once versus twice daily application of potent or moderately potent corticosteroids. These observations suggest that once-daily application of topical corticosteroids may be as effective as twice daily, while decreasing the risks of side effects, tachyphylaxis, and cost of therapy, and improving patient compliance.[44] Tachyphylaxis has been demonstrated in experimental conditions by diminished vasoconstriction, rebound of DNA synthesis, and recovery of histamine wheals after application of topical steroids in patients with a history of long-term topical steroid usage.[45]

As a working rule in adults, no more than 45 g/week of potent or 100 g/week of weak or moderately potent topical corticosteroid should be applied (without occlusion) if systemic absorption is to be avoided.[46]

INITIATING THERAPY

Some general principles should be remembered when initiating topical corticosteroids; these are outlined in Box 216-1.[1,47]

MONITORING THERAPY

Application of corticosteroids to large surface areas, occlusion, higher concentrations, or more potent derivatives directly increases the risk of hypothalamic–

BOX 216-1 PRINCIPLES WHEN INITIATING TOPICAL STEROID THERAPY[40]

- Initiate lowest potency to sufficiently control disease.
- Prolonged use of an agent of insufficient potency should be avoided.
- When large surface areas are involved, treatment with low to medium potency preparations is recommended.
- Highly responsive diseases will usually respond to weak steroid preparations, whereas less-responsive diseases require medium or high-potency topical steroids.
- Low-potency, ideally nonhalogenated preparations should be used on the face and intertriginous areas.
- Very potent corticosteroids, frequently under occlusion, are usually required for hyperkeratotic or lichenified dermatoses and for involvement of palms and soles.
- Because of increased body surface area to body mass index ratio and increased risk of systemic absorption, high potency preparations and halogenated-medium potency preparations, should be avoided in infants and young children, other than for short-term application.

pituitary–axis (HPA) suppression. If the latter is suspected, laboratory analyses that include a complete blood cell count, a chemistry panel, and a baseline morning cortisol level should be performed. In a patient with confirmed HPA suppression, gradual reduction of potency and amount of topical steroid, and possibly the simultaneous institution of oral steroid supplementation, are needed.[48]

RISKS AND PRECAUTIONS

Local as well as systemic side effects have been documented with the use of topical corticosteroids. Under normal conditions, up to 99% of the applied topical corticosteroid is cleared from the skin, and only 1% is therapeutically active. Cutaneous adverse effects can result from the small percentage of percutaneously absorbed corticosteroid or may also result from its transient presence onto the skin. Continued use of topical corticosteroids may also lead to tachyphylaxis.[49]

Considerations for prescribing topical corticosteroids to prevent side effects should be followed[1,47,50,51] (Box 216-2).

COMPLICATIONS

Local adverse effects of topical corticosteroid use are more prevalent than systemic reactions. They are largely due to the antiproliferative effects of these agents.[49]

BOX 216-2 CONTINUING USE OF TOPICAL STEROIDS

- Highly potent formulations should be used for short periods (2 to 3 weeks) or intermittently.
- Once disease control is partially achieved, the use of a less potent compound should be initiated.
- Reduce frequency of application (e.g., application only in the morning, alternate-day therapy, weekend use) once disease control is partially achieved.
- Topical corticosteroids should be avoided on ulcerated or atrophic skin, and on skin with coexistent infectious dermatoses.
- Sudden discontinuation should be avoided after prolonged use to prevent rebound phenomena.
- Special guidelines should be followed when treating certain body areas (e.g., intertriginous areas) or certain populations (e.g., children or the elderly) to prevent the occurrence of local or systemic adverse effects.
- Laboratory tests should be considered if systemic absorption of corticosteroids is suspected.
- Use combination therapy when clinically indicated (e.g., addition of topical calcineurin inhibitor, tretinoin or calcipotriene).

ATROPHIC CHANGES

Skin atrophy is the most prominent cutaneous adverse effect, and involves both the epidermis and dermis. Dermal atrophy develops from the direct antiproliferative effects of topical corticosteroids on fibroblasts, with inhibition of collagen and mucopolysaccharide synthesis, resulting in loss of dermal support. Decreased synthesis of types I and III collagens after topical glucocorticoid use has been shown in numerous studies.[52–54] Reduction of glycosaminoglycan production has also been described.[55] Levels of hyaluronan, the major glycosaminoglycan in the skin, are also rapidly decreased after short-term glucocorticoid treatment, because of decreased of hyaluronan synthesis.[56] Fragmentation and thinning of elastic fibers develop on the upper layers, whereas deeper fibers form a compact and dense network. As a result of these atrophic changes, there is vascular dilatation, telangiectasias, purpura, easy bruising, stellate pseudoscars (purpuric, irregularly shaped, and hypopigmented atrophic scars), and ulceration. Although atrophy is, to some extent, reversible, formation of striae, visible linear scars that form in areas of dermal damage presumably during mechanical stress, are permanent.[46]

ACNEIFORM REACTIONS

The development or exacerbation of dermatoses of the face, including steroid rosacea, acne, and perioral dermatitis, is a well-known side effect of topical corticosteroids. Although steroids initially lead to the suppression of inflammatory papules and pustules, patients become addicted because they notice that the lesions flare when treatment is withdrawn. This frequently leads to the continued use of greater potency topical corticosteroids. For these reasons, steroid use should be discouraged in the treatment of rosacea and perioral and periocular dermatitis.

Prolonged corticosteroid treatment can also result in "steroid acne," which is characterized by crops of dense, inflamed pustules in the same developmental stage. These lesions occur on the face, chest, and back (see Chapter 80). Patients with psoriasis are also susceptible to a papulopustular flare after withdrawal of high-potency, topical corticosteroid therapy to an extensive surface area for a prolonged period of time.[40]

HYPERTRICHOSIS

Hypertrichosis occurs rarely in women and children who apply potent corticosteroids to the face. The mechanism is still unknown.[1]

PIGMENTARY CHANGES

Decreased pigmentation is a common side effect of topical steroid use. The pigment generally returns after discontinuation of therapy.

TABLE 216-2
Classification of Corticosteroids by Cross-Reactivity

Structural Class	A	B	C	D1	D2
Type	Hydrocortisone	Triamcinolone Acetonide	Betamethasone	Betamethasone dipropionate	Methylprednisolone aceponate
Structure	C16-no methyl substitution Probable C21-short chain ester		C16 methyl substitution	C16 methyl substitution C17/21 long chain ester	C16-no methyl substitution, no halogenation
Cross-reactions	Cross-reacts with D2	Budesonide specifically cross-reacts with D2			Cross-reacts with A and budesonide
Patch-test substance	Tixocortol-21-pivalate	Budesonide Triamcinolone acetonide		Clobetasol-17-propionate	Hydrocortisone-17-butyrate

Adapted from Jacob SE, Steele T: Corticosteroid classes: a quick reference guide including patch test substances and cross-reactivity. *J Am Acad Dermatol* **54**(4):723-727, 2006

DEVELOPMENT OF INFECTIONS

Topical corticosteroids are responsible for exacerbating and/or masking cutaneous infectious diseases. The incidence of skin infection during corticosteroid therapy varies but is probably between 16% and 43%.[57] Tinea versicolor, disseminated *Alternaria* infection, and dermatophytosis, including tinea incognito (masked dermatophyte infection), can develop. Granuloma gluteale infantum, characterized by reddish–purplish granulomatous lesions on the diaper area, is a well-known complication of diaper dermatitis that is being treated with corticosteroids. *Candida albicans* is commonly recovered in these patients. Topical corticosteroids have also an effect on prolongation or worsening of herpes simplex, molluscum contagiosum, and scabies infection.

ALLERGIC REACTIONS

Allergic contact dermatitis from steroids should be suspected when its use worsens the dermatitis, does not lead to improvement or changes the clinical pattern of disease. It occurs more commonly in patients with an impaired barrier function, such as patients with stasis dermatitis, leg ulcers and atopic dermatitis.[58] The prevalence of topical corticosteroid sensitization ranges between 0.2% and 6.0%, and increases with prolonged exposure and selection of certain drugs.[49,59,60] In a 6-year retrospective study, 127 of 1,188 patients (10.7%) patch tested with topical corticosteroids showed a positive reaction to at least one agent, with 56 patients reacting to multiple topical corticosteroids.[61] Topical corticosteroids were recognized as the American Contact Dermatitis Society's 2005 allergen of the year based on their prevalence.[62] A classification has been created to determine cross-reactivity among the various available preparations. This classification has four groups on the basis of structure and cross-reactivity patterns (Table 216-2). Each class is represented by an agent.[63] Class A is represented by the hydrocortisone type, class B by the acetonide steroids, class C by the betamethasone type and class D, subdivided into two groups, D1 represented by betamethasone dipropionate and D2 by methylprednisolone aceponate. Patch-test reactions to class A steroids are most common, whereas patch-test reactions to class C steroids are extremely rare. When an allergy to a topical corticosteroid is highly suspected and patch testing is not available, the clinician should prescribe a class C steroid with a vehicle that contains no allergens. Desoximethasone 0.25% ointment and 0.05% gel are the only two products that meet these criteria.[64] The vehicle or the preservative can also be responsible for the allergy to the corticosteroid preparation. A systematic review of ingredients in corticosteroid vehicles was recently published. The authors found seven vehicle ingredients that are commonly used in topical corticosteroid preparations and are well-known allergens: (1) propylene glycol, (2) sorbitan sesquioleate, (3) formaldehyde-releasing preservatives (imidazolidinylurea and diazolidinylurea), (4) parabens, (5) methylchloroisothiazolinone/methylisothiazolinone, (6) lanolin, and (7) fragrance (see Box 216-3). Of 166 topical corticosteroids, 128 (including all creams) had at least one of

BOX 216-3 POTENTIAL ALLERGENS IN TOPICAL CORTICOSTEROIDS VEHICLES

- Propylene glycol
- Sorbitan sesquioleate
- Methylchloroisothiazolinone/methylisothiazolinone
- Lanolin
- Parabens
- Formaldehyde releasing preservatives (imidazolidinylurea/diazolidinylurea)
- Fragrance

these vehicle components. More generic products were free of allergens than were the branded products. Solutions and ointments were the least allergenic vehicles. The most commonly present potential allergens were propylene glycol and sorbitan sesquioleate.[64]

SYSTEMIC ADVERSE EFFECTS

OCULAR EFFECTS. The development of glaucoma from the use of topical corticosteroids around the eye has been described.[65–67] Prolonged corticosteroid use has also led to vision loss.[68]

SUPPRESSION OF THE HYPOTHALAMIC–PITUITARY–ADRENAL AXIS. Suppression of the HPA axis has been described with the use of potent topical corticosteroids. Iatrogenic Cushing syndrome and corticosteroid-related Addison crises have been described after prolonged use of potent topical corticosteroid preparations. A dose of 14 g/week of clobetasol propionate or 49 g/week of betamethasone dipropionate is sufficient to suppress plasma cortisol levels.[19] It is generally assumed that systemic effects are more prevalent with high potency topical corticosteroids; however, a recent case report described a pediatric patient with Netherton syndrome who developed Cushing syndrome from percutaneous absorption of hydrocortisone 1%, a low-potency corticosteroid agent.[69] Literature reviewing the potential effect of topical corticosteroids and vertical growth in atopic dermatitis is overall reassuring but has mixed results. Cross-sectional studies have demonstrated that children with atopic dermatitis have diminished growth,[70,71] while others have found that temporary changes in cortisol levels do not affect eventual adult height.[72] A recent controlled questionnaire study found that the overall height of children with atopic dermatitis treated with topical corticosteroids was unaffected.[73]

METABOLIC SIDE EFFECTS. Increased glucose production and decreased glucose use induce hyperglycemia and may lead to diabetes mellitus. Femoral avascular necrosis rarely has been associated with the use of topical corticosteroids.[74–76]

KEY REFERENCES

Full reference list available at www.DIGM8.com

DVD contains references and additional content

1. Brazzini B, Pimpinelli N: New and established corticosteroids in dermatology. *Am J Clin Dermatol* **3**:47, 2002
32. Tadicherla S et al: Topical corticosteroids in dermatology. *J Drugs in Dermatol* **8**(12):1093, 2009
43. Chi C-C et al: Systematic review of the safety of topical corticosteroids in pregnancy. *J Am Acad Derm* **62**(4):694-705, 2010
49. Hengge UR et al: Adverse effects of topical glucocorticosteroids. *J Am Acad Dermatol* **54**:1, 2006
63. Sharon E. Jacob, Tace Steele: Corticosteroid classes: A quick reference guide including patch test substances and cross-reactivity. *J Am Acad Dermatol* **54**(4):723, 2006
64. Coloe J, Zirwas MJ: Allergens in corticosteroid vehicles. *Dermatitis* **19**(1):38, 2008

Chapter 217 :: Topical Retinoids

:: Anna L. Chien, John J. Voorhees, & Sewon Kang

RETINOIDS AT A GLANCE

- Definition: any molecule that by itself or through metabolic conversion binds to and activates retinoic acid receptors.
- Retinoid receptors: ligand-dependent transcription factors.
- Predominant retinoid receptors in human skin: retinoic acid receptor-γ (RAR-γ) and retinoid X receptor-α (RXR-α).
  - RAR-γ/RXR-α heterodimers bind to retinoic acid-responsive elements and are responsible for retinoid signaling.
- Clinical use of topical retinoids:
  - Approved indications—acne, psoriasis, cutaneous T-cell lymphoma, Kaposi sarcoma, melasma, and photoaged skin.
  - Unapproved indications with clinical studies supporting benefit—postinflammatory hyperpigmentations early stretch marks and natural aging.
- Local skin irritation: mainly due to retinoid-induced epidermal hyperplasia. Clinical use should be titrated based on the severity of local reactions.

In topical preparations, retinoids are widely used as prescription drugs as well as cosmeceuticals. In some of these products, retinoids are naturally occurring compounds while others are synthetic molecules. All retinoids, however, share predictable pharmacology in eliciting human skin responses due to the fact that retinoid effects are primarily mediated through their intranuclear retinoid receptors acting as transcription factors. Indeed, the discovery and characterization of retinoic acid receptors (RARs) and retinoid X receptors (RXRs) have been pivotal to our understanding of the retinoid action mechanism and gave rise to the idea that retinoids act similarly to hormones.[1,2] In 1976, Michael Sporn and his colleagues originally defined retinoids as both the naturally occurring compounds with vitamin A activity and the synthetic analogs of retinol. This concept is no longer adequate. Now, retinoid is defined as any molecule that, by itself or through metabolic conversion, binds to and activates the RARs, thereby eliciting transcriptional activation of retinoic acid-responsive genes that results in specific biologic responses.

MECHANISM OF ACTION

RETINOID RECEPTORS

The discovery and characterization of RARs as having molecular features that are similar to steroid/thyroid hormone receptors were landmark findings.[1,2] A characteristic common to these receptors is that they bind to regulatory regions in DNA called *hormone response elements*, or *target sequences*, and activate gene transcription in a ligand-dependent manner. Therefore, they are referred to as *ligand (hormone)-dependent transcription factors*. These receptors bind to specific DNA sequences as dimers. Unlike receptors for the steroid hormones, which form homodimers (two identical monomers); RAR, vitamin D receptor (VDR), and thyroid hormone receptors (TR) bind to their elements with greater affinity as heterodimers (two different monomers). The critical partner for heterodimerization and ultimate functioning of RAR, VDR, and TR is the RXR,[3] whose physiologic ligand is 9-*cis*-retinoic acid.[4] The ability of RXRs to interact with many receptors suggests their importance as regulatory proteins. There are three different members of RAR (α, β, and γ) and RXR (α, β, and γ), each encoded by different genes. Furthermore, each of the receptors has isoforms, adding to the diversity of retinoid receptors.

RECEPTOR-SELECTIVE RETINOIDS

The identification and functional characterization of retinoid receptor families cleared the way for drug discovery. Many synthetic compounds have no structural similarities to all-*trans*-retinol or retinoic acid, yet are still considered retinoids by virtue of their ability to activate the receptor(s), therefore mediating the retinoid effect. Adapalene, tazarotene, and bexarotene are three synthetic retinoids that fit this description and have been used topically in humans (Fig. 217-1). Adapalene has restricted receptor specificity, possessing poor affinity for RAR-α, higher affinity for RAR-β and -γ, and no interaction with RXR-α.[5] Tazarotene cannot directly bind to RARs or RXRs. However, its metabolite, tazarotenic acid, has receptor selectivity for RARs (RAR-β > RAR-γ > RAR-α),[6] and is felt to be the principal active form. Bexarotene is an RXR-selective retinoid (rexinoid), which is 100-fold more potent at binding to RXR than to RAR receptor.[7]

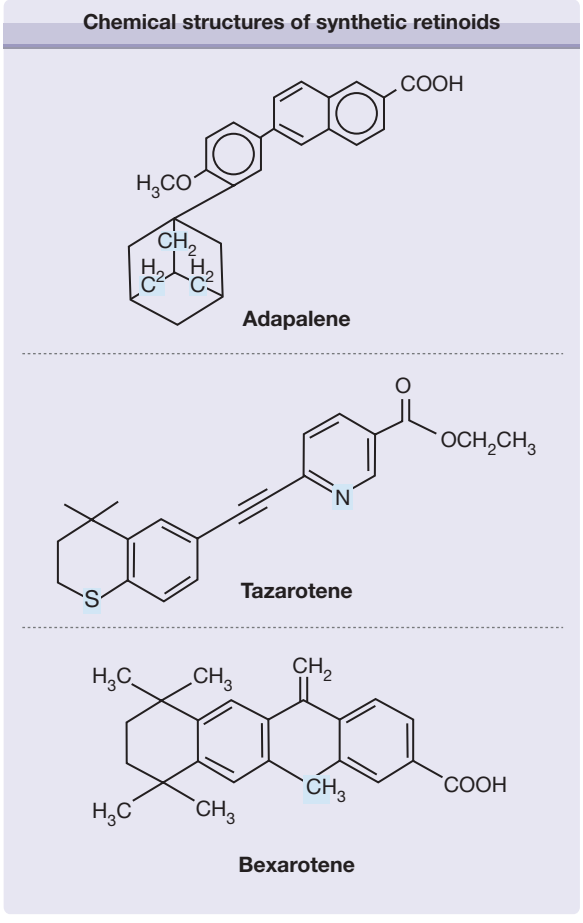

Figure 217-1 Chemical structures of the synthetic retinoids adapalene, tazarotene, and bexarotene.

RETINOID RECEPTORS IN HUMAN SKIN

Systematic analysis of relative levels of each RAR and RXR has been made in human skin and shows that the human epidermis expresses RAR-α, RAR-γ, RXR-α, and RXR-β messenger RNAs (mRNAs).[8,9] The relative levels of retinoid receptor mRNAs mirror their relative protein levels. In nuclei from human epidermal cells, there are five times more total RXRs than RARs.[9] For RAR proteins, 87% are RAR-γ and 13% are RAR-α with no detectable RAR-β. Of the RXR proteins, 90% are RXR-α. Furthermore, only RXR-α and RAR (mostly γ) heterodimers bind to retinoic acid-responsive

elements (RAREs).[9,10] At their physiologic levels, RARs and RXRs in human skin bind RAREs as heterodimers and transactivate these response elements in response to RAR, but not to RXR ligands. However, the RXR is key, as the heterodimer will not bind to the RARE without the presence of the RXR protein. Ultraviolet (UV) irradiation of human skin causes a rapid and significant reduction of retinoid receptors, both RAR-γ and RXR-α.[11] Although this decrease in the receptor levels is transient and returns to pre-UV treatment levels within 2 days, UV irradiation results in functional impairment of receptor-dependent retinoid responsiveness in human skin. Interestingly, pretreatment of skin with all-*trans*-retinoic acid before UV irradiation reduces receptor loss and accelerates receptor recovery.[11]

RETINOID TARGET GENES AND THEIR ACTIVATION CASCADE IN HUMAN SKIN

Retinoid actions are mediated by retinoid receptors. Given that the receptors are transcription factors, the ultimate skin effects of retinoids (phenotypic changes) must be accomplished through regulated gene expression. The best-established mechanism by which retinoid receptors modulate gene expression is activation of retinoid target genes through direct binding to RARE in the gene promoter, thereby stimulating the basal transcriptional machinery. In skin, cellular retinoic acid binding protein (CRABP) II, cellular retinol binding protein (CRBP), retinoic acid 4-hydroxylase (CYP26), and keratin 6—all of which contain RAREs—are regulated by all-*trans*-retinoic acid.[12–15] However, the products of these genes are unlikely to be the effectors of the retinoid response and thus cannot account for the pleiotropic effects of retinoids in skin. Undoubtedly, additional RARE-regulated genes will be identified that encode for proteins that function to modulate cutaneous growth and differentiation either directly or indirectly. A likely scenario is that these protein products, in turn, activate other non-RARE-containing genes in a cascading reaction to produce the clinical features of retinoid action in skin (Fig. 217-2).

Molecular description responsible for the most striking histologic feature of all-*trans*-retinoic acid-treated skin, the marked thickening of the epidermis, illustrates this point.[12,16] The epidermal hyperplasia is caused by the increased proliferation of basal keratinocytes. There is also an increase in differentiation markers involucrin, loricrin, filaggrin, and epidermal transglutaminase.[15] These epidermal changes collectively translate to clinical desquamation and peeling. This hyperproliferative response of epidermis to retinoic acid is mediated by its nuclear receptor.[17,18] Among the genes regulated by retinoid receptors involved in the cell growth control (keratinocyte proliferation), ligands for epidermal growth factor (EGF) receptor appear to be critically important. In human skin in vivo, topical retinoic acid induces heparin-binding (HB)-EGF and amphiregulin (AR), which stimulate basal cell growth via the cell surface EGF

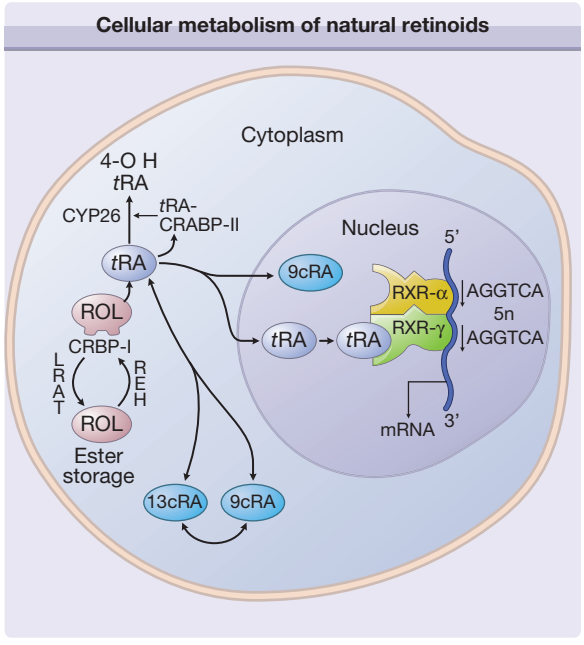

Figure 217-2 Cellular metabolism of natural retinoids and molecular mechanism of retinoid specific gene activation. Retinol (ROL) delivered to a cell is bound to cellular retinol binding protein-I (CRBP-I). ROL can be esterified, via lecithin:retinol acyltransferase (LRAT), and stored as ROL-esters. Hydrolysis of ROL-ester by its hydrolase (REH) yields free ROL. Sequential oxidation of ROL generates retinoic acid (RA), which is bound to cellular retinoic acid binding protein (CRABP). All-*trans*-RA (*t* RA) can be isomerized to 9-*cis*-RA (9*c* RA). Hydroxylation of *t* RA by cytochrome-P_{450} enzyme CYP26 generates 4-OH RA, which is relatively inactive. RARs and RXRs are intranuclear receptors for retinoids. In human skin, RAR-γ and RXR-α heterodimers bound to RA-response elements (such as AGGTCA direct repeats) transduce retinoid effects in the presence of RAR ligands. mRNA = messenger RNA.

receptor activation.[19,20] Interestingly, neither HB-EGF nor AR possesses any putative RARE. Therefore, a direct modulation of HB-EGF or AR by RARE promoters seems unlikely. Rather, RAR/RXR is likely regulating other transcription factor(s) that would, in turn, regulate AR and HB-EGF gene expression (Fig. 217-3). The identity of such transcription factor(s) remains to be determined.

PHARMACODYNAMICS

NOMENCLATURE

All-*trans*-retinoic acid (tretinoin), which binds to and activates RARs, is derived from sequential oxidation of all-*trans*-retinol (or vitamin A) and all-*trans*-retinaldehyde. It is a 20-carbon molecule that consists of a cyclohexenyl ring, a side chain with four double bonds (all arranged in *trans*-configuration), and a carboxylic-acid end group (Fig. 217-4A). The numbering of the carbon atoms is as shown in Figure 217-4B. The terms *9-cis-* (alitretinoin) and *13-cis-retinoic acid* refer to stereoisomers

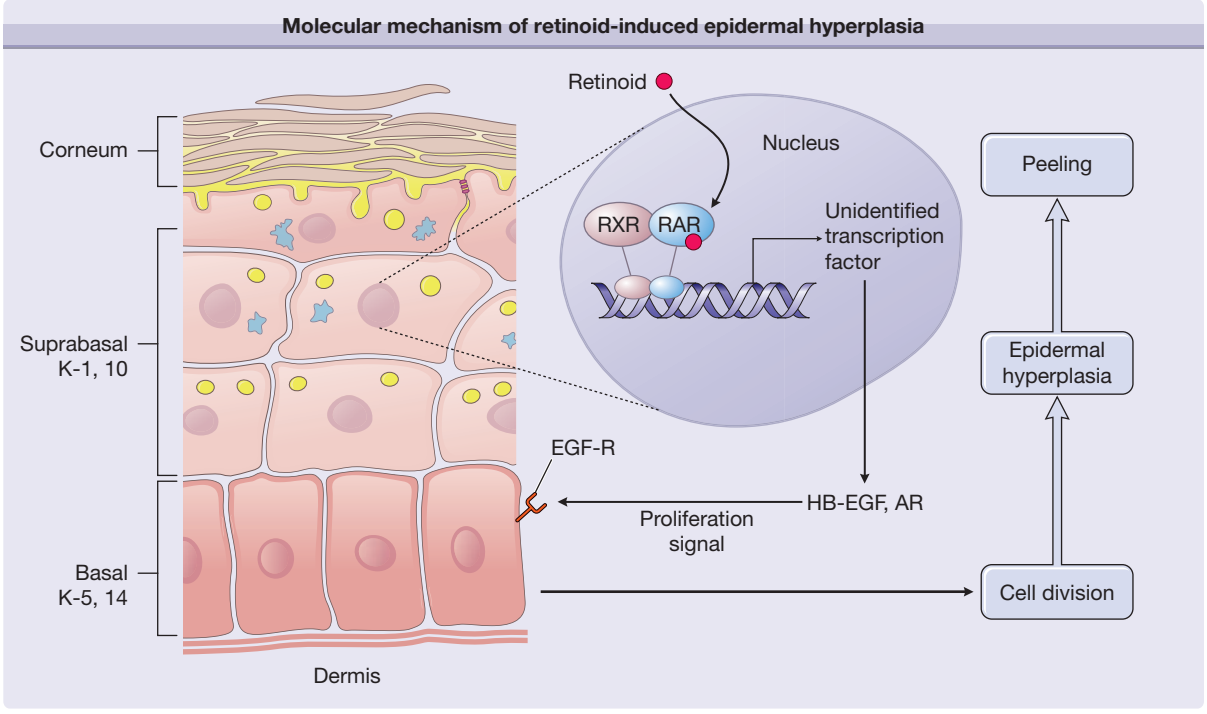

Figure 217-3 Molecular mechanism of retinoid-induced epidermal hyperplasia. Topical application of a retinoid activates retinoic acid receptor/retinoid X receptor (RAR/RXR) heterodimers in suprabasal keratinocytes, causing activation of yet unidentified transcription factors. These, in turn, activate the synthesis of heparin-binding epidermal growth factor (HB-EGF) and amphiregulin (AR). Through activation of epidermal growth factor-receptor (EGF-R), HB-EGF and AR cause proliferation of basal keratinocytes, thereby inducing thickened epidermis and consequent peeling/flaking of the stratum corneum. K = keratin.

of all-*trans*-retinoic acid in which the double bond that begins with the ninth and thirteenth carbon atoms, respectively, is in the *cis*- rather than *trans*-configuration. The *9-cis-retinoic acid* binds to the RXR-α receptor with high affinity, being 40 times more potent than all-*trans*-retinoic acid on RXR-α. *9-cis-retinoic acid* can also bind RAR receptors thus at times referred to as a *panagonist* of retinoid receptors.[4,21] The fourth carbon atom is located in the cyclohexenyl ring of retinoic acid and is involved in a hydroxylation reaction to generate 4-hydroxy-retinoic acid (see Fig. 217-4C). The addition of a hydroxyl group to the cyclohexenyl ring renders the molecule more polar, making it more amenable to excretion/elimination from cells and organisms. It is also much less active biologically. 4-Hydroxy-all-*trans*-retinoic acid can be further oxidized to 4-oxo-retinoic acid.

A group of compounds referred to as *retinyl esters* functions as the molecular storage form of retinol. The compounds are formed by esterification of retinol with fatty acids (see Fig. 217-4D), which specify the ester. For example, retinyl palmitate is generated when retinol is esterified with palmitic acid. Hydrolysis of retinyl esters regenerates retinol. Finally, β-carotene is a symmetric 40-carbon molecule (twice the number of carbons in retinol or retinoic acid) present in green and yellow–orange fruits and vegetables. As suggested by stoichiometry, one molecule of this carotenoid can potentially generate two molecules of retinol by cleavage of the central double bond (see Fig. 217-4E).

ESTERIFICATION AND OXIDATION OF RETINOL

Topical treatment of human skin with all-*trans*-retinol increases retinyl ester levels in the epidermal layer by more than tenfold.[12] This reaction is catalyzed by two enzymes: (1) lecithin/retinol acyltransferase and (2) acyl-coenzyme A/retinol acyltransferase. In human keratinocytes, lecithin/retinol acyltransferase has the predominant retinol-esterifying activity.[22]

Sequential oxidation of all-*trans*-retinol forms all-*trans*-retinoic acid, with all-*trans*-retinaldehyde as the intermediate metabolite. The first step (oxidation of all-*trans*-retinol to all-*trans*-retinaldehyde) is rate limiting for all-*trans*-retinoic acid formation. Topical application of all-*trans*-retinol to human skin results in histologic and molecular alterations that mimic those following all-*trans*-retinoic acid treatment.[12] These include epidermal hyperplasia, epidermal spongiosis, compaction of the stratum corneum, and induction of CRBP, CRABP-II, and CYP26.[22,23] In retinol-treated skin, all-*trans*-retinoic acid is minimally detectable and is no different from levels found in untreated normal skin. The lack of significant accumulation of all-*trans*-retinoic acid in retinol-treated skin is a result of the tightly regulated conversion of retinol to retinaldehyde and the effective hydroxylation of all-*trans*-retinoic acid that is formed by CYP26. The observation that all-*trans*-retinol and retinoic acid elicit similar responses in

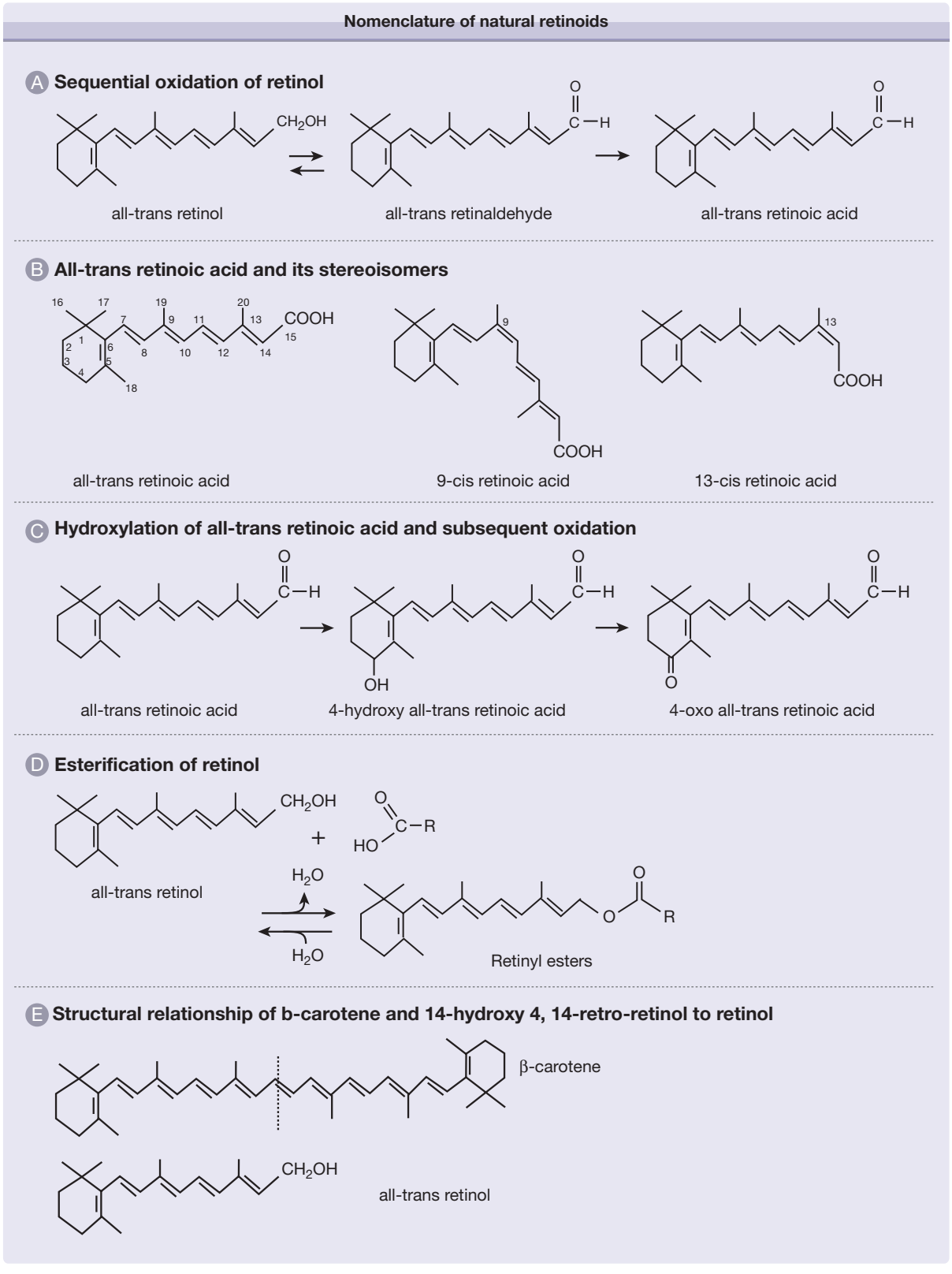

Figure 217-4 **A–E.** Nomenclature of natural retinoids.

human skin, but that retinol does so without detectable increases in retinoic acid levels, indicates that endogenously synthesized retinoic acid is a much more efficient activator of retinoid pathways than exogenously supplied retinoic acid.

HYDROXYLATION OF ALL-*TRANS*-RETINOIC ACID

In human skin all-*trans*-retinoic acid is catabolized primarily to the more polar 4-hydroxy-all-*trans*-retinoic acid, which is further metabolized to 4-oxo-retinoic acid. 4-Hydroxy-retinoic acid is tenfold less potent in inducing retinoid responses in human keratinocytes and mouse skin than all-*trans*-retinoic acid.[24] In untreated normal human skin, CYP26 activity is minimally detectable. Topical administration of all-*trans*-retinoic acid or all-*trans*-retinol to human skin, however, increases its activity several fold.[23,25] This hydroxylase activity is also induced in skin treated with 9-*cis*- or 13-*cis*-retinoic acid, but remarkably, it has substrate specificity for the all-*trans*-retinoic acid isomer only and does not hydroxylate 9-*cis*- or 13-*cis*-retinoic acid, retinol, or retinaldehydes.[23] With all-*trans*-retinoic acid, CYP26 activity is maximally induced after 24 hours of occlusive treatment. The CYP26 activity can be effectively inhibited by ketoconazole and a related azole, liarozole.[16,25] By blocking this major inactivation pathway of all-*trans*-retinoic acid, topical liarozole can serve as a retinoic acid mimetic or amplify human skin responses to all-*trans*-retinol and all-*trans*-retinoic acid.[16] This approach of targeting CYP26 has given rise to a novel class of new chemical entities referred to as *retinoic acid metabolism blocking agents* (RAMBAs). A study involving another RAMBA, talarozole, demonstrated that topical application led to increased mRNA expression of CRABP II and CYP26.[26] The drug development progress for RAMBA has been slow. A challenge for RAMBAs of the future is to selectively target CYP26 without affecting other enzymes such as steroid metabolizing aromatase or 17,20-lysase.

INDICATIONS

Until recently, clinical use of topical retinoids has been limited to all-*trans*-retinoic acid, which is approved in the United States for the treatment of acne, photoaged skin, and melasma. Topical adapalene and tazarotene have also received approval for acne; tazarotene has received approval for psoriasis and photoaging. More recently, bexarotene was approved for management of cutaneous T-cell lymphoma and alitretinoin was approved for patients with Kaposi sarcoma.

It is widely accepted that topical retinoids are extremely effective for acne therapy, especially for comedonal lesions. Of the different classes of antiacne medications, retinoids are thought to be the best, if not the only, agents to normalize the abnormal follicular epithelial differentiation/desquamation important in the pathogenesis of acne lesions. Therefore, the use of retinoids can also provide protection against the development of new lesions. This prophylactic property is the basis for including topical retinoid in almost all antiacne regimens. A potential for aggravating inflammation exists in treating inflammatory acne (i.e., papules and pustules) with topical retinoids, but when properly administered, this type of acne also responds well to retinoids (see Section "Dosing Regimen").

Fine wrinkles and dyspigmentation are two features of photoaged skin that are improved by topical tretinoin or tazarotene. Several weeks of treatment are required before clinical improvement is appreciated.[27–29] For the effacement of fine wrinkles by topical tretinoin, partial restoration of markedly reduced levels of collagen in sun-exposed skin toward those seen in sun-protected skin appears to be responsible.[28,30] Tretinoin's ability to improve photoaging is specific and does not result from the irritation or retinoid dermatitis frequently produced by this compound.[29] Topical adapalene is not approved for the treatment of photoaging; however, a recent study indicates that it also holds promise in ameliorating the clinical features of photodamage.[31]

Primary cutaneous T-cell lymphomas are characterized by clonal proliferation of skin-homing malignant T lymphocytes. As an RXR-selective retinoid, bexarotene inhibits tumor cell growth, encourages terminal differentiation, and induces apoptosis.[7] It may also play a role in chemoprophylaxis.[32,33]

Alitretinoin gel was approved in 1999 for the management of cutaneous Kaposi sarcoma (KS), which is caused by human herpes virus 8 (HHV-8). Alitretinoin's mechanism of action in KS is not entirely clear, but presumably relates to inhibition of cellular proliferation as well as induction of apoptosis seen with other retinoids. Other topical retinoids such as all-*trans*-retinoic acid and 13-*cis*-retinoic acid have been shown to inhibit KS cellular proliferation via inhibition of autocrine growth factors such as oncostatin M, tumor necrosis factor-α, and IL-6.[34–36] Furthermore, altretinoin and tretinoin have been reported to inhibit herpes simplex virus replication thus alitretinoin may have an antiviral role against HHV-8.[37] Alitretinoin has also been shown to have anti-inflammatory properties.[38] In clinical trials, most patients saw improvement after 4–8 weeks of treatment with the most significant response occurring after 14 weeks of therapy.[39]

Besides the approved indications, topical retinoids have been demonstrated to be effective in the treatment of several other conditions. Most studies have used tretinoin because it is the first topical retinoid to be developed and has been available the longest. Studied conditions include, but are not limited to, postinflammatory hyperpigmentation in blacks,[40] actinic dyspigmentation in Chinese and Japanese individuals,[41] and early stretch marks.[42] The controlled studies show more than therapeutic efficacies. They also provide valuable information to dispel some of the myths about retinoid use in humans. For example, African-Americans and Asians tolerate topical tretinoin as well as, if not better than,[40,41,43] Caucasians.[28,44] Furthermore, the often observed retinoid dermatitis does not usually lead to postinflammatory hyperpigmentation in those with greater constitutive pigmentation.

Many other skin disorders have been reported to be improved by topical retinoids, but most of these have not been rigorously studied; thus, their therapeutic claims should be interpreted with caution. Molluscum contagiosum, warts, and various forms of ichthyosis may be improved by topical retinoids to a variable degree. In psoriasis, especially, irritation of treated skin has limited the use. Topical tazarotene, which is approved for psoriasis, does not appear to have fully overcome the irritation problem[45]; thus, it is typically used in combination with topical steroids.

With such a wide variety of skin conditions treatable by topical retinoids, their use has included all age groups, perhaps with the exception of neonates. The use of topical retinoids in pregnancy is an emotional issue. As discussed in Section "Risks and Precautions," teratogenicity is not caused by topical retinoids. However, because none of the dermatologic conditions seen in pregnancy that may respond to topical retinoids (i.e., acne, melasma, stretch marks) is life-threatening to the mother or the fetus, it seems prudent to delay the treatment until after delivery. In a study that demonstrated that early, inflammatory stretch marks were improved by topical tretinoin, all pregnancy-related stretch marks were treated postpartum.[42] Therefore, even in this pregnancy-associated condition, the therapeutic benefit could be achieved by instituting the treatment after delivery.

DOSING REGIMEN

For decades, tretinoin was the only topical retinoid available for clinical use sold under the trade name Retin-A. Now, tretinoin is also available in other formulations (eTable 217-0.1 in online edition). Adapalene is also available in varying formulations and more recently, combination medications have been introduced (eTable 217-0.1 in online edition). For acne and psoriasis, topical tazarotene is available and for photoaging treatment, tretinoin and tazarotene are approved for use. Tretinoin 0.05%/hydroquinone 4%/fluocinolone 0.1% is a topical combination approved for the treatment of melasma. Different formulations allow some flexibility in terms of tailoring the therapy to an individual's skin dryness or oiliness. Finally, more recently approved topical retinoids include bexarotene and alitretinoin, sold in gel formulations.

Regardless of the retinoid preparation or the patient's age, the most important element in topical therapy is patient/guardian education. It must be clearly explained to each patient that, as part of the treatment, local skin irritation, characterized by redness and peeling, can be expected. The concept that clinical improvement correlates with the degree of irritation has been erased through a large, controlled clinical study in which 0.025% and 0.1% tretinoin were shown to be equally efficacious, but the former was significantly less irritating than the latter.[29] Therefore, unlike most medications for which the dosing schedule may be set as once or twice daily, administration of a topical retinoid should be titrated depending on the skin reaction. For some individuals, it may be applied only twice a week, for others four times a week, and this can be increased, as tolerated, to a once-daily regimen. This method of individualizing topical therapy minimizes unwanted acute retinoid dermatitis.

Under the nonprescription category, there are countless "natural retinoid" preparations with various claims (mostly antiaging) being sold throughout the world. Most of these contain retinyl esters, especially retinyl palmitate, retinaldehyde, or retinol. Whether any of these products can deliver retinoid activity to human skin is subject to question. Percutaneous absorption (especially for retinyl esters), adequate concentrations, and stable formulations (especially for retinol) are some of the important unknowns for this group of products. Based on human in-vivo work, all-*trans*-retinol and all-*trans*-retinaldehyde hold the most promise of these natural retinoids in being biologically active,[12,46] provided the stability of the compound can be maintained with a proper formulation. When the sun-protected skin of individuals older than 80 years of age was treated for 7 days with 1% retinol, fibroblast growth and dermal collagen were increased significantly.[47] Concomitantly, retinol markedly reduced the levels of matrix-degrading metalloproteinases that are elevated in aged skin. These findings suggest that retinol may reverse and partially prevent skin atrophy that accompanies intrinsic aging. A recent clinical study has confirmed that topical retinol improves the fine wrinkles associated with atrophic, naturally aged skin of the elderly.[48]

RISKS AND PRECAUTIONS

ADVERSE EFFECTS

By far the most common adverse effect associated with topical retinoid use is local skin irritation characterized by erythema, peeling, dryness, tightness, and burning sensation. This predictable skin response is temporary, but troubling, for many patients. It tends to peak within the first month of treatment and diminishes thereafter. It responds to a temporary reduction in the frequency or amount of retinoid application and to liberal use of emollients. The requirement for RAR/RXR receptors in retinoid stimulation of basal keratinocyte proliferation was presented in Section "Retinoid Target Genes and Their Activation Cascade in Human Skin." Retinoid activation of the receptors is followed by subsequent induction of HB-EGF and AR in human skin in vivo[19,20] (see Fig. 217-3). The importance of this signaling pathway in the hyperplastic response of the epidermis to topical retinoids was recently demonstrated when pharmacologic antagonists of EGF receptor tyrosine kinase activity blocked retinoid-induced epidermal thickening in human skin organ culture and in vivo.[19,20] This observation suggests that it may be possible to reduce the clinically undesirable effects of retinoids on epidermal keratinocytes. However, the erythema response following topical retinoic acid may not be retinoid-receptor mediated because all-*trans*-retinol, which induces epidermal hyperplasia and CRABP-II mRNA-like retinoic acid (two indicators of

receptor activation), is minimally associated with clinical erythema.[12]

For the more recently approved bexarotene and alitretinoin, local irritation is also the most common side effect. With alitretinoin, the local erythema can increase to edema and vesiculation with continued use. However, most reactions are mild-to-moderate with only 7% of patients requiring treatment withdrawal in clinical trials.[39] Finally, the central hypothyroidism seen with systemic bexarotene is not observed in the gel formulation.[49,50]

Systemic retinoid exposure has been well documented and established as a cause of embryonic death and congenital malformation, and understandably, there is concern about potential teratogenicity from long-term topical retinoid use. Systemic absorption of retinoids from topical application is negligible, and the levels of endogenous retinoic acid in the blood are not increased by twice daily application of 0.025% tretinoin to more than 40% of body area over 1 month. Furthermore, controlled topical administration of tretinoin at doses used for acne therapy (2 g of 0.025% gel applied daily to the face, neck, and upper part of the chest for 14 days) has less influence on plasma levels of endogenous retinoids than diurnal and nutritional factors.[51] Indeed, a large, population-based study demonstrated no excess risk of birth defects in offspring born to mothers who were exposed to topical tretinoin during pregnancy.[52] Therefore, no evidence exists for teratogenicity of topical tretinoin in humans.

"Sun sensitivity" is a frequently discussed subject with topical retinoid use and requires clarification. When formally tested in humans, topical tretinoin does not lower the minimal erythema dose of UVB light.[53] Because its presence in human skin does not increase the likelihood of sunburn reaction, tretinoin is not a phototoxic agent. The patients who complain of such sun sensitivity, describe an uncomfortable skin sensation that is felt within minutes of being in the sun rather than hours later. This timeline is not consistent with a typical sunburn reaction, which takes a few hours to be noticed. Furthermore, this sensation is often said to be accentuated in warmer temperatures, which suggests participation of infrared irradiation (heat).

Related to sun sensitivity is the issue of photocarcinogenesis. In an animal model of photocarcinogenesis, topical tretinoin has caused skin cancer. However, when human skin was grafted onto mice with severe combined immunodeficiency disease, gross inadequacy of the commonly used rodent model of photocarcinogenesis was demonstrated.[54] Specifically, the traditional rodent models significantly overestimate the human carcinogenic potential of tested agents. Topical retinoids, on the contrary, appear to have a protective effect against UV-induced premalignant and malignant lesions. In those predisposed by nevoid basal cell carcinoma syndrome or xeroderma pigmentosum to the development of nonmelanoma skin cancer, systemic retinoids have provided effective protection. In this regard, topical tretinoin's ability to prevent UV induction of c-Jun is relevant.[55] c-Jun is a proto-oncoprotein that is minimally detectable in normal human skin in vivo. Its partner c-Fos; however, is constitutively expressed. UV irradiation to human skin does not affect the level of c-Fos expression, but it markedly induces c-Jun protein, which can then heterodimerize with c-Fos, forming a complete active AP-1 transcription factor.[55] The critical importance of AP-1 in mediating carcinogenic transformation of papillomas has been demonstrated.[56] In human squamous cell carcinomas, c-Jun expression is elevated, and systemic retinoids prevent carcinomas of the head and neck. Mechanisms involved in this chemopreventive effect of the retinoid likely include c-Jun suppression. These clinically observed anticarcinogenic activities of retinoids are also supported by in vitro data, demonstrating that tretinoin treatment of human skin upregulates the antigen-presenting activity of Langerhans cells without concomitant increase in autoreactivity.[57] Such a retinoid effect would improve cutaneous immune responsiveness to tumor antigens. Therefore, topical retinoic acid is not a carcinogen in humans.

DRUG INTERACTION AND COMPATIBILITIES

Retinoids, in general, are photolabile and therefore can be photoinactivated. Based on this chemistry, it is prudent to apply the agents in the evening rather than before the start of the day. Because the major avenue of tretinoin inactivation is through CYP26, drugs that modulate the activity of this enzyme can potentially cause drug interactions. Ketoconazole and liarozole are effective inhibitors of CYP26 and, therefore, are RAMBAs.[16,25] Concurrent use of these azoles and topical tretinoin can increase the amount and prolong the half-life of tretinoin locally in the skin, thereby aggravating local side effect. Other than retinoids, no other compounds have been shown to induce CYP26.

The use of vitamin D_3 and its analogs has increased in dermatology, and, in particular, for psoriasis. Vitamin D effects in human skin are largely mediated via its nuclear receptor VDR. As previously discussed in Section "Retinoid Receptors," VDR is a member of the steroid/retinoic acid/thyroid hormone receptor superfamily. Like RAR, VDR functions in human skin mainly as a heterodimer with RXR (VDR-RXR). In contrast with retinoid signaling via RAR-RXR, in which the presence of RXR-ligand confers no additional effect, RXR-ligand provides a synergistic effect with VDR-ligand in vitamin D signaling.[58] Therefore, topical retinoids that possess, or through metabolic conversion, acquire RXR selectivity can positively influence vitamin D pharmacology in human skin.

KEY REFERENCES

Full reference list available at www.DIGM8.com

DVD contains references and additional content

1. Petkovich M et al: A human retinoic acid receptor which belongs to the family of nuclear receptors. *Nature* **330**:444, 1987
9. Fisher GJ et al: Immunological identification and functional quantitation of retinoic acid and retinoid X receptor proteins in human skin. *J Biol Chem* **269**:20629, 1994

16. Kang S et al: Liarozole inhibits human epidermal retinoic acid 4-hydroxylase activity and differentially augments human skin responses to retinoic acid and retinol in vivo. *J Invest Dermatol* **107**:183, 1996
17. Feng X et al: Suprabasal expression of a dominant-negative RXRα mutant in transgenic mouse epidermis impairs regulation of gene transcription and basal keratinocyte proliferation by RAR-selective retinoids. *Genes Dev* **11**:59, 1997
20. Rittié L et al: Retinoid-induced epidermal hyperplasia is mediated by epidermal growth factor receptor activation via specific induction of its ligands heparin binding-EGF and amphiregulin in human skin in vivo. *J Invest Dermatol* **126**:732, 2006
55. Fisher GJ et al: Retinoic acid inhibits induction of c-JUN protein by ultraviolet radiation that occurs subsequent to activation of mitogen-activated protein kinase pathways in human skin in vivo. *J Clin Invest* **101**:1432, 1998

Chapter 218 :: Topical Antibiotics

:: Mark W. Bonner & William D. James

TOPICAL ANTIBIOTICS AT A GLANCE

- Topical antibiotics are useful in the treatment of acne and rosacea.
- Use in impetigo may obviate the need for oral antibiotics.
- Use of topical antibiotics to prevent wound infection after clean surgical procedures is unnecessary.

Topical antibiotics play an important role in the management of many common dermatologic conditions (Table 218-1). They are prescribed most often by dermatologists for the management of mild-to-moderate acne vulgaris or as adjunctive treatment with oral agents. For localized superficial infections, such as impetigo, the use of a topical agent (e.g., mupirocin or retapamulin) may eliminate the need for oral antibiotics and the accompanying problems of compliance, gastrointestinal side effects, and potential drug interactions. Topical antibiotics are still frequently prescribed as prophylactic agents after minor surgery or cosmetic procedures (chemical peel or laser resurfacing) to reduce the risk of postoperative wound infection and to speed wound healing. The use of topical antibiotics for prophylaxis after such minor procedures has been proven to be unnecessary and incurs risk of inducing allergy. Petrolatum is recommended for use after clean surgical procedures.

AGENTS USED IN THE TOPICAL TREATMENT OF ACNE AND ROSACEA

The efficacy of topical antibiotics for the treatment of acne vulgaris and rosacea may be due to their direct antibiotic effect, but many of the topical antibiotics exhibit anti-inflammatory properties by suppressing neutrophil chemotactic factor or by other mechanisms.[1] There are concerns about the use of topical antibiotics in the treatment of acne vulgaris because of the increasing levels of antibiotic resistance. Combining the antimicrobial benzoyl peroxide with antibiotics reduces the development of antibiotic resistance.

ERYTHROMYCIN

Erythromycin belongs to the group of macrolide antibiotics and is active against both Gram-positive cocci and Gram-negative bacilli. It is used principally as a topical agent in the treatment of acne. Erythromycin binds to the bacterial 50S ribosome and blocks translocation of the peptidyl-transfer RNA (tRNA) molecule from the acceptor to the donor site, interfering with the formation of the polypeptide chain and inhibiting protein synthesis. In addition to its antibacterial properties, erythromycin has anti-inflammatory activity. Erythromycin is available as a 1.5% to 2.0% solution, gel, pledgets, and ointment as a single agent. It is also available in combination with benzoyl peroxide.

CLINDAMYCIN

Clindamycin is a semisynthetic lincosamide antibiotic that is derived from lincomycin. The mechanism of action is very similar to that of erythromycin, with binding to the 50S ribosome and suppression of bacterial protein synthesis. Clindamycin is used topically as a 1% gel, solution, suspension (lotion), and foam primarily for the treatment of acne. It is also available as a combination with benzoyl peroxide, which may slow the development of antibiotic resistance to clindamycin. Pseudomembranous colitis rarely has been reported to occur with the topical use of clindamycin.[2]

METRONIDAZOLE

Metronidazole, a topical nitroimidazole, is currently available as a 0.75% gel, cream, or lotion and as a 1%

TABLE 218-1
Topical Antibiotics

Name	Form Available	Mechanism of Action	Bacteria[a]
Bacitracin	O	Cell wall inhibitor	Gr+
Polymyxin B	O	Detergent	Gr–
Gramicidin	O	Ion channel	Gr+
Mupirocin	O, C	Transfer RNA inhibitor	Gr+
Neomycin	O	30S ribosome inhibition	Gr–
Erythromycin	S, G, P, O	50S ribosome inhibition	Gr±
Clindamycin	S, G, L	50S ribosome inhibition	
Fusidic acid	NA	Interferes with EF-G	
Silver sulfadiazine	C		
Mafenide acetate	O	Enzyme inhibition	Gr±
Nitrofurazone	C, S	Enzyme inhibition	Gr±
Metronidazole	G, C, L	Electrochemical	Anaerobes
Clioquinol	C, O	Unknown	Broad spectrum
Azelaic acid	C, G	Protein synthesis inhibition	Gr+

C = cream; EF-G = elongation factor G; G = gel; Gr+ = Gram-positive; Gr– = Gram-negative; Gr± = Gram-positive or -negative; L = lotion; NA = not available in the United States; O = ointment; P = pledget; S = solution.
[a]Bacteria refers to bacteria usually susceptible to antibiotic.

cream or gel for the topical treatment of rosacea. In the lower strength, it is applied twice daily, and in the higher strength, it is used once daily. Orally, metronidazole has broad-spectrum activity against many protozoal organisms and anaerobes.

AZELAIC ACID

Azelaic acid is a dicarboxylic acid found in food (whole-grain cereals and animal products). There is a normal human plasma level (20–80 ng/mL); topical application does not significantly alter this level. The mechanism of action is thought to be normalization of the keratinization process (decreased thickness of the stratum corneum, decreased number and size of keratohyaline granules, and decreased amount of filaggrin). There are reports of in-vitro activity against *Propionibacterium acnes* and *Staphylococcus epidermidis*, which may be due to protein synthesis inhibition. In aerobic microorganisms, there is inhibition of oxidoreductive enzymes (such as tyrosinase, mitochondrial enzymes of the respiratory chain, 5α-reductase, and DNA polymerases). In anaerobic bacteria, there is disruption of glycolysis. Azelaic acid is used principally in the treatment of acne vulgaris and rosacea, although there are some advocates for its use in the treatment of hyperpigmentation (such as melasma for which it was initially developed). However, the US Food and Drug Administration has not approved the drug for this indication. Azelaic acid is available as a 15% gel or 20% cream preparation.

SULFONAMIDES (SULFACETAMIDE)

Sulfacetamide is a topical sulfonamide used in the treatment of rosacea and acne. The antibacterial mechanism of action for most sulfonamides is competition with *para*-aminobenzoic acid (PABA) during the synthesis of folic acid. The mechanism of action for topical treatment of rosacea is not understood. Sulfacetamide is available as a 10% lotion and in combination with 5% sulfur in a gel, cream, suspension, cleanser, cloths, and mask.

DAPSONE

Topical 5% dapsone gel is approved by the FDA for the topical treatment of acne. The mechanism of action of dapsone in acne vulgaris is not known at this time; however, it is possible that inhabitation of neutrophils activity may be important. If benzoyl peroxide is applied after topical dapsone, temporary orange/yellow discoloration of skin and facial hair have been noted.

AGENTS USED FOR THE TOPICAL THERAPY OF SUPERFICIAL BACTERIAL INFECTIONS AND BURNS

Localized impetigo, superficial dirty abrasions, and secondarily infected chronic dermatoses are commonly treated with topical antibiotics. However, widespread

impetigo, infection of the lower extremities, or disease occurring in immunocompromised individuals should be treated with systemic antibiotics to reduce the risk of serious complications. Topical antibiotics are still at times used following minor surgical procedures. The result of a large study comparing bacitracin and petrolatum in more than 1,200 minor surgical procedures demonstrated that bacitracin did not statistically decrease the already low rate of infection. Several patients were, however, shown to be allergic to bacitracin. Petrolatum proved to be cheaper, of equal efficacy and to have fewer side effects than bacitracin.[3] When clean wounds are made during minor surgery, there is no need to use antibacterial ointment to aid in healing or prevent infection. Because burns produce a fertile ground for life-threatening secondary infection, prophylactic topical therapy is often used.

MUPIROCIN

Mupirocin, which was formerly known as *pseudomonic acid A*, is a topical antibiotic agent derived from *Pseudomonas fluorescens*. The drug reversibly binds to isoleucyl-tRNA synthetase and inhibits bacterial protein synthesis. The activity of mupirocin is limited to Gram-positive bacteria, especially staphylococci and most streptococci. Its activity is enhanced in an acid pH environment (5.5), which is the normal pH of the skin. Mupirocin is somewhat temperature-sensitive, and thus loses efficacy if exposed to high temperatures. Mupirocin ointment 2% is applied three times daily and is principally indicated for the treatment of localized impetigo caused by *S. aureus* and *Streptococcus pyogenes*. One study in the Tennessee Veterans' Affairs Hospital demonstrated that prolonged use of mupirocin ointment to control methicillin-resistant *S. aureus* (MRSA) carriage, especially in bedridden patients with decubitus ulcers, led to significant resistance.[4] Furthermore, Japanese researchers found that low serum concentrations of mupirocin are achieved after intranasal application and postulated that this might explain the selection of mupirocin-resistant strains of *S. aureus*.[5] A small pilot study using intranasal application of a combination antibiotic ointment containing bacitracin, polymyxin B, and gramicidin successfully decolonized 80% (9 out of 11) of MRSA-positive patients who remained clear after a mean follow-up of 2 months. All cases of mupirocin-sensitive MRSA were eradicated, whereas only three of five cases of mupirocin-resistant were eliminated.[6] New formulations that involve the use of the calcium salt of mupirocin (the calcium salt aids in chemical stability in the intranasal preparation) are available for intranasal use as a 2% ointment and a 2% topical cream.

RETAPAMULIN

Retapamulin is approved for topical treatment of impetigo in patients older than 9 months of age. It is a semisynthetic pleuromotilin antibiotic derived from fermentation in *Clitopilus paseckerianus* with activity against staphylococci. The antibacterial mechanism of action is inhibition of protein synthesis via 50S bacterial ribosomes at protein L3, near the peptidyl tranferase center. Retapamulin binding inhibits peptidyl tranferase and partial inhibition of binding of initiator tRNA to P-site of ribosome. Allergic contact dermatitis to the active ingredient has been reported.[7]

BACITRACIN

Bacitracin is a topical polypeptide antibiotic originally isolated from the Tracy-I strain of *Bacillus subtilis*. Bacitracin is a cyclic polypeptide with multiple components (A, B, and C). Bacitracin A is the major component of commercial products and is often used as the zinc salt. Bacitracin interferes with bacterial cell wall synthesis by binding to and inhibiting the dephosphorylation of a membrane-bound lipid pyrophosphate. It is active against Gram-positive cocci such as staphylococci and streptococci. Most Gram-negative organisms and yeast are resistant to the drug. It is available as bacitracin ointment and as zinc bacitracin, with 400 to 500 units per gram.

Topical bacitracin is effective for the treatment of superficial bacterial infections of the skin such as impetigo, furunculosis, and pyodermas. It is often combined with polymyxin B and neomycin as a triple antibiotic ointment applied several times daily for the treatment of secondarily infected eczematous dermatitis such as atopic dermatitis, nummular dermatitis, or stasis dermatitis. Unfortunately, the topical application of bacitracin carries with it the risk of allergic contact sensitization and, rarely, anaphylactic shock.[8]

POLYMYXIN B

Polymyxin B is a topical antibiotic derived from a spore-forming soil aerobe *B. polymyxa*. Polymyxin B is a mixture of polymyxin B_1 and B_2, which are both cyclic polypeptides. They function as cationic detergents that interact strongly with bacterial cell wall membrane phospholipids, thus disrupting the integrity of the cell membrane.

Polymyxin B is active against a wide range of Gram-negative organisms, including *P. aeruginosa*, *Enterobacter*, and *Escherichia coli*. Polymyxin B is available in ointment form (5,000 to 10,000 units per gram) in combination with bacitracin or as triple antibiotic ointment with bacitracin and neomycin. It should be applied one to three times a day.

TOPICAL AMINOGLYCOSIDES (NEOMYCIN AND GENTAMICIN)

The aminoglycosides are an important group of antibiotics used both topically and systemically for the treatment of infections caused by Gram-negative bacilli. Aminoglycosides exert their bactericidal effects by binding to the 30S ribosomal subunit and interfering with protein synthesis.

Neomycin sulfate, the aminoglycoside most often used topically, is a fermentation product of

Streptomyces fradiae. Commercial neomycin is a mixture of neomycin B and C, whereas framycetin, used in Canada and some European countries, is pure neomycin B.[9] Neomycin sulfate has activity against aerobic Gram-negative bacteria and is used most commonly for prophylaxis against infection in superficial abrasions, cuts, and burns. It is available in ointment form (3.5 mg/g) and is also packaged in combination with other antibiotics such as bacitracin, polymyxin, and gramicidin. Other agents, such as lidocaine, pramoxine, or hydrocortisone, also are available in combination with neomycin.

Neomycin is not recommended by many dermatologists because it is responsible for a large number of cases of allergic contact dermatitis. The prevalence of contact dermatitis is high, with 6% to 8% of patients undergoing patch testing being positive.[10] Neomycin sulfate (20%) in petrolatum is used to assess for contact allergy.

Gentamicin sulfate is derived as a fermentation product from *Micromonospora purpurea*. It is available as a topical 0.1% cream or ointment. It is used by some dermatologic surgeons when operating on the ear, especially in diabetic or other immunocompromised patients, to provide prophylaxis against malignant otitis externa due to *P. aeruginosa*. The ophthalmic formulation is useful in caring for operative wounds in the periorbital area.

SULFONAMIDES (SILVER SULFADIAZINE AND MAFENIDE ACETATE)

The sulfonamides are structurally similar to PABA and compete with it during the synthesis of folic acid. Sulfonamides are used to treat acne vulgaris, acne rosacea, and burns. Silver sulfadiazine is thought to release silver slowly and exerts its effect on the bacterial cell walls and membranes. The mechanism of action of mafenide is not the typical sulfonamide mechanism of action because PABA does not antagonize its performance. Mafenide acetate, if used over large areas of skin, has the potential to cause metabolic acidosis, and it can cause intense pain on topical administration. Both agents are broad-spectrum antibacterials useful in the treatment of burns. *Candida* superinfection may be a problem with mafenide cream.

NITROFURAZONE

Nitrofurazone (Furacin) is a nitrofuran derivative used for the treatment of burn patients. The mechanism of action involves the inhibition of bacterial enzymes involved in the aerobic and anaerobic degradation of glucose and pyruvate. Nitrofurazone is available as a 0.2% cream, solution, or soluble dressing, and its spectrum of activity includes staphylococci, streptococci, *E. coli*, *Clostridium perfringens*, and *Proteus* sp.

MISCELLANEOUS AGENTS

GRAMICIDIN

Gramicidin is a topical antibiotic derived from *B. brevis*. The gramicidins are linear peptides that form stationary ion channels in susceptible bacteria. The antibiotic activity of gramicidin is restricted to Gram-positive bacteria.

CLIOQUINOL

Clioquinol (also known as *iodochlorhydroxyquin*) is a broad-spectrum antibacterial/antifungal topical that is currently indicated for the treatment of inflammatory skin disorders and tinea pedis and has been used for minor bacterial infections. It is a synthetic hydroxyquinoline whose mechanism of action is unknown. The disadvantages of clioquinol include discoloration of clothing, skin, hair, and nails and the potential to cause irritation. Clioquinol may interfere with thyroid function determination when taken orally and possibly topically if used extensively. The iodine moiety interferes with tests that rely on iodine uptake (this effect can last for up to 3 months after application). However, clioquinol does not interfere with testing for T3 or T4.

Chapter 219 :: Topical Antifungal Agents

:: Whitney A. High & James E. Fitzpatrick

TOPICAL ANTIFUNGAL AGENTS AT A GLANCE

- Preferred treatment for superficial fungal infection of limited extent.
- Low cost, low incidence of drug interactions, few side effects and complications, ease of use.
- Use systemic agent when superficial fungal infection affects large surface area, involves terminal hair or nails, or is resistant to topical management.
- Topical antifungal classes: imidazoles, allylamines, benzylamines, polyenes.
- Ciclopirox olamine: unique topical antifungal with broad-spectrum activity, variety of indications.
- Side effects: irritant dermatitis, allergic contact dermatitis, urticarial reactions.
- Combination agents (antifungal and steroid): watch for side effects due to glucocorticoids.
- Combination agents: higher rate of treatment failure, disease relapse.

Superficial fungal infections, including dermatophytoses, candidiasis, and pityriasis versicolor, are most often restricted to the epidermis. In treating these infections, the clinician must select between topical or systemic management. Factors guiding management include, but are not limited to, the:

- extent and severity of the infection,
- site of involvement,
- comorbid conditions or potential drug interactions, if any,
- anticipated efficacy of treatment,
- cost and access to medication, and
- ease of use.

Patients with limited fungal infections confined to glabrous skin are usually best treated with topical agents. Conversely, those with extensive or recalcitrant disease, or with involvement of terminal hair or nails, may be better suited for systemic management. In some cases, either treatment option may be reasonably chosen.

Treatment with topical antifungal therapy enjoys several advantages over systemic management, including:

- fewer side effects,
- fewer drug interactions,
- localization of treatment, and
- generally lower cost.

Numerous topical antifungal medications are available (Table 219-1). For the most part, specific antifungal agents have replaced nonspecific topical treatments, such as keratolytics (salicylic acid) or antiseptics (gentian violet or Castellani paint), which were once the cornerstones of management.

The "ideal" topical antifungal is easily defined (Table 219-2), and is in sum, efficacious, inexpensive, well tolerated, and has low resistance within targeted fungi. Despite widespread availability, few topical antifungal agents have been directly compared with one another in clinical trials. Studies sponsored by the manufacturer often compare just the active agent to the vehicle. Extrapolation between studies is further complicated due to differences in study design, duration of therapy, site of infection, selection methodology, or treatment endpoint.

Most topical antifungals belong to one of three classes: (1) imidazoles, (2) allylamines and benzylamines, and (3) polyenes. Agents that do not fit well into this schema are discussed separately.

IMIDAZOLES

Imidazoles represent a broad class of antifungal medications. Certain of these, such as clotrimazole, have been around for decades, while others, such as sertaconazole, have only become available recently.

MECHANISM OF ACTION

Imidazoles impede synthesis of a component of the fungal cell wall through inhibition of lanosterol 14α-demethylase, a cytochrome P_{450}-dependent enzyme, which converts lanosterol to ergosterol.[1] Depletion of ergosterol results in membrane instability and hyperpermeability; changes incompatible with growth and survival of the fungus. Imidazoles are considered fungistatic in practical application, with the possible exception of sertaconazole when used to treat some *Candida* species.[2] While all imidazoles possess the same mechanism of action, in-vitro studies demonstrate that not all dermatophytes are uniformly susceptible to an imidazole at an equivalent concentration, and this may explain some treatment failures.[3–5]

Topical imidazoles possess anti-inflammatory activity via inhibition of neutrophil chemotaxis, calmodulin activity, synthesis of leukotrienes and prostaglandins,

TABLE 219-1
Topical Antifungal Agents Commonly Used in Dermatology

Generic Name(s)	Trade Name(s)	Formulation	Pregnancy Class	Rx/OTC
Imidazoles				
Clotrimazole	Cruex Lotrimin AF Mycelex[a]	1% cream, lotion, lozenges/troches	C	OTC and Rx
Econazole	Spectazole	1% cream	C	Rx
Ketoconazole	Nizoral Nizoral AD	1% and 2% cream and shampoo[b]	C	Rx and OTC
Miconazole	Micatin Monistat-Derm Lotrimin AF Zeasorb AF Vusion[c]	2% cream, lotion, powder, spray powder, spray liquid	C	Rx and OTC
Oxiconazole	Oxistat	1% cream, lotion	B	Rx
Sertaconazole	Ertaczo	2% cream	C	Rx
Sulconazole	Exelderm	1% cream, solution	C	Rx
Allylamines				
Naftifine	Naftin	1% cream, gel	B	Rx
Terbinafine	Lamisil AT	1% cream, gel, spray solution	B	OTC
Benzylamines				
Butenafine	Mentax Lotrimin Ultra	1% cream	B	Rx and OTC
Polyenes				
Nystatin	Bio-Statin Mycostatin Nystop Pedi-Dri	100,000 U/g cream, lozenge/troche, ointment, powder, solution	C[d]	Rx
Other Topical Antifungals				
Ciclopirox olamine	Loprox Penlac	0.77% cream or lotion, 1% shampoo or solution, 8% nail lacquer	B	Rx
Tolnaftate	Equate (Wal-Mart) Tinactin	1% cream, powder, spray powder, spray solution, solution	N/A	OTC
Undecylenic acid	Elon Dual Defense[e] Sally Hansen No More Fungus Fungi-Nail	25% cream, 25% liquid	N/A	OTC
Combination Agents				
Clotrimazole-betamethasone dipropionate	Lotrisone	1% clotrimazole and 0.05% betamethasone dipropionate in cream or lotion	N/A	Rx
Nystatin-triamcinolone acetonide	Mycolog II	100,000 U/g nystatin and 0.1% triamcinolone acetonide	N/A	Rx

N/A = not applicable; OTC = over-the-counter agent; Rx = prescription agent.
[a]Only troches; only sold as branded drug available by prescription.
[b]Recently developed 2% gel (Xolegel™) and 2% foam (Extina™) are approved for seborrheic dermatitis only.
[c]Combination ointment of miconazole nitrate (0.25%), zinc oxide (15%), and white petrolatum (81.35%) with indication for diaper dermatitis complicated by candidiasis.
[d]Varying pregnancy class depends on form; majority of forms are Category C.
[e]Contains also tea tree oil and grapefruit seed extract.

TABLE 219-2
Properties of an Ideal Topical Antifungal Agent

- Broad spectrum of action
- Fungicidal at therapeutic concentration
- Absence of resistance within the targeted fungi
- Keratinophilic with penetration of the cornified envelope without systemic absorption
- Nonirritating and hypoallergenic
- Possess anti-inflammatory properties
- Once-per-day application (or less)
- Short duration of therapy for cure
- Availability in multiple formulations (cream, solution, etc.) and sizes
- Inexpensive

TABLE 219-3
Indications for the Use of Topical Imidazoles

- Dermatophytoses
  - Tinea pedis/tinea manum
  - Tinea cruris
  - Tinea corporis
  - Tinea faciei (the unbearded face)
- Pityriasis versicolor
- Mucocutaneous candidiasis[a]
  - Cutaneous candidiasis
  - Vulvovaginal candidiasis[b]
  - Oral candidiasis (thrush)[c]
  - Perlèche
- Seborrheic dermatitis[d]

[a]Oxiconazole and sulconazole have relatively weaker activity against *Candida*.
[b]Clotrimazole, econazole, miconazole, terconazole, and tioconazole are available as vaginal preparations.
[c]Clotrimazole-dissolving troches are used for oral thrush.
[d]Ketoconazole is used for seborrheic dermatitis, and this includes newer formulations using a foam- or gel-based vehicle (see Table 219-1).

and histamine release from mast cells.[6–8] Some agents, such as ketoconazole, yield anti-inflammatory effects equivalent to 1% hydrocortisone.[9] Topical imidazoles also demonstrate limited antibacterial properties, particularly with respect to Gram-positive organisms.[10,11]

PHARMACOKINETICS

All marketed imidazoles demonstrate excellent penetration of the stratum corneum with strong keratinophilic behavior. Sulconazole may be detected in the stratum corneum up to 96 hours after application.[12] Similarly, sertaconazole, the newest of all marketed imidazoles, has a half-life within the stratum corneum of more than 60 hours.[13] Because of this high affinity for keratin, systemic absorption of imidazoles is low, with urinary excretion usually in the range of 0.3%–1.0% of the applied dose. Even when applied to inflamed skin, absorption of imidazoles does not usually exceed 4% of the applied dose. Again, sulconazole is unique in that percutaneous absorption in the range of 8%–11% of the applied dose exceeds that of all other imidazoles.[12]

INDICATIONS

Indications for topical imidazole use are detailed in Table 219-3. Because of inherent antibacterial activity, some topical imidazoles have demonstrated modest efficacy in treating erythrasma, impetigo, and ecthyma. Because there are more potent antibacterial agents, this is *not* a preferred indication for imidazole use.[9,14,15]

Cure rates for superficial fungal infection treated with imidazoles are variable and often depend upon study design. For example, topical miconazole has demonstrated a 63%–100% cure rate, depending upon the study quoted. A thorough review of the literature provides no compelling evidence that significant differences in cure or relapse exist among the various topical imidazoles; however, other considerations may dictate selection of a particular imidazole.

Topical imidazoles are available as a cream or lotion. Although lotions are better suited for use over large areas or upon hair-bearing skin, limited studies suggest a cream may be marginally more effective. In studies performed by the manufacturer, oxiconazole cream yielded a clinical and mycologic cure in 52% of tinea pedis cases while the lotion yielded the same cure in just 41% of cases. Additionally, the potential for irritancy must be considered. In one study of topical clotrimazole for treatment of tinea cruris, erosive reactions developed in 4 of 27 patients while sulconazole did not cause any erosions in the same population.[16] Similarly, in a second study, severe irritant reactions were reported with miconazole use but not with sulconazole use.[17] Until formal studies of irritancy are performed, we often recommend use of sulconazole in sensitive areas such as the groin. Finally, ease of use may be a factor to consider, as some imidazoles are specifically approved for once-daily dosing (see Section "Dosing Regimen").

DOSING REGIMEN

Topical imidazoles are available in a multitude of forms (see Table 219-1). Econazole, ketoconazole, and oxiconazole are approved for once-daily dosing but twice-daily dosing is recommended for the remainder. Nevertheless, although twice-daily dosing is recommended for sulconazole, a study comparing once-daily to twice-daily dosing in tinea corporis and tinea cruris reported an identical rate of cure.[16] This might have been predicted based upon the 60-hour half-life within the stratum corneum.[13] Application of all topical antifungals, including imidazoles, should include normal skin for a radius of 2 cm beyond the affected area. Duration of treatment with imidazoles has varied. In general, tinea corporis and tinea cruris require treatment for approximately 2 weeks, whereas tinea pedis may require treatment for up to 4 weeks.[18] Treatment should be continued for at least 1 week after all symptoms have abated.[19]

TABLE 219-4
Adverse Reactions to Topical Antifungals

- Irritant contact dermatitis (worsened by occlusion)
- Allergic contact dermatitis (to active agent or more likely to other ingredients/preservatives)
- Urticarial reactions (rare)
- Inappropriate treatment due to misdiagnosis (more likely with over-the-counter agents)

RISKS AND PRECAUTIONS

Risks associated with the use of topical imidazoles include those inherent to all topical medications (Table 219-4), and consist chiefly of irritant and allergic reactions. Additionally, clotrimazole is marketed in combination with the topical glucocorticoid, betamethasone dipropionate. It was assumed that the addition of the steroid would more rapidly relieve inflammation, scaling, and pruritus. Early studies demonstrated the combination was indeed more effective than clotrimazole alone in alleviating symptoms.[20,21] However, betamethasone dipropionate is a potent topical steroid, and striae and other cutaneous side effects from the steroid component may occur.[22] Longer term studies also reported a higher relapse rate (36%) with the combination product.[23,24]

This combination product may comprise 50% or more of antifungal prescriptions by primary care providers, compared to less than 7% among dermatologists.[25] It is likely that overuse by nonspecialists occurs because of the mistaken assumption either that the steroid agent is mild, or that the combination will be a "better choice" when the differential diagnosis is unresolved.[26] The US Food and Drug Administration has twice revised the product warnings for clotrimazole-betamethasone dipropionate, discouraging use on thin skin, for prolonged periods, or when the diagnosis is in doubt.

COMPLICATIONS

Use of topical imidazoles is associated with few complications. Because of low systemic absorption, drug reactions with topical imidazoles are rare. Nevertheless, in a single study, increased serum tacrolimus levels were observed in renal transplant recipients who used clotrimazole troches for mucocutaneous candidiasis.[27] For this reason, use of nystatin may be preferred when treating thrush in transplant patients using tacrolimus.

Concerns of resistance must also be considered. Resistance of *Candida albicans* to clotrimazole has been described in human immunodeficiency virus-positive patients with mucocutaneous candidiasis.[28] Low levels of in-vitro resistance of various *Candida* species to other topical imidazoles has also been documented.[29] Often, this resistance is associated with resistance to oral fluconazole.

ALLYLAMINES AND BENZYLAMINES

Allylamines and benzylamines are closely related compounds. Currently, two topical allylamines and single topical benzylamine are marketed in the United States (see Table 219-1).

MECHANISM OF ACTION

Allylamines and benzylamines share impede synthesis of ergosterol through inhibition of squalene epoxidase, an enzyme that converts squalene to squalene oxide.[30] Depletion of ergosterol results in membrane instability and hyperpermeability. Allylamines and benzylamines are considered fungicidal because the accumulation of intracellular squalene leads directly to cell death. The clinical significance of this cidal action is unclear. Unlike imidazoles, the activity of allylamines and benzylamines is independent of the cytochrome P_{450} enzyme system. When compared to naftifine, terbinafine demonstrates a 10–100-fold increased potency in vitro, although this does not appear to be relevant in clinical use.

Like imidazoles, allylamines, and benzylamines demonstrate anti-inflammatory activity.[6,31] Naftifine inhibits adhesion of polymorphonuclear cells to endothelium, interrupts chemotaxis, and inhibits the 5-lipoxygenase proinflammatory pathway.[32,33] It is assumed that terbinafine and butenafine yield anti-inflammatory effects through similar mechanisms. Allylamines and benzylamines also demonstrate limited antibacterial properties. A recent study showed lowered minimum inhibitory concentrations for both bacteria and fungi when terbinafine was used in combination with benzoyl peroxide.[34]

PHARMACOKINETICS

Allylamines and benzylamines are highly lipid soluble and efficiently penetrate the stratum corneum, where they may persist for extended durations.[35] Butenafine has been detected within the stratum corneum at minimum inhibitory concentration for at least 72 hours after application,[36] and terbinafine may persist at a similar level for up to 7 days after application.[37] Systemic absorption of these agents is quite low, with typical urinary excretion in the range of 3%–5% of the applied dose.[37]

INDICATIONS

Indications for the use of topical allylamines and topical benzylamines are detailed in Table 219-5. Despite antibacterial properties, terbinafine has proven inferior to mupirocin for treatment of impetigo,[38] and a traditional antibacterial agent should be used. Similarly, although allylamines and benzylamines do demonstrate activity against fungi involved in systemic infection, such as *Sporothrix schenckii*, *Blastomyces dermatitidis*,

TABLE 219-5
Indications for the Use of Topical Allylamines and Benzylamines

- Dermatophytoses
  - Tinea pedis/tinea manum
  - Tinea cruris
  - Tinea corporis
- Tinea faciei (the unbearded face)
- Pityriasis versicolor[a]

[a]Although butenafine is approved by the US Food and Drug Administration for use in pityriasis versicolor, the availability of numerous, more cost-effective remedies limits use in this clinical situation.

and *Histoplasmosis capsulatum*, topical therapy is inappropriate.

Limited evidence suggests that topical allylamines or benzylamines may be preferred over topical imidazoles for certain dermatophyte infections. Some trials for tinea pedis indicate that 1 week of topical terbinafine is as effective as 4 weeks of topical imidazoles, with cure resulting in 53%–95% of cases.[39–42] Use of this abbreviated treatment with terbinafine has been confirmed in trials using the active agent versus vehicle alone.[43] In some instances, resolution of tinea pedis using terbinafine has occurred with as few as three doses.[44]

Generic terbinafine 1% cream is more expensive than an equivalent amount of clotrimazole 1%,[45] but considering the frequency of application, the amount of medication required, the likelihood of patient compliance and ease of use, and the rapidity of results, some experts recommend topical terbinafine over topical imidazoles for tinea pedis.[46–48]

DOSING REGIMEN

Topical allylamines and benzylamines are available in a number of forms (see Table 219-1). Each agent has a slightly different dosing regimen based upon the formulation and the location and severity of infection (Table 219-6).

RISKS AND PRECAUTIONS

Risks associated with use of topical allylamines and benzylamines are those inherent to all topical medicaments (see Table 219-4).

COMPLICATIONS

A recent case report highlighted a possible interaction between topical terbinafine and acenocoumarol, and speculated this might be due to high protein binding of terbinafine, with displacement of the anticoagulant,[49] but this is likely exceptional; complications arising from use of topical allylamines or benzylamines are few.

POLYENES

Polyenes were among the first agents discovered to possess specific antifungal properties. The two major topical polyene antifungals are nystatin and amphotericin B. Only topical nystatin is actively marketed in the United States (see Table 219-1).

MECHANISM OF ACTION

Like all polyenes, nystatin binds irreversibly to membrane sterols present in susceptible species of *Candida*.[50] The polyene molecules demonstrate a higher affinity for fungal sterols, including ergosterol, than for human sterols, yielding imperfect selective toxicity. This irreversible binding alters membrane permeability, causing leakage of essential intracellular components and fungal death. In low concentrations, nystatin

TABLE 219-6
Recommended Use of Topical Allylamines and Benzylamines

	Recommendations	
Agent	**Frequency of Application**	**Duration of Application**
Naftifine	Cream—once daily Gel—twice daily	General instructions for use 2 weeks beyond resolution of symptoms
Terbinafine	Tinea pedis (interdigital)—twice daily Tinea pedis (plantar)—twice daily Tinea elsewhere—once or twice daily	At least 1 week At least 2 week At least 1 week, up to 4 weeks
Butenafine	Tinea pedis—once to twice daily Tinea elsewhere—once daily Pityriasis versicolor—once daily[a]	At least 1 week if twice daily, and at least 4 weeks if once daily At least 2 weeks At least 2 weeks

[a]Although butenafine is approved by the US Food and Drug Administration for use in pityriasis versicolor, the availability of numerous, more cost-effective remedies limits use in this clinical situation.

is fungistatic, but, at high concentrations, it may be fungicidal.[51]

PHARMACOKINETICS

Nystatin is insoluble in water and is not absorbed from intact skin, the gastrointestinal tract, or the vagina.[52]

INDICATIONS

Topical nystatin is used to treat mucocutaneous candidiasis caused by *C. albicans*, and other susceptible species such as *C. parapsilosis*, *C. krusei*, and *C. tropicalis*. Repeated studies have demonstrated that topical imidazoles are more effective than nystatin in treating vulvovaginal candidiasis, and use of nystatin for this indication has diminished in recent years.[53,54] Nystatin is not effective against dermatophytes or *Pityrosporum*; and hence, it is not indicated for treatment of tinea or pityriasis versicolor.

DOSING REGIMEN

Nystatin is available as a powder, cream, ointment, suspension, and pastille. To treat oral candidiasis (thrush), the suspension or pastille is used four to five times daily, usually for 2 weeks. To treat cutaneous infection, the powder, cream, and ointment are used twice daily for approximately 2 weeks.

RISKS AND PRECAUTIONS

Risks associated with use of topical nystatin are those inherent to all topical medicaments (see Table 219-4). A significant number of cases of allergic contact dermatitis attributed to nystatin alone have been reported. These reactions have been reported with topical and oral use.[55,56] Anaphylaxis has been described with use of nystatin-containing vaginal suppositories but the reaction was attributed to ingredients other than nystatin.[57]

A combination agent consisting of nystatin and triamcinolone acetonide is widely marketed. The addition of triamcinolone may provide additional benefit over nystatin alone during the first few days of treatment when inflammation is maximal.[58] After this initial period, the manufacturer recommends a transition to nystatin alone or to other topical antifungal agents. Although triamcinolone acetonide is only a midpotency agent, cutaneous sequelae, including striae, skin atrophy, and steroid-induced acne, have been reported.[59] Because candidiasis often involves thin and fragile skin, such as that of the intertriginous areas, the risk of damage is likely potentiated. Finally, many of the combined formulations contained, or may still contain, ethylenediamine, a sensitizer that may cause allergic contact dermatitis.[60] As with clotrimazole-betamethasone dipropionate, the combination agent of nystatintriamcinolone acetonide is more often prescribed by nondermatologists.

COMPLICATIONS

Complications with topical polyenes are few. Nystatin resistance may be encountered in some *Candida* sp.[61,62] This resistance may either be seen in wild strains (primary type) or it may be induced during therapy (secondary type). Although *C. albicans* maintains a low rate of spontaneous resistance to nystatin,[63] particularly in comparison to resistance to imidazoles,[64] other species, such as *C. tropicalis*, *C. guilliermondi*, *C. krusei*, and *C. stellatoides*, rapidly acquire resistance upon exposure to nystatin.

OTHER AGENTS

Some topical antifungals, such as ciclopirox olamine, tolnaftate, and undecylenic acid, do not fit well into the major classes and are instead discussed separately.

CICLOPIROX OLAMINE

Ciclopirox olamine is a hydroxypyridone antifungal agent with a unique structure and mode of action.

MECHANISM OF ACTION. Unlike most other topical antifungals, ciclopirox olamine does not interfere with sterol synthesis.[65] Instead, it interrupts active membrane transport of essential cellular precursors, particularly trivalent cations.[66] Ultimately, this disrupts cellular function, leading to demise of the fungus. If concentrations of the drug are high enough, the membrane integrity of the fungus may actually be impaired.

Ciclopirox olamine also has inherent anti-inflammatory activity exerted through inhibition of prostaglandin and leukotriene synthesis within polymorphonuclear cells.[67] Broad-spectrum antibacterial properties have also been attributed to ciclopirox olamine. In one study, topical ciclopirox olamine had broader coverage against Gram-positive and Gram-negative organisms than did topical imidazoles or topical allylamines.[68]

PHARMACOKINETICS. When applied to the skin, ciclopirox olamine remains in high concentration within the epidermis and upper dermis. Ciclopirox olamine penetrates keratin easily, with cadaveric skin demonstrating concentrations in the epidermis that were 10–15 times the minimum inhibitory concentration for a sensitive species.[67] This ability to penetrate keratin recommends use for onychomycosis, as the drug is also capable of penetrating the nail plate material.[69] Studies of drug metabolism have demonstrated that, with typical use, approximately 10% of the administered dose is excreted in the urine.[70]

INDICATIONS. Ciclopirox olamine is indicated for the treatment of dermatophytoses and onychomycosis, candidiasis, pityriasis versicolor, seborrheic dermatitis, and even cutaneous infections with unusual saprophytes.[71] In tinea pedis, a mycologic cure rate of up

to 85% has been observed, and in seborrheic dermatitis, a significantly larger percentage of users had >75% improvement with 2 weeks of use than those using the shampoo vehicle alone.[72,73]

Although treatment with ciclopirox olamine for tinea pedis and seborrheic dermatitis has yielded results on par with other modalities, use in onychomycosis has met with more modest success. Often, an assessment of efficacy depends upon whether a mycologic cure (culture-negative) or clinical cure (a disease-free nail) defines success.[74] Although a disease-free nail is often the patient's true goal, ciclopirox olamine achieved such a response in just 5.5%–8.5% of those treated with a standard 48-week course.[74,75] Two recent trials demonstrated increased efficacy when using oral terbinafine in combination with topical ciclopirox olamine, as opposed to oral terbinafine alone.[76,77] Debate regarding the use of ciclopirox olamine as an independent or adjunct treatment for onychomycosis is ongoing.

DOSING REGIMEN. Ciclopirox olamine is available in a wide range of forms (see Table 219-1). Cutaneous candidiasis, dermatophytoses, and pityriasis versicolor should be treated twice daily for 2 weeks to 1 month, but treatment for tinea pedis should continue 1 month or longer. When using ciclopirox shampoo for seborrheic dermatitis, treatment may continue twice weekly for an indefinite duration. Improvement is generally noted in 2–4 weeks. Finally, in treating onychomycosis, the nail lacquer is applied daily to the nail and hyponychium for 48 weeks and excess medication is removed weekly with alcohol.

RISKS AND PRECAUTIONS. Risks associated with use of topical ciclopirox olamine are those inherent to all topical medicaments (see Table 219-4). Allergic contact dermatitis has been reported only rarely, and ciclopirox olamine is considered a weak sensitizer.[78] In patients with an allergic reaction to ciclopirox, imidazoles may be used with relative safety because of a markedly different chemical structure.

COMPLICATIONS. Serious complications with topical ciclopirox olamine are few.

OLDER AGENTS

Tolnaftate and undecylenic acid are older agents now available only in over-the-counter products (see Table 219-1). Repeated studies have now demonstrated that they are approximately equal in efficacy,[79,80] and that both are less efficacious than topical imidazoles, allylamines, benzylamines, and ciclopirox olamine. Additionally, tolnaftate is ineffective for treating candidiasis. Topical tolnaftate and topical undecylenic acid share the same risks and precautions inherent to all topical medications (see Table 219-4). Additionally, topical forms of undecylenic acid may yield an unpleasant "fishy smell" that further discourages use. Both agents are considered less efficacious than imidazoles.

TOLNAFTATE

Tolnaftate is a thiocarbamate first developed in the 1960s but now contained only in over-the-counter antifungal remedies.

MECHANISM OF ACTION. The precise mechanism of action for tolnaftate is unknown. It is thought to impair ergosterol synthesis via inhibition of squalene epoxidase but in a different manner than that of allylamines and benzylamines.[80] Tolnaftate may be fungistatic or fungicidal, depending upon the concentration. No antibacterial properties have been attributed to tolnaftate.

PHARMACOKINETICS. Little data exists regarding the pharmacokinetics of tolnaftate. Like other topical antifungals, systemic absorption is assumed to be negligible from a clinical standpoint.

INDICATIONS. Tolnaftate is indicated for the treatment of dermatophytosis and pityriasis versicolor. Early studies demonstrated a cure rate for tinea pedis as high as 73 percent to 93 percent, but later studies demonstrated lower efficacy, essentially equivalent to undecylenic acid.[77,81] Although direct comparisons are lacking, topical tolnaftate is widely considered less effective than topical imidazoles, allylamines, and benzylamines. Tolnaftate is ineffective for candidiasis.

DOSING REGIMEN. Tolnaftate is available in a variety formulations (see Table 219-1). Twice-daily use for at least 2 to 4 weeks, and up to 6 weeks on hyperkeratotic skin, is recommended. To diminish the incidence of recurrence, others simply recommend treatment be continued 2 weeks beyond apparent resolution.

RISKS AND PRECAUTIONS. Risks associated with use of topical tolnaftate are those inherent to all topical medicaments (see Table 219-3). Allergic contact dermatitis has been reported on occasion.[82,83]

COMPLICATIONS. Serious complications with use of topical tolnaftate are few.

UNDECYLENIC ACID

MECHANISM OF ACTION. Despite more than 60 years of use, the mechanism of action for undecylenic acid is largely unknown. It appears that the organic acid interacts with components in the fungal cell wall. In *C. albicans,* the inhibition of germ tube formation has been recently identified, and a similar effect has been noted in conidia formation in *Trichophyton rubrum.*[84,85]

PHARMACOKINETICS. Undecylenic acid is available as a zinc, calcium, or copper salt. As tissue pH rises, this salt fails to dissociate, and the antifungal properties of the medication diminish.[86] The acid is practically insoluble in water, but is miscible in ethanol, water, or ether. With topical use, systemic absorption is

negligible. The zinc contained in the zinc undecylenate form, the most common in clinical use, provides some astringent action that may aid in reducing rawness and irritation.

INDICATIONS. Topical undecylenic acid is used for the treatment of dermatophytosis and candidiasis. Although early studies indicated a cure rate in excess of 80 percent, subsequent studies demonstrated cure rates of 53 percent or less.[87] Undecylenic acid and its salts are widely considered less effective than miconazole, clotrimazole, or tolnaftate in the treatment of tinea pedis.

A trial of topical undecylenic acid for herpes labialis demonstrated a decreased incidence and duration of viral shedding, with a decrease in pain and tenderness.[88] The antiviral effect was of short duration and most pronounced when acid was applied during the prodrome. Other long chain alcohols enjoy specific approval for abbreviation of herpes labialis and appear more effective.[89]

DOSING REGIMEN. Undecylenic acid and its salts are available as a powder, aerosol, cream, and solution. Standard dosing for children and adults is twice-daily for 4 weeks of use.

RISKS AND PRECAUTIONS. Risks associated with use of topical undecylenic acid are those inherent to all topical medicaments (see Table 219-3). Allergic contact dermatitis has been recently reported, and a protocol for patch testing exists if such an allergy is suspected.[90] Topical forms of undecylenic acid may yield an unpleasant "fishy smell" that discourages use.

COMPLICATIONS. Complications with topical undecylenic acid are few. Because undecylenic acid is widely accepted to be less effective than imidazoles, clinical monitoring for treatment failure is indicated.

FUTURE DEVELOPMENTS

Amorolfine is a morpholine derivative unapproved for use in the United States. Elsewhere in the world, it is approved for use as a 5% nail lacquer. Amorolfine is fungicidal against most dermatophytes, yeasts, and some molds. With 6 months of biweekly use, amorolfine 5% nail lacquer resulted in complete cure in up to 54% of patients.[91] Side effects were similar to those of ciclopirox nail lacquer. Also, similar to ciclopirox olamine, a recent study using amorolfine lacquer and oral terbinafine in combination resulted in a significantly higher cure rate and lower cost per patient cured.[92] In the future, approval of amorolfine in the United States may be pursued.

Benzoxaboroles, derivatives of boronic acid, represent a burgeoning new class of topical antifungal agents. The most explored of these compounds, 5-fluoro-1,3-dihydro-1-hydroxy-2,1-benzoxaborole (AN2690), inhibits an aminoacyl–transfer RNA (tRNA) synthetase that catalyzes attachment of the correct amino acid to corresponding tRNA during translation of the genetic code, blocking protein synthesis.[93] The active agent penetrated well the nail plate when applied in an ethanol/propylene glycol vehicle, leading to considered use in onychomycosis.[94] Future discovery with regard to this new class of antifungal agents is anticipated.

CONCLUSIONS

Because of relatively low cost, acceptable efficacy, ease of use, and low potential for side effects, complications, or drug interactions, topical antifungals are preferred for most superficial fungal infections of limited extent. Alternatively, use of a systemic agent is justified when a superficial fungal infection covers a large surface area, involves terminal hair or nails, or has proven recalcitrant to prior topical management. Imidazoles provide a reasonable balance of efficacy and affordability and are indicated for treatment of dermatophytoses, mucocutaneous candidiasis, and pityriasis versicolor. Despite higher cost, allylamines and benzylamines may be advantageous in some cases of tinea pedis, due to shorter treatment courses. Ciclopirox olamine is a topical antifungal with a unique mechanism of action and a broad range of indications. Topical nystatin is useful in treating mucocutaneous candidiasis, but is ineffective for dermatophyte infections. Use of tolnaftate and undecylenic acid is decreasing due to lower efficacy compared with other available agents. New topical agents for treatment of onychomycosis are being pursued.

KEY REFERENCES

Full reference list available at www.DIGM8.com

DVD contains references and additional content

6. Rosen T, Schell BJ, Orengo I: Anti-inflammatory activity of antifungal preparations. *Int J Dermatol* **36**:788, 1997
19. Weinstein A, Berman B: Topical treatment of common superficial tinea infections. *Am Fam Physician* **65**:2095, 2002
25. Greenberg HL et al: Clotrimazole/betamethasone diproprionate: A review of costs and complications in the treatment of common cutaneous fungal infections. *Pediatr Dermatol* **19**:78, 2002
48. Crawford F et al: Topical treatments for fungal infections of the skin and nails of the foot. *Cochrane Database Syst Rev* **18**:CD001434, 2007
67. Gupta AK, Plott T: Ciclopirox: A broad-spectrum antifungal with antibacterial and anti-inflammatory properties. *Int J Dermatol* **43**:3, 2004
76. Avner S, Nir N, Henri T: Combination of oral terbinafine and topical ciclopirox compared to oral terbinafine for the treatment of onychomycosis. *J Dermatolog Treat* **16**:327, 2005

Chapter 220 :: Topical and Intralesional Cytotoxic Agents

:: Aieska De Souza, Megan M. Moore, & Bruce E. Strober

TOPICAL CYTOTOXIC AGENTS AT A GLANCE

- Topical and intralesional cytotoxic agents are effective in the treatment of skin cancers and inflammatory and infectious dermatologic conditions.
- They aim for maximum efficacy against cutaneous targets while sparing normal tissue and minimizing systemic toxicity.
- They comprise 5-fluorouracil, nitrogen mustard, carmustine, vinblastine, bleomycin, methotrexate, podophyllin, and miltefosine.

5-FLUOROURACIL

MECHANISM OF ACTION AND FORMULATIONS

Topical 5-fluorouracil (5-FU) has been used in clinical practice since the 1960s. It is a structural analogue of thymine that blocks DNA synthesis by inhibiting thymidylate synthetase (Table 220-1). Topical 5-FU is commercially available as a 0.5% cream carried in a microsphere vehicle, as a 1% solution or 1% cream, as a 2% or 5% solution, and as a 5% cream. The solution can also be used for intralesional injection.

INDICATIONS

5-FU 5% cream has been approved by the US Food and Drug Administration (FDA) since 1970 for the treatment of actinic keratoses in any location and superficial basal cell carcinomas; 5-FU 0.5% cream is FDA approved for treatment of actinic keratoses of the face and anterior scalp. 5-FU is used twice daily until an inflammatory response is seen, usually 2–4 weeks. The 0.5% cream can be used once daily. 5-FU may also be a useful adjunct before cryosurgery of actinic keratoses.[1] Pretreatment with a keratolytic agent, prolonged therapy, more frequent applications, or the use of occlusive dressings may increase therapeutic response.

TREATMENT CONSIDERATIONS

Irritation during treatment sometimes requires reduction or interruption of treatment and the addition of emollients or topical corticosteroids to help quell brisk inflammation. A number of approaches to decrease irritation have been devised; whether or not efficacy is preserved is disputed.[2] Weekly pulse dosing involves applying the medication for 1–2 days per week for 6–7 weeks. Use of the 0.5% 5-FU cream with microsphere vehicle may allow for a more tolerable irritation profile.[3]

During 5-FU treatment, previously subclinical actinic keratoses, basal cell carcinomas, and squamous cell carcinomas may become apparent and respond to treatment. A systematic review of 13 randomized controlled trials on the effectiveness of 5-FU for the treatment of actinic keratoses demonstrated that about 50% of patients obtain complete clearance after treatment and an overall reduction of 80% in lesion count can be expected.[1] However, about two-thirds of patients will require retreatment after 1 year. Histological cure rates for superficial basal cell carcinomas after 5-FU treatment are between 90% to 93%; however, it is not recommended in nodular and high-risk, basal cell carcinomas since the drug does not seem to control deeper tumor growth,[4] and there is a possibility that treatment can mask the persistence or recurrence of basal cell cancer.

Verrucae vulgaris, verrucae plana, plantar warts, and condylomata acuminata have been treated with varying response rates with topical and intralesional 5-FU. Additionally, actinic cheilitis, mucosal leukoplakia, radiodermatitis, Bowen disease, Bowenoid papulosis, and erythroplasia of Queyrat have all been reported to respond to treatment with topical 5-FU. Further, there are reports of the successful treatment of both psoriasis and keratoacanthomas with topical and intralesional 5-FU,[4] and of infantile digital fibromatosis treated with intralesional 5-FU.[5] Combined use of ablative Er:Yag laser and topical 5-FU is an effective treatment option for giant keratoacanthomas if surgery is contraindicated.[4] Intralesional 5-FU has also been reported to be effective in the treatment of keloids and hypertrophic scars.[6,7] Controversial results have been observed with treatment of nail psoriasis with 5-FU: one trial demonstrated a 25% reduction in pitting and hyperkeratosis in twenty patients with nail psoriasis treated with 1% 5-FU solution for 6 months,[4] while a second randomized, double-blind study failed to demonstrate difference between the treatment group and placebo.[4] Vitiligo patients may benefit from the combination of dermabrasion and 5% 5-FU cream, or 5-FU alone under occlusive dressings.[4]

The systemic absorption of topically applied 5-FU is limited, with absorption selectively greater from abnormal skin than from surrounding normal skin. Microsphere-based formulations may retain 5-FU at

TABLE 220-1
Topical and Intralesional Cytotoxic Agents Used in Dermatology: Mechanism of Action, Formulation, Main Indications, and Common Side Effects

Drug	Mechanism of Action	Formulations	Indications	Common Side Effects
5-fluorouracil	Blockage of DNA synthesis by inhibition of thymidylate synthetase	0.5% cream (microsphere vehicle) 1%, 5% cream 1%, 2%, 5% solution Intralesional injection	Actinic keratoses Superficial basal cell carcinomas	Local irritation, erythema, pain, swelling, pruritus, dyspigmentation, allergic contact dermatitis, photosensitivity
Mechlorethamine (nitrogen mustard)	Alkylating activity, immune stimulation	Compounded: 0.01%–0.04% aqueous solution, ointment	Mycosis Fungoides Stages IA, IB	Irritant or allergic contact dermatitis, immediate-type hypersensitivity, secondary cutaneous malignancies, dyspigmentation
Carmustine	Alkylation agent: inhibits DNA, RNA, and protein synthesis	Compounded: solution or ointment 10 mg or 20 mg/dL	Mycosis fungoides Stages IA, IB	Myelosupression, leukopenia, erythema, skin tenderness, and telangiectasia
Vinblastine	Antimitotic agent: acts by disrupting microtubules, blocking cell division in metaphase	Intralesional injection: 0.1–0.6 mg/mL in saline solution	Kaposi sarcoma	Local pain, hyperpigmentation Rarely: mononeuropathy, transient flu-like syndrome
Bleomycin	Disrupts DNA synthesis and causes scission of DNA strands	Intralesional injection: 1 U/mL solution	Viral warts, hemangiomas, keloids and hypertrophic scars	Local pain and swelling
Methotrexate	Antimetabolite: interferes with DNA synthesis (inhibition of dihydrofolate reductase)	Intralesional injection: 5–75 mg	Keratoacanthoma	Hematologic toxicity, hepatotoxicity, nausea, abdominal pain, oral aphthae, reversible alopecia, pancytopenia
Podophyllin	Binds tubulin, disrupting the cellular cytoskeleton	0.5% ethanol 0.15% cream	Anogenital warts Facial angiofibromas	Erythema, erosions, tenderness
Miltefosine	Cytotoxic: promotes phospholipid turnover and modulates membrane signal transduction by inhibition of protein kinase C	6% solution	Cutaneous metastases of breast cancer Cutaneous lymphomas Cutaneous mastocytosis	Local: burning, erythema, and fine scaling

the target site, with less drug reaching the systemic circulation.[8] Rarely, systemic effects of 5-FU include nausea and anorexia, stomatitis, diarrhea, myelosuppression, alopecia, and cardiac and neurologic toxicity. Side effects of the topical preparation include local irritation, erythema, pain, swelling, pruritus, dyspigmentation, allergic contact dermatitis, and photosensitivity. Unusual reactions may include onycholysis, onychodystrophy, and the appearance of telangiectasias. The use of injectable preparations may be complicated by pain, local ulceration, erosion, desquamation, and dyspigmentation.[6]

MECHLORETHAMINE (NITROGEN MUSTARD)

MECHANISM OF ACTION AND FORMULATIONS

Mechlorethamine [methyl-*bis* (2-chloroethyl) amine hydrochloride] was the first nitrogen mustard (NM) to be used in clinical medicine. Mechlorethamine acts as an alkylating agent and is not cell-cycle specific;

however, its greatest effect is on cells in the late G1 or S phases. The primary target of mustard is the 7-nitrogen atom of guanine. The main role of topical NM in dermatology is in the treatment of the patches and plaques of cutaneous T-cell lymphoma (CTCL). The utility of NM in treating mycosis fungoides (MF), the most common type of CTCL, was first described in 1959. The topical activity of NM has been attributed not only to its alkylating activity, but also to its potential for immune stimulation. The delayed-type hypersensitivity reaction induced by nitrogen mustard is mediated by Th1-type response, while the malignant T-cells in MF express Th2-type cytokines. The contact hypersensitivity reaction can potentially stimulate malignant T-cells to shift from Th2 to Th1-type cytokine expression and activity leading to apoptosis of the malignant T-cells and tumor regression.[9]

Mechlorethamine hydrochloride (Mustargen) is available in powder form, 10-mg per glass vial. Topical NM is prepared as either an aqueous solution or an ointment preparation. A variety of ointment bases can be used, including Aquabase®, Aquaphor®, hydrophilic petrolatum, a 50/50 mixture of liquid paraffin-white soft paraffin, and white soft paraffin.[10] Aqueous solutions can be made to desired concentrations by dissolving the NM powder in tap water (one vial of 10-mg powder dissolved in 100-mL water yields a 10 mg% concentration). The solution is unstable and should be applied immediately to the skin using a sponge or cloth. Ointment preparations can be compounded by pharmacists.[9] Nitrogen mustard compounded in Aquaphor® formulations showed higher stability than in Transcutol®, Labrasol®, and Aquaphilic® ointments. However, a significant increase in stability can be obtained when the free radical inhibitor BHT (butylated hydroxytoluene) is added to Transcutol® or Labrasol® formulations.[10]

With either preparation, concentrations of 10–20 mg% are generally used and are applied daily, with increases in concentration and frequency of application pending clinical response. One approach is to apply the preparation to the entire body (sparingly to intertriginous sites, and excluding the genitalia) initially to avoid missing areas of subclinical involvement and thus theoretically increase the potential for cure.[10] Alternatively, treatment may be limited to only clinically affected areas. Treatment should be continued daily until complete response is attained. The benefit of a prolonged maintenance period in preventing disease relapse has not been shown.[9] With proper application, there is minimal contamination of the surrounding environment, but those assisting in the application of the drug should limit their exposure and wear protective gloves. Effort should be made to dispose of empty vials or unused solution in accordance with Environmental Protection Agency guidelines.

INDICATIONS

Many large retrospective series support the use of topical NM in MF. NM has been reported to produce complete response rates of 67%–80% for MF patients with limited patch/plaque disease (stage IA) and 35%–68% for patients with generalized patch/plaque (stage IB) disease.[9] Relapses are common even with the continuation of therapy.[11] The efficacy of aqueous and ointment-based preparations is similar.[9] Topical NM as primary monotherapy has limited use in patients with tumor stage or erythrodermic disease.[9] Topical NM has also been used in the treatment of psoriasis,[12] alopecia areata,[13] and histiocytosis X.[14]

TREATMENT CONSIDERATIONS

Unlike the systemic preparation, there are no reports of systemic side effects following topical NM application. Furthermore, topical NM has been used safely in pediatric patients.[9] Local side effects include irritant or allergic contact dermatitis, immediate-type hypersensitivity, secondary cutaneous malignancies, and dyspigmentation. Irritant contact dermatitis is generally mild and resolves with reduction in concentration and/or frequency, or with topical steroid treatment. Allergic contact dermatitis has been reported to develop in up to 35%–66% of patients on long-term treatment with aqueous NM and in fewer than 10% of those using the ointment preparation.[9] If hypersensitivity occurs, patients may be treated with dilutions below the threshold for clinically observable contact dermatitis. However, delayed-type hypersensitivity may be of therapeutic benefit. Twice-weekly dosing of topical NM in combination with betamethasone cream may offer a balance of tolerability and efficacy.[15] Up to 8% of patients may develop an urticarial immediate-type hypersensitivity to topical NM, often necessitating treatment discontinuation. Changes in pigmentation may also occur secondary to use of topical mechlorethamine. Hyper- and hypopigmentation are prone to develop in areas of previous CTCL and tend to resolve spontaneously, although slowly.

There have been reports of secondary cutaneous malignancies developing in patients treated with NM, including basal and squamous cell carcinomas, keratoacanthomas, and isolated reports of lentigo maligna and primary melanoma.[9] It is difficult to determine causality in these cases, as many of these patients were treated with multiple therapies, including known carcinogenic therapies such as psoralen and ultraviolet A phototherapy and radiation.

BLEOMYCIN

MECHANISM OF ACTION AND FORMULATIONS

Bleomycin is a cytotoxic antibiotic produced by *Streptomyces verticillatus*. Bleomycin disrupts DNA synthesis and causes scission of DNA strands by causing oxidative damage to the deoxyribose of thymidylate and other nucleotides.[19] The result is an arrest in cell cycle with subsequent apoptosis and leakage of intracellular components, triggering the innate immune response. Individual eosinophilic keratinocytes with small dark

pyknotic nuclei, subepidermal and intraepidermal hemorrhage, and neutrophil accumulation with formation of microabcesses in the granular layer can all be observed after bleomycin injection.[19] Bleomycin also has a sclerosant effect on endothelial cells. In dermatology, intralesional bleomycin has largely been used in the treatment of recalcitrant viral warts.[21]

Bleomycin is available as a powder (Blenoxane). It should be reconstituted with sterile saline to the desired concentration, generally 1 U/mL solution. Stability in this formulation has been shown at 6–8 weeks if the preparation is refrigerated at 4°C (39.2°F), and for several months if stored at –20°C (–4°F). Drug uptake can be greatly increased by the combination with local anesthetics such as lidocaine, procaine, dibucaine, butacaine, and tetracaine, since local anesthetics can disrupt cell membrane structure.[19] Proper injection is indicated by the blanching of the skin.

INDICATIONS

There have been no large, randomized, double-blind, placebo-controlled studies of intralesional bleomycin treatment of viral warts, however smaller studies have demonstrated its efficacy. A study comparing intralesional bleomycin with cryotherapy showed significantly higher clearance rates for patients treated with bleomycin injection (94.9%) when compared to cryotherapy (76.5%).[22] A paired, controlled study of intralesional bleomycin 1 U/mL injected intralesionally until blanching in resistant warts in 38 patients reported a 77% cure rate for warts on extremities; however, the rate fell to about 48% for plantar warts.[23] To overcome the problem of adequate infiltration of the wart without unwanted infiltration of normal skin, various approaches, including repeated pricking of the wart,[21] the use of bifurcated needles,[24] and pretreatment with pulsed dye laser,[25] have been described. An uncontrolled study of 70 patients with plantar, palmar, mosaic, and periungual warts treated monthly with "pricking" of 1 U/mL bleomycin solution using a Monolet needle reported a 92% success rate.[21]

Multiple prospective studies of vascular malformations and hemangiomas treated with intralesional bleomycin have reported significant reduction in the size of lesions in approximately three-fourths of patients.[19] Imaging with magnetic resonance to evaluate the extent of soft tissue and bone involvement is indicated before any injections are made. A reduced dose of bleomycin should be used in children: 0.2–0.4 mg/kg diluted in normal saline.[19] Successful treatment of keloids and hypertrophic scars[26] has been reported in several case series, with complete regression in one-half to three-fourths of cases. A small, randomized, controlled trial and open-label prospective study have described the benefit of topical 1% bleomycin in dimethylsulfoxide in treating oral leukoplakia.[27] Isolated case reports and small series have reported benefit from topical bleomycin ointment in treating recurrent Paget disease of the vulva[28] and from intralesional bleomycin in treating keratoacanthomas.[29]

TREATMENT CONSIDERATIONS

Bleomycin has relatively low toxicity. Flu-like symptoms have been reported after intralesional use, but significant systemic toxicity is rare. Pulmonary fibrosis has been well described in association with systemic bleomycin chemotherapy but is dose related. Local side effects of pain and swelling are common with intralesional use. Combinations of bleomycin and lidocaine may reduce the pain associated with injection, but children may require general anesthesia for treatment. Local injection for periungual warts may result in permanent nail loss or dystrophy.[30] Raynaud phenomenon, dyspigmentation, ulceration, cellulitis, and superficial scarring may also occur.[24,31] There is a case report of flagellate hyperpigmentation after intralesional injection of bleomycin.[32] Contraindications include Raynaud phenomenon, peripheral vascular disease, pregnancy, and nursing.[19]

METHOTREXATE

MECHANISM OF ACTION AND FORMULATIONS

Methotrexate (MTX) is an antimetabolite that interferes with DNA synthesis through inhibition of dihydrofolate reductase. MTX also alters the metabolism of adenosine, an endogenous anti-inflammatory mediator.[33]

INDICATIONS

In multiple case reports[34] and small case series,[35] intralesional methotrexate has been used to effectively treat solitary, giant, and eruptive keratoacanthomas, demonstrating up to 92% complete response rate.[35] The proposed mechanism of action is the cessation of thymidylate synthesis by inhibition of dihydrofolate reductase in the rapidly dividing tumor cells, with consequent blockage of DNA synthesis.[34] Intralesional MTX should be considered as a treatment option for biopsy-confirmed keratoacanthomas located in aesthetically important areas or for which surgery is contraindicated.[34] Injection parameters have included total doses from 5–75 mg, in 1 to 5 injections, with single doses ranging from 5–50 mg, and intervals of 1–2 weeks between injections. Leakage of roughly 50% of the injection dose is expected due to poor cohesion between tumor cells. In a review of 38 cases treated with MTX, the clearance rate was 83% with an average cumulative dose of 38.2 mg and injections spaced 12–38 days apart.[35]

TREATMENT CONSIDERATIONS

Methotrexate has well-studied adverse effects, including hematologic toxicity, hepatotoxicity, nausea, abdominal pain, oral aphthae, and reversible alopecia. Pancytopenia has been reported in two patients after

receiving a single 25-mg dose of intralesional MTX. Both patients had renal failure and were hemodialysis dependent.[35] Caution is warranted when using methotrexate in patients with renal insufficiency, advanced age, hepatic disease, or the concomitant use of medications that may interfere with its excretion.[34] Pregnant or breastfeeding patients must be excluded. Injections have been reported to be generally well tolerated, with moderate pain and minimal scarring.

PODOPHYLLIN AND PODOPHYLLOTOXIN

MECHANISM OF ACTION AND FORMULATIONS

Podophyllin is a crude resin derived from either the American mandrake, *Podophyllum peltatum*, or the Indian podophyllum, *P. emodi*. Podophyllotoxin is an extract of podophyllin with antineoplastic and antiviral activity. Podophyllotoxin binds tubulin disrupting the cellular cytoskeleton, blocking mitosis and arresting the cell cycle at G2.[36]

Podophyllin is produced as a 10%–40% ethanolic or benzoin crude extract. Composition is not standardized, and the most potent active ingredient, podophyllotoxin, rapidly crystallizes out, leading to a short shelf life.

INDICATIONS

In dermatology, topical podophyllin and podophyllotoxin are used in the treatment of anogenital warts. A recent report describes the successful use of podophyllin 25% extract in benzoin tincture for treatment of facial angiofibromas of tuberous sclerosis in a 27-year-old female. Most of the lesions regressed after 3 monthly applications.[37]

TREATMENT CONSIDERATIONS

Podophyllin should be applied under medical supervision with a protective inert ointment to surrounding skin and washed off 4–6 hours after application. Treatment is generally at weekly intervals.[38] Podophyllotoxin, the purified active ingredient of podophyllin, is available as 0.5% ethanol and 0.15% cream formulations. These preparations are to be self-applied in one or several 3-day cycles.[38] Self-treatment with podophyllotoxin has been shown to be more effective and more cost effective compared with podophyllin applied in the clinic, although relapse rates are high with both treatments.[39] Systemic toxicities—including central nervous system and respiratory depression—have been reported after excessive podophyllin treatment of large anogenital warts, subdermal injection, or accidental ingestion, and podophyllin is reported to have mutagenic potential.[38] Local side effects, such as erythema, erosions, and tenderness, are common with both podophyllin and podophyllotoxin. Scarring or depigmentation rarely occurs. Given reports of the low efficacy, high toxicity, and mutagenicity profile of podophyllin, some authors have urged that it be removed from clinical treatment protocols and replaced by podophyllotoxin or other treatments.[38]

MILTEFOSINE (HEXADECYLPHOSPHOCHOLINE)

MECHANISM OF ACTION AND FORMULATIONS

Miltefosine (hexadecylphosphocholine) is a cytotoxic alkyl phosphocholine that exerts its effects on the cell membrane. Miltefosine promotes phospholipid turnover and modulates membrane signal transduction, including inhibition of protein kinase C. Miltefosine is considered to be a prototype lipid raft modulator. The compound inhibits anti-IgE induced histamine release from human skin mast cells. In addition, miltefosine significantly attenuated the allergic sensitization in the model of ovalbumin-induced delayed-type hypersensitivity in mice.[40] Miltefosine is available as a 6% solution in a defined mixture of three short-chain glycerol ethers that increases penetration (Miltex).

INDICATIONS

Miltefosine has shown promise as a treatment for cutaneous metastases from breast cancer and CTCL. In a phase II trial of milfetosine in 12 patients with CTCL, the response rate was 58% with a median duration of response of 12 months.[41] However, limited skin penetration, local metabolism, and clearance via dermal blood vessels may interfere with efficacy. There are also isolated reports of the successful use of miltefosine in the treatment of cutaneous metastases of squamous cell carcinoma.[42] Milfetosine was found to be effective in treating cutaneous mastocytosis, with significant reduction of mast cell number in the upper dermis.[43] Furthermore, the compound modulates T-cell function in models for Th1 and Th2 related activity,[40] suggesting that it can be used for the treatment of T-cell-related allergic diseases.

TREATMENT CONSIDERATIONS

Application in clinical trials and case series is generally daily for a week, then twice daily thereafter. Miltefosine 6% solution applied in this manner showed modest efficacy against cutaneous metastases of breast cancer in a randomized, double-blind, placebo-controlled, multicenter trial.[44]

When administered systemically, miltefosine causes significant gastrointestinal toxicity. However, systemic side effects, such as nausea, vomiting, and anorexia, have rarely been observed with topical application.[43] Local skin reactions are common, including burning, erythema, and fine scaling, but rarely necessitate discontinuation of therapy.

KEY REFERENCES

Full reference list available at www.DIGM8.com

DVD contains references and additional content

1. Askew DA et al: Effectiveness of 5-fluorouracil treatment for actinic keratosis—A systematic review of randomized controlled trials. *Int J Dermatol* **48**:453-463, 2009
9. Kim Y: Management with topical nitrogen mustard in mycosis fungoides. *Dermatol Ther* **16**:288, 2003
11. Whittaker SJ, Foss FM: Efficacy and tolerability of currently available therapies for the mycosis fungoides and Sezary syndrome variants of cutaneous T-cell lymphoma. *Cancer Treat Rev* **33**:146-160, 2007
19. Saitta P, Krishnamurthy K, Brown LH: Bleomycin in dermatology: A review of intralesional applications. *Dermatol Surg* **34**:1299-1313, 2008
33. Chan E, Cronstein B: Molecular action of methotrexate in inflammatory diseases. *Arthritis Res* **4**:266, 2002
35. Annest NM et al: Intralesional methotrexate treatment for keratoacanthoma tumors: A retrospective study and review of the literature. *J Am Acad Dermatol* **56**:989-993, 2007
36. Canel C et al: Podophyllotoxin. *Phytochemistry* **54**:115, 2000
41. Dumontet C et al: A phase II trial of miltefosine in patients with cutaneous T-cell lymphoma. *Bull Cancer* **93**:E115-sE118, 2006
43. Hartmann K et al: Effects of topical treatment with the raft modulator miltefosine and clobetasol in cutaneous mastocytosis: A randomized, double-blind, placebo-controlled trial. *Br J Dermatol* **162**(1):185-190, 2010; [Epub Aug 3, 2009]

Chapter 221 :: Topical Immunomodulators

:: Edward M. Esparza & Robert Sidbury

Topical immunomodulators are nonsteroidal agents that target the immune system for therapeutic effect in the skin. The macrolactams, pimecrolimus and tacrolimus, act as anti-inflammatory agents by binding immunophilin and inhibiting cytokine production. The imidazoquinoline amine, imiquimod, induces interferon (IFN) production and enhances immune responses, although several more potent analogs are under clinical investigation.

MECHANISM OF ACTION

TOPICAL CALCINEURIN INHIBITORS

Intracellular signaling pathways are tightly controlled to maintain immune homeostasis. The nuclear factor of activated T cells (NFAT) family of transcription factors has emerged as a central regulator in immune signaling pathways that control lymphocyte activation and cytokine production.[1] In the absence of receptor-mediated, calcium-dependent signaling, NFAT is sequestered in the cytoplasmic compartment in an inactive, phosphorylated state (Fig. 221-1). Signaling pathways emanating from antigen receptors induce calcium-dependent activation of calcineurin, which removes the phosphorylation from NFAT that leads to nuclear translocation and upregulation of proinflammatory gene expression. Tacrolimus and pimecrolimus turn off inflammation by interacting with FK-506 binding protein (FKBP). This drug-protein interaction prevents calcineurin from dephosphorylating NFAT, thereby inhibiting its nuclear translocation.[2] The pleiotropic effects of calcineurin inhibitors include decreased T-cell proliferation and reduced inflamma-

TOPICAL CALCINEURIN INHIBITORS: PIMECROLIMUS AND TACROLIMUS AT A GLANCE

- Topical nonsteroidal anti-inflammatory agents.
- US Food and Drug Administration approved for the short-term and intermittent long-term therapy of atopic dermatitis in patients older than 2 years.
- Approved in Europe for twice weekly prophylactic therapy for atopic dermatitis in patients older than 2 years.
- Extensively studied with an excellent record of short-term safety and efficacy when used appropriately.
- Burning and stinging at the application site is the most common adverse event occurring in 10%–40%.
- Theoretical risk of systemic immunosuppression and malignancy has resulted in the addition of a postmarketing, black-box warning label.
- Widespread off-label use has been discouraged until long-term safety is more definitely established.

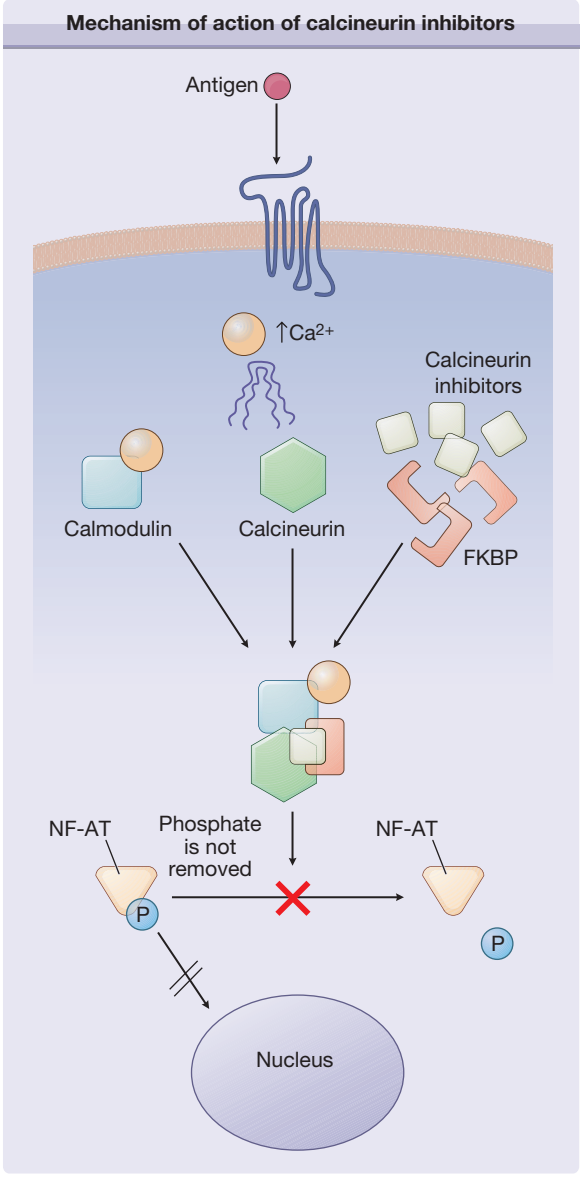

Figure 221-1 Mechanism of action of calcineurin inhibitors. Ca = calcium; FKBP = FK-506 binding protein; NF-AT = nuclear factor of activated T cells.

tory cytokine production of interleukin-2 (IL-2), IL-3, IL-4, IL-12, tumor necrosis factor, and IFN-γ.

Compared to cyclosporine, tacrolimus is 10–100 times more potent, has lower molecular weight, and penetrates the skin better. These enhanced pharmacological properties of tacrolimus provided a basis for experiments demonstrating topical inhibition of contact hypersensitivity and subsequent development as an ointment for treating atopic dermatitis.[3,4] With topical tacrolimus therapy, more than 70% of patients have had moderate-to-excellent improvement in 3-week controlled trials, and 30%–40% have had greater than 90% improvement.[5] In general, response to topical tacrolimus has been best observed in treating thinner skin areas such as the face and neck. During remissions, dosing may be reduced in frequency, but flares occur with discontinuance. Response is slow (over days to weeks), often incomplete on extremities (especially hands and feet), and in patients with lichenified lesions. Roughly 25% of patients, especially those with the most severe disease, do not have a satisfactory therapeutic response. Additionally, patients should realize that exacerbations of atopic dermatitis may occur and require occasional intervention with topical or systemic corticosteroid therapy. The main advantage of topical tacrolimus is the provision of chronic maintenance therapy without the need for continuous topical corticosteroids. Koo et al demonstrated up to 91% reduction in affected body surface area in a study of nearly 8,000 adults and children using topical tacrolimus for up to 18 months without significant adverse events.[6] Other long-term studies with tacrolimus have specifically shown no evidence of cutaneous atrophy, little or no increased infectious risk other than a slightly increased rate of herpes simplex virus in some trials, hypertension, renal toxicity, or cumulative blood levels in patients older than 2 years of age.[7]

Adverse effects have been primarily an intense burning and itching in 30%–40% of patients at application sites, especially in areas of flaring, excoriation, and erosion.[5,7,8] These symptoms usually subside in a few days, in concert with healing of the skin. However, some patients continue to have bothersome burning, and this effect seems to be more prominent when the skin is exposed to heat such as during summer weather, or in baths or hot tubs. In general, these problems with burning sensations seem to be less in children. Up to 10% of adults experience symptoms of flushing with alcohol ingestion.[9] Both acneiform and rosaceiform eruptions have been observed in conjunction with tacrolimus and pimecrolimus use and should be monitored.[10–12] Other common side effects include flu-like symptoms and headache.[3]

Infections have not been a notable problem in tacrolimus-treated patients.[3,5,7] Occasional staphylococcal skin infections occur, but they are no worse than before treatment, and studies actually demonstrate a reduction in *Staphylococcus aureus* colonization during prolonged therapy. In spite of the theoretical concern about immunosuppression, there have been no significant increases in frequency or severity of warts, varicella, or molluscum contagiosum infections. Some cases of eczema herpeticum have been noted in clinical trials, but the risk of this complication may also stem from underlying atopic dermatitis.

Immunosuppression with systemic calcineurin inhibitors is known to raise the relative risk of post-transplant lymphoproliferative disorder and ultraviolet light-induced cutaneous carcinomas in transplant patients, which carries theoretical concern for malignancy with long-term use of topical formulation of the same agents. A smattering of postmarketing reports of lymphoma or malignancy in patients using topical tacrolimus and a biologically plausible risk related to TCI use were the major factors in the US Food and Drug Administration (FDA) calling for a black-box warning label. Recently, a case-control study evaluated the association between topical immunosuppressants and lymphoma in a cohort of patients with atopic dermatitis and found no increased risk of lymphoma with the use of TCIs.[13] Extensive review of the case reports by independent oncologists and allied task forces has

not found evidence of an increased risk of lymphoma or other malignancy.[14–16] However, predisposition to malignancy may require several years of constant immunosuppression. Therefore, close surveillance is indicated if TCIs are used chronically.

In addition to the concerns about hematologic malignancy, there have been reports of pigmented neoplasms in association with TCI use. In a case series of three patients, focal pigmented lesions developed where TCIs were used that were confirmed histologically to represent lentigines.[17] Similarly in our experience, lentigines have arisen at the location of TCI use. The implication of these cases is whether chronic TCI use predisposes to melanoma. There has been a case report of rapid growth of melanoma develop in a child during the course of treating vitiligo with topical tacrolimus.[18] Although this remains an isolated case report, it would be prudent to counsel patients to use sun protection while using TCIs. Furthermore, the utility of self-surveillance of changing moles and thorough clinical skin examination should be discussed when using TCIs.

Pimecrolimus has a similar structure to tacrolimus and interacts with the same FKBP to inhibit calcineurin activation of NFAT.[19] However, clinical efficacy is less than that of tacrolimus as reflected by decreased protein-binding affinity, which necessitates a higher drug concentration in the topical medication.[7] Topical pimecrolimus also appears to have little systemic immunosuppressive effect, which may reflect a wider margin of safety. Clinical trials have included infants as young as 3 months of age, although FDA approval has been limited to 2 years of age and older. A recent study of 76 infants and children revealed sustained benefit without significant adverse effect with pimecrolimus therapy for 2 years.[20] Two patients in the study developed eczema herpeticum. As with tacrolimus, occasional postmarketing reports of lymphoma and malignancy moved the FDA to affix the black-box warning label to the entire class of medication, but these concerns remain at present theoretical.[16] Blood levels have been detected in occasional patients, but no high or prolonged levels have been detected. Initial studies of oral pimecrolimus were promising, but, in the wake of the black-box controversy, development has been suspended.

IMIQUIMOD

Imiquimod is unique in that it appears to enhance both acquired and innate immune function (Fig. 221-2).

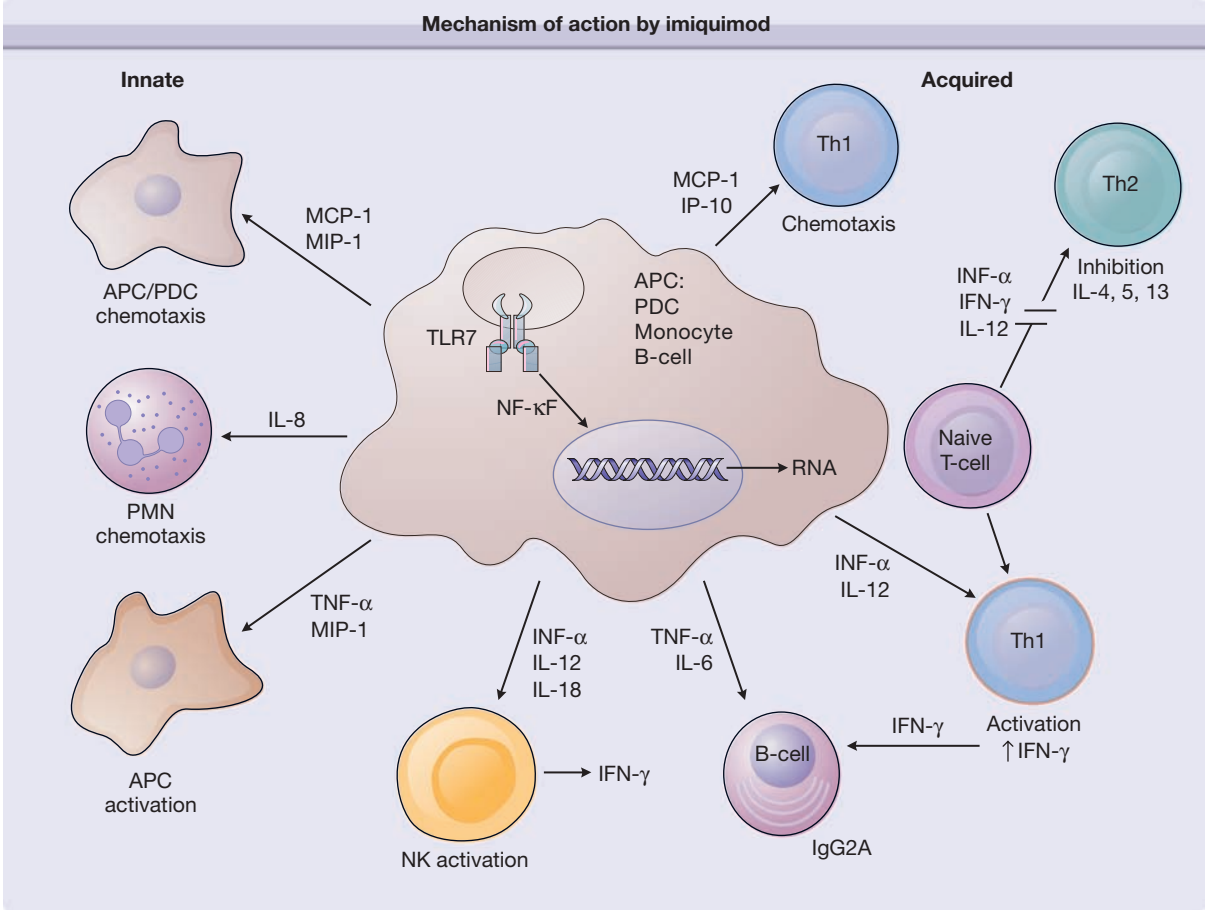

Figure 221-2 Mechanism of action by imiquimod. APC = antigen-presenting cell; IFN = interferon; IgG2A = immunoglobulin G2A; IL = interleukin; IP-10 = interferon-inducible protein 10; MCP-1 = macrophage chemoattractant protein 1; MIP = macrophage inflammatory protein; NF-κB = nuclear factor κB; NK = natural killer cell; PDC = peripheral dendritic cell; PMN = polymorphonuclear neutrophil; Th = T helper; TLR = Toll-like receptor; TNF-α = tumor necrosis factor-α.

IMIQUIMOD AT A GLANCE

- Topical immunotherapy indicated for anogenital warts, superficial basal cell carcinoma, and actinic keratosis.
- Small molecule immune response modifier in the imidazoquinoline family.
- Induces heterogeneous, immune-mediated responses including antiviral, antitumoral, antiangiogenic, and vaccine adjuvant activity.
- Targeted therapy that results in production of the inflammatory cytokines tumor necrosis factor-α and IFN-γ, thereby enhancing cell-mediated immune response.
- Application site stinging and irritant contact dermatitis are the most common adverse events.

Topically applied imiquimod induces local cytokine production from keratinocytes and other cells.[21,22] Imiquimod acts as an agonist of the Toll-like receptor (TLR)-7 and -8-mediated signaling cascades, resulting in the secretion of proinflammatory cytokines, such as IFN-α and IFN-γ, tumor necrosis factor-α, IL-1, IL-1 receptor antagonist, IL-6, IL-10, IL-12, granulocyte colony-stimulating factor, granulocyte-monocyte colony-stimulating factor, and the chemokines IL-8, macrophage inflammatory protein 1α, and monocyte chemotactic protein 1.[23,24] Imiquimod also stimulates the innate immune response by increasing natural killer cell activity, activating macrophages and Langerhans cells, and inducing proliferation and maturation of B lymphocytes. Additionally, imiquimod has direct proapoptotic activity on tumor cells.

Imiquimod has been shown to be an effective treatment for anogenital warts. A 16-week study of 311 immunocompetent adults with external anogenital warts compared three times weekly 5% imiquimod cream, 1% imiquimod cream, and placebo.[25] Clearance was achieved in more than 70% of women and 30% of men with the 5% cream and with both strengths significantly better than placebo. Response rates greater than 30% have been seen in uncircumcised males treated under the foreskin, suggesting that increased moisture may account for this gender discrepancy. Similarly, local factors may account for lower response rates in nongenital warts. The primary benefit of imiquimod cream relative to other available wart therapies is ease of administration. In adults, home therapy for genital warts is preferred, given the sensitive nature of this problem. Likewise in children, genital warts may be a result of sexual abuse (although in the minority of younger children), and an atraumatic topical therapy that can be rapidly applied in a nonthreatening environment is ideal. Recurrence rates following use of imiquimod cream have ranged from 13%–19%.[25]

In vitro evidence of antitumor effects formed the basis for evaluation of imiquimod in the treatment of cutaneous neoplasms. A multicenter, randomized, open-label dose-response trial showed an almost 90% histologic clearance rate of superficial basal cell carcinoma (BCC) when 5% imiquimod cream was applied daily for 6 weeks. Twice daily application led to an improved response rate but a higher incidence of local skin reactions.[26] Geisse et al subsequently reported that two phase III double-blind, randomized, vehicle-controlled trials showed histologic clearance of 82% with five times weekly treatment.[27] Daily therapy was no more effective, and response was positively correlated with signs of inflammation, including erythema, erosion, and crusting. These studies formed the foundation for using imiquimod to treat small, superficial BCC in low-risk locations such as the trunk and extremities. These are anatomical sites that may tolerate the lower cure rates better than more cosmetically sensitive areas.[23] The use of imiquimod as monotherapy in this context was endorsed by a recent systematic review.[28]

Imiquimod has also been approved as a treatment for actinic keratosis of the head and neck. Hadley et al recently reviewed the use of imiquimod for actinic keratoses. In five randomized controlled trials lasting 12–16 weeks involving 1,293 patients, complete clinical clearance was seen in 50% of imiquimod patients versus 5% using vehicle. Adverse events were significantly higher in imiquimod-treated groups, including erythema (27%), crusting/scabbing (21%), flaking (9%), erosion (6%), edema (4%), and weeping (3%).[29] Lower potency imiquimod preparations (2.5, 3.75%) are currently under development for the treatment of head and neck AKs. These compounds theoretically permit increased frequency of use without prohibitive application site reaction, while also allowing a greater surface area to be treated. Early safety and efficacy trials are promising.[30]

Although not yet clinically indicated as an antiangiogenic agent, imiquimod has demonstrated antiangiogenic properties in vitro and in a series of case reports. The antiangiogenic properties of imiquimod stem from the production of antiangiogenic cytokines, including IFN-γ, IL-10, and IL-12; the upregulation of endogenous antiangiogenic mediators, including tissue inhibitor of matrix metalloproteinase; and downregulation of the proangiogenic factors, basic fibroblast growth factor, and matrix metalloproteinase 9.[31] In a mouse model of hemangioendothelioma, imiquimod application resulted in fewer and smaller tumors.[32] Numerous clinical reports have noted clinical response treating vascular neoplasms, including hemangiomas of infancy and pyogenic granulomas.[33–36] Ongoing clinical trials are further defining the role of imiquimod in the treatment of various vascular lesions.[37]

Derived from its antiviral effects, imiquimod has been used successfully to treat molluscum contagiosum. In an observer-blinded, randomized trial of 74 children, imiquimod resulted in slower clearance with higher expense, but was tolerated with less pain and improved cosmesis when compared to liquid nitrogen.[38] There have been few cases in which imiquimod

was effective in treating granuloma annulare when used for 6–12 weeks.[39,40] Whether the efficacy is the result of proapoptotic effects of imiquimod remains to be determined. While not intended to be exhaustive, other published off-label uses of imiquimod include treating extramammary Paget disease, scar cosmesis, low-grade vulvar intraepithelial neoplasms, dysplastic nevi, lentigo maligna, ecthyma contagiosum, porokeratoses, and lymphomatoid papulosis.[41–47] These off-label uses of imiquimod await confirmation and precise dosing recommendation from randomized clinical trials.

Adverse effects relate primarily to cutaneous irritation at the application site, leading to moderate erythema and erosion in roughly one-third and one-tenth of patients, respectively. Studies suggest that both the response rate, particularly in males, and the likelihood of side effects will increase with daily therapy. Imiquimod is a category C drug, and it is not known to what extent topically applied imiquimod is excreted in the breast milk of nursing mothers. Imiquimod has not been thoroughly studied in children younger than 18 years of age. Imiquimod has been investigated for a variety of other infectious conditions with varying degrees of success.

PHARMACOKINETICS

PIMECROLIMUS AND TACROLIMUS

Tacrolimus ointment, 0.03% and 0.1% applied twice daily, was studied extensively in clinical trials that included adults and children as young as 2 years of age.[2] Pharmacokinetic studies showed low percutaneous absorption initially in 10%–20% of patients with atopic dermatitis, but generally blood levels were undetectable by 1 week as healing and re-establishment of the skin barrier occurred. Rarely were blood levels greater than 2 ng/mL, in contrast with trough levels of 5–15 ng/mL in transplant patients treated systemically with tacrolimus.[5] The notable exception is the use of topical tacrolimus in patients with Netherton syndrome, where blood levels within or above the established therapeutic trough range for oral tacrolimus in organ transplant recipients may be observed.[48]

In an open label study of twice-daily pimecrolimus use in infants ranging in age from 5.7–11.9 months at baseline with moderate-to-severe atopic dermatitis, Lakhanpaul et al found no accumulation of the drug and systemic levels ranging from below the limit of detection to 1.94 ng/mL.[49] There were no significant adverse events over the course of this 1-year-long trial.

IMIQUIMOD

The half-life of systemically administered imiquimod, either oral or subcutaneous, is 2–4 hours in healthy volunteers. The half-life of intravenously administered imiquimod is 14 hours, and less than 1% of the drug is recovered in the urine after a single topical application. The major systemic metabolite of imiquimod, S26704, is a hydroxylation product that achieves plasma concentrations of less than 20% of the parent compound.[50]

BOX 221-1 INDICATIONS FOR USE

PIMECROLIMUS AND TACROLIMUS
- Second-line therapy for atopic dermatitis
- Children older than 2 years
- Adults
- Short-term, noncontinuous chronic therapy

IMIQUIMOD
- External anogenital warts
- Actinic keratosis
- Superficial BCC smaller than 2 cm on trunk, neck, extremities
- Immunocompetent adults
- When surgical options less appropriate
- Biopsy confirmed

Higher levels have been noted with both intravaginal administration in healthy volunteers or systemic administration in chronically ill patients. With topical administration in healthy volunteers, there is very little measurable imiquimod and no detectable S26704.

INDICATIONS

(Box 221-1)

CONTRAINDICATIONS

(Box 221-2)

DOSING REGIMENS

(Table 221-1)

INITIATING THERAPY

PIMECROLIMUS AND TACROLIMUS

In light of concerns with long-term safety and questions raised by the widely publicized black-box warn-

BOX 221-2 CONTRAINDICATIONS

PIMECROLIMUS AND TACROLIMUS
- Immunocompromised
- Netherton syndrome
- Active bacterial or viral infection
- Phototherapy

IMIQUIMOD
- Immunocompromised
- Refractory, thicker, actinic keratoses

TABLE 221-1
Recommended Dosing Regimens of Tacrolimus, Pimecrolimus, and Imiquimod

Agent	Strength and Vehicle	FDA Indication	Dosing
Tacrolimus Pimecrolimus	0.1% and 0.03% ointment 1% cream	Atopic dermatitis	2×/day
Imiquimod	5% cream	Anogenital warts Actinic keratosis Superficial BCC	3×/week, Maximum: 16 weeks 2×/week for 16 weeks 5×/week for 6 weeks

FDA = Food and Drug Administration; BCC = basal cell carcinoma.

ing label, initiation of TCI therapy should begin by addressing parental and patient concerns. These agents should be considered second line and are indicated when standard therapy, including topical steroids and emollients, are either ineffective or harmful. Comparisons of these agents with standard therapy have not as yet consistently shown a relative clinical or pharmacoeconomic benefit compared with topical steroids.[51] Once the decision to initiate TCI therapy has been made, consideration must be given to the choice of either pimecrolimus or tacrolimus. Pimecrolimus is available as a 1% cream formulation and is indicated for mild-to-moderate atopic dermatitis. Tacrolimus is available as an ointment in two strengths, 0.03% for children 2–15 years old as an on-label indication, and 0.1% in patients 16 years and older. Topical tacrolimus is indicated for moderate to severe atopic dermatitis. In Europe, the application twice weekly to prevent recurrence at sites of repeated flares is an approved indication; this 2–3 times weekly application to sites of involvement during quiescence has been shown to decrease the requirement for topical steroid use.[52]

Both products have been extensively studied and have excellent safety and efficacy records compared with placebo in the short term. Therefore, patient vehicle preferences and disease severity help determine the appropriateness of either agent for an individual patient. Paller et al found tacrolimus to be more effective than pimecrolimus with a similar side effect profile in three comparison trials.[53]

Pimecrolimus or tacrolimus should be applied sparingly only to affected areas of skin twice daily. The smallest amount of medicine should be used, and therapy should be discontinued where signs and symptoms of redness and itch have resolved for 1 week. Adjunctive therapies, such as emollients, should be continued. If applied after bathing, as often recommended, pimecrolimus or tacrolimus should be applied first to affected areas, and emollients subsequently to unaffected skin. Application site stinging from TCIs may be more severe in areas of excoriation. Efforts to limit these open areas of skin by pretreating for 2–7 days with a topical steroid may improve adherence to therapy.

IMIQUIMOD

Imiquimod should be applied sparingly to affected areas when treating warts or superficial BCC. A broader but circumscribed treatment area is recommended either on the face or scalp, but not both, when treating actinic keratosis. For anogenital warts, initial frequency should be three times weekly. If little or no effect is seen after 2–4 weeks, advancing to daily use may enhance efficacy, although risk of an irritant dermatitis commensurately will increase. Application before sleeping is generally recommended and imiquimod should be left on the skin for 6–10 hours. It should be made clear to patients treating warts that imiquimod therapy does not eliminate the risk of transmission of human papilloma virus to physical contacts. The frequency of application for the treatment of superficial BCC (five times weekly) and actinic keratosis (two times weekly) differs as noted in the Table 221.1.

MONITORING THERAPY

PIMECROLIMUS AND TACROLIMUS

If effective, TCIs may be incorporated into the long-term therapeutic regimen for atopic dermatitis. Prescribing physicians must ensure that patients are using these products intermittently and only to treat active dermatitis. Adverse events, including application site reactions, should be monitored. Patients should be evaluated for cutaneous infections with particular vigilance against eczema herpeticum, which was noted with slightly increased frequency in some premarketing trials. Any evidence of lymphadenopathy should be documented and followed closely. Skin examinations for signs of cutaneous malignancy are prudent. No routine serologic monitoring is indicated; however, if clinical evidence suggests the possibility of systemic immunosuppression, serum levels of tacrolimus or pimecrolimus may be obtained. If blood levels are sought, care must be taken to first remove any residual medication, particularly at the antecubital location, a common site for both venipuncture and atopic dermatitis. Failure to do so may lead to spuriously elevated drug levels. Despite reassuring safety data, the lesson of the black-box controversy is that definitive long-term safety has not been established; and therefore, ongoing vigilance for potential TCI adverse effects, including immunosuppression and malignancy, must continue.

IMIQUIMOD

Imiquimod therapy for warts, if tolerated, should be continued until complete clearance of warts or a maximum of 4 months before declaring a treatment failure. If no response or clinical deterioration is seen at 8 weeks, other therapeutic options should be entertained. If an incomplete response is obtained, continuing therapy may be warranted. Increasing from three times weekly to daily treatment may be indicated if imiquimod is well tolerated. No serologic monitoring is necessary. Irritant reactions may be treated initially by temporary cessation of therapy in addition to or followed by appropriate topical anti-inflammatory intervention. Imiquimod therapy can then be resumed as necessary at a decreased frequency as indicated. Similar principles govern the use of imiquimod for superficial BCC and actinic keratosis, but closer clinical follow-up is indicated.

RISKS AND PRECAUTIONS

(Box 221-3)

BOX 221-3 RISKS AND PRECAUTIONS

PIMECROLIMUS AND TACROLIMUS

- Application site reactions, including itch, burning, stinging, redness, flushing with alcohol
- Avoid use on premalignant or malignant skin conditions, including cutaneous T-cell lymphoma
- Skin infections, including *S. aureus*, dermatophytosis, and herpes simplex
- Lymphadenopathy
- Light exposure, including phototherapy
- Immunocompromised
- Netherton syndrome
- Renal insufficiency
- Pregnancy category C
- Lactation
- Flu-like symptoms
- Worsening acne

IMIQUIMOD

- Erythema, erosion, edema, ulceration, excoriation/flaking
- Hypo- or hyperpigmentation
- Pregnancy category C
- Safety not established in children younger than 12 years old
- Soreness
- Flu-like symptoms
- Myalgia
- Headache
- Multiple treatment courses for superficial BCC or actinic keratosis at same site
- Basal cell nevus syndrome
- Superficial BCC of the head, neck, or anogenital area
- Xeroderma pigmentosum

BOX 221-4 COMPLICATIONS

PIMECROLIMUS AND TACROLIMUS

- Elevated blood levels and risk of systemic immunosuppression
- Unclear long-term risk of lymphoproliferative disease
- Unclear long-term malignancy risk
- Eczema herpeticum

IMIQUIMOD

- Irritant contact dermatitis
- Ulceration
- Incomplete treatment of malignancy

COMPLICATIONS

(Box 221-4)

KEY REFERENCES

Full reference list available at www.DIGM8.com

DVD contains references and additional content

1. Baine I, Abe BT, Macian F: Regulation of T-cell tolerance by calcium/NFAT signaling. *Immunol Rev* **231**:225, 2009
6. Koo JY et al: Tacrolimus ointment is safe and effective in the treatment of atopic dermatitis: Results in 8000 patients. *J Am Acad Dermatol* **53**:S195, 2005
13. Arellano FM et al: Risk of lymphoma following exposure to calcineurin inhibitors and topical steroids in patients with atopic dermatitis. *J Invest Dermatol* **127**:808, 2007
14. Berger TG et al: The use of topical calcineurin inhibitors in dermatology: Safety concerns. Report of the American Academy of Dermatology Association Task Force. *J Am Acad Dermatol* **54**:818, 2006
25. Edwards L, Ferenczy A, Eron L, et al: Self-administered topical 5% imiquimod cream for external anogenital warts. HPV Study Group. Human PapillomaVirus. *Arch Dermatol* **134**:25, 1998
26. Marks R et al: Imiquimod 5% cream in the treatment of superficial basal cell carcinoma: Results of a multicenter 6-week dose-response trial. *J Am Acad Dermatol* **44**:807, 2001
27. Geisse J et al: Imiquimod 5% cream for the treatment of superficial basal cell carcinoma: Results from two phase III, randomized, vehicle-controlled studies. *J Am Acad Dermatol* **50**:722, 2004
28. Love WE, Bernhard JD, Bordeaux JS: Topical imiquimod or fluorouracil therapy for basal and squamous cell carcinoma: A systematic review. *Arch Dermatol* **145**:1431, 2009
29. Hadley G, Derry S, Moore RA: Imiquimod for actinic keratosis: Systematic review and meta-analysis. *J Invest Dermatol* **126**:1251, 2006
37. McCuaig CC et al: A phase II, open-label study of the efficacy and safety of imiquimod in the treatment of superficial and mixed infantile hemangioma. *Pediatr Dermatol* **26**:203, 2009

Chapter 222 :: Other Topical Medications

:: Craig N. Burkhart & Kenneth A. Katz

OTHER TOPICAL MEDICATIONS AT A GLANCE

- Topical medications not sufficiently covered in other sections of this text comprise:
  - Analgetics.
  - Anti-inflammatory agents.
  - Antimicrobial and antiparasitic agents.
  - Antiperspirants, antipruritics, and astringents.
  - Bleaching and keratolytic agents.
  - Topical psoriasis and wart therapies.

This chapter reviews topical therapies not covered elsewhere in the text that are used to treat dermatologic diseases. The topic headings are those of the drug designation of the US Pharmacopeia and at times reflect clinical usage rather than specific pharmacologic mechanisms. All topicals when applied to large areas of skin, particularly in the presence of skin disease or to infants and children, have the potential for systemic side effects.

ANALGESICS

CAPSAICIN

Capsaicin is the molecule that confers the "hotness" to hot peppers of the genus *Capsicum*, including cayenne, jalapeno, and Tabasco peppers.[1] Initial topical application results in itching, pricking, and burning as nociceptor activate. Repeated applications, however, are hypothesized to lead to degeneration of epidermal nerve fibers and nociceptor desensitization, thereby producing hypalgesia.[1]

Topical capsaicin has been used to treat postherpetic neuralgia, diabetic neuropathy, reflex sympathetic dystrophy, Raynaud phenomenon, nostalgia paresthetica, arthralgias, plantar warts, diabetic neuralgia, and hemodialysis-related pruritus.[1] A recent placebo-controlled trial of a high-concentration capsaicin dermal patch showed that the patch significantly reduced postherpetic neuralgia pain with transient application site pain reactions managed effectively with analgesics.[2] Other therapies for postherpetic neuralgia should also be considered.[3]

TOPICAL ANESTHETICS

Numerous topical anesthetics are available.[4] Eutectic mixture of local anesthetics (EMLA) cream contains the sodium-channel-blocking amide anesthetics lidocaine 2.5% and prilocaine 2.5%. Application under occlusion to intact skin or genital mucous membranes for at least 1 hour before performance of a painful procedure, including debridement of venous leg ulcers,[5] can provide local anesthesia that may persist for up to 2 hours. The cream may cause transient local blanching followed by transient local erythema. Like all products containing lidocaine, it should not be used in patients with hypersensitivity to amide anesthetics. Additionally, the prilocaine component has been linked to cases of methemoglobinemia in patients for whom applications exceeded the recommended dose, application area, or application time.[6] Those particularly susceptible to methemoglobinemia include patients who are very young, those with glucose-6-phosphate dehydrogenase deficiency, and those taking oxidizing drugs such as sulfonamides and antimalarials.

Caution regarding dosing should also be used in patients susceptible to systemic effects of lidocaine or prilocaine, including acutely ill, debilitated, and elderly patients. Finally, as EMLA is ototoxic, it should not be used if there is a concern that it could penetrate or migrate beyond the tympanic membrane to the middle ear.

Various topical anesthetic products contain only lidocaine, typically at concentrations of 4% or 5%, which may be applied with or without occlusion. Systemic toxicity from topical lidocaine prepared in a 30% concentration has been reported.[7] In 2007, FDA reported that two women, aged 22 and 25, experienced seizure, coma, and death after using compounded topical formulations of lidocaine and tetracaine, under occlusion, prior to laser hair removal procedures. Cases of arrhythmia and apnea were also reported. Those adverse events prompted FDA to warn the public about potential hazards of use of topical numbing products for cosmetic procedures,[8] and pharmacies against violating regulations in compounding such products.[9]

ANTI-INFLAMMATORY AGENTS

COAL TAR

Coal tar has been used to treat inflammatory dermatoses for up to 2 millennia, although currently it is used primarily to treat psoriasis.[10] Coal tar has been shown to inhibit DNA synthesis and mitosis in epidermal cells, an effect potentiated by ultraviolet A exposure.[11] Coal tar also has anti-infective, antipruritic, photosensitizing, and vasoconstrictive effects and, with

repeated applications, causes epidermal atrophy. The precise mechanism by which it treats inflammatory skin diseases has not been fully described.

In 1925, Goekerman pioneered the concomitant use of coal tar and ultraviolet B therapy for psoriasis.

Coal tar has historically been messy to use, has an unpleasant odor, and can stain clothing, making its use challenging for some. Newer formulations, however, might be better tolerated.[12,13] Systemic adverse effects are uncommon, whereas local adverse effects can include tar folliculitis, acneiform eruptions, irritant dermatitis, burning, and stinging, allergic contact dermatitis, atrophy, telangiectases, pigmentation, exfoliative dermatitis, and keratoacanthomas.[10] Although occupational exposure to coal tar has been associated with increased risk of developing skin cancer, epidemiologic studies of coal tar-treated psoriasis have not demonstrated an increased risk of skin cancer due to coal tar.[14]

WOOD TAR

Produced by distillation of wood under controlled conditions, wood tar can be added to arachis oil (peanut oil) or other bases. The preparation is then typically used to treat scalp psoriasis. Most commonly derived from juniper (oil of cade), wood tar may also be derived from beech, birch, and pine. Contact sensitivity to wood tar has been reported.[15]

SHALE OIL

Shale oil (also referred to as *ammonium bituminosulphonate*, *ichthyol*, *ichthammol*, or *black salve*) is derived from oil shale, a sulfur-rich sedimentary rock. Further processing of extracted shale oil yields light- and dark-colored components. The light component is also referred to as *pale sulfonated shale oil* (PSSO) or *ichthyol pale*.[16] Shale oil decreases inflammation by inhibiting lipoxygenase.[17] A recent trial of PSSO cream for atopic dermatitis showed that it was more effective than vehicle in treating atopic dermatitis.[18] A study of PSSO to treat venous leg ulcers showed that the size of ulcers treated with PSSO gel, compared with vehicle, significantly decreased, although there was no difference in complete epithelialization of granulation of ulcers.[19] PSSO has also been used to treat acne, psoriasis, seborrhea, eczema, rosacea, and pruritus.[16,20]

ANTIMICROBIAL AGENTS

(Table 222-1)

CHLORHEXIDINE

Chlorhexidine gluconate is a bisbiguanide that binds to the stratum corneum, providing sustained bactericidal and fungicidal activity for over 6 hours, even when wiped from the field. Although it does not kill bacterial spores or mycobacteria, it does inhibit their growth. Because it does not lose its effectiveness in the presence of organic material, such as whole blood, it is an important antiseptic, disinfectant, antibacterial dental rinse, and preservative. Due to ototoxicity and the risk of conjunctivitis and corneal ulceration, chlorhexidine is not recommended for preoperative preparation of the face or head.

DYES

Dyes are useful topical treatments because they are inexpensive and chemically and physically stable. The topical antiseptic dyes used in dermatology, gentian violet (methylrosaniline chloride), brilliant green (*p*-diethylamine triphenylmethanol), malachite green, and fuchsine, are all derivatives of triphenylmethane. The dyes are effective against *Candida* species and several aerobic Gram-positive bacteria, including methicillin-resistant *Staphylococcus aureus*. Gentian violet is a known contact sensitizer and may cause skin necrosis in concentrations greater than 2% aqueous solution or when used undiluted in skin folds.[21]

HYDROGEN PEROXIDE

Hydrogen peroxide has been used for a number of years as a cleansing agent and for the removal of debris. It has antibacterial properties against both Gram-positive and -negative bacteria, and its effervescent quality helps débride wounds.

IODINATED COMPOUNDS

Iodine solution is bactericidal, sporicidal, and viricidal. Iodophors are complexes of iodine with a carrier that slowly liberates inorganic iodine on contact with reducing substances. This preserves the antimicrobial activities of iodine without the irritant effects of the free tincture. Iodophors must be applied to dry skin as they are inactivated by contact with blood, serum proteins, and sputum.

POVIDONE-IODINE. Povidone iodine has a wide spectrum of in-vitro activity against Gram-negative and -positive bacteria, fungi, and viruses. Systemic absorption can occur with resultant renal and thyroid dysfunction if large or prolonged quantities are used.

CLIOQUINOL. Clioquinol, 5-chloro-8-hydroxy-7-iodoquinolinol, is weakly antifungal and antibacterial. It is effective alone or combined with a topical steroid to treat inflammatory dermatoses, especially in intertriginous areas. Adverse reactions include a yellowish discoloration on clothing or skin, delayed contact hypersensitivity, and contact dermatitis. In the early 1970s, it was linked to subacute myelo-optic neuropathy in Japan[22] and was banned in many countries, including the United States. This link was questioned by subsequent epidemiologic studies,[23] but product

TABLE 222-1
Topical Antimicrobials and Astringents

Drug	Group	Antibacterial Mechanism	Antimicrobial Spectrum	Major Side Effects or Contraindications	Use (Selected)	US Food and Drug Administration Pregnancy Category
Chlorhexidine	Bisbiguanide	(1) Binds to negatively charged bacterial cell wall and cytoplasmic components leading to altered osmotic equilibrium and (2) precipitation of cytoplasmic components	Gram-positive, Gram-negative bacteria, enveloped viruses, and fungi	Keratitis, ototoxicity	Antiseptic surgical hand scrub and surgical site preparation	B
Gentian violet	Dye	Unknown	Some vegetative Gram-positive bacteria (e.g., *Staphylococcus* sp.) and yeast	Potential skin necrosis at high concentrations or when occluded; stains skin and clothing; tattooing when applied over granulation tissue; mutagenic	Impetiginized eczema; mycotic skin infections; oral candidiasis; superficial skin infections	C
Brilliant green	Dye	Unknown	Similar to gentian violet	Potential skin necrosis; stains skin and clothing	Similar to gentian violet	Not used in Western medicine
Hydrogen peroxide	Peroxide	Oxidizes microbial molecules	Broad spectrum antimicrobial	Avoid in abscesses; bleaches hair	Cleansing of wounds, suppurating ulcers, and local infections	—
Povidone-iodine	Iodophor	Oxidation and release of free iodine	Gram-positive, Gram-negative, enveloped viruses, fungi, sporicidal, *Mycobacterium tuberculosis*	Caution in patients with thyroid disorders; potential systemic toxicity in neonates or when applied to large body surface area; neutralized by blood, serum proteins, and sputum	Antiseptic surgical hand scrub, prevention or treatment of topical site infection associated with surgery, burns, minor cuts/scrapes	C
Clioquinol	Iodophor	Oxidation and release of free iodine; chelates bacterial surface and trace metals needed for bacterial growth	Gram-positive, Gram-negative, enveloped viruses, fungi, sporicidal, *M. tuberculosis*	Possible irreversible optic atrophy and peripheral neuropathy (oral); contraindicated in children <2 years of age; contraindicated for diaper rash; stains skin yellow; neutralized by blood, serum proteins, and sputum	Approved for fungal infections; also used for pyoderma, folliculitis, and impetigo	—

(continued)

TABLE 222-1
Topical Antimicrobials and Astringents (Continued)

Drug	Group	Antibacterial Mechanism	Antimicrobial Spectrum	Major Side Effects or Contraindications	Use (Selected)	US Food and Drug Administration Pregnancy Category
Metronidazole	Imidazole	Creation of reduced intermediate compounds and free radicals	Anaerobes, protozoa, and microaerophilic bacteria	Contraindicated during first trimester of pregnancy	Rosacea	B
Mupirocin	Fermentation product of *Pseudomonas fluorescens*	Inhibits bacterial isoleucyl-t-RNA synthetase	Gram-positive, some Gram-negative, spares normal flora	Potentially toxic amounts of polyethylene glycol contained in vehicle may be absorbed in patients with extensive burns or open wounds	Non-bullous impetigo, eradication of nasal carriage of *S. aureus*	B
Retapamulin	Pleuromatilin	Inhibits 50S subunit of prokaryotic ribosome	Gram-positive	Allergic contact dermatitis [dermatitis 2009]	Non-bullous impetigo	B
Azelaic acid	Dicarboxylic acid	Possibly through inhibition of microbial respiratory chain	*Propionibacterium acnes* and *S. epidermidis*	Hypopigmentation	Acne	B
Benzoyl peroxide	Peroxide	Oxidizes microbial molecules	Broad-spectrum antimicrobial	Bleaches dark clothing	Acne	C
Aluminum salts	Astringent	Coagulation of proteins	Broad-spectrum antimicrobial	Do not use under impervious material to prevent evaporation	Weeping, impetiginized skin disorders	—
Potassium permanganate	Astringent	Oxidizes microbial molecules	Broad-spectrum antimicrobial	Skin discoloration; caustic at high concentrations or with contact of undissolved crystals	Weeping, impetiginized skin disorders	—
Silver nitrate	Astringent	Precipitation of bacterial proteins by free silver ions	Gram-positive and Gram-negative bacteria	Black skin discoloration, caustic at high concentrations; potential methemoglobinemia	Weeping, impetiginized skin disorders, cauterization of wounds, removal of granulation tissue, aseptic prophylaxis of burns	C

labeling still warns of possible irreversible optic atrophy and peripheral neuromuscular disease.

METRONIDAZOLE

Metronidazole is an imidazole with activity against anaerobic bacteria and protozoa that is most often used in dermatology for rosacea. In addition to its antibiotic properties, its mode of action in rosacea may involve the impedance of leukocyte chemotaxis and selective suppression of cellular immunity.

MUPIROCIN

Mupirocin, also known as *pseudomonic acid*, is bactericidal at the concentration achieved with topical application to the skin and mucous membranes. As mupirocin has a unique mechanism of action, in which it prevents the incorporation of isoleucine into proteins by inhibiting bacterial isoleucyl-t-RNA synthetase, there is no cross-resistance with other antimicrobials.[25] It has activity against staphylococci, streptococci, and certain Gram-negative bacteria, but is inactive against much of the normal skin flora. It is the treatment of choice for nonbullous impetigo and the most effective topical antibiotic for the elimination of *S. aureus* nasal colonization.[24]

RETAPAMULIN

Retapamulin is a member of the pleuromatilin class of antibiotics prescribed as a 1% topical ointment. It is bacteriostatic and inhibits the elongation phase of protein synthesis through selective binding to the 50S subunit of prokaryotic ribosomes. It is FDA approved for treatment of methicillin sensitive *S. aureus* and *Streptococcus pyogenes*, but is effective in vitro against isolates resistant to B-lactams, macrolides, quinolones, fusidic acid, and mupirocin.[25]

AZELAIC ACID

Azelaic acid is a naturally occurring aliphatic dicarboxylic acid that is a competitive inhibitor of tyrosinase. Azelaic acid is a reversible inhibitor of cytochrome P_{450} reductase and 5α-reductase in microsomes and a reversible inhibitor of some enzymes in the respiratory chain. In-vitro azelaic acid has antimicrobial affects against *Propionibacterium acnes* and *Staphylococcus epidermidis*. Its efficacy against acne and rosacea is attributed to activity against *P. acnes*, normalization of keratinization, and a direct anti-inflammatory effect.[26]

BENZOYL PEROXIDE

Benzoyl peroxide is a nonspecific bactericidal agent that derives its biologic function through decomposition into benzoyloxy and phenyl radicals that react with numerous constituents of microbial cells. This effect may be enhanced by the addition of antibiotics or other molecules containing tertiary amines or transitional metals. As a topical therapy, benzoyl peroxide is mainly used for acne, although it is also occasionally used to speed healing of chronic wounds. When used for acne, it is frequently combined with topical antibiotics, as such combination therapy may reduce the development of antibiotic resistance by *P. acnes*.[27]

ANTIPARASITIC AGENTS

(See Chapter 208; Table 222-2)

CROTAMITON

Crotamiton (crotonyl-*N*-ethyl-*O*-toluidine) is a colorless or pale yellow oil used in the treatment of scabies, pediculosis capitis, and pruritus. Its mode of action is unknown. Other antiparasitic formulations, such as lindane (see next section) 1% and permethrin cream (see later) 5%, are more effective than crotamiton,[28] which is rarely a sensitizer. It is approved for use in infants and children, but is pregnancy category C.

γ-BENZENE HEXACHLORIDE

γ-Benzene hexachloride, also known as *hexachlorocyclohexane* or *lindane*, is a chlorinated hydrocarbon pesticide that is effective against lice, scabies, and fleas as a 1% lotion or shampoo. Scabies and lice resistant to γ-benzene hexachloride have been reported.[28] Furthermore, multiple side effects of topical application including central nervous system toxicity, seizures, and aplastic anemia have been reported leading to the US Food and Drug Administration recommendation that γ benzene hexachloride only be used as a second-line agent.[29] Patients with seizure disorders, children weighing less than 50 kg, and patients with acutely inflamed or raw skin should avoid γ benzene hexachloride.

MALATHION

Malathion is an organophosphate insecticide that acts by irreversibly binding to acetylcholinesterase.[30] It is approved in the United States as a 0.5% lotion for the treatment of head lice. The lotion, containing 78% isopropyl alcohol, is flammable. Safety for children younger than 6 years of age has not been established, and it is pregnancy category B.

PERMETHRIN

Permethrin is a synthetic pyrethroid modeled after the natural insecticide found in the pyrethrum flower, *Chrysanthemum cinerariaefolium*. It acts on parasitic nerve cell membranes, causing paralysis and death.

TABLE 222-2
Topical Antiparasitic Agents

Treatment	Group or Composition	Mechanism	Major Side Effects or Contraindications	Use	US Food and Drug Administration Pregnancy Category
Permethrin (1% or 5%)	Synthetic pyrethroid	Inhibits nerve cell sodium ion influx	Itching and stinging on application; contraindicated for infants <2 months of age	Lice and scabies; used on clothing as an insect repellant	B
Synergized pyrethrins	Natural botanical	Pyrethrins inhibit nerve cell sodium ion influx; piperonyl butoxide inhibits cytochrome P_{450}	Itching and stinging on application; ragweed or chrysanthemum allergy	Lice	C
Malathion (0.5%)	Organophosphate	Cholinesterase inhibitor	Flammable; not approved for children <6 years of age	Lice	B
Crotamiton (10%)	Crotonyl-*N*-ethyl-*O*-toluidine	Unknown	Poor efficacy	Scabies	C
Lindane (1%)	Organochlorine	Cholinesterase inhibitor	May cause seizures, muscle spasms, aplastic anemia; not for use in children <3 years, pregnant or breastfeeding women, patients with underlying neurologic disorders, or over broken skin	Lice and scabies	C
Spinosad (0.9%)	Fermentation product	Generalized central nervous system excitation leading to paralysis	No major side-effects in preclinical trials	Lice	Not rated

It is available over-the-counter as a 1% cream rinse, which is left on dry hair for 10 minutes. A single application is often effective against head lice and nits. Due to increasing resistance, however, two applications, 7–10 days apart, are generally recommended. There is a lack of safety data for its use in children younger than 2 months of age, and in pregnant and breastfeeding women. Prescription strength permethrin 5% cream is also effective against pediculosis capitis resistant to the 1% cream, pediculosis pubis, scabies, and mite infestations including cheyletiella.[31] The 5% cream is applied to dry skin and hair overnight (8–14 hours).

PYRETHRINS

Pyrethrins are the naturally occurring esters of chrysanthemumic acid. In combination with piperonyl butoxide, it is available as a liquid, gel, oil, aerosol spray, foam, and shampoo. Pyrethrins are neurotoxins, and piperonyl butoxide inhibits pyrethrin metabolism, potentiating the effects of pyrethrins. It is also effective against fleas, mosquitoes, and houseflies. As it is derived from the extract of chrysanthemums, the American Academy of Pediatrics suggests that individuals who are sensitive to chrysanthemums or ragweed should avoid this medication.[32] However, this recommendation is controversial as patch and prick testing of commercially available synergized pyrethrins fail to elicit a response in ragweed-allergic patients.[33] The aerosol spray should never be prescribed to patients with a history of asthma.

SPINOSAD

Spinosad is a fermentation product of the soil bacterium *Saccharopolyspora spinosa* that causes widespread excitation of the insect central nervous system resulting in paralysis. It is being developed as a 0.9% cream rinse for the treatment of head lice. It is both pediculocidal and ovicidal with a 10-minute application.[34]

ANTIPERSPIRANTS

ALUMINUM COMPOUNDS

Aluminum chloride solutions are typically used as a first-line therapy for hyperhidrosis in 15% to 20% solutions in the axilla and up to 30% on the palms and soles.[35] The solution is applied for a week at night, when eccrine glands are less active, and if tolerated up to twice daily. After control is achived, it can be applied every 1–3 weeks as maintenance therapy. Use may lead to irritation.[35]

IONTOPHORESIS

Iontophoresis is a procedure in which current is used to transport ions through the skin.[36] The mechanism by which iontophoresis acts to decrease sweating is not fully understood,[37] although it is hypothesized that ion channels in eccrine glands are reversibly disrupted. In an iontophoretic treatment, a hyperhidrotic area of skin to be treated is covered with lukewarm tap water. Electrodes are then inserted into the water and a direct current delivered, usually at 8–20 amperages. The amperage is increased until a tingling sensation is experienced and applied for 10–20 minutes three to four times weekly. Improvement is typically noted in approximately 2 weeks and full improvement within 1 month. Maintenance treatments once or twice weekly can be helpful thereafter. Anticholinergic agents such as glycopyrronium bromide may be added to the tap water for refractory patients. Adverse effects may include irritation, hyperesthesia, and blisters.[36] Iontophoresis using botulinum toxin type A for treatment of palmar hyperhidrosis has also been reported.[38,39]

ANTIPRURITIC AGENTS

(Table 222-3)

ANTIHISTAMINES

(See Chapter 229.)

DOXEPIN

(See Chapter 229.)

TABLE 222-3
Topical Antipruritics

Drug	Group	Mechanism	Precautions	US Food and Drug Administration Pregnancy Category
Diphenhydramine	Antihistamine	Local anesthesia; histamine antagonism	Significant percutaneous absorption; potential sensitization with cross-sensitization to oral diphenhydramine and related compounds	B
Doxepin	Tricyclic antidepressant	Histamine antagonism, interference with neuronal synaptic communication; decreased awareness through production of drowsiness	Potential contact sensitization; significant systemic absorption resulting in drowsiness and drug interactions; contraindicated in patients taking monoamine oxidase inhibitors	B
Menthol	Cyclic terpene alcohol	Counter-irritant. The cooling sensation may be the result of a direct interaction of menthol with cold receptors and/or nerve fibers.[39,44]	—	C when combined with camphor (i.e., Sarna)
Phenol	—	Local anesthesia	Avoid in pregnant women and infants[45]; irritant in diaper area and skin folds	Should be avoided[45]
Pramoxine hydrochloride	Surface anesthetic	Local anesthesia	—	C

MENTHOL

Menthol is a highly lipid-soluble cyclic terpene alcohol, often used with camphor. It is derived from naturally occurring plant oils or prepared synthetically. Menthol is a counterirritant that, by induction of a cool sensation, "crowds out" the sensation of itch. The cooling sensation may be the result of a direct interaction of menthol with cold receptors and/or nerve fibers.[40,41]

PHENOL

Phenol in low concentrations (0.5% to 2.0%) acts as an antipruritic agent through its anesthetic effect. It is percutaneously absorbed and should be avoided in pregnant women and infants.[41] In higher concentrations, it is caustic and is used for deep chemical peels (see Chapter 251).

PRAMOXINE HYDROCHLORIDE

Pramoxine hydrochloride is effective in cases of mild to moderate pruritus. As with other local anesthetics, it inhibits conduction of nerve impulses by altering the cell membrane permeability to ions. The onset of action of pramoxine products is 2–5 minutes.

ASTRINGENTS

In medical practice, astringents are agents that cause contraction of the tissues, arrest of secretion, or control of bleeding. The US Food and Drug Administration more strictly defines astringent drugs as "a drug product that is applied to the skin or mucous membranes for a local and limited protein coagulant effect."[42]

ALUMINUM SALTS

Aluminum acetate tablets diluted 1:10 to 1:40 (Burow solution) are an effective astringent and germicidal agent. Over-the-counter aluminum sulfate and calcium acetate (Domeboro) are available and, when dissolved in water, a chemical reaction occurs forming aluminum acetate and a precipitate of calcium sulfate (modified Burow solution). These solutions may be used as wet dressings, compresses, or soaks.

POTASSIUM PERMANGANATE

Potassium permanganate is an oxidizing agent, astringent, antiseptic, and antifungal that may be used to clean or deodorize wounds. Solutions of 1:4,000 to 1:16,000 may be used as wet compresses to reduce weeping or at 1:25,000 as a medicated bath. This agent may cause permanent staining of clothing and ceramics and temporary brown or bright purple staining of the skin, which may be removed with a weak solution of oxalic acid or sodium thiosulfate.

SILVER NITRATE

Silver nitrate in 0.5% aqueous solution is an astringent and antimicrobial that is applied as a wet dressing in the treatment of infected eczema, gravitational ulcers, and other weeping and/or infected skin lesions caused by Gram-positive or Gram-negative bacteria. It is also available in a solid form that may be used as a hemostat. At low concentration (0.5% formulation, used clinically), it is bacteriostatic, while bactericidal at higher concentrations (10%). As methemoglobinemia has been noted secondary to topical treatment, methemoglobin levels should be followed with prolonged use.[43]

BLEACHING AGENTS

HYDROQUINONE

Usually used in concentrations of 2% to 5%, hydroquinone decreases pigmentation by inhibiting tyrosinase, thereby blocking the conversion of dopa to melanin.[44] It may also act by inhibiting DNA and RNA synthesis, degrading melanosomes, and destroying melanocytes. Hydroquinone 4% in combination with tretinoin 0.05%, and fluocinolone acetonide 0.01% has been shown to be effective in the treatment of melasma.[45] Adverse effects include irritant dermatitis, contact dermatitis, postinflammatory pigmentation, and cutaneous ochronosis. In 2006, FDA announced that it was considering new rules on marketing of hydroquinone, based on safety concerns.[46] The American Academy of Dermatology and others have argued that stricter rules are not necessary.[47,48]

TRETINOIN (RETINOIC ACID)

(See also Chapter 217.)

Tretinoin is thought to inhibit transcription of tyrosinase, leading to decreased pigmentation.[44] It is typically used in concentrations of 0.05% to 0.1% to treat melasma.[44] Local adverse effects include erythema and desquamation, and postinflammatory hyperpigmentation has been reported. Concerns about systemic toxicity of topical tretinoin, including mortality resulting from lung and cardiovascular disease seen in a randomized controlled trial, have also been raised,[49,50] although others have defended tretinoin's safety.[51,52]

AZELAIC ACID

Azelaic acid is hypothesized to mediate decreased pigmentation by inhibition of mitochondrial oxidoreductase activity, DNA synthesis, and tyrosinase. Treatment of melasma is typically with concentrations of 15% to 20%. Side effects include burning, itching, and erythema.

MONOBENZYL ETHER OF HYDROQUINONE

Occasionally used to depigment skin in individuals with widespread vitiligo, monobenzyl ether of

hydroquinone typically causes irreversible depigmentation by causing melanocyte necrosis.[53]

KERATOLYTIC AGENTS

(Table 222-4)

Keratolytics are agents that cause keratolysis, or peeling, of the epidermis. At low concentrations, most keratolytics act as humectants, or moisturizing agents.

α-HYDROXY ACIDS

(See Chapter 251.)

α-Hydroxy acids (lactic acid, glycolic acid, citric acid, glucuronic acid, and pyruvic acid) reduce the thickness of hyperkeratotic stratum corneum by an incompletely understood mechanism wherein the acids may directly solubilize the protein components of desmosomes or activate endogenous hydrolytic enzymes by changing the pH of the stratum corneum, resulting in keratolysis. Also, by diffusing into the stratum corneum and binding water, the acids act as humectants increasing the water content of the stratum corneum. This decreases the formation of dry scales on the skin surface and allows gentle rubbing of the skin during bathing to mechanically remove cornified tissue. The concentration of α-hydroxy acid, pH of the preparation, and composition of the base in which they are compounded are important in determining their efficacy. In general, more anhydrous preparations are less irritating, allowing higher concentrations of acid to be tolerated.

PROPYLENE GLYCOL

Propylene glycol is a humectant, occlusive, and keratolytic agent. It is often combined with other medications to enhance their penetration. A combination of 20% propylene glycol with 5% lactic acid in a semiocclusive cream base is used as a highly effective and well-tolerated keratolytic in patients with lamellar ichthyosis and may be used in various other hyperkeratotic diseases.[54]

SALICYLIC ACID

Salicylic acid has been used in concentrations ranging from 0.5% to 60% in almost any base. In concentrations of 3% to 6%, it causes shedding of scales by softening the stratum corneum, dissolving the intracellular matrix, and

TABLE 222-4
Topical Keratolytic Agents

Agent	Dosage	Indications (Selected)	Side Effects/ Comments	US Food and Drug Administration (FDA) Pregnancy Category
α-Hydroxy acids	2%–20% as nonpeeling agent, >20% as peeling agent	Photoaging, scaling, hyperkeratosis, acne, hyperpigmentation	Increased photosensitivity	Not contraindicated in pregnancy[61]
Propylene glycol	40%–60% under occlusion qhs; may be combined with salicylic acid (Keralyt gel) or Lactic acid (Epilyt); 2% vehicle in many preparations	Ichthyosis, hyperkeratosis, psoriasis	Enhances absorption of other topical agents; possible central nervous system effects	—
Salicylic acid	Scaly dermatoses: FDA-approved bid–qid at 1.8%–3.0%; callouses, corns, and warts: FDA-approved at 12%–40% for plaster vehicles, 12.0%–17.6% in collodion-like vehicles[62]	Hyperkeratosis, scaling	Salicylism (headache, drowsiness, and tinnitus). Maximum topical dose of 2 g/24 hours in adults	C
Urea	Bid–qid in 10%–40% creams and lotions	Xerosis, pruritus, hyperkeratosis, eczema, ichthyosis, psoriasis, nail avulsion	Some patients experience burning; enhances absorption of other topical agents	C
Lactic acid (an α-hydroxy acid)	Bid–qid in 5%–12% preparations	Ichthyosis, xerosis, eczema, photoaging	Hypothetical risk of metabolic acidosis	Not contraindicated in pregnancy[61]

loosening connections between corneocytes.[55] In concentrations higher than 6%, salicylic acid is destructive to tissue. Salicylism has been reported with widespread and prolonged use, especially in children who should apply no more than 2 g (33 mL of a 6% solution) to their skin in a 24-hour period. Sensitization is rare, and irritation can be minimized if introduced at lower concentrations.

UREA

Urea is a humectant that is proteolytic at high concentrations. Urea has been added to some topical glucocorticoid preparations to possibly increase their penetration.[56] It is in preparations for dry skin and nail plate destruction.

LACTIC ACID

Lactic acid is a humectant and keratolytic that is available at concentrations up to 12%. In addition to being a keratolytic, lactic acid increases ceramide production by keratinocytes improving water barrier function.[57]

PSORIASIS THERAPIES

(See Chapter 18.)

ANTHRALIN

(See Chapter 18.)

CALCIPOTRIENE

(See Chapter 18.)

A vitamin D analog, calcipotriol inhibits epidermal proliferation, induces epidermal differentiation, and exerts anti-inflammatory effects. Its effectiveness in psoriasis has been demonstrated in systematic reviews.[58,59] Hypercalcemia may occur if more than 100 g is used per week. It is applied initially twice daily, and maximal improvement can be expected within 6–8 weeks. Cutaneous irritation may occur in up to 20% of patients, particularly when used on the face or in intertriginous areas. Calcipotriene is currently marketed in the United States only as a combination product with betamethasone dipropionate for treatment of psoriasis.[60,61] Other Vitamin D analogs, including calcitriol and tacalcitol, are available and used to treat psoriasis outside of the United States.[61]

WART THERAPIES

DIPHENYLCYCLOPROPENONE

Diphenylcyclopropenone (DPCP), also known as *diphencyprone*, is a potent contact allergen used in the treatment of viral warts and alopecia areata. It is not available in pharmaceutic quality. Theories for its mechanism of action include alterations in cytokine levels, nonspecific inflammation causing wart regression, and binding of DPCP to wart protein inducing a specific immune response.[62] Cross-sensitivity to other chemicals, apart from its precursor, α,α-dibromodibenzyl ketone, has not been reported.[62] Many clinics recommend avoiding DPCP in children younger than 12 years of age, although children with alopecia areata less than 12 years of age have been successfully treated with DPCP.[62]

SQUARIC ACID DIBUTYL ESTER

Squaric acid dibutyl ester is a potent topical sensitizer with a similar mechanism of action and use as DPCP. It requires refrigeration to maintain its potency.

DINITROCHLOROBENZENE

Dinitrochlorobenzene is a potent sensitizer with a similar mechanism of action and use as DPCP. Although dinitrochlorobenzene is mutagenic in vitro, there is no evidence of carcinogenicity in clinical practice.[62]

5-FLUOROURACIL

(See Chapter 220.)

FORMALDEHYDE

Formaldehyde is a powerful disinfectant that causes anhidrosis, desiccation, and sometimes, hypersensitivity when applied to skin. It can cause hardening and fissuring of the skin, so normal surrounding skin should be protected from it by petrolatum, zinc paste, or meticulous application. Individuals with eczema or allergies should avoid formaldehyde as sensitization is problematic being that it is a ubiquitous component of many personal products.

GLUTARALDEHYDE

Glutaraldehyde is viricidal. It also combines chemically with keratin producing polymers that harden the wart surface thereby facilitating paring.

MONO-, DI-, AND TRICHLOROACETIC ACIDS

Monochloroacetic acid, dichloroacetic acid, and trichloroacetic acid in concentrations of 50% to 90% are all effective in the management of warts.[59] Trichloroacetic acid is also commonly used at lower concentrations (10% to 35%) for facial peels (see Chapter 252). Anal and vaginal lesions are occasionally treated with trichloroacetic acid, whereas monochloroacetic acid is most commonly used on plantar warts under salicylic acid plaster occlusion. The application needs to be repeated at 1- to 2-week intervals until complete resolution.

PODOPHYLLIN RESIN

(See Chapter 196.)

PODOFILOX

Podofilox is podophyllotoxin, the active ingredient of podophyllin. It does not contain any of the ingredients responsible for the toxicity of podophyllin. It should not be used during pregnancy unless the potential benefit justifies the potential risk for the fetus.

SALICYLIC ACID

The effectiveness of salicylic acid in treating warts is thought to be related to keratolysis and local irritation of the skin in which the virus is present. Salicylic acid is the most established agent in terms of efficacy and safety in the treatment of viral warts.[63]

SINECATECHINS

Sincatechins ointment is an extract of green tea leaves from *Camellia sinensis* used in the treatment of external genital warts. It is available as a 15% ointment applied three times daily until all warts have cleared up to a maximum of 16 weeks. The mechanism of clearance may be related to the immunostimulatory, antiproliferative, and antitumor properties of catechins within sinecatechins ointment. It appears to have a clinical efficacy comparable to the other currently available topical therapies for external genital warts.[64,65]

KEY REFERENCES

Full reference list available at www.DIGM8.com

DVD contains references and additional content

22. Tsubaki T, Honma Y, Hoshi M: Neurological syndrome associated with clioquinol. *Lancet* **1**:696-697, 1971
32. American Academy of Pediatrics: Pediculosis capitis (head lice). In: *Red Book 2009 Report of the Committee on Infectious Diseases*, edited by LK Pickering. Elk Groove Village, IL, American Academy of Pediatrics, 2009, p. 495
33. Fisher AA: *Contact Dermatitis*, 3rd edition. Philadelphia, Lea & Febiger, 1986.
44. Rendon M et al: Treatment of melasma. *J Am Acad Dermatol* **54**:S272-S281, 2006
58. Ashcroft DM et al: Combination regimens of topical calcipotriene in chronic plaque psoriasis: Systematic review of efficacy and tolerability. *Arch Dermatol* **136**:1536-1543, 2000

Chapter 223 :: Photoprotection

:: Henry W. Lim

PHOTOPROTECTION AT A GLANCE

- Photoprotection measures include seeking shade during the peak ultraviolet (UV) B hours of 10:00 am to 2:00 pm and the use of high sun protection factor broad-spectrum sunscreen, clothing, wide-brimmed hat, and sunglasses.
- New generation photostable UV filters are now available in Europe and many parts of the world and are beginning to enter the US market.
- UV protection factor is a UV protection rating for fabrics. Several chemical treatments can increase the natural UV protection factor.
- Glass that filters out more than 99.9% of UV from 300–380 nm is now commercially available.
- Sunglass standards, mandatory in Australia and voluntary in the United States, specify a maximum percentage of light allowed to be transmitted and a minimum vertical dimension of sunglasses.

With increased attention to physical fitness and outdoor recreational activities, daily exposure to sunlight is common. Although sun exposure may have beneficial effects such as mood elevation and vitamin D_3 photosynthesis, unwanted effects are well known. Acute effects of sun exposure include sunburn and delayed tanning. Chronic sun exposure is strongly associated with photoaging, actinic keratoses, and squamous cell carcinoma; intermittent sun exposure is associated with basal cell carcinoma and melanoma. Complete avoidance of sun exposure is neither necessary nor practical, nor will it be accepted by the general public. As such, behavioral modification of seeking shade during peak ultraviolet B (UVB) hours of 10:00 am. to 2:00 pm and the use of photoprotective measures, such as sunscreen, clothing, wide-brimmed hat, and sunglasses, and when appropriate, intake of vitamin D supplements, have become the public health message to deliver. This chapter discusses the currently available, commonly used photoprotective measures.[1]

SUNSCREEN

HISTORY

The first UVB filter, PABA (*para*-aminobenzoic acid), was patented in 1943, and the first UVA filter, a

benzophenone, was introduced in 1962. In 1972, the US Food and Drug Administration (FDA) reclassified sunscreens from cosmetics to over-the-counter (OTC) drugs, resulting in more stringent regulation. In 1979, long UVA filters, dibenzoylmethane derivatives, became available. In 1990s, the need for protection against UVA, as well as against UVB, was recognized, which led to further development of UVA filters.

SUN PROTECTION FACTOR

The sun protection factor (SPF) was first developed by an Austrian, Franz Greiter, in 1962 and was adopted by the FDA in 1978.[2] Current FDA guidelines specifically require that products be tested using a solar simulator with emission spectrum covering the wavelength range of 290–400 nm, and that the sunscreen product be applied at a concentration of 2 mg/cm^2.

By definition, SPF is the ratio of minimal erythema dose (MED) of a subject's sunscreen-protected skin over the MED of the unprotected skin. Because the end point is erythema, SPF is a reflection of protection against the biologic effect of UVB (290–320 nm), and to a lesser extent, UVA2 (320–340 nm) (see Chapter 90). The effect of sunscreens with different SPFs on the transmission of erythemogenic rays is shown in Figure 223-1.[3] If an individual develops slight erythema after 10 minutes of sun exposure, 30 minutes of unprotected sun exposure result in a 3 MED sunburn. In contrast, when wearing an SPF 15 or SPF 30 sunscreen, the same 30-minute exposure would result in only 20% or 10%, respectively, of an MED. With chronic exposure, the added protection from an SPF 30 sunscreen halves the cumulative UV damage compared to the SPF 15 sunscreen, even though both products prevent sunburn.

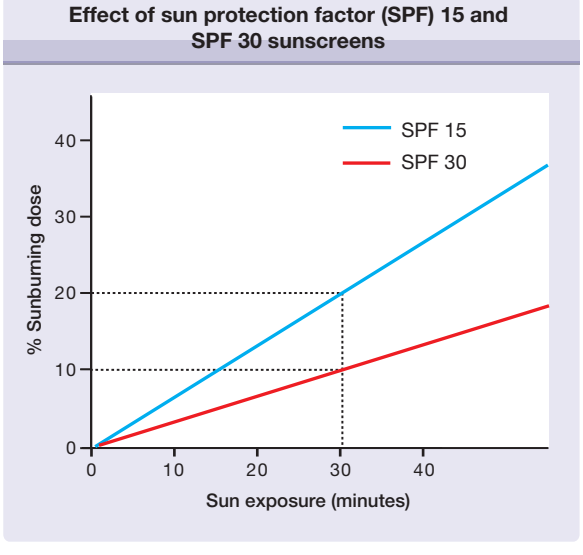

Figure 223-1 Effect of sun protection factor (SPF) 15 and SPF 30 sunscreens on an individual who would develop minimal erythema after 10 minutes of unprotected sun exposure. After a 30-minute sun exposure, 20% of a sunburning dose is achieved after the application of SPF 15 sunscreen; after the application of SPF 30 sunscreen, only 10% of a sunburning dose reaches the skin.

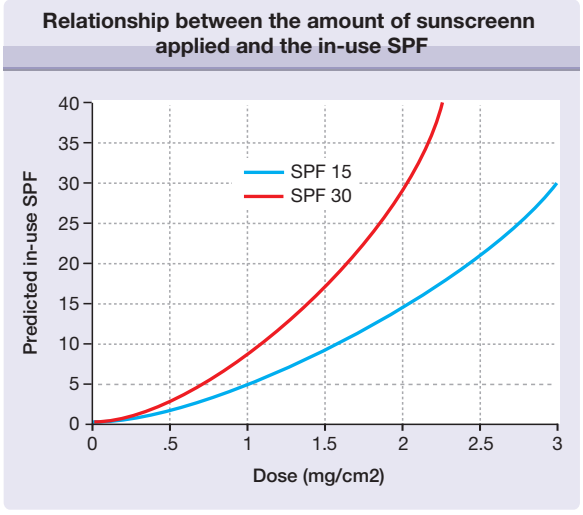

Figure 223-2 Relationship between the dose of sunscreen applied and the in-use sun protection factor (SPF). (Used with permission from JF Nash, Procter & Gamble, Cincinnati, OH.)

The concentration of sunscreen specified for SPF testing (2 mg/cm^2) is the equivalent of 1 oz (30 mL) of sunscreen to cover the entire body surface. Studies of the actual sunscreen usage by individuals have consistently demonstrated that the amount of sunscreen applied is closer to 0.5–0.8 mg/cm^2, so that the actual in-use SPF is significantly lower than the label SPF.[4] The relationship is not linear, and an SPF 30 product (at 2 mg/cm^2) has an SPF of only 3 if applied at 0.5 mg/cm^2 (Fig. 223-2).[5] This situation causes many users to overestimate their degree of photoprotection and also confounds epidemiologic studies that rely on self-reported sunscreen use to judge the efficacy of sun protection in preventing, for example, skin cancer, including melanoma.

ASSESSMENT OF ULTRAVIOLET A PROTECTION

SPF is accepted as the worldwide standard for the assessment of protection against the erythemogenic effects of UVB and UVA2. Among the several methods to evaluate protection against UVA, the persistent pigment darkening (PPD) method has become the most widely used in the past few years.[5,7] In the PPD method, the dose of UVA required to induce persistent pigment darkening observed 2–24 hours after exposure of sunscreen protected skin is compared to that of sunscreen-unprotected skin; the ratio is then expressed as the UVA protection factor (UVA-PF). In June, 2011,

the US FDA decided to use an in vitro critical wavelength test as an assessment of UVA protection of sunscreens sold in the US.[8]

IMMUNE PROTECTION FACTOR

SPF for a sunscreen product correlates poorly with its ability to protect against immunosuppression. This has resulted in the development of the concept of immune protection factor (IPF), quantifying the ability of sunscreen products to prevent immunosuppression.[9] Several different methods have been used, including contact sensitization, and intradermal injection, all of which are quite laborious and time consuming to perform. Until the time that a simple and reliable method can be easily performed in a large number of test subjects, it is unlikely that IPF will be used to rate commercial products.

ULTRAVIOLET FILTERS

There are three different nomenclatures used by the sunscreen industry and regulatory agencies around the world: (1) International Nomenclature of Cosmetic Ingredients (INCI), (2) United States Adopted Name (USAN), and (3) trade name. USAN is the nomenclature used in the FDA Sunscreen Monograph. For example, for a widely used UVA1 filter, the INCI name is butyl methoxydibenzoylmethane, the USAN is avobenzone, and a trade name is Parsol 1789. In this chapter, when available, the USAN nomenclature is used.

The term *sunblock* is commonly used to refer to sunscreens and their active ingredients, but it is a misnomer, and the FDA Sunscreen Monograph does not sanction the term. All sunscreen active ingredients are filters that absorb part of the incident UV radiation, but a portion of the radiation is always transmitted. Microfine inorganic filters additionally reflect and scatter UV radiation.

In the United States, all active sunscreen ingredients are regulated by the FDA as OTC drugs.[6] Only UV filters listed in the Sunscreen Monograph issued by the FDA may be marketed in the United States (16 active ingredients; Table 223-1). In addition, filters approved by the FDA as active ingredients of final products through the New Drug Application (NDA) process can also be marketed in the US, as was done for the latest UVA filter available in the US market, ecamsule (Mexoryl SX™). In 2002, the FDA instituted the Time and Extend Application (TEA) process as an alternate to filing the NDA.[10] With the TEA process, for the first time, data generated outside the United States can be used for the application, provided that the sunscreen product has been marketed for OTC purchase for a minimum of 5 years in the country where testing was performed. In the EU, South America, many Asian countries, and Africa, sunscreens are regulated as cosmetics, resulting in a simpler and more expeditious approval process compared to the United States, usually resulting in approval within 1–2 years of filing.

UV filters can be divided into two categories, *organic* and *inorganic*. These terms are recommended by FDA to replace the term *chemical* and *physical* filters, respectively. Organic filters can be subdivided further into UVB filters and UVA filters. The most widely used UVB filter worldwide is octinoxate (ethylhexyl methoxycinnamate), whereas the most widely used UVA filter is oxybenzone (benzophenone-3). Currently, unless products are approved as new drugs through the NDA process, the FDA guidelines do not allow avobenzone to be combined with inorganic filters (titanium dioxide, zinc oxide).

ULTRAVIOLET FILTERS AND PHOTOSTABILITY.

Avobenzone (butyl methoxydibenzoylmethane; Parsol 1789) is an excellent UVA1 filter but is photounstable and degrades during UV exposure. There are several other UV filters with this characteristic, including UVB filters padimate O (ethylhexyl dimethyl *para*-aminobenzoic acid) and octinoxate (ethylhexyl methoxycinnamate).[11] It is possible to incorporate other agents to increase the photostability of the final product (Fig. 223-3). Most of these agents are photostable UV filters (e.g., octocrylene, salicylates, oxybenzone) that absorb photons to minimize the effect on the photounstable UV filter; they also serve as receptor molecules for energy transfer from excited state photounstable filter, hence minimizing the photodegradation of the latter (see Fig. 223-3).[4,12]

In vitro, sunscreens containing photostabilized avobenzone have been shown to retain up to 90% of the active filter following 25 MED (50 J/cm^2) of solar simulated radiation, the equivalent of approximately 5 hours of sun exposure.[12] Under ideal circumstance, this would allow user to apply sunscreen only once daily. However, it should be noted that sunscreens do migrate on skin surface towards follicular orifices, resulting in an uneven distribution of UV filters; furthermore, sunscreens do get removed from rubbing and water or sweat exposure. That is the reason that the FDA, in the final rule, advises that sunscreen should be reapplied every 2 hours.[6]

ULTRAVIOLET FILTERS AND PHOTOALLERGY.

Oxybenzone (benzophenonone-3) is the most common cause of UV filter photoallergy. In contrast, the most widely used UVB filter, octinoxate (ethylhexyl methoxycinnamate), is rarely a photoallergen.[13] It should be noted that although UV filters are the most common cause of photoallergy in many studies in the United States and the United Kingdom, considering the number of individuals using sunscreens, the prevalence of photoallergy to UV filters is very low (well less than 1%). No photoallergy has been reported with inorganic UV filters (titanium dioxide and zinc oxide), the organic filter meradimate

TABLE 223-1
Ultraviolet (UV) Filters Listed in the US Food and Drug Administration Sunscreen Monograph

US Adopted Name[a]	International Nomenclature of Cosmetic Ingredients	λ_{max} (nm); or Absorption Range	Comment
Organic filters: UVB			
▪ PABA derivatives			
▪ PABA	PABA	283	Stains clothing. Not widely used
▪ Padimate O	Ethylhexyl dimethyl PABA	311	Most commonly used PABA derivative. Photounstable
▪ Cinnamates			
▪ Octinoxate	Ethylhexyl methoxycinnamate	311	Most widely used UVB filter. Photounstable
▪ Cinoxate	Cinoxate	289	—
▪ Salicylates			
▪ Octisalate	Ethylhexyl salicylate	307	Weak UVB absorbers. Improves photostability of other filters
▪ Homosalate	Homosalate	306	
▪ Trolamine salicylate	Triethanolamine salicylate	260–355	Weak UVB absorbers. Good substantivity—used in water-resistant sunscreens and hair-care products
▪ Others			
▪ Octocrylene	Octocrylene	303	Photostable. Improves photostability of photolabile filters
▪ Ensulizole	Phenylbenzimidazole sulfonic acid	310	Water soluble. Enhances sun protection factor of the final product
Organic filters: UVA			
▪ Benzophenones			
▪ Oxybenzone	Benzophenone-3	288, 325	Most commonly used UVA filter. Most common cause of photoallergic contact dermatitis to UV filters.
▪ Sulisobenzone	Benzophenone-4	366	—
▪ Dioxybenzone	Benzophenone-8	352	—
▪ Others			
▪ Avobenzone	Butyl methoxydibenzoylmethane	360	Photounstable. Enhances the photodegradation of octinoxate.
▪ Meradimate	Menthyl anthranilate	340	A weak UVA filter. No sensitization reaction reported.
Inorganic filters			
▪ Titanium dioxide	Titanium dioxide	See below[b]	No report of sensitization reaction. Photostable; used to enhance photostability of the final product. Micronized zinc oxide has better UVA1 protection compared to microfine titanium dioxide. Micronized zinc oxide has lower refractive index compared to microfine titanium dioxide and thus appears less white. Commonly coated with dimethicone or silica to maintain effectiveness as sunscreen.
▪ Zinc oxide	Zinc oxide	See below[b]	

PABA = *para*-aminobenzoic acid.
[a]This is the name used by the US Food and Drug Administration in the listing.
[b]λ_{max} ranges from visible to UVA to UVB range, depending on the particle size. As titanium dioxide is micronized (10–50 nm in diameter), λ_{max} shifts toward UVB; microfine zinc oxide maintains a flat absorption profile spanning from UVB to UVA.
Data from Kullavanijaya P, Lim HW: Photoprotection. *J Am Acad Dermatol* **52**:937, 2005 and Department of Health and Human Services, Food and Drug Administration: Sunscreen drug products for over-the-counter human use; final monograph. *Federal Register* **64**: 27666, 1999

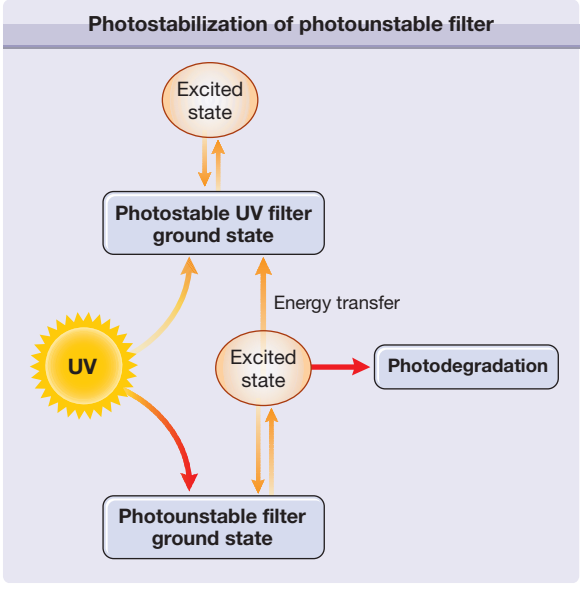

Figure 223-3 Photostabilization of photounstable filter. Photostable ultraviolet (UV) filter absorbs a portion of incident photons, hence decreasing the number of photons absorbed by the photounstable filter. Photostable UV filter also serves as a receptor for energy transfer from the excited-state photounstable filter, minimizing the photodegradation of the latter.

(menthylanthranilate), or the new photostable organic filters listed in Box 223-1.[14]

SUNSCREEN USE IN CHILDREN

Because of the concern about percutaneous absorption of sunscreens, the 1999 FDA Sunscreen Monograph recommends that the physician should be consulted on the use of sunscreens in children under the age of 6 months.[6] For this group of patients, it is prudent to use other means of photoprotection such as clothing.[4]

BOX 223-1 NEW GENERATION PHOTOSTABLE UV FILTERS

UVA FILTERS

- Mexoryl SX (ecamsule)[a]
- Neoheliopan AP
- Uvinul A Plus

UVB + UVA FILTERS

- Mexoryl XL (silatriazole)
- Tinosorb M (bisoctrizole)
- Tinosorb S (bemotrizinol)

[a]Names in parenthesis are the US Adopted Names (USAN). Ecamsule is the only one in this list that has been approved by the US FDA through an NDA process.

CONTROVERSIES

NON-MELANOMA SKIN CANCER AND MELANOMA. While there have been questions in the past, the protective role of sunscreens in the prevention of skin cancer development has now been established. In a 4.5 years study with an 8 years follow up of over 1,600 individuals in Australia, it was shown that the group that was assigned to use SPF 16, broad spectrum sunscreen had a decrease of incidence of squamous cell carcinoma and basal cell carcinoma by 38%, and 25%, respectively.[15] In a 10 years follow up, 11 melanomas developed in the sunscreen group, compared to 22 in the control group.[16]

VITAMIN D. Another area of controversy is the concern that photoprotection may compromise health by decreasing serum vitamin D level, specifically the level of the highly variable "storage form" (25-OH-vitamin D) that is the precursor to the tightly regulated active form [1,25-$(OH)_2$-vitamin D)]. There are only three sources of vitamin D. Exposure to the UVB spectrum of sunlight converts 7-dehydrocholesterol in the skin to previtamin D and thus allows its subsequent hydroxylation by the liver and kidney to the active form of the vitamin. The peak action spectrum for previtamin D synthesis is 300 ± 5 nm. Another source is dietary intake, although only a few naturally occurring foods contain a significant amount of vitamin D [e.g., oily salt water fish (herring, salmon, and sardines), cod liver oil, and egg yolk]. In the United States, milk, orange juice, margarine, butter, cereals, and chocolate mixes are fortified with vitamin D. Last, vitamin D supplements are readily available as vitamin D_3 (cholecalciferol, the form produced in skin) or vitamin D_2 (ergocalciferol); at present, vitamin D_3 is more commonly used than vitamin D_2 because the former is considered to be more stable.[17]

The effect of application of sunscreens on vitamin D levels has been evaluated. A recent review of all the published evidence concluded that normal usage of sunscreens does not generally result in vitamin D insufficiency,[18] this is primarily due to the inadequate application of sunscreens, and people using sunscreens may expose themselves to more sun than nonusers. However, in patients who practiced diligent photoprotection (for example, those with lupus erythematosus and those with erythropoietic protoporphyria), a large percentage of them did have inadequate serum vitamin D levels.[19,20] A comprehensive review by the US Institute of Medicine, released in November 2010, concluded that the strongest evidence for the beneficial effect of vitamin D on health is only for bone health; for extraskeletal outcomes, the IOM indicated that the current evidence is inconsistent and inclusive, and as such is insufficient to make public health recommendation.[21] Because the action spectrum for cutaneous vitamin D synthesis (i.e., UVB) is the same as for DNA damage and photocarcinogenesis, it is not advisable to use sun exposure as a means of obtaining vitamin D. For those individuals who are concerned or are at risk for vitamin D insufficiency, a balanced diet and

a daily 600 IU vitamin D_3 supplement, along with 1 g of calcium, is recommended.[21,22] This recommendation applies especially to elderly individuals who are homebound or dark-skinned individuals with modest sun exposure, and those who practice rigorous photoprotection.

NANOPARTICLES. Metal oxide inorganic UV filters, titanium dioxide and zinc oxide, have been widely used in microfine form. This is to minimize the reflection of visible light, thus enhancing the esthetic appearance of the final product. Nanoparticles are defined as particles less than 100 nm. In vitro, these particles can induce free radical formation in the presence of UV radiation, resulting in cell damage. In 2009, the Australian Government Therapeutic Goods Administration concluded that the weight of current evidence shows that these particles remain on the surface of the skin[23]; however, further studies are warranted, especially if these are used on inflamed skin, or in infants.

GARMENTS

CLOTHING AS A PHOTOPROTECTIVE MEASURE

Clothing, including hats, is an integral part of photoprotection. Compared to sunscreens, they are easy to put on, durable, and a social necessity. However, in most cultures, there are body sites that are infrequently covered by clothing, such as the face, the V area of neck, and dorsal hands. During hot (and sunny) weather, garments tend to cover even less skin.

ULTRAVIOLET PROTECTION FACTOR

UV protection factor (UPF) is the in vitro measurement used in many countries, including the United States, to quantify the ability of fabrics to protect against UV. Because erythema is the factor considered, similar to the SPF, UPF is a better reflection of UVB than UVA protection.[24] In the United States, garments are classified as having good protection (UPF 15–24), very good protection (UPF 25–39), or excellent protection (UPF 40–50+).

As summarized in Box 223-2, several factors affect the UV protectiveness of garments.[4,24] Polyester fibers are the best UV absorber, whereas cotton and rayon are the poorest.[25] Laundering garments made from cotton or rayon increases the UPF because of shrinkage, causing a decrease in the porosity of the fabrics. Wetness decreases the UV-protection of a light colored (especially white) garment. This is because the protective effect of white cotton fabric is mainly due to light-scattering at the fiber/air interface: when wet, the fabric no longer scatters light, and the garment becomes more transparent to both UV and visible light. In contrast, dark-colored garments absorb light and thus do not become see-through or less UV protective when wet. Chemical treatments include the incorporation of UV absorbers to the fabrics during the manufacturing (mill finishing) process, addition of UV absorber as laundry additives, and addition of optical whitening agents widely incorporated in many laundry detergents in the United States and Europe. These latter agents absorb UV radiation at 360 nm and convert it to visible light wavelength of 430 nm; therefore, these agents decrease UV transmission through the fabric. The emission of visible light from the fabric makes the fabric look "brighter."

It is a common misperception that color of the fabric linearly correlates with the UPF. In experiments with cotton fabric with UPF of 4.1, red fabric with the same dye concentration had UPF of 41, 31, and 20, depending on the type of red dye used. A yellow fabric had UPF of 25, whereas a violet one had UPF of 24.[24,26] This is because color is a reflection of the *visible light* that the eye would see and the brain would perceive; it does not therefore necessarily correlate with the transmission of UV rays through the fabric.

BOX 223-2 FACTORS AFFECTING SUN PROTECTION OF GARMENTS

- Style of garment
- Number of layers
- Fabric thickness
- Type of fibers (polyester > wool, silk, nylon > cotton, rayon)
- Stretching
- Laundering
- Wetness
- Chemical treatments

Modified from Lim HW, Hönigsmann H: Photoprotection. In: *Photodermatology*, edited by HW Lim, H Hönigsmann, JLM Hawk. New York, Marcel Dekker, 267, 2007.

GLASS

GLASS USED IN BUILDINGS AND CARS

It is well known that UVB is effectively filtered by glass.[27] Many types of glass now also have very good UVA2 and UVA1 protection (up to 380 nm). It should be noted that windshields of cars are made of laminated glass, which allows less than 1% of UV (300–380 nm) to pass through, whereas side and rear windows are usually made from nonlaminated glass that allows a higher level of UVA transmission. This explains why common sites of involvement for patients with a photodermatosis are the side of the face and forearm closest to the side window of the car.[28]

SUNGLASSES

Australia has led the world in sunglass standards, developing the world's first national mandatory standard for sunglasses for general use in 1971; it was last

revised in 2003 (AS/NZ 1067:2003).[29] The amount of visible light transmitted through the lens is called *luminous transmittance*; a lens with 20% luminous transmittance would allow 20% of the visible light to pass through. Lenses are grouped into five categories (0 to 4), ranging from fashion sunglasses (lens category 0) to special-purpose sunglasses for very high sun-glare reduction (lens category 4); category 4 lens are not to be worn during driving. Category 0 lenses are allowed to have luminous transmission of 80% to 100%, whereas category 4 transit 3% to 8%. The Standard requires that the UVB transmittance be 5% of the luminous transmittance, specifically, if the luminous transmittance is 20%, then the allowed UVB transmittance is 5% of 20%, which is 1%. The UVA transmittance for lens categories 0 to 2 must be no more than the luminous transmittance, while for lens categories 3 and 4, 50% of the luminous transmittance. The Standard also mandates that the minimum vertical diameter for adult sunglasses is 28 mm, and for children, 24 mm. The 2003 Australian Standard is similar to the European Standard EN 1836:2005, which has four transmittance ratings.

The US sunglass standard was first published in 1972 by the American National Standards Institute and last revised in 2001 (ANSI Z80.3-2001). However, unlike the Australian Standard, compliance with the US Standard is voluntary and is not followed by all manufacturers[30]; therefore, consumers share the burden of responsibility. The US Standard classified sunglasses as Normal Use (e.g., from home to the car to the office) or High or Prolonged Exposure (e.g., at the beach, fishing, skiing). Lenses are classified for intended function as special, dark, general purpose, or cosmetic tint. For example, for general purpose sunglasses, ANSI Z80.3 requires less than 1% of the wavelengths below 310 nm to be transmitted. No minimum vertical dimension of the sunglasses is stated in the US Standard.

KEY REFERENCES

Full reference list available at www.DIGM8.com

DVD contains references and additional content

4. Kullavanijaya P, Lim HW: Photoprotection. *J Am Acad Dermatol* **52**:937-958, 2005
6. Wang, SQ, Lim, HW: Current status of the sunscreen regulation in the United States: 2011 Food and drug administration's final rule on labeling and effectiveness testing. *J Am Acad Dermatol* **65**:863-869, 2011.
16. Green AC, Williams GM, Logan V, Strutton GM: Reduced melanoma after regular sunscreen use: randomized trial follow-up. *J Clin Oncol* **29**:257-263, 2011
21. Ross AC, Manson JE, Abrams SA et al: The 2011 report on dietary reference intakes for calcium and vitamin D from the Institute of Medicine: what clinicians need to know. *J Clin Endocrinol Metab* **96**(1):53-58, 2011
24. Hatch KL, Block L, Gies P: Photoprotection by fabric. In: *Clinical Guide to Sunscreens and Photoprotection*, edited by HW Lim, ZD Draelos. New York, Informa Healthcare, 2009, p. 223-241
27. Tuchinda C, Srivannaboon S, Lim HW: Photoprotection by window glass, automobile glass and sunglasses. *J Am Acad Dermatol* **54**:845-854, 2006

SECTION 37 Systemic Therapy

Chapter 224 :: Systemic Glucocorticoids

:: Victoria P. Werth

SYSTEMIC GLUCOCORTICOIDS AT A GLANCE

- Systemic glucocorticoids are potent immunosuppressives and anti-inflammatory agents frequently used for severe dermatologic diseases.
- Complications are increased with fluorinated compounds, higher doses, longer duration of therapy, and more frequent administration.
- Intralesional, intramuscular, intravenous, and oral routes of administration can be used.
- Careful monitoring of electrolytes, glucose, triglycerides, cholesterol, weight, fevers, skeletal or abdominal pain, bone density, and eyes are important.
- New treatments to prevent glucocorticoid-induced osteoporosis should be used in most patients.

Glucocorticoids (GCs) are a mainstay of dermatologic therapy because of their potent immunosuppressive and anti-inflammatory properties. In 1949, Hench and coworkers[1] described the beneficial effects of cortisone in patients with rheumatoid arthritis. By understanding the properties and mechanisms of action of glucocorticoids, one can maximize their efficacy and safety as therapeutic agents.

MECHANISM OF ACTION

The major naturally occurring glucocorticoid is cortisol (hydrocortisone). It is synthesized from cholesterol by the adrenal cortex. Normally, less than 5% of circulating cortisol is unbound; this free cortisol is the active therapeutic molecule. The remainder is inactive because it is bound to cortisol-binding globulin (CBG, also called transcortin) or to albumin. The daily secretion of cortisol ranges between 10 and 20 mg, with a diurnal peak around 8:00 am.[2] Cortisol has a plasma half-life of 90 minutes. It is metabolized primarily by the liver, although it exerts hormonal effects on virtually every tissue in the body. The metabolites are excreted by the kidney and the liver.

The mechanism of glucocorticoid action involves passive diffusion of the glucocorticoids through the cell membrane, followed by binding to soluble receptor proteins in the cytoplasm.[3] This hormone-receptor complex then moves to the nucleus and regulates the transcription of a limited number of target genes. There are three main mechanisms of glucocorticoid action. The first is direct effects on gene expression by the binding of glucocorticoid receptors to glucocorticoid-responsive elements, leading to the induction of proteins like annexin I and MAPK phosphatase 1. Annexins reduce phospholipase A_2 activity, which reduces the release of arachidonic acid from membrane phospholipids,[4] limiting the formation of prostaglandins and leukotrienes.[5,6] The second mechanism is indirect effects on gene expression through the interactions of glucocorticoid receptors with other transcription factors. Some of the most important appear to be inhibitory effects on the transcription factors AP-1 and NF-κB, coupled with increased IκB, an inhibitor of NF-κB,[7] This decreases the synthesis of a number of proinflammatory molecules, including cytokines, interleukins, adhesion molecules, and proteases. The third is glucocorticoid-receptor-mediated effects on second messenger cascades through nongenomic pathways such as the PI3K-Akt-eNOS pathway.[8,9]

The human GC receptor (GR) messenger RNA has alternative splice variants, glucocorticoid receptor–α and –β. The relative levels of these two variants influence the cell's sensitivity to glucocorticoid, with higher levels of GR-β being one of many mechanisms leading to glucocorticoid resistance.[9,10]

There is usually a delay in the onset of pharmacologic activity of glucocorticoids relative to their peak blood concentrations, which is probably consequent to altering the transcription of genes,[8] although some actions appear to be independent of transcription.[11] Glucocorticoids may also exert their effects by nongenomic mechanisms such as membrane-bound receptors and/or physicochemical interactions with cellular membranes.[12] Some effects of glucocorticoids

are too rapid to be mediated by genomic glucocorticoid action.[13] This mechanism might explain the additive benefits of very high-pulse glucocorticoids.

The recognition that desired clinical effects of GC treatment on the GR are mediated by transrepression mechanisms, while transactivation mediates side effects, have led to the development of compounds—selective GR agonists (SEGRAs)—that potentially will give glucocorticoid effects without the same amount of toxicity.[8,14,15] The multiplicity of biologic effects produced by glucocorticoids emphasizes that currently there is no unifying hypothesis to explain the therapeutic efficacy of these extremely potent anti-inflammatory and immunosuppressive agents.

CELLULAR EFFECTS OF CORTICOSTEROIDS

Glucocorticoids profoundly affect the replication and movement of cells. They induce monocytopenia, eosinopenia, and lymphocytopenia and have a greater effect on T cells than on B cells.[16] The lymphocytopenia appears to be caused by a redistribution of cells as they migrate from the circulation to other lymphoid tissues, and it has been suggested that glucocorticoids induce apoptosis.[17] The increase in circulating polymorphonuclear leukocytes is related to demargination of cells from the bone marrow and a diminished rate of removal from the circulation, at least partially mediated by the increase in annexin 1[18]; there also appears to be inhibition of neutrophil apoptosis.[19]

Glucocorticoids affect cell activation, proliferation, and differentiation. They modulate the levels of mediators of inflammation and immune reactions, as seen with the inhibition of interleukin-1, -2, and -6 (IL-1, -2, -6), and tumor necrosis factor synthesis (or release).[20,21] Macrophage functions—including phagocytosis, antigen processing, and cell killing—are decreased by cortisol,[22,23] and this decrease affects immediate and delayed hypersensitivity.

BOX 224-1 MOST COMMON INDICATIONS OF SYSTEMIC STEROIDS

- Serious blistering diseases (pemphigus, bullous pemphigoid, cicatricial pemphigoid, linear IgA bullous dermatoses, epidermolysis bullosa acquisita, herpes gestationis, erythema multiforme, toxic epidermal necrolysis)
- Connective-tissue diseases (dermatomyositis, systemic lupus erythematosus, mixed connective-tissue disease, eosinophilic fasciitis, relapsing polychondritis)
- Vasculitis
- Neutrophilic dermatoses (pyoderma gangrenosum, acute febrile neutrophilic dermatosis, Behçet disease)
- Sarcoidosis
- Type I reactive leprosy
- Hemangioma of infancy
- Panniculitis
- Urticaria/angioedema

Glucocorticoids suppress monocyte and lymphocyte function (both Th1 and Th2 cells) more than polymorphonuclear leukocyte function.[24] This effect is clinically important because granulomatous infectious diseases, such as tuberculosis, are prone to exacerbation and relapse during prolonged glucocorticoid therapy. The antibody-forming cells, B lymphocytes and plasma cells, are relatively resistant to the suppressive effects of glucocorticoids. Very high doses of glucocorticoids are needed to suppress antibody production.[25]

INDICATIONS

There is a long list of indications for skin disorders (see Box 224-1). In addition, short courses of glucocorticoids may be used for a variety of forms of severe

TABLE 224-1
Glucocorticoids

	Equivalent Glucocorticoid Potency (mg)	Mineralocorticoid Potency	Plasma Half-Life (min)	Duration of Action (h)
Short-acting				
Hydrocortisone (Cortisol)	20	0.8	90	8–12
Cortisone	25	1	30	8–12
Intermediate-acting				
Prednisone	5	0.25	60	16–36
Prednisolone	5	0.25	200	12–36
Methylprednisolone	4	0	180	12–36
Triamcinolone	4	0	300	12–36
Long-acting				
Dexamethasone	0.75	0	200	36–54

dermatitis, including contact dermatitis, atopic dermatitis, photodermatitis, exfoliative dermatitis, and erythrodermas. Low doses of glucocorticoids may be administered at bedtime if acne and hirsutism result from adrenogenital syndromes and are unresponsive to more conservative therapy. The use of glucocorticoids is controversial in the treatment of erythema nodosum, lichen planus, cutaneous T-cell lymphoma, and discoid lupus erythematosus.

DOSING REGIMEN

Systemic glucocorticoids can be administered intralesionally, orally, intramuscularly, and intravenously. The route and regimen are determined by the nature and extent of the disease being treated.

Intralesional glucocorticoid administration allows direct access to either a relatively few lesions or a particularly resistant lesion. The concentration depends on the site of injection and the nature of the lesion. Lower concentrations (2–3 mg/mL) are used on the face to prevent atrophy of the skin, whereas keloids may require concentrations of 40 mg/mL. In conditions requiring sustained effects, such as keloids and alopecia areata, longer-acting glucocorticoids, such as Aristospan, can be administered alone or mixed with the more typically used Kenalog. It is best to limit the total monthly dose of Kenalog to 20 mg to ensure that the hypothalamic-pituitary-adrenal (HPA) axis will not be suppressed.[27]

There are serious drawbacks to intramuscular administration because of erratic absorption and lack of daily control of the dose. Because Kenalog is longer-acting than prednisone, Kenalog has more potential side effects, including increased HPA suppression and myopathy.

When oral glucocorticoids are prescribed, prednisone is most commonly selected. Glucocorticoids are usually administered daily or every other day; although for acute disease split, daily doses can be administered. The initial dose is most often daily to control the disease process and can range from 2.5 mg to several hundred milligrams daily. If used for less than 3–4 weeks, glucocorticoid therapy can be stopped without tapering. The lowest possible dose of a short-acting agent every other morning minimizes side effects. Because cortisol levels peak at around 8 A.M., the HPA axis is least suppressed with this morning dosage, and maximal feedback suppression of adrenocorticotropic hormone (ACTH) secretion by the pituitary is already occurring. The low levels of glucocorticoids at night allow for normal secretion of ACTH. Low doses of prednisone (2.5–5 mg) at bedtime have been used to maximize adrenal suppression in cases of acne or hirsutism of adrenal origin.

Intravenous glucocorticoids are used in two situations. One is for stress coverage for patients who are acutely ill or are undergoing surgery and who have adrenal suppression from daily glucocorticoid therapy. The other is for patients with certain diseases—such as resistant pyoderma gangrenosum, severe pemphigus or bullous pemphigoid, serious SLE, or dermatomyositis—to gain rapid control of the disease and thus minimize the need for long-term, high-dose, oral steroid therapy.[28] Methylprednisolone is used at a dose of 500 mg to 1 g daily because of its high potency and low sodium-retaining activity. Serious side effects associated with intravenous administration include anaphylactic reactions, seizures, arrhythmias, and sudden death. Other adverse reactions include hypotension, hypertension, hyperglycemia, electrolyte shifts, and acute psychosis. Slower administration over 2–3 hours has minimized many of the serious side effects, and as long as vital signs are determined frequently, patients without underlying renal or cardiac disease do not need to be treated in a monitored bed.[29] It is important to monitor serum electrolytes before and after pulse therapy, particularly when patients are on concomitant diuretic therapy. Some studies question whether there is a role for high-dose IV pulse therapy.[27]

INITIATING THERAPY

FUNDAMENTAL PRINCIPLES

Before therapy with glucocorticoids is begun, the benefit that can realistically be expected should be weighed against the potential side effects. Alternative or adjunctive therapies should be considered, especially if long-term treatment is contemplated. Coexisting illnesses such as diabetes, hypertension, or osteoporosis need to be considered. The predisposition of the patient to side effects should be included in an assessment of risk.

CHOOSING AMONG GLUCOCORTICOIDS

A number of considerations bear on the choice of glucocorticoids. First, a preparation with minimal mineralocorticoid effect is usually picked to decrease sodium retention. Second, the long-term oral use of prednisone or a similar drug, with an intermediate half-life and relatively weak steroid-receptor affinity, may reduce side effects. Long-term use of drugs like dexamethasone, which has a longer half-life and high glucocorticoid-receptor affinity, may produce more side effects without any better therapeutic effects. Third, if a patient does not respond to cortisone or prednisone, the substitution of the biologically active form, cortisol or prednisolone, should be considered. In general, even in severe liver disease, substitution has not proved to be very important. Fourth, methylprednisolone is used for pulse therapy because of its low sodium-retaining characteristics and high potency.

EVALUATION BEFORE TREATMENT

To minimize potential problems, the baseline evaluation should include a personal and family history, with special attention to predisposition to diabetes, hypertension, hyperlipidemia, glaucoma, and associated diseases that could be affected by steroid therapy.

Baseline blood pressure and weight should be measured. If prolonged administration is anticipated, an eye examination and a purified protein derivative (PPD) test should be performed and an anergy panel applied. Examination for other covert infections should be based on history and physical examination. For instance, a stool culture for *Strongyloides* should be performed for immigrants from third-world countries and for Vietnam veterans.[30] If long-term administration of glucocorticoids is anticipated, baseline spinal bone-density measurement should be obtained by quantitative computed tomography (CT), dual-photon absorptiometry, or dual-energy X-ray absorptiometry (DEXA).[29]

MONITORING THERAPY

At follow-up visits, patients receiving chronic glucocorticoid therapy should be questioned about polyuria, polydipsia, abdominal pain, fevers, sleep disturbances, and psychological effects. There may be serious changes in effects on affect and even psychosis in patients treated with high doses of glucocorticoids. Weight and blood pressure should be monitored. Serum electrolytes, fasting blood sugar, and cholesterol and triglyceride levels should be measured on a regular basis. Stool should be examined for occult blood. Follow-up eye examinations should be performed with careful monitoring for the development of cataracts and glaucoma.

RISKS AND PRECAUTIONS

(Table 224-2)

DIET

Diet should be low in calories, fat, and sodium, and high in protein, potassium, and calcium. Protein intake is important to reduce steroid-induced nitrogen wasting.[31] Use of alcohol, coffee, and nicotine should be minimized. Exercise should be encouraged.

INFECTIONS

Patients with a positive PPD or Quantiferon TB Test should be given prophylaxis with isoniazid.[32] Anergic patients should have a baseline chest X-ray to search for evidence of previous tuberculosis. Fevers or focal findings should be evaluated with appropriate cultures and diagnostic approaches. Some advocate use of Bactrim prophylaxis (1 DS Bactrim 3 days a week) against *Pneumocystic carinii* when patients receive concomitant cytotoxic therapy.[26]

IMMUNIZATIONS

Immunization with live vaccines can be done if the duration of glucocorticoid use is less than 2 weeks at any dose, if the dose of glucocorticoid is <2 mg/kg or

TABLE 224-2
Preventive Measures for Chronic (≥3 months) Glucocorticoid Use

Side Effect	Preventative Measures
Hypertension	Blood pressure (baseline; repeat with each visit)
Weight gain	Weight (baseline; repeat with each visit)
Reactivation of infection	Purified protein derivative, anergy panel at baseline (can be done up to 12 days after starting prednisone) Hepatitis screen Consider *Pneumocystis carinii* pneumonia prophylaxis (Bactrim 1 DS three times a week)
Metabolic abnormalities	Electrolytes, lipids, glucose [baseline; repeat early after starting therapy; repeat annually; more frequent monitoring with known factors (e.g., diabetes, hyperlipidemias)]
Osteoporosis	Bone density (baseline; repeat annually is early bone prophylaxis done) Instruct about diet, exercise, other measures Calcium and vitamin D supplementation Start bisphosphonate for men, postmenopausal women Evaluate postmenopausal women for hormone replacement therapy Serum testosterone after treatment started in men; if low (<300 ng/mL), check prostate specific antigen, prostate examination before starting testosterone replacement
Eyes	
Cataracts	Slit-lamp examination (every 6–12 months)
Glaucoma	Intraocular pressure examination (at 1 month and every 6 months)
Peptic ulceration	In patients with two or more risk factors, consider prophylaxis with and H_2-antagonist or proton pump inhibitor
Suppression of hypothalamic-pituitary-adrenal axis	Single, early morning doses, preferably every other day Check 8:00 am serum cortisol before tapering prednisone <3 mg/day. If <10 g/dL, repeat every 1–2 months and maintain low prednisone dose until baseline cortisol adequate

20 mg/day of any duration, and if long-term alternate-day treatment with short-acting preparations is done. Immunization with live vaccines should not be done for at least 3 months after receiving high doses of glucocorticoids (>2 mg/kg or greater than 20 mg/day) for more than 2 weeks.[33]

GASTROINTESTINAL COMPLICATIONS

Although there is controversy about whether an increase in the incidence of peptic ulcer disease occurs in otherwise unaffected patients receiving glucocorticoids, there is almost a ninefold increase in patients taking both glucocorticoids and nonsteroidal anti-inflammatory agents.[32,34,35] In patients with two or more risk factors (such as those taking nonsteroidal anti-inflammatory medications, a previous history of peptic ulceration, advanced malignant disease, or a total dose of glucocorticoids >1,000 mg), prophylaxis may be considered. Prophylaxis can include antacids, H_2-receptor blockers (cimetidine, ranitidine, nizatidine, or famotidine with the evening meal), or proton pump inhibitors (Prilosec or Prevacid).

ADRENAL SUPPRESSION

Patients receiving daily glucocorticoid therapy for longer than 3–4 weeks must be assumed to have adrenal suppression that requires tapering of the glucocorticoids to allow for recovery of the HPA axis. Tapering is best performed by switching from a single daily dose to alternate-day doses, followed by a gradual reduction of the amount of the drug. The daily dose is first gradually tapered to 40 or 50 mg of prednisone. Then either the dose can be kept constant on one day and reduced on the alternate day by 5-mg decrements down to 5 mg/day, or, the steroid dose can be increased on one day and reduced by a similar amount on the alternate day. More studies are needed to determine optimal tapering schedules.[36]

After the prednisone dose is tapered to 5 mg on alternate days, the need for maintenance therapy must be assessed. The 8:00 am plasma cortisol level is measured 4 weeks after the 5-mg dose has been reached. The morning dose of prednisone is held until the plasma cortisol level is determined. If the plasma cortisol level is less than 10 µg/dL, the alternate-day prednisone dose should be decreased by 1 mg every 1–2 weeks to a maintenance dose of 2 mg/day. Then the 8:00 am plasma cortisol level should be rechecked every 2 months until it is greater than 10 µg/dL, at which point maintenance glucocorticoids can be terminated.[37] Recovery of the HPA axis can take longer than 9 months.[38] At that point and at any point when the patient is receiving tapering doses of steroids, a stress caused, for example, by trauma, surgery, diarrhea, or fever >38°C (101°F) can precipitate acute adrenal insufficiency related to an inadequate stress response. Patients should wear bracelets or carry cards indicating that they are receiving glucocorticoids. During such stressful situations, it is necessary to give high doses of glucocorticoids, generally 25–70 mg/day of prednisone or 100–300 mg/day of cortisol in divided doses.[39] Patients must be educated about the need for stress coverage.

The amount of glucocorticoids to give for coverage for surgery should probably be individualized to the severity of the operation. Minor operations lasting less than 1 hour are associated with, at most, 50 mg/day (12.5-mg prednisone) of cortisol in response to the surgery. Moderate-to-major surgeries are associated with the production of 75–200 mg/day of cortisol.[40,41] Thus, recent guidelines suggest that adrenally suppressed patients receive 25 mg of hydrocortisone equivalents for minor surgeries, 50–75 mg for moderate surgeries, and 100–150 mg for major surgery for 2–3 days, beginning when the patient is on call for surgery.[40] Only two randomized controlled trials have been done, and data is sparse, with one recent study suggesting even lower doses are adequate.[42,43]

In general, adrenal insufficiency resolves within 1 year of the termination of glucocorticoid therapy. An ACTH (cosyntropin) stimulation test may be performed after maintenance glucocorticoids are terminated to assess adrenal reserve. This test is performed in the office by determining a baseline cortisol level, giving an injection of 0.25 mg of cosyntropin, and measuring the serum cortisol level again 1 hour later.[37] The adrenal response is suppressed if the serum cortisol level fails to increase by at least 5 µg/dL to a stimulated value 60 minutes later of more than 20 µg/dL. If adequate adrenal response to stress is demonstrated, there is less concern about the endogenous cortisol response to stress.[26] However, such a response is not a guarantee of adequate adrenal reserves if severe stress occurs, and many physicians would choose routine stress coverage with glucocorticoids without performing an ACTH stimulation test.[44]

COMPLICATIONS

Complications associated with systemic glucocorticoid therapy (eBox 224-0.2 in online edition)[45,46] increase with higher doses, longer duration of therapy, and more frequent administration. However, osteoporosis and cataracts develop with alternate-day dosing, and avascular necrosis (AVN) can be seen after only short courses of glucocorticoids.

OSTEOPOROSIS

Osteoporosis occurs in 40% of individuals treated with systemic glucocorticoids; it is especially prominent in children, adolescents, and postmenopausal women.[47] Approximately one-third of patients have evidence of vertebral fractures after 5–10 years of glucocorticoid treatment, but this proportion is higher in postmenopausal women.[48,49] Bone loss occurs most rapidly in the first 6 months of glucocorticoid use, but continues at a slower rate after that, with loss of 3%–10% of bone per year in many patients.[47,50] Recent studies show that even low doses of prednisone

(2.5 mg per day) adversely affect bone and increase vertebral and hip fractures.[51,52] Some of the bone loss may be reversible after glucocorticoids are stopped, at least in the young.[53]

Glucocorticoids inhibit osteoblasts, increase calcium excretion by the kidney, decrease intestinal calcium absorption, and, concomitantly, increase bone resorption by osteoclasts. They also reduce estrogen and testosterone levels, which is likely to be an important factor in the pathogenesis of osteoporosis. Serum osteocalcin, a measure of osteoblast function, decreases within a day after a dosage regimen of as little as 10 mg of prednisone a day is begun; a dosage regimen of 7.5 mg of prednisone a day or more often causes significant bone loss and an increased fracture rate.[54–56] Trabecular bone is primarily affected, leading to painful vertebral fractures.

AVASCULAR NECROSIS

AVN is manifest by pain and limitation of motion in one or more joints. There is intraosseous hypertension, leading to bone ischemia and necrosis.[57] It is likely that intraosseous lipocyte hypertrophy causes this intraosseous hypertension in persons taking glucocorticoids. In addition, glucocorticoids induce apoptosis of osteoblasts, likely contributing to AVN. Underlying diseases, such as systemic lupus erythematosus (SLE), increase the likelihood of steroid-induced AVN.[58] Studies suggest that many patients who develop AVN have either thrombophilia or hypofibrinolysis, which leads to thrombotic occlusion of venous outflow from the bone, decreased arterial perfusion, and subsequent infarction of bone.[59]

ATHEROSCLEROSIS

Glucocorticoids enhance many risk factors that are associated with atherosclerosis, including arterial hypertension, insulin resistance, glucose intolerance, hyperlipidemia, and central obesity. It is thus not surprising that patients taking glucocorticoids have an increased risk of atherosclerosis.[60] Patients with untreated Cushing disease have a four times higher mortality rate from cardiovascular complications, including coronary artery disease, congestive heart failure, and cardiac stroke.[61] The risk factors for atherosclerosis persist for at least 5 years after normalization of the serum cortisol level in Cushing disease, and similar findings may be true in those treated with chronic glucocorticoids.[62]

SUPPRESSION OF THE HYPOTHALAMIC–PITUITARY–ADRENAL AXIS

The hypothalamic–pituitary–adrenal (HPA) axis is rapidly suppressed after the onset of glucocorticoid therapy. However, if therapy is limited to 1–3 weeks, the recovery of the HPA axis is rapid. Longer daily glucocorticoid therapy is associated with suppression of the HPA axis for up to 1 year after therapy is terminated.[38] Symptoms of adrenal suppression include lethargy, weakness, nausea, anorexia, fever, orthostatic hypotension, hypoglycemia, and weight loss.

There also exists a steroid withdrawal syndrome, in which patients experience symptoms of adrenal insufficiency despite having an apparently normal cortisol response to ACTH. Symptoms most commonly include anorexia, lethargy, malaise, nausea, weight loss, desquamation of the skin, headache, and fever. Less commonly, vomiting, myalgias, and arthralgias occur. These patients have adjusted to high levels of glucocorticoids, and symptoms disappear after the glucocorticoids are restarted. This problem can be treated by slower tapering of the glucocorticoids, often by 1 mg of prednisone every few weeks.[63]

PSYCHIATRIC EFFECTS

Mood and cognitive changes are dose dependent and can appear shortly after the start of glucocorticoids. Hypomania and mania are the most common symptoms early, but prolonged use is associated more frequently with depression. Antipsychotics, antiseizure medications, and antidepressant can help normalize mood changes, although there are not controlled trials.[64]

DRUG INTERACTIONS

Glucocorticoids are associated with a number of important drug interactions. Drugs such as barbiturates, phenytoin, and rifampin, which induce hepatic microsomal enzymes, may accelerate the metabolism of glucocorticoids.[65] Drugs such as cholestyramine, colestipol, and antacids, impair absorption of glucocorticoids. Glucocorticoids reduce the serum salicylate level and necessitate a higher dose of warfarin for anticoagulation.

IMMUNOLOGIC SIDE EFFECTS

Glucocorticoids impair delayed-type hypersensitivity reactions because of their inhibition of lymphocytes and monocytes. Prednisone at daily doses of 15 mg or more suppresses the response to tuberculin, although it takes an average of 13.6 days for oral prednisone at 40 mg/day to inhibit the response to tuberculin.[66] Thus, even in situations requiring immediate use of prednisone, it is possible to perform simultaneously a PPD test of tuberculin and an anergy panel. Overall, there is an increased incidence of infections attributable to both the glucocorticoids and the immunologic changes related to the underlying disease.[67]

CONCERNS DURING PREGNANCY AND LACTATION

Glucocorticoids cross the placenta, but they are not teratogenic. Exposed infants as well as breast-fed infants

of mothers receiving glucocorticoids should be monitored for adrenal and growth suppression. Based on animal experiments, there is some concern about the contribution of glucocorticoids to low-birth weight and childhood cognition.[68]

ISSUES SPECIFIC TO PEDIATRICS. In the pediatric population, glucocorticoids cause growth retardation and early osteoporosis.[69,70] Growth retardation is caused by a direct action on cell metabolism, effects on calcium and phosphorus metabolism, and a decrease in growth hormone secretion, with inhibition of bone matrix formation. Growth retardation is not prevented by alternate day GC regimens.[71] Recent studies show that human growth hormone replacement has a significant effect on growth, as well as a significant effect on lean body mass.[72]

Osteoporosis. Attention to the prevention of osteoporosis is becoming increasingly important as newer therapies that may deter bone loss become available. Calcium and vitamin D supplements, sex hormone replacement, a weight-bearing exercise program, and sodium restriction are suitable first-line therapies.[73,74] Calcium and vitamin D together, but not calcium alone, preserve bone mass in patients receiving long-term treatment with glucocorticoids at an average of 15 mg/day.[73,74] Patients taking glucocorticoids should be given elemental calcium, 1,500 mg/day, and vitamin D_2, 400 units twice daily. Activated forms (alfacalcidiol, 1 µg/day, or calcitriol, 0.5–1 µg/day) can be given, but more frequent monitoring is required for hypercalciuria and hypercalcemia. Patients with a history of renal stones should not receive supplemental calcium and vitamin D.[75,76] For patients receiving calcium and vitamin D_2, calcium levels should be measured in serum and in 24-hour urine collections every 3 months or whenever glucocorticoid doses are substantially altered. If the urinary calcium level exceeds 250–350 mg/dL, the addition of 12.5–25 mg/day of thiazide will reduce the renal excretion of calcium.[77] If thiazide is not added, calcium and vitamin D supplementation should be adjusted.

Atherosclerosis. Blood pressure, serum lipids, and glucose levels should be measured serially. Abnormalities should be treated with dietary manipulation and medication as necessary. Patients who smoke should be encouraged to stop. Female sex hormones protect against the development of atherosclerosis, and thus HRT for postmenopausal women on glucocorticoids makes sense. However, recent data suggest that women with established atherosclerosis actually do worse with HRT, and there was a 58% increase in coronary heart disease events in the first year after myocardial infarction in patients treated with an estrogen/progestin combination.[80] If patients develop increased levels of cholesterol or triglycerides while taking glucocorticoids, there are now good approaches to treatment, particularly with some of the newer statins, that impact on the development of atherosclerosis and prevent myocardial infarctions. Patients should be treated or referred for treatment on the basis of guidelines that emphasize the importance of assessing the risk of atherosclerosis. These guidelines recommend treatment when patients have low-density lipoprotein (LDL) cholesterol levels greater than 160 mg/dL and fewer than two coronary heart disease risk factors (high LDL cholesterol, smoking, hypertension, diabetes, male sex, family history of premature heart disease), LDL cholesterol levels greater than 130 mg/dL with two or more additional risk factors for heart disease, and LDL cholesterol levels greater than 100 mg/dL for patients with established coronary artery disease.[120] High-density lipoprotein (HDL) cholesterol levels lower than 35 mg/dL independently predict increased coronary mortality rates in men and should be taken into account in therapeutic decisions. Several trials have demonstrated reduction in both coronary heart disease and total mortality rates with statin therapy.[121–123] Patients should supplement the diet with folate and B_6 to control any elevations in homocysteine.

Avascular Necrosis. Early detection is important because early intervention may prevent progression to degenerative joint disease requiring joint replacement. Twenty percent of patients with AVN have normal X-rays. Bone scan and magnetic resonance imaging (MRI) are more sensitive techniques for evaluating AVN. Patients should be regularly questioned about pain and limitation of motion of joints. If abnormalities develop, an X-ray, bone scan, or MRI should be ordered. If imaging shows AVN, an orthopedic surgeon skilled in early intervention with core decompression may be able to halt progression of the disease. Patients with AVN have an increased risk that other joints will be affected. The progression of AVN to destructive joint disease may require joint replacement surgery.[124]

KEY REFERENCES

Full reference list available at www.DIGM8.com

DVD contains references and additional content

8. Rhen T, Cidlowski JA: Antiinflammatory action of glucocorticoids—New mechanisms for old drugs. *N Engl J Med* **353**:1711, 2005
36. Richter B et al: Glucocorticoid withdrawal schemes in chronic medical disorders. A systematic review. *Endocrinol Metab Clin North Am* **31**:751, 2006
43. Yong SL et al: Supplemental perioperative steroids for surgical patients with adrenal insufficiency. *Cochrane Database Syst Rev* (4):CD005367, 2009
51. Ton FN et al: Effects of low-dose prednisone on bone metabolism. *JBone Miner Res* **20**:464, 2005
72. Grote FK et al: Growth hormone treatment in children with rheumatic disease, corticosteroid induced growth retardation, and osteopenia. *Arch Dis Child* **91**(1):56, 2006
75. de Nijs RN et al: Prevention and treatment of glucocorticoid-induced osteoporosis with active vitamin D3 analogues: A review with meta-analysis of randomized controlled trials including organ transplantation studies. *Osteoporos Int* **15**:589, 2004

Chapter 225 :: Dapsone

:: Joni G. Sago & Russell P. Hall III

DAPSONE AT A GLANCE

- Dapsone (4,4′-diaminodiphenylsulfone) is classified as sulfonamide but has unique pharmacologic properties.
- Diseases with consistent response to dapsone are dermatitis herpetiformis, erythema elevatum diutinum, linear immunoglobulin A dermatosis/chronic bullous disease of childhood and bullous eruption of systemic lupus erythematosus.
- Diseases with sporadic response to dapsone encompass a wide spectrum and are as diverse as collagen vascular/autoimmune diseases and acne. In these diseases, dapsone can be used as a corticosteroid sparing agent.
- A unifying feature of responsive diseases is neutrophilic and eosinophilic granulocytes.
- Dapsone is also effective in certain infections such as leprosy, actinomycetoma, or rhinosporidiosis.
- Adverse effects are hemolysis and methemoglobulinemia. Glucose-6-phosphate dehydrogenase (G6PD) level should be obtained before beginning dapsone treatment. Dapsone should only be given with great caution to patients with G6PD deficiency.
- Other adverse effects are neuropathy, a mononucleosis-like hypersensitivity syndrome termed the *sulfone syndrome*, and agranulocytosis.

MECHANISM OF ACTION

Dapsone's interference with the folate biosynthetic pathway accounts for its antibiotic effect and it is still sometimes used as an antibiotic in pneumocystis pneumonia prophylaxis (PCP) and in combinations for treatment of leprosy and malaria. However, dapsone is used in dermatology for its anti-inflammatory effect, the mechanisms of which are still incompletely characterized. Dapsone inhibits migration of neutrophils to areas of inflammation by inhibiting neutrophil chemotaxis to the chemoattractant signals F-met-leu-phe[1,2] and leukotriene B_4 (LTB_4).[3–5] In addition to this effect on neutrophil migration, dapsone also inhibits the adherence of neutrophils to skin-localized IgA[6] and endothelium.[7] Additionally, dapsone has been shown to inhibit the release of inflammatory mediators including interleukin-8 (IL-8),[8] PGD_2, and tumor necrosis factor-α (TNF-α).[9] Finally, dapsone has been shown to inhibit the myeloperoxidase H_2O_2-halide-mediated cytotoxic system,[10–11] perhaps by inhibiting the calcium flux necessary for these events.[12] Myeloperoxidase is the enzyme in the azurophilic granules of neutrophils and in the lysosomes of monocytes that catalyzes the conversion of hydrogen peroxide and chloride ions into hypochlorous acid, a potent oxidant that causes cell damage.

PHARMACOLOGY

Figure 225-1 shows the chemical structure of dapsone [4,4′-diaminodiphenylsulfone].[13,14] Although dapsone is classified as a sulfonamide, cross-reactions occur in only 7%–22% of sulfa-allergic patients. They are usually mild and do not necessitate stopping dapsone.[15,16] If side effects are substantial, sulfapyridine may be tried. Sulfapyridine is thought to have similar mechanisms of action although with a reduced activity level and a lower incidence of toxicity. However, in the United States, it is available only on a compassionate-use basis from the manufacturer.

Dapsone tablets are available in 25- and 100-mg sizes; therapeutic doses for various conditions range from 25 mg to approximately 400 mg. Dapsone is well absorbed from the gut with peak levels being reached 2–6 hours after a single dose. The steady-state half-life, however, is quite long (approximately 30 hours) due to enterohepatic recirculation.[17] This allows for once-daily dosing and explains the utility of activated charcoal in reducing drug levels during accidental or intentional overdose.[18] Dapsone and its metabolites

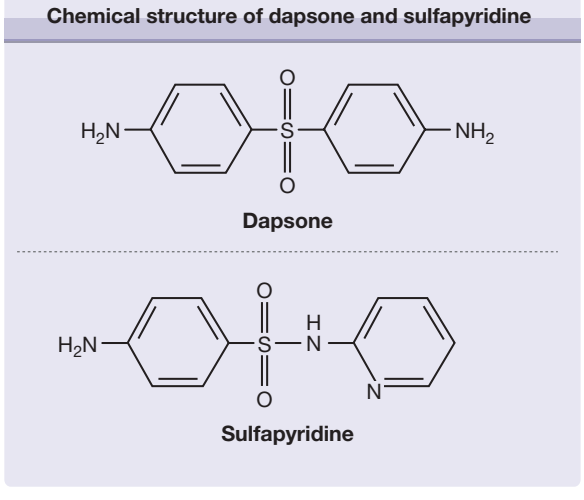

Figure 225-1 Chemical structure of dapsone and sulfapyridine.

may be transmitted through human milk, and hemolysis has occurred in nursing infants.[19–21] No teratogenicity has been observed, although no controlled studies have been performed in humans, and it is classified as pregnancy category C.[22,23]

Topical dapsone in a 5% gel formulation was approved in 2005 for acne vulgaris.[24,25] Twice daily application on up to 22% of subjects' body surface area resulted in systemic levels of dapsone and its metabolites that were 100-fold less than oral dapsone at a therapeutic dose. There was no hemolytic anemia or methemoglobinemia, even in patients who were glucose-6-phosphate dehydrogenase (G6PD) deficient.[26–29] Therefore, in 2008, the US Food and Drug Administration removed the requirement for pretreatment G6PD testing.

Dapsone is metabolized in the liver. The two major metabolic pathways involve acetylation[30,31] and *N*-hydroxylation.[32–34] Dapsone is acetylated polymorphically, i.e., some patients rapidly acetylate dapsone to monoacetyldapsone (MADDS) whereas in others, this process occurs slowly. However, in all patients, MADDS is rapidly deacetylated. Thus, equilibrium between MADDS and dapsone is quickly reached and sustained. Dapsone's efficacy, half-life, and toxicities appear unrelated to the rate of acetylation and checking acetylator phenotype is unnecessary prior to use of dapsone.

The most clinically significant metabolic pathway involves hydroxylation of one of the amino groups by cytochrome 2C19,[32] 3A4, and, to a lesser extent, 2C9 and 2C8[33] to form dapsone hydroxylamine. Dapsone hydroxylamine is a potent oxidant that is important in the development of methemoglobinemia, hemolysis and liver injury (see Section "Risks and Precautions").[34–37] Dapsone hydroxylamine is reduced back to the parent compound dapsone by methemoglobin reductase in erythrocytes and cytochrome b_5 reductase and cytochrome P2D in hepatocytes. Reduced levels of these enzymes have been detected in dapsone-treated patients who developed symptomatic methemoglobinemia; genetic variability in detoxifying enzymes may therefore explain patients' differential development of this side effect.[38] Recent studies have also shown that dapsone can be hydroxylated by keratinocytes themselves. These hydroxylated metabolites then form drug-protein adducts that generate stress signals, which are delivered to draining lymph nodes. This may be important in the pathogenesis of some of the cutaneous side effects of dapsone.[39–41]

Although extensively hepatically metabolized, a small study of dapsone administration in cirrhotic patients demonstrated no need for dose adjustment.[42] However, caution is still recommended when using dapsone in patients with hepatic insufficiency.

Probenecid[43] and trimethoprim[44] have been shown to lead to higher blood levels of dapsone; exercise caution when using them concurrently. Conversely, rifampicin reduces dapsone blood levels by upregulating the P_{450} system.[45] Interestingly, cimetidine and omeprazole, which block *N*-hydroxylation of dapsone, have been used to mitigate some of the side effects of dapsone. Cimetidine dosed 400 mg three times a day has reduced methemoglobin levels in reported patients by 27%–60%.[47–50]

Dapsone and its metabolites are excreted by the kidneys, hence the recommendation to check a pretreatment creatinine and avoid dapsone in patients with significant renal impairment.

INDICATIONS

Since its introduction into clinical medicine, dapsone has had therapeutic trials and anecdotal successes in a multitude of diseases (see Box 225-1). However, there are only a few conditions for which dapsone is considered the drug of choice. These are: dermatitis herpetiformis,[51,52] erythema elevatum diutinum,[53,54] linear IgA dermatosis/chronic bullous dermatosis of childhood,[55–58] and the bullous eruption of systemic lupus erythematosus.[59,60] Patients with these disorders achieve a clinical response within 24–48 hours and their condition flares over the same time course with drug withdrawal.

Other noninfectious conditions in which dapsone has found sporadic success span the spectrum of dermatologic disease (see Box 225-1).[60–135] As a unifying feature, most of these diseases have granulocytes (neutrophils or eosinophils) as the predominant infiltrating cell, especially early in the pathologic process. The response to dapsone therapy is not as rapid, regular, or predictable in any of these diseases. However, dapsone may have a role as a second-line or steroid-sparing agent. Trials may need to last 3–6 months to ascertain effect.

A therapeutic clinical response to dapsone can usually be seen at doses ranging from 25–200 mg per day. Rarely, patients may require 300 mg per day before a response is seen. The initial dosage chosen should be between 50–100 mg per day in order to minimize potential pharmacologic adverse effects. If a therapeutic trial of dapsone is successful, the dose of dapsone should be decreased to a point at which lesions recur to be sure that the improvement was indeed due to dapsone and that there is a continuing need for the drug. An ongoing effort to reduce the dose of dapsone to the lowest effective dose is an important means to minimize potential adverse effects.

Topical dapsone (5% gel) is FDA approved for acne vulgaris in adults[24–29] and adolescents[61] down to age 12. It has demonstrated low rates of irritation and erythema and in clinical trials resulted in a mean total lesion count reduction of between 39% and 49%.[24,27,29,61] Greater activity has been noted for inflammatory than noninflammatory lesions. It can be used in conjunction with other acne medications, including adapalene and benzoyl peroxide gel[62]; however, if topical dapsone is used at the same time as benzoyl peroxide, a chemical reaction causes it to turn a yellow-orange that is washable from skin but may stain clothing.[63]

RISKS AND PRECAUTIONS

Dapsone therapy, although generally well tolerated, has important pharmacologic and idiosyncratic side effects. The pharmacologic side effects—hemolysis and methemoglobinemia—develop to some degree in all treated patients in a dose-dependent fashion.[136] These adverse effects are caused by the hydroxylated

BOX 225-1 THERAPEUTIC INDICATIONS FOR DAPSONE

FIRST LINE (CONSISTENT RESPONSE SEEN IN 24–48 HOURS)

- Dermatitis herpetiformis
- Erythema elevatum diutinum
- Linear IgA dermatosis/chronic bullous dermatosis of childhood, idiopathic or drug-induced
- Bullous SLE

SECOND LINE (OFTEN USED IN COMBINATION)

- Autoimmune blistering diseases
  - Pemphigus (foliaceus, vulgaris, and IgA variants)
  - Bullous pemphigoid, especially in children
  - Epidermolysis bullosa acquisita, especially in children
  - Mucous membrane pemphigoid
  - Lichen planus pemphigoides, especially in children
- Neutrophilic dermatoses
  - Subcorneal pustular dermatosis (Sneddon-Wilkenson), both idiopathic and drug-induced
  - Acute febrile neutrophilic dermatosis (Sweet syndrome)
  - Pyoderma gangrenosum
- Autoimmune diseases
  - Rheumatoid arthritis
  - Rheumatoid papules
  - Relapsing polychondritis
  - Subacute cutaneous lupus
  - Chronic cutaneous lupus
  - Lupus panniculitis
- Vasculitidies
  - Cutaneous polyarteritis nodosa (PAN)
  - Urticarial vasculitis
  - Henoch-Schönlein purpura (although reports suggest it is effective only for the cutaneous manifestations and does not prevent nephritis or relapse)
  - Chronic leukocytoclastic vasculitis without internal organ involvement
  - Behcet disease
- Acne and related conditions
  - Acne, including agminata and conglobata variants, although high required doses and availability of systemic retinoids have relegated dapsone to third line
  - Hidradenitis suppurativa
  - Granuloma faciale
  - Perifolliculitis capitis abscedens et suffodiens (dapsone with isotretinoin)
- Miscellaneous inflammatory conditions
  - Chronic idiopathic thrombocytopenic purpura (ITP)
  - Chronic urticaria
  - Aphthous stomatitis
  - Granuloma annulare
  - Psoriasis
  - Brown recluse spider envenomation
  - Mesotherapy complications, including granulomatous reaction and panniculitis
  - Melkersson-Rosenthal syndrome
  - Eosinophilic fasciitis
  - Alpha-1-antitrypsin deficiency-related panniculitis
  - Neutrophilic eccrine hidradenitis
  - Insect bite-like reaction in patient with leukemia and presumed immune dysregulation
  - Erythema multiforme
  - Rosai-Dorfman
  - Idiopathic angioedema
- Infectious diseases (details of treatment beyond the scope of this chapter)
  - Malaria
  - Leprosy
  - Leishmania
  - Nocardia
  - Pneumocystis prophylaxis

metabolite, dapsone hydroxylamine, which is a potent oxidant.[137–144] Within erythrocytes, dapsone hydroxylamine generates reactive oxygen species which oxidize oxyhemoglobin into methemoglobin. The oxidized hemoglobin becomes microscopically visible as Heinz bodies. These Heinz bodies and hydroxylated metabolite/cellular protein adducts may label the red blood cells as senescent, targeting them for removal by the spleen. Glutathione within the erythrocytes is responsible for reversing oxidative damage; however, production of glutathione is largely dependent on glucose-6-phosphatase dehydrogenase (G6PD). Patients with G6PD deficiency are less tolerant of pharmacologic oxidative stress and are at risk for substantial hemolysis. There are two types of G6PD deficiency that are screened for with the same laboratory assay: "A-type" G6PD deficiency occurs in African-Americans and is more mild than the type seen in patients of Mediterranean heritage.[145] G6PD deficiency should be ruled out before initiating therapy in all patients.[146] Hemolysis is more profound at the initiation of therapy and should be accompanied by a compensatory reticulocytosis. Patients with preexisting iron or B_{12}/folate deficiency may not be able to mount appropriate erythropoesis and are at greater risk for symptomatic drops in hemoglobin. Thus, baseline anemias should be worked up before starting dapsone. The frequency of symptomatic anemia is 10%,[147] but might be higher in certain populations such as solid organ allograft recepients (23%).[148,149] This higher rate of hemolysis may be due to the greater frequency of renal insufficiency in this patient population or a potential interaction with medicines such as sirolimus. If dapsone therapy is efficacious but hemolysis is limiting therapy,

coadministration of darbepoetin may allow continuation of drug at therapeutic doses.[150,151]

Methemoglobinemia is another predictable consequence of dapsone therapy, again due to dapsone hydroxylamine's generation of reactive oxygen species.[152–159] Methemoglobin is the form of hemoglobin in which the iron molecule is in the oxidized ferric (Fe^{3+}) state rather than in the ferrous state (Fe^{2+}). As such, the standard complete blood count will show the hemoglobin value as normal (or slightly low due to hemolysis) but the molecule itself is unable to carry oxygen or carbon dioxide.[154] The signs and symptoms of methemoglobinemia are those of poor oxygenation, including cyanosis, headache, shortness of breath, chest pain, and fatigue. And although some degree of methemoglobinemia occurs in most patients, symptomatic methemoglobinemia is rare. Symptoms usually occur with methemoglobin levels of 20%–30%.[158,159] Patients with an inability to tolerate decreased oxygen carrying capacity, such as those with preexisting cardiopulmonary disease or anemia, may develop symptoms at a lower percentage methemoglobin. Pulse oximetry is a reasonable screening test for methemoglobinemia, as a normal value excludes significant methemoglobin levels. However, an abnormal value must be followed up with a direct methemoglobin determination.[158–160] This is because the pulse oximeter measures light absorbance at two wavelengths, 660 and 940 nm, for oxy- and deoxyhemoglobin, respectively. It calculates the oxygen saturation via the ratio of light absorbance. In the presence of a dyshemoglobin such as methemoglobin, carboxyhemoglobin, or inherited abnormal hemoglobins such as hemoglobin Rothchild, this method is not accurate in determining oxygen saturation. Clinical cyanosis is a very insensitive indicator of methemoglobinemia and should not be relied upon. Since methemoglobin does not carry oxygen, supplemental oxygen generates little improvement until the methemoglobin level is reduced. As mentioned previously, cimetidine, which blocks the hydroxylation of dapsone, has been used intentionally to lower methemoglobin levels in dapsone-treated patients by 27%–60%.[46–50] Lipoic acid, a dietary supplement with antioxidant properties, as also been shown in vitro to decrease methemoglobin formation and 90 mg daily of lipoic acid daily has been suggested for dapsone-treated patients.[161]

While G6PD-deficient individuals are at greater risk for hemolytic anemia and methemoglobinemia, the clinician should remember that these events are also seen in patients without G6PD deficiency.[162] Therefore, all patients should undergo regular monitoring. (See Section "Initiating and Monitoring of Dapsone Therapy.")

The other adverse effects of dapsone are idiosyncratic or allergic in nature.[163–206] Most common are rashes of various morphologies and nonspecific symptoms such as fatigue and headache (see Box 225-2). However, the clinician should be alert for rashes that present with fever and other systemic symptoms, as these may be manifestations of a serious hypersensitivity reaction called the sulfone syndrome.[163–179] Incidence of this syndrome ranges from 0.2%–5% of treated patients.[163–166] The sulfone syndrome is a drug-induced hypersensitivity syndrome like those seen with some anticonvulsants and other medications.[167–168] These syndromes are postulated to be due to drug-allergy-induced immunosuppression[39,40,167,168] leading to a reactivation of human herpesvirus 6 (HHV6) or other latent viruses such as CMV and EBV. They develop between 2 and 7 weeks after initiating the medication and inevitably include the triad of fever, rash, and hepatitis. The rash is most often an exfoliative dermatitis,[169] but maculopapular and Stevens–Johnson-like lesions have occurred. The hepatitis has a mixed hepatocellular and cholestatic picture with elevations in both transaminases[170–175] and alkaline phosphatase.[176] Features of the sulfone syndrome are listed in Table 225-1. Treatment of the sulfone syndrome involves prompt discontinuation of dapsone. Corticosteroids have proved helpful but doses up to 1g/day of methylprednisolone for 3 days may be required, followed by a prednisone taper over 4–6 weeks. It is the reactivation of HHV6 that is thought to cause the late flaring of rash, fever, and hepatitis that is characteristically

BOX 225-2 ADVERSE EFFECTS OF DAPSONE

- Pharmacologic effects
  - Hemolysis
  - Methemoglobinemia
- Sulfone syndrome (see Table 225-1)
- Cutaneous
  - Morbilliform eruptions
  - Erythema nodosum eruptions
  - Erythema multiforme
  - Exfoliative dermatitis
  - Stevens–Johnson syndrome/toxic epidermal necrolysis[139]
  - Photosensitivity (12 reports)[210–212]
- Gastrointestinal
  - Nausea
  - Anorexia
  - Gastric irritation
  - Cholestatic jaundice
  - Transamimitis
  - Hypoalbuminemia
- Neuropsychiatric
  - Psychosis
  - Peripheral neuropathy (almost always motor)
  - Acute myopia
- Hematologic
  - Leukopenia, including agranulocytosis
  - Pure red cell aplasia
  - Aplastic anemia
  - Hemophagocytic syndrome
- General
  - Fatigue
  - Headache

Data from Lang PG: Sulfones and sulfonamides in dermatology today. *J Am Acad Dermatol* **1**:479, 1979; Katz SI et al: Dermatitis herpetiformis: The skin and the gut. *Ann Intern Med* **93**:857, 1980; Alexander JO: Dermatitis herpetiformis. In: *Major Problems in Dermatology*, edited by Rook A. Philadelphia, Saunders, 1975, p. 291.

TABLE 225-1
Features of the Sulfone Syndrome

- General signs/symptoms
  - Fever (92%)
  - Lymphadenopathy (81%)
  - Pallor (77%)
  - Elevated ESR (92%)
  - Weakness
  - Sore throat
  - Headache
- Cutaneous signs
  - Rash (100%), most commonly maculopapular progressing to exfoliative (69%)
  - Itching (85%)
- Gastrointestinal system involvement
  - Liver dysfunction
    - Elevated transaminases (100%)
    - Elevated bilirubin (85%)
  - May be clinically jaundiced (81%)
  - Cholangitis
    - Hepatomegaly (73%)
    - Hypoalbuminemia (42%)
- May have coincident pedal edema (54%) or even anasarca
  - Pancreatitis
- Hematologic abnormalities
  - Leukocytosis (69%)
    - Atypical lymphocytosis
    - Leukemoid reaction
  - Anemia (46%)
- Other major organ system findings
  - Renal hypersensitivity vasculitis
    - May progress to renal failure
  - Hypersensitivity (eosinophilic) pneumonitis
    - Pleural effusions
  - Hypersensitivity myocarditis
    - With complete arterioventricular block
  - Thyrotoxicosis

seen in this class of drug reactions, necessitating such a long steroid taper.[167] Additionally, any other end-organ damage must be managed supportively (dialysis for renal failure,[165] diuretics for myocarditis,[163] etc.) Plasma exchange has also been successfully used in a case where tapering of steroids led to recrudescence of symptoms.[179] Rechallenge with dapsone followed resolution of the sulfone syndrome is contraindicated as reinitiation of drug can produce severe symptoms within 2 to 6 hours.

The other reported side effects of dapsone are rare. These include various gastrointestinal complaints such as nausea, stomach irritation, and abnormalities in liver function tests[180–181] in the absence of the sulfone syndrome. Also reported are varied neurologic side effects, including a distal motor neuropathy, most often without a sensory component.[182–184] This is reversible with dose decrease or discontinuation. Checking a patient's distal motor strength at follow-up visits may alert the clinician to its development. Other neurologic side effects include the induction of acute psychosis.[185–187] There is a single report of dapsone-induced acute myopia that was reversible with drug discontinuation[188] and one report of anterior ischemic optic neuropathy.[189]

Agranulocytosis is another rare, idiosyncratic side effect that has been estimated to occur in 0.2%–0.4% of treated patients.[136,146,162,190–195] If agranulocytosis occurs, its onset is almost always during the first 3 months of therapy. Although usually reversible within days when patients stop therapy, it may be fatal due to superseding infection. Symptoms of agranulocytosis often include fever, pharyngitis, dysphagia, and oral ulcerations.[136,146] Patients should be warned to seek medical care immediately if these symptoms develop, especially within the first three months. Recombinant granulocyte colony stimulating factor has been used to produce a more rapid resolution of agranulocytosis.[196] Individual case reports of other hematologic sequelae of dapsone include two cases of pure red cell aplasia[197] and a single case of hemophagocytic syndrome induced by dapsone.[198]

In the case of accidental or intentional overdose, the clinician should be prepared for significant hemolysis (which may be delayed by up to 9 days due to enterohepatic recirculation) and methemoglobinemia.[199–202] Massive intravascular hemolysis seen in dapsone overdose has been linked to optic ischemic injury.[203–205] Although dapsone is 50%–80% protein bound in the circulation, the unbound portion can be dialyzed off and repeated dialysis has been helpful in the case of overdose.[206] Because of dapsone's enterohepatic recirculation, administration of activated charcoal will reduce drug levels by removing drug from the gut. Intravenous methylene blue, 1% solution given 1–2 mg/kg slowly IV,[207,208] can be used to decrease the degree of methemoglobinemia. Methylene blue is a cofactor for methemoglobin reductase after first being reduced by cellular stores of NADPH to leukomethylene blue. G6PD-deficient patients should not be given methylene blue, as they may have insufficient NADPH and unreduced methylene blue is its own direct hemolytic agent. Ascorbic acid 1,000 mg intravenously every twelve hours has also been used in a case of overdose and certainly could be used until G6PD status is reviewed so that methylene blue can be administered. Ascorbic acid's effect is due to its ability to increase methemoglobin reductase activity.[200]

INITIATING AND MONITORING OF DAPSONE THERAPY

Before therapy with dapsone is commenced, a targeted history and physical examination to screen for significant preexisting cardiopulmonary disease (these patients might be poorly tolerant of anemia or methemoglobinemia) or peripheral neuropathy should be completed. Initial labs should include a complete blood cell count to determine baseline white blood cell count and hemoglobin. G6PD deficiency should be ruled out, as should significant hepatic or renal dysfunction. After therapy has begun, a white blood cell count with differential and hemoglobin levels should be obtained weekly for the first month and then twice a month during the next 2 months.[136,146] A drop in hemoglobin of 1–2 g/dL should be anticipated and, in the absence of symptoms, should not prompt drug discontinuation. Monitoring reticulocyte counts will also provide an estimation of the adequacy of compensation for hemolysis. A profoundly elevated reticulocyte count suggests that

erythropoiesis is at its maximum and that further dose increases are not likely to be well tolerated. Even during long-term therapy, complete blood cell counts should be obtained periodically. Checking methemoglobin levels is unnecessary in the absence of symptoms. Follow-up visits should include pulse oximetry (any abnormal value should be followed up with methemoglobin determination), checking distal muscle strength, peripheral reflexes and reminding patients to not alter their dosage without physician guidance (to limit their risk for dose-dependent methemoglobinemia and hemolysis). Patients should also be told to carry a medication card so that in event of an emergency, treating physicians will know they are on a drug with hemolytic and methemoglobin-generating potential. It is important that all patients be made aware of the potential clinical manifestations of adverse events. Especially during the first three months of therapy when the risk of agranulocytosis and the sulfone syndrome is highest, patients should be reminded to seek medical attention immediately for significant fever, pharyngitis, dysphagia, swollen lymph nodes, oral ulcerations, and rash.[136,146] Patients with diabetes should also be made aware that dapsone causes falsely low HgA1c values due to the accelerated RBC turnover; monitoring fructosamine levels avoids this potential confounder.[209] It might be suggested to patients who have mild symptoms of anemia or methemoglobinemia to take cimetidine 400 mg three times daily and lipoic acid 90 mg a day to see if these might ameliorate symptoms enough for dapsone administration to continue.[47–50,161]

KEY REFERENCES

Full reference list available at www.DIGM8.com

DVD contains references and additional content

16. Beumont MG et al: Safety of dapsone as *Pneumocystis carinii* pneumonia prophylaxis in human immunodeficiency virus-infected patients with allergy to trimethoprim/sulfamethoxazole. *Am J Med* **100**:611, 1996
17. Zuidema J, Hilbers-Modderman ESM, Merkus FWHM: Clinical pharmacokinetics of dapsone. *Clin Pharmacokinetics* **11**:299, 1986
46. Coleman MD et al: The use of cimetidine to reduce dapsone-dependent methaemoglobinaemia in dermatitis herpetiformis patients. *Br J Clin Pharmacol* **34**:244, 1992
142. Jollow DJ, Bradshaw TP, McMillan DC: Dapsone-induced hemolytic anemia. *Drug Metab Rev* **27**:107, 1995
171. Prussick R, Shear NH: Dapsone hypersensitivity syndrome. *J Am Acad Dermatol* **35**:346, 1996
184. Daneshmend TK: The neurotoxicity of dapsone. *Adv Drug React Ac Pois Rev* **3**:43, 1984
190. Hornsten P, Keisu M, Wiholm BE: The incidence of agranulocytosis during treatment of dermatitis herpetiformis with dapsone as reported in Sweden, 1972 through 1988. *Arch Dermatol* **126**:919, 1990
209. Froud T et al: Dapsone-induced artifactual A1c reduction in islet transplant recipients. *Transplanation* **83**(6): 824-825, 2007

Chapter 226 :: Aminoquinolines

:: Susannah E. McClain, Jeffrey R. LaDuca, & Anthony A. Gaspari

AMINOQUINOLINES AT A GLANCE

- Aminoquinolines have been used in clinical medicine for more than a century, initially as antimalarial compounds.
- Multiple mechanisms of action, particularly impaired lysosomal acidification by antigen presenting cells, inhibition of natural killer and T-cell activation, and inhibition of lipid mediators of inflammation.
- Propensity for melanin pigment, absorb ultraviolet light, and exhibit photoprotective properties against ultraviolet-mediated injury of the skin.
- Aminoquinolines used to treat dermatologic conditions include hydroxychloroquine, chloroquine, and quinacrine.
- Hydroxychloroquine is the most commonly used aminoquinoline for skin conditions and is well studied for chronic cutaneous lupus erythematosus.
- Other aminoquinoline-responsive conditions: porphyria cutanea tarda, polymorphous light eruption, cutaneous sarcoidosis, dermatomyositis, and other conditions.
- Laboratory monitoring is mandatory during aminoquinoline therapy to detect hematologic abnormalities (hemolysis and drug-induced cytopenias), liver injury, and ophthalmologic toxicity (retinopathy).
- Children are especially susceptible to aminoquinoline toxicities, and lower doses must be used than in adults.
- Drug interactions are possible, and cigarette smoking decreases efficacy of aminoquinolines by inducing cytochrome P_{450} enzymes.

Antimalarial compounds have been used to treat skin diseases for more than a century. Three compounds, chloroquine (CQ), hydroxychloroquine (HCQ), and quinacrine (QE), have been most studied. The 4-aminoquinolines are a family of compounds derived from quinine, a naturally occurring alkaloid originally procured from the South American cinchona bark tree.[1] CQ and HCQ, the principal members of this class of compounds, are the most often used for therapeutic use in dermatology. QE, classified as an acridine, has also been used in dermatologic therapy. Interestingly, the use of these medications for treatment and prophylaxis of malaria is waning due to increased resistance.

MECHANISM OF ACTION

The precise mechanisms by which antimalarial compounds exert their actions are still unknown. However, several discrete mechanisms for each compound have been determined. In the treatment of malaria, aminoquinolines concentrate in the *Plasmodium* digestive vacuole and prevent polymerization of toxic heme released during proteolysis of hemoglobin.[2] Mechanisms by which these compounds influence skin diseases are varied and include, among others, their effects on antigen presentation, cytokines, toll-like receptors, and prostaglandins.

CQ and HCQ are lipophilic weak bases that pass through plasma membranes in their protonated state, become trapped, and accumulate inside acidic vesicles such as lysosomes,[1,3,4] accounting for their effects in *Plasmodium*. HCQ induces signs of lysosomal and mitochondrial membrane permeabilization.[5] By raising intralysosomal pH from 4–6, acidic proteases become inactivated and subsequent proteolysis is inhibited. Subsequently, antigen processing and presentation by dendritic cells may be impaired because of an inability to digest these foreign antigens within the lysosomal compartment.[6] Additionally, CQ has been shown to disrupt antigenic peptide loading on class II MHC molecules and subsequent presentation to the opposing T cell.[1,7] Inhibition of calcium signaling within the T cell may be an additional mechanism.[8] Conversely, CQ has been more recently shown to enhance human $CD8^+$ T cell responses.[9] QE inhibits Na-K adenosine triphosphatase activity and stabilizes cell membranes.[10] It also concentrates in lysosomes. The effects are most appreciated in macrophages and phagocytic cells where phagocytosis and chemotaxis are impaired.[11,12] Additionally, cellular enzymes and receptors dependent on lysosomes for function or activation are also affected, thus altering cells' responsiveness to mitogenic stimuli.[3]

Antimalarials decrease T-cell release of interleukin (IL)-1, IL-6, tumor necrosis factor-α, and interferon-γ.[13,14] IL-1, IL-6, and tumor necrosis factor-α play a role in the hepatic production of acute-phase reactants.[15] Low concentrations of CQ and QE inhibit the pro-IL-6 stimulatory effect of cytosine-phosphorothiolated guanine-oligodeoxynucleotides on human peripheral blood mononuclear cells.[16,17] More recently, it has been found that CQ elevated the expression of B7–2 (CD86, a costimulatory molecule) and intercellular adhesion molecule-1 (CD54, an adhesion molecule) in peripheral mononuclear cells, thus increasing IL-10-producing cells.[18] CQ has also been implicated in the inhibition of natural killer cell activity, decreased production of IL-2 from activated lymphocytes, and alteration of antigen-antibody complexes. QE also inhibits natural killer cells and blocks the primary proliferative response of cytotoxic T cells to allogeneic non-T-cell antigens.[15] Last, the arachidonic acid pathway is affected by antimalarial compounds. CQ inhibits phospholipase A_2 and C.[15] QE also inhibits phospholipase A_2 production[19,20] and increases nitric oxide release.[21] Thus prostaglandin, leukotriene, bradykinin, and histamine levels can all be decreased. QE antagonizes the generation of superoxide anions.[22]

A novel mechanism of action of the antimalarials has recently been elucidated with respect to its inhibition of toll-like receptor (TLR) 9 family receptors.[1] TLRs are intracytoplasmic receptors whose activation of the innate immune system in response to microbial peptides induces a significant inflammatory response. Additionally, further research has highlighted the importance of the innate immune response underlying the pathogenesis of systemic lupus erythematosus (SLE).[23] Consequently, these TLRs who, as a class, are known as "pattern recognition receptors" (PRRs), have become a subject of intense investigation underlying the pathogenesis of SLE. It has recently been shown that host immune complexes containing DNA or RNA play an important role in activating endogenous TLRs (especially TLR-9 and TLR-7), thus leading to the eventual activation of the innate immune system, of which interferon alpha plays a crucial role.[24,25] Additionally, TLR-9 expression is strongly associated with SLE activity.[25] These specific nucleic acid binding TLRs bind their ligands in the lysosome, where an acidic environment promotes this binding.[26] As the antimalarial agents specifically target microsomes by disrupting endosomal maturation and changing the pH, they block the TLR interaction (TLR-3, -7, and -9) with nucleic acid ligands.[27] In vitro studies have identified that nanomolar concentrations of chloroquine specifically were potent inhibitors of IL-6 production by monocytes, an effect now known to be directly mediated by the inhibition of TLR-9.[1] Antigen presenting cells are the primary targets of these interactions, thus accounting for a clinically slower response, as they initiate and prime the subsequent immune reactions.[1] The 4-aminoquinolines have an affinity for melanin pigment. In the epidermis (as well as retina), they bind in high concentrations. In the skin, CQ absorbs ultraviolet (UV) light in a concentration-dependent manner.[28] There is an increase in minimal erythema doses (MEDs) to UVB in lupus patients after taking oral chloroquine for 3 months, theoretically resulting from the anti-inflammatory and/or photoprotective mechanisms of the drugs.[1,29] Topical CQ applied before UV irradiation protects against UVB- and UVA-induced erythema.[30] QE has also been shown to inhibit photodynamic actions.[31] It has been proposed that the beneficial effect of the HCQ and CQ in various photodermatoses may result from the ability of these drugs to enhance the protective early limb of the UV response.[32]

CQ and QE have been shown to bind cellular DNA by intercalation between base pairs, thus stabilizing the DNA.[33–35] RNA transcription and subsequent translation are inhibited. These may be the mechanisms by which these molecules affect lupus.[36]

Antimalarial compounds also exhibit a myriad of ancillary effects. HCQ has been shown to improve lipid profiles, specifically causing a 15%–20% reduction in serum total cholesterol, triglycerides, and LDL levels.[37] Both CQ and HCQ improve glucose profiles by decreasing insulin degradation[38,39] and inhibit platelet aggregation.[40] High doses of CQ may produce an antioxidant effect.[41] Through membrane stabilization, antimalarials can produce a local anesthetic effect.[3] In vitro, HCQ has been shown to induce apoptosis in B-chronic lymphocytic leukemia cells.[42] CQ, HCQ, and QE have all been shown to interfere with human immunodeficiency virus type 1, SARS coronavirus, and influenza replication and function possibly due to disruption of protein glycosylation.[43–46]

PHARMACOKINETICS

The molecular structures of CQ, HCQ, and QE are closely related (Fig. 226-1). CQ and HCQ are 4-aminoquinolines, with HCQ differing from CQ by the presence of a hydroxyl group at the end of the side chain.[1] The addition of a benzene ring classifies QE as an acridine. The pharmacokinetics and pharmacology of these compounds are similar, but importantly there is no cross reactivity between the aminoquinolines and QE (Table 226-1). All are bitter, water-soluble, and readily absorbed from the gastrointestinal tract with relatively good bioavailability, achieving peak concentrations within 8–12 hours. CQ and HCQ have large volumes of distribution (over 100 L/kg) and prolonged half-lives.[47] The volume of distribution for QE may be even larger than that of CQ and HCQ. QE is extensively bound to plasma proteins, whereas CQ and HCQ are only partially bound (60%).[48–50] The half-life of QE is substantially less than the other compounds.[50] CQ is metabolized (dealkylated) in the liver by P_{450} enzymes into two active metabolites, desethylchloroquine and bisdesethylchloroquine.[51] The metabolic fate of QE is less certain. CQ and its metabolites are stored in relatively high concentrations in the liver, spleen, lungs, adrenals, and kidneys with the highest concentration found in melanin-containing cells of the retina and skin.[52] Approximately 50% of CQ is eliminated by the kidneys unchanged.[48] HCQ is also metabolized in the liver (*N*-desethylated) into three chief metabolites: (1) desethylhydroxychloroquine, (2) desethylchloroquine, and (3) bisdesethylchloroquine.[47] The parent compound and metabolites are taken up by lysosomes and concentrated in lysosome-rich tissues. Renal clearance accounts for approximately 15%–25% of the total clearance.[53] The renal excretion of CQ, HCQ, and QE can be enhanced with acidification of the urine.[54] QE is excreted in urine, bile, sweat, and saliva.[50] Renal excretion only accounts for approximately 11% of its clearance. The highest tissue concentrations of QE are found in the liver and spleen.[52] Equivalent doses of these

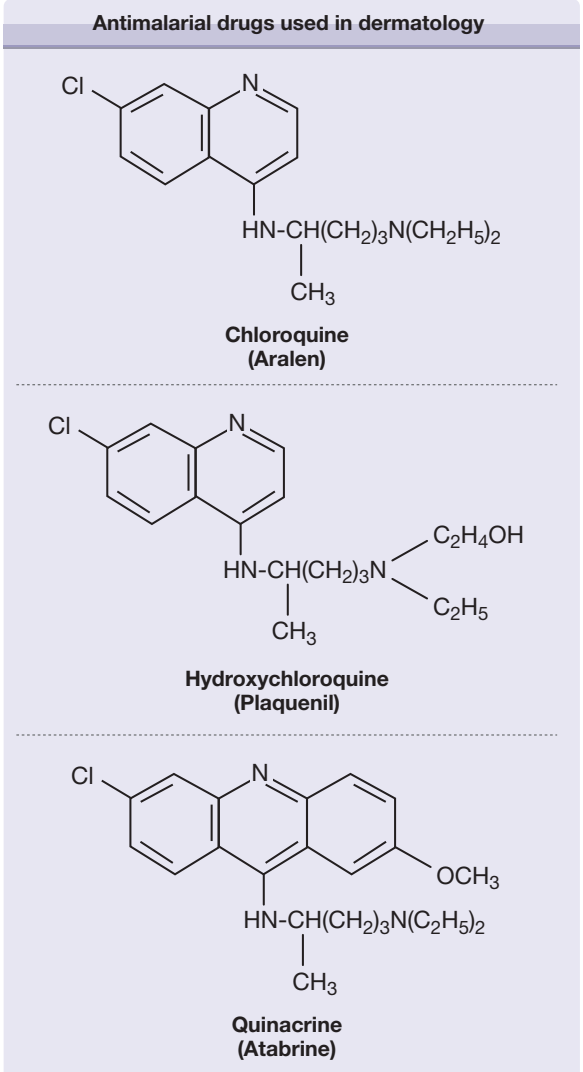

Figure 226-1 Antimalarial drugs used in dermatology.

compounds are 250 mg of CQ, 400 mg of HCQ, and 100 mg of QE. Smoking may alter the pharmacokinetics of antimalarial compounds, as clinical evidence of decreased efficacy of these medications in smokers has been documented.[55] Decreased absorption, increased plasma clearance, or induction of the cytochrome P_{450} system may be mechanisms by which smoking alters the metabolism of these compounds.[56]

A recent study has highlighted the relationship between whole blood concentrations of HCQ and disease activity in SLE patients.[57] Results of whole blood levels in 143 SLE patients who had received 6 months of HCQ at a dose of 400 mg/day demonstrated large variability in blood concentrations (possibly due to compliance). The mean concentration of patients with inactive disease was 1,079 ng/mL compared with the mean level of patients with active disease, which was 694 ng/mL. Additionally, the authors found that a low blood level of HCQ was associated with disease exacerbation in the follow-up period. The conclusion was that whole drug concentrations of HCQ should

TABLE 226-1
Pharmacology and Pharmacokinetics of Antimalarial Compounds

	Chloroquine (Aralen)	Hydroxychloroquine (Plaquenil)	Quinacrine (Atabrine)
Bioavailability	80%–90%	75%–100%	80%–100%
Peak levels	4–8 hours	~4 hours	8–12 hours
Protein binding	50%–65%	45%–50%	80%–90%
Volume of distribution	13,000–65,000 L	5,500–43,000 L	—
Clearance	130 mL/min (blood) 1,100 mL/min (plasma)	95 mL/min (blood) 700 mL/min (plasma)	— —
Half-life	20–60 days	40–50 days	5–14 days
Metabolism	Dealkylated (liver)	Deethylated (liver)	—
Metabolites	Desethylchloroquine Bisdesethylchloroquine	Desethylhydroxychloroquine Desethylchloroquine	None
Renal elimination	50%	15%–25%	11%
Storage	Liver, spleen, lungs, adrenals, pigmented tissues	Adrenals, pituitary, liver, spleen, leukocytes, pigmented tissues	Liver, spleen, lung, adrenals
Equivalent doses	250 mg	400 mg	100 mg

be maintained above 1,000 ng/mL, indicating a need for regular drug assaying and individualized dosing schedules to maintain this level.

Typical doses used in dermatology are 250–500 mg/day for CQ, 200–400 mg/day for HCQ, and 100–200 mg/day for QE. Evidence of efficacy is generally seen after 1–3 months of use, but it may take up to 3–6 months to achieve maximum clinical efficacy. After this time, the dose may be tapered to a minimum effective dose. Again, there is no cross-reactivity between QE and CQ and HCQ.[58] Thus, the use of QE in combination with HCQ and/or CQ has been deemed safe, and an adverse reaction to the 4-aminoquinolone group does not preclude the use of QE. In refractory skin conditions, addition of QE to HCQ or CQ has been deemed beneficial, and response may be seen in 6–8 weeks after the addition of QE.[59] If QE is added to CQ, the dose of CQ may need to be decreased to reduce potential for toxicity. Triquin, a combination of CQ (65 mg), HCQ (50 mg), and QE (25 mg) was used in the early 1970s. Nevertheless, the concomitant use of CQ and HCQ increases the risk for retinopathy (see Section "Complications"). Thus, this combination should be restricted to only severe cases. QE is not currently commercially available; production stopped in 1992. QE powder (veterinary grade, Sigma) can be formulated into capsules. Panorama Pharmacy in California, with an additional purification step, will prepare QE capsules.

INDICATIONS

The US Food and Drug Administration-approved indications for CQ, HCQ, and QE are limited. As is often seen in dermatology, these compounds are frequently used in an off-label manner. Treatment of malaria is the only indication shared by all three drugs. HCQ has the most labeled uses, including rheumatoid arthritis, discoid lupus, and systemic lupus erythematosus. Extraintestinal amebiasis is the only other approved use for CQ. QE had been approved for treatment of giardiasis when it was manufactured. Experience with HCQ in dermatology is more extensive. Its lower incidence of ocular toxicity (see Section "Complications") makes it a favored choice. In recalcitrant disease, CQ is often substituted with increased efficacy. The current difficulty in obtaining QE may account for the relatively fewer indications (Table 226-2).

CUTANEOUS LUPUS ERYTHEMATOSUS

(See Chapter 155)

Antimalarial drugs have been used for the cutaneous manifestations of lupus (acute cutaneous, subacute cutaneous, and chronic cutaneous LE) since the 1930s.[60] CQ and QE were found to be effective in the treatment of cutaneous lupus also during World War II.[61] A double-blind trial of HCQ for discoid lupus showed a 70% response rate and that it was more efficacious than placebo at 3 months and 1 year of treatment.[62] A review of 20 clinical trials involving the use of QE for cutaneous lupus showed an overall 73% response rate.[63] Antimalarials are typically used as steroid-sparing agents in patients whose symptoms cannot be controlled by topical steroids and sun protection. Widespread cutaneous lesions, hypertrophic and verrucous lesions,

TABLE 226-2
Uses of Antimalarial Agents

Hydroxychloroquine (Plaquenil)	Chloroquine (Aralen)	Quinacrine (Atabrine)
■ Malaria[a] ■ Rheumatoid arthritis[a] ■ Discoid lupus[a] ■ Systemic lupus erythematosus[a] ■ Juvenile arthritis ■ Sarcoid and associated hypercalcemia ■ Porphyria cutanea tarda ■ Chronic cutaneous vasculitis ■ Solar urticaria ■ Psoriatic arthritis ■ Lymphocytic infiltrates ■ Panniculitis ■ Cutaneous features of dermatomyositis ■ Oral lichen planus ■ Reticular erythematous mucinosis ■ Pemphigus foliaceus ■ Generalized granuloma annulare ■ Generalized eruptive histiocytosis ■ Atopic dermatitis ■ Localized scleroderma ■ Sjögren syndrome ■ Multicentric reticulohistiocytosis ■ Chronic graft-versus-host disease ■ HIV	■ Malaria[a] ■ Extraintestinal amebiasis[a] ■ Rheumatoid arthritis ■ Discoid lupus ■ Systemic lupus erythematosus ■ Juvenile arthritis ■ Polymorphous light eruption ■ Porphyria cutanea tarda ■ Chronic cutaneous vasculitis ■ Solar urticaria ■ Psoriatic arthritis ■ Lymphocytic infiltrates ■ Panniculitis ■ Necrobiosis lipoidica diabeticorum ■ HIV	■ Malaria[a] ■ Giardiasis[a] ■ Discoid lupus ■ Systemic lupus erythematosus ■ Intrapleurally for prevention of recurrent pneumothorax ■ Polymorphous light eruption ■ Nonsurgical female sterilization ■ Panniculitis ■ HIV

HIV = human immunodeficiency virus.
[a]US Food and Drug Administration approved.

and longstanding discoid lesions do not respond as well. Systemic symptoms such as fever, renal, or hematologic abnormalities seen in systemic lupus erythematosus typically do not respond to antimalarial therapy, but fatigue, arthralgias, myalgias, serositis, and mucosal ulcerations do respond to therapy.[64] In addition, antimalarials have effectively treated nonspecific cutaneous manifestations of LE, such as mucosal ulcerations, calcinosis cutis, lupus panniculitis, and photosensitivity.[65] Lupus panniculitis specifically has been reported to respond well to antimalarial therapy, with 23 out of 33 patients in one study demonstrating clinical improvement.[66] The onset of action for antimalarial therapy is typically 4–8 weeks; after which time, one may consider adding or changing therapies. More rapid response may be seen with the addition of QE.[63] When HCQ is ineffective as a monotherapy, CQ may be more efficacious, but the combination of HCQ and CQ is generally avoided to prevent retinal toxicity. The use of QE alone or in combination with either HCQ or CQ has also been suggested as providing a response in recalcitrant patients. A recent report evaluating 34 patients unresponsive to HCQ therapy alone identified the majority of patients rapidly and significantly responded to the addition of QE to their therapeutic regimen.[67] Triquin, a combination of all three drugs, has also been used in cutaneous lupus erythematosus with success.

POLYMORPHOUS LIGHT ERUPTION

(See Chapter 91)

Polymorphous light eruption (PMLE) is an inflammatory reaction seen on sun-exposed skin. IL-1, -6, and -8 may play a role in the inflammatory process.[68] Chloroquines decrease IL-1 and -6 and release and absorb UVA light. Although generally not used as first-line treatments, these drugs have been used for PMLE for several years[69,70] and placebo-controlled trials have proven efficacy for this indication.[71] Two trials demonstrated increased sun tolerance and moderate clinical improvement identified by skin rash reduction, which was statistically significant.[1,72,73] Intermittent HCQ at doses of 200–400 mg/day prior to sun exposure can be effectively tried if photoavoidance and/or prophylactic UVB/UVA are not viable options. Topical sunscreens should also be used in conjunction with antimalarial therapy. In northern climates, discontinuation of therapy during winter months may decrease cumulative side effects of antimalarial therapy.

PORPHYRIA CUTANEA TARDA

(See Chapter 132)

The first reported case of CQ therapy for porphyria cutanea tarda (PCT) was published in 1957,[74] and its use

can lead to long-term remission.[1,75] Chloroquines inhibit porphyrin synthesis and mobilize lysosomal stores of porphyrins, allowing for the formation of water-soluble complexes, which are then excreted by the kidneys.[76] Although phlebotomy remains the primary treatment of choice for PCT, antimalarial therapy may be used in conjunction with phlebotomy or when phlebotomy is contraindicated or has previously been used without success. Hepatotoxicity is a concern, and liver enzymes should be followed closely during therapy. Headache, nausea, fever, elevated transaminases, and urinary excretion of porphyrins occur 3–4 days after initiation of therapy with CQ at 250 mg/day.[77] Prolonged remissions have been reported with short courses of high dose HCQ (250 mg three times daily), but high doses routinely lead to marked increases in liver transaminases.[78] Low-dose CQ therapy (125 mg twice weekly for 2 weeks followed by 250 mg twice weekly thereafter) gave a 94% response rate in one study of 53 patients.[79] Alternatively, HCQ used at 100 mg three times weekly for 1 month, then 200 mg three times weekly for 1 month, then advanced to 200 mg daily has been proposed.[80] These lower dosing schedules seem to alleviate the severe acute hepatotoxicity. A combination of phlebotomy before initiation of CQ therapy may also reduce the severity of hepatotoxicity.[81]

SARCOIDOSIS

(See Chapter 152)

Antimalarial therapy for cutaneous manifestation of sarcoidosis was first described nearly half a century ago. Original reports on the efficacy of antimalarials in the treatment of sarcoidosis demonstrated initial clinical improvements on treatment during a 6-month course, with little further improvement after 1 year, indicating the treatment was likely suppressive rather than curative.[82] Additionally, relapses off of these medications are common, further supporting the notion that these therapies are not curative.[82–87] The proposed mechanism of action relies on the antimalarials' capacity to block antigen processing and presentation to CD-4$^+$ T cells, thus inhibiting granuloma formation.[83,88] A 1996 review of the subject concluded that antimalarials were highly effective, with greater than 70% response rate.[89] Two to three mg/kg/day of HCQ has been reported as being effective in 12 of 17 patients treated.[90] CQ therapy initiated at 500 mg/day for 2 weeks, then a maintenance dose of 250 mg/day has been described as safe and effective.[91] Therapy may also be effective for associated hypercalcemia. Another granulomatous disease, generalized granuloma annulare, has also been reported to respond to HCQ.[1,92–94]

CUTANEOUS DERMATOMYOSITIS

(See Chapter 156)

Although the muscle disease in this condition often responds well to systemic corticosteroids, the cutaneous lesions are generally recalcitrant to this therapy. Cutaneous symptoms unresponsive to traditional therapies have been reported to respond well to antimalarial therapy. It is in these patients that antimalarial therapy be strongly considered, as well as in those patients with cutaneous involvement without any muscle involvement ("amyopathic dermatomyositis").[1] Monotherapy with either HCQ 200 mg bid (less than 6.5 mg/kg/day) or CQ 250 mg qd (less than 3.5 mg/kg/day) is often adequate to control skin manifestations. The addition of QE to either HCQ or CQ has been shown to be beneficial in patients who do not respond to a 4-aminoquinolone alone.[59]

ORAL LICHEN PLANUS

Because the lesions of oral LP are clinically indistinct from those of mucosal LE, an open trial enrolling oral LP patients was undertaken to assess their response to HQC.[95] Nine out of the ten enrollees exhibited a rapid, excellent response to therapy with 200–400 mg/day HQC, with a minority flaring after discontinuation of therapy (3 months). Although corticosteroids are the first-line therapy for this disorder, recalcitrant lesions may respond to antimalarial therapy.

CHRONIC ULCERATIVE STOMATITIS

There are only a handful of cases reported in the literature describing this rare disorder which occurs primarily in older female patients. Clinicopathologically, this disease mimics erosive lichen planus but is traditionally unresponsive to corticosteroid therapy. The cases reported, however, demonstrated a complete response to antimalarial therapy lasting for several months to years. These medications are now considered first-line therapy for this rare condition.[96]

MISCELLANEOUS

Antimalarials have been reported to be useful in cases of epidermolysis bullosa, eosinophilic fasciitis, atopic dermatitis, solar urticaria, scleroderma, urticarial vasculitis, and reticular erythematous mucinosis, and Sjögren syndrome.[1,96–101]

DOSING REGIMENS

Use of antimalarial compounds in dermatology is varied. Each disease state is treated differently with special concerns pertaining to the disease entity. As such, dosing for each condition is dependent on the underlying pathology. Usual starting doses for HCQ are between 200 and 400 mg/day. Equivalent dosing for CQ is 250–500 mg/day, and for QE, 100–200 mg/day. However, initiation of therapy and maintenance dosing may be different for each disease. Combination therapy with these medications also alters the dosing.

INITIATING THERAPY

Given the degree of variation among dermatoses potentially responsive to antimalarials, many principles govern the initiation of therapy. Of utmost importance is the establishment of the correct diagnosis through clinical, histologic, and serologic evaluations. Next, one must make the determination as to whether antimalarials have been shown efficacious in the diagnosed dermatosis (see Table 226-2). After an established diagnosis has been made, one should determine whether the patient is an appropriate candidate for antimalarial therapy based on comorbid conditions and medication interactions. A rigorous laboratory monitoring protocol must be established, as adverse hematologic and metabolic side effects have been reported with the use of these medications. Patients who are deficient in the glucose-6-phosphate dehydrogenase (G6PD) enzyme are more prone to a hemolytic anemia. Thus, baseline evaluation of G6PD enzyme, complete blood cell count, and serum chemistry panel should be performed before initiation of therapy in all patients. Ocular toxicity is a serious side effect associated with the use of HCQ and CQ, and baseline evaluation by an ophthalmologist is necessary. Slit-lamp assessment, fundoscopic examination, and assessment of visual acuity and fields should be included.

MONITORING THERAPY

Laboratory monitoring should include a complete blood count performed monthly for 3 months to evaluate for the presence of hemolytic (or, less commonly, aplastic) anemia. Thereafter, quarterly to semiannual complete blood counts should be obtained. A comprehensive metabolic panel should be checked monthly for 3 months, then every 4–6 months thereafter, paying special attention to the liver enzymes, particularly in those patients who are taking hepatotoxic medications and in those patients with porphyria. Quarterly to semiannual chemistries should be followed while on maintenance therapy.

Proposed guidelines for monitoring for the development of ocular toxicity vary widely in the literature. At baseline and on each follow-up visit, patients must be asked about any changes in visual acuity and simple screening tests for acuity may be sufficient. Should patients report changes in vision, an ophthalmologist referral is then appropriate. Current American Academy of Ophthalmology (AAO) screening guidelines recommend that patients be prescribed doses of hydroxychloroquine ≤6.5 mg/kg/day or chloroquine ≤3mg/kg/day.[102,103] Additionally, the guidelines divide patients into those who are "low risk" (receive lower dose for <5 years) and "high risk" (receive higher doses, have other risk factors such as high body fat level, concomitant kidney, liver, or retinal disease, or >60 years of age). Patients should have a baseline ophthalmologic examination within 1 year of beginning the medication, which includes a baseline slit-lamp, fundoscopic, visual field, and acuity examinations. The "low-risk" group requires no further testing (if they have a normal baseline evaluation) until the 5-year therapy mark has been reached; the "high-risk" group should have annual ophthalmologic examinations. After 5 years of continuous therapy, annual examinations are recommended because of the risk for ocular toxicity reported in patients on long-term therapy.[103]

COMPLICATIONS

Most side effects of antimalarial therapy are reversible (Box 226-1). Decreased dosing or drug withdrawal may completely alleviate a majority of side effects encountered with these drugs. Without proper monitoring, however, these drugs have the potential for serious and permanent side effects.[104]

Gastrointestinal complaints of anorexia, nausea, vomiting, diarrhea, and weight loss are the most commonly encountered side effects (10% for HCQ; 20% for CQ; 30% for QE).[105] Acute symptoms from high doses of CQ and HCQ include blurred vision, cardiovascular toxicities, hypotension, neurotoxicity, and respiratory or cardiac arrest.[48,49] In children, as little as 0.75 g of CQ can be fatal (2.25–3.0 g in adults).[106] Lethal doses of HCQ are considered to be in a similar range.[48,49] Several cases of overdose have been reported. Management of overdose consists of gastric lavage, ventilation, and inotropic support.[107–111] As little as one or two tablets of CQ or HCQ can be dangerous in children. Appropriate monitoring is necessary after accidental ingestion.[112] A lethal dose of QE has not been determined.

Patients with G6PD deficiencies are susceptible to CQ- and HCQ-induced hemolytic anemia, although rarely when taken in therapeutic ranges. Aplastic anemia with QE[113,114] and agranulocytosis with CQ or QE have also been reported. All of the antimalarials have reportedly caused severe, reversible leukopenia.[1]

Adverse cutaneous effects can be seen with antimalarial therapy. Exacerbation of preexisting psoriasis in as many as 18% of patients with psoriasis has been documented with the use of these medications.[115] CQ is responsible for most psoriatic flareups, while QE is more likely to induce exfoliative erythroderma. HCQ is much less likely to exacerbate psoriasis.[116]

In the general population, incidence of pruritus and rashes secondary to antimalarial use is reported to be 10%–20%.[117] Dose-related QE-induced drug eruptions were reported during World War II. One in 2,000 soldiers taking 100 mg daily reported an adverse reaction, whereas 1 in 600 soldiers taking 200 mg daily had an adverse reaction.[114] Lichenoid reactions accounted for approximately 20% of the cutaneous reactions in this series.

The antimalarials have a high affinity for melanin, which may account for the blue-black cutaneous discoloration in 10% to 30% of patients treated with these compounds for a prolonged course. The shins, face, hard palate, and nail beds are most commonly affected.[118,119] The discoloration may fade slowly over

BOX 226-1 RISKS AND PRECAUTIONS

- Possible side effects from antimalarial compounds
  - Gastrointestinal: anorexia, nausea, vomiting, diarrhea, weight loss, hepatotoxicity
  - Hematologic: hemolytic anemia (glucose-6-phosphate dehydrogenase deficiency), aplastic anemia, agranulocytosis, pancytopenia
  - Mucocutaneous: pigmentation—blue gray, yellow (quinacrine), rashes (urticaria, morbilliform, lichenoid, exfoliative dermatitis, acute generalized exanthematous pustulosis), pruritus, worsening psoriasis
  - Ophthalmologic: neuromuscular eye toxicity (diplopia, blurred vision, loss of accommodation), corneal deposits (halos around lights, photophobia), retinopathy (pre-maculopathy—reversible and true retinopathy—irreversible; not seen with quinacrine therapy)
  - Neuromuscular: nightmares, vertigo, tinnitus, nervousness, irritability, toxic psychosis, seizures, neuromyotoxicity, myasthenia-like syndrome, ototoxicity, rhabdomyolysis
  - High doses: cardiovascular toxicities, hypotension, neurotoxicity, respiratory or cardiac arrest, death
- Drug interactions
  - Penicillamine and digoxin levels may be increased with concurrent use of CQ or HCQ
  - Cyclosporin levels may be increased with use of CQ
  - Metoprolol levels may be increased with use of HCQ
  - Ampicillin bioavailability may be decreased when used with CQ
  - Antacids and kaolin may decrease gastrointestinal absorption of CQ
  - Cimetidine may increase CQ levels
  - Mefloquine used with CQ may increase risk of seizures
  - Smoking decreases efficacy of antimalarial drugs by inducing the cytochrome P_{450} system
- Special precautions
  - Dosing in children must consider weight to decrease risk of toxicity
  - Use in pregnancy is relatively contraindicated (congenital defects are rare)
  - Use in breastfeeding is relatively contraindicated (CQ and HCQ are excreted in breast milk)

CQ = chloroquine; HCQ = hydroxychloroquine.

months after the drug is discontinued. QE may cause an even more pronounced hyperpigmentation than that seen with CQ or HQC. Histopathological evaluation of lesional skin sections shows the presence of melanin granules and hemosiderin deposition within the dermis. More commonly, a dose-related yellowish staining occurs with QE and affects the skin, sclera, and bodily secretions. This discoloration also fades after drug withdrawal. Stevens-Johnson syndrome has also been reported in a patient treated with HCQ.[120]

Ocular toxicity is the most worrisome side effect of antimalarial therapy. Neuromuscular eye toxicity, corneal deposits, and potentially irreversible retinopathy can all occur. Blurred vision and reduction in accommodation power can occur from the depressive effect on ocular muscles during the initial weeks of therapy (transient and self-limited). CQ is deposited in the basal epithelium of the cornea. Deposition of HCQ can also occur but is less likely at therapeutic doses.[121] These depositions can be responsible for patient complaints of blurred vision, halos around lights, and photophobia upon initiating therapy.[122] The corneal deposits are dose related, reversible with cessation of therapy, and not a contraindication for continued therapy. CQ has an affinity for retinal pigment epithelium and can be stored there for years, even after discontinuation of therapy. Antimalarial-induced retinopathy can be reversible (premaculopathy) or irreversible (true retinopathy). Premaculopathy includes changes in visual fields or fundoscopic examination, not associated with vision loss. These changes may progress to irreversible disease if the offending drug is continued. True retinopathy is associated with bilateral, permanent visual field abnormalities. Risk of true retinopathy from antimalarial therapy has been studied and debated. It appears as though the risk is greater for CQ than HCQ.[121,123] Doses less than 3.0 mg/kg/day for CQ and less than 6.5 mg/kg/day for HCQ are believed to decrease the risk of a true retinopathy.[124] Higher doses and impaired renal function may increase the risk. The true risk of HCQ-induced retinopathy is felt to be quite rare. As such, the question of screening as a cost-effective measure is debated. A case of bull's eye maculopathy has been associated with QE therapy for malaria.[125]

Other, less likely side effects of antimalarial therapy include neurotoxicity (most commonly headaches and nightmares),[1] myotoxicity (myalgias, fatigue),[126] ototoxicity,[127,128] acute generalized exanthematous pustulosis,[129] cardiotoxicity (conduction disturbances, congestive heart failure),[57] and rhabdomyolysis.[130]

DRUG INTERACTIONS

There are several important medication interactions to consider when prescribing antimalarials. Most importantly, it is recommended that HCQ and CQ not be coadministered due to the potential for retinal toxicity. CQ or HCQ may increase penicillamine and digoxin levels when used simultaneously with these medications.[48,49] Cyclosporine levels may be increased by CQ.[48] Metoprolol levels may be increased with use of HCQ.[131] CQ may reduce the bioavailability of ampicillin.[48] Antacids and Kaolin may decrease the

GI absorption of CQ. A minimum of 4 hours should exist between administration of antacids and antimalarials.[48] Cimetidine may increase CQ levels,[48] increasing potential for other side effects. Concurrent use of CQ and mefloquine may increase the risk of seizures. CQ increases the risk of hepatotoxicity when administered with other hepatotoxic agents. Monitoring liver enzymes is recommended.[48] Finally, smoking induces the cytochrome P_{450} enzyme system and may alter the bioavailability of antimalarial therapy. Decreased efficacy of antimalarial therapy in smokers has been published.[132]

PEDIATRIC USE

CQ and HCQ have been used in the pediatric population.[133,134] However, concern over toxicity exists.[135,136] Antimalarials are now considered generally safe in children when treating rheumatic disorders, such as lupus erythematosus, dermatomyositis, juvenile rheumatoid arthritis, and morphea, as well as in panniculitis and PCT.[137] When the dose is appropriately adjusted for body weight, the risk for toxicity in children is felt to be no greater than for adults.

PREGNANCY

Use of antimalarial drugs in pregnancy is now generally accepted as safe. It is recognized that 4-aminoquinalines cross the placenta and accumulate in fetal tissues.[52] Congenital defects have been rarely reported with antimalarial drug use in pregnancy.[138] In one study of 27 pregnancies exposed to HCQ or CQ, no congenital anomalies were identified.[139] Another review of 33 lupus patients with 36 pregnancies exposed to HCQ reported no evidence of teratogenic effects.[140] Larger reviews in Britain and North America support the use of 4-aminoquinalines during pregnancy.[141–143] In addition, discontinuation of antimalarial therapy for the treatment of lupus may cause a significant flare-up of disease, which can be associated with prematurity, growth retardation, and increased fetal loss.[144–147] The safety of QE is less well documented.

BREASTFEEDING

Antimalarial use during breastfeeding is relatively contraindicated. CQ and HCQ are both excreted in breast milk, albeit in small amounts.[1,148] In the case of HCQ, infants are exposed to 2% of the maternal dose per kilogram per day and 1% of the maternal dose of CQ.[58] As the half-life is long and elimination slow, potential exists for accumulation of drug in the infant.[149]

KEY REFERENCES

Full reference list available at www.DIGM8.com

DVD contains references and additional content

1. Kalia S, Dutz JP: New concepts in antimalarial use and mode of action in dermatology. *Dermatol Ther* **20**:160-174, 2007
2. Sullivan DJ et al: On the molecular mechanism of chloroquine's antimalarial action. *Proc Natl Acad Sci* **93**:11865, 1996
3. Homewood CA et al: Lysosomes, pH and the antimalarial action of chloroquine. *Nature* **235**:50, 1972
4. Kaufmann AM, Krise JP: Lysosomal sequestration of amine-containing drugs: Analysis and therapeutic implications. *J Pharm Sci* **96**:729-746, 2007
5. Boya P et al. Mitochondrial membrane permeabilization is a critical step of lysosome-initiated apoptosis induced by hydroxychloroquine. *Oncogene* **22**:3927, 2003
6. Ohkuma S, Poole B: Fluorescence probe measurement of the intralysosomal pH in living cells and the perturbation of pH by various agents. *Proc Natl Acad Sci USA* **75**:3327-3331, 1978

84. Morse SI: The treatment of sarcoidosis with chloroquine. *Am J Med* **30**:779-784, 1961

89. Jones E, Callen J: Hydroxychloroquine is effective therapy for control of cutaneous sarcoidal granulomas. *J Am Acad Dermatol* **23**:487, 1990

117. Wintroub BU, Stern R: Cutaneous drug reactions. Pathogenesis and clinical classification. *J Am Acad Dermatol* **13**:167, 1985

120. Leckie MJ, Rees RG: Stevens-Johnson syndrome in association with hydroxychloroquine treatment for rheumatoid arthritis. *Rheumatology* **41**:473, 2002

Chapter 227 :: Cytotoxic and Antimetabolic Agents

:: Whitney A. High & James E. Fitzpatrick

CYTOTOXIC AND ANTIMETABOLIC AGENTS AT A GLANCE

- Cytotoxic and antimetabolic agents are used in dermatology to treat serious, life-threatening, and recalcitrant disease.
- Common agents used in dermatology include methotrexate, azathioprine, mycophenolate mofetil, thioguanine, hydroxyurea, cyclophosphamide, chlorambucil, and liposomal doxorubicin.
- Methotrexate is US Food and Drug Administration (FDA) approved for treatment of psoriasis and advanced mycosis fungoides, whereas cyclophosphamide is FDA approved for advanced mycosis fungoides only, and liposomal doxorubicin is approved for acquired immunodeficiency syndrome-related Kaposi sarcoma; other uses of the agent in this chapter occur on an "off-label" basis.
- Cytotoxic and antimetabolic agents act through inhibition and/or interruption of the cell cycle.
- Side effects and complications with these potentially dangerous medications are numerous, and close clinical follow-up and laboratory evaluation is necessary.
- Cytotoxic agents used in dermatology, as well as those initiated for other purposes, may yield distinctive cutaneous eruptions and cutaneous sequelae.

Cytotoxic and antimetabolic agents may be used to treat severe or refractory skin disease. The toxicities of such agents are significant and must be balanced against therapeutic advantage. In treating skin disease, most of these agents are utilized at immunomodulatory rather than cytotoxic dosages.

Cytotoxic and antimetabolic drugs modulate the behavior of inflammatory and other cells through inhibition of cell growth and development. The cell cycle represents a conceptual schema for the sequence of growth experienced by essentially all cells (see Chapter 46). The cycle begins with the G_1 phase, which is directed toward preparing the cellular apparatus for DNA synthesis. The S phase follows G_1 and is devoted to DNA synthesis. At the end of DNA synthesis, the G_2 phase occurs. The G_2 phase is followed by the M phase, or actual cell division. Some cells may also enter a resting state of indeterminate length, termed G_0. Specific cytotoxic drugs may be effective at different stages of the cell cycle.

The cytotoxic drugs commonly used in dermatology fall into two classes: (1) antimetabolites and (2) alkylating agents. Antimetabolites mimic natural molecules and are most active while DNA is being synthesized (S phase). Alkylating agents exert effect through physicochemical interactions with DNA, such as alkylation, cross-linking, and carbamylation. The effects of alkylating agents are generally independent of the cell cycle.

The immunosuppressive properties of cytotoxic agents (see also Chapter 233) provide benefit in immunologically mediated disease, yet these agents may predispose to infection as well. Potentially lethal infections may arise quickly in an immunosuppressed patient. Those placed on cytotoxic agents should be queried at each visit for symptoms of infection, such as fever, chills, sweating, shortness of breath, cough, headache, dysuria, and arthritis. Prompt reporting of symptoms should be encouraged.

ANTIMETABOLIC AGENTS

METHOTREXATE

Methotrexate remains one of the most frequently employed antimetabolic agents in dermatology. With appropriate monitoring, an impressive record of safety with methotrexate has accumulated. Concerns regarding use of methotrexate are best addressed through increased drug awareness, rational patient selection, appropriate laboratory monitoring, and, most recently, folate supplementation.

MECHANISM OF ACTION. Methotrexate (Fig. 227-1) is an analog of folate that competitively and irreversibly inhibits dihydrofolate reductase (Fig. 227-1). Methotrexate also partially inhibits thymidylate synthetase. Through inhibition of these enzymes, methotrexate decreases the availability of reduced folate and thymidylate necessary for RNA and DNA synthesis. Other inhibitors of folate metabolism, such as trimethoprim-sulfamethoxazole, may potentiate the toxicity of methotrexate (see Section "Drug Interactions").

Like folate itself, the activity of methotrexate is enhanced by glutamylation. Glutamylation also yields additional anti-inflammatory properties.[1] First, by inhibiting aminoimidazole carboxamide ribonucleoside transformylase, methotrexate-polyglutamate increases the local tissue concentration of adenosine, which has potent anti-inflammatory action. Second, by decreasing available tetrahydrofolate, methotrexate decreases the production of S-adenyl methionine, which also results in decreased inflammation.

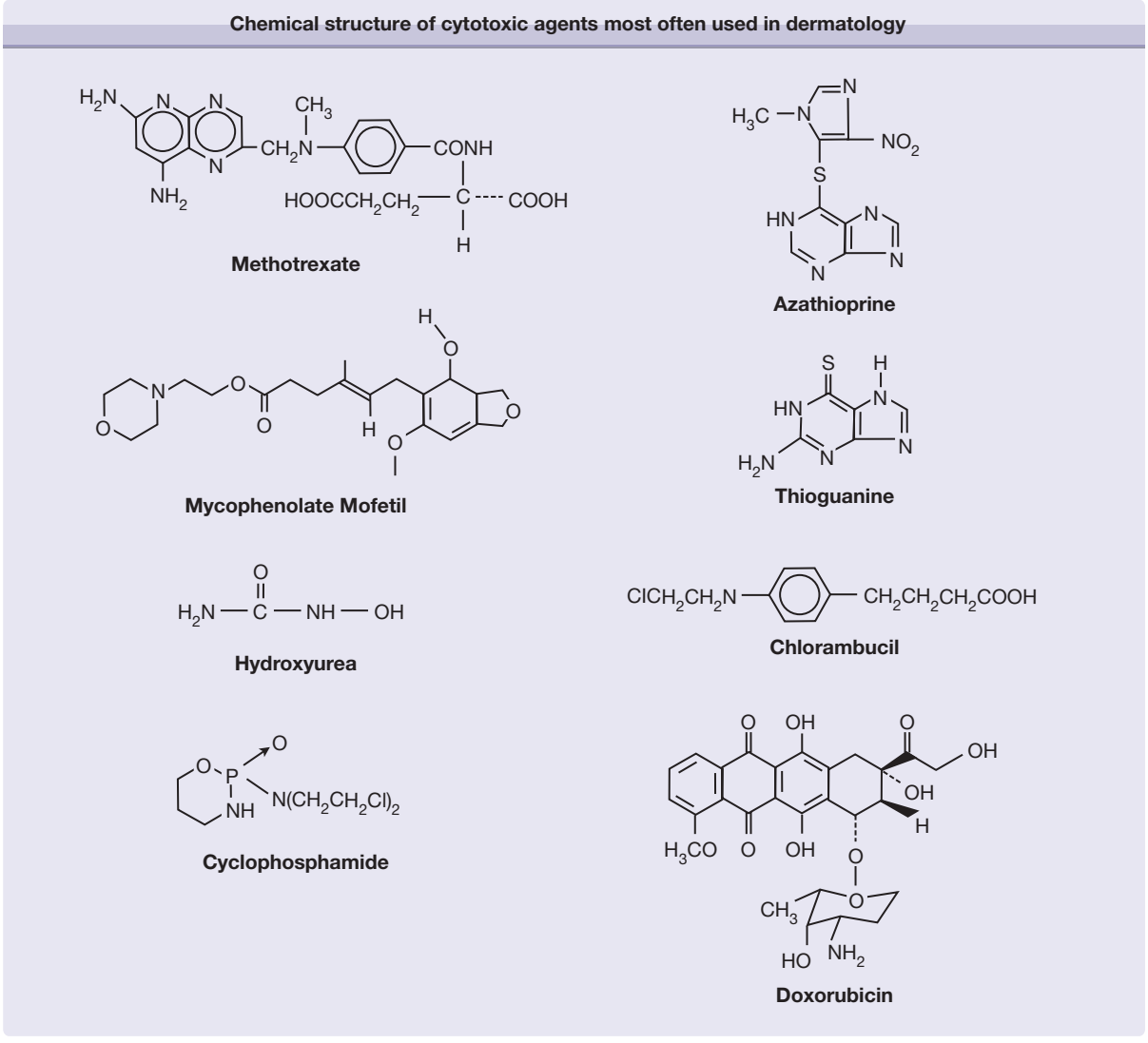

Figure 227-1 Chemical structure of cytotoxic agents most often used in dermatology.

PHARMACOKINETICS. Oral methotrexate is absorbed rapidly through the gastrointestinal tract. In children, absorption is decreased by concurrent ingestion of food and milk, but this has not been observed in adults. In adults, the mean bioavailability is 67% of the administered dose. Peak plasma levels occur 1–3 hours after administration. The half-life of the drug is 4–5 hours. For doses higher than 25 mg/week, gastrointestinal absorption is more erratic, and some experts recommend intramuscular dosing above this level.[2]

Methotrexate is eliminated chiefly by the kidneys, with 60%–95% excreted unchanged. Decreases in glomerular filtration or tubular secretion may lead to methotrexate toxicity. Approximately 50% of methotrexate within the blood is protein bound. Weak organic acids, such as aspirin or many other nonsteroidal anti-inflammatory agents, may displace methotrexate, altering blood levels and renal excretion (see Section "Drug Interactions").

INDICATIONS. Methotrexate is used for many purposes in dermatology, but its chief indication is for treatment of severe psoriasis. The effects of methotrexate in psoriasis were first recognized in the late 1950s and 1960s,[3] and by the late 1980s, more than one-half of dermatologists reported using methotrexate to treat severe psoriasis.[4] The impact of an increasing number of systemic treatments for psoriasis (the "biologics"; see Chapter 234) on the use of methotrexate has not been fully studied, but recent analysis has confirmed that methotrexate represents the most affordable and a very effective systemic treatment for psoriasis.[5] Methotrexate has also been used in a variety of other autoimmune and connective tissue diseases, vasculitides, inflammatory dermatoses, and papulosquamous conditions (Box 227-1).

DOSING REGIMEN. Typical oncologic doses of methotrexate (100–250 mg/m^2/week) are cytotoxic; however, lower doses (7.5–25.0 mg/week) are

BOX 227-1 USES FOR METHOTREXATE IN DERMATOLOGY

- US Food and Drug Administration-approved indications
  - Severe psoriasis (± psoriatic arthritis)
  - Mycosis fungoides (advanced disease)
- "Off-label" uses
  - Dermatomyositis
  - Cutaneous lupus erythematosus
  - Scleroderma
  - Pemphigus vulgaris
  - Bullous pemphigoid
  - Cutaneous polyarteritis nodosa
  - Behçet disease
  - Pyoderma gangrenosum
  - Lymphomatoid papulosis
  - Pityriasis lichenoides et varioliformis acuta
  - Pityriasis rubra pilaris
  - Sarcoidosis
  - Severe atopic dermatitis
  - Chronic hand dermatitis

immunomodulatory. In dermatology, methotrexate doses are typically less than 30 mg/week, and are often less than 17.5 mg/week. Cumulative dose should be tracked and recorded, as this may impact monitoring with continued use (see Section "Monitoring Therapy").

Methotrexate is available in 2.5-mg tablets. For those with economic limitations, methotrexate liquid (25 mg/mL) may be more affordable for peroral use.[6] Either a single weekly dose or a weekly dose divided into three portions separated by 12 hours is used. These dosing regimens are equally efficacious, but split dosing may lessen gastrointestinal upset.

INITIATING THERAPY. Evaluation before methotrexate use includes a careful history and physical examination, and assessment of concomitant conditions or medications that may limit methotrexate use. Exclusion of patients inappropriate for methotrexate therapy is an important first step in management. Relative contraindications to methotrexate use include abnormalities in renal or liver function (including viral hepatitis), cirrhosis, excessive alcohol consumption, concomitant use of hepatotoxic drugs, active infection, immunosuppression, recent vaccination (particularly live vaccines), obesity (body mass index >30), diabetes mellitus, poor reliability, and an active desire to conceive (men and women).[7] In general, the elderly are often less amenable to methotrexate therapy due to declining renal function. Administration of methotrexate to pregnant women or nursing mothers is strictly contraindicated. While use of methotrexate is often avoided in the setting of HIV, it may be appropriate in select circumstances; caution is advised.[8]

Baseline laboratory studies (Table 227-1) include a complete blood cell count (CBC); platelet count; liver function testing; serologic assessment for hepatitis A, B, and C antibodies (if indicated or preferred by the clinician); renal function assessment; and pregnancy and HIV screening (where indicated).[7] While a baseline screen for tuberculosis using purified protein derivative (PPD) is not expressly mandated, the Centers of Disease Control and Prevention recommends consideration of such testing for any patient placed on immunosuppressive medication.[9] Similarly, screening for strongyloides infection may be appropriate in some populations.[10]

Initiation of methotrexate therapy typically involves use of a single 5- to 10-mg test dose. Repeat laboratory studies, a skin examination, and a review of systems are conducted 1 week later. Performance of repeat laboratory studies sooner than 5–6 days after dosing yields only expected elevated liver transaminases and may confound interpretation.

If the test dose is tolerated and laboratory studies are satisfactory, weekly therapy may commence using a typical starting dose of 7.5–10 mg/week, depending on the severity of disease, overall health, and ideal body weight of the patient. Some authorities may begin with a dose as high as 15 mg/week in certain settings. The dose may be increased by 2.5–5.0 mg every 4–8 weeks until adequate control is achieved or toxicity ensues.[7] When improvement has stabilized, the dose may be tapered in 2.5-mg decrements to a point at which disease activity increases slightly. The goal is to allow for mild- or low-grade psoriasis to avoid an unacceptably high dose. It is important to discuss this expectation with the patient to prevent confusion regarding the endpoint. Concomitant topical therapy may also lower the methotrexate dose needed for satisfactory control.

If a patient does not demonstrate satisfactory improvement on a dose of 20–25 mg/week, consideration of alternative agents is indicated. Occasional patients with refractory disease may respond better to parenteral methotrexate, typically intramuscular dosing. In refractory cases, methotrexate may be combined with ultraviolet B (UVB) phototherapy, psoralen and UVA light (PUVA), cyclosporine, oral retinoids, or biologics to enhance efficacy.[7]

MONITORING THERAPY. Ongoing laboratory evaluation during methotrexate therapy (Table 227-1) should include a CBC with manual differential and platelet count and liver function tests weekly for 2–4 weeks for the first few months, then every 1–3 months.[7] Repeat testing with any dose escalation or intercurrent illness. Liver function testing should not be performed earlier than 5 days after dosing to avoid confounded results. Renal function tests should be performed every 2 to 3 months,[7] or with any suspicion of altered renal function.

Recent developments have altered recommendations regarding liver biopsy in the setting of methotrexate use for psoriasis. For patients without risk factors for liver injury (Table 227-2), current recommendations for liver biopsy are similar to those issued by the American College of Rheumatology with regard to use

TABLE 227-1
Safety Monitoring for Methotrexate Use

Initial Evaluation	Ongoing Laboratory Monitoring
■ Careful history and physical examination ■ Identification of proper patient characteristics and risk factors	■ CBC with differential/platelets ■ Every 2–4 weeks for first few months ■ Then approximately every 1–3 months in a stable patient ■ Repeat approximately 1 week after any dosage escalation
■ Survey for interacting medications (aspirin, nonsteroidal anti-inflammatory drugs, trimethoprim-sulfamethoxazole, etc.)	■ Liver function tests ■ Monthly for first 6 months (but perhaps more often if hepatic risk factors exist) ■ Then every 1 to 3 months thereafter ■ Perform at least 5–6 days after any dose to prevent confounding ■ Repeat with any dose escalation
■ Baseline laboratories: ■ CBC with differential/platelets ■ Liver function tests (AST, ALT, alkaline phosphatase, serum albumin) ■ Serology for hepatitis A/B/C ■ Renal function testing (serum creatinine/blood urea nitrogen) ■ Human immunodeficiency virus screening (if applicable) ■ Pregnancy testing (if applicable)	■ Renal function tests ■ Perform at 2–3 month intervals or with any possible change in renal function ■ Liver biopsy ■ Low risk patient (see Table 227-3)—follow ACR guidelines similar to use in rheumatoid arthritis ■ High risk patient (Table 227-3)—consider delayed baseline biopsy (2–6 months after initiation) and at 1.0–1.5 g cumulative dose

CBC = complete blood cell count; AST= aspartate aminotransferase; ALT = alanine transaminase.

of methotrexate in rheumatoid arthritis. However, for patients with risk factors for methotrexate-induced liver injury, a delayed baseline liver biopsy should be considered (usually after 2–6 months of use, when it is apparent the medication is efficacious, well tolerated, and likely to be continued), and again at a cumulative dose of 1.0–1.5 g. Monitoring via measurement of the aminoterminal peptide of procollagen III (PIIINP) is popular in some European countries, but the test is not approved for use in the United States.[7]

RISKS AND PRECAUTIONS. Absolute and relative contraindications and common adverse effects of methotrexate are summarized in Box 227-2.

TABLE 227-2
Risks Factors for Liver Injury with Methotrexate Use and Recommendations for Hepatic Monitoring/ Liver Biopsy Based on Risk

Risk Factors for Hepatic Toxicity	Recommendations for Low-Risk Patients
■ History of or current alcohol consumption ■ Persistent abnormal liver function tests ■ History of liver disease (including Hepatitis B or Hepatitis C) ■ Family history of inheritable liver disease ■ Diabetes mellitus ■ Obesity ■ Hyperlipidemia ■ History of significant exposure to hepatotoxic agents ■ Lack of folate supplementation	■ No baseline liver biopsy ■ Monitor liver function (per Table 227-2) ■ for minor elevations in liver enzymes (<2× normal) repeat in 2–4 weeks ■ for moderate elevations in liver enzymes (2–3× normal) closely monitor, repeat in 2–4 weeks, dose reduction if necessary ■ for persistent elevations in AST in 5 of 9 studies over 12 months or for decline in albumin with good nutrition perform liver biopsy ■ Consider liver biopsy after cumulative dose of 3.5–4.0 g, *OR* switch to alternative agent, *OR* continue to follow as above without liver biopsy. **Recommendations for High-Risk Patients** ■ Consider an alternative agent ■ Consider baseline biopsy after 2–6 months of use (when it is apparent that use will continue) ■ Repeat liver biopsy at cumulative dose of 1.0–1.5 g

BOX 227-2 RISKS AND PRECAUTIONS WITH METHOTREXATE USE

- Absolute contraindications
  - Pregnancy (Category X)
  - Lactation
- Relative contraindications
  - Renal dysfunction (dose may be reduced)
  - Hematologic disease (dose may be reduced)
  - Hepatic disease or hepatic dysfunction
  - Unreliable patient
  - Excessive alcohol consumption
  - Diabetes mellitus and/or obesity
  - Active infection and/or potential reactivation of infection (tuberculosis)
  - Human immunodeficiency virus infection
  - Man or woman contemplating impending conception
- Common adverse effects
  - Gastrointestinal distress (minimized with folate supplementation)
  - Myelosuppression (acute)
  - Toxic hepatitis
  - Liver fibrosis/cirrhosis (chronic)

COMPLICATIONS. Adverse reactions to methotrexate range from the trivial to life threatening.

Gastrointestinal Effects. Nausea and vomiting with oral administration is common and dose related. Such effects may be seen with parenteral dosing as well. Indeed, 10%–30% of all patients placed on methotrexate may experience some gastrointestinal upset. Symptoms may even occur before dosing or 24–36 hours afterward, suggesting a psychosomatic or anticipatory basis in select cases. Supplementation with folate (1–5 mg/day) reduces gastrointestinal symptoms without compromising efficacy.[11–14] A recent study on folate supplementation (5 mg daily) suggested a slight decrease in methotrexate efficacy,[15] but others questioned the methodology,[16] and most authorities continue to advocate strongly for supplementation.[7]

Hepatic Effects. Induction of liver fibrosis is a major concern with methotrexate use. Methotrexate is hepatotoxic, and some elevation in liver transaminases is expected with use. These elevations occur near to administration and are not strictly predictive of those predisposed to fibrosis. Dose reduction or discontinuance is indicated if transaminases exceed two- to threefold normal values when measured at least 5–6 days after the last dose.

The gold standard for assessing methotrexate-induced liver fibrosis is percutaneous needle biopsy. The procedure is not without risk; minor bleeding occurs in 1 in 1,000 patients, and the risk of death is estimated at 1 in 10,000.[17] Liver specimens are assessed for lobular architecture, inflammation and fibrosis, and fat infiltration. A grading scheme using a scale of I to IV is widely employed (Table 227-3). Patients with grades I and II histology may continue methotrexate, those with grade IIIA histology may continue with a repeat liver biopsy in 6 months, and those with grades IIIB and IV histology should discontinue methotrexate.[7]

A noninvasive test for liver fibrosis would be ideal. Ultrasound alone has demonstrated conflicting results.[18,19] Radionuclide scans and the aminopyrine breath test have proven inadequate for independent detection of methotrexate-induced fibrosis.[20,21] Serum assay of the PIIINP may suggest fibrosis; however, specificity is limited. PIIINP is simply a marker of fibrogenesis, and it may be elevated during fibrosis of any organ system.[22] It is unreliable in patients with psoriatic arthritis. A compelling argument has been made to use an amalgam of tests, such as ultrasound, dynamic radionuclide scanning, and PIIINP assay, to reduce the number of required liver biopsies. Nevertheless, at present, percutaneous liver biopsy remains the gold standard for evaluation when methotrexate-induced liver disease is suspected.[23]

Hematologic Effects. The most important acute adverse effect of methotrexate is myelosuppression. Anemia, neutropenia, and thrombocytopenia may result from methotrexate use. Risk factors for bone marrow toxicity include advanced age, poor renal

TABLE 227-3
Classification of Liver Biopsy Findings for Methotrexate Use

Biopsy Grade	Histopathologic Findings	Recommended Action
I	Normal; fatty infiltration (mild), portal inflammation (mild)	Continue methotrexate
II	Fatty infiltration (moderate to severe), portal inflammation (moderate/severe)	Continue methotrexate
IIIA	Fibrosis (mild)	Continue methotrexate; repeat biopsy in 6 mon
IIIB	Fibrosis (moderate to severe)	Discontinue methotrexate
IV	Frank cirrhosis	Discontinue methotrexate

function, and concurrent administration of conflicting medications (see Section "Drug Interactions").

Mucosal and Cutaneous Effects. Oral ulcerations or stomatitis may be noted with methotrexate use. Skin ulceration, particularly of the lower legs, may herald bone marrow suppression. In patients treated with methotrexate for psoriasis, rapid ulceration of psoriatic plaques may also suggest toxicity.[24] Laboratory studies and dose reduction or complete discontinuance is indicated when mucocutaneous ulcerations or skin ulcerations develop, respectively. Methotrexate may also engender a cutaneous "recall reaction" in areas of prior irradiation or recent sunburn.[25] Mild alopecia has been described with methotrexate use. Other cutaneous manifestations include acral erythema, epidermal necrosis, and vasculitis.

Carcinogenecity. Low-dose methotrexate use has not been definitively associated with carcinogenesis, but a recent study examining patients using methotrexate for rheumatoid arthritis demonstrated a 50% increased risk of malignancy relative to the general population, with a threefold increased risk in melanoma, a fivefold increased risk in non-Hodgkin lymphoma, and a nearly threefold increase in lung cancer.[26] Conversely, in a cohort study from the United Kingdom, a slight increase in lymphoma was observed among psoriatic patients, but use of methotrexate was not discriminatory.[27]

Mutagenecity and Teratogenecity. Methotrexate is a Category X agent during pregnancy, and administration is absolutely contraindicated (see Box 227-2). Pregnancies that occur after the discontinuation of methotrexate appear unaffected, but it is generally advocated that men wait 3 months after discontinuance before attempting conception; women should wait one complete menstrual cycle. Reliable contraception is requisite while taking methotrexate.[7]

Pulmonary Effects. Acute pneumonitis and pulmonary fibrosis have been reported with methotrexate use in psoriasis, although such reactions are more common in rheumatoid arthritis patients.[28] Pulmonary toxicity likely represents an idiosyncratic reaction. Chest radiographs and pulmonary function testing are not useful in the detection or prevention of pulmonary fibrosis.[29] A chest X-ray should be performed in those with symptoms of pneumonitis. Discontinuance is recommended if examination findings are concerning.

Opportunistic Infections. Opportunistic infections (e.g., *Pneumocystis* pneumonia, cryptococcosis, and histoplasmosis) have been reported in otherwise healthy individuals receiving low-dose methotrexate.[10,30–33] Admittedly, such patients were often using other immunosuppressive medications as well; often prednisone.

Anaphylaxis. Systemic anaphylaxis with low-dose methotrexate has been reported.[34] Many patients suffering from anaphylaxis had received methotrexate before, at comparable doses, without untoward effects.

Folate and Folinic Acid Supplementation. Daily supplementation with 1–5 mg of folate has reduced nausea, vomiting, stomatitis and oral ulceration, elevated transaminases, and mild myelosuppression without compromising the efficacy of methotrexate.[11–14] Pneumonitis, and moderate-to-severe myelosuppression are not mitigated by folate supplementation. Elevated homocysteine levels, common with methotrexate use and an independent risk factor for coronary artery disease, are decreased with folate supplementation.[35]

Folinic acid may also be used as supplementation, but it should not be given concurrently with methotrexate dosing. Instead, it is dosed at 5 mg by mouth every 12 hours for 3 doses, beginning 12 hours after the last weekly methotrexate dose. Unlike folinic acid, folate does not compete with methotrexate for cellular uptake, and it can be taken daily. Both are available as generic medications. One drawback to folate supplementation is the potential masking of vitamin B_{12} deficiency. Use of folate supplementation with methotrexate therapy is well established.[7]

Overdose. Methotrexate overdose is more likely in patients with declining renal function, in those who misunderstand dosing directions, or in those concomitantly exposed to a second folate antagonist, such as trimethoprim-sulfamethoxazole. Overdose should be treated promptly with folinic acid (leucovorin). Folinic acid is metabolized in vivo to tetrahydrofolate in the absence of dihydrofolate reductase, providing an alternative supply of DNA and RNA precursors.

Folinic acid should be given early, preferably within the first 24–36 hours after overdose. Folinic acid itself has very little toxicity. Therefore, an oral dose of 10 mg/m^2 should be given on first suspicion of methotrexate overdose without delay for a serum assay.[7] Peroral or parenteral doses may be continued every 6 hours until the serum concentration of methotrexate falls to less than 10^{-8} M. Practically speaking, or when a serum assay is unavailable, this recommendation is often equivalent to 15–25 mg of folinic acid by mouth every 6 hours for six to ten doses.

Drug Interactions. Although any drug that may enhance methotrexate toxicity should be avoided during therapy, there are several near-absolute contraindications (Box 227-3), including aspirin, many nonsteroidal anti-inflammatory agents, probenecid, and trimethoprim-sulfamethoxazole.[36] Conversely, many cyclooxygenase-2 selective inhibitors, like celecoxib, do not impact the pharmacokinetics of methotrexate.[7]

BOX 227-3 DRUG INTERACTIONS OF METHOTREXATE[a]

- Aspirins
- Nonsteroidal anti-inflammatory agents
- Probenecid
- Trimethoprimsulfomethoxazole

[a]Near absolute contraindications

AZATHIOPRINE

Azathioprine is a synthetic analog of natural purine bases used in RNA and DNA synthesis (see Fig. 227-1). Although many thiopurine derivatives exist, azathioprine is the agent most often used in dermatology.

MECHANISM OF ACTION. Azathioprine is a prodrug that is metabolized in the body to 6-mercaptopurine (6-MP). 6-MP is further anabolized via hypoxanthine-guanine phosphoribosyl transferase (HGPRT), ultimately to a purine analog, 6-thioguanine (6-TG), that inhibits RNA and DNA synthesis and repair, yielding immunosuppression. HGPRT activation is critical. Yet patients with Lesch-Nyhan syndrome (HGPRT deficiency) experience no immunosuppression or untoward effects while taking azathioprine.[37]

PHARMACOKINETICS. Azathioprine and its metabolite, 6-MP, are equally potent when administered parenterally, but azathioprine enjoys improved bioavailability, with 88% of the oral dose being absorbed through the gastrointestinal tract. After absorption, azathioprine is converted to 6-MP, mostly within erythrocytes. The fate of 6-MP is determined by one of three competing metabolic pathways: (1) it may be anabolized to an ultimate active form (6-TG) via HGPRT, (2) it may be catabolized to an inactive form via xanthine oxidase (XO), or (3) it may be catabolized to an inactive form by thiopurine methyltransferase (TPMT).[38]

Elucidation of the TPMT-dependent catabolic pathway has revolutionized the clinical use of azathioprine. In humans, expression of TPMT is variable due to genetic polymorphisms. Patients may be categorized into three subgroups: (1) a large majority possesses high levels of TPMT expression (~90%), (2) intermediate expression is demonstrated in ~10%, and (3) less than 1% demonstrate very low TPMT activity (about 1 in 300 persons).[39] Commercial assays for TPMT activity allow for graduated azathioprine dosing, with improved efficacy and a lesser incidence of unforeseen side effects (see Section "Dosing Regimen").[40,41]

XO is another enzyme involved in the catabolism of 6-MP. Allopurinol, used in the treatment of gout, is a potent inhibitor of XO; toxicity may result in those taking both medications.[42] Unlike TPMT, there is very little genetic variation in XO expression, and it is unnecessary to assess innate XO expression before azathioprine dosing. A careful medication history, however, is critical (see Section "Drug Interactions").

INDICATIONS. In dermatology, azathioprine is used "off-label" chiefly as a steroid-sparing agent for immunobullous disorders, including pemphigus, cicatricial pemphigoid, and severe or recalcitrant bullous pemphigoid (Box 227-4).[43] In a prospective, long-term study of pemphigus vulgaris patients treated with glucocorticoids and azathioprine, 45% achieved remission.[44] The steroid-sparing effect of azathioprine in pemphigus has been challenged in literary review, but not in a clinical trial; it remains a common regimen among practicing dermatologists.[45]

BOX 227-4 USES FOR AZATHIOPRINE IN DERMATOLOGY

- US Food and Drug Administration-approved indications
  - None
- "Off-label" uses
  - Dermatomyositis
  - Severe cutaneous lupus erythematosus
  - Scleroderma
  - Relapsing polychondritis
  - Pemphigus vulgaris
  - Bullous pemphigoid
  - Cicatricial pemphigoid
  - Cutaneous polyarteritis nodosa
  - Severe or recalcitrant leukocytoclastic vasculitis
  - Behçet disease
  - Pyoderma gangrenosum
  - Sarcoidosis
  - Severe psoriasis
  - Severe lichen planus
  - Severe atopic dermatitis
  - Chronic actinic dermatitis
  - Severe contact dermatitis
  - Severe polymorphous light eruption

DOSING REGIMEN. Azathioprine is supplied as 50-mg tablets and also as an injectable. Traditionally, a dose of 1–2 mg/kg/day of azathioprine was used, often concurrent with high-dose prednisone. Increasingly, the appropriate dosage is now based on a patient's own TPMT expression (Table 227-4).[40] Impaired renal function may be associated with greater toxicity, and the dosage may still be adjusted for this reason.

INITIATING THERAPY. Before therapy, the patient should receive a complete history and physical examination. Exclusion of patients with severe comorbidities,

TABLE 227-4
Dosing of Azathioprine Based on Thiopurine Methyltransferase (TPMT) Enzyme Assay[41]

TPMT Erythrocyte Assay	Maximum Azathioprine Dose
>19.0 U (high expression)	2.5 mg/kg/day
13.7–19.0 U (intermediate expression)	1.5 mg/kg/day
5.0–13.7 U (low expression)	0.5 mg/kg/day
<5.0 U (very low expression)	Do not use

active infections, or the possibility of reactivation of an infection (tuberculosis) is recommended. All women of childbearing age should receive a pregnancy test. Patients with a history of exposure to alkylating agents should likely not receive azathioprine unless unavoidable, as an increased risk of lymphoproliferative disease exists when used in succession.

Baseline laboratory tests include a CBC with manual differential and platelet count, renal and liver function testing, and an erythrocyte TPMT activity assay should be performed. There are reports of mycobacterial infection in those taking azathioprine, and tuberculin screening should be considered. In steroid-responsive bullous disorders and in connective tissue disease, experienced practitioners often initiate azathioprine concurrently with high-dose steroids.

MONITORING THERAPY. During therapy, a CBC with manual differentiation and platelet count should be obtained biweekly for the first 2 months, monthly for the next 2 months, and every 2 months thereafter; liver function testing should occur every month for 3 months and then bimonthly thereafter.[46] Additional laboratory testing is necessary with dosage increases or if an initial TPMT level cannot be determined. Biannual physical examinations should pay particular attention to evidence of possible lymphoreticular disease and skin cancer, particularly squamous cell carcinoma (SCC). Safety guidelines used during azathioprine therapy are summarized in Box 227-5.

Recently, optimal erythrocyte levels of 6-TG necessary for disease remission in patients with immunobullous disease treated with azathioprine were determined.[47] Optimal levels of 6-TG in erythrocytes for disease remission were 150–300 pmol/8×10^8 erythrocytes. Lower levels were observed in lesser disease states. High levels of the inactive metabolite 6-methylmercaptopurine and induction of TPMT were associated with recalcitrant disease.

In fact, TPMT induction (>10 U from baseline) explains why some patients fail to respond to high azathioprine doses (at least 2.5 mg/kg/d), even when baseline measurement suggested an intermediate level of enzyme activity within erythrocytes. Experts were quick to recognize the clinical value of this observation; this type of nonresponder should be switched to an alternative agent.[48] Similarly, measurement of TPMT activity (at baseline and during use) and 6-TG levels within erythrocytes allows for an algorithmic approach to discriminate among the underdosed, noncompliant, and those experiencing TPMT-induction (Table 227-5).[47,48] Furthermore, TPMT genotype determination may be used when RBC enzyme activity is near the cutoff between high activity and intermediate activity, to allow for more aggressive azathioprine dosing.[47]

RISK FACTORS AND PRECAUTIONS. Absolute and relative contraindications and common adverse effects of azathioprine are summarized in Box 227-6.

COMPLICATIONS. With careful monitoring, azathioprine is generally safe. Adverse effects tend to occur in those patients with lower TPMT activity levels, higher doses of azathioprine, or concomitant use of allopurinol.

BOX 227-5 SAFETY MONITORING FOR AZATHIOPRINE USE

- Initial evaluation
  - Careful history and physical examination
  - Identification of proper patient characteristics and risk factors
  - Survey for interacting medications (allopurinol, aminosalicylates)
  - Baseline laboratories:
    - Thiopurine methyltransferase erythrocyte assay
    - CBC with differential/platelets
    - Basic serum chemistry profile
    - Liver function tests
    - Urinalysis
    - Pregnancy testing for women of child-bearing age
    - Tuberculin testing (if indicated)
    - Consider TPMT genotype assay if borderline intermediate/high expression by erythrocyte measurement
- Ongoing laboratory monitoring
  - CBC with differential/platelets
    - Biweekly for 2 mon, monthly for 2 mon, then bimonthly thereafter
  - Liver function testing
    - Monthly for 3 mon, then bimonthly monthly thereafter
  - Consider erythrocyte 6-TG level, repeat TPMT (to check for induction)
- Follow-up clinical evaluation
  - Biannual complete physical examinations
    - Particular attention to possible lymphoreticular disease (adenopathy)
    - Careful survey for non-melanoma skin cancer (squamous cell carcinoma)

CBC = complete blood cell count.

Hematologic Effects. Myelosuppression is a major side effect of azathioprine use. Generalized depression of all blood cell lines is most common,[49] but depression of any single lineage may be observed. Thrombocytopenia is a common initial presentation of bone marrow toxicity. Bone marrow suppression tends to occur at higher doses,[50] and in those with lower TPMT expression. Discontinuance usually results in complete marrow recovery.

Opportunistic Infections. Most patients treated with azathioprine also receive large doses of glucocorticoids. Therefore, it is often difficult to quantify the independent role of azathioprine in any predisposition toward infection. Herpes virus infections, human

TABLE 227-5
Use of Erythrocyte Assay of TPMT and Azathioprine Metabolites to Categorize Patient Subtypes

Test/Value	Optimal Responder	Underdosed	Noncompliant	TPMT Induction
TPMT (erythrocyte)	Near baseline	Near baseline	Near baseline	Elevated above baseline (>10 U)
6-Thioguanine (active metabolite)	Optimal	Low	Low	Low
6-Methylmercaptopurine (inactive metabolite)	Elevated	Low	Low	Elevated significantly
Azathioprine dose	Adequate	Inadequate, potentially will respond to increase[a]	Presumed adequate[a]	May respond to increase[b]

TPMT = thiopurine methyltransferase.
[a]With a dose escalation, an underdosed patient will move toward the profile of an optimal responder. With improved compliance, a noncompliant patient will move toward an optimal responder or will emerge as an underdosed or TPMT-induction.
[b]If the maximal safe dose has not been exceeded, it is possible that a patient with TPMT induction may respond to dose escalation; but, if a maximal dose has been reached and there is an inadequate response, trial of a different agent is indicated.

papilloma infection, and scabies infestation have been reported in those taking azathioprine.[50]

Gastrointestinal Effects. Patients receiving high doses of azathioprine may experience nausea, vomiting, and diarrhea. Such symptoms are not usually treatment limiting and may be reduced by administration with food.

Hepatic Effects. Toxic hepatitis has developed in approximately 1% of patients treated with azathioprine for rheumatoid arthritis, and it is usually reversible.[51] Other adverse effects include hepatic veno-occlusive disease and associated pancreatitis. Discontinuance is warranted with evidence of liver toxicity.

BOX 227-6 RISKS AND PRECAUTIONS WITH AZATHIOPRINE USE

- Absolute contraindications
  - Hypersensitivity to azathioprine
  - Active or ongoing infection
- Relative contraindications
  - Pregnancy/lactation (Category D, but myelosuppression of fetus/infant common—avoid)
  - Allopurinol use (dose must be reduced by 75%)
  - Prior lymphoproliferative disease or prior use of alkylating agents
- Common adverse effects
  - Gastrointestinal distress (minimized by administration with food)
  - Myelosuppression
  - Possible increased risk of lymphoproliferative disease or skin cancer
  - Possible opportunistic infections

Anaphylaxis. Azathioprine-induced shock and hypersensitivity reactions have been reported in patients with cutaneous disease. In most cases, hypotensive collapse occurred within hours of the initial dose. Drug fever has also been reported with azathioprine (see Chapter 41).

Carcinogenesis. An increased risk of lymphoproliferative disease has been documented in renal transplant recipients, rheumatoid arthritis patients, and, most recently, inflammatory bowel disease patients treated with chronic azathioprine.[52–54] In one study, the relative risk was increased roughly 10- to 13-fold, or one lymphoma per 1,000 patient-years of azathioprine treatment. Dermatologic doses of azathioprine are often lower and the duration of treatment shorter, leading to speculation that the risk of lymphoma is probably lower in those treated for cutaneous disease. However, the most recent meta-analysis of patients treated with azathioprine for inflammatory bowel disease who developed lymphoma included those on "low-dose" regimens.[54] In light of this information, it seems prudent to inform patients that the exact magnitude of any increased risk for lymphoma with "low-dose" azathioprine is largely unknown. Patients with a prior exposure to alkylating agents may have a prohibitive risk of lymphoma if treated subsequently with azathioprine; great caution is suggested in this population.

Aggressive behavior of SCC has been described in patients taking azathioprine for eczema, atopic dermatitis, and chronic actinic dermatitis.[55] It was recently suggested that azathioprine used in solid organ transplant recipients may sensitize DNA to UVA radiation, leading to the increased incidence of SCC in this population.[56] Admittedly, confounding risk factors exist, but a later small series confirmed a reduced minimal erythema dose to UVA irradiation with coadministration of azathioprine.[57] Dermatologists should be aware of

this emerging research, as only broad spectrum sunscreens mitigate UVA exposure, and such rays are not blocked by glass.

Mutagenecity and Teratogenecity. Azathioprine is a Category D agent during pregnancy. The prodrug and the active metabolites readily cross the placenta. The rate of congenital malformation appears to be low (4.3%), but myelosuppression and immunosuppression are significant occurrences in neonates and breastfed infants. Fertility of men or women appears unaffected by azathioprine.[58]

Drug Interactions. A major drug interaction occurs between azathioprine and allopurinol. When allopurinol must be used concurrently, the azathioprine dose must be decreased by 75%. There is evidence that aminosalicylates may inhibit TPMT activity, and it may be prudent to minimize or avoid such medications in patients using azathioprine.

THIOGUANINE

Thioguanine (see Fig. 227-1) is a less utilized member of the thiopurine family of drugs. It has a metabolism and mechanism of action similar to that of azathioprine.

MECHANISM OF ACTION.

Thioguanine is a prodrug that produces nucleoside analogues through the action of purine nucleoside phosphorylases present in tissues. These guanine analogues undergo enzymatic conversion to nucleotides and ultimately yield cytotoxic activity via incorporation into cellular DNA. Apoptosis is induced preferentially against activated T lymphocytes. The clinical response to thioguanine has been correlated to decreased T lymphocyte counts in psoriatic skin lesions, irrespective of systemic lymphocyte counts.[59]

PHARMACOKINETICS.

Thioguanine is administered orally, but it has incomplete and unpredictable absorption. Peak plasma concentrations may vary tenfold and occur 2–4 hours after ingestion.[60]

INDICATIONS.

In dermatology, thioguanine is used chiefly for the treatment of psoriasis, particularly in those with recalcitrant disease or with contraindications to other systemic therapies (Box 227-7). In a recent retrospective study of patients with recalcitrant psoriasis, 14 of 18 patients experienced greater than 90% improvement with thioguanine, including patients with psoriatic arthritis, palmoplantar disease, or scalp involvement.[61] Thioguanine has been used effectively, although infrequently, to treat lupus and atopic dermatitis.

BOX 227-7 USES FOR THIOGUANINE IN DERMATOLOGY

- US Food and Drug Administration-approved indications
  - None
- "Off-label" uses
  - Severe psoriasis
  - Severe cutaneous lupus erythematosus
  - Severe atopic dermatitis

DOSING REGIMEN.

Thioguanine is supplied as 40-mg tablets. Classically, treatment was initiated with a 40 mg/day dose, with close monitoring for myelosuppression. After 1 month, if the clinical response was inadequate, the dose was increased to 80–120 mg/day. A pulsed regimen of 100 mg to 120 mg twice weekly, increasing up to 160 mg three times per week, has been reported effective.[62] The most recent guidelines suggest an amalgam of these strategies, beginning with a dose of 80 mg twice weekly with possible advancement by 20 mg every 2 to 4 weeks, to a maximum dose of 160 mg three times weekly.[46]

Similar to azathioprine, use of commercial assays for TPMT activity improve thioguanine dosing. The latest review of thioguanine use in severe psoriasis recommends an assessment of TPMT levels before treatment so as to guide the selection of an adequate starting dose.[61] Patients with high levels of TPMT expression can likely tolerate higher initial doses.

INITIATING THERAPY.

All patients should undergo a thorough history and physical examination before initiation of treatment. Patients with severe comorbidities, particularly hematologic disturbances, or active infection should be excluded. Women of childbearing age should receive a pregnancy test. Recommended baseline laboratory studies include a CBC with manual differential and platelet count, liver function studies, and a TPMT activity assay.

MONITORING THERAPY.

Repeat blood counts and liver function tests should be followed weekly at first, transitioning to biweekly as the dose stabilizes, then monthly for 3 months, and quarterly thereafter. Always perform complete and broad laboratory testing when a dose is escalated or there is a change in the patient's health status. Safety guidelines used during thioguanine therapy are summarized in Box 227-8.

RISKS AND PRECAUTIONS.

Absolute and relative contraindications and common adverse effects of thioguanine are summarized in Box 227-9.

COMPLICATIONS.

Common adverse effects of thioguanine include myelosuppression and gastrointestinal disturbances. In the largest series of patients using thioguanine for psoriasis, just less than one-half experienced myelosuppression, yet only 20% required complete discontinuance.[63] In one series, thrombocytopenia was the earliest indicator of myelosuppression.[61] Pulsed dosing of thioguanine has been associated with a lower rate of myelosuppression, but, admittedly, TPMT testing was not performed in this study.[62]

Gastrointestinal disturbances include nausea, excessive flatulence, taste changes, esophageal reflux, and

BOX 227-8 SAFETY MONITORING FOR THIOGUANINE USE

- Initial evaluation
  - Careful history and physical examination
  - Identification of proper patient characteristics and risk factors
  - Survey for interacting medications (aminosalicylates)
- Baseline laboratories:
  - Thiopurine methyltransferase erythrocyte assay
  - CBC with differential/platelets
  - Liver function tests
  - Renal function testing (creatinine/blood urea nitrogen)
- Ongoing laboratory monitoring
  - CBC with differential/platelets and liver function tests
    - Perform weekly initially, then
      - Transition to biweekly as the dose stabilizes, then
      - Monthly for 3 mon and quarterly thereafter
      - Perform laboratory testing with any dose escalation

CBC = complete blood cell count.

diarrhea, symptoms that are often tolerated without discontinuance. In a single study, elevated liver transaminases occurred in 25% of patients, yet many had been taking methotrexate before the study.[63] Generally, thioguanine is not considered particularly hepatotoxic; liver biopsy is not indicated during treatment. Rare cases of toxic hepatic veno-occlusive disease have been described in patients using thioguanine for psoriasis.[64] Low-dose thioguanine use in pregnant women has been reported with inflammatory bowel disease; however, use during pregnancy is generally avoided.[65]

BOX 227-9 RISKS AND PRECAUTIONS WITH THIOGUANINE USE

- Absolute contraindications
  - Hypersensitivity to thioguanine
- Relative contraindications
  - Pregnancy/lactation (Category D)
  - History of hepatovenular occlusive disease
  - Hematologic disorders
- Common adverse effects
  - Myelosuppression (most common side effect)
  - Gastrointestinal distress (often tolerated)
  - Toxic hepatitis (less common than with other cytotoxic agents)

Drug Interactions. Thioguanine metabolism is not dependent on XO; it may be administered concurrently with allopurinol without dose reduction. Aminosalicylates may inhibit TPMT activity, and it may be prudent to minimize or avoid such medications in patients taking thioguanine.

HYDROXYUREA

Hydroxyurea was first synthesized in 1869, and through the years it has been used to treat a variety of conditions, including hematologic malignancies, sickle cell anemia, and psoriasis.

MECHANISM OF ACTION. Hydroxyurea impairs DNA synthesis through inhibition of ribonucleotide diphosphate reductase, an enzyme that reduces nucleotides to deoxynucleotides. This inhibition limits the supply of DNA bases available for synthesis. Strand breakage and cell death result. Hydroxyurea also prevents cells from repairing damage from UV or ionizing radiation, acting as a radiosensitizer. Finally, hydroxyurea yields hypomethylation of genes, altering expression,[66] and this may contribute to normalization of psoriatic skin through improved keratinocyte differentiation. Hydroxyurea is most active in cells with a high proliferative index. It is preferentially concentrated within leukocytes.

PHARMACOKINETICS. Hydroxyurea is a small molecule that is well absorbed after oral administration. Serum levels peak within 2 hours of dosing. Hydroxyurea has a rapid onset of action, with tissue effects noted within 5 hours. The actual metabolism of hydroxyurea is incompletely understood, but at least 80% is excreted by the kidney. Within 24 hours of dosing, negligible amounts of hydroxyurea remain in the body.

INDICATIONS. In dermatology, hydroxyurea is used chiefly for treatment of psoriasis (Box 227-10).

BOX 227-10 USES FOR HYDROXYUREA IN DERMATOLOGY

- US Food and Drug Administration-approved indications
  - Squamous cell carcinoma of the head and neck (rare use)
  - Metastatic melanoma and gastrointestinal melanoma (rare use)
- "Off-label" uses
  - Severe psoriasis (often an option for those with liver disease that limits other options)
  - Pyoderma gangrenosum
  - Sweet syndrome
  - Cryoglobulinemia
  - Scleromyxedema
  - Hypereosinophilic syndrome

Efficacy has been demonstrated in plaque, pustular, and erythrodermic forms. Still others believe hydroxyurea is only moderately effective and prefer to reserve use as a maintenance therapy once initial clearance has been achieved via other modalities.

In a large series of 60 patients treated with hydroxyurea for severe psoriasis, 50%–60% achieved a response.[67] A more recent study compared use of methotrexate (15–20 mg/week) and lower-dose hydroxyurea (3–4.5 g/week) and found a 77% mean reduction versus a 49% mean reduction in the mean PASI score, respectively.[68] When hydroxyurea is effective, a response generally occurs within 2–3 weeks, with maximal improvement at 6–8 weeks. Because hydroxyurea has relatively little hepatic toxicity, it may be a viable alternative for those with liver disease, which precludes use of methotrexate.

DOSING REGIMEN. Hydroxyurea is available as 500-mg tablets. Typical doses range from 1–2 g daily, usually as a divided dose. Doses above 2 g daily are unlikely to yield additional benefit and are increasingly toxic.[69] Hydroxyurea is usually well tolerated, but if dyspepsia occurs, the medication may be taken with food, milk, or antacids.

INITIATING THERAPY. Patients placed on hydroxyurea should have a complete history and physical examination. Exclusion of patients with severe comorbidities or active infections is often indicated. All women of childbearing age should receive a pregnancy test. Baseline laboratory evaluation should include a CBC with manual differential and platelet count, a serum chemistry evaluation, and urinalysis. Older patients and those with renal impairment are more susceptible to toxicity with hydroxyurea and should receive starting doses of only 500 mg/day.

MONITORING THERAPY. CBCs should be repeated weekly during early therapy; this may be increased to biweekly, and, later, to monthly if results remain stable. Liver function studies and urinalysis should be monitored monthly. Close surveillance for non-melanoma skin cancer at follow-up visits is indicated. Discontinuance of hydroxyurea is indicated if a satisfactory response is not achieved with 8 weeks of therapy. Safety guidelines used during hydroxyurea therapy are summarized in Box 227-11.

RISKS AND PRECAUTIONS. Absolute and relative contraindications and common adverse effects of hydroxyurea are summarized in Box 227-12.

COMPLICATIONS. In one large study of hydroxyurea for psoriasis, 57% of those who received 1.5 g/day of hydroxyurea experienced no side effects, and only 18% discontinued therapy because of adverse effects.[70] The most common adverse effect with hydroxyurea is myelosuppression. Mild megaloblastic changes are ubiquitous among patients receiving hydroxyurea and are not a reason for discontinuance. Frank anemia is present in 12%–34% of treated patients, leukopenia in 7%, and thrombocytopenia in 2%–3%. Myelosuppression due to hydroxyurea usually resolves rapidly on discontinuance.

Patients taking hydroxyurea may experience a variety of cutaneous side effects, including a dermatomyositis-like eruption,[71,72] a lichenoid drug eruption, leg ulcers, alopecia, photosensitivity with radiation

BOX 227-11 SAFETY MONITORING FOR HYDROXYUREA USE

- Initial evaluation
  - Careful history and physical examination
  - Identification of proper patient characteristics and risk factors
  - Survey for interacting medications (cytarabine)
  - Baseline laboratories:
    - CBC with differential/platelets
    - Basic serum chemistry profile
    - Urinalysis
    - Renal function testing (creatinine/ blood urea nitrogen)
- Ongoing laboratory monitoring
  - CBC with differential/platelets
    - Perform weekly initially, then
      - Transition to biweekly or monthly after 1 mon
      - Perform testing with any dose escalation
      - Decrease/discontinue if hemoglobin decreases by 3 g/dL, white blood cell count <4,000/mm^3, or platelets <100,000/mm^3
  - Serum chemistry and urinalysis
    - Perform monthly initially, then
      - Transition to every 3–6 months if stable
      - Perform testing with any dose escalation

CBC = complete blood cell count.

BOX 227-12 RISKS AND PRECAUTIONS WITH HYDROXYUREA USE

- Absolute contraindications
  - Hypersensitivity to hydroxyurea
- Relative contraindications
  - Pregnancy/lactation (Category D)
  - History of hepatovenular occlusive disease
  - Chronic anemia
  - Renal disease
- Common adverse effects
  - Myelosuppression (most common side effect)
  - Dermatomyositis-like drug eruption
  - Renal toxicity (elevated creatinine/blood urea nitrogen, hematuria, proteinuria)
  - Increased risk of secondary hematologic malignancies when used for polycythemia vera

recall, and hyperpigmentation of the skin and nails. In patients treated with hydroxyurea for myeloproliferative disorders, nonmelanoma skin cancer has been reported as an association.[73,74] It is unclear if this represents a true risk factor for those treated for cutaneous disease or if confounding circumstances exist.

Other reported side effects of hydroxyurea include lupus erythematosus, mild gastrointestinal distress, and secondary malignancies when used in patients with primary hematologic disorders, such as polycythemia vera. A rare but important adverse effect of hydroxyurea is fever with a flu-like illness. Hydroxyurea is a Category D agent during pregnancy, and use is generally avoided. There is a single report of hydroxyurea use for polycythemia vera during pregnancy without any apparent fetal or neonatal complications.[75]

Drug Interactions. Hydroxyurea appears to have few significant drug interactions, with the exception of coadministration with other myelosuppressive agents and cytarabine. Use of such agents with hydroxyurea may lead to additive bone marrow toxicity.

MYCOPHENOLIC ACID AND MYCOPHENOLATE MOFETIL

Mycophenolic acid (MPA) (see Fig. 227-1) is a lipid-soluble, weak organic acid with antifungal, antibacterial, antiviral, and immunosuppressive properties. MPA was first used as an oral agent for moderate-to-severe psoriasis in the 1970s, but use was discontinued due to intolerability. Mycophenolate mofetil (MMF) represents a derivative of MPA, with greater bioavailability, improved tolerance, and enhanced immunosuppression. Properties and use of this agent is discussed in detail in Chapter 233.

ALKYLATING AGENTS

CYCLOPHOSPHAMIDE

Cyclophosphamide (see Fig. 227-1) is a derivative of nitrogen mustard, and it acts primarily by cross-linking DNA. In oncology, cyclophosphamide is used as an antineoplastic agent. In dermatology, it is used as an immunosuppressive and steroid-sparing agent, particularly for autoimmune blistering disorders and systemic vasculitis (Box 227-13).

BOX 227-13 USES FOR CYCLOPHOSPHAMIDE IN DERMATOLOGY

- US Food and Drug Administration-approved indications
- Mycosis fungoides (advanced disease)
- "Off-label" uses
  - Granulomatosis with polyangiitis (Wegener's)
  - Lymphomatoid granulomatosis
  - Polyarteritis nodosa
  - Severe and recalcitrant leukocytoclastic vasculitis
  - Dermatomyositis
  - Scleroderma
  - Relapsing polychondritis
  - Severe cutaneous lupus erythematosus
  - Pemphigus vulgaris
  - Bullous pemphigoid
  - Pyoderma gangrenosum
  - Scleromyxedema/lichen myxedematosus
  - Multicentric reticulohistiocytosis
  - Cytophagic panniculitis
  - Severe and recalcitrant eczematous conditions

MECHANISM OF ACTION. Cyclophosphamide is a classic cell-cycle nonspecific drug; its cytotoxic effect is independent of the proliferative index. Active metabolites of cyclophosphamide form covalent bonds with the nucleophilic centers of DNA. This alkylation leads to DNA cross-linking, abnormal base-pair formation, imidazole ring cleavage with depurination, and chain scission. Ultimately, these mutations lead to cell death and possibly mutagenesis and carcinogenesis. Cyclophosphamide has a greater effect on B lymphocytes than T lymphocytes and a greater effect on suppressor T cells than helper T cells.[76] Resistance to cyclophosphamide may occur due to decreased cellular penetration, increased competition from other nucleophilic substances, improved DNA repair, or increased drug metabolism.

PHARMACOKINETICS. Oral cyclophosphamide has a bioavailability of 74%. Peak plasma levels are achieved within 1 hour of administration. The half-life of the drug is between 2 and 10 hours. Cyclophosphamide undergoes hepatic metabolism via the cytochrome P_{450} system.[77] It is first converted to 4-hydroxycyclophosphamide, an active molecule that exists in equilibrium with aldophosphamide. Aldophosphamide may be cleaved to phosphoramide mustard, another active metabolite, and acrolein, an inactive metabolite. Aldehyde dehydrogenase may also convert aldophosphamide into a second inactive metabolite, carboxyphosphamide. The kidneys excrete just 10%–20% of the drug unchanged but excrete 50% of the active metabolites.

INDICATIONS. In dermatology, cyclophosphamide is used chiefly as a steroid-sparing agent for life-threatening diseases (Box 227-13). In particular, pemphigus vulgaris may be treated with cyclophosphamide in combination with steroids, and evidence supports its steroid-sparing benefits.[78] Cyclophosphamide has also been used for the treatment of cicatricial pemphigoid and has been cautiously and inconsistently reported as beneficial in Stevens-Johnson syndrome and toxic epidermal necrolysis.[79,80]

Survival of patients with many forms of vasculitis has been improved with combination therapy with

cyclophosphamide and steroids.[81] Diseases such as granulomatosis with polyangiitis (Wegener's), Churg-Strauss syndrome, polyarteritis nodosa, and lymphomatoid granulomatosis often require cyclophosphamide therapy. Other diseases that may respond to cyclophosphamide include lupus erythematosus, Behçet disease, pyoderma gangrenosum, lichen planus, and lichen myxedematosus; yet, with the availability of safer immunosuppressive agents, cyclophosphamide is not a typical choice for nonlethal inflammatory diseases.

DOSING REGIMEN. Cyclophosphamide is available as 25- and 50-mg tablets and also as an injectate. Oral doses are typically 1–3 mg/kg/day either divided or as a single morning dose. Intravenous pulse dosing of 0.5–1.0 g/m^2 monthly may be associated with fewer side effects than daily oral dosing. Vigorous hydration, beginning 24 hours before and continuing throughout therapy, is recommended to reduce bladder toxicity.

INITIATING THERAPY. Patients being considered for cyclophosphamide therapy should have a thorough history and physical examination. Cyclophosphamide is contraindicated in patients with a history of transitional cell carcinoma of the bladder.[82] Patients with a history of a lymphoproliferative disorder must be treated with extreme caution. Use in pregnant or lactating patients is contraindicated. Baseline laboratory evaluations include a CBC with manual differential, serum chemistry profile, liver function testing, and urinalysis. Initiation of cyclophosphamide therapy is often contraindicated if the total white blood cell count is less than 5,000/mm^3 or if the granulocyte count is less than 2,000/mm^3.

MONITORING THERAPY. Blood counts and urinalysis should be repeated weekly but may be reduced to biweekly or monthly over 2–3 months. Liver function testing should continue monthly but may be reduced to every 3 months, if stable. Urine cytology is indicated when the cumulative dose exceeds 50 g and every 6 months thereafter, or on any occasion of hemorrhagic cystitis. Some authorities recommend a chest X-ray every 6 months. Follow-up physical examination should pay particular attention to any evidence of lymphoproliferative disease (lymphadenopathy). Patients taking cyclophosphamide should have all age-appropriate cancer screening, including stool guaiac examination and Papanicolaou smears for women. Safety guidelines used during cyclophosphamide therapy are summarized in Box 227-14.

RISKS AND PRECAUTIONS. Absolute and relative contraindications and common adverse effects of cyclophosphamide are summarized in Box 227-15.

COMPLICATIONS. Because of its activity independent of the cell cycle, the toxic effects of cyclophosphamide are significant and numerous.

Gastrointestinal Effects. Nausea and vomiting are the most common gastrointestinal side effects associated with cyclophosphamide use. Coadministration of ondansetron and dexamethasone reduces these side effects. The addition of aprepitant to this combination therapy may provide even greater antiemetic action.[83]

Hematologic Effects. Hematologic disturbances are frequent with cyclophosphamide, especially leukopenia and thrombocytopenia. A nadir in blood counts occurs 8–12 days after initiation of therapy. Myelosuppression is not requisite to immunosuppression, but it often represents a dose-limiting side effect.

Genitourinary Effects. Bladder toxicity is a well-recognized consequence of cyclophosphamide use. Hemorrhagic cystitis occurs in 5%–40% of patients treated with oral cyclophosphamide.[84] This cystitis occurs during therapy and is believed to be caused by the metabolite, acrolein. A scavenging agent, mesna (sodium 2-mercaptoethane sulfonate), binds acrolein in the bladder and reduces irritation. Mesna is used primarily with high-dose cyclophosphamide regimens, but it may be used in low-dose therapy as well.[85] It may be administered orally or intravenously

BOX 227-14 SAFETY MONITORING FOR CYCLOPHOSPHAMIDE USE

- Initial evaluation
  - Careful history and physical examination
  - Identification of proper patient characteristics and risk factors
  - Survey for interacting medications (allopurinol, cimetidine)
  - Baseline laboratories:
    - CBC with differential/platelets
    - Basic serum chemistry profile
    - Urinalysis
    - Renal function testing (creatinine/ blood urea nitrogen)
- Ongoing laboratory monitoring
  - CBC with differential/platelets and urinalysis
    - Perform weekly initially, then
      - Transition to biweekly or monthly after 2–3 months
      - Perform testing with any dose escalation
      - Decrease/discontinue if white blood cell count <4,000/mm^3, or platelets <100,000/mm^3
      - Discontinue and refer to urologist if red blood cells appear in urine
  - Basic serum chemistry and liver function tests
    - Perform monthly initially, then
      - Transition to every 3–6 months if stable
  - Urine cytology testing
    - Perform when cumulative dose >50 g or if patient has hemorrhagic cystitis

CBC = complete blood cell count.

BOX 227-15 RISKS AND PRECAUTIONS WITH CYCLOPHOSPHAMIDE USE

- Absolute contraindications
  - Hypersensitivity to cyclophosphamide (can cross-react with chlorambucil)
- Relative contraindications
  - Pregnancy/lactation (Category D; fetal loss common)
  - History of transitional cell carcinoma of the bladder
  - Depressed bone marrow function
  - Impaired hepatic or renal function
- Common adverse effects
  - Gastrointestinal distress (minimized with antiemetic medications)
  - Myelosuppression (often dose limiting)
  - Hemorrhagic cystitis due to elimination of toxic metabolites (minimized with mesna)
  - Carcinogenicity (transitional cell carcinoma of bladder, lymphoproliferative disease)
  - Reproductive consequences (amenorrhea, azoospermia, gonadal failure)

and may cause a maculopapular drug rash in some patients. Hemorrhagic cystitis and untreated bladder toxicity are thought responsible for the markedly increased risk of transitional cell carcinoma of the bladder (8- to 10-fold increased risk) among those taking chronic cyclophosphamide. Bladder cancer may arise years after therapy, and continued monitoring of the lower urinary tract is indicated.

Carcinogenecity. Cyclophosphamide therapy has been associated with non-Hodgkin lymphoma, leukemia, transitional cell carcinoma of the bladder, and SCC. Much of these data involves transplant and oncology patients exposed to chronic use or higher doses, but a slight increased risk of non-Hodgkin B-cell lymphoma has been demonstrated in those treated for rheumatologic conditions as well.[86,87] The risk of cancer in those using cyclophosphamide for dermatologic conditions is likely lower than that for other indications.

Cutaneous Effects. Anagen effluvium has been reported in 5%–30% of those treated with cyclophosphamide.[88] In some cases, the hair loss is permanent, but generally, it is not. A permanent pigmented band on the teeth is another consequence of cyclophosphamide therapy. Diffuse hyperpigmentation of the skin and nails and acral erythema has been described. Rarely, urticaria, mucosal alterations, or induction of Stevens-Johnson syndrome have been reported.[89]

Mutagenicity and Teratogenicity. Cyclophosphamide is a Category D agent during pregnancy. A report of four pregnant women exposed to cyclophosphamide for systemic lupus resulted in uniform pregnancy loss in all cases.[90] Azoospermia and amenorrhea may also occur with cyclophosphamide use. The risk of amenorrhea has ranged from 27%–60% of women treated, with up to 80% of those so affected manifesting premature ovarian failure.[91] Age and cumulative dose are most determinative of the risk of gonadal failure. In men, testosterone administration may lessen the risk of gonadal failure, whereas in women, leuprolide acetate may provide a similar partial protection.[92,93] Cryopreservation of reproductive material may be used, but it is far more practical and economical for men than women. Cyclophosphamide should not be a first-line therapy for men or women who wish to conceive after treatment.

Drug Interactions. Because the microsomal enzyme system responsible for activation of cyclophosphamide is involved in the metabolism of many other drugs, the potential for multiple drug interactions exists. Allopurinol, cimetidine, and chloramphenicol all increase cyclophosphamide toxicity. The effects of succinylcholine are potentiated by cyclophosphamide. Digoxin absorption is diminished with coadministration of oral cyclophosphamide.

CHLORAMBUCIL

Chlorambucil is another alkylating agent derived from nitrogen mustard. In comparison to cyclophosphamide, chlorambucil is used infrequently in dermatology.

MECHANISM OF ACTION. Like cyclophosphamide, chlorambucil exerts its affects independent of the cell cycle through cross-linking of DNA.

PHARMACOKINETICS. Chlorambucil is well absorbed, with 87% bioavailability after oral administration. The drug is 99% protein bound in plasma. It has a plasma half-life of approximately 1.5 hours. Less than 1% of the drug is excreted by the kidney. Although the drug is extensively metabolized by the liver, it does not require hepatic activation, unlike cyclophosphamide. In comparison to cyclophosphamide, chlorambucil has a slower onset of effect.

INDICATIONS. Chlorambucil is rarely used in dermatology. Isolated reports detail use of chlorambucil as a steroid-sparing agent in pemphigus vulgaris, bullous pemphigoid, primary cutaneous B-cell lymphoma, aggressive pyoderma gangrenosum, and Behçet disease (Box 227-16). Interestingly, chlorambucil use has also been described in erythrodermic cutaneous T-cell lymphoma and necrobiotic xanthogranuloma.[94,95] Complicating management decisions, the US Food and Drug Administration-approved package insert states that chlorambucil should not be used for nonmalignant diseases.

DOSING REGIMEN. Chlorambucil is supplied as 2-mg tablets. The recommended dosage is 0.05–0.2 mg/kg/day. Doses for cutaneous disease should usually remain toward the lower end of this range.

BOX 227-16 USES FOR CHLORAMBUCIL IN DERMATOLOGY

- US Food and Drug Administration-approved indications
  - None
- "Off-label" uses
  - Granulomatosis with polyangiitis (Wegener's)
  - Lymphomatoid granulomatosis
  - Dermatomyositis
  - Scleroderma
  - Relapsing polychondritis
  - Severe cutaneous lupus erythematosus
  - Pemphigus vulgaris
  - Bullous pemphigoid
  - Epidermolysis bullosa acquisita
  - Pyoderma gangrenosum
  - Scleromyxedema/lichen myxedematosus
  - Langerhans cell histiocytosis
  - Mycosis fungoides/Sézary syndrome
  - Necrobiotic xanthogranuloma with paraproteinemia
  - Sarcoidosis
  - Severe disseminated granuloma annulare

INITIATING THERAPY. Patients being considered for chlorambucil therapy should have a thorough history and physical examination. When considering chlorambucil use, patients with a history of a lymphoproliferative disorder must be approached with extreme caution. Use in pregnant or lactating patients is contraindicated. Baseline laboratory evaluations should include a CBC with manual differential, serum chemistry profile, liver function testing, and urinalysis.

MONITORING THERAPY. Blood counts should be repeated weekly initially but may be reduced to biweekly or monthly with time. Liver function testing and urinalysis should continue monthly but may be reduced to every 3 months if stable. Some authorities recommend a chest X-ray every 6 months. Follow-up physical examination should pay particular attention to any evidence of lymphoproliferative disease (lymphadenopathy). Patients taking chlorambucil should have all age-appropriate cancer screening, including stool guaiac examinations and Papanicolaou smears for women. Safety guidelines during chlorambucil therapy are summarized in Box 227-17.

RISKS AND PRECAUTIONS. Absolute and relative contraindications and common adverse effects of chlorambucil are summarized in Box 227-18.

COMPLICATIONS. Chlorambucil is considered the least toxic nitrogen mustard. Common side effects include nausea and vomiting, azoospermia, amenorrhea, pulmonary fibrosis, seizures, and hepatotoxicity.

BOX 227-17 SAFETY MONITORING FOR CHLORAMBUCIL USE

- Initial evaluation
  - Careful history and physical examination
  - Identification of proper patient characteristics and risk factors
  - Survey for interacting medications (vaccinations, other immunosuppressives)
  - Baseline laboratories:
    - CBC with differential/platelets
    - Basic serum chemistry profile
    - Urinalysis
    - Renal function testing (creatinine/ blood urea nitrogen)
- Ongoing laboratory monitoring
  - CBC with differential/platelets and urinalysis
    - Perform weekly initially, then
      - Transition to biweekly or monthly after 2–3 months
      - Perform testing with any dose escalation
      - Decrease/discontinue if white blood cell count <4,000/mm3, or platelets <100,000/mm3
  - Basic serum chemistry and liver function tests
    - Perform monthly initially, then
      - Transition to every 3–6 months if stable

CBC = complete blood cell count.

Chlorambucil increases the risk of lymphoproliferative disorders among transplant recipients. Increased SCC, particularly of the skin, has also been demonstrated in this same population. It is unclear how these risks are manifested when chlorambucil is used

BOX 227-18 RISKS AND PRECAUTIONS WITH CHLORAMBUCIL USE

- Absolute contraindications
  - Hypersensitivity to chlorambucil (can cross-react with cyclophosphamide)
- Relative contraindications
  - Pregnancy/lactation (Category D)
  - Active infection (dependent on severity)
  - Impaired hepatic function
  - Childhood (may have increased risk of seizures)
- Common adverse effects
  - Myelosuppression (often dose-limiting)
  - Gastrointestinal distress (minimized with antiemetic medications)
  - Carcinogenicity (lymphoproliferative disease, squamous cell carcinoma)
  - Reproductive consequences (amenorrhea, azoospermia)

for dermatologic disease. Other cutaneous side effects of chlorambucil include alopecia, a morbilliform rash, urticaria, and mucosal ulcerations. Chlorambucil is a Category D agent during pregnancy, and it is generally avoided in this setting.

Drug Interactions. Through strong immunosuppression, chlorambucil may decrease the efficacy of viral vaccinations. Concomitant use of additional immunosuppressive drugs may potentiate any risk of infection or carcinogenesis.

ANTHRACYCLINES

Anthracyclines are antibiotic molecules that possess potent antineoplastic properties. These agents act specifically during the S phase of cell division. Pegylated liposomal doxorubicin (PLD) (see Fig. 227-1) is an anthracycline sometimes employed in dermatology for the treatment of Kaposi sarcoma.[96,97]

MECHANISM OF ACTION.

Anthracyclines, such as doxorubicin, are intercalated within DNA and RNA. Through template disorder and steric obstruction, this incorporation leads to defective synthesis. Cell death typically results, but mutagenesis and carcinogenesis may also occur.

PHARMACOKINETICS.

PLD has pharmacokinetic properties similar to standard doxorubicin; however, the liposomal formulation results in improved tolerance. Encapsulating liposomes have a diameter of approximately 100 nm and are designed to prevent phagocytosis of the agent by the reticuloendothelial system. The result is a plasma half-life of more than 55 hours and improved tumor penetrance.

INDICATIONS.

PLD is approved by the US Food and Drug Administration for the treatment of acquired immunodeficiency syndrome-related (epidemic) Kaposi sarcoma.

DOSING REGIMEN.

PLD is administered at a dose of 20–30 mg/m^2 infused intravenously over 30–60 minutes once every 2–3 weeks.

INITIATING THERAPY.

A thorough history and physical examination is required before initiation of therapy with PLD. Prior use of anthracyclines is an indication for caution, as additive cardiotoxicity may occur. Physical evidence of existing cardiac failure should be sought. Baseline laboratory studies should include a CBC with manual differential and platelet count, a CD4 count, an HIV viral load assay, and liver function studies, including a total bilirubin.

MONITORING THERAPY.

Before each dose of PLD, all patients should have a repeat blood count, CD4 count, and liver function tests with total bilirubin. Specific tests for cardiotoxicity, such as a multiple-gated acquisition scan, are indicated for cumulative doses greater than 450 mg/m^2 or if signs or symptoms of congestive heart failure develop.

BOX 227-19 RISKS AND PRECAUTIONS WITH DOXORUBICIN USE

- Absolute contraindications
  - Hypersensitivity to anthracyclines
- Relative contraindications
  - Pregnancy/lactation (Category D)
- Common adverse effects
  - Myelosuppression
  - Gastrointestinal distress
  - Toxic hepatitis
  - Hyperpigmentation of the skin and nails

RISKS AND PRECAUTIONS.

Absolute and relative contraindications and common adverse effects of doxorubicin are summarized in Box 227-19.

COMPLICATIONS.

Myelosuppression is the most common side effect of PLD. A nadir in blood counts is expected during the second week of therapy. Any resultant neutropenia should be treated aggressively with granulocyte-macrophage colony-stimulating factor or granulocyte colony-stimulating factor. Characteristically, the HIV viral load does not change substantially during treatment, but CD4 counts may be lowered slightly. Abrupt or precipitous decreases in a CD4 count may be a reason to suspend treatment.

Although it is presumed that PLD has myocardial toxicity, it would appear less cardiotoxic in comparison to nonliposomal forms of doxorubicin. Although many still encourage testing for congestive heart failure with cumulative doses in excess of 450 mg/m^2, multiple studies have shown no adverse cardiac impact with cumulative doses of up to 1,040 mg/m^2. Hepatotoxicity has been described with PLD, and this may be additive to any such toxicity caused by antiretroviral medications. Nausea and vomiting with dosing is also common. Doxorubicin is a Category D agent during pregnancy. It is embryotoxic and an abortifacient and should be avoided in women who are pregnant or who are planning to conceive during treatment.

A small percentage of patients may experience an initial infusion reaction, which typically resolves and does not occur with later dosing. Other cutaneous effects include hyperpigmentation of the skin and nails, alopecia, acral erythema and dysesthesias, urticaria, radiation recall reactions, or a pustular psoriasiform drug eruption.

Drug Interactions. To date, no drug interaction studies have been conducted with PLD, but it is reasonable to conclude it may interact with drugs known to interact with conventional doxorubicin, specifically digoxin, cyclosporine, calcium channel blockers, and ciprofloxacin, to name a few.

Despite continued introduction of highly targeted immunomodulating drugs ("biologics") (see Chapter 234), cytotoxic agents remain as important medications

TABLE 227-6
Summary of Cytotoxic Agents Commonly Used in Dermatology

Drug	Common Indications	Mechanism of Action	Typical Dose	Key Side Effects
Methotrexate	Psoriasis Connective tissue disease	Inhibition of dihydrofolate reductase	10.0–17.5 mg/week	Myelosuppression Toxic hepatitis Liver fibrosis/cirrhosis
Azathioprine	Bullous disorders Connective tissue disease	Forms purine analogues that interrupt DNA/RNA synthesis	0.5–2.5 mg/kg/day (dependent on innate TPMT expression)	Myelosuppression Gastrointestinal distress Increased risk of malignancy
Mycophenolate mofetil	Psoriasis Connective tissue disease	Inhibition of inosine monophosphate dehydrogenase	1.5–2.0 g/day	Gastrointestinal distress Myelosuppression
Thioguanine	Psoriasis	Forms purine analogues that interrupt DNA/RNA synthesis	80–120 mg/day or 120–160 mg 3×/week (dependent on innate TPMT expression)	Myelosuppression
Hydroxyurea	Psoriasis	Inhibition of ribonucleotide diphosphate reductase	1–2 g/day	Myelosuppression Dermatomyositis-like reaction
Cyclophosphamide	Vasculitis Connective tissue disease Advanced cutaneous T-cell lymphoma	Metabolites undergo physiochemical reactions with DNA (alkylation)	1–3 mg/kg/day or 0.5–1.0 g/monthly	Gastrointestinal distress Myelosuppression Hemorrhagic cystitis Bladder carcinogenesis
Chlorambucil	Vasculitis Connective tissue disease	Physiochemical reactions with DNA (alkylation)	0.05–0.2 mg/kg/day	Gastrointestinal distress Myelosuppression Increased risk of malignancy
Doxorubicin (liposomal)	Acquired immunodeficiency syndrome-related Kaposi sarcoma	Intercalation into DNA with termination of synthesis	20–30 mg/m^2 every 2–3 week	Gastrointestinal distress Toxic hepatitis Possible cardiotoxicity Infusion site reactions

TPMT = thiopurine methyltransferase.

in the therapeutic arsenal of dermatologists. Table 227-6 summarizes the major indications, principal mechanism of action, and common toxicities of these agents.

MUCOCUTANEOUS REACTIONS TO CYTOTOXIC AGENTS

Specific cytotoxic agents may be used by dermatologists for treatment of severe and recalcitrant dermatologic disease, but typically only certain agents are employed, and dosages are typically less than those used for other indications. Mucocutaneous reactions to these medications initiated by other providers are commonly seen in patients during consultation. A morphologic approach to those reactions is useful. To this end, subcategories of mucocutaneous reactions to various cytotoxic agents are examined, paying particular attention to those that may provoke characteristic mucocutaneous reactions.

HAIR FOLLICLE COMPLICATIONS

ALOPECIA. One of the most widely recognized cutaneous effects of cytotoxic agents is alopecia, often creating great distress within the patient. Cytotoxin-induced alopecia is typically a form of anagen effluvium caused by interruption of the rapidly dividing cells of the hair matrix. The particular agent, dose, schedule, and route of administration impact the degree of hair loss; yet, at equivalent dosages, intravenous administration is generally more deleterious than oral administration. Numerous cytotoxic agents produce alopecia, but doxorubicin, cyclophosphamide, and vincristine are often implicated (Box 227-20).[98,99]

Cytotoxin-induced alopecia usually begins 2–4 weeks after therapy and may progress for several months. Up to 85%–90% of the hair may be lost; the remaining fraction spared is that normally in telogen. Loss of hair on the scalp and eyebrows is most noticeable, but eyelashes and body hair may be shed as well

BOX 227-20 CYTOTOXIC AGENTS ASSOCIATED WITH ALOPECIA

- Bleomycin
- Busulfan (significant risk of permanent loss)
- Cytarabine
- Dacarbazine
- Daunorubicin
- Docetaxel
- **Doxorubicin**
- Etoposide
- Fluorouracil
- **Hydroxyurea**
- **Methotrexate**
- Nitrogen mustard derivatives (**cyclophosphamide**, **chlorambucil**)
- Nitrosoureas
- Paclitaxel
- Procarbazine
- Thiotepa
- Vinca alkaloids

Agents in **bold** represent a medicine more often employed by dermatologists in treating cutaneous illness.

(Fig. 227-2). The alopecia typically resolves with cessation of treatment, although regrowth may occur with a different color, quality, or texture. Permanent alopecia has occurred most often with high-dose busulfan.[100] Scalp cooling has been used with limited success to minimize hair loss, likely by reducing biochemical activity, but it may create a haven for malignant cells; it remains a controversial intervention, particularly for hematologic malignancies.[98,101] Topical minoxidil shortened the duration of alopecia in breast cancer patients receiving adjuvant chemotherapy and in patients with gynecologic malignancies who received cyclophosphamide, doxorubicin, or cis-platinum, but it did not induce significant regrowth in patients with permanent alopecia due to busulfan or cyclophosphamide.[98,102]

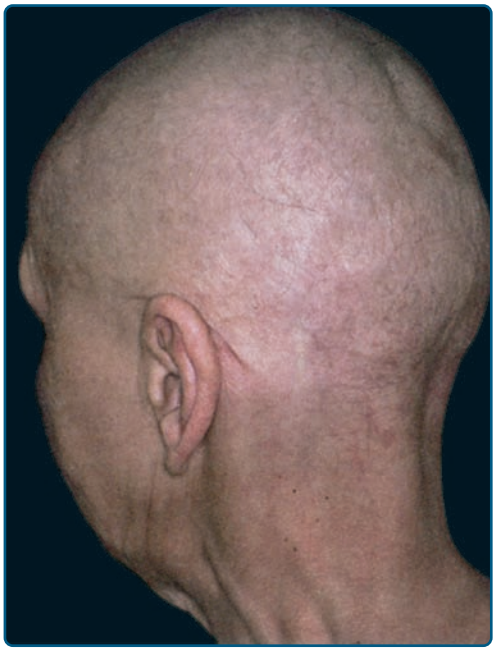

Figure 227-2 Alopecia after the administration of combined chemotherapy with cyclophosphamide, doxorubicin, and vincristine.

FOLLICULITIS ("ACNEIFORM" ERUPTION).

Classic cytotoxin-induced folliculitis begins as erythematous macules, followed in days by the appearance of papules, and then pustules. Lesions predominate on the face and upper trunk. The eruption typically resolves over 2 weeks, but comedones may persist, or postinflammatory hyperpigmentation may result. Simple acne vulgaris may also be aggravated by androgens used in conjunction with chemotherapeutic agents in some multidrug regimens. Folliculitis is most often associated with actinomycin D and less often with methotrexate or cisplatin.[103] Recently, a case of eosinophilic folliculitis with combined therapy with cyclophosphamide, methotrexate, and fluorouracil was reported.[104]

NAIL COMPLICATIONS

MALFORMED NAIL PLATES (DYSTROPHY).

Nail changes are often noted with cytotoxic agents (Box 227-21). Mild nail reactions produce Beau lines. Severe reactions may produce onycholysis or onychomadesis (Fig. 227-3). The great toenail is most often affected.[105] Less common nail problems due to cytotoxic drugs include nail bed pain, thickening or thinning of the nail plate, and splinter hemorrhage or subungual hemorrhage. Anthracyclines (doxorubicin) and taxanes (paclitaxel, docetaxel) most often yield onychodystrophy, with paclitaxel and docetaxel producing nail changes in up to 30%–40% of those treated.[105,106]

NAIL PIGMENTATION.

Cytotoxins may yield leukonychia or hyperpigmentation of the nail plate.

BOX 227-21 CYTOTOXIC AGENTS ASSOCIATED WITH NAIL PLATE MALFORMATIONS (DYSTROPHY)

- Bleomycin
- **Cyclophosphamide**
- Daunorubicin
- Docetaxel
- **Doxorubicin**
- Fluorouracil
- **Hydroxyurea**
- Mitoxantrone

Agents in **bold** represent a medicine more often employed by dermatologists in treating cutaneous illness.



Figure 227-3 Presence of proximal indented Beau line and distal band of leukonychia due to cyclophosphamide 3 months after bone marrow transplantation.

Leukonychia produces a white discoloration in the nail; the mechanism is unknown, but is presumed to be cytotoxic in nature. An excellent example of patterned leukonychia are Mees lines, which were described in 1919 as transverse white lines with arsenic exposure.[107] Cytotoxic agents that most often lead to leukonychia are doxorubicin, vincristine, cyclophosphamide, methotrexate, and 5-fluorouracil.[108]

Nail hyperpigmentation usually develops weeks or months after chemotherapy. Hyperpigmentation of the nail may be oriented longitudinally, horizontally, diffusely, or in a perilunar fashion.[109] Various mechanisms have been proposed, including genetic predisposition, toxic effect on the nail matrix, photosensitization, or focal stimulation of melanocytes. Blacks are more often affected, presumably due to increased numbers of melanocytes within the nail matrix.[110] Cyclophosphamide, doxorubicin, hydroxyurea, and bleomycin are most often implicated in nail hyperpigmentation.[111] Typically, leukonychia or nail hyperpigmentation due to cytotoxic agents resolves with cessation of therapy.

ECCRINE GLAND COMPLICATIONS

NEUTROPHILIC ECCRINE HIDRADENITIS.

Neutrophilic eccrine hidradenitis (NEH) consists of tender, erythematous macules, papules, and plaques on the trunk, neck, and extremities that develop days to months after exposure to cytotoxic agents (Fig. 227-4).[112,113] Lesions resolve spontaneously over a period of days. Histologic changes include a perieccrine neutrophilic infiltrate. Apocrine gland involvement has also been identified.[114] Concentration of the cytotoxic agent within sweat is the likely mechanism of injury. NEH is most often associated with cytarabine, but other agents have been implicated (Box 227-22). A similar condition unassociated with cytotoxic agents is recognized, suggesting the lesions represent a final common pathway of adnexal injury. In a single case report, prophylactic dosing of dapsone prevented NEH in a patient who had had multiple prior eruptions due to lomustine, an alkylating agent.[115]

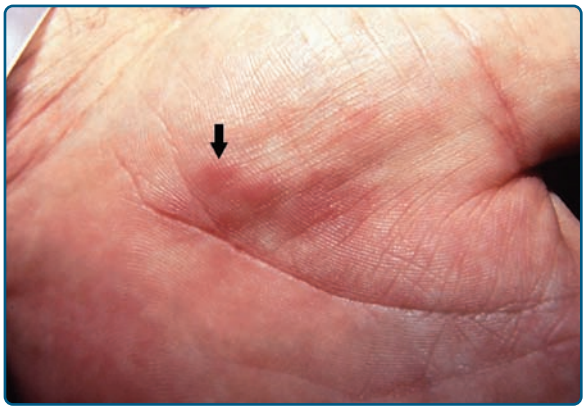

Figure 227-4 Neutrophilic eccrine hidradenitis (*arrow*). (From the Archives of Fitzsimmons Army Medical Center.)

SYRINGOSQUAMOUS METAPLASIA.

Chemotherapy-induced syringosquamous metaplasia (CISM) is closely related to NEH. Like neutrophilic hidradenitis, direct cytotoxic injury of sweat ducts is implicated. Clinically, CISM presents as erythematous papular eruptions, similar to miliaria, which erupt 2–39 days after administration of the cytotoxic agent.[116,117] The papules resolve approximately 4 weeks after discontinuance. Histologic examination demonstrates prominent squamous metaplasia of the upper sweat duct, with necrotic ductal epithelial cells; inflammation is minimal. On occasion, CISM may even mimic SCC.[118] Cytarabine has been most often associated with CISM (see Box 227-22).

BOX 227-22 CYTOTOXIC AGENTS ASSOCIATED WITH ADNEXAL TOXICITY

NEUTROPHILIC ECCRINE HIDRADENITIS	ECCRINE SYRINGOSQUAMOUS METAPLASIA
Bleomycin	Bleomycin
Chlorambucil	Cytarabine (common)
Cytarabine (common)	
Daunorubicin	Daunorubicin
Doxorubicin (common)	**Doxorubicin**
Mitoxantrone	Mitoxantrone
Vincristine	Suramin

Agents in **bold** represent a medicine more often employed by dermatologists in treating cutaneous illness.

EPIDERMAL COMPLICATIONS

CHEMOTHERAPY-INDUCED ACRAL ERYTHEMA. Multiple cytotoxic agents may yield a distinct cutaneous reaction known as *acral erythema*. The reaction usually develops 4–23 days after initiation of chemotherapy as painful, sharply demarcated erythema of the palmoplantar surfaces, with associated edema (Fig. 227-5).[119] In severe cases, large bullae may extend over the dorsum of the hands and feet.[120] Pain may limit ambulation or use of the hands. Therapy is limited mostly to analgesics and emollients, although pyridoxine supplementation may improve dysesthesias. The reaction is self-limited and resolves over 2–4 weeks. Recurrence with subsequent exposure is highly variable. The cause of acral erythema is unknown, but concentration of cytotoxic agents within eccrine structures of acral skin has been proposed. In support of such a theory, coexistent syringosquamous metaplasia has been demonstrated.[121,122] Acral erythema is most common with cytarabine, doxorubicin, fluorouracil, and methotrexate (Box 227-23). Long-term hydroxyurea therapy may produce a unique form of acral erythema that is linear and resembles dermatomyositis, without any corresponding muscle findings (drug-induced pseudodermatomyositis); rarely, the face may be involved.[71,72]

INFLAMMATION OF ACTINIC KERATOSES. A number of different cytotoxic agents and chemotherapeutic protocols yield inflammation of actinic keratoses. Systemic fluorouracil is the most common cause of inflamed actinic keratoses, and this should come as no surprise to dermatologists.[123] The reaction usually develops within 1 week of initiating chemotherapy. The actinic keratoses may resolve or remain after completion of the therapy. A similar reaction within seborrheic keratoses has been reported to occur with cytarabine and may mimic the sign of Leser-Trélat or herpes zoster.[124,125]

CUTANEOUS HYPERPIGMENTATION. Bleomycin may produce a unique form of flagellate (linear) hyperpigmentation of the skin in 8%–66% of those exposed; typically after cumulative doses of 90–285 mg.[126,127] Lesions begin as linear, erythematous, pruritic lesions that are slowly replaced by hyperpigmentation and are present hours to weeks after dosing (Fig. 227-6). The eruption usually resolves without treatment over weeks to months. The pathogenesis is unknown, but some investigators have induced flagellate lesions by rubbing the skin during bleomycin administration; others have been unable to replicate this result. Bleomycin may also produce patchy pigmentation in areas of pressure, within the palmar creases, or within striae distensae. Other unique forms of cutaneous hyperpigmentation are recognized, such as the serpentine supravenous hyperpigmentation that may accompany fluorouracil infusions[128] or the polycyclic bands of pigmentation on the scalp occurring with daunorubicin.[110]

BOX 227-23 CYTOTOXIC AGENTS ASSOCIATED WITH ACRAL ERYTHEMA

- Bleomycin
- **Cyclophosphamide**
- Cytarabine
- Daunorubicin
- Docetaxel
- **Doxorubicin**
- Etoposide
- Fluorouracil
- **Hydroxyurea** (dermatomyositis-like eruption possible)
- Lomustine
- Mercaptopurine
- **Methotrexate**
- Paclitaxel
- Suramin
- Vinblastine

Agents in **bold** represent a medicine more often employed by dermatologists in treating cutaneous illness.



Figure 227-5 Cytarabine-induced painful acral erythema with edema.



Figure 227-6 Flagellate hyperpigmentation occurs 2 weeks after administration of bleomycin.



Figure 227-7 Hyperpigmentation at sites of occlusion during administration of thiotepa.

Numerous antineoplastic drugs may yield other forms of hyperpigmentation, including patchy, acral, photoaccentuated, polycyclic, occlusion accentuated, pressure accentuated (Fig. 227-7), or generalized patterns (Box 227-24).[103] The cause of cutaneous hyperpigmentation is largely unknown. Postulated mechanisms include a direct toxic effect on melanocytes, increased drug deposition due to increased blood flow, local toxicity due to concentration in sweat, associated endocrinologic abnormalities, and drug-induced depletion of tyrosinase inhibitors.[109]

BOX 227-24 CYTOTOXIC AGENTS ASSOCIATED WITH SKIN HYPERPIGMENTATION

DRUG	PATTERN OF PIGMENTATION
Bleomycin	Flagellate
Busulphan	Dusky, may appear similar to Addison disease
Cisplatin	Pressure-induced
Cyclophosphamide	May be localized to palms, soles, or nails
Dactinomycin	Diffuse
Daunorubicin	Sun-exposed areas
Doxorubicin	Diffuse, particularly nails
Etoposide	Occluded areas
Fluorouracil	Sun-exposed areas, areas of prior irradiation, nails
Hydroxyurea	Diffuse, particularly nails
Ifosfamide	Hands, feet, and occluded areas
Methotrexate	Sun-exposed areas, hair may develop "flag sign"
Nitrosoureas	Occluded areas
Paclitaxel	Localized
Plicamycin	Localized
Procarbazine	Diffuse
Tamoxifen	Hair pigmentation
Thiotepa	Occluded areas
Vinca alkaloids	Localized

Agents in **bold** represent a medicine more often employed by dermatologists in treating cutaneous illness.

PHOTOSENSITIVITY. Most chemotherapy-induced photosensitivity is phototoxic rather than photoallergic in nature (Box 227-25; see also Chapter 92). Phototoxic reactions begin rapidly after administration and often mimic sunburns, with burning, erythema, and even vesicles or bullae. Photoallergic reactions typically present as a more eczematous process. Furthermore, photoallergic processes are dependent on sensitization and may be delayed weeks or months after an initial exposure.

RADIATION RECALL REACTION. Recall reactions consist of erythema confined to an area of prior radiation exposure or sunburn. Severe cases may

BOX 227-25 CYTOTOXIC AGENTS WITH RADIATION REACTIONS

- Photosensitivity
  - Dacarbazine
  - Fluorouracil
  - **Hydroxyurea**
  - **Methotrexate**
  - Mitomycin
  - **Thioguanine**
  - Vinblastine
- Radiation enhancement
  - Bleomycin
  - Cisplatin
  - Dactinomycin
  - **Doxorubicin**
  - Fluorouracil
  - **Hydroxyurea**
  - **Methotrexate**
- Radiation recall reaction
  - Bleomycin
  - Cytarabine (common)
  - Dactinomycin
  - **Doxorubicin**
  - Etoposide1
  - Fluorouracil
  - **Hydroxyurea**
  - Lomustine
  - **Methotrexate**
  - Melphalan
  - Mitomycin
  - Paclitaxel
- Sunburn recall reaction
  - **Methotrexate**
  - Suramin

Agents in **bold** represent a medicine more often employed by dermatologists in treating cutaneous illness.



Figure 227-8 Reactivation of solar erythema 2 days after high-dose methotrexate administration to a young woman with choriocarcinoma. (From Bronner AK, Hood AF: Cutaneous complications of chemotherapeutic agents. *J Am Acad Dermatol* **9:**645, 1983, with permission.)

develop vesiculation (Fig. 227-8). True radiation recall may occur years after irradiation, and the pathogenesis is unknown. It has been postulated that radiation-damaged keratinocytes are further damaged by the administration of the cytotoxic agent (see Box 227-25).[129] Methotrexate often engenders a unique recall reaction to sunburn when dosed 1–3 days after exposure, although at least one case occurred as late as 8 days afterward.[130] Folinic acid supplementation (leucovorin rescue) does not prevent UV sunburn recall reactions due to methotrexate.

RADIATION ENHANCEMENT REACTIONS. Radiation enhancement is a synergistic reaction between an antineoplastic agent and irradiation. This radiosensitization is often desired in antineoplastic treatment, but it may lead to adverse effects on the skin. The result may be radiation dermatitis that presents initially as pain and erythema followed by desquamation and hyperpigmentation. Although a number of chemotherapeutic agents may produce this reaction, doxorubicin and dactinomycin are most often implicated (see Box 227-25).[103]

DERMAL COMPLICATIONS

LOCAL INJURY. Extravasation of chemotherapeutic agents may occur in up to 6% of adults treated with infusions and is likely an even more common occurrence among pediatric patients.[109,131] As expected, the degree of injury is related to the drug used, the rate of delivery, the concentration of the agent, and the amount extravasated.

Agents with minimal toxicity on extravasation may produce only a chemical cellulitis or phlebitis and are classified as irritants. Chemical cellulitis manifests as erythema, induration, and pain at the injection site. Sometimes it may follow the course of a vein. It is often of short duration and resolves without treatment.



Figure 227-9 Severe tissue necrosis after extravasation of doxorubicin.

Chemotherapy-induced phlebitis manifests as linear cords, often with accompanying discomfort.

Vesicants are agents, which on extravasation yield direct-tissue necrosis. Chemotherapy-induced tissue necrosis can be a devastating complication. Extravasation should always be treated by immediate discontinuance of the infusion and the application of either hot or cold packs. Cold packs are used for all chemotherapeutic agents except vinca alkaloids to localize the drug and promote degradation. Vinca alkaloids are treated with hot packs because application of cold promotes tissue necrosis.[132] Doxorubicin is perhaps the most dangerous of all vesicants, and extravasation of this agent may yield ulcers that progress for months that may even erode into tendon or bone (Fig. 227-9). Severe ulcerations caused by extravasation may require wide excision and skin grafting.

Other treatments advocated for specific situations include: (1) topical dimethyl sulfoxide (DMSO); (2) local injection of hyaluronidase; or (3) potent topical, intralesional, or oral steroids. DMSO is a topical solvent that has free-radical scavenging and antioxidant properties; it may hasten removal of extravasated drugs. Studies suggest that topical DMSO may have benefit in anthracycline-induced skin ulceration.[133,134] Hyaluronidase degrades hyaluronic acid, breaking down subcutaneous tissue, and promoting drug diffusion through the interstitial space. It appears effective in vinca alkaloid, epipodophyllotoxin, and paclitaxel extravasations, but should not be used in anthracycline extravasation.[135,136] Hyaluronidase is contraindicated in sites involved with malignancy or superinfection. Finally, histologic examination of extravasation injuries has demonstrated surprisingly few inflammatory cells in areas of tissue damage, perhaps explaining why corticosteroids are, in general, of little value in management.[137,138]

SCLEROTIC DERMAL REACTIONS. Bleomycin and docetaxel produce sclerotic tissue reactions that may be localized, regional, or diffuse in extent.[139,140] Localized tissue reactions may mimic morphea or systemic sclerosis. Melphalan has been reported to produce a unique form of reticulate scleroderma

after limb perfusion. The mechanism of tissue sclerosis has not been well established. Biopsies of cytoxin-induced dermal sclerosis may be indistinguishable from morphea or systemic sclerosis. In some cases, the sclerosis resolved after withdrawal of the offending agent.

RAYNAUD PHENOMENON. Secondary Raynaud phenomenon, with or without digital ulceration, is most often associated with bleomycin, vincristine, cisplatin, or cisplatin with gemcitabine.[141–143] This reaction may occur with systemic chemotherapy or after intralesional injection to treat verruca vulgaris. The mechanism of development is unknown, but bleomycin is known to be toxic to endothelial cells. In a large study of 90 patients receiving bleomycin for testicular cancer, 37% developed Raynaud phenomenon, with 7% having transient disease.[141] Risk factors for the development of Raynaud phenomenon include combination therapy with vinblastine or high cumulative doses of bleomycin.

MUCOSAL COMPLICATIONS

Oral complications may occur in up to 40% of those receiving chemotherapy. Because of a high inherent proliferative index, the mucosa is susceptible to the effects of multiple cytotoxic agents. Young patients and those with preexisting oral disease appear even more susceptible.[109]

MUCOSITIS/STOMATITIS. A wide range of cytoxic agents has been implicated in stomatitis (Box 227-26).

BOX 227-26 CYTOTOXIC AGENTS ASSOCIATED WITH MUCOSITIS

- Bleomycin
- **Cyclophosphamide**
- Cytarabine
- Dactinomycin
- Daunorubicin
- Docetaxel
- **Doxorubicin**
- Fluorouracil
- **Hydroxyurea**
- Mercaptopurine
- **Methotrexate**
- Mitomycin
- Nitrosoureas
- Paclitaxel
- Plicataxel
- Plicamycin
- Procarbazine
- Vinblastine

Agents in **bold** represent a medicine more often employed by dermatologists in treating cutaneous illness.



Figure 227-10 Stomatitis induced by combined chemotherapy with cytarabine, doxorubicin, and methotrexate. (Used with permission from Allan C. Harrington, MD.)

Patients with cytoxin-induced stomatitis typically note burning and mucosal erythema days after administration. Painful erosions and ulcerations often follow (Fig. 227-10). The mouth is most often affected, especially the buccal mucosa and tongue, but any mucosal surface may be involved. Mucositis may be complicated by secondary bacterial or fungal infection. Meticulous, but not overly aggressive, hygiene may reduce the incidence of secondary infection, and antibiotics and antifungal agents are often used. A recent meta-analysis of treatments for chemotherapy-induced mucositis found that simple modalities, such as ice chips, had equivalent benefit as more aggressive interventions.[144] Finally, oral hemorrhage may be secondary to chemotherapy-induced thrombocytopenia, and a careful clinical examination is always required.

MUCOSAL HYPERPIGMENTATION. Many cytotoxic agents induce mucosal hyperpigmentation. Mucosal hyperpigmentation may manifest various patterns, including linear, patchy, and macular forms. Some agents tend to affect certain anatomic areas such as the gingival margin (cyclophosphamide) or tongue (fluorouracil). The mechanism of mucosal hyperpigmentation is not well understood. Typically, cytotoxin-induced hyperpigmentation resolves slowly over weeks to months after discontinuance. One notable exception is mucosal hyperpigmentation caused by cyclophosphamide, which may be permanent. Cyclophosphamide may also produce a permanent pigmented band on the teeth.

KEY REFERENCES

Full reference list available at www.DIGM8.com

DVD contains references and additional content

7. Kalb RE et al: Methotrexate and psoriasis: 2009 National Psoriasis Foundation Consensus Conference. *J Am Acad Dermatol* **60**:824, 2009
16. Brownell I et al: Folate with methotrexate: Big benefit, questionable cost. *Br J Dermatol* **157**:213, 2007
46. Menter A: Guidelines of care for the management of psoriasis and psoriatic arthritis: Section 4. Guidelines of

care for the management and treatment of psoriasis with traditional systemic agents. *J Am Acad Dermatol* **61**:451, 2009
47. el-Azhary RA et al: Thioguanine nucleotides and thiopurine methyltransferase in immunobullous diseases: Optimal levels as adjunctive tools for azathioprine monitoring. *Arch Dermatol* **145**:644, 2009
48. Wolverton SE. Optimizing clinical use of azathioprine with newer pharmacogenetic data. *Arch Dermatol* **145**:707, 2009
56. O'Donovan P et al: Azathioprine and UVA light generate mutagenic oxidative DNA damage. *Science* **309**:1871, 2005
57. Perrett CM et al: Azathioprine treatment photosensitizes human skin to ultraviolet A radiation. *Br J Dermatol* **159**:198, 2008
65. de Boer NK et al: 6-Thioguanine for Crohn's disease during pregnancy: Thiopurine metabolite measurements in both mother and child. *Scand J Gastroenterol* **40**:1374, 2005
68. Ranjan N et al: Methotrexate versus hydroxycarbamide (hydroxyurea) as a weekly dose to treat moderate-to-severe chronic plaque psoriasis: A comparative study. *J Dermatolog Treat* **18**:295, 2007
71. Elliott R, Davies M, Harmse D: Dermatomyositis-like eruption with long-term hydroxyurea. *J Dermatolog Treat* **17**:59, 2006
79. Sacher C, Hunzelmann N: Cicatricial pemphigoid (mucous membrane pemphigoid): Current and emerging therapeutic approaches. *Am J Clin Dermatol* **6**:93, 2005
82. Volkmer BG et al: Cyclophosphamide is contraindicated in patients with a history of transitional cell carcinoma. *Clin Rheumatol* **24**:319, 2005
93. Somers EC et al: Use of a gonadotropin-releasing hormone analog for protection against premature ovarian failure during cyclophosphamide therapy in women with severe lupus. *Arthritis Rheum* **52**:2761, 2005
97. DiLorenzo G et al: Activity and safety of pegylated liposomal doxorubicin as first-line therapy in the treatment of non-visceral classic Kaposi's sarcoma: A multicenter study. *J Inv Dermatol* **128**:1578, 2008
98. Trüeb RM: Chemotherapy-induced alopecia. *Semin Cutan Med Surg* **28**:11, 2009
103. Koppel RA, Boh EE: Cutaneous reactions to chemotherapeutic agents. *Am J Med Sci* **321**:327, 2001
109. Susser WS, Whitaker-Worth DL, Grant-Kels JM: Mucocutaneous reactions to chemotherapy. *J Am Acad Dermatol* **40**:367, 1999

Chapter 228 :: Retinoids

:: Anders Vahlquist & Jean-Hilaire Saurat

RETINOIDS AT A GLANCE

- The biologic functions and actions of retinoids (excluding vision) include:
  - Reproduction, embryonic growth, and morphogenesis.
  - Modulation of proliferation and differentiation of epithelia.
  - Decrease in sebaceous gland size (isotretinoin).
  - Immunologic and anti-inflammatory effects.
  - Tumor prevention and treatment.
  - Effect on extracellular matrix components.
- Four types of oral retinoids and the major indications for their use are isotretinoin (acne), alitretinoin (chronic hand eczema), acitretin/etretinate (psoriasis, keratinizing disorders), and bexarotene (cutaneous T-cell lymphoma). Contraindications to their use include pregnancy, breastfeeding, and nonadherence to contraceptive regimen. Retinoids should always be taken with food or milk to enhance intestinal absorption. Dosing once a day is usually sufficient.
- Mucocutaneous side effects (cheilitis, xerosis, skin peeling, conjunctivitis) are common, as are reversible abnormal results on laboratory tests [hyperlipidemia, increased liver enzyme levels, and hypothyroidism (bexarotene)]. Musculoskeletal and central nervous system side effects are rare.

Retinoids include both naturally occurring molecules and synthetic compounds that have specific biologic activities that resemble those of vitamin A or bind to the nuclear receptors for retinoids. Vitamin A from natural sources was already being used in the 1930s in high dosages to treat certain hyperkeratotic diseases, often with toxic side effects. Three generations of synthetic retinoids have since been developed (Fig. 228-1).

First generation: All-*trans*-retinoic acid (tretinoin, ATRA), a naturally occurring metabolite of retinol, was the first retinoid synthesized but had no significant advantages over vitamin A in treatment of dermatologic diseases. It is used as a differentiation-inducing agent to treat acute promyelocytic leukemia.

Isotretinoin (13-*cis*-retinoic acid), clinically available since the 1970s, was found to cause prolonged remissions in patients with previously treatment-resistant cystic acne [it has been approved by the US Food and Drug Administration (FDA) for this indication since 1982].[1]

The latest approved systemic retinoid is alitretinoin (9-*cis*-retinoic acid), which is approved in several

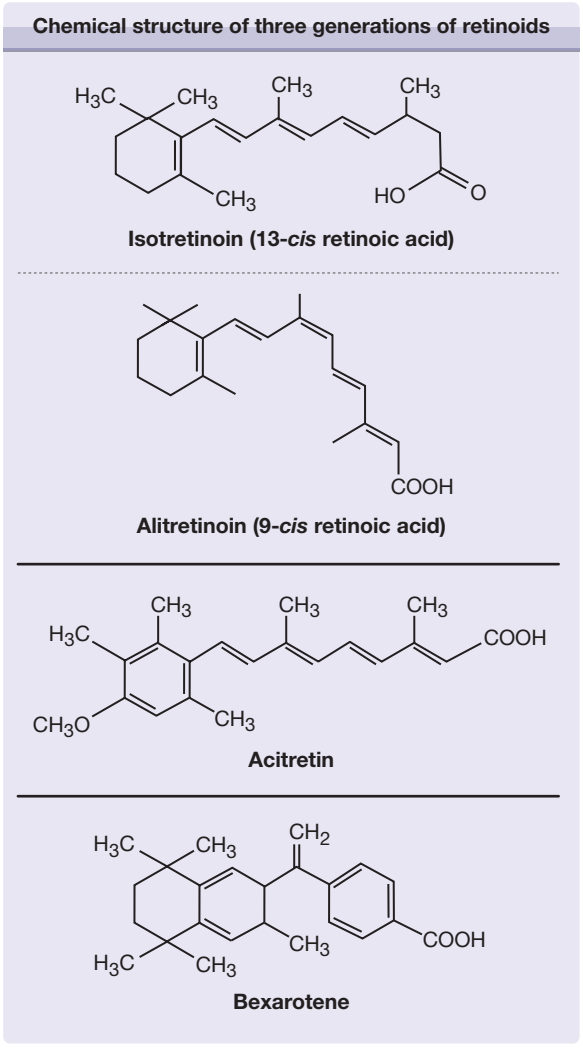

Figure 228-1 Chemical structure of three generations of retinoids. Isotretinoin is first generation; in second-generation (e.g., acitretin) the β-ionone ring, is replaced with an aromatic structure. Bexarotene is an example of a third-generation retinoid.

European countries and Canada for treatment of chronic hand eczema.

Second generation: Through replacement of the β-ionone ring in ATRA with an aromatic structure, newer retinoids with better therapeutic margins were synthesized in the 1970s. Etretinate and its free acid metabolite, acitretin, showed a therapeutic index ten times more favorable than that of ATRA. Etretinate (approved in Europe 1983 and by the FDA in 1987) and acitretin (approved 1987 and 1997, respectively) became a standard treatment for psoriasis. Acitretin has replaced etretinate in most countries, but not in Japan and a few other countries.

Third generation: The discovery of retinoic acid receptors (RARs)[2,3] allowed research directed toward receptor-specific, third-generation retinoids with a safer therapeutic index and a more selective action. Bexarotene, approved by the FDA in 1999 for systemic use in treating cutaneous T-cell lymphoma (CTCL), is a prime example. Bexarotene belongs to a subclass of arotinoids called *rexinoids*, because they bind to the retinoid X receptors (see Section "Bexarotene").

MECHANISM OF ACTION

Retinoids affect cell growth and differentiation, exert immunomodulatory action, and alter cellular adhesiveness.[4] Their effect on RARs is discussed in detail in Chapter 217.

Under normal conditions, virtually all effects of vitamin A in the skin are mediated by ATRA, the cellular level of which is meticulously controlled. Endogenous ATRA has been at the focus in the development of a new class of compounds called *retinoic acid metabolism-blocking agents*, which are basically cytochrome P_{450} (CYP) enzyme 26 inhibitors that impede the oxidative degradation of ATRA and thus increase the retinoid activity in target tissues.[5] Two such drugs (liarozole and rambazole) are under development and are not yet on the market.

PHARMACOKINETICS

Isotretinoin, alitretionin, acitretin/etretinate, and bexarotene differ not only in their spectra of clinical efficacy but also in their toxicities and pharmacokinetics. Due to their lipophilicity, the oral bioavailability of all retinoids is markedly enhanced when they are administrated with food, especially with fatty meals. Retinoids are metabolized mainly by oxidation and chain shortening to biologically inactive and hydrophilic metabolites, which facilitates biliary and/or renal elimination. The oxidative metabolism is induced primarily by the retinoids themselves and other agents that induce hepatic CYP isoforms.[6]

ISOTRETINOIN AND OTHER FIRST-GENERATION RETINOIDS

Isotretinoin, alitretinoin, and ATRA are three partially interconvertible isomers that differ in their elimination half-lives—approximately 20 hours for isotretinoin and 1 hour for ATRA. Isotretinoin undergoes first-pass metabolism in the liver and subsequent enterohepatic recycling. In plasma, isotretinoin is more than 99% bound to plasma protein, mainly albumin. It is stored in neither the liver nor adipose tissue, in sharp contrast to vitamin A and etretinate. The major metabolite is 4-oxoisotretinoin, which has reduced bioactivity; both compounds are excreted in urine and feces. After the end of treatment, endogenous concentrations of isotretinoin and its major metabolite are reached within 2 weeks. Therefore, a 1-month post-therapy period of contraception provides an adequate safety margin.[7] No clear affinity for any RARs has been identified with isotretinoin, whereas ATRA binds to RARs and alitretinoin uniquely binds to both RARs and RXRs.

ACITRETIN AND ETRETINATE

Etretinate is a prodrug of acitretin that undergoes extensive hydrolysis in the body to yield the corresponding acid metabolite. In animal studies and in clinical studies in patients with severe keratinizing disorders, acitretin is as effective as etretinate.[8] However, acitretin has a great pharmacokinetic advantage because it is eliminated more rapidly than etretinate.[9] Etretinate is approximately 50 times more lipophilic than acitretin and binds strongly to plasma lipoproteins, whereas acitretin binds to albumin. This fact has a profound influence on the respective pharmacokinetic properties of the two drugs.

Even when etretinate and acitretin are taken with food, the absorption of the two drugs varies.[10] Etretinate is stored in adipose tissue from which it is released slowly; it has a terminal half-life of up to 120 days. In contrast, acitretin has an elimination half-life of only 2 days.[9] However, small amounts of etretinate can be formed in patients receiving acitretin if it is taken simultaneously with alcohol.[11] This has prompted the manufacturer to extend the time of compulsory contraception in patients taking acitretin to 2 years (3 years in the United States).[12] Acitretin still has a pharmacokinetic advantage over etretinate; however, all women must strictly avoid alcohol consumption during treatment and for 2 months thereafter.[9]

Acitretin metabolism primarily involves isomerization instead of oxidation. The major metabolite of acitretin is its 13-*cis*-isomer, which is inactive. Paradoxically, acitretin activates all three RAR subtypes but binds poorly to them.[13]

BEXAROTENE

Bexarotene is approximately 100-fold more potent in activating retinoid X receptors than RARs. Its absorption is particularly increased by taking it with fatty meals. In plasma, bexarotene is highly bound (more than 99%) to proteins that have not yet been characterized, and the ability of bexarotene to displace drugs bound to plasma proteins and the ability of drugs to displace bexarotene is unknown. Bexarotene probably has a clearance profile similar to that of isotretinoin with a terminal half-life of between 7 and 9 hours.[14] Bexarotene is metabolized by CYP 3A4 and generates its own inactive oxidative metabolites via hepatic CYP 3A4 induction. Neither bexarotene nor its metabolites are excreted in urine; elimination is thought to occur primarily via the hepatobiliary system.[15]

INDICATIONS

ACNE

Isotretinoin is remarkably effective in curing acne, possibly because it affects—primarily or secondarily—all etiologic factors implicated in the pathogenesis of acne: sebum production, comedogenesis, and colonization with *Propionibacterium acnes*.[16] Of all the natural and synthetic retinoids used in humans, only isotretinoin suppresses sebum excretion and reduces sebaceous gland size.

In the early 1980s, isotretinoin treatment was restricted to patients with severe nodulocystic acne. With increasing experience, however, its use has been extended to patients with less severe disease who respond unsatisfactorily to conventional therapies such as long-term antibiotics because of the increased resistance of *P. acnes* to many antibiotics.[17,18]

PSORIASIS

The retinoid of first choice for oral treatment of psoriasis is acitretin. Acitretin appears to be as effective as etretinate and can be used in the same combination regimens.[19–23] The best results have been obtained in pustular psoriasis of the palmoplantar or generalized (von Zumbusch) type.[19,24,25] Rebound does not usually occur after treatment is stopped, and reintroduction of the drug when it does occur produces a beneficial response.[26] Although complete clearing of plaque-type psoriasis is achieved in only approximately 30% of treated patients, significant improvement is obtained in a further 50%.[5,27,28] The decrease in the psoriasis area and severity index is approximately 60%–70%, depending on the dosage.[5,8] Approximately 20% of patients may be considered to experience treatment failures. Combination of acitretin with other antipsoriatic agents may then be required (see Section "Dosing Regimens").

In a 20-week treatment study,[29] six of eleven patients (54%) with HIV infection who had psoriasis showed good-to-excellent responses to acitretin monotherapy (75 mg/day). Both skin and joint manifestations responded to acitretin therapy in most patients. The adverse effects were moderate and well tolerated, and measures of immune parameters did not indicate exacerbation of immunosuppression in most patients.

Isotretinoin has less effect on psoriasis than acitretin or etretinate, although some efficacy has been shown in combination with psoralen plus ultraviolet A light (PUVA) therapy.[12] Nevertheless, some dermatologists use isotretinoin to treat women with psoriasis who need systemic retinoids to avoid the long postacitretin contraception period required.

CHRONIC HAND ECZEMA

Alitretinoin was recently approved in several European countries and in Canada for treatment-resistant chronic hand eczema. Between 3 and 6 months of therapy is usually required to fully appreciate the effect.[30]

Acitretin and etretinate have been used for many years "off-lable" to treat hyperkeratotic (tylotic) hand and foot eczema.

CUTANEOUS T-CELL LYMPHOMA

In 1999, the FDA approved bexarotene as oral therapy for the treatment of CTCL that is refractory to at least

one systemic therapy. In early (IA-IIA) and advanced (IIB-IVB) stages of CTCL (see Chapter 145), oral bexarotene monotherapy produced approximately 60% and 50% response rates, respectively, at a dosage of 300 mg/m^2 or more per day within the first 2 months in most patients.[32,33]

Older studies showed that etretinate may induce clinical improvement in patients with CTCL (e.g., mycosis fungoides or Sézary syndrome) with no internal involvement; better results were obtained when etretinate was combined with PUVA treatment or interferon-α therapy. Use of the combination of acitretin or isotretinoin with oral vitamin D_3 (calcitriol) to obtain synergistic effects in the treatment of CTCL has been reported.[31]

CLINICAL USES NOT APPROVED BY THE US FOOD AND DRUG ADMINISTRATION

Multiple other skin disorders respond to retinoids, but for only a few of them is the effect established in controlled studies.[34] In many reports the choice of etretinate/acitretin rather than isotretinoin was based not on pharmacologic considerations but on availability of the product. Bexarotene and alitretinoin have not been tested extensively for indications other than CTCL and hand eczema, respectively.

ICHTHYOSIS. Among the different types of ichthyosis, the best results are obtained with acitretin for autosomal recessive congenital ichthyoses such as lamellar ichthyosis. Treatment of epidermolytic ichthyosis (bullous ichthyosiform erythroderma) may lead to an initial increase in bullae. Good results also have been achieved in treating recessive X-linked ichthyosis, ichthyosis vulgaris, and palmoplantar keratoderma; if they are of limited severity, these diseases often do not require retinoid therapy (see Chapters 49 and 50).

DARIER DISEASE. Moderate-to-severe forms of Darier disease (Darier-White disease) are good indications for retinoid therapy. Care should be taken to initiate therapy with a low dosage, such as 10 mg/day of acitretin, to prevent initial exacerbation of the disease; usually 20 mg/day is sufficient for significant improvement. Long-term treatment is usually needed to prevent relapse. Low-dose isotretinoin therapy has been used especially in women with Darier disease. Combination of retinoids with antibiotics may enhance the clinical effects, because skin lesions are frequently infected (see Chapter 51).

PITYRIASIS RUBRA PILARIS. Early treatment with retinoids appears to offer the best chance for clearing of pityriasis rubra pilaris. In extensive cases, concomitant use of methotrexate may be advantageous, but this combination carries an increased risk for toxicity. Etretinate is considered to be superior to isotretinoin in the treatment of adult-onset pityriasis rubra pilaris (see Chapter 24).[35]

ROSACEA. In severe forms or in treatment-resistant rosacea, isotretinoin therapy may be more effective for inflammatory lesions than for vascular lesions.[36] A low daily dose (10 mg) is often sufficient. The best indications are severe cases of rosacea associated with significant seborrhea (see Chapter 81).

HIDRADENITIS SUPPURATIVA. Isotretinoin has limited effect on hidradenitis suppurativa, but some investigators recommend this therapy during the weeks or months preceding surgical treatment. Prolonged therapy with acitretin/etretinate has been used with some success, especially in treating extensive, inflammatory lesions unsuitable for surgery (see Chapter 85).[37,38]

PREMALIGNANT AND MALIGNANT SKIN LESIONS. Etretinate and acitretin are effective in the treatment of premalignant skin lesions, including human papillomavirus-induced tumors and actinic keratoses. In basal cell nevus syndrome and in xeroderma pigmentosum, these drugs reduce dramatically the incidence of malignant degeneration of the skin lesions. A double-blind study demonstrated that acitretin at a dosage of 30 mg/day for 6 months prevented the development of premalignant and malignant skin lesions in renal transplant recipients (see Chapters 113, 114, 115 and 116.)[39]

LICHEN SCLEROSUS. Acitretin/etretinate is an effective treatment for severe lichen sclerosus et atrophicus of the vulva and may be recommended intermittently for patients who are intolerant of or resistant to local therapies (see Chapter 65).[40]

LUPUS ERYTHEMATOSUS. Both isotretinoin and acitretin have been used successfully in patients with various forms of lupus erythematosus. However, the lesions recur after completion of treatment as quickly as the initial improvement appeared. Acitretin and hydroxychloroquine are equally effective in the treatment of chronic discoid lupus erythematosus and subacute cutaneous lupus erythematosus (see Chapter 155).[12]

DOSING REGIMENS

(Table 228-1)

ISOTRETINOIN

The initial consensus was that optimal benefit in acne would be achieved with a high daily dose of isotretinoin, approximately 1 mg/kg of body weight per day.[16] This high dose induces undesirable side effects, however, and similar short-term therapeutic results are obtained with a dose below 0.5 mg/kg provided the treatment is maintained over a longer period of time.[41] Empirical data from several centers indicate that post-therapy relapse is minimized by administering a cumulative dose of at least 120 mg/kg,[42] and no

TABLE 228-1
Dosing Regimens (mg/kg/day) of Retinoids in Major Indications

Drug	Indication	Initially	Sustained	Length of Therapy (months)
Isotretinoin	Acne	0.3–0.5	0.5–1.0	4–6
Acitretin	Psoriasis DOK[a]	0.2–0.5 0.3–0.6	0.3–0.8 0.5–1.0	>3 >3
Alitretinoin	hand eczema	10–30[b]	210–30[b]	>6
Bexarotene	CTCL	4–8	2–4 (8)	>2

[a]Lower dosing is recommended for Darier-White disease.
[b]Daily dose in milligrams.

further therapeutic gain is seen beyond approximately 150 mg/kg.[18] This implies 6–8 months of therapy. A lag period of 1–3 months may occur before the onset of the therapeutic effect. A flare-up of disease during the first few weeks of treatment and the evolution of acne cysts into lesions resembling pyogenic granuloma may be observed (see Chapter 80).

Continued healing of acne after the discontinuation of therapy regularly occurs. Approximately one-third of patients with acne require a second course of therapy for either persistent disease or relapse. The only factors predictive of resistance to isotretinoin treatment are the presence of closed comedonal acne and microcystic acne.[43]

ALITRETINOIN

The recommended dose in chronic hand eczema is 10–30 mg/day. Treatment periods of up to 6 months are often needed before a full evaluation of the therapeutic effects can be made (see Chapter 16 and 48).

ACITRETIN AND ETRETINATE

The maintenance dosage in most acitretin-responsive diseases, except Darier-White disease and epidermolytic ichthyosis, is 0.5–1 mg/kg (30–70 mg/day); the treatment is usually continued for at least 3 months. In psoriasis, a therapeutic dosage scheme with an initially low dose (10–25 mg/day) of acitretin (etretinate usually requires 20%–30% higher dosing, partially because of a higher molecular weight), followed by progressively increasing doses, seems to avoid the increase in the extent of the psoriatic lesions that may occur within a few days of the start of treatment at dosages of 0.5–1.0 mg/kg/day.[10]

Although the efficacy of a dosage of 10 mg/day was not significantly different from that of the placebo in one psoriasis study,[10] individual patients may respond to dosages as low as 5 mg/day. Possibly these patients have a reduced pharmacokinetics or increased pharmacodynamics of acitretin as compared to other patients.

Total clearing of the lesions often requires a combination of treatments, such as retinoids plus topical glucocorticoids, topical vitamin D derivatives, dithranol (anthralin), ultraviolet B irradiation, or photochemotherapy (PUVA treatment) (see Chapter 238).[44–48]

BEXAROTENE

The recommended initial dosage of bexarotene is 300 mg/m^2/day, administered as a single oral dose with meals. Based on the severity of adverse effects, the dosage may be adjusted down to 100 or 200 mg/m^2/day, or administration may be suspended temporarily. If CTCL does not respond after 8 weeks of therapy, the dosage may be increased to 400 mg/m^2/day with careful monitoring (see Chapter 145).[32,33]

INITIATION AND MONITORING OF THERAPY

ISOTRETINOIN

Women with childbearing potential must have a negative result on a pregnancy test and must practice effective contraception during treatment and for 1 month (2 months in some countries) after the completion of therapy.[49] The iPLEDGE program (http://www.ipledgeprogram.com) has been put into effect by the FDA and the manufacturer to minimize the risk of isotretinoin teratogenicity. Similar but less strict programs exist in Europe and elsewhere.

ALITRETINOIN

In addition to the usual precautions during systemic retinoid therapy, patients should be asked about headaches and also be screened for thyroid hormone levels.

ACITRETIN AND ETRETINATE

Ensuring that the patient avoids pregnancy during therapy is as imperative when prescribing acitretin and etretinate as when prescribing isotretinoin. However, because of the frequent prospect of long-term

treatment of more chronic diseases (e.g., psoriasis and ichthyosis) and the slow elimination of aromatic retinoids from the body after interruption of therapy, acitretin (or etretinate) therapy is usually not recommended for female patients with childbearing potential.

Additional precautions before initiating acitretin therapy include measurement of baseline serum lipid and liver enzyme levels, and exclusion by history of skeletal abnormalities. It is also important to inform the patient beforehand about the possibility of increased hair shedding and other mucocutaneous side effects that will appear during therapy.

Monitoring of serum lipid and liver enzyme levels for the first 2 months and then at 3-month intervals is adequate in patients with normal baseline levels and absence of risk factors (obesity, high alcohol intake, diabetes).

BEXAROTENE

The recommendations given for the other retinoids should also be followed for bexarotene, and, in addition, patients who will receive bexarotene should be screened for thyroid disease. Thyroid hormone and lipid levels in blood should be monitored frequently during therapy.

RISKS AND PRECAUTIONS

(Table 228-2)

Teratogenesis is the most serious adverse effect of oral retinoids. The side effects of systemic retinoids qualitatively resemble hypervitaminosis A syndrome, although important differences exist. The acute retinoid toxicities include mucocutaneous lesions (most patients) and abnormal laboratory test results (less common but may be substantial), whereas the chronic retinoid toxicities involve bony changes (rare).

TERATOGENIC EFFECTS

Retinoid-induced birth defects include auditory, cardiovascular, craniofacial, ocular, axial and acral skeletal, central nervous system (hydrocephalus, microcephaly), and thymus gland abnormalities.[50] The putative mechanism is toxic effects on neural crest cells, particularly with exposure during the fourth week of gestation.[51]

In men, retinoid therapy does not appear to produce abnormalities in spermatogenesis, sperm morphology, or sperm motility.[52] However, it is usually recommended that men who are actively trying to father children avoid systemic retinoid therapy.

SKIN AND MUCOUS MEMBRANE ADVERSE EFFECTS

Most patients receiving retinoids develop dryness of the lips, skin, and mucous membranes. These dose-related effects reflect mainly decreased sebum production, reduced stratum corneum thickness, and altered skin barrier function. Cheilitis is the earliest and the most frequent sign, followed by blepharoconjunctivitis, dry eyes, dry nose, and dry mouth. Xerosis of the skin, associated with pruritus and peeling, especially of the palms and soles, occurs frequently. Skin fragility and fissuring of fingertips sometimes create a problem, especially for those who work with their hands. Photosensitivity is observed especially with isotretinoin and probably reflects the reduction of thickness of the stratum corneum. Bexarotene appears to induce fewer mucocutaneous and ocular side effects than other classes of retinoids; localized or extensive exfoliative dermatitis is the most common cutaneous side effect with bexarotene.[14] *Staphylococcus aureus* colonization tends to correlate with isotretinoin-induced reduction in sebum production and may lead to overt cutaneous infections.[53] Various ill-defined skin eruptions, called

TABLE 228-2
Adverse Effects of Systemic Retinoids: A Summary

	isotretinoin	Alitretinoin	Acitretin	Bexarotene
Teratogenicity	+	+	+	+
Mucocutaneous	+	+	+	+
Ocular	++	+	+	+
Alopecia	(+)	+	+	+
Headache	+	++	+	+
Musculoskeletal	++	+	+	+
Hepatotoxicity	(+)	(+)	+	+
Neutropenia	–	–	–	+
Hyperlipidemia	++	+	+	++
Hypothyreodism	–	+	–	+

retinoid dermatitis, are observed frequently. The erythema is sometimes difficult to differentiate from an underlying psoriasis or atopic dermatitis.

OCULAR ADVERSE EFFECTS

Blepharoconjunctivitis occurs with varying severity in about one-third of patients treated with isotretinoin and may prevent the use of contact lenses. Bacterial conjunctivitis occurs to a lesser extent than *S. aureus* colonization.[54] If artificial tears and topical ophthalmologic antibiotic therapy fail to alleviate the conjunctivitis, ophthalmologic consultation should be sought. Alterations in visual function, mainly poor night vision, excessive glare sensitivity, and changes in color perception, also have been reported.[55]

HAIR FOLLICLE AND OTHER APPENDEAL COMPLICATIONS

Diffuse or localized hair loss (telogen effluvium), which is more severe during treatment with acitretin than with isotretinoin, is a common complaint, although objective alopecia tends to occur only at higher dosage levels and after several months of therapy. Nail thinning and paronychia-like changes with periungual granulation tissue may occur.

MUSCULOSKELETAL ADVERSE EFFECTS

Skeletal toxicity was first observed in retinoid-treated patients maintained on a high dosage and after an extended period of continuous treatment for disorders of keratinization. Bone pain without objective evidence of any abnormalities and without sequelae is frequent in retinoid-treated patients. Several reports with conflicting results have implicated synthetic retinoids in the formation of diffuse idiopathic skeletal hyperostosis (DISH) syndrome-like bone changes and calcification of tendons and ligaments.[56–58] Prospective studies have shown that the hyperostotic effects of retinoids are mostly asymptomatic and likely involve worsening of pre-existing skeletal overgrowth rather than de novo changes.[59,60] Osteoporosis has been observed with hypervitaminosis A and after long-term therapy with etretinate and to a lesser extent isotretinoin.[61,62] In children, only a few cases of skeletal abnormalities and premature epiphyseal closure[63–65] have been reported. No baseline radiographs are required, although monitoring patients at high risk who receive prolonged high-dose retinoid treatment may be useful.

Muscle pain and cramps rarely occur in patients taking etretinate or acitretin; however, these muscle effects are not infrequent with isotretinoin, particularly in individuals involved in vigorous physical activity (sometimes accompanied by elevations in creatine phosphokinase levels). Increased muscle tone and axial muscle rigidity and myopathy were reported to be related to etretinate and acitretin therapy.[66]

CENTRAL NERVOUS SYSTEM AND OTHER NEUROLOGIC ADVERSE EFFECTS

Central nervous system side effects are rare. Although individual signs of increased intracranial pressure such as headache, nausea, and vomiting are observed occasionally, the complete syndrome with papilledema (pseudotumor cerebri) and impaired vision is exceptional.[67] Concomitant use by isotretinoin-treated patients of tetracyclines, which rarely produce increased intracranial hypertension, is the major risk factor for development of pseudotumor cerebri.

Anecdotal reports suggest a causal association between isotretinoin therapy and severe depression with suicide attempts.[68] However, large-scale epidemiologic studies provide no evidence that isotretinoin exposure is associated with any greater risk of psychiatric disorders than is antibiotic use in patients with acne.[69]

PANCREATITIS

One case of fatal fulminant pancreatitis with acitretin treatment has been reported.[70] Pancreatitis occurred in three patients treated with oral bexarotene, 300 mg/m^2 or more per day, in association with marked elevations of fasting serum triglyceride levels.[32]

HYPOTHYROIDISM

Clinical and biochemical central hypothyroidism occurred in 40% of patients in the trials of bexarotene therapy for CTCL. It was rapidly and completely reversible with cessation of therapy without any clinical sequelae.[32,71] The same adverse effect has been noted with alitretinoin, which is not unexpected since both drugs bind to RXR that dimerizes with the nuclear thyroid receptor.

RENAL ADVERSE EFFECTS

Renal toxicity has not been a characteristic consequence of retinoid administration. Isotretinoin has been administered safely to patients with end-stage kidney disease who were undergoing hemodialysis. However, case reports describing reversible renal function impairment during etretinate therapy advise monitoring of renal function, particularly in patients with a history of renal disorders.[72]

INFLAMMATORY BOWEL DISEASE

In very rare cases, isotretinoin has been linked to exacerbation of inflammatory bowel disease. A 5-year prospective study did not demonstrate an increased risk of inflammatory bowel disease or of cancer, diabetes, or cardiovascular disease in association with long-term etretinate use for psoriasis[70]; similar safety of

long-term acitretin, bexarotene or alitretinoin therapy has not been established.

HYPERLIPIDEMIA

Serum lipid changes are the most frequent abnormalities in laboratory test results seen with retinoid therapy. Depending on the type and dosage of retinoid, triglyceride levels are elevated in 50%–80% and cholesterol levels in 30%–50% of treated patients.[32,56,73] Disturbance of blood lipid levels is generally higher with isotretinoin and bexarotene than with acitretin. In cases of severe retinoid-induced hypertriglyceridemia, eruptive xanthomas and acute pancreatitis may occur. Discontinuation of therapy is required if the triglyceride level reaches 800 mg/dL. A less severe increase may be treated by dosage reduction or reduction in alcohol and tobacco consumption. In some instances, use of lipid-lowering agents may be indicated.[74] Coadministration of atorvastatin with bexarotene is recommended.[14] Retinoids probably cause hyperlipidemia by increasing the expression of apolipoprotein-C3, which prevents the uptake of lipids from very-low-density lipoproteins into cells.[75]

LIVER TOXICITY

Transitory abnormal elevations in serum transaminase levels have been reported in approximately 20% of patients treated with etretinate or acitretin and occur much less frequently with other retinoids. Changes in liver function test results usually occur between 2 and 8 weeks after therapy is begun. Transaminase elevations of more than three times the upper normal range should lead to discontinuation of retinoid therapy. Severe or persistent hepatotoxic reactions occur in fewer than 1% of patients. No cross-reaction with nonaromatic retinoids has been observed. Acitretin therapy elicited no biopsy-proven hepatotoxicity in a 2-year prospective study.[76] No specific studies have evaluated the use of retinoids in patients with hepatic insufficiency, although this is likely to interfere with drug elimination.

HEMATOLOGIC TOXICITY

A high incidence (28%) of dose-related neutropenia has been reported with the use of bexarotene therapy for CTCL, occurring as early as 2–4 weeks after initiation of treatment.[32] Hematologic abnormalities are much less common with other retinoids. Bleeding complications due to isotretinoin-induced fibrinolysis has been reported.[77]

COMPLICATIONS

Most adverse effects associated with retinoids are preventable and manageable with proper patient selection, dosage adjustments, discontinuation of treatment, and routine monitoring for potential toxicity. Absolute contraindications are pregnancy or an attempt to become pregnant, nonadherence to a contraceptive regimen, and breastfeeding. Relative contraindications are leukopenia, alcoholism, elevated cholesterol, or triglyceride levels, significant hepatic or renal dysfunction, and hypothyroidism (bexarotene and alitretinoin).

The concurrent use of retinoids with other therapies having similar side effects may increase the risk of these adverse events. Tetracyclines (increased intracranial pressure, phototoxicity), alcohol (increased conversion of acitretin to etretinate, hepatoxicity), methotrexate (hepatoxicity), and vitamin A supplements (hypervitaminosis A) should be avoided. The concomitant administration of bexarotene and gemfibrozil may result in increased plasma concentrations of bexarotene, at least partially related to CYP 3A4 inhibition by gemfibrozil. In addition, retinoid drug levels may increase with the use of CYP inhibitors such as azoles and macrolides and the CYP competitor cyclosporine, whereas antituberculosis drugs (rifampicin) and anticonvulsants (phenytoin and carbamazepine) actually decrease the drug levels via CYP 3A4 induction.

KEY REFERENCES

Full reference list available at www.DIGM8.com

DVD contains references and additional content

5. van de Kerkhof P, Verfaille C: Retinoids and retinoic acid metabolism blocking agents in psoriasis. In: *Retinoids and Carotenoids in Dermatology*, edited by A Vahlquist, M Duvic. New York, Informa Healthcare, 2007, p. 125
7. Wiegand UW, Chou RC: Pharmacokinetics of oral isotretinoin. *J Am Acad Dermatol* **39**:S8, 1998
9. Wiegand UW, Chou RC: Pharmacokinetics of acitretin and etretinate. *J Am Acad Dermatol* **39**:S25, 1998
18. Cunliffe WJ et al: Roaccutane treatment guidelines: Results of an international survey. *Dermatology* **194**:351, 1997
30. Ruzika T et al Oral alitretinoin (9-cis retinoic acid) therapy for chronic hand dermatitis in patients refractory to standard therapy. *Arch Dermatol* **140**:1453-1459, 2004
33. Duvic M et al: Bexarotene is effective and safe for treatment of refractory advanced-stage cutaneous T-cell lymphoma: Multinational phase II-III trial results. *J Clin Oncol* **19**:2456, 2001
59. van Dooren-Greebe R et al: Prolonged treatment with oral retinoids in adults: No influence on the frequency and severity of spinal abnormalities. *Br J Dermatol* **134**:71, 1996

Chapter 229 :: Antihistamines

:: Robert A. Wood

ANTIHISTAMINES AT A GLANCE

- H_1 are first-line therapy for chronic idiopathic and physical urticarias.
- H_1 may be useful in treating other conditions with histamine-driven pruritus.
- Limited evidence supports the use of H_1 in treatment of atopic dermatitis.
- Certain special patient populations, including children, the elderly, and patients with renal or hepatic impairment, may require dosage adjustments when using H_1 antihistamines.
- The use of H_1 is contraindicated in patients who have narrow angle glaucoma or who are also taking monoamine oxidase inhibitors.
- H_2 antihistamines may be a useful adjunct to H_1 antihistamine therapy in refractory cases of chronic idiopathic urticaria/angioedema and pruritus.

Histamine is a low-molecular-weight amine derived from L-histidine that is produced throughout the body. By means of four known types of receptors, histamine affects cellular growth and proliferation, modulates inflammation, and acts as a neurotransmitter. Both H_1 and H_2 histamine receptors are widely expressed. H_1 receptors are found on neurons, smooth muscle, epithelium and endothelium, and multiple other cell types. H_2 receptors are located in the gastric mucosa parietal cells, smooth muscle, epithelium and endothelium, heart, and other cell types as well. H_3 and H_4 receptors have more limited expression. H_3 receptors are found primarily on histaminergic neurons, whereas H_4 receptors are highly expressed in bone marrow and on peripheral hematopoietic cells.

H_1 ANTIHISTAMINES

MECHANISM OF ACTION

H_1 antihistamines are inverse agonists that reversibly bind and stabilize the inactive form of the H_1 receptor, thereby favoring the inactive state[1] (Box 229-1). The backbone structure of H_1 antihistamines is depicted in Fig. 229-1. By means of the H_1 receptor, H_1 antihistamines decrease production of proinflammatory cytokines, expression of cell adhesion molecules, and chemotaxis of eosinophils and other cells (Fig. 229-2).[2] H_1 antihistamines may also decrease mediator release from mast cells and basophils through inhibition of calcium ion channels. In addition to having antihistamine actions, first-generation H_1 antihistamines can also act on muscarinic, α-adrenergic, and serotonin receptors and cardiac ion channels. Some of the more serious adverse effects associated with first-generation H_1 antihistamines, such as urinary retention, hypotension, and cardiac arrhythmias, are mediated through these other receptors. The first-generation antihistamines are divided into six groups on the basis of chemical structure: (1) ethylenediamines, (2) ethanolamines, (3) alkylamines, (4) phenothiazines, (5) piperazines, and (6) piperidines[3] (see Fig. 229-1). The presence of multiple aromatic or heterocyclic rings and alkyl substituents enhances the lipophilicity of these compounds, which allows penetration of the blood-brain barrier.

Many of the low-sedating or second-generation H_1 antihistamines are chemically derived from first-generation agents.[2] For example, cetirizine is a metabolite of hydroxyzine. The second-generation H_1 antihistamines bind noncompetitively to the H_1 receptor. They are not easily displaced by histamine, dissociate slowly, and have a longer duration of action than first-generation H_1 antihistamines.[3] Due to the selectivity of second-generation drugs for the H_1 receptor and their reduced lipophilicity, these drugs are far less likely to

BOX 229-1 BASIC PHARMACOLOGY OF ANTIHISTAMINES

- Both H_1 and H_2 are inverse agonists that reversibly bind and stabilize the inactive form of the histamine receptor, thereby favoring the inactive state.
- First-generation H_1 are relatively lipophilic, which enhances penetration of the blood-brain barrier and leads to sedation.
- Second-generation, nonsedating H_1 bind selectively to peripheral H_1 receptors and have fewer central nervous system effects.
- H_1 may interact with other drugs metabolized by the hepatic cytochrome P_{450} system.
- Double-blind, placebo-controlled trials show no evidence of the development of tolerance or tachyphylaxis in the suppression of skin test reactivity by H_1.
- Suppression of skin test reactivity may be observed for up to 7 days after discontinuation of a regularly used sedating H_1 antihistamine.

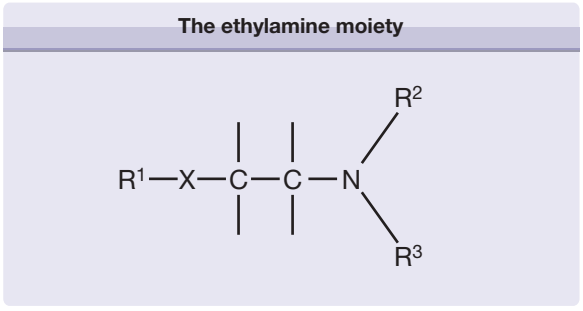

Figure 229-1 The ethylamine moiety is the backbone structure of most of the first-generation H_1 antihistamines. R = aromatic and/or heterocyclic groups; X = linkage such as nitrogen, oxygen, or carbon.

cause sedation and have different safety profiles than the first-generation drugs.

Some low-sedating H_1-type antihistamines affect the trafficking of cells in the skin and other tissues, presumably by modulating the release of inflammatory mediators and the expression of adhesion molecules. In a skin chamber challenge model, cetirizine administration reduced eosinophil influx after allergen challenge. This effect seems to be specific to cutaneous allergic responses, because similar studies involving nasal challenges have not shown any decrease in eosinophil accumulation in nasal secretions. In vitro, cetirizine inhibits eosinophil, monocyte, and T-lymphocyte chemotaxis to *N*-formyl-methionyl-leucyl-phenylalanine and platelet-activating factor.[4] H_1 antihistamines may also modulate the expression of cellular adhesion molecules such as antigen-induced intercellular adhesion molecule 1 on keratinocytes, Langerhans cells, and endothelium, and influence the release of inflammatory mediators from leukocytes.[5] Desloratadine and emedastine were found to inhibit platelet-activating factor-induced eosinophil chemotaxis, tumor necrosis factor-α-induced eosinophil adhesion, and spontaneous and phorbol myristate-induced superoxide generation.[6,7]

PHARMACOKINETICS

SEDATING, FIRST-GENERATION H_1 ANTIHISTAMINES. After oral administration, effects of sedating H_1 antihistamine can be observed within 30 minutes to 1 hour and generally persist for 4–6 hours, although the effects of some agents may last for 24 hours and longer.[8] For example, after oral administration of a single dose, the serum half-lives of brompheniramine, chlorpheniramine, and hydroxyzine exceed 20 hours in adults. H_1 antihistamines are metabolized by hepatic cytochrome P_{450} (CYP) enzyme 3A4, forming glucuronides before excretion in urine.

The potency and relative concentration in the skin of H_1 antihistamines can be compared by their inhibition of the cutaneous wheal-and-erythema response to histamine injected cutaneously. In placebo-controlled,

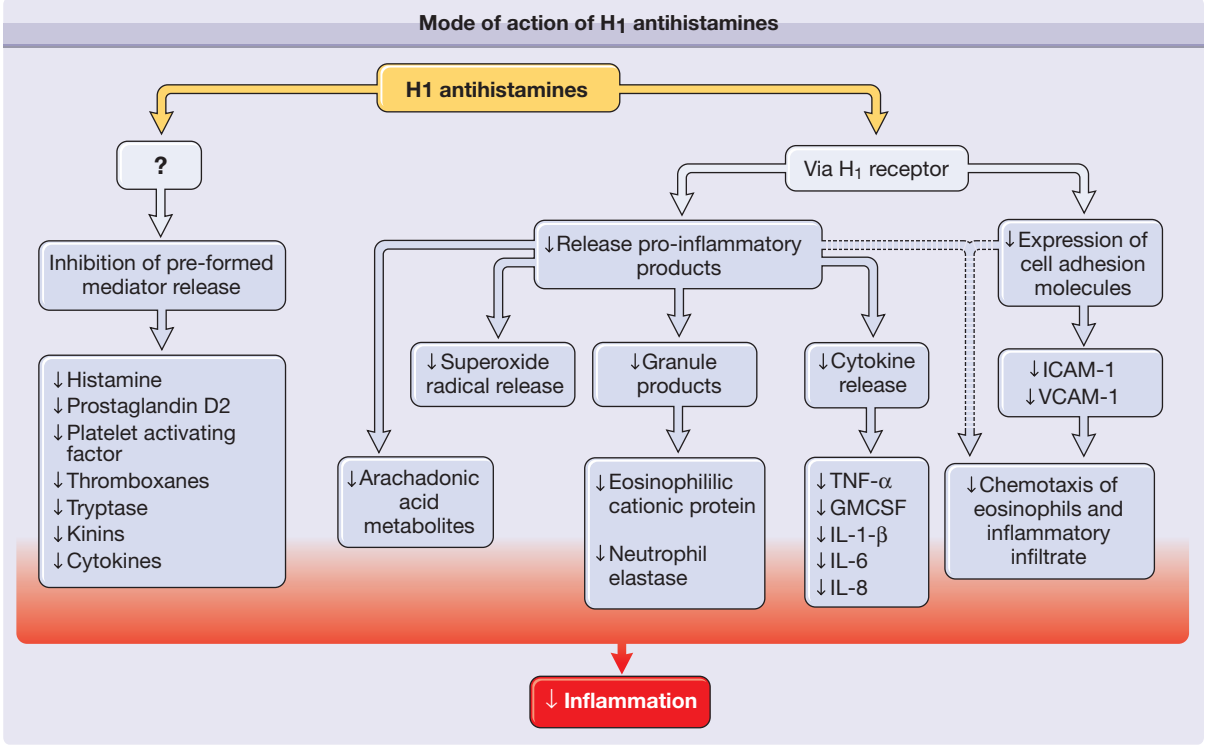

Figure 229-2 Mode of action of H_1 antihistamines. By means of the H_1 receptor, H_1 antihistamines inhibit the release of preformed mediators and decrease the production of proinflammatory cytokines, the expression of cell adhesion molecules, and chemotaxis of eosinophils and other cells. ↓ = decreased; GMCSF = granulocyte-macrophage colony-stimulating factor; ICAM-1 = intercellular adhesion molecule 1; IL-1β, IL-6, IL-8 = interleukin-1β, interleukin 6, interleukin 8; TNF-α = tumor necrosis factor-α; VCAM-1 = vascular cellular adhesion molecule 1.

double-blind studies, no evidence of tolerance or tachyphylaxis was demonstrated in suppression of skin test reactivity over a 3-month period.[2] Suppression of skin test reactivity may be observed for up to 7 days after discontinuation of a regularly used sedating H_1 antihistamine.

Oral sedating H_1-type antihistamines are typically administered in divided doses at intervals of 4–8 hours (see Section "Dosing Regimens"), although once-daily dosing may suffice for agents with longer serum half-lives. Topical formulations for dermatologic use are available, although these preparations tend to be less effective and are associated with the development of delayed contact reactions.

LOW-SEDATING, SECOND-GENERATION H_1 A ANTIHISTAMINES. Most low-sedating, or second-generation, H_1 antihistamines are administered once or twice daily and achieve peak plasma concentrations within two half-lives, although this interval can vary among different drugs and individuals. These drugs generally achieve higher concentrations in the skin than their first-generation counterparts, and a single dose can suppress the wheal and erythema reaction from 1–24 hours.[9–12] Regular use prolongs this effect; for example, 6 days of daily cetirizine use results in 7 days of suppression of the wheal and erythema response.

Terfenadine, astemizole, loratadine, acrivastine, mizolastine, ebastine, and oxatomide are metabolized in the liver via the hepatic enzyme CYP 3A4. Cetirizine, fexofenadine, levocabastine, desloratadine, and levocetirizine undergo minimal hepatic metabolism, which reduces the likelihood of interactions with other drugs.[8]

In healthy adults, cetirizine and levocetirizine reach peak concentrations around 1 hour after administration, with an elimination half-life of approximately 8 hours.[13] Lower dosages are used in patients with impaired renal or hepatic function. Fexofenadine generally reaches peak concentration at 2–3 hours, with an elimination half-life of 14 hours.[13] Dosage adjustment is recommended for patients with decreased creatinine clearance, including the elderly; however, patients with hepatic disease do not require dosage adjustment because fexofenadine undergoes almost no hepatic metabolism.[13] Loratadine's half-life ranges on average from 8–24 hours, depending on hepatic function. Ebastine, which is metabolized to form its carboxylic acid metabolite, carebastine, has a half-life of 15 hours.[13] The dosage should be adjusted in patients with impaired renal function. Pharmacogenetics may also influence drug metabolism and clearance. In a series of pharmacokinetic studies, approximately 7% of all subjects and 20% of African-Americans were slow metabolizers of desloratadine.[14] Comparable differences may exist for other H_1 antihistamines.

INDICATIONS

(Box 229-2)

H_1 antihistamines are used to treat pruritus of various etiologies, urticaria, and angioedema (Box 229-2). In particular, H_1 antihistamines appear to be effective in treating physical urticarias and dermatographism, in addition to chronic idiopathic urticaria. They are not as effective in treating hereditary and acquired angioedema syndromes and urticarial vasculitis. Few well-controlled, blinded studies of the first-generation H_1-type drugs exist. The general tendency for most chronic urticarias to improve with time and the difficulty in making quantitative assessment of the condition further complicate clinical studies. Comparative studies of the groups of H_1-type antihistamines have shown them to be of equal efficacy.[2] If an agent from one therapeutic group of H_1-type antihistamines proves ineffective, then a trial with an agent from another group may be initiated. In several double-blind, placebo-controlled, or parallel studies, the low sedating H_1-type antihistamines terfenadine, astemizole, cetirizine, loratadine, fexofenadine, desloratadine, acrivastine, mizolastine, azelastine, ebastine, and oxatomide were superior to placebo in the treatment of urticaria and angioedema.[15–20] Trials comparing different second-generation antihistamines with one another have not shown any one agent to be consistently superior, although cetirizine and levocetirizine have overall fared best in comparative trials.[2,15,21–24]

Both sedating and low-sedating H_1 antihistamines are used to treat pruritus in patients with atopic dermatitis, although their efficacy has not been proved by rigorous clinical trials. In the 18-month Early Treatment of the Atopic Child study, cetirizine afforded a steroid-sparing benefit to children with the most severe atopic dermatitis, but no consistent benefit was observed in children with more moderate disease.[25] A meta-analysis of 16 studies conducted from 1966 through 1999 does not indicate a major role for either first- or second-generation H_1 antihistamines in the treatment of atopic dermatitis, although no randomized, double-blind, placebo-controlled studies are included in this analysis.[26]

H_1 antihistamines are commonly used to treat cutaneous and systemic mastocytosis, although large comparative treatment trials are not available.[27] One early double-blind, placebo-controlled study demonstrated the efficacy of H_1 and H_2 antihistamines in the treatment of systemic mastocytosis.[28] In a later small trial, azelastine compared favorably with chlorpheniramine in the suppression of pruritus in patients with mastocytosis.[29]

Pruritus associated with other conditions, such as allergic contact dermatitis and other forms of eczematous dermatitis, lichen planus, systemic mastocytosis, mosquito bites, infestations, and pruritus secondary to

BOX 229-2 INDICATIONS FOR TREATMENT WITH H_1 ANTIHISTAMINES

- Acute urticaria
- Chronic idiopathic urticaria
- Physical urticarias and dermatographism
- Atopic dermatitis (less evidence)
- Systemic mastocytosis
- Pruritus associated with other conditions

underlying medical disorders or idiopathic pruritus, also may be relieved by H_1 antihistamines, although controlled trials do not exist.[30] In these conditions, the sedative effects of the first-generation agents may be advantageous, permitting more restful sleep. H_1 antihistamines are also used as pretreatment before certain procedures for patients with a history of radiocontrast media and transfusion reactions.

DOSING REGIMENS

The dosing regimens for H_1 antihistamines are shown in Table 229-1. Doses of second generation antihistamines as high as four times the recommended dosage have been advocated in international guidelines on chronic urticaria[31,32] However, the limited number of published studies evaluating this approach have not demonstrated a clear increase in efficacy.[33]

INITIATION OF THERAPY

The H_1 antihistamines are considered first-line therapy in the treatment of chronic idiopathic and physical urticarias and may be useful in treating other conditions in which histamine-driven pruritus is a major feature. The lowest effective dosage is preferred to minimize dose-related side effects, such as sedation. After several days of therapy, the dosage may be increased and titrated. Occasionally, gradual escalation of dosing permits the development of tolerance to sedation,

TABLE 229-1
Dosing Regimens for H_1 Antihistamines[2,3,8,13,14,28]

Drug	Formulation	Dosage	Conditions Requiring Dosage Adjustment
First-generation H_1			
Chlorpheniramine	2-, 4-, 8-, 12-mg tablet 2 mg/5 mL syrup	Adult: 4 mg tid, qid; 8–12 mg bid Age 6–11 years: 2 mg q4–6h	Hepatic impairment
Cyproheptadine	4-mg tablet 2 mg/5 mL syrup	Adult: 4 mg tid, qid Age 7–14 years: 4 mg bid, tid	Hepatic impairment
Diphenhydramine	25-, 50-mg tablet 12.5 mg/5 mL syrup 50 mg/15 mL syrup 6.25 mg/5 mL syrup 12.5 mg/5 mL syrup	Adult: 25–50 mg q4–6h Age 6–12 years: 12.5–25 mg q4–6h Age <6 years: 6.25–12.5 mg q4–6h	Hepatic impairment
Hydroxyzine	10-, 25-, 50-, 100-mg tablet 10 mg/5 mL syrup	Age ≥6 years: 25–50 mg q6–8h or qhs Age <6 years: 25–50 mg qd	Hepatic impairment
Tripelennamine	25-, 50-, 100-mg tablets	Adult: 25–50 mg q4–6h	Hepatic impairment
Second-generation H_1 antihistamines			
Acrivastine[a]	8-mg tablet	Adult: 8 mg tid	Renal impairment
Azelastine	2-mg tablet[b] 0.1% nasal spray	Adult: 2–4 mg bid Age 6–12 years: 1–2 mg bid 2 sprays/nostril bid	Renal and hepatic impairment
Cetirizine	5-, 10-mg tablet 5 mg/mL syrup	Age ≥6 years: 5–10 mg qd Age 2–6 years: 5 mg qd Age 6 months–2 years: 2.5 mg qd	Renal and hepatic impairment
Desloratadine	2.5-, 5-mg tablet 5 mg/mL syrup	Age ≥12 years: 5 mg qd Age 6–12 years: 2.5 mg qd Age 1–6 years: 1.25 mg qd Age 6–12 months: 1 mg qd	Renal and hepatic impairment
Ebastine[b]	10-mg tablet	Age ≥6 years: 10–20 mg qd Age 6–12 years: 5 mg qd Age 2–5 years: 2.5 mg qd	Renal impairment
Fexofenadine	30-, 60-, 120-, 180-mg tablet	Age ≥12 years: 60 mg qd, bid; 120–180 mg qd Age 6–12 years: 30 mg qd, bid	Renal impairment
Levocetirizine	5-mg tablet	Age ≥6 years: 5 mg qd	Renal and hepatic impairment
Loratadine	10-mg tablet 5 mg/mL suspension	Age ≥6 years: 10 mg qd Age 2–9 years: 5 mg qd	Renal and hepatic impairment
Mizolastine[b]	10-mg tablet	Adult: 10 mg qd	Hepatic impairment

[a]Available in the United States only as a fixed-dose combination with pseudoephedrine hydrochloride, 120 mg.
[b]Not currently available in the United States.

BOX 229-3 FACTORS FOR RISK-BENEFIT ASSESSMENT OF H_1 ANTIHISTAMINE THERAPY

- Risks
  - History of cardiac arrhythmias, particularly ventricular arrhythmias
  - First trimester of pregnancy
  - Prostatic hypertrophy
- Contraindications
  - Narrow-angle glaucoma
  - Concomitant use of monoamine oxidase inhibitors

BOX 229-4 ADVERSE EFFECTS OF H_1 ANTIHISTAMINES

- Sedation (primarily first-generation agents)
- Other central nervous system disturbances
  - Dizziness
  - Tinnitus
  - Blurred vision
  - Irritability or nervousness
  - Insomnia
  - Tremor
- Gastrointestinal complaints
  - Nausea and vomiting
  - Diarrhea or constipation
  - Anorexia
- Anticholinergic effects
  - Dry mucous membranes
  - Urinary retention
  - Postural hypotension
- Cardiac arrhythmias (particularly prolongation of the QT interval, ventricular arrhythmias, torsades de pointes)
- Hypersensitivity reactions (rare)

which allows higher dosages to be used to treat certain conditions, such as refractory chronic urticaria. Ingestion of the medication with food may alleviate any gastrointestinal discomfort, although patients should be advised to avoid taking fexofenadine with antacids, which can interfere with drug absorption. Individuals with comorbid conditions, such as renal or hepatic disease, may require lower dosages due to impaired metabolism of these drugs. Certain special patient populations, including children, the elderly, and pregnant or breastfeeding women, may also need dosage adjustments (see Section "Special Patient Populations"). Some situations may call for more careful assessment of H_1 antihistamine therapy[2] (Box 229-3).

MONITORING OF THERAPY

Therapeutic endpoints are evaluated by observation of clinical signs and symptoms (e.g., severity of pruritus; wheal number, size, and frequency). As for drug toxicity, no particular monitoring beyond the usual surveillance for adverse effects is required in most cases. Certain individuals, such as patients with impaired metabolism or other comorbid conditions and those taking other medications, may require closer monitoring and counseling regarding the use of H_1 antihistamines. Because of reports of hepatotoxicity, some sources recommend periodic liver transaminase evaluation when cyproheptadine is used.[34]

RISKS AND PRECAUTIONS

Adverse effects are listed in Box 229-4. Sedation is the most commonly reported problem, primarily with first-generation H_1 antihistamines.[2,3,8] The sedative effect is more pronounced with the ethanolamine and phenothiazine groups and is less marked with the alkylamine group. The sedative effect may diminish after a few days of continual use of H_1-type antihistamines. If tolerance to sedation does not occur, an agent from another group should be tried. The use of H_1-type antihistamines has been associated with an increase in occupational injuries and automobile accidents.[35] Other central nervous system (CNS) effects include dizziness, tinnitus, disturbed coordination, inability to concentrate, blurred vision, and diplopia. Stimulatory CNS effects, which occur especially with the alkylamine group, include nervousness, irritability, insomnia, and tremor.

Gastrointestinal complaints, including anorexia, nausea, vomiting, epigastric distress, diarrhea, and constipation, are another frequent side effect, especially with the ethylenediamine group.[3] The administration of these agents with food may reduce these manifestations.

Anticholinergic effects include dry mucous membranes, urinary retention and hesitancy, postural hypotension, dizziness, erectile dysfunction, and constipation.[2] These effects are often associated with the ethanolamine, phenothiazine, and piperazine groups. The anticholinergic effects of H_1-type antihistamines preclude their use in patients with narrow-angle glaucoma and require close monitoring in patients with prostatic hypertrophy (see Box 229-3 and Box 229-4).

Arrhythmias, particularly prolongation of the QT interval and torsades de pointes, are the most serious cardiac toxicity.[2,3] These dose-dependent effects are mediated through blockade of potassium channels unrelated to the H_1 histamine receptor. Transient hypotension may develop after intravenous therapy, especially if the drug is administered rapidly.[36]

The occurrence of cutaneous reactions after the administration of oral H_1-type antihistamines is uncommon. Reported reactions include eczematous dermatitis, allergic contact dermatitis, urticaria, petechiae, fixed drug eruptions, and photosensitivity. Some of these reactions may be secondary to excipients in the drug.

Due to the selectivity of the low-sedating H_1 antihistamines for peripheral H_1 receptors, these drugs lack

both the sedative and anticholinergic side effects commonly associated with the first-generation drugs.[37] For the second-generation drugs, sedation is most often reported in a subset of patients taking cetirizine and acrivastine. Although far less sedating than its parent compound hydroxyzine, cetirizine causes sedation in approximately 10%–15% of users.[38] This effect appears to be dose dependent and can often be mitigated by dosing adjustment.[39] Fifteen percent to thirty-five percent of patients report somnolence secondary to acrivastine use.[40] In contrast, fexofenadine, loratadine, and desloratadine cause negligible sedation.[41]

Two early second-generation H_1 antihistamines, terfenadine and astemizole, have been removed from the US market due to risk of QT interval prolongation and torsade de pointes. Other second-generation agents have an approximately 1,000-fold lower affinity for cardiac ion channels, and ventricular arrhythmias have not been associated with later second-generation agents.[2] A theoretical risk remains, however, and may be a consideration before initiating therapy in patients susceptible to tachyarrhythmias.

DRUG INTERACTIONS

The H_1 antihistamines may interact with other drugs metabolized by the hepatic CYP system, such as imidazole antifungals, cimetidine, and macrolide antibiotics.[3] Diphenhydramine, chlorpheniramine, clemastine, promethazine, hydroxyzine, and tripelennamine inhibit the hepatic enzyme CYP 2D6 in vitro.[42] In vivo, diphenhydramine has been noted to increase levels of other drugs metabolized by the CYP 2D6 system, including metoprolol and venlafaxine.[43,44] H_1-type antihistamines are contraindicated for patients receiving monoamine oxidase inhibitors.

Central depressive effects may be accentuated when H_1-type antihistamines are combined with alcohol or other CNS depressants such as benzodiazepines. These interactions are generally not observed with second-generation H_1 antihistamines.[3]

In rare circumstances, antihistamines of the phenothiazine group may block and reverse the vasopressor effect of epinephrine. If individuals receiving a phenothiazine require a vasopressor agent, norepinephrine or phenylephrine should be used.

SPECIAL PATIENT POPULATIONS

CHILDREN. Many of the sedating and low-sedating H_1 antihistamines can be safely used in children with appropriate dosing. Children may be more susceptible to certain side effects associated with first-generation drugs, such as excitation and insomnia. Acute poisoning may develop but is rare; hallucinations, ataxia, incoordination, athetosis, and convulsions are the major features.

ELDERLY. Caution should be used when treating elderly patients, and decreased creatinine clearance, comorbid conditions, and potential drug interactions should be taken into account. Older individuals may also be more susceptible to anticholinergic effects, particularly urinary retention and hesitancy, constipation, and postural hypotension.[3]

PREGNANT WOMEN. There are limited guidelines for the use of H_1 antihistamines to treat pregnant women. Most H_1 antihistamines are classified as US Food and Drug Administration (FDA) pregnancy category B or category C. Based on earlier reports linking H_1 antihistamines to fetal malformations, particularly cleft palate defects, H_1 antihistamines are customarily avoided in the first trimester of pregnancy.[45] However, more recent studies, including a meta-analysis of 200,000 first-trimester exposures to first-generation antihistamines, do not indicate any increased risk of congenital malformations associated with H_1 antihistamine use.[46] In a prospective trial, astemizole administered to pregnant women was not associated with intrauterine growth retardation or perinatal complications.[47] The rate of birth malformations was identical to that in the control group and to that in the general population.

BREASTFEEDING WOMEN. No formal studies have been performed on the safety of H_1 antihistamines during breastfeeding. Theoretically, first-generation drugs may diminish milk supply via anticholinergic effects. Clemastine, diphenhydramine, promethazine, triprolidine, cetirizine, loratadine, fexofenadine, desloratadine, and levocetirizine are all known to be excreted in breast milk; their effects on the nursing infant are not known.[3]

H_2 ANTIHISTAMINES

MECHANISM OF ACTION

Similar to their H_1-binding counterparts, H_2 antihistamines are inverse agonists that bind H_2 receptors located throughout the body, including epithelial and endothelial cells. More recently, there is evidence that H_2 receptors are expressed on mast cells and dermal dendritic cells as well. Through binding of these receptors, H_2 antihistamines may mediate cutaneous vascular permeability, local release of inflammatory mediators and cellular recruitment, and antigen presentation, but these pathways remain poorly understood, and their clinical significance is unknown.

PHARMACOKINETICS

H_2-type antihistamines are rapidly absorbed from the gastrointestinal tract with peak levels occurring between 1 and 2 hours after administration. They undergo extensive hepatic metabolism with renal clearance. Only a small proportion of cimetidine is absorbed from the stomach; most of its absorption occurs in the small intestine. The half-life of cimetidine in plasma is 2 hours. Approximately 69% is excreted unchanged in the urine.[48] The plasma half-life of ranitidine is 2–3 hours in healthy adults, longer in individuals with liver or kidney disease and in the elderly.[49] The drug and

BOX 229-5 DERMATOLOGIC INDICATIONS FOR TREATMENT WITH H_2 ANTIHISTAMINES

- Acute allergic reactions
- Chronic urticaria
- Urticaria pigmentosa and systemic mastocytosis
- Pruritus associated with other conditions

its metabolites are excreted principally in the urine. Famotidine has a plasma half-life of 3–8 hours. In patients with renal failure, the half-life of famotidine may exceed 20 hours.[50] Nizatidine has a plasma half-life of 1–2 hours, and its duration of action is up to 10 hours.[51] Nizatidine is primarily eliminated by the kidneys within 16 hours. The oral bioavailability of nizatidine is not affected by food. These agents are relatively lipophilic with limited penetration of the blood-brain barrier.

INDICATIONS IN DERMATOLOGY

There are few data from controlled studies supporting the use of H_2 blockers to treat dermatologic conditions (Box 229-5). Most often, these agents are used in addition to H_1 antihistamines in refractory cases of chronic urticaria and angioedema. In a double-blind crossover study, greater reductions in pruritus and wheal number, size, and severity were observed with the combination of hydroxyzine and cimetidine than with hydroxyzine alone.[52] Similar observations have been made for chlorpheniramine combined with cimetidine.[53] Combination H_1 and H_2 antihistamine therapy may also be helpful in reducing the pruritus and whealing associated with systemic mastocytosis and urticaria pigmentosa. A double-blind crossover trial of chlorpheniramine and cimetidine suggested that the combination was effective in reducing the pruritus and whealing.[28]

There are anecdotal reports of the use of cimetidine to treat pruritus secondary to various medical conditions such as polycythemia vera[54] and carcinoid flush.[55] High doses of cimetidine were successful in the treatment of verruca vulgaris in some individuals.[56]

DOSING REGIMENS

The dosing regimens for H_2 antihistamines are given in Table 229-2.

INITIATION OF THERAPY

For treatment of dermatologic conditions, H_2 antihistamines are generally used in conjunction with H_1 antihistamines, usually following an unsuccessful trial of H_1 antihistamines alone. In most cases, treatment with H_2 antihistamines may be initiated without any particular laboratory screening. The inhibition of the hepatic CYP system and the potential for drug interactions is usually the greatest concern, and patients' medication lists should be reviewed carefully before initiating therapy. Ranitidine is less inhibitory of the CYP system than cimetidine and may be the preferred H_2 antihistamine in situations in which drug interactions are a particular concern.[49] Patients with decreased creatinine clearance require dosage adjustment.[57] In patients taking the cardiac drug dofetilide, cimetidine is absolutely contraindicated because of the risk of prolongation of the QT interval and life-threatening cardiac arrhythmias.[58]

MONITORING OF THERAPY

Therapeutic endpoints are evaluated by observation of clinical signs and symptoms (e.g., severity of pruritus;

TABLE 229-2
Dosing Regimens for H_2 Antihistamines[42–45]

Drug	Formulation	Dosage	Conditions Requiring Dosage Adjustment
Cimetidine	100-, 200-, 300-, 400-, 800-mg tablet 300 mg/5 mL syrup 200 mg/20 mL syrup	Adult: 400–800 mg bid	Renal or hepatic impairment
Ranitidine	75-, 150-, 300-mg tablet 15 mg/mL syrup 150-mg granules	Adult: 75–150 mg bid Pediatric: 5–10 mg/kg/day divided in two doses	Renal impairment
Famotidine	10-, 20-, 40-mg tablet 40 mg/5 mL syrup	Adult: 20–40 mg bid Age 1–16 years: 1 mg/kg/day Divided in two doses, up to 40 mg bid	Renal impairment
Nizatidine	150-, 300-mg capsule 15-mg/5-mL syrup	Age ≥12 years: 150 mg qd, bid	Renal impairment

BOX 229-6 ADVERSE EFFECTS OF H_2 ANTIHISTAMINES

- Central nervous system disturbances
  - Confusion
  - Headache
  - Dizziness
  - Drowsiness
- Gastrointestinal effects
  - Nausea or vomiting
  - Diarrhea or constipation
  - Abdominal pain
  - Increased transaminases and hepatitis (rare)
- Gynecomastia
- Increased susceptibility to pneumonia
- Hematologic (rare)
  - Thrombocytopenia
  - Anemia
- Hypersensitivity to H_2 (uncommon)
- Drug interactions
- Cardiac effects (with concomitant administration of dofetilide; dofetilide use is therefore a contraindication)

wheal size, frequency, and intensity). As far as drug toxicity is concerned, no particular monitoring beyond the usual surveillance for adverse effects is required in most cases. For patients with a history of thrombocytopenia, a complete blood count may be warranted once H_2 antihistamine therapy is initiated, because thrombocytopenia has been reported as an idiosyncratic effect of these drugs in a few individuals.[59]

RISKS AND PRECAUTIONS

H_2 antihistamines may have several CNS effects, including confusion, headache, and dizziness[60] (Box 229-6). These effects seem to be partly dose related. Other side effects include drowsiness, malaise, muscular pain, diarrhea, and constipation. There are rare reports of granulocytopenia. By their suppression of gastric acid secretion, H_2 antihistamines may facilitate oral infections and increase the risk of pneumonia in immunocompromised individuals, including diabetic patients, the elderly, and patients with immunodeficiency.[61] As a class, these drugs may mask symptoms of gastric carcinoma. Cimetidine and ranitidine both inhibit alcohol dehydrogenase activity, which leads to increased blood alcohol levels.

Uncommon side effects of cimetidine include gynecomastia with or without elevated prolactin levels in men; galactorrhea with elevated prolactin levels in women; and loss of libido, impotence, and reduction of sperm counts in young men.[48,62] Modest elevations in serum creatinine levels and hepatic transaminase levels have both been reported and are reversible after the drug is withdrawn.[49,62] Rare dermatologic adverse effects, including alopecia and urticarial vasculitis, have also been reported.[63]

Ranitidine does not bind to androgen receptors and does not enhance cell-mediated immune responses.[49] Ranitidine may affect physiologic autonomic control of the cardiovascular system by altering parasympathetic and sympathetic control functions.[64] This altered cardiac sympathovagal balance may lead to a susceptibility to arrhythmias, particularly bradyarrhythmias, after intravenous infusion.

Famotidine and nizatidine are associated with few side effects; they also cause less inhibition of the CYP system and therefore are involved in fewer drug interactions.[54,51]

DRUG INTERACTIONS

Through inhibition of the CYP system, cimetidine increases the serum levels of numerous drugs, including some of the most common medications used in the care of the medical patient.[62] Of note, cimetidine increases levels of warfarin and may cause dangerous increases in prothrombin time and risk of bleeding. Cimetidine also interacts with many cardiac drugs—several β blockers, calcium channel blockers, amiodarone, antiarrhythmic agents, among others. As already mentioned (see Section "Initiation of Therapy"), cimetidine use is contraindicated in patients taking dofetilide. Other common drugs with which cimetidine interacts are phenytoin, several benzodiazepines, metformin, sulfonylureas, and selective serotonin reuptake inhibitors.

Although ranitidine interacts with other medications less frequently than does cimetidine, significant interactions with fentanyl, metoprolol, midazolam, nifedipine, theophylline, and warfarin have been observed.[49] Ranitidine may decrease the absorption of diazepam and reduce its plasma concentration by 25%. Famotidine and nizatidine are associated with fewer drug interactions.

SPECIAL PATIENT POPULATIONS

CHILDREN. Of the H_2 antihistamines, ranitidine and famotidine have pharmacokinetics that have been relatively well studied in children, and these drugs have acceptable safety profiles with appropriate dosing. Cimetidine and nizatidine are not recommended for children for uses other than reducing gastric acidity. One adverse effect unique to children is an uncommon but drug class-wide risk of necrotizing enterocolitis in neonates.[65]

ELDERLY. Older patients may require downward adjustment of dosage to accommodate decreased creatinine clearance, as well as careful review of medication lists. Elderly patients also appear more susceptible to CNS disturbances such as confusion and dizziness.

PREGNANT WOMEN. The H_2 antihistamines are classified as FDA pregnancy category B drugs. Cimetidine, ranitidine, famotidine, and nizatidine are all

excreted in breast milk; potential effects on the nursing infant have not been studied.[49–51,62]

OTHER THERAPEUTIC AGENTS WITH ANTIHISTAMINIC ACTIVITY

TRICYCLIC ANTIDEPRESSANTS

Tricyclic antidepressants bind both H_1 and H_2 receptors. The tricyclic antidepressant most commonly used in dermatology is doxepin. Oral doxepin has been used successfully in the treatment of refractory chronic idiopathic urticaria, physical urticaria, and pruritus associated with systemic conditions.[66,67] In a double-blind, crossover study (n = 50), doxepin proved more efficacious than diphenhydramine in the treatment of chronic idiopathic urticaria.[68] Topical preparations are also available. In double-blind, vehicle-controlled trials, topical doxepin cream reduced pruritus in patients with atopic dermatitis and lichen simplex chronicus.[69]

Sedation is the most common adverse effect with both the oral form and the topical form, which is absorbed percutaneously, although some patients may develop tolerance with regular use. Oral doxepin has been classified by the FDA as a pregnancy category C drug; topical doxepin is classified as a pregnancy category B drug.[70] Use of both oral and topical forms is contraindicated during breastfeeding. The safety and efficacy of doxepin therapy in children under the age of 12 has not been established. The drug should be used with caution in elderly patients, who may be more susceptible to its anticholinergic effects, including urinary retention and blurred vision.[66] Doxepin should not be used concurrently with monoamine oxidase inhibitors, and all patients with underlying depression should be closely monitored for signs of suicidal ideation when initiating drug therapy. Doxepin may also cause a sudden increase in intraocular pressure and should not be used in patients with glaucoma.

KETOTIFEN

Ketotifen, a benzocycloheptathiophene derivative, is an H_1-type antihistamine with additional mast cell- and basophil-stabilizing properties.[1] Ketotifen has been used successfully in the treatment of chronic idiopathic urticaria, physical urticaria, and urticaria pigmentosa.[71–73] In a double-blind trial involving 305 patients with chronic idiopathic urticaria ketotifen alleviated pruritus more effectively than clemastine or placebo.[74] More recent studies comparing ketotifen with low-sedating H_1 antihistamines are not available. Results of one early open-label trial suggested that ketotifen not only reduces the pruritus and pain of neurofibromatosis but also slows the growth of neurofibromas[75]; however, these results have not been confirmed by other investigators. Sedation and atropine-like effects are common.[76] There are no studies evaluating the safety of ketotifen in pregnant or breastfeeding women. Ketotifen is available in the United States only as an ophthalmic solution.

MIRTAZAPINE

Mirtazapine is a tetracyclic antidepressant with H_1 antihistamine properties.[67] Several case series have reported its successful use in reducing pruritus attributable to uremia, cholestasis, and various cancers, but it has not been well studied as a primary dermatologic agent. Patients taking mirtazapine require monitoring of blood counts and lipid levels for hyperlipidemia and the rare but serious adverse effects of agranulocytosis and neutropenia. Mirtazapine carries an FDA black-box warning of possible increased risk of suicide, particularly during initiation of therapy, and its concomitant use with monoamine oxidase inhibitors is contraindicated. It is classified as an FDA pregnancy category C drug, and its safety during breastfeeding and in children has not been established.

KEY REFERENCES

Full reference list available at www.DIGM8.com

DVD contains references and additional content

2. Simons FE: Advances in H_1-antihistamines. *N Engl J Med* **351**:2203, 2004
3. Passalacqua G, Canonica GW: Structure and classification of H_1-antihistamines and overview of their activities. In: *Histamine and H_1-Antihistamines in Allergic Disease*, 2nd edition, edited by FER Simons. New York, Marcel Dekker, 2002, p. 65
8. Simons FER, Simons KJ: Clinical pharmacology of H1-antihistamines. In: *Histamine and H_1-Antihistamines in Allergic Disease*, 2nd edition, edited by FER Simons. New York, Marcel Dekker, 2002, p. 141
26. Klein PA, Clark RAF: An evidence-based review of the efficacy of antihistamines in relieving pruritus in atopic dermatitis. *Arch Dermatol* **135**:1522, 1999
31. Zuberbier T et al: EAACI/GA(2)LEN/EDF/WAO guideline: management of urticaria. *Allergy* 64:1427, 2009
32. Powell RJ et al: BSACI guidelines for the management of chronic urticaria and angio-oedema. *Clin Exp Allergy* 37:631, 2007

Chapter 230 :: Antibiotics

:: Christopher C. Gasbarre, Steven K. Schmitt & Kenneth J. Tomecki

ANTIBIOTICS AT A GLANCE

- β-Lactam antibiotics (penicillins and cephalosporins) are mainstays of therapy for the treatment of uncomplicated skin and soft-tissue infections (SSTI).
- Empiric therapy of uncomplicated SSTIs is largely successful.
- Antibiotic resistance is a growing concern. Culture and sensitivity testing may allow for better management of these infections.
- β-Lactam antibiotics (penicillins and cephalosporins) and vancomycin act by inhibition of bacterial cell wall synthesis.
- Several antibiotic classes interfere with bacterial protein synthesis by binding ribosomal subunits: tetracyclines at 30S; lincosamides(clindamycin), macrolides, streptogramins, and oxazolidinones (linezolid) at 50S.
- New agents approved for the treatment of SSTIs include linezolid, quinupristin/dalfopristin, daptomycin, ertapenem, and tigecycline.

Antibiotics are soluble compounds produced by an organism that inhibit bacterial growth; the term also includes synthetic compounds such as fluoroquinolones. The majority of skin and soft-tissue infections (SSTI) are caused by Gram-positive organisms, most of which are susceptible to well-known agents with a relatively narrow spectrum of antimicrobial activity. In these cases, β-lactams, macrolides, and fluoroquinolones have been the mainstays of therapy.[1] Increased use and misuse of these antibiotics has led to selection and propagation of resistant bacteria. Community-acquired resistant pathogens, such as methicillin-resistant *Staphylococcus aureus* (MRSA), have recently emerged as causes of SSTIs such as cellulitis, folliculitis, furunculosis, impetigo, erysipelas, and abscesses. More ominous is the emergence of complicated SSTIs with resistant pathogens, for example, MRSA and vancomycin-resistant *Enterococci* (VRE). Complicated cutaneous infections include those involving deeper tissues, those requiring surgical intervention, or those coincidental with underlying diseases that may complicate therapy. Combination therapy with well-established antimicrobials has been effective in many cases, and new antibiotics have broadened treatment options. However, given the relative paucity of new antimicrobials on the horizon, dermatologists are likely to be faced with growing treatment challenges. Understanding the pharmacologic properties of antibiotics ensures the most judicious use of these agents, and familiarity with antibiotic dosing schedules and adverse events will lead to therapeutic choices that achieve the highest degree of patient compliance.

PENICILLINS

MECHANISM OF ACTION

One of the oldest and largest groups of antibiotics, penicillins are members of the β-lactam family.[6] All penicillins have a nucleus composed of a thiazolidine ring and β-lactam ring, which is required for antibiotic activity. Different side chains alter activity and resistance to degradation, but all β-lactams share a similar bacteriocidal mechanism of action. They bind to specific penicillin binding proteins (PNBs), inhibit cell-wall peptidoglycan synthesis, and inactivate an inhibitor of autolytic enzymes present on bacterial cell walls.

There are several groups of penicillins, largely separated by their chemical structure and resistance to bacterial degradation. The natural penicillins exhibit the narrowest spectrum of activity and are susceptible to enzymatic degradation by β-lactamases. Penicillin G is the most useful drug in this group. Administered parenterally, it is active against *Streptococcus*, *Neisseria meningitidis*, *Clostridium* sp., spirochetes, *Pasteurella multocida*, *Eikenella corrodens*, *Erysipelothrix rhusiopathiae* and non-β-lactamase producing *Staphylococci*. Penicillin G is the treatment of choice for *Treponema pallidum* infection in all forms. Penicillin V is the oral form of the drug and is generally less potent than Penicillin G because of lower achievable blood levels.

Aminopenicillins (ampicillin, amoxicillin), carboxypenicillins (carbenicillin, ticarcillin), and ureidopenicillins (piperacillin) provide a broader spectrum of activity. All of these semisynthetic agents are susceptible to β-lactamase. Aminopenicillins are oral agents and have limited activity against *Staphylococci* and enteric organisms. They are routinely used for infections of the upper airway, head, and neck (bronchitis, sinusitis, otitis), and have no activity against *Pseudomonas* sp. Carboxypenicillins have some activity against *Pseudomonas* sp. and *Proteus* sp., and are often administered with aminoglycosides for the treatment of serious pseudomonal infections. The ureidopenicillins have a similar Gram-positive profile. Derived from ampicillin, they have greater activity against Gram-negative bacteria than the carboxypenicillins. Amoxicillin, ticarcillin, and piperacillin are often coupled

with β-lactamase inhibitors to enhance activity against *S. aureus*. β-Lactamase inhibitors include tazobactam, clavulanic acid, and sulbactam, and work best against β-lactamases encoded on plasmids.

The final group of penicillins (oxacillin, dicloxacillin, and nafcillin) are inherently β-lactamase resistant and exhibit excellent activity against *S. aureus*; they have no activity against *Enterococci* or enteric Gram-negative organisms. β-lactamase-resistant penicillins remain an excellent choice for empiric therapy of uncomplicated SSTIs such as folliculitis, impetigo, furunculosis, and cellulitis where community-acquired MRSA is not suspected.

PHARMACOKINETICS

Absorption of oral penicillins is variable and depends on each compound's acid stability and amount bound to food. Most oral penicillins should be taken at least 1 hour before or 1 hour after meals. Absorption of amoxicillin is unaffected by food. Unabsorbed penicillin is degraded by gastrointestinal flora. Penicillin G, nafcillin, carbenicillin, ticarcillin, and piperacillin are poorly absorbed and unstable at low pH; as such, they are administered parenterally. Penicillins are widely distributed in body fluids and tissues, but areas of poor availability include the cerebrospinal fluid, prostate, and intraocular fluid. These drugs do not typically cross the blood-brain barrier, but can reach effective levels in patients with meningitis due to increased meningeal permeability. Natural penicillins can interact with amines (such as procaine and benzathine) to form salts with relatively low solubility; administered intramuscularly, penicillin is released more slowly, prolonging drug delivery. Most free penicillin is excreted renally. Penicillins are excreted in breast milk in low quantity, and are considered safe to use during breastfeeding. Indications are listed in Box 230-1.

DOSING REGIMEN

(See Table 230-1)

BOX 230-1 INDICATIONS FOR PENICILLIN THERAPY

- Syphilis and nonvenereal treponematoses
- SSTIs caused by *Streptococcus* sp. (erysipelas, scarlet fever, impetigo, etc.)
- Erysipeloid
- Anthrax (if sensitive)
- Lyme disease (where tetracyclines are contraindicated)
- Actinomycosis
- Listeriosis
- Leptospirosis
- Infected human and animal bites

Dosing adjustment for patients with renal insufficiency is necessary.

RISKS AND PRECAUTIONS

(See Box 230-2)

COMPLICATIONS

(Table 230-2)

Hypersensitivity reactions are the most common adverse events reported with penicillins.[7] Reported incidence varies from 0.7%–10%, and manifestations range from mild to severe (Table 230-2). Penicillin hypersensitivity is probably overreported by patients, but 2%–4% of true allergic reactions are life threatening. For true penicillin-allergic patients, treatment warrants use of another class of antibiotic. If penicillin allergy is uncertain and if penicillin treatment is required, skin prick testing may be performed to detect type I hypersensitivity, followed by intradermal testing if negative. Negative testing may be followed by a challenge dose of oral penicillin under observation. Approximately 10%–20% of patients with a history of "penicillin allergy" have a positive skin test, and approximately 3% of those with a negative skin test and a history of allergy have an allergic response after a challenge dose of penicillin. These reactions tend to be mild. Patients with positive skin tests can undergo desensitization therapy when a β-lactam must be given.

CEPHALOSPORINS

MECHANISM OF ACTION

Cephalosporins are β-lactams with the same mechanism of action as penicillins, i.e., they inhibit bacterial cell-wall synthesis by blocking peptidoglycan incorporation.[8] Cephalosporins differ structurally from penicillins by their dihydrothiazine ring versus the thiazolidine ring of penicillins. Most cephalosporins have some activity against both Gram-positive (excluding *Enterococci*) and Gram-negative organisms, though the spectrum of activity varies widely among the group. The cephalosporins are comprised of four "generations" based on spectrum of activity and evolution of development. The first generation includes cephalexin, cefadroxil, and the parenteral agents cefazolin and cephalothin, all of which have good activity against methicillin-sensitive *S. aureus* and *Streptococcus* sp. and limited activity against Gram-negative organisms; for example, *Escherichia coli* and *Klebsiella* sp. The second generation includes cefprozil, cefaclor, cefuroxime axetil, and the parenteral agents cefotetan, cefoxitin, and cefuroxime, offering expanded Gram-negative activity over the first generation agents, specifically against *Hemophilus influenzae* and *Moraxella catarrhalis*. Third generation agents include cefdinir, cefditoren, and the parenteral agents cefotaxime, ceftriaxone, ceftazidime, and

TABLE 230-1
Dosing Regimens of Commonly Prescribed Antibiotics for the Treatment of SSTIs

Class	Generic Name	Route	Adult Dosing
β-Lactam	penicillin G	IM, IV	2–24 million units qd divided q 4 hours[a] (18–24 million units qd for neurosyphilis)
	benzathine pen G	IM	2.4 million units ×1 (early syphilis)[a] 2.4 million units weekly × 3 (syphilis >1 year)
	dicloxacillin	PO	500 mg q 6 hours
	nafcillin	IM, IV	IM: 500 mg q 4–6 hours IV: 0.5–2 g q 4–6 hours
	oxacillin	IM, IV	1–2 g q 4–6 hours
	amoxicillin	PO	500 mg q 8 hours[a]
	amoxicillin/clavulanate	PO	875 mg q 12 hours[a]
	cephalexin	PO	500 mg q 6 hours
	cefdinir	PO	300 mg q 12 hours
	cefprozil	PO	250 mg q 12 hours
Tetracycline	tetracycline	PO	500 mg q 6 hours (bid for acne)[a]
	doxycycline	PO	100 mg q 12–24 hours[a]
	minocycline	PO	100 mg q 12 hours[a]
Macrolide	erythromycin base	PO	500 mg q 6 or 12 hours
		IV	1 g q 6 hours[a]
	clarithromycin	PO	250–500 mg q 12 hours
	azithromycin	PO	500 mg on day 1, then 250 mg qd × 2—5 Chlamydia: 1-g single dose
		IV	500 mg q 24 hours
Fluoroquinolone	ciprofloxacin	PO, IV	gonorrhea: 500 mg × 1[b] gonococcemia: 500 mg q 12 hours × 7 days[c] chancroid: 500 mg q 12 hours × 3 days cutaneous anthrax: 10–15 mg/kg q 12 hours ×60 days
	levofloxacin	PO, IV	uncomplicated: 500 mg q 24 hours[a] complicated: 750 mg q 24 hours[a]
Lincosamide	clindamycin	PO	150–450 mg q 6 hours
		IV	600–900 mg q 8 hours
Trimethoprim-sulfamethoxazole (cotrimoxazole)		PO	180 mg/ 800 mg (DS) q 12 hours[a]
		IV	5 mg/kg q 6–8 hours[a]

[a]Adjustments in dose or frequency of administration may be required in patients with renal impairment.
[b]CDC recommendations for the treatment of gonococcal urethritis/cervicitis include concomitant therapy with azithromycin or doxycycline.
[c]Following a single dose of 1-g ceftriaxone IM/IV.

cefoperazone. They exhibit an expanded spectrum of activity against Gram-negative pathogens, but are less effective against Gram-positive organisms. As such, they are extremely helpful for Gram-negative nosocomial infections. Cefotaxime and ceftriaxone cross the blood-brain barrier and are effective treatment for meningitis caused by *H. influenzae*, *N. meningitidis*, and penicillin-sensitive *S. pneumoniae*. Ceftazidime and cefoperazone are active against *Pseudomonas aeruginosa*, and cefdinir and cefditoren are useful in the treatment of SSTIs due to their activity against *S. aureus* as well as *Streptococcus* sp. The only "fourth generation" cephalosporin available in the United States is cefepime, a parenteral agent with good activity against a broad spectrum of Gram-positive and Gram-negative organisms, including *P. aeruginosa*.

BOX 230-2 RISKS AND PRECAUTIONS OF PENICILLIN THERAPY

- Known hypersensitivity to penicillin
- Increased penicillin levels with probenecid and disulfiram
- Enhanced effect of methotrexate and warfarin

PHARMACOKINETICS

Cephalosporins are a chemically diverse class of antibiotics with unique pharmacokinetic and pharmacodynamic properties. Most orally administered

TABLE 230-2
Adverse Events

Antibiotic Class	Pregnancy Class	Common Adverse Effects	Uncommom Adverse Effects
Penicillins	B	Hypersensitivity reactions: Exanthem, urticaria Diarrhea	Hypersensitivity reactions: Exfoliative dermatitis, SJS, vasculitis, AGEP Angioedema, anaphylaxis, serum sickness Anaphylactoid reaction Hepatitis, interstitial nephritis Neurotoxicity (high dose) Pulmonary infiltrate with eosinophilia (PIE) Immune-mediated hematologic reactions Pseudomembranous colitis
Cephalosporins	B	Hypersensitivity as above Diarrhea	Hypersensitivity as above Renal tubular necrosis Disulfiram-like reaction (specific) Thrombophlebitis (IV site) Serum sickness-like reaction (cefaclor, cefprozil) Pseudocholelithiasis (ceftriaxone)
Tetracyclines	D	Skin and nail hyperpigmentation (minocycline) Dental hyperpigmentation (infants, children) Gastrointestinal irritation	Photosensitivity (doxycycline) Photo-onycholysis Fixed drug eruption Pseudotumor cerebri Esophageal erosion/stricture Skeletal hypoplasia Serum sickness Renal toxicity Vestibular toxicity (minocycline) Fanconi Syndrome (outdated tetracycline) Thyroid discoloration SJS, TEN Pancreatitis Blood dyscrasias (long-term use) Hypersensitivity reactions (various) Pseudomembranous colitis
Fluoroquinolones	C	Nausea, vomiting Cephalgia, dizziness	Exanthem, photosensitivity Delerium, seizure Tendon rupture, arthropathy (in the immature) QT prolongation Hepatitis (trovafloxacin-withdrawn from United States)
Trimethoprim-sulfamethoxazole	C	Exanthem, photosensitivity Nausea, vomiting, anorexia Glossitis, stomatitis (Rare/ severe reactions are more common in HIV/AIDS patients)	SJS, TEN, vasculitis, urticaria Pustular eruption, Sweet syndrome Cholestatic hepatitis, hepatic necrosis Blood dyscrasias Severe hypersensitivity reaction Cephalgia, hallucination, tremor Nephrolithiasis, interstitial nephritis
Lincosamides (Clindamycin)	B	Diarrhea Exanthem, urticaria	Pseudomembranous colitis Erythema multiforme, SJS, TEN Elevated hepatic transaminases (reversible) Blood dyscrasias Neuromuscular blockade
Macrolides	B/C	Nausea, diarrhea, abdominal pain Dysguesia (clarithromycin)	Cholestatic hepatitis Pseudomembranous colitis Prolonged QT/Torsade de points Anaphylaxis SJS

AGEP = acute generalized exanthematous pustulosis, SJS = Stevens-Johnson Syndrome, TEN = toxic epidermal necrolysis.

BOX 230-3 INDICATIONS OF CEPHALOSPORIN THERAPY

- Uncomplicated SSTIs due to *Staphylococcus aureus* and *Streptococcus pyogenes* (first- and second-generation agents, plus cefdinir and cefditoren)
- Gonorrhea
- Lyme disease (ceftriaxone: meningitis and late disease; cefuroxime: early disease)
- Bacterial meningitis (ceftriaxone, cefotaxime)

cephalosporins can be taken without food. The esterified cephalosporins (cefuroxime and cefpodoxime) should be taken with food to prolong mucosal contact time since they require enzymatic cleavage in the intestinal tract. Agents that lower the gastric pH may also reduce absorption of these two drugs. Cefaclor is an extended release formulation and should similarly be given with food. Most cephalosporins are renally excreted. Cephalosporins are excreted in breast milk to varying degrees. First, second, and third generation cephalosporins are compatible with breastfeeding, and excretion in breast milk occurs in varying degrees.

INDICATIONS

(See Box 230-3)

DOSING REGIMEN

(Table 230-1)

RISKS AND PRECAUTIONS

(See Box 230-4)

COMPLICATIONS

(Table 230-2)

BOX 230-4 RISKS AND PRECAUTIONS OF CEPHALOSPORIN THERAPY

- Known hypersensitivity to cephalosporin or penicillin (see Section "Complications")
- Reduced absorption of cefdinir with antacids and iron salts
- Increased cyclosporin levels with ceftriaxone and ceftazidime
- Altered effect of warfarin with cefotetan, cefamandole, cefoperazone, cefixime, and cefaclor
- Impaired renal excretion of most cephalosporins with probenecid

Cephalosporins cross-react with penicillin in up to 20% of penicillin allergic patients, with most reactions occurring between penicillins and first- or second-generation cephalosporins.[9] The common β-lactam ring is responsible for the shared mechanism of action and some antigenic cross-reactivity, and the respective side chains for hypersensitivity reactions. Cephalosporins and penicillins with similar side chains are more likely to produce a cross-reactive hypersensitivity reaction in penicillin allergic patients. Cefoxitin, cefamandone, cefaloram, cephalothin, and cephaloridine have side chains structurally similar to penicillin, while cefaclor, cephalexin, cefprozil, cephradine, and cefadroxil have side chains similar to amoxicillin or ampicillin. Some oral agents that lack side chain similarity to penicillin, ampicillin, or amoxicillin include cefdinir, cefpodoxime, cefditoren, and cefuroxime, and these agents may be safer for use in patients reporting a penicillin class allergy. Patients reporting a penicillin allergy with a negative penicillin allergy skin test have no greater risk of an allergic reaction to β-lactams than the general population. Cephalosporins, due to their greater variety of metabolite structures than other β-lactams, are able to elicit cephalosporin-specific allergic responses.

TETRACYCLINES

MECHANISM OF ACTION

Tetracyclines inhibit bacterial protein synthesis by binding to the 30s ribosomal subunit and blocking transfer RNA binding to the mRNA-ribosome complex.[10] Doxycycline and minocycline are semisynthetic second-generation tetracyclines most commonly used in dermatology. More lipophilic, they generally exhibit greater activity than tetracycline, especially versus *S. aureus* and community-acquired strains of MRSA.[11] As a class, tetracyclines have a broad spectrum of activity, including many Gram-positive and Gram-negative bacteria, spirochetes, *Mycoplasma, Rickettsia, Chlamydia*, and some protozoa. Doxycycline is preferred therapy for the treatment of infections due to *Borrelia* sp., *Brucella* sp., *Chlamydia* sp., *Ehrlichia sp.* (monocytic and granulocytic ehrlichiosis), *Calymmatobacterium granulomatis* (granuloma inguinale), *Coxiella burnetii* (Q fever), *Leptospira* sp., *Mycoplasma* sp., *Rickettsia* sp., and *Francisella tularensis*. It is also treatment for infections caused by *Actinomyces* sp., *Bacillus anthracis*, *Mycobacterium marinum*, and *Vibrio vulnificus*. In patients allergic to penicillins, doxycycline is commonly used to treat animal bites and syphilis. Tetracyclines can be helpful for the treatment of acne, rosacea, perioral dermatitis, autoimmune blistering disease (bullous pemphigoid, linear IgA bullous dermatosis, and dermatitis herpetiformis), and confluent and reticulated papillomatosis (Gougerot-Cartaud), probably because of their anti-inflammatory properties.

PHARMACOKINETICS

Tetracycline is incompletely absorbed primarily in the stomach and small intestine, necessitating its ingestion on an empty stomach. Doxycycline and minocycline are unaffected by the presence or absence of food and have longer half-lives than tetracycline, requiring less frequent dosing. They also have much greater lipid solubility than tetracycline, allowing for excellent tissue penetration, with rapid availability in secretions of the prostate, respiratory tract, female reproductive tract, and bile. Nonetheless, patients should avoid concurrent ingestion of iron preparations, aluminum hydroxide gels, calcium and magnesium salts, or milk products, as these significantly lower absorption of the entire class. Tetracycline is excreted primarily by the kidneys, and patients with renal failure require dosing adjustment. Doxycycline is excreted in the feces and no adjustments for renal or hepatic failure are necessary. Minocycline is largely metabolized before excretion, but does not accumulate in patients with hepatic failure. Tetracyclines cross the placenta and appear in high concentrations in breast milk. Because of their ability to accumulate in developing bone and teeth, their use during pregnancy, while nursing, and throughout childhood should be avoided.

INDICATIONS

(See Box 230-5)

DOSING REGIMEN

(Table 230-1)

BOX 230-5 INDICATIONS FOR TETRACYCLINE THERAPY

- Actinomycosis
- Animal bites (*Pasteurella multocida*)
- Anthrax (*Bacillus anthracis*) infections
- Bacillary angiomatosis
- *Borrelia* sp. infections
- *Chlamydia* sp. infections
- Ehrlichiosis
- Lyme disease
- MRSA infections
- *Mycobacterium marinum*
- *Nocardia* sp. infections
- Rhinoscleroma
- Rickettsial diseases
- Syphilis (penicillin-allergic granuloma inguinale patients)
- Tularemia
- *Vibrio vulnificus* infections
- *Yersinia pestis* infections

BOX 230-6 RISKS AND PRECAUTIONS OF TETRACYCLINE THERAPY

- Patients with renal failure (impaired excretion and antianabolic properties)
- Photosensitivity (doxycycline)
- Nursing, pregnancy, and childhood years (<9 years of age)
- Impaired absorption by calcium, magnesium, aluminum (other cations), iron, sodium bicarbonate, and cimetidine
- Increased metabolism of doxycycline with the use of phenytoin, carbamazepine, barbiturates, and alcohol
- Reduced insulin requirements in diabetic patients
- Increased serum levels of digoxin, lithium, and warfarin
- Methoxyflurane anesthesia (renal failure)

RISKS AND PRECAUTIONS

(See Box 230-6)

COMPLICATIONS

(See Table 230-2)

CLINDAMYCIN

MECHANISM OF ACTION

Clindamycin is a lincosamide antibiotic derived through chemical modification of lincomycin.[12] Its absorption and spectrum of activity are better than its predecessor, which is now obsolete. Clindamycin binds to the bacterial 50s ribosomal subunit and inhibits protein synthesis through blockade of peptide chain initiation. The binding site overlaps the sites of other antibiotics that bind the 50s subunit such as macrolides (erythromycin), accounting for the antagonism noted between the drugs. Clindamycin facilitates opsonization and phagocytosis and decreases bacterial adhesion (to host cells) and production of staphylococcal exotoxin. Persistent binding at the 50s subunit leads to prolonged antibiotic effect in some organisms. Drug resistance by mutation at the 50S ribosomal binding site.

Clindamycin is effective against most Gram-positive cocci, anaerobes, and some protozoa. In dermatologic practice, it is active against most *Streptococcus* species (including *S. viridans*), methicillin-sensitive *S. aureus*, and *S. epidermidis*. Its anaerobic spectrum of activity includes *Peptococci*, *Peptostreptococci*, propionibacteria, *Clostridium perfringens*, and fusobacteria. *Toxoplasma gondii* is often effectively treated with combinations including clindamycin. It is ineffective against strains of *Enterococcus* and JK group corynebacteria.

BOX 230-7 INDICATIONS FOR CLINDAMYCIN THERAPY

Uncomplicated SSTIs due to susceptible bacteria and protozoa (see Mechanism of Action)

- Deep tissue infections: streptococcal myositis, necrotizing fasciitis, or infections with *Clostridium perfringens* in conjunction with surgical debridement
- Surgical prophylaxis in penicillin allergic patients
- Prophylaxis for recurrent staphylococcal infection
- Diabetic foot ulcers (in combination with agents for Gram-negative infection)
- Hidradenitis suppurativa
- Bacterial vaginosis

PHARMACOKINETICS

Clindamycin is not inhibited by food intake and reaches therapeutic levels in most tissue except cerebrospinal fluid. The drug preferentially accumulates in polymorphonuclear leukocytes, which may explain its benefit as treatment for abscesses. Clindamycin is primarily metabolized by the liver and excreted in the bile, though 10% is excreted in the urine. Dosing adjustments are necessary for patients with hepatic failure or combined hepatic and renal failure. It is not removed by dialysis.

INDICATIONS

(See Box 230-7)

DOSING REGIMEN

(Table 230-1)

RISKS AND PRECAUTIONS

(See Box 230-8)

COMPLICATIONS

(Table 231-2)

Clindamycin frequently causes gastrointestinal upset and diarrhea (2%–20% of patients), and may occasionally cause pseudomembranous colitis attributed to *Clostridium difficile*, a life-threatening complication reported in 0.1%–10% of patients. Despite its classic association with clindamycin, pseudomembranous colitis may occur following administration of virtually any antibiotic. Treatment includes discontinuation of the drug and administration of metronidazole.

BOX 230-8 RISKS AND PRECAUTIONS OF CLINDAMYCIN THERAPY

- Hepatic failure
- Enhancement of neuromuscular blockade with tubocurare and pancuronium
- Possible antagonism with erythromycin

MACROLIDES

MECHANISM OF ACTION

Erythromycin is the prototypical macrolide antibiotic; derivatives include dirithromycin, clarithromycin, and azithromycin. All are bacteriostatic and inhibit bacterial protein synthesis by reversibly binding the 50s ribosomal subunit. Structural modifications of clarithromycin and azithromycin confer increased acid stability, tissue penetration, and spectrum of activity.[13] The macrolides have good but varied activity against Gram-positive pathogens: clarithromycin > erythromycin > azithromycin. Streptococcal resistance to macrolides is fairly common (up to 40% of group A isolates), and *S. aureus* may be variably susceptible to erythromycin. Streptococcal resistance to macrolides is class-wide rather than drug specific. Erythromycin has poor activity against most Gram-negative pathogens, but azithromycin and clarithromycin have good activity against *H. influenzae, N. gonorrhoeae, M. catarrhalis, Chlamydia, Mycoplasma pneumoniae, H. pylori, Toxoplasma gondii, Treponema pallidum, Borrellia burgdorferi,* and nontuberculous mycobacteria. Azithromycin has good activity against *Pasteurella multocida* and *Eikenella corrodens*, making it a useful alternative in the treatment of infected bites. Clarithromycin is the most active macrolide against *M. leprae* and is widely used for skin infections with several other nontuberculous mycobacteria, notably *M. chelonae, M. abscessus*, and *M. fortuitum*.

PHARMACOKINETICS

Macrolides accumulate intracellularly in polymorphonuclear leukocytes and macrophages, and in part account for their activity against intracellular pathogens. Erythromycin base is absorbed in the small intestine and inactivated by gastric acidity, hence its availability as enteric-coated tablets or capsules. (Food lowers gastric pH and may delay absorption.) Erythromycin esters (erythromycin estolate, stearate, and ethylsuccinate) are less acid labile than the base form. Except its extended-release formulation, which should be given with food, clarithromycin may be given with or without food. Tissue concentrations of macrolides typically exceed plasma levels. Concentrations of erythromycin in breast milk are approximately 50% of maternal serum levels. Erythromycin can cross the placenta, but except clarithromycin (pregnancy category C), the macrolides are category B. Clarithromycin and azithromycin have longer half-lives, allowing for less frequent dosing (Table 230-1). Azithromycin remains in tissue longer and accumulates at high levels intracellularly (tissue fibroblasts) allowing for daily short-term dosing after a loading dose. Clarithromycin is metabolized by

BOX 230-9 INDICATIONS FOR MACROLIDE THERAPY

- Uncomplicated SSTIs (folliculitis, erysipesas, cellulitis, etc.)
- *Bartonella* infections (except Orroyo fever-*Bartonella bacilliformis*)
- Bites—animal and human *(Pasteurella multocida, Eikenella corrodens*—azithromycin)
- Lyme disease
- Chlamydia
- Nontuberculous mycobacterial skin disease (clarithromycin)

the liver and excreted by the kidneys. Patients with renal failure require dosing adjustments. Adjustments are not necessary for erythromycin, azithromycin, or dirithromycin, which primarily undergo hepatic metabolism. Erythromycin and clarithromycin interact with the cytochrome P-450 system, which can prompt numerous potential drug interactions (see Risks and Precautions). Erythromycin and clarithromycin inhibit CYP 3A4, and erythromycin also inhibits CYP 1A2.

INDICATIONS

(See Box 230-9)

DOSING REGIMEN

(Table 230-1)

RISKS AND PRECAUTIONS

(See Box 230-10)

BOX 230-10 RISKS AND PRECAUTIONS OF MACROLIDE THERAPY

- CYP 3A4 inhibition-
  - Increased drug toxicity (increased serum levels)
    - Warfarin, carbamazepine, buspirone, benzodiazepines, corticosteroids (methylprednisolone), HMG CoA reductase inhibitors, oral contraceptives, cyclosporine, tacrolimus, disopyramide, felodipine, ergot alkaloids
- CYP 1A2 inhibition-
  - Increased drug toxicity (increased serum levels)
    - Theophylline, omeprazole
- Other
  - Digoxin (levels elevate due to change in drug metabolism by gut flora)
  - Fluconazole (increased clarithromycin levels)

COMPLICATIONS

(See Table 230-2)

FLUOROQUINOLONES

MECHANISM OF ACTION

Fluoroquinolones are fluorinated derivatives of the first quinolone, nalidixic acid.[14] They act by inhibiting the action of bacterial topoisomerases II (DNA gyrase) and IV, leading to impaired DNA replication, transcription, and repair. In Gram-positive organisms, the primary target is topoisomerase IV; in Gram-negative bacteria the target is topoisomerase II. Agents available in the United States are ciprofloxacin, levofloxacin, ofloxacin, moxifloxacin, and gemifloxacin.[15,16] Fluoroquinolones have a broad spectrum of activity, with appreciable bacteriocidal activity against a variety of Gram-negative organisms including *Salmonella, Shigella, Enterobacter, Campylobacter*, and *Neisseria*. Ciprofloxacin is most active against *Pseudomonas aeruginosa*. As a class, the fluoroquinolones have limited anaerobic activity, but the newer agents gemifloxacin and moxifloxacin exhibit lower MICs against these organisms. These newer fluoroquinolones have better activity against Gram-positive organisms. Moxifloxacin, in particular, has been approved for the treatment of uncomplicated SSTIs. Some of the newer fluoroquinolones (levofloxacin, moxifloxacin) exhibit good activity against *Streptococcus*, but often develop resistance to *S. aureus* rapidly. They should not be first line therapy for uncomplicated SSTIs, but they should be instrumental in the treatment of complicated, polymicrobial, and/or Gram-negative infections such as diabetic ulcers or deep tissue infections. Ciprofloxacin and levofloxacin are effective agents for gonorrhea, chlamydia, erysipeloid, granuloma inguinale, and chancroid (see Indications). Ciprofloxacin, ofloxacin, levofloxacin, moxifloxacin, and gatifloxacin are effective against some *Mycobacterium* species including *M. tuberculosis, M. chelonae, M. fortuitum*, and *M. kansasii*, though available data are limited.

PHARMACOKINETICS

Fluoroquinolones are rapidly absorbed after oral ingestion with a large volume of distribution. Food does not inhibit absorption. Unlike β-lactams, fluoroquinolones act in a concentration-dependent manner and can be administered twice daily. Most are excreted by the kidneys, and adjustments for renal failure are usually necessary. Moxifloxacin is eliminated in the liver by conjugation with glucuronide and sulfate. None of the fluoroquinolones are removed by dialysis. Most are excreted in breast milk in small and almost negligible quantities, but rare side effects have occurred in breast-feeding infants. Ciprofloxacin has been associated with phototoxicity, pseudomembranous colitis, and green teeth upon eruption. Norfloxacin is not found in the

BOX 230-11 INDICATIONS FOR FLUOROQUINOLONE THERAPY

FIRST-LINE THERAPY

Anthrax
Skin and soft-tissue infections (SSTIs) due to Gram-negative pathogens (see Mechanism of Action)
Pseudomonas aeruginosa infections[a] (otitis externa, ecthyma gangrenosum, SSTI)
Rhinoscleroma

SECOND-LINE THERAPY

Bartonella sp.infections
Chancroid
Chlamydia
Ehrlichiosis
Erysipeloid
Gonorrhea
Granuloma inguinale
Rickettsia sp.
Vibrio vulnificus infections

[a]ciprofloxacin

breast milk of mothers taking the drug, while ofloxacin and levofloxacin are excreted in smaller quantities than ciprofloxacin. Ciprofloxacin and ofloxacin are compatible with breastfeeding according to American Academy of Pediatrics guidelines.

INDICATIONS

(See Box 230-11)

DOSING REGIMEN

(Table 230-1)

RISKS AND PRECAUTIONS

(See Box 230-12)

BOX 230-12 RISKS AND PRECAUTIONS OF FLUOROQUINOLONE THERAPY

- Decreased bioavailability with antacids (aluminum, magnesium, alum), iron, zinc, and sucralfate
- Inhibited theophylline/aminophylline metabolism (ciprofloxacin)
- Arthropathy in studies of immature animals
- Tendon rupture (in patients with renal disease, hemodialysis, or steroid use)
- Decreased seizure threshold
- Decreased warfarin and cyclosporin metabolism

COMPLICATIONS

(See Table 230-2)

TRIMETHOPRIM/ SULFAMETHOXAZOLE

MECHANISM OF ACTION

Trimethoprim/sulfamethoxazole (cotrimoxazole) is a combination of trimethoprim (TMP) and sulfamethoxazole (SMX) in a 1:5 ratio. Both compounds inhibit nucleic acid synthesis by inhibiting two enzymes in the bacterial tetrahydrofolic acid synthesis pathway. Together, these compounds exhibit synergistic action that is relatively specific to bacterial cells.

TMP/SMX is a broad-spectrum antibiotic with good activity against many aerobic Gram-positive cocci including *S. aureus*, *S. pyogenes*, and *S. viridans*; it is often effective in the treatment for community-acquired MRSA.[11] Other susceptible pathogens include: *H. influenzae, E. coli, Proteus mirabilis, Klebsiella pneumoniae, Shigella, Yersinia, and Brucella*. While *Pseudomonas aeruginosa* is resistant, other *Pseudomonas* species and *Stenotrophomonas maltophilia* are generally sensitive. TMP/SMX can be effective therapy for infections with *Nocardia* and atypical mycobacteria. The drug has no activity against anaerobes.

PHARMACOKINETICS

TMP and SMX are well absorbed but achieve different serum concentrations following administration of equal quantities of drug. A serum ratio of 1:20 (TMP:SMX) is necessary for optimal synergy against the largest variety of pathogens, which can be achieved by administration of the drug in a fixed 1:5 ratio. Both compounds are rapidly distributed to tissues, including the CSF and sputum. Excretion is via the kidneys.

INDICATIONS

(See Box 230-13)

DOSING REGIMEN

(Table 230-1)

BOX 230-13 INDICATIONS FOR TMP-SMX THERAPY

- Community-acquired MRSA
- *Nocardia asteroides* infections
- Uncomplicated SSTIs due to susceptible pathogens (see Mechanism of Action)
- Granuloma inguinale; chancroid

BOX 230-14 RISKS AND PRECAUTIONS OF TMP-SMX THERAPY

- More severe reactions in patients with HIV/AIDS
- Prolonged prothrombin time in patients on warfarin
- Contraindicated in patients on methotrexate

RISKS AND PRECAUTIONS

(See Box 230-14)

COMPLICATIONS

(Table 230-2)

NEWER OR LESS COMMONLY USED AGENTS

While the aforementioned compounds comprise the vast majority of antibiotics used in dermatologic practice, several new or infrequently used medications bear mentioning for the treatment of complicated SSTIs or systemic infections due to resistant pathogens.[17] In many hospitals, these drugs have restricted use, predicated on approval by an infectious disease specialist.

VANCOMYCIN

Vancomycin (Vancocin) is a glycopeptide antibiotic effective against Gram-positive bacteria only; specifically Gram-positive infections resistant to β-lactams or when their use is contraindicated.[18] In dermatology, vancomycin has been a first-line therapy for complicated and/or severe SSTIs due to hospital-acquired MRSA. In recent years, vancomycin-resistant isolates of *S. aureus* and *Enterococcus faecium* have been isolated. Vancomycin inhibits bacterial-cell-wall peptidoglycan synthesis. Dosing is determined by the patient's weight (15–20 mg/kg), and frequency of administration by the patient's creatinine clearance. As such, renal function requires monitoring during therapy. Potential adverse reactions include nephrotoxicity, ototoxicity, phlebitis at the injection site, hypersensitivity reactions, and leukopenia. "Red man syndrome," secondary to histamine release, is an uncommon reaction, thought to be due to drug impurities. More refined preparations and slower infusions minimize this reaction. Drug-induced linear IgA disease is a rare cutaneous side effect. Two new glycopeptides, dalbavancin and oritavancin, are currently in clinical trials for the treatment of SSTIs.

LINEZOLID

Currently the only available oxazolidinone, linezolid (Zyvox) is currently approved by the FDA for the treatment of complicated SSTIs due to MRSA, as well as other drug-resistant Gram-positive infections including vancomycin-resistant *Enterococcus faecium* (VRE) and vancomycin-resistant *S. aureus* (VRSA).[19] Its spectrum of activity includes Gram-positive organisms (including anaerobes), as well as nontuberculous mycobacteria such as *M. chelonae* and *M. fortuitum*. Largely bacteriostatic, linezolid inhibits the initiation of protein translation by binding to the 23S portion of the 50S ribosomal subunit, a unique mechanism of action which minimizes cross-resistance to other antibiotics. Nonetheless, linezolid-resistant enterococcal infections have occurred. Though renally excreted, dosing adjustments for renal failure are not necessary. Linezolid is generally well tolerated, but reversible thrombocytopenia and leucopenia occur in approximately 2% of patients, which seems to correlate with duration of therapy. This dictates monitoring of complete blood counts during therapy. Dosing for complicated infections is 600 mg twice daily, usually intravenously at first. The ability to convert to oral administration makes this drug an attractive option.

QUINUPRISTIN/DALFOPRISTIN

Quinupristin/dalfopristin (Synercid) is a streptogram in antibiotic combination in a fixed 60:40 ratio.[17] Both quinupristin and dalfopristin irreversibly inhibit bacterial protein translation by binding to different sites on the 50s ribosomal subunit. They exhibit synergistic, largely bacteriocidal activity against a variety of multidrug-resistant Gram-positive organisms including MRSA and VRE. Like linezolid, they have also been used in the treatment of VRSA infections. The recommended dose is 7.5 mg/kg intravenously twice daily for at least 7 days, with lower dosing for those patients with hepatic insufficiency. Patient tolerability can be a problem, especially phlebitis (75%), if administered peripherally; arthralgia; and myalgia. Quinupristin/dalfopristin is metabolized by the liver and excreted in the bile. Elevation of hepatic transaminases and bilirubin has been reported, and concomitant administration with drugs metabolized by the CYP3A4 system is contraindicated. Quinupristin/dalfopristin should be used with caution in patients taking cyclosporine or agents that prolong the QT interval.

DAPTOMYCIN

Daptomycin (Cubicin) is a cyclic lipopeptide; a new class of antibiotic derived from the fermentation of *Streptomyces roseosporus*.[20] Daptomycin was recently approved in the United States for the treatment of complicated SSTIs caused by *S. aureus* (including methicillin-resistant strains), *Streptococcus pyogenes*, *Streptococcus agalactiae*, *Streptococcus dysgalactiae* subsp. *equisimilis* and *Enterococcus faecalis* (vancomycin-susceptible strains only). Its mechanism of action is unclear, but it acts rapidly and is bacteriocidal against Gram-positive bacteria. Dosing is 4 mg/kg intravenously every 24 hours for 7–14 days. Daptomycin is excreted primarily by the kidneys (78%), requiring

TABLE 230-3
Recommended Therapies

Organism	First-Line Therapy	Alternative Therapy
Actinomyces israelii	ampicillin or penicillin G	doxycycline, ceftriaxone, clindamycin, erythromycin
Bacillus anthracis	doxycycline or ciprofloxacin	penicillin G or amoxicillin (if penicillin sensitive)
Bartonella sp.	azithromycin (cat-scratch)	clarithromycin, ciprofloxacin erythromycin or doxycycline (BA)
Borrellia burgdorferi	doxycycline or amoxicillin	ceftriaxone, cefuroxime, cefotaxime
Borrellia recurrentis	doxycycline	erythromycin
Calymmatobacterium granulomatis	doxycycline or TMP/SMX	erythromycin, azithromycin, ciprofloxacin
Chlamydia trachomatis	doxycycline or azithromycin	erythromycin, ofloxacin, levofloxacin
Clostridium perfringens	penicillin G +/– clindamycin	doxycycline
Coxiella burnetii	doxycycline	erythromycin
Ehrlichia sp.	doxycycline	tetracycline, rifampin, ciprofloxacin
Eikenella corrodens	penicillin G or ampicillin	amoxicillin/clavulanate, TMP/SMX, fluoroquinolones
Erysipelothrix rhusiopathiae	penicillin G or ampicillin	fluoroquinolones
Francisella tularensis	streptomycin	gentamicin, tetracycline, chloramphenicol
Hemophilus ducreyi	azithromycin or ceftriaxone	erythromycin, ciprofloxacin
Klebsiella rhinoscleromatis	fluoroquinolones	rifampin[a] + TMP/SMX
Neisseria gonorrhoeae	ceftriaxone	fluoroquinolones, cefixime
Nocardia asteroides	TMP/SMX	minocycline, linezolid
Nocardia brasiliensis	TMP/SMX	amoxicillin/clavulanate
Pasteurella multocida	penicillin, ampicillin, or amoxicillin	doxycycline, TMP/SMX
Pseudomonas aeruginosa	ciprofloxacin	antipseudomonal penicillin or cephalosporin
Rickettsia sp.	doxycycline	chloramphenicol, fluoroquinolone
Staphylococcus aureus (MSSA)	oxacillin or nafcillin	clindamycin, macrolides
Staphylococcus aureus (HAMRSA)	vancomycin	linezolid, daptomycin, quinupristin/dalfopristin, tigecycline
Staphylococcus aureus (CAMRSA)	TMP/SMX	minocycline, clindamycin, rifampin[a], as above
Streptococcus pyogenes	penicillin	other β-lactams, macrolides
Treponema pallidum	benzathine penicillin G	doxycycline, tetracycline
Vibrio vulnificus	doxycycline + ceftazidime	cefotaxime, fluoroquinolones

BA = bacillary angiomatosis; CAMRSA = community-acquired MRSA; HAMRSA = hospital-acquired MRSA; TMP/SMX = trimethoprim/ sulfamethoxisole.
[a]Rifampin is not recommended as monotherapy due to significant development of resistance.

dosing adjustment for patients with renal impairment (C_{Cr} <30 mL/min). The drug is generally well tolerated, with headache and constipation being reported most commonly (4%). The primary serious adverse event is myopathy, which usually occurs at higher doses.

ERTAPENEM

Ertapenem (Invanz) is a long-acting carbapenem with a broad spectrum of antimicrobial activity similar to the older carbapenems, imipenem-cilastatin, and meropenem.[17] Unlike imipenem, it has poor activity against *Pseudomonas* and *Enterococci*. In clinical trials, it was comparable to piperacillin/tazobactam in the treatment of complicated SSTIs. Active against both Gram-positive and Gram-negative aerobes and anaerobes, its use should be reserved for polymicrobial infections not otherwise sensitive to agents with more narrow spectra of activity. An extended half-life allows for once daily intravenous administration (1 g per day for 7–14 days), but it should be used cautiously in patients with renal impairment. CNS effects and hypersensitivity reactions have been noted.

TIGECYCLINE

Tigecycline (Tygacil) is a glyclcycline antibiotic indicated for the treatment of complicated SSTI due to susceptible organisms, which include MRSA and VRE.[21] A derivative of minocycline, tigecycline shares the same 30s ribosomal binding site and has a spectrum of activity similar to the classic tetracyclines. However, tigecycline demonstrates a greater volume of distribution, better activity against organisms with tetracycline resistance, and better activity against *Streptococcus* species. Tigecycline dosing is 50 mg intravenously twice daily following a 100-mg loading dose. Renal dosing is not required, but lower dosing is necessary for patients with severe hepatic disease. The same precautions taken with the tetracycline class of antibiotics should be observed with tigecycline.

KEY REFERENCES

Full reference list available at www.DIGM8.com

DVD contains references and additional content

2. Fritsche TR, Jones RN: Importance of understanding pharmacokinetic/pharmacodynamic principles in the emergence of resistances, including community-associated *Staphylococcus aureus*. *J Drugs Dermatol* **4**(Suppl. 6): s4-s8, 2005
7. Thethi AK, Van Dellen RG: Dilemmas and controversies in penicillin allergy. *Immunol Allergy Clin North Am* **24**(3):445,61, vi, 2004
8. Del Rosso JQ: Cephalosporins in dermatology. *Clin Dermatol* **21**(1):24-32, 2003
14. Suh B, Lorber B: Quinolones. *Med Clin North Am* **79**(4): 869-894, 1995
17. Schweiger ES, Weinberg JM: Novel antibacterial agents for skin and skin structure infections. *J Am Acad Dermatol* **50**(3):331,40; quiz 341-342, 2004

Chapter 231 :: Antiviral Drugs

:: Dirk M. Elston

ANTIVIRAL DRUGS AT A GLANCE

- Antivirals are now approved for treatment of a variety of viral infections.
- Antiviral resistance is a growing concern, especially in the treatment of human immunodeficiency virus infection.
- Antivirals work in a number of different ways, and their spectra of activity can be very specific (amantadine) or quite broad (ribavirin).
- The use of prodrugs of acyclovir and ganciclovir has greatly increased the oral bioavailability of these agents, which allows outpatient treatment of many herpesvirus infections.

The pace of development of new antiviral drugs has been accelerated by the human immunodeficiency virus (HIV) epidemic. Progress in our understanding of the molecular biology and pathogenesis of viral diseases has been remarkable. This chapter focuses on the antiviral drugs most likely to be used by dermatologists, as well as those that cause cutaneous side effects. The age of effective antiviral therapy is here, and they are used throughout all disciplines of medicine. We need to be prepared to evaluate patients on a wide variety of antiviral drugs, especially those currently used to treat HIV.

DRUGS FOR THE TREATMENT OF HERPESVIRUS INFECTIONS

(See Chapters 193 and 194)

ACYCLOVIR

MECHANISM OF ACTION. Acyclovir, 9-[(2-hydroxyethoxy) methyl] guanine, was the first orally available drug to be widely used for the treatment of herpes simplex virus (HSV) and varicella-zoster virus (VZV) infections. The triphosphate form of the drug is the active form, which has a potent inhibitory effect on herpesvirus-induced DNA polymerases but relatively little effect on host cell DNA polymerase. As such, it has a tremendous margin of safety when used to treat herpetic infections. Acyclovir triphosphate causes premature termination of the nascent viral DNA chain. HSV- and VZV-induced thymidine kinases result in efficient phosphorylation of acyclovir to acyclovir monophosphate, the first step in drug metabolism. This step is not accomplished efficiently by normal cellular kinases, resulting in greater concentrations of active drug in infected cells.

PHARMACOKINETICS. While acyclovir is available in oral, intravenous, and topical formulations, the oral bioavailability is only in the range of 15%–30%. Excretion is almost entirely renal, with approximately 85% of renally excreted drug being unmetabolized. Because of this reliance on renal excretion, the dose must be reduced for patients with a creatinine

clearance of less than 50 mL/min. Acyclovir is water soluble and achieves good levels in a variety of body fluids, including the contents of vesicles, cerebrospinal fluid, and vaginal secretions. Acyclovir has been marketed as a 5% ointment, but the efficacy is limited compared with systemic administration.

INDICATIONS

- Treatment of symptomatic primary or recurrent mucocutaneous HSV-1 or HSV-2 infection
- Suppression of recurrent HSV-1 and HSV-2 infections
- Treatment of mucocutaneous HSV infections in immunocompromised patients
- Prevention of perinatal HSV-1 and HSV-2 infection and treatment of neonatal HSV infection
- Treatment of primary VZV infection in adults and immunocompromised children
- Treatment of VZV infection to reduce the risk of postherpetic neuralgia
- Treatment of HSV-1 encephalitis
- Postexposure prophylaxis and treatment for *Herpes simiae* in the setting of a monkey bite

It has been suggested that suppression of genital HSV recurrences may reduce the risk of acquisition of HIV. It is common for those with HIV-1 infection to have outbreaks of HSV and frequent reactivation is associated with increased plasma and genital levels of the HIV-1 virus. Unfortunately, a randomized, placebo-controlled trial of suppressive acyclovir did not reduce the risk of disease transmission in couples in whom only one was initially seropositive for HIV-1. The failure to prevent transmission occurred despite a reduction in plasma HIV-1 RNA of 0.25log(10) copies per milliliter as well as a 73% reduction in the occurrence of genital HSV.[1] Acyclovir can produce direct suppression of HIV-1.[2] Newer monophosphorylated acyclovir derivatives (including those with the phosphate group masked by lipophilic groups) have greater potential to prevent viral transmission, as they suppress both HIV-1 and HSV-2 more effectively.[3] It is important to note that acyclovir can select for the HIV-1 V75I reverse transcriptase variant in vitro. While this variant has decreased sensitivity to some nucleoside analogs, it demonstrates an increased sensitivity to zidovudine.[4] [See Section "Drugs for the Treatment of Human Immunodeficiency Virus (HIV) Infection."]

Acyclovir given in late pregnancy to women with recurrent genital herpes has been shown to decrease the frequency of genital lesions as well as subclinical viral shedding. This can result in a decrease in the number of Caesarean sections performed.

Unfortunately, breakthrough lesions and viral shedding can still occur and recent evidence suggests that standard oral dosing of acyclovir in late pregnancy often results in insufficient levels at delivery to prevent viral shedding.[5]

Resistance is a growing problem, and data from corneal HSV-1 isolates suggests that infections commonly represent mixtures of acyclovir-sensitive and resistant viruses with different *thymidine kinase* gene sequences. The acyclovir-resistant HSV-1 can establish latency and reactivate intermittently to cause acyclovir-refractory disease.[6]

DOSING REGIMENS. Compliance with five times daily dosing regimens is poor, so the dosing regimens commonly used in clinical practice differ from those reflected in drug labeling (Table 231-1).

INITIATION OF THERAPY. Treatment for mucocutaneous HSV disease should begin as early as possible. For recurrent disease, treatment may be in the form of continuous suppression or episodic treatment beginning during the prodromal period. Treatment for varicella is most effective if it can be started within 24 hours of onset of vesicles. In immunocompetent patients, treatment for zoster has proven benefit if started within 72 hours of onset of the eruption.

MONITORING OF THERAPY. The dose should be adjusted for patients with a creatinine clearance level of less than 50 mL/min, but drug level assays are not routinely performed.

RISKS AND PRECAUTIONS. Renal (5% incidence of adverse reactions)

- Crystallization in renal tubules leading to obstructive nephropathy
- Interstitial nephritis

Central nervous system (1% incidence)

- Lethargy
- Tremors
- Confusion
- Seizures

Miscellaneous

- Phlebitis with intravenous administration
- Rash
- Recall dermatitis
- Fixed drug eruption
- Elevated liver function tests
- Neutropenia

COMPLICATIONS. Acyclovir is generally very well tolerated. The major risk is renal tubular crystallization with rapid intravenous administration. Caution must be exercised with high doses and in the setting of dehydration. Interstitial nephritis has also been reported. Central nervous system toxicity is uncommon, but may manifest as lethargy, tremors, or seizures. Patients with these side effects commonly have underlying diseases involving the central nervous system. Thrombophlebitis is a known complication of infusion, and appears to be related to the high pH of the reconstituted solution (pH 11). The plasma half life is only 2.5 hours, requiring repeated administration, but newer nanoparticle preparations are being developed with an increased half-life to reduce the need for repeat parenteral administration.[7] Nanoparticle technology is also being used to improve the bioavailability of oral forms of the drug.[8] In the future, antiviral susceptibility testing may allow selection of the optimal drug in

TABLE 231-1
Commonly Used Dosing Regimens for Acyclovir

Condition	Dosage	Route	Duration
Primary HSV infection, immunocompetent host	400 mg tid	Oral	7–10 days
Recurrent genital HSV infection, immunocompetent host	400 mg tid *or* 800 mg tid	Oral Oral	5 days 2 days[4]
Recurrent oral labial HSV infection, immunocompetent host	400 mg 5×/day *or* 5% cream 6×/day	Oral Topical	5 days 7 days
Oral labial HSV infection, immunocompromised host	5 mg/kg q8h *or* 400 mg 5×/day	IV Oral	7 days 14–21 days
Perinatal HSV infection	10–20 mg/kg q8h	IV	10–21 days
Chronic suppression of HSV infection	400 mg bid *or* 800 mg qd	Oral	
HSV-1 Encephalitis	10 mg/kg q8h	IV	14–21 days
Varicella: adolescent/adult	800 mg 5×/day	Oral	5–7 days
Varicella: pneumonia or third trimester pregnancy	800 mg 5×/day *or* 10 mg/kg q8h	Oral IV	5 days 5 days
Herpes zoster: normal host or not severe disease in immunocompromised host	800 mg 5×/day	Oral	7–10 days
Herpes zoster: severe disease or immunocompromised host	10–12 mg/kg q8h	IV	7–14 days

HSV = herpes simplex virus.

those at increased risk for adverse reactions.[9] These assays show the greatest potential in the setting of concurrent HIV infection.[10]

VALACYCLOVIR

MECHANISM OF ACTION AND PHARMACOKINETICS.

Valacyclovir, the L-valine ester of acyclovir, was developed to provide increased oral bioavailability of the active drug acyclovir.[11] Valacyclovir is readily absorbed from the gastrointestinal tract and almost entirely converted to acyclovir by intestinal and hepatic esterases. The mechanism of action and spectrum of activity of valacyclovir are identical to those of acyclovir. Following a 1-g oral dose of valacyclovir, peak plasma concentrations of acyclovir in the range of 5.7 µg/mL are achieved in 1.75 hours, and area-under-the-curve (AUC) concentrations are similar to those achieved with 5 mg/kg of acyclovir given intravenously.

INDICATIONS

- Treatment of initial and recurrent HSV genital infections
- Suppression of frequently recurring genital HSV infections
- Treatment of herpes zoster

The cost-effectiveness of long-term herpes suppression and intermittent therapy has been debated, but patients are generally quite appreciative of therapy.[12,13] Treatment decreases the frequency of clinical outbreaks as well as the incidence of viral shedding. In the setting of HSV-2 seropositive subjects without a history of symptomatic genital herpes infection, 84% of subjects had no shedding while receiving 1 g daily of valacyclovir versus 54% of subjects on placebo (P <0.001).[14] Recent data suggest a higher frequency of total and subclinical HSV-2 shedding following newly diagnosed HSV-2 infection than reported in earlier studies. Valacyclovir 1 g daily resulted in a 78% reduction in viral shedding in this population compared to placebo, and 79% of subjects had no clinical recurrences while receiving valacyclovir compared with 52% of subjects receiving placebo (P <0.01).[15]

The drug has been used to suppress recurrence of ocular disease.[16] In the setting of oral herpes simplex, valacyclovir has been used alone or combined with oral corticosteroids. In one study, there were more aborted lesions in the valacyclovir-clobetasol arm than in the placebo group (50% vs. 15.8%, P = 0.04)[17], but further study is needed to assess the independent contribution of the corticosteroid.

Valacyclovir demonstrates in-vitro activity against Epstein-Barr virus (EBV). It is being studied in the settings

TABLE 231-2
Dosing Regimens for Valacyclovir

Condition	Dosage	Route	Duration
Primary HSV infection, immunocompetent host	1,000 mg bid	Oral	10 days
Recurrent genital HSV infection, immunocompetent host	500 mg bid	Oral	3 days
Recurrent oral labial HSV infection, immunocompetent host	2,000 mg bid	Oral	1 day
Oral labial HSV infection, immunocompromised host	500 mg bid	Oral	5–10 days
Chronic suppression of HSV infection	1,000 mg qd	Oral	Undefined/ indefinite
Varicella: adolescent/adult	1,000 mg tid	Oral	5 days
Herpes zoster: normal host or not severe disease in immunocompromised host	1,000 mg tid	Oral	7 days

HSV = herpes simplex virus.

of infectious mononucleosis, hepatitis, encephalopathy, and post-transplant lymphoproliferative disease. Unfortunately, in a recent trial, valacyclovir treatment was not effective in decreasing peripheral blood EBV viral loads in pediatric liver transplantation patients.[18] In healthy volunteers, long-term administration of valacyclovir effectively reduces the number of EBV-infected B cells, although it does not reduce the number of EBV DNA copies per B cell.[19]

DOSING REGIMENS. Standard doses for adults with herpetic infections are listed in Table 231-2.[20] The drug has also been evaluated in children with malignancy.[21] In this setting, valacyclovir (15 mg/kg) was well tolerated and demonstrated excellent bioavailability.[22] Those less than 3 months of age demonstrate decreased clearance of the drug. Among children 3 months through 11 years of age, a 20-mg/kg dose of an extemporaneously compounded valacyclovir oral suspension produced favorable acyclovir blood levels and was well tolerated. The authors noted that among children 2 through 5 years of age, a dose increase from 20–25 mg/kg resulted in near doubling of the peak concentration [C(max)] and the area under the curve (AUC)[23]

INITIATION OF THERAPY. As with acyclovir, valacyclovir therapy should be initiated as soon as possible after the onset of an HSV or VZV infection.

RISKS AND PRECAUTIONS. In addition to side effects noted with acyclovir, thrombotic thrombocytopenic purpura/hemolytic uremic syndrome (TTP/HUS) can occur in patients with advanced HIV disease and in transplant recipients receiving dosages of 8 g/day. The drug has also been reported to produce both immediate hypersensitivity and a symmetrical drug-related intertriginous and flexural exanthem.[24,25]

COMPLICATIONS. Most adverse effects are those that also occur with acyclovir, including a potential for CNS effects.[26] Severe and even fatal cases of TTP/HUS have been reported in patients with acquired immunodeficiency syndrome (AIDS) and transplant recipients who were given high dosages of valacyclovir. The basis for and causal relationship have not been completely established, and TTP/HUS has not been reported in patients taking conventional dosages (up to 3 g/day) of valacyclovir. In a study of high-dose valacyclovir administered to six subjects with normal renal function and three subjects with chronic renal impairment (CrCl approximately 15–30 mL/min), average steady-state concentrations of acyclovir and its metabolites, 9-[(carboxymethoxy) methyl]guanine and 8-hydroxy-acyclovir were greater in both serum and CSF among the subjects with impaired renal function. In contrast, the CSF penetration of each metabolite did not differ based on renal function. This suggests that it is simply the higher concentrations in the systemic circulation that result in proportionally higher concentrations in the CSF.[27]

FAMCICLOVIR AND PENCICLOVIR

MECHANISM OF ACTION. Famciclovir, [9-(4-hydroxy-3-hydroxy-methylbut-1-yl) guanine, is the prodrug of penciclovir, [9-(4-hydroxy-3-hydroxy-3-hydroxymethylbut-1-yl) guanine]. Once absorbed, penciclovir is phosphorylated to penciclovir triphosphate. The initial phosphorylation of penciclovir to penciclovir monophosphate is efficiently carried out by HSV- or VZV-induced thymidine kinases in a manner similar to that of the initial phosphorylation of acyclovir. Phosphorylation to diphosphate and triphosphate forms of penciclovir then occurs via cellular kinases. Penciclovir triphosphate inhibits viral DNA polymerases and inhibits extension of the nascent viral DNA chain in a manner similar to acyclovir; however, because of the presence of the hydroxyl group on the acyclic side chain of penciclovir, some DNA chain extension may occur.

PHARMACOKINETICS. Famciclovir is marketed as an oral formulation, which is converted to penciclovir by deacetylation and oxidation in the liver and

intestine. The bioavailability of oral famciclovir is 77%, with a peak plasma concentration of 3.3 µg/mL reached 1 hour after oral administration of 500 mg of famciclovir. The plasma half-life of penciclovir is 2 hours, and 60%–70% of the drug is excreted unchanged in the urine. This occurs via both glomerular filtration and tubular secretion. As with acyclovir, the dose of penciclovir should be reduced in patients with advanced renal dysfunction. Compared with the intracellular half-life of acyclovir triphosphate, that of penciclovir triphosphate is markedly prolonged in both HSV-infected cells (10–20 hours) and VZV-infected cells, allowing the drug to be administered two to three times daily. Penciclovir is available as a 1% ointment for the treatment of recurrent oral HSV. At least in some vehicles, topical penetration of penetration of penciclovir is superior to that of acyclovir.[28] Microemulsion and nanoparticle formulations are being evaluated.[29,30,31]

INDICATIONS

- Treatment of initial and recurrent HSV genital infections
- Suppression of frequently recurring genital HSV infections
- Treatment of herpes zoster

DOSING REGIMENS. Standard adult doses are given in Table 231-3.[32] In one study of recurrent genital HSV, a 2-day course of 500 mg initially, then 250 mg twice daily was noninferior to the standard 5-day course of 125 mg twice daily.[33] In another study, single-day famciclovir (1,000 mg administered twice daily) was similar in efficacy to 3-day valacyclovir (500 mg administered twice daily) for the treatment of recurrent genital herpes.[34] Single day treatment is associated with high patient satisfaction.[35] Some data suggest that suppressive treatment may be superior to episodic treatment.[36] Studies in children are ongoing, and currently the drug is used less commonly in this population.[37,38] While famciclovir has shown efficacy in general populations, one study of patient-initiated episodic treatment of recurrent genital herpes in immunocompetent black patients showed efficacy similar to that of placebo.[39]

RISKS AND PRECAUTIONS. Like acyclovir and valacyclovir, famciclovir is generally well tolerated. The dose should be reduced for patients with a creatinine clearance less than 60 mL/min. The drug has been used safely along with hydration in patients with prior renal toxicity related to acyclovir.[40] Leukocytoclastic vasculitis has been reported with the drug.[41] Common side effects include:

- Headache
- Nausea
- Diarrhea
- Dizziness

COMPLICATIONS. Serious toxicity is uncommon. Prolonged high-dose administration of famciclovir to rats has been associated with an increased incidence of mammary adenocarcinomas in females, but the clinical significance of this observation for humans treated with the drug is unknown.

TRIFLURIDINE

MECHANISM OF ACTION AND PHARMACOKINETICS. Trifluridine, 5-trifluoromethyl-2′-deoxyuridine, is a pyrimidine nucleoside analog. Trifluridine monophosphate acts as an irreversible competitive inhibitor of thymidylate synthetase, and trifluridine triphosphate inhibits HSV DNA polymerase. Trifluridine triphosphate also inhibits cellular DNA polymerases, although it does so to a lesser extent than viral DNA polymerases. Because of systemic toxicity, trifluridine is approved only for topical application in the form of a 1% ophthalmic aqueous solution. The elimination half-life for the ophthalmic solution is 12–18 minutes.

TABLE 231-3
Dosing Regimens for Famciclovir and Penciclovir

Condition	Dosage	Route	Duration
Primary HSV infection, immunocompetent host	250 mg tid	Oral	7–10 days
Recurrent genital HSV infection, immunocompetent host	125 mg bid or 1,000 mg bid	Oral Oral	5 days 1 day
Recurrent oral labial HSV infection, immunocompetent host	500 mg bid *or* 1% penciclovir cream q2h	Oral Topical	7 days 5 days or until lesions healed
Oral labial HSV infection, immunocompromised host	500 mg bid	Oral	7 days
Chronic suppression of HSV infection	250 mg bid	Oral	Up to 1 year
Varicella: adolescent/adult	500 mg tid	Oral	5 days
Herpes zoster: normal host or not severe disease in immunocompromised host	500 mg tid	Oral	7 days

HSV = herpes simplex virus.

TABLE 231-4
Dosing Regimens for Trifluridine

Condition	Dosage	Route	Duration
Primary HSV conjunctivitis	1 drop 1% solution q2h (maximum, 9 drops/24 hours)	Topical	Maximum, 21 days
Recurrent HSV epithelial keratitis	1 drop 1% solution q2h (maximum, 9 drops/24 hours)	Topical	Maximum, 21 days
Acyclovir-resistant HSV infection in AIDS	1% solution q8h	Topical	10–14 days or until lesions resolve

AIDS = acquired immunodeficiency syndrome; HSV = herpes simplex virus.

INDICATIONS

- Treatment of primary HSV conjunctivitis
- Treatment of recurrent HSV keratitis
- Treatment of acyclovir-resistant mucocutaneous HSV infections in patients with AIDS

EFFICACY. A recent meta-analysis of data from 99 randomized trials including a total of 5,363 participants concluded that the topical application of trifluridine, vidarabine, acyclovir, or ganciclovir all resulted in a high proportion of participants healing within 1 week of therapy and no agent emerged as significantly better than the others for the treatment of dendritic epithelial keratitis.[42] Other authors have suggested that although the drug is effective, it may result in delays in re-epithelialization.[43] There may be additional benefit from topical interferon in those treated with this agent.[44]

DOSING REGIMENS. Standard dosing regimens are given in Table 231-4.

RISKS AND COMPLICATIONS

- Mild burning
- Palpebral edema
- Punctate keratopathy
- Stromal edema

DRUGS FOR THE TREATMENT OF CYTOMEGALOVIRUS INFECTIONS

GANCICLOVIR AND VALGANCICLOVIR

MECHANISM OF ACTION AND PHARMACOKINETICS

Valganciclovir,L-valine2-[(2-amino-1,6-dehydro-6-oxo-9H-purin-9-yl) methoxy]-3-hydroxypropyl ester, is the L-valyl ester of ganciclovir. It is more efficiently absorbed and acts as a prodrug for ganciclovir. After oral administration, valganciclovir is converted to ganciclovir by intestinal and hepatic esterases. The oral availability of valganciclovir is approximately 60% and is increased by administration with food. After a 900-mg dose of valganciclovir, the maximum plasma concentration of ganciclovir is 5.61 g/mL, and the plasma concentration–time curve is similar to that achieved with ganciclovir given intravenously at a dose of 5 mg/kg.

INDICATIONS

- Treatment of CMV retinitis in patients with AIDS
- Suppression and prevention of CMV disease in transplant recipients

Viral clearance varies, even in the face of adequate plasma levels, so patients should be monitored for clinical response.[45,46] The drug has some activity against herpesvirus 6, but resistance has been reported.[47]

DOSING REGIMENS. Standard dosing regimens are provided in Table 231-5. Pediatric dosing regimens have also been published.[48]

RISKS AND COMPLICATIONS. Potential side effects include diarrhea, nausea, loss of appetite, headache, dizziness, confusion, nervousness, vivid dreams, tremor, weakness, peripheral edema and pain at the injection site.

FOSCARNET

MECHANISM OF ACTION. Foscarnet, trisodium phosphonoformate, is a pyrophosphate-containing antiviral drug that noncompetitively inhibits viral DNA polymerases at the pyrophosphate binding site. In contrast to the nucleoside analogues, foscarnet does not require phosphorylation and is therefore active against many strains of virus that are resistant to acyclovir, famciclovir, or ganciclovir as a result of absent or reduced kinase activity.[49–51] Salvage therapy with foscarnet plus a thymidine analog has been shown to be effective in patients with advanced-stage HIV disease and viruses harboring multiple drug-resistance mutations including thymidine-associated mutations.[52] Unfortunately, resistance to combined ganciclovir and foscarnet therapy has been reported in the setting of dual-strain cytomegalovirus coinfection.[53] Valproic acid has been reported to impair the antiviral activity of ganciclovir, cidofovir, and foscarnet.[54]

TABLE 231-5
Dosing Regimens for Valganciclovir

Condition	Dosage	Route	Duration
CMV retinitis	Induction: 900 mg bid Maintenance: 900 mg qd	Oral Oral	21 days Until CD4 count >100 after 6 mon of HAART

CMV = cytomegalovirus; HAART = highly active antiretroviral therapy.

PHARMACOKINETICS. Foscarnet is available as an intravenous preparation that has poor solubility and must be administered by an infusion pump in a dilute solution over 1–2 hours. The plasma half-life of the drug includes an initial phase of 4–8 hours and a terminal component of 88 hours or longer, which reflects a deposition in bone of up to 20% of the dose. Eighty percent of the dose is excreted unaltered by the kidney. The dose must therefore be reduced in patients with renal dysfunction.

INDICATIONS

- Treatment of CMV retinitis in patients with AIDS
- Treatment of CMV colitis
- Treatment of CMV polyradiculopathy in combination with ganciclovir
- Treatment of acyclovir-resistant HSV infections
- Treatment of ganciclovir-resistant CMV infections

DOSING REGIMENS. Standard dosing schedules are provided in Table 231-6.

RISKS AND COMPLICATIONS. Renal (30% incidence)

- Increased creatinine levels
- Proteinuria
- Nephrogenic diabetes insipidus
- Hypokalemia, hypocalcemia, hypomagnesemia

Miscellaneous

- Headache
- Fatigue
- Fever
- Seizures
- Low white blood cell count, anemia

MONITORING OF THERAPY. Renal toxicity is the major risk with foscarnet, and close monitoring of renal function is required. Saline hydration before administration and slow infusion of the drug may reduce nephrotoxicity. Electrolyte and metabolic abnormalities including hypocalcemia and hypercalcemia, hypophosphatemia and hyperphosphatemia, hypomagnesemia, and hypokalemia have been described.

CIDOFOVIR

MECHANISM OF ACTION. Cidofovir, (S)-1-[3-hydroxy-2(phosphonylmethoxy)-propyl] cytosine, is a phosphonate nucleotide analog.[55] In contrast to the nucleoside analogues, it does not require initial phosphorylation by virus-induced kinases. Rather, it is converted by host cell enzymes to cidofovir diphosphate, a competitive inhibitor of viral DNA polymerases.

PHARMACOKINETICS. Cidofovir is approved for intravenous administration. A topical formulation has been developed and compounded formulas have been used. An intravenous dose of 5 mg/kg results in a peak plasma concentration of 11.5 g/mL. The plasma half-life of cidofovir is 2.6 hours, and the drug is excreted almost entirely by the kidney. Cidofovir diphosphate has a markedly prolonged intracellular half-life (in excess of 48 hours), and may be given at a dose of 5 mg/kg twice a week for the first 2 weeks, followed by one dose every 2 weeks.

INDICATIONS

- CMV retinitis in AIDS
- Treatment of resistant HSV and CMV infections

TABLE 231-6
Dosing Regimens for Foscarnet

Condition	Dosage	Route	Duration
CMV retinitis	Induction: 90 mg/kg q12h Maintenance: 90 mg/kg q24h	IV IV	14–21 days Until CD4 count >100 on 6 months of HAART
Acyclovir-resistant HSV infection	40 mg/kg q8h *or* 60 mg/kg q12h	IV IV	 2–3 week or until clinical resolution

CMV = cytomegalovirus; HAART = highly active antiretroviral therapy; HSV = herpes simplex virus.

TABLE 231-7
Dosing Regimens for Cidofovir

Condition	Dosage	Route	Duration
CMV retinitis	Induction: 5 mg/kg every week Maintenance: 5 mg/kg every 2 week	IV IV	2 week Until CD4 count >00 after 6 months on HAART

CMV = cytomegalovirus; HAART = highly active antiretroviral therapy.
Note: Cidofovir IV administration must be accompanied by prehydration and probenecid.

Cidofovir also has antiviral activity against pox and parapoxviruses, including vaccinia and variola (small pox), orf, monkeypox, and molluscum contagiosum.[56,57] It has been used successfully off-label in topical form for the treatment of the lesions of human papillomavirus infection, Kaposi sarcoma, and HSV infection.[58–64] Coadministration of cidofovir with smallpox vaccine reduced the incidence of side effects but interfered with the vaccine-elicited immune responses and immunity to monkeypox.[65]

DOSING REGIMENS.

Standard dosing regimens are provided in Table 231-7. Data regarding the use in pediatric patients are accumulating.[66]

RISKS AND COMPLICATIONS.

Renal (59% incidence)

- Renal tubular damage
- Dose-dependent proximal tubular injury (Fanconi-like)
- Proteinuria
- Elevated serum creatinine levels

Proteinuria, serum creatinine elevations of ≥0.4 mg/dL, or decreased creatinine clearance ≤55 mL/min, occurred in 79 of 135 patients at a maintenance dose of 5 mg/kg every other week.

Miscellaneous

- Nausea (48% incidence)
- Alopecia (16% incidence)
- Rash
- Fever
- Myalgia

PRECAUTIONS.

The incidence of nephrotoxicity can be reduced by vigorous hydration before and after infusion, along with the administration of probenecid. Renal function must be assessed prior to each dose. Cidofovir has been used to treat human papillomavirus (HPV)-related recurrent respiratory papillomatosis,[67] but there are reports of squamous cell carcinoma associated with intralesional injection of cidofovir in this setting and evidence that the drug can both increase cell survival and induce alterations in gene expression associated with malignant transformation.[68,69] There are reports that the drug can induce HPV E6 protein expression.[70] Herpes simplex virus stomatitis has been reported to occur during prophylactic cidofovir therapy despite in vitro susceptibility of HSV to the drug.[71]

RISKS AND COMPLICATIONS

- Adverse reactions noted during placebo-controlled and open-label studies include asthenia, headache, abdominal pain, diarrhea, nausea, dyspepsia, flatulence, increased creatinine, pancreatitis, and hypophosphatemia.
- The drug should not be used concurrently with tenofovir disoproxil fumarate.
- Resistance to adefovir dipivoxil can result in viral load rebound and liver decompensation. In order to reduce the risk of resistance, adefovir dipivoxil should be used in combination with lamivudine and not as monotherapy.
- In patients with underlying renal dysfunction, chronic administration may result in nephrotoxicity. Patients should be monitored closely. The dosing

TABLE 231-8
Dosing Regimens for the Interferons

Condition	Dosage	Route	Duration
Condyloma acuminata	IFN-α2b 1 million units 3×/week	Intralesional	3 week
Chronic hepatitis C (with ribavirin)	PegIFN-α2a 180 μg once a week *or* PegIFN-α2b 1.5 μg/kg once a week	Subcutaneous	Dependent on response and genotype
Chronic hepatitis B	PegIFN-α2a 180 μg once a week *or* PegIFN-α2b 1.5 μg/kg once a week	Subcutaneous	At least 1 year

IFN = interferon; PegIFN = peginterferon.

TABLE 231-9
Antiretroviral Agents

Multiclass Combination Products	
Brand Name	**Generic Name**
Atripla	efavirenz, emtricitabine and tenofovir disoproxil fumarate
Nucleoside Reverse Transcriptase Inhibitors (NRTIs)	
Brand Name	**Generic Name**
Combivir	lamivudine and zidovudine
Emtriva	emtricitabine, FTC
Epivir	lamivudine, 3TC
Epzicom	abacavir and lamivudine
Hivid	zalcitabine, dideoxycytidine, ddC (no longer marketed)
Retrovir	zidovudine, azidothymidine, AZT, ZDV
Trizivir	abacavir, zidovudine, and lamivudine
Truvada	tenofovir disoproxil fumarate and emtricitabine
Videx EC	enteric coated didanosine, ddI EC
Videx	didanosine, dideoxyinosine, ddI
Viread	tenofovir disoproxil fumarate, TDF
Zerit	stavudine, d4T
Ziagen	abacavir sulfate, ABC
Nonnucleoside Reverse Transcriptase Inhibitors (NNRTIs)	
Brand Name	**Generic Name**
Intelence	Etravirine
Rescriptor	delavirdine, DLV
Sustiva	efavirenz, EFV
Viramune	nevirapine, NVP
Protease Inhibitors (PIs)	
Brand Name	**Generic Name**
Agenerase	amprenavir, APV
Aptivus	tipranavir, TPV
Crixivan	indinavir, IDV,
Fortovase	saquinavir (no longer marketed)
Invirase	saquinavir mesylate, SQV
Kaletra	lopinavir and ritonavir, LPV/RTV
Lexiva	Fosamprenavir Calcium, FOS-APV
Norvir	ritonavir, RTV
Prezista	darunavir
Reyataz	atazanavir sulfate, ATV
Viracept	nelfinavir mesylate, NFV
Fusion Inhibitors	
Brand Name	**Generic Name**
Fuzeon	enfuvirtide, T-20
Entry Inhibitors—CCR5 coreceptor antagonist	
Brand Name	**Generic Name**
Selzentry	maraviroc
HIV integrase strand transfer inhibitors	
Brand Name	**Generic Name**
Isentress	raltegravir

interval should be modified in adult patients with baseline creatinine clearance <50 mL/min.
- HIV resistance may emerge in chronic hepatitis B patients with unrecognized or untreated HIV.

INTERFERON

(see also Chapter 234)

MECHANISM OF ACTION. Interferons are cytokines derived from a variety of cells. They have broad antiviral and immunomodulating effects.

PHARMACOKINETICS. Interferon is commonly given subcutaneously, but may also be administered intravenously or intramuscularly. It has a plasma half-life of 2–3 hours after intravenous administration, and 4–6 hours after subcutaneous or intramuscular administration. A prolonged half-life can be obtained with pegylated interferon.

INDICATIONS. Interferon therapy has been used for a variety of viral infections as well as for a number of neoplastic diseases, including melanoma and mycosis fungoides. In the setting of viral infections, interferon-α has been studied most extensively.

VIRAL DISEASES TREATED WITH INTERFERON

- Condylomata acuminata (intralesional treatment)
- Chronic hepatitis C infection in combination with ribavirin
- Chronic hepatitis B infection

DOSING REGIMENS. Common dosing regimens are provided in Table 231-8.

RISKS AND COMPLICATIONS. Side effects with interferon are common and often result in discontinuation of the drug. The most common cutaneous side effects include injection site reactions, alopecia, psoriasis, fixed drug eruptions, eczematous drug reactions, sarcoidosis, lupus, pigmentary changes and lichenoid eruptions.[82,83] Blood counts and metabolic panels should be monitored and patients must be monitored for depression, cognitive changes, and peripheral neuropathy.

Major Side Effects

- Flu-like syndrome
- Myalgia/arthralgia
- Gastrointestinal symptoms
- Granulocytopenia/thrombocytopenia
- Neurotoxicities
  - Depression
  - Cognitive disorders
- Alopecia
- Hepatotoxicity
- Autoantibody formation and induction of autoimmunity (including lupus erythematosus and Sjögren syndrome)[84]
- Induction of sarcoidosis[85]

TABLE 231-10
Dosing Regimen for Enfuvirtide

Drug	Dosage	Considerations Special	Main Toxicities	Principal Drug Interactions
Enfuvirtide (Fuzeon)	90 mg subcutaneously bid	Rotate injection sites Must be reconstituted ≤24 hours before use	Local injection site reactions Peripheral neuropathy Insomnia Increased risk of bacterial pneumonia	None known

Precautions. Interferon-α can cause serious depression in up to one-third of patients, and this must be monitored closely. Interferon-α should not be used to treat hepatitis B-related cirrhosis or decompensated liver disease because hepatitis flares could lead to further decompensation.

ACKNOWLEDGMENT

The authors thank Drs. Hay and Reichman for their work on this chapter in previous editions.

KEY REFERENCES

Full reference list available at www.DIGM8.com

DVD contains references and additional content

3. Vanpouille C et al: A new class of dual-targeted antivirals: Monophosphorylated acyclovir prodrug derivatives suppress both human immunodeficiency virus type 1 and herpes simplex virus type 2. *J Infect Dis* **201**(4):635-643, 2010; [Epub Jan 19, 2010]
4. McMahon MA et al: Sensitivity of V75I HIV-1 reverse transcriptase mutant selected in vitro by acyclovir to anti-HIV drugs. *AIDS* **24**(2):319-323, 2010
5. Leung DT et al: Inadequacy of plasma acyclovir levels at delivery in patients with genital herpes receiving oral acyclovir suppressive therapy in late pregnancy. *J Obstet Gynaecol Can* **31**(12):1137-1143, 2009
40. Htwe TH, Bergman S, Koirala J: Famciclovir substitution for patients with acyclovir-associated renal toxicity. *J Infect* **57**(3):266-268, 2008
54. Michaelis M et al: Valproic acid interferes with antiviral treatment in human cytomegalovirus-infected endothelial cells. *Cardiovasc Res* **77**(3):544-550, 2008
55. De Clercq E: Emerging antiviral drugs. *Expert Opin Emerg Drugs* **13**(3):393-416, 2008

Chapter 232 :: Oral Antifungal Agents

:: Reza Jacob & Nellie Konnikov

ORAL ANTIFUNGALS AT A GLANCE

- Indicated for extensive fungal skin infections, tinea pedis, onychomycosis, and tinea capitis.
- Preventive therapy for the immunosuppressed.
- Major classes of antifungal medications used in outpatient settings are the allylamines (terbinafine), triazoles (itraconazole, fluconazole) and imidazoles (ketoconazole), griseofulvin, polyenes (nystatin, amphotericin B), and ciclopirox olamine.
- Speciation of fungal infections can be important in defining length of treatment and choosing the appropriate medication.

Oral antifungal agents are widely and frequently used for the treatment of fungal infections of the skin, nails, and mucous membranes.[1] This chapter summarizes the four most widely used oral antifungal agents in dermatology: (1) terbinafine, (2) itraconazole, (3) fluconazole, and (4) griseofulvin.

ALLYLAMINES: TERBINAFINE

Terbinafine hydrochloride is a topical and oral antimycotic agent that belongs to the family of compounds known as the *allylamines*. Naftifine, a topical antifungal agent, also belongs to this class. All allylamine derivatives possess a tertiary allylamine, a structural component crucial for antifungal activity (Fig. 232-1).[2] In vitro, terbinafine is highly active against dermatophytes but less active against molds, dimorphic fungi, and yeasts.[2]

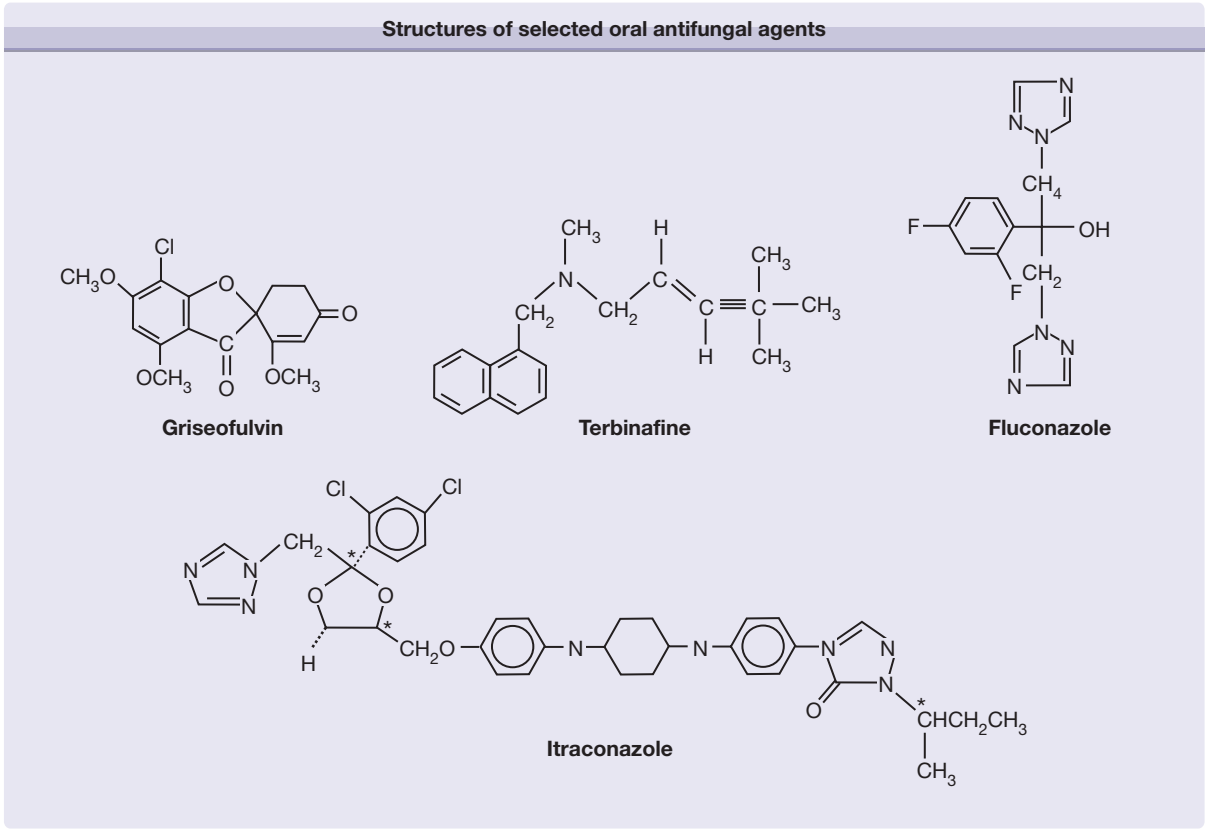

Figure 232-1 Structures of selected oral antifungal agents.

MECHANISM OF ACTION

Terbinafine inhibits the enzyme squalene epoxidase in the fungal cell membrane, thereby blocking the biosynthesis of ergosterol (Fig. 232-2).[3] Squalene epoxidase, a complex, microsomal noncytochrome P450 enzyme, catalyzes the first enzymatic step of ergosterol synthesis: the conversion of squalene into squalene epoxide. Consequently, terbinafine causes an abnormal intracellular accumulation of squalene and a deficiency in ergosterol.[4] In-vitro accumulation of squalene accounts for the drug's fungicidal activity by weakening the cell membrane, while deficiency of ergosterol is associated with the drug's fungistatic activity, as ergosterol is a component of fungal membranes required for normal growth.[4]

PHARMACOLOGY

Terbinafine is well absorbed from the gastrointestinal tract, mostly in chylomicrons. The distribution half-life is 1.5 hours, and the elimination half-life is 22 hours.[5] Terbinafine is highly lipophilic and keratophilic in nature and, therefore, is widely distributed upon absorption throughout skin and adipose tissue. Terbinafine is extensively biotransformed by the liver through oxidation by CYP2D6. More than 80% of the drug is excreted in urine; the rest is eliminated with feces.[6]

INDICATIONS

The US Food and Drug Administration has approved terbinafine tablets for the treatment of onychomycosis

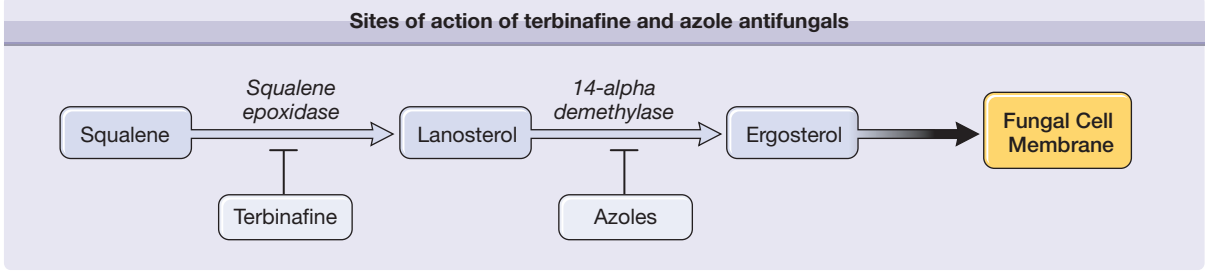

Figure 232-2 Sites of action of terbinafine and the azole antifungals.

BOX 232-1 TERBINAFINE TREATMENT OF FUNGAL INFECTIONS

- US Food and Drug Administration indications
  - Onychomycosis due to dermatophytes (tinea unguium of fingernails and toe-nails)
  - Tinea capitis in patients older than 4 years
- Other common uses
  - Onychomycosis due to *Candida* sp.
  - Tinea corporis and its subtypes
  - Tinea cruris
  - Tinea pedis

due to dermatophytes. Terbinafine oral granules are approved for the treatment of tinea capitis in patients over 4 years old. Terbinafine also has clinically proven efficacy for select cases of tinea corporis, tinea pedis, or tinea cruris that are widespread, severe, or resistant to topical treatment (Box 232-1).

PEDIATRIC. For the treatment of tinea capitis in children, terbinafine oral granules may be sprinkled over food such as pudding. The dosage is based on weight, with children weighing less than 25 kg receiving 125 mg/day, children weighing between 25 and 35 kg receiving 187.5 mg/day, and children weighing over 35 kg receiving 250 mg/day.[7] The standard treatment course is 6 weeks.[7] A study comparing a 6-week course of terbinafine 5–8 mg/kg versus a 6-week course of griseofulvin 10–20 mg/kg showed that mycological cure and complete (mycological plus clinical) cure rates were significantly higher for terbinafine than for griseofulvin.[8] However, subgroup analysis revealed that among patients infected with *Microsporum canis*, mycological and complete cure rates were superior with griseofulvin.[8] Conversely, among patients infected with *Trichophyton tonsurans*, mycological and complete cure rates were superior with terbinafine.[8]

Terbinafine can also be safely used in children for onychomycosis when dosed by weight as for tinea capitis.[9]

ADULT. Terbinafine is indicated for the treatment of onychomycosis of the toenails and fingernails caused by dermatophytes.[10] A dose of 250 mg/day for 12 weeks is typically used.

Several studies have compared the standard 12-week regimen of terbinafine to itraconazole, used in either a continuous or pulsed fashion. Terbinafine produced higher rates of clinical and mycological cures.[11–14] In a study comparing continuous terbinafine with intermittent itraconazole (1 week of treatment per four weeks) in the treatment of toenail onychomycosis, terbinafine was significantly more effective than pulsed itraconazole.[11] At week 72, the mycological cure in those patients treated with a 3-month daily course of terbinafine was 76%, compared with a mycological cure rate of 38% in those patients treated with a 3-month course of intermittent pulse therapy with itraconazole. A longer follow-up of these patients at an average of 54 months revealed 46% cure after continuous terbinafine versus 13% cure after the pulsed itraconazole[12]; similar results were found by others at 2-year follow-up.[13] Twelve weeks of terbinafine 250 mg/day is clearly superior to itraconazole 200 mg/day, with mycological cure rates of 73% versus 46% after 48 weeks of follow-up.[14]

Studies comparing various intermittent dosing regimens of terbinafine to the gold standard of continuous 12-week therapy for toenail onychomycosis have yielded mixed results.[15,16]

No increase in mycological cure rate is gained by aggressive debridement of the toenail when combined with terbinafine; however, the clinical appearance of the nail is improved with debridement.[17] Additionally, aggressive nail debridement, when combined with oral terbinafine, improves treatment satisfaction and reduces symptom frequency.[18] The addition of a topical lacquer such as ciclopirox 8% lacquer or amorolfine 5% lacquer (see Chapter 219) enhances clinical efficacy when used with terbinafine and then continued for 6–9 months after the cessation of terbinafine.[19,20]

Tinea corporis, tinea cruris, and tinea pedis can be treated with oral terbinafine with high clinical and mycological cure rates. In a study of 22 patients with tinea corporis and tinea cruris who used terbinafine 250 mg daily for 1 week, 100% clinical and mycological clearing was observed at 6 weeks.[21] In a study of moccasin tinea pedis and tinea manuum, after a 2-week course of terbinafine, 250 mg daily, there was an 86% mycological cure rate at 8 weeks.[22] Two placebo-controlled trials demonstrated that a 4- to 6-week course of terbinafine 250 mg daily is effective in the treatment of seborrheic dermatitis[23,24] (see Chapter 22). Interestingly, terbinafine is not effective orally for the treatment of tinea versicolor,[21] but twice daily application of topical terbinafine 1% solution, cream or gel, has been effective in randomized placebo-controlled trials.[25]

GERIATRIC. Terbinafine is well tolerated by the elderly and requires no further cautions than those for the general population.[26] A study of 504 patients older than 65 years of age confirmed efficacy and tolerance of the standard adult regimen for onychomycosis, with no reported drug interactions.[27]

PREGNANCY CONSIDERATIONS. Terbinafine is a pregnancy category B drug.[10]

DOSAGE SCHEDULES AND FORMULATIONS

Terbinafine is supplied as a 250-mg tablet or packets of oral granules. See Table 232-1.

INITIATING THERAPY

Positive tests [potassium hydroxide (KOH), culture, histology] for fungal infection should be documented before initiation of oral terbinafine therapy. Pretreatment

TABLE 232-1
Terbinafine Oral Dosing Regimens

	Adult	Pediatric
Onychomycosis	Fingernails: 250 mg/day × 6 weeks Toenails: 250 mg/day × 12 weeks	3–6 mg/kg/day × 6–12 weeks
Tinea capitis	250 mg/day × 2–8 weeks	Under 25 kg: 125 mg/day × 6 weeks 25–35 kg: 187.5 mg/day × 6 weeks Over 35 kg: 250 mg/day × 6 weeks
Tinea corporis, tinea cruris	250 mg/day × 1–2 weeks	3–6 mg/kg/day × 1–2 weeks
Tinea pedis (moccasin)	250 mg/day × 2 weeks	
Seborrheic dermatitis	250 mg/day × 4–6 weeks	

serum transaminase tests are advised for all patients before taking terbinafine, and the drug is not recommended for patients with liver or renal disease.[22]

MONITORING THERAPY

Many physicians advocate monitoring liver function after 6 weeks of therapy, although the incidence of hepatic toxicity is very low [see Sections "Complications (Adverse Effects)" and "Risks and Precautions"]. Because of transient lymphopenia observed in patients on terbinafine, complete blood cell counts should be monitored in immunodeficient patients who are receiving terbinafine for longer than 6 weeks.[28] If signs or symptoms of secondary infection occur in patients while on terbinafine, a complete blood count should be performed to rule out neutropenia.[28] Cautions and monitoring in children are the same as for adults, but there is evidence that children may suffer fewer adverse events.[9]

COMPLICATIONS (ADVERSE EFFECTS)

Because of its high selectivity, terbinafine is generally well tolerated with a low incidence of adverse side effects. The most common side effects after oral administration are of a gastrointestinal nature (3.5%–5.0%).[29] Other rare side effects include headache, exanthematous eruption, acute generalized exanthematous pustulosis, pustular psoriasis, subacute cutaneous lupus erythematosus, chest pain, elevated laboratory parameters, loss of taste, fatigue, and malaise.[28–33] A few cases of hepatocellular injury (including fulminant hepatic failure),[34,35] reversible agranulocytosis,[36] and severe skin reactions, including toxic epidermal necrolysis and erythema multiforme, were also reported.[37]

RISKS AND PRECAUTIONS

Terbinafine should be prescribed with caution in patients with hepatic disease or history of hepatic toxicity with other medications (Box 232-2). Furthermore, there is insufficient data to recommend its use in patients with renal impairment. Because terbinafine rarely causes a lupus-like rash and neutropenia, patients with known systemic lupus erythematosus or immunodeficiency also may not be good candidates for this medication.[10]

DRUG INTERACTIONS

Terbinafine is not contraindicated with any specific drug. However, cytochrome P450 (CYP) enzymes metabolize terbinafine. Plasma clearance of terbinafine is increased by the P450-inducer rifampin and decreased by the P450-inhibitor cimetidine.[38] Terbinafine is also reported to decrease cyclosporine levels by increasing cyclosporine clearance.[22,39] Isolated reports of interactions with warfarin have been reported; however, prospective pharmacokinetic studies have not revealed any clinically significant reactions.[39] It was shown that terbinafine inhibits CYP2D6, a cytochrome P450 isoenzyme that metabolizes tricyclic antidepressants and other psychotropic drugs.[40] Other drugs predominantly metabolized by this enzyme include β-blockers, selective serotonin reuptake inhibitors, and monoamine oxidase inhibitors type B.[22] In a postmarketing surveillance study of patients on terbinafine, no adverse drug interactions with CYP2D6 substrates

BOX 232-2 TERBINAFINE RISKS AND PRECAUTIONS

- Contraindications
  - Hypersensitivity to terbinafine
- Precautions
  - Pregnancy (category B) and lactation
  - Chronic or active hepatic impairment[a]
  - Renal impairment (creatinine clearance <50 mL/min)
  - Immunodeficiency or immunosurpression[b]

[a]If clinical or laboratory evidence of liver injury exists, terbinafine should be discontinued.
[b]In these patients, CBC at baseline and every 6 weeks while under treatment is recommended. Terbinafine should be discontinued if the neutrophil count is less than 1000/mm^3.

were reported.[41] However, there have been two reports of nortriptyline intoxication induced by terbinafine.[42,43]

TRIAZOLES

Both itraconazole and fluconazole are triazole antimycotic agents sharing a common structural moiety—a triazole ring—not found in azoles of the imidazole family.

ITRACONAZOLE

Itraconazole (Fig. 232-1) is a highly lipophilic compound that has a wide spectrum of activity.[44] In vitro, it is fungistatic and effective against dermatophytes, yeast, molds, and dimorphic fungi.[45–47]

MECHANISM OF ACTION. Itraconazole inhibits 14-α-demethylase, a microsomal cytochrome P450 enzyme, in the fungal membrane (Fig. 232-2).[48] 14-α-Demethylase is necessary for the conversion of lanosterol to ergosterol, which is the principal structural component of the fungal cell membrane.[46] Consequently, the accumulation of 14-α-methylsterols leads to the impairment of membrane permeability and membrane-bound enzyme activity and to the arrest of fungal cell growth.

PHARMACOLOGY. The serum concentration of itraconazole is influenced by several parameters, including food and gastric acidity.[49,50] Itraconazole is extensively metabolized, primarily by the CYP3A4 isoenzyme system to more than 30 metabolites. Hydroxyitraconazole is the main metabolite. Approximately 54% of the metabolized drug is excreted in the feces, and 34% is excreted in the urine. After single-dose administration, the terminal elimination half-life is 21 hours for itraconazole and 12 hours for its active metabolite. The pharmacokinetic variables of itraconazole are not affected in patients with renal insufficiency.[51] In patients with liver cirrhosis, the absorption is slightly increased and the half-life is prolonged because of a reduced first-pass metabolism. Absorption of the standard tablet formulation is decreased in patients with acquired immunodeficiency syndrome as a result of gastric hypochlorhydria.[51] A new hydroxypropyl-β-cyclodextrin oral solution formulation is better absorbed in a fasting state than with food,[52] appropriate for patients who cannot ingest large amounts of food or have high gastric pH. Young children, especially those less than 5 years of age, have lower serum levels than adults and usually require twice daily dosing.[53]

INDICATIONS. Itraconazole has the broadest efficacy compared to other commonly prescribed antifungals.[47] Thus, it is a first-line therapy for infections due to *Candida* and other nondermatophyte species (Box 232-3).

Pediatric. Itraconazole can be used to treat tinea capitis in children. It is more often prescribed in the capsule formulation with food or acidic beverages such as colas because the cyclodextrin in the liquid form of itraconazole causes more gastrointestinal side effects such as diarrhea and also due to reports of neoplasms associated with high doses in murine and rat models.[54] Nevertheless, for children who cannot swallow capsules or take capsules with food, the solution has a pleasant taste and is considered to be safe.[55] Itraconazole is dosed at 5 mg/kg per day for 4–6 weeks.[56] Children who weigh between 15 and 30 kg require one 100 mg capsule daily; children weighing 30–40 kg require 100 mg 1 day alternating with 200 mg the next day, to average 150 mg daily.[57] Children weighing over 50 kg can be dosed as adults.[55] Tinea capitis caused by *T. tonsurans* requires a course lasting 2–4 weeks[58]; however, a longer treatment course is recommended for *M. canis*.[59] Because onychomycosis is less common in children than in adults, there is much less data available for treatment of pediatric onychomycosis. For better compliance due to decreased adverse effects, lower cost, and overall reduced exposure to drug, one can prescribe a pulsed regimen of 5 mg/kg/day for 1 week alternating with 3 weeks off; two pulses are recommended for fingernail involvement and three pulses for toenail involvement.[9]

The oral solution is a good option for oropharyngeal or esophageal candidiasis in children, even in fluconazole-resistant infections.[53]

Adult. Itraconazole has been approved for the treatment of onychomycosis caused by dermatophytes[54] and is effective as continuous or pulse therapy. A 2-month course of itraconazole pulse therapy is necessary for fingernail onychomycosis, while toenail onychomycosis requires a 3-month course. A single course consists of 200 mg twice daily for 1 week per month. Itraconazole pulse therapy is at least equal in efficacy, if not superior, in the treatment of toenail onychomycosis

BOX 232-3 ITRACONAZOLE TREATMENT OF FUNGAL INFECTIONS

- US Food and Drug Administration indications
  - Onychomycosis due to dermatophytes in immunocompetent patients
    - Continuous therapy for fingernails and toenails
    - Pulsed therapy for fingernails
  - Systemic mycoses (blastomycosis, histoplasmosis, aspergillosis)
  - Empiric antifungal therapy in febrile neutropenia (oral solution)
  - Oropharyngeal candidiasis (oral solution)
  - Esophageal candidiasis (oral solution)
- Other common uses
  - Onychomycosis due to *Candida* sp.
  - Tinea corporis and its subtypes
  - Tinea cruris
  - Tinea pedis
  - Tinea capitis

when compared to continuous itraconazole therapy.[60] Itraconazole has been used for the treatment of tinea pedis. A 1-week course of itraconazole, 200 mg twice daily, is more effective than 200 mg or 100 mg daily for 2–4 weeks.[61] Nonetheless, itraconazole is less effective in the treatment of dermatophyte infections than terbinafine (see Section "Allylamines: Terbinafine"). Itraconazole at a dose of 200 mg daily for 5–7 days is effective in the treatment of pityriasis versicolor.[62] Recurrence, which is common in this disease, can be prevented by taking 200 mg twice daily for 1 day a month.[62]

Geriatric. Itraconazole (pulse) therapy is effective and safe in the elderly and only requires caution in the setting of comorbidities and drug interactions [see Section "Complications (Adverse Effects)"].[26]

Pregnancy Considerations. Itraconazole is a pregnancy category C drug, and therefore, is not recommended during pregnancy or while nursing because it is excreted in human milk.[54]

DOSAGE SCHEDULES AND FORMULATIONS.

Itraconazole is supplied in 100-mg capsules, a 10-mg/mL oral solution, and an intravenous solution. Capsules should be taken with a full meal to ensure maximum absorption[54] (see Table 232-2).

INITIATING THERAPY.

Positive tests (KOH, culture, histology) for fungal infection should be documented before initiation of oral itraconazole therapy. Baseline evaluation of hepatic function is recommended in patients with preexisting liver disease, or if lengthy treatment is anticipated.[54]

MONITORING THERAPY.

Hepatic function monitoring is indicated through therapy only for those patients with preexisting liver disease or those with a history of hepatic toxicity with other medications.[54,63] When itraconazole must be administered with medications, it is known to compete with for hepatic enzymes, appropriate monitoring for drug levels or toxic effects of these medications is indicated (see Section "Drug Interactions").

COMPLICATIONS (ADVERSE EFFECTS).

The most common reported side effects associated with itraconazole therapy are of a gastrointestinal nature.[64] Less-frequent adverse effects are hypertriglyceridemia, edema,[65] urticaria, anaphylaxis, erythema multiforme, headache, neuropathy, impotence, hypertension, leukopenia, nephrotic syndrome, and mildly elevated liver enzymes.[54,64] Instances of hepatic injury and, rarely, fulminant hepatotoxicity are associated with the administration of itraconazole. There are also rare reports of congestive heart failure and pulmonary edema. When administered intravenously to dogs and healthy human volunteers, negative inotropic effects were noted.[66]

RISKS AND PRECAUTIONS.

Administration of itraconazole to patients with a history of heart failure is contraindicated, and it is not recommended for patients with a history of liver disease.[54] There are also several significant drug interactions to be aware of (see Box 232-4).

DRUG INTERACTIONS.

Itraconazole inhibits 14-α-demethylase, a fungal P450 enzyme[48] and a member of the same group of enzymes present in the human liver that is responsible for the metabolism of many drugs (Fig. 232-2). Itraconazole specifically inhibits CYP3A4, and consequently, may increase plasma concentrations of drugs metabolized by this pathway. The concomitant use of itraconazole and sildenafil can lead to a reduction in sildenafil clearance.[67] Cisapride, terfenadine, quinidine, dofetilide, oral midazolam, pimozide,

TABLE 232-2
Itraconazole Oral Dosing Regimens

	Adult	Pediatric
Onychomycosis	Fingernails: 200 mg bid × 1 week/month × 2 pulses Toenails: 200 mg/day × 12 weeks *Or* 200 mg bid × 1 week/month × 3 pulses	Fingernails: 5 mg/kg/day × 1 week/month × 2 pulses[a] Toenails: 5 mg/kg/day × 1 week/month pulsed × 3 pulses
Tinea capitis	250 mg/day × 2–8 weeks	*Trichophyton* infections: 5 mg/kg/day × 2–4 weeks Microsporum infections: 5 mg/kg/day × 4–8 weeks
Tinea corporis, tinea cruris, tinea pedis	200 mg bid × 1 week *or* 100–200 mg/day × 2–4 weeks	Dose by weight × 1–4 weeks
Oropharyngeal candidiasis Pityriasis versicolor	Swish and swallow solution 100–200 mg/day 200 mg/day × 5–7 days, prevent recurrence with 200 mg bid once/month	Swish and swallow solution by weight[a]

[a]Pediatric weight-based dosing: 100 mg/day (15–30 kg), 100 mg/day alternating with 200 mg/day (30–40 kg), 200 mg/day (>40 kg).

BOX 232-4 ITRACONAZOLE RISKS AND PRECAUTIONS

- Contraindications
  - Hypersensitivity to itraconazole or vehicle components
  - **Coadministration with certain drugs metabolized by CYP3A4**, including cisapride, midazolam, pimozide, quinidine, dofetilide, and levacetylmethadol (levomethadyl); serious cardiovascular events, including QT prolongation, torsades de pointes, ventricular tachycardia, cardiac arrest, or sudden death may occur
- Risks and precautions
  - Hypersensitivity to other azoles
  - Hepatic disease or insufficiency
  - History or risk of **heart failure** or **ventricular dysfunction**, angina, or valvular disease (negative inotropic effect observed)
  - Pregnancy (category C) or lactation
  - Achlorhydria (drug not absorbed)
  - Co-administration with certain drugs metabolized by CYP3A4, including midazolam, triazolam, lovastatin, and simvastatin

Boldfaced type indicates a US Food and Drug Administration Black Box warning.

triazolam, and 3-hydroxy-3-methylglutaryl coenzyme A–reductase inhibitors metabolized by CYP3A4, such as lovastatin and simvastatin, are contraindicated with itraconazole. Because itraconazole is metabolized by CYP3A4, inducers or inhibitors of CYP3A4 may alter itraconazole levels. Absorption of itraconazole may be decreased by the concomitant administration of antacids, H_2-blockers, and proton pump inhibitors.[3]

FLUCONAZOLE

Fluconazole (Fig. 232-1) is fungistatic in vitro[68] and is effective against many yeasts (with the exception of *Candida krusei*) and dermatophytes.[69]

MECHANISM OF ACTION. Fluconazole, like itraconazole, inhibits 14-α-demethylase, a microsomal cytochrome P450 enzyme, in the fungal membrane (Fig. 232-2).[48]

PHARMACOLOGY. The pharmacokinetic parameters of fluconazole are similar for both intravenous and oral administration.[69] Near complete absorbtion of the triazole appears to be comparable in both postprandial and fasting states; absorbtion is not dependent on stomach acidity.[50,70] Fluconazole exhibits a long half-life of 25–30 hours, and a steady-state level is reached after 7 days of once-daily administrations. Fluconazole is only weakly bound to plasma proteins, with about 90% of the drug circulating free in the plasma. The drug is resistant to hepatic metabolism, and hence, approximately 80% of fluconazole is excreted unchanged in urine, with 2% in feces and approximately 11% as metabolites in urine.[71] The ability to diffuse substantially into the cerebrospinal fluid distinguishes this compound from many other antimycotic agents.[72] The levels of fluconazole in cerebrospinal fluid, saliva, vaginal tissue, sputum, skin, and blister fluids are reported to be comparable with or to exceed simultaneous plasma concentrations.[73] Altered fluconazole pharmacokinetics, including decreased plasma clearance, are detected in patients with cirrhosisand renal impairment.[74,75] In children over 3 months of age, fluconazole clearance is more rapid than in adults.[53]

INDICATIONS. Fluconazole is established as a first-line therapy for mucocutaneous candidiasis (Box 232-5). It is useful for its convenient once-weekly dosing schedule (Table 232-3).

Pediatric. Fluconazole has been used successfully to treat tinea capitis at 6 mg/kg/day for 20 days for *T. tonsurans* infection and at 5 mg/kg/day for 30 days.[57,76] A course as brief as 2 weeks may be equally effective as terbinafine and itraconazole for *Trichophyton* infections.[58] When *M. canis* is present, a longer treatment course is recommended.[59] A 6-week course of fluconazole 6 mg/kg/day produced comparable mycological and clinical cure rates compared to griseofulvin 11 mg/kg/day microsize formulation.[77]

Adult. Vaginal candidiasis can conveniently and safely be treated with a single 150-mg dose of fluconazole, or weekly for 6 months or longer in the case of recurrent vulvovaginal candidiasis.[78] Interestingly, a daily oral probiotic *Lactobacillus* supplement enhances

BOX 232-5 FLUCONAZOLE TREATMENT OF FUNGAL INFECTIONS

- US Food and Drug Administration indications
  - Vaginal candidiasis
  - Oropharyngeal and esophageal candidiasis
  - Cryptococcal meningitis
  - Prophylaxis against candidiasis in bone marrow transplant patients
- Other common uses
  - Onychomycosis due to dermatophyte and *Candida* sp.
  - Cutaneous and chronic mucocutaneous candidiasis
  - Tinea corporis and its sub-types
  - Tinea cruris
  - Tinea pedis
  - Tinea capitis
  - Pityriasis versicolor
  - Sporotrichosis

TABLE 232-3
Fluconazole Oral Dosing Regimens

	Adult	Pediatric
Oropharyngeal candidiasis	200 mg once, then 100 mg/day × 14 days	6 mg/kg once, then 3 mg/kg/day × 14 days[a]
Vaginal candidiasis	150 mg once	
Tinea pedis, cruris, or corporis	150 mg/week × 3–4 weeks	
Tinea capitis		6 mg/kg/day × 2–6 weeks

[a]For neonates 0–14 days: 6 mg/kg on the first day, followed by 3 mg/kg every 72 hours.

rates of clinical and mycological cure in vulvovaginal candidiasis after treatment with 150-mg single-dose fluconazole.[79]

When used to treat oropharyngeal candidiasis, fluconazle is typically given at doses of 200 mg on day 1 followed by 13 days of 100 mg per day. However, a single dose of 750 mg is as effective as the standard 14-day regimen in patients with HIV and offers greater convenience.[80]

For the treatment of tinea pedis, weekly doses of fluconazole 150 mg have been given for a period of 3–4 weeks,[81] with a 75% mycological cure rate at 4 weeks. Fluconazole at a dose of 150 mg weekly for 24 weeks is significantly inferior to terbinafine 250 mg daily for 12 weeks in the treatment of onychomycosis.[82] Pityriasis versicolor can be effectively treated with a single 400-mg dose of fluconazole.[83] In a small, open-label randomized study of pityriasis versicolor treatment comparing a single 400-mg dose of fluconazole with a single 400-mg dose of itraconazole, fluconazole led to greater cure than itraconazole (65% vs. 20%, respectively) with fewer relapses noted (35% vs. 60%, respectively) at an 8-week follow-up assessment by KOH and culture tests.[84] Oral fluconazole is not the treatment of choice for seborrheic dermatitis, as two 300 mg doses spaced one week apart showed essentially no improvement over placebo.[85]

Geriatric. Fluconazole is well tolerated in the elderly; however, dose modification is required in elderly patients with renal impairment.[73,86]

Pregnancy Considerations. Fluconazole is a pregnancy category C drug and is not recommended in pregnant or nursing mothers.[87]

DOSAGE SCHEDULES AND FORMULATIONS. Fluconazole is available in 50-mg, 100-mg, 150-mg, and 200-mg tablets; in 10-mg/mL and 40-mg/mL oral solutions; and in an intravenous form. It is approved for use in children age 6 months and older, although not specifically for tinea capitis (see Table 232-3).

INITIATING THERAPY. Positive tests (KOH, culture, histology) for fungal infection should be documented before initiation of oral fluconazole. There are no specific recommendations for baseline laboratories before starting fluconazole therapy.[87]

MONITORING THERAPY. There are no specific monitoring recommendations other than drug levels in renal disease. Because fluconazole is prescribed as a one-time dose or once weekly, there is little need for laboratory monitoring other than that indicated by side effects.[87]

COMPLICATIONS (ADVERSE EFFECTS). The most common recognized side effects of fluconazole therapy are gastrointestinal.[88] Adverse reactions such as fixed drug eruptions, thrombocytopenia, transient amenorrhea, elevated liver function tests, mild increase in levels of serum creatine phosphokinase, dizziness, anorexia, and alopecia have been observed, and most resolve with continuing fluconazole therapy.[87,89] There are rare reports of fatal hepatotoxicity associated with fluconazole, but most studies in both humans and rats have shown less hepatoxicity when compared to other azoles.[90] There are even fewer reports of torsades de pointes, with or without concomitant medications or underlying cardiac arrhythmias.[91]

RISKS AND PRECAUTIONS. To prevent serious hepatic and cardiac toxicity, one should exercise caution when prescribing to patients with multiple comorbidities, immunosuppression or preexisting liver or cardiac disease; close monitoring may be helpful in these patients (see Box 232-6).

DRUG INTERACTIONS. In humans, fluconazole inhibits both CYP3A4 and CYP2C9 in a dose-dependent manner,[3] and consequently may increase plasma concentrations of drugs metabolized by these pathways. Therefore, a number of drugs that are metabolized by CYP3A4 or CYP2C9 are contraindicated or require close monitoring. Coadministration of terfenadine or cisapride with fluconazole is contraindicated.[87] (See Box 232-6.)

VORICONAZOLE

Voriconazole is a second-generation triazole agent available in oral and intravenous formulations that is

BOX 232-6 FLUCONAZOLE RISKS AND PRECAUTIONS

- Contraindications
  - Hypersensitivity to fluconazole
  - Coadministration with cisapride
- Risks and precautions
  - Hypersensitivity to other azoles
  - Proarrhythmic cardiac conditions
  - Hepatic impairment
  - Renal impairment (dose adjustment required)
  - Pregnancy (category C) or lactation

used widely outside of dermatology for the treatment of invasive fungal diseases, particularly invasive aspergillosis.[92] Although this drug in infrequently prescribed by dermatologists, voriconazole has several important adverse effects that the dermatologist should be familiar with.[93] Cutaneous adverse effects occur in fewer than 10% of patients taking voriconazole.[94] Voriconazole can induce a spectrum of photosensitivity reactions, ranging from sunburn-like reactions after minimal photoexposure[94,95] to premature photoaging in patients on long-term treatment[96] to pseudoporphyria, with erythema and blistering in photoexposed areas accompanied by cheilitis.[97,98] Photosensitivity and pseudoporphyria induced by voriconazole disappear promptly after discontinuation of the drug.[93–98] In addition to photosensitivity, voriconazole is also a known cause of Steven-Johnson syndrome and life-threatening toxic epidermal necrolysis, although these reactions are rare.[99,100] Skin cancers including melanoma in situ has been reported.[101]

IMIDAZOLES: KETOCONAZOLE

Ketoconazole was introduced in the 1970s as the first effective oral azole antifungal. However, because of the drug's many adverse reactions and the availability of safer, efficacious medications, it is no longer used as a first-line agent for the treatment of dermatophyte or yeast infections.

MISCELLANEOUS: GRISEOFULVIN

Griseofulvin (Fig. 232-1; Box 232-7) has been used since 1958 for the treatment of dermatophyte infections.[59] Griseofulvin is not effective for candidiasis, deep fungal infections, or pityriasis versicolor.

MECHANISM OF ACTION

Griseofulvin is fungistatic in vitro,[59] and has a narrow spectrum of antimycotic activity. It disrupts microtubule mitotic spindle formation, thereby causing mitotic arrest at the metaphase stage.[102]

BOX 232-7 GRISEOFULVIN TREATMENT OF FUNGAL INFECTIONS

- US Food and Drug Administration indications
  - Onychomycosis due to dermatophytes (tinea unguium of fingernails and toenails)
  - Tinea capitis
  - Tinea corporis
  - Tinea cruris
  - Tinea barbae
  - Tinea pedis

PHARMACOLOGY

The absorption of griseofulvin is enhanced by several factors, including concurrent intake of a fatty meal and a smaller particle size formulation. Griseofulvin is mainly metabolized by the liver before excretion.[103]

INDICATIONS

As one of the early antifungal medications, griseofulvin has been US Food and Drug Administration approved for several dermatophyte infections. However, because of its limited spectrum of coverage compared to other agents and the lengthy courses required, griseofulvin is not used as a first-line therapy for fungal infections other than tinea capitis.

PEDIATRIC. Griseofulvin is an acceptable choice for the first-line treatment of tinea capitis in children.[68] Griseofulvin is recommended at a dosage higher than that suggested by the manufacturers at 20–25 mg/kg/day (microsize), or 15–20 mg/kg/day (ultramicrosize) to complete a minimum course of 6–8 weeks for *T. tonsurans*.[57] However, longer treatment with griseofulvin is recommended for *M. canis* infections.[57]

ADULT. Although griseofulvin is indicated for the treatment of fingernail and toenail onychomycosis, therapy is prolonged with low cure and high relapse rates, requiring approximately 6 months for the treatment of fingernails and 12 months for toenails.[102]

GERIATRIC. The safety of griseofulvin therapy in the elderly has not been formally evaluated in trials. However, studies including elderly patients have not specifically reported an increased incidence of adverse effects among this age group.[104,105]

PREGNANCY CONSIDERATIONS. Griseofulvin is a pregnancy category C drug. Because griseofulvin interferes with chromosomal distribution during cell division, males should wait at least 6 months after completing griseofulvin therapy before fathering a child.[106]

TABLE 232-4
Griseofulvin Oral Dosing Regimens

	Adult		Pediatric (over 2-years-old)	
	Microsize	**Ultramicrosize**	**Microsize[a]**	**Ultramicrosize[b]**
Tinea corporis or cruris	500 mg/day × 2–4 weeks	300–375 mg/day × 2–4 weeks	10–20 mg/kg/day × 2–4 weeks	5–10 mg/kg/day × 2–4 weeks
Tinea capitis	500 mg/day × 4–8 weeks	300–375 mg/day × 4–8 weeks	15–20 mg/kg/day × 6–12 weeks	5–10 mg/kg/day × 6–12 weeks
Tinea pedis	750–1,000 mg/day × 4–8 weeks	660–750 mg/day × 4–8 weeks	10–20 mg/kg/day × 4–8 weeks	5–10 mg/kg/day × 4–8 weeks
Fingernail onychomycosis	750–1,000 mg/day × 4 months	660–750 mg/day × 4 months	10–20 mg/kg/day × 4 months	5–10 mg/kg/day × 4 months
Toenail onychomycosis	750–1,000 mg/day × 6 months	660–750 mg/day × 6 months	10–20 mg/kg/day × 6 months	5–10 mg/kg/day × 6 months

[a]Max dose of 1000 mg/day.
[b]Max dose of 750 mg/day.

DOSAGE SCHEDULES AND FORMULATIONS

Griseofulvin is formulated as ultramicrosize tablets in 125-mg, 165-mg, 250-mg, and 330-mg doses.[107] It is also formulated as griseofulvin microsize and is available as 250-mg and 500-mg tablets and in a 125-mg/5-mL suspension.[108] To maximize absorption, it should be taken with fatty foods. The manufacturers recommend 5–10 mg/kg/day (ultramicrosize) or 10–20 mg/kg/day (microsize). See Table 232-4.

INITIATING THERAPY

Positive tests (KOH, culture, histology) for fungal infection should be documented before initiation of therapy. There are no specific recommendations for baseline laboratories before starting griseofulvin therapy.

MONITORING THERAPY

There are no specific monitoring recommendations.

COMPLICATIONS (ADVERSE EFFECTS)

The most common side effects are related to the gastrointestinal tract and the central nervous system, such as headache, dizziness, and insomnia.[102] The drug is reported to precipitate lupus erythematosus and, rarely, severe skin reactions, including Stevens-Johnson and angioedema. As a result of impaired porphyrin metabolism, griseofulvin therapy is associated with photosensitivity reactions. Griseofulvin is contraindicated in patients with porphyria and hepatocellular failure.[107]

RISKS AND PRECAUTIONS

Patients should be warned about potential photosensitivity induced by griseofulvin and the possibility of lupus erythematosus or a lupus-like syndrome.[108] See Box 232-8.

DRUG INTERACTIONS

Griseofulvin induces CYP3A4, leading to lower plasma levels of drugs metabolized by this pathway.[3] Two important examples are decreased anticoagulation by warfarin and potential decreased effectiveness of oral contraceptive pills.

ORAL ANTIFUNGALS IN THE IMMUNOCOMPROMISED

Oral antifungal therapy is increasingly important for the treatment and prevention of infection in

BOX 232-8 GRISEOFULVIN RISKS AND PRECAUTIONS

- Contraindications
  - Hypersensitivity to griseofulvin
- Risks and precautions
  - Hepatic impairment
  - Porphyrias (drug interferes with porphyrin metabolism)
  - Systemic lupus erythematosus (drug can exacerbate SLE)
  - Pregnancy (category C) or lactation

immunocompromised individuals, even in an outpatient setting. For example, as more patients survive organ transplantation,[109,110] more fungal infections are likely to be observed. In one report of 100 consecutive liver transplant patients seen by a dermatology clinic, fungal infections were much more common (19% of total skin infections) than bacterial (5%) or viral (2%).[111]

Candidiasis and aspergillosis are the most common opportunistic fungal infections in many immunocompromised populations. The extensive use of fluconazole prophylactically in patients with acquired immunodeficiency syndrome, transplants, hematologic malignancies, and other causes of immunosuppression has led to decreased susceptibility of some *Candida* infections to fluconazole.[112] Itraconazole solution, 100 mg/day for 14 days, is equivalently effective as fluconazole, 100 mg/day for 14 days, with the added advantages of broader coverage than fluconazole, greater bioavailability than itraconazole capsules on an empty or hypochloridic stomach, easier swallowing by dysphagic patients, and potential effectiveness in cases of fluconazole-resistant strains of *C. albicans*.[113,114] Itraconazole solution has shown superior prevention of death from disseminated candidiasis and aspergillosis than fluconazole solution in immunosuppressed pediatric patients.[53] One should keep in mind, however, that itraconazole solution has more drug interactions and potential compliance issues due to nausea and diarrhea. *Posaconazole* is an extended-spectrum triazole with activity against strains of fluconazole-resistant *Candida*. In patients with oropharyngeal candidiasis and HIV/AIDS, a comparison of a two-week course of posaconazole to fluconazole demonstrated that posaconazole was as effective as fluconazole in producing a successful clinical outcome, yet posaconazole was more effective in sustaining clinical success after treatment was stopped.[115]

New antifungal medications with activity against resistant species and excellent safety profiles continue to be developed. The new class of antifungals, *echinocandins*, provides both benefits by specifically targeting fungal cell wall β-1,3-D-glucan synthesis (absent in mammalian cells). However, poor oral bioavailability currently limits these drugs to intravenous formulations.[116]

EVIDENCE-BASED MEDICINE CONSIDERATIONS

Interpretation of competing studies continues to be difficult because endpoints have not been uniform. Such endpoints may be mycological cure, clinical cure, complete cure, and effective treatment. Criticisms of these studies include the fact that many were open label, leading to investigator bias.[117] Many studies fail to take into account the physiology of nail growth.[13] Toenails can take up to 18 months to grow out fully. Therefore, studies at 48–52 weeks might not accurately reflect clinical or mycological cure.

Several studies of the treatment of tinea pedis did not specify the type of tinea pedis, despite known variations amongst forms of tinea pedis in response rate to therapy. Studies of moccasin tinea pedis are preferred, as successful treatment usually indicates that the antifungal drug will be effective in the milder forms of tinea pedis as well as tinea corporis and tinea cruris.[117] Finally, the efficacy of antifungal agents depends on the sensitivity of the dermatophyte. For example, in the treatment of tinea capitis, if the causative organism is *M. canis*, longer treatments may be needed than if the organism is *T. tonsurans*.[44] In North America, most tinea capitis is caused by *T. tonsurans*, while surveys in the United Kingdom demonstrate that the predominant dermatophyte is *M. canis*.[59] Consequently, trials assessing the efficacy of a drug may be influenced by the culprit dermatophyte and indirectly by the location of the study.

EMERGING PARADIGMS

Both tinea capitis and onychomycosis due to dermatophytes remain challenging infections to cure. Oral terbinafine has emerged as a safe and effective treatment of tinea capitis, surpassing griseofulvin in mycological and complete cure rates for patient infected with *T. tonsurans*.[8] Oral terbinafine has remained the most effective monotherapy for onychomycosis.[11–14] Moreover, the addition of a topical antifungal lacquer such as ciclopirox 8% lacquer or amorolfine 5% lacquer enhances clinical efficacy when used with terbinafine and then continued for 6–9 months after the cessation of terbinafine.[19,20]

KEY REFERENCES

Full reference list available at www.DIGM8.com

DVD contains references and additional content

8. Elewski BE et al: Terbinafine hydrochloride oral granules versus oral griseofulvin suspension in children with tinea capitis: Results of two randomized, investigator-blinded, multicenter, international, controlled trials. *J Am Acad Dermatol* **59**:41-54, 2008
17. Jennings MB et al: Treatment of toenail onychomycosis with oral terbinafine plus aggressive debridement: IRONCLAD, a large, randomized, open-label, multicenter trial. *J Am Podiatr Med Assoc* **96**:465-473, 2006
19. Avner S, Nir N, Henri T: Combination of oral terbinafine and topical ciclopirox compared to oral terbinafine for the treatment of onychomycosis. *J Dermatolog Treat* **16**:327-330, 2005
20. Baran R et al: A multicentre, randomized, controlled study of the efficacy, safety and cost-effectiveness of a combination therapy with amorolfine nail lacquer and oral terbinafine compared with oral terbinafine alone for the treatment of onychomycosis with matrix involvement. *Br J Dermatol* **157**:149-157, 2007
48. Vanden Bossche H et al: Biochemical basis for the activity and selectivity of oral antifungal drugs. *Br J Clin Pract Suppl* **71**:41-46, 1990
80. Hamza OJ et al: Single-dose fluconazole versus standard 2-week therapy for oropharyngeal candidiasis in HIV-infected patients: A randomized, double-blind, double-dummy trial. *Clin Infect Dis* **47**:1270-1276, 2008

Chapter 233 :: Immunosuppressive and Immunomodulatory Drugs

:: Jeffrey P. Callen

IMMUNOSUPPRESSIVE AND IMMUNOMODULATORY DRUGS AT A GLANCE

- The main goals in immunotherapy are safety and effectiveness.
- Unlike immunomodulators, immunosuppressive drugs are all characterized by a narrow therapeutic window requiring precise dosing and close side-effect monitoring.
- The highest level of safety and effectiveness in immunotherapy therapy is currently accomplished by the use of combined regimens.
- An additive or synergistic combined immunotherapeutic regimen allows significant reduction of dose-dependent drug side effects maintaining or improving the effectiveness, respectively.
- A comprehensive knowledge of the pathophysiology of the treating disease as well as of the pharmacokinetics and pharmacodynamics concepts is crucial for delineating the most effective and safest therapeutic regimens.

There has been significant progress in the search for selective immunomodulation; the most significant advance in immunotherapy has been the reduction of systemic corticosteroid therapy by the early or concomitant introduction of immunosuppressive therapies. Immunosuppressants are characterized by (1) a low therapeutic index (narrow window between the therapeutic and toxic range) and (2) intra- and interindividual variation of the pharmacokinetics of these agents. These obstacles are usually overcome by precise drug dosing (ideal/lean body weight) as well as close monitoring of drug levels (parent and metabolite serum peak and trough levels) and end-organ toxicity. The main goals in immunotherapy are safety and effectiveness, which currently are accomplished by the use of combination therapy.[1,2] (See Fig. 233-1.) Although in transplantation medicine, agents are often combined, in dermatologic usage, these agents are usually used as corticosteroid-sparing agents and are less frequently used in combination except perhaps with methotrexate.[3] Within the dermatologic community, the use of cyclosporine and related macrolactam drugs has fallen with the introduction of biologic agents targeted more precisely at the presumed pathogenetic factors. In addition, many of the biologic agents have less toxicity than these broad-spectrum immunosuppressive therapies. However, the use of mycophenolate mofetil has increased within the dermatologic community.

MYCOPHENOLATE MOFETIL

Mycophenolate mofetil (MMF) is an ethyl ester of its active metabolite, mycophenolic acid (MPA)—a product of several *Penicillium* species.

MECHANISM OF ACTION

MMF is the reformulated product of MPA, but with enhanced bioavailability. MPA inhibits the type II isoform of inosine monophosphate dehydrogenase in the de novo pathway of purine synthesis. The proliferation of both T- and B-lymphocytes are susceptible to this drug effect, because they minimally use the hypoxanthine–guanine phosphoribosyl transferase salvage pathway for purine synthesis. Decreased delayed hypersensitivity and immunoglobulin levels have been observed in treated patients.

PHARMACOKINETICS

The drug is rapidly absorbed after oral administration, and antacids and cholestyramine may decrease its absorption. Approximately 5% of the drug is bound to albumin. It is nearly completely metabolized by glucuronyl transferase, and more than 90% of the drug is eliminated by the kidneys. The MMF glucuronide metabolite, which is increased in renal failure, increases MMF clearance by competing for its binding sites on albumin. MMF pharmacokinetics seems not to be affected by the concomitant administration of cyclosporine A (CsA). As with many other immunosuppressive agents, doses up to 20% higher may be required for children due to a physiologic increased liver metabolism. A new oral formulation of MPA, mycophenolate sodium-enteric coating (MP-EC), has been proved to be as effective as MMF at conversion dose as follows: 250 mg of MMF = 180 mg of MP-EC and 500 mg of MMF = 360 mg of MP-EC. This new formulation is less expensive and appears to have less gastrointestinal side effects.

INDICATIONS

There are no approved indications for MMF in dermatology. However, it has been used for immunoblistering diseases, particularly pemphigus; for collagen

Modified median effect formula for combined therapeutic effect

$$Cix = \frac{A \text{ combined with } B}{A} + \frac{B \text{ combined with } A}{B}$$

Cix: index inhibition (Igs, disease activity, etc)
Cix: = 1 additive
< 1 synergistic
> 1 antagonistic

Figure 233-1 A modified, median-effect formula is widely used in organ transplant, which helps in finding the therapeutic windows of immunosuppressive drugs as well as the synergistic, additive, or antagonistic effect of a postulated drug combination. Igs = immunoglobulins. (From Chou TC, Talalay P: Quantitative analysis of dose-effect relationships: The combined effects of multiple drugs or enzyme inhibitors. *Adv Enzyme Regul* **22**:27, 1984.)

vascular diseases, including cutaneous lupus erythematosus, morphea and dermatomyositis; papulosquamous diseases including psoriasis, lichen planus and lichen planopilaris; pyoderma gangrenosum, cutaneous vasculitis, sarcoidosis, and chronic atopic dermatitis.[3,18,19] There is no high level of evidence for any of these conditions being effectively treated with MMF. MMF may be combined with other traditional immunosuppressive agents because of potential synergism, however, the risk of infection and neoplasia likely increase in patients utilizing combined regimens.

DOSING REGIMEN

(Table 233-1)

INITIATING THERAPY

MMF is commonly used in synergistic and safe combination with CsA and corticosteroids.

MMF is commonly used with systemic corticosteroids as adjuvant therapy. The full therapeutic effect of MMF or MP-EC, namely on antibody-mediated diseases, should not be expected until 2 or 3 months after therapy initiation. The therapeutic and toxic profiles of MMF have led this drug to be the substitute of azathioprine.

MONITORING THERAPY

Measurement of serum levels of MPA shows inconsistent predictive value to monitor effectiveness and toxicity in MMF-treated patients, and therefore is rarely used in the clinical setting. There is no specific monitoring guideline, but it seems prudent to monitor a complete blood cell count and a liver-derived enzyme on a regular basis at the onset of therapy and perhaps quarterly during chronic therapy.

RISKS AND PRECAUTIONS

Gastrointestinal side effects, occasionally with intractable diarrhea, namely in elderly patients, are common, but in the vast majority of the cases they disappear with continuation of therapy, dividing the total daily dose (e.g., three or four times a day), and taking the drug with food. Increased risk of herpes zoster virus reactivation is rather common, namely, in elderly patients and patients with autoimmune blistering disease (author's personal observation). Significant cytopenias could be expected when combined with mTORIs. Dose reduction should be made for patients with liver diseases. MMF is a pregnancy category D agent and therefore should be avoided in women of child-bearing age unless they are on adequate contraception.

COMPLICATIONS

Expected toxicities include nausea, upset stomach, vomiting, and diarrhea. There is no increase in nephrotoxicity, hepatotoxicity, hypertension, or neurotoxicity when MMF is used in conjunction with CsA and corticosteroids. The hematologic and gastrointestinal side effects are dose dependent and usually clinically insignificant. An increased incidence of lymphoproliferative diseases and lymphoma is reported with its use, as well as predisposition for infectious complication, and as a predisposition for infectious complications including progressive multifocal leukoencephalopathy.[30–38]

Other antimetabolite and immunosuppressive agents are discussed in Chapter 227.

TABLE 233-1
Mycophenolate Mofetil Dosing Regimen

	Daily Oral Dose
Cytotoxic T-cell mediated diseases	25–35 mg/kg
Antibody-mediated diseases	35–55 mg/kg

Note: 180 mg of mycophenolate sodium enteric coating is the equivalent of 250 mg of mycophenolate mofetil; 360 mg of mycophenolate sodium enteric coating is the equivalent of 500 mg of mycophenolate mofetil.[27,28]

MACROLACTAM DRUGS

Macrolactam drugs are immunomodulators derived from microorganism fermentation products that include calcineurin inhibitors (CnIs) [e.g., cyclosporine, tacrolimus (TCL), and pimecrolimus] and mammalian target of rapamycin inhibitors (mTORIs) [e.g., sirolimus (SRL) and everolimus (EVL)]. Macrolactams are versatile immunomodulators that selectively suppress T-cell response and have synergistic therapeutic effects when they are combined with virtually any other immunosuppressive drug.[1,2]

CALCINEURIN INHIBITORS

MECHANISM OF ACTION. (Figure 233-2). CnIs inhibit T-cell stimulation initiated by several pathways, of which the T-cell receptor (TCR) CD3 is the best understood.[3] Mechanisms involving B-7 and CD28/cytotoxic T lymphocyte antigen-4, and other costimulatory pathways seem not to be affected by CsA or other CnIs. The high-affinity receptor for CsA is a 17-kd immunophilin called *cyclophilin A* (*CyPA*). The other CnIs (TCL and pimecrolimus) bind a structurally unrelated, different immunophilin called *macrophilin-12* also known as *FK-506 binding protein-12* (*FKBP-12*). The drug-immunophilin complex binds to calcineurin (Cn), a serine/threonine protease composed of two subunits: (1) CnA and (2) CnB. CnA constitutes the catalytic unit possessing binding sites for CnB and calmodulin. Cn activity strictly correlates with interleukin-2 (IL-2) production via CD3 activation. Cn is also involved in the induction of apoptosis and degranulation of cytotoxic T lymphocytes. Experimental data show that the CsA, TCL, and pimecrolimus/Cn complex inhibits the nuclear translocation of the nuclear factor of activated T cells c molecule by blocking its dephosphorylation. This is thought to be the key step by which these drugs uncouple TCR activation from IL-2 transcription. TCL is 10- to 100-fold more potent than CsA in vitro in the inhibition of Cn activity.

In summary, CsA inhibits the T-cell activation mediated by antigen, but it does not inhibit the early phases of lymphocyte signal transduction occurring after antigen-mediated activation. The immunomodulatory effects of these drugs are intricate and subject to constant discoveries. A simplified explanation of the mechanism of action of these drugs is presented in the following sections and is illustrated in Fig. 233-2.

CYCLOSPORINE A. CsA is a hydrophobic lipophilic undecapeptide extracted from fungi.

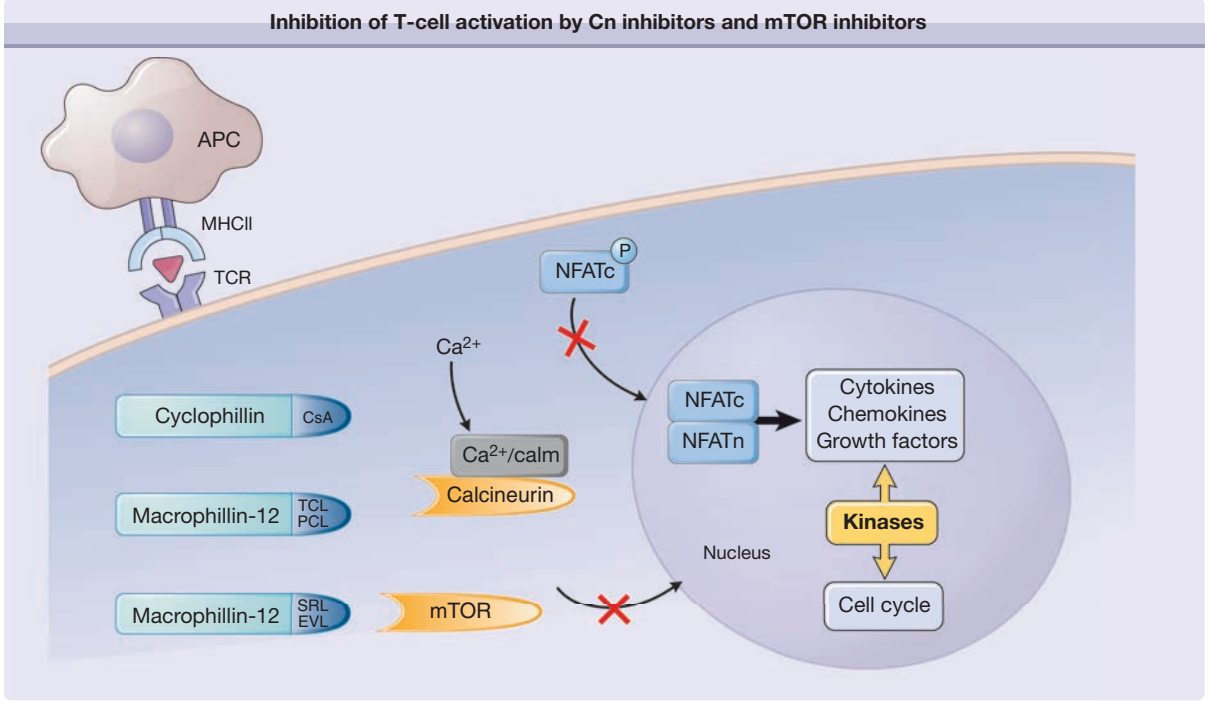

Figure 233-2 This diagram outlines the key mechanisms by which calcineurin (Cn) inhibitors and mammalian target of rapamycin (mTOR) inhibitors inhibit T-cell activation triggered by presentation of antigen via the T-cell receptor (TCR). The first step in antigen presentation involves presentation of a peptide that is bound within the peptide-binding groove of the major histocompatibility complex (MHC) class II molecule. This complex is then presented to the TCR. This causes transmembrane signaling that increases intracellular calcium concentrations. The liberated calcium, bound to calmodulin (calm), interacts with Cn, a calcium-dependent serine/threonine phosphatase that dephosphorylates nuclear factor of activated T cells (shown here as NFATc), and this causes NFAT to translocate to the nucleus. There it binds to other nuclear components of NFAT (shown here as NFATn). This complex regulates the transcription of many *cytokine* genes, shown in the diagram. Cyclosporine (CsA), tacrolimus (TCL), and pimecrolimus (PCL) diffuse freely into the cytoplasm of T cells and bind with their respective immunophilins. This drug/immunophilin complex binds to Cn and blocks its ability to dephosphorylate NFAT, and thereby inhibits the production of cytokines, chemokines, and growth factors [interleukin 2 (IL-2), IL-3, IL-4, tumor necrosis factor-α, interferon-γ, granulocyte-macrophage colony-stimulating factor, etc.] that would normally be induced after T-cell activation via the TCR. Sirolimus (SRL) has a more complex intracellular mechanism of action. Although SRL and everolimus (EVL) bind macrophilin-12 (also known as *FKBP-12*), the immunophilin of TCL and PCL, its mechanism of action does not appear to be mediated by Cn inhibition. mTOR inhibitors block cell kinases that would have a direct effect on the cell cycle by also an indirect effect in chemokine, cytokine, and growth factor synthesis. APC = antigen-presenting cell.

Pharmacokinetics. The microemulsion-based formulation of CsA has an improved bioavailability giving the drug more predictable absorption.[3,4]

CsA can also be administered intravenously as a 50-mg/mL solution made up in an ethanol-polyoxyethylated castor oil mixture. The accumulation of CsA in erythrocytes and leukocytes is the reason that whole-blood monitoring of CsA levels is much more accurate than measurement of plasma levels. Peak levels occur from 1.3–4.0 hours after oral administration. After gaining access to the circulation, CsA distributes widely and has a large apparent volume of distribution (13 L/kg). CsA is metabolized into greater than 30 cyclic, partly active metabolites by the liver cytochrome P_{450} 3A enzyme (CYP 3A).[5,6] Thus, drugs that compete for binding to CYP 3A will increase CsA levels, and drugs that induce P_{450} will accelerate metabolism and decrease blood levels (eTable 233-1.1 in online edition). Certain foods rich in bioflavonoids, especially grapefruit, seem to increase the drug's bioavailability through an interaction with cytochromes. Its elimination half-life is 6–12 hours in the absence of severe hepatic disease, and biliary excretion accounts for more than 90% of its elimination. CsA solution does have some penetration of mucosal surfaces, but this is not true of cornified epithelium.

Indications

- *Psoriasis*: Cyclosporin is approved for use in patients with moderate-to-severe psoriasis, but the approved dosage is 2.5–3.0 mg/kg/d which in author's experience is too low a dosage to achieve adequate control of most patients. The dosage that appears adequate is between 4 and 5 mg/kg/d, but, at this level, the risk of nephrotoxicity occurs with continued use. There are some patients that are able to achieve response, whose response is held at lower doses that can be used for longer periods. The use of cyclosporin in combination with methotrexate seems synergistic, but combination with biologic therapies has not been well studied and should be avoided other than for short periods of time. Although this drug is approved, its use has lessened except for short-term usage.
- *Pyoderma gangrenosum*: It was one of the first diseases in dermatology in which cyclosporin was noted to be beneficial. Even now in the age of biologic therapy, some patients are effectively managed with this and other macrolactams.
- *Paraneoplastic pemphigus*: Patients have been treated with cyclosporin, but it should be used cautiously because of its potential to allow tumors to grow. With the advent of rituximab usage for lymphoma and pemphigus, cyclosporin would not in my opinion be a first-line therapy.
- *Lichen planus*: Multiple case reports and small case series have demonstrated that cyclosporin is effective in patients with lichen planus, particularly those with oral or esophageal erosive disease. This is not a first-line therapy in this condition.
- *Atopic dermatitis*: Severe atopic dermatitis can be one of the most challenging dermatologic conditions to manage. While cyclosporin might be useful, as will all chronic diseases, its indefinite use is associated with increasing frequency of toxicity. Therefore, most of the patients treated should only have relatively short-term use.
- *Behçet disease*: Ocular and mucocutaneous forms; moderate to severe cases.
- *Dermatomyositis*: Patients with inflammatory myopathies have responded to cyclosporin. However, in author's experience, it is the rare patient whose skin disease will be controlled with cyclosporin.
- *Alopecia areata*: Since this drug or others in its class have not been demonstrated to alter the long-term course of the disease, it is a rare patient who can be treated.
- *Epidermolysis bullosa acquisita*: This is often a difficult disorder to control. There are no therapies that have been proven to be effective in well designated studies. Cyclosporin has been used in individual patients and has been reported to be effective and potentially corticosteroid-sparing in some patients.

Dosing Regimen. (Table 233-2)

Initiating Therapy. Doses higher than 5 mg/kg/day are not advisable other than for short periods of time. Some patients with acute uncontrolled disease might be treated with 'loading' doses in hopes of achieving more rapid control of their disease. The US Food and Drug Administration has approved CsA for psoriasis in doses up to 4 mg/kg/day, with a recommended starting dose of 2.5 mg/kg/day. Dosage increases should be performed after 4 weeks of therapy, and dose reductions are permitted at any time. Dosage increases should not exceed 0.5–1.0 mg/kg/day at 2- to 4-week intervals. Intravenous CsA formulation can be infused slowly over a period of 2–6 hours at about one-third of the usual oral dose, or about 2–3 mg/kg per day.[7]

Monitoring Therapy. When psoriatic patients improve, defined clinically, the CsA dose should be down-titrated. It is not clear with what rapidity this de-escalation of therapy should occur, but some have suggested that at least a 4-week interval should occur prior to further dose reduction. As therapy is decreased, there is a risk of relapse. Rebound is also possible, but is a relatively uncommon phenomenon.

Patients who seemingly do not respond to CsA should be assessed for compliance and absorption by measuring a trough level. The two most common assays for trough levels—high-performance liquid chromatography (HPLC) and radioimmunoassay—are performed in EDTA-containing whole blood. The recommended range is 200–400 ng/mL. Routine use of CsA levels in dermatology patients is not necessary.

Children have comparable bioavailability of orally ingested CsA, but have a higher renal drug clearance rate (11.8 mL/min per kg vs. 5.7 mL/min per kg in adults), and a correspondingly shorter blood level half-life (7.3 hours vs. 10.7 hours in adults). Children may therefore require somewhat higher dosages and more frequent administration to achieve comparable trough levels to adults.

TABLE 233-2
Dosing of Macrolactam Immunosuppressive Agents

Drug	Adult Dosage	Children's Dosage mg/kg/day
Cyclosporin—oral	2.5–5.0 mg/kg/day	5–7 mg/kg/day
Cyclosporin—intravenous	2–3 mg/kg/day	3–5 mg/kg/day
Tacrolimus—oral	150–200 µg/kg/day	200–300 µg/kg/day
Tacrolimus—intravenous	25–50 µg/kg/day	50–100 µg/kg/day
Sirolimus	3–10 mg/day for Patients of African or Asian descent 0.5–3 mg/d for Caucasian patients	1.5 mg/m^2
Everolimus	0.8–1.2 mg/m^2/day	0.75–1.5 mg twice daily

Risks and Precautions. Serum creatinine levels should be carefully monitored during CsA therapy. If creatinine levels increase more than 30% above baseline, the dosage should be reduced for 1–2 weeks. If, after that time, the creatinine levels decrease below the 30% elevation mark, continuation at the lower dose is advisable. In cases where the creatinine remains elevated by more than 30%, discontinuation of CsA is recommended until the creatinine returns to levels within 10% of pretreatment levels. More accurate studies monitoring the glomerular filtration rate clearance are used in individualized cases. From a practical standpoint, adequate monitoring of CsA dosage can be achieved by the avoidance of CsA doses higher than 5 mg/kg/day, evaluation of clinical response, and vigilance for signs of toxicity. This requires a detailed physical examination, including blood-pressure monitoring with threshold concern triggered by a persistent diastolic blood pressure above 90 mm Hg, a complete history with emphasis on concomitant drug ingestion and medical conditions that may potentiate CsA toxicity, and laboratory evaluations for complete blood count, creatinine and blood urea nitrogen, uric acid, liver enzymes, serum electrolytes and magnesium, and a urinalysis. In patients receiving long-term CsA therapy (>6 months), the serum creatinine and its clearance may not be a reliable predictor of altered renal function, and potentially irreversible chronic cyclosporine nephrotoxicity may ensue. In such circumstances, more reliable studies for the evaluation of renal function may be indicated.

Complications

Renal Function, Liver, and Neurologic. Overall, one in four patients taking CsA develops clinical and laboratory evidence of altered renal function, including hypertension. Two types of CsA-induced nephrotoxicity are encountered in dermatologic patients. The first type usually starts within 2–3 weeks after drug initiation, and it is usually associated with high CsA blood levels. In this toxicity, there is an insidious decrease in glomerular filtration rate along with hypertension, and tubular dysfunction in association with a complete recovery of renal function upon dose-lowering or discontinuing therapy. The second type is likely a result of cumulative subclinical chronic renal toxicity. This may occur in the absence of any detectable elevation of creatinine or blood pressure. Histologic changes include interstitial fibrosis, tubular atrophy, and some degree of vasculopathy. Although renal function can improve somewhat after discontinuation of the drug, this type of toxicity is generally irreversible. In psoriatic patients receiving 5 mg/kg/day CsA, elevation of serum creatinine may persist for more than 4 months after discontinuation of the drug. Several mediators, including endothelin-1, angiotensin II, osteopontin, and transforming growth factor-β1, have been implicated in the pathogenesis of CsA-associated nephrotoxicity and hypertension. Calcium channel antagonists exert beneficial effects on CsA-induced hypertension and nephrotoxicity, presumably through the inhibition of endothelin-1. Other drugs, including angiotensin converting inhibitors (enalapril, lisinopril, etc.) and angiotensin receptor blockers (losartan, valsartan, etc.), are also effective mainly when used in combination with other antihypertensive drugs. New drugs, such as endothelin A receptor blockers (bosentan, darusentan, etc.) and renin inhibitors (aliskiren), appear to be promising for CsA-treated patients.[8–10] Diuretics and nephrotoxic drugs should be used with caution in CsA-treated patients. Another uncommon adverse renal complication is the development of thrombotic microangiopathy/hemolytic uremic syndrome,[11,12] especially in allogenic bone marrow transplant patients receiving CsA for acute graft-versus-host disease. Hypomagnesemia and hyperkalemia or hypokalemia are not uncommonly encountered.

Nausea, vomiting, anorexia, and diarrhea commonly occur with the use of CsA. Elevations of liver enzymes greater than 100% over baseline should be managed by reduction of the CsA dose by 25% weekly, until enzyme levels normalize.

Headache is a common complaint, especially in patients with a history of migraines. It tends to resolve spontaneously as therapy continues. CsA-induced seizures appear to be associated with hypomagnesemia and concomitant use of high doses of systemic corticosteroids. Thus, serum magnesium levels should be always monitored and kept above the lower normal range in

CsA-treated patients. Cortical blindness, lethargy, confusion, seizures, hemiplegia, tremors, and paresthesias have also been described in patients receiving CsA.[8]

There is evidence of impaired fibrinolysis and endothelial damage and proliferation associated with CsA. Hypercoagulability seems to contribute to the progression of atherosclerosis and glomerular damage in CsA-treated patients. Significant cytopenias have rarely been reported with the use of CsA.

Hypercholesterolemia, elevation of low-density lipoproteins, and hypertriglyceridemia may be seen with CsA.

Cancer. CsA-treated transplant recipients have a relative risk for all skin cancers of 6.8 versus 2.2–5.5 in patients receiving other immunosuppressive therapies. CsA-treated dermatologic patients also have a higher risk of skin cancers, including squamous cell carcinomas, basal cell carcinomas, human papilloma virus-associated anogenital carcinoma, and Kaposi sarcoma. The high incidence of squamous cell carcinoma in psoriatic patients treated with CsA could be biased by previous exposures to psoralen and ultraviolet A light or ultraviolet B. Approximately 25% of nonvisceral Kaposi sarcomas can be expected to undergo complete or partial remission following cessation or reduction of immunosuppressive therapy. Epstein-Barr virus-associated post-transplant lymphoproliferative disorder (PTLD) is quite rare in dermatologic patients. PTLD frequently usually fails to respond to chemotherapy, but it may regress spontaneously after reduction and/or cessation of immunosuppression. The incidence of lymphoma in CsA-treated dermatologic patients appears to be less than 0.2%. The incidence of lymphoma in transplant patients receiving CsA alone or in combination with corticosteroids is less than 1%, whereas for those receiving CsA in conjunction with other immunosuppressive drugs is as high as 8%. In contrast to the high mortality rate attributed to lymphomas arising in immunosuppressed patients, lymphomas developing in CsA-treated patients seem to carry a better prognosis despite of having a shorter latency period seems.[13–15] In rheumatoid arthritis patients treated with CsA, there was no increase in malignancies in comparison with a matched control group of patients with rheumatoid arthritis who were not treated with CsA. Other neoplasms, including melanoma, are also reported in CsA-treated patients, although their true incidence is unknown.

Other Adverse Effects. Hypertrichosis occurs in virtually all patients on long-term CsA therapy. It is not limited to androgen-dependent, hair-bearing areas, and shows no tendency to spontaneous remission. Gingival hypertrophy is reported in up to 70% of CsA-treated patients; it is more common in children, individuals with poor oral hygiene and concomitant use of calcium channel drugs. Improvement of this gingival complication with topical or systemic azithromycin and metronidazole can be seen. An acneiform eruption, indistinguishable from that seen in steroid-induced acne, is frequently reported. A disseminated comedonal or cystic acneiform eruption can also occur. These side effects can appear at any time during CsA therapy, although they are more commonly described at the time of initiation of CsA therapy. Keratosis pilaris, sebaceous hyperplasia, warts, and epidermal inclusion cysts occur in up to one-third of CsA-treated patients.

Osteoporosis seems to result from the CsA's action on osteoblasts and osteoclasts, and by altering lymphokine release. CsA can induce hyperuricemia in up to 15% of patients, and it is also an indicator of early CsA-induced nephrotoxicity. Myopathy has been reported in transplant patients receiving high doses of CsA, and thus, cation should be used with the concomitant use of statins.

Pregnancy. CsA is categorized as a pregnancy category C and as such should only be used when the benefits outweigh the risks.[8] It does not seem to be mutagenic or teratogenic, although there is a higher than expected incidence of preterm newborns, fetal growth retardation, abortions, preeclampsia, and hypertension in mothers taking CsA, and these occurrences are magnified in transplant patients. There are no reports of neonatal complications in children born to fathers receiving CsA. Adequate contraceptive measures are recommended in women of childbearing potential. CsA crosses the placenta and is excreted in breast milk. CsA-treated transplant patients seem to have a relative risk for infectious, life-threatening complications that is much lower than that seen in patients receiving azathioprine and prednisolone. However, increased vigilance for infectious complications is recommended in CsA-treated patients.

TACROLIMUS.

TCL, a CnI formerly known as *FK506*, is a macrolactam drug first isolated from *Streptomyces tsukubaensis*.

Mechanism of Action.

The postulated mechanisms of action of TCL are similar, if not identical, to the ones described for CsA (see Section "Macrolactam Drugs").[16]

Pharmacokinetics.

TCL can be administered orally, topically, and intravenously. The pharmacokinetics of systemic TCL are characterized by a two-compartment model with a rapid initial drop and a long elimination half-life of 12–21 hours. TCL is metabolized in the liver with less than 1% of the drug excreted intact. TCL has not proved to be more effective than CsA, but it appears to have a better bioavailability. The topical formulations have a concentration of 0.3% and 0.1% in an ointment vehicle, and for more detailed information, see Chapter 221.

Dosing Regimen. (Table 233-2)

Initiating Therapy.

The dosage of systemic TCL should be reduced in the presence of hepatic dysfunction by 10%–30% of the standard dosing.

Monitoring Therapy.

There is a good correlation between enzyme-linked immunosorbent assay and HPLC mass spectrometry measurements in monitoring of whole blood concentrations of TCL. Enzyme-linked immunosorbent assays may also detect metabolites of the drug, and thus, caution should be taken in patients with liver diseases or with concomitant use of

CyP4503A-binding drugs. Blood levels of 5–15 ng/mL are recommended.

Risks and Precautions. The risks and precautions are quite similar to the ones applied for CsA. However, neurotoxicities and glucose intolerance are somewhat higher than with CsA use, and thus, close monitoring of magnesium and glucose serum levels and, if indicated based on personal or family history, glucose tolerance tests are strongly recommended. The risk for PTLD seems to be higher in children with hepatic transplants who received both TCL and anti-OKT3, but it has not been definitively proved in dermatologic patients or in different clinical scenarios. Dose reduction and close monitoring of TCL levels by HPLC mass spectrometry in patients with liver diseases are strongly recommended. A lesser graft-versus-leukemia effect in comparison with the one seen with CsA is observed in bone marrow transplant patients. A great deal of concern has been raised regarding the potential risk of lymphoproliferative diseases with this drug, which led to a highly controversial placement of a black-box warning by the US Food and Drug Administration with the topical formulation (see Chapter 221).

Complications. Mucocutaneous and metabolic side effects seem to be less frequent with the use of TCL. However, nephrotoxicity seems to be comparable to that seen with the use of CsA. The rest of the side effects are comparable with those seen with CsA use.

Indications. There are no approved indications for tacrolimus in dermatology. Its mechanism of action suggests that any patient who might be responsive to CsA would likely respond to tacrolimus. Therefore it might be useful in patients with psoriasis, pyoderma gangrenosum, dermatomyositis, lupus erythematosus, atopic dermatitis, and graft-versus-host disease, among other potential indications.[17–21]

Systemic TCL can be used virtually in any inflammatory and autoimmune skin disease in which systemic CsA has proved effective. For topical use of TCL, see Chapter 221.

PIMECROLIMUS.

Pimecrolimus, also known as *ASM 981*, is a derivative of the parent compound ascomycin originally isolated from the fermentation products of *S. hygroscopicus* var. *ascomyceticus*. Pimecrolimus has a similar mechanism of action as that of other CnIs. Pimecrolimus is formulated in vehicle cream at concentrations of 0.2%, 0.6%, and 1.0% (see Chapter 221).

MAMMALIAN TARGET OF RAPAMYCIN INHIBITORS

MECHANISM OF ACTION.

SRL and its derivatives EVL and temsirolimus are most widely known as *mTORIs*. Although mTORIs bind to FKBP-12 (macrophilin-12), this drug-immunophilin complex inhibits gene transcription through a complex mechanism that is independent from the one involving Cn.

PHARMACOKINETICS.

African and Asian descent patients require a higher initial and maintenance dose of SRL than Caucasians. EVL bears a stable 2-hydroxyethyl chain substitution at position 40 on the SRL structure, which has given a greater polarity than SRL, improving the pharmacokinetic and particularly its oral bioavailability. Oral EVL is absorbed rapidly and reaches peak concentration after 1.5 hours. In adults, EVL pharmacokinetic characteristics do not differ according to age, weight, or sex, but body weight-adjusted dosages are necessary in children.[25–26] The target trough concentration of EVL should range between 3 and 15 ng/dL. SRL topical formulation (2.2% and 8.0%) has been used in psoriasis patients (see Chapter 221).

INDICATIONS.

There are no approved indications for everolimus in dermatology. Its mechanism of action suggests that any patient who might be responsive to CsA or tacrolimus would likely respond to everolimus. Therefore, it might be useful in patients with psoriasis, pyoderma gangrenosum, dermatomyositis, lupus erythematosus, atopic dermatitis, and graft-versus-host disease, among other potential indications.

DOSING REGIMEN. (Table 233-2)

INITIATING THERAPY.

As mentioned in Table 233-2, due to ethnic differences, the SRL recommended oral loading dose is 6 mg and oral maintenance dose is 2 mg per day for Caucasian patients, and the oral loading dose is 10 mg and oral maintenance dose is 5 mg per day for African Americans. Asians also appear to require higher doses of this drug. EVL starting dose are the same regardless of sex and race. The usual dosing for adults is 0.75–1.5 mg bid and for children 0.8–1.2 mg/m^2.

MONITORING THERAPY.

Due to significant intra- and interindividual variability, measuring trough levels is critical with the use of mTORIs. Trough levels for SRL and EVL are 5–20 ng/dL and 3–15 ng/mL, respectively. Complete blood cell count, electrolytes, liver function test, and a lipid profile, along with a comprehensive clinical examination with periodic blood pressure measurement, are mandatory.

RISKS AND PRECAUTIONS.

Concomitant use of antimetabolite drugs, including mycophenolate mofetil (MMF) and azathioprine in patients with mTORIs of upper normal or higher trough blood levels (e.g., SRL: equal or higher than 20 ng/dL or EVL: equal or higher than 5 ng/mL), raises the risk of cytopenias, namely thrombocytopenia. Concomitant use of CnIs, namely TCL, may increase the risk of thrombotic microangiopathy/hemolytic uremic syndrome, and thus, monitoring of blood cell count, dyslipidemia, electrolyte abnormalities, edema, and increase of liver function tests are also associated with high trough levels of these drugs. Patients with extensive psoriasis treated with SRL should be monitored closely for capillary leak syndrome, a rare complication reported only in one series.[27]

COMPLICATIONS.

Cytopenias, namely thrombocytopenia, hypertriglyceridemia, hypercholesterolemia,

arthralgias, edema, and impaired wound healing, have been frequently associated with the use of mTORIs. Occurrence of cytomegalovirus appears to be lower than that observed with the use of CnIs. No gingival hyperplasia has been observed with SRL. Tremor or any other neurologic complications are not frequent. Hypertension and malignancies are significantly reduced in comparison with the use of CnIs. This is most likely related to the endothelial, mesangial antiproliferative and antineoplastic properties of mTORIs.

ACKNOWLEDGMENT

The author thanks Carlos H. Nousari and Grant J. Anhalt who authored this chapter in the seventh edition.

KEY REFERENCES

Full reference list available at www.DIGM8.com

DVD contains references and additional content

1. Madan V, Griffiths CE: Systemic ciclosporin and tacrolimus in dermatology. *Dermatol Therapy* **20**:237-250, 2004
6. Lee CS, Koo JYM: Cyclosporin. In: *Comprehensive Dermatologic Drug Therapy*, 2nd edition, edited by SE Wolverton. Philadelphia, Elsevier, 2007, pp. 219-237
8. Dubertret L: Retinoids, methotrexate and cyclosporine. *Curr Probl Dermatol* **38**:79-94, 2009
13. Lebwohl M, Ellis C, Gottlieb A, Koo J, Krueger G, Linden K, Shupack J, Weinstein G: Cyclosporine consensus conference with emphasis on the treatment of psoriasis. *J Am Acad Dermatol* **39**:464-475, 1998
15. Paya CV, Fung JJ, Nalesnik MA, Kieff E, Green M, Gores G, Habermann TM, Wiesner PH, Swinnen JL, Woodle ES, Bromberg JS: Epstein-Barr virus-induced posttransplant lymphoproliferative disorders. ASTS/ASTP EBV-PTLD Task Force and The Mayo Clinic Organized International Consensus Development Meeting. *Transplantation* **68**(10):1517-1525, 1999
18. Edge JC, Outland JD, Dempsey JR, Callen JP: Mycophenolate mofetil as an effective corticosteroid-sparing therapy for recalcitrant dermatomyositis. *Arch Dermatol* **142**(1): 65-69, 2006
19. Eaton PA, Callen JP: Mycophenolate mofetil as therapy for pyoderma gangrenosum. *Arch Dermatol* **145**(7):781-785, 2009
24. Mimouni D, Anhalt GJ, Cummins DL, Kouba DJ, Thorne JE, Nousari HC: Treatment of pemphigus vulgaris and pemphigus foliaceus with mycophenolate mofetil. *Arch Dermatol* **139**(6):739-742, 2003

Chapter 234 :: Immunobiologicals, Cytokines, and Growth Factors in Dermatology

:: Stephen K. Richardson & Joel M. Gelfand

IMMUNOBIOLOGICALS, CYTOKINES, AND GROWTH FACTORS AT A GLANCE

- Immunobiologicals are drugs, defined as compounds engineered from living organisms that induce or alter immune responses by interacting with specific biologic targets.
- Used to treat conditions with immune abnormalities.
- Those used to treat cutaneous disease include recombinant cytokines and growth factors, monoclonal antibodies, and fusion proteins.
- Targeting the immune system with biologics may result in an increased risk of infections and malignancies.

Immunobiologicals are compounds synthesized in living organisms that exhibit immune modulatory properties. They consist of recombinant cytokines, growth factors, antibody-based agents, and fusion proteins. Those with dermatologic indications are discussed in this chapter and are listed in Table 234-1. Fig. 234-1 illustrates the molecular targets of these compounds. Fig. 234-2 depicts the cellular events that mediate cutaneous inflammation and identifies the molecular interactions affected by specific immunobiological agents.

RECOMBINANT CYTOKINES AND GROWTH FACTORS

Cytokines are low-molecular-weight polypeptides that exhibit paracrine and/or autocrine activity in the mediation of immune responses. They may act as growth factors by inducing the proliferation of specific immune cell populations. A particular cytokine may also influence the production of other cytokines and the behavior of cellular populations that express its receptor. Over the past two decades, recombinant cytokines have proven to be invaluable for the treatment of conditions in which immunologic aberrations exist or among which some clinical benefit might be derived from augmentation or suppression of the host immune response.

RECOMBINANT INTERFERONS

(See also Chapters 231 and 235)

TABLE 234-1
Immunobiologicals, Cytokines, and Growth Factors

	Action	Dosing for Dermatologic Indications
Recombinant interferons		
Interferon-α and Interferon-γ	▪ Enhances cell-mediated cytotoxicity against viral disease and malignancy via promotion of MHC expression and suppression of Th2 cytokine production	▪ Variable
Recombinant Interleukins and growth factors		
Interleukin 2	▪ Maintains helper T-cell populations ▪ Enhances natural killer cell cytotoxicity and lymphokine activated cell activity	▪ Variable
Interleukin 1 receptor antagonist	▪ Blocks the interaction between IL1 and its receptor ▪ Suppresses IL1 mediated inflammatory responses (e.g., leukocyte recruitment, osteoclast activation)	▪ Variable
Granulocyte-macrophage colony-stimulating factor	▪ Promotes the proliferation and differentiation of myeloid precursors	▪ Variable
Platelet-derived growth factor	▪ Promotes wound healing via angiogenic activity and proliferative effects on fibroblasts and smooth muscle cells	▪ Daily application of gel to affected site
Antibody-based therapeutics		
Anti-TNF-α	▪ Infliximab: chimeric monoclonal antibody; neutralizes both membrane-bound and soluble TNF-α ▪ Adalimumab: human monoclonal antibody; neutralizes both membrane-bound and soluble TNF-α	▪ 5-mg/kg IV at week 0, 2, and 6, then q8wk 80-mg SC followed by 40-mg SC 1 week later, then 40-mg SC qow ▪ 80 mg SC followed by 40 mg SC 1 week later, then 40 mg SC qow
Anti-IL12/IL23	▪ Ustekinumab: human monoclonal antibody; inhibits IL-12 and IL-23 mediated inflammatory processes	▪ Patients <100 kg: 45-mg SC followed by same dose at week 4, and q12wk thereafter (▪ Patients >100 kg: receive 90 mg)
Anti-LFA-1	▪ Efalizumab: humanized monoclonal antibody; interferes with lymphocyte activation, cytotoxicity, and trafficking to the skin; *withdrawn from US market in 2009 because of PML*	▪ 0.7-mg/kg SC followed by 1 mg/kg qwk
Anti-CD20	▪ Rituximab: chimeric monoclonal antibody; promotes a reduction in $CD20^+$ cells (B-cells)	▪ Variable
Fusion proteins		
Alefacept	▪ Human IgG1 Fc region fused to LFA-3 extracellular domain; interferes with T-cell activation by blocking the interaction between LFA-3 and CD2	▪ 15 mg IM qwk for 12 weeks
Etanercept	▪ Human IgG1 Fc region fused to TNF type II receptor domain; neutralizes soluble TNF-α	▪ 50-mg SC biw for 12 weeks, then 50-mg SC qwk
Denileukin Diftitox	▪ Diphtheria-toxin component fused to IL2; promotes apoptosis of T-cells expressing the high affinity IL2 receptor, CD25	▪ Variable

INTERFERON-α. IFN-α is a Type I interferon produced by plasmacytoid dendritic cells. It enhances cell-mediated cytotoxicity against viral disease and malignancy by increasing MHC I expression by antigen-presenting cells, stimulating NK cell activity, promoting the development of Th1 cells, and suppressing the production of Th2 cytokines.[1,2]

Recombinant IFN-α may be administered as a subcutaneous or intramuscular injection and has been utilized for a broad range of dermatologic conditions that include cutaneous T-cell lymphoma, melanoma, nonmelanoma skin cancer, Kaposi sarcoma, Behcet disease, hemangiomas, condyloma acuminatum, verruca vulgaris, and keloids.[3] A pegylated form (containing polyethylene

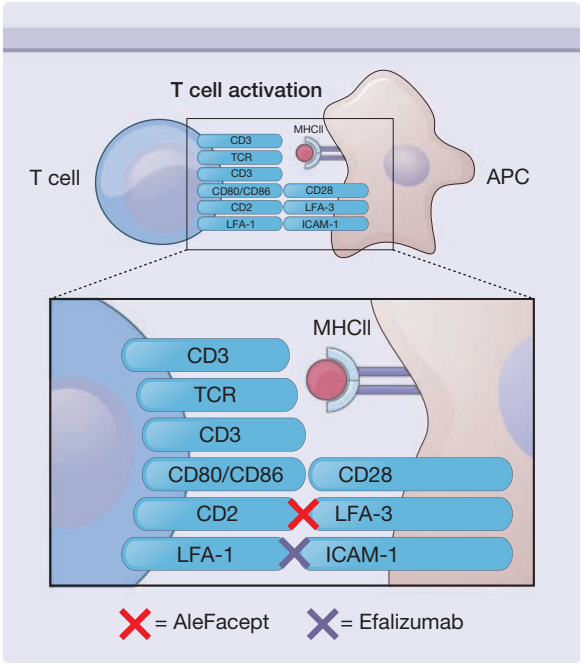

Figure 234-1 Immunobiologicals may modify immune responses via inhibition of T-cell activation. Efalizumab blocks interactions between leukocyte function-associated antigen 1 (LFA-1) and intercellular adhesion molecule 1 (ICAM-1), whereas alefacept interferes with interactions between CD2 and LFA-3. MHC II = major histocompatibility complex II; TCR = T–cell receptor.

glycol) of this compound is currently available which has a longer half-life and increased patient tolerability.[2] Prior to the availability of pegylated IFN-α, treatment was typically administered 3×/week with dosing dependent upon the condition being treated and patient response to therapy. Pegylated IFN-α may be administered once weekly with a steady state plasma level achieved within 5–9 weeks.[4]

There is extensive experience using IFN-α for the treatment of cutaneous T-cell lymphoma (CTCL). Objective clinical responses have been noted among 50%–75% of CTCL (Stage Ia–IVa) patients treated with different IFN-α dosing regimens.[5] Typically, it is administered subcutaneously at a starting dose of 1.5–3.0 million units three times per week. When combined with other immunodulatory therapies, high clinical responses have been achieved among patients with Sézary syndrome.[6]

The most common side effect associated with IFN-α therapy is "flu-like" symptoms characterized by fever, sweats, chills, myalgias, and arthralgias. These symptoms typically resolve over the first ten days of therapy and can be managed with acetaminophen. Patients may also experience injection site reactions. Other associated side effects include fatigue, depression, weight loss, photosensitivity, peripheral neuropathy, psychosis, hypothyroidism, and sexual dysfunction.[2,7] Laboratory abnormalities include elevated hepatic transaminases and leukopenia. Liver function tests and a complete blood count should be evaluated every 1 to 2 weeks upon initiation of therapy, or with any increase in dosing.[2]

IFN-α is contraindicated for use in patients with a known hypersensitivity to the drug or any of its components. Relative contraindications include a history of cardiovascular disease, renal disease, hepatic disease, central nervous system disorders, and/or preexisting mental illness. IFN-α is a pregnancy category C medication with unknown safety during lactation. Multiple case reports have suggested that IFN-α may induce, exacerbate, or unmask autoimmune disorders including immune-mediated thyroid disease, anemia, thrombocytopenia, sarcoidosis, and connective tissue disorders. IFN-α should be used with caution among patients with $CD8^+$ CTCL, as multiple cases of disease progression have been reported in this setting.[8–10] This finding may be explained by the inherent ability of Th1 cytokines to augment $CD8^+$ T-cell activity.

INTERFERON-γ. IFN-γ is a cytokine produced by Th1 lymphocytes. Similar to IFN-α, it enhances cell-mediated cytotoxicity and suppresses Th2 cytokine production. IFN-γ has also been shown to enhance MHC 2 expression and interleukin 12 (IL12) production by antigen-presenting cells. In the dermatologic setting, it is reported to exhibit clinical efficacy in the management of chronic granulomatous disease and CTCL.

Children with chronic granulomatous disease treated with IFN-γ exhibited a significant reduction in the frequency of infections and associated hospitalizations.[11] This has been attributed to its ability to partially correct defects in oxidative metabolism and promote superoxide release, thus enhancing phagocytes' ability to combat infection.[12]

Studies regarding the use of IFN-γ in the treatment of CTCL are limited. Partial clinical responses have been reported among patients treated with IFN-γ during all stages of disease.[13] This has been attributed, in part, to its ability to suppress the production of Th2 cytokines by malignant cells.[14] Thus, IFN-γ offers an alternative therapeutic option for patients who may not tolerate or respond to IFN-α therapy secondary to the formation of neutralizing antibodies, cognitive dysfunction and/or fatigue—which are more frequently associated with IFN-α therapy.[15]

IFN-γ is administered via intravenous, intramuscular, and subcutaneous routes. The recommended dosing for children with chronic granulomatous disease is 50 μg/m^2 three times a week for life.[16] We have utilized IFN-γ doses ranging from 50–100 μg three times a week for the treatment of adult CTCL patients.[2]

Adverse effects associated with IFN-γ are similar to those reported for IFN-α and include flulike symptoms, elevated hepatic transaminases, leukopenia, and thrombocytopenia. IFN-γ is a pregnancy category C medication with unknown safety during lactation. Its contraindications are similar to those reported for FN-α.

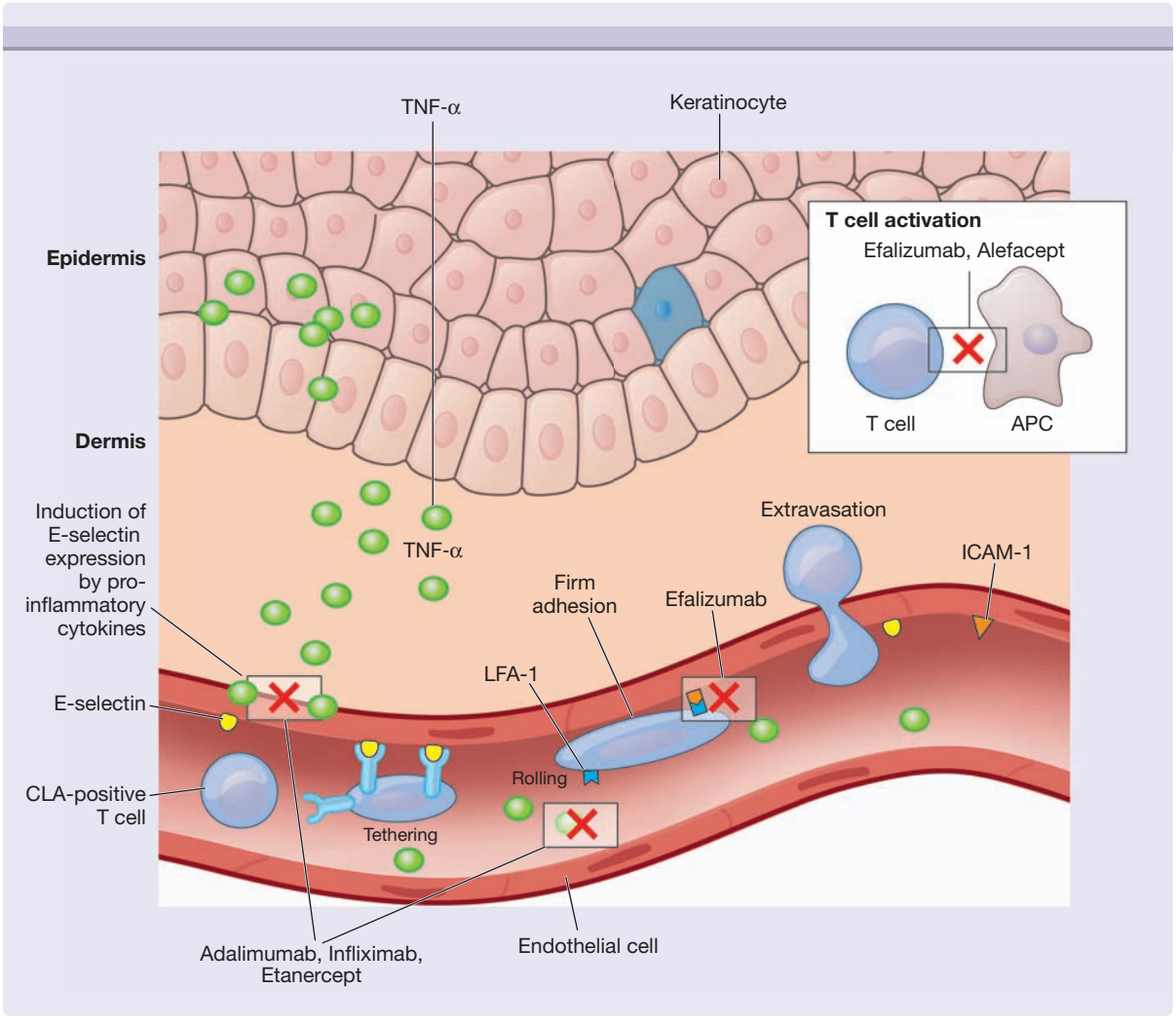

Figure 234-2 Cutaneous inflammation results in the production of inflammatory cytokines that induce keratinocyte proliferation and increase expression of molecules such as E-selectin. Immunobiologicals may interfere with immune cell trafficking by binding to specific cell surface receptors, deplete target cell populations through direct binding to cell surface proteins, suppress cytokine activity through the action of cytokine targeting compounds, and alter immune responses via the activity of recombinant cytokines with inhibitory or proinflammatory properties. The cellular interactions and cytokines targeted by several of the immunobiological agents discussed in this chapter are depicted. CLA = cutaneous lymphocyte-associated antigen; ICAM-1 = intercellular adhesion molecule 1; LFA-1 = leukocyte function-associated antigen 1; TNF-α = tumor necrosis factor-α.

RECOMBINANT INTERLEUKINS AND GROWTH FACTORS

INTERLEUKIN 2. Interleukin 2 (IL2) is a Th1 cytokine with antitumor activity produced by $CD4^+$ lymphocytes in response to activation by antigen-presenting cells. IL2 has been shown to promote the proliferation and maintenance of helper T-cell populations. In addition, it has been shown to enhance both natural killer cell cytotoxicity and lymphokine-activated cell activity.[17] In the dermatologic setting, recombinant human IL2 has been used for the treatment of melanoma.

Several studies have reported durable clinical responses among melanoma patients treated with IL2 therapy. This finding led to the FDA approval of this medication for the treatment of patients with metastatic disease. In early studies, high dose intravenous IL2 therapy (600,000–720,000 IU/kg) led to a 15% to 20% overall response among melanoma patients, with 4% to 6% achieving a complete clinical response.[18–20] Unfortunately, prolonged responses are only achieved by a minority of patients. Over the past two decades, IL2 has been combined with other treatment modalities in an attempt to enhance clinical response rates and overall survival among melanoma patients.[21]

Adverse effects associated with infused IL2 include fever, chills, hypotension, thrombocytopenia, vascular leak syndrome, pulmonary edema, cardiac arrhythmias, renal compromise, and exfoliative erythroderma.[2,3] IL2

is contraindicated for use in patients with a known hypersensitivity to the drug or any of its components. It is also contraindicated for patients with a history of an abnormal thallium stress test, abnormal pulmonary function tests, or organ allograft transplantation. IL2 is a pregnancy category C medication with unknown safety during lactation.

INTERLEUKIN 1 RECEPTOR ANTAGONIST.

Interleukin 1 (IL1) is a proinflammatory cytokine produced by monocytes/macrophages that are involved in the recruitment of leukocytes to inflamed tissue, the generation of acute phase reactants, activation of osteoclast activity, induction of collagenase production by chondrocytes, and fever induction. In combination with other inflammatory cytokines, IL1 has been implicated in the pathogenesis of conditions that include rheumatoid arthritis and neonatal-onset multisystem inflammatory disease (NOMID).

The potentially damaging effects of prolonged IL1-α and/or IL1-β exposure are normally balanced by a naturally produced interleukin-1 receptor antagonist (IL1ra), which counters the effects of excessive IL1 exposure. If this protective mechanism is overcome, tissue damage may ensue. Anakinra is a recombinant IL1ra that was approved by the Food and Drugs Administration (FDA) in 2001 for the treatment of moderate-to-severe rheumatoid arthritis among adult patients who failed to respond to other antirheumatic drugs. It binds to the IL1 Type 1 receptor and competitively inhibits IL1 binding. The interaction between anakinra and the IL1 receptor does not activate the IL1 receptor accessory protein, thus no signal transduction cascade ensues.

Aside from adult rheumatoid arthritis, anakinra has been reported to exhibit clinical efficacy in the management of other inflammatory conditions, including Still disease, polyarticular juvenile rheumatoid arthritis, Muckle-Wells syndrome, and NOMID. This is a chronic inflammatory condition which presents during early childhood with a constellation of clinical findings that include an urticarial cutaneous eruption, central nervous system abnormalities, and bone deformities. A recent study to address the efficacy of anakinra in the management of NOMID reported a rapid clinical response to daily injections (1–2 mg/kg) with all patients achieving marked clearing of their cutaneous disease.[22] A small study to address the long-term safety and efficacy of anakinra among NOMID patients reported sustained clinical improvement for 26–42 months (the duration of follow-up) with no adverse events aside from mild injection-site reactions.[23]

Clinical trials have suggested a small increased risk for infection among anakinra treated patients. Thus, treatment should not be initiated among patients with an active infection. The use of this drug in combination with TNF-inhibitor therapy should be avoided. Anakinra is contraindicated among patients with known allergies to *Escherichia coli*-derived proteins. The most common side effect associated with treatment is injection site reaction.

GRANULOCYTE-MACROPHAGE COLONY-STIMULATING FACTOR.

Granulocyte-macrophage colony-stimulating factor (GM-CSF) is a growth factor that induces the proliferation of myeloid precursors and is involved in the proliferation, differentiation, and migration of dendritic cells.[24] In the dermatologic setting, GM-CSF has been reported to exhibit efficacy as a wound-healing agent by promoting the proliferation of keratinocytes in the setting of ulcerated, diseased skin.[25,26] It has also been utilized as an antitumor agent in the treatment of melanoma and CTCL.

Regression of in-transit melanoma and cutaneous metastases have been reported with the administration of intralesional recombinant GM-CSF.[27,28] A phase II trial in which GM-CSF was administered to postsurgical, clinically disease-free, stage III or IV melanoma patients reported enhanced survival among treated patients compared to matched historical controls.[29] It has also been used as an adjuvant in combination with other treatment modalities for the treatment of melanoma.[30,31]

GM-CSF has been shown to induce the differentiation and proliferation of antigen-presenting cells,[32] and may contribute toward disease improvement in CTCL through its ability to replete antigen-presenting cell populations, which are reduced in Sézary syndrome patients. Recombinant human GM-CSF has been used as adjuvant therapy in the treatment of patients with Sézary syndrome. Clinical improvement was reported in a patient treated with an aerosolized form of the medicine.[33] Recombinant human GM-CSF dosing for the treatment of dermatologic disease has not been standardized. GM-CSF was used in combination with other immune modulating therapies for the treatment of Sézary syndrome leading to enhanced clinical responses in a non-placebo controlled study.[6] Associated side effects include fatigue, myalgia, injection site reactions, and generalized cutaneous reactions. GM-CSF is contraindicated for use in patients with a known hypersensitivity to the drug or any of its components. Administration of this drug concurrently with chemotherapy is not recommended, as some combinations may increase myelosuppression. GM-CSF is a pregnancy category C medication with unknown safety during lactation.

RECOMBINANT HUMAN PLATELET-DERIVED GROWTH FACTOR.

(see also Chapter 235) Platelet-derived growth factor (PDGF) is a peptide produced by platelets, macrophages, neutrophils, and smooth muscle cells that has proven to be of clinical benefit for the management of chronic wounds. It consists of two polypeptide chains (A and B) that form dimers linked by disulfide bonds. The PDGF-BB homodimer has been shown to promote granulation tissue formation, wound angiogenesis, re-epithelialization, and the proliferation of fibroblasts and smooth muscle cells in the cutaneous microenvironment. It is currently the only growth factor approved by the FDA for the treatment of diabetic foot ulcers.

Several randomized control studies have reported the efficacy of PDGF-BB for the treatment of pressure

ulcers and lower extremity ulcers in diabetic patients. A phase III study reported significant efficacy of PDGF-BB in the time required to achieve complete wound closure for the treatment of chronic diabetic neuropathic ulcers of the lower extremities.[34] This multicenter, double-blind, placebo-controlled study reported a 43% increase in the incidence of wound closure, and a 32% reduction in the time required to achieve complete wound closure compared to patients receiving a placebo gel. When combined with good wound care, daily application of PDGF has been found to substantially improve time to healing of chronic diabetic neuropathic foot ulcers.[35]

PDGF-BB (100 μg/g) is distributed as a topical gel that should be applied daily and refrigerated when not in use. Studies addressing the safety of recombinant human PDGF-BB found no increased risk for cardiovascular, respiratory, musculoskeletal, or central nervous system disorders among patients with lower extremity diabetic neuropathic ulcers treated with topical PDGF-BB compared to patients treated with placebo or general ulcer care.[36] Patients receiving PDGF-BB therapy did not develop neutralizing antibodies to the drug, nor did they exhibit an increase in mortality relative to placebo. Cutaneous eruptions have been reported but are uncommon. Recombinant PDGF-BB is contraindicated for use in patients with a known hypersensitivity to the drug or any of its components. It also should not be applied to sites affected by cutaneous neoplastic disease. PDGF-BB is a pregnancy Category C medication with unknown safety during lactation. In 2008, a black box warning was added to the safety labeling of this drug as it was associated with an increase in cancer mortality among patients treated with three or more tubes (15 g/tube) of the gel.

ANTIBODY-BASED THERAPEUTICS

Advances in immunobiology have led to our ability to synthesize antibodies that target specific cytokines and cell surface receptors. By utilizing them to interrupt specific signaling cascades, we have been able to manipulate immune responses through the activation or suppression of pathways mediating inflammation, tolerance, and antitumor immunity. The structural nature of a recombinant antibody can be determined by the suffix associated with its name [*-ximab*: chimeric monoclonal antibody (a hybrid antibody consisting of human and murine antibody components), *-zumab*: humanized monoclonal antibody, *-umab*: human monoclonal antibody, *-cept*: antibody fusion protein that mimics immunoglobulin].

ANTIBODIES AGAINST CYTOKINES

(See Chapter 11)

ANTITUMOR NECROSIS FACTOR. Antitumor necrosis factor-α (anti-TNF-α) is a cytokine that has been linked to the pathogenesis of psoriasis and other inflammatory conditions including psoriatic arthritis, rheumatoid arthritis, and inflammatory bowel disease. It is produced by multiple cell types in the skin (keratinocytes, Langerhans cells, and dermal mast cells),[37] which are believed to contribute to the pathogenesis of inflammatory dermatoses (see Fig. 234-2). TNF triggers its effects by binding to its p55 and p75 receptors expressed primarily on the surface of keratinocytes, neutrophils, endothelial cells, and fibroblasts. In combination with other proinflammatory cytokines, it is believed to be involved in the recruitment of immune cells to the cutaneous microenvironment.[38] TNF may also contribute to both the inhibition of keratinocyte apoptosis and the induction of keratinocyte proliferation in psoriasis.[39,40]

Psoriasis is a chronic inflammatory condition of the skin that affects over 2% of the adult population.[41] Elevated levels of TNF-α have been detected in the cutaneous lesions of psoriasis patients.[42] Murine studies support a role for TNF-α in the activation and proliferation of lymphocytes, which induce psoriatic lesions.[43] Elevated TNF-α levels have also been reported in patient serum and has been shown to correlate with disease activity.[44,45]

Three biologics, which inhibit TNF-α are approved for psoriasis: (1) infliximab, (2) adalimumab, and (3) etanercept. Infliximab and adalimumab are antibody-based therapeutics, whereas, etanercept is a fusion protein. Although all three drugs inhibit TNF-α, they are structurally different and have unique pharmacodynamic and pharmacokinetic profiles. Given their shared molecular target, certain of their properties will be discussed together as a "class" for comparative purposes in this section. Etanercept will be reviewed in more detail in the Section "Fusion Proteins."

Infliximab and adalimumab bind to both soluble and membrane-bound TNF, whereas etanercept binds primarily to soluble TNF.[46] Infliximab and adalimumab also have a greater propensity to induce lymphocyte apoptosis compared to etanercept, as they can lyse cells with membrane-bound TNF through complement activation and/or antibody-dependent, cell-mediated cytotoxicity.[47] Given its inability to effectively associate with membrane-bound TNF, etanercept is incapable of activating complement-mediated apoptotic pathways. In terms of pharmacokinetics, the subcutaneous administration of adalimumab and etanercept yields smooth and uniform concentration time profiles at steady state, whereas the intravenous dosing of infliximab results in very high peak-to-trough ratios.[48] Infliximab binds TNF quickly and irreversibly, whereas etanercept sheds about 50% of soluble TNF within 10 minutes of binding.[47] The pharmacodynamic, pharmacokinetic, and structural differences between TNF inhibitors may result in differing safety and efficacy profiles. While infliximab appears to be more efficacious than etanercept in the management of autoimmune granulomatous diseases such as Crohn disease, sarcoidosis, and granulomatosis with polyangiitis (Wegener's); its use[47] has been associated with a higher risk of granulomatous infections.[49]

Indications. Etancercept, infliximab, and adalimumab are FDA approved for the treatment of

moderate/severe plaque-stage psoriasis and psoriatic arthritis. Additionally, etanercept is FDA approved for rheumatoid arthritis, ankylosing spondylitis, and juvenile rheumatoid arthritis; infliximab is approved for rheumatoid arthritis, Crohn disease, ulcerative colitis, and ankylosing spondylitis; and adalimumab is approved for rheumatoid arthritis, juvenile idiopathic arthritis, ankylosing spondylitis, and Crohn disease. Other TNF inhibitors, without dermatologic indications, have also been approved by the FDA and include golimumab (for the treatment of rheumatoid arthritis, psoriatic arthritis, and ankylosing spondylitis) and certolizumab pegol (for the treatment of Crohn disease and rheumatoid arthritis).

Case reports and small case series suggest potential efficacy of TNF-α inhibitors for the management of numerous inflammatory dermatologic conditions that include apthous stomatitis, Behcet disease, cicatricial pemphigoid, dermatomyositis, eosinophilic fasciitis, hidradenitis suppurativa (HS), multicentric reticulohistiocytosis, necrobiosis lipoidica diabeticorum, pityriasis rubra pilaris, pyoderma gangrenosum, sarcoidosis, scleroderma, Sneddon-Wilkinson syndrome, and SAPHO (synovitis, acne, pustulosis, hyperostosis, and osteitis) syndrome.[50] A phase 2, randomized, placebo-controlled trial conducted at a single institution reported a higher response rate among HS patients treated with infliximab (5 mg/kg on weeks 0, 2, and 6) compared to placebo. More specifically, a greater percentage of infliximab-treated patients achieved a >50% reduction in baseline HS Severity Index (HSSI) score at week 8 compared to placebo.[51] In addition, 60% of infliximab-treated patients achieved a 25% to 50% reduction in HSSI compared to 6% of placebo.

Initiating Therapy and Monitoring. TNF inhibitors have been the most extensively studied class of biologics and therefore they have detailed and relatively robust safety data compared to other biologics. TNF inhibitors are immunosuppressive, and therefore, patients should be carefully screened for signs and symptoms of malignancy and infection prior to initiating therapy as well as during the course of treatment. Product labeling and published guidelines recommend screening for latent tuberculosis infection with a tuberculin skin test prior to initiating therapy with etanercept, infliximab, and adalimumab.[52] A whole blood test, such as QuantiFERON-TB gold or T-SPOT. TB assay, is an alternative screening method that offers higher specificity and comparable sensitivity to the traditional tuberculin skin test. It is particularly useful among BCG-vaccinated individuals who are more likely to exhibit a false-positive PPD reaction. TNF inhibitors should be used with caution in patients with a history of congestive heart failure—infliximab at doses >5 mg/kg is contraindicated in patients with moderate-to-severe congestive heart failure.

Infliximab may be associated with liver function test abnormalities, which, in rare cases, have led to hepatic failure. Additionally, TNF inhibitors have been associated with reactivation of hepatitis B in patients who are chronic carriers. Some of these cases have been fatal; therefore, one should consider monitoring liver function tests during TNF therapy and screening at-risk patients for hepatitis B. Small cases series suggest that TNF inhibitors can be used safely in patients with Hepatitis B when lamivudine is given concurrently. Larger studies, however, will be necessary to further substantiate these findings.[53] No exacerbation of liver disease has been reported among hepatitis C-positive patients receiving TNF inhibitor therapy. In fact, it has been suggested that TNF inhibitor therapy may contribute toward improving clinical outcomes among this patient population given their potential to suppress TNF-induced hepatic inflammation and fibrosis.[54,55] A recent multicenter study addressing the efficacy of etanercept in the treatment of alcoholic hepatitis reported increased mortality among patients with moderate-to-severe disease after 6 months of therapy; thus, the use of TNF inhibitors in this setting should be avoided if possible.[56]

Risks, Precautions, and Complications

Infection. TNF inhibitors are associated with serious infections including pneumonia, sepsis, tuberculosis, histoplasmosis, coccidioidomycosis, and other invasive fungal infections, thus accounting for the black box warning for infection. Product labeling also indicates that for patients who have resided in regions where histoplasmosis and coccidioidomycosis are endemic, the risks and benefits of TNF inhibitor therapy should be carefully considered. A recent meta-analysis of rheumatoid arthritis patients treated with infliximab or adalimumab in randomized controlled trials suggested that use of these agents result in one excess serious infection for every 59 patients treated for a period of 3–12 months.[57] Use of etanercept with anakinra has been associated with an increased risk of serious infections, and therefore, it is recommended that anakinra not be used concurrently with any TNF inhibitor. One prospective study reported an increased incidence of herpes zoster among rheumatoid arthritis patients treated with anti-TNF monoclonal antibodies (adalimumab, infliximab) compared to conventional disease-modifying antirheumatic drugs (DMARDs).[58] A meta-analysis addressing the risk of serious infections (infection requiring antibiotic treatment and/or hospitalization) among rheumatoid arthritis patients treated with adalimumab and infliximab reported a significantly increased risk for such infections compared to placebo.[57] Another meta-analysis addressing the risk of serious infections among RA patients treated with adalimumab, etanercept, or infliximab, with and without adjustment for exposure, reported no increased risk of serious infection at manufacturer recommended doses, however, there was a two-fold increased risk of serious infection among patients treated with higher doses (two to three times the recommended dose).[59]

Malignancy. A black box warning for malignancy was added to the product labeling of TNF inhibitors after cases of lymphoma and other malignancies were reported among adult and pediatric patients.

A meta-analysis [data from 9 randomized controlled trials (RCTs)] of 3,493 RA patients treated with adalimumab or infliximab demonstrated an increased risk of solid organ malignancies.[57] This increased risk proved to be dose dependent. Nonmelanoma skin cancers accounted for the majority of reported malignancies followed by lymphoma in this study. Infliximab has been associated with aggressive hepatosplenic T-cell lymphomas in postmarketing surveillance of patients with Crohn disease treated with concomitant azathioprine or 6-mercaptopurine. Additionally, aggressive cutaneous T-cell lymphomas have been reported in patients receiving TNF inhibitors.[60] A meta-analysis integrating data from 18 randomized control trials, involving 8,808 RA subjects, reported no increased risk for lymphoma, nonmelanoma skin cancer, and melanoma among patients treated with adalimumab, etanercept, and infliximab.[59]

A comprehensive review of the literature addressing the risk of lymphoma among patients receiving biologic therapy suggests the use of such agents to be safe with respect to lymphoma risk among those treated for a limited time (up to 4 years).[61] A meta-analysis addressing the risk of malignancies among rheumatoid arthritis patients reported a higher point estimate of malignancy among etanercept-treated patients compared to placebo, however, the results were not statistically significant.[62] Current data are insufficient to definitively rule out an increased risk of lymphoma, or causal relationship between biologic therapies and lymphoma. The largest observational study to date suggests a slightly higher risk of lymphoma associated with adalimumab and infliximab compared to etanercept in the French population.[63]

It remains unclear whether the excess risk of lymphoma reported in observational studies is due to the TNF inhibitor or the severity of the underlying disease (e.g., rheumatoid arthritis), which itself may portend a greater risk of lymphoma. Psoriasis patients may also have an increased risk of lymphoma, independent of biologic therapy and therefore additional studies will be necessary to determine if long-term exposure to biologics impacts lymphoma risk in psoriasis patients.[64]

Neurological Events. TNF inhibitors have been associated with rare cases of new onset demyelinating disease and with exacerbation of clinical and radiologic findings in patients with a history of demyelinating disease (e.g., multiple sclerosis).

Autoimmunity. TNF inhibitors may be associated with the development of antinuclear antibodies and antidouble-stranded DNA antibodies compared to placebo, the clinical significance of which is unknown. Rarely, TNF inhibitors have been associated with lupus-like syndromes and vasculitis.

Immunizations. TNF inhibitors may lower the titer response to immunizations; however, the clinical significance of this observation is unknown. Most patients with psoriatic arthritis receiving etanercept were able to mount effective B-cell immune responses to pneumococcal polysaccharide vaccine. Live vaccines should not be used in patients taking TNF inhibitors.

Hematologic Events. Rare cases of serious hematologic events have been associated with TNF inhibitors.

Other Events. Cases of worsening congestive heart failure, in addition to new onset cases, have been reported. Psoriasiform eruptions, both pustular and plaque-like, have also been reported among patients treated with TNF inhibitors. The onset of this paradoxical reaction may occur anywhere from one month to several years after initiation of therapy. The majority of cases have been reported among RA patients and have been primarily pustular in nature.[65,66] Discontinuation of the medication and initiation of oral immunosuppressants (methotrexate, cyclosporine, prednisone) +/− topical steroid therapy has led to clinical improvement/resolution of the lesions.

Pregnancy and Lactation. TNF inhibitors are pregnancy category-B medications with unknown safety during lactation.

INFLIXIMAB. Infliximab is a 149-kDa monoclonal chimeric antibody that consists of a murine antigen-binding region with specificity for human TNF-α fused to a human IgG1 constant region. A phase III, double-blind, placebo-controlled trial in patients with psoriasis reported that 80% of patients treated with infliximab (5 mg/kg) achieved a PASI 75 at week 10, whereas, at week 50, 61% of patients achieved a PASI 75.[67] This decrease in response over time has been reported in other clinical settings as well. When utilized as a monotherapy for Crohn disease, a shorter duration of response and higher risk for infusion reactions has been attributed to the formation of antibodies against infliximab.[68]

By nature of its chimeric structure, infliximab may be targeted by the host immune system if the murine portion of its structure is identified as foreign.[69] Neutralizing antibodies generated against infliximab have also been reported among patients treated for rheumatoid arthritis and psoriasis.[67,70] Strategies to decrease the formation of neutralizing antibodies include use of concomitant immunosuppressive medications (e.g., methotrexate), and regular (as opposed to intermittent) dosing of the drug. Infliximab is also associated with the development of ANA and antidouble-stranded DNA antibodies, the clinical significance of which is unknown. (See Section "Anti-TNF-α" for greater detail on indications, initiating, and monitoring therapy, risks, precautions, and complications.)

Infliximab is administered intravenously as a 5-mg/kg dose over 2–3 hours on weeks 0, 2, 6, and every 8 weeks thereafter. Infliximab has a serum half-life of ~9 days. Through its ability to neutralize both membrane-bound and soluble TNF-α, infliximab is believed to decrease cutaneous inflammation and promote keratinocyte differentiation in psoriatic plaques. In-vitro studies also suggest that infliximab may promote disease improvement through an ability to induce apoptosis of lesional keratinocytes.[71]

Although infliximab has demonstrated marked clearing of psoriasis, several recent reports have

suggested the potential for infliximab to induce or exacerbate psoriatic disease via unknown mechanisms.[72]

ADALIMUMAB. Adalimumab is a fully human 148-kDa monoclonal antibody against TNF-α. Similar to infliximab, it inhibits TNF-α signaling by binding to both soluble and membrane-bound forms. Adalimumab is administered as a subcutaneous injection with a serum half-life of 10–20 days. Psoriasis patients receive an 80-mg dose at week 0, followed by a 40-mg dose 1 week later and then every other week thereafter.

The short- and long-term efficacy of adalimumab has been evaluated among 1,212 patients with moderate-to-severe chronic plaque psoriasis in a phase III randomized, double-blind, placebo controlled trial.[73] After 16 weeks of treatment, 71% of adalimumab-treated patients achieved a PASI 75 compared to 7% of placebo. At week 33, adalimuab-treated patients who had achieved a PASI 75 were rerandomized 1:1 to continue receiving adalimumab or placebo through week 52. Among these patients, 5% of those who continued to receive adalimumab experienced a loss of adequate response (i.e., a <50% improvement in PASI response relative to baseline) compared to 28% of patients who were rerandomized to placebo. These findings, in combination with the results of the open-label extension study of this trial, support the notion that continuous therapy may be necessary to achieve sustained clinical responses among patients.[73] A randomized trial comparing the efficacy and safety of adalimumab to methotrexate reported the superior efficacy of adalimumab after 16-weeks of therapy.[74] More specifically, 80% of the adalimumab group achieved PASI 75 compared to 36% and 19% of the methotrexate and placebo groups, respectively. Two severe adverse events were reported in each treatment group.

Antibody formation against adalimumab has also been reported. One study addressing the clinical implications of this phenomenon found that psoriasis patients with low serum adalimumab trough concentrations, secondary to antibody formation, were more likely to exhibit a lack or loss of response to treatment compared to patients with higher trough concentrations.[75] Injection site reactions occur with adalimumab, however, they are generally mild and self-limited. (See Section "Anti-TNF-α" for greater detail on indications, initiating, and monitoring therapy, risks, precautions, and complications.)

ANTI-INTERLEUKIN 12 /INTERLEUKIN 23. Ustekinumab is a human IgG1k monoclonal antibody that is FDA approved for the treatment of moderate-to-severe plaque psoriasis. Ustekinumab targets the p40 subunit of IL12 and interleukin 23 (IL23). These cytokines are involved in the activation of natural killer cells and the differentiation of naive $CD4^+$ T-cells into Th1 and Th17 effector cells. Upon activation, Th17 cells secrete multiple cytokines, including interleukin 17 (IL17) and interleukin 22 (IL22). IL22 has been shown to contribute to the epithelial dysregulation and abnormal proliferation of keratinocytes characteristic of psoriasis and has been strongly implicated in its pathogenesis. High levels of p40 mRNA have been detected in psoriatic plaques; whereas, a notable reduction in its expression has been reported in clinically improved lesions after treatment.[76]

Several studies have addressed the efficacy and safety of ustekinumab for the treatment of patients with moderate-to-severe psoriasis. A phase III, double-blind, placebo-controlled trial found that 66.7% of patients receiving ustekinumab 45 mg (at weeks 0, 4, and every 12 weeks thereafter) achieved a PASI 75 by week 12, compared to 75.7% of patients receiving ustekinumab 90 mg, and 3.7% placebo.[77] A study comparing ustekinumab to the TNF inhibitor etanercept among patients with moderate-to-severe psoriasis reported superior efficacy of ustekinumab at a dose of 45 or 90 mg (at weeks 0 and 4) compared to etanercept at a dose of 50 mg twice weekly over a 12 week period.[78] A PASI 75 was achieved by 73.8% and 67.5% of ustekinumab treated patients at doses of 45 mg and 90 mg, respectively, compared to the etanercept treatment group, among whom 56.8% achieved a PASI 75 at week 12 ($p \leq 0.01$). A higher incidence of injection site reactions was reported among the etanercept treatment group; otherwise, the proportion of adverse events was comparable between the two treatment groups.

Indications. Ustekinumab was approved by the FDA in 2009 for the treatment of adult patients with moderate-to-severe plaque psoriasis who are candidates for systemic and/or phototherapy.

Initiating Therapy and Monitoring. Ustekinumab should only be administered by a healthcare provider. Dosing of the medication is weight based. Patients under 100 kg receive an initial 45-mg SC dose, which is repeated 4 weeks later. Subsequent dosing is administered every 12 weeks. Patients weighing over 100 kg receive a 90-mg dose with the same aforementioned dosing schedule. The serum half-life for ustekinumab has been reported to range from 14.9 +/− 4.6 days to 45.6 +/− 80.2 days according to the package insert. Ustekinumab is a pregnancy category-B medication with unknown safety during lactation.

Risks, Precautions, and Complications. The most commonly reported adverse events associated with ustekinumab were nasopharyngitis, upper respiratory tract infections, headache, and fatigue. Injection site reactions have also been reported but are less common.

Given its immunosuppressive properties, ustekinumab may increase one's risk for infection and certain cancers. Studies among patients with an inherited deficiency of IL12/IL23 have shown an increased risk for viral and bacterial infections (*Salmonella* and mycobacterial).[79–81] Thus, prospective patients should be screened for tuberculosis prior to initiating therapy. Ustekinumab should not be administered to patients with active or latent tuberculosis until they have undergone treatment. The BCG vaccine should be avoided for at least one year before, during, or after treatment with ustekinumab.

One case of reversible posterior leukoencephalopathy syndrome (RPLS) was reported among patients

treated with ustekinumab during its clinical development. RPLS is a noninfectious syndrome characterized by headache, visual changes, seizures, and confusion. It has multiple ascribed etiologies including hypertension, electrolyte abnormalities, and a reaction to medications. Patients should be monitored for RPLS symptoms during the course of therapy. Live vaccines are contraindicated during treatment. The safety and efficacy of ustekinumab beyond 2 years of therapy remains undetermined. Large long-term studies of ustekinumab will be necessary in order to define the risk of cancer and serious infections with this novel agent.

ANTIBODIES AGAINST CELL SURFACE RECEPTORS

EFALIZUMAB. Efalizumab is a recombinant humanized monoclonal IgG1 antibody against the α-subunit of the leukocyte function-associated antigen 1 [LFA-1, CD11a (Fig. 234-1)]. LFA-1 is a member of the β-2 integrin family and is involved in lymphocyte activation, enhanced cytotoxic T-cell function, and the trafficking of lymphocytes to the skin (see Fig. 234-2). In both short- and long-term studies, efalizumab has exhibited efficacy in the treatment of patients with moderate-to-severe psoriasis. Efalizumab was withdrawn from the United States market in April 2009 after three cases of progressive multifocal leukonencephalopathy (PML) were reported among patients receiving the drug. PML is a rare, life-threatening infection that is most prevalent among immunosuppressed individuals. It is caused by the JC virus, a typically harmless virus among immunocompetent individuals.

RITUXIMAB. Rituximab is a humanized chimeric monoclonal antibody against CD20, a cell surface protein expressed by mature and pre-B cells. It has been shown to induce the depletion of B-cells in vivo. CD20 expression is lost during the differentiation of B-cells to plasma cells. Aside from playing a crucial role in antibody production, B-cells may also serve as antigen presenting cells and have been shown to provide costimulatory signals, which promote $CD4^+$ T-cell expansion and effector cell function.[82]

Rituximab is FDA approved for the treatment of patients with moderate-to-severe rheumatoid arthritis and for the treatment of relapsed or chemorefractory (low-grade or follicular) $CD20^+$ non-Hodgkin B-cell lymphomas and has been shown to transiently reduce the population of $CD20^+$ cells in the circulation.[83] This effect is achieved by its ability to enhance antibody and complement-mediated cytotoxicity, and promote the apoptosis of malignant $CD20^+$ cells.[84] Aside from its role in the treatment of lymphoma and rheumatoid arthritis, rituximab has been increasingly used off-label for the management of other autoimmune diseases. More specifically, reports have suggested its efficacy for the treatment of paraneoplastic and refractory pemphigus, autoimmune hemolytic anemia, granulomatosis with polyangiitis (Wegener's) hypocomplementemic urticarial vasculitis, systemic lupus erythematosus (SLE), cutaneous B-cell lymphoma, chronic graft-versus-host disease, and epidermolysis bullosa acquisita.

Caution, however, should be taken before initiating therapy with rituximab for off-label use. Two cases of PML were reported to the FDA in 2006 involving patients who received rituximab for the treatment of SLE.[85] Recent reports have also noted marked progression of Kaposi sarcoma among patients treated for autoimmune hemolytic anemia and Castleman disease.[86,87]

In a case series of patients receiving rituximab for autoimmune bullous disorders (pemphigus vulgaris, bullous pemphigoid, and mucous membrane pemphigus), severe adverse reactions were noted in three of seven patients.[88] These reactions, which consisted of serious infections, enteropathy, and pulmonary embolism, were believed to be associated with concurrent high-dose adjuvant immunosuppression and underlying malignancy among the affected individuals. In a study involving 11 patients with refractory pemphigus vulgaris treated with rituximab and intravenous immune globulin, no infections or other clinically significant adverse effects were noted.[89] Additionally, no severe adverse effects were reported in case series and open-label studies among patients treated with intralesional and/or intravenous rituximab for cutaneous B-cell lymphoma and dermatomyositis.[90] A study addressing the safety of rituximab for the treatment of diffuse cutaneous systemic sclerosis (among 15 patients) reported mild infusion reactions (affecting 46% of patients), urinary tract infection and a dental abscess affecting a single patient, and one case of prostate cancer at six month follow-up.[91]

Indications. Rituximab is FDA approved for the treatment of $CD20^+$ non-Hodgkin's B-cell lymphomas and moderate-to-severe rheumatoid arthritis.

Initiating Therapy and Monitoring. No specific dosing regimen has been established for the off-label use of this medicine in the dermatologic setting. Rituximab is usually administered at a standard dose of 375-mg/m^2 body surface area at weekly intervals. Premedication with acetaminophen and antihistamines should be considered to decrease the risk for infusion reactions. Monitoring of blood cell counts and serum antibody levels may be pursued every 2–3 months while on therapy. A rapid depletion of $CD20^+$ B-cells occurs after treatment and may last from 2–6 months before recovery. Live vaccines should not be administered to patients prior to and during therapy.

Rituximab is a pregnancy category C medication with unknown safety during lactation.

Risks, Precautions, and Complications. Reported adverse effects associated with rituximab therapy include fatal infusion reactions, vasculitis, hepatitis B reactivation, tumor lysis syndrome, renal toxicity, severe mucocutaneous reactions, cardiac arrhythmias/angina and bowel obstruction/perforation. Cases of PML have been reported among patients

with lymphoid malignancies and SLE treated with rituximab.[92]

FUSION PROTEINS

ALEFACEPT

Alefacept is a bioengineered protein consisting of the human IgG1 antibody Fc region fused to the first extracellular domain of human lymphocyte function-associated antigen-3 (LFA-3). LFA-3 is a member of the immunoglobulin superfamily and is expressed on the surface of antigen presenting cells (see Fig. 231-2). It normally binds to CD2 which is preferentially expressed on the surface of effector/memory T-cells, an interaction that plays an important role in the activation of T-cells in response to antigen. Alefacept is believed to prevent the activation of T-cells by blocking this interaction (see Fig. 231-1).[93] In addition, it may induce the apoptosis of memory T-cells via binding of its IgG1 portion to the CD16 receptor of natural killer cells.[94]

INDICATIONS. Alefacept was the first biologic agent FDA approved for the treatment of psoriasis in 2003. Studies have evaluated the efficacy of both intravenous and intramuscular dosing (7.5-mg IV qwk and 15-mg IM qwk), however, only the IM form is commercially available at this time. A randomized, placebo-controlled phase III trial of adult patients with chronic plaque psoriasis involving at least 10% body surface area was performed to address the efficacy and safety of alefacept therapy (15-mg IM qwk) for 12 weeks.[95] PASI 75 responses were achieved by 21% of treated patients. Among this group, 71% maintained at least a PASI 50 in the 12-week follow-up period. No opportunistic infections or disease rebound was noted during this time.

Reports of off-label use of alefacept in the treatment of other inflammatory dermatoses such as graft versus host disease, lichen planus and alopecia areata have been published.[96,97] A randomized, double-blind , placebo-controlled study found alefacept to be ineffective for the treatment of patients with severe alopecia areata.[98] Alefacept has shown promise in the treatment of psoriatic arthritis as a monotherapy and in combination with methotrexate.[99,100]

INITIATING THERAPY AND MONITORING. Alefacept is contraindicated in patients with HIV infection and should not be used in patients with a $CD4^+$ T lymphocyte count that is below normal. On the basis of published studies and manufacturer recommendations, alefacept treatment is typically initiated as a 15-mg intramuscular dose administered on a weekly basis for 12 weeks, followed by a 12-week period of nontreatment observation. The serum half-life of alefacept is approximately 12 days. Improved efficacy may be achieved by increasing the initial treatment course to 16 weeks.[101] Phase III clinical trials have shown increased efficacy of alefacept after successive courses of treatment (up to five courses) with no observed compromise in safety or tolerability.[102,103]

Upon initiation of therapy, CD4 and CD8 T-cell counts should be monitored every 2 weeks and treatment should be withheld if the CD4 count drops below 250 cells/μL; counts should then be monitored weekly. If the CD4 count remains below 250 for over 4 weeks, treatment should be discontinued. In general, alefacept should not be initiated in patients with low CD4 counts or an active infection within 2 weeks of therapy. Treatment of patients with a history of a prior malignancy should be pursued with caution.

Alefacept is a pregnancy category B medication with unknown safety during lactation.

RISKS, PRECAUTIONS, AND COMPLICATIONS. Alefacept is well tolerated with a limited side effect profile. Pooled data from randomized controlled trials revealed a low incidence of malignancy among treated patients, which was similar to untreated patients. Abnormalities in liver function tests were more frequent compared to placebo, and serious liver reactions have been reported in postmarketing studies. No correlation between $CD4^+$T-cell counts and infection has been reported. $CD4^+$ T-cell mediated antibody titer responses to external antigens appear to remain intact after treatment.[104] Large, long-term follow up studies will be necessary to determine if the immunosuppressive properties of alefacept increase the risk of serious infections and malignancies.

ETANCERCEPT

Etanercept is a fusion protein consisting of the human TNF type II receptor linked to a human IgG1 Fc region, already briefly discussed with the anti-TNF agents. It blocks the effects of TNF-α by binding to it in the circulation, thus preventing it from associating with its cell surface receptor. In a double-blind, placebo-controlled study, 49% of psoriatic patients treated with high-dose etanercept (50 mg twice weekly) for 12 weeks achieved at least a PASI 75, whereas only 4% of patients in the placebo group attained this result.[105] Continued clinical improvement was noted in the subsequent weeks with 59% of high-dose etanercept-treated patients achieving PASI 75.

In a study addressing the efficacy of etanercept for the treatment of children and adolescent patients with moderate-to-severe plaque psoriasis, patients were randomly assigned to a double-blind trial of weekly subcutaneous etanercept (0.8 mg/kg to a maximum of 50 mg) or placebo.[106] After 12 weeks, 57% of patients receiving etanercept achieved a PASI 75 compared to 11% of placebo ($p<0.001$). Over the following 24 weeks, both groups received open-label etanercept. Four serious adverse events were reported (three infections and one ovarian cyst removal). Overall, etanercept may offer a relatively safe and efficacious treatment option for pediatric patients with advanced plaque psoriasis.

For adults, etancercept is initiated at a dose of 50-mg SC 2×/week for 12 weeks, then reduced to 50-mg qwk (or 25-mg SC twice weekly). The median time to relapse

after discontinuation of therapy after 6 months is estimated at 70–91 days.[107] The serum half life of etanercept is between 4 and 25 hours. Injection site reactions may occur with etanercept; however, they are generally mild and self-limited. (See Section "Anti-TNF-α" for greater detail on indications, initiating and monitoring therapy, risks, precautions, and complications.)

DENILEUKIN DIFTITOX

Denileukin diftitox (DAB389-IL2) is a ligand-toxin fusion protein consisting of a fragment of diphtheria toxinfused to interleukin-2 (IL2). DAB389-IL2 is believed to associate with malignant cells expressing the high-affinity IL2 receptor. Upon binding to the receptor, it is internalized within endosomes, where its ADP-ribosyltransferase region is cleaved and translocated into the cytoplasm. In the cytoplasm, it interrupts protein synthesis, eventually leading to apoptosis of the affected cell.

CD25 represents the α-chain of the IL2 receptor. It serves both as a marker for activated T-cells, as well as for a unique population of $CD4^+$ T-cells that express the transcription factor, FoxP3, called regulatory T-cells ($CD4^+CD25^+FoxP3^+$). Naturally occurring regulatory T-cells exhibit immunosuppressive properties and have been shown to play an important role in the induction of immune tolerance. Murine melanoma models indicate a role for regulatory T-cells in suppressing antitumor immunity.[108] In addition, the in-vivo use of anti-CD25 specific antibody was shown to deplete regulatory T-cell populations and enhance tumor regression in the murine system.[109] Because of its ability to deplete $CD25^+$ T-cells, DAB389-IL2 may contribute to antitumor immunity by eliminating regulatory T-cells in addition to malignant cells that express the CD25 component of the IL2 receptor.

A recent study examining the ability of DAB389-IL2 to eliminate regulatory T lymphocytes among human patients with metastatic melanoma revealed neither any significant change in Foxp3 levels nor objective clinical response among treated patients.[110] Studies of other human malignancies in which large populations of regulatory T cells were present exhibited a notable reduction in circulating regulatory T-cells and enhanced effector T-cell activation in response to DAB389-IL2.[111] Thus, the ability of DAB389-IL2 to eliminate regulatory T cells and enhance antitumor immunity in human malignancies requires further study. In addition, its effects on $CD25^+$ nonregulatory effector T-cells, which also play an important role in antitumor immunity, is under investigation.

In a phase III double-blind, placebo-controlled study, patients with advanced or refractory cutaneous T-cell lymphoma were randomized to receive DAB389-IL2 by infusion at doses of 9μg/kg/day or 18μg/kg/day.[112] All patients had failed at least one prior therapy (the median number of prior therapies was five) and were shown to have at least 20% CD25 expression among tumor cells in the skin. Treatment was administered for 5 consecutive days and was repeated every 3 weeks for up to eight treatment cycles. Intent to treat analysis revealed a 30% clinical response rate among all treated patients, characterized by a 50% reduction in tumor burden. Ten percent of patients achieved a complete clinical response characterized by no evidence of cutaneous disease. The majority of patients exhibited a clinical response within the first three treatment cycles. The durability of response was higher among complete responders with a median of 9 months. The median duration of response among partial responders was 4 months. No statistically significant difference in response was noted between the two dosing groups. Another study reported a direct correlation between CD25 expression by lesional skin in CTCL patients and response to DAB289-IL2. More specifically, 78.5% of patients with high CD25 expression, which correlated with advanced CTCL, exhibited a clinical response to DAB289-IL2, in comparison to only 20% of patients with low-to-undetectable CD25 expression.[113]

DAB389-IL2 is FDA approved for the treatment of cutaneous T-cell lymphoma in which the malignant cell population expresses the CD25 receptor. Studies have reported clinical efficacy with the use of DAB289-IL2 in the treatment of patients with moderate-to-severe plaque psoriasis; however, it is not approved for this indication.[114,115]

INITIATING THERAPY AND MONITORING.

DAB389-IL2 is administered intravenously over at least 15 minutes. Doses at 9 μg/kg/day and 18 μg/kg/day have been utilized for the treatment of cutaneous T-cell lymphoma.

DAB389-IL2 is a pregnancy category C medication with unknown safety during lactation.

RISKS, PRECAUTIONS, AND COMPLICATIONS.

Infusion-reactions represent the most common adverse effect associated with DAB389-IL2 treatment and may be characterized by fever, hypotension, arthralgias, dyspnea, rash, and chest/back tightness. DAB389-IL2 has also been associated with flu-like symptoms, a reversible transaminitis, vascular leak syndrome, and a morbilliform cutaneous eruption. DAB389-IL2 is contraindicated among patients with a known hypersensitivity to any of its components.

CONCLUSION

In this chapter, we have discussed a number of biologic agents currently available for the management of dermatologic disease. Large, prospective, long-term, follow-up studies will be necessary to fully discern the safety of these agents. As we have discussed, targeting of the immune system with biologics may result in an increased risk for serious infections and malignancies. The emergence of PML among patients treated with efalizumab, 5 years after its approval, highlights the need for ongoing pharmacovigilance of novel therapeutic agents.

Immunobiologics require complex and expensive manufacturing processes, which may ultimately limit their utilization. Because these drugs generally exhibit reduced efficacy over time, long-term disease control remains a challenge for many patients. As we further characterize the immunopathogenesis of cutaneous disease, new potential targets may be identified, thus improving our ability to manage conditions that may otherwise be poorly responsive to current therapeutic modalities.

KEY REFERENCES

Full reference list available at www.DIGM8.com

DVD contains references and additional content

2. Rook AH, Kuzel TM, Olsen EA: Cytokine therapy of cutaneous T-cell lymphoma: interferons, interleukin-12, and interleukin-2. *Hematol Oncol Clin North Am* **17**(6):1435-1448, ix 2003
11. Sechler JM et al: Recombinant human interferon-gamma reconstitutes defective phagocyte function in patients with chronic granulomatous disease of childhood. *Proc Natl Acad Sci USA* **85**(13):4874-4878, 1988
15. Kim EJ et al: Immunopathogenesis and therapy of cutaneous T cell lymphoma. *J Clin Invest* **115**(4):798-812, 2005
21. Jilaveanu LB, Aziz SA, Kluger HM: Chemotherapy and biologic therapies for melanoma: Do they work? *Clin Dermatol* **27**(6):614-625, 2009
22. Goldbach-Mansky R et al: Neonatal-onset multisystem inflammatory disease responsive to interleukin-1beta inhibition. *N Engl J Med* **355**(6):581-592, 2006
34. Wieman TJ, Smiell JM, Su Y: Efficacy and safety of a topical gel formulation of recombinant human platelet-derived growth factor-BB (becaplermin) in patients with chronic neuropathic diabetic ulcers. A phase III randomized placebo-controlled double-blind study. *Diabetes Care* **21**(5):822-827, 1998
39. Gottlieb AB et al: Pharmacodynamic and pharmacokinetic response to anti-tumor necrosis factor-alpha monoclonal antibody (infliximab) treatment of moderate to severe psoriasis vulgaris. *J Am Acad Dermatol* **48**(1):68-75, 2003
47. Wallis RS, Ehlers S: Tumor necrosis factor and granuloma biology: Explaining the differential infection risk of etanercept and infliximab. *Semin Arthritis Rheum* **34**(5 Suppl. 1):34-38, 2005
50. Alexis AF, Strober BE: Off-label dermatologic uses of anti-TNF-a therapies. *J Cutan Med Surg* **9**(6):296-302, 2005
51. Grant A et al: Infliximab therapy for patients with moderate to severe hidradenitis suppurativa: A randomized, double-blind, placebo-controlled crossover trial. *J Am Acad Dermatol* **62**(2):205-217, 2010
54. Parke FA, Reveille JD: Anti-tumor necrosis factor agents for rheumatoid arthritis in the setting of chronic hepatitis C infection. *Arthritis Rheum* **51**(5):800-804, 2004
55. Zein NN: Etanercept as an adjuvant to interferon and ribavirin in treatment-naive patients with chronic hepatitis C virus infection: A phase 2 randomized, double-blind, placebo-controlled study. *J Hepatol* **42**(3):315-322, 2005
57. Bongartz T et al: Anti-TNF antibody therapy in rheumatoid arthritis and the risk of serious infections and malignancies: Systematic review and meta-analysis of rare harmful effects in randomized controlled trials. *JAMA* **295**(19):2275-2285, 2006
59. Leombruno JP, Einarson TR, Keystone EC: The safety of anti-tumour necrosis factor treatments in rheumatoid arthritis: Meta and exposure-adjusted pooled analyses of serious adverse events. *Ann Rheum Dis* **68**(7):1136-1145, 2009
64. Gelfand JM et al: The risk of lymphoma in patients with psoriasis. *J Invest Dermatol* 126(10):2194-2201, 2006
65. Ubriani R, Van Voorhees AS: Onset of psoriasis during treatment with TNF-{alpha} antagonists: A report of 3 cases. *Arch Dermatol* **143**(2):270-272, 2007
73. Menter A et al: Adalimumab therapy for moderate to severe psoriasis: A randomized, controlled phase III trial. *J Am Acad Dermatol* **58**(1):106-115, 2008
77. Papp KA et al: Efficacy and safety of ustekinumab, a human interleukin-12/23 monoclonal antibody, in patients with psoriasis: 52-week results from a randomised, double-blind, placebo-controlled trial (PHOENIX 2). *Lancet* **371**(9625):1675-1684, 2008
78. Griffiths CE et al: Comparison of ustekinumab and etanercept for moderate-to-severe psoriasis. *N Engl J Med.* **362**(2):118-128, 2010
89. Ahmed AR et al: Treatment of pemphigus vulgaris with rituximab and intravenous immune globulin. *N Engl J Med* **355**(17):1772-1779, 2006
95. Lebwohl M et al: An international, randomized, double-blind, placebo-controlled phase 3 trial of intramuscular alefacept in patients with chronic plaque psoriasis. *Arch Dermatol* **139**(6):719-727, 2003
105. Leonardi CL et al: Etanercept as monotherapy in patients with psoriasis. *N Engl J Med.* **349**(21):2014-2022, 20, 2003

Chapter 235 :: Antiangiogenic Agents

:: Ricardo L. Berrios, Michael Y. Bonner, Jonathan Hofmekler, & Jack L. Arbiser

ANTIANGIOGENIC AGENTS AT A GLANCE

- "Direct" antiangiogenic agents act directly on untransformed endothelial cells to prevent proliferation, migration, and survival.
- "Indirect" antiangiogenic agents inhibit tumor-produced oncogene proteins that promote a proangiogenic state.
- Antiangiogenic agents are a promising class of drugs because they are effective against slow-growing tumors.

In 1971, Judah Folkman published a landmark paper hypothesizing that all tumor growth is dependent on angiogenesis and that inhibitors of angiogenesis could be used to treat cancers.[1] The ensuing years have proven him correct and have seen the development of new agents that, either alone or in adjunct, have shown promise not only in oncology but in a variety of dermatologic conditions as well.

Antiangiogenic drugs can be classified as either "direct" or "indirect," the former acting directly on untransformed endothelial cells to prevent proliferation, migration, or survival, a process that normally occurs upon stimulation by proangiogenic molecules; and the latter by inhibition of tumor-produced oncogenic protein products that promote proangiogenic states. Angiogenesis inhibitors as a drug class provide a unique approach to cancer treatment because they are also effective against slow-growing tumors, while traditional therapies, such as chemotherapy and radiation, work best on rapidly dividing cells. In the future, the switch to an angiogenic phenotype may be able to be blocked in clinically undetectable cancers, thus preventing disease progression using therapies directed, in part, by angiogenesis biomarkers.[2,3] Current applications of these agents center on oncologic and ophthalmologic diseases but dermatologic indications are also promising.

Figure 235-1 shows the key points of action of some of the antiangiogenic drugs discussed in this chapter in normal skin, inflammatory conditions, precancerous lesions, and malignancy.

INTERFERON-α 2B (INTRON A)

(See also Chapters 231 and 234)

Interferon-α (IFN-α) made history in 1988 as the first antiangiogenic therapy used in humans, for the successful treatment of pulmonary hemangiomatosis in a pediatric patient. IFN-α 2b is a synthetic cytokine made from the bacterium *Escherichia coli* transformed with recombinant DNA, and has similar actions to its natural endogenous counterpart, IFN-α, a type I IFN produced naturally by the immune system.

MECHANISM OF ACTION

The IFNs act through the Janus kinase-signal transducers and activators of transcription (Jak-STAT) pathway. IFN-α, which is both a direct and indirect antiangiogenic agent, was first observed to impair capillary endothelial cell migration. Its properties as an indirect antiangiogenic agent include the ability to decrease tumor cell production of basic fibroblast growth factor (bFGF), which may explain its success in treating hemangiomata.[3] IFN-α has well-known antiviral activity and antitumor activity, which may be mediated in part by upregulating major histocompatibility complex class I antigen expression, activating natural killer cells, controlling progression through cell cycle checkpoints, and activating apoptosis.

INDICATIONS

Interferon-α 2B is currently indicated for the treatment of chronic hepatitis B (which may be chemopreventive against hepatocellular carcinoma), chronic hepatitis C, acquired immunodeficiency syndrome (AIDS)-associated Kaposi sarcoma, and condylomata acuminata. It is also indicated in the following malignancies: malignant melanoma (adjuvant to surgical therapy in patients at high risk of systemic recurrence; must be administered within 56 days postoperatively), hairy cell leukemia, and follicular lymphoma.[4] Off-label uses in dermatology include cutaneous T-cell lymphoma (CTCL, mycosis fungoides) and basal and squamous cell skin cancer. It has also been used in the treatment of infantile hemangiomas along with corticosteroids or in the event of corticosteroid resistance; however, given rising concerns over the risk of spastic diplegia (especially in children under 1 year of age), its utility in this setting has been somewhat tempered.[5]

CONTRAINDICATIONS

(See Box 235-1)

PHARMACOKINETICS

IFN-α 2b comes as a powder that, upon reconstitution, should be used immediately but may be stored up to

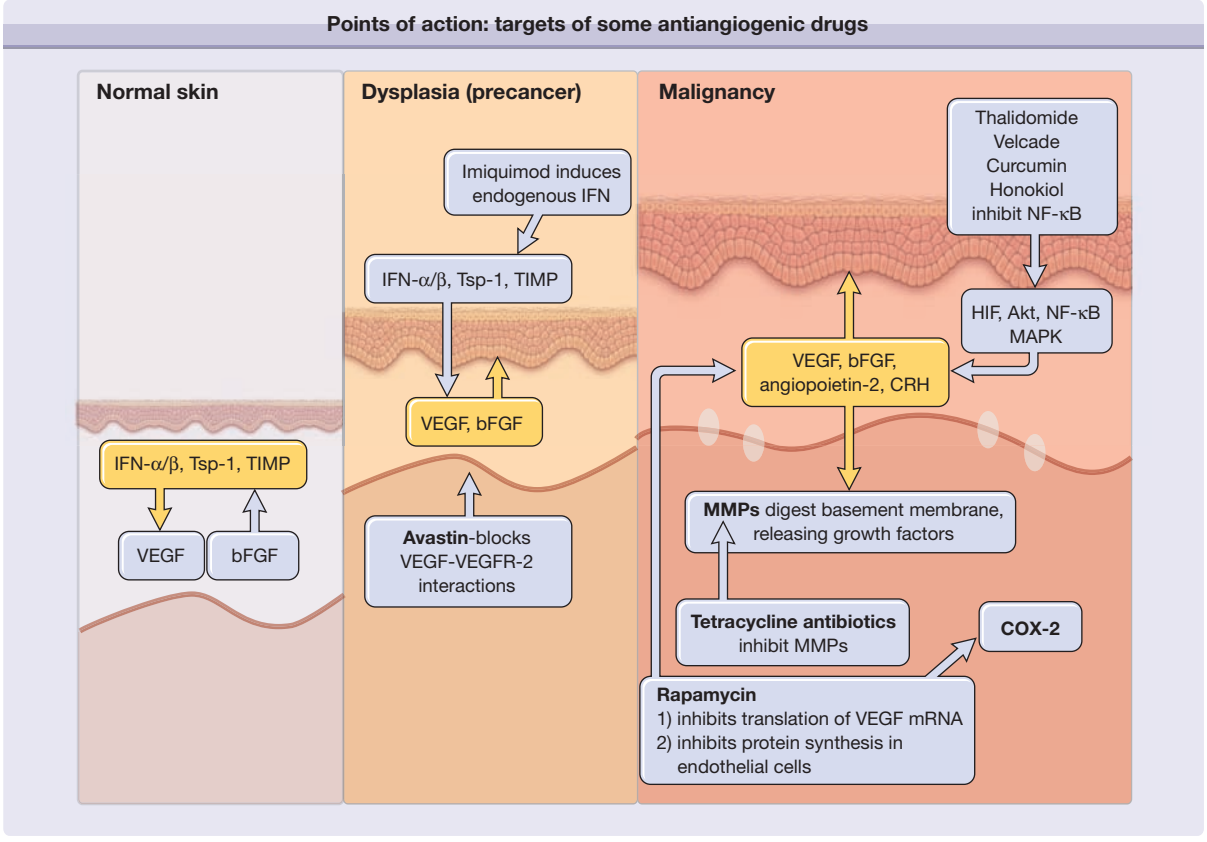

Figure 235-1 Schematic depiction of the key points of action of some of the antiangiogenic drugs discussed in this chapter in normal skin, precancerous lesions, and malignancy. bFGF = basic fibroblast growth factor; COX-2 = cyclooxygenase 2; CRH = corticotropin-releasing hormone; HIF = histoplasma inhibitory factor; IFN = interferon; MAPK = mitogen-activated protein kinase; MMP = matrix metalloproteinase; mRNA = messenger RNA; NF-κB = nuclear factor κB; TIMP = tissue inhibitor of metalloproteinases; Tsp-1 = thrombospondin 1; VEGF = vascular endothelial growth factor; VEGFR-2 = vascular endothelial growth factor receptor 2.

24 hours at 2°C–8°C (36°F–46°F). It can be given by subcutaneous (SC), intramuscular (IM), intravenous (IV), or intralesional routes. Its half-life is 3–12 hours when given SC or IM and 30 minutes when given IV. The drug is likely metabolized by the kidneys. Polyethylene glycol IFN-α 2b has a 10-fold increase in the half life, decreased toxicity, and increased compliance.[4,6] For dosing, see Table 235-1.

BOX 235-1 CONTRAINDICATIONS TO INTERFERON-α

- Hypersensitivity to IFN-α or any drug components
- Combination IFN-α and ribavirin therapy in pregnancy or in males whose female partners are pregnant
- Autoimmune hepatitis
- Personal history of a hemoglobinopathy (e.g. sickle cell disease, thalassemia major)
- Renal insufficiency (creatinine clearance <50 mL/minutes)

COMPLICATIONS[4]

(See Box 235-2)

RISKS AND PRECAUTIONS[4]

- Pregnancy category: C
- Pediatrics

The safety and efficacy in children has not established for any indications other than chronic hepatitis B and C.

BEVACIZUMAB (AVASTIN)

MECHANISM OF ACTION

Bevacizumab is a recombinant, humanized, immunoglobulin G1 monoclonal antibody against vascular endothelial growth factor (VEGF). VEGF is a growth factor that promotes angiogenesis by supporting endothelial cell replication and survival as well as vascular permeability. This potent proangiogenic molecule is

TABLE 235-1
Interferon-α 2B Dosing[4]

Disease	Dose
Malignant melanoma high-dose regimen	Induction: 20 million IU/m^2 IV infusion over 20 minutes, 5 consecutive days/week for 4 weeks Maintenance: 10 million IU/m^2 SC three times/week for 48 weeks
Malignant melanoma adjuvant low-dose regimen (in clinical trials)	Maintenance: 3 million U SC three times/week for 1 year
Acquired immunodeficiency syndrome-related Kaposi sarcoma	30 million IU/m^2 SC or IM three times/week until disease progression or maximal response has been achieved after 16 weeks
Condylomata acuminata	1 million IU per lesion (maximum of five lesions per course) three times/week on alternate days for 3 weeks. May administer additional courses at 12–16-week intervals
Hemangiomas	3 million U/m^2/day for at least 6 months.[7]

upregulated in a majority of human tumors and serves to alter tumor vasculature.

Binding of bevacizumab to VEGF is direct and specific. The antibody also competitively binds VEGF receptor 1 (VEGFR-1) and VEGFR-2, preventing VEGF from binding to its receptors and initiating the signaling cascade. It has also been shown to reduce and normalize tumor vascularity.[8]

BOX 235-2 COMPLICATIONS OF INTERFERON-α

- Flu-like symptoms (headache, fatigue, fever, chills, tachycardia, myalgia, and anorexia)
- Depression (new-onset depression or worsening of pre-existing depression; patients should be monitored during therapy for severe depression, and therapy should be discontinued if necessary)[4]
- Sarcoidosis (observed in combination IFN-α-ribavirin therapy)
- Spastic diplegia (a form of cerebral palsy that is a neuromuscular condition characterized by hypertonia and spasticity in the muscles of the lower extremities; Little disease)[5]
- Gastrointestinal perforation with associated intra-abdominal abscess or fistula formation

BOX 235-3 COMPLICATIONS OF BEVACIZUMAB

- Wound dehiscence (Incisions should be healed completely before treatment initiation; drug should be held for at least 28 days prior to elective surgery)
- Serious hemorrhagic events including hemoptysis, gastrointestinal bleeding, central nervous systems (CNS) hemorrhage, epistaxis, vaginal bleeding, and pulmonary hemorrhage. Use in patients with active hemorrhage or recent history of hemoptysis is not advised.
- Arterial thromboembolic events including cerebral infarction, transient ischemic attacks, myocardial infarction, angina, and others.
- Reversible posterior leukoencephalopathy syndrome (RPLS), a neurological disorder characterized by headache, seizure, lethargy, confusion, blindness and other visual or neurologic disturbances, that is diagnosed and confirmed by magnetic resonance imaging (MRI)
- Hypertension (monitoring every two to three weeks during course of treatment is advised)
- Proteinuria
- Infusion reactions

INDICATIONS

Bevacizumab was the first antiangiogenesis drug approved by the US Food and Drug Administration (FDA) in February 2004 for the first-line treatment of metastatic colorectal carcinoma when given in combination with intravenous 5-fluorouracil-based chemotherapy but also has indications for nonsmall cell lung cancer, metastatic human epithelial growth factor-2-negative breast cancer, glioblastoma, and metastatic renal cell carcinoma.[9] Bevacizumab, in combination with either other antiangiogenic agents or chemotherapy, is currently being investigated in metastatic melanoma, hemangioendothelioma, and angiosarcoma. Other than a history of hypersensitivity, no known contraindications to bevacizumab therapy exist.[9]

COMPLICATIONS[9]

(See Box 235-3)

CETUXIMAB (ERBITUX)

MECHANISM OF ACTIONS

Cetuximab is a chimeric, human-murine monoclonal antibody against the epithelial growth factor receptor (EGFR), and, as such, competitively inhibits the

BOX 235-4 COMPLICATIONS OF CETIXUMAB THERAPY

- Serious infusion reactions
- Acneiform neutrophilic folliculitis—appearance correlates with clinical response
- Pruritus
- Electrolyte disturbances
- Abdominal pain and upset
- Infections associated with neutropenia

BOX 235-5 COMPLICATIONS OF PANITUMUMAB

- Severe dermatologic toxicities (dermatitis acneiform, pruritus, erythema, rash, skin exfoliation, paronychia, dry skin, skin fissures)
- Photosensitivity
- Pulmonary fibrosis
- Electrolyte disturbances
- Infusion reactions

binding of epithelial growth factor (EGF), transforming growth factor (TGF), and other associated ligands. Downstream signaling blockade results in myriad of antitumor properties including decreased proliferation, cellular motility, and invasive potential via downregulation of signaling molecules such as basic fibroblast growth factor (bFGF, a product of keratinocytes) and interleukin 8 (IL-8).[14,15] Angiogenesis is also inhibited through decreased EGFR-mediated VEGF expression.

INDICATIONS

Cetuximab is currently indicated for the treatment of metastatic colorectal carcinoma and squamous cell carcinoma of the head and neck, either alone or in combination with radiation or chemotherapy.[16] Additionally, its use in squamous cell carcinoma of the skin is currently under investigation. Given the demonstrated role of bFGF in melanoma, cetuximab may also play an eventual role in its treatment. Other than a history of hypersensitivity, there are no known contraindications.

COMPLICATIONS[16]

(See Box 235-4)

PANITUMUMAB (VECTIBIX)

MECHANISM OF ACTION

Panitumumab is an entirely human monoclonal antibody directed against EGFR. Like cetuximab, it blocks ligand interactions associated with the EGFR (EGF, TGF) and downstream signaling molecule like VEGF, bFGF, and IL-8; however, because panitumumab is not chimeric, the hypothesized benefit is better overall efficacy and immunologic tolerance.[17]

INDICATIONS

Panitumumab is currently indicated for progressing, metastatic colorectal carcinoma in combination with or as a single agent following chemotherapy.[18] No known dermatologic uses or investigations into potential uses exist at this time, but, given its similarity to cetuximab, possible investigations into panitumumab's utility in cutaneous squamous cell carcinoma and melanoma is warranted. Other than a history of hypersensitivity, there are no known contraindications.

COMPLICATIONS[18]

(See Box 235-5)

In 1965, Sheskin prescribed thalidomide for psychosis in one of his patients and accidentally discovered that thalidomide effectively treated his/her erythema nodosum leprosum (ENL). The FDA approved thalidomide in 1998 for the treatment of ENL and currently classifies it as an orphan drug.

As interest in thalidomide's ability to treat a wide variety of refractory diseases grows, a promising class of drugs named ImiDs® or immunomodulatory thalidomide analogues has come under development and investigation. One member of this new class of drugs, lenalidomide (CC-5013, Revlimid), has been approved for the treatment of multiple myeloma, myelodysplastic syndromes, and chronic lymphocytic leukemia. However, phase III clinical studies of lenalidomide for the treatment of metastatic melanoma did not show a significant effect.[28]

MECHANISM OF ACTION

Thalidomide exhibits a wide range of effects in vitro and in vivo. Its mechanisms of action are still unclear, but, exhibiting antineoplastic, immunomodulatory, and antiangiogenic properties, thalidomide downregulates the expression of VEGF, bFGF, and possibly tumor necrosis factor-α (TNF-α), IFN-α, insulin-like growth factor-1 (IGF-1), nuclear factor-κB (NF-κB), IL-6, and IL-12.[29,30] Its antiangiogenic properties may be the basis for its antineoplastic activity, but its myriad of other effects likely accounts for its teratogenicity.[31] Apart from its hypnosedative properties, thalidomide's eventual effects on the immune system result in a reduction in helper T-cell:suppressor T-cell ratio and decreased leukocyte chemotaxis and monocyte phagocytosis.[32] Additionally, human keratinocytes demonstrate increased migration and proliferation when exposed to thalidomide.[33]

INDICATIONS

Thalidomide is currently approved and considered first-line therapy for the acute treatment of the cutaneous manifestations of moderate-to-severe erythema nodosum leprosum (ENL) as well as maintenance therapy for prevention and suppression of the cutaneous manifestations of ENL recurrence. In combination with dexamethasone, it is also approved for the treatment of newly diagnosed multiple myeloma.[34] Off-label uses include Kaposi sarcoma, hemangioendotheliomas, severe aphthous stomatitis (especially in patients with AIDS), psoriasis, and a variety of other dermatologic conditions.[30]

CONTRAINDICATIONS

(See Box 235-6)

INITIATING THERAPY

Thalidomide therapy should be reserved for patients with debilitating, serious diseases that have proven refractory to other therapies. The manufacturer of thalidomide has developed a restricted distribution program called System for Thalidomide Education and Prescribing Safety (S.T.E.P.S.®), which requires both prescribers and dispensing pharmacists to be registered, and it is mandatory for patients to be informed about the program, adhere to its requirements, and demonstrate in writing an understanding of these warnings. Female patients of childbearing potential (defined by the program as sexually mature women who have not undergone a hysterectomy or who have not been postmenopausal for at least 24 consecutive months) must have a negative pregnancy test (with a β-human chorionic gonadotropin sensitivity of at least 50 milliunits/mL) within 24 hours of treatment initiation. Patients must use reliable contraception (two effective methods unless using the abstinence method) for a period of at least 1 month before initiating therapy and must continue this practice during and for 1 month after therapy is completed. Male patients are required to use latex condoms, even in patients who have had a vasectomy.[34]

MONITORING THERAPY

S.T.E.P.S.® requires patient monitoring during therapy. Strict guidelines for pregnancy testing are outlined for males and females of childbearing potential to prevent possible fetal damage. If, during the course of therapy, a patient becomes pregnant, the drug should be stopped immediately and the exposure reported to the FDA and the manufacturer (Celgene; Summit, New Jersey, USA). Patients should then see an obstetrician/gynecologist with experience in reproductive toxicity.[34]

BOX 235-6 CONTRAINDICATIONS OF THALIDOMIDE THERAPY

- Pregnancy class: X
- Hypersensitivity to the drug or its components

BOX 235-7 RISKS AND PRECAUTIONS OF THALIDOMIDE THERAPY

- Hypersensitivity
- Bradycardia
- Stevens-Johnson syndrome and toxic epidermal necrolysis
- Seizures
- Pregnancy category: X

RISKS AND PRECAUTIONS[34]

(See Box 235-7)

COMPLICATIONS

(See Box 235-8)

SIROLIMUS (RAPAMUNE)

(See also Chapter 233)

MECHANISM OF ACTION

Isolated from the bacterium *Streptomyces hygroscopicus*, sirolimus is a macrocyclic lactone antibiotic with immunosuppressant, antifungal, and antineoplastic properties. After forming a complex with FK binding protein-12 (FKB-12), sirolimus acts by inhibiting the interaction of the mammalian target of rapamycin (mTOR) with its substrates; mTOR is a serine-threonine protein kinase activated by several growth factors whose downstream targets affect cell cycle control and angiogenesis in normal and neoplastic cells.[49] Sirolimus has been shown to decrease levels of hypoxia inducible factor-1α (HIF-1α), significantly inhibit VEGF-mediated vascular endothelial cell stimulation, bFGF-induced angiogenesis, and T-cell activation and proliferation.[50] Via suppression of mTOR complex 2, it also inhibits Akt activation.[51] Of the drugs used in the solid organ transplant setting including cyclosporine and tacrolimus, rapamycin has the greatest antiangiogenic activity. To that effect, it may be useful for the prevention of squamous cell carcinoma and lymphoma in the immmunosuppressed, transplant population.

INDICATIONS

Rapamycin is currently approved for prophylaxis against renal transplant rejection, as well as an agent in drug-eluting cardiac stents to prevent restenosis

BOX 235-8 COMPLICATIONS OF THALIDOMIDE THERAPY

- Teratogenicity
  - Thalidomide's embryopathy is well documented. Thalidomide is pregnancy category X, and patients selected for therapy must follow strict contraceptive measures as directed by the program. Thalidomide-induced defects in limb formation may be due to bFGF inhibition, as bFGF has been shown to induce embryologic limb formation.[35]
- Peripheral neuropathy
  - Thalidomide is neurotoxic and may result in a sensory, symmetrical distal polyneuropathy, which may later evolve to include motor symptoms as well. Neurotoxicity can be permanent. Incidence of peripheral neuropathy in patients receiving thalidomide ranges from 0.5%–25.0%. Patients with preexisting peripheral neuropathy should not begin treatment. Baseline nerve conduction studies should be obtained before treatment initiation along with monthly monitoring during the first three months decreasing to 6-month intervals thereafter during treatment. A 40% decrease in nerve conduction necessitates treatment discontinuation.[34]
- Neutropenia
  - Because of the risk of neutropenia, baseline measurements should be obtained (with a white blood cell count with differential) then monitored regularly during the treatment course. Treatment should not be initiated in patients with an absolute neutrophil count (ANC) of less than 750/mm^3.[3,34]
- Other side effects
  - Other side effects include drowsiness, orthostatic hypotension, rash, fever, and increases in human immunodeficiency virus (HIV) viral loads.[34,36]

after coronary artery angioplasty.[52] Off- label uses in dermatology include the treatment of psoriasis, Kaposi sarcoma, tuberous sclerosis, angiofibromatosis, and lymphangioleiomyomatosis.[53–57] There are also case reports of its efficacy in nephrogenic systemic fibrosis (NSF), scleroderma, and dermatomyositis.[58–60] On-going clinical trials are looking into the utility of sirolimus in the prevention of nonmelanoma skin cancer in patients following kidney transplant, that of topical sirolimus in basal cell nevus syndrome (Gorlin-Goltz syndrome), and in combination with pulse dye laser in port wine stain. Other than a history of hypersensitivity to it or other rapamycin derivatives, there are no known contraindications.

COMPLICATIONS

(See Box 235-9)

BOX 235-9 COMPLICATIONS OF SIROLIMUS

- Systemic toxicities
  - Complications that may occur include headache, thrombocytopenia, arthralgia, interstitial pneumonitis, and hypercholesterolemia.[52]
- Cutaneous toxicities
  - Cutaneous side effects of therapy include angioedema, leukocytoclastic vasculitis, xerosis, and aphthous ulceration, which all resolve with discontinuation of therapy.[52,61]
- Increased susceptibility to infections and malignancies[52]

BORTEZOMIB (VELCADE)

MECHANISM OF ACTION

Bortezomib is the first proteasome inhibitor to gain FDA approval. This novel class of drugs acts by impairing the ability of the proteasome to degrade a variety of ubiquitinated proteins. Proteasome inhibitors may promote a proapoptotic state by preventing the degradation of tumor-suppressor proteins, such as p53 and inhibitors of NF-κB. NF-κB upregulates the transcription of genes involved in neoplastic progression including VEGF.[67] Bortezomib also acts directly to inhibit chemotaxis, capillary formation, and transcriptions of VEGF, IL-6, IGF-1, ang-1, and ang-2.[68] Because it has been shown to correlate with NF-κB activity, chemoresistance might also be lessened in the presence of bortezomib.

INDICATIONS

Bortezomib is currently indicated for the treatment of recurrent or refractory multiple myeloma and mantle cell lymphoma.[68] Investigational applications include CTCL, squamous cell carcinoma, and metastatic melanoma.[69]

CONTRAINDICATIONS

- Hypersensitivity to bortezomib, boron, or mannitol[70]

COMPLICATIONS[70]

- Hypotension
- Peripheral neuropathy and RPLS
- ARDS
- Blood dyscracias (neutropenia, thrombocytopenia)
- Fatigue, malaise, and weakness
- CYP3A4 drug metabolism interactions

CORTICOSTEROIDS

(See Chapter 224)

The role of corticosteroids in angiogenesis is a bit of a mixed picture, with neutral, anti-, and proangiogenic effects having been observed in various cases. In the setting of uveal melanoma, El Filali et al demonstrated no significant differences in levels of VEGF, PDGF, or TSP-1 in in-vitro models treated with triamcinolone acetate.[71] In vivo and in vitro models of prostate cancer have shown potentiation of antiangiogenesis by docetaxel when concurrently exposed to dexamethasone as measured by levels of VEGF, IL-8, and chemokine ligand-1 (CXCL-1).[72] Contrastingly, sequential deliveries of dexamethasone followed by VEGF showed an increase in vascularity in a biosensor-model implant into murine subcutaneous fat.[73] Whatever the ultimate mechanism and role, the clinical utility of steroids as anti-inflammatory and antiangiogenic is readily apparent.

BECAPLERMIN (REGRANEX)

(See also Chapter 234)

Chronic wounds have become increasingly prevalent in recent years with the rise in incidence of diabetes and the increasingly aging population. Treatment of these wounds is particularly challenging because normal wound-healing processes have been disrupted.

MECHANISM OF ACTION

Becaplermin [recombinant human platelet-derived growth factor (rhPDGF) BB] is the first FDA-approved angiogenesis-stimulating therapy. Endogenous PDGF is chemotactic for several cell types necessary for wound healing, and is also a mitogen for fibroblasts, the source for extracellular matrix components like glycosaminoglycans and fibronectin. Thus, PDGF is an important factor in the formation of granulation tissue.

INDICATIONS

Becaplermin gel is currently indicated for the treatment of lower extremity, diabetic, neuropathic ulcers. The ulcers must be adequately vascularized and reach at least the subcutaneous tissue.[74,75] Off-label uses include the application of becaplermin to ulcerated hemangiomata, surgical wounds, grafts, and flaps.[77,78,79]

CONTRAINDICATIONS

Becaplermin gel is contraindicated in patients with known cancer in the treatment area or a history of hypersensitivity.[75]

BOX 235-10 RISKS AND PRECAUTIONS OF BECAPLERMIN THERAPY

- Because becaplermin gel is nonsterile, it should not be applied to wounds closed by primary intention.
- An increased rate of mortality due to malignancy has been observed in patients treated with 3 or more tubes of becaplermin gel, and caution should be used in patients with a known history of malingnacy.
- Pregnancy category: C
- The safety and efficacy of becaplermin has not been evaluated in children less than 16 years of age.

DOSING REGIMEN

Becaplermin gel should be applied topically once daily with the dose depending on the size of the lesion; generally, every square inch of ulcer requires 2/3 or 1⅓ inches of gel from a 15-g or 2-g tube, respectively. After application, the area should be covered with a saline-moistened dressing then left in place for approximately 12 hours. The dose should be recalculated every 1–2 weeks to ensure accurate dosing as the wound changes size. Becaplermin gel should be used along with proper ulcer care.[75]

MONITORING THERAPY

If there is less than a 30% decrease in size after 10 weeks or if the wound has not completely healed after 20 weeks of treatment, the treatment plan should be reevaluated.[75]

RISKS AND PRECAUTIONS[75]

(See Box 235-10)

Complications of Becaplermin therapy are rash, hypersensitivity reaction (most often to the paraben or *m*-cresol components) and ulcer-related complications (incidence was similar in becaplermin vs. placebo groups).[75]

KEY REFERENCES

Full reference list available at www.DIGM8.com.

DVD contains references and additional content

10. Million RP: Therapeutic area crossroads: Anti-angiogenesis. *Nature Reviews Drug Discovery* **7**:115-116, 2008
21. Nguyen A: Angiogenesis in cutaneous disease: Part I. *J Am Acad Dermatol* **61**(6):921-942, 2009
30. Rosenbach M, Werth VP: Dermatologic therapeutics: Thalidomide. A practical guide. *Dermatol Ther* **20**: 175-86.
56. Hofbauer GF et al: The mTOR inhibitor rapamycin significantly improves facial angiofibroma lesions in a patient with tuberous sclerosis. *Br J Dermatol* **159**:473-475, 2008

Chapter 236 :: Drug Interactions

:: Stephen E. Wolverton

INTRODUCTION

The topic of drug interactions is strikingly complex and rapidly evolving. Even experts in this area of pharmacology must rely on print and electronic resources pertaining to drug interactions on a regular basis. With these facts in mind, this chapter focuses on a wide variety of principles, with selected drug interactions utilized to illustrate these principles, as opposed to providing extensive lists of potential drug interactions. Furthermore, there will be an attempt to provide a stratification of risk, putting the greatest emphasis on the drug interactions with the greatest risk to individual patients.

DEFINITIONS

The most basic definition of a drug interaction is when two drugs are being administered simultaneously in a patient, and one drug alters the other's serum/tissue levels or mechanism of action. The drug interaction can affect the *efficacy* or increase the likelihood of *adverse effects* from one or both drugs. Furthermore, a drug interaction can occur without clinically evident alteration of efficacy or adverse effects. In contrast, drug interactions which induce either a loss of drug efficacy or new adverse effects are known as *adverse drug interactions*. The topic of drugs interactions is important to physicians in all aspects of medicine regardless if the clinician (a) prescribes the drug "responsible" for a given drug interaction, or (b) the drug previously prescribed by this same clinician is the "victim" of a drug prescribed by another clinician.

PRINT AND ELECTRONIC RESOURCES

In reviewing this chapter, the reader is encouraged to strive for a "recognition recall" level of memory; no one can possibly master and retain all important drug interactions. Through learning key principles that assist in attaining the broadest possible understanding of the multitudes of potential drug interactions, a clinician may best be able to interpret and react to new clinician situations involving potential drug interactions. One should always attempt make things "make sense" using the general principles that follow. It is always acceptable to (1) call a drug information pharmacist, (2) call or e-mail an expert in drug interactions, or (3) look up possible interactions in various print and electronic resources. Selected resources for drug interactions are listed in Table 236-1.

P-GLYCOPROTEIN

The topic of *P*-glycoprotein and the role in drug interactions has been relatively recently documented. *P*-glycoprotein is most common at important points of entry into body or important body structures (gastrointestinal tract, blood brain barrier) as a means to ensure protection against various "toxins". *P*-glycoprotein is important for a number of drugs with highly variable absorption, such as digoxin and cyclosporine. Although the topic is not discussed further in this chapter, the interested reader can find additional information in a review by Shapiro and Shear.[1]

PHARMACOKINETIC AND PHARMACODYNAMIC DRUG INTERACTIONS

DEFINITIONS

All drug interactions can be divided into either *pharmacokinetic* or *pharmacodynamic* interactions, which is true

TABLE 236-1
Databases for Information on Drug Interactions

Database Sources	Format	Additional Information
Indiana University Department of Medicine	Electronic	http://www.drug-interactions.com
E-pocrates	Electronic	http://www.epocrates.com Both PDA and desktop/laptop versions available
The Medical Letter of Drugs and Therapeutics	Print/electronic	Medical Letter Drug Interaction program, http://www.medletter.com
Facts & Comparisons	Electronic	CliniSphere 2.0 CD-ROM
Hansten & Horn's Top 100 Drug Interactions	Print	Textbook: Hansten PD, Horn JR: *The Top 100 Drug Interactions: A Guide to Patient Management*, 2010 edition. Freeland, WA, H&H Publications, LLP, 2010

TABLE 236-2
Pharmacokinetic (PK) Steps Pertaining to Drug Metabolism and Interactions

PK Step	Primary Interactions	Examples
Absorption	Loss of efficacy	Divalent cations and tetracyclines or fluoroquinolones ↑ gastric pH (antacids) and itraconazole or ketoconazole
Distribution	Toxicity	NSAIDs and methotrexate Sulfonamides and methotrexate
Metabolism	Loss of efficacy *and* toxicity	Examples in eTable 236-3.1 in online edition and Tables 236-7 through 236-10
Excretion	Toxicity	Sulfonamides and methotrexate Digoxin and cyclosporine

↑ = increase; NSAIDs = nonsteroidal anti-inflammatory drugs.

regardless of whether they are an *adverse* drug interaction or an interaction without loss of drug efficacy or the onset of new toxicity.[2] Conceptually pharmacokinetics deal with "what the body does to the drug", while pharmacodynamics deals with "what the drug does to the body". In the most basic sense, these definitions relate to the normal pharmacology of a given drugs therapeutic effects, as well as in the clinical setting of drug interactions.

VARIOUS SUBTYPES OF PHARMACOKINETIC DRUG INTERACTIONS

Pharmacokinetic drug interactions are much more common than pharmacodynamic drug interactions. This category of interactions results from alterations in a drug's serum and/or tissue levels. The ADME model (see Sections "Various Subtypes of Pharmacodynamic Interactions" and "Subtypes of Metabolic Drug Interactions") of studying pharmacokinetics pertains to this category of interactions. The steps from entry of the drug into the body until excretion of the drug and/or its metabolites includes (1) *a*bsorption, (2) *d*istribution, (3) *m*etabolism, and (4) *e*xcretion. The importance of each of these steps is detailed elsewhere.[2] Examples of drug interactions involving each of these steps are included in Table 236-2.

VARIOUS SUBTYPES OF PHARMACODYNAMIC INTERACTIONS

Pharmacodynamic drug interactions are much less common than pharmacokinetic drug interactions. This category of interactions deals with alterations in the mechanism of either the desired pharmacologic effect or mechanism for an adverse effect. The drug levels are not of central importance in this category of interactions. The two primary subtypes of interactions include (1) agonist—similar "polarity" of the pharmacologic effects for the two interacting drugs, and (2) antagonist—opposite "polarity" of the pharmacologic effects for the two interacting drugs. Both agonist and antagonist interactions can produce either a positive (improved therapeutic response) or negative (toxicity) biologic response. Selected examples to illustrate this innately confusing terminology are listed in Table 236-3. Conceptually the various aspects of drug pharmacodynamics occur between the "distribution" and "metabolism" steps of the pharmacokinetics sequence. An exception to this principle would be for any prodrug that requires metabolic conversion to the active drug form to generate a pharmacologic response. Two examples would be the conversion of valacyclovir (prodrug) to acyclovir (corresponding active drug) and of famciclovir (prodrug) to penciclovir (corresponding active drug).

TABLE 236-3
Pharmacodynamic Categories of Drug Interactions

Category	Examples	Comments
Agonist interaction—same "polarity" of mechanism		
Positive pharmacologic effect	Prednisone and azathioprine	"Steroid-sparing" effects
Negative pharmacologic effect	Hydroxychloroquine and chloroquine	↑ risk of retinopathy
Antagonist interaction—opposite "polarity" of mechanism		
Positive pharmacologic effect	Methotrexate and folic acid	↓ methotrexate adverse effects
Negative pharmacologic effect	β-blockers[a] and epinephrine[b]	Unopposed α-adrenergic effects, ↑↑ blood pressure

[a]Noncardioselective β-blockers.
[b]Epinephrine at very high doses if very high volumes of lidocaine with epinephrine are utilized during a procedure (very rare).
↑ = increase; ↓ = decrease; ↑↑ = large increase.

SUBTYPES OF METABOLIC DRUG INTERACTIONS

The four steps of the "ADME" model for drug pharmacokinetics all have potential drug interactions, with either loss of efficacy or toxicity. By far the greatest number of important drug interactions occurs at the "metabolism" step. Drugs need to be relatively lipophilic to the entire body and travel to the site(s) of intended pharmacologic effect. Subsequently drugs must be converted to relatively hydrophilic metabolites to be excreted in bile or urine. Only a small fraction of drugs are excreted in their active form.

The body has two categories of drug metabolizing enzymes to accomplish the biotransformation of a relatively lipophilic drug form to a more hydrophilic form in order to facilitate renal or biliary excretion. These categories are phase I and phase II metabolic enzymes. It is important to note that these phases do not necessarily occur in a set sequence from phase I to phase II. Phase I enzymes are primarily cytochrome P-450 (CYP) mixed function oxidative enzymes which typically create a somewhat more polar site of attachment for the subsequent phase II (conjugation) enzymes. Examples of the phase I and phase II enzymes which are of greatest importance to drug interactions are listed in eTable 236-3.1 and eTable 236-3.2 in online edition. Several of these enzymes have polymorphisms of importance to explaining the spectrum of risk between various patients in various ethnic groups.[3]

ISOFORMS OF CYP OF GREATEST IMPORTANCE TO DRUG INTERACTIONS

The importance of cytochrome P-450 (CYP) 3A4 and CYP 2D6 lies in the fact that these isoforms metabolize about 50% and 20%–25% of all drugs, respectively. Due to some overlap of drug substrates that are metabolized by both CYP isoforms, roughly two-thirds of all drugs are metabolized by at least one of these two pathways. Other CYP isoforms of greatest potential importance to drug interactions include CYP 2C9, CYP 2C19, CYP 1A2, and CYP 2E1.

DRUG SUBSTRATES, INHIBITORS, AND INDUCERS

DRUG SUBSTRATES

A substrate is basically a drug in the process of being metabolized to a more water-soluble form (metabolite) to enable excretion. A substrate may "travel" down one or more than one metabolic pathway, including possibly more than one CYP isoform. The metabolic pathway may be either a CYP isoform, a non-CYP pathway (phase II), or both. Furthermore, a substrate may also be an inhibitor or inducer of the drug's metabolic pathway. An example would be cyclosporine, which is both a substrate and inhibitor of CYP 3A4.

Warfarin has both an *S*-enantiomer ("super" warfarin—more potent) and *R*-enantiomer (less potent). The *S*-enantiomer is metabolized predominantly by CYP 2C9, while CYP 3A4 and CYP 1A2 metabolize the *R*-enantiomer. Drug interactions involving the *S*-enantiomer are overall more important because of (a) the greater "potency" of the *S*-enantiomer, and (b) the fact that it is metabolized only by one pathway (thus, no alternative metabolic pathways), should a CYP 2C9 enzyme inhibitor be utilized in the same patient.

Substrates of greatest interest for three of the most important CYP isoforms are listed in Table 236-4. References listed in Table 236-1 can be consulted for more comprehensive lists of CYP isoforms and pertinent drug substrates.

SUBSTRATES WHICH ARE NARROW THERAPEUTIC INDEX DRUGS

A given drug's "therapeutic index" is merely the ratio of the drug dose producing the desired therapeutic response versus the drug dose producing toxicity. A drug with a "narrow" therapeutic index would represent drugs for which the ratio is relatively close to the number "1" regardless of which is the numerator and denominator. Several examples of relatively narrow therapeutic index drugs are listed in Table 236-5.

ENZYME INHIBITORS

An enzyme "inhibitor" is a drug that slows/decreases the rate of metabolism of another drug substrate. Visualizing this process in a traffic analogy, the inhibitor blocks the flow of traffic (drug metabolism) on a shared road (CYP isoform or a phase II metabolic pathway). Drug interactions involving enzyme inhibitors are characterized by three generalizations. The net result is (1) immediate, (2) resultant increased substrate drug levels, and (3) resultant drug toxicity. In these interactions, the risk of toxicity is greatest with narrow therapeutic index drugs such as methotrexate, cyclosporine, and warfarin. In addition, drug substrates with just a single metabolic pathway are at greater risk for toxicity than similar drugs with more than one metabolic pathway. In the above traffic analogy, conceptually the backed up traffic can be diverted to an alternative highway if the substrate can be metabolized by another metabolic pathway (CYP isoform or phase II conjugation enzyme).

Two of the strongest inhibitors of CYP 3A4 are erythromycin (macrolide antibiotic) and ketoconazole (azole antifungal agent). In each of these drug groups, there are alternatives that have little or no inhibitory effect on the CYP isoform involved in the potential drug interaction of interest. Examples of variations of enzyme inhibition within a drug group are listed for inhibitors of CYP 3A4, CYP 2D6, and CYP 2C9 in eTable 236-5.1 in online edition.

TABLE 236-4
Some Important Substrates for Several Important CYP Isoforms

CYP 3A4 Substrates	CYP 2D6 Substrates	CYP 2C9 Substrates
Antibacterial agents	Analgesics	Antibacterial agents
Erythromycin	Codeine	Sulfonamides
Rifampin	Meperidine	Anticoagulants
Anticoagulants	Morphine	*S*-warfarin enantiomer
R-warfarin enantiomer	Antidysrhythmics	Anticonvulsants
Antidysrhythmics	Encainide	Phenytoin
Amiodarone	Flecainide	Valproic acid
Digoxin	Mexelitine	NSAIDs
Lidocaine	Propafenone	Diclofenac
Calcium channel blockers—all	β-Blockers	Ibuprofen
H_1 antihistamines[a]	Metoprolol	Piroxicam
Fexofenadine	Propranolol	Statins
Loratadine	SSRI antidepressants	Fluvastatin
Statins	Fluoxetine	Rosuvastatin
Atorvastatin	Paroxetine	
Lovastatin	Tricyclic antidepressants	
Simvastatin	Amitriptyline	
Hormonal contraceptives	Clomipramine	
Immunosuppressive agents	Desipramine	
Cyclosporine	Doxepin	
Tacrolimus		

[a]Terfenadine and astemizole are 3A4 substrates—have been taken off the market in the United States.
Note: This table is intended to give important examples and is far from comprehensive; for more complete information, consult database of Dr. David Flockhart at Indiana University Department of Medicine (see Table 236-1).
Adapted from Shapiro LE, Shear NH: Drug interactions. In: *Comprehensive Dermatologic Drug Therapy*, 2nd edition, edited by SE Wolverton. London, Elsevier, 2007, p. 949–975

ENZYME INDUCERS

An enzyme "inducer" is a drug that speeds up the metabolism of a drug substrate. The inducer facilitates traffic on the "highway" (metabolic pathway) for drug metabolism. The generalizations involving enzyme inducers result in (1) delayed effects, (2) lowered drug levels, and (3) loss of drug efficacy. Drug interactions involving enzyme induction are delayed somewhat (typically up to a week or more) because they require synthesis of new protein (most notably a synthesis of a given CYP isoform). Conceptually from a traffic analogy standpoint, this synthesis would equate to creating a new lane that once opened would facilitate more rapid and efficient transport of vehicles (drug substrates).

Most CYP enzyme inducers affect more than one CYP isoform. Some of the strongest enzyme inducers include rifampin and the aromatic anticonvulsants phenytoin, phenobarbital, and carbamazepine. Griseofulvin is also

TABLE 236-5
Selected Narrow Therapeutic Index Drugs

Category	Drug Name	CYP Isoform	Most Important Acute Toxicities
Anticoagulants	Warfarin	2C9, 3A4, 1A2	Hemorrhage (thrombosis if warfarin effect inhibited)
Antidepressants	Doxepin[a]	2D6	Excessive sedation, tachyarrhythmias
Bronchodilators	Theophylline	1A2	Central nervous system toxicity
Immunosuppressive agents	Cyclosporine Methotrexate	3A4 None[b]	Renal toxicity, hypertension, hyperlipidemia Pancytopenia, liver toxicity
Inotropic agents	Digoxin	3A4	Cardiac tachyarrhythmias, atrioventricular block

[a]Overall doxepin is the "safest" drug on this list; however, in the presence of strong CYP 2D6 inhibitors, CNS and cardiac toxicity is an important issue.
[b]As opposed to CYP inhibition with other drugs above, the greatest risk of methotrexate toxicity is with concomitant use of drugs such as trimethoprim (dihydrofolate reductase inhibitor) and sulfamethoxazole (dihydropteroate synthetase inhibitor), which also inhibit enzymes important to folate metabolism.

TABLE 236-6
Clinical Scenarios in Which Enzyme Inducers Lead to Loss of Efficacy

Substrate	Enzyme Inducer	CYP Isoform	Clinical Result
Warfarin	Rifampin[a]	3A4	Thrombosis if significant loss of anticoagulant effect
Hormonal contraceptives	Rifampin[a] Griseofulvin	3A4 3A4	Possible unintended pregnancy Possible unintended pregnancy
Cyclosporine, tacrolimus	Rifampin[a]	3A4	Loss of organ transplanted (graft)

CYP = cytochrome P-450
[a]Given that enzyme induction generally takes a week or more to reach clinical significance, a 7–10 day course of rifampin (as commonly prescribed for community-acquired MRSA may fall short of the time period for maximal risk; however, appropriate caution (ideally avoid coprescribing) is required in these clinical settings.
Note: The drugs listed in this table are drugs that are commonly prescribed by dermatologists; the aromatic anticonvulsants—carbamazepine, phenobarbital, and phenytoin, and several other drugs are also important enzyme inducers.

an enzyme inducer, albeit a relatively weak inducer. Some clinical scenarios pertinent to dermatology of enzyme induction of significant importance are listed in Table 236-6.

GENETIC POLYMORPHISMS[3]

The term "polymorphism" as it pertains to drug metabolism merely represents a mutation in a phase I or phase II enzyme that results in clinical importance differences of enzyme activity compared to normal. Conceptually "variability" results in a unimodal distribution (a single bell-shaped curve), whereas a genetic polymorphism creates a bimodal distribution (at least two bell-shaped curves) when putting enzyme activity on a graph. Clinically significant polymorphisms involving drug metabolizing enzymes most notably include both phase I enzymes (CYP 2D6 and CYP 2C9) and phase II enzymes (*N*-acetyl transferase 2 and thiopurine methyltransferase). These polymorphisms can result in (1) drug interactions, (2) altered metabolism of a drug used as monotherapy, (3) cutaneous drug reactions or (4) systemic drug interactions. Table 236-7 summarizes examples of the clinical outcomes in these three categories from the above four drug metabolic enzyme polymorphisms.

CLINICAL SCENARIOS

VARYING RISK OF INDIVIDUAL DRUG INTERACTIONS

Not all drug interactions are "adverse" drug interactions; these pharmacokinetic and pharmacodynamic interactions do not result in an adequate change in drug levels or mechanisms of action to have clinical importance. Furthermore, only a small percentage of drug interactions have a life-threatening potential. At the conclusion of the chapter, twelve of the most potentially serious drug interactions pertinent to dermatology are highlighted. In between these two extremes is where the majority of drug interactions exist. In these clinical settings, the clinician has a great deal of flexibility concerning therapeutic choices. From these three categories, one can derive one additional traffic analogy:

TABLE 236-7
Clinical Relevance of Drug Metabolism Enzyme Polymorphisms

Polymorphism	Specific Drug	Drug Interaction	Monotherapy Result	Drug Reaction
Phase I enzymes				
CYP 2D6	Doxepin	Paroxetine, fluoxetine (↑ severity in IM, PM)	Toxicity (sedation) PM Loss of efficacy EM, URM	*None*
CYP 2C9	Warfarin	Fluconazole	Toxicity (hemorrhage) PM Loss efficacy (thrombosis) URM	*None*
Phase II enzymes				
N-acetyl transferase-2	Isoniazid	*None*	*None*	Drug-induced lupus erythematosus
Thiopurine methyltransferase	Azathioprine	Allopurinol (↑ risk in IM, PM)	Toxicity (pancytopenia) IM, PM Loss of efficacy EM	*None*

↑ = increase; CYP = cytochrome P-450; URM = ultrarapid metabolizer; EM = extensive metabolizer; IM = intermediate metabolizer; PM = poor metabolizer.

- Adverse drug interactions with life-threatening potential (*red* light)—do *not* proceed (e.g., fluconazole and warfarin; the clinician must choose an alternative antifungal agent such as itraconazole or terbinafine).
- Adverse drug interactions of clinical importance, but not life threatening (*yellow* light)—proceed with caution [see examples in Section "Therapeutic Options with "Proceed with Caution" (Yellow Light) Clinical Scenario"].
- Other drug interactions of no clinical risk due to minor effect of "interaction" on drug levels or mechanisms of action (*green* light)—can proceed with the drug combination and can reassure the patient.

THERAPEUTIC OPTIONS WITH "PROCEED WITH CAUTION" (YELLOW LIGHT) CLINICAL SCENARIO

Typically, there is substantial latitude concerning these clinical scenarios. The clinician may choose to avoid the drug combination altogether if there are suitable drug alternatives or if the disease being treated presents minimal risk to the patient. Alternatively, the clinician may choose one or several of the following options: (1) lower the drug dose—azathioprine and allopurinol, for which a 75% reduction of azathioprine dose is recommended, (2) monitor closely from a clinical standpoint—doxepin and an SSRI antidepressant such as paroxetine or fluoxetine, following the level of sedation closely, and/or (3) appropriate laboratory testing—can order an AM doxepin serum levels when the drug is administered with CYP 2D6 inhibitors such as paroxetine or fluoxetine. Concerning the doxepin/SSRI interaction described above, the clinician may choose to use an SSRI antidepressant alternative that does not inhibit the CYP 2D6 pathway (e.g., citalopram, escitalopram, or sertraline). From a proactive standpoint, baseline genetic testing of either the CYP 2D6 and CYP 2C19 polymorphisms are readily available. This genetic testing may determine in advance the rate of metabolism by the specific CYP isoform in that individual. Possibilities with genetic testing include the following (listed in descending order from the most rapid to the slowest rate of drug metabolism):

- Ultrarapid metabolizer (URM)—uncommon, may involve gene "duplication".
- Extensive metabolizer (EM)—most common subset, homozygous for the "wild type" (full metabolic activity) gene.
- Intermediate metabolizer (IM)—relatively frequent, heterozygous for the "wild type" gene.
- Poor metabolizer (PM)—also uncommon, homozygous for the gene mutation (low/absent metabolic activity).

Some additional examples of the "proceed with caution" scenarios illustrating these therapeutic options are listed in Table 236-8.

TABLE 236-8
Options with "Proceed with Caution" Type of Drug Interactions

Clinical Option[a]	Examples
Clinical Scenario: want to prescribe doxepin for pruritus in patient on either paroxetine or fluoxetine	
Clinical monitoring	Watch closely for sedation
Laboratory monitoring	Order an AM doxepin level
Lower drug dose	Dose doxepin very conservatively
Alternative drugs to prescribe	Have primary physician switch to an alternative SSRI antidepressant or a nonselective reuptake inhibitor antidepressant *or* could prescribe hydroxyzine, cetirizine, etc.
Baseline genetic testing	Could order base CYP 2D6 genotype testing to see if patient a poor metabolizer
Clinical Scenario: want to prescribe erythromycin for acne to a patient on simvastatin	
Clinical monitoring	Could monitor for muscle pain or weakness (by itself, never an option)
Laboratory monitoring	Monitor muscle enzymes (CPK, aldolase)
Lower drug dose	Lower dose of either erythromycin or simvastatin
Alternative drugs to prescribe	Azithromycin, a suitable macrolide *or* prescribe an alternative antibiotic group; also request primary physician to consider fluvastatin, rosuvastatin, pravastatin
Clinical Scenario: want to prescribe itraconazole for extensive tinea corporis to a patient on warfarin[b]	
Clinical monitoring	Could monitor for bruising/hemorrhage elsewhere (by itself, never a viable option)
Laboratory monitoring	Follow INR values very closely
Lower drug dose	Lower dose of either the itraconazole or warfarin (through primary physician)
Alternative drugs to prescribe	Terbinafine and topical antifungals are primary alternatives

[a]In each clinical scenario, more than one option may be undertaken simultaneously.
[b]With patients on warfarin, for whom clinicians wish to give fluconazole these "proceed with caution" options are not pertinent; fluconazole and warfarin is a "red light" scenario in which coprescribing these drugs must be totally avoided.

TABLE 236-9
A Dozen Critical Drug Interactions

Number	Specific Toxicity	Category		CYP	Substrates	Precipitant Drugs
1.	Torsades de pointes	PK	Tox	3A4	Terfenadine, astemizole, cisapride	Erythromycin, ketoconazole, itraconazole
2.	Pancytopenia	PK	Tox	—	Methotrexate	Trimethoprim/sulfamethoxazole
3.	Agranulocytosis	PK	Tox	—	Azathioprine	Allopurinol
4.	Hemorrhage	PK	Tox	2C9	Warfarin	Fluconazole
5.	Thrombosis/embolism	PK	LOE	3A4	Warfarin	Rifampin, Rifabutin
6.	Sedation	PK	Tox	2D6	Doxepin	Fluoxetine, paroxetine
7.	Sedation	PD	Tox	—	Doxepin	H_1 antihistamines – sedating
8.	Renal failure/rhabdomyolysis	PK	Tox	3A4	Cerivastatin	Gemfibrozil (and other 3A4 inhibitors)
9.	Renal toxicity	PK	Tox	3A4	Cyclosporine	Erythromycin, clarithromycin, ketoconazole, itraconazole
10.	Renal toxicity	PD	Tox	—	Cyclosporine	Gentamicin (and other potentially renal toxic drugs)
11.	Liver toxicity	PD	Tox	—	Methotrexate	Acitretin (previously etretinate)
12.	Loss of transplanted organ	PK	LOE	3A4	Cyclosporine	Rifampin, rifabutin

CYP = cytochrome P-450; PK = pharmacokinetic; PD = pharmacodynamic; Tox = toxicity; LOE = loss of efficacy.
Note: These critical drug interactions are listed roughly in descending order of risk.

LESSONS TO BE LEARNED FROM DRUGS TAKEN OFF THE MARKET

There are some important lessons to be learned from drugs interactions that produced life-threatening risk, which led to several drugs being taken off the market. Two issues are worth highlighting concerning the drug interactions, which led to drug removal. In both cases, a known CYP enzyme inhibitor (CYP 3A4 inhibitors) was commonly coprescribed with a CYP 3A4 drug substrate with a narrow therapeutic index. Secondly, in each case, the US Food and Drug Administration published warnings in the form of "Dear Doctor" letters (subsequently known as "Dear Health Care Professional" letters) that in retrospect did not bring about an adequate change of clinician prescribing habits to warrant drug continuation. Several of the potentially life-threatening drug interactions leading to drug withdrawal include the following:

- H_1 antihistamines terfenadine and astemizole—a form of ventricular tachycardia (torsades de pointes) seen with (strong CYP 3A4 inhibitors erythromycin or ketoconazole commonly coprescribed with these drugs).
- HMG CoA reductase inhibitor cerivastatin (a "statin")—rhabdomyolysis (a strong CYP 3A4 inhibitor gemfibrozil commonly coprescribed with this drug).

CONCLUSION: A DOZEN DRUG INTERACTIONS OF IMPORTANCE TO PRACTICING DERMATOLOGISTS

There are numerous potential drug interactions for the clinician to consider. When trying to pick a starting point to understand adverse drug interactions, it is logical to start with the most potentially serious drug interactions. With this principle in mind, I have compiled a list of a dozen drug interactions which are potentially serious, and thus, of great importance to practicing dermatologists and other clinicians utilizing these drugs (Table 236-9).

With proper awareness of drugs for which potential interactions need to be considered and regular usage of drug interaction databases, clinicians can reduce the incidence of adverse drug interactions. Patient education is likewise essential to minimizing this risk. In the vast majority of cases, a less risky therapeutic alternative is typically available if the print/electronic resources indicate a potential drug interaction. Finally, when in doubt, do not prescribe the drug or drugs in question until a definitive answer on the safety of coprescribing the medications in question can be answered.

SECTION 38

Physical Treatments

Chapter 237 :: Phototherapy

:: Jennifer A. Cafardi, Brian P. Pollack, & Craig A. Elmets

PHOTOTHERAPY AT A GLANCE

- Phototherapeutic devices have varying properties with respect to depth of UV penetration into the skin, effects on cells and molecules, potency, side effects and diseases in which they are most effective.
- In use today are narrowband and broadband UVB, UVA as part of psoralen photochemotherapy (PUVA), UVA1 and targeted phototherapy (excimer lasers and nonlaser monochromatic excimer light sources).
- Narrowband UVB is currently preferred to treat psoriasis, other inflammatory skin diseases, and vitiligo.
- Psoralen-UVA photochemotherapy (PUVA) combines oral or topical psoralen compounds with UVA light sources. Its main uses are treatment of cutaneous T-cell lymphoma, vitiligo, and psoriasis that is resistant to narrowband UVB.
- UVA1 phototherapy is particularly effective for sclerotic skin diseases such as localized scleroderma, acute flares of atopic dermatitis and urticaria pigmentosa.
- Targeted phototherapy allowing relatively high UV doses to be delivered to diseased skin while sparing normal skin.

Diseases amenable to phototherapy include psoriasis, atopic dermatitis, cutaneous T-cell lymphoma, vitiligo, localized and systemic scleroderma, pruritus, photodermatoses, lichen planus, pityriasis lichenoides, urticaria pigmentosa and granuloma annulare.

Phototherapy is the use of ultraviolet radiation or visible light for therapeutic purposes. Its beneficial effects in vitiligo were first recognized thousands of years ago in India and Egypt, and its activity is now well established for a variety of other dermatologic conditions. The enduring appeal of phototherapy is based on its relative safety coupled with an ongoing interest in its molecular and biological effects. The manufacture of light sources that emit selective wavelengths of radiant energy, identification of photosensitizers with unique photochemical properties, and the development of novel methods for the delivery of light to cutaneous and noncutaneous surfaces have all contributed to its expanded use for dermatologic and nondermatologic conditions. Aside from lasers, high output incoherent light sources, and visible light sources employed for photodynamic therapy, the main phototherapic devices that are in use today are broadband UVB (BB-UVB), narrowband UVB (NB-UVB), UVA1, and UVA for psoralen photochemotherapy (PUVA). Ideally, devices used for therapeutic ultraviolet radiation (UVR) should do so in a safe, efficient and cost-effective manner. Understanding the basic principles of these devices is important for dermatologists and other providers utilizing phototherapy for the management of dermatologic diseases.[1–2]

MECHANISMS OF PHOTOTHERAPY

The different wavelengths of ultraviolet radiation used for phototherapy each have distinct photochemical and photobiologic properties, which include differences in depth of penetration and the range of molecules in the skin with which they interact. As a consequence, each form of phototherapy has unique properties with respect to potency, side effects, and diseases in which they are effective.

Most UVB radiation (290–320 nm) is absorbed by the epidermis and superficial dermis.[3] This form of radiant energy produces many different types of DNA damage[4]; however, pyrimidine dimers and 6,4 pyrimidine-pyrimidone photoproducts are thought to be particularly important for both its efficacy and its toxicity. UVB also causes photochemical changes in *trans*-urocanic acid, converting it to the *cis*-form of the molecule. Urocanic acid is a breakdown product

of histidine and is present in large amounts in the stratum corneum. Originally considered to be a natural photoprotectant, there is now a substantial evidence that *cis*-urocanic acid is a mediator of the UVB-induced immunosuppression.[5] A third direct target of UVB radiation is the amino acid tryptophan. UVB converts tryptophan into 6-formylindolo[3,2-*b*]carbazole (FICZ), which binds to the intracellular arylhydrocarbon hydroxylase (Ah) receptor, initiating a series of events that culminates in activation of signal transduction pathways. One such pathway results in expression of cyclooxygenase-2, an enzyme required for synthesis of prostaglandin E_2.[6] Finally, there is evidence that UVB exposure leads to the generation of reactive oxygen intermediates, which has downstream effects such as DNA damage in the form of 8-oxo-deoxyguanosine, lipid peroxidation, activation of signal transduction pathways and stimulation of cytokine production.[7]

In contrast to UVB radiation, which has a relatively superficial depth of penetration, UVA radiation (320–400 nm) can reach the mid- or lower dermis.[3] It is therefore more effective than UVB for skin diseases in which the cutaneous pathology lies deeper than the superficial dermis. Like UVB, UVA radiation can produce pyrimidine dimers in DNA, but, on a per photon basis, it is much less effective at doing so.[8] In most situations, the major biological effects of UVA radiation are due to the generation of reactive oxygen intermediates.[9] Following UVA exposure, reactive oxygen intermediates are formed in mitochondrial enzyme complexes during oxidative phosphorylation. Although the skin contains antioxidants, reactive oxygen intermediates formed during phototherapy exceed the amount that can be neutralized by endogenous photoprotective activities. UVA-induced oxidants are capable of harming DNA, lipids, structural and nonstructural proteins and organelles such as mitochondria. The generation of oxidants following UV exposure has been implicated in photoaging of the skin and skin cancer.

In psoralen photochemotherapy, psoralen photosensitizers are activated by UVA radiation, and the depth of penetration of PUVA is the mid-dermis. The major photochemical effect of psoralen photochemotherapy is damage to DNA. The changes in DNA differ from those of UVB and UVA without psoralens.[10] Psoralens used for photochemotherapy have two double bonds that can absorb UVA radiation. When administered to an individual, these compounds intercalate with DNA. Following UVA exposure, they form a single adduct with DNA and then become a bifunctional adduct, cross-linking the DNA strands in the double helix when a second photon is absorbed. There is also some evidence that photochemotherapy augments the production of reactive oxygen intermediates such as singlet oxygen. This effect has been implicated in induction of the cyclooxygenase enzyme and activation of arachidonic acid pathways.[11]

EFFECTS ON THE IMMUNE SYSTEM

(See also Chapter 90)

The photoimmunological effects of phototherapy are thought to provide an explanation, at least in part, for its efficacy in cutaneous diseases in which T-cell hyperactivity predominates (e.g., psoriasis, atopic dermatitis, lichen planus). Under normal circumstances, both effector and regulatory T-cells are generated, with the overall intensity of the immune response dependent on the relative proportion of effector and regulatory T-cells populations that are present. UVB exposure inhibits activation of effector T-cells, whereas it leaves formation regulatory T-cells unaltered.[12] As a result, the equilibrium of effector and regulatory T-cells is biased toward a diminished cell-mediated immune response. This perturbation in the balance of effector and regulatory T-cells reflects disruption of the activities of dendritic cells within the skin, the major function of which is to present antigen to T-lymphocytes. This is due to direct effects of UVB on dendritic cells and indirectly through the production of IL-10 and prostaglandin E_2, both of which have been shown to diminish the capacity of dendritic cells to present antigen to effector T-cells and to suppress T-cell responses.[13] Increased levels of IL-10 have been found after UVB, UVA1, and PUVA exposure. PGE_2 production occurs through UVB effects on keratinocytes[14–16]; UVB is an inductive stimulus for cyclooxygenase-2, which is important for PGE_2 production. Other immunosuppressive soluble mediators that have been reported to be increased following UVB exposure including agonists of the platelet-activating factor receptor,[17] MSH, and calcitonin gene-related peptide.[18]

PUVA has effects that are similar to UVB with respect to antigen presenting cells within the skin, the balance between effector and regulatory T-cells, and the production of soluble immunosuppressive mediators.[12] There is limited information on the effect of UVA1 on antigen presenting cells and on effector and regulatory T-cells.

In addition to its actions on cutaneous antigen presenting cells, phototherapy causes cell death by apoptosis in T-cells present in cutaneous lymphoid infiltrates. This has been demonstrated for UVA1 phototherapy in the lymphocytic infiltrate in atopic dermatitis,[19] and for narrowband UVB in psoriasis.[20]

Another immunological effect of phototherapy is on expression of ICAM-1 (CD54) and other adhesion molecules. ICAM-1 is not normally present on epidermal keratinocytes, but can be induced in a variety of inflammatory skin conditions. It facilitates T-cell binding to keratinocytes, through its interaction with LFA-1 that is present on T-cells. UVB, UVA1, and PUVA have all been shown to interfere with keratinocyte expression of ICAM-1, and this effect of phototherapy may therefore contribute to its efficacy in diseases, which have increased keratinocyte ICAM-1 expression.[12]

EFFECTS ON MAST CELLS

Both UVA1 and PUVA have deleterious effects on mast cells, although the mechanisms of action differ.[21–22] PUVA is not cytotoxic for mast cells, and because of this the reduction in mast cell concentrations in the dermis of PUVA-treated skin is relatively small. However, it does stabilize mast cell membranes and in so

doing limits the release of histamine and other mediators when these cells are stimulated to degranulate.[22] In contrast, chronic therapy with UVA1 results in apoptosis of mast cells with a marked reduction in their concentrations in the dermis, which can last for several months.[20] Both PUVA and UVA1 have been employed to treat selective mast cell–mediated diseases.

EFFECTS ON COLLAGEN

One of the downstream effects of UVA-induced generation of reactive oxygen intermediates is activation of matrix metalloproteinase-1 (MMP-1),[23–24] the major biologic activity of which is degradation of collagen. UVA radiation also increases the production of IL-1 and IL-6, which are stimuli for MMPs.[25] PUVA has also been shown to increase MMPs.[26] These effects of UVA1 and PUVA on MMP-1 and collagen degradation provide the rationale for its use in sclerotic skin diseases.

EFFECTS ON THE EPIDERMIS (KERATINOCYTES)

UVB, PUVA, and UVA all cause acanthosis of the epidermis and thickening of the stratum corneum.[27] This effect accentuates light scattering and increases its absorption by the upper levels of the epidermis. As a consequence, phototherapy treatment doses must be progressively increased so that an equivalent number of photons can reach the lower levels of the epidermis and dermis where therapeutic targets lie. On the other hand, this attribute of phototherapy has been exploited for the management of chronic photosensitivity disorders because this "hardens" the skin, permitting individuals afflicted with these disorders to tolerate greater amounts of sun exposure.

EFFECTS ON MELANOCYTES

Exposure to ultraviolet radiation is also known to stimulate melanogenesis,[28] which is at least in part a consequence of DNA damage and/or its repair.[29–32] Experimental studies have shown that treatment of melanocytes with DNA repair enzymes increases the melanin content of melanocytes,[33] and application of small fragments of thymidine dinucleotides to guinea pig skin produces a tanning response.[30–32] The stimulatory effects on melanogenesis increase the tolerance of patients with some photosensitivity disorders to ambient sun exposure, but also decrease the efficacy of phototherapy unless the doses of ultraviolet radiation are gradually increased.

Narrowband UVB and PUVA are also employed to repopulate vitiliginous skin with melanocytes. The mechanism by which phototherapy stimulates repigmentation of vitiliginous skin is incompletely understood, but may involve stimulation of hair follicle melanocyte proliferation and migration.[34] Cytokines and other inflammatory mediators released from other cells, such as keratinocytes, are thought to stimulate inactive melanocytes in the outer root sheath of hair follicles to proliferate, mature, and migrate to repopulate the interfollicular epidermis.[35]

PHOTOTHERAPY APPARATUSES

In the ideal situation, the wavelengths that are most effective for the treatment (i.e., the action spectrum) for every dermatologic condition would be known and there would be a device capable of delivering those wavelengths specifically to lesional skin. For some skin diseases such as psoriasis, great strides have been made toward this ideal and targeted therapy using devices such as excimer lasers[36] and nonlaser devices known as monochromatic excimer light (MEL) devices[37] that can deliver wavelengths of UVR at or close to those that are most effective at clearing psoriatic plaques have been evaluated and are being used clinically. Unfortunately, for most dermatologic conditions this information is unknown. However, the increased availability of improved phototherapy devices and novel treatment approaches are providing new options for patients and clinicians. In addition, as more studies are conducted utilizing phototherapy devices, a better understanding of how best to use older technologies is being obtained.

BASIC PRINCIPLES OF PHOTOTHERAPY DEVICES AND TYPES OF LAMPS

Phototherapy devices generate light by the conversion of electrical energy into electromagnetic energy. Filters and fluorophores are used to modify the output such that the desired wavelengths are emitted. There are several types of lamps (or bulbs) used to generate therapeutic UVR. These include incandescent lamps, arc lamps, and fluorescent lamps.

Incandescent lamps generate UVR by passing an electric current through a thin tungsten filament, which, in turn, generates heat and light. Because much of the electrical energy is converted to heat, these lamps are relatively inefficient light sources and have relatively short life spans. By sealing the tungsten filament in a quartz envelope that contains a halogen (bromine or iodine), the filament can be made to emit more energetic photons without reducing the longevity of the bulb. These lamps are called quartz halogen lamps and can emit wavelengths within the UV, visible, and IR ranges. In clinical dermatology, these lamps are employed primarily for situations such as phototesting and photodynamic therapy that require visible light.

Arc or gas discharge lamps were the first effective artificial sources of UVR. Arc lamps take advantage of the fact that when a high voltage is passed across two electrodes in the presence of a gas, the electrons of the gas atoms become excited. The *arc* of an arc lamp refers to the electric arc generated when the gas is ionized (ionized gas is also known as *plasma*) by a high electric current. When the gas electrons return to their ground state, light is emitted. The type of gas incorporated into the lamp determines the wavelengths

that are emitted (i.e., spectral output). The output of arc lamps can be modulated by altering the gas pressure within the bulb such that at high pressures, the peak wavelength output broadens. High-pressure arc lamps typically contain mercury or xenon gas whereas low-pressure arc lamps utilize fluorescent material. In addition to altering the gas pressure to modify the spectral output of arc discharge lamps, the addition of metal halides broadens the output spectrum such that it becomes nearly continuous across the UV spectrum. For example, when mercury arc lamps are operated at high pressures, they have output emission peaks (so called mercury lines) seen at 297, 302, 313, 334, and 365 nm. In contrast, if a metal halide is added to the mercury, the output between these peaks is increased and is thus more continuous. The use of optical filters can then further refine the output of these lamps such that only the desired wavelengths are emitted. The advantage of metal halide lamps is the high output, which allows for shorter treatment times. However, they are more costly and more difficult to operate than fluorescent lamps. One example of a metal halide lamp currently in clinical use is the UVA1 light source.

Fluorescent lamps are the most commonly used sources of therapeutic UV light. These lamps take advantage of the fact that chemicals called *phosphors* (a specific type of chromophore also called a *fluorophore*) absorb and then reemit light. The light that is reemitted is of lower energy (and thus longer wavelength) than the inciting light. Using this principle, the UVC irradiation (that peaks at 254 nm) generated from a low-pressure mercury lamp can be converted to the longer UVB and UVA wavelengths of light that are desirable for phototherapy. The final output of a fluorescent lamp is dictated by the specific phosphor of the bulb. An important advance in photodermatology came with the development of a modified fluorescent lamp that emits largely at 311 nm.[38] Broadband UVB and UVA light sources used for PUVA are other examples of fluorescent lamps.

Because different forms of phototherapy are used to treat different diseases, it is important and practical to divide devices based upon wavelength. Devices to deliver broadband UVB (BB-UVB), 311-nm narrowband UVB (NB-UVB), UVA (for use in psoralen photochemotherapy), and UVA1 (340–400 nm) are available in the United States and in most other countries. In addition to differing by spectral output, phototherapy devices range in the surface area that they are designed to treat (whole body, localized regions, or only lesional skin). Devices used for large body surface areas resemble booths (which patients enter for each treatment). These devices come in a variety of styles from round cylinders to folding units that can be unfolded for treatments and then collapsed while not in use. Devices have been developed to treat more limited areas (such as the palms and soles) and as such they are substantially smaller in size. Finally, targeted therapy utilizes devices that can deliver therapeutic ultraviolet radiation only to lesional skin and range in size from small handheld units to devices with a handheld wand attached to a larger UVR-generating component.

BROADBAND UVB AND NARROWBAND UVB

Originally used for psoriasis therapy, artificial sources of broadband UVB (BB-UVB) have been used therapeutically since the early twentieth century. In particular, UVB combined with the topical application of coal tar (as developed initially by William Goeckerman) was a mainstay of psoriasis treatment for many decades.[39] More recently, with the development and availability of narrowband UVB, some dermatologists have concluded that BB-UVB is obsolete.[40] However, BB-UVB is still widely used in the United States for a variety of conditions including psoriasis, atopic dermatitis, prurigo nodularis, and uremic pruritus.[36] In addition, some patients who are unable to tolerate NB-UVB will respond to BB-UVB.[36]

The most commonly employed devices that deliver BB-UVB utilize fluorescent lamps. These devices emit UVR over a broad spectral range. Approximately, two-thirds of the output is in the UVB range and the rest is primarily in the UVA. However, because wavelengths within the UVB have nearly much more energy than wavelengths within the UVA, the UVA emitted contributes little to the therapeutic efficacy, assuming the patient is not taking a photosensitizing medication. BB-UVB and NB-UVB have been specifically designed to limit output below <290 nm (i.e., in the UVC range).

The wavelengths that most efficiently clear psoriasis are approximately 313 nm.[41] In contrast, wavelengths less than 300 nm are the most efficient at causing erythema and nonmelanoma skin cancer. Based on this knowledge, light sources, termed narrowband UVB (NB-UVB), have been produced.[38] These light sources emit only wavelengths between 308 and 313 nm, and have largely supplanted BB-UVB UV radiation sources for phototherapy. Although originally used to treat psoriasis, they have now been used to treat a number of other inflammatory skin diseases as well.

The initial starting dose of both broadband and narrowband UVB is determined in one of two ways (Tables 237-1 and 237-2). In the first, the minimal erythema dose (MED) is determined by exposing 6 one cm^2 areas of skin on the inner aspect of the forearm or lower back to gradually increasing amounts of UV radiation from the same device that will be used for phototherapy. Twenty-four hours later, the UV exposed areas of skin are examined and the smallest UV dose that results in uniform erythema over the entire area, considered the MED, and phototherapy is initiated at 50% to 70% of that amount. Alternatively, the initial dose of phototherapy is established based empirically on Fitzpatrick skin phototype[42] (see Tables 237-1 and 237-2). Subsequent exposures are given 2–5 times per week and the dose is increased at each treatment, assuming the patient has not developed an erythema response. If an erythema response has occurred, then, depending on its severity, the dose is either reduced or the treatment is delayed (see Tables 237-1 and 237-2). The maximum NB-UVB dose that should be administered is 2,000–5,000 mJ/cm^2 depending on the photoreactive skin type. If patients miss treatments, dosage

TABLE 237-1
Narrowband UVB Phototherapy[a]

I. MED-based
  A. MED determination
    Expose 1-cm^2 areas on the lower back or inner aspect of the forearm to 200, 400, 600, 800, 1,000, 1,200 mJ/cm^2; read at 24 h
  B. Initial exposure: 50%–70% of MED
  C. Subsequent exposures: 2–5 times per week
    Increase UV dose by 10%–20% with each treatment
II. Fitzpatrick skin phototype–based
  Initial exposure based on Fitzpatrick skin phototype; subsequent exposures as above

Fitzpatrick Skin Phototype	Initial NB-UVB Dose (mJ/cm^2)	Maximum Dose (mJ/cm^2)
I	130	2,000
II	220	2,000
III	260	3,000
IV	330	3,000
V	350	5,000
VI	400	5,000

[a]Modified from references 1, 330, and 331.

modifications should be made to avoid burns (see Table 237-5).

PUVA

Psoralen-UVA photochemotherapy (known by the acronym PUVA) combines the oral ingestion or topical application of psoralens with exposure to UVR in the UVA range. Although psoralens and sunlight had been employed for thousands of years for the treatment of vitiligo, it was not until 1947 that PUVA in its modern form was described, initially for the treatment of vitiligo, and subsequently for the treatment of psoriasis.[43]

Three forms of psoralen are used in photochemotherapy regimens: 8-methoxypsoralen (8-MOP), 5-methoxypsoralen (5-MOP), and 4,5′,8-trimethylpsoralen (TMP). In the United States, only 8-methoxypsoralen is available. There are two oral formulations of 8-MOP, a micronized form which is typically given at a dose of 0.6 mg/kg 120 minutes prior to UVA exposure or a dissolved form which is given at a dose of 0.4–0.6 mg/kg 90 minutes before UVA exposure. The dissolved preparation is absorbed faster and yields higher and more reproducible serum levels and is therefore more commonly employed as a part of PUVA phototherapy regimens.

The most common sources of radiation for PUVA therapy are UVA fluorescent lamps, which have a maximum emission at 352 nm, near the absorption maximum for psoralens. For oral PUVA therapy, UVA radiation is usually initiated at a dose that corresponds to the 50%–70% of the minimum phototoxic dose (MPD) or according to the Fitzpatrick skin phototype (Table 237-3). The MPD is determined by having the patient take the dose of the oral psoralen to be used for the photochemotherapy treatment and exposing 6 one-cm^2 areas of skin to gradually increasing doses of UVA. The MPD is evaluated 72 hours after UVA exposure and is the lowest amount of UVA that produces a uniform erythema over the entire area. In the United States, it is more common to initiate therapy based on the Fitzpatrick skin phototype (see Table 237-3). Treatments are usually given 2–4 times per week, avoiding consecutive days. The amount of UVA that is to be given is increased with each treatment. UVA dose

TABLE 237-2
Broadband UVB Phototherapy[a]

I. MED-based
  A. MED determination
    Expose 1-cm^2 areas on the lower back or inner aspect of the forearm to 20, 40, 60, 80, 100, 120 mJ/cm^2; read at 24 h
  B. Initial exposure: 50%–70% of MED
  C. Subsequent exposures: 2–5 times per week
    Increase UV dose by 25% with each treatment for the first 10 treatments; 10% per treatment thereafter
II. Fitzpatrick Skin Phototype–based
  Initial exposure based on Fitzpatrick skin phototype; subsequent exposures as above

Fitzpatrick Skin Phototype	Initial NB-UVB Dose (mJ/cm^2)
I	20
II	25
III	30
IV	40
V	50
VI	60

[a]Modified from references 1, 330, and 331.

TABLE 237-3
Oral PUVA Photochemotherapy[a]

I. Psoralen Dose
8-MOP micronized 0.6 mg/kg; 120 minutes before UVA
8-MOP dissolved 0.4–0.6 mg/kg; 90 minutes before UVA
MPD-based
A. MPD Determination
Expose 1-cm^2 areas on the lower back or inner aspect of the forearm to 0.5, 1.0, 2.0, 3.0, 4.0, 5.0 mJ/cm^2 UVA; read 72 h after UVA exposure
B. Initial exposure: 50%–70% of MPD
C. Subsequent exposures: 2–4 times per week
Increase UVA dose per table entries each week (not each exposure)

II. Fitzpatrick Skin phototype-based
A. Initial exposure based on Fitzpatrick skin phototype; subsequent exposures as above

Fitzpatrick Skin Phototype	Initial NB-UVB Dose (mJ/cm^2)	Dose Increases (per week after the first week)
I	0.5	0.5
II	1.0	0.5
III	1.5	1.0
IV	2.0	1.0
V	2.5	1.5
VI	3.0	1.5

[a]Modified from Refs. 1, 330, and 331.

modifications are made if an erythema response develops or treatments are missed (see Table 237-3).

Delivery of psoralens in bathwater is popular in some areas of the world because it provides a uniform drug distribution over the skin surface, is associated with very low psoralen plasma levels, and rapid elimination of free psoralens from the skin. This form of psoralen delivery circumvents gastrointestinal side effects and possible phototoxic hazards to the eyes associated with the oral form. Skin psoralen levels are highly reproducible, and photosensitivity lasts no more than two hours. Bath-PUVA consists of 15–20 minutes of whole-body immersion in solutions of 1-mg 8-MOP per liter of body temperature bathwater (Table 237-4). 5-MOP and trimethylpsoralen are also employed for bath PUVA. Irradiation is performed immediately after bathing, as photosensitivity decreases rapidly. Bath PUVA is started at 30% of the MPD. Treatments are typically given twice weekly. Guidelines for bath, local immersion, and other topical PUVA forms have been published by the British Photodermatology Group.[44] A cost-effectiveness analysis of data collected across four centers in Scotland revealed that courses of both bath PUVA and other topical PUVA were consistently more expensive than oral PUVA.[44] This is related predominantly to the increased nursing time required, although the cost of topical preparations also tends to be greater than oral preparations.

More recently, cream PUVA has been developed, which can be used to treat local and more widespread disease. Thirty minutes following the application of a psoralen-containing cream, patients are exposed to UVA irradiation.

AVOIDANCE AND MANAGEMENTS OF BURNS

Sunburn-like reactions are the most common short-term adverse effect of phototherapy. UVB burns usually peak at 12–24 hours, and PUVA burns at 24–48 or even 72 hours, with more severe burns peaking later than mild ones. Severe burns over a large portion of

TABLE 237-4
Bath PUVA Photochemotherapy[a]

I. Psoralen Dose
8-MOP dissolved in bath water for a final concentration of 1.0 mg/L
Bath water is at body temperature (98.6°F) Duration of bath is 15–20 minutes

II. UVA Exposure
A. MPD Determination
Expose 1-cm^2 areas on the lower back or inner aspect of the forearm; read 72 h after UVA exposure
Fitzpatrick skin phototype I or II: 0.5, 1.0, 2.0, 3.0, 4.0 and 5.0 J/cm^2 UVA
Fitzpatrick skin phototype III or IV: 1.0, 2.0, 4.0, 6.0, 8.0 or 10.0 J/cm^2 UVA
B. UVA exposure immediately after bathing
C. Initial exposure: 30% of MPD
D. Subsequent exposures: 2 times per week
Increase UVA dose by 20% each week

[a]Modified from Refs. 1, 330, and 331.

TABLE 237-5
Modification of Phototherapy Dose for Erythema or Missed Sessions[a]

No erythema	Increase by 25%
Erythema with no pain	No increase
Erythema with pain	Hold treatment until symptoms subside
Erythema with pain and blistering	Hold treatment until symptoms subside and then reduce dose by 50% from last dose
Modification of phototherapy dose for missed treatments:	
<1 week	No increase in dose
1–2 weeks	Decrease dose by 50% (BB-UVB) or 25% (NB-UVB or PUVA)
2–3 weeks	Decrease dose by 75% (BB-UVB) or 50% (NB-UVB PUVA)
>3 weeks	Restart at initial exposure dose

[a]Modified from Refs. 1, 330, and 331.

the skin surface produce systemic toxicity with fever and malaise in addition to pain. Severe PUVA burns, which extend well into the dermis, can lead to epidermal sloughing and are an indication for admission to a burn-care hospital facility. To avoid exacerbating a still developing PUVA burn, it is recommended that PUVA treatments not be given on consecutive days. Table 237-5 specifies the UVB or UVA dose adjustments in the event of a burn reaction during phototherapy. A burn reported by the patient at the next visit, even if no longer visible, should be managed in the same manner as a still-visible reaction. Burns over limited body areas, such as just the face or breasts, can be managed by local application of an appropriate sunscreen before or part way through subsequent treatments, especially if the area is not affected by the disease being treated. However, care must be taken to consistently protect the same area(s) in order to avoid a sudden full treatment to previously shielded skin.

Repeated UV-irradiated skin develops tolerance to subsequent exposures, allowing and indeed mandating progressively larger doses for optimal therapeutic effect. However, this tolerance is rapidly lost when exposures cease, requiring downward adjustments of dose after as little as 1 week (Table 237-5) to avoid burns.

UVA1. Because of its longer wavelength, UVA1 phototherapy (340–400 nm) is able to penetrate more deeply into the skin than UVB or shorter range UVA called UVA2 (i.e., 320–340 nm). The first report describing a device capable of emitting UVA1 occurred in 1981.[45] It was not until 1992 when the therapeutic benefit of UVA1 was demonstrated for atopic dermatitis that greater interest in the therapeutic properties of UVA1 occurred.[46–47] Initially, one obstacle to the widespread use of the initial UVA1 devices was the intense heat that they generated. Newer UVA1 phototherapy units incorporating a specialized filtering and cooling system that removes nearly all wavelengths above 530 nm have largely eliminated this problem. Though not widely available in the United States, these light sources are useful for the management of a variety of dermatological conditions for which other forms of phototherapy are not helpful.[48–49]

UVA1 is administered 3–5 times per week. There have been several studies, which have attempted to establish the optimal amount of UVA1 to administer at each treatment session.[50–54] Three dosing regimens have been used: (1) low dose (10–30 J/cm^2), (2) medium dose (40–70 J/cm^2), and (3) high dose (130 J/cm^2).[50–54] Although several comparison studies have been performed, at this point, there is no consensus as to which dose is best. In general, patients are started at 20–30 J/cm^2 and increased to the full dose within 3–5 treatments.[55] The risk of burns is far less than with UVB or PUVA therapy.

TARGETED PHOTOTHERAPY

Unlike the previously described phototherapy devices that expose both lesional and uninvolved skin to UVR, targeted phototherapy delivers therapeutic doses of UVR only to lesional skin. Targeted phototherapy has also been called focused phototherapy, concentrated phototherapy, and microphototherapy. Several devices are available to deliver targeted phototherapy including both monochromatic (one wavelength) and polychromatic systems. There are several advantages to targeted phototherapy. These devices spare normal skin, thereby allowing higher fluences to be delivered to diseased skin while decreasing the risk of acute and chronic side effects to normal skin. Targeted therapy can be used on treatment-resistant lesions and on difficult anatomic locations (such as the scalp, chin, and nails). The handheld nature of a targeted phototherapy device may be easier for young children than receiving treatments in a phototherapy booth, which can be large and intimidating. The limitations of targeted phototherapy are device expense and the fact that it may not be practical for patients with more than 10% to 20% of body surface area involved to receive treatments in this manner. The preventive action of phototherapy on uninvolved but at-risk skin is also lost. Targeted phototherapy devices include excimer lasers and nonlaser devices known as monochromatic excimer light (MEL) devices.[37] Both types of devices have been used to deliver targeted therapy to treat specific lesions of diseases such as psoriasis and vitiligo.[36–37] While both types deliver monochromatic UVB irradiation (most commonly at 308 nm), they differ in several respects. Lasers typically deliver UVR to a smaller area but are capable of emitting higher amounts of radiation over a shorter period of time. In contrast, MEL devices deliver monochromatic irradiation to a larger area but with a lower power density. There are also several devices that emit polychromatic UVA or UVB (BB- or NB-UVB)

to targeted areas. These devices typically utilize fiberoptic systems coupled with UVB generating sources. These devices have spot sizes from 1–3 cm. In addition, they have multiple delivery programs and automatic calibration, which makes treatment with predetermined dosages possible. These devices are smaller, less expensive, and have less maintenance problems than lasers.[56–57] Treatment protocols with targeted phototherapy vary depending on the type of device that is employed.

SAFETY OF PHOTOTHERAPY

Safety principles are common to most phototherapy devices. Equipment should be checked on a regular basis by the clinical staff or the manufacturer's engineer, since bulb output may change over time, and internal dosimetry components may fail. While phototherapy is usually delivered without incident, the risk of overtreatment is real, although the exact incidence of adverse events attributable to phototherapy is unknown and varies depending on the device. Importantly, with the exception of PUVA therapy for which formal long-term follow-up studies established an increased risk of lentigines, squamous cell carcinoma and melanoma, other forms of phototherapy appear to be remarkably safe.[36,58] Newer therapies such as narrowband UVB and UVA1 appear to be relatively safe especially compared to nonphototherapeutic options for the same diseases, but await longer follow-up.

UVB

Repeated exposure of the skin to UV irradiation does result in cumulative actinic damage regardless of the source. With respect to nonmelanoma skin cancer, most studies have shown that there is little risk beyond that associated with habitual sun exposure with either BB-UVB or NB-UVB phototherapy.[59–60] Greater than 300 treatments BB-UVB is associated with a modest but significant increase in SCC and BCC.[61] However, the carcinogenic risk of a single PUVA treatment is about seven times greater than a single UVB treatment.[62] As a result of its safety profile and efficacy, NB-UVB has emerged as a leading therapy for a number of skin diseases. Several studies have also shown that long-term exposure to BB-UVB combined with topical tar preparations is not associated with an increased risk of SCC.[63]

PUVA

ACUTE SIDE EFFECTS. The side effects of PUVA include drug intolerance reactions as well as the combined action of psoralens plus UVA radiation. Oral 8-MOP may cause nausea (10% of patients) and vomiting, and this occasionally necessitates discontinuation of treatment. These side effects are more common with liquid preparations rather than with crystalline preparations, probably because of higher psoralen serum levels. The nausea may be minimized or avoided by instructing the patient to take 8-MOP with milk, food, or ginger (e.g., ginger cookies, ginger ale, ginger supplements)[64] or to divide the dose into two portions, taken approximately one-half hour apart. Other reported effects include nervousness, insomnia, and depression. With 5-MOP, nausea is rare, even with doses up to 1.8 mg/kg body weight.

Following exposure to UVA, approximately 10% of patients undergoing PUVA therapy will experience pruritus. In most cases, this can be alleviated by bland emollients. Some patients with severe pruritus may require systemic treatment. A stinging pain may rarely occur, and the mechanism for this is unknown. The symptoms are usually unresponsive to antihistamines, and, in most instances, subside when the treatment is discontinued.

Mild and often transient focal erythema after PUVA therapy occurs frequently. Any area showing erythema with tenderness or blistering should be shielded during subsequent UVA exposures until the erythema has resolved. As noted above, erythema appearing within 24 hours may signal a potentially severe phototoxic reaction, and may worsen progressively over the next 24 hours, since peak erythema with PUVA characteristically occurs at least 48 hours after the treatment. In that situation, patients should be protected from further UVA exposures and sunlight, and should be monitored closely until the erythema has resolved.

Very rare side effects of PUVA include polymorphous light eruption-like rashes, acne-like eruptions, subungual hemorrhages caused by phototoxic reactions of the nail beds, onycholysis of the nails, and occasionally hypertrichosis of the face. These disappear when treatment is discontinued. Analysis of laboratory data in several large studies revealed no significant abnormal findings in patients receiving PUVA over prolonged periods of time.[65–67]

Chronic Actinic Damage. Chronic exposure to PUVA may result in skin changes that resemble photoaging, and which is aggravated by chronic natural sun exposure. PUVA lentigines are small brown macules with irregular borders and uneven pigmentation[68] and are histologically characterized by proliferation of large melanocytes.[69] In contrast to solar lentigines, melanocytes in PUVA lentigines often display an increased size of melanosomes, clustering and binucleation with nuclear hyperchromatism, and cellular pleomorphism. T1799A B-type Raf (BRAF) mutations have been found to be present in PUVA lentigines,[70] but the full significance of this is not yet understood, as both cutaneous malignant melanoma and benign melanocytic nevi often have BRAF mutations.[71–74] The presence of these lesions is directly related to the number of PUVA treatments and total UVA dose that has been administered. The absence of PUVA lentigines serves as a useful indicator of a lower risk of PUVA malignancy.[75]

Carcinogenesis. Cutaneous malignancies are the major concern of long-term and repeated PUVA treatments. The risk of nonmelanoma skin cancer and possibly malignant melanoma increases in a dose-dependent

manner. In laboratory animals, 8-MOP and 5-MOP have unequivocally induced skin cancer at levels of drug and UVA irradiation comparable to those used in PUVA therapy.[76] Cancer development is thought to stem from both DNA damage and down-regulation of the immune system. The PUVA Follow-up Study, which evaluated 1,380 patients who began PUVA treatment for psoriasis in 1975 and 1976 has documented major health events in these individuals in a prospective manner. Overall, patients who were treated with at least 337 PUVA treatments exhibited a 100-fold increased risk of SCC compared to that expected from population incidence rates.[77] Moreover, almost 4% of patients with SCC developed metastases, most commonly originating in the genital area. There is uncertainty about PUVA being the sole factor as many of the patients in the long-term follow-up studies also had significant exposure to sunlight and to treatments with carcinogenic potential, including arsenic, UVB, and methotrexate. The risk of developing SCC with PUVA may be further potentiated by the use of cyclosporine and, for this reason, cyclosporine is contraindicated in individuals who have been treated with PUVA.[78] Oral retinoids used concurrently with PUVA, on the other hand, reduce the risk of SCC.[79]

Individuals treated with PUVA are at increased risk of cutaneous malignancies of the genitalia, and this has led to standard protection of the genitalia during phototherapy.[80] The risk is dose-dependent, with a 90-fold increased risk of genital tumors among patients exposed to high doses of PUVA compared with that expected in the general population. Men treated with high-dose exposures to both PUVA and topical tar/UVB have the greatest risk of genital tumors.[80–81] There is currently no standardized regimen for genital shielding. There are pouches for genital shielding that are commercially available, but the cost and availability may be prohibitive. Factors influencing the effectiveness of UV irradiation protection include fiber composition, porosity (intrinsic to which is number of layers, weave type, and thread count), mass, and color.[82–83] Commonly used protective agents include surgical masks, paper towels, blue surgical towels, and underwear. The efficacy of these materials has been studied, and surgical masks were found to provide insufficient protection against UV irradiation most likely due to increased porosity (looser weave) and decreased mass.[84]

The relationship between PUVA and melanoma has also been examined in detail. The PUVA Follow-Up Study has provided evidence that individuals with at least 250 treatments and at least 15 years from the first PUVA treatment were at increased risk of developing melanoma.[85] Patients who developed a phototoxic reaction more easily were at higher risk for melanoma than those with darker skin.[86] As a result of those studies, a personal or family history of melanoma or a history of greater than 200 PUVA treatments is considered to be a relative contraindication to further PUVA therapy.[86]

In patients employing PUVA therapy in combination with methotrexate for at least 36 months, the incidence of lymphoma was more than 7 times higher than that of cohort members earlier in the study who had not taken methotrexate.[87]

Ophthalmologic Effects. UVA is absorbed in the lens and in the presence of UVA, psoralens can bind protein, DNA, and RNA. Because the lens never sheds its cells, protein-bound 8-methoxypsoralen accumulates in the lens, increasing the risk of irreversible opacification.[88] There have been reports of various ocular problems in patients on PUVA including cataracts, 89–90 conjunctival hyperemia,[91] and decreased lacrimation.[91]

A 25-year prospective study[92] sought to evaluate the effect of PUVA on the eyes. Participants were instructed to use UVA-blocking eyewear when outside or looking outside through window glass during daylight for a minimum of 12 hours, although current labeling calls for 24 hour protection. This study found no relationship between increasing numbers of PUVA sessions and visual impairment or cataracts, and demonstrates that increasing exposure to PUVA does not increase cataract risk among middle-aged and older persons using eye protection as practiced by this cohort.[92] Other smaller studies have also found no increase in cataract formation or visual impairment.[93–96]

UVA1

UVA1 phototherapy is generally well tolerated.[52–53] Reported side effects include intense tanning, erythema, pruritus, urticaria, tenderness, a burning sensation, polymorphous light eruption, eczema herpeticum and bacterial superinfection.[48–49,54] However, because UVA1 phototherapy has only been available since the 1990s, the long-term effects are still under investigation.

SPECIAL CONSIDERATIONS

HIV. The safety of phototherapy and photochemotherapy in HIV-positive patients has been debated. Ultraviolet radiation may activate HIV by the induction of NF-κB,[97–99] and UVB therapy increases *HIV-1* gene expression in the skin.[100–102] However, BB-UVB phototherapy does not appear to affect plasma HIV levels nor does it have an effect on CD4 counts.[101,103–104] In general, phototherapy is thought to be safe for HIV patients.[105] A consensus statement published by the American Academy of Dermatology in 2010 concluded that for moderate-to-severe psoriasis in HIV-positive patients, phototherapy and antiretrovirals are the recommended first-line therapeutic agents.[106]

CHILDREN. NB-UVB is now preferred to PUVA in children for most skin conditions, because of concern about PUVA side effects including phototoxicity, carcinogenicity, photoaging, and the potential development of cataracts.

MISCELLANEOUS. Patients who have had arsenic exposure are at increased risk for cutaneous

TABLE 237-6
Diseases Amenable to Phototherapy

	NB-UVB/BB-UVB	PUVA	UVA1
Psoriasis	+	+	–
Atopic dermatitis	+	+	+ (acute flares)
Cutaneous T-cell lymphoma	+	+	+
Vitiligo	NB-UVB	+	–
Photodermatoses	+/–	+	–
Pruritus of chronic renal failure	+	–	–
Cholestatic pruritus	+	–	–
Aquagenic pruritus	–	+	–
Pruritus of polycythemia vera	+	+	–
Localized and systemic scleroderma	–	+	+
Chronic GVHD	+	+	+
Pityriasis lichenoides	+	+	–
Lymphomatoid Papulosis	+	–	+
Telangiectasis macularis eruptiva Perstans	–	+	+
Urticaria pigmentosa	–	+/–	+
Granuloma annulare	–	+	+
Lichen planus	+	+	–
Chronic hand eczema	+	+	+
Perforating disorders	+	+	–

malignancies and should avoid phototherapy. Transplant patients have a much higher risk of skin cancer compared to the general population and, in that patient population there is a relative contraindication to phototherapy. Photosensitizing medications should theoretically be avoided during phototherapy treatment, although in practice many patients uneventfully receive phototherapy while taking tetracycline, hydrochlorothiazide, or other photosensitizing drugs. There are anecdotal reports of an association between chronic use of voriconazole and the development of aggressive cutaneous malignancies including melanoma.[107–110]

DISEASES AMENABLE TO PHOTOTHERAPY

(Table 237-5)

Responses of the diseases listed in eTable 237-6 are discussed in detail online. See also Chapter 238.

KEY REFERENCES

Full reference list available at www.DIGM8.com

DVD contains references and additional content

1. Menter A et al: Guidelines of care for the management of psoriasis and psoriatic arthritis: Section 5. Guidelines of care for the treatment of psoriasis with phototherapy and photochemotherapy. *J Am Acad Dermatol* **62**(1):114-135, 2010
12. Krutmann J, Morita A, Elmets CA: Mechanisms of Photo(chemo)therapy. In: *Dermatological Phototherapy and Photodiagnostic Methods*, edited by J Krutmann, H Hönigsmann, and CA Elmets. Berlin, Springer-Verlag, 2009, pp. 63–77
40. Schneider LA, Hinrichs R, Scharffetter-Kochanek K: Phototherapy and photochemotherapy. *Clin Dermatol* **26**(5):464-476, 2008
60. Hearn RM et al: Incidence of skin cancers in 3867 patients treated with narrow-band ultraviolet B phototherapy. *Br J Dermatol* **159**(4):931-935, 2008
124. Asawanonda P, Nateetongrungsak Y: Methotrexate plus narrowband UVB phototherapy versus narrowband UVB phototherapy alone in the treatment of plaque-type psoriasis: A randomized, placebo-controlled study. *J Am Acad Dermatol* **54**(6):1013-1018, 2006

Chapter 238 :: Photochemotherapy and Photodynamic Therapy

:: Herbert Hönigsmann, Rolf-Markus Szeimies, & Robert Knobler

PHOTOCHEMOTHERAPY AND PHOTODYNAMIC THERAPY AT A GLANCE

- Photochemotherapy [psoralen and ultraviolet A light (PUVA)] has been successfully used for more than 30 years. Its effectiveness has profoundly influenced dermatologic therapy in general, providing treatment for a number of diverse disorders besides psoriasis and vitiligo.
- PUVA can be combined with topical treatments and with some systemic agents (retinoids, methotrexate, and, perhaps, biologics) to enhance efficacy and to reduce the number of exposures.
- The most important adverse effects of oral PUVA consist of an increased risk of squamous cell carcinoma and a possible risk of melanoma. No such increased risk was found so far with bath-PUVA.
- Extracorporeal photochemotherapy (ECP) was introduced in the 1980s for the palliative treatment of erythrodermic cutaneous T-cell lymphoma.
- ECP appears to have a major impact in the treatment of graft-versus-host disease after allogeneic bone marrow transplantation where it allows progressive reduction or even discontinuation of the concomitant immunosuppressive therapy without an increase in graft-versus-host disease activity. Several other indications are under investigation.
- No serious side effects have been reported with ECP.
- Photodynamic therapy (PDT) for skin tumors started with the introduction of topical photosensitization by a porphyrin precursor (5-aminolevulinic acid) that would avoid generalized light sensitivity over many weeks.
- Current experience with PDT of epithelial cancers and precancerous conditions suggests that actinic keratoses, Bowen disease, superficial and nodular basal cell carcinomas, and early squamous cell carcinomas can be treated curatively.
- The only significant side effect of topical PDT is a stinging pain during and shortly after irradiation. PDT has neither mutagenic nor carcinogenic potential.

PHOTOCHEMOTHERAPY

Photochemotherapy with psoralens combines the use of oral or topical psoralens (P) and ultraviolet A radiation (UVA), termed *PUVA*. Psoralens are phototoxic compounds that enter cells and then absorb photons to produce photochemical reactions that alter the function of cellular constituents.[1] This interaction results in a beneficial therapeutic effect after repeated controlled phototoxic reactions. Psoralens can be administered orally or applied topically to the skin in the form of solutions, creams, or baths. This therapy is currently used in the treatment of several common and uncommon skin diseases.

HISTORICAL BACKGROUND

In the 1970s, it was shown that orally administered 8-methoxypsoralen (8-MOP) and subsequent irradiation with artificial UVA was a highly effective treatment for psoriasis.[2,3] Psoralen baths (soaking in a dilute psoralen solution) and subsequent UVA exposure (bath-PUVA), which originated in Scandinavia,[4] is also being used in many European institutions. The effectiveness of all variants of PUVA has been widely confirmed and has profoundly influenced dermatologic therapy, in general, providing treatment for numerous disorders in addition to psoriasis (Table 238-1). A major advance in phototherapy was the development of fluorescent bulbs that emitted narrowband UVB radiation at 311–313 nm in the mid-1980s. This narrow spectrum is slightly inferior in clearing psoriasis or mycosis fungoides. However, due to the fact that it is easier to perform and possibly safer than PUVA, it is now more frequently used in many phototherapy centers. Narrowband UVB phototherapy is also beneficial for a variety of other dermatoses that were previously treated with PUVA. Nevertheless PUVA has still remained the mainstay for recalcitrant diseases.

TABLE 238-1
Phototherapy-Responsive Diseases

Therapy of Disease	Prevention of Disease Symptoms
■ Psoriasis	■ Polymorphous light eruption
■ Palmoplantar pustulosis	■ Hydroa vacciniforme[a]
■ Mycosis fungoides (stages IA, IB)	■ Solar urticaria
■ Vitiligo	■ Erythropoietic protoporphyria[a]
■ Atopic dermatitis	■ Chronic actinic dermatitis[a]
■ Generalized lichen planus	
■ Urticaria pigmentosa	
■ Cutaneous graft-versus-host disease	
■ Generalized granuloma annulare	
■ Pityriasis lichenoides*	
■ Lymphomatoid papulosis[a]	
■ Pityriasis rubra pilaris[a]	
■ Localized scleroderma[a]	

[a]Experience limited to small number of patients.

PRINCIPLES OF PHOTOCHEMOTHERAPY

The rationale for PUVA therapy is to induce remissions of skin diseases by repeated, controlled phototoxic reactions. These reactions occur only when psoralens are photoactivated by UVA. Due to the penetration characteristics of UVA, absorption of photons is confined to the skin. However, there is also some evidence that PUVA may exert systemic effects through circulating lymphocytes affected while transiting through the skin. Clinically, PUVA-induced phototoxic reactions are characterized by a delayed sunburn-like erythema and inflammation.

PSORALENS. Three psoralens are used in PUVA therapy. Methoxsalen or 8-methoxysporalen (8-MOP), obtained from the seeds of a plant called *Ammi majus*, is most widely used and the only psoralen available in the United States. Bergapten or 5-methoxypsoralen (5-MOP) and trioxsalen or 4,5′,8-trimethylpsoralen (TMP) are available in Europe and elsewhere.

Psoralen Photochemistry.[5–7] Psoralens intercalate between apposing DNA base pairs in the double helix in the absence of UV radiation. Absorption of photons in the UVA range results in the formation of a 3,4- or 4,5-cyclobutane addition product (adduct) with pyrimidine bases of native DNA. In the first step of this photochemical reaction, a monofunctional adduct with thymine or cytosine is formed. Some psoralens, including 8-MOP, TMP, and 5-MOP, can absorb a second photon, and this reaction leads to the formation of a bifunctional adduct with a 5,6 double bond of the pyrimidine base of the opposite strand, thus producing an interstrand cross-link of the double helix (Fig. 238-1). This intercalation of psoralens with epidermal DNA suppresses both DNA synthesis and cell division, and it was originally assumed that this was the therapeutic mechanism in psoriasis. However, cross-linking does not appear to be a prerequisite for the therapeutic effect,[7] and successful PUVA treatment of other skin diseases is unlikely to be directly caused by this molecular reaction; psoralens also react with RNA, proteins, and other cellular components, and indirectly modify proteins and lipids via singlet oxygen-mediated reactions or by generating free radicals.[7] Perhaps these mechanisms contribute to the effects of PUVA in diseases that are not hyperproliferative in nature.

The formation of mono- and bifunctional photoadducts in DNA results in the immediate inhibition of DNA synthesis. The interstrand cross-links are believed to be largely responsible for eliciting skin photosensitization reactions of linear psoralens such as 8-MOP. Excessive production of these cyclobutane adducts causes cell death. Mutation and skin carcinogenesis also result from photoconjugation of psoralens to DNA because the cells surviving this DNA damage tend to repair it through an error-prone repair process.[7]

In type II reactions (see Chapter 90), reactive oxygen species ($^1O_2$, O_2, or OH) induce the oxidation of cellular lipoprotein membrane lipids and destruction of membrane-bound cytochrome P450. The membrane-damaging events activate the arachidonic acid metabolism pathway, which results in an increase of secondary oxidation products that contribute to the increased synthesis of eicosanoids. Furthermore, the reactive oxygen species can directly damage DNA by generating DNA strand breaks.[7]

Mechanisms of Photochemotherapy. Hypotheses about the mechanism of action in psoriasis are based on the known photoconjugation of psoralens to DNA with subsequent suppression of mitosis, DNA synthesis, and cell proliferation, expected to revert increased cell proliferation rates in psoriasis to normal. However, PUVA also alters the expression of cytokines and cytokine receptors, downregulates certain lymphocyte and antigen-presenting cell functions, influences adhesion molecule expression, and diminishes Langerhans cell numbers within the epidermis. In addition, PUVA affects immune effector cells such as lymphocytes or polymorphonuclear leukocytes. Because there is evidence that psoriasis is caused primarily by the action of blood-derived immunocytes, it is reasonable to speculate that PUVA therapy may act by affecting immune function through a direct phototoxic effect on lymphocytes in skin infiltrates. This is consistent with the observation that several other disorders that are not hyperproliferative in nature but immunomediated also respond well to PUVA. PUVA can revert pathologically altered patterns of keratinocyte differentiation and reduce the number of proliferating epidermal cells. Infiltrating lymphocytes are strongly suppressed by PUVA, with variable effects on different T-cell subsets. Lymphocytes are far more likely to undergo apoptosis than keratinocytes[8] in

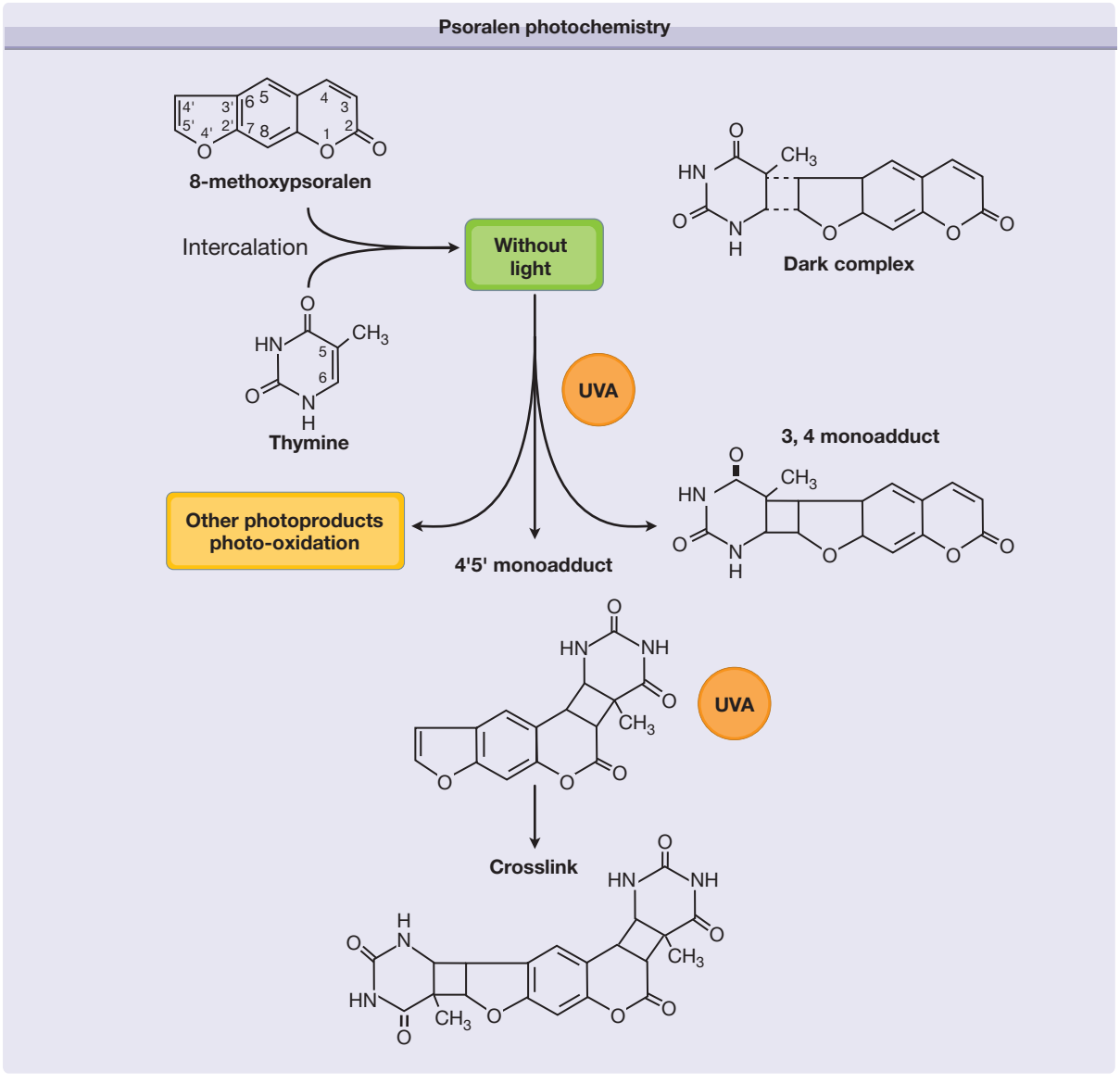

Figure 238-1 Psoralen photochemistry. Psoralens intercalate between apposing DNA base pairs forming a "dark complex." Absorption of ultraviolet A (UVA) photons leads to a 3,4- or 4,5-cyclobutane monoadduct with pyrimidine bases of native DNA. The absorption of a second photon results in a bifunctional adduct producing an interstrand cross-link of the double helix.

response to PUVA, which may explain the high efficacy in cutaneous T-cell lymphoma (CTCL), as well as in inflammatory skin diseases including psoriasis that is now recognized to be in part T-cell mediated as well as hyperproliferative. Although much is known about pathways and mechanisms of psoralen photosensitization, the interactions and relative contributions to the clearing of a specific disease are not well understood.

Psoralens also stimulate melanogenesis. This involves the photoconjugation of psoralens to DNA in melanocytes, mitosis, and subsequent proliferation of melanocytes, an increased formation and melanization of melanosomes, an increased transfer of melanosomes to keratinocytes, and activation and increased synthesis of tyrosine mediated in part by stimulation of cAMP activity.

Pharmacokinetics. The important steps between the ingestion of a psoralen and its arrival at the site of action include absorption, first-pass effect, blood transportation, and tissue distribution. The absorption rate of a psoralen from the gut depends mainly on the physical characteristics of the preparation and the fat content of the concomitant food intake. Liquid preparations of 8-MOP and 5-MOP give higher and earlier peak serum levels than do crystalline formulations. In addition, peak serum levels are achieved by liquid preparations after a relatively reproducible time interval in all subjects, whereas wide time variability occurs with crystalline formulations. Before reaching the skin via the circulation, psoralens are metabolized during passage through the liver. Plasma levels of 8-MOP administered orally at different doses show a

strong nonlinearity, indicating a saturable first-pass effect. The unpredictable pharmacokinetic behavior is probably due to inter- and intraindividual variations of intestinal absorption, first-pass effect, blood distribution in the body, metabolism, and elimination of the drug.

Within the same individual, serum levels of 8-MOP correspond fairly well with skin reactivity, the peak of skin phototoxicity coinciding with peak serum levels. However, phototoxic responses to PUVA show large interindividual variations. Hence, measurement of serum psoralens is a research tool and not used to monitor clinical therapy.

The pharmacokinetics of 8-MOP after topical treatment depend on the method of application. 8-MOP topically applied as a 0.15% emulsion or solution leads to plasma levels comparable to those found with oral treatment if large areas of the body are treated. In contrast, plasma levels after bath-PUVA treatment of almost the total body surface are very low. Bathwater-delivered psoralens are readily absorbed in the skin but are promptly eliminated without cutaneous accumulation.[8]

Ultraviolet A Radiation. UVA sources commonly used for PUVA therapy are fluorescent lamps or high-pressure metalhalide lamps. The typical fluorescent PUVA lamp has an emission peak at 352 nm and emits approximately 0.5% in the UVB range. UVA doses are given in Joules per centimeter^2, usually measured with a photometer with a maximum sensitivity at 350–360 nm. Although the action spectrum of antipsoriatic activity and phototoxic erythema peaks at 335 nm, longer wavelengths have proved equally effective for clearing psoriasis if delivered in an adequate dose to obtain an equal erythemogenic response.[9]

Photosensitivity Effects of Photochemotherapy. PUVA treatment produces an inflammatory response that manifests as delayed phototoxic erythema, proportional to the dose of both drug and UVA as well as to the individual's sensitivity to phototoxic reactions. 8-MOP dose changes within individuals, over a narrow but clinically relevant range, appears to significantly alter the threshold for PUVA erythema, but not the rate of increase in erythema intensity with increasing UVA dose.[10] Importantly, the time course of PUVA erythema differs from sunburn or UVB erythema that appears after 4–6 hours and peaks 12–24 hours after exposure. PUVA erythema does not appear before 24–36 hours and peaks at 72–96 hours, or even later. Hence, daily PUVA treatments can result in unexpected severe delayed cumulative phototoxicity. PUVA erythema has a shallower dose-response curve than UVB erythema (by a factor of approximately 2) and this difference is maintained even at the point of maximum erythema.[11] Severe PUVA reactions may lead to blistering and to superficial skin necrosis. Overdoses of UVA are frequently followed by swelling, intense pruritus, and, sometimes, by a stinging sensation in the affected skin area, possibly as a consequence of damage of superficial nerve endings. Erythema is at present the only available parameter that allows an assessment of the magnitude of the PUVA reaction; thus, it represents an important criterion for dose adjustments.[9]

Pigmentation is the second important effect of PUVA. It may develop without clinically evident erythema, especially when oral 5-MOP or TMP is used; this is particularly important in the treatment of vitiligo and for the preventive therapy of certain photodermatoses. In unaffected skin, PUVA pigmentation is maximal approximately 7 days after a PUVA exposure and may last from several weeks to months. As with sun-induced pigmentation, the individual's ability to tan is genetically determined, but the dose-response curve is much steeper. A few PUVA exposures result in a much deeper tan than that produced by multiple exposures to solar radiation.

TREATMENT PROTOCOLS

Topical Treatment. Application of 8-MOP in creams, ointments, or lotions followed by UVA irradiation is effective in clearing psoriasis but has several disadvantages. The nonuniform distribution on the skin surface induces unpredictable phototoxic erythema reactions and irregular patches of cosmetically unacceptable hyperpigmentation. Furthermore, if numerous lesions are present, the application is laborious and time consuming, and the treatment does not prevent the development of new active lesions in previously unaffected, untreated areas. Therefore, topical PUVA with psoralen creams, ointments, or lotions is now used only for limited plaque psoriasis and for palmoplantar disease.

Bath Photochemotherapy. The use of bathwater delivery of psoralens provides for a uniform drug distribution over the skin surface, very low psoralen plasma levels, and rapid elimination of free psoralens from the skin. Bathwater delivery of 8-MOP circumvents gastrointestinal side effects and possible phototoxic hazards to the eyes because there is no systemic photosensitization. Skin psoralen levels are highly reproducible, and photosensitivity lasts no more than 2 hours. The higher incidence of unwanted burn reactions can be prevented by a lower starting dose [50% of the minimal phototoxic dose (MPD)] and a more cautious dosimetry in the initial treatment phase. A major drawback in many treatment facilities is the requirement for a bathtub. Originally, bath-PUVA was performed with TMP, but 8-MOP and 5-MOP are now being used as well. Bath-PUVA consists of 15–20 minutes of whole-body immersion in solutions of 0.5- to 5.0-mg 8-MOP per liter of bathwater. Irradiation needs to be performed immediately, as photosensitivity decreases rather rapidly. TMP is more phototoxic after topical application and is used at lower concentrations than 8-MOP. Minimal phototoxicity dose (MPD) determination for bath-PUVA must take into account that the phototoxic threshold declines during the early treatment phase,[8] in contrast to oral PUVA. Guidelines for bath, local immersion, and other topical PUVA forms have been published by the British

Photodermatology Group and are based, where possible, on the results of controlled studies, or otherwise on consensus.[12]

Oral Treatment. In oral PUVA, 8-MOP is administered orally (0.6–0.8 mg/kg body weight) 1–3 hours before exposure, depending on the absorption characteristics of the particular drug brand. Liquid drug preparations are absorbed faster and yield higher and more reproducible serum levels than microcrystalline forms. For 5-MOP, the usual dosage is 1.2- to 1.8-mg/kg body weight.

The initial UVA doses are determined by either the patient's skin type[13–15] or by MPD testing.[9] The MPD is defined as the minimal dose of UVA that produces a barely perceptible, but well-defined, erythema when template areas of the skin are exposed to increasing doses of UVA. Erythema readings are performed 72 hours after testing, at which time the psoralen phototoxicity reaction usually reaches its peak. The MPD test should be performed on previously nonexposed skin (e.g., buttocks). Although the MPD test is more time-consuming than phototyping, it allows for more accurate and higher UVA doses during initial treatment. Table 238-2 shows recommendations for dosimetry in bath and oral PUVA.

Repeated exposures are required to clear PUVA-responsive diseases, with gradual dose increments as pigmentation develops. Lower doses quite frequently result in failure of treatment except in those diseases in which induction of pigmentation is the desired objective. In most dermatoses amenable to PUVA, the frequency of treatments is reduced after satisfactory clearing of disease, and the last UVA dose is used as a maintenance dose, if maintenance treatment is planned. The duration of this maintenance phase and the frequency of treatments depend on the particular disease being treated and its propensity to relapse.

INDICATIONS FOR PHOTOCHEMOTHERAPY

PHOTOCHEMOTHERAPY FOR PSORIASIS.

Basically all types of psoriasis respond to PUVA (Figs. 238-2 and 238-3), although the management of erythrodermic or generalized pustular psoriasis is more difficult.[8] The effectiveness of oral PUVA in inducing and maintaining remission of psoriasis has been widely documented and confirmed by large-scale clinical trials (see Figs. 238-2 and 238-3).

Administration. Three studies have compared bathwater delivery of 8-MOP with oral administration.[8] In two reports, initial doses were determined by skin typing, and treatments were given two to three times weekly. Dose increments were instituted with every treatment in one study, whereas smaller increments were given every third treatment in the other. In the third report, patients were treated according to the standard European regimen for oral PUVA, which is still in use (treatments four times weekly with an intermission on Wednesdays until clearing). This showed the lowest incidence of treatment failures and overdose phenomena, despite the potential burn risk of back-to-back PUVA treatments. Compared with oral 8-MOP, bath-PUVA showed equal clearing rates with fewer exposures.[8] The greater therapeutic efficacy could be because of a higher penetration of psoralens through the abnormal stratum corneum overlying psoriatic plaques, as compared with healthy perilesional skin where phototoxicity is monitored during the therapy. The incidences of erythema and pruritus were similar or lower compared with oral therapy. Systemic intolerance, such as nausea and vomiting, were not observed.

Oral 5-MOP–PUVA represents an alternative to oral 8-MOP–PUVA. Psoriatic lesions are cleared with a

TABLE 238-2
Recommended Treatment Schedule for Photochemotherapy[a]

Determination of MPD	Reading	After 96–120 hours (Bath-PUVA) After 72–96 hours (Oral PUVA)
Start of treatment	First therapeutic dose	30% of MPD (bath-PUVA) 50%–70% of MPD (oral PUVA)
Treatments two to four times weekly	No erythema, good response No erythema, no response Minimal erythema Persistent asymptomatic erythema Painful erythema (with or without blistering)	Increase once weekly by 30% Increase by 30% per session No increase No increase No treatment until symptoms subside
Resumption of treatment after missed sessions	After resolution of symptoms	Reduction of last dose by 50%; next increase by 10%

MPD = minimal phototoxic dose; PUVA = psoralen and ultraviolet A light.
[a]Exact practices vary between the U.S. and Europe and among practitioners in specific locales, based on historical teaching and individual experiences. See also Chapter 237.



Figure 238-2 Twenty-three-year-old patient with generalized psoriasis (seborrheic type). **A.** Before photochemotherapy treatment. **B.** After treatment. (From Wolff K et al: Photochemotherapie bei Psoriasis. Klinische Erfahrungen bei 152 Patienten. *Dtsch Med Wochenschr* **100**:2471, 1975 with permission.)

comparable number of treatments, but at the expense of significantly higher cumulative UVA doses. This difference may be due to the lower phototoxicity potential of 5-MOP and of its higher tanning activity. However, 5-MOP–PUVA therapy is not associated with nausea and vomiting and has a lower incidence of pruritus and severe phototoxic erythema.[8]

On complete clearing, patients are often assigned to maintenance therapy, during which the frequency of treatments is gradually reduced. The purpose of maintenance therapy is to achieve longer remission. Maintenance therapy in the original European regimen consisted of 1 month of twice-weekly treatments, with the last UVA dose used for clearing, followed by



Figure 238-3 Twenty-three-year-old patient with generalized psoriasis (plaque-type). **A.** Before photochemotherapy treatment. **B.** After treatment. (From Wolff K, Hönigsmann H: Clinical aspects of photochemotherapy. *Pharmacol Ther* **12**:381, 1981 with permission.)



Figure 238-4 Eighteen-year-old patient with pustular psoriasis (von Zumbusch type). **A.** Before photochemotherapy treatment. **B.** After treatment. (From Hönigsmann H et al: Photochemotherapy for pustular psoriasis (von Zumbusch). *Br J Dermatol* **97**:119, 1977, with permission.)

another month of once-weekly exposures. According to other recommendations,[16] maintenance treatment should be considered only on rapid relapses, because patients with a stable remission may be overtreated, and long-term risks of PUVA are related to the total cumulative phototoxic doses. In one recent left-right comparison study with psoriatics, PUVA maintenance treatment over 2 months did not increase the length of remission.[17] Thus, maintenance treatment should be given only in selected cases.

Erythrodermic and generalized pustular psoriasis (von Zumbusch type) respond to PUVA (Fig. 238-4), but the time required to induce remission is considerably longer, more treatments are needed, and higher failure rates are reported, compared with plaque or guttate varieties. Pustular eruptions of palms and soles are quite recalcitrant to treatment, regardless of whether they are true localized pustular psoriasis, nonpsoriatic palmoplantar pustulosis or pustular psoriasis, or pustular eczema. Oral PUVA alone can produce a slow but definite remission in many cases, but a considerable number of patients require adjunctive therapy for clearing. As mentioned above, the combination with topically applied 8-MOP can be beneficial, but bath-PUVA appears to be also quite effective in such cases.

PUVA alone can produce definite remissions in many patients with psoriasis, but a considerable number require additional therapies for clearing. Such combination therapy improves efficacy and may reduce side effects.

Combination Treatments

Topical Combinations. Topical adjuvant therapies with glucocorticoids, anthralin, and tar preparations, and, more recently, with calcipotriol and tazarotene, have yielded good results. However, adjunctive topical therapy is unacceptable to some patients.

Methotrexate. A combination of PUVA and methotrexate can reduce the duration of treatment, number of exposures, and total UVA dose and is also effective in clearing patients unresponsive to PUVA or UVB alone.[18] This combination appears to be safe if used during the clearing phase only. However, if used for long-term treatment, PUVA and methotrexate may act synergistically in the development of skin cancers.[19]

Cyclosporine. Cyclosporine plus PUVA dramatically enhances skin carcinogenesis. This is in keeping with the observation of a greatly increased risk of cutaneous squamous cell carcinomas in patients with solid organ transplants maintained on this immunosuppressant. Thus, this combination should be definitely discouraged.[8,20–22]

Retinoids. The therapeutic efficacy of PUVA therapy is dramatically increased by daily oral retinoid (etretinate, acitretin, isotretinoin; 1 mg/kg) administration beginning 5–10 days before the initiation of PUVA, and continued throughout the clearing phase. This so called *RePUVA* characteristically reduces the number of exposures by one-third and the total cumulative UVA dose by more than one-half. RePUVA also often clears "poor responders" who are not brought into complete remission by PUVA alone.[23]

The mechanism of the synergistic action of retinoids and PUVA is unknown, but may be a result of the accelerated desquamation that optimizes the optical properties of the skin and reduction of the inflammatory

infiltrate. As an additional theoretic benefit, etretinate and other retinoids may protect against long-term carcinogenic effects of PUVA. In one study, patients with psoriasis treated with PUVA in combination with systemic retinoids showed a reduced risk of squamous cell carcinoma but not a significantly altered incidence of basal cell carcinoma (BCC).[24] Although retinoid toxicity is generally not a concern because the administration is limited to the clearing phase, the potential teratogenicity of retinoids represents a serious concern for women of childbearing age. In these patients, the use of isotretinoin is advisable because contraception is necessary for only 1 month after discontinuation of therapy, in contrast to etretinate and acitretin, which require 2 years of contraception because of their slower elimination.[8]

Biologics. The mechanism of action of biologic agents suggests that there may be additive effects in treating psoriasis with PUVA, but this remains to be further defined in clinical trials.[25,26] Presently, there are no long-term studies evaluating the safety and efficacy of the combination of any biologics with PUVA.

PUVA FOR CUTANEOUS T-CELL LYMPHOMA (CTCL, MYCOSIS FUNGOIDES).

Since the first promising results with PUVA in CTCL in 1976,[27] numerous investigators from the United States and Europe have confirmed the efficacy of PUVA for CTCL.[28] Treatment schedules and dosimetry are essentially the same as for psoriasis. The treatment consists of a clearing phase (Fig. 238-5), a maintenance phase consisting of two exposures per week for 1 month and one exposure per week for another month, and a follow-up phase without therapy. Remission should be confirmed by histologic examination of previously involved skin sites. After therapy is discontinued, the patient is monitored monthly and later bimonthly. If a relapse occurs, the patient is again subjected to a full PUVA course. Some investigators advocate permanent maintenance treatment consisting of treatments once monthly or every other month. However, the course of CTCL varies considerably from patient to patient, and clinical experience suggests that patients benefit most from individualized treatment schedules.[8]

Relapses often respond as well as the initial lesions when PUVA is resumed. Clinical remissions appear to be directly related to phototoxic destruction of the malignant lymphocytes that infiltrate the skin. Thus, complete clearing may be induced when the cells are confined to the epidermis and superficial dermis, the depth of effective UVA penetration into the skin.

Present knowledge indicates that PUVA is an excellent treatment option that may induce long-lasting disease-free intervals in CTCL if used in the early stages of the disease.[28] In later stages, PUVA may reduce the tumor cell burden and thus may act synergistically with other treatment. It improves quality of life and may prolong survival when used in combination with more aggressive treatment modalities. Prolonged remissions were observed with combinations of PUVA with retinoids, bexarotene,[29,30] or interferon-α 2a.[31–33]

Patients with tumor-stage CTCL exhibit a high rate of early recurrences and, therefore, require indefinite maintenance treatment. PUVA causes complete tumor resolution only when used in combination with local x-ray treatment and/or systemic chemotherapy. Most follow-up studies have demonstrated that the great majority of patients with early disease can be kept in remission with or without maintenance therapy for several years, but tumor-stage patients (IIB) usually experience multiple recurrences despite aggressive



Figure 238-5 Forty-six-year-old patient with cutaneous T-cell lymphoma (mycosis fungoides) stage IB. **A.** Before photochemotherapy treatment. **B.** After treatment (clearing phase).

combination therapies and eventually die within a few years.[28] Currently, no therapeutic regimen is known to alter the disease course of CTCL. Psoralen UV-A is an effective treatment for MF, inducing long-term remissions and perhaps in some cases disease "cure." Thirty percent to 50% of patients remain disease free for 10 years, but late relapses occur.[34]

Successful treatment of erythrodermic CTCL (Sézary syndrome) has been reported with extracorporeal PUVA (photopheresis) [see Section "Extracorporeal Photochemotherapy (Photopheresis)"]. Possible long-term hazards related to frequent PUVA treatments are better justified for patients with CTCL, compared with patients with benign conditions.

PHOTOTHERAPY FOR ATOPIC DERMATITIS. Many patients with atopic eczema can benefit from PUVA therapy.[35] The treatment guidelines are the same as for psoriasis. However, the condition is more difficult to treat, and quite often a higher number of treatments are required to clear the eczema. There is a high and early recurrence rate, requiring frequent maintenance exposures. However, in a recent study, PUVA provided a better short- and long-term response than medium-dose UVA1 in patients with severe atopic eczema.[36] A combination of PUVA with topical glucocorticoids appears to be superior to PUVA alone in maintaining remissions. Because the average patient is young, long-term maintenance therapy is problematic; and combination of PUVA with topical immune modulators (tacrolimus, pimecrolimus), although effective, cannot be recommended until more data are available. The mechanism of action of PUVA in atopic eczema is unclear; current concepts support an alteration of lymphocytes in the dermal infiltrate.

PHOTOTHERAPY FOR LICHEN PLANUS. In generalized lichen planus, PUVA can provide an effective alternative to systemic glucocorticoid treatment, although it appears to be more resistant to PUVA than psoriasis when treated according to a similar schedule. More exposures and higher cumulative UVA doses are required for clearing, and not all patients respond satisfactorily. An exacerbation during PUVA treatment has been reported in a few patients. In patients who clear, relapses respond equally well when PUVA is resumed. Bath-PUVA can also clear lichen planus, and combined PUVA-etretinate regimen may be considered.[37]

PHOTOCHEMOTHERAPY FOR CUTANEOUS MASTOCYTOSIS. In cutaneous mastocytosis (urticaria pigmentosa), PUVA leads to a temporary involution of skin lesions[38] probably due to chronic degranulation of the mast cells. The treatment results in loss of Darier sign, relief of itching, and flattening and even complete disappearance of cutaneous papules and macules. Surprisingly, even systemic symptoms such as histamine-induced migraine and flushing improve gradually as treatment is continued.[38] In most patients, the manifestations of the disease recur several months after discontinuation of PUVA, but the recurrences respond as well as the original lesions.

Because treatment of cutaneous mastocytosis has been unrewarding with other modalities, the use of PUVA, although not curative, seems to be warranted in patients when the disease is causing severe distress.

PHOTOTHERAPY FOR MISCELLANEOUS DERMATOSES. Both acute and chronic pityriasis lichenoides[37] respond to PUVA, and favorable results have been reported for lymphomatoid papulosis.[39] However, the experience with these conditions is limited to a few anecdotal cases. In pityriasis rubra pilaris, the results are quite inconsistent. Some cases seem to respond well, others may flare, and some require combination treatment with retinoid or methotrexate therapy. Generalized granuloma annulare has been reported to clear completely, but long-term maintenance treatment was required to maintain remissions.[40] Regrowth of hair was noted in alopecia areata with either topical or systemic PUVA exposures localized to the alopecia areas. Follow-up studies of larger patient groups concluded that PUVA is generally not an effective treatment for alopecia areata.[41] The experience of the present authors has also not been encouraging. Localized scleroderma and panscleroticmorphea have been successfully treated with bath-PUVA and oral PUVA.[42,43]

PHOTOCHEMOTHERAPY FOR CHRONIC GRAFT-VERSUS-HOST DISEASE. Acute and chronic cutaneous graft-versus-host disease (GVHD) has become indications of increasing importance. Because of the clinical and histologic similarities of idiopathic lichen planus and lichenoid GVHD, PUVA treatment was evaluated for the latter.[44] PUVA cleared or improved this lichen planus-like eruption in patients who had not responded to conventional immunosuppressive therapy alone. PUVA can also improve acute GVHD,[45] although results of PUVA treatment for scleroderma-like variants of cutaneous GVHD are controversial. According to our own experience, the more circumscribed, localized forms appear to respond to PUVA with softening of the fibrotic, sclerotic connective tissue, but more widespread, disseminated lesions hardly respond.

Improvement of mucosal erosions followed by healing, observed during treatment of chronic lichenoid GVHD with PUVA, suggests that PUVA may exert both local and systemic effects, but this is not proven. There is no improvement of GVHD of other organs, such as the liver. The therapeutic regimen used for the treatment of chronic GVHD is basically the same as for psoriasis. UVA doses should not be increased too aggressively, to avoid erythema and possible (re)activation of GVHD. In general, increase of the UVA dosage by 0.5 J/cm^2 at maximum after every second to fourth exposure is recommended. Patients are exposed to UVA radiation three to four times weekly. After clearing of skin lesions, the frequency of exposures is reduced.

Because there appears to be an overall increased risk of secondary malignancies for all bone marrow/peripheral stem cell recipients, patients should be examined on a regular basis for the development of cutaneous malignancies, independent of whether they have been treated with PUVA.

PHOTOCHEMOTHERAPY FOR VITILIGO. Vitiligo was the first disease treated with an ancient form of psoralen PUVA in India and Egypt. PUVA in its modern form stimulates melanogenesis, melanocyte proliferation, and migration, and *can* reconstitute the normal skin color in *many* vitiligo patients *although the actual response rate has still not been defined*. However, it is less used now since narrowband UVB phototherapy has been shown to be effective and possibly safer alternative for repigmentation of this condition (see later).

To induce maximal repigmentation, patients need long-term therapy with 100–200 exposures given twice or thrice weekly. Approximately 70% of patients respond after 12–24 months (Fig. 238-6), defined as the development of perifollicular macules of repigmentation. If there is no response after 6 months or approximately 50 treatments (as defined as perifollicular macules of repigmentation), PUVA should be terminated. If treatment is discontinued, this newly acquired repigmentation may be lost. The permanency of PUVA-induced repigmentation in vitiligo is poorly documented. Some investigators have reported continuing pigment loss following PUVA, while others have reported the repigmentation to be long lasting.[46]

Patient selection appears to be particularly important in vitiligo treatment. Lips, distal dorsal hands, tips of fingers and toes, areas of bony prominences, palms, soles, and nipples are very refractory to treatment, and patients with involvement limited to these areas should be excluded. Segmental vitiligo tends to show a variable response. Because of the different response in different body areas, total repigmentation is only rarely achieved, and some 30% of patients do not respond at all despite many months of therapy. Duration of the disease before PUVA therapy does not affect response rate.[46] It should be mentioned here that in a recent trial of nonsegmental vitiligo, narrowband-UVB therapy resulted in a better color match than oral PUVA.[47]



Figure 238-6 Twelve-year-old patient with generalized vitiligo of 4 years' duration. **A** and **C.** During the initial phases of photochemotherapy treatment. **B** and **D.** One month after treatment (8-methoxypsoralen + artificial ultraviolet A) with thrice-weekly exposures for 10 months.

The mechanisms by which PUVA induces repigmentation in vitiligo skin are speculative. However, PUVA's known effect on a number of immunologic reactions suggests a suppression of the autoimmune stimulus for melanocyte destruction.

PHOTOCHEMOTHERAPY AS PREVENTION FOR PHOTODERMATOSES. Tolerance to sunlight can be induced in several photodermatoses by PUVA therapy.[48] In polymorphous light eruption, the most common photodermatosis, PUVA is the most effective preventive treatment.[49] In approximately 70% of patients with this condition, a 3- to 4-week PUVA course of two to three treatments per week suffices to suppress the disease on subsequent exposure to sunlight such as a holiday trip or the arrival of summer. The initial exposure and dose increments during therapy should be performed according to the guidelines outlined for psoriasis. PUVA has the advantage of a rapid and intense pigment induction at relatively low UVA doses that usually remain well below the threshold doses for eliciting the rash. Approximately 10% of patients develop typical lesions during the initial phase of PUVA, but these usually disappear when treatment is continued. The authors' treatment schedule consists of three to four treatments per week for 3–4 weeks in early spring. PUVA protects only temporarily, but subsequent sun exposures usually maintain protection and many patients remain protected for 2–3 months even after their pigmentation has faded.

The mechanism by which phototherapy induces tolerance to sunlight is not clear. Hyperpigmentation and thickening of the stratum corneum may be important factors, but other mechanisms, such as modulations of cutaneous immune function, may also be involved.[49]

There is also some experience with PUVA prophylaxis of other photodermatoses. In solar urticaria, PUVA therapy appears to be the most effective preventive treatment available and is certainly better than antihistamines. Tolerance to sunlight can be increased 10-fold or more after a single treatment course.[50] The suppressive effect may last throughout the summer if the patients have regular sunlight exposures, which seems to be necessary to maintain tolerance. Problems may arise during the first PUVA exposures, because, in some patients, the urticaria threshold dose is very low. In these cases, careful conditioning by stepwise UVA irradiation of single quadrants of the body surface a few hours before each PUVA treatment has proved useful. Treatments with PUVA are then given during the refractory period of presumed mast cell degranulation.

Successful PUVA therapy has also been reported in occasional cases of chronic actinic dermatitis and hydroa vacciniforme. Limited experience in patients with erythropoietic protoporphyria indicates that, with a very cautious approach and in combination with β-carotene, PUVA may increase light tolerance considerably.[51,52]

Extended treatment is usually not required in polymorphous light eruption but may be necessary in solar urticaria and chronic actinic dermatitis. There exist no ready-to-use schedules for these latter conditions, and PUVA is usually just one part of the management.[51]

PHOTOCHEMOTHERAPY IN HUMAN IMMUNODEFICIENCY VIRUS-INFECTED PATIENTS. The use of phototherapy and PUVA in human immunodeficiency virus (HIV)-infected patients with skin diseases is controversial. Both therapies can induce systemic immune suppression and may modify the immune status of the patient in a way that would worsen HIV disease.[53] Both UV radiation and psoralen photosensitization activate the HIV promoter, which could boost viral gene transcription and, eventually, virus production,[54] although available data and theoretic considerations indicate that UVB is more likely to be a hazard than PUVA in an HIV-infected population.[55,56] Nevertheless, oral PUVA treatment of psoriasis does not detectably accelerate progression of HIV disease or increase PUVA side effects, and hence PUVA is not considered contraindicated for HIV-positive patients with responsive skin diseases.[57]

SIDE EFFECTS AND TOXICITY OF PHOTOCHEMOTHERAPY

(Table 238-3)

ACUTE SIDE EFFECTS. The side effects of PUVA include drug intolerance reactions as well as side effects of the combined action of psoralens plus UVA radiation. Oral 8-MOP (0.6–0.8 mg/kg) has a high incidence of nausea (30% of patients) and vomiting (10% of patients), and this may occasionally require discontinuation of the treatment. The mechanism of this adverse effect is unknown. These side effects are more common with liquid preparations than with crystalline preparations, probably because of higher psoralen serum levels. With 5-MOP, nausea occurs rarely, even with doses of up to 1.8 mg/kg body weight.

Undesired acute effects of the combined action of psoralens and UVA include unexpectedly severe delayed erythema reactions. Severe burns with blistering can occur and may rarely require hospitalization. When large areas of skin are affected, systemic symptoms of excess phototoxicity, such as fever and general malaise, may occur. Nonsteroidal anti-inflammatory drugs and topical and systemic corticosteroids may be required to alleviate the symptoms but have to be given early. Some patients experience persistent pruritus during PUVA treatment, particularly after slight UVA overdosage, and, in rare cases, a stinging pain may develop in circumscribed areas. The mechanism is unknown although a phototoxicity reaction affecting cutaneous nerves is postulated, and the symptoms are unresponsive to antihistamines. These complaints usually subside on continuation of treatment. Overdosage phenomena occur mostly in body areas not usually exposed to natural sunlight. Cautious dosimetry can minimize these side effects. The danger of overdosage is much less with 5-MOP than with 8-MOP.

Very rare side effects of PUVA include polymorphous light eruption-like rashes, acne-like eruptions, subungual hemorrhages caused by phototoxic reactions in the nail beds, and occasional hypertrichosis of the face. These disappear when treatment is

TABLE 238-3
Side Effects and Toxicity of Photochemotherapy

Acute Side Effects	
Drug intolerance	Nausea, vomiting with oral MOP, but not with 5-MOP.
UVA overdosage	Can range from an increased delayed erythema reaction to severe burns with blistering. When large areas of skin are affected, systemic symptoms of excess phototoxicity, such as fever and general malaise, can occur.
Pruritus	Some patients experience persistent pruritus during photochemotherapy (PUVA) treatment, particularly after slight UVA overdosage.
Laboratory data	No significant abnormal findings in patients receiving PUVA over prolonged periods of time.
Potential Long-Term Risks	
Chronic actinic damage	Chronic exposure to PUVA may produce changes in the skin that resemble photoaging. PUVA lentigines and generalized PUVA lentiginosis result from repeated and prolonged treatment and are commonly associated with high cumulative doses of UVA and a large number of treatments. So far, no increased risk of cutaneous melanoma associated with these lentigines has been recorded.
Carcinogenesis	The risk of squamous cell carcinoma, but not of basal cell carcinoma, is significantly increased in comparison with matched controls, and the magnitude of the increase appears to be dose-dependent. There is still uncertainty about PUVA being the sole factor—many of the affected patients had previous exposure to excessive sunlight and to treatments with carcinogenic potential, including arsenic, UVB, cyclosporine, and antimetabolite therapy. No increased risk was found so far with bath-PUVA.
Melanoma	Stern et al. reported from patients enrolled in the PUVA Follow-up Study (16-Center Study [69]) that, beginning 15 years after first exposure to PUVA, an increased risk of melanoma was observed. This risk was greater in patients exposed to high doses of PUVA and appeared to be increasing with the passage of time. The conclusions of this study have been questioned, and the authors now agree that the observed risk of melanoma does not represent an absolute contraindication to PUVA or that PUVA therapy should be abandoned. Rather, the risks of both melanoma and squamous cell carcinoma in PUVA should be weighed against the substantial efficacy of PUVA and the risks of other therapies.
Ophthalmologic effects	Several studies have shown no indication that psoralen-induced cataracts occur in patients undergoing long-term photochemotherapy, even in patients who neglected eye protection.

MOP = 8-methoxypsoralen; PUVA = psoralen and ultraviolet A light.

discontinued. Single case reports note exacerbation of systemic lupus erythematosus and bullous pemphigoid during PUVA.

LABORATORY DATA. Analysis of laboratory data in several large-scale studies showed no significant abnormal findings in patients receiving PUVA over prolonged periods of time.[13,14,58] Serial laboratory examinations performed over a period of several years have not revealed any substantial evidence for impairment of hepatic function. Liver biopsies after 1 year of therapy did not reveal hepatotoxicity.[59] No evidence exists suggesting impairment of renal function.[13] Several large-scale studies have negated a suggested relation between PUVA therapy and the occurrence of antinuclear antibodies.[60]

POTENTIAL LONG-TERM RISKS OF PHOTOCHEMOTHERAPY

Chronic Actinic Damage. Repeated photodamage to the skin can be expected to result in cumulative injury regardless of whether it is induced by sunlight, artificial UV radiation, or PUVA. Chronic exposure to PUVA may produce changes that resemble photoaging and that may compound the injury induced by sunlight.

PUVA lentigines and generalized PUVA lentiginosis result from repeated and prolonged treatment and are commonly associated with high cumulative doses of UVA and a large number of treatments.[14] The lentigines exhibit irregular borders and uneven pigmentation. No increased risk of cutaneous melanoma has been associated with these lentigines, but the cosmetic effect may be quite disturbing.

Carcinogenesis. Cutaneous carcinogenicity is the major concern for long-term PUVA treatment associated with high cumulative UVA doses. PUVA is a photocarcinogen (see Chapter 112). In laboratory animals, 8-MOP and 5-MOP have been unequivocally shown to induce skin cancer at levels of drug and UVA irradiation comparable to those used in PUVA therapy.[61,62] This risk is related to DNA damage, but PUVA-induced down-regulation of immune responses may play an additional role. This risk has to be assessed against the potential therapeutic benefit.

Long-term follow-up PUVA studies are confounded by the fact that patients, particularly those with severe psoriasis, are likely to have been exposed previously to

other carcinogenic treatments, such as ionizing radiation, UVB therapy, methotrexate, tar, or arsenic, and accurate exposure data are often lacking.

In PUVA patients, the risk of squamous cell carcinoma, but not of BCC, is significantly increased in comparison with matched controls and the magnitude of the increase appears to be dose dependent.[19,62] However, there is uncertainty about PUVA being the sole factor—many of the affected patients had previous exposure to excessive sunlight and to treatments with carcinogenic potential, including arsenic, UVB, and antimetabolite therapy.[63] Particularly, high levels of UVB exposure appear to increase the risk of nonmelanoma skin cancer in PUVA-treated patients.[64] An increased risk of any skin cancer with oral PUVA has not been shown in the non-Caucasian population.[65] According to one study, the genitalia in men previously treated with tar and UVB appeared to be particularly susceptible to PUVA carcinogenesis,[66] but in a separate population the risk seemed not to be increased if only PUVA was used.[67] In a retrospective study from France comprising 5,400 patients treated with PUVA between 1978 and 1998, no case of genital skin cancer was found, despite the fact that the genital area had not been protected.[68] This makes it unlikely that genital shielding is absolutely necessary.

Carcinogenicity of 5-MOP–UVA therapy in PUVA-treated patients is not documented, but 5-MOP has shown mutagenicity similar to 8-MOP in model systems.

Stern et al reported that of the cohort of 1,380 patients enrolled in the so-called *16 Center PUVA Follow-up Study,* 23 patients have developed 26 invasive or in-situ cutaneous melanomas over a period of roughly 25 years. Beginning 15 years after first exposure to PUVA, this constituted an increased risk of melanoma.[69,70] This risk was greater in patients exposed to high doses of PUVA and appeared to increase with the passage of time. Still, the authors conclude that the observed risk of melanoma does not represent an absolute contraindication to PUVA. Rather, the risks of both melanoma and squamous cell carcinoma in PUVA should be weighed against the substantial efficacy of PUVA and the risks of other therapies.[70,71] As well, no increased risk of melanoma has been observed so far in any large-scale study from Europe; and several other US studies did not show an increased risk of melanoma in patients treated with PUVA[72,73] Of note, PUVA's long-term risks have been subject to much greater scrutiny than the risks of other therapies advocated for severe psoriasis, such as methotrexate and, particularly, immunosuppressive therapies such as cyclosporine. These latter therapies greatly increase cancer risk in populations less likely to have substantial exposures to other known cutaneous carcinogens such as UVB than are patients with severe psoriasis. Early detection through careful, long-term follow-up and education of PUVA patients may reduce the long-term morbidity and mortality associated with this therapy, as can low cumulative dosage regimens.[74]

Studies of 944 Swedish and Finnish patients[75] and 158 Finnish patients[76] with psoriasis showing no association between cutaneous cancer and TMP or 8-MOP bath-PUVA, respectively, are also reassuring. Mathematic model studies indicate that the observed risk of squamous cell carcinoma is much higher with PUVA than with UVB,[77] but the carcinogenic risk of narrowband UVB in comparison with PUVA is unknown, and it will be crucial to monitor its long-term effects in psoriatics.

Ophthalmologic Effects. Data from animal studies indicate a risk of premature cataract formation due to PUVA, but clinical evaluation suggests no increase in lens opacities, even in patients who neglect careful eye protection during long-term PUVA.[78,79]

PATIENT SELECTION AND CONTRAINDICATIONS

In view of the potential short-term and long-term hazards of PUVA, the assignment of patients should be based on consideration of the risks and the benefit for the individual patient. If only a short-term course of therapy is planned, as, for example, in prevention of photodermatoses, the benefit very probably outweighs the risk. In the treatment of a malignant condition such as CTCL, long-term risks may be discounted because other treatment options bear even greater long-term risks. The major concerns relate to long-term treatment of psoriasis, by far the most common indication for PUVA. Careful patient selection is mandatory, bearing in mind that long-term risks of alternative therapies may simply be less well documented rather than less. Guidelines have been published.[15]

PUVA is not recommended during pregnancy, and women should be advised to use contraceptive measures while on PUVA. This precaution is only for reasons of absolute safety as there is no evidence that 8-MOP alone is teratogenic, and UVA does not penetrate through the abdominal and uterine walls. Further, a retrospective study in 256 deliveries among the cohort of the 16-Center PUVA Follow-Up Study revealed no birth defects.[80] However, it has to be emphasized that RePUVA bears the risk of retinoid teratogenicity.

Severe impairment of hepatic and renal functions is usually considered a contraindication to PUVA because metabolism and excretion of psoralens may be inadequate. PUVA is also contraindicated in patients with known light-aggravated or light-induced diseases such as lupus erythematosus, porphyria (but, as mentioned earlier, light tolerance can be induced by PUVA in erythropoietic protoporphyria), and xeroderma pigmentosum. Pemphigus vulgaris and bullous pemphigoid may be exacerbated by PUVA. Patients with chronic actinic damage and a history of skin cancers may be at higher risk for the development of new cancers. Previous arsenic intake and previous treatment with ionizing radiation also seem to increase the risk of nonmelanoma skin cancers. Immunosuppressed patients should probably not receive PUVA, although this is not yet clearly defined. As outlined earlier, PUVA can be used in HIV-positive patients. Cataracts and aphakia are not contraindications if adequate eye protection is employed.

CONCLUSIONS AND PERSPECTIVES

PUVA is a highly effective treatment for several dermatologic diseases. Although there exists comprehensive clinical experience documenting PUVA's short-term safety when used according to standardized methods, potential long-term sequelae are still being studied. Thus, treatment decisions should take into account whether other equally effective forms of therapy that carry a lower risk are available. Risk-versus-benefit varies with the disease being treated.

Severe widespread psoriasis is a devastating disease that may impair professional, social, and private life. After more than three decades of experience with PUVA for the treatment of psoriasis, it is evident that this therapy offers innumerable patients the chance to resume a normal life. For disabling psoriasis, the choice of therapies lies not between risk and safety but among modalities (methotrexate, cyclosporine, UVB, and biologics), none of which is absolutely safe.[71]

EXTRACORPOREAL PHOTOCHEMOTHERAPY (PHOTOPHERESIS)

Extracorporeal PUVA (ECP) was introduced in the 1980s for the palliative treatment of erythrodermic CTCL,[81] a disorder characterized by circulating malignant lymphocytes. Its efficacy was subsequently confirmed by several clinical trials and approved in 1988 by the US Food and Drug Administration for this indication. At the International Consensus Conference on Staging and Treatment Recommendations for CTCL in 1994[82] and at the European Organization for Research and Treatment of Cancer Consensus Recommendations in 2006,[83] ECP was recommended as the first line of treatment for patients with erythrodermic CTCL.

Attempts to better characterize those CTCL patients likely to respond to ECP revealed a significant association between response and CD4:CD8 ratio. Patients with a ratio less than 10 are more likely to respond than patients with a ratio greater than 10. There is also a marginally significant association between response and lactic acid dehydrogenase (LDH) level, with patients whose LDH is not elevated at the start of treatment responding better than patients with an elevated LDH.[84]

Besides CTCL, ECP also plays an important role in the treatment of chronic GVHD after allogeneic bone marrow transplantation with excellent response rates. ECP has also been used in uncontrolled studies in several other autoimmune diseases including systemic sclerosis, acute allograft rejection among cardiac, lung, and renal transplant recipients[85–87] and Crohn disease, with some success.

TREATMENT METHOD

ECP originally involved the oral administration of 8-MOP followed by phlebotomy at the time of peak photosensitization passage of blood fractions from one arm vein through a photopheresis machine and back. A discontinuous flow cell separator harvests peripheral blood mononuclear cells (PBMCs) in a buffy coat collection and returns the red cell fraction to the patient without further treatment. The collection of PBMC is then exposed to 2.0 J/cm^2 of UVA using a photopheresis device that ensures exposure of individual PBMC in a thin film to the light source and then reinfused into the patient. More recently, 8-MOP is administered directly to the heparinized plasma and buffy coat fraction as it flows through a UVA exposure system, thereby avoiding 8-MOP-induced nausea and unintended phototoxicity with subsequent incidental sun exposure.[88] This treatment is customarily repeated on 2 successive days at 2- to 4-week intervals.

MECHANISM OF ACTION

The mode of action of ECP remains unknown. The PUVA exposures likely induce apoptosis of circulating malignant lymphocytes. However, it has also been shown that infusion of autologous haptenated cells in which apoptosis had been initiated by 8-MOP/UVA induces immunologic tolerance. This tolerance is likely due primarily to regulatory T cells because transfer can be achieved in an animal model. Induction of regulatory T cells could also explain why ECP exerts a beneficial effect in a wide variety of immune-mediated diseases and why generalized immunosuppression does not occur with ECP.[89,90]

SIDE EFFECTS

No serious side effects have been reported with ECP. With oral ingestion of 8-MOP, transient nausea is not uncommon (as in oral PUVA therapy) and, rarely, episodes of hypotension and vasovagal reflex due to volume shifts during treatments have been noted. However, these events usually do not interfere with the treatment.

TREATMENT RESULTS

CUTANEOUS T-CELL LYMPHOMA. Erythrodermic CTCL (Sézary syndrome) was the first disease for which ECP was evaluated. A response occurs in up to 75% of the patients, with complete remissions in up to 25%. In Sézary syndrome patients who do not sufficiently respond to ECP alone, ongoing studies are evaluating possible synergistic effects with other treatments such as interferon-α, methotrexate, bexarotene, and total-skin electron-beam therapy.[91–94]

GRAFT-VERSUS-HOST DISEASE AND ALLOGRAFT REJECTION. ECP appears to have a major impact in the treatment of GVHD after allogeneic bone marrow transplantation.[95,96] In patients with either acute or chronic GVHD, ECP allows reduction or even discontinuation of immunosuppressive therapy without an increase in GVHD activity. More

TABLE 238-4
Indications for Photopheresis (As Seen by Regulatory Agencies in 2006)

Sufficient evidence available	
Erythrodermic cutaneous T-cell lymphoma	Chronic graft-versus-host disease
Acute graft-versus-host disease	Organ transplant rejection
Experimental and investigational	
Scleroderma	Nephrogenic fibrosing dermopathy
Bullous dermatoses	Lichen planus
Crohn disease	Multiple sclerosis

than 450 patients with chronic (even steroid refractory cases), GVHD treated with ECP have been reported, with mean response rates of 63% (range 29%–100%). Responses were highest for those patients with cutaneous or mucous membrane involvement. Positive results have also been published for acute GVHD.[87,97] ECP is especially useful for patients affected by GVHD resistant to conventional treatment.

As mentioned above, ECP is effective in the treatment of acute allograft rejection among lung, cardiac, and renal transplant recipients. ECP is effective for patients resistant to conventional treatments, particularly if started early. Benefit is obtained without the complications typically encountered with immunosuppressive regimens used to control organ rejection.[98,99] Table 238-4 shows indications for photopheresis as currently approved by regulatory agencies.

PHOTODYNAMIC THERAPY

Photodynamic therapy (PDT) aims to destroy the desired target selectively thereby minimizing damage to normal tissue. The photodynamic reaction consists of the excitation of photosensitizers (usually porphyrins) by visible light in the presence of oxygen, resulting in the generation of reactive oxygen species, particularly singlet oxygen. These reactive oxygen species mediate cellular and vascular effects, depending on the tissue localization of the photosensitizer, and results in a direct or indirect cytotoxic effect on the target cells.[100] In dermatology, PDT has been used effectively for precancerous and malignant conditions such as actinic keratosis, BCC, Bowen disease, and superficial squamous cell carcinoma, as well as for inflammatory and infectious dermatoses such as localized scleroderma, acne vulgaris, and leishmaniasis. A relatively new approach is the treatment of ageing skin with PDT (photochemorejuvenation).

PRINCIPLES OF PHOTODYNAMIC THERAPY

PHOTOSENSITIZERS. The ideal photosensitizer for PDT in dermatology should meet the following criteria: (1) chemical purity, (2) high singlet-oxygen quantum yield, (3) significant light absorption at wavelengths that penetrate the skin sufficiently deeply, (4) high tissue selectivity, and (5) efficacy after topical application.

Porfimer sodium (Photofrin), a systemically administered mixture of several hematoporphyrin derivative (HpD) ethers and esters, has a low selectivity for skin tumors and leads to long-lasting photosensitivity; consequently, it is far from ideal for dermatologic use. In contrast, 5-aminolevulinic acid (ALA), an intermediate in heme biosynthesis or its methyl ester (MAL) leads to synthesis of photosensitizing protoporphyrin IX in the target tissue.[101] In this case, the concentration of the photosensitizer depends on the metabolic status of the diseased tissue with photosensitization greatest in precancerous or malignant tissue. ALA in combination with the blue light and MAL in combination with red light are approved by the US Food and Drug Administration for the treatment of actinic keratoses. In Europe, New Zealand, Australia, and South America, MAL has also been registered for superficial and nodular BCCs, and Bowen disease.

Most photosensitizers generate singlet oxygen with a quantum yield between 5% and 20%. A high quantum yield means that less sensitizer is required in the target tissue to induce sufficient PDT effects. The light absorption maxima of the current sensitizers are in the visible range (400–700 nm). In this range, light penetration in tissue is only up to 3 mm, limiting PDT to superficial tumors unless interstitial light propagation is used. A high selectivity for sensitizer accumulation in target tissue is necessary to avoid damage to surrounding normal tissue, and this is particularly important when larger areas are treated (e.g., actinic keratoses). ALA and MAL show reasonably high selectivity after topical application, with the ratio of porphyrin induction in skin tumors to the surrounding tissue higher than 10:1,[102] likely due to a combination of enhanced ALA-MAL penetration through an abnormal stratum corneum and altered metabolism and accumulation within the premalignant or malignant cells.

LIGHT SOURCES AND DOSIMETRY. Light penetration into skin increases with longer wavelengths up to 1,100 nm. Although porphyrins absorb maximally in the Soret band (400–410 nm, blue light), there are minor absorption peaks at longer visible light wavelengths. To increase depth of penetration while matching the absorption maxima of porphyrin photosensitizers, wavelengths around 630 nm are often used. Lasers are effective but they are quite expensive, require regular maintenance, and have a small treatment aperture. Hence, simpler incoherent light sources represent a valuable alternative. Fluorescent lamps or light-emitting diodes with appropriate red or blue light emission are commercially available and designed for treatment of large surface areas. Also, intense pulsed light sources are used for dermatologic PDT. Dosimetry depends on the photosensitizer and light source used, as well as on the condition to be treated. For PDT of epithelial cancer, photosensitization must be sufficient to induce necrosis or apoptosis. With current incoherent light sources (lamps, light-emitting diodes),

the treatment duration, apart from of ALA-MAL incubation time, is approximately 10–15 minutes. For treating inflammatory dermatoses, significantly lower doses suffice because the goal appears not to be cell death but rather sublethal damage or modulation of cellular functions.

MECHANISM OF ACTION. PDT-induced effects are mediated by photo-oxidative reactions. During irradiation, the photosensitizer absorbs light (energy) and is converted to an excited (triplet) state. The energy can then be transferred to molecular oxygen (type II photo-oxidative reaction), resulting in the generation of reactive oxygen species, mainly singlet oxygen. The biologic effects can be divided into primary cellular and secondary vascular damage. With HpD, early visible damage consists of cell membrane defects as a consequence of lipid peroxidation with consequent cell lysis. Depending on the intracellular localization of the photosensitizers, damage to subcellular structures, such as mitochondria, lysosomes, or endoplasmic reticulum, also occurs, whereas DNA is not a primary target. These direct effects probably play a key role in topical PDT, whereas vascular effects after systemic administration of photosensitizers appear to be the decisive event. These effects consist of vasoconstriction, blood stasis, and thrombosis of tumor vessels leading to tumor ischemia and subsequent necrosis.[103]

PHOTODYNAMIC THERAPY IN DERMATOLOGY

Table 238-5 lists current applications for PDT described in the literature. In contrast to other organs, the skin can be sensitized by either intravenous, topical, or intralesional routes of administration of the photosensitizer.

TABLE 238-5
Current Indications for Photodynamic Therapy

Oncologic	Nononcologic (All Off-Label Uses)

■ Actinic keratosis[a]
■ Bowen disease[b]
■ Actinic Cheilitis *(off-label use)*
■ Superficial BCC[b]
■ Nevoid BCC syndrome *(off-label use)*
■ Keratoacanthoma *(off-label use)*
■ Superficial SCC *(off-label use)*
■ Kaposi sarcoma *(off-label use)*
■ Cutaneous metastases *(off-label use)*
■ Cutaneous T-cell lymphoma *(off-label use)*
	■ Localized scleroderma
	■ Human papillomavirus-associated dermatoses
	  ■ Epidermodysplasia verruciformis
	  ■ Verrucae vulgaris
	  ■ Condylomata acuminata
	■ Leishmaniasis
	■ Acne vulgaris
	■ Rosacea
	■ Photochemorejuvenation of sun-damaged skin

BCC = basal cell carcinoma; SCC = squamous cell carcinoma.
[a]Approved in the United States, European Union, Austarila–New Zealand, and Brazil.
[b]Approved in the European Union, Austarila–New Zealand, and Brazil.

SYSTEMIC PHOTODYNAMIC THERAPY. PDT after systemic administration of HpD and porfimer sodium has been used for both skin cancers and inflammatory dermatoses. Standard therapeutic procedures do not yet exist.

Systemic Photodynamic Therapy for Oncologic Indications.

Systemic PDT with porfimer sodium for Bowen disease is very effective,[104] but invasive squamous cell carcinomas respond less well, with recurrence rates of up to 50% within 6 months. Systemic PDT for BCCs, first used in 1981,[105] has been reported by Oseroff and coworkers[106] to give initial complete responses in 92.2% of 77 patients with sporadic BCC or nevoid BCC syndrome.[106] In these patients, the 5-year recurrence rate was 15%.

Benzoporphyrin-derivative monoacid ring A (verteporfin), registered for the ophthalmologic indication of age-related macular degeneration, is also under investigation for PDT of BCC and offers a duration of cutaneous photosensitization of less than 72 hours, significantly shorter than that of porfimer sodium.[107]

Systemic Photodynamic Therapy for Nononcologic Indications.

The use of PDT with HpD was reported for the treatment of psoriasis as early as 1937; better results were reported using red light instead of UVA,[108] and systemic PDT with verteporfin was also investigated in a phase I study of 15 patients in whom clinical severity scores for psoriatic plaques improved after five weekly treatments.[109]

TOPICAL PHOTODYNAMIC THERAPY. Small hydrophilic molecules like ALA or MAL penetrate well into the skin, particularly if the stratum corneum is abnormal, as is the case in some epidermal tumors.[101] In addition, epidermal cells and the pilosebaceous unit synthesize porphyrins to a much greater extent than fibroblasts, myocytes, or endothelial cells[102]; epithelial tumors generally synthesize much higher amounts of protoporphyrin IX than the surrounding tissue and can therefore be destroyed without equivalent damage to healthy skin (Fig. 238-7).[101,110] Topical ALA-MAL-induced photosensitivity thus preferentially affects the target area. Systemic porphyrin induction is not observed after topical application.[111] The only significant side effect of topical ALA-MAL PDT is a stinging pain during and shortly after irradiation, proportional to the intensity of the phototoxicity reaction.

Topical Photodynamic Therapy for Oncologic Indications.[112–118]

The experience with treatment of epithelial cancers and precancerous conditions with PDT to date suggests that actinic keratoses,[112,113] Bowen disease (Fig. 238-8),[114] superficial and nodular BCCs,[115–117] and SCCs (tumor thickness less than 2 mm) are suitable for topical ALA/MAL-PDT. For this purpose, both photosensitizers are applied topically for variable incubation periods, with or without occlusion, followed by visible light exposure.

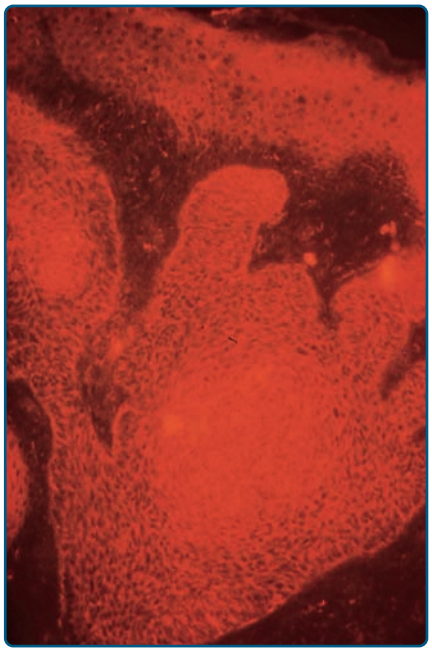

Figure 238-7 Endogenous porphyrin fluorescence after topical application of 20% aminolevulinic acid formulation to a solid basal cell carcinoma. Twelve hours after aminolevulinic acid application, there was strong fluorescence of the tumor-bearing areas, and weak-to-no fluorescence of the surrounding dermis. Also visible is fluorescence in the overlying epidermis. (From Szeimies RM, Sassy T, Landthaler M: Penetration potency of topical applied & alpha-aminolevulinic acid for photodynamic therapy of basal cell carcinoma. *Photochem Photobiol* **59**:73, 1994.)

Actinic keratoses have been studied most extensively and respond to PDT as readily as to local cryotherapy or to broad area 5-fluorouracil (see Chapter 220) or imiquimod therapy (see Chapter 221) administered over weeks to months. Topical application of a 20% ALA solution for 14–18 hours followed by irradiation with blue light (417 nm) for 1,000 seconds (10 J/cm^2) clears more than 80% of actinic keratoses after 1–6 months,[113] and 90% complete clearance at 1 and 5 months was observed after one full face treatment using a 1- to 3-hour incubation period.[113,114] However, cutaneous metastases of malignant melanoma, pigmented BCC, and sclerodermiform variants of BCC respond poorly to ALA-PDT, probably because of insufficient porphyrin synthesis and/or penetration of light within the lesions.[110] Treatment efficacy is enhanced by repeated treatment sessions.[117]

In superficial and nodular BCCs, two randomized phase-III studies have been reported so far comparing MAL-PDT with either surgery or cryotherapy. After an observation period of 60 months, MAL-PDT for superficial BCC showed a similar recurrence rate as cryotherapy (22% versus 20%). In nodular BCC, MAL-PDT was compared with simple excision; recurrence rates after 60 months were 14% and 4%, respectively. In both studies, the cosmetic outcome was considered superior for the PDT-treated groups.[115,116] Indeed, these and other reports[117] suggest that a major theoretic benefit of ALA/MAL-PDT is elimination of skin cancers without scarring, as well as prevention of such lesions in high-risk patients treated periodically with broad area PDT.



Figure 238-8 Bowen disease. **A.** Lesion located on the right lower leg. **B.** Twelve months after topical aminolevulinic acid-photodynamic therapy [10% aminolevulinic acid ointment, application for 4 hours, irradiation with argon-pumped dye laser (175 mW/cm^2; 180 J/cm^2)], clinically and histologically, there were no signs of tumor residue.

CTCL (mycosis fungoides) also responded in eight single case reports to ALA-MAL PDT after several treatment sessions. Controlled investigations are currently not available, and, as with PUVA treatment of single lesions, this treatment would not be expected to prevent the appearance of new lesions in other areas.[118]

Topical Photodynamic Therapy for Non-Oncologic Indications.[119–135] Few data are available regarding the treatment of inflammatory and proliferative skin conditions. These include psoriasis, localized scleroderma, human papilloma virus (HPV)-associated conditions, leishmaniasis, acne, and rosacea.

ALA/MAL-PDT is also effective for acne and rosacea, although optimal protocols have not been developed. In two separate studies,[128,129] 22 patients with mild-to-moderate acne on the back received 20% ALA cream under occlusion for 3 hours. The areas were then exposed to broadband (550–700 nm) or laser light (635 nm) using various protocols. The authors observed a significant reduction in inflammatory acne lesion counts compared with baseline that persisted at least 20 weeks in some patients.[128] One study found a reduction in sebaceous gland size and sebum secretion, as well as reduced fluorescence attributable to *Propionibacterium acne*,[128] although the other did not.[129]

PDT with ALA has also been demonstrated to enhance the treatment of photodamaged skin with a variety of lasers and light sources. Improvement of global appearance, fine lines, tactile skin roughness, mottled hyperpigmentation, and telangiectasias has been described.[132–135] Mode of action is based on the degradation of altered collagen and elastotic material and the formation of newly synthetized collagen directly underneath the epidermis.[136,137]

PERSPECTIVES

The efficacy of PDT in the treatment of superficial neoplastic skin lesion, particularly actinic keratoses, Bowen disease, and superficial BCCs, has been sufficiently documented. PDT may also find a place in the treatment of selected patients with inflammatory dermatoses. Nonetheless, the limitations of both systemic and topical PDT have to be kept in mind. Crucial issues are the depth of the penetration of light, as well as of the sensitizer, into the skin, and inability to ensure complete eradication of malignancy by histologic criteria.

KEY REFERENCES

Full reference list available at www.DIGM8.com

DVD contains references and additional content

1. Pathak MA, Fitzpatrick TB: The evolution of photochemotherapy with psoralens and UVA (PUVA): 2000 BC to 1992 AD. *J Photochem Photobiol B Biol* **14**:3, 1992
2. Hönigsmann H: Phototherapy for psoriasis. *Clin Exp Dermatol* **6**:343, 2001
9. Wolff K et al: Phototesting and dosimetry for photochemotherapy. *Br J Dermatol* **96**:1, 1977
15. Menter A et al. Guidelines of care for the management of psoriasis and psoriatic arthritis Section 5. Guidelines of care for the treatment of psoriasis with phototherapy and photochemotherapy. *J Am Acad Dermatol* **62**: 114, 2010
20. Marcil I, Stern RS: Squamous-cell cancer of the skin in patients given PUVA and ciclosporin: Nested cohort crossover study. *Lancet* **358**:1042, 2001
23. Hönigsmann H, Wolff K: Results of therapy for psoriasis using retinoid and photochemotherapy (RePUVA). *Pharmacol Ther* **40**:67, 1989
31. Tanew A, Hönigsmann H: Ultraviolet B and psoralen plus UVA phototherapy for cutaneous T-cell lymphoma. *Dermatol Ther* **4**:38, 1997
64. Lim JL, Stern RS: High levels of ultraviolet B exposure increase the risk of nonmelanoma skin cancer in psoralen and ultraviolet A-treated patients. *J Invest Dermatol* **124**:505, 2005
69. Stern RS: The PUVA follow-up study. The risk of melanoma in association with long-term exposure to PUVA. *J Am Acad Dermatol* **44**:755, 2001
71. Wolff K: Should PUVA be abandoned? [editorial]. *N Engl J Med* **336**:1090, 1997
83. Trautinger F et al: EORTC consensus recommendations for the treatment of mycosis fungoides/Sézary syndrome. *Eur J Cancer* **42**:1014, 2006
117. Braathen LR et al: Guidelines on the use of photodynamic therapy (PDT) for non-melanoma skin cancer—An international consensus. *J Am Acad Dermatol* **56**:125-143, 2007

Chapter 239 :: Lasers and Flashlamps in Dermatology

:: Michael Landthaler, Wolfgang Bäumler, & Ulrich Hohenleutner

LASERS AND FLASHLAMPS AT A GLANCE

- Lasers are the most precise and selective surgical tools in existence.
- Nonscarring treatment of vascular lesions, pigmented lesions, tattoos, and hair follicles relies on a process called *selective photothermolysis*. For each of the aforementioned broad indications, there are lesion variants that are highly responsive to laser therapy, lesions that are occasionally responsive, and lesions for which laser treatment is contraindicated.
- Pulse duration strongly influences safety and efficacy, and, in general, should be approximately equal to the thermal relaxation (cooling) time of specific targets in a given patient.
- Port-wine stains are congenital neurovascular lesions best treated in early childhood that respond well, but rarely completely, to laser treatment.
- Laser treatment is useful for treatment of ulcerated infant hemangiomas.
- Fractional resurfacing is a technique in which thousands of laser microbeams per square centimeter are used to stimulate epidermal and dermal remodeling. It is a less invasive treatment for photoaging than is ablative laser resurfacing.
- Use of any laser or flashlamp (intense pulsed light) for hair removal poses a severe risk of eye injury when used near the eye. Other risks include fires, inhalation of the vaporized tissue plume, electrocution, and a host of side effects such as stimulation of facial hair growth, pigmentary changes, and scarring.

PRINCIPLES AND SAFETY

INTRODUCTION

Laser emits radiation whose properties are fundamentally different compared to radiation of other sources. Laser radiation is monochromatic in a range from 100 nm to 3 mm, appears as strictly parallel beam, can be either continuous or pulsed in a range from seconds to femtoseconds (10^{-15} s), and can show intensities of more than 10^{10} W/cm^2.

A few years after development of lasers in 1960, physicians such as Leon Goldman started to apply this new and exciting radiation in dermatology. Since 1963, numerous physicians have investigated the use of various types of lasers to treat different skin disorders. When laser radiation is absorbed in tissue, radiation energy is predominantly converted to heat. Because of its exceptional nature, laser radiation can be applied to cut, vaporize, coagulate, or ablate skin. It was identified as able to achieve selective destruction of targets inside skin. Laser pulses precisely destroy even very small targets in skin such as small vessels or melanosomes. By manipulating the appropriate laser parameters such as wavelength, pulse duration, and radiant exposure, the destruction of a target occurs without damage to the adjacent tissue, which substantially minimizes the risk of side effects like scarring. The selection of the appropriate laser parameters for an effective and precise destruction of targets in skin were summarized as the rules of selective photothermolysis.[1]

A newer light source appeared in dermatological practice some years ago: the intense pulsed light source (IPL).[2,3] It mainly consists of a flashlamp that emits white light ranging from about 250–1,400 nm. The spectrum is narrowed (~500–1,000 nm) by applying optical edge-filters (cut-off filters) and water film in front of the flashlamp. In contrast to lasers, IPL emission shows a broad spectral range of up to 500 nm and the pulse duration is limited to milliseconds. IPL radiation can be successfully applied for some dermatological indications by achieving partially selective photothermolysis.

LASER PRINCIPLES

Electromagnetic radiation can be described as a plane wave that is propagating in space with a constant velocity c of 299,790 km/s. The major properties of radiation are wavelength λ and frequency ν, which are correlated:

$$c = \lambda \cdot \nu$$

Radiation also can be considered as particles, which are called photons, with a specific energy

$$E = h \cdot \nu = \frac{h \cdot c}{\lambda}$$

where h is Planck's constant ($6.6\ 10^{-34}$ Js). The energy of radiation increases with decreasing wavelength. The spectrum of electromagnetic radiation exhibits a broad range, with wavelengths ranging from a few nanometers to thousands of meters. Only a small part of the spectral range is visible for human eyes (400–700 nm); this, and only this, is light.

The generation of laser radiation is a complex process. The acronym LASER is derived from the most important elements: ***L****ight* ***A****mplification by* ***S****timulated* ***E****mission of* ***R****adiation*.

The process of spontaneous emission of photons describes the emission of radiation from a usual light source such as light bulb. After excitation, atoms or molecules can emit photons at different times, in any direction and usually with different wavelengths. Therefore, such a radiation is incoherent, divergent and spectrally broadband.

In contrast, a laser medium consists of identical atoms or molecules (photon emitter, Table 239-1), which are excited by different means such as electrical discharge (gas lasers) or optical radiation (flashlamp pumped lasers). These photon emitters are placed in a substrate, which is either gas, liquid, or solid state. Together the photon emitters at a certain concentration and the substrate represent the laser medium. After excitation, which is called pumping, the atoms or molecules return from the excited to the ground state and thereby emit photons with a specific wavelength λ_L that is determined by the energy difference ΔE of the excited and the ground state with

$$\Delta E = \frac{h \cdot c}{\lambda_L}$$

If one considers the same transition in all atoms or molecules in a specific laser medium, the emitted photons have the same wavelength λ_L leading to the monochromatic nature of laser radiation. If the ground state and the excited state are spectrally broadened, then laser transition is possible in a certain wavelength range and a laser is tunable to different wavelength λ_L within this spectral range.

The combination of such identical transitions and photons with the same wavelength λ_L in a confined volume (laser medium) allows another process to come to the fore: the stimulated emission of photons, as described and published by Albert Einstein in 1917.[4]

TABLE 239-1
Laser, Media and Parameters

Name	Wavelength (nm)	Photon Emitting Medium	Substrate	Type	Typical Mode Pulse Duration
Excimer laser	308	Excited dimer molecules (Xe-Cl)	Different gases	Gas	Pulsed µs–ms
"KTP" laser (Nd:YAG laser) frequency doubled) with KTP crystal)	532	Nd^{3+}	Crystal: Yttrium-aluminum Garnet ($Y_3Al_5O_{12}$)	Solid state	Pulsed ms–ns
Dye laser	585–600	Dyes, e.g., Rhodamines	Organic solvents	Liquid	Pulsed ms
Ruby laser	694	Cr^{3+}	Al_2O_3	Solid state	Pulsed ms–ns
Alexandrite laser	755	Cr^{3+}	Chrysoberyl ($BeAl_2O_4$)	Solid state	Pulsed ms–ns
Diode laser	Different wavelengths (e.g. 810, 940)	InGaAs AlGaAs	Semiconductor material	Solid state	Pulsed ms
Nd:YAG laser	1,064	Nd^{3+}	Crystal: Yttrium-aluminum Garnet ($Y_3Al_5O_{12}$)	Solid state	cw, pulsed ms–ns
Er:YAG laser	2,940	Er^{3+}	Crystal: Yttrium-Aluminum Garnet ($Y_3Al_5O_{12}$)	Solid state	Pulsed ms
CO_2 laser	10,600	CO_2	Different gases	Gas	cw, pulsed ms

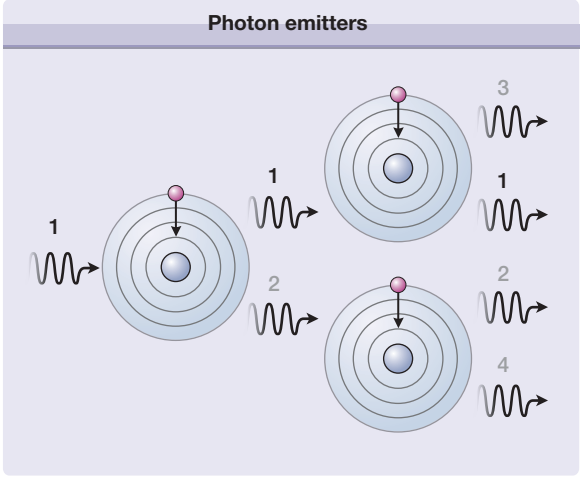

Figure 239-1 All photon emitters in a laser medium are excited, which is indicated by an electron in the highest energy level of an atom. A first photon (1) stimulates the next atom to emit a photon (2); these two photons provoke the next photons (3 and 4).

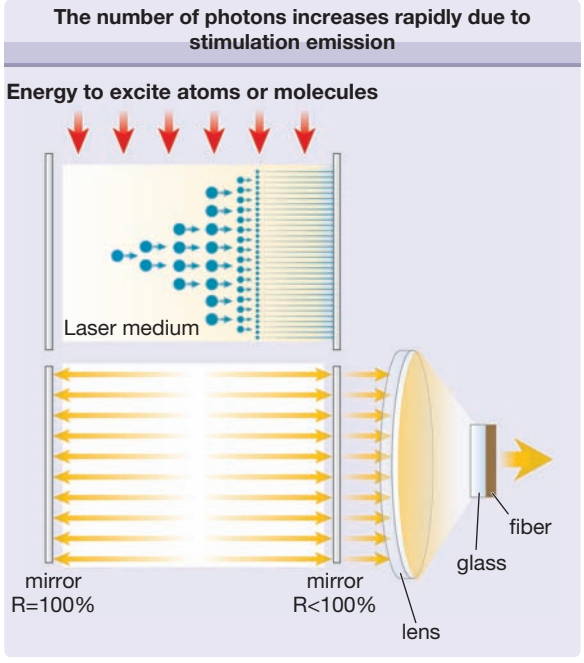

Figure 239-2 The number of photons increases rapidly due to stimulated emission (*top*). As the laser medium is placed between two mirrors, the stimulation of emission of radiation is continued by reflection of photons back and forth (*bottom*). The reflectivity (R) of one mirror is less than 100% and a small fraction of radiation can traverse this mirror (therapeutic radiation). This laser radiation is focused by a lens and fed into an optical fiber, which delivers it to the patient.

Figure 239-1 shows the basic process of stimulated emission of radiation. One photon stimulates the next atom or molecule to emit a photon. The resulting two photons stimulate the next two atoms or molecules that results in four photons and so on. A laser medium consists of up to 10^{20} photon emitting atoms or molecules, which provides an immense number of stimulated photons. For example, a laser pulse with energy of 1 Joule and a wavelength in the visible spectrum contains about 10^{19} photons. Thus, the light amplification is actuated by the stimulated emission of radiation, as described by the acronym LASER. The process of light amplification does not change the energy of photons but increases their number exponentially.

To promote the stimulated emission of radiation and hence to optimize the process of light amplification, the laser medium is placed in an optical resonator that consists of two or more mirrors (Fig. 239-2). Due to the reflection of laser photons inside the resonator, the laser starts to oscillate and the number of photons continues to increase exponentially. Laser action can be achieved when the gain of photons in the laser medium is higher than the loss caused by spontaneous emission or absorption of photons. The temporal behavior of the laser emission depends on the temporal behavior of the excitation of the atoms or molecules. That is, when the energy supply to the laser medium is continuous, the emission of the laser is continuous wave (cw). When the energy supply is limited to a certain time interval by gas discharge or flashlamp, we speak of pulsed excitation, and the laser emits pulses accordingly. The laser pulse duration can vary from microseconds to milliseconds.

To achieve very short pulse durations in the nanosecond range, the resonator is additionally equipped with an optical polarizer and a nonlinear crystal. The polarizer sets the linear polarization of the laser beam that passes through the crystal. However, if an appropriate electrical voltage is applied to the crystal, the polarization of the photons is changed inside the crystal and subsequently blocked by the optical polarizer. This prevents photons from running back and forth inside the resonator (oscillation), which hampers light amplification and which is equivalent to a low circuit quality of the resonator. In such a case, the stimulated emission is minimized and the pumping of the laser medium produces a maximum number of excited atoms or molecules in the laser medium. When this maximum number is achieved, the electrical voltage of the crystal is switched off within nanoseconds and the photons can easily pass the crystal, which is equivalent to a high circuit quality of the resonator. Now, the laser oscillation immediately starts and the light amplification yields a very high number of photons per time unit due to the high number of excited atoms or molecules in the laser medium. The outcome of this circuit quality switch (Q-switch) is a very intense laser pulse with pulse duration in the range of nanoseconds.

IPL PRINCIPLES

The major component of an IPL is the flashlamp that emits radiation from the ultraviolet to the far-infrared part of the electromagnetic spectrum (Fig. 239-3). The broad emission spectrum is narrowed to match the absorption spectra of the different chromophores in skin. The infrared part is usually blocked for wavelengths longer than 950 nm using water in front of the

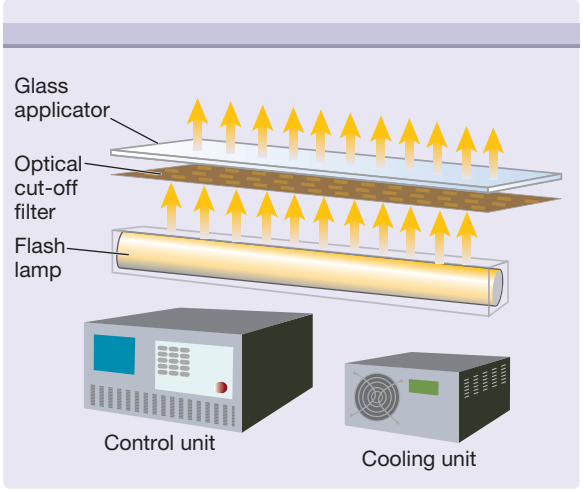

Figure 239-3 The flashlamp of IPL emits radiation that is filtered by a cut-off filter and water in front of the flashlamp. During therapy, the glass applicator is in contact with the skin surface. The control unit operates radiant exposure and pulse duration.

glass applicator. The short wavelengths are blocked by an optical edge filter (cut-off filter), which is only transparent for radiation with wavelengths longer than the cut-off wavelength (e.g., 500 nm, 650 nm). The choice of cut-off filter depends on the chromophore and the target in the skin. A 500 nm cut-off is usually employed for vascular lesions, while a 650 nm cut-off is preferred for the melanin chromophores employed in hair removal. This cut-off also reduces the unwanted interaction with oxyhemoglobin in the vessels.

BASIC PARAMETERS OF OPTICAL RADIATION

The main parameters of optical radiation are wavelength, optical power, intensity, the exposure time and radiant exposure. In the medical literature the phrase fluence is frequently used instead of radiant exposure. The correlation of these parameters are shown in Table 239-2, where the unit for energy is Joule (J); optical power Watt (W); intensity (W/cm^2); radiant exposure (J/cm^2); the exposure time second (s); and the area of irradiation on skin surface (cm^2). After being transported through a glass fiber or articulated arm, laser radiation is usually applied as circular spot to the skin surface by means of a lens in a holder. The spot size and the energy of the laser radiation determine the radiant exposure (J/cm^2). The distal end of a bare glass fiber can be placed inside tissue through a hollow needle for interstitial laser application. The IPL applicator directly contacts the skin through an ultrasonic gel. Thus, the radiant exposure of IPL emission is determined by the size of the applicator and the energy of radiation (J/cm^2).

ENERGY AND INTENSITY. The photon is the smallest unit of radiation. The energy of a single photon at 532 nm (fd Nd:YAG laser, KTP) is about 4 10^{-19} J, which requires a high number of such photons in the order of 10^{19} photons to generate a single laser or IPL pulse. Table 239-3 shows examples of typical intensities that are emitted by IPL or lasers in medical applications. These intensities are substantially higher as compared to typical radiation sources in our daily life, such as light bulbs or solar radiation.

EXPOSURE TIME. To achieve various therapeutic objectives, physicians use different exposure times of radiation, which range from a few nanoseconds to seconds. In case of cw lasers, the exposure time is in the range of seconds, which correlates simply to the time span of pressing the laser foot switch. In most medical treatments, the exposure time is predefined by the pulse duration of a single laser or IPL pulse. In case of pulsed radiation, the exposure time is equivalent either to a single pulse or to a train of single pulses. The broad range of pulse durations implies a broad range of intensities that is important for safety issues. Therefore, lasers are classified by cw (>0.2 s), pulsed (0.2 s–>1 µs), or giant pulsed lasers (Q-switched lasers) (1 µs–1 ns) in safety regulations.

RADIANT EXPOSURE. The most frequently modified parameter in laser treatments is the radiant exposure or fluence. It is the product of light intensity and exposure time (Table 239-2). When taking the total range of medical treatments into account, the radiant exposure varies from about 1–400 J/cm^2 for pulsed radiation. This range can be exceeded for

TABLE 239-2
Parameters of Optical Radiation

Parameter	Formula	Units
Energy	Energy = power × time	J = W × s
Intensity	$\text{Intensity} = \frac{\text{power}}{\text{area}}$	$\frac{W}{cm^2}$
Radiant exposure ("fluence")	$\text{Radiant exposure} = \frac{\text{power} \cdot \text{time}}{\text{area}}$	$\frac{J}{cm^2} = \frac{W \cdot s}{cm^2} = \frac{W}{cm^2} \cdot s$

TABLE 239-3
Typical Parameters for Medical Lasers

Radiation	Intensity $\frac{W}{cm^2}$	Exposure Time ms	Radiant Exposure $\frac{J}{cm^2} = \frac{W}{cm^2} \cdot s$
IPL	1,500	10	15, broadband
fd Nd:YAG laser (e.g., telangiectases)	500	50	25
Pulsed dye laser (e.g., port wine stains)	12,000	0.5	6
Q-switched ruby laser (e.g., tattoos)	25×10^8	0.00002	5

cw applications. Table 239-3 shows a few examples for different intensities and exposure times that are employed in the treatment of different skin lesions. It is striking that the values of radiant exposures are within a rather narrow range, whereas the respective intensities and pulse durations vary in an inversely proportional manner by orders of magnitude.

SKIN OPTICS

Propagation of optical radiation through normal media such as air or glass can be described in a straightforward fashion, in particular, for monochromatic and collimated laser light. Reflection, refraction and absorption dominate the propagation. However, when optical radiation penetrates turbid media like skin, we also must consider scattering of radiation inside tissue that hampers light propagation in a complex manner.

When optical radiation strikes skin, part of the photons is reflected back due to the different refractive index of air and skin. This effect necessitates the wearing of safety goggles during laser therapy. Photons inside the skin do not propagate straight on but frequently and abruptly change their direction due to collision with skin constituents, which is called scattering (Fig. 239-4). The mode and the extent of scattering depend on the size of the scattering objects and the wavelength of the radiation. The size of the scattering objects range from a few nanometers (small cell organelles, cell membranes) to a few microns (large cell organelles, cells, collagen) and to a hundreds of microns (hair follicle, sweat glands). The small objects follow the principle of isotropic Rayleigh scattering, the large objects the non-isotropic scattering. In both processes, the extent of scattering decreases with increasing wavelength. With increasing wavelength, photons are less deflected on their path into skin. Thus, the longer the wavelength, the higher is the penetration depth of radiation in skin. Ultraviolet B radiation (around 300 nm) penetrates skin up to a few tenths of millimeters only, whereas infrared radiation (e.g. Nd:YAG, 1,064 nm) achieves a penetration depth of up to a few millimeters. However, the increase in penetration depth with increasing wavelength reverses for wavelengths longer than about 1,100 nm because radiation is increasingly absorbed by water in skin.

Fortunately, the scattering in skin is mainly forward and many photons penetrate the skin. Unfortunately, the scattering changes the beam geometry in the skin and thereby substantially affects the dosimetry. It is complex to determine the number of photons that reach a target (for example, a vessel) in the skin. The higher the number of photons reaching the target, the more heat can be produced inside the target.

The propagation of broadband radiation such as IPL emission is more complex than that of lasers. Photons with different wavelengths in the broadband emission (~500–950 nm) penetrate skin to different depths. While propagating through the skin, photons can be absorbed by the different chromophores at any time.

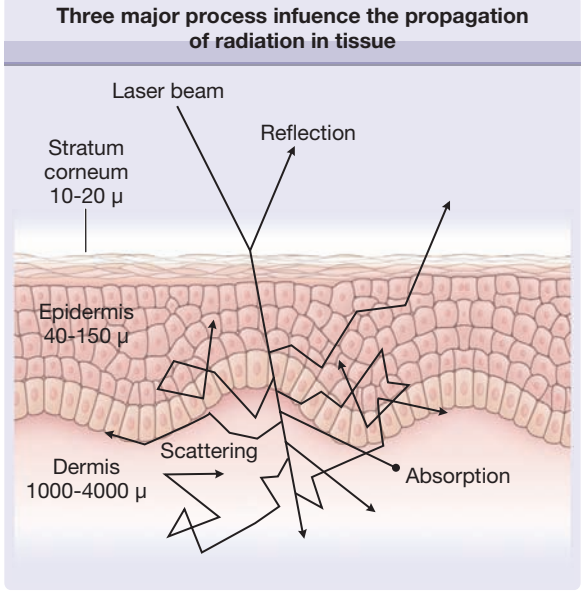

Figure 239-4 Three major processes influence the propagation of radiation in tissue: reflection, absorption, and scattering.

INTERACTION OF RADIATION WITH SKIN

For monochromatic lasers, photons with single wavelength are absorbed according to the absorption coefficient of the respective chromophores at this single wavelength (Fig. 239-5). The absorption of broadband radiation of IPL is complex (Fig. 239-6). The photons with wavelengths in the range of 500–950 are absorbed to a different extent. This clearly complicates dosimetry of IPL in clinical use. In addition, the different IPL in the market emit radiation with considerable different spectra, even though the same cut-off filters are used. This precludes a comparison of radiation dosimetry for different IPL, which impedes clinical studies.

When monochromatic laser radiation or broadband IPL emission is absorbed by the different skin chromophores oxyhemoglobin, melanin, or water, the radiation energy is converted to either heat or chemical reactions. Nd:YAG laser (frequency doubled at 532 nm) and pulsed dye lasers (585–600 nm) preferentially interact with oxyhemoglobin. Radiation of ruby laser (694 nm), alexandrite (755 nm), and diode laser (around 810 nm) is less absorbed by oxyhemoglobin and more suitable for pigmented lesions including hair removal. Radiation of Nd:YAG laser (1,064 nm) is minimally absorbed by all chromophores. Nevertheless, at high radiant exposures (J/cm^2), this laser can be used for unspecific coagulation of tissue (cw mode) or vascular lesions (pulsed mode). The latter is also possible for diode and alexandrite lasers. Infrared lasers such as Er:YAG and CO_2 lasers interact solely with water heating up tissue for vaporization or ablation.

In contrast to lasers, IPL emission is broadband and may be absorbed by all chromophores simultaneously. Using a 500 cut-off filter, the radiant exposure (J/cm^2) is assembled by photons of different wavelengths

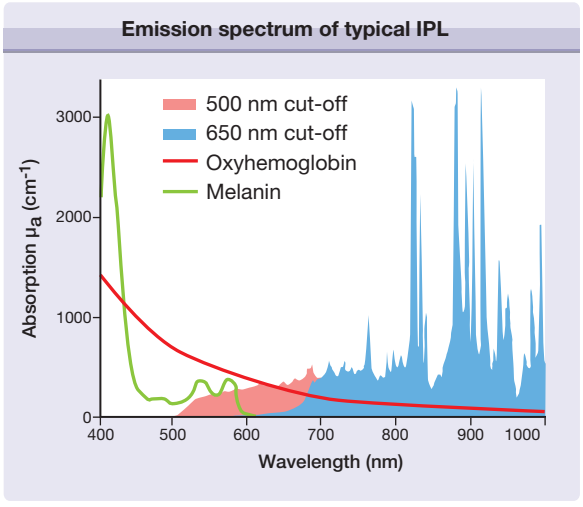

Figure 239-6 The emission spectrum of a typical IPL should match the absorption spectrum of the respective chromophores. 500-nm cut-off filters provide an overlap with the absorption of oxyhemoglobin; 650-nm cut-off filter predominantly with melanin.

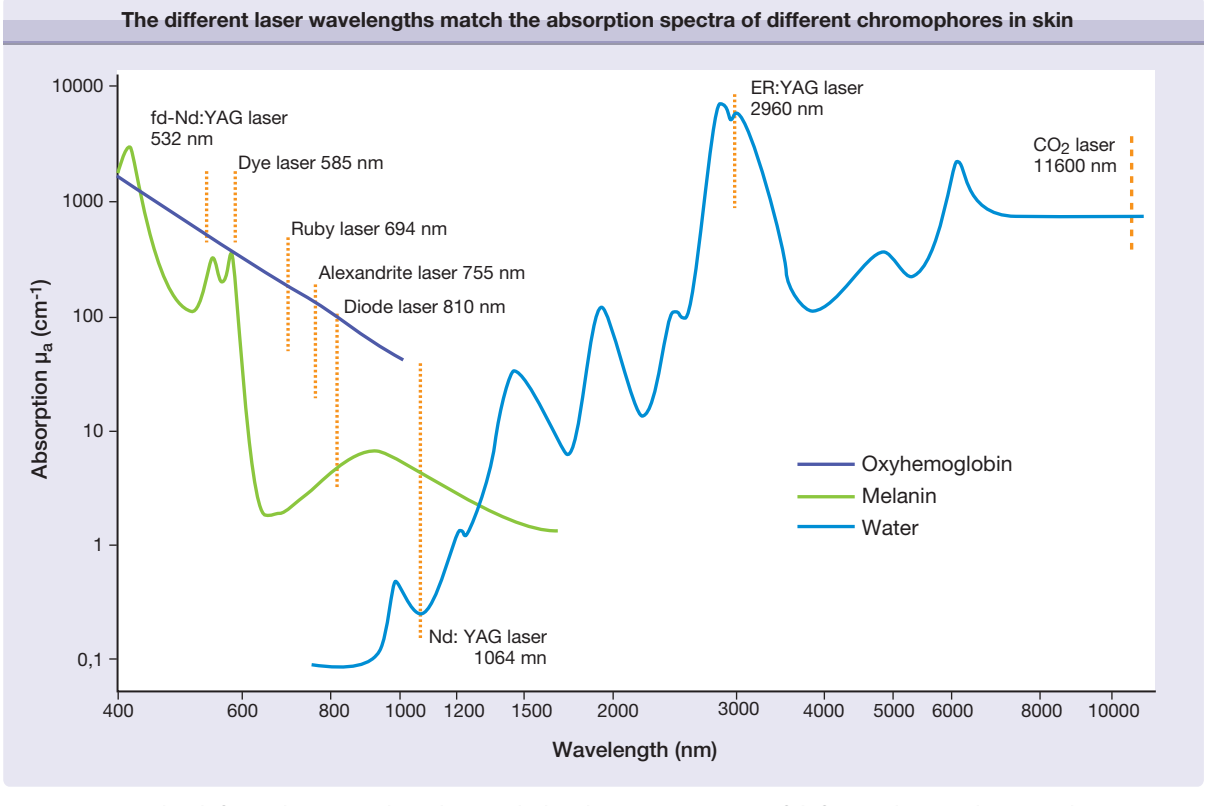

Figure 239-5 The different laser wavelengths match the absorption spectra of different chromophores in skin.

(~500–950 nm), which are diversely absorbed by a skin chromophore like oxyhemoglobin. In addition, these photons reach different depths in skin as explained in skin optics. Thus, the conversion of IPL radiation to heat energy in a target at a certain depth is quite different as compared to laser radiation.

While photochemical reactions require only a small intensity, photothermal reactions necessitates a high intensity. After being absorbed in a chromophore of a specific target (e.g., oxyhemoglobin in a blood vessel), the energy of these photons causes an increase of temperature inside the target. At the same time, the elevated temperature provokes a flow of heat energy to outside the target. This counteracts the heat generation and thereby limits the temperature increase to a maximum value.

For low intensities and long exposure times (pulse duration), the application of laser or IPL radiation causes moderate temperature increase. The temperature ranges from body temperature to 100°C (coagulation), which is achieved with exposure times from milliseconds to continuous wave (cw). When tissue is heated toward the boiling point, radiation causes vaporization of the skin. The use of short CO_2 laser pulses heat up tissue very rapidly leading to a rapid vaporization. This effect precisely causes small holes with minimal thermal damage of the adjacent tissue.

The use of sufficient high intensity and pulse duration of microseconds is suitable to perform skin ablation at temperatures higher than 100°C. When using very high intensities (10^7–10^9 W/cm^2) and very short pulse durations (nanoseconds), the temperature of the target can reach hundreds of degrees celsius. This very short and intense heating may cause explosion of the target. Since the total energy of the laser pulse is limited, ablation and explosion in laser medicine can be restricted to a very small volume. Such high intensities at short pulse durations are accomplished only with lasers and not with IPL.

When pulsed radiation is delivered to skin, the radiant exposure (J/cm^2) stays in a narrow range of about two orders of magnitude. In contrast to that, the intensity and the pulse duration may vary with 5 orders of magnitude at least (Table 239-3). As a rule of thumb, we can say that the higher the intensity (W/cm^2) and the shorter the pulse duration, the higher the maximum temperature inside the targeted volume. By changing the parameters intensity and pulse duration, the temperature can be adapted to achieve coagulation, vaporization or explosion of a specific target in skin.

SELECTIVE PHOTOTHERMOLYSIS

It is a major goal to destroy precisely a specific target (such as vessel, pigment) in skin without permanent damage to the adjacent skin structures. This goal can be achieved by applying pulsed radiation and the principle of selective thermolysis.[1] To destroy selectively a target by heating, the following issues must be considered. The wavelength of the applied radiation should be preferentially absorbed in the chromophore of the target (Fig. 239-6), which is difficult to accomplish for broadband IPL emission (Fig. 239-7). The energy of the radiation pulse should be high enough to achieve thermal destruction of the entire target.

The pulse duration should be comparable to the thermal relaxation time (t_R), which mainly depends on the diameter of the target (D)

$$t_R = \frac{\rho c}{16k} D^2 \sim D^2$$

where ρ, c, k are thermal parameters of the target).[5] The thermal relaxation time is the time it takes to decrease the temperature in the target to 50% of the maximum value. The thermal relaxation time is roughly proportional to the square of the mean diameter of the target. Many of the calculated times match the pulse durations that are used in clinical practice (Table 239-4).

Pigmented lesions containing small melanin or tattoo pigment particles are treated with nanosecond pulses of Q-switched lasers. Besides the short pulse duration, the treatment requires high light intensities to achieve explosion of the pigment particles in the skin.

The use of millisecond pulse duration of either IPL or laser is appropriate to coagulate small blood vessels with diameter of 50–150 µm.[6–8] Figure 239-7 illustrated coagulation of a blood vessel in the dermis. Pulsed radiation penetrates the skin and the radiant exposure (J/cm^2) is reduced from the known value (J/cm^2 at skin surface) to a smaller value due to scattering. The reduced value represents the radiant exposure to be absorbed in the blood vessel. Initially, only the temperature in the vessel increases, coagulating

TABLE 239-4
Thermal Relaxation Times for Common Laser Targets in Skin

Target	Mean Diameter	Thermal Relaxation Time
Pigment (melanosome)	~0,1 µm	5 ns
Small vessel (e.g., port-wine stain)	~50 µm	1.1 ms
Hair follicle	~0,2 mm	18 ms
Large vessel (e.g., leg veins)	~1,5 mm	1,023 ms

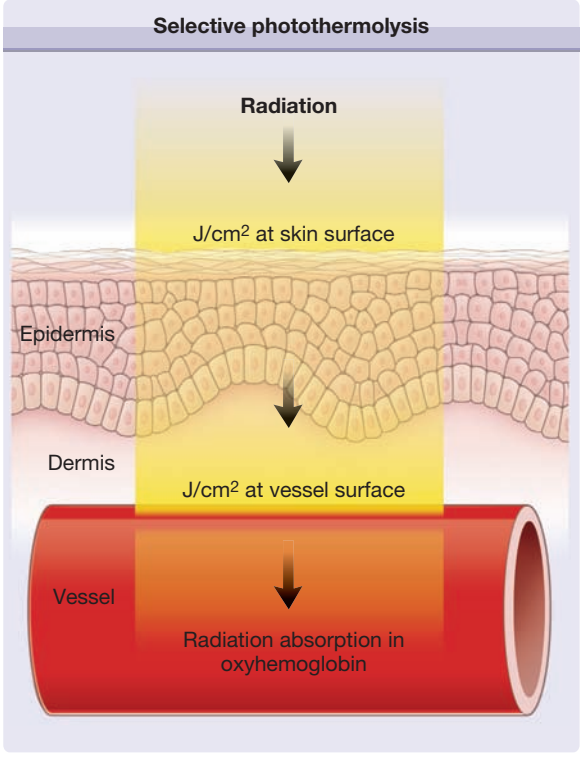

Figure 239-7 The interaction of pulsed radiation with a vessel in skin demonstrating the concept of selective photothermolysis.

the vessel. Due to the temperature increase inside the vessel, however, heat energy starts to flow to the adjacent dermis. At this point, the radiation pulse should be terminated to achieve selective vessel destruction. Pulse duration longer than the thermal relaxation time results in excessive heat flow to the dermis, which may cause unnecessary adverse reactions.

The thermal destruction of hair follicles is achieved by using radiation pulses in the range of 10–50 ms.[9–11] The same range of pulse durations is applied for the treatment of large vessels such as leg veins.[12] However, the calculated value (Table 239-4) does not match this range. In case of voluminous targets, the selective photothermolysis must be aligned to a new parameter, which is the cooling down of heated target. The larger the target, the slower is the cooling down and hence the higher the probability of effective coagulation.[12]

FRACTIONAL PHOTOTHERMOLYSIS

Laser radiation is usually applied on the skin surface as a circular spot showing spot sizes in the range of millimeters. The use of fractional photothermolysis leads to spatially distributed zones of microthermal injury within the treatment area, called microscopic treatment zones (MTZs). These are generated in the skin by focused laser irradiation. MTZs consist of sharply confined tissue denaturation with a diameter of about 100 µm that is surrounded by viable tissue, at intervals of about 200 µm.[13] MTZs are produced either in the ablative or in the nonablative mode. Fractional photothermolysis is a new concept for skin restoration. The MTZs are placed not manually but using computer-assisted scanner device to produce a periodic grid of thermal injuries.

SKIN COOLING

Laser therapy of skin disorders require high radiant exposure to be delivered to the skin surface. Most of the targets are located at the epidermal-dermal junction or within the dermis. To reach these targets, the photons have to traverse the epidermis, which can partly absorb the incoming radiation. In addition, excess heat, caused by the absorption of radiation in the dermis, may provoke damage of dermal and epidermal structures. To avoid unwanted thermal damage especially to the epidermis, the skin surface is frequently cooled before, during, and after laser impact by a variety of measures.

The simplest and cheapest cooling is accomplished by applying ice cubes on the skin surface prior to or even during laser impact.[14] An application time of 10 seconds can result in skin surface temperature of about 10°C. About the same results are achieved by applying actively cooled metal or glass to the skin surface[15] Instead of contact cooling, some laser systems are equipped with spray cooling. Shortly before laser impact, a burst of cold gas (usually tetrafluoroethane) is applied to skin surface reducing the temperature of the epidermis to about 5°C.[10] Cooling is also achieved by exposing the treatment area to cold airflow that is provided by a special air conditioner.

SAFETY

It was recognized early that radiation of any wavelength can pose a risk to humans, in particular, to unshielded eyes and skin.[16,17] This risk is caused by the absorption of photons leading to photochemical or photothermal alterations of tissue.[18,19] These alterations may affect tissue integrity for a short period of time or damage tissue permanently. When lasers or intense pulsed light sources are used to treat skin lesions, a variety of safety measures are required.

The use of lasers in medical care is governed by rules and standards that are established in the Safety of Laser Products of the International Electrotechnical Commission (IEC) (http://www.iec.ch/) or American National Standards Institute (ANSI) (http://www.ansi.org/). The safety rules are based on IEC 60825-1 or ANSI Z136.1 for all laser systems, including medical lasers. Lasers have been classified in four groups based on the accessible emission limits (AEL). The rules are applicable to safety of laser products emitting laser radiation in the wavelength range 180 nm to 1 mm. These regulations unfortunately do not cover the use of IPL; there is no existing FDA performance standard for IPL products. We provide some advice regarding IPL safety, based on comparisons with laser systems. IPL systems emit high radiant exposures (J/cm^2) that

are comparable to lasers and have therefore the potential to cause substantial damage to the eyes and skin.

When using lasers for tissue vaporization, laser plume must be evacuated by using an appropriate device to avoid contact with infectious material.

EYE SAFETY

The high radiant exposures, high intensities and short pulse durations in laser therapy not only can harm the skin but also can severely damage the eyes even causing complete loss of eyesight. The side effects of radiation to the eyes are comparable to those effects at the treatment site. It is inevitable that radiation partly reaches the eyes due to reflection and scattering at the treatment site. Other reasons are accidental and careless handling of lasers and IPL during treatment.

In the spectral range of about 370–1,000 nm, radiation readily penetrates the cornea and the lens reaching the choroid and retina. The radiation of this spectral range is well absorbed by the hemoglobin in the choroid vessels that may lead to thermal damage of the retina. Refraction by the lens and cornea increases the intensity of the incoming radiation by several orders of magnitude.

For wavelengths shorter than 370 nm and longer than 1,000 nm, radiation is predominantly absorbed in water (Fig. 239-1) and do not completely traverse lens and cornea. The short wavelengths can cause injury of the cornea (cornea ablation) or cataract formation in the lens. With increasing wavelengths above 1,000 nm, the penetration of radiation decreases leading again to cataract formation (Fig. 239-3). For wavelengths around 3 µm, the water absorption is maximal for causing cornea ablation. At even longer wavelengths, vaporization of the cornea may occur.

The eyes try to protect themselves from damage that could be induced by excess radiation energy. The eyelid is closed automatically in case high radiation energy is detected. However, the corresponding time span is about 250 ms, which is longer than most of the pulse durations used for lasers and IPL. Radiation that is invisible for the eyes (UV, IR) will not trigger an eye blink.

Users of lasers or IPL should always keep in mind that even small intensities reaching the open pupil can cause severe damage of the retina, which, in most cases, is irreversible and may entail a complete loss of vision. Radiation of lasers or IPL can also damage skin outside the treatment area.

For nearly all medical laser systems, even scattered radiation can be dangerous to eyes. To shield the eyes, it is mandatory to wear safety goggles during treatment with lasers or IPL according to EN 207 in Europe or to ANSI Z136 in the United States. To achieve maximal safety for the eyes, it is important to adjust the optical filters of the safety goggles to the radiation source used (laser or IPL). The important parameters of the radiation sources are wavelength, pulse duration, intensity, and radiant exposure. These parameters of a laser or IPL system determine the characteristics of the safety goggles. Each laser or IPL requires special safety goggles that are labeled for their use, which are wavelength range of protection, laser mode, and scale number of protection. The manufacturer of lasers or IPL must provide sufficient information about the appropriate safety goggles, which can be found in the handbook of each laser or IPL device.

SAFETY OF LASERS AND IPL SYSTEMS

All laser systems, including the medical lasers, sold in Europe must be certified to EN 60825-1. In the United States, several organizations concern themselves with laser safety including ANSI and the Center for Devices and Radiological Health (CDRH). There are some basic categories of controls useful in laser environments. These are engineering controls, personal protective equipment, administrative and procedural controls, special controls, and correct labeling of the laser products. It is required and mandatory to appoint a laser safety officer (LSO). This person has the authority to monitor and enforce the control of laser hazards and effect the knowledgeable evaluation and control of laser hazards. The LSO administers the overall laser safety program where the duties include items such as confirming the classification of lasers and ensuring that the proper control measures are in place, approving substitute controls and conducting medical surveillance. The LSO should receive detailed training including laser fundamentals, laser bioeffects, exposure limits, classifications, control measures (including area controls, eye wear, barriers, etc.), and medical surveillance requirements. Nearly all medical lasers are assigned to class III or class IV. The class of a laser can be found on the label present on the laser device and in its handbook. Class III means moderate power lasers (cw: 5–500 mW, pulsed: 10 J/cm^2 or the diffuse reflection limit, whichever is lower). In general, Class IIIB lasers will not be a fire hazard, nor are they generally capable of producing a hazardous diffuse reflection. Specific controls are recommended. Class IV means high power lasers (cw: >500 mW, pulsed: 10 J/cm^2 or the diffuse reflection limit) are hazardous to view under any condition (directly or diffusely scattered) and are a potential fire hazard and a skin hazard. Significant controls are required of Class IV laser facilities (http://www.osha.gov/dts/osta/otm/otm_iii/otm_iii_6.html). When using medical lasers, it is unavoidable that part of the beam path from a Class IIIB or Class IV laser is not sufficiently enclosed and/or baffled to ensure that radiation exposures will not exceed the MPE. Then a "laser-controlled area" is required. Although recommendations for the safe use of IPL in medical practice are currently not available, many of the items mentioned for lasers can be applied as well for IPL, in particular regarding eye protection.

THERAPEUTICAL APPLICATION

Since the introduction of lasers in dermatology by L. Goldman[20] and the development of selective photothermolysis in the 1980s,[1] laser therapy has become an

indispensable therapeutic modality and more than 80 indications are documented.

PORT-WINE STAINS (PWS)

PWS are asymmetric usually congenital capillary vascular lesions present in up to 2% of newborns. In childhood, they are pale red macules and patches. In adults they tend to become darker (port wine) and develop an irregular surface sometimes with blue-red papules and nodules. PWS are probably secondary to abnormal vascular innervation leading to a reduced vascular tone.[21–26]

In hypertrophic PWS with nodular surface, besides the vascular abnormalities extensive epithelial, neural, and mesenchymal harmartomatous changes have been observed suggesting a genetically determined multilineage development field defect.[27]

More recent studies indicate that RASA1 mutations cause capillary and arteriovenous malformations and hereditary capillary malformations and limb enlargement without arteriovenous malformation.[28–30]

Vascular endothelial growth factor (VEGF) and VEGF-receptor 2 expression is significantly increased in PWS compared to controls, indicating that VEGF and VEGF-R2 may contribute to vessel proliferation and vasodilatation.[31]

PWS are often associated with other malformations (Sturge-Weber-Krabbe syndrome, Cobb syndrome, Klippel-Trenaunay syndrome, Parkes-Weber syndrome).

Acquired PWS are rare but may be caused by trauma, hormonal imbalances or medications.

The introduction of the pulsed dye laser (PDL) in the 1980s ($\lambda = 585$ nm, $t = 0{,}45$ ms, $\varnothing = 5$ mm) greatly improved the treatment options for PWS. In the past two decades, important advances include the use of wavelengths of 585–600 nm, longer exposure times and increasing the diameter of the beam. In addition cryogen spray cooling is used to protect the epidermis, allowing a higher fluence to be delivered to the dermis.

Standard parameters for treating a PWS are a wavelength between 585 and 600 nm, a fluence of 4–20 J/cm^2, a pulse duration of 1.5–10 ms, a beam diameter between 7 and 10 mm and cryogen cooling of the skin surface, also known as dynamic cooling device (DCD). Larger beam diameters require a lower fluence. In some studies, longer wavelengths produced better results than 585 nm.[32–34]

The results depend on the age of the patient, the location, the color of the PWS and the number of treatment sessions.[35,36] The success rate for children and adolescents is around 65% with the best results obtained when treatment is started in the first year of life (Fig. 239-8). Reyes and Geronemus[37] treated 73 children less than 14 years old; 45% got over 75% lightening and 42% obtained 50% improvement. A complete disappearance can be expected in only 15% of patients. In a prospective study by van der Horst et al[38] the benefit of early treatment could not be confirmed, although these authors did not employ a laser system with dynamic cooling.

The location of a PWS is also a significant factor. PWS on the face and back respond much better than those at other sites. Those on the legs respond worst. Even on the face, there is considerable variation. PWS in the midface and distribution of the second trigeminal branch lighten less than those in the periorbital region, forehead, neck and nape.[39–41] The size also affects the response. Small lesions respond better than large ones, and, often in the latter case, uniform lightening is impossible to achieve.[42,43] Repeated treatments



Figure 239-8 **A.** PWS in a 6-months-old female baby prior to PDL therapy. **B.** Result of five PDL therapies at the age of 3 years.

lead to an improved response, and sometimes more than 10 sessions may be required.

The risk of scarring with PDL is quite low, around 1%. It is higher in patients on isotretinoin therapy. The main complications are hypo- or hyperpigmentation and rarely the development of a pyogenic granuloma.[44–47] After the treatment is concluded, up to 15% of the patients may develop partial recurrences of their PWS, but not to the same extent and size as prior to treatment.[48–50]

When PWS are resistant to PDL, there are other laser options. Deeper vessels can be treated with the alexandrite laser (755 nm) and the pulsed Nd:YAG laser (1,064 nm).[51–54] McGill et al were able to produce additional improvement in 10 of 18 patients treated with PDL with an alexandrite laser.[55]

In a study comparing pNd:YAG laser and PDL, both systems produced 50%–75 % improvement. Patients preferred the Nd:YAG laser because it caused less purpura. On the other hand, the risk of scarring was clearly higher with the pNd:YAG laser, which should be used for PWS only by experienced laser therapists.

KTP lasers can also produce improvement in PSW but the results are worse than with PDL and the risk of scarring is greater.[56]

There is also good experience using IPL to treat PWS.[3,57,58] In a comparison study in 20 patients, both PDL and IPL produced improvement but the extent of lightening was significantly better with the PDL.[59] In contrast, in our own study, IPL was slightly superior to PDL.[60]

In individual patients with a nodular component to their PWS, vaporization of the individual lesions with the cwCO_2 laser has proven helpful.

HEMANGIOMAS IN INFANCY

Hemangiomas are benign proliferative tumors, which occur in about 5% of children. They are more common in premature infants and following amniocentesis. In general, they are not present at birth but appear in the first weeks of live as pale or telangiectatic macules, which then rapidly develop into nodular tumors. After a growth period of 9–10 months, there is a stable period, followed by a regression phase that can last until 10 years of age. About 50% of patients have residual lesions such as scars, fibrofatty nodules, or telangiectases. Complications of hemangiomas include ulceration, bleeding, and distortion of orifices (nose, eyes, mouth, and anogenital region). We distinguish between superficial, cutaneous-subcutaneous, and deep subcutaneous hemangiomas. They may be circumscribed nodules, plaques in a segmental distribution or multiple. The tumors cells express FCR II (CD32), merosin, and GLUT1, a pattern similar to placental cells.

Congenital hemangiomas are much less common; they are divided into noninvoluting congenital hemangiomas (NICH) and rapidly involuting congenital hemangiomas (RICH).

The treatment of hemangiomas is controversial, as most of them regress spontaneously.[36] Nonetheless, numerous studies have shown that small and initial hemangiomas respond very well to PDL (Fig. 239-9). Growth is arrested in over 60% of treated tumors with just a few PDL sessions: only 15% disappear completely.[61–64] Ulcerated hemangiomas also respond well to laser therapy; they become lighter and re-epithelize quicker.[65] Deep subcutaneous components of the hemangiomas do not respond.[66]

In a prospective randomized and controlled study, 121 children with uncomplicated hemangiomas were treated with PDL (585 nm, pulse duration 0.45 ms, spot size 3–5 mm, fluence 6-7.5 J/cm^2, no cooling). After a year 30% of the lesions in the treated group had completely disappeared; in the control group, it was only 5%. Residual changes were found in 42% of the treated children and 44% of the control group. Complications were much higher in the treated group with 45% versus 15% in the controls. In the treated group, the hemangiomas had increased in size by 61%; in the control group, 160%.[67]

In another study, a PDL with a longer pulse duration and surface cooling (595 nm, 7-mm spot size, pulse duration up to 20 ms, 9–15 J/cm^2 fluence) was compared to a standard PDL without cooling (585 nm, 7 mm, 0.45 ms, up to 7 J/cm^2); treatment with the longer pulse time led to better results with fewer side effects.[68]

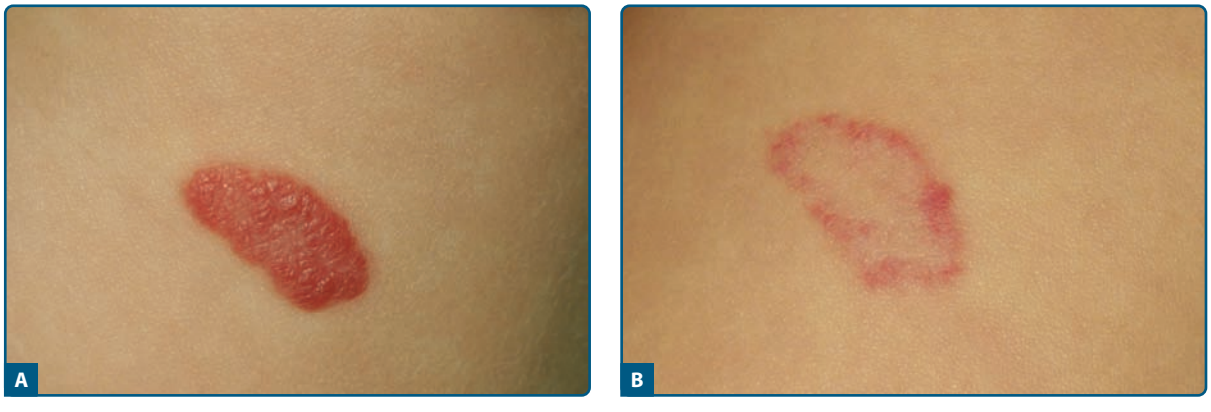

Figure 239-9 **A.** Childhood hemangioma in a 2-months-old female baby. **B.** After two PDL treatments, stoppage of growth and induction of regression.



Figure 239-10 **A.** Rubeosis faciei (red face) in a 45-years-old female patient. **B.** Improvement in two PDL test spots. **C.** Result of one complete treatment.

Because of the introduction of propranolol to treat infantile hemangiomas, it is necessary to reexamine the role of lasers in this problem. Cutaneous-subcutaneous hemangiomas and rapidly proliferating hemangiomas in complicated locations respond well to systemic propranolol. They are no longer an indication for cwNd:YAG laser or intralesional laser therapy with bare fibers. Propranolol can be combined with PDL.[69,70]

Residual telangiectases after the regression of hemangiomas can be improved with either PDL or IPL.

TELANGIECTASES

Telangiectases are permanently dilated small venules, which may be solitary or matted together to form larger flat lesions. Primary or essential telangiectasia is often familial, but no underlying cause has been found. Special forms are progressive, essential disseminated telangiectasia, which increase in numbers on lesions on the extremities, trunk and face, as well as unilateral nevoid telangiectasia syndrome (UNTS).

Telangiectases are a good indication for laser and IPL therapy. PDL with large beam size and midrange fluences are employed; the pulses are set to lightly overlap. Many patients consider the resulting purpura after PDL as inacceptable. Pulse stacking has been tried, using a series of impulses all beneath the purpura threshold to reduce problems. The number of sequential impulses is based on the visible vasoconstriction. Using these techniques, good clinical effects can be obtained without increasing the complication rate.[71] In a comparative study, long-pulsed PDL proved more effective than two IPL devices.[72]

KTP lasers also produce good results for this indication.[73,74] Infrared laser such as diode lasers or the pulsed Nd:YAG laser can also be used. In a comparison study, a 940-nm diode laser was more effective than a KTP laser.[75]

The pulsed Nd:YAG laser is best suited for vessels with a diameter of more than 1 mm; the treatment is relatively painful and the risk of scarring greater than with other lasers.[77,78]

When telangiectases are grouped together and more diffusely red, IPL can be very effective (Fig. 239-10). A major advantage is that the large rectangular impulses can be very precisely placed next to each other.

Poikiloderma of Civatte is also a good indication for PDL and IPL; we prefer the latter.[79]

STARBURST VEINS AND VARICOSITIES OF THE GREAT SAPHENOUS AND SMALL SAPHENOUS VEINS

A phlebology evaluation is required prior to treating these venous problems. Vessels with a diameter of up to 1 mm are a good indication for PDL with a variety

of wavelengths (585, 590, 595, and 600 nm) and a longer pulse duration. For this purpose, oval handpieces with a spot size of 2 × 7 mm are available. Fluences between 12 and 20 J/cm^2 are used, and skin cooling is mandatory; despite these measures, sometimes hyperpigmentation cannot be avoided.[80,81]

The alexandrite laser is well established for treating starburst veins. Using relatively high fluences (60–80 J/cm^2) and pulse durations of 3 ms with surface cooling, 65% of patients experienced an improvement of at least 75% when the vessel diameters were between 0.3 and 2 mm. Hyperpigmentation developed in 35%.[82] In a study comparing alexandrite, diode, and pulsed Nd:YAG lasers for starburst veins with a caliber of 0.3 and 3 mm, the Nd:YAG laser was most effective.[83]

Treatments with a 940-nm diode laser produce greater than 75% improvement in 46% of patients.[84,85] For vessels greater than 1 mm in diameter, the pulsed Nd:YAG laser with surface cooling is very effective.[77,83,86–88] In direct comparison studies, the pulsed Nd:YAG laser was just as effective as sclerotherapy.[89–91]

A new use for lasers in phlebology is sealing the great saphenous and small saphenous veins with endoluminal laser therapy. Diode lasers, Nd:YAG lasers, and radio frequency ablation devices have all been employed. In a prospective randomized study, radiofrequency ablation produced just as good results as operative vein stripping.[92–95]

OTHER VASCULAR LESIONS

The superficial component of congenital or acquired lymphangioma circumscriptum can be vaporized with the CO_2 laser. Although improvement is produced, sometimes for many years, the lesions eventually recur.[96–99]

Venous lakes respond well to treatment with PDL KTP, diode or Nd:YAG lasers.[100]

Low-flow venous malformations can be treated with cw Nd:YAG or long-pulsed Nd:YAG lasers or with the intralesional bare fiber technique.[101–104]

Small angiofibromas in tuberous sclerosis can be treated with the KTP laser. When multiple lesions are being treated, then ablative approaches such as a flash scanned CO_2 laser or Er:YAG laser are preferred.[105–110]

Cherry angiomas respond well to KTP laser and PDL.[111] The pulsed Nd:YAG laser can also be used.

The ectatic vessels of hereditary hemorrhagic telangiectasia (Osler-Rendu-Weber syndrome) are best treated with the KTP, diode, or long-pulsed Nd:YAG lasers. The pNd:YAG laser can also be used for larger ectatic vessels but the treatment is painful.[112]

The matted telangiectases in angioma serpiginosum respond well to PDL and IPL therapy, but recurrences are common.[113]

BENIGN TUMORS

Xanthelasmas and Syringomas can be coagulated with a KTP laser[114] or destroyed with the cw-CO_2 laser; there is a certain risk of scarring. Better choices, because they cause less thermal damage, are pulsed or flash scanner-CO_2 laser systems. Another reliable approach is the very exact ablation with the Er:YAG laser.[115,116]

Trichoepitheliomas are usually skin-colored, so that coagulation with a semiselective coagulating laser is not very helpful. Ablation with the CO_2 or Er:YAG laser makes it possible to obtain good cosmetic results even when treated multiple aggregated lesions.[117–119]

Neurofibromas can also be removed with the CO_2 laser if they are not too large. Using relatively high power, the dome-shaped neurofibroma is circumferentially incised around its base; then the neural tissue generally herniates up with a little lateral pressure, so it can be vaporized or destroyed at its base. Although large deep defects may result, they heal amazingly well.[120]

Eruptive vellus hair cysts can be vaporized with the CO_2 laser. In patients with *steatocystoma multiplex*, one can open the cysts with a focused CO_2 laser beam, express the contents, and then coagulate the cyst wall with a defocused beam. Cosmetically pleasing results are not always possible.[121]

Similarly, a *digital mucous cyst* can be opened with a focused beam of a CO_2 laser and then emptied of its gelatinous contents. Then the base and wall of the cyst can be vaporized with the defocused beam. Using this method makes it possible to completely remove digital mucous cysts without a complicated surgical approach.[122]

EPIDERMAL AND ORGANOID NEVI

VERRUCOUS EPIDERMAL NEVI. Soft papillomatous epidermal nevi can be treated relatively effectively by coagulation with an argon or KTP laser or ablation with a CO_2 or Er:YAG laser. In contrast, the hard or verrucous epidermal nevi often fail to respond to laser therapy and typically recur.

A KTP laser can be used to completely coagulate small circumscribed nevi. For more extensive nevi, a chessboard or line-by-line pattern is recommended. About 80% of large but soft epidermal nevi can be successfully treated in this manner.[123]

Destruction with the CO_2 laser (cw, pulsed or with flash scanner) is especially useful for markedly exophytic components of nevi.[124,125] (See Fig. 239-11) The Er:YAG laser makes possible a very exact removal of relatively flat lesions on the face without any significant side effects.[126,127] A test area should be tried before a complete lesion is treated, especially in problem areas like the neck and face, since hypertrophic scars can develop. After successful removal, the appearance may remain stable for years, but up to one-third of patients eventually develop some degree of recurrence.[127]

For hard verrucous nevi or ILVEN, a CO_2 laser ablation is worth trying, although only about 30% of patients get a good response.[123] For ILVEN, treatment with PDL (585 nm) can reduce the pruritus and produce partial remissions.[128]

SEBACEOUS NEVI. The exophytic part of sebaceous nevi can be removed with CO_2 lasers (cw,



Figure 239-11 **A.** Extensive papillomatous epidermal nevus in the groin of a 32-years-old patient. **B.** Late result 8 months after CO_2-laser-vaporization.

pulsed, or flash scanner) as well as with the Er:YAG laser. The intradermal component remains behind, so that the color of lesion is not changed and recurrences are common. Surgical excision is thus preferred if it seems likely to leave a good cosmetic result or if there is concern for malignant degeneration.

INFECTIOUS DISEASES

Genital Warts. The vaporization of genital warts is one of the most common indications for the CO_2 laser. Condylomata acuminata are generally vaporized at settings of 10–20 W; very exophytic lesions may require higher settings. By using short pulses and low fluences, it is possible to remove warts in problem areas such as over perianal ectatic veins or on hemorrhoids.

Prior to treatment, the entire area should be soaked with 3%–5% acetic acid solution for a few minutes to bring out clinically inapparent lesions, which turn white and can then be seen and treated. Viral DNA is found in the perilesional clinically normal skin around a wart; thus, we recommend superficially ablating a 5- to 10-mm rim of normal skin around each lesion.

One should avoid deep destruction because such lesions heal slowly and painfully, and may scar, or even lead to functional impairment.[129] Viral DNA is present in the laser plume[130]; therefore the patient, physician, and nursing personal must all be protected by masks and vacuum exhaust systems.

Genital warts can also be vaporized with the Er:YAG laser. One disadvantage is the tendency of the well-vascularized papillomas to bleed, so that this laser is best suited for flat lesions.

The Nd:YAG laser can also be used to treat genital warts.[131,132] They should be coagulated until they turn completely white. Postoperatively, the lesions become necrotic and drop off; the exudative wounds may take weeks to heal. Because of both the long and painful recovery period and the risk of scarring, we only use the Nd:YAG laser in patients infected with HIV and hepatitis C virus, as there is no risk of infection through a smoke plume.

As far as the recurrence rate is concerned, laser therapy is not superior to other destructive measures such as electrosurgery or argon-plasma coagulation.[133,134] No matter what technique is used, the recurrence rate for genital warts is 40%–60%, and even as high as 80% in some series.

Patients with bowenoid papulosis (an HPV-induced intraepithelial neoplasm) can often be treated successfully with the CO_2 laser, avoiding a mutilating procedure. Recurrences are once again common; because of the greater risk of development of an invasive carcinoma, close clinical control is mandatory.

Common Warts. Common warts, just like genital warts, can be easily vaporized with the CO_2 laser.

Filiform warts can be removed with 5–10 W and a diagonal cutting plane. The adjacent normal skin can be protected with moist compresses. The base of the wart is removed exactly down to the skin surface, often using a lower setting. Deeper removal is more likely to cause scarring.

Thicker and more keratotic warts should be treated with keratolytic agents prior to laser therapy. The macerated white skin over the wart can be vaporized at relatively high settings (15–20 W) to produce superficial vaporization and charring, but is not completely removed. After a few seconds of treatment, the horn plug can be removed with a forceps from the base of the wart. Sometimes one must reheat the lesion again

to facilitate this. The well-vascularized and circumscribed base of the wart is then vaporized with a lower setting until the lesion is entirely destroyed, as evidenced by a restored papillary pattern to the dermis. Cure rates of 50%–70% are reported for the vaporization of warts.[135–137] Since the treatment brings considerable postoperative pain and can produce painful scars, especially for plantar warts, it should be reserved for warts, which have failed to respond to consequent standard therapy. On weight-bearing surfaces, we view laser vaporization as a last resort.

Warts can also be treated with PDL. Here the dilated capillary loops in the wart are destroyed, hastening its demise. Just as with vaporization, the thickened stratum corneum must first be removed with keratolytics, as the laser beam cannot penetrate this tissue. Multiple sessions are always needed; the cure rate is between 60% and 70%[138,139] with especially good results for facial warts.[140]

Mollusca Contagiosa. The treatment of mollusca contagiosa with the PDL appears very effective. After 1 or 2 treatments with fluences of 6 and 8 J/cm^2, cure rates between 95% and 100% are described.[141,142] The treatment is also well tolerated by children; topical anesthetics or cold aircooling are helpful. Even with far lower fluences of 4 J/cm^2, similar results (96%–100%) have been reported.[143]

INFLAMMATORY DERMATOSES

Lichen Sclerosus et Atrophicus. The removal of genital or extragenital lesions of lichen sclerosus et atrophicus with the CO_2 laser leads to regression or cure in most patients,[144–146] if the standard therapy with topical steroids were ineffective. The vaporization must extend into the normal underlying dermis. Recurrences can be seen both at the border and in the healed areas. They usually appear after 2–3 years, and the patient can be treated once again in the same way.[146]

Cutaneous Lupus Erythematosus. The selective destruction of vessels with a flashlamp pumped, pulsed dye laser can produce improvement in lupus erythematosus. Areas of chronic erythema and telangiectases,[147] as well as plaques[148] may respond. A test site should be treated before larger areas are tackled, as lupus erythematosus can be exacerbated by the laser exposure.[149]

Chondrodermatitis Nodularis Helicis. Vaporizing the cutaneous nodule and the underlying damaged cartilage with the CO_2 laser under local anesthesia is an effective way of treating this troublesome disorder. The defect usually heals without complications and the patient is free of symptoms. With larger lesions, a depressed scar is unavoidable.[150,151]

Psoriasis Vulgaris. While vaporization of chronic stationary plaques of psoriasis with the CO_2 laser is possible, there is not a great deal of clinical experience. Because of the high infection rate[152] and the risk of scarring,[153] laser vaporization should only be considered for isolated therapy-resistant plaques.

The treatment with PDL is directed against the abnormal large vessels in the dermal papillae of psoriatic lesions. The success rate is around 50% after repeated treatments at 2- to 3-week intervals; the response is generally short-lived and complete responses are uncommon.[153–155]

Psoriasis is better treated with excimer lasers or lamps, which deliver high-intensity UV IIA radiation at 308 nm (Table 239-5). Only the psoriatic lesions are treated, so that normal skin is not exposed. In addition, a higher dose of UV can be delivered to the lesions. The higher the individual UV dose, the better the response, although the side effects also become more common including dermatitis, blistering, and hyperpigmentation. High-dose therapy plans are more effective, but less acceptable to the patients because of blistering and crusting. They are also somewhat controversial, because with low and medium dosages, one tries to avoid blistering and crusting, just as with classical UV therapy for psoriasis.

The 308-nm phototherapy of psoriasis is unquestionably effective, just like the classic 311-nm UV therapy. When high doses are used, the duration of therapy is shorter and the cumulative dose lower. Long-term effectiveness is comparable to standard measures, with disease-free intervals of 4–6 months,[156–162] although some groups have reported responses lasting up to 2 years.[163,164]

Using the excimer laser is very time-consuming because of the relatively small spot size and the device is very expensive. In summary, the laser therapeutic approaches to psoriasis are mostly experimental and not clinical standard.

Hailey-Hailey Disease. Surgical methods such as dermabrasion or excision have long been used in Hailey-Hailey disease. Similarly wide vaporization with the CO_2 or Er:YAG laser with local or general anesthesia is also effective.[165] The damaged skin must be removed, completed, noted by reaching the chamois-colored superficial dermis; otherwise, prompt recurrences are the rule. Laser vaporization can provide relief for up to several years, even though recurrences at the edge or within the lesion must be expected. A test patch should be treated prior to embarking on more widespread therapy and evaluated after 6 months in order to exclude patients whose lesions quickly recur and those who develop hypertrophic scars.

Acne Vulgaris. Laser and IPL therapy of acne vulgaris has recently attracted considerable attention. The information on different devices and their effectiveness is incomplete, or even in some instances contradictory.[166,167]

PDL have been employed in two randomized studies with conflicting results. Seaton et al[168] compared a treated group (n = 31, 5 mm spot size, 1.5 or 3 J/cm^2) to a group treated with simulated or placebo therapy (n = 10). After just one treatment, 12 weeks later, the treated group showed a significant reduction in the Leeds acne score for the total lesions and number of inflammatory lesions. In contrast, Orringer et al[169] were unable to show any improvement using a half-face study with one or two treatments (7 mm, 2.5–3 J/cm^2).

TABLE 239-5
Commonly Used Dermatologic Lasers

Laser (nm)	Target	Effect in Target	Mode (Pulse Duration)	Applications
Excimer (XeCl) (308)	DNA, proteins	Photochemical reactions	Pulsed (μs)	Comparable to narrow band UVB (311 nm)
Argon (488/514)	Vascular lesions Tissue	Semiselective coagulation Coagulation	Pulsed (ms)	Telangiectases, spider nevi, venous lakes Syringoma, xanthelasma, epidermal nevi
Frequency-doubled Nd:YAG (532)	Vascular lesions	Selective coagulation ("KTP" laser)	Pulsed (ms)	Telangiectases, spider nevi, venous lakes
Frequency-doubled Nd:YAG (532)	Pigmented lesions	Selective and fast heating (explosion)	Pulsed (ns)	Benign melanin-containing lesions, tattoos (red)
Flashlamp pulsed dye (585–600)	Vascular lesions Tissue	Selective Coagulation	Pulsed (ms)	PWS, telangiectases, rosacea, spider nevi Scars, keloids, warts, photoaging
Ruby (694)	Pigmented lesions	Selective and fast heating (explosion)	Pulsed (ns)	Benign melanin-containing lesions, tattoos (black, blue, green)
Alexandrite (755)	Vascular lesions Tissue Pigmented lesions	Selective coagulation Selective and fast heating (explosion)	Pulsed (ms) Pulsed (ns)	Large vessels (leg veins, hypertrophic PWS) Hair removal Benign melanin-containing lesions, tattoos (black, blue, green)
Diode (810)	Vascular lesions Tissue	Selective coagulation	Pulsed (ms)	Large vessels (leg veins, hypertrophic PWS) Hair removal
Nd:YAG (1,064)	Vascular lesions Vascular lesions Tissue Pigmented lesions	Unspecific coagulation Selective coagulation Selective and fast heating (explosion)	Continuous wave (cw) Pulsed (ms) Pulsed (ns)	Vascular malformations, tumors Large vessels (leg veins, hypertrophic PWS) Hair removal Benign melanin-containing lesions, tattoos (black, blue, green)
Diode (1,450)	Tissue	Selective coagulation (nonablative)	Pulsed (ms)	Skin remodeling, photoaging
Er:YAG (2,960)	Tissue	Selective and fast heating (ablation)	Pulsed (ms)	Skin resurfacing, epidermal ablation
CO_2 (10,600)	Tissue	Unspecific coagulation (vaporization) Selective and fast heating (ablation)	cw Pulsed (ms)	Vaporization of tissue Skin resurfacing, epidermal ablation

The 1,450-nm diode laser has been approved by the FDA for acne therapy. This device administers 12–14 J/cm^2 to the face and 18 J/cm^2 to the back coupled with spray cooling. Even though a single treatment can be effective[170]; generally, multiple treatments at intervals of several weeks are preferred. In 19 acne patients with facial lesions, one treatment led to a 37% reduction in lesions; two sessions, 58%; and three sessions, 83%[171] Four sessions produced a reduction of at least 50%, which held for 6 months in 13 patients, once again with facial acne.[172] After a single treatment (n = 20), Mazer and Fayard[170] observed an average improvement of 79% that was almost stable (74%) after 12–18 months. Similar results were obtained on the back; in a half-side

study, 24 weeks after 4 treatments, there was a significant, almost complete improvement on the treated side ($n = 15$).[173]

Rosacea. Rosacea appears to respond to PDL. After two treatments (585 nm, 1.5 ms, 5 mm spot size, 8 J/cm^2), the symptoms of pruritus, burning, flushing, and dryness all improved by about 60%.[174] After three treatments (585 nm, 450 µs, 6 J/cm^2), the erythema had improved by 50%; the telangiectases, 75%; and the flushing, 55%. The overall severity of the rosacea clearly improved, but not the number of inflammatory lesions.[175] The benefits are not very long lasting.[176]

Vitiligo. One therapy option for stable vitiligo is the transplantation of the autologous cultured cells. With the Er:YAG laser the necessary de-epithelization can be accomplished quickly and elegantly, analogous to a very fine dermabrasion.[177]

Treatment with the 308-nm excimer laser is another option. Hadi et al treated 55 vitiligo lesions in 32 patients (2× weekly, starting with 100 mJ/cm^2 with careful increase by about 50 mJ/cm^2 per treatment depending on side effects). More than 75% repigmentation was achieved in 53% of patients with an average of 23 sessions. About 20% of the lesions completely repigmented.[178] Facial lesions responded far better than those on the extremities or trunk.

Hong et al[179] compared excimer laser irradiation with narrowband UVB therapy in 8 patients with a half-side model. The 308 nm laser therapy produced a quicker and significantly better repigmentation than the UVB. The face once again responded best; the extremities were worst.

Other studies show similar results.[180–183] Thus, the effectiveness of the 308-nm excimer laser in vitiligo seems well established. One advantage is that the adjacent normal skin s not exposed and does not tan; in conventional UVB therapy, this enhances the contrast between normal and vitiliginous skin. The response rate depends heavily on the location of the lesions (face, neck, trunk better than extremities) and the treatment takes a long time, at least 12 weeks.

Adding topical tacrolimus to the excimer laser therapy improves the response. In one study, there was over 75% repigmentation in 70% of the lesions treated with both modalities, as compared to 20% in the group treated just with laser.[184,185]

Alopecia Areata. The 308 nm excimer laser has also been tried recently for alopecia areata. Gundogan et al[186] treated two patients, each with 12 sessions, and were able to achieve almost complete regrowth. The regrown hairs remained stable for 18 and 5 months, but there were no control areas. Zakaria et al[187] treated nine patients but were able to obtain complete regrowth in only two, with >75% improvement in two, >50% in one, and no response in four.

SCARS AND KELOIDS

Hypertrophic Scars. Since hypertrophic scars are well vascularized, they are usually treated with PDL. Even with repeated treatments, the hypertrophic tissue usually regresses but a little, but the pruritus and spontaneous pain may improve more.[188] Removal with an ablative laser is generally not advised because of the risk of recurrence.

Keloids. Erythematous keloids can be treated such like hypertrophic scars with the PDL. In addition, the cw-CO_2 laser can be used for tumor reduction in large keloids before starting cryotherapy and compression therapy. Otherwise, we do not consider keloids an indication for laser therapy.

Acne Scars, Atrophic Scars and Other Superficial Skin Irregularities. The exact nature of the scar helps determine what approach is most likely to be helpful. Flat dish-like scars or sharply punched out scars that are less than 1 mm deep respond best to laser therapy. Deep or burrowed scars respond much less well, as all laser approaches are relatively superficial.

When confronted with broad scars, flat acne scars on the face, or flat reticular scars, an ablative laser system can be used in a manner similar to dermabrasion.[189] When treating older patients, one wants the side effect of "collagen shrinking" to tighten the skin; this is undesirable when treating scars in younger individuals. Thus one should choose laser systems that produce little thermal damage, as this ensures quicker healing and fewer side effects. The usual choice is the Er:YAG laser, but CO_2 lasers with flash scanner and a short tissue interaction time also seem promising.

Other lasers can also be used; the fluence, number of passes, and overlapping of the pulses (when applicable) should be kept as small as possible to reduce thermal damage and minimize side effects.

If the indications are appropriate and the operator skilled, suitable scars can be treated with satisfactory to good results. General clinical improvement of 50%–70% can be obtained; sometimes the 90% level is reached.[190–193]

Almost all laser and IPL systems that are available for nonablative skin rejuvenation can also be used for acne scars. Most experience exists with the 1,320-nm Nd:YAG with spray cooling and the 1,450-nm diode laser. Unfortunately, the results vary greatly; improvement from as high as 70% down to only 10% have been reported after multiple sessions.[194–198] In summary, all of the nonablative treatments are inferior to ablative approaches, but also have few side effects. Good results with ablative fractional laser therapy are also possible in nonacne atrophic scars.[199]

Fractional laser therapy falls somewhere in between nonablative and ablative approaches. It is capable of producing 26%–50% improvement without side effects.[200] The ablative variant of this approach also appears superior to the nonablative, but is once again more aggressive with more side effects.

Striae Distensae. It is worth trying a PDL for erythematous striae, although the supporting data is unclear. Both improvement, especially in early, still erythematous striae,[201,202] as well as lack of effectiveness has been reported.[203] Fractional laser therapy with 1,550 nm appears somewhat more effective.[204]

EPILATION

PRINCIPLES. The basic principle of photoepilation is the absorption of light by the pigmented structures of the hair follicle with resultant thermal damage. The target chromophore is eumelanin; pheomelanin is found in red and blond hairs and has such different absorption characteristics that these hairs, just like light and white hairs, are hard to remove with photoepilation.

Exactly which structures have to be destroyed to ensure long-term epilation is still not certain.[205] According to DiBernardo[206] both the hair bulb and the bulge region must be destroyed since they contain pluripotential stem cells, which could lead to regeneration of hairs. Tope[207] speaks of permanent follicular destruction when just the bulge and its stem cells are destroyed, as this is the region where anagen is initiated and hair production started. Ross et al[208,209] indicates that destroying the bulb induces the catagen and telogen phases, so that hairs regrow, but lighter and thinner. On the other hand, when the bulge is destroyed, then miniature or vellus-like hairs result.

Photoepilation generally causes a slower regrowth of hairs as well as some degrees of miniaturization, but only rarely produces complete follicle destruction and permanent alopecia.

Optimal thermal damage can only be obtained when the follicles (and the hairs) are sufficiently pigmented; in addition, the radiation parameters must make it possible to deliver sufficient energy to the follicle. Longer wavelengths between 700 and 1,000 nm penetrate deep into the dermis reaching the follicle and are well absorbed by melanin. Large spot sizes enhance the depth of penetration further. The optimal impulse duration is not known, but appears to vary depending on system and wavelength, but probably is in the millisecond range (a few ms to 100 ms).[205,210,211]

DEVICES FOR PHOTOEPILATION

Alexandrite Laser (755 nm). In comparison to the ruby laser, which did not prove effective for epilation, the alexandrite laser delivers 20% less energy to melanin and proportionally more to oxyhemoglobin; thus, reducing the epidermal damage, especially for dark skin. The epidermis is further protected by cooling during the procedure. The spot size can be varied from 5–12.5 mm and makes possible the rapid treatment of larger areas.

Diode Laser (800/810 nm). At this wavelength, the energy is well absorbed in the follicle but less absorbed by competing chromophores like oxyhemoglobin or water. In addition, a penetration depth of 3 mm can be reached. The laser light is scarcely absorbed by the epidermis, making the device well suited to dark skin. The long impulse duration (up to 50 ms) and high fluences make epidermal cooling mandatory.

Pulsed Nd: YAG Laser (1,064 nm). This laser penetrates very deep (5–7 mm), so that even deep-lying follicles receive enough energy for epilation. There is also very little epidermis absorption, making the device well suited for dark skin (FDA approval also for skin types IV–VI)[212] Once again surface cooling is essential to reduce pain and side effects. Of the devices used for laser epilation, the Nd:YAG laser has the fewest side effects but is most painful.

High-energy Flashlamps (590–1,200 nm). These sources have a broad emission spectrum extending into the near infrared region, which allows for excellent depth of penetration and have the largest spot sizes (around 5 cm^2) of all the photoepilation units, which make rapid treatment possible. In the epilation mode, a cut-off filter at 600 nm is usually employed in order to filter out shorter wavelengths destined to be absorbed in the epidermis. The impulse durations are 0.5–25 ms, while 20 ms is usually chosen. Many different systems are available, and one should follow the manufacturer's recommendation. A cooling gel is used to improve the coupling of light into the skin, cool the epidermis, and reduce pain. This is a method well suited for all skin types and with few complications.[213,214]

SIDE EFFECTS. Just after treatment one sees discrete erythema and perifollicular edema. Temporary hypo- and hyperpigmentation is common, varying with the system. Occasionally folliculitis, vesicles, crusts and rarely tiny scars may develop. Uncommon complications are a paradoxical hypertrichosis either in or adjacent to the treatment area or leukotrichia.[215–217] Melanocytic nevi in the treatment field are best not treated, especially if there is a history of dysplastic nevi or familial melanoma, since there are reports on changes in nevi after photoepilation.[218]

RESULTS. It is hard to compare the many studies on laser and IPL epilation because of the different devices, treatment parameters, hair colors, treatment areas and intervals. Reductions in the amount of hair are achievable with all the devices (Fig. 239-12).

The current status of photoepilation can be summarized as follows[211,219–222]:

- Reduction of hair numbers between 40% and 80% (100%) after multiple treatments.
- Multiple treatments produce better results.
- The loss of hairs is generally not permanent; to maintain an epilated condition, the therapy must be repeated at intervals.
- Dark and thick hairs respond better than light and thin hairs.
- When hairs regroup after epilation, they are often thinner and lighter.
- While permanent epilation is possible, it can never be promised or guaranteed.

MELANOTIC AND MELANOCYTIC SKIN LESIONS

LENTIGINES. Lentigines can be treated with the Qs-ruby-, Qs-Nd:YAG at 532 and 1,064 nm and



Figure 239-12 **A.** Hypertrichosis of the upper lip in a 35-years-old female patient. **B.** Reduction of hair growth after five IPL treatments.

Qs-alexandrite lasers. Lower fluences than required for tattoos can be employed; for example, the Qs-ruby laser uses 4–6 J/cm^2 at 40 ns. Blisters or crusts are rare; the area is generally healed in a few days. The results are good to outstanding,[223–225] while side effects are rare. The Er:YAG and the CO_2 laser with flash scanner can be employed to superficially ablate lentigines.[226]

CAFE-AU-LAIT-MACULES, NEVI SPILI, AND BECKER NEVI. The same laser systems used for lentigines are employed, but the results are variable and hard to predict. Both incomplete lightening and recurrences are possible.[227–231] A test spot should be treated and observed for an adequate period of time to assess both efficacy and likelihood of recurrence.

NEVUS OF OTA, NEVUS OF ITO. The Qs-ruby laser produces good results for nevus of Ota and nevus of Ito. In addition the results are generally stable.[232] The time of intervention appears important. When children less than 10 years old are treated, fewer sessions are needed and the complication rate is lower.[233] The Qs-alexandrite and the Qs-Nd:YAG laser appear to produce somewhat worse results with more side effects.[234] Acquired bilateral Nevus of Ota-like macules (Hori spots) respond very well to laser therapy and can generally be completely removed in just a few sessions.[235–237]

MELANOCYTIC NEVI. The superficial removal of melanocytic nevi with an ablative laser often leads to recurrences,[238] while destruction deep into the dermis invariably causes scarring. In addition, no histological examination is possible. Thus, ablative lasers are not suitable for treating melanocytic nevi. An exception is the early dermablation of congenital melanocytic nevi with the Er:YAG laser analogous to a dermabrasion, as described by Petres and other authors.[239] When deep dark congenital nevi are superficially ablated for the first weeks of life, they often become much lighter, even though recurrences are common,[240] and the associated hypertrichosis is not influenced.

The treatment of melanocytic nevi, whether congenital or acquired, with pigment-selective lasers (Qs-ruby, Qs-Nd:YAG, Qs-alexandrite lasers) can completely destroy strictly junctional nevi. The dermal component cannot be removed both because of the limited penetration of the lasers and the invariable presence of relatively nonpigmented nests of melanocytes, which are not affected; thus recurrences are very common.[241–245] It is unclear if the melanocytes that survive a laser treatment have an increased risk of malignancy; long-term studies are needed.[246–248]

There are many reasons why we do not consider melanocytic nevi an indication for laser therapy, except in special cases: clearing often requires many sessions and is not impressive, residual nevus cells are always left behind, the long-term effects are unknown and no histological evaluation is possible.

Lasers can be tried in giant congenital melanocytic nevi when no other therapy options are open. Using the combination of long pulsed and Qs-ruby lasers over many treatments has produced very good results in some cases.[249]

MELASMA. Both the pigment-selective lasers and IPL have produced disappointing results in melasma or chloasma; in addition, the risk of reactive hyperpigmentation is great.[229,250–253] Somewhat better results seem possible with fractional laser therapy, although the results are highly variable and not always good.[200,254]

TATTOOS AND OTHER EXOGENOUS PIGMENTATION

DECORATIVE TATTOOS. Procedures often used to remove tattoos like excision, dermabrasion, salabrasion or CO_2 laser ablation always cause scarring. The introduction of the Qs laser technology has revolutionized the field, making it possible to remove tattoos almost without scarring.[255]

The exact mechanisms by which lasers remove tattoos are still poorly understood. Laser therapy leads to changes in the optical qualities of the tattoo pigment, either by destruction or by changes through thermal, photochemical, or photoacoustic reactions.[256–259] The



Figure 239-13 **A.** Professional tattoo at the back of a 34-year-old male patient. **B.** Result of eight treatments with a Qs Ruby laser.

additional improvement that occurs weeks later probably has a cellular explanation. Histologic studies have demonstrated that macrophages or their lysosomes laden with tattoo pigment rupture and the free but degraded pigment particles can be transported to the lymph nodes. Whatever pigment remains at the site of the tattoo is rephagocytosed and after 4 weeks, is once again intracellular.[257,260] This process of damaging pigment, moving it about, and then finally cellular reuptake probably explains the clinical clearing.[256,259,260]

The usual choices are Qs-ruby (694 nm), Qs-Nd:YAG (1,064 and 532 nm) and Qs-alexandrite lasers (755 nm), all with pulse durations in the ns range. The ruby lasers work best for black, blue-black, and dark blue tattoos (Fig. 239-13). For blue and green tones, the results are

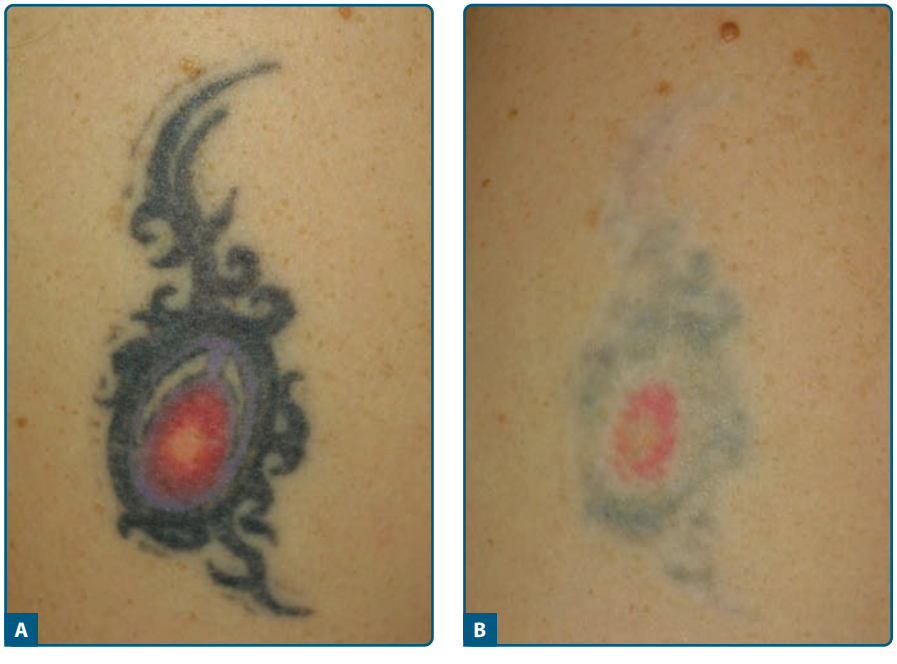

Figure 239-14 **A.** Professional tattoo at the upper arm of a 31-year-old female patient. **B.** After five treatments with a Qs Ruby laser, lighting of the black color, no change in the red color.

TABLE 239-6
Lasers for Tattoo Removal

Tattoo Colours and Suitable Q-Switched Lasers

Laser	Wavelength	Pulse Duration	Tattoo Colour
Nd:YAG laser	532 nm	10 ns	Red
Ruby laser	694 nm	30 ns	Black, blue, green
Alexandrite laser	755 nm	50–100 ns	Black, blue, green
Nd:YAG laser	1,064 nm	10 ns	Black, blue

highly variable. Red, yellow-orange, and light blue tattoos respond poorly to the ruby laser (Table 239-6, Fig. 239-14).[230,261,262]

With the Qs-Nd:YAG laser, the clinical improvement at 1,064 nm is comparable to the ruby laser.[263,264] Using 532 nm makes it possible to destroy some red tattoo pigments.[257,261,265]

The 755-nm laser produces good results for blue-black tattoos, as well as with green, red, and purple colors.[258,259,261,265,266]

The treatment can generally be done without anesthesia; the impulses are placed close together without overlapping. Right after the treatment, there is a broad-based swelling with whitening of the skin, while histological examination shows vacuole formation by steam bubbles. The whitening disappears in a few minutes. When higher fluences are used, sometimes there are punctate hemorrhages. Blisters and crusts commonly develop a few days after the treatment. Topical antiseptic agents should be used after the treatment to reduce the risk of infection.

The complete destruction of a tattoo requires multiple sessions, no matter which laser system is chosen. The literature suggests that at least 3 and usually 10 or more sessions are needed.[265,267] Amateur tattoos generally have less pigment so they respond quicker and better than do professional ones. Blue-black tattoos absorb nearly all the available wavelengths and respond better than do more colorful tattoos.[255] Multicolored tattoos are often impossible to remove completely, even when several lasers are employed. Green, purple, and yellow tones are most stubborn.[265,267,268]

Scarring is rare, but slight atrophic changes in the skin surface are possible. Patients hardly notice them in their elation. The most troublesome side effect is a change in color of a treated tattoo, which does not disappear. Lighter colors (red, pink, white) can become black, gray-black or dark green[258,269,270]; the same phenomenon can also be seen less often with yellow, green, purple, and violet pigments.[261] While the resultant darker pigment may respond to additional laser treatments,[270] this is not always the case. Some patients get a permanent aesthetic worsening.[269] If there is any doubt about the responsiveness of a color, a test patch is advised.

In vitro, it has been shown that when two commonly used red azo dyes are treated with lasers, toxic or carcinogenic degradation products are formed.[271,272] Whether this is relevant for the clinical treatment of tattoos is unclear, but cannot be completely excluded. The clinical relevance of these products is probably quite low since they are produced in extremely small amounts.

ACCIDENTAL TATTOOS. Without question, the best approach to accidental tattoos (powder burns, explosions, road dirt after falls) is prompt removal. Ideally, the area is pretreated with wet compresses and then cleaned with scrub brushes, as well as fine tweezers or punch excisions for residual pieces. This should be completed within 24 hours of the accident.

For residual pigment or when the early treatment was not accomplished, the same Qs lasers used for decorative tattoos can be employed with good benefit. Dirt, soot, coal, and powder usually respond well; harder materials such as metal fragments or stones usually do not. Generally, a test area should be treated to see if a laser treatment is likely to offer benefits.

PIGMENTATION FROM MEDICATIONS

Minocycline, amiodarone, and doxorubicin hyperpigmentation generally respond well to treatment with the pigment-selective Qs lasers.[273–276] On the other hand, a Qs laser treatment, no matter what the indication is, can cause patchy hyperpigmentation in patients who have taken gold products systemically; this is termed laser-induced chrysiasis.[277,278]

KEY REFERENCES

Full reference list available at www.DIGM8.com

DVD contains references and additional content

35. Galeckas KJ: Update on lasers and light devices for the treatment of vascular lesions. *Semin Cutan Med Surg* **27**;276-284, 2008
36. Stier MF, Glick SA, Hirsch RJ: Laser treatment of pediatric vascular lesions: Port wine stains and hemangiomas. *J Am Acad Dermatol* **58:**261-285, 2008
49. Huikeshoven M et al: Redarkening of port-wine stains 10 years after pulsed-dye-laser treatment. *N Engl J Med* **356:**1235-1240, 2007
51. Galeckas KJ, Ross EV, Uebelhoer NS. A pulsed dye laser with a 10-mm beam diameter and a pigmented lesion window for purpura-free photorejuvenation. *Dermatol Surg* **34:**308-313, 2008

58. Bjerring P, Christiansen K, Troilius A: Intense pulsed light source for the treatment of dye laser resistant port-wine stains. *J Cosmet Laser Ther* **5:**7-13, 2003
59. Faurschou A et al: Pulsed dye laser vs. intense pulsed light for port-wine stains: A randomized side-by-side trial with blinded response evaluation. *Br J Dermatol* **160**;359-364, 2009
75. Tierney E, Hanke CW: Randomized controlled trial: Comparative efficacy for the treatment of facial telangiectasias with 532 nm versus 940 nm diode laser. *Lasers Surg Med* **41:**555-562, 2009
167. Haedersdal M, Togsverd-Bo K, Wulf HC: Evidence-based review of lasers, light sources and photodynamic therapy in the treatment of acne vulgaris. *J Eur Acad Dermatol Venereol* **22:**267-278, 2008

Chapter 240 :: Radiotherapy

:: Roy H. Decker & Lynn D. Wilson

RADIOTHERAPY AT A GLANCE

- Radiotherapy is a collection of versatile treatment modalities including brachytherapy, external beam radiation, and charged particle therapy.
- The clinical effects of radiotherapy include acute and late skin changes:
  - Acute effects include inflammatory reactions and desquamation.
  - Late effects include fibrotic changes and atrophy of skin adnexa.
  - Radiation-induced malignancy is a rare but serious side effect presenting at a median 10 years after treatment.
- Radiotherapy is indicated for selected benign, proliferative disease after more conservative measures have failed.
- Radiotherapy is a valuable option for primary or adjuvant therapy of malignant skin disease.

The first documented use of radiation as a therapeutic treatment was for a cutaneous malignancy, in a patient with squamous cell cancer of the nose, in 1900. Over the next century, radiotherapy was widely used in the treatment of both malignant and benign disorders of the skin, in both adults and children. As the long-term consequences of radiotherapy became evident, particularly the risk of radiation-induced malignancy, its use in the treatment of children and benign diseases declined. Radiotherapy continues to have a small but important role in the management of benign proliferative diseases of the skin, but is more commonly used as a valuable adjunct or alternative to surgery for both premalignant and malignant lesions.

RADIATION MODALITIES

There are several choices for radiation modalities, some commonly available and others only in specialized centers. The selection is made on the basis of the anatomic location and size of the target, tumor biology, the nature of critical surrounding structures, and availability. In particular, with respect to the cutaneous targets, the depth of the lesion plays a large role in determining the optimal therapy.

High-energy photons, in the form of γ- or X-rays, are most commonly produced by a linear accelerator (linac) and are available in a spectrum of energies. Incident radiation deposits its energy as it passes through matter, becoming attenuated as a function of distance and the density of the tissue. Higher energy beams deliver increased dose at depth in tissue, and proportionally less at the surface. Lower energy radiation deposits dose primarily at the target surface, sparing deeper matter. The most commonly available treatment energies are in the megavoltage range, which deposit their dose at a range practical for the treatment of targets in human tissue. Such beams were designed to relatively spare surface structures such as skin, which would otherwise be dose limiting, in the interest of delivering higher dose to deeper target structures. This is in contrast to more superficial radiation energies, which are often more appropriate for cutaneous targets. Depth dose curves demonstrating the absorption of X-rays as a function of their energy are demonstrated in Fig. 240-1A. Most linear accelerators in clinical use provide radiation in the range of 6–18 megavolts (MV).[1]

Orthovoltage X-rays refer to lower energy photons with maximum energy in the range of 125–400 kilovolts (kV), often used in dermatologic applications because the dose at the skin surface dose is maximized. The dose is then rapidly attenuated as the beam penetrates deeper into soft tissue. Half of the incident energy has been absorbed within the first few centimeters, ideal for treating superficial targets and minimizing dose to deeper normal tissue. Orthovoltage X-rays are produced by specialized treatment units, and are not as commonly available as megavoltage treatment units.

Grenz rays are even lower energy X-rays in the range of 5–15 kV, and therefore deposit their dose at more

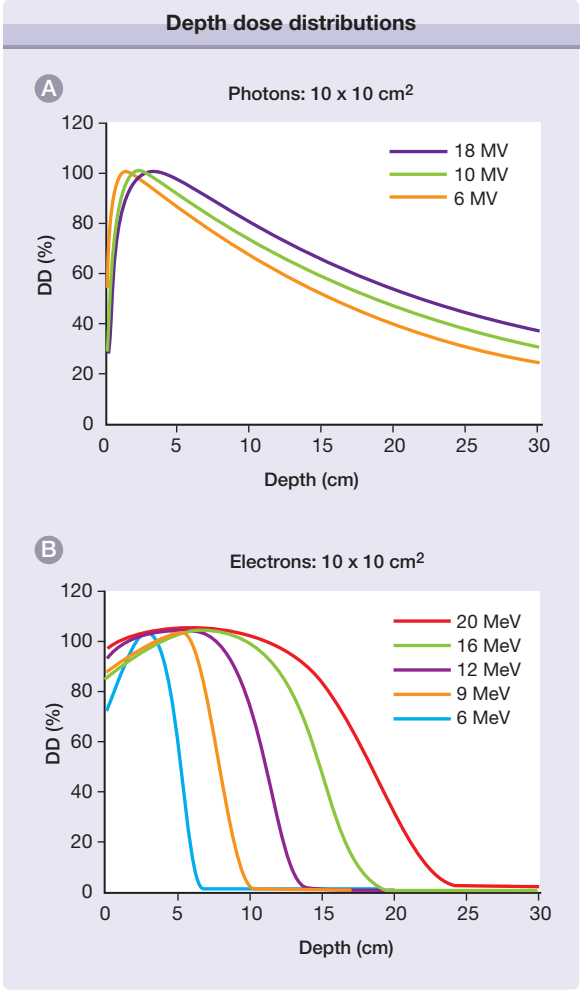

Figure 240-1 Depth dose distributions. **A.** The percent of the maximum radiation dose (DD) deposited at depth in tissue (in cm), as a function of the photon (X-ray) energy. As photon energy increases, the percent dose at superficial depth decreases, and the percent dose in deeper tissue increases. **B.** A similar relationship for electron therapy. In contrast to photons, the percent dose deposited at both superficial and deep tissue increases with electron energy. Note the difference in scale; electron energy is almost completely absorbed at shallower depths, compared to photons.

shallow depths than orthovoltage. These were historically used to treat superficial, benign skin disease. In these cases, the majority of the target processes are occurring within 1 mm of the skin surface. Grenz rays are no longer recommended as first-line therapy for routine treatment of benign cutaneous disease.

Charged particle therapy is also commonly used in cancer treatment, including both electrons, which are commonly available, and protons, available at select regional centers. Electrons are the product of the same linear accelerators used to produce megavoltage energy photons. Electron beams are commonly used in dermatologic applications as they are capable of delivering high skin-surface dose, and the deposited dose rapidly falls to negligible values at depth in tissue. Electron-depth dose, like that of photons, is a function of voltage. Higher energy electrons deliver dose to a greater depth, similar to the depth/dose relationship of photon energy. Unlike the skin-sparing properties of higher energy photons, as electron energy increases the skin dose also increases. The depth dose characteristics of electrons are described in Fig. 240-1B.

Protons are charged particles that are the product of large and expensive cyclotrons or synchrotrons, available at a small number of specialized centers. Due to their large mass, there is little side scatter during penetration of a proton beam. The dose is largely delivered within a few millimeters of the end of the particle range (the Bragg peak), rather than at shallower or deeper depths. By modulating the energy of the proton beam, radiation absorption can be more precisely delivered to deep tumor targets, with less incidental radiation of surrounding normal tissue.

MODULATION OF EXTERNAL BEAM RADIATION

Radiation treatment planning involves a complex set of decisions regarding the appropriate radiation modality, radiation energy, beam orientation, patient positioning, and the use of treatment devices. The latter can help increase the radiation dose to targeted structures, and block or reduce radiation exposure of normal tissue. "Bolus" is tissue-density material commonly used in radiation treatment of superficial skin malignancies. It can be custom designed in varying thicknesses and applied to the patient's skin during daily treatment. It serves several potential purposes: for higher energy X-rays (e.g., MV energy), or low-energy electrons, the surface dose is low compared to that in deeper tissue. By placing the appropriate thickness of bolus, the skin dose can be raised to therapeutic levels. This is demonstrated in Fig. 240-2. Another function of bolus can be to attenuate the incident beam to lower the dose to deeper structures, for example, during treatment of a skin cancer on the temple, to decrease the dose that penetrates into the underlying brain. Bolus material can also be used to compensate for complex topography, and smooth the dose distribution for treatment of the skin around the nose and ears, as seen in Fig. 240-3.

Beams can be shaped by a variety of devices depending on their energy. Megavoltage treatment beams may be shaped by custom-designed, 7-cm thick, lead alloy blocks to conform to the desired shape; most modern linear accelerators have a multileaf collimator (MLC), which contains sliding leaves of tungsten that conform to the desired treatment aperture. Electron beam radiation is normally blocked with custom-made lead or lead alloy blocks. Orthovoltage radiation is blocked using thinner custom lead shielding, typically placed on the patient's skin. Examples of blocking devices are shown in Fig. 240-4.

Traditionally, external beam radiation beams are designed using blocks or static MLCs to conform to a target that is delineated clinically or using CT or other imaging. Multiple beams, beam angles, and energies

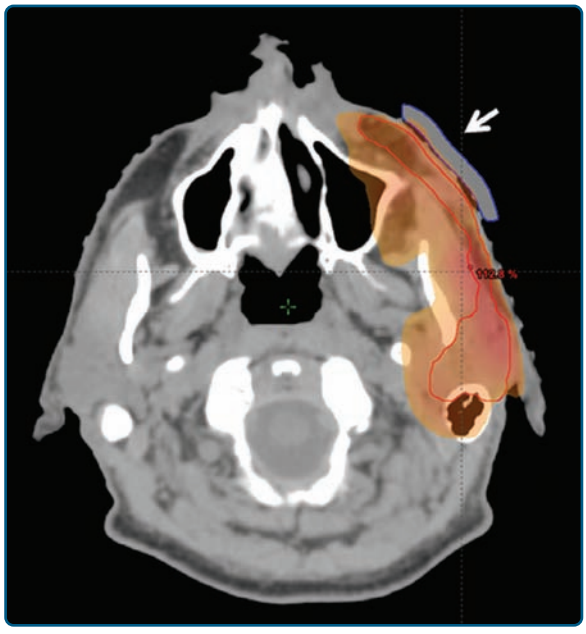

Figure 240-2 Bolus to increase the skin dose. A 61-year-old male underwent resection of a deeply invasive squamous cell carcinoma overlying the zygoma, with involvement of parotid lymph nodes and facial nerve. The tumor bed was treated, along with the remaining parotid gland and course of the facial nerve, using megavoltage photons. A tissue-density bolus (*white arrow*) was placed over the tumor bed to increase the skin dose to 100% in that area.



Figure 240-4 A custom lead shield placed on the patient's face, with a cutout to allow orthovoltage treatment of a cutaneous malignancy of the left lower eyelid.

are chosen to avoid specific normal structures, and the dose is calculated with iterative changes until an acceptable plan was generated. An "inverse planned" method is now increasingly used when the tumor target lies in proximity to a dose-limiting structure. Intensity modulated radiation therapy (IMRT) incorporates individual radiation beams that are not static; the aperture changes during the treatment to finely adjust

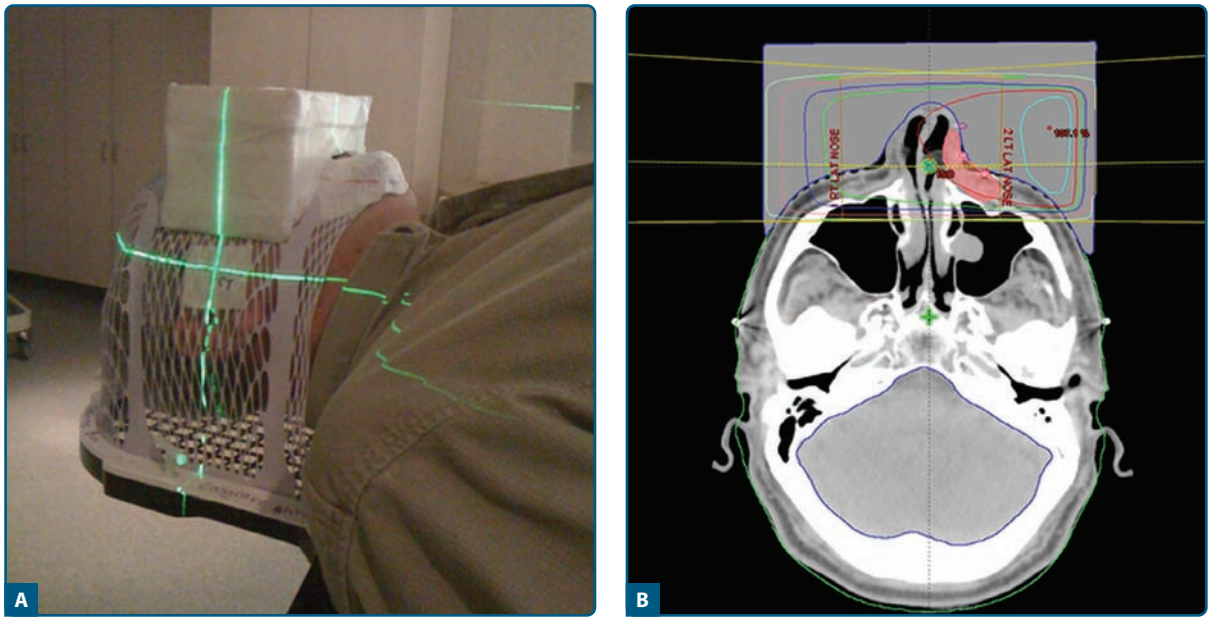

Figure 240-3 Bolus as a tissue compensator. A deeply invasive basal cell carcinoma was excised from the left nasal ala. **A.** The patient was immobilized for treatment in a thermoplastic mask. A rectangular, tissue-density, box was constructed overlying the nose to compensate for the irregular tissue contours in this area. **B.** The patient was treated with right and left lateral megavoltage photon beams, weighted left greater than right. The 100% isodose line (*red line*) covers the tumor bed (*red-shaded area*) with full dose at the skin surface and good dose homogeneity.

beam fluence. This requires a dynamic MLC, in which the leaves slide during beam-on time. During the pretreatment-planning phase, the treating physician contours the target volume and those of the normal tissue organs at risk. Dose constraints for each contoured structure are chosen, and the physician, physicist, and dosimetry staff use dedicated treatment planning software algorithms to optimize the treatment plan. This is a time intensive, expensive technique that can generate plans to treat complex shaped tumor targets and spare adjacent critical normal tissue structures.

MECHANISM OF ACTION

The most common form of radiotherapy used in clinical practice are X-rays, or γ rays. Both represent photon particles or electromagnetic waves that differ only in the method of their generation: γ rays are emitted by nuclear reactions, whereas X-rays are emitted by energy transitions in orbital electrons. Ionizing radiation includes that part of the electromagnetic spectrum of sufficient energy to impart energy to target tissue by the ejection of orbital electrons. This is the primary means of energy absorption in human tissue following exposure to therapeutic radiation. Since cells are largely composed of water, it is in water molecules that the majority of the ionization occurs and the result is the generation of short-lived free radicals, such as hydroxyl radicals. The effectiveness of radiation in tissue is therefore dependent upon the availability of oxygen. This is clinically manifest in reduced radiation response in hypoxic tissue, and is the reason that higher radiation doses are used in the postoperative setting when there is diminished microcirculation.

The primary mediator of cell death in response to ionizing radiation, in both tumor and normal tissue, is damage to DNA by indirect ionization by radiation-induced free radicals.[2] Indirect DNA damage is characteristic of sparsely ionizing radiation including not only X-rays, but also commonly used charged particles such as electron and proton therapy. In contrast, densely ionizing radiation (e.g., neutrons, αparticles) with a higher linear energy transfer (LET) deposit their energy densely along their incident tracks, and therefore more commonly induce double-strand DNA breaks directly, without the intermediate ionization of cellular water.

The initial deposition of radiation energy in tissue and the resulting DNA damage occur within thousandths of a second of exposure. The biological response to DNA damage includes modulation of cell death, differentiation, and survival pathways, and activation of DNA repair. These biologic processes occur orders of magnitude more slowly than the initial DNA damage. The ultimate cellular response to radiation can be repair, senescence, differentiation, or cell death. The latter may occur via apoptosis, a relatively rapid process, but more commonly occurs as a mitotic cell death. Misrepair of double-stand DNA breaks generates chromosomal abnormalities, and cells die during failed mitosis, often several generations later.

DOSE AND FRACTIONATION SCHEDULE

The Systeme International d/Unites (SI) unit of radiation dose is the *gray* (Gy), which is defined as a joule of energy absorbed per kilogram of tissue. An alternate unit of absorbed dose, largely replaced by the gray, is the rad (an acronym for radiation absorbed dose); one gray is equal to 100 rads. Dose is specified to the target volume as defined by the treating radiation oncologist. Most epithelial malignancies are treated to a total dose in the range of 50–80 Gy, lymphoid malignancies typically respond to doses of 15–40 Gy. Select benign conditions can be treated with lower doses; hypertrophic scars and keloids are commonly prescribed doses in the range of 4–20 Gy.

Fractionation refers to the delivery of specified radiation dose in temporally separate treatments, and is recommended to both increase the efficacy of effects on target tissue and to allow normal irradiated tissue to repair radiation damage. Thus, the schedule of radiation fractionation can be used to both increase efficacy of the dose to the target and minimize radiation damage to normal tissue. Common fractionation schemes using conventional radiotherapy deliver treatments at intervals ranging from twice daily to once per week.

The effectiveness of radiation treatment is highly dependent upon the treatment schedule; both the total number of days over which the treatment is spread and the fraction size. The common daily fraction size is 1.8–2 Gy per day, treated 5 days per week. Different fractionation schedules can be compared using a mathematical conversion to a biologically effective dose (BED), using a formula that accounts for the number of fractions, fraction size, and the DNA-repair characteristics of the target tissue.

CLINICAL AND MOLECULAR ASPECTS OF RADIATION DERMATITIS

Skin changes after radiation exposure follow a predictable course dictated by radiation dose, timing, and the biology of the human inflammatory reaction.[3] The earliest reaction is erythema that may occur and resolve within hours, and is normally only evident after relatively high-dose exposure. The threshold dose is 2 Gy or greater skin dose, and is not normally noted after daily fractionated treatment of visceral organs with skin-sparing megavoltage radiation. This effect is noted in therapeutic courses aimed at cutaneous targets, where the skin receives full dose, or during treatment regimens that use large fraction sizes. Microscopically, there is a vasodilation and a transiently increased capillary permeability that results in mild erythema and edema at 2–24 hours following exposure. Prior to the adaptation of SI units of radiation dose, skin erythema dose (SED) was used as a crude clinical measure of patient radiation exposure. This

transient acute reaction is no longer commonly noted due to the increased use of high-energy, relatively skin-sparing, radiation energies, and the increased use of lower fraction sizes. Acute, transient skin erythema is still reported following interventional diagnostic and therapeutic procedures with prolonged fluoroscopy times.

The more sustained, common, and relevant reactions take place over a matter of weeks following initial exposure. Acute radiation dermatitis progresses through characteristic stages of severity based on the accumulation of radiation-induced changes to dermal vasculature, appendageal structures, epidermal stem cells, and the activation of inflammatory pathways. Radiation dermatitis is a distinct adverse event graded by the National Cancer Institute Common Terminology Criteria for Adverse Events (CTCAE). This scale is graded on severity, and primarily describes the acute reaction of skin exposed to therapeutic radiation. Chronic skin changes may occur months to years after exposure, and include a spectrum of changes characterized by fibrosis and atrophy. Common acute and late adverse events attributable to radiation are summarized in Table 240-1.

Grade 1 dermatitis first manifests as faint skin erythema within the treatment area. Erythema is seen in two contexts: first, there may be a transient vasodilation in the hours after a single fraction skin exposure of 2 Gy or higher. More commonly, erythema or hyperpigmentation develops over the first 2 to 3 weeks of fractionated radiation with accumulated exposure. Vasodilation and increasing vascular permeability occur early, and the resulting perivascular inflammation results in clinically characteristic erythema and edema. Moderate-to-brisk erythema is grade 2.

With continuing or higher dose radiation exposure, damage to the basal cells in the epidermis may progress until this stem cell population is lost in localized areas, which results in dry desquamation (CTCAE grade 1). Further damage to the basal layer leads to more widespread desquamation, and the production of a fibrinous exudate due to increased arteriole permeability, loss of basement membrane integrity, and edema in the underlying dermis. This is characteristic of moist desquamation. The CTCAE differentiates moist desquamation based on whether it is patchy and localized to areas subject to trauma such as skin folds (grade 2), or confluent and present in a more widespread area (grade 3). Radiation damage to the underlying dermis may lead to ulceration, bleeding, or necrosis (grade 4). Skin adnexal cells are relatively radiosensitive, and may not regenerate following exposure. The process of epilation begins within days of radiation exposure. Sebaceous glands have similar sensitivity, and eccrine sweat glands become dysfunctional shortly afterward in a fractionated radiation treatment course. Histologically, these glandular structures demonstrate apoptosis, necrosis, and loss of normal mitotic activity. Chronically, there can be fibrotic replacement and loss of the supporting microvasculature. This leads to both acute and chronic hypohidrosis or anhidrosis.

Regeneration of areas of desquamation occurs through replacement of epidermal basal cells either from islands of intact cells within the epidermis or by the migration of such cells from adjacent, uninvolved areas. Normal healing of the radiation wound becomes clinically evident approximately 2 weeks after exposure, consistent with the basal cell turnover time. Widespread confluent mucositis (grade 3), or more severe toxicity such as necrosis of the epidermis or

TABLE 240-1
Commonly Observed Adverse Events Attributable to Radiation

Adverse Event	Grade 1	2	3	4	5
Radiation Dermatitis	Faint erythema Dry desquamation	Moderate-to-brisk erythema Patchy moist dequamation (mostly confined to skin folds and creases) Moderate edema	Moist desquamation (other than skin folds and creases) Bleeding induced by minor trauma or abrasion	Skin necrosis Ulceration of full thickness of dermis Spontaneous bleeding	Death
Alopecia Atrophy Dry Skin Hypo or Hyperpigmentation Induration or Fibrosis Telangiectasia	Thinning or patchy Detectable Asymptomatic Slight or Localized Increased Density on Palpation Few	Complete Marked Symptomatic Marked or Generalized Moderate Impairment; marked increase in density; minimal retraction Moderate	— — Interfering with ADLs — Dysfunction Interfering with ADLs; very marked density; retraction or fixation Many and Confluent	— — — — —	— — — — —

ADLs = Activities of Daily Living.

underlying dermis, may not undergo complete regeneration of the structural and adnexal elements. Instead, there can be prolonged inflammation, fibroblast activation, and collagen deposition. This fibrosis is often termed a consequential late effect, since it is a consequence of the severity of the acute reaction. It is in contrast to the more common late fibrosis, which arises following the regeneration of relatively normal-appearing skin and can occur years after treatment.

Late radiation toxicity occurs months to years following exposure, following a period during which the skin may not exhibit significant abnormalities. The risk and severity of true late skin changes are a function of the irradiation dose and volume. A landmark study of normal tissue radiation tolerance determined that the risk of grade 4 or greater acute toxicity (i.e., ulceration or necrosis) was 5% when 10 cm^2 of skin was treated to 70 Gy, or when 30 cm^2 was treated to 60 Gy.[4] Comorbid medical disease may exacerbate this risk; clinical risk factors associated with increased symptom severity include advanced patient age, diabetes, peripheral vascular disease, tobacco use.[5] The concurrent administration of radiosensitizing drugs significantly increase the severity of acute radiation dermatitis and prolong healing of the radiation wound. Collagen vascular diseases with a fibrotic cutaneous component (e.g., scleroderma and systemic lupus erythematosus) are associated with a pronounced and often debilitating late subcutaneous fibrosis following radiation treatment.[6,7] Certain genetic syndromes, particularly inherited defects in DNA damage repair (e.g., ataxia telangiectasia) predispose to a severe, acute, and late radiation response in exposed normal tissue.

The late skin toxicity with the most functional consequence is subcutaneous fibrosis. Replacement of the subcutaneous adipose tissue with fibrous tissue leads to loss of normal range of motion, contraction, pain, and poor cosmesis. Even in cases where dermal and subcutaneous fibrosis is not clinically evident, there may be atrophy of the skin adnexa. Hair follicles, sebaceous, and sweat glands may be absent in previously irradiated skin because these are not regenerated during normal radiation wound repair. Loss of glandular elements leads to anhidrosis when extensive skin areas are irradiated, such as in total skin electron therapy. The microvasculature of the dermis and subcutis may exhibit abnormal myointimal proliferation, leading to hypoperfusion. Tortuosity within small vessels, and micro thrombi, results in visible telangiectasia. Irregular regeneration of the basal layer of the epidermis may be evident as dyspigmentation. Paradoxically, there may be a decrease in the population of resident skin fibroblasts in atrophic skin, with loss of the normal collagen structure leading to impaired tissue remodeling, increased skin fragility and poor wound healing.

The pathophysiologic mechanism of late changes, particularly fibrosis, in response to radiation is incompletely understood.[8,9] Transforming growth factor-beta (TGF-β) is a secreted protein that serves a complex regulatory role in normal tissue inflammation and remodeling by controlling proliferation, differentiation, and secretory function. TGF-β levels are increased within hours of radiation exposure, and this elevation has been correlated with late fibrotic changes. Abrogation of downstream mediator SMAD3, a proinflammatory signaling molecule induced in response to TGF-β, appears to protect tissue from late fibrotic changes after radiation exposure in laboratory models. TGF-β is a complex regulator of inflammation that increases fibroblast proliferation, differentiation, and activation, and thereby increasing secretion of extracellular matrix components. TGF-β promotes its own secretion by fibroblasts in a self-amplifying cascade, and decreases the production of matrix proteinases. Epithelial cell proliferation is diminished, and there is chemotaxis of mast cells and macrophages. The result is increasing production, processing, and deposition of collagen (fibrosis), and loss of epithelial reconstitution of normal tissue structure.

The initiating event in TGF-β activation in response to radiation is poorly understood. Latent TGF-β in the extracellular matrix may be activated by proteolytic enzymes that act in the presence of radiation-induced reactive oxygen species. Other potential sources of TGF-β include endothelial cells, fibroblasts, epithelial cells, and tissue macrophages, which may release TGF-β in direct response to radiation, or as a generalized response to tissue damage.

RADIATION RECALL REACTIONS

Radiation recall is a phenomenon first described several decades ago, describing a cutaneous reaction in the area of previous radiation exposure, in response to specific systemic agents. The most commonly cited chemotherapeutic agents are anthracyclines, taxanes, and gemcitabine. Other systemic agents implicated in radiation recall reactions include standard chemotherapeutic agents, newer targeted therapeutics, hormonal agents, as well as nononcologic medications; a list of such agents from case reports is compiled in Table 240-2.

The clinical manifestations of radiation recall occur with the initial administration of the systemic agent: within minutes to days with intravenous drug, or days to weeks with oral medication. The timing of presentation may be related to the drug dose, and both the severity and timing of the reaction may be related to the prior radiation dose. The duration of the response may range from weeks to months. Interestingly, readministration of the same systemic agent does not consistently lead to recurrence of the phenomenon.[10]

While a recall reaction can occur in any organ, skin is the most common site. It occurs in a well-demarcated area defined by the borders of the previous treatment field, and can occur despite the lack of any clinically significant skin reaction during the previous radiation treatment. The clinical signs and symptoms mimic an acute radiation dermatitis, ranging from erythema to desquamation and necrosis. A localized maculopapular rash, characteristic of a hypersensitivity reaction, has also been described.

The pathogenesis of radiation recall is not well understood. An early hypothesis was that tissue stem

TABLE 240-2
Radiation Recall Reactions

Agents implicated in inducing a radiation recall reaction include chemotherapy drugs, targeted and hormonal agents, and nononcologic medications.

- Chemotherapy
  - Arsenic Trioxide
  - Bleomycin
  - Capecitabine
  - Cyclophosphamide
  - Cytarabine
  - Dacarbazine
  - Dactinomycin
  - Daunorubicin
  - Docetaxel
  - Doxorubicin
  - Epirubicin
  - Etoposide
  - Fluorouracil
  - Gemcitabine
  - Hydroxyurea
  - Idarubicin
  - Lomustine
  - Melphalan
  - Methotrexate
  - Paclitaxel
  - Vinblastine
- Targeted anticancer drugs
  - Bevacizumab
  - Pemetrexed
- Hormonal agents
  - Tamoxifen
- Nononcologic drugs
  - Gatifloxacin
  - Isoniazid
  - Levofloxacin
  - Simvastatin

cells remained depleted long after radiation, making the tissue more sensitive to cytotoxics. This does not explain, however, radiation recall reactions elicited by noncytotoxics or the lack of a reaction to subsequent drug exposure in some cases. The clinicopathologic manifestations are best explained by a localized, acquired hypersensitivity reaction. Prior radiation therapy may alter the normal dermal immunologic response by changing basal and stimulated cytokine production. This is consistent with histologic findings of acute inflammation (vasodilation, infiltration of inflammatory cell mediators) in affected tissue. Radiation recall dermatitis responds to treatment with topical or oral corticosteroids.

CLINICAL APPLICATIONS OF RADIATION

BENIGN DISEASE

The use of ionizing radiation for benign disease has decreased considerably, due both to improvements in alternative therapy as well as an increasing awareness of the rare but serious side effects of radiotherapy.[11] This includes not only fibrotic changes in the affected skin, but more significant is the risk of secondary malignancy. It is estimated that the relative risk of malignancy following radiation treatment increases by 10%–50%; the absolute risk remains very low. These malignancies occur at a median of 10 years following treatment. The risk appears to be greater in younger patients, and in those treated to anatomic areas at highest risk for malignancy (i.e., breast or thyroid tissue). For this reason, radiotherapy should be considered in benign disease only after other therapeutic options have been exhausted, should be avoided when possible in children and young adults, and should be delivered with attention to sparing radiation exposure to sensitive normal tissue.

Radiotherapy is effective symptomatic treatment of several inflammatory dermatoses, including eczema, psoriasis, and lichen planus at relatively low dose exposure (i.e., less than 10 Gy of fractionated treatment). These conditions are only rarely treated with radiation, given the number of other anti-inflammatory options. Benign lymphoproliferative disorders are sensitive in a similar fashion, and disorders such as lymphomatoid papulosis, lymphoid hyperplasia, and lymphocytoma cutis have an excellent response to radiotherapy. These may be treated with radiation after other options have been exhausted, and are approached using lymphoma regimens. Other benign proliferative processes that can be treated with radiotherapy include keratocanthomas, and hemangiomas. A list of diagnoses for which radiotherapy may be indicated can be found in Table 240-3.

A number of large series and one randomized trial have examined the efficacy of localized, low-dose irradiation for the prevention of recurrence of hypertrophic scars or keloids following excision.[12–14] This should be undertaken after failure of other therapies.

TABLE 240-3
Cutaneous Indications for Primary or Adjuvant Radiotherapy[a]

Benign	Malignant
Eczema	Squamous carcinoma
Psoriasis	Basal cell carcinoma
Lichen planus	Melanoma
Benign lymphoid hyperplasia	Merkel cell carcinoma
Keratocanthoma	Eccrine and apocrine carcinoma
Keloids/hypertrophic scars	Cutaneous T- and B-cell lymphoma
	Kaposi Sarcoma
	Angiosarcoma
Premalignant	
Actinic keratoses	
Lentigo melanoma	
Bowen disease	
Erythroplasia of Queyrat	
Lymphocytoma cutis	

[a]Radiotherapy is not recommended as first-line therapy for all the listed indications, particularly the benign disorders.

The most common treatment regimen is to use kilovoltage X-rays or electrons to a total dose of 10–20 Gy delivered over several days. The treatment is usually initiated within 24–48 hours of excision. The recurrence risk after surgery and radiation is approximately 20% or less. The use of radiation without excision on existing keloids is not as effective.

MALIGNANT DISEASE

BASAL AND SQUAMOUS CARCINOMA. Radiation has been used as primary treatment for basal and squamous cell carcinoma, as an alternative to excision, with local control rates of 90% or greater for small lesions.[15] There is concern for progressive late skin atrophy and necrosis decades after radiation, and for this reason surgical excision is usually felt to be a better option in younger patients (i.e., those less than 55). The control rate for primary treatment is a function of tumor size and T stage. For small lesions radiation is felt to offer local control that approximates that seen with excision.

Radiation is also an effective adjuvant treatment, following excision or Mohs micrographic surgery. The clearest indication for treatment is positive margins; other considerations include tumor depth greater than 4 mm in the case of squamous cell cancer and tumor size greater than 2 cm. Involvement of cartilage or bone is a strong predictor of local recurrence and consensus guidelines recommend adjuvant treatment. Perineural invasion has been correlated with both local and nodal recurrence following excision, and is an indication for treatment.[16,17] Involvement of large, named nerves should prompt consideration of extension of the clinical target volume to include the proximal nerve tract. Other relative indications for treatment include poorly differentiated tumors, adenosquamous subtype, and limitations imposed on excision by anatomic location. Patient factors include the presence of neurologic symptoms, implying underlying nerve involvement, and immunosuppressed host status. For squamous cell carcinoma, locally advanced lesions may have a significant risk of nodal metastasis. In patients being treated adjuvantly or definitively for locally advanced primaries with risk factors, draining lymphatics should be electively included.

Dose fractionation schemes represent a balance between patient convenience and the relative risk of poor cosmesis. A total of 60–66 Gy in 2 Gy fractions is appropriate for gross disease, with higher doses indicated for lesions greater than 2–4 cm. Published experience with relatively hypofractionated treatment has shown equivalent locoregional control after 45–50 Gy in 2.5 Gy fractions, or radiobiologically equivalent doses in fraction sizes of 3 or 4 Gy.

Tumors or postoperative areas that are at superficial depth may be treated with orthovoltage radiation to spare the deeper normal tissue. An alternative is electron therapy, with the appropriate bolus to maximize the surface dose. When the target volume is deeper, then megavoltage X-rays, with appropriate bolus, may be required. Target structures such as lymph node basins or nerve tracts, in close proximity to critical normal structures, may require IMRT.

MELANOMA. The role of radiotherapy in the management of localized melanoma has not been conclusively established. Radiotherapy is frequently used for palliation of unresectable lesions, and there is evidence that selected patients at increased risk of local or regional failure may benefit from adjuvant radiation.[18] Risk factors such as tumor thickness greater than 4 mm, ulceration, satellitosis, positive surgical margins, mucosal origin, perineural invasion, and desmoplastic histology are predictive of local relapse after wide excision. Patients with positive lymph nodes at high risk of recurrence after node dissection may benefit from postoperative radiation directed at the nodal basin.[19,20]

Melanomas are frequently treated with hypofractionated radiation, with fraction sizes of 4–6 Gy (i.e., 30 Gy in five fractions) using megavoltage X-rays. The recurrence risk for melanoma after radiation is significantly higher than that for squamous or basal cell carcinoma.

CUTANEOUS LYMPHOMAS. Cutaneous T-cell lymphomas include numerous subtypes, the most common of which are mycosis fungoides (MF) and anaplastic large cell lymphoma. MF is exquisitely sensitive to radiotherapy and patients may present with localized or disseminated skin disease. Anaplastic large cell lymphoma (CD-30 positive) is also a common CTCL, but has an incidence which is less frequent than MF. The clinical presentation is also somewhat different, and these cells generally demonstrate a CD-4 positive phenotype (which can be seen in MF), and also express cutaneous lymphocyte antigen. As opposed to MF, these cells are typically not epidermotropic and do stain positive for CD-30. Lymphomatoid papulosis is also CD-30 positive and may be associated with anaplastic large cell lymphoma. Anaplastic lymphoma kinase (ALK) is usually not overexpressed in patients suffering specifically from cutaneous lymphoma of the CD-30 positive variety, though it may be expressed in patients with noncutaneous anaplastic large cell lymphoma.

There are also a variety of subtypes of cutaneous B-cell lymphoma, but the most commonly encountered are diffuse large B-cell, marginal zone, and follicular center cell. Diffuse large B-cell lymphoma may express CD-20 and CD-79 and lesions involving the lower extremities may express BCL-2, BCL-6, and MUM-1. Marginal zone lymphoma can be identified via expression of CD-20 and CD-79 and often BCL-2, but typically BCL-6 is not noted as a marker in this case. The follicular center cell variant may express CD-20 and CD-79, but expression of BCL-2 and MUM-1 is unusual.

Localized radiotherapy fields may be incorporated into the management of patients with limited disease but, in some cases, patients have extensive areas of skin which are involved and a total skin electron beam therapy (TSEBT) technique may be incorporated for adequate disease control.

Localized radiotherapy is typically provided utilizing an electron technique and bolus material is applied to the skin in an effort to maintain an appropriate

deposition of dose at the skin surface. Typically the 90% isodose curve is utilized to provide homogeneous coverage of the area in question of the skin and margins of 2–3 cm radially are incorporated into the treatment plan. Doses of 30–36 Gy in 2 Gy fractions are used. With this type of regimen for most CBCLs, the complete response (CR) rate is greater than 95% with 5-year local control of approximately 75%.[22,23] Some patients may not be able to logistically receive daily therapy over several weeks, but are in need of palliation of lesions which are bleeding, uncomfortable, unsightly, or impairing function. Such patients may be candidates for an abbreviated regimen of 2 Gy × 2 to a total of 4 Gy, which has been found to provide excellent response rates with reasonable durability in selected patients with low grade CBCL.[24]

TSEBT is significantly more complicated to provide and is typically utilized in patients suffering from extensive MF. It provides excellent response rates for patients with various levels of disease and has also been successful in patients with tumors of the skin, assuming that a supplemental boost be provided to the region involved by tumor. More superficial patches and plaques have an excellent response rate to TSEBT when it is used in the management of patients with MF and the response rate is 100%. The CR rate is variable and decreases with the degree of thickness associated with cutaneous lesions. A typical course of therapy is provided over approximately 8–10 weeks and, based on a Stanford technique, involves 36 fractions to the total skin utilizing six fields with blocking of the eyes, hands, fingernails and feet based on dosimetric parameters resulting from the individualized treatment program.[25]. The patient is treated in a variety of standing positions. TSEBT is best performed in centers that have a significant amount of experience with the technique given its degree of complexity. An important feature to be considered following response to TSEBT is a maintenance program, and such maintenance can be provided in a variety of forms. For MF patients with T1 and T2 level disease, effective regimens, which have been documented in the literature, include the use of PUVA and mechlorethamine.

Both cutaneous T- and B-cell lymphomas are very sensitive to radiotherapy, and it is generally accepted that all lesions will respond and that localized CBCL lesions have a CR rate approaching 100%. CTCL lesions have CR rates that are also excellent but are more dependent on extent of disease.

KEY REFERENCES

Full reference list available at www.DIGM8.com

DVD contains references and additional content

1. Khan FM: *The Physics of Radiation Therapy*, 4th edition. Philadelphia, Lippincott Williams & Wilkins, 2010, p. 42-43
10. Azria D et al: Radiation recall: a well recognized but neglected phenomenon. *Cancer Treat Rev* **31**(7):555-570, 2005
11. Lahaniatis JE et al: Radiation treatment for benign disease. A survey of current treatment programs. *Front Radiat Ther Oncol* **35**:1-17, 2001
14. Sclafani AP et al: Prevention of earlobe keloid recurrence with postoperative corticosteroid injections versus radiation therapy: A randomized, prospective study and review of the literature. *Dermatol Surg* **22**(6):569-574, 1996
16. McCord MW et al: Skin cancer of the head and neck with clinical perineural invasion. *Int J Radiat Oncol Biol Phys* **47**(1):89-93, 2000
18. Ballo MT, Ang KK: Radiotherapy for cutaneous malignant melanoma: Rationale and indications. *Oncology (Williston Park)* **18**(1):99-107, 2004
21. Decker RH, Wilson LD: Role of radiotherapy in the management of merkel cell carcinoma of the skin. *J Natl Compr Canc Netw* **4**(7):713-718, 2006
24. Neelis KJ et al: Low-dose palliative radiotherapy for cutaneous B- and T-cell lymphomas. *Int J Radiat Oncol Biol Phys* **74**(1):154-158, 2009

SECTION 39

Complementary and Alternative Dermatology

Chapter 241 :: Complementary and Alternative Medicine in Dermatology

:: Alan Dattner

COMPLEMENTARY AND ALTERNATIVE MEDICINE AT A GLANCE

- Complementary medicine is a holistic approach to diagnosis and treatment.
- Many dermatologic therapies developed in ways similar to the complementary approach and were subsequently scientifically validated.
- Attention to the environment and its impact on the patient is a fundamental principle of complementary dermatology. This means our world dermatology organizations have an obligation to speak out about what is harming the skin, health, as it is related.
- Herbal therapeutics, supplements, diet, and digestive system aid are four of the primary interventions used in holistic dermatology.

Complementary and alternative medicine (CAM) in dermatology encompasses a wide variety of methods of diagnosis and treatment that either supplement or substitute for conventional dermatologic practice. It is also referred to as *holistic dermatology* because it considers and addresses the entirety of the individual, including the physical, mental, emotional, and spiritual aspects of the individual's life, as appropriate. Holistic dermatology draws on an expanded knowledge base that includes CAM, conventional practice, and the latest research findings. Its diagnostic and therapeutic choices are made by combining these three knowledge bases, in what might also be termed *integrative dermatology*.

The alternative healthcare systems considered by holistic dermatology may include time-honored practices such as ancient traditional Chinese medicine, Ayurvedic medicine, American folk medicine, homeopathy along with more recently developed techniques from chiropractic, energetic medicine, functional medicine, and psychosomatic modalities. Furthermore, holistic dermatology includes any other technique that works or makes sense based on science or observation.

Increasingly, patients are using CAM methods in addition to conventional dermatological treatment as cosmeceutical, nutraceutical, and even pharmacological manufacturers more routinely offer these products. CAM practitioners and dermatologists are being called upon to respond to their patients' expectations, preferences and demands for therapeutic modalities and treatments that avoid or minimize use of prescription drugs, and are safe, natural, and effective.

Alternative medicine often embraces treatment that not only presages but also may ultimately be incorporated into conventional practice. Good CAM practice is rooted in basic science, clinical experience and good medicine, but it often lacks the sanctioned level of proof we have come to demand for scientific, allopathic dermatology. Further, CAM practices arise and are developed differently from conventional practices. For example, when a growing body of anecdotal experience is supported by the understanding of underlying mechanisms of pathology, particular CAM approaches to illness are employed, even before the methods are validated in the usual ways. Many of these methods are difficult to study or assess using conventional research methods because they relate to the individual rather than to the disease or condition itself.

Many CAM methods and practices have slowly been incorporated into more conventional practice and some have gained widespread acceptance and use. Examples include the increasing use of probiotics, which had its tentative beginnings in the 1980s, to counter *Candida* overgrowth in the gut, which was later shown to enhance barrier function in the intestines and skin. The CAM use of essential fatty acids (EFA) as anti-inflammatory agents preceded the growing literature on this subject.

CAM practice also identified trans-saturated fats as disrupters of cellular functioning, inhibiting the δ-6-desaturase and thus the production of anti-inflammatory prostaglandins. This tenet of CAM medicine was set forth by Horrobin and others in the 1980s, decades before products containing transfats were removed from the shelves and castigated as deleterious for health.[1,2]

Similarly, kitchen herbalists and small companies were producing herbal skin applications long before the current popularity of cosmeceuticals. And while historically CAM practices have gradually been adopted by mainstream practitioners, in dermatology, the pace of adoption has quickened in recent years. Perhaps most telling is that much of the herbal pharmacopoeia of CAM dermatology referenced in the last edition of this text is now described in the dermatologic literature or is available in products designed for the skin.

HERBAL MEDICINE

Eclectic practice and off-label use of pharmaceutical drugs has always been a part of dermatology, perhaps more so than in medicine in general. These practices provide novel and often effective approaches to disorders of uncertain etiology by incorporating methods from other spheres or from observed benefit. Many of the commonly used pharmacological agents used in conventional allopathic medicine are derived from herbal medicine.[3] The American "herbal" tradition dates to the Eclectics, a school of physicians who, during the nineteenth and early twentieth century codified the use of Western herbs according to specific indications.[4] Today a wide variety of herbs is used, and the methods of selecting specific herb combinations also originate in other traditions. For example, psoralens have been used in China and India for repigmentation of the skin for more than 4,000 years. Other herbs used in treating the skin include mayapple (podophyllin) for condyloma, horse chestnut for leg veins, bloodroot (sanguinaria) for skin tumors, and oatmeal (*Avena sativa*) to soothe rough, itchy, or inflamed skin.[3]

In addition to specific herbal remedies, some of the philosophical tenets of herbal medicine have been incorporated as key concepts in dermatology. For example, the principle of using a crude preparation as opposed to a purified single ingredient as tends to be used in a pharmaceutical product, was one of Sulzberger's observations regarding the use of tar.[5] It was the crude tar product from the distillery and not its purified derivative that had activity in treating psoriasis. In fact, variation in batch efficacy was assumed to be an indication of the heterogeneous nature of the preparation.

A virtual explosion in the availability of herbs in cosmeceuticals, herbal supplements, and new pharmaceuticals has occurred during the past 15 years. This growth has been accompanied by a substantial increase in peer-reviewed publications seeking to clarify the mechanism of action of herbs and their components and case studies detailing knowledge inferred from their traditional use. Each herb has a number of different activities and actions, which depend on growth conditions, the extent to which they have been challenged to fend off pathogens and predators, method of extraction, and the culture that utilized the herb or herbal preparation.

One of the advantages of knowing the traditional uses of herbs and their rich history of folk use is the ability to more fully appreciate their spectrums of action. For example, oats, *A. sativa*, are well known for their soothing anti-inflammatory effects on the skin as a topical soak. The milky white sap from green oats is known for its calming properties as a relaxant to the nervous system. In the context of its use as a folk and home remedy, it is easier and intuitively correct to seek out oat extracts for their calming effects on the nervous tissue in the skin, i.e., soothing and anti-pruritic actions as well.

ANTIOXIDANTS

Antioxidants prevent damage from both exogenous and endogenous free radicals. Ultraviolet radiation from the sun is a major source of free radical damage to the skin, but is beneficial for the production of vitamin D. A symphony of antioxidants prevents excessive damage to either the somatic tissues or DNA of the cells. Plants also must develop their own complex of antioxidants in order to withstand excessive damage from the sun. A young sprout or a plant placed prematurely in full sun will wither and die. It is the complex of antioxidants and light absorbing pigments that plants develop which function to protect them from this damage. Therefore, some argue that eating whole plants, with their functional spectrum of antioxidants, is more protective than isolating the most active fraction, such as β-carotene, and administering it alone.

Nutritional supplementation can supply external antioxidants, or support the generation of endogenous antioxidants. Carotenoids and polyphenols (bioflavonoid) are two major classes of plant-derived antioxidants. Bioflavonoids are especially protective of the capillaries and blood vessels. Oxidative damage and glycation damage induce metalloprotease activity, which destroys the integrity of collagen and elastic tissue in both the skin and the vasculature, and antioxidant protection may slow this process.

APPROACH TO DISEASE

The hallmark of CAM is a search for the elements in the causal chain of functional disturbances that lead to a skin disorder. For inflammatory disorders, an attempt is made to identify exposures, which could stimulate and/or disturb immune responses with secondary targeting of skin structures. CAM focuses on correcting probable underlying causes, often with treatments that are not proven in the traditional scientific method. The patient not only assumes the responsibility of making the necessary lifestyle changes but also the risk of using protocols that are neither conventional nor necessarily well researched.

Individual specificity is key to CAM dermatology. Long before knowledge of specific pathogens and genetic polymorphisms, other systems of healing such as Ayurvedic medicine developed classification and treatment paradigms that are still used today, and extend well beyond diagnosis. The long-awaited studies and meta-analyses of CAM in dermatologic disorders such as psoriasis[6] will continue to be of very limited usefulness because they persist in classifying

patients solely by disease and fail to choose herbs and supplements for time-tested indications in traditional systems, or based on CAM or individual-specific disease mechanism parameters. Appreciation of these distinctions will lead to the design of research studies that truly indicate how to integrate CAM into dermatology as well as how to accurately evaluate the efficacy of CAM practices.

"FOOD ALLERGY" DETERMINATION AND ELIMINATION. In addition to classic immunoglobulin E-mediated allergic response, the term *food allergy* also includes other types of allergy such as immune complex, delayed, and Toll-like receptor activation. There is also nonallergic sensitivity. Food allergies develop to the many common foods such as wheat, milk, soy, yeast, and corn. Some believe that a hallmark of food allergy is food craving with repetitive eating of the same food each day.[19] A 5-day elimination and rechallenge on the sixth day is an effective way to determine if the food under consideration is the cause of the symptoms of concern.

Other symptoms beyond the skin could include digestive upset, nasal stuffiness, fatigue after eating, or even "brain fog." *Brain fog* is a popular term for a sense of mental confusion, sluggishness, and slowness that may sometimes include a feeling of unreality or disorientation. Small peptides from casein digestion known as *caseomorphins*, which can also derive from gluten, rice, bovine albumin, and even spinach, have psychoactive properties.[20] Treatment involves elimination, substitution with other foods, and food rotation. Enhancing digestion with digestive enzymes and adding metabolites to enhance the gut permeability barrier (and reduce the impact of leaky gut) helps to prevent sensitization to disease inducing cross-reactive antigens.[21,22]

Food Allergy Diagnosis. Diagnosing food allergy is best initiated by a careful history of the specific foods that preceded a reaction; these include foods consumed a few hours or even few days prior to the reaction. A food and reaction diary helps to reinforce memory and document instances of food consumption and reactions. Elimination and challenge is the gold standard for identifying food allergens. Intradermal testing can be helpful, and is far more useful than scratch tests because the latter detect IgE or immediate allergy only.

ESSENTIAL FATTY ACIDS. EFAs play an essential role in skin health. EFAs are the precursors of the eicosanoids produced when phospholipase cleaves a lipid fragment, arachidonate, from the cell membrane. Arachidonate, a common pathway byproduct from most foods, leads, via cyclooxygenase, to production of the proinflammatory prostaglandin E_2(PGE_2), or via lipoxygenase to production of proinflammatory leukotrienes.[25] Specific ω-6 unsaturated EFAs such as γ linolenic acid, found in borage oil, evening primrose oil, and human breast milk, lead to formation of the anti-inflammatory PGE_1. ω-3 unsaturated fatty acids such as those found in fish oils contain eicosapentaenoic acid (EPA), which leads to formation of the anti-inflammatory and anticlotting PGE_3. Flaxseed oil has an ω-3-EFA known as *α-linolenic acid,* which requires two carbon chain elongation to become EPA, requiring activity of the δ-6-desaturase enzyme. That enzyme has cofactor requirements of zinc, magnesium, vitamins C, B3 and B6, and low insulin levels. ω-3 EFAs also play a role in formation of the barrier lipid in the brick and mortar structure of the stratum corneum barrier. Partially hydrogenated oils not only lead to proinflammatory PGE_2 formation, but also inhibit the δ6-desaturase, which is crucial for formation of anti-inflammatory γ-linolenic acid.

Shifting the balance toward anti-inflammatory EFAs by removing foods with proinflammatory oils and increasing foods and supplements with anti-inflammatory oils (e.g., cod liver oil) is a strategy useful in most conditions involving inflammation and dry skin. It is especially useful in seborrhea and eczema. Rare problems with excessive fish oil include increased bleeding tendency[26] and high-birth weight, postmature babies.[27]

A number of studies have shown the effectiveness of ω-3-EFAs in psoriasis and other inflammatory and autoimmune diseases.[28] EFAs also confer powerful protection from UV exposure and have been used to reduce inflammation and promote wound healing in burn victims.[29,30]

HOMEOPATHY

Homeopathy pushes the boundaries of the scientific mind because it works by invoking the energy of the substance rather than the substance itself, with greater dilutions having greater potency.[32] A key aspect of homeopathy is that substances diluted homeopathically often, but not always, work by counteracting the very symptoms that the undiluted substance produces. For example, Nux vomica is used to counteract nausea, and *Coffea*, from coffee, is used to induce sleep. Some herbalists also use the information from the provings, the homeopathic repertory, for seeking further insight into the characteristics of herbs.[33]

COMPLEMENTARY AND ALTERNATIVE MEDICINE APPROACHES TO SPECIFIC DERMATOLOGIC CONDITIONS

Several dermatologic disorders, particularly those that are inflammatory in nature, may benefit from the CAM approach.

SEBORRHEIC DERMATITIS

(See Chapter 22)

Seborrheic dermatitis[34] involves inflammation in sebaceous follicular areas of the scalp, eyebrows, and nasolabial folds. All of these regions harbor the yeast

Malassezia, which is normal follicular flora. There is evidence that *Malassezia* is cross-reactive with *Candida albicans*,[35] and it is postulated here that a cross-reactive attack against antigenic epitopes on the *Candida* and other yeasts and molds becomes directed against the *Malassezia* organisms in the follicle, causing the inflammation that incites the erythema and desquamative changes characteristic of seborrhea.

An altered pattern of EFAs in infantile seborrheic dermatitis implicates impaired function of the δ-6-desaturase.[36] Some of the B vitamins previously reported as helpful in seborrhea may function as cofactors for this enzyme.[37–39] The tendency toward inflammation is exacerbated by a predominance of arachidonic acid precursors in the cell membranes derived from dietary sources. Treatment by substituting EPA-rich fish oil in the diet and removing partially hydrogenated and saturated oils can reduce this inflammatory state by favoring the generation of anti-inflammatory PGE_3.[40–42] Flaxseed oil is another ω-3-fatty acid and PGE_3 precursor, but the active ω-3-EFA in it, α-linolenic acid, requires chain elongation to be converted to EPA, and this process is not uniform among individuals.[43]

ATOPIC DERMATITIS

(See Chapter 14)

Atopic dermatitis is an inflammatory disorder of the skin linked to asthma and hay fever. In the past, dermatologists observed cases in which food was considered a trigger, but were generally puzzled that there did not seem to be a specific food that caused the eczema. One challenge was that eczema could be aggravated by one food, and then after diet change, would be exacerbated by the newly substituted food.

One theory articulated by practitioners of CAM relates to what is known as *leaky gut*.[44] Disruption of the gut barrier can result from inflammation of the intestinal lining. This inflammation may be caused or precipitated by parasites, *Candida* overgrowth, food sensitivity, foods containing lectins that punch holes in cell membranes, or pathogenic microorganisms. In addition, nonsteroidal anti-inflammatory drugs are irritating to the gut lining, as are alcohol and aspirin. Any food introduced repeatedly into such an environment can lead to sensitization to that food. In these cases, it is believed that the uncontrolled atopic becomes sensitive to whatever he/she eats repeatedly to avoid that which caused trouble initially. For example, the milk-allergic infant switched to soy protein soon becomes "allergic" to soy. Inflammation in the gut wall stimulated by soy causes allergy to whichever nutrient is next exposed to the gut immune system. This "vicious cycle" could account for the name *atopic*, which was used to describe the changeable nature of the factors initiating the dermatitis.

Treatment consists of removing abnormal microbes and restoring normal flora, removing irritants, eliminating exacerbating foods, enhancing enzymatic breakdown of foods (digestion), coating the gut with mucilaginous herbs, and providing the nutrients needed to support an intact gut barrier.

Proper colonization of the gut with *Lactobacillus acidophilus* and similar strains has a protective effect against atopy.[45] A corollary of this observation is that repeated use of antibiotics favors overgrowth of *C. albicans*, and simple starches and sugars support *Candida* growth. It is presumed that consumption of large amounts of yeast, mold, and their byproducts, such as bread, beer, wine, and cheese, could both induce high-dose antigen tolerance to intestinal *Candida*, and perhaps even sensitize to other antigenic determinants. High-dose tolerance is a lack of immunoreactivity to specific antigenic determinants or substances due to the presence of large quantities of these determinants in the system. Treatment consists of removing the dietary factors that favor *Candida* and then treating with herbal or other natural remedies to reduce the yeast population. *Artemisia annua* and short-chain fatty acids such as undecylenic or caprylic acid are a few such treatments. Next, probiotics may be added to prevent *Candida* from overtaking gut flora.

Only when these measures have been taken should pharmaceuticals be used in a progressive fashion. Otherwise, there is the risk of selecting for resistant strains. Nystatin may be considered, followed by ketoconazole and fluconazole. Nystatin should be slowly increased in dosage from 500,000 units/day in divided doses to 6 million units, over 10–12 days. Highly yeast-sensitive individuals absorb cell content material through an already leaky gut wall and are known to develop exacerbation of previous symptoms and sometimes fever, with a Herxheimer-like reaction. All of these drugs have more potential effectiveness when the environment is changed by dietary restrictions on sugars, simple carbohydrates, and foods high in or derived from yeast.

Anti-inflammatory EFAs, such as EPA from fish oils, appear to help some atopics.[46] Hempseed oil, rich in ω-3- and –6-EFAs, improved the serum fatty acids, and the condition of atopics, in a study conducted in Finland.[47] There has been a consistent increase in the number of studies showing that γ-linolenic acid from borage or evening primrose oil[48] effectively resolves various aspects of atopic dermatitis, and there is clear indication that it is beneficial for some patients with eczema. The results of a small study performed in Germany showed that GLA supplementation from EPO reduced total IgE in the first year of life, but did not prevent atopic dermatitis. Another study found decreased GLA levels in children with eczema and elevated IgE levels and others with atopy, but not in eczema patients with normal IgE levels.[49] Meta-analyses to the contrary[50] are likely contaminated by issues discussed under EFAs, above, and should not dissuade physicians or patients from a proper trial of EFAs in atopic patients, once oxidative stress has been calmed down. Furthermore, a balance of anti-inflammatory EFAs is likely most effective for allergic individuals. It should be remembered that the industrialization of our food supply over the past half-century, including partial hydrogenization of nearly

all food products that required shelf life, hardening oils for convenience in food, importing southern oils where unsaturated northern oils were local, and farm feeding grains to fish, poultry, and livestock that previously consumed local cold grown plants naturally rich in unsaturated fatty acids, all have served to dramatically reduce the proportion of anti-inflammatory EFAs in our diets and thus cell membranes. Some of the increase in atopy, inflammatory, and autoimmune disorders we are now seeing may be in response to the "hair trigger" this shift is placing on the prostenoid aspect of the immune response.

There has been scant attention paid to primary prevention of atopic dermatitis. Although conventional wisdom has held that breastfeeding is associated with reduced incidence of atopic dermatitis in children, recent research questions this, especially when the mother herself is allergic. In fact, it seems likely that dietary allergens present in breast milk of these allergic mothers may actually trigger or contribute to the development of atopic dermatitis in offspring. For this reason, it may be prudent to suggest that mothers of infants at risk for atopic dermatitis avoid dietary allergens. There also is some evidence of benefit from the use of probiotics and supplementation with EFAs.[51]

ACNE

(See Chapter 80)

Before the availability of tetracycline, diet change was a mainstay in acne treatment. With the advent of antibiotics for acne, many dermatologists argued that the stress produced by restricting favorite foods was itself acne causing, and consensus evolved to minimize the role of diet in acne. This view was supported by seminal papers that demonstrated that common agents such as chocolate did not cause acne.[52] More recent data do reveal a relationship between milk consumption, both full-fat and especially nonfat, and acne in teenage girls[53] and boys[54,55] Darby and others posit that hormones normally present in milk as well as added to enhance milk production may be responsible for this effect. This includes progesterone-related hormones and 5-α-pregnanedione, which is converted directly into dihyrotestosterone.[56] Milk protein allergy causing an inflammatory response that blocks the infundibular apparatus also may contribute.[44] It now appears that diet may influence a number of mechanisms related to acne development.[57]

Bovine milk production by postpartum cows contains placenta-derived progesterone and dihydrotestosterone precursors. Other hormones in addition to steroids in milk also may stimulate acne. The most frequently implicated substance is IGF-1 (insulin-like growth factor), which also increases during the teenage years as a result of growth hormone. IGF-1 is present in organic milk and increased in milk from cows treated with bovine growth hormone. IGF-1 increases lipogenesis in sebocytes.[58] It stimulates 5-α-reductase and androgen synthesis. It has also been shown that excess carbohydrate consumption increases insulin, which increases IGF-1, which in turn worsens acne.[59] IGF-1 and dihydrotestosterone levels in women both correlate with acne.[60]

Melnik has elegantly suggested the role of deficiency or displacement of nuclear transcription factor Fox01 from suppressing the androgen receptor and the promoter of PPAR-γ as the key initiator of the activation of the genes for sebocyte proliferation, sebum synthesis, and inflammatory cytokines.[61] He observes that retinoids increase Fox01, and that all known acne-inducing factors work by decreasing it.

Milk elimination and reduced carbohydrate ingestion can produce a substantial improvement in some acne patients, as does reduction of proinflammatory fats from fried and partially hydrogenated sources. In women with perimenstrual flaring, reduction of dietary estrogens, and pseudoestrogens may be helpful.

The holistic perspective posits that the initiator of the inflammatory process that leads to acne is derived from antigens and informational molecules derived from an improper diet and environment, and that the mechanism of inflammation, so elegantly described in the classic and emergent literature, is a key precipitating step in that cascade.

Recent evidence indicates that inflammation in the pilosebaceous unit may precede the follicular plugging and *Corynebacterium acnes* proliferation,[62,63] and that the predominant presence of CD^+ memory/effector cells suggests a specific antigenic T-cell inflammatory, rather than nonspecific, immune response. Timed immunofluorescent studies reveal a type IV delayed hypersensitivity response, and, therefore, point to a soluble antigen stimulus initiating the acne lesion.[64] A primary response to antigen in a structure that concentrates antigenic material from the blood, which ultimately comes predominantly from the digestive tract, makes acne an inflammatory disorder that should respond to the alteration of gut-derived antigens described in this chapter.

There is evidence from animal studies that carbon-14-radiolabeled α-linolenic acid, dietary ω-3-EFA found in flaxseed, is preferentially found in the coat of guinea pigs, suggesting sebaceous excretion of this dietary lipid.[65] There is reason to believe that all of the lipids, and indeed all of the other molecular moieties that are secreted or synthesized into secretions in the pilosebaceous unit, are derived either from diet, body stores, microbial metabolites, or topical absorption. The infundibular apparatus concentrates and excretes both water-soluble wastes in the sweat, and lipid and proteinaceous material in the sebum. Medications, such as ketoconazole, have been found in sebum.[66]

HIDRADENITIS SUPPURITIVA

Hidradenitis suppuritiva (HS) may respond to treatment that enhances digestive function, gut barrier function, and elimination of reaction to allergenic foods. HS is increasingly being recognized as a disorder of immune function, at least in the local tissues.

KEY REFERENCES

Full reference list available at www.DIGM8.com

DVD contains references and additional content

3. Dattner A: From medical herbalism to phytotherapy in dermatology: Back to the future. *Dermatol Ther* **16:**106, 2003
6. Smith N, et al: Complementary and alternative medicine for psoriasis: a qualitative review of the clinical trial literature. *J Am Acad Dermatol* **61**(5):841-856, 2009
7. Untersmayr E, Jensen-Jarolim E: The effect of gastric digestion on food allergy. *Curr Opin Allergy Clin Immunol* **6**(3):214, 2006
14. Walker WA, Isselbacher KJ: Uptake and transport of macromolecules by the intestine: Possible role in clinical disorders. *Gastroenterology* **67:**531, 1974
18. Adebamowo CA et al: High school dietary dairy intake and teenage acne. *J Am Acad Dermatol* **52:**207, 2005
24. Kalliomaki M et al: Probiotics in primary prevention of atopic disease: A randomized placebo-controlled trial. *Lancet* **357:**1076, 2001
36. Tollesson A et al: Essential fatty acids in infantile seborrheic dermatitis. *J Am Acad Dermatol* **28:**957, 1993

SECTION 40

Surgery in Dermatology

Chapter 242 :: Anatomy and Approach in Dermatologic Surgery

:: Sumaira Z. Aasi & Brent E. Pennington

INTRODUCTION TO DERMATOLOGIC SURGERY AT A GLANCE

- Profound knowledge of the anatomy, particularly of the head and neck region, is essential.
- Preoperative assessment includes a thorough medical, drug, and medication history.
- Asepsis and antisepsis are required.
- The choice of the anesthetic is determined by the nature and duration of the procedure and by patient factors such as allergy or renal or hepatic impairment.
- Side effects of local anesthetics are pain, a vasovagal reaction, or (uncommon) allergic reactions. Anesthetic toxicity is rare.
- Infiltrative anesthesia, nerve blocks, and topical anesthesia (for minor procedures) can be performed.
- Types of suture material and suturing technique depend on the surgical procedure.
- Postoperative care is essential.

Dermatologic surgery has rapidly become a cornerstone of the practice of dermatology. Factors such as the epidemic of skin cancer, the interest in maintaining a youthful appearance for an aging population that is living longer, and the financial pressures to perform surgery in less expensive outpatient settings have led to an increase in the number of surgical procedures performed in dermatologic practice.

ANATOMY

Anatomy is often called the language of surgery.[1,2] Knowledge of anatomy is critical for a number of reasons, including communicating precisely with colleagues, performing efficient and safe procedures, obtaining optimal functional and aesthetic reconstruction, understanding the lymphatic drainage, and anticipating the metastatic spread of malignancies. As the majority of cosmetic and surgical procedures are performed on the face, and because of its complexity, this chapter focuses on the superficial cutaneous anatomy of this critical region.

COSMETIC UNITS AND LANDMARKS

Landmarks and cosmetic units help localize areas of the face accurately and precisely for purposes of communication with colleagues and to perform the surgery itself. For instance, it is more helpful to describe a lesion on the face if it is said to be located on the "left nasal sidewall" versus left nose or "right triangular fossa" versus right ear. Cosmetic units are zones of tissue that share cutaneous features such as color, texture, pilosebaceous quality, pore size, and degree of actinic exposure. These cosmetic units are demarcated by junction lines that can be discrete (eyebrows) or subtle (nasofacial sulcus). Cosmetic units can also be further divided into subunits. Because of the tissue similarity, it is often best to reconstruct a surgical defect within a cosmetic unit or subunit or borrow tissue from nearby units. In addition, scar lines can be hidden easily in junction lines between the cosmetic units. The more complex regions of the face that have multiple subunits include the nose, ears, and lips (Figs. 242-1 and 242-2).

The subunits of the nose include the glabella (the area between the eyebrows), the root (the deep sulcus below the glabella and uppermost portion of the nose), dorsum or bridge (the area overlying the nasal bone), lateral side walls (the sides of the nose), nasal tip, the nasal ala (the nostril), alar groove and nasolabial crease (the grooves that demarcate the alae superiorly from the lateral nasal sidewall and alae inferiorly from the lip, respectively), and the columella (the mobile linear structure separating the alae inferiorly) (see Fig. 242-1).

The lateral surface of the ear is rimmed by the helix, a curved cartilaginous structure that begins at the crus

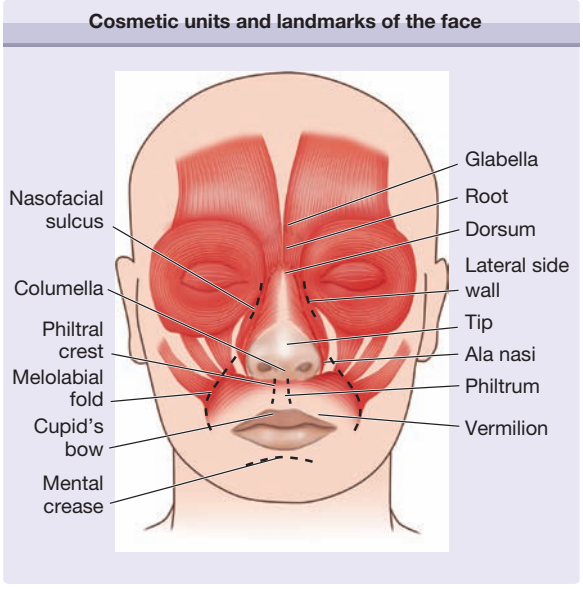

Figure 242-1 Cosmetic units and landmarks of the face.

just above the external auditory canal and continues around the ear to end at the fleshy lobule. The central concavity within which the external auditory meatus lies is the concha. The concha is divided by the crus of the helix into a superior portion, the cymba, and an inferior portion, the cavum. The posterior border of the concha is formed by another cartilaginous structure called the *antihelix*. Superiorly, the antihelix originates from two legs (*crus* is Latin for *leg*): (1) the superior crus and (2) inferior crus. The region between the crura is referred to as the triangular fossa. The groove between the helix and antihelix is the scaphoid fossa. The triangulated cartilaginous structure just anterior to the auditory canal is called the *tragus*, and just posterior to this is the triangulated end of the antihelix, referred to as the *antitragus*. The inferior region between the tragus and antitragus is the intertragic notch (see Fig. 242-2).

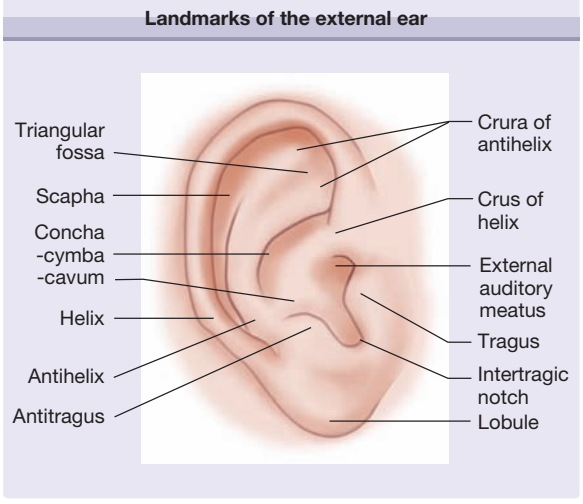

Figure 242-2 Landmarks of the external ear.

The cutaneous upper lip has a concave depression in the center, called the *philtrum*, which is bounded by two ridges, the philtral crests. There is a prominent crease, the mental crease, which divides the cutaneous lower lip from the chin. The boundary between the red mucosal surface of the lips and the cutaneous surface is called the vermillion border. The raised contoured area of the inferior portion of the philtrum is a critical aesthetic landmark known as the *Cupid's bow* (see Fig. 242-1).

RELAXED SKIN TENSION LINES

Relaxed skin tension lines (RSTLs) are another characteristic of the face that help guide surgical reconstruction and allow the structural camouflage of scar lines. RSTLs are creases on the face that form over time due to factors such as loss of elastic tissue tone, lengthening of the collagenous fibrous septae that connect the dermis to the underlying facial muscles, development of excessive skin, gravity, and ultraviolet radiation exposure. Fig. 242-3 illustrates a surgical defect on the upper lip of an elderly woman with prominent RSTL. RSTLs are most obvious on the face because unlike other muscles in the body that connect tendons and bones, facial muscles attach to the overlying skin. These lines can be induced by facial muscle movement in the young but inevitably become more pronounced with age. RSTLs usually run perpendicular to the underlying muscles. In most situations, the long axis of the excision should be placed parallel to the RSTL because they are often in the direction of the least tension for a scar. It is preferable to design flaps such that the majority of the scar lines fall within the RSTL.

DANGER ZONES

There are three main danger zones that are critical to understand while performing surgical procedures

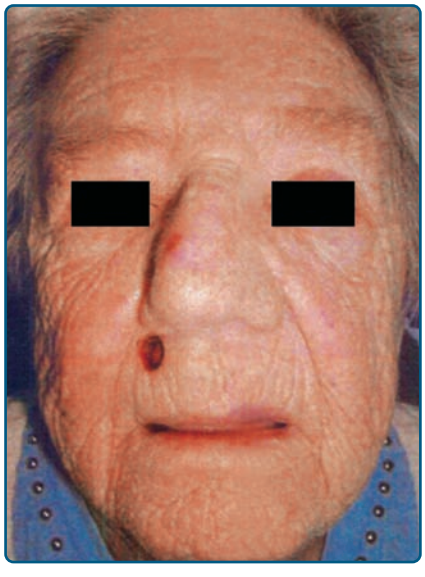

Figure 242-3 Relaxed skin tension lines of the face.

on the head and neck. Each of these zones involves a motor nerve and the muscles it innervates. It is important to confirm the proper function of these muscles before performing a procedure in these areas so that it can be readily determined whether an injury occurred during surgery.

TEMPORAL BRANCH OF THE FACIAL NERVE. The temporal branch of the facial nerve is at greatest risk for injury where it crosses the zygomatic arch. Injury to the temporal branch of the facial nerve leads to an inability to elevate the eyebrows and brow ptosis and paralysis. Asymmetric appearance of the forehead can also occur because there will be a loss of the lines and wrinkles on the affected side. One easy method to delineate the danger area of the temporal nerve is to draw a line from the earlobe to the lateral edge of the eyebrow, and another line from the tragus to just above and behind the highest forehead crease (Fig. 242-4). In the area between these lines, over the zygomatic arch is where the nerve is superficial, and it is critical in this area to undermine just below the dermis in the superficial fat above the fascia.

MARGINAL MANDIBULAR NERVE. Damage to the marginal mandibular nerve results in contralateral and upward pull on the mouth while the affected ipsilateral side of the mouth is fixed in a grimace with a lip droop. As it crosses the angle of the mandible at the inferoanterior border of the masseter, the marginal mandibular nerve is covered only by skin, subcutaneous fat, and fascia, which may be thin in this location, particularly in the elderly.

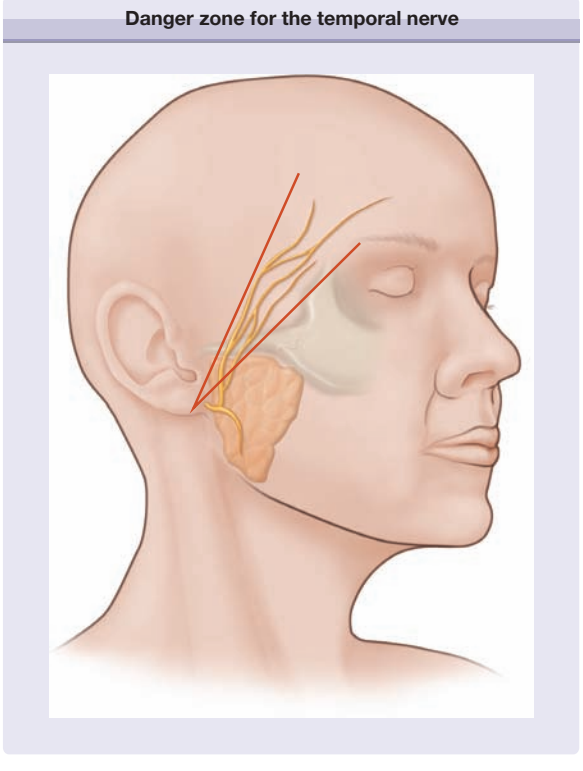

Figure 242-4 Danger zone for the temporal nerve.

SPINAL ACCESSORY NERVE. Injury to the spinal accessory nerve leads to the paralysis of the trapezius with winging of the scapula, shoulder drop, inability to shrug the shoulder, difficulty with abducting the arm and chronic shoulder pain. Transection of the spinal accessory nerve can occur when operating in the posterior triangle of the neck. This region is delineated by the clavicle inferiorly, the sternocleidomastoid muscle anteriorly, and the trapezius muscle laterally and posteriorly. One can anticipate the location of the spinal accessory nerve by drawing a line connecting the angle of the mandible with the mastoid process. A vertical line is then drawn from the midpoint of this line 6 cm inferiorly. The point at which this line intersects the posterior border of the sternocleidomastoid muscle is Erb's point. The spinal accessory nerve emerges approximately from this point and lies superficially here, covered only by skin and fascia.

UNDERMINING PLANES

SUPERFICIAL MUSCULOAPONEUROTIC SYSTEM. The term *fascia* refers to connective tissue that contains both fibrous and fat tissue in various amounts. Superficial fascia is the subcutaneous tissue that is immediately below the dermis. The deep fascia consists of more compact and highly organized collagen fibers. The superficial musculoaponeurotic system (SMAS) is the fascial system that envelops the muscles of the face. It stretches over the cheeks between the temporalis and frontalis muscles above and the platysma muscle below. The SMAS also attaches to the orbicularis oculi muscles anteriorly, the trapezius muscle posteriorly, and includes the fascia of the forehead and galea of the scalp. Most of the superficial muscles of the scalp and face insert into the skin either directly through fibrous bands running in the subcutaneous tissue or indirectly by attachment to the SMAS, which, in turn, is attached to the skin. In the lateral areas of the face, the SMAS is organized and more visible but becomes less discrete medially. Because of its attachment to the skin superficially and muscles deep, the SMAS coordinates a wide range of facial expressions. In addition, the SMAS is an important landmark because most major arteries and nerves run within or deep to it. Thus, dissection above the SMAS allows one to safely avoid injuring branches of the facial nerve.

SCALP. The scalp is classically divided into five layers that are often referred to by the mnemonic SCALP. These layers from superficial to deep are: *s*kin, sub*c*utaneous tissue, *a*poneurosis (galea aponeurotica), *l*oose connective tissue, and *p*eriosteum. Because the majority of the nerves and vessels of the scalp are superficial to the subgaleal space, this is an ideal undermining plane. However, it is also known as the *danger zone* because hematomas and infection can develop here and pass through the emissary veins into the meninges.

FOREHEAD. The forehead is best undermined immediately above the superficial fascia of the frontalis

muscle. There may be little subcutaneous fat in this area. The temple should be undermined in the high fat/subdermal region to avoid damaging the temporal branch of the facial nerve.

EYELIDS. The eyelids possess the thinnest skin of the body. The skin of the eyelids lies directly on the orbicularis muscle. Undermining should be performed above the muscle fascia to avoid causing significant bleeding and scars/contractures that can lead to ectropion.

CHIN AND LIPS. The large, thick muscles of the lips and chin can make undermining challenging. The chin, in particular, has muscles broadly attached directly to the skin. Sharp undermining performed just above the superficial muscular fascia is appropriate. These areas are at high risk for bleeding, made even more precarious by functions such as talking and chewing.

NOSE. The nose requires different levels of undermining in different regions. The dorsal nose can be easily undermined above the periosteum, especially when performing reconstruction with flaps. The distal, more sebaceous portion of the nose must be undermined in the subfibrofatty layer to allow the greatest tissue movement.

CHEEKS. The cheeks can be safely mobilized in the high or mid subcutaneous fat. Care must be taken when undermining in the hair-bearing regions of the cheek in men, however. Here, undermining should be performed in the deep subcutis to avoid transecting hair follicles.

NECK. The neck can be safely undermined while staying above the superficial fascia. One must be careful in the posterior triangle of the neck. This region is delineated by the clavicle inferiorly, the sternocleidomastoid muscle anteriorly, and the trapezius muscle laterally and posteriorly. The spinal accessory nerve lies superficially here, covered only by skin and fascia.

SENSORY NERVES

The trigeminal nerve (cranial nerve V) provides the majority of the sensory innervation of the face (Fig. 242-5). It exits the skull via three foramina located bilaterally in the midpupillary line, the supraorbital, infraorbital, and mental foramina. The first branch, the ophthalmic nerve (V_1), has several branches that supply the innervation to the superior portion of the face: the supraorbital, supratrochlear, infratrochlear, external nasal, and lacrimal nerves. The supraorbital (lateral) and supratrochlear (medial) nerves supply the forehead and anterior scalp and are branches of the frontal nerve (the largest branch of the ophthalmic nerve). They exit from two notches along the orbital rim: (1) supraorbital foramen or notch laterally, and (2) supratrochlear notch, medially. The infratrochlear branch (of the nasociliary nerve) supplies the glabella, nasal root, and bridge. The external nasal branch (or the dorsal nasal nerve) is a branch of the anterior ethmoidal nerve of the nasociliary branch of V_1. The external nasal branch supplies the dorsal nose and provides the anatomical explanation of Hutchinson sign that can occur in some cases of herpes zoster of the ophthalmic nerve. Vesicles on the nasal tip indicate that the eye may be involved because the nasociliary branch of V_1 sends branches both to the nasal tip and the cornea. The lacrimal branch supplies sensation to the upper eyelid.

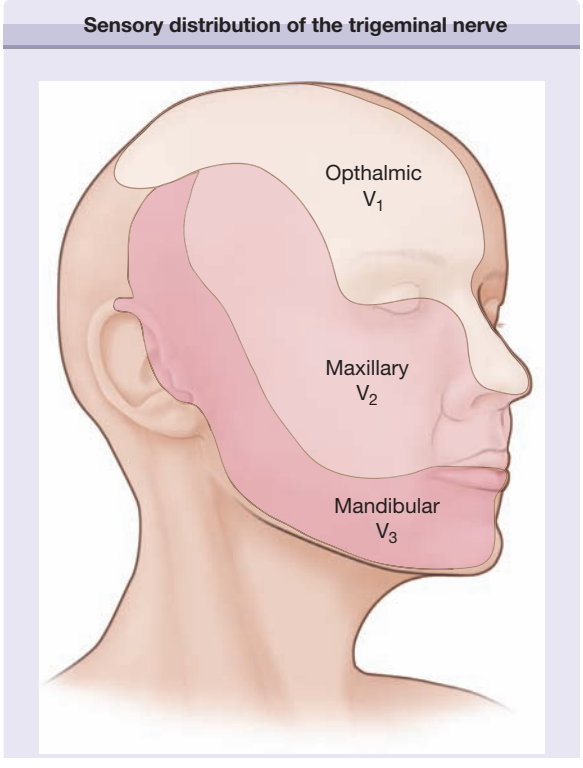

Figure 242-5 Sensory distribution of the trigeminal nerve.

The second branch of the trigeminal nerve is the maxillary nerve (V_2). The maxillary nerve supplies sensation to the lateral nose, lower eyelid, superior cheek, and anterior temple. The maxillary nerve gives off two main branches that supply the skin of the face. The zygomatic branch of the maxillary nerve gives rise to the zygomaticofacial nerve, which exits the skull through the lateral zygomatic bone and supplies a small area of the lateral canthus. In addition, the zygomatic branch also gives rise to the zygomaticotemporal nerve, which exits the skull through the anterior temporal fossa and supplies skin of the anterior temporal region. The largest branch of the maxillary nerve is the infraorbital nerve that exits the skull through the infraorbital foramen of the maxilla. This supplies sensation to the eyelid and superior cheek.

The third branch of the trigeminal nerve is the mandibular nerve (V_3). Its branches provide sensory innervation to the lower lip, chin, mandibular and preauricular cheek, anterior ear, and the central temporal scalp. The mandibular nerve gives off three major cutaneous branches: (1) the auriculotemporal, (2) buccal, and (3) mental nerves. The auriculotemporal

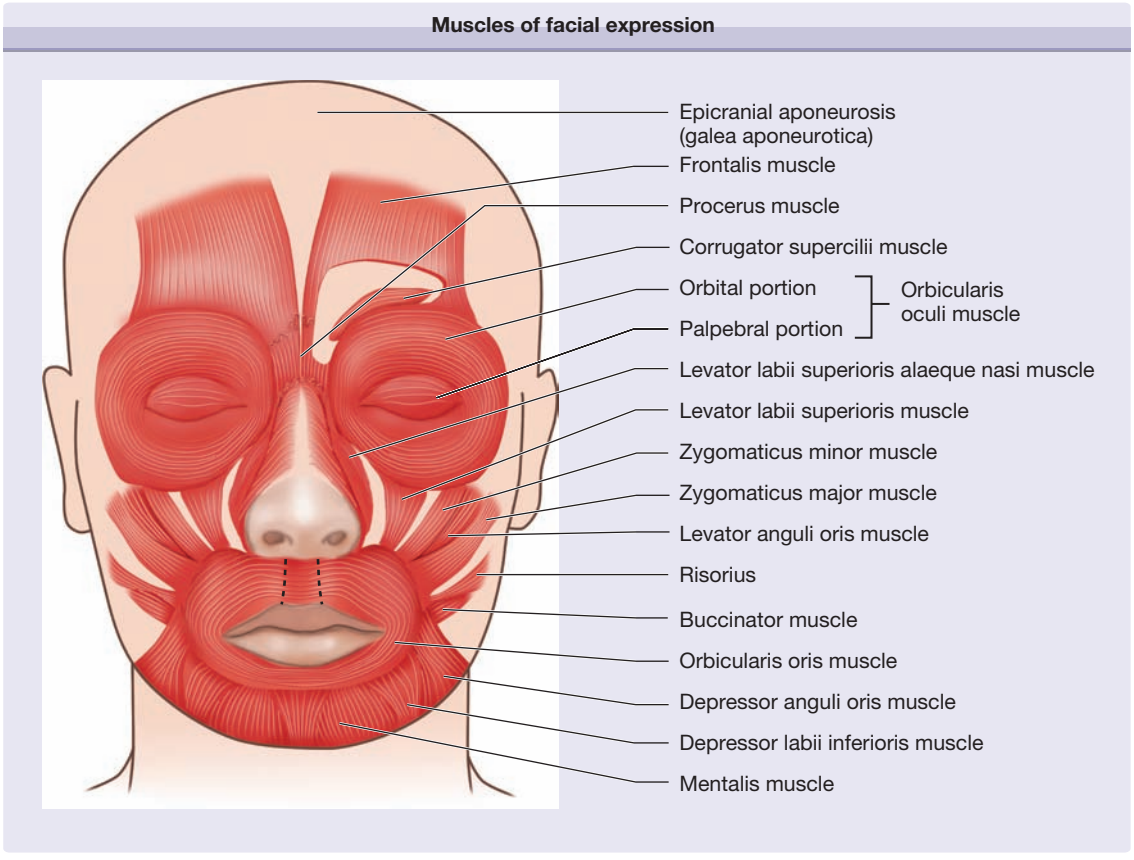

Figure 242-6 Muscles of facial expression.

nerve innervates most of the temple, the temporoparietal scalp, the anterior ears, parts of the external ear canal, and the tympanic membrane. The buccal nerve lies deep to the parotid gland and supplies the skin over the buccinators, buccal mucosa, and the gingiva. The mental nerve exits through the mental foramen and is a continuation of the inferior alveolar nerve. The mental nerve supplies sensation to the lower lip and chin.

MUSCLES

The scalp has two muscles overlying it, the frontalis anteriorly and the occipitalis posteriorly. These muscles are joined by a thick fascia centrally over the scalp, the galea aponeurotica. The frontalis muscle also covers the forehead and elevates the eyebrows. The eyebrows move medially and downward with contraction of the corrugator supercilii muscles. The procerus lies between the supercilii muscles and draws the skin of the forehead inferiorly to create the horizontal creases at the root of the nose. The orbicularis oculi muscle surrounds the eye and consists of an orbital and palpebral portion. The orbicularis oculi muscle serves to close the eyes with the palpebral part with both reflexive and voluntary control and the orbital part with voluntary control. The central sphincter-like muscle around the mouth is the orbicularis oris. This muscle helps purse the lips to form certain sounds and whistle. The lip depressors are depressor anguli oris, depressor labii inferioris, and the mentalis. The lip elevators are the zygomaticus major, zygomatic minor, levator anguli oris, levator labii superioris, and the levator superioris alaeque nasi. The risorius helps retract the corner of the mouth. The buccinators and masseter muscles help with mastication (Fig. 242-6).

MOTOR NERVES

The facial nerve (cranial nerve VII) provides innervation to all the muscles of facial expression. It exits the skull via the stylomastoid foramen, which lies deep in the infra-auricular sulcus and anterior to the mastoid process. The facial nerve enters the parotid gland at the level of the intertragic notch and usually divides into five branches within the substance of the gland. The well-known mnemonic "*t*o *Z*anzibar *b*y *m*otor *c*ar" can be used to remember the five main branches: (1) *t*emporal, (2) *z*ygomatic, (3) *b*uccal, (4) *m*andibular, and (5) *c*ervical. For the most part, these nerves enter the muscles they innervate posteriorly and deep. A nice rule of thumb is that if one transects a nerve lateral to the midpupillary line, permanent paralysis can result and if the nerve is cut medial to this demarcation, most nerves will regenerate or have arborizations that will help provide additional innervation.

The temporal branch of the facial nerve exits the superior part of the parotid gland and crosses the zygomatic arch to innervate the frontalis, upper portion of the orbicularis oculi, and corrugator supercilii. Injury to the temporal branch leads to an inability to raise the eyebrows and brow ptosis. The zygomatic branch innervates the orbicularis oculi, nasal muscles, lip elevators, and the buccinators. Damage to the zygomatic nerve results in lower eyelid ptosis and an inability to close the eyes completely. The buccal branch also innervates the buccinators and lip elevators, as well as the orbicularis oris and risorius. Damage to the buccal branch leads to an inability to whistle. The marginal mandibular branch crosses the angle of the mandible at the inferior-anterior border of the masseter. It innervates the depressors of the mouth.

VASCULAR SUPPLY

The blood supply of the face is almost entirely derived from branches of the external carotid artery (Fig. 242-7). Just posterior and medial to the angle of the mandible, the facial artery branches off the external carotid artery. The facial artery continues anteriorly and superiorly toward the angle of the mouth, giving off the inferior labial artery and superior labial arteries that supply the lips. The continuation of the facial artery in the nasofacial sulcus is called the *angular artery*. The angular artery continues superiorly to enter the orbit immediately over the medial canthal tendon where it anastomoses with the ophthalmic artery, a branch of the internal carotid artery. After giving off the facial artery, the external carotid artery then passes deep to the sternocleidomastoid muscle and enters the body of the parotid gland where it gives off the posterior auricular artery that supplies the postauricular scalp, the maxillary artery, and the superficial temporal artery. The terminal branch of the maxillary artery exits the infraorbital foramen with the infraorbital nerve as the infraorbital artery to supply the lower eyelids and infraorbital cheek.

The terminal branches of the internal carotid artery are the ophthalmic artery branches, the supraorbital artery, and the supratrochlear artery. The supraorbital artery emerges from the supraorbital foramen, whereas the supratrochlear artery emerges more medially. The internal and external carotid systems join in two places: (1) where the supratrochlear branch and the dorsal nasal artery anastomose with the angular artery and (2) where the forehead branches of the supraorbital and supratrochlear arteries anastomose with branches of the superficial temporal artery.

The veins of the face parallel and lie posterior to the arteries. Unlike the veins of the trunk and extremities, facial veins have no valves. This allows blood to flow in either direction. Thus, in the central face where there are anastomoses between branches of the ophthalmic vein and of the angular vein, infection has easy access to travel along the ophthalmic vein to the cavernous

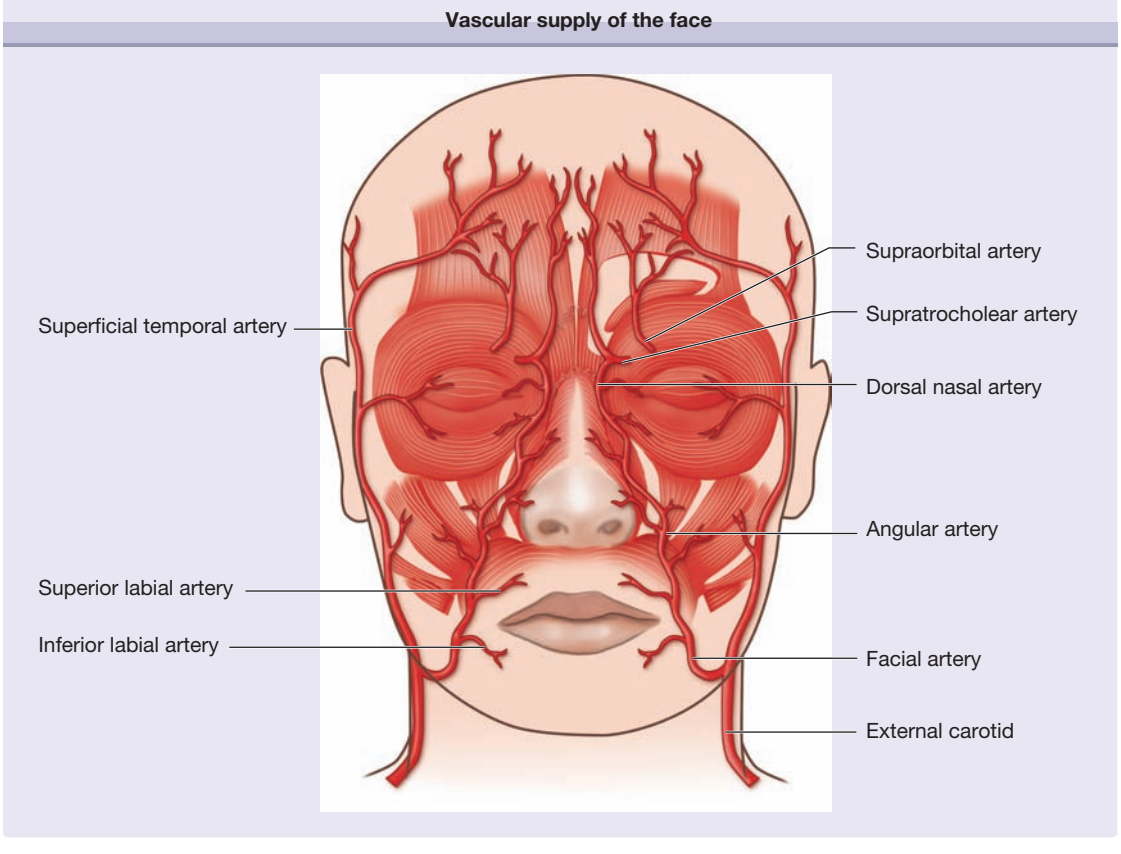

Figure 242-7 Vascular supply of the face.

sinus. The angular vein also communicates with the deep facial vein and pterygoid plexus.

LYMPHATICS

The lymphatic vessels of the face generally drain from superficial to deep and medial to lateral and caudad. While the general drainage patterns are described here, variations can occur. The posterior scalp drains to the postauricular and occipital nodes. The lateral and superior face, the forehead, and the lateral eyelids drain to the parotid nodes. The medial and inferior face, including the medial eyelids and lateral lips, drain to the submandibular nodes. The middle two-thirds of the lower lip and the chin drain to the submental nodes. These nodes can be optimally palpated by performing a bimanual exam with a gloved hand feeling through the floor of the mouth.

The lymph nodes of the head and neck eventually drain into a terminal series of nodes (deep cervical nodes) and finally into the lateral internal jugular chain.

PREOPERATIVE ASSESSMENT

Preoperative assessment is critical for a successful procedure. It allows one to anticipate and possibly correct factors that predispose to adverse outcomes and minimize complications. A fairly thorough medical, drug, and medication allergy history provides an accurate picture of the patient's health status. Questioning the possibility of pregnancy in women of childbearing age should not be overlooked, as local anesthetics and antibiotics may be contraindicated. Patients with inherited bleeding disorders can also be identified and, when possible, given clotting factors to correct for these disorders. Uncontrolled hypertension may predispose to increased intraoperative and postoperative bleeding. In addition, poorly controlled diabetes and immunosuppression with use of systemic steroids for medical conditions, such as autoimmune disorders or organ transplantation, may affect healing time. Information from the social history can also have a bearing on the surgery. For instance, healing can be adversely affected if the patient smokes, and this may impact the decision to perform a flap or graft. Alcohol consumption can increase the risk of bleeding because of its qualitative effect on platelets. Finally, knowledge of the patient's resources and support at home is helpful when providing instructions for postoperative care.

ANTIBIOTICS

A well-planned and executed surgical procedure can be significantly compromised by an infection. Infections can lead to poor cosmesis, inconvenience, added expense, and patient dissatisfaction. Because every surgical procedure violates the epidermal barrier, no surgical procedure is absolutely sterile. Hence, all surgical wounds are contaminated by bacteria because of the inevitable resident flora in humans. However, not all contaminated wounds become infected. Infection depends on a large number of factors: the pathogenicity of the microbe, the quantity of the microbe, the length of surgery/timing of infection, the presence of foreign material (sutures, devitalized tissue), presence of dead space, poor suturing/surgical technique, poorly designed reconstruction, compromised vascular supply, and the host and wound's resistance to infection. Usually a wound that contains greater than 10^5 bacteria per gram of tissue is considered infected.[3] The American College of Surgeons has defined wounds as: clean (nontraumatic, without break in aseptic technique), clean-contaminated (minor break in aseptic technique, wounds in oral cavity, axillae, perineum), contaminated (acutely inflamed, major break in aseptic technique), and dirty (encountering pus, fecal, or urinary discharge). Antibiotics can be considered for some clean-contaminated, contaminated, and dirty wounds. Most wounds in dermatologic surgery are clean-contaminated wounds and do not require antibiotics. The most common organism is *Staphylococcus aureus* and a first generation cephalosporin (or clindamycin for the penicillin allergic) is appropriate when necessary. Studies show that to prevent or change the course of infection, antibiotics must be given within 2–3 hours after inoculation and that antibiotics give maximal suppression against infection if given before bacteria colonize tissue. In addition, there is concern that, with increasing time, the wound is sealed off with blood clots and fibrous exudates, and the antibiotic is unable to reach the wound effectively. Routine use of antibiotics postoperatively is discouraged due to the risk of encouraging the development of antibiotic resistance amongst bacteria.

Although specific criteria for the use of prophylactic antibiotics to prevent endocarditis do not exist for dermatologic procedures, most dermatologic surgeons follow the revised American Heart Association guidelines. Cardiac conditions for which prophylaxis is reasonable include prosthetic cardiac valve, previous infective endocarditis, congenital heart disease (limited particularly to unrepaired cyanotic congenital heart disease, completely repaired congenital heart defect with prosthetic material during the first 6 months after the procedure, repaired congenital heart disease with residual defects at the site or adjacent to the site of a prosthetic patch or prosthetic device) and cardiac transplantation recipients who develop cardiac valvulopathy. Appropriate antibiotic regimen for prophylaxis for cutaneous procedures is 2 g of cephalexin (or 600 mg of clindamycin in penicillin-allergic patient) 1 hour before the procedure.[4]

MEDICATIONS

The use of blood anticoagulants, such as warfarin, dipyridamole, clopidogrel, and aspirin, are common in the aging population. In the past, patients were often told to discontinue their blood thinners before surgery. However, recent reports show that discontinuing these medications prior to dermatologic surgery can lead

to episodes of thrombotic events such as stroke and pulmonary embolism.[5] Furthermore, remaining on such medications does not lead to significant adverse events. However, patients who are taking aspirin and other nonsteroidal anti-inflammatory drugs for non-physician-recommended "preventive" purposes are advised to discontinue these drugs preoperatively. These agents are typically withheld for 7–14 days prior to surgery.

Many patients may be taking herbal or over-the-counter drugs that also interfere with clotting. These are not often considered "drugs" by patients, and thus they may not volunteer taking such supplements unless they are specifically asked. Some common preparations in this category include vitamin E, garlic, gingko, ginseng, feverfew, or ginger. Alcohol can also interfere with platelet aggregation, and it is important to instruct patients to avoid drinking a few days before and after the surgery. Most dermatologic surgeons advise patients to avoid alcohol, herbal products, and nutritional supplements several days before surgery.

Nonselective β blockers (i.e., propanolol) can occasionally potentiate the effect of epinephrine and lead to complications such as malignant hypertension and bradycardia.

Other preoperative considerations include latex allergy or allergy to topical antibiotics or adhesives in tapes. Use of systemic steroids can prolong the wound healing time.

PACEMAKERS AND DEFIBRILLATORS

Electrosurgery is widely used in dermatologic surgery to obtain hemostasis. However, electrosurgery can disrupt the function of pacemakers and implantable cardioverter-defibrillators (ICDs) by oversensing, inhibiting firing, device reprogramming, battery depletion, or direct damage to the device.[6] Thus, it is important to identify patients with such devices and to use proper precautions. Fortunately, newer pacemakers and ICDs have improved shielding and are more resistant to the electromagnetic interference that can be produced by electrosurgery. ICDs are more sensitive to electromagnetic interference, and this interference can cause the defibrillator to discharge, leading to significant morbidity and possible mortality for the patient. If electrosurgery is necessary, recommendations, such as using short bursts of electricity (less than 5 seconds) and avoiding its use directly around the area of the pacemaker, may minimize risks. In addition, bipolar electrosurgery creates little interference and is safer. Heat cautery does not cause any interference and is the safest but is not as effective for hemostasis with larger or complicated procedures.

SMOKING

Smoking should also be discussed preoperatively with patients. Tobacco use creates vasoconstriction, which impairs wound healing and jeopardizes the reconstruction, especially with more complicated procedures such as flaps and grafts. Patients should be strongly encouraged to cease tobacco use at least 1 week before surgery and 1 week postoperatively. It is also important to clarify that a nicotine patch is not ideal, and patients must avoid nicotine exposure through patches or gum.

SURGICAL HISTORY

A discussion of scars and healing after previous procedures can be informative for the patient and surgeon. The physician can determine if the patient is predisposed to forming hypertrophic scars or keloids and plan reconstruction and postoperative care appropriately. The patient may have a misunderstanding of wound healing and feel that a well-healed visible scar on a high-tension area is a keloid. This can be an opportunity to anticipate patient expectations and educate them on the process of wound healing.

SURGICAL TECHNIQUE

SKIN PREPARATION AND ASEPTIC TECHNIQUE

The normal skin is colonized by a host of bacteria, primarily aerobic cocci. *Staphylococcus aureus* is the most common cause of cutaneous wound infections in dermatologic surgery. Other bacteria commonly identified on the skin include *Staphylococcus epidermidis, Pseudomonas, Propionibacterium,* streptococci, and micrococci. *Pseudomonas* is frequently the pathogen identified in infections of cartilaginous regions such as the ear. The aim of aseptic solutions is to significantly reduce the amount of normal bacterial flora, as complete sterilization of the skin is not possible due to the presence of bacteria in pilosebaceous units. The ideal antiseptic would be nonirritating, nontoxic, nonsensitizing, be effective against all resident and transient microbes, and long-lasting. In prepping the field, shaving the hair creates multiple superficial microabrasions in which bacteria may reside and is associated with an increased incidence of local wound infections. Hair removal, if needed, has the lowest risk of associated infection if done by clipping or depilatory agents.[7]

Iodophors, which act through oxidation of cell membranes by free iodine, are common topical antiseptics. The most common form of this antiseptic is povidone-iodine. This antiseptic has broad antimicrobial activity against both Gram-positive and Gram-negative bacteria, as well as fungi, viruses, and mycobacteria. Iodophors have bactericidal activity that persists for several hours after application. On contact with blood or serum, the bactericidal activity is lost, but some bacteriostatic activity is retained. This class offers relatively rapid onset of action with full bactericidal activity being achieved within 1–3 minutes for most bacteria. Side effects of povidone-iodine include allergic contact dermatitis, irritant contact dermatitis, and possible tissue necrosis with prolonged exposure to large amounts in open wounds.

Chlorhexidine also functions through disruption of cell membranes. It has broad antimicrobial activity with excellent Gram-positive coverage and very good Gram-negative activity. It has some degree of activity against viruses but little effect on mycobacteria or fungi. Chlorhexidine offers a more rapid onset of action than povidone-iodine, providing almost immediate bactericidal activity upon application, which persists for many hours after application. It provides superior decontamination of the skin as compared to iodophors with resulting decreased rates of postoperative infection.[8] As a result, chlorhexidine is preferred over povidone-iodine as a surgical antiseptic agent if the surgical site does not limit its usage. The primary side effect of chlorhexidine is the potential for ototoxicity and keratitis. As a result, it should not be used around the eyes or ears. Similar to iodophors, prolonged exposure of chlorhexidine in open wounds has been reported to be toxic to the tissue.

Isopropyl alcohol and ethyl alcohol are effective antiseptics for minor skin procedures. They function through the denaturation of microbial proteins. They display good activity against Gram-positive and Gram-negative bacteria, mycobacteria, viruses, and fungi. Alcohols have a rapid onset of activity at the site of application, but there is no persistence of this activity over time. The antimicrobial activity of alcohols is not as extensive as that of chlorhexidine or iodophors. In addition, the flammable nature of alcohols limits their use in procedure requiring electrocautery.

Hexachlorophene is rarely used as a skin antiseptic solution. It has excellent Gram-positive activity but limited activity against Gram-negative organisms or fungi. It is also readily absorbed through the skin and has the potential for neurotoxicity, especially in infants.

LOCAL ANESTHESIA

Effective anesthesia is critical to the successful performance of dermatologic surgery. The overwhelming majority of cutaneous surgical procedures can be performed with local anesthesia. Local anesthesia provides the benefits of rapid onset of action, ease of use, decreased cost, and minimal associated morbidity and mortality.

Nerves transmit stimuli through the opening of sodium channels, which results in an influx of sodium ions into the nerve cell. This influx results in depolarization of the axon generating an action potential. Local anesthetics exert their effect on nerves by blocking the sodium channels on nerve axons. This blockage inhibits depolarization and the formation of an action potential. Local anesthetics affect the smaller unmyelinated C-type nerve fibers, which carry the sensation of pain and heat, more rapidly and effectively than myelinated A-type nerve fibers, which transmit the sensation of pressure and innervate muscle fibers. Thus, adequate anesthesia can be achieved while motor function and pressure sensation are maintained.

Local anesthetics structurally are composed of three subunits: (1) a hydrophobic aromatic ring, (2) a hydrophilic amine group, and (3) an intervening group connecting the hydrophobic and hydrophilic units. The hydrophobic aromatic ring is responsible for the molecule's ability to diffuse through axonal membranes. The hydrophilic amine maintains the solubility of the compound in aqueous solution and accounts for blockage of the sodium channels of nerve axons. The region connecting the hydrophilic and hyphobic regions may be either an amide group or an ester group. Amide anesthetics, which include lidocaine, prilocaine, bupivacaine and mepivacaine, are metabolized in the liver through dealkylation and hydrolysis by microsomal enzymes. Ester anesthetics, which include procaine, benzocaine, tetracaine, and cocaine, are metabolized by plasma pseudocholinesterase and are excreted renally.

SELECTING THE APPROPRIATE ANESTHETIC

The nature of the procedure determines which local anesthetic is ideal (Table 242-1). The primary variables to consider in choosing between anesthetics are the onset of action and the duration of anesthesia. Patient factors to consider in this selection are a history of allergy to an anesthetic class or renal or hepatic impairment. For simple biopsies and excisions, a rapid-onset anesthetic, like lidocaine, with medium duration of action provides effective anesthesia. For more extensive procedures, an anesthetic with a longer duration of action, such as bupivacaine, may be desired. Some practitioners choose to mix a rapid-onset anesthetic with one of long duration into one injectable solution.

EPINEPHRINE

Local anesthetics, with the exception of cocaine, are vasodilators. This vasodilatory effect produces unwanted bleeding at the operative site. Epinephrine with its potent vasoconstrictive effects is often added to local anesthetic preparations to reduce bleeding. Concentrations ranging from 1:100,000–1:500,000 are effective in reducing bleeding at the surgical site. In addition to its hemostatic effect, epinephrine reduces the dispersion of the local anesthetic from the operative site. This prolongs the duration and efficacy of the anesthesia by 100%–150%. It also limits the potential for systemic toxicity, as less anesthetic is allowed to enter the systemic circulation.

Epinephrine is a potent agonist of α- and β-adrenergic receptors. Absolute contraindications to its use with local anesthetics are pheochromocytoma and hyperthyroidism. Relative contraindications to the use of epinephrine include severe coronary artery disease, uncontrolled hypertension, peripheral vascular disease, pregnancy, and acute angle glaucoma. In addition, epinephrine should be used with caution in patients on β blockers, monoamine oxidase inhibitors, phenothiazines, and tricyclic antidepressants as these individuals demonstrate greater sensitivity to its effects. Although uncommon, severe hypertension may be encountered in patients on β blockers due to the unopposed α-receptor stimulation of the epinephrine.

The use of epinephrine-containing local anesthetics on anatomic regions with minimal collateral circulation,

TABLE 242-1
Local Anesthetics

Generic Name	Primary Use	Relative Potency	Onset	Duration[a] Plain	Maximum[b] Dose Plain (mg)	Maximum[b] Dose with Epinephrine (mg)
Bupivacaine	Infiltration	8	2–10 minutes	3–10 hours	175	250
Dibucaine	Topical	—	Rapid	Short	—	—
Etidocaine	Infiltration	6	3–5 minutes	3–10 hours	300	400
Lidocaine	Infiltration/ topical	2	Rapid	1–2 hours	300	500 (3,850 dilute)
Mepivacaine	Infiltration	2	3–20 minutes	2–3 hours	300	400
Prilocaine	Infiltration	2	Rapid	2–4 hours	400	600
Prilocaine/ lidocaine	Topical	—	30–120 minutes	Short	—	—
Benzocaine	Topical	—	Rapid	Short	—	—
Chloroprocaine	Infiltration	1	Rapid	0.5–2.0 hours	600	—
Cocaine	Topical	—	2–10 minutes	1–3 hours	200	—
Procaine	Infiltration	1	Slow	1.0–1.5 hours	500	600
Proparacaine	Topical	—	Rapid	Short	—	—
Tetracaine	Infiltration	8	Slow	2–3 hours	20	—
Tetracaine	Topical	—	Rapid	Short	—	—

[a]In clinical practice, the duration of anesthesia appears to be less than stated above, especially for head and neck areas, and addition of epinephrine prolongs anesthesia by a factor of two.
[b]Maximum doses are for a 70-kg person.

such as the digits, penis, and nasal tip, is a matter of controversy. Reports of local tissue necrosis in these areas with limited perfusion attributed this result to the potent vasoconstrictive effects of the epinephrine. More recent observations indicate this necrosis to actually be the result of excessive volume of anesthetic used, which physically tamponades the vessels. Thus, local anesthetics with epinephrine are now considered safe for use on the digits, penis, and nasal tip, when used judiciously in small volumes. Consideration may be given to using a lower concentration of epinephrine (1:500,000) for those sites with severely limited perfusion.

Self-limited, systemic side effects may also be experienced with the administration of epinephrine-containing anesthetics. These include anxiety, fear, palpitations, tachycardia, diaphoresis, tremor, and hypertension. Serious side effects of excessive epinephrine administration include arrhythmias, cardiac arrest, and cerebrovascular hemorrhage. These serious side effects are extremely rare when used at appropriate dosages in individuals without significant contraindication.

SIDE EFFECTS

The most common side effect of local anesthetics is the pain of its administration. Premixed local anesthetic preparations containing epinephrine are manufactured as an acidic solution with a pH of between 3 and 5 in order to maintain the stability of epinephrine. Injection of this acidic solution into tissue often produces significant discomfort. To avoid this, the pH of the solution can be adjusted before injection closer to the physiologic pH of 7.4 through the addition of sodium bicarbonate. The standard formula for this is the combination of one part of 8.4% sodium bicarbonate with 10 parts lidocaine. This buffered solution must be used soon after preparation as the epinephrine gradually degrades at a rate of approximately 25% per week. Alternatively, the epinephrine and anesthetic may also be mixed immediately before use, which also provides a neutral solution. In each instance, the neutral or slightly alkaline solution has the added advantages of quicker onset of action and increased anesthetic effect as the pH of the solution is closer to the pKa of the anesthetic, meaning more of the anesthetic is in its active ionized cationic form.

Slow injection of the anesthetic through a small gauge needle (27 gauge to 30 gauge) also minimizes the pain of injection. Smaller syringes, such as 1–3 mL, create less pressure at the site of anesthetic administration. Based on the gate theory of pain perception, repeated pinching or vibration of the immediate surrounding area lessens the perception of the stick at site. Verbal distraction of the patient is also useful in lessening the anxiety and discomfort of the anesthetic.

Injection of anesthetic into the subcutaneous tissue is less painful than injection into dermal tissue; however, a quicker onset of action and longer duration of anesthesia are observed with dermal injection. If a large area is to be anesthetized, the initial injection should be placed near the origination of sensation and proceed distally. Subsequent injections, if necessary, should be made through previously anesthetized tissue. For large areas, consideration should also be given to the use of nerve blocks to minimize discomfort.

One side effect of local anesthetic administration that is not uncommon is the vasovagal reaction. This may be manifested as pallor, weakness, bradycardia, hypotension, diaphoresis, and nausea. Placement of the patient in Trendelenburg position usually results in complete resolution of these symptoms within several minutes. A cool compress on the forehead and fanning the patient are often helpful in comforting the patient during this episode. Patients should be injected in a recumbent or Trendelenburg position to minimize the likelihood of a vasovagal response. These positions also allow providers to be better prepared to deal with the reaction should it occur. Pain and anxiety of anesthetic injection can precipitate a vasovagal reaction; thus, the aforementioned techniques for lessening the discomfort of injection are critical in reducing the likelihood of a vasovagal response.

Allergy to a local anesthetic is an uncommon side effect in dermatologic surgery. Amide anesthetics are more likely to be the culprit of allergic reactions whereas allergic reactions to ester anesthetics are exceedingly rare. True allergic reactions are typically immediate type I immunoglobulin E-mediated reactions, which may produce urticaria, angioedema, bronchospasm, tachycardia, hypotension, and, possibly, cardiovascular collapse. For severe reactions, administration of epinephrine and cardiopulmonary support is indicated. Less commonly, type IV-delayed hypersensitivity reactions may be observed. These present similar to an allergic contact dermatitis in the days following the injection of the anesthetic.

For those patients in whom an allergy to an anesthetic is unclear, intradermal prick testing to ester anesthetics, amide anesthetics, and any added preservatives, such as sodium metabisulfite and methylparabens may be helpful. Alternatively, for smaller procedures, the intradermal injection of diphenhydramine hydrochloride solution provides temporary anesthesia without risk of an allergic response. Antihistamine side effects, including significant drowsiness, may be encountered with its use. The intradermal injection of normal saline with preservative may also be used for very brief procedures. The temporary anesthesia it provides is attributed to a combination of the tamponade effect on nerves and the mild anesthetic effect of the preservative benzoyl alcohol.

Anesthetic toxicity is a rare complication given the typical volumes required for dermatologic surgery. Signs of toxicity are usually not observed with dosages less than 5.0 mg/kg of plain lidocaine and 7.0 mg/kg of lidocaine with 1:100,000 epinephrine. For tumescent anesthesia, the maximum safe dose increases to 55.0 mg/kg of 0.05% –0.1% lidocaine with 1:1,000,000 epinephrine. The initial presenting signs are circumoral numbness and tingling, tinnitus, lightheadedness, nausea, and numbness of the distal extremities. With additional anesthetic, more extensive central nervous system depression may occur with hallucinations, seizures, and respiratory depression. Cardiovascular toxicity may also occur, but does so at much higher levels of anesthetic than the initial central nervous system toxicity. The manifestations include hypotension, arrhythmias, and cardiac arrest.

Both central nervous system and cardiovascular toxicity are directly related to serum levels of the anesthetic. Thus, direct intravenous or intra-arterial injection is to be avoided when anesthetizing an area. This can be done by drawing back on the syringe after needle insertion prior to infiltration of the anesthetic to confirm that the needle is not in a vascular structure. The risk of toxicity can be elevated by other medical problems affecting the metabolism of the anesthetic. In particular, patients with liver disease experience increased serum levels of amide anesthetics due to an impaired ability to metabolize and clear the anesthetic. Thus, a lower dosage of an amide anesthetic or a switch to an ester anesthetic is advisable in these patients.

TOPICAL ANESTHETICS

Several local anesthetics are also available as topical preparations. When used properly, these agents provide suitable anesthesia for minor dermatologic procedures, such as shave biopsies or superficial laser treatments. Their efficacy on normal skin is limited by their ability to penetrate the stratum corneum. Thus, most of the preparations require extended application times and/or occlusion for effectiveness.

LMX is a topical lidocaine cream in a liposomal vehicle. It is available in 4% and 5% concentrations. Eutectic mixture of local anesthetics (EMLA) cream consists of a combination of 2.5% lidocaine and 2.5% prilocaine. LMX and EMLA have been shown to be more effective than other topical preparations of 4% tetracaine gel and Betacaine-LA (a mixture of prilocaine and lidocaine in a liquid paraffin ointment). LMX typically requires an application time of 30 minutes with or without occlusion, whereas EMLA requires 1 hour with occlusion. Multiple studies have demonstrated the 30-minute application of LMX without occlusion to provide equal anesthesia as 1-hour application of EMLA with occlusion. Caution should be exercised in the use of large amounts of prilocaine-containing topical preparations in infants or those with an impaired skin barrier, as prilocaine has the potential to induce methemoglobinemia.

Cryogens, such as ethyl chloride, also provide brief anesthesia at a site for minor procedures or the insertion of a needle. Similarly, an ice cube placed on an injection site often significantly reduces the discomfort of injection in the anxious patient.

Mucosal membranes are readily anesthetized using topical preparations due to the ease of penetration in the absence of a stratum corneum. Tetracaine or proparacaine drops rapidly provide effective anesthesia of

the conjunctiva and cornea for insertion of eye shields. Benzocaine and lidocaine preparations provide prompt anesthesia for intraoral procedures or before nerve blocks.

NERVE BLOCKS

The use of regional nerve blocks can be of immense value to the dermatologic surgeon. Regional nerve blocks allow large cutaneous areas to be anesthetized with small volumes of anesthetic. They are based on the injection of a local anesthetic into the immediate vicinity of a sensory nerve as it emerges from deeper planes of tissue. This provides effective anesthesia for the patient while minimizing the discomfort of multiple injections. Nerve blocks have the added benefits of limiting the possibility of anesthetic toxicity as well as minimizing tissue distortion. The primary risk of nerve blocks is nerve trauma with resultant neuropraxia.

The standard anesthetic used for regional blocks is 1% lidocaine with 1:100,000 epinephrine; however, bupivacaine may be added if more lasting anesthesia is desired. A 1 inch, 30 gauge is suitable for the performance of most nerve blocks. The proper execution of nerve blocks is predicated on a thorough knowledge of the anatomy of the region being anesthetized.

The cutaneous sensation of the face is primarily supplied by the trigeminal nerve, with a small fraction of the periphery being supplied by the cervical plexus. As its name implies, the trigeminal nerve consists of three major divisions: (1) the ophthalmic (V_1), (2) maxillary (V_2), and (3) mandibular (V_3) divisions. Each of these divisions has major branches, which are amenable to regional nerve blocks.

The ophthalmic division of the facial nerve gives off the supraorbital, supratrochlear, and infratrochlear nerves. The supraorbital nerve exits through the supraorbital foramen, which is a readily palpable bony notch located along the orbital rim just medial to the midpupillary line. The supratrochlear branch exits along the orbital rim approximately 1.5 cm medial to the supraorbital notch. The infratrochlear nerve exits just above the medial canthus. All three of these branches can be anesthetized with a single injection by inserting the needle 2–3 mm lateral to the supraorbital notch and advancing medially through the subcutaneous tissue to the medial canthus. The anesthetic is then injected as the needle is slowly withdrawn in one smooth motion. This single injection provides anesthesia to the ipsilateral forehead, frontal scalp, upper eyelid, medial canthus, and superior nasal sidewall and root.

The infraorbital nerve, a branch of the mandibular division, exits through the infraorbital foramen, which is located in the midpupillary line approximately 1 cm below the infraorbital rim. This nerve may be blocked by either an intraoral or a percutaneous approach. The percutaneous method involves insertion of the needle directly over the infraorbital foramen and advancement directly down to the maxillary bone, where the anesthetic is delivered. With the intraoral approach, the sulcus located just above and lateral to the canine tooth is identified by manual palpation. The needle is inserted in the superior portion of this sulcus and advanced upward approximately 1 cm in the midpupillary line. At this position, the anesthetic is slowly injected. The intraoral approach is less painful than the percutaneous one, and may be further aided by the use of a topical lidocaine or benzocaine gel on the oral mucosa. This block provides anesthesia to the ipsilateral lower eyelid, medial cheek, upper lip, and upper teeth.

The mental nerve is a branch of the mandibular division, which exits through the mental foramen just medial to the midpupillary line. This nerve is easily accessed via an intraoral injection. It is located just opposite of the first bicuspid on the mucosa of the lower lip, and is often visible to the naked eye as a thin glistening white strand. It is anesthetized with an injection in the immediate vicinity of its inferior portion. This provides anesthesia to the ipsilateral lower lip and chin.

In addition to the above branches, there are other branches of the trigeminal nerve that are also amenable to regional nerve blocks. These include the buccal, auriculotemporal, anterior ethmoidal (external nasal branches), and zygomaticotemporal nerves. A block of the greater auricular nerve off the cervical plexus provides anesthesia to the posterior auricle and angle of the mandible.

Nerve blocks can be a valuable tool for nonfacial locations as well. In particular, digital nerve blocks are very useful for procedures involving the digit or nail unit. The cutaneous sensation of a digit is supplied by two nerves coursing down each of the lateral aspects of the digit. For a block, the needle is inserted perpendicularly into the lateral aspect of each side of the digit and advanced until bone is reached. At this position, a small volume of anesthetic is administered. The delivery of a large volume (greater than 1 mL) of anesthetic in the digits can result in tamponade of the digital circulation with subsequent necrosis. This tamponade effect now appears to be more critical factor in cases of digital necrosis than the use of epinephrine.

ELECTROSURGERY AND ELECTROCAUTERY

(See Chapter 246)

SUTURE MATERIALS. The proper selection of suture material for any dermatologic procedure is vital to its successful outcome. There are several intrinsic characteristics of each suture material, which will influence this selection process (Table 242-2). Sutures are produced in both absorbable and nonabsorbable forms. An absorbable suture is classified as one, which loses half of its tensile strength within 2 months. Absorbable sutures are primarily used for the approximation of dermal and subcutaneous tissue. As wounds have achieved less than 10% of their final tensile strength at 2 weeks, these sutures maintain the structural support of wounds during the initial healing phase. The time that a suture maintains its tensile strength is dependent on the material of which it is composed.

TABLE 242-2
Suture Materials

	Type	Memory	Tissue Reactivity	Tensile Strength Half-Life
Nonabsorbable				
Cotton	Twisted	Low	Very high	—
Nylon	Monofilament	High	Low	—
Nylon	Braided	Low	Low	—
Polybutester	Monofilament	High	Low	—
Polyester, uncoated	Braided	Low	Low	—
Polyester, coated	Braided	Low	Low	—
Polypropylene	Monofilament	Very high	Very low	—
Silk	Braided/twisted	Very low	High	—
Stainless steel	Monofilament/braided/twisted	Very high	Very low	—
Absorbable				
Catgut, fast absorbing/mild chromic	Twisted	Very high	High	2 days
Catgut	Twisted	Very high	High	4 days
Catgut, chromic	Twisted	Very high	High	1 wk
Polyglactin 910	Braided	Very low	Low	2 wk
Polyglycolic acid	Braided	Very low	Low	2 wk
Poliglecaprone 25	Monofilament	Low	Very low	1 wk
Polyglyconate	Monofilament	Low	Very low	1 mo
Polydioxanone	Monofilament	High	Very low	1 mo

Data from Melton JL, Hanke WC: Wound closure materials. In: *Principles and Techniques of Cutaneous Surgery*, edited by GP Lask, RL Moy. New York, McGraw-Hill, 1996, p. 77; and Garrett AB: Wound closure materials. In: *Cutaneous Surgery*, edited by RG Wheel. Philadelphia, Saunders, 1994, p. 199.

Nonabsorbable sutures are predominantly used for external suturing with subsequent removal in the days after the procedure. In this instance, these sutures are used more for fine epidermal approximation than structural support. On occasion, nonabsorbable sutures are also used for the placement of subcutaneous tissue, muscle, and fascia, when a more permanent placement of the tissue is desired.

Sutures are produced as monofilaments (single-strand) or multifilaments (multiple-braided strands). Monofilaments offer the advantage of increased ease of pull-through tissue, less risk of infection, and decreased tissue reactivity. The disadvantage of monofilaments is the increase in memory, or the tendency for a material to revert to its original shape. This memory results in decreased ease of handling of the suture and decreased knot security for monofilaments. Multifilaments, or braided sutures, offer ease of handling and increased knot security. However, the strands of a multifilament have the capability to trap fluid and bacteria resulting in an increased risk of infection with their use.

In general, the smallest suture, which provides adequate tensile strength for a defect, should be utilized. Suture size is measured in multiple of zeros based upon the diameter of the suture material. The higher the number preceding the zero, the smaller the diameter of the suture. Typically, 5-0 and 6-0 sutures are used on regions of low tension, such as the face, eyelids, and ears. Areas of higher tension, such as the trunk, extremities, and scalp, require 3-0 and 4-0 sutures. Areas of intermediate tension, such as the neck, may be closed with either 4-0 or 5-0 sutures. There are a wide range of needles whose nomenclature varies with manufacturer. In general, most skin surgery procedures are best performed with plastic surgery needles.

SUTURING TECHNIQUE.

Meticulous suturing technique is fundamental to obtaining excellent aesthetic and functional results. Properly placed sutures allow for approximation of wound edges, wound-edge eversion, minimization and redistribution of tension, elimination of dead space, maintenance or restoration of natural anatomic contours, and avoiding permanent suture marks on the skin surface. The suturing technique selected for a specific wound closure depends on the anatomic location, tension, thickness of the wound edges, and goals of the surgeon.

Interrupted Sutures.

The simple interrupted suture is the most basic and versatile suture used by dermatologic surgeons. Absorbable, buried interrupted sutures are used as part of the layered wound closure. These sutures provide support for the wound until tensile strength has increased sufficiently to prevent wound dehiscence and reduce tension on the wound edges. To achieve good eversion of the wound edges, these are best placed in the deep dermis and subcutis in a heart-shaped configuration (Fig. 242-8).[9] Wounds in which one skin edge appears higher than the other can be appropriately aligned by taking a larger bite from the lower edge and a smaller, more superficial bite from the higher edge.

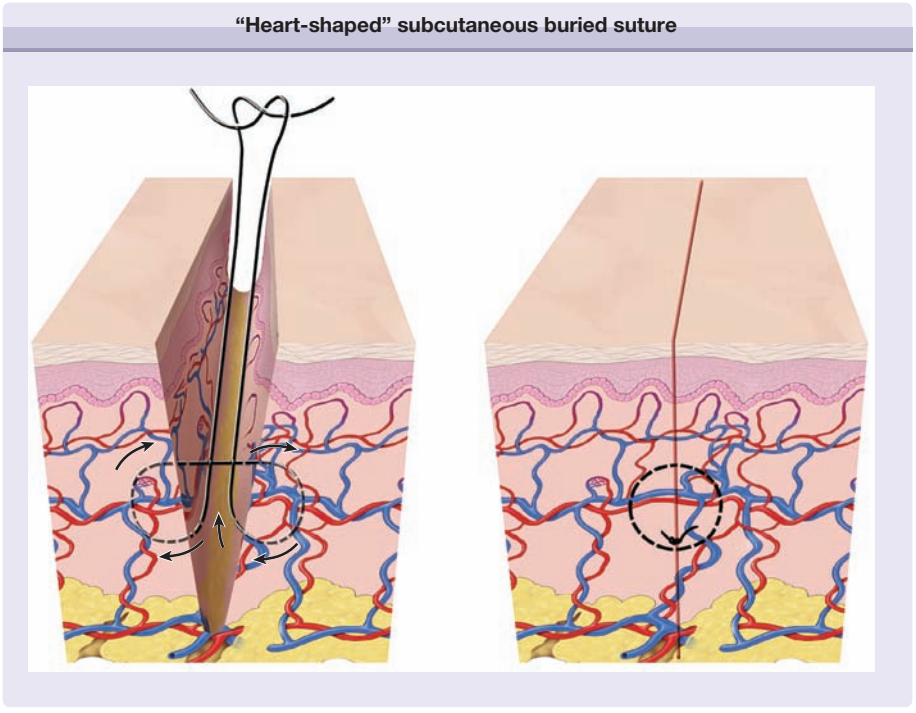

Figure 242-8 "Heart-shaped" subcutaneous buried suture.

Epidermal simple interrupted sutures, used to obtain optimal alignment of the epidermal edges of the wound, are more time-consuming to place and remove than continuous running sutures. In settings where wound healing may be impaired because of the patient's underlying medical condition or in areas of high tension, interrupted sutures may be preferred. This type of suture usually provides greater tensile strength and less potential to cause edema, induration, and impaired microcirculation than running sutures. In addition, in areas of high tension, the risk of wound dehiscence can be assessed by removing alternate sutures. If it seems that dehiscence is likely, the remaining sutures may be left in place for 3–4 additional days.

The vertical mattress suture provides wound-edge eversion, reduces dead space, and minimizes tension across the wound (Fig. 242-9). It achieves the same effect as a buried dermal suture and an epidermal suture. Because this suture requires four entry points in the skin, significant crosshatching can be expected if the suture is not removed within 5–7 days. This suture by nature is a tightly placed suture and can be difficult to remove because of its tendency to become embedded in the skin.

The horizontal mattress suture has been used to reduce tension across wound closures that are under significant tension (Fig. 242-10). This technique also creates wound eversion. This suture can be placed as an initial tension-reducing or -holding suture and to bring the wound edges closer together, so that subcutaneous sutures can be placed to distribute tension and close the wound. At this point, if the tension has been adequately distributed, the horizontal mattress suture may be removed. If tension across the wound persists, the horizontal mattress suture may be left in place for a few days while early wound healing proceeds and removed before suture tracks have had a chance to form. The main disadvantage of this suture is the possibility of wound-edge necrosis as this suture can easily strangulate the dermal plexus between its limbs. This problem is minimized by taking large bites with the needle to encompass large amounts of tissue, by using bolsters, by tying the suture only as tight as necessary to accomplish the task of bringing the wound edges together, and by removing the suture as soon as possible. Before contemplating the use of a horizontal mattress suture for tension reduction, the surgeon should consider other means of reducing tension across the wound, including appropriate use of undermining and closure orientation, flaps from areas of tissue excess, preoperative or intraoperative tissue expanders, serial excisions, and subcutaneous sutures.

The half-buried horizontal mattress suture is primarily indicated for the positioning of various corners and tips including flap tips, M-plasty tips, and V-Y closure tips. It can also align the edges of tangential flaps and flaps with ischemic wound edges. The buried limb of this suture is placed in the potentially ischemic area in order to minimize interference with the dermal vascular plexus. A superficial simple interrupted suture through a flap tip may also work without resulting in increased risk of flap tip necrosis.

Running Sutures. The simple running suture can be used in situations where the wound edges are of equal thickness without tension, closely approximated, and with an absence of subcutaneous dead space. This suture is most useful for wounds that have already

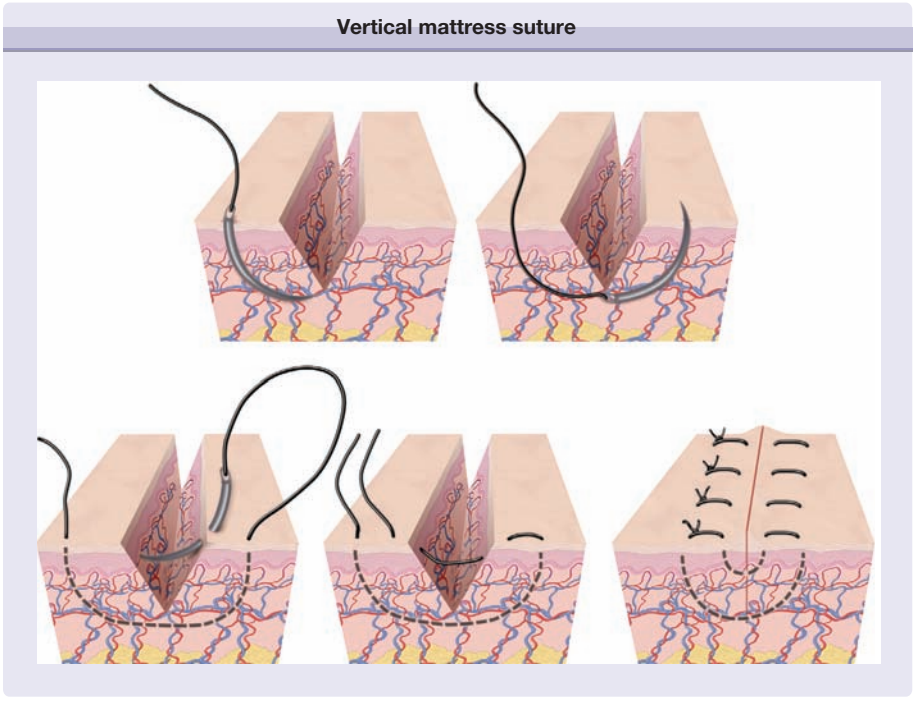

Figure 242-9 Vertical mattress suture.

been closed by buried sutures, for the attachment of full-thickness or split-thickness skin grafts, and in areas of thin skin such as the eyelids, ears, neck, and scrotum. By eliminating all but two knots, there is less suture material resting against the skin, resulting in the development of fewer scars from suture marks. However, fine adjustments along the suture line are difficult to make and the suture has a tendency to pucker when very lax and thin skin, such as eyelid skin, is being sutured. In thin skin, the knots at each end may be tied over small bolsters to prevent them from cutting into the tissue.

The running locking suture is a variant of the simple running suture in which, after the placement of each loop, the needle is passed through the previous loop prior to starting the next loop. It is intended for the closure of well-vascularized wounds under a moderate amount of tension. The wound edges should be stiff and of equal thickness without a tendency for inversion. It is stronger than a simple running suture. However, if it is placed too tightly or if significant postoperative swelling develops, tissue strangulation with wound-edge necrosis may ensue.

The running subcuticular suture is a buried running suture that is usually not absorbable. It is ideal for the closure of wounds in areas such as the trunk and extremities where the suture must remain in place for more than 7 days. As the suture is buried, there are no suture marks and the suture may be left in place for several weeks, even months. When

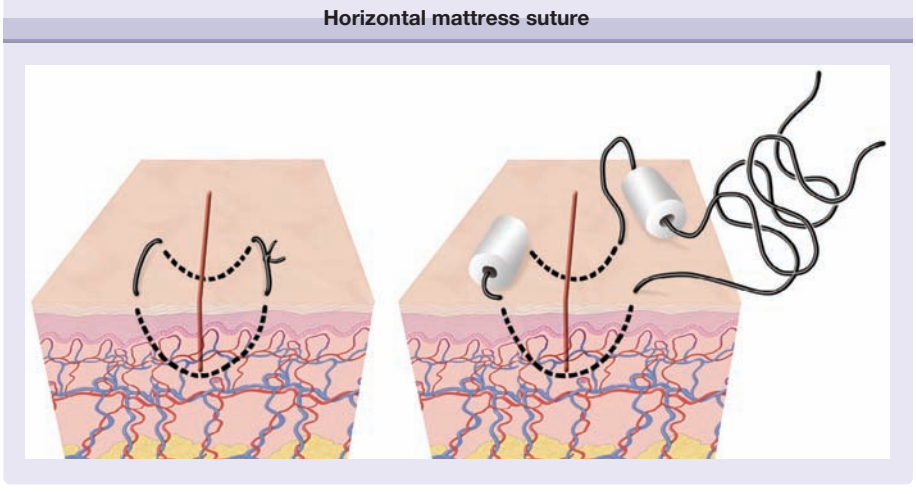

Figure 242-10 Horizontal mattress suture.

absorbable suture material is used, it may be left in place until it is absorbed. As this suture is capable of only modest wound-edge alignment, it should be reserved for wounds in which the tension has been eliminated with deep sutures and the wound edges, of approximately equal thickness, are closely approximated. The running subcuticular suture should be placed with a nonreactive monofilament suture such as polypropylene to facilitate suture removal and prevent suture breakage within the wound. Some surgeons use a permanent suture left in place indefinitely, as this can reduce scar stretching. If nonabsorbable sutures are selected clear, nonreactive suture material should be used.

SUTURE REMOVAL. Timing of suture removal must balance two factors: (1) leaving the sutures in place long enough to allow wound healing and prevent dehiscence and (2) removal before the development of suture track marks along the scar line. These suture track marks occur because reepithelialization occurs around the suture. In general, the less the blood supply to an area and the greater the tension across a wound, the longer the sutures should be left in place. On the face and ears, most skin sutures should be removed within 5–7 days. Eyelid sutures can be removed in 3–5 days. Neck sutures should be removed in 7 days and scalp sutures in 7–10 days. On the trunk and extremities, risk of wound dehiscence takes precedence over suture marks. Sutures on the trunk and upper extremities should be left in place for 7–14 days. Lower extremities may require up to 21 days of suture support, though, with proper deep suture placement, epidermal sutures can generally be removed in 7–10 days.

Absorbable sutures are not removed, but some patients develop suture reactions, consisting of sterile suture abscesses and suture extrusion through the wound. If this happens, the suture should be picked up carefully with small forceps and cut out of the wound. Any purulent material should also be drained.

STAPLE CLOSURE. Staple closure of wounds is an alternative to suture closure. The staples have the advantage of very quick placement, minimal tissue reaction, and very strong wound closure. Staples are most often used with long wounds, especially on the scalp, where the suture line is hidden by scalp hair. Potentially contaminated wounds that are closed with staples appear to be more resistant to infection than wounds closed with sutures. Staples provide efficient wound closure; but when exact wound-edge alignment is required, sutures should be used. Staples are easily removed with a staple remover.

POSTOPERATIVE CARE

Most wounds can be cleaned appropriately with tap water and mild soaps. A diluted acetic acid solution can be helpful to prevent *Pseudomonas* infection in sites predisposed to this. Small amounts of hydrogen peroxide can help debride wounds that have developed significant crusting and exudate. However, in large amounts, hydrogen peroxide can be toxic to the development of new cells and thus inhibit wound healing. Most wounds are also best dressed with petrolatum and a nonadherent dressing. Petrolatum is relatively inert, nontoxic, nonsensitizing, and nonirritating. Although not common knowledge for the layperson, it has been well proven for years that covered or occluded wounds reepithelialize and heal faster than dry wounds.[10] There is a significant risk for allergic contact dermatitis with topical antibiotics, and they have not been shown to be superior to petroleum jelly in preventing wound infections. For wounds with significant drainage, dressings such as gauze, foam dressings, or alginates provide absorption.

KEY REFERENCES

Full reference list available at www.DIGM8.com

DVD contains references and additional content

1. Leffell DJ, Brown MD: *Manual of Skin Surgery*, 2nd edition, PMPH-USA, Shelton, CT, 2011
4. Wilson W et al: Prevention of infective endocarditis: guidelines from the American Heart Association: A guideline from the American Heart Association Rheumatic Fever, Endocarditis, and Kawasaki Disease Committee, Council on Cardiovascular Disease in the Young, and the Council on Clinical Cardiology, Council on Cardiovascular Surgery and Anesthesia, and the Quality of Care and Outcomes Research Interdisciplinary Working Group. *Circulation* **116**:1736, 2007
5. Alam M, Goldberg LH: Serious adverse vascular events associated with perioperative interruption of platelet and anticoagulant therapy. *Dermatol Surg* **28**:992, 2002
7. Tanner J, Woodings D, Moncaster K: Preoperative hair removal to reduce surgical site infection. *Cochrane Database Syst Rev* **2**:CD004122, 2006
8. Daarouiche RO et al: Chlorhexidine-alcohol versus povidone-iodine for surgical site anti-sepsis. *N Engl J Med* **362**:18, 2010

Chapter 243 :: Excisional Surgery and Repair, Flaps, and Grafts

:: Jessica M. Sheehan, Melanie Kingsley, & Thomas E. Rohrer

EXCISIONAL SURGERY AND REPAIR, FLAPS, AND GRAFTS AT A GLANCE

- Excisional surgery is one of the most common surgical procedures in dermatology
- The goal of excisional surgery is to remove the lesion with appropriate margins and obtain the best cosmetic result.
- The planning and execution of dermatologic surgery procedures must balance risk and benefit and consider all options to achieve a particular outcome. Wounds should be closed under minimal tension, with scars placed along cosmetic unit junctions or skin tension lines, without distorting critical anatomic structures and landmarks.
- The closure must preserve sensory and motor nerve function.
- An elliptical or fusiform excision is the fundamental procedure in dermatologic surgery and typically allows for a linear, side-to-side closure.
- Flap or graft repair may be considered when linear closure is not feasible.
- Flaps are commonly classified according to their primary movement as advancement, rotation transposition, or interpolation.
- The three basic types of skin grafts are full-thickness, split-thickness, and composite.

The goal of any excisional surgery is to remove the lesion with appropriate margins and leave the least noticeable scar possible. In order to consistently attain aesthetically pleasing results, time must be taken long before the first incision to appropriately plan the procedure. While excisional surgery is as much an art form as it is a science, there are many principles to keep in mind when planning the surgical excision and closure. Wounds should be closed under minimal tension, with scars placed along cosmetic unit junctions or skin tension lines, without distorting critical anatomic structures and landmarks (eyelid, eyebrow, nose, lip, hairline, etc.). Biologically, the closure must be such that the mobilized skin and associated adenexal structures are viable, and there is maximal preservation of sensory and motor nerve function.

Knowledge of underlying anatomy is critical in both the design and execution of the excision (see Chapter 242).

The planning and execution of dermatologic surgery procedures varies from case to case. A skilled surgeon evaluates the risks and benefits of various options in each patient and anticipates potential complications. Key elements of dermatologic surgery procedures include proper patient selection and preparation; comprehension of risks and necessary precautions; obtaining effective local anesthesia; use of sterile or clean technique; informed procedure design and meticulous technique in performing the incision and repair; diligent postoperative wound care and patient education.

RISKS AND PRECAUTIONS

It is important that both the patient and practitioner be aware of the risks of dermatologic surgery. In fact, professional standards dictate that these risks be documented for proper patient consent.[1] The main risks of excisional surgery include pain and discomfort; bleeding, bruising, and hematoma formation; nerve damage; wound infection; wound dehiscence; and undesirable scar or contracture.

- While the injection of local anesthesia is not without pain, there are several ways to minimize the discomfort. Some of the most effective ways to diminish pain on injection is the addition of sodium bicabonate to the anesthetic agent, using small-gauge needles, inserting the needle into the skin through a pore, and injecting very slowly and into the subcutaneous tissue. In addition, starting at the proximal aspect of the neural innervation and working distally will help minimize discomfort. Postoperative pain is typically minimal and controlled with over-the-counter analgesics such as acetaminophen. Meticulous operative technique will also help minimize postoperative pain. More severe pain may require the prescription of narcotics.
- Excessive bleeding, subsequent bruising, and possible hematoma formation are also risks. Most dermatologic surgeons now recommend that medically necessary anticoagulation, including aspirin, clopidogrel, heparin, and warfarin, be continued perioperatively.[2] Herbal supplements such as ginseng or garlic, vitamin E, aspirin, and nonsteroidal anti-inflammatory agents that are not prescribed by

a physician should be discontinued 2 weeks prior to surgery if possible.[2] The consumption of alcohol should also be restricted immediately before and after the procedure. Meticulous hemostasis with electrocautery or coagulation, ligation of larger arteries, and the application of a compression bandage minimize the risk of bleeding.

- Risk of infection exists whenever the skin barrier is breached. Wound infection is relatively uncommon[3] and occurs more frequently in particular patient populations, such as those who are diabetic, smokers, or immunosuppressed, and at certain surgical sites, such as the ear or lower leg.[4] Sterile technique and atraumatic tissue handling minimizes this risk. Prophylactic antibiotics may be administered for high-risk patients, or if the wound base or suture perforates into nonsterile areas, such as the nasal or oral cavities. Guidelines for antibiotic usage are outlined in Table 243-1).
- Wound dehiscence occurs in wounds under high tension, or in cases of poor wound healing or infection. This risk is reduced by proper planning of the closure, the use of buried subcutaneous sutures, fascial plication to relieve tension on wound edges where indicated, and minimizing activity and immobilization of the wound edges for 1 to 2 weeks after surgery.
- Undesirable scars are always a possibility. While many steps can be taken to minimize the appearance of the final scar, it is important for the patient to understand that all excisional surgery will result in the formation of some form of a scar. Many factors must be considered with respect to formation. Free margins must be respected and never distorted. Closures are best hidden when they are placed on along cosmetic unit junctions and contained in as few cosmetic units as possible. The long axis of the excision and/or design of a repair should

TABLE 243-1

Guidelines[a] for Patient Selection for Antibiotic Prophylaxis for the Prevention of Endocarditis and Prosthesis Infections as well as Surgical Site Infections

Risk Stratification for Endocarditis and Prosthesis Infection

High-Risk Patient	Low-Risk Patient
History of bacterial endocarditis	History of CABG surgery
Prosthetic valve	Pacemaker, defibrillator
Any cardiac valvular dysfunction Hypertrophic cardiomyopathy	No valvular dysfunction (including history of rheumatic fever or Kawasaki disease)
Mitral valve prolapse with regurgitation, all mitral valve prolapse in men >45 years	Mitral valve prolapse without regurgitation Physiologic heart murmur
Cardiac malformation	Atrial septal defect or ostium secundum
CNS shunts	>6 mon since repair of ASD, VSD, PDA
Shunt/fistula near inflamed/infected tissue	Arterial grafts/stents
Orthopedic prosthesis	Nonorthopedic prosthesis (i.e., penile prosthesis, breast implants)

Antibiotic Prophylaxis for the Prevention of Endocarditis and Prosthesis Infection

Risk	Procedure	Skin Condition	Location	Prophylaxis
High	Mohs	Any	Any	Yes
High	Excision, biopsy, ED&C, ablative laser, cryotherapy	Intact or eroded[a] Infected/Inflamed	Skin Mucosa Any	No Yes Yes
Low	Any	Any	Any	No

Potential Antibiotic Prophylaxis for the Prevention Surgical Site Infection

Inflamed or infected skin close to surgical site
Flap or graft reconstruction on nose and ear
High-tension closures
Below-the-knee procedures
Hand surgery
Multiple simultaneous procedures
Mucosal/anogenital sites in immunocompromised patients

[a]Unless prosthetic valve.

Adapted from: Maragh SL et al: Antibiotic prophylaxis in dermatologic surgery: updated guidelines. *Dermatol Surg* 2005 Jan;**31**(1):91-93.

be placed in the direction of rhytides or relaxed skin tension lines. It is best to plan an excision with the patient in an upright position, and animation using the underlying muscles of facial expression may also be helpful. On the trunk or extremities, the direction of skin tension may be tested by moving/pinching the area. The incision should be made perpendicular to the skin surface, and an even depth of resection and undermining across the base of the wound should be maintained. Remove standing cones of redundant tissue. Buried vertical mattress sutures should be placed to attain good wound eversion and minimize the tension on the wound edges as it heals. Wounds heal under the optimal conditions of a clean, occluded environment.

EQUIPMENT

PROCEDURE ROOM

- Basic: mechanical table, overhead procedure lights, electrocautery, vital signs monitor, Mayo stand (1 or 2), receptacle for contaminated waste.
- Optional: depending on the location and scope of the procedure, suction may be needed.

SURGICAL TRAY

The specific instruments selected depend on the scope of the procedure and personal preference of the surgeon. It is helpful to set up the basic elements on the tray in the same layout each time. Consistency in placement of sharps prevents inadvertent injury with contaminated instruments to the surgeon or the assistant.

A basic excisional surgery tray (eFig. 243-0.1 in online edition) contains:

- Instruments: curette, No. 3 or No. 7 Bard-Parker scalpel handle with a No. 15 or No. 10 blade (or a Beaver blade in some cases), small forceps (e.g., Bishop-Harmon) and/or smooth-toothed Adson forceps, delicate standard skin hook or double-prong skin hook, curved iris scissors, blunt-tipped undermining scissors, hemostat, towel clamps, needle holder, suture scissors. For larger procedures, such as flaps, additional hemostats or hooks may be needed. Special procedures will need other instruments added to this tray (e.g., split-thickness skin grafts require a dermatome).
- Disposable material: marking pen, gauze sponges, cotton tip applicator sticks, scratch pad for electrocautery tip, electrocautery handpiece and tip, surgical drapes, foam or magnetic pad for discarded needles
- Suture

PREPARATION

Before starting a surgical procedure, it is important to review the patient's medical history, drug allergies, and current medications, including over-the-counter medications. The entire procedure should be explained in detail, and the patient must sign an informed consent. Vital signs should be taken and recorded.

The patient should be positioned in a manner that allows maximum exposure of the surgical site and is comfortable enough that the patient can remain still for the procedure. It is also important to be sure the patient is positioned in an optimally ergonomic way for the surgeon. Patients should be positioned so that the surgeon and assistance are comfortable and not leaning excessively over the table. A back flexion angle of greater than 15° increases the risk of significant back injury. Likewise, the patient should be elevated to a height that is comfortable for the surgeon. While many occupational therapists suggest working at a height that is in line with the elbow, most find bringing the working surface up higher to reduce the angle of the surgeon's neck to be significantly more comfortable. Operating with a cervical neck angle greater than 15° can lead to serious neck injuries and disabilities (eFig. 243-0.2 in online edition).

If hair removal is deemed necessary, it may be trimmed. The operative field is cleansed in a sterile fashion with one of several scrubs, including chlorhexidine (with or without isopropyl alcohol), iodophors, or triclosan.[5] The boundaries of the skin prep should be much wider than the planned incision and take into account the path of suture material in the surgical field. For procedures on the face, the patient should be advised to keep the eyes closed and caution should be used not to get any of the prep into the eyes. Sterile towels or a sterile drape should be placed around the edges of the field. In addition, draping the eyes may add additional comfort to the patient by helping avoid the glare of the operative lights.

ANESTHESIA

Most excisions are performed with local anesthesia only.[6] The most common agent utilized is 1% or 2% lidocaine, injected in a ring around the involved area. Other anesthetics used include bupivicaine, mepivicaine, or articaine. The addition of epinephrine 1:100,000 causes local vasoconstriction and helps increase the amount of total anesthesia that may be safely administered, increases the duration of anesthetic activity,[7] and decreases intraoperative bleeding. Plain lidocaine should be used when the administration of epinephrine is contraindicated, such as in patients with known cardiac arrhythmias, unstable angina, and narrow-angle glaucoma. It should be used with care in patients who are hypertensive, pregnant, or with known anxiety disorders.

The administration of local anesthetic is painful, particularly on sensitive sites such as the perioral and perinasal areas. There are several ways to decrease this discomfort.[8] Lidocaine is slightly acidic, and the addition of sodium bicarbonate 1:10 raises the pH of the solution closer to physiologic levels. Liquid injected at room temperature or warmer is less uncomfortable than that delivered at cooler temperatures. At the

injection site, the application of ice or vibration may also decrease the sensation of pain. Placement of the needle through an enlarged pore, especially on the nose, may also limit discomfort. Superficial dermal injection induces anesthesia more quickly than that injected into the deep dermal-subcutaneous tissue region, yet since the tissue is less distensible, it is uniformly more painful. Therefore, lidocaine should first be delivered to the deep dermal-subcutaneous tissue and then more superficially as the needle is withdrawn. Anesthesia should be delivered slowly through a small caliber needle. A 30-gauge needle typically is used in these circumstances. The surgical site should also be anesthetized from the proximal to the distal aspect of the local sensory nerve if possible. For example, when injecting around a lesion on the forehead, start the injections at the inferior aspect and move more superiorly with subsequent injections. In this manner, by the time the superior injections are performed, the area may already be numb since the supraorbital nerve had been anesthetized from the inferior injections.

For larger procedures, nerve block anesthesia is helpful because a large area can be anesthetized with a limited volume of anesthesia. Tissue distortion is also limited with nerve block anesthesia, and the vascular perfusion of the flap is not impaired.

EXCISIONAL SURGERY

ELLIPICAL EXCISION

Excisional surgery is one of the most frequently performed dermatologic surgery procedures. Specifically, the elliptical or fusiform excision allows for a linear, side-to-side closure. Mastery of elliptical excision and closure is fundamental to more advanced procedures, including variations on the ellipse itself and planning and executing more complex flaps. An elliptical excision is indicated for the removal of small- to moderate-sized benign or malignant neoplasms as well as for excisional biopsy and scar revision.

PLANNING THE ELLIPSE. In planning the excision, the lesion to be excised should first be identified and confirmed by the patient. Using an appropriate marker a circle is drawn around the lesion with the appropriate margins. The size of the surgical margin is dependent on the nature of the lesion.[9,10]

Once the margins of the lesion have been marked, the ellipse is planned. When planning a fusiform excision with linear closure, one must consider several factors, including the impact of the procedure on form and function. Free margins are of primary concern. Any distortion of a free margin will be aesthetically unacceptable. Closures should be planned such that tension vectors are perpendicular to free margins so no distortion occurs. For optimal cosmetic results, the long axis of the fusiform excision should be oriented along the relaxed skin tension lines, which are generally perpendicular to the direction of the pull of the underlying muscle (Fig. 243-1). These lines should be identified while the patient is sitting upright, and may be highlighted by asking the patient to make certain facial expressions. If the relaxed skin tension lines are not obvious, the direction of laxity may be identified by manipulating tissue manually. Relaxed skin tension lines rarely follow published diagrams, and closures should mimic the subtle arcs in the facial lines of expression. When possible, excisions should be restricted to one of the major cosmetic units (e.g., forehead, nose, periorbital area, lips and perioral area, chin, and cheeks) (Fig. 243-2). Placing the incision line at the junction of the cosmetic units may also minimize the appearance of the resultant scar. An adequate reservoir of surrounding tissue or skin laxity must be present. When the elliptical excision and closure that has been designed cannot include these conditions consideration must be given to other forms of repair such as flaps, grafts, partial purse sting closures, or healing by second intention.

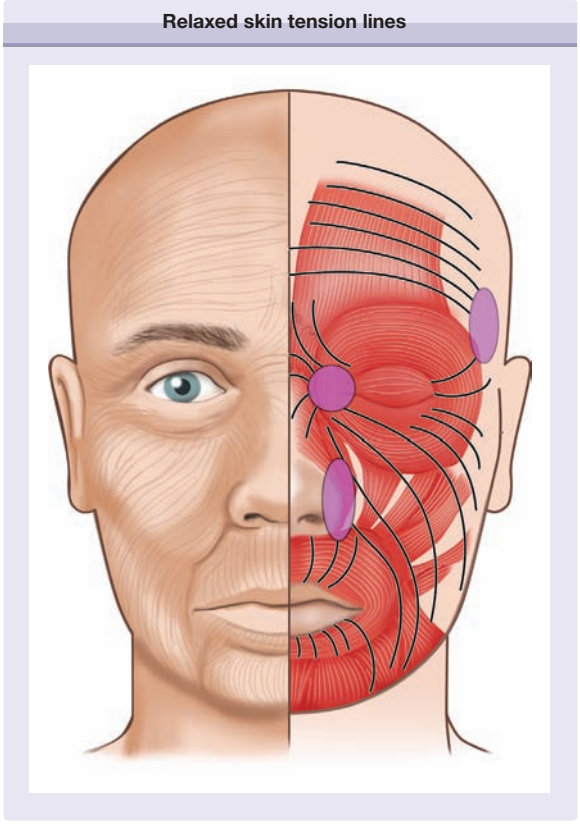

Figure 243-1 Relaxed skin tension lines. Relaxed skin tension lines generally form perpendicular to underlying muscles of facial expression. Closure lines heal better and with a thinner less noticeable scar when placed in relaxed skin tension lines.

The simple ellipse is based on an optimal length to width ratio of 3.5:1 to minimize the formation of redundant tissue at the apices, otherwise known as "dog-ears," "puckers," or "standing cones skin." The ratio may be increased to 4:1 or greater in locations with less tissue distensibility or decreased to 3:1 in areas where the tissue is more lax. The apical angle between the two arciform incisions ranges from of 37°–74°, depending on the length to width ratio.[11] As

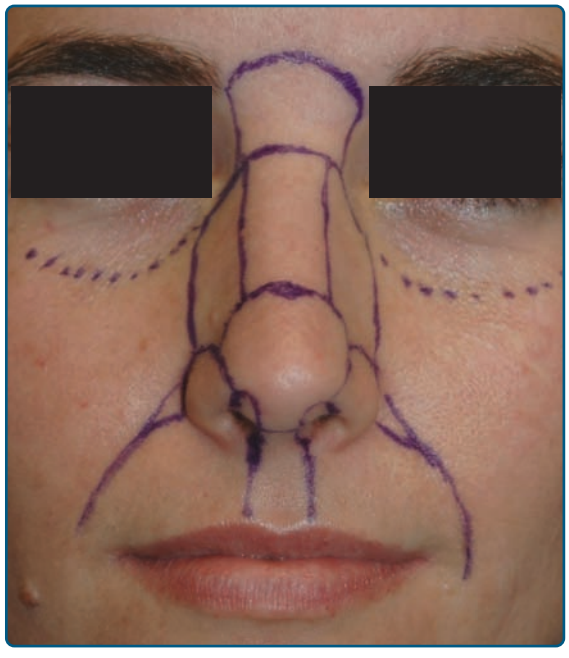

Figure 243-2 Cosmetic units. The face can be divided into many cosmetic units. The cosmetic units are differentiated from each other by alterations in skin texture, color, or contour. Incisions hide very well when placed in cosmetic unit junctions.

the ratio becomes larger, the apical angle decreases; thus, for a ratio of 5:1, which may be needed for scalp surgery, the apical angle approaches 30° (Fig. 243-3).

It is important to note that as a wound is closed in a linear fashion, the length of the resultant scar will be longer than the distance between the two distal points drawn out in the preoperative design of the ellipse. The arc of the two sides of the closure that are brought together is necessarily longer than a straight line drawn between the distal points of the ellipse. Mathematically, with the angles used in excisional surgery, the arcs are roughly 20% longer than the straight line drawn down the middle of the ellipse. In most cases this becomes

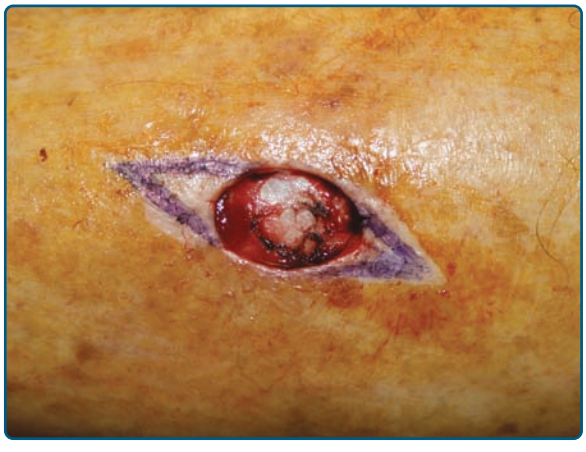

Figure 243-3 Acute apical angle. Certain areas such as the convex surface of an extremity or the nasal dorsum require a length to width ratio of greater than 3:1.

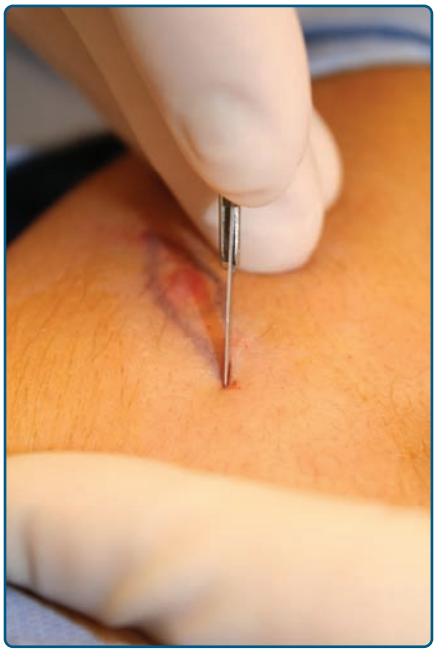

Figure 243-4 Incision. Incisions should be made 90° (perpendicular) to the skin surface and continued down through the dermis into the subcutaneous tissue.

irrelevant as there is contraction along the long axis of a scar and the tissue around the closure distends and absorbs this small difference without any noticeable distortion. In areas such as the upper lip, however, this small difference may be enough to distort the lip margin and be disfiguring. Lengthening the elliptical closure and bringing it around the lip to the wet mucosal margin will often help hide this potential distortion.

TECHNIQUE. After the ellipse is planned and drawn, the field is anesthetized, prepped, draped, and the first incision is made using a scalpel (Fig. 243-4). In most instances, a number 15 blade is used to score the epidermis or to cut through to the fat on the first pass; however, thick back skin may require the use of a No. 10 blade. The surgery begins with the point of the blade at the apex distal from the surgeon's position. As the incision progresses toward the arc of the ellipse, the belly of the blade is held perpendicular to the skin surface, preventing a beveled incision. As the opposite apex of the incision is approached, the blade rocks back up onto its tip, which allows the surgeon to clearly see the apex of the incision under the advancing hand. This prevents extending the incision beyond the planned apex. To prevent bunching of the tissue ahead of the pressure exerted by the blade, traction on the surrounding skin is held with the nondominant hand; in addition, an assistant may aid with traction. The depth of the excision is, again, dependent on the nature of the neoplasm being excised. When a side-to-side closure is planned, the depth of the incision must be full thickness, or into the superficial subcutaneous fat. The proximal apex of the ellipse is grasped gently with a toothed forceps to elevate the tissue. The base of the specimen is dissected in an even plane with a scalpel or scissors. The depth at the apices should be

the same as the depth at the center; there is a tendency to remove the specimen with the depth at the apices more superficially. When the depth of the excision is not uniform, a more noticeable standing cone of tissue may surround the tips as the wound is closed.

CLOSURE. Undermining is performed to increase mobility of the surrounding tissue, aid in wound eversion, decrease tension on the wound edges, and diffuse scar contraction.[12] The subcutaneous tissue is undermined at the same level around all edges of the wound, including the apices, utilizing iris or blunt-tipped scissors. The tissue may be snipped or bluntly dissected by inserting the tip of the scissors and spreading. The plane of undermining will vary depending on body site but should be uniform in depth at all edges. Knowledge of anatomy is extremely important and careful attention must be given to surrounding vital structures. Patients receiving anticoagulants or with reduced platelet number or function may benefit by limiting the extent of undermining as the risk of bleeding and hematoma formation is decreased.

Electrocoagulation or electrocautery is employed to attain meticulous hemostasis of the bed of the wound. A skin hook is used to elevate the wound edges to expose vessels that were injured during the excision or undermining. Blood that accumulates in the wound must be cleared with gauze or cotton swabs to allow for visualization of pinpoint bleeding and to allow for a relatively dry field. The cautery tip may be applied directly to the vessel until bleeding ceases. Alternatively, indirect coagulation is achieved by using small forceps to grasp the vessel and applying the cautery tip to the forceps. Indirect cautery limits the residual thermal damage surrounding the cauterization and may speed wound healing. Theoretically it could reduce the risk of infection but in facial skin, where much dermatologic surgery is performed, the excellent blood supply often minimizes the risk of infection. No matter which method is used, care should be taken to stop all significant bleeding while minimizing cautery char. Larger, more high-pressured arteries may require ligation with absorbable suture.

Suturing technique (see Chapter 242) reduces and redistributes wound tension, everts the skin edge, eliminates dead space, and maintains or restores natural anatomic contours, while minimizing the formation of permanent suture marks on the skin surface. Most wounds are closed in two layers: (1) absorbable deep sutures and (2) nonabsorbable superficial sutures. Deeper wounds or those with significant dead space may benefit from a third, deep layer in the subcutaneous fat or fascia.

Ideally, the wound is closed by first placing the deep sutures using the rule of halves to minimize the formation of dog-ears (Fig. 243-5). The first suture is placed in the center of the wound. Each half of the remaining defect is closed in a similar manner, which is repeated until a suitable numbers of sutures have been placed. A wound gains only 7% of its final strength after 2 weeks.[13] As most skin sutures are removed within 1 to 2 weeks of placement, absorbable buried sutures are an important part of a layered wound closure.[14] Buried sutures typically dissolve over the course of months and provide support for the wound until epidermal tensile strength has increased sufficiently to prevent wound dehiscence.

Buried vertical-mattress sutures aid significantly in wound eversion by reducing or eliminating tension on the wound edge and producing thinner less noticeable scars (Fig. 243-6). This type of buried suture should be used in nearly all closures. Subcutaneous sutures help minimize or eliminate dead space and align deep structures such as skeletal muscle or fascia. They can

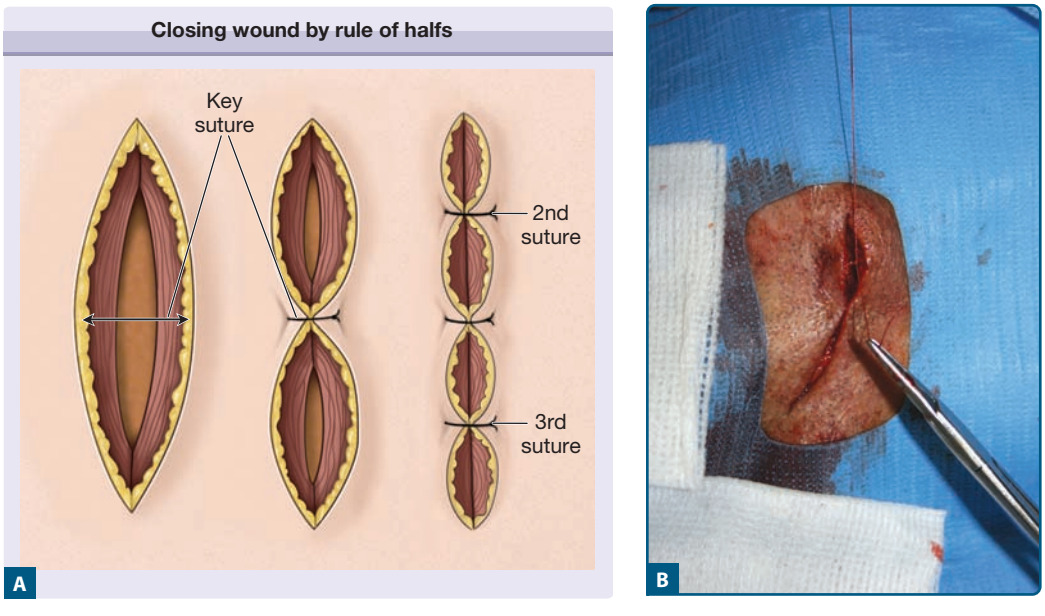

Figure 243-5 **A** and **B.** Closing wound by rule of halves. Sutures are placed at the midpoint of any open area of the defect.

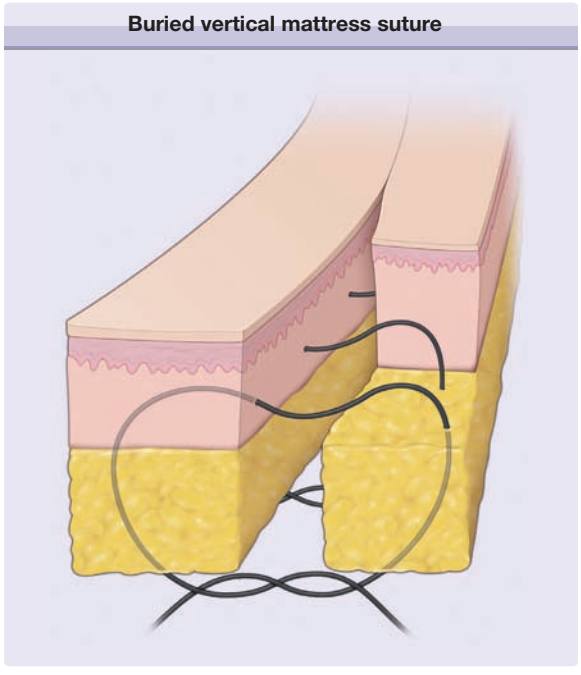

Figure 243-6 Buried vertical mattress suture. The buried vertical mattress suture gives excellent eversion to the wound edge and should be used for most if not all subcutaneous sutures.

also be used to anchor overlying tissue to underlying fixed structures, such as periosteum, to prevent distortion of free margins or maintain proper facial contour and function. This is exemplified by anchoring a melolabial flap to the maxillary periosteum. When tying a buried suture, it is important not only to keep both free ends of the suture on the same side of the loop created, but also to tie the suture in such a manner that draws the knot down on the same side so it will tuck up under the loop and not get hung up on it (Fig. 243-7). Buried sutures should align the wound edges such that they are perfectly approximated with good wound eversion before the placement of epidermal sutures.

Epidermal sutures are placed to approximate the margins of the skin edge. They should be evenly spaced and placed at roughly the same distance from the wound as the combined dermal epidermal depth. Therefore, sutures placed on the eyelid will be much closer together than those placed on the thick skin of the back. Most practitioners use a running nonabsorbable minimally-reactive monofilament suture, such as polypropylene, that requires subsequent removal.[15] Alternatives include running absorbable fast-acting gut[16], absorbable or nonabsorbable running subcuticular sutures[17], simple interrupted nonabsorbable sutures, and polymethylmethacrylate tissue glue. Simple interrupted sutures are more time-consuming to place and remove than a running suture. In settings, where wound healing may be impaired due to the patient's advanced age or underlying disease, interrupted sutures compared with running sutures may be preferred, as interrupted sutures may have, with all other factors being equal, greater tensile strength and less potential to cause edema, induration, and impaired microcirculation.[18]

SUTURE REMOVAL.

The risk of crosshatch marks across the suture line can be minimized by removing the sutures within a week of placement, before the formation of epithelial suture tracks develop. On the face and ears, most skin sutures are removed within 5 to 7 days. Neck sutures should be removed in 7 days and scalp sutures in 7 to 10 days. On the trunk and extremities, risk of wound dehiscence mandates that epidermal sutures may be left in place longer, typically 10–14 days, to provide additional support. In repairs under high tension or when dehiscence is likely, sutures may be left in place for 3–4 additional days. However, if sufficient buried sutures have been placed and the wound as well approximated at 7–10 days, epidermal sutures can be removed. The use of a running subcuticular suture for well-approximated wounds will prevent the formation of suture tracks and should be used in most cases that require sutures be left for more than 7 days.

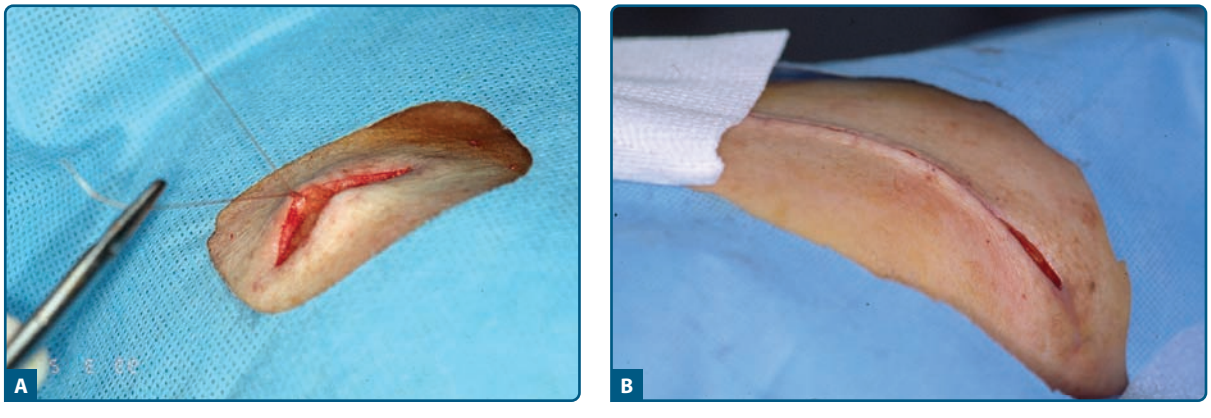

Figure 243-7 **A** and **B.** Tying deep sutures. It is important to keep the knot forming from the two free ends on the same side of the loop in the middle so they do not get hung up on the loop. This will allow the knot to cinch up under the loop and draw the wound edges together. The wound should be together with skin edges nicely opposed and everted.

EXCISION WITHOUT CLOSURE

There are certain locations and situations where allowing a wound to heal by second intention is the preferred method of closure. Wounds in patients who are poor surgical risks for reconstructive surgery, where there is relatively minimal tissue mobility (scalp, distal lower extremities), and where there is a high risk of infection healing by second intention may be indicated. (eFig. 243-7.1 in online edition).

Wounds located in concave areas such as the medial canthus, ear concha, alar crease (if small), temple region, and postauricular sulcus lend themselves well to healing by second intention.[19] Wounds allowed to heal by second intention contract significantly and may decrease in size as much as 50% or more.[20] Superficial wounds heal with less wound contraction, because there is less deposition of collagen. Therefore, a very superficial wound, even on a convex surface such as the forehead or the nose, can potentially heal well. Because all wounds contract to some degree, it is important that there be no free margin along one side of the wound that can be elevated during wound contracture and cause distortion at the site. This may be encountered along the eyelid margins, ear margins, eyebrow, nasal ala, and lip vermillion border. These areas are almost always better managed with appropriate reconstructive surgery.

When a lesion is excised with the intention of allowing the wound to heal by second intention, appropriate margins should be included and the resulting defect will typically be circular in nature. The incision through the skin is beveled inward to provide exposure of the base of the wound. The depth need not reach the subcutaneous fat if the lesion can be removed satisfactorily by transecting the dermis.

Wounds that are allowed to granulate are more resistant to infection and do not form a hematoma. In addition, the size of the final scar is kept to a minimum by negating the need to remove standing cones. These wounds, however, require more time to heal than those that are closed primarily and exhibit increased contracture. In some cases there is an unpredictable cosmetic result.[20] Employing a purse string suture can significantly decrease the size of the wound and abbreviate the healing time considerably.

REVISION OF STANDING CONES OF TISSUE

Under certain circumstances, a circular excision may be performed when the orientation of the ellipse is difficult to anticipate. This may occur when the precise direction of relaxed skin tension lines and least tension is difficult to determine, when the length of the ellipse for an optimal outcome is unclear, or when alternative repairs may be considered, such as a local flap. Nonelliptical defects require revision of the cones or dog-ears. First, the wound is closed with a few centrally placed sutures; bilateral standing cones of excess tissue form on either side of the central closure. In addition, tissue redundancies may persist at one or both ends of a planned fusiform excision if the apical angle is too wide, if the sides are of unequal lengths, or on convex surfaces and the techniques for addressing these redundancies are similar under both clinical circumstances [21] Skillful repair of the redundant standing cones extend the incision line by removing an additional triangle of tissue at the tip (Fig. 243-8). The apex of the standing cone is lifted with forceps or

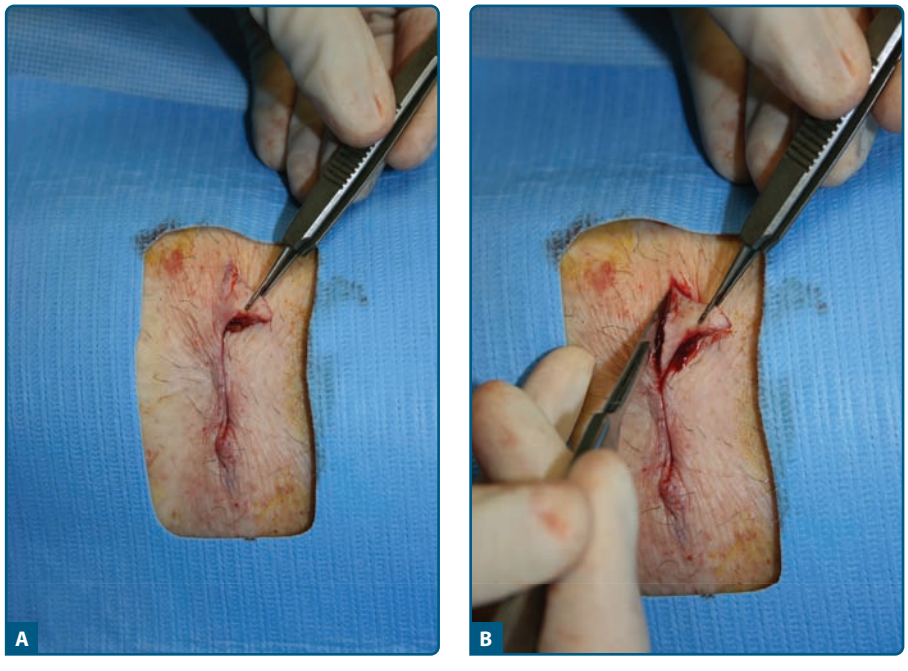

Figure 243-8 **A** and **B.** Standing cones. Redundant tissue may be removed by incising one side, draping the excess skin over the wound, and excising the resultant triangle.



Figure 243-9 **A–C.** S-plasty closures are often used to give a wound a curvilinear line and to alter the tension vectors so they do not all pull along the long axis of the wound and cause noticeable contraction. The S-plasty is especially useful on convex surfaces where wound contraction may cause the scar to sink down and appear depressed.

a skin hook and manipulated to determine where to place the incision that releases the redundant tissue. The incision is made with a scalpel and the dog-ear is undermined. The free end of the cone is pulled over the incision and the remaining incision is made such that the resultant wound edges lie flat.[22] The freed cone is termed a *Burow's triangle*. This technique results in a linear extension of the scar. Variations on the revision of tissue cones include a curved extension, an angled extension, and an M-plasty.

VARIATIONS OF THE ELLIPSE

CURVED ELLIPSE. The classic fusiform excision creates a linear scar. At times, it is aesthetically preferable to create a curvilinear scar. The curvilinear repair is useful on the cheek and around the chin. The curved ellipse is created by intentionally designing it with one side longer than the other. The wound is closed by the rule of halves.

S-PLASTY. An S-shaped repair is useful on convex surfaces such as the extremities where a linear repair may result in persistent standing cones or indentations. The tension vectors of a standard elliptical incision are perpendicular to the long axis of the ellipse. Since wounds contract along their long axis, designing the closure with an S-plasty, displaces the tension over a greater length and a variety of angles (Fig. 243-9) and does not create a contracting in one direction with resulting indentation over a convex surface such as an extremity.

M-PLASTY. An M-plasty allows the length of a scar to be shortened. Rather than extending the end of an ellipse or removing a Burow's triangle, the redundant tissue may be excised inward, forming a M-shaped scar. The long axis of the incision is reduced by the length equivalent to the inverted triangle which makes the center of the M. This technique is useful for confining a scar to a single cosmetic unit, that is, the chin, or when an incision approaches a free margin. The scar may be camouflaged in locations where rhytides bifurcate, such as the crow's feet in the periorbital area or around the lips. It is important to advance the inverted triangle up into the rest of the ellipse to take full advantage of the scar-shortening effect.

PARTIAL CLOSURE. Partial closure is used when more extensive repairs are limited by lack of local tissue reservoirs or the patient's health or coagulation status. The wound is closed from the ends toward the

center. When wound tension prevents further closure, the area remains open to heal by second intention. The final scar is usually linear and may resemble a spread scar in the middle. Alternatively, a purse-sting suture is placed around the wound and tissue is drawn together circumferentially. The purse-string suture is closed just to the point of minimal tissue buckling. Additional guiding sutures may then be placed across the partially closed wound to attain better alignment and even further closure.

SERIAL EXCISION. In some cases, the length of an ellipse required to excise a lesion with a 3 or 4:1 ratio is too long for an acceptable cosmetic or functional outcome. In such instances, the lesion may be removed with a series of staged excisions. A partial excision is performed, ideally an ellipse that accommodates the full length of the lesion, with primary linear closure. During the following months, the surrounding tissue stretches and the tension in the area decreases. Additional excisions are performed in a similar manner, removing the remaining lesion as well as the scar or scars created from the first steps of the procedure. This is typically used to minimize the length of the final scar in large circumference neoplasms that are benign or low risk.

FLAPS

When simple primary closure cannot be done because a wound is too large, there is excessive tension, or an unacceptable functional or cosmetic result would ensue from a linear scar, a tissue-movement procedure, such as a flap or a graft, should be considered. A local skin flap is a portion of full-thickness skin and subcutaneous tissue transferred from an adjacent donor site into the surgical defect. The flap maintains its blood supply via a vascular pedicle that remains connected to the donor site.

Random pattern flaps, the most widely used in dermatologic surgery, are supported by the small arterioles and capillaries of the subdermal vascular plexus found in the mid-to-superficial fat. Therefore, undermining and flap mobilization must be done at or below this level to ensure adequate blood supply. If undermining occurs too superficially, the intradermal vaculature alone will often not be able to support a flap. In certain areas other than the face, the perfusion pressure of even the subdermal vascular plexus is often not sufficient to support a random pattern flap. Fortunately, the blood supply of the face is rich, estimated to be ten times greater than necessary to support the skin's basic metabolic needs so it can support a wide variety of random pattern flaps.

The vascular perfusion pressure, that is the force of blood flow through a vessel, is greatest at the proximal end of a vessel and decreases steadily as it travels more distal into the flap. To ensure flap survival, the perfusion pressure must be great enough to keep the distal capillaries of the flap open. If the pressure falls below a certain critical level, the capillaries close and insufficient blood is supplied to the distal end of the flap.

For years, it was believed that the viable length of a flap was directly proportional to the width of the pedicle. In 1970, Milton discovered that axial flaps in a pig model under the same conditions of blood supply survive only to a finite length regardless of width.[23] Daniel and Williams, as well as Stell confirmed Milton's findings and concluded that there was an upper limit of flap length that cannot be increased by increasing the pedicle width.[24,25] The maximal flap length is determined by vascular supply, not simply pedicle width. The greater the perfusion pressure in the flap pedicle, the longer the flap can be without undergoing necrosis.[26] In addition, the greater the perfusion pressure in the pedicle, the narrower the pedicle may be. Axial pattern flaps have the highest perfusion pressure at the base and therefore can support very narrow long flaps (generally greater than 4:1 length to width ratio). Musculocutaneous flaps have the next greatest vascular perfusion pressure, followed by fasciocutaneous flaps, and finally random pattern flaps. Stell discovered the greatest length of a viable axial flap was 60% greater than that of a random pattern flap. In general, random pattern flaps on the face should have a maximal length to width ratio of 3:1.[27,28] This is however only a rough guideline and individual patient characteristics such as tobacco use, sebaceous nature of skin, prior radiation or surgical procedures, and precise location all affect vascular perfusion. To help ensure flap survival the pedicle length-to-width ratios should not exceed 2:1 on the trunk and extremities.

The two movements involved in repairing a defect with a flap are the primary movement, which is the action of placing the flap into the defect and the secondary movement of tissue in the donor area, which closes the secondary defect and facilitates primary flap movement. Both movements are important in terms of distributing tension in the proper direction and over a larger area so as to minimize tension on the flap itself, which might compromise its survival.[29] Flaps are commonly classified according to their primary movement—advancement flaps, rotation flaps, transposition flaps, and interpolation flaps. This classification underplays the reality that many flaps have more than one primary movement, e.g., a rotation flap usually has a component of advancement to fill the distal portion of a wound. Therefore, another way to classify flaps is by whether the primary movement is sliding, which displaces tissue redundancy at a site distant from the defect (advancement and rotation) or lifting, where a flap is moved over intact skin, reorienting wound tension (transposition and interpolation).

As with elliptical excisions, the flap should be planned paying attention to the concepts discussed above, such as free margins, skin laxity, relaxed skin tension lines, cosmetic units, and attention to function. The flap and possible resultant Burow's triangles should be drawn out with a marking pen while the patient is in an upright position. It is advisable to plan the flap prior to administering anesthesia, as the injected volume may distort the tissue and alter its movement.

Flap incisions should be made perpendicular to the skin and the recipient wound edges should similarly be

squared off. The thickness of the flap should be uniform and should approximate the thickness of the wound edge. The area around the flap should be widely undermined.

ADVANCEMENT FLAPS

The primary movement of an advancement flap is the one-dimensional sliding of tissue directly into a defect. In essence, incisions are made tangentially to the defect to free up neighboring tissue. With the wound edge acting as the free margin of the flap, the tissue is advanced into place, displacing tissue cones. While some adjacent tissue laxity may be tapped into with an advancement flap, the tension vectors of the closure remain the same and therefore the primary advantage of an advancement flap is the displacement of closure lines into more cosmetically acceptable locations.

SINGLE ADVANCEMENT. The simplest example of a pure advancement flap is the U-plasty, whereby double, parallel incisions are made tangential to what is most often a round defect. The flap is undermined, advanced into the defect, and secured with sutures, creating a U-shaped scar (eFig. 243-9.1 in online edition). Redundant tissue cones may be sewn out using the rule of halves or removed as Burow's triangles at the base of the flap. While the U-plasty is occasionally used to make the majority of lines in the repair of a forehead defect run in the horizontal direction with the natural skin tension lines; the fact that it does not alter tension vectors and does not significantly free tissue up limits its usefulness.

An L-plasty or O-to-L advancement is a single tangent flap where an incision is made at one end of a defect extending outward for some length, and the tissue mobilized is then advanced into the defect (Fig. 243-10). Tissue redundancy is created on the side of the defect opposite the flap incision and must be removed. While this type of advancement flap may tap into some distant laxity, it is generally minimal. Advancement flaps also do not change the tension vectors of the closure. Advancement flaps spread the tension out over a longer distance and offer some of the closure line to be perpendicular to the vector of tension. O-to-L advancement flaps are particularly useful with defects where the limb of the flap may be incorporated into RSTLs or cosmetic unit junctions or where a linear closure may otherwise cross a free margin or cosmetic unit junction, as may be the case on the eyebrow, nose, or upper lip.

A larger single advancement flap is the cheek advancement flap, used to repair medium-to-large defects of the medial cheek and/or lateral nose (Fig. 243-11). The incision may be placed in the alar crease or nasolabial fold by removing tissue above and below the defect to allow the cheek to advance into the nasofacial sulcus. It is usually advantageous to tack the leading edge of a cheek advancement flap into periosteum at the nasal sidewall cheek junction, even if the defect is on the nasal sidewall. Tacking the flap to periosteum at the nasal sidewall cheek junction will take pressure off the leading edge and recreate the natural concave surface of the area and prevent unnatural webbing. When a defect involves both the cheek and the ala, a cheek advancement flap may be used to cover the defect on the cheek and a full-thickness skin graft may be used to repair the alar part of the defect (Fig. 243-12). This will keep the cosmetic units separate and place the scar lines along the cosmetic unit junctions.

Helical rim advancement flaps may be used to repair defects of the helix, utilizing the tissue laxity of the lobule. Traditionally, this flap was created with a through and through incision inferior to the defect along the scaphoid fossa, terminating in the lobule, and creating a narrow pedicle to be advanced (conceptually similar to the U-plasty). The survivability of this flap is

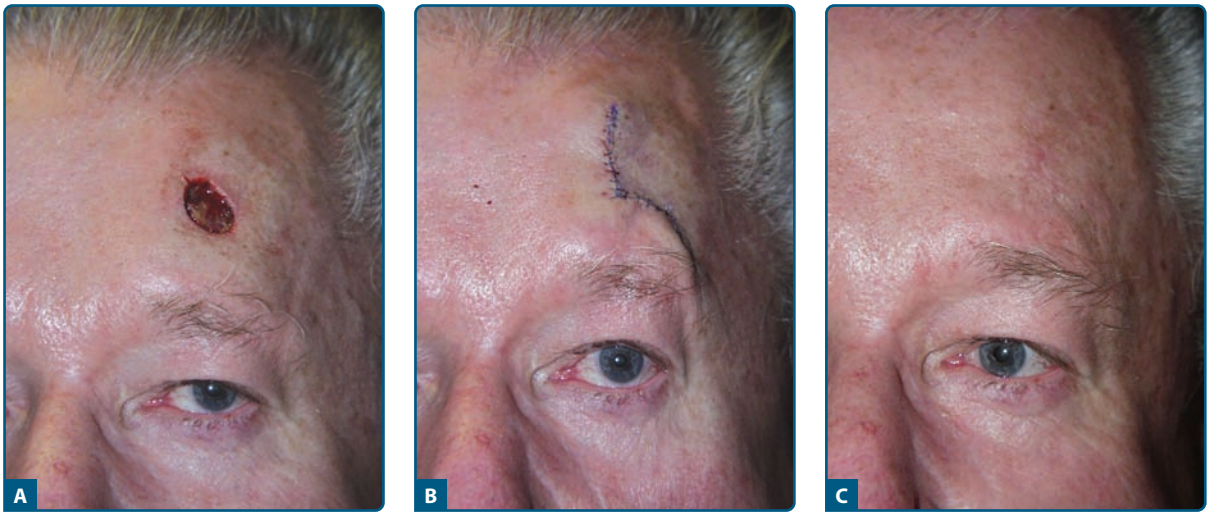

Figure 243-10 **A–C.** A to L advancement flap. Here, one line of the closure is drawn and incised perpendicular to the closure.

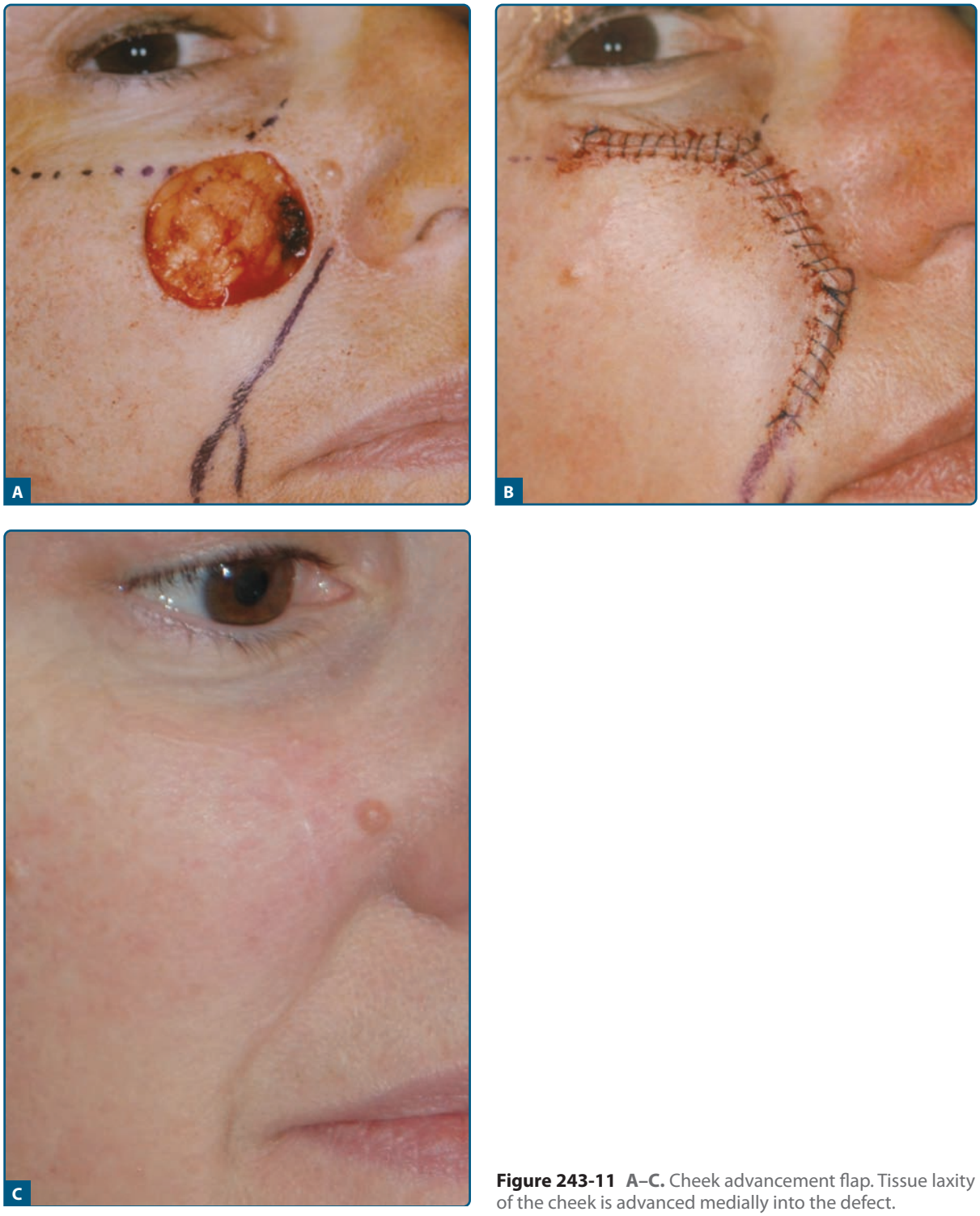

Figure 243-11 **A–C.** Cheek advancement flap. Tissue laxity of the cheek is advanced medially into the defect.

proportional to the length-to-width ratio and could only be performed on inferior helical defects where this ratio will not exceed 3–4:1. A more popular modification of this flap is to use a single tangent incision along the scaphoid fossa, leaving the posterior auricular skin intact[30] (conceptually analogous to the L-plasty) (Fig. 243-13). This allows for the maintenance of a more reliable blood supply via the tissue inferiorly and posteriorly and permits the repair of defects more distant from the lobule. It is important to have good eversion when closing this flap at the helical rim as forces of contraction during healing will tend to invert the wound edge and create an aesthetically unpleasant notch.

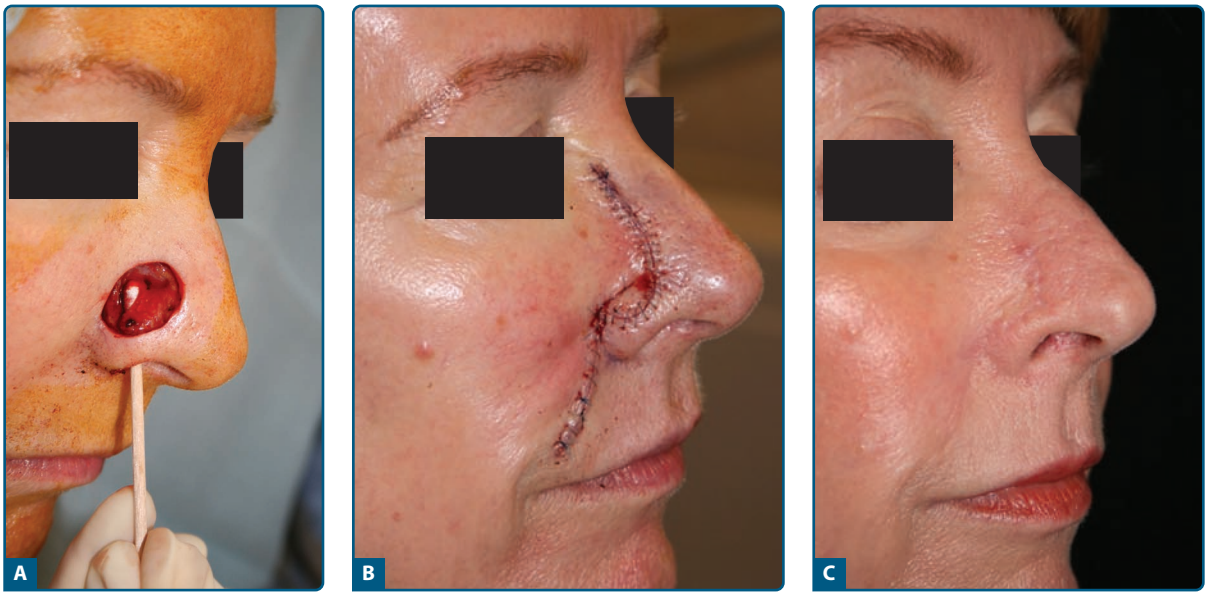

Figure 243-12 **A–C.** Cheek advancement flap with full-thickness skin graft. When the defect involves both the cheek and the ala, it is often best to utilize separate closures for each of the cosmetic units. Here a cheek advancement flap was used to close the part of the defect on the cheek, and a conchal bowl full-thickness skin graft was used to close the alar aspect of the defect.

BILATERAL ADVANCEMENT. If two sets of parallel incisions are made symmetrically on both edges of the defect, a bilateral advancement flap, termed an *H-plasty*, has been created. This flap is essentially a bilateral U-plasty and is occasionally used on the forehead and upper lip to hide incision lines along relaxed skin tension lines and cosmetic unit junctions.

Another commonly employed bilateral advancement flap is an O-to-T flap, also termed an *A-to-T* or a *T-plasty* (eFig. 243-13.1 in online edition), analogous to a bilateral L-plasty. This flap is essentially a bilateral O to L flap. The standing cone is removed from one end of the defect, creating a triangle, or transforming on "O" into an "A". Single incisions extend from the base of this triangular defect, and the two sides of the triangle slide together along this baseline. The T-plasty is best performed with the broad base along a free margin or cosmetic unit junction (e.g., lip, eyebrow).

CRESCENTIC ADVANCEMENT FLAP. The crescentic advancement flap utilizes the removal of small crescent of tissue along an advancement flap to either

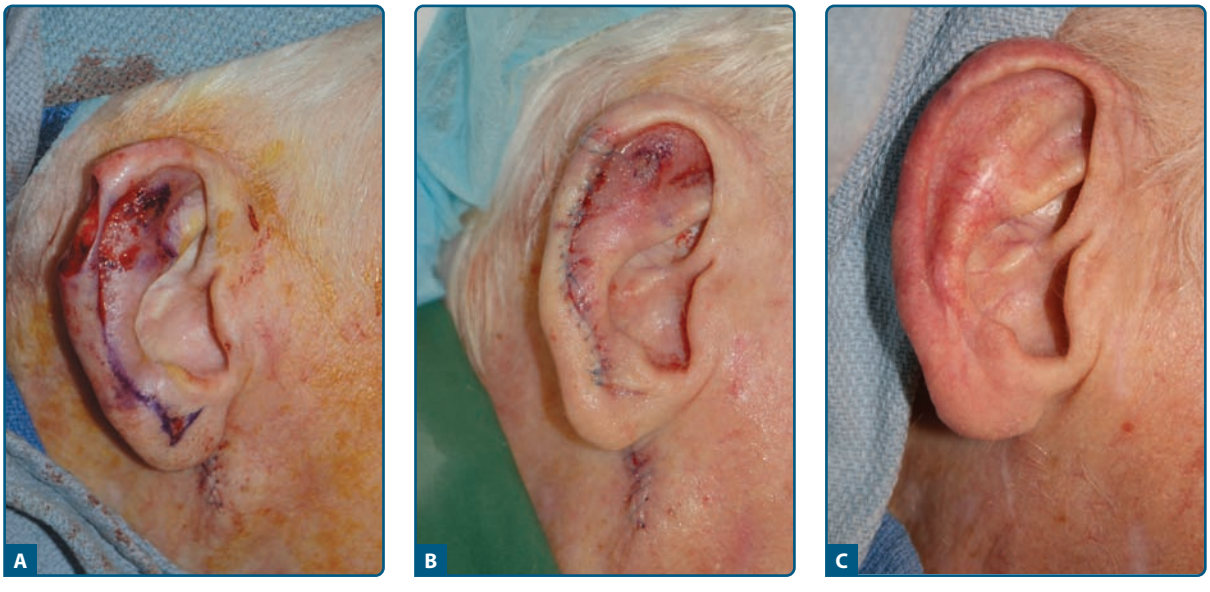

Figure 243-13 **A–C.** Helical rim advancement flap. An incision is made along the anterior helical rim down to the ear lobule. A "dog ear" is taken out on the posterior aspect of the ear. The helix is advanced superiorly to close the defect with everting sutures. This allows for consistent reconstruction of the helical rim.



Figure 243-14 **A–C.** Crescentic advancement flap. A crescent of tissue is removed around the lateral aspect of the ala and the cheek is advanced medially.

better hide the scar line or increase the length of the line to prevent distortion. This flap is particularly useful for the repair of upper lip and perialar defects. The superior standing cone is removed in a crescentic shape around the ala such that the superior scar line is placed in the perinasal sulcus (Fig. 243-14).[31] For defects on the upper cutaneous lip, the inferior cone is removed along relaxed skin tension lines and extended through the vermilion border and around to the wet mucosa to prevent a downward distortion of the vermilion. A modification of the crescentic advancement includes the repair of a small, perialar defect of the medial cheek where both cones are removed around the ala, and the entire scar line is placed in the nasal sulcus, similar to the cheek advancement. Another modification includes incorporating a crescent along the vermilion border to an advancement flap closing a defect just superior to the vermilion border. Removing a crescent here increases the length of flap and helps minimize the differences in length between the flap and the total length of the closure (flap + defect). This will take some of the horizontal tension off the flap and minimize distortion of the lip and modeolus (Fig. 243-15).

ISLAND PEDICLE FLAP. A subcutaneous island pedicle flap, also referred to as a V-to-Y advancement flap, may be considered as a variation of an advancement flap that has had all of its connections to the epidermis and dermis severed, maintaining its blood supply through a subcutaneous tissue pedicle (eFig. 243-15.1 in online edition).[32] The flap is designed

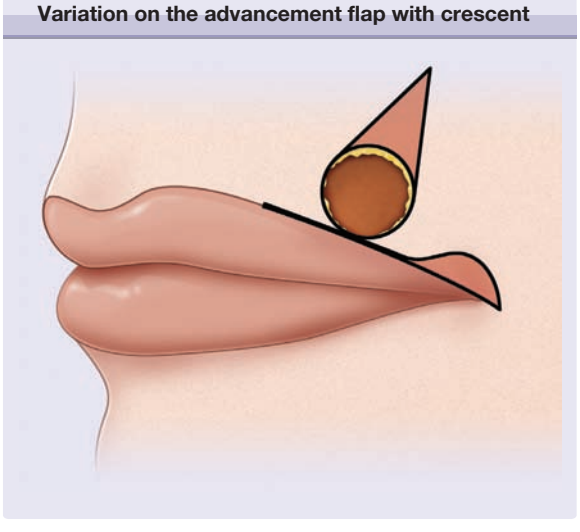

Figure 243-15 Variation on the advancement flap with crescent. Removing the crescent of tissue elongates the incision and compensates for the length mismatch of the incision vs. the incision + defect.

within cosmetic units when possible and, as with all repairs, it is optimal for the incision lines to run along cosmetic junctions. The island pedicle flap is frequently used on nasal and perioral closures where free margins are at risk for distortion. The tension vectors of an island pedicle flap are primarily in the same direction as that of a primary closure; however, they are displaced distal to the wound (i.e., superior to the nasal tip, superior or lateral to the vermilion border) and help avoid distortion of the area around the defect.

An island pedicle flap is created by extending two nonparallel tangential incisions to meet at an approximate 30° angle, similar to when planning a Burow's triangle. The difference is that the incision lines stay parallel for a short distance before converging, creating a slightly larger triangle than would be created with a Burow's triangle. This extra length gives tissue that closely approximates the size of the defect and minimizes local distortion. The triangle may be designed larger or smaller depending on how much tension sharing is desired. The incisions are made just to the superficial subcutaneous tissue. The tip and sides of the flap are undermined widely extending outward from the flap in the subcutaneous plane. The triangular flap is also undermined slightly to help mobilize it. The flap is then advanced into the defect and sutured into place. In order for the flap to fit properly into a circular defect, either the corners of the flap must be trimmed or the defect squared off. The flap must be undermined with attention both to the mobility of the tissue as well as to the maintenance of a subcutaneous vascular pedicle. While the initial design should have a broad pedicle, if mobility is limited the pedicle may be progressively diminished (particularly at the trailing tip of the flap).

When closing defects on the nasal dorsum and tip, a muscular flap is often created laterally on one or both sides. For this musculocutaneous island pedicle flap, undermining is performed both above and below the nasalis muscle. If there is not enough laxity to close the defect without upward tension on the nasal tip, the muscular flap is released horizontally at the superior and inferior edge to create a muscular sling that advances with the flap into place. The muscular attachment gives a robust blood supply to the flap and helps ensure its survival.

ROTATION FLAPS

In a rotation flap, skin moves into the defect by rotating around a pivot point (Fig. 243-16). This is classically used to close relatively large defects on the cheek, temple, or scalp. The design of the traditional rotation flap uses a curvilinear incision along an arc adjacent to the primary defect. Adjacent lax tissue is recruited while the closure tension is redirected in multiple directions away from the primary defect. The flap is designed with attention to its length and curvature.[33] Rotation flaps often require long incision lines, as a larger arc of the rotation vector allows closure with minimal tension on the flap's tip while simultaneously decreasing the width of the secondary defect. The ideal arc of a rotation flap extends up to five times the width of the defect and makes up approximately one quarter of the circumference of a circle.

As the flap is raised and undermined, the adjacent tissue laxity allows the flap to rotate into the primary defect. The stiffness about the pivot point may hinder the flap's movement,[33] and undermining the area of pivotal restraint improves flap mobility. If restraint of motion keeps the tip from moving into the distal defect, a back cut can increase tissue movement in areas of limited tissue laxity, such as the nose. The back cut cannot extend so far across the base of the flap that it interferes with blood flow into the flap.

DORSAL NASAL ROTATION FLAP.

Also known as the *Rieger flap*, this flap is employed to repair nasal defects involving the distal dorsum or tip.[34] The tissue

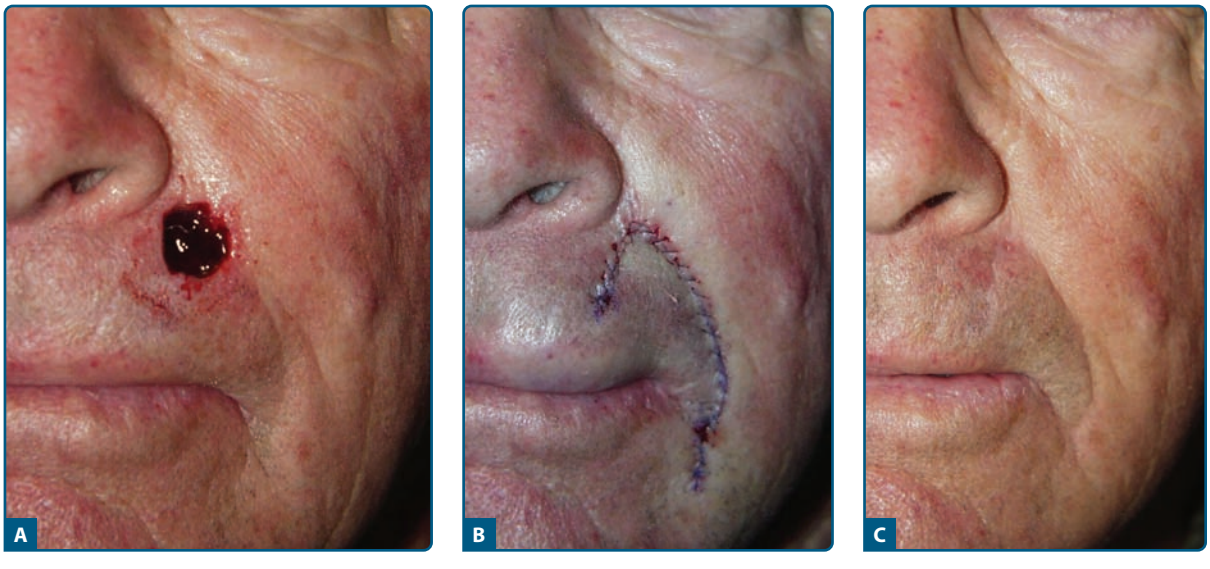

Figure 243-16 **A–C.** Rotation flap. An arcuate incision is made from one end of the defect and the flap is rotated into the defect. Rotation flaps help spread tension vectors out in multiple directions radiating from the arc.



Figure 243-17 **A–C.** Hatchet flap. The hatchet flap is a rotation flap with a cutback. The cutback gives the flap extra length and aides in its movement.

reservoir of the nasal root and glabella allows for the movement of the dorsal nasal skin superior to the defect. A long, sweeping arc is created that extends into the nasofacial sulcus and terminates in the glabella. A back cut in the glabella improves the rotational mobility of this flap and is termed a *hatchet flap* (Fig. 243-17). If the arc of this flap is not long enough or there is too much tension on the leading edge of the flap, elevation of the nasal tip will result. Wide undermining at the level of the perichondrium is required.

BILATERAL ROTATION FLAP. At times, the size of the defect or the tension on the flap mandates a bilateral rotation flap, in which tissue is rotated into a defect from two opposite sides. The vectors of rotation may be mirror images of each other, recapitulating the premise of the A–T advancement flap. This may be utilized for large defects on the scalp and larger defects on the lower lip (Fig. 243-18). The vectors of movement may also be in opposition, creating an O-to-Z flap.

TRANSPOSITION FLAPS

A transposition flap is a random pattern flap, which borrows skin laxity from an adjacent area in order to fill a defect in an area with little or no skin laxity. In its travel from the donor site to the recipient site, the flap



Figure 243-18 **A–C.** Bilateral rotation flap of the lip. Incisions are made bilaterally along the vermillion border and a redundant tricone of tissue is removed posteriorly into the wet mucosal lip. Both wings of the flap are rotated together and sutured with braided suture.

is lifted or "transposed" over a segment of intervening tissue. When the secondary defect is closed, the transposition flap pushes tissue into a defect rather than pulling it, as with the advancement and rotation flaps. While moving to the recipient site, the flap actually follows a rotational path and must be designed so it does not rotate too far and pull too tightly on its pedicle.

Transposition flaps have several advantages over other closures. Their primary function is to redistribute and redirect tension. This is useful in the closure of defects, which would otherwise close under high tension or distort a nearby anatomical structure leading to functional or aesthetic impairment. Transposition flaps are usually smaller in size than advancement and rotation flaps. The resulting scars are geometric broken lines that may be less noticeable than longer linear closures in certain areas. This geometric broken line scar, however, may also be thought of as a disadvantage because such a scar is difficult to completely place along a relaxed skin tension line or cosmetic unit junction. One of the major advantages of transposition flaps are that they utilize adjacent skin and provide an excellent color and textural match.

The most common transposition flaps in cutaneous surgery include rhombic flaps (and their variations), bilobed flaps, and banner flaps such as the nasolabial flap. Knowledge of the tissue dynamics used in these three basic transposition flaps can be carried over to the planning and execution of the numerous variations of these flaps.

RHOMBIC FLAP. First described by Lindberg in 1963, the classic rhombic flap was designed to create a secondary defect perpendicular to the primary defect.[35] When closed, it would not only provide tissue to the primary defect, but also redirect the tension vector by 90°. This allowed the primary defect to be closed under almost no wound edge tension. Subsequent modifications by DuFourmental and Webster provide more tension sharing between the primary and secondary defects. These modifications are useful in situations where some laxity around the primary defect is available.[36]

The classic Lindberg rhombic flap is designed by conversion of the primary defect into a four-sided parallelogram with each side of equal length and tip angles of 60° and 120°.[35] This rhombus forms the recipient site for the flap as well as the template on which to plan the flap incisions. In its classic configuration (Fig. 243-19), the incisions are designed by extending a line (line a-b) outward from one of the obtuse tips for a length equal to that of one side of the rhombus. From the free end of the extended line (point b), a second line (line b-c) is drawn. The tip angle in this configuration is 60°. The flap is lifted and transposed into place. The tension vector is redirected from that of closing the primary defect, to that of closing the new secondary defect created in the design of the flap. This allows the tension vector to be shifted and redirected by 90°.

There are four possible flap designs off of the short axis of any rhomboid defect (Fig. 243-20). Which of these four flap configurations is selected depends on

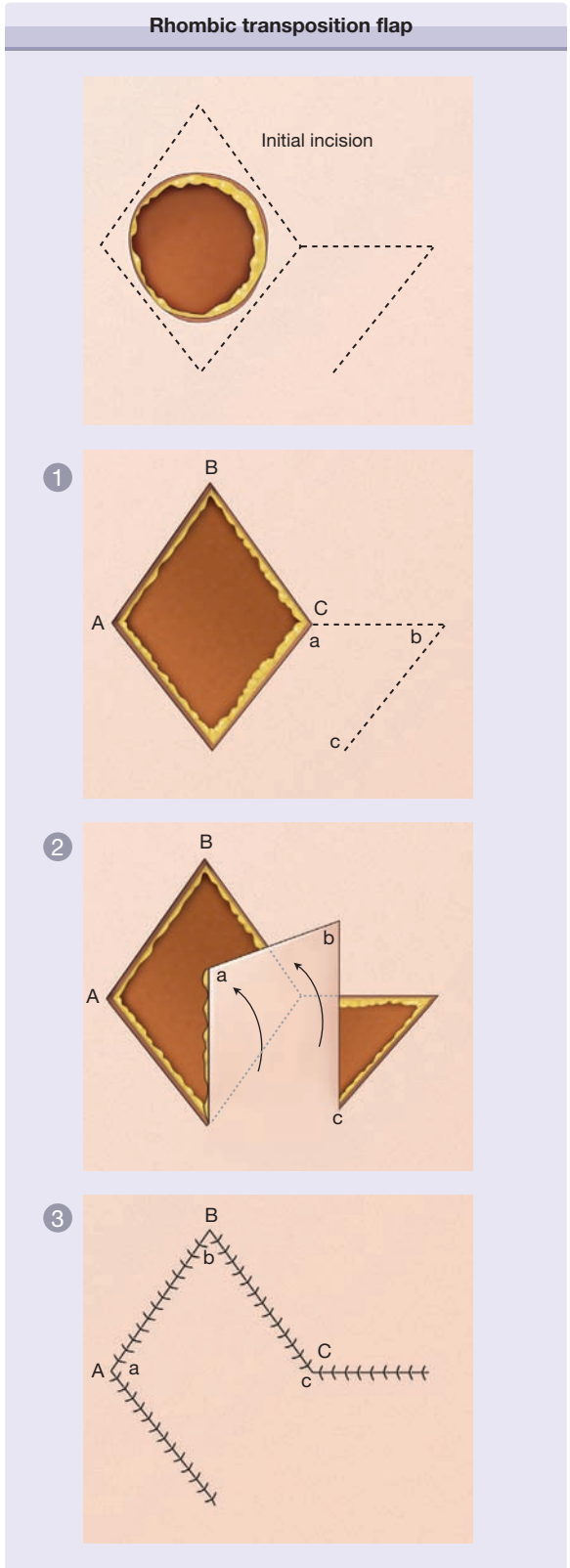

Figure 243-19 Rhombic transposition flap. Classic rhombic flaps alter the vectors of tension in a closure by 90° and leave a broken geometric scar shape. The tension is taken completely by the closure of the secondary defect as the flap is pushed into the primary defect.

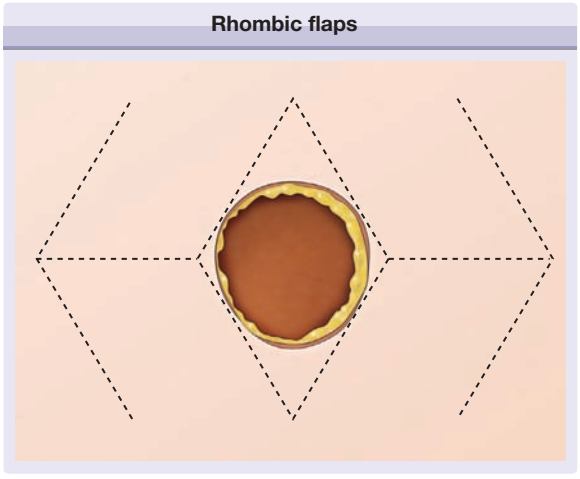

Figure 243-20 Rhombic flaps may be drawn in any of four directions off of the short axis of any rhomboid shaped defect.

several factors that affect the final outcome. These factors include adjacent anatomic structures, adjacent skin type, and where the scar line will be best hidden. Though the classic rhombic transposition flap can be designed and executed off of the long axis of the rhombus, there are two advantages to designing it off of the short axis of the defect. First, it keeps the flap as small as possible while filling the defect completely. Second, it minimizes the arc through which the flap must rotate to fit into the defect.

In designing the flap from the circular defect, the length of the line extended out from the defect should be drawn longer than the diameter of the circular defect. This will account for the fact that the diameter of the circular defect is shorter than the short axis of a rhombus drawn around the defect. A second line of the same length is drawn, keeping the tip angle at 60° to complete the flap. The triangle of tissue redundancy created by the rotation of the transposition flap is removed by trimming a Burow's triangle at the pivot point. The transposed tissue may be rounded to fit the circular defect, or the defect may be squared off to accommodate the angular flap. This choice can be made based upon which option yields the best aesthetic result.

As with any closure, understanding the tension forces is essential to the planning, execution, and outcome of the repair. There are two main tension forces associated with the classic rhombic flap. The first set of tension forces are realized during the approximation and closure of the secondary defect. The second set of tension forces are generated at the tip of the flap when moving it into the primary defect. These forces are due to the resistance to rotation at the flap's pedicle as well as shortening of the length of the flap during rotation into the recipient site. Dzubow describes these forces as pivotal restraint.[33] Securing the flap into the recipient site under high tension is not advised because it may lead to tip ischemia and necrosis. Two modifications in design can be utilized to assist in minimizing the shortening of the flap and subsequent tension at the flap tip.

- By lengthening both the leading edge and the secondary limb of the flap, the flap can be enlarged and lengthened. This lengthening can compensate for the shortening resulting from pivoting at the base, thus, reducing tension at the tip when secured in the recipient defect.
- An alternate method to lengthen the flap is by designing the flap with a slightly more obtuse (greater than 120°) flap angle. Widely undermining around the flap also assists in the redistribution of tension vectors as well as redistribution of contractile forces during the healing phase.

THE DUFOURNMENTAL FLAP.

The DuFournmental flap modification differs from the classic rhombic transposition flap (Fig. 243-21) in that it utilizes a narrower flap tip angle and a shorter arc of rotation, allowing easier closure of the secondary defect, and some sharing of the tension between the primary and secondary defects. Given that there is generally some tissue laxity at the site of the surgical defect, the DuFournmental modification is utilized by this author more than any of the classic rhombic flap.

As with the classic rhombic flap, it is designed by extending the first line from the short axis of the rhomboid defect. However, the angle at which the first line is extended differs from the classic rhombic flap in that it bisects the angle formed by the first line of the classic rhombic flap (which extends straight out from the short axis of the rhombic defect) and the line formed by extending one of the sides of the rhombus from the same corner of the rhombus. The length of the first line is equal to that of a side length of the rhombus. The second line originates from the free end of the first

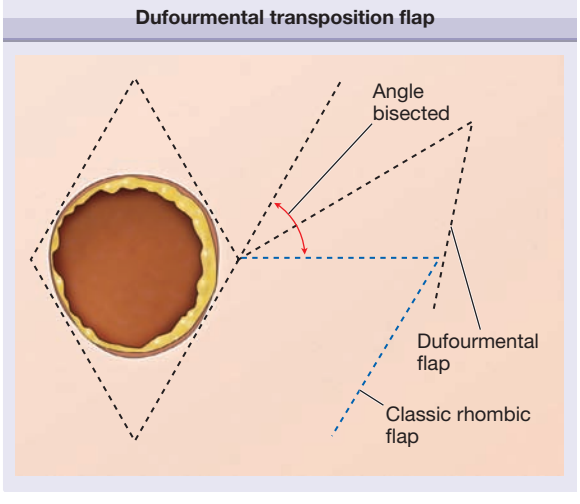

Figure 243-21 DuFourmental transposition flap. The flap is designed with a narrower tip angle and a shorter arc of rotation. This allows easier closure of the secondary defect and allows some sharing of tension between the primary and secondary defects. The vectors of tension are altered by 45° not the full 90° seen in a classic rhombic flap.

line, and is drawn parallel to the long axis of the rhombus. This second line's orientation results in a slightly widened pedicle, a decrease in the tip volume, and a decrease in the degree of rotation necessary to execute the flap. The tissue redundancy at the base of the leading edge of the flap can be removed by taking a slightly larger Burow's triangle.

THE 30° ANGLE WEBSTER FLAP. The 30° angle Webster modification of the classic rhombic flap utilizes a more acute angle than other rhombic transposition flaps allowing for even greater tension sharing between the primary and secondary defects. A Webster 30° angle flap is planned similarly to the DuFourmental flap; however, its distal tip angle is designed to be 30° (Fig. 243-22). This gives the flap a slimmer design and narrower pedicle. The flap area is only 50% of the area of the primary defect; therefore, it only relieves half of the tension from the primary defect. This modification is used in situations where a fair amount of laxity exists in the horizontal axis of the rhombic shaped defect. Since this design places more tension on the primary defect, care must be taken not to close with too much lateral tension or distort adjacent anatomic structures.

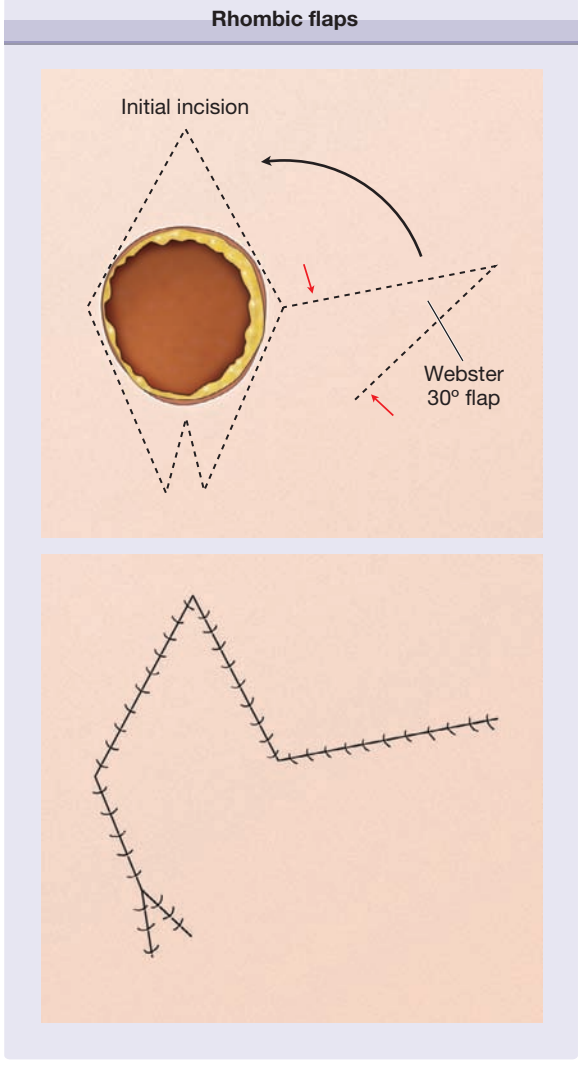

Figure 243-22 30° Webster flap. The angle of the rhombic flap is made even more acute and more of the closure tension is shared with the primary defect.

Rhombic transposition flaps are very versatile and may be used to reconstruct a variety of defects. Transposition flaps are generally used when there is insufficient laxity in the immediate surrounding area of closure and/or the tension vectors need to be redirected. This is particularly important when repairing defects near free margins such as the eyelids and the nose. The most common areas they are employed include the nasal dorsum, nasal sidewall, medial and lateral canthus, lateral forehead, temple, cheek, perioral region, inferior chin, and the dorsal hand.

THE BANNER FLAP. Banner type flaps are random pattern finger-shaped cutaneous flaps that, like other transposition flaps, tap into adjacent skin to borrow laxity and fill a defect.[37] This flap is most commonly planned as a melolabial transposition to repair defects of the nasal ala or from the pre- or postauricular area to close defects on the ear. For an optimal cosmetic result, the scar is generally placed at the junction of two cosmetic units, providing excellent camouflage (in the nasolabial fold or preauricular sulcus) (Fig. 243-23).

The fundamental design of the banner flaps consist of a finger-shaped flap drawn with a width that is equal to the width of the defect and a length equal to the distance from the pivot point to the far edge of the defect. The flap is transposed and rotated in an arc around the pivot point to fill the defect. Since this is a long random pattern flap with a narrow pedicle, the risk of vascular compromise may be high if the entire length of the flap is used and its pedicle originates from an area of minimal vascularity. To minimize risk of vascular compromise, the flap is typically designed to rotate through an angle of 60 to 120° instead of the originally described 180°. Additionally, when designing the backcut and removing the redundancy at the base of the flap, it should be designed in a direction away from the pedicle of the flap to avoid further narrowing of the pedicle thereby maximizing flap viability. Typical locations for use of Banner type flaps include the nasal ala, the superior helix of the ear, and the medial anterior ear.

BILOBED FLAP. The bilobed flap used today is a highly evolved transposition flap. The bilobed flap was first described by Esser in 1918. It became a workhorse flap only after the modifications described by Zitelli were published in 1989 (Fig. 243-24). The design of the bilobed flap actually consists of two transposition flaps executed in succession, which follow the same direction of rotation over intervening tissues. The basic premise of this flap is to fill the defect with the primary lobe, while filling the secondary defect with the secondary lobe, leaving a triangle-shaped tertiary defect to be closed primarily. This series of transposition flaps allows the surgeon to further the reach of the flap, and borrow laxity from donor sites at a greater distance from the defect while decreasing the arc of rotation of the pedicle.



Figure 243-23 **A–C.** Banner transposition flap. A finger-shaped flap is incised and draped into the primary defect. These closure lines are generally placed along cosmetic unit junctions such as the preauricular sulcus.

The Zitelli modification of the bilobed flap is designed by placing the lobes over a 90° arc from the center of the defect, with the primary lobe rotating from a pivot point that is created by removing a Burow's triangle at one pole of the defect .[38] The width of the primary lobe should be equal to the width of the defect and should be long enough to just extend past the edge of the defect. The secondary lobe must be trimmed to match the secondary defect left by the transposition of the primary lobe.

As with the rhombic flap, the bilobed flap redirects the principal tension vector and takes advantage of tissue laxity of the donor site. This flap is predominantly used for small-to-medium sized defects of the lower nose as the tension is redirected to a near vertical vector, preventing distortion of the alar rim (eFig. 243-24.1 in online edition, Fig. 243-25).

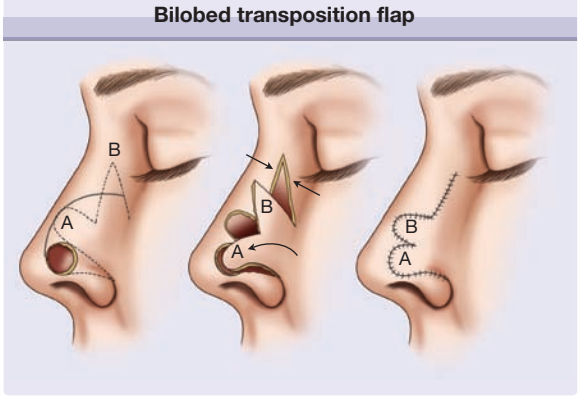

Figure 243-24 Bilobed transposition flap. The bilobed flap is designed with two adjacent transposition flaps elevated and rotated into position. The Zitelli modification (shown here) is designed placing the lobes over a 90° arc.

INTERPOLATION FLAPS

Interpolation flaps are more complex repairs that import pedicle-based tissue from a site distant to the defect. They are typically utilized on defects that are either too wide or too deep to reconstruct with local flaps or grafts. Many interpolation flaps may be classified as axial flaps if their vascular pedicle is based on a large, named artery. They are also commonly referred to as staged flaps as more than one stage is required to complete the repair. Interpolation flaps require careful planning, substantial time in executing, and significant, albeit temporary, disfigurement of the patient.

The first stage of an interpolation flap involves the design and creation of the flap, including repair of the secondary defect. The flap is designed around a substantial artery and therefore is able to support a larger mass of tissue than random flaps. Because the flap is used to repair defects distant from the donor site, the vascular pedicle must temporarily be left in place to ensure adequate blood supply. The distal end of the flap is thinned to match the depth of the defect and sutured in place. The area is bandaged and kept moist. The second stage generally takes place 2- to 3-weeks later, by which time the flap has established a local blood supply from the donor site. The pedicle is then divided from the donor site and the proximal portion of the flap is secured into the original defect. Due to granulation tissue formation, this portion of the flap may need to be thinned out subcutaneously to approximate the depth of the defect. The pedicle is also separated from the donor site which will then require further steps for complete repair.

PARAMEDIAN FOREHEAD FLAP. The paramedian forehead flap is useful to repair large, deep nasal defects that may or may not require cartilage grafts. Tissue is mobilized from the forehead, based on one

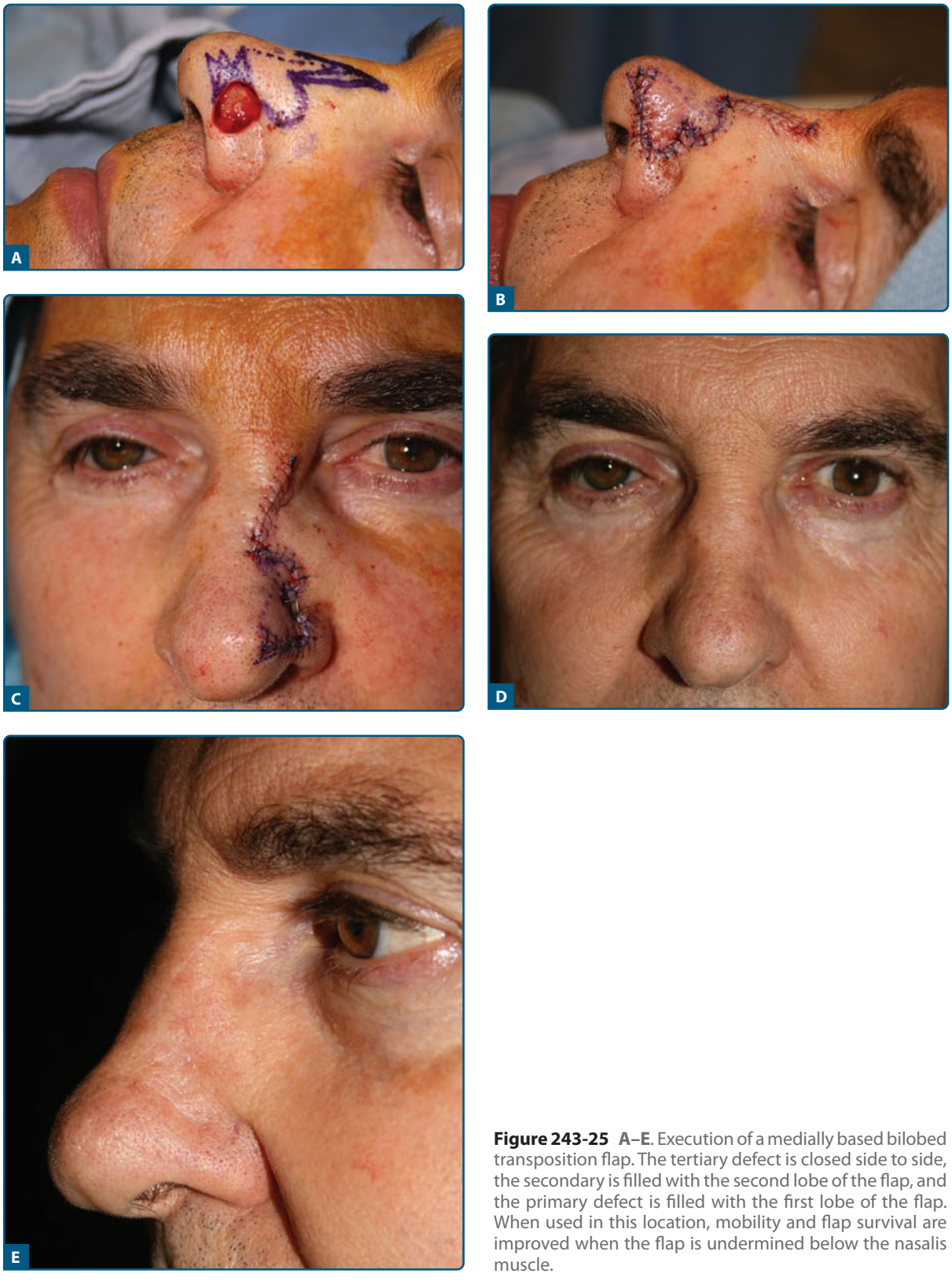

Figure 243-25 **A–E.** Execution of a medially based bilobed transposition flap. The tertiary defect is closed side to side, the secondary is filled with the second lobe of the flap, and the primary defect is filled with the first lobe of the flap. When used in this location, mobility and flap survival are improved when the flap is undermined below the nasalis muscle.

of the supratrochlear arteries, and transposed to repair large distal nasal defects with the pedicle remaining attached in the glabellar region (Fig. 243-26). The supratrochlear artery is located at the medial border of the eyebrow, approximately 1.5–2 cm from the midline.

The aesthetics of the repair are often improved when the defect is enlarged to include the total cosmetic subunit. The portion of the flap that will fill the defect is the superior portion closest to the hairline; the width here should be equal to the widest portion of the defect, although the pedicle itself need be no wider than 1–1.5 cm. Its height must be equal to the distance from the base of the flap to the distal edge of the defect. In designing the flap, it is important that the vertical height of the forehead is able to accommodate the necessary length of the flap. The tissue is rotated approximately 180° around its pedicle and should be rotated medially as to minimize obscuration of the medial visual field of the ipsilateral eye; therefore, the flap will require less rotation if it is harvested from the forehead supplied by the supratrochlear artery contralateral to the defect.

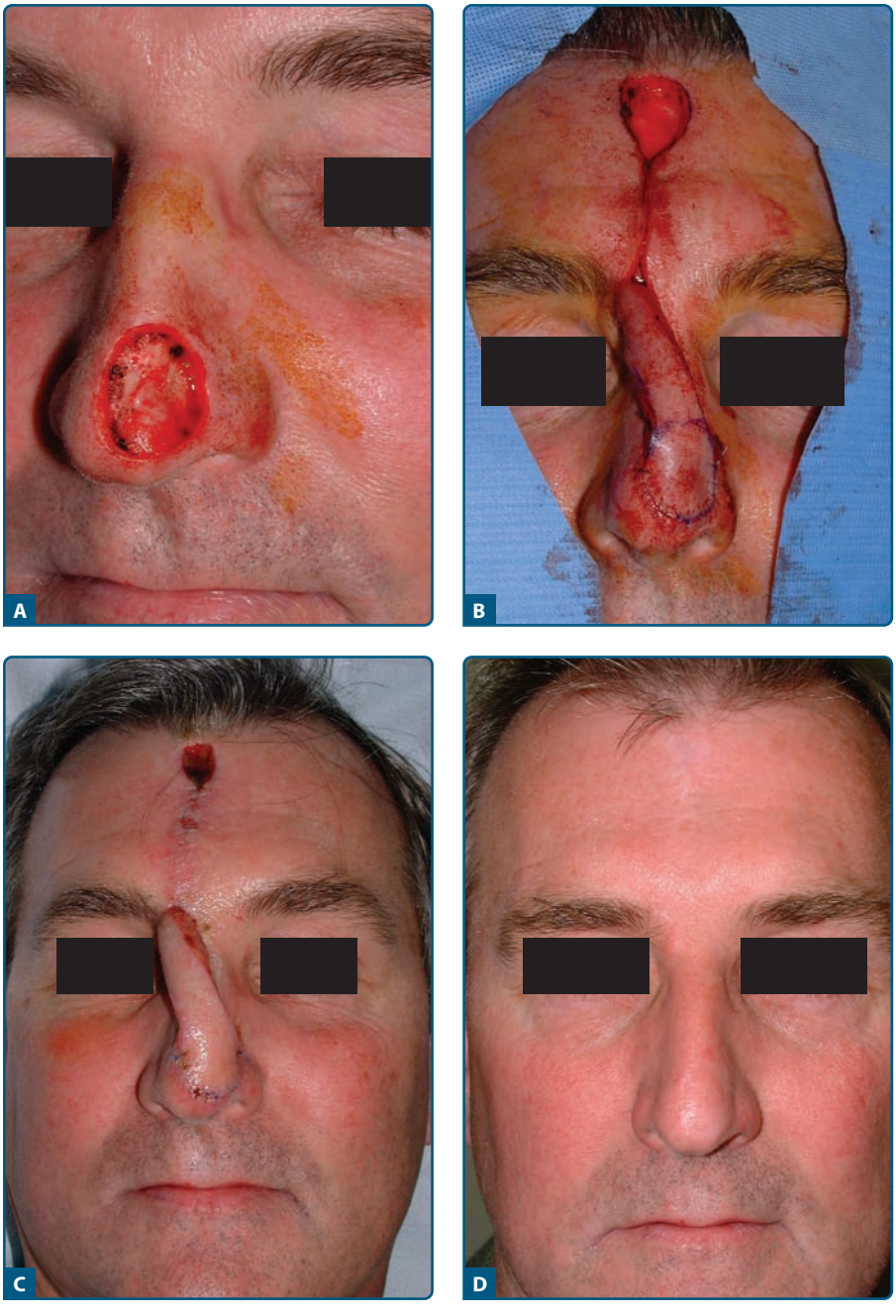

Figure 243-26 **A–D.** Paramedian forehead flap. For deep defects on the nose, a pedicled flap is created on the forehead based on the hearty vasculature of the supratrochlear arterial system and rotated down into place. The pedicle is divided and removed approximately 3 weeks after the inset of the flap (c).



Figure 243-27 **A–D.** Nasolabial interpolation flap. The pedicle is created from excess skin lateral to the nasomelial fold and rotated into the defect. The pedicle is divided and removed approximately 3 weeks after the inset of the flap (c).

The donor site is undermined and closed primarily as far superiorly as it will close. The distal aspect of the flap is debulked to the depth of the defect and secured at the distal margin with sutures. The proximal margin, by design, cannot be secured until the pedicle is divided. The donor site is repaired with a side-to-side closure, resulting in a long linear scar. The superior portion of the defect will be the widest, as it is here that the width of the defect must be accommodated, and thus, generally this portion of the wound is too tight to be closed and is left to heal by secondary intention. The pedicle should be circumferentially wrapped with Vaseline or Xeroform gauze or Surgicel to prevent desiccation.

The second stage takes place 3 weeks subsequently. The pedicle is separated from the brow, the wound edges are freshened, and the donor defect is closed. After the pedicle is separated from the defect, the tissue is further debulked and trimmed, and the remaining edge is secured.

NASOLABIAL INTERPOLATION FLAP.

This flap is utilized to repair complex defects of the ala, particularly in instances when cartilage grafting is also required to restore the structural integrity of the alar rim. The flap is harvested from the medial cheek and nasolabial fold and is based on branches of the angular artery (Fig. 243-27).

The aesthetics of the repair is often improved when the defect is enlarged to include the entire alar lobule. The flap is designed around a pedicle that will be placed at the alar groove, extending as an ellipse that will be easily closed in the nasolabial fold. Through-and-through nasal defects will require the repair of the mucosa, and thus, the width of the flap must take this into account. This myocutaneous flap is dissected from the donor site, rotated downwardly, debulked and trimmed, and secured to the widely undermined defect.

As with the paramedian forehead flap, the pedicle may be wrapped with Vaseline or Xeroform gauze or Surgicel. Three weeks later, the pedicle is separated, the wound edges are freshened, and the donor defect is closed. After the pedicle is separated from the defect, the tissue is further debulked and trimmed, and the remaining edge is secured.

The reverse nasolabial flap, also known as a *Spear's flap*, is employed when the defect involves the alar groove. The motion of this flap is an upward rotation,

opposite of the traditional nasolabial interpolation flap.

ABBÉ FLAP. The Abbé flap is also known as the *lip-switch flap* and is reserved for repair of large, deep defects, typically of the upper lip. It is particularly useful for defects that involve up to half of the lip without crossing the midline and those that penetrate into the muscularis. The Abbé flap is harvested from the ipsilateral lower lip and is based on the inferior labial artery. This artery is located deep to or within the orbicularis oris muscle and runs along the mucosal aspect of the vermillion border.[39]

The vermillion border and flap design must be properly marked out. The defect should be full thickness (including muscularis and oral mucosa) and may be enlarged to encompass the total cosmetic unit, which includes the ipsilateral upper cutaneous lip. The flap, also designed to be full-thickness to fill the enlarged defect, is rotated upon a vascular pedicle that makes up the lateral aspect of the flap. The inferior labial artery will be visualized as it is transected at the mobilized (medial) edge of the flap. The pedicle itself should be about 1 cm thick, containing the robust blood supply.

The donor site is undermined and closed first to facilitate the movement of the flap. It should be closed in layers as in the repair of a lip wedge resection: mucosa, muscularis, subcutaneous, then cutaneous. The flap is rotated superiorly and also inset with a layered closure. Careful attention should be given to aligning the vermillion borders at the donor site and defect.

The pedicle of the Abbé flap should not be circumferentially wrapped, but kept moist with occlusive ointment. As with other interpolation flaps, the pedicle will remain in place for at least 3 weeks. During this time, the oral aperture will be significantly distorted, and the patient must be counseled. The pedicle is divided and the final repair takes place, again with careful attention to the placement of the vermillion borders.

RETROAURICULAR FLAP. The retroauricular flap is a two-staged interpolation flap useful for large defects of the helix. Defects in this location typically involve the perichondrium and are not suitable for grafts. This flap is considered a random flap as it is not based on a large named artery. It is harvested from the richly vascularized skin of the postauricular scalp and is advanced over intervening intact skin to fill the helical defect; the pedicle remains attached to the posterior scalp (Fig. 243-28). The flap should be thinned to match the depth of the defect and carefully sewn into place. The pedicle is circumferentially dressed, and the patient is warned of likely postoperative bleeding and discomfort. The donor site is not repaired until pedicle take-down and often, due to its inconspicuous location, is allowed to heal secondarily.

GRAFTS

Skin grafts are transplanted skin from a donor to recipient site with the goal of closing a surgical defect or wound. They are typically used in reconstruction after removal of a cutaneous malignancy; however, they are also used in the treatment of chronic skin ulcerations, full-thickness burns, epidermolysis bullosa, and vitiligo. Grafts are completely detached from the donor site and receive all nutrients from the wound bed of the recipient site. The three basic types of skin grafts are full-thickness skin grafts (FTSG), split-thickness skin grafts (STSG), and composite grafts. FTSGs consist of epidermis with full-thickness dermis, while STSGs consist of epidermis with partial-thickness dermis. Composite grafts are full-thickness skin grafts with cartilage attached to the graft. Skin grafts are also categorized by their donor origin. These include autografts (donor = recipient), allografts (human to human), and xenografts (animal to human).

FULL-THICKNESS SKIN GRAFTS

FTSGs are useful for defects in which complex linear closures or a flap would not be suitable, where close monitoring of the site is advisable, and in certain areas where they provide optimal aesthetic reconstruction. When possible, FTSGs are chosen over STSGs because of their similarity in thickness and texture to surrounding skin and their relative lack of significant wound contraction. Since STSGs generally result in a depressed, hypopigmented, scar without normal epidermal texture, they are reserved for larger wounds that cannot be covered with FTSGs. When wounds are too deep for even a FTSG to cover without creating a depression (when the depth of the wound exceeds the thickness of a graft), second intension healing may be employed for a period of time to build the base of the wound up to the point where a FTSG would completely fill the defect.

FTSGs have essential nutrient requirements and, therefore, should not be placed at a site where the vascular supply is poor. FTSGs will not survive if transplanted directly over bone, cartilage, or tendon.

DETERMINING DONOR SITE. When planning your graft, there are many factors to be taken into consideration. The donor site should be well matched to the skin surrounding the defect in terms of thickness, texture, sun exposure, and adnexal structures.[40] Donor sites can be differentiated by thickness, for example, thin (eyelids, postauricular sulcus), medium thickness (preauricular, conchal, cervical), and thick (supraclavicular, clavicular, nasolabial fold, forehead).[41] However, examining for tissue similarity, such as adnexal structures and sun exposure, is also pertinent.

Common sites for FTSGs for nasal defects include preauricular, postauricular, nasolabial fold, forehead, and conchal bowl skin. Preauricular skin can be used to repair most nasal defects, has similar sun exposure and skin quality and heals with minimal scar visibility.[42,43] Conchal bowl grafts are particularly well matched for nasal tip and alar defects due to the similarity in texture and concentration of sebaceous glands

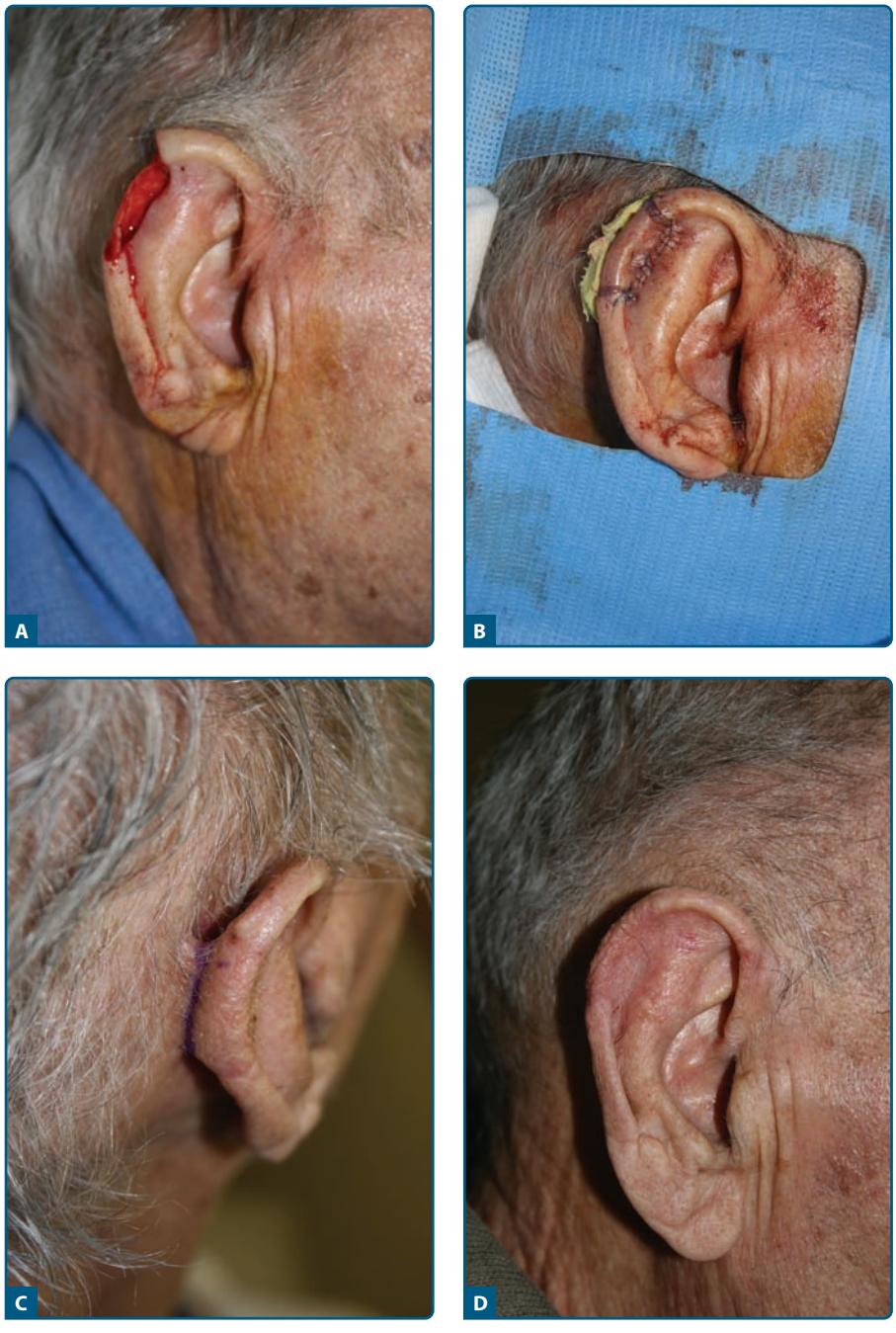

Figure 243-28 **A–D.** Retroauricular pedicle flap. A pedicled flap is developed posterior to the ear in a shape similar to the U-Shaped advancement flap. The flap is advanced over the postauricular sulcus and over the auricular cartilage of the helix and sutured into place. The pedicle is divided and set back into place 3 weeks after the inset of the flap (c). The area surrounding the postauricular sulcus is allowed to heal in by second intention.

(Fig. 243-29) as well as the ability to allow the donor site to heal by secondary intention.[44] Nasolabial fold and forehead skin offer excellent matches but leave secondary scars in more visible areas.

HARVESTING. Once the donor site has been established, the graft can be harvested. To ascertain the size and shape of the graft needed to fill a given defect, many surgeons will create a template using a nonstick dressing, pressing it against defect. The template is cut out and then traced with a marking pen onto the donor skin. Although some authors have recommended grafts be designed 3% to 5% larger than the defect to accommodate contraction of the graft skin once it is removed[45]; oversizing grafts can lead to unsightly pincushoining. For this reason, the authors size their grafts at or just under the size of the defect. If the donor site is to be closed primarily, an ellipse is planned around the designed graft (see Section "Excisional Surgery").



Figure 243-29 **A–D.** Conchal bowl full-thickness skin graft. The graft is harvested from the conchal bowl because, like skin of the nasal tip and ala, the sebaceous density in the conchal bowl is high. The defect in the conchal bowl is allowed to heal by second intention.

Defatting the graft before securing it to the recipient bed is critical. The subcutaneous tissue is poorly vascularized and, therefore, hinders graft survival. Defatting can be performed with an iris scissors by trimming away the yellow fat to expose the shiny white dermis. If the area being repaired is uneven, thin areas of fat may be left on the graft to more closely approximate the natural contours. Alternatively, at times, it may be necessary to thin the dermis slightly to ensure similar thickness between graft and donor tissue. If this is the case, minimal thinning is recommended to avoid structural damage of adnexae. Once the graft has been prepared, it should be placed in the recipient bed as soon as possible. The recipient bed should have good hemostasis without devitalizing the tissue with overuse of cautery.

Grafts generally need to be trimmed at the edges to ensure a perfect match to the donor site. Survival of the graft is also dependent on the surgical technique during placement. The graft must be manipulated and grasped gently.

Small caliber nonabsorbable or fast-absorbing cat gut sutures are commonly utilized for FTSGs on the face. Insertion of sutures should be from graft to recipient tissue to minimize graft movement and best approximate wound edges. It is helpful to place the initial four sutures at intervals of approximately 90° from each other to ensure proper placement and to secure the graft. These are followed by interrupted sutures or, at times, running sutures to complete closure. When grafts are large or placed over concave areas, basting sutures help keep good graft to bed contact. This will stabilize the graft and minimize sheering forces. Several authors recommend the use of bolster dressings. While bolster dressings may assist in prevention of

hematomas and seromas they also compromise vascularity and can increase the risk of necrosis.

For larger defects or those with exposed bone or cartilage at the periphery, a purse-string approach may be introduced. A purse-string suture is placed subdermally along the defect edges, then tightened to advance edges into the defect circumferentially. This technique helps protect exposed tissue as well as reduce the defect size, thereby allowing the surgeon to use a smaller graft.

Sutures should be removed in one week for grafts on the face. Healthy grafts are pink in color. Although a purple color indicates relative hypoxia, most grafts with this color will survive. A white color on the surface of a graft generally represents maceration and may do fine when no longer occluded. If the white color is full thickness, it may represent necrosis. Black grafts are necrotic. Gentle wound care without debridement is the best treatment for graft necrosis. The necrotic graft will act as a biologic wound dressing, promote dermal healing, and generally avoid contraction. Antibiotics should also be started to minimize the risk of infection.

BUROW'S/REGIONAL GRAFT.

Burow's or regional grafts essentially use the Burow's triangle or dog-ear, often from a partial linear closure, to act as an FTSG (eFig. 243-29.1 in online edition). This utilizes removed skin that might otherwise have been thrown away and eliminates the need for removing tissue from a separate donor site. Because these are often local grafts, the tissue match is generally excellent.[46] Since a circular defect has a much larger surface area than a standard triangle taken in an elliptical closure, the triangle must be designed more like that of an island pedicle with a wider and longer body.

STAGES OF WOUND HEALING

- First 24 hours: plasmatic imbibition or ischemia: the graft affixes to the recipient bed via fibrinous material
- 48–72 hours: anastomosis and proliferation of vessels
- 4–7 days: reestablishment of full circulation

Stress on the wound should be avoided to provide the best results. Overstimulation of the patient may lead to increased blood flow to graft site leading to fluid overload and disruption of vascularity. The patient should be advised not to undergo strenuous activity for at least 1–2 weeks.

COMPOSITE GRAFTS

Composite grafts consist of one or more adjacent tissues, often involving a typical FTSG with underlying cartilage.[47] Small full-thickness defects of the nasal ala and helical rim most commonly require such a graft. Donor sites for composite grafts frequently include the helix and conchal bowl. It is desirable to harvest the graft in a manner that allows the underlying cartilage to extend beyond overlying tissue. This extension allows for the cartilage to insert under the surrounding defect margins. Two small pockets are generally made across from each other at a level below the dermis in the recipient site to accommodate the cartilaginous wings on the composite graft. The cartilage may or may not be sutured, and the remaining FTSG is sutured and secured as described earlier in this section. After being sutured into place, a composite graft with cartilage at its base receives its blood supply from its lateral margins only. Therefore, composite grafts should remain less than 2 cm^2, as a larger graft will not receive sufficient nutrients to allow its central portion to survive.[48]

FREE CARTILAGE GRAFTS

Free cartilage grafts consist of cartilage and perichondrium. This type of graft assists in structural support (e.g., prevent nasal valving) and retention of natural facial contours (e.g., ala and helical rim). Elastic cartilage from the ear, versus hyaline cartilage from the nose, is the best for recontouring. A strip or disc of cartilage is usually harvested through an incision in the postauricular sulcus or conchal bowl. As is done with a composite graft, the strip of cartilage harvested is slightly longer than the size of the defect and the edges are inserted into pockets made under the dermis. The cartilage is sutured lightly into place with absorbable sutures. The site is then typically closed with a flap. Full-thickness skin grafts may be placed over very thin cartilage struts but as the size of the cartilage increases, the vascular supply to the graft becomes increasingly compromised and decreases graft survival. The addition of cartilage helps with structural support such as preventing collapse of the nasal valves which results in disruption of air flow. It also helps retain the patient's original facial contours and prevents concavity and/or contraction of the repair.

SPLIT THICKNESS SKIN GRAFTS

STSGs are composed of epidermis and partial dermis. Because these grafts are much thinner than FTSGs, they have a less rigorous demand for vascular support and have an increased survivability profile. Unfortunately, since they lack the full thickness of dermis and dermal appendageal structures, STSGs appear more like scar tissue than skin; they are depressed, hypopigmented and have a shiny texture. They are used to cover large defects unable to be closed by other methods, to allow better wound bed surveillance, to line tubed pedicle flaps, or to resurface mucosa.[49] STSGs are often harvested from the upper inner arm, thigh, or buttock. If small, STSGs may be harvested with a blade by hand. When they are larger STSGs are harvested with a dermatome, which provides a more precise width and depth. Once the graft is obtained, it is placed in sterile saline on the meshing plate. Meshing is beneficial since it expands the donor tissue, allows wound exudate to drain preventing seroma and hematoma formation, and has been found to increase graft survival. Increased wound contraction and decreased cosmesis, however, are associated with meshing. After harvesting is complete, STSGs are placed over the defect and secured similarly to FTSG. For larger defects, surgical staples are often used to secure the graft.

STSGs size can vary. They are categorized as thin (0.013–0.033 cm), medium (0.033–0.046 cm), or thick

(0.046–0.076 cm). The amount of dermis present determines the chance of survival of the graft on a poor vascular bed. Generally, the thinner the graft, the higher the "take rate" but the poorer cosmesis. The donor site re-epithelializes rapidly and relatively painlessly with the use of bio-occlusive dressings.

The main advantage of an STSG is that it survives even in locations with poor vascularization, such as over bone or cartilage. It also allows for early detection of tumor recurrence. Cosmetically, the final outcome of this graft is suboptimal with absent appendages, poor color match, and frequent wound contracture under the graft. For this reason, second intention healing and skin substitutes are often employed for defects once covered with STSGs. These methods avoid the wound care and generally unsightly appearance of the STSG harvest site.

PUNCH AND PINCH GRAFTS. A subset of STSGs includes punch and pinch grafts. These are useful for accelerating the healing phase of a chronic ulcer. Several grafts are harvesting from a donor site and placed in the wound bed. Instruments used are a 4-mm punch for punch grafts or a scalpel (Weck knife) for pinch grafts. The rate of survival of these grafts is good if the site has meticulous postoperative care; however, the cosmetic outcome is suboptimal due to the variable thickness throughout the wound.

SKIN SUBSTITUTES

Tissue which has been cultured or processed prior to grafting is known as a *skin substitute*. There are a few different types: autologous epidermal, allogenic dermal, and xenogenic and allogenic bilayered.

Epidermal skin substitutes are derived by culturing the patient's own skin. These are good for covering a wound and stimulating the healing process.

Dermal skin substitutes are allografts developed from cadaver skin. They often consist of neonatal foreskin-harvested allogenic fibroblasts with an overlying silicone epidermis. These are helpful in replacing the dermis in a defect and can be covered by a STSG. There are several different types available commercially including Alloderm, Integra, Trancyte, and Dermagraft.

Bilayered skin substitutes are made from allogenic neonatal foreskin-derived fibroblasts and keratinocytes and bovine collagen. They are useful for protection of large wounds where donor tissue is insufficient to cover. Commercially available products include Apligraf and Orcel.

POSTOPERATIVE CARE

Meticulous postoperative wound care is necessary to ensure an optimal outcome. Attention must be made to limit postoperative bleeding of all surgical wounds, particularly flaps and grafts, as hemorrhage or hematoma formation may jeopardize tissue survival and increase the risk of infection. Meticulous intraoperative hemostasis and good postoperative compression dressings are very important in minimizing postoperative bleeding. A pressure dressing should be applied and left intact for 24–48 hours. This dressing includes a layer of ointment applied directly to the wound, a nonstick bandage such as Telfa, gauze for pressure, and surgical tape. Finally, elastic dressing materials, such as Flexinet or Coban, may be helpful for wounds on the scalp or extremities.

For the aforementioned procedures, it is important that the wound be kept clean, moist, and covered until suture removal. This will eliminate desiccation and promote re-epithelialization,[50] reduce bacterial contamination, and aid in hemostasis. Verbal and written instructions regarding home wound care should be reviewed and then provided in writing to the patient. After removal of the pressure dressing, the wound should be cleaned once or twice daily with attention to gently removing any crust and debris that may form. This is followed by a layer of ointment. A bland, nonmedicated ointment, such as petrolatum or Aquaphor is preferred over topical antibiotics such as Neomycin. The use of these topical antibiotics following cutaneous surgery increases the risk of contact dermatitis[51] without imparting a significant reduction in infection rates.[52] The patient should be advised to limit activity for 1 to 2 weeks after surgery, particularly, movement that stretches or adds tension to the wound area and may result in wound dehiscence or a widened scar.

The signs and symptoms of hemorrhage and wound infection should be reviewed as early intervention can reduce serious complications. To better prepare patients, it is helpful to educate him or her about what to expect during normal wound healing. The patient should be provided with the physician's contact information and should be encouraged to call with any questions or concerns.

COMPLICATIONS OF DERMATOLOGIC SURGERY

Early complications of all forms of cutaneous surgery and closure are bleeding, pain, and infection. Bleeding typically occurs in the first 24 hours after surgery and must be addressed promptly. Low flow ooze may be treated by compression. Patients should be instructed to apply direct pressure for at least 20 minutes without peeking to see if it is working. Frank arterial hemorrhage or large hematoma formation will require partial or complete suture removal, evacuation of clot, and exploration of the wound to allow visualization and closure of the bleeding vessel. Patients should be instructed to call if they see an enlarging mass below or around the wound.

Pain is usually manageable with non-narcotic pain relievers such as acetaminophen. Acetaminophen may be administered at the time of surgery and continued for 24 hours to reduce the risk of postoperative discomfort. It is generally easier to get ahead of pain than it is to catch up to it. Patients should be instructed to avoid non-prescribed nonsteroidal anti-inflammatory medication for up to 48 hours postoperatively to reduce bruising and bleeding from platelet dysfunction. While more severe pain may require the

administration of prescription pain medication, it should be investigated to be sure more significant issues such as infection or hematoma are not occurring.

Signs of infection usually will occur within the first week after surgery and include increased pain, erythema, and heat around the wound, purulent and sometimes foul-smelling drainage, and fever. When wound infection is suspected, a culture must be obtained for pathogen identification and antibiotic susceptibility, and treatment with a broad-spectrum antibiotic should be initiated. Common pathogens on skin and mucosal surfaces are Gram-positive cocci, notably staphylococci or, less commonly, streptococci. However, Gram-negative aerobes and anaerobic bacteria contaminate skin in the groin/perineal areas. Gram-negative bacilli may also be cultured from ear and lower leg wounds, particularly in diabetic patients. Methicillin resistant *Staphylococcus aureus* (MRSA) infections are increasing dramatically in frequency and should be vigilantly watched for.[53]

An expected consequence of surgery is the formation of a scar. While the goal of reconstructive surgery is to minimize the appearance of the resultant scar, at times they may widen, or even become hypertrophic. With time, hypertrophic scars tend to flatten and soften. Their course may be hastened with the administration of intralesional steroids and laser treatment. In areas under tension and or motion, such as the upper back and arms over the deltoids, scars may spread or become atrophic. While scar spread may become less noticeable with time as the initial dark pink color fades, the width generally does not change significantly. Erythema and telangiectasia often form around scars during the healing phase and may persist for extended periods of time. Highly vascular areas (rosacea) and those under high tension are more likely to develop persistent erythema and telangiectasia. This can be effectively treated with lasers, such as the pulsed dye laser, KTP, or intense pulsed light.

Spitting sutures or suture granulomas from buried sutures may occur. Placing the buried dermal sutures in the appropriate plane will help minimize the occurrence. If the spitting suture becomes visible it may be trimmed out, but it is unadvisable to aggressively go after these as a scar may result.

In the case of a flap repair, additional complications may be encountered. In the early postoperative period, partial or complete flap necrosis may occur. This may be due to inadequate blood supply from the wound bed, which is more commonly encountered in smokers, or when an underlying hematoma is present. Flap design may also lead to vascular compromise and flap necrosis, as when the pedicle is too narrow to support the mass of the flap, when there is too much torque, or when there is too much tension at the flap's leading edge. Areas of partial necrosis will heal secondarily and may lead to a less appealing scar, which can be revised after wound healing is complete. Later in the postoperative period, a trapdoor deformity may occur in which the center of the flap becomes elevated and the suture line becomes depressed. It may resolve spontaneously over a period of 6–12 months. However, if the trapdoor effect or pin-cushioning persists, it may respond to intralesional steroids, flap elevation with flap thinning, and/or dermabrasion. The trapdoor effect may be prevented with wide undermining around the primary defect, proper thinning of the flap, proper size of the flap, and the use of a geometric shape for the flap.

Complications of grafting include graft failure in the early postoperative period and results from inadequate nutrient supply to the tissue. This is often due to poor vascular health of the wound bed as encountered in smokers or diabetics, inadvertent shearing forces or trauma to the graft, hematoma formation, or infection. Later complications typically are attributed to the cosmetic appearance of the graft, usually related to mismatch of thickness, color, or texture. Contraction may be considerable, particularly with thinner grafts, which may result in the distortion of free margins.

MONITORING AND FOLLOW-UP

If nonabsorbable epidermal sutures are placed, the patient should return for suture removal at the appointed time. If the defect has been left to heal secondarily, the wound should be checked in approximately 4 weeks. The surgical site should then again be evaluated 3 to 4 months postoperatively to ensure wound healing is progressing as expected. Patients who have been treated for malignancy should be counseled regarding proper follow-up for full skin examination to monitor for new or recurrent skin cancers.

KEY REFERENCES

Full reference list available at www.DIGM8.com

DVD contains references and additional content

1. Berg JWAP, Lidz CW, Parker LS: The legal requirements for disclosure and consent: history and current status. In: *Informed Consent: Legal Theory and Clinical Practice*, 2nd edition. New York, Oxford University Press, Inc., 2001, p. 41–74
4. Dixon AJ et al: Prospective study of wound infections in dermatologic surgery in the absence of prophylactic antibiotics. *Dermatol Surg* **32**(6):819-826; discussion 826–817, 2006
6. Grekin RC, Auletta MJ: Local anesthesia in dermatologic surgery. *J Am Acad Dermatol* **19**(4):599-614, 1988
17. Alam M et al: Aesthetic and functional efficacy of subcuticular running epidermal closures of the trunk and extremity: a rater-blinded randomized control trial. *Arch Dermatol* **142**(10):1272-1278, 2006
17. Alam M et al: Aesthetic and functional efficacy of subcuticular running epidermal closures of the trunk and extremity: a rater-blinded randomized control trial. *Arch Dermatol* **142**(10):1272-1278, 2006
22. Book SEAS, Leffell DJ: Ellipse, ellipse variations and dog-ear repairs. In: *Surgery of the Skin: Procedural Dermatology*, edited by JK Robinson CH, RD Sengelmann, DM Siegel. Philadelphia, Elsevier Mosby, 2005, p. 265
29. Dzubow LM: Flap dynamics. *J Dermatol Surg Oncol* **17**(2):116-130, 1991
38. Zitelli JA: The bilobed flap for nasal reconstruction. *Arch Dermatol* **125**(7):957-959, 1989
50. Eaglstein WH: Moist wound healing with occlusive dressings: a clinical focus. *Dermatol Surg* **27**(2):175-181, 2001

Chapter 244 :: Mohs Micrographic Surgery

:: Joseph Alcalay & Ronen Alkalay

BACKGROUND

MOHS MICROGRAPHIC SURGERY AT A GLANCE

- Mohs micrographic surgery (MMS) is a precise method of treating skin cancer that results in the highest cure rate with maximal tissue conservation, cosmesis, and function.
- MMS is indicated for the treatment or basal cell cancer and squamous cell cancer and certain less common skin cancers.
- Specific indications for MMS include location in high-risk anatomic sites, aggressive histology, recurrent tumor, and when there is a need for maximal preservation of tissue.
- Advances in processing and staining techniques and the use of immunostains have increased the speed and accuracy of MMS as a cost-effective means of skin cancer extirpation.

Mohs micrographic surgery (MMS) is a surgical technique developed to excise skin cancer under complete microscopic control. The fresh frozen tissue technique is used, which permits immediate examination of the specimen, and the tissue is oriented in a way to permit evaluation of all surgical margins. This is distinct from the traditional bread loafing technique used to process tissue specimens. A special orientation is combined with a precise mapping technique, which leads to maximal conservation of normal tissue. The technique was developed by Dr. Frederick Mohs approximately 80 years ago using a fixed tissue technique that relied on zinc chloride paste. The original term, *chemosurgery* refers to the use of the tissue fixative which is no longer used. As a result, the term chemosurgery is considered archaic.[1] MMS has been described by various names such as chemosurgery, microscopically controlled excision, and microscopically oriented histographic surgery. The latter is an attempt at creating an acronym to replace the eponymous term *Mohs*.

In the past several decades, the mapping component has been retained but the procedure has been refined using frozen tissue rather than fixed tissue, which has permitted more efficient patient care. The advantages of MMS over conventional excisional surgery include maximum cure rate and optimal preservation of healthy tissue. The latter serves to enhance cosmetic outcome and preserve function where applicable. MMS is now recognized as the standard of care for the treatment of various skin cancers in indicated circumstances. The most common cancers treated by this method are basal cell carcinoma (BCC, 73%) and squamous cell carcinoma (SCC, 23%).[2] A defining characteristic of MMS is that the surgeon acts to interpret the histopathologic specimens. Specifically, the MMS procedure requires a single physician to act in two integrated but separate distinct capacities as surgeon and pathologist. MMS is a highly technical procedure that requires meticulous attention to detail and considerable training and experience to achieve the expected high cure rates.

THE PROCEDURE

Mohs surgery is performed under local anesthesia in the office setting or in an ambulatory center. In unusual cases, where multiple cancers or complex malignancies are to be removed, sedation may be used.[3] Prior to surgery, it is essential to have the patient affirmatively identify the biopsy site as very often the biopsy site may fade due to postbiopsy healing. It has been shown that in 25% of patients, who had prior biopsy, no remnants of tumor were found during MMS. [4] This is consistent with the fact that the inflammatory process may contribute to elimination of residual cancer cells after biopsy. The fundamental elements of MMS are listed in Table 244-1. A complete medical history and list of medications should be documented before surgery is performed. Anticoagulants are not contraindicated and data have shown that they should not be discontinued prior to MMS. [5] Once the patient is properly positioned, it is important to mark the clinical tumor border with a surgical pen. Local anesthesia is then obtained by injection (Fig. 244-1). Marking the clinical borders of the tumor is necessary since the local anesthetic may cause blanching that can obscure the tumor borders. The most commonly used local anesthetic is 1% or

TABLE 244-1
Fundamentals of Mohs Micrographic Surgery

Injection of local anesthesia
Curettage to determine gross clinical margins
Excision of the first layer with the scalpel beveled at 45° (first MMS stage)
Color coding and mapping of the tissue
Horizontally cut frozen sections
Tissue staining
Microscopic examination of the tissue by the surgeon
Repetition of the tumor excision cycle until cancer is removed
Reconstruction



Figure 244-1 Recurrent basal cell carcinoma on the right temple-forehead junction. Marking the clinical borders of the tumor.

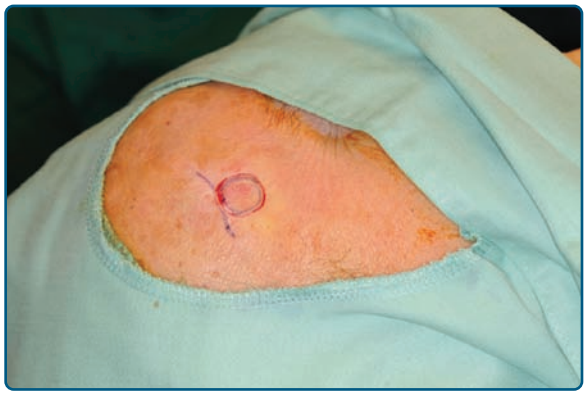

Figure 244-3 Debulking stage. Tumor is cut in its visual clinical borders.

2% lidocaine with 1:100,000–200,000 epinephrine (Fig. 244-2). After the surgical site is gently curetted to determine the clinical extent of the cancer, a specimen is taken using the Mohs technique. (Fig. 244-3). This is considered the first Mohs stage. A thin layer of tissue is excised using a scalpel and incising the skin at a 45° angle. Nicks are made in the surrounding tissue to denote tissue orientation and mapping (Fig. 244-4). In some cases, double nicks can help in the orientation of the tissue.[6] Mapping of the tissue is a crucial step in MMS. The topographic map allows the Mohs surgeon to relate the microscopic findings to the excised tissue and the anatomic reference points at the surgical site (Fig. 244-5) The Mohs map is typically created by drawing freehand, using a template or digitally using computerized software (Fig. 244-6). The tissue is brought to the adjacent laboratory (another key element of the Mohs technique is the presence of a contiguous lab under the supervision of the Mohs surgeon). Color coding of specimens is critical. The Mohs technician or the surgeon marks the borders of the tissue with different colors to allow orientation relative to the Mohs map. Usually two dyes are used such as red and black or black and yellow (Fig. 244-7). One of the dyes is represented on the map as a solid line and the other as a dotted line.

The tissue is then processed by a technician who is specifically trained in the *en face* method of sectioning. The tissue is frozen and is cut horizontally on a microtome. In contrast to traditional paraffin sections, which are cut vertically (bread-loaf sections) the Mohs sections theoretically allows 100% of the tumor margins (depth and periphery) to be examined. Most Mohs surgeons use hematoxylin-eosin stain (83%) and a minority use toluidine blue as the preferred stain. The latter stain helps distinguish basal cell carcinoma from hair follicles by highlighting mucopolysaccharides in the stroma.[7] In between the Mohs stages, the wound is dressed temporarily and the patient waits either in the procedure room or in a dedicated waiting room. Slide preparation takes 20–30 minutes on average. Examination of the slides by the surgeon is then performed in the laboratory. Residual cancer noted microscopically is marked on the Mohs map and the process of excision, mapping,



Figure 244-2 Injection of local anesthetic.



Figure 244-4 First stage of Mohs surgery. Nicks are made in the tissue.



Figure 244-5 The Mohs map. Tissue is placed on Telfa in its actual position. A digital image is taken by the Mohs technician.

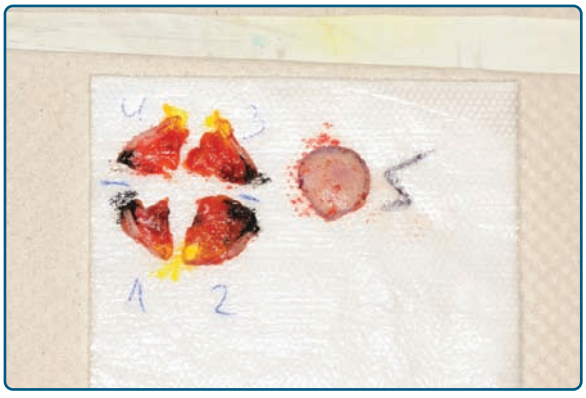

Figure 244-7 Color coding of the tissue in the laboratory.

and processing is repeated until all margins are free of tumor (Figs. 244-8, 244-9). High quality frozen sections are mandatory for the success of MMS[8] Figs. 244-10 and 244-11 illustrate how the Mohs technique ensures complete tumor removal. Once MMS is complete, the wound is evaluated and reconstruction is either performed at that time by the Mohs surgeon or the wound is allowed to heal by second intention. In complex cases, collaboration with other reconstructive surgeons may be indicated. Reconstructive surgery has become an important and integral aspect of the care of the skin cancer patient. The original chemosurgery defects healed by second intention, but the current defects that result from the fresh tissue technique permit primary closures, adjacent tissue transfer, and grafts. As a result, parallel advances in reconstructive surgery have been significant in the evolution of MMS.

INDICATIONS

Currently, the major indications for MMS are based on the anatomic location of the tumor, tumor size, histology, and patient considerations. Mohs surgery is typically used on the head and neck and for difficult or biologically challenging tumors elsewhere.

MOHS SURGERY FOR BASAL CELL CARCINOMA

BCC accounts for approximately 75%–80% of all cases of non-melanoma skin cancer. This tumor has a predilection for the head and neck as it is related to ultraviolet light exposure. Despite an extremely low metastatic rate (0.0028%), BCC can be locally aggressive and cause significant tissue destruction. Of special importance are high-risk BCCs: those in the midfacial location (the so-called H zone which includes the nose, periocular region, lips, ears), recurrent and incompletely excised tumors, BCC with aggressive histological characteristics (sclerosing, basosquamous, infiltrative, and micronodular), BCC with perineural involvement, and BCC in which tumor size exceeds 2 cm. MMS is also very helpful in treating BCC with indistinct clinical borders. The aggressive tumor subtypes tend to be large, have ill-defined borders, and tend to recur when treated with other modalities. MMS has been shown to result in superior cure rates for high-risk BCCs compared with other approaches. Rowe et al found in their meta-analysis a recurrence rate of 10.1% for primary BCCs treated with simple excision, whereas MMS–treated lesions had only a recurrence rate of 1%.[10] Other studies have confirmed that MMS yields the highest cure rate in primary tumors (98.6%–99%) and in recurrent tumors[11,12] In the case of recurrent cancers,

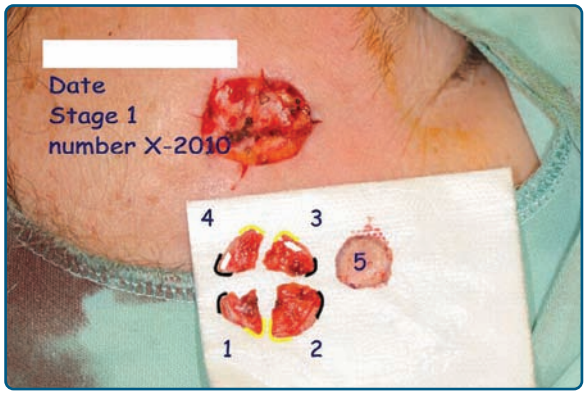

Figure 244-6 Digital image of the Mohs map.

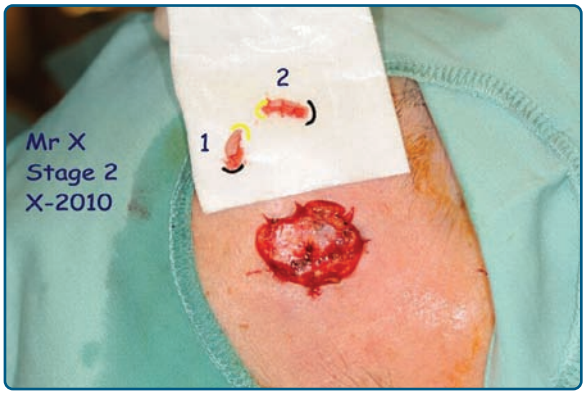

Figure 244-8 A Mohs map of the second stage.



Figure 244-9 Reconstruction by linear closure.

the 5-year recurrence rate of recurrent BCCs was 17% with simple excision and only 4.5% with MMS.[11,13] A recent study in Europe showed that MMS is preferred over surgical excision for the treatment of recurrent facial BCC on the basis of significantly fewer recurrences after MMS than after surgical excision. However, because there was no significant difference in recurrence of primary BCC between treatment groups, treatment with surgical excision is probably sufficient in most cases of routine primary BCC.[14] BCCs located on the ear, nose, eyelids, and lips have higher recurrence rates when treated by simple excision. The reason is believed to be the tendency of the surgeon to conserve as much tissue as possible, thus risking incomplete excision. Some of the aggressive subtypes of BCC (morpheaform, infiltrative) tend to recur in those locations. These aggressive subtypes may spread along scars, perichondrium, periosteum, perineurium, and fascial planes. The advantage of MMS as a tissue sparing technique was demonstrated for higher-risk BCCs requiring multiple stages of MMS.[15] Large BCCs (>2 cm) tend to be more aggressive, and have a higher recurrence rate than smaller cancers. They are usually present for longer duration, allowing the cancer to penetrate the surrounding tissue more extensively. MMS is especially advantageous in this situation. Incompletely excised tumors tend to recur as more aggressive tumors 12%–41% of the time. Recurrent tumors tend to be subtle at first, but when they clinically reappear they can be aggressive, demonstrating extension along deep tissue planes. MMS for recurrent cancer yields the highest cure rates (93%–96%) compared to 80%–83% for other modalities.[14]

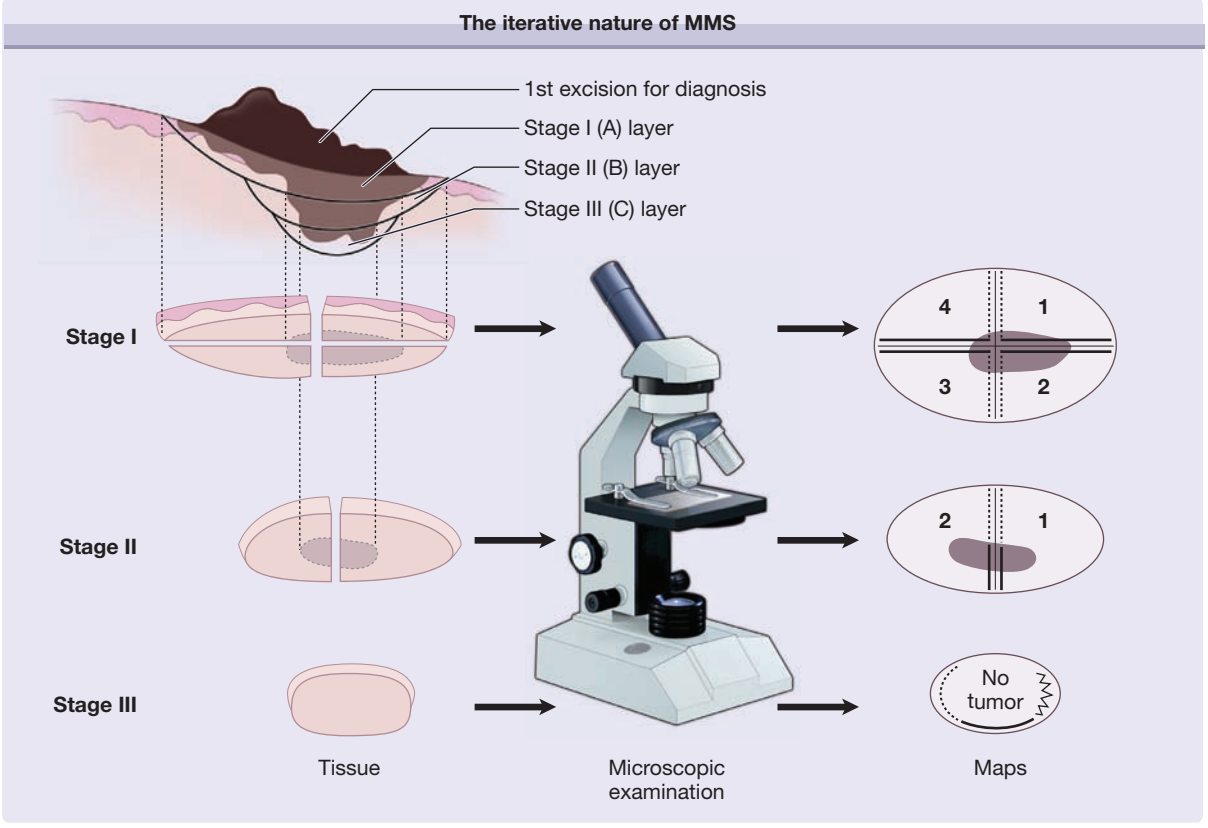

Figure 244-10 This schematic illustrates how the Mohs technique assures complete tumor removal. Obvious cancer (black) is obtained to determine subtype (upper left). Cancer discovered by microscopic examination is outlined by dots in each layer. In Stage I, a layer was removed and divided into four specimens (as viewed from the bottom); after microscopic examination, residual tumor was found only in the central area of all four specimens. In Stage II, a central layer was excised and bisected; after microscopic examination, residual tumor was found only in the center of specimens 1 and 2. In Stage III, another small block specimen was removed; after microscopic examination no residual tumor was found. In this case, the Mohs procedure consisted of three stages of excision and the microscopic examination of seven specimens. (From *Mohs Micrographic Surgery*, 2nd ed., edited by SN Snow and GR Mikhail 2004. The university of Wisconsin Press, with permission.)

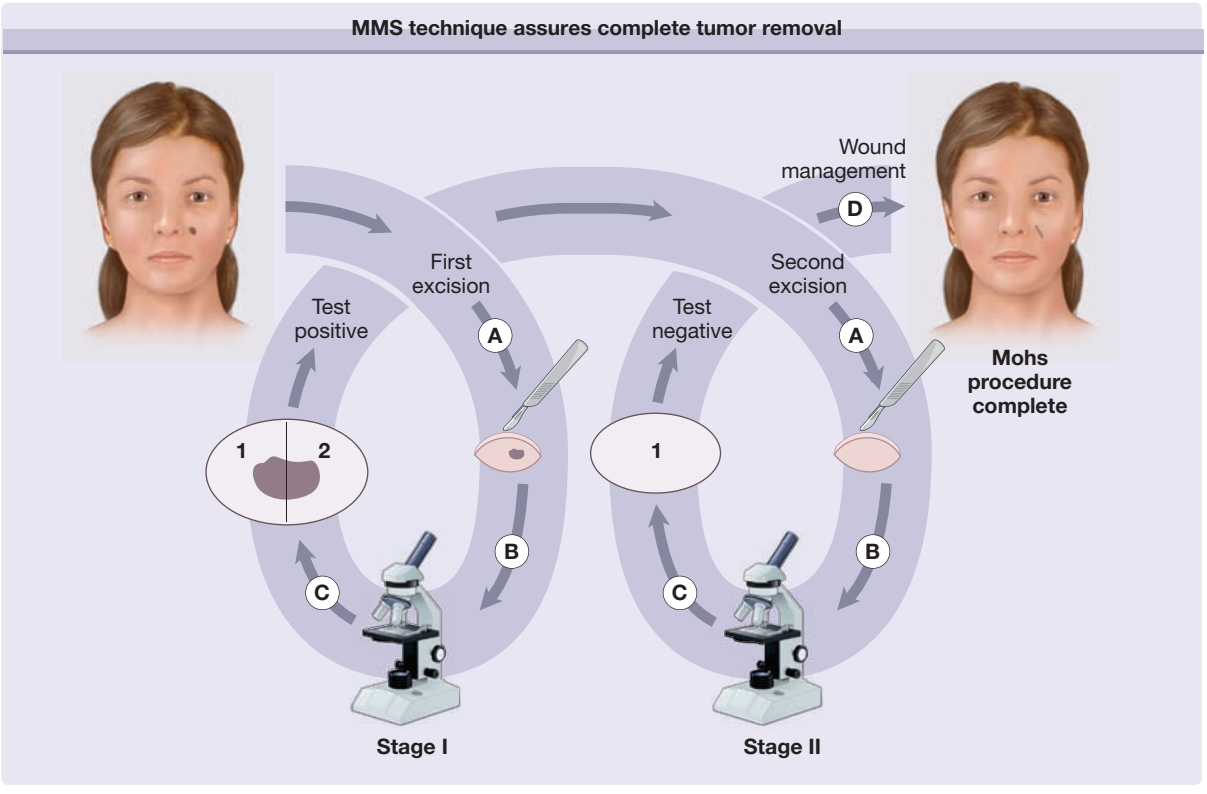

Figure 244-11 This schematic illustrates the cyclic nature of Mohs surgery. The four main components are the excision of a disc of tissue (a), microscopic examination (b), the appropriate marking of the map when residual cancer is found (c), and wound management (d). In Stage A, the tumor was removed, examined with the microscope. Residual tumor (black) was found throughout specimens 1 and 2. In Stage B, a deeper layer was removed and examined microscopically. In the second layer, no remaining cancer could be found. The defect was then allowed to heal by second intention. (From *Mohs Micrographic Surgery*, 2nd ed., edited by SN Snow and GR Mikhail 2004. The university of Wisconsin Press, with permission.)

MOHS SURGERY FOR SQUAMOUS CELL CARCINOMA

Squamous cell carcinoma (SCC) is the second most common skin cancer among whites.[16] More than 200,000 new tumors are estimated to occur in the United States each year, and there is a significant increase in the incidence of SCC around the world.[17] Most cases of primary cutaneous SCC are induced by UV radiation. SCC may also occur on nonexposed skin in the pelvic area including the penis where the cause is usually infection with carcinogenic subtypes of human papilloma virus. Although SCCs and BCCs are treated similarly, they are biologically distinct. SCC metastasizes at a much higher rate and accordingly has a higher mortality rate than BCC even though its metastatic rate remains very low on an absolute basis. Metastases are more common in the setting of chronic scar (37.9%), or certain anatomic locations.[18] The indications for MMS are similar to BCC, but additionally involve identifying and reducing the risk for metastasis. MMS permits tracking SCC along nerves or when the histology is highly infiltrative, thus increasing the chance of complete extirpation. As with BCC, histologic pattern is important in determining the potential aggressiveness. Tumors that are poorly differentiated and/or have perineural involvement have a worse prognosis. Locations such as the ear, penis, lip, and digits, lesions greater than 2 cm, and those occurring in scars carry a higher risk of metastasis and local recurrence. The five-year cure rate for primary SCC of the skin with MMS is 97.4% to 96.9% versus 92% (95%–82%) with simple excision, and 90% for radiation therapy.[19] The difference in cure rate increases with the location such as primary SCC of the lip (97.7% vs. 89.5%) and ear (94.7% vs. 81.3%). For recurrent SCC, the cure rate with MMS is 94.1% to 90% versus 76.7% for simple excision and 65%–50% with radiation therapy. (Tables 244-2 and 244-3). The importance of MMS in the treatment of SCC with perineural invasion has also been documented.[20,21] MMS has also been proven to be effective for treating Bowen disease with a 5-year recurrence rate of approximately 6%.[22] Immunosuppressed patients including organ transplant patients have a disproportionate number of SCCs and also carry a greater risk of more aggressive disease. Recent studies show that SCC is up to 65 times as likely to develop in transplant recipients as in age-matched controls.[23] Increased incidence, younger age at onset, higher incidence of multiple tumors, and increased biologic aggressiveness of SCC in these patients is manifested by an increased risk of local recurrence, regional and distant metastasis, and mortality. MMS is an important treatment option in these high-risk patients to minimize recurrence and mortality risks.[24]

TABLE 244-2
Five-Year Recurrence Rate After Mohs Micrographic Surgery in Relation to Previous Recurrence of Squamous Cell Carcinoma

5-year Recurrence	Primary SCC (N = 229)	Previously Recurrent SCC (N = 152)	Overall Patients with 5 years Follow-up (N = 381)
Yes	6	9	15
No	223	143	366
%*	2.6	5.9	3.9

* $p < .001$.
Reprinted with permission from Leibovitch I, Huilgol SC, Selva D et al: Cutaneous squamous cell carcinoma treated with Mohs surgery in Australia. I. Experience over 10 years. *J Am Acad Dermatol* **53**:253, 2005.

MOHS SURGERY FOR CUTANEOUS MELANOMA

The role of MMS for management of malignant melanoma is highly controversial. Melanoma in situ (MIS), which typically occurs on sun-damaged skin, can be difficult to interpret on frozen section. A review of MMS for melanoma in situ indicated that the recurrence rates for melanoma in situ post-MMS varied from 0%–3.6%.[25] One author claims that MMS for melanoma in situ can maximize the cure rate.[26] At some centers, a modified MMS is used in which a 2- to 3-mm margin is excised beyond the final frozen section margin and submitted for permanent paraffin-embedded sections. These sections are processed in the MMS en-face method so that 100% of the peripheral margins are visualized. In addition, a technique of rush permanent sections has been described.[27] The introduction of immunohistochemistry (IHC) staining may make MMS more reliable as a treatment for MIS. In one study 100% correlation was found between frozen sections stained with MART-1 and paraffin-embedded sections.[28] Many surgeons who do perform Mohs surgery for MIS have begun to use intraoperative IHC to identify melanocytes in frozen sections, and MART-1 is currently the preferred immunostain. S100 and HMB-45 have traditionally been used to identify melanocytes but have variable sensitivity and specificity. Although the processing time of MMS frozen sections is less than with paraffin sections, it is still more labor intensive than traditional hematoxylin and eosin-based frozen sections. The need for more accurate diagnosis of MIS in MMS has led to the development of rapid permanent paraffin-embedded sections (R13) and rapid IHC staining.[29]

MOHS SURGERY FOR DERMATOFIBROSARCOMA PROTUBERANS

Dermatofibrosarcoma protuberans (DFSP) is a rare spindle cell cutaneous tumor with low-grade malignancy. It is a slow growing tumor and, for many years, wide local excision has been the treatment of choice. MMS has become the preferred treatment in most clinical circumstances with recurrence rates as low as 1.3%.[30]

TABLE 244-3
Comparative Clinical and 5-year Recurrence Data on Mohs Micrographic Surgery for Squamous Cell Carcinoma

	Mohs[18,19]	Robin et al[20,21]	Holmkvist & Roenigk*	Leibovitch et al**
Study years	NA	1965–1980	1986–1989	1993–2002
Tumor location	Head	Head	Lips	Mainly head and neck
Overall number of tumors with 5-y follow-up (1°/2°)	2551 (NA)	414 (1°)	50 (NA)	381 (229/152)
Overall 5-y recurrence (%) (1°/2°)	5.6 (NA)	6.7 (1.8/3.4)	8.0 (NA)	3.9 (2.6/5.9

1° = Primary; 2° = recurrent; NA = not available.
*Holmkvist KA, Roenigk RK. Squamous cell carcinoma of the lip treated with Mohs micrographic surgery: outcome at 5 years *J. Am Acad Dermatol* 1998;**38:** 960–6.
Reprinted with permission from Leibovitch I, Huilgol SC, Selva D et al: Cutaneous squamous cell carcinoma treated with Mohs surgery in Australia. I. Experience over 10 years. *J Am Acad Dermatol* **53:253, 2005.

MOHS SURGERY FOR OTHER CUTANEOUS MALIGNANCIES

MMS has been used to treat a wide range of cutaneous malignancies. The consensus indications outlined by the American Academy of Dermatology[31] include verrucous carcinoma, keratoacanthoma, dermatofibrosarcoma protuberans, atypical fibroxanthoma, malignant fibrous histiocytoma, leiomyosarcoma, adenocystic carcinoma of the skin, sebaceous carcinoma, extramammary Paget disease, erythroplasia of Queyrat, oral and central facial paranasal sinus neoplasms, microcystic adnexal carcinoma, apocrine carcinoma of the skin, certain aggressive locally recurrent benign tumors, and Merkel cell carcinoma. All cutaneous malignancies that exhibit a contiguous pattern of radial growth and can be interpreted on frozen section should theoretically be amenable to MMS.

However, less than 2% of the tumors treated with MMS are rare cutaneous malignancies. For this reason, it is important to remember that because a lesion can be treated by MMS does not mean that it should be treated in that way. If the Mohs surgeon does not have experience in reading rare tumors and cannot collaborate with a dermatopathologist, the lesion is best treated in another fashion or by a more experienced Mohs surgeon. The introduction of immunostains in MMS in the last decade has created the opportunity to explore its use in treating other cutaneous tumors.[32]

Microcystic adnexal carcinoma has been shown to have only 5% recurrence rate with MMS.[33] Treatment of primary sebaceous carcinoma of the eyelid with MMS has yielded excellent results.[34] MMS is more effective and superior to standard surgical excision in the treatment of extramammary Paget disease.[35] The effectiveness of MMS in the treatment of dermal spindle cell tumors has also been suggested.[36]

SAFETY, PATIENT SATISFACTION AND COMPLICATIONS

MMS is performed in an office or ambulatory center setting rather than hospital operating rooms. A study performed in almost 4,000 patients that underwent MMS showed that MMS can safely be performed in the office or outpatient hospital setting.[37] Patients treated with MMS have well-established long-term satisfaction.[38]

KEY REFERENCES

Full reference list available at www.DIGM8.com

DVD contains references and additional content

1. Mohs FE: Chemosurgery: a microscopically controlled surgery for skin cancer—past, present and future. *J Dermatol Surg Oncol* **4**:41, 1978
10. Rowe DE et al: Long-term recurrence rates in previously untreated (primary) basal cell carcinoma: Implications for patient follow-up. *J Dermatol Surg Oncol* **15**:315, 1989
13. Rowe DE et al: Mohs surgery is the treatment of choice for recurrent (previously treated) basal cell carcinoma. *J Dermatol Surg Oncol* **15**:424, 1989
15. Muller FM et al: Randomized comparison of Mohs micrographic surgery and surgical excision for small nodular basal cell carcinoma: Tissue sparing outcome. *Dermatol Surg* **35**:1349, 2009.
16. Garcia-Zuazaga J, Olbricht SM: Cutaneous squamous cell carcinoma. *Adv Dermatol*. 24:33, 2008.
19. Leibovitch I, et al: Cutaneous squamous cell carcinoma treated with Mohs surgery in Australia. I. Experience over 10 years. *J Am Acad Dermatol* **53**:253, 2005
25. Dawn ME, Dawn AG, Miller SJ: Mohs surgery for the treatment of melanoma in situ. A review. *Dermatol Surg* **33**:395, 2007

Chapter 245 :: Nail Surgery

:: Robert Baran

The main objectives of nail surgery are to aid diagnosis by biopsy, to treat infection, to alleviate pain, to remove local tumors, and to ensure the best cosmetic results in acquired and/or hereditary and congenital abnormalities.

PATIENT SELECTION

Providing the patient with an exact illustration of the operation is helpful to give the patient insight into the procedure and its expected outcome. A thorough discussion regarding postoperative morbidity is essential.

RISKS AND PRECAUTIONS

Factors to be considered include the following:

- History of systemic disease
- History of allergies
- Concomitant drug use

Preoperative photographs as well as any taken during surgery may be useful medicolegally. Careful history taking may reveal systemic disease such as diabetes mellitus, blood dyscrasia, vascular disease, vascular collagen disease (scleroderma), allergy, chronic pulmonary disease, or immune impairment. Any of

these may at times be contraindications to surgery or may call for alteration of the technique to be used. Surgery of the nail is not recommended in patients with high-risk conditions. A history of concurrent use of drugs may be relevant, because these drugs may affect anesthesia (e.g., monoamine oxidase inhibitors or phenothiazines), prolong bleeding (e.g., aspirin and anticoagulants), delay healing (e.g., glucocorticoids), or have toxic effects on the nail apparatus (e.g., retinoids). There may be a history of allergy to lidocaine or mepivacaine or to parabens contained in both as a preservative. A knowledge of previous antitetanus immunization is important, because administration of tetanus toxoid may be advisable in association with surgery involving the toenail or traumatic lesions that come into contact with soil.

A magnifying lens may be useful to observe the color, surface, and structure of the periungual tissue and to compare the unaffected contralateral digit. It may be necessary to probe in order to localize pain, to obtain a radiograph to rule out underlying bone involvement, or to ask for ultrasonography and magnetic resonance imaging when a tumor is suspected.

The basic requirements for nail surgery include a detailed knowledge of the anatomy and physiology of the nail apparatus on the part of the surgeon. Full aseptic conditions, regional block anesthesia, and local hemostasis are indispensable.

ANATOMY[1]

(See Chapter. 89)

The nail plate is the permanent product of the nail matrix. Its normal appearance and growth depend on the integrity of the perionychium and the bony phalanx (Fig. 245-1). The nail is a semihard horny plate covering the dorsal aspect of the tip of the digit. The nail is inserted proximally in an invagination that is practically parallel to the upper surface of the skin and laterally in the lateral nail grooves. This pocket-like invagination has a roof, the proximal nail fold, and a floor, the matrix from which the nail is derived. The matrix extends approximately 6 mm under the proximal nail fold, and its distal portion is only visible as the white semicircular lunula. The general shape of the matrix is a crescent, concave in its posteroinferior portion. The lateral horns of this crescent are more developed in the great toe and are located at the coronal plane of the bone. The ventral aspect of the proximal nail fold encompasses both a lower portion, which continues the matrix, and an upper portion (roughly three-quarters of its length), called the *eponychium* (see eFig. 245-1.1 in online edition). The germinal matrix forms the bulk of the nail plate. The proximal element forms the superficial third of the nail plate, whereas the distal element provides its inferior two-thirds. The ventral surface of the proximal nail fold adheres closely to the nail for a short distance and forms a gradually desquamating tissue, the cuticle, made of the stratum corneum of both the dorsal and the ventral sides of the proximal nail fold. The cuticle seals and protects the nail cul-de-sac.

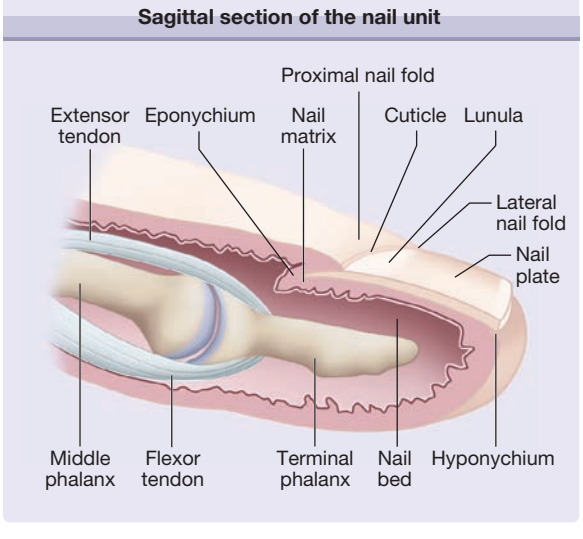

Figure 245-1 Sagittal section of the nail unit.

The nail plate is bordered by the proximal nail fold, which is continuous with the similarly structured lateral nail fold on each side. The nail bed extends from the lunula to the hyponychium. It has parallel, longitudinal rete ridges.

In contrast to the matrix, the nail bed has a firm attachment to the nail plate. Colorless but translucent, this highly vascular connective tissue, containing glomus organs, transmits a pink color through the nail. Avulsion of the overlying nail plate denudes the nail bed.

Distally, adjacent to the nail bed, lies the hyponychium, an extension of the volar epidermis under the nail plate, which marks the point at which the nail separates from the underlying tissue. The distal nail groove, which is convex anteriorly, separates the hyponychium from the fingertip.

The circulation of the nail apparatus is supplied by two digital arteries that course along the digits and give off branches to the distal and proximal arches. The sensory nerves to the distal phalanx of the three middle fingers are derived from fine, oblique, dorsal branches of the volar collateral nerves. Longitudinal branches of the dorsal collateral nerves supply the terminal phalanx of the fifth digit and also the thumb.

Among its multiple functions, the nail provides counterpressure to the pulp that is essential to the tactile sensation involving the fingers and to the prevention of hypertrophy of the nail bed.

INSTRUMENTS AND DRAPING

The instruments used in nail surgery are, in general, the same as those used in cutaneous surgery with the addition of the instruments listed in Box 245-1.

Draping is accomplished by means of a sterile glove on the involved hand. The tip of the glove is cut off on the finger that is to undergo surgery. The remaining open finger of the glove is then rolled back down the digit. This exsanguinates the digit and provides a

BOX 245-1 INSTRUMENTS REQUIRED FOR NAIL SURGERY

- Nail elevators
- Single- or double-pronged skin hooks
- Double-action nail splitter (bone rongeur)
- Clippers, splitting scissors, English nail splitter
- Pointed scissors (Gradle scissors), curved iris scissors
- Small-nosed hemostats
- Disposable biopsy punches
- Penrose drains
- Luer-Lok syringe, 30-gauge needles

tourniquet when it reaches the proximal part of the finger. For toenail surgery, the foot is draped in the usual aseptic manner with sterile towels secured by towel clamps.

ANESTHESIA

Local anesthesia should be administered while the patient is reclining or in a supine position. Lidocaine is widely used because the incidence of allergy to this agent is very low. Because the benefit of epinephrine is still debatable, it is preferable to use 2% lidocaine alone. A tourniquet can provide prolonged hemostasis when a bloodless operative field is required. It has been claimed that using tepid lidocaine minimizes the burning sensation associated with its administration. The use of one part 7.5% bicarbonate with nine parts lidocaine for the same purpose has also been advocated.

Anesthetics are administered via a 30-gauge needle on a Luer-Lok syringe using either a proximal digital block or a distal digital block (wing block) procedure. Other techniques, such as median distal anesthesia or transthecal block, have not replaced the classic routes of anesthesia. Although emergencies related to minor surgery occur rarely, the ready availability of resuscitative equipment and expertise is essential.

PROXIMAL DIGITAL BLOCK

The proximal digital block procedure is less painful than the distal block procedure, but the anesthesia takes 5–10 minutes to become established. The hand is laid down flat, with the fingers spread, so that 1–2 mL of anesthetic can be administered by a dorsal injection, with a thin needle inserted and directed tangentially to the sides of the bony phalanx at the base of the involved finger and as far as the lateral side of the flexor tendon (Fig. 245-2). A tourniquet effect may inadvertently be produced by injecting more than 5 mL of anesthetic and should be avoided. The absence of blood reflux in the syringe should be verified before injection if a nondental syringe is used. When the operation is strictly localized to a lateral region, a block limited to the nerves ipsilateral to the lesion suffices, as in the case of a partial distolateral nail avulsion.

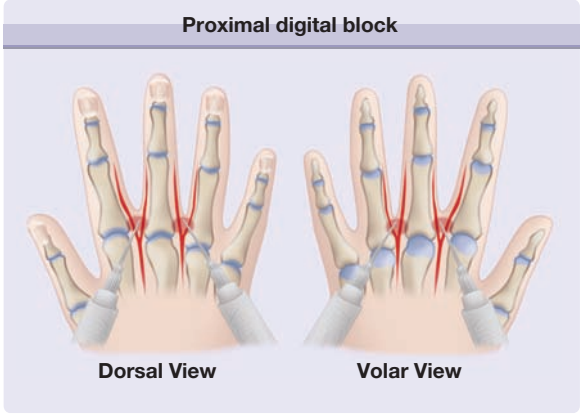

Figure 245-2 Proximal digital block.

DISTAL DIGITAL BLOCK

The distal digital block procedure is more painful than the proximal block procedure, but anesthesia occurs immediately. This method is absolutely contraindicated, however, when bacterial infection in the region is being addressed. The latter requires wrist block or general anesthesia.

For a distal digital block, the needle is inserted just behind the junction of the proximal nail fold and a lateral nail fold and a few tenths of a milliliter of anesthetic is injected, which whitens the region. The injection is continued by aiming the needle toward the pad. One then returns to the initial area to inject the proximal fold transversely. Finally, at the junction of the proximal fold with the lateral fold on the opposite side, one proceeds as described earlier (Fig. 245-3). The anesthesia is almost immediate, and when the procedure is done correctly, injections rarely have to be extended to the distal area of the finger.

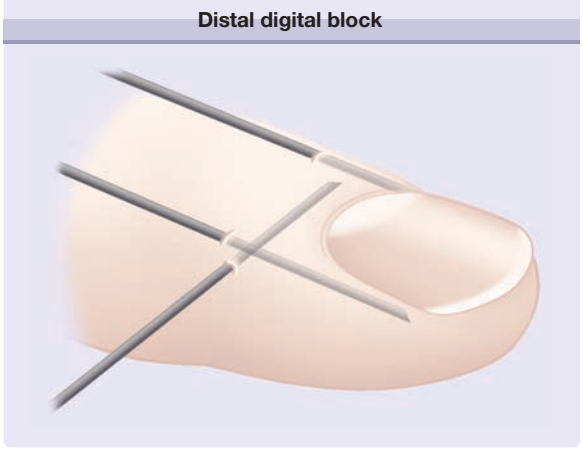

Figure 245-3 Distal digital block.



Figure 245-4 Median distal block.

Median distal administration is relatively simple and quick (Fig. 245-4). The needle is introduced at a 30-degree angle into the middle of the proximal nail fold and advanced distally into the underlying matrix. Anesthetic is injected slowly as the needle pierces first the nail plate, then the matrix, and finally the adjacent nail bed. The nail plate is soft and offers little resistance. Blanching confirms the delivery of anesthetic to the nail matrix and bed. Pain is brief and anesthesia nearly instantaneous. This method is suitable for most procedures performed on the proximal half of the nail unit. It is not suitable for matricectomy or complete nail avulsion.

TRANSTHECAL BLOCK

The flexor tendon sheath may be used as an avenue for introducing anesthetic to the core of the digit. Through centrifugal anesthetic diffusion all four digital nerves are anesthetized rapidly. This technique involves palmar percutaneous injection of 2 mL of lidocaine into the potential space of the flexor tendon sheath at the level of the palmar flexion crease using a 3-mL syringe and a 25-gauge hypodermic needle.

WRIST BLOCK

There are several circumstances under which it is useful to have anesthesia of more than one digit at the same time. A wrist block may be appropriate in the surgical treatment of numerous warts and in the infiltration of more than one finger with triamcinolone in the treatment of nail unit psoriasis. This should be undertaken with the guidance of an experienced clinician.

TOURNIQUETS

For brief intraoperative hemostasis (e.g., nail avulsion, punch biopsy of the nail bed), squeezing the sides of the digits is effective. If a prolonged bloodless field is required, a Penrose drain may be placed around the base of the digit and secured with a hemostat for use as a tourniquet. It is preferable not to leave it on for more than 15–20 minutes. The tourniquet application can be interrupted for a few minutes during longer procedures.

To complement anesthesia and facilitate establishment of a bloodless field, use of an exsanguinating tourniquet is recommended.[1] A wide Penrose drain is wound tightly in loops that overlap in a distal to proximal fashion, with an exposed loose end left distally (eFig. 245-4.1 in online edition). This "milks" the blood from the digit. The loose end is then grasped and the drain unwound, again from distal to proximal, until the nail unit is exposed with the final proximal loop.

DRESSING AND POSTOPERATIVE CARE

At the end of the operation, either the digit is cleansed with sterile 10% hydrogen peroxide solution and sprayed with a colorless disinfectant, or an antiseptic with hemolytic action is applied. The nail area is then covered with an antiseptic or antibiotic ointment on gauze or pads. Dressing must be done in a way that takes into account oozing, pain, and sensitivity. A bulky dressing provides a cushion against local trauma.

Dressings should be changed every other day or daily if there is infection. Several layers of sterile gauze should be kept in place by Micropore (2.5-cm) tape placed first on the dorsal aspect of the finger or toe, then on the ventral aspect, and last on the lateral edges in a U shape (a circular dressing should never be applied in the first week). Finally, use of an X-span tube dressing or Surgitube will give the patient more freedom to use the hand, but care must be taken that dressings do not constrict blood flow. During the first 48 hours the arm must be kept in a sling. Stitches are removed after 7–12 days.

When the feet are treated, daily chlorhexidine baths precede the care just described.

For all operations involving the toes, the patient should wear an appropriate shoe or sandal after the dressing has been applied. The patient should be recumbent for 24–48 hours, with the foot elevated to 30°.

POSTOPERATIVE COMPLICATIONS

BLEEDING

Bleeding is seen after the tourniquet is removed but can be stopped by compressing the lateral edges of the distal interphalangeal joint. In cases of persistent bleeding, 35% aluminium chloride solution or a cellulose application (Gelfoam) should be applied.

PAIN

Pain threshold varies from patient to patient. Postoperative pain can be almost nonexistent if, in the absence of infection, the operation is followed by a periungual injection of 0.6 mL of 0.5% bupivacaine with 0.4 mL of 4 mg/mL dexamethasone. While the dressing is being put in place, the patient must be told what precautions to take. Providing a supply of moderately potent oral analgesics will help the patient feel in control of any pain, even if the patient chooses not to take the tablets. Sometimes postoperative pain may be severe, and it is alleviated by elevating the extremity as much as possible for 2 days. Pulsating pain beginning after 36–48 hours may indicate an infection, which should be treated according to the results of bacterial culture of the organism. Any bulky dressing that is blood stained after 24 hours should be changed.

INFECTION

Prophylactic antibiotic treatment is mandatory for patients with valvular heart disease, including those with a prosthetic valve. Peripheral vascular disease and young age (in childhood, the nail matrix is extremely fragile and behavior is less sanitary) are further indications. If there are ragged surfaces to the nail, which makes thorough preoperative cleaning difficult, antibiotics may prevent wound infection.

Postoperative infection may be caused by preoperative colonization or infection. Culture of preoperative swab specimens will indicate the best choice of drug after initial coverage with a broad-spectrum antibiotic.

Attention to detail is important. Carelessness may result in serious infectious complications in the soft tissue and occasionally in bone. Routine or preoperative nail cleansing softens the nail plate and keeps contamination to a minimum.

MISALIGNED NAIL

Misaligned nail may result from a lateral longitudinal nail biopsy, especially if the routine 3-mm width is exceeded.

RELAPSE

Relapse will depend on the nature of the lesion treated. Warts, ingrown nails, and myxoid cysts can be difficult to eradicate.

RESIDUAL DYSTROPHY

Residual dystrophies are not unusual when surgery involves the proximal area of the matrix.

UNPREDICTABLE COMPLICATIONS

Implantation epidermoid cysts can occur in operation scars. Reflex sympathetic dystrophy after nail biopsy, although exceptional, has been reported.

NAIL AVULSION

The removal of the nail plate can be carried out using distal or proximal approaches. In both techniques, inserting the blunt instrument back and forth between the horny layer of the proximal nail fold and the nail plate loosens the proximal nail fold adherence.

DISTAL APPROACH

In the more commonly used distal approach, a Freer septum elevator or a dental spatula is inserted between the nail plate and nail bed (Fig. 245-5A). The nail is separated from its nail-bed attachment using proximal force applied in anterior-posterior movements so as not to injure the longitudinal ridges of the nail bed. The detachment is completed by firmly pushing the instrument into the posterolateral corners of the nail plate. Then, one of the lateral edges is grasped with a sturdy hemostat, and extracted with an upward and circular movement to accomplish the removal of the nail plate.

PROXIMAL APPROACH

The proximal approach for nail avulsion is advisable when the subungual distal area adheres strongly to the nail plate and when the hyponychium may be injured by the subungual introduction of the spatula. The proximal nail fold is freed as described in Distal Approach. The spatula is then used to reflect the proximal nail fold, and is delicately inserted under the base of the nail plate where adherence is normally weak (see Fig. 245-5B). The instrument is advanced distally

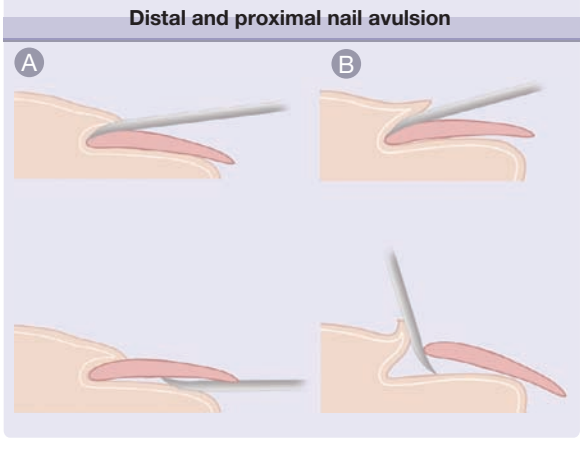

Figure 245-5 A. Distal nail avulsion. **B.** Proximal nail avulsion.

following the natural cleavage plane, and this operation is repeated on the entire width of the subungual region. After the last attachments are freed, the nail plate is easily pulled out.

Total surgical removal should be discouraged, however, because the distal nail bed may shrink and become dislocated dorsally. In addition, the loss of counterpressure produced by the removal of the nail plate allows expansion of the distal soft tissue, and the distal edge of the regrowing nail then embeds itself. In patients at high risk, nonsurgical removal of the nail plate should be considered when necessary. This can be accomplished by applying 40% urea paste directly to the nail after protecting the surrounding skin. Urea acts on the bond between nail keratin and diseased nail plate, sparing only the normal nail tissue.

PARTIAL NAIL AVULSION

The problems that can arise after total nail avulsion may be overcome by partially avulsing the nail. Partial distal avulsion requires only separation of the nail from the distal nail bed. This procedure can be performed under local anesthesia in selected patients, when, for instance, a fungal infection is of limited extent. An affected portion of the nail plate may be removed in one session, even when the disease has reached the deeper regions of the subungual tissue beneath the proximal nail fold. Commonly, an English anvil nail splitter or a double-action bone rongeur is used for this procedure.

Partial surgical section of the lateral and/or medial segment of the nail plate may be sufficient for the treatment of distal lateral subungual onychomycosis. In the toe, this procedure leaves enough normal nail to counteract the upward forces exerted on the distal soft tissue when walking, and this will prevent the appearance of a distal nail wall.

In proximal subungual onychomycosis, removal of the nonadjacent base of the nail plate, cut transversely, leaves the distal portion of the nail in place (Fig. 245-6), which decreases discomfort. Similarly, an acute paronychia that does not respond to appropriate antibiotics within 48 hours should be treated surgically by removing the base of the nail plate.

TRAP DOOR NAIL AVULSION

This technique minimises trauma in nail surgery when accessing the nail bed and matrix. Trap door nail plate avulsion entails separation of all periungual attachments except for that between the dorsum of the nail and the ventral aspect of the proximal nail fold. Both are then reflected in bloc in the manner of a trap door, utilising the same oblique incisions normally made for reflection of the PNF alone.

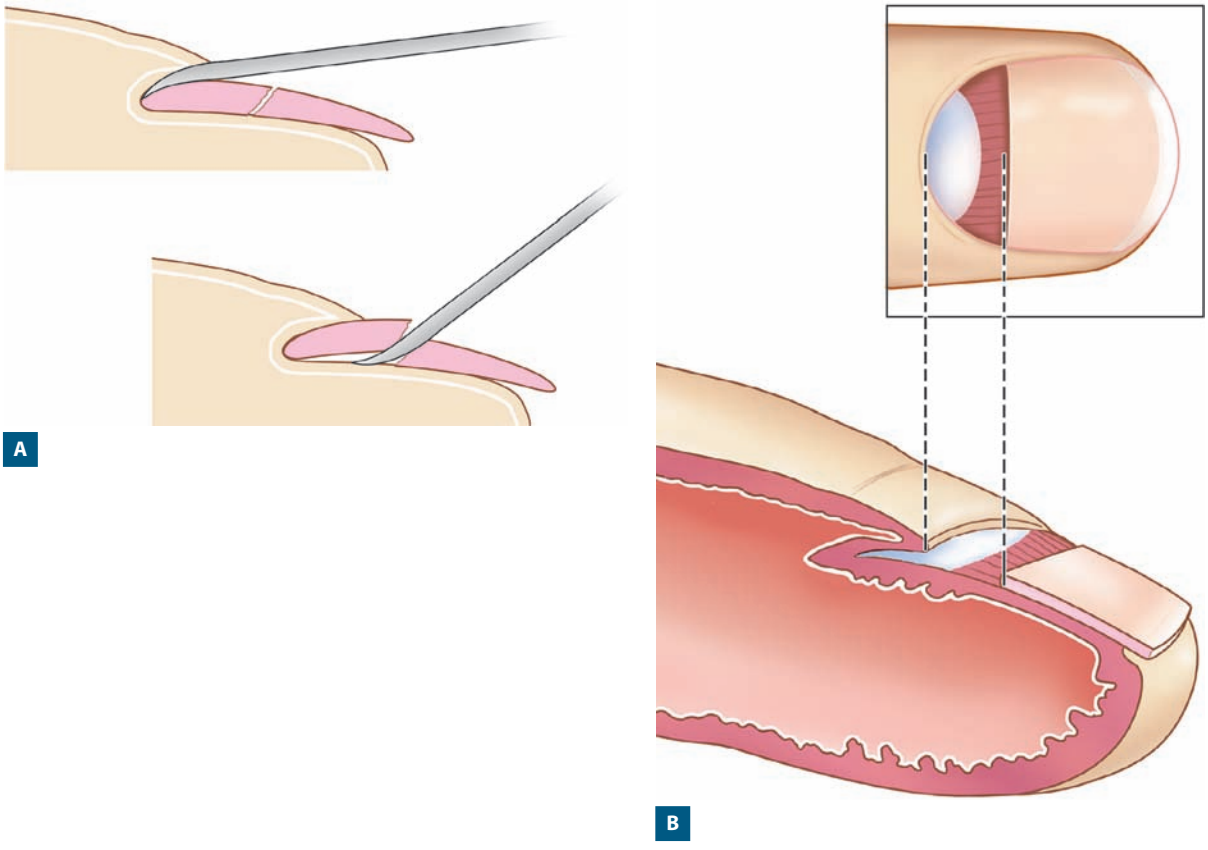

Figure 245-6 **A** and **B.** Technique of removal of the base of the nail plate.

SURGICAL APPROACHES TO THE DIFFERENT TISSUES OF THE NAIL APPARATUS

NAIL MATRIX

When surgery involves the nail matrix, there are three primary approaches, including (1) a reduction in its width or (2) its length for removal of tumors, for instance, by using a cold steel procedure or (3) a 2-to 3-mm punch biopsy. In contrast to these three procedures, complete matricectomy, that is, ablation of the nail-forming tissue, is rarely performed because the nail is permanently lost (eFig. 245-12.1 in online edition).

After reduction of the nail matrix width, one is left with a narrower nail and after reduction of the length, with a diminution in the thickness of the nail. Reduction of the matrix width is a useful and/or necessary procedure in the following major circumstances:

- Need for lateral-longitudinal biopsy
- Lateral nail splitting
- Benign or malignant tumor in the lateral third of the nail apparatus
- Longitudinal melanonychia in a lateral location
- Ingrown nail
- Racquet nail

Reduction of the matrix length is necessary only in limited cases: to obtain a transverse elliptical biopsy specimen, to treat tumors that are 3 mm wide or larger, and to thin thick nails in patients with dystrophic congenital and/or hereditary disorders.[2]

BIOPSY.[3–5] Biopsy of the nail matrix is performed to determine the histopathologic features of a lesion or to clarify an uncertain clinical diagnosis.

A 3-mm punch biopsy may be performed through the nail plate into the matrix. Three millimeters is the maximum size that does not produce serious dystrophy, although even biopsies of this size can cause such effects if carried out in the most proximal portion of the nail matrix. When a punch biopsy is used to sample longitudinal melanonychia of less than 3 mm in width, the circumferential incision is made around the origin of the band, through the nail plate (Fig. 245-7A). This area may be distal enough to be reached by pushing back the cuticle (Fig. 245-7B), but if it is more proximal, the proximal nail fold may have to be reflected using a posterolateral incision. The next step is to remove the proximal third of the nail plate (see Fig. 245-7B and C), while leaving the cylinder of tissue containing the origin of the longitudinal melanonychia still in place. This technique allows the surgeon to inspect the surrounding nail matrix and bed with a magnifying lens to determine whether pigment extends around the punch incision (see Fig. 245-7C and D) and facilitates the removal of the cylinder of biopsy tissue with a Gradle scissors.

For lateral longitudinal biopsy (Fig. 245-8), an elliptical incision may be made on either side of the nail plate and proximal nail fold. For the most part, the incisions parallel the lateral edge of the nail plate. Beginning in the lateral nail groove, the incisions should include a 3- to 4-mm nail segment reaching to the bone. This ensures that a full-thickness fragment of the matrix with its lateral horn is obtained. Slightly curved iris scissors are useful for separating the tissue from the bone. Starting at the tip of the digit, one proceeds proximally while maintaining contact with the bony phalanx. Lateral longitudinal biopsy is the advised procedure when longitudinal melanonychia[3] is located in the lateral part of the nail plate.

For transverse biopsy (Fig. 245-9), two small oblique incisions are made on each side of the proximal nail fold. The fold is then reflected to expose the matrix area. The proximal third of the nail plate is avulsed. Then, the lesion is removed by excising an elliptical or crescent-shaped wedge of tissue with the convex portion of the crescent paralleling the anterior border of the lunula. When longitudinal melanonychia lies within the midportion of the nail plate, the potential for postoperative dystrophy is great, and selection of the optimal biopsy method is difficult (eFig. 245-10.1 in online edition) (Haneke's releasing flap technique derived from Schernberg's releasing flat method). It is important to establish the matrix origin (proximal or distal) of longitudinal melanonychia preoperatively, because the more proximal the origin, the greater the risk of nail dystrophy.[3] The origin of pigmentation may be determined by microscopic examination of Fontana-Masson–stained clippings from the free edge of the nail.

Tangential matrix biopsy (Fig. 245-10) for longitudinal melanonychia is a new technique devised by E. Haneke. Cutting, then reclining the proximal portion of the nail plate (1), after reflecting the proximal nail fold (2), the pigmented lesion is exposed. An incision is made around the lesion, followed by its tangential removal. Finally the proximal nail plate is replaced and the oblique incisions of the proximal nail fold are maintained by micropore. This technique is claimed to give the best cosmetic results.

RACQUET NAIL

SPLIT-NAIL DEFORMITY.[6] The common causes of split-nail deformity include trauma, surgery, lichen planus, and tumors. Split-nail deformity may occur in either the lateral or the medial region. The appropriate surgical technique varies accordingly.

If the split is located within the lateral third of either portion of the nail, especially when it is close to the lateral margin, the best method is the technique recommended for lateral longitudinal nail biopsy, that is, the removal of the lateral portion of the nail with the defect. If the split is located in the middle region of the nail and involves its whole length, the proximal nail fold is carefully freed from the underlying nail plate, obliquely incised at both sides, and reflected to expose the whole matrix area (Fig. 245-11). The nail plate bordering the split is cautiously cut as a rectangular block approximately 1 mm wider than the scar that has to be excised. The nail bed and matrix of the defective tissue

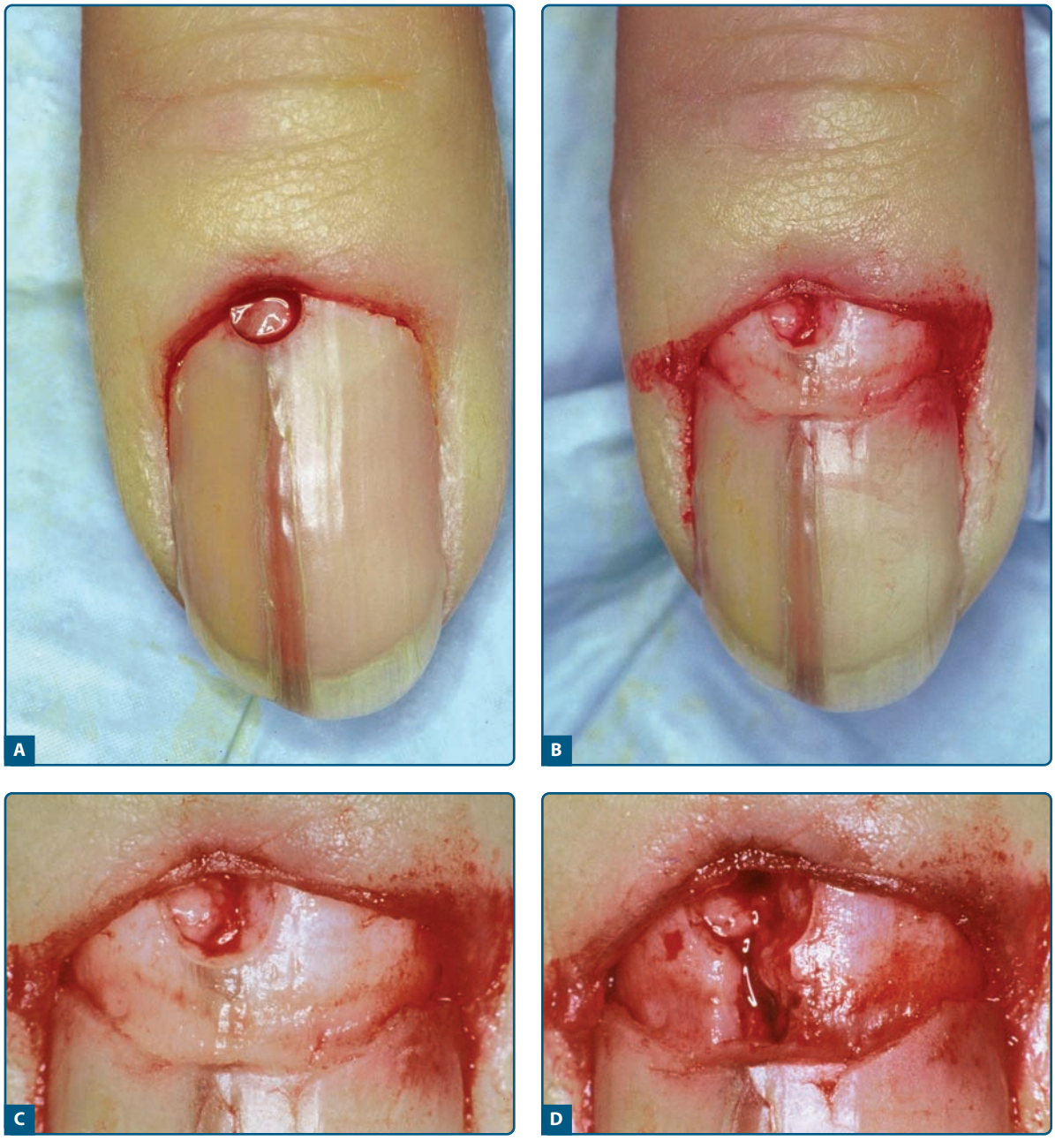

Figure 245-7 **A.** Punch biopsy of longitudinal melanonychia of less 3 mm in width. **B–D.** Removal of the base of the nail plate (**B**) to allow easy removal of the biopsied cylinder of matrix tissue (**C**) and pigment left distally (**D**).

are dissected from the bone to allow an exact approximation of the remaining bed and matrix, which are sutured with 6-0 monofilament absorbable sutures. To prevent the sutures from tearing the tissue, 3-0 sutures are put through the nail plate. When these threads are knotted firmly, the matrix and nail bed are further approximated, which relaxes the 6-0 sutures.

If the scar is too wide to allow primary closure of the defect, relaxing longitudinal incisions along the lateral nail grooves down to the bone usually permit suturing. An alternative approach is the formation of a Schernberg nail bed–matrix flap with an L-shaped incision of the lateral aspect of the finger (eFig. 245-11.1 in online edition).

NAIL ABLATION AND ISOLATED MATRICECTOMY. Nail ablation (eFig. 245-12.1A in online edition) is the definitive removal of the entire nail organ and matricectomy (eFig. 245-12.1B in online edition), the complete extirpation of the nail matrix, which results in permanent nail loss. The principle of nail ablation is the complete removal of the nail unit with hyponychium, nail bed, matrix, and lateral and proximal nail folds. Except for treatment of malignant tumors of the nail apparatus,



Figure 245-8 Lateral longitudinal biopsy of longitudinal melanonychia located within the lateral third of the nail plate.

nail ablation is rarely indicated. It may be necessary in the case of an excessively painful nail treated several times without success, but this should be an exception. Scalpel excision is strongly advocated whenever the surgical specimen needs histopathologic examination. If periungual pigmentation is associated with longitudinal melanonychia or if the latter is wider than 6 mm or the full thickness of the nail is pigmented, a large portion of the matrix would necessarily be involved. Under these circumstances, the underlying disease process is unlikely to be benign. The entire portion of the involved nail apparatus has to be excised en bloc.

The defect from nail ablation (see Fig. 245-12B) may be covered with a free graft (split-thickness, full-thickness, reversed dermal graft), which usually takes on the bone in this particular location. A cross-finger flap is a very useful alternative to a free graft. The use of the skin from the intermediate phalanx of a neighboring finger is more convenient for the patient than skin from the thenar area of the palm.

If only permanent nail matrix removal is necessary, the procedure is less extensive.

In cases in which pathologic examination of the removed tissue is unnecessary, phenol cautery, rather than scalpel excision, is the preferred technique for matricectomy. Most patients return to normal ambulation and activity as early as 1 day after the operation.

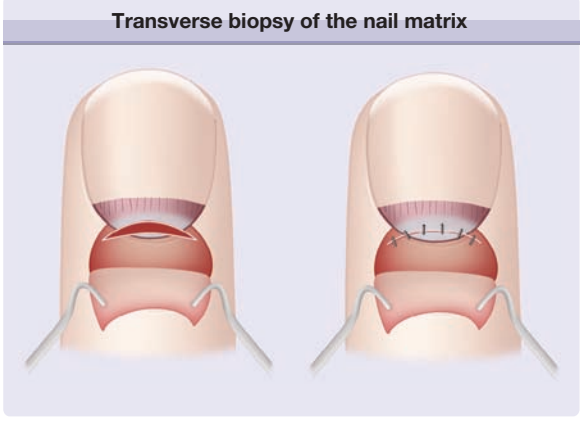

Figure 245-9 Transverse biopsy of the nail matrix.

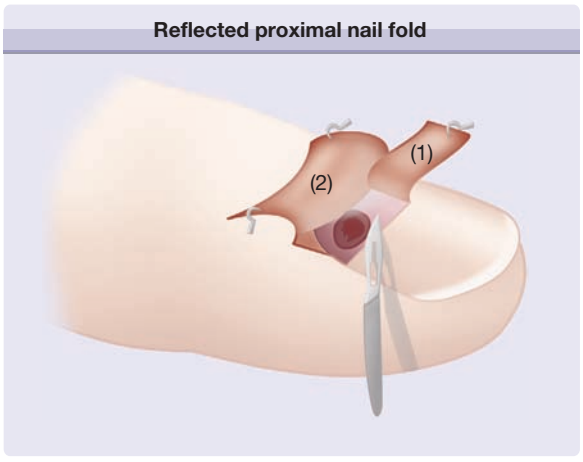

Figure 245-10 Reflected proximal nail fold and removal of the proximal portion of the nail plate exposing the pigmented lesion. Around the latter is made an incision followed by its tangential removal Haneke's matrix tangential biopsy technique.

NAIL BED

Nail-bed surgery is performed for biopsy, removal of tumors, and treatment of nail dystrophies such as onychogryphosis.

BIOPSY. Biopsy (Fig. 245-13) may be useful in any pathologic condition involving the nail bed.

Punch biopsy is done with a 3- or 4-mm diameter punch, which is driven perpendicularly into the nail plate in a circular motion down to the bone. However, it is not always easy to extract the cylinder cut with an area this small. One useful technique is to perforate the nail plate with a 6-mm punch without injuring the underlying tissue (see Fig. 245-13A). The covering nail is then detached by using the tip of the scalpel to remove the disk of nail, and the biopsy is performed easily by using the 4-mm punch to the bone. The tissue can then be released from its tether with fine scissors. It is advisable to replace the 6-mm disk of nail keratin, after cleaning with 10% hydrogen peroxide, to cover the hole. If the

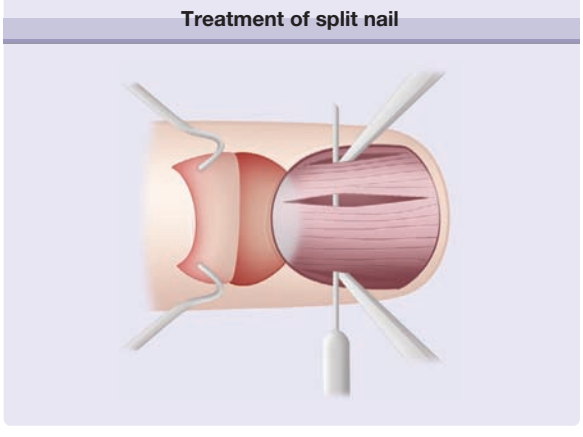

Figure 245-11 Treatment of split nail in the middle region of the nail plate.

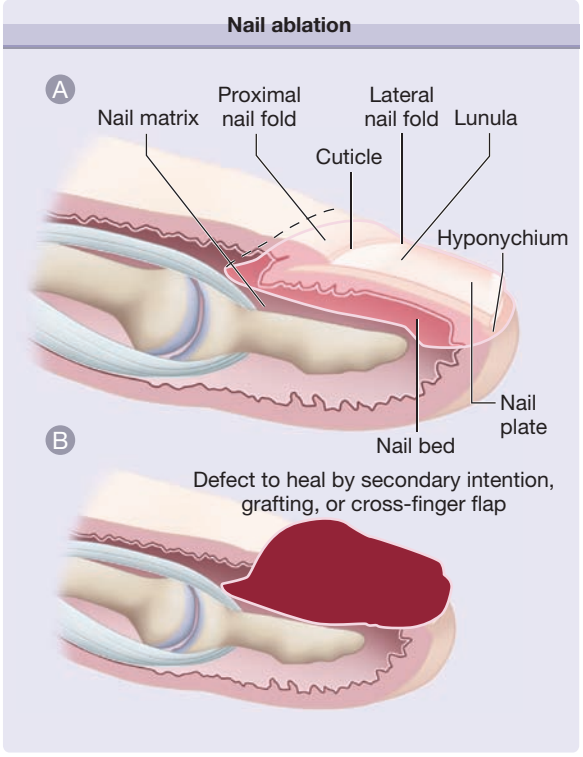

Figure 245-12 Nail ablation. **A.** Area of excision. **B.** Remaining defect.

nail plate is thick, rotating grinders can be used to thin it down and facilitate the transungual biopsy.

If a larger nail bed fragment is needed, fusiform biopsy with a major longitudinal axis can be performed after partial avulsion of the lateral half of the nail (see Fig. 245-13B) or after total avulsion if the fragment is central. After excision, the nail bed is undermined to facilitate reapproximation of both sides. The suture needle is used generously on these fragile subungual tissues. The wound is stitched with 6-0 resorbable thread. It is sometimes useful to make relaxing incisions at the most lateral margins of the nail bed.

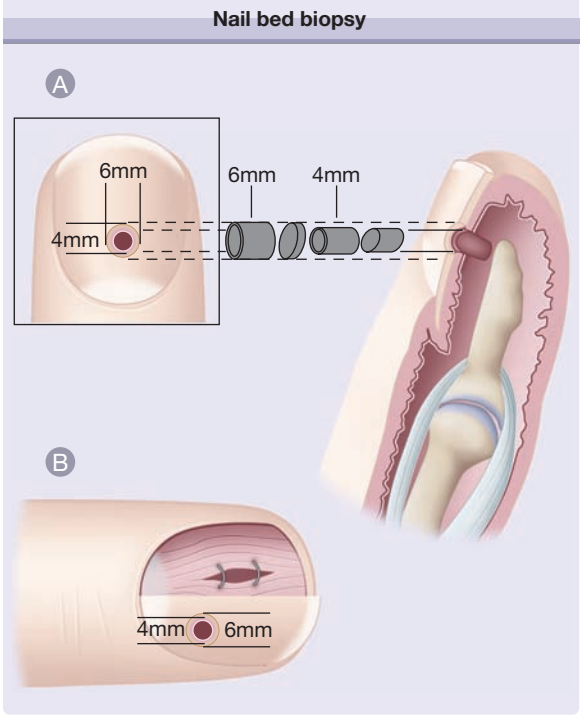

Figure 245-13 Nail bed biopsy. **A.** Punch biopsy. **B.** Fusiform biopsy.

SUBUNGUAL HEMATOMA. In cases of subungual hematoma, acute trauma with severe pain is always remembered by the patient. Depending on the site and intensity of the injury, the hematoma may be visible almost immediately or it may grow out from under the proximal nail fold within a few weeks.

When the hematoma is partial (less than 25% of the visible portion of the nail), it should be drained with a pointed scalpel or by hot paperclip cautery over the center of the dark spot (Fig. 245-14). This will produce relief from pain. Sometimes the nail sloughs as the new nail regenerates beneath the old one.

Small hematomas may be included in the nail, but they cannot be degraded to hemosiderin and results of the Prussian blue test will be negative. Therefore, to demonstrate the nature of the blackish pigment, scrapings are boiled in a small test tube with Hemostix, which gives a positive benzidine result.

A hematoma involving more than 25% of the visible portion of the nail is a sign of significant nail bed injury. A radiograph is mandatory, because the phalanx may be fractured. The nail plate is carefully removed and the hematoma evacuated. Traumatic nail bed laceration or wounds need a surgical approach to avoid delayed complications.

Nail bed lacerations can be sutured after thorough cleaning with antiseptics, using 6-0 resorbable monofilament material. The avulsed nail plate should be put back to cover the wound and then kept in place by suturing to the lateral nail folds or the fingertip.

Nail bed defects larger than 4 mm can be repaired using a split-thickness graft taken either from the nail bed of the same digit or from the nail bed of a great toe.

The torn nail bed should be sutured with 6-0 resorbable thread, and large bites of tissue should be taken

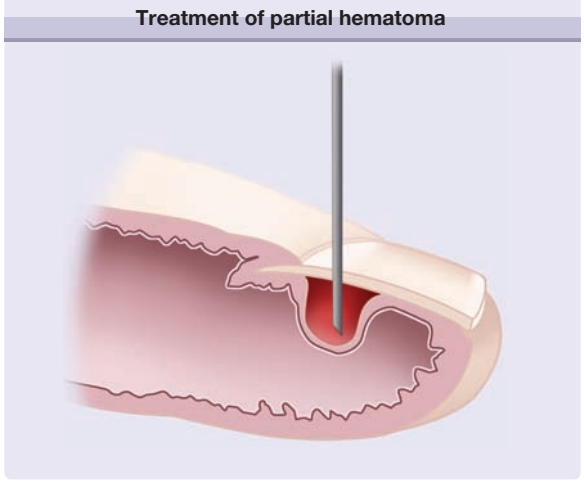

Figure 245-14 Treatment of partial hematoma.

so that the suture material does not pull through when it is tied. The nail plate is cleaned, shortened, and slightly narrowed, and then replaced with sutures into the lateral nail folds. The stitches are left in for 2 weeks.

Chronic hematomas are usually painless and are caused mainly by repeated microtrauma from either ill-fitting footwear or sporting activities. A notch is made with a scalpel blade at the distal and proximal border of the pigmented spot. Observation over a 3-week period will demonstrate whether the nail grows independently of the pigmentation or with it. However, chronic hematoma may resemble subungual melanoma and pose a distressing problem, and nonmigrating hematoma should be ruled out.

PROXIMAL NAIL FOLD

BIOPSY. A 2- to 3-mm punch may be used for biopsy of a tumor. A blister may be completely removed by shave biopsy using half a razor blade (see eFig. 245-14.1 in online edition). Excision of a 3-mm crescent-shaped tissue segment in the proximal region of the lateral nail folds may be helpful in the evaluation of collagen disease.

RECALCITRANT CHRONIC PARONYCHIA. Presence of a foreign body (e.g., hair) under the proximal nail fold is the main cause of recalcitrant chronic paronychia. The disorder manifests as a red swelling that is painless except when pressed, with secondary retraction of the paronychial tissue whose cuticle has disappeared and with recurrent episodes of acute paronychial inflammation.

For crescentic excision, a Freer septum elevator is inserted under the proximal nail fold to protect the matrix and extensor tendon. A No. 15 Bard-Parker blade is used to excise, en bloc, a crescent-shaped full-thickness skin segment, 4 mm at its greatest width, that extends from one lateral nail fold to the other. Use of a beveled incision prevents accidental damage to the proximal nail matrix and the most proximal portion of the proximal nail fold, which is responsible for the normal shine of the nail plate (see eFig. 245-14.2 in online edition).

In patients who experience repeated acute flares associated with chronic paronychia, additional removal of the base of the nail is useful.

TUMORS OF THE PROXIMAL NAIL FOLD. Different techniques can be used to treat tumors of the proximal nail fold, depending on the nature of the tumor, its location, and the length of its long axis.

Crescentic excision is useful for small distal tumors. The crescent should not exceed 4 mm at its greatest width.

Tumors of the proximal nail fold that are situated in a median position and have a longitudinal axis longer than 4–5 mm can be excised with a wedge of proximal nail fold whose base is located at the free margin and whose apex points proximally (Fig. 245-15A). Two relaxing lateral incisions are then made in the proximal nail fold to allow suturing of the wedge-shaped defect after the undersurface of the proximal nail fold has been released from the nail plate (see Fig. 245-15B).

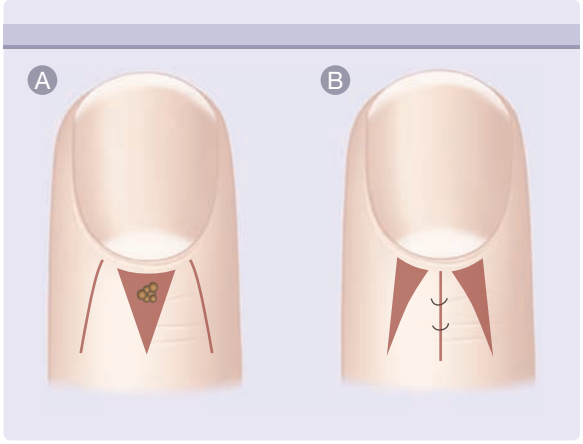

Figure 245-15 **A.** Tumor of the proximal nail fold situated in a median position. **B.** Suturing of the defect after relaxing lateral incisions are made and the proximal nail fold has been released from the nail plate.

The resulting symmetric narrow defects on both sides heal rapidly by secondary intention.

A small tumor on the lateral part of the proximal nail fold may be treated using a wedge-shaped excision (see eFig. 245-15.1 in online edition). Only one lateral relaxing incision is made at the opposite region of the proximal nail fold. To obtain better healing of the secondary defect, which is wider than in the procedure using two relaxing incisions, the surgery may be supplemented by making a relaxing crescent-shaped incision in the proximal nail fold.

A dorsal flap can be raised from the proximal nail fold by using two dorsolateral incisions and a horizontal one proximal to the cuticle. This gives complete exposure of subcutaneous tumors.

RECONSTRUCTION OF THE PROXIMAL NAIL FOLD. Reconstruction of the proximal nail fold may be necessary after any injury (accident, burn, avulsion caused by rapidly rotating belts and sanders, etc.). If the irregular tissue is excised, it is sometimes possible to recreate the distal curve of the proximal nail fold, which may produce a nearly perfect restoration. The proximal nail fold may also be restored by using two long, narrow, V-shaped transposition flaps from the lateral aspects of the terminal phalanx.

LATERAL NAIL FOLD

A 2- to 4-mm punch can remove a tumor of the lateral nail fold (see eFig. 245-15.2 in online edition). Benign tumors may be removed by taking an elliptical wedge of tissue from the lateral nail fold and lateral nail wall. Malignant tumors, such as in Bowen disease, are treated by excision of the whole lateral nail fold or by Mohs micrographic surgery followed by healing by second intention.

INGROWN NAILS. Ingrown nail is a condition that occurs mainly in the great toe. It is created by impingement of the nail plate into the dermal tissue distally or

into the distolateral nail groove. Irrespective of the initial cause, the condition finally presents with a nail bed that is too narrow for its nail plate. Logical treatment is therefore aimed at correcting this disparity.

Distal Toenail Embedding. Surgical avulsion or the loss of the toenail from trauma, such as tennis toe, may initiate the pathology. The distal subungual tissues released from the physiologic counterpressure of the nail plate become hypertrophic, and the newly formed nail plate abuts this distal wall. To treat the condition, a crescentic wedge-shaped excision is made around the distal phalanx (see eFig. 245-15.3 in online edition). The wedge should be 4 mm at its greatest width and must be dissected from the bone. The defect is closed with 5-0 monofilament sutures, which should be removed after 12–14 days.

Retronychia. Retronychia represents proximal regrowth of the nail that occurs when the nail embeds backwards into the proximal nail fold. Sonography is a useful tool to diagnose easily this condition. Nail-plate avulsion with supplementary medical management is curative.

Juvenile (Subcutaneous) Ingrown Nails. Juvenile or subcutaneous embedded nail is the most common type of ingrown nail. The nail is usually embedded medially, but both sides are often affected. In an effort to relieve the pain, the patient often tries to cut off the offending corner under the inflamed and swollen soft tissue. The remaining portion gives rise to a nail spicule piercing the epithelium of the lateral nail groove, which produces secondary infection and excessive granulation tissue.

Treatment at the early stage must be conservative but demands a high degree of patient compliance. The foot is soaked in warm water with povidone-iodine soap; then, under local anesthesia, the nail spicule is removed and a wisp of cotton wool is placed between the nail and the lateral nail groove. It should be moistened repeatedly with a disinfectant.

For definitive cure, surgical excision or, better, chemical suppression of the lateral horn of the nail matrix permanently narrows the nail. The lateral fifth of the nail plate is freed with a nail elevator from the proximal nail fold and the subungual tissues. It is then cut longitudinally with an English nail splitter or nail-splitting scissors and extracted using a sturdy hemostat. The lateral matrix horn is cauterized with a freshly made solution of liquefied phenol (88% solution) (see eFig. 245-15.4 in online edition). Above all, a bloodless field is needed, because blood inactivates phenol. Hemostasis is therefore accomplished with a tourniquet, and the blood is carefully cleaned from the space under the proximal nail fold using sterile gauze. The surrounding skin is protected with petroleum jelly. The phenol is rubbed onto the matrix epithelium for 3 minutes with a cotton-tipped swab that is changed two or three times. Postoperative pain is minimal because phenol has a local anesthetic action and is antiseptic. The matrix epithelium is sloughed off, and oozing is usual for 2–6 weeks. Daily warm foot baths with povidone-iodine soap accelerate healing.

Besides phenol and sodium hydroxide, 100% trichloracetic acid has been performed for partial matricectomy. The wound almost always heals within 2 weeks without prolonged exsudative discharge. Pain is mild and transient.

Pincer Nail.[7] Overcurvature of the nails may affect the great toe alone or all the digits. This condition may be so painful that even contact with a bedsheet becomes unbearable.

When the condition is mild, the nail brace technique aims at correcting the inward distortion of the nail by maintaining continuous tension on the nail plate. A stainless steel wire brace is fitted to the nail plate. A series of adjustments adapted to the gradual decrease of curvature is made over a period of 6 months and results in a painless correction of the pincer nail. Because the underlying bone pathology remains untreated, however, relapse is usual. Therefore, the definitive cure—the use of phenol cautery on the lateral matrix horns—is undoubtedly the simplest effective treatment modality.

Hypertrophy of the Lateral Nail Fold. Hypertrophic lateral nail folds are usually the result of long-standing ingrown nails. Inflammation may range from the subclinical to the severe. For treatment, approximately one-fifth of the nail digging into the lateral nail fold is removed. Then an elliptical wedge of tissue is taken from the lateral nail wall of the toe, down to the bone (see eFig. 245-15.5 in online edition). Suturing of the defect pulls the lateral nail fold away from the offending lateral nail edge. In severe cases, this procedure may be combined with phenol cautery of the lateral horn of the matrix. In contrast to adult-acquired hypertrophy of the lateral nail fold, congenital lateral hypertrophic lips disappear progressively and spontaneously within 12 months.

Congenital Malalignment of the Great Toenail.[8] In congenital malalignment of the nail of the great toe, typically the nail is malaligned laterally, with transverse furrows on a thick brownish or greenish nail. In 50% of cases, this condition corrects itself without therapy before the age of 10. If the appearance is extreme, surgery diminishes the risk of permanent dystrophy.

Treatment requires rotation of a bulky nail unit flap, including the entire nail, nail bed, and matrix (see eFig. 245-15.6 in online edition). This demands creation of an external Burow's triangle. An eccentric crescent-shaped excision is made to undermine the nail unit, with the maximum width located on the internal side of the foot, corresponding to the side to which the nail needs to be redirected. This crescent ends on each side 3–4 mm behind the most proximal part of the proximal nail fold. The nail bed and the matrix are then undermined and lifted until the fibers of the extensor tendon are visible on its bony insertion, and the dorsal expansion of the lateral ligament of the distal interphalangeal joint is cut.

Suturing the edges of the excised triangle together reduces the loss of cutaneous substance. The nail unit is rotated inwardly, because the maximum cutaneous resection is mostly distal and medial.

Chapter 246 :: Cryosurgery and Electrosurgery

:: Justin J. Vujevich & Leonard H. Goldberg

CRYOSURGERY, CRYOBIOLOGY, AND CROYGENS

Cryosurgery refers to the use of extreme cold to destroy cells of abnormal or diseased tissue. The earliest use of a cold refrigerant in medicine is attributed to White, a New York dermatologist, in 1899.[1,2] Using a cotton-tipped applicator dipped into liquefied air, he successfully treated warts, nevi, and precancerous and cancerous lesions. In 1907, Whitehouse, another New York dermatologist, reported the utilization of the spray method in the cryosurgical treatment of skin cancers.[3]

Cryobiology refers to the study of the effects of subzero temperature on living systems. Tissue destruction from cryotherapy results from direct cell injury, vascular stasis, and the local inflammatory response.

Rapid freezing of cells causes intracellular ice crystal formation with the disruption of electrolytes and pH changes, whereas slow freezing causes extracellular ice formation and less cell damage. Therefore, tissue effects and cell death are most readily achieved when tissue is frozen rapidly.[4]

During thawing, recrystallization occurs when ice crystals fuse to form large crystals that disrupt cell membranes. As the ice melts further, the extracellular environment becomes hypotonic, causing water to infuse into sells a cell lysis.[5] The longer the thawing time, the greater damage to the cells because of increased solute effect and greater recrystallization.[5]

After freezing, stasis within the vasculature occurs. This loss of circulation and resultant anoxia is a major mechanism of injury from cryosurgery. As the tissue thaws over 0°C (32°F), a brief hyperemic response ensues, with resultant edema and inflammation.

Liquid nitrogen is the cryogen of choice in dermatology. It is easy to store and use, environmentally friendly, nonflammable, inexpensive, and at –195.8°C (–320.4°F), has the lowest temperature of all the common cryogens, causing rapid freeze of treated tissue.

Other available cryogens include fluorinated hydrocarbons, solid carbon dioxide, and nitrous oxide (Table 246-1). Fluorinated hydrocarbons are used as topical sprays to provide temporary anesthesia before the removal of skin lesions or the administration of vaccinations. Cryogen spray cooling is also used to reduce the pain of laser surgery and eliminate overheating of the epidermis.[6]

TABLE 246-1
Cryogens Used in Cryosurgery

Agent	Boiling Point (°C/°F)
Freon	–40.8/–41.4
Solid CO_2	–79.0/–110.2
Nitrous oxide	–89.5/–129.1
Liquid nitrogen	–195.8/–320.4

PATIENT SELECTION AND CONSIDERATIONS FOR CRYOSURGERY

Cryosurgery is a destructive modality used to treat benign and malignant skin neoplasms. Several factors, including lesion type, size, depth, border, location, and patient skin type, should be considered when cryosurgery is a treatment choice.

Absolute contraindications to cryosurgery include lesions that require histopathology for diagnosis and recurrent nonmelanoma skin cancers. Relative contraindications to cryosurgery include patients with cold urticaria, abnormal cold intolerance, cryoglobulinemia or cryofibrinogenemia, or tumors with indistinct borders or darkly pigmented melanotic features.

RISKS AND PRECAUTIONS

Precautions should be undertaken when:

- Treating lesions overlying nerves, such as the postauricular nerve on the neck or digital nerves on medial and lateral fingers and toes. Damage may result in regional paresthesia or motor dysfunction.
- Treating sites prone to scarring with retraction, such as the eyelids, mucosa, nasal ala, and auditory canal.
- Treating patients with darkly pigmented skin, may result in hypopigmentation at treated sites.

PATIENT POSITIONING

Patients may be seated or lying on a examination table at a angle but the spray canister should be held upright. Tilting the canister sideways will result in the sudden release of vapor from the canister.

EQUIPMENT

- Cryogen storage container
- Cryogen
- Cryosurgical spray unit

ANESTHESIA

For the majority of patients, anesthesia is not used prior to a cryosurgical procedure. However,

cryosurgery is painful, especially in children. 1% lidocaine with 1:100,000 epinephrine may be locally injected prior to treatment. For longer cryosurgery treatment times, such as treatment of skin neoplasms (up to 30 seconds), local anesthesia is mandatory. Topical anesthesia can be applied approximately 1 hour prior to the procedure to minimize pain. A single-center, double blinded, randomized placebo-controlled, parallel-group trail comparing a lidocaine/prilocaine 5% cream applied 1 hour prior to cryosurgery for warts, however, did not demonstrate a statistically significant difference in pain during the procedure.[7] For longer cryosurgery treatment times, such as treatment for skin neoplasms (up to 30 seconds), 1% lidocaine with 1:100,000 epinephrine can be locally injected prior to treatment.

TECHNIQUES FOR CRYOSURGERY

Table 246-2 lists targets of cryosurgery with associated cell death temperatures. Melanocytes are the most sensitive to cryosurgery, with cell destruction at –4°C to –7°C (24.8°F–19.4°F).[8] Depigmentation may occur, especially in darkly pigmented individuals. Keratinocytes require longer freezing to –20°C to –30°C until cell death and are more resistant to cooling effects. Fibroblasts are the most resistant to freezing and do not undergo cell death until –30°C to –35°C (–22°F to –31°F). A temperature of –50°C to –60°C (–58°F to –76°F) is needed for destruction of malignant lesions, whereas lesser degrees of freezing are needed for benign lesions.

There are several cryosurgical techniques that can be used in treating skin lesions. The open spray method is most frequently used. This method uses a handheld cryosurgical unit with fingertip trigger (eFig. 246-0.1 in online edition). Spray tips with varying-sized apertures are attached to the unit, emitting a stream of liquid nitrogen toward the lesion from a distance of 1–2 cm. A new model has been released, which measures the temperature on the skin surface.[9]

Although freeze times vary for lesion types, an intermittent spray in a solid, circular, or paintbrush pattern is normally used. Longer spray times are required for thicker, keratotic lesions or malignant lesions; shorter times are required for thinner, atrophic, or benign lesions. The intermittent spray helps localize treatment to the lesion with a small freeze halo, thus minimizing collateral normal tissue damage. This is particularly important when treating lesions around the orbital, nasal, auricular, genital, or periungual regions.

As the lesion is treated, a lateral freeze spreads beyond the margins of the lesion. The measurement of the surface radius of the freeze is equal to the central depth of the freeze into the skin.[5] Temperature gradients exist within the freeze, with colder temperatures in the middle and warmer temperatures toward the periphery. In general, superficial lesions should have a clinical freeze margin of 2–3 mm, and malignant or deeper lesions should have a clinical freeze margin of 5 mm to ensure successful treatment.

The closed technique uses a copper cryoprobe that is attached to the cryosurgical unit. Once the metal probe is pressed against a lesion on the skin, the trigger of the unit is squeezed, and liquid nitrogen leaves the unit through a conduit line that maintains it in a closed system. This technique is useful for treating small, well-circumscribed lesions or lesions found in confined locations.

Similarly, a metal, cone-sized chamber can be attached to the cryosurgical unit and held in contact with the lesion. This allows liquid nitrogen spray to enter the cone and rapidly freeze the lesion. Another cone-apparatus option includes holding an otoscope cover tip against the lesion with one hand while freezing with the cryosurgical unit in the other hand. Treatment times using the cone method should be decreased because the final temperature at the orifice of the cone is obtained faster, when compared with an open spray.

If a cryospray unit is not available, the dipstick technique can be used. First, a small amount of liquid nitrogen is poured into a polystyrene cup or other insulated container. Cotton-tipped swabs are placed tip-down in the container and cooled. Using firm pressure, the cotton-tips are placed against the lesion until a 2- to 3-mm halo forms around the treated lesion. This method is useful where surrounding tissue must be spared, such as periorbital, mucosal, nail, and genital regions.

Alternatively, tissue forceps can be placed in the container and allowed to cool. This method is useful for treating filiform lesions such as verrucae and skin tags. The metal forceps cool rapidly, so gloves should be worn while holding the forceps to prevent freeze injury to the practitioner's fingers.

TABLE 246-2
Tissue Target Cell Death Temperatures

Cell	Temperature (°C/°F)
Melanocytes	–4 to –7 (24.8 to 19.4)
Keratinocytes	–20 to –30 (–4 to –22)
Fibroblasts	–30 to –35 (–22 to –31)

OUTCOMES ASSESSMENT FOR COMMON BENIGN LESIONS

SEBORRHEIC KERATOSIS

The spray technique is an effective modality for treating this common lesion. Although longer freeze times of 10–15 seconds with a 1- to 2-mm halo are required for these raised growths, too aggressive freezing may result in scarring or hyperpigmentation. For cosmetic purposes and to prevent pigmentation changes, a lighter freeze followed by curettage may be preferential. Forewarn patients that a second



Figure 246-1 Warts on hand treated with liquid nitrogen.

treatment may be required, especially for thicker seborrheic keratoses.

VERRUCAE

Warts are a common problem, with a high prevalence in the population.[10] Although cryosurgery for warts has sustained a common practice in dermatology, varying techniques have been offered with regard to freezing method, number of freeze-thaw cycles, and frequency of treatment sessions. Cryosurgery using the spray technique is probably the most common method due to its quick, convenient use and ease of obtaining a freeze halo around the lesion (Fig. 246-1). The cotton-tip applicator technique is cheaper and may be less frightening to the patient, particularly children. Care must be undertaken not to cross contaminate the liquid nitrogen by reintroducing the cotton-tip applicator into a common flask.

Combination therapy with cryosurgery has also been advocated to treat verrucae. Berth-Jones and Huchinson[11] demonstrated a 52% cure rate at 3 months with the combination of cryotherapy, keratolytic wart paint, and paring. The authors also noted that paring the wart before cryotherapy improved the cure rates for plantar warts, but not hand warts.

SOLAR LENTIGO

As shown in Table 246-2, pigmented cells are highly susceptible to freezing. Therefore, these lesions require a shorter freeze time of 3–5 seconds with minimal halo. For darker-skinned individuals, care must be taken not to induce hypopigmentation at treatment sites. Therefore, a test site in a cosmetically less noticeable region may be performed first before treating multiple lesions on sun-exposed areas. In addition, sunscreen with ultraviolet A and ultraviolet protection should be advocated post-treatment.

KELOIDS AND HYPERTROPHIC SCARS

Treatment of keloids and hypertrophic scars is frequently unsatisfactory. Cryosurgery is a less common but effective means of treating these recalcitrant lesions. Freeze times of 30 seconds are required over 1-month interval sessions until flattening is achieved. Zouboulis et al reported a prospective study of 93 keloids and hypertrophic scars treated with 30-second freeze times over one to three sessions.[12] Improved responses were seen in patients treated with three or more sessions (79%), compared with subjects treated once or twice (33%).

DERMATOFIBROMA

Treatment time may be 60 seconds due to the fibrotic nature of the lesion and the need to treat cells located in the deep dermis. A retrospective study of 393 dermatofibromas treated with cryosurgery reported 65% clearance of a visible and palpable lesion.[13]

SEBACEOUS HYPERPLASIA

These benign lesions may be a cosmetic concern for patients. Freeze times of 5–10 seconds are required, using the cryoprobe technique with the probe applied directly into the central punctum of the lesion. Patients must be advised that retreatment is frequently necessary.

OUTCOMES ASSESSMENT FOR PREMALIGNANT LESIONS

ACTINIC KERATOSIS

Cryosurgery is an effective modality for the treatment of actinic keratoses (AKs). The open spray technique, using a single freeze-thaw cycle of 8–10 seconds, is the treatment of choice (Fig. 246-2). Hypertrophic AKs

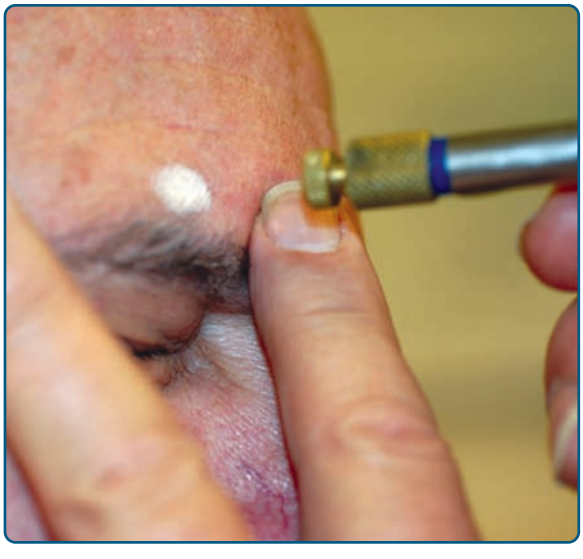

Figure 246-2 Actinic keratosis on forehead treated with liquid nitrogen.

require longer freeze times while atrophic AKs and AKs on thin-skinned regions require shorter freeze times. A 1- to 2-mm freeze margin around the lesion is adequate. For thicker lesions, pretreatment of emollients or curetting may shorten freezing times.

Although cryosurgery is widely utilized in dermatology for treatment of AKs, there are few well-designed studies assessing cure rates. Lubritz and Smolewski[14] treated 1,018 AKs on 70 patients with cryosurgery with 20–45 seconds thaw times. At 1-year post-treatment, they reported a cure rate of 99%.

Another prospective, multicenter study of 421 AKs over 5 mm in diameter on the face and scalp demonstrated a complete response of 39% with a 5-second freeze, 69% for a 5- to 20-second freeze, and 83% for a 20 second freeze.[15]

Goldberg et al treated a number of AKs with monitoring of the skin surface temperature, and achieved a 100% cure rate after 6 weeks.

In patients with diffuse actinic damage, extensive cryosurgery or cryopeeling, may be useful. Chiarello[16] reported cryopeeling was twice as effective as 5-fluorouracil in treating AKs, and preventing squamous cell carcinomas at 1–3 years postoperatively.

MALIGNANT LESIONS

Cryosurgery appears useful in well-defined lesions for situations where surgery is less favorable, either for technical or cosmetic reasons, or when the patient prefers this treatment option. The goal of cryosurgery is to cure the patient by destroying the lesion in a single treatment. The margins of destruction of the lesion cannot be assessed using cryosurgery of malignant tumors.

BOWEN DISEASE

Ahmed et al[17] treated 26 BDs using 3-mm clinical margins and spray technique with two 5- to 10-second freeze-thaw cycles. After 2 years, 50% of the lesions had recurred. The average healing time was 46 days, with lesions on the lower leg taking longer to heal (90 days). Although the cure rate using cryosurgery for BD was low in this study, the authors did use a lower freeze time to minimize side effects postprocedure.

BASAL CELL CARCINOMA

Several studies have reported treating basal cell carcinomas (BCCs) with cryosurgery with cure rates ranging between 95% and 99%.[18–20] Although excellent cure rates have been claimed, few studies have demonstrated histologically that the BCC is no longer present post-treatment. Furthermore, there are no good studies comparing cryosurgery with other known treatment modalities, such as Mohs micrographic surgery, excision with clinical margins, and electrodesiccation and curettage.

Postsurgical cosmetic appearance is a concern to patients. Kokoszka and Scheinfeld[21] reported good cosmetic results in their review of the literature. Thissen et al,[22] however, compared the cosmetic results of surgical excision compared with cryosurgery for BCCs of the head and neck and concluded that cosmetic results after excision are better than after cryosurgery.

SQUAMOUS CELL CARCINOMA

Similar cure rates to BCCs are evident when treating squamous cell carcinomas (SCCs) with cryosurgery. In a study of 563 primary SCCs, of which most were between 0.5 and 1.2 cm in diameter, Graham and Clark[23] reported a cure rate of 97.3%. Treatment technique with cryosurgery for SCCs is the same as for BCCs.

LENTIGO MALIGNA

With proper patient selection, cryosurgery can be an effective treatment option for lentigo maligna (LM) due to the sensitivity of melanocytes to cold. With the aid of a Wood's lamp, a clinical margin of 5 mm is drawn around the visible borders of the lesion. The lesion is subsequently treated with a double freeze-thaw cycle of 30–60 seconds each cycle. Because atypical melanocytes may extend along the length of the hair follicles, treatment must freeze the tissue to this depth.

Stevenson and Ahmed[24] reviewed cure rates from more than 200 LMs treated with cryotherapy, with an overall recurrence rate of less than 9%. However, the recurrence rates in these studies ranged from 0%–50%.

Advantages of cryotherapy for LM include its efficiency and avoidance of large surgical scars. One major disadvantage of cryosurgery is the inability to assess whether the lesion has been completely destroyed. In addition, because no tissue is obtained for definitive confirmation of cancer removal, the chance exists that recurrent melanoma may develop and that it may be invasive. Overlying scars may conceal the cancer.

COMPLICATIONS

PAIN

In addition to pain during freezing, patients will experience some discomfort several hours posttreatment. Typically, pain is controlled with acetaminophen. Lesions such as periungual warts, digital lesions, or mucous membrane lesions may require stronger analgesics due to intense swelling and throbbing.

BLEEDING

Patients on anticoagulant therapy should be warned of bruising due to tissue necrosis. If painful hemorrhagic bullae form, they may be drained with an 18-gauge needle inserted into the lateral blister skin.

Care should be undertaken not to remove the surface of the bullae, as this tissue acts as a natural wound dressing.

PIGMENTATION CHANGES

Hypo- or hyperpigmentation is the most disconcerting complication postcryosurgery. As previously described, pigmented cells are sensitive at temperatures of –4°C to –7°C (24.8°F–19.4°F). Although pigmentation changes are usually transient, prolonged freezing greater than 30 seconds may result in permanent pigment loss. Topical steroids, glycolic acids, retinoids, and hydroquinone may aid in reducing the incidence of hypopigmentation.

NERVE DAMAGE

Treatment of lesions overlying nerves, such as the postauricular nerve on the neck or digital nerves on medial and lateral fingers and toes, may result in regional paresthesia or motor dysfunction. Digital neuropathy occurring postcryosurgery of digital warts has been reported.[25]

SCARRING

Fibroblasts are the most resistant to freezing and do not undergo cell death until –30°C to –35°C. Therefore, most benign and premalignant lesions treated with cryotherapy heal with little scarring. Scars due to second intention may occur after malignancies treated with cryosurgery.

ALOPECIA

Freeze times longer than 20 seconds may result in alopecia. This is especially the case in treating malignant lesions.

MONITORING/FOLLOW-UP

Benign and premalignant lesion sites typically heal in 1–2 weeks, with malignant lesion sites requiring 3–4 weeks of healing. Clinically suspicious actinic keratoses not responsive to cryosurgery should be biopsied to rule out invasive Squamous Cell Carcinoma.

PATIENT INSTRUCTIONS

Patients should be given simple verbal and written wound care instructions post-treatment. Edema, vesicles, bullae, and weeping should be expected from treated areas within 24 hours post-treatment. Treated sites may be rinsed with soap and water and patted dry with a towel daily. If actively weeping, the wound site may be bandaged.

ELECTROSURGERY

Electrosurgery is a technique that uses the transmission of electricity to cut tissue, destroy tissue, and cauterize vessels. Variations in current wavelength result in different biologic effects on tissue. For cutaneous procedures, electrosurgery can be categorized into six different treatment modalities: (1) electrofulguration, (2) electrodesiccation, (3) electrocoagulation, (4) electrosection, (5) electrocautery, and (6) electrolysis.

MODALITIES OF ELECTROSURGERY

ELECTROFULGURATION

Electrofulguration uses a damped sine wave, high-voltage, low-amperage alternating current to generate a spark from a monoterminal electrode to the tissue via the air. There is no contact between the electrode and the tissue. This modality is the least tissue damaging of all of the high-frequency electrosurgery techniques, resulting in rapid tissue healing. Most of the tissue damage is superficial, primarily involving the epidermis.

ELECTRODESICCATION

Electrodesiccation uses a damped sine wave, high-voltage, low-amperage alternating current to generate a current from direct contact of a monoterminal electrode to the tissue. Superficial tissue damage occurs as heat is transferred to tissue, causing cell death. The extent of tissue damage is directly related to electrode contact time with the skin. Although skin injury is greater with electrodesiccation compared to electrofulguration, most of the tissue damage remains superficial.

ELECTROCOAGULATION

Electrocoagulation uses a moderately damped sine wave, low-voltage, high-amperage alternating current to generate a current from direct contact of a biterminal electrode to the tissue. Tissue damage is deeper than with electrofulguration and electrodesiccation, providing tissue coagulation through the generation of heat in the tissue.

Another distinguishing feature of electrocoagulation is the involvement of the patient within the circuit. This allows the use of a lower voltage and higher amperage to generate more coagulation.

ELECTROSECTION

Electrosection uses an undamped or slightly damped sine wave, low-voltage, high-amperage alternating current to cut tissue with minimal peripheral heat

damage. The "Bovie" knife incorporates a blended undamped and damped sine wave that provides both cutting and coagulation at the same time.

ELECTROCAUTERY

Electrocautery uses a heating filament tip connected to a low-voltage, high-amperage direct current, usually a battery. Heat is transferred from the filament to the target tissue, causing protein denaturation and tissue coagulation. There is no electric current transfer to the target tissue, and the patient is not part of the circuit loop.

Electrocautery is most used for patients with pacemakers or implantable cardiac defibrillators (ICDs) who are high-risk candidates for receiving electrosurgery. In addition, because patients are not part of the circuit loop, electrocautery is useful for nonconductive tissue areas of the body, such as the cartilage, bone, and nails.

ELECTROLYSIS

Electrolysis uses low-voltage, low-amperage direct current from a negative electrode to the positive electrode. The negative electrode is applied to the target tissue where electrons are released. The electrons interact with the tissue to produce sodium hydroxide and hydrogen gas resulting in tissue liquefaction. Acids are produced at the positive electrode resulting in tissue coagulation. The main use of electrolysis is for hair removal.

PATIENT SELECTION

When taking preoperative history for surgery, patients should be asked if they have a cardiac pacemaker or ICD. High-frequency electrosurgery may interfere with their function or damage the pacemaker or defibrillator, resulting in patient morbidity or mortality.

Patients commonly present for cutaneous surgery with either a cardiac pacemaker or an ICD. Although technologic advances, such as titanium shielding, have provided safeguards against electromagnetic interference (EMI), electrosurgical devices may cause these cardiac devices to malfunction.

Fixed-rate pacemakers are not influenced by EMI from electrosurgery.

ICDs deliver an electrical response to an abnormal ventricular rhythm. Some ICDs have a combination of a pacemaker and defibrillator to respond to both bradycardia and tachycardia. EMIs from electrosurgical devices may mimic a cardiac arrhythmia and cause the unit to discharge.

RISKS AND PRECAUTIONS

Recommendations have been published for the preoperative and intraoperative management of patients with pacemakers and ICDs during dermatologic surgery.[26–31] Patients should be asked when scheduling surgery if they have one of these devices. If present, a preoperative evaluation by the patient's cardiologist should be arranged before the surgical procedure. For management of patients with pacemakers or ICDs undergoing surgical procedures, consider the following recommendations:

- Provide continuous electrocardiography monitoring throughout the procedure.
- Have advance cardiac life support (ACLS) staff and crash-cart equipment available.
- Place the dispersing electrode in a location that directs the current pathway away from the cardiac device.
- Use a bipolar forcep device to maintain the electrical circuit between the forcep tips.
- Use minimal power and short electrosurgical bursts of 5 seconds or less.
- Consider using a disposable heat cautery device.
- Do not discharge the electrosurgical electrode on the skin directly over the pacemaker power source.

PATIENT POSITIONING

Patients should be supine or prone on the examination table. The dispersing electrode (grounding pad) should be placed in a location that directs the current pathway away from the cardiac device (usually the right lower leg). If a pedal is used, it should be placed near the surgeon's feet.

EQUIPMENT

Electrosurgical equipment uses either direct or alternating current. In direct current, electrons flow in one direction, while in alternating current, electron flow reverses direction. With the exception of electrocautery or electrolysis, electrosurgical units used in dermatologic procedures have high-frequency alternating current.

The terms *monopolar* and *bipolar* refer to the number of tissue-containing tips at the end of a surgical electrode. Monopolar denotes one tip, and bipolar denotes two tips. *Monoterminal* refers to the use of a treatment electrode without an indifferent or dispersing electrode. *Biterminal* refers to the use of both treatment and indifferent electrodes.

ANESTHESIA

During electrosurgery, local anesthesia such as lidocaine with epinephrine is required for patient comfort.

TECHNIQUE

HEMOSTASIS

The most common application of electrosurgery is its use in maintaining hemostasis in the operative field.



Figure 246-3 Electrodesiccation of bleeding vessel during Mohs micrographic surgery.

Different techniques of electrosurgery can be used based on the type of electrosurgical unit used during surgical procedures. Coagulation can be achieved using electrofulguration electrodesiccation or electrocoagulation by direct application of the electrode to the bleeding vessel. This provides conduction of heat to the vessel, resulting in tissue coagulation (Fig. 246-3).

Alternatively, vessels can be grasped by a forcep or hemostat, followed by application of the active electrode. When electrical current is placed against the metal instrument, heat is transferred from the electrode through the metal tip to the vessel. This technique is best used when the surgical field cannot be visualized due to bleeding (Fig. 246-4).

ELECTROSURGERY OF BENIGN LESIONS

Electrodesiccation is an effective treatment modality for papular or plaque-like tumors of the epidermis, such as seborrheic keratoses, verrucae, dermatosis papulosis nigra, molluscum, or flat warts. First, the area around the lesion is anesthetized with lidocaine-containing epinephrine. Then, the lesion is touched with the low-power electrode until a gray, superficial charred layer involves the entire lesion. The charred tissue is removed from the treated lesion by wiping with a sterile gauze or curetting. The process is repeated until the lesion is removed at the level of the surrounding skin. This method results in minimal bleeding and scarring because just the epidermal components are removed.

ELECTRODESICCATION AND CURETTAGE OF MALIGNANT LESIONS

Curettage and electrodesiccation (C+D) is a commonly used treatment option for BCCs and SCCs. Certain tumor characteristics, however, should be present to ensure high cure rates and acceptable cosmetic outcome. Tumors should be primary, have distinct clinical borders, be located on sites of low recurrence such as the trunk, extremities, or non-"H"-zone regions of the face (see Chapters 114 and 115), have a superficial or nodular histologic subtype, and have a diameter of <1 cm on the face and <2 cm on the trunk and extremities. In addition, C+D is a viable treatment option for patients with high morbidity cofactors that make surgical excision too risky or patients who cannot make regular follow-up visits.

Tumors not acceptable for C+D include those with indistinct borders, tumors on the "H"-zone of the face, tumors with an aggressive histologic pattern, tumors with high metastatic potential, and tumors that require histologic diagnosis. For patients with cardiac pacemakers or ICDs, electrocautery may be substituted for electrodesiccation.

The tumor outline should be marked, and lidocaine with epinephrine should be injected to provide adequate local anesthesia (Fig. 246-5). With firm counterpressure, the lesion is then curetted in a checkerboard pattern until the clinical appearance of the lesion is



Figure 246-4 Electrocurrent applied to forcep to cauterize bleeding vessel during Mohs micrographic surgery.



Figure 246-5 Clinical outline of skin tumor before curettage and electrodesiccation.



Figure 246-6 Curettage of skin tumor during curettage and electrodesiccation procedure.

removed (Fig. 246-6). This is followed by electrodesiccation on high power of the base and periphery of the lesion (Fig. 246-7). This C+D procedure is repeated up to two more times until a resultant atrophic defect without clinical evidence of residual tumor is achieved. Some advocate the inclusion of a 2- to 4-mm rim of clinically normal skin during the C+D procedure, and individual variations of the protocol are established. If curettage of the BCC extends into subcutis, then an extensive invasion of a BCC has occurred, and excision should be performed.

The advantages of treatment with C+D include time efficiency, ease of surgical technique, and minimal post-treatment morbidity. Disadvantages of treating with C+D include nonconfirmation of histologic tumor clearance, practitioner-dependent efficacy, and potentially long (3- to 4-week) healing times via second-intention healing. Furthermore, the cosmetic result may show hypopigmentation, atrophy, persistent erythema, and hypertrophic scarring.



Figure 246-7 Electrodesiccation of skin tumor during curettage and electrodesiccation procedure.

OUTCOMES ASSESSMENT

The 5-year cure rates for C+D have been reported to be 74%–100% for BCCs[32–42] and 96%–100% for SCCs.[32] Although some authors have reported that 20%–40% of tumors remain immediately post-C+D, the 5-year cure rates demonstrate an additional factor may be contributing to the destruction of the treated malignancy. Some authors have speculated that the inflammatory response or a specific antitumor humoral response following electrosurgery may be responsible for the low recurrence rate.[43,44]

C+D in combination with other topical treatments may have a synergistic effect in tumor clearance. In a double-blinded, placebo-controlled pilot study by Spencer,[45] ten BCCs were treated with C+D and ten patients were treated with C+D followed by 1 month of daily topically applied imiquinod cream. The author reported a substantially reduced frequency of residual BCC and improved cosmetic appearance in the C+D/imiquinod group compared with the C+D alone group. Another study by Wu et al[46] reported excellent efficacy and cosmetic results for nodular BCCs of the trunk and limbs treated with curettage (no electrodessication) followed by daily topical application of imiquinod cream for 6–10 weeks. In that study, 32 of 34 (94%) lesions demonstrated no residual histological evidence of tumor.

COMPLICATIONS

Although electrosurgery is safe, the surgeon must recognize several dangers while using this technique.

BURNS

There are several situations in which burns may occur with electrosurgery. Thermal injury can occur if there is inadequate contact between the patient and the dispersing electrode plate, when there is inadvertent contact between the dispersing electrode and the patient or surgeon, and if the patient or surgeon may "ground" him- or herself by touching a metal component of the table. Metal jewelry near the electrosurgical site should also be removed.

FIRE

Electrosurgical current will ignite flammable substances like alcohol. When prepping the patient before electrosurgery, nonflammable disinfectants such as iodine or chlorhexidine should be used. If an alcohol-based disinfectant is used, the surgical area must be allowed to dry for at least 90 seconds prior to electrosurgery. In addition, electrosurgery should not be used near the presence of nasal cannulas, masks, or endotracheal anesthesia

administering oxygen. Finally, care should be taken not to ignite paper surgical drapes in the surgical field.

CHANNELING

High-frequency electrosurgical current can be conducted along neurovascular bundles, causing pain and tissue damage distant to the local electrosurgical site. Using low-current settings or bipolar forceps may minimize this.

INFECTION AND MUTAGENICITY

A plume of smoke is generated during electrosurgery. This traveling plume has been shown to contain carbonized tissue and blood, airborne particles, and various chemicals and gases. In addition, smoke created from treating lesions such as warts may contain infectious material, such as bacteria and viruses that may transmit infection.

No known long-term risk for neoplasia or infection is known. The Occupational Safety and Health Administration recommends that surgical smoke be removed and properly filtered by a smoke evacuation system as close to the surgical site as possible.[47] Furthermore, protective equipment, such as face shields and respiratory masks, should be worn during electrosurgery.

COMPLICATIONS WITH PACEMAKERS/ICDS

Complications resulting from using electrosurgery for cutaneous surgery in patients with pacemakers or ICDs are uncommon. Matzke et al published a 3-year retrospective review of 173 patients with pacemakers and 13 patients with ICDs undergoing dermatologic surgery and reported no documented complications from electrosurgery.[48] El-Gamal et al reported a rate of 0.8 cases per 100 years of surgical practice from 166 completed surveys from members of the American College of Mohs Surgery and Cutaneous Oncology.[49] In this study, the types of interference reported were skipped beats, reprograming of a pacemaker, firing of an ICD, asystole, bradycardia, and depletion of pacemaker battery life.

MONITORING/FOLLOW-UP

For all treatment groups, wound areas should be covered with a pressure bandage consisting of a topical petroleum product directly on the wound, an overlying nonstick bandage, and firmly applied gauze with adhesive tape.

PATIENT INSTRUCTIONS

After 24–48 hours, the pressure bandage is removed, and the wound site is cleaned with tap water or saline gently rinsing over the wound. Petroleum jelly and bandage is changed daily after rinsing, for 3–4 weeks or until healed.

KEY REFERENCES

Full reference list available at www.DIGM8.com

DVD contains references and additional content

1. Mikhail GR: The application of chemosurgery in cancer. *Henry Ford Hosp Med J* **17**:217-224, 1969
11. Berth-Jones J, Hutchinson PE: Modern treatment of warts: cure rates at 3 and 6 months. *Br J Dermatol* **127**:262-265, 1992
18. Kuflik EG, Gage AA: The five-year cure rate achieved by cryosurgery for skin cancer. *J Am Acad Dermatol* **24**:1002-1004, 1991
26. Krull KA, Pickard SD, Hall JC: Effects of electrosurgery on cardiac pacemakers. *J Dermatol Surg* **1**:43-45, 1975
28. Burke MC, Knight BP: Management of implantable pacemakers and defibrillators at the time of noncardiac surgery. *ACC Curr J Rev* **14**:52-55, 2005
48. Matzke TJ et al: Pacemakers and implantable cardiac defibrillators in dermatologic surgery. *Dermatol Surg* **32**:1155-1162, 2006

Chapter 247 :: Surgical Complications

:: Richard G. Bennett

SURGICAL COMPLICATIONS AT A GLANCE

- Complications in dermatologic surgery are relatively uncommon.
- Complications are best avoided by
  - Obtaining patient history of medications, prior bleeding episodes, allergies, and prior surgeries.
  - Observing asepsis during procedure.
  - Gentle handling of tissue.
  - Complete cessation of bleeding at time of surgery.
  - Good wound care by patient after surgery.

Surgical complications are unexpected problems that arise in association with an operation. Although the surgeon is always vigilant to minimize complications, adverse outcomes will inevitably occur. This chapter focuses on preventing, identifying, and treating common complications seen with skin surgery. One recently discussed method to minimize complications is the use of a surgical checklist similar to one used by airplane pilots.[1]

COMPLICATIONS AT THE TIME OF SURGERY

Most complications that occur on the day of surgery involve the patient's underlying medical problems, reactions to administered anesthetics, and bleeding. Allergy, hypersensitivity, or toxic reactions to local anesthetics and fainting with or without seizure can also occur.

PATIENT'S MEDICAL PROBLEMS

Before surgery, it is important to obtain a medical history and perform a physical examination. The level of physical examination is commensurate with the extensiveness of the surgery that is planned. For example, a small cyst excision would only require a cursory physical exam (i.e., general appearance) and vital signs, whereas an extensive liposuction procedure using a large volume of tumescent anesthesia would require a full physical examination and diagnostic testing, if indicated.

The patient's medical history, including allergies, medications, and past surgeries, is important to obtain. Medications such as anticoagulants, pain medications, and certain herbs can affect bleeding at the time of surgery (Table 247-1).[2,3] Excessive bleeding with prior surgeries, especially if requiring transfusions, can be associated with a prolonged bleeding time. It is important to determine if the patient has a cardiac pacemaker, defibrillator, or any other implantable medical devices. Also, if the patient has an artificial heart valve or a rheumatic heart valve, preoperative antibiotics will be required.

Some of the common problems associated with skin surgery include fainting, seizures, and diaphoresis. Fainting is almost always a vasovagal reaction, and the best treatment is to position the patient in the Trendelenburg position. Seizures sometimes occur with the vasovagal reaction and are short lived. Usually, when patients faint, there is a history of fainting episodes, pointing out the importance of inquiring about this in the medical history. Diaphoresis may occur associated with a vasovagal reaction, angina, or hypoglycemia.

Certain equipment is necessary to address emergencies. A "crash cart" includes a heart monitor with defibrillator and common medications to manage

TABLE 247-1
Medications That Inhibit Platelet Function

- Persantine
- Trental
- Sulfinpyrazone
- Clofibrate
- Salicylates
- Aspirin
- Sulfasalazine
- Vitamin E
- Plavix
- Herbs
  - Ginkgo biloba
  - Garlic
  - Feverfew
  - Ginger
  - Asian ginseng
  - Turmeric
- Nonsteroidal anti-inflammatory drugs
  - Piroxicam
  - Diclofenac
  - Fenoprofen
  - Meclofenamate
  - Phenylbutazone
  - Indomethacin
  - Sulindac
  - Tolmetin
  - Ibuprofen
  - Ketoprofen
  - Naproxen

emergencies. Oxygen tanks with appropriate masks or nasal cannulas should be ready for use and checked regularly. In addition, a blood pressure cuff, heart rate monitor, and pulse oximeter should be available. Although we now live in a "911" culture, the operating physician is still responsible for handling medical problems, and the dermatologic surgeon should be certified in basic or advanced cardiac life support. Furthermore, ancillary staff should be similarly certified and know their role in emergency situations.

ANESTHESIA-RELATED COMPLICATIONS

Because almost all cutaneous surgery performed by dermatologists is done with local anesthetic, this section only discusses local anesthetic complications. Fortunately, problems with local anesthetics are extremely rare. Thus, physicians have been lulled into a false sense of security. Allergy to lidocaine is rare if it happens at all; generally, the allergy is to the paraben preservative.[4]

Problems with local anesthetic toxicity are most often related to the total dosage and the addition of epinephrine (see Chapter 242). The total dosage (for a 70-kg patient) should not exceed 500 mg of lidocaine if epinephrine is used and 200 mg if epinephrine is not used.[5] Alternative anesthetics such as bupivacaine have a different recommended total dosage. The initial sign of lidocaine toxicity is tongue and circumoral numbness. If this occurs, oxygen should be administered and an intravenous line established.

The addition of epinephrine to local anesthetics is commonplace. However, epinephrine can cause an increase in heart rate, increased contractility of heart muscle, and vasoconstriction. This phenomenon often occurs with inadvertent direct injection into a blood vessel or it could represent a hypersensitivity reaction especially if the patient is hyperthyroid. Epinephrine should be given cautiously in patients with severe hypertension or cardiac arrhythmias. In these situations, epinephrine, which is present in prepackaged anesthetic in a dilution of 1:100,000, can be diluted further to 1:200,000 or less without decreasing hemostasis. If patients have a history of sensitivity to epinephrine, it is best to use lidocaine without epinephrine. However, in the absence of epinephrine, the anesthetic duration and level of anesthesia will decrease, and the onset time will increase. Also, the absence of epinephrine in local anesthetic can contribute to increased intraoperative bleeding.

Anesthetic containing epinephrine should not be injected into the digits. Although there is some controversy about this, a patient with unknown diabetes may be at high risk for tissue necrosis. Anesthetic containing epinephrine may be injected into the nose, earlobes, and penis; however, it maybe preferable to do a pudendal nerve block in the latter site.

BLEEDING

During and after surgery, a cardinal goal is to minimize blood loss. A medical history helps identify medical problems that might promote bleeding, such as thrombocytopenia, coagulopathy, or hypertension. Several medications inhibit platelet function (see Table 247-1). Anticoagulants should be specifically queried. Extensive intake of garlic, ginkgo, vitamin E, and some other herbs can promote bleeding. During surgery, meticulous hemostasis will help minimize postoperative bleeding.

One medication with specific importance in dermatologic surgery is warfarin (Coumadin). Patients on warfarin should not discontinue this medication before cutaneous surgery. In some patients who stop and start warfarin, the blood becomes hypercoagulable, which may lead to blood clots or strokes.[6] Aspirin, on the other hand, is generally safe to stop 10–14 days before surgery, unless the patient has had a history of strokes or transient ischemic attacks.[7]

COMPLICATIONS IN THE IMMEDIATE POSTOPERATIVE PERIOD

Some specific complications occur from the day of surgery until approximately 1–2 weeks later. It is important to give the patient a way to immediately contact the physician in case complications arise, and it is prudent to call the patient the day after surgery to inquire how he or she is doing.

INFECTION

Wound infection can occasionally sterile occur despite every effort to adhere to appropriate surgical technique. Three types of infection occur most commonly with cutaneous surgery: (1) *Streptococcus pyogenes*, (2) *Staphylococcus aureus*, and (3) *Mycobacterium* (especially *M. fortuitum* and *M. chelonei*).[8,9] Generally, all three are quite different in clinical presentation and timing. *Streptococcus* occurs early, within 24–48 hours of surgery, and appears as a spreading, painful erythema. *Staphylococcus* infection appears at 2–5 days after surgery and is usually associated with pus formation. Finally, *Mycobacterium* infection appears 2–4 weeks after surgery.[8] Clinically, it appears as ulcerating papules or nodules that will not heal or that repeatedly heal and break down.

Recently a particular form of *S. aureus* resistant to methicillin, so-called *methicillin-resistant S. aureus* (MRSA), has appeared in an increasing number of wounds.[10] It is therefore important to culture wounds that appear infected so that the proper antibiotic can be selected. Antibiotics that generally work well against methicillin-resistant *S. aureus* are doxycycline and trimethoprim-sulfamethoxazole.

The risk of infection with MRSA is increased fourfold if a patient is a nasal carrier of MRSA.[11] This fact has led to physicians in plastic surgery, orthopedics, and cardiac surgery now recommending use of mupirocin ointment in the nasal vestibule prior to surgery.[12] However, in one study, MRSA was resistant to mupirocin 12% of the time.[13]

Infections with herpes simplex or herpes zoster are rare after cutaneous surgery. One exception to this is the development of herpes infection after whole-face dermabrasion or laser resurfacing. With these procedures, an antiviral medication, such as acyclovir, valacyclovir, or famciclovir, should be started before surgery, especially in those patients who have a history of herpes simplex infections (see Chapter 193).

CONTACT DERMATITIS

Allergic reactions can occur to antibiotic ointments used in routine wound care to keep wounds moist. The patient most often has a contact allergy to neomycin or bacitracin.[14] Although bright-red, poorly marginated erythema appears around the operative site with the antibiotic allergy (Fig. 247-1), the diagnosis is usually obvious because the patient will complain of marked pruritus. This symptom is in contrast to that of an infection where the patient complains mainly of pain and pruritus is minimal or absent. Allergic reactions to bandage materials such as Telfa and Micropore paper tape are extremely rare.

Contact dermatitis can also occur to disinfectant surgical solutions (e.g., chlorhexidine) used to clear the skin prior to surgery.[15]

PAIN

Significant pain is rarely present after cutaneous surgery. Patients should take plain acetaminophen for uncomplicated pain. Occasionally, if the surgery is extensive, acetaminophen with codeine or hydrocodone may be used. On rare occasions, stronger narcotics may be necessary.

BLEEDING AND HEMATOMA FORMATION

After suturing a wound, roll a cotton-tipped applicator over the wound with pressure to express any trapped blood and then place a secure pressure dressing on the wound. The less residual blood in the wound, the faster healing will occur.

Occasionally, patients will continue to bleed from their wound, whether sutured or open. If the patient is on warfarin, an international normalized ratio should be checked. If the patient has unexplained, continuous bleeding, he or she should be evaluated for a coagulopathy.

Occasionally, a large collection of blood may occur under a sutured wound (Fig. 247-2A). This may be more common in men and those with hypertension.[16] If this occurs within a few hours of surgery to up to 24 hours postoperatively, it is best to unsuture the wound, locate the source of bleeding (see Fig. 247-2B), and obtain hemostasis. Almost always, an artery is found that is pumping blood; it is advisable to ligate it and then resuture the wound (see Fig. 247-2C). If the patient returns after a few days with a large fluctuant hematoma, aspirate the wound using a large bore needle or, if available, a blunt microliposuction canula. It is not usually necessary to remove the sutures at that point, as the hematoma will probably not reform. However, if the hematoma does reform, it may become necessary to remove the sutures, locate the bleeder, excise the wound edges, and resuture the wound.



Figure 247-1 Contact dermatitis to Polysporin® ointment near skin flap.

NECROSIS

If the blood supply is inadequate, tissue death can occur. This phenomenon can occur with a skin flap or skin graft (Fig. 247-3); it rarely occurs with a side-to-side wound repair but may develop if an extremely tight pressure dressing is applied. Inadequate blood supply can occur due to factors intrinsic to the wound itself such as hematoma or factors extrinsic to the wound such as the patient's medical condition or local tissue problems.

Intrinsic factors causing tissue necrosis include excess wound tension, infection, and hematoma formation. For a skin graft, excessive thickness may inhibit vascularization. A skin flap may necrose if the base is too small or the flap is too thin or kinked (see Chapter 243).

Extrinsic factors that can lead to tissue necrosis include local tissue considerations such as poor blood supply due to anatomy, prior radiation, or prior surgery. Other extrinsic factors are systemic diseases such as diabetes, medications, or malnutrition. Smoking may also cause tissue necrosis, probably as a result of decreased blood flow due to nicotine. The smoking effect appears to be dose related: patients who smoke one pack per day do not have an increased likelihood of necrosis, whereas those smoking two packs per day do.[17]

DEHISCENCE

Despite careful wound apposition and suturing, wound edges can pull apart. Often, this dehiscence occurs due to excess tension on the wound edges, but it may result from suture breakage or unraveling. To

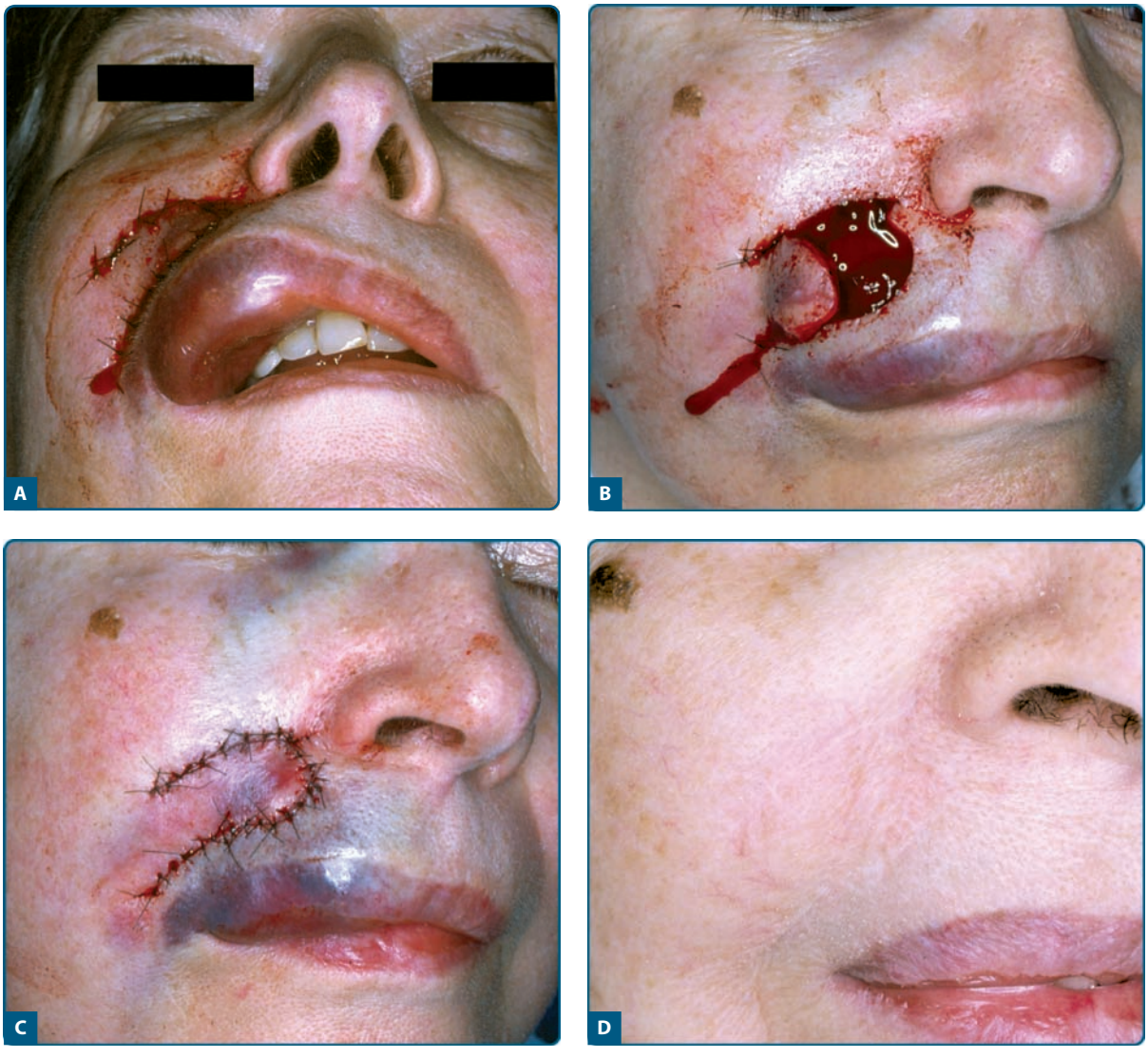

Figure 247-2 **A.** Swelling of right upper lip 2 hours after skin flap. **B.** Flap unsutured, exposing blood coagulated below. Arteriole bleeder found and tied off. **C.** Flap immediately resutured. **D.** Healed flap 3 months later.

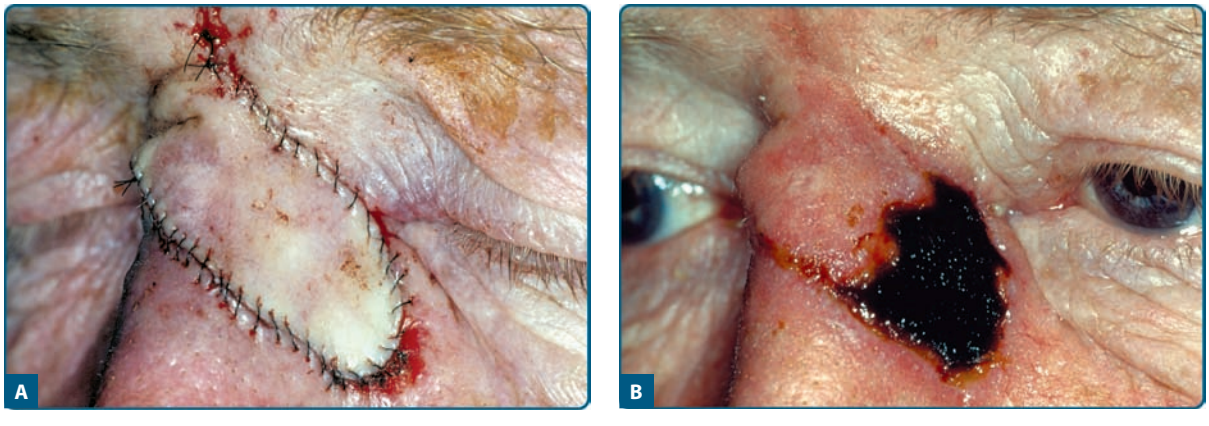

Figure 247-3 **A.** Flap from glabella to left dorsal nose. **B.** Necrosis in flap 1 week postoperatively.

prevent dehiscence, vertical mattress sutures are quite useful because they provide an increase in tensile strength earlier than do interrupted sutures. This phenomenon is especially true for thin skin or skin with abundant large sebaceous glands (e.g., the nose).

If the dehiscence occurs within a day of suturing, the wound can be resutured without freshening the wound edges. If the dehiscence occurs more than 48 hours after the initial surgery, the wound edges should be freshened by excising 1 mm of normal skin before resuturing the wound.

In the presence of infection, necrosis, or extreme wound edge tension, it may be best not to immediately resuture a dehisced wound but, rather, allow the wound to heal by granulation.

Dehiscence can also occur after suture removal. To prevent this problem, percutaneous sutures may be left in place for more than 7 days. In wounds under tension, such as on the back, or in locations where wound healing is slow (i.e., the leg), sutures may remain for up to 2 to 3 weeks. Another approach to a wound under tension is to remove a fraction of the sutures at 7 days and the balance several days later. To further help prevent dehiscence, apply a glue (Mastisol®) and Steri-Strips™ across the wound immediately after suture removal. The patient is instructed to keep the wound dry so the Steri-Strips™ will stay in place for about 1 week after placement. In some anatomic locations (e.g., scalp, bearded areas in men), Steri-Strips™ placement will not work well because of hair.

COMPLICATIONS IN THE DISTANT POSTOPERATIVE PERIOD

After sutures have been removed, the wound continues to heal. Patients may be followed up to 1 year postoperatively to address any problems that might arise.

MILIA OR KERATINOUS CYSTS

Occasionally, during surgery, small pieces of epidermis may be buried or a follicle may be transected by the suture needle. When this happens, a milial cyst may occur adjacent to the suture line. It is easily removed with a comedone expressor after a needle incision. Larger cysts can occasionally grow, associated with scars. However, one should be wary if a cyst appears where a skin cancer was excised; the "cyst" may indeed prove to be a skin cancer on pathologic examination.

SUTURE TRACK MARKS

Suture track marks can occur due to suture material cutting into tissue (Fig. 247-4A). These scars can be minimized by using polypropylene suture material, which stretches, rather than nylon suture, which does not. Also, when suturing, the surgeon should be careful not to tie knots too tightly or pull on the suture too



Figure 247-4 **A.** Suture track marks around forehead scar. **B.** Dermabrasion of scar at 5 weeks after being sutured. **C.** Healed scar 2 months later. Suture track marks have disappeared.



Figure 247-5 Keloid of earlobe and posterior auricular sulcus. Patient underwent an ear pinning procedure.

tightly when tying or cutting. If caught early, within 1 or 2 months, dermabrasion works well to eliminate suture track marks (see Fig. 247-4B and C).[18]

Other methods to avoid suture track marks include use of the over-and-over running suture that distributes tension along the wound length and the buried intradermal (running intradermal subcuticular) suture.

HYPERTROPHIC SCAR

Occasionally, scars will become elevated and stay within the boundaries of the wound. This is known as a *hypertrophic scar* in contrast to a *keloid scar* that grows beyond the boundaries of a wound (Fig. 247-5; Table 247-2; see Chapter 66). Both keloids and hypertrophic scars are treated by pressure massage; they also respond well to intralesional triamcinolone acetonide 10 mg/cc (Fig. 247-6A and B). Other useful methods that have been reported to improve keloids include excision, intralesional 5-fluorouracil or interferon-α, cryosurgery, and radiotherapy.

Scar lines may also appear lumpy due to buried sutures. Usually this lumpiness disappears in 2–3 months as sutures absorb.

Patients occasionally ask about various commercially available products to use for scar improvement. Some of these products contain silicone or polyurethane foam. It may be that the use of these products improves scars by increasing the moisture of the scar or by the constant application of pressure. Similar improvement may be seen by using paper tape on wounds for 3 months after surgery.[19]

DEPRESSED OR FURROW-LIKE SCARS

A depressed or furrow-like scar is common in skin with an abundance of sebaceous glands. In this circumstance, wound edges often cannot be held together without tearing. With tearing of the skin, varying degrees of wound separation occur that result in depressed scars. To correct this problem, the depressed scar is excised, and the wound edges are undermined and resutured. At the time of resuturing, use of several buried sutures and vertical mattress sutures will even up and tightly oppose the wound edges, minimizing recurrence of the depressed scar. The vertical mattress suture grasps more tissue laterally than does a simple interrupted suture. Thus, there is less chance for sutures to tear through tissue. It is also important when working in very sebaceous skin to use suture no finer than 5-0.

SPREAD SCARS

Scar spreading occurs with tension on wound edges. Sometimes, this tension is unavoidable due to anatomic considerations, such as on the chest or upper back. Sometimes spread scars occur where there is great tension on the wound edges that exceeds the holding

TABLE 247-2
Comparison of Hypertrophic Scar and Keloid

	Hypertrophic Scar	Keloid
Incidence	Common	Uncommon
Race	All	Usually dark skin
Injury	Yes	Sometimes
Location	Anywhere, especially perpendicular to maximal skin tension lines	Earlobes, trunk, rare on central face
Growth	Within scar line	Beyond scar line
Resolution	Usually	No
Recurs with excision	Usually no	Usually yes

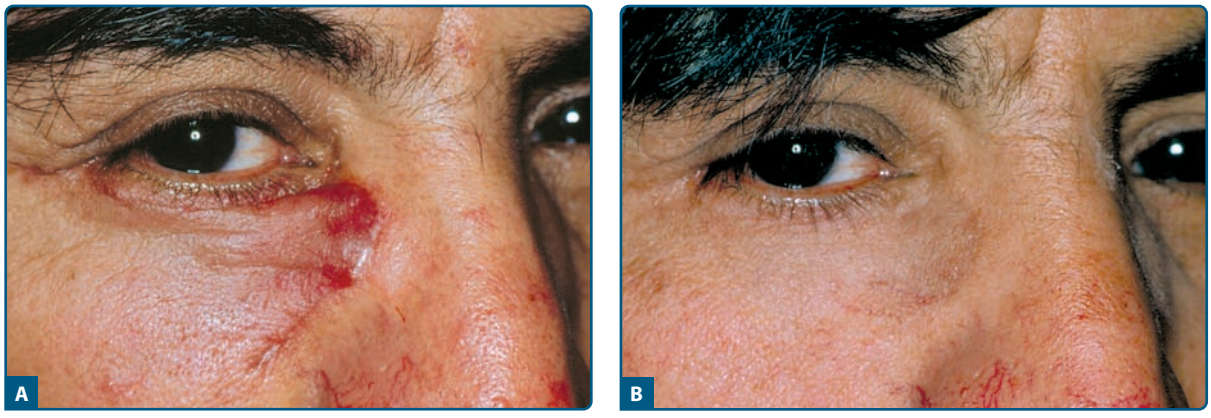

Figure 247-6 **A.** Hypertrophic flap on right nose and cheek. Injected with triamcinolone acetonide, 10 mg/cc. **B.** Flap 2 months later.

power of the sutures or the healing wound edges after suture removal. Stretching of scars is quite common on the scalp, trunk, and extremities. It is prudent to explain this phenomenon to the patient in advance.

BURIED SUTURE EXTRUSION

Buried dissolvable sutures may occasionally extrude through the wound edges about 3–4 weeks after placement. This problem is very common. Usually pulling or cutting the extruding suture out will help the wound edges heal faster.

TELANGIECTASIA

The appearance of fine red vessels adjacent to a suture line or on top of a flap or graft can be quite noticeable. This is a normal occurrence, and the vessels usually fade with time; thus, we encourage patients to wait about 6 months after surgery before treating these vessels. Vascular ablating lasers (e.g., the 585- to 595-nm pulsed dye laser and the 532-nm potassium-titanyl-phosphate laser) generally do an excellent job of eliminating the vessels (see Chapter 252).

ERYTHEMA

All sutured wounds are at first erythematous, but generally with time (3–12 months), the erythema fades. Occasionally, however, the redness does not fade. Like telangiectasias, persistent redness is treated with vascular lasers (see Chapter 252). Telangiectasias and redness may be more common in women, especially those on estrogenic medication, than in men.

HYPOPIGMENTATION

As redness fades, all scars become hypopigmented to some extent. The hypopigmentation may be very noticeable if surrounded by erythema, especially in those patients with a ruddy complexion or rosacea. Generally, nothing is done with hypopigmented scars, as the problem will recur if excised. However, if the hypopigmented area is relatively enhanced by surrounding erythema, laser treatment of the adjacent redness may make the hypopigmentation less noticeable.

Occasionally, full-thickness skin grafts become hypopigmented. This pigmentation problem often occurs because the skin graft is excessively thinned before placement. One way to rectify the color in this circumstance is to tattoo the graft to match the surrounding skin color.

HYPERPIGMENTATION

Scars rarely become darkly pigmented, but, occasionally, this can occur. Most often hyperpigmentation appears in individuals with darker complexions and brown eyes. Patients with this type of complexion should be advised to keep their scars out of direct sunlight and to wear a sunscreen that protects against ultraviolet A.

ANESTHESIA

Loss of sensation in the area of surgery is very common, especially with flaps and grafts. Almost always, the sensation returns slowly over 3–18 months, depending on the location and size of the surgery.

Loss of sensation in a few anatomic locations is worthy of special mention. If one operates on the forehead and transects the supraorbital nerve, all sensation superiorly, up to the top of the scalp, will be lost. However, usually, the patient regains most of the sensation slowly over 6 months to 2 years. On the lateral neck, if the great auricular nerve is severed, loss of sensation will occur to most of the lower anterior ear. Unfortunately, in this location, the anesthesia will be permanent.

MOTOR LOSS

(See Chapter 242)

KEY REFERENCES

Full reference list available at www.DIGM8.com

DVD contains references and additional content

2. Pribitkin ED, Boger G: Herbal therapy. What every plastic surgeon must know. *Arch Facial Plast Surg* **3**:127, 2001
5. Erickson E: *Illustrated Handbook in Local Anesthesia*. Philadelphia, W.B. Saunders Co., 1980, p. 13
6. Schanbacher CF, Bennett RG: Postoperative stroke after stopping warfarin for cutaneous surgery. *Dermatol Surg* **26**:785, 2000
10. Del Giudice P et al: Emergence of two populations of methicillin-resistant *Staphylococcus aureus* with distinct epidemiological, clinical, and biological features, isolated from patients with community-acquired skin infections. *Br J Dermatol* **154**:118, 2006
16. Baker DC, Stefani WA, Chiu EU: Reducing the incidence of hematoma requiring surgical evacuation following male rhytidectomy: a 30-year review of 985 cases. *Plast Reconstr Surg* **116**:1973, 2005
17. Goldminz D, Bennett RG: Cigarette smoking and flap and full thickness graft necrosis. *Arch Dermatol* **127**:1012, 1991

Chapter 248 :: Mechanisms of Wound Repair, Wound Healing, and Wound Dressing

:: Vincent Falanga & Satori Iwamoto

WOUND REPAIR AT A GLANCE

- Acute and chronic wounds are different but overlap.
- In acute wounds, there is an orderly progression from injury to coagulation, inflammation, proliferation, cell migration, and tissue modeling.
- In the initial phases, a wide range of growth factors, including platelet-derived growth factor and transforming growth factor-β1, play an important role. In the proliferation/migration and modeling phases, tissue matrix metalloproteinases (MMPs), integrins, basic fibroblast growth factor, and endothelial growth factor are critical. MMP-1, MMP-9, and MMP-10 are essential for remodeling.
- Moist wounds heal faster, and a variety of wound dressings are now available to fit this requirement. They include transparent films, hydrocolloids, foams, alginates, gels, and collagen-based products.
- Chronic wounds are different from acute wounds in that the one-way relationship between the different phases is lost. Chronic wounds are the complex result of ischemia, pressure, and infection; healing is highly dependent on these factors.
- Wound healing of skin grafts is also different, as it is completely dependent on revascularization, be it true neovascularization or inosculation.

INTRODUCTION

The terms "wound healing", "wound repair", or "tissue repair" are often used interchangeably, but actually "healing" and "repair" point to different sets of events and outcomes. First of all, before any distinction is made, one must recognize the rather obvious fact that "healing" and "repair" are not confined to the skin, but can encompass any organ system. Technically, wound healing is a term that should be used only in the context of true regeneration, when the original architecture and structure of an organ or anatomic part is completely restored to the way it was before injury. More primitive animals, such as small amphibians and reptiles, are still capable of this type of regeneration. However, as animals became larger and more complex during evolution, true regeneration was no longer possible. The human fetus is still largely capable of regeneration (especially in the early stages) but, in adults and with the possible exception of the liver (probably a compensatory enlargement and not regeneration), true regeneration does not take place. Rather, man and other higher vertebrates heal by a process of repair (wound repair or tissue repair), whereby the eventual outcome is not true anatomic restoration but a functional compromise. Still, because of well established terms and the published literature, even within our discussion here, we may at times use "healing" and "repair" interchangeably; we will be more specific when truly referring to the process of tissue regeneration.

There are probably evolutionary reasons for why repair occurs in higher vertebrates compared to true healing or regeneration. Teleologically and from an evolutionary standpoint, the process of repair for higher animals needed to be rapid, economical from an energy standpoint, and allow for the immediate survival of the organism. However, by necessity, repair leads to a rapid solution to injury and thus to

scarring. Another important consideration is that most of the mechanisms of wound repair that have evolved are aimed at addressing acute tissue injury and not chronic conditions. Again from an evolutionary standpoint, humans were not meant to develop degenerative diseases or live long enough to develop arterial, venous and pressure ulcers, or neuropathic ulcers from diabetes. Therefore, humans are quite unprepared for these types of chronic wounds, and there are no specific mechanisms that have evolved to deal with them in a truly effective way.[1–3] It should be noted that the extent of injury and its depth are important considerations. Thus, shallow wounds (i.e., shave biopsies) that retain skin appendages (hair follicles, sweat glands, etc.) in the wound bed have the capacity to heal from the "inside", since keratinocytes associated with those skin appendages are still present. On the other hand, full-thickness wounds (punch biopsies are a good example) have to rely on keratinocyte migration and proliferation from the edges (Fig. 248-1). Not surprisingly, full-thickness wounds are associated with delayed healing and more scarring.[2] Some animal models, particularly those in which certain genes are overexpressed or knocked-out, are providing greater understanding of the role of certain proteins and mediators.[4–7] Impaired healing is found in mice with combined deficiency of molecules critical in inflammation (E- and P-selectins), and in mice without plasminogen, uPA and tPA (double knock-out), fibroblasts growth factor-2 (basic FGF or bFGF), or inducible nitric oxide (iNOS). On the other hand, impaired or delayed healing occurs in transgenic mice overexpressing some tissue metalloproteinases (MMP-1) and antisense to CD44, the receptor for hyaluronic acid. Some induced mutations lead to accelerated healing, as reported with Smad-3 or skn-1a knock-out mice.[8] In the future, it may be possible to use these clues to stimulate the healing process in humans.

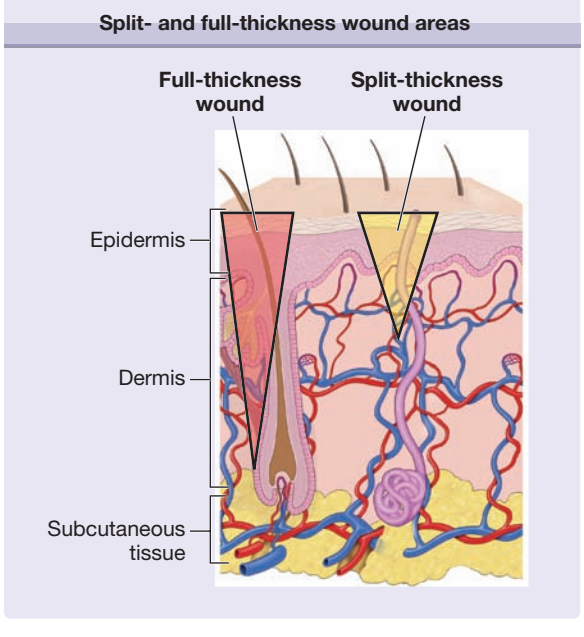

Figure 248-1 Diagrammatic representation of the skin, with two inverted triangles representing either a split- or full-thickness wound. Extending the injury below the reservoir of keratinocytes present in skin appendages (full-thickness wound) removes the ability for the keratinocytes to populate the defect from within the wound bed; healing has to occur from the wound edges and, moreover, more scarring takes place.

PHASES OF WOUND HEALING

In general, there are four recognized phases that characterize the cutaneous repair process: (1) coagulation, (2) inflammatory phase, (3) proliferative and migratory phase (tissue formation), and (4) remodeling phase. The coagulation and inflammatory phases ore sometimes grouped together, so great is the overlap of mediators that are released. In a diagrammatic form, Fig. 248-2 illustrates these phases of healing in sequence, while Fig. 248-3 shows specific events that take place during the different phases. We will discuss these phases and identify the main components and events that characterize them. The cell types primarily involved in wound healing have been regarded to be the platelets, neutrophils and macrophages, fibroblasts, endothelial cells, epithelial cells. More recently, increasing importance is accumulating for the role of lymphocytes, either directly or indirectly.[9] However, it should be noted that breaking down the overall process of wound repair into these seemingly defined phases is artificial, as they overlap considerably.[2,3] Another consideration is that the occurrence and hypothesis of these phases of wound healing has been determined in laboratory animal experiments; it is assumed that the same processes are involved in human tissue repair.

COAGULATION AND INFLAMMATORY PHASES

Although we have shown these as separate phases, the degree of overlap is such that it is appropriate to discuss them together. These early phases begin immediately after an acute injury. Disruption of blood vessels leads to local release of blood cells and blood borne elements resulting in clot formation. While the blood clot within the vessel lumen provides hemostasis, the clot within the injury site acts as a provisional matrix for cell migration,[10] further formation of new extracellular matrix (ECM),[11] and a reservoir for cytokines and growth factors.[12] The initial component of this phase is dominated by the platelet, which directs clotting of the fresh wound by the intrinsic and extrinsic pathways. Platelets also release a number of chemotactic factors that attract other platelets, leukocytes, and fibroblasts to the site of injury. Leukocytes are slowed down within the blood stream through the expression of selectins, which, coupled with integrins, bring inflammatory white cells into the wound.[5] These cells have multiple roles, including debridement of necrotic material and bacteria, as well as the production of certain critical cytokines. A case in point is the production of connective tissue growth factor (CTGF) by inflammatory cells

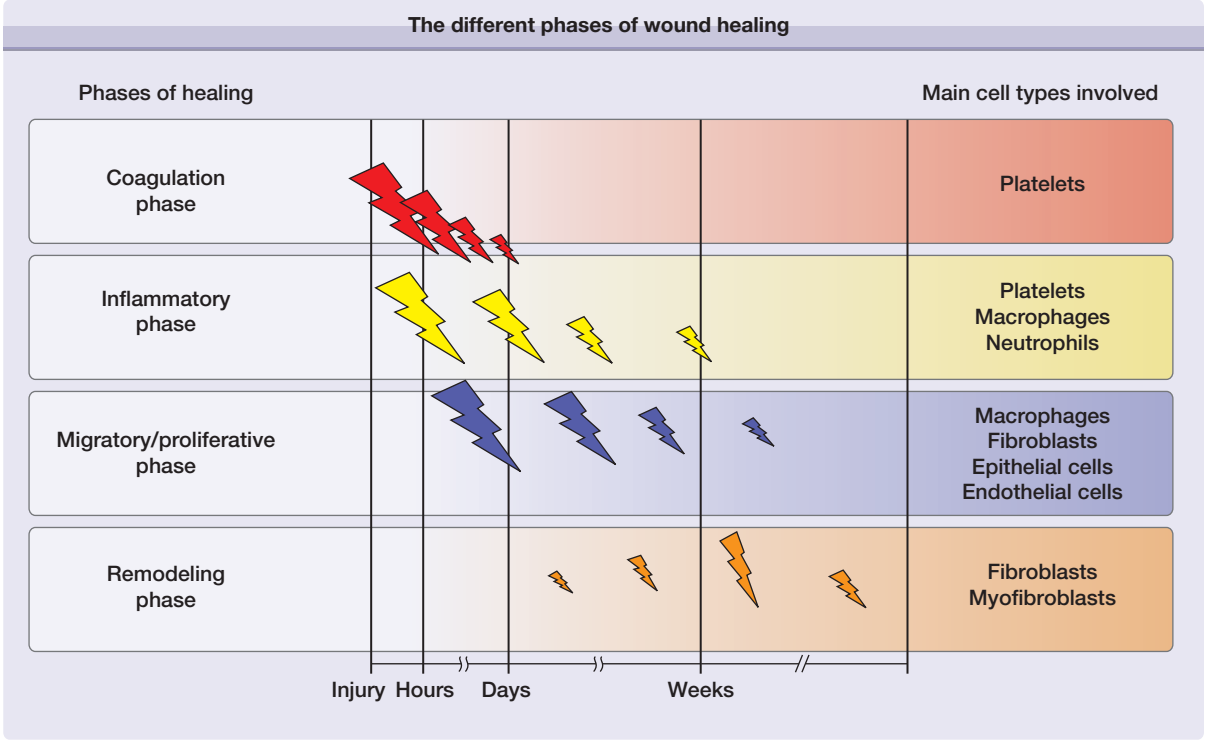

Figure 248-2 Schematic representation of the different phases of wound healing.

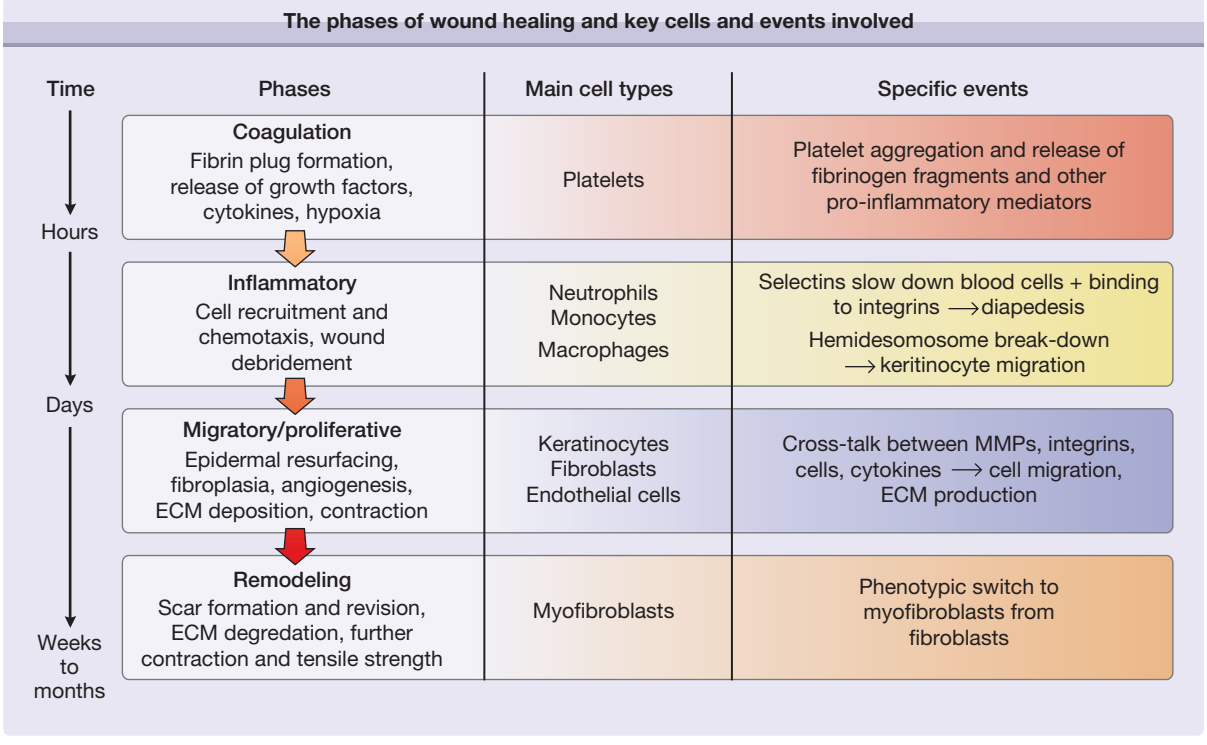

Figure 248-3 The phases of wound healing, and key cells and events involved. (Redrawn from Falanga V: Wound healing and its impairment in the diabetic foot. *Lancet* **366**:1736–43, 2005)

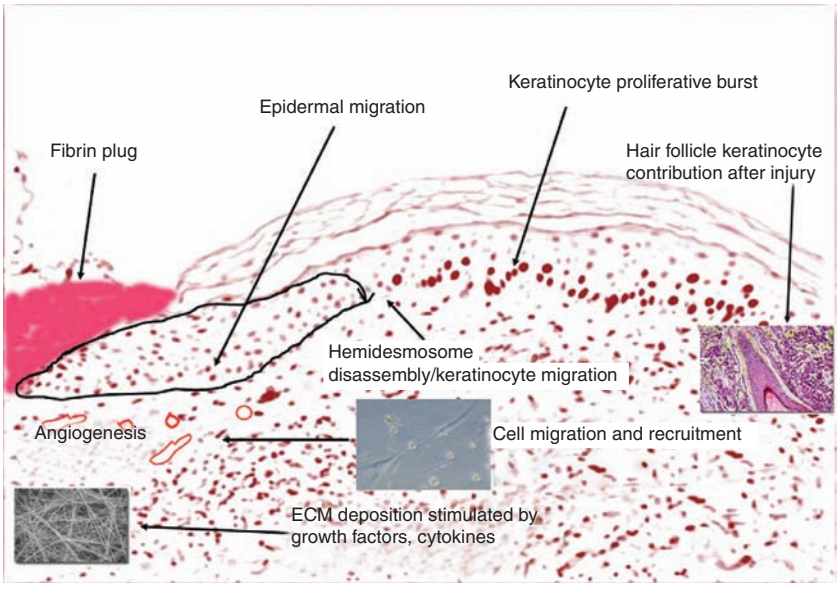

Figure 248-4 Schematic representation, using a modified photomicrograph section, of the events taking place shortly after injury, including formation of a fibrin plug, epidermal migration, and ECM deposition.

and expressed in wounds.[13] After the first few days, the neutrophils are removed by macrophages.

Fig. 248-4 is a diagrammatic representation, using a tissue section, of the events that take place after injury. The fibrin plug resulting from the initial injury provides a temporary wound coverage and consists of platelets embedded within a complex meshwork of mainly polymerized fibrinogen (fibrin), fibronectin, vitronectin, and thrombospondin.[3,14] Cross-linking of fibrin by Factor XIII also appears to be critical, and there is evidence that the function and probably migration of keratinocytes is impaired by uncross-linked fibrin.[15] As they immediately aggregate, platelets release a wide range of growth factors, including platelet-derived growth factor (PDGF) and transforming growth factor-β1 (TGF-β1). In fact, platelets are the main storage site for the TGF-β1 isoform. The acute injury environment, with its hypoxia, proteases, and low pH, contributes to the activation of these growth factors.[2] The principal mediators themselves produce others from their fragmentation or polymerization. A classic example is the chemotactic fibrinopeptides A and B, which are produced from the action of thrombin on fibrinogen.[15,16] Another example is the formation of bradykinins, as well as C3a and C5a, which are activated by Hageman factor.[17]

As the inflammatory component of this early phase continues, within 24–48 hours after injury, monocytes replace neutrophils and become the predominant leukocyte. Monocytes are attracted to the injury site by some of the same chemoattractants responsible for recruitment of neutrophils, such as kallikren, fibrinopeptides, and fibrin degradation products.[18] Other, more specific chemoattractants then take over in recruiting monocytes, and they include fragments of collagen, fibronectin, elastin, and TGF-β1. Monocytes undergo a phenotypic change to tissue macrophages and, unlike neutrophils, they are critical for the progression of wound healing.[19,20] Macrophages phagocytose and kill bacteria, and scavenge tissue debris.[21] They also release several growth factors, including PDGF, fibroblast growth factor (FGF), TGF-β, thereby stimulating migration and proliferation of fibroblasts, as well as production and modulation of extracellular matrix. The macrophage is generally regarded as the master cell in wound healing.[22] However, this is an oversimplification, as it is important to consider that what may delay or impair healing is not so much the presence or absence of inflammation and certain cells but, rather, an inappropriate inflammatory response.[17] For example, there is evidence that healing may occur in the absence of an inflammatory infiltrate.[23,24] Conversely, experiments in mice constitutively expressing the chemotactic cytokine IP-10 show that an intense inflammatory infiltrate can impair neovascularization and the formation of appropriate granulation tissue.[25] Therefore, the true role of inflammation in tissue repair remains somewhat controversial from an experimental point of view.[26,27] From the clinical standpoint, one observes that in certain cutaneous wounds, such as pemphigus or pyoderma gangrenosum, downregulation of inflammation with the use of corticosteroids is effective. Possibly, modulation and "correction" of the inflammatory response by corticosteroids may be helpful in these selected clinical entities.[28]

PROLIFERATION/MIGRATION AND REMODELING PHASES

Fig. 248-4 illustrates a representation of the fibrin plug in place and certain events that occur in the next two phases of healing, the proliferative/migratory and remodeling phases. As inflammation has already played its major role early on after injury, the most important event in cutaneous wound healing now

becomes reepithelialization. This critical event is not based on keratinocytes alone, because there is a high interdependence between keratinocyte movement through the provisional fibrin matrix, recruitment of fibroblasts and endothelial cells, and extracellular matrix formation (Figs. 248-2 and 248-3). Tissue matrix metalloproteinases (MMPs) and other enzymes (tPA and uPA) are critical to the movement of cells through provisional structural matrix components, as well as for freeing the keratinocytes at the edge of the wound from their hemidesmosomal and desmosomal attachments. Another critical set of molecules that help guide this migratory components are the integrins.[29,30] The integrins, consisting of at least 24 αβ heterodimers (18 α and 8 β subunits), are transmembrane cell surface receptors that bind the extracellular matrix (ECM) to cytoskeletal structures.[31] The integrin profile is very dynamic during the repair process. For example, dermal fibroblasts undergo a switch from α2 to α3 and α5 integrin subunits. As another example, endothelial cells cannot respond to angiogenic stimuli without the expression of αvβ5 integrin. Certain polypeptide growth factors are absolutely essential to angiogenesis, including basic fibroblast growth factor (bFGF) and vascular endothelial growth factor (VEGF).[3,31] Table 248-1 shows some of the main cytokines and growth factors shown to play a role in the repair process. One must realize that such tables are oversimplifications of very complex biologic properties of these polypeptides. Only the main effects are noted, and it must be borne in mind that the actions of growth factors are often context specific and not the same in every biological situation.

Evidence points to low oxygen tension as an important early stimulus for fibroblast (and endothelial cell) activation. Fibroblast replication and longevity are enhanced in hypoxia,[32] and low oxygen tension stimulates clonal expansion of dermal fibroblasts seeded as single cells.[33] Moreover, the synthesis of a number of growth factors is enhanced in hypoxic cells. Macrophages secrete an angiogenic substance only when they are exposed to low oxygen tension. This reversible effect was observed at an oxygen tension of 15–20 mm Hg.[34] TGF-β1 transcription and peptide synthesis are enhanced in cultures of human dermal fibroblasts exposed to a similar level of hypoxia.[35] In addition, hypoxia upregulates the synthesis of endothelin-1,[36] PDGF B chain,[37] and VEGF[38] in endothelial cells. It appears that, at least in some cases, the effect of hypoxic conditions is mediated by hypoxic inducible factor-1 (HIF-1), a DNA binding complex shown to contain at least two basic helix-loop-helix PAS-domain proteins.[39]

The importance of the hemidesmosome and desmosome is well known for many dermatological diseases where specific defects in their overall structural integrity are present (i.e., pemphigus, bullous pemphigoid, epidermolysis bullosa, etc.). Now, however, during the healing process and for keratinocyte migration to occur, there is a need to break down these complex structures anchoring the basal keratinocytes to the basement membrane and neighboring keratinocytes. This breaking down process is just as complex as the structure itself, and involves interactions between MMPs, integrins, growth factors, and structural proteins. In the normal resting state, laminin-5 is bound to α6β4 integrin, the latter linking the intracellular keratin filaments of keratinocytes to the basement membrane. In large part due to the interactions of integrins (including their phosphorylations status) with the ECM and receptor clustering on the surface of keratinocytes, there are important morphological changes (such as lamellipodia formation) that are required for keratinocyte locomotion.[3,40–42] Molecular GTPases switches (Rho, Rac, Cdc42) are involved. Partially as a result of phosphorylation of the α6β4 integrin, α3β1

TABLE 248-1

Partial List of Growth Factors and Cytokines in the Context of Wound Repair and Their Roles in Some Cellular Functions and Matrix Production

Responses	EGF	FGF	GMCSF	IL-1	PDGF	TGF-β1	VEGF	CTGF	IGF
Fibroblast proliferation	+	+		+	++	+		+	+
Keratinocyte proliferation	+	+		+		–			+
Angiogenesis	+	+	+	+	+	+	++		
Matrix formation		+			++	++		++	+
Inflammatory cell migration/ chemotaxis			++	+		+			

EGF = epidermal growth factor; FGF = fibroblast growth factor; GMCSF = granulocyte-macrophage colony-stimulating factor; HGF = hepatocyte growth Factor; IL-1 = interleukin-1; IGF-1 = insulin growth factor-1; PDGF = platelet-derived growth factor; TGF-β1 = transforming growth factor-β1, VEGF = vascular endothelial growth factor, CTGF = connective tissue growth factor.
Blank cell: no definite response
+ = definite but mild response
++ = definite and marked response

integrin promotes lamellipodia formation and keratinocyte locomotion. It has often been stated that migration of keratinocytes is key to resurfacing of the wound and that in fact such resurfacing is not dependent on proliferation.[3] Overall, one must add, epithelial-mesenchymal transition (EMT), also important in cancer and epithelial adhesion and gain of mesenchymal features, empowers the epithalial cells to migrate in a way that is reminiscent of the embryonic stage. Recently, this process was reconstituted in vitro by exposure of epithelial cells to tumor necrosis factor-α (TNF-α), which led to the expression of vimentin, FSP1, and MMPs. The TNF-α mediated EMT may be secondary to bone morphogenetic proteins (BMP).[43]

In addition to the critical role of migration, keratinocytes do proliferate within the first hours after injury, and this is certainly more evident when the gap or size of the defect cannot be bridged temporarily with cell movement alone and is dependent on the cells beyond.[2,3] By a week after injury, the repair process is well underway. Cytokines and growth factors (EGF, PDGF, TGF-β, FGFs, VEGF), matrix components, and MMPs continue to play an active role. In addition to the growth factors themselves, signaling proteins are critical. For example, certain kinases (MAPK) are activated in basal and suprabasal keratinocytes by further action of integrins or the release of interleukin (IL)-1α. Ion fluxes, including calcium levels and entry into the cells, are also critical to the overall process of keratinocyte migration and skin resurfacing.[44] There is evidence that, in addition to lamellipodia extension, wound edge suprabasal keratinocytes may "leap-frog" over the basal cells near the wound. However, this system may not be very efficient, certainly not to the extent of the purse-string mechanism occurring in fetal healing and corneal healing, which is accompanied by other important differences in matrix deposition and growth factor profile.[5,45] Wound contraction, rather than epithelialization, is common in major injuries, including burns. It is also the preferred mode of repair in many animal species, such as rodents. In experiments using knockout mice, MMP-13 has been implicated in keratinocyte migration, angiogenesis, and contraction, while the role of MMP-9 appears critical in keratinocyte migration.[46]

The remodeling of the ECM, as well as the movement of cells, is highly dependent on MMPs and serine proteases.[47] A very important component of this dependence on MMPs is the MMPs-driven degradation of ECM and the resultant exposure of selective bioactive ECM segments that influence cell behavior, including migration and proliferation.[47] The remodeling phase begins 5–7 days after injury.[11] Upregulation of tPA and uPA are important for keratinocyte migration, which may depend on cross-talk and interactions between α3β1, keratinocytes, and collagen. These events lead to the induction of MMP-1 (collagenase-1 or interstitial collagenase), important in keratinocyte migration and epithelialization.[11] MMP-9 plays a fundamental role in "cutting" Type IV and type VII collagen, which are essential components of the basement membrane and anchoring fibrils, and it also promotes inflammation and neutrophil migration. MMP-10 (stromelysin) breaks down other noncollagenous ECM components and facilitates migration.[2,11,14,48] Other mediators, such as thymosin-β, have been found to upregulate MMPs during wound repair.[49] Of critical importance during the remodeling process is the phenotypic switch in certain cell subpopulations from fibroblasts to myofibroblasts.[2,50] Therefore, while the early process of healing relies heavily on matrix accumulation, which in turn facilitates cell migration, there is now a need to dampen the ECM formation and degrade it to a level that at least approximates the preinjury state. However, the remodeling phase is more than a breakdown of excess macromolecules formed during the proliferative phase of wound healing. Cells within the wound are returned to a stable phenotype, extracellular matrix material is altered (i.e., collagen type III to type I), and the granulation tissue that was so exuberant during the early phases of wound healing disappears.[2,3]

Over the last several years, considerable attention has turned to the role of stem cells from the follicular and interfollicular epidermis in wound healing. Using murine models, it has been reported that, at least after injury, cells from the hair-follicle bulge are recruited to the epidermis and migrate to the center of the wound.[51] In subsequent studies, it has been shown that hair follicles form de novo after wounding and that epidermal cells in the wound assume a hair follicle stem cell phenotype. Some of these findings may be dependent on Wnt signaling.[52]

EXTRACELLULAR MATRIX (ECM)

In wound healing, the extracellular matrix (ECM) comprises four main components:[47] (1) structural proteins (i.e., collagen, elastin); (2) multidomain adhesive glycoproteins (i.e., fibronectin, vitronectin, laminin); (3) matricellular proteins, including secreted protein acidic and rich in cysteine (SPARC), thrombospondin 1 and 2, tenascins, osteopontin; and (4) glycosaminoglycans (GAG), including hyaluronic acid and proteoglycans, that is, syndecans, perlecan (such as chondroitin sulfate and heparan sulfate). The glycosaminoglycan (GAG) hyaluronic acid (hyaluronan) is a particularly abundant component of the provisional matrix, and one whose deposition needs to be modified during the remodeling process. GAGs are often around other ECM proteins, including collagen and elastin.[47] High levels of hyaluronic acid and fine reticular collagen are present in the early embryo, where they are thought to offer less resistance to cell migration.[53] Indeed, embryonic wound repair is characterized by a hyaluronic acid–rich environment, thought to be at least in part responsible for the "scarless" healing of embryonic wounds. Fibroblasts from early granulation tissue produce large amounts of hyaluronic acid, and proliferating cells express CD44, which is the receptor for this GAG molecule.[54,55] Besides the issue of offering less resistance to cell movement, hyaluronic acid may stimulate cell motility by altering cell-matrix adhesion. One example of this is that hyaluronic acid weakens the adhesion of heparan sulfate and fibronectin.[56] Perhaps more importantly from a physical/spatial

standpoint is that hyaluronic acid creates a highly hydrated structure leading to tissue swelling and interstitial spaces, and thus an environment more conducive to cell movement.[2,57] The effects of hyaluronic acid are also regulated by growth factors and cytokines. Upregulation of the hyaluronic acid expression and its receptors (for example RHAAMM) by TGF-β1 stimulates fibroblast motility.[58] Eventually, as remodeling occurs, hyaluronic acid is degraded by hyaluronidase and replaced by sulfated proteoglycans, which contribute a stronger structural role in late granulation tissue formation and in scars, while being less able to stimulate cellular movement. Two major proteoglycans, chondroitin-4-sulfate and dermatan sulfate, are produced by mature scar fibroblasts.

Three main classes of collagens are present normally in connective tissue: (1) fibrillar collagens (types I, III, and V), (2) basement membrane collagen (type IV), and (3) other interstitial collagens (types VI, VII, and VIII). These are examples of the different types of collagen present in skin. Importantly, however, the fibrillar collagens serve as the major structural collagens in all connective tissues.[2,57,59] During the initial phases of wound repair, it appears that the wound tends to recapitulate the processes involved in embryogenesis.[45] Thus, granulation tissue is initially comprised of large amounts of type III collagen, which is a minor component of adult dermis and indeed is present in larger amounts in fetal wound repair. During the phase of remodeling, type III collagen is gradually replaced by Type I collagen. Type I collagen replacement is associated with increased tensile strength of the scar. However, the final tensile strength of a scar is only about 70% of that of preinjured skin.[3,57] The process of converting the collagen content of the dermis from type III to type I collagen is controlled by interactions involving synthesis of new collagen with breakdown of old collagen.[14] Key to this process of conversion are matrix metalloproteinases (MMPs) and, specifically, the collagenases.

Matrix-degrading metalloproteinases (MMP) are proenzymes that need to be activated, and are considered to be the physiologic mediators of matrix degradation.[48] The prototypic MMP is interstitial collagenase, but over 20 such enzymes (zinc-dependent endopeptidases) have been described.[11] We have already mentioned these critical proteinases in the context of keratinocyte migration, but it is important to go over them in more detail. Five groups of these enzymes have been identified: (1) collagenases, (2) gelatinases, (3) stromelysins/matrilysins, (4) membrane-type MMPs, and (5) other types. Table 248-2 is a summary of certain MMPs that have a prominent effect in wound healing, and which supplements this discussion. The collagenases include interstitial collagenase (fibroblast collagenase, MMP-1), which acts on collagens I, II, III, VII, and X. Collagen type II is a particularly good substrate for MMP-1. Another important member of the collagenase class is neutrophil collagenase (MMP-1),

TABLE 248-2
Some MMPs That Have a Well-Established Functional Effect on Wound Healing

Effect	Common Names	Corresponding MMP Designation	Some Specific Effects
Keratinocyte Proliferation and Migration	Collagenase 1 Gelatinase A Stromolysin 2 Matrilysin-1 Epilysin	MMP-1 MMP-2 MMP-10 MMP-7 MMP-28	Increased migration
Endothelial cell (EC) migration	Collagenase 3 Gelatinase A MT1-MMP	MMP-13 MMP-2 MMP-14	Increases (EC) migration Needed for angiogenesis Needed for angiogenesis
Cell migration	Stromolysin 1 Stromolysin 2 Matrilysin-2	MMP-3 MMP-10 MMP-26	Required for excisional wounds
Inflammation	Collagenase 2 Gelatinase A Gelatinase B Matrilysin-1	MMP-8 MMP-2 MMP-9 MMP-7	Anti-inflammatory Anti-inflammatory Promotes inflammation
Neutrophil Migration	Gelatinase B MT6-MMP	MMP-9 MMP-25	Increases neutrophil migration
Apoptosis	Collagenase 2 MT1-MMP MT2-MMP MT6-MMP	MMP-8 MMP-14 MMP-15 MMP-25	Prevents apoptosis Antiapoptotic

MMP = matrix metalloprotease; MT = membrane type.

which also degrades type II and III collagens but is particularly active against type I collagen. Gelatinases break down denatured collagen (gelatin). Among the most important gelatinases are gelatinase A (MMP-2), which breaks down gelatins, collagen IV, and elastin. Another key gelatinase is gelatinase B (MMP-9), which is produced by many cell types, including macrophases, neutrophils, and keratinocytes. Stromelysins have a relatively broad substrate specificity. Both stromelysin 1 (MMP-3) and 2 (MMP-10) act on proteoglycans, fibronectin, laminin, gelatins, and collagens III, IV, and IX. Another member of the stromelysin family, matrilysin (MMP-7) degrades mainly fibronectin, gelatins, and elastin. A member of the MMPs family is epilysin (MMP-28), which appears to be produced by proliferating keratinocytes distal to the wound edge. It may be needed to restructure the basement membrane.[3,48,57] Deficiency of MMP-7 (matrilysin-1), which regulates inflammation, epithelialization, and inhibits apoptosis, is reported to lead to the most severe wound healing defect associated with MMPs.[11]

MOIST WOUND HEALING AND THE REPAIR PROCESS

One of the most important clinical observations of the last several decades is the realization that wounds kept moist re-epithelialize faster.[60–63] The evidence for this is best for acute wounds. However, even in chronic wounds, the moisture-retentive dressings that have been developed to create moist wound conditions do lead to a number of desirable outcomes, such as pain control, painless autolytic debridement, and stimulation of granulation tissue.[63–66] There have been fears that keeping the wound moist will cause infection, but this fear is unfounded.[67–69] Nevertheless, occlusion of the wound is still contraindicated in the presence of infection. There are a variety of wound dressings available to the clinician and which fit the particular clinical situation.[65,66,70,63] The main types of dressings include transparent films, hydrocolloids, foams, gels, alginates, and the relatively new collagen products (Table 248-3). In determining the most appropriate dressing for a particular wound, the clinician must take into consideration the need for absorption of excessive exudate (foams and alginates), whether the wound is too dry and needs additional moisture (gels or hydrogel materials) and whether the wound and its epithelial edges can tolerate the often subtle but serious trauma that comes from removal of adhesive dressings such as films. Thin contact layers, consisting of different polymeric materials with perforations, allow wound fluid to escape and are useful in preventing tissue injury upon dressing changes by minimizing removal of the primary dressing in direct contact with the wound.

The exact mechanisms by which moist wound conditions facilitate keratinocyte migration are unknown.[2,66,70] A number of explanations, some supported by experimental work, have been proposed and appear plausible. Intuitively, a dry wound bed and the presence of a scab

TABLE 248-3
Representative Types of Wound Dressings and Their Properties

Products and Properties	Other Advantages	Disadvantages	Other Indications
Absorb exudate			
ALGINATES	Hemostatic, nonadherent, fewer dressing changes	Require secondary dressings; foul-smelling gel	Highly exudative wounds, partial- or full-thickness wounds, postoperative wounds
FOAMS	Conforms to body contours, applicable to many wounds	Opaque, require secondary dresssings, may adhere to the wound	Partial-thickness exudative wounds, pressure relief. May be used in many uncertain clinical situations
HYDROFIBERS	Soft, interacts with exudate to form gel	May be opaque and require secondary dressings, sometimes difficult to remove	Deep wounds, packing
Keep moisture level			
FILMS	Transparent, partial bacterial barrier, adherent	Adheres to fragile periwound skin; can cause fluid accumulation	Donor sites, superficial burns, partial-thickness wounds with minimal exudate
HYDROCOLLOIDS	Fibrinolytic, enhance angiogenesis, barrier to bacterial and physical agents	Opaque, foul smelling after interaction with exudate; generally highly adherent	Partial- or full-thickness wounds, pressure ulcers
Increase moisture levels			
HYDROGELS	Donate water to a dry wound, nonadherent	May require secondary dressings	Especially painful wounds, postlaser surgery, chemical peels, contact dermatitis, partial- or full-thickness wounds

or crust may render keratinocyte migration more difficult. Some have proposed that the electrical gradient is altered in a beneficial way when wounds are occluded and kept from getting dry. Certainly, there is considerable amount of work indicating that electrical currents can indeed affect the healing process.[71–73] Retention of growth factors and cytokines in the wound bed has been proposed as yet another explanation for how moisture retentive dressings work. The wound fluid taken from acute wounds has been shown in vitro to stimulate the proliferation of a number of cell types, including fibroblasts and endothelial cells.[74] Conversely, there is work indicating that the opposite is true for wound fluid harvested from chronic nonhealing wounds.[75] Whether this difference in the wound fluid characteristics helps explain the greater effect of moist wound healing on keratinocyte migration in acute wounds remains unknown. Indeed, another view has been to remove the wound fluid from chronic wounds, which can be accomplished with certain devices consisting of a film dressing applied to the wound and connected to a source of negative pressure.[76]

WOUND HEALING OF SKIN GRAFTS

The biology of acute wound healing has direct clinical application to dermatologic surgery. For example, reconstructions following Mohs micrographic surgery routinely involve the four main forms of acute wound healing that include secondary intention healing, side to side closure, cutaneous flaps, and skin grafts. Secondary intention healing is a variation of acute wound healing in which the wound is left to heal on its own. The biology of this process is characterized by all of the usual steps of wound healing but differs in the predominance of the inflammatory reaction and granulation tissue, as well as that of wound contraction.[77] Side to side and flap closures are examples of primary intention healing and follow all of the phases of wound healing described previously.

The healing of a skin graft, however, is quite different from what was described earlier with acute injury. One distinguishing feature of a skin graft is the complete dependence of the graft on the recipient wound bed for revascularization,[78–80] a feature that requires several unique physiological events. On the basis of histological studies, graft healing has classically been divided into three identifiable phases: (1) imbibition, (2) inosculation, and (3) neovascularization.[81]

IMBIBITION PHASE

As in conventional acute wound healing, the immediate event is the formation of a fibrin clot at the graft interface,[82] an event that is also accompanied by infiltration of leukocytes from the recipient to the graft.[83] What distinguishes a skin graft from a conventional wound is the diffusion of plasma from the recipient site into the overlying skin graft, resulting in a weight increase of the graft of up to 40% within the first day.[84] This net diffusion of the plasma into the graft was termed *imbibition*, and its significance had initially been thought to be limited to keeping the graft moist and the graft vessels patent.[84,85] Other investigators had hypothesized that imbibition also played a role in providing nutrition to the graft,[86,87] but support for this nutritional role was only demonstrated years later, when bromodeoxyuridine was shown to incorporate into skin graft cells after systemic injection in a mouse model.[88]

The imbibition phase ends as the venous and lymphatic drainage is reestablished, with a concomitant reduction in the weight of the graft.[84] In a rabbit graft model, lymphatic drainage of contrast material has been shown to begin slowly on day 2 and to improve until day 12, with histologically visible anastomoses of the graft and recipient lymphatic vessels by day 4.[89] A fundamental biological issue of skin graft healing has been to determine the relative contributions of the graft and the recipient tissues to vasculature of the graft, a more precise understanding of which has been achieved by recent molecular biological approaches.

REVASCULARIZATION PHASES OF INOSCULATION AND NEOVASCULARIZATION

Inosculation was originally proposed as the anastomoses of graft blood vessels with the recipient-derived vessels, and neovascularization as the ingrowth of new blood vessels from the recipient wound bed into the graft. The early histological studies had suggested that the graft maintained its own vasculature after grafting,[90,91] in support of the idea of inosculation. However, others felt that histological studies could not distinguish graft (or donor-derived) from recipient-derived vessels. Lambert concluded that at least during the first several days, the vessels of a skin graft were donor-derived[92] based on combined histology and radiographic methods. Using a human tissue–engineered skin equivalent with a network of endothelialized vessels,[93] Auger and his group demonstrated a significantly increased speed of vascularization by inosculation compared to the rate of vascularization of the nonendothelialized skin equivalent,[94] highlighting the higher efficiency of inosculation over that of neovascularization.

More precise dissection of the relative roles of graft and recipient in the creation of the final vasculature had to await molecular biologic methods to distinguish graft cells from recipient cells. Specific in-situ hybridization and immunolabeling were used to distinguish graft from recipient in studies of human split thickness skin grafted onto nude mice. It was found that the recipient endothelial cells grew into the preexisting donor capillary tubes, decisively supporting the process of immediate inosculation.[95] Most recently, transgenic mice were used to distinguish donor-derived from recipient-derived vascular growth to reveal an even more precise picture. Capla and colleagues showed regression of the graft vessels starting

at day 3, with simultaneous vessel ingrowth from the recipient primarily into the graft's preexisting vascular framework, resulting in inosculation by day 7.[96] Presumably, neovascularization without anastomosing with the graft's vascular framework is not the predominant event. Using a mouse bone marrow transplant model, the same investigative group further showed that bone marrow-derived endothelial progenitor cells contributed 20% of the recipient-derived endothelial growth within the graft.[96]

OTHER PROCESSES IN SKIN GRAFTS

As with the blood vessels, there have been analogous issues about the relative contributions of graft and recipient tissue for the final reinnervation of the graft.[97] In a porcine graft model, there was a suggestion based purely on histological studies that recipient nerves enter the graft and follow the course of the graft tissue's preexisting neurolemmal sheaths.[98] In another study, human skin was grafted onto nude mice in which the graft structures could be distinguished from recipient tissue using species-specific antibodies. In that report, neurites from the recipient were shown to grow into the graft but did not appear to connect with preexisting donor graft nerve trunks.[95] Using histochemical labeling of cholinesterases, other studies had suggested that the reinnervation of the graft also involved chemotactic attraction of growing neurites to adnexal structures.[99]

Much of the remainder of skin graft healing involves events in common with the normal wound healing process. Infiltration by fibroblasts in the graft occurs 3 to 5 days after grafting, followed by a progressive increase in both graft and recipient fibroblasts within the graft.[95] Full-thickness skin grafts are thought to reduce wound contraction compared to the significant contraction found in secondary intention healing, with one study suggesting that a graft in the exact size of the original defect minimizes this contraction.[100] Hyperpigmentation can be an occasional undesirable side effect of grafting, and histological changes of melanocytes have been observed after grafting.[101] It has been proposed that skin grafts, in a fashion similar to that of cultured autografts, may also stimulate wound healing of the recipient site, especially after prewounding of the donor site from which the grafts were harvested.[102,103] In further support of this hypothesis, expression of keratinocyte Ki-67 and β-1 integrin after grafting has been noted, in addition to the production of stimulatory growth factors and cytokines. This may imply an additional phase of graft healing.[104]

Finally, the mechanisms of contraction of the actual graft are unclear; however, a working model proposes that keratinocytes and myofibroblasts separately contract the graft in two phases. During the initial phase, which occurs during the first two days, epidermal cells contract the graft in a purse string fashion.[105] The initial epidermally mediated contraction is followed, starting at 3–5 days, by a longer contractive phase mediated by myofibroblasts (which have differentiated from fibroblasts).[106] The contraction phases have been modeled in vitro using collagen gels[106] and tissue engineered skin.[107] Among the findings from in-vitro studies is that TGF-β does not drive graft contraction as it does hypertrophic scarring.[108]

CHRONIC WOUNDS AND IMPAIRED HEALING

The previous discussion has focused on cutaneous wound repair after acute injury. It must be recognized, however, that the applicability of those events and processes is limited when it comes to chronic wounds, such as in diabetes, venous, and arterial insufficiency, and in a variety of situations complicated by inflammatory processes and faulty host response. The linear and one-way relationship between the different phases of wound repair is lost in chronic wounds (Fig. 248-5).

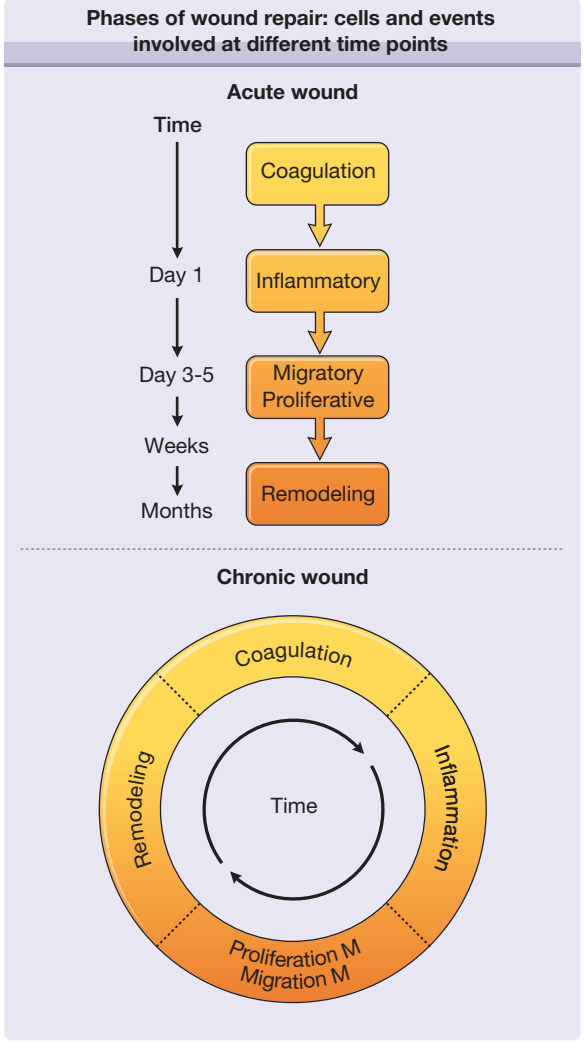

Figure 248-5 Schematic representation of the different phases of wound repair, the cells and events involved at different time points. The left side of the diagram shows the linear progression observed with the healing of acute wounds. The right side is an attempt to show that chronic wounds are in disarray, and that the linear progression is lost.

There is no specific orderly sequence, and parts of the chronic wound may be in different phases at different times. Acute wounds, such as those created by surgery or by trauma, have a predictable time-frame for healing and generally heal quite readily. However, chronic wounds display what has been called a "failure to heal" or impaired healing. A number of observations have been made with regard to chronic wounds, and hypotheses have been proposed for impaired healing. It must be noted that it has proven difficult to study chronic wounds from a pathophysiological standpoint. A major drawback has been the unavailability of animal models that truly display impaired healing.

Some chronic wounds are the complex result of ischemia, pressure, and infection. A case in point for this pathophysiological triad is the diabetic ulcer.[3] There is still considerable controversy whether hyperglycemia itself plays a pathophysiological role in the development of diabetic ulcers, although neutrophil function is impaired and thus the propensity to infection is enhanced in the diabetic state.[3] Importantly, the notion of "small vessel disease" in diabetes has been more properly evaluated and shown not to be an obstructive phenomenon, but rather a more physiological one.[109] This being the case, revascularization of the diabetic foot is now viewed as the right approach in the presence of large vessel disease and good run-off circulation. Perhaps the best example of truly impaired healing, not related to undue pressure and poor arterial supply, is venous ulceration. The underlying abnormality in the development of venous ulcers is *venous hypertension*, which refers to the inability of venous pressure in the foot to decrease in response to exercise.[110] There have been several hypotheses proposed for how venous hypertension then results in venous ulceration or the development of lipodermatosclerosis. Some of these hypotheses have emphasized the accumulation of fibrin around dermal blood vessels and defects in fibrinolytic activity. Another hypothesis has centered on damage to the microvascular endothelial cells, which then results in leakage of fibrinogen and dermal pericapillary fibrin cuffs. The leakage of macromolecules from the blood vessels into the dermis in venous disease is substantial, prompting other investigators to propose that such molecules can trap growth factors and other important components and render them unavailable to the healing process or the maintenance of tissue integrity.[111–115] There is evidence that growth factors in chronic wounds are bound to and trapped by macromolecules leaking into the dermis, such as albumin, fibrinogen, α-2-macroglobulin. The latter molecule is a scavenger for growth factors, including PDGF.[114,115]

We have earlier discussed at some length the critical importance of MMPs in cutaneous wound repair, particularly in the context of keratinocyte migration. However, in chronic wounds, MMPs may contribute to the overall failure to heal. For example, in venous ulcers and other types of chronic wounds, the wound fluid contains excessive amounts of metalloproteinases, which break down the extracellular matrix and, most likely, cytokines and growth factors.[116,117]

It should also be recognized that tissues around chronic wounds are not normal, and indeed they are altered by the primary pathogenic mechanisms or in the face of inability to heal readily. Clinically, the best example of this is the intense fibrosis surrounding venous ulcers, which is termed lipodermatosclerosis.[118] Once lipodermatosclerosis becomes established, it can lead to ulcers, and becomes the site of ulcer recurrence. Indeed, venous ulcers surrounded by lipodermatosclerosis are much more difficult to heal. The reason for these observations may lie in an increasing body of evidence suggesting that the cellular makeup of wounds that do not heal is altered. Thus far, most likely because of the ease with which they are grown and studied in culture, the best evidence is with wound fibroblasts. We now know that ulcer fibroblasts are senescent,[119] and unresponsive to certain selected cytokines and growth factors.[120–122] For example, it has been shown that venous ulcer fibroblasts are unresponsive to the action of transforming growth factor-β1 (TGF-β1)[120,121] and platelet-derived growth factor (PDGF)[122] The unresponsiveness of venous ulcer fibroblasts to TGF-β1 may be due to decreased expression of type II TGF-β receptors. This receptor abnormality also leads to decreased phosphorylation of key TGF-β signaling proteins, including Smad2, Smad3, and MAPK.[121,123] The synthetic program of cells in diabetic ulcers may also be altered, so that such chronic wounds are said to be "stuck" in a certain phase of the repair process.[124] A close relationship has been reported between some of these abnormalities and the inability to heal.[119]

BASIC STANDARDS OF CARE

Arterial ulcers need vascular reconstruction; anything less is a temporary measure and ultimately leads to amputation. The latter may be the only option in inoperable patients. Arterial ulcers that are necrotic and stable with an overlying eschar should probably not be disturbed unless a vascular reconstructive plan is in place.[3] Leg elevation and limb compression are the fundamental therapy for venous ulcers. Contact dermatitis is extremely common in patients with venous disease and, therefore, avoidance of topical agents is required in many patients.[125] Pentoxifylline has been tested in several large randomized trials for its ability to accelerate the healing of venous ulcers. The results have varied, and it may be that a high dose of pentoxifylline, at 800 mg three times a day, is more effective than the usual dose of 400 mg three times a day.[126] Whether the use of pentoxifylline should be considered standard therapy for venous ulcers is unclear at the moment. The anabolic steroid stanozolol has been effective in diminishing the induration of lipodermatosclerosis, which is the fibrotic component of venous ulcers, and in the acute and painful phase of lipodermatosclerosis, when compression bandages and stockings are too painful to use.[127] However, this agent is no longer available; danazol may be a useful substitute (V. Falanga, unpublished). For now, the only known medical approach for decreasing recurrence of venous

ulcers seems to be graded elastic stockings, with a pressure at the ankle in the range of 40 mm Hg. Stockings should be considered a lifelong therapy to help prevent ulcer recurrence and the other manifestations of venous disease.

The triad of neuropathy, ischemia, and trauma is the main pathophysiological underpinning for the development and recurrence of foot ulcerations in patients with diabetes.[3] Measures addressing these components will accelerate healing. Glucose control and optimal management of other systemic complications of diabetes, including renal failure, are an important aspect of therapy for diabetic foot ulcers. From a local wound care standpoint, off-loading is critical and is the main standard of care for neuropathic ulcers. Patients with diabetic ulcers due to vascular insufficiency or with ulcers that are mixed in etiology, that is, having both a neuropathy and surgical compromise, need to be referred immediately for vascular studies and surgical consultation.[3]

Aggressive surgical debridement of the necrotic tissue and the callus surrounding the ulceration has recently become part of standard care in the management of diabetic ulcers.[128] The callus probably provides additional pressure and perpetuates the ulceration. As with neuropathic diabetic ulcers, off-loading is the standard of care for pressure (decubitus) ulcers. Turning and shifting the position of the patient every 2 hours is said to be effective but actually is not proven to be so.

SURGICAL APPROACHES TO CHRONIC WOUNDS

In the management of venous ulcers, surgical therapy may be considered in the absence of deep vein obstruction and when significant superficial or perforator incompetence is documented. Recently, considerable promise has come from less invasive ligation of perforators using subfascial endoscopic perforator surgery (SEPS). This approach, sometimes combined with or followed by more definitive procedures, such as the removal of the long saphenous vein (Linton procedure), may be effective in healing the ulcers.[129] However, it is yet unclear whether this type of therapy prevents ulcer recurrence.

The realization a few years ago that the concept of an occlusive microangiopathy in diabetic ulcers is incorrect brought about a fundamental change in how revascularization of the diabetic foot is viewed; it has now become common practice to revascularize the diabetic limb.[109,130] Therefore, standard vascular surgical techniques are applicable to diabetic patients as long as there are adequate distal vessels. Vascular reconstruction may need to be combined with limited digital, ray, or forefoot amputation. Ostectomy procedures can alleviate pressure from bony prominences in selected cases.

Ostectomy can also be useful in the management of pressure ulcers, to broaden bony prominences. In the appropriately selected patient, random or musculocutaneous flaps are indicated.

OTHER THERAPIES FOR IMPAIRED HEALING

Growth factors are polypeptides with a variety of potent effects on cell proliferation and synthetic capacity (Table 248-1). To date, the only growth factor that has proven clinically effective is topically applied platelet-derived growth factor (PDGF). The PDGF-BB isomer, becaplermin, is approved by the FDA for the treatment of diabetic neuropathic foot ulcers. Several clinical trials have tested the effectiveness of becaplermin gel (30 μg/g) in diabetic foot ulcers.[128,131] The results showed an incidence of wound closure of up to 48% compared to 33% for the control group. Becaplermin must only be used when combined with optimal wound bed preparation and elimination of other factors that impair healing.

In the last decade, a number of tissue engineering products have become available for clinical use.[132,133] Two main types of bioengineered skin have been tested and proven to be effective in venous and diabetic neuropathic foot ulcers. One construct, approved for use in diabetic neuropathic ulcers, is comprised of neonatal foreskin fibroblasts in an absorbable suture material.[134] The other type of construct, approved for use in both venous[135,136] and diabetic neuropathic foot ulcers,[137] is bilayered and consists of both fibroblasts and keratinocytes from neonatal foreskin. The exact mechanism of action of bioengineered skin is unknown, but there is no prolonged engraftment of cells.[138] In clinical trials, both constructs were applied repeatedly to the wound, in order to stimulate healing. However, in clinical practice, it appears that a more limited number of applications is required. As with the use of becaplermin, optimal preparation of the wound bed is required for these constructs to be effective. Moreover, there is evidence that bioengineered skin is only helpful in ulcers that are of long duration and have not responded to conventional therapy.[136] However, the field of tissue engineering is extensive, making use of viable or nonviable cells and matrix constructs, which can be dermal, epidermal, and dermal–epidermal (bilayered).

Even more recently, stem cell therapy of difficult to heal wounds is becoming a reality and is considered a great promise in the field of regenerative medicine, including cutaneous wound healing.[139] We have discussed the possible role of stem cells generated from hair follicles.[51,52] However, in addition to the still controversial use of human embryonic stem cells, the hope is that the recently achieved reprograming of adult differentiated cells (i.e., skin fibroblasts) into induced pluripotential stem cells (iPS) would lead to the possibility of either accelerating the repair process or true regeneration. The iPS have been generated from adult differentiated cells for the most part through the use of key transcription factors "cocktails". For the most part, though the field is rapidly evolving, two different combinations of transcription factors were originally used: (1) (NANOG, OCT3, SOX2, LIN28)[140] and (2) (OCT3/4, SOX2, KLF4, AND c-MYC). Many if not all of the characteristics of embryonic stem cells are present with iPS cells, but we keep learning more about the consistency or lack thereof of iPS and how to control differentiation.[141] An exciting new development is the use

of very small embryonic-like stem cells (VSELs), which are present in adults and are pluripotential.

While rapid developments are occurring with the use of embryonic stem cells and iPS cells, extensive progress is also being made with the use of adult multipotent stem cells, that is, from bone marrow. We can only address representative studies here. Most studies of adult stem cell therapy of human wounds have used cultured bone marrow–derived mesenchymal stem cells (MSCs).[142] In pilot studies, clearly defined MSCs have been used successfully in the treatment of nonhealing chronic wounds and in acute wounds resulting from Mohs micrographic surgery defects not amenable to reconstruction.[143] In that study, the MSCs were applied to the wounds using a novel fibrin spray delivery method. The improvement of wounds with adult stem cells may be due to either integration of the stem cells or by their paracrine effects.[144]

PREDICTING WOUND CLOSURE

Several recent studies have now placed us in the position to predict from simple observation and in the first 3–4 weeks of therapy whether a wound will heal in a timely fashion. The methods used to predict wound closure range from simple measurements of wound size (width and length) and change in wound area, to computerized planimetric analysis and assessment of migration of the wound edge.[145] In a study of 56,488 wounds, it was shown that a percent change in area of approximately 30% at 4 weeks could predict wound closure with a sensitivity of 0.67, a specificity of 0.69, and had a positive and negative predictive value of 0.80 and 0.52, respectively.[146] In even more practical terms, the appearance of the wound edge is important, so that steep edges imply no progress of the wound, while in healing wounds the edges become less steep and begin to migrate toward the center. The ability to predict closure is very important. By four weeks, the clinician should be able to make a determination of whether the present therapy should be continued or whether a change is required, including a complete reassessment of the clinical situation. The prognostic value of the healing rate by 4 weeks of therapy has been confirmed by additional investigators.[147]

CONCLUSIONS

Characterizing the events occurring after tissue injury and their overlaps represents a rather daunting task. Yet, over the last several decades, the orderly progression from injury to inflammation and coagulation, to the development of a provisional matrix, to the formation of granulation tissue and to tissue remodeling, has been elucidated to a high degree. Although somewhat artificial, the different phases of wound repair described here are the platform on which more knowledge can be built. Much still needs to be learned, but the framework is there for understanding tissue repair and for developing ways to accelerate it. Indeed, due to breakthrough in science and technology, progress has been exponential in the last few years. Today, we are in the position of using smart dressings and stem cells. With the use of cultured adult stem cells or even iPS cells or VSELs that are pluripotent, we can aim for skin regeneration and not simply for tissue repair. There are still challenges, in terms of improving traditional dressings, smart biological dressings, bioengineered skin, stem cell therapy; we will need continued and increased understanding of the science involved. It is also possible that lessons learned from failure to heal, as in chronic wounds, will provide valuable lessons for the general principles of surgical and acute wound healing.

KEY REFERENCES

Full reference list available at www.DIGM8.com

DVD contains references and additional content

3. Falanga V: Wound healing and its impairment in the diabetic foot. *Lancet* **366**:1736-1743, 2005
6. Alexopoulou AN, Multhaupt HA, Couchman JR: Syndecans in wound healing, inflammation and vascular biology. *Int J Biochem Cell Biol* **39**:505-528, 2007
11. Xue M, Le NT, Jackson CJ: Targeting matrix metalloproteases to improve cutaneous wound healing. *Expert Opin Ther Targets* **10**:143-155, 2006
26. Heber-Katz E, Gourevitch D: The relationship between inflammation and regeneration in the MRL mouse: potential relevance for putative human regenerative(scarless wound healing) capacities? *Ann N Y Acad Sci* **1172**:110-114, 2009
28. Panuncialman J, Falanga V: The science of wound bed preparation. *Surg Clin North Am* **89**:611-626, 2009
45. Martin P, Parkhurst SM: Parallels between tissue repair and embryo morphogenesis. *Development* **131**:3021-3034, 2004
63. Ovington LG: Advances in wound dressings. *Clin Dermatol* **25**:33-38, 2007
106. Harrison CA, MacNeil S: The mechanism of skin graft contraction: an update on current research and potential future therapies. *Burns* **34**:153-163, 2008

Chapter 249 :: Treatment for Varicose and Telangiectatic Leg Veins

:: Robert A. Weiss & Margaret A. Weiss

TREATMENT FOR VARICOSE AND TELANGIECTATIC LEG VEINS AT A GLANCE

- 53% of patients over 50 years of age show some venous reverse flow.
- Pregnancy, body mass, age, and family history can all affect incidence of venous reflux.
- Sclerotherapy and laser are main cosmetic treatments for spider veins.
- For larger varicose veins, sclerotherapy, phlebectomy, endovenous occlusion by radiofrequency or laser are standard approaches.

INTRODUCTION

Bulging varicose veins and unsightly "roadmap" telangiectatic webs affect millions of patients around the world. The incidence is highest in Caucasian patients in which telangiectasias comprise the most common of all cosmetic complaints. This is borne out by epidemiologic surveys in which leg telangiectasia are reported in 70% of women.[1] These same 24 city studies of thousands of patients indicate that 53% of the population over 50 years of age show some venous reverse flow.[1] Women are at least 4 times more likely than men to develop telangiectasia, while males have double the risk of developing large varicose veins.[2] Women aged over 50 years are five times more likely than women aged 29 or less to develop large varicose veins. Pregnancy increases the risk of varicose vein development by a factor of 1.5× to 3× and is associated with higher risks following three pregnancies.[1,3,4] Increased body mass index correlates with a higher risk of reverse flow or reflux which leads to pain, swelling and abnormalities of the saphenous system.[5,6] A positive familial history of disease is well known to increase the risk for varicose veins. Varicose veins may cause significant morbidity including chronic stasis dermatitis, ankle edema, spontaneous bleeding, superficial thrombophlebitis, recurrent cellulitis, lipodermatosclerosis and skin ulceration on the ankle and foot.

The incidence of varicose veins increases with each decade of life. Increased incidence has led to increased demand for treatment of varicose and telangiectatic veins as the average age of the US population grows. While 41% of women in the fifth decade have varicose veins, this number rises to 72% in the seventh decade.[7] Statistics for men are similar with 24% incidence in the fourth decade, increasing to 43% by the seventh decade. Six million workdays per year may be lost in the United States due to complications of varicose veins, although this number is being affected by endovenous ablation techniques.[8] Treatment is now much less complicated as an outpatient procedure avoiding dreaded stripping. As such noninvasive treatments are more frequently utilized so that lost workdays may actually be decreasing, although these statistics do not exist.

The main techniques employed in the dermatologist's office for treatment of cosmetic spider veins are sclerotherapy and lasers. For larger varicose veins, dermatologic surgeons employ sclerotherapy (with or without Duplex ultrasound guidance), ambulatory phlebectomy, and endovenous ablation by radiofrequency or laser. *Sclerotherapy*, which is defined as the intravascular introduction of a sclerosing substance, is the most frequently utilized procedure. We recommend that the term be changed to "endovascular chemoablation" which more accurately describes the procedure, although sclerotherapy is so entrenched that this will be unlikely to occur.

Sclerotherapy gained acceptance in the United States as a highly effective treatment during the early 1990s as it can be utilized for veins of all sizes.[9] With the addition of foaming the sclerosant, utility has been expanded further.[10] Sclerotherapy is also an important adjunctive therapy to surgical techniques such as ambulatory phlebectomy for saphenous tributaries[11,12] and endovenous ablation of refluxing saphenous veins.[13,14] Knowledge of venous anatomy and physiology, principles of venous insufficiency, methods of diagnosing venous abnormality, uses and actions of sclerosing solutions and proper use of compression are essential elements of successful venous therapy.

HISTORICAL ASPECTS

Primitive stripping and cauterization were practiced by Celsus, while ligation was mentioned by Antillus (30 AD). In the second century AD, Galen proposed tearing out the veins with hooks, a precursor to the modern day technique of ambulatory phlebectomy originated by Swiss dermatologist Robert Muller in the late 1960s.

A crude concept of sclerotherapy appeared in 1682, as Zollikofer described injection of acid into a vein to create a thrombus. By the late 1700s, the critical role of saphenofemoral reflux in the pathogenesis of varicose veins had been recognized by a Swiss surgeon, Rima. Reports of use of absolute alcohol as a sclerosing agent appeared from 1835–1840. In 1851, Pravaz attempted

sclerotherapy with ferric chloride using his new invention, the hypodermic syringe.

The foundation of modern sclerotherapy can be traced to World War I when Linser and Sicard both noticed the sclerosing effect of intravenous injections used to treat syphilis which often resulted in vein sclerosis. Tournay greatly refined the sclerotherapy technique in Europe. It was not until 1946, when a safe sclerosant, Sotradecol (sodium tetradecyl sulfate) had been tested and described that sclerotherapy began to be seriously studied in the United states.[15]

Another key to success and acceptance of the treatment of varicose veins by sclerotherapy was the addition of compression. Sigg and Orbach in the 1950s and Fegan in the 1960s emphasized the importance of combining external compression immediately following injections. Starting in the 1980s, Duffy promoted the technique among dermatologists and advocated the use of polidocanol (POL) and hypertonic saline as safe and effective sclerosing solutions.[16] In March 1999, the first endovenous obliteration technique utilizing radiofrequency was cleared by the US Food and Drugs Administration (FDA). Dermatologic surgeons were instrumental in developing this technique.[14,17,18] Goldman's first American textbook of sclerotherapy integrated the world's phlebology literature, introduced new sclerosing solutions and validated dermatology's claim to expertise in vein treatment.[19] Several additional textbooks by dermatologic surgeons have firmly established phlebology within the domain of dermatology.[20,21] The newest development in sclerotherapy has been the FDA approval of polidocanol (Asclera, Merz Aesthetics/Bioform, San Mateo, CA) in late spring of 2010. The advantages of this solution are discussed later.

PATIENT SELECTION—VENOUS ANATOMY AND PHYSIOLOGY, SYMPTOMS, AND CONTRAINDICATIONS

The venous system is comprised of a primary deep venous compartment and superficial compartment with thousands of small veins (perforating veins) connecting the two systems. The deep compartment, "the muscle pump," normally acts as a conduit for 85%–90% of venous return from the leg. During contraction of the calf muscles, the valves of the perforating veins and associated superficial veins close, allowing blood to flow only proximally at high pressures through the deep system. This generates primary propulsive force returning venous blood to the heart (Fig. 249-1).

The superficial venous system consists of three primary territories: (1) great saphenous vein (GSV) (2) small saphenous vein (SSV) and (3) subdermic lateral venous system (LVS) (Fig. 249-2). Comprising the three major patterns are multiple collateral veins (accessory) and multiple tributary veins emptying into all 3 major superficial systems of the GSV, SSV and LVS. The

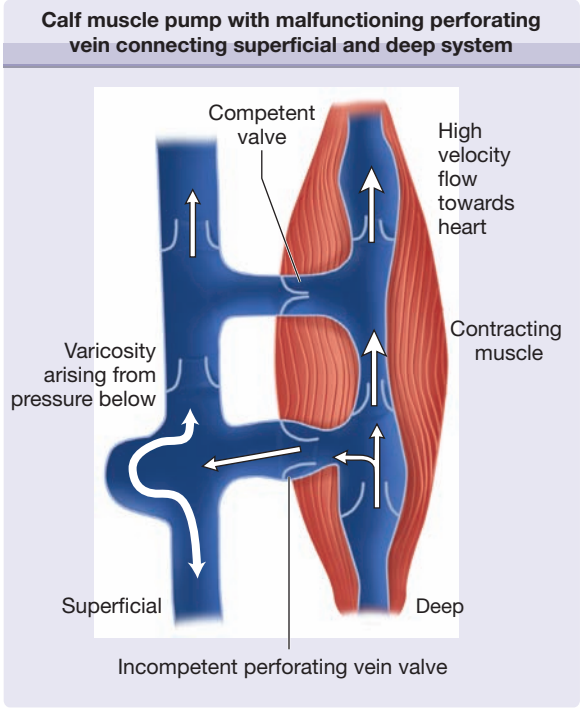

Figure 249-1 Schematic of the calf muscle pump with malfunctioning perforating vein connecting the superficial and deep system. High pressures are generated when the gastrocnemius muscle contracts to pump blood proximally. A malfunctioning valve is shown diverting pressure to the skin surface. Competent valve directs flow proximally.

points of connection (perforating veins) between the superficial and the deep system play important roles as these are sites through which reflux or reverse flow often develops (Fig. 249-3). Due to gravitational hydrostatic pressure, sequential retrograde breakdown of venous valve function often follows a leak at one point leading to propagation of a varicosity. Increased diameter between valve leaflets with failure to oppose properly caused by genetically weak venous wall or venous valve structure may initiate these events. Calf muscle pump pressure plus gravitational hydrostatic forces are transmitted directly via the incompetent perforating vein or communicating veins to the surface veins. Venous hypertension may reach levels higher than systolic arterial blood pressure in the cutaneous venules with the patient erect. Transmission of pressure may result in venular dilatation over a wide area of skin including the formation of telangiectatic webs and more serious consequences such as ulceration.[22] This leads to a number of symptoms with heaviness, fatigue, and aching of the legs.[23]

When present in significant quantity, the volume of blood sequestered and stagnant in reticular veins and associated telangiectatic webs (particularly of the lateral venous system) may cause enough distention to produce symptoms.[24] Symptoms are relieved by the wearing of support hose or with rest and elevation of the legs. Prolonged standing or sitting without calf muscle contraction worsens symptoms. The size of

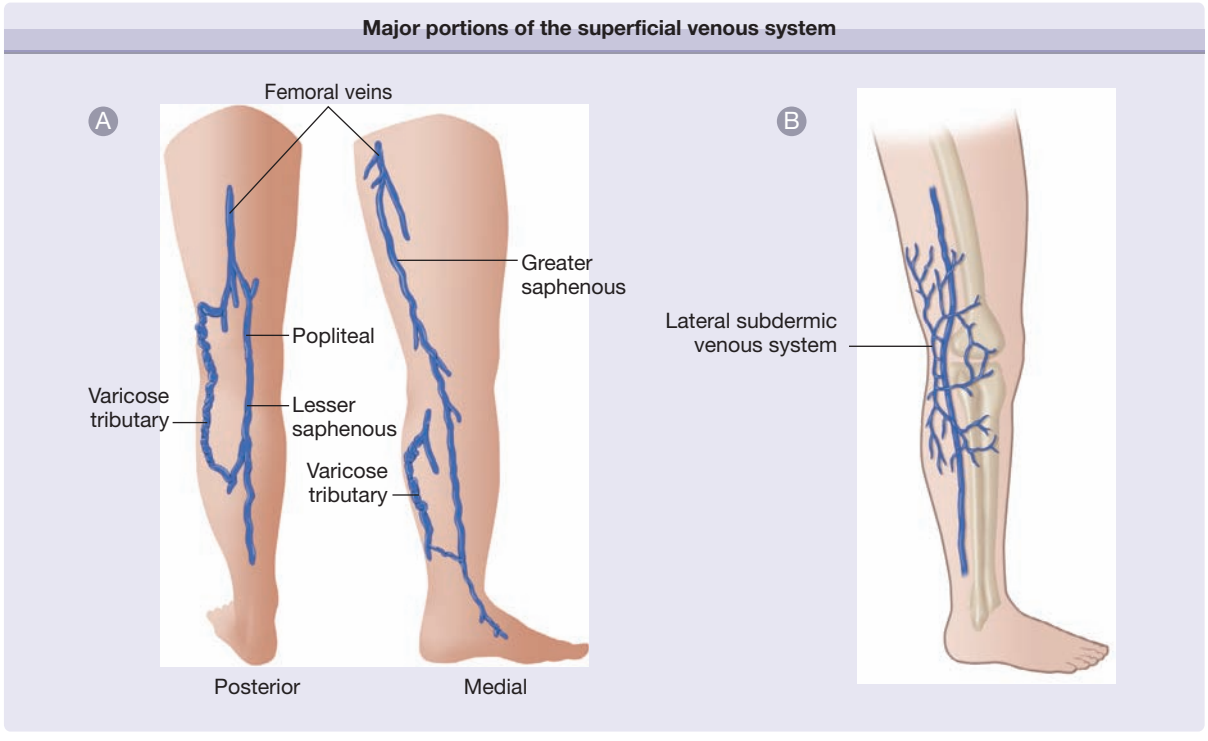

Figure 249-2 Schematic of the major portions of the superficial venous system. **A.** Greater saphenous vein and lesser saphenous vein. **B.** Subdermic lateral venous system. When varicosities or telangiectatic webs are present within the distribution of these saphenous veins, the source of pressure must be elucidated. The lateral venous system is the most common source of telangiectasias.

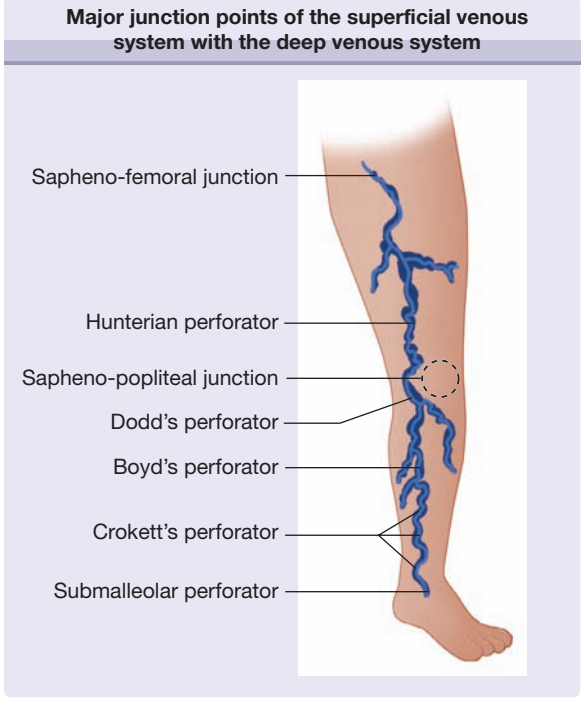

Figure 249-3 Diagram indicating major junctions points of the superficial venous system with the deep venous system. Larger surface varicose veins may originate from any of these points.

the vessels causing moderately severe symptoms may be as small as 1–2 mm in diameter. Sclerotherapy has been reported to yield an 85% reduction in these symptoms as well as superb cosmetic results.[24]

CONTRAINDICATIONS TO TREATMENT OF SPIDER VEINS

(Table 249-1)

Vein treatment and, in particular, foam sclerotherapy may be performed safely and effectively in virtually all types of veins, except when reflux exists at the saphenofemoral junction. Since the goal of sclerotherapy is to eliminate reflux at its origin, the goal of noninvasive diagnostic evaluation is to uncover primary sources of high reverse flow pressure. A high rate of recurrence for sclerotherapy is commonly seen when reflux originates at the major saphenous junctions. The techniques of endovenous ablation by radiofrequency or laser are the means by which reflux occurring at the termination point of the saphenous veins is now treated. Five-year data indicates that these techniques are as effective as the old surgical techniques of ligation and stripping to eliminate saphenous veins.[25] Our experience at ten years show that these techniques are superior to older surgical techniques. Recent studies show high recurrence rates (30%–50%) following ligation and stripping.[26] Archaic and invasive stripping techniques are no longer recommended for primary treatment of saphenous reflux.

TABLE 249-1

Indications and Contraindications for Sclerotherapy

Indications	Contraindications
Pain	Reflux at saphenofemoral or sahenopopliteal junction[a]
Major tributaries of greater and lesser saphenous veins	Nonambulatory patient
Major perforator reflux	Obesity
Lateral venous system varicosities	Deep venous thrombosis
Cosmetic	Known allergy to sclerosing agent Arterial obstruction Pregnancy

[a]Relative contraindication, success has been reported under the right conditions, proper sclerosing solutions (not available in the US) and/or the use of Duplex-guided sclerotherapy.

Endovenous ablation techniques have been embraced due to the high degree of safety and efficacy, without morbidity and downtime of general anesthesia and invasive technique required by stripping.[27]

Venous treatment is contraindicated in a bedridden patient since ambulation is important for minimizing risks of thrombosis. Similarly, patients under general anesthesia for nonrelated procedures should not undergo simultaneous sclerotherapy. Severely restricted arterial flow to the legs necessitates postponement of vein treatment. A history of deep venous thrombosis (DVT) or previous trauma to the leg (e.g., auto accident) should preclude sclerotherapy until adequately evaluated by Duplex ultrasound. Previous urticaria or suspected allergy to a sclerosing agent should serve as a relative contraindication to use of that particular sclerosing agent.

Pregnancy should be considered a contraindication during the first and second trimester, although extremely painful or bleeding, varices may be treated in the last trimester by endovenous ablation techniques. Treatment is typically postponed since varicosities and telangiectasias may resolve spontaneously 1–6 months postpartum.

Obesity should be considered a relative contraindication since maintaining adequate external compression is difficult. Sclerotherapy of larger varicosities should be postponed until weight reduction is achieved. During hot summer months, heat-induced vasodilatation and inability to comply with wearing of compression hose may also require postponement of treatment.

TREATMENT TECHNIQUES

PRETREATMENT EVALUATION

Physical examination is performed by viewing the patient's legs in a 360° rotation. Palpation is performed along the saphenous vein distributions to rule out early large axial varicosities which cannot be seen. Based on the history and physical examination, noninvasive diagnostic vascular tests are performed as necessary.[28] Those patients with a family history of large varicose veins are more likely to have early axial (saphenous) reflux even when presenting with telangiectasias alone.[11] Previous venous surgery warrants further testing before treatment.

Once the patient is judged to be a candidate for vein treatment, informed consent is obtained. Any veins visible or palpable suggestive of saphenous system involvement should be minimally evaluated by handheld Doppler ultrasound, which is equivalent to using an enhanced "stethoscope" to hear vein flow. It is generally recommended to supplement Doppler with Duplex ultrasound as this method of visualization of venous anatomy is more reliable and more prevalent. For Doppler to generate or augment an audible signal of flow, a maneuver such as manual compression of the calf must be performed by the examiner. When compression is released, gravitational hydrostatic pressure causes reverse flow to cease within 0.5–1 second when valves are competent, but a long flow sound is audible when valves are incompetent.

The most essential part of the Doppler examination is the examination of the saphenofemoral junction below the inguinal fold just medial to the femoral arterial signal. During a Valsalva maneuver, a continuous and pronounced reflux signal is a reliable sign of valvular insufficiency. An equivocal result may require a duplex ultrasound examination for a definitive answer. Methods of complete Doppler examination are detailed in other texts.[11]

The gold standard of noninvasive examination of the venous system is duplex ultrasound. This allows direct visualization of the veins and identification of flow through venous valves. An image is created by an array of Doppler transducers, which are switched on and off sequentially. The Duplex examination is often used to uncover hidden sources of reflux prior to beginning any method of treatment or delineate reflux sources when patients experience poor results from sclerotherapy. The declining price and increasing portability of Duplex ultrasound is rapidly making this examination the standard and reducing Doppler ultrasound to a relic of the past.

SCLEROTHERAPY OR ENDOVENOUS CHEMOABLATION SOLUTIONS

Sclerosing solutions have been classified into groups based on chemical structure and effect: hyperosmotic, detergent, and corrosive agents (chemical toxins—salts, alcohols, and acid or alkaline solutions). Commonly employed sclerosing solutions are summarized in Table 249-2.

HYPERTONIC SALINE. Although approved by the FDA only for use as an abortifacient, it is still commonly used in the United States in spite of its shortcomings. Used at a concentration of 23.4% (HS), a theoretical

TABLE 249-2
Comparison of Commonly Employed Sclerosing Agents

Sclerosing Solution	Category	Advantages	Disadvantages	Vessels Treated	Concentrations
Sodium tetradecyl sulfate (Sotradecol)	Detergent	FDA approved Painless—unless injected extravascularly	May cause breakdown rarely—rare allergic reaction	All sizes	0.1%–0.2% telangiectasias 0.2%–0.5% reticular 0.5–1.0% varicose 1.0–3.0% axial varicose
Polidocanol	Detergent	Painless Low ulceration risk at low concentrations—low skin toxicity	Not FDA cleared until 2010 Rare allergic reaction	Small to medium	0.25–0.5% telangiectasias 0.5%–1.0% reticular 1.0%–3.0% varicose
Hypertonic saline	Hyperosmolar	Low risk of allergic reactions	Ulcerogenic Painful to inject	Small	23.4%–11.7% telangiectasias 23.4% reticular
Hypertonic saline + dextrose (Sclerodex)	Hyperosmolar	Low risk of allergic reaction Mild stinging Low ulcerogenic potential	Not FDA approved Relatively weak sclerosant	Small	Undiluted–telangiectasias Undiluted–reticular
Sodium morrhuate (Scleromate)	Detergent	FDA approved	Allergic reactions highest	Small	Undiluted–telangiectasias Undiluted–reticular
Chromated glycerine (glycerine with 6% chromium salt (Scleremo)	Chemical irritant	Low skin ulcer potential	Not FDA approved Very weak sclerosant	Smallest	Undiluted to strength–telangiectasias
Glycerine – plain	Chemical irritant/ hyperosmolat	Painless, low-risk or allergic reaction, decreased risks of pigmentation and matting	FDA approved for reduction of cerebral edema	smallest	50%–72%
Polyiodinated iodine (Varigloban)	Chemical irritant	Highly corrosive—allows treatment of largest veins	Not FDA approved Avoid in iodine allergic patients painful to inject	Largest	1%–2% for up to 5mm veins 2%–6% for the largest veins

advantage of HS is its total lack of allergenicity when unadulterated. HS has been commonly used in various concentrations from 10% to 30%, with occasional addition of heparin, procaine, or lidocaine. Additional agents typically provide no benefit. Therefore, HS is used either unadulterated or diluted to 11.7% with sterile water for smaller telangiectasias.[29]

With hypertonic solutions, damage of tissue adjacent to injection sites may easily occur. Skin necrosis may be produced by extravasation at the injection site, particularly when injecting very close to the skin surface. Injection of hyaluronidase into sites of extravasation may significantly reduce the risks of skin necrosis with HS.[30] The pain of injection with risks of ulceration of this solution, makes it highly undesirable for modern vein treatment. We strongly recommend against the use of HS, especially with newer safer and less painful sclerosing agents approved by the US FDA.

HYPERTONIC SALINE AND DEXTROSE

(HSD) (*Sclerodex*, Omega Laboratories Ltd, Montreal, Canada). HSD is a viscous mixture of dextrose 250 mg/mL, sodium chloride 100 mg/mL, propylene glycol 100 mg/mL, and phenethyl alcohol 8 mg/mL. HSD is a relatively weak sclerosant for local treatment of small vessels, with a total volume of injection not to exceed 10 mL per visit with 0.1–1.0 mL per injection site. HSD is marketed predominately in Canada. Although a slight burning sensation occurs, pain is far less than with HS.

POLIDOCANOL

(Asclera™, Merz Aesthetics, Bioform, San Mateo, CA/Aethoxysklerol, Kreussler & Co, Wiesbaden-Biebrich, West Germany). The detergent-based POL, a urethane compound, was originally developed as an anesthetic, but was found to have the property of sclerosing small diameter vessels after intradermal injection. POL contains hydroxypolyethoxydodecane dissolved in distilled water with 5% ethanol as a stabilizer. First used as a sclerosing agent in the late 1960s in Germany, POL is popular worldwide for smaller vessels due to painless injection and lowest incidence of cutaneous necrosis with intradermal injection. Lower concentrations of POL were initially suspected to have a lower incidence of hyperpigmentation than HS or STS, but recent clinical trials indicate a significant percentage of hyperpigmentation occurs.[31] Asclera was recently approved by the FDA and now represents a safe, virtually painless sclerosing solution available to US dermatologists. The European data indicates safe utilization for over 30 years with recent studies adding to the safety and efficacy data.[32,33]

SODIUM TETRADECYL SULFATE. Sodium tetradecyl sulfate (STS) (Sotradecol™, Bioniche Pharmaceutical, Bioniche Pharma USA LLC, Lake Forest, IL; Fibrovein, S.T.D. Pharmaceuticals, United Kingdom) is an anionic surfactant which occurs as a white, waxy solid which must be carefully purified for sterile injection. It is a highly effective sclerosing agent used worldwide. Approved for use in the United States since 1946, it has been popular with vascular surgeons since the 1960s and first described for use in telangiectasias in the 1970s. A relatively high incidence of postsclerosis pigmentation was reported at inappropriately high doses (1% STS). More appropriate concentrations for superficial telangiectasias are 0.1%–0.2%. Other concentrations are 0.2%–0.5% in reticular veins or small varicosities (1–3 mm diameter), and 0.5% to 3% in larger varicosities related to major sites of valvular reflux. When foamed, this is used in half the concentrations listed above. In repeated studies, both POL and STS are found to be roughly equivalent.[34] More data will be available as widespread use of POL becomes routine in the United States with the official approval of polidocanol as Asclera.

SODIUM MORRHUATE

(Scleromate™, Palisades Pharmaceuticals, Inc., Tenafly, NJ, USA). Sodium morrhuate is a 5% solution of the salts of saturated and unsaturated fatty acids in cod liver oil. Approximately 10% of its fatty acid composition is unknown and use is limited by reports of fatalities secondary to anaphylaxis.[19] Although sodium morrhuate is approved by the FDA for the sclerosis of varicose veins, use in treatment of telangiectasias is not common due to the caustic qualities with potential for cutaneous necrosis and higher risks of allergy. This agent is reserved primarily for sclerosis of esophageal varices. We recommend not using this agent for leg veins.

CHEMICAL IRRITANTS. The chemical irritants include polyiodinated iodine (very caustic) and chromated glycerine (very weak) and are believed to have a direct toxic effect on the endothelium. After injection of polyiodinated iodine salt, the endothelium near the site of injection is destroyed within seconds. The corrosive action is limited due to rapid inactivation by blood proteins. At the sites of endothelial destruction, the chemical can penetrate further and diffuse into deeper layers of the vessel wall causing further destruction. These agents are not cleared by the US FDA.

Recently glycerine (nonchromated) has been rediscovered a valuable sclerosant for telangiectasias. Glycerine (50%–72%) has a low incidence of side effects and minimizes telangiectatic matting and pigmentation. At lower concentration, glycerine may share properties with hypertonic agents rather than having a pure toxic effect. The exact mechanism of action is still being investigated.

SCLEROTHERAPY TECHNIQUE

A basic principle of treatment is to begin at the largest (reflux sources) and progress to the smallest varicosities and then finally to telangiectasias. When present without larger varicosities, telangiectasias are approached by combined injection of visibly connected reticular veins, venulectases, and telangiectatic webs or networks. Reticular veins are treated only after all sources of reflux from major varicosities have been treated by sclerotherapy and/or surgery. When no clear feeder vessel is seen or identified by Doppler, transillumination (Veinlite, 3Gen, Dana Point, CA, USA) is another method, which may be used to identify the "feeding" reticular vein. (Fig. 249-4). When unable to locate an associated reticular vein, then the point at which the telangiectasias begin to branch out is the site at which to begin injection. Injection of telangiectasias is simultaneously performed with injection of reticular veins in the hopes of decreasing the number of treatments.[35]



Figure 249-4 Transillumination of a reticular vein. The reticular vein shows up as a dark curvilinear object against a light background.

TABLE 249-3
Sclerotherapy Tray

- Cotton balls soaked with 70% isopropyl alcohol
- Protective gloves
- 3-cc disposable syringes
- 30-g disposable transparent hub needles
- Cotton balls or STD pads for compression
- Transpore and/or paper tape
- 2% nitroglycerine paste (for prolonged blanching or extravasation)

Sclerosing solutions:

1. Sodium tetradecyl sulfate (ranging concentrations 0.1%–0.5%)
2. Hypertonic saline (11.7–23.4%)
3. Hypertonic saline (10%) and dextrose (25%) (may be mixed by local pharmacy)
4. Polidocanol (0.5%–1%)
5. 3-way stopcock to foam solutions (1:4-sclerosant:air)

The injection method for telangiectasia is basically as previously described by Goldman, Weiss, and Duffy.[16,20,36] The sclerotherapy tray is prepared with the necessary equipment (Table 249-3). A 30-gauge needle, bent to an angle of 10°–30° with the bevel up, is placed on the skin so that the needle is parallel to the skin surface. A 3-cc syringe filled with 1.5–2 cc of solution is held between the index and middle fingers while the fourth and fifth finger support the syringe against the leg in a fixed position facilitating accurate penetration of the vessel. The nondominant hand is used to stretch the skin around the needle and may offer additional support for the syringe (Fig. 249-5). Magnifying lenses or operating loops on the order of 1.5× to 3× may help cannulation of the smallest telangiectasias.

The initial treatment of telangiectatic webs begins with lowest possible concentration that will cause a telangiectasia to sclerose over a period of 1–6 months postinjection. This typically is 0.1% sodium tetradecyl sulfate or 0.2% polidocanol. The approval of polidocanol has increased our use of this solution in addition to use of 50% to 72% glycerine in water. Both of these solutions have seen increasing use in our practice of sclerotherapy. When ineffective sclerosis occurs judged at a subsequent visit, the concentration but *not* the volume per site of sclerosing solution is increased. Post-treatment compression consists of graduated 20–30 mm Hg or 30–40 mm Hg support hose for 2 weeks for larger veins and OTC 15 mm Hg compression for smaller veins. Treatment intervals vary but allowing 4–8 weeks between treatments helps minimize the number of necessary sessions. Typical results are shown in Fig. 249-6.

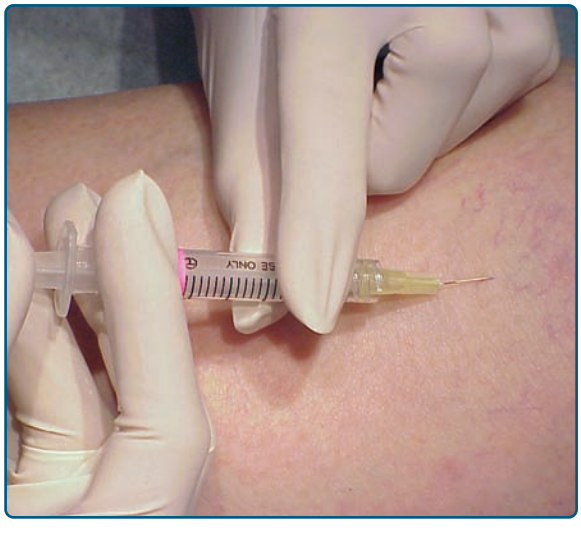

Figure 249-5 Position of the hands for sclerotherapy. While the dominant hand holds the syringe and creates a platform with the fifth digit, the nondominant hand stretches the skin and acts as a support for the needle hub so that fine changes in position are permitted.

FOAM SCLEROTHERAPY

Foam sclerotherapy has become a standard of treatment for veins larger than 1 mm as foam completely fills and displaces the blood in the vein. The microbubbles of foam allow maximal contact with the highest concentration of the sclerosant thereby resulting in maximal endothelial cell injury and subsequent fibrosis of the vein wall. This results in more effective sclerotherapy which leads to less treatment sessions. Less total amount of solution is required with foam. This has the additional benefit of decreasing systemic toxicity. An additional advantage of foam is that Duplex-guided sclerotherapy becomes more precise as the foam is very echogenic and easily visualized on ultrasound.

The most utilized technique for foam sclerotherapy is the Tessari technique.[37] A luer to luer connector is utilized. One syringe is filled with air and one syringe is filled with a detergent type of sclerosant. The optimal ratio of solution to air is 1:4. The contents of the syringes are shifted back and forth quickly approximately 10–20 times and the turbulent flow generates the foam. (Fig. 249-7) The foamed solution should be used immediately since it degrades within 60–90 seconds. The nature of the foam allows for the same therapeutic effect with approximately half the concentration of sclerosant. For instance, one can substitute 0.1% STS foam for 0.2% STS liquid or 0.25% polidocanol foam for 0.5% liquid. Lower concentrations are used for all size veins. Foamed solution should only be used for varicosities, perforating veins, reticular veins, and larger telangiectasias (1.0–2 mm). Smaller telangiectasia run the risk of increased pigmentation and matting as more inflammation occurs with the relatively increased concentration interacting with the vein wall.[38] Liquid sclerosants such as 0.5% POL are recommended for telangiectasias.

SIDE EFFECTS AND COMPLICATIONS OF SCLEROTHERAPY

POSTSCLEROTHERAPY HYPERPIGMENTATION. Postsclerosis pigmentation is defined as the appearance of increased visible pigmentation along



Figure 249-6 Typical results following sclerotherapy. **A.** Large varicose vein treated twice with 0.5% STS. **B.** Excellent clinical results at 15 month follow-up.

the course of a treated vein of any size. Initially, perivascular hemosiderin deposition, and not increased melanin production, causes this appearance[39]; however, over time, the hemosiderin is replaced by melanin. The incidence of pigmentation is related to dilution and type of sclerosing agent as well as diameter of treated vessel.[40] Pigmentation incidence ranges from 11%–30% using HS,[24] 11%–30% with POL[16,41] and up to 30% with

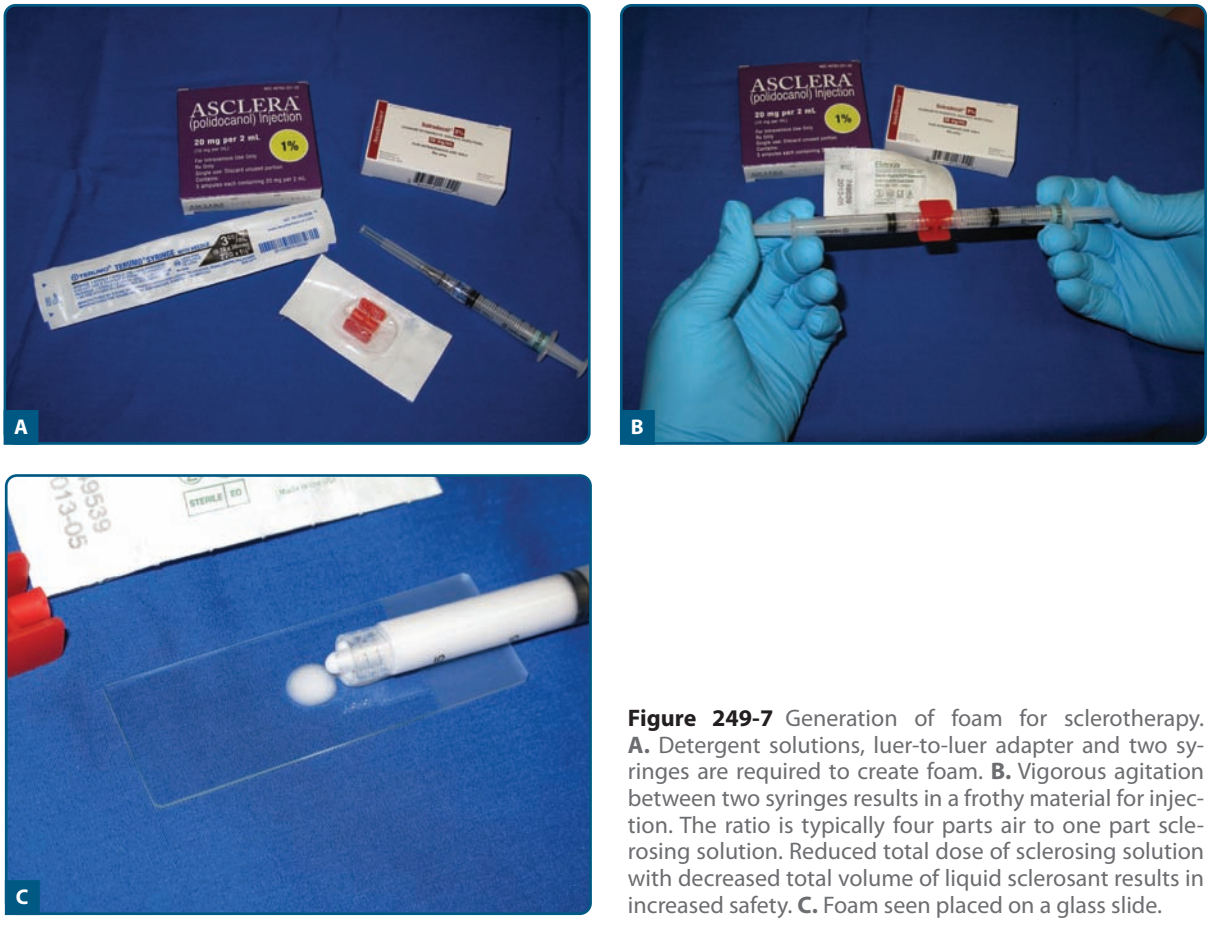

Figure 249-7 Generation of foam for sclerotherapy. **A.** Detergent solutions, luer-to-luer adapter and two syringes are required to create foam. **B.** Vigorous agitation between two syringes results in a frothy material for injection. The ratio is typically four parts air to one part sclerosing solution. Reduced total dose of sclerosing solution with decreased total volume of liquid sclerosant results in increased safety. **C.** Foam seen placed on a glass slide.

STS. The incidence of pigmentation may be reduced in varicose veins by expressing the dark, viscous blood thought to be a liquefied coagulum or intravascular hematoma, which may accumulate 1–4 weeks following sclerotherapy.

Pigmentation clears in 70% within 6 months but rarely persists for greater than a year.[40] Attempts to hasten resolution of pigmentation have been mostly unsuccessful as the pigment is dermal hemosiderin and not epidermal melanin. Bleaching agents, exfoliants such as trichloroacetic acid or phenol, cryotherapy, various lasers and intense pulsed light have achieved limited success.[42,43] The Q-switched ruby laser has been found to be the most consistently effective for treatment of postsclerosis pigmentation.[44]

TELANGIECTATIC MATTING. Telangiectatic matting is defined as the appearance of groups of new, fine (<0.2 mm diameter) telangiectasias surrounding or replacing a previously treated area in a blush-like manner. A retrospective analysis of over 2,000 patients reports an incidence of 16% in patients treated with HS and POL.[45] Resolution usually occurs spontaneously within a 3–12 month period with 70%–80% spontaneous resolution within the first 6 months.[46]

Matting may also occur as a result of trauma to the leg, in association with pregnancy or hormonal therapy or in scars around previous sites of surgical stripping. Predisposing factors include predilection for certain areas of the leg, such as the medial lower thigh, obesity, hormonal therapy with estrogen, family history, and a longer history of telangiectasias.[45] The relative risk factor for development of telangiectatic matting is 3.17 times greater for female patients taking hormonal supplements.[47] Successful treatment of matting can be performed with long pulsed dye laser (LPDL) using pulse durations of 6–20 msec.[48] The use of enhanced visualization with a cross-polarized light source (Syris Scientific, LLC, Grey, MA) has been found to assist injection of sclerosing solution into telangiectatic matting. Treatment is often not required since matting will resolve spontaneously except when sustained by a source of reflux superiorly.

CUTANEOUS NECROSIS/ULCERATION. Cutaneous ulceration may occur with all sclerosing solutions in spite of the most skilled technique. Unavoidably, a tiny amount of sclerosing solution may be left along the needle tract as the needle is withdrawn. Sclerosing solution may also leak out into the skin through the small puncture sites of vessel cannulation. The varicose vein may have a fragile, thin wall, with the injection causing rapid injury leading to sudden unexpected rupture with perivascular accumulation of sclerosant. Additionally, injection may inadvertently occur into a small arteriole associated with telangiectatic varicosities with resultant necrosis and ulceration.

When the dermatologic surgeon recognizes that extravasation has occurred, the risk for necrosis can be minimized by injecting normal saline in a ratio of 10:1 over sclerosant into the extravasation site. Extensive massage of small subcutaneous blebs to spread the trapped sclerosing agent as quickly as possible will minimize prolonged blanching of the area. We have found that application of topical 2% nitroglycerine paste applied immediately to the suspected extravasation site greatly reduces the risks of necrosis but will not always prevent it.

SUPERFICIAL THROMBOPHLEBITIS. This complication is most commonly mistaken for the normal nodular fibrosis (endosclerosis) that occurs with proper sclerotherapy. After sclerotherapy, a *nontender,* nonpigmented, nonerythematous fibrotic cord may normally be palpable along the course of a treated 4- to 8-mm vein. This frequent finding is due to a liquefied intravascular hematoma with surrounding vein wall sclerosis and is not a thrombosis. In contrast, superficial thrombophlebitis is characterized clinically by a very tender, indurated, linear erythematous swelling. Incidence of superficial thrombophlebitis is quite variable estimated at 1%–0.01% following sclerotherapy,[49] although a recent report indicates that the incidence is higher than previously suspected.[50] Treatment consists of leg elevation and/or compression and regular administration of aspirin or other nonsteroidal anti-inflammatory drugs. Extension of superficial thrombophlebitis into the deep system is extremely rare.

PULMONARY EMBOLISM. Pulmonary emboli probably occur from extension of a superficial thrombus into the deep venous system. Evidence of extension from superficial thrombus to deep thrombophlebitis should be treated promptly by anticoagulation. The incidence of pulmonary embolism has been associated with injection of large quantities of sclerosant at a single site. The incidence is extremely low with less than 1 case in 50,000.

ARTERIAL INJECTION. This dreaded medical emergency is fortunately extremely rare. Classic warning signs include immediate intense pain far beyond the normal discomfort at the initiation of injection, although leakage of sclerosant into the arterial circulation may present in an atypical fashion. Continuous intense burning pain with immediate bone white cutaneous blanching over an area of several square centimeters is the usual initial sign. Progression to a sharply demarcated cyanosis within minutes is typical for arterial injection. Emergency treatment involves immediate application of ice, attempts to flush the inadvertently injected artery with normal saline and/or heparin, injection of 3% procaine to inactivate STS and vascular surgery consultation for intravenous anticoagulation. Rarely arterial injection may not be accompanied by any pain or cutaneous signs. This is not widely known. Atypical or nonclassic cases of arterial injection in which signs or symptoms are not seen for up to 24 hours are suspected to arise from A-V malformations.[51] Arterial injection may lead to wide areas of skin necrosis and damage to subcutaneous tissue and muscle, which take months to heal. Typically a malpractice lawsuit will be initiated, although the cause can rarely be pinpointed and is often not a result of negligent injection.

MODERN MINIMAL SURGICAL APPROACHES FOR VARICOSE VEINS

ENDOVENOUS ABLATION/OCCLUSION TECHNIQUES

Endovenous ablation techniques were first developed by dermatologic surgeons.[14,13] When it has been determined by ultrasound that the originating point of reverse flow or reflux is the great saphenous vein (GSV) or small saphenous vein (SSV), endovenous radiofrequency or laser techniques are utilized. Ligation and stripping are antiquated techniques that should no longer be utilized. When saphenous system reflux is present, the endovenous occlusion techniques must be performed prior to treatment of visible and associated varicosities, reticular veins, or telangiectasias. Without elimination of reflux, a patient will be doomed to recurrence after recurrence following local treatment.

RADIOFREQUENCY

The efficacy for radiofrequency (RF) elimination of reflux is 90% at 2 years and 80% at 5 years.[17,25] Our unpublished experience is presently 90% at 10 years with supplemental foam sclerotherapy at follow-up visits. RF endovenous ablation involves the placement of an RF catheter within the varicose vein through a small puncture or incision. The catheter is threaded up to the saphenofemoral junction typically under duplex ultrasound guidance. Critical to the safety and success of the technique is placement of tumescent local anesthesia, which involves first infiltrating the tissue under the skin including thigh muscles to push the saphenous vein further away from the skin and then creating a space between the fascia and the saphenous vein so as to hydro-dissect the vein away from structures such as nerves and arteries. Tumescent anesthesia was developed and perfected by dermatologic surgeons. Once a hydrodissection has been performed with high volume, low concentration of local anesthetic (0.1% lidocaine), or tumescent anesthesia, energy is applied as the catheter is slowly withdrawn. This results in heat directly applied to the vein wall via a computer controlled thermocouple feedback loop. This results in a collagen shrinkage accompanied by complete vein wall occlusion. The newest system is designated ClosureFast and can seal the vein in under 5 minutes.

LASER (HEMOGLOBIN PREDOMINANT ABSORPTION—810, 940, AND 980 nm)

Endovenous laser treatment is similar to RF in that energy which ultimately releases heat in order to produce endothelial and vein wall shrinkage with subsequent fibrosis. The target for lasers with 810-, 940-, and 980-nm wavelengths is intravascular red blood cell absorption of laser energy. These techniques are highly dependent on correct placement of tumescent local anesthesia so as to protect surrounding nerves from injury. Direct thermal effects on the vein wall without the presence of blood probably do not occur. The extent of thermal injury to tissue is very much dependent on the amount and duration of heat to which the tissue is exposed, which for these lasers is dependent on multiple factors including the presence of blood in the lumen, rate of pullback, and amount of tumescent anesthesia placed around the vein. One in-vitro study model showed that thermal gas production by laser heating of blood in a 6-mm tube results in 6 mm of thermal damage.[52,53] Histologic examination of one excised vein demonstrated thermal damage along the entire treated vein with evidence of perforations at the point of laser application described as "explosive-like" photodisruption of the vein wall. This produced the homogeneous thrombotic occlusion of the vessel. Formation of bubbling blood is the proposed mechanism of action for heating surrounding tissue.[53] We have found superheating of blood during these procedures to a maximum of approximately 1,200°C.[18]

These endovenous lasers have short-term efficacy of 90% occlusion over the first year, but the rate decreases with time.[54,55] In addition, most patients experience major degrees of postoperative ecchymosis and discomfort. Saphenous nerve injury, skin burns, and deep venous thrombosis have occurred due to the high temperatures of blood heating from these wavelengths, although the overall safety and efficacy record is better than for stripping.[56–58]

LASER (WATER PREDOMINANT ABSORPTION—1,320, 1,440, AND 1,470 nm)

A variation of the endovenous laser, 1,320 nm, was developed by dermatologic surgeons in 2003 in an attempt to bypass the problems associated with laser wavelength absorption of hemoglobin. Tissue water is the target and the presence or absence of red blood cells within the vessels is unimportant. For more controlled release of laser energy, it is coupled with an automatic pull-back device variable from 0.5–1 mm/s. The penetration of the 1.32-μm wavelength is unique with far less heat and risks than with the hemoglobin absorbing wavelengths.

Endovenous ablation appears best accomplished not by hemoglobin heating but by heating water within collagen in the vein wall as a target. Proebstle et al demonstrated a statistically reduced rate of postoperative pain accompanied by a higher initial success rate using 1,320 nm versus 940 nm.[59] Our own experience reflects this, with a reduction in pain and bruising of 80% when switching from 810 nm endovenous to 1,320 nm endovenous. Having treated over 500 greater saphenous veins with 1,320 nm, our incidence of mild pain is 5%. No significant pain interfering with walking has been observed as observed with 50% of 810-nm treatment. A clinical example of varicose veins

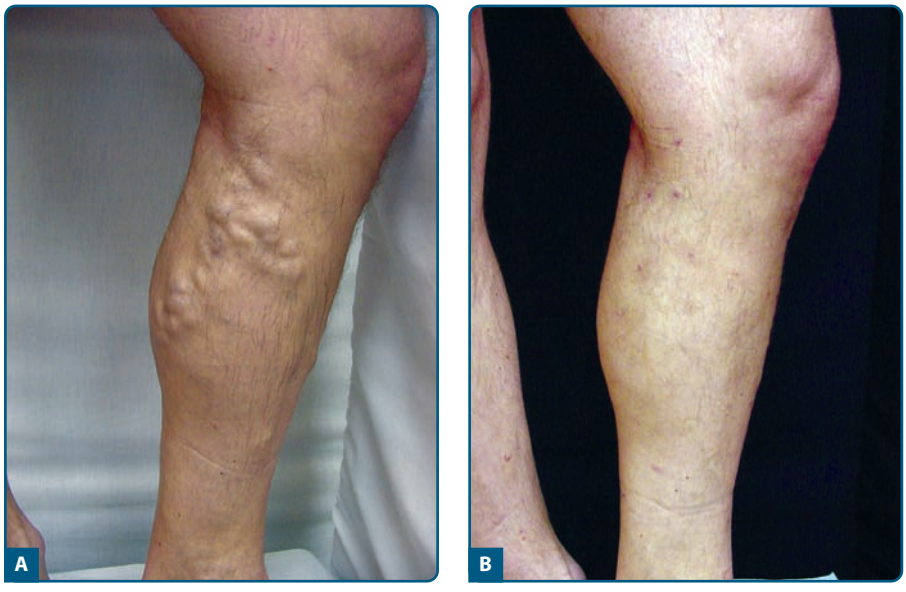

Figure 249-8 Endovenous ablation of the great saphenous vein (GSV) results in the improvement of associated varicosities. Adjunctive ambulatory phlebectomy was performed during the endovenous procedure.

resulting from reflux at the saphenofemoral junction is shown in Fig. 249-8. Recent data indicates that the 1,440-nm or 1,470-nm wavelengths may also be effective.[60] but data is preliminary and there is no comparison data on efficacy between the different water predominant wavelengths.

AMBULATORY PHLEBECTOMY. This technique, originally described by Robert Muller and further refined by another Swiss dermatologist (Albert-Adrien Ramelet) involves the use of tiny incisions through which the varicose vein is removed by a small hook.[61,62] This safe, outpatient local anesthesia technique allows removal of almost any varicose vein except the saphenofemoral or saphenopopliteal junction, which are treated initially by endovenous ablation techniques. Areas or veins that are resistant to foam sclerotherapy are particularly indicated for ambulatory phlebectomy (Fig. 249-9). Risks minimized compared with sclerotherapy are deep venous thrombosis, postsclerotherapy pigmentation, skin necrosis, and superficial phlebitis. In many cases larger varicose veins coexist with smaller reticular veins and associated telangiectatic webs. It is reasonable to treat larger varicose veins



Figure 249-9 Ambulatory phlebectomy of a large truncal varicose vein. **A.** Marked just prior to surgery. **B.** Clinical results with complete disappearance at 6 weeks. Bruising usually lasts no longer than 2 weeks.

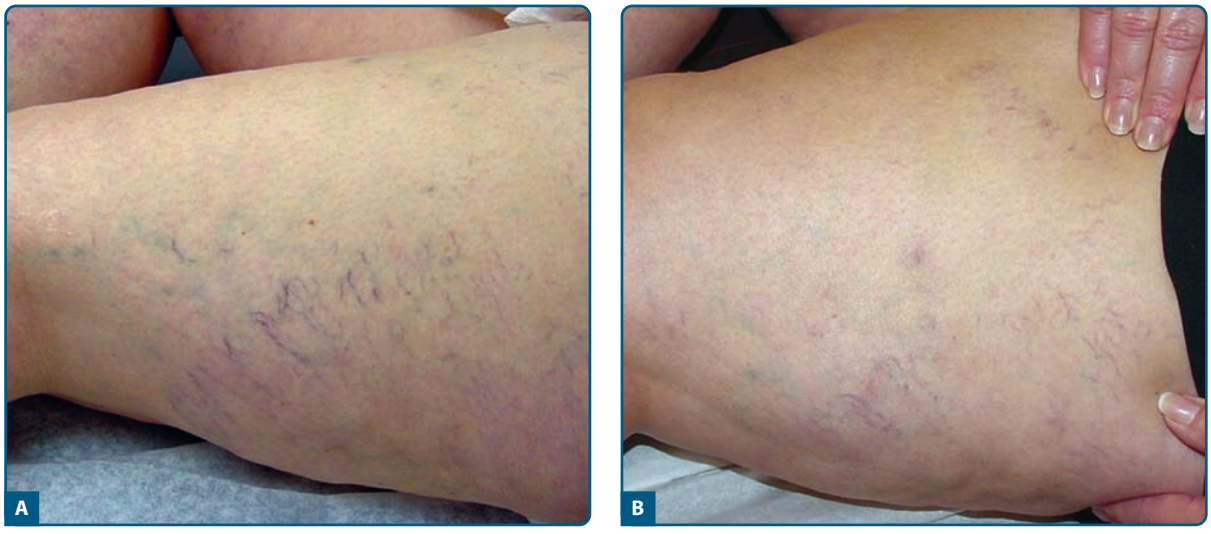

Figure 249-10 Clinical results with treatment of reticular veins with sclerotherapy and telangiectasias with 1,064 nm laser (CoolTouch Varia™, CoolTouch Corp, Roseville, CA). Sclerosant used was 0.25% foamed POL and laser parameters were 150 J/cm2, 3 mm spot, 20 msec pulse duration. **A.** Before and **B.** 3 months after treatment. Treatment parameters are single 16-ms pulse, 6-mm spot size, 120 J/cm^2.

by various surgical techniques and follow up with sclerotherapy of the remaining reticular networks.

Lasers and Light Sources. New trends for improved results with lasers and light sources for spider veins include longer wavelengths, larger spot sizes and cooling to protect the skin (Fig. 249-10). The first report of 1,064-nm Nd:YAG laser indicated that 75% improvement was possible after a single treatment at 3 months.[63] These findings were confirmed and mechanism of action explained as heat-induced vessel damage and subsequent fibrosis.[64] Recent reports also indicate effectiveness of 940-nm diode laser.[65] Shorter wavelengths used in the past, like pulsed dye laser, have limited utility on leg veins although many devices are now being adapted to longer pulse durations up to 40-ms. In our practice, the vast majority of laser treatments are performed using 1,064-nm Nd:YAG in the millisecond domain on isolated telangiectasias, sclerotherapy-resistant telangiectasias, ankle telangiectasias and suspected A-V malformations. Even associated reticular veins with telangiectasias can be treated with 1,064 nm, however, the larger the vein, the more painful the treatment due to increased absorption of infrared energy.[66]

KEY REFERENCES

Full reference list available at www.DIGM8.com

DVD contains references and additional content

1. Chiesa R et al: Chronic venous insufficiency in Italy: the 24-cities cohort study. *Eur J Vasc Endovasc Surg* **30**(4):422-429, 2005
3. Jukkola TM et al: The effects of parity, oral contraceptive use and hormone replacement therapy on the incidence of varicose veins. *J Obstet Gynaecol* **26**(5):448-451, 2006
10. Darke SG, Baker SJ: Ultrasound-guided foam sclerotherapy for the treatment of varicose veins. *Br J Surg* Aug;**93**(8):969-974, 2006
38. Alos J et al: Efficacy and safety of sclerotherapy using polidocanol foam: a controlled clinical trial. *Eur J Vasc Endovasc Surg* **31**(1):101-107, 2006
40. Weiss RA, Weiss MA: Incidence of side effects in the treatment of telangiectasias by compression sclerotherapy: hypertonic saline vs. polidocanol. *J Dermatol Surg Onc* **16**:800-804, 1990
58. Mozes G et al: Extension of saphenous thrombus into the femoral vein: a potential complication of new endovenous ablation techniques. *J Vasc Surg* **41**(1):130-135, 2005
59. Proebstle TM et al: Endovenous treatment of the great saphenous vein using a 1,320 nm Nd:YAG laser causes fewer side effects than using a 940 nm diode laser. *Dermatol Surg* **31**(12):1678-1683, 2005

SECTION 41

Cosmetic Dermatology

Chapter 250 :: Cosmetics and Skin Care in Dermatology

:: Leslie Baumann

COSMETICS AND SKIN CARE IN DERMATOLOGY AT A GLANCE

- Nonmedical skin care and cosmetic use of over-the-counter products represent a major growth area among consumers.
- Understanding variations in skin types using a new system of classification facilitates patient selection of over-the-counter products.
- Cosmetics and skin-care products can be a source of a range of adverse reactions including irritation and allergy.

According to recent data, the US sales of skin-care cosmeceuticals (cosmetics with attributed biologic effects) range between $3.5 and $6.4 billion, with forecasts of steady continued growth despite the global recession.[1–3] A plethora of skin-care products are currently available to account for this substantial sales volume. The range of products and their associated claims is so extensive and complex that physicians and consumers are often confused about their indications and effectiveness. One approach to understanding these many options is to consider how the products are used to treat specific skin types.

For the purposes of choosing the most appropriate cosmetics and other skin-care products, facial skin can be grouped into four main categories that in practice represent up to 16 skin types: dry (D) or oily (O), sensitive (S) or resistant (R), pigmented (P) or nonpigmented (N), and wrinkled (W) or unwrinkled [or "tight" (T)]. These "skin types" are not static and can be affected by a range of intrinsic and extrinsic factors such as environment, aging, and disease. The key to proper skin-care recommendations is to take all four parameters into consideration. The various permutations of the four skin-type parameters yield 16 possible skin types. For example, a person may have dry, sensitive, pigmented, wrinkled skin, and her needs would significantly differ from someone with oily, sensitive, pigmented, and wrinkled skin.

This chapter discusses the basic science and defining characteristics of the four parameters. Certain extrinsic or intrinsic factors, such as a move to a different climate, a change in stress levels, pregnancy, menopause, and other stressors, can result in a skin type change. The Baumann Skin Type Indicator, a questionnaire developed to determine skin type, is helpful in assessing skin type initially and again after major life events.[4]

SKIN HYDRATION

OILY VERSUS DRY

Xerosis or "dry skin" describes skin that is characterized by dull color (usually gray white), rough texture, and an elevated number of ridges.[5] The etiology of this common condition is multifactorial. The most significant factor in the development of xerosis is the role of the *stratum corneum (SC)* and its capacity to maintain skin hydration. Rawlings et al showed that patients with dry skin have a perturbation in the lipid bilayer of the SC, which is associated with increased fatty acid and decreased ceramide levels.[6] Defects or deficiencies in this barrier layer of the skin cause a spike in water evaporation, known as transepidermal water loss (TEWL). This leads to abnormal desquamation of corneocytes[7]because desmosomes remain intact at higher levels of the SC, and desmoglein I levels remain elevated in the superficial SC of individuals with dry skin as compared to controls. This occurs because the enzymes necessary for desmosome digestion are impaired when the water level is insufficient, which leads to abnormal desquamation resulting in visible "clumps" of keratinocytes that cause the skin to appear rough and dry.[8] Recent studies suggest that both the initial cohesion and the ultimate desquamation of corneocytes from the SC surface may be orchestrated by localized changes in pH, which selectively activate different classes of extracellular proteases in a pH-dependent fashion.[9] Impairment of the lipid bilayer of the SC can be caused by various exogenous factors such as ultraviolet (UV) radiation,

detergents, acetone, chlorine and prolonged water immersion.

The SC is composed of three primary groups of compounds: (1) ceramides, (2) fatty acids, and (3) cholesterol. When present in the proper amount and balance, these components help protect the skin and keep it watertight (see Fig. 250-1). When the barrier is impaired, however, the skin is rendered dry, because of the inability to retain water, and sensitive, because of increased vulnerability to extrinsic elements. Several other factors play a causative role in dry skin.

Natural moisturizing factor (NMF), derived from the breakdown of the protein filaggrin, is integral in maintaining water within skin cells. Filaggrin provides structural support and strength in the lower layers of the SC. It is broken down in higher levels (stratum compactum) of the SC by a still-uncharacterized, cytosolic protease into free amino acids, including histidine, glutamine (glutamic acid), and arginine.[10] These osmotically active amino acids remain inside the keratinocyte and avidly bind to water. The pace at which filaggrin is broken down into NMF is thought to be regulated by aspartate protease (cathepsin), which initiates this cascade and determines the amount of NMF that is present.[11] Interestingly, this putative aspartate protease (cathepsin) is regulated by changes in external humidity. In other words, in low-humidity environments, the pace of NMF production increases. This acclimation process typically occurs over the course of several days[12] and cannot yet be regulated artificially via products or procedures.

Hyaluronic acid (HA), which can bind 1,000 times its weight in water, is another substance found in the skin that may help it retain and maintain water. HA is produced mainly by fibroblasts and keratinocytes in the skin, and has an estimated turnover rate of 2–4.5 days in mammalians.[13] HA is localized not only in the dermis but also in the epidermal intercellular spaces, especially the middle spinous layer, but not in the SC or stratum granulosum.[14] Aged skin, which is less plump than youthful skin, is characterized by decreased levels of HA. The role of HA in skin hydration is not clear, and HA does not penetrate the skin upon topical application[15]; however, this has not stopped many companies from putting HA in topical skin-care products and claiming efficacy.

Bricks and mortar structure of the epidermis



Figure 250-1 Bricks and mortar structure of the epidermis.

Aquaporin-3 (AQP3) is a member of a family of homologous aquaporin water channels that facilitate fluid transport. Other aquaporins in this family are well known to contribute to water transport in kidney and lung epithelia. AQP3 is a member of a subclass of aquaporins called aquaglyceroporins, which transport not only water but also glycerol and possibly other small solutes. AQP3 was recently found to be expressed at the plasma membrane of epidermal keratinocytes in human skin[16] (eFig. 250-1.1 in online edition). There is evidence for a high concentration of solutes (Na^+, K^+, and Cl^-) and a low concentration of water (13%–35%)[17] in the superficial SC, producing in the steady-state gradients of both solutes and water from the skin surface to the viable epidermal keratinocytes.[18,19] Although transepithelial fluid transporting properties have been studied extensively in kidney and lung epithelia, the molecular mechanisms of fluid transport across epidermal keratinocyte layers remain poorly understood, as is the relationship between keratinocyte fluid transport and SC hydration. It has been proposed that AQP3[16] might facilitate transepidermal water permeability to protect the SC against desiccation by evaporative water loss from the skin surface and/or dissipate water gradients in the epidermal keratinocyte cell layer. Water permeability of human epidermal keratinocytes was inhibited by mercurials and low pH, consistent with the involvement of AQP3.[16] A study[20] looking at skin phenotype in transgenic mice lacking AQP3 showed significantly reduced water and glycerol permeability in AQP3 null mice proving that AQP3 is functional as a plasma membrane water/glycerol transporter in the epidermis. Conductance measurements showed remarkably reduced SC water content in AQP3 null mice in most areas of the skin. However, epidermal cell water permeability is probably not a major determinant of SC hydration because water movement across AQP3 is very slow compared with other tissues.[21] Pharmacologic manipulation of AQP3 may be used in the future to treat skin disorders of excess and decreased hydration. At this time, only *Ajuga turkestanica* extract has been shown to play a role in regulating AQP3.[22] *Ajuga turkestanica* is found as an ingredient in a high-end line of skin-care products.

Sebum production may also be a factor in the pathogenesis of xerosis. The oily secretion of the sebaceous glands contains wax esters, sterol esters, cholesterol, di- and triglycerides, and squalene,[23] and is thought to confer protection to the skin from environmental influences and, when production is decreased, play a part in dry skin.[24] Because sebaceous-gland-impoverished skin, such as that in prepubertal children, exhibits normal basal barrier function,[25] it has been assumed that sebum does not influence epidermal permeability barrier function. Furthermore, when sebaceous glands are involuted pharmacologically with supraphysiologic doses of isotretinoin,[26,27] both barrier function and SC lamellar membranes remain unaltered.[28] Although sebum levels may not influence barrier function, sebum may still play a role in dry skin types, especially dry, resistant types that exhibit dry skin but not increased skin sensitivity. Lipids from modified sebaceous glands in the eye, called *meibomian glands*, help

prevent dry eyes by preventing tear evaporation[29,30]; therefore, it makes intuitive sense that sebum-derived fats form a lipid film over the skin surface, preventing TEWL. Credence is given to this theory by a study that examined permeability barrier homeostasis and SC hydration in asebia J1 mice that demonstrate sebaceous gland hypoplasia.[31] Normal barrier function was found in these sebum-deficient mice and can be explained by the unaltered levels of the three key barrier lipids, ceramides, free sterols, and free fatty acids, as well as the persistence of normal SC extracellular membranes. However, the mice were found to have decreased SC hydration. These results show that an intact intercellular membrane bilayer system, although sufficient for permeability barrier homeostasis, does not always suffice for normal SC hydration. Interestingly, the researchers found that topically applied glycerol returned the SC to normal hydration levels. In normal skin, sebaceous gland-derived triglycerides are hydrolyzed to glycerol prior to delivery to the skin surface. Replacing this glycerol in sebum-deficient skin may be a way to decrease skin dryness in sebum-deficient individuals. Glycerol has also been shown to be effective in accelerating barrier recovery.[32]

Patients rarely complain about decreased sebum production. However, it seems certain that sebum production plays a role in dry skin. For example, prepubertal children (>2 years and <9 years) commonly display eczematous patches (pityriasis alba) on the face and trunk that disappear coincidentally with the onset of sebaceous gland activation. Conversely, increased sebum production, which results in oily skin that can lead to acne, is a common complaint. It is well understood that an age-related change is seen in sebaceous gland activity, with levels typically low during childhood, rising in the mid-to-late teens, and generally remaining stable for decades until trailing off in the seventh and eighth decades as endogenous androgen production declines.[33] The level of sebum production is also influenced by diet, stress, hormone production, and, to a degree, by genetics. In a study of 20 pairs each of identical and nonidentical like-sex twins, the identical twins exhibited essentially the same sebum excretion rates, with significantly divergent acne severity, whereas the nonidentical twins differed significantly according to both parameters, implying both the genetic influence of sebum and the mediation of exogenous factors in lesion development.[34]

SKIN CARE FOR THE O–D PARAMETER

In the context of the oily–dry parameter, ideal skin is typically characterized by an intact SC with an intact barrier, sufficient NMF levels, normal levels of HA, normal expression of AQP3, and balanced sebum secretion. In skin that falls on the oily side of the spectrum, increased sebum secretion is usually the culprit. This may or may not be accompanied by acne. If acne is a concern, then the patient would also fall into the sensitive skin category and would be labeled as an oily-sensitive skin type. The skin-care treatments would focus on decreasing sebum with retinoids, decreasing skin bacteria with antibiotics, benzoyl peroxide or other antimicrobials, and adding anti-inflammatory ingredients. If acne is absent, the individual would be labeled as an oily-resistant skin type. Skin care would focus only on decreasing sebum production unless other parameters such as dyspigmentation and wrinkling are also factors. Oral ketoconazole[35] and oral retinoids[36] have been shown to decrease sebum secretion, but this has not been shown with topical agents. Sebum-absorbing polymers and talcs are also useful for camouflaging unwanted sebum in people with oily-resistant skin.

In skin that falls on the dry side of the continuum, one must decide which factors are contributing to the dry skin. Clues can be derived by looking at the other skin parameters. If a patient has dry and sensitive skin, it is likely that the skin barrier is impaired and care should be taken to use products that repair the skin barrier, such as those that contain fatty acids, cholesterol, ceramides and glycerol. If the skin is photodamaged and wrinkled as a result, decreased HA likely plays a role. Topically applied HA is not absorbed, so using skin-care products with HA is not helpful; however, studies have suggested that glucosamine supplements may contribute to an increase in HA levels.[37] One small single-blind study showed improvement of wrinkles but no change in skin hydration so the role of glucosamine is unclear.[38] Dry skin that endures ongoing sun exposure likely suffers from an impaired skin barrier and decreased levels of NMF. At this time, there are no products that increase NMF, so skin care should focus on repairing the skin barrier and providing adequate sun protection.

All patients with dry skin are advised to avoid harsh foaming detergents that remove hydrating lipids and NMF from the skin. These detergents are found in laundry and dish cleansers in addition to body and facial cleansers. All dry skin patients should also abstain from taking protracted baths, particularly in hot or chlorinated water. In addition, people with very dry skin are advised to use humidifiers in low-humidity environments and apply moisturizers two to three times a day and after bathing.

In addition to targeting the causes of dry skin, there are many moisturizers on the market that help hydrate the skin in a more basic or generic manner. These products can be categorized as occlusives, humectants, or emollients (Table 250-1).

OCCLUSIVES

Occlusives coat the SC to retard TEWL. An occlusive provides an emollient effect as well as decreases TEWL. The best occlusive ingredients currently available are petrolatum and mineral oil. Petrolatum, for example, has a water vapor loss resistance 170 times that of olive oil.[39] However, petrolatum has a greasy feeling that may make agents containing it cosmetically unacceptable to many patients. Other commonly used occlusive ingredients include paraffin, squalene, dimethicone, soybean oil, grapeseed oil, propylene glycol, lanolin,

TABLE 250-1
Types of Ingredients in Moisturizers for Topical Skin Care

Barrier Repair
- Ceramides
- Cholesterol
- Fatty acids

Occlusives
- Petrolatum[a]
- Mineral oil[a]
- Paraffin
- Squalene
- Dimethicone
- Soybean oil
- Grapeseed oil
- Propylene glycol
- Lanolin[a]
- Beeswax

Humectants
- α-Hydroxy acids
- Glycerin
- Hyaluronic acid
- Propylene glycol
- Sodium hyaluronate
- Sorbitol
- Sugars
- Urea

[a]Also confer emollient effects

and beeswax.[40] These agents are only effective while present on the skin; once removed, the TEWL returns to the previous level. Interestingly, it is not desirable to decrease TEWL by more than 40% because maceration with increased levels of bacteria can result.[41] Therefore, occlusives are usually combined with humectant ingredients.

HUMECTANTS

Humectants are water-soluble materials with high water absorption capabilities. They are able to attract water from the atmosphere (if atmospheric humidity is greater than 80%) and from the underlying epidermis. Although humectants may draw water from the environment to help hydrate the skin, in low-humidity conditions they may absorb water from the deeper epidermis and dermis resulting in increased skin dryness.[42] For this reason, they are more effective when combined with occlusives. Humectants are also popular additives to cosmetic moisturizers because they prevent product evaporation and thickening, which increases the shelf-life of products. Some humectants have bacteriostatic activity as well.[43] Humectants draw water into the skin, causing a slight swelling of the SC that gives the perception of smoother skin with fewer wrinkles. Examples of commonly used humectants include glycerin, sorbitol, sodium hyaluronate, urea, propylene glycol, alpha hydroxy acids, and sugars.

EMOLLIENTS

These are substances added to cosmetics to soften and smooth the skin. They function by filling the spaces between desquamating corneocytes to create a smooth surface.[44] Emollients provide increased cohesion causing a flattening of the curled edges of the individual corneocytes.[45] This leads to a smoother surface with less friction and greater light refraction. Many emollients function as humectants and occlusive moisturizers as well. Lanolin, mineral oil, and petrolatum are examples of occlusive ingredients that also confer an emollient effect.

SKIN SENSITIVITY AND COSMETIC INTOLERANCE SYNDROME

SENSITIVE VERSUS RESISTANT

Sensitive skin is much more challenging to describe than resistant skin. The latter is characterized by a strong SC that confers potent cutaneous protection, shielding the skin from allergens and irritating substances. As the term implies, resistant skin rarely exhibits erythema (unless overexposed to the sun) or acne (unless it is so affected due to stress or hormonal fluctuations). People with resistant skin can use most skincare products without fear of developing an adverse reaction such as a rash, acne, or a stinging sensation. The disadvantages of such skin include an inability to detect different effects among cosmetic products and, more important, having too high a threshold for penetration, so that few products are likely to cross the SC and impart beneficial changes.

The concept and presentation of sensitive skin is much more complex. Data from the early 1990s suggested that more than 40% of people presenting to a dermatologist reported having sensitive skin.[46] In fact, in a recent epidemiological study of 1,039 people not selected based on sensitive skin-related criteria, questionnaire results indicated that 68.4% of the study population stated that their skin was sensitive to some degree, 77.3% claimed sensitive facial skin, 60.7% claimed sensitive body skin, and 56.3% claimed sensitive genital skin.[47] Healthy women of child-bearing age comprise the majority of people that complain about this type of skin. With increasing age, the incidence of sensitive skin appears to decline. There are numerous cosmetic products available that are marketed for sensitive skin. However, sensitive skin itself is a relatively complex dermatologic phenomenon.

Cosmetic intolerance syndrome is not a single entity but rather a symptom complex of multiple exogenous and endogenous factors and represents an extreme of the continuum of patients who complain of sensitive skin. The syndrome is an uncommon clinical phenomenon in which patients complain bitterly of facial burning and discomfort associated with application of most skin-care products. Their skin may show overt inflammatory changes, or symptoms may be subjective only. These patients seriously challenge the diagnostic skills

and even empathy of practitioners because the severity of symptoms does not match objective signs of disease. Many patients affected with this syndrome have tried numerous cosmetics and topical medications.

Fisher[48] coined the term *status cosmeticus* for the condition in which patients no longer tolerate the use of any facial cosmetic product. Some of these patients initially experience subjective or objective irritation in response to use of cosmetics and become intolerant to many other topical agents during the evolution of this disorder. Other patients have occult allergic contact dermatitis, allergic photocontact dermatitis, contact urticarial reaction, or a combination of these conditions. In such patients, causal agents can be documented by careful clinical review and patch testing.

Strictly observing a prolonged program of eliminating cosmetics is an important therapeutic intervention. Some patients are able to return gradually to using other cosmetics after 6–12 months. Subsequent additions to the skin-care regimen can be made one at a time every 2 weeks. For the final regimen, the number of cosmetics and frequency of their use should remain limited.

Other patients experience facial burning continuously, without showing objective signs. Cotterill[49] described these patients as having "dermatologic nondisease." Many of these patients have a disturbed body image or body dysmorphic disorder—that is, they complain of physical defects that lack objective evidence. Many are depressed and need psychiatric help, which they frequently reject.

Sensitive skin covers the same range of pathophysiology as cosmetic intolerance syndrome, but it is generally less severe. Most of these consumers manifest sensory skin irritation.

Indeed, there are four very distinct variations of sensitive skin: (1) acne type (prone to developing acne, black heads, or white heads); (2) rosacea type (featuring a tendency toward recurrent flushing, facial redness, and experiencing hot sensations); (3) stinging type (predilection to stinging or burning sensations); and (4) allergic type (more likely to exhibit erythema, pruritus, and skin flaking).

Each of these subtypes of sensitive skin presents a unique challenge to the practitioner regarding appropriate treatment and recommendations regarding over-the-counter cosmetic skin-care products. The common process among these four subtypes is inflammation. Therefore, treatments for any kind of sensitive skin should focus on reducing and eliminating inflammation. Treatment can be further complicated when a patient displays a proclivity toward more than one sensitive skin subtype.

ACNE TYPE

Definitive data on the prevalence of acne in the United States or worldwide are challenging to collect, but acne is generally considered the most pervasive skin condition in the United States. An overwhelming majority of these patients, roughly 70%–80%, are adolescents and young adults between 11 and 25 years old.[50] (Fig. 250-2.) Adult women manifesting a hormonal component to their acne comprise most of the remainder of acne sufferers. There are three primary factors in the pathogenesis of acne: (1) elevated sebum production (which falls into the oily skin type); (2) clogged pores, characterized by dead skin cells inside the hair follicles adhering more than in those without acne (increased sebum production may also play a role in causing these skin cells to clump); and (3) the presence of the bacteria *Propionibacterium acnes*. Although acne can be a dynamic condition with various causal pathways or contributing factors, the essential pathognomonic feature is that increased amounts of sebum cause dead skin cells in the hair follicles to adhere, thereby clogging the follicle and creating a papule or pustule. *P. acnes* then migrate into the hair follicle, attacking the collected sebum and dead skin cells. This stimulates the release of cytokines and other inflammatory factors that engender the inflammatory response with the clinical correlates of redness and pus.



Figure 250-2 Sensitive skin types often suffer from acne. Salicylic acid and benzoyl peroxide are over-the-counter options in these patients.

Some skin and hair care cosmetics cause acneiform eruptions. *Acnegenicity* encompasses both *comedogenicity*, which refers to follicular keratin impaction,[51] and papulopustular formation. The time course for the appearance of facial papulopustules and comedones is different: papulopustules may appear in just a few days, whereas the appearance of comedones is delayed. Considerable confusion derives from the testing techniques: for example, isopropyl myristate in concentrations as low as 10% in petrolatum rapidly induces comedones in the rabbit ear but yields papulopustules in humans. Even common emulsifiers such as sodium lauryl sulfate produce pustules in a dose-related manner. The mechanisms appear to be related in spite of varied morphology. The European Union's ban on animal testing of final products, which took effect in March 2009, will result in stronger reliance on human testing, whether this takes the form of use tests or application of a cosmetic under occlusion to the back for 4 weeks and subsequent cyanoacrylate or cationic polymer biopsies (to identify microcomedones), or both.

In 1996, the clinical significance of cosmetics in precipitating postadolescent acne in women was called



Figure 250-3 Rosacea patients fall into the sensitive skin type category and should be treated with anti-inflammatory ingredients.

into question by one of the authors of the original paper on "acne cosmetica."[52,53] Consequently, it is best to advise female acne patients to keep their cosmetic regimen simple and gentle, using products from manufacturers who test for acnegenicity.

ROSACEA TYPE

Typically afflicting adults between 25 and 60 years of age, rosacea affects tens of millions of Americans. Like acne, this condition is characterized by facial redness, flushing, and papules, but is also distinguished by the formation of prominent telangiectasias (see Fig. 250-3). Topical skin care for rosacea is primarily geared toward preventing exacerbation of the condition, and using anti-inflammatory ingredients to decrease inflammation. Ingredients with anti-inflammatory activity include feverfew, sulfur, zinc, sulfacetamide, quadrinone, niacinamide, licorice extract, cucumber extract, aloe vera, colloidal oatmeal, and chamomile (Table 250-2).

STINGING TYPE

Burning, stinging, or itching caused by application of a cosmetic or topical medicament without detectable visible or microscopic change is termed *sensory irritation*. The afferent limb of this reaction is carried by C nerve fibers that are present throughout the dermis and viable epidermis. The stinging occurs on the face within an hour of application in susceptible individuals. In a segment of the population, this sensory response is caused by many ingredients at dosages that do not produce clinical objective irritation.

TABLE 250-2
Anti-Inflammatory Products for Topical Skin Care (Over-the-Counter)

- Licorice extract
- Licochalcone
- Quadrinone
- Cucumber
- Aloe vera
- Chamomile
- Colloidal oatmeal
- Arnica
- Feverfew (has anti-inflammatory and antioxidant capabilities)
- Niacinamide (also known as nicotinamide)
- Salicylic acid
- Zinc
- Witch hazel

Nonallergic stinging is a phenomenon that a discrete subset of people experience in response to certain triggers. Some patients may indeed be more sensitive than others and are referred to as "stingers" by dermatologists. Stingers do not have a higher incidence of atopy or dry skin, but do report frequent adverse reactions to cosmetics. Strontium nitrate and chloride inhibit sensory irritation caused by α-hydroxy acids, ascorbic acid, and aluminum salts.[54] These blockers are incorporated into skin-care products such as those containing α-hydroxy acids.

Several tests have been devised to identify stingers or the stinging propensity. The lactic acid stinging test is a widely accepted standard method for evaluating individuals who report invisible and subjective cutaneous irritation. In an early study, Frosch and Kligman applied 5% lactic acid to subjects' nasolabial folds during profuse sweating, which resulted in 20% of participants reporting an unpleasant sensation.[55] In a similar study in which lactic acid (10%) was applied to nasolabial folds, Seidenari et al observed that individuals with "sensitive skin" experienced a much stronger stinging sensation than those in the healthy control group.[56] The stinging sensation is not necessarily associated with erythema as many patients feel stinging without experiencing redness or irritation.[57] However, patients with rosacea distinguished by facial flushing are more susceptible to stinging from lactic acid exposure. It is recommended that patients with the stinging subtype of sensitive skin avoid products that contain the following ingredients: α-hydroxy acids (particularly glycolic acid), benzoic acid, bronopol, cinnamic acid compounds, Dowicel 200, formaldehyde, lactic acid, propylene glycol, quaternary ammonium compounds, sodium lauryl sulfate, sorbic acid, urea, or vitamin C.

ALLERGIC TYPE

According to the findings of a 2004 epidemiologic survey in the United Kingdom, over the course of a year, 23% of women and 13.8% of men experience an adverse reaction to a personal care product (e.g., deodorants

and perfumes, skin-care products, hair-care products, and nail cosmetics).[58] To identify allergies to cosmetic ingredients patch testing can be performed. Various studies reveal that approximately 10% of patch-tested dermatologic patients are allergic to at least one ingredient common in cosmetic products.[58] Approximately 80% of reactions occur in patients aged 20–60 years, with the majority seen most often in women.[59] Fragrances and preservatives are the most common allergens. Individuals who use several skin-care products with a commensurately high number of ingredients are more likely to develop allergies to ingredients, simply due to such overexposure. Patients with an impaired SC, manifested by xerosis (the dry skin type), are likely to have an increased incidence of allergic reactions to allergens placed on the skin.[60]

SKIN IRRITATION AND ALLERGY DUE TO COSMETICS AND SKIN-CARE PRODUCTS

Skin irritation is defined as localized inflammation that is not mediated through the immune system and is caused by endogenous and environmental factors. Hair straighteners, permanents, and depilatories can cause *acute reactions* if directions for their safe use are not strictly followed. Cleansers are frequently responsible for causing *irritant dermatitis*. Moisturizers or emollient creams, in which water and oleaginous materials are blended, contain surfactants and emulsifiers that are often mild irritants. When these cosmetics are applied to the face or to dry or eczematous skin, where the SC is a less efficient barrier, *irritant reactions* may result. Morphologic features include scaling, which may rapidly clear with avoidance of exposure but become erythematous with recurrent dosing and may evolve into chronic irritant dermatitis. Some cosmetics produce irritation only after repeated application; this phenomenon is termed *cumulative irritation*. Friction, injury, and *mechanical irritation* can be caused by popular cosmetics containing granules or by devices (e.g., synthetic sponges) used to exfoliate the skin (Table 250-3).

TABLE 250-3
Diagnosis and Treatment of Patients Whose Skin Is Intolerant to Cosmetics

Examine every cosmetic and skin-care product
Administer patch and photopatch tests to rule out occult allergic and photoallergic dermatitis
Test for contact urticaria
Do careful repeat open application testing (ROAT)
Treat endogenous inflammatory disease
Limit skin-care to:
Water washing without soap or detergent
Lip cosmetics as desired, if lips are clear
Eye cosmetics as desired, if eyelids are asymptomatic
Face powder
Glycerin and rose water as a moisturizer, if necessary
Avoiding other cosmetics for 6–12 months

Sensitive bioengineering techniques used to evaluate the pathophysiology of irritation include TEWL, skin impedance, conductance resistance, and blood flow velocity.[61] By using predictive testing in animals and humans, manufacturers can recognize strong or moderate irritant ingredients or products. In premarket testing, mild irritants are more difficult to detect and quantify.

Bergamot oil (5-methoxypsoralen) is a *phototoxic* fragrance ingredient that was used in cosmetics but has been removed. As interest in "natural" ingredients increases,[62] new phototoxins may be inadvertently introduced that could provoke serious consequences if they are not recognized clinically.

NATURAL AND ORGANIC PRODUCTS AND SKIN IRRITATION

A product labeled "natural" is not necessarily organic. It may contain aloe, vitamin E, or other natural ingredients, but also chemicals intended to act as preservatives or to improve texture. Only products that are truly organic are legally permitted to include the Organic Seal. In organic farming of food crops or those intended for topical products, farmers do not use synthetic pesticides, hormones, genetically modified crops, or chemical products. Nevertheless, adverse reactions to organic as well as natural ingredients can occur. For example, coconut oil, a popular organic ingredient, can cause acne. Also, it is worth noting that because producers of topical products were not able to label their products as organic until August 2005, there have not been sufficient clinical research trials on the organic products on the market.

Allergies can develop in response to the use of many essential oils and botanicals. Many natural and organic brands contain certain fragrances and essential oils that can cause dermatitis. For example, strong essential oils like peppermint or rosemary can irritate or inflame sensitive skin. Chamomile, which is generally considered a gentle and soothing herb, can provoke allergies in some individuals, particularly those allergic also to wheat. In addition, a "perfume mix" is included in various conventional as well as some natural products to mask the odor of other ingredients. These perfume mix ingredients are rarely listed on the product label because each company uses its own proprietary blend. A perfume mix sufficient to elicit an allergic response can be present in a product listed as 95% organic.

ORGANIC PRODUCTS BY SKIN TYPE

For a patient with nonpigmented skin, an organic body lotion containing whole soy oil is likely suitable. However, that same product could activate the proclivity for melasma and other hyperpigmentation in a patient with pigmented skin. In this case, a nonorganic product would be more appropriate because only fractionated soy (also known as "active soy"), which is not organic, removes the pigment-inducing estrogenic components of soy, thus allowing this patient to derive the benefits

of soy. Another example of factoring organic products into the identification of proper skin-care selections based on skin type might include a patient with dry, wrinkled skin who would benefit from using green tea formulations, of which several options are organic. A patient who strictly uses organic products (e.g., food, clothes) but who has oily, wrinkle-prone skin, however, would cutaneously benefit from using retinoids, even though they are not organic.

OTHER SKIN REACTIONS DUE TO COSMETICS

CONTACT URTICARIA SYNDROME

Contact urticaria syndrome typically consists of a wheal-and-flare response developing within 30–60 minutes after the skin is exposed to certain agents. Symptoms range from the mildest manifestations (e.g., itching, tingling, burning, and erythema) to the most severe (e.g., anaphylaxis and death). Diagnosis of immediate contact urticaria is based on a thorough medical history (including notation of burn, sting, or itch resulting from skin contact; urticaria; or respiratory symptoms) and skin testing using suspected substances.[63]

Contact urticaria syndrome is divided into two subtypes—nonimmunologic and immunologic—based on proposed pathophysiologic mechanisms.[64] Nonimmunologic contact urticaria, the most common form, occurs in the absence of previous exposure and remains localized, causing no systemic symptoms. Typically, the strength of the reaction varies by ingredient concentration and location of use. The mechanism is not completely delineated. Benzoic acid, cinnamic acid, and cinnamal are commonly used in cosmetics and are potent substances capable of eliciting this response.

Immunologic contact urticaria is an immediate type I allergic reaction that occurs in sensitized individuals and is induced more frequently in atopic individuals. The eliciting chemicals react with specific IgE molecules on mast cell membranes. Localized urticaria can extend beyond the site of contact, or may be accompanied by other symptoms such as rhinitis, conjunctivitis, asthma, and anaphylaxis. In this manner, methylparaben, ethylparaben, henna, and ammonium persulfate have been associated with systemic reactions.[65]

DELAYED HYPERSENSITIVITY REACTIONS

Adverse reactions to cosmetics constitute a small but significant portion of contact dermatitis cases treated by dermatologists. In a study conducted by the North American Contact Dermatitis Group, patch testing showed contact dermatitis related to cosmetics in 5% of more than 13,000 patients evaluated.[66] These figures underestimate the total number of cases, because most mild reactions are not investigated by dermatologists. In the North American Contact Dermatitis Group study, 59% of the cosmetic-induced reactions occurred on the face and 79% were seen in women, but a relation to cosmetics was suspected by the dermatologist or patient initially in fewer than half the cases. Diagnosis of allergic contact dermatitis is based on a compatible history and examination supported by results of patch testing. Most cosmetics are not strong irritants and closed patch testing can be applied in the usual manner; however, notable exceptions exist. Weakly positive reactions should be confirmed by medical history, test repetition, and patch testing of ingredients. Ingredient testing is a problem in the United States because of the limited number of chemicals available on the thin-layer rapid use epicutaneous (TRUE) test screening tray. It is important to recognize which of these allergens are found in cosmetics. Cosmetic Industry on Call[67] provides information for contacting manufacturers who may provide ingredients for patch testing. De Groot et al[68] provide reference information on chemical concentrations and vehicles to use in testing cosmetic ingredients.

The provocative use test, also called the *repeat open application test*,[69] is a practical way to screen for allergy to cosmetics, including fragrances[70] or to confirm the clinical significance of weak positive reactions. The cosmetic is applied twice daily for up to 4 weeks to an approximately 5-cm area on the flexor surface of the forearm near the cubital fossa.

Most photoallergic ingredients in cosmetics are sunscreening agents or fragrances. To test for photoallergy, the patch site is exposed to between 5 and 10 J of UVA 24 hours after application; after 48 hours, the photo patch site is compared with a nonirradiated site similarly patch tested.

Most allergic reactions to cosmetics are caused by fragrances, preservatives, and a small number of miscellaneous ingredients. Familiarity with these allergens will enable clinicians to diagnose many of these cases accurately (Table 250-3).

SKIN REACTIONS DUE TO FRAGRANCES

Fragrance allergy is common, affecting approximately 1% of the general population; dermatitis may develop on the face, neck, hands, and axillae, or it may be generalized.[71] Fragrances also represent several of the 15 most frequently positive allergens as identified by the North American Contact Dermatitis Group.[72] In fact, fragrances consistently placed among the top 10 contact dermatitis allergens, represent the second most common allergen family (behind nickel) associated with allergic contact dermatitis, and are the most often cited cause of such reactions to cosmetic products.[73]

Fragrances are ubiquitous: in addition to cosmetics and toiletries, they are added to household goods or cleansers in the workplace, and some are used as flavorings. Paradoxically, "unscented" cosmetics may contain a masking fragrance. A new method of promoting fragrances is to claim that scents have mood-altering effects—so-called aromatherapy. Inevitably, troublesome sensitization has occurred in consumers

who have doused themselves and their surroundings with fragrance. Since 1966, toxicologic information related to fragrance ingredients has been assembled and assessed by the industry-sponsored Research Institute for Fragrance Materials.[74] Based on this information, the International Fragrance Association publishes guidelines that industry members generally agree to follow.

Photosensitization (see Chapter 92) occurred more commonly before methyl coumarin and musk ambrette were eliminated from fragrances. Sensitization to musk ambrette left an extensive legacy of so-called persistent light eruptions. Because fragrance allergy is not frequently suspected by either the patient or the physician, patch testing is an important tool for reaching this diagnosis. Balsam of Peru, cinnamal, fragrance mix (now known as Fragrance Mix I), and colophony are recognized markers for fragrance allergy on patch-test screening series. Fragrance Mix I (marketed by Hermal and by Chemotechnique and also marketed in the TRUE test) contains eight ingredients: (1) eugenol, (2) isoeugenol, (3) oak moss absolute, (4) geraniol, (5) cinnamal, (6) α-amyl cinnamic aldehyde, (7) hydroxycitronellal, and (8) cinnamic alcohol. In an international study of 165 patients with probable fragrance allergy, the fragrance mix detected 86% of positive reactions. The addition of ylang-ylang oil, narcissus oil, sandalwood oil, and balsam of Peru raised this rate to 96%. Ethnic and geographic distinctions exist; for instance, Japanese patients tested were more frequently reactive to benzyl salicylate. Such racial differences were highlighted by the epidemic of bizarre facial hyperpigmentation seen in Japanese women in the 1960s and 1970s caused by allergy to fragrances and coaltar dyes used in some cosmetics; elimination of these allergens solved the problem.

Fragrance Mix II [Hydroxyisohexyl 3-cyclohexene carboxaldehyde (Lyral), citral, farnesol, coumarin, citronellol, and α-hexyl cinnamal] was introduced during the early part of the new millennium after 1,701 consecutive patients in 6 European countries were patch-tested to evaluate 14 frequently used chemicals.[75–77] Allergy to fragrance can be tested by using the repeat open application test for up to 4 weeks. Balsams, cinnamic alcohol, cinnamaldehyde, benzyl alcohol, and benzaldehyde are among the fragrance ingredients that can evoke contact urticaria not detected by closed patch testing. It is also important to note that fragrance-based chemicals are sometimes included in products labeled as "fragrance-free" if incorporated for an indication other than as a fragrance.[73]

SKIN REACTIONS DUE TO PRESERVATIVES

Preservatives are added to prevent contamination of cosmetics by microorganisms, which degrade the product or cause infection in consumers; but the term *preservative* may encompass agents that prevent degradation induced by oxidation or UV light. Approximately 60 chemicals are commonly used as preservatives in cosmetics. Preservatives may consist of a single ingredient or a mixture of ingredients (e.g., Euxyl 400 is a mixture of methyldibromoglutaronitrile and phenoxyethanol). Use of specific preservatives varies among American, European, and Asian markets; consequently, the incidence of allergic reactions to individual agents also varies. Adverse reactions have prompted development of preservative-free cosmetics. Strategies for developing such products include modification of the manufacturing and packaging processes as well as use of botanicals that have antimicrobial activity. The increasing complexity of cosmetics and their vehicles makes this goal even more difficult to achieve.

Paraben esters, the most widely used group of preservatives in cosmetics[78] and used in most skin-care formulations,[79] are effective against fungi and Gram-positive (but not Gram-negative) bacteria. Parabens rarely sensitize but may do so when applied to eczematous skin. Sensitized patients frequently tolerate parabens in cosmetics applied to normal skin.

Propylene glycol, a popular solvent and humectant, has antimicrobial properties but is used in some "preservative-free" cosmetics. A review of the literature and observations in patch-tested patients suggest that propylene glycol is a mild irritant that only occasionally sensitizes.[80]

Formaldehyde and formaldehyde releasers are widely used preservatives.[81] Formaldehyde is formulated in wash-off products such as shampoos. Quaternium-15, imidazolidinyl urea, diazolidinyl urea, DMDM hydantoin, and 3-bromo-2-nitropropane-1,3-diol are commonly used preservatives that release formaldehyde. They may sensitize themselves or cause reactions secondary to formaldehyde release in formaldehyde-sensitive patients, and cross-reactions in the group are reported. The tolerance of products containing preservatives to which patients are sensitive is modified by the site of application and their degree of sensitivity. For example, some formaldehyde-sensitive individuals can tolerate low levels of formaldehyde releasers on normal skin.

A mixture of methyldibromoglutaronitrile and phenoxyethanol (Euxyl 400) used initially in Europe has gained popularity and is being reported more frequently as an allergen.[82,83] Butylated hydroxyanisole, butylated hydroxytoluene, tocopherol, propyl gallate, and t-butyl hydroquinone used as antioxidants are sometimes reported as allergens. Other ingredients reported frequently as allergens in cosmetics include paraphenylenediamine, toluene sulfonamide/formaldehyde resin (tolysamide/formaldehyde resin), acrylates, lanolin, glyceryl thioglycolate, and UV light–absorbing agents (Table 250-4).

SKIN PIGMENTATION

PIGMENTED (P) VS. NONPIGMENTED (N)

The third primary skin characterization parameter gauges the tendency to develop unwanted hyperpigmentation or dyschromia on the face or chest. For the

TABLE 250-4
Frequently Identified Cosmetic Ingredients Causing Allergic Contact Dermatitis: North American Contact Dermatitis Group (NACDG) Study

Paraphenylenediamine (PPD)
Lanolin and derivatives
Glyceryl thioglycolate
Propylene glycol
Toluene sulfonamide/formaldehyde resin
Sunscreens and other UV absorbers
Methacrylates

Adapted and reproduced by permission of the authors and publisher from Adams and Maibach.[62]

TABLE 250-5
Cosmeceuticals That May Be Effective in Pigmentation

- Arbutin
- Hydroquinone
- Kojic acid
- Licorice extract
- Mulberry extract
- Niacinamide
- Pycnogenol
- Retinol
- Soy
- Vitamin C

purposes of describing a skin type to a patient and assisting the individual in selecting appropriate skin-care products, the focus should be on the pigmentary changes that can be improved with skin-care products rather than surgery. For example, skin-care products can be used to prevent or treat conditions such as melasma, solar lentigos, and ephelides. Patients with these concerns would be called pigmented types (see Fig. 250-4).

Skin pigment (melanin) is produced by melanocytes, which transfer the pigment via melanosomes to keratinocytes. Melanin is derived from the enzymatic breakdown of tyrosine by tyrosinase into 3,4-dihydroxyphenylalanine, which yields two forms of melanin (eumelanin and pheomelanin).[84] In darker-skinned people, melanocytes produce more melanin; the melanosomes are larger to accommodate this greater supply of pigment and, thus, are broken down at a slower rate than in lighter-skinned people.[85] Two primary mechanisms can be employed to impede the development of skin pigmentation: (1) inhibiting tyrosinase, which prevents melanin formation, and (6) preventing melanosome transfer into keratinocytes. Tyrosinase inhibitors include vitamin C, hydroquinone, kojic acid, arbutin, mulberry extract, and licorice extract (Table 250-5).

Small proteins present in soy, such as soybean trypsin inhibitor and Bowman-Birk inhibitor, have been suggested to inhibit skin pigmentation. These soy proteins were found not only to have depigmenting activity, but also to prevent UV-induced pigmentation both in vitro and in vivo.[86] According to Paine et al,[86] these soy proteins exert their effect via the inhibition of the cleavage of protease-activated receptor 2. Protease-activated receptor 2 is a seven transmembrane G-protein coupled receptor that is activated by a serine protease cleavage. It is expressed in keratinocytes, but not in melanocytes. By inhibiting this cleavage, soybean trypsin inhibitor and Bowman-Birk inhibitor are believed to affect melanosome transfer into keratinocytes, and thus, pigmentation. Niacinamide, a derivative of vitamin B_3, has also been shown to inhibit melanosome movement from melanocytes to keratinocytes.[87]



Figure 250-4 This patient has a pigmented skin type and would require lightening ingredients in skin-care products.

UV RADIATION AND SKIN COLOR

Melanogenesis results from the exposure of skin to UV radiation and serves as the skin's major defense against further UV damage. Melanocyte cells increase the production of melanin, melanoctye transfer from melanosomes to keratinoctyes is increased,[88] and this process manifests in exogenous skin darkening. Sun avoidance is the most effective method of preventing pigmentary changes, thus broad-spectrum sunscreens are an important component of any skin-care regimen geared toward reducing hyperpigmentation.

SKIN AGING

WRINKLED VERUS TIGHT

Aging of the skin is a complex phenomenon reflecting natural intrinsic and extrinsic processes. Intrinsic aging is a function of individual heredity and results

from the passage of time. This process is, of course, inevitable and beyond voluntary control.

Telomeres, specialized chromosomal components, play a central role in cellular aging: they shorten or diminish with age, so telomeric loss or erosion has become an important measure of aging, a veritable internal aging clock.[89] The enzyme telomerase stabilizes or lengthens telomeres; it is expressed in about 90% of all tumors but absent in many somatic tissues.[89] Interestingly, one of the few regenerative tissues to express telomerase is the epidermis.[90] In fact, recent evidence suggests that telomerase acts against excessive telomere loss in human epidermis throughout the life-long regeneration process.[91] At this time, no skin-care products target telomerase because not enough is known about the safety of extending telomere length.

Exogenous factors, such as smoking, poor nutrition, and sun exposure, are at the root of extrinsic aging. This process is not inevitable and reflects premature skin aging. In fact, 80% of facial aging is believed to be due to solar exposure.[92] Exposure to UV irradiation, by dint of its damaging effect on DNA and its acceleration of telomere shortening, can also be said to influence intrinsic aging. In addition, UV exposure results in skin damage through several mechanisms including sunburn cell formation, creation of thymine dimers, collagenase production, and provoking an inflammatory response. Signaling through p53 following telomere disruption is also a common feature observed in aging as well as photodamage.[93] Although much remains to be learned about the mechanisms through which UV irradiation unleashes a chain of cascading health effects, photoaging, photocarcinogenesis, and photoimmunosuppression are well known results of UV exposure.[94] Nevertheless, a recent paper suggests that the melanogenesis and photoaging induced by UV exposure is also associated with telomere-based DNA damage signaling that may actually represent a cancer-avoidance protective response.[95]

The most obvious manifestation of aging skin is the development of rhytides. Wrinkles are caused by changes in the dermis. Although consumers spend millions of dollars on "antiaging" skin-care products, few skin-care product ingredients can penetrate far enough into the dermis to affect deep wrinkles. The dermatologic focus of antiaging skin care should be to prevent the formation of rhytides in the first place.[96] To this end, the goal is to halt the degradation of the three main structural components of the skin—collagen, elastin, and HA—all of which are known to be diminished in aged skin. Because inflammation can contribute to the breakdown of these key skin constituents, one focus must be to reduce inflammation. Antioxidants protect the skin from free radicals through several mechanisms that are just beginning to be elucidated. Free radicals can act directly on growth factor and cytokine receptors in keratinocytes and dermal cells, leading to skin inflammation. Growth factors and cytokines certainly play a role in skin aging, but their exact mechanisms of action in this context are not well understood. It is apparent that they function together in a complex process requiring many types of growth factors and cytokines.[97] The direct effects of free radicals on the aging process are better understood. Kang et al. have shown that free radical activation of the mitogen-activated protein kinase pathways results in production of collagenase, which leads to degradation of collagen.[98] Blocking this pathway with antioxidants is thought to prevent photoaging by preventing the production of collagenase. Research supporting this theory was performed on human skin by Kang. In this study, he showed that when human skin was pretreated with the antioxidants genistein and N-acetyl cysteine, the UV induction of the cJun-driven enzyme collagenase was blocked. Many antioxidants are available in skin-care products including vitamins C and E, ferulic acid, coenzyme Q10, green tea, pycnogenol, silymarin, and idebenone.

PREVENTION IS THE BEST MEDICINE

Most antiaging products and procedures are geared to salvage collagen, elastin, and HA. However, products containing collagen, elastin, or HA are ineffective; they cannot effectively penetrate the epidermis. While there are no products that can replenish these important skin structures, there are some products that stimulate production of these components. Collagen synthesis has been shown to be increased through the use of retinoids,[99] vitamin C,[100] and copper peptide. Retinoids have also been demonstrated in animal models to increase production of HA[101] and elastin.[102] Oral vitamin C is also believed to have the capacity to increase collagen synthesis[103] and, again, glucosamine supplementation may augment HA levels.[37]

Some new products on the market employ electrical currents to stimulate fibroblasts to produce collagen and elastin. This technology utilizes copper and zinc to create a 10 mV current that is postulated to result in increased collagen and elastin synthesis. Notably, elastin is more complicated than collagen. Collagen is released from fibroblasts in a final triple helix stage, while elastin is excreted as tropoelastin, which represents unbound units of elastin in an immature form. These tropoelastin elements must bind a microfibrillar backbone to form mature elastin. New unpublished proprietary data suggest that dill weed can increase the binding of tropoelastin to microfibrillin while blackberry extract may increase the production of tropoelastin. Although these data are new, it is certain that elastin will be an important topic in the skin-care world in the coming year.

In the future, it is likely that the potential of electric current, growth factors, cytokines, telomerase and/or telomeres will be harnessed through advances including tissue engineering and gene therapy.[102,105] In the meantime, avoiding exposure to the sun, cigarette smoke, and pollution, as well as using sunscreen, taking oral antioxidant supplements or topical antioxidant formulations, and eating a diet high in fruits and vegetables can help reduce or prevent skin aging. Regularly using prescription retinoids can also help treat and prevent unwanted wrinkles.

TABLE 250-6
Baumann Skin Type Determined by the BSTI

	Oily, Pigmented	Oily, Nonpigmented	Dry, Pigmented	Dry, Nonpigmented
Wrinkled, Sensitive	OSPW	OSNW	DSPW	DSNW
Tight, Sensitive	OSPT	OSNT	DSPT	DSNT
Wrinkled, Resistant	ORPW	ORNW	DRPW	DRNW
Tight, Resistant	ORPT	ORNT	DRPT	DRNT

BSTI = Baumann skin type indicator; D = dry; N = nonpigmented; O = oily; P = pigmented; R = resistant; S = sensitive; T = tight; W = wrinkled.

COMBINATIONS OF TYPES

The four skin parameters can be combined to form 16 skin types (Table 250-6). Using this typing system will help consumers focus on their problem areas. For example, a person with oily, sensitive, nonpigmented, wrinkled skin would use products with retinoids and antioxidants whereas an individual with dry, sensitive, nonpigmented, tight skin would use products with barrier repair ingredients. Certain skin problems are more typically associated with particular skin combinations: pigmented, wrinkled skin is more likely exhibited by a person with a significant history of sun exposure manifested by wrinkles and solar lentigos. Eczema is more often observed in dry, sensitive skin types. Acne is most common among oily, sensitive types. Oily, sensitive, nonpigmented, wrinkled types with lighter skin are most prone to develop rosacea. Light skin is more common among nonpigmented, wrinkled types; dark skin is more common among pigmented, tight types.

CONCLUSION

For the purposes of optimal treatment and cosmetic selection, a classification of skin types that defines four different polarities is suggested: (1) dry or oily; (2) sensitive or resistant; (3) pigmented or nonpigmented; and (4) wrinkled or unwrinkled. Characterizing a patient's skin based on all the permutations and combinations of these skin types can facilitate treatment by physicians and help patients select the most appropriate over-the-counter skin formulations.

KEY REFERENCES

Full reference list available at www.DIGM8.com

DVD contains references and additional content

4. Baumann L: *The Skin Type Solution*. New York, Bantam Dell, 2006
10. Elias PM: The epidermal permeability barrier: from the early days at Harvard to emerging concepts. *J Invest Dermatol* **122**(2):xxxvi-xxxix, 2004
20. Ma T et al: Impaired stratum corneum hydration in mice lacking epidermal water channel aquaporin-3. *J Biol Chem* **277**(19):17147-17153, 2002
31. Fluhr JW et al: Glycerol regulates stratum corneum hydration in sebaceous gland deficient (asebia) mice. *J Invest Dermatol* **120**(5):728-737, 2003
47. Farage MA: How do perceptions of sensitive skin differ at different anatomical sites? An epidemiological study. *Clin Exp Dermatol* **34**:e521-e530, 2009
51. Simion AF: Acnegenicity and comedogenicity testing for cosmetics. In: *Handbook of Cosmetic Science and Technology*, edited by AO Barel, M Paye, HI Maibach. New York, Marcel Dekker, 2001, p. 837
65. Hannuksela M: Cosmetics, cosmetic ingredients, emulsifiers, and moisturizers, In: *Contact Urticaria Syndrome*, edited by S Amin, A Lahti, HI Maibach. Boca Raton, FL, CRC Press, 1997, p. 111
72. Zug KA et al: Patch-test results of the North American Contact Dermatitis Group 2005–2006. *Dermatitis* **20**(3):149-160, 2009
90. Boukamp P: Skin aging: a role for telomerase and telomere dynamics? *Curr Mol Med* **5**(2):171-177, 2005
92. Uitto J: Understanding premature skin aging. *N Engl J Med* **337**(20):1463-1465, 1997
95. Gilchrest BA, Eller MS, Yaar M: Telomere-mediated effects on melanogenesis and skin aging. *J Investig Dermatol Symp Proc* **14**(1):25-31, 2009

Chapter 251 :: Ablative Lasers, Chemical Peels, and Dermabrasion

:: Elizabeth L. Tanzi & Tina S. Alster

SKIN RESURFACING AT A GLANCE

- Several approaches are available for the treatment of photodamage, rhytides, and scarring.
- Popular treatment options include fully ablative and fractional ablative laser skin resurfacing and chemical peels.
- Selection of the appropriate technique requires that patient factors as well as the risks and benefits of the procedure be weighed.

Years of damaging ultraviolet light exposure manifest clinically as a sallow complexion with roughened skin surface texture and variable degrees of dyspigmentation, wrinkling, and laxity.[1,2] Other cutaneous insults such as scars from acne, trauma, or surgery also affect the appearance of the skin. Histologically, these extrinsic aging and traumatic effects are usually limited to the epidermis and upper papillary dermis and, thus, amenable to treatment with a variety of ablative and nonablative lasers, chemical peeling agents, and dermabrasion. The armamentarium of lasers and chemical peeling agents available to treat cutaneous photodamage, and textural irregularities is larger than ever. The most appropriate treatment technique is dependent on the severity of the photodamage or scarring, the expertise of the dermasurgeon, and the expectations and lifestyle of the individual patient.

ABLATIVE LASER SKIN RESURFACING

For years, fully ablative laser skin resurfacing (LSR) with the carbon dioxide laser (CO_2) was the gold standard in skin resurfacing. Developed in the mid-1990s, traditional multipass ablative LSR with a CO_2 laser demonstrated excellent efficacy for the treatment of rhytides, photodamage, and scars.[3–6] However, popularity of the procedure waned due to the extended postoperative recovery required, the inability to treat nonracial areas, and the significant risk of side effects and complications including persistent erythema, permanent hypopigmentation, and scarring.[7,8]

To mitigate the problems associated with traditional ablative LSR, nonablative laser devices were subsequently introduced.[9–30] The 532-nm-potassium titanyl phosphate (KTP),[18,19] 585- to 595-nm pulsed dye,[11,12] 1,064- and 1,320-nm Neodymium:yttrium-aluminum-garnet (Nd:YAG),[17–21] and 1,450-nm diode lasers,[9,10,25,26] and a 550- to 1,200-nm intense pulsed light device (IPL)[12–15] were developed to stimulate dermal neocollagenesis without epidermal injury or significant recovery. Each of these systems demonstrated histologic changes in dermal collagen, a series of treatments often yielded limited clinical improvement. Nonablative LSR is described in detail in Chapter 252.

A novel concept in skin resurfacing, termed fractional photothermolysis, was developed by Manstein and colleagues in 2004.[31] Fractional photothermolysis involves the creation of microscopic thermal wounds regularly interspersed within areas of nontreated skin. The intact nontreated skin forms bridges between the microscopic treatment zones (MTZ), thereby leading to rapid healing. The wound healing response differs from fully ablative techniques because the epidermal tissue that is spared between the thermal zones contains viable transient amplifying cells that are capable of rapid re-epithelialization.

Fractional photothermolysis devices include a 1,550-nm erbium-doped fiber, 1,540-nm erbium glass, and 1,320-nm or 1,440-nm Nd:YAG laser.[32–37] Their midinfrared wavelengths target water-containing tissue to effect photocoagulation of narrow columns of skin at depths of 200–500 µm at intervals of 200–300 µm. Histologic evaluation of skin immediately after treatment reveals thermal injury sharply confined to these narrow columns extending from the epidermis to the mid-dermis. Microscopic epidermal necrotic debris (MEND) exfoliate within days, producing a bronzed appearance to the skin. Since the stratum corneum has a low water content, it remains intact immediately after treatment. Although there is gradual exfoliation of the epidermis with resultant improvement in superficial dyspigmentation, these devices are considered nonablative due to the lack of significant epidermal disruption after treatment. As such, nonablative fractional laser resurfacing procedures offer patients a treatment option with little postoperative recovery. However, a series of treatments is required for the best results and, to date, nonablative fractional LSR demonstrates only modest improvement of severe photodamage, laxity, and rhytides compared to ablative LSR.[38–41]

A continued desire for superior clinical results while maintaining a manageable recovery and side effect profile gave rise to the combination of ablative laser devices that adhere to the concept of fractional photothermolysis. Ablative fractional resurfacing (AFR) with either a CO_2 or erbium:YAG (Er:YAG) laser ablates a fraction of both the epidermis and dermis allowing rapid re-epithelialization with a favorable side-effect profile. Pedicles of thermally induced dermal coagulation extend to far greater depths than those delivered by nonablative fractional devices, thereby inducing greater tissue contraction and neocollagenesis. Due to

the less invasive nature of AFR, nonfacial areas such as the neck, chest, and dorsal hands can be safely treated. In addition, the fractional characteristics of treatment reduces recovery time, postoperative discomfort, side effects, and complications associated with traditional multipass ablative LSR.[43]

PATIENT SELECTION

The ideal patient for ablative cutaneous laser resurfacing has a fair complexion [skin phototype (SPT) I or II], rhytides, other signs of photodamage, or atrophic scars that are amenable to treatment, and realistic expectations of the treatment.[3] Adequate preoperative patient evaluation and education are essential to optimize the clinical outcome (Table 251-1). Proper patient selection is paramount because ablative LSR can be complicated by a prolonged postoperative recovery, pigmentary alterations, or unexpected scarring. The patient's emotional ability to tolerate an extended convalescence is an important factor in determining the most appropriate choice of laser. Although CO_2 or modulated Er:YAG LSR produces the most dramatic clinical results, some patients may be unable to tolerate the intensive recovery period that is required. For patients who acquiesce to a moderate amount of recovery, AFR may be a more appropriate choice as intense erythema and serosanguinous drainage are evident for 2–3 days, followed by complete reepithialization and diminution of erythema by day 6 or 7 compared to fully ablative LSR in which re-epithelialization and intense erythema extends to 5–7 days and several weeks, respectively. For patients either unable or unwilling to tolerate more than 1 or 2 days of postoperative healing, a nonablative laser procedure may be a more suitable choice (see Chapter 252).

Currently, no consensus exists among laser experts regarding the most appropriate preoperative regimen for ablative LSR patients. The use of topical retinoic acid compounds, hydroquinone bleaching agents, or α-hydroxy acids for several weeks before ablative cutaneous resurfacing has been touted by some as a means of speeding recovery and decreasing the incidence of postinflammatory hyperpigmentation; however, others have shown that these preparations do little to affect postoperative pigmentation, in particular.[44] Topical tretinoin enhances penetration of chemicals through the skin and has been shown to accelerate postoperative re-epithelialization after dermabrasion or deep chemical peels.[45] Because ablative laser–induced wounds are intrinsically different from those created by physically destructive methods, laser skin penetration is not typically affected by the topical application of any of these medications.[46]

Due to the moist, de-epithelialized state of ablative laser–resurfaced skin and the possibility of bacterial contamination and overgrowth, many laser surgeons advocate oral antibiotic prophylaxis. This practice remains controversial, due to the findings of a controlled study that demonstrated no significant change in post–laser resurfacing infection rate in patients treated with prophylactic antibiotics.[47]

EQUIPMENT

CARBON DIOXIDE LASER. The first system developed for cutaneous laser resurfacing was the CO_2 laser, which was approved by the US Food and Drug Administration (FDA) in 1996. The earliest systems were continuous-wave CO_2 lasers, which were effective for gross lesional destruction; however, these systems could not reliably ablate fine layers of tissue

TABLE 251-1
Ablative Laser Skin Resurfacing: Patient Selection, Risks and Precautions

- Are the lesions amenable to ablative laser skin resurfacing? All suspicious lesions require biopsy before treatment.
- Has the patient ever had the areas treated before? Ablative laser resurfacing can unmask hypopigmentation or fibrosis produced by prior dermabrasion, cryosurgery, or phenol peels. Patients with prior lower blepharoplasties using an external approach are at greater risk of ectropion formation after infraorbital ablative skin resurfacing.
- What is the patient's skin phototype? Patients with lighter skin tones (skin phototype I or II) have a lower incidence of postoperative hyperpigmentation than patients with darker skin tones after ablative laser skin resurfacing.
- Does the patient have a history of herpes labialis? All patients should be treated with prophylactic antiviral medication before ablative laser skin resurfacing in the perioral region, because reactivation and/or dissemination of prior herpes simplex infection can occur. The de-epithelialized skin is also particularly susceptible to primary inoculation by herpes simplex virus.
- Does the patient have an immunologic deficiency or autoimmune disease? Intact immunologic function and collagen repair mechanisms are necessary to optimize the tissue healing response due to the prolonged recovery associated with ablative resurfacing.
- Is the patient taking any medications that are contraindicated? Concomitant isotretinoin use could potentially lead to an increased risk of postoperative hypertrophic scar formation due to its detrimental effect on wound healing and collagenesis. A safe interval between the use of oral retinoids and ablative laser skin resurfacing is difficult to determine; however, most advocate a delay in treatment for at least 6 months after discontinuation of the drug.
- Does the patient have a tendency to form hypertrophic scars or keloids? Patients with a propensity to scar will be at greater risk of scar formation after laser skin resurfacing, independent of the laser's selectivity and the operator's expertise.
- Does the patient have realistic expectations of the procedure and will he or she adhere to postoperative instructions? Those who cannot physically or emotionally tolerate the prolonged postoperative course should be dissuaded from pursuing ablative laser skin resurfacing procedures.

because of their prolonged tissue-dwell times which were responsible for unacceptably high rates of scarring and dyspigmentation.[48–52] With the subsequent development of high-energy pulsed lasers, it became possible to safely apply higher energy densities with exposure times that were shorter than the thermal relaxation time of water-containing tissue, thereby lowering the risk of thermal injury to surrounding nontargeted tissue.[3,4,53]

Two of the first high-energy pulsed-laser systems developed were the Ultra-Pulse 5,000 and SilkTouch lasers (Lumenis Corp., Yokeam, Israel). The UltraPulse emits individual CO_2 pulses (ranging from 600 µs to 1 ms) with peak energy densities of 500 mJ, whereas the SilkTouch is a continuous-wave CO_2 system with a microprocessor scanner that continuously moves the laser beam so that light does not dwell on any one area for more than 1 ms. The peak fluences delivered per pulse or scan range from 4–5 J/cm^2, which are the energy densities necessary for complete tissue vaporization.[5,6,50,54] Studies with these and other pulsed and scanned CO_2 laser systems have shown that after a typical skin resurfacing procedure, water-containing tissue is vaporized to a depth of approximately 20–60 µm, which produces a zone of thermal damage ranging from 20–150 µm.[6,50,55–57]

ERBIUM:YTTRIUM-ALUMINUM-GARNET LASER. The short-pulsed Er:YAG laser was introduced as an alternative to the CO_2 laser for skin resurfacing in an attempt to minimize the recovery period and limit side effects while maintaining clinical benefit. The Er:YAG laser is a more precise ablative tool than is the CO_2 laser and emits 2,940-nm light that corresponds to the 3,000-nm absorption peak of water. The absorption coefficient of Er:YAG light is 12,800 cm^{-1} (compared with 800 cm^{-1} for that of the CO_2 laser), which makes it 12–18 times more efficiently absorbed by water-containing tissue than CO_2 laser energy.[58] The pulse duration (mean, 250 µs) is also much shorter than that of the CO_2 laser, thereby resulting in decreased thermal diffusion, less effective hemostasis, and increased intraoperative bleeding that often hampers deeper dermal treatment. In addition, because of limited thermal skin injury, the amount of collagen contraction is also reduced with Er:YAG treatment compared with that observed to CO_2 laser irradiation.[5,59]

The Er:YAG laser's efficient rate of absorption, short exposure duration, and direct relationship between fluence delivered and amount of tissue ablated leads to 2–4 µm of tissue vaporization per Joule per square centimeter, which produces a shallow level of tissue ablation. Much narrower zones of thermal necrosis, averaging only 20–50 µm, are therefore produced.[58,60–62]

Conditions amenable to short-pulsed Er:YAG laser resurfacing include superficial epidermal or dermal lesions, mild photodamage, and subtle dyspigmentation. The major advantage of short-pulsed Er:YAG laser treatment is the shorter recovery period after therapy. Re-epithelialization is completed within an average of 5.5 days, compared with 8.5 days for multipass CO_2 procedures.[60–62] Postoperative pain and duration of erythema are reduced after short-pulsed Er:YAG laser resurfacing, with postoperative erythema resolving within 3–4 weeks. Because there is less thermal injury and trauma to the skin, the risk of pigmentary disturbance is also decreased, which makes the short-pulsed Er:YAG laser a good alternative in treating patients with darker skin phototypes.[3,63] The major disadvantages of the short-pulsed Er:YAG laser are its limited ability to effect significant collagen shrinkage and its failure to induce new and continued collagen formation postoperatively.[3,60,64] Because of this, the final clinical result is often less impressive than that produced by CO_2 laser skin resurfacing for deeper rhytides.

Through the natural progression of technology, modulated Er:YAG lasers systems were developed to improve hemostasis and increase the amount of collagen remodeling produced.[65] The Er:YAG–CO_2 hybrid laser system delivers both ablative Er:YAG and coagulative CO_2 laser pulses. The Er:YAG component generates fluences of up to 28 J/cm^2 with a 350-µs pulse duration, and excellent hemostasis is provided by the CO_2 component, which can be programed to deliver 1- to 100-ms pulses at 1–10 W of power. Zones of thermal necrosis measuring as much as 50 µm have been observed depending on the treatment parameters used, and significant increase in collagen thickness has been noted 3 months after four passes with a device using this hybrid technology.[66] Another modulated Er:YAG device is a dual-mode Er:YAG laser that emits a combination of short (200- to 300-µs) pulses and long coagulative pulses to achieve tissue ablation depths of up to 200 µm per pass.[65,66] The desired depth of ablation and coagulation can be programed through a touch-screen control panel. Several investigators have studied the histologic effects of dual-mode Er:YAG laser resurfacing and found a close correlation between the programed and actual measured depths of ablation.[67,68] The actual zones of thermal injury correlate well with the first-pass parameters, with decreasing coagulative efficiency on subsequent passes. The variable-pulsed Er:YAG laser system delivers pulse durations ranging from 500 µs to 10 ms. Shorter pulse durations are used for tissue ablation and longer pulses are used to effect coagulation and zones of thermal injury as with the CO_2 laser.[69–71]

ABLATIVE FRACTIONAL LASERS

Since the introduction of the first fractional laser in 2004, numerous devices have been developed to apply the concept of fractional photothermolysis.[72] Initially, ablative fractional treatments were simply traditional CO_2 or Er:YAG lasers with software modifications to deliver smaller spot sizes and lower density scans. With advances in technology, there are currently a wide range of fractional ablative lasers that incorporate either a 10,600-nm CO_2, 2,940-nm Er:YAG or 2,790-nm yttrium scandium-gallium-garnet (YSGG) wavelength. Differences in depth of ablation and coagulation, variation in available spot size and shape, application of energy (stamped vs. rolling), and ergonomics of the handpiece distinguish one laser from the other. Little difference in overall clinical improvement has been demonstrated using several different fractional ablative resurfacing lasers[73]; however, further investigation is necessary to

elucidate the most appropriate treatment parameters and subsequently maximize clinical outcomes for each individual device.

ANESTHESIA

Most ablative laser resurfacing is performed as an outpatient procedure in an ambulatory surgery facility. Regional laser skin resurfacing (perioral or periorbital) can be performed with local anesthesia with no additional analgesia. Full-face LSR often requires additional analgesia, including one or more of the following: oral sedation, nerve blocks, tumescent anesthesia, topical anesthetic creams, and intravenous (IV) sedation. Topical anesthesia protocols have been outlined using either lidocaine cream application for several hours before LSR to enhance tissue hydration and anesthetic penetration[74] or a cream-based formulation that dries to a flexible membrane, which is peeled away from the skin before laser irradiation.[75]

Despite their obvious advantages, these topical regimens are frequently more time consuming and less uniformly effective. For this reason, deeper forms of anesthesia for full-face ablative laser procedures is often used, including regional nerve blockade and IV sedation to provide more complete anxiolysis, amnesia, and sedation.[76] If IV sedation or general anesthesia is used, special precautions must be taken in the presence of oxygen. High-powered lasers have been reported to be the source of operating room fires, so care must be taken to eliminate exposure to flammable objects. A smoke evacuator also must be used to avoid inhalation of the laser plume.

TECHNIQUE

CARBON DIOXIDE LASER SKIN RESURFACING.

The objective of ablative LSR is to vaporize tissue to the level of the papillary dermis. Limiting the depth of penetration decreases the risk of scarring and permanent pigmentary alteration. When choosing treatment parameters, several factors should be given consideration, including anatomic site to be resurfaced, the skin phototype of the patient, and previous skin treatments delivered.[5,77] In general, thinner skin (e.g., periorbital) requires fewer laser passes and laser resurfacing of nonfacial skin (e.g., neck, chest) should be avoided due to the relative paucity of pilosebaceous units in these areas.[77] To reduce the risk of excessive thermal injury during multipass procedures, partially desiccated tissue should be removed manually with wet gauze after each laser pass to expose the underlying dermis.[78]

The depth of ablation is directly correlated with the number of passes performed and usually is restricted to the epidermis and upper papillary dermis.[79] However, stacking laser pulses by treating an area with multiple passes in rapid succession or by using a high-overlap setting on a scanning device leads to excessive thermal injury to the skin with subsequent increased risk of scarring.[7,78] An ablative plateau is reached which results in less effective tissue ablation and increased tissue heating. This effect is most likely caused by reduced tissue water content after initial desiccation, thereby diminishing selective energy absorption.[78] The avoidance of pulse stacking and incomplete removal of partially desiccated tissue is paramount to prevention of excessive thermal accumulation with the use of any laser system.

In an attempt to address many of the difficulties associated with multipass CO_2 LSR, refinements in surgical technique have been developed. A minimally traumatic single-pass CO_2 laser resurfacing procedure has been described that results in faster re-epithelialization and a more improved side effect profile than have been reported with the multiple-pass technique.[80] Partially desiccated tissue is not removed (as is standard with multipass procedures); rather, the lased skin is left intact to serve as a biologic wound dressing. Additional laser passes can then be applied focally only in areas of more extensive involvement to limit unnecessary thermal and mechanical trauma to less involved skin. Subsequent reports have substantiated the improved side effect profile of this less aggressive procedure.[81–83]

ERBIUM:YTTRIUM-ALUMINUM-GARNET LASER SKIN RESURFACING.

The short-pulsed Er:YAG laser fluences used most often range from 5–15 J/cm^2, depending on the degree of photodamage and anatomic location. On irradiation, laser-induced ejection of desiccated tissue from the target site produces a distinctive popping sound. Thermal energy is confined to the selected tissue, with minimal collateral thermal damage. Because little tissue necrosis is produced with each pass of the laser, manual removal of desiccated tissue is often unnecessary. The ablation depth with the short-pulsed Er:YAG laser does not diminish with successive passes because the amount of thermal necrosis is nominal. It takes three to four times as many passes with the short-pulsed Er:YAG laser to achieve similar depths of penetration as with one pass of the CO_2 laser at typical treatment parameter settings.[3,5] To ablate the entire epidermis with the short-pulsed Er:YAG laser using a fluence of 5 J/cm^2, at least two or three passes must be performed, which increases the possibility of uneven tissue penetration. Treatment of deeper dermal lesions or areas of the face with extensive photodamage and dermal elastosis may require up to 9 or 10 passes of the short-pulsed Er:YAG laser, whereas the CO_2 laser would effect similar levels of tissue ablation in 2 or 3 passes.[6,50,58]

Pinpoint bleeding caused by inadequate hemostasis and tissue color change after multiple short-pulse Er:YAG passes can impede adequate clinical assessment of wound depth. Irradiated areas whiten immediately after treatment and then quickly fade. These factors render it more difficult to determine treatment endpoints and, thus, require extensive knowledge of laser-tissue interaction on the part of the operator. Modified Er:YAG ablative laser resurfacing provides better hemostasis and visualization of the treatment area because of the added thermal effects on the tissue.[84]

ABLATIVE FRACTIONAL RESURFACING

After appropriate informed consent, eye protection, and sedation are employed, ablative fractional laser skin resurfacing is best performed in a sequential fashion adhering to cosmetic units. Meticulous technique with placement of nonoverlapping rows will minimize bulk heating during treatment. Additional passes are delivered perpendicular to the previous pass until a desired number of passes has been reached. Optimal settings will vary depending upon the laser device used and the severity of the condition being treated. Average settings for a common fractional CO_2 laser (*Repair*, Solta Medical Inc., Hayward, CA) range 40–70 mJ with a coverage density of 30% to 50%. Treatment of the periocular and neck skin require a decrease in both fluence and coverage density. Although patient satisfaction and clinical results may improve with the use of higher fluences, increased adverse events such as pain, erythema, and postoperative dyspigmentation are more often observed when higher treatment densities are applied.[85] Ablative fractional lasers generally require only one treatment to achieve patient satisfaction; however, reappraisal of photodamage, rhytides, or scarring can be performed 6–12 months postoperatively to assess if additional treatments are clinically warranted.

OUTCOMES ASSESSMENT

The clinical and histologic benefits of cutaneous laser resurfacing are numerous. With the CO_2 laser, most studies have shown at least a 50% improvement over baseline in overall skin tone and wrinkle severity (Fig. 251-1).[4,86–90] The greatest advantages associated with CO_2 laser skin resurfacing are the excellent tissue contraction, hemostasis, prolonged neocollagenesis, and collagen remodeling that result. Histologic examination of laser-treated skin demonstrates replacement of epidermal cellular atypia and dysplasia with normal, healthy epidermal cells from adjacent follicular adnexal structures.[50,56] The most profound effects occur in the papillary dermis, where coagulation of disorganized masses of actinically induced elastotic material are replaced with normal compact collagen bundles arranged in parallel to the skin's surface.[91,92] Immediately after CO_2 laser treatment, a normal inflammatory response is initiated, with granulation tissue formation, neovascularization, and increased production of macrophages and fibroblasts.[56]

Persistent collagen shrinkage and dermal remodeling are responsible for much of the continued clinical benefits observed after CO_2 laser resurfacing and are influenced by several factors.[92,93] Thermal effects of laser irradiation of skin produce collagen fiber contraction at temperatures ranging from 55°C–62°C (131°F–143.6°F) through disruption of interpeptide bonds, which results in a conformational change to the collagen's basic triple-helical structure.[94,95] The collagen molecule is thereby shortened to approximately one-third of its normal length. Collagen fibers with laser-induced shrinkage may act as the contracted scaffold for neocollagenesis, which leads to subsequent production of the newly shortened form. In turn, fibroblasts that migrate into laser wounds after resurfacing may upregulate the expression of immune-modulating factors that serve to enhance continued collagen shrinkage.[96]

Because modulated Er:YAG lasers were developed to produce a greater thermal effect and tissue contraction than did their short-pulsed predecessors, investigators compared collagen tightening induced by the CO_2 laser with that of the CO_2–Er:YAG hybrid laser system.[69] Intraoperative contraction of approximately 43% was produced after three passes of the CO_2 laser, compared with 12% contraction after Er:YAG irradiation. At 4 weeks; however, the CO_2 laser– and Er:YAG laser–treated sites were contracted to the same degree which highlights the different mechanisms of tissue tightening observed after laser treatment. Immediate



Figure 251-1 Facial photodamage and rhytides before (**A**) and several months after (**B**) ablative CO_2 laser skin resurfacing.



Figure 251-2 Facial photodamage and rhytides before (**A**) and 6 months after (**B**) fractional ablative CO_2 laser skin resurfacing.

thermal-induced collagen tightening was the predominant response seen after CO_2 irradiation, whereas modulated Er:YAG laser resurfacing did not produce immediate intraoperative contraction, but instead induced slow collagen tightening.[65,69]

Fractional ablative lasers have been used to successfully treat facial and nonfacial photodamage and a variety of scars, including atrophic, hypertrophic, hypopigmented, and traumatic scars.[43,73,97–100] (Figs. 251-2 and 251-3) Improvement in post-CO_2 laser-induced hypopigmentation, residua from infantile hemangioma, and actinic cheilitis has also been reported.[42,43] Others suggest a supportive role for fractional ablative lasers during Q-switched laser tattoo removal.[101]

Clinical improvement of photodamage and rhytides following AFR has been demonstrated in several published studies. A 2,940-nm Er:YAG fractional device was used to treat 28 patients with photodamaged skin. Two months after a single treatment, 75% of patients rated the results as good to excellent with improvement lasting 6–9 months.[102] Another study using a fractional CO_2 laser on 32 patients demonstrated more than 50% improvement in wrinkles, epidermal pigment, and solar elastosis 6 months after one treatment session.[97] In a pilot study of 12 patients, 51% to 75% improvement of photodamage and acne scars after two successive fractional CO_2 laser treatments was reported.[103]

Ablative fractional laser skin resurfacing has been used to improve skin topography in both atrophic and hypertrophic scars. In a study of 15 patients with SPT I-IV and moderate-to-severe atrophic scarring, an average of 66.8% improvement in scar depth after 2–3 fractional CO_2 laser treatments was achieved.[98] Good clinical improvement in 23 of 25 subjects with moderate-to-severe atrophic scarring who received up to 3 treatments with a fractional CO_2 laser was demonstrated in yet another published report.[99] Sustained improvement of atrophic scars and an overall improvement of clinical appearance including pigmentation and rhytides was noted. Quantitative volumetric improvement of nonacne atrophic traumatic or surgical scars has also been reported. Twenty-two atrophic scars received three fractional CO_2 laser treatments with image analysis at 6 months demonstrating clinical and volumetric improvement as evidenced by



Figure 251-3 Atrophic scars before **(A)** and 6 months after (**B**) fractional ablative CO_2 laser skin resurfacing.

mean reduction of scar volume and depth by 38% and 36%, respectively.[100]

SIDE EFFECTS AND COMPLICATIONS

Side effects associated with CO_2 laser skin resurfacing vary and are related to the expertise of the operator, the body area treated, and the skin phototype of the patient (Table 251-2). Certain tissue reactions, such as erythema and edema, are expected in the immediate postoperative period and are not considered adverse events. Erythema can be intense and may persist for several months after the procedure. The degree of erythema correlates directly with the depth of ablation and the number of laser passes performed.[3,104] It may also be aggravated by underlying rosacea or dermatitis. Postoperative erythema resolves spontaneously but can be reduced with the application of topical ascorbic acid, which may serve to decrease the degree of inflammation.[105,106] It should not be used for at least 4 weeks after the procedure to avoid irritation. Likewise, other topical agents such as retinoic acid derivatives, glycolic acid, fragrance- or chemical-containing cosmetics, and sunscreens should be strictly avoided in the early postoperative period until substantial healing has occurred.[104]

Mild side effects of LSR include milia formation and acne exacerbation, which may be caused by the postoperative use of occlusive dressings and ointments particularly in patients who are acne prone.[7,77,104,107] Milia and acne usually resolve spontaneously as healing progresses and the application of thick emollient creams and occlusive dressings ceases. Oral antibiotics may be prescribed for acne flares that do not respond to topical preparations.[90,104,107] Contact dermatitis, either irritant or allergic, can also develop from various topical medications, soaps, and moisturizers used postoperatively. Most of these reactions are irritant in nature due to decreased barrier function of the newly resurfaced skin.[104,108]

TABLE 251-2
Side Effects and Complications of Ablative Laser Skin Resurfacing

- Expected side effects
  - Erythema
  - Edema
  - Pruritus
- Complications
  - Mild
    - Prolonged erythema
    - Milia
    - Acne
    - Contact dermatitis
  - Moderate
    - Infection (bacterial, viral, fungal)
    - Dyspigmentation
  - Severe
    - Hypopigmentation
    - Hypertrophic scarring
    - Ectropion

Wound infections associated with ablative laser resurfacing include *Staphylococcus* and *Pseudomonas* infections and cutaneous candidiasis and should be treated aggressively with an appropriate systemic antibiotic or antifungal agent.[109] The most common infectious complication is a reactivation of labial herpes simplex virus (HSV) infection, most likely caused by thermal tissue injury and epidermal disruption produced by the laser.[7,104] All patients undergoing full-face or perioral ablative resurfacing should receive antiviral prophylaxis even if they report no history of HSV infection. After CO_2 resurfacing, approximately 7% of patients develop a localized or disseminated form of HSV infection.[104] These infections develop within the first postoperative week and can present as erosions without intact vesicles because of the denuded condition of newly lased skin. Even with appropriate prophylaxis, a herpetic outbreak can occur in upward of 10% of patients and must be treated aggressively.[5] Oral antiviral agents such as acyclovir, famciclovir, and valacyclovir are effective agents against HSV infection, although IV therapy may be required in severe (disseminated) cases. Patients should begin prophylaxis by the day of surgery and continue it for 7–10 days postoperatively.[8]

Hyperpigmentation is one of the more common side effects of cutaneous laser resurfacing and occurs to some degree in all patients with darker skin tones.[96,109] The reaction is transient, but its resolution can be hastened with the postoperative use of a variety of topical agents, including hydroquinone and retinoic, azelaic, kojic, and glycolic acid. Regular sunscreen use is also important during the healing process to prevent further skin darkening. Postoperative hypopigmentation is often not observed for several months and is particularly difficult because of its tendency to be intractable to treatment. The use of an excimer laser or topical photochemotherapy to stimulate repigmentation has proven successful in some patients.[110,111] Others report improvement of hypopigmentation after the use of a nonablative, 1,550-nm fractional resurfacing laser.[112]

The most severe complications associated with ablative cutaneous laser resurfacing are hypertrophic scars and ectropion formation.[79,96] Although the risk of scarring has been significantly reduced with the newer pulsed systems, inadvertent pulse stacking or scan overlapping as well as incomplete removal of desiccated tissue between laser passes can cause excessive thermal injury that could increase the development of fibrosis. Focal areas of bright erythema with pruritus, particularly along the mandible, may signal impending scar formation.[8,38] Potent topical corticosteroid preparations should be applied to decrease the inflammatory response. A pulsed dye laser also can be used to improve the appearance and symptoms of laser-induced burn scars.[113]

Ectropion of the lower eyelid after periorbital laser skin resurfacing is rarely seen but, if encountered, usually requires surgical correction.[77] It is more likely to occur in patients who have had previous lower blepharoplasty or other surgical manipulation of the periorbital region. Preoperative examination is essential to determine eyelid laxity and skin elasticity. If the

infraorbital skin does not return briskly to its normal resting position after a manual downward pull (snap test), then ablative laser resurfacing near the lower eyelid margin should be avoided. In general, lower fluences and fewer laser passes should be applied in the periorbital area to decrease the risk of lid eversion.

Side effects and complications after Er:YAG laser resurfacing are similar to those observed after CO_2 laser skin resurfacing, but they differ in duration, incidence, and severity.[114,115] Although greater postoperative erythema is seen after modulated Er:YAG laser treatment than is usually produced with a short-pulsed Er:YAG system, the side effect profile and recovery period after modulated Er:YAG laser skin resurfacing remain more favorable than after multipass CO_2 laser treatment. In an extended evaluation of 50 patients, investigators reported complete re-epithelialization in an average of 5 days after dual-mode Er:YAG laser skin resurfacing, with only three patients experiencing prolonged erythema beyond 4 weeks.[66] In a split-face comparison of 16 patients after pulsed CO_2 and variable-pulsed Er:YAG laser skin resurfacing, other investigators reported decreased erythema, less edema, and faster healing on the Er:YAG laser–treated facial half.[71]

Postinflammatory hyperpigmentation is not uncommon after any cutaneous laser resurfacing procedure. Although hyperpigmentation after modulated Er:YAG laser skin resurfacing (mean duration, 10.4 weeks) can last longer than after treatment with a short-pulsed Er:YAG laser, it is not as persistent as that observed after multiple-pass CO_2 laser resurfacing (mean duration, 16 weeks).[66] However, when the most current ablative LSR techniques are compared (single-pass CO_2 versus multiple-pass, long-pulsed Er:YAG), postoperative healing times and complication profiles are comparable, even in patients with darker skin phototypes. In a retrospective review and analysis of 100 consecutively treated patients, investigators found that average time to re-epithelialization was 5.5 days with single-pass CO_2 and 5.1 days with long-pulsed Er:YAG laser resurfacing.[83] Postoperative erythema was observed in all patients, lasting an averaging 4.5 weeks after single-pass CO_2 and 3.6 weeks after long-pulsed Er:YAG laser treatment. Hyperpigmentation was seen in 46% of patients treated with a single pass of the CO_2 laser and 42% of patients treated with the long-pulsed Er:YAG laser (average duration, 12.7 weeks and 11.4 weeks, respectively).

The main advantage of ablative fractional lasers when compared with fully ablative LSR techniques is the excellent side effect profile and low incidence of complications.[7,9,43,104] Postoperative recovery is more favorable and predictable after AFR treatment with pinpoint bleeding and serosanguinous discharge resolved within 24–48 hours. Intense erythema and crusting are typical for 3–6 days postoperatively. Moderate erythema lasts days to weeks which stands in sharp contradistinction to the months of erythema often experienced with traditional multipass ablative laser skin resurfacing. The intensity and duration of erythema may be slower to resolve in patients with SPT I-II and those receiving more aggressive AFR treatments. Particular care must be taken in anatomic sites with a relative paucity of pilosebaceous units such as the eyelids, neck, and chest as excessive thermal injury with subsequent hypertrophic scarring has been reported. With proper technique; however, excellent clinical results can be achieved with an exceedingly low risk of scarring and hypopigmentation.[43]

POSTOPERATIVE CARE AND PATIENT INSTRUCTIONS

Proper wound care during the immediate postoperative period is vital to the successful recovery of ablative laser–resurfaced skin. During the re-epithelialization process, an open or closed wound treatment technique can be prescribed. Partial-thickness cutaneous wounds heal more efficiently and with a reduced risk of scarring when maintained in a moist environment because the presence of a dry crust or scab impedes keratinocyte migration.[116] Although there is consensus on this principle among laser surgeons, disagreement exists regarding the optimal dressing for the laser-ablated wound. The "open" technique involves frequent application of thick healing ointment to the de-epithelialized skin surface, whereas occlusive or semiocclusive dressings are placed directly on the lased skin in the "closed" technique. Although the open technique facilitates wound visualization, the closed technique requires less patient involvement and may also decrease postoperative pain. Proposed advantages of closed dressings include increased patient comfort, decreased erythema and edema, increased rate of re-epithelialization, and decreased patient involvement in wound management[116,117] however, additional expense and a higher risk of infection have been associated with their use.[107,109]

In addition to postoperative wound care, ice pack application and the administration of anti-inflammatory medications should be prescribed. Furthermore, pain medication during the first few postoperative days is particularly important for patients undergoing fully ablative laser skin resurfacing. Although pinpoint bleeding, serosanguinous drainage, and edema can be significant during the first 24–36 hours after AFR, minimal (if any) discomfort is present.

CHEMICAL PEEL

The controlled application of one or more exfoliating agents to the skin is a highly efficient and versatile way to improve photodamaged skin. Chemical peels create a more compact stratum corneum associated with a

TABLE 251-3
Chemical Peel Classification

Type	Depth of Penetration
Superficial	Epidermis to upper papillary dermis
Medium	Papillary dermis to upper reticular dermis
Deep	Midreticular dermis

TABLE 251-4
Superficial Chemical Peeling Agents

- Trichloroacetic acid 10%–25%
- Jessner solution
- Modified Unna resorcinol paste
- Solid carbon dioxide
- α-Hydroxy acids
- Salicylic acid
- Tretinoin solution

TABLE 251-5
Medium-Depth Chemoexfoliants

- Trichloroacetic acid (TCA) 35%–50%
- Solid CO_2 and 35% TCA
- Jessner solution and 35% TCA
- 70% Glycolic acid and 35% TCA
- 88% Phenol

thicker epidermis and more uniform distribution of melanin.[118] The level of injury and the depth of penetration into the skin determine the classification as a superficial, medium, or deep chemical peel (Table 251-3). Although superficial peeling agents aimed at removing all or part of the epidermis are useful for superficial dyspigmentation, acne, and solar lentigines, they have minimal effect on rhytides and require multiple treatments for the best clinical results (Table 251-4). More complete skin rejuvenation requires the application of a medium or deep chemoexfoliant.[118,119]

MEDIUM-DEPTH PEELS

Medium-depth chemical peels are defined as those causing injury to the skin at or through the papillary dermis (Table 251-5).[118–121] Trichloroacetic acid (TCA) at concentrations of 35%–50% is the classic agent in this category. Because 50% TCA may produce an unpredictable response with subsequent hypopigmentation and scarring, the combination of a superficial peeling agent such as Jessner solution or glycolic acid before the application of 35% TCA is advocated to achieve more consistent results with an increased margin of safety (Fig. 251-4).[122–125]

The Jessner solution–TCA peel is performed after thorough cleansing of the treatment area with soap followed by degreasing with an alcohol and acetone solution. Jessner solution (Table 251-6) is applied in one or two coats to achieve a pale, uniform frost. The TCA is then applied evenly over the skin surface. Those portions of the face with a high concentration of sebaceous glands (T-zone) may receive additional acid in a second application. The observed white frost indicates protein denaturation of keratin and completion of the chemical peel reaction. Cool water compresses and emollient creams are then applied for symptomatic relief. Postoperatively, erythema, edema, and desquamation are expected, with increased severity of side effects noted at the higher acid concentrations and greater number of applications.

DEEP CHEMICAL PEELS

Phenol is a keratocoagulant that is the only deep peeling agent widely used. Application of phenol, as described by Baker and Gordon in the 1960s, causes wounding that penetrates to the midreticular dermis.[126–128] Baker-Gordon formula (Table 251-7) should be freshly prepared and stirred continuously before and during the procedure to ensure even application of the solution. For a full-face phenol peel, regional nerve blocks in combination with analgesics such as propofol (Diprivan) and anxiolytics such as midazolam can be used. Because phenol is partially detoxified in the liver and excreted by the kidney, hydration with lactated



Figure 251-4 Facial dyspigmentation before (**A**) and 6 months after (**B**) treatment with a 30% trichloroacetic acid peel.

TABLE 251-6
Jessner Solution

- Lactic acid 14 g
- Salicylic acid 14 g
- Resorcinol 14 g
- Ethanol 95% in quantity sufficient to yield 100 mL

Ringer solution before and during the treatment is warranted to limit toxicity. Furthermore, because phenol is cardiotoxic, close patient monitoring is necessary during and after the procedure.[129]

After degreasing the skin with hexachlorophene (Septisol), fresh Baker solution is applied systematically over aesthetic units using cotton-tipped applicators. Sufficient time (10–15 minutes) should elapse between treatment of different regions in order to minimize excessive absorption which can lead to systemic toxicity. The solution can be feathered beyond the margins of the treated areas to reduce the line of demarcation between treated and untreated skin.

Postoperatively, an open wound care technique has been favored over a closed dressing due to the lower risk of infection and scarring and speedier re-epithelialization.[129] Petrolatum is applied liberally to the wound until re-epithelialization is complete, usually within 7–10 days.

SIDE EFFECTS AND COMPLICATIONS

The risk of side effects and complications (Table 251-8) increases proportionately with the depth of the chemical peeling agent. Superficial peels are associated with the lowest risk of adverse reactions, whereas medium-depth peels can cause dyspigmentation and, rarely, scarring. Phenol peels are further associated with hepatic, renal, and cardiac toxicity.[129]

DERMABRASION

Modern techniques for dermabrasion were initially described by Paul Kurtin in 1953.[130] Dermabrasion involves the mechanical removal of the epidermis and dermis in a controlled fashion. Indications for treatment include rhytides, facial scars, rhinophyma, epidermal nevi, syringoma, and many other benign skin conditions.[131–134] Dermabrasion is highly operator dependent and the practitioner must have extensive knowledge and experience to obtain excellent results while maintaining high levels of safety. The use of dermabrasion, except for spot treatment of specific lesions or scars, has been largely supplanted by treatment with a variety of ablative lasers.

TABLE 251-7
Baker-Gordon Phenol Peel

- Phenol USP 88% 3 mL
- Croton oil (three drops)
- Hexachlorophene (Septisol) liquid soap (eight drops)
- Distilled water 2 mL

USP = United States Pharmacopeia.

TABLE 251-8
Side Effects and Complications of Chemical Peels

- Persistent erythema
- Infection
- Milia
- Dyspigmentation
- Textural changes
- Fibrosis and scarring
- Cardiac, renal, and hepatic toxicity (associated with phenol peels)

Before dermabrasion is performed, a thorough patient consultation and evaluation is necessary to identify abnormal scarring tendency, prior treatments to the area, drug allergies, clotting or pigmentary disorders, and koebnerizing skin conditions. Preoperative antiviral prophylaxis is warranted for perioral or full-face procedures.[132,133] Although isotretinoin use within 6–12 months is traditionally considered an absolute contraindication to dermabrasion.[135] Bagatin et al described normal re-epithelialization with no evidence of abnormal wound healing in 7 patients on concomitant isotretinoin who received dermabrasion on a small test area.[136] The recommendation to delay dermabrasion for 6–12 months after oral isotretinoin use is, thus, in question.

Dermabrasion is performed using a wire brush or diamond fraise powered by a hand engine.[131–134] Fraises are available in multiple sizes, shapes, and degrees of coarseness. Pear-shaped fraises and cones are most often used around the nose and oral commissure, whereas wheels are used over flat, broad skin surfaces.[133] In general, diamond fraises offer a greater margin of safety than does the wire brush type, which removes a greater amount of tissue (Fig. 251-5).

The form of anesthesia used for dermabrasion varies depending on the surgeon, the area to be dermabraded, the desired depth of treatment, and the patient's pain tolerance. The use of liquid refrigerants can be problematic because of their potential for excessive skin injury; however, cryoanesthesia has the advantage of providing a firm surface on which to treat. Tumescent anesthesia with 0.05%–0.1% lidocaine solution (with or without the concomitant use of nerve blocks and oral anxiolytics) is an effective form of anesthesia for full-face dermabrasion. A volume of 250–350 mL is typically adequate for the full face.[133]

Dermabrasion is performed in the operating room under strict universal precautions due to the risk of aerosolization of viral particles. The area to be dermabraded is stabilized manually without distortion of the normal skin contour. Some operators use an aerosol refrigerant to stiffen the skin surface to enhance depth control. The device is pulled rather than pushed over



Figure 251-5 **A.** Perioral rhytides before wire brush dermabrasion. **B.** Improved perioral rhytides 6 months after the procedure.

the cutaneous surface, which itself is positioned parallel to the floor. The dermabrasion is performed to the desired depth by closely monitoring the skin surface appearance. Decreased skin pigmentation is observed on epidermal removal, followed by punctate, pinpoint bleeding when the papillary dermis has been reached. The level of the reticular dermis is signaled by a whitish yellow appearance with fewer blood vessels. The goal of dermabrasion is to penetrate to the level of the dermis while avoiding the lower dermis and subcutaneous layer to reduce the risk of scarring. Feathering at the margins of the treatment area can soften the transition between treated and untreated skin.

On completion of a full-face dermabrasion, a dilute lidocaine and epinephrine solution can be used topically to soothe the treated area and improve hemostasis. The use of various biologic and nonbiologic sterile dressings has been advocated, but the choice is determined by the preference of the surgeon.[137] Depending on the total area and depth of dermabrasion, re-epithelialization is typically complete within 7–10 days. Meticulous wound care and close observation during the period of re-epithelialization permits the early detection of and intervention for such potential complications as herpetic, bacterial, and fungal infections. Side effects and complications after dermabrasion are similar to those seen after an ablative laser skin resurfacing procedure (see Table 251-2); however, the incidence of permanent hypopigmentation is markedly higher after dermabrasion (20%–30%) than after ablative laser treatment.

KEY REFERENCES

Full reference list available at www.DIGM8.com

DVD contains references and additional content

3. Alster TS: Cutaneous resurfacing with CO_2 and erbium:YAG lasers: preoperative, intraoperative, and postoperative considerations. *Plast Reconstr Surg* **103**:619-632, 1999
31. Manstein D et al: Fractional photothermolysis: a new concept for cutaneous remodeling using microscopic patterns of thermal injury. *Lasers Surg Med* **34**:426-438, 2004
39. Metelitsa AI, Alster TS: Fractionated laser skin resurfacing treatment complications: a review. *Dermatol Surg* **36**:299-306, 2010
42. Brightman LA et al: Ablative and fractional ablative lasers. *Dermatol Clin* **27**:479-489, 2009
118. Fabbrocini G, Pia De Padova M, Tosti A: Chemical peels: what's new and what isn't new but still works well. *Facial Plast Surg* **25**:329-336, 2009
133. Spencer JM, Harmon CB: Microdermabrasion and dermabrasion. In: *Surgery of the Skin*, edited by J Robinson et al. Philadelphia, Elsevier, 2005, pp. 611-624

Chapter 252 :: Cosmetic Applications of Nonablative Lasers and Other Light Devices

:: Elliot T. Weiss, Anne M. Chapas, & Roy G. Geronemus

COSMETIC APPLICATIONS OF NONABLATIVE LASERS AND OTHER LIGHT DEVICES AT A GLANCE

- A wide range of lasers and other light devices can be used to treat skin problems of cosmetic concern.
- Photorejuvenation can be achieved with nonablative devices and fractional nonablative devices.
- Vascular and pigmented lesions benefit from treatment with lasers capable of selective photothermolysis.
- Patient selection and patient expectation are critical for optimum outcome.
- All safety precautions must be followed during treatment.

Over the last 40 years, the explosive advancement of laser technology has revolutionized the treatment of numerous skin conditions. The principle of selective photothermolysis set forth in 1983 by Anderson and Parrish[1] has formed the basis for the development of lasers that selectively target and destroy tissues containing water, hemoglobin, and pigment. Lasers exhibiting such selective action were first applied to improve various potentially disfiguring medical conditions such as port-wine stains, hemangiomas, and pigmented birthmarks. More recently, these same principles have been implemented in an effort to improve the cosmetic appearance of normal and aging skin. The principle of fractional photothermolysis (FP) set fort by Manstein and Anderson[2] has further revolutionized nonablative and ablative resurfacing by improving safety and shortening patient recovery times. Because laser treatments target all aspects of photoaging, from ameliorating the appearance of fine and deep rhytides to softening skin texture and improving pigmentation and skin laxity, they are becoming an indispensable tool in the armamentarium of the cosmetic dermatologist. A thorough understanding of the benefits and limitations of each laser technique and the expectations and lifestyle of the individual patient allow the practitioner to achieve the most satisfying cosmetic results.

NONABLATIVE SKIN REJUVENATION

Skin rejuvenation by laser was originally performed with devices that resulted in the destruction or ablation of the epidermis and elements of the dermis. The demand for less invasive procedures with shorter recovery times than those of traditional ablative laser resurfacing has led to the development of nonablative laser surgery. Many of these systems emit light in the infrared portion of the electromagnetic spectrum (1,000–1,500 nm), which is absorbed by water in deeper tissues while leaving the epidermis intact. This type of dermal wounding stimulates new collagen and elastin formation, which can improve the appearance of skin with mild-to-moderate photodamage. In general, the results are not comparable to those achieved with ablative lasers, but many patients are willing to accept more modest clinical improvements in exchange for fewer side effects and shorter recovery times. The advent of fractional nonablative laser technology has enabled the delivery of higher energy fluences to treat a fraction of the skin surface. This technology generally allows more effective and safer treatments for photoaging compared to traditional nonablative lasers.

PATIENT SELECTION

Proper patient selection is the key to successful nonablative laser resurfacing (see Chapter 251 for ablative laser procedures). Patients with realistic expectations who have mildly to moderately photodamaged skin are the best candidates for nonablative procedures. Results from nonablative laser treatments are generally gradual and progressive, with textural irregularities and pigment irregularities improving more than rhytides. Patients who seek immediate dramatic results are likely to be disappointed with the overall clinical outcome. The practitioner must distinguish and educate patients on the difference between static and dynamic rhytides. Static rhytides in general respond more favorably and completely to laser therapy whereas dynamic rhytides are best addressed with appropriate injection of available botulinum toxin preparations.

RISKS AND PRECAUTIONS

As with ablative laser resurfacing, the heat produced by nonablative systems can reactivate prior herpes simplex infections (Table 252-1). Patients with a strong history of herpes labialis should receive prophylactic oral antiviral

TABLE 252-1
Nonablative Resurfacing: Risks and Precautions

- Contraindicated in patient with prior isotretinoin treatment
- May lead to postinflammatory hyperpigmentation
- May cause reactivation of herpes simplex virus infection

medication before treatment. Although nonablative laser procedures have an extremely low risk of scarring, these risks are increased in patients who have received isotretinoin in the previous year. Therefore, these patients should not undergo nonablative resurfacing. Patients with darker skin phototypes may develop a temporary postinflammatory hyperpigmentation after nonablative laser treatment. In order to ensure a safe treatment and to minimize the risk of adverse reactions, practitioners must use appropriate energy settings and correct treatment techniques to avoid bulk heating (heat accumulation) and injury to the treatment area.

PATIENT POSITIONING

Nonablative laser resurfacing can be performed in the physician's office, with both the patient and clinical personnel wearing proper eye protection.

EQUIPMENT

Several visible-light lasers have been developed to target discrete chromophores to stimulate dermal remodeling (Table 252-2). One of the first approaches to photorejuvenation used pulsed dye lasers (PDL) emitting light at wavelengths of either 585 nm or 595 nm. The ability of PDL treatment to improve the appearance of hypertrophic scars, striae distensae, and acne scars suggests that PDL treatment stimulates new collagen formation. A small clinical study confirmed that a single treatment with a PDL (585 nm, 450 ms) induced clinical improvement in 75%–90% of mild-to-moderate rhytides and 40% of moderate-to-severe rhytides.[3] Longer-wavelength lasers such as the 1,064-nm Q-switched neodymium:yttrium-aluminum-garnet (Nd:YAG) laser, the 1,320-nm Nd:YAG laser, the 1,450-nm diode laser, and 1,540-nm erbium:glass laser have also been shown to induce dermal remodeling. Multiple treatments are necessary at 2- to 4-week intervals. The effects are often gradual due to ongoing collagen formation, which may occur up to 6 months after the last treatment.

TABLE 252-2
Nonablative Resurfacing: Equipment

- Visible-light lasers: 585 nm, 595 nm, long-pulse 1,064-nm neodymium:yttrium-aluminum-garnet, 1320 nm, 1,450 nm, 1,540-nm, 1,550-nm erbium:glass, 1,927-nm, fractional photothermolysis
- Intense pulsed light devices
- Radiofrequency devices (monopolar, bipolar, fractionated)
- Focused ultrasound devices

Treatment with intense pulsed light (IPL) devices, which emit a broad, continuous spectrum of light from 515 nm to 1,200 nm, has been shown to successfully rejuvenate photodamaged skin. Filters can be placed over the beam to eliminate the shorter wavelengths, which target hemoglobin and melanin, depending on the clinical application. Studies have shown that IPL treatment produces substantial clinical improvement in the dyspigmentation and telangiectasias that are associated with photoaging but only mild improvement in rhytides.[4]

In contrast to visible-light lasers creating large sheets of thermal damage, the lasers used for fractional photothermolysis are mid-infrared (1,440 nm, 1,540 nm, 1,550 nm, 1,927 nm) devices that create columns of thermal injury to various depths into the dermis, similar to pixels in a digital photograph.[5] The epidermis rapidly heals around these columns of thermal damage, which stimulate progressive collagen remodeling. Treatments are generally scheduled at 3- to 4-week intervals for a total of 3 to 6 sessions. Photodamage of the face, neck, chest, and hands; acne scars (Fig. 252-1); striae distensae (Fig. 252-2); and melasma have all been shown to respond to fractional photothermolysis.

Several nonablative devices that deliver energy deep into the dermis have been shown to cause skin tightening. The direct application of infrared light, with pretreatment and post-treatment contact cooling of the skin, has been shown to heat deep collagen to the point of contraction. In appropriate patients, this contraction results in a visible tightening of redundant skin. Skin tightening can also be achieved by the use of monopolar and bipolar radiofrequency devices generating electric current, which produces heat through resistance in the dermis. Periorbital rhytides and middle and lower face laxity generally require 1 to 3 treatments at 4-week intervals, with tightening noted 1–3 months after the last treatment[6] (Fig. 252-3). A new infrared device that emits light at 1,100–1,800 nm in multisecond cycles has also been shown to induce skin contraction. Focused ultrasound has recently been incorporated into a device designed to generate dermal and subcutaneous heating with subsequent neocollagenesis in treated skin. Selective cryolipolysis is utilized by a novel noninvasive device to cool and selectively treat localized subcutaneous fat deposits.

ANESTHESIA

Nonablative laser procedures are generally more easily tolerated than ablative procedures. The degree and type of anesthesia required depends on the patient's pain tolerance and the amount of heat energy generated by the device. A topical anesthetic such as lidocaine or a eutectic mixture of lidocaine and prilocaine applied 1 hour before the procedure is usually sufficient. Forced-air cooling can also make the procedure more tolerable. Higher-energy procedures such as fractional photothermolysis occasionally require



Figure 252-1 Acne scarring treated with fractional photothermolysis. **A.** Before treatment. **B.** After treatment.

nerve blocks, oral or intramuscular analgesics, and anxiolytics.

TECHNIQUE

Nonablative visible-light laser systems require different treatment parameters depending on the skin type and condition to be treated. To protect the epidermis, all of these devices are used in conjunction with a contact cooling handpiece or cryogen spray delivered several milliseconds before the laser pulse. IPL devices are used with various filters and at different energy levels depending on the desired treatment effect. A transparent water-based gel is used to protect the epidermis. Fractional photothermolysis is performed in the presence of forced-air cooling. Various density and energy settings are used depending on the indication and clinical endpoint desired.

Finally, tightening procedures are performed by holding the handpiece in firm contact with the treated skin. Several investigators have shown that multiple passes using radiofrequency at relatively low-to-medium energies are effective and more tolerable for patients than high-energy treatments.

OUTCOMES ASSESSMENT

Because nonablative laser treatments stimulate collagen remodeling over several months, objective clinical improvements after a series of treatments may take weeks or months to be achieved. Reassurance by the physician as well as the use of pretreatment



Figure 252-2 Striae distensae treated with fractional photothermolysis. **A.** Before treatment. **B.** Three months after treatment.



Figure 252-3 Facial laxity treated with a monopolar radiofrequency device. **A.** Before treatment. **B.** Two months after treatment. **C.** Four months after treatment. **D.** Six months after treatment.

photographs may help patients to better appreciate their progress. Setting realistic goals and targeting the aspects of photoaging that are important to the patient will also yield a more favorable outcome and enhance patient satisfaction.

COMPLICATIONS

Nonablative laser surgery is not without risks, but side effects are much milder than with ablative laser treatment. Depending on the treatment, patients may have erythema and edema, which resolves in hours to days. Rarely are treatments associated with blistering, transient hyperpigmentation, or scarring. In some cases, post-treatment hyperpigmentation has been caused by excessive use of cryogen spray but has resolved with topical bleaching agents. IPL treatment of tanned skin or darker skin phototypes should be used cautiously due to the increased risk of adverse events including blistering, hypopigmentation, and scarring. To avoid reactivation of latent herpes simplex virus (HSV) infections with fractional resurfacing, appropriate oral antiviral prophylaxis should be considered for all patients regardless of reported HSV status.

PATIENT INSTRUCTIONS

Because the epidermis remains intact after nonablative laser procedures, minimal postoperative care is required. Ice can be applied to decrease erythema and

swelling, and occasionally systemic glucocorticoids may be required.

TREATMENT OF VASCULAR LESIONS

A wide range of vascular lesions are amenable to safe and effective treatment by a class of lasers that take advantage of the principle of selective photothermolysis (see also Chapter 239).

PATIENT SELECTION

Vascular lesions can be a significant cosmetic concern for some patients and are generally amenable to laser treatment. Telangiectasias are small, superficial cutaneous blood vessels often appearing on the nose, cheeks, and chin in fair-skinned individuals as a result of actinic damage or rosacea. Other causes of telangiectasias include collagen vascular disease, genetic disorders, hormonal disorders, primary cutaneous disease, and radiation dermatitis. Telangiectasias are often associated with facial erythema, which can manifest as a flushing or blushing disorder. Various laser treatments can target this background erythema in addition to treating the discrete vascular lesions.

Other types of vascular lesions, including cherry and spider hemangiomas, venous lakes, and angiokeratomas, may respond to vascular laser treatment (Fig. 252-4). Poikiloderma of Civatte, which manifests as a combination of telangiectasia, irregular pigmentation, and atrophic changes in fair-skinned individuals with actinic damage, can also be treated with vascular lasers. Extreme caution must be used when treating this condition, because overly aggressive treatment can worsen the atrophy and hypopigmentation.

In addition to improving vascular lesions, vascular laser treatments can improve the appearance of hypertrophic scars and keloids. Vascular lasers not only reduce the erythema by eliminating the underlying dilated microvasculature in a scar, they can also reduce the height of the scar and improve the skin surface texture. Multiple treatment sessions are required, and the treatment can be augmented by intralesional injections of corticosteroid with 5-fluourouracil. Newly formed atrophic scars, such as striae rubra, can sometimes be greatly improved with vascular laser treatment, whereas older lesions are less responsive.

TABLE 252-3
Treatment of Vascular Lesions: Associated Risks

- Postinflammatory hyperpigmentation
- Postinflammatory hypopigmentation
- Atrophic scarring
- Hypertrophic scarring

RISKS AND PRECAUTIONS

Laser treatment of vascular lesions is relatively safe but not without risks (Table 252-3). Higher-energy treatments or treatments with overlapping passes can result in atrophic or hypertrophic scarring. Alterations in pigmentation may result due to the concomitant absorption of 532-nm light by epidermal melanin. Patients with tans or darker skin types must be treated with caution to avoid pigmentary changes.

PATIENT POSITIONING

Most cosmetic vascular laser treatments are performed in the office. The patient's eyes are protected with laser surgery goggles or with intraocular metal eye shields if treatment around the eye is required. All clinical personnel must wear laser surgery glasses that specifically absorb the wavelength of light used in the treatment. Flammable gases and other materials must not be present, because vascular lasers are capable of igniting fires.

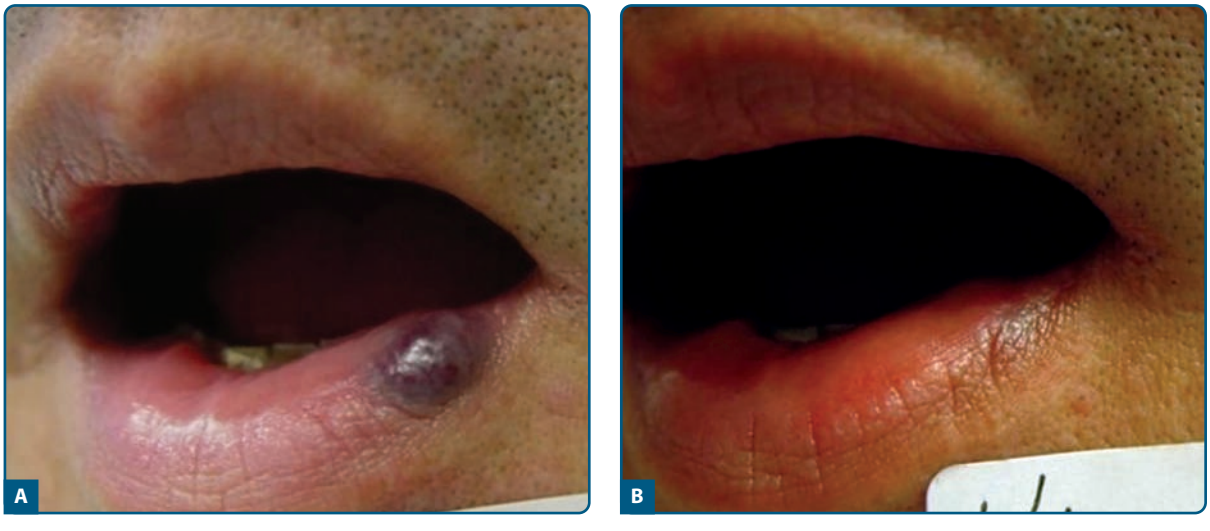

Figure 252-4 Venous lake treated with a potassium-titanyl-phosphate laser. **A.** Before treatment. **B.** After treatment.

EQUIPMENT

Vascular lesions were one of the first targets of treatment with early lasers. These early lasers, such as the argon laser (488 nm, 514 nm), argon-pumped tunable laser (488–638 nm), copper and bromide lasers (578 nm), potassium-titanyl-phosphate (KTP) laser (532 nm), and krypton laser (568 nm), emitted continuous energy that was absorbed by oxyhemoglobin in cutaneous blood vessels (Chapter 239). Their use was limited because the continuous thermal energy often resulted in scarring and pigmentary alterations. The development of pulsed lasers in the 1980s allowed for more precise targeting of the oxyhemoglobin-containing vessels with less thermal and mechanical injury of surrounding tissues (Table 252-4). It is believed that pulsed energy delivered with short pulse widths causes intravascular cavitation, vessel wall fragmentation, and hemorrhage, whereas pulsed energy delivered over longer intervals causes intravascular coagulation and collagen contraction within the vessel wall and surrounding tissue. To reduce epidermal damage, all vascular lasers use an epidermal cooling system, with a cryogen spray or contact cooling.

The flashlamp-pumped PDL uses a high-power flashlamp to excite an organic dye (rhodamine) and produces a pulse of yellow light that is absorbed by oxyhemoglobin. The newer PDLs can deliver a variety of fluences over variable pulse durations (0.45–40 ms) to effectively treat many cosmetic conditions (see also Chapter 239). These PDLs can deliver high-energy, shorter pulses of light to treat striae distensae rubra, keloids, CVM, and infantile hemangioma. Purpura often results at these settings but resolves within 1–2 weeks. However, the device is most useful in treating facial erythema and facial telangiectasias at longer pulse durations that do not lead to purpura, which is a barrier to treatment for some patients.

The long-pulse, frequency-doubled Nd:YAG-KTP lasers emit a green 532-nm light that can also improve telangiectasias with minimal purpura. The current KTP lasers deliver energy with pulse durations of 1–100 ms through a fiberoptic handpiece with contact cooling. Although the 532-nm light is strongly absorbed by hemoglobin, the laser has a limited depth of penetration, which makes it useful for treatment of superficial facial vessels. Because melanin also absorbs 532-nm light, this laser should be used with caution in patients with darker skin phototypes.

Long-pulsed infrared lasers such as the alexandrite (755 nm), diode (800 nm), and Nd:YAG (1,064 nm) lasers allow deeper penetration into the skin, but their light is absorbed less specifically by hemoglobin than is the light of other vascular lasers (see also Chapter 239). There is still enough absorption, however, to treat superficial and deep reticular veins (up to 3 mm in diameter) in patients with a variety of skin types. More recently, multiplex lasers have been developed that sequentially deliver a PDL (595-nm) pulse followed by an Nd:YAG (1,064-nm) pulse at precise intervals. It is theorized that the first PDL pulse induces blood clot formation and methemoglobin conversion, which allows for greater absorption of the Nd:YAG energy. Studies are ongoing to delineate the cosmetic and medical indications for multiplex laser treatment.

IPL devices with cutoff filters that deliver increments of light ranging from 515–590 nm have been shown to be effective in the treatment of cosmetic vascular conditions. IPL devices produce a variety of fluences (up to 80 J/cm^2) over 2–10 ns in single-, double-, or triple-pulse modes. The light is delivered by a fiber through an 8×15 mm or 8×35 mm glass window that is pressed directly against the skin. A coupling gel is applied to the skin before light application to protect the epidermis from overheating and improve light penetration. Compared with PDLs, IPL devices require a longer treatment session and potentially a greater number of treatments to achieve similar results.

TABLE 252-4
Treatment of Vascular Lesions: Equipment

- Pulsed potassium-titanyl-phosphate lasers
- Pulsed dye, long-pulsed dye, variable-pulsed dye lasers
- Long-pulsed infrared lasers: alexandrite, diode, neodymium:yttrium-aluminum-garnet (Nd:YAG)
- Multiplex lasers: sequential pulsed dye + Nd:YAG
- Intense pulsed light devices

ANESTHESIA

Vascular lasers and light sources used for cosmetic indications produce a brief stinging or burning sensation. Treatments are generally tolerated without anesthesia. Because discomfort can build with cumulative laser pulses, treatment of lesions with large surface areas may require topical anesthesia with a eutectic mixture of prilocaine and lidocaine or topical lidocaine. Topical anesthetics are removed a few minutes before treatment to reduce vasoconstriction and interference with laser light delivery. Rarely, local anesthesia with lidocaine or nerve blocks are required for full-face treatment.

TECHNIQUE

The technique for treatment of vascular lesions will depend on the type and size of vessel to be treated and the patient's skin type. PDL treatments are delivered through a handheld fiber-optic device with a spot size ranging from 2–12 mm. The pulses are placed adjacent to each other with approximately 18% overlap to avoid missing areas between pulses. In general, lower fluences are used to treat macular lesions, whereas higher fluences are used to treat more hypertrophic lesions. At short pulse durations, a light gray discoloration of the treated area is the therapeutic endpoint, whereas at long pulse durations transient purpura lasting 1–2 seconds is the desired endpoint. Pulsed KTP laser treatment is delivered using a handpiece held perpendicular to the skin surface, and the vessels are traced individually at a speed that heats them without causing epidermal damage. Effective treatment will cause vessels to disappear with a subtle blanching effect.

IPL is delivered with a shorter-wavelength filter (515 nm) in single-pulse mode to treat fine superficial vessels in patients with skin phototype I. Longer cutoff filters (570–590 nm) and double- or triple-pulse modes are needed to treat large and deeper vessels. A layer of cool water gel 1–2 mm thick is applied to the skin, and then test spots are treated at increasing fluences until a faint erythema without epidermal damage is achieved. The individual pulses are applied adjacent to each other with minimal overlap. A second pass may be made perpendicular to the first pass to prevent reticulation.

OUTCOMES ASSESSMENT

The efficacy of laser and light treatment of vascular lesions depends on the caliber and depth of treated vessels. Small superficial vessels are more responsive than larger, deeper vessels. Lesions with a high blood flow, such as some spider angiomas, are also more difficult to treat. Patient response is assessed at 4–6 weeks after treatment, and treatments are repeated if necessary.

COMPLICATIONS

Immediately after treatment, patients may experience erythema and edema, which may last for the next 1–2 days. Patients who are treated with a PDL at short pulse durations will develop purpura, which gradually resolves in 1–2 weeks. Crusting, blistering, and scarring may result from overtreatment with any vascular laser. With all long-pulsed infrared lasers, adequate epidermal cooling is critical to minimizing the risk of epidermal damage and scarring. Given the overlapping absorption spectrum of epidermal melanin, vascular laser treatment can cause hyperpigmentation or hypopigmentation, but this is rarely observed. Suntanned patients and patients with darker skin phototypes should not be treated with KTP, PDL, or IPL devices.

PATIENT INSTRUCTIONS

Application of cold dressings or ice can help minimize the erythema and edema that develop in the first 24 hours after vascular laser treatment. Crusted or blistered areas should be treated twice a day with petrolatum until they have resolved. Patients requiring multiple treatments should wear sunscreen daily to prevent the risk of laser energy absorption by epidermal melanin in subsequent treatments.

TREATMENT OF COSMETIC PIGMENTED LESIONS

PATIENT SELECTION

The treatment of pigmented lesions depends on the type of pigmented lesion being targeted, its anatomic location in the tissue, and whether the pigment is intracellular or extracellular within this tissue. The background skin color must also be considered so that treatment can be directed toward the abnormal pigment while leaving the normal pigmentation intact.

The success of cosmetic treatment of pigmented lesions also depends on certain patient factors. A complete medical history should be taken with specific emphasis on poor wound healing, postinflammatory hyperpigmentation, bleeding disorders, gold therapy, and isotretinoin use in the previous year. Should any of these factors be present, the surgeon should proceed with extreme caution. In addition, all pigmented lesions should be properly evaluated, and biopsy should be performed on any questionable lesions. Laser treatment does not yield tissue for histopathologic analysis. Before treatment, patients should be counseled that the lesion may require multiple treatments and the lesion may not clear completely.

RISKS AND PRECAUTIONS

Pigmentary and textural changes are the most common complications observed when treating pigmented lesions (Table 252-5). Pigmentary changes occur more commonly in patients who are tanned or have darker skin phototypes. Transient hypopigmentation and, rarely, long-term depigmentation may develop. Hyperpigmentation has been reported in up to 16% of cases and is more commonly seen in patients with darker skin phototypes.[7] To avoid pigmentary alterations, patients with tanned skin should be treated very cautiously, because this increases their risk of adverse effects. The risk of scarring is small, but the use of Q-switched Nd:YAG lasers at 1,064 nm may cause textural change, although this occurs in fewer than 5% of cases.

Patients and practitioners must also be aware that laser treatments can alter tattoo pigments, causing a local or systemic reaction. Local allergic reactions to cadmium sulfide and chromium have been reported, and patients with known allergies to these substances should generally not undergo laser treatment for tattoo removal. Q-switched lasers may also alter cosmetic tattoos containing ferric or titanium oxide pigment, creating an immediate paradoxical darkening. It is advised that these eyeliner and lip tattoos first be treated in test spots with single pulses and then observed 2 weeks later to assess clinical outcomes. Often ablative lasers are more effective at removing these lesions without the risk of paradoxical darkening.[8]

TABLE 252-5
Treatment of Cosmetic Pigmented Lesions: Associated Risks

- Postinflammatory hyperpigmentation
- Postinflammatory hypopigmentation
- Allergic reaction to tattoo pigment
- Localized chrysiasis

TABLE 252-6
Treatment of Cosmetic Pigmented Lesions: Equipment

- Pigment-targeted pulsed dye laser
- Q-switched neodymium:yttrium-aluminum-garnet laser (532/1,064 nm)
- Q-switched ruby laser
- Q-switched alexandrite laser
- Diode laser
- Pulsed light source
- Fractionated 1,440-nm, 1,540-nm, 1,550-nm, 1,927-nm lasers

Patients should also be questioned regarding medications because Q-switched lasers have been reported to cause localized chrysiasis in patients who have received parental gold therapy.[9] It is believed that the laser causes a physiochemical transformation of the gold pigments, similar to its darkening effect on cosmetic tattoos.

PATIENT POSITIONING

Most laser treatments of cosmetic pigmented lesions are performed in the office, with the patient and all clinical personnel wearing appropriate eye protection. The treatment site is thoroughly cleansed to remove all makeup, sunscreen, and topical anesthetic, which can hinder delivery of the laser energy. If alcohol has been used to clean the area, it must be thoroughly removed before laser treatment, because it could be a source of flash fire development. Because treatment with Q-switched 1,064-nm Nd:YAG lasers can cause some tissue and blood splatter, universal precautions should be followed at all times.

EQUIPMENT

Lasers used for the treatment of pigmented lesions (Table 252-6) can be categorized as highly selective Q-switched lasers, less pigment-selective lasers, and non–pigment-selective lasers. The Q-switched lasers, including the Q-switched ruby laser (694 nm), the Q-switched alexandrite laser (755 nm), and the Q-switched Nd:YAG laser (1,064 nm), are capable of targeting superficial epidermal and deeper dermal pigment. Epidermal pigment–based lesions can also be treated with the Q-switched frequency-doubled Nd:YAG laser (532 nm) and the flashlamp-pumped PDL (510 nm). Long-pulsed pigment-specific lasers, such as the long-pulsed ruby laser, long-pulsed alexandrite laser, long-pulsed diode laser, and long-pulsed Nd:YAG laser, have pulse durations in the millisecond range. These lasers have been shown to treat certain nevi by targeting nests of cells rather than individual melanosomes.[10]

Nonspecific ablative lasers such as the CO_2 laser (10,600 nm) and erbium:YAG laser (2,940 nm) can remove pigmented superficial lesions secondary to their ablative actions. IPL devices can be used to treat mild pigmentary changes due to photodamage. Fractionated 1,440 nm, 1,540 nm, 1,550 nm, and, more recently, 1,927 nm lasers have demonstrated efficacy for a variety of dermal and epidermal pigmentary disorders. The 1,927 nm wavelength creates superficial thermal injury ideally suited for resurfacing of epidermal pigmentary disorders.

ANESTHESIA

Treatment of the majority of pigmented lesions does not require topical or infiltrative anesthesia. However, treatment of larger tattoos and lesions with large amounts of dermal pigment may require local anesthesia or nerve blocks.

TECHNIQUE

Superficial epidermal pigmented lesions such as ephelides, solar and labial lentigines, café-au-lait macules, and flat pigmented seborrheic keratoses can be effectively treated with Q-switched ruby (694-nm) lasers, Q-switched alexandrite (755-nm) lasers, 532-nm lasers, short-pulsed dye (510-nm) lasers, and IPL devices (Fig. 252-5; see also Chapter 239). Most lesions respond to 1 or 2 treatments spaced 4–6 weeks apart. The response of café-au-lait macules is variable, with up to a 50% recurrence rate. In general, the



Figure 252-5 Solar lentigines treated with a Q-switched ruby laser. **A.** Before treatment. **B.** After treatment.



Figure 252-6 Tattoo treated with Q-switched ruby laser. **A.** Before treatment. **B.** After treatment.

laser handpiece is held perpendicular to the skin, and parameters are selected based on the melanin content of the lesion and background skin type. Lower fluences are used for targets containing an abundance of melanin. The desired endpoint is a uniform but faint whitening of the skin without epidermal disruption.

Dermal pigmented lesions such as nevus of Ota and pigmentation due to medication can also be improved with the Q-switched pigment-targeted lasers described previously in Equipment. Dermal tattoos are generally treated with lasers that are selective for the various colors of inks (see also Chapter 239). Q-switched ruby and alexandrite lasers are best for treating blue, black, and green ink, whereas short-wavelength lasers such as the short-pulsed dye (510-nm) and Q-switched 532-nm ND:YAG lasers are best for treating red pigments. Yellow-pigmented tattoos are usually relatively resistant to Q-switched laser treatment. Dermal lesions and tattoos are treated similarly to epidermal lesions, with the desired endpoint being a whitening of the skin with intact epidermis. Treatments are spaced 6–8 weeks apart, because clearing of dermal pigment depends on the slow mechanism of phagocytosis (Fig. 252-6).

OUTCOMES ASSESSMENT

Patients should be evaluated 4–6 weeks after small test spots within the larger lesion are treated. They should be informed that often multiple treatments are needed to achieve the desired clinical outcome.

COMPLICATIONS

Immediately after laser surgery, the treated area develops a whitening response that typically fades in 20–30 minutes. Some patients may develop an urticarial reaction, which can subside within an hour and responds to antihistamines. A crust will form in the treated area; it resolves in 7–10 days on the face but may take longer to resolve on nonfacial areas. In rare cases, blisters, vesicles, scarring, and pigmentary changes may occur.

PATIENT INSTRUCTIONS

After laser treatment of pigmented lesions, patients may use ice packs, cool compresses, and hydro-occlusive dressings to reduce any postoperative pain. Daily cleansing of the treated areas with soap and water followed by application of occlusive ointments is recommended until the crusts have resolved. All patients are advised to avoid excessive sun exposure and apply broad-spectrum sunscreen daily.

SUGGESTED READINGS

Weiss RA et al: Clinical trial of a novel non-thermal LED array for reversal of photoaging: Clinical, histologic, and surface profilometric results. *Lasers Surg Med* **36**:85-91, 2005

David J. Goldberg: Nonablative laser surgery for pigmented skin. *Dermatol Surg* **31**:1263-1267, 2005

Atiyeh BS, Dibo Sa: Nonsurgical nonablative treatment of aging skin: Radiofrequency technologies between aggressive marketing and evidence-based efficacy. *Aesthetic Plast Surg* **33**:283-294, 2009

Issa MCA et al: Photorejuvenation with topical methyl aminolevulinate and red light: A randomized, prospective, clinical, histopathologic, and morphometric study. *Dermatol Surg* **36**:39-48, 2010

KEY REFERENCES

Full reference list available at www.DIGM8.com

DVD contains references and additional content

1. Anderson RR, Parrish JA: Selective photothermolysis: Precise microsurgery by selective absorption of pulsed radiation. *Science* **220**:524, 1983
4. Weiss RA, Weiss MA, Beasley KL: Rejuvenation of photoaged skin: 5 years results with intense pulsed light of the face, neck, and chest. *Dermatol Surg* **28**:1115, 2002
5. Rokhsar CK, Lee S, Fitzpatrick RE: Review of photorejuvenation: devices, cosmeceuticals, or both. *Dermatol Surg* **31**:1166, 2005; discussion 1178
6. Fisher GH et al: Nonablative radiofrequency treatment of facial laxity. *Dermatol Surg* **31**:1237, 2005; discussion 1241

Chapter 253 :: Liposuction

:: William G. Stebbins, Aimee L. Leonard, & C. William Hanke

LIPOSUCTION AT A GLANCE

- Liposuction is one of the most commonly performed cosmetic procedures and is widely practiced by dermatologic surgeons.
- The tumescent technique of local anesthesia is one of the most important innovations in liposuction surgery.[1]
- Liposuction performed with tumescent local anesthesia allows for the removal of large volumes of fat safely and effectively.
- Liposuction is characterized by unparalleled safety, rapid patient recovery, and low postoperative morbidity.
- Importantly, liposuction has been demonstrated to be very safe to perform in the office setting, the preferred venue for the procedure when carried out by dermatologic surgeons.

PATIENT SELECTION

Liposuction should be regarded not as a method of weight reduction or an alternative to diet and exercise, but as a body-contouring procedure. The ideal candidate is a healthy patient near his or her ideal body weight who has disproportionate, localized adipose deposits resistant to diet and exercise. Liposuction should be avoided in patients with unrealistic treatment goals and those with emotional or psychological instability (i.e., presence of an eating disorder or body dysmorphic disorder). A comprehensive preoperative consultation including a screening questionnaire is used to identify patients who are appropriate candidates. During the consultation, the risks, goals, anticipated results, and expected postoperative course are discussed.

PREOPERATIVE EVALUATION

Taking a thorough medical history will screen for patients who may be poor surgical candidates for liposuction (see Section "Risks and Precautions"). Patients at risk for complications should receive medical clearance before surgery.[2,3] A careful review of all medications is essential. All anticoagulant medications, including vitamins and herbal supplements, should be discontinued 2 weeks before surgery. Use of medically necessary anticoagulant therapy is a contraindication for tumescent liposuction. Medications that are metabolized by the hepatic cytochrome P450 3A4 enzyme system should be identified. These medications may interfere with the hepatic metabolism of lidocaine, which leads to the potential for toxicity. They should be discontinued or tapered off 2 weeks before surgery if permitted by the prescribing physician. For patients who are unable to interrupt therapy, a lower maximum dose of lidocaine may be used (i.e., less than 35 mg/kg).

Preoperative laboratory testing includes complete blood count with differential and platelet count, prothrombin time, partial thromboplastin time, and chemistry panel (including liver function tests); serologic testing for human immunodeficiency virus and hepatitis B and C viruses; and serum pregnancy test (for females).[2] An electrocardiogram may be considered when the patient is over the age of 60 or when indicated based on the patient's history or a review of systems.

RISKS AND PRECAUTIONS

Risks and precautions concerning liposuction are presented in Box 253-1.

BOX 253-1 RISKS AND PRECAUTIONS FOR LIPOSUCTION

CONTRAINDICATIONS TO LIPOSUCTION

- Severe cardiovascular disease
- Severe coagulation disorders, including hemophilia
- Pregnancy

CONDITIONS THAT PUT PATIENTS AT RISK FOR COMPLICATIONS

- History of bleeding diathesis, thrombophlebitis, or emboli (fat or thrombotic)
- History of infectious disease (including hepatitis and human immunodeficiency virus infection)
- Poor wound healing
- Diabetes mellitus
- Immunosuppression
- Prior extensive abdominal surgery
- Hepatic disease
- Renal disease
- Morbid obesity
- Underlying systemic disease with functional limitations
- Use of anticoagulant medications, vitamins, or herbal supplements
- Use of medications metabolized by cytochrome P450 3A4 enzyme system

PATIENT POSITIONING

Proper patient positioning is essential for safe and effective removal of adipose tissue. Specific positioning maneuvers differ by anatomic target site and are used to avoid important anatomic structures and optimize cannula access to fatty deposits.

EQUIPMENT

Liposuction requires the following equipment (Figs. 253-1 and 253-2):

- Tumescent local anesthetic solution
- Infiltration needles and/or cannulas
- Intravenous or peristaltic pump tubing
- Infiltration pump
- Liposuction cannulas (manual and/or powered)
- Aspiration tubing
- Aspiration pump with aspirate receptacles
- Monitoring device and emergency equipment

ANESTHESIA

Lidocaine is the preferred anesthetic for tumescent liposuction.[2] The maximum dose reported to be safe is 55 mg/kg.[4] Normal saline (0.9% sodium chloride) is typically used as a vehicle. Sodium bicarbonate is used to buffer the solution, and epinephrine is added to augment hemostasis and slow the absorption of lidocaine. The compositions of tumescent lidocaine solutions ranging from 0.05%–0.1% are shown in Table 253-1. Higher concentrations of lidocaine provide better analgesia and are useful in treating small or sensitive areas. Lower concentrations provide adequate anesthesia and are used when treating large or multiple areas. Accurate recordkeeping of tumescent anesthetic solution preparation and administration is critical to avoid lidocaine toxicity.



Figure 253-1 A selection of liposuction cannulas, including hand cannulas (*left*) and powered cannulas (*right*). (Used with permission from C. William Hanke, MD.)



Figure 253-2 Liposuction equipment including (from top to bottom) tumescent anesthetic solution, infiltration pump and tubing, aspirate receptacles, and aspiration pump. (Used with permission from C. William Hanke, MD.)

TECHNIQUE

With the patient standing, the target areas for treatment as well as entry sites for cannula insertion are outlined with a permanent marker. The patient is brought to the procedure table and undergoes sterile preparation. Entry sites are anesthetized locally using 1% lidocaine with 1:100,000 epinephrine. These sites are then incised with a No. 11 blade. A blunt-tipped infiltration cannula or 21-gauge needle is inserted, and tumescent anesthesia fluid is delivered to the subcutaneous space. Rates of infiltration and amounts of fluid delivered vary depending on target area and patient tolerance.

Liposuction aspiration cannulas vary in diameter, tip style, and tip configuration. One innovation is powered liposuction using a motorized cannula. In general, larger cannulas with tapered tips and multiple distal apertures allow easier fat removal but also increase tissue injury. The choice of cannula depends on anatomic site as well as surgeon preference and experience. The cannula is inserted into entry sites with the tip apertures facing downward, away from the dermis. Tunneling with the cannula is performed in linear, even strokes with the surgeon's dominant hand, with the nondominant hand, or "smart hand," controlling cannula tip position at all times. The majority of suctioning should be aimed parallel to the axis of lymphatic drainage to minimize tissue trauma. Uneven or overly aggressive suctioning can lead to contour irregularities and should be avoided. Endpoints can be measured as the time spent in a given area, the amount of fat suctioned, patient discomfort, and assessment of the target area by palpation. The transition from yellow adipocyte-rich aspirate into fat-sparse serosanguineous

TABLE 253-1
Tumescent Liposuction Solutions

	0.1%	0.075%	0.05%
Sodium chloride 0.9%	1,000 mL	1,000 mL	1,000 mL
Lidocaine 1%	100 mL	75 mL	50 mL
Epinephrine 1:1,000	1 mL	1 mL	1 mL
Sodium bicarbonate 8.4%	10 mL	10 mL	10 mL

tumescent fluid is an additional endpoint. Comparative suctioned aspirate volumes and vital signs are also recorded throughout the procedure.

OUTCOMES ASSESSMENT

Several studies support the excellent safety profile and high rates of patient satisfaction observed with tumescent liposuction. A 1995 survey of dermatologic surgeons who performed tumescent liposuction on 15,336 patients found no fatalities or serious complications. There were no adverse events that necessitated hospitalization.[5] In 2002, Housman et al reported a serious adverse event rate of 0.68 per 1,000 cases in a survey of 267 dermatologic surgeons who performed 66,570 liposuction procedures. No deaths were reported.[6] In a prospective study involving 688 liposuction patients, Hanke et al found a major complication rate of only 0.14% and a minor complication rate of 0.57 percent. Eighty-four percent of patients reported high levels of satisfaction with the procedure[7] (Figs. 253-3 and 253-4).

COMPLICATIONS

The majority of medical and surgical complications from tumescent liposuction, such as bleeding, hematoma, infection, and lidocaine toxicity, can be avoided by comprehensive perioperative patient evaluation and adherence to published guidelines of care. Aesthetic complications such as surface irregularities, persistent edema, and suboptimal target area fat reduction can be minimized by proper patient selection, patient education, and good technique. Dermatologic surgeons performing liposuction should be knowledgeable about the prevention and management of all potential intraoperative and postoperative complications.

PATIENT INSTRUCTIONS

Anticipated sequelae of tumescent liposuction include copious drainage from cannula entry sites, ecchymoses, edema, soreness, postural dizziness, and temporary dysesthesia. Proper education and instructions regarding diet, activity, and use of compression garments prepare patients for the postoperative period. The patient must be discharged to the care of a family member or friend. Patients are encouraged to ambulate and avoid immobilization. Heavy exercise and hot baths and showers should be avoided.

MONITORING AND FOLLOW-UP

A series of follow-up visits is scheduled to assist the patient through the immediate postoperative period and to assess the long-term surgical outcome. Postoperative healing from liposuction is characterized by a protracted period of edema resolution followed by subsequent skin contracture, which leads to a delayed

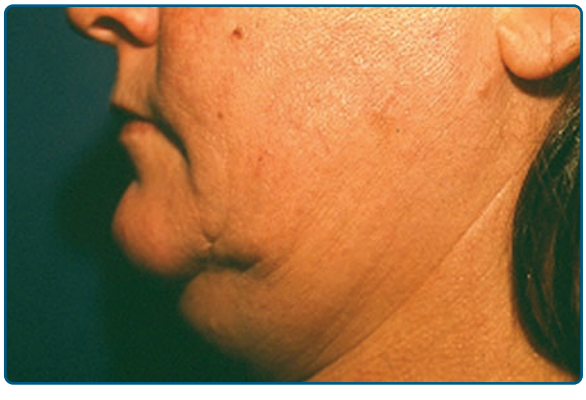

Figure 253-3 Liposuction of the neck, preoperative. (Used with permission from C. William Hanke, MD.)

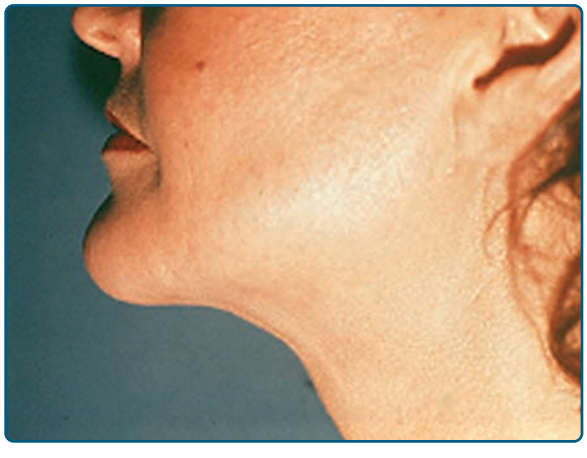

Figure 253-4 Liposuction of the neck, postoperative. (Used with permission from C. William Hanke, MD.)

final treatment result. Taking preoperative and postoperative photographs and weight measurements is essential to address patients' concerns and assess treatment response. Patients are encouraged to wait at least 6 months before judging the final cosmetic result. The performance of touch-up procedures in a treated area should be deferred for at least 1 year.

KEY REFERENCES

1. Klein JA: The tumescent technique for liposuction surgery. *Am J Cosmet Surg* **4**:263, 1987
2. Hanke CW, Sattler G: *Liposuction*. Philadelphia, Elsevier, 2005
3. Coldiron B et al: ASDS guidelines of care for tumescent liposuction. *Dermatol Surg* **32**:709, 2006
4. Ostad A, Kageyama N, Moy RL: Tumescent anesthesia with a lidocaine dose of 55 mg/kg is safe for liposuction. *Dermatol Surg* **22**:921, 1996
5. Hanke CW, Bernstein G, Bullock S: Safety of tumescent liposuction in 15,336 patients. National survey results. *Dermatol Surg* **21**:459, 1995
6. Housman TS et al: The safety of liposuction: results of a national survey. *Dermatol Surg* **28**:971, 2002
7. Hanke CW et al: Tumescent liposuction report performance measurement initiative: national survey results. *Dermatol Surg* **30**:967, 2004

Chapter 254 :: Soft Tissue Augmentation

:: Lisa M. Donofrio

SOFT TISSUE AUGMENTATION AT A GLANCE

- Soft-tissue augmentation is an excellent way to restore the contours of youthful fullness to an aging face.
- Most common cosmetic procedures performed in dermatology practices.
- Soft-tissue fillers vary in their longevity, allergenic potential, safety, and applications. There is no perfect filler at this time, but the ideal soft-tissue filler should be nonallergenic, noncarcinogenic, nonteratogenic, biocompatible, nonmigratory, and affordable, and should provide effects that are reproducible and long lasting yet reversible.
- Hundreds of soft-tissue fillers are available worldwide.
- Fillers for treatment of lipodystrophy, including antiretroviral therapy–related lipodystrophy are discussed in Chapter 71.

METHOD AND TECHNIQUE

Soft-tissue fillers (Table 254-1) are either injected through a sharp needle or through a blunt cannula. The level of injection into the skin and the chosen length of the needle depend on the type of filler injected, the properties of the filler, the area injected, and the desired result. Threading is a technique in which the needle is inserted into the skin and the filler is deposited in a linear fashion along the track of the needle as it is being withdrawn. Fanning is a type of threading in which, instead of inserting the needle into a new area each time, the needle is just withdrawn so that a new track can be made radially adjacent to the last. In the "push-ahead" technique, an injection is made in an antegrade direction, so that the injectable material flows from the tip of the needle and hydrodissects the tissues as it flows. This technique is often used in areas in which bruising is more likely to occur along the needle track, such as the upper lid and brow. In the depot method of injection, small "pearls" of material are deposited serially, usually along a fold or deep by bone. Cross-hatching is an approach used to diffusely cover an area with the injected material. In this method, linear threads are lined up in succession and a second series of rows is then layered at right angles on top of the first. Figure 254-1 illustrates the different injection techniques. In addition to the methods just described, highly viscous fillers emerging on the US market will most likely be injected in a deep subcutaneous bolus through a blunt cannula or large bore needle. Whatever the technique chosen, care should be taken in highly vascular areas to avoid intravascular injection of filling material. The plunger of the syringe should be pulled back to check for blood flow, and if it is found, the needle should be withdrawn and repositioned.

COLLAGENS

Once considered the "gold standard" of dermal fillers, collagens (bovine, human, and porcine) are no longer available on the US market.

HYALURONIC ACIDS

PATIENT SELECTION

Hyaluronic acid–derived fillers are a good choice for patients who desire a long period of correction or more volume enhancement. They are approved for

TABLE 254-1
Clinical Features of Soft Tissue Fillers

Filler	Uses	Type	Placement	Complications	Longevity
Hyaluronic Acid	Treatment of medium-to-deep folds, lips, acne scars, periorbital hollows, facial contouring	Non–animal-derived stabilized hyaluronic acid	Mid-to-deep dermis or superficial subutis	Allergic reaction or inflammation, blue discoloration, misplacement, lumps	6–12 months
Calcium hydroxylapatite	Treatment of deep folds, nipple reconstruction, nasal reconstruction, jawline, malar augmentation	Calcium hydroxylapatite	Deep dermis to superficial subcutis	Nodules (especially in lips and periorbitally), misplacement with demarcation of product	6–18 months
Poly-l-lactic Acid	Treatment of HIV lipoatrophy, nasolabal fold, cheek, and temple hollows	Poly-L-lactic acid	Superficial subcutis	Visible and palpable papules	2 years or longer
Autologous fat	Pan-facial filling, especially periorbital area	Autologous fat	Subcutaneous tissue	Bumps, vascular occlusive events with injudicious placement	5 years or longer
Silicone	Treatment of scars, HIV lipoatrophy, lips, deep folds	Silicone oil	Deep dermis	Delayed granuloma formation, migration	

augmentation of the nasolabial fold, but other common areas of treatment include the labiomental crease, lips, cheeks, and periorbital areas. Patients often feel that the hyaluronic acid fillers are softer and more natural in appearance than the collagens were, but they need to be warned about the risk of increased erythema, edema, and bruising associated with these products.

FORMULATIONS

Hyaluronic acid (HA) is a polysaccharide that is homologous throughout the animal kingdom. Injectable FDA-approved forms include non–animal-derived stabilized hyaluronic acid products (NASHA) made through a bacterial fermentation process and an avian-derived version isolated from cocks' combs. Brands of injectable hyaluronic acids differ not only in their derivation but also in their concentration of hyaluronic acid per milliliter of product, type of cross-linking or stabilizing agents, viscosity, and particle size. Some hyaluronic acid products exist as biphasic gels containing both crosslinked and uncrosslinked particles and some as monophasic gels containing only crosslinked particles. The biphasic NASHA products are made en bloc initially and then passed through a sieve to create particles ranging in size from 10,000 per mL to 100,000 per mL with a hyaluronic acid concentration of 20 mg/mL. The smaller particle size permits injection through smaller-gauge needles into finer wrinkles and the larger particle size is best for volumetric filling. The small amount of non-cross-linked HA allows for smooth flow with low injection pressures. Monophasic hyaluronic acid gels are produced by varying the amount of high- and low-molecular weight hyaluronic acid producing a hydrogenous gel. The monophasic product is available in two formulations, one containing 24 mg/mL of hyaluronic acid and one containing 30 mg/mL of hyaluronic acid. The crosslinking agent used in both the mono- and biphasic products is BDDE (1,4 butanediol diglycidyl ether). The avian derived hyaluronic acid, contains 6 mg/mL of hyaluronic acid highly cross-linked with divinyl sulfide. All hyaluronic acid products are prepackaged in filled syringes that require no refrigeration.

ANESTHESIA

Due to their high viscosity hyaluronic acid products can cause significant discomfort on injection so most hyaluronic acids are available combined with lidocaine. Topical anesthetic can also be applied before injection. This usually results in adequate anesthesia for periorbital, nasolabial fold, and labiomental crease injections; however, if lips or perioral rhytides are being treated, an ancillary local infiltration of 1% lidocaine or segmental nerve block may be indicated.

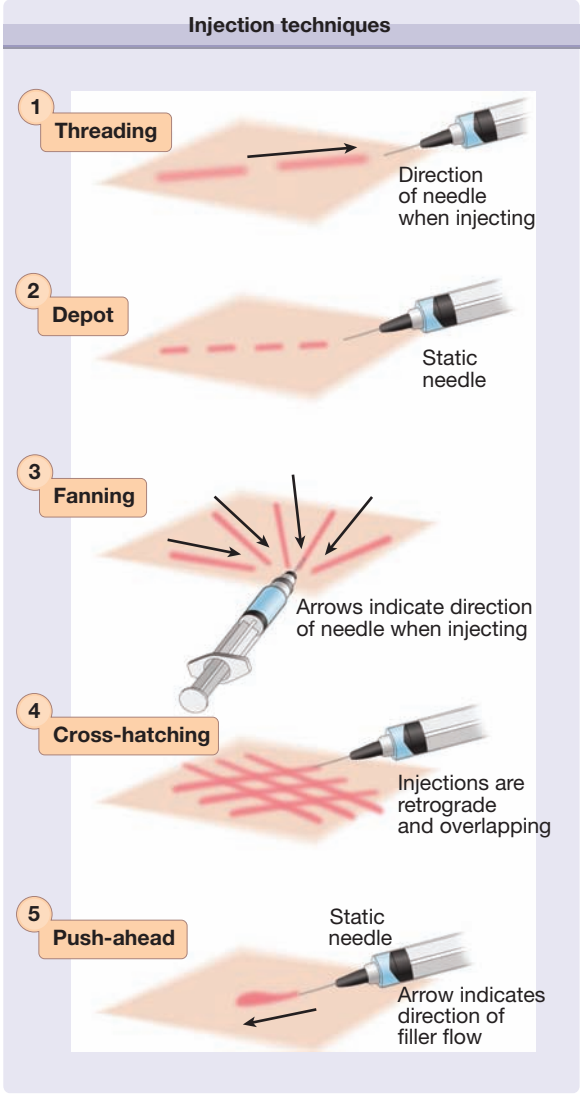

Figure 254-1 Injection techniques.

TECHNIQUE

Hyaluronic acids should be injected with the patient in a position that elicits the defect or creases to be treated and offers ease of injection to the operator. This is best accomplished by reclining the patient to a 45° angle. All the hyaluronic acid products come with a needle in the gauge of choice for ease of injection and preservation of the physical properties of the gel. Due to their viscoelastic properties, however, hyaluronic acids can often be injected through needles tailored to the area or level of injection. For instance, a 32-gauge needle allows for more precise injection of vertical lip rhytides and a 1½ inch needle may facilitate injection into distal sites. Hyaluronic acids are injected in most areas via threading, depot, or fanning. They are particularly amenable to cross-hatching in areas in which a greater density of augmentation is desired. In particular, when hyaluronic acid is injected into the nasolabial fold it is important to span the width of the fold with a serial threading technique and then crosshatch at right angles. This gives structural integrity to the fold and prevents the undesirable result of merely moving the fold medially. In addition, it is often necessary to "suspend" the fold by augmenting the cheek. This is usually done with a deep bolus injection of a high density HA. The labiomental crease can be injected similarly to the nasolabial fold, again blending the product so as not to move the fold medially. Lip injections are made using a depot or threading technique, either along the vermillion border, in the body of the lip, or in a combination of both. Perhaps one of the most exciting off-label applications of hyaluronic acids is the correction of tear trough deformity or suborbital hollows. Injections are made either under the orbicularis oculi muscle near the orbital bone or subdermally above the muscle. Intramuscular injections are to be avoided since the movement in this area increases the risk of lumping of the product. A depot method of injection is preferred in which very small amounts of hyaluronic acid are deposited on each pass, but threading can also be helpful to ensure even blending into neighboring areas. The push-ahead technique is preferred for the sub-brow area. After injection the periorbital area should be vigorously massaged to disperse the product and minimize aggregation of gel particles. Although periorbital injection of hyaluronic acid results in high levels of patient satisfaction, it is an advanced injection method best left to those with the greatest injecting experience.

POSTPROCEDURE INSTRUCTIONS

The application of ice immediately after the procedure and periodically throughout the day is recommended after the injection of hyaluronic acid. Patients are instructed to avoid manipulation of the treated area and extremes of temperature for the first 48 hours after injection. If the lips were treated in a patient with a history of cold sores, then an antiviral medication should be administered prophylactically on the day of the procedure. Patients are instructed to return to the office if they experience any problems such as redness, purulence, or nodule formation.

UNIQUE COMPLICATIONS

Most complications result from improper application of the product. Placement of this clear gel too superficially results in a blue discoloration. Placement of too large an aliquot can result in a noninflammatory bump. Most ill-placed hyaluronic acid can be released by incising with a 20-gauge needle and expressing the material. Hyaluronic acid products also contain small amounts of impurities that can cause hypersensitivity reactions. Patients can react to sterile bacterial proteins or avian proteins by forming sterile abscesses or granulomatous inflammatory nodules. It has been shown that these nodules, which appear clinically to be granulomas, may in fact be small foci of infection. Treatment with an antistaphylococcal antibiotic is the initial treatment of choice. If no resolution occurs, dilute intralesional

corticosteroids can be administered, or hyaluronidase can be injected to cause rapid dissolution of the product.[1]

LONGEVITY

In general, the longevity of augmentation is greater for the more highly cross-linked or stabilized forms and increases with increasing viscosity and particle size. Hyaluronic acid–based products are broken down via isovolemic degradation; they maintain a constant volume throughout their degradation because of their ability to bind water. This property makes possible a very long-lasting product.

In a double-blind multicenter study, the biphasic hyaluronic acid gel was found superior to bovine collagen at al postinjection time points. At 6 months, 67.2% of collagen-treated folds had returned to their baseline severity, as opposed to only 29.9% of hyaluronic acid–treated folds.[2] In a study comparing large particle biphasic NASHA to avian derived hyaluronic acid, at 6 months after treatment, the proportion of patients showing improvement in the Wrinkle Severity Rating Scale score of the nasolabial folds was higher in the group treated with the NASHA product (75%) than in the group treated with the avian product (38%).[3] In a head-to-head study comparing the tolerability and efficacy of small particle biphasic NASHA versus avian hyaluronic acid in the treatment of nasolabial folds, the NASHA product demonstrated higher efficacy and patient satisfaction ratings than the avian product at 12 weeks.[4] The bi- and monophasic NASHA products last up to 12 months quite consistently. To this date, no head-to-head studies between these products has been published. Figure 254-2 shows a 35-year-old woman before and after treatment of the nasolabial folds with a NASHA gel.

POLY-L-LACTIC ACID

PATIENT SELECTION

Poly-L-lactic acid is FDA approved both for the treatment of lipoatrophy associated with human immunodeficiency virus (HIV) infection and for the cosmetic correction of shallow-to-deep contour deficiencies. Currently in the United States, PLLA is gaining popularity as a no-downtime, long-lasting filler with a wide range of applications. PLLA's uniqueness lies in the fact that it is not a direct filling agent but rather a biostimulatory agent, eliciting tissue thickening over the course of many months and many treatment sessions. It is therefore the ideal filler for someone desiring a gradual, subtle change. Because PLLA works by initiating a foreign-body tissue response, it is not suited for patients taking immunosuppressive or anti-inflammatory drugs, and it appears to work most efficiently in younger patients. PLLA can be used for volume enhancement in the nasolabial fold, labiomental crease, chin, jawline, buccal hollows, and temples. Some practitioners have found it to provide good filling for the dorsum of the aging hands but in this area there is a moderate risk of nodule formation. It is not recommended for use in the lips and should be used with care in the periorbital area.

FORMULATION

PLLA is the same substance used in the formulation of absorbable suture material and is biocompatible and biodegradable. It is supplied in a glass bottle as a lyophilized powder containing carboxymethylcellulose as an emulsifier and mannitol as an osmotic agent. Injection of PLLA on repeated occasions presumably initiates an immune response that eventually leads to fibroblast activation and collagen deposition. High-level ultrasonographic images taken before and after a series of treatments in study patients confirms the presence of a zone of dermal thickening, but the exact mechanism is unknown.

ANESTHESIA

PLLA must be reconstituted at least 2 hours in advance of use; however, current standard of care is reconstitution at least 8 hours before treatment to fully suspend and hydrate the particles of PLLA. The package insert recommends reconstitution with 3–5 mL of sterile



Figure 254-2 Thirty-five-year-old woman before **(A)** and after **(B)** infiltration of Restylane into the nasolabial folds.

water, but the consensus of physicians currently using the product is to reconstitute with 5 mL of diluent at a minimum. It is therefore possible to reconstitute the product in advance with 4 mL or more of sterile water and immediately before injection to add 1 mL of 1% lidocaine to the bottle. This tempers the pain on injection. In addition, patients may want to apply a topical anesthetic containing either 4% lidocaine or 20% tetracaine in advance of treatment.

TECHNIQUE

Because of the diffuse panfacial nature of PLLA injections, it is helpful to inject the patient in a supine position. PLLA is injected through a 25- to 26-gauge needle. Because of the risk of particle clumping, the bottle must be agitated frequently throughout the course of treatment. The operator must maintain maximum control over injection amounts, so drawing the material up into 1-mL syringes is highly recommended. The injection technique used when infiltrating PLLA is diffuse crosshatching and threading. Depot deposition of product is no longer recommended. The principle is to inject PLLA into areas that will eventually display a direct impact from local volume change or affect neighboring areas by filling and suspending tissues upstream. Lower-face injections are performed diffusely over a wide surface area and involve the placement of 0.1-mL linear threads of solution 2 mm apart. The recommended technique is to inject across folds to distend them, rather than filling them directly. No attempt at volumetric correction is made during treatment; rather, the intent is to place the PLLA solution diffusely. The level of injection in the lower face (cheek, nasolabial fold, jawline, labiomental crease, chin) is subdermal. In the upper face (temples and periorbital area) treatment is via diffuse threading of 0.05 mL of PLLA solution under or close to periosteum. No more that 0.5 mL total should be distributed in this fashion. If clogging of the needle occurs, it should be withdrawn and either changed or cleared before proceeding. Many practitioners have found that the use of long needles (1½ inch) better facilitates even dispersion of the product.

POSTPROCEDURE INSTRUCTIONS

Immediately after injection, treated areas must be vigorously massaged to distribute the suspension evenly into the tissues. No blebs of material should be palpable. When the practitioner is satisfied that this is the case, the massage may then be continued in a gentler manner by an assistant for the next 5 minutes. Ice is then applied to the face for 20 minutes. The patient may then apply makeup and resume normal activities. The patient must massage the areas of injection for 5 minutes, 5 times a day for 5 days. Because minimal augmentation is achieved in each session, patients are instructed to return at 6-week intervals for additional treatments. The motto "Treat, wait, assess" is an important one to follow when using PLLA. Resultant augmentation can take 4 months or longer to occur, so patience is necessary to avoid overcorrection. For the average patient with cosmetic concerns, between three and six treatments will be required for ample augmentation to occur (Fig. 254-3). For patients with severe lipoatrophy, a minimum of six sessions will be required, often with injection of two vials per session.

UNIQUE COMPLICATIONS

Superficial injection of PLLA most often results in visible papule formation. Reconstitution with inadequate amounts of fluid may also increase this risk. Delayed formation of subcutaneous papules has been reported in the literature. These palpable papules are most often nonvisible, asymptomatic, and noninflammatory, and



Figure 254-3 Thirty-nine-year-old woman before **(A)** and 4 months after **(B)** the last of two Sculptra treatments to the lower face.

require no treatment. If they are of concern to the patient, an attempt can be made to break apart the papules by injecting sterile water into them or by teasing them apart with a 27-gauge needle. Results of an 8-year injectable filler safety study found evidence to support a decreased risk of nodules with increasing dilutions.[5] Rarely large visible nodules can be seen as a late-onset side effect. Intralesional cortisone may be of help since they are often inflammatory or granulomatous in nature. Surgical removal is also an option for large unresponsive or deforming nodules.

LONGEVITY

The results from PLLA infiltration are thought to last 2 years or longer, with gradual resorption and breakdown of the product to lactic acid over the course of 2–3 years.

CALCIUM HYDROXYLAPATITE

PATIENT SELECTION

Patients requiring augmentation of the nasolabial folds, labiomental crease, mandibular ramus, cheeks, or prejowl sulcus are candidates for treatment with calcium hydroxylapatite (CaHA). CaHA has also been used with success in the correction of atrophic acne scars, in the recontouring of nasal defects, and in nipple reconstruction after failed nipple areolar reconstruction. Due to the risk of lump formation, CaHA is not recommended for lip augmentation and should be used judiciously in the periorbital area.

FORMULATION

Originally approved for use by the FDA as a radiographic marker and for the correction of oral and maxillofacial defects and the treatment of vocal cord insufficiency, CaHA has recently gained approval as a nasolabial fold filler. All other areas mentioned above are common off-label uses. The microspheres of CaHA, once injected into the deep dermis, form a scaffold to support the growth of autologous collagen so there is overlap with this product as not only a temporary filler, but also as a biostimulatory agent. CaHA microspheres are suspended in a polysaccharide carrier, which holds the microspheres in place until it is resorbed and neocollagenesis takes place. CaHA contains no animal or human tissues, so allergy testing is not indicated.

ANESTHESIA AND TECHNIQUE

Injection of CaHA is quite uncomfortable, so it is almost always necessary to anesthetize the area first with 1% lidocaine. A current popular practice is to mix 0.2 cc of 1% lidocaine with the CaHA via a female-female adapter. This not only provides adequate anesthesia but also thins the product to allow for smoother injection. Due to its viscosity CaHA must be injected through a 27- to 28-gauge needle. Placing the patient in a supine or at 45 degrees, a threading technique is used, with infiltration staying at the dermal–subcutaneous junction in the area of the nasolabial fold and at the deep fat or supraperiosteal region in the areas of the cheek and mandible. CaHA appears to work best if patients undergo retreatment or touchup at 3 months.

POSTPROCEDURE INSTRUCTIONS

There can be marked swelling and bruising after the injection of CaHA, so post-treatment icing is recommended. Many physicians advocate immediate postinjection massage but feel that continued massage is unwarranted.

UNIQUE COMPLICATIONS

The majority of complications with CaHA (nodules) are seen in the lips, but it is possible for nodules lasting 1–2 years to occur anywhere the substance is injected. There is a paucity of studies of the use of CaHA for soft-tissue augmentation. One small study noted a 3% nodule rate in 29 patients treated with CaHA for soft-tissue augmentation. Nodules are supposedly noninflammatory, and often the material can be extruded from a puncture incision. Persistent nodules may have to be surgically removed. If CaHA is injected too superficially or at appropriate levels in thin skin, its opacity can be seen. Demarcation of product is especially evident in the periorbital area, as is prolonged erythema.

LONGEVITY

In a 12 month, multicenter prospective randomized split face trial comparing CaHA to NASHA in the nasolabial folds, CaHA was found to provide significantly greater correction at all time points. In practice, though, longevity appears variable, with effects lasting from 6–18 months.[6]

AUTOLOGOUS FAT

PATIENT SELECTION

Autologous fat transfer (AFT) is a practical option for those patients desiring a more dramatic global change in facial appearance. Recent anatomic research suggests that facial fat is delineated in discreet fat compartments that change morphologically over time.[7] Therefore, using fat as a filler is done with the intent of restoring the youthful architecture to these fat compartments. This provides broader rejuvenation to the aging face affected by volume loss. Fat is a versatile filler, effective in the periorbital area as well as the lips. Because it is autologous, it is the filler of choice for patients with collagen vascular disease or proven allergic reactions to collagens or hyaluronic acids. AFT is

a more involved surgical procedure than the injection of the other fillers previously discussed. Exclusion criteria for treatment include concomitant anticoagulant treatment and poor health.

TECHNIQUE

PREPARATION AND ANESTHESIA. For 2 weeks before the initial AFT procedure, the patient must stop taking all nonsteroidal anti-inflammatory drugs, vitamin E, ω-3 fatty acid supplements, and ginkgo, ginger, or ginseng supplements. The patient is instructed to begin therapy with an appropriate antistaphylococcal antibiotic starting the day before procedure. On the day of the procedure, the donor fat site and the face are both washed with an antibacterial soap. The physician then delineates the area to be suctioned with a marking pen. Every attempt should be made to choose a donor site that benefits a patient aesthetically. The outer thighs and hips in women and the flanks in men are usually good sites for fat harvesting.

In preparation for fat transfer, a pattern is drawn on the face delineating the areas in which fat is to be placed and highlighting any scars or baseline asymmetry. The patient is then placed on a sterile, draped operating table and the areas requiring fat suctioning are infiltrated with dilute local anesthesia until turgid (tumescent technique; Table 254-2; see Chapter 253).

It takes at least 20 minutes for the epinephrine in the tumescent fluid to achieve hemostasis. The face is then anesthetized diffusely with dilute 0.5% lidocaine with epinephrine 1:200,000, and segmental nerve blocks are established where appropriate. For safety, the total lidocaine dose in the tumescent fluid should not exceed 35 mg/kg of body weight.

FAT HARVESTING. Suctioning of the fat used for transplantation should be done by hand with an open-tipped harvesting cannula attached to a 10-mL syringe. After a hole is made with a 1.5-mm punch or No. 11 blade, the cannula is inserted into the deep fat and moved back and forth while the plunger on the syringe is retracted. Fat collection usually occurs quite rapidly and, due to the vasoconstrictive properties of the tumescent fluid, is nearly bloodless. After fat extraction, the syringes may be placed into a centrifuge and spun at 3,400 rpm for 20 seconds or left to stand for 20 minutes to allow separation of the hydrophilic tumescent fluid from the lipophilic fat. The infranate of tumescent fluid should then be decanted before the fatty layer is transferred to 1-mL syringes in preparation for injection into the face. Any supranate of ruptured fat cells (triglycerides and free fatty acids) should be discarded.

FAT TRANSFER. All AFT to the face is performed with the patient fully supine using an 18-gauge or smaller blunt cannula for infiltration. Incision sites can be made with an 18-gauge needle, a NoKor needle (Becton, Dickinson and Co., USA), or the tip of a No. 11 blade scalpel. Fat is infiltrated in a retrograde manner; that is, fat is injected only as the cannula is withdrawn. Injection is in small aliquots of 0.1 mL or less using a threading or depot method. Placement of fat always starts closest to bone when possible and then proceeds up through muscle and into subcutaneous fat. Fat is deposited in a crosshatched three-dimensional lattice and thus imparts structure as well as augmentation to the tissues. All areas of the face should be addressed to achieve filling laterally as well as anteriorly. The goal is to advance tissues forward and thereby elevate them away from the bone, fill in areas of shadow, and restore youthful contours.

TABLE 254-2
Tumescent Anesthesia Solution

- 1 L normal saline
- 50 mg lidocaine
- 0.5–1 mg epinephrine
- 12.5 mEq sodium bicarbonate

POSTPROCEDURE INSTRUCTIONS

Immediately after the procedure and on and off for the next 2 days, ice should be applied to the face. The area suctioned is dressed with absorbent pads, and a snug garment is applied. Incision sites on the body and face are left unsutured. The patient is instructed not to submerge the body in water until all incisions are healed (approximately 1 week). Antibiotics must be continued for 6 days after the initial procedure. Intramuscular triamcinolone may be given to reduce postoperative edema.

UNIQUE COMPLICATIONS

Postoperative edema and ecchymoses are common and last for approximately 2 weeks. Undercorrection with a gradual decrease in augmentation is common and usually represents a decline in edema rather than absorption of the fat. For this reason, fat transfer should never be recommended as a one-time procedure but rather as a series of treatments with cumulative augmentation and long-term results. Small, persistent lumps can occur that represent either fat cysts or accumulation of fat. They can be treated, usually to resolution, with intralesional injection of triamcinolone (2–4 mg/mL). If a larger fat lump is present, the best option is to feather it into the surrounding tissues with an infiltration cannula. Irregularities can also occur at the harvest site, but operator experience and judicious removal of fat makes this a highly unlikely event. Rarely, infections such as atypical mycobacteria can be seen and should be in the differential diagnosis for any nodules occurring up to 1 year following AFT.

LONGEVITY

Many authors using a standardized, multilevel microinjection technique have published photodocumentation of



Figure 254-4 Fifty-five-year-old woman before **(A)** and 20 months after **(B)** full-face fat transfer treatment series.

long-term follow-up demonstrating persistence of autologous fat (Fig. 254-4).[8] However, the controlled, double-blinded, multicenter studies available for evaluation of other fillers have not been done.

INJECTABLE SILICONE

PATIENT SELECTION

Injectable silicone is categorically a permanent filler with a wide range of applications. It appears to provide permanent, cosmetically superior augmentation for treatment of HIV lipoatrophy, plantar defects, and scars. Historically, silicone injection has been associated with disfiguring tissue distortions and migration of product. These side effects can almost always be traced to the use of large-volume injections or non–medical grade silicone. Because of the controversial nature of silicone augmentation, patient selection for cosmetic indications is currently complex, and use of the procedure should be reserved for those physicians who have extensive experience in the injection of silicone as a filler and understand the concepts outlined in the Technique section.

Patients with a known history or autoimmune disease or with a history of a chronic or active infection should be excluded from treatment.

FORMULATION

Perhaps no other filler has both inspired such a loyal following and provoked such vehement opposition as injectable silicone. The most widely used available form of silicone oil is FDA approved for the treatment of retinal tamponade. It is not approved for the indication of soft-tissue augmentation. It is a sterile, impurity-free, medical-grade silicone oil at a 1,000-centistoke viscosity. It is noncarcinogenic and does not appear to be associated with arthritic disease in mice. After injection, silicone is encapsulated in collagenous fibrous tissue, so that final augmentation is a result of both volume of injected silicone and host tissue response.

ANESTHESIA

Currently available forms of silicone do not contain an anesthetic solution, because such small volumes are injected on each visit that ancillary anesthesia is not often required. If desired, a topical anesthetic agent containing 20% tetracaine or 4% lidocaine may be applied before the procedure.

TECHNIQUE

Improper technique in the injection of silicone oil will almost guarantee permanent adverse sequelae. It is therefore absolutely necessary that a physician considering the use of silicone apprentice with an experienced practitioner. Silicone (1,000 centistoke) is highly viscous and must be injected through either a 26-gauge needle on a 1-mL syringe or a 30-gauge needle on a 0.3-mL syringe. Use of a microinjection technique is paramount to success with silicone, so large-bore needles are never to be used. The microdroplet injection technique involves injecting 0.01 mL of silicone oil, with the needle bevel down, into the deep dermis in a depot fashion at 1- to 3-mm intervals. Note that 100 droplets are therefore required to empty a 1-mL syringe. Except

in the treatment of HIV cheek atrophy, it is rare to use more that 0.3 mL total per injection session. Treated areas are always undercorrected, and patients are instructed to return for multiple injection sessions at monthly intervals until full augmentation occurs.

POSTPROCEDURE INSTRUCTIONS

There is very little postoperative discomfort, edema, or ecchymosis after microinjection with liquid silicone. Ice may be applied if needed to lessen the risk of postinjection ecchymosis. Patients may apply makeup and pursue their daily activities as usual after injection.

UNIQUE COMPLICATIONS

Most authorities on silicone use agree that the incidence of serious complications after the proper use of medical-grade silicone is very low. In an FDA-authorized study involving 1,400 patients over a 20-year period, 2 patients experienced serious side effects: one case involved migration of silicone after treatment with large volumes, and the second involved inflammation and necrosis in a patient with concomitant Weber-Christian disease and rheumatoid arthritis. Local granulomatous nodularities can occur many years after the cessation of treatment and are usually preceded by a systemic infection. Treatment regimens for granulomas include intralesional or systemic steroids, minocycline, and topical imiquimod.[9]

LONGEVITY

The augmentation derived from liquid silicone injection is permanent. Many authors have published reports of long-term studies, some with 30-year follow-up, showing persistence of improvement. Patients receiving liquid silicone injections will continue to age, and, for this reason, additional augmentation may be required should neighboring areas of age-related atrophy develop.

COMPLICATIONS ASSOCIATED WITH THE USE OF ALL FILLERS

Vascular occlusion is perhaps the most devastating complication associated with the use of all fillers. This can manifest as local necrosis, central nervous system infarction, or blindness. Blindness and middle cerebral artery infarction have been described most often after fat transfer, but vascular occlusion with ensuing sequelae has occurred after the use of collagen and hyaluronic acid fillers as well. In theory, the central occlusive events have occurred from high-pressure injections with retrograde flow into arterioles that connect with the internal carotid system. It is therefore of utmost importance to keep the needle or cannula moving during withdrawal while depositing filler and to exert as little pressure as possible on the syringe. For similar reasons, when fat transfer is performed, only blunt cannulas should be used for infiltration.

Other complications common to the use of all fillers include ecchymosis, edema, extrusion or drifting of the filling substance, foreign-body reactions, changes in pigmentation, injection site scarring, overcorrection, undercorrection, misplacement, and infection.

KEY REFERENCES

1. Lowe NJ, Maxwell CA, Patnaik R: Adverse reactions to dermal fillers: review. *Dermatol Surg* **31**:1616, 2005
2. Narins RS et al: A randomized, double-blind, multicenter comparison of the efficacy and tolerability of restylane versus zyplast for the correction of nasolabial folds. *Dermatol Surg* **29**:588, 2003
3. Carruthers A et al: Randomized, double-blind comparison of the efficacy of two hyaluronic acid derivatives, Restylane Perlane and Hylaform, in the treatment of nasolabial folds. *Dermatol Surg* **31**:1591, 2005
4. Rao J et al: Clinical comparison between two hyaluronic acid-derived fillers in the treatment of nasolabial folds: hylaform versus restylane. *Dermatol Surg* **31**:1587, 2005
5. Rossner F et al: Decrease of reported adverse events to injectable polylactic acid after recommending an increased dilution: 8 year results from the injectable filler safety study. *J Cosmet Dermatol* **8**:14-18, 2009
6. Moers-Carpi MM, Tefet JO: Calcium hydroxylapatite versus nonanimal stabilized hyaluronic acid for the correction of the nasolabial folds: a 12 month, multicenter, prospective, randomized, controlled, split-face trial. *Dermtol Surg* **34**:210-215, 2008
7. Rohrich RJ, Pessa JE: The fat compartments of the face: anatomy and clinical implications for cosmetic surgery. *Plast Reconstr Surg* **119**:2219-2227, 2007
8. Donofrio LM: Panfacial volume restoration with fat. *Dermatol Surg* **31**:1496, 2005
9. Duffy DM: Liquid silicone for soft tissue augmentation. *Dermatol Surg* **31**:1530, 2005

Chapter 255 :: Botulinum Toxin

:: Richard G. Glogau

On April 15, 2002, the US Food and Drug Administration (FDA) approved Allergan, Inc.'s Botox Cosmetic* (botulinum toxin type A) for "temporary improvement in the appearance of moderate-to-severe glabellar lines in adult men and women 65 or younger." This was the first elective cosmetic indication for which any commercially available botulinum toxin on the US market had been approved.

The toxin had previously been approved and was marketed as Botox® for the treatment of strabismus, blepharospasm, and cervical dystonia but existing off-label cosmetic use of the toxin had already propelled annual sales to $250 million per year in 2002. With FDA recognition of the cosmetic indication, sales of both Botox® and Botox Cosmetic® surpassed $1 billion per year by the end of 2009.

The commercial introduction of Allergan's product into the US market has given unprecedented brand name equity to the drug, surpassed only by Pfizer's product Viagra® (sildenafil citrate). Botox has passed into vernacular usage as a trademark used to loosely refer to a class of biologic neurotoxins in the manner of other well-known trademarks such as Coke® and Kleenex®. The clinical utility of the neurotoxin is so widely known today that the word *Botox* has become a generic term in the public mind for all agents used in cosmetic neurotoxin therapy, although the term is properly reserved for Allergan's trademarked commercial version of the type A neurotoxin complex.

In April 2009, the FDA approved a third commercial neurotoxin, a serotype A product, Dysport® (Ipsen [UK]/Medicis [US]) to join Allergan's Botox® /Botox® Cosmetic and a previously approved serotype B product, Myobloc® (Solstice Neurosciences [US]). In July 2011, the FDA approved a fourth commercial neurotoxin for the US market, a serotype A product, Xeomin® (Merz Pharma GmbH [Germany]). To emphasize the noninterchangeability of these biological toxins, the FDA in August 2009 required the manufacturers to adopt new drug names: onabotulinum toxin A (Botox®/Botox® Cosmetic), abobotulinum toxin A (Dysport®), rimabotulinum toxin B (Myobloc®), and incobotulinum toxin A (Xeomin®).

One other commercial serotype A toxins is presently awaiting FDA approval: PurTox® (Mentor [US]). There are at least two other commercial serotype A toxins in use outside of the United States: Meditoxin®/Neuronox® (Medy-Tox [Korea]) and Hengli®/Prosigne® (Lanzhou [China]). Presumably the FDA will supply new drug names for these products when and if they complete the approval process.

*It is the editors' policy not to use trade names in this book. However, in certain instances, the editors had to depart from this policy to avoid confusion.

PHARMACOLOGY

TOXIN STRUCTURE

Botulinum neurotoxins are currently categorized into seven distinct serotypes: A, B, C1, D, E, F, and G.[13] The molecules vary in their biosynthesis, size, cellular sites of action, binding kinetics, duration of effect, and stability. The serotypes currently commercially available, serotypes A and B, are derived from different strains of *Clostridium botulinum*. They both have 150-kDa dichain polypeptides with a heavy chain and light chain linked by disulfide bonds. During biosynthesis, the molecules of A and B can be surrounded by proteins to form a neurotoxin complex, ranging from 500 kDa to 900 kDa (Fig. 255-1). Xeomin® (incobotulinum toxin A) consists of the 150 kDa dichain without accessory proteins.

MECHANISM OF ACTION

The toxin enters the nerves by binding to surface protein receptors and undergoing endocytosis into internalized vesicles. The light chain is released into the nerve cytosol, and the SNARE (soluble *N*-ethylmaleimide-sensitive factor attachment protein receptor) protein complex is cleaved to inhibit exocytosis of the neurotransmitters such as acetylcholine (Fig. 255-2).

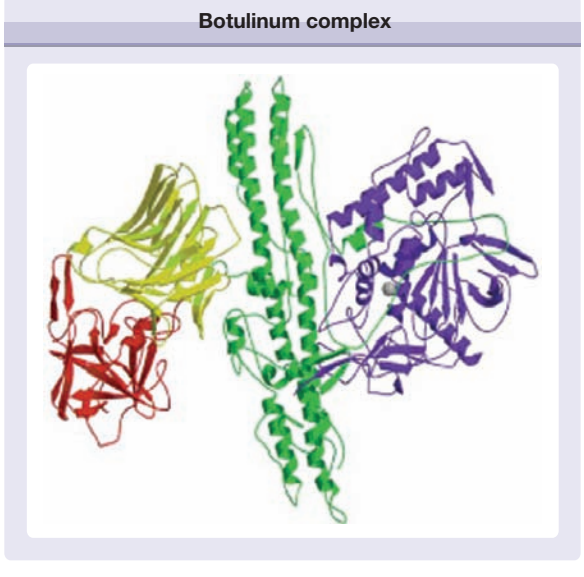

Figure 255-1 Schematic of the botulinum complex showing the binding domain with the *N*-terminus (*yellow*) and the *C*-terminus (*red*), together with the translocation domain (*green*) and the light chain (*blue*). (Used with permission from Turton K, Chaddock JA, Acharya KR: Botulinum and tetanus neurotoxins: structure, function and therapeutic utility. *Trends Biochem Sci* **27**:554, 2002.)

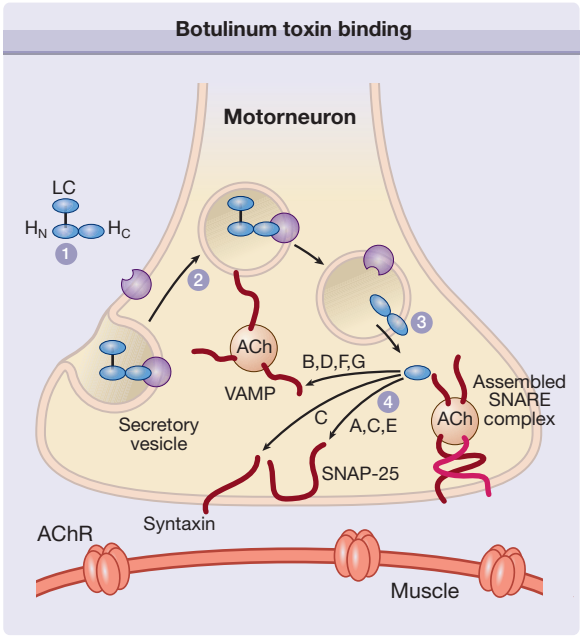

Figure 255-2 The heavy chain domain of the botulinum neurotoxin complex binds to the plasma membrane receptor (1) and the complex is internalized (2). The light chain fragment is then released into the cytoplasm (3), where it cleaves the SNARE (soluble N-ethylmaleimide-sensitive factor attachment protein receptor) protein complex at a site determined by the neurotoxin serotype (4). This disruption of the SNARE complex prevents exocytosis of acetylcholine (ACh) into the synaptic space of the neuromuscular junction. A through G = neurotoxin serotypes; AChR = acetylcholine receptor; LC = light chain; H_C = heavy chain *C*-terminus; H_N = heavy chain *N*-terminus; SNAP-25 = synaptosome-associated protein of 25 kDa; VAMP = vesicle-associated membrane protein. (Used with permission from Turton K, Chaddock JA, Acharya KR: Botulinum and tetanus neurotoxins: Structure, function and therapeutic utility. *Trends Biochem Sci* **27**:555, 2002.)

Type A toxin cleaves SNAP-25 (synaptosome-associated protein of 25 kDa), whereas type B cleaves VAMP (vesicle-associated membrane protein), also called *synaptobrevin* (Fig. 255-3). These proteins are necessary for the release of acetylcholine from vesicles within the cytoplasm of the motor nerve endings. The binding characteristics of each serotype dictate the locus of action on the intracellular SNARE protein complex (Table 255-1).

The end result is a chemodenervation of the cholinergic neurons, either motor nerves or autonomic nerves, leading to localized absence of skeletal muscle activity or autonomic control of target organs such as the eccrine sweat glands. The way in which the nerves escape the effect of the neurotoxin is partially understood.[14] The chemodenervated nerve endings develop collateral sprouting near the primary terminus of the nerve. These sprouts eventually make proximate contact with the targets, either muscle or gland, and begin to overcome the loss of neurotransmitter at the end organ synaptic junctions.

Once these sprouts have reestablished chemical contact with their targets, muscles resume activity and glands begin to secrete. Simultaneously, the original chemodenervated terminal nerve ending begins to degrade the blocked SNARE proteins and develop new proteins to resume the chemical exocytosis of acetylcholine. While these repairs are underway, and while the original terminal nerve ending reacquires communication with the target organ, the collateral sprouts begin to slowly resorb until anatomically nothing is left but the original terminal ending with restored junctional activity.

Four commercially available preparations of botulinum neurotoxin were on the market in the United States and Europe in late 2011, and one was pending approval. All but one are serotype botulinum toxin A, and one is a serotype botulinum toxin B. The products differ in their methods of manufacture, commercial form, and biologic profiles. (Table 255-2).

The units by which these products are described are not interchangeable because of the nature of the assays used to determine their potency. The mouse assays used differ in the diluents used and are not comparable. There is no such thing as a standard neurotoxin unit, hence there is no "International Unit" for neurotoxin. Thus, there is no way of standardizing neurotoxin units to compare a serotype A products to each other, let alone to other serotype B products.

Although the molecule complexes are unique, similar uses are based on clinical observations. For example, in the glabellar frown line pivotal trials, 20 units of Botox® or Xeomin® and 50 units of Dysport® were used.[16,17] Botox® is generally diluted with either 1.0 or 2.5 mL of saline per 100 units, producing concentrations of either 10 units per 0.1 mL or 4 units per 0.1 mL respectively. Xeomin® is diluted with 2.5 ml per 100 unit vial. Allergan's pivotal trial used the 4 unit per 0.1 mL dilution. Dysport® is usually diluted with 1.5 mL of saline per 300 unit vial producing a concentration of 10 units in 0.05 mL as used in the pivotal trial. Notice that the Dysport® pivotal trial used injection volumes that were half those used in the Allergan trial: 0.05 mL (10 U) per injection point (Dysport®) versus 0.1 mL (4 U) per injection site

TABLE 255-1
Binding Sites in the SNARE Protein Complex of the Seven Known Botulinum Toxin Serotypes

Serotype	Intracellular Protein
A	SNAP-25
B	VAMP/synaptobrevin
C1	SNAP-25 and syntaxin
D	VAMP/synaptobrevin
E	SNAP-25
F	VAMP/synaptobrevin
G	VAMP/synaptobrevin

SNAP-25 = synaptosome-associated protein of 25 kDa; SNARE = soluble *N*-ethylmaleimide-sensitive factor attachment protein receptor; VAMP = vesicle-associated membrane protein.

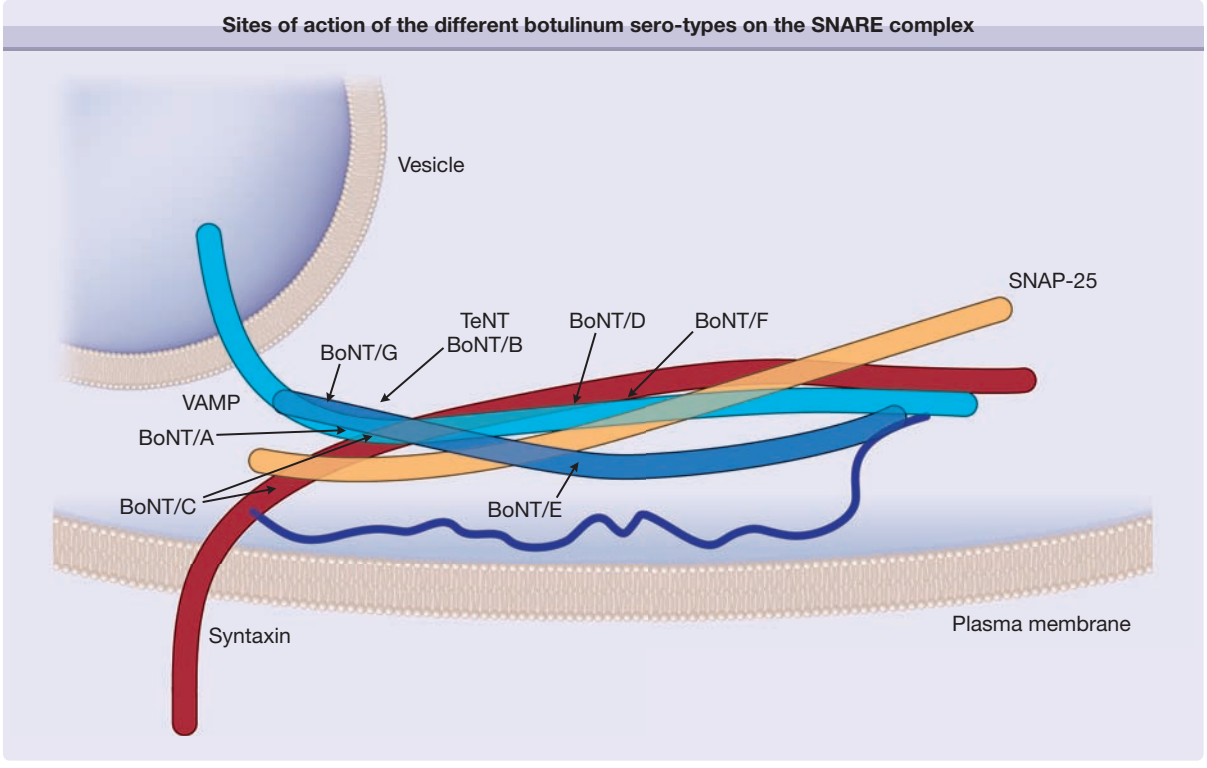

Figure 255-3 Schematic representation showing the sites of action of the different botulinum serotypes on the intracellular protein complex known as the SNARE (soluble *N*-ethylmaleimide-sensitive factor attachment protein receptor) proteins responsible for exocytosis of acetylcholine from the nerve. Botulinum A serotype cleaves SNAP-25 (synaptosome-associated protein of 25 kDa). Other serotypes impact VAMP (vesicle-associated membrane protein), synaptobrevin, or syntaxin. BoNT/A through BoNT/G = botulinum neurotoxin serotypes A through G; TeNT = tetanus neurotoxin.

(Botox®). It is unclear whether such differences in volume may contribute to behavioral differences between the two products in terms of diffusion and persistence.

The use of sterile saline with preservative (benzyl alcohol) as a diluent appears to lessen the sting of injection with Botox® and Dysport®. Myobloc®, the B serotype, causes more discomfort on injection because of its low pH, but it is stable in liquid form at room temperature for many months.

In addition to the drug name changes, which the FDA required of the manufacturers in 2009, the agency instituted a Risk Evaluation and Mitigation Strategy (REMS), and a boxed warning for these products that warned of the possibility of spread distant from the injection site with potentially life-threatening consequences. Emphasizing the non-interchangeability of these commercial products, the FDA wished to minimize the possibility of medication errors as well as draw attention to the need for tailoring specific doses of each toxin product to specific situations.

IMMUNOLOGY

The possibility of antibody-mediated resistance appears to be largely theoretical. Original Botox® batch No. 79–11, widely used in ophthalmology and neurology for years, produced rare cases of nonresponse in the treatment of torticollis and blepharospasm. Newer batches introduced in 1997, No. 91223US and No. BCB2024, have significantly less protein load. Although cases of primary nonresponse may be rarely encountered, immunologic resistance to Botox® and Botox Cosmetic® does not appear to be clinically relevant in dermatology, even at the dosages used to treat hyperhidrosis, which can average 400 units per treatment session. In addition, the treatment interval does not appear to be a significant factor in clinical resistance for the newer batches and at the smaller dosages used in cosmetic facial treatment, although exposure to the toxin at increasingly shorter intervals may be associated with development of neutralizing antibodies.

INDICATIONS

Botulinum toxin is used in cosmetic dermatology primarily for the treatment of dynamic expression lines in the upper third of the face (the glabellar brow furrow, horizontal frontalis forehead lines, periocular rhytides, or crow's feet) and for the treatment of axillary hyperhidrosis. Less common and therapeutically more challenging indications are platysmal banding in the neck, perioral rhytides, marionette lines at the corners of the mouth from the action of the depressor anguli oris, shaping the lower face with masseter volume reduction, postsurgical synkinesis in the lower face, and palmar/plantar and forehead/scalp hyperhidrosis.

TABLE 255-2

Comparison of the Properties of the Commercially Available Forms of Botulinum Toxin in Current Medical Use in the US (Four) and Outside the United States (Three)

Proprietary Name	Botox® Botox® Cosmetic	Dysport®	Myobloc®	Xeomin®	PurTox®	Meditoxin® Neuronox®	Hengli®/Prosigne®
Nonproprietary Name (FDA)	Onabotulinumtoxin A	Abobotulinumtoxin A	Rimabotulinumtoxin B	Incobotulinumtoxin A	Pending FDA approval	Outside US only	Outside US only
First approval	1989 (US) 2002 (US)	1991 (UK)	2000 (US)	2005 (Germany)	Pending	2006 (Korea)	1993 (China)
Manufacturer	Allergan (US)	Ipsen (UK)	Solstice Neurosciences (US)	Merz (Germany)	Mentor Worldwide (US)	Medy-Tox (Korea)	Lanzhou (China)
Commercial US	Yes	Yes	Yes	Yes	Pending US	No	No
Serotype	A	A	B	A	A	A	A
Strain	Hall (Allergan)	Hall	Bean	Hall	Hall	Hall	Hall
Process	Crystallization	Chromatography	Chromatography	Chromatography	Chromatography	Chromatography	Crystallization
Excipients	HSA (500 µg) Sodium chloride	HSA (125 µg) Lactose	HSA (500 µg/ml) Sodium succinate Sodium chloride	HSA (1 mg/vial) Sucrose (5 mg/vial)	HSA Trehalose	HSA (500 µg) Sodium chloride	Porcine gelatin 5 mg Dextran 25 mg Sucrose 25 mg
Receptor/Target	SV2/SNAP-25	SV2/SNAP-25	Syt II/VAMP	SV2/SNAP-25	SV2/SNAP-25	SV2/SNAP-25	SV2/SNAP-25
Complex mw uniformity	~ 900 kD homogeneous	~ 500 kD heterogeneous	~ 700 kD homogeneous	~ 150 kD	~ 150 kD	~ 150 kD	~ 500 kD heterogeneous
Stabilization Solubilization pH	Vacuum dried Normal saline ~ 7	Lyophilization Normal saline ~ 7	Solution N/A 5.6	Vacuum dried Normal saline ~ 7.4	Lyophilization Normal saline ~ 7	Lyophilization	Lyophilization
Package (units per vial)	100, 200	300, 500	2500/5000/10,000	100	100	50/100	100
Neurotoxin protein per vial (ng/Vial)	~ 5 (100U vial)	4.35 (500U vial)	25/50/100	0.6 (100U vial)	1 (100U vial)	?	?

SNAP-25 = synaptosome-associated protein of 25 kDa; VAMP = vesicle-associated membrane protein; SV2 = synaptic vesicle protein; syt II = syntaxin II; HSA = human serum albumen; N/A = not applicable.

TREATMENT

GLABELLAR BROW FURROWS

A firm understanding of the underlying facial anatomy is the *sine qua non* of successful aesthetic therapy with botulinum toxin. Depending on the muscle mass present and the degree of atrophy from prior treatment, 20–35 units of Botox® or Xeomin® or 50–75 units of Dysport® may be placed in five separate injection points to treat the corrugators and procerus muscle in the average brow (Fig. 255-4). A 30-gauge, 31-gauge, or even 32-gauge needle and a tuberculin or diabetic syringe are used to minimize the trauma of the intramuscular injections. The corrugator injections are placed (1) just at or above the medial brow and (2) in or just medial to the midpupillary line, at least 1 cm above the bony orbital rim (see Fig. 255-4). The fifth injection is placed in the procerus at the midline at a point just above the horizontal creases created in the glabella at the bridge of the nose. Figure 255-5 shows the results of the procedure.

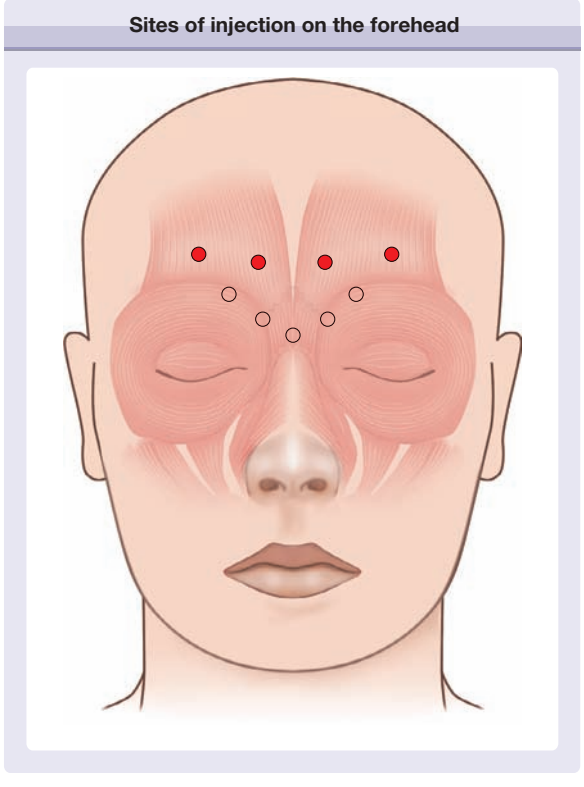

Figure 255-4 Sites of injections on the forehead. The corrugator and procerus muscles are weakened by carefully positioning five injections of botulinum toxin of 5 units each (Botox®) (*open circles*). If Dysport® is used, 10 units would be placed in the 3 central injection points but the lateral corrugator injection points (represented by the red circles) are a little medial and slightly higher than the lateral injection points used for Botox,® in most cases, according to Ascher.[15] Forceful knitting of the brow is prevented. To weaken the frontalis muscle, injections are placed in four or five divided doses along the forehead equator (*closed circles*).



Figure 255-5 Before botulinum toxin treatment of the corrugator and procerus muscles (*upper panel*) and 1 week after treatment (*lower panel*).

Based on earlier experience with ophthalmologic periocular injections for treatment of muscle spasms, patients have been instructed to remain upright for 2–3 hours to limit the incidence of eyelid ptosis, which occurs with diffusion of the toxin down into the levator muscles of the lid (Fig. 255-6). With operator experience, the incidence of ptosis after injection of the brow should be less than 2%.

Temporary stimulation of Müller muscle in the lid can be achieved with 0.5% apraclonidine or 2.5% phenylephrine eyedrops (see Fig. 255-6). These will produce 2–3 mm of elevation of the lash margin, and administration may be repeated at intervals until the distant diffusion effect of the botulinum toxin on the levator muscle disappears, usually in 2–3 weeks.

HORIZONTAL FOREHEAD LINES

The frontalis is treated at the horizontal equator of the forehead or above to avoid inactivation of the lower third of the frontalis muscle, which is responsible for suspension and movement of the eyebrows (see Figs. 255-4 and 255-7). Twelve to twenty units of Botox® or 20–50 units of Dysport® are placed in four or five divided doses equidistantly along the forehead equator. If too large a dose is applied or injection sites are placed too low, brow



Figure 255-6 Patient who developed ptosis of the right upper eyelid due to diffusion of the botulinum toxin from the area above the midbrow down into the levator muscle of the upper eyelid. The lower photograph shows the patient approximately 1 minute after instillation of two drops of apraclonidine 0.5% ophthalmic solution into the right eye. Direct adrenergic stimulation of Müller muscle occurs, which lifts the lid temporarily. The drops may be administered every 4 hours as needed. The botulinum-induced ptosis resolves spontaneously, usually in 3 weeks or less.



Figure 255-7 The upper half of the frontalis muscle is weakened by injecting four or five sites equidistantly along the equator of the forehead with a total of 16–20 units of Botox® or 30–50 units of Dysport®. Patient is shown before treatment (*upper panel*) and 1 week after treatment (*lower panel*).

ptosis and loss of brow arch are produced, which leads to an unpleasant, heavy sensation in the brow as well as an aesthetically unattractive appearance.

Unlike in the treatment of eyelid ptosis, there is no comparable adrenergic agent available to reverse brow ptosis induced by botulinum, and the patient must wait several weeks for the effect to wear off. In a patient, who has never received botulinum toxin before, it is wise to separate the glabellar area from the forehead area and to wait a couple of weeks between treating the two to avoid the possibility of overtreatment and brow ptosis. Many patients find even the smallest drop in brow position very bothersome, and great care should be taken to avoid this complication of aesthetic treatment.

CROW'S FEET

The rhytides at the corners of the eye respond favorably to injections of toxin; however, patients frequently confuse true crow's-feet rhytides with the dynamic expression lines that appear across the malar eminence laterally in conjunction with smiling and contraction of the zygomaticus muscles. Toxin may successfully ameliorate true crow's-feet, which radiate directly from the lateral canthus and are associated with contraction of the orbicularis oculi muscles by themselves. But the "smile lines" that appear over the malar eminence often lie in wait for the unwary injector. Placing toxin at or below the malar eminence in an attempt to weaken these lines may lead to paralysis of the zygomaticus muscles and a drooping corner of the mouth that cannot spontaneously be raised, so that the patient may acquire a poststroke appearance.

To safely approach crow's feet, the toxin is usually placed at one-to-three injection points approximately 1 cm lateral to the lateral canthus. Some practitioners place all of the drug at one point, and others distribute the dose evenly among three points. Typical doses range from 10–18 units of Botox® or 25–30 units of Dysport® depending on the estimate of muscle mass and activity.

Great care must be taken to make the injections into the skin only, raising wheals or blebs that can be gently massaged down. Intramuscular injection in this area will reliably produce unwanted bruising because of the rich venous plexus underlying the skin in this region. The toxin will readily diffuse from the blebs into the underlying orbicularis muscle, relaxing the grip on the overlying skin and smoothing out the wrinkles. As previously mentioned, care must be taken to avoid injecting too low down onto the malar eminence, where diffusion may affect the zygomaticus major muscle and disrupt the symmetrical movement of the corner of the mouth in smiling.

The patient being treated for crow's feet should have good lower eyelid tarsal tone to avoid the appearance of senile ectropion from too much laxity of the lower eyelid. Pretreatment of the crow's-feet area is very useful as an adjunctive technique before laser resurfacing. It prevents the problem of rhytides being readily reformed by repeated squinting during the postoperative healing period; in which case, the resurfacing may give rise to more noticeable lines than existed before the resurfacing.

COMBINATION THERAPY

As clinical experience accumulated with these commercial botulinum toxin products, experts in soft-tissue augmentation soon recognized that a synergy exists between soft-tissue fillers and neurotoxins.[16] Concomitant with the rise in the use of botulinum neurotoxin for cosmetic applications, the marketplace for soft-tissue augmentation expanded with the introduction of injectable hyaluronic acid gels (see Chapter 254). These agents provided the first new directions in cosmetic therapy since the introduction of solubilized bovine collagen in the mid-1970s. The ability to control both muscles of expression and their secondary lines and folds, and to repair age-related volume changes in subcutaneous tissue has revolutionized minimally invasive cosmetic techniques.

Many patients have eagerly embraced simultaneous treatment with both fillers and botulinum toxin to achieve a natural look and forego more traditional incisional surgery. As an example, patients frequently combine treatment of the upper third of the face (glabellar frown lines, horizontal forehead lines, and crow's feet) with volume restoration of the lower and middle face (lip enhancement, filling of nasolabial fold and marionette lines, chin and cheek augmentation) (see Chapter 254).

HYPERHIDROSIS

Focal axillary hyperhidrosis is successfully treated with botulinum toxin by using Minor starch-iodine test to map out the extent of surface area in the axillary vault that is affected. Anesthesia may be achieved with a eutectic mixture of local anesthetics but is usually not needed due to the relative insensitivity of the axillary skin. Doses of 2.5–4.0 units of Botox® are placed every 1–2 cm as intradermal injections in axillary skin. Reliable anhidrosis is produced within 72 hours and will last for 8–12 months with doses of 50–100 units of Botox® per axilla (Fig. 255-8). The duration of effect appears to be dose related, and doses of up to 200 units (Dysport®) per axilla have been reported to produce dryness for up to 29 months.[17] Aside from insignificant bruising from the needle trauma, there are no apparent side effects.

Palmar hyperhidrosis (Fig. 255-9) is more challenging to treat because of (1) the more limited diffusion of the toxin in palmar skin, (2) the pain on injection, and (3) the generally predictable incidence of temporary weakness in the hand.[9] Anesthesia is achieved with regional wrist blocks of the median, ulnar, and radial nerves using lidocaine 1%–2% without epinephrine. Approximately, 100–150 units of Botox® are needed to treat a single palm, divided into 50–60 intradermal injections of 2–3 units each. Onset of anhidrosis peaks in 5–7 days and is accompanied by minor weakness of the intrinsic muscles of the hand, which makes tasks requiring strength and stability (e.g., pushing a button through a buttonhole) difficult to perform. The weakness usually subsides within 3 weeks, whereas the anhidrosis persists for several months. There is wider variation in response to palmar treatment than to axillary treatment, with anhidrosis lasting from 4–12 months, which probably reflects the technical difficulties in achieving even dispersion of the toxin through the palmar skin.



Figure 255-8 Minor starch-iodine test is used to demonstrate the area of axillary sweating (*top panel*). The pattern of intradermal botulinum toxin injections is shown with the starch-iodine material in place to highlight the injection points (*middle panel*). One week later the treated axilla shows a negative result on the starch-iodine test (*bottom panel*).

SIDE EFFECTS AND COMPLICATIONS

Minor needle trauma and bruising on injection with a 30-gauge needle are insignificant short-term



Figure 255-9 Hands showing response to Minor starch-iodine test. The left hand was not treated. The right hand received 100 units of intradermal Botox® 1 week before the photograph was taken.

complications of botulinum toxin injection, and use of a smaller-gauge needle (31 gauge or 32 gauge) will minimize needle trauma. Minor discomfort can be made more tolerable in some patients by pretreating the injection site areas with topical anesthetic and using sterile saline with preservative as a diluent, which greatly reduces the sensation of injection.

The more problematic complications to consider are eyelid ptosis, which can occur after injections in the glabellar brow (see Fig. 255-6); brow ptosis from overzealous treatment of the frontalis muscle; transient lid edema from periocular injections; headaches after injections anywhere in the upper third of the face; and palmar weakness after injections for hyperhidrosis.

Antibody-mediated resistance appears to be an exceedingly rare event and of little clinical consequence in cosmetic dermatologic uses of botulinum toxin. Although millions of doses have been given to date, there is no well-documented evidence of the development of immunologic resistance in patients treated with cosmetic doses. Resistance continues to be observed in patients treated for cervical dystonia, albeit at much lower rates than in the early years, probably due to the lower protein content of current formulations.

Eyelid ptosis is thought to be best avoided by carefully placing the midbrow injections at a minimal distance of 1 cm from the superior orbital rim, keeping the injection rate slow and gentle, and having the patient avoid prone positions and sleeping for 2 hours after injection.

Restricting injections to the upper two-thirds of the frontalis and reducing doses to the minimum necessary to produce the desired clinical effect may minimize brow ptosis. Headaches as a rebound phenomenon after facial injections of botulinum toxin may be triggered by unopposed muscle groups, but their etiology is unclear. Usually nonsteroidal anti-inflammatory agents are sufficient to treat them, unless the patient experiences migraines; in which case, the patient's usual migraine medication will be required.

In hyperhidrosis, palmar weakness is a predictable consequence of injecting the palms. It is transient and dealt with by clear preinjection counseling. There is no similar effect of any clinical significance in either the axillae or the feet.

SUMMARY

The development of botulinum toxin treatment has brought great creativity and capability to cosmetic dermatologic therapy. Further evolution will occur as new serotypes come to market and greater therapeutic synergies evolve as developers of soft-tissue augmentation systems strive to achieve similar effect and elegance. The high degree of efficacy and safety in the use of botulinum toxins in cosmetic dermatology has produced a great level of satisfaction in patients and physicians alike.

KEY REFERENCES

Full reference list available at www.DIGM8.com

DVD contains references and additional content

5. Carruthers JD: Ophthalmologic use of botulinum a exotoxin. *Can J Ophthalmol* **20**:135, 1985
8. Carruthers J, Carruthers A: The evolution of botulinum neurotoxin type A for cosmetic applications. *J Cosmet Laser Ther* **9**:186, 2007

9. Glogau RG: Treatment of hyperhidrosis with botulinum toxin. *Dermatol Clin* **22**:177, 2004
10. Kim CC et al: Predicting migraine responsiveness to botulinum toxin type A injections. *Arch Dermatol* **146**:159, 2010
13. Aoki KR: Pharmacology and immunology of botulinum toxin serotypes. *J Neurol* **248**(Suppl. 1):3, 2001
15. Ascher B et al: A multicenter, randomized, double-blind, placebo-controlled study of efficacy and safety of 3 doses of botulinum toxin A in the treatment of glabellar lines. *J Am Acad Derm* **51**:225, 2004
17. Glogau RG: Hyperhidrosis and botulinum toxin A: patient selection and techniques. *Clin Dermatol* **22**:45, 2004

Chapter 256 :: Hair Transplantation and Alopecia Reduction

:: Walter P. Unger, Robin H. Unger, & Mark A. Unger

HAIR TRANSPLANTATION AND ALOPECIA REDUCTION AT A GLANCE

- Most patients undergoing surgical procedures for hair loss have either male pattern baldness (MPB) or female pattern hair loss (FPHL).
- Surgical techniques used to treat hair loss include hair transplantation, alopecia reduction (AR) and transposition flaps.
- Follicular units (FU) are the building blocks of modern hair transplantation [follicular unit transplanting (FUT)] (Fig. 256-1).
- The major advantage of FUT over older punch-grafting techniques is that the results appear natural after a single surgery.
- Minoxidil or finasteride may arrest or partially reverse MPB and FPHL so a trial of treatment is appropriate prior to surgery, or concurrent with surgery.[1,2]

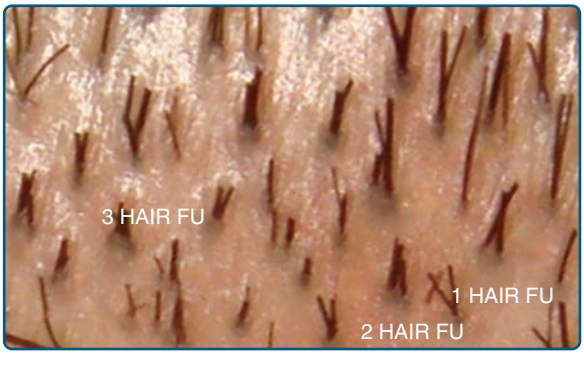

Figure 256-1 A relatively small number of single hairs emerge from the scalp. Most often, hairs grow in small groupings of two to five hairs, as shown in the above photo. These groupings are referred to as *follicular units*.

BACKGROUND

Hamilton and Norwood described the degrees of severity of MPB from a mild Type I to a severe Type VII[3,4] (Fig. 256-2). Fortunately, a large majority of male patients do **not** progress past Types VI: Norwood found that at age 79 only 11% of men have Type VII MPB (Table 256-1), and Unger found that among men older than 65 only 13.7% have Type VII MPB[5] (Table 256-2). Thus, if one treats all or most patients as if they will develop Type VI MPB, one is being reasonably cautious. An exception is for cases with a family history of Type VII MPB, in which case it is wiser to assume an evolution to Type VII MPB.

Ludwig described three degrees of FPHL[6] (Fig. 256-3), while Olsen developed a distinct classification system based on her observation of a "Christmas-tree" pattern of hair loss[7] (Fig. 256-4). According to Hamilton's study, 79% of postpubertal females develop at least a mild Hamilton/Norwood pattern of hair loss.[3] Most female patients do not have a sufficiently high density donor rim to surgically treat all of the affected alopecic areas. For this reason, some practitioners believe that women are rarely candidates for hair restoration surgery (HRS)—a view shared by the general public. In the authors' experience, however, the opposite is true.[8] A poor donor/recipient ratio does not preclude surgery, but does require a treatment plan that focuses on cosmetically strategic areas. In women, this corresponds to the frontal area and the part-line, which is usually a 5-mm-wide anteroposterior corridor (Fig. 256-5). The thickened hair in these areas can then be styled in a way that camouflages untreated areas. When this is done, the cosmetic improvement is significant, and patient satisfaction is high.

In men, the transplantation of areas of MPB should be conceptualized as consisting of four areas: (1) a frontal area extending from the proposed hairline to a coronal line drawn perpendicularly between the tragus of each ear; (2) a midscalp area extending from the posterior border of the frontal area to a point where the caudal scalp changes its orientation from parallel to the ground to more or less vertical; (3) a vertex area that consists of the remainder of

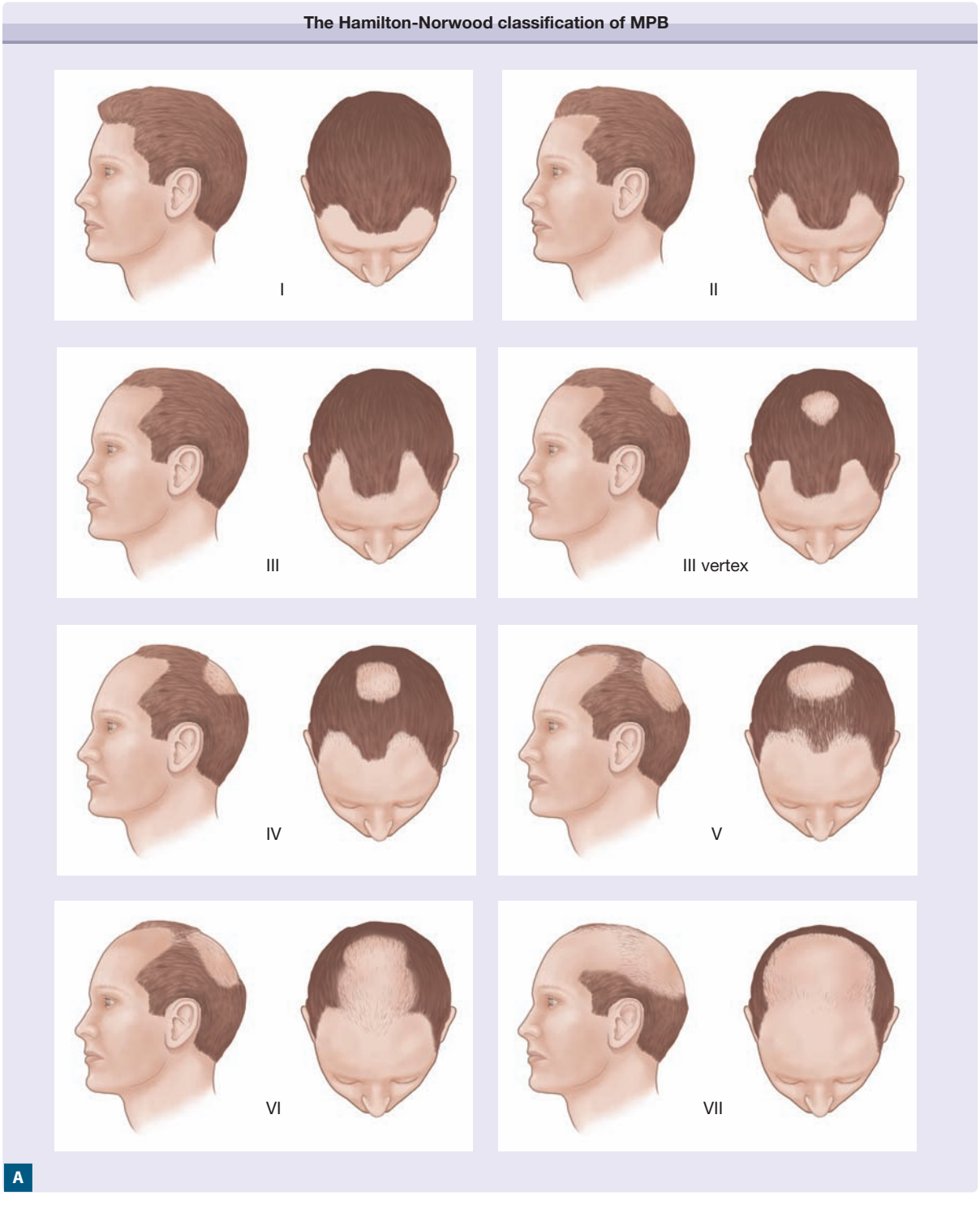

Figure 256-2 **A.** The Hamilton-Norwood classification of MPB. (*continued*)

the alopecic regions; and finally (4) evolving areas of alopecia adjacent to the aforementioned three major areas, which on close inspection contain relatively sparse hair (Figs. 256-6–256-8). Commonly, each transplant session treats one of the three major areas, plus adjacent evolving areas. Occasionally, the treatment of evolving areas of hair loss is deferred to later sessions in order to transplant a larger proportion of obvious areas of hair loss. In such cases, sufficient numbers of grafts must be left in reserve to permit the future treatment of these areas, unless an isolated frontal forelock is the ultimate goal.

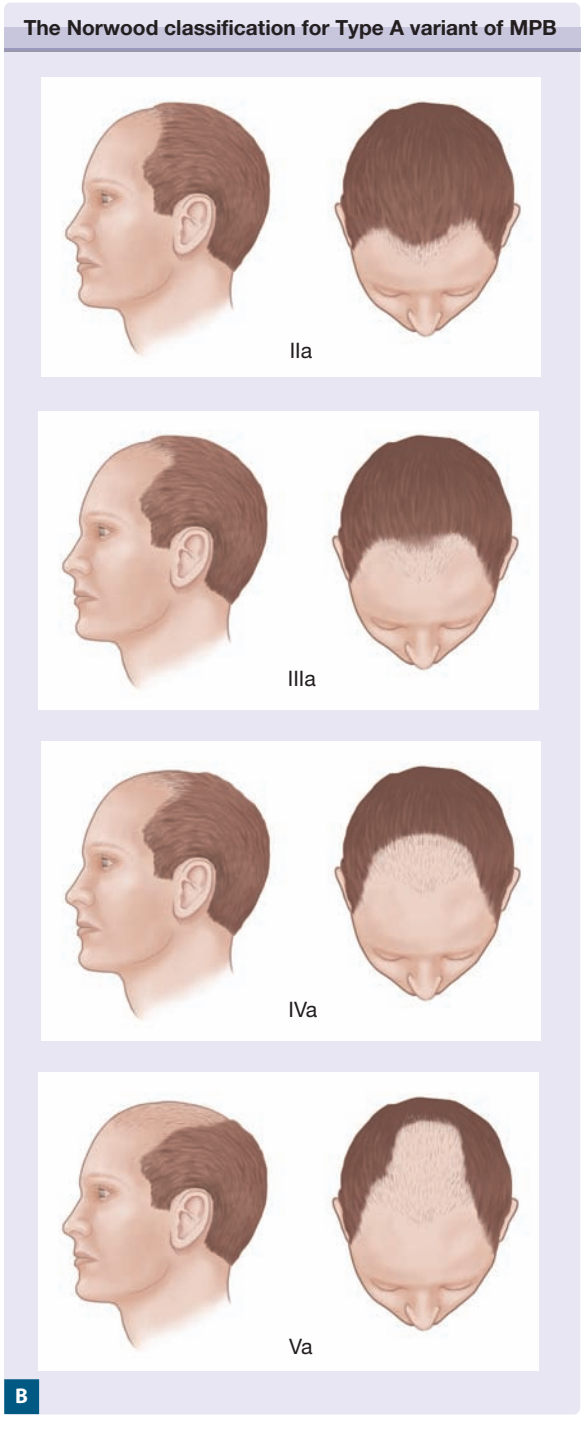

Figure 256-2 (*Continued*) **B.** The Norwood classification for Type A variant MPB.

In Unger's study of 328 males over the age of 65 years, he delineated an area within the zone of rim hair that contained 8 or more hairs per 4-mm circle[5] (Fig. 256-9). He referred to this as the safe donor area (SDA). For most patients, the equivalent of 3–5 strips, each of which is 10 mm, can be excised from the SDA during their lifetime. Each of those strips produces 1,500–2,750 FU, depending on the density of the donor hair.

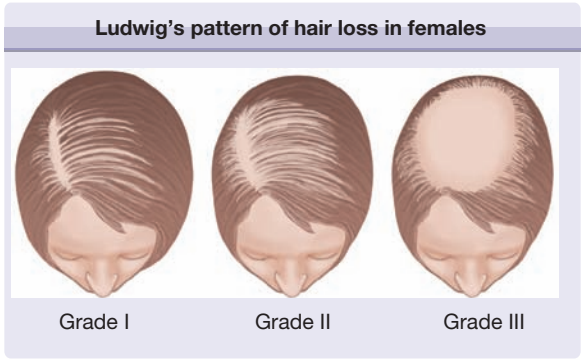

Figure 256-3 Ludwig pattern of hair loss in females.

PATIENT SELECTION

During the initial consultation, surgeons must clarify whether the hair loss is temporary or responsive to medical treatment. A comprehensive discussion of this subject is available elsewhere in this textbook. Provided this is not the case, the first step in the surgical evaluation of a patient is to assess the current and expected size of the donor and recipient areas. An accurate assessment of the donor/recipient ratio depends on professional experience, the family history of patterned hair loss and most importantly the patient's age. The second step is to evaluate hair characteristics. Box 256-1 lists the hair characteristics of the best hair transplant candidates. Not all of these characteristics are necessary for a satisfactory result, but each one improves the final cosmetic appearance (Fig. 256-10).

The authors do not follow any strict rules on patient selection with respect to the stage of hair loss, age, or gender. In regards to the stage of hair loss, it is important to note that the recipient area does not need to be completely alopecic in order to successfully operate. In fact, there are important advantages to transplanting at an earlier stage of MPB, although treating such areas demands a high degree of skill. Similarly, there are no definite age requirements, although younger patients, especially those under the age of 25, should have more conservative treatment plans. As part of this planning, such patients are encouraged to use medical treatment to delay or partially reverse the progression of MPB. In addition, surgeons should leave enough hair in the safe donor area to permit at least one future surgery in the event of unexpected areas of hair loss.

BOX 256-1 IDEAL HAIR CHARACTERISTICS

High density hair in the safe donor area
A mixture of fine and coarse hair
Minimal contrast between the skin and the hair color
Wave or curl

TABLE 256-1
Hamilton Study of Incidence of MPB (Norwood-Hamilton Scale) by Age

	Age (years)						
	18–29	**30–39**	**40–49**	**50–59**	**60–69**	**70–79**	**≥80**
Type I	110 (60%)	60 (36%)	55 (33%)	45 (28%)	29 (19%)	18 (17%)	12 (16%)
Type II	52 (28%)	43 (26%)	38 (22%)	32 (20%)	24 (16%)	20 (19%)	11 (14%)
Type III	14 (6%)	30 (18%) (3V)[a]	37 (20%) (15V)[a]	34 (23%) (15V)[a]	22 (15%) (10V)[a]	16 (16%) (7V)[a]	12 (16%) (8V)[a]
Type IV	4 (3%)	16 (10%)	15 (10%)	21 (9%)	17 (12%)	13 (13%)	9 (12%)
Type V	3 (2%)	10 (6%)	13 (8%)	15 (10%)	22 (15%)	13 (13%)	9 (12%)
Type VI	2 (1%)	4 (3%)	7 (4%)	10 (7%)	19 (13%)	11 (11%)	10 (13%)
Type VII	0	2 (1%)	5 (3%)	4 (3%)	16 (10%)	11 (11%)	14 (17%)
Total	185 (100%)	165 (100%)	165 (100%)	156 (100%)	149 (100%)	102 (100%)	77 (100%)

[a]Numbers in parentheses under Type III represent Type III Vertex individuals.

With respect to gender, it is worth mentioning again that women are more often than generally thought, excellent candidates for hair restoration surgery, despite the strong disagreement of a few surgeons. In an effort to discern the consensus opinion, the authors informally polled a group of leading experts in the field. From among this group, a majority (13 out of 22) felt that more than 50% of women had enough donor hair to permit *at least* one transplant.[9] In the authors' opinion, the percentage is even higher provided that the patient's expectations are commensurate with what is realistically possible given their donor/recipient ratio and hair characteristics. A strategically planned surgery, with a focus on transplanting the frontal zone and part-line, usually produces a cosmetically significant improvement, and leaves female patients very satisfied (Fig. 256-11).

RISKS AND PRECAUTIONS

Before proceeding with surgery, the patient's physician is contacted in order to discuss any areas of major medical concern. For safety, the operating room should be equipped with the medications and equipment needed for basic monitoring and advanced life support. While

TABLE 256-2
Unger Study of Incidence of MPB (Norwood-Hamilton Scale) in Men Older Than 65

	Age (years)			
Type	**65–69**	**70–74**	**75–79**	**80+**
I	2 (3.6%)	5 (6.2%)	4 (5.5%)	2 (1.7%)
II	9 (16.4%)	7 (8.6%)	7 (9.6%)	12 (10.1%)
III	4 (7.3%)	15 (18.5%)	18 (24.7%)	11 (9.2%)
IV	10 (18.2%)	16 (19.8%)	8 (11.0%)	10 (8.4%)
V	6 (10.9%)	7 (8.6%)	10 (13.7%)	16 (13.4%)
VI	13 (23.6%)	19 (23.5%)	16 (21.9%)	37 (31.1%)
VII	11 (20.0%)	12 (14.8%)	10 (13.7%)	31 (26.1%)
Total	55 (100%)	81 (100%)	73 (100%)	119 (100%)

Note:
- in age group 65–69 if one excludes Type I and II, 33 of the remaining 44 (75%) have Types III–VI (83.3% Norwood);
- in age group 70–74 if one excludes Type I and II, 57 of the remaining 69 (82.6%) have Types III–VI (82.8% Norwood);
- in age group 75–79 if one excludes Type I and II, 52 of the remaining 62 (83.9%) have Types III–VI;
- in age group 80+ if one excludes Type I and II, 74 of the remaining 105 (70.5%) have Types III–VI (74.0% Norwood).







Figure 256-4 The "Christmas-tree" pattern of hair loss as described by Olsen. **A** is mild; **B** is moderate; and **C** is severe. (Photos used with permission from Elise Olsen, MD.)





Figure 256-5 **A**. A 54-year-old female patient with significant hair loss in the hairline and temple regions. **B.** The same patient 2.5 years after a session of 1,248 FU and 264 DFU. The frontal view shows the effect that can be achieved for the overall appearance.

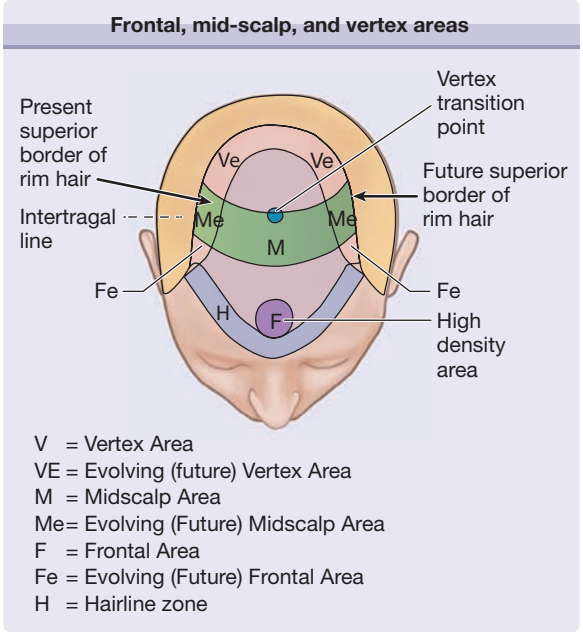

Figure 256-6 A schematic showing frontal, midscalp, and vertex areas, as well as evolving areas of MPB in a patient with Type VI MPB. Ideally, each of the three major areas is treated at the same time as the evolving areas of MPB lateral to them. Typically, only one major area and evolving area are treated during each session, though "touch-up" thickening of previously transplanted sites may also be carried out concomitantly.

rarely necessary, the authors prefer operating with anesthetist when patients have significant underlying health risks, including serious cardiovascular conditions, certain respiratory problems and seizure disorders. Box 256-2 presents a list of significant potential intraoperative complications.

BOX 256-2 MAJOR INTRAOPERATIVE RISKS

Lidocaine toxicity
Respiratory depression secondary to sedatives or narcotics
Excessive intraoperative bleeding

PATIENT POSITIONING

When removing the donor strip, the authors' patients are placed in a prone position, with their head in a doughnut ("prone") pillow that allows them to breathe comfortably. During the creation of the recipient sites and the insertion of the grafts, patients remain in a semisupine position except when working on the inferior portion of the vertex, in which case a prone position facilitates the work of both the surgeon and technicians.

TECHNIQUE

RECIPIENT AREA DESIGN[11]

On the morning of the surgery, a grease pencil is used to outline the treatment area. The frontal recipient area is designed by first drawing the proposed hairline. The midline, anterior-most point of the hairline should be as superior as acceptable to the patient, but always lies within the area in which the vertical forehead changes into the essentially horizontal caudal scalp.



Figure 256-7 **A.** A patient with early MPB. The grease pencil line outlines the areas to be treated, including the supratemporal humps that are currently hair bearing, but can be reasonably expected to lose hair with the passage of time. Designing and transplanting these regions has the advantage of allowing the lateral points of the new hairline to be placed more superiorly than they otherwise could be. This is because if the supratemporal humps were not transplanted and proceeded to lose their hair, the new hairline would eventually end in alopecic areas. **B.** The same patient six months after being transplanted 2,137 FU. The hairline in this patient intersected the temporal humps relatively inferiorly. His family history and examination suggested that he would ultimately develop Type V or, at worst, Type VI MPB, and he had relatively dense hair in his donor area.



Figure 256-8 **A.** A 67-year-old patient, with Type VII MPB and a relatively sparse donor area before treatment. The black crayon lines outline the areas to be treated. Reconstruction of the supra-temporal humps permits a more superior position for the new hairline. This decreases the anteroposterior length of the frontal area, resulting in the consumption of fewer grafts. This hairline runs parallel to the ground when viewed laterally, despite its more superior positioning. **B.** A side view of the same patient 11 months after his second hair transplant and a total of 3,211 FU (one session was to the frontal area and one was further posterior). The advantages of recreating the supratemporal humps are more obvious for patients with Type VII MPB than for patients who have, or will, develop less severe MPB. **C.** A frontal view of the same patient. **D.** The donor area scar 9 months after the third transplant in this patient.

The lateral borders are determined by outlining the supratemporal humps—semihemispheric areas that are superior to the temporal areas in all males, with the exception of those with Type VII MPB. Some of this area may or may not have persisting original hair but, regardless, should be transplanted. The lateral ends of the hairline are then joined to the supratemporal humps with a slight flare, to produce a rounded corner that creates a natural shape, but leaves patients with a mature looking hairline that includes frontotemporal recessions. In some patients, the anterior border of temporal hair is significantly receded, and it may need to be recreated at the same time as the anterior supratemporal humps are being transplanted. The posterior border of the frontal area is completed with an arc that helps create a natural pattern of hair loss in the event that the patient decides not to transplant any further posterior, or does not have sufficient donor hair to do so. When transplanting the midscalp, the posterior aspects of the supratemporal humps are included, and the posterior border of the transplant is similarly finished in an arc. For the vertex area, either the entire region or its periphery can be transplanted, depending on the available donor supply and patient goals.

DONOR AREA DETERMINATION

Choosing the optimal location and width of the donor strip is one of the most important decisions made during hair transplanting. For the first surgery, the authors typically choose a donor area that lies in the middle of the densest zone of the fringe hair, and extends into the temporal region in males, but ends posterior to the ears in females. This location is the most logical, since hair is progressively lost from the superior and inferior borders of the fringe hair in MPB, and hence this position provides the greatest degree of likelihood that transplanted hair is permanent. Each subsequent harvest includes any scar from prior session(s), as well as donor

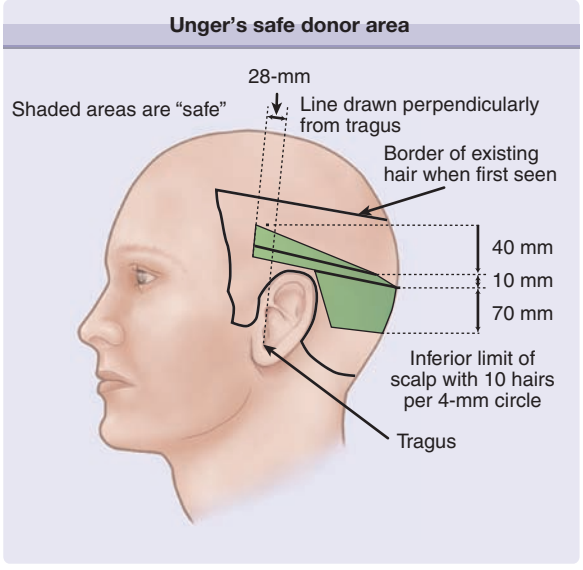

Figure 256-9 Unger's safe donor area for 80% of patients under the age of 80 years, as determined from studies of 328 men aged 65 years or older.[5]

hair immediately superior and inferior to the scar. This results in the presence of only one scar, regardless of the number of sessions carried out (Fig. 256-13). In order to determine the location of the densest zone, it is sometimes helpful to wet the hair to determine the superior and inferior margins of current areas of thinning. Once the donor area is identified, hair in an 10- to 14-mm wide zone is clipped short and cleansed with alcohol- and an iodine-based antiseptic.

DONOR SITE EXCISION[12]

Prior to starting the excision, the effectiveness of the anesthetic block is verified. Scalp laxity is clinically assessed in order to determine the appropriate width of the donor strip, which in the authors' practice is typically 8–12 mm wide. A prudent decision is to take a slightly narrower strip than the examination suggests is possible, thus permitting a margin of error that will minimize the possibility of a high-tension donor closure.

BOX 256-3 INSTRUMENTS NEEDED IN HAIR TRANSPLANTATION

- Double-bladed cutting knife handle
- #10 scalpel blade
- #15 scalpel blade
- Small curved surgical scissors
- Small straight Iris scissors
- Gauze
- Hyfrecator
- Smoke evacuation system
- Needle driver
- Suture material
- Toothed curved forceps
- Straight Adson forceps
- Hypodermic needles (various sizes)
- Clear plastic cutting boards
- Mantis microscope with under-lighting
- Double-sided razor blades
- Razor blade holder
- Divided Petri dishes
- Lepaw coolers
- #5 Planting jeweler's forceps
- #2 Jeweler's forceps
- Telfa pads
- Kerlix Dressing
- Aluminum rat tail comb
- Curved Metzenbaum scissors
- China marker grease pencil
- Syringes (various sizes)
- Stainless steel bowls



Figure 256-10 **A.** A patient before transplanting. **B.** One year after a first FUT session (1947 FU). This unusually dense result was mostly due to the patient's relatively high caliber and wavy hair.







Figure 256-11 **A.** A 52-year-old female patient before hair transplanting in a frontal midline area with embarrassingly low hair density. **B.** 7 years after a hair transplant consisting of 843 FU and 113 DFU (a total of 1,069 FU). The patient was being seen for possible transplanting posterior to the first recipient area. **C.** A photo taken at the same time as B with the hair combed back for critical evaluation. A little hair placed properly and with good hair survival goes a long way cosmetically. The fear that transplanted hair will be lost soon after surgery is misplaced if the donor area has been appropriately chosen.

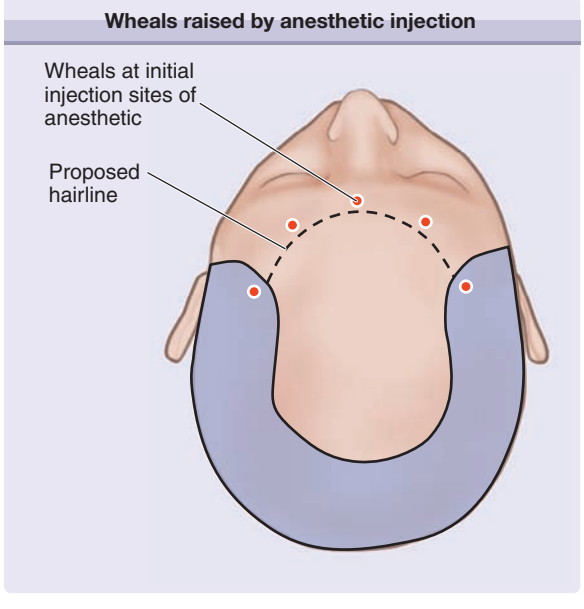

Figure 256-12 A photo showing the wheals raised by anesthetic injection in the midline, middle of the left and right hairline, and lateral ends of the hairline. These wheals are gradually extended left and right, by inserting the needle through them after the onset of anesthesia, to complete the field block almost painlessly.



Figure 256-13 The hair was clipped short in the donor area prior to the fourth session. The narrow scar that can be seen in this photo is the only scar he had after three sessions as we typically excise any scar from prior surgery as part of subsequent donor strips. Scars are usually 0.2–1.5 mm wide regardless of the number of strips that have been excised. We believe that this is mainly because we nearly always try to choose strip widths that create wounds that will close with what we call "minus 1" (-1) to "minus 2" (-2) tension, that is, we believe we could have taken a strip that was 1.0–2.0 mm wider than what we actually took.

Immediately prior to donor tissue excision, the donor area is tumesced with 10–40 mL of normal saline. This increases tissue turgor, thereby minimizing bleeding, but also limiting follicle bending that might otherwise result in FU transection. The authors use a single or double-bladed scalpel to cut donor tissue parallel to the exit angle of the hair: a double-bladed scalpel is used when the angle of hair at the superior and inferior aspects of the donor strip are aligned, and a single-bladed scalpel is used if there is a discrepancy, in order to prevent FU transection at one edge. This usually means that a double-bladed scalpel is used on the initial surgery, and a single-bladed scalpel in subsequent surgeries, since scarring from prior session(s) often distorts hair angle.

The incision begins and ends approximately 2 cm medial to the ends of the clipped donor area. To reduce the likelihood of "dog ears" forming, the two ends are tapered to a 30° angle using a No. 15 scalpel. The depth of the incision can vary significantly. In the first surgery, the blades are placed in high subcutaneous fat, in order to minimize underlying neurovascular damage. In subsequent surgeries, where fibrous scar tissue has formed deep to the original donor site, the depth of the incision is greater in order to permit its removal. This is an important step, since scar tissue is avascular, space occupying, and tethers the edges of the wound, thereby increasing donor closing tension and interfering with wound healing.

The entire strip is removed in three sections, which provides greater control of bleeding. Vessels with exuberant bleeding are cauterized using a unipolar hyfrecator. The wound is closed with a running suture. In practice, the authors use a 2.0 or 3.0 Supramid (a nylon suture) with a CL50 cutting needle.

Rarely, the authors will employ a "trichophytic closure," in order to minimize scar visibility in individuals who have previously healed with a wider than usual scar. In such instances, a wedge-shaped portion of the epidermis of the inferior wound edge is removed prior to donor closure, using either curved scissors or a bent razor blade. This transects the upper portion of hair follicles, and when the two opposing edges of the wound are apposed, most of these transected follicles will lie under the line of closure. If properly done, these hairs then grow *through* the donor scar, thus reducing the noticeability of scar tissue.

An alternative method of donor harvesting referred to as *follicular unit extraction (FUE)*. Using this technique, each individual FU is created directly from the scalp, rather than from a strip of donor tissue.[13,14] FU are excised using a small, sharp cylindrical punch (generally 0.8–1.2 mm in diameter), which incises the skin around each FU. The FU can then be carefully removed with forceps and gentle traction.

On the one hand, this technique offers distinct advantages. Most importantly, it does not leave a linear scar. The resultant punctate scars are minimally noticeable, even with the hair closely cropped (Fig. 256-14). Thus, this is a useful procedure for individuals who have a strong dislike or fear of linear scars, or who are more likely to produce wider than average linear scars. On the other hand, FUE is associated with important disadvantages. Chief amongst them, if a patient is destined to develop greater than Type V MPB, and therefore need more than 6,000 transplanted FU, many of these grafts will need to be harvested from areas outside the boundaries of the SDA (Fig. 256-14). This is because FUE involves the extraction of every third or fourth FU, and therefore the donor area would have to be 3–4 times as large as the donor area required for strip harvesting. The hair within many of these FU is therefore less likely to be permanent. Equally important, the transection rates during graft harvesting are substantially higher for FUE than for strip excision. In FUE, each FU is at risk of transection when it is extracted blindly from the scalp. In contrast, in strip



Figure 256-14 **A.** This is an intraoperative photo of a patient who had a linear scar from prior conventional strip harvesting, and who was undergoing FUE with the intention of placing grafts within the linear scar, and in areas of alopecia. The FUE was carried out by another surgeon. The round holes are the sites of FU extraction. The superimposed rectangle outlines the safe donor area (SDA). Many of the FUE sites were outside of the SDA, and the hair in these harvested grafts will likely be lost with time as MPB progresses. **B.** A photo taken 9 months postoperatively demonstrates the most important, immediately recognizable advantage of FUE: namely the ability for the patient to cut the donor area to any length without visible scarring. The previous linear scar has been effectively concealed with grafting.

harvesting only grafts at the edges of the strip are vulnerable, since other FU are prepared with magnified, direct visualization (see below). For these reasons, in the authors' practices, FUE is used to complement strip harvesting, but not to replace it. In particular, FUE may be used to obtain FU for placement into linear scars produced by strip harvesting. This is desirable when the scar is wider than average or when no further strip harvesting is planned. Such an approach combines the main advantage of strip harvesting—the maximization of the number of permanent hair—with the main advantage of FUE, the lack of a linear scar. Additional points of comparison between FUE and strip harvesting are outlined in Box 256-4.

BOX 256-4 ADVANTAGES AND DISADVANTAGES OF FOLLICULAR UNIT EXTRACTION

ADVANTAGES

- Reduced postoperative pain
- Rapid donor healing
- Absence of linear scar
- Ability to selectively choose FUs according to desired size or texture

DISADVANTAGES

- Difficult to obtain large numbers of grafts without exceeding the limits of the safe donor area
- Higher follicular transection rates
- More difficult post-operative camouflage because hair needs to be clipped short for harvesting
- Longer operative times

GRAFT PREPARATION

The preparation of grafts is accomplished using either stereoscopic microscopes or magnifying loupes or glasses. After removal of a donor strip, the first step is "slivering" the donor strip, in which slices, one FU wide, are carefully produced from the strip, much like cutting a loaf of bread into individual slices (Fig. 256-15A). These slivers, composed of 4–10 FU, are then further divided into individual FU. Occasionally, two very closely spaced FU, that combined are small enough to fit into a typical FU recipient site, are not divided. Such a graft is referred to as a follicular family (FF). Compared with larger multi-FU grafts, FU and FF are far more susceptible to injury during graft preparation, storage, and insertion.[15] Therefore, technicians must have thorough and prolonged training, excellent manual dexterity, an appropriate temperament, and ongoing supervision.

The ideal FU has most of its epidermis removed and is tear shaped, with the tapered end near the epidermis, and the rounded end in the subcutaneous tissue (Fig. 256-15B). The donor tissue is kept moist at all times, and prepared FU are stored in a sectioned Petri dish filled with normal saline, or an alternative physiologic solution.[16] This dish sits on a Lepaw cooler filled with ice. Within the sectioned dish, FU are distributed into labeled compartments depending on the number and caliber of hairs. In this way, the individuals planting grafts can immediately find the type of graft that they need for a particular recipient site. Hairs that are partially transected are not discarded, provided that the distal two-thirds or proximal half is intact. They are, however, placed in less cosmetically important regions, since hair growth from these grafts is unpredictable.

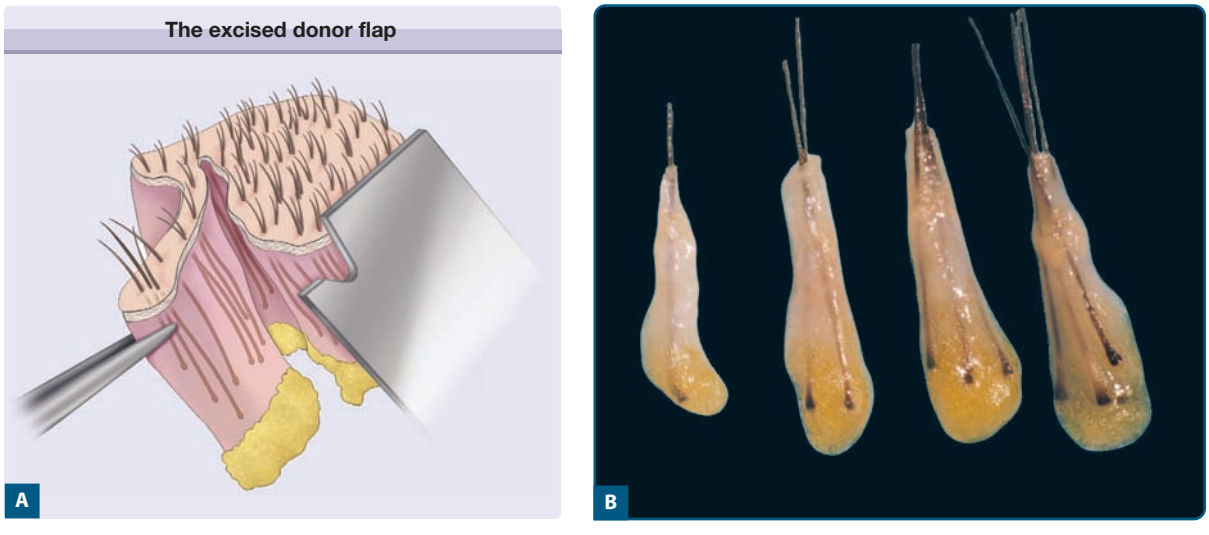

Figure 256-15 **A.** The excised donor strip is initially sectioned into slices that are one FU in width, much as one cuts bread into slices. **B.** Pear-shaped; chubby; one-, two-, three-, and four-haired FU grafts. Note the intact sebaceous glands and the fat pads below the dermal papillae. (Photos used with permission from Dr. David Seager.)

RECIPIENT SITE CREATION[17]

Recipient sites are created using hypodermic needles or small blades cut to match the size of grafts. During this process, a 1/50,000 epinephrine solution or normal saline is injected intermittently and superficially into the recipient area to provide better hemostasis. Such infiltration offers the additional advantage of spreading existing recipient area hairs apart, thus minimizing the risk of injury when making incisions. Furthermore, as the solutions dissipate, the recipient sites move closer together, which ultimately produces higher hair density.

The incisions are made at the same angle and direction as the persisting terminal or vellus hairs. Much of the art of hair transplanting resides in the ability of the surgeon to do this, as both angle and direction vary considerably from patient to patient, and between different areas of the scalp (Fig. 256-16). If one fails to do this, the resultant appearance will be unnatural and preexisting hair in the recipient area can be lethally damaged. Therefore, recipient site creation should be done very slowly in order to ensure accurate angling and direction. Typically, it will take between 1½ and 2½ hours to make 2,000–2,500 sites, depending on the density of preexisting hair in the recipient area and the amount of bleeding.

If hair survival is high, a density of 20–30 FU/cm^2 produces very good cosmetic results while preserving donor hair for future areas; consequently, this is the density that the authors' prefer. Higher density grafting is limited to small cosmetically strategic areas of the recipient area, including an oval in the anterior midline of the frontal area (Fig. 256-6). Greater density in this particular area gives an impression of higher density across the entire frontal area.

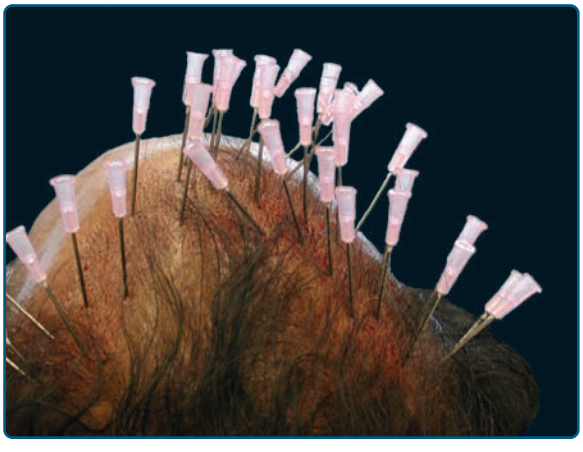

Figure 256-16 Although various directions and angles of hairs in different areas of the scalp have been described, none of these generalities apply to all patients. Hair directions and angles can change dramatically in relatively small areas, as indicated in the above photo showing needles inserted at the angle and direction of hair at these locations. The surgeon should follow what they observe rather than any general rule concerning hair angle and direction.

A second reason for grafting at 20–30 FU/cm^2 is that most studies on hair survival have demonstrated a tendency for unacceptable decreases in hair survival at higher FU densities, especially when the total incision length exceeds 3.0 cm/cm^2.[18,19] In part, this may be because higher densities require smaller recipient sites and, therefore, more graft handling. Although hair survival at high FU densities has improved substantially in the last few years, good cosmetic results can be achieved with 20–30 FU/cm^2, and thus higher densities are reserved for individuals with publicly visible professions. For other individuals, especially younger patients with uncertain long-term donor/recipient ratios, it is an inappropriate use of a limited resource.

With regards to "mega-sessions" of 3,000–5,000 FUs, it should be pointed out that the average recipient site is 1 mm long, and while 1 mm seems quite small, the *total* length of a 3,000, 4,000, or 5,000 graft session is respectively 9.99 ft, 13.33 ft, and 16.67 ft. Obviously, the larger the area treated, the more worrisome any given number of incisions and the resulting vascular damage. It seems reasonable to be cautious about creating 10–16 ft. of incisions on the scalp until high hair survival rates in such sessions have been confirmed.

In order to determine the optimal size of the recipient site, several grafts containing varying numbers of hairs are tested in different sized incisions. The needle or blade size is adjusted accordingly. Typically, 1-hair FU and fine 2-hair FU fit into sites made with 20G needles, coarser 2-hair FU fit into 19G sites, and 3-hair and 4-hair FU fit into sites made with 18G needles. The ideal graft fit is one that is "snug," but not so tight as to require significant handling during insertion. In general, sites for 1 or 2 fine-haired FU are created in the hairline zone, and sites for 2 or 3 coarse-haired FU are created in areas that need greater hair density.

GRAFT INSERTION

After the recipient sites have been created, the surgeon reviews with their assistants the locations where the various sized FUs should be placed. Usually, two or three technicians work on a single patient simultaneously. A group of grafts is removed from the fluid filled wells of the Petri dish, placed in a "ring" filled with saline on the finger, and from there placed in its recipient site. In this way, grafts are kept moist. With an appreciation of the angle and direction of the recipient site, a skilled technician can then insert a graft with one or two swift movements. The recipient area is kept clean by regularly using a mixture of saline (75%) and peroxide (25%), and the grafts are left slightly elevated to help in identifying sites that have not yet been filled. At the end of the procedure, grafts are repositioned to the level of the epidermis, or left slightly elevated, but never depressed as this can cause pitting, or depressions, in the perifollicular skin.

REPAIR SURGERY

The appearance of the recipient area of patients who have visible, unnatural grafting from prior surgeries, in



Figure 256-17 **A.** This 39-year-old patient had a "FUT" procedure carried out by another physician 3 years before this photograph was taken. A number of errors had been made. These included a failure to transplant into evolving areas of hair loss, and the placement of grafts that contained too many hairs, of too coarse a texture, in the hairline zone. The black crayon outlines the area that we proposed to treat. **B.** The patient returned 9 months after his first repair consisting of 1973 FU. A new hairline had been created using finely textured 1- and 2-haired grafts. The rest of the frontal area was repaired by surrounding prior grafts with FU, and by extending the transplant into adjacent areas of evolving hair loss. A third session, this time to the midscalp, was carried out 2 months after this photo was taken.

particular from MFU grafting, can be greatly improved with modern hair transplanting techniques, primarily by placing FU anterior and peripheral to these larger grafts.[20] If FU with too many hairs or too coarse hairs have been inappropriately placed in the hairline zone, these can be dealt with similarly, by surrounding them with properly selected FU (Fig. 256-17). For larger grafts, the excision of all or a portion of any larger grafts may also be useful in minimizing "plugginess," while providing additional hair that can be transplanted elsewhere in the recipient area (Fig. 256-18). For patients in whom poor planning resulted in the unnatural placement of grafts, for example, a hairline that is too far anterior, the grafts can be excised either individually or by employing an "en bloc" excision.

In the donor area, multiple rows of scarring can often be reduced by excising a strip of tissue that contains two rows of scar tissue and an intervening zone of hair-bearing skin (Fig. 256-19). This converts 2 scars into a single scar, while providing additional hair for use in the recipient area. It is important, however, that the removed strip is not so wide as to prevent a tension free closure.Alternatively, donor scarring can be improved by grafting into abnormally wide scars.

SIDE EFFECTS AND COMPLICATIONS

The potential side effects and complications of hair restoration surgery are listed in Box 256-5.[21] Below we elaborate on a few of them:

1. Edema: Severe postoperative edema is unusual, but can be unsightly if it occurs in the frontal region, or interfere with healing if it occurs in the donor area. The risk is minimized by prescribing perioperative corticosteroids, by proper postoperative patient positioning, and by using ice compresses.
2. Infection: Although rare, infection can present as early folliculitis in the recipient area, or more seriously wound dehiscence in the donor area. A number of measures reduce the risk of superficial surgical site infection, and it is worth mentioning that prophylactic antibiotics are one such measure.

BOX 256-5 SIDE EFFECTS AND COMPLICATIONS

SIDE EFFECTS
- Minor bleeding
- Scalp hypoesthesia
- Edema
- Crusting
- Pruritus
- Postoperative effluvium

MEDICAL COMPLICATIONS
- Wound Infection
- Wound dehiscence
- Neuralgia and neuromas
- Arteriovenous fistulas
- Central recipient area necrosis
- Folliculitis

AESTHETIC COMPLICATIONS
- Visible scarring
- Hypertrophic and keloid scarring
- Unnatural appearance
- Poor density

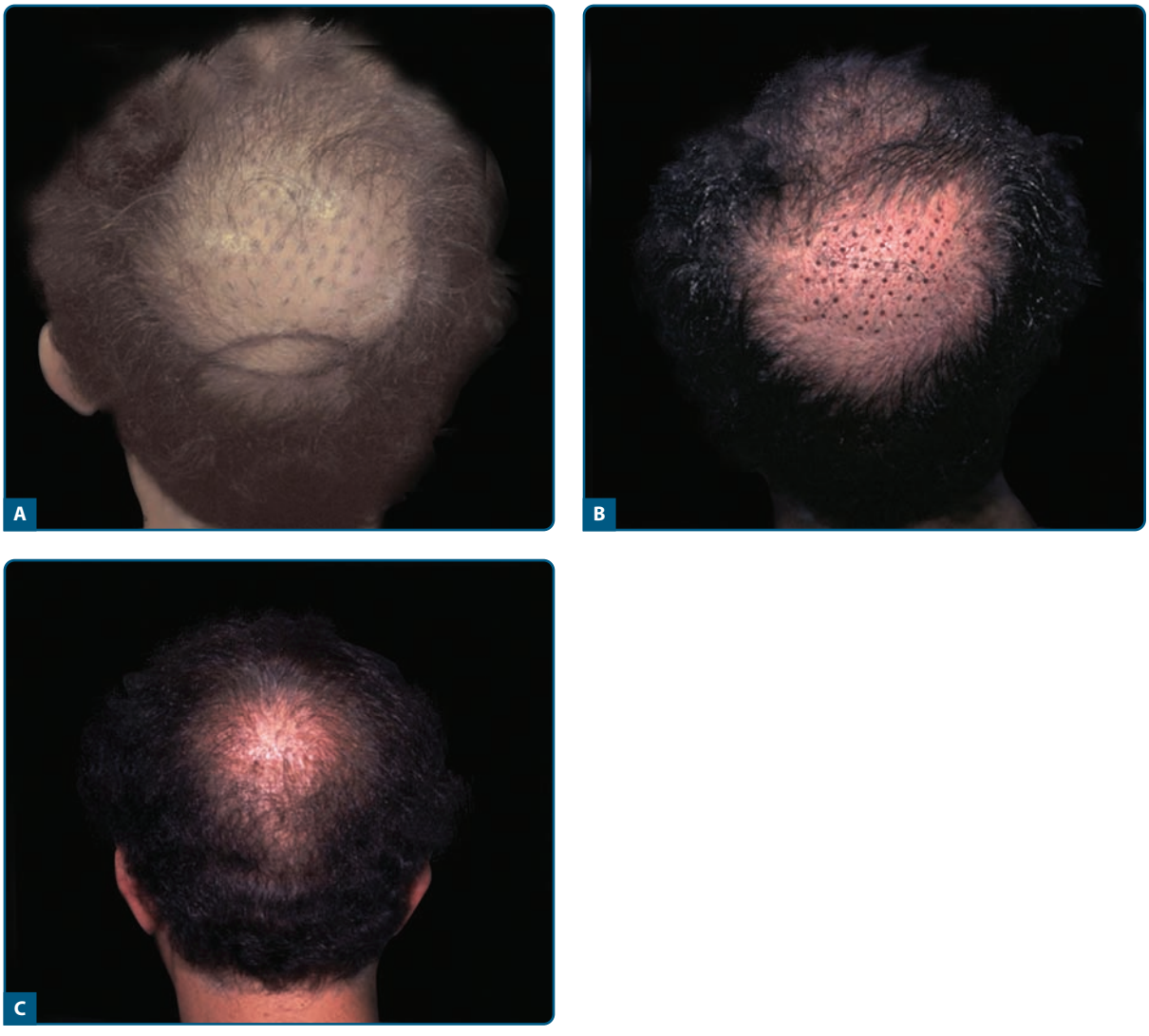

Figure 256-18 **A.** The vertex area of the patient shown above had been transplanted with standard round grafts. His original intention was to correct poor transplanting in the frontal and midscalp areas, but he was so happy with the progress in those areas that that he decided to correct the vertex problem. Because I was concerned about running out of donor tissue, he had an alopecia reduction (AR) performed on the right and posterior aspects of the vertex 3 months prior to the above photo. The hair in the standard grafts had been cut short to facilitate the excision of a portion of each of them. **B.** An intraoperative photo showing the holes where a 2-mm punch had been used to excise a portion of each of the standard grafts. At the same time 129 FUs, 398 DFU, and fifteen 1.5-mm-round grafts were scattered throughout the vertex area, some of which were obtained from the excised portions of the old grafts. A faint scar from the AR can also be seen in the posterior aspect of the vertex. **C.** Nine months later, a light but very natural looking coverage of hair was present in the vertex. The ultimate results of the transplanting in the midscalp and frontal areas can also be appreciated in the above photo. The hair in the vertex has been parted for critical evaluation with regard to both hair density and the minimal noticeability of the multi-FU grafts.

3. Bleeding: Minor donor area bleeding can occur in the first few days postoperatively. Usually this resolves with firmly applied pressure, but rarely extra suturing is required.
4. Donor area scarring: In the authors' office significant attention is given to measures that minimize the likelihood of wide donor scarring: the wound is closed with the absolute minimum of tension; postoperative edema is minimized through the aforementioned measures; and postoperative care is meticulous. Although this prevents wide scars in most patients, intrinsic poor wound-healing characteristics and severe scarring from old surgeries can result in wider than average scars. In such situations, grafts harvested from FUE can be transplanted into the scar, or alternatively trichophytic closures or double-layer suturing can be carried out during subsequent strip excisions.
5. Poor density: This may reflect poor graft growth, suboptimal graft distribution, or poor postoperative care. This problem is probably entirely avoidable.

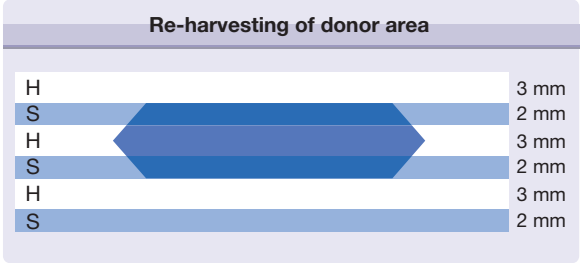

Figure 256-19 The shaded area represents a zone excised from a previously harvested donor area consisting of alternating bands of hair (H) and scar (S). *Note:* (1) As much or more scar tissue is excised as hair-bearing tissue. (2) Two hair-bearing strips are left adjacent to each other after the excision. The result is that the hair will appear to be denser in that general area, despite the removal of additional hair from it.

6. Postoperative effluvium: This problem may occur in hair-bearing areas in the recipient or donor areas. It is presumably due to the interruption of blood supply and is always temporary. Approximately 10%–20% of male patients and 50% of females experience some degree of postoperative effluvium.

PATIENT FOLLOW-UP

In the authors' practice, all patients are seen the day after surgery for bandage removal. The hair and scalp are thoroughly washed and postoperative instructions are reviewed. A clean cap is used to cover the surgical area before sending the patient home. All patients are seen 7–10 days postoperatively to check the surgical area and remove sutures. A follow-up appointment is generally booked for 6–12 months later to assess the surgical results and determine the need for further treatment.

ALOPECIA REDUCTION

Alopecia reduction (AR), or scalp reduction, is defined as the excision of an area of alopecia or future alopecia.[22] In the past, the technique was used in conjunction with hair transplantation as a means of reducing the size of the prospective recipient area, and thus conserving grafts for cosmetically vital areas of the scalp. Unfortunately, the technique is technically demanding, and the high frequency of medical and aesthetic complications, in inexperienced hands, led to the procedure falling out of favor. Currently, the technique is used to repair esthetically unsatisfactory hair transplanting or to excise areas of cicatricial alopecia.

TECHNIQUE

A variety of AR patterns have been described, but the most common patterns employed are the ellipse, the inverted-Y pattern, and the "lazy-S" shape. The inverted-Y pattern should be used if one anticipates insufficient donor tissue to transplant the entire bald area, even after AR. This design avoids a scar in areas that cannot later be covered with transplanted hair.

AR is usually carried out on an outpatient basis under sterile conditions. The procedure begins by drawing the chosen pattern on the scalp, followed by the creation of a field block. If the pattern is an ellipse, a variant of an ellipse or a "lazy S," an incision is made through the galea aponeurotica along one side of its entire length, usually in a staged fashion. Care is taken to angle the blade so as to not injure any adjacent follicles. If previously transplanted grafts are nearby, a 2-mm margin of safety is observed. Initially, Mayo scissors are used to undermine the region between the periosteum and galea aponeurotica. Undermining can usually be completed with blunt finger dissection, for a total of at least 10 cm on either side of the wound.

The amount of redundant scalp tissue is estimated by overlapping the tissues, followed by perpendicular incisions made through the top flap, stopping at the points where the flaps meet. The perpendicular cuts are then joined and the excess tissue is removed. If the AR is done in the shape of an inverted Y, each arm of the Y is treated as a separate ellipse. ARs are closed in two layers and an overnight dressing is applied. If the wound is closed with minimal tension, less than 10% of the original gain is lost through "stretchback."

As a variation of conventional AR, Patrick Frechet has incorporated the use of scalp "extenders".[23] In this procedure, a thin, stretched sheet of silicone elastomer is inserted into the subgaleal space. Rows of titanium hooks are attached to the lateral ends of the "extender," and subsequently hooked into the galea. The wound is then sutured closed in two layers. The extender has a natural tendency to return to its original size, thus stretching of the tissue located lateral to the hooks and contracting the scalp between them. After a period of approximately 30 days, the extender is removed. Substantial scalp laxity is then present, permitting a second consecutive AR session. Another extender can be inserted at the time of the second and even a third AR. Eight to twelve centimeters of alopecic skin can be excised after each extender is removed, yielding substantial results rapidly (Fig. 256-20). Disadvantages include considerable discomfort during a postoperative 2- to 7-day period, an infection rate of approximately 0.5%, and a slot defect that must be repaired if the entire area of alopecia is excised. Because of the steep learning curve, this potentially valuable procedure is currently carried out by fewer than 10 practitioners in the world.

COMPLICATIONS

Complications of AR include postoperative bleeding, infection, nerve damage, persistent hair thinning or loss in the fringe areas, disorientation of hair direction,

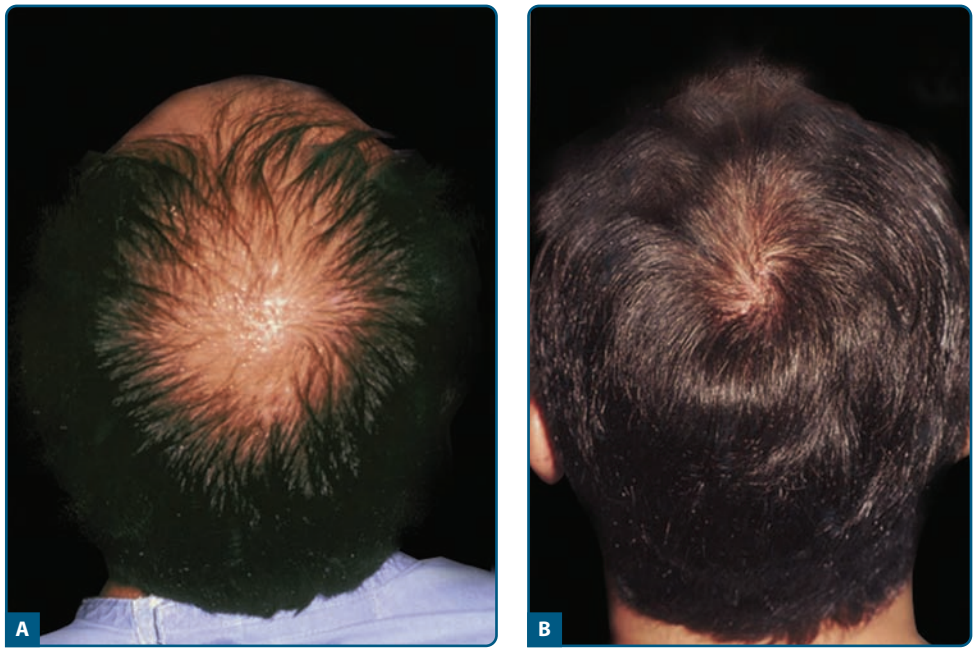

Figure 256-20 **A.** This photo shows a patient with a 10-cm-wide area of alopecia before treatment. **B.** The same patient 30 days later, after one scalp extension plus slot correction. (Photos used with permission from Dr. Patrick Frechet.)

and poor scars. All of these occur infrequently or not at all if the procedure is carried out properly. With the passage of time, excision scars may become noticeable as hair is lost in areas through which the scar passes. This is obviously a problem of poor planning rather than an intrinsic unavoidable complication of the procedure.

CONCLUSION

The evolution of hair transplanting, over the last 10–15 years, has resulted in a remarkable increase in the number of patients who are candidates for the procedure and an even more impressive improvement in the naturalness of the results. Unfortunately, these new techniques also require far more skill and patience from not only the surgeon, but also their surgical team. Additionally, hair restoration surgeons, are not miracle workers, and individuals must be educated as to what they can realistically expect from hair transplanting. When this is done, the reward is nearly always a satisfied and grateful patient.

KEY REFERENCES

Full reference list available at www.DIGM8.com

DVD contains references and additional content

4. Norwood OT: Classification and incidence of male pattern baldness. In: *Hair Transplant Surgery*, 2nd edition, edited by OT Norwood, R Shiell. Springfield, Charles C. Thomas, 1984, p. 3-14
5. Unger WP, Cole J: Donor harvesting. In: *Hair Transplantation*, 4th edition. Unger WP, R Shapiro. New York, Marcel Dekker, 2004, pp. 301-349
6. Ludwig E: Classification of the types of androgenetic alopecia (common baldness) occurring in the female sex. *Br J Dermatol* **97**:247-254, 1977
8. Unger WP, Unger RH: Hair transplanting: an important but often forgotten treatment for female pattern hair loss. *J Am Acad Dermatol* **49**(5):853-860, 2003
13. Rassman WR, Bernstein R, McLellan R, et al: Follicular unit extraction: minimally invasive surgery for hair transplantation. *Dermatol Surg* **28**:698-703, 2002
17. Unger WU, Shapiro R: The hairline. In: *Hair Transplantation* 5th edition, edited by WP Unger, R Shapiro, RH Unger, MA Unger. New York, Informa USA, 2011, pp. 372-373
19. Beehner M: Studying the Effect of FU Planting Density on Hair Survival. *Hair Transplant Forum Intl* **16**(1):247-248, 2006

INDEX

NOTE: Bold numbers indicate the start of the chapter that contains the main discussion of the topic; page numbers followed by b, f, and t refer to boxes, figures, and tables.

A

Abacavir, 2795t
  in HIV infection, 2448
Abatacept in lupus erythematosus, 1924t, 1970
ABCA1, 492
ABCA12/ABCA12, 71t
  in ichthyosis, 511t, 520t, 527
ABCC4 in Hermansky-Pudlak syndrome, 787
ABCC6/ABCC6, 65
  in pseudoxanthoma elasticum, 1651
ABCD checklist in melanoma diagnosis, 1429, 1429b
Abdominal pain, 1832–1834, 1832b
  in acute intermittent porphyria, 1541–1542, 1562b
  in helminthic infections, 2557
  in variegate porphyria, 1833
Abdominal stoma procedures, skin problems in, **1105**–1110
Ablative lasers, **3021**–3028. *See also* Nonablative lasers
  fractional lasers, 3023
    anesthesia in, 3024
    skin resurfacing, 3025–3026
  postoperative care, 3028
  side effects and complications, 3027–3028
  skin resurfacing, 3021–3026
    carbon dioxide laser, 3022, 3024
    Er:YAG laser, 3023, 3024
    equipment, 3022
    patient selection, 3022
Abrikossoff tumors, 1479
Abscess, 37
  in drug abuse, 1171f
  in limb amputation and prosthesis use, 1099, 1099f
  in scrofuloderma, 2228–2229
  in staphylococcal infections, 2136
    methicillin-resistant, 1116
  of vulva, 888
Absidia in zygomycosis, 2327
Absorption of drugs
  drug interactions in, 2834, 2835t
  in topical therapy, 2643, 2644–2645
    corticosteroid, **2659**–2665
    cutaneous metabolism affecting, 2657–2658
    with ointments, 2647
    penetration pathways in, 2656
    pharmacokinetics in, **2652**–2658, 2660
    regional anatomic differences in, 2644, 2644b
    and resorption, 2658
    stratum corneum affecting, 2644, 2655–2656
    systemic toxicity in, 2650–2651
  in transdermal delivery, 2651
Absorption of radiation, 1037–1038, 2852–2853, 2853f, 3006
  excited state molecules in, 1038
  in photodynamic therapy, 2852
  and scattering, 2852–2853, 2853f
  and selective photothermolysis, 2875
  skin color and, 3018
Abuse
  of children. *See* Child abuse
  of drugs. *See* Drug abuse
  of elderly, 1181, 1182t
Acanthamoeba, 2542–2543
Acanthaster planci (starfish), 2591
Acantholysis, 43–44, 44f, 46, **550**–562
  in Darier-White disease, 44f, 550–556
    acral darier disease, 556–557
  and dyskeratosis, 44, 44f, 46
  epidermal cohesion in, 46
  in Grover disease, 560–562
  in Hailey–Hailey disease, 557–560
  in pemphigus, 46, 588
    histopathology in, 594
    pathophysiology in, 588
  primary, 46
  secondary, 46
  vesicles in, 36
Acanthoma
  clear cell, 1330
  Degos, 1330
  fissuratum, 1331
  pale cell, 1330
  pilar sheath, 1355–1356
Acanthosis, 43, 44f
  in epidermal nevus, 1325, 1326
  nigricans, 1823, 1841–1843, 1882–1884
    acrochordons in, 1842, 1842f
    classification of, 1883
    clinical findings in, 1842, 1883
    complications of, 1884
    in Cushing syndrome, 1860
    in diabetes mellitus, 1841–1843
    disorders associated with, 1883
    drug-induced, 1841
    epidemiology of, 1841, 1883
    estrogen levels in, 1863
    etiology and pathogenesis in, 1842, 1883
    Leser-Trélat sign in, 1883, 1886
    malignancy-associated, 1883–1884
    oral cavity disorders in, 1842, 1883
    of palm, 1883
    prognosis and clinical course in, 1884
    treatment of, 1843, 1884
    tripe palm in, 1883, 1885
  palmaris, 1885
Acarina bites, 2604–2605
Acclimatization. *See also* Sweat
  thermoregulatory responses in, 1078
Acetylcholine, 1139t, 1140t, 1142–1143
  in cutaneous active vasodilation, 1077
  in inflammatory response, 1139t, 1140t
  in sweat glands, 929, 930f, 931, 934f, 1077
Acetylcholine receptor-3 in Sjögren syndrome, 1978
Achilles tendon
  in reactive arthritis, 246b, 247
  xanthoma of, 1603f, 1607
Acid chemicals, occupational exposure to, 2615
Acid sphingomyelinase, 491f, 491–492
Acitretin, 2761
  in actinic keratosis, 2762
  chemical structure of, 2760f
  complications of, 2766
  in Darier-White disease, 556, 2762
  dosing regimens, 2763
  in exfoliative dermatitis, 277b
  in hidradenitis suppurativa, 2762
  initiation and monitoring of therapy, 2763
  in lichen planus, 309b, 310, 311b
  in lupus erythematosus, 9124t, 1925, 2762
  in lymphocytic infiltration of skin, 1781b
  in palmoplantar keratoderma, 549

Acitretin—*continued*
in palmoplantar pustular eruptions, 256, 257b, 258
in perforating disorders, 731t
pharmacokinetics of, 2761
in pityriasis lichenoides, 295b
in pityriasis rubra pilaris, 283, 283b
in premalignant skin lesions, 2762
in psoriasis, 221t, 227–228, 2761
in combination with other agents, 223t, 2761, 2857
of nails, 1024
in pregnancy, 224b
in squamous cell carcinoma prevention, 342–343
in T-cell lymphoma, 2761–2762
Acne, **897**–917
aestivalis, 917
androgen levels in, 1864–1865
apert syndrome, 917
clinical findings in, 900
in coal tar exposure, 2629
comedonal, 32, 32f, 898–899, 905t
complications in, 904
in congenital adrenal hyperplasia, 915
conglobata, 905t, 913
cosmetica, 3014
differential diagnosis of, 903, 904b, 922, 1595
chloracne in, 2629
in drug abuse, 1120, 1173
drug-induced, 915
in corticosteroid therapy, 923, 2663
from cytotoxic agents, 2753
with endocrine disorders, 915
epidemiology of, 897
etiology and pathogenesis of, 890–900
excoriations in, 914, 1163
fulminans, 913–914
gram-negative folliculitis, 916
in infants and neonates, 900, 913, 915, 1189, 1200
keloidalis, alopecia in, 1000
laboratory tests in, 900, 903
in laser skin resurfacing, 3027
laser therapy in, 912, 2885
mechanica, 914, 2629
in athletes, 1120
necrotica, 1000
neonatal, 913
nodules in, 889, 900, 905t
nodulocystic, 900
nutritional factors in, 912, 2903
in occupational exposures, 916, 2629
in oil contact, 2629
in oily skin type, 3011
outcome measures in, 13
in PAPA syndrome, 914
papules in, 900, 905t
penile, 872
photo-exacerbated, 1063
in polycystic ovary syndrome, 903, 904, 915
pseudoacne of nasal crease, 917
prognosis and clinical course in, 904–905
with pyogenic arthritis and pyoderma gangrenosum
clinical findings in, 1594
differential diagnosis in, 1595
in SAPHO syndrome, 914
scarring in, 903f
in sensitive skin type, 3013
with solid facial edema, 915
Toll-like receptors in, 110, 900
treatment of, 905–913, 905t
antibiotics in, 908–909, 2673–2674
complementary and alternative approaches to, 2903
hormonal therapy, 909
laser therapy in, 912–913, 912, 2885
photodynamic therapy in, 912–913
retinoids in, 906, 2761
systemic therapy, 908–909
topical agents, 906–908
tropical, 917
vulgaris, 897–913
in adolescents, 900, 1200
antibiotics in, 906, 2673–2674
differentiated from chloracne, 2629–2630
retinoids in, 906, 906, 908
treatment, 905–913
Acneiform lesions, **915**–917
acne aestivalis, 917
in athletes, 1120
drug-induced, 915
from corticosteroids, 2663
from cytotoxic agents, 2753
in irritant contact dermatitis, 503
in occupational exposures, 916, 2629
radiation acne, 916
in steroid folliculitis, 915
topical acne, 917Acral distribution of lesions, 41
Acral erythema, chemotherapy-induced, 2754
Acremonium, 2292
Acrivastine, 2769, 2770t
Acroangiodermatitis
in amputation stump, 1100
of Mali, 1101
papular, 1835
Acrocephalosyndactyly, 917
Acrochordons, 712, 1842
in acanthosis nigricans, 1842, 1842f
Acrocyanosis, 1741
in cold exposure, 1085–1086
in cryoglobulinemia, 2059b
differential diagnosis of, 2060
in polycythemia vera, 1741, 1742
Acrodermatitis
acidemica, 1527
chronica atrophicans, in Lyme disease, 2267–2269
continua, **256**–258
clinical findings, 257
differential diagnosis, 258
epidemiology, 257
etiology and pathogenesis, 257
histopathology, 258
laboratory findings, 258
nail changes in, 1018, 1024
prognosis/clinical course, 258
treatment, 257b, 258
enteropathica, in zinc deficiency, 1521–1522, 1834
papular
in children and infants, 2350–2352
in hepatitis B, 1835
Acrokeratosis
paraneoplastic, of Bazex, 191, **1887**–1889
clinical findings in, 1888
differential diagnosis of, 191, 1889
nail changes in, 1888
stages of, 1888
treatment of, 1889
verruciformis, 556–557
Acromegaly, 1866–1867
approach to patient with, 1866b
clinical findings in, 1866–1867
hyperhidrosis in, 941, 1866
Acro-osteolysis, occupational, 2629
Acropachy, thyroid, 1855
treatment of, 1856
Acroparesthesia in Fabry disease, 1618, 1620
Acropigmentation of Dohi, reticulate, 825
Acrospiroma, eccrine, 1352
Acrosyringium, 946
Acrylics, occupational exposure to, 2616t, 2617t
ACTH. *See* Adrenocorticotropic hormone
Actin
cytoskeletal defect in, 1728t
in melanocyte dendrites, 774
Actinic cheilitis, 846, 1253, 1264, 1265f
Actinic dermatitis, chronic, 1057–1060, 2848, 2862
clinical features in, 1058–1059
diagnosis of, 1060b
differential diagnosis in, 1060b
laboratory tests in, 1059–1060
in photosensitivity, 1060, 1071
treatment of, 1060
photochemotherapy in, 1060
Actinic keratosis, 1253, **1261**–1270
characteristics of, 1253
clinical findings in, 1263–1264
conjunctival, 1264t
cutaneous horn in, 1264, 1265t
in cytotoxic drug therapy, 2755
diagnosis and differential diagnosis in, 567, 567b, 1264
epidemiology of, 1251–1252, 1262
erythematous, 1263
etiology and pathogenesis in, 1262–1263
histopathology in, 1264t
hypertrophic, 1263
in immunosuppressed host, 343, 1262
p53 in, 1262, 1263f
pigmented, 1262
prevention of, 1269–1270
prognosis and clinical course in, 1264–1266
proliferative, 1261

risk factors for, 1261, 1262, 1264
squamous cell carcinoma in
risk for, 1264–1266
subtypes and variants of, 1263, 1264t
treatment of, 1266–1269, 1266b
approach to, 1267f
cryotherapy in, 1266, 2970–2971
curettage, 1266
field therapies in, 1268–1269
5-fluorouracil in, 1268b, 1269, 2685
imiquimod in, 1268b, 1269
lesion-targeted, 1266
photodynamic therapy in, 1268, 2865
retinoids in, 1269
and xeroderma pigmentosum, 1659, 1660f, 1661, 1662
Actinic porokeratosis
disseminated superficial, 564–565
Actinic prurigo, 1053–1055
clinical features in, 1053–1054
differential diagnosis in, 1055b
treatment of, 1055
Actinobacillus actinomycetemcomitans, 2242
Actinomadura madurae, 2248
Actinomadura pelletieri, 2248
Actinomyces gerencseriae, 2242
Actinomyces israelii, 2242
diagnosis of, 2126
Actinomyces meyeri, 2242
Actinomyces naeslundii, 2242
Actinomyces odontolyticus, 2242
Actinomyces viscosus, 2242
Actinomycetoma, 2248–2252, 2313, 2314, 2315
clinical findings in, 2249–2250, 2314
differential diagnosis of, 2251–2252, 2251b
laboratory tests in, 2314
treatment of, 2252
Actinomycosis, **2241**–2244, 2327
abdominal, 2244
cervicofacial, 2243
clinical findings in, 2243–2244
differential diagnosis of, 2244, 2245b
pelvic, 2244
punch or fist, 2244
thoracic, 2243
treatment of, 2245
Action spectrum of ultraviolet radiation, 1040, 1042–1043, 2843
Activator protein 1, 1221
Activin receptor-like kinase 1, 71t, 73
Acyclovir, 2787–2789
adverse effects of, 2788
dosage of, 2788, 2789t
in herpes simplex virus infections, 2376, 2377b
in herpes zoster, 13
indications for, 2788
mechanism of action, 2787
pharmacokinetics of, 2787–2788
in pityriasis rosea, 463, 463b
in varicella-zoster virus infections, 2394
ADA, 1712t
Adalimumab, 2819–2820
in lichen planus, 312
in psoriasis, 229
and arthritis, 241
in rheumatoid arthritis, 1970, 2822
Adamantiades-Behçet disease, **2033**–2041. *See also* Behçet disease
Adams-Oliver syndrome, 1699
Adamson's fringe, 965
ADAMTS-2/ADAMTS-2, 674t, 676
in Ehlers-Danlos syndrome, 1625t
Adapalene, 2666
in acne vulgaris, 906
chemical structure of, 2666f
indications for, 2670
receptor selectivity of, 2666
Adaptive immunity, 105, 113–126, 401, 2123
cell types in
antigen presenting cells, 117–119
dendritic cells, 119–121
dermal dendritic cells, 124
inflammatory dendritic cells, 124–125
Langerhans cells, 121–124
cellular, 401. *See also* Cell-mediated immunity
compared to innate immunity, 106, 106f, 1991
endothelium in, 1997–1998
humoral, 401
Adaptor proteins, 771
Addison disease, 1861–1862
hyperpigmentation in, 818, 1861–1862
oral cavity disorders in, 844
vitiligo in, 795, 1861
Addressins, 1994t, 1998, 1999
Adenocarcinoma
aggressive digital papillary, 1353–1354
apocrine, 1347
eccrine, 1353
Adenoma
aggressive digital papillary, 1353–1354
eccrine, 1351
of nipple, 1344
of pituitary, acromegaly in, 1866–1867
sebaceous, 1341
toxic, 1852
tubular, 1351
Adenomatous polyposis, familial, 709t, 1356
Adenosine deaminase deficiency, 1712t
Adenosine monophosphate, cyclic
in melanogenesis, 772, 773
response element, 772
Adenylate cyclase in melanogenesis, 773, 777
Adherence stage in dermatophyte infections, 2278
Adhesion, intercellular, 61, 62, **569**–585
calcium in, 61, 62
desmosomes in, 570–574
eosinophil receptors in, 358–359
neutrophils in, 347–349
Adipocytes, 67
Adipose tissue
panniculitis and, 732–733
subcutaneous, 56, 57, 67. *See also* Subcutaneous fat
Adiposis dolorosa, 1491
ADME model on pharmacokinetic drug interactions, 2836
Adnexal carcinoma, microcystic, 1354–1355
Adolescents, 1200
dermatology
acne vulgaris in, 900, 1200
axillary hyperhidrosis, 1201
indoor tanning, 1201
Adrenal gland disorders, **1859**–1865
acute crisis in, 1861
Addison disease in, 1861–1862
and candidiasis, chronic mucocutaneous, 1708t
congenital hyperplasia, 1864
in corticosteroid therapy, 2660, 2718, 2719
Cushing syndrome in, 1859–1861
hemorrhage
in meningococcal infections, 2179–2182
in Waterhouse-Friderichsen syndrome, 2181, 2182, 2200
hirsutism in, 1005–1008
α-Adrenergic receptors
in melanogenesis regulation, 778
α-Adrenergic stimulation, sweating in, 944
β-Adrenergic receptors
in melanogenesis regulation, 778
β-Adrenergic stimulation, sweating in, 942
Adrenergic urticaria, 421
Adrenocorticotropic hormone
in Addison disease, 1861–1862
corticosteroid therapy affecting, 2716, 2717, 2718, 2719
in Cushing syndrome, 1859–1861
ectopic, hyperpigmentation in, 819
as melanogenic stimulator, 776
in sebaceous gland activity and sebum production, 896
Adson maneuver in Raynaud phenomenon, 2067
ADULT syndrome, 1696, 1699
Adult-onset Still's disease (AOSD), 1971
Advancement flaps, 2931–2935
Aeromonas hydrophila infections, 2221, 2598t
cellulitis in, 2192
in immunocompromised host, 332
myonecrosis in, 2193
Aerosol drug formulations, topical, 2648–2649
African endemic Kaposi sarcoma, 1483
African histoplasmosis, 2321
African tick bite fever, 2463
African trypanosomiasis, 2537–2540
Agalsidase alfa in Fabry disease, 1623
Agalsidase β in Fabry disease, 1623
Agammaglobulinemia, X-linked, 1703–1705

Age. *See also* Aging; Children; Elderly
in allergic contact dermatitis, 152–153
in irritant contact dermatitis, 501
and melanoma prognosis, 1434
and mortality rates, 4
and prevalence of skin disease, 5
in psoriasis onset, 197
Aggrecan, 686
Aging, **1213**–1226, 3018–3020. *See also* Rejuvenation of skin
atrophy in, 32
cellular, 1213–1214
cutaneous, 1214–1223
histologic features in, 1215t
mechanisms in, 1215
smoking affecting, 1223
effects of, 1213
hyaluronic acid levels in, 3010, 3019
immune function in, 1214
melanocyte, 780
photoaging. *See* Photoaging
premature, 1214, 3019
proteoglycan and glycosaminoglycan changes in, 690
replicative senescence in, 1214
retinoid therapy in, 2670, 2671
wrinkling of skin in, 1218, 1219, 1220f, 1221, 3018–3020
prevention, 3019
Agouti protein, 773, 972
AGPAT2 in lipodystrophy, 756, 756t
Agranulocytosis
in dapsone therapy, 2725
in drug interactions, 2840t
Agrin, 580–581
Ainhum, **724**–726
Airborne irritant dermatitis, 2613
AIRE, 1902
Ajuga turkestanica, 3010
Alagille syndrome, 1611
steatocystoma multiplex in, 1335
Alanine aminotransferase levels in dermatomyositis, 1935
Albendazole, 2560, 2561, 2562
in enterobiasis, 2561
in hookworm infections, 2560
in larva migrans, 2560
in strongyloidiasis, 2562
Albinism, **781**–791
complications in, 790
differential diagnosis of, 781b
epidemiology of, 781
etiology and pathogenesis of, 782–786
OCA1, 783–784
OCA2, 784
OCA3, 786
oculocutaneous, 783–786
genetic factors in, 783–786
skin cancer risk in, 1258
treatment of, 791
type 1 (OCA1A), 783–784
type 1 (OCA1B), 783–784
type 1 (temperature-sensitive), 784
type 2, 784–786
type 3, 786
pathogenesis, 786
prognosis and clinical course in, 791
treatment of, 791
Albright hereditary osteodystrophy, 1653–1654, 1859
Albright's sign, 1653, 1859
Albumin serum levels
in decubitus ulcersin exfoliative dermatitis, 272
in psoriasis, 216
Alcohol use and alcoholism, 1820
clinical findings associated with, 1168
folate (vitamin B9) deficiency in, 1514
gout in, 1973
porphyria cutanea tarda in, 1549
spider nevi in, 1827
vitamin B_3 deficiency in, 1512
vitamin B_6 deficiency in, 1513
vitamin C deficiency in, 1515
zinc deficiency in, 1521
Aldehyde dehydrogenase, fatty, 70
ALDH3A2, 534
ALDH10, 534
Aldolase serum levels in dermatomyositis, 1935
Aldosterone and sweat gland function, 934
Alefacept, 2815t, 2824
in palmoplantar pustulosis, 256
in psoriasis, 229, 2824
and arthritis, 241, 2824
Alemtuzumab, 361
Aleppo boil, 2530
Alezzandrini syndrome, 795
Alfacalcidiol in corticosteroid therapy and osteoporosis, 2720
Alginate dressings, 2991, 2991t
Alitretinoin, 2763
in vesicular palmoplantar eczema, 193
Alkali chemicals, occupational exposure to, 2615
Alkaline phosphatase levels, 1874
Alkaptonuria, 1526t, **1533**–1537
clinical features in, 1534–1536
diagnosis and differential diagnosis of, 1536–1537
epidemiology of, 1533
etiology and pathogenesis in, 1534
genetic factors in, 1534
intervertebral disk calcification in, 1536, 1536f
laboratory findings in, 1536
prognosis and clinical course in, 1537
treatment of, 1537
Alkylamine, 2771
Alkylating agents, 2747–2752
Allelic heterogeneity, 81
Allen test, 2067–2068
Allergens. *See also* Patch testing
in allergic contact dermatitis, 152, 162
in occupational exposures, 2617t
of vulva, 882
in atopic dermatitis
in immunotherapy, 178
as triggering factor, 177–179
in cosmetic products, 3016–3017
in photoallergy, 1072
in urticaria and angioedema, 418
Allergic angiitis and granulomatosis, 2022
Allergic contact dermatitis, **152**–164. *See also* Irritant contact dermatitis
of amputation stump, 1102–1103
in athletes, 1119
barrier function of skin in, 496
clinical approach in
diagnosis consideration, 154
history taking, 155
clinical manifestations in
cutaneous findings, 155–156
topographic approach, 156–157
common allergens causing, 152, 162
in occupational exposures, 2617t
complications in, 164
in corticosteroid therapy, 158, 159, 2664
from cosmetic products, 157, 158, 161, 3013, 3016
developments in, new, 154b
diagnosis of, 155, 156
differential diagnosis in, 163–164, 163b, 164b
drugs-induced, 159
epidemiology of
age, 152–153
gender and race, 153
erythema-like, 153, 153f
etiology and pathogenesis in, 153
elicitation phase, 154
sensitization phase, 153–154
frequency approach to, 160
bacitracin, 161
cobalt, 161
formaldehyde and formaldehyde releasing preservatives, 161
fragrances, 160
MDGN/PE, 161
neomycin, 160
nickel, 160
para–phenylenediamine (PPD), 161–162
history-taking in, 155
lichenoid, 156
lymphomatoid, 156
noneczematous variants of, 156
in occupational exposures, 155, 158, 160, 164, 2617
common allergens in, 2617, 2617t
diagnosis of, 2617
patch testing in, 163. *See also* Patch testing
complications of, 164
T.R.U.E. Test, 162
pathologic reactions in, 48
pigmented, 156
postoperative, 2979
prognosis in, 164
purpuric, 156
stages, 159t
systemic, 159
systemic reactions in, 159

T cell response in, 117, 153, 154
topographic approach
axillae, 158
eyelids, 157
face, 157
hands and feet, 158
lips, 157, 158
neck, 158
scalp, 157
torso, 158
treatment in, 164
of vulva, 882
Allergic contact purpura, 156
Alloknesis, 1148
Allylamine antifungal agents
oral, 2796–2800
topical, 2680–2681
Alopecia
androgenetic, 980–987
clinical findings in, 982
differential diagnosis of, 984b
epidemiology of, 981–982
etiology and pathogenesis in, 982
treatment of, 984–987
areata, 991–994
in children and infants, 1190
clinical features in, 991–992
differential diagnosis of, 992b
epidemiology of, 991
etiology and pathogenesis in, 991
nail changes in, 1026
prognosis in, 992
treatment of, 992–994, 2885
cicatricial or scarring, 995–1001
central centrifugal, 998
primary, 995–997, 998, 999
secondary, 1001
in cryotherapy complication, 2972
hair restoration surgery in, 986, 3075–3076
in ichthyosis follicularis, alopecia, and photophobia syndrome, 978
in keratosis follicularis spinulosa decalvans, 976
laser therapy and, 2885
in lichen planus, 303, 304
mucinosa, 998
in pattern hair loss
hair transplantation in, 3075–3076
pressure, 1002
reduction, **3075**–3076
complication, 3075–3076
technique, 3075
temporal triangular, 994
traction, 1001
treatment of
hair transplantation in, 3075–3076
photochemotherapy in, 994, 998
Alport syndrome, 577
Alternaria in immunocompromised host, 340
Alternative and complementary medicine, **2899**–2904
antioxidants in, 2900
disease, approach to, 2900–2901
food allergy determination and elimination, 2901
food allergy diagnosis, 2901
essential fatty acids in, 2901
herbal medicine, 2900
homeopathy, 2901
for specific disease conditions, 2901
acne, 2903
atopic dermatitis, 2902–2903
hidradenitis suppuritiva, 2903
seborrheic dermatitis, 2901–2902
Altitude, and cold injuries in high altitude, 1081
Aluminum
chloride as antiperspirant, 2703
salts as astringent, 2704
Amalgam, dental
pigmentation changes from, 843
Amantadine, livedo reticularis from, 2106
Amblyomma ticks, 2604
Ambras syndrome, hypertrichosis in, 1008
Amebas, opportunistic, 2542–2543
Amebiasis, cutaneous, 2541–2542
American trypanosomiasis, 2540–2541, 2607
Amikacin in actinomycetoma, 2252
Amino acids
metabolism disorders, **1525**–1537
δ-Aminolevulinic acid
in heme biosynthesis, 1539
Aminolevulinic acid dehydratasedeficiency of, 1571–1572
δ-Aminolevulinic acid synthase
in heme biosynthesis, 1538
Aminoquinolines, **2726**–2734
Aminoglycosides, topical, 2675
Amoxicillin
in actinomycetoma, 2252
Amphotericin B
in coccidioidomycosis, 2324
Amputation, **1095**–1104
abscess in limb, 1099, 1099f
acroangiodermatitis in, 1100
in diabetes mellitus, 1096
in foot problems, 1841, 1845
edema in, 1100
skin problems in, **1095**–1104
stump
allergic contact dermatitis of, **152**–164
bacterial infections, 1101
contact dermatitis of, 1102–1103
dermatitis of, 1098, 1100, 1102
ulcers in, 1097
types of limb prostheses in, 1095
Amyloidosis, **1574**–1583, 1831
clinical findings
AA amyloidosis, 1576
AL amyloidosis, 1576
hereditary amyloidosis, 1577
complications
AA amyloidosis, 1582
AL amyloidosis, 1582
hereditary amyloidosis, 1582
localized cutaneous amyloidosis, 1582
cutaneous manifestations
anosacral cutaneous amyloidosis, 1578
familial primary localized cutaneous amyloidosis, 1578
hereditary amyloidosis, 1578
insulin-derived amyloidosis, 1578
lichen amyloidosis, 1578
localized cutaneous AL amyloidosis, 1578
macular amyloidosis, 1578
systemic AL amyloidosis, 1577
diagnostic approach to, 1576f
differential diagnosis, 1582b
epidemiology, 1574
etiopathology and pathogenesis
hereditary amyloidosis, 1575
localized amyloidosis, 1575
systemic AA amyloidosis, 1574
systemic AL amyloidosis, 1574
genetic sequencing, 1581
histology, 1579–1581
imaging amyloid in vivo, 1581
cardiac imaging, 1581
SAP scintigraphy, 1581
laboratory testing, 1579
physical findings
hereditary amyloidosis, 1579
systemic AA amyloidosis, 1579
systemic AL amyloidosis, 1578
prognosis/clinical course
AA amyloidosis, 1582
AL amyloidosis, 1582
hereditary amyloidosis, 1582
localized cutaneous amyloidosis, 1582
treatment
AA amyloidosis, 1583
AL amyloidosis, 1583
hereditary amyloidosis, 1583
lichen amyloidosis, 1583
localized cutaneous AL amyloidosis, 1583
macular amyloidosis, 1583
systemic AL amyloidosis, 1583
Anabolic steroid abuse, cutaneous signs of, 1173
Anagen, 967–968
effluvium, 990–991
loose anagen syndrome, 988
short anagen syndrome, 988
Anal and perianal disorders
intraepithelial neoplasia, 1277
in lichen planus, 303
in syphilis. *See* Syphilis
in warts. *See* Warts, anogenital
Analgesics
topical, 2697
Anaphylaxis
exercise-induced, 421
Anaplasma phagocytophilum, 2272, 2468
Anaplasmosis, 2468
clinical and laboratory findings in, 2468
epidemiology of, 2468
histopathology in, 2468
treatment of, 2470

Ancylostoma braziliense, 2545t, 2547
occupational exposure to, 2626
Ancylostoma caninum, 2545t
Ancylostoma duodenale, 2545t, 2562
Andean sickness, 2531
Anderson-Fabry disease, 1833
Androgens, 1864–1865
in acne, 1864–1865
excess levels of, 1864–1865
in hair loss, 980–987, 1864–1865
in hirsutism, 1864
in polycystic ovary syndrome, 1864
in sebaceous gland activity and sebum production, 896, 1864–1865
Anemia, 1740–1741
of endocrine disorders, 1741
Fanconi. *See* Fanconi anemia
hematologic disorders, 1740–1741
hemolytic. *See* Hemolytic anemia
iron deficiency, 1520, 1740
macrocytic, 1740
microcytic, 1740
skin color in, 813
in visceral leishmaniasis, 2534
Anesthesia, 2913–2915
in cryosurgery, 2968–2969
epinephrine addition to, 2913–2914
in electrosurgery, 2973
in excisional surgery, 2923–2924
in laser therapy
for skin rejuvenation, 3033
for skin resurfacing, 3024
for vascular lesions, 3037
local, 2913
in liposuction, 3042
in nail surgery, 2958
nerve block use and, 2916
selection of, 2913
side effects and complications of, 2914–2915, 2983
in soft tissue augmentation, 3045, 3047–3051
topical agents in, 2697, 2915
Anesthesia complication of surgery, 2914–2915, 2978, 2983
Anetoderma, **718**–720
clinical findings in, 718
differential diagnosis of, 719–720
epidemiology, 718
in premature infants, 1192–1193
treatment of, 720
Angelman syndrome, 85
Angel's kiss, 2078
Angiitis
allergic, 2022
and granulomatosis, 2022
polyangiitis
leukocytoclastic, 2024
systemic, 2022
thromboangiitis obliterans, 2104–2106
Angioblastoma of Nakagawa, 1467
Angiodermatitis, disseminated pruriginous, 2052
Angioedema, 414
after direct mast cell degranulation, 424
angiotensin-converting enzyme inhibitors and, 422–424
arachidonic acid metabolism abnormalities, 424
in blood product administration, 424
bradykinin in, 417–418, 422
clinical findings in, 418–425
complement system in, 422
diagnostic approach in, 425–426
differential diagnosis of, 427b
drug-induced, 452
eosinophilia and, 388, 389, 390
epidemiology of, 414
in exercise-induced anaphylaxis, 421
hereditary, 1725
histopathology in, 427–428
idiopathic, 425
immunoglobulin IgE in, 418
laboratory findings in, 426–428
pathogenesis in, 414–418
treatment of, 428–430
and venulitis, 424
vibratory, 419
Angioendothelioma, 1467–1468
Angiofibroma, 712
facial, in tuberous sclerosis, 1674, 1674f
pearly penile papules in, 856
Angiogenesis
chemokines in, 149
cutaneous, 1999–2001
glucocorticoid therapy in, 2833
regulation of, 2000–2001
in wound healing, 2988
Angiography
magnetic resonance, 2097
Angiokeratoma
circumscriptum, 2088–2089
clinical manifestations of, 2088–2089
corporis diffusum, 1833
in Fabry disease, 1614
clinical manifestations of, 1614, 1620t
differential diagnosis in, 1620b, 1621t
histopathology of, 1614, 1616f
locations and distribution of, 1617
treatment of, 1622
genital, 856
Angioleiomyoma, 1471
Angiolipoma, 1492–1493
Angiolymphatic invasion of melanoma, 1434
Angiolymphoid hyperplasia
with eosinophilia, 394, 1768t
clinical findings in, 394, 1774–1775
differential diagnosis in, 396, 396b, 1775, 1775b
treatment of, 396, 1776, 1776b
Angioma. *See also* Vascular malformations
sudoriparous, 1468–1469
tufted, 1467
Angiomatosis
bacillary. *See* Bacillary angiomatosis
cutaneovisceral, with thrombocytopenia, 1468
eruptive pseudoangiomatosis, 2363–2364
Angiomyxolipoma, 1490
in tuberous sclerosis, 1676
Angioplasty in peripheral arterial disease, 2099
Angiopoietins, 2000t
Angiosarcoma, **1486**–1488
clinical manifestations of, 1487
histopathology in, 1487
post-irradiation, 1486–1488
treatment of, 1488
Angiotensin-converting enzyme, 1138
Angiotensin-converting enzyme inhibitors
angioedema associated with, 422–424
Angular cheilitis, 847
in candidiasis, 2300
in HIV infection, 2452
in Sjögren syndrome, 1980
Anhidrosis, 944–947
acquired, 945
chronic idiopathic, 941
classification of, 938t
due to toxins and pharmacologic agents, 943
in ectodermal dysplasia, 1691–1695. *See also* Ectodermal dysplasia, anhidrotic or hypohidrotic
physical agents, damage due to, 944
Animal exposure
anthrax in, 2211, 2623
bites in, **2578**–2598, **2599**–2610
brucellosis in, 2624
cat-scratch disease in, 2202–2205
erysipeloid in, 2624
glanders in, 2217
leptospirosis in, 2223
listeriosis in, 2218–2220
milker's nodules in, 2414–2415, 2625
mites in, 2572–2573, 2573t
monkeypox in, 2411–2414, 2625
occupational skin diseases in, 2623–2624
orf in, 2416–2417, 2625
paravaccinia virus infections in, 2414–2415
Pasteurella infections in, 2217–2218, 2579
rabies in, 2580–2581
rat-bite fever in, 2218
seal finger in, 2218, 2584
toxoplasmosis in, 2543–2544
tularemia in, 2214–2215, 2624
Animal models
of autoimmune disorders, 1905, 1906
of porphyria cutanea tarda, 1549–1550
of skin cancer, 1242–1245
of venulitis, cutaneous necrotizing, 2003
of vitiligo, 805
Ankle-brachial index
in peripheral arterial disease, 2095f, 2097
in peripheral venous disorders, 2114

Ankyloblepharon filiforme adnatum–ectodermal dysplasia–cleft palate syndrome, 1696–1697
Annular lesions, 38
in erythema annulare centrifugum, **463**–466
in erythema epidermolytic, 525
in granuloma, **467**–472, 1848
in lichen planus, 300
in psoriasis, 212f
Anopheles mosquitoes, 2605
Anthracyclines, 2751
Anthralin
in alopecia areata, 994
in palmoplantar pustulosis, 257b
in psoriasis, 224
Anthrax, 2211–2213
in bioterrorism, 2633–2636
clinical findings in, 2211, 2635
cutaneous, 2211
inhalational, 2211, 2635
in occupational exposures, 2623
treatment of, 2213, 2636
vaccination against, 2636
Anthrenus scrophulariae (carpet beetle), 2606
Anti-angiogenic agents, **2827**–2833
becaplermin, 2833
bevacizumab, 2828–2829
bortezomib, 2832
cetuximab, 2829–2830
corticosteroids, 2833
IFN- α2b, 2827–2828
panitumumab, 2830
sirolimus, 2831–2832
thalidomide, 2830–2831
Antibiotics, **2776**–2787. *See also specific drugs*
in acne vulgaris, 906, 908–909, 2673–2674
in bacterial infections, 2126–2127
cephalosporins, 2777–2780
clindamycin, 2781–2782
daptomycin, 2785
in decubitus ulcers, 1128
ertapenem, 2786
fluoroquinolone, 2783–2784
linezolid, 2785
macrolide, 2782–2783
quinupristin/dalfopristin, 2785
penicillins, 2776–2777
resistance to, 2127
in bacterial infections, 2127
in soft tissue infections, 2176
for *staphylococcal* infections, 2165–2168
for *streptococcal* infections, 2168
tetracyclines, 2780–2781
tigecycline, 2787
topical agents, 2127, **2673**–2676
trimethoprim-sulfamethoxazole, 2784–2785
vancomycin, 2785
Antibodies
B cell. *See also* Complement system
activation and antibody function, 405–407
and antibodies in disease, 407
to CAM5.2, 1366
CD20 and anti-CD20, 2815t
classes, 402–403
IgA, 402–403
IgD, 402
IgE, 403
IgG, 403
IgM, 402
deficiency disorders, 1703–1707, 1705t
diversity of, 403–404
effector functions, 406
natural, 406
structure of, 401–402
therapies based on, 2815t, 2819–2824
Anticoagulant drugs
in atheromatous embolism, 2103
in Degos disease, 2073f, 2075b, 2076
skin necrosis from, 455
Anti-dsNDA antibodies in lupus erythematosus, 1919t
Anti-EJ antibodies in idiopathic inflammatory dermatomyopathies, 1930t
Anti-Fer antibodies in idiopathic inflammatory dermatomyopathies, 1930t
Antifungal agents
allylamine, 2796–2800
oral, 2796–2800
topical, 2680–2681
benzylamine, 2680–2681
evidence-based medicine on, 2806
fluconazole, 2802–2803
griseofulvin, 2804–2805
imidazole, 2804, 2677–2680
in immunocompromised host, 2805–2806
for lichen planus, 310
oral, **2796**–2806
polyene, 2681–2682
in seborrheic dermatitis, 266
topical, **2677**–2684
triazole, 2800–2802
voriconazole, 2803
Antigen presentation, 108, 117–125
in atopic dermatitis, 167
CD1-dependent, 119
class I MHC-restricted, 118–119
class II MHC-restricted, 119
dendritic cells in, 119–121, 124–125
Langerhans cells in, 121–124
Antihelix of ear, 2906
Antihistamines, **2767**–2775
in atopic dermatitis, 179
in children, 2772, 2774
complications and risk factors of, 2771–2772, 2771b, 2774
dosing regimens, 2770, 2770t, 2773t
drug interactions, 2772, 2774
in elderly, 2772, 2774
in exfoliative dermatitis, 277b, 278
H_1-type, 2767
first-generation, sedating, 2768–2769
second-generation, low-sedating, 2769–2770
H_2-type, 2772
indications for, 2769–2770, 2769b, 2773, 2773b
initiation of therapy, 2770–2771, 2773
mechanism of action, 2767, 2772
monitoring of therapy, 2771, 2773
pharmacokinetics of, 2767b, 2768, 2772
in pregnancy, 2772, 2774
in pruritus, 1155, 1156
in urticaria and angioedema, 428
Antihistone antibodies in lupus erythematosus, 1919t
Anti-inflammatory agents
in atopic dermatitis, 175–176
in herpes zoster virus infections, 2396–2397
nonsteroidal
in psoriatic arthritis, 239
urticaria and angioedema from, 424–425
topical, 2697–2698
coal tar, 2697–2698
shale oil, 2698
wood tar, 2698
Anti-Jo antibodies in dermatomyositis, 1930t
Anti-KJ antibodies in idiopathic inflammatory dermatomyopathies, 1930t
Anti-Ku antibodies, 1919t
in idiopathic inflammatory dermatomyopathies, 1930t
Anti-La/SS-B antibodies
in lupus erythematosus, 1919t
Antimalarial drugs, **2726**–2734
chemical structures of, 2728f
in children, 2734
in chronic ulcerative stomatitis, 2731
dosing regimens for, 2731
indications for, 2729–2731
initiation of therapy with, 2732
interaction with other drugs, 2733
in lupus erythematosus, 2729–2730
mechanism of action, 2727–2728
monitoring of therapy with, 2732
in oral lichen planus, 2731
pharmacokinetics of, 2728–2729
in polymorphic light eruption, 2730
in porphyria cutanea tarda, 2730–2731
in pregnancy, 2734
in sarcoidosis, 2731
side effects and complications of, 2732–2734
hepatotoxicity in, 2731
ocular toxicity in, 2733
Anti-Mas antibodies in idiopathic inflammatory dermatomyopathies, 1930t
Antimetabolites, 2735–2747
in atopic dermatitis, 180
Anti-Mi-2 antibodies in dermatomyositis, 1930t
Antimicrobial functions of skin, 2122–2123
Antimicrobial peptides, 107, 2123
in dermatomyositis, 1930t
Anti-OJ antibodies in dermatomyositis, 1930t

Antioxidants
in alternative and complementary medicine, 2900
Antiparasitic agents, topical, 2701–2702
Anti-PCNA antibodies, 1919t
Antiperspirants, 2703
Anti-PL-7 antibodies in dermatomyositis, 1930t
Anti-PL-12 antibodies in dermatomyositis, 1930t
Anti-Pm-Scl antibodiesin dermatomyositis, 1930t
Antipruritic agents, topical, 2703–2704, 2703t
Antipsychotic drugs, 1153, 1160
Antiretroviral therapy in HIV infection. *See also* HIV infection and AIDS
adverse effects of, 2446, 2447t, 2795t
and histoplasmosis, 2321
and Kaposi sarcoma, 1485
lipodystrophy in, 763
Antirheumatic drugs, disease-modifying, 240–242
Anti-Ro antibodiesin dermatomyositis, 1930t
in lupus erythematosus, 1919t
Anti-rRNP antibodies, 1919t
Anti-Se antibodies in dermatomyositis, 1930t
Antiseptics
dye preparations as, 2698
in preoperative skin preparation, 2912–2913
Anti-Sm antibodies in lupus erythematosus, 1919t
Anti-SRP antibodies in dermatomyositis, 1930t
Anti-ssDNA antibodies, 1919t
in dermatomyositis, 1930t
Antithrombin, 2200
Anti-U1RNP antibodies
in dermatomyositis, 1930t
in lupus erythematosus, 1919t
Anti-U2RNP antibodies in dermatomyositis, 1930t
Antivenin, 2586. *See also* Bites and stings
Antiviral agents, **2787**–2796
in cytomegalovirus infections, 2792–2796
cidofovir, 2793
ganciclovir, 2792
foscarnet, 2792
valganciclovir, 2792
in herpes simplex virus infections, 2787–2792
acyclovir, 2787–2789
famciclovir, 2790–2791
penciclovir, 2790–2791
trifluridine, 2791–2792
valacyclovir, 2789–2790
in HIV infection, 2792–2796
interferons, 2795
in varicella-zoster virus infections, 2394
in prevention, 2398–2399
Aortic valve disorders
in Ehlers-Danlos syndrome, 1627–1628
in Marfan syndrome, 1630–1631
nail signs in, 1824
in syphilis, 2483
Aortitis in syphilis, 2498
APECED syndrome, 1707, 1709
Apert syndrome, 917
Aphthae
oral, 830
in Behçet disease, 2036, 2036t
classification of, 830
clinical and laboratory features in, 830
systemic disorders associated with, 830
of penis, 866
of vulva, 887–888
Aplasia cutis congenita, 1192
Aplastic crisis in parvovirus B19 infections, 2345
treatment of, 2346b
Apocrine glands, **935**–936
anatomy, 935
in bromhidrosis, 948–949
in chromhidrosis, 949–951
disorders of, **947**–959
embryonic and fetal development of, 75
in Fox-Fordyce disease, 951–952
functions of, 935
in hidradenitis suppurativa, 953–959
nevi of, 1344
secretion
composition, 935
control, 936
mode, 936
tumors of, 1342–1348
Apocrine secretion odor-binding proteins, 935
Apocrinitis, 953
Apolipoproteins, 1604
apo-A, 1605
deficiency of, 1609
apo-C, 1605
deficiency of, 1609
apo-E, 100, 1605
in chylomicron metabolism, 1605f, 1606
in xanthoma, 1609
Aponeurotic fibroma, calcifying, 714
Apoptosis, 1003
in DNA damage, 1258–1259
in lichen planus, 297
and programmed cell death 1 protein, 1902
in radiation response, 1067
Toll-like receptors in, 110
Appendage tumors of skin, **1337**–1361
with apocrine differentiation, 1342–1347
apocrine adenocarcinoma, 1347
apocrine fibroadenoma, 1344
apocrine hidrocystoma, 1343–1344
apocrine nevus, 1344
cylindromas, 1346–1347
erosive adenomatosis of nipple, 1344
hamartomas and hyperplasias, 1343–1347
hidradenoma papilliferum, 1344–1345
malignant lesions, 1347
syringocystadenoma papilliferum, 1345–1346
classification of, 1337, 1338t
differential diagnosis in, 1337–1339
with eccrine differentiation, 1348–1355
aggressive digital papillary adenoma and adenocarcinoma, 1353–1354
chondroid syringoma, 1353
eccrine hidrocystomas, 1348
eccrine nevus, 1348
eccrine spiradenoma, 1350–1351
eccrine syringofibroadenoma, 1350
hamartomas and hyperplasias, 1348–1353
malignant neoplasms, 1353–1354
microcystic adnexal carcinoma, 1354
mucinous eccrine carcinoma, 1354
nodular hidradenoma, 1352
papillary eccrine adenoma, 1351
poromas, 1349–1350
syringomas, 1348–1349
with follicular differentiation, 1355
basaloid follicular hamartoma, 1355
benign neoplasms, 1355–1361
desmoplastic trichoepithelioma, 1358–1359
dilated pore of Winer and pilar sheath acanthoma, 1355–1356
fibrofolliculoma, 1356
fibrous papule, 1356
follicular infundibulum tumor, 1361
hair follicle nevus, 1355
hamartomas and hyperplasias, 1355
pilomatricoma, 1359–1360
proliferating trichilemmal cyst, 1361
trichilemmoma, 1360–1361
trichoadenoma, 1359
trichoblastoma, 1357
trichodiscoma, 1356
trichoepithelioma, 1357–1358
trichofolliculoma, 1356
histopathology in, 1338
immunohistochemical findings in, 1338
with sebaceous differentiation, 1339–1342
benign neoplasms, 1341
hamartomas and hyperplasias, 1339–1340
malignant neoplasms, 1341–1342
Muir and Torre syndrome, 1342
nevus sebaceous of Jadassohn, 1339
sebaceous adenoma, 1341
sebaceous carcinoma, 1341–1342
sebaceous hyperplasia, 1340
treatment of, 1339

Appendages, epidermal
blood vessels of, 65–66
embryonic and fetal development of, 73–75
hair, 73–74
nails, 74
sebaceous glands, 74
sweat glands, 75
tumors. *See* Appendage tumors of skin
Apple jelly appearance, 34t, 40t
Aquagenic urticaria, 421
Aquagenic pruritus, 421
Aquagenic wrinkling of palms (AWP) syndrome, 946–947
Aquaporins, 3010
Arachidonic acid metabolism, 424–425
urticaria and angioedema in disorders of, 424–425
Arachnida bites and stings, 2600–2605
Arachnidism, necrotic, 2602
Araneae bites, 2600–2603
Arc lamps, 2843
Arcuate lesions, 38
Argininosuccinase deficiency, 1526t
Argininosuccinate synthetase deficiency, 1526t
Argininosuccinic aciduria, 1526t, **1532**–1533, 1836
hair defects, 1533
clinical/morphologic features, 1533
molecular nature, 1533
trichorrhexis nodosa in, 1532
urea cycle disorders, 1532
Aripiprazole, 1160f
Armadillo proteins, 571, 573
Aromatherapy, fragrance allergy in, 3016
Arrangement of multiple lesions, 39
Arrhythmias. *See also* Cardiovascular disorders
pacemakers and implanted defibrillators in, 2912, 2976
and electrosurgery, 2912, 2976
Arsenic exposure
Bowen disease in, 1270, 1274
cancer risk in, 1240, 1241
keratosis in, 1270
clinical findings in, 1270
prognosis and clinical course, 1270
treatment of, 1270
occupational risks associated with, 2631
Artemis deficiency, 1712t
Arterial disorders
of coronary artery. *See* Coronary artery disorders
giant cell arteritis, 2026
peripheral
atheromatous embolism, 2100–2103
livedo racemosa, 2106–2109
livedo reticularis, 1375t, 2106–2109
obstructive, 2094–2100
thromboangiitis obliterans, 2104–2106
sclerotherapy sideeffect arterial injection, 3005
Arteriovenous fistula, 2090
pulmonary, 1830
treatment of, 2093
Arteriovenous malformations, 2090–2093
and capillary malformations, 2091
clinical characteristics of, 2091–2092
differential diagnosis of, 2093b
imaging study in, 2092
nidus of, 2090
prognosis and clinical course in, 2093
Schobinger classification of, 2091t
stages of, 2091t
treatment of, 2093
Arteritis. *See also* Vasculitis
Takayasu, 2026
temporal (giant cell), 2026
Arthritis
adult-onset Still's disease (AOSD), 1971
pediatric granulomatous arthritis, 1598
psoriatic, **232**–242. *See also* Psoriatic arthritis
pyogenic, with pyoderma gangrenosum and acne
clinical findings in, 1594
differential diagnosis of, 1595
reactive, **243**–252. *See also* Reactive arthritis
rheumatoid, **1965**–1971. *See also* Rheumatoid arthritis
Arthrochalasia type of Ehlers-Danlos syndrome, 1625t
Arthropathy
in alkaptonuria, 1535
hypertrophic osteoarthropathy, 1826
Arthropod bites and stings, **2599**–2609
centipede, 2605
cutaneous lymphoid hyperplasia in, 1769, 1770
differential diagnosis of, 2601b
histopathology in, 2599
millipede, 2605
mite, 2572
occupational exposure to, 2626
prevention of, 2609
rickettsial infections in, 2456
scorpion, 2603–2604
spider, 2600–2603
tarantula, 2603
tick, 2604–2605. *See also* Ticks
treatment of, 2599
Ascariasis, 2562
Ascaris lumbricoides, 2562
Ascaris suum, 2562
Ascorbic acid, 1515–1516. *See also* Vitamin C
Aseptic technique, 2912–2913
Ashkenazi Jews, Bloom syndrome in, 1668
ASOB (apocrine secretion odor-binding proteins), 935
Aspartylglycosamidase, 1526t
Aspartylglycosaminuria, 1526t
Aspergillosis
in immunocompromised host, 333–334
in HIV infection, 2453
as opportunistic fungal infection, 333–334
Aspergillus flavus, 333
Aspergillus fumigatus, 333
Aspergillus terreus, 333
Aspirin
in Kawasaki disease, 2048–2049
urticaria and angioedema from, 424
Assassin bug, 2607
and Chagas disease, 2540, 2607
Astemizole. *See also* Antihistamines
interaction with other drugs, 2772
for pregnant women, 2772
low sedating, second generation, 2769
removal from market (early drugs), 2772
Astringents, 2704
Asymmetrical periflexural exanthem of childhood, 2365–2366
A-T–plasty, 2933
Ataxia
cerebellar, 1715
and erythrokeratodermia, 530
and telangiectasia, 1714–1716
clinical findings in, 1714–1716
epidemiology of, 1714
genetic factors in, 1715
prognosis/clinical course/treatment of, 1716
Atheroma, 2100–2103
Atherosclerosis
of coronary artery, 1829, 1839
in corticosteroid therapy, 2719, 2720
issues in children, 2720
embolism in, 2100–2103
of peripheral arteries, 2094–2100
acute limb ischemia in, 2096, 2096b
approach to patient, 2095f
clinical findings, 2095–2097
complications, 2098
differential diagnosis, 2098, 2098b
epidemiology, 2094
etiology and pathogensis, 2094–2095
prevention, 2100
prognosis and clinical course, 2098–2099
treatment, 2099–2100
Athletes, **1115**–1121
actinic damage in, 1119
blood borne pathogens transmission, 1117
cold and heat injuries in, 1118
fungal infections in, 1117
herpes simplex virus infections in, 1117
nodules, 1118
viral infections in, 1117

Atkins diet, 648
Atopic dermatitis, **165**–182
  barrier function of skin in, 166, 498
  cell types involved in
    antigen-presenting cells, 167
    keratinocytes, 168
    T cells, 167–168
  chronic, 170
  clinical features in, 166t, 169–170
  complications in
    exfoliative dermatitis, 174
    hand dermatitis, 174
    infections, 174
    ocular problems, 173–174
  cytokines and chemokines in, 167
  diagnosis and differential diagnosis, 171–173, 173b
  education as intervention, 182
  eosinophils in, 166, 361
  epidemiology of, 165
  etiology and pathogenesis in, 166
  genetic factors in, 168–169
  herpetic eczema in, 174
  immunopathology of, 166
  interferon-γ in, 180
  keratinocytes in, 131, 132, 168
  laboratory tests in, 170–171
  neuropeptides in, 1143
  nutrition in, 178
  phototherapy in, 179
  prognosis and clinical course in, 175
  prurigo in, 170f, 171f
  pruritus in, 169, 1151
    treatment, 179
  psychological factors in, 178
  severity-of-disease measures in, 7
  smallpox vaccination in, 174
  Staphylococcus aureus infections in, 166, 172, 174
  superantigens in, 2159
  sweat composition in, 946
  systemic therapy for
    antimetabolites, 180
    cyclosporine, 180
    systemic glucocorticoids, 180
  T cells in, 167–168
    helper, 168
  topical therapy for, 175–177
    anti-inflammatory therapy, 175–176
    calcineurin inhibitors, 177
    glucocorticoid therapy, 177
    treatment ofallergen immunotherapy, 180–181
    antihistamines in, 179
    approach to, 175, 176f
    Chinese herbal medications, 181
    complementary and alternative medicine approaches to, 2902–2903
    extracorporeal photopheresis, 181
    hospitalization, 179
    interferon-γ, 180
    omalizumab, 180
    oral vitamin D, 181
    photochemotherapy in, 179, 2859
    phototherapy in, 179
    pimecrolimus in, 177
    probiotics, 181
    systemic therapy in, 180
    tacrolimus in, 177
    tar preparations in, 179
  topical therapy in, 175–177
  triggering factors in, 177–179
    emotional stressors, 178
    infectious agents, 178–179
    specific allergens, 178
  in Wiskott-Aldrich syndrome, 1710, 1711f
Atopic eruption of pregnancy, 1211–1212
Atopy
  irritant contact dermatitis in, 501
ATP2C1
  in Hailey-Hailey disease, 557–560
Atresia, pyloric, epidermolysis bullosa with, 655
Atrial myxoma, 1829
Atrial natriuretic peptide, 1143
Atrichia
  with papular lesions, 988
Atrophic papulosis, malignant, **2072**–2075. *See also* Papulosis, malignant atrophic
Atrophie blanche, 2113
Atrophoborreliosis, 2270
Atrophoderma
  follicular, 722
    syndromes with, 975
  of Pasini and Pierini, 722, 824
  vermiculatum, 722–723, 975–976
Atrophy, 32. *See also* Lipoatrophy
  in aging, 32
  in corticosteroid therapy, 2661
  epidermal, 32, 43
Attagenus megatoma (black carpet beetle), 2606
Atypical nevus. *See* Dysplastic nevus
Augmentation of soft tissues. *See* Soft tissue augmentation
Auspitz sign
  in psoriasis, 208, 210f
Autism, and measles-mumps-rubella vaccine, 2340
Autoantibodies
  in dermatomyositis, 1930t, 1935–1936
    140-kd, 1930t
    155-kd, 1930t
  in lupus erythematosus, 1918–1919, 1919t
  in Sjögren syndrome, 1978
Autoimmune disorders, **1901**–1908
  Addison disease in, 1861–1862
  alopecia areata in, 991
  APECED syndrome in, 1707, 1709
  Behçet disease in, 2034–2035
  blistering, 399
  in complement deficiencies, 1724, 1725t
  cryoglobulinemia in, 2056
  dendritic cells in, 1906–1907
  in dermatitis herpetiformis, 647
  drug-induced, 1907
  environmental factors in, 1907–1908
  epidermolysis bullosa acquisita in, 635, 636
  erythema elevatum diutinum in, 2032t
  erythromelalgia in, 2108
  genetic factors in, 1901–1903
  hemolytic anemia in, 1908
  infections as causative factor in, 1908
  mechanisms of, 1901–1908
  pathogenesis of tissue damage in, 1908
  pemphigus in, 587, 587b
    paraneoplastic, 600
  pernicious anemia in, 1741
  polyglandular
    type 1, 1902
    type 2, 1905
  psoriasis in, 205, 206
    and arthritis, 205, 233
  regulatory T cells in, 1905–1906
  relapsing polychondritis in, 1964
  rheumatoid arthritis in, 1901
  Sjögren syndrome in, 1976–1977
  thrombocytopenia in, 1908
  of thyroid, 1470, 1902
  tolerance in, 1904–1906
  toll-like receptors in, 1907
  from tumor necrosis factor inhibitors, 2821
  urticaria and angioedema in, 415
  vitiligo in, 792–793
  in Wiskott-Aldrich syndrome, 1710
Autoinflammatory diseases
  differential diagnosis of, 1589
  systemic,
    familial cold autoinflammatory syndrome, 1585–1589
    Muckle–Wells syndrome, 1585–1589
  neonatal-onset multisystem inflammatory disease, 1585–1589
  treatment of, 1589
Autologous fat transfer for soft tissue augmentation, 3049–3051
Autolytic débridement in decubitus ulcers, 1128
Autonomic dysreflexia, hyperhidrosis in, 938t
Autonomic nervous system, 1138
  anatomy of, 1142–1143
  parasympathetic, 1142
  in sweat gland regulation, 1143
    anhidrosis in disorders of, 938t
    hyperhidrosis in disorders of, 938t
  sympathetic. *See* Sympathetic nervous system
Autosensitization dermatitis, **194**–196
  clinical findings, 195–196
  differential diagnosis, 196b
  epidemiology, 194
  etiology and pathogenesis, 194–195
  prognosis and clinical course, 196
  treatment, 196
Autosomal disorders
  dominant, 81–82, 82f
  recessive, 82, 82f
    ichthyosis in, 508t, 509t, 511t, 512t, 513t

Avascular necrosis in corticosteroid therapy, 2719, 2720
management of, 2720
Avian influenza virus in bioterrorism, 2636t, 2638
Avian mites, 2033
Avobenzone in sunscreens, 2709
Avulsion of nail plate, surgical
distal approach, 2960
partial, 2961
proximal approach, 2960–2961
trap door, 2961
Axilla
allergic contact dermatitis of, 158
hyperhidrosis of, 1201
trichomycosis axillaris of, 2147
Azathioprine, **2741**–2744
in atopic dermatitis, 180
dosing regimen, 2741
indications for, 2741
initiation of therapy, 2741–2742
interaction with other drugs, 2744
in lichen planus cutaneous, 311
mechanism of action, 2741
monitoring of therapy, 2742
in pemphigus, 597–598
pharmacokinetics of, 2741
side effects and complications of, 2742
in vesicular hand dermatitis, 193
Azelaic acid, 2674, 2701
in acne vulgaris, 2674
as bleaching agent, 2704
in rosacea, 2674
Azelastine, 2770t. *See also* Antihistamines
Azul. *See* Pinta

B

B cell(s), **401**–407
activation and antibody function, 405–407
in adaptive immune response, 113
anf antibodies in disease, 407
antigens bound by, 405
maturation, 404–405
common lymphoid progenitors, 404
follicular, 405
memory, 405
pre-B cell, 404
pre-B cell receptors, 404
pro-B cell, 404
surrogate light chains, 404
transitional B-cell, 405
receptors, 406
stimulating factor 2, 138. *See also* Interleukins, IL-6
B-cell lymphoma, 323, 1762–1766
in borreliosis, 1762
classification of, 1745, 1746b
follicle center cell, 1763–1764
treatment of, 1764
intravascular cutaneous, 1765
large cell, 1764–1765
of leg, 1764–1765
marginal zone, 1764
treatment of, 1764
staging of, 1765
treatment of, 1765–1766
radiation therapy in, 1765–1766
B-cell stimulating factor 2, 138. *See also* Interleukins, IL-6
Babesia microti, 2272
Bacillary angiomatosis, 2206–2208
Bartonella infection in, 2206–2208
clinical manifestations of, 2206
differential diagnosis of, 2207b
histopathology in, 2207
in immunocompromised host, 2206, 2207, 2208
in HIV infection and AIDS, 2206
treatment of, 2208
Bacille Calmette-Guérin vaccination, tuberculosis after, 2233
Bacillus anthracis
in anthrax, 2211–2213
in bioterrorism, 2633–2636
diagnosis of infection, 2211
occupational exposure to, 2623
treatment of infection, 2213
vaccine, 2636
Bacitracin, 2675
contact dermatitis from, 161
with polymyxin B and neomycin, 2675
Bacteremia, 2122
in bartonellosis, 2205
in decubitus ulcers, 1128
Bacterial colonization
in decubitus ulcers, 1128
and preoperative skin preparations, 2912–2913
Bacterial infections. *See also specific infections*
actinomycetoma in, 2248–2252, 2313, 2314, 2315
of amputation stump, 1101
antibiotics in, 2674–2676, 2126–2127
doasage administration, 2126
resistance to, 2127
topical agents, 2127
toxicity, 2126–2127
in bite wounds, 2579
classification of, 2125
diagnosis of, 2125–2126
direct examination of aspirates and biopsies, 2125
fluorescent antibody, 2126
PCR reaction, 2126
in elderly, 1225
endocarditis in, 1829–1830
gangrene, progressive bacterial synergistic, 2172
gram positive infections associated with toxin production, **2148**–2159
recalcitrant erythematous desquamating disorder, 2156–2157
scarlet fever, 2158
staphylococcal scalded-skin syndrome, 2148–2152
superantigenic toxins, diseases caused by, 2152–2159
superantigens-initiated diseases, 2159
toxic shock syndrome, 2154–2156
toxin-mediated erythema (recurrent toxin-mediated perineal erythema), 2158–2159
hypersensitivity to bacterial antigens in, 2125
in immunocompromised host, 332
in acute immunosuppression, 332
in chronic immunosuppression, 336–337
inflammatory reaction in, 2123
invasive properties of microorganisms in, 2123–2124
mycobacterial. *See* Mycobacterial infections
in occupational exposures, 2623–2624
pathogenesis of, 2122–2125
infection patterns, 2124
microorganism pathogenicity, 2123–2124
natural resistance of skin, 2122–2123
neutrophilic conditions as infection response, 2125
portal of entry, 2122
pitted keratolysis in, 2145–2146
portal of entry in, 2122
resistance of skin to, 2122–2123
antimicrobial peptides in, 2123
host inflammatory response to cutaneous infection, 2123
resistance to drugs in, 2127
staphylococcal, **2128**–2139
streptococcal, **2139**–2147
topical medications for, 2674–2676
vaginal, 2524–2526
virulence of, 2123–2124
waterborne, 2598
Bacteroides, 2192
Baghdad boil, 2530
Baker-Gordon chemical peel, 3029
Balamuthia, 2542
Balanoposthitis, 871–872
spirochetal, 873
Balding process
pattern, 1828. *See also* Pattern hair loss
Barrier function of skin, **486**–498
in allergic contact dermatitis, 496
in atopic dermatitis, 166, 498
calcium and potassium levels affecting, 495–496
connexins in, 494
cytokine signaling in, 495
desmosomal proteins in, 494
epidermal proliferation and differentiation in, 492
experimental disruption of, 493
in ichthyosis, 498
in irritant contact dermatitis, 496
lipids in, 490–492
neurotransmitters in, 496
in opportunistic infections, 331t
in pathophysiology of skin disorders, 496–498
proteases in, 494

Barrier function of skin—*continued*
in psoriasis, 498
stratum corneum in, 487–492
tight junctions in, 494
treatment implications, 498
types of barriers in, 487t
Bartholin's cyst and abscesses, 888–889
Bartonella bacilliformis, 2202–2209
Bartonella elizabethae, 2202
Bartonella grahamii, 2202
Bartonella henselae, 2202
Bartonella quintana, 2202, 2574
Bartonella vinsonii, 2202
Bartonella washoesis, 2202
Bartonellosis, **2201**–2209
bacillary angiomatosis in, 2206–2208
bacteremia in, 2205
cat-scratch disease in, 2202–2205
endocarditis in, 2205
in immunocompromised host, 2206–2208
Oroya fever in, 2208–2209
peliosis of liver and spleen in, 2206–2208
trench fever in, 2205
verruga peruana in, 2208–2209
Basal cell(s), 45, 47
Basal cell carcinoma, **1294**–1303
animal models of, 1246–1247
biologic behavior of, 1297–1298
clinical manifestations in, 1296–1297
course and prognosis in, 1303
diagnosis of, 1298
differential diagnosis in, 1300b
epidemiology of, 1295
etiology and pathogenesis in, 1296–1297
hedgehog pathway in, 1302
histopathology in, 1298–1299
metastasis of, 1303
neurotropic, 1303
treatment of, 1299–1303
cryotherapy in, 1301, 2971
electrosurgery in, 2974–2975
excisional surgery in. *See* Excisional surgery, in basal cell carcinoma
5-fluorouracil in, 1302
imiquimod in, 1301–1302
Mohs micrographic surgery in, 1300, 2952–2953
photodynamic therapy in, 2866
radiation therapy in, 1032, 2897
Basal cell nevus syndrome, **1304**–1311
clinical findings in, 1306–1307
complications, 1310
diagnosis of, 1307–1308
differential diagnosis in, 1308–1310
epidemiology of, 1304
etiology and pathogenesis in, 1304–1306
genetic factors in, 1304–1306
prognosis and clinical course in, 1310
treatment in, 1310–1311
Basal layer of epidermis, 60–61
Basement membrane, 47, 64, 574–585
biochemical characterization of, 576–581
collagen IV, 577
fibulins, 581
laminins, 577–580
nidogens, 580
proteoglycans, heparan sulfate, 580–581
cellular origin of, 585
damage and photoaging, 1222
embryonic and fetal development of, 73
epithelial-specific components in, 581–585
anchoring fibrils, 584–585
anchoring filaments, 583–584
epidermal adhesion complexes, 581–582
epithelial lamina densa, 584
hemidesmosome, 581
lamina lucida, 47
of nails, 1012
structural and functional characteristics of, 574
Basidiobolus haptosporus, 2317
Basidiobolus ranarum, 2317
Basidiobolomycosis, 2317
Basophils in urticaria and angioedema, 416–417
Bay sore, 2531
Bazex acrokeratosis paraneoplastica, 1887–1889
clinical findings in, 1888
differential diagnosis of, 1889
nail changes in, 1888
stages of, 1888
treatment of, 1889
Bazex-Dupre-Christol syndrome, 723
Beals syndrome, 1632b
Beau's lines, 1013–1014
Becaplermin, 2833
Becker's nevus, 823
Bedbugs, 2606
Bee stings, 2608
Beetles, 2606
Behavioral therapy in pruritus, 1157
Behçet disease, 1827, 2033–2041
clinical course and prognosis in, 2039
clinical findings in, 2035–2038
diagnostic criteria on, 2036t
differential diagnosis of, 2040b
epidemiology of, 2033–2034
etiology and pathogenesis in, 2034–2035
immunologic mechanisms in, 2035
infectious precipitants in, 2035
eye disorders in, 2037
genetic factors in, 2034–2035
genital ulcers in, 866
histopathology in, 2038
oral ulcers in, 1827, 2036
prevention of, 2041
special tests in
pathergy test, 2038
treatment of, 2039–2041, 2041b
Bejel. *See* Syphilis, endemic
Belesh. *See* Syphilis, endemic
Benzene hexachloride. *See* Lindane
Benzocaine, 2916
Benzoyl peroxide, topical, 2701
Benzyl benzoate lotion in scabies, 2571b
Benzylamine antifungal agents, 2680–2681
Beryllium, occupational exposure to, 2613t, 2616t
Betamethasone dipropionate
in atopic dermatitis, 176
Betel, 1174
Bevacizumab, 2828–2829
Bexarotene, 2761
dosing regimens, 2763
initiation and monitoring of therapy, 2764
Bias, 2
information, 2
publication, 10
selection, 2
Bier's spots, 813
Bilateral symmetrical lesions, 41
Biliary disorders, 1834
in helminthic infections, 2557
Bioengineered skin in wound healing problems, 2995
Biomarkers in hidradenitis suppurativa, 959
Biopsy
in bacteria identification, 2125–2126
in children, 1196, 1197t
in decubitus ulcers, 1126
in dermatomyositis, 1936
in melanoma, 1438
of nail bed, 2964–2965
of nail fold, proximal, 2966
of nail matrix, 2962
Bioterrorism, **2633**–2642
anthrax in, 2633–2636
brucellosis in, 2637–2638
category A, 2633–2637
category B, 2637–2638
category C, 2638–2639
glanders in, 2638
melioidosis in, 2638
plague in, 2636
smallpox in, 2637
tularemia in, 2637
Biotin, 1516–1517
deficiency of, 1516–1517
food sources of, 1517
Biotinidase, 1526t
Birthmarks, 1190
Biskra button, 2530
Bites and stings, **2578**–2598, **2599**–2610
from aquatic organisms, 2584–2597
arthropod, 2626
in athletes, 1119
bacterial infections in, 2579
clinical approach to, 2578–2579
epidemiology of, 2578
fish, 2584–2588, 2597
jellyfish, 2584–2588
human bites in, 2579
from land animals, 2578

bacterial infections, 2579
dog bites, 2578
viral infections, 2580–2581
wild animals, 2581
monkey bites, 2579
occupational exposure to, 2626
rabies, 2580
seal
bite, 2584
finger in, 2218
snake, 2581–2583
Black carpet beetle, 2606
Black death, 2215. *See also* Plague
Black fly bites, 2606
Blaschkoid distribution of lesions, 39, 41
Blaschko's lines, 39, 41
Blastomycosis, 2317
keloidal, 2317
North American, 2321–2323
clinical findings, 2321
differential diagnosis of, 2322
epidemiology, 2321
treatment, 2323
in occupational exposures, 2626
South American, 2324
Bleaching agents, 2704
Bleeding. *See* Hemorrhage
Bleeding disorders
in Wiskott-Aldrich syndrome, 1710, 1711
Bleomycin, 2687–2688
indications for, 2688
side effects and complications of, 2688
Blepharitis
seborrheic, 266
Blepharoconjunctivitis
in retinoid therapy, 2765
Blister beetles, 2606
Blisters
at dermal-epidermal junction, 47–48, 47t
dermolytic, 47t, 48
junctional, 47, 47t
in dermatitis herpetiformis, 48
eosinophils in, 399
in occupational exposures, 2626
subepidermal, 47–48
sucking, in neonates, 1189
vesicles and bullae in, 36
Blood vessels, 65–66, **1986**–2002
of dermis, 66
deep, 51
superficial, 51
embryonic and fetal development of, 72–73
of face, 2910–2911
malformations of. *See* Vascular malformations
of nails, 1012
neural control of, 1141t, 1142, 1143
in thermoregulation, 1077
peripheral arterial disease of, **2094**–2109
peripheral venous disorders of, **2110**–2120
vasculitis of. *See* Vasculitis
vasoconstriction of. *See* Vasoconstriction
vasodilation of. *See* Vasodilation
Bloom syndrome, 1657t, 1658t, **1667**–1668
clinical features in, 1667
DNA damage and repair in, 1668
genetic factors in, 1668
Blue nevus, 1392–1396
cellular, 1393, 1394
clinical findings in, 1393
common, 1393
deep penetrating, 1393, 1394
differential diagnosis in, 1396b
disorders associated with, 1395
epidemiology of, 1392
etiology and pathogenesis in, 1392
histopathology in, 1393–1395
large plaque, 1393
malignant, 1393, 1394
treatment of, 1396
BMP. *See* Bone morphogenetic proteins
Body art, **1129**–1136
branding in, 1130
definitions, 1130
extraocular implants in, 1130
painting in, 1130
piercing in, 1134–1136
scarification in, 1130
tattooing in, 1130–1133
tongue splitting in, 1130
Body dysmorphic disorder, 1164
Body lice, 2576
Boil. *See also* Furuncles
Bone disorders
in occupational exposures, 2628–2629
in osteogenesis imperfecta, 670
in retinoid therapy, 2765
Bone marrow
transplantation of. *See* Stem cell transplantation
Bonnet-Dechaume-Blanc syndrome, 2092
Borrelia afzelii, 2263
Borrelia bissettii, 2263
Borrelia burgdorferi
detection of, 2272
life cycle of, 2264
in Lyme disease, **2263**–2275
in lymphoid hyperplasia, 2270
Borrelia garinii, 2263
Borrelia lonestari, 2263
Borreliosis
Lyme disease in, **2263**–2275
lymphoid hyperplasia in, 2270
Bortezomib, 2832
Botfly bites, 2606
Botryomycosis, 2136–2137
Botulinum toxin, **3053**–3060. *See also* Soft tissue augmentation
in anhidrosis, 943
in cosmetic facial procedures
in combination therapy, 3059
in crow's feet, 3058–3059
in glabellar brow furrows, 3057
in horizontal forehead lines, 3057–3058
indications, 3055
immunology, 3055
mechanism of action, 3053–3055
pharmacology of, 3053
in hidradenitis suppurativa, 959
in hyperhidrosis, 943, 3059
immune response to, 3055
indications for, 3055
side effects and complications of, 3059–3060
structure, 3053
Bouton d'orient, 2530
Bowen disease, 1273–1276
in arsenic exposure, 1270, 1274
clinical findings in, 1274–1275
diagnosis and differential diagnosis in, 1275–1276, 1275b
epidemiology of, 1273–1274
etiology and pathogenesis of, 1274
histopathology in, 1275
intertriginous, 1275
prognosis and clinical course in, 1276
squamous cell carcinoma in, 1273–1276
treatment of, 1276, 1276b
cryotherapy in, 2971
Bowenoid papulosis, 1271, 1272–1273, 2426
Brachioradial pruritus, 1151
Bradykinin
in urticaria and angioedema, 417–418, 422
Brain-skin axis, 1138
Breast
Paget disease of, 1899
Bromine, occupational exposure to, 2613t
Brucellosis, 2217
in bioterrorism, 2637–2638
in occupational exposures, 2624
Brugia malayi, 2563
Brugia timori, 2563
Bruises
in children, 1178t, 1178–1179
in domestic violence, 1182
Brunsting-Perry pemphigoid, 620
Buba. *See* Yaws
Buerger disease, 2104–2106. *See also* Thromboangiitis obliterans
Buffalo hump
Bullae, 36
in helminthic infections, 2555
in impetigo. *See* Impetigo, bullous
in pemphigoid. *See* Pemphigoid, bullous
Bullous disease
of hemodialysis, 1838
of childhood, chronic, **623**–629
clinical findings in, 625–628
differential diagnosis in, 628–629
diseases associated with, 628
epidemiology of, 624
etiology and pathogenesis in, 624–625
histopathology in, 628
treatment and prognosis of, 629

Burdwan fever, 2534
Burkholderia mallei
in bioterrorism, 2638
in glanders, 2217
Burkholderia pseudomallei
in bioterrorism, 2638
in melioidosis, 2222
Burning sensation
chronic atypical, 1165
Burns, **1089**–1094
chemical
in occupational exposures, 2612, 2613t, 2615t
in child abuse, 1178t, 1180
classification of, 1090f
clinical findings in, 1090–1091
complications in, 1091, 1091t
in electrosurgery, 2975
epidemiology of, 1089
etiology and pathogenesis in, 1089–1090
in occupational exposures
chemical, 2612, 2613t, 2615t
electrical, 2628
thermal, 2627–2628
prognosis and clinical course, 1092–1093
prevention of, 1094
in sun exposure. *See* Sunburn
in thermal injuries
in occupational exposures, 2627–2628
treatment of, 1093–1094
inpatient, 1093–1094
outpatient, 1093
topical antibiotics in, 1094, 2674–2676
Burrows, 33
Buschke-Ollendorff syndrome, 1643–1644
Bypass surgery
coronary artery, 1839
gastric, 1834

C

C chemokines, 142
C nerve fibers, 1148–1149
in pruritus, 1152, 1154
Cadherins, 61
desmosomal, 571–573
embryonic and fetal, 68
vascular endothelial, 1990
Café-au-lait spots
and hypermelanosis, congenital circumscribed, 818
laser therapy in, 2887
Calcification, **1650**–1653
aberrant, 1650
in aponeurotic fibroma, 714
dystrophic, 1650–1651
in cutaneous neoplasms, 1651
in dermatomyositis, 1650
in Ehlers–Danlos syndrome, 1651
in infections, 1651
in inherited disorders, 1651
in panniculitis, 1650–1651
iatrogenic, 1653
idiopathic, 1652–1653
metastatic, 1651–1652
in calciphylaxis, 1651–1652
in hypervitaminosis D, 1652
in kidney disorders, 1651–1652, 1837
in milk–alkali syndrome, 1652
in tumoral calcinosis, 1652
Calcineurin inhibitors, 2690–2692, 2809–2813
adverse effects of, 2696b
in atopic dermatitis, 177
contraindications to, 2694b
cyclosporine. *See* Cyclosporine
indications for, 2690–2692
initiation of therapy with
mechanism of action, 2809
monitoring of therapy with, 2696
pimecrolimus. *See* Pimecrolimus
in psoriasis, 226
in seborrheic dermatitis, 265
tacrolimus. *See* Tacrolimus
in vitiligo, 799
Calcinosis, 32
in dermatomyositis, 32
scrotal, 873–874
Calcipotriene
in palmoplantar pustular eruptions, 258
Calcipotriol
in palmoplantar pustular eruptions, 258
in combination with other agents, 2706
in seborrheic dermatitis, 266
Calcitonin and calcium serum levels, 1649
Calcitonin-gene-related peptide (CGRP), 1138, 1139t, 1141t, 1143, 1145
in inflammatory response, 1141t
in urticaria, 1144
in wound healing, 1145
Calcium, 1649
and calcification disorders, **1650**–1653
hydroxylapatite, 3049
serum levels of, 1649
in hypercalcemia. *See* Hypercalcemia
parathyroid hormone affecting, 1649
vitamin D affecting, 1649
Calcium hydroxide, occupational exposure to, 2613t
Callus formation, **1111**–1114
Calymmatobacterium granulomatis. See Klebsiella granulomatis
CAM5.2
antibodies to, 1366
Candida albicans
occupational exposure to, 2625–2626
Candida folliculitis, 2302
Candidiasis, **2298**–2311
balanitis and balanoposthitis in, 2301, 2306
diaper dermatitis in, 1198
in neonates, 1187
chronic mucocutaneous, 1707, 2303–2305
classification of, 1708t, 2303t
clinical findings in, 1707–1709
with endocrinopathy, 1707, 1708t, 1709
epidemiology of, 1707
familial, 1707, 1708t
and hypoparathyroidism, 1709
and keratitis, 1708t
localized, 1708t
nail changes in, 1708
oral, 1708, 1709f
of scalp, 1708
prognosis/clinical course, 1709
and thymoma, 1708t
treatment in, 1709
clinical findings in
in chronic mucocutaneous disease, 1707–1709
cutaneous, 2302, 2306
diaper dermatitis in, 1198
disseminated, 2305
differential diagnosis of, 2305b
treatment of, 2307
and ectodermal dysplasia, 1708t
epidemiology
frequency, 2298
etiology and pathogenesis, 2298–2299
generalized, 2302
in immunocompromised host, 331t, 333, 338
intertriginous, 2301
mortality/morbidity in
age, 2298
sex, 2298
in occupational exposures, 2625
oral, 836, 2299–2300
differential diagnosis of, 2301b
treatment of, 2306
systemic, 2327
treatment of, 2306
in chronic mucocutaneous disease, 2307
in disseminated disease, 2307
vaginal and vulvovaginal, 2300–2301
treatment of, 2306
Canities, 813
subita, 813
in pruritus, 1155
Cantharidin, 2606
malformations of, 2078–2083
with arteriovenous malformations, 2091
clinical characteristics in, 2080
complications, 2082
differential diagnosis of, 2081, 2082b
histopathology in, 2080
imaging studies in, 2081
in Klippel-Trénaunay syndrome, 2080
laser therapy in, 2082
locations of lesions in, 2080
prevention, 2083
prognosis and clinical course in, 2082
treatment, 2082
Capillaritis, unilateral linear, 2053

Capnocytophaga canimorsus
in bite wounds, 2579
Capsaicin, 2697
Capsid, viral, 2330t, 2331, 2332
Captopril, pemphigus from, 593
Caput medusae, 1832
Caput succedaneum, 1188
Carate. *See* Pinta
Carbon dioxide
in laser skin resurfacing, 3022, 3024
complications in, 3027–3028
Carbuncles, 33, 2136
abscess in, 2136
laboratory tests in, 2136
prognosis and clinical course in, 2136
treatment of, 2136
Carcinogenesis
in chemical exposure, **1239**–1250
constitutional modifiers of, 1248–1249
exogenous modifiers of, 1249–1250
in photochemotherapy, 2848–2849
in ultraviolet radiation exposure, **1251**–1260
in photochemotherapy, 2862–2863
prevention of, 1259
therapeutic approaches, 1259–1260
viral sensitivity, 1259
Carcinoid syndrome
hyperpigmentation in, 819
Carcinoma
basal cell. *See* Basal cell carcinoma
eccrine
mucinous, 1354
Merkel cell. *See* Merkel cell carcinoma
microcystic adnexal, 1354–1355
sebaceous, 1341–1342
squamous cell. *See* Squamous cell carcinoma
syringomatous, 1348–1349
Cardiovascular disorders, 1828
in amyloidosis, 1831
in atrial myxoma, 1829
coronary artery bypass surgery in, 1889
earlobe crease sign of, 1828
in endocarditis, 1829
in exfoliative dermatitis, 272, 274
hair loss patterns in, 1828
in hyperlipidemia, 1828
in LEOPARD syndrome, 1829
in lupus erythematosus, 1830
Cardiomyopathy, 1828
Carotenemia, 1506–1507
Carotenoderma, 1506–1507
Carpet beetles, 2606
Cartilage-hair hypoplasia syndrome, 1709
Carvajal syndrome, 547
Castleman disease, 1768t, 1776–1777
differential diagnosis in, 1776
herpesvirus 8 in, 1776
multicentric, 1776
paraneoplastic pemphigus in, 1777
plasma cell variant, 1776
treatment of, 1777, 1777b
Cat(s)
bites from, 2579
Cat fleas, 2607
Cat-scratch disease, 2202–2205
clinical findings in, 2203–2204
differential diagnosis of, 2205b
treatment of, 2204–2205
Catagen, 968
Catecholamine, 777
Cathelicidins, 107
Causal inferences in epidemiologic studies, 2–3
Caveolins, 1990
CC chemokine(s), 142
CC chemokine ligands
CCL2, 147
CCL7, 147
CCL11
in atopic dermatitis, 148
CCL17, 112, 117
in atopic dermatitis, 148, 167
in psoriasis, 149
CCL18 in atopic dermatitis, 148
CCL20, 112, 147
in psoriasis, 149
CCL21, 147
CCL27, 112, 117, 147
in atopic dermatitis, 148
CC chemokine receptors, 143t
CCR1, 143t 146
CCR2, 143t, 146
CCR3, 117, 143t, 146, 147
in atopic dermatitis, 148
CCR4, 116, 117, 143t, 146, 147
in atopic dermatitis, 148
in psoriasis, 149
CCR5, 117, 143t, 146, 147
in infectious diseases, 151
CCR6, 112, 117, 143t, 146, 147
in cancer, 149
in psoriasis, 149
CCR7, 116, 143t, 146
in melanoma, 150
CCR8, 117, 147
CCR9, 143t
in melanoma, 150
CCR10, 112, 117, 143t, 148
in melanoma, 150
CCR. *See* CC chemokine receptors
CD1
in antigen presentation, 119
CD3, 111
$CD4^+$ T-cells, 114
in hematodermic neoplasm, 1766
$CD8^+$ T-cells, 114
in lichen planus, 297
CD20, and anti-CD20 antibodies, 2815t
CD40, 111
$CD56^+$ hermatodermic neoplasm, 1766
CD80, 111
CD86, 111
CD95
in lichen planus, 298
CEDNIK syndrome, 528
Cell death. *See also* Apoptosis
programmed cell death 1 (PD-1) in autoimmune disorders, 1902
Cell-mediated immunity
in lichen planus, 297–298
Cellular receptors for proteins of ECM, 688–689
Cellulitis, 2160
in *Aeromonas hydrophila* infections, 2192
in bite wounds, 2164
classical, 2162–2163
clinical findings in, 2162–2164
clostridial, 2175
crepitant, 2175, 2192
diagnostic techniques in, 2165
differential diagnosis of, 2165
gangrenous, 2175
in immunocompromised host, 2192
in pressure ulcers, 2164
prevention, 2168
prognosis and clinical course in, 2164–2165
in surgical wounds, 2163
synergistic necrotizing, 2172
prognosis and clinical course in, 2172
treatment of, 2172
treatment of, 2165–2168
Centipede bites, 2605
Centruroides scorpion stings, 2603
Cephalohematoma, 1188
Cephalosporins, 2777–2780
adverse effects of, 2780b
indications for, 2780b
mechanism of action, 2777–2778
pharmacokinetics of, 2778–2779
Ceramides, 490–492
protein-bound, 491
synthesis of, 491, 491f
Cercarial dermatitis, 2566, 2592
Cerebrospinal fluid
in syphilis, 2490
Cerebrovascular disorders
hyperhidrosis in, 938t
Cetirizine, 2770t. *See also* Antihistamines
Chagas disease, 2540–2541, 2607
stages of, 2541b
transmission of, 2541, 2607
Chancre
tuberculous, 2228–2229
Chancroid, **2501**–2505
clinical findings in, 2501–2502
complications of, 2503, 2504t
differential diagnosis of, 2502, 2503b
and HIV infection, 2504, 2505
prevention of, 2505
treatment of, 2504
variants of, 2503t
Charcot-Leyden crystals, 357
Chédiak-Higashi syndrome, 1721–1723
accelerated phase, 787, 1721–1723
clinical findings in, 1721–1722
epidemiology of, 1721
etiology and pathogenesis in, 787, 1721
granules in, 787, 1721
treatment in, 1722–1723
Cheek surgery. *See also* Flaps
anatomy in, 2908

Cheilitis
actinic, 846, 1253, 1264, 1265f
allergic contact cheilitis, 157, 158
angular, 847
in candidiasis, 2300
in HIV infection, 2452
in Sjögren syndrome, 1980
exfoliative, 847–848
glandularis, 641–642
apostematosa, 642
granulomatous, 846–847
Cheiropompholyx, 188
Chemical carcinogens, **1239**–1250
chemistry and metabolism of, 1241–1242
genotoxic and nongenotoxic, 1242
initiating and promoting agents in, 1240–1241, 1240t
Chemical exposures
burns in
in occupational exposures, 2612, 2613t, 2615t
carcinogenesis in, **1239**–1250
chloracne in, 2629
occupational, 2612, 2613t, 2615t
Chemical peels, 3028–3030
classification of, 3028t
deep, 3029–3030
medium-depth, 3029
side effects and complications of, 3030
superficial, 3029t
Chemical weapons, 2638–2641
Chemokine(s), 140, **142**–151, 1144
in atopic dermatitis, 148, 167
C subfamily, 142
in cancer, 149–150, 150f
CC subfamily, 142
CXC subfamily, 142
CXXXC (CX3C) subfamily, 142
and dendritic cell trafficking, 147–148
desensitization of, 145
in eosinophil recruitment, 357
in infectious diseases, 150–151
in leukocyte
mobilization and binding, 140
trafficking, 145–148, 148f
nomenclature on, 142
in psoriasis, 148–149, 203
structure of, 142
and T-cell migration, 145–147
therapeutic applications of, 151
in tumor formation, 149–150
Chemokine receptors, 144–145
activation of, 145
of CC subfamily. *See* CC chemokine receptors
and signal transduction, 144–145, 144f
in skin biology, 143t
Chemotherapy
cytotoxic agents in. *See* Cytotoxic agents
in hemangioma of infants, 1465
in meningococcal conjunctivitis, 2182
in melanoma, 1443
in Merkel cell carcinoma, 1370
in Paget disease, 1375–1376
photo. *See* Photochemotherapy
Chiclero ulcer, 2531
Chigoe fleas, 2607
Child abuse, **1177**–1181, 1203
agencies and resources for assistance in, 1178t
battered child, 1179–1180
bruises in, 1178t, 1178–1179
burns in, 1178t, 1180
differential diagnosis of, 1178
epidemiology of, 1178
sexual abuse in, 1180–1181
CHILD syndrome, 528
Children and infants, **1185**–1203
abuse of, 1177–1181, 1203
acne in, 913, 915
in adolescents, 900, 915, 1200
in neonates, 913, 1189
acrodermatitis in, 2350–2352
asymmetrical periflexural exanthem in, 2365–2366
atopic dermatitis in, 170, 175
bathing frequency for, 1187
biopsy of skin lesions in, 1196, 1197t
candidiasis in, 1198, 2301, 2452, 2664
diaper dermatitis in, 1197–1199
in neonates, 1187
diaper dermatitis in, 1197–1199
differential diagnosis of dermatoses in, 1191b
drug therapy in, 1201–1203
drug labeling aspects, 1201
systemic, 1202–1203
topical, 1201–1202
examination of, 1187, 1195–1196
in adolescents, 1196
in neonates, 1187
exfoliative dermatitis in, 274, 277
fluconazole in, 1203
Fournier gangrene in, 873
genitalia in
examination of, 1187, 1196
glucocorticoids therapy in, 1202, 2720
glucocorticoids therapy
complications in, 2720
atherosclerosis, 2720
avascular necrosis, 2720
osteoporosis, 2720
gonorrhea in
gluteale infantum, 1198
griseofulvin in, 1203
hair loss in, 1190
alopecia areata, 1190
telogen effluvium, 1190
tinea capitis, 1190
triangular temporal alopecia, 1190
hemangioma in, 1190
hemorrhagic edema in, acute, 2007
itraconazole in, 1203
Kawasaki disease in, **2042**–2049
lichen planus in, 299–280
Lyme disease in, 2272
lymphhangiomas in, 1191
milia in, 1188
miliaria rubra in, 1189, 1198
Mongolian spots in, 1190
neonatal. *See* Neonates
nummular eczema in, 182
parakeratosis in
granular, 1198
parvovirus B19 infections in, 2343
perineal protrusion in, 1197
pityriasis rubra pilaris in, 281
psoriasis in, 1198, 1199f
pyramidal protrusion in, 1197
sebaceous glands in
hyperplasia of, 1188
seborrheic dermatitis in, 261–263
adult, 262
infantile, 261–262
differential diagnosis of, 261–262
treatment of, 265–266
Spitz nevus in, 1398–1341
terbinafine in, 1203
tinea capitis in, 1190, 1199
transient dermatoses in, 1187–1189
ultraviolet radiation exposure in, 2849
urticaria in, 425
varicella-zoster virus infections in, treatment of, 2394
Chilopoda bites, 2605
Chin, surgical anatomy of, 2908
Chironex fleckeri stings, 877, 2586
Chlamydia trachomatis, **2519**–2521. *See also* Gonorrhea
elementary body of, 2520
and gonorrhea coinfection, 2518
treatment of, 2518–2519
in lymphogranuloma venereum, 2505–2509
in neonate, 2520
in reactive arthritis, 243, 2521
treatment of infection, 2521, 2521b
in gonorrhea coinfection, 2518–2519
Chloracne, 916, 2629–2630
acne and, 916
Chlorambucil, 2749
complications of, 2750–2751
dosing regimen, 2749
indications for, 2749
mechanism of action, 2749
Chlorhexidine, 2698
in oral lichen planus, 309
in preoperative skin preparation, 2913
Chlorpheniramine, 2770t. *See also* Antihistamines
Cholesterol
embolism from, 1839
metabolism of, 1604
in stratum corneum, 490
Cholinergic stimulation
urticaria in, 420
Chondritis
Chondrodermatitis nodularis helicis, 1331–1332, 2883
Chondrodysplasia punctata, 528–530
rhizomelic, 529
X-linked dominant, 529–530
X-linked recessive, 529
Chondroid syringoma, 1353

Chromhidrosis
Chromic acid, occupational exposure to, 2615
Chromoblastomycosis, 2315–2316
  in occupational exposures, 2626
Chromomycosis, 2315–2316
  cystic, 2317
  clinical findings, 2316
  differential diagnosis of, 2316
  epidemiology, 2315–2316
  treatment, 2316
Chromosome 4 short arm deletion, 84t
Chromosome 5 short arm deletion, 84t
Chromosome 17, 77, 77f
Chromosome 18 long arm deletion, 84t
Chromosomes
  band 17q21.2, 77, 77f
  disorders of, 83–85, 84t
  number of, 83
  structure of, 76–78
    in balanced translocation, 83
    deletion affecting, 83, 84t
    in reciprocal translocation, 83
  tests of integrity and breakage, 1235
    sister chromatid exchange assay in, 1235
Chronic venous insufficiency. *See* Venous disorders, chronic
Chrysaora sea nettles, 2585
Chrysops bites
  loiasis in, 2564
Churg-Strauss syndrome, 2023
Chylomicron(s), 1606
Chylomicronemia
  familial syndromes, 1611
  xanthoma in, 1611
Cicatrix. *See* Scars
Ciclopirox, 2682–2683
Cidofovir, 2793–2794
  in herpes simplex virus infections, 2793–2794
  in HIV infection and AIDS, 2793–2794
Cimex bedbugs, 2606
Cimicidae, 2606
Ciprofloxacin
  in children, 1203
  in *Klebsiella* infections, 2193
Cirrhosis
  nail changes in, 1824
Citrullinemia, 1526t
CLA. *See* Cutaneous lymphocyte antigen (CLA)
Cladophialophora carrionii, 2315, 2316
Clam digger's itch, 2566, 2592
Claudication, 2096
  intermittent
    differential diagnosis of, 2098
    in peripheral artery atherosclerosis, 2098
    treatment of, 2099
  neurogenic, 2098
Clavi, **1111**–1114
Cleansing agents, 3015
  in decubitus ulcers, 1127–1128
  as occupational irritants, 2614
  in preoperative skin preparation, 2912–2913
Clear cells
  in acanthoma, **1330**–1331
Climate therapy in psoriasis, 227
Clindamycin, 2781–2782
  in acne vulgaris, 2673
  adverse effects of, 2782b
  dosage of, 2778t
  indications for, 2782b
  mechanism of action, 2781
  pharmacokinetics of, 2782
Clinical Evidence. *See* Evidence-based medicine
Clinical trials, 1–2
Clioquinol, 2676, 2698
Clobetasol propionate
  in lichen planus, oral, 309
Clofazimine
  in actinomycetoma, 2252
Clonal dermatitis, 286, 286f
Clostridium botulinum
  botulinum toxin derived from, 3053. *See also* Botulinum toxin
Clostridium perfringens
  in soft tissue infections
    myonecrosis in, 2176
Clostridium septicum, 2176
Clothing, protective
  in occupational exposures, 2620, 2712t
  in ultraviolet radiation exposure, 2712
Club drugs, 1168
  in hypertrophic osteoarthropathy, 1826
  of nails, 1825
Coagulation
  disseminated intravascular, 2199–2201
  intrinsic pathway, in angioedema, 417
  in wound healing, 2985, 2986f, 2987
Coal tar preparations, 2697–2698
  in atopic dermatitis, 179
  occupational exposure to, 2629
  in psoriasis, 224–225
  side effects and complications of, 2698
    melanosis in, 2629
    phototoxicity in, 2629
    skin cancer in, 1240
Cobalamin, 1514–1515. *See also* Vitamin B_{12}
Cobalt
  contact dermatitis from, 161
Cobb syndrome, 2092
Cocaine, 1169–1170
Coccidioides immitis, 2323–2324
  in immunocompromised host, 2324
  occupational exposure to, 2626
Coccidioidin skin test, 2324
Coccidioidomycosis, 2323–2324
  disseminated, 2323
  in immunocompromised host, 2453
  in occupational exposures, 2626
Cochrane Collaboration, 11
Cochrane Library, 11
  Central Register of Controlled Trials in, 11
  Database of Abstracts of Reviews of Effectiveness, 11
  Database of Systematic Reviews in, 11
  Health Technology Assessment Database in, 11
Cockayne syndrome, 1658t, 1663, **1665**
  cellular hypersensitivity in, 1665
  clinical features in, 1665
  laboratory abnormalities in, 1665
  prenatal diagnosis of, 1665
  support groups for patients with, 1665
  and xeroderma pigmentosum, 1658t, 1663, 1665
Codons
  premature termination mutation, 78
Coenurosis, 2567
COFS syndrome
Coherence of epidemiologic studies, 3
Cohesion
  dermal-epidermal, 47–48, 574
  epidermal, 45–46, 570–574
Cohort studies, 4–5
COL1A1/COL1A1
  in Ehlers-Danlos syndrome, 1625t
  in osteogenesis imperfecta
COL1A2/COL1A2
  in Ehlers-Danlos syndrome, 1625t
COL3A1 in Ehlers-Danlos syndrome, 1625t
COL5A1, in Ehlers-Danlos syndrome, 1624, 1625t
COL5A2 in Ehlers-Danlos syndrome, 1624, 1625t
COL7A1, 81
Cold. *See also* Cryotherapy
  injuries from, **1079**–1089
    acrocyanosis in, 1085–1086
    chilblains in, 1086–1087
    classification of, 1081, 1083t
    erythrocyanosis in, 1086
    erythromelalgia in, 1088
    frostbite in, 1082–1085
    in neonates, 1088
    nonfreezing, 1085
    in occupational exposures, 2628
    panniculitis in, 1088
    polymorphous eruption in, 1087
    sclerema neonatorum in, 1088
    urticaria in, 1087–1088
    winter xerosis in, 1085
  physiologic response to, 1080
  urticaria and angioedema from, 419–420
Cold auto-inflammatory syndrome, familial, 1585–1589
Coleoptera, 2606
Colitis, ulcerative, 1833
Collagen, **666**–679
  cross-linking of, 55, 676
  degradation of, 677
  in dermis, 72, 517
    embryonic and fetal, 72
  diseases of, 689
  embryonic and fetal, 71t

Collagen—*continued*
fibrinoid degeneration of, 689
genetic heterogeneity of, 668–672, 669t
injection for soft tissue augmentation, 3044
phototherapy effect on, 2843
structure of, 667f
synthesis of, 55
control of, 676–677
disulfide bonding in, 675
fiber formation and cross-linking in, 676
post-translational modifications of polypeptide chains in, 672–675
procollagen conversion in, 675
triple-helix formation in, 667–668, 675
vascular disease
dermatomyositis, 1889
progressive systemic sclerosis, 1890
Collagen type I
embryonic and fetal, 71t
Collagen type IV, 73
embryonic and fetal, 71t
Collagen type VII, 73
embryonic and fetal, 71t, 73
mutation, 78
Collagen-vascular disease, 1830
cardiovascular disorders in, 1830
respiratory disorders in, 1831–1832
Collagenoma, 712
Collodions, topical medications formulated as, 2648
Colonization, bacterial
in decubitus ulcers, 1128
and preoperative skin preparations, 2912–2913
Colony-forming ability assay, 1234
Colony-stimulating factors
granulocyte-macrophage. *See* Granulocyte-macrophage colony-stimulating factor
Color changes. *See also* Skin of color
of nails, 1824–1825
Comedo, 32, 32f
closed, 32
open, 32
Comet assay, 1236
Complement C1, 408
Complement C1 inhibitor, 411
deficiency of, 412
angioedema in, 422
Complement C1q, 408
in lupus erythematosus, 413
Complement C1r, 408, 409
Complement C1s, 408, 409
Complement C2, 409
deficiency of, 2009
Complement C3, 409
deficiency of, 412
in lupus erythematosus, 413
Complement C3 convertase, 411
in lupus erythematosus, 412
Complement C3a, 409, 410
Complement C3b, 409
Complement C3d, 410
and B cell activation, 405–406
in lupus erythematosus, 412
Complement C4, 408, 409
Complement C4a, 410
Complement C4b, 409
Complement C5, 409
Complement C5a, 409, 410
Complement C6, 410f
Complement C7, 410f
Complement C8, 410f
Complement C9, 410f
Complement control protein repeats, 411
Complement receptors, 411
CR1, 411
in lupus erythematosus, 412
CR2, 411
and B cell activation, 406
in lupus erythematosus, 413
CR3, 411
CR4, 411
Complement system, **407**–413
activation of, 407–410
alternative pathway, 106, 408
classical pathway, 106, 408–409
lectin pathway, 409
regulation of, 411–412
in angioedema, 412
and B-cell activation, 405–407
in cardiovascular disorders, 412
deficiency disorders, 412–413
lupus erythematosus in, 412–413
functions of, 410
genetic abnormalities of, 412
in HIV infection, 413
in humoral immunity, 407–413
in innate immunity, 407
microbial evasion or subversion of, 413
in vascular disorders, 413
Complementary and alternative medicine, **2899**–2904
Complete lymph node dissection, 1441–1442
Cone shell envenomations, 2594
Confounding in epidemiologic studies, 2
Congenital disorders, 1193–1194
nevomelanocytic nevi in, 1377–1382
nevus spilus in, 1382–1384
Conidiobolomycosis, 2317
Conidiobolus coronatus, 2317
Conjunctival lichen planus, 304
Conjunctivitis
in helminthic infections, 2557
meningococcal, 2182–2183
in retinoid therapy, 2765
Connective tissue diseases
inherited, **1624**–1644
in occupational exposures, 2628–2629
Raynaud phenomenon in, 2068
Connective tissue nevus, 712
Conradi-Hünermann syndrome, 723–724
Constricting bands in ainhum and pseudoainhum, **724**–726
Contact dermatitis
allergic. *See* Allergic contact dermatitis
of amputation stump, 1102–1103
irritant. *See* Irritant contact dermatitis
postoperative, 2979
Contact urticaria, 421
from cosmetic products, 3016
Coolant agents in pruritus, 1155
Copper, 1518
deficiency of, 1518
diffuse hypopigmentation in, 812
food sources of, 1518
in Menkes syndrome, 1518–1519
Corals, 2589
Corn(s), **1111**–1114
Corneodesmosin, 574
Cornification
excessive, 34. *See also* Hyperkeratosis
Cornified envelope, 484
Coronary artery disorders
bypass surgery in, 1839
and hyperlipidemia, 1829
Corpuscular receptors, 67
Corticosteroid therapy. *See* Glucocorticoid therapy
Corticotropin-releasing hormone, 1139t, 1143
Corynebacterium minutissimum, 2146
Cosmetic intolerance syndrome, 3012–3015
Cosmetic products and procedures, **3009**. *See also* Aging
complications and reactions to, 3016–3017
acne in, 3013
allergic contact dermatitis in, 3015
allergic type, 3014–3015
contact urticaria syndrome in, 3016
delayed hypersensitivity reactions in, 3016
to fragrances, 3016–3017
intolerance syndrome in, 3012–3015
irritant contact dermatitis in, 3015
irritation and allergy (natural/organic products), 3015–3016
to preservatives, 3017
rosacea type, 3014
stinging or burning in, 3014
emollients, 3012
ethnic and racial consideration aspects, 101–102
humectants, 3012
natural and organic products, 3015
occlusives, 3011
organic products, 3015
by skin type, 3015–3016
skin types in
combination, 3020
oily or dry, 3009–3011
pigmented, 3017
sensitive or resistant, 3012–3013
wrinkled or tight, 3018–3019

Costs of skin diseases, 8
Counseling, genetic, 88–89
Cowpox virus. *See* Paravaccinia virus
Crab lice, 2576–2577
Cranial nerves
  surgical anatomy of, 2908
Creams, topical medications formulated as, 2647
Critical appraisal of evidence, 11–14
Crohn disease, 1833
  metastatic cutaneous, 1833
Cronkhite-Canada syndrome, 1833
Crotamiton, 2701
  in scabies, 2571, 2571b
Crow's feet appearance
  botulinum toxin injection for, 3058–3059
Crusts and encrusted exudates, 35
  in impetigo, 35, 35f
Cryofibrinogenemia, **2063**–2065
  classification of, 2063
  differential diagnosis of, 2061b
  treatment of, 2065
Cryogens
  in cryotherapy, 2968
  in local anesthesia, 2915
Cryoglobulinemia, **2055**–2063
  classification of, 2056, 2057t
  clinical findings in, 2058–2059
    abnormal liver function tests, 2058
    hyperviscosity, 2059
    musculoskeletal complaints, 2058
    neurological manifestations, 2058
    renal involvement, 2058
  complications, 2060
  differential diagnosis of, 2060, 2061b
  epidemiology of, 2055–2056
  etiology of, 2056–2058
  laboratory findings in, 2059–2060
  pathogenesis of, 2056–2058
  prognosis and clinical course, 2060–2061
  treatment of, 2061
  type I, 2057t, 2061–2062
  type II, 2057t
    HCV-associated, 2062
    not associated with HCV, 2063
  type III, 2057t
    HCV-associated, 2062
    not associated with HCV, 2063
    reclapse of HCV-associated, 2062–2063
Cryopyrinopathies, **1585**–1589
Cryotherapy, **2968**–2972. *See also* Electrosurgery
  in actinic keratosis, 2970
  anesthesia in, 2968–2969
  in basal cell carcinoma, 1301, 2971
  in Bowen disease, 2971
  complications of, 2971
    alopecia, 2971
    bleeding, 2971
    nerve damage, 2971
    pain, 2971
    pigmentation changes, 2971
    scarring, 2971
  cryogens used in, 2968
  in dermatofibroma, 2970
  equipment and techniques in, 2968
  in hidradenitis suppurativa, 959
  in keloids and hypertrophic scars, 2970
  in lentigo maligna, 2971
  in malignant lesions, 2971
  risks and precautions, 2968
  in squamous cell carcinoma, 2971
  in sebaceous hyperplasia, 2970
  in seborrheic keratosis, 2969
  in solar lentigo, 2970
  techniques for, 2969
  in warts, 2970
Cryptococcosis, 2325–2327
  in immunocompromised host, 2452
    HIV infection and AIDS, 2327
  primary cutaneous, 2326
  treatment, 2327
Cryptococcus neoformans, 2325
CTACK. *See* Cutaneous T cell–attracting chemokine (CTACK)
Ctenocephalides felis fleas, 2607
Curettage
  in actinic keratosis, 1266
  and desiccation, 2974–2975
    in basal cell carcinoma, 1301, 2974–2975
Cushing disease, 1860
Cushing syndrome, 1859–1861
  clinical findings in, 1860
  hyperpigmentation in, 818, 1860
  striae in, 1860
  treatment of, 1861
Cutaneous field stimulation in pruritus, 1157
Cutaneous lymphocyte antigen (CLA)
  in T-cell lymphoma, 1747
Cutaneous T cell–attracting chemokine (CTACK), 112
  in atopic dermatitis, 167
  in melanoma, 150
Cuticle
  of hair follicle, 965
Cutis laxa, **1638**–1643
  acquired, 1642
  cardiovascular disorders in, 1819
  clinical manifestations in, 1641
  differential diagnosis of, 1642
  elastic fiber disorders in, 1638
  etiology and pathogenesis in, 1638
  fibulins in, 1638
  general skin changes in, 1641
  genetic factors in, 1638, 1641
  with joint laxity and developmental delay, 1638
  treatment of, 1643
  X-linked, 1641
Cutis marmorata telangiectatica congenita, 1191
Cutis verticis gyrata, 717
CX3C (CXXXC) chemokines, 142
CX3CR1, 143t
CXC chemokine(s), 142
  in tumor formation, 149–150
CXC chemokine ligands
  CXCL12, 142
  CXCL14, 147
CXC chemokine receptors, 116
  CXCR1, 143t
    in cancer, 149
    in psoriasis, 149
  CXCR2, 143t
    in cancer, 149
    in psoriasis, 149
  CXCR3, 117, 143t
    in cancer, 149
  CXCR4, 143t
    in infectious diseases, 151
    in melanoma, 150
CXXXC (CX3C) chemokines, 142
Cyanea sea nettles, 2585
Cyanosis, 1742–1743, 1820
  central, 1742, 1820
  in cold exposure, 1085–1086
  in cryoglobulinemia, 2059b
  differential diagnosis of, 1742b, 2060
  in polycythemia vera, 1741–1742
  skin changes aspects, 1820
Cyclophosphamide, 2747–2749
  complications and side effects of, 2748–2749
  dosing regimen, 2748
  indications for, 2747
  interaction with other drugs, 2749
  mechanism of action, 2747
  with mesna, 2748
  monitoring of therapy with, 2748
  in pemphigus, 598
  pharmacokinetics of, 2747
Cyclosporine, 2809–2812
  in alopecia areata, 994, 2810
  in atopic dermatitis, 180, 2810
  in Behçet disease, 2810
  combination with phototherapy, 2857
  complications and side effects of, 2811
    cancer risk in, 2812
    hepatotoxicity in, 2811
    hypertrichosis in, 2812
    nephrotoxicity in, 2811
    pregnancy, 2812
  in dermatomyositis, 2810
  in epidermal necrolysis, 447
  in exfoliative dermatitis, 278
  indications for, 2810
  initiation of therapy with, 2810
  in lichen planus, 2810
    oral, 310
  monitoring of therapy with, 2810
  in palmoplantar pustulosis, 256
  pharmacokinetics of, 2810
  in psoriasis, 228, 2810
    and arthritis, 240
    in combination with other agents, 2857
  in pyoderma gangrenosum, 2810
  in vesicular palmoplantar eczema, 192
Cylindroma
  eccrine, 1346–1347

Cyproheptadine, 2770t. *See also* Antihistamines
Cyproterone acetate
in hidradenitis suppurativa, 957
in hair loss, 986
Cyst, 30–31, 31f
branchial cleft, 1336
dermoid, 1335–1336
epidermoid, 1333–1334
in Gardner syndrome, 1333
posttraumatic, 1333
genital, 888–889
in hidradenoma, 30–31, 31f
in hidrocystoma
apocrine, 1343
laser therapy for
hair cysts, 2881
mucous cysts, 2881
keratin
postoperative, 2981
myxoid, 1021
phaeomycotic, 2317
pilar, 1334
preauricular, 1336
trichilemmal, 1334, 1361
Cystathionine β-synthetase, 1526t
Cysticercosis, 2567–2568
differential diagnosis of, 2568
neurologic disorders in, 2568
Cytochrome P_{450} enzymes
in drug metabolism, 2836
Cytokeratins. *See also* Keratin
cytokeratin-7, 1367
cytokeratin-20, 1366
Cytokine(s), **126**–141, 1138, 1144
in antigen presentation, 119, 121, 123–125
in atopic dermatitis, 167
chemoattractant. *See also* Chemokine(s)
classification of, 127–128
structural, 128
concept of, 126
endothelial-activating, 357
eosinophil-activating, 357
in innate immunity, 107, 107f, 108, 109, 110, 111, 112
interleukin 1 family, 132–134, 133f
of keratinocytes, 112–113
in lichen planus, 297
neurophilic, 1144
pleiotropism of, 127
primary, 127
in pruritus, 1144
in psoriasis, 203
redundancy of, 127
secondary, 127, 140. *See also* Chemokine(s)
signal transduction pathways, 128–129
Jak/STAT pathway, 131–132, 132f
NF-κB, inhibitor of κB, and primary cytokines, 129, 131
T cell-derived, 127–128
therapeutic applications, 141
transforming growth factor-β, 140
tumor necrosis factor, 134–135, 135f
Cytokine receptors, 136–140
class I, 136–139
class II, 139–140
major families of, 129t
in signal transduction pathways, 128–129, 131, 132
Cytomegalovirus infections, 2352–2356
clinical findings in, 2353
congenital, 2353
blueberry muffin lesions in, 2355b
clinical findings in, 2353
diagnosis of, 2353
epidemiology of, 2352
in immunocompromised host, 2353–2354
adults and children, 2353
bone marrow transplant patients, 2354
clinical findings in, 2353
HIV infected patients, 2354
solid organ transplant recipients, 2354
mononucleosis in, 2356b
perinatal, 2353
prevention, 2356
Cytotoxic agents, **2735**–2758
extravasation of, 2757
mucocutaneous reactions to, 2752–2758
topical, **2685**–2689
Cytotoxic T cell(s), 114
in lichen planus, 297
Cytotoxic T cell differentiation factor, 138. *See also* Interleukins, IL-6

D

DAB389-IL2, 2815t, 2825
Dabska tumor, 1469
Dactylitis
streptococcal blistering distal, 2143
Danger zones in head and neck surgery, 2906–2907
Dapsone, **2721**–2726
in acne, 2674
adverse effects of, 2722–2725
sulfone syndrome in, 2724, 2724b
chemical structure of, 2721f
indications for, 2722
in lichen planus, oral, 310
mechanism of action, 2721
metabolism of, 2722
monitoring of therapy, 2725–2726
in pemphigus, 598
pharmacology of, 2721–2722
Daptomycin, 2785
Darier-White disease, **550**–556
acantholysis in, 550–556
acral, 556–557
calcium signaling and transport in, 551
clinical findings in, 551–554
differential diagnosis in, 555, 555b
dyskeratosis in, 554, 555
etiology and pathogenesis in, 550–551
histopathology in, 554–555
localized, 555
nail changes in, 553, 553f, 554f, 1026
treatment of, 555–556
retinoids in, 2762
Dark-field microscopy in syphilis, 2486–2487
Deafness
in Tietz syndrome, 790
in Waardenburg syndrome, 788–789
Death fever, 2534
Débridement in decubitus ulcers, 1128
Decorin, 687
Decubitus ulcers, **1121**–1129
bacterial colonization in, 1128
clinical findings in, 1122–1126
complications in, 1126t
epidemiology, 1122
etiology and pathogenesis in, 1122
friction in, 1127
laboratory tests in, 1126
pain management in, 1128
prevention of, 1129
risk factors for, 1124t
shear forces in, 1127
staging of, 1124, 1125t
treatment of, 1126–1129
wound management in, 1127–1128
Defensins, 107–108
in psoriasis, 203
Defibrillators, implanted
in electrosurgery, 2912, 2976
Degos disease, **2072**–2075. *See also* Papulosis, malignant atrophic
Dehiscence of surgical wounds, 2920, 2979, 2981–2982
Deletion, 83
Delusions of parasitosis, 1159–1161
differential diagnosis of, 1160
treatment in, 1160
Demodex brevis, 2572
Demodex folliculorum hominis, 2572
Dendritic cells, 119–121
chemokines in trafficking of, 147–148
dermal, 121, 124
definition of, 121
life cycle of, 120–121
migration to lymphoid tissues, 120
phenotypic properties of, 120, 121
in psoriasis, 201
response to danger signals, 124
epidermal
in psoriasis, 202
inflammatory, 121
in psoriasis, 202
and Langerhans cells. *See* Langerhans cell(s)
plasmacytoid, 125–126
in psoriasis, 202
in psoriasis, 201–202
Denileukin diftitox, 126, 2815t, 2825
Depigmentation. *See also* Bleaching agents
in vitiligo, 802
Depressed skin lesions, 32–33
Dermabrasion, 3030–3031
Dermacentor ticks, 2604
and tularemia, 2637

Dermal-epidermal junction, 47, 64
adhesion, 574
anchoring filaments and fibrils in, 47, 64
basement membrane in, 47, 64, 574–575
cellular origin of, embryonic and fetal, 73
embryonic and fetal, 73
blistering disorders of, 47, 64
congenital, 73
disturbances of, 47–48
development of, 73
proteins involved, 71t
embryonic and fetal development of, 73
hemidesmosomes in, 47, 64, 73
lamina lucida in, 47
ultrastructure of, 575–576
Dermatitis. *See also specific types of dermatitis*
actinic chronic, 1057–1060
allergic contact, **152**–164
of amputation stump, 1098, 1100, 1102
artefacta, 1161–1162
and arthritis in meningococcal infections, 2180
atopic, **165**–182
autosensitization, **194**–196
bristleworm, 2592
cercarial, 2566, 2592
chronic vesiculobullous hand, 190
clonal, 286, 286f
exfoliative, **266**–278
herpetiformis, **642**–648, 1836
irritant contact, **499**–506
in low humidity, 2614t
marine, 2593
from marine worms bites, 2592–2593
nummular, 182
perioral, **925**–928
radiation, 2893–2895
sea anemone, 2588
sea cucumber, 2591
seborrheic, **259**–266
sponge, 2590
Streptococcal (genital), 867
Dermatitis herpetiformis, **642**–648
associated problems in, 647
clinical findings, 644–645
differential diagnosis of, 648, 648b
epidemiology of, 642
etiology and pathogenesis in, 642–644
and gluten sensitivity, 642–644, 647
adherence to gluten-free diet in, 648
histopathology in, 646–647
HLA system in, 644, 646
immunoglobulin IgA in, 643, 645–646
and linear IgA dermatosis, 646
laboratory tests in, 645–647
malignancies associated with, 647
pathologic reactions in, 50–51
treatment of, 648
dapsone in, 648
Dermatofibroma, 710–712
cryotherapy in, 2970
Dermatofibrosarcoma protuberans, 1446–1449
clinical findings in, 1447
differential diagnosis of, 1447b
histopathology in, 1448–1449
Mohs micrographic surgery in, 1449, 2955
treatment, 1449
Dermatomal distribution of lesions, 39
Dermatomyofibroma, 715
Dermatomyopathy, idiopathic inflammatory, 1927. *See also* Dermatomyositis
autoantibodies in, 1930t
Dermatomyositis, 1823, **1926**–1942
amyopathic, 1928
approach to patient with, 1930
arthritis in, 1935
autoantibodies in, 1930t, 1935–1936
calcification in, 1938
classic, 1927–1928
differential diagnosis of, 1936b
epidemiology of, 1927–1928
laboratory tests in, 1935–1936
prognosis and clinical course in, 1939
classification of, 1927
clinical findings in, 1930–1935
cutaneous, 1930–1933
systemic, 1933–1935
clinically amyopathic, 1928
clinical features in, 1930–1935
differential diagnosis of, 1936b
epidemiology of, 1928
prognosis and clinical course in, 1939–1940
treatment of, 1941–1942
complications of, 1938–1939
diagnostic criteria in, 1927
differential diagnosis of, 1936b
drug-induced, 1928
epidemiology of, 1927–1928
etiology and pathogenesis of, 1928–1929
hallmark changes in, 1930–1933
anatomic distribution of, 1932t
idiopathic inflammatory, 1927
laboratory tests in, 1935–1937
malignancies in, 1449, 1939
muscle enzymes, 1935
muscle weakness in, 1933–1934
laboratory tests in, 1935, 1936
opportunistic infections in, 1939
in panniculitis, 749–750
prognosis and clinical course in, 1939–1940
respiratory disorders in, 1934–1935
and scleroderma, 1933
sine myositis, 1927
specific skin diseases in, 1927
susceptibility phase in, 1928
treatment of, 1940–1942
antimalarial drugs in, 1940
immunosuppressive therapy in, 1941
ultraviolet radiation exposure in, 1928
Dermatopathy. *See* Dermatosis
Dermatophyte infections, **2278**–2297. *See also* Fungal infections
adherence stage in, 2279
culture, 2281, 2282, 2284
diagnostic procedures in, 2280–2284
genetic factors in, 2280
histopathology, 2284
host response, 2280
invasion stage, 2279
laboratory characteristics in, 2281t
in occupational exposures, 2625
pathogenesis in, 2279
taxonomy and epidemiology, 2278–2279
anthropophilic, 2279
geophilic, 2279
zoophilic, 2279
Dermatophytid reactions, 2291
Dermatophytoses, 2284–2297. *See also* Fungal infections
piedra, 2297
tinea barbae, 2287
tinea capitis, 2284–2286
tinea corporis, 2288
tinea cruris, 2289
tinea favosa, 2286–2287
tinea mannum, 2290
tinea nigra, 2296
tinea pedis, 2290
treatment, 2293–2297
Dermatoscopy. *See* Dermoscopy
Dermatosis. *See also specific disorders*digitate, 287
linear immunoglobulin A, **623**–629
nephrogenic fibrosing, 1838
neutrophilic, **362**–370
perforating, **727**–730
in kidney disorders, 1838
pigmented purpuric, **2049**–2054
in pregnancy, **1204**–1212
pustular
alopecia in, 1000
subcorneal, **383**–385
in Sneddon-Wilkinson disease, **383**–385
in Sweet syndrome, **362**–370
thyroid, 1854–1855
elephantiasic, 1854
treatment of, 1856
transient
in neonates, 1187
Dermatosparaxis type of Ehlers-Danlos syndrome, 1625t
Dermcidin, 108, 730
Dermis, 64. *See also* Aging
atrophy of, 32
cellular components of, 65
collagen in, 64
dendritic cells in. *See* Dendritic cells, dermal
development, 72
blood vessels and nerves, 72–73
embryogenesis aspects, 70t

Dermis—*continued*
lymphatics, 73
nerves, 73
proteins involved, 71t
elastic connective tissue in, 64
embryonic and fetal development of, 72
fibroblasts in, 65
fibrous, 55–56, 64–65
fibrous tumors of, malignant, **1445**–1455
hypertrophy of, **707**–717
lymphatics of, 73
mast cells in, 64
matrix of, 64–65
diffuse, 65
fibrous, 64–65
filamentous, 65
of nails, 1012
nerves in, 73, 1138
papillary, 64
of hair follicle, 966
pathologic reactions of, 51–56
granulomatous, 54–55
infiltrates in, 53
molecular and cellular mechanisms for reaction patterns affecting dermis, 56
reticular layer of, 51–56, 64. *See also* Reticular dermis
vascular system of, 64
deep, 64
superficial, 64
Dermographism, 418–419
cold, 419
Dermolytic epidermolysis bullosa, 658–660. *See also* Epidermolysis bullosa, dystrophic
Dermopathy. *See* Dermatosis
Dermoscopy
in dysplastic nevus, 1413
Desert rheumatism, 2323–2324
Desloratadine, 2770t. *See also* Antihistamines
Desmocollins, 573
Desmoglea, 571
Desmoglein(s), 572
functions of, 573
Desmoglein 1, 572
Desmoglein 2, 572
Desmoglein 3, 572
Desmoglein 4, 573
Desmoid tumors, 713, **1449**–1451
extra-abdominal, 713
intra-abdominal, 713
Desmoplakin, 571, 574
Desmoplastic fibroblastoma, 716
Desmosomes, 45–47, 570–574
biochemistry of, 570–574
in cellular adhesion, 571
disruption of, 61–62, 62t
embryonic and fetal, 68
structure and function of, 572–574
desmoplakin, 573
desmosomal cadherins, 571–573
plakoglobin, 573
plakophilins, 574
ultrastructure of, 570
Desquamation, 34
contact, 834
latent, 34
Detergents and soaps as occupational irritants, 2614
Dextrose, 3001
Diabetes insipidus, 1790, 1802
Diabetes mellitus, **1840**–1868
acanthosis nigricans in, 1841–1843
approach to patient with, 1841b
bullosis diabeticorum in, 1849–1850, 1849b
candidiasis in, 1856
cellulitis in, 2192
cutaneous infections in, 1845
dermopathy in, 1848–1849
epidemiology of, 1840
etiology and pathogenesis in, 1840–1841
foot problems in, 1845, 1846f, 1847b
corns and calluses in, 1845, 1847b
infections in, 1841
limb amputation in, 1841, 1845
prevention of, 1847
ulcers in, 1845
granuloma annulare in, 1848
hand syndrome in, 1844
joint mobility limitations in, 1843–1844
limb amputation in, 1845
in foot problems, 1841, 1845
lipid metabolism in, 1841
necrobiosis lipoidica in, 1847–1848
necrotizing fasciitis in, 1841b, 1845t
neuropathy in
and foot ulcers, 1845
perforating dermatosis in, 1849
scleredema in, 1844
thickening of skin in, 1843
type 1, 1840
type 2, 1840, 1842–1843
ulcers in, 1845–1847
in necrobiosis lipoidica, 1848, 1848f
xanthomas in, 1844–1845
Diagnosis, **26**–41
critical appraisal of evidence on tests in, 11–14
complete patient examination
barriers, 27
ideal conditions, 27
scope, 27
technique, 29
tools for, 28
dermatologic, approach to patient, 26
history-taking in, 26–27, 28t
pointers and pitfalls, 41t
lesions
morphology, 29–37
shape/arrangement/distribution of, 37–42
physical examination in, 29
Diaminodiphenyl sulfone. *See* Dapsone
Diaper dermatitis, 1197–1199
Candida, 1198, 2301, 2452, 2664
irritant, 1198
treatment of, 1198–1199, 1198t
complications in, 2664
Diarrhea, 1834
in helminthic infections, 2557
in rotavirus infections, 2364
Differentiation
of epidermal cells, 43–45, 60–63, 68
in granular layer, 62–63
in spinous layer, 61
in fetal skin development, 68, 70, 71t, 72–75
Diffusion
laws of, 2652
of topical medications, 2652–2653
Dihydropterine reductase, 1526t
Dilated pore of Winer, 1355–1356
Dinitrochlorobenzene in warts, 2706
Dioxin, chloracne from, 2629
Diphenhydramine, 2770t. *See also* Antihistamines
Diphenylcyclopropenone in warts, 2796
Diphtheria, 2225
Diplopoda, 2605
Diptera bites, 2605–2606
Dirofilaria immitis, 2563
Dirofilaria repens, 2563
Dirofilaria tenuis, 2563
Dirofilaria ursi, 2563
Dirofilariasis, 2563
Discoid lesions, 38
Disease burden in population, measures of, 3–8
Disease-modifying antirheumatic drugs in psoriatic arthritis, 240
Disease outbreak investigation, 3
Disomy, uniparental, 83
heterodisomy, 83
isodisomy, 83
Distribution of multiple lesions, 39, 41
Dithranol. *See* Anthralin
DNA, 76
cellular responses to damage of, 1256–1257
regulation of, 1231–1233
double-stranded, 1919t
repair of, **1227**–1138
apoptosis and, 1258–1259
diagnostic tests of, 1234–1236, 1238
genes in, 1229–1231, 1231t
types of damage and pathways in, 1228t
sequencing analysis, 1237
single-stranded, 1919t, 1930t
synthesis of
unscheduled, 1235–1236
ultraviolet radiation-induced damage of. *See* Ultraviolet radiation exposure, DNA damage in
Domestic violence, 1182–1183
agencies and resources for assistance in, 1178t
Doppler imaging
in varicose veins, 3000

Doucas and Kapetanakis purpura, 2052
Down syndrome, 84t
Doxepin
in atopic dermatitis, 179
Dracunculus medinensis, 2563
Dressings
in atopic dermatitis, 175
chemical peeps and, 3030
in decubitus ulcers, 1128
in nail surgery, 2959
Drug abuse, **1166**–1177
complications, 1175
criteria for, 1167b
diagnosis, 1176
differential diagnosis in, 1176
epidemiology of, 1167
pathogenesis in, 1167
treatment in, 1176–1177
Drug-induced disorders
anhidrosis in, 938t
from antipsychotic drugs, 1153, 1160
bullous eruptions in, 453–454
cutaneous reactions in, **449**–457
diagnosis and management of, 456–457
epidemiology of, 449
etiology of, 449
morphology of, 450–456
pathogenesis in, 449–450
prevention of, 457
in drug abuse. *See also* Drug abuse
in drug-drug interactions, 449
epidermal necrolysis in, **439**–448
exanthematous eruptions in, 450, 450f
exfoliative dermatitis in, 270t
fixed drug eruptions in, 454–455
genital
in female, 887
in male, 866–867
hyperhidrosis in, 938t
lichen planus in, 304, 455
lichenoid eruptions in, 455
linear IgA dermatosis in, 453–454
of liver. *See* Liver disorders, drug-induced
lupus erythematosus in, 456
necrosis of skin in, anticoagulant-induced, 455
pemphigoid in, bullous, 454
pemphigus in, 453t, 454
pigmentation changes in. *See* Pigmentation, drugs affecting
pseudolymphoma in, cutaneous, 1769
pseudo-mycosis fungoides in, 1777
pseudoporphyria in, 453
psoriasis exacerbation in, 218
pustular eruptions in, 452–453
scaling lesions in, 35t
seborrheic dermatitis in, 260
serum sickness-line reaction in, 451t, 452
severe, clinical features warning of, 457t
Stevens-Johnson syndrome in, 454
urticaria and angioedema in, 452
vasculitis in, 456
Drug interactions, 449, **2834**–2840
adverse, 2838–2839
ADME model on, 2836
clinical scenarios, 2838–2840
critical, 2840t
CYP isoform, 2836, 2837t
drug substrates in, 2836
enzyme inducers, 2837
enzyme inhibitors, 2836
genetic polymorphism, 2838
metabolic, 2836
option to proceed with caution in, 2839, 2839t
P–glycoprotein, 2834
pharmacodynamic, 2835
pharmacokinetic, 2835
resources on, 2834
therapeutic index, 2836, 2837t
Drug therapy. *See also specific types of drugs*
anti-angiogenic, 2827–2833
interactions of drugs in, **2834**–2840
preoperative assessment of, 2911–2912
Dry skin, 3009–3011. *See also* Xerosis
Dumdum fever, 2534
Dupuytren contracture
and Peyronie disease, 715
Dutasteride, 985
Dyes, antiseptic, 2698
Dyschromatosis
hereditaria symmetrica, 790
hereditaria universalis, 825
Dyskeratosis, 44, 45
and acantholysis, 44f
congenita, **1669**–1671, 1670f
cancer risk in, 1670
clinical features in, 1669–1670
pigmentation disorders and, 815
genetic factors in, 1670
in Darier-White disease, 44, 44f
Dysphagia, 1827–1828
Dysplasia
ectodermal, **1691**–1702. *See also* Ectodermal dysplasia
human papillomavirus induced, 2444
mucoepithelial hereditary, 978
Dysplastic nevus, **1410**–1416
clinical findings in, 1412
complications of, 1414
diagnostic criteria on, 1412
diameter of, 1412, 1413f
differential diagnosis of, 1415b
distribution of, 1411f
epidemiology of, 1411
etiology and pathogenesis of, 1411–1412
histopathology in, 1412–1414
laboratory tests in, 1412–1414
melanoma risk in, 1411, 1414
prevention of, 1416
prognosis and clinical course in, 1415
treatment of, 1415
Dysraphism
cranial, 1195
spinal, 1195
Dysreflexia, autonomic, hyperhidrosis in, 938t
Dystopia canthorum in Waardenburg syndrome, 789
Dystrophic epidermolysis bullosa. *See* Epidermolysis bullosa, dystrophic
Dystrophy. *See* Lipodystrophy

E

E6 gene and protein of papillomaviruses, 2429–2431
in epidermodysplasia verruciformis, 2429–2431
E7 gene and protein of papillomaviruses, 2429–2431
in epidermodysplasia verruciformis, 2429–2431
Ear
cosmetic units and landmarks of, 2905–2906
crease of earlobe, 1828
seborrheic dermatitis of, 263b
Ebastine, 2770t. *See also* Antihistamines
Eccrine glands, 929–934
anatomy of, 929
in chromhidrosis, 939
composition of sweat, 932–933
disorders with changes in, 938t
cytotoxic drugs affecting, 2754
disorders of, **936**–947
classification of, 938t
duct of, 930–931
reabsorption in, 934
embryonic and fetal development, 75
emotional sweating, 931
energy metabolism in, 932
innervation of, 931
and denervation hypersensitivity, 931
mechanisms of sweat secretion, 933–934
neural control of eccrine sweating, 931
nevi of, 1348
pharmacology of, 932
myoepithelial, 932
sweat gland and sweat rate, 932
secretory coil of, 929–930
syringofibroadenoma, 1350
tumors of, 1348–1355
Echinococcosis, 2568
differential diagnosis of, 2568
Echinococcus granulosus, 2568
Echinococcus multilocularis, 2568
Ecthyma
contagiosum, in occupational exposures, 2625
gangrenosum
in *Pseudomonas* infections, 2186
staphylococcal, 2133–2134
Ectoderm, embryonic and fetal, 68, 72, 74, 75

Ectodermal dysplasia, **1691**
alopecia in, 987, 1695, 1696f
anhidrotic or hypohidrotic, 1691–1695
X-linked, 83, 1691–1694, 1693f, 1694f
with ankyloblepharon filiforme adnatum and cleft palate, 1696–1697
in Christ-Siemens-Touraine syndrome, 1691–1695
classification of, 1691
in Clouston syndrome, 1695–1696
dermatologic manifestations, 1692, 1695, 1696–1697, 1699, 1700, 1701
differential diagnosis of, 1694b
with ectrodactyly and cleft lip/palate, 1699
in focal dermal hypoplasia of Goltz, 1701–1702
genetic factors in, 1691–1692
in Hay-Wells syndrome, 1696
hidrotic, 1695–1696
alopecia in, 1695, 1696f
with immunodeficiency, 1713–1714
nail changes in, 1016
in Rapp-Hodgkin syndrome, 1696, 1698f
with split hand, split foot, and cleft lip/palate, 1699
in tooth and nail syndrome, 1699–1701
Ectodysplasin (EDA), 1691–1692
in ectodermal dysplasia, 1691–1692
Ectodysplasin receptor (EDAR), 1692
in ectodermal dysplasia, 1692
Ectopia
lentis
of neural tissue, 1480
meningeal, 1480
neuroglial, 1480
Ectropion
in laser skin resurfacing, 3027
Eczema
atopic, **165**–182. *See also* Atopic dermatitis
chronic hand, 2761
herpeticum
in atopic dermatitis, 174
nummular, **182**–184
differential diagnosis in, 184b
vesicular palmoplantar, **187**–193
Edema
angioedema. *See* Angioedema
eosinophils in, 398
in helminthic infection, 2554
in limb amputation and prosthesis use, 1100
lymphedema. *See* Lymphedema
pigmentation aspects, 813
EDN (eosinophil-derived neurotoxin)
in Waardenburg syndrome, 788–789
Educational interventions in public health programs, 23, 24
Edward syndrome (trisomy 18), 84t
Edwardsiella lineata, 2593
Efalizumab, 2823
complications of, 2823
in psoriasis, 229, 2823
Effluvium
anagen, 990–991
telogen, 988–990, 1190
acute, 989
chronic, 989–990
in infants, 1190
treatment, 990
Ehlers-Danlos syndrome, **1624**–1629
cardiovascular disorders in, 1819
classical, 1624–1627
clinical findings in, 1625–1627
hypermobile, 1626–1627, 1627t
treatment and prevention of, 1628–1629
vascular, 1627–1628
clinical findings in, 1627–1628
Ehrlichia chaffeensis, 2468
Ehrlichiosis, **2468**–2470
clinical and laboratory findings in, 2468
differential diagnosis of, 2468
epidemiology of, 2468
histopathology in, 2468
treatment of, 2470
Eicosanoids
in psoriasis, 203
Elastic fibers, **679**–684
in anetoderma, 719
biology of, 679–682
in cutis laxa, 1638
in dermis, 64
embryonic and fetal, 72
elastin in, 679–681
microfibrillar proteins in, 680–684
in mid-dermal elastolysis, 720–721
pathology in cutaneous diseases, 690, 691t
in pseudoxanthoma elasticum. *See* Pseudoxanthoma elasticum
structure and development of, 679
Elastin. *See also* Aging
biosynthesis of, 681
cross-links of, 681
degradation and remodeling, 681
fibrillogenesis, 681
gene of, 679
constitutive and alternative splicing, 680
cytokine and hormonal regulation, 681
regulation of expression, 681
structure of, 679
protein structure, 679
tropoelastin, 679
Elastofibroma dorsi, 716
Elastolysis
generalized, **1638**–1643. *See also* Cutis laxa
mid-dermal, 720–721
differential diagnosis in, 721
treatment in, 721
perifollicular, 721
Elastoma, isolated, 712
Elderly, 1223–1226
abuse of, 1181
agencies and resources for assistance in, 1178t
legal issues in, 1182
risk factors in, 1182t
types of, 1182t
aging in, 1223–1226. *See also* Aging
basal cell carcinoma in, 1224, 1224t
bullous pemphigoid in, 1224t, 1226
common cutaneous disorders in, 1224t
decubitus ulcers in, 1226
drug eruptions and, 1226
exfoliative dermatitis in, 274
herpes zoster in, 1226
infections in, 1224t, 1225
Merkel cell carcinoma in, 1224t, 1225
nummular eczema in, 182
pruritus in, 1224t, 1225
scabies in, 1225–1226
squamous cell carcinoma in, 1224t
Elective lymph node dissection, 1442
Electrical burns in occupational exposures, 2628
Electrocautery, 2972
Electrocoagulation, 2972
Electrodesiccation, 2972
in basal cell carcinoma, 2975
indications for, 2974–2975
Electrofulguration, 2972
Electrolysis, 2972
Electromagnetic radiation, 1034
properties of, 1034
wavelengths of, 1034
and frequency, 1034
Electromyography in dermatomyositis, 1936
Electrosection, 2972
Electrosurgery, **2972**–2976. *See also* Cryotherapy
anesthesia in, 2973
in benign lesions, 2974
complications of, 2975
burns, 2975
channeling, 2976
infection and mutagenicity, 2976
fire, 2975
equipment for, 2973
in malignant lesions, 2974–2975
modalities in
electrocautery, 2973
electrocoagulation, 2972
electrodesiccation, 2972
electrofulguration, 2972
electrolysis, 2973
electrosection, 2972–2973
in pacemakers and defibrillators, 2912, 2976
patient selection aspects, 2973
postoperative care in, 2976
principles of, 2972
risk and precautions, 2973
technique
hemostasis, 2973
Elejalde syndrome, 806
Embolism
atheromatous, 2100–2103
pulmonary, in sclerotherapy complications, 3005

Emollients
as moisturizing products, 3012
in neonatal care, 1187
in psoriasis, 226
Emotional stress
and atopic dermatitis, 178
Emtricitabine in HIV infection, 2795t
Emulsions, topical medications formulated as
oil-in-water, 2647
water-in-oil, 2647
Endocarditis, **2194**–2197
Janeway lesions in, 1829–1830
Osler nodes in, 1829
Roth spots in, 1829
splinter hemorrhage of nails in, 1829
subacute bacterial, 1829–1830
Endocrine disorders,. *See also specific disorders*
acne with, 915
adrenal, **1859**–1865
of androgenic hormones, 1864–1865
anemia in, 1741
candidiasis with, 1707, 1708t, 1709
in corticosteroid therapy, 2651
diabetes mellitus in, **1840**–1868
estrogen and progesterone levels in, 1862–1864
growth hormone levels in, 1865–1868
multiple endocrine neoplasia syndrome, 1476
parathyroid, **1856**–1859
pruritus in, 1152
thyroid, **1851**–1856
Endoderm, embryonic and fetal, 68
Endopeptidase, neutral, 1138
Endothelin
as melanogenic stimulators, 776
in Waardenburg syndrome, 788–789
Endothelin converting enzyme, 1138
Endothelium, **1986**–2002
in adaptive immunity, 1997–1998
functions of, 1987–1988
in inflammation, 1991–2002
and leukocyte activation, 1996
and leukocyte adhesion, 1993–1996
and leukocyte extravasation, 1996–1997
skin microvessels in inflammation and repair, 1998–2002
and vascular leakage, 1997
and vasodilator synthesis, 1993
in innate immunity, 1991–1997
junctions in, 1990
molecular markers of, 1991
morphology of cells in, 1988–1991
organelles in, 1988–1990
Entamoeba dispar, 2541
Entamoeba histolytica, 2541
Enteric gram-negative bacilli, 2192–2193
Enterobiasis, 2560–2561
treatment of, 2561
Enterobius vermicularis, 2545
Enteroviruses, 2359–2363
in hand-foot-mouth disease, 2360–2362
in herpangina, 2362–2363
Entomophthoromycosis, 2317
Environmental factors. *See also* Occupational exposures
in climate therapy for psoriasis, 227
in Sjögren syndrome, 1977
in squamous cell carcinoma, 1285
ultraviolet radiation exposure, 1032–1033. *See also* Ultraviolet radiation exposure
Envoplakin, 571, 574
Eosinophil(s), **351**–361, **386**–400
activation of, 360–361
in angiolymphoid hyperplasia, 394–396
in atopic dermatitis, 166, 361
biologic functions of, 353–354
in cutaneous diseases, 355–356, **386**–399
granules in
composition of, 353, 356
in hypereosinophilic syndromes, 356, 387–391
in immune function, 354–355
in Kimura disease, 396
major basic protein, 356
ontogeny and development of, 351
pharmacologic manipulation of, 361
in pustular folliculitis, 396–397
recruitment of, 359, 360
surface receptors of, 358
tissue effects of basic proteins, 356
tissue trafficking, 359
in toxic oil syndrome, 400
in tumors, 355, 400
ultrastructure of, 353
in vasculitis, 400
in Wells syndrome, 391–394
Eosinophil cationic protein, 357
Eosinophil-derived neurotoxin (EDN), 357
in Waardenburg syndrome, 788–789
Eosinophil peroxidase, 356
Eosinophilia, 355, 356, 386–399
and angioedema, 388, 389, 390
and angiolymphoid hyperplasia, 394–396
apoptosis in, 359
diagnostic criteria in, 388t
fasciitis in, 359, 399
in helminthic infections, 2558
lymphocytic, 388–391
and myalgia syndrome, 399
myeloproliferative, 388
pustular folliculitis in, 396–397
tumors associated with, 355
Wells syndrome in, 391–394
Ephelides (freckles), 824
Epidemiologic studies, **1**–8
bias in, 2
causal inferences in, 2–3
coherence of, 3
confounding in, 2
definition of skin disease in, 3
on disease burden in population, 3–8
clinical severity of disease, 7
cohort patterns, 4–5
costs, 8
incidence, 4
lifetime risk, 5–6
morbidity, 6–7
mortality, 4
number of physician visits, 6
patient-reported outcomes, 7–8
prevalence, 5, 6t
skin disease, 3
in disease outbreak, 3
experimental design, 3
replication of, 2
types of, 2
validity of, 7
Epidermal growth factor receptor inhibitor therapy, acneiform eruption in, 916
Epidermal necrolysis, **439**–448
body surface area involved in, 442
clinical findings in, 441–442
complications in, 445–446
diagnostic approach in, 441f
differential diagnosis in, 444–445, 445b
drug-induced, 439–448
high-risk medications in, 440, 440t
epidemiology of, 439–440
etiology of, 440–441
extracutaneous symptoms in, 442
and graft-versus-host disease, 440
histopathology in, 444
laboratory tests in, 442–444
pathogenesis in, 441
prevention of, 448
prognosis and clinical course in, 446
scoring system on, 440t, 443, 447
Stevens-Johnson syndrome in. *See* Stevens-Johnson syndrome
treatment of, 446–448
tumor necrosis factor in, 441, 447
Epidermal nevus, **1323**–1329
apocrine, 1327
comedonicus, 1326–1327
eccrine, 1327
sebaceous, 1325–1326
syndromes in, 1327–1329
clinical features of, 1328
verrucous, 1323–1325
Epidermis, 42–46, 58, 60–63, **478**–485
adhesion and cohesion in, 570–574
atrophy of, 30
cell types in, 70
age-related changes in, 964–966
cohesion of, 45–46, 570–574
differentiation of, 43–45, 60–61, 63, 68, 478–485
in embryonic and fetal development, 68–70
kinetics of, 43
lateral migration of, 474
cholesterol in, 490
cornified envelope of, 484
and dermal-epidermal junction, 47, 64

Epidermis—*continued*
differentiation of, 478–484
keratins and, 478–484
development
early fetal development (morphogenesis), 68–70
embryogenesis, 69t
embryonic development, 68
late fetal development (differentiation), 70
proteins involved, 71t
specialized cells within epidermis, 70
embryonic and fetal development of, 68–70
excoriations of, 35
functions of, 58, 59t
as gene therapy target, 477
growth and proliferation of, 60, 473–477
in hyperproliferation and hyperplasia, 60f
in psoriasis, 4960f, 476
regulatory mediators in, 475, 476
in seborrheic dermatitis, 260
in skin barrier function, 492
stratification in, 478
homeostasis of, 43, 476, 476t
keratin in, 60, 478–484
layers of, 60–63
basal, 60–61
granular, 62–63
spinous, 61–62
stratum corneum, 63
melanocytes in, 63
necrolysis of, **439**–448. *See also* Epidermal necrolysis
phototherapy effect on, 2843
sensory nerves in, 1138, 1142
stem cells in, 61, **473**–477
thickness of, 60
transit-amplifying cells in, 476
Epidermodysplasia verruciformis, 1273
papillomaviruses in
sensitivity to, 1259
types of, 1273
squamous cell carcinoma in, 1273
Epidermoid cysts
in Gardner syndrome
in limb amputation and prosthesis use, 1098–1099
Epidermolysis
bullosa. *See* Epidermolysis bullosa
and hyperkeratosis, **521**–523
in palmoplantar keratoderma, 541
diffuse, 543
Epidermolysis bullosa
acquisita, **634**–641
Brunsting-Perry pemphigoid-like presentation in, 638
bullous-pemphigoid-like presentation in, 637
cicatricial pemphigoid-like presentation in, 638
classic presentation in, 636–637, 636f, 637f
clinical findings in, 635–639
collagen VII in, 634–636, 638
complications in, 640–641
diagnostic criteria on, 640t
differential diagnosis in, 640, 640b
diseases associated with, 639
epidemiology of, 634
etiology and pathogenesis in, 634–635
histopathology in, 639
HLA system in, 634
immunofluorescence in, 639–640
immunoglobulin IgA bullous dermatosis-like presentation, 638
laboratory tests in, 639
and lupus erythematosus, 634
treatment in, 641, 641b
anchoring fibrils in, 651
classification of, 653t
collagen VII in, 634–636, 638, 651, 664–665
collagen XVII in, 651, 664
dystrophic, 658
Cockayne-Touraine type, 658
collagen VII in, 659–660
dominant, 658
Hallopeau-Siemens variant, 659
localized, 658
molecular pathology in, 659–660
Pasini type, 658
recessive, 658–659
squamous cell carcinoma in, 658–659, 663
treatment in, 662–665
hemidesmosomes in, 650
inherited, **649**–665
clinical findings in, 653–660
diagnosis of, 660–662
differential diagnosis in, 653b
etiology and pathogenesis in, 649–652
genetic counseling in, 662
treatment in, 662–665
junctional, 656–658
collagen XVII in, 658
generalized atrophic benign, 657, 657f, 658
gravis (Herlitz), 656
localized, 657
minimus, 657
mitis, 657
molecular pathology in, 657–658
treatment in, 662
nail changes in, 1016
simplex, 653
generalized (Koebner variant), 654
herpetiform (Dowling-Meara), 653–654
localized (Weber-Cockayne), 654
molecular pathology of, 655–656
with mottled pigmentation, 655
with muscular dystrophy, 655
of Ogna, 655
Epidermolytic hyperkeratosis, **521**–523
Epigenetics, 87–88
Epigenomics, 88
Epinephrine, 2913–2914
side effects of, 2914
Epithelial tumors
benign, **1319**–1336
premalignant, **1261**–1282
Epithelioid sarcoma, **1454**–1455
Epstein-Barr virus, 2346–2350
clinical findings, 2347
course, 2349
complications, 2349
differential diagnosis of, 2349b
epidemiology, 2347
etiology and pathogenesis, 2347
in genital ulcers, 2347
in Gianotti-Crosti syndrome, 2347
histopathology, 2349
in lymphoproliferative disorders, 2350
in mononucleosis, 2347, 2348, 2349
differential diagnosis of, 2349b
prevention, 2350
transmission of, 2347
treatment, 2349
Epstein's pearls, 1188
Erbium:yttrium-aluminum-garnet laser in skin resurfacing, 3023, 3024
complications of, 3028
ERCC2, 81
Erosions, 32, 32f
in Jacquet dermatosis, 1198
Ertapenem, 2785
Eruptive pseudoangiomatosis, 2363–2364
Erysipelas, 2161, 2163
differential diagnosis of, 2166b
histopathology in, 2165
prognosis and clinical course in, 2164
treatment of, 2167b
Erysipeloid, 2222–2223
in occupational exposures, 2624
treatment of, 2223
Erysipelothrix rhusiopathiae, 2222–2223, 2624
treatment of, 2223
in waterborne infections, 2222–2223
Erythema, 33, 1820–1821
ab igne, 822
in occupational exposures, 2628
annulare centrifugum, **463**–466
clinical findings in, 464–466
differential diagnosis in, 466, 466b
epidemiology, 463–464
etiology and pathogenesis, 464
histopathology in, 465
treatment in, 466
color changes in, 1820
differentiated from purpura, 33
dyschromicum perstans, 824–825
elevatum diutinum, 2008, **2029**–2032
clinical features in, 2030
disorders associated with, 2031
histopathology in, 2031f
treatment of, 2031–2032
gyratum repens, 1890–1891
wood-grain pattern in, 1890, 1890f
infectiosum, 2342–2346
multiforme, **431**–438
approach to patient with, 433f
classification of, 431

clinical findings in, 432–436
complications of, 437–438
continuous or persistent, 438
differential diagnosis in, 437, 437b
epidemiology of, 431
etiology of, 431–432
exudativum, 431
in herpes simplex virus infections, 431, 432, 436–438
histopathology in, 436
laboratory findings in, 436–437
oral cavity disorders in, 434
pathogenesis in, 432
pathologic reactions in, 49
prevention of, 438
recurrent, 438
Stevens-Johnson syndrome in. *See* Stevens-Johnson syndrome
in *Streptococci* infections, 2144
subtypes of, 431b
target lesions in, 433–434, 434f
treatment of, 438
necrolytic migratory, 1891–1892
differential diagnosis in, 1892b
in glucagonoma, 1891–1892
nodosum, 734–736
clinical appearance in, 734–735
etiology in, 734
treatment in, 735–736
nodosum leprosum, 2260
thalidomide in, 2831–2832
palmar, 1826
postoperative, 2983
skin changes aspects, 1820–1821
toxicum neonatorum, 1188
toxin-mediated recurrent perineal, 2158–2159
Erythermalgia, 1826, 2108–2109. *See also* Erythromelalgia
Erythrasma, 2146–2147
Erythroderma, 33, 1824
desquamativum, 263
Erythrogenic exotoxin in streptococcal infections, 2149t
Erythrokeratodermia
with ataxia, 530
en cocardes, 530
progressive symmetric, 531
variabilis, 530–531
Erythromelalgia, 1826, 2108–2109
clinical findings in, 1826, 2109
disorders associated with, 1826, 2109
etiology and pathogenesis in, 2108
primary, 1826, 2108
secondary, 1826, 2108
treatment of, 1826, 2109
Erythromelanosis follicularis faciei et colli, 973–974
Erythromycin, 2673
in acne vulgaris, 2673
Erythronychia, longitudinal, 1015
Erythroplakia, 1281–1283
oral, 839, 1281–1283
Erythroplasia, 1281–1283. *See also* Erythroplakia
Eschar, 36, 36f
in burns, 36, 36f
*Escherichia coli*in cellulitis, 2192
Esophagus, 1827–1828
cancer of, 1827–1828
lichen planus of, 303, 1827
Esterification of retinol, 2668–2670
Estradiol
in pattern hair loss, 986
Estrogen, 1862–1864
in acne vulgaris, 1863
in dermatitis, 1863
in hereditary angioedema
hyperpigmentation from, 1863
in lupus erythematosus, 1864
in menopause, 1862–1863
ET. *See* Endothelin
Etanercept, 2815t, 2824
complications of, 2824
dosage of, 2824
in exfoliative dermatitis, 278
indications for, 2824
initiation and monitoring of therapy with, 2824
pharmacokinetics of, 2824
in psoriasis, 2824
in rheumatoid arthritis, 2824
in vesicular hand dermatitis, 193
Ethanol, intake of. *See* Alcohol use and alcoholism
Ethanol, topical
in preoperative skin preparation, 2913
Ethinyl estradiolin hidradenitis suppurativa, 958
Ethnic and racial differences. *See also* Skin of color
in allergic contact dermatitis, 153
in irritant contact dermatitis, 501
Etretinate, 2761
dosing regimens, 2763
initiation and monitoring of therapy, 2763
in lichen planus
cutaneous, 311
oral, 310
in palmoplantar pustulosis, 256
Evidence-Based Dermatology, 10
Evidence-based medicine, **9**–14
applied to specific patient, 14
compared to reliance on personal experience, 11
critical appraisal of evidence in, 11–14
on diagnostic tests, 10t
on harmful effects, 10t
on therapy and prevention, 12–14
evidence
best evidence in, 9–11
grades, 10t
hierarchy, 9
meta-analysis in, 9–10
sources, useful, 11
systematic review in, 9–11
Exanthema
asymmetrical periflexural of childhood, 2365–2366
Boston exanthem disease, 2364
subitum
in herpesvirus-6 infections, 2357
in herpesvirus-7 infections, 2359
unilateral laterothoracic, 2365–2366
in viral infections, **2337**–2366
Excisional surgery, **2921**–2949. *See also* Flaps; Grafts
in alopecia reduction, **3075**–3076
anesthesia in, 2923–2924
in basal cell carcinoma, 1301
incomplete resection in, 1303
complications of, 2948–2949
ellipse variations and,
curved, 2929
M-plasty, 2929
partial closure, 2929–2930
serial excision, 2930
S-plasty, 2929
elliptical excision in, 2924–2927
closure, 2926–2927
ellipse planning, 2924–2925
technique, 2925
suture removal, 2927
equipment in, 2923
excision without closure, 2928
flaps in, 2930–2944
partial closure in, 2929–2930
preparation in, 2923
postoperative care in, 2948
revision of standing tissue cones in, 2928–2929
risks and precautions in, 2921–2923
Excoriations, 35
Exercise
and skin problems in athletes, **1115**–1121. *See also* Athletes
Exfoliative cheilitis, 847
Exfoliative dermatitis, **266**–278
atopic, 174
clinical findings in, 269–271
complications in, 174, 274
cytokine and chemokines in, 267
diagnostic approach to, 271f
differential diagnosis in, 269b
diseases associated with, 268t
drug-induced, 270t
epidemiology of, 267
etiology and pathogenesis of, 267
histopathology in, 274, 275t, 276t
laboratory tests, 272, 274
mortality rate in, 274
neonatal, 267
palmoplantar keratoderma in, 272f
prevention of, 278
prognosis and clinical course in, 274, 276, 277
treatment of, 277–278, 277b
Exocytosis
reaction pattern, 49
Exogen, 969
Exons, 1630
Exophiala jeanselmei, 2317
Exostosis, subungual, 1021
Exotoxins
staphylococcal, 2139
Expressivity, 81
Extensor lesions, 41
Extracellular matrix, 55–56
diseases,
dermal ECM, 689
emerging disease mechanisms, 690
in wound healing, 2989–2991

Extracorporeal
photochemotherapy, 310. *See also* Photopheresis
in lichen planus, 310
photopheresis, 181
Eye disorders
in atopic dermatitis, 173–174
drug-induced
from corticosteroids, 2665
in helminthic disease, 2557
in lichen planus, 304
in nevus of Ota, 815
in reticulohistiocytosis, multicentric, 1831
in Sjögren syndrome, 1979, 1982
treatment of, 1984
Eyelids
allergic contact dermatitis of, 157
ptosis from botulinum toxin, 3060
seborrheic dermatitis of, 263b
surgical anatomy of, 2908
swelling in helminthic infections, 2558
Eyes, 1827
safety and radiation therapy, 2877

F

Fabry disease, **1613**–1623
angiokeratoma in. *See* Angiokeratoma, in Fabry disease
angiomas and telangiectasias, 1614–1616
clinical findings in
facial features, 1616–1617
gastrointestinal, 1619
lower limb edema, 1617
lymphedema, 1617
neurologic, 1618
organ damage, 1619
Raynaud phenomenon, 1618
sensory organ, 1619
sweating abnormalities, 1618
diagnosis of, 1619
differential diagnosis of, 1620–1622, 1620b, 1621t
epidemiology of, 1613
etiology and pathogenesis in, 1613
genetic counseling in, 1622
histopathology in, 1614
natural history of, 1614f
prognosis and clinical course in, 1622
quality of life issues in, 1623
treatment of, 1622–1623
enzyme replacement therapy in, 1623
genetic counseling, 1623
symptomatic therapies, 1622
Face
allergic contact dermatitis of, 157
sensory nerves in
anesthetic block of, 2916
skin types of
combination, 3020
oily or dry, 3009–3011
pigmented, 3017
sensitive or resistant, 3012–3013
wrinkled or tight, 3018–3019
spider nevus of, 1827
surgical anatomy of, 2906
Facial nerve, 2907, 2909. *See also* Nerve blocks
surgical anatomy of, 2907
temporal branch of, 2907
as danger zone in surgery, 2907
Factitious disorders, 1161–1163
dermatitis artefacta, 1161–1162
Famciclovir, 2790–2791
dosage of, 2791, 2791t
in herpes simplex virus infections, 2790–2791
in varicella-zoster virus infections, 2790–2791
Familial cold autoinflammatory syndrome, 1585–1589
differential diagnosis of, 1589
treatment of, 1589
Familial hypercholesterolemia, 1607
Familial Mediterranean fever, 1589–1592
Family, domestic violence in, 1182–1183
Fanconi anemia, 1655, 1657t, 1658t, 1669
clinical features in, 1669, 1670f
diagnosis of, 1669
genetic factors in, 1669
resources on, 1669
Fas and Fas ligand
in lichen planus, 298
Fascia, 2907
Fasciitis
necrotizing, 2169, 2171
cervical, 2172–2173
craniofacial, 2172–2173
histopathology in, 2174
in *Klebsiella* infections, 2192
laboratory studies in, 2173
prognosis and clinical course in, 2175
type I, 2172
nodular, 715–716
Fasciola gigantica, 2566
Fasciola hepatica, 2566
Fascioliasis, 2566
differential diagnosis of, 2566
Fat
autologous, in soft-tissue augmentation, 3049–3051
subcutaneous. *See* Subcutaneous fat
Fat embolism syndrome, 1830
Fatty acids
in complementary and alternative medicine, 2901
deficiency of, 1503–1504
free, 490
in stratum corneum, 490
FBLNs. *See* Fibulins
FBNs. *See* Fibrillins
Febrile neutrophilic dermatosis, acute, **362**–370. *See also* Sweet syndrome
Felon (whitlow)
staphylococcal, 2138–2139
Female genital disorders, **878**–892. *See also* Vulvar disorders
abscess in, 888
aphthae, 887–888
in cicatricial pemphigoid, 887
clinical findings in, 878–879
in contact dermatitis, 882
in Crohn disease, 888
differential diagnosis in, 880, 880b
epidemiology of, 878
etiology and pathogenesis in, 878
fissure of vulva, 885
laboratory tests in, 879–880
in lichen planus, 303, 304, 885–887
in lichen sclerosus, 883–885
in lichen simplex chronicus, 881
in Paget disease, 1371–1376
clinical findings in, 1371–1372
prognosis and clinical course in, 1374
treatment of, 1375–1376
in pemphigus vulgaris, 887
prognosis and clinical course in, 880
in psoriasis, 882
treatment in, 880–881
Fever
in acute neutrophilic dermatosis, **362**–370. *See also* Sweet syndrome
Familial Mediterranean fever, 1589–1592
in helminthic infections, 2558
hyperhidrosis in, 941
hyperimmunoglobulinemia D with periodic fever, 1592–1594
Fexofenadine, 2770t. *See also* Antihistamines
Fibrillins, 683
FBN1, 683
FBN2, 683
FBN3, 683
Fibrillopathies, 1630
Fibroadenoma of breast, 1344
Fibroblast(s)
in dermis, 65
functions of, 65
growth factor stimulating, 777
Fibroblast growth factor
basic, 777
in sebaceous gland activity and sebum production, 896–897
Fibroblastoma
Fibrofolliculoma, 712, 1356
Fibrokeratoma, acral, 716
Fibrokeratoma of nails, 1021
Fibroma
collagenous, 716
of nails, 1021
pleomorphic, 716
Fibromatosis
aggressive, 713
in children and infants, 713
aggressive, 713
digital, 714
in myofibromatosis, 713
colli, 714
desmoid tumors in, 713

hyaline, 714
palmar, 715
of penis, 715
Fibrous tumor
of dermis, malignant, **1445**–1455
solitary, 716–717
Fibroxanthomas
atypical, **1451**–1452
clinical findings in, 1451
histopathology in, 1451
treatment of, 1451–1452
Fibulins, 683–684
Fick's laws, 2652
Filaggrin, 78, 82
gene, 78
Filariasis, 2563
cutaneous, 2564
Loa loa, 2564
lymphatic, 2563
mansonelliasis, 2564
onchocerciasis, 2564–2565
Finasteride
in hair loss, 985
Fingers. *See* Hand
Fire accidents
in electrosurgery, 2975
Firjal. *See* Syphilis, endemic
First aid
in sea urchin injuries, 2591
Fish
bite wounds from, 2597
and seafood ingestion and poisoning, 2598
with venomous spines, 2595–2597
catfish, 2595
prevention, 2596
scorpionfish, 2596
stingrays, 2595
treatment, 2597
weeverfish, 2596
Fissures, 35
in contact dermatitis, 35
in nails, longitudinal, 1014
in vulva, 885
Fistula
pulmonary, 1830
FK-506. *See* Tacrolimus
Flaps, 2930–2944. *See also* Excisional surgery; Grafts
advancement, 2931–2935
bilateral, 2932
crescentic, 2932–2934
island pedicle, 2934–2935
single, 2931–2932
interpolation, 2940–2944
Abbé, 2944
nasolabial, 2943
paramedian forehead, 2940–2943
retroauricular, 2944
rotation, 2935–2936
bilateral, 2936
dorsal nasal, 2935–2936
transposition, 2936–2940
30° angle Webster, 2939
banner, 2939
bilobed, 2939–2940
DuFourmental, 2938–2939
rhombic, 2937–2938
Flashlamps
high-energy, 2886
in intense pulsed light therapy, 2886
Flat skin lesions, 33
Fleas, 2607
Flexor lesions, 41
Flower cells in adult T-cell leukemia, 2436
Fluconazole, 2802–2803
adverse effects of, 2803
in coccidioidomycosis, 2324
in dermatophyte infections, 2294
dosage of, 2803t
pediatric, 2803t
indications for, 2802
adult, 2802–2803
elderly, 2803
pediatric, 2802
interaction with other drugs, 2803
mechanism of action, 2802
pharmacokinetics of, 2802
Fluid-filled lesions, 36–37
Fluocinolone acetonide in oral lichen planus, 309
Fluocinonide in oral lichen planus, 309
Fluorescent antibody detection
in syphilis, 2487–2488
Fluorescent lamps, 2844
in phototherapy, 2844
Fluoroquinolones, 2783–2784
adverse effects of, 2784b
indications for, 2784b
mechanism of action, 2783
pharmacokinetics of, 2783
5-Fluorouracil, 2685–2686
indications for, 2685
side effects of, 2685
Flushing
color changes in, 1821
disorders associated with, 1821
Foam sclerotherapy for varicose veins, 3003
Folate, 1514
Follicular tumors, 1355–1361, 1361
in infundibulum, 1361
Follicular unit transplantation for hair loss, 3070–3071
extraction technique in, 3070
Folliculitis
classification of, 2134b
decalvans, 999
deep, 2135
dissecting, 999–1000
Pityrosporum, 2310–2311
differential diagnosis of, 2311b
treatment of, 2311
spinulosa decalvans, 977
staphylococcal, 2134–2135
superficial, 2134
Food
allergies to, 2900
atopic dermatitis in, 171, 178
determination and elimination, 2901
diagnosis, 2901
and gustatory sweating, 938t
seafood ingestion and poisoning, 2598
Foot
in diabetes mellitus. *See* Diabetes mellitus, foot problems in
plantar skin of. *See* Palmoplantar skin
pustular eruptions of, **253**–256
ulcers of
differential diagnosis of, 2098b
Fordyce granules, 828
Forehead
botulinum toxin injections in
complications of, 3060
for glabellar brow furrows, 3057
for horizontal lines, 3057–3058
surgical anatomy of, 2907–2908
Formaldehyde
allergic contact dermatitis from, 161
as preservative, 3017
in warts, 2706
Foscarnet, 2792–2793
in herpes simplex virus infections, 2792–2793
Fournier gangrene, 873, 2173
Fractional photothermolysis, 3021
for skin resurfacing, 2876
Fragrance allergy, 3015
contact dermatitis in, 160, 3016–3017
Framboesia tropica. *See* Yaws
Francisella tularensis. *See also* Tularemia
in bioterrorism, 2637
occupational exposure to, 2624
in tularemia, 2214–2215
Frederickson hyperlipidemia, 1610–1611
Friction
blisters in athletes from, 1118
decubitus ulcers from, 1127
Frostbite, 1082–1085
Fumaric acid esters
in palmoplantar pustulosis, 256
in pityriasis rubra pilaris, 284
in psoriasis, 228
Fungal infections, **2277**–2297, **2312**–2328. *See also specific infections*
of amputation stump, 1101
anthropophilic, 2277
in athletes, 1117
in children and infants, 1190
diaper dermatitis in, 1197–1199
deep, **2312**–2328
geophilic, 2277
in occupational exposures, 2625–2626
onychomycosis, 2292–2293
distolateral subungual, 2292
proximal subungual, 2292
white superficial, 2292
oral, 832
superficial, **2277–**2297. *See also* Dermatophytoses
culture procedures in, 2281
diagnostic procedures in, 2280–2284
epidemiology of, 2278

Fungal infections—*continued*
genetic factors in, 2280
microscopic examination in, 2280
pathogenesis in, 2279
treatment of, 2293–2297
systemic, 2317–2328
route of infection and dissemination in, **2298**–2311
zoophilic, 2277
Furocoumarins, phototoxicity from, 1071
Furuncles, 37, 2135
abscess in, 2136
differential diagnosis of, 2136b
prognosis and clinical course in, 2136
treatment of, 2136
Furunculosis, 2135
recurrent, 2137b
Fusarium
in immunocompromised host (fusariosis), 335

G

G protein coupled receptor, 1138
Ganglioneuroma, 1480
Ganciclovir, 2792
Gangrene
cellulitis, gangrenous, 2175
ecthyma gangrenosum
immunosuppression and, 332, 332f
in *Pseudomonas* infections, 2186
Fournier. *See* Fournier gangrene
gas, 2176
Meleney, 2172
progressive bacterial synergistic, 2172
pyoderma gangrenosum. *See also* Pyoderma, gangrenosum
acne with, 1594, 1595
cyclosporine for, 2810
neutrophils in, 350
pyogenic arthritis with, 1594–1595
skin problems in ostomates, 1109
streptococcal, 2172
histopathology in, 2172
Gardner syndrome, 1833
Gas gangrene, 2176
Gastrointestinal disorders, 1832–1834
abdominal pain in, 1832–1833
in helminthic infections, 2557
hemorrhage, 1832
drug-induced, 1832
in pseudoxanthoma elasticum, 1832
oral ulcerative lesions associated with, 831
in lichen planus, 298
Gender differences
in allergic contact dermatitis, 153
in irritant contact dermatitis, 501
in melanoma prognosis, 1435
Gene therapy, 90–91
inhibition type, 90
natural, in revertant mosaicism, 87
replacement type, 90
skin as target in, 90
viral vectors in, 90
Generalized lesions, 41
Genetic counseling. *See* Counseling, genetic
Genetics, **75**–91
in atopic dermatitis, 168–169
in autosomal dominant inheritance, 82f
in autosomal recessive inheritance, 82f
balanced translocation, 83
in carcinogenesis, **1227**–1138
animal models of, 1242–1245
oncogenes in, 1242
tumor suppressor genes in, 1242
chromosome disorders, 83–85
chromosome structure, 76–78
in complex traits, 85–86
counseling on. *See* Counseling, genetic
in cutis laxa, 1638, 1641
in Darier-White disease, 550–551
database resources on, 76, 76t
deletion, 83
in DNA repair, 1229–1231, 1231t
in dyskeratosis congenita, 1670
in dysplastic nevus, 1411–1412
in Ehlers-Danlos syndrome, 1624–1625
of elastin, 679–681
in constitutive and alternative splicing, 680
cytokine and hormonal regulation, 681
gene expression in, 681
gene structure in, 679
in epidermolysis bullosa, 660–662
genetic counseling in, 662
epigenetics, 87–88
gene expression, 78–79
gene identification, 79–80
gene structure, 76–78
gene therapy. *See* Gene therapy
histocompatibility antigen disease association, 88
in homocystinuria, 1304
human genome, 75–76
in immunodeficiency disorders, **1703**–1725
inheritance pattern
autosomal dominant, 82f
autosomal recessive, 82f
dominant, 82
pseudodominant, 82
semidominant, 82
X-linked dominant, 82f
X-linked recessive, 83f
of keratin, 61t, 68, 69t, 70, 77–78, 77t
in Mendelian disorders, 81
in Merkel cell carcinoma, 1089
mitochondrial disorders, 85
in mosaicism
epigenetic, 87
gonadal, 86
gonosomal, 86
revertant, 87, 87f
somatic, 86
mutations and polymorphisms, 80–81
detection and identification of, 79–80
in piebaldism, 790
in pigmentation disorders, **781**–791
prenatal diagnosis, 89–90, 89f
promoter elements in, 78
in pseudoxanthoma elasticum, 65
in Tietz syndrome, 789–790
in Waardenburg syndrome, 790
in X-linked dominant inheritance, 82f
in X-linked recessive inheritance, 83f
Genital disorders, **852**–892. *See also* Sexually transmitted infections
in female, **878**–892. *See also* Female genital disorders
in Fournier gangrene, 873
in hidradenitis suppurativa, 955f, 956
in lichen planus, 298
in male, **852**–877. *See also* Male genital disorders
in mycoplasmal infections, 2521–2524
clinical findings, 2522
complications, 2522
epidemiology, 2521
etiology and pathogenesis, 2522
laboratory tests, 2522
prognosis and clinical course, 2523
treatment, 2523
in Paget disease, 1371–1376
clinical findings in, 1371–1372
prognosis and clinical course in, 1374
treatment of, 1374–1376
in syphilis, 2474–2476
in trichomoniasis, 2523–2524
in warts. *See* Warts, anogenital
Genome. *See also* Genetics
instability, **1227**–1138
hereditary, **1654**–1671
Genome-wide association studies, 85–86
Genomic controls, 85
Genomic imprinting, 83
Gentamicin, 1693, 2676
in actinomycetoma, 2252
Gianotti-Crosti syndrome, 1835, 2350–2352
differential diagnosis of, 2352b
Epstein-Barr virus in, 2351
hepatitis B virus in, 2351
rotavirus in, 2351
treatment of, 2352
Giant cell arteritis, 2026
Glabellar brow furrows, botulinum toxin in, 3057
Glanders, 2217
in bioterrorism, 2638
Glass, in photoprotection, 2712–2713
Global health in dermatology (B), **15**–20
global burden of disease (GBD), 16
health and global interdependence, 15–16
risk identification, 19–20
skin care, practical problems in, 19
skin disease in resource poor environments, 18–19

skin disease pattern at community level and international initiatives, 20–21
data on skin disease, 20
education and training, 20
initiatives effectiveness, 21
skin disease spreads, 16–18
Glomus tumor
of nails, 1021
Gloves-and-socks syndrome, papular purpuric, in parvovirus B19 infections, 2344
Glucagonoma, 1824
Glucocorticoid therapy, **2714**–2720
adrenal suppression in, 2660, 2718, 2719
in alopecia areata, 993
in angiogenesis, 2833
anti-inflammatory effects of, 2659
anti-proliferative effects of, 2659
in atopic dermatitis, 177
systemic therapy, 180
topical therapy, 177
cellular effects, 2715
in children, 1202
atherosclerosis, 2720
avascular necrosis, 2720
complications of, 2720
osteoporosis, 2720
complications of, 2718–2720
atherosclerosis, 2719, 2720
avascular necrosis, 2719, 2720
immunologic effects, 2719
osteoporosis, 2718, 2720
pregnancy concerns, 2719
psychiatric effects, 2719
in diaper dermatitis, 1197–1199
dosing regimen in, 2716
gastrointestinal disorders in,
in giant cell arteritis, 2026
in hemangioma of infants, 1463–1464
in hidradenitis suppurativa, 958
immunosuppressive effects of, 2659
indications for, 2715–2716
infectious complications in,
initiation of, 2716–2717
interaction with other drugs,
intralesional, 2716
intramuscular, 2716
intravenous, 2716
in lichen planus
cutaneous, 310–312
mucosal, 309–310
mechanism of action, 2714–2715
monitoring of, 2717
in necrotizing venulitis, 2027
in pemphigus, 597
pulsed intravenous, 599
in pregnancy, 2719
in psoriasis, 223–224
in psoriatic arthritis, 239
risks and precautions in, 2717–2718
adrenal suppression, 2718
diet, 2717
gastrointestinal complications, 2718
immunizations, 2717
infections, 2717
in seborrheic dermatitis, 265–266
topical, 2659
in atopic dermatitis, 177
complications of, 2663
dosing regimen in, 2662
indications for, 2661–2662
initiation of, 2662
mechanism of action, 2659–2660
monitoring of, 2662
pharmacokinetics in, 2660–2661
risks and precautions in, 2663
in vitiligo, 799
withdrawal of, 2719
Glutaraldehyde, 2706
Glycerin sclerotherapy for varicose veins, 3002
Glycoproteins
gp130, 137–138
Glycosaminoglycans, **684**–688
chains, 684–685
in dermis, 64–65
functions of, 687–688
Glypicans, 685
Gnathostoma spinigerum, 2565
Gnathostomiasis, 2565
cutaneous, 2565
differential diagnosis of, 2565
Goiter, 1851. *See also* Thyroid disorders
clinical findings in, 1856
epidemiology of, 1852
etiology and pathogenesis in, 1852
toxic multinodular, 1852
Gold
for psoriatic arthritis, 240
Gonorrhea, **2514**–2519
and chlamydial infection, 2516, 2517, 2518. *See also Chlamydia trachomatis*
clinical findings in, 2515–2517
differential diagnosis of, 2518b
disseminated disease, 2517
management, 2519t
treatment of, 2519t
epidemiology of, 2514–2515
etiology and pathogenesis of, 2515
and HIV infection, 2514
laboratory tests in, 2517
in men, 2515–2516
in newborns and children, 2517, 2519b
transmission of, 2514, 2515
treatment of, 2518, 2518b, 2519b
in women, 2516–2517
Gorham-Stout syndrome, 2089
Gorlin syndrome. *See* Basal cell nevus syndrome
Gout, **1973**–1976
acute arthritis in, 1974
histopathology in, 1974–1975
hyperuricemia as risk factor, 1974–1975, 1975t
panniculitis in, 583
tophi in, 1975f
treatment in, 1975–1976
Grafts. *See also* Excisional surgery; Flaps
in hair transplantation, 3071
density of, 3072
insertion of, 3072
preparation of, 3071
harvesting process and, 2945–2947
skin, 2944–2948
Burow's/regional, 2947
composite, 2947
full-thickness, 2944–2947
free cartilage, 2947
healing of, 2992–2993, 2947
punch and pinch, 2948
skin substitutes, 2948
split-thickness, 2947–2948
in vitiligo, 800
wound healing of, 2992–2993, 2947
imbibition phase in, 2992
reinnervation in, 2993
revascularization in, 2992–2993
Graft-versus-host disease, **316**–329
acute
clinical findings, 318, 319, 322
complications in, 325
diagnosis and differential diagnosis in, 326b
histopathology in, 323, 324t
laboratory testings, 325
in peripheral stem cell transplantation, 317
prevention, 329
staging of, 325t
stem cell transplantation and, 317
treatment of, 326–327, 2864–2865
chronic,
clinical findings, 319, 320, 322
complications in, 325
diagnosis and differential diagnosis in, 326b
histopathology of, 324
laboratory testings, 325
lichenoid, 306, 317, 319–322
organ system manifestations, 319b
prevention, 329
sclerodermoid, 319–320
stem cell transplantation and, 317
treatment of, 327–328
oral and vulvo-vaginal disease, 328–329
photochemotherapy in, 2864–2865
clinical findings in, 318–324
clinical manifestations, 319f
complications in, 325
differential diagnosis in, 325b
epidemiology of, 317
etiology and pathogenesis of, 317–318
hematopoietic stem cell transplantation procedures, 317
and lymphocyte recovery eruption, 318
prevention of, 329
prognosis in, 325–326
risk factors, major, 317
treatment of, 326–329
photopheresis in, 326, 327t, 328
thalidomide in, 327t
Gramicidin, 2676
Granular cell tumor, 1479–1480

Granular layer of epidermis, 62–63
Granulocyte-macrophage colony-stimulating factor, 2815t, 2818
Granuloma
  actinic, 468
  annulare, **467**–472
    in bites, 467
    clinical course and prognosis, 472
    clinical findings, 468–470
    in diabetes mellitus, 468, 1848
    differential diagnosis in, 471b
    elastolytic giant cell, 468
    epidemiology of, 467
    etiology and pathogenesis in, 467–468
    generalized, 469genital, 866
    in HIV infection, 467
    infections and immunizations for, 467–468
    laboratory testing, 470–472
    localized, 468–469
    malignancy and, 468
    palisading, 470f
    patch type, 469
    pathogenetic mechanisms, 468
    perforating, 469
    photosensitive, 468
    subcutaneous, 469
    in sun exposure, 468
    treatment of, 472b
  coccidioidal, 2324
  faciale, **380**–382
    clinical findings in, 380
    complications, 382
    differential diagnosis in, 381, 381b
    epidemiology, 380
    etiology and pathogenesis, 380
    laboratory findings in, 380–381
    treatment in, 382, 383b
  gluteale infantum, 1198
  inguinale, 2510–2514
    clinical findings in, 2511–2512
    complications of, 2513
    diagnosis of, 2512
    differential diagnosis of, 2512b
    etiology of, 2510–2511
    prevention of, 2514
    transmission of, 2510
    treatment of, 2513–2514, 2513b
  in occupational exposures, 2627
  paracoccidioidal, 2324
  pyogenic, 1469
Granulomatosis
  lymphomatoid, 1831
  orofacial, 846
  Wegener. *See* Wegener granulomatosis
Granulomatous disorders
  chronic, 1716–1719
  of dermis, 54–55
Graves disease
  as autoimmune disorder, 1902
  cutaneous findings in, 1854–1855
  epidemiology of, 1851–1852
  genetic factors in, 1902
  vitiligo in, 795, 1854–1855
Gray patch tinea capitis, 2285, 2285f
Green nails, 1018
  in *Pseudomonas* infections, 1018
Grenz ray therapy, 2890
Griscelli syndrome, 804–806, 1723–1724
  accelerated phase in, 804–806, 1724
  clinical findings in, 1724
  silvery gray hair in, 804, 1722t, 1723–1724
  treatment of, 1724
  types of, 1724
Griseofulvin, 2804–2805
  in adult, 2804
  adverse effects of, 2805
  in children, 1203, 2804
  in dermatophyte infections, 2293
  in elderly, 2804
  interaction with other drugs, 2805
  pregnancy considerations, 2804
Grönblad-Strandberg syndrome. *See* Pseudoxanthoma elasticum
Grooves in nails, longitudinal, 1014
Grouped lesions, 39
Grover disease, 560–562
  clinical findings in, 561
  differential diagnosis in, 562, 562b
  epidemiology, 560
  etiology and pathogenesis, 561
  histopathology in, 562
  treatment in, 562
Growth hormone, 1865–1868
  deficiency of, 941, 1867
  elevated levels in acromegaly, 1866–1867
Growth hormone releasing hormone, 1866
Gustatory sweating, 941

H

Habit tic deformity of nails, 1028
Haemophilus ducreyi
  in chancroid, 2501–2505
  differential diagnosis of, 2502
  treatment of infections, 2504
Haemophilus influenzae, 2188–2190
Hailey-Hailey disease, 557–560
  calcium signaling and transport in, 558
  clinical manifestations in, 558–559
  differential diagnosis in, 559–560, 559b
  etiology and pathogenesis, 557–558
  histopathology in, 558–559
  treatment of, 560, 560t
    radiation therapy in, 2883
Hair
  anatomy of, 963–966
  cytotoxic agents affecting, 2752–2753
  diagnostic techniques in disorders of, 979
  embryonic and fetal development, 74
    laser therapy in, 2881
  loss of, 980–987. *See also* Alopecia
    diffuse, 987–988
    in leprosy, 1790
    in infants, 1190
    pattern. *See* Pattern hair loss
  nutrition affecting, 1828
  skin of color and
    biochemical composition, 95
    combing properties, 96
    hair characteristics variation, 95–97
    hair disorders, 97, 98t
    hair shape, 95–96
    hair structure, 96
    moisture content and static electricity, 97
    physical properties comparison (Asian/Caucasian/African), 95t
    tensile strength, 96
  in trichorrhexis. *See* Trichorrhexis
  in trichothiodystrophy. *See* Trichothiodystrophy
  in Waardenburg syndrome, 788–789
  woolly, 1004
Hair bud, 963
Hair collar sign, 1192
Hair follicles
  anatomy of, 963–966
  and appendeal complications, 2765
  biology of, **960**–972, 979
  cycle of, 966–969
  cytotoxic agents affecting, 2752–2753
  embryology, 961–962
  evolution and function, 961
  inflammation of. *See* Folliculitis
    tumor of, 1361
  inner root sheath, 965
  innervation, 966
  mature, 963
  melanocytes in, 766, 768f, 969–972
    and stem cells, 969
  nerve endings and receptors at, 67
  nevi of, 1355
  outer root sheath, 964
  perifollicular sheath, 966
  stem cells in, 966–969
  tumors of
    in infundibulum, 1361
Hair peg, bulbous, 963
Hair placode, 962
Hair shaft, 965
  disorders of, 1002–1005
Hair transplantation, **3061**–3075
  donor areas in, 3063
    determination of, 3067–3068
    excision of, 3068–3071
  equipment in, 3068b
  gender differences in, 3063–3064
  follicular unit extraction, 3070
  graft preparation in, 3071
  patient selection aspects, 3063
  recipient site in
    creation of, 3072
    design of, 3066–3067
    graft density in, 3072
    graft insertion in, 3072
  for repair of previous procedures, 3072–3073
  risks and precautions in, 3064, 3066
  side effects and complications of, 3073–3075
  technique in, 3066–3073
  vertex transition point in, 3066f

Hairdressers, occupational exposures to, 2618
Hallux, congenital malalignment of, 1017
Hamartomas
angiomatous
congenital eccrine, 1468–1469
basaloid
follicular, 1355
dermal melanocyte, 816
fibrous, of infancy, 713
of nerves, fibrolipomatous, 1492
smooth muscle, 1472–1473
Hand, 1826
allergic contact dermatitis of, 158
atopic dermatitis of, 174
differential diagnosis in, 174
dyshidrotic dermatitis of, 188
erythema of, 1826
erythromelalgia of, 1826
hyperkeratotic dermatitis of, 188
clinical findings in, 180
in hypertrophic osteoarthropathy, 1826
pustular eruptions of, **253**–256
in reflex sympathetic dystrophy, 1826
seal finger of, 2218, 2584
in shoulder-hand syndrome, 1826
vesiculobullous chronic dermatitis of, 188
clinical findings in, 190
Hand-arm vibration syndrome, 2628
Hand-foot-mouth disease, 2360–2362
Haploinsufficiency, 81
Harlequin color change in infants, 1189
Hartnup disease, 1526t
Haverhill fever, 2182
Head lice, 2573–2575
differential diagnosis of, 2574b
drug resistant, 2575
nits in, 2574
treatment of, 2574–2575
Healing. *See* Wound healing
Health, definition of, 21
Hearing
in Tietz syndrome, 790
in Waardenburg syndrome, 788–789
Heat
chronic exposure to occupational, 2627–2628
nerve receptors sensitive to, 1138
thermal injuries from, **1089**–1094
in occupational exposures, 2627–2628
urticaria from, 421
Heat rash in diaper area, 1198
in Behçet disease, 2035
Heat stroke, anhidrosis in, 944
Hedgehog pathway, 1255
in basal cell carcinoma, 1302
PTCH1 in, 1306
Helminthic infections, **2544**–2568
approach to patient with, 2549
dermatologic history and physical findings, 2549
exposure history, 2549
medical history, general, 2549
associated symptoms, 2556–2558
fever, 2558
gastrointestinal disease, 2557
lymphadenopathy, 2558
neurologic disease, 2557
ocular disease, 2557
pulmonary disease, 2557
cestode, 2567–2568
complications, 2556
dermatologic history and physical findings, 2549–2558
diagnosis, 2559
edema, localized, 2554
eyelid edema, 2554
limb edema, 2554
epidemiology, 2545–2547
etiology and pathogenesis, 2547, 2549
laboratory and diagnostic evaluation in, 2558–2559
life cycle and transmission of helminthes, 2546–2547
migratory lesions, 2550–2555
nematode, 2562–2566
papular and macular lesions, 2553–2554
pigmentation in, 2555
pruritus in, 2554
subcutaneous nodules and masses, 2553
skin diseases in
immigrants/refugees, 2546
travelers, 2546
treatment, 2559
trematode, 2566–2567
urticaria in, 2554
Heloma, **1111**–1114. *See also* Corn(s)
Helper T cells, 114
in adaptive immune response, 114
CD4+, 114, 115
follicular (Tfh), 116
Th1, 115
Th2, 115, 117
Th17, 115, 117
in allergic contact dermatitis, 117, 153, 154
in atopic dermatitis, 117, 167
in basal cell carcinoma, 117
in cutaneous T-cell lymphoma, 117
cytokine production, 115
cytokine regulation of, 138
and interleukin IL-4, 115, 136
in leishmaniasis, 117
in leprosy, 117
in lichen planus, 297
in Lyme disease, 117
in psoriasis, 117
in syphilis, 117
Hemangioendothelioma
kaposiform, 1467–1468
spindle cell, 1468
Hemangioma, **1456**–1469
congenital, 1465–1466
noninvoluting, 1465–1466
nonprogressive, 1465
rapidly involuting, 1465–1466
in infants, 1190, 1456–1464
atypical, 1458
in "beard area," 1460–1461
classification of, 1458
clinical findings in, 1457–1462
complications in, 1462–1463
epidemiology of, 1456
etiology and pathogenesis in, 1456
growth characteristics, 1457
hepatic, 1462
history, clinical, 1457, 1457b
lumbosacral, 1461
multifocal, 1462
perineal, 1461
periocular, 1460
in PHACE syndrome, 1458–1460
prognosis and clinical course in, 1463
risks, 1458
treatment of, 1463–1465
in infants, 1465, 2879–2880
sclerosing, 710–712
targetoid hemosiderotic, 1469
Hematodermic neoplasm, CD4+/CD56+, 1766
Hematologic disorders, **1726**–1744
anemia, 1740–1741
of endocrine disorders, 1741
iron deficiency aspects, 1740
macrocytic, 1740
microcytic, 1740
cutaneous signs and symptoms in, 1727t, 1728t, 1729t, 1730t, 1731t. *See also* Purpura
in cyanosis, 1742–1743
flushing, 1741, 1741b
in folate deficiency, 1741
hemostasis, 1726
infiltrative lesions in
extramedullary hematopoiesis, 1743–1744
leukemia cutis, 1744
jaundice, 1743
pallor, 1740
in polycythemia vera, 1741–1742
in retinoid therapy, 2766
Hematoma
postoperative, 2979
subungual, 1028
surgery in, 2965
Hematopoietin receptors
γ_c chain, 136–137
glycoprotein 130 using, 137–138
IL-3 receptor β chain, 137
T helper responses regulating, 138
Hematoxylin and eosin stain in Merkel cell carcinoma, 1365
Hemidesmosomes
embryonic and fetal, 68, 70, 73
Hemiptera, 2606–2607
Hemochromatosis
nail changes in, 1824
pigmentation changes in, 820, 1821
Hemodialysis
bullous disease in, 1838
in epidermal necrolysis, 447
pigmentation changes in, 813
Hemoglobin
absorption of radiation, 3006

Hemorrhage
drugs associated with, 1832
gastrointestinal, 1832
drug-induced, 1832
postoperative, 2978, 2979
in cryosurgery, 2971
in nail surgery, 2959
splinter, of nails, 1015
in liver disease, 1824
surgical complication, 2978
in Wiskott-Aldrich syndrome, 1710
Hemostasis
electrosurgery for, 2973–2974
Henoch-Schönlein purpura, 2007
Heparin
in lichen planus, 312
Hepatitis, 1835–1836
in helminthic infections, 2557
in occupational exposures, 2624–2625
Hepatitis A, 1835–1836
Hepatitis B, 1835
occupational exposure to, 2624–2625
vaccination, 1835
Hepatitis C, 1835
lichen planus in, 306, 1835
occupational exposure to, 2625
Hepatocyte-stimulating factor, 138. *See also* Interleukins, IL-6
Hepatomegaly, 1836
in helminthic infections, 2557
Herbal preparations, 2900
in atopic dermatitis, 181
Hereditary cancer syndromes, 1242
Heroin, 1170–1172
Herpangina, 2362–2363
differential diagnosis of, 2363b
Herpes gestationis, **630**–634, 1206t, 1207. *See also* Pemphigoid, gestationis
Herpes gladiatorum
in occupational exposures, 2624
Herpes labialis
in occupational exposures, 2624
Herpes simplex virus infections, **2367**–2382
in atopic dermatitis, 178
classification of, 2373t
clinical manifestations of, 2368–2373
complications, 2374
eczema herpeticum in, 2372
epidemiology of, 2367
etiology and pathogenesis in, 2368
immune response, 2368
virus, 2368
eye disorders in, 2374
treatment of, 2379b
genital, 2369–2371
in neonate, 2375
treatment in, 2376, 2378b
immune response to, 2368
in immunocompromised host, 2374
complications of, 2374
laboratory tests in, 2373–2374
in neonates, 1193–1194, 2375
neonatal herpes, 2375
treatment of, 2380b
neurologic disorders in, 2374–2375
in occupational exposures, 2624
orofacial, 2368–2369
persistent, 1375t
in pregnancy
treatment of, 2375
prevention of, 2381–2382
treatment of, 2375
antiviral therapy, 2376–2381
drug resistance in, 2381
vaccines, 2381–2382
vaccination against, 2381–2382
whitlow in
in occupational exposures, 2624
Herpes zoster virus infections, **2384**–2400
clinical findings in, 2387–2389
pain of, 2389
prodrome of, 2387
rash of, 2388–2389
complications of, 2393, 2393t
diagnosis of, 2391
differential diagnosis of, 2390b
epidemiology of, 2384–2385
genital, 867
in immunocompromised host, 2389, 2396
prevention, 2400
laboratory tests in, 2391
pathogenesis of, 2386
prevention of, 2399–2340
treatment of, 2395–2397
analgesics, 2397
anti-inflammatory therapy, 2396–2397
antiviral therapy, 2395–2396
in immunocompromised, 2396
topical therapy, 2395
Herpesviruses
HHV-4. *See also* Epstein-Barr virus
HHV-5. *See also* Cytomegalovirus infections
HHV-6, 2356–2358
clinical findings, 2357
complications, 2358
epidemiology, 2356
etiology and pathogenesis, 2356
in exanthem subitum, 2357
in HIV patients, 2357
in immunocompromised host, 2357
in pityriasis rosea, 2357
prevention, 2358
prognosis and clinical course, 2358
in Rosai–Dorfman disease, 2357
in transplant receipients, 2357
treatment, 2358
HHV-7, 2358–2359
clinical findings, 2359
complications, 2359
course, 2359
differential diagnosis of, 2359b
epidemiology, 2358
etiology and pathogenesis, 2358
in exanthem subitum, 2359
in lichen planus, 2359
in pityriasis rosea, 2359
treatment, 2359
simiae (B virus), 2581
Herpetiform lesions, 39
Heterodisomy, uniparental, 83
Heterogeneity, genetic, 81
Heteroplasmy of mitochondrial DNA, 84
Heterotopia. *See* Ectopia
Heterozygote, compound, 82
Hexachlorobenzene, 2701
Hexachlorocyclohexane, 2701
Hexachlorophene in preoperative skin preparation, 2913
Hibernoma, 1493–1494
eosinophilic subtype, 1494
histologic features in, 1494–1495
mixed subtype, 1494
pale cell subtype, 1494
Hidradenitis
neutrophilic eccrine
anhidrosis in, 945
suppurativa, **953**–959
adnexal structures, 953
associated disease, 954
bacterial infections, 954
clinical findings in, 956
complications of, 956
complementary and alternative medicine approaches to, 2903
differential diagnosis of, 955b
epidemiology of, 953
etiology and pathogenesis in, 953–954
genetic factors in, 954
hormones and androgens, 954
obesity in, 954
pathology in, 956
quality of life issues in, 956
retinoids in, 2762
sinus tracts in, 956
smoking and, 954
stages of, 957
treatment of, 956–959, 2762, 2903
of vulva, 889–890
Hidradenoma
apocrine papillary, 1344–1345
eccrine, 1352
nodular, 1352
Hidrocystoma
apocrine, 1343–1344
eccrine, 1348
Hidrosis. *See* Sweating
Hip dislocation, congenital, in Ehlers-Danlos syndrome, 1629
Hirsutism, 1005
epidemiology of, 1005
laboratory tests in, 1007
treatment of, 1008
Histamine
mediated reactions and athletes, 1120
in urticaria and angioedema, 414–415
Histamine receptors
and H_1-antihistamines, 2767–2772
and H_2-antihistamines, 2772–2774
Histidase, 1526t
Histidinemia, 1526t
Histiocytes in granulomatous reactions, 55
Histiocytoma
benign fibrous, 710–712

Histiocytosis, **1782**–1808
generalized eruptive, 1796, 1796t, 1800–1801
clinical findings in, 1800–1801
differential diagnosis in, 1801b
epidemiology of, 1796
etiology and pathogenesis in, 1797
histopathology in, 1801
Langerhans cell (class I), **1782**–1795. *See also* Langerhans cell histiocytosis
non-Langerhans cell (class II), **1795**–1808
diagnostic approach to, 1797f
disorders categorized as, 1796t
epidemiology of, 1796–1797
etiology and pathogenesis of, 1797–1798
prevention of, 1808
treatment of, 1808
progressive nodular, 1796t, 1801
clinical findings in, 1801
differential diagnosis of, 1802b
epidemiology of, 1796
histopathology of, 1802
prognosis/clinical course, 1802
reticulohistiocytosis. *See* Reticulohistiocytosis
sinus, with massive lymphadenopathy, 1806
clinical findings in, 1806–1807
differential diagnosis of, 1807b
epidemiology of, 1797
etiology and pathogenesis in, 1798
treatment in, 1808
Histocompatibility antigens, 88. *See also* HLA system
Histones, 1919t
Histoplasma capsulatum, 2317
Histoplasma farciminosum, 2318
Histoplasmin skin test, 2320
Histoplasmosis, 2317, **2318**–2321
disseminated, 2320
in immunocompromised host, 2320, 2453
in HIV infection and AIDS, 2320
treatment of, 2321
large-form or African, 2321
primary cutaneous, 2320
respiratory disorders in, 2320
small-form or classic, 2317–2321
acute progressive disseminated, 2320
acute pulmonary, 2320
chronic progressive disseminated, 2320
chronic pulmonary, 2320
clinical findings, 2319
differential diagnosis of, 2320
epidemiology, 2319
primary cutaneous, 2320
treatment, 2321
HIV infection and AIDS, **2439**–2455
acute infection in, 2440–2441
clinical findings in, 2441
antiretroviral therapy, adverse effects of, 2446, 2447t
aspergillosis in, 2453
Bartonella infection in, 2451
basal cell carcinoma in, 2448
candidiasis in, 2452
chemokines in, 151
clinical findings
acute HIV syndrome, 2441–2442
clincallly latent HIV infection, 2443
immune reconstitution, 2442–2443
coccidioidomycosis in, 2324, 2453
cryptococcosis in, 2452
cutaneous disorders in, 2448–2455
cancers, 2448
cytomegalovirus infections in, 2354
dermatophyte infections, 2452
drug eruptions, adverse effects of, 2446
antiretroviral therapy, 2446, 2447t
drug-induced disorders in, 2446, 2448
lipodystrophy in, 2446, 2448
metabolic syndrome, 2446
eosinophilic folliculitis in, 2449–2450
erythroderma in, 2451
etiology of, 2439–2440
fungal infections in, 2452–2454
herpes simplex virus infections in, 2445
HSV 1 and HSV 2, 2445
histoplasmosis in, 2453
immune reconstitution, clinical findings in, 2442–2443
Kaposi sarcoma in, 1483–1484
genital, 868
treatment of, 1486
keratoacanthoma in, 1314
Klebsiella infections and rhinoscleroma in, 2192
leishmaniasis in, 2455
visceral, 2534
lipoatrophy in, 2446
poly-L-lactic acid augmentation in, 3047
silicone augmentation in, 3051
lipodystrophy in, 760, 2446–2447
metabolic syndrome, 2446
molluscum contagiosum in, 2454
mycobacterial infections in tuberculosis in, 2225–2226
natural history in, 2440–2441
course after primary infection, 2441
in occupational exposures, 2624–2625
opportunistic infections in, 2451–2455
human papillomavirus infections, 2444
oral cavity disorders in, 2444
in oral hairy leukoplakia, 2451
in papillomavirus infections, 2444
oropharynx disorders, 2451
papillomavirus infections in, 2444–2445
and cancer risk, 2444
papular pruritic eruption in, 2450
pathogenesis in, 2440
Penicillium marneffei infection in (penicilliosis), 2325, 2453
photochemotherapy in, 2849
photosensitivity in, 2450–2451
pruritus in, 2449
differential diagnosis of, 2449b
in papular pruritic eruption, 2450
psoriasis in, 2443
vulgaris, 2443
scabies in, 2454–2455
seborrheic dermatitis in, 259, 264, 2443
histopathologic finds, 265
sexually transmitted diseases in, 2446
squamous cell carcinoma in, 2444, 2448
stages of, 2440t
Staphylococcus infections in, 2445
T-cell lymphotropic virus infections in, 2454
treatment of, 2787, 2795t. *See also* Antiviral agents
entry inhibitors in, 2795t
nonnucleoside reverse transcriptase inhibitors in, 2795t
nucleoside reverse transcriptase inhibitors in, 2795t
protease inhibitors in, 2795t
tuberculosis infections, 2225–2226, 2452
valacyclovir complications in, 2790
varicella-zoster virus infections in, 2445–2446
warts in, 2444
HLA system, 88
in Behçet disease, 88
class I, 88
class II, 88
in dermatitis herpetiformis, 88
in lichen planus, 297
in pemphigus, 88
in psoriasis, 88
HLA-Cw6, 204
in reactive arthritis, 88
Hobo spider bites, 2603
Holistic dermatology. *See* Complementary and alternative medicine
Holocarboxylase synthetase, 1526t
deficiency of, 1526t
Holothurin, 2592
Homeopathy, 2901
Homocysteine, 1304
Homocystinuria, 530t, 1526t, **1633**
Homogentisic acid oxidase deficiency of, 1526t
Homozygote, 82
Hookworm infections, 2560, 2562
cutaneous larva migrans in, 2560
Hori nevus, 823
Horizontal forehead lines, botulinum toxin injection for, 3057–3058
Hormonal therapy in hidradenitis suppurativa, 958
Horn, 32
in verruca vulgaris, 32

Horn pearls in squamous cell carcinoma, 1290
Hospitalization in atopic dermatitis, 179
Host cell reactivation assay, 1236
Howel-Evans syndrome, 546
H-plasty, 2933
HTLV infections, **2434**–2438. *See also* T cell lymphotropic virus infections
Humectants as moisturizing products, 3012
Humidity, environmental
  and cold injuries, 1081
  and low humidity dermatitis, 2614t
Humoral immunity, **401**–413
  complement system in, 407–413
Hunting reaction of Lewis, 1080
Huriez syndrome, 544–545
Hyalinosis
  cutis et mucosae, 1288, 1831
Hyaluronic acid
  in soft tissue augmentation, 3044–3047
  in xerosis, 3010
Hydration of skin
  in atopic dermatitis, 175
  in oily and dry types, 3009–3011
Hydroa vacciniforme, 1055–1057
  clinical findings in, 1056
  differential diagnosis in, 1056–1057, 1057b
  epidemiology, 1056
  etiology and pathogenesis, 1056
  treatment of, 1057
    phototherapy in, 1057
Hydrocarbon base of ointments, 2647
Hydrocarbon exposure
  keratosis in, 1271
Hydrofluoric acid, occupational exposure to, 2615
Hydrogen peroxide, 2698
Hydroquinone
  as bleaching agent, 2704
α-Hydroxy acids, in topical preparations
  keratolytic, 2705
Hydroxychloroquine
  in lichen planus
    cutaneous, 311
    oral, 310
Hydroxykynureninuria, 1526t
Hydroxyurea
  complications of, 2746–2747
  dosage regimen, 2746
  drug interactions, 2747
  indications for, 2745–2745
  mechanism of action, 2745
  monitoring of therapy with, 2746
  in psoriasis, 228
Hydroxyzine, 2770t. *See also* Antihistamines
Hymenoptera stings, 2608
Hypercalcemia
  clinical findings in, 1857
  differential diagnosis of, 1857
  in hyperparathyroidism, 1856–1857
  in malignancy, 1857, 1859
  treatment of, 1859
Hypercholesterolemia, 1607–1608
  in biliary obstruction, 1610
  familial heterozygous, 1607–1608
  familial homozygous, 1607–1608
  xanthoma in, 1607–1608
Hypereosinophilia, 387–391. *See also* Eosinophilia
  clinical findings and course, 388–389
  differential diagnosis, 390
  epidemiology, 388
  etiology and pathogenesis, 388
  laboratory tests in, 389–390
  mucocutaneous manifestations in, 389t
  revised diagnostic criteria, 388t
  treatment, 390–391
Hyperesthesia in African trypanosomiasis, 2540
Hyperglobulinemic purpura, 1979
  hypergammaglobulinemic purpura, 1979–1980
Hyperglycemia in diabetes mellitus, skin changes related to, 1840
Hyperhidrosis
  in acromegaly, 941, 1866
  axillary, 940b, 1201
  causes (secondary), 941
    drug-induced, 942, 942t
    gustatory sweating, 941
    malignancy, 941
    metabolic and systemic medical problems, 941
  classification of, 938t
  in cold-induced sweating syndrome, 939
  compensatory, 939, 941
  craniofacial, 939, 940b
  drug-induced, 942, 942t
  episodic hypothermia in, 938t
  generalized, 942
  gustatory, 938t, 941
  localized, 941–944
    causes, 941–944
  and malignancy, 941–942
  olfactory syndrome, 938t
  palmoplantar, 3059
  primary focal, 939–941
    clinical manifestations of, 939
    diagnosis of, 939
    treatment of, 939–941, 940b
  segmental, 938t, 939
  sympathectomy in
    anhidrosis after, 941
    compensatory hyperhidrosis after, 941
  treatment of, 939, 940b, 941
    botulinum toxin in, 939, 3059–3060
      complications of, 3060
    sympathectomy in, 941
  in tumors, 938t
  unilateral circumscribed, 938t
Hyper-IgD syndrome, 1592–1594
  clinical findings in, 1593
  differential diagnosis of, 1593
  with periodic fever, 1592–1594
  treatment of, 1594
Hyper-IgE syndrome, 1719–1721
Hyper-IgM syndrome, 1710
Hyperkeratosis, 34
  epidermolytic. *See* Epidermolytic hyperkeratosis
  in hand dermatitis, 190
    clinical findings in, 190
    treatment of, 192
  in lichen planus, 304
  subungual, 1016
Hyperlipidemia, 1829
  coronary artery atherosclerosis in, 1829
  in diabetes mellitus, 1841
  Frederickson classification, 1610–1611
  in retinoid therapy, 2766
  treatment
    lifestyle therapy for, 1612
    pharmacologic agents, 1612
  xanthoma in, 1610–1611
Hypermelanosis, **813**–825
  acquired
    circumscribed, 822, 823–825
    diffuse nonfigured, 818–821
    diffuse reticular, 822–823
  congenital
    circumscribed, 815–818
    diffuse, 813–815
  with dermal melanocytosis, 815–816
  with lentiginosis syndromes, 816
  linear and whorled, 813
  mixed with hypomelanosis, 825
  oral, 844
  toxin/drug-induced, 821–822
Hyperostosis
  idiopathic skeletal, in retinoid therapy, 2765
  in SAPHO syndrome, 914
Hyperparathyroidism, **1856**–1859
  approach to patient with, 1857b
  calciphylaxis in, 1858
  clinical findings in, 1857–1859
  epidemiology of, 1856
  primary, 1857
  secondary, 1857
  tertiary, 1857
  treatment of, 1859
Hyperpigmentation. *See also* Hypermelanosis
  in acanthosis nigricans, 1843
  bleaching agents in, 2704. *See also* Bleaching agents
  in cryotherapy complication, 2972
  drug-induced, 821–822
    from cytotoxic drugs, 2755–2756
  idiopathic eruptive macular, 825
  in laser therapy complications
    in skin resurfacing, 3027–3028
  laser therapy in, in occupational exposures, 2625
  oral, 844
  periorbital familial, 824
  post-inflammatory, 824
  postoperative, 2983
  in sclerotherapy for varicose veins, 3003–3006
  topical therapies (race and ethnicity considerations), 101, 102t

Hyperplasia
angiolymphoid. *See* Angiolymphoid hyperplasia
giant lymph node, 1776
lymphoid cutaneous, 1767–1774
clinical findings, 1768–1769
complications, 1773
differential diagnosis, 1772–1773, 1772b
epidemiology, 1767
etiology and pathogenesis, 1767
histopathology, 1769–1700
prognosis and clinical course, 1773–1774
treatment, 1774, 1774b
sebaceous, 1188, 1340, 2970
Hyperprolinuria, 1526t
Hyperpyrexia, anhidrosis in, 944
Hypersensitivity
delayed-type
from cosmetic products, 3016
immediate type I
occupational skin disorders and, 2619
Hyperthyroidism
approach to patient with, 1853b
congenital, 1852
cutaneous signs of, 1853–1855
dermopathy in, 1854–1855
epidemiology of, 1851–1852
etiology and pathogenesis in, 1852–1853
hyperpigmentation in, 819, 1855
radioiodine uptake in, 1852
treatment of, 1856
Hypertonic saline
and dextrose, 3001
solution in sclerotherapy for varicose veins, 3000–3001
Hypertrichosis, 1008
acquired, 1008
congenital, 1008
lanuginosa, 1823
Hypertriglyceridemia
familial, 1607–1608
xanthoma in, 1607–1608
Hypertrophic osteoarthropathy, 1826
Hypertrophic scars. *See* Scars, hypertrophic
Hypertrophy
dermal, **707**–717
lateral nail fold, 2967
Hyperuricemia, 1974–1975, 1975t
gout in, 1974–1975, 1975t
Hyperviscosity disorders
Raynaud phenomenon in, 2069
Hypervitaminosis D, 1652
Hypoalbuminemia in exfoliative dermatitis, 274
Hypocalcemia
clinical findings in, 1857, 1857t
in hypoparathyroidism, 1859
Hypochondriacal disorders, 1164
Hypodermis, 56–57, 67–68
embryonic and fetal development of, 73
functions of, 57
Hypogonadism, diffuse hypopigmentation in, 812
Hypohidrosis, 944–945
classification of, 938t
in ectodermal dysplasia, 1691–1695. *See also* Ectodermal dysplasia, anhidrotic or hypohidrotic
in ichthyosis
with follicular atrophoderma and hypotrichosis, 976t
Hypomelanosis, **804**–813
acquired diffuse, 811–813
acquired localized, 806–811
congenital, 804–806
diagnostic algorithm on, 804
idiopathic, 812
of Ito, 71–72, 83
macular
progressive, 813
in tuberous sclerosis, 1673, 1673f, 1674f
mixed with hypermelanosis, 825
Hyponatremia in acute intermittent porphyria, 1566
Hyponychium, 1011–1012
horny layer of, 1011
Hypoparathyroidism, **1856**–1859
approach to patient with, 1859b
and candidiasis, chronic mucocutaneous, 1859
clinical findings in, 1859
primary, 1857
pseudo, 1859
PTH-resistant, 1859
secondary, 1857
treatment of, 1859
Hypopigmentation, 30, **804**–813
in acquired hypomelanosis
diffuse, 811–813
localized, 806–811
in congenital hypomelanosis, 804–806
in cryotherapy, 2972
occupational, 2628
postoperative, 2983
in selenium deficiency, 1519
Hypopituitarism
growth hormone deficiency in, 1867
pigmentation changes in, 812, 1868f
Hypoplasia
in cartilage-hair hypoplasia syndrome, 1709
focal dermal
of Goltz, 1701–1702
Hyposplenism, opportunistic infections in, 269t
Hypotension
in meningococcemia, 2179, 2180
in septic shock, 2198
Hypothalamus
in corticosteroid suppression of adrenal-hypothalmic-pituitary axis, 2665
Hypothermia
in cold injuries, 1081
with frostbite, 1082–1085
episodic, with hyperhidrosis, 938t
Hypothyroidism
approach to patient with, 1855b
congenital, 1852
cutaneous findings in, 1855–1856
epidemiology of, 1852
etiology and pathogenesis in, 1853
hypopigmentation in, diffuse, 812
Raynaud phenomenon in, 2069
in retinoid therapy, 2765
treatment of, 1856
vitiligo in, 812
Hypotrichosis
localized autosomal recessive, 1004
Marie Unna, 1005
simplex, 987

I

ICAMs. *See* Intercellular adhesion molecules (ICAMs)
Ichthyoacanthotoxicosis, 2595
Ichthyosis, **507**–537
acquired, 535
pityriasis rotunda, 535
with alopecia and photophobia, 978
annular epidermolytic erythema, 525
autosomal dominant, 508t
autosomal recessive, 519–520, 528
autosomal semidominant, 508t
of bathing suit area, 521
bullosa, of Siemens, 523, 525
in CEDNIK syndrome, 528
in Chanarin-Dorfman syndrome, 528
in CHILD syndrome, 528
in chondrodysplasia punctata, 528–530
classification of, 508t
clinical presentation in, 507
congenital
ichthyosiform erythroderma, 521, 530
with epidermolytic hyperkeratosis, 521–523
in newborn, 526
etiology and pathogenesis of, 515
erythrokeratodermias, 530–531
harlequin, 526–527
in HIV infection and AIDS, 535
hystrix
of Curth and Macklin, 525
in kava dermatopathy, 535
with keratitis and deafness, 531–532
lamellar, 520–521in lymphoma, 535
in Netherton syndrome, 527–528
in newborn, 526–528
with sclerosing cholangitis, 532
in peeling skin syndromes, 532
prematurity sysndrome, 531
prenatal diagnosis of, 537
in Refsum disease, 533
resources on, 537
in Rud syndrome, 533
in Sjögren-Larsson syndrome, 533–534
skin barrier function in, 515
treatment of, 536–537
retinoids in, 536–537, 2762

Ichthyosis—*continued*
in trichothiodystrophy, 534
vulgaris, 515–517
and keratosis pilaris, 515, 516
X-linked
recessive, 517–519
ICHYN in ichthyosis, 520t
Id reaction, 188
autoeczematization response, 2159
clinical findings in, 190
Imbibition phase in skin graft healing, 2992
Imidazole antifungal agents, 2804, 2677–2680
adverse effects of, 2680
indications for, 2679
Iminodipeptiduria, 1526t
Imipenem in actinomycetoma, 2252
Imiquimod, 2692–2694
in actinic keratosis, 2693, 2695
in hemangioma of infants, 1465
indications and contraindications to, 2692–2694
initiation of therapy in, 2695
pharmacokinetics of, 2694
Immune response, **105**–126
adaptive, 113–126. *See also* Adaptive immunity
cellular. *See* Cell-mediated immunity
costimulatory molecules in, 121
danger signals in, 120–121, 120f
in helminthic infections, 2547
innate, **106**–113. *See also* Innate immunity
ultraviolet radiation exposure affecting, 2842
in psoralen and PUVA therapy, 2842
Immunity, **105**–126
adaptive, 113–126. *See also* Adaptive immunity
cellular. *See* Cell-mediated immunity
humoral, **401**–413
innate, **106**–113. *See also* Innate immunity
Immunobiologic agents, **2814**–2826
antibodies against cell surface receptors, 2823
efalizumab, 2823
rituximab, 2823
antibodies against cytokines
adalimumab, 2822
anti IL12/IL23 (ustekinumab), 2822
antitumor necrosis factor, 2819–2821
infliximab, 2821
fusion proteins
alefacept, 2824
denileukin diftitox, 2825
etanercept, 2824–2825
recombinant interferons and growth factors
IFN-α, 2815–2816
IFN-γ, 2816
recombinant interleukins and growth factors
granulocyte-macrophage colony stimulating factor, 2818
IL-1 receptor antagonist, 2818
IL-2, 2817
recombinant human platelet-derived growth factor, 2818–2819
Immunodeficiency disorders, **1703**–1725
in antibody deficiency disorders, 1703–1707, 1705t
ataxia and telangiectasia, 1714–1716
in cartilage-hair hypoplasia syndrome, 1709
in cellular deficiencies, 1705t, 1707–1709
in chronic mucocutaneous candidiasis, 1707–1709
clinical findings in, 1703
in combined antibody and T cell deficiency, 1710
common variable, 1705–1707
clinical findings in, 1705
in complement deficiency disorders, 1705t, 1724, 1725t
ectodermal dysplasia with, 1713–1714
in hereditary angioedema, 1725
in hyper-IgM syndrome, 1710
in neonates and infants, 1706f
in phagocytosis and cell killing disorders, 1705t, 1716–1724
severe combined, 1711–1713
differential diagnosis in, 151
graft-versus-host disease in, 1711
types of, 1712t
in Wiskott-Aldrich syndrome, 1710–1711
in X-linked agammaglobulinemia, 1703–1705
clinical findings, 1705
epidemiology of, 1703
treatment/prognosis/clinical course of, 1705
Immunofluorescence
Immunoglobulins
complementarity-determining regions of, 402
hypervariable regions of, 402
in linear dermatosis, **623**–629
in pemphigus, 599
IgE
in exfoliative dermatitis, 269
in urticaria and angioedema, 418
contact, 421
IgG
in autoimmune disorders, 1903
Immunomodulators
therapy in in morphea, 701
topical, 1154, 1375, **2690**–2696
Immunoreceptors
tyrosine-based activation motifs, 406
tyrosine-based inhibition motifs, 406
Immunosuppression, **330**–344
actinic keratosis in, 343
acute, 330–335
bacterial infections in, 332
fungal infections, 332–335
viral infections, 335
aspergillosis in, 333–334
bacillary angiomatosis in, 337
bacterial infections in, 332, 336–338
blastomycosis in, 340
cancer risk in, 342–344
candidiasis in, 333, 338–339
cellulitis in, 2192
chronic, 335–344
bacterial infections in, 336–338
fungal infections, 338–341
viral infections, 341–342
coccidioidomycosis in, 340, 2324
cryptococcosis in, 339–340
cytomegalovirus infections in, 342
in dermatophytosis, 339
ecthyma gangrenosum in, 332, 332f
fungal infections in, 332–335, 338–341
fusariosis in, 335
herpes simplex virus infections in, 341–342
herpesvirus-6 infection in, 341–342
histoplasmosis in, 340
in HIV infection and AIDS. *See* HIV infection and AIDS
Kaposi sarcoma in, 344
melanoma in, 343
Merkel cell carcinoma in, 344
mycobacterial infections in, 336
necrotizing fasciitis in, 337, 338f
nocardiosis in, 337
nonmelanoma skin cancer in, 342–343
onychomycosis in, 338, 339f
papillomavirus infections in, 342
in pemphigus therapy, 596–599
Penicillium marneffei infection in, 340–341, 2325
polyomavirus infections in, 342
Pseudomonas aeruginosa infections in, 332
scabies in, 342
squamous cell carcinoma in, 342–342
prevention of, 1036
toxoplasmosis in, 2010
trichosporonosis in, 335
varicella-zoster virus infections in, 335, 341
Vibrio vulnificus infections in, 337, 338f
viral infections in, 335, 341–342
warts in, 342
zygomycosis in, 334–335
Immunotherapy
in alopecia areata, 994
in atopic dermatitis, 180–181
in melanoma, 1443
in vesicular hand dermatitis, 193
Impetigo
Bockhart
bullous, 2131–2132, 2149–2151
clinical features in, 2131
differential diagnosis of, 2132b
exfoliative toxins in, 2149
histopathology in, 2130
treatment of, 2132
nonbullous, 2130
differential diagnosis of, 2131b

staphylococcal, 2129–2133
histopathology in, 2130
treatment of, 2132, 2133b
streptococcal, 2141–2142
treatment of, 2142
vesicles in, 36
Implantation
extraocular, 1130
subdermal, 1130
Imprinting, genomic, 83
Inborn errors of amino acid metabolism, **1525**–1537
Incandescent light sources, 2843
Incidence of disease, 4
and lifetime risk, 5–6
and number of physician visits, 6
Incontinentia pigmenti, 814
anhidrosis in, 945
Infants. *See* Children and infants
Infarction, 37
cerebral, hyperhidrosis in, 938t
in cholesterol emboli, 37, 38f
Infections. *See also specific infection*
atopic dermatitis complication, 174
autoimmune disorders in, 1908
bacterial. *See* Bacterial infections
chemokines in, 150–151
congenital, 1193
in decubitus ulcers
management of, 1128
in electrosurgery, 2976
fungal. *See* Fungal infections
in neonates, 1193–1194
in occupational exposures, 2623–2326
postoperative, 2978–2979
in nail surgery, 2960
psoriasis and, 218
surgical complication, 2978
viral, **2329**–2463
Infiltrates
lymphocytic, 53–54. *See also* Lymphocytic infiltration of skin
atypical, 54
nodular, 53, 54
nonfollicular, 53
perivascular, 53
superficial perivascular, 53
polymorphonuclear leukocyte, 54
Inflammatory bowel disease, 2765–2766
early-onset, 1599
Inflammatory reactions
nerves in, 1139t–1141t
in sunburn, 1040
ultraviolet radiation-induced
UVA, 1041–1042
UVB, 1040–1041
in wound healing, 2986f, 2987
Infliximab, 2821
in exfoliative dermatitis, 278
in hidradenitis suppurativa, 958b
in psoriasis, 193, 2821
and arthritis, 193
in rheumatoid arthritis, 2821
Infraorbital nerve, 2916
Ingrown nails
surgery in, 2966–2967
Injection techniques
with botulinum toxin. *See* Botulinum toxin
in soft tissue augmentation
with autologous fat, 3050
with calcium hydroxylapatite, 3049
with hyaluronic acids, 3046
with poly-L-lactic acid, 3048
with silicone, 3051
Innate immunity, **106**–113, 1906, 2123
antimicrobial peptides in, 107–108, 2123
cell types in, 110–112, 1991
keratinocytes, 111–112
natural killer cells, 111
phagocytes, 110
compared to adaptive immunity, 106, 106f, 1991
complement system in, 106–107, 2123
cytokines in, 107, 107f, 108, 109, 110, 111, 112
endothelium in, 1991–1997
interleukin IL-1β in, 1996
keratinocytes in, 111–112
natural killer cells in, 111
pattern recognition receptors in, 108–109, 1907
phagocytes in, 110
physical barriers in, 106
sebaceous glands and, 895
Toll-like receptors in, 110, 1907, 1991, 2123
tumor necrosis factor in, 1993–1997
Insect bites and stings, 2605–2609
Integrins
in embryonic and fetal development, 68, 71t, 72, 73
in lichen planus, 298
in multistep model of leukocyte recruitment, 145
in psoriasis, 204
Intense pulsed light therapy. *See also* Laser therapy
for hair removal, 2881
principles, 2871–2871
safety of, 2876–2877
Intercellular adhesion molecules (ICAMs)
in adhesion of leukocytes to endothelial cells, 1995–1996
Interferon(s), 139, 2795
and Jak/STAT pathway, 131–132
type I, 139
and toll-like receptors, 139
type III, 139
for viral disease treatment, 2795
Interferon-α, 139, 2827–2828
and autoimmunity, 1907
complications of, 2829b
contraindications to, 2828
in hemangioma of infants, 1465
indications for, 2827
mechanism of action, 2827
in pregnancy, 2816
recombinant, 2815t, 2815–2816
Interferon-α 2b, 2827–2828
dosing regimen, 2829t
indications for, 2827
in lichen planus, 311b
mechanism of action, 2827
in melanoma, 1442
Interferon-β, 139
Interferon-β2, 138. *See also* Interleukins, IL-6
Interferon-γ, 2815t, 2816
in atopic dermatitis, 180, 167, 180
in granulomatous disease, chronic, 2816
in lichen planus, 297
physiologic role of, 139
in pregnancy, 2816
production of, 139
in psoriasis, 205–206
and T helper cells, 139, 2816
Interleukins (ILs)
IL-1, 127, 132
in Hodgkin disease and hyperhidrosis, 941
IL-1 receptor, 132
IL-1 receptor antagonist, 132, 1589, 2818
IL-1α, 132
IL-1β, 132
IL-2, 127, 2815t, 2817
deficiency of, 1712t
and helper T cells, 136
IL-2 receptor, 136
IL-3, 137
IL-3 receptor, 137
IL-4, 136–137
in atopic dermatitis, 167
functions of, 130t
IL-5, 137
functions of, 130t
IL-6, 137–138
functions of, 130t
IL-6 receptor, 137–138
IL-7, 137
functions of, 137
IL-7 receptor, 137, 1712t
IL-8
IL-9, 137
IL-10, 139–140
as anti-inflammatory cytokine, 139–140
in ultraviolet radiation exposure, 140
IL-10 receptor, 139–140
IL-12, 138
functions of, 130t
in psoriasis, 229
IL-13, 136–137
in atopic dermatitis, 167
functions of, 130t
IL-13 receptor, 136–137
IL-15, 136
IL-15 receptor, 136
IL-17, 135
in psoriasis, 205–206
IL-18, 133–134
IL-18 receptor, 133–134

Interleukins (ILs)—*continued*
IL-19, 140
IL-20, 140
IL-20 receptor, 140
IL-21, 137
IL-21 receptor, 137
IL-22, 130t, 140
IL-23, 130t, 138
in psoriasis, 205–206, 229
IL-24, 140
IL-26, 140
IL-27, 138
IL-27 receptor, 138
IL-31, 169
IL-33, 133, 134
Intertriginous lesions, 41
Iodine, 2698
occupational exposure to, 2615t
Iodophors
in preoperative skin preparation, 2912
Ionizing radiation
hyperpigmentation and, 820
occupational skin cancer risk and, 2631
squamous cell carcinoma and, 1285
Iontophoresis, 2703
in hyperhidrosis, 193
for vesicular dermatitis, 193
Iron, 1520
deficiency of, 1520, 1834
hair in, 1520, 1834
nail changes in, 1520
food sources of, 1520
overload of, 1520
Irritant contact dermatitis, **499**–506
acneiform or pustular, 503
acute, 501
delayed, 502
in occupational exposures, 2612
chronic, 502
clinical types of, 501–503
common irritants in, 504
airborne, 502t
chemical, 503t
from cosmetic products, 502, 503, 3015
cross-over phenomenon in, 500
cumulative, 502–503
cumulative, in occupational exposures, 2612
diagnostic criteria in, 505b
diaper dermatitis in, 1198
differential diagnosis in, 504, 504b
allergic contact dermatitis in, 504
endogenous factors in, 501
epidemiology of, 499–500
etiology and pathogenesis in, 500
exogenous factors in, 500
exsiccation eczematid, 503
friction, 503
irritant reaction, 501
nonerythematous (suberythematous), 503
in occupational exposures
airborne substances in, 2613
common substances causing, 2614, 2614t
diagnosis of, 2614
and low humidity, 2612
patch testing in, 505
prevention of, 506
prognosis in, 506
subjective (sensory) irritation, 503
transepidermal water loss in, 504
traumatic, 503
traumiterative, 502
treatment in, 506
Irritant ingredients in cosmetic products, 503, 504
Island pedicle flap, 2934
Isodisomy, uniparental, 83
Isolated limb perfusion procedure in melanoma therapy, 1442–1443
Isoniazid
in actinomycetoma, 2252
Isopropyl alcohol
in preoperative skin preparation, 2913
Isotretinoin, 2760
dosing regimens, 2762
in hidradenitis suppurativa, 957, 958
initiation and monitoring of therapy, 2763
in lichen planus, oral, 310
in seborrheic dermatitis, 266
Isovaleric acidemia, 1526t
Isovaleryl-coenzyme A dehydrogenase, 1526t
Itching. *See* Pruritus
Itraconazole, 2800–2802
in adult, 2800
in children, 2800
in coccidioidomycosis, 2324
in dermatophyte infections, 2293
dosage of, 2801
in elderly, 2801
indications for, 2800–2801
interaction with other drugs, 2801–2802
mechanism of action, 2800
in palmoplantar pustulosis, 256
in paracoccidioidomycosis, 2325
pharmacology of, 2800
side effects and complications of, 2801
Ivermectinin scabies, 2572
in strongyloidiasis, 2562
Ixodes ticks, 2604

J

Jacquet erosive dermatitis, 1198
Jak/STAT pathway, 131–132, 132f
interferons in, 139
and interleukin IL-10, 139
Janus kinase
deficiency of, 1712t
Jaundice, 1743, 1821–1822
classification of, 1822b
clinical features in, 1821–1822
in neonates, 1822
pathogenesis in, 1822
Jellyfish stings, 877, 2585–2588
first aid in, 2587t
prevention of, 2587–2588, 2587t
Jessner's solution in chemical peels, 3029
Jopling's reactions in leprosy, 2259–2260
Junctional epidermolysis bullosa. *See* Epidermolysis bullosa, junctional
Juvenile idiopathic arthritis, 1971

K

Kala-azar, 2534. *See also* Leishmaniasis
leishmaniasis
Kandahar sore, 2530
Kaposi sarcoma, **1481**–1486
African endemic, 1483
AIDS-associated, 1483–1484
genital, 868
treatment of, 1486
classic, 1482–1483
treatment of, 1486
etiology and pathogenesis in, 1481–1482
herpesvirus-8 in, 1481–1482
histogenesis in, 1482
histopathology in, 1484–1485
in immunosuppressive therapy, 1483
treatment of, 1486
treatment of, 1485–1486, 1485b
Kaposiform hemangioendothelioma, 1467–1468
Karyotype, 83
Kasabach-Merritt phenomenon, 1468
Kaschin-Beck disease in selenium deficiency, 1519
Kawasaki disease, **2042**–2049
acute phase of, 2045f
clinical findings, 2044–2046
clinical manifestations of, 2046b
complications, 2047
convalescent phase of, 2044
coronary artery disorders in, 2046b
diagnostic criteria on, 2043b, 2044
differential diagnosis of, 2046–2047, 2047b
epidemiology of, 2043
etiology and pathogenesis in, 2043–2044
eye disorders in, 2045
historical aspects of, 2042
incomplete, 2047, 2048b
laboratory findings in, 2046
liver disorders in, 2046b
oral cavity disorders in, 2045
strawberry tongue in, 2045
pathology in, 2046
prognosis in, 2047–2048
stages of, 2044
systemic disorders in, 2046b
treatment of, 2048–2049
Keloidalis, alopecia in, 1000
Keloids, 32, 2885. *See also* Scars
blastomycosis, 2317
compared to hypertrophic scars, 708–710
cryotherapy in, 2970
laser therapy in, 2885

Keratin
genes, 78
in spinous layer of epidermis, 61
differentiation-specific, 61
keratinization-specific, 61
Keratin 1, 61t
embryonic and fetal, 68, 71t
in lichen planus, 298
Keratin 2, 61t
Keratin 3, 61t
Keratin 4, 61t
in lichen planus, 298
Keratin 5, 61t
embryonic and fetal, 68, 71t
Keratin 6, 61t, 91
embryonic and fetal, 70
in lichen planus, 298
Keratin 8, 61t
embryonic and fetal, 68
Keratin 9, 61t
embryonic and fetal, 71t
Keratin 10, 61t
embryonic and fetal, 68, 71t
in lichen planus, 298
Keratin 12, 61t
Keratin 13, 61t
in lichen planus, 298
Keratin 14, 61t
embryonic and fetal, 68, 71t
gene encoding, 78
Keratin 16, 61t
embryonic and fetal, 69t, 70
in lichen planus, 298
Keratin 17, 61t
in lichen planus, 298
Keratin 18, 61t
embryonic and fetal, 68, 69t
Keratin 19
embryonic and fetal, 68, 69t, 70
Keratin 20
Keratin cyst
postoperative, 2981
Keratinization, 43, 45, 60
Keratinocyte(s), 42, 44
apoptotic, 45
in lichen planus, 298
in atopic dermatitis, 168
cytokines and chemokines of, 112
differentiation of
in psoriasis, 208
in innate immunity, 111–113
and melanocytes
in melanosome transfer, 775–776
in psoriasis, 202
in ultraviolet radiation exposure, 2843
Keratinocyte carcinoma, epidemiology of, 4
Keratoacanthoma, **1312**–1318
centrifugum marginatum, 1316
clinical findings in, 1314–1317
systemic associations, 1315
variants, 1315
epidemiology of, 1312–1313
etiology and pathogenesis of, 1313–1314
Ferguson-Smith type, 1316
giant, 1315
of Grzybowski, 1316
histopathology in, 1317
in Muir-Torre syndrome, 1342
mucosal regions, 1316
multiple, 1316
prevention of, 1318
prognosis in, 1318
squamous cell carcinoma in, 1313
subungual, 1316
treatment of, 1318
Keratoconjunctivitis
in Sjögren syndrome, 1979, 1982
Keratoderma, 36
acquired, 36
inherited, **538**–550
palmoplantar, **538**–550
and cardiomyopathy, 547
clinical findings in, 540–548
desmosomes in, 539
differential diagnosis in, 549, 549b
diffuse, 541, 542
epidemiology, 539
epidermolytic, 541, 543
epidermolytic, non-, 543
in esophageal cancer, 546
etiology and pathogenesis in, 539–540
focal, 543
with impaired hearing, 547
investigation, 548–549
mutilating, 545, 546
nail changes in, 545, 546, 547
with neuropathy, 547–548
with oral mucosal hyperkeratosis, 546–547
with periorificial keratotic plaques, 544
punctate, 541
and spastic paraplegia, 548
striate, 543–544
treatment of, 549
and woolly hair, 547
Keratolysis
pitted, 2145–2145
Keratolytic agents, topical, 2705–2706
Keratosis
actinic, **1261**–1270. *See also* Actinic keratosis
in arsenic exposure, 1270
follicularis
Darier-White disease in. *See* Darier-White disease
spinulosa decalvans, 976
hydrocarbon, 1270
lichenoid, 306
in limb amputation and prosthesis use, 1098
in mucoepithelial dysplasia, hereditary, 978
palmoplantar. *See* Keratoderma, palmoplantar
pilaris, **973**–978
atrophicans, 723, 974–977
diseases associated with, 973
rubra atrophicans faciei, 974
radiation, 1271
in scars, 1271
seborrheic, 1319–1323
clinical features in, 1319
clonal, 1322
etiology of, 1320
irritated, 1322
Leser-Trélat sign in, 1322
reticulated, 1321
and skin cancers, 1322
stucco, 1321
treatment, 1322–1323
thermal, 1270
viral, 1272–1273
Keshan disease in selenium deficiency, 1519
Ketoconazole
in paracoccidioidomycosis, 2325
in seborrheic dermatitis, 264
infantile, 265
Ketotifen
antihistaminic activity of, 2775
Kidney disorders, 1837–1839
calciphylaxis in, 1837–1838
fibrosing dermopathy in, 1838
metastatic calcification in, 1837–1838
perforating dermatosis in, 1838
in polyarteritis nodosa, 2025
pruritus in, 1838
Kimura disease, 1768t, 1774–1776
complications of, 1775
differential diagnosis of, 1775, 1775b
treatment of, 1776, 1776b
Kininogen in angioedema, 422
Kissing bugs, 2607
and Chagas disease, 2607
KIT/Kit
in piebaldism, 790
Klebsiella
in cellulitis, 2192
in necrotizing fasciitis, 2192
in rhinoscleroma, 2192, 2193
treatment of infections, 2193
Klebsiella granulomatis, 2510, 2511
Klebsiella pneumoniae subspecies *rhinoscleromatis,* 2192, 2193
Klein-Waardenburg syndrome, 790
Klinefelter syndrome, 84t
Klippel-Trénaunay syndrome
capillary malformations in, 2080–2081
Knuckle pads, 715
Koch's phenomenon, 2226–2227
Koebner phenomenon, 134
in lichen planus, 300, 300f
Koilonychia, 1015, 1824
hereditary, and keratosis pilaris, 977
Ku transcription factor, 1919t, 1930t
Kynureninase, 1526t

L

Lactic acid
in topical preparations
keratolytic, 2706
Lactobacillus in atopic dermatitis, 181, 2902
Lamivudine in HIV infection and AIDS, 2795t

Langerhans cell(s), 43, 63, 72, 121–124
in antigen presentation, 63
functions of, 63
in psoriasis, 201
Langerhans cell histiocytosis, **1782**–1795
approach to patient with, 1786f
classification of, 1784–1785, 1785t
clinical findings in, 1784–1790
complications of, 1792
cutaneous lesions in, 1785–1786
differential diagnosis of, 1793b, 1794b
in elderly, 1789f
epidemiology of, 1783–1784
etiology and pathogenesis in, 1784
familial, 1784
granulomatous reaction in, 1791, 1792f
histopathology in, 1791–1792
laboratory tests in, 1790–1792, 1790t
nail changes in, 1786, 1788f
oral cavity disorders in, 1786
prognosis and clinical course in, 1792–1794
proliferative reaction in, 1791
treatment of, 1794–1795
xanthomatous reaction in, 1791, 1792f
Larva migrans
cutaneous, 1830, 2546, 2559–2560
hookworm-related, 2560
syndrome in, 2559–2560
treatment of, 2560
visceral, 1830
Laser therapy, **2869**–2889. *See also* Optical radiation
ablative, **3021**–3028. *See also* Ablative lasers; Nonablative lasers
Alexandrite, 2886
in acne, 2885
in benign tumors, 2881
digital mucous cyst, 2881
eruptive vellus hair cysts, 2881
neurofibromas, 2881
syringomas, 2881
trichoepitheliomas, 2881
xanthelasmas, 2881
in café-au-lait spots, 2887
cooling methods in, 2876
diode, 2886
in epidermal and organoid nevi, 2881
sebaceous nevi, 2881–2882
verrucous epidermal nevi, 2881
epilation
devices, 2886
principle, 2886
side effects, 2886
eye safety aspects, 2877
for hair removal, 2881
in hemangiomas
in infants, 1465, 2879–2880
in hidradenitis suppurativa, 959
in hypertrophic scars, 2885
in infectious diseases, 2882
common warts, 2882
general warts, 2882
mollusca contagiosa, 2882
in inflammatory dermatoses
acne vulgaris, 2883
alopecia areata, 2885
chondrodermatitis nodularis helicis, 2883
cutaneous lupus erythematosus, 2883
Hailey-Hailey disease, 2883
lichen sclerosus et atrophicus, 2883
psoriasis vulgaris, 2883
rosacea, 2885
vitiligo, 2885
in keloids, 2885
laser-skin interactions in, in lentigines, 2886–2887
in melanocytic nevi, 2887
in melasma, 2887
in nevus of Ota and nevus of Ito, 2887
nonablative lasers, 3032–3035
photothermolysis in
fractional, 2876
selective, 2875–2876
for pigmentation from medications, 2889
in pigmented lesions, 3038–3040
anesthesia application, 3039
complications, 3040
equipment in, 3039
postoperative instructions, 3040
risks and precautions in, 3038
technique, 3039
in port-wine stains, 2878–2879
principles, 2869–2871
in psoriasis, 226
pulsed
Nd:YAG, 2886
Q-switching in, 2889, 2889t
safety of, 2876–2877
in scars, 2885
for skin rejuvenation, 3032–3035
for skin resurfacing, 3021–3026
fractional, 3023
in striae, 2885
for tattoo removal, 2887–2889
accidental tattoos, 2889
decorative tattoos, 2887–2889
in telangiectases, 2880
in vascular lesions, 3036–3038
anesthesia application, 3037
complications, 3038
equipment in, 3037
postoperative instructions, 3038
risks and precautions in, 3036
technique, 3037
in venous disorders
in varicose veins, 2880–2881, 3006–3008
in vitiligo, 800
Latent transforming growth factor-β–binding proteins, 683
Latrodectus spider bites, 2601
Lectin
in multistep model of leukocyte recruitment, 145
Leech bites, 2592
Leg. *See* Lower limb
Legal issues in elder abuse, 1182
Leiner disease, 263
Leiomyoma, 1470–1471
Leiomyosarcoma, 1471–1472
Leishmania aethiopica, 2537t
Leishmania braziliensis, 2531
Leishmania donovani, 2528
Leishmania donovani infantum, 2534
Leishmania guyanensis, 2531
Leishmania infantum, 2528, 2531
Leishmania major, 2528
Leishmania mexicana, 2527, 2531
Leishmania tropica, 2528, 2534
Leishmaniasis, 2527–2537
clinical findings in, 2530–2535
cryptic, 2530
cutaneous, 2527–2537
acute, 2530–2532
chronic, 2532–2535
complications of, 2532
differential diagnosis of, 2536b
diffuse, 2533
dry or urban type, 2530t
localized, 2530–2531
moist or rural type, 2530t
New World, 2531
Old World, 2530–2531
satellitosis in, 2531, 2532f
treatment of, 2536–2537
vectors and reservoir hosts in, 2528
volcano sign in, 2531, 2532f
diagnosis of, 2535–2536
epidemiology of, 2527
etiology and pathogenesis in, 2528–2529
etiology and life cycle, 2528
helper T cells in, 2528
and HIV infection, 2455, 2534
lupoid, 2533
mucocutaneous, 2533
in occupational exposures, 2626
post-kala-azar dermal, 809, 2534
prevention of, 2537
prognosis and clinical course in, 2536
recidivans, 2532–2533
treatment of, 2536–2537
local therapy in, 2537b
systemic therapy in, 2538t
vaccines for, 2537
visceral, 2534
viscerotropic, 2534
Leishmanid, 2535
Leishmanin skin test, 2536
LEKTI, 168
Lentigo (lentigines)
genital, 868
in LEOPARD syndrome, 1829
maligna and lentigo maligna melanoma
cryotherapy in, 2971
laser therapy in, 2886–2887
treatment of, 2970, 2886–2887
simplex, 1402–1406
clinical findings in, 1403–1404
differential diagnosis of, 1405
epidemiology of, 1402
etiology and pathogenesis of, 1403

histopathology in, 1404
treatment of, 1405–1406
solar, 1406–1410. *See also* Solar lentigo
LEOPARD syndrome, 818, 1829
Lepidoptera, 2608–2609
Lepidopterism, 2609
Leprosy, **2253**–2262
anhidrosis in, 2254
biopsy index in, 2253
borderline, 2255
clinical findings in, 2253–2261
complications of, 2262
delayed-type hypersensitivity reaction in, 2259
diagnosis of, 2261
differential diagnosis of, 2256b
erythema nodosum leprosum in, 2260
granulomatous spectrum in, 2254
in HIV infection and AIDS, 2259
hypopigmentation in, 809
indeterminate, 2258
laboratory tests in, 2261
lepromatous, 2255–2258
borderline, 2255–2257
polar, 2254
neurologic disorders in, 2254
in pregnancy and postpartum period, 2258
prognosis and clinical course in, 2262
reactional states of, 2259–2261
Jopling's type 1 reaction (reversal reaction), 2259–2260
Jopling's type 2 reaction (erythema nodosum leprosum), 2260
Lucio's phenomenon, 2260–2261
treatment of, 2262b
relapsing, 2259
treatment/management of, 2261b, 2262, 2262b
antibacterial, 2261b
tuberculoid
borderline, 2254–2255
polar, 2254
Leptospira interrogans, 2223–2225
Leptospirosis, 2223
treatment of, 2224
Leser-Trélat sign
in acanthosis nigricans, 1883, 1886
seborrheic keratoses, 1322
Lesions, skin, 29–41
arrangement, 39
distribution, 39–41
morphology, **29**–37
depressed, 32, 33
flat and macular, 33
fluid-filled, 36–37
purpura/vascular, 37
raised, 30–32
surface-change, 34–36
shape, 38–39
Leukemia
genital disorders in, 868
T-cell, adult, 2435–2438. *See also* T-cell leukemia, adult
Leukocyte adhesion deficiency, 1719
Leukocytes
chemokines in mobilization of, 140
cutaneous trafficking of, 145–148, 148f
multistep model of recruitment, 145
Leukocytoclasia
in pyoderma gangrenosum, 376
in Sweet syndrome, 367
in vasculitis. *See* Vasculitis, leukocytoclastic
Leukoderma. *See also* Hypomelanosis; Hypermelanosis
acquisitum centrifugum, 1386
chemical, 809–810
melanoma-associated, 810
occupational, 2628
perinevoid, 1386
punctata, 812
vagabond, 825
Leukoedema, 834
Leukonychia
apparent, 1016
true, 1014–1015
Leukoplakia, 839–840, **1278**–1281
differential diagnosis in, 1280–1281, 1280b
and erythroplakia, 1279, 1280b
hairy oral
in Epstein-Barr virus infections, 837
as premalignant lesion, 839
proliferative verrucous, 839
squamous cell carcinoma in, 1280–1281
treatment of, 1281
Leukotrienes
inhibitors, 193
Levocetirizine, 2770t. *See also* Antihistamines
LFA. *See* Lymphocyte function-associated antigens
Lice infestation, 2573–2578. *See also* Pediculosis
Lichen amyloidosis, 1578
treatment in, 1583
Lichen aureus, 2052
Lichen myxedematosus, **1959**–1961
Lichen nitidus, **312**–316
clinical findings in, 313–314
compared to lichen planus, 313t
differential diagnosis in, 315b
epidemiology of, 312
etiology and pathogenesis of, 313
genital, 866
pathology in, 314–315
prognosis and clinical course in, 315
treatment of, 315, 316t
Lichen planopilaris, 301
cicatricial alopecia in, 997
Lichen planus, **296**–312
actinic, 302
alopecia in, 301, 303
annular, 300
antigen recognition aspects, 297
atrophic, 300–301
bullous, 301
clinical findings in, 298–307
differential diagnosis in, 308b
drug-induced, 304
epidemiology of, 296
erosive, 301
esophageal, 303, 1827
etiology and pathogenesis in, 297–298
follicular, 301
gene responses (specific and global), 298
generalized, 299
genital
in female, 303
in male, 303, 865
in graft-versus-host reaction, 306
in hepatitis C, 306
hypertrophic, 300, 308
inverse, 304
Koebner phenomenon in, 299, 300f
and lichen nitidus, 313t
and lichenoid keratosis, 306
linear, 300
and lupus erythematosus, 304–305
malignant transformation in, 306–307
mucosal, 303–304
treatment, 309–310
nail changes in, 304, 1024–1025, 1824
differential diagnosis of, 1024
treatment of, 310, 311, 1025
oral cavity disorders in, 837–839
malignant transformation in, 306–307
palmoplantar, 304
papules in, 298, 300–301
pathology in, 307
pemphigoides, 305–306
pigmentosus, 302
prognosis and clinical course in, 307–309
sawtooth appearance in, 307–307f
of scalp, 302–303
squamous cell carcinoma in, 306–307, 307f
stages of, 297–298
antigen recognition, 297
keratinocyte apoptosis, 298
lymphocyte activation, 297–298
subtropicus, 302
treatment of, 309–312
in nail changes, 310, 311
photochemotherapy in, 310, 311
ulcerative, 301
vesiculobullous, 301
Lichen purpuricus, 2052
Lichen sclerosus, 54, **702**–707, **870**–871
clinical findings in, 702, 704, 870–871
complications in, 705, 871
diagnosis and differential diagnosis of, 705, 705b, 871b
epidemiology of, 702, 870
etiology and pathogenesis in, 702, 870
genital, 870–871
histopathology in, 704
laboratory tests in, 704

Lichen sclerosus—*continued*
pigmentation in, 810
prevention of, 707
prognosis and clinical course in, 706
treatment of, 706–707, 871, 2762, 2883
Lichen scrofulosorum, 2233–2234
Lichen simplex chronicus, **184**–187
clinical findings
cutaneous lesions, 185
history, 185
complications, 186
differential diagnosis of, 186b
epidemiology, 184
etiology and pathogenesis, 185
lichenification in, 185, 186f
oral, 835
prognosis/clinical course, 186
special tests, 185
treatment of, 186–187
Lichen spinulosus, 301
Lichen striatus, **1329**
clinical features in, 1329
differential diagnosis in, 1329
treatment of, 1329
Lichenification, 35, 36f
in atopic dermatitis, 170, 171f
in helminthic infections, 2555
in lichen simplex chronicus, 36, 36f, 185, 186f
Lichenoid disorders
in contact dermatitis, 304
in dermatosis of Gougerot and Blum, 2052
keratoses, 306
in phototoxicity, 1070
pityriasis. *See* Pityriasis, lichenoides
Lidocaine, 2915
in EMLA cream, 2915
in liposuction, 3042
side effects of, 2915
toxicity of, 2915
Lifestyle factors, 1612
Lifetime risk for disease, 5–6
Light eruptions
polymorphic, 1049–1053
and actinic prurigo, 1053–1055
approach to diagnosis of, 1050f
clinical features in, 1051–1052
differential diagnosis of, 1049b
hardening or tolerance to sunlight in, 1051
phototesting in, 1052
prevention, 1052–1053
prognosis, 1052
treatment, 1053
Light therapy
with intense pulsed light. *See* Intense pulsed light therapy
low-level for hair loss, 986
Limb amputation. *See* Amputation
Lime burns, 1118
Lindane
in scabies, 2571b
Lindsey's nails, 1824
Linea alba, 828
Linear immunoglobulin A dermatosis, **623**–629
clinical findings in, 625–628
disease associations, 628
mucosal involvement, 627
differential diagnosis of, 628–629, 629b
epidemiology of, 624
etiology and pathogenesis in, 624–625
histopathology in, 628
treatment of, 629
Linear lesions, 38
in immunoglobulin A dermatosis, **623**–629
Linezolid
in actinomycetoma, 2252
Liniments, topical medications formulated as, 2648
Linuche unguiculata in sea bather's eruption, 2593
Lip
allergic contact cheilitis of, 157, 158
cheilitis of. *See* Cheilitis
in cleft lip and palate with ectodermal dysplasia, 1699
erythroplakia of, 1283
nodules, 848
surgery of, 2925
anatomy in, 2908
cosmetic units and landmarks in, 2908
Lipids
in cornified envelope, 484
metabolism of, 1604–1607
in serum
in hyperlipidemia, 1610–1611. *See also* Hyperlipidemia
in retinoid therapy, 2766
in stratum corneum, 490–492
Lipoatrophy. *See also* Lipodystrophy
in HIV infection, 2446
in HIV infection, 2446
poly-L-lactic acid augmentation in, 3047
silicone augmentation in, 3051
Lipoblastoma, 1494
Lipoblastomatosis, 1494
Lipodermatosclerosis, 737–740, 2112
Lipodystrophy, **755**–763
acquired, 759–760
generalized, 759–760
localized, 760
partial, 759
approach to patient algorithm, 760
complications, 762
congenital generalized, 756
differential diagnosis, 761
familial partial, 757–758
genetic, 755–759
histopathology in, 760
in HIV infection and AIDS, 760
laboratoring testing in, 761
mandibuloacral dysplasia, 758
prevention, 763
prognosis and clinical course, 762–763
treatment in, 763
Lipoid proteinosis, **1644**–1648
respiratory disorders in, 1831
Lipoma, 1489–1493
angiolipoma, 1490, 1492–1493
angiomyxolipoma, 1490
dermal, 1490
fibrolipoma, 1490
histologic features in, 1490
intramuscular, 1490
multiple familial, 1489
myolipoma of soft tissue, 1490
myxolipoma, 1490
pleomorphic, 1493
spindle cell, 1493
Lipomatosis, 1490–1492
familial, 1489
of nerve, 1492
pelvic, 1491
symmetric, 1491
Lipopolysaccharide
and Toll-like receptors, 108
Lipoproteins, 1604–1607
chylomicrons, 1606
high-density, 1607, 1609
low-density, 1606
plasma, 1604–1605
very-low-density, 1606
in xanthoma, 1604–1607
Liposarcoma
dedifferentiated, 1496
myxoid, 1496–1497
pleomorphic, 1497
round cell, 1496–1497
well-differentiated, 1494–1496
Liposome-based drug formulations, 2655
Liposuction, **3041**–3044
anesthesia application, 3042
complications of, 3043
equipment in, 3041
indications for, 3041
outcome assessment in, 3043
patient selection, 3041
preoperative evaluation, 3041
postoperative patients instructions, 3043
risks and precautions in, 3041b
technique, 3042
Liquid nitrogen cryosurgery
in actinic keratosis, 1266
Lisch nodules in neurofibromatosis, 1684–1685, 1684f
Listeria monocytogenes, 2218–2220
Listeriosis, 2218–2220
treatment of, 2219
Lithium in seborrheic dermatitis, 266
Livedo racemosa, 2106–2109
antiphospholipid antibodies in, 2107
clinical findings in, 2106–2107
differential diagnosis of, 2107
disorders associated with, 2108t
treatment of, 2108
Livedo reticularis, 2106–2109. *See also* Vasculitis
clinical findings in, 2106–2107

differential diagnosis of, 2107
treatment of, 2108
Livedoid vasculopathy, 2009
Liver disorders, 1834–1836. *See also* Amyloidosis
in amebiasis, 2541
from antimalarial drugs
from azathioprine, 1837t
from cyclosporine, 1837t
from methotrexate, 1837t
from retinoids, 1837t, 2766
from terbinafine, 1837t
drug-induced, 1837
in graft-versus-host disease, 1836
in helminthic infections, 2557
in Kawasaki disease, 1836
and lichen planus, 306
in mastocytosis, 1836
nail changes in, 1824–1826
in psoriasis, 1836
spider nevi in, 1827
LL-37 effector molecule, 108
LMX, 2915
Loa loa, 2564
in helminthic disease, 2557
Lobo disease, 2317
Lobomycosis, 2317
Lobule of ear, 2905–2906
Localized lesions, 41
Loeffler syndrome
and helminthic infections, 2557
Loiasis, 2564
Loratadine, 2770t. *See also* Antihistamines
Loricrin
in cornified envelope, 484
in keratoderma, 544
Lotions, topical medications formulated as, 2648
Louis-Bar syndrome, 1714–1716
Lower limb, 1838
amputation in, **1095**–1104. *See also* Amputation
cholesterol emboli in, 1839
ulcers of
in chronic venous insufficiency, 2113–2114
differential diagnosis in, 2114b
treatment in, 2115
venous system of
as donor site in coronary artery bypass surgery, 1839
Loxosceles spider bites, 2601–2603
LTBP (latent transforming growth factor-β–binding proteins), 683
Lucio phenomenon in leprosy, 2260
Lumbosacral area
congenital skin lesions with risk of occult spinal dysraphism, 1195
Lunula
azure, 1824
Lupus anticoagulant
in Degos disease, 2073f
Lupus erythematosus, **1909**–1926, 1830
acute cutaneous, 1909
clinical findings in, 1913–1914
differential diagnosis of, 1922b
histopathology in, 1920
immunohistology in, 1920
prognosis and clinical course in, 1921
treatment of, 1923
autoantibodies in, 1918–1919, 1919t
chronic cutaneous, 1909
clinical findings in, 1915–1918
histopathology in, 1920
immunohistology in, 1920
prognosis and clinical course in, 1923
treatment of, 1923
classification of, 1909, 1910t, 1911t
clinical features in, 1912–1918
differential diagnosis of, 1921–1922b
epidemiology of, 1909–1910
etiology of, 1911–1912
histopathology in, 1920
immunohistology in, 1920–1921
laser therpy for, 2883
laboratory tests in, 1918–1920, 1919t
and lichen planus, 304–305
oral cavity disorders in, 842
pathologic reactions in, 49–50
photodermatose, 1073
pigmentation changes in, 808
preventive measures in, 1926
prognosis and clinical course in, 1921–1923
respiratory disorders in, 1831
subacute cutaneous, 1909
clinical findings in, 1914–1915
differential diagnosis of, 1922b
histopathology in, 1920
immunohistology in, 1920
prognosis and clinical course in, 1921–1922
treatment of, 1923
treatment of, 1923–1926
retinoids in, 2762
Lupus vulgaris, 2230–2231
clinical findings, 2330
complications, 2231
course, 2331
diagnosis of, 2231
differential diagnosis of, 2231b
epidemiology, 2230
etiology and pathogenesis, 2230
histopathology, 2230
Lutzomyia sandfly bites, 2606
leishmaniasis in, 2531
Lymantria dispar, 2609
Lyme disease, **2263**–2275
acrodermatitis chronica atrophicans in, 2267–2269
diagnosis and differential diagnosis of, 2269
approach to patient with, 2274f
atrophoborreliosis in, 2270
cardiac involvement, 2271
in children, 2272
clinical manifestations in, 2265–2272
complications of, 2272
diagnosis of, 2272–2273
B. burgdorferi detection, 2273
serologic tests in, 2273
epidemiology of, 2263
erythema migrans in, 2265–2267
diagnosis and differential diagnosis of, 2267
histopathology in, 2266
etiology and pathogenesis of, 2264–2265
immunology in, 2265
laboratory tests
direct detection of organism, 2272
serologic disease diagnosis, 2273
lymphoborreliosis in, 2270
lymphoid hyperplasia in, T-cell, 2270
musculoskeletal manifestations, 2271
neurologic disorders in, 2271
in occupational exposures, 2626
perinatal, 2272
prevention of, 2274–2275
prognosis and clinical course in, 2272
scleroborreliosis in, 2279
serologic diagnosis of, 2273
treatment of, 2273–2274, 2275t
vaccination against, 2275
Lymph nodes
dendritic cell trafficking to, 147–148
sentinel. *See* Sentinel lymph nodes
Lymphadenopathy
in helminthic infections, 2558
Lymphangioendotheliomatosis with thrombocytopenia, multifocal, 1468
Lymphangioma
in infants, 1191
Lymphangitic distribution of lesions, 41
Lymphangitis
acute, 2143
differential diagnosis of, 2143
sclerosing, 874
Lymphatic system, 66
of face, 2911
lymph flow in, 66
malformations in, 2086–2089
clinical characteristics of, 2087–2089
complications, 2089
differential diagnosis of, 2089b
histopathology in, 2087
prognosis and clinical course in, 2089
treatment of, 2089
Lymphedema, 66, 2116–2120
clinical findings in, 2118–2119
congenital, 2089
distichiasis, 2118
genetic factors in, 66
localized areas of, 2120
in lymphatic malformations, 2089
in Milroy disease, 2118
primary, 2117, 2118
secondary, 2117, 2118–2120
signs and symptoms, 2119b
treatment of, 2119–2120
Lymphoborreliosis, 2270

Lymphocyte(s)
in adaptive immune response, 113–114
B cell. *See* B cell(s)
cytotoxic lymphocytes activation and lichen planus, 297–298
in normal and diseased skin, 116
T cells. *See* T cell(s)
Lymphocyte function-associated antigens
LFA-1, 2815t, 2823
LFA-3, 2824
Lymphocytic infiltration of skin, 53–54, 1768t, 1780–1781
differential diagnosis in, 1780–1781, 1781b
treatment of, 1781, 1781b
Lymphogranuloma venereum, 2505–2510
acute anorectal syndrome in, 2507
acute genital syndrome in, 2507
clinical findings in, 2505–2508
complications of, 2509
differential diagnosis of, 2508, 2509b
epidemiology of, 2505
etiology and pathogenesis of, 2505
and HIV infection, 2507
laboratory tests in, 2508
prevention of, 2509–2510
transmission of, 2506
treatment of, 2509, 2509b
Lymphoid hyperplasia. *See* Hyperplasia, lymphoid cutaneous
Lymphoid tissue lymphoma
mucosa-associated, 285
skin-associated, 285
Lymphoma, **1745**–1766
anaplastic large cell, 1754–1755
B cell. *See* B-cell lymphoma
epidemiology of, 5, 1745
genital, 868
T-cell, 106, 2761–2762. *See also* T-cell lymphoma
Lymphomatoid contact dermatitis, 1768t, 1779–1780
clinical findings in, 1779
differential diagnosis of, 1779, 1780b
etiology and pathogenesis, 1779
treatment of, 1780, 1780b
Lymphoproliferative disorders
in Epstein-Barr virus infections, 2350
Lysosomal associated membrane protein (LAMP), 771–772
Lytta vesicatoria (Spanish fly), 2606

M

Macrolactam drugs, 2808–2814
Macrolide antibiotics, 2782–2783
adverse effects of, 2783b
indications for, 2783
mechanism of action, 2782
pharmacokinetics of, 2782
Macrophage(s)
in dermis, 65
in innate immune system, 111
in psoriasis, 202
Macules, 33
melanotic oral, 843–844
Madura foot, 2313–2315
in occupational exposures, 2626
Maduromycosis, 2313–2315
Mafenide acetate, 2676
Magnetic jewelry, 1136
Magnetic resonance imaging
in psoriatic arthritis, 237
Majeed syndrome, 1599
Major basic protein (MBP), 356
Major histocompatibility complex, 88. *See also* HLA system
class I, 88, 116
alternative pathway, 119
and CD8+ T cells, 88, 116
classic pathway, 118
deficiency of, 1712t
class II, 88
and CD4+ T cells, 88
deficiency of, 1712t
in restricted antigen presentation, 119
and Toll-like receptors, 110
methylation of CpG dinucleotides in, 88
Mal de Meleda, 545
Mal de pinta. *See* Pinta
Malabsorption, 1834
diarrhea and, 1834
nail changes in, 1834
in skin disorders, 1834
Malassezia dermatis, 2307, 2902
Malassezia equi, 2307
Malassezia furfur, 2307
in seborrheic dermatitis, 260
in tinea versicolor, 2307–2310
Malassezia globosa, 2307
in pityriasis versicolor, 806
in tinea versicolor, 2307
Malassezia japonica, 2307
Malassezia nana, 2307
Malassezia obtusa, 2307
Malassezia pachydermatis, 2307
Malassezia restricta, 2307
Malassezia slooffiae, 2307
Malassezia sympodialis, 171, 2307
in acne of neonates, 2307
in pityriasis versicolor, 806
Malassezia yamatoensis, 2307
Malathion, 2701
Male genital disorders, **852**–877
clinical findings in, 854–855
congenital, 856, 862
differential diagnosis in, 857b-861b
epidemiology of, 852
etiology and pathogenesis in, 852–854
laboratory tests in, 855–856
in lichen planus, 303
in reactive arthritis, 862–863
Malingerers, 1163
Malignant atrophic papulosis, **2072**–2075. *See also* Papulosis, malignant atrophic
Malnutrition
nail changes in, 1824
protein-energy, 1500–1503
Mandibular nerve
anesthetic block of, 2916
marginal, injury in surgery, 2907
surgical anatomy of, 2907
Manganese, 1520
deficiency of, 1520
Mansonella ozzardi, 2563
Mansonella perstans, 2564
Mansonella streptocerca, 2555, 2564
Marfan syndrome, **1629**–1633
neonatal, 1631
in pediatric patients, 1631
Marginal mandibular nerve injury in surgery, 2907
MART-1
in melanosomes, 771
Mast cells
in dermis, 65
functions of, 65
in hyperpigmentation, 820
phototherapy effect on, 2842–2843
phototoxic response, 1546
in psoriasis, 202
in urticaria and angioedema, 414–415, 424
Mastocytosis, **1809**–1818
classification of, 1810–1811, 1810t
cutaneous, 1810–1812
diagnosis of, 1814–1815
differential diagnosis of, 1816, 1816b
diffuse, 1812, 1812f, 1816b
prognosis of, 1816
treatment of, 1817t
diagnosis of, 1814–1815
epidemiology, 1809
gastrointestinal disorders in, 1813, 1816b
treatment of, 1817, 1817t
histopathology in, 1814f
liver disorders in, 1811, 1813, 1815
pathogenesis, 1809–1810
prognosis in, 1816–1817
systemic
aggressive, 1810t, 1811, 1813, 1814, 1816, 1818
with associated clonal hematologic nonmast cell lineage disease, 1810t, 1811, 1813, 1814, 1816, 1818
diagnostic criteria on, 1810t
differential diagnosis of, 1816, 1816b
indolent, 1810, 1810t, 1812f, 1816
treatment of, 1817t
treatment of, 1817–1819
antihistamines in, 1817, 1817t
photochemotherapy in, 1818
tryptase levels in, 1814
urticaria pigmentosa in, 1810, 1810t, 1811f, 811–812
Matrix metalloproteinases
in lichen planus, 298
MMP-9
in lichen planus, 298
Maxillary nerve
anesthetic block of, 2916
surgical anatomy of, 2908

McCune-Albright syndrome, 818
Measles, 2337–2340
  atypical, 2338
  clinical findings in, 2337–2338
  complications of, 2338–2339
  differential diagnosis of, 2339b
  treatment of, 2339, 2339b
  vaccination, 2339–2340
Mebendazole
  in enterobiasis, 2561
Mechanoreceptors, 1148
Mechlorethamine hydrochloride, 2686–2687
  side effects of, 2687
Mediterranean fever, familial, 1589–1592
  clinical findings, 1590
  complications, 1591
  differential diagnosis of, 1591
  treatment and prevention, 1592
Mediterranean spotted fever, 2463–2465
  differential diagnosis of, 2664b
  treatment of, 2465
Megalopyge opercularis, 2609
Meibomian glands, 687, 3010
Melanin
  absorption of radiation, 3018
  biosynthesis, 773–774
  embryonic and fetal, 69t, 71
  synthesis of. *See* Melanogenesis
Melanoacanthoma, 1321
  oral, 845
Melanocortin, 896
Melanocortin receptors, 773
Melanocyte(s), 43, 63, 72
  aging and photoaging, 780
  biology of, **765**–780
  dendrites of, 774–775
  disorders of, 63
  embryonic and fetal development, 70, 72
  function of, 63
  hair follicle, 766
  and keratinocyte interactions, 63, 72
  and melanization, 768
  melanogenic proteins, 769–773
  melanosome biogenesis, 768–769
  melanosome transport, 775–776
    to keratinocytes, 775–776
    within melanocytes, 775
  in nevi. *See also* Melanocytic nevi
  regulation of, 776–777
    melanogenic inhibitors in, 777
    melanogenic stimulators in, 776–777
    signaling pathways in, 777–778
  site-specific, 765
  stem cells, 765–768
  transplantation technique in vitiligo, 797, 802
  in ultraviolet radiation exposure, 778–780, 2843
Melanocytic nevi
  nodal, 1401–1402
  of penis, 856
  Spitz, 1398–1341
Melanogenesis
  DNA damage in, 780
  inhibitors in, 777
  proteins in, 769–773
  stimulators in, 776–777
  ultraviolet radiation-induced, 778, 780
    in tanning response, 778
Melanoma, **1416**–1444
  acral lentiginous, 1425–1427
    differential diagnosis in, 1425–1427, 1427b
  in children, 1428–1429
  clinical findings in, 1420–1427
  dermoscopy in, 1429–1430
  desmoplastic, 1427
  differential diagnosis of, 1427b
  epidemiology of, 1416
  ethnic and racial considerations in, 99
  etiology and pathogenesis of, 1417–1420
    melanocytic nevi, 1418
    skin phenotype, 1418
    sun exposure, 1417
  familial, 1418
  genetic factors in, 1418–1420
  genital, 877
  histopathology in, 1430–1431
  hyperpigmentation and, 820
  immunohistochemistry in, 1432
  lentigo maligna, 1422–1425
    differential diagnosis in, 1426b
    treatment in, 1441
  leukoderma in, 810
  lymphatic system in progression of, 66
  metastasis of, 1436–1437
    distant, 1436, 1440–1441, 1443
    macroscopic, 1438, 1441
    microscopic, 1438, 1440, 1442
    regional, 1436, 1438–1440, 1441–1443
    satellite or in-transit, 1442
    staging of, 1437
    unknown primary site in, 1437
  mortality rate in, 4
  mucosal, 1427
  of nails, 1022
  nevoid, 1427
  nodular, 1420–1421, 1441
    differential diagnosis of, 1423b
  oral, 845–846
  in pregnancy, 1427–1428
  prevention of, 1444
  primary dermal, 1440
  prognosis and clinical course in, 1432–1437
  spitzoid, 1427
  staging of, 1432–1433, 1437, 1435t
    mitotic rate, 1433
    molecular, 1154
    tumor thickness, 1433
  and sunscreen use, 2711
  superficial spreading, 1420
    diagnosis of, 1422b
  treatment of, 1438–1444
    adjuvant therapy, 1442
    isolated limb perfusion in, 1442–1443
    Mohs micrographic surgery in, 1154, 2955
    radiation therapy in, 1442
  tumorigenesis and tumor progression in, 1420
  ulceration of, 1433
  vaccines in management of, 1442
Melanoma antigen recognized by T cells (MART-1)
Melanonychia, 1015
Melanosis
  in cirrhosis, 1821
  genital, 868
  Riehl, 824
  transient neonatal pustular, 1188
Melanosomes, 93, 768–773
  embryonic and fetal, 72
  melanogenic proteins in, 769–773
  transport of, 775–776
Melasma
  in hypermelanosis, 819
  treatment of
    laser therapy in, 2887
Melioidosis, 2222
  in bioterrorism, 2638
Mendelian disorders, 81–83
Meningitis
  in coccidioidomycosis, 2324
  in helminthic infections, 2557
Meningococcal infections, **2178**–2183. *See also Neisseria meningitides*
Meningococcemia
  acute, 2179–2181
    clinical findings in, 2179–2180
    differential diagnosis of, 2181b
    hypotension in, 2179, 2180
  chronic, 2181–2182
Menkes syndrome
  pili torti in, 1003
Menopause
  facial hirsutism in, 1219
  hair loss in, 1218–1219
  structural and functional skin changes in, 1219–1220
Mental nerve
  anesthetic block of, 2916
Menthol in pruritus, 2704
Merkel cell(s), 43, 63, 72
  in embryonic and fetal development, 72
  in hair follicles, 63
  immunohistochemical markers of, 63, 1366
  polyomavirus, 1364
  sensory function of, 63
Merkel cell carcinoma, **1362**–1370
  clinical course and complications in, 1370
  clinical features of, 1364, 1364t
  in elderly, 1363
  epidemiology of, 1363
  etiology and pathogenesis in, 1363–1364
    age greater than 65, 1363
    immunesuppression, 1363
    sun exposure, 1363

Merkel cell carcinoma—*continued*
hematoxylin and eosin stain in, 1365
in immunocompromised host, 1363
in HIV infection and AIDS, 1363
immunohistochemistry in, 1365–1367
intermediate type, 1365
pathology in, 1364
perinuclear dot pattern in, 1366
radiologic imaging studies in, 1368
recurrent, 1368
sentinel lymph node biopsy in, 1367
small cell type, 1365
staging and prognosis in, 1367–1368
treatment of, 1368–1370
Meroisodisomy, 83
Mesoderm, embryonic and fetal, 68, 72
Messenger RNA, 78
Meta-analysis, 10
Metalloproteinases
matrix. *See* Matrix metalloproteinases
tissue inhibitors of
in lichen planus, 298
Metastasis
to genitalia, 868
of melanoma. *See* Melanoma, metastasis of
to scalp, 1824
umbilical, 1824
Methamphetamine, 1172–1173
Methicillin-resistant staphylococcal infections, 2161–2162
in athletes, 1115–1117
in surgical wounds, 2978
Methionine
defective transport, 1526t
malabsorption syndrome, 1526t
Methotrexate, 2688–2689, 2735
in atopic dermatitis, 180
chemical structure of, 2736f
combination with phototherapy, 2857
complications and side effects of, 2738–2739
anaphylaxis, 2740
carcinogenicity in, 2740
drug interactions, 2740
folate and folinic acid supplementation, 2740
gastrointestinal effects, 2739
hematologic effects, 2739
hepatic effects, 2739
liver disorders in, 2740
mucosal and cutaneous effects, 2740
mutagenecity and teratogenecity, 2740
myelosuppression in, 2740
opportunistic infections, 2740
overdose, 2740
in psoriasis, 2740
pulmonary effects, 2740
recall reaction in, 2740
dosing regimen, 2736–2737
indications for, 2688, 2736
initiation of therapy with, 2737
in lichen planus, 311
mechanism of action, 2688, 2735
monitoring of therapy with, 2737–2738
in palmoplantar pustulosis, 256
pharmacokinetics of, 2736
in pityriasis rubra pilaris, 283
in psoriasis, 227
and arthritis, 240
topical, 2688–2689
in vesicular palmoplantar eczema, 192
Methyldibromoglutaronitrile/Phenoxyethanol (MDGN/PE), 161
Metronidazole, 2701
in lichen planus, 311
in rosacea, 2673–2674
in seborrheic dermatitis, 266
Mevalonate aciduria, 1592
Mi-2 antibodies in dermatomyositis, 1930t
MICA/MICB, 111
Micrococcus sedentarius, 2145
Microcystic adnexal carcinoma, 1354–1355
Microfibrils in elastic fibers, 682–684
Microphthalmia-associated transcription factor, 772–773
in melanocyte proliferation and survival, 772
regulation of, 772
in Tietz syndrome, 790
in Waardenburg syndrome, 789
Micro-RNA, 69
Microsatellite instability, 1236
Microsatellite markers, 79
Milia, 1188, 1334–1335
acquired, 1334
congenital, 1334
plaque-type, 1334
postoperative, 2981
Miliaria, 946
anhidrosis in, 946
crystallina, 946
profunda, 946
pustulosa, 946
rubra, 946
diaper dermatitis in, 1198
Milker's nodules, 2414–2415, 2625
clinical findings in, 2414
differential diagnosis of, 2415, 2415b
Millepora alcicornis (fire coral), 2589
Millipede exposure, 2605
Milroy disease, 2118
lymphedema in, 2118
recurrent erysipelas in, 1722
Miltefosine, 2689
Mineralization, cutaneous, **1649**–1654
Minerals, dietary, 1518–1523
Minoxidil
in alopecia, 984–985, 993–994
Mirtazapine
antihistaminic activity of, 2775
Mites, 2573t. *See also* Ticks
animal, 2572
dust, 2573
follicle, 2572
fowl, 2572
harvest, 2572
occupational exposure to, 2626
rickettsialpox from, 2465–2466
scabies. *See* Scabies
scrub typhus from, 2467–2468
straw itch, 2572
MITF/Mitf
in Tietz syndrome, 790
in Waardenburg syndrome, 789
Mitochondrial disorders
in photoaging, 1222
Mizolastine, 2770t. *See also* Antihistamines
MLH1
hypermethylation of, 88
in Muir-Torre syndrome, 1342
MMP. *See* Matrix metalloproteinases
Mohs micrographic surgery, **2950**–2956
in basal cell carcinoma, 1300, 2952–2953
complications, 2956
in dermatofibrosarcoma protuberans, 2955
indications for, 2952
in melanoma, 2955
in Paget disease, 1375, 2955
procedure, 2950–2952
in squamous cell carcinoma, 2954
in verrucous carcinoma, 2955
Moisture and skin hydration
in atopic dermatitis, 175
Molluscum contagiosum, **2417**–2420
clinical findings in, 2418
diagnosis of, 2419
differential diagnosis of, 2419, 2419b
genital, 863
in HIV infection and AIDS, 2454
in occupational exposures, 2625
prevention of, 2419–2420
treatment of, 2419, 2420t
Mollusks, injuries caused by, 2594–2595
Mongolian spots, 815
Monilethrix, 977
hair shaft abnormality, 1004
Monkeypox virus infections, 2411–2414
clinical findings in, 2412
differential diagnosis of, 2413
histopathology in, 2413
in occupational exposures, 2625
prevention of, 2413
treatment of, 2413
vaccination against, 2414
Monobenzyl ether of hydroquinone (MBEH), 2704
Monochloroacetic acid in warts, 2706
Morbidity measures in skin diseases, 6–7
accuracy of, 7
number of physician visits, 6
quality of life issues in, 7
quantification issues in, 7–8
reliability and validity of, 7
severity of disease scales in, 7
Morphea, **692**–701
circumscribed, 695
clinical findings in, 694–697
complications in, 697
deep, 696–697

epidemiology of, 693
etiology and pathogenesis in, 693
generalized, 695
histology and laboratory testing role, 700
imaging studies, 697
linear, 696
prognosis and clinical course in, 698
serum abnormalities in, 697
treatment of, 698–701
adjunctive therapy, 701
antimicrobials in, 701
immunomodulators, 701
phototherapy in, 700–701
vitamin D derivates, 701
Morphology of skin lesions, 29–37
depressed
atrophy, 32
burrow, 33
erosion, 32, 32f
poikiloderma, 33
sclerosis, 33
sinus, 33
striae, 33
ulcers, 32, 32f
flat and macular
erythema, 33
erythroderma, 33
macule, 33
patch, 33
fluid-filled
abscess, 37
furuncle, 37
pustule, 36–37
vesicle and bulla, 36
purpura/vascular
infarct, 37
purpura, 37
telangiectasia, 37
raised
calcinosis, 32
comedo, 32, 32f
cyst, 30–31, 31f
horn, 32
nodule, 30, 31f
papule, 30
plaque, 30, 31f
scar, 31
wheal, 31, 31f
Mortality rates in skin diseases
age-adjusted, 4
cohort patterns in, 4
Mosaicism, 86
epigenetic, 87
gonadal, 86
gonosomal, 86
revertant, 87, 87f
somatic, 86
Morsicatio mucosae oris, 834
Motor nerves, facial, 2909
Mottling in neonates and infants, 1189
Mouth disorders. *See* Oral cavity disorders
Moynahan (LEOPARD) syndrome, 1829
M-plasty, 2929
MSH2 in Muir-Torre syndrome, 1342
Mucinous carcinoma, eccrine, 1354
Muckle-Wells syndrome, 425, 1585–1589
Mucormycosis, 2317, 2327. *See also* Zygomycosis
Mucosal lichen planus, 303
treatment, 309–310
Mucositis
chemotherapy-associated, 832
Mucous membranes
in lichen planus, 303, 309–310
Muir-Torre syndrome, 1342
keratoacanthoma in, 1342
Multiceps, 2567
Multiple endocrine neoplasia syndrome, 1476
type 2B, 1476
Mupirocin, 2675, 2701
Muscles
of face, surgical anatomy of, 2909
tumors of, 1470–1474
of smooth muscle, 1470–1473
of striated muscle, 1473–1474
Mushroom dermatitis, flagellate, 822
Mustard gas as chemical weapon, 2638, 2641
Mutations, 78, 80–81
candidate gene approach to, 79
epigenetic, 87–88
genome-wide linkage studies, 85–86
identification and detection techniques, 79–80
mitochondrial, 85
mosaicism in, 86–87
nonsense, 80
and polymorphisms, 80–81
premature termination codon mutation, 77f, 78
silent, 80
splice site, 81
Mycetoma, 2313–2315
bacterial. *See* Actinomycetoma
clinical findings in, 2314
differential diagnosis of, 2314
fungal (eumycetoma), 2313–2315
laboratory tests in, 2314
in occupational exposures, 2626
treatment, 2315
Mycobacterial infections, 2225–2240
in immunocompromised host, 2225–2226
in HIV infection, 2225–2226
in occupational exposures, 2624
other than *M. tuberculosis* infections, 2236–2240
mycobacteria identification, 2236, 2238
treatment, 2237t
treatment of, 2235–2236
tuberculosis in, **2226**–2233. *See also* Tuberculosis
Mycobacterium abscessus, 2240
Mycobacterium africanum, 2237t
Mycobacterium avium-intracellulare, 2226, 2240
Mycobacterium balnei, 2238
Mycobacterium bovis
in cutaneous tuberculosis, 2228
occupational exposure to, 2624
Mycobacterium chelonae, 2240, 2978
Mycobacterium fortuitum, 2236, 2240, 2978
Mycobacterium genavense, 2240
Mycobacterium gordonae, 2237t
Mycobacterium haemophilum, 2240
Mycobacterium kansasii, 2226, 2239
differential diagnosis of, 2240b
treatment of infections, 2237t
Mycobacterium leprae, 2253. *See also* Leprosy
Mycobacterium marinum, 2236, 2238–2239
clinical findings in infections, 2236, 2237t
differential diagnosis of, 2239b
occupational exposure to, 2624
treatment of infections, 2237t
Mycobacterium scrofulaceum, 2240
Mycobacterium szulgai, 2240
Mycobacterium tuberculosis, 2225, **2226**–2233. *See also* Tuberculosis
occupational exposure to, 2624
Mycobacterium ulcerans, 2236, 2238
differential diagnosis of, 2239b
treatment of infections, 2237t
Mycophenolate mofetil, 2807–2808
in atopic dermatitis, 180
dosage regimen, 2808
in exfoliative dermatitis, 278
indications for, 2807–2808
initiation of therapy with, 2808t
in lichen planus, cutaneous, 311
mechanism of action, 2807
monitoring of therapy with, 2808
in pemphigus, 598
pharmacokinetics of, 2807
in psoriasis, 228
side effects and complications of, 2808
in vesicular palmoplantar eczema, 192
Mycophenolic acid, 2747
Mycoplasma, in seal finger, 2218, 2584
Mycoplasma fermentas, 2522
Mycoplasma genitalium, 2522
Mycoplasma hominis, 2522
Mycosis fungoides, 1748–1752
clinical manifestations of, 1748–1750
deck chair or folded luggage sign in, 1750
differential diagnosis of, 1751b
pseudo-mycosis fungoides in, 1777–1779
erythroderma in, 1750
follicular or folliculotropic, 1751, 1752f
granulomatous slack skin in, 1752, 1753f
histopathology of, 1750–1751
hypopigmented, 808, 1751
pagetoid reticulosis in, 1752
patch-stage, 1748, 1749f, 1751b
Pautrier microabscess in, 1750, 1751f
pigmented purpuric, 1749
pruritus in, 1750
and pseudo-mycosis fungoides, 1777–1779

Mycosis fungoides—*continued*
staging of, 1757, 1757t, 1758b
treatment of, 1751
photochemotherapy in, 2858
tumor-stage, 1749, 1751b
variants of, 1751–1752
Myofibroma, 716
Myofibromatosis, infantile, 713
Myonecrosis, 2176
Myositis
clostridial, 2176
necrotizing cutaneous, 2175
Myxofibrosarcoma, **1452**–1453
Myxoma
atrial, 1829
mucocutaneous, 1829

N

Nail(s), **1009**–1029, **1824**–1826
biology of, 1009–1013
biting of, 1028
clubbing of, 1825
disorders of, 1016–1029
drug-induced disorders of, 1027–1028
embryonic and fetal development, 74
environmental factors affecting, 1019–1020
fragile, 1019
ingrown, 1029
in iron deficiency, 1824
in lichen planus, 304, 1824
in liver disease, 1824
nutrition affecting, 1824
in iron deficiency, 1824
in onycholysis. *See* Onycholysis
in onychomycosis. *See* Onychomycosis
in paronychia. *See* Paronychia
in psoriasis. *See* Psoriasis, nail changes in
splinter hemorrhages of
in liver disease, 1824
surgery of, **2956**–2967
systemic diseases affecting, 1026–1027
traumatic disorders of, 1028–1029
tumors of, 1021–1022
watch-glass deformity of, 1824
white, 1824
yellow, 1825–1826
Nail bed, 1011, 2957, 2964
biopsy of, 2964
embryonic and fetal development of, 74
lacerations of, 2965
surgical approaches to, 2964–2965
Nail fold, 2957
lateral
congenital malalignment, 2967
distal toenail embedding, 2967
hypertrophy of, 2967
ingrown nails, 2966
juvenile (subcutaneous) ingrown nails, 2967
pincer nail, 2967
retronychia of, 2967
surgical approaches to, 2966–2967
proximal, 1009–1010
biopsy of, 2966
embryonic and fetal development of, 74
recalcitrant chronic paronychia in, 2966
reconstruction of, 2966
retronychia of, 1029
surgical approaches to, 2966
tumors of, 2966
Nail matrix, 1010–1011, 2957
ablation and matricectomy procedure, 2963–2964
biopsy of, 2962
embryonic and fetal development of, 74
keratinocytes in, 1011
Langerhans cells in, 1011
melanocytes in, 1011
Merkel cells in, 1011
surgical approaches to, 2962–2964
Nail patella syndrome, 1017
Nail plate, 1009, 2957
chemical properties of, 1012
cytotoxic agents affecting, 2753–2754
embryonic and fetal development of, 74
growth of, 1012
physical properties of, 1012–1013
surgical removal of, 2962
Nail surgery, **2956**–2967
ablation procedure in, 2963–2964
anatomy in, 2957
anesthesia in, 2958
distal digital block in, 2958
proximal digital block in, 2958
transthecal block in, 2958
wrist block in, 2959
complications of, 2959
bleeding, 2960
infection, 2960
misaligned nail, 2960
pain, 2960
relapse, 2960
residual dystrophy, 2960
contraindications to, 2958
draping in, 2957
dressings and postoperative care in, 2959
equipment and instruments in, 2957
matricectomy, isolated, 2963–2964
nail avulsion
distal approach, 2960
partial, 2961
proximal approach, 2960–2961
trap door, 2961
of nail bed, 2964
biopsy of, 2964
subungual hematoma in, 2965–2966
of nail fold
lateral, 2967
proximal, 2966
of nail matrix, 2962–2964
biopsy of, 2962
nail plate, 2957
patient selection aspects, 2956
racquet nail, 2962
risks and precautions in, 2956–2957
in split-nail deformity, 2962–2963
tourniquet application in, 2959
Nasal conditions. *See* Nose
Natural killer cells (NK cells)
in innate immunity, 111
killer inhibitory receptors, 111
Natural killer T cells (NKT cells)
in psoriasis, 200–201
Natural moisturizing factor, 3010
Naxos disease, 547, 1829
NC16A in lichen planus pemphigoides, 306
Necator americanus, 2552
Neck
allergic contact dermatitis of, 158
surgical anatomy of, 2908
Necrobiosis
in xanthogranuloma. *See* Xanthogranuloma, necrobiotic
Necrolysis, epidermal. *See* Epidermal necrolysis
Necrolytic migratory erythema, 866
Necrosis
in fasciitis. *See* Fasciitis, necrotizing
postoperative, 2979
in sclerotherapy complications, 3005
of subcutaneous fat. *See* Subcutaneous fat, necrosis of
in vasculitis. *See* Vasculitis, necrotizing
Necrotizing infections, 2176–2177
Needlestick injuries, 2624
Neisseria gonorrhoeae
in gonorrhea, **2514**–2519
Neisseria meningitidis, **2178**–2183
in acute meningococcemia, 2179–2181
in arthritis-dermatitis syndrome, 2180
in chronic meningococcemia, 2181–2182
in conjunctivitis, 2182–2182
epidemiology of, 2179
localized Shwartzman reaction to, 2179
treatment of infections, 2183–2183
vaccination against, 2183
Nelson syndrome, 818
Nematode infections, 2562–2566
intestinal, 2562
tissue, 2563–2566
Neomycin, 2675–2676
for atopic dermatitis, 178
contact dermatitis from, 160
Neonatal-onset multisystem inflammatory disease, 1585–1589
Neonates, **1186**–1195
acne in, 913, 1189
bathing frequency for, 1187
biopsy of skin lesions in, 1196, 1197t
birthmarks, 1190, 1191t
candidiasis in, 1187
congenital disorders in, 1194–1195

examination of, 1187
hair loss in, 1190
hemangiomas, 1190
herpes simplex virus infections in, 1193–1194
infections in, 1193–1194
lymphangiomas, 1191
neonatal skin, 1186–1187
nevus flammeus in, 2078
postmature, 1186
premature, 1186
anetoderma in, 1192–1193
subcutaneous fat necrosis in, 1191
transient dermatoses in, 1187–1189
viral infections in, 1193–1194
Nerve blocks, 2916
digital, 2916
facial, 2916
Nerve growth factor
in prurigo nodularis, 185
Nerve sheath tumors, 1476–1479
benign, 1476–1478
malignant, 1478–1479
Nerves, 66–67
anatomy of, 1137–1138
cold sensitivity of, 67
damage, cryotherapy complication, 2972
embryonic and fetal development, 73
of nails, 1012
sensory, 66–67, 1142
A fibers, 1142
anatomy of, 1142
C fibers, 1142
embryonic and fetal development of, 72–73
Nervous system
autonomic. *See* Autonomic nervous system
central, 1138
cutaneous, 66–67, **1137**–1146
anatomy of, 1142–1143
biochemistry of, 1143–1144
embryonic and fetal development, 72–73
in skin pathophysiology, 1144–1146
in sweat gland regulation, 1143
anhidrosis in disorders of, 938t
hyperhidrosis in disorders of, 938t
Netherton syndrome, 1201–1202
trichorrhexis invaginata in, 1003
Neuralgia, postherpetic, 1151, 2386, 2397
pain in, 2386
risk factors for, 2396
symptoms in, 2396
treatment of, 2397–2398
oral agents, 2397–2398
topical therapy, 2397
Neurilemmoma. *See* Schwannoma
Neurinoma. *See* Schwannoma
Neurobiology of skin, **1137**–1146
Neuroectodermal tumor
Neurofibromas, 1478
discrete, 1682–1683
treatment of, 1687
laser therapy for, 2881
plexiform, 1683–1684, 1683f, 1684f
treatment of, 1688
Neurofibromatosis, **1680**
epidemiology of, 1680
mosaicism in, 83, 1680, 1689
type 1, **1680**–1688
café-au-lait spots in, 1681–1682, 1682f, 1687
cancer risk in, 1686
clinical findings in, 1681–1685
complications in, 1685–1687
diagnostic criteria in, 1680t
etiology and pathogenesis in, 1680–1681
genetic factors in, 1680–1681
hypermelanosis in, 818
laboratory tests in, 1685
and legius syndrome, 1689
Lisch nodules in, 1684–1685
mosaicism in, 1680, 1689
and Noonan syndrome, 1689
optic pathway tumors in, 1684, 1688
radiography in, 1685
segmental, 1689
support groups for patients and families, 1687
treatment of, 1687–1688
xanthogranuloma in, 1686
type 2, 1688–1690
diagnostic criteria on, 1689t
genetic factors in, 1689
schwannoma in, 1680, 1690
Neurolemmoma. *See* Schwannoma
Neurologic disorders
anhidrosis in, 938t
claudication in, 2098
drug-induced
from thalidomide, 2832b
in helminthic infections, 2557
hyperhidrosis in, 938t
in polyarteritis nodosa, 2025
pruritus in, 1156
Raynaud phenomenon in, 2069
seborrheic dermatitis in, 260
in xeroderma pigmentosum, 1660
Neuroma, 1474–1476
ganglion cells, 1480
mucosal, 1476
in multiple endocrine neoplasia syndrome, 1476
oral, 1476
oral, 1476
palisaded encapsulated, 1475–1476
histopathology of, 1475–1476
staining of, 1475t
traumatic, 1474–1475
staining of, 1475t
Neuropathy. *See also* Neurologic disorders
in thalidomide therapy, 2832b
Neuropeptide(s), 1143
NPY, 1143
Neuropeptide receptors, 1143
Neurosyphilis, 2483–2484
Neurotic excoriations, 1162–1163
Neurotoxin
botulinum, **3053**–3060
eosinophil-derived
in Waardenburg syndrome, 788–789
Neurotrophins
as melanogenic stimulators, 776
nerve growth factor. *See* Nerve growth factor
Neutral endopeptidase, 1138
Neutrophilic eccrine hidradenitis. *See* Hidradenitis, neutrophilic eccrine
Neutrophils, **345**–350
adhesion of, 347–349
bacterial infection and neutrophilic conditions, 2125
chemoattractants and chemotaxis, 346–347
free-flowing or rolling, 347
functions of, 108, 345–346
granules in, 349
in Chédiak-Higashi syndrome, 346
composition and function of, 345–346
deficiency of, 346
primary, 345–346, 346t
secondary, 346, 346t
ontogeny and development, 345
oxygen-dependent pathways, 350
oxygen-independent pathways, 349–350
in phagocytosis, 349
pharmacologic manipulation of, 350
in psoriasis, 202
in pyoderma gangrenosum, 350
reduced number of. *See* Neutropenia
tissue trafficking, 346–350
Nevi. *See also specific nevi*
Becker's
laser therapy in, 2887
eccrine, 1348
flammeus
neonatorum, 2078
of hair follicle, 1355
of Ito, 815, 2887
lipomatosus superficialis, 1492
melanocytic, 1377–1410
of nail matrix, 1021
nodal, 1401–1402
oral, 845
of Ota, 815
laser therapy in, 2887
pigmented spindle cell, 1396–1398
sebaceous, 1339–1340
of Jadassohn, 1339–1340
laser therapy for, 2881–2882
trichoblastoma in, 1347
Spitz, 1398–1341
spilus, 1382–1384
clinical findings in, 1383
congenital, 1382
differential diagnosis in, 1384b
laser therapy in, 2887
treatment, 1384
verrucous, 2881
laser therapy for, 2881

Nevoid basal cell carcinoma syndrome. *See* Basal cell nevus syndrome
Nevomelanocytic nevi
  acquired, 1384–1392
    clinical findings in, 1385–1388
    complications in, 1390
    differential diagnosis of, 1391b
    epidemiology of, 1384–1385
    etiology and pathogenesis of, 1385
    histopathology in, 1388–1390
    intradermal, 1387, 1387f
    junctional, 1387, 1387f
    laboratory tests in, 1388–1390
    prevention of, 1392
    prognosis and clinical course in, 1390–1391
    treatment in, 1391–1392
  congenital, 1377–1382
    clinical findings in, 1378–1380
    complications of, 1381
    differential diagnosis of, 1381b
    epidemiology of, 1377–1378
    etiology and pathogenesis of, 1378
    histopathology in, 1380–1381
    prevention of, 1382
    prognosis and clinical course in, 1381
    size classification, 1378
    treatment of, 1381–1382
Next generation sequencing, 80
NF-κB. *See* Nuclear factor κB
Niacin, 1512–1513
  deficiency of, 1512–1513
  food sources of, 1512
Nickel allergy, 160
Nicotinamide, 311
Nicotinic stomatitis, 835
Nipple
  Paget disease of, 1899
Nitric oxide
  as melanogenic stimulators, 777
Nitrofurazone, 2676
Nitrogen mustard. *See* Mechlorethamine hydrochloride
Njovera. *See* Syphilis, endemic
NK cells. *See* Natural killer cells (NK cells)
NKGD2, 111
NKT cells (natural killer T cells)
  in psoriasis, 200–201
Nocardia abscessus, 2246
Nocardia asteroides, 2246
Nocardia brasiliensis, 2245
Nocardia farcinica, 2246
Nocardia mexicana, 2246
Nocardia nova, 2246
Nocardia otidiscaviarum, 2246
Nocardia pseudobrasilensis, 2246
Nocardia transvalensis, 2246
Nocardia veterana, 2246
Nocardiopsis dassonvillei, 2246
Nocardiosis, **2245**–2248, 2327
  actinomycetoma in, 2249
  cellulitis in, 2247
  in immunocompromised host, 2245, 2246
  lymphocutaneous, 2247
    differential diagnosis of, 2247
    sporotrichoid pattern in, 2247
  sternal, 2247
  treatment of, 2247–2248
Nodal nevi, 1401–1402
Nodules, 30, 31f
  in diaper area, 1198
Noma, 1523–1525
  neonatorum, 1523–1524
Nonablative lasers, 3032–3035. *See also* Ablative lasers
  for skin rejuvenation, 3032–3035
    anesthesia application, 3033
    complications, 3035
    equipment, 3033
    patient selection aspects, 3033
    postoperative instructions, 3035
    risk and precautions, 3032–3033
    technique, 3034
Nose
  Klebsiella infection and rhinoscleroma of, 2193f
  surgical anatomy of, 2908
    cosmetic units and landmarks in, 2905
Notalgia paresthetica, 1152
NT. *See* Neurotrophins
Nuclear factor of activated T cells (NFAT), 141
Nuclear factor κB, 129, 131
  genes regulated by, 129
  signal transduction pathways, 129, 131, 131f
Nummular lesions, 38, **182**–184
  clinical findings, 182
  complications, 184
  differential diagnosis, 184b
  epidemiology, 182–183
  etiology and pathogenesis, 182
  laboratory tests, 183
  prognosis and clinical course, 184
  special tests, 183
  treatment, 184
Nutrition, **1499**–1525
  parenteral
    hair changes in, 1828
  and pigmentation changes, 629–630, 820

O

Obesity
  and metabolic syndrome, 1850
  psoriasis in, 218
Obsessive-compulsive disorder, 1165
Obstructive peripheral arterial disease, 2094–2100
  acute limb ischemia in, 2096, 2096b
  approach to patient, 2095f
  clinical findings, 2095–2097
    cutaneous findings, 2096
    history, 2095
  complications, 2098
  differential diagnosis, 2098, 2098b
  epidemiology, 2094
  etiology and pathogensis, 2094–2095
  prevention, 2100
  prognosis and clinical course, 2098–2099
  treatment, 2099–2100
Occlusion
  with moisturizing products, 3011
Occupational exposures, **2611**–2621, **2622**–2632
  acne in, 2629
  allergic contact dermatitis in, 2617
  bacterial infections in, 2623–2624
  barrier creams for protection in, 2620
  bites and stings in, 2626
  burns in
    chemical, 2612, 2615t
    electrical, 2628
    thermal, 2627–2628
  cold-induced disorders in, 2628
  connective tissue disorders in, 2628–2629
  diagnostic evaluation in, 2618–2619
  disability evaluation in, 2620
  epidemiology of, 2611–2612
  erysipeloid in, 2624
  fungal infections in, 2625–2626
  granuloma formation in, 2627, 2627t
  hazard identification in, 2621
  health risk assessment in, 2621
  herpetic whitlow in, 2624
  irritant contact dermatitis in, 2612–2616
  leukoderma in, 2628
  low-humidity dermatitis in, 2614t
  mechanical trauma induced disorders, 2626–2627
  parasitic infections in, 2626
  prevention and treatment of, 2619–2620
  prognosis in, 2620
  protective clothing and equipment in, 2620
  Raynaud phenomenon in, 2068–2069
  risk of skin cancer in, 2630–2631
  seal finger in, 2218, 2584
  urticaria in, 2617–2618
  vibration in, 2628
  viral infections in, 2624–2625
Ochronosis
  in alkaptonuria, 1536
  endogenous, 822
  exogenous, 822
  from hydroquinone, 822
Octopus bites, 2594
Ocular disorders. *See* Eye disorders
Oil acne, 2629
Oily skin type, 3009–3011
  compared to dry type, 3009–3011
  skin care for, 3011
Ointments, topical medications formulated as, 2647
  with absorption base, 2647
  with hydrocarbon base, 2647
  with water-soluble base, 2647
Olanzapine
  in psychogenic itch, 1153
Oleaginous base of ointments, 2647
Olmsted syndrome, 546

Omalizumab in atopic dermatitis, 180
Onchocerca volvulus, 2564
Onchocerciasis, 2564–2565
differential diagnosis of, 2565
genital, 867
pigmentation changes in, 809
Oncogenes, 1242
Onychogryphosis, 1029
Onycholysis, 1015, 1020
in phototoxicity, 1069
traumatic, 1028
Onychomadesis, 1013–1014
Onychomatricoma, 1021
Onychomycosis, 2292
candidal, 2303, 2307
differential diagnosis of, 2293b
distal subungual, 2292
histopathology in, 2293
nail, 1018
proximal subungual, 2292
treatment of, 2295–2296
topical therapy, 2295
systemic therapy, 2295
white superficial, 2292
Onychorrhexis, 1014
Ophthalmic nerve
anesthetic block of, 2916
surgical anatomy of, 2908
Opiates
endogenous, in pruritus, 1156
Opioid receptors in pruritus, 1156
Opioids
anhidrosis from, 944
Opportunistic infections
fungal systemic, 2327
Optic pathway tumors in neurofibromatosis, 1684
treatment of, 1688
Optical properties of skin, 1037, 2873
Optical radiation. *See also* Intense pulsed light therapy; Laser therapy
interaction of radiation with skin, 2874–2876
parameters of, 2872–2873
energy and intensity, 2872
exposure time, 2872
radiant exposure, 2872
skin optics, 2873
Oral cavity disorders, **827**–851, 1827–1828
actinic cheilitis, 846
anatomic structure of oral mucosa, 828
fordyce granules, 828
linea alba, 828
palatal and mandibular tori, 828
bullous disorders/red lesions, 840–843
in candidiasis. *See* Candidiasis, oral
cheilitis granulomatosa, 846–847
classification, 829–840
erythroplakia, 839–840
leukoplakia, 839–840
oral lichen planus, 837–839
squamous cell carcinoma, 840
ulcerative, 830–833
white lesions, 833–837
clinical findings in, **827**–851
drug-induced
mucositis and stomatitis in, 2758
exfoliative cheilitis, 847–848
in lichen planus, 837–839
malignant transformation in, 306
prognosis and clinical course in, 308
treatment of, 309–310
of lip, 848. *See also* Lip
melanotic macule, oral, 843–844
in melanoacanthosis, 845
in melanoma, 845–846
in nevomelanocytic nevi, 845
patient evaluation aspects, 827
in paracoccidioidomycosis, 2325
pigmentation changes in, 844–845
in Plummer-Vinson syndrome, 1827
postinflammatory hypermelanosis, 844
in Sjögren syndrome, 1978, 1982
in systemic disease and syndromes, 829
of tongue. *See* Tongue
topical medication, prescribing of, 829t
analgesics, 828
steroids, 828
in Sjögren syndrome, 1978, 1982
Orf, 2416–2417
clinical findings in, 2416
differential diagnosis of, 2415b, 2417
laboratory findings in, 2417
in occupational exposures, 2625
treatment of, 2417
Oroya fever, 2208–2209
treatment of, 2209
Orthopoxvirus, 2402–2413
Osseous lesions in NF-1, 1685
Ossification, 1653–1654
aberrant, 1650
in Albright hereditary osteodystrophy, 1653–1654
in fibrodysplasia ossificans progressiva, 1653–1654
in plate-like osteoma cutis, 1653
primary, 1653–1654
in progressive osseous heteroplasia, 1653–1654
Osteodystrophy, Albright hereditary, 1653–1654, 1859
Osteogenesis imperfecta, 670
Osteoporosis
in retinoid therapy, 2765
Ostomates
epidemiology, 1105
skin problems in, **1104**–1110
chronic papillomatous dermatitis, 1108
contact allergy, 1109–1110
granuloma, 1108
dermatitis, 1105–1108
infections, 1109
pyoderma gangrenosum, 1109
psoriasis, 1108–1109
Ostomy procedures, abdominal, skin problems in, **1104**–1110
Ota nevus, 815
Outcome measures, 7–8
in quantification of morbidity, 7–8
Oxidation of retinol, 2668–2670

P

P protein in melanosomes, 771
p40, 229
p53
in DNA damage and repair, 780
in squamous cell carcinoma, 1285–1286
as tumor suppressor gene, 1242
in ultraviolet radiation exposure, 1286
and apoptosis, 1286
clonal expansion of, 1257
p63, 70
Pacemakers, cardiac
in electrosurgery, 2912, 2976
Pachydermodactyly, 715
Pachydermoperiostosis, 717, 1826
Pachyonychia congenita
Jackson-Lawler, 545
type I, 545, 1017
type II, 545, 1017
Paederus beetles, 2606
Paget disease, **1371**–1376
clinical findings in, 1371–1374
complications of, 1374
differential diagnosis of, 1372b
epidemiology of, 1371
etiology and pathogenesis in, 1371
extramammary, 877, 1371–1376, 1899
differential diagnosis of, 1372b
prevention of, 1376
treatment of, 1374–1376
laboratory tests in, 1372–1374
malignancies associated with, 1899
mammary, 1371–1376, 1899
clinical findings in, 1371–1374
differential diagnosis of, 1372b
prevention of, 1376
treatment of, 1374
prevention of, 1376
prognosis and clinical course in, 1374
treatment of, 1374–1376
Mohs micrographic surgery in, 1375, 2955
photodynamic therapy, 1376
radiotherapy, 1375
surgery, 1375
systemic chemotherapy, 1376
topical chemotherapy and immunomodulators, 1375–1376
Pain
chronic atypical, 1165
in decubitus ulcers, 1128
genital
in male, 872
postoperative
in cryosurgery, 2971
in nail surgery, 2960

Palmoplantar skin
in acrodermatitis continua, **256**–258
in acrokeratosis paraneoplastica, 1888
in keratoderma. *See* Keratoderma, palmoplantar
in lichen planus, 304
in paraneoplastic syndromes, 1823
pustular eruptions of, **253**–256
vesicular eczema of, **187**–193
Pancreatic disorders
in retinoid therapy, 2766
Panniculitis, **732**–754
adipose tissue and, 732–733
in α_1-antitrypsin deficiency, 742–744
in cold exposure, 753
dermatomyositis-associated, 749–750
factitial, 754
histiocytic cytophagic, 750
infectious, 57, 741–742
lobular, 57
in lupus erythematosus, 746–749
nodular, 57, 733–737
pancreatic, 745–746
sclerosing, 737–740
septal, 57
subcutaneous fat necrosis of newborn, 750–753
traumatic, 57
Papillomavirus infections
anogenital cancer in
in HIV infection, 2444
dysplasia, 2444
squamous cell carcinoma in
in immunocompromised host, 2444
warts in. *See* Warts, in papillomavirus infections
Papillon-Lefèvre syndrome, 546–547
Papules, 30
in dermatosis papulosa nigra, 1321
in diaper, 1198
fibrous follicular, 1356
in urticaria, 422
Papulosis
malignant atrophic, **2072**–2075
approach to patient with, 2074f
benign, 2074
classic, 2073
clinical findings in, 2072–2074
complications, 2075
differential diagnosis of, 2075b
epidemiology of, 2072
etiology and pathogenesis in, 2072
laboratory tests in, 2074–2075
prognosis and clinical course in, 2075
secondary, 2074
treatment of, 2075–2076, 2075b
Papulosquamous disorders in elderly, 1225
Paracoccidioides brasiliensis, 2324
Paracoccidioidomycosis, 2324
oral cavity disorders in, 2324
Paragonimiasis, 2566
differential diagnosis of, 2566
Paragonimus westermani, 2566
Parakeratosis, 44
infantile granular, 1198
in psoriasis, 197
pustulosa, 1024
Paramedian forehead flap, 2940
Paraneoplastic syndromes, **1880**–1890
acrokeratosis of Bazex in, 1887–1889
bullous disorders in, 1894
collagen-vascular disease in, 1889–1890
in cutaneous metastases, 1895, 1899
dermal deposition in, 1893
dermal proliferative disorders in, 1893
dermatoses in, 1880–1882, 1892–1893
erythema in, 1890–1892
in familial cancer syndromes, 1895
hyperkeratosis in, 1882–1889
hypertrichosis in, 1894
in leukemia, 1899
in lymphoma cutis, 1899
pemphigus in, **600**–608, 1894
in pruritus, 1153
Trousseau syndrome in, 1894–1895
vasculitis in, 2006
Parangi. *See* Yaws
Paraphenylenediamine
contact allergic dermatitis from, 161–162
in temporary tattoos, 1133
Parapoxvirus infections, 2413–2417
Parapsoriasis, **285**–290
classification of, 285–286, 286t
clinical findings in, 286–287
complications in, 290
diagnosis and differential diagnosis of, 288–290, 289t, 290b
epidemiology of, 285
etiology and pathogenesis, 285–286
histopathology in, 288
large plaque or patch, 285–286, 287f, 288f, 290b
prognosis and clinical course, 290
retiform, 287, 287f
small plaque or patch, 285–286, 288f, 289f, 290b
treatment of, 290–291
Parasitic infections
helminthic, 2547, 2549
in occupational exposures, 2626
Parathyroid disorders, **1856**–1859
clinical findings in, 1857–1859
epidemiology of, 1856
etiology and pathogenesis of, 1856–1857
hyperparathyroidism. *See* Hyperparathyroidism
hypoparathyroidism. *See* Hypoparathyroidism
laboratory tests in, 1859
treatment of, 1859
Parathyroid hormone, 1856–1859
and calcium serum levels, 1856
in hyperparathyroidism, 1856
in hypoparathyroidism, 1856
Paravaccinia virus, 2402t
in milker's nodules, 2414–2415, 2625
transmission of, 2414
Paresthesia in notalgia paresthetica, 1153
Parkes Weber syndrome, 2092
Paronychia, 1016
acute, 1018
candidal, 2303
treatment of, 2306
chronic, 1019
surgery in, 2966
in paraneoplastic acrokeratosis of Bazex, 1887–1889
staphylococcal, 2138
Paru. *See* Yaws
Parvovirus B19 infections, 2342–2346
aplastic crisis in, 2345
chronic, 2345
clinical findings in
in adult, 2343
in children, 2343
differential diagnosis of, 2346b
fetal, 2345
papular purpuric gloves-and-socks syndrome in, 2344
prevention of, 2346
treatment of, 2346
Pastes, topical medications formulated as, 2648
Pasteurella multocida
in bite wounds, 2579
treatment of infections, 2217–2218
Patau syndrome (trisomy 13), 81t
Patch lesions, 33
in vitiligo, 33
Patch testing, 162–163
allergens selection in, 162
clinical relevance, assignment of, 163
complications of, 164
in lichen planus, 307
in occupational exposures, 2619
results interpretation, 162
Paterson-Kelly syndrome, 1827
Pathergy test in Behçet disease, 2038
Pathogenicity islands, 2123
Pathologic reactions, **42**–57
reticular dermis, 51–56
subcutaneous fat, 56–57
superficial reactive unit, 48–51
Pattern hair loss
in female
hair transplantation in, 3061
hair restoration surgery in, 986
in male
hair transplantation in, 3061
management of, **3061**–3075
Pattern recognition receptors in innate immunity, 108–109
PAX3
in Waardenburg syndrome, 788–789
Pediatric dermatology, **1185**–1203. *See also* Children and infants
Pediatric granulomatous arthritis, 1598
Pediculosis, 2573–2578
capitis, 2573
differential diagnosis of, 2574b
nits in, 2574
treatment of, 2574–2576

corporis, 2576
differential diagnosis of, 2576b
pubis, 862, 2576–2578
differential diagnosis of, 2577b
treatment of, 2577
Pediculus humanus, 2573
Peeling skin syndromes, 532
Peels
chemical. *See* Chemical peels
Pemphigoid
Brunsting-Perry, 620
bullous, **608**–616
clinical findings in, 612–613
complications, 615
differential diagnosis of, 614–615, 615b
diseases associated with, 613
electron microscopy in, 613
epidemiology of, 608
etiology and pathogenesis in, 609–612
histopathology in, 613–614
immunopathology in, 609
and lichen planus, 305–306
pathophysiology in, 609–612
pemphigoid antigens in, 609
prognosis and clinical course in, 615
treatment of, 615–616
cicatricial, **617**–623
clinical findings in, 618–620
complications of, 622t
differential diagnosis of, 621, 621b
epidemiology of, 617
etiology and pathogenesis in, 617
immunofluorescence in, 620
laboratory tests in, 620–621
pemphigoid antigens in, 618t
prognosis and clinical course in, 621
treatment in, 621–623, 622b
genital, 866
gestationis, **630**–634
clinical findings in, 631–632
compared to bullous pemphigoid, 632f
complications in, 632
differential diagnosis in, 632, 633f, 633b
epidemiology of, 630
etiology and pathogenesis in, 630–631
histopathology in, 632
laboratory tests in, 632
prevention of, 634
prognosis and clinical course in, 632–633
treatment of, 633
oral cavity disorders in, 841
Pemphigoid antigens, bullous. *See* Bullous pemphigoid antigens
Pemphigus, **586**–599
acantholysis in, 588
pathophysiology of, 588
autoantigens, 588
diseases associated with, 593–594
drug-induced, 593
enzyme-linked immunosorbent assay in, 595–596
epidemiology of, 586–588
age of onset, 587
sex ratio, 587
erythematosus
clinical manifestations in, 592–593
etiology and pathogenesis in, 588–589
foliaceus, 592
clinical manifestations in, 592–593
genetic restriction of immune response in, 589
histopathology in, 594
immunofluorescence in, 594–595
direct, 595
indirect, 595
neonatal, 593
clinical findings, 593
neonatorum, 1697
paraneoplastic, **600**–608
clinical findings in, 601–603
diagnostic algorithm on, 606f
differential diagnosis of, 606, 606b
epidemiology of, 600
etiology and pathogenesis in, 600–601
histopathology in, 603–605
immunopathology in, 605
laboratory tests in, 603–606
prevention of, 608
prognosis and clinical course in, 606–607
treatment of, 607–608
prognosis and clinical course in, 596
treatment of, 596–599
glucocorticoids, 597
immunosuppressive agents, 597–598
vulgaris, **589**
clinical manifestations in, 589–592
oral cavity disorders in, 841
Penciclovir, 2790–2791
dosage of, 2791, 2791t
in herpes simplex virus infections, 2790–2791
Penicillin, 2776–2777
in actinomycetoma, 2252
dosage of, 2778t
indications for, 2777b
mechanism of action, 2776–2777
pharmacokinetics of, 2777
in rheumatic fever
side effects and complications of, 2777, 2778b
Penicilliosis, 2325
differential diagnosis of, 2325
in HIV infection and AIDS, 2325, 2453
Penicillium marneffei, 340, 2325
in HIV infection and AIDS, 2325
Penis
acne of, 872
carcinoma in situ of, 874–877
clinical findings in, 874–875
differential diagnosis of, 876b
histology, 876
prevention, 877
prognosis, 876
treatment in, 876–877
edema ofchronic idiopathic, 872
melanoma of, 877
pearly papules of, 856
prominent veins of, 856
squamous cell carcinoma of, 874–877
tinea of, 867
Pentamidine in African trypanosomiasis, 2540
Peptococcus, 1747
Peptostreptococcus, 2175
Perforating disorders, acquired, **727**–730
in diabetes mellitus, 727
differential diagnosis in, 729, 730b
treatment in, 730–731, 731b
Perianal disorders. *See* Anal and perianal disorders
Pericytes, 1988
Perioral dermatitis, **925**–928
clinical findings in, 926–927
differential diagnosis in, 927, 927b
granulomatous, 926
treatment in, 928
Peripheral nervous system
anatomy of, 1138
disorders of
anhidrosis in, 938t
hyperhidrosis in, 938t
leprosy affecting, 2254
in skin pathophysiology, 1144–1145
Peripheral vascular disorders
arterial, **2094**–2109
atheromatous embolism, 2100–2103
livedo racemosa, 2106–2109
livedo reticularis, 1375t, 2106–2109
obstructive, 2094–2100
thromboangiitis obliterans, 2104–2106
venous, **2110**–2120
clinical findings in, 2112–2114
complications of, 2115
differential diagnosis of, 2114b, 2115b
etiology and pathogenesis in, 2110–2112
prognosis and clinical course in, 2115
treatment of, 2115–2116
Periplakin, 574
Permethrin, 2701, 2702
in scabies, 2571b
Peroxisome proliferator-activated receptors (PPAR)
in sebaceous gland activity and sebum production, 896
Petechiae
in helminthic infections, 2555
Petroleum products, skin cancer associated with, 1240
Peutz-Jeghers syndrome, 817, 1833
Phaeohyphomycosis, 2317
Phagocytes, 110–111
effector functions of, 111
Phagocytosis, 110
disorders of, 1716–1724

Phakomatosis
pigmento-vascularis, 2080
Pharmacodynamics in drug interactions, 2835
Pharmacokinetics
of corticosteroids, 2660–2661
in drug interactions, 2835
ADME model on, 2836
of topical drugs, 2652–2658
Phenol, 2704
in chemical peels, 3029
Phenolic compounds, occupational exposure to, 2615t
Phenylalanine hydroxylase deficiency of, 1526t
Phenylketonuria, 1526t, **1530**–1532
clinical features in, 1531
differential diagnosis of, 1532
pigmentation in, 1531
treatment of, 1532
Pheochromocytoma
hyperpigmentation in, 819
Philtrum, 2906
Phlebectomy, ambulatory, in varicose veins, 3007
Phosphodiesterases type 4, 193
Phosphorus, occupational exposure to, 2616
Photoaging, 1219–1223
action spectrum in, 1222
clinical and histologic features in, 1219, 1220t
compared to intrinsic aging of skin, 1220f
heliodermatitis in, 1220, 1220f
mechanisms in, 1221–1222
basement membrane damage, 1223
membrane and nuclear signaling, 1222
mitochondiral damage, 1223
protein oxidation, 1223
smoking affecting, 1223
wrinkling of skin in, 1220t, 1221
Photoallergy, 1072
agents associated with, 1072
sunscreens, 2709
ultraviolet filters, 2709
clinical manifestations in, 1072
differential diagnosis in, 1073
histopathology in, 1072
management of, 1072
Photobiology, **1031**–1044
Photochemical reactions, 1038–1039
excited state molecules in, 1039
intersystem crossing in, 1039
photoproducts in, 1039
photosensitivity in, 1039
Photochemotherapy, **2851–**2865
for alopecia areata, 994
for atopic dermatitis, 2859
combination treatment in, 2857
biologics, 2858
cyclosporine, 2857
methotrexate, 2857
retinoids, 2857–2858
topical, 2857
contraindications to, 2863
for dermatoses, 2859
erythema in, 2854
extracorporeal, 2864–2865. *See also* Photopheresis
for GVHD disease, 2859
historical background, 2851
in HIV, 2861
indications for, 2855–2861
for lichen planus, 2859
cutaneous, 311
oral, 310
for mastocytosis, 2859
for mycosis fungoides, 2858
for photodermatoses, 2861
photosensitivity in, 2854
principles of, 2852–2855
mechanisms, 2852
pharmacokinetics, 2853–2854
photosensitivity effects, 2854
psoralens, 2852
UVA, 2854
for psoriasis, 2855–2857
risks
carcinogenesis, 2862–2863
chronic actinic damage, 2862
side effects and toxicity of, 2861–2863
acute, 2861
long-term, 2862–2863
for T cell lymphoma, cutaneous, 2858
treatment protocols in, 2854–2855
bath photochemotherapy, 2854–2855
oral, 2855
topical, 2854
for vitiligo, 799, 2860
Photodermatology, 1031
Photodynamic therapy, **2865**–2868
in acne vulgaris, 2868
in basal cell carcinoma, 1302, 2866–2867
in hidradenitis suppurativa, 958
indications for, 2866–2868
light sources and dosimetry in, 2865
mechanism of action in, 2865
in Paget disease, 1376
photosensitizers in, 2865
principles, 2865–2866
in psoriasis, 227
systemic, 2866
nononcologic indications, 2866
oncologic indications, 2866
topical, 2866–2868
nononcologic indications, 2868
oncologic indications, 2866–2868
Photoexacerated, dermatoses, 1062–1063
Photography as visual aid in diagnosis
in dysplastic nevus, 1413
Photoimmunology, **1044**–1048
Photoimmunosuppression, 1044
cellular events in, 1046–1047
cellular mediators in, 1047
Langerhans cells, 1047
T cells, 1047
macrophages, 1047
molecular targets in, 1045–1046
Photopatch testing
in photosensitivity, 1065
Photopheresis, 2864
in atopic dermatitis, 181
in graft-versus-host disease, 2864–2865
in lichen planus, 310
mechanism of action in, 2864
side effects, 2864
in T-cell lymphoma, 2864
Photophobia
with ichthyosis follicularis and alopecia, 978
in keratosis follicularis spinulosa decalvans, 976
Photoprotection, **2707**–2713
clothing in, 2712
glass in, 2712–2713
sunglasses in, 2712–2713
sunscreens in, 2707–2712
Photosensitivity, 1039, **1066**–1073
desensitization in, 1051
diagnostic approach to patient with abnormal, 1063–1065
drug-induced
from cytotoxic drugs, 2756
Photosensitizers, 2865, 3017
porphyrin as, 2865
Phototests
in actinic dermatitis, chronic, 1060
in actinic prurigo, 1054
in hydroa vacciniforme, 1056
in photosensitivity, 1064
in polymorphic light eruption, 1052
in solar urticaria, 1062
Phototherapy, **2841**–2850
in actinic dermatitis, chronic, 1060, 2848
in actinic keratosis, 1268
in actinic prurigo, 1055
action spectrum in, 1040, 1042–1043, 2843
in alopecia areata, 994
apparatuses
broadband/narrowband UVB, 2844
phototherapy devices and lamps, 2843–2844
PUVA, 2845–2846
in atopic dermatitis, 179
burns, avoidance and management, 2846–2847
disease amenable to, 2850t
DNA damage in, 2841–2842
in hidradenitis suppurativa, 959
in lichen planus, 2842
in mastocytosis, 2842
mechanisms, 2841
effects on collagen, 2843
effects on epidermis, 2843
effects on immune system, 2842
effects on mast cells, 2842–2843
effects on melanocytes, 2843
ophthalmologic effects, 2849
principles of, 2843
in pruritus, 1156

pruritus in,
with psoralen and UVA radiation, 2845–2846. *See also* Psoralen and PUVA therapy
in psoriasis, 226–227
safety of
in children, 2849
in HIV, 2849
PUVA, 2848–2849
UVA1, 2849
UVB, 2848
in seborrheic dermatitis, 266
side effects and complications of
PUVA, 2848–2849
UVA1, 2849
sunburn like reactions, 2846–2847
skin cancer risk in, 2848–2849
squamous cell carcinoma risk in, 2848–2849
targeted, 2847–2848
in T-cell lymphoma, 2858
UVA1, 2847, 2848, 2849
in vesicular palmoplantar eczema, 192
Photothermolysis
fractional, 2876
selective, 2875–2876
Phototoxicity, **1066**–1072
agents associated with, 1071
chronic actinic dermatitis in, 1071
clinical manifestations in, 1069–1071
differential diagnosis in, 1073
histopathology in, 1071
management of, 1071–1072
pathophysiology in, 1066–1069
photodynamic processes in, 1066
Phrynoderma
in vitamin A deficiency, 1505
Phycomycosis, 2327
subcutaneous, 2317
Physalia physalis, 2585
Physalia utriculus, 2585
Physical abuse, skin signs in, **1177**–1183
Physical examination, 29, 29b
Physiologic pigmentation, 843
Phytophotodermatitis, 822
Pian. *See* Yaws
Piebaldism, 790
Piedra, 2297
black, 2297
white, 2297
Piedraia hortae, 2297
Piercing of body parts, cosmetic, 1134–1136
complications in, 1134t, 1135–1136, 1135t
Pigment mosaicism, 70
Pigmentary demarcation lines, 806–807
Pigmentation
in albinism, **781**–791
in Angelman syndrome, 786
in Chédiak-Higashi syndrome, 787
in cirrhosis, 1821
congenital disorders of, **781**–791
complications in, 791
differential diagnosis in, 781b
in hypermelanosis, 813–825
in hypomelanosis, 804–813
prognosis and clinical course in, 791
treatment in, 791
drugs affecting
laser therapy in, 2889
genetic disorders of, **781**–791
of hair, 969–972
molecular control of, 971–972
in helminthic infections, 2555
in hemochromatosis, 1821
in Hermansky–Pudlak syndrome, 786–787
in hypermelanosis, **813**–825
in hypomelanosis, **804**–813
in jaundice, 1821–1822
laser skin resurfacing affecting, 3038–3040
in lichen planus pigmentosus, 302
of nails, 1016
oral, 843
piebaldism, 790
in Prader-Willi syndrome, 786
in purpuric dermatoses, **2049**–2054
race and ethnicity considerations
genetics, 93–95, 94t
topical therapies, 101, 102t
sclerotherapy for varicose veins affecting, 3003–3005
in selenium deficiency, 1519
in spindle cell nevus, 1396–1398
in Tietz syndrome, 790
in vitamin B_{12} deficiency, 1212, 1821
in vitiligo, **792**–803
in Waardenburg syndrome, 788–789
Pigmented skin type, 3017–3018
vs nonpigmented skin type, 3017–3018
Pilar sheath acanthoma, 1355
Pili annulati, 1005
Pili torti, 1003
Pilomatricoma, 1359
Pimecrolimus, 2694, 2813
in atopic dermatitis, 177
contraindications to, 2694b
initiation of therapy with, 2694–2695
in lichen planus, 310
mechanism of action, 2813
monitoring of therapy with, 2695
pharmacokinetics of, 2694
in seborrheic dermatitis, 265
side effects of, 2696b
in vesicular palmoplantar eczema, 192
Pimozide, 1153, 1160
Pincer nails, 1029
surgery in, 2967
Pinta, 2493
clinical findings in, 2494
primary stage, 2494
secondary stage, 2494
tertiary stage, 2494
differential diagnosis of, 2495b, 2498
histopathology, 2499
treatment of, 2500
Pinworm infections, 2560–2561
Pitch acne, 2629
Pitting
of nails, 1014
Pityriasis
alba, 807–808
amiantacea, 263–264
lichenoides, 285, **291**–295
chronica, 285, 291, 292, 292f, 294f, 295b
clinical findings in, 292–293
complications in, 294–295
differential diagnosis in, 294, 295b
epidemiology of, 291
et varioliformis acuta, 285, 291, 293f, 294f, 295b
etiology and pathogenesis of, 291–292
histopathology in, 293–294, 293f
prognosis and clinical course in, 295
treatment of, 295, 295b
with ulceronecrosis and hyperthermia, 292
ulceronecrotic, 292, 293f
rosea, **458**–463
Christmas tree pattern in, 458, 460f
clinical findings in, 459–461
complications in, 462
differential diagnosis in, 462, 462b
drug-induced, 462
epidemiology of, 458
etiology and pathogenesis of, 458–459
herald patch in, 459, 459f, 460f
in herpesvirus-7 infections, 458–459
history, 459
laboratory tests in, 461
prognosis and clinical course in, 462
scaling lesions in, 31t, 459–461
secondary eruption in, 460–461
treatment in, 460–461
rubra pilaris, **279–**284
classification of, 279–281, 280t
clinical findings in, 279–282
complications of, 283
differential diagnosis in, 283b
epidemiology of, 279
etiology and pathogenesis in, 279
follicular hyperkeratosis in, 281
juvenile types, 281
pathology in, 282
photochemotherapy in, 283, 283b
prevention of, 284
prognosis and clinical course in, 283
retinoids in, 283, 283b, 2762
treatment of, 283–284, 283b
versicolor, 806
Pityrosporum, 260, 262, 341, 2307–2311
Plague, 2215–2217
in bioterrorism, 2636
bubonic, 2216, 2636
in occupational exposures, 2636
pneumonic, 2216, 2636
septicemia in, 2216
treatment of, 2216
vaccination against, 2637

Plakoglobin, 571
functions of, 573
Plakophilin, 571
functions of, 574
Plaque, 30, 31f
in psoriasis, 211
Plasmacytoma growth factor, 138. *See also* Interleukins, IL-6
Plasmapheresis
in pemphigus, 599
Platelet-derived growth factor, 2815t, 2818–2819
recombinant, 2818–2819
in wound healing, 2994, 2995
in diabetes mellitus, 2818–2819
Pleomorphic fibroma, 716
Pleomorphic sarcoma, **1453**–1454
Pleural effusion
in helminthic infections, 2557
PLOD1 in Ehlers-Danlos syndrome, 1625t
Plummer-Vinson syndrome, 1827
Pmel17 in melanosomes, 771
Podofilox in warts, 2707
Podophyllin, 2689
side effects of, 2689
in warts, 2689
Podophyllotoxin, 2689
side effects of, 2689
in warts, 2689
Poikiloderma, 33
atrophicans vasculare, 287
in parapsoriasis, 287
Polidocanol
in pruritus, 1155
in sclerotherapy for varicose veins, 2998, 3002
Poliosis
in Waardenburg syndrome, 789, 789f
Polyangiitis
systemic, 2022
Polyarteritis nodosa, 2025
Polychondritis, relapsing, 1828, **1962**–1965
clinical findings in, 1962–1964
diagnostic criteria in, 1964b
differential diagnosis of, 1964b
diseases associated with, 1964b
treatment of, 1964–1965
Polycyclic aromatic hydrocarbon exposure, skin cancer risk in, 2631
Polycyclic lesions, 38
Polycythemia vera, 1741–1742
skin color changes in, 1821
treatment in, 1742
Polyene antifungal agents, 2681–2682
Poly-L-lactic acid in soft tissue augmentation, 3047–3049
Polymerase chain reaction
real-time, 1236
in tuberculosis, 2228
Polymorphic eruptions
in light, 1049–1053. *See also* Light eruptions, polymorphic
Polymorphisms, 80–81
in drug metabolism, 2838
nonpathogenic, 79
single nucleotide, 79, 80
Polymorphonuclear leukocytic infiltrates in reticular dermis, 54
Polymyositis, 1933t. *See also* Dermatomyositis
dysphagia in, 1828
Polymyxin B, 2675
Polyomavirus
Merkel cell, 1364
Polyps, 1833
hamartomatous, 1833
Polysubstance abuse, 1175
Pompholyx, 188–189
clinical findings in, 188–189
prognosis and clinical course in, 188–189
Porfimer sodium in photodynamic therapy, 2865
Porokeratosis, **563**–568
actinic
disseminated superficial, 564
in CAP syndrome, 563b, 566
in CDAGS syndrome, 566
clinical course and prognosis in, 568
clinical findings in, 564–566
coronoid lamella in, 563
differential diagnosis in, 567, 567b
disseminated superficial, 564–564
actinic, 564
in immunosuppression, 564
etiology and pathogenesis in, 563–564
genetic factors in, 563–564
genital, 867
histopathology in, 566
in immunosuppression, 564
linear, 565
of Mibelli, 564
palmaris et plantaris disseminata, 565–566
punctate, 566
palmoplantar, 566
treatment of, 567
variants of, 563b
Poroma, eccrine, 1349–1350
Porphyrias, **1538**–1573
acute, 1543, 1544t, 1546, 1565–1571
neurovisceral symptoms in, 1567–1568
pathophysiology in, 1546
treatment of, 1562b
acute intermittent, 1565–1568
clinical manifestations of, 1566
differential diagnosis of, 1567
drug-induced disorders in, 1567
epidemiology of, 1565
etiology of, 1565–1566
neurovisceral disorders in, 1567–1568
prevention of attacks in, 1568
treatment of, 1567
in δ-aminolevulinic acid dehydratase deficiency, 1571–1572
animal models on, 1573
biochemical features of, 1539
classification of, 1541–1542
complement system in, 1547
congenital erythropoietic, 1563
clinical manifestations of, 1564
differential diagnosis of, 1565
epidemiology of, 1563
etiology of, 1563
gene therapy in, 1573
histopathology in, 1565
treatment of, 1565
cutanea tarda, 1073, 1548–1556
epidemiology of, 1548
etiology and pathogenesis in, 1548–1549
hypermelanosis in, 820
dual or coexisting, 1572
erythropoietic protoporphyria, 1557–1562
gene therapy in, 1572–1573
hepatoerythropoietic, 1556–1577
hereditary coproporphyria, 1570–1571
management, 1572
molecular genetics in, 1573
nonacute, 1543, 1544t, 1544–1545, 1548–1557
pathophysiology in, 1543, 1544–1545
signs and symptoms in, 1543, 1544–1545
photosensitivity in, 1546–1547
complement system and, 1547
erythrocytes and, 1546
fribroblasts and, 1547
mast cells and, 1546
matrix metalloproteinases, 1547
polymorphonuclear cells and, 1547
reactive oxygen species and, 1546
porphyrin-heme biosynthesis in, 1539–1541
heme synthesis regulation, 1539–1541
pseudoporphyria, 1070, 1557
sideroblastic anemia and, 1572
variegate, 1568
clinical manifestations of, 1568
differential diagnosis of, 1569
epidemiology of, 1568
etiology of, 1568
neurovisceral symptoms, 1568
treatment of, 1569
X-linked dominent protoporphyria, 1562–1565
Portuguese man-of-war stings, 2585–2586
Postoperative care
in cryosurgery, 2972
in electrosurgery, 2976
in excisional surgery, 2948
in laser skin resurfacing, 3028
in nail surgery, 2959
Postphlebitic syndrome, 2112
Potassium permanganate, 2704

Povidone-iodine, 1694, 2698
in preoperative skin preparation, 2912
Powders, topical medications formulated as, 2646
Poxvirus infections, 2402–2420
molluscum contagiosum in, 2417–2420
orthopoxvirus, 2402–2413
parapoxvirus, 2413–2417
Pramoxine in pruritus, 1155, 2704
Prealbumin, 1852
Precancerous lesions, epithelial, **1261**–1282
Prednisolone
in hidradenitis suppurativa, 958
in seborrheic dermatitis, 265
Prednisone
in lichen planus, 310
Pregnancy, **1204**–1212
atopic eruption in, 1211–1212
cholestasis in, 1206t, 1207
common cutaneous changes in, 1204–1205
dermatoses in
associated with fetal risk, 1207–1210
not associated with fetal risk, 1210–1212
eczema in, 1206t, 1212
impetigo herpetiformis in, 1208–1210
melasma in, 1205t
pemphigoid gestationis in, **630**–634, 1206t, 1207
pigmentation changes in, 819, 1205t, 1211f
polymorphous eruption in, 1206t, 1210
prurigo gestationis in, 1206t, 1211
pruritic folliculitis in, 1206t, 1211
pruritic urticarial papules and plaques in, 1206t, 1210
clinical features of, 1210
differential diagnosis of, 1211b
treatment of, 1211
psoriasis in, 1208–1210
clinical features of, 1209
differential diagnosis of, 1209b
treatment of, 1209–1210
striae distensae in, 1205t, 1205f
tumor necrosis factor inhibitors in, 2821
Preimplantation testing in prenatal diagnosis, 89–90
Premalignant epithelial tumors, **1261**–1282
Premature aging syndromes, 1213
Premature infants
anetoderma in, 1192–1193
skin of, 1186–1187
thermoregulation in, 1187
Prenatal diagnosis, 89–90
of ichthyosis, 89
preimplantation testing in, 89–90
Preoperative care, 2911–2912
antibiotics in, 2911
assessment in, 2911–2912
in laser skin resurfacing, 3028
Preservatives
agents used as, 3017
allergic reactions to, 3017
Pressure ulcers, **1121**–1129. *See also* Decubitus ulcers
Pressure urticaria, 419
Pretibial myxedema, 1854
Prilocaine, 2915
in EMLA cream, 2915
side effects of, 2915
Probiotics in atopic dermatitis, 181
Procollagen peptide type III, in methotrexate therapy and liver fibrosis, 1837
Progeria
cardiovascular disorders in, 1820
Programmed cell death 1 in autoimmune disorders, 1902
Progressive pigmentary dermatosis, 2050
Prolidase, 1526t
deficiency of, 1526t
Proliferating pilar tumors, 1361
Proliferation
in seborrheic dermatitis, 260
in wound healing, 2986f, 2987–2989
Proline
Proline oxidase, 1526t
Proopiomelanocortin, 776
Propionibacterium acne, 2630, 3013
Propionibacterium propionicum
Propranolol
for infantile hemangiomas, 1464
Propylene glycol, in topical preparations
keratolytic, 2706
Prosthesis
limb, types of, 1095
Protease(s)
in psoriasis, 204
Protease inhibitors
in HIV infection and AIDS, 2795t
Protective clothing and equipment
in occupational exposures, 2620
Protective function of skin, **486**–498
as barrier. *See* Barrier function of skin
Protein
dietary
oxidation and photoaging, 1222
P-protein, 771
Protein kinase C
in melanogenesis, 770–771
Protein tyrosine phosphatase 22 in autoimmune disorders, 1902–1903
Proteinosis, lipoid, **1644**–1648
Proteoglycans, **684**–688
core proteins of, 685–687
diseases due to abnormal metabolism of, 690
in dermis, 64, 65
embryonic and fetal, 71t
function of, 687–688
structure of, 684–685
Prurigo
actinic, 1053–1055
nodularis, **184**–187
clinical findings, 185
differential diagnosis of, 187b
epidemiology, 184
etiology and pathogenesis, 185
laboratory tests, 185
prognosis/clinical course, 186
special tests, 185–186
treatment of, 186–187
papules, 170f
pigmentosa, 822–823
Pruritus, **1147**–1158
advanced age and, 1153
in angiodermatitis, disseminated pruriginous, 2052
aquagenic, 1154
in atopic dermatitis, 169, 1151
in burns and scar, 1153
brachioradial, 1151
in cholestasis, 1152, 1822–1823
chronic
eosinophils in, 398
clinical findings in, 1149
complications in, 1150
differential diagnosis in, 1151b
disorders associated with, 1822–1823
in elderly, 1153
in endocrine disorders, 1152
epidemiology, 1147
etiology and pathogenesis in, 1147–1149
helminthic infections and, 2554
in hematologic disorders, 1152
in HIV infection and AIDS, 1153
itch-scratch cycle in, 1147–1148
in kidney disorders, 1154, 1823
in lymphoproliferative disorders, 1152–1153
nerves in, 1148–1149
and transmission of itch sensation, 1148
neuropathic, 1151–1154
prognosis and clinical course in, 1151–1154
in psoriasis, 1151
psychogenic, 1153
treatment of, 1154–1157
cutaneous field stimulation in, 1157
phototherapy in, 1156–1157
systemic, 1156
therapeutic ladder in, 1154f
topical, 1154–1156
vulvae, 892
Pseudoainhum, 724
Pseudocatalase in vitiligo, 800
Pseudo-claudication, 2098
Pseudocowpox. *See* Milker's nodules
Pseudolymphoma, cutaneous, **1767**–1781
Pseudomonas aeruginosa, 2183–2188, 2170
diagnosis of infections, 2185
differential diagnosis of, 2187–2188
in ecthyma gangrenosum, 2186
epidemiology of, 2184
in gangrenous cellulitis, 2187
in nail infections, 2186

Pseudomonas aeruginosa—continued
in otitis externa, 2185
in septicemia, 2186
treatment, 2188
treatment of infections, 2188
Pseudomonas pseudomallei, 2222
Pseudomonas putrefaciens, 2188
Pseudo-mycosis fungoides, 1768t, 1777–1779
differential diagnosis of, 1777–1778
treatment of, 1778–1779, 1778b
Pseudopelade of Brocq
cicatricial alopecia in, 998
Pseudoverrucous papules and nodules in diaper area, 1198
Pseudoxanthoma elasticum, **1633**–1637
calcification in, 1635
cardiovascular disorders in, 1634, 1820
clinical findings in, 1634–1635
differential diagnosis of, 1636b, 1637
elastic fiber disorders in, 1634–1635
epidemiology of, 1633
etiology and pathogenesis in, 1634
eye disorders in, 1635
gastrointestinal hemorrhage in, 1634, 1635
general skin changes in, 1634
genetic factors in, 1634
histopathology in, 1635
localized acquired cutaneous, 1636b
monitoring studies in, 1637t
perforating periumbilical, 1636b
prevention of, 1637
support groups on, 1637
treatment of, 1637
Psoralen and PUVA therapy, 2845–2846
in actinic dermatitis, chronic, 2862
acute side effects
carcinogenesis, 2848–2849
chronic actinic damage, 2848
ophthalmologic effects, 2849
in atopic dermatitis, 2859
with cyclosporine, 2857
extracorporeal, 2864–2865
in graft-versus-host disease, 2859, 2864–2865
in HIV infection, 2861
in lichen planus, 311, 2859
in mastocytosis, 2859
with methotrexate, 2857
oral administration of psoralen in, 2846
in palmoplantar pustulosis, 256, 257b, 258
photochemical reactions in, 2852
in pityriasis rubra pilaris, 283
in psoriasis, 226, 2855–2857
with retinoids, 2857
in seborrheic dermatitis, 260
skin cancer risk in, 2862–2863
in T-cell lymphoma, 2858, 2864
topical application of psoralen in, 2857
in UVA light tumors, 1256
in vesicular palmoplantar eczema, 193
in vitiligo, 2860
Psoriasiform lesions
Psoriasin, 108
Psoriasis, **197**–231
age of onset, 197
annular, 212f
arthritis in, **232**–242. *See also* Psoriatic arthritis
chronic stationary, 208
clinical findings in
clinical patterns of skin presentation, 208, 211, 213–215
cutaneous lesions, 208
history, 208
complications of, 217–218
cytokines and chemokines in, 148–149, 201, 203
dendritic cells in
dermal, 201–202
inflammatory dendritic epidermal cells (IDECs), 202
Langerhans cells, 201
plasmacytoid, 202
diagnostic algorithm on, 209f
differential diagnosis of, 217b
drug-induced exacerbation of, 218
early macules and papules of, 199
elephantine, 210
endothelial cells in, 202–203
epidemiology of
age of onset, 197
prevalence, 197
erythrodermic, 211, 213f
differential diagnosis in, 211
prognosis in, 211
etiology and pathogenesis in, 197
cellular participants in, 200–203
histopathology, 199f
lesions development, 197, 199–200
exfoliative dermatitis in, 271f
fibroblasts in, 203
flexural, 213f
genetic factors in, 204–208, 206f
HLA-Cw6, 204
IFN-γ/IL-23/IL-17 signaling, 205–206
inflammatory DC function, 207–208
keratinocyte differentiation, 208
NF-kB signaling, 206–207
non-MHC genes, 204–208
genital
in male, 864–865
geographic tongue in, 216
geographica, 208
guttate, 211, 212f
differential diagnosis in, 211
and streptococcal infections, 211, 2144
histopathology of, 199f
in HIV infection and AIDS, 218
HLA system in, 84, 197, 204
inverse, 211
keratinocytes in, 202
Koebner phenomenon in, 208, 211f, 227
laboratory tests in, 216–217
Langerhans cells in, 201
laser therapy for, 2883
linear, 215
liver disorders in, 1836
macrophages in, 202
modifying factors
drugs, 218
infection, 218
smoking, 218
nail changes in, 215, 215t, 216f, 1022
and arthritis, 235
differential diagnosis in, 1023
onycholysis, 215t, 216f
pitting, 215, 215t, 216f
salmon patches, 215, 215t
treatment of, 1023
napkin, 213f, 215
neutrophils in, 202
NKT cells in, 200–201
ostraceous, 210
pathologic reactions in, 49
plaque in, 208, 212f
chronic, 212f
small, 211
in pregnancy, 224b
prognosis and clinical course in, 218
pruritus in, 218, 222t
treatment of, 226
psychological factors in, 218
pustular, 215
annular, 215
exanthematic, 214
generalized, 211, 213–214, 214f
localized variants, 215
nail changes in, 1024
in pregnancy, 224b
treatment of, 256
remission periods in, 218
rupioid, 210, 212f
sebopsoriasis, 215, 261
and seborrheic dermatitis, 261
signaling molecules in
cytokines and chemokines, 203
eicosanoids, 203
growth factors, 203
innate immune mediators, 203
integrins, 204
proteases and inhibitors, 204
signal transduction, 204
stages of, 198f
superantigens in, 2159
susceptibility loci, 207t
T cells in, 200
treatment of
alefacept in, 229
algorithm on, 209f
biologic agents in, 229, 230t, 231
calcipotriene in, 224
in children, 224b
coal tar preparations in, 224
combination therapy, 223t, 228–229
cyclosporine in. *See* Cyclosporine, in psoriasis
efalizumab in, 229
general considerations in, 218
hepatotoxicity of drug therapy in, 221t, 229
laser therapy in, 220t, 226
methotrexate in. *See* Methotrexate, in psoriasis

in nail changes, 215t, 216f
photochemotherapy in, 2855–2857
photodynamic therapy in, 227, 2866
phototherapy in, 220t, 226–227, 2855
in pregnancy, 224b
psoralen and PUVA therapy in. *See* Psoralen and PUVA therapy, in psoriasis
retinoids in, 2761
systemic, 221t, 222t, 227–228
topical, 219t, 223–226
tumor necrosis factor-α in, 200, 201f, 2819
antagonists therapy, 229
as therapy target, 229, 2819–2822
Von Zumbusch type, 211, 213, 214, 214f
vulgaris, 26f, 208
Woronoff ring in, 210, 212f, 813
Psoriatic arthritis, 216, **232**–242
CASPAR criteria, 233b
classification of, 232
clinical features in, 233
extra-articular manifestations, 235
nail involvement, 235
skin involvement, 235
course and prognosis in, 237
comorbidities, 237
mortality, 238
definition of, 232
diagnostic criteria on, 238–239, 238t
differential diagnosis in early diagnosis, 238–239, 238t
etiology and pathogenesis, 232–233
genetics, 232
pathogenesis, 233
genetic factors in, 232
laboratory investigations, 235
mortality in, 238
pathogenesis and pathology in, 233
patterns of joint involvement in, 235b
radiology in, 235
CT scan, 237
MRI, 237
plain radiographs (X-rays), 235–236, 236f
ultrasound imaging, 237
treatment of
alefacept in, 241
algorithm on, 251f
disease-modifying antirheumatic drugs in, 240–242
drug therapy, 239, 239b
GRAPPA group recommendations, 242
in HIV infection, 244
surgical, 242
Psychiatric disorders, **1159**–1166
Psychocutaneous diseases, **1159**–1166
classification of, 1159
nonpharmacologic treatment in, 1165
psychotropic medications in, 1165
Psychological factors, **1158**–1166
Psychotropic medications, 1165
PTCH1/PTCH1
in basal cell nevus syndrome, 1305–1306
functions of, 1305
in hedgehog signaling pathway, 1306
PTEN/PTEN
in hamartoma tumor syndrome, 2091
Public health, **21**–25
approaches in dermatology, 24–25
benefit and harm balancing, 23
definition of, 22
future trends in, 25
high-risk approach to, 22–23
historical aspects of, 22
low-risk approach to, 22–23
skin cancer as concern in, 22–24, 1239
Publication bias, 10
Purpura, 37, 1726–1740
annularis telangiectodes, 2050–2051
in child abuse, 1178t, 1179, 1179f
differential diagnosis of, 1731
algorithm on, 1736f
in child abuse, 1179, 1179f
erythema in, 33
in nonpalpable purpura, 1733, 1733t, 1737
in palpable purpura, 1734t, 1735t, 1738
in retiform purpura, 1734t, 1735t, 1738
in disseminated intravascular coagulation, 1739
of Doucas and Kapetanakis, 2052
fulminans, 1739–1740
Henoch-Schönlein. *See* Henoch-Schönlein purpura
itching, 2052
in leukocytoclastic vasculitis, 37
Majocchi, 2050–2051
in mycosis fungoides, 2053
palpable, 37, 1734t, 1735t, 1738
differential diagnosis of, 1734t, 1735t, 1738
in pigmented dermatosis, **2049**–2054
diagnosis, 2054
granulomatous, 2053
histopathology, 2053–2054
segmental, 2053
management, 2054
retiform, 1734t, 1735t, 1738
differential diagnosis of, 1734t, 1735t, 1738
thrombocytopenic, 1735–1737
idiopathic, 1735
thrombotic, 1736–1737
Pustules, 36–37
in neonatal melanosis, transient, 1188–1189
palmoplantar, **253**–258
in pyoderma
superficial, 37
subcorneal, **383**–385
Pustulosis
benign cephalic, 1189
palmoplantar, **253**–256
clinical findings, 254, 254b
diagnosis and differential diagnosis in, 255–256, 256b
diseases associated with, 254, 254b
histopathology in, 254
laboratory findings, 254
management and prevention, 256, 257b
prognosis/clinical course, 256
treatment in, 256
in SAPHO syndrome, 254
Pyemotes tritici, 2572
Pyemotes ventricosus, 2572
Pyoderma, 2129
gangrenosum, **371**–379
bullous, 373, 375f, 376
clinical findings in, 373–376
complications of, 377
diagnostic algorithm in, 372f
diagnostic criteria in, 377
differential diagnosis in, 374b, 375b, 377
epidemiology of, 371
etiology and pathogenesis of, 372
genital, 374b, 866
histopathology in, 376
laboratory tests in, 376
pathergic phenomenon in, 373
prevention of, 379
prognosis and clinical course in, 377
pustular, 373, 374b, 375–377
treatment of, 377–379
ulcerative, 371, 373, 374b, 375–377
vegetative, 371, 373, 375–378
wound care in, 378
staphylococcal, 2129–2139
Pyogenic arthritis with pyoderma gangrenosum and acne, 1594–1595
clinical findings in, 1594
differential diagnosis of, 1595
Pyogenic granuloma, 1469
Pyramidal protrusion, infantile, 1197
Pyrethrin, 2702
Pyridoxine, 1513–1514
deficiency of, 1513–1514
food sources of, 1513

Q

Quality of care, 8
Quality of life
in allergic contact dermatitis, 164
in hidradenitis suppurativa, 956
Quincke pulsation, 1824
Quinolone in children, 1203
Quinupristin-dalfopristin, 2785

R

Rabies, 2580–2581
clinical, 2581
Racial differences. *See* Ethnic and racial differences

Radiation
absorption of. *See* Absorption of radiation
and optical properties of skin, 2872–2876. *See also* Optical radiation
and radioprotectors
photoprotection methods in, **2707**–2713
for recalcitrant dyshidrotic eczema, 193
ultraviolet, 1032–1033. *See also* Ultraviolet radiation exposure
Radiation dermatitis
clinical and molecular aspects of, 2893–2895
Radiation recall reaction, 2895–2896
drug-induced, 2756–2757
Radiation therapy, **2890**–2898
in B-cell lymphoma, 2897–2898
in basal cell carcinoma, 2897
in benign skin diseases, 2896
charged particle therapy, 2891
dosimetry in, 1036
dose and fractionation schedule, 2893
in malignant skin diseases, 2897–2898
mechanism of action, 2893
in melanoma, 2897
in Merkel cell carcinoma, 1369
orthovoltage X-rays, 2890
radiation modalities, 2890–2891
radiation modulation, external beam, 2891–2893
recall reactions, 2895–2896
in squamous cell carcinoma, 1293, 2897
in T-cell lymphoma, 2897
in vesicular hand dermatitis, 193
Radiodermatitis. *See* Radiation dermatitis
Radio-frequency technique
in varicose veins, 3006
Radiography
in psoriasis arthritis, 235–236
Radioprotectors
and photoprotection methods, **2707**–2713
Radiotherpy. *See also* Radiation therapy
in hidradenitis suppurativa, 959
in Paget disease, 1375
for vesicular hand dermatitis, 193
RAG1 and *RAG2*, 1712t, 1713
Raised skin lesions, 30–32
RANTES
in atopic dermatitis, 169
Rapamycin inhibitors, mammalian target of, 2813–2814
Rat-bite fever, 2218
Rat flea, 2607
Raynaud phenomenon, **2065**–2071
clinical findings in, 2066–2067
differential diagnosis of, 2067
drug-induced, 2069
epidemiology of, 2065
etiology and pathogenesis in, 2066
laboratory tests in, 2067
in occupational exposures, 2068–2069
primary, 2067–2068
diagnostic criteria on, 2068t
secondary, 2068–2069
treatment of, 2070–2071
Reactive arthritis, **243**–252
acute symptoms, 246b
articular, 246–247, 246b, 247b
chronic symptoms, 247b
cardiac, 246b, 247b, 250
clinical manifestations, 245, 247–250
cutaneous, 246b, 247b, 248–249
diagnosis, 250
diagnosis algorithm, 251f
enthesitis, 246b, 247b, 247–248
etiology and pathogenesis, 243
HLA-B27 role in, 245
host factors, 244–245
mucosal, 246b, 247b, 249–250
ocular, 246b, 247b, 249
pathophysiology, 245
treatment, 250, 252
triggering organisms, 243, 244b
Campylobacter, 243
Chlamydia, 243
Salmonella, 243
Shigella, 243
Yersinia, 243
Reactive oxygen species, 357
in photosensitivity, 1546
Reduviid bugs, 2607
Reflex sympathetic dystrophy, 1826
Regulatory T cells, 116
Rejuvenation of skin
with laser therapy, 3032–3035
anesthesia application, 3033
complications, 3035
equipment, 3033
patient selection aspects, 3033
postoperative instructions, 3035
risk and precautions, 3032–3033
technique, 3034
Relapsing polychondritis, 1828, **1962**–1965
Relaxed skin tension lines of face, 2906
Reliability, 7
Repeat open application test, 3016
Resistant skin type, 3012–3013
compared to sensitive type, 3012–3013
Respiratory disorders, 1830–1832
in amyloidosis, 1831
in coccidioidomycosis, 2324
in fat embolism syndrome, 1830
in larva migrans, 1830
in lipoid proteinosis, 1831
in paracoccidioidomycosis, 2325
in rheumatoid arthritis, 1831
in systemic sclerosis, 1831–1832
Resurfacing of skin, **3021**–3026
with chemical peel, 3028–3030
with dermabrasion, 3030–3031
with laser therapy, 3021–3026
anesthesia in, 3024
carbon dioxide, 3022, 3024
equipment in, 3022
erbium:yttrium-aluminum-garnet, 3023, 3024
fractional, 3023
postoperative care in, 3028
patient selection, 3022
preoperative assessment in, 3028
side effects and complications of, 3027–3028
Retapamulin, 2675, 2701
Reticular dermis, 51–56
in drug eruption, 52–53
embryonic and fetal, 70
fibrous dermis and extracellular matrix, 55–56
granulomatous reactions, 54–55
infiltrates in
lymphocytic, 53–54
polymorphonuclear leukocytic, 54
lymphatics of, 66
vascular system of
deep, 51
superficial, 51
Reticular lesions, 38, 38f
Reticulohistiocytosis
diffuse cutaneous, 1796, 1796t, 1804
multicentric, 1796t, 1803–1805, 1831
clinical findings in, 1803–1804
differential diagnosis of, 1805b
epidemiology of, 1796
etiology and pathogenesis in, 1797
histopathology in, 1804–1805
nail changes in, 1803
oral cavity disorders in, 1804f
respiratory disorders in, 1831
treatment in, 1808
13-*cis*-Retinoic acid. *See* Isotretinoin
all-*trans*-Retinoic acid. *See* Tretinoin
Retinoids, **2759**–2766
acitretin. *See* Acitretin
in acne, 2761
in actinic keratosis, 1269
all-trans-retinoic acid, 2670
bexarotene. *See* Bexarotene
combination with phototherapy, 2857–2858
dosing regimens, 2762–2763
in eczema, 2761
indications for, 2761–2762
initiation and monitoring of therapy, 2763–2764
isotretinoin. *See* Isotretinoin
in lichen planus
cutaneous, 311
oral, 310
mechanism of action, 2760
pharmacokinetics of, 2760–2761
in pityriasis rubra pilaris, 283
in psoriasis, 2761
in sebaceous gland activity and sebum production, 896
side effects and complications of, 2764–2766

in T-cell lymphoma, 2761–2762
topical, **2665**–2672
adverse effects of, 2671–2672
dosage schedules and forms in, 2671
indications, 2670–2671
interaction with other drugs, 2672
mechanism of action, 2666–2667
nomenclature related to, 2667–2668
in pregnancy, 2671
risks and precautions, 2671–2672
tretinoin. *See* Tretinoin
Retinol, 1504–1506. *See also* Vitamin A
Revascularization
in skin graft healing, 2992–2993
Rhabdomyoma, 1473–1474
Rhabdomyosarcoma, 1474
Rheumatic fever, **1972**–1973
acute, 2182
erythema marginatum in, 1972
Jones criteria on, 1972b
treatment, 1973
Rheumatoid arthritis, 1831, **1965**–1971
articular manifestations in, 1966–1967
clinical features in, 1966–1969
diagnostic criteria on, 1966t
differential diagnosis of, 1969b
epidemiology of, 1965
etiology and pathogenesis in, 1965–1966
extraarticular manifestations in, 1969
laboratory findings, 1969
treatment of, 1969–1971
Rhinoscleroma in *Klebsiella* infections, 2192, 2193
Rhinosporidiosis, 2317
Rhinosporidium seeberi, 2317
Rhipicephalus ticks
Mediterranean spotted fever from, 2463
Rhombic transposition flaps, 2937–2938
Rhytides, 3019. *See also* Wrinkling of skin
Riboflavin, 1511–1512
deficiency of, 1511
food sources of, 1511
Ribonucleoproteins, 1919t, 1930t
Ribosomal RNA, 76
Ribozymes, 78
Rickettsia conorii, 2463
Rickettsia prowazekii, 2574, 2607
Rickettsia rickettsii, 2456
Rickettsial infections, 2456–2463
differential diagnosis of, 2462, 2463b
spotted fever group, 2456
treatment of, 2462–2463
typhus group, 2456
Rifampin
in actinomycetoma, 2252
Rituximab, 2823
in cicatricial pemphigoid, 622b, 623
complications of, 2823
in dermatomyositis, 1941
indications for, 2823
in lupus erythematosus, 1924t
in lymphoma, 2823
in pemphigus, 598
in rheumatoid arthritis, 2823
River blindness, 2557, 2564
RNA, 77, 78
heteronuclear, 78
inhibition pathway, 91
short inhibitory, 91
synthesis inhibition, 1236
viral, 2330, 2330t
RNA polymerase II, 78
Rocky Mountain spotted fever, 2456–2463
clinical and laboratory findings in, 2460–2461
diagnosis and differential diagnosis of, 2462
histopathology in, 2461
treatment of, 2462–2463
Rosacea, **918**–925
classification and staging of, 918
clinical features in, 919–921
differential diagnosis in, 921–923
epidemiology of, 918
etiology and pathogenesis in, 918–919
histopathology in, 921
ocular, 925
phymatous, 925
treatment of, 923–925
antibiotics in, 2673–2674
laser therapy in, 924, 2885
oral therapy, 924
retinoids in, 2762
topical therapy, 923
Rose of Jericho, 2530
Rotation flap, 2935–2936
Rotavirus infections, 2364–2365
clinical findings, 2364
complications, 2364
course, 2365
epidemiology, 2364
prevention, 2365
treatment, 2365
Rothmund-Thomson syndrome, 1665, 1667t, 1668t, **1668**–1669
clinical features in, 1668
DNA damage and repair in, 1669
genetic factors in, 1669
Round lesions, 38
Roundworm infections, 2562
Rubber
allergic contact dermatitis from in occupational exposures, 2617
occupational exposure to, 2617, 2618
contact urticaria in, 2617, 2618
Rubella, **2340**–2342
clinical findings in, 2340
complications of, 2341
congenital, 2341
differential diagnosis of, 2341b
in pregnancy, 2341, 2342
treatment of, 2342
vaccination, 2342
Rubeola. *See* Measles

S

Sagartia sea anemones, 2588
Salicylic acid, topical, 2706
in pruritus, 1154
in psoriasis, 226
in warts, 1922, 2707
Salivary gland disorders
xerostomia in, 1978, 1982
Salivary gland scintigraphy, 1982
Salmon patches, 2078
Salmonella infections, **2190**–2192
reactive arthritis in, 243, 245
San Joaquin Valley fever, 2323–2324
Sand fleas, 2607
Saphenous veins, 2880–2881
varicose, 3006
SAPHO syndrome, 914
Sarcoidosis, **1869**–1879
alopecia in, 1873
bilateral hilar adenopathy in, asymptomatic, 1876–1877
cardiovascular disorders in, 1874
treatment of, 1877, 1878t
clinical findings in, 1870–1874
diagnosis of, 1876
differential diagnosis of, 1876b
epidemiology of, 1869
etiology and pathogenesis in, 1869–1870
eye disorders in, 1874
gallium scan in, 1875
hypopigmentation in, 808
laboratory tests in, 1875
liver disorders in, 1458, 1874
treatment of, 1877, 1878t
nail changes in, 1873
natural history and prognosis in, 1877
neurologic disorders in, 1874
treatment of, 1877, 1878t
papular, 1871, 1871f
pathology in, 1875–1876
respiratory disorders in, 1874
treatment of, 1877, 1878t
in scars, 1872
treatment of, 1877–1879
antimalarial drugs in, 1878
Sarcoma
angiosarcoma, **1486**–1488
epithelioid, **1454**–1455
clinical findings in, 1454–1455
treatment of, 1455
Kaposi, **1481**–1486. *See also* Kaposi sarcoma
myxofibrosarcoma, **1452**–1453
undifferentiated pleomorphic, **1453**–1454
Sarcoptes scabiei, 2570
Satellite metastasis of melanoma, 1434, 1442–1443
Scabies, 862, **2569**–2572
burrows in, 2570
clinical findings in, 2570–2571
complications in, 2571
crusted, 2570
diagnosis of, 2570
differential diagnosis of, 2571b

Scabies—*continued*
in immunocompromised host
in HIV infection and AIDS, 2454–2455
in occupational exposures, 2626
prevention of, 2572
transmission of, 2570
treatment of, 2571–2572, 2571b
Scald injuries in child abuse, 1180
Scaling lesions, 34, 35t
in pityriasis rosea, 35t
in psoriasis vulgaris, 34, 35t
Scalp
allergic contact dermatitis of, 157
lichen planus of, 302–303
metastasis to, 1824
seborrheic dermatitis of, 263b
surgical anatomy of, 2907
Scarification as body art, 1130
Scars, 31–32
atrophic, 32
in cryotherapy complication, 2972
hypertrophic, 32
compared to keloids, 708–710
cryotherapy in, 2970
postoperative, 2982
keloid, 32, 2885
laser therapy in, 2885
in pemphigoid, cicatricial, **617**–623
postoperative
depressed or furrow-like, 2982
hypertrophic, 2982
spreading, 2982
Scattered generalized dermatitis (SGD), 158–159
Scattered lesions, 39
Schamberg disease, 2050
clinical findings in, 2050
pathogenesis in, 2050
Schistosoma haematobium, 2567
Schistosoma intercalatum, 2567
Schistosoma japonicum, 2567
Schistosoma mansoni, 2567
Schistosoma mekongi, 2567
Schistosomal infections, 2566–2567
Schistosomiasis, 2567
differential diagnosis of, 2567
genital lesions in, 867
in occupational exposures, 2626
in swimmers, 2567
Schöpf-Schulz-Passarge syndrome, 546
Schwannoma, 1476–1477
cellular, 1477
immunohistochemistry of, 1477
malignant, 1478
Scleredema, **1957**–1959
clinical findings in, 1958
histopathology in, 1958
treatment, 1959
Sclerema neonatorum, 1192
Sclerodactyly
in Huriez syndrome, 544–545
Scleroderma, **1942**–1956
hypopigmentation in, 808
linear
anhidrosis in, 945
localized, **692**–701. *See also* Morphea
systemic, **1942**–1956
cardiopulmonary disorders in, 1830, 1949–1950, 1954–1956
classification, 1946
clinical findings in, 1946–1951
differential diagnosis of, 1951, 1952b
environmental factors, 1945
etiology and pathogenesis in, 1943–1945
fibrosis in, 1944–1945
gastrointestinal disorders in, 1950–1951, 1956
genetic factors in, 1943
histopathology in, 1951
immune events, 1943–1944
kidney disorders in, 1951, 1956
localized cutaneous, 1948–1949
Raynaud phenomenon in, 1953t
respiratory disorders in, 1831–1832, 1949–1950
treatment of, 1952–1956
vasculopathy, 1944, 1946, 1952, 1954
tuberous. *See* Tuberous sclerosis
Scleromyxedema, 1893, **1959**–1961
clinical findings in, 1960
histopathology in, 1961
treatment, 1961
Sclerosis, 33
dermis reaction in, 55
in morphea, 33. *See also* Morphea
systemic, 1830, 1831–1832, **1942**–1956. *See also* Scleroderma, systemic
tuberous. *See* Tuberous sclerosis
Sclerotherapy
in varicose veins, 2997, 2998, 3002–3005
agents used in, 3000–3002
contraindications to, 2998–3000
foam techniques, 3003
inadvertent arterial injection in, 3005
in varicose veins side effects and complications of, 3003–3005
arterial injection, 3005
cutaneous necrosis/ulceration, 3005
postsclerosis pigmentation, 3003–3005
pulmonary embolism, 3005
superficial thrombophlebitis, 3005
telangiectatic matting, 3005
Scombroid food poisoning, 2598
Scopulariopsis, 2292, 2295
SCORAD (Severity Scoring of Atopic Dermatitis), 7, 181
Scorpaena scorpionfish, 2596
Scorpion stings, 2603–2604
clinical findinga, 2603
management of, 2604
Scorpionfish stings, 2596
Scurvy, 1516b
Scytalidium dimidiatum, 2292
Se autoantigen in dermatomyositis, 1930t
Sea anemones, 2588
Sea bather's eruption, 2593–2594
prevention of, 2594, 2594t
Sea cucumber dermatitis, 2592
Seafood ingestion and poisoning, 2598
Sea urchin injuries, 2590–2591
nodular reactions to, 2591
spine removal in, 2591
Seal finger, 2218
Seatworm infection, 2560–2561
Sebaceous glands
anatomy of, 893–894
biology of, **893**–897
embryonic and fetal, 74, 894
factors regulating sebum production, 895–896
functions of, 895
histology of, 893
holocrine secretion process, 894–895
hyperplasia of
cryotherapy for, 2970
lipids of, 895
location of, 893–894
perineal
prominence of, 856
physiology of, 894
tumors of, 1339–1342
Sebopsoriasis, 261
Seborrheic dermatitis, **259**–266
aberrant epidermal proliferation in, 260
in adults, 261–262
treatment of, 265–266
clinical findings in, 261
differential diagnosis of, 263b
drug as triggering factor, 260
epidemiology of, 259
erythroderma desquamativum (Leiner's disease) and, 263
etiology and pathogenesis in, 260
genetic factors, 261
genital, 863–864
histopathology in, 265, 265t
in HIV infection and AIDS, 264, 265t
immunology, 260
in infants
comparison to adults, 261–262
differential diagnosis of, 262b
treatment of, 265
microbial effects, 260
neurotransmitter abnormalities associated with, 260
nutritional disorders and, 261
physical factors, 260
pityriasiform, 263–264, 264f
prognosis and clinical course in, 261
and psoriasis, 261
scaling lesions in, 35t
seborrheic stage in, 261
treatment of, 265–266
complementary and alternative medicine approaches to, 2901–2902
Seborrheic keratosis, **1319**–1323
cryotherapy in, 2969
reticulated, 1321
Sebum
function of, 895
lipid composition of, 895

production of
embryonic and fetal, 74
regulation of, 895–897
in xerosis, 3010
production regulating factors, 895–897
androgens, 896
fibroblast growth factor receptors, 896–897
melanocortins, 896
peroxisome proliferator activated receptors, 896
retinoids, 896
Sedatives
abuse of, 1172
Selectins
E-selectin
in multistep model of leukocyte recruitment, 145
in necrotizing venulitis
P-selectin, 1988
endothelial expression of, 1988
Selection bias, 2
Selenium, 1519–1520
deficiency of, 1519
hypopigmentation in, 812, 1519
excess, 1519–1520
food sources of, 1519
toxicity of, 1519
Sensitive skin type, 3012–3013
with acne, 3013
allergic, 3014–3015
cosmetic intolerance syndrome in, 3012–3013
with rosacea, 3014
with stinging, 3014
Sensory system
nerves and receptors in, 1142
anatomy of, 1142, 2908
anesthetic block of, 2916
embryonic and fetal development of, 72–73
facial, 2907, 2909, 2916
Sentinel lymph nodes
in melanoma, 1438, 1440
Sepsis, **2197**–2199
differential diagnosis of, 2199b
disseminated intravascular coagulation in, 2199–2201
in immunocompromised host, 2198, 2198f
shock in, **2197**–2199
Serglycin, 685
Serpiginous lesions, 38
Serum sickness, 424
Sexually transmitted infections. *See also specific infections*
chancroid, **2501**–2505
gonorrhea, **2514**–2519
granuloma inguinale, **2510**–2514
lymphogranuloma venereum, **2505**–2510
nonvenereal endemic treponematosis, **2493**–2500
syphilis, **2471**–2492
vaginosis, 2524–2526
Sézary syndrome, 274
and exfoliative dermatitis, 274, 276
Shahib disease, 2534
Shah-Waardenburg syndrome, 789
Shake lotions, topical medications formulated as, 2648
Shale oil, 2698
Shampoo products
Shapes of skin lesions, 38–39
Shave excision in actinic keratosis, 1268
Shear forces, decubitus ulcers in, 1127
Shingles, 867
Shock, septic, **2197**–2199
Shoulder-hand syndrome, 1826
Shprintzen-Goldberg syndrome, 1632b
Sialometry, 1982
Sicca symptoms in Sjögren syndrome, 1979
Signal recognition particle (SRP) in dermatomyositis, 1930t
Signal transduction
chemokine receptors and, 144–145
cytokine-receptor mediated, 128–129, 131–132
in psoriasis, 204
Sikari disease, 2534
Silicone injections, 3051–3052
Silver nitrate, 2704
Silver sulfadiazine, 2676
Silvery hair syndromes, 1721–1724
Sincatechins, 2707
Sinus histiocytosis with massive lymphadenopathy, 1796, 1796t, 1806–1808
clinical findings in, 1806–1807
differential diagnosis in, 1807b
epidemiology of, 1797
etiology and pathogenesis in, 1798
treatment in, 1808
Sinus tracts, 33
in hidradenitis suppurativa, 33
Siphonaptera, 2607
Sirolimus, 2831–2832
complications of, 2832b
indications for, 2831–2832
mechanism of action, 2831
Sister chromatid exchange assay of chromosome integrity, 1235
Sister Joseph nodules, 1824
Sjögren syndrome, **1976**–1985
anhidrosis in, 945
autoantibodies in, 1978
classification criteria, 1982b
clinical manifestations in, 1978–1981
diagnosis of, 1981–1982
environmental factors in, 1977
epidemiology of, 1976
epithelial cell activation in, 1977–1978
exocrine gland disorders, 1978–1979
extraglandular manifestations in, 1981
treatment of, 1984
eye disorders in, 1979
genetic factors in, 1977
histopathology in, 1982–1983
lymphoproliferative disease, 1981
musculoskeletal manifestations, 1981
neurologic manifestations, 1981
nonexocrine gland disorders, 1979–1980
oral cavity disorders in, 1978, 1982
treatment of, 1984
pathogenesis of, 1976–1978
pregnancy and, 1981
prognosis in, 1983
treatment of, 1983–1985
vascular manifestations, 1981
visceral manifestations, 1981
Skin barrier function. *See* Barrier function of skin
Skin cancer. *See also specific types of cancer*
basal cell carcinoma, **1294**–1303
physical examination in, 29
in ultraviolet radiation exposure, **1251**–1260
genetics of, 1253–1255
immune surveillance for, 1258
novel therapeutic approaches to, 1259–1260
prevention of, 1259
risk factors for, 1258–1259
Skin changes
in acanthosis nigricans, 1823
in cardiac disease, 1819–1820
color changes aspects, 1820
in cyanosis, 1820
in dermatomyositis, 1823
in erythema, 1820–1821
in erythroderma, 1824
flushing, 1821
in hypertrichosis lanuginosa, 1823
jaundice, 1821–1822
in liver disease, 1820
in malignancy, 1823–1824
pigmentary changes, 1821
cirrhosis, 1821
hemochromatosis, 1821
vitamin deficiency, 1821
in pruritus, 1822–1823
cholestatic, 1822
renal, 1823
in relapsing polychondritis, 1829
in renal disease, 1820
specific organ and system changes
cardiovascular system, 1828–1830, 1828b
ears, 1828
eyes, 1827
face, 1827
fingers, 1826
gastrointestinal system, 1832–1834
hair, 1828
hepatobiliary system, 1834–1837
mouth and esophagus, 1827
nails, 1824–1826
renal system, 1837–1839
respiratory system, 1830–1832
sweating, alterations in, 1823
Skin color. *See also* Skin of color
UV radiation and, 3018. *See also* Pigmentation
Skin grafts. *See* Grafts, skin
Skin irritation, 3015–3016. *See also* Cosmetic products and procedures
cumulative, 3015
mechanical, 3015

Skin of color, **91**–102. *See also* Ethnic and racial differences
  definition of, 92–93
  hair characteristics variation, 95–97
  hair disorders and, 97, 98t
  pigmentation genetics and, 93–95, 94t
  race and ethnicity considerations, 91, 92t
    on skin disease and therapy, 92
  skin disease diagnosis and treatment, 97
    cosmetic and procedural dermatology, 99, 100t, 101t
    cosmetic camouflage, 101
    patient individualization, 102
    preventive measures, 101
    procedural dermatology, 102
    skin cancer, 99
    topical therapies for hyperpigmentation, 101, 102t
  skin disease diagnosis and treatment, 99f
  structure and function in, 93
Skin rejuvenation. *See* Rejuvenation of skin
Skin resurfacing. *See* Resurfacing of skin
Skin tags, 1322
Skin tests
  coccidioidin, 2324
Slate-gray pigmentation in phototoxic reactions, 1070
SLC, 127 94
SLC24A5 in melanosomes, 94, 771
SLUG/SNA12 in Waardenburg syndrome, 789
Smallpox, 2402–2411
  in bioterrorism, 2637
  clinical findings in, 2404–2405
  complications of, 2406
  diagnosis of, 2637b
  differential diagnosis of, 2406, 2406b
  epidemiology of, 2402–2404
  etiology and pathogenesis in, 2404
  flat or malignant, 2404
  hemorrhagic, 2405
  histopathology in, 2406
  laboratory tests in, 2405–2406
  modified, 2404
  prevention, 2407
  prognosis and clinical course in, 2406–2407
  treatment of, 2407
  types of, 2404
  vaccination, 2407–2411
    adverse effects of, 2408–2409
    complications, 2410
    prevention, 2410–2411
    treatment, 2410
    vaccinia virus in, 2407–2411
Smoking
  preoperative assessment of, 2912
  psoriasis in, 218
Smooth muscle tumors, 1470–1473
SNARE protein complex, 3053–3054, 3054f, 3054t
Sneddon-Wilkinson disease. *See* Subcorneal pustular dermatosis
Soaps
  as occupational irritant, 2614
Sodium morrhuate in sclerotherapy for varicose veins, 3002
Sodium tetradecyl sulfate in sclerotherapy for varicose veins, 3002
Soft tissue augmentation, **3044**–3052. *See also* Botulinum toxin
  with autologous fat, 3049–3051
  with calcium hydroxylapatite, 3049
  with collagen, 3044
  complications of
    with autologous fat, 3050
    with calcium hydroxylapatite, 3049
    with hyaluronic acids, 3046
    with poly-L-lactic acid, 3048–3049
    with silicone, 3050
  with hyaluronic acid, 3044–3047
  with poly-L-lactic acid, 3047–3049
  with silicone, 3051
Soft tissue infections, **2169**–2177
  clinical findings in, 2171–2176
  differential diagnosis of, 2174b
  epidemiology of, 2169
  etiology and pathogenesis in, 2169–2170
  histopathology in, 2174
  laboratory studies in, 2173
  prevention of, 2175
  treatment of, 2176–2177
Solar lentigo, 1406–1410
  clinical findings in, 1407–1409
  differential diagnosis in, 1409b
  epidemiology of, 1406–1407
  etiology and pathogenesis in, 1407
  histopathology in, 1409
  prognosis and clinical course in, 1409–1410
  treatment of, 1410
    cryotherapy in, 2970
Solar urticaria, 421, 1060–1062
  approach to diagnosis of, 1061–1062
  clinical features in, 1061
  differential diagnosis in, 1062b
  subtypes of, 1060
  treatment in, 1062
Solenopsis fire ant stings, 2608
Solutions, topical medications formulated as, 2648
Somatoform disorders, 1163–1165
Somatization disorders, 1164
South American blastomycosis, 2324
SOX10 in Waardenburg syndrome, 789
Sparganosis, 2568–2569
Spider bites, 2600–2603
Spider nevus, 1827
Spider veins, 2999–3000
Spinal accessory nerve injury in surgery, 2907
Spinal cord, 1138
Spinal cord injury, hyperhidrosis in, 938t
SPINK5/SPINK5, 168
Spinosad, 2702
Spinous layer of epidermis, 61–62
Spiradenoma, eccrine, 1350–1351
Spirometra erinacei, 2569
Spirometra mansoni, 2569
Spirometra mansonoides, 2569
Spirometrosis, 2569
Spironolactone
  in hair loss, 986
Spitz nevus, 1398–1341
  clinical findings in, 1399
  differential diagnosis of, 1401b
  histopathology in, 1400
Splendore-Hoeppli phenomenon
  in zygomycosis, 2317
Splinter hemorrhages of nails, 1015
  differential diagnosis of, 2196b
  in endocarditis, 2195, 2196
  in liver disease, 1824
Split hand-split foot-ectodermal dysplasiacleft lip/palate syndrome, 1699
Split-nail deformity, 2962
Spongiosis
  epidermal cohesion in, 45
  vesicles in, 36, 45, 45f
Sporothrix schenckii
  occupational exposure to, 2626
Sporotrichosis, 2312–2313
  clinical findings, 2312
  differential diagnosis of, 2313
  epidemiology, 2312
  forms
    fixed, 2312
    lymphangitic, 2312
    systemic, 2313
  in HIV infection and AIDS, 2313
  laboratory tests, 2313
  treatment, 2313
Sports dermatology, **1115**–1121. *See also* Athletes
Spotted fever
  Mediterranean, 2463
  Rocky Mountain, 2456–2463
SPR1 and SPR2
Squamous cell carcinoma, **1283**–1294
  animal models of, 1247–1248
  clinical findings in, 1286
  differential diagnosis of, 1291
  epidemiology of, 1284
  etiology and pathogenesis, 1284–1286
  genital, 1288
    penil carcinoma, 874–877
    clinical findings in, 874–875
    differential diagnosis of, 876b
    histology, 876
    prevention, 877
    prognosis, 876
    treatment in, 876–877
  grades of, 1290
  in heat exposure, chronic, 1285
  histopathology in, 1290
  in HIV infection and AIDS, 2444
  in immunosuppression, 1285
  in keratoacanthoma, 1289
  in lichen planus, 306
  in lower lip, 1288
  metastasis of, 1289
  morphology in, 1287

mortality rate in, 986
of nails, 1021–1022
oral, 840, 1287
p53 in, 1285–1286
in papillomavirus infections. *See* Papillomavirus infections, squamous cell carcinoma in
precancerous lesions in, **1261**–1282
precursor lesions in, 1284
predisposing factors in, 1284–1285
prevention of, 1294
recurrent, 1291–1292, 1293
in scars, 1285, 1289
treatment of, 1292–1293
cryotherapy in, 2971
electrosurgery in, 2974
Mohs micrographic surgery in, 1292, 2954
radiation therapy in, 1293, 2897
topical therapy, 1292
in ultraviolet radiation exposure, 1284
verrucous, 1289
Squamous cell carcinoma in situ
Bowen disease in, 1273–1276
Squaric acid dibutyl ester in warts, 2706
Staphylococcus aureus infections, **2128**–2139
in atopic dermatitis, 178
cellulitis in, 2166–2168
clinical findings in, 2129
in drug abuse, 2129
epidemiology of, 2128
etiology and pathogenesis in, 2129
exfoliative toxins in, 2148, 2149, 2148–2152
exotoxins in, 2149t
immune response in, 2129
in occupational exposures, 2623
Staphylococcus epidermidis, 2912
Staphylococcus intermedius, 2579
Staple closure of surgical wounds, 2920
Starfish *(Acanthaster planci),* 2591
STAT (signal transducer and activator of transcription), 131–132, 132f
and interleukin IL-10, 139
Status cosmeticus, 3013
Stavudine in HIV infection, 2795t
Steatocystoma
multiplex, 1335
in pachyonychia congenita type II, 546, 1335
simplex, 1335
Steel factor, 776
as melanogenic stimulator, 776
Stem cell(s)
epidermal, **473**–477
division of, 474
niche of, 476
regulatory mediators of, 475–476
in rete ridges, 474–475
in skin cancer, 476
hair follicle, 475
melanocyte, 765
age-related changes in, 967
transplantation of. *See* Stem cell transplantation
Stem cell transplantation
graft-versus-host disease in, **316**–329
in Wiskott-Aldrich syndrome, 1711
Sternomastoid tumor of infancy, 714
Steroids
in atopic dermatitis, 175–176
glucocorticoid. *See* Glucocorticoid therapy
for mucosal lichen planus, 309–310
for psoriasis, 228for vesiculobullous hand dermatitis, 192
Stevens-Johnson syndrome, **439**–448. *See also* Epidermal necrolysis
vulvar disease in, 887
Still's disease. *See* Adult-onset Still's disease (AOSD)
Sting and bite injuries. *See* Bites and stings
Stoma procedures, abdominal, skin problems in, **1104**–1110
Stork bite, 2078
Stratum corneum, 63
Strawberry tongue
Streptococcal infections, **2139**–2147
antibody response and immunity, 2140–2141
antimicrobial therapy for, 2144
cellulitis in
treatment of, 2168
dactylitis in, 2143
gangrene in, 2172
histopathology in, 2172
group A, 2139, 2141b
classification of, 2141b
epidemiology of, 2139
etiology and pathogenesis of, 2139–2140
immune response to, 2140–2141
impetigo in, 2141–2142
intertriginous, 2142–2144
invasive, 2144
management of, 2144
poststreptococcal nonsuppurative cutaneous sequelae, 2144
toxic syndrome in, 2144
treatment/management of, 2144–2145, 2145b
group B, 2140
group C, 2140
group D, 2140
group G, 2140
group L, 2140
in occupational exposures, 2623
Streptococcal pyrogenic exotoxins, 2149t
Streptococcus iniae, 2223
prevention, 2223
Streptococcus pyogenes
portal of entry, 2122
Streptomycin
in actinomycetoma, 2252
in tuberculosis, 1775t
Striae, 33, 721
alba, 721distensae, 33
treatment in, 721
elastotic, 721
gravidarum, 721
laser therapy in, 721, 2885
rubra, 721
Wickham, 298
Striated muscle tumors, 1473–1474
Striations in nails, longitudinal, 1014
Strongyloides fuelleborni, 2561
Strongyloides stercoralis, 2561
Strongyloidiasis, 2561–2562
differential diagnosis of, 2562
disseminated, 2562
thumbprint sign in, 2562
treatment of, 2562
Sturge-Weber syndrome
capillary malformations in, 2080
Subcorneal pustular dermatosis, **383**–385
clinical findings in, 383–384
epidemiology, 383
etiology and pathogenesis, 383
differential diagnosis in, 384b, 385
histopathology in, 384
treatment of, 385, 385b
Subcutaneous fat, 56–57. *See also* Hypodermis
embryonic and fetal, 72
lipodystrophy of, **755**–763
necrosis of, 56
in neonates, 750–753, 1191
neoplasms of, **1489**–1497
pathologic reactions of, 56–57
Subcutis. *See* Hypodermis
Substance abuse. *See* Drug abuse
Substance P
in pruritus, 1156
Sulfacetamide, 2674
Sulfasalazine
in psoriasis, 228
and arthritis, 240
Sulfatase deficiency, 532
multiple, 532
Sulfonamides, 2676
Sulfur, topical
in scabies, 2571b
in seborrheic dermatitis, 265
Sunburn, 798, 1040
Sun exposure. *See also* Ultraviolet radiation exposure
distribution of lesions in area of, 41
and lesions in areas protected from, 41
melanoma risk, 1417
Merkel cell carcinoma and, 1363
as public health concern, 24
Sunglasses, 2712–2713
luminous transmittance of, 2712–2713
Sun protected areas, 41
Sun protection factor of sunscreens, 2708
effect on sunburning dose, 2708
Sunscreens, 798, 799, 1005, 2707
in children, 2710
history of, 2707–2708
immune protection factor of, 2709
and melanoma incidence, 2711
nanoparticles in, 2712
in squamous cell carcinoma prevention, 1294

Sunscreens—*continued*
sun protection factor (SPF) of, 2708
effect on sunburning dose, 2708
effect on vitamin D levels, 2711
in ultraviolet A protection, 2708–2709
in ultraviolet B protection, 2709
ultraviolet filters in, 2709
photoallergy from, 2709
photostability of, 2709, 2711b
and vitamin D levels, 2711
Superantigens, 2152–2159
in recalcitrant erythematous desquamating disorder, 2156–2157
in scarlet fever, 2157
staphylococcal, 2158
streptococcal, 2157–2158
in staphylococcal infections, 2154–2155
in streptococcal infections, 2155–2156
and T-cell activation, 2153
in toxic shock syndrome, 2154–2156
staphylococcal, 2154–2155
streptococcal, 2155–2156
Superficial musculoaponeurotic system, 2907
Superficial reactive unit, 42–49
Suramin in African trypanosomiasis, 2540
Surface changes, 34–36
Surgery
with abdominal stoma, skin problems in, **1105**–1110
anatomy in
cheeks, 2908
chin and lips, 2908
danger zones, 2906–2907
eyelids, 2908
of face, 2906f, 2907
facial nerve, temporal branch, 2907
forehead, 2907–2908
lymphatics, 2911
marginal mandibular nerve, 2907
motor nerves, 2909–2910
muscles, 2909
neck, 2908
nose, 2908
relaxed skin tension lines (RSTLs), 2906
scalp, 2907
sensory nerves, 2908–2909
spinal accessory nerve, 2907
superficial musculoaponeurotic system (SMAS), 2907
vascular supply, 2910
anesthesia in, 2913–2916
antibiotics in, 2113, 2911
complications of, 2977–2983. *See also* Surgery complications
cryosurgery in, **2968**–2972
in decubitus ulcers, 1128
electrosurgery in, **2972**–2976
excisional procedures in, **2921**–2949
flap procedures in. *See* Flaps
in hemangioma of infants, 1465
in hidradenitis suppurativa, 959
in melanoma, 1440–1441
in Merkel cell carcinoma, 1368
lymphadenectomy in, 1368
at primary site, 1368
Mohs micrographic, **2950**–2956
nail, **2956**–2967
in Paget disease, 1375
postoperative care in, 2920
preoperative assessment in, 2911
antibiotics, 2911
medications, 2911
pacemakers and defibrillators, 2912
smoking, 2912
surgical history, 2912
in psoriatic arthritis, 242
skin grafts in. *See* Grafts
skin preparation and aseptic technique in, 2912–2913
in squamous cell carcinoma, 1292
suture materials and techniques in, 2916–2920
technique
anesthesia in, 2913–2916
skin preparation and septic technique, 2912–2913
staple closure, 2920
suture materials, 2916–2917
suture removal, 2920
suturing technique, 2917–2920
in vitiligo, 800
wound healing and repair in, 2995
Surgery complications, **2977**–2983
cryotherapy, 2971–2972
in distant postoperative period
anesthesia use related issues, 2983
buried suture extrusion, 2983
depressed or furrow-like scars, 2982
erythema, 2983
hyperpigmentation, 2983
hypertrophic scar, 2982
hypopigmentation, 2983
milia or keratinous cysts, 2981
spread scars, 2982
suture track marks, 2981
telangiectasia, 2983
electrosurgery, 2975–2976
excisional, 2948–2949
in immediate postoperative period
bleeding, 2979
contact dermatitis, 2979
dehiscence, 2979, 2981
hematoma formation, 2979
infection, 2978
necrosis, 2979
pain, 2979
Mohs micrographic surgery, 2956
nail surgery, 2959–2960
sclerotherapy, 3003–3005
at the time of surgery, 2977–2978
anesthesia-related, 2978
bleeding, 2978
patient's medical problems, 2977
Suspensions, topical medications formulated as, 2648
Sutures
dehiscence of wounds in, 2920
extrusion of, 2963
interrupted, 2917–2918
materials used in, 2916–2917
mattress
horizontal, 2918, 2919f
vertical, 2918, 2919f
removal of, 2920
in excisional surgery, 2927
running, 2918–2920
track marks from, 2981–2982
technique, 2917–2920
Sweat
composition of
in cystic fibrosis, 946
disorders with changes in, 938t, 946–947
Sweat glands
apocrine. *See* Apocrine glands
eccrine. *See* Eccrine glands
embryonic and fetal development, 75
in thermoregulation
with active vasodilation, 1143
anatomy of, 1143
Sweating
anhidrosis. *See* Anhidrosis
classification of disorders, 938t
disorders associated with changes in, 1823
eccrine disorders, **936**–947
gustatory, 938t
hyperhidrosis. *See* Hyperhidrosis
hypohidrosis. *See* Hypohidrosis
Sweet syndrome, **362**–370
classic or idiopathic, 363, 363t
clinical features in, 364–367, 365t
complications of, 370
diagnostic criteria in, 363t
differential diagnosis in, 369, 369t
diseases associated with, 366–367
drug-induced, 363t, 366, 367, 370
epidemiology of, 363
etiology and pathogenesis in, 364
extracutaneous manifestations in, 366
histopathology in, 367–368
laboratory findings in, 367–369
locations of lesions in, 365t, 366
malignancy-associated, 365, 366, 368–369, 1892
neutrophil function in, 347
prognosis and clinical course in, 370
pustular variant of, 365–366
subcutaneous, 367
treatment in, 370
Swimmer's itch, 1120
Swimming-associated problems
mycobacterium infections, 2238
schistosomiasis in, 2567
Swiss cheese appearance, 57
Symmetrical bilateral lesions, 41
Sympathectomy
in Raynaud phenomenon, 2071
Sympathetic nervous system
anatomy of, 1142
functions of, 1142,1143
Syndecans, 685
Syphilis, 2471–2492

biology and pathophysiology, 2473–2474
clinical findings in, 2474–2486
exposure and incubation aspects, 2474
congenital, 2484–2486, 2489–2490
clinical findings in, 2485–2486
diagnosis of, 2489–2490
diagnostic tests in, 2486–2490
cerebrospinal fluid examination, 2490
darkfield microscopy, 2486–2487
direct fluorescence antibody test, 2487–2488
T. palladium direct direction, 2486–2488
differential diagnosis of, 2482b
disease reporting and management aspects, 2491–2492
endemic, 2497–2498
clinical findings in, 2497–2498
differential diagnosis of, 2498b
histopathology, 2499
treatment of, 2500
epidemiology of, 2472–2473
hair loss in, 995
histopathology in, 2488
history of, 2471–2472
and HIV infection, 2486
clinical findings, 2486
latent, 2480–2481
clinical findings, 2480–2481
neurologic disorders in, 2483–2484. *See also* Neurosyphilis
clinical findings in, 2483–2484
primary, 2474–2476
clinical findings in, 2474–2476
differential diagnosis of, 2476b
histopathologic examination, 2488
secondary, 2476–2480
clinical findings in, 2476–2480
differential diagnosis of, 2480b
histopathology in, 2488
serologic tests in, 2488–2489
nontreponemal, 2488–2489
treponemal, 2489
stages of, 2474t
tertiary, 2481–2483
clinical findings in, 2481–2483
differential diagnosis of, 2482b
histopathology in, 2488
treatment of, 2490–2491
complications of, 2491
Syringocystadenoma papilliferum, 1345–1346
Syringoma
chondroid, 1353
eccrine, 1348
laser therapy for, 2881
System for Thalidomide Education and Prescribing Safety (S.T.E.P.) program, 2831

T

T cell(s), 113–117
activation of, 113,115,116,117
in adaptive immune response, 113–117
in allergic contact dermatitis, 153, 154
helper T cells in, 117
antigen receptor, 113–114
in atopic dermatitis, 117, 167–168
helper T cells in, 168
chemokine-mediated migration of, 145–147
classification of, 113
cytokines derived from, 115, 127–128
cytotoxic, 114
in lichen planus, 297–298
helper. *See* Helper T cells
in lichen planus, 297–298
memory, 117
skin homing of, 117
naive, 114
in psoriasis, 200
regulatory. *See* Regulatory T cells
suppressor, 116
T cell leukemia, adult, 2435–2438
acute, 2436
chronic, 2436
classification of, 2435–2436
clinical findings in, 2435–2436
cutaneous type, 2436
diagnosis and differential diagnosis of, 2436–2437
diagnostic criteria on, 2435b
histopathology in, 2436
in HTLV-1 infections, 2436–2437
lymphoma-type, 2436
multi-lobated leukemic cells in, 2436, 2436f
smoldering, 2435, 2436
treatment and prognosis in, 2437–2438
T-cell lymphoma, 117, **1745**
aggressive epidermotropic, 1756
anaplastic large cell, 1754–1755
CD8+ T cells in, 1748, 1756
classification of, 1746b
provisional entities in, 1756–1757
cutaneous γ/δ, 1756–1757
cytokines in, 1747–1748
disseminated skin-limited disease, 1759
erythroderma in, 1750, 1761
etiology in, 1746–1747
extranodal nasal, 1756
Fas receptor and Fas ligand in, 1747
mycosis fungoides, 1748–1752
pathogenesis of, 1747–1748
peripheral, 1757
pleomorphic small or medium-sized, 1756
relapse and recurrence of, 1760
Sézary syndrome in, 1752–1753
staging of, 1757–1758, 1757t, 1758b
subcutaneous, and panniculitis, 1755
treatment of, 1758
carmustine in, 1759
in disseminated patch/plaque disease, 1759
in erythroderma, 1761
interferon-α therapy, 1762
maintenance therapy in, 1760
mechlorethamine in, 1760
photochemotherapy in, 1761, 2858
phototherapy in, 1759–1760, 2864
radiation therapy in, 1760, 2897
retinoids in, 1761
skin-directed therapy in, 1759
T-cell lymphotropic virus infections, **2434**–2438
type 1, 1386, 2435–2438
adult T-cell leukemia/lymphoma in, 2435–2438
dermatitis in, 2438
in HIV infection and AIDS, 2454
neurologic disorders in, 2438
type 2, 2434
T-cell receptor
antigen receptor, 113–114
T-plasty, 2933
Tacrolimus, 2694
in atopic dermatitis, 177
complications of, 2696b, 2813
contraindications to, 2694b
dosing regimen, 2811t
indications for, 2813
initiation of therapy with, 2694–2695, 2812
interaction with other drugs,
in lichen planus, 310
mechanism of action, 2812
monitoring of therapy with, 2695, 2812
pharmacokinetics of, 2694, 2812
in seborrheic dermatitis, 265
in vesicular palmoplantar eczema, 192
Taenia solium, 2567
Tanning response, 778
delayed, 778
immediate, 778
TAP (transporter associated with antigen processing), 118
Tar preparations
coal tar. *See* Coal tar preparations
phototoxicity from, 1071
Tarantula bites, 2603
Targetoid lesions, 39
Tattoos, 1130–1133
application process, 1130–1131
complications of, 1131–1132
oral, 843
pigments used in, 1131, 1132t
reactions to, 1131
removal of, 1132–1133
laser therapy in, 1133, 2887–2889
temporary, 1133
Tazarotene
in psoriasis, 225
Tegenaria spider bites, 2603
Telangiectasia, 37
and ataxia. *See* Ataxia, and telangiectasia
and cutis marmorata in neonates, 1191
hereditary hemorrhagic, 2091
laser therapy in, 2880
of leg veins
in sclerotherapy complications, 3005
sclerotherapy in, 3003
postoperative, 2983
in sun-exposed areas, 1070

Telogen, 969
  definition of, 988
  effluvium, 988, 1190
    acute, 989
    causes of, 990b
    chronic, 989–990
    drug-induced, 989
    epidemiology, 988
    treatment, 990
  immediate telogen release, 969
Telomerase, 77
Telomeres, 77
  length of, 77
Temporal artery
  giant cell arteritis of, 2026
  surgical anatomy of, 2910
Temporal nerve, 2909–2910
Tenofovir in HIV infection and AIDS, 2795t
Terbinafine, 2796–2800
  in adult, 2798
  chemical structure of, 2797f
  in children, 2798
  in dermatophyte infections, 2293
  drug interactions, 2799
  dosage of, 2799t
    pediatric, 2798
  in elderly, 2798
  indications for, 2797–2798
  interaction with other drugs, 2799
  mechanism of action, 2797
  pharmacokinetics of, 2797
  side effects and complications of, 2799
Terrorism attacks
  biologic weapons in, 2633–2638. *See also* Bioterrorism
  chemical weapons in, 2638–2641
  radiologic weapons in, 2641
Terry's nails, 1824
Tetracycline, 2780–2781
  in actinomycetoma, 2252
  in children, 1203
  indications for, 2781b
  mechanism of action, 2780
  pharmacokinetics of, 2781
  in seal bite, 2218, 2584
  side effects and complications of, 2781b
TGM. *See* Transglutaminase, tissue
Thalidomide, 2830–2831
  contraindications to, 2831b
  indications for, 2831
  initiation and monitoring of therapy, 2831
  in lichen planus, 310, 311
  mechanism of action, 2830
  in pruritus, 1156
  side effects and complications of, 2830, 2832b
    in pregnancy, 2832b
Thermal injuries, **1089**–1094
  in chronic heat exposure. *See* Heat, chronic exposure to
  complications, 1091
  hyperpigmentation in, 820
  keratosis in, 1270
  lightning strikes, 1091
  in occupational exposures, 2627–2628
Thermoregulation, **1075**–1079
  anatomy in, 1076–1077
  cutaneous regulation mechanism, 1077
  factors altering response to, 1078
  heat transfer in, 1075–1076
  Hunting reaction and, 1080
  neural control of, 1077
  sweat glands in, 1077
Thiabendazole
Thiamine, 1510–1511
  deficiency of, 1510–1511
  excess of, 1510
  food sources of, 1510
Thin-Layer Rapid Use Epicutaneous (T.R.U.E.) patch test, 162
Thioguanine, 2744–2745
  complications of, 2744–2745
  drug interactions, 2745
  dosage regimen, 2744
  indications for, 2744
  mechanism of action, 2744
  monitoring of therapy with, 2744
  in psoriasis, 228
Threadworm, 2560–2561
Three-compartment model on drug pharmacokinetics, 2653–2657
  skin barrier
    appendages, 2655–2656
    inter- and intraindividual variation, 2656–2657
    penetration pathways, 2656
  skin surface
    formulations, 2655
    liposomes, 2655
    reservoir, 2654–2655
    surface applications of formulations, 2654
  viable tissue, 2657
Thromboangiitis obliterans, 2104–2106
  approach to patient with, 2105
  differential diagnosis of, 2105b
  treatment of, 2104–2106
Thrombophlebitis
  superficial
    in sclerotherapy complications, 3005
Thrombosis
  of deep veins, 2116
Thymic stromal lymphopoietin (TSLP), 137
  in atopic dermatitis, 169
Thymidine incorporation, 1234
Thyroid disorders, **1851**–1856
  autoimmune, 1851
  clinical findings in, 1853–1856
  congenital, 1852
  cutaneous signs of, 1853–1856
  dermopathy in, 1854–1855
    elephantiasic, 1854
    treatment of, 1856
  drug-induced, 1852, 1853t
  epidemiology of, 1851
  etiology and pathogenesis in, 1852–1853
  hair changes in, 1852, 1856
  in hemangioma of infants, 1462
  hyperpigmentation in, 1854, 1855
  hyperthyroidism. *See* Hyperthyroidism
  hypothyroidism. *See* Hypothyroidism
  laboratory tests in, 1856
  nail changes in, 1852, 1854, 1856
  pruritus in, 1853
  in retinoid therapy, 2765
  treatment of, 1856
  and urticaria, 1855
  vitiligo in, 1854
Thyroid hormone(s), 1852–1853
  drugs affecting, 1853b
  synthesis of, 1852–1853
Thyroid-stimulating hormone, 1852–1853
Thyroid transcription factor-1 in Merkel cell carcinoma, 1366
Thyroiditis, Hashimoto, 1853
  cutaneous findings in, 1856
  Thyrotoxicosis. *See* Hyperthyroidism
Thyrotropin, 1852, 1853b
Thyrotropin-releasing hormone, 1852
Thyroxine, 1852, 1853b, 1855b
Ticks, 2604–2605
  and African tick bite fever, 2463
  and Mediterranean spotted fever, 2463
  and Rocky Mountain spotted fever, 2456–2463
Tietz syndrome, 790
Tigecycline, 2787
Tight skin, 3018–3019
TIMP (tissue inhibitors of metalloproteinases)
  in lichen planus, 298
Tinctures, topical medications formulated as, 2648
Tinea barbae, 2287
  differential diagnosis of, 2287b
  treatment of, 2295
Tinea capitis, 2284–2286
  black dot, 2285
  in children and infants, 1190, 1199
  differential diagnosis of, 2277t
  histopathology in, 2286
  inflammatory, 2285
  treatment of, 2293–2295
Tinea corporis, 2288
  differential diagnosis of, 2288b
  treatment of, 2295
Tinea cruris, 2289
  differential diagnosis of, 2290b
  treatment of, 2295
Tinea favosa, 2286–2287
Tinea mannum, 2290
  treatment of, 2295
Tinea nigra, 2296
Tinea pedis, 2290
  acute ulcerative, 2291
  chronic hyperkeratotic, 2291
  differential diagnosis of, 2291b
  Id reaction in, 2291
  interdigital type, 2290

and onychomycosis, 2292–2293
treatment of, 1818b, 1819, 2295
vesiculobullous, 2290
Tinea unguium, 2292
Tinea versicolor, 2307–2310
diagnosis of, 2308
differential diagnosis of, 2308b
pathology in, 2308
treatment of, 2308–2310
Tissue inhibitors of metalloproteinases
in lichen planus, 298
Tissue transglutaminase. *See* Transglutaminase, tissue
TLR. *See* Toll-like receptors
Tobacco, abuse of, 1173–1174
Tobacco exposure
in cigarette smoking. *See* Smoking
oral changes in, 835
from cigarette smoking, 835
leukoplakia in, 835
from pipe smoking, 835
Toes. *See also* Foot
congenital malalignment of great, 2967
distal toenail embedding, 2967
Tolerance
and autoimmunity, 1904–1906
central, 1904
peripheral, 1904-
Toll-like receptors, 109–110
in acne vulgaris, 108
activation of, 108
in innate immunity, 110
MΦ and DC Differentiation, 110
TLR-induced antimicrobial activity, 110
TLR-induced cytokine release, 110
in reactive arthritis, 245
Tolnaftate, 2683
Tongue, **848**–851
fissures and furrows in, 849
geographic, 850
glossitis of, 848. *See also* Glossitis
hairy, 848–849
lingual tonsil, 851
macroglossia, 850–851
nodules, 851
splitting procedure as body art, 1130
Tooth and nail syndrome of Witkop, 1699–1701
Topical medications, **2643–**2651
absorption of, 2644–2645
cutaneous metabolism affecting, 2643
factors affecting, 2644–2645
occlusion, 2644
penetration pathways in, 2656
stratum corneum affecting, 2644, 2656
in actinic keratosis, 1268
adherence, 2645
rebound effect, 2645
tachyphylaxis, 2645
analgesic, 2697
anesthetics, 2697
antibiotics, **2673**–2676
in acne and rosacae, 2673–2674
in bacterial infections and burns, 2674–2676
anti-inflammatory, 2697–2698
anti-microbial, 2698–2701, 2699t, 2670t
anti-parasitic agents, 2701–2702
antiperspirant, 2703
antipruritics, 2703–2704, 2703t
application of, 2645
frequency of, 2644
with occlusion, 2644
quantity of, 2644
astringent, 2704
in atopic dermatitis, 175–177
anti-inflammatory, 175–176
calcineurin inhibitors, 177
glucocorticoids, 176
hydration, 175
bleaching agents, 2704
in children, 1201–1203
hemangioma of infants, 1465
combination with phototherapy, 2857
cytotoxic, **2685**–2689
in dermatitis
allergic contact, 2650
atopic dermatitis, 175–177
irritant contact dermatitis, 2649–2650
subjective/sensory irritant contact dermatitis, 2650
endocrine system, effect on, 2651
enhancers, penetration
chemical enchancers, 2649
physical enchancers, 2649
hypersensitivity reactions, type I, 2650
immunomodulators, **2690**–2696
keratolytic, 2705–2706
in lichen planus
mucosal, 309–310
in malignancies, 2650
local effects, 2650
systemic effects, 2650
in palmoplantar pustulosis, 256
pharmacokinetics of, 2652
barrier function of skin affecting, 2655–2657, 2658
diffusion in, 2652
resorption in, 2658
skin metabolism in, 2657
three-compartment model of, 2653–2657
photodynamic therapy, 2866–2868
in pityriasis rubra pilaris, 283–284
in psoriasis, 2706
reservoir on skin surface in, 2654
in seborrheic dermatitis, 265
stabilizers in, 2649
thickening agents, 2649
toxicity of, 2649
local, 2649–2650
systemic, 2650–2651
vehicle formulations of
aerosol, 2648–2649
liquid, 2648
ointment, 2647–2648
paste, 2648
poultice, 2647
powder, 2646–2647
for vesiculobullous hand dermatitis, 192
in vitiligo, 799, 800
in warts, 2706–2707
Torso,
allergic contact dermatitis of, 158
Toxic epidermal necrolysis, **439**–448. *See also* Epidermal necrolysis
Toxic oil syndrome
eosinophils in, 400
Toxic shock syndrome, 2154–2156
in body piercing complications, 1134t
clinical findings in, 2154–2155
differential diagnosis of, 2155
staphylococcal, 2154–2155
streptococcal, 2155–2156
treatment and prognosis in, 2155–2156
Toxic shock syndrome toxin 1 (TSST-1), 2154–2155
Toxocara canis, 2566
Toxocariasis, 2566
Toxoplasma gondii, 2543
Toxoplasmosis, 2543–2544
acquired, 2543
congenital, 2543
differential diagnosis of, 2543–2544
in immunocompromised host, 2543
transmission of, 2543
treatment, 2544
Trachyonychia, 1014
nail dystrophy, 1025–1025
Track marks
from sutures, 2981, 2982
Tragus of ear, 2906
and antitragus, 2906
TRAM, 131
Transepidermal water loss
in dry skin, 3009
Transfer RNA, 76
Transforming growth factor-β, 112, 140
latent transforming growth factor-β–binding proteins (LTBP), 683
radiation therapy and, 2895
receptor for, 140
Transforming growth factor-β1, 140
immunoregulatory role of, 140
in wound healing, 2994
impaired, 2994
Transfusions
Translocation
Balanced, 83
reciprocal, 83
Transplantation
stem cell. *See* Stem cell transplantation
Transposition flaps, 2936-2940
30° angle Webster, 2939
banner, 2939
bilobed, 2939–2940
DuFourmental, 2938–2939
rhombic, 2937–2938
Trapdoor nail avulsion, 2961

Trauma
in child abuse, **1177**–1181
in cold injuries, **1079**–1089
in domestic violence, 1182–1183
in elder abuse, **1181**–1182
hair loss in, 1001–1002
of spinal cord, hyperhidrosis in, 938t
in thermal injuries, **1089**–1094
Treg cells. *See* Regulatory T cells
TREM proteins, 109
Trematode infections, 2566–2567
Trench fever, 2205
Treponema pallidum
differential diagnosis of, 2502
in syphilis, 2471, 2473–2474. *See also* Syphilis
Treponematosis
nonvenereal endemic, **2493**–2500
clinical manifestations of, 2499t
diagnosis of, 2498–2499
histopathology, 2499–2500
hypomelanosis in, 809
treatment of, 2500
venereal syphilis in. *See* Syphilis
Tretinoin
as bleaching agent, 2704
in lichen planus, 310
Triamcinolone acetonide
in lichen planus, 310
Triatoma kissing bugs, 2606
Triazole antifungal agents, 2800–2803
Trichilemmal cyst, 1361
Trichilemmoma, 1360–1361
Trichinella spiralis, 2566
Trichinosis, 2566
Trichloroacetic acid
in chemical peels, 3029
Trichoadenoma of Nikolowski, 1359
Trichoblastoma, 1357
Trichoclasis, 1003
Trichodiscoma, 712, 1356
Trichoepithelioma, 1357–1358
desmoplastic, 1358
laser therapy for, 2881
multiple, 1357–1358
solitary, 1357
Trichofolliculoma, 1356
Trichomonas vaginalis, 2523–2524
Trichomoniasis, 2523–2524
and HIV infection, 2524
laboratory tests in, 2523–2524
strawberry cervix in, 2523, 2523f
treatment of, 2524, 2524b
vaginal pH in, 2523
Trichomycosis
axillaris and pubis, 2147
Trichophyton concentricum, 2284, 2284t, 2288
Trichophyton gourvillii, 2278t, 2284t
Trichophyton interdigitale, 2278, 2278t, 2292
Trichophyton megninii, 2278t, 2284t, 2287, 2292
Trichophyton mentagrophytes, 2278t, 2285t
occupational exposure to, 2625
in tinea barbae, 2287
in tinea capitis, 2285t
in tinea favosa, 2286
in tinea pedis and manus, 2291
Trichophyton rubrum, 2278, 2278t, 2279
occupational exposure to, 2625
in onychomycosis, 2292
in tinea barbae, 2287
in tinea corporis, 2288
in tinea cruris, 2289
in tinea pedis and manus, 2291
Trichophyton schoenleinii, 2278t
in favus, 2286
in tinea barbae, 2287
in tinea capitis, 2285b
Trichophyton soudanense, 2278t, 2284t
Trichophyton tonsurans, 2278t, 2284t
in onychomycosis, 2292
in tinea capitis, 2285b
in tinea corporis, 2288
Trichophyton verrucosum, 2284t
in tinea barbae, 2287
in tinea corporis, 2288
in tinea cruris, 2289
Trichophyton violaceum, 2278t, 2284t
in favus, 2286
in tinea barbae, 2287
Trichophyton yaoundei, 2278t, 2284t
Trichorrhexis
invaginata, 1003
nodosa, 1002
Trichoschisis, 1003
in trichothiodystrophy, 1003
Trichosporonosis, 335
Trichothiodystrophy, 1655, 1656t, **1665**–1667
clinical features in, 1666f, 1666–1667
genetic factors in, 1655
photosensitivity in, 1667
tiger tail appearance in, 1666, 1666f
trichoschisis in, 1003, 1666, 1666f
Trichotillomania, 1002
Tricyclic antidepressants
antihistaminic activity of, 2775
Trifluridine, 2791–2792
Trigeminal nerve
anesthetic block of, 2916
surgical anatomy of, 2908
Trimethoprim-sulfamethoxazole, 2784–2785
dosage of, 2778t
indications for, 2784b
mechanism of action, 2784
pharmacokinetics of, 2784
side effects and complications of, 2785b
Tripe palms, 1885–1886
in acanthosis nigricans, 1842, 1883, 1885
in paraneoplastic syndromes, 1881t
Tripelennamine, 2770t. *See also* Antihistamines
Trisomy, 84
Trisomy 13, 84t
Trisomy 18, 84t
Trisomy 21, 84t
Tropoelastin, 679
T.R.U.E. patch test, 162
Truncal lesions, 41
Trypanosoma brucei, 2607, 2539
Trypanosoma cruzi, 2607
Trypanosomiasis
African, 2537–2540
treatment, 2540
American, 2540–2541
stages of, 2541b
transmission of, 2540, 2607
treatment, 2541
Tuberculids, 2233–2234
lichen scrofulosorum, 2233–2234
differential diagnosis of, 2234b
papulonecrotic, 2234
differential diagnosis of, 2234b
Tuberculin reaction, 2226–2227
Tuberculosis, 2225, **2226**–2233
from Bacille Calmette-Guérin vaccination, 2233
chancre in, 2228–2229
classification of, 2227t
colliquativa cutis, 2231
cutaneous, **2226**–2233
epidemiology of, 2226
host, 2226
infection route, 2227
mycobacteria, 2226
tuberculin reaction (Koch phenomenon), 2226–2227
extensively drug resistant, 2236
granuloma in, 2238
histopathology in, 2227
in immunocompromised host
in AIDS, 2225–2226
lichen scrofulosorum in, 2233–2234
lupus vulgaris in, 2230–2231
differential diagnosis of, 2231b
in occupational exposures, 2624
oral cavity disorders in, 2232–2233
differential diagnosis of, 2233b
orificial tuberculosis, 2232–2233
papulonecrotic tuberculid in, 2234
polymerase chain reaction (PCR) procedure, 2228
primary inoculation, 2228–2229
QFT-G test in, 2228
scrofuloderma in, 2231–2232
differential diagnosis of, 2232b
skin test in, 2228
treatment of, 2235–2236
ulcerosa cutis et mucosae, 2232
verrucosa cutis, 2229
differential diagnosis of, 2230b
warty, 2229–2230
differential diagnosis of, 2230b
treatment, 2235–2236, 2235t
Tuberous sclerosis, **1671**–1679
affect on organs
brain, 1676
eyes, 1676
GI tract, 1676
heart, 1676
kidney, 1676
lungs, 1676
cardiac rhabdomyoma in, 1676
clinical findings in, 1672–1677
complications of, 1677

confetti skin lesion in, 1673, 1674f
dental pitting in, 1676
diagnostic criteria on, 1672, 1673t
differential diagnosis of, 1678b
epidemiology of, 1671
etiology and pathogenesis of, 1671–1672
facial angiofibromas in, 1674, 1674f
facial plaque in, fibrous, 1674, 1675f
genetic factors in, 1671, 1672f
counseling on, 1679
diagnosis of, 1677
histopathology in, 1677
hypomelanotic macules in, 1673, 1673f, 1674f
laboratory tests in, 1677
nail changes in, 1675
oral firbomas in, 1676
prognosis and clinical course in, 1677–1678
shagreen patch in, 1675, 1675f
treatment of, 1678–1679
ungual fibromas in, 1675, 1675f
Tufted angioma, 1467
Tularemia, 2214–2215
in bioterrorism, 2637
in occupational exposures, 2624
oculoglandular, 2214–2215
pulmonary, 2637
treatment of, 2215, 2637
typhoidal, 2515
ulceroglandular, 2214
vaccination against, 2637
Tumor necrosis factor, 112, 134–135, 193
Tumor necrosis factor-α, 112, 134–135
in lichen planus, 297
in psoriasis, 229
and arthritis, 240–241
as therapy target, 2815t, 2819–2822
complications in, 2820–2821
in psoriasis, 2819–2822
in rheumatoid arthritis, 2819–2822
Tumor necrosis factor receptor
periodic syndrome associated with, 1595–1598
clinical findings in, 1596
differential diagnosis of, 1598
Tumors. *See also specific tumor types*
appendage tumors of skin, **1337**–1361
atrial myxoma, 1829
basal cell carcinoma, **1294**–1303
biology and biochemistry of, 1245–1250
carcinogenesis in. *See* Carcinogenesis
chemokines in, 149–150
of dermis
benign, **707**–717
malignant fibrous, **1445**–1455
epithelial
benign, **1319**–1336
premalignant, **1261**–1282
field cancerization concept in, 1279
keratoacanthoma, **1312**–1318
in lichen planus, 306
melanocytic, **1377**–1444
melanoma, **1416**–1444
of nails
of proximal nail fold, 2966
of nerves, 1470–1480. *See also* Neuroma
paraneoplastic syndromes in, **1880**–1890
pemphigus in, **600**–608
skin changes associated with, 1823–1824
in cutaneous paraneoplastic syndromes, **1880**–1890
of small bowel, 1457
squamous cell carcinoma, **1283**–1294
of subcutaneous fat, **1489**–1497
vascular, **1456**–1469
classification of, 2077t
virus-associated, 995t, 1259
Tunga fleas, 2607
Tyloma, **1111**–1114. *See also* Callus formation
Typhus, 2466
endemic, 2466
differential diagnosis of, 2466
murine or flea borne, 2466
treatment of, 2466
epidemic (louse borne), 2466–2467
treatment of, 2467
scrub, 2467–2468
TYR, 94
Tyrosinase-related proteins
in melanocyte development, 769–770
in melanogenesis, 771
Tyrosine
in alkaptonuria, 1534
Tyrosine aminotransferase, 1526t
Tyrosine kinase receptors, 778
Tyrosinemia, **1527**–1530
type I, 1527
type II (oculocutaneous), 548, 1527, 1526t
clinical features in, 1527–1529
differential diagnosis of, 1530
genetic factors in, 1529
laboratory findings in, 1529
treatment of, 1530
type III, 1527

U

Ulcerative colitis, 1833
Ulcers, 32
in amputation stump, 1097
decubitus. *See* Decubitus ulcers
in dermatomyositis, 1938
in helminthic infections, 2555
in lichen planus, 301
M. ulcerans, 2238
of male genitalia
spontaneous, 872–873
oral, 830–833
aphthous, 830–831
in sclerotherapy complications, 3005
venous, 2113, 2114b
Ulcus molle. *See* Chancroid
Ulerythema ophryogenes, 974–975
Ultrasonography
cutaneous, 43
Doppler. *See* Doppler imaging
Ultraviolet filters in sunscreens, 2709, 2710t
photoallergy from, 2709
photostability of, 2709
Ultraviolet radiation exposure, 1032–1033
absorption of radiation in. *See* Absorption of radiation
in atopic dermatitis, 179
induced mutations, 1253
carcinogenesis in, 1241, **1251**–1260
melanoma mutations, 1256
color of skin and, 3018
DNA damage in, 1253
p53 in, 1255
signature mutations in, 1255
glass in protection from, 2712–2713
immunosuppression from, 1044–1048. *See also* Photoimmunosuppression
melanoma in. *See* Melanoma, in ultraviolet radiation exposure
occupational, 2630–2631
photoaging in. *See* Photoaging
photoallergy in. *See* Photo-allergy
photochemical reactions in. *See* Photochemical reactions
in photochemotherapy, **2851**–2865. *See also* Photochemotherapy
photosensitivity in. *See* Photosensitivity
in phototherapy. *See* Phototherapy
pigmentation changes in, 820
in pityriasis rubra pilaris, 284
protection from. *See* Photoprotection
with psoralen. *See* Psoralen and PUVA therapy
in psoriasis therapy, 226
in seborrheic dermatitis, 266
skin cancer in. *See* Skin cancer, in ultraviolet radiation exposure
skin color and, 3018
sources of, 1034–1036
stem cell populations in, 1257
sunburn in. *See* Sunburn
sunglasses in, 2712–2713
sunscreen use in. *See* Sunscreens
tanning response in. *See* Tanning response
in vesicular palmoplantar eczema, 193
vitamin D synthesis in
in sunscreen use, 2711
Ultraviolet radiation UVA. *See also* Phototherapy
in atopic dermatitis, 179
in pityriasis rubra pilaris, 284
with psoralen. *See* Psoralen and PUVA therapy
in psoriasis therapy, 226
in seborrheic dermatitis, 266
tanning response to, 778–780
in vesicular palmoplantar eczema, 193

Ultraviolet radiation UVB
in atopic dermatitis phototherapy, 179
broadband, 2844
immunosuppression from, 1044–1045
induced inflammation, 1040
narrowband, 2844, 2845t
in psoriasis therapy, 226
in seborrheic dermatitis, 266
in vitiligo, 798–799
Umbilicus, metastasis to, 1824
Uncombable hair syndrome, 1004
Undecylenic acid, 2683–2684
Universal distribution of lesions, 41
Urban trench fever, 2205
Urea
in topical keratolytic preparations, 2706
Ureaplasma, 2522
Urticaria, **414**–431
acute, 414
in infections, 424
treatment of, 428
adrenergic, 421
aquagenic, 421
bradykinin in, 417–418, 422–424
cholinergic, 420
cold, 419
chronic, 415
autoimmune, 415
dermal infiltrates in, 415
idiopathic, 425, 429f
treatment of, 428–429, 429f
in vasculitis, 424
clinical findings in, 418–425
cold, 419
cholinergic, 420
cold contact test in, 419
delayed, 420
familial, 420
treatment of, 428
complement system in, 416, 417, 418, 420–421
contact, 421
from cosmetic products, 3016
in occupational exposures, 2617–2618
definition of, 414
diagnostic approach in, 425–426
differential diagnosis of, 427b
drug-induced, 424, 425
treatment of, 428–429
epidemiology of, 414
exercise-related, 421
in helminthic infections, 2554
histopathology in, 427–428
immunoglobulin IgE in, 418
in contact urticaria, 421
in infections, 424
laboratory findings in, 426–428
local heat, 421
neuropeptides in, 1144
papular, 422, 428
pathogenesis in, 414–418
physical, 418
pressure, 419
in serum sickness, 424
solar, 421, 1060–1062
approach to diagnosis of, 1062
clinical features in, 1061
differential diagnosis in, 1062b
subtypes of, 421, 1061
treatment in, 1062
in transfusions, 424
treatment of, 428–430
antihistamines in, 428
in vasculitis. *See* Vasculitis, urticarial
Ustekinumab, 229–230, 241, 2822

V

Vaccinations
anthrax, 2636Bacille Calmette-Guérin, tuberculosis after, 2233
Haemophilus influenzae, 2188–2190
Lyme disease, 2275
Vaccinia virus
in monkeypox vaccination, 2414b
in smallpox vaccination, 2407–2411
generalized vaccinia from, 2409
progressive vaccinia from, 2409
Vagabond leukoderma, 825
Vaginal disorders
in bacterial vaginosis, 2524–2526
in lichen planus, 303–304
in trichomoniasis, 2523–2524
Vaginosis, bacterial, 2524–2526
in pregnancy, 2525
treatment of, 2525, 2525b
Valacyclovir, 2789–2790
dosage of, 2790, 2790t
in herpes simplex virus infections, 2789–2790
indications for, 2789
side effects and complications of, 2790
in varicella-zoster virus infections, 2789–2790
Valganciclovir, 2792
Validity
of epidemiologic studies, 7
of evidence, critical assessment of, 11–14
of morbidity measures, 7
Valley fever, 2324
Valvular heart disorders
nail signs in, 1825
Vancomycin, 2785
enterococcus resistant to, 2162
Varicella-zoster virus infections, **2383**–2400
clinical manifestations of, 2386
prodromal symptoms, 2386
rash of, 2386–2387
complications of, 2392
diagnosis of, 2390
differential diagnosis of, 2390b
epidemiology of, 2383–2384
etiology and pathogenesis of, 2385–2386
in immunocompromised host, 2395
treatment of, 2395
laboratory tests in, 2391–2392
in pregnancy, 2392
prevention of, 2398–2399
treatment of, 2394–2395
antiviral therapy, 2394
complications, 2395
in children, 2394
in immunocompromised patients, 2395
topical therapy, 2394
vaccination against, 2398–2399
adverse effects of, 2399
Varicose veins, **2997**–2983
ambulatory phlebectomy in, 3007
anatomy and physiology in, 2998
contraindications to treatment in, 2999–3000
endovenous ablation and occlusion in, 3000–3002, 3006
historical aspects, 2997–2998
laser therapy in, 2880–2881, 3006–3008
hemoglobin predominant absorption, 3006
light sources for, 3008
water predominant absorption, 3006–3007
pretreatment evaluation, 3000
radio-frequency technique in, 3006
sclerotherapy in, 3002–3005. *See also* Sclerotherapy, in varicose veins
Variola virus. *See* Smallpox
Vascular cellular adhesion molecule-1, 1994t, 1995t, 1996, 1997
leukocyte adhesion and, 1996
leukocyte extravasation and, 1997–1998
in necrotizing venulitis, 2005
Vascular endothelial growth factor
in bevacizumab therapy, 2828–2829
Vascular endothelial growth factor receptors
in bevacizumab therapy, 2829
Vascular lesions
treatment, 3036–3038
Vascular malformations, **2076**–2093
arteriovenous, 2090–2093
clinical characteristics of, 2091
capillary, 2078–2083
clinical characteristics of, 2080–2081
classification of, 2077, 2077t
clinical findings in, 2077
epidemiology of, 2076
etiology and pathogenesis of, 2076–2077
fast-flow, 2077, 2091
lymphatic, 2086–2090
slow-flow, 2077
treatment of, 2077
venous, 2083–2085
clinical characteristics of, 2084
Vascular tumors, **1456**–1469. *See also* Vascular malformations
Vasculature, **1986**–2002. *See also* Blood vessels
cutaneous, 65–66
Vasculitis, 1833
angiitis. *See* Angiitis

arteritis. *See* Arteritis
in Behçet disease, 2033
classification of, 2013–2014
cutaneous necrotizing venulitis, **2003**–2011
diagnostic algorithm on, 2015f
diagnostic testing on, 2018–2022
drug-induced, 2017, 2024
eosinophils in, 2010
granulomatous, 56
leukocytoclastic, 2024
livedoid
in polyarteritis nodosa, 2025
malignancy-associated, 2024
microscopic polyangiitis, 2022
necrotizing, **2013**–2029
cutaneous venulitis, **2003**–2011
treatment, **2027–**2029
nodular, 56, *736–737*, 2008–2009
physical examination in, 2017
polyarteritis nodosa, 571, 2025
systemic necrotizing, **2013**–2029
clinical findings in, 2016t, 2017t
diagnostic testing of, 2018–2019
epidemiology of, 2013
laboratory tests in, 2019–2022
physical examination, 2017
urticarial, 2007–2008
venulitis. *See* Venulitis, cutaneous necrotizing
in Wegener granulomatosis, 2022–2023
Vasculopathy, 1686–1687, 1938
Vasoconstriction. *See also* Thermoregulation
in cold response, 1077
in corticosteroid therapy, 2659–2660
neural control of, 1077
Vasodilation
cold-induced, 1077
in heat response, 1076, 1077
neural control of, 1077
in hunting reaction of Lewis, 1080
Vasospasm in Raynaud phenomenon, 2071
treatment of, 2071
Venereal diseases, 862
Venereal warts. *See* Warts, anogenital
Venom. *See also* Bites and stings
in hymenoptera stings, 2608
in scorpion stings, 2603–2604
in snake bites, 2581–2583
in spider bites, 2600–2603
Venous disorders. *See also* Lymphedema
chronic, **2110**–2120
approach to patient with, 2112f
clinical findings, 2112–2114
differential diagnosis of, 2114b
epidemiology, 2110
etiology and pathogenesis, 2110–2111
prevention, 2116
signs and symptoms, 2111b
treatment in, 2115–2116, 2115b
ulcers in, 2113, 2114b
malformations, 2083–2085
clinical characteristics of, 2084
differential diagnosis of, 2085b
histology, 2083
pathogenesis, 2084
thrombosis
of deep veins, 2116
varicose veins, **2997**–2983. *See also* Varicose veins
Venulitis, cutaneous necrotizing, **2003**–2011
clinical findings in, 2005–2010
differential diagnosis of, 2011
disorders associated with, 2006–2010
drug-induced, 2007
epidemiology of, 2003
etiology and pathogenesis in, 2003–2005
histopathology in, 2010–2011
laboratory findings in, 2010
treatment of, 2011
urticaria in, 424
Verruca. *See* Warts
Verrucous carcinoma
treatment of
Mohs micrographic surgery in, 2955
Verrucous hyperplasia in limb amputation and prosthesis use, 1100
Verruga peruana, 2208–2209
differential diagnosis of, 2209b
treatment of, 2209
Versican, 686
Vesicles, 36
epidermal cohesion in, 45, 45f
formation of, 45, 45f
in helminthic infections, 2555
in palmoplantar eczema, **187**–193
in spongiosis, 45, 45f
Vesicular palmoplantar eczema, **187**–193
clinical findings in
chronic vesiculobullous dermatitis, 190
hyperkeratotic hand dermatitis, 190
id reaction, 190
pompholyx, 188–190
complications, 192
diagnosis of, 191
differential diagnosis in, 191, 191b
epidemiology of, 188
etiology and pathogenesis in, 188
exacerbating factors in, 188
laboratory findings in, 190
pathology in, 190
prevention of, 193
prognosis and clinical course in, 192
treatment of, 192b
immunotherapy, 193
iontophoresis, 193
leuokotriene inhibitors, 193
radiation therapy, 193
systemic therapy, 192
topical therapy, 192
Vesiculobullous lesions
in lichen planus, 301
Vibration exposure
occupational, 2628
Vibrio, waterborne, 2220–2221
Vibrio carchariae, 2597
Vibrio cholerae, 2220, 2221
Vibrio vulnificus, 2220–2221
complications, 2221
differential diagnosis, 2221
etiology and epidemiology, 2220
prevention, 2221
treatment of infections, 2221
in waterborne infections, 2220–2221
Vibrio parahaemolyticus, 2221
Virion, 2330, 2331, 2331f, 2332f, 2334
Viruses, **2329**–2463. *See also specific viruses*
and antiviral drugs, **2787**–2796
cellular consequences of infections, 2333
classification of, 2330–2331
clinical manifestations of infections, 2334–2335
diagnosis of infections, 2335–2336
epithelial precancerous lesions, viral associated, 1271–1273
exanthems associated with, **2337**–2366
host response to, 2334
pathogenesis of skin infections, 2333
prevention of infections, 2336
replication of, 2331–2333
treatment for infections, 2336
tumors associated with
squamous cell carcinoma, 1285
Visible radiation, 1033–1034
absorption of, 1037
dosimetry in, 1036
and optical properties of skin, 1037
sources of, 1034–1036
Vitamin A, 1504–1506
deficiency of, 1504–1505, 1834
pityriasis rubra pilaris in, 283
food sources of, 1504
toxicity of, 1505–1506
Vitamin B_1, 1510
Vitamin B_2, 1511–1512
Vitamin B_3, 1512–1513
deficiency of, 1513
food sources of, 1512
Vitamin B_6, 1513–1514
Vitamin B_9. *See* Folic acid
Vitamin B_{12}, 1514–1515
deficiency of, 1514–1515, 1834
pigmentation changes in, 1821
Vitamin C, 1515–1516
deficiency of, 1834
Vitamin D, 1507–1509
for atopic dermatitis treatment, 181
deficiency of, 1507–1509
derivatives in morphea, 701
photobiology, 1042–1044
in psoriasis, 224
in seborrheic dermatitis, 266
sources of, 1507
and ultraviolet light exposure, 1507
in sunscreen use, 2711
in vitiligo, 800
Vitamin D receptor, 110

Vitamin D_2, 1507
Vitamin D_3, 1507
in seborrheic dermatitis, 266
Vitamin E, 1509
deficiency of, 1509
food sources of, 1509
Vitamin K, 1509
deficiency of, 1509, 1834
food sources of, 1509
Vitamins, 1504–1517
fat-soluble, 1504–1509
water-soluble, 1510–1517
Vitiligo, **792**–803
acrofacial, 793
in Addison disease, 795, 1861
biochemical hypothesis, 793
classification of, 793–795
clinical findings in, 793–795
comorbid associations, 795
confetti type, 795
in diabetes mellitus, 820
diagnosis, 796–796
differential diagnosis in, 797b
disorders associated with, 793–795
epidemiology of, 792
etiology and pathogenesis in, 792–793
autoimmune hypothesis, 792–793
focal, 794
generalized, 793
genetics of, 792
genital, 863
HLA system in, 792
Koebner phenomenon in, 794, 794f, 797
in lupus erythematosus, 808
melanocyte suspensions for, 802
micropigmentation for, 802
mixed, 794
mucosal, 794
patch lesions in, 33
pentachrome, 795
perinevoid, 1386
pigmentation changes in, 33
ponctue, 795
prevention of, 803
prognosis and clinical course in, 797
quadrichrome, 795
in scleroderma, 808
segmental, 792
in thyroid disorders, 792, 795, 812, 1854
treatment of, 797–802
camouflage/sun protection, 802
corticosteroids, 799
depigmentation, 802
laser therapy in, 800, 2885
photochemotherapy in, 799, 2860
phototherapy in, 799
trichrome, 795
universal, 794
vulgaris, 793
Von Recklinghausen disease. *See* Neurofibromatosis, type 1
Von Zumbusch psoriasis, 211, 213, 214, 214f
Vulvar disorders, **878**–892
abscess, 888
aphthae, 887–888
in cicatricial pemphigoid, 887
clinical findings in, 878–879
in contact dermatitis, irritant and allergic, 882
in Crohn disease, 888
differential diagnosis of, 880, 880b
epidemiology of, 878
fissures, 885
laboratory tests in, 879–880
in lichen planus, 303–304
in lichen sclerosus, 883–885
in lichen simplex chronicus, 881
in Paget disease, 1371–1376
prognosis and clinical course in, 1374
treatment of, 1375–1376in pemphigus vulgaris, 887
prognosis and clinical course in, 880
in psoriasis, 882
treatment in, 880–881
vulvodynia, 890–892
Vulvo-vaginal gingival syndrome, 304
Vulvodynia, 890–892

W

Waardenburg syndrome, 788–789
epidemiology of, 782
etiology and pathogenesis in, 788–790
type 1, 788–789
type 2, 789
type 3, 790
type 4, 790
Wangiella dermatitidis, 2317
Warts, 2421–2433
anogenital, 862, 2425, 2882
clinical findings in, 2425
differential diagnosis in, 2428
epidemiology of, 2424
histopathology in, 2428
in HIV infection and AIDS, 2444
prevention of, 2433
treatment of, 2432
Bowenoid papulosis, 2426
clinical findings in, 2425–2428
common (verruca vulgaris), 2425, 2882–2883
in HIV infection and AIDS, 2444
complications in, 2429–2431
cancer, 2429–2431
differential diagnosis of, 2428–2429, 2430b, 2431b
epidemiology of, 2424
in epidermodysplasia verruciformis, 2426
etiology and pathogenesis, 2421–2424
filiform, 2425
flat or plane (verruca plana), 2425
histopathology in, 2428
histopathology in, 2427–2428
mosaic, 2425
in occupational exposures, 2625
oral, 2426
in HIV infection and AIDS, 2444
palmar, 2425
in papillomavirus infections, **2421**–2433
cancer and, 2429
clinical findings in, 2425
complications in, 2429
differential diagnosis of, 2428–2429
epidemiology of, 2424
histopathology in, 2427–2428
in immunocompromised host, 2444–2445
prevention of, 2433
treatment of, 2432
plantar, 2425
prevention of, 2433
treatment of, 2706–2707, 2432
cryotherapy in, 2970
laser therapy in, 2882–2883
viral, 862, 863b, 2625
Warty dyskeratoma, 1331
Warty tuberculosis, 2229–2230
differential diagnosis of, 2230b
Watch-glass deformity of nails, 1824
Water
bacterial infections associated with, 2598
Gnathostoma in, 2565
predominant absorption (laser therapy aspects), 3006–3007
sports activities in
actinic damage in, 1119
in ocean sports, 1119–1120
skin problems associated with, 1119–1120
wound infections from, 2597–2598
Waterless hand cleaners as occupational irritants, 2615
Water-soluble base of ointments, 2647
Wegener granulomatosis, 2022–2023
Weibel-Palade bodies, 1988
Weill-Marchesani syndrome, 1632b
Wells syndrome, 391–394
clinical findings in, 391
differential diagnosis of, 394
disorders associated with, 393t
flame figures in, 394f
treatment of, 394
Werner syndrome, 1213, 1214, 1655, 1657t, 1658t, **1668,** 1898t
cancer risk in, 1668
clinical features in, 1668
DNA damage and repair in, 1668
general skin changes in, 1820genetic factors in, 1668
subcutaneous tissue in, 67–68
Westerhof syndrome, 825
Western immunoblot assay, 1237
Wheal, 31, 31f
in dermatographism, 31, 31f
WHIM (warts, hypoimmunoglobulinemia, infections, myelokathexis), 1721
White leprosy, 2531
White nails, 1824
White sponge nevus
oral cavity disorders in, 833
Whitlow
staphylococcal, 2138
WHN, 1712t

Whorled lesions, 39
Wickham striae
in lichen planus, 298
Wigs and hairpieces in alopecia, 987, 994
Wilson disease, nail changes in, 1824
Wind chill index, 1081
Wiskott-Aldrich syndrome, 1710–1711
differential diagnosis in, 172
genetic counseling in, 88
Wood tar preparations, 2698
Wood's light examination, 2284
Woolly hair, 1004
Workplace
accommodations in, 2620
exposures in. *See* Occupational exposures
hazard identification in, 2621
Wound healing, **2984**–2996
in chronic wounds, 2993–2995
basic standards of care, 2994
surgical approach to, 2995
extracellular matrix in, 2989–2991
impaired, 2993–2996
bioengineered skin in, 2995
chronic wounds and, 2993–2995
platelet-derived growth factor therapy in, 2994, 2995
prediction of wound closure, 2996
in laser skin resurfacing, 3028
moisture affecting, 2991–2992
neuropeptides in, 1145
phases of, 2947, 2985
coagulation and inflammation in, 2985–2987
proliferation, migration, and remodeling in, 2987–2989
by second intention
in excisional surgery without closure, 2928
of skin grafts, 2992–2993
imbibition phase in, 2992
revascularization phase of, 2992–2993
track marks from sutures in, 2981–2982
Wound closure, predicting of, 2996
Wound infections
in surgical wounds, 2978
Wound management in decubitus ulcers, 1127–1128
Wrinkling of skin
in aging, 3018–3020
Wuchereria bancrofti, 2118, 2549, 2563

X

X-linked disorders, 81–83
dominant, 81, 82, 82f
ichthyosis in, 82
recessive, 81, 83, 83f
severe combined immunodeficiency in, 1712t
Wiskott-Aldrich syndrome in, 1710
Xanthelasma
laser therapy for, 2881
Xanthogranuloma
juvenile, 1796, 1796t
clinical findings in, 1798–1799
differential diagnosis of, 1799b
en plaque, 1798
epidemiology of, 1796
etiology and pathogenesis in, 1797
giant, 1798
histopathology in, 1799
nodular form, 1796, 1798, 1798f, 1799b
papular form, 1796, 1798, 1798f, 1799b
prognosis and clinical course, 1800
treatment in, 1808
necrobiotic, 1730t, 1796, 1796t, 1805–1806
clinical findings in, 1805–1806
differential diagnosis of, 1806b
epidemiology of, 1797
etiology and pathogenesis in, 1797
treatment in, 1808
in neurofibromatosis type 1, 1686, 1799
Xanthoma, **1600**–1612
in children, 1611
in chylomicronemia, 1611
clinical findings in, 1600–1604
differential diagnosis of, 1604b
disseminatum, 1796, 1796t
clinical findings in, 1802
differential diagnosis of, 1803b
epidemiology of, 1796
histopathology in, 1802–1803
treatment in, 1808
in dysbetalipoproteinemia, 1609
eruptive, 1610
in hypercholesterolemia, 1607
in hypertriglyceridemia, 1610–1611
lipids
level testing and, 1611
and lipoprotein metabolism aspects, 1604–1607
marked HDL deficiency in, 1609
in phytosterolemia, 1608–1609
tendinous, 1607–1609
tuberous, 1609
verruciform, 874, 1611
Xanthomatosis
cerebrotendinous, 1609
in familial hypercholesterolemia, 1607
Xanthurenic aciduria, 1526t
Xenopsylla fleas, 2607
Xeroderma pigmentosum, 982t, 1654, 1656t, **1659**
and actinic keratosis, 1659, 1660f, 1661, 1662
basal cell carcinoma in, 1659, 1660f, 1661f
cancer risk in, 1659, 1660f, 1661f, 1662
cellular hypersensitivity in, 1660
clinical features in, 1659–1660
and Cockayne syndrome, 1658t, 1663, 1665
complementation groups in, 1661, 1662–1664
DNA damage and repair in, 1656t, 1657t, 1659–1667
in drug and chemical hypersensitivity, 1661
nucleotide excision pathway in, 1655, 1661
in ultraviolet radiation exposure, 1661
epidemiology of, 1659
genetic factors in, 1655, 1656t, 1658t
heterozygotes, 1664
laboratory findings in, 1660, 1662
melanoma in, 1659, 1662
prenatal diagnosis of, 1661
squamous cell carcinoma in, 1659, 1662
support groups for patients with, 1664–1665
treatment of, 1661–1662
and trichothiodystrophy, 1667
and ultraviolet radiation exposure, 1659
DNA damage and repair in, 1659
laboratory findings in, 1660
protection from, 1661–1662
variant of, 1664
Xeroderma Pigmentosum Society, 1664–1665
Xerosis, 3009–3011
compared to oily skin type, 3009–3011
hyaluronic acid levels in, 3010
moisturizing products in, 3010
in retinoid therapy, 2764
sebum production in, 3010
skin care for, 3011
Xerostomia
in Sjögren syndrome, 1978
45 XO (Turner syndrome), 84t
49 XXXXY, 84t
47 XXY (Klinefelter syndrome), 84t, 87
48 XXYY, 84t
47 XYY, 84t

Y

Yaws, 2494–2497
clinical findings in, 2494–2497
crab, 2496
differential diagnosis of, 2498b
histopathology, 2499
primary or mother lesion in, 2495
relapsing, 2496secondary or daughter lesion in, 2495–2496
tertiary stage, 2497
treatment of, 2500
Yeast infections, 2298
candidiasis, 2298–2307
Yellow nails, 1026, 1825–1826
Yersinia pestis, 2636. *See also* Plague
in bioterrorism, 2636
diagnosis of, 2215–2216
in plague, 2215–2217
portal of entry, 2122

Z

ZAP-70 deficiency, 1712t
Zidovudine
  in HIV infection and AIDS, 2788, 2795t
  hyperpigmentation in, 821
Zinc, 1520–1523
  deficiency of, 1521–1523, 1834
    acrodermatitis enteropathica, 1521–1522
    acquired, 1522–1523
  food sources of, 1520–1521
  functions of, 1520
  supplementation of, 1521
    pediatric dosage in, 1521
  toxicity of, 1523
Zinc oxide, 2709
  in sunscreens, 2710t
Zinc pyrithione in tinea capitis, 2294t
Zinsser-Engman-Cole syndrome, 1669
Zonal occluding proteins, 494
Zonisamide, anhidrosis from, 943t, 944
Zoon balanitis, 868–870
  differential diagnosis of, 869b
Zosteriform distribution of lesions, 39
Zygomatic nerve, 2907, 2908, 2910
Zygomycosis, 2327
  in diabetes mellitus, 334, 2327
  in immunocompromised host, 334
  oral cavity disorders in, 832–833
  rhinocerebral, 334, 832–833
  subcutaneous, 2317